

**Practical Handbook
of Advanced
Interventional
Cardiology**

Practical Handbook of Advanced Interventional Cardiology

EDITED BY

Thach Nguyen, MD

Director of Cardiology
Community Healthcare System
St. Mary Medical Center
Hobart, IN, USA

Dayi Hu, FACC, FESC

Director of the Intervention Center at
Peking University People's
Hospital Beijing, Dean of Clinical
Research Institute at Shanghai's Fudan
University, Shanghai, China

Shao Liang Chen, MD, FACC

Vice President & Chief of Cardiology,
Nanjing First Hospital;
Professor of Internal Medicine &
Cardiology,
Nanjing Medical University;
President of Nanjing Heart Center,
Nanjing, China

Moo-Hyun Kim, MD, FACC, FSCAI

Director, Regional Clinical Trial Center
Professor, Department of Cardiology
Dong-A University Hospital
Busan, Korea

Shigeru Saito, MD, FACC, FSCAI, FJCC

Chief, Division of Cardiology and
Catheterization Laboratories
Heart Center, Shonan Kamakura
General Hospital
Kanagawa, Japan

Cindy Grines, MD

Vice President of Academic and Clinical
Affairs, Detroit Medical Center
Cardiovascular Institute
Professor of Medicine, Wayne State
University School of Medicine
Detroit, MI, USA

C. Michael Gibson, MD

Chief of Clinical Research
Division of Cardiology
Beth Israel Deaconess Medical Center
Boston, MA, USA

Steven R. Bailey, MD, FSCAI, FACC

Janey Briscoe Distinguished Professor of
Medicine and Radiology
Chief, Janey and Dolph Briscoe Division
of Cardiology
University of Texas Health Science Center
San Antonio, TX, USA

FOURTH EDITION

 **WILEY-BLACKWELL**

A John Wiley & Sons, Ltd., Publication

This edition first published 2013, © 2013 by John Wiley & Sons, Ltd

Wiley-Blackwell is an imprint of John Wiley & Sons, formed by the merger of Wiley's global Scientific, Technical and Medical business with Blackwell Publishing.

Registered office: John Wiley & Sons Ltd, The Atrium, Southern Gate, Chichester, West Sussex, PO19 8SQ, UK

Editorial offices: 9600 Garsington Road, Oxford, OX4 2DQ, UK
The Atrium, Southern Gate, Chichester, West Sussex, PO19 8SQ, UK
111 River Street, Hoboken, NJ 07030-5774, USA

For details of our global editorial offices, for customer services and for information about how to apply for permission to reuse the copyright material in this book please see our website at www.wiley.com/wiley-blackwell

The right of the author to be identified as the author of this work has been asserted in accordance with the Copyright, Designs and Patents Act 1988.

All rights reserved. No part of this publication may be reproduced, stored in a retrieval system, or transmitted, in any form or by any means, electronic, mechanical, photocopying, recording or otherwise, except as permitted by the UK Copyright, Designs and Patents Act 1988, without the prior permission of the publisher.

Designations used by companies to distinguish their products are often claimed as trademarks. All brand names and product names used in this book are trade names, service marks, trademarks or registered trademarks of their respective owners. The publisher is not associated with any product or vendor mentioned in this book. This publication is designed to provide accurate and authoritative information in regard to the subject matter covered. It is sold on the understanding that the publisher is not engaged in rendering professional services. If professional advice or other expert assistance is required, the services of a competent professional should be sought.

The contents of this work are intended to further general scientific research, understanding, and discussion only and are not intended and should not be relied upon as recommending or promoting a specific method, diagnosis, or treatment by physicians for any particular patient. The publisher and the author make no representations or warranties with respect to the accuracy or completeness of the contents of this work and specifically disclaim all warranties, including without limitation any implied warranties of fitness for a particular purpose. In view of ongoing research, equipment modifications, changes in governmental regulations, and the constant flow of information relating to the use of medicines, equipment, and devices, the reader is urged to review and evaluate the information provided in the package insert or instructions for each medicine, equipment, or device for, among other things, any changes in the instructions or indication of usage and for added warnings and precautions. Readers should consult with a specialist where appropriate. The fact that an organization or Website is referred to in this work as a citation and/or a potential source of further information does not mean that the author or the publisher endorses the information the organization or Website may provide or recommendations it may make. Further, readers should be aware that Internet Websites listed in this work may have changed or disappeared between when this work was written and when it is read. No warranty may be created or extended by any promotional statements for this work. Neither the publisher nor the author shall be liable for any damages arising herefrom.

Practical handbook of advanced interventional cardiology / edited by Thach Nguyen, Dayi Hu, Shao Liang Chen, Moo-Hyun Kim, Shigeru Saito, Cindy Grines, C. Michael Gibson, Steven R Bailey. – 4th ed.

p. ; cm.

Advanced interventional cardiology

Includes bibliographical references and index.

ISBN 978-0-470-67047-7 (pbk. : alk. paper)

I. Nguyen, Thach. II. Gibson, Michael, 1959– III. Bailey, Steve R.

IV. Title: Advanced interventional cardiology.

[DNLM: 1. Cardiovascular Surgical Procedures—methods—Handbooks.

2. Cardiovascular Diseases—surgery—Handbooks. WG 39]

617.4'12—dc23

2012008541

A catalogue record for this book is available from the British Library.

Wiley also publishes its books in a variety of electronic formats. Some content that appears in print may not be available in electronic books.

Cover design by Andy Meaden

Cover image: Balloon angioplasty of the heart; © Alan Pol, ISM/Science Photo Library

Set in 8/10pt Frutiger Light by Toppan Best-set Premedia Limited, Hong Kong

Contents

Preface, ix

List of Contributors, xiii

Foreword to the First Edition, xxiii

Acknowledgements, xxv

1 Vascular Access, 1

Thach N. Nguyen, Quoc Nguyen, Pham Quoc Khanh,
Tuan D. Nguyen

2 Angiographic Views, 27

Thach N. Nguyen, Sim Kui Hian, Timothy J. Yee,
Aung Kyaw Zaw, Hoang Trong Minh Tuan,
Pham Nhu Hung, Hung D. Huynh, Dan Le

3 Guides, 51

Dobrin Vassilev, Thach N. Nguyen, Yidong Wei

4 Wires, 87

Dobrin Vassilev, Satoru Sumitsuji, Thach N. Nguyen,
Hai Yun Wu

5 Balloon Angioplasty, 105

Thach N. Nguyen, Tung Mai, Dominic Nguyen, Hau Tran,
Ainol Shareha Sahar

6 Stenting, 119

Thach N. Nguyen, Vo Thanh Nhan, Dinh Duc Huy,
Nguyen Huynh Khuong, Nikola Bakraceski

7 Transradial Approach, 141

Jack P. Chen, Xian Kai Li, Thach N. Nguyen, Phan Nam
Hung, Tejas Patel, Shigeru Saito

8 Slender Transradial Intervention, 171

Yuji Ikari

9 Left Main, 185

Run Lin Gao, Debabrata Dash, Bo Xu, Thach N. Nguyen

10 Chronic Total Occlusion, 207

Thach N. Nguyen, Satoru Sumitsuji, Yaling Han,
Shigeru Saito

11 Ostial Lesions, 255

Szabolcs Szabo, Huynh Trung Cang, Yadav Bhatta,
Thach N. Nguyen

**12 Acute ST-segment Elevation Myocardial
Infarction, 269**

James Nguyen, Marko Noc, Thach N. Nguyen, Lefeng Wang,
Hung M. Ngo, Tan Huay Cheem, Michael Gibson

- 13 Interventions in Patients after Coronary Artery Bypass Graft Surgery, 293**
Thach N. Nguyen, Nguyen Quang Tuan,
Muhammad Munawar
- 14 Bifurcation Lesion, 313**
Shao Liang Chen, Dobrin Vassilev, Nguyen K. Nguyen,
Gim Hooi Choo, Thach N. Nguyen, Tak Kwan, Junjie Zhang
- 15 Complications, 347**
Ashok Seth, Nguyen Ngoc Quang, Vijay Dave,
Thach N. Nguyen
- 16 High-risk Patients, 399**
Ramesh Daggubati, Rajasekhar Nekkanti, Vinh N. Pham,
Nguyen Duc Cong, Phan D. Phong, Dan D. Le,
Ali Oto, Vijay Dave, Thach N. Nguyen
- 17 Removal of Embolized Material, 419**
Thach N. Nguyen, Tung Mai, Quoc Nguyen,
Katrina Nguyen, Kirk Garrat
- 18 Inoue Balloon Mitral Valvuloplasty, 437**
Jui-Sung Hung, Kean-Wah Lau
- 19 Retrograde Percutaneous Aortic Valvuloplasty, 475**
Ted Feldman, Thach N. Nguyen
- 20 Percutaneous Implantation of Aortic Valvular Prostheses, 487**
Stefan Toggweiler, John Webb
- 21 Subclavian Artery Interventions, 501**
Gianluca Rigatelli, Paolo Cardaioli, Aravinda Nanjundappa
- 22 Endovascular Repair of Abdominal Aortic Aneurysm, 517**
Aravinda Nanjundappa, Damras Tresukosol,
Thach N. Nguyen
- 23 Renal Artery Interventions, 537**
Gianluca Rigatelli, Ho Thuong Dung, Paolo Cardaioli
- 24 Carotid Artery Occlusive Disease, 553**
Gianluca Rigatelli, Paolo Cardaioli, Horst Sievert
- 25 Iliac Artery Stenosis, 579**
Timothy C. Dy, Gianluca Rigatelli, Paolo Cardaioli,
Rosli Mohd Ali, Aravinda Nanjundappa
- 26 Infrainguinal and Infragenicular Interventions, 603**
Jasrai Gill, Robert Dieter, John Lopez, Gianluca Rigatelli,
Thach N. Nguyen, Paolo Cardaioli, Prakash Makham,
Aravinda Nanjundappa

**27 Percutaneous Intervention of Cardiac
Congenital Anomalies, 629**

Gianluca Rigatelli, Zhang Shuang Chuan, Nguyen Thuong
Nghia, Nguyen Lan Hieu, Do Huan Quang

Index, 657

Preface

ADVANCED INTERVENTIONAL CARDIOLOGY ART AND SCIENCE

In 2013, more than 30 years after its humble beginnings, interventional cardiology has become a mature and major player in the management of complex cardiovascular problems. Thanks to the miniaturization of equipment, as a result of modern micro-technology and nano-engineering, interventional cardiology techniques have made a giant leap forward to become ever-more effective and user-friendly. These techniques can be formulated as a sequence of rigorously controlled maneuvers which can be taught to fellows or staff (or even programmed into robots).

To understand and explain the physical, chemical, biologic, and engineering mechanisms of any of these techniques or maneuvers is a science. To perform a procedure both cost- and time-effectively in a humane manner is an art. In any interventional laboratory, a lesion could be dilated with one guide, wire, balloon or stent by a senior operator or by x (>1) numbers of devices by a beginner. This is where science and art mix.

Which is the Best Option to Apply to this Real-Life Situation? During a procedure, each operator has the luxury (*and the responsibility*) to select, change, or modify the direction or position of a device, the drug of use, and the strategy of choice; or to be forced to use one when the others are not available. These options are frequently listed and discussed *ad nauseam* elsewhere in print and electronic media. However, the main question always remains: which is the best option, with the equipment available, in any given real-life situation?

In the fourth edition of this handbook, the authors have tried to answer this very question and to give practical advice derived from their own considerable experience within the cardiac interventional setting.

In the "Strategic Mapping" boxes, the operator visualizes a global schema of procedural sequences he or she would execute in order to achieve success. This strategic map also includes preventive or corrective measures to deal with crisis situations such as unexpected complications or suboptimal performance of any tactic or strategy.

In the "Tactical Move" boxes, the authors break up the whole strategy into detailed procedural sequences with limited local goals. At the beginning, it is how to select an appropriate device, e.g. guides, to achieve success at the first attempt. Then, if a device does not function as expected, there are many simple maneuvers to correct or reverse the situation. In any case, the

operators will try to exhaust the full potential of any device first without prematurely and wastefully discarding it.

However, at the same time, while there are many parallel competing tactics or strategies, how does one objectively select the one that is best in any given situation? This is the role of critical thinking: a subjective change of tactics that could save the whole procedure and lead to success or alternatively – to our worst nightmare – failure. In this section, each maneuver is graded according to time spent, the cost of any extra equipment required and the risk of complication. For every extra 10 minutes, one more hour can be added to the clock. One dollar sign means that an extra \$100.00 US are spent. One drop of blood is the symbol for moderate complication; two drops indicate high risk.

In the “Caveat” boxes, we warn the readers of any deceiving signs or treacherous wrong moves that harbinger impending disaster. This information is combined with operator experience from past personal failures, near death experiences of the patient and successful (*often almost miraculous*) resolution of the critical events. Altogether they constitute a collective memory of how to avoid failure and how to achieve success i.e. what we call experience! If these hard earned lessons of collective memory were applied in real life, the rate of procedural success would be higher and the incidence of complications much lower.

The rate of complication depends on the operator’s skill, the technology available, and patient selection. Rigorous preventive measures learned from that collective memory (i.e., experience) pre-empt the appearance of complications (*although one of the best ways to avoid EVERY complication is to perform NO procedures!*). With the use of current low-profile balloons and high torqueable wires, most patients with “simple” stenoses will have good results, even in the hands of relatively inexperienced operators. However, in patients with complex anatomy or when simple cases become complicated, experienced operators are likely to have superior outcomes. This is why we value experience so much [1].

The authors and editors, who are all your friends and colleagues, labor every day in the cardiac interventional laboratory, as you do yourself. We write from our limited subjective experience and from our hearts. This handbook contains practical advice aimed at you, the reader, and at us, the authors and editors ourselves. We practice what we preach. They are not pronouncements from some ivory tower: they are practiced by those with experience and also by beginners, by the young and old, by men and women, by serious operators and by part timers; so there are no distinctions here between class, age, sex or race.

In this book, we try to highlight these practical suggestions with all of the dramatic ups and downs – reminiscent of an Italian opera – which happen daily in the interventional cardiology laboratory. However, we hope the outcome of these procedures is both happy and beautiful, as the end of any Chinese martial arts movie. The bottom line is that we practice interventional cardiology in a responsible manner: both cost- and time-effective without causing more harm (*prima non nocere*). All of us are equal in this

quest of striving for the best procedural and clinical success. This is the only goal of this handbook.

REFERENCE

1. Ellis S. Elective coronary angioplasty: Techniques and complications. In Topol EJ, editor. *Textbook of Interventional Cardiology*, 3rd edition. Lippincott-Raven Publishers. pp. 147–62, 1998.

List of Contributors

ROSLI MOHD ALI, MD

Head, Department of Cardiology
National Heart Institute, Kuala Lumpur, Malaysia

STEVEN R. BAILEY, MD, FACC, FSCAI

Chief of Cardiology
University of Texas Health Center
San Antonio, TX, USA

NIKOLA BAKRACESKI, MD

Head of Interventional Cardiology Department
Director, Institute of Cardiovascular Disease
Ohrid, Macedonia

YADAV BHATTA, MD

Professor and Head Department of Cardiology
Sahid Gangalal National Heart Institute
Kathmandu, Nepal

BO XU, MD

Director
Catheterization Laboratories
Fu Wai Hospital, Beijing, China
National Center for Cardiovascular Diseases, Beijing, China

HUYNH TRUNG CANG, MD

Director of Interventional Cardiology Unit
Vice Chief of Department of Cardiology
Kien Giang General Hospital, Rạch Gia, Vietnam

PAOLO CARDAIOLI, MD

Head, Cardiovascular Diagnosis and Endoluminal Interventions Unit
Rovigo General Hospital, Rovigo, Italy

TAN HUAY CHEEM, MD

Singapore National Hospital
Singapore

JACK P. CHEN, MD, FACC, FSCAI, FCCP

Medical Director of Cardiology
Northside Hospital-Atlanta, GA, USA

SHAO LIANG CHEN, MD, FACC

Vice President of Nanjing First Hospital, Nanjing Medical
University
Professor of Internal Medicine & Cardiology, Nanjing Medical
University
Chief of Cardiology, Nanjing First Hospital, Nanjing Medical
University
President of Nanjing Heart Center, Nanjing, China

GIM HOOI CHOO, MD, FACC, FSCAI, FNHAM, FAsCC

Sime Darby Medical Centre, Subang Jaya, Malaysia
National Heart Institute, Kuala Lumpur, Malaysia

ZHANG SHUANG CHUAN, MD

Director and Professor of Pediatrics
Pediatric Department Peking University Shenzhen Hospital
Guest Professor of Shenzhen Children's Hospital
National Member of Pediatric Cardiology of Chinese Medical Association
Shenzhen Guangdong, China

NGUYEN DUC CONG, MD, PhD

Director, Thong Nhat Hospital
Deputy Chairman of Geriatric Department-University of Medicine and Pharmacy, Ho Chi Minh City, Vice President of Vietnam Internal Medicine Association
Vice President of Hochiminh City Geriatric Association
Ho Chi Minh City, Vietnam

RAMESH DAGGUBATI, MD

Program Director of Interventional Cardiology
Clinical Associate Professor
Department of Cardiovascular Sciences
Brody School of Medicine at East Carolina University
Director of Cardiac Catheterization Laboratories
East Carolina Heart Institute at Pitt County Memorial Hospital
Greenville, NC, USA

DEBABRATA DASH, MD, DM, FICC, FCCP, FAPSC, FSCAI

Head & Senior Interventional Cardiologist, Fortis Raheja Hospital, Mumbai, India
Visiting Consultant and Interventional Cardiologist, Cumballa Hill Hospital, Mumbai, India

VIJAY DAVE, MD

Director of Medical Education
St Mary Medical Center
Community Healthcare System
Hobart, IN, USA

ROBERT S. DIETER, MD, RVT

Associate Professor
Vascular & Endovascular Medicine
Interventional Cardiology
Loyola University Medical Center
Chief of Vascular Medicine and Cardiovascular Interventions
Medical Director, Cardiovascular Collaborative
Hines VA Hospital, Hines, IL, USA

HUAN QUANG DO, MD, PhD

Chief of Cardiology
The Heart Institute
Ho Chi Minh City, Vietnam

HO THUONG DUNG, MD, PhD, FSCAI

Vice Director of Thong Nhat Hospital, Ho Chi Minh City
Vice Chairman of Interventional Cardiology Association
Ho Chi Minh City, Vietnam

TED FELDMAN, MD, FSCAI, FACC, FESC

Director Cardiac Catheterization Laboratory, Evanston
Hospital
Clinical Professor of Medicine, University of Chicago
Cardiology Division,
Evanston, IL, USA

RUN LIN GAO, MD, FACC, FSCAI

Professor of Medicine
Chief Cardiologist
Fu Wai Hospital
National Center for Cardiovascular Diseases, Beijing,
China

KIRK N. GARRATT, MD

Associate Director, Division of Cardiac Interventions,
Lenox Hill Hospital, New York, NY, USA

C. MICHAEL GIBSON, MD

Director, TIMI Data Coordinating Center; *and* Associate
Professor, Harvard Medical School;
Chief of Clinical Research, Division of Cardiology, Beth Israel
Deaconess Medical Center, Boston MA, USA

JASRAI GILL, MD

Interventional Cardiology Fellow
Loyola University Medical Center
Maywood, IL, USA

CINDY GRINES, MD

Vice President of Academic and Clinical Affairs
Detroit Medical Center Cardiovascular Institute
Professor of Medicine, Wayne State University School of
Medicine
Detroit, Michigan USA

YALING HAN, MD

Professor of Medicine
Director, Cardiovascular Department
Shenyang Northern Hospital, Shenyang, China

SIM KUI HIAN, MD

Visiting Senior Consultant Cardiologist, Dept of Cardiology and
Visiting Senior Researcher, Clinical Research Centre (CRC)
Sarawak General Hospital Heart Centre, Kota Samarahan,
Malaysia,
Adjunct Professor, Faculty of Medicine & Health Sciences
University Malaysia Sarawak (UNIMAS), Kuching, Malaysia

NGUYEN LAN HIEU, MD, PhD

Vice-Director, Cardiac Catheterization Laboratories
Vietnam Heart Institute, Bach Mai General Hospital
Hanoi, Vietnam

DAYI HU, MD, FACC, FESC

Director of the Intervention Center at Peking University People's Hospital Beijing, China

Dean of Clinical Research Institute at Shanghai's Fudan University Shanghai, China

Immediate past President of the Chinese Society of Cardiology (CSC)

President of the China Committee of Cardio-Cerebral-Vascular Diseases of GSC

Past president of the Chinese College of Cardiovascular Physicians (CCCCP)

Member of The International Academy of Sciences for Europe and Asia (IASEA).

Beijing, China

PHAM MANH HUNG, MD, PhD, FACC, FESC

Associate Professor of Medicine, Hanoi Medical University

Secretary General, Vietnam National Heart Association

Director, Cardiac Catheterization Laboratory

Vietnam Heart Institute, Hanoi, Vietnam

PHAN NAM HUNG, MD

Chief, Cardiovascular Medicine Department, Binh Dinh General Hospital

Vice President, The Internal Medicine Society of Binh Dinh Province

General Secretary, The Internal Medicine Society of Vietnam

PHAM NHU HUNG, MD, PhD, FACC, FSAACC

Consultant of Cardiology and Electrophysiology

Bach Mai Hospital (Affiliated with Hanoi Medical University)

Guest Faculty of Hanoi University of Pharmacy, Hanoi, Vietnam

JUI-SUNG HUNG, MD, FACC, FAHA

Professor of Medicine, China Medical University

Taichung, Taiwan

DINH DUC HUY, MD

Deputy Director

Chief, Department of Interventional Cardiology

Tam Duc Cardiology Hospital

Ho Chi Minh City, Vietnam

HUNG D. HUYNH

Senior Research Associate, Community Healthcare System, St Mary Medical Center, Hobart, IN; and Webmaster, Riverside, CA, USA,

YUJI IKARI, MD, PhD, FACC

Professor, Department of Cardiovascular Medicine,

Tokai University, Japan

PHAM QUOC KHANH, MD, PhD

Director Cardiac Electrophysiology Lab of Vietnam Heart Institute

Vice President Vietnamese Interventional Cardiology Society

President Vietnamese Society of Cardiac Electrophysiology and Pacing

Vice director Vietnam Heart Institute,

Hanoi, Vietnam

NGUYEN HUYNH KHUONG, MD, PhD

Chief of Vascular Disease
Tam Duc Heart Hospital
Ho Chi Minh City, Vietnam

MOO-HYUN KIM, MD, FACC, FSCAI

Director, Regional Clinical Trial Center
Professor, Dept. of Cardiology, Dong-A University Hospital
Busan, Korea

TAK KWAN, MD

Professor of Medicine, Albert Einstein College of Medicine
Executive Chief, Asian Service Center
Senior Associate Director of Cardiac Catheterization Laboratory
and Interventional Cardiology, Beth Israel Medical Center, NY, USA

KEAN-WAH LAU MBBS, FRCP, FACC

Consultant Cardiologist
Gleneagles Medical Center
Singapore

DAN D.LE, MD

Fellow, Heart Failure and Transplant, Division of Cardiovascular
Disease
University of Alabama at Birmingham, Birmingham, Alabama, USA

XIAN KAI LI, MD, PhD

Cardiology Department, Shanghai Tenth People's Hospital of
Tongji University, Shanghai, China

JOHN LOPEZ, MD

Director, Interventional Cardiology Research
Co-Director, Acute MI Program
Professor, Department of Medicine
Loyola University Stritch School of Medicine Maywood, IL, USA

TUNG DINH MAI, BS

Class of 2014, College of Osteopathic Medicine
Michigan State University
Lansing, MI, USA

PRAKASH MAKHAM, MD

Community Health System
Community Hospital
Munster, IN, USA

MUHAMMAD MUNAWAR, MD, PhD

Bina Waluya Cardiac Center/Department of Cardiology and
Vascular Medicine, Faculty of Medicine, University of Indonesia,
Jakarta, Indonesia.

ARAVINDA NANJUNDAPPA, MD, FACC, FSCAI, RVT

Associate Professor of Medicine and Surgery
West Virginia University, Charleston, WV, USA

RAJASEKHAR NEKKANTI, MD, FACC, FASE, CCDS

Assistant Professor of Medicine
Director of Echocardiography
Program Director of Cardiology Fellowship
East Carolina Heart Institute
East Carolina University-The Brody School of Medicine. Greenville,
NC, USA

NGUYEN THUONG NGHIA, MD, FSCAI

Co Director of Interventional Cardiology and Cardiac
Catherization Laboratory, Cho Ray Hospital,
Ho Chi Minh City, Vietnam

HUNG MINH NGO, MD, MMed, FSCAI

Consultant Cardiologist, Department of Interventional Cardiology
Cho Ray Hospital, Ho Chi Minh City, Vietnam

NHUYEN HUU KHOA NGUYEN, MD

University of Medicine and Pharmacy, Ho Chi Minh City,
Vietnam
Chief of Interventional Cardiology Division
Trung Vuong Emergency Hospital
Ho Chi Minh City, Vietnam

DOMINIC NGUYEN

Undergraduate Program,
The University of California at Riverside
Riverside, CA, USA

JAMES NGUYEN, MD

Cardiology fellow, The University of Arizona Medical Center
Tucson, AZ, USA

KATRINA NGUYEN

Undergraduate Program, University of California at San Diego,
San Diego, CA, USA

QUOC NGUYEN, BS

University of Indianapolis, Indianapolis, IN, USA

THACH NGUYEN, MD, FACC, FSCAI

Associate-editor-in-chief, *Journal of Geriatric Cardiology*; and
Editorial Consultant,
Journal of Interventional Cardiology; Hoboken, NJ, and *Chinese
Medical Journal*, Beijing, China and Honorary Professor of
Medicine, Hanoi Medical University, Hanoi, Vietnam, and
Capital University of Medical Sciences, Beijing, China; and The
Institute of Geriatric Cardiology, 301 General Hospital of the
Chinese People's Liberation Army, Beijing, China and Friendship
Hospital, Beijing, and Visiting Professor, Nanjing First Hospital,
Nanjing Medical University, Nanjing, China; and Clinical
Assistant Professor of Medicine, Indiana University, Indianapolis,
IN, USA; and Director of Cardiology, Community Healthcare
System, St Mary Medical Center, Hobart, IN, USA

TUAN D. NGUYEN, MD

Staff Research Associate,
School of Public Health, University of California at Los Angeles,
Los Angeles, CA, USA

VO THANH NHAN, MD, PhD, FACC

Associate Professor of Clinical Cardiology, University of Medicine and Pharmacy; and Director of Interventional Cardiology and Cardiac Catheterization Laboratory, Cho Ray Hospital, Ho Chi Minh City, Vietnam

MARKO NOC, MD, PhD

University of Indianapolis, Indianapolis, IN, USA
Center for Intensive Internal Medicine, University Medical Center, Zaloska Ljubljana, Slovenia

ALI OTO, MD, FESC, FACC, FHRS

Professor of Medicine and Cardiology
Hacettepe University Faculty of Medicine
Ankara, Turkey

TEJAS PATEL, MD, FACC, FSCAI

Professor and Head, Department of Cardiology, Sheth V.S. General Hospital, Ahmedabad, India

PHAN DINH PHONG, MD

Fellow of Electrophysiology, Vietnam Heart Institute
Hanoi, Vietnam
Lecturer of Cardiology Department, Hanoi Medical University
Hanoi, Vietnam

NGUYEN NGOC QUANG, MD, PhD, FASCC

Consultant of Interventional Cardiology
Department of Cardiology, Hanoi Medical University
Coronary Intensive Care Unit, Vietnam National Heart
Institute
Bach Mai Hospital, Hanoi, Vietnam

GIANLUCA RIGATELLI, MD, PhD, EBIR, FACP, FACC, FESC, FSCAI,

Cardiovascular Diagnosis and Endoluminal Interventions Unit,
Rovigo General Hospital, Rovigo, Italy

AINOL SHAREHA SAHAR, MD, FACC

Director of Invasive Cardiac Catheterization Laboratory
Department of Cardiology, Penang Hospital
Penang, Malaysia

ASHOK SETH MD, FRCP (London), FRCP (Edinburgh), FRCP (Ireland), FACC, FSCAI (USA), FIMSA, FCSI, D.Sc. (Honoris Causa), Awarded 'Padma Shri', Chairman, Fortis Escorts Heart Institute, Chief of Cardiology, Chairman, Cardiology Council, Fortis Group of Hospitals President – Cardiological Society of India
Fortis Escorts Heart Institute, New Delhi, India

SHIGERU SAITO, MD, FACC, FSCAI, FJCC

Chief, Division of Cardiology and Catheterization Laboratories
Heart Center, Shonan Kamakura General Hospital
Kanagawa, Japan,

HORST SIEVERT, MD

Professor of Medicine, CardioVascular Center Frankfurt,
Frankfurt, Germany

SATORU SUMITSUJI, MD

Associate Professor of Advanced Cardiovascular Therapeutics
Osaka University, Osaka, Japan

STEFAN TOGGWEILER, MD

Fellow in Interventional Cardiology and Structural Heart Disease,
St Paul's Hospital, Vancouver, British Columbia, Canada

HAU TRAN, MD

Interventional Cardiology Unit
Hoan My Cuu Long Hospital
Cantho ,Vietnam

DAMRAS TRESUKOSOL, MD

Associate Professor
Division of Cardiology
Department of Medicine
Faculty of Medicine Siriraj Hospital
Bangkok, Thailand

HOANG TRONG MINH TUAN, PhD CANDIDATE

Bioinformatics and Computational Biology
George Mason University, Fairfax, VA, USA

NGUYEN QUANG TUAN, MD, PhD

Interventional Cardiology Vietnam National Heart Institute
Hanoi, Vietnam

DOBRIN VASSILEV, MD, PhD

Assistant Professor of Cardiology
Cardiac Catheterization Laboratory, National Heart Hospital
Sofia, Bulgaria

PHAM NGUYEN VINH, MD, PhD, FACC

Associate Professor of Medicine
Deputy Chief of Department of Internal Medicine
Pham Ngoc Thach University of Medicine
Medical Director Tam Duc Heart Hospital
Ho Chi Minh City, Vietnam

LEFENG WANG, MD, PhD

Professor of Medicine,
Deputy Director of Heart Center
Director of Cardiac Catheter Laboratory
Beijing Chaoyang Hospital, Affiliate of Capital Medical
University
Beijing, China

JOHN G WEBB, MD

McLeod Professor in Valvular Heart Disease Intervention
Director, Interventional Cardiology, St. Paul's Hospital,
Vancouver, British Columbia, Canada

YIDONG WEI, MD, FACC

Professor, Chief, Department of Cardiology
Shanghai Tenth People's Hospital of Tongji University
Shanghai, China

HAI YUN WU, MD

Clinical Professor, Institute of Geriatric Cardiology
Chinese PLA General Hospital
Beijing, China

TIMOTHY YEE

Class of 2016, University of Michigan, School of Medicine
Ann Arbor, MI, USA

**AUNG KYAW ZAW, MD, MBBS, M.Med.Sc.(Int.Med),Dr.Med.
Sc.(Cardiology), FACC, FSCAI, FAPSIC, FESC, FASCC**

Senior Consultant, Clinical and Interventional Cardiology
Pun Hlaing Hospital,Hlaing-Thar-Yar
Yangon, Myanmar

JUNJIE ZHANG, MD, FSCAI

Cardiovascular Department
Nanjing Medical University affiliated Nanjing First Hospital
Nanjing, China

Foreword to the First Edition

Interventional cardiovascular medicine has evolved from an extremely crude method of opening femoral arteries initiated by Dotter, to a field that has now been recognized as having a sufficient fund of knowledge to require boards sanctioned by the American Board of Internal Medicine. From Andreas Gruentzig's development of the noncompliant balloon method, we have seen an explosion of bio- engineering technology. The discipline of interventional cardiovascular medicine has perhaps initiated more registries and clinical trials than any other discipline in medicine. Indeed, the whole emphasis on evidence-based medicine has evolved during the era of interventional cardiology. Many basic science breakthroughs have been stimulated by the advances produced in interventional cardiology, as well as the problems and complications created by the new technologies.

However, no matter how advanced the science becomes, the success of solving a patient's problem with interventional techniques usually depends on the operator's technical ability. This ability springs from the wealth of experience the operator has acquired to deal with routine situations as well as complex and almost unique problems that may present themselves. Because of the large number of interventional cardiologists and the rapidly expanding number of procedures that can be performed, it is difficult for many cardiologists to experience all of the situations that can be helpful in building this database.

Dr Thach N. Nguyen has prepared a remarkable book, rich with tips and tricks for performing interventional cardiovascular medicine procedures. He has enlisted numerous experts on various aspects of interventional cardiovascular medicine to describe their areas of expertise. Rather than let them recite the evidence from registries and trials that are available elsewhere, he forces the contributors to provide the practical tips that they have learned. It is almost as though Dr Nguyen is trying to simulate the type of scenarios that exist in the catheterization laboratories with new cardiology fellows or less experienced operators. It is the type of advice that he has often given to cardiologists in developing countries who are bringing interventional techniques to help cope with the rapidly expanding new threat in these countries, vascular disease. Since new techniques are constantly appearing, all operators, experienced or not, can benefit from these tips. Whereas every operator will not agree with every approach to a problem or a complication, it is always instructive to understand many potential approaches. In this regard, the book does a masterful job of collecting not only the authors' experiences, but those of many others collected from the published literature, from numerous postgraduate courses, and from one-on-one demonstrations throughout the world.

This book should be a valuable resource to trainees in formal programs that have now evolved in the United States and other countries, as well as the many preceptorships that are the major

means of training in other countries. In addition, operators of all levels of experience will find many useful pearls of wisdom. Dr Nguyen and his colleagues are to be congratulated for compiling this most practical guide.

Spencer B. King III, MD
Atlanta, Georgia

Acknowledgements

For the completion of this book, we owe much to our teachers, friends, colleagues, families, staff and patients. I (TNN) am indebted to Dr Spencer King III, who wrote the foreword, for his invaluable encouragement, very kind words and advice. My deepest appreciation goes to my fellow editors and contributors and to my family, with the dedicated support (and my lost time always away for work) of Thien C. Tran, Vancouver WA; my parents Sau N. Nguyen (+ 2012) and Hanh T.H. Tran, and my family in Irvine CA; Dr Le Dinh Phuong, Franco-Vietnamese Hospital, Saigon, Vietnam; Dr Huynh Duong Hung, Webmaster Riverside CA; Special assistance was given by Cindy Macko at the Library of St Mary Medical Center, Hobart, IN and Yin Rong-Xiu at the Institute of Cardiovascular Disease, Capital University of Medical Sciences, Beijing, China. We appreciate the help and efforts of the staff at the Cardiac Catheterization laboratories of St Mary Medical Center, Hobart, IN.

Above all, we are indebted to our patients – the purpose of our care, the source of our quests, the inspiration of our daily work. To them we give our heartfelt thanks.

CHAPTER 1**Vascular Access**

Thach N. Nguyen, Quoc Nguyen, Pham Quoc Khanh,
Tuan D. Nguyen

Challenges 2

Femoral Approach 2

Standard of Technical Excellence 2

Technique The fluoroscopically guided micropuncture access 3

Technical Tips 4

**Angiography to check the location of femoral entry
through a dilator 4

Preparations in obese patients 4

*Directing the needle 4

*If the wire cannot be inserted 5

*Sequential order for arterial and venous puncture 5

**Kinked wire 5

**Puncture of pulseless femoral artery 5

Trouble-shooting Tricks 6

Puncture of femoral bypass graft 6

Technique Bypass graft puncture 6

Trouble-shooting Tricks 6

***Parallel technique 6

***Insertion of intra-aortic balloon pump through diseased
iliac artery 6

**Two catheters inserted with one puncture technique 7

Antegrade Puncture 7

Technique Common femoral artery antegrade puncture 7

Technical Tips 7

**Manipulation of wire 7

**Puncture of CFA with high bifurcation 8

**Puncture with abduction and external rotation of the thigh 8

Brachial Approach 8**Axillary Puncture 8****Transeptal Approach 10****Closure Devices 10**

Collagen Plug Device: Mynx 10

Clip Device: Starclose 10

The Perclose 11

Technique Preclosure of large arterial access 11

Technique Preclosure of large venous access 11

Technical Tips 11

***Differences in technical details for preclosure of venous
access 11

*Basic; **Advanced; ***Rare, exotic, or investigational

\$, <\$US100.00 extra; \$\$, >\$US100.00 extra

⌚, <10 min extra; ⌚⌚, >10 min extra

♣, low risk of complications; ♣♣, high risk of complications

***Double Angio-Seal closure for a 10-Fr vascular access 12

***Double Mynx closure for a 14-Fr arterial access 12

Discriminating Differences 12

Which vascular closure devices for which patients? 12

Trouble-shooting Tricks 14

***Management of intra-arterial deployment of collagen plug 14

Complications 14

Hematoma 14

Arteriovenous Fistula 15

Acute Arterial Thrombosis 15

Technique Mechanical thrombectomy for acute thrombosis 15

Limb Ischemia 15

Trouble-shooting Tricks 16

***Temporary relief of iatrogenic ischemic limb: percutaneous technique for in vivo femoral artery bypass 16

Retroperitoneal hematoma 17

Mechanism of clinical symptoms 17

Discriminating Differences 18

Medical and surgical management of retroperitoneal Hemorrhage 18

Technical Tips 18

**How to detect retroperitoneal hematoma in a 1-second maneuver? 18

Technique How to seal a perforation with a balloon 18

Technique How to close a perforation with microcoil or injection of thrombin 19

Perforation 22

Technique How to seal a perforation with a covered stent 22

Pseudoaneurysm 22

Femoral Dissection 23

CHALLENGES

To gain vascular access without early or late bleeding is a major challenge for every operator during diagnostic or interventional cardiovascular procedure.

FEMORAL APPROACH

Usually the femoral artery is palpated below the inguinal ligament that runs from the anterosuperior iliac spine to the pubic tubercle. The true position of the inguinal ligament is 1–2 cm below that line.

STANDARD OF TECHNICAL EXCELLENCE

Ideal Location of Femoral Access An ideal “landing zone” is defined by vascular entry above the femoral bifurcation and below an upper margin, conservatively defined as several centimeters below the inferior excursion of the inferior epigastric artery (IEA). The IEA descends, but does not cross, distal to the inguinal ligament; thus, entry above the lowest point of the course of this vessel, which typically then turns cranial to supply circulation to the epigastrium, can be used to define an unequivocally high puncture [1].

The technique employs visualization of the femoral head under fluoroscopy in a posteroanterior projection, and by starting the skin puncture at the level of the lower border of the head of femur with an eventual goal of arterial cannulation at the mid-third of the head of femur. However, even with this technique, punctures below the bifurcation of the common femoral artery (CFA) cannot be completely avoided. This is due to variability in the site of femoral artery bifurcation in reference to the femoral head. Although in most cases (approximately 77%) the bifurcation is below the level of the femoral head, in approximately 23% of cases the femoral artery bifurcation site is higher. Ninety-seven percent of patients have the femoral artery lying on the medial third of the femoral head. Only 3% have the artery totally medial to the femoral head. So one of the ways to perform a near-perfect femoral puncture is to use the fluoroscopically guided micropuncture access [2] (Figure 1.1).

TECHNIQUE The fluoroscopically guided micropuncture access

The micropuncture vascular access technique involves the use of needles and wires typically in the 21-gauge and 0.018" range. For femoral access, these needles are usually 7 cm in length. The outer diameter of this needle is 0.8mm; in contrast, the 18-gauge needle used by most operators is 56% larger, resulting in as much as six times the blood flow rate through an inadvertent back wall puncture or from an arterial entry with failed sheath placement.

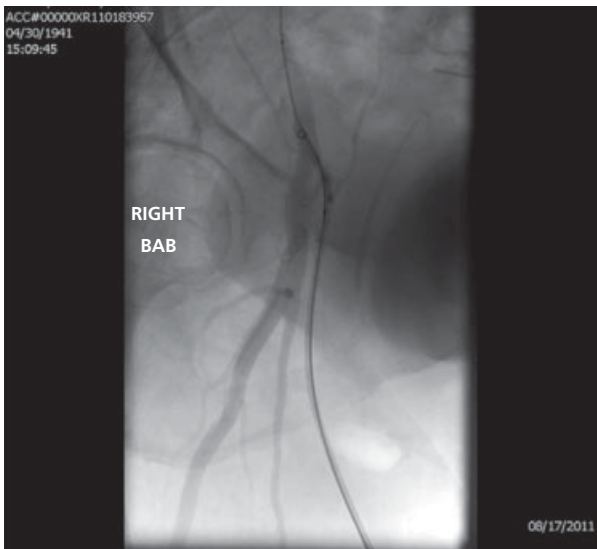


Figure 1.1 Ideal puncture location of the common femoral artery is above the bifurcation of the profunda femoral artery and below the origin of the inferior epigastric artery. In this iliofemoral angiogram, the sheath is seen entering the common femoral artery at a point above the origin of the inferior epigastric artery. This is an unacceptable high stick. (Courtesy of Dr Aravinda Nanjundappa.)

The CFA is punctured under fluoroscopic guidance using the mid-third of the femoral head to guide the needle to the anticipated puncture site, although restricting puncture to a point below the centerline of the femoral head may be the most prudent approach. Following the initial localization of the bottom of the femoral head, repeat fluoroscopy is performed after the needle has been placed deep in the tissue track, but not yet into the femoral artery to achieve an ideal location of puncture. The path of the needle could be adjusted several times if necessary, as it traverses deep into the subcutaneous tissue [1].

Once the needle is in the vessel and there is blood return, some operators perform a limited femoral angiogram via the micropuncture needle using a 3-ml syringe. If acceptable CFA access location is confirmed, a 0.018-inch wire is advanced through the needle. A 4-Fr micropuncture sheath is advanced over the wire and exchanged for a 0.035-inch wire to support passage of a larger sheath size. There are also larger, highly tapered sheaths designed to go directly over the micropuncture wire. This technique allows relatively safe removal of the micropuncture needle or sheath after unfavorable location entry, with manual pressure applied for 3–5 minutes before attempt of a new puncture based on the angiogram.

Technical Tips

****Angiography to check the location of femoral entry through a dilator** Some operators do not favor injecting through the micropuncture needle, a technique that incurs additional radiation for the operator and has potential risks of losing intraluminal positioning as well as vessel dissection. A modification, therefore, is to access the vessel with the micropuncture needle, advance the 0.018-inch wire and place the small inner dilator of the micropuncture sheath over the 0.018-inch wire and use this small dilator for angiography rather than injecting directly through the micropuncture needle or the larger outer 4-Fr sheath.

Preparations in obese patients The femoral pulse at the inguinal crease is not a reliable landmark for the CFA, particularly in obese or elderly patients whose crease tends to be much lower than the inguinal ligament. The protruding abdomen and panniculus should be retracted, and taped to the chest with 3- to 4-inch tapes that are in turn secured to the sides of the catheterization table. Keep the tissue layer above the artery as thin and taut as possible, so the needle will not be deflected from the projected angle and selected pathway.

***Directing the needle** Once the needle tip is near the artery, it tends to pulsate except in those patients with severe local scarring (following many prior remote femoral artery cannulations, total hip replacement, in severely calcified arteries, etc.). If the hub inclines to the right, the needle should be withdrawn by 1 cm and the tip redirected to the right before advancing forward. If the hub inclines to the left, the tip is redirected to the left before

pushing in. If the needle pulsates on the vertical axis, it just needs to be pushed slowly deeper.

***If the wire cannot be inserted** Most often, this is because the needle hit the contralateral wall. Just move the needle by a slight pull or rotate it a little; it may then be possible to insert the wire. If there is a problem, it is better to withdraw the needle and re-puncture the artery rather than dissect the artery with a slippery wire. After the sheath has been inserted where there is strong arterial back flow and the wire is not able to negotiate the tortuous iliac artery, pull the sheath a little (to disengage it from under a plaque if that is what has happened) and a gentle injection of contrast may help to delineate the anatomy and determine the reason why the wire could not be advanced. If there is no strong back flow, then the sheath is not in the arterial lumen. In a very tortuous iliac artery, a diagnostic Judkins right (JR) catheter can be inserted with caution and advanced in order to help steer the wire tip. Injection through the JR would also help to find out why there is a problem advancing the wire.

***Sequential order for arterial and venous puncture** The order of arterial and venous access is often a matter of personal preference. We prefer to puncture the vein first and insert a wire inside the vein to secure the access. Then, less than a few seconds later, after puncturing the artery, we would insert the sheath into the artery and the vein. As there is only a wire in the vein, there is minimal distortion of the arterial puncture site. There could be more anatomical shifting caused by the placement of the venous sheath. Less than 1 minute without a sheath will not produce a hematoma at the venous site. If inadvertently the artery is punctured first, we would cannulate the artery, then inject contrast into the arterial sheath. Puncture the vein under fluoroscopy, with the needle medial and parallel to the contrast-filled arterial sheath.

The reason why we should not puncture the artery with a venous sheath in place is because, if the venous sheath is entered by mistake, we may not be able to stop the bleeding from the puncture hole in the extravascular segment of the venous sheath by manual pressure.

****Kinked wire** It is not unusual that the wire will pass into the lumen easily but attempts to advance any dilator over the wire result in kinking of the wire at the point of vascular entry. Instead of exchanging the wire, if the wire is not too crooked, the first best maneuver is to advance the wire further, so the dilator can be advanced to dilate the entry site on a straight and stiff segment of the wire. If the wire is too soft, then the second best maneuver is to exchange the soft wire for a stiffer wire over a 4-Fr dilator.

****Puncture of pulseless femoral artery** As usual, the artery should be punctured over the middle of the medial third of the femoral head. Localize the skin puncture site by fluoroscopy just below the inferior border of the femoral head in order to prevent

high punctures (above the lowest border of the inferior epigastric artery). However, these proportions are valid only in the antero-posterior (AP), neutral position. Internal or external rotation of the femur can considerably change the relationship of the femoral artery to the femoral head. Another way to puncture the femoral artery is to use Doppler guidance with the SmartNeedle, which is an arteriotomy needle that incorporates a continuous Doppler probe, and enable the identification of arterial or venous vessels by means of continuous auditory feedback. This technique is very helpful in puncturing an artery with a very weak pulse or a pulseless artery, especially when the standard anatomy is disturbed by a large hematoma, or thick scar after surgery for artificial femoral head replacement [3].

Trouble-shooting Tricks

Puncture of femoral bypass graft The problems involving puncture of an old vascular graft in the femoral area include: uncontrollable bleeding and hematoma formation because of the non-vascular nature of the punctured graft; disruption of the anastomotic suture line with subsequent false aneurysm formation; infection of the graft site; and catheter damage, kinking, and separation due to scar tissue in the inguinal area and firmness of the healed graft material. Inadvertent entry to the native arterial system may lead to the dead-end stump in the CFA or iliac artery.

TECHNIQUE Bypass graft puncture As the exact location of the suture line is not known, to avoid puncture of the anastomotic site, it is best to puncture the proximal end of the inguinal incision site or as close to the inguinal ligament as possible. To avoid kinking of the catheter at the puncture site, it is better to introduce the needle at an angle of approximately 30–45° to the estimated long axis of the graft. Sometimes, as a result of severe scarring, the entry site has to be prepped by sequential dilation with small to progressively larger dilators up to 1-Fr size larger than the sheath selected for the procedure.

Trouble-shooting Tricks

******Parallel technique*** If the native artery is punctured and the wire could not be advanced because the artery ends up with a dead-end pouch, then leave the small 4-Fr sheath inside as a landmark. Palpate again the femoral artery and try to feel the two pulsations there: the first one is the native artery with the 4-Fr sheath and the second is the bypass graft if the graft is superficial or is not well palpable as a result of the thick wall of the bypass graft. Then puncture the second pulsatile artery while avoiding the one with the sheath in it. This can be done under fluoroscope guidance to avoid any puncture near the first sheath.

******Insertion of intra-aortic balloon pump through diseased iliac artery*** When an intra-aortic balloon pump (IABP) needs to be inserted and an iliac lesion is found, the lesion should be dilated first. Insert the balloon pump, then perform stenting

of the lesion later after the IABP has been removed. When a balloon pump is to be inserted through a previously stented iliac artery, do it under fluoroscopy to be sure that the balloon does not get stuck on the stent struts. Chronic endothelialization of the stent struts should diminish this problem.

*****Two catheters inserted with one puncture technique**

Used in situations such as angioplasty for chronic total occlusion (CTO) when there is a need for contralateral injection. Another puncture higher or lower than the puncture site of the first site of vascular access, or in the contralateral artery, is suggested. However, if there is no need for another puncture, then change the sheath to an 8-Fr introducer. The two 4-Fr diagnostic catheters can be inserted and attached to separate manifolds [4].

ANTEGRADE PUNCTURE

The antegrade femoral puncture can be greatly simplified and is more successful if the tissue thickness between the skin surface and the artery is as thin as possible. In obese patients, fatty panniculus may have to be retracted away from the puncture site manually and taped in position before the puncture is attempted [5]. The technique of antegrade puncture of the femoral artery is discussed in details in chapter 26.

TECHNIQUE Common femoral artery antegrade puncture

The first step is to localize the CFA and its bifurcation under fluoroscopy. The CFA usually overlies the medial third of the femoral head and the bifurcation occurs below the lower border of the femoral head. Once the landmark is located, to make the puncture the needle may be directed toward the superior aspect of the femoral head, under fluoroscopy. The purpose of this maneuver is to prevent the inadvertent puncture of either or both the superficial femoral artery (SFA) or the profunda femoral artery (PFA). It is important to puncture the femoral artery as high above the bifurcation as possible so that there will be enough space between the puncture site and the bifurcation for catheter exchanges and manipulation of catheters into the SFA. Using fluoroscopy, the site of the intended arterial puncture is identified (upper or middle third of the femoral head). The femoral pulse is palpated against the femoral head. Local anesthetic is infiltrated 2–3 cm cranial to the intended site of puncture. A 18-gauge needle is advanced at 45–60° directed caudally, aiming at the intended site of arterial puncture. Once pulsatile flow is obtained, a soft-tip wire is inserted toward the SFA. The wire should follow a straight caudal course into the SFA. Lateral deviation indicates entry into the PFA. The wire can be withdrawn and the needle tip deflected laterally to redirect the wire into the SFA [5] (see Figure 26.1).

Technical Tips

****Manipulation of wire** If the wire was inserted into the PFA, it can be withdrawn and redirected by angling the tip of the

needle medially toward the SFA. The other option is to have a wire with a curved tip and manipulate it so that the tip points toward the SFA. The needle may be exchanged for a short dilator with a gently curved tip, which can be directed toward the SFA. This dilator can be withdrawn slowly from the PFA while injecting the contrast agent. Once the orifice of the SFA is seen under fluoroscopy, it can be selectively catheterized or it can be used to direct a wire into the SFA [5].

****Puncture of CFA with high bifurcation** In patients with high bifurcation, one single puncture can result in entries of both the SFA and PFA. When this occurs, the first spurt of blood may indicate that the PFA is punctured. Do not remove the needle completely. Instead, withdraw it slowly and watch for a second spurt of blood. At this point, the contrast injection may show that the needle is in the SFA. In the rare cases of high bifurcation, it may not be possible to puncture the CFA that is excessively high in the pelvic area [5]. When the bifurcation is located more proximally, puncture of the CFA is more challenging, especially in obese patients. In these cases, it may be acceptable to selectively puncture and cannulate the SFA, if this appears without significant atherosclerotic disease and of adequate size [5].

****Puncture with abduction and external rotation of the thigh** Another option to cannulate the SFA is with the thigh in abduction and external rotation. The goal of this maneuver is to facilitate a more mediolateral puncture site in the CFA. In the usual antegrade puncture, the needle is seen to point more toward the PFA which is lateral to the SFA. In the abduction and external rotation position, the needle points more toward the SFA, and the PFA is seen medial to the SFA. This relationship is important when observing the course of the wire during its intended selective entry into the SFA. If the patient is punctured in this position, after the procedure, the local compression of the artery should be in the abduction and external rotation of the thigh because the puncture site is more mediolateral than usual [5].

BRACHIAL APPROACH

Even though the radial artery is the most common location used in the upper extremity, the brachial artery is still the access site of choice for procedures requiring a large sheath: Subclavian artery stenting, renal stenting, or aortic aneurysm exclusion. The radial access is discussed in Chapter 7.

AXILLARY PUNCTURE

Anatomically, the distal third of the axillary artery has three branches: The subscapular artery, anterior humeral circumflex artery, and posterior humeral circumflex artery. The location between the origin of the subscapular artery and the origins of the anterior and posterior humeral circumflex arteries is the ideal location for percutaneous access of this vessel (Figure 1.2). The

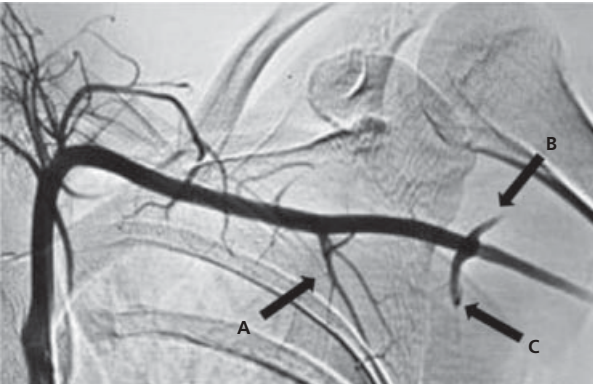


Figure 1.2 Normal subclavian and axillary artery angiogram. Subscapular artery (A) and anterior and posterior humeral circumflex arteries (B, C) are labeled in the third part of the axillary artery [6].

axillary artery was chosen over the subclavian artery due to its accessibility outside the chest wall, which would allow manual compression should closure procedures fail, and was chosen over the brachial artery due to its larger diameter and presence of collateral circulation that would decrease the likelihood of limb ischemia during the procedure [6].

It is important to note the structures that bound the axillary artery in this region in order to be aware of complications that may occur with this approach. In front of the artery is the medial head of the median nerve and the medial antebrachial cutaneous nerve. Medial to the axillary artery is the axillary vein. In between the axillary artery and vein is the ulnar nerve. The medial brachial cutaneous nerve is medial to the axillary vein. Laterally, there is the lateral branch of the median nerve and the musculocutaneous nerve. Behind the axillary artery are the axillary and radial nerves [6].

Both procedures were performed under conscious sedation with fentanyl and midazolam. Before obtaining access in the left axillary artery, a 7-Fr sheath was inserted into both the right and left radial arteries. An angiogram of the right radial artery was obtained to ensure that there were no contraindications for using this approach for the percutaneous coronary intervention (PCI). An angiogram of the left upper extremity was then obtained to establish the patency of the axillary artery and identify the optimal location for cannulation of the third part of the vessel, proximal to the origin of the anterior and posterior humeral circumflex arteries and distal to the subscapular artery. A 0.038-inch J-wire was then inserted through the left radial artery sheath extending to the axillary artery. A micropuncture needle was used to gain access to the axillary artery using the J-wire as a fluoroscopic guide, and a 6-Fr sheath was placed via the modified Seldinger technique (Figure 1.3).

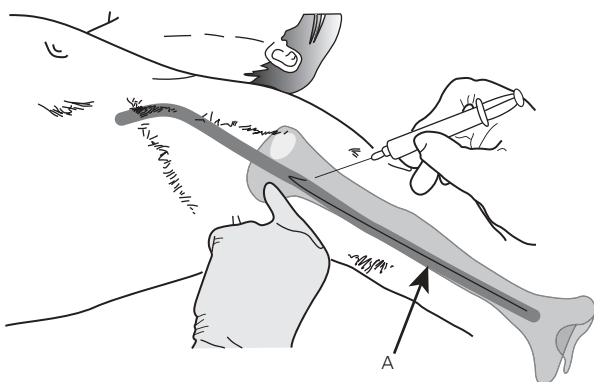


Figure 1.3 Patient in supine position with left arm abducted. J-wire (A) inserted via 7-Fr left radial sheath is visualized under fluoroscopy and marks the ideal location for needle insertion between origin of subscapular and humeral circumflex arteries [6].

TRANSEPTAL APPROACH

Femoral and radial access is universally used for interventional procedures. However, in some patients with pulseless disease (Takayasu's arteritis), there are no arterial pulses in four extremities, then the PCI has to be done through the femoral vein approach. Tips and tricks for puncturing the septum are discussed and illustrated extensively in Chapter 18.

CLOSURE DEVICES

Closure device can be used after any procedure such as PCI, valvuloplasty, intra-aortic balloon pump (IABP) or due to inadvertent arterial puncture such as after cannulation of a subclavian artery. The choice between collagen plugs and suture closure is largely a matter of personal preference and experience.

Collagen Plug Device: Mynx

The Mynx Vascular Closure device (AccessClosure, Inc, Mountain View CA, USA) features a polyethylene glycol sealant ("hydro-gel") that deploys outside the artery while a balloon occludes the arteriotomy site within the artery. The Mynx device is inserted through the existing procedural sheath and a small semicompliant balloon is inflated within the artery and pulled back to the arterial wall, serving as an anchor to ensure proper placement. The sealant is then delivered just outside the arterial wall where it expands to achieve hemostasis. Finally, the balloon is deflated and removed through the tract, leaving behind only the expanded, conformable sealant [7].

Clip Device: Starclose

The Starclose device (Abbott Vascular, Redwood City, CA, USA) achieves hemostasis with a 4-mm nitinol clip implant. The device

is inserted into the arterial lumen, then “wings” are deployed such that when the device is withdrawn the wings are pulled against the arterial wall, indicating proper positioning. The clip is then deployed just outside the arterial wall. The clip grasps the edges of the arteriotomy, drawing them together for closure. The Starclose device is labeled for diagnostic and interventional procedures and for closure of 5- to 6-Fr arteriotomies, but has been used with 7- to 8-Fr arteriotomies [7].

The Perclose (Abbott Vascular, Redwood city, CA, USA)

TECHNIQUE Preclosure of large arterial access In cases where a large-sized sheath is needed (e.g. for aortic valvuloplasty), preplacement of untied sutures using the Perclose percutaneous suture delivery system before placement of a large intended sheath can be done. A 5- to 6-Fr sheath may be used for arterial angiography to identify appropriate anatomy for suture delivery in the CFA (no calcification, not close to a lesion), and then a suture device is used to place untied sutures. At the end of the procedure, the existing “purse string” is then closed around the arteriotomy [8].

TECHNIQUE Preclosure of large venous access The technique of “preclosure” involves preloading a 6-Fr Perclose suture closure device into the femoral vein after access with a 6- or 8-Fr dilator, before insertion of a 14-Fr venous introducer sheath used for antegrade aortic valvuloplasty. Intravenous placement of the Perclose device within the venous system is then verified by either back bleeding from the marker port, or contrast injection through the marker port. Then the needles are pulled and the sutures clipped and, after the sutures have been deployed, a wire is placed into the femoral vein through the Perclose device. An exchange is made over the wire for a 14-Fr sheath while the sutures are laid alongside of the puncture and covered with betadine-soaked gauze. Upon completion of the valvuloplasty procedure, a wire is passed through the 14-Fr sheath to secure the vessel in case the suture closure fails. Heparin is not reversed. The sheath is then removed through the existing sutures, and the sutures are tied around the wire. If hemostasis is successfully achieved with the suture, the wire is gently removed, and the knot pushed further to complete the closure. [8]

Technical Tips

*****Differences in technical details for preclosure of venous access** As veins are comparatively thin walled, the amount of tension applied when pulling back the Perclose device is necessarily **less** than for arterial closure. It is possible to securely contact the vessel wall with the foot of the device while applying steady pressure, with **less** force than needed for arterial closure. Back bleeding through the marker port occurs in the vast majority of cases. Due to the lower pressure in the venous system, back flow is less prominent than in arterial closure. Usually, a slow dribbling of blood from the marker port can be noted. There is a delay in the appearance of back bleeding due also to the low venous

pressure, and this may be accentuated by having the patient take in a deep breath or by performing the Valsalva maneuver [8].

*****Double Angio-Seal closure for a 10-Fr vascular access** Although Angio-Seal (St. Jude Medical, Inc. St Paul MN USA) labeling indicates compatibility with 8-Fr or smaller procedural sheaths, the Angio-Seal has been used successfully to close 10-Fr arteriotomies utilizing a “double-wire” technique. With this technique, at the conclusion of the procedure, the Angio-Seal wire and a second additional wire are placed through the sheath. The Angio-Seal is deployed in standard fashion using the Angio-Seal wire, leaving the second adjacent wire in place. If hemostasis is achieved, the second wire is carefully removed while maintaining pressure on the collagen plug. If hemostasis is not achieved, the second wire serves as a “back up/safety” to allow deployment of a second Angio-Seal device next to the first [9].

*****Double Mynx closure for a 14-Fr arterial access** Two Mynx closure devices were simultaneously passed through the 14-Fr arterial sheath and both distal semicompliant balloons were inflated with a 3:1 saline:contrast mixture to allow balloon visualization. Under fluoroscopic guidance, the Mynx balloons were withdrawn to the distal end of the 14-Fr sheath, and then both balloons and sheath tip drawn back to the previously visualized arteriotomy. The polyethylene glycol sealant from each Mynx device was advanced into the 14-Fr sheath in a sequential fashion, and the sheath then withdrawn, allowing hydration and expansion of the sealant in an extra-arterial position over the arteriotomy site. After 2 min, the balloons were deflated and Mynx delivery catheters removed, and manual compression held for an additional 2 min. Closure of the 14-Fr arteriotomy was confirmed to be complete with no bleeding, vascular compromise, or hematoma on inspection [10].

Discriminating Differences

Which vascular closure devices for which patients? Vascular closure devices (VCDs) are not for all patients, and caution is required when considering the use of these devices in patients with peripheral vascular disease, extremely obese patients, those with small femoral arteries (diameters <4–5 mm), or those with arterial cannulation at or below the bifurcation. Apart from the above patient- and artery-specific factors, factors related to the mechanism of action of VCDs should also be taken into consideration, *i.e.* presence of an intravascular component of the closure device [11].

In devices with a significant intravascular component, such as the Angio-Seal device, usage is not recommended for bifurcation punctures, because there is a risk of obstruction by the intravascular portion of the device of the smaller branches. Moreover, accurate alignment of the intravascular part might be difficult due to the complex angles at the site of bifurcation. In addition, there is also a risk of deployment of the collagen plug intravascularly (Figure 1.4). Thus, access-site closure in patients with bifurcation

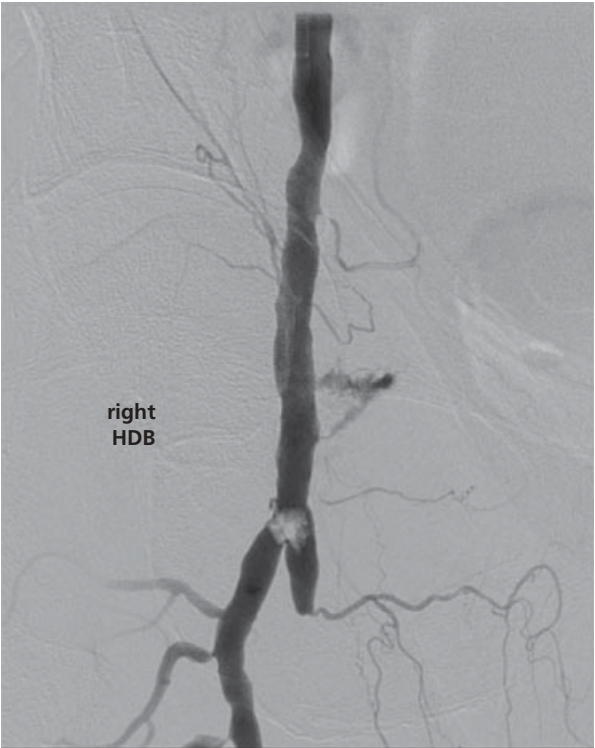

Figure 1.4 An emergency angiogram showed total occlusion of the superficial femoral artery while there is contrast extravasation at the puncture site. An intravascular foreign body is seen at the bifurcation of the superficial and profunda femoral arteries. (Courtesy of Dr Aravinda Nanjundappa.)

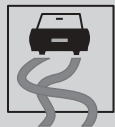punctures continues to be a challenge. Devices that do not have any significant intravascular component (such as Starclose or Mynx) are especially attractive in this group of patients.

Do not use VCDs in high arterial punctures because they have been associated with an odds ratio as high as 17:1 for retroperitoneal hemorrhage [11].

CAVEAT

Suspecting intra-arterial deployment of collagen plug

During deployment of an Angio-Seal device, the intra-arterial deployment of the collagen plug can be due to inadequate tension on the suture, vigorous tamping, too deep insertion of device into the artery causing anchor to be caught in the posterior wall, etc. Suspicion of a problem is aroused when there is a long travel distance of the tamper tube or continued bleeding [12].



Trouble-shooting Tricks

*****Management of intra-arterial deployment of collagen plug** In a case report of possible intra-arterial deployment of the collagen plug by the Angio-Seal, while inserting the tamper tube, it was observed that the tube was inserted much deeper than usual. The patient continued to bleed, so a tension spring was placed as usual. At that period, a hemostat was used to secure the end of the suture, and a FemoStop compression device was applied above the Angio-Seal to stop bleeding. After 4 hours, the anchor, which is composed of an absorbable polymer material, becomes softened and therefore pliable. A hemostat was placed on the suture at the level of skin. If the suture were to break during traction, the hemostat would prevent the anchor and the collagen plug from embolizing. Then steady traction was applied to the suture, perpendicular to the femoral artery. The pressure should not be excessive. After 20 min, the plug was removed. The FemoStop was reapplied and hemostasis was achieved [12]. The management is summarized in Box 1.1.

COMPLICATIONS

Hematoma

The frequency of hematomas increases with the increasing size of the sheath, increasing level of anticoagulation, and the obesity

BOX 1.1 WHAT TO DO IF COLLAGEN IS INSERTED INTRA-ARTERIALLY [11]

- 1 Prevent the problem: Always maintain tension on the suture and avoid tamping with excessive force
- 2 Recognize the problem: Absence of resistance during tamping and inadequate hemostasis are clues
- 3 Duplex ultrasonography can document intra-arterial collagen
- 4 Apply tension string in the usual fashion; secure suture with hemostat at the skin level to add security
- 5 **Do not cut suture:** Embolization of the anchor and plug may occur
- 6 If there are signs of embolism and thrombosis, obtain vascular surgery consultation
- 7 Wait at least 4 hours to allow softening of the anchor
- 8 Steady vertical traction on suture with approximately 10 lb (4.5 kg) of force
- 9 If removal of the device is achieved, maintain manual compression to achieve hemostasis
- 10 FemoStop device should be ready for rapid deployment after device is removed
- 11 Remove the collagen plug by atherectomy device (not needed)

of the patient. Surgical evacuation is not required even for large hematomas, unless there is undue tension on adjacent structure or in the case of a truly huge hematoma. Surgical evacuation and arterial repair are required when the hematoma is pulsatile and expanding, an indication of communication between the hematoma and femoral artery, and the presence of a false aneurysm.

Arteriovenous Fistula

This happens rarely (>0.4%) when the puncture is made where the artery overlies the vein. Most small arteriovenous fistulas (AVFs) are asymptomatic and usually close spontaneously. A large AVF with symptoms of high-output failure needs to be corrected surgically.

Acute Arterial Thrombosis

Occlusion of the femoral artery may occur due to thrombosis or local arterial injury. It happens mostly in women with small femoral arteries that are completely blocked by the catheter during the procedure, and in patients whose SFA is catheterized rather than the CFA.

TECHNIQUE Mechanical thrombectomy for acute thrombosis

If thrombosis of the femoral artery is suspected, access is obtained from the contralateral side and 5000 units of heparin are given. A 6-Fr crossover sheath is placed in the external iliac artery over a 0.035-inch stiff Amplatz guidewire. The occluded/thrombosed/embolized segment of the artery is crossed with a 0.014-inch or 0.018-inch wire. Any thrombectomy device is then introduced over the wire and tries to remove any thrombi. If normal distal flow is established without any residual stenosis, the procedure is terminated. If there is still residual thrombus, the segment is dilated with a peripheral balloon, and if the post-percutaneous transluminal angioplasty (PTA) result is not optimal, a self-expanding stent may be deployed [13] (Figure 1.5).

If a heavy thrombotic burden still persists after mechanical thrombectomy, then tissue plasminogen activator (tPA) 0.05 mg/kg can be given, along with heparin, through a multi-hole delivery catheter (e.g. 5-Fr Mewissen); 4 hours later, an angiogram can be performed to check the progress and, if there is persisting thrombus, the patient can undergo longer infusion (12–18 h) [13].

Limb Ischemia

Patients who develop acute limb ischemia after femoral artery catheterization must be carefully and immediately evaluated by duplex ultrasonography. Angiography is mandatory and should not be delayed. The purpose of angiography is to identify the location (aortoiliac inflow circulation, infrainguinal outflow circulation, or run-off circulation) and cause (dissection, thrombosis, distal embolization, sheath/vessel mismatch) of ischemia, because these factors will help to determine the treatment strategy (vascular surgery, percutaneous revascularization, thrombectomy,

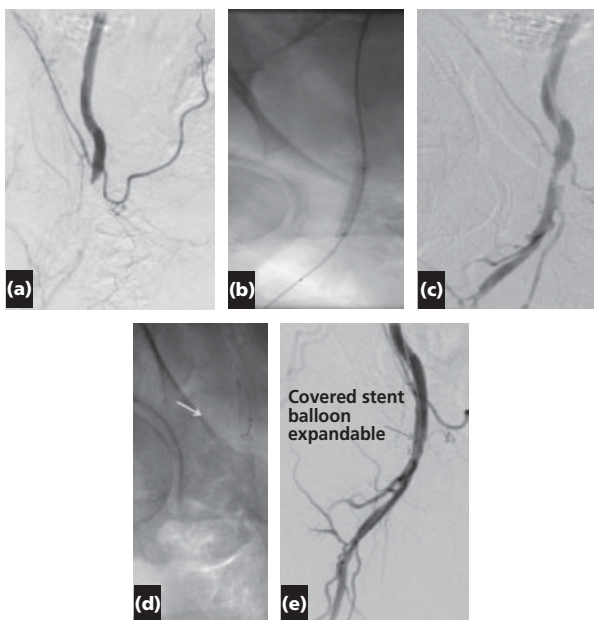


Figure 1.5 (a) An emergency angiogram showed total occlusion of the common femoral artery at the puncture site where patient had a closure device with intravascular component. (b) A balloon is advanced to the obstruction site and inflated. (c) There is renormalization of the blood flow; however, the lesion is still significant. (d) A snare failed to remove the intravascular anchor. (e) The patient received successfully a covered stent to stop the bleeding. (Courtesy of Dr Aravinda Nanjundappa.)

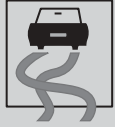intra-arterial thrombolytic infusion). In most cases, digital subtraction angiography is best, because cineangiography may not permit adequate visualization of the runoff circulation [14].

Trouble-shooting Tricks

*****Temporary relief of iatrogenic ischemic limb: percutaneous technique for in vivo femoral artery bypass** During PTA of high-risk patients, if the acute limb ischemia arises during femoral artery catheterization, the antegrade sheath in the a femoral artery and the retrograde sheath in the contralateral common femoral artery can be connected using standard 12-inch pressure tubing and a male-to-male adapter. This technique is considered a temporary method to restore blood flow, minimize the metabolic consequences of acidosis and muscle necrosis, permit more definitive percutaneous or surgical revascularization as indicated, and allow the use of devices for invasive hemodynamic support, when such devices cause limb ischemia and there are no other therapeutic alternatives [14].

CAVEAT**Preventing limb ischemia**

The steps to prevent limb ischemia include: (1) Careful examination of femoral pulses and bruits before catheterization; (2) angiography before insertion of any hemodynamic support device; (3) angioplasty and stenting of suitable aortoiliac stenoses before device insertion; and (4) use of a sheathless IABP which might reduce the risk of ischemic complications in patients with diffuse aortoiliac disease or small vessels [14].



Retroperitoneal hematoma The clinical clues of retroperitoneal hematoma (RPH) include hypotension without apparent reason, blood loss without possible source, suprainguinal tenderness and fullness, and flank discomfort. A small hematoma is not able to cause any hemodynamic disturbances or any increase of the retroperitoneal cavity pressure to cause neurological symptoms (Figure 1.6).

An RPH in close proximity to the iliopsoas muscle will often present with severe muscle spasm, resulting in severe pain in the groin or hip area with radiation to the lower back and anterior thigh on any attempt to extend the hip. With an expanding hematoma, femoral nerve compression typically occurs along the iliopsoas gutter with a characteristic pain in the anteromedial thigh. Usually, bleeding into the retroperitoneal site is self-limiting unless the patient is anticoagulated.

Mechanism of clinical symptoms The femoral nerve is formed by the second to fourth lumbar nerve roots and provides

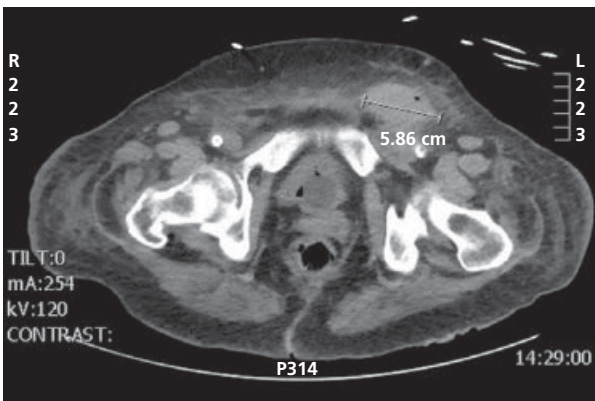


Figure 1.6 Retroperitoneal bleeding (arrow) due to high femoral puncture. (Courtesy of Dr Aravinda Nanjundappa.)

motor innervations to quadriceps, sartorius, pectineus, and iliopsoas. It supplies sensory innervation to the anteromedial thigh and medial leg. The nerve lies in the groove between the iliacus and psoas muscles. Entrapment of the femoral nerve by an iliopsoas hematoma is the most likely cause of the femoral nerve palsy. Weakness of the quadriceps muscle and decreased patellar reflex are the most striking examination findings [15].

The management includes stopping heparin and reversing anticoagulation with protamine, then rapid fluid resuscitation to reverse hypovolemia. Transfusion may be needed. The decision of when to intervene with evidence of persistent hemorrhage remains controversial and a vascular surgical consultant should be involved at an early stage. The RPH will often have a tamponade effect on the site of persistent hemorrhage. Surgery could potentially reduce the effect of the tamponade with catastrophic consequences. With this in mind, there is a trend towards such techniques as stent grafts or intra-arterial embolization to halt the persistent hemorrhage. Open surgery should be considered if the patient remains hemodynamically unstable with the above measures being unsuccessful [16].

Discriminating Differences

Medical and surgical management of retroperitoneal hemorrhage After PCI, the presence of RPH was associated not only with a higher frequency of post-procedure cardiac complications, including myocardial infarction and congestive heart failure, but also with a higher frequency of infection and/or sepsis, gastrointestinal bleeding, and contrast nephropathy. Of the patients who developed RPH, 92.3% were treated medically and 7.7% underwent surgical repair. A trend toward a higher in-hospital mortality was observed in patients with RPH treated surgically than in those treated medically, possibly reflecting the fact that a surgical approach might be performed in more unstable patients in whom fluid resuscitation and blood transfusions are inadequate in re-establishing a stable hemodynamic status [17].

Technical Tips

****How to detect retroperitoneal hematoma in a 1-second maneuver?** Just an AP view of the pelvic area under fluoroscopy may give a clue to the problem. Usually, the bladder is seen round, filled with contrast. If the opacified bladder is seen displaced and its round shape is dented, RPH is strongly suspected (Figure 1.7). However, significant blood needs to be sequestered before unilateral external compression of the bladder occurs. [19]

TECHNIQUE How to seal a perforation with a balloon

The initial angiogram revealed laceration of the inferior epigastric artery arising at the origin of the right CFA. A 6-Fr crossover sheath is positioned in the right external iliac artery, and a 6-Fr right Judkins-4 guide is then advanced over the crossover sheath to select the ostium of the lacerated inferior epigastric artery. A 0.014-inch Balanced Middleweight wire is advanced into the inferior epigastric artery, and the tip positioned distal to the

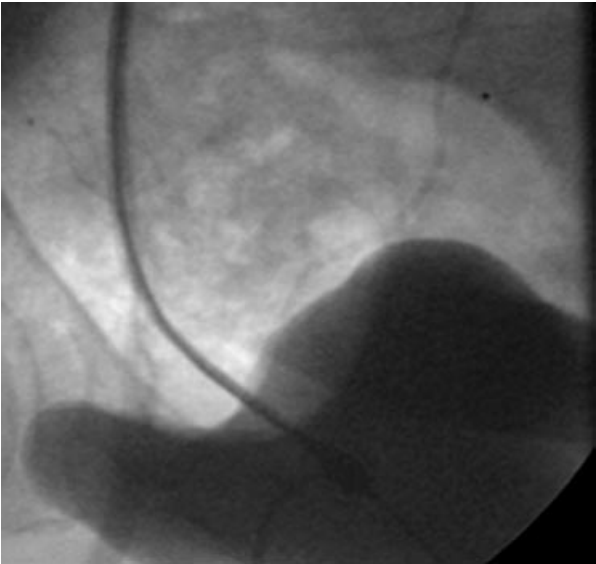


Figure 1.7 A dented bladder due to retroperitoneal hematoma. It looks different from the round shape of the bladder. (Courtesy of the Cardiac Catheterization Laboratories of Community Healthcare System, St Mary Medical Center.)

lacerated area. A 2 mm × 10 mm balloon catheter is then advanced and parked at the level of the laceration and inflated at 1 atm on three sequential occasions for up to 20 min. Adequate balloon occlusion can be confirmed by injecting contrast through the guide. Nevertheless, if the angiogram reveals persistent and significant bleeding after each balloon deflation, attempts should be made to thrombose the lacerated vessel in order to stop the hemorrhage.

TECHNIQUE How to close a perforation with microcoil or injection of thrombin

Microcoils can be used for closure of the small artery. If there are no microcoils available, infusion of thrombin through the lumen of the inflated over-the-wire (OTW) balloon can be done. Careful positioning and sealing of the vessel are confirmed with injection of contrast from the guide and through the balloon lumen to ensure that there is no spilling of contrast from the vessel lumen into the CFA. Thrombin-JMI is to be diluted in 0.9% saline at a concentration of 50 IU/ml. Subsequently, a total of three consecutive doses of 100 IU thrombin can be administered through the balloon catheter lumen. Contrast can be injected through the balloon lumen after each dose of thrombin. When there is no further evidence of blood flow and no extravasation of contrast through the laceration, the balloon can be deflated [18] (Figures 1.8–1.11).

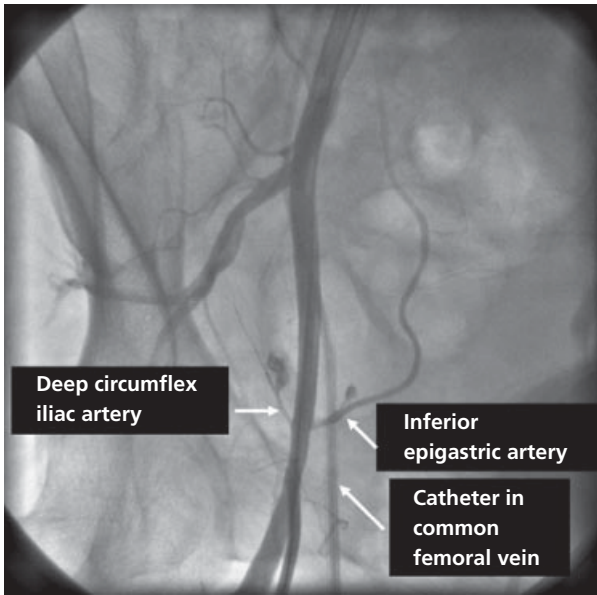


Figure 1.8 The iliofemoral angiography showed blood extravasation in the deep circumflex iliac artery and the inferior epigastric artery. (Courtesy of Dr Aravinda Nanjundappa.)

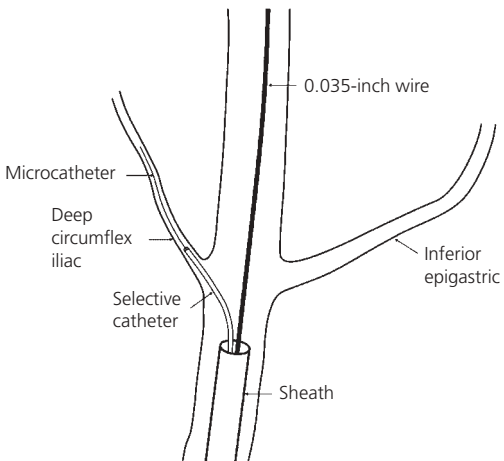


Figure 1.9 A microcatheter was inserted into the deep circumflex iliac artery. (Courtesy of Dr Aravinda Nanjundappa.)

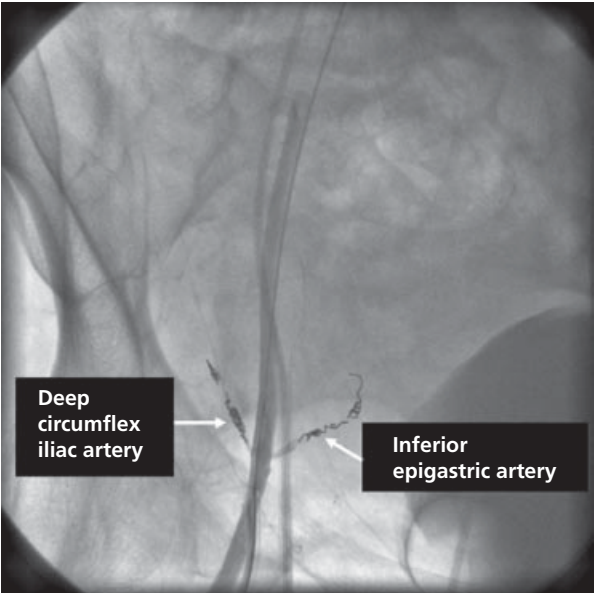


Figure 1.10 Coil embolization was successful in stopping the bleeding of the inferior epigastric for an expanding rectus sheath hematoma and of the deep circumflex iliac artery for expanding lateral abdominal wall hematoma. (Courtesy of Dr Aravinda Nanjundappa.)

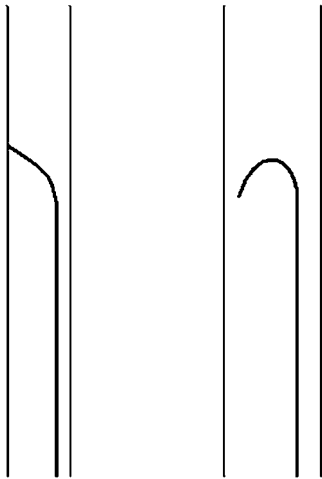


Figure 1.11 Cause of perforation in the branches of the iliofemoral artery, if the patient does not have a large common femoral artery and if a large J-wire is used. In a small vessel the J tip cannot be formed and the laterally pointing tip will preferentially direct the wire into side branches of the main artery and lead to perforations, as seen in this case. Be careful when advancing a wire up the femoral artery in a patient with small stature and low weight. (Courtesy of Dr Aravinda Nanjundappa.)

Perforation If a balloon bursts and perforates a peripheral artery below the inguinal ligament, the local bleeding can be controlled by direct pressure. In the case of higher perforation, a large peripheral balloon should be inflated above or at the rupture site to stop the bleeding and seal the puncture site [18].

TECHNIQUE How to seal a perforation with a covered stent Access is gained via the left femoral artery for a retrograde approach to right iliofemoral angiography. A 6-Fr internal mammary catheter is inserted over a 0.035-inch guidewire, and this wire is used to cross into the right SFA. This wire is exchanged for a 0.035-inch Amplatz super stiff wire, and an 8Fr × 65cm long Superflex sheath, advanced under fluoroscopy over the aortoiliac bifurcation to give good support in the right external iliac artery. Balloon tamponade of the perforation site is performed with a 5-minute inflation of a balloon at 2 atm with persistent extravasation of contrast. An under-sized, self-expanding, covered stent is then placed across the perforation site with a persistent leak. The stent graft can then be post-dilated with a balloon at 8 atm with complete hemostasis and resolution of the free-flow contrast into the retroperitoneum.

Pseudoaneurysm The main cause of a pseudoaneurysm (PA) is inadvertent puncture of the SFA. A femoral PA forms when the puncture site does not close and there is continuous flow into a small perivascular space contained by the surrounding fibrous tissue and hematomas. It is suspected by the presence of a laterally pulsatile mass, an arterial bruit, and tenderness at the vascular access site. Confirmation is made by ultrasonography, which shows a hypoechoic cavity with flow through a neck directly visible by color Doppler, and pulsed Doppler evidence of to-and-fro flow between the cavity and the arterial lumen during systole and diastole [20]. Hematomas are seen as hypoechoic collections without any Doppler flow movement.

Indications for aggressive management include: large size of the PA, whether it has increased in size, and the need for continued anticoagulation. Usually the small PAs (<3 cm in diameter) will close spontaneously, presumably due to thrombosis. A follow-up ultrasound scan 1–2 weeks later often demonstrates spontaneous thrombosis and obviates the need for surgical repair. The >3-cm diameter PAs are less likely to close spontaneously. When PAs persist beyond 2 weeks or expand, the risk of femoral artery rupture necessitates correction. The simplest method of treatment is to use a mechanical compression device (FemoStop St. Jude Medical, Inc. St Paul MN USA). The success rate is 74% with a mean compression of 33 min [20]. The failed patients underwent successful compression guided by ultrasonography.

Contraindications to mechanical compression are listed in Box 1.2. Ultrasound-guided compression is commonly used with success related to the anticoagulation status and a PA that can be readily visualized and compressed [20]. However, the best modality of treatment is to inject thrombin into the PA. The technique is simple, quick, and painless. Surgery is indicated rarely




BOX 1.2 CONTRAINDICATIONS TO MECHANICAL COMPRESSION OF A PSEUDOANEURYSM

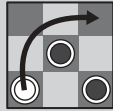
- 1 Sign of local infection
- 2 Critical limb ischemia
- 3 Large hematoma with overlying skin necrosis
- 4 Injuries above the inguinal ligament

when the above-mentioned management fails. Occasionally thrombin may escape into the peripheral circulation with formation of an intra-arterial thrombosis (seen in less than 2% of cases) and is usually managed conservatively.

TACTICAL MOVE

BEST options for exclusion of femoral pseudoaneurysm

- 1  **FIRST Best option:** Mechanical compression therapy if there is no thrombin available
- 2  **SECOND Best option:** For patients who fail empirical compression: ultrasound-guided compression
- 3  For patients on anticoagulant or having contraindication to compression: percutaneous injection of thrombin



Femoral Dissection

Femoral artery dissection is a recognized complication of the Perclose (and other) closure devices, and could occur if the needles are deployed too early and they interact with the posterior wall of the vessel, or if the needles are deployed through a plaque in the anterior wall of the vessel. Meticulous attention and gentle manipulations while puncturing the artery and advancing the wire may lower the risk of access site complications. Routine femoral angiography during cardiac catheterization could lead to early diagnosis not only of arterial dissections, but also of other complications, such as bleeding from laceration of the inferior epigastric artery.

Open surgical repair has historically been the treatment of choice for flow-limiting femoral access dissections, but percutaneous techniques are increasingly being used to treat these injuries. The CFA stenting is not recommended because of the high risk of stent fracture. Balloon angioplasty or atherectomy of the CFA might be better alternatives to stenting if they provide an acceptable angiographic result.

Patients with non-flow-limiting iliac artery dissections can often be treated conservatively, because the blood flow tends to “tuck”

iliac dissections caused during retrograde insertion of catheters, wires, or other equipment. Conservative management for non-flow-limiting dissections consists of bed rest with follow-up non-invasive imaging and clinical exams. If dissections are flow limiting, then stenting (using self-expanding stents for the external iliac artery or either self-expanding or balloon-expandable stents for the common iliac artery) may be the treatment of choice.

CASE REPORT

Retrograde abdominal and thoracic dissection from the iliac artery

A patient with suspected coronary disease was prepared for cardiac catheterization via the femoral approach. A standard right femoral artery puncture was performed and the wire passed easily to the mid-aorta. However, there was difficulty advancing the wire and the catheter beyond the aortic arch and the procedure was abandoned. Half an hour later, the patient complained of severe back pain and became temporarily hypotensive. A CT scan confirmed the aortic dissection, with the entry point in the iliac artery extending to the aortic arch. Initially, the patient was managed conservatively but she had recurrent transient episodes of severe back pain associated with transient hypotension (75/40 mmHg). So under fluoroscopic guidance, a 10 mm × 4 cm stent was placed in the right common iliac artery via the contralateral femoral approach. The new stent occluded the entry point. Follow-up CT showed thrombosis of the false lumen and sealing of the dissection flap. The favorable outcome in this patient was likely due to two factors: (1) the retrograde direction of the dissection, in contrast to the antegrade direction of the usual spontaneous aortic dissection; and (2) the absence of re-entry, which contributed to stagnation of blood flow in the false lumen, resulting in the formation of thrombus and the rapid disappearance of the retrograde dissection [21].

REFERENCES

1. Cilingiroglu M, Feldman T, Salinger MH, et al. Fluoroscopically-guided micropuncture femoral artery access for large-caliber sheath insertion. *J Invasive Cardiol* 2011;**23**:157–61.
2. Bangalore S, Vidi VD, Liu CB, et al. Efficacy and safety of the nitinol clip-based vascular closure device (StarClose) for closure of common femoral arterial cannulation at or near the bifurcation: A propensity score-adjusted analysis. *J Invasive Cardiol* 2011;**23**:194–9.
3. Mehan VK. Doubtful arterial puncture during cardiac catheterization in cyanotics. *Catheter Cardiovasc Diagn* 1990;**19**:148–9.
4. Nicholson WJ, Rab T. Simultaneous diagnostic coronary angiography utilizing a single arterial access technique. *Catheter Cardiovasc Interv* 2006;**68**:718.
5. Biondi-Zoccai GG, Agostoni P, Sangiorgi G, et al. Mastering the antegrade femoral artery access in patients with symptomatic lower limb ischemia: Learning curve, complications, and technical tips and tricks. *Catheter Cardiovasc Interv* 2006;**68**:835–42.

6. Lotun K, Shetty R, Patel M, Arain SA. Percutaneous left axillary artery approach for Impella 2.5 liter circulatory support for patients with severe aortoiliac arterial disease undergoing high risk percutaneous coronary intervention. *J Interven Cardiol* 2012;**25**:210–13.
7. Schwartz B, Burstein S, Economides C, et al. Review of vascular closure devices. *J Invasive Cardiol* 2010;**22**:599–607.
8. Feldman T. Femoral arterial preclosure: Finishing a procedure before it begins. *Catheter Cardiovasc Interv* 2001;**53**:448.
9. Bui QT, Kolansky DM, Bannan A, Herrmann HC. “Double wire” Angio-Seal closure technique after balloon aortic valvuloplasty. *Catheter Cardiovasc Interv* 2010;**75**:488–92.
10. Korngold EC, Inglessis I, Garasic JM. A novel technique for 14 French arteriotomy closure after percutaneous aortic valvuloplasty using two Mynx closure devices. *J Interven Cardiol* 2009;**22**:179–83.
11. Bangalore S, Vidi VD, Liu CB, et al. Efficacy and safety of the nitinol clip-based vascular closure device (Starclose) for closure of common femoral arterial cannulation at or near the bifurcation: A propensity score-adjusted analysis. *J Invasive Cardiol* 2011;**23**:194–99.
12. Stein B, Terstein P. Non-surgical removal of Angio-Seal device after intraarterial deposition of collagen plug. *Catheter Cardiovasc Interv* 2000;**50**:340–2.
13. Samal A, White C. Percutaneous management of access site complications. *Catheter Cardiovasc Interv* 2002;**57**:12–23.
14. Merhi WM, Turi ZG, Dixon S, et al. Percutaneous ex-vivo femoral arterial bypass: A novel approach for treatment of acute limb ischemia as a complication of femoral arterial catheterization. *Catheter Cardiovasc Interv* 2006;**68**:435–40.
15. Raja Y, Lo TS, Townend JN. Don’t rule out retroperitoneal bleeding just because the angiogram was done from the radial artery. *J Invasive Cardiol* 2010;**21**:E3–E4.
16. Frank JJ, Kamalakannan D, Kodenchery M, Savoy-Moore RT, Rosman H. Retroperitoneal hematoma in patients undergoing cardiac catheterization. *J Interven Cardiol* 2010;**23**:569–74.
17. Trimarchi S, Smith DE, Share D, et al. Retroperitoneal hematoma after percutaneous coronary intervention: Prevalence, risk factors, management, outcomes, and predictors of mortality a report from the BMC2 (Blue Cross Blue Shield of Michigan Cardiovascular Consortium) Registry. *J Am Coll Cardiol Interv* 2010;**3**:845–50.
18. Silva JA, Stant J, Ramee SR. Endovascular treatment of a massive retroperitoneal bleeding: Successful balloon-catheter delivery of intra-arterial thrombin. *Catheter Cardiovasc Interv* 2004;**64**:218–22.
19. Chambers CE, Griffin DC, Omarzai RK. The “dented bladder”: Diagnosis of a retroperitoneal hematoma. *Catheter Cardiovasc Diagn* 1993;**34**:224–6.
20. Zahn R, Thoma S, Fromm E, et al. Pseudoaneurysm after cardiac catheterization: Therapeutic interventions and the sequelae: Experience in 86 patients. *Catheter Cardiovasc Diagn* 1997;**40**:9–15.
21. Prasad A, Compton PA, Prasad A, et al. Incidence and treatment of arterial access dissections occurring during cardiac catheterization. *J Interven Cardiol* 2008;**21**:61–6.

CHAPTER 2**Angiographic Views**

Thach N. Nguyen, Sim Kui Hian, Timothy J. Yee, Aung Kyaw Zaw, Hoang Trong Minh Tuan, Pham Nhu Hung, Hung D. Huynh, Dan Le

Challenges 28

Standard of Technical Excellence 28

Guidelines for Moving the Image Intensifier 28**Technical Tips 30**

**How to fully expose the LCX (1) 30

**How to fully expose the LCX (2) 30

**How to fully expose the LAD by moving away the LCX 31

Two views in a case of left main disease 31

**How to purposely expose the LAD 31

**To completely scrutinize the LAD, do we need a LAO cranial view? 32

**Angulations to separate the LAD from diagonals 32

Left Main 32**Technical Tips 33**

**How to expose the LM, when the heart is horizontal 33

**How to expose the LM, when the LM is long and has a downward direction 33

Left Anterior Descending Artery 34**The AP Cranial View 34****The LAO Cranial View 35****Technical Tips 36**

**Exposure of the high diagonal 36

**Best view for ostial and proximal LAD in horizontal heart or short LM 36

**Best view for ostial and proximal LAD in patients with long LM 36

Left Circumflex Artery 36**Right Coronary Artery 37****The LAO View 37****The RAO View 38****Saphenous Vein Graft 38****Internal Mammary Artery 39****Technical Tips 39**

***Non-selective angiogram of the LIMA 39

Magnification Artifacts for Balloon or Stent Sizing 40**Radiation 41****Angulations that give the Most Radiation 41****Coronary Artery Anomalies 43**

*Basic; **Advanced; ***Rare, exotic, or investigational

\$, <\$US100.00 extra; \$\$, >\$US100.00 extra

⌚, <10 min extra; ⌚⌚, >10 min extra

♣, low risk of complications; ♣♣, high risk of complications

Technical Tips 43

**The dots and the eyes 43

The single coronary artery 43

The LCX from the right sinus 44

The Right Coronary Anomalies 45

Anterior Position of the ostium 45

Anomalous origin of the RCA from the left sinus 45

The LAD Anomalies 45

LAD from the RCA or right sinus anterior free wall course 45

LAD from the RCA or right sinus septal course 46

The Left Main Coronary Artery Anomalies 46

The septal course 46

The anterior free wall course 46

The retroaortic course 47

The interarterial course 47

Anatomic consideration of the ostial segment 47

Mechanism of ischemia due to anomalous pathway 48

Left main from the posterior sinus 48

Right coronary artery from the pulmonary trunk 48

The goal of coronary angiography is to delineate clearly a lesion in two orthogonal views, so that its morphology can be assessed accurately, the subsequent results of interventions compared more objectively, and the changes due to complications detected early. Accurate views of the ostial segment of the artery involved, and the direction and course of the segments proximal to the target lesion are also needed to plan the accurate and timely movement of interventional devices.

CHALLENGES

To evaluate difficult eccentric lesions, multiple views may be needed at slightly different angles. However, when a vessel bends in more than one plane, no single angiographic view can overcome multiple foreshortenings. So one must individualize and select the degree of angulation that best visualizes the problem area.

STANDARD OF TECHNICAL EXCELLENCE

The art of coronary angiography is to expose the most by showing the least foreshortened coronary artery segment at an angulation that causes the lowest radiation to the operators and by the least number of radiographs needed.

**GUIDELINES FOR MOVING THE
IMAGE INTENSIFIER**

There are a few rules that govern the visualization of the artery by moving the image intensifier (camera tube) above the patient. The first rule is that the left circumflex artery (LCX) goes with the

Table 2.1 Movement of vessels and landmarks according to direction of the camera tube

Same direction	Opposite direction
LCX	LAD
Spine	Diagonals
Diaphragm	

image intensifier and the left anterior descending artery (LAD) goes in the opposite direction. In other words, moving the image intensifier leftward to the left anterior oblique (LAO) view will project the LCX to the left on the screen and the LAD to the right (rule 1). Cranial angulation will elevate the LCX up and pull the LAD down. It is the reverse with caudal angulation. The same rule is applied to the diaphragm and the spine (Table 2.1). The second rule is that, in order to straighten a very tortuous coronary segment, the image intensifier should be moved to an angle that is more or less 90° opposite to the current one, so the tortuous area will then be seen as straightened (rule 2). The goal of these maneuvers is to view the arterial segment in its most direct (orthogonal) angle, with the least angled projection effect.

STRATEGIC MAPPING

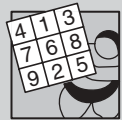
Sequences of a coronary angiogram

There are many ways to start a coronary angiogram: The anteroposterior (AP) or right (RAO) or left anterior oblique (LAO) view.

However, after a first basic view, the next picture should either show a lesion or prove the patency of a major branch. In the left coronary angiogram there are a few areas to be scrutinized: The left main (LM), proximal, mid-, and distal LAD, proximal and distal LCX, obtuse marginal (OM), and diagonals. The areas of interest in the right coronary angiogram are: The ostial, proximal, mid-, and distal RCA, with the right ventricular (RV), posterior descending artery (PDA), posterior lateral branch (PLB), and sinus node branches. Usually, the operator likes to identify the culprit lesion quickly within a specific area of interest.

First neutral AP view

We prefer the first view as the neutral AP view because, in this view, we have a global assessment of the LM, the proximal segment of the LCX and the exact position of the LCX in comparison with the LAD. In this AP view, usually the distal LM, and proximal LAD and LCX would overlap each other so



(Continued)

that this view would dictate the next area to be elucidated and, practically, the next move of the image intensifier.

RAO and AP caudal views

After a global assessment of the LM, and to be sure there is no LM disease with the AP view, a severe LCX lesion can be ruled in or out very quickly by only one RAO caudal or AP caudal view. Most of the time, with only two views, we can rule out severe LM and LCX disease, then we can concentrate on scrutinizing the distal LM and the proximal LAD.

Technical Tips

****How to fully expose the LCX (1)** After the first plain AP view, the goal of the next angulation is to see clearly the LM at the same time as the LCX. If the LCX were below or at the same level as the LAD in the plain AP view, then the next view would be any caudal view or maneuver that pulls the LCX down further. Deep inspiration would elongate the LCX more, so that there is no foreshortening in the proximal segment or overlapping by the LAD (Figure 2.1). These are the two views: RAO caudal and AP caudal. If the proximal segment of the LCX is quite tortuous in the AP view then the RAO caudal view will elongate the LCX and straighten the proximal segment (rule 2). If, in the AP view, the proximal segment of the LCX is just foreshortened without being too tortuous, then the next view should be the AP caudal view, with deep inspiration to elongate the heart, depress the diaphragm, and so pull the LCX straight down further (rule 1). These two views (RAO caudal and AP caudal) will best expose the whole LCX. Most of the time, just after a second injection, almost all the segments of the LM and the LCX arteries are completely scrutinized.

****How to fully expose the LCX (2)** If the LCX is seen above the LAD on the plain AP view, then the best maneuver is still to

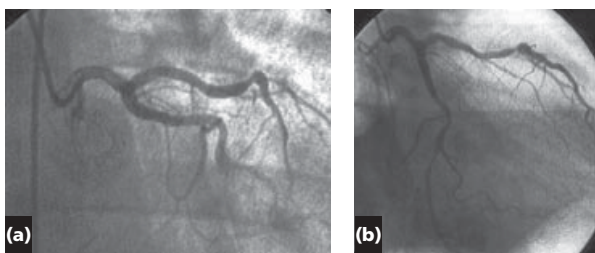


Figure 2.1 Angulation when the LCX is below the LAD: (a) The LCX is below the LAD in this plain AP view. It is also tortuous so the next view would be the RAO caudal view. (b) In this RAO caudal view, the LCX is well elongated and therefore fully exposed. (Courtesy of the Cardiac Catheterization Laboratories of Community Healthcare System, St Mary Medical Center, Hobart, IN.)

Table 2.2 How to expose the LCX

Location of LCX	Best next view
If the LCX is below or same level as the LAD in the AP view	RAO or AP caudal
If the LCX is above the LAD in the plain AP view	RAO or AP caudal LAO caudal (best alternative view) LAO cranial (best alternative view)

try to elongate the LCX by pulling it down further in the RAO caudal or AP caudal view. The reason is that all cranial angulations will project and foreshorten the LCX further above the LAD. Then a LAO cranial or caudal (spider) view will be a good alternative view for the proximal LCX; however, it will be seen over the hazy background of the spine. The LAO caudal view will show the ostial LCX very well and is very helpful for wire entry into the LAD, LCX, and ostium of the first OM (Table 2.2).

****How to fully expose the LAD by moving away the LCX** If, in the AP view, the LCX is clearly below the LAD, the next view has to be any caudal view to pull the LCX down further, in order to remove overlapping of the LCX with the proximal LAD (rule 1). This view could have been used to expose the LCX and LAD at the same time. If the LCX is at the same level as LAD, the next angulation is still any caudal view with deep inspiration to pull the LCX down and uncover the proximal LAD overlapped by the LCX. Usually, at this stage, the above views would have given enough information about the mid- and distal segment of the LAD or LCX.

****Two views in case of left main disease** In case of left main disease, it is not safe to take too many pictures. The surgeon may need only the mid- and distal LAD and the OM, so that they can insert the bypass grafts. There are therefore only two views that show all the left system (LM, LAD, LCX) needed for coronary artery bypass graft (CABG): the AP caudal and AP cranial views. If the patient is going to have percutaneous coronary intervention (PCI), more views of the distal LAD and LCX are needed.

****How to purposely expose the LAD** If the LAD is seen to be tortuous in the RAO caudal view (which is usually the second or third view of the angiographic sequence), the next view to straighten the LAD is the RAO cranial view (rule 2). To remove the LCX overlapped on the LAD, if the LCX was seen above the LAD, really deep inspiration will elevate the LCX further above the LAD. If the LCX was seen below the LAD in the AP view, no deep inspiration is needed; if not, the LCX would be elevated and overlap the proximal LAD. These maneuvers can be repeated for the AP cranial view.

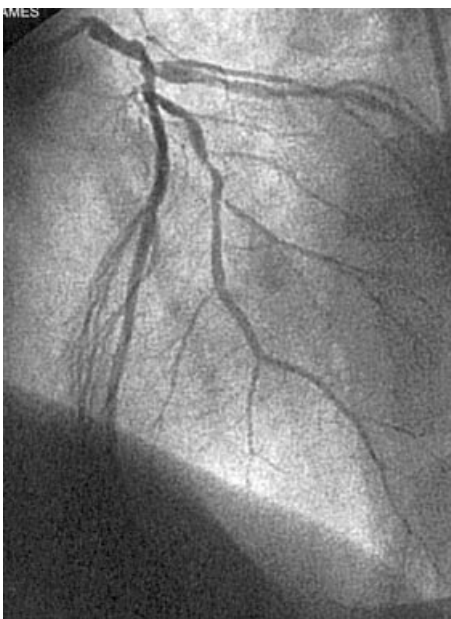


Figure 2.2 Boundaries of the LAO cranial view: A triangle created by the diaphragm, spine, and edge of the intensifier. The LAD should be seated at the top of this triangle for adequate visualization. The diagonals are on the right side and the septal arteries on the left side of the screen. (Courtesy of the Cardiac Catheterization Laboratories of Community Healthcare System, St Mary Medical Center, Hobart, IN.)

****To completely scrutinize the LAD, do we need an LAO cranial view?** A full exposure of the LAD always requires the LAO cranial view to separate the LAD and the diagonals, and expose the lesions at the ostium or bifurcations of the diagonals (Figure 2.2). In patients with a prominent abdomen, the AP cranial view with really deep inspiration would move the LCX up high above the LAD (rule 1) and the diaphragm down in order to uncover the whole LAD.

****Angulations to separate the LAD from diagonals** In the RAO view, if the first diagonal is above the LAD and overlaps the proximal LAD, a cranial angulation would separate the LAD and its diagonals well. However, the LCX would be moved up and overlap the proximal LAD. If the diagonals were seen below the LAD in the plain RAO view, a caudal angulation would help to separate the LAD and its diagonal branches (Table 2.3).

LEFT MAIN

The left main has variable length (1–10 mm) and no side branches, and bifurcates into the LAD and LCX. Occasionally, there is no

Table 2.3 How to expose the LAD and the diagonals**Exposing the LAD**

First AP view	Next view with deep inspiration
If the LCX is below the LAD	RAO cranial or AP cranial
If the LCX is the same level	RAO cranial or AP cranial
If the LCX is above the LAD	RAO cranial or AP cranial with deep inspiration

Separating the LAD and the diagonal

First RAO view	Next view
If the first diagonal is above the LAD	RAO cranial view
If the first diagonal is below the LAD	RAO caudal view

functional or very short LM, and the LAD and LCX arise from separate ostia. The LM artery is examined through all the views that expose the LAD and LCX. It is an important part of the scrutinization of the coronary artery system, because a lesion on the LM is the main cause of mortality even from diagnostic coronary angiography. The first basic views of the LM are the AP view or the shallow RAO view. If these two views do not show the LM clearly, various views can be taken according to the vertical or horizontal positions of the heart and the length of the LM.

Technical Tips

****How to expose the LM, when the heart is horizontal** The LM is short and the proximal LAD has a cephalad orientation; the LAO caudal view is better than the LAO cranial view. The LAO caudal view would help to show the length of the LM, the direction of bifurcation of the LAD or LCX where the wire needs to be directed (see Figure 2-3). To have the best LAO caudal (or spider) view, the tip of the guide should be positioned at the center of a full half-circle extending from 12 to 6 o'clock, formed by the shadow of the cardiac silhouette. However, angulation that is too steep would cause foreshortening of the LM and overlap by the diaphragm and spine.

****How to expose the LM, when the LM is long and has a downward direction** As in vertical hearts, the LAO cranial view will show the LM and its bifurcation to the LAD and LCX best. An LAO/cranial angulation that is too steep would further foreshorten the LM and, together with poor inspiration, would produce a hazy background due to diaphragm overlap. If the above views could not clearly delineate the LM lesions, other possible views include all the possible combinations of angulation

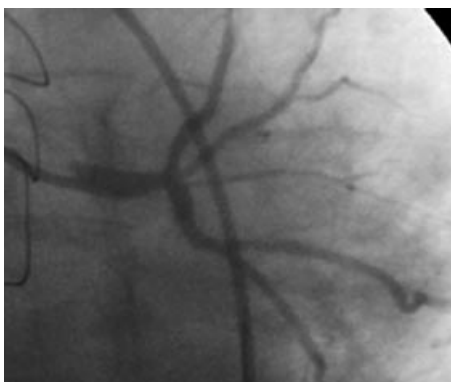

Figure 2.3 The LAO caudal view of the left main: In this (spider) view, the left main is seen very clearly at the bifurcation into the LAD and LCX. (Courtesy of the Cardiac Catheterization Laboratories of Community Healthcare System, St Mary Medical Center, Hobart, IN.)

Table 2.4 Other possible angles to delineate the left main

Vessel segment	Routine views	Adjunctive views
Ostial	LAO caudal	AP caudal
Body	RAO caudal RAO cranial	AP caudal
Distal	LAO caudal	LAO cranial RAO caudal

set by an image intensifier (except the AP cranial and lateral views) (Table 2.4).

LEFT ANTERIOR DESCENDING ARTERY

The proximal LAD is defined as the segment from the ostium to the origin of the first septal. The distal end of the mid-segment is less rigorously defined and is typically the location where the LAD dips downward on an RAO view.

The AP Cranial View

This is one of the best first views that may delineate the ostial segment, then the mid- and distal segment of the LAD. In patients with long left main, during PCIs in the proximal or mid-LAD lesion, this view is very useful to show the course when the wire enters the LAD and goes forward without interference from the septal and diagonal branches. The AP cranial view can be taken while the patient breathes in deeply if there is the intention to elevate the LCX above the proximal LAD. If the LCX is way below the LAD, inspiration is not needed because it will elevate the LCX to overlap the LAD.

The LAO Cranial View

This view delineates clearly the course of the LAD, from its origin to the apex, and the correlation with its septals and diagonals. In this view, the LAD is best seen if the tip of the guide is positioned in a triangle made with the spine, diaphragm, and edge of the intensifier, over a clear lung background (see Figure 2.2). To move the spine away from the center, just move the tube to the left so the spine will be moved to the left (rule 1). If the result is suboptimal, better definition of the proximal LAD can be achieved by changing the steepness of the cranial angulation and having the patient take a deep breath, to lower the diaphragm, thus making the heart more vertical. This LAO cranial view would help to delineate any lesion on the LAD, especially at the bifurcations with the diagonals and septals. It helps to show the pathway of the wire. However, in this view, the proximal LAD is foreshortened so it does not give an accurate evaluation of the result of angioplasty or stenting in the very proximal LAD.

CRITICAL THINKING

How to identify the LAD, diagonals, and septals

The LAO cranial view is the best view to identify and confirm the identity of the LAD.

The diagonals would be in the left of the screen and the septals would come out from the right of the LAD. It is almost unthinkable if a LAD has no septals.

This view would confirm the identity of a compensatory enlarged diagonal because of chronic total occlusion of the LAD. The diagonals would point more to the left side; however, a long LAD in a very dilated left ventricle (LV) could have the apex moved toward the left of the screen as well. Another way to differentiate the septals from the diagonals is that the diagonals move (buckle) during systole, whereas the septals are straighter and move very little with ventricular contraction. The presence of the septals would confirm the identity of the artery to be the LAD.

The AP cranial view

To see the proximal and mid-segment of the LAD with its bifurcation clearly, the AP cranial view could show very clearly the ostial and proximal segments of the LAD, if the LCX can be moved totally above the LAD. The mid-segment and distal segments of the LAD are well exposed in a single view on the screen, so this view is a favorite view during PCI where the operator can monitor the position of the tip of the guide, movement of the devices in the proximal segment, and position of the tip of the wire at the distal segment.



(Continued)

The lateral view

To highlight a lesion at the bifurcation of the LAD and the diagonals, the lateral view can help to pinpoint its location and assess its severity. It is more useful for a diagnostic injection rather than an interventional procedure, because a prolonged position of the arm above the head would make any patient tired and uncomfortable.

Technical Tips

****Exposure of the high diagonal** Usually the ostium of a high diagonal is not well seen in the RAO cranial view because the area is overlapped by an elevated LCX, so the LAO with steep cranial view (LAO 10, cranial 40) can be tried. However, a good spider view with steep caudal angulation is most likely the best view to expose a high diagonal (Figure 2.3).

****Best view for ostial and proximal LAD in horizontal heart or short LM** When the heart is horizontal, the LM is short and the proximal LAD has a cephalad orientation; the LAO caudal view is better than the LAO cranial view because of proximal circumflex overlapping. Positioning the proximal end of a stent during PCI of the ostial LAD can be done best in this caudal view. However, the proximal LAD segment is foreshortened so it is not the best for checking the complete deployment of a stent or the appearance of a new dissection in this view.

****Best view for ostial and proximal LAD in patients with long LM** If the LM is long, the AP cranial view should be the first view, especially if the LCX can be moved above the LAD. If the LAD cannot be assessed in this view, the next best view is the RAO cranial which will best show the LM and its bifurcation to the LAD and LCX. Thus, the best views for distal LM or ostial LAD can be with AP, RAO, or LAO cranial angulation. If not, the next try would be the LAO caudal view.

LEFT CIRCUMFLEX ARTERY

The proximal segment of the LCX starts from the ostium up to and including the origin of the first obtuse marginal (OM). The distal LCX is beyond this point. When looking at the LCX, a standard RAO caudal view may provide much needed information. However, a shallow angulation has two limitations: (1) it can foreshorten the proximal segments of the LCX, so the exact morphology of a lesion in that segment cannot be optimally assessed or the direction or its tortuosity is overlooked; and (2) the ostial segment may be overlapped and is not seen clearly. The more caudal the view, the better the proximal part is seen. To complement the limitations of the RAO shallow caudal view, an AP caudal or LAO caudal view can help to clarify the problem in

the ostial and proximal LCX (see Figure 2.3). While taking this view, the patient is asked to take a deep breath, which moves the diaphragm downward and clears the field for optimal vessel opacification.

In the case of mid- or distal LCX–OM intervention, an RAO caudal view can foreshorten the proximal LCX and could mask the severity of the takeoff angle with the LM, and the tortuosity and severity of any possible obstructive lesions at the proximal LCX segment. On many occasions, only after unsuccessful advancement of balloons and stents across the proximal segment is the severity of the lesions and tortuosity of the proximal segment of the LCX appreciated. If properly taken, the AP caudal or LAO caudal (spider) view would give a sharp delineation of the ostium and proximal segment of the LCX, so a wire can be shaped to enter the artery and the proximal segment without unexpected difficulty.

RIGHT CORONARY ARTERY

The proximal segment of the right coronary artery (RCA) originates at the ostium and ends after the first curve. The mid-segment begins with the first curve and ends at the second curve, and is usually considered the straight segment in the RAO view. The distal segment is the remainder of the artery. The origin of the RCA is extremely variable, from a straight perpendicular takeoff from the aorta, to a marked caudal direction, to a superior takeoff with the shepherd's crook configuration. A strong hand injection into the low right coronary cusp may help to show the origin of the RCA. If it is not seen, it may originate anteriorly, or from the left sinus of Valsalva, or above the sinotubular ridge.

The LAO View

In the LAO projection, the artery appears like a letter C, whereas, in the RAO position, it appears like a letter L. To check the correct alignment of the catheter with the ostial RCA, the best view is the RAO-shallow cranial projection. In this location, the tip of the catheter is seen head-on as a circle (Figure 2.4a). If there is an angle formed by the tip of the catheter with the proximal RCA, there is no coaxial alignment of the catheter (Figure 2.4b). There would be friction at the angle of transition, which may diminish the forwarding force, the torquing capacity, and obstruct the smooth advancement of interventional hardware across a tight lesion.

When imaging an ostial lesion, it is useful to place the catheter just under the coronary ostium and inject a large volume of contrast to define both the extent of the lesion and its precise position on the aortic wall. This is a particularly important view when contemplating deployment of a stent in the ostial RCA. The exact location of the ostium can often be best seen in an extreme LAO position ($>50^\circ$) or the LAO with caudal angulation. To view the ostial segment of the RCA, the best view is the LAO caudal view that exposes the ostial and proximal segment of the RCA well. To

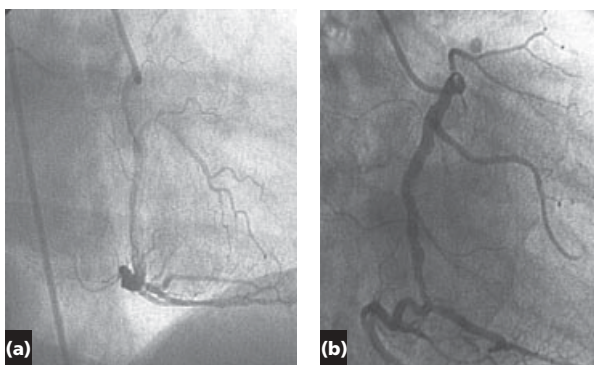


Figure 2.4 (a) The RAO view of RCA: In this view, the guide is truly coaxial, so the tip of guide will be seen head-on as a circle. (b) The RAO view of a RCA anomaly with the ostium in the anterior position: As the location of the ostium in this case is abnormal, the tip of the guide points to the left. (Courtesy of the Cardiac Catheterization Laboratories of Community Healthcare System, St Mary Medical Center, Hobart, IN.)

view the distal PDA, the LAO cranial view coupled with deep inspiration, which moves the diaphragm outside the field, will expose the distal RCA and its bifurcation with the PDA. If there is a need for further exposure of the distal RCA, an AP cranial view with deep inspiration is best.

The RAO View

In the LAO view, the mid-segment may not be visualized well because of overlap of the right ventricular (RV) branch. The RAO view would separate the mid-segment of the RCA from the RV branches (Figure 2.4a). When wiring the RCA, an LAO view would help to direct the wire from the guide into the proximal segment. It also helps to appropriately select the different PDAs in the distal segment. However, because of the presence of a few marginal branches, an RAO view would help to direct the wire at the mid-segment, avoid the marginal branches, and advance it easily to the distal segment.

SAPHENOUS VEIN GRAFT

The principle of selecting the best angle for a venous or arterial graft is to angle a 90° view from the direction of the bypass graft. In the case of the saphenous vein graft (SVG) to the OM, the direction of the SVG is up to down (or cranial to caudal), and the best view is the RAO caudal view, because the RAO caudal forms a 90° angle with the SVG on the vertical plane and with the OM on the horizontal plane. The best view for the ostium or body of the SVG to the LAD and diagonals is the LAO view, the LAO cranial view for the distal PDA, and the RAO cranial for the LAD or diagonals. There is detailed discussion of the views for SVG in Chapter 13.

INTERNAL MAMMARY ARTERY

Usually the left internal mammary artery (LIMA) graft is inserted into the LAD, so the basic views of the LAD and its insertion site should be the LAO cranial or RAO cranial views. The insertion site of the LIMA to the LAD can also be seen well in the lateral view because, in this view, the X-ray beam will arrive at the LIMA insertion site at a 90° angle with the distal end of the LIMA graft on the vertical plane, whereas it will be at 90° with the LAD on the horizontal plane.

Although the LIMA catheter is usually engaged on the AP view, to check the position of the catheter tip in relation to the ostium, the best views are the 60° LAO or 45° RAO. These angulations would elongate the aortic arch and separate the subclavian artery to identify clearly the LIMA ostium.

Technical Tips

*****Non-selective angiogram of the LIMA** In rare case where there is difficulty engaging the left and right IMAs, a non-selective angiogram of the subclavian artery with the tip of the catheter just in the vicinity of the ostia can be done. Complete opacification of the subclavian artery and its branches can be achieved with a 10-ml manual injection with a blood pressure cuff inflated 10mmHg above the systolic pressure on the ipsilateral arm [1].

CAVEAT

Deceiving angiographic views

There are angiographic views that minimize the severity of an angulated segment or the severity of a lesion. The most common situation is the RAO caudal view for a lesion in the proximal LCX. This view foreshortens the proximal segment of the LCX so the ostial lesion of the LCX can be missed and the lesions in the proximal segment can be overlooked.

In the RAO cranial or LAO cranial views, the lesion in the distal LM can also be missed; if there is a problem advancing the device or thrombus formation after manipulation of interventional hardware, the severity of the lesion is appreciated much more. In the LAO cranial view, the lesion in the proximal LAD can be missed, because it is foreshortened and can be seen better in the RAO cranial, AP cranial, or LAD caudal view.

During PCI in the RCA, the guide is thought to be coaxial in the LAO view; however, after failing to advance the interventional devices or difficulty in withdrawing them, it is found that the guide is not coaxial in the RAO view (Table 2.5).

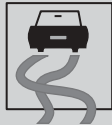

Table 2.5 How to select the angle for the camera

Problems	Solutions
The LAD is not central in the LAO cranial view	Move camera tube more LAO
The LAD is too tortuous or foreshortened in the LAO cranial view	Move camera more or less cranial
If LCX overlaps LAD in the RAO cranial view	Move the camera more cranial and deeper inspiration to lift the LCX more above the LAD or change to AP cranial view
If the LCX is clearly below the LAD in the AP view	RAO caudal view with deep inspiration
If the proximal LCX is too tortuous in the AP view	Deep inspiration and take RAO caudal view
If the proximal LCX is foreshortened in the AP view	Make view more caudal with deep inspiration
If there is difficulty in cannulating the RCA	Take an RAO view to check coaxial position of the guide

Table 2.6 Suboptimal and deceiving angiographic views

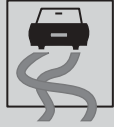- 1 RAO caudal views for the ostial and proximal LCX
Better view: AP caudal with deep inspiration (or vice versa)
- 2 LAO view of the proximal or ostial RCA
Better view: LAO caudal to have better delineation of the ostium. RAO view to check coaxial position
- 3 LAO view for origin of distal PDA
Better view: LAO cranial or AP cranial view with deep inspiration in order to depress the diaphragm further
- 4 AP view of the distal LM
Better view: LAO caudal (spider view), or cranial angulation
- 5 LAO cranial view for the proximal LAD
Better view: AP cranial

MAGNIFICATION ARTIFACTS FOR BALLOON OR STENT SIZING

In the RAO caudal view, the size of the tip of the guide is projected smaller than the projected size of the LCX, OM, or distal RCA because the LCX, OM, and distal RCA are more posterior to the image intensifier and the RCA is more enlarged than the tip of the guide. We encounter the same problem measuring the size of the distal LAD in the RAO cranial view. In all circumstances, the image intensifier should be as close to the patient's chest as possible. Precautions when measuring the size of the arteries are listed in Table 2.6.

CAVEAT**Missing lesions**

Coronary angiography or “luminography” is well known to miss severe lesions, especially the short, napkin-ring lesion or short aorto-ostial lesions. The reason is that, when the lesion is viewed from an angled projection, the lesion is not seen because the adjacent contrast-filled vessel segments are projected over the short and diseased segment, masking it. In the case of an ostial lesion, the tip of a small catheter can be engaged too deeply without causing ventricularization of blood pressure, and spill-over of contrast in the aorto-ostial area would mask the short, severe, ostial lesion. This is the same problem for PCI in ostial lesions, where it is difficult to position the proximal end of the stent because an angiogram would spill contrast over the ostial area.

**OVERSIZING the vessel in mid- and distal segments**

In many patients undergoing PCI in the LCX, the reference size of the mid-segment of the LCX is measured on the RAO caudal view. In this view, the tip of the guide at the LM ostium is more anterior whereas the mid-segment of the LCX is more posterior, at the level of the aorta, so the mid-segment of the LCX (and the shaft of the guide compared with its tip) is projected bigger on the screen. This is why the size of the LCX, as measured by quantitative coronary angiography (QCA), can be quite deceptive, and is the cause of balloon or stent oversizing in PCI of the LCX. The same problem happens with the distal RCA in the AP cranial view and the mid- and distal segments of the LAD in the RAO cranial view (Table 2.7 and Figure 2.5).

UNDERSIZING the vessel

In the LAO cranial view, the mid-LAD looks smaller because the tip of the guide is posterior and the artery is near the image intensifier, so the guide is projected larger on the screen whereas the LAD looks smaller. In consequence, the size of the balloon or the stent looks smaller than it is in reality.

RADIATION

The operator should be cautious in using the X-ray generator in order to protect him- or herself, and the staff, from radiation exposure.

Angulations that give the Most Radiation

The steep LAO cranial angulation is the view that causes the most radiation exposure for the operator using the right femoral approach. It is due to radiation from the X-ray generator below the table, and the X-ray beam is redirected and scattered off

Table 2.7 Best views for balloon or stent sizing

Segment	Best View
The LAD	
Proximal or mid-LAD	RAO or AP cranial
Distal LAD	RAO cranial (caution for magnification artifact)
The LCX	
Proximal LCX	RAO caudal and AP caudal
Distal LCX or OM	RAO caudal (caution for magnification artifact)
The RCA	
Proximal, mid-RCA	RAO, LAO
Distal RCA, PDA, PLB	AP, LAO cranial (caution for magnification artifact)

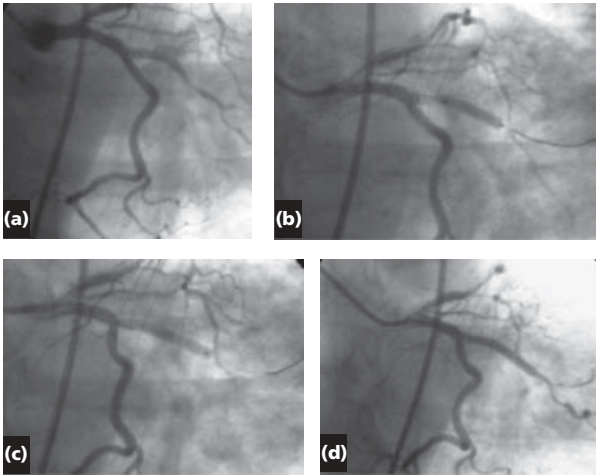


Figure 2.5 False magnification of the LCX: (a) With the size of the guide tip as reference, the OM was measured as 3.8 mm proximally and 3.3 mm distally to the lesion. Therefore, a 3.25-mm balloon was selected for predilatation. (b) During inflation, an angiogram showed total occlusion of the artery, so the balloon fits well. (c) The body of the guide looked bigger than the tip, so a 3.0-mm stent was selected and deployed. The angiogram during inflation also showed the same size between the proximal segment and the stent size. (d) The post-stenting angiogram showed that there was no discrepancy between the diameter of the lumen in the stented area and its proximal segment. The real diameter of the artery was around 3.00 mm, not 3.8 mm as measured with the tip of the guide as reference. (Courtesy of the Cardiac Catheterization Laboratories of Community Healthcare System, St Mary Medical Center, Hobart, IN.)

when meeting the patient. This radiation scatters toward the operator, and there is increased scatter produced by the higher kilovoltage level required for hemiaxial angulation [2]. During PCI of obese patients, to permit adequate X-ray penetration, avoid deep angulation, especially caudal angulation. The image magnification should also be lower, to reduce patient and operator radiation exposure and limit the amplitude of table panning, thus reducing motion artifacts. In selected suspicious areas, the areas will be re-imaged with higher magnifications.

CORONARY ARTERY ANOMALIES

The most common anomaly is the variation of the coronary artery origin from the aorta. Usually, this is of no clinical significance, except in the case of the origin of the LAD from the right sinus or the RCA from the left sinus which is compressed, resulting in ischemia and sudden death [3]. When the LCX originates from the RCA or right sinus, usually it takes the retroaortic course to supply the lateral wall of the ventricle and is benign. The LCA or RCA can originate from the posterior sinus (very rare) or the ascending aorta, similar to a bypass graft [4]. Besides an ectopic origin, the anatomical course is usually normal. These anomalies are considered benign. When the LCA or RCA originates from the opposite sinus, there are four pathways: The rare form is the interarterial course and the most common the septal course; the other two forms are the retroaortic and anterior courses. The interarterial course is the most serious one because it can cause ischemia, leading to sudden death.

The septal pathway is recognized by the fish-hook picture of a selective coronary angiogram in the RAO view. This is because the LM goes down to the septum and then comes up to the epicardium, making a picture of a fish hook. The LCX would then curve backward and form the "eye," with the LCX as the upper border [5]. In the anterior (pathway) the LM is in front of the pulmonary artery. This pathway is recognized by the "eye," with the LM as the upper border and the LCX as the inferior border (Figure 2.6).

Technical Tips

****The dots and the eyes** The course of an anomalous coronary artery is suggested by non-selective coronary angiography during the filming of a 30° RAO left ventriculogram. In this visualization, a dot representing the artery seen end-on is noted. The most severe one, the interarterial pathway of an anomalous LM crossing between the aorta and the pulmonary artery, is recognized by the position of the "dot" anterior to the aorta. If the "dot" is behind the aorta, this is the retroaortic benign pathway [5] (Figure 2.6).

The single coronary artery Defined as an artery that arises from an arterial trunk and supplies blood for the entire myocardium, a single coronary artery (SCA) is rare.

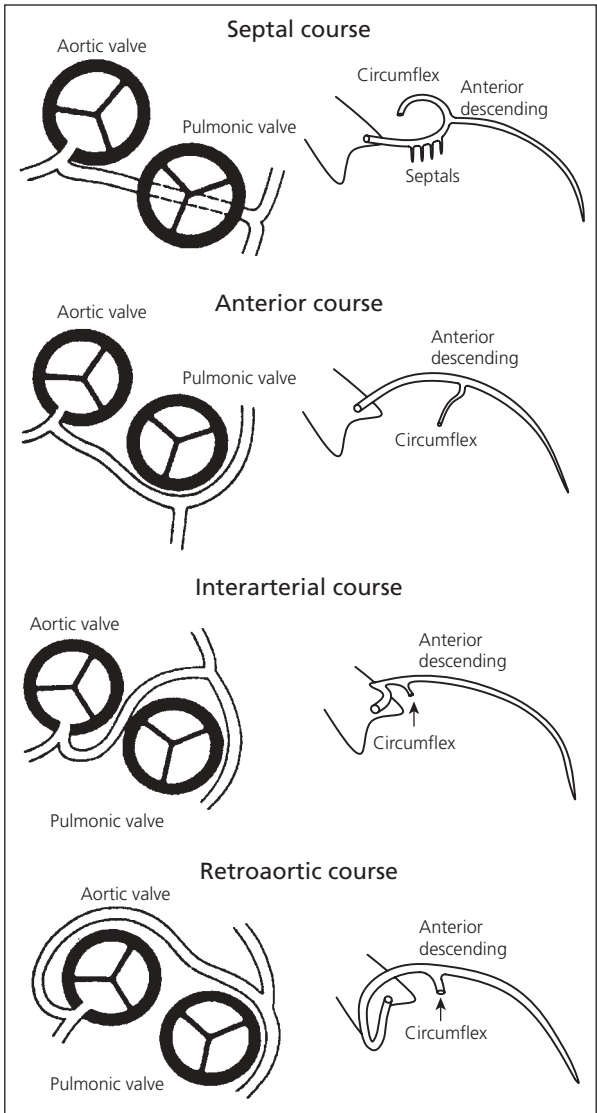


Figure 2.6 General view of coronary anomalies. (Adapted from Serota et al. with permission from Elsevier [5].)

The LCX from the right sinus The second most common coronary anomaly is the LCX arising from the proximal RCA. This variant is benign. When the LCX arises from the right coronary cusp or the proximal RCA, it invariably follows a retroactive course, with the LCX passing posteriorly around the aortic root to its normal location. The LAD would be a large artery without

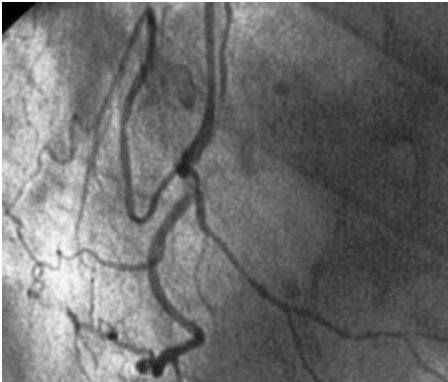

Figure 2.7 In this RAO view, the LCX that originates from the RCA is seen in a retroaortic pathway as the dot is seen behind the aorta and the artery curves posteriorly. (Courtesy of the Cardiac Catheterization Laboratories of Community Healthcare System, St Mary Medical Center, Hobart, IN.)

the LCX. In a 30° RAO view, the LCX will be seen curving in the posterior area and is seen head-on, as a dot, posterior to the aorta [5] (Figure 2.7). When the LCX originates from the proximal RCA, near the ostium, if the catheter tip is engaged too deeply, it can pass over the ostium of the anomalous LCX and miss opacifying the LCX.

The Right Coronary Anomalies

Anterior position of the ostium If the origin of the RCA is minimally displaced anteriorly, the tip of the right Judkins catheter may not be directed to the right, but rather looks foreshortened in the familiar LAO view. Directing the tip to the right in the usual fashion using the LAO view permits easy cannulation of the anteriorly directed RCA orifice. In the RAO view, there would be an angle between the catheter tip and the ostium, with the tip pointing toward the left (see Figure 2.4b).

Anomalous origin of the RCA from the left sinus When the RCA arises from the left sinus or from the proximal LM in the RAO view, the RCA will be seen head-on, as a dot anterior to the aorta [5]. Figure 2.8 shows a middle-aged nurse with acute myocardial infarction. Two years later her son had an angiogram that showed exactly the same anomaly (Figure 2.8).

The LAD Anomalies

LAD from the RCA or right sinus anterior free wall course The LAD crosses the anterior free wall of the RV in front of the pulmonary artery, then at the mid-septum turns toward the apex. On the 30° RAO view, the LAD will pass to the left and upward before turning to the apex. This coronary anomaly is benign [5].

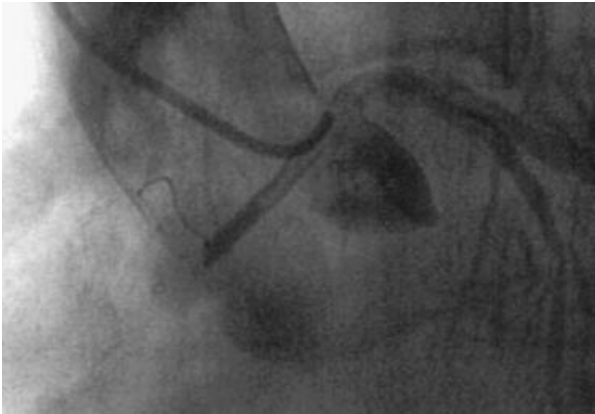

Figure 2.8 In this left coronary injection, an anomalous RCA originating from the left sinus was seen. It was occluded because of acute myocardial infarction. It was then successfully opened. (Courtesy of the Cardiac Catheterization Laboratories of Community Healthcare System, St Mary Medical Center, Hobart, IN.)

LAD from the RCA or right sinus septal course The LAD runs an intramuscular course through the septum along the floor of the RV outflow tract. It then surfaces at the mid-septum and turns toward the apex. In the RAO view, the LAD will pass to the left and downward before turning toward the apex. This type of coronary anomaly is considered benign without ischemia [5].

The Left Main Coronary Artery Anomalies

The incidence of LM originating from the right sinus is very low (1.3%). The artery, seen in the RAO view, may course in front of the pulmonary artery (anterior course), through the septum (septal course), between the aorta and the pulmonary artery trunk (interarterial course), or behind the aorta (retroaortic course) (see Figure 2.6). Accurate diagnosis is prognostically important because of fatal events associated with the interarterial pathway.

The septal course The LM runs an intramuscular course through the septum along the floor of the RV outflow tract. It then surfaces at the mid-septum where it bifurcates into the LAD and LCX. As the artery divides at the mid-septum, the initial portion of the LCX curves above the LM toward the aorta (the normal position of the LAD) and forms an ellipse with the LM (similar to the shape of an eye, with the LM as the inferior border), seen best at the 30° RAO view. The LAD is relatively short because only the mid- and distal LADs are present. One or more septal vessels can originate from the LM. This type of coronary anomaly is considered benign without ischemia [5] (Figure 2.9).

The anterior free wall course In the anterior course, the LM crosses the free wall of the right ventricle, in front of the pulmonary

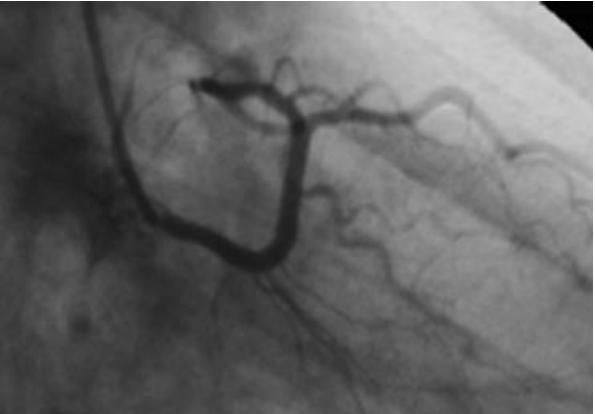

Figure 2.9 The LM from the right sinus by the septal course: The LM forms the inferior border of the eye whereas the LCX forms the superior border. (Courtesy of the Cardiac Catheterization Laboratories of Community Healthcare System, St Mary Medical Center, Hobart, IN.)

artery, and divides into the LAD and LCX at the mid-septum. The LCX would curve back toward the aorta (the position of the normal LAD). On the 30° RAO view, the LCX forms an ellipse ("eye") with the LM on the superior border. There is no myocardial ischemia associated with this coronary anomaly [5].

The retroaortic course In this type, the LM goes around the aortic root to its normal position on the anterior surface of the heart. It divides into the LAD and LCX at its normal point, so the LAD and LCX have normal length and course. In the RAO view, the LM is seen head-on, as a circle, posterior to the aorta. This retroaortic dot is diagnostic of a posteriorly coursing artery. There are only rare cases of ischemia reported with this type of anomaly [5].

The interarterial course In this type, the LM courses between the aorta and the pulmonary artery to its normal position on the anterior surface of the heart. In the RAO view, the LM is seen head-on, as a dot, on the anterior aspect of the aorta. The circumflex arises with a caudal orientation. This type of anomaly is associated with exertional angina, syncope, and sudden death at young age [5] (Figure 2.10).

Anatomic consideration of the ostial segment Not every anomaly has a wide ostium onto which the tip of the guide can hook, or a narrowing at the opening that needs to be stented. There have been several reports that an anomalous RCA from the LCA can leave the aorta in oblique fashion, so the ostium has a slit-like configuration formed by flaps of aortic and coronary tissues. During exercise, the aorta can expand its part of the flap, narrowing further the slit-like opening and causing ischemia [6].

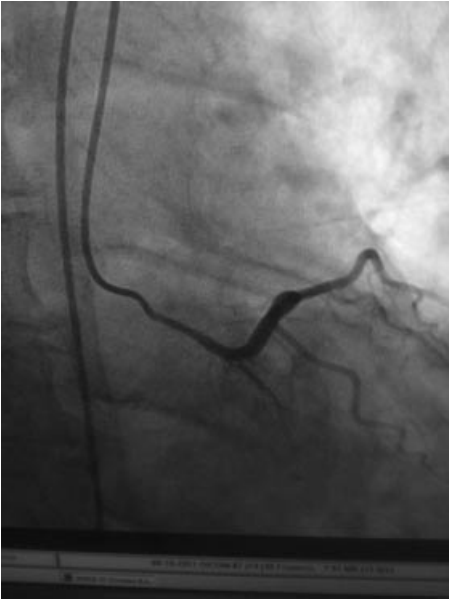


Figure 2.10 The LM originating from the right coronary sinus going between the aorta and the pulmonary artery (the interarterial approach) in an AP view. (Courtesy of the Cardiac Catheterization Laboratories of Community Healthcare System, St Mary Medical Center, Hobart, IN.)

Mechanism of ischemia due to anomalous pathway If an anomalous artery has to course between the aorta and the pulmonary artery, the expansion of the aorta during exercise can cause narrowing of the mid-segment and subsequent ischemia. If it happens in young patients, there is an indication for corrective surgery. If the anomaly is found incidentally in asymptomatic elderly patients, surgery is indicated only if objective signs of ischemia can be demonstrated. The reason is that the hardened aorta in older patients does not expand much anymore, so it does not cause as much exercise-induced ischemia as in young patients. Some anomalous coronary arteries with an intramural course may adhere to the wall of the aorta, and can even share a common medium with the aorta without intervening adventitia [7].

Left main from the posterior sinus In the AP view, the non-coronary cusp is on the right side and inferior to the left aortic sinus. However, it is seen best in the RAO view, in its posterior location, and identified by the catheter tip in the posterior direction. An injection in the sinus would outline the artery and the posterior wall of the aorta [8].

Right coronary artery from the pulmonary trunk

This anomaly is very rare. The RCA originates from the pulmonary trunk. As a result of the low pulmonary resistance, the fully

oxygenated blood arriving in the anomalous coronary artery, via collaterals from the normal coronary artery, is stolen by the pulmonary trunk, resulting in myocardial ischemia. The treatment includes surgical ligation of the RCA and bypass or reimplantation of the RCA [9].

REFERENCES

1. Bhatt S, Jorgensen MB, Aharonian VJ, et al. Nonselective angiography of IMA: A fast, reliable and safe technique. *Catheter Cardiovasc Diagn* 1995;**36**:194–8.
2. Wagner L. Operational radiation management for patients and staff. In: King S, Yeung A (eds), *Interventional Cardiology*. New York: McGraw Hill, 2007: 121–44.
3. Barth CW III, Robert WC. Left main coronary artery originating from the right sinus of Valsava and coursing between the aorta and pulmonary trunk. *J Am Coll Cardiol* 1986;**7**:366–73.
4. Santucci P, Bredikis A, Kavinsky C, et al. Congenital origin of the LMCA from the innominate artery in a 37 year old man with syncope and right ventricular dysplasia. *Catheter Cardiovasc Interv* 2001;**52**:378–81.
5. Serota H, Barth III CW, Seuc CA, et al. Rapid identification of the course of anomalous coronary arteries in adults: The “dot and eye” method. *Am J Cardiol* 1990;**65**:891–8.
6. Cheitlin MD, DeCastro CM, McAllister HA. Sudden death as a complication of anomalous left coronary origin from the anterior sinus of Valsava: A not so-minor congenital anomaly. *Circulation* 1974;**50**:780–7.
7. Topaz O, Edwards JE. Pathologic features of sudden death in children, adolescents and young adults. *Chest* 1985;**87**:476–82.
8. Lawson MA, Dailey SM, Soto B. Selective injection of a left coronary artery arising anomalously from the posterior aortic sinus. *Catheter Cardiovasc Diagn* 1993;**30**:300–2.
9. Vijitbenjaronk P, Glancy L, Ferguson B, et al. RCA arising from the pulmonary trunk in 63-year-old man. *Catheter Cardiovasc Interv* 2002;**57**:545–7.

CHAPTER 3

Guides

Dobrin Vassilev, Thach N. Nguyen, Yidong Wei

Challenges 53

Standard of Technical Excellence 53

Practical Analysis of Guide Design 54

The Judkins Guide 54

The Amplatz Guide 54

The Multipurpose Guide 54

The Extra Backup Guide 55

Guide Manipulations 55

Safety Measures 55

Technical Tips 55

*Advancement through tortuous iliac artery 55

**Manipulations to enter the left main ostium 55

*Dampening of arterial pressure 56

*Simple coaxial position or active support position? 56

**How important is the guide *external diameter* in ostial obstruction? 56

***If the guide is too long 56

Advanced and Exotic Technique How to Shorten a Guide 57

Technical Tips 60

**When should a guide with a side hole be used? 60

Advanced and Exotic Technique: How to Make a Sidehole from a Regular Guide? 60

***Guides for unusually wide ascending aorta 61

Advanced and Exotic Technique: Shaping the Guide 61

Technical Tips 61

**How to stabilize a guide with ostial stented lesion? 61

**Safety when using a large guide 61

***Double guides for complex PCI 61

**Guide support 62

Selection of Guides 62

Judkins Guide 62

Technical Tips 62

**Non-coaxial position of a small Judkins guide 62

*Guide that is too large 63

*Guide that is too small 63

*Engagement of a Judkins right guide 63

*Basic; **Advanced; ***Rare, exotic, or investigational

\$, <\$US100.00 extra; \$\$, >\$US100.00 extra

⌚, <10 min extra; ⌚⌚, >10 min extra

♣, low risk of complications; ♣♣, high risk of complications

Amplatz Guide 63

Technical Tips 64

- **Optimal position of an Amplatz guide 64
- *Withdrawal of an Amplatz guide 65
- **Withdrawal of an Amplatz guide after balloon inflation 65

Multipurpose Guide 66

How to position the distal tip 66

Extra Backup Guide 66

Catheter For Left Main Lesions 66

Technical Tips 67

- *Catheter position in suspected LM 67
- **How many views do you need after detecting an LM lesion? 67
- **Dampening pressure 67

Guide for LAD Lesions 68

Guide for LCX Lesions 68

Technical Tips 68

- *Pointing toward the LCX 68
- **Selection of guides for PCI 68
- ***Rotational Amplatz maneuver 69

Guide for RCA Lesions 70

Technical Tips 70

- **Selection of guides for horizontal takeoff angle 70
- **Selection of guides for superiorly oriented takeoff angle 70
- **Selection of guides for inferiorly oriented takeoff angle 70
- **Avoiding selective entry of the conus branch 70
- **Deep-seating a RCA guide 70
- ***Rotational Amplatz maneuver for the RCA 71
- *Why do active support maneuvers work? 71

Guide for Saphenous Vein Graft 72

Catheters for Aortic Aneurysm and Dissections 72

Technical Tips 72

- **Simple maneuver to determine supra-aortic vessel involvement 72
- **Which approach is BEST and SAFE for aortic dissection? Radial or femoral? 72
- **Is the catheter in the true lumen? 72
- **Ascending aortogram 73
- **Engagement of the coronary catheter 73

Guides For Coronary Anomalies 74

Technical Tips 74

- ***Guides for right aortic arch 74
- ***Guides for anomalous coronary arteries arising above the sinotubular ridge in the ascending aorta 75
- ***Guides for anomalous coronary arteries arising from the left sinus 75
- ***Guides for anomalous coronary arteries arising from the right sinus 75
- ***Guide for coronary arteries arising from the posterior sinus 75
- **Guide for missing arteries 76
- ***Guides of the ectopic RCA from the anterior half of the left sinus 76

Manipulation of Guide During PCI 77**Technical Tips 77**

***Difficult engagement of a guide but easy engagement by a diagnostic catheter 77

**Deep-seating maneuver 77

**Stabilizing a guide with the "buddy" wire technique 78

**Stabilizing a guide with anchoring balloon 78

**Stabilizing a guide with a long sheath 78

***How to extend the tip of a guide 79

***Strengthening the guide with another guide or catheter 79

Technique Five-in-six guide strengthening 79

Equipment 79

Technical Tips 81

**Guide insertion made easy 81

Advantages and Limitations: When Advancing a Stent through the GuideLiner 82

***Extreme measure for strengthening the guide with two other guides or catheters 82

Advantages and Limitations 83**Technical Tips 83**

**Changing a guide with wire across lesion 83

Technique Exchange of a guide without removing the wire 83

Technical Tip 84

**How to untwist a twisted guide 84

CHALLENGES

An optimal guide provides a stable platform for the operator to advance devices successfully through tortuous arterial segments and across tight lesions.

STANDARD OF TECHNICAL EXCELLENCE

Once engaged in the ostial segment, the tip of the guide is to be positioned with atraumatic coaxial alignment. Under fluoroscopic guidance, forward advancement of the guide should demonstrate a tendency to further intubate the coronary artery, rather than prolapse into the aortic root. Any guide with its tip held still, not being displaced, while being pushed forward will be the ideal guide for the procedure.

The guide is selected according to the size of the ascending aorta, the location of the ostia to be cannulated, and the degree of tortuosity and calcification of the coronary segment proximal to the target area.

In a simple case with easy access, the Judkins guide, even in a relaxed position (just in front of coronary artery ostium) in the aortic sinus, can provide an adequate platform to advance the device. It is the ideal guide position in aorto-ostial lesion stenting.

In complex cases, where more resistance is encountered, any selected guide, with its secondary curve well positioned and standing firm against the opposite aortic wall, would provide the strong and stable platform needed for device advancement. This chapter discusses the guide through the femoral approach. The guide of the transradial approach is discussed in Chapters 7 and 8.

Practical Analysis of Guide Design

The most commonly used guides are the Judkins, Amplatz, and extra backup (EBU) guides. The others that have a niche in various situations include the Multipurpose for the right coronary artery (RCA) bypass or a high left main (LM) takeoff, and the left internal mammary artery (LIMA) guide for the superiorly oriented graft and the right and left coronary bypass graft.

In the literature there is discussion about guides with passive or active support. Passive support is the strong support given by the inherent design of a guide with good backup against the opposite aortic wall or aortocoronary sinus, and stiffness from manufactured material. Additional manipulation is generally not required. Active support is typically achieved by either manipulation of the guide into a configuration conforming the aortic root or subselective intubation with deep engagement of the guide into the coronary vessels [1].

The Judkins Guide The Judkins left (JL) guide is designed for coronary angiography with its primary (90°), secondary (180°), and tertiary (35°) curves fitting the aortic root anatomy so that it can engage the LM ostium without much manipulation. It knows where to go unless thwarted by the operator (in the transfemoral approach). However, in the transradial approach, much more manipulation is required to engage the coronary ostium. As a result of the 90° bend at its tip, the JL does not make perfect coaxial alignment. On many occasions, even when the secondary curve does not sit well on the opposite aortic wall or coronary sinus, diagnostic angiography can still be performed satisfactorily although there is no adequate support for advancement of interventional devices during percutaneous coronary interventions PCI [1].

The Amplatz Guide The Amplatz left (AL) guide is designed with its secondary curve resting against the non-coronary posterior aortic cusp, whereas, in the right Amplatz guide, the secondary curve rests against the left aortic cusp. This guide offers a firm platform for advancement of the device. It is best in the case of a long LM, with downgoing left circumflex artery (LCX) or in superior takeoff. However, as the tip of an AL is pointing slightly downward, there is higher danger of ostial injury causing dissection. So there are short-tip Amplatz guides, which provide the same level of support and a decreasing risk of coronary ostia trauma.

The Multipurpose Guide This guide is straight with a single minor bend at the tip. With the exception of a few cases of high LM takeoff or downward RCA, which can be cannulated well with

this multipurpose guide, it is not routinely used for native coronary PCI.

The Extra Backup Guide The names of these extra backup (EBU) guides vary (Voda or XB, EBU, C, Q, or geometric curve guides) according to manufacturers. The common design is that the long tip forms a fairly straight line with the LM axis or the proximal ostial RCA, so they can provide a better transition angle with less local friction. They also have a long secondary curve that is designed to abut the opposite aortic wall, so that the tip in the coronary artery is not easily displaced and hence provides a very stable platform [2].

GUIDE MANIPULATIONS

Safety Measures

In any situation, the basic safety measures should be applied rigorously when manipulating guides. They are listed in Box 3.1.

Technical Tips

***Advancement through tortuous iliac artery** As a result of excessive tortuosity of the iliac artery, rotations at the proximal end do not transmit similar motion to the distal tip. If not constantly watched, the guide can twist on itself. Simple gentle movement of the guide in and out, often over a very short distance, transmits torque to the tip [3]. In these situations, a 23-cm sheath may help to overcome the problem of iliac tortuosity. A simple technique is by torquing a guide still cannulated inside by a stiff 0.38-inch wire inserted through a Y adapter. Manipulate the tip near the ostium, remove the stiff wire, flush the guide, and then engage the tip to the ostium [3].

****Manipulations to enter the left main ostium** After placing the JL guide into the left sinus, by a slight push-and-pull

BOX 3.1 STANDARD SAFETY TECHNIQUES

- 1 Aspirate the guide vigorously after it is inserted *into the ascending aorta* for any thrombus or atheromatous debris floating into the guide
- 2 Insist on generous bleed back and introduce devices into the Y adapter on flush to avoid air embolism
- 3 Flush frequently to avoid stagnation of blood and thrombus formation inside the guide
- 4 Constantly watch the tip when withdrawing the interventional device from coronary artery and especially in patients with ostial or proximal plaques
- 5 Watch the blood pressure curve for dampening to avoid inadvertent deep engagement of the tip
- 6 During injection, keep the tip of the syringe pointed down so that any air bubbles will float up and are not injected into the coronary system

movement with minimal *counterclockwise torque* the left coronary artery is engaged. If the guide does not select the LM ostium, then a small injection of the coronary sinus could locate the LM ostium. If the LM is above the tip of the guide, pull the guide back and repeat the counterclockwise torque. If the LM is anterior to the tip of the guide, make a small counterclockwise torque to twist the tip anteriorly. If the LM is seen posterior to the tip, make a small clockwise torque to point the tip of the guide posteriorly. This is a general maneuver that could be used with any guide, when the catheter or guide does not enter the artery directly.

***Dampening of arterial pressure** The guide can cause fall of diastolic pressure (ventricularization) or of both systolic and diastolic pressure (dampened pressure). The causes can be due to significant lesion in the ostium, coronary spasm, non-coaxial alignment of the guide, or mismatch between the diameter of the guide and the arterial lumen. When dampening of the aortic pressure is caused by a small coronary artery, the guide can be exchanged to one with side holes, which allows passive blood flow into the distal coronary artery. The drawbacks include sub-optimal opacification of the artery because contrast escapes through side holes and, very rarely, decreased backup support due to weakened guide shaft and kinking of the guide at the side holes, if the guide is excessively manipulated. However, the most common cause of ventricularization is ostial lesion. If the blood pressure is dampened – not due to ostial lesion while a balloon, stent, or wire is already in the coronary artery – then advancing any of these devices further will back out the guide and restore the normal blood pressure tracing.

****Simple coaxial position or active support position?** Coaxial guide alignment with the ostium is more important than an active support or “power position” because it allows the operator to gently advance and retract the guide as needed, ensuring proper stent position and contrast opacification. As almost all interventional devices (stent, cutting balloon, directional, rotational ablative, thrombectomy, distal protection devices, etc.) are rigid and of large profile, a non-coaxial alignment of the guide may lead to injury, endothelial denudation causing thrombus or dissection of the ostium of the coronary vessel. Aggressive guide intubation prevents stent deployment at an aorto-ostial lesion [1].

****How important is the guide external diameter in ostial obstruction?** The external diameter of a guide could cause significant obstruction to the coronary artery flow. This is especially true for 7- and 8-French (Fr) guides if the artery is small or there is plaque at the ostium. It can cause periprocedural ischemia [4] (Figure 3.1).

*****If the guide is too long** In cases of interventions through long saphenous vein graft (SVG) or internal mammary artery (IMA) grafts, care must be taken to ensure that there is sufficient

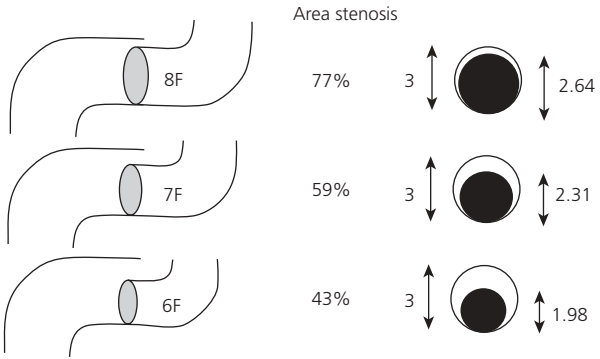


Figure 3.1 Decrease of coronary flow according to the diameter of the guide. (Modified from De Bruyne et al. [4], with permission from Wiley.)

guide length to reach distal sites with extra-long (145 cm) balloon catheters or short guides (80 cm), or the guide can be shortened and capped with a flared, short sheath one size smaller.

Advanced and Exotic Technique: How to shorten a Guide

First cut the proximal end of the guide with a scalpel. While the guide is still engaging the artery with a wire across the lesion, the guide should be clamped by a hemostat to prevent blood loss during the shortening procedure. Care must be taken that the scalpel does not damage the wire. Next, a standard sheath, i.e. 1 Fr size smaller than the guide, is cut with 2 cm of sheath attached to the hub. The newly shortened sheath tip is then "flared" with a vessel dilator that is 1 Fr size larger than the sheath. This is done by inserting the tapered end of the dilator in a retrograde fashion into the sheath tip. Remove the dilator and reinsert it into the shortened sheath in the antegrade fashion, and thread the sheath on the indwelling wire through the dilator. Finally, the flared end of the sheath stub is advanced over the cut end of the guide with a firm friction fit. The hemostatic clamp is removed and the side port is attached to the manifold. The newly assembled system is carefully aspirated through the manifold to assure that no air is trapped within it [5] (Figure 3.2).

During complex intervention, if there is a need for the double-balloon technique, the minimal required lumen diameter is calculated by adding 0.006 inch to the combined diameter of the largest portions of the two balloon catheters. As the lumen size becomes larger due to innovations from manufacturers, the selection of any guide is up to the size of the lumen and its accommodating capacity (Table 3.1). In general, in modern large internal diameter 6-Fr guides (mainly Launcher) it is possible to accommodate most of two 3.5-mm balloons for kissing inflation, or a combination of one 4.0-mm plus one 3.0-mm balloon. In the classic crush technique, a 7-Fr guide is needed whereas only a 6-Fr guide is needed for a step-crush technique. To do a control

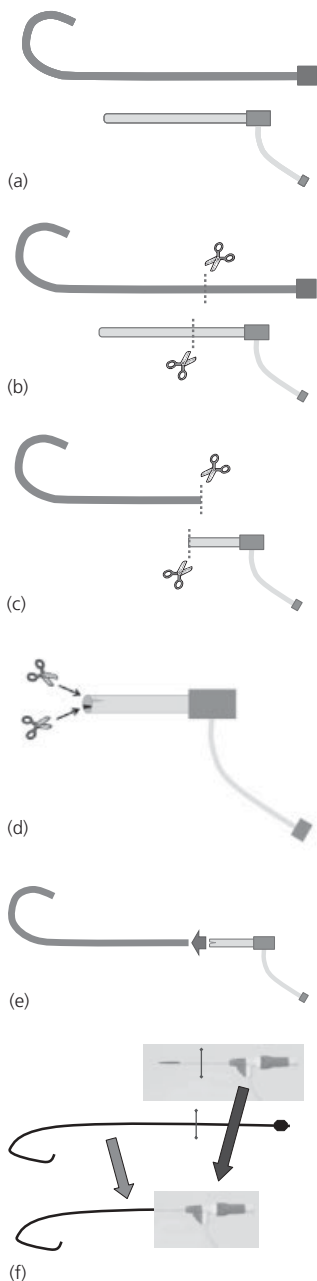


Figure 3.2 How to shorten a guide: (a) There is need of a guide and a sheath (one size smaller); (b,c) Cut the guide at the required length. The sheath is also cut. (d) For easy engagement of the guide into the sheath, the sheath should be nicked by the scissor at two sites, or advance the tip of the dilator in a retrograde fashion to one size larger to enlarge the new distal end of the sheath. (e) The sheath is inserted into the proximal end of the guide. (f) Summary of the process.

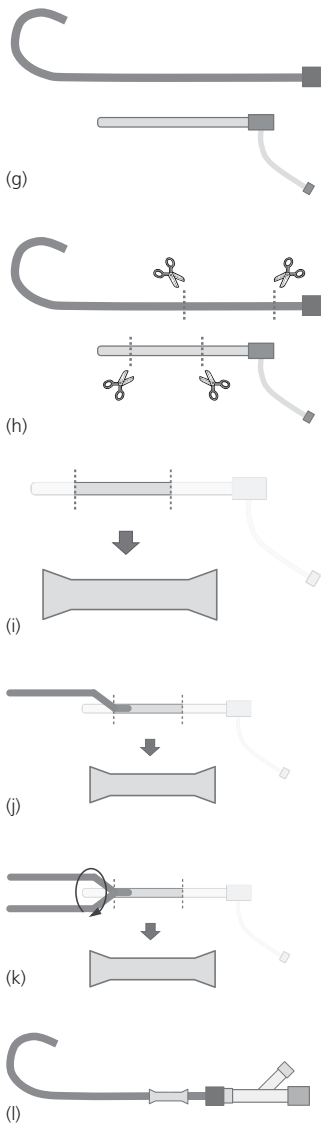


Figure 3.2 (Continued) (g) Use a (1-Fr) “smaller” size sheath compared with the guide (e.g. 5-Fr sheath for 6-Fr guide, 6-Fr sheath for 7-Fr guide). (h) Cut the guide and the sheath. To know the length that we can cut, advance the guide to the coronary ostium and check the extra length of the guide outside the sheath. This length of the distal end of the guide should be shorter than 2 cm. The distal segment of the sheath is tapered so that it should be discarded. (i) Use a dilator one size bigger than the sheath to flare the two ends of the cut segment of the sheath. (j,k) Connect the two segments of the guide carefully and slowly, otherwise the connecting tube can be easily damaged. (l) The new shorter guide is ready and can be connected to Y connector. (Courtesy of Dr Satoru Sumitsuji.)

Table 3.1 Inner lumen size and accommodating capacity

Size (inches)	Accommodating capacity
5 Fr (0.058–0.059)	Balloon angioplasty
5-Fr guide (wide lumen)	Some stent and cutting balloon if <2.5 mm
6 Fr (0.070–0.073)	Standard angioplasty and stenting, AngioJet catheter
6-Fr guide (wide lumen)	Some bifurcation angioplasty (including kissing balloons), IVUS catheters
7 Fr (0.078–0.081)	2.0-mm Rotablator burrs, two rapid-exchange balloon catheters
8 Fr (0.080–0.090)	Two over-the-wire balloon catheters, 2.25 mm Rotablator burrs, directional coronary atherectomy
9 Fr (0.098–0.101)	Maximum Rotablator burr: 2.5 mm

IVUS, intravascular ultrasound.

Table 3.2 The internal diameters of guides

	Vista Brite Tip (inches)	Mach 1 (inches)	Launcher (inches)
5 Fr	0.056	N/A	0.058
6 Fr	0.070	0.070	0.071
7 Fr	0.078	0.081	0.081
8 Fr	0.088	0.089	0.091

angiogram, one of the balloons has to be removed in order to have good opacification of the artery. If two microcatheters are intended for use in chronic total occlusions (CTOs), a 7-Fr guide is necessary. If there is a need for a microcatheter and an intravenous ultrasound (IVUS) catheter, it is obligatory to start with 8-Fr guide. The internal diameters of different guides are listed in Table 3.2.

Technical Tips

****When should a guide with a side hole be used?** When there is ventricularization or dampening of aortic pressure, corrective measures by using a guide with side holes can give false security because the tip of the guide could be located under a plaque, and manipulation or injection of contrast could cause severe dissection. A guide with side holes could be used ideally in PCI of CTOs of the RCA in cases of antegrade collaterals. This generally guarantees antegrade flow even during deep guide intubation, which permits distal opacification during contrast injections, thus avoiding possible ischemia.

Advanced and Exotic Technique: How to make a Sidehole from a Regular Guide?

The diagnostic 0.035-inch wire is inserted into the guide and a 12–14 gauge (G) regular needle is used to puncture a hole 3–5 cm

from the tip. The needle is rotated to form a good hole and material removed from the wall of the guide is carefully discarded.

*****Guides for unusually wide ascending aorta** In extremely enlarged aortas, due to long-standing aortic insufficiency or hypertension, the usual guides do not fit the large size to cannulate the ostium. If the guide has a Judkins shape, the primary curve is prolonged to 7, 8, or 9 cm in length. For the Amplatz catheter, it is similar to the AL-5 or AL-6. However, the radius of curvature is increased so that the tip remains lower. For the guide with the EBU curve, the length of the distal tip is prolonged to fit the extra-wide aortic sinus.

Advanced and Exotic Technique: Shaping the Guide

Stainless steel wires (0.035 inch) are mounted into the desired shapes and kept in sterile conditions. 6-Fr Multipurpose guides are mounted on the preformed wires and heated using an industrial warm air blower. Then the guides are immersed in cold saline and the wire removed. However, it is best accomplished with polyethylene catheters, which are quite rare today [6].

Technical Tips

****How to stabilize a guide with ostial stented lesion?** Often it is difficult to selectively intubate the ostium of a coronary artery with prior stenting when there is in-stent restenosis. The ostial stent could extend into the aortic sinus and has various degrees of in-stent restenosis. Not every guide could engage the ostium; a first wire could therefore be passed into the stent via a lower stent strut and used as a support to lift the guide, making it more coaxial with the stent ostium. A second working wire could be advanced through the central lumen into the distal vessel. The Amplatz-type guides are probably better situated in these cases because, by pushing the guide, its tip would lift up. This allows placement of the tip at the central lumen of the previously implanted stent (this is almost impossible to do with the Judkins guides). By using a wire with a large loop at the tip, the wire could finally enter the main lumen of the stent [7].

****Safety when using a large guide** When using a large diameter guide, there is often a significant step-off/transition between the inner diameter of the guide and the outer diameter of the wire. This transition may act as a wood plane or cheese grater, damaging endothelium and collecting debris as the guide is advanced. A smaller diagnostic catheter within the guide may smooth the transition from wire/diagnostic catheter/guide for advancement (4 Fr within a 6-Fr guide, or 5 Fr within a 7-Fr guide). Once inside the coronary ostium, the diagnostic catheter may then be removed [8].

*****Double guides for complex PCI** If there is a need for two guides, in complex PCI of vessels with a large ostium, two smaller guides can be used. The disadvantages are that there are two punctures and two sets of guides. However, with two guides,

there is more room for contrast injection so the visualization of the coronary arteries during PCI can be sharper (rather than one large guide cramped with many devices inside). With two guides, the movements of interventional (stent, balloon), diagnostic (IVUS), or distal protective (filter) devices can be smoother. If the sheath can be changed to a larger one, two diagnostic catheters can be inserted into one 8-Fr sheath or one guide, and one diagnostic catheter can be inserted into a 9- or 10-Fr sheath without the need for a new puncture [8].

****Guide support** Excellent guide support can significantly facilitate every PCI step, including wiring and balloon or stent delivery, and can be accomplished by (1) using large-diameter (7 or 8Fr) guides, (2) using more supportive shapes (such as Amplatz or EBU), (3) assuring coaxial alignment of the guide with the coronary ostium, and (4) applying deep guide intubation. Deep guide intubation carries the risk of pressure dampening, compromising blood flow and leading to ischemia, and causing coronary dissections.

SELECTION OF GUIDES

Judkins Guide

A Judkins guide is selected according to the width of the aortic root, the location of the ostia to be cannulated, and the orientation of the coronary segment proximal to the target lesion. The segment between the primary and secondary curve of the JL guide should fit the width of ascending aorta: 3.5cm, 4cm, 4.5cm, 5cm, 6cm, etc. The locations of the ostia can be low, high, anterior, or posterior. The ostial or proximal segment can be directed upward, downward, or horizontally. For the average American patient, a 4-cm JL guide is often adequate, when working with the transfemoral approach. A half-size down is necessary for the transradial approach, i.e. JL 3.5cm must be a first choice. For Asian patients, a 3.5cm JL guide usually fits well. In patients with a very superior direction of the left anterior descending artery (LAD) or in those with a narrow aortic root, a smaller size guide with a tip pointed more anteriorly will provide a coaxial position of the tip. In patients with horizontal or wide aortic root (e.g. chronic aortic insufficiency or uncontrolled high blood pressure), a JL guide with long secondary curve (size 5 or 6) will fit the width of the ascending aorta well (Figure 3.3). Once in the left coronary sinus, gentle counterclockwise rotations of the guide will frequently direct the tip anteriorly and enter the LM.

Technical Tips

****Non-coaxial position of a small Judkins guide** If a small JL guide is chosen, with its tip not coaxial to the LM, that tip will point superiorly to the wall. In that position, even though there is no dampening of aortic pressure, an injection of contrast agent in young patients may not cause dissection, but in elderly patients with many unsuspected plaques, it can cause a small localized dissection.

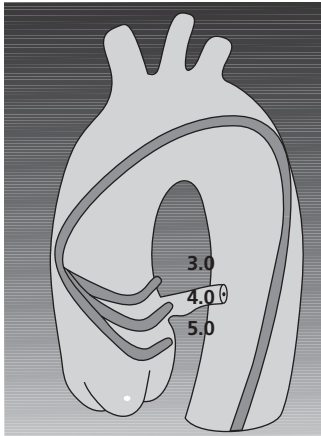


Figure 3.3 The importance of catheter size on coaxial position of the catheter tip against the coronary ostium. The smaller guide tends to curve on itself, whereas larger guides will stay widely opened, prolapsing in the left sinus, below the coronary ostium. Illustrated by Quoc Nguyen.

***Guide that is too large** The JL tip points in a cranial direction, depending on the length between the primary and secondary curves, and how far the heel or secondary curve is advanced into the aortic root. As a guide is advanced down the aortic sinuses, if its tip remains in the vertical axis of the ascending aorta and does not curve upward to reach the left ostium, this catheter is too large. It should be changed for a smaller one (Figure 3.3).

***Guide that is too small** If the JL guide is smaller than needed, or the distance between the primary and secondary curves too short, the guide would be advanced too far into the aortic root. It would double back on itself inside the sinuses of Valsalva (Figure 3.3).

***Engagement of a Judkins right guide** The basic maneuver for cannulation of the RCA is by advancing the guide into the aortic root, then rotating the shaft clockwise while gently withdrawing it, so that its tip can select the RCA ostium. When the RCA arises more anteriorly or above the right cusp, the tip of the Judkins right (JR) guide will not stay coaxial inside the right ostium. The coaxial position can best be appreciated by viewing the tip of the guide as a ring in a head-on position with the 30° right anterior oblique (RAO) view (Figure 3.4 and see Figure 2.4a).

Amplatz Guide

Selection of the proper size for an Amplatz guide is essential. Size 1 is for the smallest aortic root, size 2 for normal, and size 3 for large roots. Attempts to force engagement of a preformed Amplatz guide that does not conform to a particular aorta, aortic root, or aortic sinus only waste time and increase the risk of

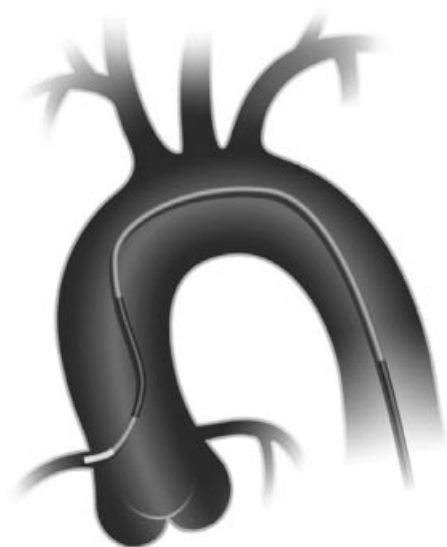

Figure 3.4 The tip of the Judkins right guide can cannulate easily the right coronary artery ostium; however, as the shaft of the Judkins right does not rest on the opposite aortic wall, so the backup force of the Judkins right is low. Illustrated by Quoc Nguyen.

complications. If the tip does not reach the ostium and keeps lying below it, the guide is too small. If the tip lies above the ostium, or the loop cannot be opened, the guide is too large. When the right coronary ostium is very high, the left Amplatz guide may be used to engage the right ostium.

For arteries that lie in the mid-portion of the right sinus or lower, a right Amplatz guide with a much smaller hook should be used. The guide is advanced into the ascending aorta behind the long soft distal segment of the wire, with the tip pointed toward the patient's left until the guide lies on the posterior or non-coronary sinus. The best projection to use is 30° RAO – it clearly defines anterior and posterior directions. Moreover, the projection permits clear verification of coaxial position of the guide. After being flushed well, the guide is then advanced slowly with the tip pointing upward and anteriorly. The guide should be torqued counterclockwise, when the initial position of the tip is anterior, in order to point the tip more anteriorly while being pushed more superiorly. The tip is rotated, and retracted until it engages the LM ostium. If the guide points toward the non-coronary sinus, it must be slightly pushed and turned clockwise to engage the LM and counterclockwise to engage the RCA (Figure 3.5).

Technical Tips

****Optimal position of an Amplatz guide** Once the tip of the Amplatz guide is inside the LM or RCA ostium, the primary and secondary curves of the guide should form a closed loop with



Figure 3.5 The Amplatz left guide for the right coronary artery: With the extra support from the contralateral wall, the Amplatz left provides a sturdy platform for stent/device delivery Illustrated by Quoc Nguyen.

the tip coaxial to the ostial segment. This is the appropriate guide position. If the guide is pulled back, its tip could dip farther into the LM and increase the risk of LM dissection. Under fluoroscopy, while the guide is in a relaxed mode, the undesired position is a more open loop with the tip pointing down the inferior wall of the ostial segment.

***Withdrawal of an Amplatz guide** Amplatz catheters must be carefully disengaged from the coronary artery. A simple withdrawal from the vessel in a manner similar to a Judkins catheter can cause the tip to advance further into the vessel and cause dissection. To disengage the Amplatz catheter, first advance the guide slightly under fluoroscopy to prolapse the tip out of the ostium, then rotate the guide so that its tip is moved away from the ostium before pulling the guide – this is called the “push-and-turn” maneuver.

****Withdrawal of an Amplatz guide after balloon inflation** After angioplasty or deployment of a stent, the balloon is deflated. If the latter is pulled out, the tip of the Amplatz (or any) guide would have the tendency to be sucked in deeper. This is a situation to avoid. The first best technique is to pull the balloon out while simultaneously pushing the guide in to prolapse it out. The procedure has to be done under fluoroscopy to monitor the calculated movement of the guide tip. If the above maneuver fails, the second technique can be used. The deflated balloon should be advanced slowly to back out the guide. As the guide

stops backing out, it is withdrawn slowly, while watching the tip in order to avoid scratching the inferior aspect of the ostial segment. Once it is sensed that the tip points unsafely down the ostial segment, the balloon is advanced again to lift the tip and back out of the guide farther. This maneuver is repeated until the tip of the guide is totally out of the ostium. Then the guide and the interventional device can be retracted as needed. The tip is less likely to cause damage if retracted over the shaft of a device catheter.

Multipurpose Guide

Most operators start by placing the tip of the multipurpose (MP) guide at the posterior sinus or non-coronary cusp in the 30° RAO position. The guide is advanced with the tip pointed toward the spine until the guide begins to buckle (or **above** the level of the target ostium). When a loop is formed, slight clockwise rotation flips the tip to the left cusp. Withdrawal of the guide at the moment of that flip is usually required to maintain the correct position. If the tip does not enter the left coronary artery directly, advancing the tip by gentle counterclockwise rotation will cannulate the LM ostium.

The RCA is approached in the 45° left anterior oblique (LAO) position. From the left cusp, the tip is directed anteriorly and to the patient's right (**above** the level of the RCA ostium). Then the guide is rotated clockwise and slightly withdrawn to engage the right ostium. The MP guide is also very useful in situations where the aorta is dilated and it is not possible to obtain a stable position with other catheters. A simple push and pull could regulate the length of catheter curve.

How to position the distal tip The key is how to make the secondary curve long enough to cover the aortic sinus then position the tip higher than the target ostium, so when the guide is pulled back, the tip will descend and enter the ostium.

Extra Backup Guide

Most operators advocate the advancement of the tip of the guide with a wire protruding into the ascending aorta, at the aortic valve sinus, below the coronary ostium. Then the wire is removed. The guide is flushed, advanced, or withdrawn gently while torquing clockwise to point it up; after this it can be torqued clockwise to move the tip posteriorly or counterclockwise to move the tip anteriorly, similar to an Amplatz guide, until it enters the LM or RCA (Figure 3.6). The EBU is very useful for RCA when extra support is needed and in cases of shepherd's crook.

Catheter for Left Main Lesions

A significant lesion in the LM can be suspected when there is: (1) typical angina at low level of activity or exercise testing; (2) typical angina at rest; (3) typical angina after a large meal; (4) significant diffuse ST-T segment depression at low level of exercise testing; and (5) no increase or decrease of blood pressure on exercise stress testing.



Figure 3.6 The extra backup (EBU) guide for the left system: A long segment of the shaft of the EBU guide rests steadily on the contralateral aortic wall so that the EBU guide provides the strongest support for device advancement. The tip of the EBU guide has the best coaxial orientation. This EBU guide is indicated when deep intubation is needed such as in long left main and when the left circumflex artery forms a 90° angle with the left main. Illustrated by Quoc Nguyen.

Technical Tips

***Catheter position in suspected LM** Once an LM lesion is suspected, a short-tip JL catheter should be chosen in the AP position. The catheter is positioned below the LM ostium, beneath the cusp, where an injection of 10ml contrast may opacify the cusp and give a general assessment of the LM segment. The tip of the catheter is then manipulated to slowly engage the LM ostium, avoiding the uncontrolled jump into the artery due to its preshaped configuration. If there is no dampening or ventricularization of the aortic pressure, then a small amount, 2–3ml, of contrast is injected in the AP, shallow RAO, or shallow LAO with caudal tilt (spider view) view to detect the severity of the LM.

****How many views do you need after detecting an LM lesion?** Once an LM lesion is confirmed, only two more views are needed: The AP cranial and the AP caudal. These two views give the full information of the LAD and LCX needed for bypass surgery. If LM PCI is contemplated then the LAD and LCX need to be visualized in more views, especially the ostial segment of both branches.

****Dampening pressure** Dampening of the aortic pressure can be due to an LM lesion and, more frequently, to mismatch between the large-size catheter and a small coronary ostium.

Gradual repositioning and withdrawal of the catheter may eliminate pressure dampening. An injection of contrast agent in case of dampening of pressure, even a small amount, can further lift the plaque and really cause a dissection that can become disastrous.

Guide for LAD Lesions

To reach an LAD lesion, the guide has to engage the LM ostium. The LM is located in the superior and anterior position, so any guide with a tip pointing superiorly, such as the JL guide, would provide a stable and coaxial alignment. In patients with a very superior direction of the LM, or in those with narrow aortic root, a smaller size guide will point the tip more anteriorly or the EBU guide would help to provide stronger backup. In the case of high coronary takeoff, an MP or an Amplatz guide would easily cannulate the LM ostium. In patients with horizontal or wide aortic root, a Judkins guide with long secondary curve (size 5 or 6), or a left Amplatz-type guide may be needed.

Guide for LCX Lesions

Cannulation of the LM for PCI in the LCX can usually be achieved with the JL guide if the LM is short. In the case of high coronary takeoff, use a MP or an Amplatz guide. In patients with horizontal or wide aortic root, a Judkins guide with long secondary curve (size 5 or 6) or a left Amplatz-type guide may be needed. As the tip of the Judkins guide points superiorly, better axial support for LCX lesions can be obtained using an Amplatz or EBU guide.

Technical Tips

***Pointing toward the LCX** In the case of short LM or separate ostium of the LCX, if the tip of the first Judkins guide does not point toward the LCX, slightly withdraw the guide and turn clockwise. The tip will point posteriorly, toward the LCX. If this maneuver does not achieve satisfactory results, change to a larger size or to an Amplatz-type guide with a tip pointing down. If the LM is very short, a JL is good. A size 1.5 Amplatz guide will allow acceptable cannulation without over-engagement. However, watch for dissection caused by a too-engaging tip (Box 3.2).

****Selection of guides for PCI** If the LM is short and there is no acute angle at the bifurcation with the LCX, a JL guide may be the first best choice. If the LM is long and the angle between the LM and LCX is acute, an EBU guide should be chosen. The

BOX 3.2 DIRECTION OF TORQUING DURING DEEP-SEATING MANEUVER

- | | | |
|----------|----------------|---------------------------|
| 1 | Toward the LAD | counterclockwise rotation |
| 2 | Toward the LCX | clockwise rotation |
| 3 | In the RCA | clockwise rotation |

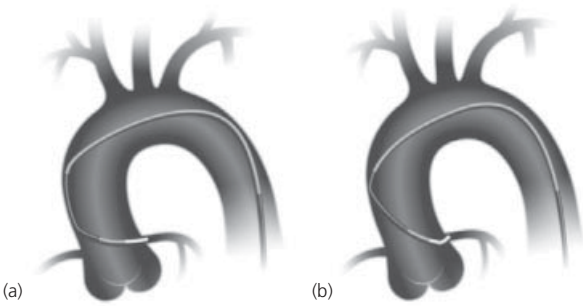


Figure 3.7 Comparison between (a) the extra backup (EBU) and (b) the Judkins curves. A long segment of the shaft of the EBU guide rests against the contralateral aortic wall whereas only a short segment of the Judkins left does so. This explains the higher backup force of the EBU guide. Illustrated by Quoc Nguyen.

rationale for this choice is that the tip of an EBU guide is very close to the ostium of the LCX, so the acuity of the LM and LCX angle is nullified, making the transition between the LM and LCX smoother (Figure 3.7).

*****Rotational Amplatz maneuver** To enhance the support role of a JL guide (active support or “power position”), if the length of the guide is appropriate, with the tip hooked in the LM, the JL guide is gently pushed down until the whole curve sits well in the left sinus, while torqued gently clockwise so that the tip still points to the LM and the whole guide simulates the position achieved by an Amplatz guide. The guide should be torqued over the shaft of an interventional device (stent, balloon, IVUS, etc.). This is called a rotational Amplatz maneuver. The operator should not feel any resistance when attempting this maneuver. After the interventional device is advanced and positioned in place, the guide is withdrawn from the artery by reversing the earlier torquing energy: Gentle clockwise rotation so the guide can untwist itself while pulling the guide back slowly.

This technique should be performed with a soft-tip guide in a coronary artery large enough to accommodate the guide. There should be no disease at the ostium, or proximal or distal segment of the LM. It is important that the size of the Judkins guide in most of the cases must be half a size larger than that necessary to engage the artery, e.g. if a JL 3.5 guide is good for engagement, it is in most cases not good enough for the Amplatz maneuver; a JL 4.0 guide is much better. However, an alternative way is to exchange the J L guide for an Amplatz or EBU guide that can provide stronger (passive) support, less friction at the LM–LCX bifurcation, and safer advancement of interventional hardware without excessive manipulation, resulting in unintended or unexpected prolapse of the tip of the guide outside the LM [10].

Guide for RCA Lesions

The RCA usually arises anterolaterally from the right coronary cusp. In the large majority of cases, its proximal segment has a horizontal configuration and forms a 90° angle with lateral border of the aorta. In the case of an acutely angled takeoff, the “shepherd’s crook”, the angle is smaller than 90°. When the RCA is directed caudally, the downward angle is more than 90°. However, there are other minor variations, including the slightly anteriorly or posteriorly placed ostium, or the one with anomalous origins that can make cannulation or alignment of the guide difficult.

Technical Tips

****Selection of guides for horizontal takeoff angle** In most cases of RCA with horizontal takeoff, a JR 4 guide can easily engage the ostium. When a JR guide fails to cannulate the right ostium, a right Amplatz guide would be the next option. If this fails, a left Amplatz guide with backup from the opposite wall of the aorta will usually achieve cannulation of the ostium and provide the required backup.

****Selection of guides for superiorly oriented takeoff angle** When the shepherd’s crook or a markedly superior orientation of the RCA is encountered, guides with the tip pointing up are necessary. The JR guide, which is effective in diagnostic angiography, may not provide sufficient backup; therefore the AL guide is usually selected. Other guides with a superiorly directed tip, such as the hockey stick, the left saphenous venous bypass, the IMA, or the EBU guides can cannulate the vessel, although they offer poor backup support. These preshaped guides may eliminate the need for extensive torquing and are particularly useful in elderly patients or in patients with very tortuous iliac arteries, which sometimes make guide manipulation very difficult.

****Selection of guides for inferiorly oriented takeoff angle** In this caudal orientation of the proximal segment of the RCA, aggressive engagement of the tip from a regular JR tip can abut the lateral wall and cause dissection. The guides with inferiorly directed tips, such as the right saphenous venous bypass, MP, and Amplatz guides, may achieve more effective coaxial alignment with the proximal vessel segment.

****Avoiding selective entry of the conus branch** If the guide keeps entering the conus artery, do one of two things: (1) Change the guide for a larger one or (2) approach the RCA from a posterior direction – position the guide above the sinus, rotate the guide counterclockwise to enter the main RCA first.

****Deep-seating a RCA guide** In a non-coaxial situation, backup support will not be adequate for advancement of interventional devices. Thus, the guide should be better aligned by additional clockwise rotation to allow the tip to engage deeper into the ostium. This maneuver is performed in the LAO view.

When the interventional device is advanced into the coronary artery by the right hand, additional pressure should be put on the guide by the left hand placed firmly on the patient's thigh, near the femoral sheath so that the guide does not back out. While the device catheter is advanced, the assistant should pull the wire back slowly to decrease friction inside the device catheter, thus facilitating its advancement. If the guide needs to be deep-seated, then it is advanced over an interventional device (stent, balloon catheter, etc.) while applying clockwise torque. Once the guide is deep-seated, the interventional device is advanced and positioned. After achieving the position needed, the guide is withdrawn with gentle counterclockwise rotation to outside the coronary ostium. This procedure should be attempted only if the artery is large enough to accommodate the guide, there is no ostial or proximal lesion, and the guide tip is soft.

*****Rotational Amplatz maneuver for the RCA** To enhance the support role of a Judkins guide (active support or "power position"), the guide is torqued counterclockwise, and simultaneously pushed down gently to make a loop in the coronary sinus in such a manner that it takes a 90° bend on its shaft. The original secondary curve is hence obliterated, and in fact displaced proximally to obtain direct support from the opposite aortic valve. This maneuver is distinct from deep-seating of the guide, where no support is derived from the opposite aortic wall. This can be done with small and soft guide (6 Fr). If the guide is stiff or a smaller curve size, it will tend to prolapse into the ventricle with the wire pulled back into the aorta. Such a catastrophe can be avoided by carefully monitoring the shape and position of the guide as the maneuver is carried out. Having rotated the guide in a counterclockwise direction while advancing it, it is essential to have the distal part of the guide on a plane parallel to the aortic valve. If the catheter moves downward, toward the aortic valve, further advancement will result in prolapse of the guide into the ventricle. At that point, the guide must be gently pulled back and rotated further counterclockwise before its advancement. If prolapse tends to recur, this maneuver should be abandoned [10]. It is also very important to avoid excessive rotation that may lead to kinking of the guide and impede and/or dislodge stent passage. This maneuver is also not useful when a JR guide cannot engage a RCA because of an ostial lesion. However, an Amplatz or EBU guide could provide the same support without excessive manipulation of the guide and unexpected complications.

***Why do active support maneuvers work?** In general, clockwise rotation leads to deep engagement of the guide and counterclockwise leads to "amplatzing" (both for left and right coronary arteries). The reason is that both left and right sinuses of Valsalva limit free movement of the guide shaft when turned clockwise, and rotation is transmitted linearly, leading to deep insertion into the artery. In reverse, with counterclockwise rotation, because there is enough space from the non-coronary sinus,

it is possible for the shaft to torque inside the non-coronary sinus and obtain support from the contralateral aortic wall.

Guide for Saphenous Vein Graft

The selection and manipulation of guides for saphenous vein graft (SVG) and internal mammary grafts are discussed in detail in Chapter 13.

CATHETERS FOR AORTIC ANEURYSM AND DISSECTIONS

When performing procedures in patients with an aneurysm in the ascending aorta, the technical problems could be loss of catheter control or inadequate catheter length to reach the coronary arteries. In the case of aortic dissection, the arterial entry route chosen may not allow access to the true aortic lumen. Other risks include extending a dissection plane by advancement of the catheter or wire into the false lumen, perforation of the aorta by manipulation or injection in a false lumen, or displacement of thrombotic material from an aneurysm [11]. For these reasons, careful discussion of the goals of angiography should be carried out with the surgeon. The role of aortic angiography is to visualize the origin and flow into the coronary arteries. Many surgeons do not require extensive angiography when multislice computed tomography (MSCT) or magnetic resonance angiography (MRA) can confirm **better** the size and the extent of the dissection in the aortic arch, and the need for angiography can be avoided.

Technical Tips

****Simple maneuver to determine supra-aortic vessel involvement** When planning to perform angiography for a patient with a suspected ascending aortic dissection, the difference in blood pressure between the two arms will pinpoint the involvement of the supra-aortic arch vessel. If the blood pressure in the right arm is higher than that in the left arm, there is a possibility of the dissection involving the left subclavian artery without involving (or distal to) the innominate artery, so the femoral, right radial, or brachial approach is preferable.

****Which approach is BEST and SAFE for aortic dissection? Radial or femoral?** In cases of aneurysm or dissection limited to the thoraco-abdominal aorta, the radial or brachial approach is preferred. When the CT scan shows involvement of the great vessels or carotids, the radial or brachial approach should be avoided. When there is involvement of lower extremities, access from the involved limb is avoided. When extensive ascending and thoraco-abdominal aneurysmal disease is present, the femoral approach is chosen because of the greater ease of catheter exchange and manipulation [11].

****Is the catheter in the true lumen?** In patients with aortic dissection requiring ascending aortography, at first an attempt is made to enter the left ventricle directly with a pigtail catheter.

After a pressure measurement is taken, the catheter is pulled back and aortography is performed. In this way, one can be assured of being in the true aortic lumen. It is risky to attempt to cross the aortic valve against resistance. A straight-type catheter with a blunt tip such as the Sones or the MP should be used cautiously in known or suspected aortic dissection due to the possibility of advancing it into the false lumen [11]. As most of the dissection occurs in the lateral wall of the aorta, the pigtail catheter can be positioned in the true lumen by advancing, while hugging the medial aspect of the aortic arch in a shallow AP view. In the true lumen, selective cannulation of the coronary artery is possible as is direct entry into the LV.

****Ascending aortogram** An ascending aortogram in the LAO projection is obtained with 45–60 ml contrast with a flow rate of 15–20 ml/s. The aortogram is frequently helpful in defining the shape and size of the aorta, showing the position and orientation of the coronary ostia, and in choosing appropriate coronary catheters. Injection is never made if the aortic pressure is dampened or there is no brisk blood return through the catheter. If the test injection showed delayed washout or swirling of contrast, it is assumed that the catheter is in the false lumen. It is withdrawn and redirected into the true lumen with a 0.035-inch high-torque floppy wire [11].

****Engagement of the coronary catheter** When the aortic root is horizontal, the JL-6 catheter is often successful in cannulating the LM. Most often it has to be “pulled into” the LM by a combination of advancement of the catheter below the ostium with simultaneous retraction of the wire, which is curled up into the left sinus. Due to frequent prolapse of the catheter, this maneuver often needs to be repeated many times before successful engagement is achieved. Thus a 0.038-inch wire is inserted through the Y adapter and left ready in the catheter, so that the above maneuver can be repeated quickly if needed. When the aortic root is vertical, the AL-4 is more frequently successful in engaging the LM. The catheter is engaged by curling the wire well up the left sinus and tracking the guide up just below the LM. The wire is then retracted and the guide is gently advanced into the LM [11]. The engagement of the RCA is frequently problematic because its origin is often distorted. Usually it is displaced low in the floor of the right sinus of Valsalva (particularly in a horizontal root) but its origin may occasionally be abnormally high. In many cases, the dissecting plane begins above the RCA. Therefore, the aortic diameter may be normal at the level of the RCA that is usually easily engaged with the standard JR-4 or -5 catheter [11]. In contrast to the patient with an aneurysm, the aorta diameter in dissection may be narrower due to systolic compression of the true lumen by the hematoma. One particular problem is a lack of support from the dissecting aortic wall to the Judkins catheter. The Amplatz catheters require support from the aortic valve cups for manipulation and, due to the weakening of

the aortic apparatus by dissection, the catheters are more difficult to use, prolapsing frequently into the left ventricle [11].

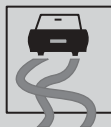GUIDES FOR CORONARY ANOMALIES

Regardless of the rarity, an experienced interventionalist should be aware of all variations of coronary anomalies and systematically search in other aortic sinuses when the vessel in question does not arise from its usual location. For PCI, the location of the ostium of the anomalous artery and the geometry of the proximal segment should be the prime determinants dictating selection of a specific guide. An RCA with a long horizontal segment in the LAO view may appear to have an angle of proximal vessel orientation favorable for use of a Judkins curve, but the long segment usually represents an ectopic origin, appreciated more readily in the RAO projection. Coaxial engagement of these arteries may be more difficult and require considerable manipulations. To cannulate the anomalous artery from the right sinus, the best guides are the left, right Amplatz and MP guides. For the artery originating from the left sinus, the best guides are the larger JL, AL, and MP guides. In some very unusual anomalies, "trial-and-error" guide selection or reshaping guides may be necessary [12]. Approach from the radial artery may offer a better chance of success.

CAVEAT

Anatomic anomalies at the ostial segment

Not every anomaly has a wide ostium that the tip of the guide can hook onto, or a narrowing at the opening that needs to be stented. An anomalous RCA from the left sinus or a LM from the right sinus can leave the aorta in oblique fashion, so the ostium has a slit-like configuration formed by flaps of aortic and coronary tissues. During exercise, the aorta can expand its part of the flap, narrowing farther the slit-like opening and causing ischemia [13]. It is generally advisable to start before intervention with aortography in LAO and RAO projections to obtain a clear view of ostial positioning, which saves time and decreases risks of unnecessary maneuvering for cannulation.



Technical Tips

*****Guides for right aortic arch** In patients with right aortic arch, dextrocardia, or corrected transposition of situs inversus, a left coronary catheter may be used to cannulate any artery originating from the right aortic sinus. A right coronary catheter will be used for an artery originating from the left sinus. The catheter is torqued in a counterclockwise fashion rather than the usual clockwise one, and is based on mirror-image angles.

*****Guides for anomalous coronary arteries arising above the sinotubular ridge in the ascending aorta** Patients can have coronary arteries arising above the sinotubular ridge. In this situation, the best guide would be an Amplatz-type guide. A MP guide could help if the ostium is not situated too high [14].

*****Guides for anomalous coronary arteries arising from the left sinus** When the RCA arises from the left cusp, usually it is anterior and cephalad to the LM, so, in principle, it can also be cannulated by a JL guide with the secondary curve one size larger than the one used for the patient's LM. This larger Judkins guide should be pushed deep in the left sinus of Valsalva, while making a small counterclockwise rotation, causing the tip to make an anterior and cephalad-pointing U-turn. The EBU guide is also useful because of its preshaped configuration. The larger curve will prevent the guide engaging the patient's LM [15]. Using the same principle, an AL-2 guide with a tip pointed more anteriorly would help to cannulate the artery, by being torqued counterclockwise while being pushed gently [15]. Others reported the use of a JL-4 guide with an eccentric tip to cannulate the anomalous RCA from the left sinus. The primary curve of the type G catheter is out of plane with the remainder of the catheter in an anterior orientation, so avoiding the normal left coronary ostium [15].

*****Guides for anomalous coronary arteries arising from the right sinus** This artery usually arises from the very proximal RCA or a separate orifice in the right cusp. The most frequent variant is LCX arising from the RCA or right sinus of Valsalva. It appears anteriorly and inferiorly. An AL guide is well suited for cannulating this vessel and will do so selectively rather than entering the RCA. When the JR guide could not provide a stable platform to advance the hardware, an Amplatz right guide can cannulate the ostium easily [16]. When the origin of the artery is in the base of the aortic sinus, deep engagement of the guide is key. Contralateral wall support is not always feasible due to the downward orientation of the ostium. An MP guide or AL-1 or 0.75 should be used in this situation. These "anteriorly displaced RCAs" could not be visualized with conventional right coronary catheters and were selectively imaged with an AL 0.75–1.0 guide in 80% of the cases and by an Amplatz right 2 guide in 20% of the cases. [17]

*****Guide for coronary arteries arising from the posterior sinus** The most common anomaly is an anomalous LCX originating from the right sinus. A JR-4 guide can cannulate the artery by torquing the guide clockwise so that its tip will point more posteriorly, working in an RAO projection. An AL guide can be cannulated too and its tip should be oriented posteriorly by torquing clockwise in order to successfully engage the ostium of the anomalous LCX [17].

Table 3.3 Guides for missing arteries

Missing arteries	Guide selection
Missing LCX due to very short LM	Use large guide with short tip and turn clockwise to point the tip more posteriorly
Missing LCX originated from RCA	Guide with short tip Amplatz left pointing anterosuperior to the RCA ostium
No RCA in right sinus	Judkins left one side larger, pointing anterosuperior to the LM ostium
No LM	In right sinus Amplatz left pointing anterosuperior to the RCA ostium

****Guide for missing arteries** When there is missing LCX or RCA, possible abnormal locations are suggested in Table 3.3. A few guidelines with guide selection may then help to pinpoint where the missing arteries can be and where their ostia can be engaged (see Table 3.1). A good starting point is to do aortography in the LAO and RAO, which saves time, fluoroscopy, and contrast.

*****Guides of the ectopic RCA from the anterior half of the left sinus** In all these cases the ectopic RCA originated from the anterior half of the left cusp, either anterior or superior to the LMCA. A wide variety of diagnostic and interventional catheters was used to selectively image these arteries, including MP 1–2 (50%), EBU (37.5%), and AL 2–3 (12.5%).

Step 1 After failing to selectively image the RCA with conventional RCA diagnostic catheters, perform a right sinus injection at the LAO 30–40° projection (or biplane imaging when available). This injection should delineate the RCAs originating from the posterior two-thirds of the right sinus, and will provide information about takeoff and orientation of these RCAs. If the RCA cannot be visualized at all, proceed to Stage 2.

Step 2 Use an AL-0.75 to -1.0 (depending on the size of the aorta), and in the RAO 30–40° projection, with the catheter pointing anteriorly and slightly caudal, attempt to image the RCA originating from the anterior third of the right coronary sinus (also known as an “anteriorly displaced RCA”). If subselective injections fail to image the RCA at this location, it is very likely that the RCA originates from the anterior half of the left sinus.

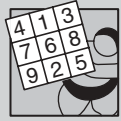
Step 3 Using the same AL-1 in the AP view, locate the LM. Turn the catheter counterclockwise in order to twist the tip anteriorly and then push forward to advance the tip higher. The ostium of the RCA is suspected to be anterior and cephalad to the LM.

Step 4 If the RCA cannot be seen, repeat the injection above the left coronary ostium to image the ectopic RCA with a higher left sinus takeoff [16].

MANIPULATION OF GUIDE DURING PCI

STRATEGIC MAPPING

Factors Which Constitute the Strength of a Guide



In order to advance interventional devices to the intended position, a guide needs to give enough backup support. Three factors were found to be associated with increased backup of a guide.

- The first factor is the size of the guide, i.e. diameter (larger is stronger, if the same material in the construction of the shaft)
- The second factor is the angle between the wall of the ascending aorta and the segment of the guide spanning the aortic root. This segment is the long tip of the EBU, MP, or Amplatz guide, or the segment between the primary and secondary curve in the JL guide. The maximal angle is 90° (perpendicular to the opposite wall of the ascending aorta). In a relaxed position, the backup force of a JL is weak. However, as the guide is deep-seated, this angle changes and becomes bigger so that the backup force is better
- The third factor is the aortic wall area on which the secondary curve of the guide rests (the larger the area the better (up to 25 cm).

For all three criteria, the EBU guide fares the best. The Amplatz design shows a very long line resting on the opposite wall of the ascending aorta, and this is the mechanism of strong backup of the AL. In summary, the guide size, the angle between the guide and the ascending aorta, as well as the contact area with the ascending aortic wall with the guide have been found to be associated with increased backup force.

Technical Tips

*****Difficult engagement of a guide but easy engagement by a diagnostic catheter** Sometimes a diagnostic catheter can engage an artery easily but it is very difficult with an interventional guide. After the diagnostic catheter engages the artery, a long 0.014-inch wire is advanced into the artery and then the wire is replaced with the guide. In a similar situation, when there is difficulty in deeply engaging a guide, a 0.014-inch wire is advanced into the artery as a rail for tracking the guide. The wire with gradual tip transition should be selected to avoid prolapsing at its point of transition and disengagement of the guide.

****Deep-seating maneuver** To provide further support for an interventional device to cross a tight lesion, some operators

suggest deeply engaging the tip of the guide in the ostium. For the RCA, the interventional device is retracted as the guide is advanced over the wire and gently rotated clockwise. For the LAD, counterclockwise rotation while advancing the guide provides the best deep-seating. To point the guide toward the LCX, clockwise rotation is suggested (Box 3.2).

****Stabilizing a guide with the “buddy” wire technique** When working with an unstable guide, after unsuccessful advancement of interventional hardware, a second angioplasty wire can be advanced parallel to the first one. It straightens the tortuous vessel and provides better support for device tracking. A second wire in a side branch can be very useful in “anchoring” the guide (e.g. second wire in the LCX when dilating an LAD lesion). This provides for better “backup” and allows retraction of the guide when necessary, without loss of position. It also prevents the guide from being “sucked in” beyond the LM when pulling back high-profile, poorly rewrapped, balloon catheters after stent deployment or post-stent dilation. However, a second wire in a non-diseased branch would cause unnecessary denudation of endothelium in that vessel.

If one extra wire does not help maybe two or three buddy wires may help to advance any devices.

*****Stabilizing a guide with anchoring balloon** When working with an unstable guide, a second small balloon (1.5–2.5 mm diameter) can be inserted in a small proximal branch and inflated at 2–5 atm, in order to anchor the guide (without letting the guide back out).

*****Stabilizing a guide with a long sheath** When working with an unstable guide, a long sheath can stiffen and support the guide, depending on how close it is to the tip of the guide. The closer it is, the more supportive the system becomes. At first, the sheath tip is positioned high in the ascending aorta. If further backup is required, the sheath can be advanced further. As the sheath advances over the guide, it straightens the secondary and tertiary curves of the latter, causing the tip of the guide to move forward. Therefore, the guides with relatively simple curves (Amplatz, MP, EBU) are probably safer and better suited for this technique. To avoid proximal coronary dissection, instead of fixing the guide in place as the sheath is advanced, a gentle reverse traction on it is advised, so that the guide tip does not move forward. The operator should watch the guide tip continuously on fluoroscopy during this maneuver, and ensure coaxiality of the guide in two orthogonal views. Also, disengaging the guide from the coronary ostium should be performed only after the sheath is retrieved away from it, probably to the descending aorta, with the guide fixed in place. After PCI, it is possible that, by just pulling the sheath away from the ostium, the guide will disengage because of reconstitution of its curves. A larger-diameter sheath can be used if even more support is deemed necessary. The sheath size can be selected depending on the amount of support needed

(larger Fr size will give more support) and the height of the patient (taller patients will require longer sheaths) [8].

*****How to extend the tip of a guide** In an extremely enlarged aorta, the tip of a guide could be extended with the help of a catheter. First, a coronary guide with a large bend, usually the AL guide is advanced into the ascending aorta. A 6-Fr size is sufficient because the inner lumen is 0.070 inch (1.78 mm). Inside this guide, a longer (125 cm) 5-Fr MP catheter (internal diameter 0.058 inch) is advanced. The 5-Fr catheter is longer than the guide and can serve as an extended tip to the 6-Fr guide. The inner catheter can be rotated independently of the guide and thus it is possible to adjust the orientation of the system and intubate the coronary arteries deeply [8].

*****Strengthening the guide with another guide or catheter** To stabilize a guide, a 5-Fr Heartrail straight catheter with 120 cm length can be inserted inside a 6-Fr guide (100 cm long). The 5-Fr Heartrail catheter has a very soft 13-cm end-portion. This soft end-portion can easily negotiate the tortuous coronary artery with the minimal damage, and then it can be inserted more deeply into the artery. The inner lumen of the 5-Fr Heartrail catheter is 0.059 inch in diameter; it can accept normal balloons or stent delivery systems <4.0 mm in diameter. The inner lumen of the outer 6-Fr catheter needs to be more than 0.071 inch in diameter to accommodate the 5-Fr Heartrail catheter [18].

TECHNIQUE Five-in-six guide strengthening When a lesion could not be crossed by a balloon or a stent in the regular 6-Fr system, the five-in-six system could be tried ("mother in child"). First, the balloon or the stent is removed from the 6-Fr guide, while the wire and the 6-Fr guide remain in place. Next, a 5-Fr guide is inserted over the wire inside the 6-Fr guide. At this point, the 5-Fr guide should not protrude out of the tip of the 6-Fr guide. Finally, the Y connector is connected to the 5-Fr guide and PCI could be restarted. Before the 5-Fr guide is advanced into the target artery, a balloon catheter is advanced near the target lesion in the artery. Keeping a slight tension on the balloon catheter, the 5-Fr guide is pushed out slowly in order to avoid possible injury to the coronary artery by the tip of the 5-Fr guide [18] (Figure 3.8).

Equipment The GuideLiner is a flexible catheter that is 1 Fr size smaller than the guide and is delivered through the guide. It has a rapid-exchange design and is advanced over standard-length wires, with a monorail length of 20 cm and a working length of 135 cm. The GuideLiner extends beyond the guide and is seated deeply in the coronary artery, allowing support and coaxial alignment for advancement of wires, balloons, and stents during coronary interventions. It also allows coaxial alignment when an unusual coronary ostium takeoff prevents appropriate guide engagement. Although the extension is 20 cm long, a maximum

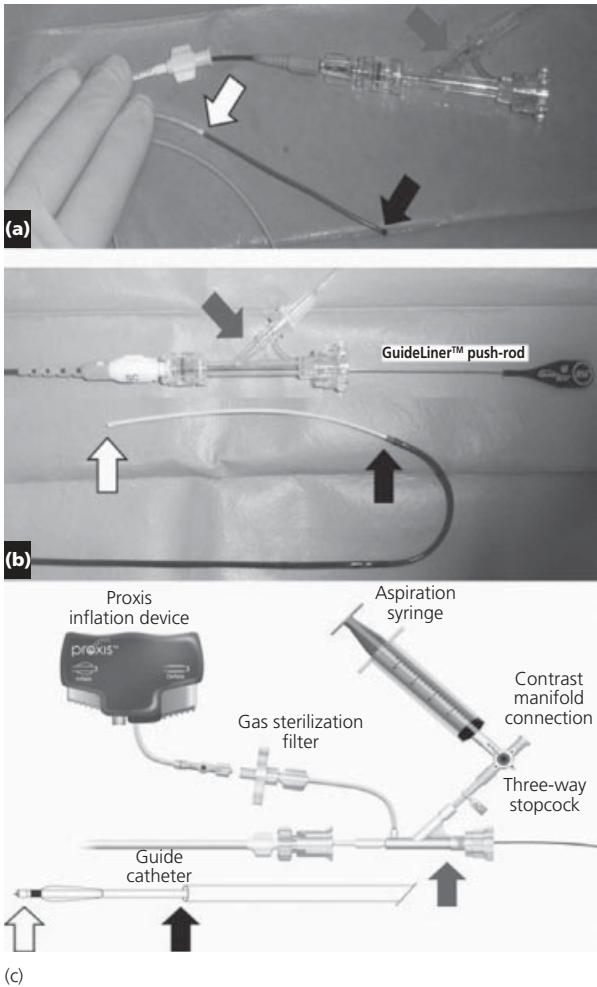


Figure 3.8 Illustrations of (a) the Heartrail, (b) the GuideLiner, and (c) the Proxis guide catheter extension systems. As depicted, the Heartrail and Proxis catheters incorporate an over-the-wire exchange system, whereas the GuideLiner system involves a monorail rapid exchange system by using a push-rod to introduce the device through the mother guide. The black arrow represents position of guide catheter tip and the white arrow the distal tip of extension catheter. The light color arrow represents the standard Y connector used with both (a) Heartrail and (b) GuideLiner extension catheters and adapted Y connector already attached to (c) the Proxis device.

extension of only 10cm beyond the guide tip is recommended and has a silicone coating for lubricity. The GuideLiner is available in three sizes: 6 Fr (5-Fr GuideLiner that goes inside a 6-Fr guide, therefore called “5-in-6” system), 7 Fr, and 8 Fr. Most devices and coronary stents will fit through a 5-in-6 system. In light of its size,

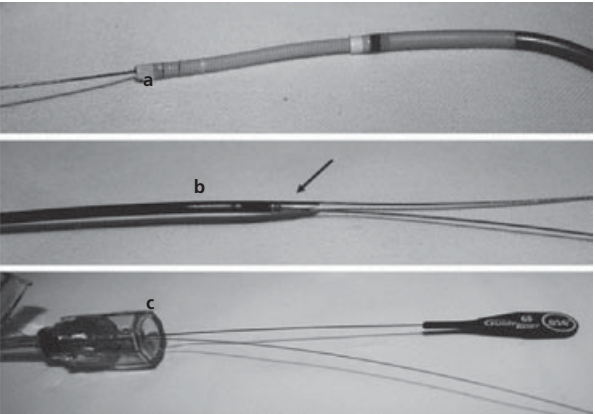


Figure 3.9 The 5-Fr GuideLiner catheter: (a) GuideLiner flexible 20-cm distal segment, the guide extension, made of an inner polytetrafluoroethylene liner, a middle stainless steel coil, providing maximum flexibility while retaining radial strength, and an outer polyether block amide (Pebax) polymer extrusion – the same material as a guide catheter. (b) The GuideLiner metal collar (arrow) connecting the flexible catheter extension with a 115-cm stainless steel shaft to a proximal positioning tab. (c) The proximal end of the GuideLiner while used inside the catheter through the hemostatic valve, like a regular balloon.

the GuideLiner is contraindicated in vessels that are <2.5 mm in diameter (Figure 3.8b and 3.9).

The GuideLiner has a coil backbone that provides superior flexibility while retaining radial strength, and it can be seated much deeper than the guide. This allows advancement of a device through a tortuous, angulated, or calcified proximal segment without getting exposed to friction from the vessel wall [19].

Technical Tips

****Guide insertion made easy** When inserting the GuideLiner into the guide, the flat push tube should be oriented in a lateral position and further advanced without rotation to avoid wrapping of the wire.

Deep-vessel engagement by the GuideLiner can be facilitated by passage of a balloon catheter over the primary wire into the distal vessel, followed by low-pressure balloon inflation. This acts as an anchor to support gentle advancement of the GuideLiner [20].

Stents should be advanced through the GuideLiner over the primary wire, because secondary wires may wrap around the GuideLiner and obstruct stent insertion.

In cases of resistance while inserting a wire or stent through the GuideLiner, the location of the wire or stent in relation to the metal collar of the GuideLiner should be checked and the stent inspected for signs of damage before readvancement. To correct any resistance that occurs at (or proximal to) the collar:

- If a secondary wire is in use, check for wrapping of the secondary wire around the GuideLiner. If wire wrap is evident, consider pulling back the secondary wire and readvancing it. Alternatively, if the primary wire is still in place, consider advancing the stent over the primary wire. [20]
- If a stent continues to encounter resistance at the metal collar, pull the stent and wire back together 3–5 cm and try readvancing the stent and wire together through the metal collar. If resistance is again encountered, check the stent for signs of damage and either choose a lower-profile stent or change the wire.

Advantages and Limitations: When Advancing a Stent through the GuideLiner

One limitation is a small risk that large/bulky stents can get damaged entering the collar; so the use of low-profile stents is recommended with this system, avoiding stents >4 mm diameter. In case of resistance while inserting a stent through the GuideLiner catheter, the location of the device in relation to the metal collar should be checked and the stent checked for damage. Even a low-profile stent with 2.25 mm diameter can get damaged. The reason is that the stent may get stuck at the metallic collar if it coincides with a bend of the catheter. Gentle retrieval of the GuideLiner to place the collar in a more straight segment of the guide therefore helps to get the stent into the catheter extension [21–22].

*****Extreme measure for strengthening the guide with two other guides or catheters** To stabilize further a guide, the working guide can be inserted with two guides or catheters such as a smaller guide and a GuideLiner. This is called grandmother-and-daughter technique. It was tried successfully by one of the authors in Japan.

DEDICATED EQUIPMENT

The Heartrail II catheter

This is a 120 cm, 5-Fr, soft, straight-tipped catheter that is delivered within a standard 6-Fr coronary guide. Up to 13 cm of this 5-Fr catheter may extend beyond the coronary guide, allowing deep engagement of the target coronary artery in an atraumatic fashion. This facilitates delivery of intracoronary devices, especially stents, and is particularly useful where tortuous coronary anatomy exists.

The Heartrail “5-in-6” system involves insertion of an extra-length, 5-Fr, soft-tipped catheter into a standard 6-Fr guide so that the distal tip of the 5-Fr catheter can extend or “telescope” up to 16 cm beyond the tip of the 6-Fr catheter. The hemostatic valve is disconnected from the guide once the guide and coronary wire are in position [18].



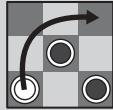
Advantages and Limitations

The initial set-up can take more time and suboptimal opacification of the coronary artery can occur. This highlights the importance of compiling detailed angiograms before proceeding with this Heartrail 2 catheter to comprehensively delineate the target lesion(s). The operator must be aware of possible anatomical distortion of the artery with delivery of this 5-Fr catheter, similar to the effect seen with stiff wires. Another danger is the risk of air entrainment leading to air embolism, and careful back bleeding is mandatory before injection. Finally particular care is required when advancing the Heartrail to avoid inducing a dissection [20].

TACTICAL MOVE

BEST technique in strengthening a guide

- 1 \$ **FIRST Best maneuver:** Add a second stiffer wire
- 2 \$ ∞ **SECOND Best maneuver:** Change to stronger guide
- 3 \$\$ ∞ ♦ **THIRD Best maneuver:** Advance a small balloon to a side branch and inflate the balloon to prevent the guide from backing out
- 4 \$ ∞ Change the current sheath to a very long sheath
- 5 \$ ∞ Double-guide technique: Insert a smaller guide in current guide



Technical Tips

****Changing a guide with wire across lesion** Changing a guide is more difficult if the lesion has already been crossed by a wire. If a wire placement was difficult, it is desirable not to recross the lesion. Techniques have been developed to allow exchange of guides over regular length angioplasty wires. The use of exchange wires with long radio-opaque tips facilitates this procedure by minimizing the chance of failing to notice a redundant loop of radiolucent wire in the aortic root.

TECHNIQUE Exchange of a guide without removing the wire

If the operator works on regular length wire it is advisable to insert microcatheter or over-the-wire (OTW) balloon and to exchange the wire with a 300-cm one. Next, remove the balloon or microcatheter to ensure enough space for free consecutive movement. First withdraw the guide a few centimeters without losing position of the wire across the lesion. When the proximal end of the guide meets the proximal end of the wire, attach a syringe full of fluid into the guide. Under fluoroscopy, withdraw the guide while keeping the wire immobile by continuing to inject fluid into the guide from the syringe. By this, the guide is removed slowly. Once the guide is out of the sheath, the new guide is inserted over the two wires: The angioplasty wire across the lesion and a 0.035-inch wire. When the guide is at the ascending aorta

level, the 0.035-inch wire is removed. A balloon catheter with very small size (1.25 × 10mm or 1.5 × 10mm) is inserted as far as possible to provide a good rail for guide insertion. Once the balloon catheter is at the ostium of the coronary artery, the new guide is then advanced over the shaft of the balloon catheter, which can provide a better rail for the guide than the wire alone would [23].

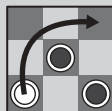
TACTICAL MOVE

BEST technique for changing a guide with wire across lesion

1 \$ ⌘ **FIRST Best technique for American operators:** Change the guide through the extension of the existing angioplasty wire

2 No extra cost. **FIRST Best technique for European and Asian operators:** Remove the guide while injecting contrast from a syringe and insert the new guide through a second stiff 0.035-inch wire while the angioplasty wire is kept immobile across the lesion [23]. Reinsert the guide through a balloon catheter

3 \$ ⌘⌘ **Third option:** Remove the whole system, change the guide, and re-cross the lesion



Technical Tip

****How to untwist a twisted guide** When the iliac artery is very tortuous, a torquing maneuver can twist the guide at its proximal segment. Usually the pressure curve would disappear on the screen. The patient can complain of pain in the lower quadrant area because, when the guide becomes twisted, it forms a sharp bend pointing laterally and can cause perforation. When seeing a twisted guide, the first thing to do is to move the twisted segment to a large area by advancing it into the aorta rather than leaving it in the iliac artery. Then cannulate the guide with a 0.035-inch wire, and move its tip to the twisted area. Next try to untwist the guide by torquing in the opposite direction. If you turned the guide clockwise more in the last few minutes, then try counterclockwise now (or vice versa); work on a trial-and-error basis. However, as you torque, slowly advance the wire to secure the segment that you just untwisted. If you see on the fluoroscope that the guide becomes more tortuous, this means that you are making the situation worse. Try the opposite direction. Advance the wire gently as you torque. In a matter of less than 1 or 2 minutes, the damaged guide should be entangled, straightened, and removed.

REFERENCES

1. Tenaglia A, Tchong J, Phillips III HR. Coronary angioplasty: Femoral approach. In: Stack R, Roubin G, O'Neill W (eds), *Interventional Cardiovascular Medicine, Principles and Practice*, 2nd edn. Edinburgh: Churchill Livingstone, 2002: 477–89.

2. Voda J. Long tip catheter: Successful and safe for left coronary angioplasty. *Catheter Cardiovasc Diagn* 1992;**27**:234–42.
3. Hill JA, Lambert CR, Vlietstra RE, Pepine CJ. Review of general catheterization techniques. In: Pepine CJ, Hill JA, Lambert CR (eds), *Diagnostic and Therapeutic Cardiac Catheterization*, 3rd edn. Baltimore, MA: Williams & Wilkins, 1998: 107.
4. De Bruyne B, Stockbroeckx J, Demoor D, et al. Role of side holes in guide catheters: Observations on coronary pressure and flow. *Catheter Cardiovasc Diagn* 1994;**33**:145–52.
5. Stratienco AA, Ginsberg R, Schatz RA, et al. Technique of shortening angioplasty guide catheter length when therapeutic catheter fails to reach target stenosis. *Catheter Cardiovasc Diagn* 1993;**30**:331–3.
6. Abhyankar AD. Modified catheter shapes for engaging left coronary ostium in unusually wide ascending aorta. *Catheter Cardiovasc Diagn* 1996;**39**:327.
7. Chetcuti SJ, Moscucci M. Double-wire technique for access into a protruding aorto-ostial stent for treatment of in-stent restenosis. *Catheter Cardiovasc Interv* 2004;**62**:214–17.
8. Takahashi S, Saito S, Tanaka S, et al. New method to increase a backup support of a 6 French guiding coronary catheter. *Catheter Cardiovasc Interv* 2004;**63**:452–6.
9. Farooq V, Mamas MA, Fath-Ordoubadi F, Fraser DG. The use of a guide catheter extension system as an aid during transradial percutaneous coronary intervention of coronary artery bypass grafts. *Catheter Cardiovasc Interv* 2011;**78**:847–63.
10. Abhaichand RK, Lefevre T, Louvard D, et al. Amplatzing a 6Fr JR guiding catheter for increased success in complex RCA anatomy. *Catheter Cardiovasc Interv* 2001;**53**:405–9.
11. Israel DH, Sharma SK, Ambrose JA, et al. Cardiac catheterization and selective coronary angiography in ascending aortic aneurysm or dissection. *Catheter Cardiovasc Diagn* 1994;**32**:232–7.
12. Topaz O, DiSciascio G, Goudreau E, et al. Coronary angioplasty of anomalous coronary arteries: Notes on technical aspects. *Catheter Cardiovasc Diagn* 1990;**21**:106–11.
13. Cheitlin MD, DeCastro CM, McAllister HA. Sudden death as a complication of anomalous left coronary origin from the anterior sinus of Valsava: A not-so-minor congenital anomaly. *Circulation* 1974;**50**:780–7.
14. Lee BI, Gist HC, Morris EI. Percutaneous coronary artery stenting of an anomalous right coronary artery with high anterior takeoff using standard size 7 French left Judkins guiding catheters. *J Invasive Cardiol* 2004;**15**:682–4.
15. Lawson MA, Dailey SM, Soto B. Selective injection of a left coronary artery arising anomalously from the posterior aortic sinus. *Catheter Cardiovasc Diagn* 1993;**30**:300–2.
16. Solanki P, Gerula C, Randhawa P, et al. Right coronary artery anatomical variants: Where and how? *J Invasive Cardiol* 2010;**22**:103–6.
17. Sarkar K, Sharma SK, Kini AS. Catheter selection for coronary angiography and intervention in anomalous right coronary arteries. *J Intervent Cardiol* 2009;**22**:234–39.
18. Hynes B, Dollard J, Murphy G, et al. Enhancing back-up support during difficult coronary stent delivery: single center case series of experience with the Heartrail II catheter. *J Invasive Cardiol* 2011;**23**:E43–6.
19. Cola C, Miranda F, Vaquerizo B, Fantuzzi A, Bruguera J. The Guide-Liner™ catheter for stent delivery in difficult cases: Tips and tricks. *J Intervent Cardiol* 2011;**24**:450–61.
20. Hanna H, Dasari TW, Hennebry TA. Use of the guideliner catheter for the treatment of a bifurcational total occlusion of the native left

anterior descending artery through a tortuous composite venous graft. *J Invasive Cardiol* 2011;**23**:E40–2.

21. Saeed B, Banerjee S, Brilakis ES. Percutaneous Coronary intervention in tortuous coronary arteries: associated complications and strategies to improve success. *J Interven Cardiol* 2008;**21**:504–11.
22. Kumar S, Gorog DA, Secco GG, et al. The Guideliner “child” catheter for percutaneous coronary intervention – early clinical experience. *J Invasive Cardiol* 2010;**22**:495–8.
23. Azrin MA, Fram DB, Hirst JA. Maintenance of coronary wire position during guide catheter exchange. *Cathet Cardiovasc Diagn* 1996;**37**: 453–4.

CHAPTER 4**Wires**

Dobrin Vassilev, Satoru Sumitsuji, Thach N. Nguyen, Hai Yun Wu

Challenges 88

Standard of Technical Excellence 88

Discriminating Differences 88

Nitinol and Stainless Steel Wires 88

Hydrophilic Wires 88

Stiff Wires 89

Wiring the LAD 90

Wiring the LCX 90

Wiring the RCA 90

Advancing a Wire 90**Technical Tips 90**

**Directing the wire when navigating the LAD 90

**Entering the LCX without wire prolapsing 91

**Crossing coronary aneurysm with stenosis 92

**Measure the length of a lesion with a wire 92

**Pseudolesions 92

Advancing a wire through a tortuous segment 93

Entering Side Branch 93

Steering and advancing a wire through severely angulated side branch 93

Technical Tips 94

**Reverse SB wiring technique 94

***ADVANCED reverse SB wiring technique 94

Technical Tips 96

***Deflecting the tip of a wire by a distal inflated balloon 96

**Crossing a stent cell to access sidebranches 99

Exchanging Balloon Catheters 100**Technical Tips 100**

**Advancement of an over-the-wire balloon catheter over a regular-length wire 100

***Exchanging balloon catheter over a regular-length wire 100

**Use a second balloon to immobilize the wire 100

Failure to cross a Lesion 101

Avoiding entangled IVUS catheter and wire 102

ADVANCED TECHNIQUE How to pace with an angioplasty wire?
102

*Basic; **Advanced; ***Rare, exotic, or investigational

\$, <\$US100.00 extra; \$\$, >\$US100.00 extra

⌚, <10min extra; ⌚⌚, >10min extra

♣, low risk of complications; ♣♣, high risk of complications

CHALLENGES

To advance a wire across the lesion and position the tip distally on a timely basis is a great challenge during any interventional procedure.

STANDARD OF TECHNICAL EXCELLENCE

The wire should be such that it can be advanced gently and pass smoothly through the proximal vessel segment and the stenotic lesion. The tip of the wire should be placed as distally as possible, so the stiff part of the wire is across the lesion where the stent or other interventional devices are to be tracked successfully.

A wire consists of two main components: (1) a central shaft of stainless steel or nitinol and (2) a distal flexible tip shaped as a spring coil made with platinum or tungsten. Core material and diameter at the tip of the wire affect the flexibility and support of the wire. The longer and gradual taper of the core facilitates tracking but provides less support. On the opposite side, the shorter the taper the greater the support that the wire has, but at the expense of its susceptibility to prolapse. In general, the flexible wires are less steerable and stiffer wires offer more torque control [1].

Discriminating Differences

Nitinol and Stainless Steel Wires Wires with a nitinol core are kink resistant whereas those with a stainless steel one are more susceptible to kinking. A core that extends to the distal tip provides for better torque transmission and tactile feel. The nitinol core increases wire trackability, including the ability to traverse acute artery angulations without wire prolapse (so-called “balanced force transmission”). Nitinol wire might be more capable of entering a retroflexed circumflex takeoff than a stainless steel core wire. The limitation of nitinol core wire is that it tends to store, rather than to transmit and torque [1].

Hydrophilic Wires The hydrophilic wires are kink-resistant, flexible wires covered with a hydrophilic polyurethane coating. The core is constructed with super-elastic titanium–nickel alloy that offers extreme flexibility and kink resistance, thus optimizing pushability. A hydrophilic polymer coating results in low thrombogenicity and extreme lubricity when wet [1]. Hydrophilic, polymer-coated wires, such as the Choice PT, Asahi Prowater, Whisper, and Runthrough, have low friction and may advance easier through tortuosity, but may also carry a higher risk of dissection or perforation, especially if they select a small branch. Soft delivery catheters, such as the transit catheter or the dual-lumen Twin-Pass catheter, can improve the steerability of the wire by decreasing friction at the proximal segment. The Venture deflectable-tip catheter can help guide the wire through tortuous

coronary segments, but is likely more useful in large coronary arteries, similar to the Steer-It deflectable-tip wire.

Stiff Wires The stiff wires can straighten the curved segment, change the vessel shape and cause wrinkles or pseudolesions. Removing the stiff part of the wire while leaving the radio-opaque flexible end across the pseudolesions, exchanging for a more flexible wire or a flexible transit catheter or pulling the wire completely out, would abolish these pseudolesions. Other disadvantages of stiff wire include difficulty of tracking stents, because of the wire bias inducing coronary spasm, even obstruction of flow induced by vessel kinking, and wire buckling due to sharp transitions. In these situations, the wire should be exchanged and use of atherectomy devices avoided because of excessive wire bias (Figure 4.1).

STRATEGIC MAPPING

The wire should be advanced gently and not be forced or jammed blindly because it can disrupt the plaque, cause thrombus formation and ultimately acute occlusion. Withdrawal and reorientation of the wire is required when buckling occurs. Any bend in the body of the wire makes the one-to-one (1:1) torquing of the tip impossible. A more forceful but cautious push could be applied only during opening of chronic total occlusions. Repeated rotation of 180° in clockwise and counterclockwise directions also seems to aid wire advancement and reduces subselection of unwanted small branches [1].

Never rotate the wires through 360°. This may result in entanglement with a second wire or fracture of the tip if it is caught in a small branch. The radius of the curve on the tip of the wire should have a diameter a little bit larger than a diameter of segment, which has to be crossed, especially if side branch entry is intended. A double or triple bend can be useful if there are two different angulated segments to cross [1].

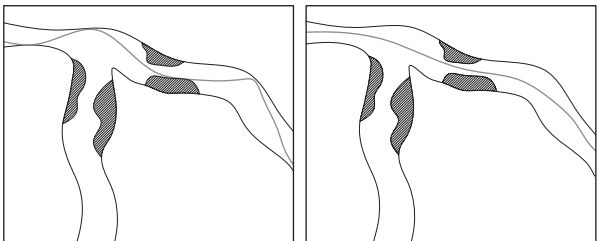
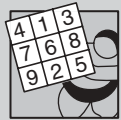


Figure 4.1 Effects of wire with different level of stiffness: (a) Path of stiff wire; (b) path of less stiff wire. Illustrated by Quoc Nguyen.

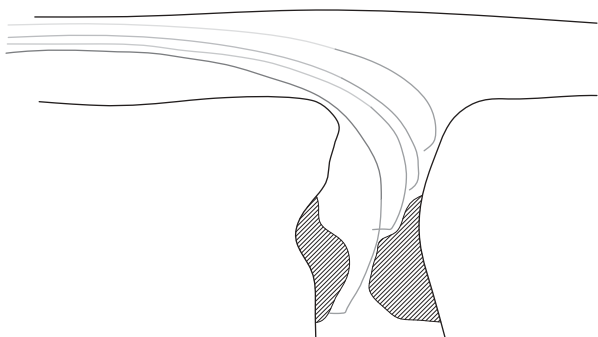


Figure 4.2 Broad transition wire. Illustrated by Quoc Nguyen.

The operator should keep in mind the space orientation of branches and direct the wire tip with minimal manipulation, minimizing endothelial trauma.

Wiring the LAD The left anterior descending artery (LAD) typically has little tortuosity, so the wire transition point between the flexible tip and the more rigid body is usually not a major problem.

Wiring the LCX For left circumflex artery (LCX) interventions, the wire needs to pass the left main (LM), turn into the LCX, and then move forward to cross the lesion. Many times it requires a broad secondary curve to successfully enter the LCX and a smaller primary curve to cross into the obtuse marginal. Wires with gradual transition from the body to the spring tip are preferred to avoid continuous prolapsing into the LAD [1] (Figure 4.2).

Wiring the RCA When the origin of the right coronary artery (RCA) is relatively normal, a conventional soft wire with good steerability is usually selected to avoid side branches. When the RCA arises anteriorly, the wire sometimes may be required as an aid to guide ostial intubation. In this situation, wires with improved tip transition or soft hydrophilic wires are selected to avoid prolapsing at the point of transition and disengagement of the guide [1].

ADVANCING A WIRE

In order to enter a tortuous proximal LAD, the best view is the left anterior oblique (LAO) caudal view (spider view). Once the wire is far enough in the LAD, the angle is changed to the right anterior oblique (RAO) cranial view so that the wire can be moved to the mid- and then the distal LAD.

Technical Tips

****Directing the wire when navigating the LAD** When navigating the LAD, on the LAO caudal view, the wire should point to the right of the screen. The left is toward the diagonal. Once inside the proximal segment the better view is the LAO

cranial view. Here the wire should move downward. Any stray to the left will point to the diagonal, and to the right will point to the septals. If the LAD is entered in the RAO cranial position and the wire is pointing downward, most likely it enters the LCX. If the wire moves widely, then it may enter ramus intermedius which buckles with contraction of the left ventricle (LV) similar to the diagonals. Usually it is worthwhile to place a little extra curve at the tip of the wire because there is more angulation at the takeoff of the LAD than is apparent in the RAO projection [1].

****Entering the LCX without wire prolapsing** Sometimes it is difficult to curve a wire into a branch of a large artery (such as from the LM to the LCX then to the obtuse marginal [OM]) because of the short stem of the second main branch. Despite persistent manipulation, the wire keeps buckling under pressure and prolapsing into the main branch (LAD). The reason is the abrupt transition between the short tip and the main shaft (a sharp bifurcation of the LCX). There are many options to solve this problem.

The first option is to deep seat the guide so that the distance between the tip of the guide and the ostium of the LCX is shorter. The second option is asking the patient to take a deep breath, so the heart is more elongated, the angle between the LCX and LM being less acute. During this short window of opportunity, advance the wire.

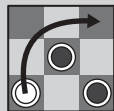
The next option is to change the current wire to a wire with a gradually tapered core so that, as the tip is deeply advanced, it stabilizes the wire and the stiffer shaft can negotiate the angle better, without prolapsing into an unintended area (or LAD) [1]. Once the soft part of the tip passes the acute corner, torque the wire slowly while advancing the wire. The rotational energy will advance the wire distally. The tip of the wire needs to be shaped in order to conform with the diameter of the LM at the entry angle with the LCX (Figure 4.2).

Another option is to advance a small transport catheter into the proximal LCX. The new catheter prevents buckling of the wire, and helps the wire cross the tight lesion by shortening the distance between the tip of the catheter and the lesion, nullifying the acuteness of the angle between the LM and LCX [1].

TACTICAL MOVE

BEST maneuver for entering the LCX without wire prolapsing

- 1 **FIRST Best Maneuver:** Deep seating the guide
- 2 **\$\$ SECOND Best Maneuver:** Change the wire with a gradual tapered core tip
- 3 **THIRD Best Maneuver:** Ask the patient to take a deep breath
- 4 **\$\$ FOURTH Best Maneuver:** Use a transport catheter



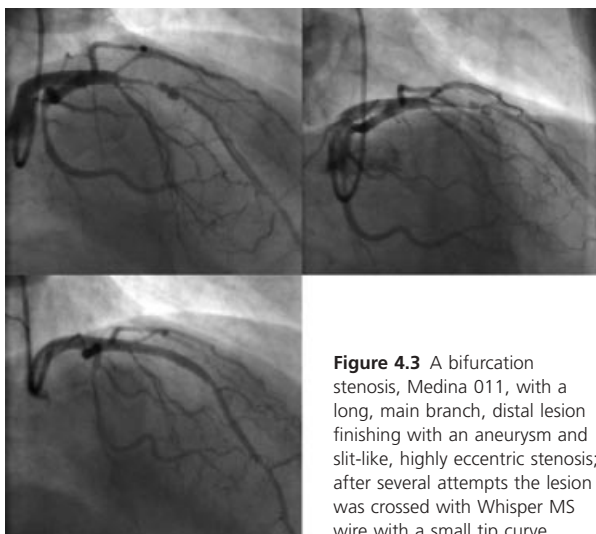


Figure 4.3 A bifurcation stenosis, Medina O11, with a long, main branch, distal lesion finishing with an aneurysm and slit-like, highly eccentric stenosis; after several attempts the lesion was crossed with Whisper MS wire with a small tip curve.

****Crossing coronary aneurysm with stenosis** A slit-like stenosis in combination with coronary aneurysm is sometime very challenging to cross. A soft wire with good torque control (BMW, Prowater, or Runthrough) or soft hydrophilic wire (Whisper) should be a first choice with a small primary curve to engage the slit-like stenosis and a large secondary curve to navigate the aneurysmal lumen) (Figure 4.3).

****Measure the length of a lesion with a wire** It is not easy to guess accurately the length of a lesion if some segments are foreshortened because of tortuosity. When a vessel bends in more than one plane, no single angiographic view can overcome multiple foreshortenings. Most radiolucent wires have a 20- to 30mm radioopaque distal end. Position this radioopaque segment across the lesion so that the length of the lesion can be estimated – another way to measure the lesion length with a balloon that has markers at its two ends or using a marker wire.

****Pseudolesions** Use of a stiff coronary wire can potentially straighten the vessel tortuosity and facilitate stent delivery, but it can occasionally lead to excessive vessel kinking and development of coronary “pseudolesions,” making stent delivery more difficult. When this occurs exchange of the wire with a softer wire or a soft delivery catheter, such as the transit catheter, may result in resolution of the pseudolesions.

Placement of another wire could be facilitated by using a dual-lumen catheter: the twin-pass catheter has both a rapid-exchange distal lumen and an over-the-wire (OTW) lumen, is very soft and malleable, and can be used to introduce a second buddy wire or to exchange the existing wire without losing distal wire position.

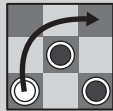
Sometimes, use of a softer or 0.012-inch wire may be advantageous by causing less vessel deformation. Although not widely available, magnetic wires could significantly facilitate wiring tortuous vessels, especially in the hands of experienced operators [2].

Advancing a wire through a tortuous segment When the manipulation of a wire becomes difficult after it passes through too many curves, there are many options to solve this problem. The first option includes use of hydrophilic wires, which are very sleek and kink resistant. However, as the hydrophilic wires are so smooth, the operator has little tactile feedback, and they can easily go subintimally or cause distal perforation if inadvertently advanced into a small and short branch. So, when manipulating a hydrophilic wire, always watch the distal tip, to avoid inadvertent migration and perforation. Probably the best solution is to use hybrid wire with hydrophobic distal tip (distal 1–3 mm) and hydrophilic body with a hybrid nitinol–stainless steel core (Runthrough, Balanced middle weight [BMW]). Another option is to advance a balloon catheter near the wire tip in order to improve wire support, torque control, and steerability. Another (better, but more expensive) option is to use soft microcatheter (Transit, Progreat or Finecross, Corsair,), which has a softer and shorter tip (easy to advance), in order to improve the wire support, torque control, and steerability. A microcatheter also permits wire exchange with another wire.

TACTICAL MOVE

BEST maneuver for advancing a wire across tortuous segments

- 1 **FIRST Best Maneuver:** Select a hydrophilic wire
- 2 **SECOND Best Maneuver:** Advance a balloon near the tip of the wire
- 3 **THIRD Best Maneuver:** Advance a microcatheter to near the tip of the wire



ENTERING SIDE BRANCH

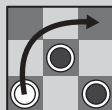
Steering and advancing a wire through severely angulated side branch In rare instances, a wire has to enter a very acutely angulated side branch. The first maneuver is to make a large diameter curve at the tip, sometimes like a large hook with second shallow curve (1–2 cm) behind. A microcatheter could be introduced to decrease proximal friction of the wire and to facilitate its navigation. Using a stiffer or hydrophilic wire is helpful. If the wire cannot pass distally, it can be exchanged for a microcatheter to be introduced at the side-branch ostium. Then, the entry wire is to be replaced with a soft wire (Whisper, Prowater, or Runthrough).

Another option is to use a double-lumen catheter (Crusade, Kaneka) for support and wire direction. More time consuming and more demanding is the reverse wiring technique. The most costly options are to use the Venture control catheter or the Steer-it with deflecting tip in order to position the wire exactly at the ostium of the side branch.

TACTICAL MOVE

BEST maneuver for Side-branch (SB) entry

- 1 **FIRST Best Maneuver:** Making a large primary curve more than 90° in the wire tip and second shallow curve (15–30°) 1.5–2.0 cm behind (the length of the tip is equal to the diameter of the main vessel at the origin of the SB)
- 2 **\$\$ SECOND Best Maneuver:** Advance a balloon or microcatheter near the tip of the wire
- 3 **THIRD Best Maneuver:** Use a hydrophilic wire
- 4 **\$\$ Fourth Best Maneuver:** Use the wire with deflectable tip – Steer-it
- 5 **\$\$ Fifth Best Maneuver:** Use a double-lumen catheter to point the tip to the SB
- 6 **Sixth Best Maneuver:** Use the reverse-wire technique
- 7 Performing distal balloon inflation and wire deflection technique
- 8 Putting a balloon against the SB ostium to deflect wire tip



Technical Tips

****Reverse SB wiring technique** The wire is shaped to form a hairpin 3–5 cm from the tip which has itself a 3- to 5-mm curve and points to the opposite direction of the hairpin (Figure 4.4a). It is recommended to perform this technique on a soft polymer-coated wire (Fielder FC). The wire is inserted beyond the target SB. Then the wire is withdrawn to prolapse the tip into the intended SB. Rotate the wire toward the main lumen, clockwise if the tip was pointing toward the left of the patient, and counterclockwise if the tip was pointing toward the right of the patient. When there is sufficient stiff segment inside the SB (not just the soft tip), the wire will advance further, without prolapsing back. By slow withdrawal and navigation of the direction of the tip, the SB is entered (Figure 4.4b). By pulling the wire further with slight rotation, the wire is inserted deeper. Alternatively, the wire could be inserted in hairpin configuration into the guide and, after crossing the lesion, the wire is pulled back (Figure 4.4c).

*****ADVANCED reverse SB wiring technique** Make the tip curve as usual. (1) Make a “reversed bend” 30–45° in the floppy part, or make smoother curve with three to four mild bending points (Dr Kato’s comment). (2) Use a Crusade microcatheter (Kaneka, dual-port microcatheter), with a wire already crossed in

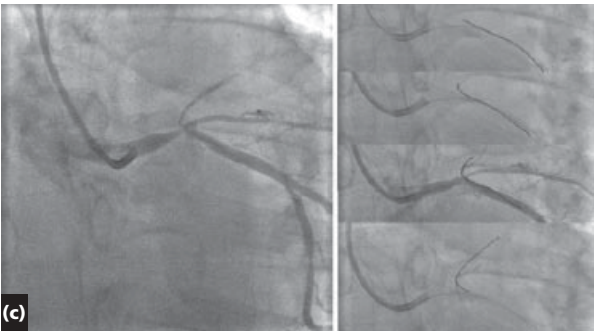
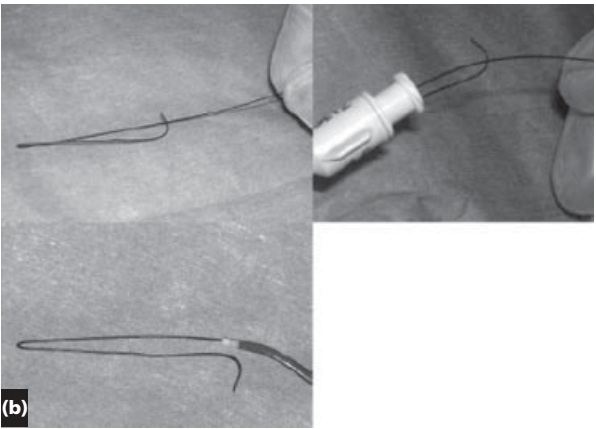
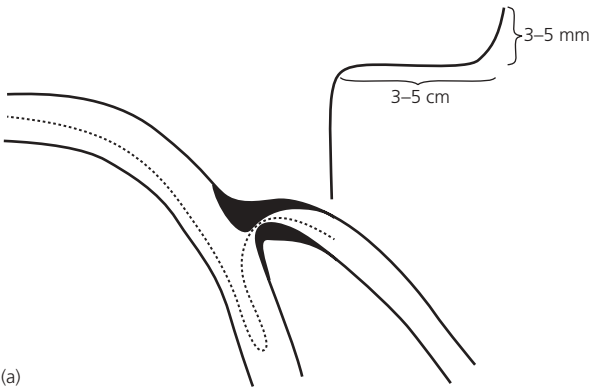


Figure 4.4 Reversed wire technique: (a) After wire preparation. (Illustrated by Quoc Nguyen.) and (b) crossing the branch divergence place, (c) it is withdrawn to prolapse the tip into the intended branch. Then rotate the wire toward the main lumen, clockwise if the tip was pointing toward the left of the patient, and counterclockwise if pointing toward the right of the patient. If there is enough stiff segment inside the side branch (not just the soft tip), the wire will advance further, without prolapsing back.

the main branch on the monorail lumen. (3) The reversed wire is inserted into the second lumen. Advance the reversed wire system into the Y connector with softly folding reversed wire. (4) The bent point of the reversed wire must be positioned at the tip of the exit port of the second lumen (Figure 4.5a).

Advance the whole "reversed wire system" well beyond the bifurcation point. Pull back the Crusade microcatheter while keeping the reversed wire immobile. Then carefully pull back the reversed wire (Figure 4.5b–d). Sometimes the wire must be rotated to point the wire tip toward the SB ostium. Once the tip is facing the ostium of the SB, pull the wire back gently which will prolapse the wire into the SB. Advance the wire deeper. If the bent point of the reversed wire gets stuck at the bifurcation, careful rotation may untwist it (Figure 4.5e–h). After straightening the bent wire, advance it distally with some minimal rotation. After the bent point crosses over the bifurcation, the wire can easily be advanced into the distal part of the SB.

However, these two tips above can be applied only for proximal lesions. In distal lesions the use of a Venture Control catheter with a double lumen is needed [3,4].

DEDICATED EQUIPMENT

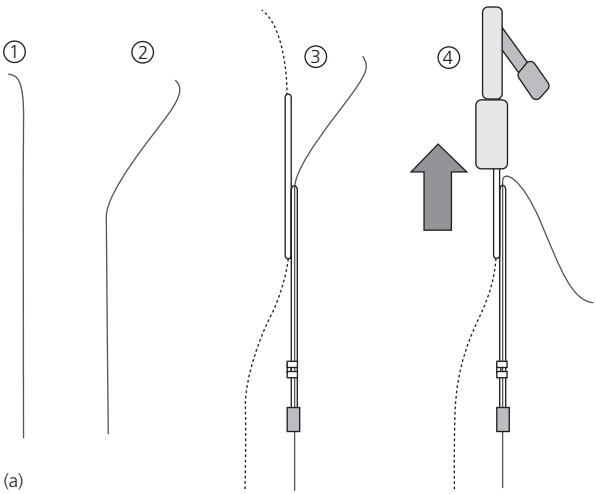
The Venture control catheter (Figure 4.6)

The Venture Control catheter is a 6-Fr-compatible, flexible, torquable support catheter, with a mechanically activated, deflectable, atraumatic, conical tip. A proximal rotating hub allows deflection of the catheter tip over a 90° arc by clockwise rotation. There is a 8-mm radioopaque tip giving a 2.5 mm bent curve after 90° rotation. The catheter is currently available at 140 cm long with over-the-wire and rapid exchange versions. The catheter is compatible with all approved 0.014-inch wires. First pass the wire distal to the intended lesion/branch, then flex the catheter tip to the desired configuration, and pull it back against the branch ostium. With exact orientation to the ostium of the SB and firm support, the wire can easily enter the SB, even through extremely difficult angulations (Figure 4.6) [5].




Technical Tips

*****Deflecting the tip of a wire by a distal inflated balloon** Sometimes, it is difficult to curve a wire into an SB with extreme angle takeoff. In case of a severe ostial lesion of an OM, which originates from the LCX at an extreme angle, the entry of the OM was unsuccessful because of repeated prolapse of the wire in the main LCX. A small balloon was then advanced to the distal LCX and inflated with its proximal end right beyond the



(a)




(b)




(c)


Figure 4.5 (1) Make the tip curve as usual. (2) Make a “reversed bend” 30–45° in the floppy part, or make smoother curve with three to four mild bending points. (3) Use a Crusade microcatheter (Kaneka, dual-port microcatheter), with a wire already crossed in the main branch on the monorail lumen. (4) The reversed wire is inserted into the second lumen. Advance the reversed wire system into the Y connector with softly folding reversed wire. (4) The bent point of the reversed wire must be positioned at the tip of the exit port of the second lumen. Advance “reversed wire system” with (b) Crusade beyond bifurcation. (c) Pull back the Crusade while keeping the reversed wire immobile.




(d)




(e)



(f)



(g)



(h)

Figure 4.5 (Continued) (d) Pull the reversed wire back. (e) Sometimes the wire must be rotated to point the wire tip toward the side branch (SB) ostium. (f) After the wire tip points toward the SB ostium, carefully pull the wire back further. (g) When the bent point of reversed wire becomes stuck at the bifurcation, careful rotation may help. (h) After the bent point goes over the bifurcation, the wire can easily be advanced into the distal part of SB.

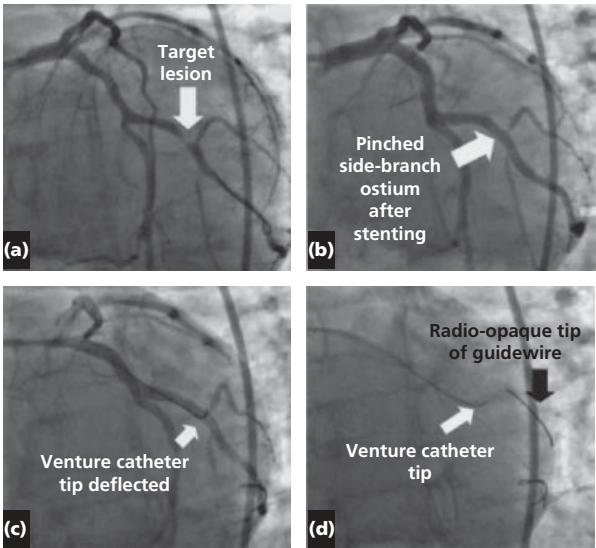


Figure 4.6 The Venture Control catheter: The catheter gives additional support, keeping the required direction for wire insertion. (a) Perpendicular occurring obtuse marginal (OM) branch; (b) after stenting, the ostium of the OM is severely compromised, (c,d) directing the wire in the side branch direction [5].

ostium of the diseased OM. A new wire was inserted and successfully entered the ostium of the OM, steering it toward the opening of the SB with extreme angle takeoff. In this case, the inflated balloon prevented the continuing prolapse of the wire and deflected the tip to the desired retrograde direction [6].

****Crossing a stent cell to access sidebranches** Generally all techniques described for difficult SB access could be used, single or in combination. If a stent needs to be re-crossed, the tip of the wire should be curved well into a wide J and the whole wire can be advanced while being rotated. This maneuver will help to avoid the inadvertent migration of the tip of the wire under a strut, changing the direction of the whole wire to outside the stent. If there is subtle resistance, wire exit through or behind the struts should be suspected. If the stented area has in-stent restenosis and a curved tip fails to cross the stent, an intermediate wire with a mildly bent tip can be manipulated to cross the stent. Try to have the pictures of the segments in two orthogonal views so that the wire can be advanced inside the lumen as best as possible. An additional post-stent inflation, with a short balloon at the proximal part of the stent at higher pressure, could open additional cells and dislodge the lateral SB wall, giving room for wire entrance. Sometimes, these maneuvers are ineffective, and “jailed” wire does not help, especially if the SB is totally occluded.

In this situation an intravenous ultrasound (IVUS) probe is inserted into the stent and exact location of the SB is identified. With IVUS in place, a medium stiffness wire is directed into the SB (an IVUS probe gives additional support to a wire and confirms its true lumen position).

EXCHANGING BALLOON CATHETERS

Technical Tips

****Advancement of an over-the-wire balloon catheter over a regular-length wire** A regular-length angioplasty wire is inserted and manipulated to cross the lesion. Be sure that the wire tip is positioned at the most distal segment of the artery. An over-the wire (OTW) balloon catheter is then advanced over the wire without manual control of the wire. This is performed with fluoroscopic guidance until the proximal end of the wire reappears through the wire port of the balloon catheter. During the passage of the balloon catheter, extreme care is taken to make the movement as smooth as possible with no tactile evidence of any hindrance. An absolute requirement is to refrain from any forceful forward motion of the balloon catheter over the wire, if any resistance is felt. This precaution would limit any forward migration of the wire. Any resistance or evidence of ventricular ectopy should prompt immediate reassessment of the wire, balloon catheter, and guide positions under fluoroscopy. There is no reported damage to the coronary artery due to inadvertent advancement of the wire. With forward motion of the balloon catheter, increased tension in the wire can back out the guide, so the tip of the guide needs to be watched. This technique is cost-effective because only one wire is used, saving the cost of an extension. It is also advantageous when the proximal end of the wire is damaged and therefore cannot be extended, if the wire is not constructed to be extended, or if there is no extension wire available.

*****Exchanging balloon catheter over a regular-length wire** The balloon catheter is pulled back over the wire until the stiff end of this wire remains just within the hub of the balloon catheter. The stiff end of a second wire is then introduced into the catheter hub in an end-to-end apposition to the first wire inside the catheter. This introduction can be facilitated by the use of a 20-gauge intravenous (IV) cannula with the tip placed inside the hub. The balloon catheter is then gradually pulled back over this combination while maintaining a forward push on the second wire. Be sure that this wire is compatible with the lumen size of the balloon catheter.

****Use a second balloon to immobilize the wire** Insert a second 2.5 × 15 mm balloon and position it 1 cm from the guide tip. When the OTW balloon is withdrawn into the guide distal to the second balloon, this balloon is inflated at 12 atm, anchoring the wire and permitting free removal of the OTW balloon (Figure 4.7).

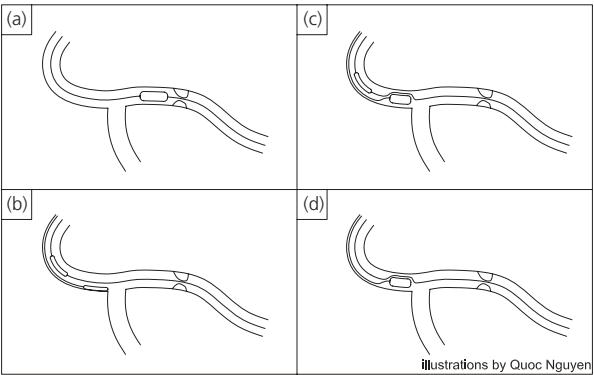


Figure 4.7 Exchange catheter (a). Insert a second balloon and position it 1 cm from the guide tip (b). When the over-the-wire (OTW) balloon is withdrawn into the guide distal to the second balloon, this second balloon is inflated and keeps the wire still (c) while the OTW balloon is removed (d).

TACTICAL MOVE

BEST options in exchanging balloon catheter over a regular-length wire

1 No Added Cost FIRST Best Maneuver:

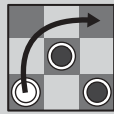
Use the back end of a regular wire

2 No Added Cost SECOND Best Maneuver:

Inject 0.9% saline through the central lumen during withdrawal of the catheter by connecting the balloon to the inflation device (filled with saline) and keeping a constant pressure of 14–15 atm during withdrawal

3 \$ THIRD Best Maneuver: Use an extension wire

4 Added Cost: An Extra Balloon: Use a second balloon to immobilize the wire



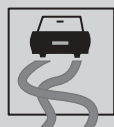FAILURE TO CROSS A LESION

When a wire does not seem to be able to cross a lesion, the most appropriate step is to check the wire position in a second orthogonal view. Maybe the tip of the wire is in an SB or has migrated outside the true lumen. Once the wire is sure to be inside the true lumen, other strategies include changing to a stiffer wire, a smaller wire or a hydrophilic wire, or passing a balloon to near the tip to increase support to the wire.

CAVEAT

Entangled wires with the IVUS catheter

In complex percutaneous coronary intervention (PCI) with advanced physiologic or imaging studies by pressure flow wire (PW) and IVUS, there is a possibility of entanglement of the



(Continued)

wires. In a caseload of 704 patients who had IVUS, 0.5% had entanglement with angioplasty wire, whereas it happened in 13% with the PW (Radi Medical System, Upsala, Sweden). The predisposing factor for these entanglements was most likely due to the short monorail segment of the IVUS catheter. To avoid entanglement of the wires, it is wise to ensure that the short monorail segment of the IVUS seats near the stiff segment of the PW or angioplasty wire. If entanglement is noticed, attempt to advance the PW or the angioplasty wire further in order to separate its kinked part from the corresponding tip of the IVUS catheter. Another option is to slide the IVUS catheter distally over the kinked wire. However, over-manipulation may be hazardous and predispose to generation of loops and further kinking of the PW. Removal of the complete system as single unit may be a last resort and a pragmatic option.

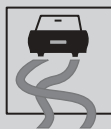Avoiding entangled IVUS catheter and wire When the proximal segment to be crossed is too tortuous and calcified, the advancement of the IVUS catheter is less than smooth. If too much force is inadvertently applied to advance the IVUS catheter, displacement of the catheter away from the wire could be induced and the wire could become kinked. If the problem is not recognized early, advancing a kinked wire can cause perforation or dissection. As the IVUS catheter slides on a short monorail distal segment, so the torquing movement is not transmitted well to the tip. This hampers its capacity to negotiate distal tortuous segment or cross tight curves, lesions, or acute angles.

CAVEAT

Inadvertent jailing of wire

Do not forget to pull a wire from an SB before stenting in the crush stent technique.

The non-radioopaque segment is not often seen and can be forgotten during the procedure, so the wire can become trapped behind the stent.



ADVANCED TECHNIQUE How to pace with an angioplasty wire? After cannulation of the coronary artery ostium with a guide, a 300-cm long, 0.014-inch angioplasty wire is advanced into the distal aspect of the coronary artery. This is connected to an external pulse generator (Medtronic 5348) using an adaptive alligator clip (Medtronic 5833SL). This pulse generator provides a variable output current while maintaining a fixed pulse width. The negative pole (cathode) is attached to the end of the angioplasty wire and the positive pole (anode) to the patient, making the angioplasty wire function as a unipolar lead. Initially, the alligator clip for the anode is attached to the skin

using a large skin surface electrode. However, the required current can be unacceptably high using the skin electrode, so to improve tissue contact, the anode is attached to a steel monofilament suture (3/0 surgical steel monofilament B&S 30) anchored in the subcutaneous tissue near the femoral access site. This steel monofilament suture is routinely used by cardiac surgeons to ground temporary epicardial pacing wires after cardiac surgery and allows lower pacemaker capture thresholds [7].

REFERENCES

1. King SB, Warren RJ. Equipment selection and techniques of balloon angioplasty In: King SB, Douglas JS (eds), *Atlas of Heart Diseases: Interventional cardiology*. St Louis, MO: Mosby, 1997: 3.1–3.15.
2. Saeed B, Banerjee S, Brilakis ES. Percutaneous coronary intervention in tortuous coronary arteries: Associated complications and strategies to improve success. *J Interven Cardiol* 2008;**21**:504–11.
3. Kawasaki T, Koga H, Serikawa T. New bifurcation guidewire technique: a reversed guidewire technique for extremely angulated bifurcation – a case report. *Catheter Cardiovasc Interv* 2008;**71**:73–6.
4. Nakhjavan FK, Najmi M. Exit block: A new technique for difficult side branch angioplasty. *Catheter Cardiovasc Diagn* 1990;**20**:43–5.
5. Violaris AG, Tsikaderis D. Tracker tricks: Applications of a novel infusion catheter in coronary intervention. *Catheter Cardiovasc Diagn* 1993;**28**: 250–1.
6. Gershony G, Hussain H, Rowan W. Coronary angioplasty of branch vessels associated with an extreme angle take-off. *Catheter Cardiovasc Diagn* 1995;**36**:356–9.
7. Mixon TA, Cross DS, Lawrence ME. Temporary coronary guidewire pacing during percutaneous coronary intervention. *Catheter Cardiovasc Interv* 2003;**61**:494–500.

CHAPTER 5**Balloon Angioplasty**

Thach N. Nguyen, Tung Mai, Dominic Nguyen, Hau Tran, Ainol Shareha Sahar

Challenges 106

Standard of Technical Excellence 106

Balloons 106**Discriminating Differences 107**

Compliant balloons 107

Non-compliant balloons 107

Marker on balloons 107

Long and short balloons 107

Over-the-wire and monorail balloons 108

Advancement, Positioning, and Inflation of Balloon 108

Failure to cross a lesion 108

Technical Tips 109

**Positioning a balloon when the blood flow is cut off 109

**Speed of inflation pressure 110

**Checking the appropriate size of the balloon or stent 110

**Looking for collaterals 110

ADVANCED TECHNIQUES Exchanging an over-the-wire balloon catheter over a regular-length wire 110

Failure to dilate a lesion 111

Technical Tips 111

**Force-focused angioplasty 111

**Balloon for calcified lesion 112

**Balloon angioplasty of large vessels 112

Failure to deflate the balloon 112

Technical Tips 112

***How to puncture an undeflated balloon? 112

Entrapment of deflated balloon during withdrawal 113

***Using a commercial snare to remove a trapped balloon 114

***Repeated balloon rupture 114

***Damage control for balloon rupture 114

Cutting Balloons 114

Technique 114

Trouble-shooting Tip 115

**Freeing an entrapped cutting blade 115

*Basic; **Advanced; ***Rare, exotic, or investigational

\$, <\$US100.00 extra; \$\$, >\$US100.00 extra

☞, <10min extra; ☞☞, >10min extra

♠, low risk of complications; ♠♠, high risk of complications

CHALLENGES

Plain old balloon angioplasty (POBA) is the basic primary procedure in coronary intervention. How to break and remodel the plaque, improve the distal coronary flow without causing dissection and early acute occlusion, and maintain these acute hemodynamic gains are great challenges to today's interventional cardiology.

Angioplasty balloons come in different diameters and are made from diverse materials (polyethylene [PE], polyethylene terephthalate [PET], etc.) to give exact or oversized diameters, with various inflation pressures and a degree of balloon hardness dependent on material characteristics (compliant or non-compliant).

The balloon catheter can be advanced over a wire that passes through the lumen inside the whole length of the shaft (over-the-wire or OTW system), just inside the distal segment (monorail system), or without an indwelling wire at all (fixed wire). A cutting balloon has microblades arranged lengthwise along the sides of the balloon.

Once inflated, the mechanism of acute lumen gain after plain balloon angioplasty (POBA) in calcified lesions is local and limited dissection whereas it is plaque compression and vessel expansion in a fibrotic lesion. Ideally, a balloon has a very low profile in its non-deployed state. However, for most lesions, low profile is less important than trackability and pushability. Trackability is the ease of advancing a balloon over a wire through an angulated coronary artery segment. Pushability is defined as the ability to push a balloon through tortuous segments or across a lesion. In the monorail system, smaller guides can be used with better opacification and reduced fluoroscopy time. However, the wire cannot be exchanged or reshaped without being removed, giving up its position or use of a transport catheter. The OTW balloon may be more trackable; the fixed-wire balloon has a much lower profile, and can be useful in tortuous arteries and extremely tight lesions.

STANDARD OF TECHNICAL EXCELLENCE

The expected result of POBA is a remodeled lumen with <10% residual stenosis without any dissection. The distal flow should be a TIMI 3 (thrombolysis in myocardial infarction grade 3) flow. If, 5 min after POBA, another angiogram shows no recoil or worsening of flow, the procedure has been successful.

BALLOONS

The choice of the exact balloon-and-wire system is less important than the operator's overall approach to the technique of dilation, the familiarity with the system chosen, the balloon size, and the capacity to treat possible complications [1]. The balloon:artery ratio should be approximately 1:1. A higher balloon:artery ratio

has been shown to be associated with dissection and acute closure.

Discriminating Differences

Compliant balloons Compliant balloons are used routinely because of their low profile and good “re-wrapping” after deflation. They are also useful when vessel size is uncertain, such as an undersized vessel, due to chronic low flow or total occlusion. Once the lesion is open and nitroglycerin has been given, the vessel may show a larger lumen; then a second dilation at a higher pressure further expands a compliant balloon (20% bigger in size). Similarly, when multiple lesions are targeted in different sized vessels, use of a compliant balloon may be more cost-effective. At first, the balloon must dilate a lesion in a small diameter vessel, after which it is moved to a larger vessel where the balloon can be inflated with higher pressure in order to achieve a higher diameter. A compliant balloon is made of a polyolefin copolymer (POC).

Non-compliant balloons Non-compliant balloons are made with PET and are needed in different situations. When post-dilating a stent, a short non-compliant balloon may be needed to maximize the stent size without overstretching the vessel at the stent edges. In a long lesion, a non-compliant balloon will not overstretch the distal segment, which is frequently smaller than the proximal segment. In hard and calcified lesions, compliant balloons may preferentially over-dilate the soft segments while being unable to break the plaque in the hard and calcified segment. The artery still looks bigger, thanks to the overstretched normal segment, which may recoil with time. In the same lesion, a non-compliant balloon would concentrate its dilating force more directly on the hard and calcified segment, without stretching the adjacent normal segment. With high pressure, it would break the plaque and shift the atherosclerotic burden equally along the longitudinal axis, and reconstruct a bigger and more stable lumen. The semi-compliant balloons are made with polyether-polyamide block copolymer, nylon, or polyurethane elastomer.

Marker on balloons A balloon with a marker in the middle should be chosen if the lesion is very tight. When the operator sees the marker at the middle of the lesion, inflation can be started. When doing percutaneous coronary interventions (PCIs) for a long lesion, a balloon with markers at two ends will be needed to be sure that the whole length of the lesion is covered.

Long and short balloons In a long lesion with diffuse disease, long balloons can distribute inflation pressure more evenly across the diseased segment, without the inconvenience of multiple short and overlapped inflations, or the danger of untreated plaques protruding into the lumen. The probability of dissection with a long balloon is believed to be lower, because a short balloon can partially disrupt an atherosclerotic plaque and allow the blood to enter the channel created behind the newly ruptured

plaque. The longer balloon also exerts less straightening force on the vessel, tending to maintain the curved configuration during balloon inflation [2]. When dilating a long lesion in an artery that tapers, the disadvantage of a long balloon is that it may under-dilate the proximal segment and over-dilate the distal segment.

Over-the-wire and monorail balloons The OTW balloon has a wire inside its core shaft so that its pushability is better. The monorail balloon has only the wire at the distal segment of the shaft so that its pushability is lower. The proximal and mid-segment of the shaft of the monorail balloon is made of either a stainless steel hypotube, or a polyamide or plastic core shaft. The core of the wire shaft is flexible; however, its profile is bigger than the hypotube shaft [3].

Advancement, Positioning, and Inflation of Balloon

The left hand of the operator advances the balloon while the right hand or another operator maintains gentle traction on the wire. The balloon should be advanced by constant pressure rather than by jerky movements. While the balloon is advanced, watch the tip of the guide carefully. As the balloon is being pushed harder, an unstable guide may back out and even become completely disengaged, forfeiting the wire position. If resistance is encountered at the lesion, gentle forward pressure on the balloon catheter, while pulling back on the wire and deeply but gently seating the guide, will often cause the balloon to cross. One way to advance the balloon through a tortuous segment is to advance the wire and guide together.

Failure to cross a lesion When advancing a balloon but the lesion is too severe, the balloon tip will not cross, and the guide would back out. Then the guide should be held steady, engaged deeper, or replaced.

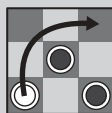
If there is excessive tortuosity of the arterial segment proximal to the lesion, the solutions are: (1) To secure a more stable position of the guide; (2) to use a stiffer wire for the balloon to be tracked on; (3) to straighten the artery by asking the patient to take a deep breath; or (4) using a "buddy" wire, placed adjacent to the primary wire. A smaller balloon with a lower profile or length may also succeed in crossing a tight lesion. Once inflated, it creates a channel sufficient for the optimally sized balloon to enter.

TACTICAL MOVE

BEST maneuver for advancing a balloon across a tight lesion

1 No Added Cost FIRST Best

Maneuver: The guide position, optimize coaxial alignment, deep seat the guide if needed, so the guide can provide sufficient support for advancing the balloon



2 No Added Cost SECOND Best Maneuver: Ask patient to take a deep breath in order to elongate the heart and the artery (less tortuosity). During this short window of opportunity, advance the balloon

3 No Added Cost THIRD Best Maneuver: Paradoxical move – constant pressure to advance the balloon while pulling the wire so that the balloon can cross the lesion. This technique is to decrease the friction between the wire and the lumen of the balloon catheter. It also helps to keep the wire straight and taut so that the balloon catheter can slide on it

4 \$ FOURTH Best Maneuver: Add a stiffer wire so that the balloon can slide on it. The guide can become stiffer and cannot slide back out. The arterial segments are also straightened (less wire bias) and the balloon can be tracked more easily

5 \$ FIFTH Best maneuver: Change to a lower profile balloon (monorail, compliant, with a marker at the center)

Technical Tips

****Positioning a balloon when the blood flow is cut off** In many cases, just advancing a balloon across a severe lesion cuts off the coronary flow. Once the balloon is in place, there is no way to check the location of the balloon before inflation. Select a balloon with a length that covers the lesion well. Inject the contrast agent while advancing the balloon. The contrast will stop in the middle of the lesion. Check the position of the balloon and be sure that the center of the balloon is at the middle of the lesion. Then the balloon can be inflated (Figure 5.1).

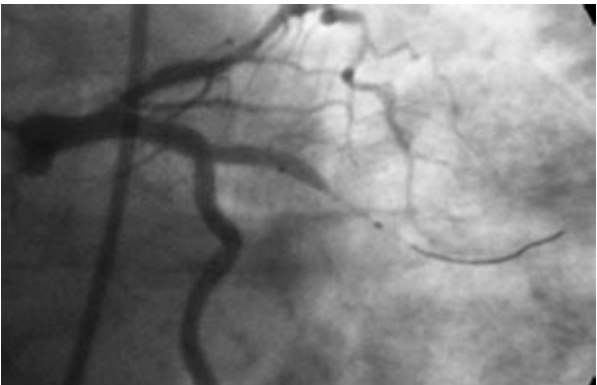


Figure 5.1 There was a tight lesion at the obtuse marginal. When the balloon was across the lesion, it obstructed the flow, so a coronary angiogram could not be done to check the exact location of the balloon. Injecting the contrast while advancing the balloon will trap the contrast exactly at the center of the lesion. (Courtesy of the Cardiac Catheterization Laboratories of Community Healthcare System, St Mary Medical Center Hobart IN.)

****Speed of inflation pressure** Most operators inflate the balloon slowly until its waist disappears. This gradual inflation will slowly rearrange the atheromatous material inside the plaque along the longitudinal and radial axes of the artery. In this way, the vessel is stretched and deformed in a more predictable fashion than with sudden inflations which are more likely to cause extensive tearing (dissection) of the vessel wall.

****Checking the appropriate size of the balloon or stent** After successful inflation of the balloon, 5 seconds before deflating it, a small injection of contrast will verify the correct fitting of the balloon with the proximal segment of the dilated lesion. If contrast agent is seen flowing around the proximal segment of the inflated balloon, the balloon is too small for the artery. This is only a rough assessment for the appropriate size of a balloon or stent, when intravascular ultrasound (IVUS) is not available (Figure 5.2).

****Looking for collaterals** Collaterals seen during the diagnostic study, or appearing with a contrast medium during balloon occlusion, project a low-risk profile for the patient and reduce the stress for the operator. They can be looked for by injecting contrast when the balloon is about to be inflated. If contrast caught in the distal vasculature the moment the balloon is fully inflated is washed out promptly, good collaterals are documented. If the contrast stays put, the territory is devoid of collateral blood flow in the event of a later vessel occlusion [4].

ADVANCED TECHNIQUES Exchanging an over-the-wire balloon catheter over a regular-length wire It is simple to exchange a balloon catheter over the monorail system. When exchanging a balloon on the OTW system, the indwelling wire

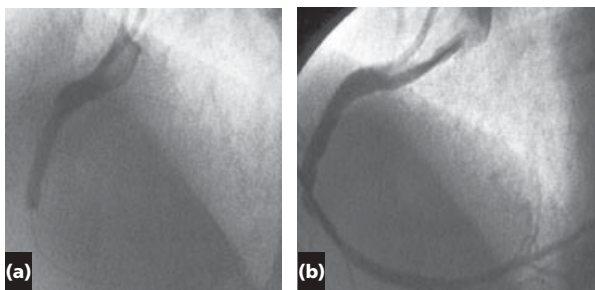


Figure 5.2 Assuring the adequate the size of the balloon and stent: (a) A balloon was inflated, and 5s before deflation, contrast agent injected. Compare the size of the balloon and the proximal segment. In this case, the size of the balloon is clearly smaller than the proximal arterial segment. (b) A larger stent was selected and deployed. A post-stenting angiogram showed larger size of the stented area compared with the proximal arterial segment. (Courtesy of the Cardiac Catheterization Laboratories of Community Healthcare System, St Mary Medical Center Hobart IN.)

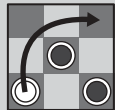
must be extended (docked) to a second wire, or a long exchange (300 cm) wire is needed. However, an OTW balloon catheter can be exchanged without the need of another wire. With the indwelling wire held immobile, the balloon catheter is removed slowly until its proximal hub meets the proximal tip of the wire. Attach a 5-ml syringe of contrast to the central lumen of the balloon catheter. Persistently inject the contrast while simultaneously withdrawing the balloon. This persistent injection will move the wire forward while the balloon is removed slowly. To accomplish this exchange successfully, the wire should not be bent and the catheter should be well flushed before starting the procedure. The Y-Tuohy catheter should be open. The catheter should be positioned on a straight line, to minimize any friction with the wire [5].

Failure to dilate a lesion A rigid lesion with heavy calcification may prevent the full expansion of a balloon, even if the balloon is inflated to near the rupture pressure. It may be successful but it exposes the patient to the risk of dissection or balloon rupture. The first option is to use force-focused angioplasty by adding one (two or three) extra wire(s) besides the inflated balloon. Another option is to exchange for a non-compliant balloon so that much higher pressure inflations can be achieved. In lesions with heavy superficial calcium, the problem can be resolved by debulking with rotational atherectomy, followed by use of a drug-eluting stent (DES). The cutting balloon is one of the best options in PCI of the undilatable fibrotic lesion.

TACTICAL MOVE

BEST maneuver for dilating undilatable lesions

- 1 \$ **FIRST Best Maneuver:** Add another wire and perform force-focused angioplasty
- 2 \$\$ **SECOND Best Maneuver:** Change to a non-compliant balloon and perform higher-pressure inflation
- 3 ♦♦ **THIRD Best Maneuver:** Cutting balloon angioplasty for non-calcified and calcified lesion
- 4 ♦♦ **FOURTH Best Maneuver:** Rotational atherectomy for calcified lesion



Technical Tips

****Force-focused angioplasty** If the balloon fails to break a plaque, it is withdrawn into the guide. A second wire is advanced beyond the lesion. The balloon is readvanced, positioned across the lesion, and inflated as usual. With the wire across the lesion, the pressure is then focused on the wire, which acts as a cutting wire to selectively apply pressure and crack the plaque. Complications include dissection, which can be treated by stenting. It is best done with an undersized non-compliant balloon, which

allows the operator to go to high pressures without concerns about balloon oversize relative to vessel size or balloon rupture.

****Balloon for calcified lesion** If there is no need for rotational atherectomy, it is better to select an intermediate-size non-compliant balloon (2.0 cm × 10 mm). If the balloon is too short it is easier to slide from the lesion; if it is too long, it is difficult for navigation of the calcified segment. The best is intermediate size and length. As it is an intermediate-size balloon the balloon can be inflated at maximal pressure (25–28 atm) and dilate the lesion without over-dilating or dissecting the artery.

****Balloon angioplasty of large vessels** Current maximum balloon size is 4 mm in diameter, so, when the coronary artery or the saphenous vein graft (SVG) is >4 mm, the hugging balloon technique or use of a peripheral balloon is suggested. The two balloons are positioned side by side and inflated simultaneously. The combined diameter will be 70% of the sum of each balloon alone and the cross-section area would be oval rather than round [6,7].

Failure to deflate the balloon Inability to deflate the balloon is a rare occurrence. Possible causes are excessive twisting: More than 360° in order to cross a distal lesion [8], or entrapment in the distal portion by a tight lesion.

TACTICAL MOVE

BEST options when the balloon fails to deflate

1 No Added Cost FIRST Best Maneuver:

Deflate the balloon with the inflation device

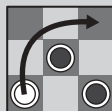
2 No Added Cost SECOND Best Maneuver: Deflate the balloon with a 50-ml syringe connected directly at the inflation port

3 No Added COST THIRD Best Maneuver: Dilute the contrast material in the deflator with saline, resulting in a decrease in fluid viscosity within the balloon. The negative pressure that was generated across the kinked balloon might be adequate to deflate the balloon

4 ♦♦ As a last resort: Inflate the balloon to rupture it. Prepare for damage control from dissection or coronary perforation

5 ♦♦ Puncture the balloon with the back end of a wire

6 ♦♦ Surgical removal of the balloon



Technical Tips

*****How to puncture an undeinflated balloon?** After exhausting all maneuvers without success, one rarely used measure is to advance a small new OTW balloon immediately next to the proximal end of the entrapped and still inflated balloon.

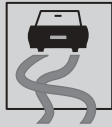Remove the 0.018-inch wire of this OTW balloon, reinsert the wire back, with the stiff **back end** in first. Inflate the new balloon at low pressure to position the sharp end of the wire at the center of the vessel lumen. Try to puncture the trapped inflated balloon.

Although there is a risk of coronary perforation, the hole would be quite small and unlikely to cause any significant complication. In addition, vessel trauma from balloon rupture can be much more extensive and more uncontrolled than a single pinhole puncture (Le Khoi, personal communication).

CAVEAT

Impending rupture due to material fatigue

Besides rupture due to excessive inflation or calcified plaque, another cause of rupture is material fatigue [9]. Balloon fatigue generally occurs after numerous inflations and deflations of a re-used balloon seen frequently outside the USA. The sign of material distress or fatigue is that there is a focal bulging in the balloon during inflation. It is suggested that, even when faced with an unyielding stenosis, inflation pressure above the rupture level marked by the manufacturer should be avoided.



Entrapment of deflated balloon during withdrawal Even though the incidence of entrapment of a deflated balloon is low, once it happens it is quite traumatic to the patient, operator, and interventional team. The entrapment can happen in any unpredictable way. Different options in freeing an entrapped balloon are listed below. There are no practical best options if based on a hypothetical scenario. Different modalities of treatment can be selected on a trial-and-error basis.

TACTICAL MOVE

BEST options for freeing an entrapped balloon

1 No Added Cost FIRST Best Maneuver:

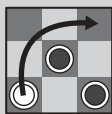
Push the balloon forward then pull it back

2 No Added Cost SECOND Best Maneuver:

Twist the balloon in an attempt to rewrap the balloon before pulling back

3 \$ Insert a stiffer wire alongside the entrapped balloon before pulling the balloon back so that the artery is straighter

4 \$\$ Advance a second wire distally, then insert an OTW balloon alongside the entrapped balloon and inflate the



(Continued)

new balloon at low pressure to free the entrapped balloon

- 5 ♠♠ If the OTW balloon cannot be advanced, then advance a balloon on a wire alongside the entrapped balloon and inflate the OTW to free the entrapped balloon
- 6 ⌚ Advance a commercial microsnare and tighten the loop as near to the balloon as possible, then pull the balloon back

*****Using a commercial snare to remove a trapped balloon** Cut the proximal end of the balloon catheter. Advance the snare using the balloon catheter as a wire. Arriving at the entrapped balloon site, loop the snare around the balloon, and tighten the loop by advancing the transport catheter. Pull the snare and the catheter together to free the balloon [10]. Be prepared to unwrap the snare and pull it back alone if it is not possible to remove the trapped balloon.

*****Repeated balloon rupture** Balloon rupture can happen repeatedly in a patient with in-stent restenosis (ISR). In one case report, the IVUS study showed a ridge of calcium protruding into the lumen. Management of this problem includes use of a stronger balloon and rotational atherectomy, which can be problematic because it can ablate the metallic stent struts [11].

*****Damage control for balloon rupture** Balloon rupture is seen under fluoroscope as a quick dispersion of contrast agent from the balloon, with short contrast opacification of the vessel or decrease in the inflation pressure. When this occurs, slowly withdraw the balloon proximal to the lesion and inject some contrast to detect if there is perforation. The balloon is then removed if not entrapped in the lesion. Stenting should be performed if there is dissection.

CUTTING BALLOONS

As a result of the presence of microblades at its side, the cutting balloon is quite stiff and difficult to curve around sharp bends. To overcome this problem, the cutting balloon is designed with very short length.

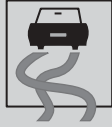TECHNIQUE While dilating the cutting balloon, a slow inflation strategy is used. There should be a 3- to 5-second interval between each atmosphere of pressure increase, to ensure that the peripheral balloon wings unfold slowly first around the blades, before inflation of the central core of the balloon. Rapid inflation could result in the blades puncturing a hole in the balloon. The manufacturer's guidelines for balloon inflation should be adhered to: 1 atm inflation every 5s for a maximum 6–8 atm. Some operators also recommend deflation of the balloon at the

same gradual rate. Finally, withdrawal of the cutting balloon should not be attempted until an adequate time interval has elapsed to allow full rewinding of the balloon.

CAVEAT

Extraction of stent by cutting balloon

The cutting balloon has its blades mounted along its length. During inflation, the blades protrude outward and are exposed. Then, during deflation, there is a mechanism of rewinding the balloons with multiple wings. During this process of rewinding, there is a possibility of creating an anchor form from the balloon and blades, or just because it is a higher-profile balloon strengthened with the blades. This can get stuck in the stent struts and prevent withdrawal of the cutting balloon. If the cutting balloon is pulled hard enough, it could pull the stent or part of the stent with it. As the lumen of the artery is removed from its stent, the lumen can become avulsed and undergo acute occlusion [12,13].



The causes of cutting balloon entrapment can be related to unsuspected passage of the coronary wire through a stent cell, which is then followed by a cutting balloon, due to locking of the microblades in the stent struts, with subsequent avulsion of the struts on attempted withdrawal, or in association with fracture of the microblade.

Trouble-shooting Tip

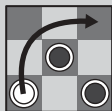
****Freeing an entrapped cutting blade** If difficulty is encountered when advancing the cutting balloon, the preliminary presumption is that there is a possibility of wire passage through the stent struts. Excessive resistance to advancement of the balloon should be interpreted as an indication of this, and rewiring be done. Where there is doubt, IVUS can be used to confirm that the wire is within the stent lumen throughout its course.

TACTICAL MOVE

BEST maneuver for freeing an entrapped cutting blade [14]

1 No Added Cost Push/Pull: An avulsed longitudinal atherotome may be trapped between the stent strut and the vessel wall.

The entrapped cutting balloon should first be advanced



(Continued)

forward and rotated either clockwise or counterclockwise to unhook the protruding microtome

- 2 **\$\$ Buddy Balloon:** If the atherotome has become deformed in its mid-portion which has snagged a stent strut, a second balloon can be introduced alongside the entrapped cutting balloon and inflated to change the configuration of the cutting balloon and release a stent strut. Although the "buddy balloon" technique may be useful in changing the configuration of the entrapped cutting balloon, the risk of balloon rupture from a protruding microtome is highly likely
- 3 **\$ Guide "Sheath":** With the extreme longitudinal arterial force sometimes required to remove an entrapped cutting balloon, the proximal vessel can sustain tractional injury, resulting in proximal coronary dissection. With some 6-Fr guides, the guide can be deep seated within the coronary artery, and the retraction force can be applied at the orifice of the guide. If the cutting balloon has been dilated through a stent strut, this maneuver is unlikely to be successful, but will lessen the degree of traction injury to the vessel
- 4 **\$\$ Snare:** If a large (>8Fr) guide has been used (or a smaller guide can be exchanged for a larger one), the hub of the cutting balloon can be cut and a snare can be placed over the shaft of the cutting balloon and its wire. The snare can then be advanced through the guide to the cutting balloon, allowing for greater traction force to be directly applied to the entrapped device
- 5 **\$\$\$ CABG:** If the entrapped cutting balloon cannot be retracted despite these maneuvers, or if antegrade flow cannot be sustained, surgical consultation for coronary artery bypass graft (CABG) and removal of the entrapped cutting balloon should be undertaken. Although this therapy is a last resort, it is required in some cases with refractory cutting balloon entrapment [15]

REFERENCES

1. Ellis S. Elective coronary angioplasty: Techniques and complications. In: Topol E (ed.), *Textbook of Interventional Cardiology*, 3rd edn. Philadelphia, PA: WB Saunders, 1999: 147–62.
2. King SB. Complications of angioplasty. In: King SB, Douglas JS (eds), *Atlas of Heart Diseases: Interventional cardiology*. St Louis, MO: Mosby, 1997: 12.1–12.15.
3. Ikeno F, Yeung A. Equipment for PCI. In: King S, Yeung A (eds), *Interventional Cardiology*. New York: McGraw Hill, 2007: 79–86.
4. Meier B. Balloon angioplasty. In: Topol E (ed.), *Textbook of Cardiovascular Medicine*, 3rd edn. New York: Lippincott-Raven, 1998: 1665–76.
5. Nanto S, Ohara T, Shimonagata T, et al. A technique for changing a PTCA balloon catheter over regular length guidewire. *Catheter Cardiovasc Diagn* 1994;**32**:274–7.

6. Krucoff MW, Smith JE, Jackman JD, et al. "Hugging balloons" through a single 8F guide: salvage angioplasty with lytic therapy in the IRA of a 40-year-old man. *Catheter Cardiovasc Diagn* 1991;**24**:45–50.
7. Feld H, Valerio L, Shani J. Two hugging balloons at high pressures successfully dilated a lesion refractory to routine coronary angioplasty. *Catheter Cardiovasc Diagn* 1991;**24**:105–7.
8. Breisblatt WM. Inflated balloon entrapped in calcified coronary stenosis. *Catheter Cardiovasc Diagn* 1993;**29**:224–8.
9. Kussmaul III WG, Marzo K, Tomaszewski J, et al. Rupture and entrapment of a balloon catheter in the LAD: Fluoroscope of impending balloon rupture. *Catheter Cardiovasc Diagn* 1993;**19**:256–9.
10. Watson LE. Snare loop technique for removal of broken steerable PTCA wire. *Catheter Cardiovasc Diagn* 1987;**13**:44–9.
11. Giluts H, Weistein J. Repeated balloon rupture during coronary stenting due to a calcified lesion: An IVUS study. *Catheter Cardiovasc Interv* 2000;**50**:212–14.
12. Kawamura A, Asakura Y, Ishikawa S, et al. Extraction of previously deployed stent by an entrapped CB due to blade fracture. *Catheter Cardiovasc Interv* 2002;**57**:239–43.
13. Harb T, Ling F. Inadvertent stent extraction six months after implantation by an entrapped cutting balloon. *Catheter Cardiovasc Interv* 2001;**53**:415–19.
14. Blackman D, Dzavik V. Inadvertent detachment of an entrapped cutting balloon from the balloon catheter during treatment of in-stent restenosis. *J Interven Cardiol* 2005;**17**:E27–9.
15. Giugliano GR, Cox N, Popma J. CB entrapment during the treatment of ISR: An unusual complication and its management. *J Interven Cardiol* 2005;**17**:168–70.

CHAPTER 6

Stenting

Thach N. Nguyen, Vo Thanh Nhan, Dinh Duc Huy,
Nguyen Huynh Khuong, Nikola Bakraceski

Challenges 120

Easy Delivery: High Longitudinal Flexibility and Low Profile 120

Perfect Deployment = Great Radial Strength and Curve Conformity 120

Practical Clinical Evaluation of a Stent 121

Is This Stent Flexible? 121

What is the Radial Strength? 121

Does this Stent Brace Itself against the Wall with a Strong Strut Network? 121

Is the Stent User Friendly? 122

Advancing a Stent 122

Technical Tips 123

**Testing the road 123

**The “buddy wire(s)” technique 123

***The distal buddy balloon technique 124

***The proximal deflecting balloon technique 124

Deploying a Stent 125

Direct Stenting 125

Predilating Balloon Angioplasty 126

Technical Tips 126

**Deployment of a stent in a tortuous artery 126

**Appropriate sizing for tapering artery 126

Advanced and Exotic Techniques 127

Deploying a stent without an angiogram 127

Technical Tips 127

***How to opacify the LIMA with high flow 127

***How to stent the LAD if the LIMA has a high flow 127

***Post-stent deployment balloon inflation 127

Assessment of the result of stenting by optical coherence tomography (OCT) 128

Re-Crossing a Stented Area 128

Technical Tips 129

**Dottering the stented area 129

**Steer the wire to a new branch 130

***Other exotic techniques 131

*Basic; **Advanced; ***Rare, exotic, or investigational

\$, <\$US100.00 extra; \$\$, >\$US100.00 extra

⌚, <10 min extra; ⌚⌚, >10 min extra

♣, low risk of complications; ♣♣, high risk of complications

***First balloon deflecting second balloon away from problematic area 131

**Re-crossing a stent with a bent stiff wire 131

**Re-crossing a stent with a movable tip wire 131

Redeploying a Stent 132

Technical Tips 133

**How to cross a crushed stent 133

Deploying a stent after failed expansion by a balloon 134

Advantages and Limitations 134

Trouble-shooting Tips 136

***Redeploying an embolized stent 136

***Management of balloon rupture 137

***Stent deployment after balloon rupture 137

Covered Stent 137

Technical Tips 138

**Hand crimp a covered stent 138

***How to check the integrity of a hand-crimped balloon before deployment 138

CHALLENGES

As a clinical cardiologist must know the pharmacological properties of a new cardiovascular drug or the mechanism of a new therapeutic device, interventional cardiologists must understand the basic physical or bioengineering principles of stenting in order that the most suitable stent for a given lesion can be selected, advanced smoothly, positioned at the intended location, and deployed with an optimal luminal diameter.

Easy Delivery: High Longitudinal Flexibility and Low Profile

A stent mounted on a delivery balloon should be able to easily negotiate the tortuous segments proximal to the target site without injuring the intima or eliciting spasm. This smooth delivery is termed “high trackability” because a stent (with excellent longitudinal flexibility) is passed easily over a wire. The two properties, high longitudinal flexibility and low profile, help to bring the stent to the target site within an allotted timeframe and with minimal manipulation. A stent can easily cross an angulated segment if its length can fit in the widest interval at the curve. If it is longer, it can be advanced as long as it can be minimally and transiently bent or curved, or the arterial segment is not too calcified to relax and compliantly accommodate the length of the stent.

Perfect Deployment = Great Radial Strength and Curve Conformity

Once deployed, a stent must have sufficient radial strength to resist the elastic recoil of the media and the shifting plaque. In

an emergency situation, it has to be strong to seal the entry of a dissection, patch a dissecting flap, or brace against the persistent compression of a growing intramural hematoma. In non-emergency situations, an expanded stent should be able to sustain its frame against the systolic compression of a myocardial bridge. In addition, an adaptively deployed stent would mold its shape along the contour of a curved segment rather than straighten it, and still provide a large desired lumen. These two properties of a deployed stent, great radial strength and curve conformity, would give an instant perfect angiographic result. After deployment, the struts should be well embedded into the arterial wall and stop any systolic contraction or diastolic relaxation. Therefore, they effectively immobilize the stented arterial segment and prevent any ongoing injury to the intima, which is the nidus for any endothelial thrombotic formation. Excellent apposition of the struts on the vessel wall will guarantee the delivery of any drug from a drug-eluting stent (DES), preventing intimal hyperplasia and ultimately in-stent restenosis.

PRACTICAL CLINICAL EVALUATION OF A STENT

Is This Stent Flexible?

In general, if a stent has no stiff longitudinal shaft along its length, it will be flexible. With better supportive equipment to advance a stent (stiffer wire, more stable guide), or in the case of minimal tortuosity, the flexibility of a stent is not a major concern in today's busy cardiac catheterization laboratories. However, most patients undergoing percutaneous coronary interventions (PCIs) are older and have more complex lesions – more tortuous proximal segment, calcified lesion, located in distal position – so the flexibility is still a major concern in selection, advancement, and deployment of a stent in the elderly patient group.

What is the Radial Strength?

Most currently available stents have adequate radial strength. However, the most important concern is the even and reliable distribution of their struts. In the left main trunk, at the anastomotic site of a saphenous vein graft (SVG), or in the lesions of elderly patients, the lesions are composed of extensive fibrotic tissue and have significant recoil pressure. In these situations, stents with high radial strength are particularly needed. It is also required for long-term success in stenting of the carotid, femoral, popliteal, or tibial arteries, which may be subjected to external compression.

Does this Stent Brace Itself against the Wall with a Strong Strut Network?

Intravascular ultrasound (IVUS) has demonstrated that stenting a lesion shifts the mass of atheromatous material along the longitudinal and radial axes. To achieve the best luminal diameter, a just-deployed stent has to provide a strong network of struts to fence off the recoiling atheromatous mass and provide a

controlled shifting of the plaque burden along the longitudinal axis. It has to be able to prevent any intraluminal herniation of the plaque through its struts and any possible distal embolization of the material from the plaque.

Is the Stent User Friendly?

In general, an elective stenting procedure should not require more than 30 min if the equipment is reliable and user friendly. Every step of the procedure should be achieved on a first try. Besides a strong guide support, the success of delivery depends on the size, flexibility of the stent–balloon complex, and compliance of the arterial segments proximal to the target site, and the adequate opening of the lesion site. A flexible and small stent can slide on a floppy wire whereas a stiffer wire is needed to track a bulky, stiffer stent. A short stent can easily negotiate a sharp bend, whereas some longer stents cannot. During delivery, a stent should hold well to the balloon, thus avoiding the risk of inadvertent embolization. In case of failure of delivery, while attempting to withdraw an undeployed stent into the guide, there should be no feeling of resistance and the stent should be watched carefully to ensure that it does not slip off the balloon. If this occurs, the guide, stent, and wire should be withdrawn en bloc. In all situations, the choice of stent depends on the operator's preference, experience with a particular design, and critical evaluation of different structural features to maximize technical and clinical benefits.

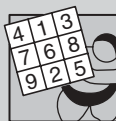
ADVANCING A STENT

STRATEGIC MAPPING

When a stent fails to move forward, it is imperative to assess the stability of the guide position, the stiffness of the wire, the tortuosity and calcification of the vessel, and the flexibility and length of the stent.

Guide The tip of the guide should be coaxial with the ostium, and advancement of the device does not back out the guide. If it does, the guide is not strong enough and should be deep seated. If the guide is deeply seated, does not back out, and the stent does not advance, then change of guide shape may not have necessarily proved successful. For a guide to be more stable, it needs to have a large contact area on the opposite aortic wall. For a guide to be stiffer, it has to have larger size, or be encased in a long (70 cm) sheath.

Wire If the guide position is stable and the artery is tortuous and calcified an extra support (as stiff as or stiffer than the first) wire may compensate sufficiently for this mildly deficient guide backup and the non-accommodating arterial segment. The mechanisms of success of this extra wire are by making the guide stiffer (with an extra wire



inside the guide), straightening the arterial segment proximal to the lesion (so that the stent can slide easier), and hopefully decreasing wire bias at the curve by projecting the wire away from the inner curve and being positioned more at the center of the lumen. However, if the guide is so unstable (e.g. a Judkins left for percutaneous coronary intervention or PCI of the left circumflex artery [LCX]) in a patient with a short long main artery (LM), an extra wire may not be sufficient to correct the problem.

Artery If the artery is moderately or severely calcified and tortuous, the problem is not from a stable guide, or a stiff wire, but from a stiff non-conforming arterial segment. One of the reasons is that the proximal segment of the LCX is encased inside the atrioventricular groove, so that the proximal LCX is less accommodating even without calcification. Is there a lesion in the proximal segment that impedes the advancement of the stent? If there is, then dilation of the proximal segment (with later stenting) is required. On rare occasions, the problem encountered is due to a hard eccentric plaque with the friction on the calcified and rough surface of the plaque too resistant for the stent to pass. The additional extra-support wire was not strong enough to divert the stent away from the plaque surface. A slippery hydrophilic wire may help the stent to pass. Plaque modification with rotational atherectomy could solve this problem easily.

Stent The most important features are stent flexibility and the smoothness of the stent surface over the balloon. Stents that have minimal flareup of the stent struts on bending typically perform best in such cases. Longer stents have a tendency to “lock” over bends, particularly if flaring up of the stent struts occurs while the stent bends. This “locking” can be released by gentle motion and steady gentle force on the stent. Sometimes pulling the wire slightly can lead to release of the lock. Shorter stents generally behave more favorably in tortuous vessels [1].

Technical Tips

****Testing the road** After the lesion has been predilated with a balloon, a stent is prepared to be advanced. If the proximal segment is tortuous, the question is whether the stent could arrive at the lesion site. One way to test the possibility is to advance the deflated balloon with its wings still out. If the balloon can re-cross the tortuous segment and lesion, there is higher chance (>50%) that a stent can do this also.

****The “buddy wire(s)” technique** The “buddy wire” approach requires one extra-support or heavy-duty wire to straighten the artery. As the stent cannot be advanced through

a first wire, advance a second stiffer wire across the lesion, and then advance the stent as usual. Once the stent has been positioned across the lesion, the buddy wire is removed and the stent deployed [2]. If one extra wire does not work, try to slide the stent on the hydrophilic wire. An additional third wire may help.

*****The distal buddy balloon technique** After many failed attempts, an over-the-wire (OTW) balloon is advanced beyond the target lesion. There the balloon is inflated to entrap the wire. While pulling the entrapped wire to keep tension on it, the stent is advanced successfully on this taut wire. The balloon is removed before deploying the stent; if not the balloon will be “jailed.” The mechanisms for success of this technique are explained in Box 6.1 [3]. The negative sides to this trick are: (1) the need for an extra balloon; (2) inflation of a distal balloon, which can cause endothelial denudation that starts the restenosis process; (3) rupture of a new plaque causing thrombosis or acute occlusion; and (4) the balloon will get stuck if it is not withdrawn before stent deployment.

*****The proximal deflecting balloon technique** A small balloon is advanced near the questionable area and occupies the eccentric dead-end space just proximal to the lesion; it is strong enough to direct the second balloon/stent over to the lesion surface smoothly. Such a technique can also be applied in other circumstances such as difficulty in passing a balloon catheter into a stent for post-deployment high-pressure dilation, and difficulty in passing a retrieval or aspiration catheter through a stent at the end of the procedure, after using distal protection devices. In a case report, because of wire bias caused by mildly calcified plaque, even after the use of a second buddy wire, the distal edge of the stent continued to get caught on the plaque, preventing it from further advancement. Gentle inflation of the buddy balloon to 2 atm provided a platform for the stent to be further deflected from the plaque, allowing it to advance to the desired position. However, there are limitations to this technique. A larger guide is needed and the vessel size needs to be large enough to accommodate two balloon catheters. Manipulation of multiple wires and balloon catheters may also induce trauma to the proximal parts of the vessel [4].

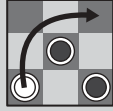
BOX 6.1 MECHANISMS OF THE DISTAL BUDDY BALLOON TECHNIQUE

- 1** Pulling on the wire will seat the guide more deeply and firmly
- 2** Trapped by the balloon, the first wire can be pulled and become a stiff rail over which the stent is easily tracked
- 3** Straightening the proximal segment of the vessel causes less (or more, and hopefully) wire bias

As there are many options to overcome the difficulty of stent delivery, which one is best for the situation? This decision requires critical thinking so that the procedure can be finished on time, without equipment being wasted.

TACTICAL MOVE

BEST maneuvers when a stent fails to advance



1 No Added Cost FIRST Best maneuver:

Secure a more stable guide position or, if possible, the guide can be deep seated safely

2 No Added Cost SECOND Best maneuver:

Constant forward pressure on the stent catheter while pulling the wire back to decrease friction inside the stent catheter lumen and to straighten the stent catheter while asking the patient to take a deep breath in order to elongate and straighten the artery

3 \$ ⌘ THIRD Best maneuver:

Advance a second stiffer wire to straighten the artery (the buddy wire technique). Advance the stent on the second stiffer buddy wire; occasionally stents may actually advance more easily over a softer wire

4 \$\$ ⌘ ⬆ Dilate the proximal segment or plaque removal to facilitate stent advancement

5 \$ ⌘ Change to a larger guide or one with a different curve to achieve better backup and less friction at the ostium

Other exotic manipulations can be done without guaranteed success:

- 1 Change the stent to a shorter one, if the problem is due to tortuosity of the proximal segment
- 2 Select a different type of stent with better flexibility
- 3 Bend the stent to conform the stent along the curve of the artery
- 4 The buddy balloon technique: Advance a second balloon beyond the deployment area; inflate the balloon to hold the first wire.

DEPLOYING A STENT

As more PCIs are done without formal surgical backup, many lesions are strategically under-predilated so that they can be stented immediately at standard size and higher pressure. Other operators suggest direct stenting without prior balloon inflation.

Direct Stenting

Direct stenting is a feasible and safe technique when used in selected coronary lesions, without significant calcifications and/or angulation. The degree of stenosis is not an important limitation,

BOX 6.2 FACTORS FAVORING SUCCESSFUL DIRECT STENTING

- 1 No calcium at the target coronary vessels
- 2 No severe proximal tortuosity

particularly in unstable angina where thrombus plays an important role. In the case of a type A lesion, there is not much difficulty in measuring the reference diameter for accurately sizing a stent. In a lesion with chronic distal vasoconstriction due to low flow, the angiographic distal reference diameter may be smaller. Sometimes the strategy of direct stenting backfires because of the potential for only partial stent deployment (e.g. due to lesion fibrosis, calcification, or balloon rupture), risk of stent loss and difficult stent retrieval, and the potential for inaccurate stent placement if there is poor distal vessel opacification. Therefore, it is important to check for the presence of heavy calcification at the lesion and in the proximal segment before angioplasty and stenting for possible rotational debulking. Fluoroscopy alone is not sensitive enough to detect superficial calcium. Do use a moderate push to attempt the passage of the stent to the desired position at the lesion site. Avoid prolonged or forceful manipulation to cross the lesion because the stent can be stripped off the balloon and embolized distally. The factors favoring successful direct stenting are listed in Box 6.2 [5].

Predilating Balloon Angioplasty

The goal of predilation is not to achieve a perfect result, but to facilitate the positioning of the stent. Perfect angioplasty may eliminate the angiographic landmark of the lesion and make the location of stent deployment uncertain and full coverage of the injured segment doubtful. However, if the lesion is not heavily calcified and fibrotic, and not fully predilated, then, when deploying a stent, it may not be possible to fully dilate the balloon, leaving a half-open stent, which is a nidus for future subacute thrombosis.

Technical Tips

****Deployment of a stent in a tortuous artery** When a stent is deployed in a very tortuous arterial segment, the vessel wall forms many invaginations beyond the struts, rather than being well stretched. To maximize the length of the stented segment along the natural curve of the tortuous artery and to ensure that the struts are well apposed to the vessel wall, the stent is deployed while the patient takes a deep breath. Deep inspiration would make the heart more vertical, elongate the artery, and, in that short window of opportunity, the stent is deployed.

****Appropriate sizing for tapering artery** After successful inflation of the balloon, 5 seconds before deflating it, a small injection of contrast agent will verify the correct size of the balloon with the proximal segment of the dilated lesion. After deploying a stent the same maneuver will verify the correct size

of the stent with the proximal segment of the dilated area. If contrast agent is seen flowing around the proximal segment of the inflated stent–balloon complex, the stent needs to be inflated with larger size balloons. If the stent is under-dilated, the now deflated balloon is pulled back a few millimeters in order to avoid over-dilating the distal end, and is inflated again with higher pressure to achieve greater size. This is only a rough assessment of the appropriate size of the balloon or stent, when IVUS is not available (see Figure 5.2).

Advanced and Exotic Techniques

Deploying a stent without an angiogram

In a case report of stenting the mid-left anterior descending artery (LAD) beyond the left internal mammary artery (LIMA) insertion, balloon angioplasty and stenting have to be done through the native artery using anatomic landmark (e.g. ribs, clips, side branches). The reason is that no contrast injection could be done through the native LAD, whereas the flow through the LIMA was too brisk for visualization. The severe tortuosity in the LIMA prevented the passage of bulky interventional devices. In such a case, balloon inflation and stent deployment were done through anatomic landmarks without an angiogram [6].

Technical Tips

*****How to opacify the LIMA with high flow** Use a guide with the tip large enough to cause flow standstill. Inject the contrast while advancing the guide. As the contrast moves forward and opacifies the distal diseased segment, the tip of the guide occludes the ostium of the LIMA and slows the coronary flow enough so that the distal segment can be seen.

*****How to stent the LAD if the LIMA has a high flow** Use a guide with the tip large enough to cause flow standstill. Inject the contrast while advancing the guide. As the contrast moves forward and opacifies the distal diseased segment, the tip of the guide occludes the ostium of the LIMA and slows the coronary flow enough so that the distal segment can be seen. If the LIMA is tortuous, advance a GuideLiner through the native LAD. Do a coronary angiogram and perform PCI through the GuideLiner. The lesion is supposed to be beyond the insertion site of the LIMA.

*****Post-stent deployment balloon inflation** After deployment of a stent, the post-dilation high-pressure balloon should be short and non-compliant. The balloon should be short so that it can fit entirely inside the length of the stent, without causing any tear at the two edges. If the balloon is longer than the stent, the segment of the balloon exceeding the length of the stent is positioned at the proximal end. This position would help to avoid the need of re-crossing the stent, if there is a rupture-induced dissection in the proximal rather than the distal end. This position also helps to avoid over-dilating the adjacent distal segment which is often smaller than the proximal reference segment. Moreover, placing excess balloon length proximal to the stent should decrease the chance of entrapment and tethering of the

ruptured balloon on the distal end of the stent, which could make retrieval of the balloon extremely difficult or impossible.

Assessment of the result of stenting by optical coherence tomography (OCT) *Stent malapposition* was identified as a clear separation between at least one stent strut and the vessel wall in the IVUS images, and was defined as a distance between the center reflection of the strut and the vessel wall of greater than the actual stent thickness + 20 μ m (optical coherence tomography [OCT] resolution limit) in the OCT images. *Stent edge dissection* was defined as disruption of the luminal vessel surface in the edge segments. *Tissue prolapse* was defined as protrusion of tissue between stent struts, extending inside a circular arc connecting adjacent struts in both IVUS and OCT images. *Thrombus* was defined as an irregular low echoic mass, often mobile and extruding into the vessel lumen and sometimes becoming detached from the vessel wall based on IVUS. On OCT image, *intracoronary thrombus* was defined as a protruding mass beyond the stent strut into the lumen with significant attenuation behind the mass (Figures 6.1 and 6.2) [7].

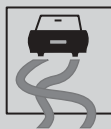RE-CROSSING A STENTED AREA

Often during PCI near a previously stented area, there is a risk of dislodging or removing the stent by any interventional hardware (balloon, rotablation, cutting balloon, IVUS, directional coronary atherectomy [DCA], AngioJet catheters, etc. [8]). The first event in a later chain of catastrophe is that a wire exits through stent struts. So, an inability to pass balloons, stents, etc. over the wire must be taken seriously as a clue to the possibility of wrong wire exit. The wire should be advanced with a wide J curve, or repositioned, avoiding the previously stented area. Angiographic views can be deceiving and misleading. Sometimes, there is no resistance when the wire exits through the struts [8]. Some caveats for PCI near a previously stented area are listed below.

CAVEAT

During PCI near a previously deployed stent

- 1 Review prior angiogram for stent position and type
- 2 Advance the wire easily with tip in wide J curve. The tip should move freely
- 3 Resistance to crossing device suggests passage between or behind struts (sometimes there is no tactile feeling of resistance by the hydrophilic wire even if it goes through a side strut)
- 4 Use two orthogonal views to assess access, avoiding damage to ostial stents by diagnostic catheter or guide
- 5 IVUS of parent vessel only. Avoid inserting the IVUS catheter deeply through the struts



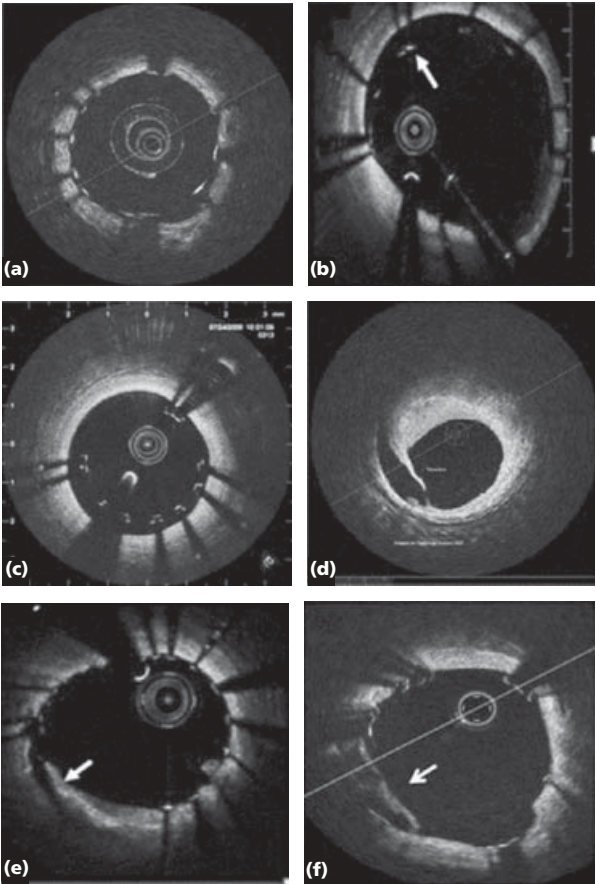


Figure 6.1 (a–c) Incomplete stent apposition; (d) edge dissection; (e) intrastent dissection; (f) tissue prolapse. (Reproduced from Ben-Dor et al. [20], with permission from Wiley.)

Technical Tips

****Dottering the stented area** Hold the interventional device (stent, balloon, cutting balloon, IVUS catheter, etc.) and advance it by gently dottering it. By moving the device forward and backward gently, the indwelling wire is also bounced gently forward and backward. As the tip of the wire cannot go further, the forward energy will be changed to the up-and-down direction which bounces the wire up and down the whole diameter of the lumen. This would make more wire centering and create a chance for the interventional device to enter the newly stented area. If the wire cannot be bounced up and down, because of the small vessel diameter, the wire being well encased in a tight area, or the monorail segment of the device (e.g. the IVUS catheter) being short and not transmitting the dottering movement, this technique does not work (Box 6.3). The stented area should be

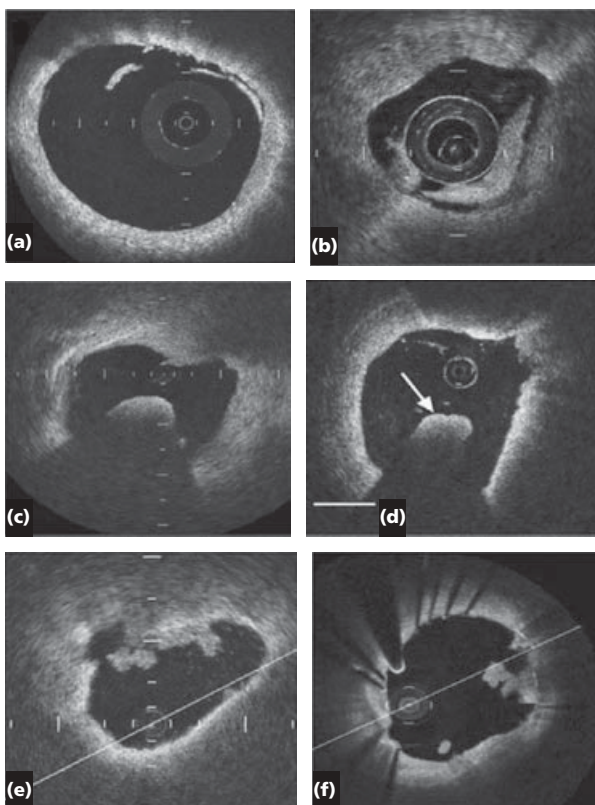


Figure 6.2 (a,b) White thrombus characterized by a signal-rich, low-backscattering projection. (c,d) Red thrombus characterized as high backscattering protrusions with signal-free shadowing. (e) Mixed thrombi. (f) Intrastent thrombi. (Reproduced from Ben-Dor et al. [20], with permission from Wiley.)

BOX 6.3 UNFAVORABLE FACTORS DURING THE DOTTERING TECHNIQUE

- 1 Suboptimal opening of stent
- 2 Wire encased in a tight area
- 3 Small vessel diameter
- 4 Too short monorail segment of the balloon or IVUS catheter

redilated with larger balloon and the proximal entry dilated well so that new devices can be inserted through.

****Steer the wire to a new branch** Steer the wire into a different direction, or to a different branch in order to lessen wire

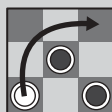
bias and increase more wire centering; hopefully, it will help to advance the stent across the newly stented segment.

*****Other exotic techniques** When crossing a stented segment of a vessel, a short stent crosses more easily than a longer one. If the stent fails to cross a stented segment while being tracked on a soft wire, a stiffer wire with less wire bias can direct the balloon–stent complex more to the center of the stented segment and help the stent to cross. If the stent fails to pass with a stiff wire in place, change to a softer one may help. If a balloon cannot cross a stent, the balloon-on-a-wire type has a higher chance of crossing the stent, because there is no “step up” from the wire to the balloon and therefore no “lip” on the balloon’s nose to get caught inside a stent strut. Unfortunately, these balloons cannot be inflated at high pressure to fully dilate a stent [9]. A new wire with a stiffer distal tip, which is flexible as a whole in its radial axis (the wiggle wire), can move up and down the tip of the stent–balloon complex as it is advanced. Recrossing a stented area that was deployed a long time before can be easier, probably due to endothelial coverage of the struts and any small gaps between them.

*****First balloon deflecting second balloon away from problematic area** In a case report, it has been suggested that a balloon should be positioned at the resistance site where the balloon could not enter the stented area. The balloon is inflated at 2 atm, and then a second balloon advanced as the working balloon. The first balloon would deflect the second balloon away from the problematic area and allow the second balloon to enter the stented segment [9].

****Re-crossing a stent with a bent stiff wire** Often there is a need to cross a stent with a balloon for high-pressure postdilatation, to perform an angioplasty in the distal area, or to patch a distal edge dissection or perform stenting in the distal segment. If a balloon fails to re-cross a stent, it is usually due to the nose of the balloon engaging the stented arterial segment eccentrically or non-axially. To facilitate coaxial entry of the balloon within the deployed stent, a stiff wire may be shaped so that a bend on the wire directs the balloon tip into the center of the stented lumen, thus facilitating passage.

****Re-crossing a stent with a movable tip wire** The Steer-It wire is a 0.014-inch diameter wire consisting of a thin filament affixed at its distal tip to that a hypotube in which it is housed. A sliding component of the proximal handle allows the operator to variably deflect the curvature of the distal end in vivo. After exit from the guide, the curvature at the tip was minimal. Then, at the proximal edge of the stent, the curvature is maximized to $>90^\circ$, and the wire is advanced through the stent. The knuckle formed while crossing the stent prevents passage behind the struts. Thereafter, the tip is relaxed again to suit the tortuosity of the distal vasculature [10].

TACTICAL MOVE**BEST maneuvers for re-crossing a stent****1 No Added Cost FIRST Best**

Technique: The technique is to gently bounce the device forward and backward and, as these movements are limited, the wire will bounce up and down (more wire centering), creating a chance to enter the lumen

2 No Added Cost SECOND Best Technique: Steer the wire into a different direction, or to a different branch or side branch to lessen wire bias and increase wire centering; hopefully, it will help to advance the stent

3 No Added Cost THIRD Best Technique: Engage the guide in a more stable position or deep seat the guide to change the entry direction of the wire, and hopefully lessen the wire bias

4 \$ ⚡ FOURTH Best technique: Insert a second stiffer wire to straighten the vessel

Other exotic techniques can be tried; however, the chance of success is lower and not guaranteed:

- 1** Change the current wire to a stiffer one
- 2** Use a shorter balloon or stent
- 3** Rotate the balloon catheter while advancing it and let the catheter enter the stent by itself through its rotational energy (such as torquing the Judkins right [JR] catheter to engage the right coronary artery [RCA] ostium).
- 4** Bend the wire and place the bent segment near the ostium of the stent to be crossed in order to position the wire more at the center of the entrance of the stented segment, and to decrease wire bias
- 5** Use a newly designed wire that wiggles its long tip up and down along the radial axis, so that the balloon–stent complex enters the lumen at the center (wiggle wire)
- 6** Use a more flexible balloon or stent
- 7** Use a fixed-wire balloon to cross the stent
- 8** Use a fixed-wire balloon to track alongside a buddy wire
- 9** Mount a stent on a balloon with the tip partially inflated
- 10** Park a balloon at the resistance site, and advance the second balloon as the working balloon. The first balloon would deflect the second balloon away from the problematic area
- 11** If the balloon only needs to enter the stented segment, inflate the balloon with 1–2 atm so that it will center the wire at the lumen and facilitate the crossing of the wire and balloon.

REDEPLOYING A STENT

With the trend of primary stenting or lower pressure balloon predilation, on many occasions a stent cannot be fully expanded,

due to unexpectedly severely calcified vessel wall. In other cases, a stent can be crushed by inadvertent insertion of the dilation balloon through a strut. How should the stent be redeployed?

Technical Tips

****How to cross a crushed stent** After failure to advance a wire through the main lumen of a crushed stent (Figure 6.3a,b), the next step would be to take another picture from another

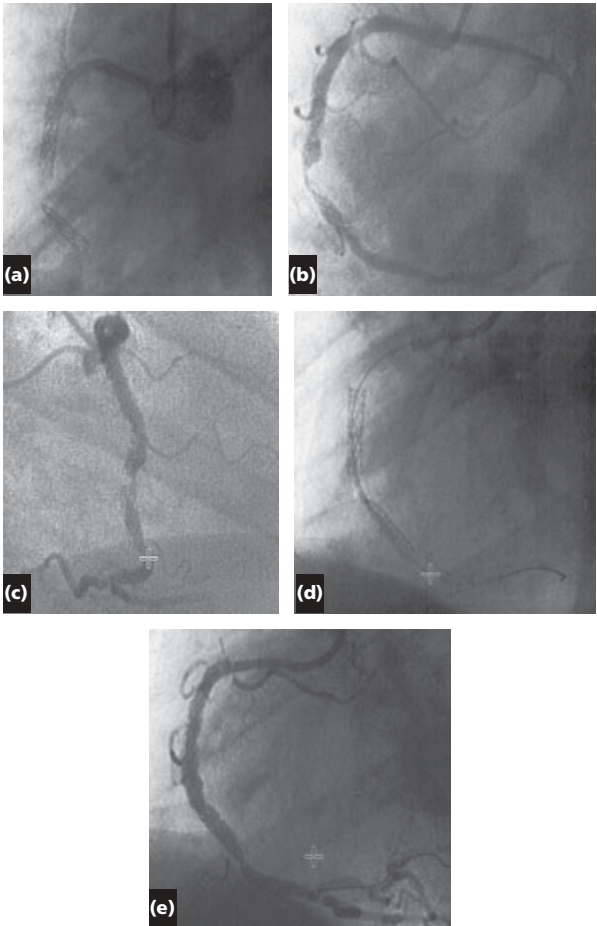


Figure 6.3 (a) The second stent is crushed at its opening. (b) The RCA in the LAO view. (c) As the wire was unable to enter the stent ostium, another angiogram was done in the RAO view (90° opposite) in order to locate the exact location of the true opening. (d) A balloon with a marker in the middle of the balloon was advanced across the stent. (e) The stent was redilated successfully. (Courtesy of the Cardiac Catheterization Laboratories of Community Healthcare System, St Mary Medical Center, Hobart, IN.)

orthogonal angle (90° opposite to the first angle) in order to locate the exact position of the possible opening (Figure 6.3c). Then a balloon with a marker in the middle is advanced. As soon as the marker is seen in the middle of the lesion, it ensures that the lesion is crossed (Figure 6.3d). From there the stent is redilated successfully (Figure 6.3e).

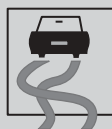Deploying a stent after failed expansion by a balloon To redeploy a stent, usually the operator would insert and inflate a non-compliant, high-pressure balloon. Even so, on occasion very high-pressure balloon inflation fails to expand the stent. Then conventional laser angioplasty in a blood medium would provoke local dissection behind the stent struts. The theory is that excimer laser irradiation of blood results in vapor bubble formation and acousto-mechanical trauma to the vessel wall, causing localized dissection. Usually, during regular laser angioplasty, intracoronary infusion of 0.9% saline is required to displace the blood, and minimize blood irradiation and the consequent arterial wall damage. In case of failure to expand a stent due to unexpected heavy calcification, excimer laser irradiation would provoke local dissection, weaken the vessel wall, and allow full expansion of the stent [11].

Rotablation through an unexpanded stent could be done in an exceptional case. However, what is the mechanism of enlarging the stent by rotational atherectomy? After rotablation, the angiogram showed an optimal result with a linear coronary dissection. IVUS showed optimal expansion by ablating away some of the struts. The main concern is that the burr could get stuck in the stent and may require surgery for its removal [12].

CAVEAT

Rotational atherectomy after stenting

Rotational ablation to freshly implanted stents has been demonstrated to be successful in side branch access through the struts of the stents in the radial (more or less perpendicular) direction. In in-stent restenotic lesions, longitudinal rotablation may be considered safe because the stents are “protected” or “scarred down” by the surrounding intimal hyperplasia (Figure 6.4).



Advantages and Limitations

There are several concerns about longitudinal rotablation of a freshly placed stent. First, compared with accessing stent-jailed side branches, more metal needs to be cut through to release the circumferential restriction of an under-expanded stent. Furthermore, the particular spatial orientation of the stent in relation to the rotational direction of the burr raises concerns about burr entrapment and untoward spinning of the stent. In addition, although particle size is known to be associated with rotation deceleration in plaque atherectomy, little is known about the

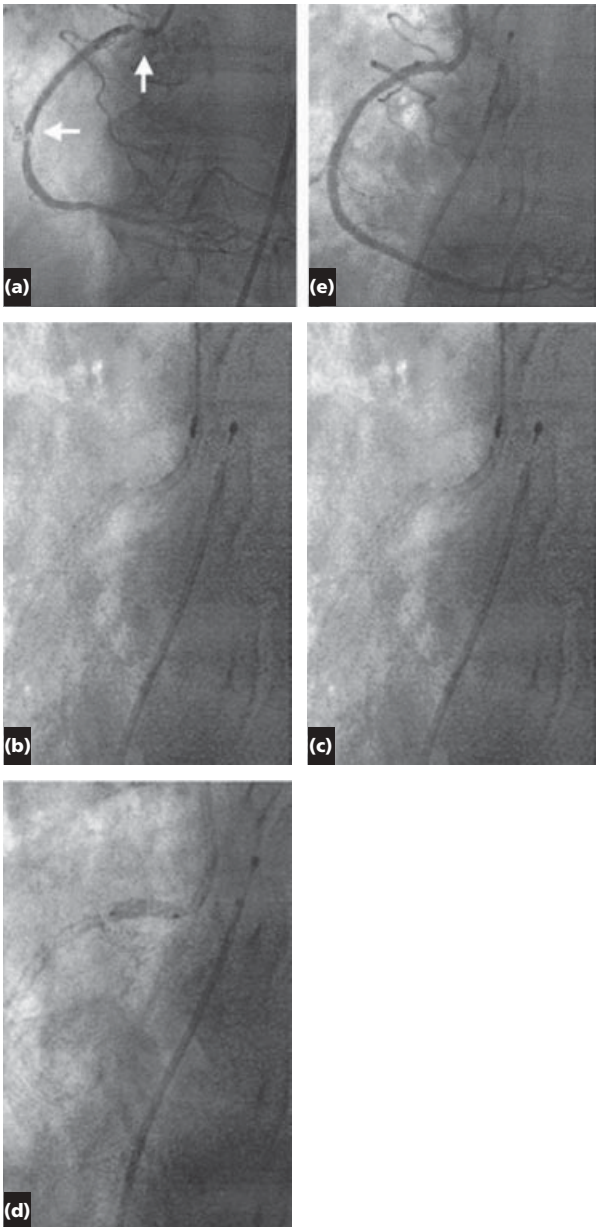


Figure 6.4 (a) Initial angiography demonstrating in-stent restenosis of 95% in the proximal and middle RCA (arrows). (b) After predilation, stent deployment showed insufficient stent expansion. Postdilation with semi-non-compliant balloons also failed to provide complete stent expansion (arrow). (c) Rotablator of the newly placed stent was performed. (d) After successful rotational ablation of the stent and the underlying resistant lesion, full balloon expansion was possible. [13].

metallic debris from rotabulating a stent. In an in vitro model of rotational atherectomy of side branches jailed by stents, the released stent fragments ranged from 1.7 mm to 17 mm in size depending on the stent types. Compared with debris-size from plaque atherectomy (mostly $<5\mu\text{m}$), some of the metallic debris (10–30 μm) may be too large to clear through distal circulations. Strict adherence to standard recommended rotational atherectomy techniques is crucial in rotabulating a stent, and include high-speed, low-deceleration, and short burr durations, gentle forward burr advancement, use of platelet glycoprotein GP IIb/IIIa inhibitors and Rotaglide.

In rotabulating a metallic stent, when the burr ceases to advance, rather than continue to push harder, a new burr with sharp cutting edges should be substituted for more effective penetration. There should be no need to alter the size of the burr, speed of rotation, or any of the other technical factors [13].

TACTICAL MOVE

BEST maneuver for redeploying a stent after prior expansion failure

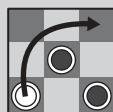
1 No Added Cost FIRST Best Maneuver:

Use the same balloon and increase inflation pressure to maximum. Be sure that the proximal end is well inflated. Inflate the balloon with maximum possible high pressure so at least the proximal end is opened as much as possible in order to facilitate the reinsertion of a new balloon. It is not always easy to reinsert a new balloon inside an under-deployed stent

2 \$ ⚠️ SECOND Best Maneuver: Change current balloon to a high-pressure and non-compliant balloon

3 \$\$ ⚠️ ⚠️ 🔥 Laser angioplasty in a blood medium to cause local dissection behind the stent struts, then re-inflate the balloon to re-deploy the stent

4 \$\$ ⚠️ ⚠️ 🔥 🔥 🔥 Rotablation (for experienced operators)



Trouble-shooting Tips

****Redeploying an embolized stent* In case of inadvertent embolization of an undeployed or partially deployed stent, the best way to resolve the problem is to make sure that the wire is stable inside the main lumen, and to reinsert the same balloon and reinflate it (especially the proximal half, so that any further attempt to insert a new balloon will be facilitated). To insert a new non-compliant balloon into the stent is not easy. If successful, deploy the stent with prolonged higher pressure. However, it is difficult and/or it will take a lot of time, patience, skill, and luck to advance a new balloon across a partially deployed stent. If not successful, the stent has to be removed.

Be careful when moving the balloon because the stent is at (not all the time stuck to) the lesion and can easily be dislodged if the

distal end is small and the proximal end large, such as at the insertion site of an SVG. It is easier to dislodge a stent in a retrograde fashion with a large, winged, and bulky, poorly rewrapped inflated balloon.

******Management of balloon rupture*** Not infrequently after deployment of a stent, especially if it is a used balloon, the balloon can rupture. Rarely, as proved by IVUS, an irregular jagged-appearing calcified lesion can penetrate into the lumen of the stented area, and cause repeated perforation and rupture of the balloon. In a case report, although a balloon made with polyethylene terephthalate (PET) ruptured twice, the nylon material of a third balloon was able to withstand high pressure without being punctured [14]. If the heavy calcification were detected earlier, rotablatinal atherectomy would have been helpful. However, once the lesion has been stented, ablation with the burr is not an ideal option as the stent abuts the calcified plaque (even it can be done).

******Stent deployment after balloon rupture*** When a balloon ruptures during stent deployment, withdrawal of a partially inflated balloon can dislodge the stent into the proximal segment. To deploy the stent, some experienced senior operators suggest: (1) Keeping the ruptured balloon in place; (2) using a 20-ml syringe filled with contrast; and (3) injecting 2–3 ml very quickly to inflate the balloon in order to deploy the stent. Keelan et al. were able to partly deploy the stent using an automatic power injector. Using 50% diluted contrast at a rate of 20 ml/s over 0.25 s and a pressure limit of 200–400 lb/in² (psi), they found that 1 ml was injected before the pressure maximum was exceeded. The stent was sufficiently deployed with the damaged balloon to allow the removal of the balloon [15]. Many times, the balloon ruptures because of a tiny pinhole, so these quick injections can sufficiently inflate a balloon and partially deploy a stent; however, these injections can cause a jet injury at the arterial wall and may cause perforation.

COVERED STENT

Two PEFT-covered stents are available on the market: The JoStent coronary graft (Jomed), in lengths 9–26 mm and a maximum achievable diameter of 5.0 mm, and Symbiot covered stent system, 20–45 mm in length and a maximum 5.0 mm in diameter. The JoStent has been constructed by a sandwich technique: Expandable PTFE membrane, 50 μm thick, has been placed between two JoStent Flex stents made of 316L steel. The Symbiot stent is a self-expanding nitinol stent encased in a thin porous expanded PTFE membrane. The JoStent GraftMaster can be delivered through a 6-Fr (inner diameter 0.068 inch) guide, whereas the Symbiot stent requires a 8-Fr (inner diameter 0.086 inch) guide [16].

BOX 6.4 CHECKING THE INTEGRITY OF A BALLOON BEFORE ADVANCING IT INTO THE CORONARY ARTERY

- 1 No air bubble in the fluid inside the inflation device
- 2 No blood back inside the shaft of the balloon catheter lumen after the catheter is inserted into the guide
- 3 While the plunger of the inflation device is in the aspiration position, it does not return rapidly to the neutral position as it is released

Technical Tips

****Hand crimp a covered stent** If the stent has to be hand crimped, most of the hand crimping should be applied to the middle of the stent and not the ends, to make sure that the balloon material is not damaged. Always inflate the balloon first before mounting the stent, because the winged balloon material tends to hold the crimped stent in position more reliably than an uninflated balloon [17].

*****How to check the integrity of a hand-crimped balloon before deployment** To avoid crimping a stent on a ruptured balloon, three observations to confirm the integrity of the balloon should be checked before advancement (Box 6.4). In the case of a hand-crimped stent, the balloon–stent complex can be checked again when the stent is at the tip of the guide, before engaging the coronary artery, so there is still time to retrieve it if needed [18].

CASE REPORT

Exclusion of coronary aneurysm with covered stent

The usual approach to exclude a coronary aneurysm is a technique that involves deployment of a covered stent to be anchored from the distal to the proximal non-aneurysmal segments of the artery.

In this specific case, the length of the segment to be covered with a stent was approximately 32.6 mm as measured by quantitative coronary angiography. In addition, it might be difficult to advance a long PTFE-covered stent through the steep bend in the proximal RCA. Therefore, sequential deployment of shorter stents was a reasonable choice. Stent deployment in the proximal part of the RCA could first straighten the sharp bend and make distal stenting easier. Therefore, implantation of the stents from proximal to distal was attempted. A 2.5–5.0 × 26 mm JoStent coronary stent graft (Jomed) was mounted and hand crimped on to a 4.0 × 30 mm Maverick balloon catheter. The JoStent stent graft was positioned in the proximal portion of the RCA to cover the proximal part of the entry site of the aneurysm. The aneurysm was partially excluded from the coronary lumen. To make the passage of the second stent easier, the JoStent in the proximal

RCA was postdilated with a 4.5 × 20 mm Bypass Speedy balloon catheter to 14 atm. A 3.5 × 19 mm premounted JoStent stent graft was positioned in the mid-segment, partially overlapping the proximal JoStent stent graft, and deployed at 18 atm. Postdilatation of the overlapping segment between the two JoStent stent grafts was performed with a 4.5 × 20 mm Bypass Speedy balloon catheter inflated to 12 atm [19].

REFERENCES

1. Caputo RP, Simons A, Giambartolomei A, et al. Transradial cardiac catheterization in elderly patients. *Catheter Cardiovasc Interv* 2000;**51**:287–90.
2. Saucedo JF, Muller DW, Moscucci M. Facilitated advancement of the PS stent delivery system with the use of an adjacent 0.01 stiff wire. *Catheter Cardiovasc Diagn* 1996;**39**:106–10.
3. Lowell BH. Push-pull angioplasty: ACE balloon-facilitated stent passage technique. *Catheter Cardiovasc Interv* 1999;**48**:93–5.
4. Li SSL, Cheng CW. Coronary angioplasty on an impassable calcified stenosis using a buddy balloon technique. *Catheter Cardiovasc Interv* 2004;**62**:35–7.
5. Cheralier B, Royer T, Guyon P, et al. Predictive factors of direct stenting failure in a single center of 1500 patients. *J Am Coll of Cardiol* 2000;**2**:89A.
6. Deploying a stent without angiogram. Available at: www.tctmd.com/csportal/appmanager/tctmd/main (accessed July 19, 2007).
7. Kawamori H, Shite J, Shinke T, et al. The ability of optical coherence tomography to monitor percutaneous coronary intervention: Detailed comparison with intravascular ultrasound. *J Invasive Cardiol* 2010;**22**:541–5.
8. Grantham J, Tiede D, Holmes D. Technical considerations when intervening with coronary devices in the vicinity of previously deployed stents. *Catheter Cardiovasc Interv* 2001;**52**:214–17.
9. Abernethy W, Choo JK, Oesterle S, et al. Balloon deflection technique: A method to facilitate entry of balloon catheter into a deployed stent. *Catheter Cardiovasc Interv* 2000;**51**:312–19.
10. Chen J. The steerable guidewire: A simple method to recross deployed stents. *J Invasive Cardiol* 2006;**18**:575.
11. Sunew J, Chandwaney R, Stein D, et al. Excimer Laser facilitated PCI of a non-dilatable coronary stent. *Catheter Cardiovasc Interv* 2001;**53**:513–17.
12. Hadjimiltiades S, Tsikaderis D, Louridas G. Rotational ablation of an unexpandable sirolimus-eluting stent. *J Invasive Cardiol* 2005;**17**:116–7.
13. Ho PC, Weatherby TM, Dunlap M. Burr erosion in rotational ablation of metallic coronary stent: An electron microscopic study. *J Interven Cardiol* 2010;**23**:233–9.
14. Zellner C, Sweeney JP, Ko E, et al. Use of balloon ultrasound in evaluating repeated balloon rupture during coronary stenting. *Catheter Cardiovasc Diagn* 1997;**40**:52–4.
15. Keelan ET, Nunez BD, Berger P, et al. Management of balloon rupture during rigid stent deployment. *Catheter Cardiovasc Diagn* 1995;**35**:211–15.
16. Rogers JH, Chang D, Lasala JM. Percutaneous repair of coronary artery bypass graft-related pseudoaneurysms using covered JoStents. *J Invasive Cardiol* 2003;**15**:533–5.

17. Antonnellis J. How to avoid having a stent mounted on a ruptured balloon in a coronary artery. Letter to the editor. *Catheter Cardiovasc Diagn* 1996;**38**:102–3.
18. Sattler L, Pichard A, Kent K. Guidelines for repeat PCI in patients with previously deployed stents. *Catheter Cardiovasc Interv* 2001;**52**: 218–19.
19. Orlic D, Vitrella G, Corvaja N, Colombo A. New technique to seal a long giant coronary aneurysm with PTFE-covered stents: A case report. *Catheter Cardiovasc Interv* 2005;**67**:41–5.
20. Ben-Dor I, Mahmoudi M, Pichard AD, Satler LF, Waksman R. Optical Coherence Tomography: A New Imaging Modality for Plaque Characterization and Stent Implantation. *J Interven Cardiol* 2011;**24**:184–92.

CHAPTER 7

Transradial Approach

Jack P. Chen, Xian Kai Li, Thach N. Nguyen, Phan Nam Hung,
Tejas Patel, Shigeru Saito

Challenges 143

Patient Selection 143

Contraindications 143

Arterial Access 143

Radial Artery Puncture 143

Technical Tips 145

**Where is the missing artery? 145

Right or left radial approach 145

Technical Tips 145

**When left radial access is preferred 145

Radial sheaths 145

PCI without Radial Sheath 146

Technique Access for occluded radial artery 147

Advantages and Limitations 148

Technique Proximal radial access in a patient with an occluded radial artery 148

Advantages and Limitations 149

Hemostasis 150

Wires 151

Technical Tip 152

**External side compression of radial artery 152

Catheters 152

Single Catheter 153

Advancement of Catheters 153

Technical Tip 153

***How to overcome the problems of loops, remnants, high takeoff 153

****What to do when encountering Problems with Aorto-subclavian Tortuosity? 154**

Don't panic. Use the MAGIC TRICK: Ask the patient to take a deep breath! 154

Technical Tip 155

**How to overcome tortuous arteries 155

Limitation due to Anatomic Variations 155

Technical Tips 156

*Basic; **Advanced; ***Rare, exotic, or investigational

\$, <\$US100.00 extra; \$\$, >\$US100.00 extra

⌚, <10min extra; ⌚⌚, >10min extra

♣, low risk of complications; ♣♣, high risk of complications

***Arteria lusoria 156

Learning curve 156

Alternative Access Sites 156

Ulnar Approach 156

Guides 157

Guide for Left Coronary Arteries 157

Guides for Right Coronary Arteries 158

Radial Artery Diameter for TRI 158

Technical Tip 159

**Advancement of guide through tortuous subclavian artery
159

Coronary Cannulation 160

Left Coronary Artery 160

Technical Tip 160

**Taming the tiger 160

Right Coronary Artery 160

Technical Tips 160

**If the tiger keeps going into the conus? 160

**Manipulation of the Q curve guide for both right and left
coronary arteries 161

Discriminating Differences 161

Venous and Arterial Bypass Grafts 162

Technical Tips 162

***Intubation of the LIMA from the right radial approach (1)
162

***Intubation of the LIMA from the right radial approach (2)
162

Other Procedures 162

Right Heart Catheterization 162

Bifurcations 163

Chronic Total Occlusion 163

Complications 163

Spasm 163

Technical Tip 163

*How to avoid radial spasm 163

Radial Occlusion 163

Technical Tip 163

**Patent hemostasis 163

Bleeding, Iatrogenic Radial Artery Perforation 164

Technical Tip 164

**How to continue the procedure when a perforation has
occurred 164

Distant Hematoma 165

Management of Pseudoaneurysm 165

Retroperitoneal Bleeding from the Radial Approach 165

Technical Tip 166

***Reduction of knotted coronary catheter in the radial
artery 166

Compartment Syndrome in the Forearm 167

Technical Tip 167

***How to prevent CSF 167

In the last decade the scope of modern interventional cardiology has dramatically changed with new user-friendly devices and more complex interventions performed in high-risk patients. The default transfemoral approach (TFA) is burdened with relatively frequent access site bleeds (depending on definition) and rarer but potentially serious complications such as retroperitoneal hematoma (RPH), arteriovenous fistula (AVF), and pseudoaneurysm (PA). The impact of access site complications may include increased morbidity, mortality, need for surgery, blood transfusions resulting in longer hospital stay, higher costs, and worsened quality of life [1]. The recent advent of closure devices has led to faster hemostasis and ambulation but they appear to have similar overall complication rates compared with manual compression [2].

CHALLENGES

What we and our patients need is greater safety, lower costs, and early return to prior level of activities. The transradial route achieves excellent procedural success rate and virtually eliminates access site complications, allows rapid ambulation, and can even be performed in an outpatient setting [3,4]. This is due to the superficial location of the radial artery, the extensive palmar collaterals, lack of adjacent veins or nerves, and hence easy and safe hemostasis, and no ischemic sequelae or injury of surrounding structures.

Patient Selection

Patient selection for transradial (TR) coronary angiography and intervention is accomplished by checking the pulse as well as us of the Barbeau test which confirms patent collateral flow. The Barbeau test is a combination of plethysmography and pulse oximetry used to evaluate the collateral circulation. In patients undergoing a second procedure via the same radial site, a reverse Allen test should be performed. In this situation, the operator releases pressure over the radial artery rather than the ulnar artery. This may detect a proximal radial artery occlusion that is asymptomatic, thus potentially excluding this access site for a repeat procedure [5].

Contraindications

The rare contraindications include severe bilateral Raynaud phenomenon and no radial pulse.

ARTERIAL ACCESS

Radial Artery Puncture

Equipment and patient preparation are simple and similar to those for the femoral approach. The hand is positioned along the body with the palm pointing upward and obliquely. After local skin

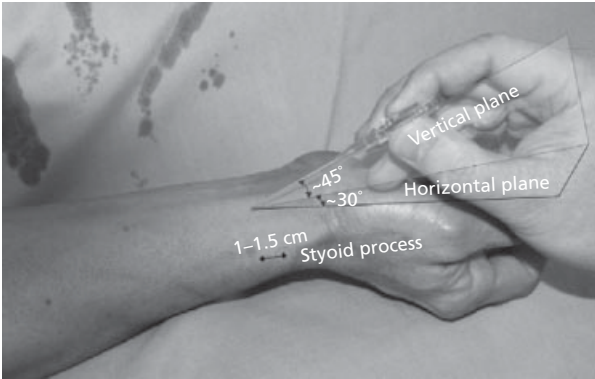


Figure 7.1 Angle of introduction for radial puncture.

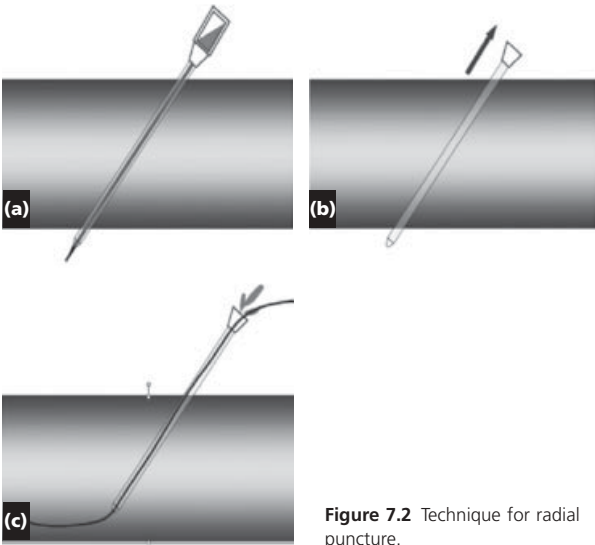


Figure 7.2 Technique for radial puncture.

anesthesia with 0.5 ml 1% lidocaine, puncture is performed with a 21- to 19-G venous cannula or bare needle. Optimal puncture site and needle angulation are shown in Figure 7.1. The puncture technique with intravenous (IV) cannula is illustrated in Figure 7.2. When blood appears in the hub (Figure 7.2a), the cannula is advanced a few millimeters in order to transfix the artery and the needle is withdrawn. Then the cannula is gently drawn back (Figure 7.2b) until backflow reappears, and a 0.021–0.032 inch wire is introduced (Figure 7.2c). For the new operator, the-through and-through access is best. For the experienced operator,

the technique of *only* anterior wall puncture could be done without frequent failure and repeated attempts.

Technical Tips

****Where is the missing artery?** In a case of an “atrophic” radial artery (radial artery is the terminal branch of the palmar arch), change the access site. Rarely, the “radial” artery is not at the right place, it is on the lateral side of the wrist (very rare: 2/1000). So don’t forget to check the pulse on the lateral side of the wrist.

Right or left radial approach The choice between right and left radial approach is more or less related to the operator’s preference. The left radial approach (LRA) requires a different table set-up and logistics. The right radial approach (RRA) is more nurse friendly because it requires standard equipment. It is also more operator friendly because, unlike the LRA, it does not require leaning over the patient to manipulate catheters, wires, and devices. However, the LRA seems preferable for slim females with small, spasm-prone radial arteries, especially in the presence of subclavian and/or brachiocephalic tortuosity. The LRA is certainly the approach of choice when the Allen test is negative on the right radial or when a left internal mammary artery (LIMA) angiography is indicated.

Technical Tips

****When left radial access is preferred** Short-statured patients, as well as patients with significant abdominal obesity, tend to have longitudinally compressed ascending aortas, and cannulation is often easier from the left radial artery. Evaluation and treatment of infradiaphragmatic pathology are best performed from the left wrist because it provides approximately 10cm of additional length. Left subclavian and left vertebral interventions are also straightforward from the left wrist. Finally, as left-sided radial procedures more closely mimic the femoral approach in terms of catheter manipulation and seating, operators, particularly those early in their learning curve, may find it easier to use more familiar femoral (Judkins) catheters [5].

Radial sheaths

The most commonly used sheaths are 5Fr for diagnostic angiography and 6Fr for intervention but sometimes 4-Fr sheaths are needed for coronary angiography via small radial arteries and 7-Fr sheaths for complex interventions. The shorter sheaths seem preferable and hydrophilic coating reduces friction on insertion and removal by 70% [6]. No skin incision is required with tapered sheaths. After insertion a cocktail of verapamil 3mg and 3000–5000 units heparin are injected through the sidearm. The operator can use single drug preparations or spasmolytic cocktails. Verapamil 3mg has proved quite safe and effective. Previous radial catheterization does not diminish responsiveness to nitroglycerin and verapamil despite some reduction in the arterial lumen diameter. Exchange devices through a sheath may cause less spasm.

PCI without Radial Sheath

IMPROVISED EQUIPMENT

For easier insertion of the guide, a “pseudo-taper” was created for the guide catheters by one of five techniques [7] (Figure 7.3):

- 1 Insertion of a 5-Fr × 125-cm Shuttle Select diagnostic catheter through a 6-Fr guide, inserted through the skin into the radial artery over a 0.035-inch standard J-tip Emerald Diagnostic wire
- 2 Insertion of a long (125-cm) 5-Fr multipurpose Infiniti Diagnostic Catheter into and through a 6-Fr guide over a 0.035-inch wire
- 3 Insertion of a 5-in-6 Guideliner catheter over a 0.035-inch wire
- 4 Insertion of the dilator from a 4-Fr × 110-cm sheath into a 5-Fr Launcher guide
- 5 Insertion of a partially inflated coronary balloon in the tip of a guide over a stiff 0.014-inch exchange-length interventional wire.

DEDICATED EQUIPMENT

The sheathless Eaucath guide catheter system



The sheathless guide catheter system employed does not require the use of a sheath introducer during percutaneous coronary interventions (PCIs). It is available in 6.5-Fr (inner diameter 0.070 inch), 7.5-Fr (inner diameter 0.081 inch), and 8.5-Fr (inner diameter 0.090 inch) sizes. The sheathless Eaucath 6.5-Fr possesses about the same outer diameter (2.16 mm) as a common 4-Fr sheath introducer (2.0 mm) and the 7.5-Fr possesses a lower outer diameter (2.49 mm) than a 6-Fr sheath introducer (2.62 mm). The hydrophilic coating of the whole catheter enhances the trackability in tortuous vessels, reducing the risk of arterial spasm during catheter manipulation. The catheter insertion involves initial radial cannulation using a standard 5-Fr or 6-Fr sheath which is used to insert a standard J-tipped 150-cm × 0.035-inch diameter exchange wire. A spasmolytic cocktail to reduce radial spasm was not routinely employed and, in case of artery spasm after the sheath insertion, direct arterial injection of nitrates or verapamil was performed. The sheath is then removed and the catheter (with its dilator) is passed over the exchange wire into the radial artery. Once the catheter has reached the proximal ascending aorta, the central dilator and the wire are removed and the catheter is advanced to achieve coronary intubation. After coronary intubation, the sheathless guide is fixed to the forearm at the radial artery entry point with a transparent sticky membrane (Oper film) to avoid slippage during the procedure. In case of need to exchange catheters during the procedure, they are exchanged over a 150-cm × 0.035-inch J-tipped wire [8].

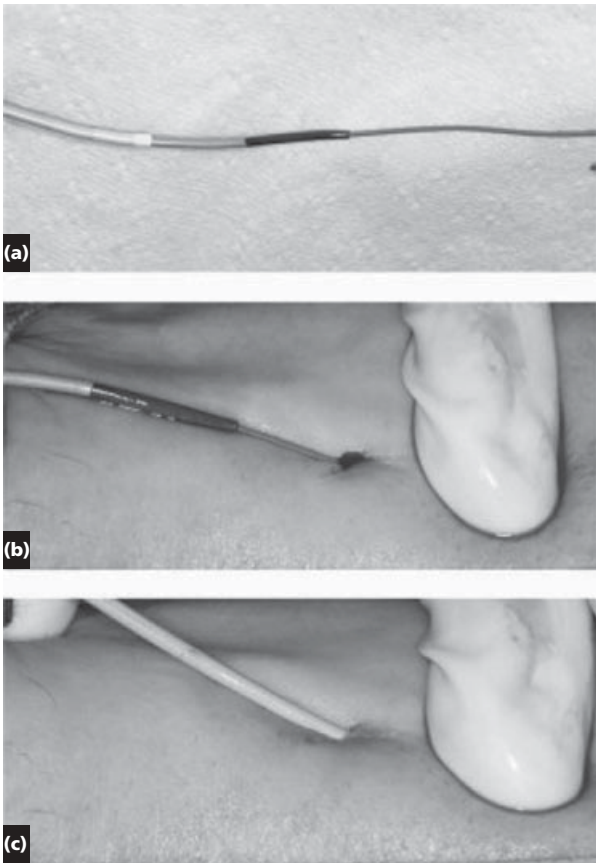


Figure 7.3 Tapering of a standard guide for sheathless insertion in the radial artery using a telescoping shuttle select diagnostic catheter. Insertion of a 5-Fr \times 125-cm Shuttle Select diagnostic catheter through a 6-Fr guide (a), inserted through the skin into the radial artery over a 0.035-inch standard J-tip Emerald Diagnostic Guidewire (b), allows for sheathless insertion of a 6-Fr guide (c). (Reproduced from Michael and Brilakis. *Catheter Cardiovasc Interv* 2011;**78**: 864–5, with permission from Wiley.)

TECHNIQUE Access for occluded radial artery The wrist is prepared and draped in a standard manner and, after local anesthesia, a 20-G Teflon cannula is placed using through-and-through puncture in the very distal portion of the right radial artery, where a low-volume collateral flow pulse is usually palpable from the palmar arch. As the cannula is withdrawn, arterial blood is observed as a non-pulsatile dribble in the hub of the cannula. A 0.021-inch wire, which is part of the Glide Sheath package, or a 0.018-inch micropuncture wire, is advanced into the cannula and, by gentle maneuvering, the pulseless portion

of the radial artery is traversed under fluoroscopic guidance to follow the imaginary path taken by the radial artery; its painless advancement is, however, almost completely guided by tactile feel. If wire advancement causes pain, the wire should be withdrawn and readvanced. A previous radial angiogram is a significant help and may serve as a roadmap. A long Angiocath or micropuncture introducer is advanced over the wire with gentle torquing motion. After removal of the wire from the microcatheter, pulsatile flow should now be present. The 0.021-inch wire is reinserted in the introducer and a Radiofocus Glide Sheath carefully advanced [9].

The wire is advanced purely based on tactile feel. Gentle forward pushing with slow-torque application is the technique used for wire advancement. Close observation is kept for even mild pain because a false lumen passage will be associated with pain. Painless advancement of the wire with little or no initial resistance is a sign of true lumen entry. The histopathologic findings confirm the process of thrombus formation as the mechanism of early occlusion. A "plug" was aspirated in successfully accessed occluded arteries [9].

Advantages and Limitations

The limitations of this technique include the blind nature of the initial procedure, and hence the risk of subintimal wire passage and perforation. Careful attention to even mild pain caused by the wire's movement will help avoid this complication. The other potential risk is the possibility of embolization of the thrombus. Careful aspiration and forward injection only after establishment of free back-bleed will help prevent this complication [9].

TECHNIQUE Proximal radial access in a patient with an occluded radial artery The patient had a positive inverse Allen test suggestive of an occluded radial artery (RA). The distal RA pulse was palpable as a result of palmar arch collaterals. However, the RA was very faintly palpable higher up in the proximal segment. After sterile preparation and draping in a standard fashion, a 20-G Teflon-sheathed needle was used to access the RA proximal to the previous point of entry where the radial pulse was very faintly palpable. On entry into the lumen, a "flash" of blood was noted in the transparent chamber at the proximal aspect of the access needle. Counterpuncture technique was used and the needle was advanced through the posterior wall. The stylet was then removed, a 0.021-inch wire was placed in the hub of the Teflon cannula, and the whole system was gradually withdrawn. Upon the appearance of the blood flow, the wire was advanced with tactile feel. Resistance-free wire advancement was feasible and the Teflon cannula was removed. A 6-Fr introducer sheath (Radifocus) was advanced over the wire. After removal of the dilator, the stopcock was opened and free pulsatile blood flow was observed. At this point, the sheath was flushed with saline and vasodilator cocktail, and unfractionated heparin was simultaneously administered intravenously [10] (Figure 7.4).

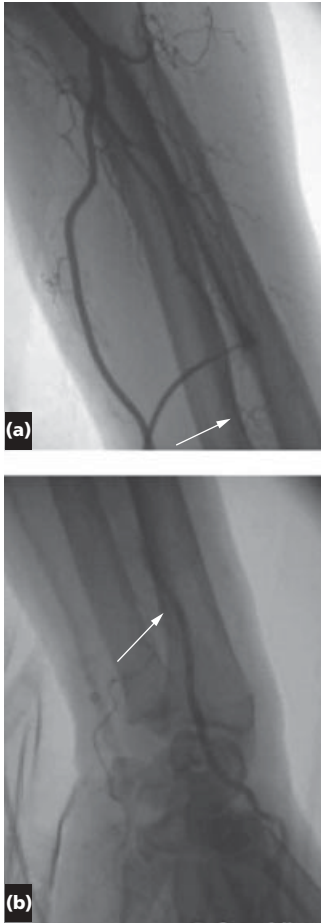


Figure 7.4 Radial artery (RA) angiogram was performed with a long cine run in a case. (a) Demonstration of retrograde filling of distal RA through palmar arch collaterals. (b) Demonstration of occluded RA segment distal to the puncture site.

Advantages and Limitations

The “proximal entry” technique described above is well suited for the “focal” RA occlusion, where this technique does not disturb the thrombus and hence has a safety advantage. It could also be used in those patients in whom the first site of access was distal, so a “stump” was not easily accessible. The potential drawbacks of this technique are its inability to recanalize the occluded portion of the RA, hence eliminating the probability of future patency. The other drawback of this technique is its proximal site of entry on the RA lumen, which may make subsequent hemostasis difficult to achieve as the RA traverses through the bellies of the surrounding muscles, leading to an inadequate

compression pressure and suboptimal hemostasis. An optimal manual compression followed by serial observations over several hours should reduce the chances of a significant hematoma. The "distal entry" technique described in the past is feasible in either subset of patients, although it involves recanalization of the thrombosed RA segment and, hence, increases the risk of complications related to dislodgement and migration of the thrombus. This technique also has the benefit of removal of the occlusive "plug," increasing the probability of subsequent RA patency as described earlier. The choice of the "proximal entry" technique described here or the "distal entry" technique described earlier should depend on the anatomic attributes as well as operator preference [10].

Hemostasis

Hemostasis can be achieved simply with a roll of gauze and a couple of elastic strips (Figure 7.5) or with dedicated devices. One of the latter is transparent, allowing visual control, and has a marker ensuring selective graded compression of the radial artery without blocking blood return (Figure 7.6). Hemostasis usually takes 3 hours.

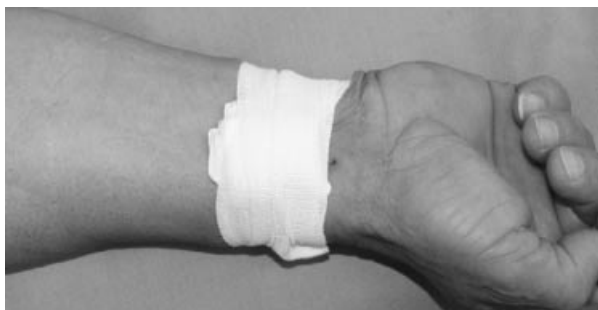

Figure 7.5 Radial artery dressing.

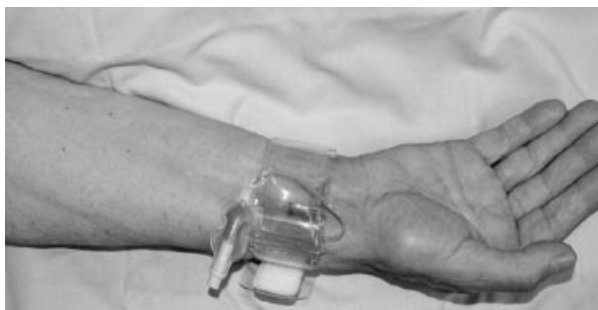

Figure 7.6 Radial artery pressure device.

WIRES

Usually the standard 0.025- or 0.03-inch (150–180 cm) J wires are used to introduce catheters. The 0.025-inch wire can be used for cannulation of the RA, whereas the J-shaped 0.035-inch wire has the advantage of avoiding most side branches in the forearm and arm, and providing better support. Advancing the wire around the shoulder of the patient should be done under fluoroscopy to ensure proper insertion into the ascending aorta without engaging the side branches (carotids, vertebrals, mammary, etc.).

The common causes of resistance are as follows:

- 1 Congenital anatomic variations such as the radial artery “loop,” early origin of the radial artery, or an accessory radial artery
- 2 Tortuosity in the axillary, subclavian, or innominate artery (especially in older hypertensive patients)
- 3 Arterial spasm.

Fluoroscopy should be utilized freely in order to avoid entering important branch vessels. If resistance is met with the J wire, a second choice is a steerable 0.035-inch wire (e.g. Glidewire or Wholey wire). These are advanced under fluoroscopy, with torquing performed as needed to avoid damage to small branch vessels. An angiogram of the arm may ultimately be necessary if the wire cannot be passed easily (Figure 7.7).

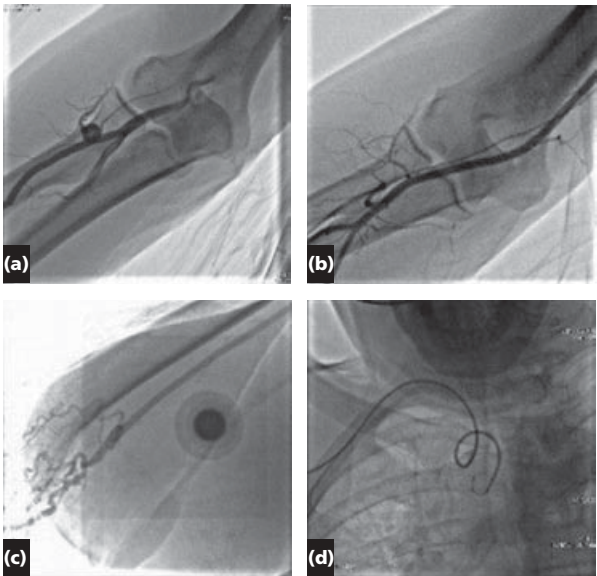


Figure 7.7 (a) Anatomic variation “radial loop”; (b) anatomic variation radial tortuosity with high takeoff radial artery; (c) occluded brachial artery; (d) subclavian/innominate artery tortuosity. (Reproduced from Caputo et al. [5], with permission from Wiley.)

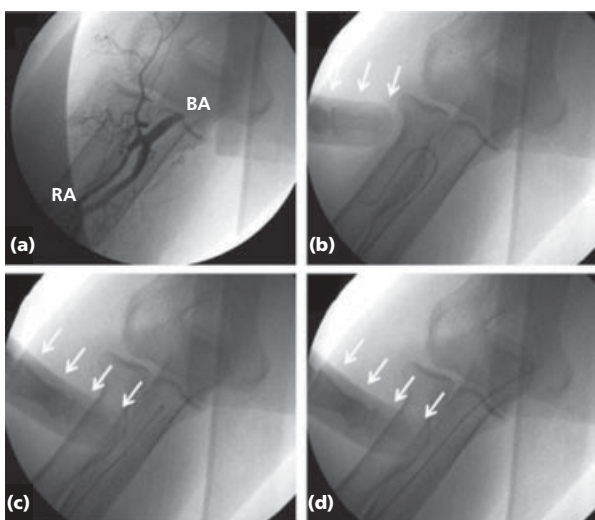


Figure 7.8 The J-tip guidewire could not be advanced into the brachial artery (BA) in spite of several attempts. (a) Angiography showed that it was always directed into the minor side branch. (b) Before the external side compression, it was still directed into the minor side branch. (c,d) However, first attempt of the external side compression resulted in successful advancement of the wire into the brachial artery. Arrows show a finger of the second operator. (Reproduced from Kurisu et al. *J Intervent Cardiol* 2011;**24**:397–400, with permission from Wiley.)

Technical Tip

****External side compression of radial artery** In patients with unsuccessful advancement of wires into the brachial artery by the conventional method, a radial angiography was performed with manual injection of non-ionic contrast medium through the sidearm of the arterial sheath. When the wire advanced into the side branch or the radial artery was tortuous, external side compression of the RA at the culprit site was performed with a finger of the second operator, and an attempt was made to get the wire into the brachial artery. When this attempt was unsuccessful, another angled hydrophilic wire was tried as the next step. When the angled hydrophilic wire was not advanced into the brachial artery, the access site was converted to brachial or femoral artery as the final step [11] (Figure 7.8).

CATHETERS

Most operators still use the Judkins catheters for coronary angiography irrespective of the approach – right or left radial. This is probably due to the fact that most radial operators were originally trained to perform transfemoral angiography and feel comfortable

with the Judkins catheters. In the Spaulding series of left transradial approach (TRA) techniques, there was high success rate for left coronary cannulation but a second catheter was needed for right coronary cannulation in every tenth patient [12]. Often successful left coronary artery (LCA) intubation is achieved with a Judkins left (JL) catheter that is 0.5 size smaller than the one chosen for transfemoral angiography. In some cases with kinked truncus brachiocephalicus or left subclavian artery, in combination with superior orientation of LCA, a choice of a smaller Judkins catheter resolves the problematic intubation, e.g. JL 3.0.

Single Catheter

Use of a single diagnostic catheter may minimize frequent exchange of hardware and thus reduce the incidence of spasm and catheter-induced cholesterol debris embolism. This also offers a cost-benefit – one less catheter is used. Several types of “multipurpose” catheters such as the Kimny, Barbeau, or Amplatz left (AL) catheter can achieve exceptionally high success rates, for both coronary arteries [5] (Figure 7.9 and Table 7.1).

Advancement of Catheters

If the wire or catheter does not advance easily, the operator should be aware of several possibilities: Spasm, small radial artery, loops, high takeoff (sometimes as high as axillary origin), remnant artery, stenosis (radial, brachial, subclavian), wire in a side branch.

Technical Tip

*****How to overcome the problems of loops, remnants, high takeoff** Loops are relatively frequent and located in the forearm, arm, and brachiocephalic segment. They represent different congenital and acquired anatomic conditions and most can

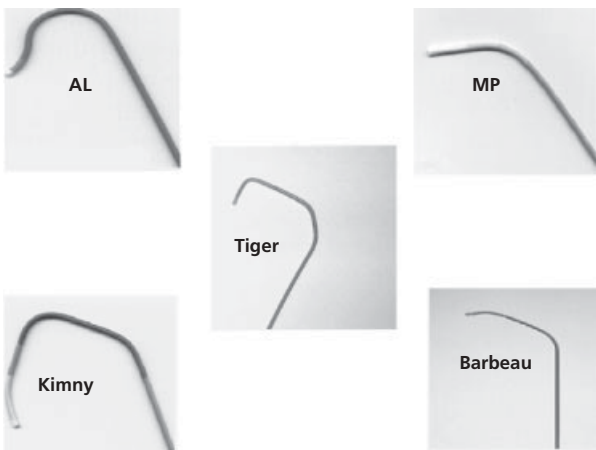
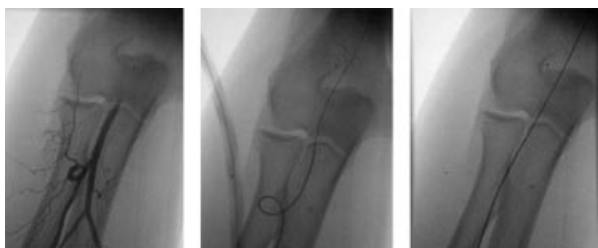

Figure 7.9 Catheters of different designs for transradial coronary angiography: Amplatz left (AL), multipurpose (MP), Tiger, Kimny, Barbeau.

Table 7.1 Catheter shapes for transradial diagnostic and/or interventional procedures

Diagnostic		Guide		
Universal	LCA, RCA	Universal	LCA	RCA
Kimny	JL-3.5, JR-4.0	Kimny	Ikari left	Ikari right
Tiger	–	MAC 30/30	LARA	MRESS
Jacky	–	Barbeau	MRADIAL	RRAD
Sones	–	PAPA	Easy Radial left	Easy Radial right
MAC 30/30	–	–	–	–

JL, Judkins left; JR, Judkins right; LCA, left coronary artery; RCA, right coronary artery.

**Figure 7.10** Loop in brachial artery straightened by wire.

be overcome with experience [13]. The really difficult ones are in the RA, sometimes with higher takeoff (axillary, brachial) or radioulnar anastomoses. The infrequent extreme loops that are generally accompanied by a remnant pose a real challenge to the operator and furthermore increase the risk of perforation. If you encounter a loop, do angiography through the sheath or catheter. Advance gently a hydrophilic 0.025-inch J or 0.014-inch PCI wire under angiographic control. This will usually solve the problem. Use a 4-Fr relatively straight catheter (e.g. multipurpose [MP] – Figure 7.10).

****What to do when encountering Problems with Aorto-subclavian Tortuosity?**

Don't panic. Use the MAGIC TRICK: Ask the patient to take a deep breath! If the wire goes only in the descending aorta, push the guide in the descending aorta, pull the wire, then slowly withdraw the guide and direct it into the ascending aorta with a counterclockwise rotation. Severe subclavian–innominate artery tortuosities and distal origin of the innominate artery result in a decreased forward force and increased friction during the progression of the wire or guide toward the ascending aorta. Use

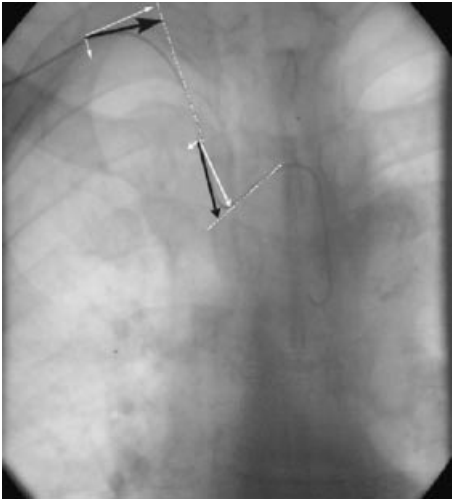


Figure 7.11 Use of a hydrophilic wire or, if not successful, an angioplasty wire combined with deep breath frequently resolves the problem of severe subclavian–innominate artery tortuosities.

of a hydrophilic wire or, if not successful, an angioplasty wire combined with deep breath frequently resolves the problem (Figure 7.11).

Technical Tip

****How to overcome tortuous arteries** In cases of subclavian/innominate artery tortuosity it may be beneficial to leave a 0.035-inch wire in the catheter while torquing the catheter into place. Right coronary arteries with an inferior takeoff from the aorta often pose a problem due to the tendency to engage the conus branch. This may also be alleviated by straightening the shaft of the catheter through the introduction of a 0.035-inch wire in the catheter and engaging the right coronary artery. When these catheters are used for left ventriculography with power injection, a lower pressure ($\leq 350 \text{ lb/in}^2$) is recommended because the presence of a single side hole does not significantly reduce the force of flow through the distal tip which could result in serious trauma to the left ventricle [5].

Limitation due to Anatomic Variations

There are a number of variations in the origin and distribution of the brachiocephalic trunk, including the bicarotid trunk and the rare retroesophageal right subclavian artery (arteria lusoria), which causes problems to the advancement of the catheter. Other limitations include stenosis, hypoplasia, radioulnar loop, and abnormal origin. The arteria lusoria is a congenital anomaly in which the right subclavian artery arises from the descending aorta

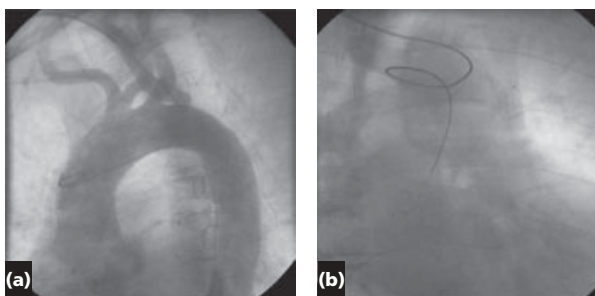


Figure 7.12 (a) Lusoria (retroesophageal course of subclavian artery); (b) brachiocephalic tortuosity.

just below the arch or the arch junction. So many times the right subclavian is lateral to the left subclavian (Figure 7.12).

Technical Tips

*****Arteria lusoria** When viewing the arteria lusoria, use a specialized catheter with a characteristic curve for arteria lusoria (Figure 7.12). If you are not sure, do an angiogram through the catheter.

Learning curve Limitations of the radial approach are the longer learning curve and lower rate of procedural success compared with the femoral approach. Proper patient selection is important at the start of the learning curve: It is preferable to start with large, easy-to-puncture arteries and simple cases, and gradually progress to more difficult ones in terms of access and interventional complexity. Factors that predict TRA failure are female gender, low body mass index (BMI), advanced age, and lack of experience. At the start of the learning curve (first 500–1000 TR procedures), it seems reasonable to exclude patients with weak pulses, low BMI, and complex interventions such as PCIs for primary angioplasty, bifurcations, and chronic total occlusions. After the inherent learning phase, the TRA failure rate is very low (about 1%), the reasons being mainly anatomic difficulties [14].

ALTERNATIVE ACCESS SITES

Ulnar Approach

The ulnar artery as an access site was an acceptable alternative with much lower success rates compared with transfemoral and transradial approaches. The mean success rates were between 38% in intention-to-treat patients and 100% in highly selected cases. The lower success rates can be explained by (1) the much deeper location of the ulnar artery, which at times lies around or just below the tendon of the muscle flexor carpi ulnaris, (2) the absence of a good bone base as in the RA (so hematoma can happen), and (3) the close proximity with the ulnar nerve, which can make puncture very painful [15–16].

GUIDES

In guide selection for transradial intervention (TRI), the operator takes into consideration factors such as target lesion features, lesion location, the presence or absence of proximal tortuosity, the size of the ascending aorta and location of the coronary ostium, the distal origin of the brachiocephalic trunk from the aortic arch, and subclavian–brachiocephalic tortuosities. Extensive manipulation of guides may provoke spasm, especially in anxious patients or those with small RAs or anatomic difficulties. The vast majority of coronary interventions are performed through 6-Fr guides, but in many patients 5-Fr or 7-Fr and 8-Fr guides can be used if necessary [17]. Appropriate guide choice is even more critical with TRI than with TFA. Selection and manipulation of these shapes are somewhat different when compared with TFI.

Guide for Left Coronary Arteries

When a JL-4 is used in patients with vertical and normal-sized aorta, the resultant backup support is 1.6 times lower compared with the one provided by the same guide if used transfemorally. The point of contact with the contralateral aortic wall during right TRA moves further up above the left coronary ostium, and this results in reduced backup force. This is why experienced operators use JL-3.5, which provides better support. JL is an appropriate guide in the setting of non-complex lesions or in left main (LM) stenosis, where good support is not a critical factor [18] (Figure 7.13).

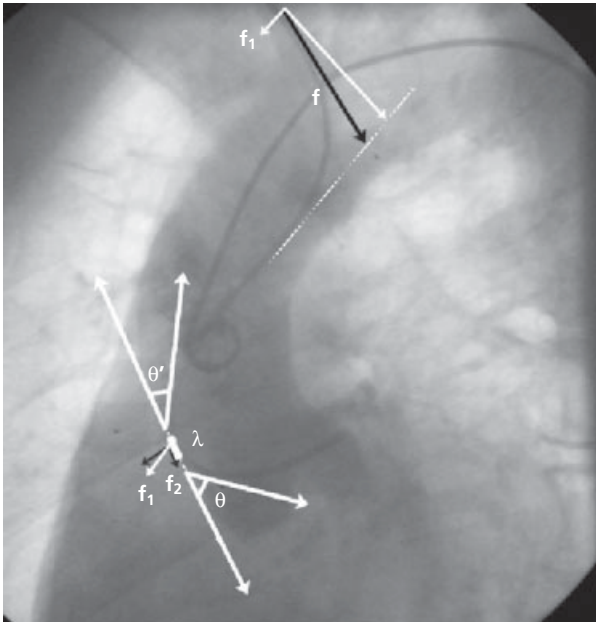


Figure 7.13 Mechanisms of backup and pushing force according to positions and properties of the guide. (Courtesy of Dr Yuji Ikari)

When the target artery is the left circumflex (LCX), a 0.5 larger size is preferred for better coaxial alignment. If active support is deemed necessary, deep seating for the left anterior descending artery (LAD) can be achieved with 5-Fr short-tip JL. This maneuver should be accomplished over the shaft of a balloon or stent with the assistance of deep inspiration and an apparent lack of LM or ostial LAD disease [18].

Extra backup guides provide greater support than JL, due to the larger contact area and the almost right angle with the opposite aortic wall. An inherent drawback of extra backup guides is the tendency for deep intubation of the LAD or LCX in the presence of short LM. In cases of complex LAD or LCX angioplasty and long LM, wide bifurcation angle or extreme proximal tortuosity, the EBU guide often becomes the first choice [18].

Amplatz left catheter (AL) 1.5 or 2.0 is suitable for complex lesions of LCX and provides greater passive support. As a result of the downward pointing AL tip, the operator should pay attention to prevent dissection caused by deep intubation when pulling the balloon or catheter out of the ostium [18].

Cannulation of the LCA ostium and obtaining optimal backup support might be fairly difficult in patients with a dilated and unfolded aorta. In cases with distal origin of the innominate artery, the guide approaches the LCA more from the left and this encumbers manipulation. Deep inspiration, leaving the wire in the guide during maneuvering or choosing guides with a brachiocephalic curve, may help in this setting.

Guides for Right Coronary Arteries

The first choice guide for non-complex or ostial RCA lesions is the Judkins right (JR) catheter in sizes similar to the ones used for TFI. In cases of dilated aorta, there is lack of contact area with the opposite aortic wall, which results in poor support. 5-Fr JR and MP are suitable for deep seating or so-called guide "amplatzing." Indeed, best support can be achieved with the AL catheter but the operator should be extremely careful not to cause dissection with the traumatic AL tip. After overcoming the learning curve, the operator becomes quite confident with most femoral curves for interventions via right TRA.

Radial Artery Diameter for TRI

A frequent argument against the radial approach has been techniques and device incompatibility for complex coronary interventions. The mean radial diameter was 3.10 ± 0.60 mm and 2.80 ± 0.60 mm in Japanese men and women, respectively. The cumulative relative frequency of RA diameter shows that 5-Fr introducers can be used in 93% of patients, 6Fr in 85% of males and 72% of females, 7Fr in 71% and 40%, and 8Fr in 45% and 24%, respectively [17] (Figure 7.14).

As most coronary interventions today are performed via 6-Fr guides, it is obvious that there are no substantial restrictions to the radial route. The same is true for many devices such as intravascular ultrasound (IVUS), a certain range of rotablation (ROTA) burrs, the cutting balloon, and dedicated thrombectomy catheters.

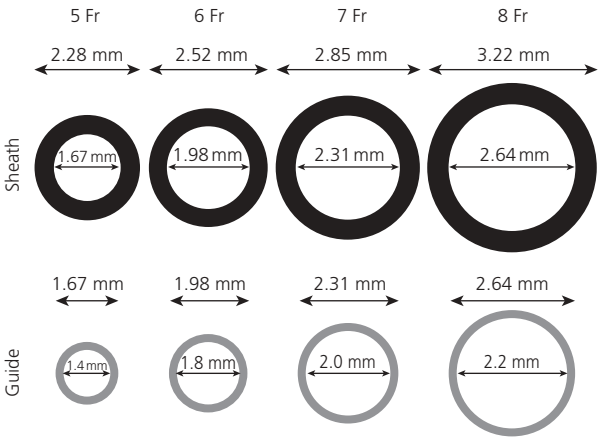


Figure 7.14 Differences in internal and external diameters of sheath and guides.

ters. When in doubt, the operator can determine the radial diameter by angiography or echography.

If the radial approach is incompatible with the intended technique or device, one obviously has to switch to the femoral approach.

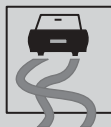Technical Tip

****Advancement of guide through tortuous subclavian artery** The operator must be very cautious when crossing tortuous subclavian segments, because of proximity and risk of damaging the carotid and vertebral arteries. Use of one or two PCI wires with careful manipulation overcomes most of the curves:

- 1 Sometimes two diagnostic wires could be used
- 2 The main purpose is for the catheter to reach the aortic arch. Alternatively, a 110- or 125-cm long diagnostic catheter is inserted into the guide (mother-in-child technique) and the assembly is carefully advanced into the aorta
- 3 Once the catheter tip is into the aorta the catheter is rotated counterclockwise with simultaneous advancement of the wire. A very useful tip is to ask the patient to take and hold a deep breath and to turn the head to the left. Sometimes, if the above maneuvers do not help, a small French size (4 or 5 Fr) diagnostic catheter could be advanced into the ascending or descending aorta and the combined guide catheter could be advanced over an extra-stiff Amplatz wire 260cm
- 4 The described maneuvers work equally well in the right or left radial approaches. If the operator selects the left radial approach, a specific tip to enter the ascending aorta once the catheter is in the *descending* aorta is pull the wire inside the JL guide and then to direct the flexed catheter with its second curve to the ascending aorta. When the target is reached, the wire is introduced to straighten the catheter and engage the coronary artery. The insertion of a very long sheath also helps to cross a very tortuous subclavian artery (See Figure 7.11).

CAVEAT

The extra-stiff wire can be used only when the catheter or guide is in the aorta. Do not cross the tortuous subclavian artery with an extra-stiff wire because it can cause dissection of the subclavian artery

**CORONARY CANNULATION****Left Coronary Artery**

The catheter is advanced into the aortic root towards the left coronary sinus (LCS) in the anteroposterior (AP) view, with the tip directed to the left of the screen. It is important that the tip is not deeply seated in the sinus. A slow and gentle clockwise rotation of the tip up to around 40–50° usually leads to engagement of the LCA ostium. If this fails, the catheter tip is rotated counterclockwise and slightly withdrawn until it eventually pops into the LCA ostium. Aimed to reduce catheter tension, this maneuver increases the success rate to over 90%. In the event of a second failure, clockwise rotation from a higher sinus location and a slight withdrawal of the catheter usually enables successful cannulation of the LCA.

Technical Tip

****Taming the tiger** In patients with a small ascending aorta and tip pointing downward, the Tiger catheter has to be pushed down into the LCS and then be bent upward while being rotated counterclockwise toward the LCA ostium. With a dilated ascending aorta, the catheter has to be rotated toward the LCA ostium with the wire tip between the primary and secondary curve of the Tiger catheter. This usually prevents the catheter bouncing upward into the dilated aorta. In cases of LCA cannulation failure, the Tiger catheter should be substituted for catheters with different curves (JL, AL).

Right Coronary Artery

Following LCA angiography, the catheter is withdrawn from the LCA ostium and rotated counterclockwise in the left anterior oblique (LAO) view so that the perpendicular segment formed by the primary and secondary curve disappears on the screen. At this moment, a gentle push would direct the tip into the non-coronary sinus (NCS). On slight withdrawal and clockwise rotation, the catheter tip turns into the right coronary sinus (RCS) and engages the RCA ostium, in a similar fashion to the JR and AL technique.

Technical Tips

****If the tiger keeps going into the conus?** If the catheter stubbornly enters the conus branch (CB), a slighter and more discrete clockwise rotation can be repeated, accompanied by a short pullback. This maneuver prevents supraseductive intubation

of the CB. Alternatively, the curve could be straightened with a wire tip, thus resembling the JR curve and/or the RCA ostium approached from a higher sinus position. Sometimes the problem can be solved with deep inspiration. If all that fails, the Tiger is to be exchanged for a JR catheter.

****Manipulation of the Q curve guide for both right and left coronary arteries** Q guides are all size 6Fr (Q3.5 and Q4 curves, Mach 1 type). The guide is advanced through the arteries of the arm to the aortic root with the wire leading. On entering the level of the coronary ostia, the wire is retracted into the guide and the guide manipulated into position. For the LCA, this typically requires the wire tip to be several centimeters short of the guide tip and for the guide to be advanced while being rotated counterclockwise to engage the left coronary ostium. For the RCA, the wire is advanced to rest in the RCS, located anteriorly in an LAO view. The guide is then gently advanced over the wire until it also reaches the level of the RCA sinus. The wire is then retracted slowly while advancing the guide and rotating it gently clockwise, until it engages the coronary artery or allows suitable imaging by virtue of close proximity to the vessel's ostium. If the proximal portion of the RCA appears to have a suitable shape and takeoff from the aortic root, the wire is then gently retracted further to allow the Q catheter to adopt its preformed shape [19].

Discriminating Differences

The Mach 1 Q guide (Boston Scientific) is an excellent default device for LCA PCI, having a good balance of manipulability, backup support, and capacity for deep engagement of the coronary while being atraumatic to the coronary ostium and left main stem. This guide has a relatively soft and easily deformable distal curve, reducing the risk of trauma and dissection at the vessel ostium. For the RCA, the Q shape might seem somewhat excessively curved. However, the Mach 1 Q guide fits the RCA well via the radial route, especially if the artery is of flat or upturned origin. Even if the guide is not ideally suited to the RCA takeoff from the aortic root, maintaining a 0.035-inch wire inside the guide (within an enclosed circuit including connected pressure wire and contrast lines) straightens the Q guide sufficiently to "look at" the RCA and assess the most suitable guide shape. Most other brands of the guide are either too rigid to take the shapes required to engage both coronaries or too specifically shaped for the left or the right coronary. This series shows that the Q guide can be used as the intended device for imaging both left and right coronaries, and treating the culprit vessel. The crossover rate to a second guide is low and is usually a result of a downturned or aberrant RCA origin. The most obvious situation in which this strategy can significantly increase procedural speed and efficacy is that where an inferior, inferoposterior, or inferolateral myocardial infarction could be due to occlusion of either a dominant circumflex or an RCA. In this situation, it can be difficult to predict whether an LCA- or RCA-shaped catheter is required, and choosing the incorrect one will add procedural time and

complexity. There are other guide shapes that might facilitate access to the RCA and LCA; the All Right and Kimny catheters are good examples. It is also possible to use an AL guide to access both coronaries. In some occasions, the tip of the Amplatz 1 is too short to engage the left coronary with good backup support, whereas the Amplatz 2 provides good backup for the left but is overaggressive on initial engagement of the right. Other similarly shaped catheters (EBU, XB) might also be suitable but were not tested in this case series. The particular combination of shape and distal curve rigidity of the EBU catheter used in this unit (Launcher) is problematic when engaging the right coronary (the tip remains too upturned, even with a wire *in situ*) [19].

Venous and Arterial Bypass Grafts

Left internal mammary artery (LIMA) and right internal mammary artery (RIMA) angiography can be easily performed with the Tiger, JR, or IM catheter from the ipsilateral RA. Most saphenous vein grafts (SVGs) can be easily cannulated with the Tiger, JR, or JL catheters via the right TRA. Frequently the insertion of a wire in the catheter may be helpful. The wire can be advanced for RCA grafts or pulled to the secondary curve for lower inserted left grafts (diagonals), and then pulled all the way back for high takeoff LCX graft ostia. When the Judkins catheter fails, probably the best option is the AL catheter.

Technical Tips

*****Intubation of the LIMA from the right radial approach**

(1) From the right RA, advance the JR-4 and a wire into the left subclavian, left brachial, and left radial arteries. Perform an external compression of the wire. This maneuver allows exchange of the JR-4 for a LIMA catheter and advances it into the subclavian artery and performs selective LIMA angiography [20].

*****Intubation of the LIMA from the right radial approach**

(2) From the right RA, advance a wire into the left subclavian, left brachial and left radial arteries. Ask the patient to flex the arm. Advance the Simmons I catheter or the Tiger into the subclavian.

OTHER PROCEDURES

Right Heart Catheterization

A small number of patients undergoing coronary angiography have indications for right heart catheterization. In keeping with the philosophy of immediate patient mobilization, right heart catheterization can be easily and safely performed from the veins of the elbow. In most cases the veins are 5Fr compatible. This allows implantation of a 5-Fr temporary pacemaker if needed. When the access site is the cephalic vein, there are sometimes difficulties navigating the wire or catheter because of the unfavorable angle with the subclavian vein. If the wire or catheter repeatedly enters the coronary sinus, it can be withdrawn and preformed with a large curve that enables entry into the right ventricle and pulmonary artery.

Bifurcations

TRA is compatible with most bifurcation techniques and new generation balloons and stents, with the exception of trifurcation PCI, certain cases with standard crush technique, kissing stents, and some dedicated devices when RAs cannot accommodate larger than 6-Fr guides.

Chronic Total Occlusion

Good guide support, which is essential for this subset of PCI, can be achieved with most femoral curves transradially. Other techniques specific for chronic total occlusion (CTO) PCI, such as the use of microcatheters, anchor balloon, double or triple wire, and deep intubation, can be easily applied via the radial approach. If needed, contralateral injection can be performed by using the left radial artery or the ipsilateral femoral artery.

COMPLICATIONS

The complication profile of TRI is different from that related to the femoral route, with no life-threatening complications and no need of vascular surgery or blood transfusions. Most radial complications are preventable.

Spasm

Radial artery spasm is the most frequent problem with transradial heart catheterization. It causes patient discomfort and reduces procedure success rate. Risk factors for spasm are patient and operator bound, and include anxiety, age, female gender, improper sheath:lumen ratio, tortuosity, hematoma, and repeated puncture. It is much more frequent at the start of the learning curve.

Technical Tip

***How to avoid radial spasm** Give the patient adequate sedation. Keep the cardiac catheterization laboratory atmosphere quiet and peaceful. Cheerful attitude may also be of help. Use and appropriate sheath size and, by preference, the hydrophilic sheaths. Use fluoroscopy to see the problem each time resistance that is encountered. Give generous dosage of vasodilators.

Radial Occlusion

Occurs in 3–5% of cases and is asymptomatic as a rule; 50% of radial occlusions spontaneously recanalize over time. Predictive factors for radial occlusion include long duration of catheterization, high sheath:artery ratio, heparin dosage, longer sheath, and prolonged compression times [21].

Technical Tip

****Patent hemostasis** After putting the bandage pressure on the RA access, release the pressure slowly until a small spurt of blood is seen. This is the ideal pressure that allows a patent antegrade flow while being strong enough to seal the radial access.

Bleeding, Iatrogenic Radial Artery Perforation

One of the most common reasons for femoral crossover is iatrogenic perforation or dissection of the RA, which can usually be treated conservatively with a proximal pressure bandage. If undetected, perforation may lead to severe forearm hematoma.

Technical Tip

****How to continue the procedure when a perforation has occurred** Insert a long sheath across the perforation or a 4-Fr MP long (130 or 150 cm) catheter and over it a 5- or 6-Fr guide. This maneuver reduces friction and the 6-Fr guide temporarily seals the dissection/perforation plane. This is especially helpful when there is accompanying spasm. The maneuver resembles the “mother-and-child” technique used for increasing support during CTO PCI. It can be used in cases of radial perforation when one wants to finish the procedure transradially or there are no other available access sites. Perforation is usually caused by the wire, and frequently there is spasm in the adjacent segments of the RA and it is usually impossible to traverse it with a 6-Fr guide. If the wire is still in place, the operator can insert a 4-Fr long MP 130 or 150 cm. Then the 6-Fr guide, which has been premounted over the 4-Fr MP before introducing the “ensemble” into the 6-Fr sheath, is navigated over the 4-Fr MP catheter, thus reducing the risk of further vessel trauma.

If the wire had been withdrawn proximal to the perforation, the operator can use a non-hydrophilic PCI wire and insert over it the MP catheter, etc. Once the guide is in the left or coronary sinus near the ostium of the target vessel, the 4-Fr MP can be withdrawn and PCI performed [22,23] (Figure 7.15).

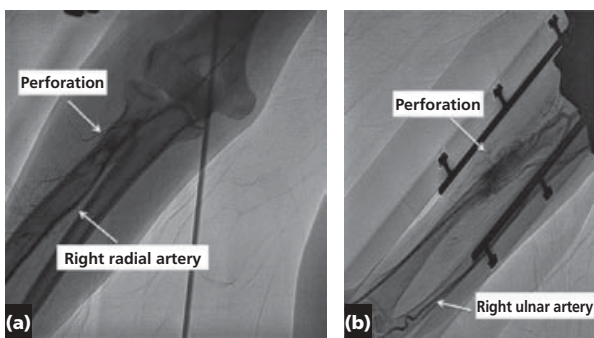


Figure 7.15 (a) An iatrogenic radial artery perforation complicating coronary intervention: Right radial artery a few millimeters from its origin shows perforation and intense spasm; the perforation is most likely induced by the tip of the wire and/or the diagnostic catheter and extravasation aggravated by antithrombotic therapy. (b) Spontaneously sealed perforation; at completion of the procedure, the perforation spontaneously enclosed. The white line in the middle of the right radial artery is the reverberation of the 0.014-inch PTCA wire. (Reproduced from Mansour et al. *J Intervent Cardiol* 2011;**24**:401, with permission from Wiley.)

STRATEGIC PLANNING

Iatrogenic RA perforation is a rare but serious complication of PCI via the radial approach which carries a potential risk of acute hand ischemia and its major sequelae. Immediate recognition of this complication and prompt action, including neutralization of heparin, crossing the perforated segment with a wire, and deployment of either a diagnostic or guide catheter across the bleeding source, are necessary. When the above measures are not successful in stopping the bleeding, external compression by sphygmomanometer cuff may help to seal the perforation. Despite a lot of the literature reporting management of this complication by such simple strategies, not every case could be treated conservatively. If these measures fail, prolonged balloon inflation across the perforated segment may help to hold bleeding; non-flow-limiting dissection may be left without further intervention. If all other measures fail to stop the bleeding, a coronary polytetrafluoroethylene (PTFE)-covered stent is an effective solution to a potential dreaded complication of compartment syndrome (Figure 7.16).

Distant Hematoma

This is associated with bleeding remote from a puncture site. Most distant hematomas are caused by perforation of a small side branch by the wire, especially with concomitant use of glycoprotein (GP) IIb/IIIa blockers. It can be effectively managed with a cuff or elastic bandage applied to the forearm. It is reasonable to lower blood pressure or reverse heparin with protamine when feasible.

Management of Pseudoaneurysm

Pseudoaneurysms are small as a rule, and can usually be treated conservatively by exerting local pressure. The TR Band was originally developed as a compression device to assist hemostasis of the radial artery after a transradial procedure. The device has a transparent plate that is positioned over the PA and secured via a Velcro strap. The inflator syringe permits accurate pressure adjustment as air is injected into the side port, which inflates the compression balloon overlaying the PA [24].

Hematoma under tension is a rare complication that may require a surgical drain for a couple of days. **Volar compartment syndrome** is an extremely rare complication for which surgical fasciotomy may be indicated. **Entry site infection/allergy** presents as delayed skin reaction (2–3 weeks post-catheterization) and is caused by sterile inflammation. It is related to transradial catheterization and the use of a particular brand of hydrophilic sheaths.

Retroperitoneal Bleeding from the Radial Approach

After PCI from the TRI, a patient then complained of left leg weakness and numbness in the medial aspect of his thigh and

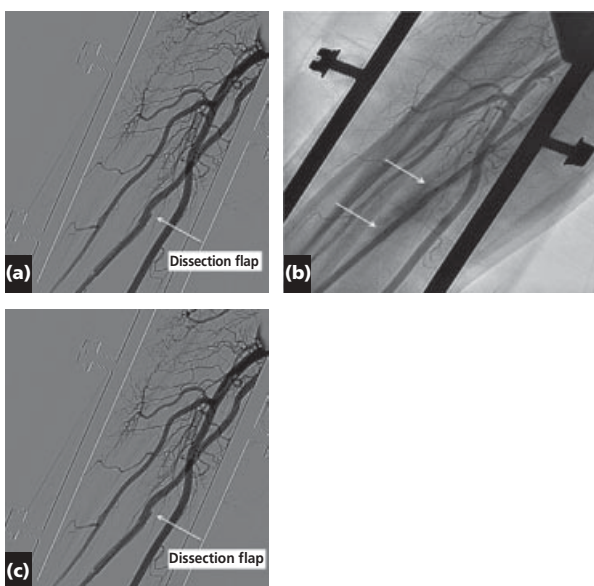


Figure 7.16 (a) Radial perforation induced by guidewire of the sheath. Before coronary angiography, perforation of right radial artery was noticed, a 0.032-inch hydrophilic Terumo glide wire meticulously crossed the perforated segment, and then coronary angiography was accomplished. (b) Conventional balloon at the perforated radial artery segment. Two arrows point out to a 3.0/15-mm conventional semicompliant balloon inflated twice at 6 atm, then 8 atm. (c) Non-flow-limiting dissection-complicated plan-only balloon angioplasty. Final right radial angiogram affirmed sealed perforation, but complicated by non-flow-limiting dissection that was left without further intervention. (Reproduced from Mansour et al. *J Interven Cardiol* 2011;**24**:401, with permission from Wiley.)

calf, and was unable to walk without support. Examination confirmed absent knee reflexes on the left side with weakness of hip flexion, consistent with a femoral neuropathy. It was noted that his hemoglobin had fallen to 10.3g/dl although he remained hemodynamically stable. A CT scan of the abdomen showed retroperitoneal bleeding [25].

Technical Tip

*****Reduction of knotted coronary catheter in the radial artery** A knot developed because of excessive clockwise rotations of the catheter while trying to intubate the RCA ostium. Significant subclavian tortuosity was possibly instrumental for significant resistance and loss of one-to-one torque, leading to excessive rotation of the catheter and development of a tight knot in the RA region. The first option is to advance a 0.035-inch standard " across the knot"; however, it would not be successful if the knot were too tight. There is always the risk of perforating

a catheter and RA if excessive force is applied. The second option is to fix the catheter in a segment distal to the knot; simple counterclockwise rotation from outside is sufficient to unravel the knot. The third option is to immobilize the distal segment of the catheter by applying manual pressure over the brachial artery in the cubital region while having counterclockwise rotation in the proximal segment. If there is inadequate fixation of the distal segment of the catheter due to fat in the cubital region, this technique would be unsuccessful. The fourth option is to apply the cuff of a sphygmomanometer in the brachial region and raise the cuff pressure up to 200 mmHg, which immobilizes the distal segment of the catheter; with this maneuver, the chance of unknotting a twisted catheter is higher [26].

Compartment Syndrome in the Forearm

The acute compartment syndrome is described as the clinical situation of an increase in tissue pressure (normal up to 9 mmHg) within a non-expandable space. The forearm contains three intercommunicated compartments: Volar, dorsal, and radial. An elevated pressure within the forearm impedes the normal capillary flow and lymphatic drainage and, as a vicious circle, it drives toward a progressive tissue edema and increased interstitial pressure, which evolve dramatically into an irreversible damage of muscular and nervous structures. Within the forearm, the muscles most prone to ischemic damage are those contained in the deep volar compartment and bordered by the radius, ulnar, and interosseous membranes (flexor digitorum profundus and flexor pollicis longus) [27].

The diagnosis of compartment syndrome in the forearm (CSF) is based on symptoms. Acute pain and swelling are the first to appear, with disturbances in distal sensitivity and distal pallor with preserved radial and ulnar pulses. The five "Ps" (pain, pallor, painful stretching of muscles, paraesthesia, and pulselessness) traditionally taught are only a way to remember the existence of CSF, but the diagnosis should be done before all five "Ps" appear. If there is no relief of pressure, the situation evolves acutely into a loss of muscular contraction, typical hand position (supination–volar exposure, wrist flexure, metacarpophalangeal extension, and interphalangeal flexure), dysesthesia, and eventually loss of macroscopic pulse. In the long term, the ischemia of muscles and nerves in the forearm produced in the setting of a CSF could result in a range of disabilities, from a slight contracture of the first three fingers with a slight loss of sensitivity to a complete contracture and disability of the whole hand and wrist (Volkmann's contracture) [27].

Technical Tip

*****How to prevent CSF** First, before the procedure, it is mandatory to check, if possible in an objective manner, the patency of the hand collateral arteries to ensure proper distal flow and to avoid ischemia within the hand during and after the procedure [27].

Second, during the procedure, a good management of radial tortuosities and anatomic variations is needed. The use of

hydrophilic wires to overcome tortuosities should be done carefully, with radial angiography in case of difficult wire advancement. At the end of the procedure, if there is a severe spasm with the removal of the sheath, an antispasmodic therapy should be given, and the removal should be done when the spasm has decreased. The hemostatic device should be placed directly onto the point of puncture and periodically reviewed until hemostasis has been achieved [27].

Third, a proper management of anticoagulants and GP IIb/IIIa inhibitors adjusted to body surface area (BSA) and creatinine clearance during and after the procedure are basic to avoid any bleeding complication [27].

Fourth, in the postprocedure period, even after several days, it is necessary to take into account every complaint of the patient about pain or swelling at any point of the arm that had been used in the percutaneous procedure, and adopt appropriate measures to avoid the bleeding and fast increase in pressure in the forearm compartment. A specific protocol was designed and is initiated promptly by nurses in order to prevent this complication.

The treatment is to inflate a blood pressure cuff 15 mmHg below the systolic pressure with distal oximetry to ensure proper distal flow [27]. Treatment is with fasciotomy or medicinal leech.

REFERENCES

1. Attubato MJ, Feit F, Bittle JA, et al. Major hemorrhage is an independent predictor of 1 year mortality following percutaneous coronary intervention: An analysis from REPLACE. *Am J Cardiol* 2004;**94**(6 suppl 1):39E.
2. Nikolsky E, Mehran R, Halkin A, et al. Vascular complications associated with arteriotomy closure devices in patients undergoing percutaneous coronary procedures: a meta-analysis. *J Am Coll Cardiol* 2004;**44**:1200–9.
3. Agostoni P, Biondi-Zoccai GG, de Benedictis ML, et al. Radial versus femoral approach for percutaneous coronary diagnostic and interventional procedures: Systematic overview and meta-analysis of randomized trials. *J Am Coll Cardiol* 2004;**44**:349–56.
4. Slagboom T, Kiemeneij F, Laarman GJ, van Der Wieken R, Odekerken D. Actual outpatient PTCA: Results of the OUTCLAS pilot study. *Catheter Cardiovasc Interv* 2001;**53**:204–8.
5. Caputo RP, Tremmel JA, Rao S, et al. Transradial arterial access for coronary and peripheral procedures: Executive summary by the transradial committee of the SCAI. *Catheter Cardiovasc Interv* 2011;**78**:823–39.
6. Kiemeneij F, Fraser D, Slagboom T, Laarman G, van der Wieken R. Hydrophilic coating aids radial sheath withdrawal and reduces patient discomfort following transradial coronary intervention: a randomized doubleblind comparison of coated and uncoated sheaths. *Catheter Cardiovasc Interv* 2003;**59**:161–4.
7. Bell MR, Rihal CS, Gulati R. Minimally invasive transradial intervention using sheathless standard guiding catheters. *Catheter Cardiovasc Interv* 2011;**78**:866–71.
8. Sciahbasi A, Mancone M, Cortese B. Transradial percutaneous coronary interventions using sheathless guiding catheters: A multicenter registry. *J Intervent Cardiol* 2011;**24**:407–12.

9. Pancholy SB. Transradial access in an occluded radial artery: A new technique. *J Invasive Cardiol* 2007;**19**:541–4.
10. Patel T, Shah S, Sanghavi K, Pancholy S. Reaccessing an occluded radial artery: a “proximal entry” technique. *J Intervent Cardiol* 2011;**24**:378–81.
11. Kurisu S, Mitsuba N, Kato Y, et al. External side-compression of radial artery: A simple technique for successful advancement of guidewires through the radial approach. *J Intervent Cardiol* 2011;**24**:397–400.
12. Spaulding C, Lefevre T, Funck F, et al. Left radial approach for coronary angiography: results of a prospective study. *Catheter Cardiovasc Diagn* 1996;**39**:365–70.
13. Louvard Y, Lefevre T. Loops and transradial approach in coronary diagnosis and intervention. *Catheter Cardiovasc Interv* 2000;**51**:250–3.
14. Louvard Y, Lefevre T, Morice MC. Radial approach: What about the learning curve? *Catheter Cardiovasc Diagn* 1997;**42**:467–9.
15. Vassilev D, Smilkova D, Gil R. Ulnar artery as access site for cardiac catheterization: anatomical considerations. *J Intervent Cardiol* 2008;**21**:56–60.
16. Agostoni P, Zuffi A, Biondi-Zoccai G. Pushing wrist access to the limit. *Catheter Cardiovasc Interv* 2011;**78**:894–7.
17. Saito S, Ikei H, Hosokawa G, Tanaka S. Influence of the ratio between radial artery inner diameter and sheath outer diameter on radial artery flow after transradial coronary intervention. *Catheter Cardiovasc Interv* 1999;**46**:173–8.
18. Ikari Y, Nagaoka M, Kim JY, et al. The physics of guiding catheters for the left coronary artery in transfemoral and transradial interventions. *J Invasive Cardiol* 2005;**17**:636–4.
19. Roberts EB, Wood A. Use of a single Q guide catheter for complete assessment and treatment of both coronary arteries via radial access during acute ST elevation myocardial infarction: A review of 40 consecutive cases. *J Intervent Cardiol* 2011;**24**:389–96.
20. Garcia-Touchard A, Fernandez-diaz J, Francisco DOJ, Goicolea-Ruigomez J. Intraarterial guidewire external compression: A simple technique for successful LIMA angiography through the right radial approach. *J Intervent Cardiol* 2008;**21**:175–7.
21. Stella PR, Odekerken D, Kiemeneij F, Laarman GJ, Slagboom T, van der Wieken R. Incidence and outcome of radial artery occlusion following transradial coronary angioplasty. *Catheter Cardiovasc Diagn* 1997;**40**:156–8.
22. Patel T, Shah S, Sanghavi K, et al. Management of radial and brachial artery perforations during transradial procedures – A practical approach. *J Invasive Cardiol* 2009;**21**:544–7.
23. Sallam MM, Ali M, Al-Sekaiti R. Management of radial artery perforation complicating coronary intervention: A stepwise approach. *J Intervent Cardiol* 2011;**24**:401–6.
24. Liou M, Tung F, Kanei Y, et al. Treatment of radial artery pseudoaneurysm using a novel compression device. *J Invasive Cardiol* 2010;**22**:293–5.
25. Raja Y, Lo TS, Townend JN. Don’t rule out retroperitoneal bleeding just because the angiogram was done from the radial artery. *J Invasive Cardiol* 2010;**21**:E3–4.
26. Patel T, Shah S, Pancholy S. A Simple approach for the reduction of knotted coronary catheter in the radial artery during the transradial approach. *J Invasive Cardiol* 2011;**23**:E126–7.
27. Tizon-Marcos H, Barbeau GR. Incidence of compartment syndrome of the arm in a large series of transradial approach for coronary procedures. *J Intervent Cardiol* 2008;**21**:380–4.

CHAPTER 8

Slender Transradial Intervention

Yuji Ikari

Challenges 171

Mechanism of Guide for Left Coronary Artery 171**Importance of the Angle (θ) 172****The Friction Force between the Guide and the Opposite Wall of the Aorta 173****Guide Size Consideration 173****Backup Mechanism of the Ikari Left Guide for the Left Coronary Artery 174****Technical Tip 177**

Engaging the ikari guides 177

Backup Mechanics for the Right Ikari Guide 177**Limitations of the 5-Fr Guide 179**

Weak backup force in a 5-fr guide 179

Kissing balloon technique in a 5-fr guide 181

Intravascular ultrasound catheter in a 5-fr guide 182

Distal protection devices in a 5-fr guide 182

Chronic total occlusion in a 5-fr guide 182

Sheathless system using 5 fr (virtual 3 fr) 182

Minimum contrast (MINICON) technique 183

CHALLENGES

Less invasive strategy is favored in coronary revascularization in order to reduce access site complications. In transradial intervention (TRI), use of a 5-French (5-Fr) guide is still technically difficult because improvement with new designs of device and invention of newer techniques are necessary in order to achieve procedural success.

MECHANISM OF GUIDE FOR LEFT CORONARY ARTERY

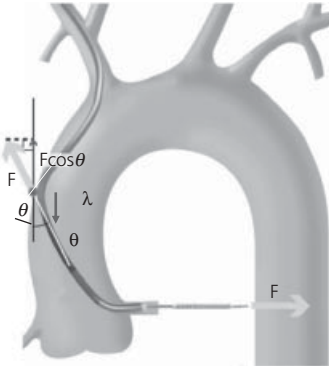
The first most important factor for stabilizing a guide is the angle θ between the guide and the opposite wall of the aorta. If force

*Basic; **Advanced; ***Rare, exotic, or investigational

\$, <\$US100.00 extra; \$\$, >\$US100.00 extra

⌚, <10 min extra; ⌚⌚, >10 min extra

◆, low risk of complications; ◆◆, high risk of complications



- $F \cos \theta = k(f \cos \theta' + \lambda)$

- $F_{\max} = k \frac{f \cos \theta' + \lambda}{\cos \theta}$

Maximum backup force is achieved if $\theta = 90^\circ$; $\theta = 0^\circ$; or λ is large.

Figure 8.1 Mechanics of backup force for the left coronary artery. F is the force necessary for a device to pass through a tight lesion. θ is the angle between the guide and the opposite wall of the aorta, and θ' is another angle between the guide and the aorta. $F \cos \theta$ is the vertical vector of F that makes the guide move upward. If $F \cos \theta$ is big enough, the guide loses engagement. Thus, maximum backup force is achieved when angle θ is 90° . (Modified from Ikari et al. [1], with permission from Journal Invasive Cardiology)

(F) is necessary for a device to cross a tight lesion, F is used at the point where the guide contacts the opposite wall of the aorta. When the vertical segment of F ($F \cos \theta$) is too big, the tip of the guide loses its engagement with the coronary artery ostium and curves upward [1].

The second important factor is the frictional force (λ) in proportion to the contact area. The hypothesis was shown to fit the following formula (Figure 8.1):

$$F_{\max} = k(\cos \theta' + \lambda) / \cos \theta$$

where k = constant determined by guide size, θ' = upside angle between guide and aorta, θ = downside angle between guide and aorta, and λ = frictional force.

Importance of the Angle (θ)

The above formula explained a number of common observations, especially the three observations below which can be explained by angle θ [1]:

- 1 The backup force of the Judkins left (JL) catheter in transfemoral intervention (TFI) is greater compared with TRI. As shown in Figure 8.2, the angle θ in TFI is greater than the angle θ in TRI even with the same JL guide. This explains the reason why the backup force of JL is greater in TFI.
- 2 In TRI, the backup force of JL-3.5 is greater than that of JL-4.0. Many operators know this fact from experience but no one could explain the reason. Based on the hypothesis, the angle θ of JL-3.5 was greater than that of JL-4.0 (Figure 8.3).
- 3 The backup force is greater with deep engagement of a guide. Based on the hypothesis, the angle θ at the deep engagement is greater than the normal position in JL guide (Figure 8.4).

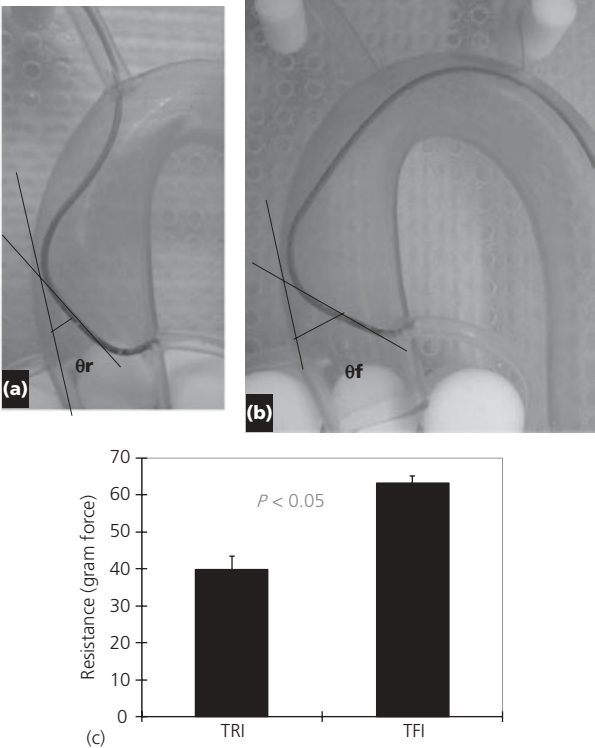


Figure 8.2 The Judkins left (JL) guide can generate greater backup force in TFI than in TRI. JL is applied in TRI (a) or in TFI (b). Then the angle between the guide and the aorta is bigger in TFI (θ_f) than in TRI (θ_r) despite the same guide. This is the reason why backup force is stronger in TFI using JL (c). (Modified from Ikari et al. [1], with permission from Journal Invasive Cardiology)

The Friction Force between the Guide and the Opposite Wall of the Aorta

The friction force correlates with the contact area between the guide and the opposite aortic wall. If there is a friction force between the guide and the opposite wall of the aorta, it can also increase the backup force. To test this idea, we made several shapes of the modified guide such as contact area lengths of 15, 25, and 35 mm (Figure 8.5). The in vitro experiment showed that the longer the length of the contact area, the greater the backup force.

Guide Size Consideration

These in vitro experiments showed guide size to be a strong element of backup force. Using the same approach site and the same shape guide, the size of the backup force is really different according to the size. An 8-Fr guide always has a greater backup force than a 7-Fr, and a 7-Fr guide has a greater one than a 6-Fr.

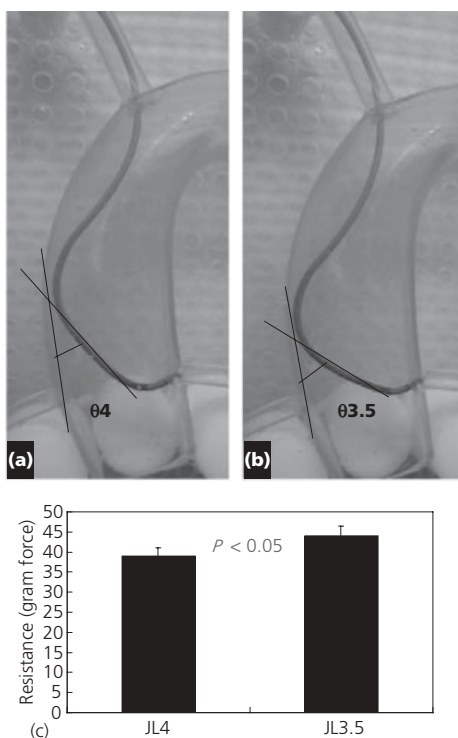


Figure 8.3 The Judkins left (JL)-3.5 can generate greater backup force in TRI than JL-4.0. (a) JL-4.0 and (b) JL-3.5 were applied from right TRI. The angle of JL-3.5 is greater. (c) The backup force of JL-3.5 is greater than JL-4.0. (Modified from Ikari et al. [1], with permission from Journal Invasive Cardiology)

Thus, a smaller guide is always weaker in terms of backup force. In other words, if you want to use a slender guide, you must use a good shaped one with excellent strength powered by a large θ angle and contact area.

Backup Mechanism of the Ikari Left Guide for the Left Coronary Artery

To get a greater backup force in TRI, which shape of the guide is ideal based on the mechanics? One of the answers is the Ikari left (IL)-type design. The IL type is different from the JL type in three areas (Figure 8.6): First, the length at the final straight position is shorter (35 mm in Ikari and 40 mm in Judkins). This makes the angle between the guide and the opposite wall of the aorta bigger.

Second, the next straight position (secondary curve) is longer (25 mm) than for the JL guide. This makes the contact area on the aorta larger and increases the friction force. A guide with these two modifications is called the Ikari F-type guide.

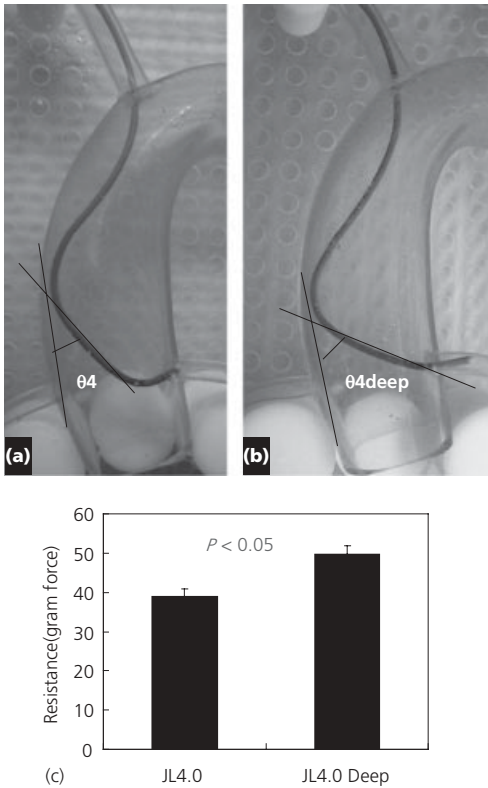


Figure 8.4 Deep engagement increases backup force in the Judkins left (JL). Many people know that the deep engagement increases the backup force. That is explained by the increased angle between the guide and the aorta. (Modified from Ikari et al. [1], with permission from Journal Invasive Cardiology)

Third, a curve at the brachiocephalic angle is added. This does not correlate with backup force but it makes guide control easier and stabilizes the guide position. A guide with all three modifications is called an IL type. Based on mechanics, an IL type is a guide with good backup force resulting from three modifications on a JL-type guide. As shown in Figure 8.7, an IL-type guide in TRI has greater angle than a JL in TFI or a JL in TRI. Furthermore, an IL-type guide has larger contact area on the aorta than the Judkins type. Therefore, the backup force of IL in TRI is greater than the JL in TFI.

The engagement technique is the same as with J L guide. If an operator is familiar with the JL guide, the IL guide can be easily manipulated. The IL-3.5 guide is a most commonly used for Asian people. If a patient has an elongated aorta, an IL-4.0 guide is suggested. These patients are older (>75 years old), hypertensive, or have aortic regurgitation.

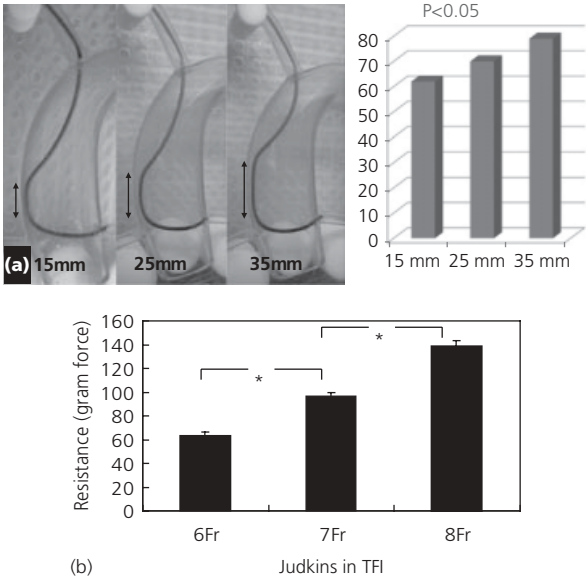


Figure 8.5 Modified Ikari left (IL) type to test the friction force in backup force. We made a different shape of the guides to test the friction force. When the contact length of the guide is longer, the backup force is stronger. The friction is another factor of the backup force. (Modified from Ikari et al. [1], with permission from Journal Invasive Cardiology)

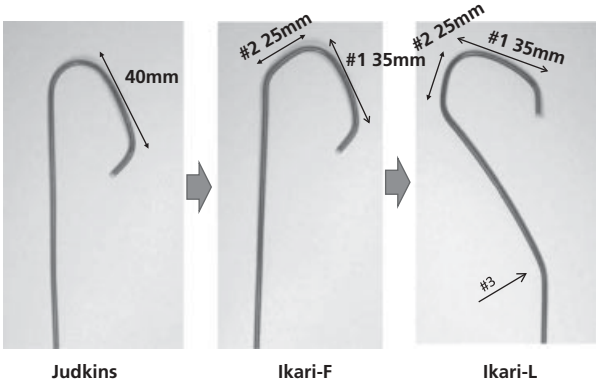


Figure 8.6 Ikari left (IL) shape compared with Judkins left (JL) shape. There are three different points between IL and JL: (1) The length at the final straight position is shorter (35mm in Ikari and 40mm in Judkins). This makes the angle between the guide and the opposite wall of the aorta bigger. (2) the second straight position is longer (25mm) than the JL guide. This makes the contact area on the aorta larger and increases the friction force. The guide with two modifications is called Ikari F type (center). Third, the brachiocephalic angle was added (right). This does not correlate with backup force but it makes guide control easier and stabilizes the guide position.

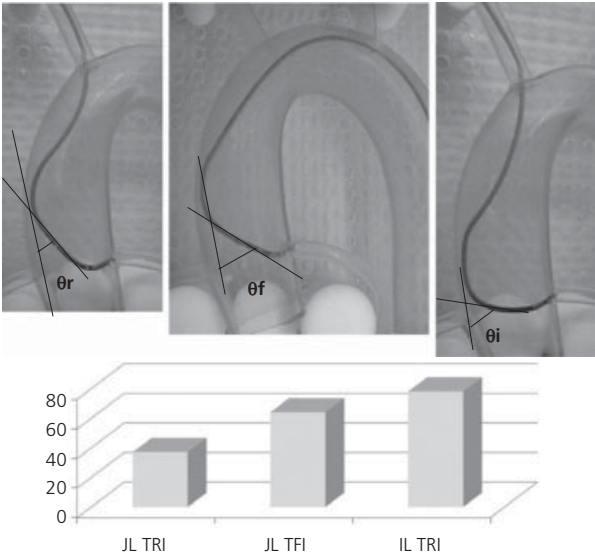


Figure 8.7 The Ikari left (IL) guide has greater backup force than the Judkins left (JL) one based on the mechanics. IL has a bigger angle and longer contact on the opposite wall of the aorta. IL in TRI generates greater backup force than JL even in TFI.

Technical Tip

Engaging the ikari guides In case of difficulty with a shorter aorta, the guide tip goes closer to the aortic valve. There are two ways to solve the problem:

- 1 Push the guide towards the aortic valve. Then bend the guide just as in the Sones technique and insert the tip into the left main ostium.
- 2 Keep the IL guide at the high position. Pull the guide while making a small counterclockwise rotation in order to engage the left coronary artery.

Some people may have concern about safety of IL for the left coronary artery (LCA). In our hospital, almost 90% cases were done using IL without left main (LM) dissection. Youssef et al. reported no LM dissection using IL for 621 consecutive cases [3]. This guide never advances deeply into the LM. Even without deep engagement, this Ikari guide can still generate strong backup force, which is the proof of the safety of this guide. On the contrary, the Voda/extra backup (EBU)/Xtra backup (XB)-type guides advance automatically into the LM with advancement of the interventional devices.

Backup Mechanics for the Right Ikari Guide [2]

For the right coronary artery (RCA) intervention, the backup mechanism is different from that for the LCA because the contact area of the RCA guide has a different approach. In TFI and left TRI, the primary contact site of the Judkins right (JR) guide is the

Judkins R

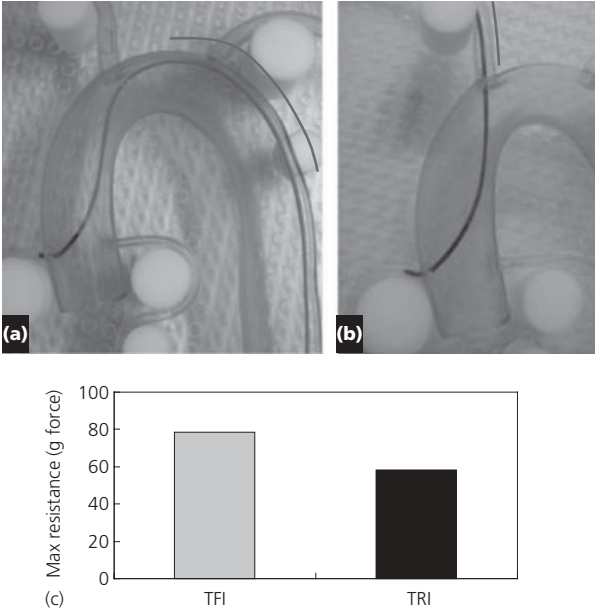


Figure 8.8 The Judkins right (JR) guide is weaker in TRI. In TFI, the primary contact site of the JR is the aortic arch. On the contrary, the primary contact site is the brachiocephalic artery in right TRI. The difference of the primary contact site is a factor that determines the backup force. (Modified from Ikari et al. [2], with permission from Journal Invasive Cardiology)

aortic arch (Figure 8.8). On the contrary, the primary contact site is the brachiocephalic artery in right TRI. The different primary contact site is a factor that determines the backup force. Thus, JR has weaker backup force in TRI compared with TFI. In the Amplatz left (AL)-type guide, the different primary contact sites are similar to those of the JR guide (Figure 8.9). However, the AL guides can brace themselves on the opposite wall of the aorta when the guide recedes due to pushing devices, generating greater backup force than the JR guide. The Ikari right (IR) guide is a modified guide of AL for the RCA. The mechanics is same as for the AL (Figure 8.10). Thus, the backup force of IR is similar to that of AL. The benefits of IR are: (1) Easier engagement than AL and (2) easy control of guide tip. When you pull the guide, the IR guide comes out according to the operator’s motion, although the reverse motion happens in AL. Recently, the IL is used for the RCA because of its strong backup force (Figure 8.11). The primary contact site of the IL guide for the RCA is the aortic arch in TFI and the brachiocephalic artery in TRI. It is the same for the JR and AL guides. However, the Ikari guide braces on the opposite wall of the ascending aorta in a power position, which can be achieved easily by a simple push. This is totally different when compared

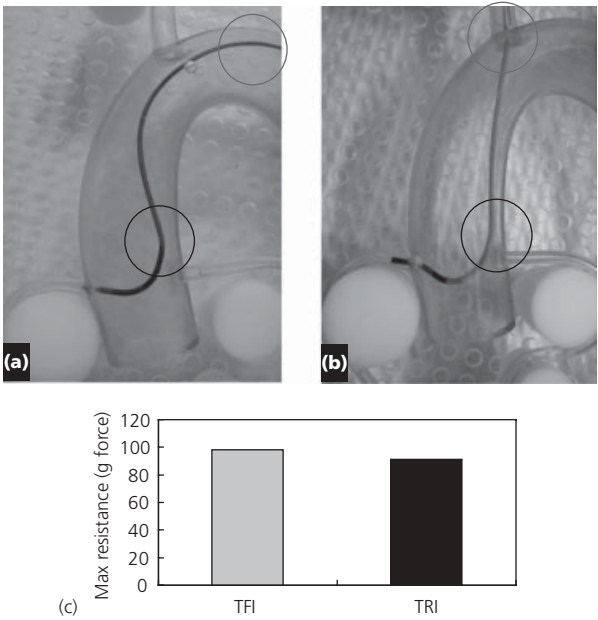
Amplatz L

Figure 8.9 The Amplatz left (AL) guide is weaker in TRI but better than Judkins right (JR). In an AL-type guide, the different primary contact sites are similar to those of the JR guide. However, AL guides can attach on the opposite wall of the aorta when the guide recedes due to pushing devices, generating greater backup force than the JR guide. (Modified from Ikari et al. [2], with permission from Journal Invasive Cardiology)

with other guides. Thus, from the in vitro experiments, the IL guide is the strongest guide for the RCA (Figure 8.12).

Limitations of the 5-Fr Guide

A 5-Fr guide has several limitations. The first is weaker backup force compared with same size guide. Second, many devices cannot pass through a 5-Fr guide such as rotablator >1.5 mm, some intravascular ultrasound (IVUS) devices, or an aspiration catheter. Third, the kissing balloon technique is also impossible because two 0.014-inch wires and two small balloons do not fit in a 5-Fr guide. Thus, percutaneous coronary intervention (PCI) for bifurcation, and calcified and thrombotic lesions is difficult with a 5-Fr guide.

Weak backup force in a 5-fr guide Backup force of the guide decreases in direct proportion with the downsizing of guide size. Thus, a weak backup force of a 5-Fr guide is a clear limitation compared with a larger guide. You should use the best shaped guide and maximum inner lumen guide in 5-Fr TRI. Selection of a guide should be uncompromising. We suggest the IL guide for

Ikari R

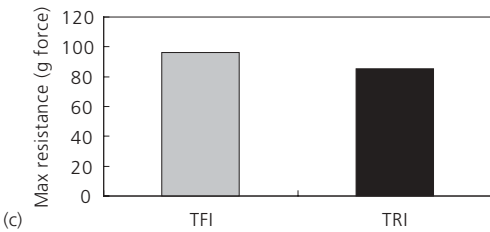
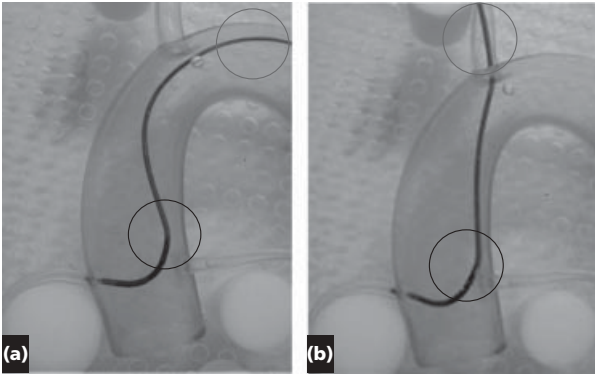


Figure 8.10 Backup force mechanics of Ikari right (IR) is similar to Amplatz left (AL). IR is a modified guide of AL for the right coronary artery. The mechanics are same as for AL. Thus, the backup force of IR is similar to that for AL. (Modified from Ikari et al. [2], with permission from Journal Invasive Cardiology)

Ikari L

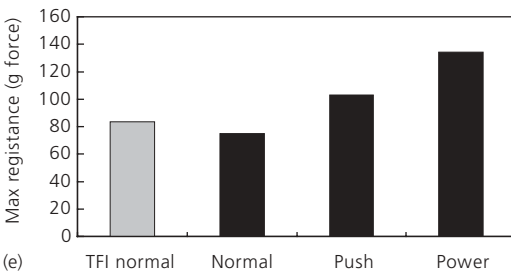
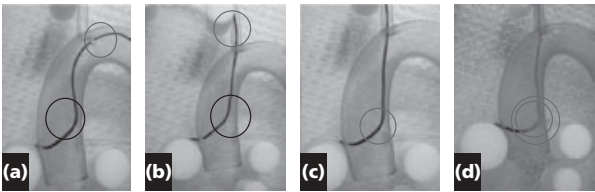


Figure 8.11 The Ikari left (IL) guide for the right coronary artery (RCA). The primary contact site of the IL guide for the RCA is the aortic arch in TFI and brachiocephalic artery in TRI – the same as for the Judkins right or Amplatz left guide. However, it attaches on the opposite wall of the ascending aorta in power position. (Modified from Ikari et al. [2], with permission from Journal Invasive Cardiology)

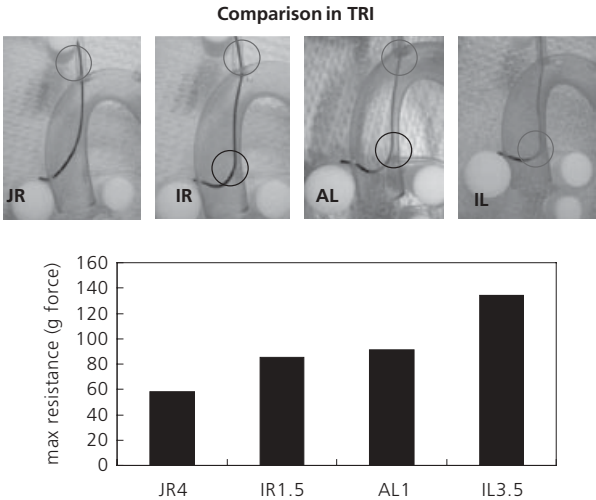


Figure 8.12 Comparison of guides in TRI for the right coronary artery: Based on the mechanics as shown in Figures 8.8–8.11, Amplatz left and Ikari right are stronger than Judkins right. Ikari left is the strongest catheter in power position. (Modified from Ikari et al. [2], with permission from Journal Invasive Cardiology)

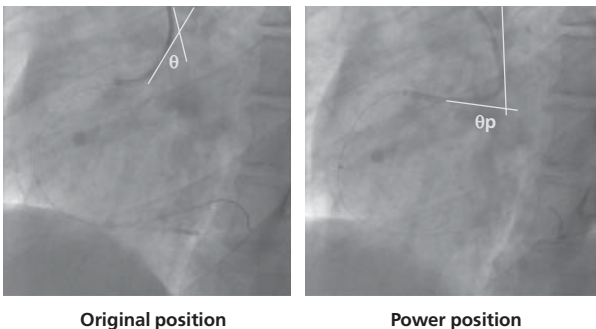


Figure 8.13 Power position of Ikari left (IL). When IL is pushed along the wire or the balloon shaft, the guide shape changes. The angle θ_p is larger than the θ of the original position. This is called the power position.

both LCA and RCA. To achieve maximum backup force, you should know about the power position of the IL guide. It is a simple pushing forward maneuver. Then, when the angle between the guide and the aorta becomes 90° , the backup force is at its maximum. Especially for the 5-Fr guide, the power position is essential to get maximum backup force of the guide (Figure 8.13). Patient selection is also important. At the current time, severe calcified lesions should be avoided in PCI with a 5-Fr guide.

Kissing balloon technique in a 5-fr guide It is impossible to perform kissing balloon technique (KBT) in a 5-Fr guide.

However, it becomes possible in a 5-Fr guide using a 0.010-inch wire-compatible system. Using the 0.014-inch system, KBT requires a 6- or 8-Fr guide [4,5]. The IKATEN registry study showed the safety and feasibility of routine use of the 0.010-inch system in real-world PCI with a clinical success rate of 99% [6].

Intravascular ultrasound catheter in a 5-fr guide In a 5-Fr guide, the Atlantis Pro IVUS catheter (Boston Scientific, Hemel Hempstead, UK) cannot be used with a 0.014-inch wire. However, it is possible if the wire is 0.010 inch. Interestingly, two 0.010-inch wires are able to pass through the Atlantis Pro IVUS catheter, even though a single 0.014-inch wire cannot. On the contrary, the Eagle Eye IVUS catheter can be used with a 0.014-inch wire in a 5-Fr guide. A new product, the ViewIT IVUS catheter, can be used with a 0.014-inch wire in a 5-Fr guide.

Distal protection devices in a 5-fr guide A guide size of 6Fr or greater is needed for accommodating an aspiration catheter. Distal protection occlusion balloon (PercuSurge) requires aspiration after stenting. Thus, PercuSurge requires a guide size of 6Fr or more. However, a 5-Fr guide is small enough to be inserted deeply into a coronary artery. Thus, the guide can be used as an aspiration catheter [7]. It is possible to use PercuSurge in a 5-Fr guide using the guide as an aspiration catheter. It is also possible to use a filter device because a 5-Fr guide can be used as a substitute for the aspiration catheter.

Chronic total occlusion in a 5-fr guide It requires strong backup force to pass a balloon or microcatheter across the chronic total occlusion (CTO) lesion. However, in some simple CTO lesions such as no calcification, short lesion, and straight lesion, they can be treated in a 5-Fr guide. Some operators are interested in a 5-Fr guide for a retrograde approach because a microcatheter passage such as the Corsair can fit into a 5-Fr guide. There are many limitations in a 5-Fr guide to treat CTO such as the parallel wire technique.

Masutani et al. suggested the 0.010-inch system for CTO lesions [8]. The PIKACHU registry study was conducted to show the efficacy of the 0.010-inch system for CTO lesions [9]. The success rate was as high as 68% of lesions treated only with the 0.010-inch system from the antegrade approach because the small-size distal tip could track the microchannels of CTO lesions.

Sheathless system using 5 fr (virtual 3 fr) If a 5-Fr guide is used without vascular access sheath, the outer diameter of the guide is equal to a 3-Fr sheath. It is called the "virtual 3Fr method" [10,11]. The incidence of skin and arterial injury is similar as when using the 3-Fr sheath; however, the inner diameter of this guide is equal to that of a 5-Fr guide. Some operators are concerned about the sheathless system because the direct motion stress on a radial artery may cause more injury despite reduction of the guide size.

Minimum contrast (MINICON) technique One of the benefits of 5Fr is reduction of contrast volume compared with a larger guide. In cases of severe chronic kidney disease, we need to reduce the amount of contrast to the minimum. This is an IVUS-assisted PCI technique. Every single step of PCI is validated solely by IVUS findings with no angiography, except for the initial and final injections. As angiography is performed only once at the start and once at the end of PCI, the contrast volume is generally <10ml. Preventive effect of contrast-induced nephropathy of this technique is excellent.

REFERENCES

1. Ikari Y, Nagaoka M, Kim JY, Morino Y, Tanabe T. The physics of guiding catheters for the left coronary artery in transfemoral and transradial interventions. *J Invasive Cardiol* 2005;**17**:636–41.
2. Ikari Y, Masuda N, Matsukage T, et al. Backup force of guiding catheters for the right coronary artery in transfemoral and transradial interventions. *J Invasive Cardiol* 2009;**21**:570–4.
3. Youssef AA, Hsieh YK, Cheng CI, We CJ. A single transradial guiding catheter for right and left coronary angiography and intervention. *EuroIntervention* 2007;**3**:475–81.
4. Yoshimachi F, Masutani M, Matsukage T, Saito S, Ikari Y. Kissing balloon technique within a 5 Fr guiding catheter using 0.010 inch guidewires and 0.010 inch guidewire-compatible balloons. *J Invasive Cardiol* 2007;**19**:519–24.
5. Matsukage T, Masuda N, Ikari Y. Simultaneous triple-balloon inflation technique within a 6 Fr guiding catheter for a trifurcation lesion. *J Invasive Cardiol* 2008;**20**:E210–14.
6. Matsukage T, Yoshimachi F, Masutani M, et al. A new 0.010-inch guidewire and compatible balloon catheter system: the IKATEN registry. *Catheter Cardiovasc Interv* 2009;**73**:605–10.
7. Yoshimachi F, Ikari Y, Matsukage T, et al. A novel method of PercuSurge distal protection in a five French guiding catheter without an export aspiration catheter. *J Invasive Cardiol* 2008;**20**:168–72.
8. Masutani M, Yoshimachi F, Matsukage T, Ikari Y, Saito S. Use of slender catheters for transradial angiography and interventions. *Indian Heart J* 2008;**60**:A22–6.
9. Matsukage T, Masutani M, Yoshimachi F, et al. A prospective multi-center registry of 0.010-inch guidewire and compatible system for chronic total occlusion: the PIKACHU registry. *Catheter Cardiovasc Interv* 2010;**75**:1006–12.
10. Matsukage T, Yoshimachi F, Masutani M, et al. Virtual 3 Fr PCI system for complex percutaneous coronary intervention. *EuroIntervention* 2009;**5**:515–17.
11. Takeshita S, Saito S. Transradial coronary intervention using a novel 5-Fr sheathless guiding catheter. *Catheter Cardiovasc Interv* 2009;**74**:862–5.

CHAPTER 9**Left Main**

Run Lin Gao, Debabrata Dash, Bo Xu, Thach N. Nguyen

Challenges 186

Standard of Excellence 186

Interventions in Ostial and Mid-Shaft Lesions 187**Technical Tip 187**

**Ostial LM stenting 187

Left Main Bifurcation Stenting 189**Technical Tips 189**

**Which lesion to stent first? the distal or the proximal lesion? 189

**When to use an intra-aortic balloon pump 191

Technique Provisional stenting 191**Provisional T Stenting 191****Technique** 192**T Stenting 192****Technique** 192**Modified T Stenting 193****T Stenting and Protrusion 193****Cone Crush-modified T Stenting 193****Crush and Mini-crush Technique 193****Technique** 193**The Double-kiss Crush Technique 195****Step-crush Technique 195****Simultaneous Kissing and V Stenting 196****Technique** 197**Technical Tips 198**

**Optimal V stenting 198

**Optimal SKS stenting 198

Culotte Stenting 200**Technical Tips 200**

**Removal of jailed wire 200

**Stent selection 200

**Proximal optimization technique 200

**Entering the side branch after main vessel stenting 201

**Which branch to stent first 202

**Debulking 202

*Basic; **Advanced; ***Rare, exotic, or investigational

\$, <\$US100.00 extra; \$\$, >\$US100.00 extra

⌚, <10 min extra; ⌚⌚, >10 min extra

♣, low risk of complications; ♣♣, high risk of complications

**Anchoring a balloon in the LCX in order to stent the distal LM 202

ADVANCED TECHNIQUES LM PCI with left ventricular assist device (LVAD) 203

PCI for LM Occlusion after transcatheter aortic valve replacement (TAVR) 203

CHALLENGES

Left main (LM) coronary artery disease (CAD) is a severe condition due to its high morbidity and mortality. Stenosis located in the ostial or mid-shaft of the LM without bifurcation disease has favorable outcome with minimal mortality and long-term complications [1]. Challenging interventions are cases where there is distal or bifurcation stenosis in the LM involving the ostium of the left anterior descending artery (LAD) and/or the left circumflex artery (LCX) [2].

STANDARD OF EXCELLENCE

After stenting, the LM artery is widely opened with good flow to the LAD and LCX.

Angiographic view Before selecting a patient for unprotected LM intervention, one should be certain that LM disease exists. This is particularly important if a patient has an ostial LM lesion evident angiographically only in the cranial angulation. This projection is notorious for artifactually enhancing the appearance of LM stenoses [3].

Intravascular ultrasound (IVUS) is the ideal method for confirming the presence of significant LM disease and also for guide selection of stent size, assessing the presence of calcification, and documenting the involvement of the distal LM vessel and its branches. Knowledge of reference lumen diameter, plaque composition, and position of the carina in relation to the major portion of the plaque volume are vital information before LM percutaneous coronary intervention (PCI) [3].

Assessing risk Many factors must come into consideration when LM PCI is planned. Patient demographics should include age, diabetes, renal function, and functional status. Angiographic data should include prior interventions, left ventricular function (ejection fraction [EF] <40%), anatomy of LM, length and location of lesion, calcification, and chronic total occlusion (CTO) or concomitant lesion in the LAD and the LCX, occlusion of a dominant right coronary artery (RCA), and left dominant circulation. Candidates with favorable outcome for LM stenting include those who have good left ventricular function, little to no calcification, and minimal risk factors [4,5]. Surgical intervention is preferable if there is heavy calcification of the LM, depressed EF, and multi-vessel disease. Additional tools to assess level of risk are the

BOX 9.1 CHECKLIST FOR LEFT MAIN INTERVENTIONS [5]

- Think it over before you embark. Does the patient have good indications for interventions?
- Anticipate potential problems
- At the outset, map out a clear strategy and a back-up plan in the event of a less than desirable result
- Ensure that all equipment is checked and ready and, if required in the event of a complication, the response must be rapid
- Ensure that you have a good guide support and clear angiographic views
- Keep balloon inflation short – the balloon inflated in the LM obstructs blood flow to almost the entire left ventricle
- Use IVUS to ensure appropriate stent selection and deployment
- Keep it simple: Provisional stenting would be appropriate and adequate in most of the LM bifurcations
- Perform two stent strategies whenever required
- Final kissing balloon inflation is mandatory in case of double-stent strategy
- Final result is more important than the technique used

EuroScore and the Syntax Score, which can be found on www.euroscore.org and www.syntaxscore.com, respectively. A checklist for LM interventions is given in Box 9.1.

INTERVENTIONS IN OSTIAL AND MID-SHAFT LESIONS

Ostial and mid-shaft lesions of the LM have favorable features for stenting. The technique is relatively simple and the immediate and long-term outcomes are good. The lesion at the mid-shaft can be predilated and then stented as any discrete lesion in other vessels. If the stenosis is not severe, direct stenting is also technically feasible. If the shaft of the LM is too short, the stent can be implanted into the LAD across the ostium of the LCX.

For the stenting of ostial lesions, the technique of anchoring a stent is shown in Figure 11.3. Select the best projections that show clearly the ostium. Usually the anteroposterior (AP) cranial and/or slightly left anterior oblique (LAO) cranial projections give the best view. The LAO caudal projection is also very good.

Technical Tip

****Ostial LM stenting** The Amplatz guides should not be used in ostial lesions. Short-tipped guides are ideal. Detailed imaging must be performed to ensure adequate visualization of the ostium and adjacent aorta. After the wire has been positioned in the distal segment, the guide should be disengaged slightly from the ostium by pushing gently on the wire. This will minimize coronary

ischemia. For imaging, the guide can then be gently moved toward the ostium, by slight traction on the wire. During positioning of the stent, the guide needs to be completely removed from the LM. The stent needs to be deployed with 1–2 mm protruding into the aorta. The time for balloon inflation should be short (<30s) and the inflation could be repeated several times (more than three). The proximal end of the stent should be flared by balloon inflation to ensure complete proximal stent apposition. This is also useful in facilitating guide or catheter engagement if further angiography is required. One must be aware that aggressive dilation at the ostium can cause dissection of the ascending aorta. IVUS should be used to ensure a satisfactory result (Figure 9.1).

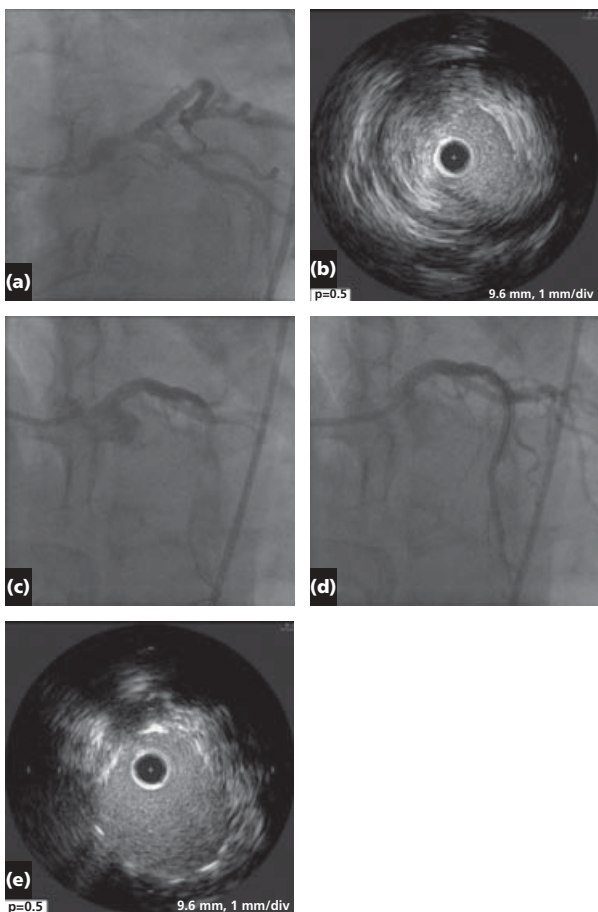


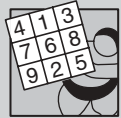
Figure 9.1 Stenting of isolated ostial left main stenosis. (a) Baseline angiogram (b) IVUS showing plaque burden in ostial left main (c) Positioning the stent with guide disengaged and stent deployment with proximal portion protruding into the aorta (d) High pressure post-dilatation (e) Final IVUS showing well apposed and expanded ostial stent.

LEFT MAIN BIFURCATION STENTING

By angiography, bifurcations are classified according to the internal angle between the main vessel (MV) and the side branch (SB). A Y-shaped lesion $<60^\circ$ allows easier wire access to the SB than a T angle. On the other hand, precise stent placement at the ostial SB is more difficult in a Y-angle lesion compared with a T-angle lesion. The LM bifurcation (LAD/LCX) is often T shaped with an average angulation of 80° . Therefore, the potential difficulty in rewiring the SB after MV stenting is an important consideration in selecting the stenting strategy for LM bifurcation stenosis. When the bifurcation angle is T shaped, it may complicate wire insertion into the SB. This angle may also impede re-crossing into the SB with a wire, balloon, or stent after MV stenting. However, the decision to electively implant a stent on the SB should be made only after wire insertion, which may favorably modify this angle [3].

STRATEGIC MAPPING

The strategy for distal LM PCI is to determine if the LCX is occluded, or its diameter ≤ 2.5 mm. If the LCX is occluded, it can be ignored and a stent can be placed between the LM and the LAD. The strategies for LM PCI are listed in Figure 9.2.



For a non-diseased LCX ostium, if the angle of bifurcation is T shaped, it is the operator's choice to place a protective wire but this is often not necessary. However, if the bifurcation angle is Y shaped, a protective wire is recommended. For a diseased LCX ostium, there are several techniques depending on the angle of bifurcation. If the angle is T shaped, the T stent or mini-crush kissing stent technique is recommended. If the angle is Y shaped, the culotte, crush, or double-kissing (DK) crush technique is recommended, whereas T stenting is not [3] (Figure 9.3).

When double stents are used, a final simultaneous inflation of both stents (kissing balloon inflation) at high pressure (>16 atm) with non-compliant balloons is considered critical to optimize outcomes. Whatever technique is chosen, a final IVUS examination should be performed to ensure adequate stent expansion, complete stent strut apposition to the vessel wall, and absence of peri-stent dissection [3].

Technical Tips

****Which lesion to stent first? the distal or the proximal lesion?** When approaching the patients with LM and significant disease downstream, it is helpful to stent all the downstream lesions first because stenting the LM vessel may make accessing the downstream lesions more difficult. However, this approach

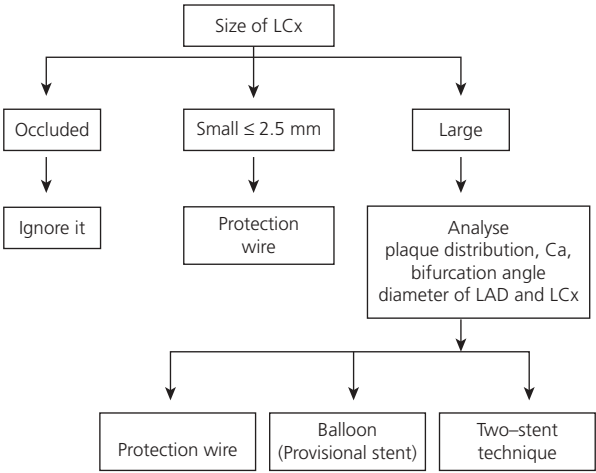


Figure 9.2 Strategies for distal left main stenting according to the size of the left circumflex artery.

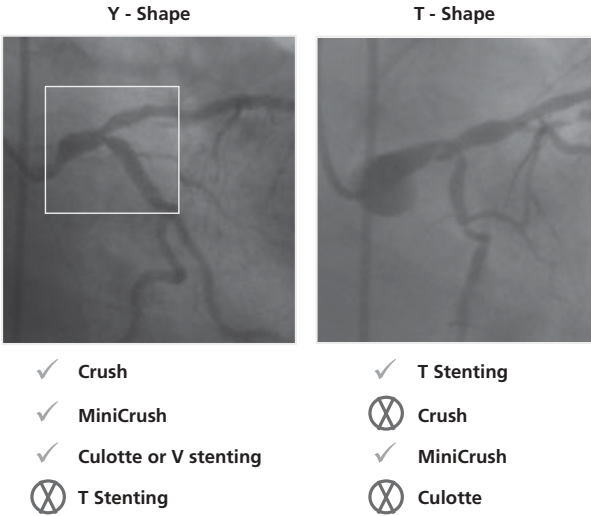


Figure 9.3 Stent strategies for distal left main stenting according to the angle of the bifurcation between the left anterior descending and the left circumflex artery.

holds true only if the patient and LMCA lesion are stable. If not, the LMCA disease should be treated first [3].

****When to use an intra-aortic balloon pump** For the patients who need interventions in the LM, a lower threshold for using an intra-aortic balloon pump (IABP) is suggested, particularly if the systolic blood pressure is <110 mmHg, the right coronary artery (RCA) is occluded, left ventricular function is severely reduced, or the LM, LAD, and/or LCX is significantly calcified [3].

TECHNIQUE Provisional stenting This is a single-stent strategy but allows the positioning of a second stent if required.

A left guide is engaged into the ostium of the LM and two wires are advanced into the LAD and LCX. A stent is positioned from the ostium of the LM to the LAD to fully cover the lesion and then deployed at 12–14 atm. If after placement of the LM stent, the result in the side branch (LCX) is poor and requires interventions, the wires are exchanged. The LAD wire can be withdrawn and passed through the stent struts to the LCX, and the “jailed” wire in the LCX can be withdrawn and advanced to the LAD. High-pressure postdilation may be applied if necessary. If the ostium of the LCX is compromised, a kissing balloon technique can be performed. If the ostium of the LCX is severely compromised, a provisional T-stenting, T-stenting-and-protrusion (TAP) technique may be applied (Figure 9.4).

Provisional T Stenting

Provisional T stenting can provide excellent results when the LCX originates at a right angle from the LM and LAD.

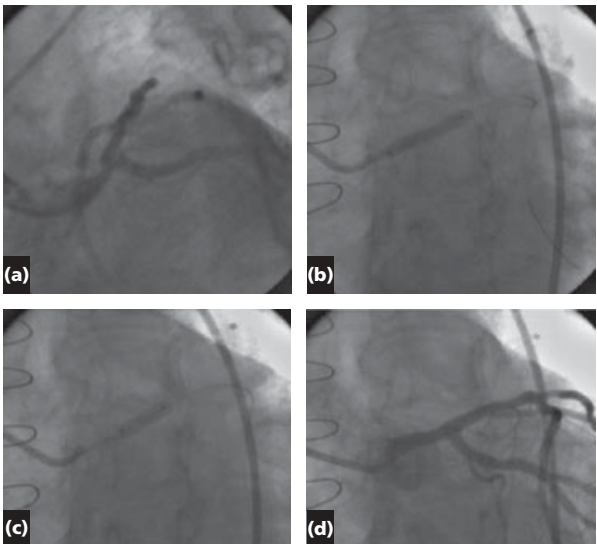


Figure 9.4 An example of provisional LM stenting. (Courtesy of Dr Debabrata Dash).

TECHNIQUE The stent is placed first in the main lumen (LM–LAD) after predilation. If, after placement of the LM stent, the result in the SB (LCX) is poor and requires stenting, a wire is passed through the LM lumen stent into the LCX. A balloon is advanced to dilate the stent strut of the ostium of the LCX and withdrawn. A stent is then passed into the LCX while another balloon is positioned in the LM lumen. The LCX stent is then deployed with its proximal margin fully covering the origin of the LCX. The pre-positioned balloon in the LM is inflated and, finally, the kissing balloon technique is performed to complete the procedure.

T Stenting

T stenting can provide excellent results when the LCX originates at a right angle from the LM and LAD. This technique is less labor intensive than the crush or culotte technique. However, this technique is associated with the risk of leaving a small gap between the MV and SB stents. This gap contributes to an uneven distribution of the drug, hence leading to ostial restenosis at the SB.

TECHNIQUE A 6-French (Fr) or 7-Fr large lumen guide with good support, such as the extra backup (EBU), Xtra backup (XB) LCA, and Amplatz left (AL), is commonly used. The wires are placed in both LAD and LCX. A stent is positioned in the SB (LCX), and a balloon catheter is positioned in the LM LAD. The stent in the SB (LCX) is deployed first with the proximal stent edge fully covering the origin of the LCX, making sure that the proximal end of the stent does not protrude too much into the LM lumen although it does not leave a large gap in the ostium. The wire and stent balloon are then removed. The previously positioned balloon in the LM LAD is inflated in order to crush the possible protrusive edge in the MV of the LCX stent. The LM balloon is removed and a stent is placed over the wire and deployed in the LM LAD across the origin of the LCX. Finally, a wire is re-crossed through the LM LAD stent into the LCX, and the origin of the LCX stent is postdilated to provide a large cell opening into the LCX, after which the kissing balloon technique is performed to finish the procedure (Figures 9.5 and see Figure 14.7).

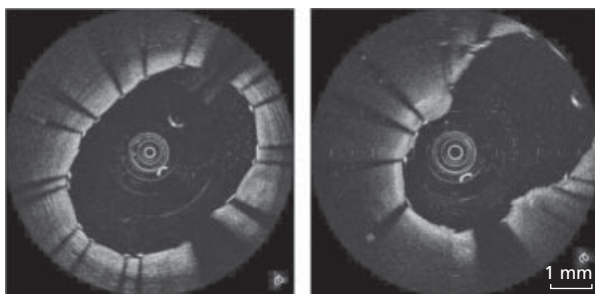


Figure 9.5 The results of T stenting as seen by optical coherence tomography. There is no protrusion of the struts into the left main. (Courtesy of Professor G. Taranni, University of Padua)

Modified T Stenting

Modified T stenting is a variation performed by simultaneously positioning stents at the LM LCX and LM LAD with LCX stent minimally protruding into the LAD, when the angle between the branches is close to 90°. The LCX stent is deployed first, and then, after wire and balloon removal from the LCX, the LAD stent is deployed. The procedure is completed with final kissing inflation (FKI) [6] (see Figure 14.9).

T Stenting and Protrusion

The TAP technique can be used for most bifurcation lesions. It can provide a good reconstruction of LM bifurcation with minimal stent overlap [7]. The MV (LM LAD) is stented, and then a stent is placed at the ostium of the LCX with a balloon left in the LM stent. After positioning the proximal edge of the LCX stent 1–2 mm inside the LM stent, the LCX stent balloon is deployed at high pressure. Then a FKI is performed in order to reshape the carina (see Figure 14.10).

Cone Crush-modified T Stenting

In this **cone crush-modified T-stenting** technique, the proximal SB (most of the time is the LCX) stent is aligned with an uninflated MV (most of the time is the LM LAD), LM-blocking balloon, or stent. The SB stent is then deployed. The SB balloon is retracted several millimeters and inflated at high pressure, creating an ostial flare or cone. The MV is then stented, covering the cone, and the SB is re-accessed for FKI [8].

Crush and Mini-crush Technique

The crush and mini-crush technique are suitable for a LM bifurcation patient with ostial and proximal stenosis of both the LAD and the LCX, in which the diameters are large and the angle between LAD and LCX is <70°. In the mini-crush technique, the proximal marker of the LCX stent may be situated in the LM at a distance of 1 or 2 mm, just fully covering the origin of the LCX. Compared with the standard crush, the mini-crush technique may be associated with more complete endothelialization and easier re-crossing of the crushed stent [9] (Figure 9.6).

TECHNIQUE A 7- or 8-Fr large lumen guide providing strong support is selected to accommodate two stents simultaneously. Two wires are placed in the LAD and the LCX respectively. After balloon predilation, two stents are advanced to the LM LAD and LCX respectively. The proximal marker of the LCX stent must be situated in the LM at a distance 3–5 mm proximal to the carina of the bifurcation, and the LM LAD stent must cover the bifurcation as well as the protruding segment of the LCX stent. The LCX stent is deployed first and the balloon and wire are then removed. The stent pre-positioned in the main LM LAD is deployed to completely cover and crush the protruding segment of the LCX stent against the vessel wall of the LM LAD. A wire is then re-crossed through the LM stent into the LCX and a balloon is advanced in the LCX to expand the LM stent struts at the origin of

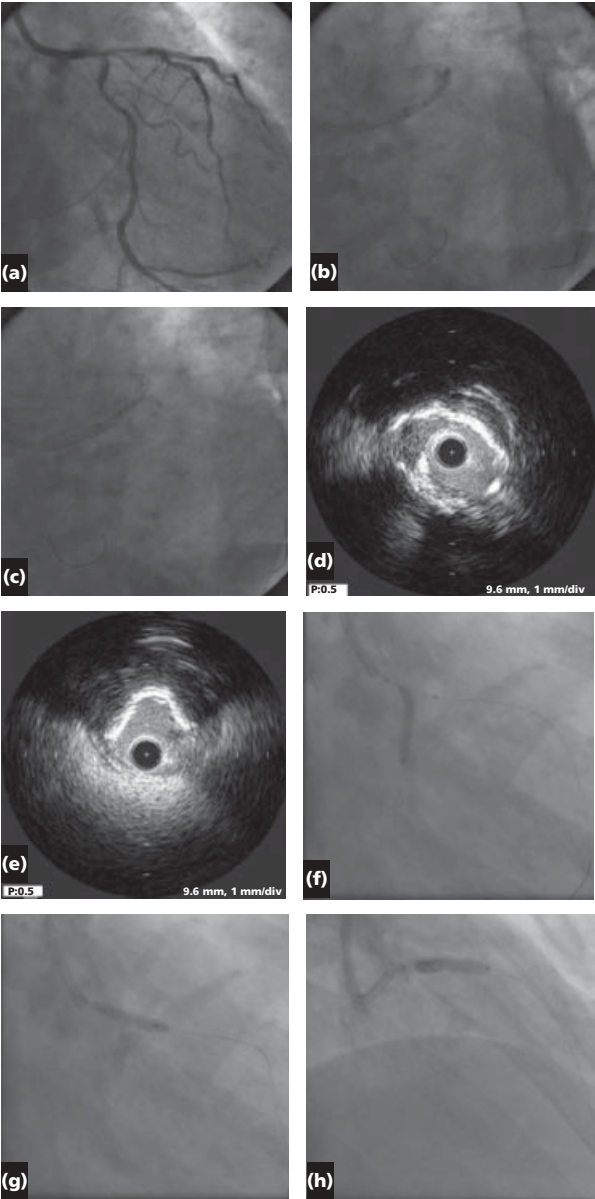


Figure 9.6 Mini-crush technique. (a) Baseline angiogram revealing significant stenosis of LM bifurcation involving proximal LAD and LCx (b) Pre-dilatation of LAD (c) Pre-dilatation of LCx (d) IVUS showing circumferential calcification of LM (e) Circumferential calcification of LAD (f) Stent to LCx with protrusion into LAD (g) Crushing of LCx stent with non-compliant balloon (h) Deployment of stent at LM-LAD.

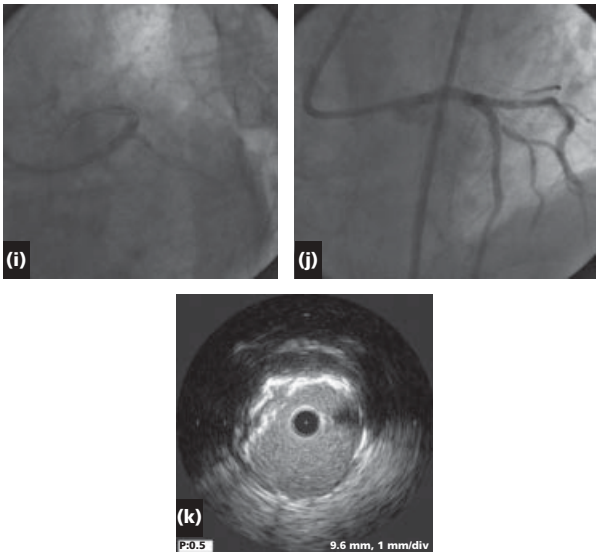


Figure 9.6 (Continued) (i) Rewiring of LCx followed by final kissing balloon inflation (j) Final angiographic result (k) Final IVUS result.

the LCX. Kissing balloon inflation is then applied to finish the procedure (Figure 9.6).

The final kissing balloon post-stent deployment dilation is very important to reduce in-hospital and long-term major adverse cardiac events (MACEs), whereas the key to successful final kissing balloon postdilation is to re-cross the wire into the LCX through three layers of stent struts.

The Double-kiss Crush Technique

This can be performed via a 6-Fr guide. A stent is placed into the LCX and a balloon placed in the LM LAD. The stent and balloon are positioned as in the standard crush technique. The LCX stent is deployed and then the wire and balloon from the LCX are removed. The pre-positioned balloon in the LM LAD is inflated to crush the protruding segment of LCX stent against LM's vessel wall. The balloon is removed and a stent deployed in the LM LAD. The wire is then re-crossed into the LCX and the final kissing balloon postdilation is applied to finish the procedure (Figure 9.7). In the DK crush technique, opening of the SB ostial struts is better [10] (Figure 9.8).

Step-crush Technique

A mini-crush through a 6-Fr guide is the "step crush" or "modified balloon crush." Both the LAD and the LCX are wired and predilated. A stent is advanced into the LCX with its proximal end protruding 1–2 mm into the LM. Then a balloon is advanced in the LAD over the bifurcation. The stent in the LCX is deployed and the balloon and wire are removed. The LM LAD balloon is

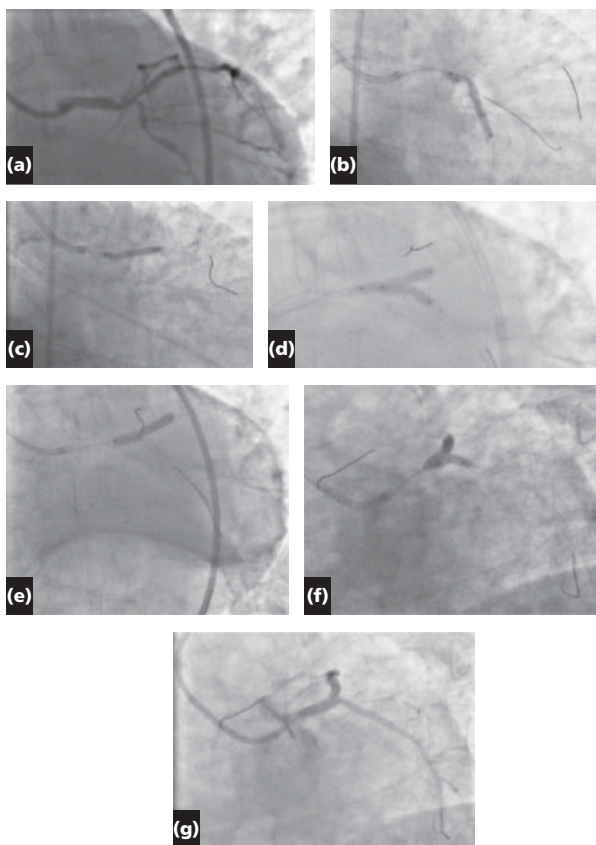


Figure 9.7 A case with distal LM bifurcation stenosis treated by Double Kiss (DK) crush technique. (a) Left main with lesion in distal left main, left anterior descending artery and left circumflex artery. (Medina 1,1,1) (b) Deploy the side branch stent first. (c) Balloon crushes the side branch stent. (d) First kissing balloon inflation. (e) Deploy another stent in the main vessel. (f) Final kissing balloon inflations (g) Final results. (Courtesy of Cardiac Interventional Laboratories, Nanjing Medical University, Nanjing, China.)

then inflated (to crush the protruding LCX stent) and removed. A second stent is advanced in LAD and deployed at 12 atm or more. The next steps are similar to mini-crush and involve re-crossing into the SB, SB stent dilation, and two-step FKI.

Simultaneous Kissing and V Stenting

Kissing stenting is indicated in patients with large LM lumen where the size of the LM will permit simultaneous high-pressure balloon inflation and when there is a relatively smaller lumen of LAD and LCX with ostial stenosis at both vessels. The advantage of these techniques is that access to both branches is always

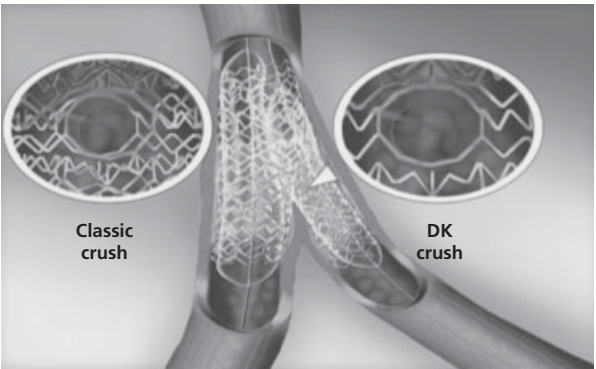


Figure 9.8 With the Double Kiss technique, the opening of the side branch ostium is larger.

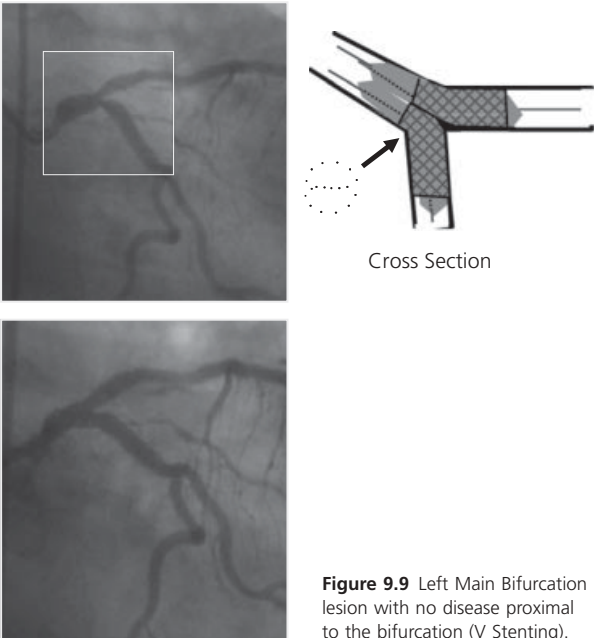


Figure 9.9 Left Main Bifurcation lesion with no disease proximal to the bifurcation (V Stenting).

preserved during the procedure without the need for rewiring any of the branches. When FKI is performed there is no need to re-cross the LCX side struts [11] (Figure 9.9).

TECHNIQUE Kissing stents are placed in both branches (LAD and LCX) of the bifurcation with minimal (V) or 4- to 5-mm (SKS)

BOX 9.2 LIMITATIONS [12]

- Possibility of dissection, progression of disease, or proximal edge restenosis due to balloon barotraumas
- Risk of leaving a gap if a stent becomes necessary to treat proximal dissection. This new proximal stent needs to be directed toward one of the two arms of the V
- Restenosis in the neocarina or at the proximal stent edge would require the crush technique, which would make re-crossing into the branch covered by crushed stent challenging
- Rewiring the stented vessels may be complicated by wire passage behind the stent struts

overlapping of the proximal stent portions [12]. Wires are placed in both LAD and LCX and, with or without predilation, stents are deployed in both the LAD and LCX with proximal overlap. This may be done with either simultaneous stent deployment with equal pressure in both balloons or sequential stent deployment followed by final simultaneous inflation of both stent balloons. Some operators prefer to deploy the stents simultaneously. When they are deployed simultaneously one must be aware of the risk of proximal MV dissection, which can be avoided by using lower deployment pressure. High-pressure, sequential, single-stent postdilation, followed by medium-pressure FKI, is performed with short and non-compliant balloon. Balloon size is selected according to the diameter of the treated vessels. If the reference vessel proximal to bifurcation is relatively small, low-pressure FKI should be performed to avoid proximal dissection (Figure 9.10). With this technique, a double-barreled lumen is created in the LM with a metallic carina not apposed to any vessel wall [12]. The limitations are shown in Box 9.2.

Technical Tips

****Optimal V stenting** The V-stent technique is probably the easiest and the one that guarantees immediate patency and access to both branches. This approach is preferable only when the disease does not extend proximal to the bifurcation (into the distal LMCA) and is the preferred technique when the LMCA is short or during emergencies. The V-stent technique is also suitable for other bifurcations, provided that the portion of the vessel proximal to the bifurcation is free of disease and there is no need to deploy a stent more proximally [11].

****Optimal SKS stenting** As it is impossible to position the proximal end of the stents exactly at the ostium of each branch, it is optimal to limit the length of the new carina to less than 5 mm. Sometimes it is necessary to advance the first stent more distally into the vessel to facilitate the advancement of the second stent. This maneuver is essential when the kissing stent technique is used to stent a trifurcation using three kissing stents (need a

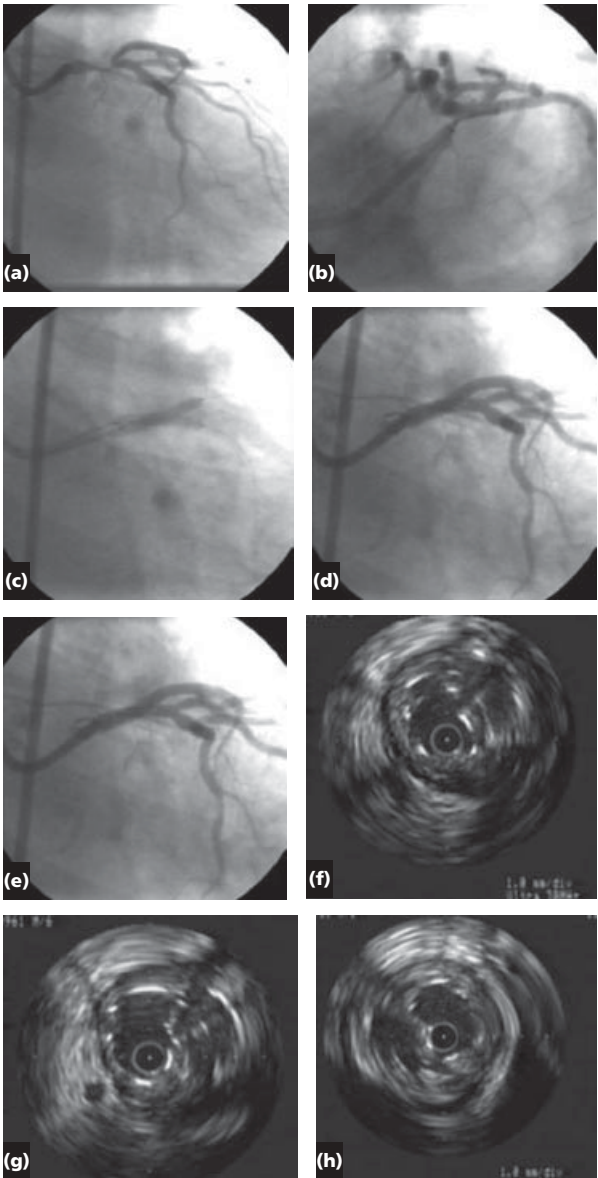


Figure 9.10 Simultaneous kissing stent technique. (a) and (b) Baseline angiogram showing tight stenosis at LM bifurcation (c) Implantation of two DES in LAD and LCx simultaneously (d) Following sequential post-dilatation (e) Final result after kissing balloon inflation (f) IVUS showing stent expansion and apposition of LAD ostium (g) IVUS revealing neo-carina at distal LM. (h) IVUS showing stent expansion and apposition of LCx ostium.

9-Fr guide). After accurate stent positioning, it is important to verify their correct placement in two projections before deploying the stents [13].

Culotte Stenting

In culotte stenting, a stent is placed in one branch, usually from the LM to the LAD, with a second stent placed through a cell of the first stent into the LCX with overlap of the proximal portions of both stents. This technique is indicated in patients with the LM LCX $<60^\circ$. Wires are initially placed in both LAD and LCX and predilation can be performed if necessary, either in sequence or simultaneously. A stent is then placed and deployed in one vessel, usually the LM LAD, covering the segment proximal and distal to the bifurcation across the opposing branch (LCX). Another wire is then advanced across the deployed stent into the LCX, and the jailed wire can be removed. A balloon is advanced over the wire and dilated to open the stent cell in preparation for stenting of the LCX. The first wire (to LAD) is then removed, and the second stent advanced over the LCX wire and deployed so as to cover the LCX lesion and widely overlap the proximal portion of the previously placed stent. A wire is re-advanced across the struts of both stents into the LAD and two balloons are advanced over both wires to perform kissing balloon postdilation (Figure 9.11).

In culotte stenting of LM bifurcation lesions, usually the first stent is implanted into the LAD; however, if the LCX is a big vessel and there is marked angulation, the first stent can also be implanted into the LCX to allow easier crossing into the opposing branch (LAD) [14].

Technical Tips

****Removal of jailed wire** The jailed wire should be pulled back with caution because it may cause proximal coronary dissection as a result of abrupt advancement of the guide. If the wire cannot be easily withdrawn, various tips are given in Chapter 14. A hydrophilic wire should be avoided for jailing due to the high risk of tip rupture or hydrophilic material that must be removed (shaved) during pull back (see Figure 14.15).

****Stent selection** The size of the stent struts is an important criterion. Stents with closed cells should be avoided. The choice of stent diameter for implantation in the MV depends on the diameter of the MV distal segment. The drawback is inadequate apposition of the stent on the proximal MV segment. This problem is solved by kissing balloon inflation and/or proximal optimization technique (POT).

****Proximal optimization technique** This technique is carried out by inflating a short bigger balloon just proximal to the origin of the SB (carina), which restores the original anatomic configuration of the bifurcation in compliance with the branching law. It facilitates the insertion of a wire, balloon and, if necessary, a stent in the SB, as well the projection of struts in the SB ostium (see Figure 14.6).

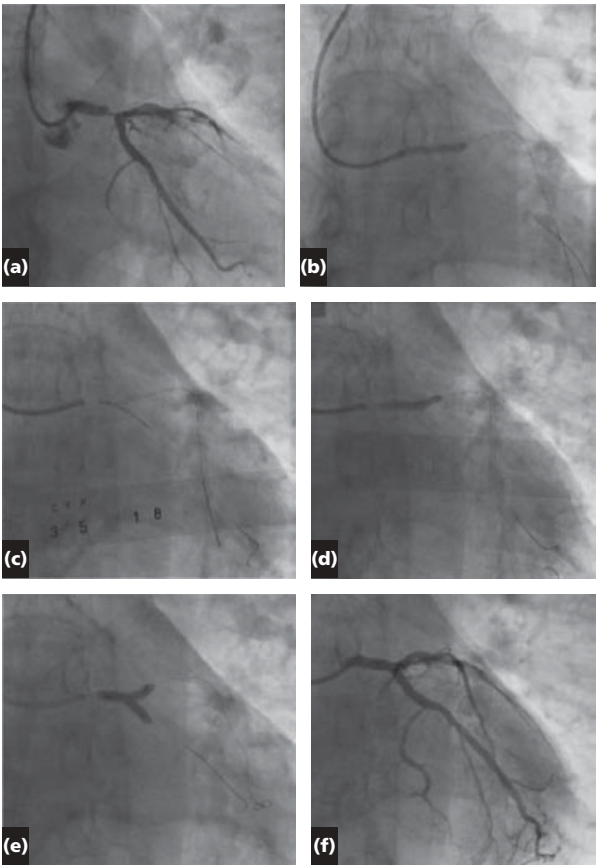


Figure 9.11 Technique of Culotte stenting. (a) Baseline angiogram (b) Pre-dilatation of LM-LAD (c) First stent deployed in LM-LCx (d) Second stent deployment in LM-LCx after wire exchange and predilatation (e) Kissing balloon inflation (f) Final result.

****Entering the side branch after main vessel stenting** When a standard wire fails to re-cross the side struts after stenting of the LM due to a wide bifurcation angle or a severe stenosis, hydrophilic coated or stiffer wire may be useful, with the caveat that these wires can easily induce dissections if not used cautiously. Some operators would use the Rinato-Prowater, Whisper, Runthrough NS. In a difficult situation, one of us (DB) has successfully used the Pilot 50 and 150, Fielder FC or Miracle 3/4.5g wires. Until complete re-crossing, the jailed wire in the SB should always be kept in place as a marker. In case of difficulty in negotiating the balloon through the struts, one of us (DB) would use a 1.5-mm Ryujin, Maverick, or Mini-Trek balloon to separate struts and allow a larger balloon to pass. If a 1.5-mm balloon fails to cross, one must consider re-crossing with a second

wire while the first wire remains in place, in order to advance the stent through a different strut. If the balloon insertion still proves unsuccessful, the MV stent should be further dilated. One should try to advance the balloon as close as is possible to the stent struts, inflate the balloon to at least 12–14 atm for 20s, and try to advance the balloon further while deflating it. Repeating this maneuver often results in the balloon being slowly advanced through the stent struts [15,16]. If all these techniques fail, re-crossing with a small fixed-wire balloon should be attempted [3]. If the SB wire advancement is still unsuccessful, utilization of POT, an orientable microcatheter (Venture) may help.

In cases of persistent difficulties, advancement and inflation of a very small balloon over the jailed wire may restore flow in the SB and enable the crossing of MV stent struts (see Figure 14.15).

****Which branch to stent first** In performing the technique, stent the branch with the sharpest angle first, which is usually the LCX. This has the advantage that re-crossing stent struts into the less angulated branch will be easier, as will passing the second stent through stent struts into a less-angulated branch. However, this conventional practice has recently been challenged by the Nordic PCI Study Group. In the Nordic Stent Technique Study, a randomized comparison of culotte and crush stenting of coronary bifurcation, the authors recommended stenting of the MV first to avoid acute closure of the MV [17]. This approach guarantees patency of the MV and may avoid the potential problems of performing the culotte technique where there is always a need to remove the wire from one of the two branches and where patency of this branch is not guaranteed [18].

****Debulking** There is no evidence to show that debulking before stenting with a drug-eluting stent (DES) can further improve the long-term outcome. The only indication for debulking may be severe superficial calcification so that the stent can be fully expanded. The operator should use slow speed and slow deceleration so that the chance for slow flow is lower.

****Anchoring a balloon in the LCX in order to stent the distal LM** After deploying the aortic valve during a transcatheter aortic valve replacement (TAVR), the electrocardiographic (ECG) monitoring showed severe ST-segment depression and transesophageal echocardiogram showed akinesia of the anterior and posterior left ventricular wall. Coronary angiography documented subocclusion of the LM stem. A 6-Fr Judkins left 4.0 guide was placed at the ostium of the LM and a hydrophilic wire (PT Graphics Intermediate) was inserted through the LM to the LCX artery. After predilation with a 1.5-mm low-profile PTCA (percutaneous transluminal coronary angioplasty) balloon, a 3-mm PCI balloon could be inserted with some difficulty. After balloon inflation, LM flow was re-established and the patient recovered hemodynamically. Stent insertion was not possible, so another PCI wire was inserted, a PCI balloon inflated in the stented region of the LCX artery, and this was used as an anchoring balloon allowing

successful insertion of a 3.5/8-mm DES in the LM. The anchoring balloon was removed, and the LM stent implanted and postdilated with good angiographic result and complete restoration of coronary blood flow [18].

ADVANCED TECHNIQUES LM PCI with left ventricular assist device (LVAD) During LM stenting in patients with severe left ventricular dysfunction, LVAD can provide more reliable hemodynamic support than IABP. Naidu et al. [19] reported an 80-year-old man with severe chronic obstructive pulmonary disease, chronic renal insufficiency, and significant carotid artery disease who presented with a 4-day history of episodic severe substernal chest pressure at rest. Echocardiography showed severe left ventricular dysfunction (EF 10%), anterior wall akinesia, and moderate mitral regurgitation. Cardiac catheterization revealed a 95% distal LM stenosis which involved the ostia of both the LCX and the LAD; the latter was also subtotally occluded, and there was a 50% stenosis in the mid-right coronary artery. The LAD had TIMI grade 1 distal flow. The patient was felt to be at high risk for surgical revascularization, so LM PCI was performed with the TandemHeart percutaneous ventricular assist device. A 21-Fr in-flow cannula was advanced using the transeptal technique into the left atrium under intracardiac guidance, a 15-Fr out-flow cannula was inserted into the right femoral artery and advanced to the right common iliac artery, and a resultant left atrial-to-distal aorta bypass was achieved with a non-pulsatile flow rate of 3.0l/min. The LAD and LCX were both wired and stented utilizing two sirolimus-eluting stents simultaneously deployed with a “kissing” technique. During balloon inflation, hemodynamic monitoring revealed a significant decrease in aortic pulse pressure due to diminished stroke volume. Despite the drop in pulse pressure, mean perfusion pressure was maintained and the patient remained hemodynamically stable without angina or arrhythmia. The final angiographic result shows percutaneous reconstruction of the distal LM and the proximal portions of the LAD and the LCX. The bypass cannulae were successfully removed immediately post-procedure, and hemostasis was achieved [19].

PCI for LM Occlusion after transcatheter aortic valve replacement (TAVR)

The clinical presentation is a rapid hemodynamic deterioration with severe hypotension and ECG signs of pronounced ischemia immediately after balloon predilation or implantation of the stent aortic valve (TAVI). LM occlusion may be expected in patients with a narrow sinus, low location of the LM coronary ostium, and bulky calcifications located to the LM coronary sinus. In addition, patients with long aortic valve leaflets, as in bicuspid aortic valve anatomy, may be at risk because the leaflets may be pressed against the aortic wall and cover the LM ostium after expansion of the stent valve.

The complication may be handled by emergency coronary bypass operation, which is not an optimal solution in these high-risk patients. It was found to be difficult to engage the LM ostium

and get proper guide backup because of the stent struts of the valve prosthesis. Furthermore, insertion of balloons was difficult because of severe LM obstruction. However, the LM artery could be dilated by progressively increasing balloon sizes. Stent insertion was not possible, so the balloon-anchoring technique was applied. This technique was originally used for treatment of complex chronic total coronary artery occlusions, where extra support was necessary to get balloons and stents through occluded and severely diseased vessels. In this technique, a second wire is typically inserted in a SB, where the anchoring balloon is inflated and may effectively stabilize the guide and facilitate insertion of balloons and stents in the target vessel.

Other techniques may be used to avoid LM occlusion and facilitate PCI during TAVI procedures. A guide may be placed close to the LM ostium and a PCI wire inserted through the main stem to keep the left main ostium open after TAVI, and enable swift insertion of balloons and stents. However, the result of this technique may be difficult to predict, because stent valve implantation is likely to interfere with both guides and PCI wires.

Aortography during the balloon predilation and assessment of coronary flow during the balloon inflation may give information about the risk of LM occlusion during the stent valve implantation and may also be used for risk assessment [18].

REFERENCES

1. Chieffo A, Park S, Valgimigli M, et al. Favorable long-term outcome after drug-eluting stent implantation in nonbifurcation lesions that involve unprotected left main coronary artery. *Circulation* 2007; **116**:158–62.
2. Serruys P, Morice M, Kappetein A, et al. Percutaneous coronary intervention versus coronary-artery bypass grafting for severe coronary artery disease. *N Engl J Med* 2009; **360**:961–72.
3. Teirstein PS. Unprotected left main intervention: Patient selection, operator technique, and clinical outcomes. *J Am Coll Cardiol Interv* 2008; **1**:5–13.
4. Park SJ, Kim YH, Lee BK, et al. Sirolimus-eluting stent implantation for unprotected left main coronary artery stenosis: comparison with bare metal stent implantation. *J Am Coll Cardiol* 2005; **45**:351–6.
5. Chieffo A, Stankovic G, Bonizzoni E, et al. Early and mid-term results of drug-eluting stent implantation in unprotected left main. *Circulation* 2005; **111**:791–5.
6. Colombo A, Stankovic G, Oric D, et al. Modified T-stenting technique with crushing for bifurcation lesions: immediate results and 30-day outcome. *Catheter Cardiovasc Interv* 2003; **60**:145–51.
7. Burzotta F, Gwon HC, Hahn JY, et al. Report of bench testing and first clinical Italian-Korean two-centre experience. *Catheter Cardiovasc Interv* 2007; **70**:75–82.
8. Rajdev S, Sarez A, Modi K, et al. "Cone Crush" a variant of modified T-stenting techniques for coronary bifurcation lesions: Bench stenting, feasibility, and in-hospital outcomes (Abstr). *J Am Coll Cardiol* 2007; **49**(suppl B):68.
9. Galassi AR, Colombo A, Buchbinder M, et al. Long term outcomes of bifurcation lesions after implantation of drug-eluting stents with the "mini-crush technique". *Catheter Cardiovasc Interv* 2007; **69**:976–83.

10. Chen SL, Santoso T, Zhang J, et al. A randomized clinical study comparing double kissing crush with provisional stenting for treatment of coronary bifurcation lesions: results from the DKCRUSH-II (Double Kissing Crush versus Provisional Stenting Technique for Treatment of Coronary Bifurcation Lesions) trial. *J Am Coll Cardiol* 2011;**57**:914–20.
11. Schampaert E, Fort S, Adelman AG, et al. The V-stent: a novel technique for coronary bifurcation stenting. *Catheter Cardiovasc Diagn* 1996;**39**:320–6.
12. Sharma SK. Simultaneous kissing drug-eluting stent for percutaneous treatment of bifurcation lesions in large-size vessels. *Catheter Cardiovasc Interv* 2005;**65**:10–16.
13. Fajadet J, Chieffo A. Current management of left main coronary artery disease. *Eur Heart J* 2012;**33**:36–50.
14. Adriaenssens T, Byrne RA, Dibra A, et al. Culottes tenting technique in coronary bifurcation disease: angiographic follow-up using dedicated quantitative coronary angiographic analysis and 12-month clinical outcomes. *Eur Heart J* 2008;**29**:2868–76.
15. Latib A, Chieffo A, Colombo A. Elective double stenting for left main coronary artery bifurcation: patient selection and technique. In: Moussa I, Colombo A (eds), *Tips and Tricks in Interventional Therapy of Coronary Bifurcation Lesions*. New York: Informa Health, 2010: 149–92.
16. Latib A, Colombo A. Bifurcation disease: What we know, what should we do? *J Am Coll Cardiol Interv* 2008;**1**:218–26.
17. Erglis A, Kumsars I, Niemela M, et al., for the Nordic PCI Study Group. Randomized comparison of coronary bifurcation stenting with the crush versus the culotte technique using sirolimus eluting stents: The Nordic Stent Technique Study. *Circ Cardiovasc Interv* 2009;**2**: 27–34.
18. Winther S, Chrustiansen EH, Thuesen L. Stenting of acute left main coronary artery occlusion using balloon anchoring technique after transcatheter aortic valve implantation. *J Intervent Cardiol* 2011;**24**: 470–3.
19. Naidu S, Rohatgi S, Herrmann HC, et al. Unprotected left main “kissing” stent implantation with a percutaneous ventricular assist device. *J Invasive Cardiol* 2004;**16**:683–4.

CHAPTER 10**Chronic Total Occlusion**

Thach N. Nguyen, Satoru Sumitsuji, Yaling Han, Shigeru Saito

Challenges 209

Standard of Technical Excellence 210

Scouting the Terrain 210**Looking for Signposts 210****Technical Tips 210**

**Contralateral injection 210

***How to use less contrast 211

Multi-slice computed topography 211

Antithrombotic and Anticoagulant 213**Vascular Access 214****Guides 215****Technical Tips 216**

*Misleading angiographic view 216

**Guide stabilization by wire anchoring 216

***Guide stabilization by balloon anchoring 216

***Guide deep seating with a balloon 216

***Stabilization of the guide with another smaller guide (daughter-in-mother or 5- in-6 technique) 217

Technique 219

***Encasing a guide with a long sheath 219

Wires 220**Discriminating Differences 220**

Spring-type and hydrophilic wires 220

The spring type 220

Hydrophilic wires 220

Piercing the Proximal Cap 220

Drilling strategy 221

Penetrating strategy 221

Sliding strategy 221

Technical Tips 224

**How to make the wire tip stronger or stiffer 224

**IVUS-guided direct wire entry 224

**Side branch IVUS guidance 224

Traversing the Length of the CTO 226**Tracking Loose Tissue 227****Technical Tips 228**

**Wire selection 228

*Basic; **Advanced; ***Rare, exotic, or investigational

\$, <\$US100.00 extra; \$\$, >\$US100.00 extra

⌚, <10 min extra; ⌚⌚, >10 min extra

♣, low risk of complications; ♠♠, high risk of complications

- **Manipulation of wires 228
- **When can hydrophilic wires be used in CTO? 228
- **Where is the wire? 228
- **How do we know that the wire is in the intima? 229
- **How to avoid entering the intima? 229
- **Parallel wire method (seesaw wiring) 229
- **Optimal projection angle 231
- ***When a wire goes the wrong way 231

Piercing the Distal Cap 232

Technical Tips 232

- **Selection of wires for piercing the distal cap 232
- **Shaping the wire tip in order to pierce the distal cap 232
- **Piercing the distal cap 232

Re-Entry of the Distal True Lumen 233

After Re-entering the Distal True Lumen 234

Technical Tips 234

- ***Importance of wire crossing from true to true lumen and minimizing the subintimal wiring 234
- **Shaping the curve at the tip 235
- **IVUS-guided wire re-entry 235
- ***How to confirm that the wire is in the true distal lumen 236

Re-entry with Dedicated Equipment 237

Technical Tips 237

- **Manipulating the wire of the Venture catheter 237
- **Removal of the stiff and bulky Venture catheter 237

Antegrade Subintimal Approach 238

The STAR technique 238

Balloon Angioplasty 238

Technical Tips 238

- **When a balloon cannot cross a CTO 238

Retrograde Approach 239

Technical Tip 239

*Angiographic search of collaterals 239

Selection of Collateral Channel 240

Technical Tips 241

- **Chance of success of epicardial wiring 241
- **Wiring a septal channel 241
- ***Wire manipulation 241

Crossing the Collateral 242

**How to know that the wire is in the intravascular compartment 243

**How to manipulate the Corsair catheter 243

**How to advance the Corsair across the CTO 243

**Factors for success of piercing the distal cap from a retrograde approach 243

Connecting the Antegrade to the Retrograde Channel 244

Retrograde Wire Crossing 244

Techniques 245

The CART technique 245

Advantages and limitations 246

The reverse CART technique 246

Advantages and limitations 246

Solutions 247

Technical Tips 247

- ***IVUS-guided re-entry 247
- ***Wires for IVUS-guided re-entry 247

Wire Crossing Technique 247

Technique Knuckle wire technique 248

Technical Tips 248

- **Never rotate the knuckled wire 248
- ***Trapping wire technique 248

Technique The double balloon inflation 248

Technical Tips 248

- ***Retrograde balloon inflation 248
- **Manipulating the retrograde wire into the antegrade microcatheter 249

Externalization of the retrograde wire 249**Technical Tips 250**

- **Steps to retrograde wire externalization 250
- ***Careful wire externalization 250

Complications 250**Septal Perforation 250****Technical Tips 252**

- **Prevention of septal perforation 252
- Management of septal artery rupture 252
- Ischemia 252

CHALLENGES

Chronic total occlusion (CTO) is defined as total occlusion with either a known duration of >3 months or the presence of bridging collaterals [1]. In the past, the traditional factors predicting procedural success (still valid for beginners or intermediate level operators) are shown in Table 10.1. At the current time, and with the high level of expertise and new equipment, only target vessel tortuosity or bending at the occlusion site and severe calcification have a significant impact on the success or failure of percutaneous coronary intervention (PCI) for CTO.

Table 10.1 Factors Influencing the Success of CTO Interventions

Factors Currently Valid

- 1 Severe calcification (most important negative factor). If a balloon is inflated in the subintimal space with heavy calcification, the chance for perforation is higher)
- 2 Target vessel tortuosity or bending at occlusion

Traditional Factors Still Valid for Beginner Operators

- 1 Long occlusive duration or unknown duration
- 2 Absence of antegrade flow
- 3 Stump occlusion
- 4 Presence of bridging collaterals
- 5 Long occlusion length

STANDARD OF TECHNICAL EXCELLENCE

After PCI of the CTO lesion, the stenting area should be wide open and there is thrombolysis in myocardial infarction (TIMI) 3 flow distally, without acute complication such as dissection or perforation.

Scouting the Terrain

In the pathological studies, the neovascular channels with a diameter of 100–200 μ m are seen in CTO of >1 year. These old neovascular channels are often connected to the vasa vasorum in the adventitia, whereas the channels in a more recent CTO (filled by thrombus aged <1 year) communicate with the distal lumen through the recanalization channels [1]. Knowledge of the lesion age is crucial for the operator to select the right type of wires. During an interview with the patient, a history of myocardial infarction would help to identify the start of the CTO: A morning angina or angina at the start of low level activity, although being relieved with further exercise is very suggestive of a CTO. The reason for angina relief with further exercise is because the myocardium recruits (or opens) the collateral channels, triggered by the ischemic stimulation (exercise). Review of a previous diagnostic angiogram, if available, would also help to time the CTO.

Looking for Signposts

The need to scrutinize the diagnostic angiography frame by frame and from different angles can never be emphasized enough. Look for any dimple at the CTO lesion, and find any potential recanalization channels or existing lumina inside the CTO. As calcification is often an indicator of the vessel shape, it can sometimes be useful to delay the injection of contrast for a few heart beats, so that a short plain cine can record a better image of the calcification.

When the proximal and distal portions of the occlusion seem to slip out of alignment with each heart beat, it is a sign of tortuosity inside the CTO.

It is crucial to have a clear image of the distal vasculature in order to guess the length of the CTO lesion. If the CTO is wrongly assessed as long, an operator could set the distal re-entry point too far down and fail to realize that a long false lumen has been created.

It is important to identify the main collateral channels, and the vessel supplying and receiving them, so a supporting balloon catheter should not obstruct the antegrade collateral flow, if the balloon-anchoring technique is needed. One pitfall is the presence of collateral from a conus branch to the left anterior descending artery (LAD). This conus branch can be separate from the right coronary artery (RCA) ostium and be missed if only angiography of the main RCA is done [1].

Technical Tips

****Contralateral injection** The information from the contralateral injection is very important to monitor the wire movement.

However, if there is interference between an interventional guide and a diagnostic catheter then one should come from the radial approach [1].

*****How to use less contrast** To reduce the amount of dye, contralateral injections may be performed by superselective injections, with a transit catheter deep in the collateral branch [1].

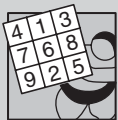
Multi-slice computed topography Multi-slice computed topography (MSCT) is an imaging modality that could outline the shadow of an angiographically invisible and totally occluded artery. The possible information provided by MSCT includes (1) visualization of an occluded artery and collateral vessels, (2) length and diameter of the vessel in the CTO lesion, and (3) morphology of a CTO lesion.

A volume-rendering (VR) image is useful to characterize an overall picture of the coronary arteries around the heart. The VR function is used to identify the location, tortuosity, calcification, and bifurcation of a CTO lesion. A slab maximum intensity projection (MIP) image can be one of the most useful adjunctive diagnostic images for CTO PCIs. The location of plaque, level of calcification, and length of the lesion on the slab MIP image are closely related to the information provided by a coronary angiography. The lesion morphology and wire direction are also detected by this function. In addition, a multiplanar reconstruction image qualitatively identifies a route for vessels and location of calcification and remodeling. It is helpful to predict the degree of calcification.

In a typical example that favors the use of MSCT on a CTO PCI, the collateral vessel could not be clearly seen on baseline angiography. However, MSCT identifies a short and soft occlusion without severe calcification that was located only in the distal artery. An intermediate wire was easily advanced into the distal artery within a few minutes of reviewing the MSCT images. As with any technique, pre-procedural MSCT is not mandatory for every CTO cases. However, it can be useful in identifying the actual occlusion length and in visualizing the collateral vessels. So MSCT should be done when the occlusion length and/or the vessel course is unclear by conventional angiography (Figure 10.1).

STRATEGIC MAPPING

During PCI of a CTO lesion, after careful examination of diagnostic angiography, the antegrade approach is usually started with an intermediate wire (Miraclebros 3) and an 8-Fr guide. When a better backup force is required, the wire or balloon anchoring technique is considered. Contralateral injection is mandatory except in the presence of antegrade bridging collaterals. Check the activated clotting time (ACT) every 30 min. When the first



(Continued)

wire fails to cross the lesion, it should be exchanged for a stiffer one. When a wire enters a false lumen, the parallel wire technique should be used. If this technique fails, the intravenous ultrasound (IVUS)-guided wiring technique is selected. If this is unsuccessful, the retrograde approach can be started. However, in re-attempted cases, the retrograde approach is performed right from the start (Figure 10.2).

The success of the retrograde techniques depends on creating a subintimal connection. However, many operators hesitate to create subintimal dissection due to the risk of vessel rupture, spiral dissection, or myocardial ischemia in the event of collateral injury.

If the IVUS-guided wiring or retrograde approach is not feasible or not working as expected by the operators, the procedure should be stopped before (rather than after) complete collapse of the distal true channel by an enlarged subintimal space. When wire perforation from a subintimal space is observed, the procedure should be temporarily stopped and appropriate treatment given to control the extravascular bleeding.

Once the problem has been controlled, the PCI can be restarted.

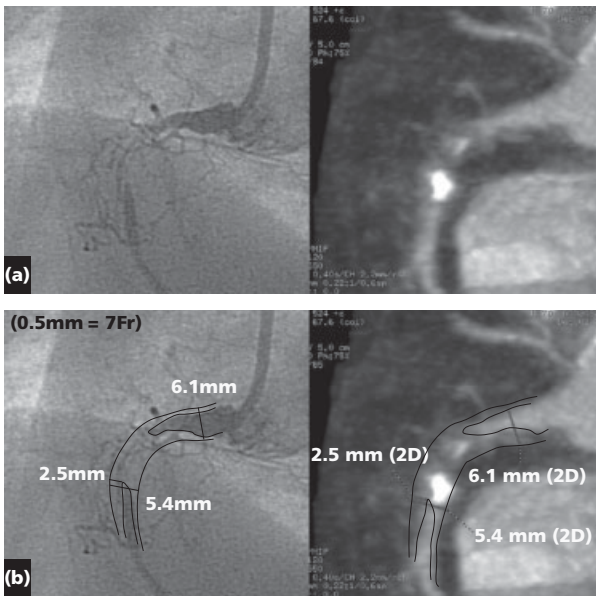


Figure 10.1 Computed tomography angiogram (CTA) for chronic total occlusion lesion. With the information from the CTA of the coronary arteries (a,b), a wire could be manipulated to cross the lesion at the beginning of the mid-segment, going around the calcified area (d). The IVUS cuts confirm the information from the CTA.

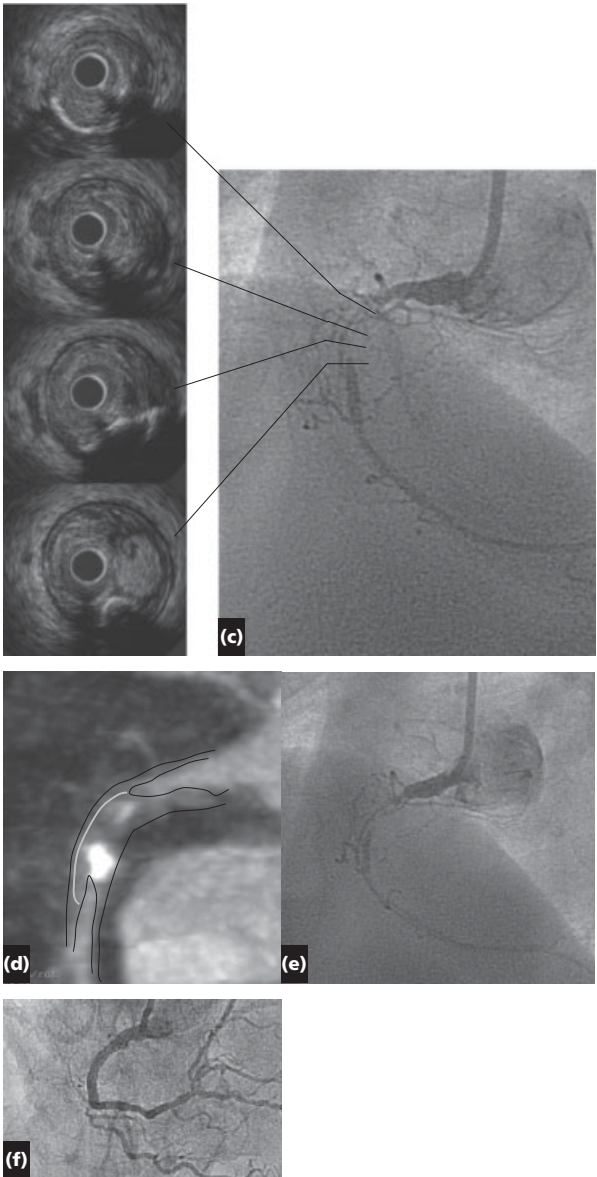


Figure 10.1 (Continued)

ANTITHROMBOTIC AND ANTICOAGULANT

Procedural anticoagulation considerations are similar for PCI of non-CTO lesions, except that direct antithrombins (DTI) and glycoprotein IIb/IIIa inhibitors (GPIs) are usually avoided because of the problem with anticoagulant reversal when there is perforation. GPIs may

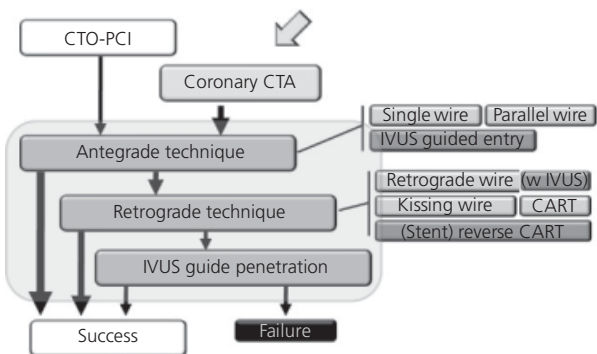


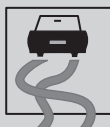Figure 10.2 Strategy of percutaneous intervention of chronic total occlusion.

be administered before angioplasty once the wire has successfully crossed the lesion and confirmed as intraluminal. Similarly, the initial heparin bolus may be reduced to achieve an ACT of approximately 200s until the wire has successfully crossed the occlusion, after which additional heparin should be administered before dilation to achieve an ACT of 250–350s (if a GPI is not used). ACT should be checked every 30 min [2].

CAVEAT

When to stop

Variables that favor terminating an unsuccessful but as-yet-uncomplicated procedure include: (1) reaching the upper limits of radiation exposure (e.g. 60 min of fluoroscopy time); (2) dye consumption (typically 600 ml in a non-diabetic patient with normal renal function; much less in patients prone to contrast nephropathy); (3) the creation of a large false lumen, especially if adventitial staining is present; (4) shearing off of collaterals, resulting in loss of visualization of the distal vessel; and (5) excessive patient or operator fatigue. A second try after a failed CTO attempt (usually performed 6–8 weeks later to allow vessel healing) may be successful in >50% of patients, especially when the mode of failure is understood and a feasible alternative strategic approach has been formulated.



VASCULAR ACCESS

Femoral artery access is preferred for CTO angioplasty by most operators, with utilization of 7- to 8-French (Fr) guides for passive support, although 6- to 7-Fr guides may be considered by

operators skilled in active guide manipulation through the radial approach. If there is a need for contralateral injections, a 4- or 5-Fr catheter can be inserted into either the contralateral femoral or radial artery [1].

GUIDES

The choice of the guide is very important because, without adequate support, it is impossible to push the wire or balloon across a CTO lesion. The principles of strong guide backup include:

- 1 Large guide size (the larger the better)
- 2 Long opposite aortic wall contact area
- 3 Great (perpendicular) angle between the ascending aorta and the main distal segment of the guide (between the primary and secondary curve).

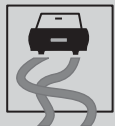A 7- or 8-Fr size guide is needed to accommodate a double microcatheter, IVUS catheter (safer in 8Fr), and anchoring technique should there be possible options in complex CTOs. Larger guides provide the versatility to pass covered stent grafts more easily should a perforation occur, a complication that must be anticipated with PCI of CTOs.

Another important factor for a guide in CTO is to have a soft tip, which is required when the guide should be deep seated in the proximal RCA, left circumflex artery (LCX), or LAD to increase backup. Usually, the Amplatz left (AL) or left extra backup (EBU) design guide is selected for the LCX or LAD lesions and a AL shape or right EBU design guide is selected for an RCA procedure. There is no role for the Judkins left (JL) guide in PCI of complex CTO because it cannot be advanced deeply (and safely) into the left main (LM) artery. The RCA guide could have side holes (if desired) to allow perfusion of the sinus node and conus branches during deep seating. Aggressive manipulation of the guide or inadvertent deep intubation (which does occur infrequently with the Amplatz guide) may dissect the RCA ostium (often requiring stenting), a complication that should be anticipated and recognized before final wire removal [1].

CAVEAT

Sudden decrease of blood pressure and tachycardia

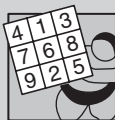
A word of caution is required to push the EBU or Amplatz-type guide in a "power position," which might create guide-induced aortic regurgitation (because the secondary curve prolapses into the ventricle causing incomplete closure of the aortic valve and so acute aortic regurgitation). Sudden development of shock or tachycardias is the warning sign of this complication and is usually resolved promptly by re-positioning the guide.



STRATEGIC MAPPING

To strengthen a guide

During PCI of CTO, if a guide keeps backing out as the wires or devices are advanced, this guide has inadequate backup. There is a need to stabilize the guide. The first



corrective maneuver is to reposition the guide, put it in a power position (active position), or deep seat it. If it works, then it is great. If not, the guide should be changed for a larger one or one with a different shape in order to have better backup support from the aorta (passive support), or better coaxial transition (less trauma, no angle between the tip of the guide and the ostial segment). If the design shape and position of the guide are optimal, the proximal segment of the index artery should be scrutinized. If there is proximal tortuosity, the next step is to add a second stiffer wire. However, if the guide has no large backup from the opposite aortic wall and the proximal segment of the index artery is tortuous or very calcified, adding another wire may not solve the inability to advance a device. This is why, if there is no lesion in the proximal RCA or LM, a soft-tip guide could be used and be inserted deeply in the RCA or LM for support, if needed [1].

Technical Tips

***Misleading angiographic view** One of the reasons why the guide is not stable in cannulating the RCA is because the RCA could come from a benign anomalous origin (too anterior in the right sinus), so it can exit the aorta on a steep angle on the sagittal plane whereas, on the anteroposterior (AP) view, it looks normal (see Figure 2.4).

****Guide stabilization by wire anchoring** Add a second stiffer wire, and advance it to a side branch proximal to the CTO lesion (Figure 10.3b). Backup strength is lower than balloon anchoring; however, the wire provides a better coaxial alignment for the guide, especially when a strong support-type wire is used [3].

*****Guide stabilization by balloon anchoring** Advance a small balloon to a side branch (SB) located proximal to the CTO and then inflate the balloon. The inflated balloon plays a role in stabilizing the guide and provides the extra backup force. However, to prevent damage to the SB, careful attention must be taken during wire positioning of balloon sizing. In this technique, a guide with a large lumen is required for accommodating the two balloons [3] (Figure 10.4).

*****Guide deep seating with a balloon** In the attempt to cross a CTO with a (first) wire, a proximal calcified fibrous cap is sometimes hard to be penetrated. In such a situation, if there is

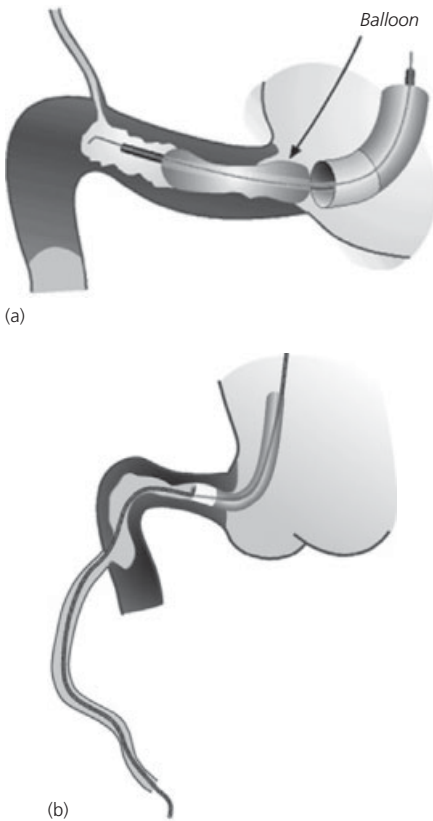


Figure 10.3 (a) When a stiff wire failed to penetrate a proximal fibrous cap, an over-the-wire balloon is inflated proximal to the occlusion as a support catheter for wire handling. Inflated balloon makes an extra backup force for the wire tip to penetrate the proximal cap. (b) Anchor wiring into a proximal branch also provides a better backup force.

some space in the lumen proximal to the CTO, an over-the-wire (OTW) balloon can be positioned there and inflated. The OTW balloon provides a better back-up force for manipulation of the wire tip (see Figure 10.3a). The guide can be deeply engaged by gently pulling back the inflated balloon system. The size of the OTW balloon must match the diameter of the segment proximal to the CTO (usually 1.25–1.5 mm diameter). Careful attention should be paid not to create a false channel in the proximal end of the CTO lesion [3].

*****Stabilization of the guide with another smaller guide (daughter-in-mother or 5-in-6 technique)** A smaller straight guide could be inserted inside a larger guide in order to strengthen it. This is the case of a 5-Fr Heartrail straight guide with 120 cm length, whereas the 6-Fr guide is 100 cm long.

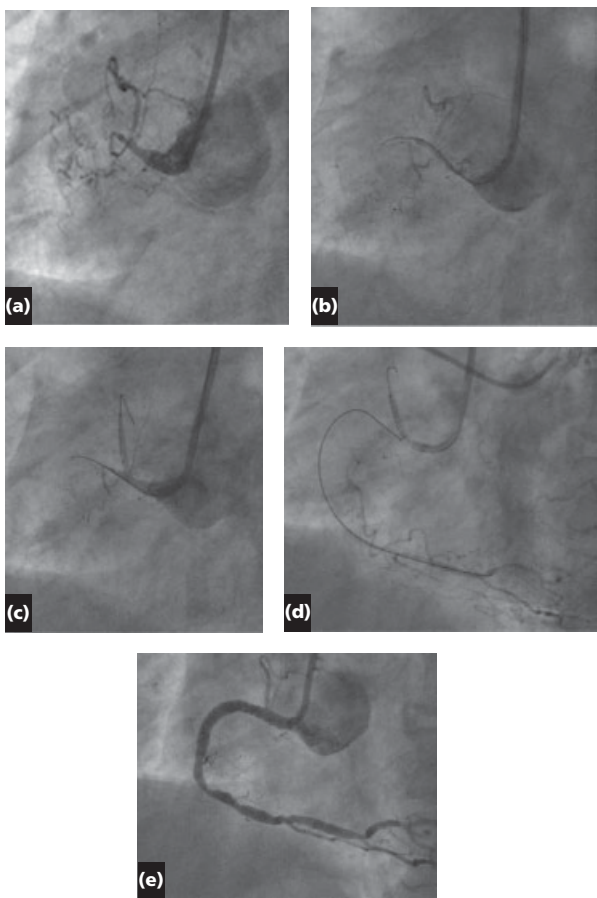


Figure 10.4 Case example with anchoring technique: (a) The proximal RCA was completely blocked with bridging collaterals. (b) A Judkins-type catheter was used to prevent the damage of the RCA ostium. However, the presence of tight plaque in the CTO causes unstable backup support of the guide during the wire handling. Hence, the wire could not be advanced intentionally. (c) Then a 2.5-mm balloon was inserted and inflated with a low pressure in the conus branch to stabilize the guide. (d) Under the use of this anchoring balloon, the wire control was improved, so that the occlusion was successfully negotiated. (e) Final angiographic result after stenting.

The 5-Fr Heartrail guide has a very soft 13-cm end-portion, which can easily negotiate the tortuous coronary artery with minimal damage. The inner lumen of the 5-Fr Heartrail guide is 0.059 inch in diameter; it can accept normal balloons or stent delivery systems <4.0mm in diameter. The inner lumen of the outer 6-Fr guide needs to be more than 0.071 inch in diameter to accommodate the 5-Fr Heartrail guide. The Launcher, Heartrail, and Radiguide guides have this large inner lumen diameter.

TECHNIQUE First, the balloon or the stent is removed from the 6-Fr guide. The Y connector is also removed. Next, a 5-Fr guide is inserted along the wire inside the 6-Fr guide. At this point, the 5-Fr guide should not protrude out of the tip of the 6-Fr guide. Finally, the Y connector is connected to the 5-Fr guide and PCI could be restarted. Before the 5-Fr guide is advanced into the target artery, a balloon catheter is advanced near the target lesion in the artery. Keeping a slight tension on the balloon catheter, the 5-Fr guide is advanced slowly in order to avoid possible injury to the coronary artery by the tip of the guide [4].

*****Encasing a guide with a long sheath** When working with an unstable guide, a long sheath can stiffen and support the guide, depending on how close it is advanced near the tip of the guide. The closer it is to the coronary ostium, the more backup the guide provides. At first, a sheath is advanced, its tip is positioned in the aortic arch, and the interventional device is advanced. If it is insufficient to position the device, then the sheath is advanced further, close to the tip of the guide. As the sheath advances over the guide, it straightens the secondary and tertiary curves of the latter, causing the tip of the guide to move forward. Therefore, guides with relatively simple curves are probably safer and better suited for this technique. To avoid injury to the coronary ostium and dissection of the proximal segment of the coronary artery, instead of holding the guide fixed in place during advancement of the sheath, a gentle reverse traction on the guide is advised, so that its tip does not move forward. The operator should watch the guide tip continuously on fluoroscopy during this maneuver and ensure coaxiality of the guide in two orthogonal views. Disengage the guide from the coronary ostium only after the sheath has been moved away from it, probably to the descending aorta, with the guide fixed in place. Just pull the sheath away; the guide will disengage due to reconstitution of its curves [5].

Of all the options mentioned above, the best options in strengthening a guide are ranked according to efficacy, user-friendly characteristics, and cost-effectiveness.

TACTICAL MOVE

Best options for strengthening a guide

1 No added cost FIRST Best Maneuver:

Put the guide in power position or deep seat the guide

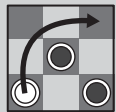
2 \$ SECOND Best Maneuver: Add a second stiffer wire

3 \$\$ THIRD Best Maneuver: Change to a stronger guide

4 \$ Use the balloon-anchoring technique

5 \$\$ Insert a smaller straight guide inside the current guide

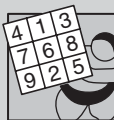
6 \$ Remove everything; change the short sheath to a longer one



WIRES

STRATEGIC MAPPING

If there is an angiographically tapered occlusion, the tapering stump is the starting place to probe the occlusion. It frequently contains small recanalized channels (200 μm in diameter), which are potential routes for wire crossing. However, if the stump is eccentrically oriented, there is higher risk of subintimal wire passage and vessel perforation. When there are extensive bridging collaterals (caput medusae), the chance of wire crossing is low, the reason being that these intracoronary collaterals consist of dilated vasa vasorum, which is very fragile and easily perforated. Blunt (non-tapered) occlusions can be difficult to cross, especially when there is a SB arising near the entry site of the CTO. The concept that a plaque typically builds up on the opposite side of the origin of a SB may help the operator to identify the true vessel course. However, the wire will often repeatedly deflect into the SB, and it may be difficult to penetrate the proximal fibrous cap [1].



To cross the CTO into the true distal lumen, the targets that the wire must overcome include: (1) Piercing the proximal cap, (2) traversing the length of the CTO, (3) piercing the distal cap, and (4) re-entry into the true distal lumen.

Discriminating Differences**Spring-type and hydrophilic wires**

The spring type Wires have a better profile of steerability, torquability, and tactile feedback from the tip compared with hydrophilic wires. When the wire should enter the occlusion with some angulation, a spring-type wire is safer as it is more controllable (and therefore less likely to dissect). If there is a dissection, it would not be a large dissection or hematoma when the tip is well controlled.

Hydrophilic wires offer good maneuverability in tortuous vessels; however, they may not respond as well to the operator's attempt to make them after a precise, predetermined path through hard plaque. The hydrophilic wires can go easily into the subintimal space without tactile feedback. Usually a hydrophilic wire is not used for CTO, except in case of CTO lesions with a straight microchannel [6].

Piercing the Proximal Cap

There are three different strategies for piercing the proximal cap: drilling, penetrating, and sliding. The drilling strategy implies the gradual step-up of the wire stiffness according to the lesion

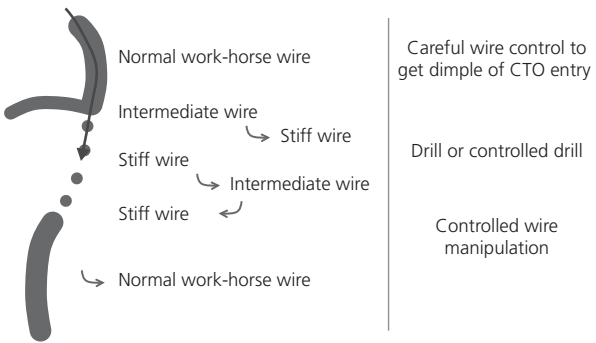


Figure 10.5 Strategies for wire selection and manipulation.

complexity, relying on visual as well as tactile feedback information from the wire tip. The penetration strategy implies the direct pressure at a point in order to cross into the distal true lumen with controlled or limited rotation of the wire. The sliding strategy is to slide a hydrophilic wire into the distal segment. Each method has advantages and disadvantages, but, overall, all three methods work pretty well for the short, focal, straight segment of the non-calcified occlusion. For the complex types of CTO lesions (i.e. calcification, long lesion, and tortuosity), choice of a spring-type wire, and subsequent step-up stiffness in the same class, would be superior to an exchange to a different family of wires (Figure 10.5).

Drilling strategy The shaping of the wire tip should be as little as 1.0 mm in length with an angle of $<45^\circ$, and the second mild curve would be preferable to improve maneuverability of the wire. The wire is rotated to and fro with the left hand while the right hand is used for rotation on $90\text{--}180^\circ$, and sometimes with a full turn (the stored energy must be released by leaving wire to untorque) with simultaneous moderated push and knocking movements.

Penetrating strategy The rotation movements are smaller ($45\text{--}90^\circ$), the wire is stiffer (Miracle 12, Conquest Pro 9–20g, tapered tip wires); the orientation of wire tip position in the operator's mind is crucial for success (see Figure 4.1).

Sliding strategy A hydrophilic wire (Fielder XT, Fielder FC, Whisper MS) is carefully manipulated (slight rotations, shallow tip curve, very gentle push). It is best when engaging microchannels, subtotal occlusions, and in-stent occlusion. The mechanical characteristics of the wires are listed in Table 10.2 [4].

In the tapered type of entry, the wire is automatically advanced into the appropriate entrance. By contrast, in the abrupt type of entry, it is necessary to look for the dimple sign that is the hallmark of the entry point. At that time, the wire must be manipulated carefully to look for the dimple with the wire-tip trapping

Table 10.2 Characteristics of wires for crossing chronic total coronary occlusions [4]

Wire	Shaft and tip diameter (inches)	Tip stiffness (g)	Additional characteristics ^a	Recommended use(s) ^b
High Torque Intermediate	0.014	2-3		1
High Torque Standard	0.014	4	a	2, 3
Cross-It 100	Shaft 0.014 Tip 0.010	2	b	1, 4, 10
Cross-It 200	Shaft 0.014	3	b	2, 3, 10, 11, 12, 13
Cross-It 300	Tip 0.010	4		
Cross-It 400	Shaft 0.014 Tip 0.010	6	b	5, 8
Whisper	0.014	1	c, d	1, 4, 6, 7, 9, 10, 13
Pilot 50	0.014	2	c	1, 4, 6, 7, 9, 10, 13
Pilot 150 and 200	0.014	4 and 6	e	3, 10, 11, 12, 13
Choice PT and P2	0.014	2	d, e, f	1, 4, 6, 7, 9, 10, 13

PT Graphix and Graphix P2	0.014	3-4	d, e, f	3, 10, 11, 12, 13
Magnum 0.014	Shaft 0.014 Tip 0.7 mm	2	g	1, 13
Miracle Brothers	0.014	3, 4, 5, 6, and 12	h, i	1 (3 g), 2, 11 (4.5-6 g), and 2, 5, 8 (12 g); 14 (all)
Confianza and Confianza Pro (Conquest and Conquest Pro)	Shaft 0.014 Tip 0.009	9 and 12	b, i, j, k	2, 5, 8, 10
Shinobi	0.014	2	c, f, l	9, 10, 11, 13
Shinobi Plus	0.014	4	c, f, l	2, 3, 9, 10
Crosswire EX (platinum)	0.016	2	e, m	1, 9, 10
Guidewire GT (gold)				

^aa, caveat: wire entrapment possible in long and hard occlusions; b, tapered tip; c, lubricious tip with non-lubricious shaft; d, difficult to shape tip; e, lubricious shaft and tip; f, poor tip memory; g, olive-shaped ball tip; h, excellent tactile feel; i, excellent torque control within occlusions and in long tortuous lesions; j, pro version has hydrophilic coating except at distal 1 mm of tip; k, pro version moves through long occlusions with little resistance; l, caveat: subintimal passage common; m, 45° and 70° angles.

^b1, recent occlusions; 2, chronic occlusions >12 months; 3, chronic in-stent occlusions; 4, functional occlusions; 5, long and hard occlusions; 6, subtotal stenoses; 7, acute occlusions; 8, puncturing of fibrous cap; 9, tortuous anatomy; 10, intracoronary microchannels; 11, chronic occlusions <12 months; 12, occluded saphenous vein grafts; 13, recent in-stent occlusions; 14, best for parallel wiring due to excellent torque control.

pointing toward the small hole of dimple. When the operator feels/senses the dimple with the wire tip, the operator should maintain that wire-tip position and then rotate the wire-tip direction 180° to insert the wire tip inside the CTO [7]. Once the wire breaks through the proximal fibrous cap, it may be exchanged if desired for a softer wire with a slightly greater primary tip bend [1].

Technical Tips

****How to make the wire tip stronger or stiffer** When the tip of the wire is deviated from the imaginary lumen and the tip does not engage into the intended direction in the proximal occlusive cap, either exchange of the wire to the stiffer one alone or wire exchange and advancement of a microcatheter close to the tip is required at this junction. The stiffer and more torquable wires are desirable (the Miracle series are a good choice) and spring-tip wires are more preferable than the tapered ones, especially in curved and/or calcified portions (i.e. Miracle 12 g, Confianza Pro).

In the case where the guide disengages with a wire tip pinpointed to the center of the occlusion, either exchange the guide to a stronger backup or use a microcatheter [8]. The use of a microcatheter (or balloon inflation of the OTW system as a coaxial anchor balloon) is preferable, because the problem is mainly considered to be related to the support of the wire. If the wire still cannot cross the proximal cap, IVUS is needed.

****IVUS-guided direct wire entry** The IVUS-guided wiring technique is a useful strategy to detect the entry site of the CTO if the branch is large enough to advance an IVUS catheter (Figure 10.4). At first, the IVUS catheter is advanced into the proximal end of the CTO lesion and investigates the surrounding area. Based on the initial IVUS images, the tip of the IVUS catheter is trying to pinpoint the central area of the main lumen at the start of the CTO lesion. This is the most suitable and desirable position for wire entry. This location of the tip of the IVUS must be identified exactly by coronary angiograms so the tip of a drilling wire can be positioned.

Then the operator seeks a dimple at the entry with careful wire manipulation. The IVUS investigation also helps to examine the composition of the plaque and its consistency (hard or soft, etc.) at the entry site as well as to check the entry point of the first wire, and where and how it goes into the (unwanted) subintimal space [9] (Figure 10.6).

****Side branch IVUS guidance** At times, if there is an SB coming out next to the proximal entry of a CTO lesion, an IVUS transducer can be placed in this proximal SB for interrogation of the CTO lesion in the main lumen. If the wire enters a false channel, an IVUS catheter can be advanced there to investigate the proximal end of the CTO and to look for a favorable entry location (Figure 10.7).

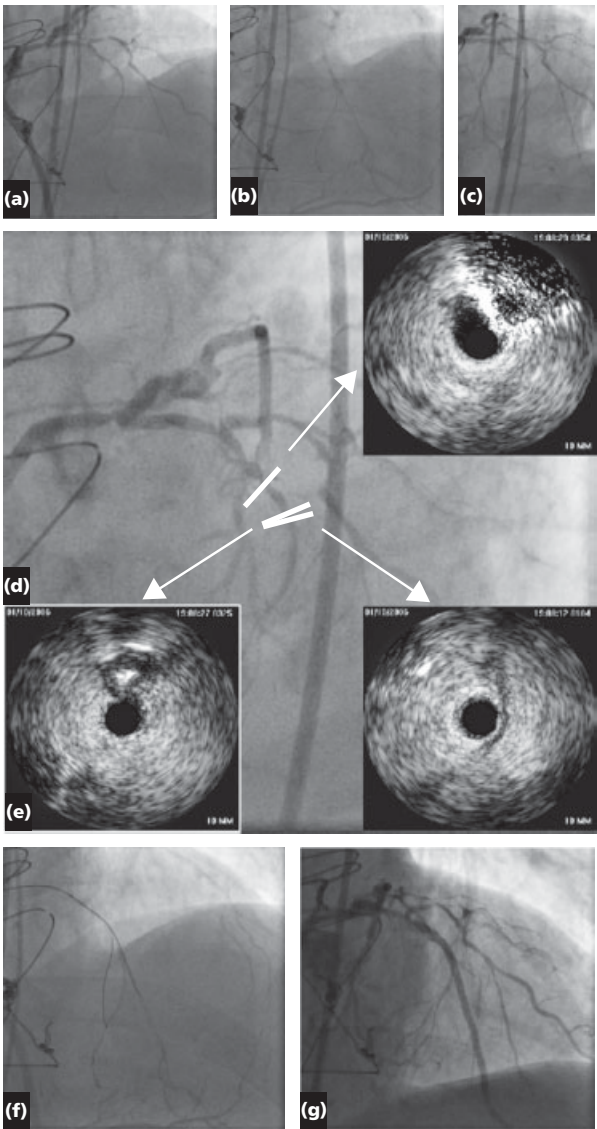


Figure 10.6 Case example with IVUS guidance through the main vessel: (a,b) Although the LAD was completely blocked around mid-portion, it was hard to identify the entrance of a CTO despite the contralateral injection that was performed. (c) Then an IVUS catheter was inserted to the septal branch. (d,e) An IVUS image was then easily identified at the CTO entrance. (f) This confirmation was also important for use of a stiff wire to penetrate the tight proximal fibrous cap. (g) Final angiographic result after stenting.

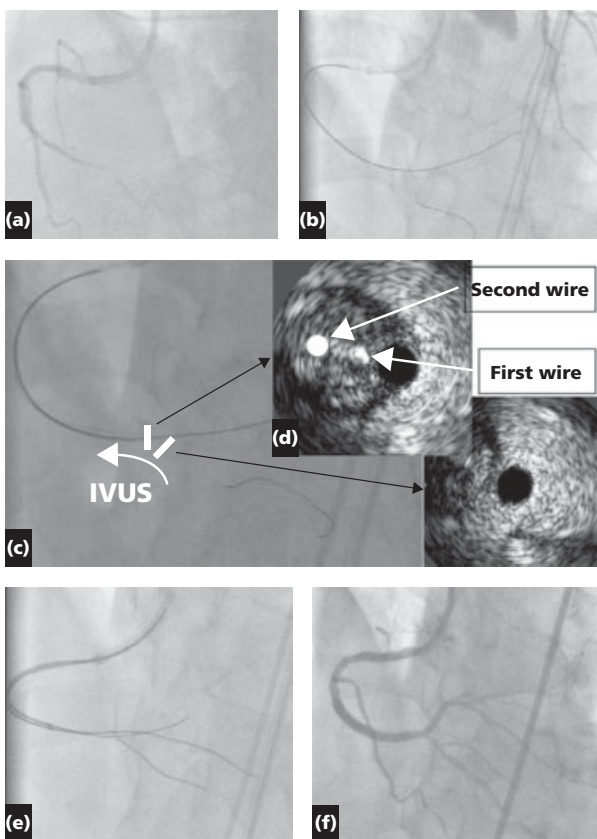


Figure 10.7 Case example with IVUS guidance through the side branch: (a) The first attempt to revascularize the distal RCA CTO failed. (b) In the second attempt, the first wire (intermediate) easily went out of the true channel. An IVUS image from the proximal small branch (c) clearly showed that the entry point of the first wire to distal RCA was too close to the branch (d) so that it easily advanced into the subintimal space. The correct position of entry point for the second wire is in the center of the obstructed true channel, which indicated the opposite direction to the branch. Therefore, the course of the next wire was intentionally changed from the CTO entrance toward the opposite direction to the branch angiographically. (e) This wire then easily got into the distal small branch. (f) Final angiographic result after stenting.

TRAVERSING THE LENGTH OF THE CTO

Once the wire crosses the proximal cap, it will be advanced slowly by the left hand while the right hand of the operator rotates it 180° back and forth. The wire, with 1 mm of its tip curved to form an abrading tool, is trying to grind through the lesion. If the wire buckles, it should be retracted, reoriented, then rotated rather than forced through the lesion. Constant forward pressure on the wire is more successful than aggressive tapping against

the occlusion (“jack hammering”), which does not transmit additional force [6].

When the wire rotates at a full angle to advance, the wire tip will create a larger area of injury, which may result in a larger area of dissection once contrast has been injected through the guide. If the angle of the rotation were limited to the more favorable direction, the chance of creating dissection could be minimal.

Tracking Loose Tissue

If the wire tip can be controlled and directed so that it will not penetrate hard atherosclerotic plaque, careful manipulation of the intermediate-strength wires, of which the tip is bent by 45–90° at the distal 2–5 mm, can lead the wires through the loose fibrous tissue track.

This is the concept of loose tissue tracking. However, it is not clear which tip strength wire should be selected for this loose tissue tracking, because each case has a different degree of tissue rigidity. Usually, loose tissue tracking is performed with a 1.0g tip-strength hydrocoated wire. Wire handling and movement in loose tissue tracking are similar to those of acute myocardial infarction cases, in that the wire is advanced easily smoothly, with minimal rotations of the wire tip [7].

However, if the intermediate-strength wires cannot penetrate the border between the loose and dense fibrous tissues, at this point, an OTW support system can be advanced and the wire is exchanged for a stiffer one with tapered-tip end (Cross-It 300 or 400 or Conquest). This stiff and tapered-tip wire has greater possibility of penetrating the dense connective tissues into the distal true lumen than conventional wires [6] (Figure 10.6).

CRITICAL THINKING

Where are the signposts?

After the proximal cap has been penetrated, the wire must be passed through the body of the CTO to the distal fibrous cap, which typically requires experience and reliance on knowledge of the natural course of the vessel, as well as collateral visualization of the distal vessel.

Lesion calcification or occluded stents serve as guideposts of the vessel course. When negotiating an angulated segment in the vessel, the wire should be steered toward the inner curve to avoid extraluminal passage [1].

The presence of a tapering distal portion and chronic buildup of jagged hard plaque around the true lumen can make it extremely difficult for the wire to penetrate the distal cap of the CTO. Another important piece of information given by the collateral is where the collateral enters the arterial segment beyond the CTO: At its distal or mid segment. The suspicion is, if there is any plaque or stenosis at the distal end, then the collaterals would enter the artery in the middle of the CTO segment [1].



Technical Tips

****Wire selection** String-type wires tend to encounter more resistance inside the lumen of the CTO than hydrophilic wires, but selective hybrid wires (especially the Miracle Brothers line – 0.014-inch tip, available in strengths of 3, 4.5, 6g, and, outside the USA, 12g) and the Confianza (also known as the Conquest – 0.009-inch tapered tip with 9 or 12g force) have exceptional torque response even within a fibrocalcific CTO.

****Manipulation of wires** Basically, there are two different types of wire manipulation. One is the “both hands maneuver” and the other the “right-hand maneuver.” In the “both hands maneuver,” the left hand is used for to-and-fro movement and the right hand for rotation. “Right-hand maneuver” means that the right hand does both movements. The wire movement in the “both hands maneuver” pertains primarily to a to-and-fro movement, and in cases where the wire-tip direction needs to be changed or the wire presents the fingers with high resistance, the rotational movement is performed with right hand.

In the “right-hand maneuver,” the wire is advanced by dissecting the tissue with the wire tip (controlled drill). The wire tip is then advanced toward the intended direction with a sector swing. Either of these approaches is appropriate for CTO PCI, and each operator will eventually have their own preference. Sometimes, operators use both methods and alter their approach according to the situation of the procedure. Above all, the operator should bear in mind the differences of wire-tip movements with both maneuvers [7].

****When can hydrophilic wires be used in CTO?** Soft-tipped hydrophilic wires such as the Whisper (the least traumatic hydrophilic wire) are preferred when a faint channel is visible, consistent with a relatively straight intracoronary microchannel which may allow easy access to the distal lumen. Care must be taken, in this circumstance, not to create a false lumen: In so doing, the operator converts a simple case into a big failure [7]. The Confianza (Conquest) Pro is a hybrid 0.014-inch wire that tapers to 0.009 inch and is hydrophilic coated except at the tip, thus reducing the friction as the wire shaft passes down the vessel and through the body of the occlusion, although theoretically retaining tactile response at the distal end. As a result of its combined stiffness, hydrophilic coating, and tapered tip, this powerful wire (which is available in 9 and 12g versions) should be reserved for experienced operators [7].

****Where is the wire?** Important feelings that should be focused on during PCI include: (1) The feeling of the dimple at the entry point, especially in the abrupt type of CTO entry, is the key to success, but the dimple does not always guarantee intimal plaque tracking; (2) the feeling of strong resistance when pulling back the wire inside the CTO body, such as when the guide is drawn into it – in this situation, the wire tip has most likely migrated into the subintima; and (3) the feeling of no resistance, and the wire tip moves freely – this most likely means that the

BOX 10.1 SENSATION FROM THE FINGERTIPS

- Body
 - Grasped: false lumen tracking or high resistance lesion
 - Sensation of getting stuck when pulling back: in the intima
 - Resistance at the tip or movement decreases: in the false lumen
- Exit
 - Free movement: in the true lumen or in the extravascular space

wire tip is in either the true lumen or the extravascular space [7] (Box 10.1).

****How do we know that the wire is in the intima?** Once the wire crosses the proximal cap, there is little tactile feel during lesion penetration. When the wire is in the true lumen, the wire seems to be advanced smoothly. The only mark for true lumen wire occurrence is relative resistance during *withdrawal* of a wire. A free movement of wire tip during rotation and resistance to advance is a mark of a subadventitial position (the wire turns around the vessel lumen, giving appearance of lengthening the tip curve). The only way to know whether the wire is in the intima is to pull it back 1–2 mm. If the tip is in the intima, the operator would feel an unusual and unmistakable sensation of being stuck. A good rule of thumb: If any crunchy sensation is felt from the hard tissue at the wire tip, the operator can be certain that the tip is in the intima [1]. The wire is considered completely in the false lumen when the resistance of the wire tip or the wire movement decreases (Box 10.1).

****How to avoid entering the intima?** When trying to cross a curved segment, avoid positioning the wire at the outer curve of the bend. If the wire goes subintimally on a straight portion then there are hard plaques inside the CTO, which deflect the wire. If a false channel has been created, then pull the wire back to the point proximal to the entry of the false channel and find a different new channel to go down [1].

****Parallel wire method (seesaw wiring)** When the wire tip goes into subintimal space at the small branch or outside the vessel, the second wire is advanced while leaving the first wire in place (the parallel wire method). The first wire has two roles: The first is to obstruct the incorrect pathway and the second is to mark the route to the true lumen during wire manipulation. With the existence of this landmark, the operator can lead the wire tip more easily to the direction of the true lumen. In the parallel wire technique, if the operator intends to use only one microcatheter, it should be pulled back and reinserted into the target vessel again with the second wire. If the operator uses two microcatheters at

a time, the procedure becomes simpler. If it is difficult for the second wire to enter the true lumen, one can exchange the roles of two wires. Using the parallel wire method with two microcatheters is called "seesaw wiring." The operator is able to move either of the two wires at any time.

The second beneficial effect of this method is to introduce the fluid (blood) into the waterless occlusion site, triggering the hydrophilic mechanism (slippery when wet) and thus preventing the hydrophilic wires from sticking to each other. If operator works transradially the seesaw technique could be performed by using two Finecross microcatheters (compatible with 6-Fr large lumen guide) (Figure 10.8).

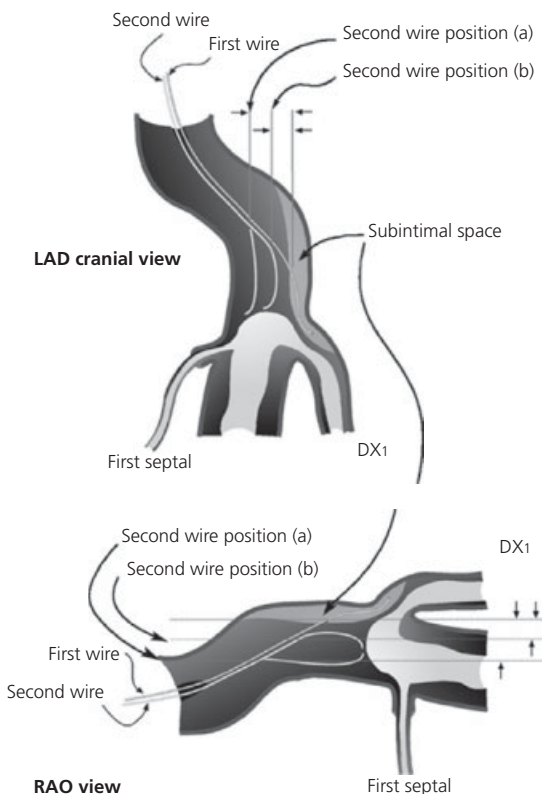


Figure 10.8 Concept of parallel wiring technique: This is a scheme of parallel wiring technique in an LAD CTO case. As shown in the images, the first wire slips into the subintimal space in the pericardial side just before the distal true lumen. In this situation, subintimal space is easily enlarged if the wire is manipulated again, possibly causing the collapse of the distal true channel. To prevent further expansion of the subintimal space, the first wire must be left there as an indicator for the second. The second wire should be stiffer than the first wire, and should be carefully advanced toward the distal true end under the marker of the first wire and must be positioned between (a) and (b). Finally, the distal fibrous cap should be penetrated from this position.

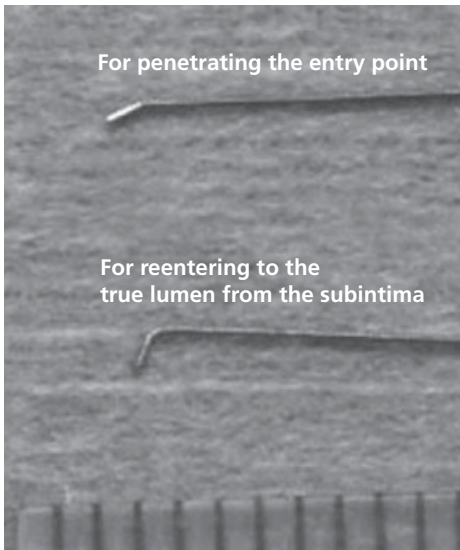


Figure 10.9 Shaping the tip of the wire for piercing the distal cap: Typical tip shapes of the tapered-tip wire (Conquest Pro or Cross It). For penetrating entry point, its 1.5- to 2.0-mm tip is bent at a curve of about 15–30° (upper panel). For re-entering the true lumen from the subintima, an almost 90° bend is required (lower panel).

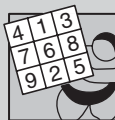
****Optimal projection angle** The best projection angles differ according to the region of interest (ROI). The operator should explore the angles in which the stump can be seen most clearly, especially at the entry point. In general, it is desirable for the two projection angles be perpendicular to the vessel axis of the ROI, and also perpendicular to each other (orthogonal projection). As the summation of the blind area is smallest in the orthogonal projection, it will be easier to lead the wire tip to the true lumen. In many cases, a stiff wire with a sharp bend at the tip (e.g. the Conquest Pro or Miracle stiff wire) in a seesaw wiring technique can be successfully steered to re-enter the true lumen (Figure 10.9).

*****When a wire goes the wrong way** When the wire tip did not direct to the intended direction with a penetration strategy, either change the tip shape or exchange the wire to a stiffer one which would be more favorable than changing the way to rotate the wire. When the angiography of at least two orthogonal views confirms the good alignment of the wire on the imaginary line of the occlusion, along with no trapping or sticking sensation of the wire tip, the wire could go through the occlusion, whereas, when a wire deviates from the imaginary line of the occlusion and a wire tip transmits the trapped or sticking sensation, it is better to leave the wire and switch to the parallel wire method.

PIERCING THE DISTAL CAP

STRATEGIC MAPPING

For the last few millimeters of the occlusion, advance the microcatheter close to the wire tip and exchange the tapered stiff wire for a minimal tip curve. Precise penetration to the distal lumen would be feasible, using the careful analysis of the two different orthogonal views and phase-adjusted contralateral injections. After wire crossing, it is highly preferable to exchange the wire over the advanced microcatheter (beyond the distal occlusion end) to the floppy-type wire for safety reasons. When the microcatheter does not enter into the occlusion deep enough, exchange it for a Tornus catheter (2.1 or 2.6Fr).



Old occlusions (>3 years) typically taper at the end to form a convex structure, making penetration of the distal fibrous cap problematic. The optimal point for the penetration of convex distal fibrous cap is its center, although the newly created proximal channel often leads laterally. In curved vessels, the optimal point to attempt to perforate the distal fibrous cap is usually on the myocardial mural side.

Technical Tips

****Selection of wires for piercing the distal cap** The greater tactile feel of spring-type wires is especially important when attempting to penetrate the distal fibrous cap of a CTO and not create a false lumen. Notably, as the wire tip becomes stiffer, torque response increases, but less tip resistance is transmitted to the operator, making it easier to enter a false channel. Thus, lower-force wires are generally used first (e.g. Miracle Brothers, 3g), with progressive use of stiffer, more powerful wires if resistance to penetration is encountered [6].

**Shaping the wire tip in order to pierce the distal cap

When trying to enter the true lumen from the false lumen, the tip of a right sharp angle (>60°) with a 1.0–2.0 mm bend depending on the lumen size is required as part of either the parallel wire technique or IVUS-guided wiring. The Confianza Pro (9 or 12 g) is the most suitable for this purpose (Figure 10.9).

****Piercing the distal cap** When the wire reaches the exit point of the CTO, the wire should be manipulated finely, gently, and carefully for the success of wire crossing. It is very important to control the wire tip intentionally in the direction of the distal true lumen, with examination of the angiogram from several different angles to understand the relationship with the distal true lumen. In most cases, once the wire tip has been advanced into the distal true lumen, the resistance from the wire tip suddenly

becomes lighter, yet it is still very important to confirm that the wire tip is overwrapping the coronary artery. This confirmation can be done by taking angiographic views to confirm that the wire tip can be advanced up to the distal end of the artery without any resistance [7].

DEDICATED EQUIPMENT

The TORNUS catheter

The Tornus catheter consists of three parts: The main shaft with surface coating, the polymer sleeve, and the hub connector.

The polymer sleeve prevents leakage of blood.

The main shaft is a coreless stainless coil that is a right-handed lay (clockwise). Eight stainless wires are stranded in the coil. The outer diameter is 0.70 mm (2.1 Fr). The inner diameter is 0.46 mm and is suitable for the 0.014-inch wire. As the coil is stranded with eight stainless wires and a length of 150 mm from the tip is tapered, the Tornus catheter provides desirable flexibility and torquability. It can cross through the severe stenosis easily with counterclockwise rotation along the wire, because the shaft is stranded clockwise. The profile of the tip is 0.62 mm (1.9Fr) in diameter, and it is made of stainless platinum alloy, which provides the tip strength and radio-opacity. If the tip of the catheter does not advance through the lesion by manipulation, it is sometimes required to release the catheter from rotational force in order to avoid the fracture of the shaft [10].

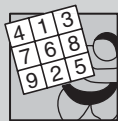


RE-ENTRY OF THE DISTAL TRUE LUMEN

STRATEGIC MAPPING

Once the wire progresses into the body of the occlusion, procedural success is largely influenced by the exit point wiring, so it is useful to be aware of the several pitfalls that herald the unfavorable signs before causing a halt in the procedure (i.e. a large dissection or perforation). Wire derail or deviation from the distal target lumen is prevalent at the exit point, which implies wire fatigue, weaker stiffness of the tip, or subintimal passage of the wire from a more proximal part of the occlusion.

When the proximal part of distal true lumen fails to visualize as the wire goes into the "lumen," this also implies the subintimal passage of the wire, compromising the true lumen. As this sign suggests that the wire is at least inside



(Continued)

the vasculature at the exit point, the parallel wire method will usually solve the problem.

When the wire is successfully entered into the one of the branches and confirms free movement in the branch, but cannot select any other branches, subintimal wiring and a return to the true lumen beyond the branching point are most likely, so that either the parallel wire technique starting from a more proximal part or IVUS-guided rewiring would be of great help to drive the wire back into the true lumen [11].

After Re-entering the Distal True Lumen

Once a stiff wire (whether non-coated or hydrophilic) has crossed the occlusion and passed into the distal vessel, and the lesion has been crossed with an OTW wire balloon dilation catheter, the stiff wire should be immediately exchanged for a floppy-tipped non-coated wire placed distally to minimize the risk of distal wire perforation or dissection [1].

Technical Tips

*****Importance of wire crossing from true to true lumen and minimizing the subintimal wiring** The antegrade approach was attempted with a Miracle 3–6 g for the CTO before and after the major septal branch of the LAD. As the tip of the first wire deviated from the distal true lumen, the IVUS-guided parallel wire method was applied with a Miracle 12 g as a second wire, which resulted in successful wiring into the distal true lumen. Although another floppy wire reached down to the septal branch to protect it, IVUS confirmed the subintimal guidewire in the highlighted portion of the LAD. A drug-eluting stent (DES) was deployed to cover the subintimal space, bridging from the true lumen. As the distal vascular bed beyond the stented segment was rather large, and other branches were preserved, final angiography concluded with a thrombolysis in myocardial infarction (TIMI) grade 3 flow to the distal end.

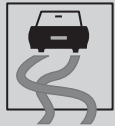Of note is a loss of the major septal branch and a small diagonal branch. Theoretically, once the wire reaches the distal true lumen, even the localized subintimal stenting in between segments might be justified in terms of less procedural time, shorter radiation time, and smaller volume of contrast. When the distal vascular bed beyond the subintimal wiring point supplies more than a modest volume of the vascular bed, subintimal stenting will result in a restoration of TIMI 3 flow at the end. Long-term patency seems to be also excellent with the use of a DES. But, in the case where the wire entered into a subintimal space first, then back to the true lumen at the distal part that supplies rather limited amounts of the vascular bed, stenting in the subintimal space may result in suboptimal flow downstream, which is associated with long-term restenosis or reocclusion. IVUS would be of great help in wire positioning and mapping a strategy of how to proceed next.

****Shaping the curve at the tip** A large curve is good when, from a false channel, it needs to locate the true channel. However, a wire with large curve can make an existing false lumen larger, so use the tip with the smallest curve as needed. The tapered curve is best to penetrate a CTO, but it can be used only when the operator can be sure that it is truly coaxial before forcing it through the plaque [6] (see Figure 10.9).

CAVEAT

When to stop

When the distal flow is suboptimal after balloon inflation due to long subintimal wiring and the patient is hemodynamically stable, stop the procedure and take a couple of weeks to stabilize the dissection. Looking again at the procedure will provide a better chance of true lumen wiring, and subsequent stent placement.



Collapse of the true lumen

Once a false lumen has been created anywhere around the vicinity of a fibrous cap, the true lumen can be easily collapsed because the false lumen uses it to extend (encircle) and dissect in a circumferential pattern around the arterial wall.

****IVUS-guided wire re-entry** IVUS can differentiate a true lumen from a false lumen by identifying the presence of SBs (which arise only from the true lumen), and intima and media (which surround the true lumen, but not the false lumen). Similarly, IVUS can confirm when the wire has re-entered the true lumen from the false lumen. With IVUS-guided wiring (false lumen) technique, the IVUS catheter is advanced through the first wire into the subintimal space. Enlargement of the subintimal space by wiring often causes collapse of the distal true lumen; therefore, this problem could not be observed or verified by contralateral angiography from the artery supplying collaterals. However, the IVUS image clearly shows the cross-sectional information, which is useful to guide the second wire into the true lumen. Stiff wires (Confianza or Miraclebros 12 g) should be used as the second wire to penetrate the true channel (Figure 10.10). Figure 10.10 illustrates the IVUS-guided wiring maneuvers in the false lumen technique. This technique sometimes requires balloon dilation in the subintimal space to deliver the IVUS catheter; however, it should never be performed when wire perforation from the subintimal space has already been detected. An 8-Fr guide is required to perform the parallel wiring technique under IVUS guidance. After successful wire crossing, multiple stenting is mandatory to fully cover the enlarged subintimal space (Figure 10.10).

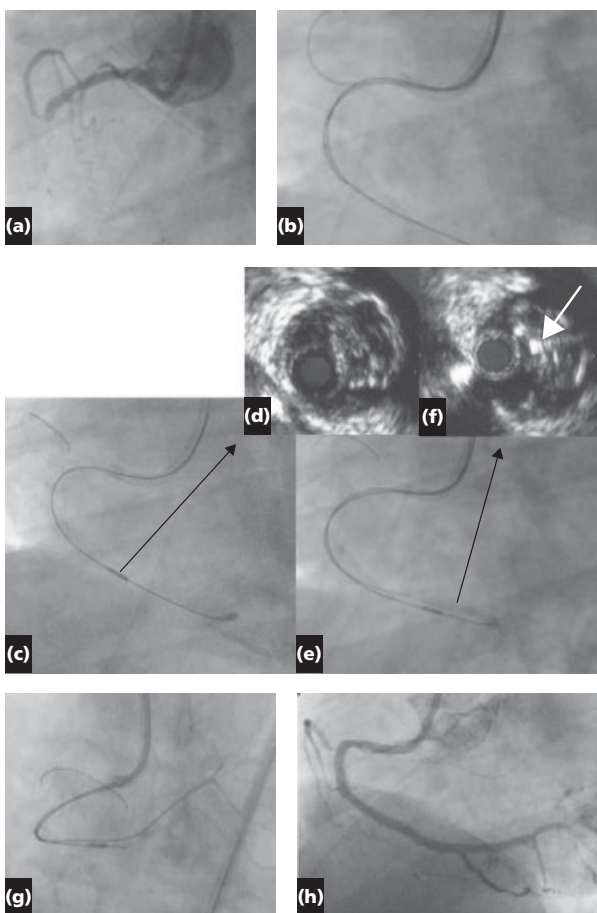


Figure 10.10 IVUS-guided wire re-entry: Case example with IVUS-guided wiring in false lumen technique. (a) The RCA had a very long occlusion including a 3-year-old in-stent reocclusion. (b) Parallel wiring technique using stiff wires could not provide successful wire crossing. (c) An IVUS catheter was advanced through the wire in the false channel. (d) The image clearly showed an expanded subintimal space and a collapsed true channel. (e,f) Then a tapered stiff wire was delivered under IVUS guidance penetrating the true channel from the subintimal space and finally this procedure succeeded. (g) After the wire was carefully advanced to the distal true lumen. (h) Final angiographic result after multiple stenting.

*****How to confirm that the wire is in the true distal lumen** Once the wire enters the distal lumen, its tip should show easy free movement and smooth retraction or advancement. If there is doubt about the intraluminal position of the wire, an angiogram of the contralateral artery may help to visualize the distal segment through collaterals. If there is no free rotation and no smooth advancement or retraction, the wire may lie subintimally or in a small collateral outside the lumen.

Re-entry with Dedicated Equipment

After subintimal passage, re-entry to the true lumen can be achieved by several types of wires or catheters, such as use of hydrophilic and tapered tip wires, using the TwinPass catheter, the Venture catheter or the Stingray CTO re-entry system.

DEDICATED EQUIPMENT

The Stingray system is a dedicated re-entry device that consists of a flat balloon which orients itself along the vessel wall after low-pressure inflation (2–4 atm), and a stiff wire with a 0.003-inch tip that is advanced through one of the two offset exit ports of the balloon, traditionally under angiographic guidance, directed toward the distal vessel true lumen [12].



The Venture catheter The Venture catheter has an 8-mm radio-opaque torquable distal tip that has a bend radius of 2.5 mm. The tip can be deflected up to 90° by clockwise rotation of a thumb wheel on the external handle. With rotation of the entire catheter, steering in all planes is possible. It is compatible with 6-Fr guide and with 0.014-inch wires. Both a rapid exchange and an OTW catheter are available. The OTW Venture catheter allows for wire exchange as well as drug delivery [13].

Technical Tips

****Manipulating the wire of the Venture catheter** The stiff Venture catheter body can enhance the penetrating ability of the coronary wire (especially when stiff-tip or tapered-tip wires are used, such as the Confianza Pro 12 wire) and increase the risk for coronary perforation. Meticulous attention should be paid to confirming the intraluminal distal position of the wire (e.g. via contralateral injections) to avoid inadvertently enlarging an area of wire perforation. The Venture catheter may not allow insertion of stiff wires when the distal tip is shaped as a sharp bend [14].

****Removal of the stiff and bulky Venture catheter** Removal of the Venture catheter using a “trapping balloon technique” requires use of a guide that is at least 8Fr, because the Venture catheter has a larger profile compared with an OTW balloon. For the same reason an 8-Fr guide would be needed to perform a parallel wire technique, when one of the wires is used through the Venture catheter [14].

The OTW Venture catheter is preferable to the rapid exchange catheter for CTO PCI because it allows wire exchanges. If the rapid exchange Venture catheter is used, meticulous attention and continuous fluoroscopy should be used during the Venture catheter removal because it has a stiff body and may inadvertently

bend and dislodge the wire, a very disheartening event after often prolonged crossing attempts [14].

Antegrade Subintimal Approach

The STAR technique The subintimal tracking and re-entry technique (STAR) technique occurs at the distal larger SB bifurcation, because the strong wire tip can be easily directed from the subintima toward the true lumen [15]. The STAR technique has the potential risk of incomplete revascularization due to SB occlusion. It is not used any more.

BALLOON ANGIOPLASTY

Once a wire crosses into the distal true lumen, an OTW balloon is advanced across the CTO and the wire removed. To confirm the position of the balloon in the true lumen is by angiography from the contralateral injection via collaterals. As a last resort, a small amount of contrast is carefully injected distally via the lumen of the OTW catheter, because it will either demonstrate the intraluminal position of the catheter or worsen a subintimal dissection, typically ending the case. After the occlusion is crossed and dilated with the OTW catheter, the true dimensions of the CTO may be appreciated and subsequent angioplasty and stenting performed with appropriate-sized devices. It should be noted that chronic low-flow spasm in the distal vessel is common after CTO recanalization, so often large and repeated doses of intracoronary nitroglycerin or other vasodilators are needed for the true reference vessel diameter not to be underestimated.

Technical Tips

****When a balloon cannot cross a CTO** Crossing a CTO with a balloon catheter may be difficult and impossible due to the presence of extensive fibrocalcific plaque, especially when the guide support is suboptimal. Methods that may be considered for such difficult situations include:

- 1** Deep guide intubation
- 2** Introduction of a second wire into a branch proximal to the occlusion to increase the support of the guide
- 3** Introduction of a wire in the true lumen adjacent to the first wire, as a buddy wire or to increase the dimension of the channel (after which the second wire is removed)
- 4** Use of larger and more supportive guides
- 5** Inflation of an angioplasty balloon either in the MV or in an SB to stabilize the guide
- 6** Use of debulking devices.

Although most studies have not demonstrated a role for debulking of CTOs to reduce restenosis, excimer laser, high-speed rotational atherectomy, or the Tornus catheter may allow balloon passage or expansion of otherwise non-dilatable CTOs. The tactical decision to cross a CTO lesion with its preferred sequence of different techniques is from simple to complex, from user friendly to labor intensive, and from low cost to expensive.

TACTICAL MOVE**BEST options for balloon to cross a CTO****1 No added Cost FIRST Best Maneuver:**

Deep seat the guide

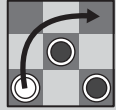
2 \$ ⌚ SECOND Best Maneuver: Advance a second wire along the first wire to straighten the artery or to widen the lumen for balloon passage

3 \$ ⌚ THIRD Best Maneuver: Advance a second wire to an SB to anchor the guide

4 \$ ⌚⌚ FOURTH Best Maneuver: Inflate an OTW balloon in the proximal segment to anchor and deep seat the guide

5 \$\$ ⌚ FIFTH Best Maneuver: Change to a stronger guide

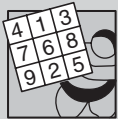
6 \$\$ ⌚⌚💧💧 Debulking atherectomy

**RETROGRADE APPROACH**

When the CTO could not be crossed by the antegrade approach, the next option is the retrograde approach. It is successful only with dedicated tools and use of a large variety of procedural options, which are not part of the regular interventional arsenal for complex non-occlusive lesions. A major factor in the successful retrograde approach is the availability of the Corsair channel dilator, which could be advanced easily through the small collateral channel, graded as collateral connection grade 1. This catheter makes collateral dilation unnecessary and wire exchange easy, and gives a stable position for wire control during retrograde wire crossing [6].

STRATEGIC MAPPING

The first key for success of the retrograde approach is to study the diagnostic images carefully and choose a best collateral branch. It is crucial to give more importance to its course (tortuous or straight) than its size (including its distal portion). Once a channel has been selected, a hydrophilic soft wire should be used to negotiate the collateral channel (CC) with the support of a microcatheter, which minimizes wire kinking. Once the distal end of the CTO has been reached, the retrograde wire is often exchanged for a stiffer wire to be advanced into the CTO lesions. Once the distal cap has been pierced, the last move is to connect the antegrade and retrograde channels.

**Technical Tip**

***Angiographic search of collaterals** Lower magnification and avoiding panning considerably helps in evaluating CCs, because CC filling will invariably occur in a dissimilar time frame from the epicardial vessels. It is often the circumstance that a single

frame or two in an entire series of angiograms will relay the appropriate information to determine the therapeutic strategy [16].

Selection of Collateral Channel

There are two types of collateral channels: Epicardial and septal channels.

Septal collaterals are the safest and should be the default choice whenever possible. Severe septal tortuosity is a severe limitation to wire advancement, whereas size is less so. Many times, straight, faintly visible, or even invisible septal collaterals can often be crossed, especially when “surfing” with the wire [16]. In general, the less tortuous septal collateral that connects should be considered as a first choice [16].

Usually the epicardial channel has a corkscrew anatomy. However, if the vessel size is big enough to advance a balloon or microcatheter through it, these epicardial channels could be used. When the epicardial channel is a major collateral source to the recipient artery, distant ischemia may occur and cause discontinuation of the PCI procedure. During the wire manipulation in the channel, there is some risk of wire perforation; however, it can usually be controlled by simple ballooning at the proximal site. Even after successful wiring, dilation of the epicardial channel should not be done because it may cause vessel rupture and cardiac tamponade. In cases of wiring the epicardial collaterals in a patient after a coronary artery bypass graft (CABG), the chance for tamponade is lower because the patient has no pericardial space [16]. There are possible complications when crossing other channels too. There are beat-to-beat movements with cardiac cycles when crossing the collaterals of the AV groove towards the septal branches. There are changes of vessel configuration due to respiration when crossing collaterals from the right ventricular branch, the posterior descending artery or the postero-lateral branch towards the septals. There are possibilities of rhythm disturbances when crossing the septals such as premature ventricular complexes or atrio-ventricular block, while there is possibility of sinus block or standstill when crossing the sinus node artery. The list of collateral channels is showed in figure 10.11.

Retrograde channels

- | | |
|---|--|
| <ul style="list-style-type: none"> ■ Septal <ul style="list-style-type: none"> ■ LAD ~ R-PD ■ LAD ~ LAD ■ RCA (Conus) ~ R-PD ■ AV groove <ul style="list-style-type: none"> ■ LCX (OM) ~ R-PL ■ Bypass graft | <ul style="list-style-type: none"> ■ Epicardial <ul style="list-style-type: none"> ■ LAD (Dx) ~ LCX (OM) ■ LAD (Dx) ~ R-PD ■ RV branch ~ LAD ■ RV branch ~ R-PD ■ Atrial and other rare ones (SAN artery; AVN artery) |
|---|--|

Figure 10.11 The possible retrograde channels. LAD: left anterior descending artery; LCX: left circumflex artery; RCA: right coronary artery; R-PD: Posterior descending artery; R-PL: posterior lateral branch; SAN: sinus node artery; AVN: Atrio-ventricular node artery. Courtesy of Paul Hsien-Li Kao, MD, Taipei, Taiwan.

Technical Tips

****Chance of success of epicardial wiring** A large and less tortuous epicardial collateral has a higher chance for success than a small and severely tortuous collateral. In general, the size is more important than tortuosity, if proper devices are available. The dedicated micro-catheter (MC) needed are the Corsair and the Finecross. The best spring-coil wires are the Sion, Sion blue, Suoh, and the hydrophilic wires are the Fielder FC, XT, XTR.

****Wiring a septal channel** Selective dye injection through a microcatheter is useful to confirm the continuous connection of the channel. Some channels show a small tricky internal formation which looks difficult to negotiate; however, a new hydrophilic tapered soft wire, the SION wire, usually works well in these types of channels. Sometimes, invisible channels can be negotiated by careful wire manipulations on a "trial-and-error" basis. If the wire perforates the channel, which usually creates a small fistula into the ventricle, no treatment is required. There is the risk of scratch injury during catheter delivery, which may cause a septal hematoma. When this happens, the patient will complain of severe chest pain and may develop a fatal event if not adequately treated, such as embolization of the septal channel or creation of a fistula connecting to the ventricle [16].

*****Wire manipulation** The key to the success of septal wiring (surfing) is to VERY GENTLY manipulate the retrograde soft (first) wire, the transit catheter and the stiffer (second wire, exchanged through the transit catheter in order to cross the CTO from its distal end) in order to avoid damage to the collaterals.

The microcatheter Corsair has a soft tapering tip and hydrophilic slippery shaft which reduce injury to collateral channels. Because of the improved crossing ability of this catheter, dilatation of septal channels with small-sized balloons can be eliminated; this may decrease the incidence of the abovementioned complications. The microcatheter can be passed easily through the septal artery.

DEDICATED EQUIPMENT

The Corsair microcatheter

This is an OTW hybrid catheter that has features of a microcatheter and a support catheter. The shaft consists of eight thin wires wound with two larger wires. This spiral structure allows the bidirectional rotation to be transmitted to the distal shaft for crossing small tortuous CCs. The working shaft length is 150cm and the distal part of the catheter within a 60-cm length is coated with hydrophilic polymer to provide lubricity. The braided portion of the catheter is covered with polyamide elastomer, and the inner



(Continued)

lumen of the shaft (excluding the connector portion) is lined with a fluoropolymer layer to enable tip injections and facilitate movement of the wire. The tip contains tungsten powder and a marker that enhances the visibility of the catheter. The maximum outside diameter is 0.93 mm (2.8Fr), and the inner diameter is 0.45 mm, which is suitable for a 0.014-inch wire [17].

Crossing the Collateral

After wire access to the selected collateral, the Corsair catheter is positioned at the start of the collateral. Once the position has been secured, the workhorse wire is exchanged for a polymer-jacketed wire to cross the CC. Appropriate wires are the non-tapered polymer-covered guidewires with small distal tip load. Outside Japan, the Fielder FC or the Pilot 50 is used, although the tapered-tip Fielder XT can sometimes help to track very tiny CCs. The distal tip of the wire is shaped with the traditional CTO tip shape consisting of a very distal 1-mm 30–45° bend. In Japan, the SION wire is replacing the Fielder (Figure 10.12).

Once the wire has been positioned at the tip of the Corsair, the wire is gently advanced along the least resistant path within the septal channels. Non-selective CC visualization from guide injection or selective visualization from the Corsair catheter is positioned in the proximal portion of the septal CC. The downside of selective visualization is the increased risk of septal rupture, which makes the septal CC unusable and creates a septal hematoma. Selective injection is a last resort after several attempts at surfing have failed. Furthermore, it is safest to inject from the LAD to the RCA than vice versa because the CCs near the RCA are much

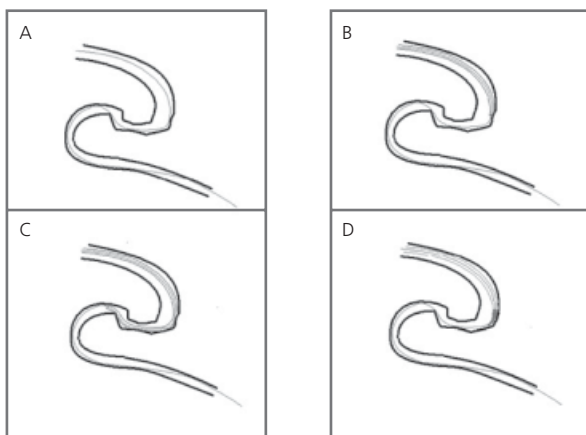


Figure 10.12 The Corsair microcatheter can be advanced easily through tortuous collateral channels (a,b) and serve as a platform so a stiffer wire can be exchanged (c,d) Courtesy of Paul Hsien-Li Kao, MD.

smaller and more prone to rupture. When performing septal surfing, identification of the wrong path is also assessed by the appearance of wire buckling. Then the wire should be retracted and the trajectory is modified slightly. On occasion, the wire appears to “flop” freely distally and this usually indicates entry into a cardiac chamber. Wire advancement into the left or right ventricles is common, as natural communications between coronaries and heart cavities exist. These events are benign as long as the Corsair is not advanced [16].

****How to know that the wire is in the intravascular compartment** Once across into the distal recipient artery, the wire classically has a “to-and-fro” movement implying intravascular position. This to-and-fro movement confirms that the wire can move freely within its path from the donor to the recipient vessel, with the heart beats. The proper position will then be confirmed by non-selective retrograde guide injection [16].

****How to manipulate the Corsair catheter** Manipulation occurs after the wire has been advanced far enough to provide support for the Corsair catheter advancement. This is performed by 5–10 alternating clockwise and counterclockwise rotations while providing forward tension. In the presence of very tortuous or severely angulated CCs, the Corsair catheter may become resistant to rotation. Advancement of the Corsair will be more effective with counterclockwise rotations. Exchange for a new Corsair is required if the Corsair cannot be advanced despite several minutes of rotation in both directions. The Corsair is then advanced and positioned near the distal end of the occlusion [16].

****How to advance the Corsair across the CTO** Anchoring the tip of the retrograde wire in the antegrade guide with an antegrade balloon (anchoring technique with 2.5 mm in a 7- or 8-Fr guide, 2.0 mm in a 6-Fr guide) can provide sufficient backup for Corsair advancement. If this fails, the Corsair should be exchanged for a long 1.5- or 1.25-mm OTW balloon, which usually has a smaller crossing profile than the Corsair, to perform retrograde CTO dilation. If this step succeeds, antegrade flow can usually be restored, and a wire can be advanced to the distal bed from the antegrade guide. At this point, the procedure is converted to an antegrade fashion and the retrograde equipment can be removed.

*****Factors for success of piercing the distal cap from a retrograde approach** After the retrograde wire crosses the collaterals, it should emerge smoothly into the distal segment of the artery beyond the CTO lesion. The problem now is to pierce the distal cap from this retrograde approach. The success depends on 2 factors. The first factor is the distance from the emerging point to the distal cap and the angle. If the distance is too short, advancement of the microcatheter is limited and the retrograde wire penetration is under-powered and could be unsuccessful. (Figure 10.13 A) The second factor is the angle between the

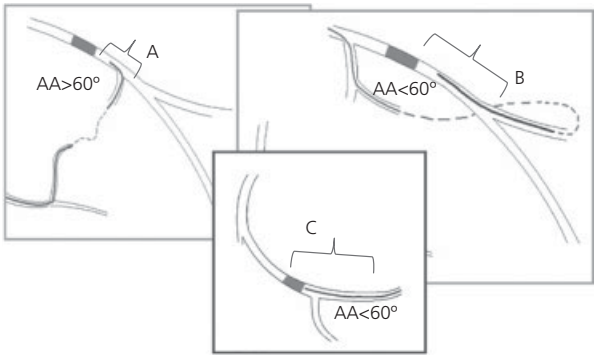


Figure 10.13 When piercing the distal cap from this retrograde approach, if the distance from the emerging point to the distal cap is too short (A), advancement of the microcatheter is limited and the retrograde wire penetration is under-powered and could be unsuccessful (compared with B and C). If the angle between the arterial segment distal to the CTO lesion and the emerging point (the attack angle) is <60 degrees, the chance for success of piercing the distal cap is high (B and C compared with A) (Courtesy of Paul Hsien-Li Kao, MD, Taipei, Taiwan).

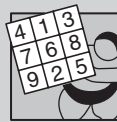
arterial segment distal to the CTO lesion and the emerging point. It is called the attack angle. If the angle is greater than 60 degrees then the chance for piercing the distal cap is low. (Figure 10.13 B and C).

CONNECTING THE ANTEGRADE TO THE RETROGRADE CHANNEL

STRATEGIC MAPPING

There are four strategies on the basis of the crossing patterns: Determine which wire crossed the CTO, antegrade wire, or retrograde wire; and determine whether ballooning was performed for wire crossing.

The case of the antegrade wire crossing the CTO lesion without ballooning is carried out with the kissing wire cross technique. The case in which the retrograde wire crosses the CTO lesion without ballooning is carried out by the retrograde wire cross technique. The case in which the antegrade wire crosses the CTO lesion with ballooning is carried out with the CART technique. Lastly, the case in which the retrograde wire crosses the CTO lesion with ballooning is done by the reversed CART technique [7].



Retrograde Wire Crossing

When a wire crosses the entire occlusion in a retrograde manner, it is called "retrograde wire crossing." After deeply advancing the

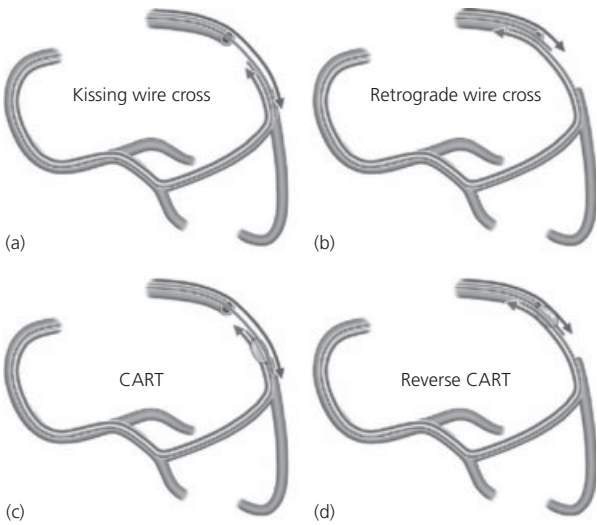


Figure 10.14 Structural illustration of the Corsair catheter. The shaft consists of eight thinner wires wound with two larger ones. This unique spiral structure allows rotation to be transmitted to the distal shaft. PTFE, polytetrafluoroethylene.

retrograde wire into the aorta or the antegrade guide, a retrograde small balloon can be easily advanced and dilated in the occlusion so that the subsequent procedure can be accomplished in the antegrade manner. This is the simplest way of all the retrograde wiring techniques and can be achieved in around 20% of all retrograde approach cases. The other techniques to connect the antegrade and retrograde channels are the CART [18], reverse CART [19], and knuckle wire (KWT) techniques (Figure 10-14).

Techniques

The CART technique The CART technique is performed by first dilating the CTO lesion with the balloon through the retrograde wire, followed by advancement of the antegrade wire into the space dilated with the retrograde balloon [18]. At first, a wire is advanced in an antegrade manner, trying to cross the CTO. When resistance is felt at the wire tip or the wire movement decreases, the wire is deemed to be entering the subintimal space. Leave the wire in this position. A second wire is advanced in a retrograde fashion through the collateral channel under the support of a balloon or microcatheter. This second wire is positioned at the distal end of the CTO and tries to penetrate in a retrograde fashion from the distal true lumen into the subintimal space at the CTO site. After advancing a small balloon (1.5–2.0 mm) over the retrograde wire into the subintima, the balloon should be inflated in the subintima, and also on the course from this subintimal space to the proximal cap of the CTO. To keep this subintimal space open, the deflated balloon should be left in place. As

a consequence, the two dissections created by the antegrade wire and the retrograde balloon lie in the subintimal space at the CTO site. Thereafter, the antegrade wire is advanced further into the distal true lumen along the deflated retrograde balloon. Then ballooning and stent implantation can be performed over the antegrade wire [20].

Advantages and limitations The main advantage of this technique is the minimization of just subintimal tracking through the length of the CTO lesion. Hence, this technique is completely different from the STAR technique [15], and a better long-term outcome after the implantation of a DES can be expected.

The limitation is that, in order to perform the standard CART technique, the retrograde balloon must be advanced inside the occlusion; however, it is not always possible, particularly in complex CTO lesions.

The second problem is the risk of creating a subintimal space extending to the proximal true lumen of the CTO, which may cause a disastrous event when the CTO is located in the proximal part of the left coronary artery system (e.g. dissection of the left main).

The reverse CART technique The reverse CART technique entails first dilating the CTO lesion with the balloon through the antegrade wire, followed by the retrograde wire being advanced into the space dilated with the antegrade balloon [19].

A wire is engaged retrogradely in the distal cap of the CTO and another is advanced antegradely in the proximal cap of the CTO. The retrograde wire is advanced in the subintimal space into the CTO lesion. The subintimal channel is enlarged by advancing and inflating an antegrade balloon to create a plaque dissection and modification of the lesion. Then the retrograde wire is advanced to cross the dissection and link up with the antegrade wire positioned in the proximal true lumen. Next, the retrograde wire is externalized through the guide and is used for subsequent antegrade angioplasty [19].

Advantages and limitations There are two potentially difficult situations for CTO crossing with this reverse CART technique. First, the antegrade ballooning does not achieve subintimal dissection if the balloon is positioned inside the intima and the balloon size is too small, so that balloon dilation may not cause intimal and medial disruption. Moreover, antegrade angiography cannot provide the information for the antegrade wire position (i.e. antegrade balloon position) and the optimal balloon size for creating medial disruption. Therefore, the antegrade and retrograde channels cannot be automatically connected. In this situation, the antegrade channel has to be intentionally punctured by the retrograde wire for successful CTO crossing. This procedure is often difficult and unpromising, just as with a conventional antegrade approach.

Recoil of connecting subintimal channel sometimes occurs even if the connecting channel between the antegrade and retrograde

channels is successfully made with antegrade balloon inflation. Moreover, blind medial disruption with the antegrade balloon potentially causes bidirectional expansion of the subintimal dissection. This makes retrograde wire crossing difficult because, in that situation, the wire easily migrates into the proximal subintimal space created by the antegrade balloon or the wire itself beyond the connecting channel.

Solutions

These difficulties could be overcome by the use of IVUS, which after predilation with small balloon (usually 2.0^mm) along the antegrade wire allows estimation of the optimal balloon size of the antegrade balloon that matches the vessel size, which can cause medial disruption based on the information about a true CTO vessel size, plaque components, and its distribution. The risk of perforation is negligible if done after IVUS guidance and appropriate selection of balloon size. In the presence of a calcified plaque, a smaller size balloon could be used to reduce any perforation risk. More importantly, the formation of medial disruption and the connecting channel could be checked by IVUS after antegrade balloon inflation. If IVUS indicates the recoil of a connection channel, redilation with a bigger balloon should be performed. IVUS also provides direct visualization of the position of the retrograde wire in the subintimal space. The retrograde wire could be advanced into the proximal true lumen under the direct visualization of IVUS [20].

Technical Tips

*****IVUS-guided re-entry** IVUS can provide direct visualization of the connecting channel after balloon dilation and, if repeat recoil is observed, the 0.014-inch snare wire (Soutenir) can be used at the recoil position to keep the connecting channel open by pushing the flap and minimizing the vessel injury.

*****Wires for IVUS-guided re-entry** It should be emphasized that, in the IVUS-guided reverse CART, the soft polymer-coated wires could be used to cross the subintimal connection, because the stiff CTO wires are unnecessary after creation of a connecting channel has been checked by IVUS. This also avoids complications such as vessel perforation or excessive expansion of the subintimal dissection. Another important precaution is to avoid contrast injections after creating antegrade subintimal dissection to prevent a spiral dissection. IVUS guidance is essential for a sophisticated retrograde approach until the retrograde wire has crossed into the proximal true lumen [21].

WIRE CROSSING TECHNIQUE

Although the antegrade wire can be advanced into the CTO to reach the retrogradely advanced wire, it is not easy to connect them in the true channel. The kissing wire technique handles both antegrade and retrograde wires so that the proximal and distal true lumina can be connected. In reality, however, it is very

difficult to align both wires, particularly in the occluded true channel, because there are many diseased layers inside the occlusion.

TECHNIQUE Knuckle wire technique [22] By completely reversing the tip of the retrograde wire (which means forming a “knuckle”) and advancing it inside the occlusion, usually a retrograde subintimal dissected space is created so that the antegrade wire in the subintimal space can be led inside this space. For this procedure, it is feasible to use a hydrophilic soft wire to make the retrograde “knuckle” formation. However, careful attention to the position of the wire tip is required so as not to make an unexpected vessel perforation, particularly in a bend occlusion. The antegrade KWT can be combined with retrograde KWT to facilitate the procedure in a complex CTO lesion; however, there is a risk of an extension of the antegrade dissected space beyond the occlusion, as seen in the STAR technique [23]. There are two major limitations of KWT: One is that the longitudinal dissected space cannot be controlled, the other that the cross-sectional dissected area is not wide enough to lead the antegrade wire [22].

Technical Tips

****Never rotate the knuckled wire** Rotation of a “knuckle wire” may cause wire knotting, making it impossible to retrieve. Therefore, knuckled wire should be pushed, never rotated

*****Trapping wire technique** After successful wiring through the occlusion in the retrograde approach, the antegrade wire can be trapped in the distal lumen by an inflated retrograde balloon to make an EBU force for balloon crossing or stent delivery. On the other hand, in cases with successful retrograde wire crossing or reverse CART technique, the retrograde wire can be trapped in the proximal lumen or in the guide when the wire is successfully advanced inside the guide, so that a retrograde balloon can be advanced inside the occlusion.

TECHNIQUE The double balloon inflation This is a technique using simultaneous confluent balloon inflation to cause the subintimal space to become confluent, allowing wire passage through the CTO. When two overlapping balloons inserted in the retrograde and antegrade subintimal spaces are inflated simultaneously, the subintimal spaces join together, with the balloon inflation leading to confluence of the subintimal space. This allows the retrograde wire to pass easily through this newly created confluent subintimal space. There are a few tips to improve this technique [24].

Technical Tips

*****Retrograde balloon inflation** The slight withdrawal of the retrograde balloon before passing the retrograde wire is useful, because sometimes the retrograde balloon tip is against the wall in the subintimal space, and this slight withdrawal allows

easier wire passage. Inflating the retrograde balloon is also helpful, because this holds the subintimal space open for wire passage.

It is important not to use balloons that are too large, as combined inflation of large balloons may lead to vessel rupture. Theoretically, this technique can also be used in conjunction with the channel dilator by inflating the antegrade balloon in a position overlapping with the tip of the channel dilator, and then pulling the dilator back to pass the wire after balloon deflation [24].

A reverse wire-trapping technique, in which a retrograde wire is caught by an antegrade snare, is another option [25].

The rendez-vous technique describes a method in which microcatheters are aligned in a guide, after which an antegrade wire is pulled into a retrograde microcatheter. In this technique, the wire has been intentionally pulled back into the coronary artery to perform the rendez-vous technique [26].

****Manipulating the retrograde wire into the antegrade microcatheter** Crucial to picking up the tip of the antegrade microcatheter is keeping its tip at the bending segment of the guide. Here, the microcatheter tip is on the outer curve of the guide and is easy to pick up [22].

Externalization of the retrograde wire

The externalization of the retrograde wire must be carried out with extreme care. These manipulations may cause deeper engagement of the retrograde guide, which needs to be avoided to prevent ostial damage. The working field on the fluoroscopy screen should always include the tip of the guide. Furthermore, when the stiffer shaft of the retrograde wire is advanced into the CC, the collateral needs to remain protected by the presence of the microcatheter or the Corsair catheter. Otherwise, it would cut through the delicate wall of the collateral connections and could cause severe damage.

Several workhorse wires come in 300 cm, although we prefer using a 300-cm Pilot 200 guidewire, because the plastic jacket eases progression of the wire within the Corsair and out into the antegrade guide. For extra length, the Rotablator floppy wire is 325 cm; however, its shaft is only 0.009 inch in diameter, and easily kinkable. The ViperWire Advance guidewire has emerged as an ideal guidewire for externalization. It is 335 cm long, the longest of 0.14-inch wires available, and passes very easily through the Corsair to the antegrade hemostatic valve. With septal CCs, as the wire and the Corsair are subjected to the contraction of the septum myocardium, the wire should be advanced slowly and the resistance to the advancement of the wire monitored. Use of the ViperWire substantially shortens this step, because its strong shaft eases pushing the wire across all resistances.

At the end of the procedure, when pulling back the retrograde wire, the microcatheter must protect the CC until the soft wire tip is back in the CC. The pulling back of the wire may be encountered with extreme resistance caused by the stiff part of the wire

engaged in the CC. Then, a gradual removal, synchronized with the heartbeat, must be tried. After successful removal of the retrograde system, a careful angiographic demonstration of the integrity of the collaterals from orthogonal views, and to check for even small extravasations, needs to be performed via the retrograde catheter [27].

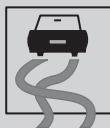Technical Tips

****Steps to retrograde wire externalization** are listed as: (1) Introduction of retrograde wire into the guide for antegrade entry; (2) retrograde microcatheter or OTW balloon is advanced into the antegrade guide with trapping the retrograde wire inside the antegrade guide with balloon inflation; (3) exchange of the shorter retrograde wire to a longer (300cm) wire; (4) longer retrograde wire tip is externalized through the hemostatic valve of the antegrade guide catheter; and (5) from the externalized tip of the longer retrograde wire, the selected PCI device (e.g. balloon, stent) is inserted for delivery into the CTO lesion [7].

*****Careful wire externalization** As the externalized wire brings tension within the coronaries, extreme care should be taken to avoid deep seating (especially when retrograde gear is pulled) and unintentional advancement of the guide catheters, mostly the retrograde one, which can lead to donor artery dissection. Use of 6-Fr catheters from the retrograde side likely reduces the risk of donor artery dissection. Moreover, care should be taken not to lose the proximal end of the long guidewire into the Corsair, from the retrograde side; it is wise to leave a torquing device on the wire or a clamp to avoid this.

CAVEAT

Care must be taken never to let the tips of the balloon and the Corsair touch each other because they can become entrapped due to dissimilar tip sizes and powerful forces generated working on the same wire. It is also crucial to maintain the Corsair in the CC as long as the retrograde wire is in position. As the externalized retrograde wire can exert significant shear stress or tension, especially in a septal CC, the Corsair protects the CC and the septum against being transected, as a "cheese-cutting" effect [16].



COMPLICATIONS

Septal Perforation

Most septal channel perforations are benign and require abandoning that channel and trying another. The channel dilator is safer than a balloon and rarely causes CC dissection or perforation, especially in channels with excessive beds and tortuosity.

Most channel injury patients do not need any further treatment. In some cases, coil embolization may be required. The septal dissections or perforation seen with large series of patients with retrograde recanalization of CTO have shown low complication rates in experienced hands (Figure 10.15).

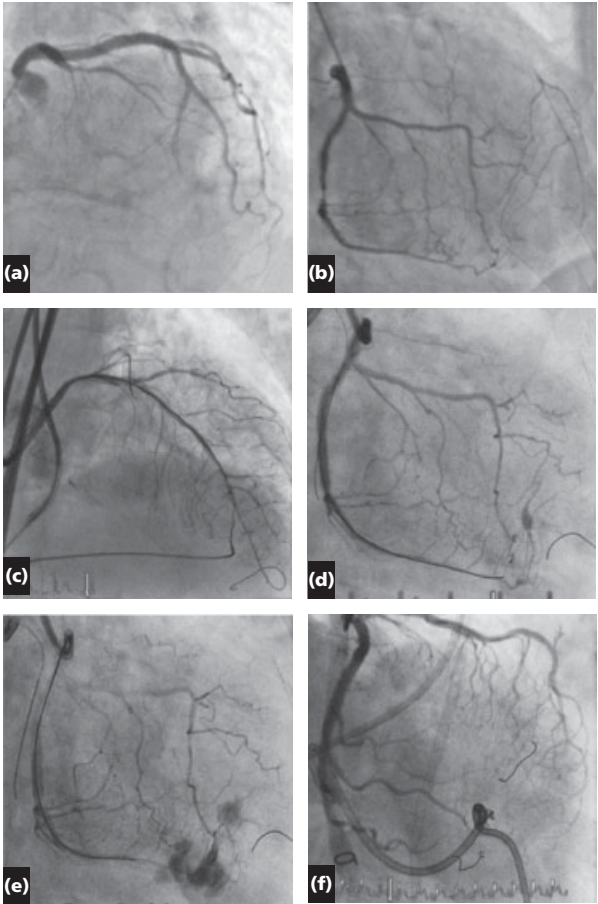


Figure 10.15 Septal perforation: Dilation of the septal collateral artery and subsequent cardiac tamponade during retrograde percutaneous coronary intervention using a microcatheter for chronic total occlusion. (a) Angiography revealed a total occlusion within a stent in the LAD. (b) There are good connections between the LAD and RCA through septal channels. (c) The retrograde guidewire and microcatheter advanced into the septal channel. (d) After the removal of the microcatheter from the septal artery, angiography revealed dilation of the septal artery. (e) The dilated septal artery spontaneously ruptured. (f) The angiography on the following day showed complete hemostasis. (Reproduced from Hashidomi and Saito [28] with permission from Journal of Invasive Cardiology)

Technical Tips

****Prevention of septal perforation** Even the use of a novel microcatheter specifically designed for the retrograde approach may result in rupture of a septal CC, which is not always a safe complication; it may lead to cardiac tamponade and, to stop the bleeding from a ruptured septal collateral artery, embolization from both the artery of origin and the recipient artery of the collateral may be required. Thus, to ensure the absence of arterial injury and/or rupture, it is clinically important to obtain angiograms from both the RCA and the LAD sides after removing the microcatheter from the septal collateral artery; the positions of the wire crossing through the artery from the RCA to the LAD side or from the LAD to the RCA side should be maintained when performing the angiography. If the wire is kept in the artery, the artery can be easily and quickly embolized. When pushing the transit catheter, if the septal wire shows excessive kinking, the wire has to be withdrawn because there is high chance of septal perforation [28].

Management of septal artery rupture Once there is a small perforation from the septal to the right or left ventricle, observations can be made. However, if there contrast spills into the epicardial artery, distal occlusion of the perforation is needed. The easiest way is to embolize the distal perforation with subcutaneous fat tissue.

Ischemia The other potential complication is obstruction of inflow into the CC after the introduction of the channel dilator. This can rarely result in reduced visualization of the distal occluded vessel and myocardial ischemia. Therefore, it is important to avoid the dominant and tortuous collaterals for the access to the distal CTO segment. However, further large-scale studies will be needed to define the safety issues.

REFERENCES

1. Katoh O. Basic Wire-handling strategies for chronic total occlusions In: King S, Yeung A (eds), *Interventional Cardiology*. New York: McGraw Hill, 2007: 367–83.
2. Stone GW, Reifart NJ, Moussa I, et al. Percutaneous recanalizations of chronically occluded coronary arteries: a consensus document: part II. *Circulation* 2005;**112**:2530–7.
3. Hirokami M, Saito S, Muto H. Anchoring technique to improve guiding catheter support in coronary angioplasty of chronic total occlusions. *Catheter Cardiovasc Interv* 2006;**67**:366–71.
4. Takahashi S, Saito S, Tanaka S, et al. New method to increase a backup support of a 6 French guiding coronary catheter. *Catheter Cardiovasc Interv* 2004;**63**:452–6.
5. Stys AT, Lawson W, Brown D. Extreme coronary guide catheter support: Report of two cases of a novel telescopic guide catheter system. *Catheter Cardiovasc Interv* 2006;**67**:908–11.
6. Saito S, Tanaka S, Hiroe Y, et al. Angioplasty for chronic total occlusion by using tapered-tip guidewires. *Catheter Cardiovasc Interv* 2003;**59**:305–11.

7. Sumitsuji S, Inoue K, Ochiai M, Tsuchikane E, Fumiaki I. Fundamental wire technique and current standard strategy of percutaneous intervention for chronic total occlusion with histopathological insights. *J Am Coll Cardiol Interv* 2011;**4**:941–51.
8. Fujita T., Tamai H. New Technique for superior guiding catheter support during advancement of a balloon in coronary angioplasty: the anchor technique. *Catheter Cardiovasc Interv* 2003;**59**:482–8.
9. Ho HH, Loh KK, Ooi YW, Ong PJ. Successful percutaneous coronary intervention of 2 cases of complex coronary lesions facilitated by use of 0.010-inch guidewire and compatible balloon catheters. *J Interven Cardiol* 2011;**24**:315–19.
10. Tsuchikane E, Katoh O, Shimogami M, et al. First clinical experience of a novel penetration catheter for patients with severe coronary artery stenosis. *Catheter Cardiovasc Interv* 2005;**65**:368–73.
11. Ito S, Suzuki T, Ito T, Kato O. Novel technique using intravascular ultrasound-guided guidewire cross in coronary intervention for uncrossable chronic total occlusions. *Circ J* 2004;**68**:1088–92.
12. Casserly IP, Rogers RK. Use of Stingray re-entry system in treatment of complex tibial artery occlusive disease. *Catheter Cardiovasc Interv* 2010;**76**:584–8.
13. Badhey N, Lombardi WL, Thompson CA, et al. Use of the Venture® wire control catheter for subintimal coronary dissection and reentry in chronic total occlusions. *J Invasive Cardiol* 2010;**22**:445–8.
14. Iturbe JM, Abdel-Karim ARR, Raja VN, Rangan BV, Banerjee S, Brilakis ES. Use of the venture wire control catheter for the treatment of coronary artery chronic total occlusions. *Catheter Cardiovasc Interv* 2010;**76**:936–41.
15. Garibaldi S, Godino C, Carlino M, et al. [Treatment of chronic total coronary occlusions by the subintimal tracking and reentry modified technique. The contrast-guided STAR technique.] *G Ital Cardiol (Rome)* 2010;**11**:584 –9.
16. Joyal D, Thompson CA, Grantham JA, et al. The retrograde technique for recanalization of chronic total occlusions: A step-by-step approach. *J Am Coll Cardiol Interv* 2012;**5**:1–11.
17. Tsuchikane E, Katoh O, Kimura M, Nasu K, Kinoshita Y, Suzuki T. The first clinical experience with a novel catheter for collateral channel tracking in retrograde approach for chronic coronary total occlusions. *J Am Coll Cardiol Interv* 2010;**3**:165–71.
18. Surmely JF, Tsuchikane E, Katoh O, et al. New concept for CTO recanalization using a controlled antegrade and retrograde subintimal tracking: the CART technique. *J Invasive Cardiol* 2006;**18**:334–8.
19. Cohen R, Hattab M, Elhadad S. Retrograde approach “reverse CART technique” with a single guide for chronic total occlusion of the right coronary artery via an anomalous left circumflex artery. *J Invasive Cardiol* 2011;**23**:E92–4.
20. Tsuchikane E, Katoh O, Kimura M, et al. Mini-focus issue: Chronic total occlusion the first clinical experience with a novel catheter for collateral channel tracking in retrograde approach for chronic coronary total occlusions. *J Am Coll Cardiol Interv* 2010;**3**:165–71.
21. Rathore S, Katoh O, Tuschikane E, et al. Mini-Focus Issue: Chronic total occlusion a novel modification of the retrograde approach for the recanalization of chronic total occlusion of the coronary arteries intravascular ultrasound-guided reverse controlled antegrade and retrograde tracking. *J Am Coll Cardiol Interv* 2010;**3**:155–64.
22. Funatsu A, Kobayashi T, Nakamura S. Use of the kissing microcatheter technique to exchange a retrograde wire. *J Invasive Cardiol* 2010;**22**:E74–7.
23. Colombo A, Mikhail GW, Michev I, et al. Treating chronic total occlusions using subintimal tracking and reentry: the STAR technique. *Catheter Cardiovasc Interv* 2005;**64**:407–11.

24. Wu E, Chan W, Yu CM. The confluent balloon technique—two cases illustrating a novel method to achieve rapid wire crossing of chronic total occlusion. *J Invasive Cardiol* 2009;**21**:539–42.
25. Niccoli G, Ochiai M, Mazzari M. A complex case of right coronary artery chronic total occlusion treated by a successful multi-step Japanese approach. *J Invasive Cardiol* 2006;**18**:E230–E233.
26. Muramatsu T, Tsukahara R, Ito Y. Rendezvous in coronary technique with the retrograde approach for chronic total occlusion. *J Invasive Cardiol* 2010;**22**:E179–E182.
27. Nombela-Franco L, Werner GS. Retrograde recanalization of a chronic ostial occlusion of the left anterior descending artery. *J Invasive Cardiol* 2010;**22**:E7–12.
28. Hashidomi H, Saito S. Dilation of the septal collateral artery and subsequent cardiac tamponade during retrograde percutaneous coronary intervention using a microcatheter for chronic total occlusion. *J Invasive Cardiol* 2011;**24**:74–6.

CHAPTER 11**Ostial Lesions**

Szabolcs Szabo, Huynh Trung Cang, Yadav Bhatta,
Thach N. Nguyen

Challenges 256

Guide Selection 256**Technical Tips 257**

*Guide selection and positioning 257

**Disengagement of guides 257

**Re-engagement of guides 258

**Two-guide technique 258

Wire Selection 258**Lesion Preparation 259****Technical Tips 259**

**Watermelon-seeding effect of aorto-ostial lesions 259

Non-dilatable lesion 259

Stent Positioning 260**Technical Tips 261**

**Stent positioning with a second wire 261

**Ostial pro device 261

***Double wire in ostial ISR lesion 261

***Stent positioning with an anchor wire 261

Stent Deployment 262**Ostial Side-branch Stenting 263****Technical Tips 263**

*Can we have perfect position of a stent for side-branch ostial lesions? 263

**How to solve the problem of wire twisting in the anchor wire technique 264

**Stent pull-back technique 264

***Cutting balloon angioplasty of a "jailed" SB ostial lesion 265

Advanced and Exotic Techniques 265

PCI of ostial in-stent restenosis lesion through side strut 265

Rotablation for stent-jailed SB stenoses 265

Ostial lesions are defined as lesions within 3 mm the ostium of the vessel at the aorto-ostial or branch ostial junction. These lesions have unique pathological and morphological/angiographic features, resulting in a challenging subset with inferior outcomes when compared with non-ostial lesions. Ostial lesions tend to

*Basic; **Advanced; ***Rare, exotic, or investigational

\$, <\$US100.00 extra; \$\$, >\$US100.00 extra

⌚, <10 min extra; ⌚⌚, >10 min extra

♣, low risk of complications; ♣♣, high risk of complications

have higher calcium and fibrous tissue content and increased elastic recoil tendency [1,2]. There is also increased intimal hyperplasia after stenting. As in other complex lesion subsets, the goal of the operator providing contemporary treatment is to deliver an optimally deployed drug-eluting stent (DES). Although the DES appears to successfully tackle this unfavorable milieu and provide reduced rates of restenosis, the data available are limited.

CHALLENGES

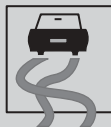However, even in the DES era, ostial location appears to correlate with poorer outcome. The location of these lesions poses inherent challenges to the operators due to: Limited angiographic views, highly variable ostial anatomy, unstable guide support, accentuated cardiac motion, and usually significant myocardium at jeopardy. A recent detailed review of a contemporary series of aorto-ostial stenting revealed a stunning 54% “geographic miss” associated with increased cardiac events [3]. It is imperative to exclude the frequently present catheter-induced ostial vasospasm before embarking on intervention.

CAVEAT

Strategic concerns for percutaneous coronary intervention (PCI) of ostial LAD and LCX

Interventions of ostial left anterior descending artery (LAD) or left circumflex artery (LCX) lesions pose many concerns:

- 1 The balloon or stent can impinge on the origin of the non-dilated artery and obstruct flow
- 2 If there is acute occlusion, there could be significant jeopardy to cardiac function or survival
- 3 Vessel size discrepancy between the left main (LM) to the LAD or LCX
- 4 Dissection at the proximal LAD and LCX could extend in a retrograde fashion into the LM segment
- 5 Stent restenosis at the proximal end could result in restenosis of the LM
- 6 Antegrade and retrograde embolization into the other artery (from LAD to LCX or vice versa, from LAD to LM and systemic embolization, etc.)



Guide Selection

Guides that provide stable alignment with the axis of the vessel at the ostium, without having a tendency to dive into the vessel, are preferred. The interventional device, especially the stent, should be maintained in a stable position while the operator moves the guide in or away from the ostium. Usually the Judkins-type guides (some with short tips) or extra backup/geometric

catheters serve well for the LCA and, in general, the Amplatz-type guides are avoided. For some right coronary arteries (RCAs), ostia with high takeoff, and RCA vein grafts, a multipurpose guide sits best.

Technical Tips

***Guide selection and positioning** As a result of the proximity of the lesion to the ostium, the guide should not be fully engaged or deep seated. The usual Judkins guide may provide sufficient backup with coaxial alignment without aggressive intubation. A guide with side holes would help; however, waste of contrast media through the side holes would mask the exact location and severity of the ostial lesion. As long as coaxial alignment is maintained, the interventional device can be advanced, positioned, and checked with the tip of the guide positioned just outside the ostium. The Ostial Pro device optimizes the guide position at the ostium [4].

****Disengagement of guides** Once the device catheter carrying the undeployed stent, balloon, or atherectomy blade is properly positioned, the guide is then gently withdrawn 1 or 2 cm into the aorta, so that the balloon or the stent is not inflated or deployed inside the guide (Figure 11.1). Gentle forward pressure

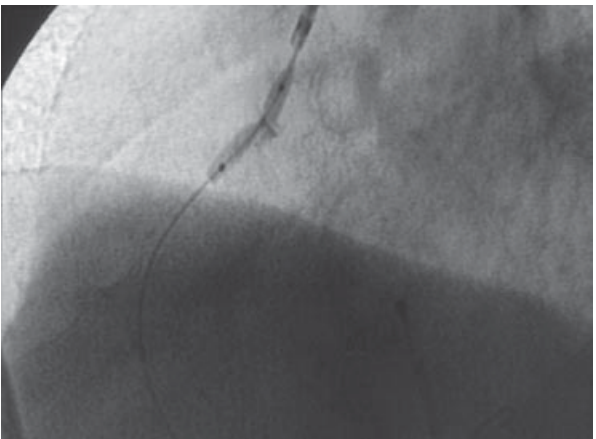
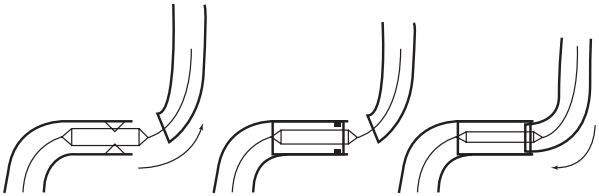


Figure 11.1 The balloon is positioned across the lesion. Next the guide is withdrawn into the aorta to expose the balloon. After inflation and stent deployment, the deflated balloon can be used to stabilize and “rail-in” the guide.

on the device catheter or low-pressure balloon inflation (1–2 atm) may help to maintain proper balloon position while the guide is retracted. Ideally a “waist” is seen in the center of the exposed balloon during pre-dilation, confirming appropriate positioning. Frequent test injections should be done to verify that the tip of the guide does not inadvertently engage beyond the ostium or the device move outside its intended area.

****Re-engagement of guides** After deployment of a stent, follow-up angiogram, postdilation, or further devices might need to be delivered. Even with appropriate guide alignment, it could be difficult to enter an ostially deployed stent. Therefore, it is helpful to re-engage the stent first, before the final angiogram, by using the stent delivery balloon to “rail in” the guide tip (Figure 11.1). Once the stent has been deployed the deflated balloon is left in place or can even be advanced slightly. Then, while applying traction on the balloon catheter, the guide tip can be advanced into the ostium of the stent to achieve perfect alignment without damaging the stent. When the balloon needs to be removed, traction on the guide should be applied first, so pulling the balloon out will not move the guide forward into the ostium. Once the coronary angiogram has been done, the guide can be backed out by a slight forward push on the wire. This maneuver should be performed while monitoring the tip of the wire, throughout the entire procedure, to avoid distal perforation of the coronary artery. It is important to handle the deployed stent with care while performing postdilation or intravenous ultrasound (IVUS) to avoid damage, dislodgement, or even extraction of the stent.

****Two-guide technique** Correct positioning of a stent at an ostial lesion can be difficult due to poor visualization once the guide has been backed out of the artery to allow deployment. The simultaneous use of a diagnostic catheter allows optimal visualization of the stent position, while maintaining a stable guide position well away from the stent. In a case report, by Lambors et al., which illustrates the technique of using a second diagnostic catheter to enhance visualization of the lesion during stent positioning, a patient underwent successful intervention for an aorto-ostial lesion in the saphenous vein graft (SVG) to the LAD [5]. An 8-French (Fr) Judkins right (JR) guide was stable and provided good support. However, with the guide in a position that would allow adequate visualization of the lesion, the tip of the guide sat on the lesion, precluding perfect stent deployment. When the guide was withdrawn slightly, visualization was poor and the proximal balloon remained within the guide, risking movement during deployment. Then a 6-Fr diagnostic catheter was introduced from the opposite side and engaged, providing excellent visual support for stent positioning [5].

Wire Selection

Usually intermediate strength wires provide adequate support because a significant part of the wire is anchored far in the distal vessel. Extra support wires may provide additional stabilization,

which is especially helpful in ostial SVG lesions. Avoid hydrophilic wires and monitor the wire tip during the entire procedure to prevent distal perforation, because maintaining stable wire position tends to be difficult during device delivery and guide positioning.

Lesion Preparation

Although significant data suggest the feasibility of direct stenting in non-ostial lesions, the operator should have a low threshold to predilate an ostial lesion. As precise positioning is crucial, without predilation the operator will have to “struggle” with the resistance of the lesion, with further limitation of angiographic landmarks and risk of watermelon seeding. It is vital to recognize a poorly yielding or “non-dilatable” lesion in this heavily calcified subset before stent deployment.

Technical Tips

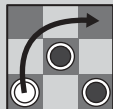
****Watermelon-seeding effect of aorto-ostial lesions** In patients with ostial lesions, while inflating the balloon, sometimes the balloon migrates proximally or distally. So the balloon should be inflated more slowly 1 atm at a time, and the balloon catheter is gently retracted to keep the balloon from migrating distally. Even so, there are cases of persistent watermelon seeding, so a buddy wire or cutting balloon would help to solve the problem, especially in in-stent restenosis.

Non-dilatable lesion Due to extra rigidity and the frequently present calcification in ostial lesions, complete expansion of the predilating balloon is needed before stenting. If the balloon cannot be fully expanded with a pressure higher than 18 atm, then cutting balloon angioplasty or rotablation should be considered. Although routine debulking and/or cutting balloon preparation is not recommended, especially in the DES era, these devices have an important role in selected patients to assure optimal stent deployment. As in all difficult lesion subsets, IVUS is very helpful to characterize the lesion and facilitate optimal deployment. When facing a non-dilatable lesion, which is the best option?

TACTICAL MOVE

Best options for ostial lesion predilation

- 1 **No added cost FIRST Best Maneuver:**
Inflate the predilation balloon to maximum
- 2 **\$ ⌚ BEST Maneuver:** Add a second buddy wire and perform focused-force angioplasty [7]
- 3 **\$\$ ⌚⌚ THIRD Best Maneuver:** Cutting balloon angioplasty
- 4 **\$\$\$ ⌚⌚⌚ ⚡ FOURTH Best Maneuver:** Rotational atherectomy; consider excimer laser for non-dilatable stent



Stent Positioning

It is frequently difficult to identify the proximal end of an ostial lesion with certainty. One reason is that the guide cannot be engaged deeply into the ostium or the lesion itself. The guide has to be seated outside the aorta so, during injection, part of the contrast would enter the ostium and part would swirl under and along the curve of the coronary sinus, thus masking the exact location and the severity of the ostial lesion. Another reason is that there is a device across the lesion during positioning, hence there is decreased contrast flow, limiting delineation of the lesion and location of the ostium. Other landmarks such as a fleck of calcium in the aortic wall may also help to identify the entry point of the ostium. The presence of a second wire curving the coronary sinus will help to prevent deep engagement of the guide (Figure 11.2). Once a stent has been deployed, it is more difficult to evaluate possible geographic miss of the short ring-like ostial segment that is left uncovered by the stent. A small guide can pass through it without causing any ventricularization of pressure and a coronary angiogram could not detect any abnormality, because the ostial segment is covered with contrast from back flow. The matter can become worse if a film of the ostial segment is taken in a non-orthogonal projection. If viewed from an angled projection, the lesion cannot be seen because the adjacent contrast-filled vessel segments are projected over the short uncovered segment and mask it. StentBoost can be helpful in such situations [6].

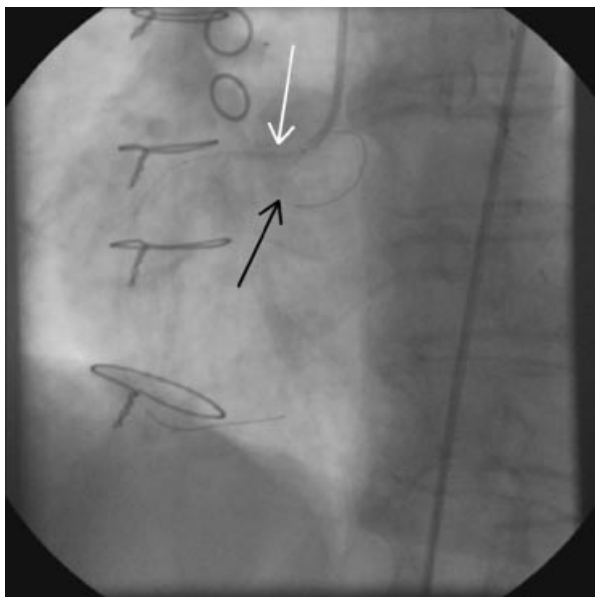


Figure 11.2 A second wire in the aorta helps to outline the sinus of Valsalva and stabilizes the guide at the ostium (black arrow). When backloaded through the last strut, it can also be used to anchor the stent at the ostium (white arrow).

Technical Tips

****Stent positioning with a second wire** Difficulty in positioning the guide during stenting, especially of an ostial RCA lesion, is sometimes made easier by use of a second, steerable, soft-tipped wire placed in the aorta just below the coronary ostium. This second wire stabilizes the guide outside the coronary artery and prevents it from moving deeply into the artery. It also defines the junction of the coronary artery and aorta, an important landmark for stent placement (Figure 11.2).

****Ostial pro device** The self-expanding feet at the tip of the guide assist in stable positioning and provide a visual aid to align the stent at the aorto-ostial junction. This simple device proved successful in optimal positioning in all the 30 cases reported in an initial series [4].

*****Double wire in ostial ISR lesion** Engaging a chronic ostial stent as in a case of restenosis could be challenging. One report describes using a wire threaded through the protruding stent strut in order to stabilize the guide position. Then a second wire is engaged and crosses the lesion [7]. This should be performed with caution because stent avulsion/migration has occurred during these manipulations [8]. It is also plausible that a DES could be at risk of migration for several months after implantation due to the lack of neointimalization or late malapposition.

*****Stent positioning with an anchor wire** This technique overcomes the angiographic- and cardiac motion-related difficulties by anchoring the stent. A second wire is placed into the aorta with the soft distal tip outlining the ostium. The second wire is back-loaded through the last proximal strut of the stent. As the stent is advanced across the lesion, this second wire anchors the last proximal strut outside the aorto-ostial junction (Figure 11.3). In the case of an ostial side branch, this technique is used to optimally position the proximal end of a stent at the ostium of the LAD [9,10]. In the case of LCX stenting, the anchor wire will be positioned in the LAD. This technique has been described as a feasible option providing good angiographic and clinical outcome in various larger series [11–13]. The technique is associated with a steep learning curve and potentially serious complications such as stent dislodgement. Recent data suggest that even this technique does not provide “perfect” positioning [14]. Stent deformation and dislodgement can be minimized by avoiding partial inflation of the stent during preparation of the anchor strut, using the floppy portion of the anchor wire and removing the anchor wire following deflating the stent balloon catheter after an initial lower pressure deployment, followed by a subsequent higher pressure final inflation.

To have optimal results of this technique, the lesion should be predilated and a stent can be used to test the crossability of the stent without the anchor wire (Figure 11.4).

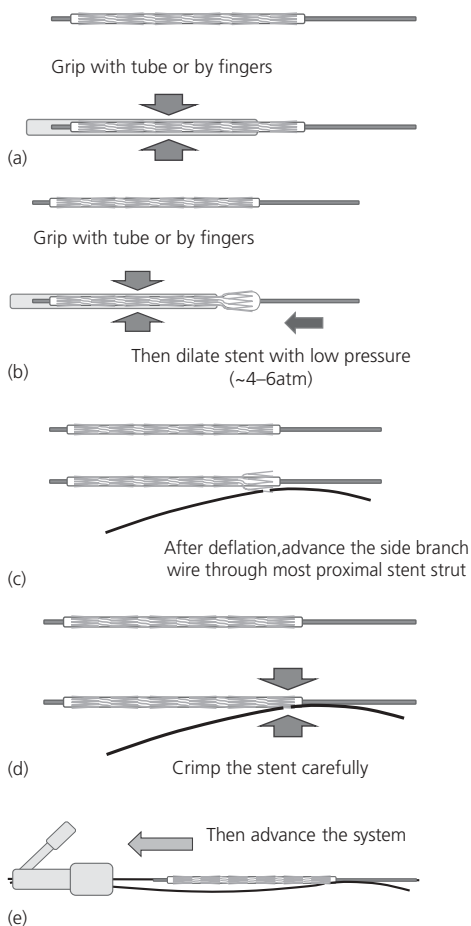


Figure 11.3 (a) Grip the stent with a tube or using the fingers. (b) Then dilate the proximal end of the stent at a low pressure (4–6 atm). (c) After deflation, advance the side-branch (SB) wire through the most proximal strut or backload the SB wire if the tip of the wire has already been advanced far into the SB. (d) Crimp the proximal end of the stent carefully again. (e) Then advance the whole system into the guide over both the primary wire and the anchor wire. (Courtesy of Dr Satoru Sumitsuji)

Stent Deployment

Once the stent is positioned across the lesion, the guide is slightly withdrawn, while maintaining some forward push to expose the balloon stent fully from the guide. Inflating the balloon partially in the guide can lead to balloon rupture. It is often helpful to use some landmarks such as a speck of calcium in the aorta during these manipulations. Contrast injections at this point might help by outlining the sinus of Valsalva. The patient can be asked to hold a breath. If significant motion is present, low-pressure inflation (1–3 atm) will provide some stabilization and allow final

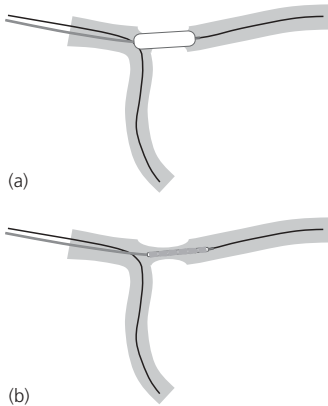


Figure 11.4 (a) Before advancing the stent with the anchor wire technique, predilation is strongly recommended. (b) Check stent cross without the anchor wire technique. (Courtesy of Dr Satoru Sumitsuji)

correction of the stent position, if needed [15]. The operator should be careful during these manipulations as well as when moving the stent catheter back and forth in the calcified lesions, especially during withdrawal back into the guide, because stripping of the stent off the balloon can occur at this specific moment and location. It is recommended to position the stent 1–2 mm protruding into the aorta to prevent recoil of the lesion at the stent edge. The operator should avoid using very short (<12 mm) stents to provide adequate anchoring of the stent and lesion coverage distally. Appropriately sized (1:1 ratio) stents should be deployed at appropriately high pressures (≥ 12 atm) to ensure optimal apposition. Usually a second higher-pressure inflation is performed with the stent balloon slightly retracted, allowing full apposition at the ostium but avoiding distal edge injury. Avoid excessive traction of the balloon because the stent could be retracted and displaced into the aorta. Routine postdilation with larger balloons and “flaring” of the ostium of the stent, although often performed, are probably not necessary and should be balanced against the risk of potential intramural dissection of the aorta.

Ostial Side-branch Stenting

It is not feasible and probably not necessary to stent every ostial lesion in various clinical and anatomic subsets, especially in the case of smaller side branches. Cutting balloon angioplasty in these situations appears to be a safe and effective option [16].

Technical Tips

***Can we have perfect position of a stent for side-branch ostial lesions?** A stent can be positioned and deployed perfectly only if the angle between the side branch (SB) and the main vessel is close to 90° . If the angle is more or less than 90° (not

perpendicular) then the proximal end of the stent can protrude into the main vessel lumen or be deployed too far inside the side branch, thus leaving the ostium uncovered. In these situations, depending also on the anatomy of the parent vessel, one has to consider the various bifurcation techniques.

****How to solve the problem of wire twisting in the anchor wire technique** Just pull back the whole system and re-advance the stent without retwisting the wire. If it does not work, advance a microcatheter as far as possible. It is best if the tip of the microcatheter is at the stent, and then pull the SB wire back and readvance it in the SB (Figure 11.5).

****Stent pull-back technique** In branch ostial lesions, inflate a small balloon at low pressure in the parent vessel, then pull back the stent to the ostium of the SB while ensuring that the balloon in the main vessel is slightly compressed. This technique would result in fewer ostial misses and the need for additional stents [17].

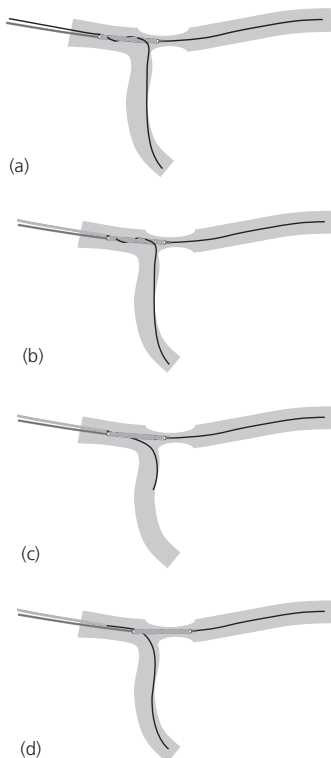


Figure 11.5 (a) To solve the wire-twisting problem, pull back the stent system and try to recross without twisting. (b) Advance a microcatheter as distally as possible. (c) Then carefully re-advance the wire into the side branch. (d) If you want to advance the stent a little bit, pull back the side-branch wire until the soft part is across the stent, and then advance it. (Courtesy of Dr Satoru Sumitsuji)

*****Cutting balloon angioplasty of a “jailed” SB ostial lesion** When there is failure to dilate an ostial lesion with POBA (plain old balloon angioplasty), cutting balloon (CB) angioplasty could be used with extreme caution. In a case reported by Hongo et al., repeated failures with POBA happened when dilating an ostial lesion through the side struts. Then a CB was inserted, with the proximal segment well inside the main vessel lumen, and the balloon was inflated with excellent results [18].

Advanced and Exotic Techniques

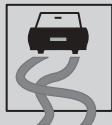PCI of ostial instent restenosis lesion through side strut In a case report by Burstein et al., despite attempts with multiple guides and wires, the protruding stent could not be engaged in a coaxial fashion, suggesting deformation of the intra-aortic segment of stent struts [19]. After failing to achieve coaxial guide alignment, a 6-Fr Amplatz right guide was placed on top of the protruding stent segment and a Whisper wire was advanced to the distal RCA through the struts of the aorto-ostial stent. A 1.5 × 14 mm Maestro balloon was inflated and widened the side struts. This was followed by consecutive balloon dilations using 2.0 × 14 mm, 2.5 × 14 mm, 3.0 × 14 mm, and 3.5 × 14 mm Maestro balloons inflated up to 18 atm. At the end, a 3.0 × 16 mm Taxus stent was successfully advanced through the widened side struts and deployed at 16 atm with 1–2 mm of the proximal stent segment protruding into the aorta for complete coverage of the RCA ostium. The fully expanded Taxus stent displaced the aortic segment of the previously placed stent inferiorly and created a new entry site into the artery, with excellent angiographic outcome.

Rotablation for stent-jailed SB stenoses In a report of jailed SB stenosis, the patients underwent rotational atherectomy, which was performed in the SB and frequently in the parent vessel using a “stepped burr” approach over a rotational atherectomy wire (RotaWire Floppy or RotaWire Extra Support). After debulking with rotational atherectomy, adjunctive balloon angioplasty was performed on all lesions. Frequent revascularization of the parent vessel was also performed with the use of the simultaneous balloon inflations in the parent and SB vessels (i.e. “kissing balloon” technique) in most cases. Rotational atherectomy was not performed in the setting of acutely stent-jailed SB stenosis. Despite the high procedural success rate, repeat revascularization was common in the study. The TVR rate of 44.8% undoubtedly reflects the unfavorable impact of variables such as small vessel size, ostial location, and high incidence of previous revascularization of the treated side branches [19].

CAVEAT

Rotablation through stent struts

An important technical consideration when using rotational atherectomy to treat SBs covered by stents is the importance of



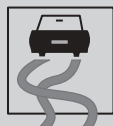(Continued)

ensuring that the SB has been well dilated through the side struts. This may facilitate passage of the burr and reduce the potential of burr entrapment. Another concern is the embolization of metallic particles during rotablation. However, there were no cases of periprocedural myocardial infarction following angiographically successful revascularization of SBs with rotational atherectomy in this series, suggesting that rotational atherectomy through the sides of stents can be performed safely.

CAVEAT

Extraction of stent by cutting balloon at ostial lesion

The CB is designed with blades mounted along its length. During inflation, the blades are protruded outward and exposed. Then, during deflation, there is a mechanism of gradual rewrapping the balloon with multiple wings over the blades. During this process of rewrapping, there is the possibility of creating a recess in the form of an acute angle formed by the balloon and the blades. This recess can get stuck in the stent struts and prevent withdrawal of the CB. If the CB is pulled strongly enough, it could pull with it the stent or part of the stent. When the CB is withdrawn, the pulling force applied on the balloon catheter will not be parallel to the vessel axis. An anchoring point will then be formed at the stiff proximal edge of the blade and the soft proximal balloon catheter. This anchoring point can be easily caught on the proximal stent struts, especially at the RCA orifice, because an almost 90° curve is formed by the proximal RCA and the aortic wall. To prevent this problem, after the deflation, the CB should be advanced first, then withdrawn gently. Other possibilities include stent strut fracture by the microblades; an under-expanded stent with inadequate strut apposition is another possible catching point [20].



REFERENCES

1. Stewart JT, Ward DE, Davies MJ, Pepper JR. Isolated coronary ostial stenosis observations on the pathology. *Eur Heart J* 1987;**8**:917–20.
2. Popma JJ, Dick RJ, Haudenschild CC, Topol EJ, Ellis SG. Atherectomy of right coronary ostial stenoses initial and long-term results, technical features and histologic findings. *Am J Cardiol* 1991;**67**:431–3.
3. Dishmon DA, Elhaddi A, Packard K, Gupta V, Fischell TA. High incidence of inaccurate stent placement in the treatment of coronary aorto-ostial disease. *J Invasive Cardiol* 2011;**23**:322–6.
4. Fischell TA, Saltiel FS, Foster MT, et al. Initial clinical experience using an ostial stent positioning system (Ostial Pro) for the accurate placement of stents in the treatment of coronary aorto-ostial lesions. *J Invasive Cardiol* 2009;**21**:53–9.

5. Lambros J, Fairshid A, Pitney MR. Simultaneous use of a diagnostic catheter to facilitate stent deployment in aorto-ostial stenosis: A case report. *Catheter Cardiovasc Diagn* 1997;**40**:210–11.
6. Vuurmans T, Patterson MS, Laarman GJ. StentBoost used to guide management of a critical ostial right coronary artery lesion. *J Invasive Cardiol* 2009;**21**:19–21.
7. Chetcuti SJ, Moscucci M. Double-wire technique for access into a protruding aorto-ostial stent for treatment of in-stent restenosis. *Catheter Cardiovasc Interv* 2004;**62**:214–17.
8. Wang H, Kao H, Liao C, et al. Coronary stent strut avulsion in aorto-ostial ISR: Potential complication after CB angioplasty. *Catheter Cardiovasc Interv* 2002;**56**:215–19.
9. Szabo S, Abramowitz B, Vaitkus PT. New technique for aorto-ostial stent placement. *Am J Cardiol* 2005;**96**:212H.
10. Kern MJ, Ouellette D, Frianeza T. A new technique to anchor stents for exact placement in ostial stenoses: The stent tail wire or Szabo technique. *Catheter Cardiovasc Interv* 2006;**68**:901–6.
11. Wong P. Two years experience of a simple technique of precise ostial coronary stenting. *Catheter Cardiovasc Interv* 2008;**72**:331–4.
12. Appelgate RJ, Davis JM, Leonard JC. Treatment of ostial lesions using the Szabo technique: A case series. *Catheter Cardiovasc Interv* 2008;**72**:823–8.
13. Gutierrez-Chico JL, Villanueva-Benito I, Villanueva-Montoto L, et al. Szabo technique versus conventional angiographic placement in bifurcations 0.10–0.01 of Medina and in aorto-ostial stenting. *EuroIntervention* 2010;**5**:801–8.
14. Vaquerizo B, Serra A, Ormiston J, et al. Bench top and clinical experience with the Szabo technique: New questions for a complex lesion. *Catheter Cardiovasc Interv* 2012;**79**:378–89.
15. Webster MW, Dixon SR, Ormiston JA, Ruygrok PN, Stewart JT. Optimal stent positioning in coronary arteries: partial balloon inflation to overcome cardiac cycle-related motion of the stent/delivery system. *Catheter Cardiovasc Interv* 2000;**49**:102–4.
16. Chung CM, Nakamura S, Tanaka K, et al. Comparison of cutting balloon vs stenting alone in small branch ostial lesions of native coronary arteries. *Circ J* 2003;**67**:21–5.
17. Kini AS, Moreno PR, Steinheimer AM, et al. Effectiveness of the stent pull-back technique for non-aorto ostial coronary narrowing. *Am J Cardiol* 2005;**96**:1123–8.
18. Hongo R, Brent B. Cutting balloon angioplasty through the stents struts of a “jailed” sidebranch ostial lesion. *J Invasive Cardiol* 2002;**14**:558–60.
19. Burstein J, Hong T, Cheema A. Side-strut stenting technique for the treatment of aorto-ostial in-stent restenosis and deformed stent struts. *J Invasive Cardiol* 2006;**18**:234–7.
20. Sperling R, Ho K, James D, et al. Treatment of stent-jailed side branch stenoses with rotational atherectomy. *J Invasive Cardiol* 2006;**18**:354–8.

CHAPTER 12

Acute ST-segment Elevation Myocardial Infarction

James Nguyen, Marko Noc, Thach N. Nguyen, Lefeng Wang, Hung M. Ngo, Tan Huay Cheem, Michael Gibson

Challenges 270

Urgent Coronary Angiography 270

Identification of High-risk Patients 270

Primary Percutaneous Coronary Interventions 272

Primary PCI without on-site surgical backup 273

Primary balloon angioplasty without stenting 273

Technical Tips 274

**Where is the IRA? 274

**Avoiding vasovagal reaction 274

Evaluation of the PCI results 275

Complex Primary PCI 277

Unprotected LM as IRA 277

Technical Tips 278

**Thrombectomy in the LM 278

PCI after thrombolysis 278

PCI in right ventricular infarction 278

PCI of Saphenous Vein Graft 278

Technical Tips 280

**Crossing the lesion 280

**How to prevent vasovagal reaction 280

**How to verify that the wire is in the true lumen 280

Primary PCI for Lesions with Thrombi 280

Technical Tips 281

**Thrombectomy by aspiration catheter 281

***Avoiding antegrade embolization 282

***Avoiding retrograde embolization 283

Advantages and Limitations 284

"Slow" or "no reflow" after stenting 284

Persistent thrombotic burden 284

PCI of STEMI Patients with Bleeding 285

Patients with Bleeding due to Leg Fracture 285

AMI in Patient with Gastrointestinal Bleeding 285

AMI in Patient with Recent Surgery 285

AMI in Patients with Concurrent Stroke 286

AMI in Patients with Recent Stroke 286

*Basic; **Advanced; ***Rare, exotic, or investigational

\$, <\$US100.00 extra; \$\$, >\$US100.00 extra

⌚, <10 min extra; ⌚⌚, >10 min extra

♣, low risk of complications; ♣♣, high risk of complications

STEMI in Patient with Atrial Fibrillation on Coumadin, INR >2 286**Advanced and Exotic Techniques 286**

AMI patients with LM compressed by an aortic dissection 286

AMI due to spontaneous coronary artery dissection 287

Imaging strategy 287

Management 287

Primary PCI in STEMI after resuscitated cardiac arrest 288

AMI in patient with large coronary aneurysm 288

AMI in acute simultaneous proximal occlusion of two major coronary arteries 289

PCI of a reconstructed prosthetic LM 289

Contrast leakage into the ventricle? is it a wire-induced perforation or impending rupture? 290

Closure of ventricular septal defect caused by AMI 290

CHALLENGES

Acute ST-segment elevation myocardial infarction (STEMI) is usually caused by acute occlusion of a major epicardial coronary artery in the absence of adequate collateral flow from other coronary territories. Prompt, complete, and sustained recanalization of the infarct-related artery, with restoration of normal myocardial perfusion, reduces the infarct size, preserves left ventricular function, and decreases mortality.

Urgent Coronary Angiography

First, the infarct-related artery (IRA) should be determined from a 12-lead ECG. Then, different views of the presumed non-IRA should be taken with a diagnostic catheter or a guide that can be used for both left and right coronary angiograms via the transradial approach (such Tiger, Kimny, or Amplatz left), in order to estimate the extent of coronary artery disease supplying the non-infarcted myocardium and assess the collateral flow to the distal segments of the IRA. Angiography of the presumed IRA should be performed with a guide so that percutaneous coronary intervention (PCI) can be started promptly. The culprit lesion should be clearly identified and characterized in terms of diameter, stenosis, angiographic evidence of thrombus, and epicardial thrombolysis in acute myocardial infarction (TIMI) flow [1] (Figure 12.1). During the diagnostic angiogram, all the major vessels and their large branches should be accounted for in order not to miss the IRA (Figure 12.2). There is no need for a routine left ventriculogram. If there is a need to assess the left ventricular (LV) dysfunction, a pigtail catheter can be inserted into the left ventricle and LV end-diastolic pressure (LVEDP) measured.

Identification of High-risk Patients

Based on clinical evaluation, hemodynamic measurements (heart rate and rhythm, arterial pressure and LVEDP if necessary), and coronary anatomy, high-risk patients should be immediately identified.

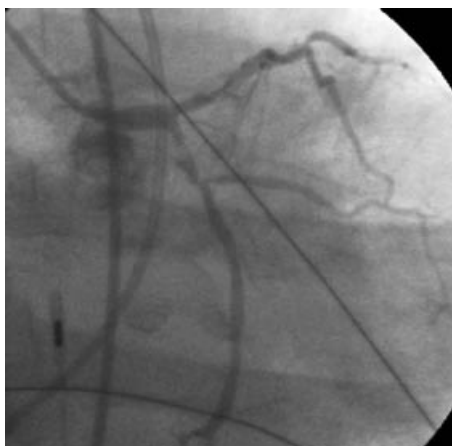

Figure 12.1 The TIMI flow: TIMI 0 flow: no antegrade flow. TIMI 1 flow: some penetration of the contrast across the lesion. TIMI 2 flow: in this figure, the left circumflex artery is completely visualized but the flow is slower than the flow in the normal branch. TIMI 3: there is a strong and brisk flow.

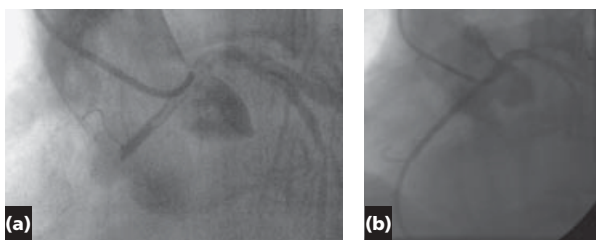


Figure 12.2 The missing RCA as an IRA. The patient arrived with typical angina and ST-segment elevation in leads 2, 3, and aVF. The LAD showed one moderate lesion in its mid-segment. The RCA was seen nowhere even with the aortogram. (a) The RCA was found to be in its usual location when it originates from the left sinus: Anterior and superior to the LM ostium. (b) The patient successfully underwent PCI of the artery. (Courtesy of Starke Memorial Hospital, Knox, IN.)

In the emergency room, if the patient presents with a heart rate of <100 beats/min and a blood pressure >100mmHg, their in-hospital mortality is very low [2]. The factors identifying the high-risk patients are listed in Box 12.1.

A low threshold should be applied for placement of an intra-aortic balloon pump (IABP) in hemodynamically unstable patients. If pulmonary edema does not respond quickly to pharmacological treatment, endotracheal intubation and mechanical ventilation are mandatory. In such cases, the interventions of a physician-intensivist are advised because it allows the interventional cardiologist to focus on the PCI procedure itself, while medical and supportive care is effectively provided.

BOX 12.1 THE FACTORS IDENTIFYING HIGH-RISK PATIENTS

- 1 >70 years of age
- 2 Ejection fraction <45%
- 3 Multivessel disease
- 4 Suboptimal PCI
- 5 Persistent arrhythmia
- 6 BP <100 mmHg and heart rate >100

BOX 12.2 ANGIOGRAPHIC EXCLUSIONS PRECLUDING PERFORMANCE OF PRIMARY PCI

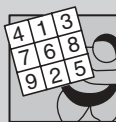
- 1 Unprotected LM >60% (only for US operators)
- 2 IRA with stenosis <70% and with TIMI 3 flow
- 3 IRA supplies small amount of myocardium: Risk vs benefits
- 4 Inability to clearly identify the IRA
- 5 Asymptomatic patient with multivessel disease with TIMI 3 flow, and CABG is indicated

PRIMARY PERCUTANEOUS CORONARY INTERVENTIONS

After defining the coronary anatomy and clinical evaluation of the patient, primary PCI should be attempted if the IRA has a significant stenosis or thrombus with inadequate epicardial flow (TIMI <3). The exclusions for primary PCI are listed in Box 12.2. In the USA, immediate surgical consultation about coronary artery bypass graft (CABG) is indicated in patients with concomitant multivessel disease or unprotected left main (LM) stenosis in excess of 50%.

STRATEGIC MAPPING

At the start of PCI, the choice of adequate guide with coaxial alignment providing good support is crucial. If the IRA opens after passing the wire, and if the distal parts are clearly visualized, direct stenting of the culprit lesion may be performed. This technique is not recommended in tortuous vessels, bifurcations, and very complex lesions. It is important to notice that potential disadvantage of direct stenting is stent undersizing, because the distal segment of the IRA may be inadequately filled by contrast due to significant residual stenosis or chronic spasm from low flow. Therefore balloon predilation using an undersized balloon (i.e. 2.5 mm) is usually suggested. If the patient is not hypotensive, intracoronary injection of nitroglycerin (100–200 μg) is useful to better appreciate the actual size and diameter of the IRA. This allows for better selection of the stent diameter and length. The goal should



be a stent:artery ratio of 1:1. Oversizing of the stent may be associated with edge dissection, distal microvascular embolization, and α -adrenergic "storm" resulting in vasospasm in the distal microvasculature. Careful attention must be applied to ensure complete coverage of the culprit plaque and any residual intimal dissection. If the culprit lesion is a bifurcation involving a significant side branch (>2mm), its protection with additional wire before stenting (the trapped wire technique) is advised. In cases of carina shift with significant ostial stenosis or occlusion after stenting the main vessel, wires should be exchanged and final "kissing balloon" inflation performed.

Systematic side-branch stenting using different techniques such as "T, V, Y, culotte, and crush" should be avoided because it does not reduce the rate of restenosis and may increase the risk of subacute stent thrombosis. At the end of the procedure, two orthogonal views of the stented segment should be obtained to confirm the optimal angiographic result. Significant stenoses of non-IRA vessels should not be treated by the index PCI, unless there is evidence of persistent ischemia, or hemodynamic or electrical instability despite adequate reperfusion of the IRA.

After stent deployment, it may be useful to avoid rapid balloon inflation to avoid a sudden "vacuum effect," which may cause thrombi to be dislodged. This is particularly important for lesions with heavy thrombus burden.

Primary PCI without on-site surgical backup PCI can be performed in hospital without on-site surgical backup if the criteria detailed in Box 12.3 are fulfilled [3].

Primary balloon angioplasty without stenting It is important to remember that not every lesion has to be stented. This is the case if optimal angiographic result (<30% residual stenosis without evidence of dissection/residual thrombosis and TIMI 3 flow) is documented after plain old balloon angioplasty (POBA).

BOX 12.3 REQUISITE CONDITIONS FOR PRIMARY PCI WITH NO SURGERY IN SITE

- 1 Experienced operators who perform regularly elective and primary PCI at tertiary centers
- 2 Nursing and technical staffs experienced in handling acutely ill patients
- 3 Catheterization laboratories must be well equipped with resuscitative equipment, IABP
- 4 Staff available 24/7
- 5 Must have protocols for emergent transfer to surgical centers (high-grade LM, unstable three-vessel disease)
- 6 Protocols should address in whom to delay PTCA (TIMI 3 flow with <70% residual stenosis, etc.) [3]

In such cases, it is reasonable to wait for 5–10 min to confirm a persistent angiographic result. If significant early elastic recoil, dissection, or residual thrombosis is discovered, the culprit lesion should be stented. POBA has to be accepted only in patients with excessive proximal tortuosity or/and calcification that prevents the passage of the stent. POBA with an acceptable angiographic result is also useful in patients with an IRA of very small diameter and in patients with contraindications for long-term antiplatelet medications such as a patient who is having active bleeding.

Technical Tips

****Where is the IRA?** During the diagnostic angiogram of a patient with STEMI, all the major vessels and their large branches should be accounted for. In a case report of a patient coming in with typical inferior wall myocardial infarction (MI) and ST-segment elevation in 2, 3, and F, an emergency angiogram showed a moderate lesion in the left anterior descending artery (LAD) whereas the right coronary artery (RCA) was nowhere to be seen, even with the aortogram. As a result of such typical symptoms and ECG change, an extraordinary effort was made to locate the RCA, which was found in its frequently seen anomalous location when the RCA originates from the left sinus: Anterior and cephalad to the left main (LM) ostium. The technique is to deliberately create further “bend” of the Judkins left (JL)-4 guide to angulate it upward by advancing it forward. Alternatively, a JL-5, Amplatz left (AL) or 6-Fr Xra backup (XB) guide can be used to locate the anomalous RCA.

In another encounter by one of the authors, a patient came in with severe chest pain. His angiogram showed patent LAD, left circumflex artery (LCX), and RCA. So where was the IRA? As there was only minor ST-segment elevation in leads I and aVL, it was suspected that the diagonal should be the IRA. A wire was advanced and probed the area suspected to be the possible origin of a large diagonal in the left anterior oblique (LAO) view. The wire was successfully entered and PCI of a large diagonal branch was performed successfully.

In another case report, the coronary angiogram showed only minor LAD lesions in a patient with typical ST-segment elevation in all the V leads. So the guide was exchanged for a larger one, and LM dissection was demonstrated clearly. It was missed by a small deeply inserted guide bypassing the LM ostial dissection [4].

****Avoiding vasovagal reaction** Rapid restoration of coronary flow, particularly to the IRA supplying the inferior territory of the left ventricle, may lead to profound hypotension and bradyarrhythmias which are usually transient and benign events. It is recommended to aggressively hydrate patients with an inferior STEMI before PCI and avoid administration of nitrates and β blockers. If bradycardia and hypotension develops, an intravenous atropine bolus (0.5–1.0mg) and rapid infusion of colloid solution are indicated. Alternatively, intracoronary atropine may be administered. The dose will have to be reduced at 0.1–0.2 mg to avoid tachycardia. This provides a rather rapid onset of action. A venous

sheath placed in the femoral vein before intervention may be useful for rapid flow of the fluid and insertion of a temporary pacemaker if necessary (but this need not be routine). It is also useful to ask conscious patients to perform a “cough cardiopulmonary resuscitation” to overcome the short period of profound hypotension and bradyarrhythmia. If clinical suspicion for development of significant bradyarrhythmia is high, the operator may place a temporary wire in the right atrium, ready to advance into the right ventricle for pacing if necessary. In case of a real emergency, we can use the 0.014-inch wire in the coronary artery as a pacing wire.

If the patient developed ventricular fibrillation or tachycardia in the emergency room or in the field, prior to arrival in the CCL, cautions measures such as having all the patches for defibrillation readily taped on the chest and back of the patient, because the patient could develop VT or VF upon reperfusion with a wire or balloon.

Evaluation of the PCI results The goal of primary PCI is to achieve successful dilation of the culprit lesion, normal epicardial blood flow, and adequate microvascular reperfusion of infarcted myocardium. Besides a simple categorical estimate of TIMI epicardial flow, one can achieve a more accurate flow evaluation by using the corrected TIMI frame count (CTFC) (Figure 12.3) [5]. CTFC is defined as the number of angiographic frames needed for dye to traverse a coronary artery. It is particularly useful because it

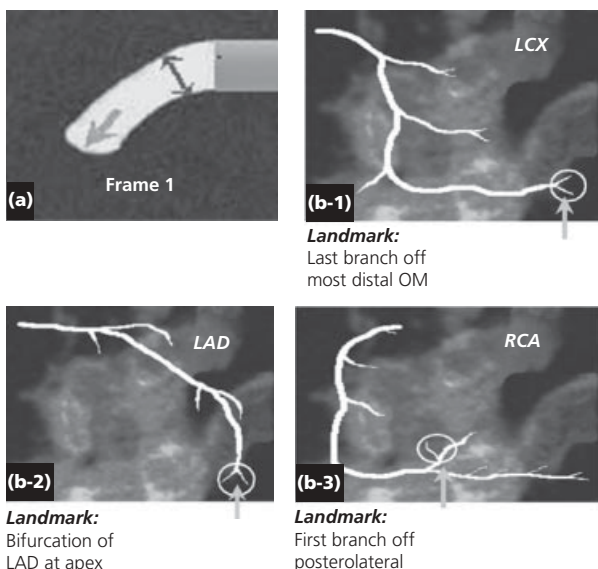
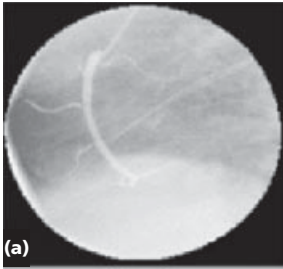


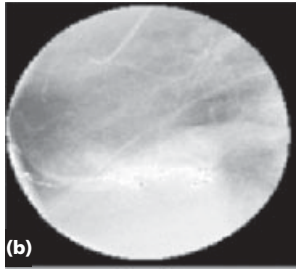
Figure 12.3 The corrected TIMI frame count: (a) The first frame is defined as the frame in which injected contrast touches the two borders, but does not fully opacify it. The end frame is defined as the first frame in which contrast appears in the distal bed of the reference vessel. The distal landmark of (b1) the LCX, (b2) the LAD, and (b3) the RCA.

can account for the rate of coronary filling and difference in epicardial vessel size and length, and also reduces interobserver variability. The CTFC is an independent predictor of in-hospital mortality from STEMI and can further stratify patients with TIMI 3 flow into low- and high-risk groups. Restoration of flow in the IRA may not be a reliable predictor of restoration of tissue perfusion supplied by the IRA. Therefore the TIMI myocardial perfusion grading (TMPG) system was designed and validated to further risk stratify patients in whom successful epicardial reperfusion was achieved (Figure 12.4). A very simple bedside indicator of microvascular reperfusion is also early ST-segment elevation resolution.

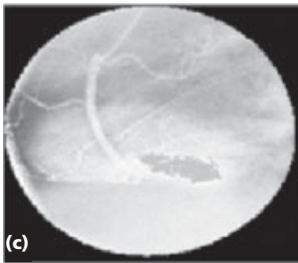
TIMI Myocardial Perfusion (TMP) Grades



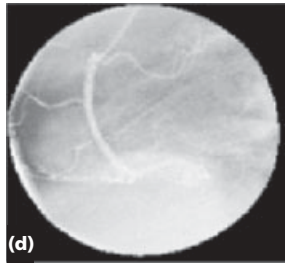
TMP Grade 0
No or minimal
blush



TMP Grade 1
stain present
Blush persists
on next injection



TMP Grade 2
Dye strongly
persistent at end
of washout Gone
by next injection



TMP Grade 3
Normal ground glass
appearance of blush
Dye mildly persistent
at end of washout

Figure 12.4 The myocardial perfusion grading system: (a) TMP grade 0: There is no dye entering the myocardium and there is minimal or no blush apparent in the distribution of the culprit artery. (b) TMP grade 1 means appearance of blush in the distribution of the culprit artery, which persists on the next injection approximately 30 seconds later. (c) TMP grade 2: There is a ground-glass appearance (“blush”) or opacification of the myocardium that is strongly persistent after three cardiac cycles of the washout phase, and either does not or only minimally diminishes in intensity during washout. (d) TMP grade 3: There is a ground-glass appearance (“blush”) or opacification of the myocardium in the distribution of the culprit artery, which clears normally and is either gone or only mildly/moderately persistent at the end of the washout phase, similar to an uninvolved artery.

COMPLEX PRIMARY PCI

Unprotected LM as IRA

Most patients with sudden thrombotic occlusion of an unprotected LM die before reaching the catheterization laboratory. Those who survive to reach the hospital usually have intermittent LM occlusion, a very dominant and patent RCA, or an anomalous origin of the LCX have a realistic chance of survival (Figure 12.5). As patients with acute LM occlusion will almost always present in profound cardiogenic shock, concomitant use of IAPB, vasopressors, inotropes, and mechanical ventilation should be started before PCI. It is very important to distinguish between unprotected LM as IRA and significant stenosis of unprotected LM with the other coronary artery as IRA. In the former, only the IRA should be treated during the index procedure if the patient is stable and ischemia free after primary PCI. Revascularization of an unprotected LM should be postponed until the patient recovers from the subacute phase of STEMI. In the setting of ongoing ischemia due to significant LM stenosis despite successful primary PCI of the IRA and adequate hemodynamic support with IAPB, immediate PCI of the unprotected LM or CABG should be seriously addressed.

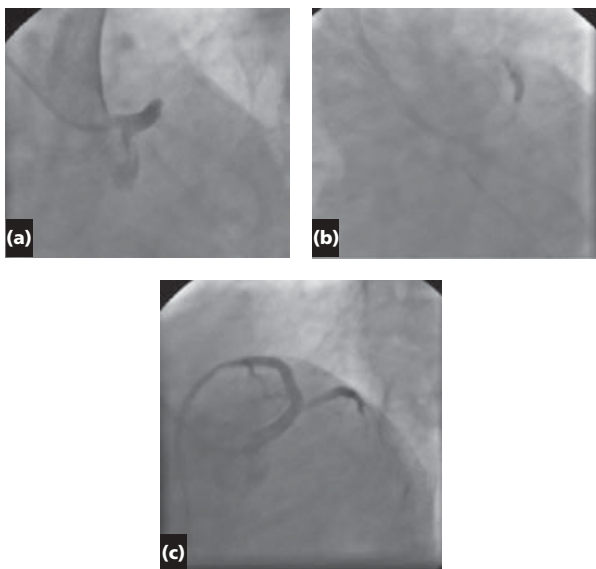


Figure 12.5 STEMI due to acute LM occlusion in a patient with small anomalous LCX arising from proximal dominant RCA. (a) Stump of the LM. (b) Following predilation, stenting with wire protection of large D1 was performed. (c) Final angiogram revealed widely patent LAD with some thrombus-plaque shift in D1 and TIMI 3 flow in both branches. As a result of cardiogenic shock, an IAPB was inserted immediately after successful primary PCI.

Technical Tips

****Thrombectomy in the LM** Should a large thrombus be visualized in the LM artery, thrombus aspiration is mandatory to avoid downstream embolization. This can be performed using the guide itself as an aspiration device by connecting a 20-ml Luer-lock syringe to the proximal end of the guide and aspirating strongly. Alternatively, any large-bore (preferably 7 French [Fr]) aspiration catheter can be used. Extreme caution should be exercised to avoid retrograde emboli causing a stroke.

PCI after thrombolysis As a result of delayed access to PCI or as PCI is not available, many patients with STEMI are treated with thrombolytic therapy (TT). Urgent PCI is indicated 3–4 hours after TT. In cases of thrombolytic failure, immediate angiography and mechanical recanalization of the IRA remains the treatment of choice [6]. As the clinical signs and ECG data of reperfusion are not precise, the guidelines of the American College of Cardiology/American Heart Association (ACC/AHA) task force suggest performing urgent angiography in any patients receiving TT with ongoing chest pain or hemodynamic instability, or in asymptomatic patients who are within less than 12 hours of symptom onset with persistent ST-segment elevation after 90 min of TT. It is important to notice that patients who require rescue PCI due to failed thrombolysis remained at increased risk for reocclusion, because they possibly had higher resistance to pharmacologic reperfusion, large thrombus burden, or platelet-rich thrombi, factors unfavorable to the performance of mechanical intervention. Rescue PCI should be performed on high-risk lesion (>75%) with TIMI ≤ 2 .

PCI in right ventricular infarction

The clinical manifestations of right ventricular infarction (RVI) include signs of acute RV failure such as hypotension, jugular vein distension, right-sided fourth heart sound, and sometimes a Kussmaul sign. Although it is very uncommon, some patients may have an isolated RVI, which may occur when a non-dominant or co-dominant RCA proximal to an acute marginal branch or an acute marginal branch itself is occluded. An isolated RVI may also occur secondarily to an acute occlusion of the RV branch following PCI. The coexistence of RVI with severe LV hypertrophy probably favored the appearance of hemodynamic manifestations in two ways. First, LV diastolic dysfunction may produce an increase in pulmonary wedge capillary pressure and thus facilitate the occurrence of RV failure. Second, the decreased LV pre-load due to RVI may be potentially more serious in the presence of LV diastolic dysfunction. On the other hand, RV myocardial abnormalities that may be present in hypertrophic cardiomyopathy, or even in hypertensive cardiomyopathy, could have contributed to the incidence of RV failure [7].

PCI of Saphenous Vein Graft

STEMI in patients with a prior history of CABG, usually related to saphenous vein graft (SVG) rather than mammary artery occlusion, affects smaller territories and presents with milder symptoms.

As a result of the large size of the SVG and high thrombotic burden, there is a significant risk of distal embolization and “slow” or “no reflow” phenomenon [8]. Therefore, PCI of the native coronary artery supplied by the graft should be first attempted if the likelihood of success is realistic. If not, the operator should proceed with PCI of the SVG. If the anatomy and site of the culprit lesion allow, a distal protection device should be used to reduce distal embolization, improve angiographic success, and improve the clinical outcome (Figure 12.6). If a large

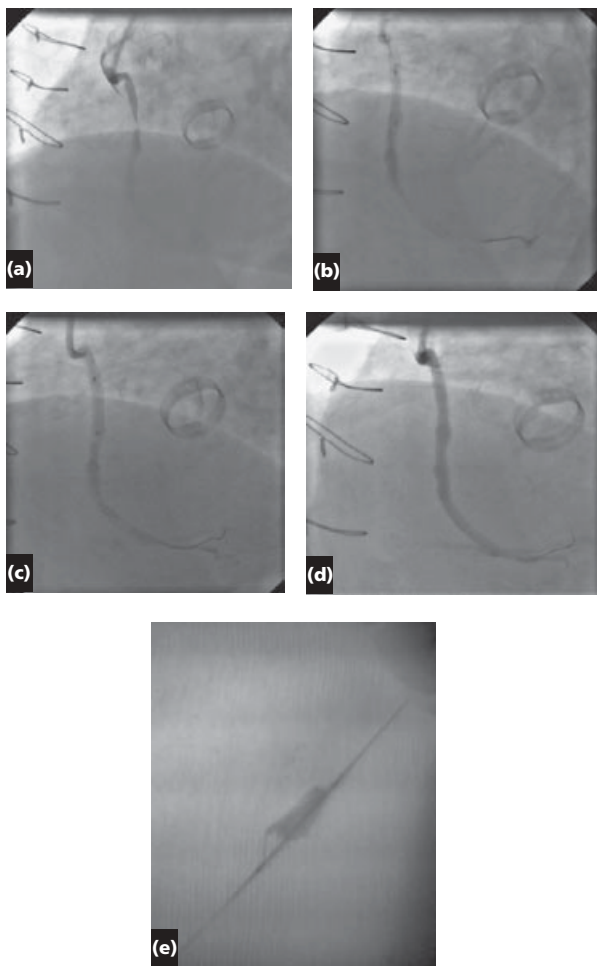


Figure 12.6 Acute occlusion of saphenous vein graft to distal RCA with evolving inferior STEMI: (a) Thrombotic occlusion of the graft with TIMI 1 flow. (b) Balloon predilation using undersized balloon with distal protection (Filterwire) in place. (c) Stenting of the culprit lesion under protection of the Filterwire. (d) Good angiographic result after removal of the Filterwire. (e) Captured thrombotic debris in the basket of the Filterwire

thrombotic burden is identified, distal protection should also be combined with thrombus aspiration.

Technical Tips

****Crossing the lesion** Usually the IRA is occluded with a soft and fresh thrombus that can be crossed easily with a steerable floppy wire. There are two types of acute occlusion. The first is occluded with a soft and fresh thrombus on top of vulnerable atherosclerotic plaque which can be crossed easily with a steerable floppy wire. The second is the IRA, which is sometimes occluded with a big ruptured atherosclerotic plaque and can be crossed only with a suitable wire into a true remaining passage located on the opposite side to the ruptured plaque and next to the remaining stable one. As the plaque used to form in the inner border of a coronary curve, it is guessed that the lumen is most likely at the outer curve of the acute coronary occlusion or in the pericardial site (rather in the myocardial site). It is easy to cause dissection if the wire goes into the ruptured plaque and advances between the media and the intima.

In case of tortuosity and a need for better wire pushability, a small balloon placed near the distal tip of the wire may help to make the tip stronger. Alternatively, an exchange microcatheter may be used. Not only can it provide enhanced support to the wire, but it may also be used to determine if the wire is in the true lumen on crossing the stenosis (by small intraluminal injection). Stiffer and hydrophilic wires are usually not required.

****How to prevent vasovagal reaction** The lesion can then be “dottered” by moving the uninflated balloon back and forth. This allows flow of stagnant blood proximal to the occlusion to seep slowly into the distal vasculature. This maneuver prevents the abrupt opening of the occluded artery, which theoretically may minimize the chance of flooding of the distal vasculature with stagnant (and possibly acidic) blood. This may decrease the probability of developing reperfusion injury and arrhythmias, especially if the IRA is a large RCA. These maneuvers also prevent embolism of thrombi due to a sudden strong antegrade flow.

****How to verify that the wire is in the true lumen** After completion of this maneuver, the operator may inject a small amount of contrast to verify the position of the wire in the true lumen (and not in a side branch). If the wire position is still ambiguous, then a small over-the-wire (OTW) balloon can be advanced, the wire removed, and contrast injected through the central lumen. This maneuver also helps in the assessment of the artery size for selection of a subsequent balloon or stent.

Primary PCI for Lesions with Thrombi

In situations of small or moderate thrombotic burden, conventional PCI should be performed. The thrombotic burden is often large in patients with prolonged symptom duration or if the IRA is a large-diameter, or ectatic, vessel such as an RCA or a SVG (Figure 12.7). In such cases, it is common sense to remove the thrombus before stenting to reduce the likelihood of distal embolization in the IRA branches or microcirculation resulting in “slow” or “no reflow” phenomenon.

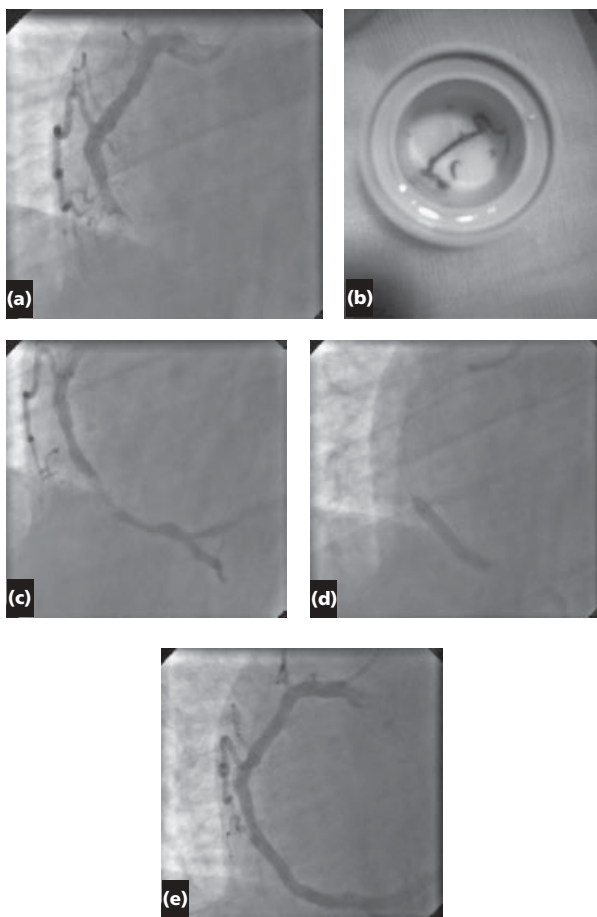


Figure 12.7 Catheter aspiration of thrombus in a patient with evolving STEMI in the territory of the dominant RCA: (a) Thrombotic occlusion of the mid-RCA. (b) Aspirated thrombus obtained after the first passage of the Diver catheter. Subsequent passages did not result in significant aspiration. (c) Angiographic finding after aspiration. (d) Direct stenting of the culprit lesion. (e) Very good final angiographic result with TIMI 3 epicardial flow, TMP 3, and significant early ST-segment resolution.

Technical Tips

****Thrombectomy by aspiration catheter** If the thrombus is small (grades 0–1), direct angioplasty and stenting may be sufficient. Moderate thrombus burden, grades 2–3, warrants pretreatment with an aspiration catheter. Passes with the aspiration catheters should be made throughout the entire length of the thrombus until there is no angiographic evidence of thrombus in the repeat diagnostic angiogram. The aspiration catheters are not perfect monorail devices and attention should be paid to the tip of the wire as these catheters advance. Thrombus could clog the

aspiration holes, halting aspiration. So, after a few passes, remove the catheter, flush it profusely, and re-advance it for a few more passes. In rare situations, the aspiration catheter could drag the tail of a long thread thrombus that may get dislodged and embolized.

*****Avoiding antegrade embolization** Embolization to one or more peripheral IRA branches distal to the culprit lesion can occur due to strong contrast injection or as a consequence of thrombus dissolution by balloon inflation or stenting. This is why manipulation of hardware in the IRA has to be gentle and minimal to avoid dislodgement of thrombus. The use of aspiration thrombectomy, which is easier to use and cheaper in cost, is effective in reducing slow-flow phenomenon and increases the chance of normal flow at the end of the procedure. If embolization in a significant distal branch occurs, another wire should be placed in the embolized branch. The lesion can then be carefully “dotted” by moving a deflated balloon back and forth. If antegrade flow is established and a significant lesion visualized, additional PCI may be performed if the branch supplies an important part of the myocardium (Figure 12.8).

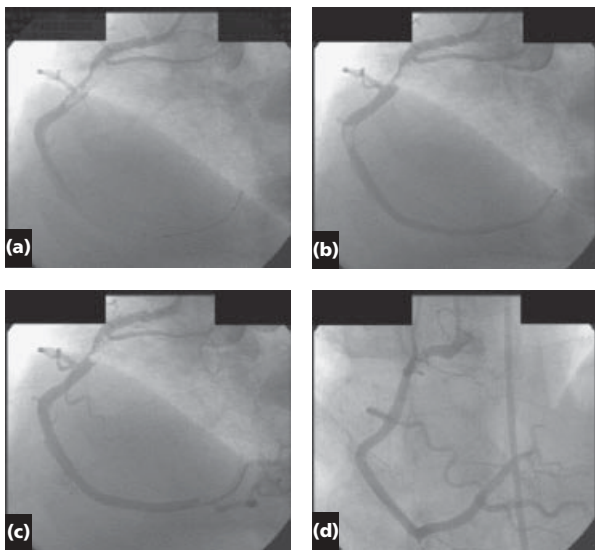


Figure 12.8 Distal embolization of large thrombus in a proximal dominant RCA in a patient with STEMI and cardiogenic shock. After smooth passage of the wire, angiography of the RCA was performed. (a) At the start of coronary injection, large proximal thrombus was identified. (b,c) During the contrast injection, a large part of the thrombus detached and traveled through the mid-portion of RCA and stopped at the crux. (d) After direct stenting of the culprit lesion and catheter aspiration of the distal thrombus, good angiographic result was obtained. For temporary hemodynamic support, an IAPB was inserted.

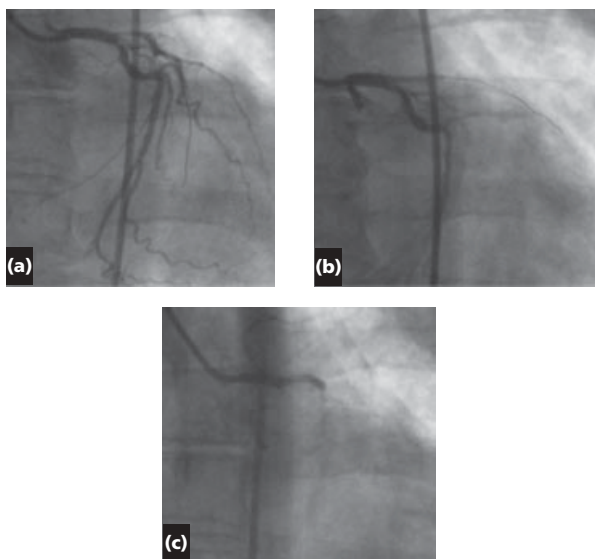


Figure 12.9 Retrograde thrombus embolization: (a) During PCI of the proximal segment of the LAD, a well-organized large thrombus was seen to be benign with balloon angioplasty. (b) The thrombus was then squeezed back during stenting. (c) This resulted in acute occlusion of the left circumflex causing cardiac arrest.

*****Avoiding retrograde embolization** During PCI or thrombectomy at the proximal segment of the LAD and LCX, fragments of large thrombi may be squeezed back and occlude the ostium of the adjacent vessel. Fragments of the thrombus can even adhere to balloons or an aspiration catheter, which when withdrawn or retracted into the guide, may lead to embolization and occlusion of the non-IRA branches. Occlusion of a large non-infarct vessel may have dramatic consequences including immediate cardiac arrest and profound cardiogenic shock. Embolization may be minimized by first opening the Y connector before injection of contrast agent and allow back flow to remove any free thrombotic material. If an ostial LAD or LCX culprit lesion is treated, it is reasonable to protect the adjacent vessel with additional wire to allow for immediate intervention if required (Figure 12.9).

DISCRIMINATING DIFFERENCES

The thrombectomy catheters

It is not always possible to achieve optimal thrombectomy, particularly in cases involving a large thrombus burden. The flow rates that can be achieved to extract thrombus using such simple thrombectomy catheters may be limited by the radius of the catheter lumen. Furthermore, in contrast to thrombus burden related to STEMI, where the thrombus is mainly fresh and may be relatively easier to extract, the thrombus burden in SVG cases is one of complex, bulky, atheromatous, well-organized, and highly

viscous. The Heartrail “five-in-six” catheter has an internal luminal diameter of 0.059 inch, whereas the Export catheter has an internal luminal diameter of 0.040 inch and the Pronto LP catheter an internal luminal diameter of 0.056 inch. Through Poiseuille’s law, flow achieved through a Heartrail catheter would be 3.2-fold greater than an Export catheter and 1.2-fold greater than a Pronto LP catheter, which may in part explain the more optimal thrombectomy results achieved in cases after use of the Heartrail catheter. Use of the Heartrail catheter in these situations would have the advantage in that many thrombectomy devices used in cases of large thrombus burden, or after suboptimal results with simple thrombectomy devices, such as the X-sizer or ThromCat devices, or hydrodynamic thrombectomy systems such as the AngioJet, are more complex to use and have had mixed outcomes in larger studies. The usual thrombectomy catheter requires 7-Fr systems whereas the Heartrail system requires only a 6-Fr guide [9].

Advantages and Limitations

An aspiration thrombectomy device can bring a large amount of thrombus into the LM coronary artery, a potentially life-threatening complication. This should be recognized as a potential complication in the left coronary system with a large thrombus burden. Important questions remain as to whether use of a larger diameter guide (i.e. 7 Fr) can reduce the risk of thrombus shearing off the tip of a thrombectomy catheter as it is withdrawn. Another important issue is the optimal technique for aspiration; manufacturer’s instructions recommend stopping negative suction before catheter removal from the target vessel, but many interventionalists remove these devices on negative suction to avoid losing thrombus as they remove the device. In addition, other devices, such as balloons, have the potential to bring thrombus back into the left main and the comparative risk with thrombectomy devices is unknown. Other potential complications of aspiration thrombectomy include stroke, air embolization, distal embolization of thrombus and vessel dissection and perforation [10].

“Slow” or “no reflow” after stenting Diminished epicardial blood flow despite widely patent IRA, known as a “slow” reflow (TIMI 2) or “no reflow” (TIMI 0 or 1) phenomenon, is due to compromised distal microvascular perfusion. The mechanism of “slow–no reflow” is probably heterogeneous and includes thrombus plaque microvascular embolization with subsequent platelet activation, release of potent vasoconstrictors, and microvascular spasm [11]. Once this problem is encountered, the flow will most likely improve after infusion of adenosine, nicorandil, calcium channel blockers, or nitroprusside.

Persistent thrombotic burden In cases of persistent thrombus after repeated balloon angioplasty, check the wire to be sure that it is inside the main lumen. If it is not, as a result of the wire, then the best management would be to attempt thrombectomy using the AngioJet device if the thrombus is large. Smaller distal thrombi can be aspirated by a Pronto or Export catheter.

Any residual thrombus could be lysed by intracoronary recombinant tissue plasminogen activator (5-mg boluses down the left coronary artery via the guide every 5 min [up to 50 mg] will usually suffice). If the vessel then looks clear of thrombus and distal coronary flow looks good, intravenous (IV) heparin over the next 24 hours should be continued (activated clotting time or ACT >200 s). If residual thrombus appears to exist or distal coronary flow appears suboptimal, glycoprotein 2b3a inhibitors should be given (intracoronary bolus followed by a 12-hour IV infusion). [12]

PCI OF STEMI PATIENTS WITH BLEEDING

In general, the principle is that PCI can be performed if the bleeding can be stopped by mechanical means (compressing or ligating the artery) and the patient can tolerate 4 hours of anticoagulant without excessive further bleeding. The favorite anticoagulant is unfractionated heparin (UFH) because of its short half-life and because it can be reversed by protamine.

Patients with Bleeding due to Leg Fracture

A patient had an acute MI (AMI) when driving a car. The patient lost control of his car and hit an oncoming vehicle. He suffered a fracture in the leg with profuse bleeding. In the emergency room the orthopedic surgeon put in splints and stabilized the extremities without doing surgery because of ongoing AMI. So the patient underwent a femoral angiogram to check whether extravasation of contrast was due to injury to the arterial system. As there was no arterial bleed in the extremities, the patient underwent PCI of the IRA with coverage by UFH and clopidogrel. After PCI of the IRA (RCA), the patient underwent leg surgery. At the current time, ongoing bleeding in the intracranial, lower intestinal, or from the esophageal varices, is the only contraindication for primary PCI.

AMI in Patient with Gastrointestinal Bleeding

A patient arrives to the emergency room with chest pain. He developed recurrent ventricular fibrillation in the waiting room and was shocked seven times. In the history, the family mentioned that the patient vomited blood 3 days before admission. The ECG showed ST-segment elevation in V2–6. The patient was brought to the cardiac catheterization laboratory and balloon angioplasty was performed for the proximal LAD. Heparin 5000 units and aspirin 81 mg of were given. The reason for heparin was that it could be reversed if the patient had more bleeding. Bivalirudin could cause less bleeding, but it has no antidote if anticoagulation needs to be reversed. As no stent is used no clopidogrel was given. The standard of technical excellence is that the IRA has TIMI 3 flow after percutaneous transluminal coronary angioplasty (PTCA). The patient underwent gastroscopy a day after and was discharged in a stable condition.

AMI in Patient with Recent Surgery

Less than 4 hours after removal of the right kidney because of cancer, a patient developed ST-segment elevation in leads 2, 3,

and aVF. So the patient was brought to the cardiac catheterization laboratory (CCL), and had balloon angioplasty of the RCA with a standard dose of heparin to achieve an ACT of 250–300s. No stent was used and no heparin given after the procedure. As the heparin use was short term, not much bleeding in the surgical area was noted and there was no long-term impact on the surgical results. If the patient has clean and limited surgery, the patient could have a drug-eluting stent (DES) because there are no long-term sequelae with antiplatelet therapy after recent surgery [13].

AMI in Patients with Concurrent Stroke

If the patient has an ischemic stroke, then, with the agreement of the neurologist on the case, the patient could be given short-term anticoagulant (UFH or direct antithrombins) and long-term oral antiplatelet drugs. Then the patient could undergo PCI and stenting. The two concerns are: (1) The risk of hemorrhagic conversion of the ischemic stroke with anticoagulant therapy; and (2) the risk of cerebral emboli from the protruding plaque in the aortic arch if they were the cause of the embolic stroke in the first place. The patient needs to have strong indication for PCI, and the family and patient need to understand the benefits and the risks of the procedure. If the benefits outweigh the risks, the patient should have PCI.

AMI in Patients with Recent Stroke

A patient developed a left-sided facial droop and MRI showed an acute right frontoparietal infarct and a right parietal subdural hematoma. His oral dual antiplatelet therapy was continued and repeat neuroimaging studies confirmed that the hematoma was stable.

On hospital day 14 the patient developed acute inferior ST-segment elevation, complicated by complete heart block and hypotension. The patient was taken to the CCL and successfully underwent PCI with bivalirudin [14].

STEMI in Patient with Atrial Fibrillation on Coumadin, INR >2

As coumadin does not have any effect on platelet, so a patient with a therapeutic international normalized ratio (INR) can have STEMI. During PCI, the patient can be given oral loading and a maintenance dose of an antiplatelet drug (e.g. aspirin or clopidogrel) as usual. If the patient has a therapeutic INR (2–3), no UFH is needed. If the INR is <2, the patient can be given UFH (similarly as in the protocol for treatment of pulmonary embolism). Primary angioplasty for STEMI can safely be performed via the transradial artery approach in patients at high risk of bleeding.

Advanced and Exotic Techniques

AMI patients with LM compressed by an aortic dissection

A patient came to the emergency room with STEMI, so a coronary angiography was performed. The initial injection revealed a very tight stenosis of the LM with persistence of contrast medium at

the LAD and LCX, despite a normal pressure curve (no ventricularization). This suggested that the LM was undergoing extrinsic compression. The guide was then withdrawn to the left coronary sinus, where a more powerful injection demonstrated an acute aortic dissection (AAD) with a false lumen compressing the LM. Subsequently, the left coronary ostium was engaged again and a more vigorous injection showed a typical image of coronary artery compression, i.e. complete resolution of the tight stenosis resulting in a wide-open LM with intermittent diastolic collapse of the lumen. With a diagnosis of AMI secondary to LM compression by AAD, direct LM stenting was performed as a bridge procedure for possible subsequent aortic surgery. After stenting, a supra-avalvular aortography was performed and showed a Stanford type A aortic dissection. The lumen size varies according to diastolic and systolic flow, producing an image of a “swinging lumen.” In cases where this phenomenon reaches maximum amplitude, diastolic interruption of coronary flow will produce a persistent contrast filling image despite perfectly normal pressure curves at the aortic level [15].

AMI due to spontaneous coronary artery dissection

Spontaneous coronary artery dissection (SCAD) in young and pregnant woman presents a number of particular challenges for PCI. The luminal compression could be extensive due to varying sized hematomas within the vessel wall. The initial and subsequent selective angiography could lead to deterioration because contrast injection increases pressure in the false lumen. During intervention, the wire can easily enter the false lumen with the associated risk of extension or extravasation. By entering into the side branches, the wire is confirmed to be in the true lumen of the vessel [16].

Imaging strategy Coronary luminal imaging using intravenous ultrasound (IVUS) or ocular coherence tomography (OCT) may help to guide the PCI procedure. This can resolve diagnostic uncertainty, e.g. where there is no contrast penetration of the false lumen, and to identify clearly the extent of the false lumen with respect to anatomical landmarks. IVUS or OCT may help to ensure accurate wire placement in the true lumen, and appropriate stent diameter, length, and optimal deployment. The necessity for ballooning or stenting can be reconsidered after imaging, because extensive stenting risks side-branch compromise, in-stent restenosis, and stent fracture [17] (Figure 12.10).

Management When extensive hematoma is present with no luminal flap and with preserved antegrade flow, stenting should probably be avoided, because stenting the angiographically evident area of stenosis may simply displace the compressive hematoma blood, either proximally or distally, to the stent. Long segments of stenting may therefore be required to completely exclude the false lumen and restore the true lumen to its normal dimensions with TIMI 3 flow. An alternative strategy of stenting just the proximal end of the dissection, or targeting the presumed

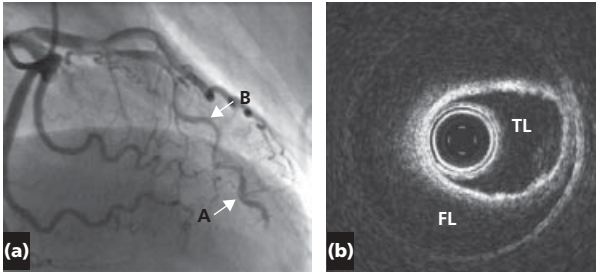


Figure 12.10 (a) Coronary angiography suggesting a spontaneous dissection in the mid-left anterior descending artery (arrow A); its proximal extent is estimated to be at the location of the stepdown in vessel caliber (arrow B). (b) Optical coherence tomographic image revealing the presence of a dissection. True lumen (TL) compressed by large intramural hematoma in the false lumen (FL). (Reproduced from Hoyer [18] with permission from Journal Invasive Cardiology.)

entry point of the hematoma identified by OCT or IVUS for stenting, has been suggested. The aim would be to “seal the flap” and allow spontaneous healing of the remaining false lumen while limiting the overall stent length. However, there are no outcome data to support either the partial or “conventional” complete stenting strategies.

Revascularization is not without its difficulties. With PCI, the true lumen of the vessel may be difficult to wire, particularly when the dissection involves the ostium of the LM stem or RCA. A strategy of PCI is therefore perhaps best limited to those patients with a relatively localized dissection, with consideration of CABG in those with more extensive or multivessel involvement. Even CABG surgery may itself be challenging, because the patient may be extremely unstable, and it is not always easy to identify the true lumen of the vessel. Surgery is less likely to be effective if the dissection involves the very distal vessel [18].

Primary PCI in STEMI after resuscitated cardiac arrest

After successful cardiopulmonary resuscitation of patients with cardiac arrest, 12-lead ECG may show evidence of STEMI. Such patients represent 5–10% of the STEMI population. According to published experience, urgent coronary angiography and primary PCI are feasible, effective, and safe with hospital survival rates of 77%. It is very important to notice that the main determinant of hospital survival in these patients is the degree of post-resuscitation brain injury. In patients who regain consciousness after re-establishment of spontaneous circulation, survival to hospital discharge is comparable to that for patients without preceding cardiac arrest. On the contrary, in patients who are still comatose in CCL, survival barely exceeds 50% with good neurological recovery in less than 30% [19].

AMI in patient with large coronary aneurysm

A patient with history of Kawasaki disease was diagnosed with an STEMI, showing thrombotic occlusion of an aneurysm in the

RCA. Thrombus removal was attempted with an aspiration catheter, but a large thrombus burden remained. The decision was made to perform intracoronary thrombolysis with a pulse infusion thrombolysis (PIT) catheter (Hand PIT) designed to allow intermittent thrombolytic agent delivery directly to the thrombus through side holes connected to a manual pump. After the PIT with a total 800 000 IU dose of tissue plasminogen activator had been used, the thrombus was noted to have disappeared. Adjunctive simple balloon angioplasty was performed, and TIMI 3 was achieved. A coronary stent was not used, to avoid malapposition and acute thrombotic occlusion. The patient was stable after the procedure during the inpatient hospital stay and had an uneventful recovery thereafter. This case suggests that PIT might be a useful strategy in case of STEMI with massive thrombus in a giant coronary aneurysm [20].

AMI in acute simultaneous proximal occlusion of two major coronary arteries

In AMI, the acute simultaneous proximal occlusion of two major coronary arteries (ASOMC) is a rare event. If more than one occluded artery are present during AMI, usually only one is an acute event, the others being chronic occlusions.

The presence or absence of collaterals affects symptoms and clinical outcomes of these patients. Patients without a history of angina can die from pump failure despite effective reperfusion therapy – the pump failure is then due to the absence of collaterals to the left coronary system from the RCA. In contrast, patients with a history of stable angina due to severe CAD and good collaterals from the RCA can fare relatively well. Concerning the latter, the incidence of normal postinfarction LV ejection fraction (LVEF) is higher than in those without significant collateral circulation [21].

PCI of a reconstructed prosthetic LM

In a case report, a patient with known Marfan syndrome and an extensive past history of complicated aortic operations presented with chest pain and ST-segment elevation in the V leads. In the past, because of aortic aneurysm, the patient had a Bentall procedure, which essentially involves the complete replacement and exclusion of the ascending aorta with a composite Dacron tube graft and implantation of an aortic valve prosthesis. The coronary arteries are then reimplanted onto the sides of aortic tube graft. As a result of aneurysmal change in the aortic graft, the patient underwent a second procedure including a re-do replacement of the ascending aorta with a 28-mm tube graft, repair of the anterior and left posterolateral sinus of Valsalva, and reimplantation of his RCA using the classic Bentall technique and reimplantation of his LM coronary ostia utilizing a 10-mm Dacron graft (Cabrol graft), involving connection of the native coronary artery ostium to the aortic tube graft (Bentall) in a side-to-side manner by utilizing an interposed 8- to 10-mm diameter Dacron tube graft. During PCI for AMI, an aortic root angiography demonstrated the usual position takeoff for the right coronary artery and a high

superolateral takeoff for the Cabrol graft. A standard JR-4 diagnostic catheter managed to cannulate the right coronary, which was angiographically unremarkable. Injections of the Cabrol graft confirmed a 90% severe hazy stenosis at the ostium of the LM at the anastomosis with the Cabrol graft. A JR-4 guide was used to engage the Cabrol graft. A 0.014-inch 300-cm supportive wire was passed into the distal LAD. The left main was stented successfully [22].

Contrast leakage into the ventricle? is it a wire-induced perforation or impending rupture?

About 10 min after primary PCI of the IRA which was a RCA, severe chest pain recurred and blood pressure fell to 70/40 mmHg. Physical findings were unremarkable and no heart murmur was audible. The ECG showed that the ST segment was elevated again in leads II, III, and aVF. The patient was brought back to the catheterization laboratory. This time, coronary angiography revealed contrast leak from small branches of the posterior descending artery. Judging from the angiogram, together with the sudden hemodynamic collapse, wire-induced coronary perforation and cardiac tamponade were suspected. Echocardiography disclosed neither pericardial effusion nor abnormal color Doppler signal. However, right heart catheterization showed equilibration of atrial and ventricular diastolic pressures at 18–20 mmHg. A 1.5-mm balloon was advanced to the posterior descending artery and inflated at 1 atm for 15 min to seal the possible perforation. After inflation, the angiogram showed persistent contrast leak. The leakage sites even increased compared with the previous angiogram. No improvement was seen after further inflation for 30 min. Blood pressure fell to 50/30 mmHg and the patient was intubated for hypoxia. Then, echocardiography was repeated. Again, pericardial effusion was not identified, but color Doppler suggested shunt flow at the posterior septum. Blood gas sampling revealed a stepup in oxygen saturation from the right atrium (RA: 41.2%) to the RV (74.8%; shunt fraction >2.8), and the diagnosis of septal rupture was confirmed.

The following findings are the keys to differentiating ventricular septal rupture from coronary perforation: First, contrast soon disappeared after injection. If the coronary perforation is caused by a wire, some contrast usually remains visible at the perforation site. The septal rupture dissected branches of the posterior descending artery during its progression, and the contrast directly drained into the ventricular cavity. Second, the contrast leak occurred from many small branches, and the number of leakage sites gradually increased. It would be unlikely for a wire to penetrate into all of these small branches [23].

Closure of ventricular septal defect caused by AMI

The post-infarction septum is felt to be vulnerable to further necrosis producing expansion of the ventricular septal defect (VSD) in the early phase, leading to failure in anchoring the device, residual shunt, continued congestive heart failure, and cardiogenic shock. In contrast, others have advocated early

closure, suggesting that extended time from presentation to repair is associated with poorer outcome. Alternatively, ventricular assist devices such as the Tandem Heart have been used as a bridge to delay repair until the myocardium has healed or undergone fibrosis. Regardless of timing, patients in refractory or progressive cardiogenic shock must be treated aggressively. During transcatheter closure of a post-MI VSD, ventricular rupture and cardiac tamponade are a catastrophic adverse outcome, whether iatrogenic or as a result of the disease process. After pericardial drainage and stabilization, the operator is faced with repair of a second defect, with similarly prohibitive surgical risk. Although no iatrogenic perforation occurred, a second defect emerged several months later in the form of a ventricular pseudoaneurysm, likely also a result of the inciting MI. This defect was closed using an Amplatzer vascular plug. Indeed, experience with transcatheter closure of free wall rupture or ventricular pseudoaneurysm has been far more limited.

Eshtehardi et al. recently described closure of an iatrogenic LV free wall rupture during an attempt to close a post-infarction VSD. During placement, the device perforated the posterolateral wall and deployed into the pericardial space. After emergency pericardiocentesis, the same device was then successfully redeployed to occlude the perforation, and closure of the VSD was completed using a second device. Other innovative techniques to successfully close ventricular perforation or pseudoaneurysm have included the use of EV3 AXIUM detachable coils (ev3 Endovascular), Amplatzer Muscular VSD Occluder, Amplatzer ASD occluder, direct injection of fibrin glue (Beriplast) into the pericardial space, and closure of a RV perforation using an Angio-Seal femoral closure device [24].

REFERENCES

1. Gibson CM. Has my patient achieved adequate myocardial reperfusion? *Circulation* 2003;**108**:504–7.
2. Lee K, Woodlief LH, Topol E, et al. for the GUSTO-I investigator. Predictor of 30-day mortality in the era of reperfusion for AML. *Circulation* 1995;**91**:1659–68.
3. American College of Cardiology/American Heart Association. ACC/AHA guidelines for the management of patients with ST-elevation myocardial infarction – Executive summary: A report of the American College of Cardiology/American Heart Association task force on practice guidelines. *Circulation* 2004;**110**:588–636.
4. Sakurai H, Saburi Y, Matsubara K, et al. A pitfall in the diagnosis of LMC obstruction due to aortic dissection. *J Invasive Cardiol* 1998;**10**: 545–6.
5. Gibson CM, Cannon CP, Daley WL, et al. TIMI frame count: a quantitative method of assessing coronary artery flow. *Circulation* 1996;**93**: 879–88.
6. Gershlick AH, Stephens-Lloyd A, Hughes S, et al., for the REACT trial investigators. Rescue angioplasty after failed thrombolytic therapy for acute myocardial infarction. *N Engl J Med* 2006;**353**:2758–68.
7. Moreno R, Alcocer A, Hernandez-AAntolin R, et al. Isolated right ventricular infarction: PCI in 3 different types of clinical presentation. *J Invasive Cardiol* 2004;**16**:393–6.

8. Brodie BR, VerSteeg DS, Brodie MM, et al. Poor long-term patient and graft survival after primary percutaneous coronary intervention for acute myocardial infarction due to sphenous vein graft occlusion. *Catheter Cardiovasc Interv* 2005;**65**:504–9.
9. Hadi HM, Fraser DG, Mamas MA. Novel use of the Heartrail catheter as a thrombectomy device *J Invasive Cardiol* 2011;**23**:35–40.
10. Alazzoni A, Velianou J, Jolly SS. Left main thrombus as a complication of thrombectomy during primary percutaneous coronary intervention. *J Invasive Cardiol* 2011;**23**:E9–11.
11. Noc M, Matetzky S, Domingo M, et al. Frequency of incomplete reperfusion in patients with acute myocardial infarction undergoing primary angioplasty. *Am J Cardiol* 2002;**90**:316–18.
12. Paolillo V, Gastaldo D. Intracoronary coagulative nightmare during recanalization of a recent total occlusion of the left anterior descending artery. *J Invasive Cardiol* 2004;**16**:727–75.
13. Berger PB, Bellot V, Bell MR, et al. An immediate invasive strategy for the treatment of acute myocardial infarction early after noncardiac surgery. *Am J Cardiol* 2001;**87**:1100–2.
14. Giugliano G, Sivalingam SK. Bivalirudin use during PCI for stent thrombosis in a patient with subacute intracranial hemorrhage. *J Invasive Cardiol* 2009;**21**:136–8.
15. Cardozo C, Rihani R, Mazen M. Acute myocardial infarction due to left main compression aortic dissection treated by direct stenting. *J Invasive Cardiol* 2004;**16**:89–91.
16. Arnold JR, West NE, Van Gaal WJ, et al. The role of intravascular ultrasound in the management of spontaneous coronary artery dissection. *Cardiovasc Ultrasound* 2008;**6**:24.
17. Adlam D, Cuculi F, Lim C, et al. Management of spontaneous coronary artery dissection in the primary percutaneous coronary intervention era. *J Invasive Cardiol* 2010;**22**:549–53.
18. Hoyer A. Spontaneous coronary artery dissection: Time for a concerted effort to better understand this rare condition. *J Invasive Cardiol* 2010;**22**:229–30.
19. Gorjup V, Radsel P, Kocjancic Tadel S, Erzen D, Noc M. Acute ST elevation myocardial infarction after successful cardiopulmonary resuscitation. *Resuscitation* 2007;**72**:379–85.
20. Inaba S, Higaki T, Nagashima M, et al. Successful revascularization by pulse infusion thrombolysis in a patient with Kawasaki disease combined with acute myocardial infarction. *J Am Coll Cardiol Intv* 2010;**3**:1091–2.
21. Maagh P, Wickenbrock I, Schrage M, Trappe HJ, Meissner A. Acute simultaneous proximal occlusion of two major coronary arteries in acute myocardial infarction: Successful treatment with percutaneous coronary intervention. *J Intervent Cardiol* 2008;**21**:483–92.
22. Hussain F, Ducas J, Gosai T. Emergent percutaneous interventions with DES of a cabrol graft to left main anastomosis in patient with Marfan syndrome. *J Invasive Cardiol* 2006;**18**:250–2.
23. Huie Lin, Balzer D, Lasala J. Transcatheter closures of a postinfarction ventricular septal defect and late ventricular pseudoaneurysm. *J Invasive Cardiol* 2010;**22**:E132–7.
24. Kawamura A, Asakura Y, Shin H, et al. Ventricular septal rupture masquerading as coronary perforation during intervention for acute myocardial infarction. *Catheter Cardiovasc Interv* 2004;**62**:466–70.

CHAPTER 13

Interventions in Patients after Coronary Artery Bypass Graft Surgery

Thach N. Nguyen, Nguyen Quang Tuan, Muhammad Munawar

Challenges 294

Early Postoperative Ischemia (<1 Month) 295

Early Postoperative Ischemia (1 Month–1 Year) 295

Late Postoperative Ischemia (>3 Years after Surgery) 295

Safety for Percutaneous Interventions 295

Indications for Surgical Revascularization 295

Native Coronary Interventions 296

Saphenous Vein Graft Interventions 296

Intervention of the aorto-ostial lesion 297

Intervention in degenerated SVGs 297

Interventions of the SVG 298

Technical Tips 299

**Guides for left bypass grafts 299

**Guides for right bypass grafts 299

*Balloon angioplasty for vein grafts 299

**Stenting for vein grafts 299

PCI in the Arterial Grafts 300

Technique Cannulation of the LIMA graft 300

Femoral or radial approach 300

Technical Tips 300

***Engaging the IMA guide with a wire 300

***Engaging the RIMA with a pigtail catheter 301

***LIMA guide 301

Technical Tips 302

**Use of a “dual-guide technique” 302

***How to overcome the problems with pseudo-lesions in tortuous LIMA 302

Treatment and Prevention of Distal Embolization 303

Distal Protection Devices 303

Proximal Protection Devices 303

Advantages and Limitations 304

Discriminating Differences 304

Selection of distal protection devices 304

Improved Equipment 306

*Basic; **Advanced; ***Rare, exotic, or investigational

\$, <\$US100.00 extra; \$\$, >\$US100.00 extra

⌚, <10 min extra; ⌚⌚, >10 min extra

♣, low risk of complications; ♣♣, high risk of complications

The guide as a suction catheter 304

Technical Tips 304

**No flow with distal filter devices 304

**Improvised distal protection device 305

Technical Tips 306

**Effective injection of drug for no-reflow 306

***Treatment of no-reflow with distal blood aspiration 306

Treatment of Thrombus in SVG 306

Medical Treatment 307

Mechanical Thrombectomy 307

The aspiration thrombectomy device 307

PCI for patients with STEMI within hours of CABG 308

PCI in the subclavian artery 309

Perforation in SVG – no pericardial effusion with hypotension 309

Luxation of stent during aneurysm exclusion 309

CHALLENGES

Patients who experience recurrence of ischemia after coronary artery bypass graft (CABG) surgery have lesions in diverse anatomic distributions (saphenous vein graft [SVG], native arteries, internal mammary, radial, gastroepiploic graft, or proximal subclavian artery). The results of percutaneous coronary interventions (PCIs) depend on the types of conduits (native artery, or arterial or saphenous vein grafts) or the locations on the conduits (proximal, mid-, distal, or at the anastomotic sites) and the age of the grafts [1].

The clinical and technical problems encountered during PCI of SVG are listed in Table 13.1.

Table 13.1 Clinical and technical problems during percutaneous coronary intervention of saphenous vein graft (SVG)

Problem	Corrective measure	Adverse outcome
Diffuse disease	Long stent	High rate of restenosis
Thrombus	Thrombectomy	Distal embolization
Degenerated SVG	Distal protection	Distal embolization
Restenosis	Off-label use of DES	High rate of restenosis
Retrograde embolization	–	CVA, distal organ emboli in SVG ostial lesion

CVA, cerebrovascular accident; DES, drug-eluting stent.

Early Postoperative Ischemia (<1 Month)

The most common cause of ischemia within hours or days of surgery is acute vein graft thrombosis (60%). Other causes are incomplete surgical revascularization (10%), kinked grafts, and focal stenoses distal to the insertion site and at the proximal or distal anastomotic sites, spasm or injury, insertion of graft to a vein causing arteriovenous (AV) fistula, or bypass of the wrong vessel.

Early Postoperative Ischemia (1 Month–1 Year)

Recurrent angina between 1 month and 1 year after the surgery is most often due to perianastomotic stenosis, graft occlusion, or mid-SVG stenosis from fibrous intimal hyperplasia. Recurrence of angina at about 3 months postoperatively is highly suggestive of a distal graft anastomotic lesion and should, in most cases, lead to evaluation for PCI.

Late Postoperative Ischemia (>3 Years after Surgery)

At this stage, the most common cause of ischemia is due to formation of new atherosclerotic plaques in the SVG. However, these plaques have less fibro-collagenous tissue and calcification, so they are softer, more friable, of larger size, and frequently associated with thrombus.

Safety for Percutaneous Interventions

PCI offers a less invasive alternative for revascularization in symptomatic post-bypass patients including many who were not candidates for repeat surgery because of contraindications (pulmonary and renal failure, old age, malignancy). Other patients who can undergo PCI with acceptable risks are patients with patent arterial grafts that would be jeopardized by reoperation, patients with relatively small amounts of ischemic, symptom-producing myocardium, and patients with no arterial or venous conduit available for graft. The status of the left anterior descending artery (LAD) and its graft significantly influences the selection process because of its impact on long-term outcome and lack of survival benefit of repeat surgery to treat non-LAD ischemia. A patent left internal mammary artery (LIMA) to LAD improves the safety and so favors the selection of PCI in the right coronary artery (RCA) or left circumflex artery (LCX) distributions. Therefore, selection of lesions for PCI must be based on careful analysis of the probabilities of initial success, complications, and for long-term safety and efficacy compared with competitive surgical strategies and medical therapies.

Indications for Surgical Revascularization

Reoperation is frequently recommended for severe disease of vein graft to the LAD.

Multiple vessel involvement, small number of patent grafts, severe vein graft disease, and a damaged ventricle are factors more likely to lead to repeat CABG (Box 13.1) [1]. In the past, PCI was not preferred for bulky atheromatous lesions or thrombus-laden

BOX 13.1 ANATOMIC FACTORS INFLUENCING REVASCULARIZATION DECISIONS IN POST-BYPASS PATIENTS

Often lead to percutaneous coronary intervention

- Patent arterial graft (especially left anterior descending artery or LAD) or more than two patent grafts
- One to three culprit lesions
- Inadequate conduit
- Near-normal left ventricle
- Difficult surgical access
- Posterior lateral target vessel
- Mediastinal scarring secondary to radiation, infection, or pericarditis
- Prior muscle transfer closure of unhealed sternotomy
- Future cardiac surgery anticipated
- *In situ* prosthetic valve
- Mild-to-moderate aortic or mitral valve disease

Often lead to coronary artery bypass graft

- Diseased SVG (saphenous vein graft) to LAD
- Ejection fraction: 25–35%
- More than three culprit lesions
- Multiple SVG lesions
- Available arterial conduits

grafts. With the advent of distal protection devices, safer results are achieved for PCI of these lesions.

Native Coronary Interventions

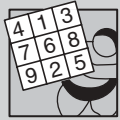
One year after bypass surgery, patients begin to develop new atherosclerotic plaques in the graft conduits or to show atherosclerotic progression in the native coronary arteries. Whenever possible, native artery lesions are targeted first because of their lower rate of restenosis. Approaches to native vessel sites in post-CABG patients include the treatment of protected left main (LM) disease, old total occlusion, or distal native artery via venous or arterial grafts.

Saphenous Vein Graft Interventions

Some 1–3 years after surgery, patients begin to develop atherosclerotic plaques in the SVG and, after 3 years, these plaques appear with increased frequency. At the early stage, dilation of the distal anastomosis can be accomplished with little morbidity and good long-term patency (80–90%). Dilation of the proximal and midsegment of the vein graft was highly successful at 90%, with a low rate of mortality (1%), Q-wave myocardial infarction (MI), and CABG (2%). The rate of non-Q-wave MI was 13%. The length of time since CABG was an important factor for restenosis as was the location of the lesion.

STRATEGIC MAPPING**Complex SVG interventions**

When evaluating the SVG lesions for intervention, the operators must consider the possible consequences of atheromatous embolism, as the entire lesion and accompanying thrombus could be fragmented, dislodged, and embolized. If the risk of major atheroembolization, which could be decreased by distal protection devices, is acceptable, compared with other therapeutic options, PCI may be appropriate [1]. Also, the relatively high subsequent coronary event rate and restenosis potential must also be factored into this decision.

**Intervention of the aorto-ostial lesion**

There is not much difference in the technique of PCI for aorto-ostial lesion of the SVG. However, as there is increased fibrotic change and more spasm, there is a question about the need for prior debulking followed by stenting or stenting alone of the aorto-ostial lesion. The technical concern during PCI of large and bulky aorto-ostial lesion is the antegrade and retrograde embolization.

Intervention in degenerated SVGs

The lesions that are bulky or associated with thrombus are considered to be high risk. The complications include distal embolization, no reflow, abrupt closure, and perforation. So different preventive approaches, such as mechanical thrombectomy and distal protection, are devised because there is much to lose from the standpoint of distal embolization causing non-Q MI and increasing long-term mortality (Box 13.2). In the case of perforation of an SVG, usually there is contained perforation rather than

BOX 13.2 ADVANTAGES AND DISADVANTAGES OF DISTAL PROTECTION DEVICES**Balloon occlusive devices***Advantages*

- Easy to use
- Aspirate large and small particles
- Reliably trap debris
- More tolerable with intermittent occlusion

Disadvantages

- No antegrade flow
- Balloon-induced injury
- Not as steerable as PTCA wire
- Difficult to image during procedure
- Balloon can move during PCI

(Continued)

Distal embolic filter devices*Advantages*

Preserve antegrade flow

Contrast imaging possible throughout the procedure

Disadvantages

May not capture all debris

Difficult to evaluate the retrieval of debris during procedure

Filters may clog

Delivery catheters may cause embolization before filter deployment

Cannot remove emboli intermittently in order to relieve overload

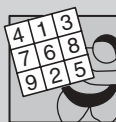
cardiac tamponade (which can still happen) due to the extrapericardial course of the grafts and extensive post-pericardiotomy fibrosis.

Interventions of the SVG

In general, in search for the location of the insertion site, the more posterior the destination of left-sided grafts, the higher they are located on the aorta. The top graft generally goes to the distal LCX, and the lowest to the LAD. Most left-sided grafts arise in a cranial direction from the aorta. Right coronary grafts are usually in the most caudal and rightward position on the aorta [1].

STRATEGIC MAPPING

If a small stent is deployed in a friable and fragile atheromatous segment of an SVG, further attempts to recross it with large a balloon would increase the risk of stent embolization. Deployment of a too-large stent would cause distal embolization due to excessive plaque extrusion. It is the same reason that overdilation of a balloon should be avoided. The length of the stent should be longer than the measured length of the lesion. The reason is that the soft atheromatous content of a plaque will be squeezed farther and rearranged along its length due to pressure by a stent. When multiple stenting is planned, the distal stent is deployed first, then the proximal one. This strategy is to avoid recrossing newly deployed stent. However, if there is very tight proximal lesion, crossing it can cause distal debris embolization. Proximal tight lesions can decrease distal contrast flow and so hamper the optimal visualization of stent position and deployment. The risk and benefit of each strategy (to stent a distal or a proximal lesion first) should be assessed well before embarking on a selected path.



Technical Tips

****Guides for left bypass grafts** The Judkins right (JR) coronary or left bypass or hockey-stick guide is effective for grafts arising anteriorly (the LAD and diagonals). The Amplatz left (AL) and the hockey-stick guide also provide the best backup for grafts arising in the inner curvature of the aorta (to the LCX). Engagement is best achieved by advancing the guide into the ascending aorta at the level of the aortic cusps, then gently withdrawing using clockwise rotation of the guide to orient the tip to the ostium in the LAO view. When the tip of the guide catches the ostium, the guide is advanced to obtain optimal backup.

****Guides for right bypass grafts** For the grafts arising from the outer curve of the aorta, (usually to the RCA), the JR guide is the best to provide excellent coaxial alignment. Engagement into the ostium is achieved by advancing the guide into the aorta, while making a clockwise rotation to point its tip toward the right, in the LAO projection, or the outer curvature; then it is slowly turned counterclockwise to engage the graft with its tip pointing down. The right bypass graft points caudally, the right modified Amplatz will cannulate the ostium of the graft with its tip pointing down. If the aorta is relatively large, a posteriorly located RCA graft may be difficult to reach with a multipurpose (MP) or JR guide but an AL will usually be successful in this situation.

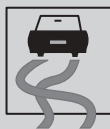***Balloon angioplasty for vein grafts** Balloons are generally sized 1:1 to venous grafts and slightly oversized for suboptimal initial results, or when dealing with restenotic lesions. Long (30–40 mm) balloons are frequently used when the lesions are long and bulky or when thrombus is present. The extra fibrosis of mature vein graft lesions often requires dilation to higher pressures (>12 atm).

****Stenting for vein grafts** The SVGs have a high degree of elastic recoil that can be overcome by stenting. Aorto-ostial vein graft lesions are most often treated with placement of stents. Non-dilatable aorto-ostial or distal anastomotic lesions have been successfully treated with rotational or directional atherectomy, then stented with a drug-eluting stent (DES).

CAVEAT

Mismatch and risk of stent dislodgment during PCI at the insertion site

Problems with interventions at the anastomotic site include: Tortuosity of the arterial segments proximal and distal to the insertion site; difference in diameter of the segment proximal and distal to the target lesion; the degree of size mismatch between the



(Continued)

distal vein graft and native vessel; and the angle of insertion of the vein graft into the native vessel. In case of stenting at the anastomotic site, the proximal part of the stent can be bigger, so the stent can have a funnel shape and is easier to dislodge backward. The size of the balloon is the size of the native segment distal to the insertion site [1].

PCI in the Arterial Grafts

Balloon angioplasty and stenting are feasible in arterial *in situ* (left or right IMA) or arterial grafts removed from the radial site. In PCI of IMA grafts, hydrophilic steerable wire is helpful in the presence of tortuosity. Care must be taken to ensure that there is short guide length (80 cm) to reach distal sites with extra-long (145 cm) balloon catheters, or the guide can be shortened and capped with a flared, short sheath one size smaller.

TECHNIQUE Cannulation of the LIMA graft On many occasions, the JR guide can more easily engage the subclavian artery because its primary curve is less acute. Then it is exchanged for the LIMA guide over a 0.038-inch wire. The usual view for cannulation of the LIMA is the anteroposterior (AP) view, with the patient's arms down by the side. Selection of the subclavian artery is achieved by placing the guide, with or without the wire protruding, around the arch beyond the origin of the desired artery. The guide is then gently withdrawn and rotated counterclockwise to direct the tip superiorly until the wire or guide tip enters the subclavian origin. An angled hydrophilic wire may facilitate passage through a tortuous subclavian. The guide can then be advanced over the wire beyond the origin of the IMA, which is usually situated inferior to the thyrocervical trunk and distal to the vertebral artery. Small flush injections of contrast and gentle withdrawal of the guide can identify the location of the ostium. Gentle counterclockwise rotation of the tip directs it anteriorly and enables it to enter the vessel selectively. If it is difficult to see the ostium, a 60° LAO or 45° right anterior oblique (RAO) projection would elongate the aortic arch, allowing excellent visualization of the origin of the IMA, so the guide tip can be engaged with precision. If it enters the left carotid artery, just withdraw it gently; it will enter the subclavian artery.

Femoral or radial approach The LIMA or RIMA can be approached by the radial approach if the takeoff and proximal course of the two IMA are descending vertically or internally. Use the femoral approach if the IMA takeoff is descending externally.

Technical Tips

*****Engaging the IMA guide with a wire** If the IMA is difficult to engage, a slippery hydrophilic or a very steerable soft wire can be used to superselect the IMA. It then functions as a rail for cannulation of the guide. This has been necessary more commonly in the RIMA with the tip of the guide nearby. Be very

gentle when cannulating the IMA because it is prone to spasm and dissection. Intracoronary nitroglycerin or verapamil can be given generously. If the subclavian artery is very tortuous, guide cannulation can be achieved through the ipsilateral radial approach.

*****Engaging the RIMA with a pigtail catheter** After failure of engaging the very tortuous right subclavian artery from the femoral approach and the brachial approach with a standard IMA catheter, a new approach with a pigtail was tried. A 5-Fr pigtail catheter was placed distally to the RIMA ostium and a long 0.014-inch coronary wire (Choice PT Extra Support) was advanced through the catheter. The more the catheter was moved distally, the more the loop of the pigtail catheter straightened. With this maneuver, in the 50° LAO view, the curvature of the pigtail could be adjusted to selectively intubate the RIMA ostium. The wire was advanced into the distal part of the vessel, across the lesion. Then the pigtail catheter was exchanged for an IMA guide for PCI. This technique using a coronary wire in a 5-Fr pigtail catheter allows the tip of the catheter to be shaped according to any specific anatomy [2].

*****LIMA guide** The VB-1 catheter was developed as a modification of a pigtail catheter. The diagnostic version of the catheter has a shape that is similar to the proximal two-thirds of the curve of a standard pigtail catheter. Proper technique during use of the VB-1 catheter is important. After obtaining access of the left subclavian artery, typically with the catheter used to image the RCA, a 175-cm length, 0.035-inch wire is positioned well beyond the origin of the LIMA and used to exchange for the VB-1 catheter. The wire is removed and the catheter flushed in the usual manner. The curvature of the distal tip of the VB-1 catheter allows it to be directed inferiorly. Slow withdrawal of the catheter toward the origin of the LIMA will allow the tip to cannulate the LIMA passively and, because of its flexible design, the catheter tip characteristically assumes a coaxial position in the proximal LIMA. In the event that the LIMA arises anteriorly from the subclavian artery, gentle counterclockwise rotation, while withdrawing the catheter, directs the tip anteriorly toward the ostium of the LIMA, again achieving a coaxial position in the vessel [3].

CHALLENGES

PCI through a LIMA graft

Attempting PCI through an IMA graft is associated with four major technical challenges. First, the IMA grafts may be difficult to engage. Second, the IMA grafts can be long and interventional equipment may not be long enough to reach the target lesion. Third, the IMA grafts can often be markedly tortuous, which may make wiring difficult. Fourth, the antegrade IMA graft flow may cease after wiring [4].

(Continued)

The first challenge, engaging the IMA, can be addressed by using various guides (such as the LIMA or JR-4), and occasionally using a wire as a rail for pulling the guide into the IMA ostium. Alternatively, a diagnostic catheter may be used to engage the IMA ostium, an exchange length wire is inserted in the LIMA, followed by exchange of the diagnostic catheter for a guide. If all else fails, an ipsilateral radial or brachial approach can allow IMA graft engagement. [4]

The second challenge, reaching the target lesion in patients with long IMA grafts, could be addressed by using shorter guides, shortening the guides, or using longer shaft balloons and stents. [4]

The third challenge, difficulty wiring the IMA, may be addressed by using hydrophilic, polymer-jacket, or transitionless wires, flexible microcatheters, such as the Transit, Prowler, Progreat, Finecross, and Renegade OTW balloons, or deflectable-tip catheters, such as the Venture catheter, although the last has a stiff shaft and may cause pseudo-lesions [4]. Addressing the fourth challenge (antegrade flow cessation after wiring) can be difficult. Although antegrade IMA flow cessation after wiring is usually caused by vessel “kinking” and pseudo-lesion formation, it can also be caused by dissection. Remove the wire over a flexible microcatheter to minimize the LIMA “accordioning” and to restore antegrade flow. This technique could render stent delivery or balloon angioplasty challenging if there are no angiographic landmarks (such as clips), due to poor visualization [4].

Technical Tips

****Use of a “dual-guide technique”** In this a second arterial access is obtained and a second guide is used to engage either the native target coronary artery (if it is patent) or another bypass graft that supplies the target artery. The second guide can be used either for balloon and stent delivery or for lesion visualization. The “dual guide ” technique has limitations. First, it requires that the target native coronary artery be supplied not only by the IMA graft but also by another vessel. If the target vessel is supplied only by the IMA graft, then immediate wire removal may be required if the patient develops IMA occlusion with angina, ECG changes, or hemodynamic instability. An alternative solution in those cases would be to perform antegrade PCI of the native coronary chronic total occlusion, using LIMA injections to help direct and verify the position of the antegrade wiring into the true distal lumen [5].

*****How to overcome the problems with pseudo-lesions in tortuous LIMA** During PCI of a lesion in the LIMA graft, the wire caused a pseudo-lesion. As there was no flow through the LIMA, the angiographic assessment of the angioplasty result was difficult.

Exchange the angioplasty wire with a flexible-shaft Transit catheter. Once the Transit catheter was in place and the wire removed,

the LIMA assumed its normal tortuous contour, thus leading to resolution of the “accordioning” of the vessel. Injection of contrast through the guide (with the Transit catheter in place inside the LIMA in order to maintain a channel for wire access) permitted visualization of the entire LIMA and allowed angiographic assessment of the angioplasty lesion site [4].

TAKE HOME MESSAGE

Intervention of IMA graft

- 1 Check the subclavian or the IMA in patients who are anticipating to go for CABG if there is a 20 mmHg difference in blood pressure between the two arms
- 2 Always check the subclavian artery in a post-CABG patient with angina
- 3 In evaluating the LIMA, check the 90° lateral view; it may be the only view that shows the distal insertion site adequately
- 4 Watch out for spasm and pseudo-stenosis of LIMA when instrumenting that vessel
- 5 Watch for guide deep intubation of the LIMA. Watch the pressure tracing. Do not inject contrast into the LIMA if you are not sure of the position of the guide. Too-deep intubation may cause dissection

TREATMENT AND PREVENTION OF DISTAL EMBOLIZATION

Distal Protection Devices

Distal filter devices have distinct advantages over occlusive balloons in which distal coronary flow is not compromised during SVG stenting, and they are technically less challenging to use. Distal filter devices have their own disadvantages. First of all, smaller particles can pass through the filter wire. Furthermore, this filter may not be able to seal the distal coronary vessel completely, leading to the passage of significant amounts of debris into the distal coronary bed. Due to the bulky filter, the passage of a filter across a lesion can be difficult or impossible. The need for predilation with an undersized balloon may itself lead to distal embolization. It also requires an appropriate zone for filter deployment, which cannot be too small or too large. In the very distal lesions, deployment of these filters can be impossible. Finally, these filters can be trapped in the stent after or during the procedure, which can lead to significant dissection, morbidity, and the need for urgent CABG for device retrieval [6].

Proximal Protection Devices

Proximal occlusive devices have also been used to prevent no-reflow. With this system, complete flow will be ceased proximal to the target lesion using an occlusive balloon before stent

deployment. This will allow complete aspiration of particles of all sizes after PCI or stenting of the lesion before restoring flow with proximal balloon deflation. (6)

Advantages and Limitations

One of the advantages of using proximal occlusion devices is the fact that no bulky device needs to cross the lesion. Furthermore, lesions with a poor distal landing zone for filter wires can be easily treated with a proximal protection device. The major disadvantage of this device is similar to that of a distal occlusive device where there is a complete cessation of coronary flow that can lead to ischemia and intolerance. Furthermore, this system is technically challenging, costly, and requires larger 8-Fr sheaths. Finally, near-ostial or ostial lesions cannot be treated with this device [6].

Discriminating Differences

Selection of distal protection devices The Spider RX allows the operator to choose any 0.014-inch wire, and the Interceptor PLUS obviates the need for a dedicated retrieval device. The Proxis device may be advantageous during PCI of SVG lesions where balloon or stent delivery is difficult, because it often provides superior support after anchoring. However, the delivery of cutting balloons, rotational atherectomy and thrombectomy (AngioJet XMI) devices through the Proxis is not possible. Yet, Proxis is the only device that provides the ability for protected crossing of the lesion and, along with the GuardWire, allows confirmation of embolic protection and a real-time road map for balloon or stent delivery with suspended contrast material within the SVG [7].

Improvised Equipment

The guide as a suction catheter If the guide is large enough, the flow in the artery can be sucked back with a large 60-ml syringe at the time of deployment of the stent or predilation or postdilation of the balloon. This reversal of flow results in removal of material so embolic material does not go down the vessel. The thing that is essential in this technique is that it is important to have guide apposition at the origin of the graft. This may be one other option for physicians where embolic protection devices are not possible. A potential limitation of the technique is the inability to protect ostial SVG lesions during stenting, because the guide may need to be disengaged from the SVG ostium, and aspiration through an un-engaged guide might increase the risk for systemic embolization (including stroke) [8].

Technical Tips

****No flow with distal filter devices** During PCI of an SVG, the filter can be overloaded with thrombi and atheromatous material, and the distal flow can be cut off. After predilating angioplasty of a SVG lesion, repeat angiography may show no flow with the contrast holding up at the filtering device. The differential diagnoses are distal embolization despite use of distal protection device or that the wire was "choked" with embolized atheromatous materials. Therefore intermittent aspiration should be performed to relieve the overloaded filter. The export catheter

syringe is first filled with saline, which is injected to “agitate” the filtered materials, then it is followed by vacuum aspiration.

****Improvised distal protection device** In any laboratories without the dedicated distal protection device, a deflated OTW balloon is advanced beyond the index lesion (e.g. the ACE balloon). Inflate it to block the flow. Perform angioplasty. Be sure that the patient can tolerate the ischemia caused by inflation of balloon. After angioplasty, advance a large transport catheter with many side holes, and aspirate the debris from the distal blood column [9]. This strategy cannot be applied to PCI with stenting because the balloon would be trapped if not removed before stenting. After positioning and inflation of the distal balloon before performing PCI, inject a column of contrast into the lumen to mark the location of the balloon and the proximal end of the column should be around the lesion to be dilated. While performing PCI, if that the distal column of contrast does not move, and there is no contrast seeping distally, it is assured that the balloon is being kept immobile and the distal protection is intact.

CRITICAL THINKING

Technical problems with distal protection devices

There are two main problems remain with distal protection device (DPD) technology. The first is that the size of the protection devices requires either predilation or dottering of the target lesion, which can cause distal embolization itself before deployment of the DPD. In complex lesions, the “buddy wire” technique and small-sized balloon predilation may be required. The second is the lack of solution for cases in which the lesion is very close to a major bifurcation. The device can be placed in only one branch. In such a case, there will be preferential flow diversion to the unprotected branch with exacerbated embolization to that branch. The placement of an occluding balloon in the side branch results in a reversal of this trend, with the flow being forced through the filter [10].



CASE REPORT

Bifurcating distal protection devices

Coronary angiography demonstrated double-vessel disease with a 70–90% stenosis in the proximal LCX and a critical thrombus-containing lesion in a dominant RCA immediately proximal to its bifurcation to the right posterior descending artery (PDA) and right posterolateral artery (PLB). An 8-Fr JR-4 guide was positioned and an intermediate wire was passed to the distal right PDA. A 1.5-mm X-Sizer thrombectomy device was placed proximal to the lesion, and aspiration was performed with only minimal benefit, as evidenced by limited thrombus extraction and improvement of the

angiographic stenosis. At this point, an EPI filter wire protection device was passed through the lesion and deployed in the large right posterolateral artery distal to the target lesion. Before the angioplasty in the target lesion, an ACE 1.5 × 20 mm balloon was placed in the right PDA and inflated at low pressure, occluding the right PDA immediately distal to the bifurcation. Angioplasty was then performed to the RCA lesion with the inflated right PDA balloon preventing flow to that vessel, with all flow diverted to the right PLB, which was protected with the pre-positioned filter. The ACE balloon was removed and the distal RCA stented with an excellent angiographic result. The filter wire was then removed. As the PDA balloon was placed slightly distal to the bifurcation on its removal, some slow flow was noted and successfully treated with, for example, adenosine, with thrombolysis in myocardial infarction (TIMI) 3 flow documented at the completion of the procedure in both branches of the RCA [10].

Technical Tips

****Effective injection of drug for no-reflow** The operator should be aware that agents administered through the guide may preferentially distribute to areas with retained flow rather than at the site of activity. Therefore, when practical, drugs should be administered through either an infusion catheter placed distally or the central lumen of an OTW balloon catheter. Intracoronary nitroglycerin is usually suggested as the first-line agent, mainly to reverse epicardial vessel spasm, even if the blood pressure is reduced. Theoretically, nitroglycerin should have little impact on arteriolar tone and hence on no-reflow because physiologically it produces little effect in the microvasculature (Box 13.3).

***Treatment of no-reflow with distal blood aspiration

Aspirate slowly using a 50-ml syringe, while the guide is deeply advanced into the graft. The aspiration was effective because the slugging contrast from the vein was removed into the catheter. The result was excellent, the no-reflow aspect disappeared, and the ECG changes normalized, concomitant with pain dissolution.

TREATMENT OF THROMBUS IN SVG

In the presence of thrombus in SVG, the first option is medical treatment with drugs. If there is equipment available, a thrombectomy can be performed. Which method is better and more cost-effective?

BOX 13.3 TREATMENT OF NO REFLOW

Adenosine 10–20 μg bolus

Verapamil 100–200 μg boluses up to 1000 μg with temporary pacer standby

Nitroprusside 50–200 μg bolus, up to 1000 μg total dose

Medical Treatment

The medical treatment of thrombus in SVG includes aspirin, clopidogrel, and glycoprotein IIb/IIIa inhibitor (GPI) such as abciximab (intra-arterial bolus plus intravenous infusion over 12 h) plus a fibrinolytic drug such as intra-arterial recombinant tissue plasminogen activator (rtPA: 100 mg over 20 min). The patient then is maintained on IV heparin over the next 48 h for an activated clotting time (ACT) between 250 and 300 seconds. However, data from large randomized trials are lacking. Prolonged infusion of GPI before PCI may allow for endogenous lysis of thrombus before intervention. This strategy is more costly because of long-term infusion of GPI. If a repeat angiogram at 48 hours after GPI does not show adequate resolution of the thrombus then mechanical thrombectomy is another option.

Mechanical Thrombectomy

If mechanical thrombectomy is intended from the start, in cases of proximal thrombi, then they can be aspirated by a large guide. Smaller distal thrombi can be aspirated by a Pronto or Export catheter. AngioJet atherectomy is the most effective method for clot removal if the thrombus is large.

The aspiration thrombectomy device

To date, the series of devices that have been tested in clinical studies and are available on the market includes the Acolysis ultrasound thrombolysis device, the excimer laser, the transluminal extraction catheter, the AngioJet rheolytic thrombectomy device, the hydrolyser hydrodynamic thrombectomy device, the X-sizer helical thrombectomy device, and the rescue thrombectomy catheter. All these devices are rather complex to use and not all are based on a rapid-exchange strategy, rendering their use problematic in emergency procedures, in particular in low-volume centers.

DEDICATED EQUIPMENT

The Pronto device

This is a dual-lumen rapid exchange aspiration thrombectomy catheter with a 0.056-inch diameter extraction lumen. It has a rounded distal tip with a sloped extraction lumen to protect the vessel wall during advancement, and is connected to a 30-ml locking vacuum syringe for extraction of the thrombus by the Venturi effect. The negative pressure should be maintained till the aspiration catheter is removed from the guide. Back bleeding will remove eventual residual thrombus fragments in the guide. Before the next passage, the aspiration catheter has to be flushed to remove thrombus fragments within the catheter [11].



(Continued)

Rheolytic thrombectomy

AngioJet rheolytic thrombectomy (RT) is a catheter-based method for thrombus removal. The catheter is attached to a drive unit with a piston pump that generates a high-pressure pulsed flow rate of 10 000 lb/in² at 60 ml/min through a hypotube. The hypotube ejects its saline at a loop in the catheter tip. The jets of high-velocity saline are directed back into an exhaust lumen. This creates a vortex, or Venturi effect tip (Bernoulli effect) that fragments and aspirates thrombus and loose debris. Transient bradycardia develops with RT catheter activation, particularly in right coronary or dominant circumflex lesions, and a right ventricular temporary pacemaker is recommended. The bradycardia is thought to be caused by the active release of adenosine from hemolysed red cells. Transient ST elevation noted on the electrocardiogram during pump activation is usually due to the release of potassium from red cells, and not active ischemia. However, based on the AngioJet in Acute Myocardial Infarction (AIMI) trial, concern with the use of this device for ST-segment elevation myocardial infarction (STEMI) patients has been raised, primarily due to the increased mortality and larger infarct size in the AngioJet treated patients [12].

PCI for patients with STEMI within hours of CABG Sometimes, shortly after returning from the operating room (OR) after CABG, the patient is found to have ST-segment elevation in one of the areas just bypassed. There is strong suspicion of acute occlusion of one of the bypass grafts. The patient could be taken back to the OR to recheck the patency of the bypass grafts, or the patient could go to the cardiac catheterization laboratories for emergency angiography. If there is a need for PCI, a full dose of unfractionated heparin (UFH) could be given. The reason is that, during CABG with the chest open, the patient was fully heparinized without extra bleeding because all the bleeding sites were well cauterized. After the chest was closed, anticoagulation was reversed with protamine. Now, when there is a need for short-term anticoagulant therapy for PCI, the patient could tolerate it without a problem. Urgent coronary angiography may reveal a compromised graft. During intervention, extreme care is warranted and balloon sizing should be conservative because of the possibility of suture line disruption and severe hemorrhagic complications [1].

Once a graft has been thrombosed, opening of the native vessel is preferable. However, if the native vessel is not a reasonable target, balloon interventions on the graft are also effective if thrombus formation is not extensive. Intracoronary thrombolytic therapy, although technically feasible, is reported only in rare cases with a third requiring mediastinal drainage due to bleeding.

Therefore, removal of thrombus by a thrombectomy device is preferred. In general, no PCI could ever be done without the patient being anticoagulated.

PCI in the subclavian artery On many occasions, in symptomatic patient after CABG surgery, non-invasive studies point towards ischemia in the distribution of a left or right IMA graft. The usual sites of obstruction include the IMA graft itself, the lesion at the insertion site, or the subclavian artery. Obstructive lesion of the subclavian artery proximal to the origin of the LIMA graft can happen even if it is rare. The lesion can be corrected by stenting the subclavian artery in order to relieve the ischemia in the territory supplied by the LIMA [13].

Perforation in SVG – no pericardial effusion with hypotension In a case report after direct stenting, the angiogram revealed a diffuse rupture of the SVG with contrast leakage into the mediastinum. The patient became hemodynamically unstable with a very low blood pressure (50/30 mmHg). Volume resuscitation along with blood transfusion was used to stabilize the situation. Transthoracic echocardiography did not show any pericardial effusion. At the same time, three polytetrafluoroethylene (PTFE)-covered Jomed stents were deployed at 14 atm. Contrast extravasation was then decreased. The CT scan showed a stable hematoma in the mediastinum, without any active bleeding. Even so it compressed the right ventricle causing hypotension [14].

Luxation of stent during aneurysm exclusion The SVG to the LAD was patent; however, the sequential SVG showed a 95% ostial lesion followed by a saccular poststenotic aneurysm which measured $12 \times 13 \text{ mm}^2$. An 8-Fr JR guide and a 0.014-inch BMW wire were chosen for support and device delivery. The lesion was pretreated with a $2.5 \times 10 \text{ mm}$ followed by a $4.0 \times 10 \text{ mm}$ cutting balloon. Repeat angiography showed an enlarged entrance to the SVG and aneurysm without dissection, perforation, or rupture. The ostial SVG lesion, along with the poststenotic aneurysmal segment, were stented with a 16-mm PTFE-covered stent (JoStent), which had been free mounted on to a $4.0 \times 20 \text{ mm}$ Maverick 2 balloon. After stent deployment, the distal end of the covered stent was seen to have dislocated into the aneurysm proper, and the outlet of the stent was not in direct alignment with the rest of the SVG. To realign the PTFE-covered stent, further stent coverage extending beyond the distal margin of the first stent was clearly necessary. Another free-mounted, PTFE-covered stent was deemed risky due to its relative rigidity, bulk, and potential for dislodgement. The decision was taken to place a conventional, low-profile, pre-mounted stent. The choice for a longer stent was to secure a mid-segment axial strength where there was no mechanical support from the adjacent vascular wall. Postdilation was performed with an excellent final angiographic outcome and minimal contrast extravasation at the distal end of the aneurysm [15].

TAKE HOME MESSAGE

After successful SVG intervention, there is a high cardiac event rate for most patient subgroups. Success rate and long-term patency of PCI in the distal anastomotic lesions are an exception. The restenotic process in vein grafts does not plateau as it does in native coronary arteries, and mild-to-moderate, non-target, vein graft lesions are associated with recurrent ischemic events in about a third of patients. If one moves from these relatively ideal candidates to the treatment of diffuse disease, recent total occlusions, the prospects for long-term patency and clinical stability diminish, whereas the acute risk of thromboembolic myocardial infarction, bleeding, and costs escalate. Although continued study is needed to develop methods (membrane-covered stent, PDP, thrombectomy, brachytherapy, etc.) to prolong the functional life of degenerating venous grafts, and after thoughtful cost-conscious consideration of risks and benefits and of resource consumption, day-to-day application of percutaneous strategies to these difficult problems must be approached with caution [1].

REFERENCES

1. Douglas J. Approaches to the patient with prior bypass surgery. In: Topol EJ (ed.), *Textbook of Cardiovascular Medicine*. Philadelphia, PA: Lippincott-Raven Publishers, 1998: 2101–18.
2. Lapp H, Haltern G, Kranz T, et al. Use of a pigtail catheter to engage a difficult internal mammary artery. *Catheter Cardiovasc Interv* 2002;**56**:489–91.
3. Warner MD, Gehrig TR, Behar VS. The VB-1 catheter: An improved catheter for difficult-to-engage internal mammary artery grafts. *Catheter Cardiovasc Interv* 2003;**59**:361–5.
4. Sharma S, Makkar RM. Percutaneous intervention on the LIMA: Tackling the tortuosity. *J Invasive Cardiol* 2003;**15**:359–62.
5. Lichtenwalter C, Banerjee S, Brilakis ES. Dual guide catheter technique for treating native coronary artery lesions. *J Invasive Cardiol* 2010;**22**: E78–E81.
6. Habibzadeh MR, Thai H, Movahed MR. Prophylactic intragraft injection of nicardipine prior to saphenous vein graft percutaneous intervention for the prevention of no-reflow: A review and comparison to protection devices. *J Invasive Cardiol* 2011;**23**:202–6.
7. Banerjee S, Brilakis E. Embolic protection during saphenous vein graft interventions. *J Invasive Cardiol* 2009;**21**:415–17.
8. Morales PA, Heuser RR. Guiding catheter aspiration to prevent embolic events during saphenous vein graft intervention. *J Intervent Cardiol* 2002;**15**:491–8.
9. Stein B, Moses J, Terstein P. Balloon occlusion and transluminal aspiration of SVG to prevent distal embolization. *Catheter Cardiovasc Interv* 2002;**51**:69–73.
10. Gerganski P, Meerkin D, Lotan C. Distal protection of bifurcating vessels: A novel approach. *Catheter Cardiovasc Interv* 2004;**61**:512–14.
11. Webb J, Vaderah S, Hamburger J. Proximal protection during saphenous vein graft angioplasty: The Kerberos embolic protection system. *Catheter Cardiovasc Interv* 2005;**64**:383–6.

12. Jim MH, MD, Ho HH, Chow WH. Export aspiration catheter-enhanced Filter Wire™ delivery: An innovative strategy for treatment of saphenous vein graft disease. *J Invasive Cardiol* 2006;**18**:569–74.
13. Kugelmass AD, Kim DS, Kuntz R, et al. Endoluminal stenting of a subclavian artery stenosis to treat ischemia in the distribution of a patent left IMA graft. *Catheter Cardiovasc Diagn* 1994;**33**:175–7.
14. D'Agate DJ, Patel S, Coppola JT, Ambrose JA. The evolving role of glycoprotein (GP) IIb/IIIa receptor blockade during percutaneous coronary intervention of saphenous vein bypass grafts. *J Invasive Cardiol* 2004;**16**:500–3.
15. Ho PC, Leung CY. Treatment of post-stenotic saphenous vein graft aneurysm: Special considerations with the polytetrafl uoroethylene-covered stent. *J Invasive Cardiol* 2004;**16**:604–5.

CHAPTER 14**Bifurcation Lesion**

Shao Liang Chen, Dobrin Vassilev, Nguyen K. Nguyen, Gim Hooi Choo, Thach N. Nguyen, Tak Kwan, Junjie Zhang

Challenges 315

Guide 318**Wires 318****Technical Tips 318**

**Which branch to wire first? 318

**Steps to facilitate SB wire removal 319

**Dilating the MV in order to access the SB 319

Lesion Preparation 319**Balloon Angioplasty 320**

Technique initial SB and MV balloon angioplasty 320

Advantages and Limitations 320**Practical Applications 320****Technical Tip 321**

**Diameter of the combined two balloons 321

Directional Coronary Atherectomy 321**Rotational Atherectomy 322****Technical Tips 322**

***Strategies for rotational atherectomy of two branches 322

**Wire bias 322

**Side-branch protection 322

Stenting 322**Selection of Stent 323****Open or Closed Cell Design 324****Stent Deformation after Side-strut Dilation 324****Provisional Side-branch Stenting 324****Advantages and Limitations 325****The T-stenting Technique 325****Advantages and Limitations 325****The Modified T-stenting Technique 325****Advantages and Limitations 326****Practical Applications 326**

Technique T stenting at provision 328

Advantages and Limitations 330**The Crush Technique 330****Advantages and Limitations 330****Double Kissing Crush Technique 330**

*Basic; **Advanced; ***Rare, exotic, or investigational

\$, <\$US100.00 extra; \$\$, >\$US100.00 extra

☞, <10 min extra; ☞☞, >10 min extra

◆, low risk of complications; ◆◆, high risk of complications

Technical Tips 331

**Crossing a balloon into the SB 331

**Advancing the MV stent with a SB balloon as an anchor 331

Advantages and Limitations 332

The Reverse Crush Technique 332

Advantages and Limitations 333

The V-stenting Technique 333

Advantages and Limitations 333

The Simultaneous Kissing Stents Technique 333

Advantages and Limitations 334

Technical Tip 335

**Perfect stenting 335

The Culotte Technique 335

Technical Tips 335

**Perfect stenting 335

**Which branch should be stented first? 335

Interventions of Side Branches 336

Side-branch Wire Entry 336

Technical Tips 337

**Warning about wire jailing 337

**Where to cross the stent side cell 337

Technique How to manipulate a wire to cross an MV side cell 337

Technical Tips 338

**Use an OTW balloon to cross the side cell into the SB 338

**Use a stiff wire to cross the side cell into the SB 338

**How to shape the wire tip 338

**Use a microcatheter 338

**Redilate the MV stent to widen the MV side cell 339

**Use a dedicated wire to cross the side cell 339

Advance a Balloon into a Side Branch 340

Technical Tips 340

**First maneuver when encountering difficulty advancing a balloon into a side branch 340

**How to advance an OTW balloon into a side branch 340

**Inflate a balloon in the MV as an anchor 340

**Inflate a balloon in the MV to open a side branch 341

***Lubricate the balloon 341

***Small balloon inflation behind the MV stent to open an SB 341

***How to withdraw the jailed SB wire 341

Side-branch Balloon Inflation 342

Technical Tips 342

**Size and pressure for SB inflation after MV stenting 342

Kissing Balloon Inflation 342

Main Vessel and Side-branch Stent Distortion 342

Unsatisfactory Kissing Results 343

Technical Tips 343

**Perfect kissing balloon inflation 343

NEW TECHNIQUE The flower petal 343

Advantages and Limitations 343

CHALLENGES

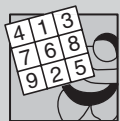
At this present time, when performing percutaneous coronary intervention (PCI) for bifurcation lesions, the highly variable bifurcated anatomy, the extent of myocardium in jeopardy, and the complexity in designing a clinical trial that will determine the optimal treatment strategy are the main challenges.

Several baseline factors contribute to the complexities of the problem and new factors arise as the PCI procedure progresses. At first, plaque and endothelial characteristics of ostial lesions appear to lead to increased recoil and risk of dissection with compromise of a side branch (SB) or main vessel (MV). During intervention in either branch, a carina shift can frequently cause new lesions. At the end, stent metal accumulation results in high residual stenosis at the ostium of the SB and distortion at the proximal half of the MV stent. Many of these factors are not present at the time of baseline angiography and not angiographically obvious post-procedure, so they cannot be quantified in a mathematical formula that allows prediction and comparison of the final results of different techniques on a bifurcation lesion [1].

As a result of these many uncontrolled concerns and factors, there is no consensus on a best strategy for treating the bifurcation subset. So these lesions are often treated less aggressively, leading to greater residual stenosis and therefore greater late restenosis, mainly at the SB ostium [2].

STRATEGIC MAPPING

In a bifurcation lesion, after evaluation of the lesion in the MV and SB and the bifurcation angle, the first and probably the most important issue is when to stent only the MV and when to treat the SB, with or without simple balloon inflation, while reserving the option to stent the SB in the event of suboptimal result(s).



The problem with intervention of an SB is that SBs are at risk of occlusion when there are diseases at their origin, when the lesion in the MV is very close to the ostium of the SB, leading to possible carina shift, and when the angle between the MV and the SB is shallow ($<45^\circ$) (Figure 14.1).

However, any SB >2.0 mm should be preserved; therefore, the very first step in treating a bifurcation is to decide the following:

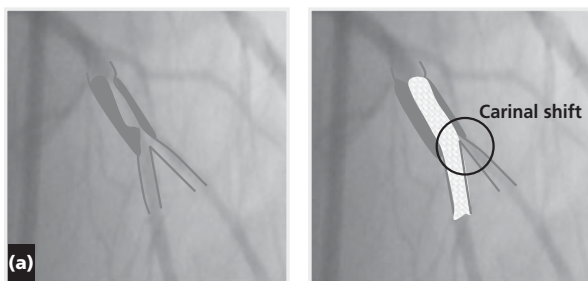
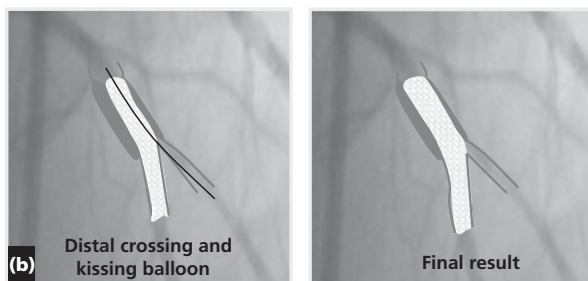
Carina shift**Final kissing balloon can restore SB patency**

Figure 14.1 Carina shift: (a) After deployment of the stent, the carina moves proximally. (b) Final kissing balloon can restore side-branch patency.

- Does the SB need wire protection?
- Does the SB need balloon dilation?
- Does the SB need a stent?
- Which technique is best to use when it becomes necessary to place a stent in the SB?

The major challenge of any technique is to ensure that the SB access is protected, and the SB ostium has a satisfactory final opening and is covered by the anti-proliferative chemical of the drug-eluting stent (DES) [3].

As the need for patency of the SB is considered, a comprehensive strategy for intervention of both MV and SB is devised using many available techniques. The provisional T-stent technique strategy is most frequently used, but there are many true bifurcation lesions where the elective use of more complex, systemic, two-stent bifurcation approaches (the crush technique, double kissing crush, T stenting, the culotte technique, etc.) is appropriate and indicated. These situations arise when the MV and SB are large vessels, the SB has more diffuse disease in its proximal segment rather than only focal disease at its ostium, and the SB serves a functionally important area (e.g. providing collateral to an occluded graft or vessel, or either of the papillary muscles) [4].

In the end, especially when the SB is dilated through the struts of the MV stent, a final kissing balloon inflation (KBI) helps restore the MV stent geometry and optimal expansion (Figure 14.2).

CRITICAL THINKING**Discriminating anatomy**

The bifurcation angle is a very important factor during PCI of bifurcation lesions. It has been shown that a T angle $>70^\circ$ increases the risk of complications. Higher long-term mortality was found in patients with highly angulated lesions treated with the crush technique. Furthermore, a steep angle is significantly associated with the risk of abrupt vessel closure, SB occlusion, and higher failure rate to recross the SB after MV stenting [5].

**Step 1 :**

Side branch size < 2.5 mm



Stent on main vessel , balloon PTCA on SB or any strategy to "Keep It Open" (KIO)

Step 2 :

(Side branch ≥ 2.5 mm)

The bifurcation is a true bifurcation

(significant stenosis on the main and side branches)

No

Provisional T stenting

Step 3 :

(Side branch ≥ 2.5 mm)

The bifurcation is a true bifurcation

(significant stenosis on the main and side branches)

No

Provisional T stenting

Yes

The disease on the side branch is very focal, localized within 3 mm from the ostium of the side branch:

Figure 14.2 Strategy for bifurcation lesion.

Step 4 : (Side branch ≥ 2.5 mm)

The bifurcation is a true bifurcation

(significant stenosis on the main and side branches)

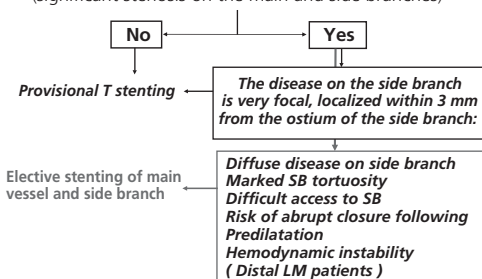


Figure 14.2 (Continued)

GUIDE

With the current generations of low-profile balloons and stents, bifurcation intervention may be performed with 6- to 8-French (Fr) guides depending on the technique. Provisional SB stenting can be performed through a 6-Fr guide (inner diameter ≥ 0.07 inch), which is also adequate for simultaneous delivery of a monorail stent and balloon or two balloons for KBI. The double kiss (DK) crush and step/balloon crush techniques also require a 6-Fr guide. Guides of 7 Fr (inner diameter ≥ 0.08 inch) or 8 Fr (inner diameter ≥ 0.09 inch) are required for two-stent techniques. The guides with great passive support (e.g. extra backup [EBU], Amplatz) are preferred. If the radial access does not allow the passage of a large guide, the use of two guides (one from the radial and another from the femoral artery) is a viable option.

WIRES

The types of wires (soft or stiff, string type, or hydrophilic) and technique (which branch to wire first, etc.) are decided by lesion anatomy. A wire may be left "jailed" in the SB during MV balloon angioplasty and stenting, to act as a landmark for rewiring through the side of the MV stent. In general, the strategy is to use a wire that is most familiar to the operator and has the highest possible steerability.

Technical Tips

****Which branch to wire first?** To avoid difficulty due to wire crossing and "wire-wrap", the most difficult branch (usually the SB) should be wired first because it needs more manipulation. The

second wire tends to track along the first, so it should then be used to cross the MV lesion with gentle torquing (no more than a wrist rotation). Keep both wires separate. An easy way is to identify the wires by having a torque device of different colors for each wire or to make a shallow curve at the proximal end of one of the wires. The basic rule is to leave wires on the table in the same places as after crossing the lesion – do not tangle the wires on the table during the procedure. Any crisscrossing will be transmitted distally after the first balloon insertion. In the two-stent techniques, preventing wire wrapping is the main technical concern when advancing devices into the MV and SB.

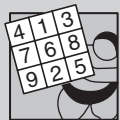
****Steps to facilitate SB wire removal** Usually, non-hydrophilic wire is preferred in the SB because of the potential risk of shearing the hydrophilic coating on removal of the “jailed” wire. However, many experienced operators still prefer the hydrophilic wires. Deployment of the MV stent at relatively low pressure (12 atm), but high enough to ensure good wall apposition, and subsequent higher pressure postdilatation, after SB wire removal, would prevent the inability to remove the intentionally jailed SB wire [2]. Another tip is to pull back the SB wire, leaving only a short distal segment inside the SB before deploying the MV stent.

****Dilating the MV in order to access the SB** One potential option after exhausting all of the tricks to wire the SB without success is to perform low-pressure balloon dilation of the MV using an undersized balloon (even 1.25 or 1.5 mm), which may modify the plaque geometry at the bifurcation site allowing access to the SB. Alternatively, rotablation of the MV with a small-sized burr (1.5 mm) could be used to change plaque configuration. If the operator fails to wire the SB (and if it is a large SB with significant disease in its ostium), then the procedure should be aborted rather than proceeding with the hope that the SB will remain open after stenting the MV.

LESION PREPARATION

STRATEGIC MAPPING

The best interventional strategy of a bifurcation lesion is to stent the MV without compromising the flow in any SB. In any situation, MV stenting can still cause further narrowing of the ostium of the SB even the ostium is devoid of plaque. Some operators suggest performing preventive low-pressure balloon inflation of the SB. However, this approach carries the risk of SB dissection



(Continued)

and is not favored in a provisional SB-stenting strategy. Also the argument against it is that there is no need to dilate a non-existing stenosis. The SB compromise in this situation is due to carina shifting. However, if there is stenosis at the SB ostium, plain old balloon angioplasty (POBA) of the SB could help to prepare the lesion by making the SB ostium less stenosed and ready for stenting. If there is a need for plaque debulking, directional (DCA) or rotational coronary atherectomy is a viable option.

BALLOON ANGIOPLASTY

Plain old balloon angioplasty uses balloon angioplasty for lesion preparation at the MV or SB to facilitate the stenting process.

Technique initial SB and MV balloon angioplasty Both branches are wired and both balloons are advanced into the MV and SB. The SB balloon is inflated first at low pressure (e.g. 2 atm). Then full inflation of the MV balloon is performed. After successful inflation, both balloons are deflated and withdrawn proximally, so a good angiogram can be done to evaluate the result while plotting the next move.

Advantages and Limitations

The theoretical advantage of this strategy is that the atherosclerotic material in the MV and SB may be better rearranged, and further MV stenting may not cause further plaque shifting. However, in reality, many times these assumptions were not true. Many SBs became severely compromised even after excellent results with balloon predilation. The limitations of balloon predilation include denudation of the SB ostium or potential rupture of a plaque, causing dissection in the proximal segment of the SB.

Practical Applications

The predilation of a SB depends on the intention to treatment. For the one-stent approach with provisional stenting, predilation of the SB is not recommended, because of the risk of dissection in the SB which may compromise flow and necessitate crossover to a two-stent strategy. In addition, the presence of a dissection flap may prevent the smooth insertion of a third wire in its true lumen and, if the flap is located close to the bifurcation carina, the preferred distal stent strut wire crossing may not be possible. Just 'keep it open' (KIO) is the basic concept of this one-stent technique whereby the aim of the treatment is to achieve stenting of the MV with less regard for the anatomic outcome at the SB, so long as there is satisfactory antegrade flow down the SB [1].

The possibility of SB dissections during predilation in a two-stent strategy also represents a challenge with the culotte technique, because there is a need to rewire one of the branches to position a second stent. Therefore, when only the culotte technique is planned, gentle predilation (if ever done) should be performed on the branch that needs to be rewired (preferably the less angulated branch) [1].

Technical Tip

****Diameter of the combined two balloons** As both balloons will inflate together in the MV proximal to the bifurcation, it is important that these balloons are not oversized. The dilating diameter of the two balloons will be less than the sum of the nominal diameters of both balloons, depending on balloon and vessel compliance and inflation pressure. The selection of two balloons should follow the Murray ($D_{\text{mother}}^3 = D_{\text{daughter } 1}^3 + D_{\text{daughter } 2}^3$) or the Finnet formula ($D = 0.67 \times [D_1 + D_2]$), where D is the proximal MV diameter, and D_1 and D_2 are the diameters of the two branches. These formulae are based on the structure–function scaling laws of the branching vascular tree.

There is an alternative Mitsudo formula which is based on flow conservation law and it estimates the theoretical mean hugging balloon diameter at the “kissing balloon segment,” i.e. based on balloon diameters rather than fractal geometry of the vascular bifurcation: $R^2 = D_1^2 + D_2^2$ where R is the theoretical mean hugging balloon diameter, D_1 the MV balloon diameter, and D_2 the SB balloon diameter [6] (Figure 14.3).

DIRECTIONAL CORONARY ATHERECTOMY

The removal of plaque with DCA has potential advantages in the treatment of bifurcation lesions in that it decreases the amount

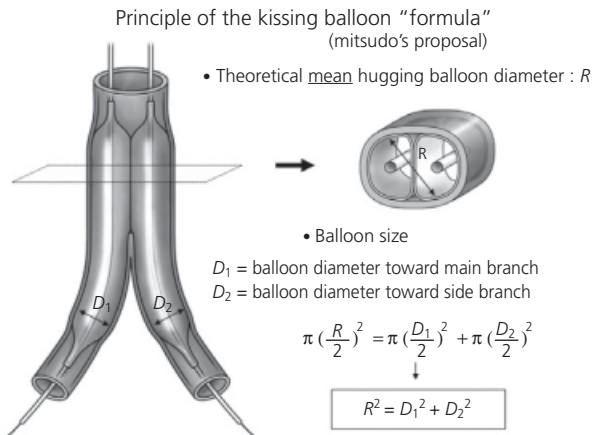


Figure 14.3 Size of two balloons. Principle of kissing balloon “formula” (Mitsudo’s proposal).

of plaque shifted toward side branches, and possibly decreases the incidence of dissection, and provides a larger, smoother lumen that could facilitate the deployment of a DES. This technique is rarely used.

Rotational Atherectomy

Lesion debulking with rotational atherectomy rather than DCA may be of particular benefit in smaller vessels, vessels that are heavily calcified, and those with significant ostial SB lesions.

Technical Tips

*****Strategies for rotational atherectomy of two branches** In general, the largest and most important limb is wired first for rotational atherectomy with a small burr (e.g. a 1.5-mm burr into a 3.0-mm limb) to secure a reliable lumen. If the lumen of the second limb is readily accessible, it can usually be accessed by withdrawing the burr just proximal to the bifurcation, placing it on Dynaglide, and manipulating the wire directly into the branch. This maneuver is not recommended if the lumen of the second limb appears to be difficult to wire. After the lumen of the second limb has been secured with rotational atherectomy, a decision has to be made about the next burr size. An ideal final burr:artery ratio is 0.6 or 0.7. Remember that a second wire cannot be present during rotational atherectomy because the burr can ablate and sever the wire within the coronary artery.

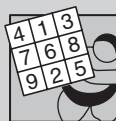
****Wire bias** Wire bias resulting in dissection and/or perforation is of particular concern in SBs with an acute takeoff angle. This may be reduced by use of a small burr and careful attention to wire bias. Wire bias in pulling or pushing a burr into or out of a lesion must be taken into account. A small burr pulled up into a lesion by a wire will ablate much more tissue than a small burr directed away from the same lesion.

****Side-branch protection** As SB compromise is seen so infrequently after rotational atherectomy, protection of branches with a second wire or predilation of SBs may not be necessary. Indeed, balloon angioplasty before rotational atherectomy should be avoided because predilation can cause dissection that would preclude the use of rotablation. As rotational atherectomy alone usually results in a suboptimal lumen, the procedure is generally completed with a “kissing” balloon inflation that can usually be accomplished with low-inflation pressures.

STENTING

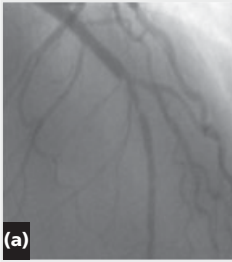
STRATEGIC MAPPING

The choice of technique is determined by the angle of bifurcation that is formed by the SB and the antegrade axis of the MV. Various techniques are preferred based on whether it

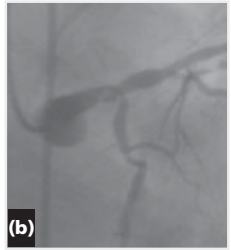


is $<90^\circ$, approximately 90° , or retroflexed and $>90^\circ$ to the antegrade MV. Usually the provisional SB-stenting technique is the first approach. For wider distal bifurcation angle, T stenting is the best choice. If the bifurcation angles are $<70^\circ$, DK crush, reversed crush, culotte, and T stenting at provision (TAP) techniques are all reasonable choices (Figure 14.4).

Influence of bifurcation angle



- ✓ Cush
- ✓ Mini-crush
- ✓ Culotte
- ⊗ T stenting



- ✓ T stenting
- ⊗ Cush
- ✓ Mini-crush
- ⊗ Culotte

Figure 14.4 Influence of the bifurcation angle on the selection of technique for bifurcation lesion: (a) Y shape; (b) T shape.

Selection of Stent

The two important criteria in stent choice are the stent design and the initial profile of the MV stent. The size of the MV stent is equal to the diameter of the main branch right distal to the bifurcation (Figure 14.5).

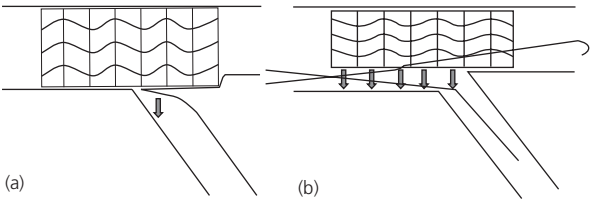


Figure 14.5 Sizing of the stent for the main vessel: (a) The main vessel stent should be sized according to the distal main branch diameter, right after the bifurcation. (b) Postdilatation, or kissing balloon inflations, are required to optimize the proximal main vessel stent diameter.

Open or Closed Cell Design

As the SBs are usually “jailed” by MV stenting, there is a need to cross into the SB through the MV stent struts. This is why it is important to recognize the differences in stent design and the result of dilation of MV side cells. In the open cell design, the stent struts are stretched and displaced with SB balloon dilation, resulting in a progressively larger opening as the balloon size increases, although not all stents respond equally. In the closed cell design, not all side cells open progressively with dilation of the SB balloon.

Different MV stent sizes and designs also offer different maximal strut size opening after dilation into the SB. This consideration is important in the presence of larger SBs, because the maximal strut opening into the SB should not be too much smaller than the SB ostium diameter. Otherwise stent struts will be traversing the SB ostium with possible altered hemodynamics. Furthermore, stretching the SB strut with too large a balloon may fracture the stent struts.

Stent Deformation after Side-strut Dilation

It has also been demonstrated that SB dilation through an MV stent consistently results in narrowing of the MV stent lumen immediately downstream from the SB. This narrowing increases in severity with increasing size and inflation pressure of the SB balloon. Redilation of the MV stent lumen alone with a larger balloon then results in some reduction in the size of the SB ostium. This is called the proximal optimization technique (POT) technique (Figure 14.6). This problem can best be corrected by ending the procedure with final KBI, although with caution to keep the proximal balloon margin within the stent and to avoid overdilation of the proximal segment of the MV stent [7]. Also, the size of the MV balloon should be the same size or larger than the MV stent.

Provisional Side-branch Stenting

Provisional SB stenting is characterized by stent implantation in the MV and, when necessary, stent implantation in the SB. If,

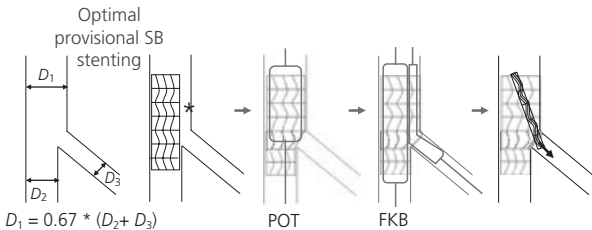


Figure 14.6 The proximal optimization technique (POT): Expansion of the stent at the carina, using a short oversized balloon that produces curved expansion of the stent into the bifurcation point and facilitates recrossing, distal recrossing, kissing inflations and ostial stent coverage of the side branch. (Courtesy of Drs O. Darremont and Goran Stankovic.)

during the pre-stenting dilation, the SB occludes, dissects, or has impaired flow, the threshold for SB stenting lowers significantly. Bailout stenting of the compromised SB appears reasonable if its diameter is ≥ 2.5 mm.

After deployment of the MV stent, if the flow in the SB is suboptimal, a wire and a balloon are passed through the side cell of the MV stent into the SB. Balloon angioplasty of the SB is performed to re-establish the blood flow with high pressure inflation of 1:1 sized balloon. If the ostium of the SB opens well, the procedure is completed. If the opening of the ostium of the SB is suboptimal, a stent is passed into the SB and deployed with its proximal margin just at the origin of the SB. Final KBI is needed to correct the deformation of the MV stent after SB dilation. Alternatively, a small balloon 1.5 or 2.0 mm (for stents 3.5 mm and more) could be inflated only at ostium at low pressure (6–10 atm). This ensures enough flow in the SB, without MV stent distortion (See also Figure 9.4).

Advantages and Limitations

The provisional T-stenting technique runs the risk of not covering fully the ostium of the SB. To optimally scaffold the SB ostium, the wire should ideally enter the SB ostium via the most distal stent cell of the MV. With balloon inflation of the SB, there will be adequate scaffold to overlap with an SB stent. Another technique to cover the SB ostium is to protrude the SB stent into the MV, creating a neocarina in the MV, but with potentially increased risk of stent thrombosis.

The T-stenting Technique

In case of a bifurcation lesion with an SB at a 90° angle, the technique of traditional T stenting is best. A wire is placed in each of the MV and SB. A stent is deployed first in the SB with the proximal stent edge at the origin of the SB, being careful that the SB stent does not protrude into the lumen of the MV. The SB wire is then removed. A stent is advanced into the MV deployed over the wire across the origin of the SB. Recross the MV stent into the SB and dilate the SB ostium to provide a larger stent cell opening, before performing final KBI (Figure 14.7).

Advantages and Limitations

T stenting can provide excellent results when the SB originates at a right angle from the MV (Figure 14.8a). When the bifurcation angle is other than 90°, the T-stenting technique runs the risk of having either an unstented gap at the origin of the SB, or protrusion of a portion of the SB stent into the MV (Figure 14.8b,c).

The Modified T-stenting Technique

In order to better cover the SB ostium, the modified T-stenting technique is suggested. First, both branches are wired; predilation is optional. A first stent is advanced into the SB and a second stent is advanced in the MV, covering the ostium of the SB. The SB stent is carefully positioned at the ostium of the SB and deployed. The balloon and wire are removed from the SB and

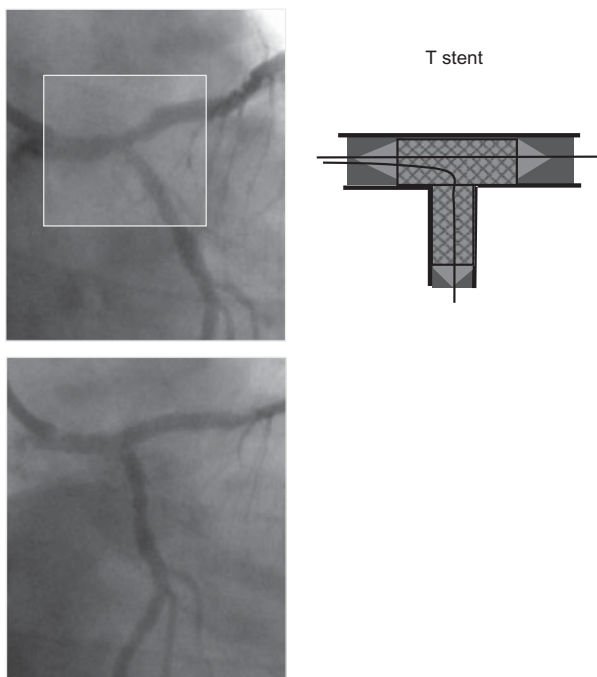


Figure 14.7 The T-stenting technique is best for bifurcational lesion with disease extending proximal to the bifurcation and side branch which has origin with about a 90° angle.

then the stent in the MV is deployed. The SB is rewired and KBI of both stents performed (Figure 14.9).

Advantages and Limitations

This technique allows exact positioning of the stent at the SB ostium. In case of slight protrusion of the SB stent into the MV, the MV stent can push the SB struts into the SB during MV stent deployment. The MV stent could be of any design, possibly with a large open side cell in order to facilitate rewiring and dilation of the SB.

The limitations include the need for a larger 7- to 8-Fr guide. This procedure is also limited to cases with near 90° SB bifurcations. However, in real life, more than three-quarters of all bifurcation lesions have angles $<70^\circ$. Also, if the stent in the SB is implanted too distally, an uncovered gap might remain at the ostium of the SB (SEE Figure 14.8b). The other disadvantage is that both stents are positioned at the same time. Movement of one stent can disturb the exact location of the other.

Practical Applications

The lumen of the MV should be well predilated to accommodate two stents without causing ischemia and to have good contrast

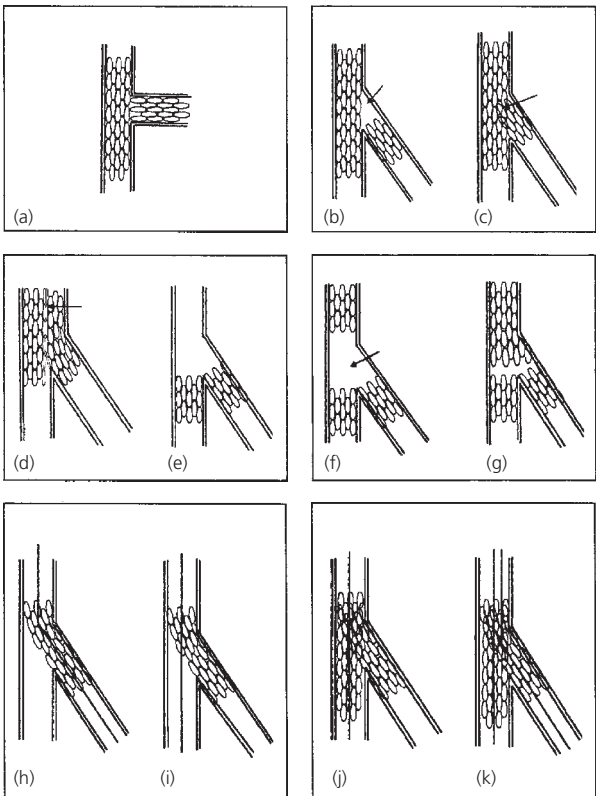


Figure 14.8 Types of bifurcation stenting: (a) T stenting with the right angle takeoff of side branch (SB) providing good coverage of lesions. (b) T stenting with acute angle takeoff of SB leaving an unstented gap at origin of the branch (arrow). (c) T stenting with a similar acute angle takeoff of the SB with coverage of the origin but protrusion of the stent into the MB (arrow). (d) "Kissing" stenting with stents in main branch (MB) and SB, and creation of double-barrel lumen in the proximal vessel (arrow). (e) V stenting, providing good coverage of MB and SB just beyond the bifurcation but leaving the bifurcation itself uncovered. (f) Y stenting similar to (e), but with placement of a third stent in the proximal vessel, the bifurcation itself remaining unstented (arrow). (g) "Trouser stenting" with the third stent advanced over two balloons into both distal branches overlapping the distal stents. (h) "Culotte stenting" with placement of the first stent in the most angulated branch, followed by advancing a guidewire through this stent into the opposing vessel (i), stenting this vessel through the first stent after predilation (j), finishing by recrossing the initial stent with a guidewire and doing simultaneous "kissing" balloon dilations in both branches (k).

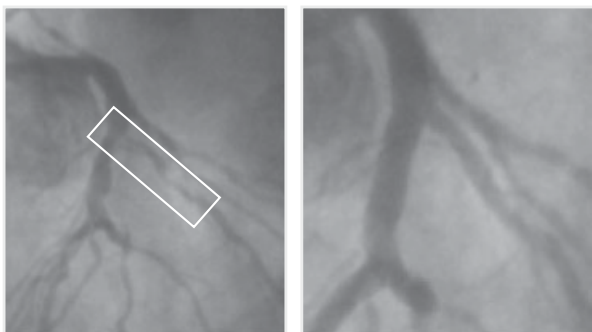


Figure 14.9 The modified T-stenting technique.

flow, in order to have good evaluation of the position of the two stents, including the proximal end of the SB stent at the SB ostium [8]. With a 7-Fr guide that may accommodate two stent catheters, the operator may expect some dampening of the blood pressure. This issue is less obvious with an 8-Fr guide.

TECHNIQUE T stenting at provision The TAP technique is a modified T-stenting technique. It works by stenting the SB with a slight protrusion into the MV through the insertion of a non-compliant balloon in the MV stent for positioning. The SB stent can be accurately positioned at the ostium without protrusion. After the SB stenting, both balloons were pulled back to the proximal part of the MV, and a final kissing inflation was performed (Figure 14.10).

CRITICAL THINKING

If final KBI is planned, SB predilation should be avoided. The reason not to predilate the SB with this strategy is that in coronary bifurcations the plaque is localized almost exclusively on the outer wall of one or both daughter vessels, with the flow divider (carina) almost always free of disease. After MV stenting, the carina (free of disease) is displaced/shifted toward the SB ostium facing the intact (not disrupted by predilation) plaque on the outer wall of the SB. Therefore during the subsequent step (rewiring the SB), it would be much easier for the operator to cross into the SB through the distal stent strut at the tip of the flow divider (distal cross). Rewiring the SB through this point of the bifurcation will ensure optimal SB ostium scaffolding after subsequent KBI. On the other hand, if final KBI is not planned, a stepwise strategy is suggested with the first step being systematic balloon angioplasty of the SB followed by stenting of the MV [9].



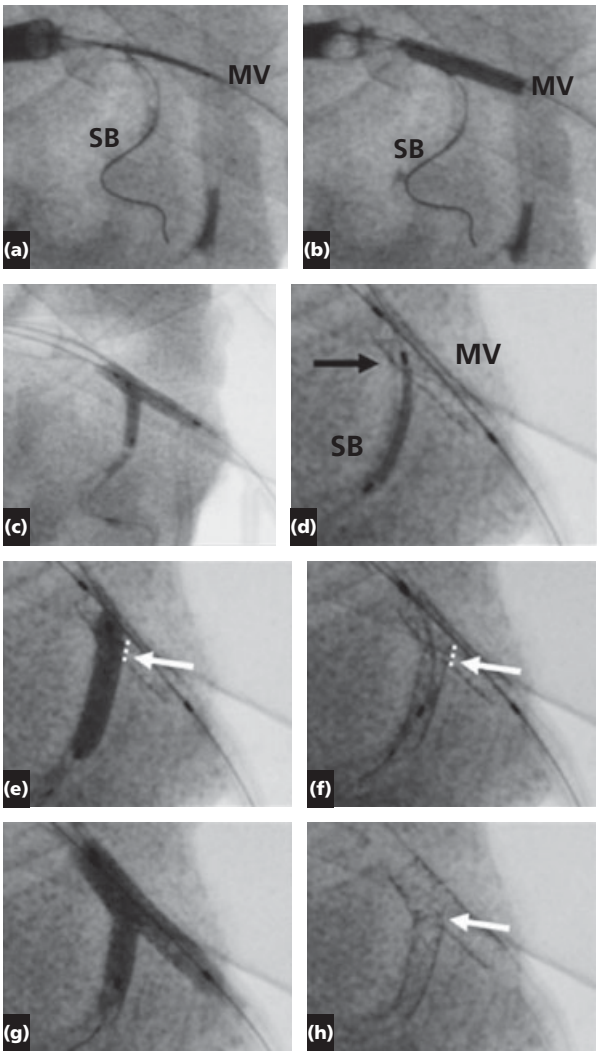


Figure 14.10 The T-stenting at provision (TAP) technique: TAP technique angiographic images of in vitro TAP stenting. (a) Stent positioning in the main vessel (MV) with jailed wire into the side branch (SB). (b) Deployment of MV stent. (c) Kissing balloon after re-wiring of the SB. (d) SB stent positioning: The position of the SB stent is adjusted to fully cover the proximal (or upper) part of the SB ostium (arrow), while an uninflated balloon is kept in the MV. (e) The SB stent is deployed with the uninflated balloon into the MV. (f) After SB stent deployment, the balloon of the stent is slightly retrieved and aligned to the MV balloon. The arrow indicates the protruding side-branch stent's struts within the MV only at the distal side of the SB ostium. (g) Final kissing balloon is performed by inflating simultaneously the SB stent's balloon and the MV balloon. (h) After kissing balloon the protruding side-branch stent struts are reoriented, resulting in a small, single stent struts, neocarina (arrow). Reproduced from Burzotta et al. *Catheter Cardiovasc Inter* 2007;**70**:75–82, with permission from Wiley.

Advantages and Limitations

The drawback of this TAP technique is that predilation of the SB could create a dissection that could hamper wire recrossing through the MV stent strut, and increase the risk of crossing a proximal strut (proximal cross), which may lead to deformation of the MV stent during subsequent KBI and increase the odds of needing provisional stent implantation. In this scenario, to optimally scaffold the SB ostium, the provisional SB stent typically protrudes into the MV, creating a neocarina in the MV, with potentially increased risk of stent thrombosis [9].

The Crush Technique

In the crush technique, both stents in the MV and SB are positioned with the proximal part of the SB stent lying well within the lumen of the MV. Importantly, it must be ensured that the proximal edge of the MV stent is more proximal than the SB stent. The SB stent is deployed first, and the balloon and wire are withdrawn while carefully ensuring the MV stent remains in position. The MV stent is then deployed, thereby crushing the proximal part of the SB stent. Then the SB is rewired and a final KBI is performed. It is always important to perform sequential balloon inflations: (1) The SB balloon (usually a non-compliant one) is inflated first at high pressures (18–20 atm) and (2) subsequently the two balloons are inflated together at medium–high pressures (10–15 atm) [10].

Advantages and Limitations

The crush technique requires a minimum 7-Fr guide. A potential limitation of the technique is the movement of the MV stent during withdrawal of the SB balloon and wire. Repositioning of the MV stent might be difficult because of protrusion of the struts of the SB stent in the MV [9]. The length of SB stent protrusion into the MV defines the subclassification of the classic crush technique: “Mini” crush (1–2 mm) and classic crush (3–5 mm) (Figure 14.11). Considering the potential increased incidence of stent thrombosis, the mini-crush technique is preferred. Another concern is that the multiple stent layers might delay re-endothelialization after DES implantation. In addition, bench studies have showed areas of suboptimal stent apposition and excess metal struts that potentially disrupt laminar hemodynamics, causing flow stagnation – all of which may increase the risk of stent thrombosis. Though not statistically significant, the CACTUS and NORDIC II trials showed a trend toward increased stent thrombosis in the crush stenting strategy when compared with provisional T-stenting and culotte techniques, respectively [11,12].

Double Kissing Crush Technique

In the DK crush technique, two wires are positioned in the MV and SB. The SB stent is positioned with its proximal end protruding 1–2 mm into the MV. The SB stent is deployed first while another balloon is positioned in the MV. The SB wire and balloon are then removed. The MV balloon is positioned with its proximal marker in line with the proximal end of the SB stent. The MV

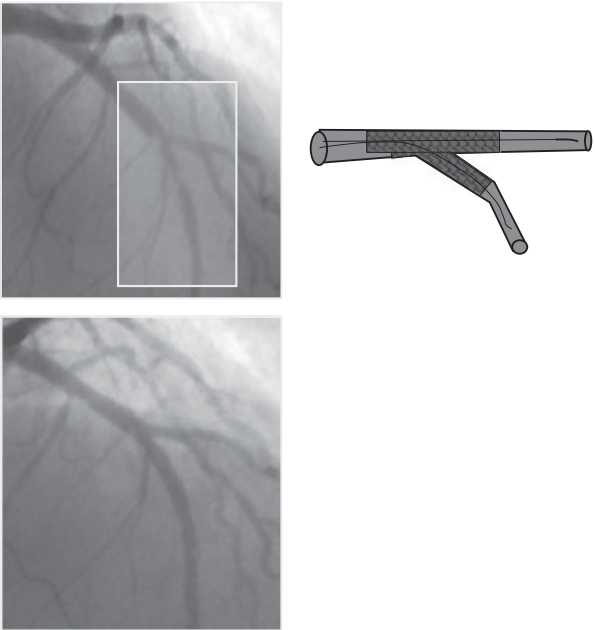


Figure 14.11 The mini-crush technique is best for bifurcational lesions with disease extending proximal to the bifurcation and side branch, which has about a 60° angle to the main vessel.

balloon is inflated to about 10 atm and crushes the SB stent in its proximal portion. The MV balloon is pushed distally. The SB stent is re-wired and a balloon is advanced into the SB stent. Then the first KBI is performed. This is the first KBI to expand the orifice of the SB. The wire and balloon from the SB are removed again. A new stent is advanced in the MV. The balloon is inflated to deploy the MV stent and to further crush the proximal portion of the SB stent. The SB is re-wired and a balloon is advanced into the SB. A second KBI is repeated [13] (Figure 14.12).

Technical Tips

****Crossing a balloon into the SB** At first, the MV balloon is inflated at low pressure (around 10 atm) and crushes the SB stent in its proximal portion. The MV balloon is pushed distally. Re-wire the SB and advance the balloon into the SB. If the balloon fails to cross the stent strut, advance a new non-compliant balloon. If this is not successful, dilate the SB ostium in a stepwise fashion, with a smaller semi-compliant balloon. If still unsuccessful, inflate the MV balloon (which is positioned distally) as an anchor to stabilize the guide so that the SB balloon can cross into the SB ostium.

****Advancing the MV stent with a SB balloon as an anchor** If there is difficulty in advancing the MV stent, inflate the SB balloon in order to anchor the guide.

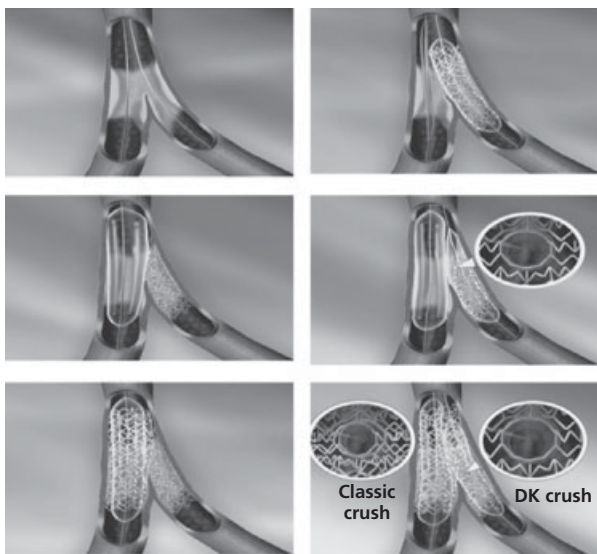


Figure 14.12 The double kiss technique.

Advantages and Limitations

The DK crush technique only requires a 6-Fr guide, similar to balloon crush. The first and final KBIs are easily performed because of the presence of only one layer of stent struts across the SB ostium. DK crush is associated with a larger SB ostial opening. The mechanism for greater success is explained below.

After the MV balloon crushes the proximal segment of the SB stent, the proximal segment of the SB stent becomes distorted and severely unexpanded. The first KBI repairs the distorted proximal segment and fully expands the orifice of the SB stent. Then the MV stent is deployed. The inflated stent in the MV almost does not touch or only barely touches the partially repaired segment of the SB stent. With fewer metal struts at the SB ostium, recrossing into the SB stent and second KBI is easier. Compared with the classic crush technique, not only do re-wiring and re-balloonng become more difficult or sometimes impossible, but they also cause more damage to the distorted SB stent if the wire ends up partially or completely under the SB stent. The main reasons contributing to these suboptimal immediate- and long-term results lie in the large metal ostial coverage gap. The additional second KBI in the DK crush technique is a key step to repairing MV stent distortion and enhancing strut scaffolding at the origin of the SB [13].

The Reverse Crush Technique

In the reverse crush technique, a stent is already deployed in the MV, and the SB is wired through the MV stent cell. After predilation of the SB ostium, a stent is positioned in a way that ensures

that the proximal part lies well within the MV. A balloon of the same size as the MV stent is positioned in the MV. The SB stent is deployed, and the SB balloon and wire are withdrawn. The SB stent is then crushed by the MV balloon. The SB is rewired and final KBI is performed.

Advantages and Limitations

This technique is useful in two situations: (1) If it is felt that it might be possible to avoid routine SB stenting, but the result of the SB is poor after the MV has been stented; or (2) for patients who return with on-going problems related to restenosis at the ostium of the SB after only MV stenting [14].

The V-stenting Technique

The V-stenting technique is performed by placing two stents in both branches of a bifurcation with overlap of the proximal stent portions. This may be done either with simultaneous stent deployment with equal pressure in both balloons, or by sequential stent deployment followed by final simultaneous inflations of both stent balloons (see Figure 14.8e). The result is that, in the proximal parts, the stents are positioned to be just abutting each other thereby creating the classic "V" configuration.

Different techniques allow a variable amount of protrusion, sometimes creating a rather long (≥ 5 mm) double barrel in the proximal MV (a difference between V and simultaneous kissing stent [SKS] technique) (see Figure 14.8d). The most appropriate stents for the "V" technique are two slotted tube stents of equal design with good radial strength to preserve the best configuration of the original carina. Lesion coverage is also complete.

The V-stenting technique provides good access to both branches of the bifurcation but should be used only in larger arteries and where the size of the proximal vessel will permit simultaneous high-pressure balloon inflations. With this technique, a double-barreled lumen is created in the proximal vessel with a metallic carina not opposed to any vessel wall (Figure 14.13).

Advantages and Limitations

The main advantage of the "V" technique is that the operators will never lose access to either of the two branches. In addition, when a final KBI is performed, there is no need to recross any stent. It is necessary to recognize that the "V" or SKS techniques cannot be applied in every bifurcation where two stents are needed.

Important limitations are the extent of disease proximal to the bifurcation and the angle (close to or $>90^\circ$) of the SB. One of the problems with this technique is that the proximal stent struts may puncture the opposing balloon. "V" technique also requires very large branches with a narrow angle of origin.

The Simultaneous Kissing Stents Technique

The SKS technique is best suited to easily accessible bifurcations with a large proximal reference diameter containing plaque in which both branches are of similar diameter. The procedure

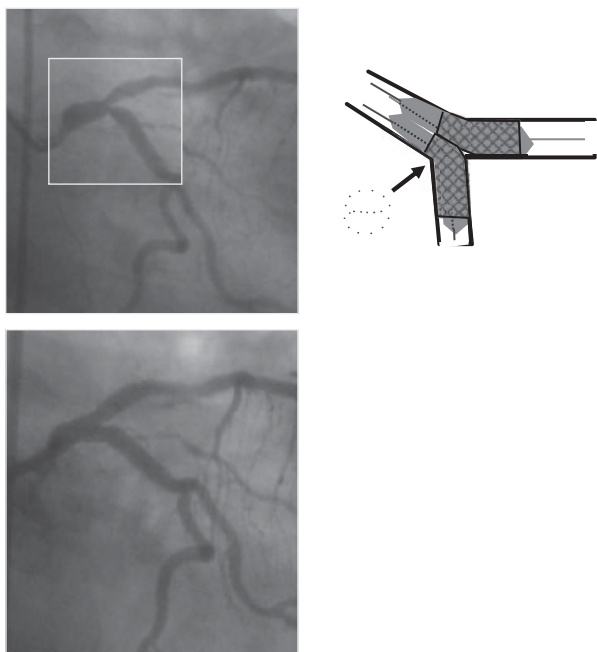


Figure 14.13 The V-stenting technique: Two stents deployed simultaneously while the “carina” is conserved or moved proximally. In this technique, there is safe, quick, continuous control of both branches. However, this technique is not applicable in all anatomies. It is best when the proximal main vessel is large

involves wiring the MV and SB, which maintains access to both for the entire procedure. Both stents are positioned side by side, creating a “double barrel” configuration and are deployed simultaneously, which also helps to minimize carina shift. By having both stents parallel, this extends the carina of the bifurcation proximally.

The main requirement to do SKS is the size of proximal vessel – it must be $\geq 70\%$ of the summed size of the distal branches (for SB 3.0 mm and MB 3.0 mm, MV must be $0.7 \times [3 + 3] = 4.2$ mm) (see Figure 14.8d and 9.10).

Advantages and Limitations

The SKS technique is the simplest and most immediate approach to treat bifurcations when two stents are needed. The limitations include the need for relatively narrow bifurcation angles and the use of large-sized guides (7 Fr minimum). This technique also does not allow provisional stenting and always forces the operator to use two stents from the very start of the procedure.

The other disadvantages are as follows: (1) A metallic carina is created with a large overlap of metal in the MV; (2) a gap forms beneath the crossing point of the two stents; (3) creation of a

double barrel makes endothelialization more unlikely; (4) the patient may require lifelong dual antiplatelet therapy; and (5) if proximal dissection occurs, converting to crush stenting or placing another stent is very difficult.

Technical Tip

****Perfect stenting** One must pay attention to carefully align the proximal ends of two stents. Sequential inflation of stents should start gently with the SB first, which should then be deflated before inflation of the MV stent. Final KBI is the essential last step. If one needs to re-wire during the SKS procedure, the wire must be manipulated very carefully within the stent rather than through the overlapping struts [12].

The Culotte Technique

In “culotte” stenting technique, a stent is placed in the first branch with a second stent placed through a cell of the first stent into the second branch with overlapping of the proximal portions of both stents (see Figures 14.8h–k). The wires are initially placed in both branches and predilation is performed, either sequentially or simultaneously. A stent is then placed in the first branch covering a segment proximal and distal to the bifurcation across the opposing (second) branch. Another wire is then advanced across the deployed stent into the unstented (second) branch. Some operators prefer leaving the initial wire in the (second unstented) branch during stenting of the first branch as a guide to recrossing, although this has the disadvantage of jailing this wire. Once the unstented (second) branch has been crossed with a wire, this branch is dilated with a balloon to open the stent cell in preparation for stenting of the (second) branch. The balloon is then removed and the second stent advanced over the (second) branch wire and positioned so as to cover the (second) branch lesion and widely overlap the proximal portion of the previously placed stent. The wire in the first branch, having been pulled back before deployment of the second stent, is then readvanced across the struts of both stents into the first vessel and balloons over both wires to finish with a KBI (See figure 9.11).

Technical Tips

****Perfect stenting** During this final inflation, it is important to be certain that both balloons are within the proximal stent and that they are inflated at relatively low pressure, being careful not to oversize the overlapped balloons.

****Which branch should be stented first?** Generally the larger, more important branch is stented first, although consideration must also be given to angulation at the bifurcation. If there is marked angulation or high calcification, it is preferable to stent the more angulated branch first to permit easier access into the opposing branch. If an important dissection or occlusion is present in one branch, this branch should be stented first, because wire removal might be risky. Accordingly, when the lesion remains T shaped (which means that the bifurcation angle is $>70^\circ$) after

wiring, if the access to the SB is difficult or if the SB lesion is long or dissected, the SB should be stented first. If the SB is going to be stented first, it should be kept in mind that visualization of the SB ostium is sometimes difficult and, before stent deployment, it is therefore important to check stent position using adequate and multiple views, to avoid a too distal or too proximal SB stent deployment. Once the MV and the SB stent are deployed, the SB ostium can be taken care of.

INTERVENTIONS OF SIDE BRANCHES

The frequency and severity of SB compromise may be decreased by balloon angioplasty, rotational atherectomy, or DCA of the SB before stent placement, although redilation is frequently required after stent deployment. Compromise of small SBs <2mm diameter is frequently of no clinical significance and may require no particular treatment. With loss of a larger SB, a second wire can usually be passed through the side struts into the compromised SB.

If the SB ostium is narrowed by carinal shift, then a relatively small balloon is sufficient to enlarge the SB ostium, whereas a larger balloon is necessary to make the SB larger should the SB ostium be compromised due to plaque shift. In this situation, it is important to avoid distal SB dissection.

In the case of some severely calcified SB lesions that seem unlikely to respond to balloon dilation, rotational atherectomy through the stent struts into the SB can be performed. When this is done, a small burr should be used initially with gradual increase in burr size to prevent burr entrapment in the SB.

Side-branch Wire Entry

Some operators leave a wire in the SB at the time of MV stent deployment as a marker for the site of origin of the SB. After the MV stent has been deployed, a wire is advanced in the MV stent and manipulated to enter the SB through the MV side cell. Care must be taken to avoid passing the new wire behind the MV stent rather than through a side cell of the MV stent into the SB. Proper positioning of the wire within the MV stent lumen is confirmed by easy, unobstructed passage across the MV side cell into the SB. Positioning of the wire under the MV stent may be indicated by inability to advance a balloon into the SB.

CRITICAL THINKING

****Risk and benefits of a "Jailed" wire**

Most of the time, a wire can be voluntarily "jailed," left in the SB while stenting the MV especially if the SB has a ostial stenosis >50%. The jailed wire strategy is part of the 'keep-it-open' concept for SB whereby any reasonably sized SB (>2.0mm), or functionally important SB, needs to be protected with an additional wire.



This SB wiring technique also favorably modifies the angle between both branches by converting a T-shaped bifurcation to one with a Y-shaped angle, thus facilitating re-wiring. The presence of this jailed wire helps to keep the SB open. Furthermore, the absence of such wire has been shown to increase risk for re-interventions in the long run. In the case of occlusion, this wire (usually a non-hydrophilic one) can be a valuable landmark to facilitate recrossing with another wire into the SB after MV stenting

Technical Tips

****Warning about wire jailing** Avoid jailing a wire between the metallic layers of the two stents during classic crush technique, as fracture of the wire may occur.

****Where to cross the stent side cell** Access to the SB through the strut of a stent is usually possible through two or three different cells (proximal, mid, and distal). The cell choice influences stent deformation and the best approach is to cross the most distal cell of the stent during wiring of the SB. After dilation of the distal cell, there are at least two or three struts protruding into the SB ostium, well apposed into the arterial wall opposite the carina. These struts would help to prevent ISR. The POT also assists in distal stent strut crossing. In this technique, the MV stent is sized according to the distal (after the SB origin) MV reference diameter. This method also prevents carinal shift secondary to an oversized stent. POT actually decreases, but does not eliminate, carinal shift.

CRITICAL THINKING

Where to insert the wire?

As the dimension of a stent cell is $1 \times 1.5 \text{ mm}$, there is a need of $1 + 1 + 1 = 3 \text{ mm}$ cells covering an SB ostium from which the operator has to choose which cell to re-cross. The classic teaching is to re-cross the most distal cell. In reality, with a 2.5 mm diameter SB with ostial stenosis of 70% after stenting, the new ostial SB diameter is 0.7–0.8 mm. In this situation, does the operator have a large selection of cells to insert the wire into (Figure 14.14)?



TECHNIQUE How to manipulate a wire to cross an MV side cell At first, the wire should be shaped to approximately 90° ; after the tip has been engaged within the struts at the origin of the SB, a slight backward movement with careful steering allows crossing the tip into the SB:

- 1 In case of no success, reshaping of the tip with a wider, $>90^\circ$ curve should be attempted
- 2 Hydrophilic-coated wire might find less friction in crossing the struts, but the risk of dissecting the SB increases

Different positions of SB wire passage

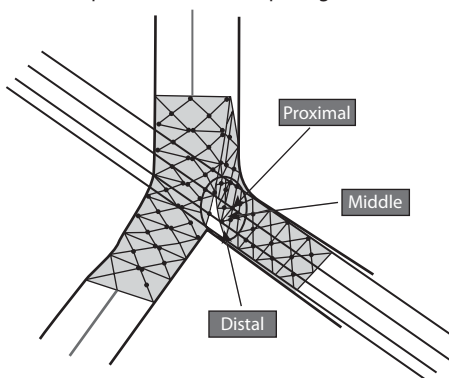


Figure 14.14 Where to cross the side branch. (Courtesy of U. Nanjing.)

3 If they also fail, then consider stiffer tapered tip wires, e.g. Miracle wire series

4 If after MV stenting, the SB has diminished thrombolysis in myocardial infarction (TIMI) flow, or the angle is $>70^\circ$, it is advised not to withdraw the jailed wire.

The MV wire should be used to enter into the SB with the jailed SB as a landmark.

Technical Tips

****Use an OTW balloon to cross the side cell into the SB** In case of no success, a 1.5-mm OTW balloon or microcatheter can be advanced close to the origin of the SB to increase the support of wire crossing. This technique is especially useful for a reverse ($>90^\circ$) angle of origin of a SB. The J tip is shaped manually depending on the angulation of the SB and the length of the tip should be equal to the diameter of the MV (Figure 14.15).

****Use a stiff wire to cross the side cell into the SB** If the distal bifurcation angle is wide, a stiff wire is needed to facilitate the advancement. After insertion of a hydrophilic wire into the SB, a microcatheter or OTW balloon can be used for exchange with a non-hydrophilic wire.

****How to shape the wire tip** In an "extreme angulated" lesion, it is usually impossible to enter the SB directly. In these cases, cross the whole MV stent first, then pull back the wire with its tip oriented towards the SB so that it can "jump" naturally into the SB ostium. Gentle torque maneuver helps to feel the lesion and cross it progressively.

****Use a microcatheter** In case of unsuccessful crossing into the SB, use a microcatheter to help the wire crossing into the SB.

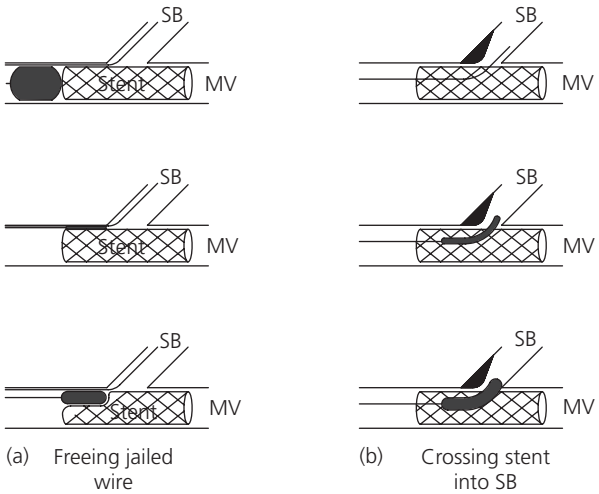


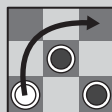
Figure 14.15 (a) Use a small balloon inflation behind the main vessel stent to open a side branch: In case of total and symptomatic occlusion of a SB, with failure to pass a wire into the SB lumen from the MV lumen, due to dissection, advance a small balloon over the jailed wire (between the stent struts and the vessel wall) and inflate the balloon. Use the smallest balloon available to increase the chance to pass under the stent struts and to avoid major deformation of the MV stent. (b) Use of an over-the-wire balloon to cross the side cell into the side branch (SB): Try to cross the main vessel (MV) stent strut with a balloon on a fixed wire. This balloon has minimal transition between the wire and balloon. If *just* the tip of the balloon crosses the side struts, inflate the balloon in order to open the side cell. Illustrated by Quoc Nguyen.

****Redilate the MV stent to widen the MV side cell** After deployment of the MV stent, a short larger balloon – sized according to the proximal MV diameter – is positioned and inflated with its distal tip at the bifurcation. Be careful to use short balloons so that the proximal end of this larger balloon is within the MV stent and does not dilate the unstented proximal segment, lest it causes vessel dissection. This technique optimizes the proximal MV stent deployment and in the process opens up the stent cells at the bifurcation, thus facilitating wire crossing at the distal struts (similar to the POT technique) (Figure 14.6) [14].

****Use a dedicated wire to cross the side cell** In the attempt to cross the MV side cell, except for the use of OTW balloon, several other devices could be useful in facilitating the advancement of a wire. The Venture catheter has a deflecting tip that could be directed to the orifice of the SB. Recently, the Crusade catheter has been tested clinically. Its advantages are similar to those of the Venture catheter. Most importantly, before the negotiation of a wire into the SB, the MV stent should be well dilated in order to have wide open cell for SB wiring.

TACTICAL MOVE**BEST OPTIONS for crossing a wire into the side branch**

- 1 FIRST Best Option:** Reshape the tip of the wire
- 2 SECOND Best:** Use a hydrophilic wire
- 3 THIRD Best:** Use a stiffer wire
- 4 FOURTH:** Use an OTW balloon
- 5 FIFTH:** Dilate the MV to make the side cell more enlarged (POT)
Use a dedicated Venture or Crusade catheter

**ADVANCE A BALLOON INTO A SIDE BRANCH**

In general, the balloon should not be advanced completely through the stent into the SB for inflation because this increases the risk of balloon entrapment. The inflation pressure should also be kept well under the rated burst pressure because balloon rupture within a stent strut can also cause balloon entrapment.

Technical Tips

****First maneuver when encountering difficulty advancing a balloon into a side branch** If a balloon cannot pass through the side cell, the location of the wire needs to be checked. Be sure that the wire is not under the MV stent strut. A crisscross wire technique can frequently be used to successfully rewire the SB wire into the MV and then to insert the MV wire into the SB. This ensures that the SB wire is not beneath the stent strut. In this technique, the MV wire is pulled back **within** the MV stent till the ostium of the SB, before guiding the tip into the SB. The SB wire is then pulled out proximal to the MV stent before being advanced back into the MV. The second reason might be because of twisting of the two wires (“wire-wrapping”). So pull the wire in the MV back to the stent, leaving only the soft tip inside the stent, and then advance the balloon across the struts to the SB.

****How to advance an OTW balloon into a side branch** If it is impossible to advance a monorail balloon across a side strut, the next alternative is to cross the MV stent strut with a balloon on a fixed wire. This balloon has minimal transition between the wire and balloon, so preserving optimal “pushability,” which allows comfortable strut crossing. Furthermore, this method is quick, because only one device needs to be inserted. If the balloon fails to advance, repeated, quick forward and backward movement (“dottering”) of the balloon, and adjusting the guide position by deeper intubation from time to time may help the balloon to cross (see Figure 14.15).

****Inflate a balloon in the MV as an anchor** If the guide backs out while advancing the wire through the SB, another

practical way is to inflate the MV balloon, serving as an anchor balloon. After gently intubating the guide, a smaller size 1.25-mm or 1.5-mm compliant balloon can usually be advanced into the SB. Inflation can be carefully done to avoid burst of the SB balloon. The MV balloon can be deflated once the SB balloon is advanced to minimize ischemia. The SB can be increased stepwise to its appropriate size.

****Inflate a balloon in the MV to open a side branch** If the balloon could not get through the struts of the MV stent to be advanced in the SB, push the balloon near the SB, with the tip across the stent struts. Inflate the balloon so that the balloon can dilate the stent, making a small opening. Try once or twice then push the balloon through. If there is problem in advancing the balloon, use a compliant monorail 1.5-mm balloon. If this balloon fails to cross, re-wire the SB through a different part of the SB orifice and reattempt balloon crossing. If this also fails, use a fixed wire balloon system.

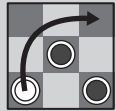
*****Lubricate the balloon** The balloon or stent can be dipped into a lubricant (Rotaglide) solution to facilitate its delivery into the SB.

TACTICAL MOVE

BEST OPTIONS for crossing a balloon into the side branch

- 1 FIRST Best Option:** Check the wire to be sure it is inside the MV lumen
- 2 SECOND Best:** Advance the tip of a fixed wire balloon across the MV side cell then inflate the balloon

In select cases, the balloon or stent can be dipped into a lubricant (Rotaglide) solution to facilitate its delivery



*****Small balloon inflation behind the MV stent to open an SB** In case of total and symptomatic occlusion of an SB, with failure to pass a wire into the SB lumen from the MV lumen, due to dissection, advance a small balloon over the jailed wire (between the stent struts and the vessel wall) and inflate it. Use the smallest balloon available to increase the chance of passing under the stent struts and to avoid major deformation of the MV stent [15] (see Figure 14.15).

*****How to withdraw the jailed SB wire** Sometimes the jailed wire is trapped and forceful withdrawal may result in broken wire and deeper intubation of the guide which could result in LM dissection. A practical way is to use a balloon, advance it through the jailed wire up the MV stent. Then gentle withdrawal of the SB wire will avoid the above complication.

In a preventive mode, it is not necessary to advance deeply a wire into the SB. Before performing the Crush technique, pull the SB wire back and leave only a short segment across the SB ostium.

Side-branch Balloon Inflation

After stenting the MV, if the ostium of a SB shows severe residual stenosis due to carinal shift, a small balloon inflation is sufficient to enlarge the ostial SB. If there is severe residual stenosis of the SB ostium due to plaque shift, a relatively larger balloon inflation at lower pressure may help to open further the ostium of the SB.

Technical Tips

****Size and pressure for SB inflation after MV stenting** When the proximal MV diameter $< 2/3 \times (MV + SB)$ by visual estimation, there are two options: Use of intravenous ultrasound (IVUS) to calculate the exact MV diameter, or calculate the MV diameter based on two branch diameters (see Finet, Murray, and Mitsudo formulae). An exception is when there is a bigger difference in diameter between the MV and SB. In such situations, the very small balloon diameter in an SB will result in unsatisfactory kissing results, leading to significant distortion of the SB stent.

Kissing Balloon Inflation

After deploying the stent in the MV and SB, to achieve optimal results in both vessels, a KBI can be done with simultaneous dilations in both branches (see Figure 14.3). This technique may, therefore, not be suitable if the proximal vessel diameter is not larger than that of the branches involved. In this case, both branches may be dilated more aggressively in sequence with a non-compliant high-pressure balloon and a final low-pressure KBI to limit stent deformation. Try not to use oversized balloons. Always first inflate the balloon in the stent and after achieving 5–6 atm start inflation of the SB balloon. When both balloons have pressure of 6 atm continue with simultaneous inflation and, accordingly, simultaneous deflation.

Main Vessel and Side-branch Stent Distortion

Stent distortion occurs when, during KBI, the MV balloon diameter is smaller than the diameter of the original delivery balloon. The distortion occurs with all stent designs and all bifurcation techniques. The distortion should be corrected by redilating the MV with an appropriately sized balloon [16]. So final KBI can fully expand the stent in the SB ostium and repair MV distortion. With SBs angled at 70° , KBI can produce these outcomes. In contrast, with SB angled at $< 70^\circ$, KBI may not expand the SB stent at the ostium. To expand the stent fully when the branch is angled at $> 70^\circ$, it may be necessary first to postdilate the SB with a balloon that protrudes only a few millimeters into the MV, so the balloon is not bent and stays fully straight. After deflation of this

balloon, the MV balloon should be dilated with an appropriately sized balloon to repair any distortion [17].

Unsatisfactory Kissing Results

Another very important concern is the occurrence of unsatisfactory kissing results (KUS). KUS is defined as the wrist phenomenon or the presence of at least 20% residual stenosis in the SB balloon during KBI. Usually, the SB balloon is opened fully during sequential inflation; however, it can be narrowed at various levels during KBI. The presence of KUS indicates the underexpansion of these struts at the SB ostium. An inappropriate smaller-sized balloon for SB used during KBI after the one-stent technique would be another reason for KUS. This is one of the possible reasons why there is increased post-stenting narrowing in ostial SB.

Technical Tips

****Perfect kissing balloon inflation** What is of paramount importance is performing a high-pressure balloon inflation in the SB to be sure that the SB stent is fully expanded. Then the KBI is performed at medium pressure, usually 15 atm (when the two balloons are inflated together), to avoid any proximal dissection. Deflating the balloons simultaneously may help to prevent any further distortion of the stent struts, thus avoiding incomplete apposition [17].

The inflation pressure for KBI is recommended not to be <16 atm. The overlapping length of two balloons in the proximal portion beyond the carinal level is as short as possible to avoid the twisting of two balloons.

NEW TECHNIQUE The flower petal The technique of “flower petal” stenting involves implanting a stent in the SB with one strut protruding into the MV. The protruding strut closest to the carina is wired and dilated to create a larger strut or “flower petal”; this protruding petal is then flattened and plastered down over the carina with a series of MV inflations, including a MV stent and kissing balloon inflations, thus ensuring complete ostial coverage and scaffolding.

Advantages and Limitations

The most challenging part of this technique is wiring a single strut close to the carina and, even for these expert operators, this required IVUS guidance and was not always successful. The proponents modified the technique to allow ex vivo wiring of the proximal strut and subsequent balloon insertion into this strut (akin to the Szabo technique) for ostial lesions. This approach needs partial inflation of the proximal segment of the stent, performed before stent insertion in the guide. By doing this, they created a bulkier dual-wire and balloon system that might suffer from the shortcomings of similar dedicated devices: Wire wrap, wire bias, and atheroma that might prevent advancement of the device. Most of the limitations of “flower petal stenting” can be overcome by applying this technique mainly in bifurcation lesions located in the distal left main [18].

TAKE-HOME MESSAGES

For PCI of bifurcation lesions, appropriate selection of devices is most important. As KBI is required in most cases after either a one- or two-stent technique, a guide with sufficient inner lumen should be carefully considered before the procedure, e.g. a 6-Fr guide meets the requirement of most procedures, with the exception of the use of two balloons or stents with diameters >3.0 mm. A 7-Fr guide can be used for all procedures including rotational atherectomy, using up to 1.75 mm sized burrs. The choice for the jailed wire in SB should be a non-hydrophilic one, and hydrophilic wire is not preferred for SB rewiring.

If the provisional SB stenting technique is used, IVUS is useful to identify the reasons for a narrowed SB ostium, i.e. either carina or/and plaque shifts. If SB ostium is narrowed by carinal shift, then a relatively small balloon is sufficient to enlarge the SB ostium, whereas a larger balloon is necessary to make the SB larger should the SB ostium compromise be due to plaque shift. In this situation, it is important to avoid distal SB dissection. Of course, if two-stent techniques are selected, sequential inflations using a non-compliant balloon for SB is critical, which is then followed by KBI at higher pressure. KUS is an independent factor for future adverse events.

REFERENCES

1. Colombo A. Bifurcational lesions: Searching the solution. *Catheter Cardiovasc Interv* 2005;**65**:17–18.
2. Iakovou I, Ge L, Colombo A. Contemporary stent treatment of coronary bifurcations. *J Am Coll Cardiol* 2005;**46**:1446–55.
3. Furuichi S, Airolidi F, Colombo A. Rescue inverse crush. A way to get out of trouble. *Catheter Cardiovasc Interv* 2007;**70**:708–12.
4. Hermiller MD. Bifurcation intervention: keep it simple. *J Intervent Cardiol* 2006;**18**:43–4.
5. Mohaved MR. Major limitations of randomized clinical trials involving coronary artery bifurcation interventions: Time for redesigning clinical trials by involving only true bifurcation lesions and using appropriate bifurcation classification. *J Intervent Cardiol* 2011;**24**:295–301.
6. Morino Y, Yamamoto H, Mitsudo K, et al. Functional formula to determine adequate balloon diameter of simultaneous kissing balloon technique for treatment of bifurcated coronary lesions clinical validation by volumetric intravascular ultrasound analysis. *Circ J* 2008;**72**:886–92.
7. Ormiston JA, Webster MWI, Ruygrok PN, et al. Stent deformation following simulated SB dilatation: A comparison of five stent designs. *Catheter Cardiovasc Interv* 1999;**47**:258–64.
8. Barlis P, Tanigawa J, Kaplan S, et al. Complex coronary interventions: unprotected left main and bifurcation lesions. *J Intervent Cardiol* 2006;**19**:510–24.
9. Kwan TW, Vales L, Liou M, et al. Tips and tricks for stenting of bifurcation coronary lesions. *J Invasive Cardiol* 2010;**22**:440–4.
10. Ge L, Airolidi F, Iakovou I, et al. Clinical and angiographic outcome after implantation of drug-eluting stents in bifurcation lesions with the crush

- stent technique: importance of final kissing balloon post-dilation. *J Am Coll Cardiol* 2005;**46**:613–20.
11. Colombo A, Bramucci E, Sacca S, et al. Randomized study of the crush technique versus provisional side-branch stenting in true coronary bifurcations: The CACTUS (coronary bifurcations: Application of the crushing technique using sirolimus-eluting stents) Study. *Circulation* 2009;**119**:71–8.
 12. Erglis A, Kumsars I, Niemelä M, et al., for the Nordic PCI Study Group. Randomized comparison of coronary bifurcation stenting with the crush versus the culotte technique using sirolimus eluting stents: The Nordic Stent Technique Study. *Circ Cardiovasc Interv* 2009;**2**:27–34.
 13. Chen SL, Ye F, Zhang JJ, et al. DK crush technique: modified treatment of bifurcation lesions in coronary artery. *Chinese Med J* 2005;**118**: 1746–50.
 14. Sianos G, Vaina S, Hoye A, et al. Bifurcation stenting with drug eluting stents: Illustration of the crush technique. *Catheter Cardiovasc Interv* 2006;**67**:839–45.
 15. Aminian A, Dolatabadi D, Lalmand J. Small balloon inflation over a jailed wire as a bailout technique in a case of abrupt Side branch occlusion. *J Invasive Cardiol* 2010;**22**:449–52.
 16. Ormiston J, Currie E, Webster M, et al. Drug-eluting stents for coronary bifurcations: Insights into the crush technique. *Catheter Cardiovasc Interv* 2004;**63**:332–6.
 17. Colombo A. Bifurcational lesions and the crush technique: Understanding why it works and why it doesn't – a kiss is not just a kiss. *Catheter Cardiovasc Interv* 2004;**66**:337–8.
 18. Colombo A, Azeem L. The artisan approach for stenting bifurcation lesions. *J Am Coll Cardiol Interv* 2010;**3**:66–7.

CHAPTER 15**Complications**

Ashok Seth, Nguyen Ngoc Quang, Vijay Dave, Thach N. Nguyen

Challenges 349

Contrast-Induced Nephropathy 349

Hydration 349

Sodium Bicarbonate 350

Medications 350

N-Acetylcysteine 350

Lower Amount of Contrast 350

Technical Tip 351

**How to do PCI with 20ml contrast? 351

Contrast Allergy 352

Prevention 352

Threatened or Acute Closure 353**Dissection 353**

Technical Tips 356

**Recognizing dissections from its look alikes 356

Management 356

Technical Tips 357

*Preventing dissection 357

*Prevention of dissection during LIMA cannulation 357

**Recrossing the dissected segment 357

**Re-entry into the true lumen in a stented area 357

**Early detection of dissection during SVG cannulation 358

Left Main Dissection 358

Technical Tips 358

**Can the LM dissection be missed by a small guide? 358

Retrograde Aortic Dissection 359

How you can make a Difference 361

Acute Thrombotic Closure 361

Causes of Acute Occlusion after Stenting 362

Stent Fracture 363**No Reflow 363**

Advantages and Limitations 364

Classification and Management of Slow Flow 365

Proximal occlusive lesion 365

Distal vascular bed dysfunction 366

Local dissection with or without antegrade flow 366

*Basic; **Advanced; ***Rare, exotic, or investigational

\$, <\$US100.00 extra; \$\$, >\$US100.00 extra

⌚, <10 min extra; ⌚⌚, >10 min extra

♣, low risk of complications; ♣♣, high risk of complications

- Severe distal disease 366
- Medical management 366
- Adenosine 366
- Nitroprusside 367
- Verapamil 367
- Nicardipine 367
- Preparation of Nitroprusside 367

Air Embolism 367

Technical Tips 367

- **Management of air embolism 367
- **Management of massive air embolism 368

Intramural Hematoma 368

Clinical Presentation and Management 368

Coronary Perforation 368

Technical Tips 371

- **Preventive measures against perforation by a wire 371
- **Preventive measures against perforation due to balloon angioplasty or stenting 372
- **Management of perforation at the proximal and midsegment 372
- **Reversal of glycoprotein IIb/IIIa inhibition 373

Discriminating Differences 374

Covered stent or coil embolization 374

Differences among Coils 375

Technique Coil embolization 375

Technique Particle embolic agents 376

Advanced and Exotic Techniques 377

Technical Tips 377

- **Embolize a distal vessel with an OTW catheter 377
- **Occlusion of the distal artery with subcutaneous tissue 377
- ***Dual guide for closure of perforation 377
- ***The switching balloon technique 377

Management of Perforation at the Distal End of an Artery 381

Pericardial Effusion and Tamponade 383

Aggravating Factors 383

Attenuating Factors 383

Clinical Presentation 384

Pulse pressure 384

Chest radiography 385

Echocardiography 385

Management 387

Technique Echo-guided pericardiocentesis 387

Technique Blind pericardiocentesis 387

Low pressure tamponade 388

Tamponade with RV and LV dysfunction 388

Coronary Aneurysm 392

- **Prevention of in-stent restenosis of covered stent 393

Cerebrovascular Accident 393

Transient and Permanent Blindness 393

Ventricular Tachycardia and Fibrillation 394

The one and only maneuver – coronary perfusion during CPR 394

Technical Tip 395

***How to differentiate between VT and supraventricular tachycardia by intracardiac ECG 395

Bradycardia or Asystole 395

Technical Tip 395

Pacing with a coronary wire 395

CHALLENGES

During percutaneous coronary interventions (PCIS), there are three possible major mechanical complications: Acute or threatened closure, perforation, and no reflow. These events can cause prolonged ischemia, hemodynamic instability, collapse, and death. The causes of acute or threatened closure are: Dissection, thrombotic formation, air embolism, extraluminal compression, antegrade aortic dissection, etc. Other complications include no reflow, retrograde aortic dissection, emboli to the central nervous system, and reaction to contrast agents. The incidence of complications depends on the operator's skill, the technology available, and patient selection. Rigorous preventive measures pre-empt the appearance of complications. Operator experience, although possibly difficult to define, is extremely important in minimizing and treating the complications of PCI. With the use of current low-profile balloons and high torquable wires, most patients with "simple" stenoses will have good results, even in the hands of relatively inexperienced operators. However, in patients with complex anatomy or when simple cases become complicated, experienced operators (who perform at least 75–150 cases a year) are likely to have superior outcomes [1]. With better equipment, more effective antiplatelet medications, and higher levels of operator experience, the incidence of complications from stenting is very low: less than 0.4% in mortality, abrupt closure, or emergency coronary artery bypass graft (CABG) surgery. This is why the level of the operator's experience should dictate the case selection in patients with multiple risk factors and complex anatomy. Prevention is always the first priority because it is better to stay out of trouble than to get out of trouble.

CONTRAST-INDUCED NEPHROPATHY

Contrast-induced nephropathy (CIN) after PCI is defined as an increase of creatinine level of >0.5 mg/dl or 25% from baseline. The risk factors for CIN are listed in Table 15.1 [1].

Hydration

The usual protocols administer a total of at least 1000 cc isotonic saline beginning at least 3 h before and continuing at least 6–8 h after the procedure. The initial infusion rates of 100–150 ml/h are recommended with adjustment post-procedure as clinically

Table 15.1 Pre-procedural clinical risk factors for contrast-induced nephropathy

Modifiable risk factors	Non-modifiable risk factors
Contrast volume	Diabetes
Hydration status	Chronic kidney disease
Concomitant nephrotoxic agents	Shock/hypotension
Recent contrast administrations	Advanced age (>75 years)
	Advanced congestive heart failure

indicated. Appropriate caution should be applied in the patient with known left ventricular dysfunction or heart failure.

Sodium Bicarbonate

The use of isotonic sodium bicarbonate has been demonstrated in only one study to be marginally superior to isotonic sodium chloride (saline) in preventing CIN in the high-risk patient [1]. This protocol used an infusion of 3 ml/kg per h isotonic sodium bicarbonate for 1 h before and 1 ml/kg per h isotonic sodium bicarbonate for 6 h after the procedure.

Medications

Pre-procedural management of patients at risk for CIN requires a review of the patient's medications and withholding, as clinically appropriate, potentially nephrotoxic drugs, including aminoglycoside antibiotics, anti-rejection medications, and non-steroidal anti-inflammatory drugs (NSAIDs) or antidiabetic drugs (e.g. metformin). Although optimizing volume status is essential, the decision to interrupt diuretic therapy must be individualized. Angiotensin-converting enzyme (ACE) inhibitor therapy may be continued but neither initiating nor changing the dose should be considered until the patient is safely past the risk period for CIN (the creatinine will increase to its peak 48h after the procedure).

***N*-Acetylcysteine**

Despite multiple single studies, as well as several meta-analyses, the true benefit of *N*-acetylcysteine (NAC) is still unclear. In the most recent American College of Cardiology/American Heart Association (ACC/AHA) guideline, NAC is considered ineffective and it has been suggested that it not be used.

Lower Amount of Contrast

Intuitively, the less contrast administered, the lower the risk for CIN. However, there are no studies that prospectively evaluate this hypothesis. Retrospective analyses have suggested that a total dose of <30ml for diagnostic studies and <100ml for interventional procedures lessen the risk for CIN [1]. The recommendations for prevention of CIN are listed in Table 15.2.

Table 15.2 Recommendations for prevention of contrast-induced nephropathy

- 1** Identify risk
 - a Low risk – estimate glomerular filtration rate (eGFR) $<60 \text{ ml}/1.73 \text{ m}^2$
 - i Optimize hydration status
 - b High risk – eGFR $<60 \text{ ml}/1.73 \text{ m}^2$
 - i Schedule outpatient for early arrival or delay procedure time to allow time to accomplish the hydration
 - ii Consider the following recommendations (2–5)
- 2** Manage medications
 - a Withhold, if clinically appropriate, potentially nephrotoxic drugs, including aminoglycoside antibiotics, anti-rejection medications and NSAIDs
 - b Administer *N*-acetylcysteine (equivocal data, see text)
 - i 600 mg administered orally every 12 h \times 4 doses beginning before contrast
- 3** Manage intravascular volume (avoid dehydration)
 - a Administer a total of at least 1 l of isotonic (0.9%) saline beginning at least 3 h before and continuing at least 6–8 h after the procedure
 - i Initial infusion rate 100–150 ml/h adjusted post-procedure as clinically indicated
 - b Sodium bicarbonate (limited data, see text)
 - i 154 mmol/l at 3 ml/kg per h starting 1 h before contrast
 - ii 154 mmol/l at 1 ml/kg per h for 6 h after contrast
- 4** Radiographic contrast media
 - a Minimize volume
 - b Low- or iso-osmolar contrast agents (ongoing data, see text)
- 5** Post-procedure: discharge/follow-up
 - a Obtain follow-up serum creatinine 48 h post-procedure
 - b Consider holding appropriate medications until renal function returns to normal, i.e. metformin, NSAIDs

Stents should be used liberally to shorten procedural time and achieve stable acute results. Intravascular ultrasound (IVUS) can be used to monitor the procedure. A variety of adjuncts such as the wire with interval markers and digital road mapping can help in positioning stents or balloons. All of these efforts are to minimize the amount of contrast agent used during the procedure. There is of course no risk of nephrotoxicity in patients already on dialysis, although volume overload should not be overlooked [1].

Technical Tip

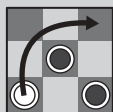
****How to do PCI with 20 ml contrast?** At the beginning of the PCI, the patient had two wires: One through the lesion and one in a branch nearby. Throughout the procedure, the positioning of the balloon and stent was determined by referring to the bifurcation of the wires. Instead of regular angiography, selective angiography with 1.5 ml contrast media was performed by injecting the contrast through the tip of a transport catheter, which was inserted into the proximal portion of the artery along the marker wire. IVUS was repeatedly performed to confirm the result of each

intervention. As a result of these efforts to minimize the dose of contrast media, the procedure was completed with the use of 15ml of contrast media [1].

TACTICAL MOVE

BEST options in minimizing contrast during PCI

- 1 \$ **FIRST Best option:** Graduated wire
- 2 \$ **SECOND Best option:** Perform selective angiography with 1.5ml contrast from the tip of a small microcatheter that was placed into the index artery
- 3 \$\$ **THIRD Best option:** IVUS only, no angiogram



CONTRAST ALLERGY

Prevention

The key to preventing contrast reactions is to identify the patients at greatest risk and use prophylactic measures to reduce their risk. Patients with previous contrast reactions or a history of atopy or asthma are at increased risk. It is common to use contrast agents with lower osmolality, e.g. iodixanol (Visipaque) in these patients. Many pretreatment protocols use the combination of corticosteroids, histamine 1 (H_1)-receptor antagonists and H_2 -receptor antagonists. Usually, prednisone 50 mg is given at 13, 7, and 1 h before the procedure. If steroids are not given before the procedure, hydrocortisone sodium succinate (Solu-Cortef) 100 mg is administered intravenously at the time of the procedure.

Mild reactions including itching, rash, or urticaria are usually self-limiting, and do not need further intervention except for prompt recognition and careful monitoring for possible progression. Reaction such as bronchospasm requires aggressive treatment with epinephrine 0.1–0.3 ml administered intramuscularly (1:1000 dilution) at first. The intramuscular (IM) injection has a problem with drug diffusion if the patient has hypotension and subsequent vasoconstriction. In the event of a severe reaction (Box 15.1), such as severe bronchospasm, laryngeal edema, or cardiopulmonary arrest, intravenous epinephrine may be given in a diluted form (1:10 000) at a dose of 1–3 ml. Infusion of epinephrine titrated to effect is better than reliance on a single intravenous bolus dose. Supplemental oxygen and ample intravenous fluid infusion can mitigate the effects of hypoxia and hypotension, respectively [2].

BOX 15.1 EARLY SIGNS OF SHOCK

Sinus tachycardia
Narrow pulse pressure
Slender aortic pressure curve

THREATENED OR ACUTE CLOSURE

Threatened closure is defined as narrowing of the artery <50% during PCI with evidence of active ischemia (chest pain or electrocardiographic [ECG] changes). The many causes of acute closure include dissection, coronary spasm, air embolism, and distal embolization of plaque and/or thrombus. However, the most feared cause is dissection.

DISSECTION

Dissection is defined as the two lumina separated by a large tissue flap. Dissection is caused by excessive iatrogenic plaque fracturing from balloon inflation or device manipulation with subsequent separation of the layers of the vessel wall.

During a diagnostic or interventional procedure, the tip of a catheter or guide can cause dissection at the ostium of a left main (LM) or right coronary artery (RCA). The dissection can propagate in an antegrade or retrograde direction.

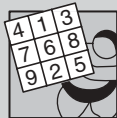
The antegrade propagating dissection could possibly stop at a previously stented area due to compression of the three layers of the arterial wall by the stent or often at the bifurcation with a big side branch. If a dissection happens in the proximal and mid-segment of the left circumflex artery (LCX), which is encased inside the atrioventricular (AV) groove, the dissection may not commonly be propagated very far distally. However, as dissection is confined in a tight space (narrow corridor), the luminal encroachment by the dissection is more severe (Figure 15.1).

Besides antegrade dissections from the LM, RCA, left internal mammary artery (LIMA), and saphenous vein graft (SVG), a dissection can propagate distally in a retrograde fashion. The LIMA can be easily dissected at the time of performing a selective angiogram or guide cannulation. Local dissection of an SVG at the proximal (especially SVG to RCA) or ostial segment, which is caused by guide manipulation, looks benign but can progress rapidly to acute occlusion.

The transition between a therapeutic fracture (balloon angioplasty) and a threatening dissection is ill defined; the National Heart Lung and Blood Institute (NHLBI) classification of dissection is shown in Box 15.2 [3] (Figure 15.2).

STRATEGIC MAPPING

The two factors defining prognosis after a dissection are (1) the length of compromised vessel; and (2) the integrity of the antegrade flow. Minor dissection that does not compromise the coronary flow does not need treatment. If the vessel diameter is <2.5 mm, then the best strategy is to repeat prolonged low-pressure balloon inflations with a slightly oversized balloon or longer balloon.



(Continued)

Dissections that are long (result in >50% residual stenosis) and impair flow are considered severe, and should be stented promptly, especially if the vessel diameter is >2.5 mm.

Securing and maintaining wire access across the occluded artery is the single most important consideration in managing acute abrupt vessel closure. In case of spiral dissection, stenting the distal end stops further propagation of the dissection and stenting the entry site stops the source of dissection. However, some dissections cannot be stented (2–3%) because of severe proximal tortuosity, small size of the vessel, etc. Most dissections not resulting in acute ischemic complications heal with time without future stenosis. Precautionary measures and tactics for prompt reversal of acute closure are listed in Box 15.3.

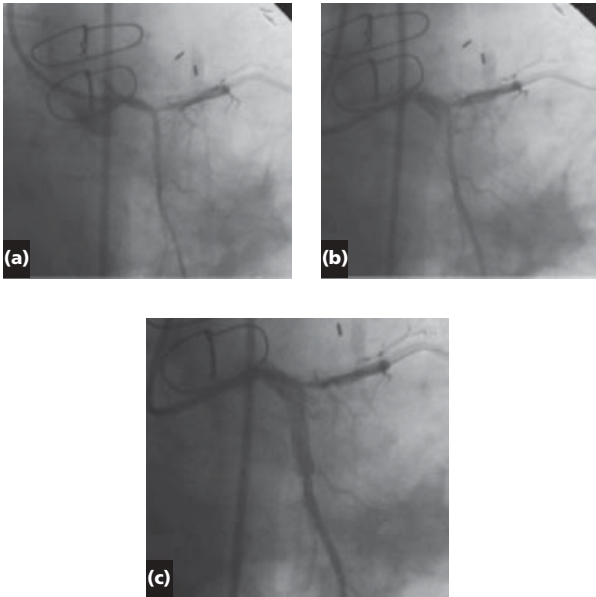


Figure 15.1 Anatomy of a left main (LM) dissection by a guide. (a) An injection that opacifies the LM and the left circumflex artery (LCX). (b) There is a lift of the entry site that propagates distally. (c) A complete dissection that encroaches the flow to the distal segment. It stops at the midsegment of the LCX. (Courtesy of the Cardiac Catheterization Laboratories of Community Healthcare System, St Mary Medical Center, Hobart, IN.)

BOX 15.2 GRADING OF CORONARY ARTERY DISSECTION

Type A: Minor radiolucency within the coronary lumen with minimal or no persistence after dye clearance







Type B: Parallel track or double lumen separated by a radiolucent area during contrast injection with minimal or no persistence after dye clearance

Type C: Extraluminal cap with persistence of contrast after dye clearance

Type D: Spiral shape-filling defects

Type E: New persistent intraluminal filling defects

Type F: Dissection leading to total occlusion without distal antegrade flow

Dissection type	Description	Angiographic appearance
A	Minor radiolucencies within the coronary lumen during contrast injection with minimal or no persistence after dye clearance.	
B	Parallel tracts or double lumen separated by a radiolucent area during contrast injection with minimal or no persistence after dye clearance.	
C	Extraluminal cap with persistence of contrast after dye clearance from the coronary lumen.	
D	Spiral luminal filling defect.	
E+	New persistent filling defects.	
F+	Those non-A-E types that lead to impaired flow or total occlusion.	

+ May represent thrombus.

Figure 15.2 Type A dissections represent minor radiolucent areas within the coronary lumen during contrast injection with little or no persistence of contrast after the dye has cleared. Type B dissections are parallel tracts or a double lumen separated by a radiolucent area during contrast injection, with minimal or no persistence after dye clearance. Type C dissections appear as contrast outside the coronary lumen (“extraluminal cap”) with persistence of contrast after dye has cleared from the lumen. Type D dissections represent spiral (“barber shop pole”) luminal filling defects, frequently with excessive contrast staining of the dissected false lumen. Type E dissections appear as new, persistent filling defects within the coronary lumen. Type F dissections represent those that lead to total occlusion of the coronary lumen without distal antegrade flow. In rare cases, a coronary artery dissection may propagate retrograde and involve the ascending aorta, illustrated by Quoc Nguyen.

BOX 15.3 PRECAUTIONARY MEASURES AND TACTICS FOR PROMPT REVERSAL OF ACUTE CLOSURE

1. Maintain wire across lesion.
2. Prompt balloon reinflation
3. Prompt placement of stent to stop the dissection.
4. Ready access to contralateral artery and vein with 5-Fr sheaths, in case intra-aortic balloon pump (IABP) hemodynamic support is needed. (unless the artery is stented promptly)
5. Before PCI, perform lower abdominal aortogram to identify patients who may not tolerate IAB) or left ventricular assist device (LVAD) placement.
6. IABP or LVAD may be inserted prophylactically in selected patients or on standby for immediate insertion in case of hypotension or ischemic complication

Table 15.3 Differential diagnoses of dissection

Causes	Corrective techniques
1. Streaming of contrast	Advance the guide deeper into the ostium with more forceful and steady injection of contrast
2. Deep guide intubation	Pull the guide a little back
3. Stiff wire straightening the vessel	Withdraw the wire with the flexible tip proximal to the new lesion
4. Overlapping of radio-opaque wire	Withdraw the tip proximal to the new lesion
5. A thin branch running parallel to the index artery	Change the angle projection of the camera

Technical Tips

****Recognizing dissections from its look alike** An intraluminal flap, or an extraluminal linear or spiral extravasation of contrast media, would suggest dissection. An intraluminal lucency with smooth contour, in an oval shape or an area with haziness, or a flat, rounded cut-off would suggest a thrombus. Spasm would have a more tapering end. Under IVUS, spasm is seen as narrowing without plaque. Other possible causes of pseudo-dissection are listed in Table 15.3.

Management

The management of the locally dissected lesion is prompt local stenting, whereas management of the ostial dissection that propagates distally is by stenting of the ostial LM or RCA first, then the distal dissected segment next. In any situations, the wire has to be maintained across the dissection.

If there is only minor dissection, there is no need for treatment. In the case of edge dissection after stent deployment, it is not imperative to cover all the edge dissections that are considered minor, with a residual lumen by IVUS >50%, or not in a strategic location (not in the LM or at the ostium of a major branch) [1].

Technical Tips

***Preventing dissection** To prevent dissection, usually the patient would have low-pressure 6–8atm balloon predilatation. However, in cases of a lesion with unexpectedly heavy calcification, due to inadequate balloon predilatation, some stents cannot be fully expanded. So the key point is that, for predilatation, a non-compliant small balloon (e.g. 2.5-mm diameter) needs to be fully inflated without a waist at its middle. Other strategies include minimal manipulation of any devices before stent placement to limit the occurrence of dissection at the ostium or the segment proximal to the lesion. Then prompt stenting of the dissecting segment would prevent further propagation of the dissecting plane.

***Prevention of dissection during LIMA cannulation** This kind of dissection can be prevented by non-selective cannulation: Insert the wire in first, advance the balloon through the ostial LIMA, and adjust the guide to a coaxial position with the balloon and wire as support devices. Use of a buddy wire parking in the subclavian artery to prevent deep engagement of guide into the diseased ostium and use of smaller guide (5 or 4 French [Fr]), are other options in preventing ostial dissection.

****Recrossing the dissected segment** Once the wire position is lost, try to recross the lesion with a very soft rather than a stiff wire. The post-angioplasty angiogram should be reviewed carefully. Look for the plane of dissection and the most likely location of entry to the true lumen by many different orthogonal views. Then the tip of the wire is positioned at that location and manipulated to enter the true lumen.

Usually, by computational fluid dynamics study, the cholesterol plaque is formed on the pericardial side of the artery due to high shear stress at the inner curve or myocardial side. So the dissecting plane is in between the plaque and the medial muscular layer. To advance the wire into the true lumen, the tip of the wire should point toward the inner curve or the myocardial aspect of the artery.

If there is a problem with recrossing the segment, or entry in the false lumen, an IVUS study should be done and the artery recrossed by a second wire parallel to the IVUS, so that it can be advanced into the true lumen under IVUS guidance.

****Re-entry into the true lumen in a stented area** When a wire attempts to cross a stent, in fact the wire can be advanced outside a stent, behind the stent struts. In this situation, the balloon is advanced along the wire, behind the stent, and inflated in the wrong path. A dissection could occur and be propagated in a retrograde or antegrade fashion. In this situation, a new wire has to enter the true lumen in order to secure persistent true

Table 15.4 Management of dissection according to site of origin

Site of origin	Wire management
Ostium	Keep the wire in place Stent the ostium first
Local (non-ostial)	Keep the wire in place Stent the local dissecting area
Local, wire in false lumen	Keep the wire in place *Insert second wire in true lumen *Remove first wire only after firm evidence that it is in a false lumen *Stent the narrowing area of the true lumen

lumen access. In any situation, do not remove the wire across the lesion unless there is strong evidence that it is in the false lumen. Careful review of the diagnostic angiography would show the origin of the dissection (local or ostial) and whether or not the wire is in the true lumen. A summary of the management of dissection is shown in Table 15.4.

****Early detection of dissection during SVG cannulation** When there is suspicion of retrograde dissection, pull the guide back and an injection of contrast in the coronary sinus would help to confirm the presence of retrograde aortic involvement.

Left Main Dissection

LM dissection is the forerunner to catastrophic vessel closure. It can be precipitated by manipulation of interventional hardware in the LM ostium or during intervention of the ostial lesion of the LAD. Sharp angulation at the LM–LAD junction appears to be a risk factor for LM dissection when an inflated balloon for an ostial LAD lesion partially covers the LM [1]. The usual management of LM injury is CABG. However, it is necessary to keep the patient stable while waiting for emergency surgery. Unprotected LM PCI is not a common procedure for most operators in the USA. Even so, to save the life of the patient, the acutely occluded LM has to be opened as a bailout emergency procedure, similar to pericardiocentesis in tamponade. The strategy is to open the LM even before inserting the temporary pacemaker and intra-aortic balloon pump (IABP). The whole emergency procedure should be finished in a matter of minutes in order to reverse the process of hemodynamic collapse, shock, or impending death. Once the patient has been stabilized, the decision about CABG can then be entertained (see Figure 15.1). The technique of LM stenting is discussed in detail in Chapter 9.

Technical Tips

****Can the LM dissection be missed by a small guide?** On many occasions there is a clear discrepancy between the dramatic

clinical presentation (severe chest pain, hypotension, ST-T change) with the paucity of coronary artery findings. In these situations, additional orthogonal views need to be taken to confirm the non-involvement of the coronary system or the presence of aortic dissection or LM dissection masquerading as acute myocardial infarction (AMI). In a diagnostic angiography, a small guide could cross the severe ostial lesion of the LM without causing ventricularization of pressure, so the ostial lesion or dissection of the LM could be missed. In situations with strong suspicion of LM dissection by ST elevation in the anterior leads, repeat angiogram should be done with a larger guide to detect the ostial lesion caused by dissection. Another way to detect the LM dissection is to pull the guide to barely outside the LM ostium and inject the contrast to opacify the whole LM segment [4].

Retrograde Aortic Dissection

Retrograde aortic dissection secondary to coronary dissection usually happens after inflation of the proximal RCA (more common) or the LAD (Figure 15.3). Even though it is rare, it must be positively ruled out when there is unexplained chest pain or hypotension or persistent opacity by contrast at the aortic root after angioplasty or stenting of any ostial or proximal lesion. If it is detected early, prompt corrective measures including prompt stenting of the ostial lesion, which is the entry site to seal off the dissection. Surgical consultation is needed, when there is

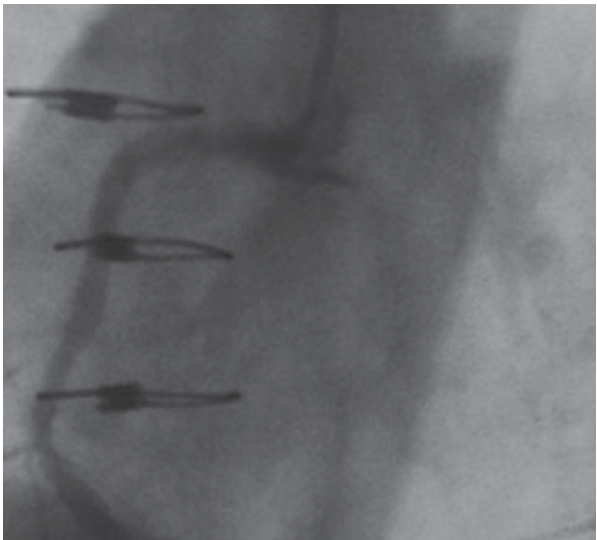


Figure 15.3 After inflation of the proximal right coronary artery (RCA), there was persistent contrast staining at the ostium of the RCA on the aortic wall area. (Courtesy of the Cardiac Catheterization Laboratories of Community Healthcare System, St Mary Medical Center, Hobart, IN.)

significant aortic regurgitation, involvement of the supra-aortic vessels, and progression of the index dissection. If none of these problems is present, a watchful waiting is the best attitude [5]. Follow-up CT scan of the chest may identify the medically stabilized patient who need no further treatment or the complicated patient who may require surgery [5].

CRITICAL THINKING

The pathophysiology of iatrogenic aortocoronary dissection is different from that of spontaneous aortic dissection, and this may explain the different management strategies and prognosis of these two entities. In spontaneous aortic dissection of the ascending aorta, the significant degeneration of the media facilitates the propagation of dissection with extensive arterial damage that warrants urgent surgical therapy [5]. On the other hand, there is no evidence to indicate that degeneration of the medial layer of the aorta is a prerequisite for the development of catheter-induced aortocoronary dissection. Moreover, the aortic supra-valvular stria, rich in collagen fibers, may limit progression of the iatrogenic dissection beyond the sinotubular junction [6].



In Patients with Retrograde Ascending Aortic Dissection, When to send for Surgery, and When to keep Patients for Medical Treatment

An "extensive" aortic dissection has arbitrarily been defined in the largest reported series to date as one that extends >40mm up the aorta from the coronary cusp [5]. Applying this definition, seven of eight extensive aortic dissections reported in the literature to date have been surgically managed, with two deaths. One patient with an extensive dissection was deemed unsuitable for surgery (due to the extent of dissection and history of prior cardiac surgery) and was successfully managed with a conservative strategy. Of the 13 patients with dissection limited to <40mm of the ascending aorta, 12 have been medically managed, with no deaths. Surgery was required in one patient who had had a limited dissection, but in this case the procedure was indicated primarily for emergency coronary bypass and not aortic repair [5]. Stents at the site of the presumed entry site for aortic dissection in the culprit coronary vessel were successfully deployed. All patients survived to hospital discharge, and only two patients required subsequent surgery (in one case due to the development of hemopericardium, in the other to the very extensive nature of the dissection, which had progressed to the aortic bifurcation) [5]. The lesson is, if the patient has extensive retrograde aortic dissection of >40mm, surgery is suggested. If the dissection is <40mm, medical therapy is suggested.

How you can make a Difference

In general, a large majority of iatrogenic dissections are limited to the coronary sinus, whereas in large minority progresses either to the ascending aorta or retrogradely causing aortic regurgitation and/or hemopericardium. In cases with limited dissection, many patients can be treated with ostial stenting and a large minority can be managed conservatively. Among the rapidly progressing dissections, stenting was successful even in cases of hemopericardium managed percutaneously with pericardiocentesis and stenting. The worst prognosis was observed in patients with rapid progression of dissection who were managed conservatively, and in those with concomitant myocardial infarction who required surgery. Hence, every effort should be made to prevent rapid progression of the dissection. This can be achieved by immediate and appropriate stenting to seal the entry site of dissection and to stop blood flow into the false lumen. Moreover, if the ostial stenting failed to halt the dissection progression, it will not compromise the chances of surgical success [6].

TAKE HOME MESSAGE

Precautionary measures that can minimize the occurrence of iatrogenic dissection include:

- 1 Avoid deep engagement of guide
- 2 Pull the guide back a little while any interventional or diagnostic device is withdrawn from the artery. Continuously monitor the tip of the guide so that it is not sucked in.
- 3 Do not keep the guide too long in deep engagement position inside the LM
- 4 Check the pressure waveform before every coronary injection. If a ventricularized pressure waveform is observed, the guide should be pulled out, or torqued slightly until a normal arterial pressure waveform is observed
- 5 Prompt recognition of dissection to prevent both further retrograde and antegrade extension. Always check proximal segment or ostium of instrumented artery before finishing a diagnostic or interventional case
- 6 Prompt stenting to seal the dissection
- 7 In the presence of hemodynamic instability, prepare/insert IABP and call the surgeon

ACUTE THROMBOTIC CLOSURE

Even when the technical aspect of a PCI is almost flawless, the possibility of acute closure by uncontrolled platelet aggregation and new occlusive thrombotic formation still exists, not infrequently with superimposed vascular spasm. A thrombus is recognized as a progressively enlarging or mobile intraluminal lucency,

surrounded by contrast. Its incidence is low in stable angina patients. However, in patients with acute coronary syndrome, lesions with thrombus, long and diffuse lesions, or in degenerated vein grafts, the probability of having an acute occlusion due to thrombotic formation or distal embolization is high [7]. After stenting, acute closure due to subacute thrombosis happens if there is incomplete apposition of stent struts against the vessel wall and unrecognized mechanical obstruction proximal or distal to the stent. To prevent thrombotic formation, in the case of a short procedure with minimal injury to the endothelium, besides anticoagulation with heparin or bivalirudin, prior treatment with oral antiplatelet drugs such as aspirin plus clopidogrel is effective enough. A bolus of 300mg clopidogrel should be given for at least 24h before 600mg for at least 6h before the procedure. In the case of extensive injury to the endothelium by interventional hardware, the prospect of recurrent thrombosis could also be preempted by prior infusion of glycoprotein IIb/IIIa inhibitors [7]. This is why minimal manipulation of the artery lumen before stent placement limits the depth and extent of vessel wall injury at the segment proximal to or around the lesion.

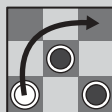
Causes of Acute Occlusion after Stenting

If stenting is the best strategy for prevention or treatment of occlusion, how can occlusion happen after stenting [7]? The usual causes of occlusion after balloon angioplasty and stenting were distal dissection and thrombus. However, after stenting, protrusion of tissue, malapposed struts could cause a compromised lumen and thrombotic formation. The common denominator of these occlusions was a compromised distal blood flow promoting thrombotic formation. Then a perfect thrombolysis in myocardial infarction (TIMI) 3 flow after stenting is the best way to prevent any significant and severe thrombotic complications [7].

TACTICAL MOVE

Dissolution or removal of occlusive intracoronary thrombus

During an interventional procedure, if there is mild haziness at the lesion site or at the proximal segments, this is the early sign of thrombotic formation. At that moment the main goal is to have TIMI-3 flow, because a perfect flow is the best prevention against thrombotic formation and against HIGH shear stress which activates platelet aggregation.



While the thrombus is being taken care of, usual emergency measures have to be taken to keep a decent blood pressure with IABP, temporary pacemaker, intravenous (IV) fluid, etc.; activated clotting time (ACT) should be >250s.

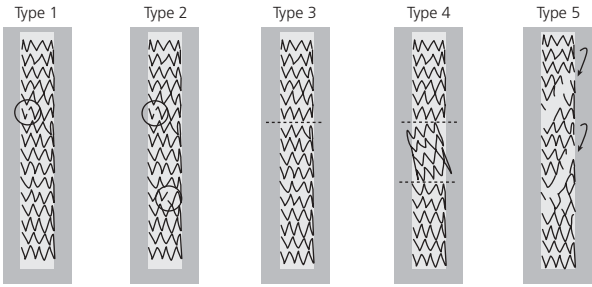


Figure 15.4 Stent fractures. (Reproduced from Adlakha et al. [7] with permission from Wiley.)

STENT FRACTURE

Restenosis associated with stent fracture is thought to occur due to drug maldistribution, for drug-eluting stents (DESs), at the strut fracture site, along with local mechanical irritation that triggers neointimal hyperplasia. Exposure of the free metal strut into the lumen can trigger platelet activation resulting in thrombosis. Thrombosis and in-stent restenosis (ISR) may present as a spectrum that includes stable and unstable angina, ST-elevation myocardial infarction (STEMI), and potentially sudden cardiac death. Focal stenosis is related to stent fracture with most stent fractures occurring in the middle portion of the stent. The classification of stent fracture is given in Figure 15.4.

The treatment of asymptomatic patients without restenosis can be followed closely without intervention; however, extension of dual antiplatelet therapy beyond 1 year might be considered. If symptoms become present, further intervention should be sought. The stent-in-stent technique is commonly employed when symptoms are present and the fracture is associated with restenosis [8].

NO REFLOW

No reflow is defined as stagnant contrast agent in the distal vasculature without apparent proximal obstruction. The incidence is 2% with plain balloon angioplasty (percutaneous transluminal coronary angioplasty [PTCA]), 7% in patients undergoing rotational atherectomy, 12% for primary angioplasty, and much higher at 42% for PCI of degenerated SVG. The causes are mainly embolization of atheromatous material (gruel), aggravated by microembolization of platelet-rich thrombi that release vasoactive agents (e.g. serotonin), leading to intense arteriolar vasospasm in the distal vasculature [8]. The differential diagnosis of an apparent no-reflow phenomenon is dissection or acute thrombotic formation in the proximal or distal segment, which is not always well appreciated by conventional angiography.

IMPROVISED EQUIPMENT

An over-the-wire (OTW) balloon, microcatheter, or aspiration catheters can help to find the cause of no reflow. The catheter should be inserted through the wire and advanced to the distal segment of the no-flow area. Then the wire is removed. The pressure gradient between the tip of the catheter and guide is measured, and contrast injection through the end-hole will help to make the distinction between no reflow and proximal obstructive lesions. Then injection of 3–5 ml contrast agent with slow withdrawal of the catheter into the guide is useful to reveal any proximal disease, however hemodynamically insignificant. Off-label use of a monorail balloon with multiple small punctures in the balloon will allow distal contrast injection through the balloon lumen if the contrast is significantly diluted.

Advantages and Limitations

The most important limitation of the improvised equipment is the inability to maintain distal wire position, particularly in the presence of a dissection. The limitation of a large size thrombectomy catheter is the potential to worsen dissection or catch on stent struts. IVUS offers an option to determine the presence of a dissection or thrombus at the flow arrest site. However, IVUS is unable to determine the distal runoff of the vessel and the presence or absence of a very distal thrombus [8]. In this situation, advance a second wire to the distal segment in order to keep vascular access.

DEDICATED EQUIPMENT**E****The Twin-Pass catheter**

With dedicated equipment such as the Twin-Pass catheter, a diagnostic approach could be performed in a safer and better environment. The Twin-Pass dual access catheter is a hydrophilically coated, dual-lumen catheter designed for use in the arterial vasculature. The catheter provides support for 0.014 inch \times 0.36 mm guidewires during interventional procedures, and the dual-lumen design allows for the delivery of a second guidewire into the distal vasculature while leaving the initial guidewire in place. The distal exit port is from a 20-cm-long monorail wire lumen, whereas the proximal exit port emanates from a lumen extending back to the hub in an “over-the-wire” configuration [9].

The Twin-Pass catheter comes with a stiffening mandrel to provide support and pushability during catheter insertion. It is compatible with a minimum guide internal diameter of 0.058 inch \times 1.47 mm. The Twin-Pass catheter has a radio-opaque marker band located approximately 1 mm proximal to the distal tip and a second radio-opaque marker

band located at the through-lumen exit port 10mm proximal to the distal tip. The crossing profile of the distal tip is <1.9 French (Fr) with a shaft crossing profile of 3Fr [10].

The maximum recommended flow rates through the OTW lumen are 0.31 ml/s for saline and 0.047 ml/s for 76% ionic contrast media according to the manufacturer's instructions for use. The Twin-Pass catheter is intended to be used together with steerable guidewires to access discrete regions of the coronary and peripheral arterial vasculature, to facilitate placement and exchange of wires, for use during two wires procedures, and to subselectively deliver diagnostic or therapeutic agents.

In each of the cases, the Twin-Pass catheter was delivered on a distally placed wire. It was advanced distal (3–5 cm) to the site of arrested flow. A solution 1–3 ml, comprising 40% contrast medium (Iomeron 350) and 60% 0.9% saline, was manually injected to allow for a combination of reduction in viscosity and adequate opacification. Repeated injections were performed following stepwise pullback to the site of flow arrest as deemed necessary [9].

The Twin-Pass catheter also allows administration of medication to the distal bed without the risk of losing wire position in the questionable presence of a proximal dissection.

With the help of a diagnostic catheter, there are five features to be observed during distal vessel injection and stepwise proximal injections during catheter withdrawal: Distal antegrade flow and its briskness, retrograde flow, myocardial blush, presence of contrast stasis in the vessel wall, and evidence of an intraluminal filling defect, and its type (local, globular, longitudinal dissection plane) and runoff to the distal bed. The results show four distinct clinical scenarios based on distinct pathological processes.

Classification and Management of Slow Flow

Proximal occlusive lesion The initial distal injection demonstrated brisk antegrade flow in the distal vessel with excellent runoff to the distal bed, marked myocardial blush, and no retrograde flow. Stepwise injections demonstrated the flap, thrombus, or distal stent edge dissection at the proximal occlusive site.

During PCI, any instrumentation of an arterial segment could break the integrity of the endothelial barrier and cause formation of thrombus. The appearance of thrombus is not the cause of the problem, but the result of any mechanical injury. So definitive treatment needs to address these mechanical problems such as plaque rupture, dissection, intimal denudation due to forceful jamming of the stent, distal thrombotic embolization, distal traumatic push by a tip of a wire that rolls into a ball, or intramural hematoma with opening into the lumen. In these cases, the lesions were treated with thrombus extraction (if appropriate) or stenting (if indicated) [9].

Distal vascular bed dysfunction The distal injection results in almost no antegrade flow, an absence of myocardial blush, and marked retrograde flow. The diagnosis is no reflow due to distal microvascular spasm and obstruction. This is a diagnosis of exclusion. The treatment is with vasodilators and prevention is by use of embolic protection devices or a glycoprotein IIb/IIIa inhibitor [9].

Local dissection with or without antegrade flow With the distal wire residing in the true lumen, in the case of severe dissection with preserved antegrade flow, distal injection is associated with normal antegrade flow, good myocardial blush, and no or minimal retrograde filling. The stepwise proximal injections reveal the dissection planes with minimal contrast stasis in the vessel wall. The inflow and outflow of the dissection can also be detected. The treatment is by stenting.

In case of severe dissection with compromised flow, an absence of antegrade flow, minimal retrograde flow, no myocardial blush, and obvious stasis within the vessel wall were observed [9].

Severe distal disease If there is no gradient, however, the pullback angiography could show a distal severe lesion that was not seen by conventional antegrade angiography through the guide because the contrast could not pass the distal segment, mimicking distal no reflow. Correction of the lesion should resolve the no-reflow phenomenon and the symptoms of the patient [9].

Medical management The treatment includes forceful injection of blood through the guide in order to raise driving pressure across the capillary bed. Another approach is to inject small boluses of nitroglycerin (100–200 μ g – very quick try) and/or calcium channel blockers (100–200 μ g verapamil) or adenosine (12–18 μ g). Verapamil is effective in 67% of cases in alleviating arteriolar spasm and restoring antegrade flow. Nitroprusside 40- μ g bolus up to 100–200 μ g can also be given with action to be seen in 2 min [10]. Epinephrine can be given, especially in patients with hypotension. The dosage ranges between 50 and 200 μ g and multiple doses can be given and adjusted according to the presence and severity of hypotension. It is important to deliver these agents into the distal artery through a balloon catheter or microcatheter. Glycoprotein IIb/IIIa inhibitors can be given as a bolus and a maintenance dose. Temporarily pacing through intracoronary wire or intravenous pacing lead and/or inotropic supports are recommended or in stand-by before drug delivery into the distal artery, especially adenosine.

Adenosine Adenosine is an endogenous purine nucleoside, a vasodilator of arteries and arterioles, and inhibits platelet activation and aggregation. Although severe bradycardia may occur due to its effect on sinoatrial and AV nodal conduction, the half-life of adenosine is very short and these effects rarely last more than a few seconds. Prophylactic administration of intragraft adenosine does not appear to decrease the risk of slow or no reflow, but it can reverse slow or no reflow with multiple boluses.

In patients who developed slow or no reflow, high doses of intragraft adenosine (five or more boluses of 24 μ g each) resulted in reversal of slow or no reflow compared with low doses (fewer than five boluses). Rapid, high-velocity injections of intragraft adenosine is successful in reversing slow or no reflow and results in TIMI flow grade in most cases [10].

Nitroprusside Nitroprusside is a direct donor of nitric oxide. During SVG intervention, intracoronary administration of nitroprusside (median dose 200 μ g) resulted in significant and rapid improvement in both angiographic flow ($p < 0.01$ compared with pre-treatment angiogram) and blood flow velocity ($p < 0.01$ compared with pre-treatment angiogram). Nitroprusside was not associated with significant hypotension or other adverse clinical events in this study, but can cause profound hypotension in patients who are volume depleted or hypotensive at baseline [10].

Verapamil Prophylactic intragraft administration of verapamil before SVG intervention tended to reduce the occurrence of no reflow compared with placebo, increase the TIMI frame count, and improve the TIMI myocardial perfusion grade.

Nicardipine Prophylactic intragraft administration of nicardipine, a potent arteriolar vasodilator, was followed by direct stenting for degenerated SVG without the use of a distal protection device [11].

Preparation of Nitroprusside One ampoule of 100mg nitroprusside (Nipride) is diluted with 250ml D5W. With a 20-ml syringe, withdraw 1 ml of the above solution and fill it with 19ml of D5W (400 μ g nitroprusside). Then give patient bolus of 3–4ml (with 1 ml = 20 μ g) [10].

AIR EMBOLISM

The incidence of air embolism should be virtually nil if meticulous safety measures are practiced. Once it happens, the patient will experience pain and hypotension similar to occlusion of a coronary artery in AMI. A small air embolus would dissipate quickly. Air embolism typically creates a column of contrast that terminates at a different site to that of the original stenosis; 100% oxygen is the best immediate therapy.

Technical Tips

****Management of air embolism** Strong hand injection of contrast may help to dissipate the air bubble into the distal microvasculature. Chest pain will disappear in less than 1 min. However, if it is a large air bubble, it usually moves to the relatively elevated position of the coronary artery rather than going toward the distal arteries, e.g. if there is a large air bubble injected into the LM, the bubble would usually go to the LAD, which is anterior to the LCX and is likely the highest position of the coronary artery tree when the patient is in a lying position. In this situation, the operator can advance an OTW balloon, microcatheter, aspiration

catheter, or even a small guide (5-Fr straight guide or 5-Fr multi-purpose diagnostic catheter) to the air bubble and aspirate the air embolus through its central lumen [11].

****Management of massive air embolism** In a case report, 35ml of air was injected into the left ventricle (LV) during a left ventricular angiogram. The patient received cardiopulmonary resuscitation (CPR) for 45 min, then recovered with percutaneous cardiopulmonary support (CPS) [12]. The patient should be put in the right lateral position, a pigtail catheter advanced into the LV, and the air withdrawn while having CPR. In case of air embolism in the right atrium (RA) or ventricle (RV) due to air entry during the subclavian or jugular vein cannulation, the patient should be put in the left lateral position so that the air can be moved to the top of the RV or RA. A catheter is then inserted in the area and the air sucked out.

INTRAMURAL HEMATOMA

Not infrequently, after inflation of a balloon, there is fracture of the atherosclerotic plaque, including rupture of the vasa vasorum, causing formation of intraplaque, periplaque, and extraluminal and intramyocardial hematoma. The degree of compression that these hematomas have on the blood flow depends on their size. The obstruction is evident as the flow is obviously impeded although there is no sign of endoluminal dissection or thrombotic formation. The cause has to be proved by IVUS.

Clinical Presentation and Management

When ECG changes and/or chest pain occur without evidence of abrupt closure at the site of the target lesion, a number of possibilities should be considered. LM dissection can be very difficult to exclude and may require multiple projections to be visualized adequately. Resistance to injection, pressure damping, severe pain, and ischemia seemingly out of proportion to lesion stenosis and hypotension are indirect signs of LM obstruction. IVUS may be helpful to ascertain this diagnosis when the results of the angiogram are equivocal. Small branch occlusions can often be discovered after a detailed review comparing angiograms performed before the procedure side by side with those at the time of the event. Spasm usually appears at the site of the balloon inflation but may appear more diffusely in the same vessel, and even in other vessels distant from the site of mechanical interventions. Although often nitrate responsive, spasm may be refractory and require therapy with calcium channel blockers. Intramural hematoma is a rarely suspected cause of ischemia, so a high degree of clinical suspicion could detect the problem by IVUS in order to have effective treatment. The management is to stent the hemodynamically significant obstructed segment [13].

CORONARY PERFORATION

Perforation of a coronary artery with a wire can be innocuous, as long as the perforation is not inadvertently enlarged by a balloon.

BOX 15.4 RISK FACTORS OF PERFORATIONS

- 1 Oversizing balloon (balloon : artery ratio >1.2)
- 2 High-pressure balloon inflation outside the stent
- 3 Stenting of tapering vessel
- 4 Stenting of contained perforations from other devices
- 5 Stenting of lesions that are recrossed after severe dissection or abrupt closure
- 6 Stenting of total occlusion when there has been recognized or unrecognized subintimal passage of the wire
- 7 Stenting of small vessels (<2.6 mm)

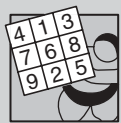
Table 15.5 Classification of perforation

Class	Definition	Risk of tamponade (%)
I	Extraluminal crater without contrast extravasation	8
II	Pericardial or myocardial “blush” without contrast agent “jetting”	13
III	Contrast agent “jetting” through a frank (<1 mm) perforation	63

With new devices and attempts to cross chronic total occlusions (CTOs), stiffer wires and laser wires harbor the risk that the wire will be forced through unrecognized subadventitial pathways into the true distal lumen. The subsequent dilation may then lacerate the adventitia and cause coronary perforation. In the most devastating scenario, there are actual rents or lacerations of the epicardial arteries with free communication of blood into the pericardial sac. This vessel rupture almost universally results in immediate hemodynamic collapse. Without control of bleeding and drainage of the pericardial sac, fatality may result [14] (Box 15.4 and Table 15.5). Coronary perforation causing localized epicardial hematoma can present as STEMI due to compression of the epicardial artery [14] (Figure 15.5).

STRATEGIC MAPPING

The treatment includes immediate inflation of the balloon at low pressure for 10 min (artery:balloon ratio 0.9:1.1) at the site of the type III perforation. As a result of the catastrophic effect of perforation, it is critical for any operator to be experienced with the pericardiocentesis technique. Prolonged balloon inflation is successful in 60–70% of perforations [14]. If sealing is not



(Continued)

successful, start giving protamine in incremental doses of 25–50 mg over 10–30 min until the ACT is <150 s; this should also be done in cases of jet extravasation and cavity spilling. Pericardiocentesis must be performed if there is hemodynamic compromise. A covered stent to seal the perforation is now available in the USA (Jostent graft) [15]. Once there is no further dye extravasation, the patient is admitted for observation, and echocardiography should be repeated to check for further effusion. Detailed management of perforation is listed in Box 15.5. Platelet transfusion is useful to reverse the antiplatelet effect in patients treated with abciximab, but not with tirofiban or eptifibatid. However, reversal of anticoagulation could lead to acute arterial occlusion or stent thrombosis. So the risk and benefit of anticoagulant reversal should be considered carefully. When a perforation is large enough to require more than conservative treatment, two major options are available: (1) Distal vessel embolization (as in some wire perforations) performed with gel foam particles, polyvinyl alcohol particles, subcutaneous fat tissues, or coils; or (2) sealing of the wall of the ruptured vessel with a covered stent [15].

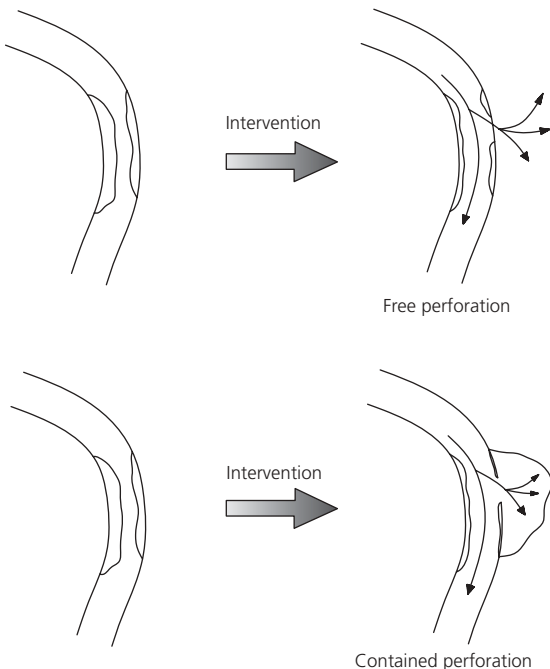


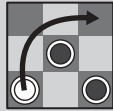
Figure 15.5 Two types of perforation: Contained or free flowing, illustrated by Quoc Nguyen.

BOX 15.5 STRATEGIES IN THE MANAGEMENT OF CORONARY PERFORATION: A STEP-BY-STEP APPROACH

- 1 First: prolonged balloon inflation at low pressure, 2–6 atm for 10 min
- 2 Pericardiocentesis with a side hole catheter inside the pericardial space if tamponade
- 3 If bleeding continues: reversal of anticoagulation:
 - (a) 1 mg protamine for every 25U heparin given in the previous 4 h: maximum 25–50 mg intravenously over 10–30 min until ACT <150 s
- 4 Covered stent for proximal or midsegment of the perforated artery
- 5 Coil (material) embolization for perforation of distal end

TACTICAL MOVE

BEST OPTIONS for removing a thrombus



- 1 **FIRST Best Maneuver** is to check the integrity of the artery and its perfect flow.

Best Maneuver: Rule out dissection. Occult dissection at the lesion site or in its proximal segment has to be ruled out by IVUS. If there is dissection that impedes the flow, prompt stenting is best
- 2 **SECOND Best Maneuver:** When there is new haziness (small thrombi) occluding the proximal or midsegment of an artery, some operators would make forceful injection of contrast or 0.9% saline. The goal is to dislodge the small and soft thrombi.
- 3 **\$\$\$ ⚠️ THIRD Best Maneuver:** Use the balloon to squeeze it, spread it to the wall
- 4 **\$\$\$ ⚠️ ⚠️ ⚠️ FOURTH Best Maneuver:** Removal of thrombus with thrombectomy catheter or devices

Technical Tips

****Preventive measures against perforation by a wire** To avoid perforation, the tip of a wire is advanced gently without any force against resistance. It should move freely. Once in the distal segment, avoid placing the tip in the small branches, because it can be inadvertently moved forward and perforate the artery. Its position should be checked frequently, especially when advancing or withdrawing any bulky devices, such as a long balloon or stent, atherectomy devices, or a long stent through tortuous and calcified lesions.

****Preventive measures against perforation due to balloon angioplasty or stenting** After inflation of a balloon keep the deflated balloon in place, watch for the ECG to see whether it reverses to baseline, and ask the patient to check the relief of chest pain after balloon deflation. Then make a small injection to check for severe dissection and perforation. If there is good flow distally and no obvious extravasation of blood, pull the balloon back into the guide. If there is any problem, dissection, or perforation, the balloon is ready to be readvanced and reinflated. Do not remove the balloon unless everything is clear. Wait for more than 2 min before the next inflation for the ischemic precondition to kick in. If there is perforation, inflate the balloon at low pressure.

****Management of perforation at the proximal and mid-segment** The treatment with prolonged balloon inflation, in some fortunate cases, may permanently cover the defect with a tissue flap and solve the problem. Nevertheless, in patients with substantial tears or lacerations, a covered stent offers a viable option. Tamponade can still happen even rarely after PCI in patients with previous CABG. The reason is that there is scar formation in the pericardial area after the pericardium was opened and removed during CABG, so there is more contained perforation, with intramuscular or mediastinal hemorrhage rather than frank bleeding or effusion (Figure 15.6). If there is covered stent available, a large perforation can be successfully stopped by deploying a covered stent. As the polytetrafluoroethylene (PTFE)-covered stent is bulkier, so the proximal segment should be predilated, the guide position should be optimal, and extra buddy wire may be needed. The hand-crimped PTFE-covered stent should not be pushed too hard because it can slip off the balloon and embolize distally. Unfortunately, the current PTFE-covered stent has limited flexibility and a large profile requiring an 8-Fr guide, and is not available in diameters <3.0 mm.

In order to successfully deliver a covered stent, a large guide is usually required, so that exchange guide technique with coronary wire *in situ* or double-guide techniques should be applied up to the hemodynamic situation.

If the hemodynamic status is stable after deflating the balloon that is covering the perforation, the balloon could be removed. A stiff 0.035- or 0.038-inch exchange wire should be parked in the aortic root, then a larger guide can be exchanged while the coronary wire is still *in situ* with the extension wire. If the hemodynamic status is unstable and the balloon needs to be inflated to prevent further bleeding, a vascular access should be established at the contralateral artery (femoral) and another guide be engaged near the first guide. Via the new larger guide, another coronary wire will be advanced through the perforation site while the first balloon is deflated and inflated accordingly. A covered stent could be advanced and successfully deployed to heal the perforation. Keep in mind that a covered stent can be shortened after inflated at high pressure [15].

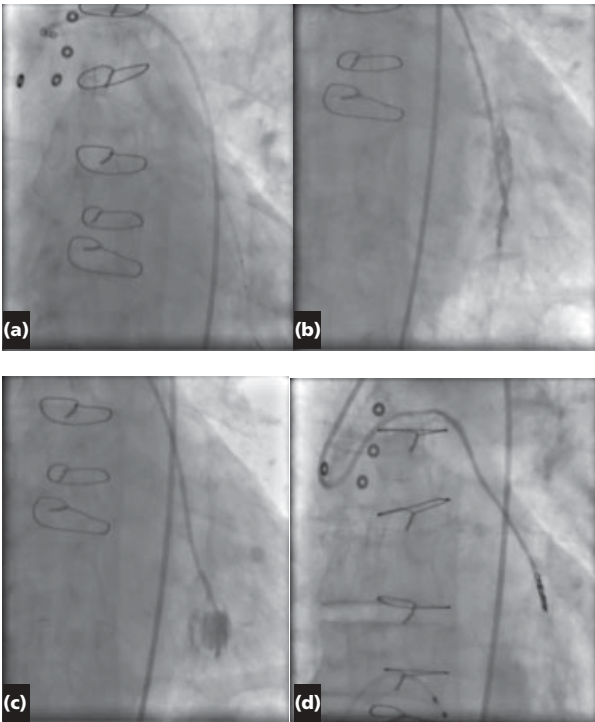


Figure 15.6 Contained coronary perforation after coronary artery bypass graft surgery. After balloon angioplasty with a 2-mm balloon, (a) there was extravasation of contrast, (b) which became more severe. So a coil was embolized to the distal segment and closed the perforation.

***IMPROVISED EQUIPMENT

How to make a covered stent with balloon material

In a case report of perforation where there is no PTFE-covered stent, cutting both ends off a lightly inflated balloon in order to have a cylinder of balloon material is suggested. Then crimp a stent over another premounted stent with the balloon cylinder in between. This results in a makeshift covered stent [16].

****Reversal of glycoprotein IIb/IIIa inhibition** The degree of platelet inhibition by the small molecule inhibitors (eptifibatid, tirofiban) is maintained through a high plasma concentration, which is proportional to platelet inhibition. So its effect disappears within 2–3 hours of drug discontinuation. In contrast, abciximab is mostly platelet bound with low plasma levels, so platelet infusion is needed to reverse the effect of abciximab.

CRITICAL THINKING**Indication and adversities due to reversal of anticoagulant**

A key question is whether dealing with the perforation signals the end of the case, or whether the operator aims to continue the PCI procedure once control of the bleeding has been established. If the case is to be discontinued, reversal of heparin using protamine sulfate is indicated. This should, however, be deferred while equipment such as balloons and wires remain in the coronary artery. Intravenous GP IIb/IIIa antagonists should be discontinued in most cases where perforation is identified. The direct thrombin inhibitor bivalirudin does not have a specific antidote, but has a short half-life with the return of coagulation 1–2 hours after discontinuation of the drug.

**Discriminating Differences**

Covered stent or coil embolization Covered stents must be used with caution in vessels with side branches because the stent graft material may occlude them. These stents may be less flexible than bare metal stents, and hence harder to be delivered in tortuous and calcified vessels, making their emergency use potentially challenging. As with all stents, they may not be easily deployed if the perforation occurs in a small vessel. Finally, covered stents have no role in perforation of the distal end-vessel.

Autologous vein-covered stents, for treating coronary perforations and ruptures, have also been described, but are far more time-consuming and involve isolating the graft (typically a cephalic vein) by cut down, mounting, and suturing on to a metallic stent. As these steps are time-consuming, this makes the use of autologous vein-covered stents an improbable emergency treatment for free-flowing perforation and pericardial tamponade.

Coil embolization of coronary perforations, especially of the distal vessel, has also been used as a percutaneous bailout treatment. In general, most studies report microcoil embolization with platinum or stainless steel coils ranging from 0.014 inch to 0.025 inch in diameter. However, larger coils have been used in coronary artery ruptures or in large segment perforations [17].

The coil size should be slightly larger than the vessel diameter to prevent dislodgement or migration of the coil. In some cases, it may be desirable to start to deploy the coil within the pericardial space, and position it across the perforation into the native coronary artery. This may be difficult in cases where the perforation tract is small. The degree to which the coil will protrude into the coronary artery depends on the location of the perforation (e.g. distal versus midsegment). Coils may also be used together with other treatment modalities such as localized thrombin injection [17].

DEDICATED EQUIPMENT**Balloon-expanded covered stents**

The iCAST-covered stent is a balloon-expandable 316-liter stainless steel stent covered with ultrathin microporous PTFE. The diameter of the stent ranges from 5 mm to 12 mm in 1-mm increments, with stent lengths of 16, 22, 38, and 59 mm, and catheter lengths of 80 and 120 cm. The stent is mounted on the Anertia Tri-Fold balloon and has a low crossing profile, allowing a 6-Fr sheath to deliver 5- to 6-mm and a 7-Fr sheath to deliver 7- to 12-mm diameter stents. This affords the iCAST Covered Stent advantages in crossing tortuous vessels, and avoids the need for larger sheaths and the potential for traumatic injury to the femoral and iliac vessels [17].

The Jostent GraftMaster coronary stent graft system is approved by the Food and Drug Administration (FDA) as a humanitarian use device (HUD) for the treatment of free perforations, defined as the free contrast extravasation into the pericardium, in native coronary vessels or saphenous vein bypass grafts >2.75 mm in diameter. The stent comes in 9, 12, 16, and 26 mm lengths and 3.0, 3.5, 4.0, 4.5, and 5.0 mm diameters. Guide of at least 7 Fr in size are required [17].

Embolization coils

Embolization coils and microcoils work by promoting localized thrombosis. They have been used in endovascular therapies aimed at thrombosing aneurysms (commonly intracerebral), arteriovenous fistulas, pseudoaneurysms, and perforations. The coils are typically made of metal, such as stainless steel, platinum, or platinum–tungsten alloy, which induces thrombosis and ultimately fibrosis. The basic design of an embolization coil involves a wire (usually of steel or platinum) that is wound tightly into a straight primary coil, and then formed into a secondary structure of various designs (such as three-dimensional loops, helices, and spheres). The coil is usually then packaged into a delivery device and upon extrusion resumes its preformed shape [17].

Differences among Coils

Stainless steel and MRI coils have greater radial strength than the platinum coils. However, platinum coils, being softer, may conform more easily within the vessel, and theoretically can provide more optimal occlusion. Coils may be non-fibered or fibered with synthetic fibers such as Dacron or nylon, with fibered coils being more thrombogenic and producing a greater degree of clot formation [17].

TECHNIQUE Coil embolization Techniques for coil embolization, to some degree, depend on the device and the manufacturer. Most modern coils have device-specific instructions for

deployment. However, some general techniques include (1) using the delivery or guide for the necessary support to deliver and form a dense coil mass, (2) using high radial force coils as a scaffold upon which small softer coils are delivered to create a dense coil mass, and (3) deploying part of the coil in a branch vessel as an anchor, and then deploying the rest of the coils in the target vessel using the anchor as support. The branch vessel is sacrificed [17].

The use of some of these coils requires specialized microcatheters and small selective catheters with sufficiently small internal lumen diameter, whereas others require specialized equipment such as coil pushers and coil-positioning catheters which allow repositioning and withdrawal of the coils before coil release [17].

Coil embolization is also suitable to close perforation at collateral vessels in complicated CTO cases with retrograde approach.

TECHNIQUE Particle embolic agents Mix 3 ml of 250- to 355- μm Contour Emboli with contrast to form a diluted, well-suspended solution; 250- to 355- μm Contour Emboli are injected through the microcatheter into the perforated segment. The relatively heavy weight of the PVA (polyvinyl alcohol) particles, and their delivery in the antegrade direction of the bloodstream after appropriately wedging the distal tip of a 2.9-Fr Progreat microcatheter in the affected segment, prevented any significant reflux in the small SBs as well as the major branches. The catheter must be small enough to allow selective catheterization of the vessel supplying the lesion, yet large enough to deliver an embolic agent. The particles must fit through the catheter without causing catheter occlusion, yet not be so small that they pass through the capillaries [17].

An OTW balloon catheter was not considered as a carrier in both cases because its maximum internal diameter is 0.36 mm compared with 0.53 mm for the microcatheter. As the PVA particle size is 250–355 μm , the chances of lumen occlusion with the OTW balloon catheter are very high [17].

IMPROVISED EQUIPMENT

Use of gel foam (absorbable gelatin – compressed sponge prepared from purified porcine skin–gelatin) and collagen of a 6-Fr Angio-Seal closure device have also been reported in almost similar situations. However, it must be cut to the appropriate size, which may be more difficult to deliver with precision into very small distal branches of the coronary system using a microcatheter. The use of microcoil embolization to manage coronary perforations has also been reported, however, appropriately sized microcoils must be available in catheterization laboratories for such an emergency. Recently, a microleak in the RCA was been successfully treated with intra-arterial glue injection. However, extra caution was required to prevent setting of the glue while in transit. Platelet perfusate is also a good option [18].

Advanced and Exotic Techniques

Technical Tips

****Embolize a distal vessel with an OTW catheter** The infusion of the particles can be performed through an OTW balloon catheter while keeping the balloon inflated to prevent further leak. It is important to utilize small-sized PVA particles ($<300\mu\text{m}$) which can pass through a 0.014-inch lumen. Extreme caution is needed to prevent reflux of embolizing materials in the more proximal vessel or even to intracranial arteries in case of guide dislocation. For this specific reason, the infusion utilizing the central lumen of an OTW proximally inflated balloon may be a most appropriate approach [19].

****Occlusion of the distal artery with subcutaneous tissue** To embolize or form thrombi in the penetrated vessel, it was planned to deliver subcutaneous tissue to the vessel. Subcutaneous tissue was extracted from the incision site of the right femoral region, where a sheath had been inserted. The tissue contained much fat. Although the tip of the microcatheter almost completely obstructed the vessel, the tissue was put into the microcatheter and pushed with a wire until the tip of the wire protruded about 1 cm from the microcatheter. The resistance to pushing the tissue gradually decreased as the wire was advanced. After the tip of the wire had protruded from the microcatheter for 2 min, it was pulled back into the microcatheter, and the microcatheter and the wire were withdrawn from the guide. Coronary angiography showed that the small vessel was obstructed with no sign of bleeding. Subcutaneous tissue could be used as an embolization material because an autologous clot could not be created due to the full dose of heparinization or the cardiac catheterization laboratory had no material for embolization (microcoils, gelatin sponges, PVA, microfibrillar collagen, and thrombin) [20].

*****Dual guide for closure of perforation** In a case of PCI of the LAD, a perforation was seen in the mid-LAD. A balloon was inflated to stop the perforation. However, every time the balloon was deflated, the blood pressure dropped. The balloon was reinflated and left femoral arterial access was achieved with an 8-Fr sheath. A 7-Fr or larger diameter guide was advanced into the coronary ostium. As the second guide was brought into position, the first guide had to be gently moved away from the ostium without disturbing the occluding balloon. A second wire was advanced through the second guide beyond the perforation. The occluding balloon was briefly deflated to allow passage of the wire. The covered stent was prepped and mounted, then advanced to the tip of the second guide. The occluding balloon then deflated and withdrawn. Quickly, the covered stent was advanced to cover the perforation, the first wire withdrawn, and the covered stent deployed at high pressure. Repeat angiography was performed to ensure closure of the perforation [21].

*****The switching balloon technique** In this technique, the covered stent is delivered while another balloon was inflated in order to stop the bleeding (Figure 15.7).

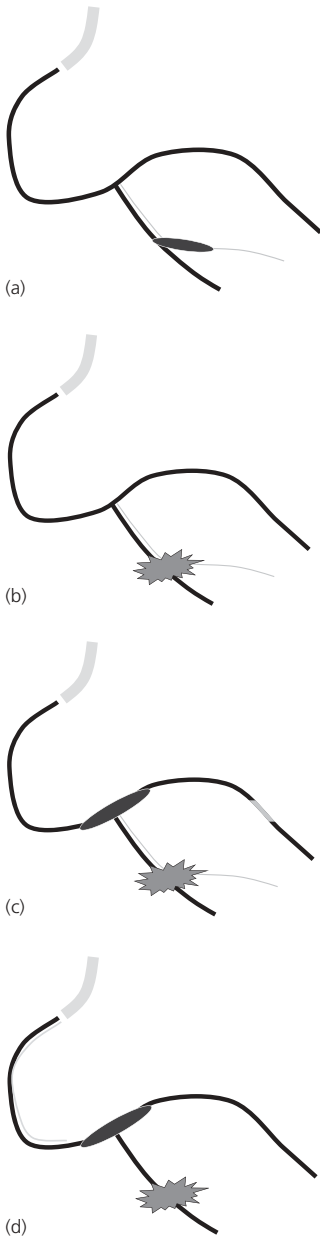


Figure 15.7 (a) A wire crossed the adventitia into the extravascular space. (b) Perforation and extravasation of blood was caused by inflation of a balloon. (c) As the wire was out of the coronary artery, ballooning at the perforation site was impossible. So a balloon was inflated at the proximal segment. (d) A microcatheter was advanced to the perforation area with the aim of embolizing the perforated branch.

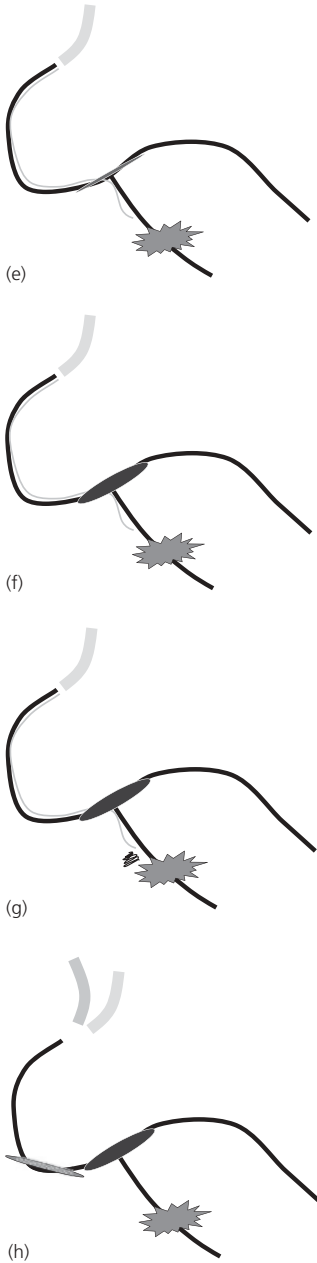


Figure 15.7 (Continued) (e) The balloon was briefly deflated so that the microcatheter could be advanced into the perforated branch. (f) The balloon was reinflated to stop the flow to the perforated branch. (g) Coils were delivered; however, they failed to close the perforation. (h) A second guide was inserted and a covered stent was advanced into the artery.

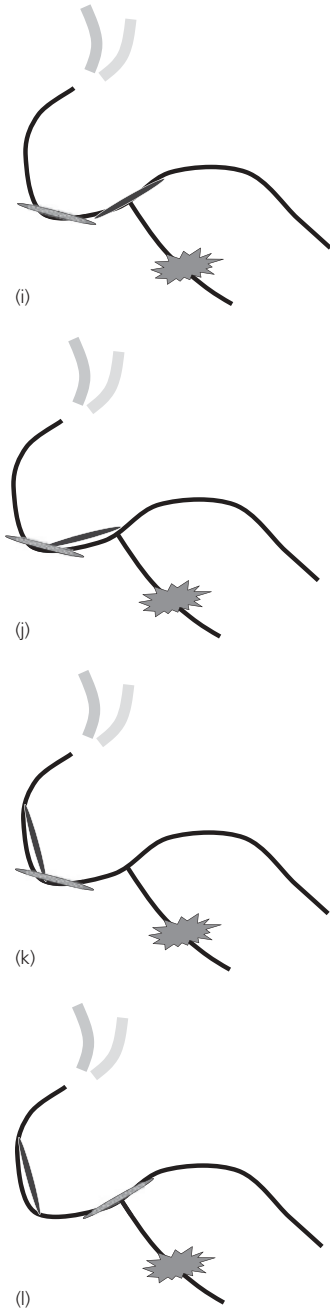


Figure 15.7 (Continued) (i–l) The first balloon was deflated and exchanged with the new covered stent.

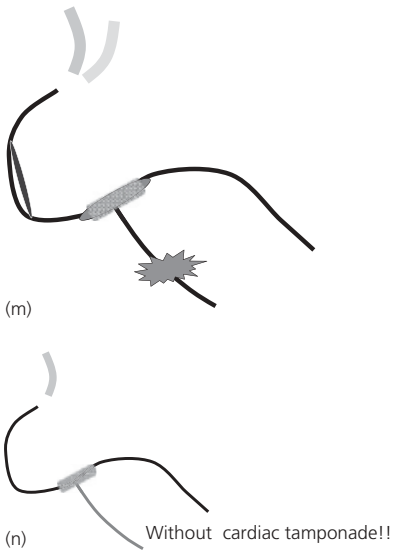


Figure 15.7 (Continued) (m) The covered stent was deployed successfully. (n).

Management of Perforation at the Distal End of an Artery

If the perforation is at the distal end of a large vessel or a branch, the treatment is by reversing the anticoagulation state, balloon tamponade of the more proximal segment if the patient can tolerate the ischemic injury, injection of thrombin to the distal branch, and closure of the perforated branch with embolized material (including platelet infusate, clotted blood, or coil material).

CRITICAL THINKING

In case of perforation, which is better: Covered stent or prolonged balloon inflation?

After perforation, there are choices either to inflate a regular balloon with reversal of anticoagulation by heparin or to deploy a PTFE-covered stent. If the patient still needs anticoagulation to keep the just dilated or stented lesion open, then covered stent is



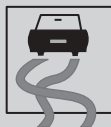(Continued)

best. If anticoagulation may not be needed after PCI, reversal of heparin and prolonged inflation of a balloon to seal off the perforation are an acceptable choice. Full reversal of heparin and prolonged ischemia due to continuous balloon inflation can cause slow flow in the distal bed or early thrombosis of the covered stent. So a covered stent is better deployed without full reversal of heparin and glycoprotein IIb/IIIa inhibition.

CAVEAT

The decision for sending the patient for CABG after perforation

After perforation, if there is no covered stent and no embolizer, and if the bleeding does not stop after long local tamponade, the patient may need surgery. However, it is not an easy and simple procedure. Many times, the area around the perforation has intramural hematoma so the whole myocardial area is edematous and swollen, especially when the perforation is near the aorta (LM or proximal LAD) or in the coronary sulcus (LCX). In this situation, it is almost impossible to locate the perforated branch, so the surgeon just ligates the more proximal segment and bypasses any other diseased arteries. Surgery does not reperfuse the perforated branch that we try to save. Surgery may not be needed if the patient can clinically tolerate the closure of a small branch or the distal end of a large vessel. Important procedural considerations for prevention of perforation are listed in Box 15.6.



BOX 15.6 IMPORTANT PROCEDURAL CONSIDERATIONS FOR PREVENTION OF PERFORATION

- 1 Constantly monitor the tip of distal wire
- 2 Treat suspected perforation seriously, especially in patients on glycoprotein IIb/IIIa inhibitors
- 3 Do pericardiocentesis in the CCL. Insert a 5- to 6-Fr pigtail catheter for drainage
- 4 Local measures to seal perforation before leaving the CCL
- 5 Admit to intensive care unit, frequent echocardiographic follow-up

PERICARDIAL EFFUSION AND TAMPONADE

Pericardial effusion is the presence of fluid in the pericardial space. In the setting of percutaneous intervention, fluid accumulation is abrupt and as little as 100 ml may result in hemodynamic decompensation. The non-compliant pericardium has a steep pressure–volume curve; as intrapericardial pressure rises, the transmural pressure results in collapse of the right atrium (RA) first, followed by collapse of the right ventricle (RV) during progressively longer portions of diastole. Compression of left-sided chambers usually occurs in severe tamponade or, in some cases, when loculation affects only a discrete portion of the left heart. There is a continuum of clinical manifestations that depends on the speed of accumulation and the absolute volume that accumulates, as well as the underlying presence or absence of associated cardiac disease.

The presentation depends in part on at least five factors: The size of the device responsible for the perforation; the structure that is perforated, such as atrial versus ventricular myocardium, RA or left LA, RV or LV; the hemodynamic state at the time of perforation; properties of the pericardium itself; and the coagulation status. After cardiac surgery, the pericardium may be absent or adherent to the myocardial reflection and may prevent the development of tamponade (see Figure 15.6b), although this is not universally the case because tamponade and hemodynamic compromise can result from a posterior localized effusion (and may be particularly difficult to reach during attempted pericardiocentesis, usually requiring surgical drainage) [22].

Aggravating Factors

The pressure within the structure that is perforated is a major determinant of the development and severity of tamponade. Thus a small perforation of the RV in a non-anticoagulated patient may not be clinically apparent; in contrast, perforation of the RV in the setting of pulmonary hypertension or anticoagulation can be catastrophic. These same considerations apply for both the RA and the LA as well [22]. In addition, the device-related potential size of perforation is crucial: A small perforation due to a coronary wire or transeptal puncture needle before giving IV heparin can be tolerated without significant hemodynamic compromise, whereas a split-like tear in cardiac structure due to the delivery system of closure devices might be fatal despite all hopeless resuscitation efforts. [22].

Attenuating Factors

The thicker wall of the LV (≥ 10 mm) may act to seal small perforations, balancing the higher intra-chamber pressures. However, even a small wire perforation may not be tolerated if it occurs in patients with resistance to LV outflow, such as in severe aortic stenosis. In this case, very high LV pressure and high afterload result in the newly created hole in the chamber acting as a “pop-off” valve, with blood preferentially driven toward an initially low-pressure intrapericardial space. [22].

In contrast, a small RA perforation may be well tolerated in some patients not on anticoagulants because of low intracardiac pressures and therefore low driving pressure. Finally, the geometry of the perforation may also be important. A slit-like perforation may result in different patterns of fluid accumulation than a circular hole, particularly if the wall of the affected chamber is thin, e.g. the LA or LA appendix [22].

Clinical Presentation

The occurrence of myocardial perforation and subsequent fluid accumulation within the pericardium should be suspected clinically during the time of procedure after some risky stages such as postdilation with high pressure, rotablation, or directional atherectomy, crossing a CTO-type stiff wire through a calcified lesions, difficult transeptal puncture, dilation of atrial transeptum, several pulls and pushes of the closure devices in the delivery system in a thin LA, and balloon dilation of calcified coarctation in adult patients. The earliest signs of perforation/tamponade in PCI are usually pericardial-type chest pain whereas the usual symptoms in congenital structural intervention (CSI) are hypotension or vasovagal reactions [22].

The typical pain of a new pericardial irritation is that of substernal discomfort sometimes radiating up into the neck and jaw. Acute pericardial irritation can also present with atypical symptoms such as shoulder discomfort, abdominal discomfort, or even nausea. In some instances, the patient may describe a sense of doom even before hemodynamic changes are observed. On other hand, the earliest finding is acute bradycardia and hypotension, reflecting a vasovagal reaction to sudden pericardial stretch with or without nausea and chest discomfort [22].

Central aortic pressure and RA pressures can provide excellent indirect evidence of perforation and subsequent tamponade. In the very early stages, the blood pressure response is variable: Although hypotension is a hallmark of tamponade, systemic aortic pressure may actually increase initially along with an increase in heart rate due to a sympathetic response to the initial pericardial irritation. However, if the tamponade is caused by split-like tear, a rapid accumulated blood volume in pericardial space is always represented by persistent hypotension, unchanged with a crystalloid or inotropic infusion [22] (Box 15.7).

Pulse pressure

Pulse pressure will, however, decrease and pulsus paradoxus develop, reflecting an exaggerated decrease in pulse pressure during inspiration. At this time, RV filling pressures will start to rise. The contour of the RA pressure will subsequently change during the early stages of tamponade. There will be a loss of the *y* descent and, in patients who remain in sinus rhythm, there will be a more prominent "a" wave at the time of atrial contraction. As pericardial tamponade develops, there will then be a significant decrease in aortic systolic pressure and a rise in RA pressure. The pulse pressure may be so narrow during inspiration that the observer will be

BOX 15.7 CARDIAC TAMPONADE**Clinical signs of cardiac tamponade**

- Tachycardia or bradycardia in early stage
- Hypotension
- Elevated jugular venous pressure with a blunted Y-descent
- Pulsus paradoxus
- Distant heart sounds
- Physical features/signs of the underlying etiology (e.g. connective tissue disorders)
- Enlarged cardiac silhouette on chest radiograph

Hemodynamic changes in cardiac tamponade

- Hypotension
- Elevation of filling pressures in all four cardiac chambers
- Diastolic equalization of pressures
- Blunted Y-descent in RA pressure waveform
- RV and LV peak systolic pressures out of phase
- Peak aortic pressure varying more than 10–12 mmHg
- Decrease in cardiac output

unable to detect individual heartbeats. Intervention is indicated in the early hemodynamic stages, once there is a noticeable pulsus paradoxus, even in the absence of a drop in overall systemic pressure [22].

Chest radiography

This may be helpful in some settings [22]. Straightening and immobility of the left heart border on fluoroscopy is a reliable and sensitive adjunctive marker of tamponade in the catheterization laboratory and occurs together with significant hemodynamic deterioration. Typically, large effusions present as globular heart with sharp margins, sometimes referred to as a “water bottle” silhouette. If the effusion develops during catheterization, it may also be identified by the development of lucent lines in the cardiopericardial silhouette – the so-called epicardial halo sign or fat-pad sign [22].

Echocardiography

The typical two-dimensional echocardiographic findings of RV collapse and RA invagination may not be seen in the early stages of tamponade, because they require transmural pressures greater than the intracardiac chamber pressures; thus these findings may also not be present or be delayed in patients who have specific forms of underlying heart disease in which intracardiac chamber pressures are elevated. This may be particularly the case in patients with RV hypertrophy where pericardial fluid may not result in initial RA and RV diastolic collapse. One of the most sensitive methods for detecting early pericardial tamponade is the

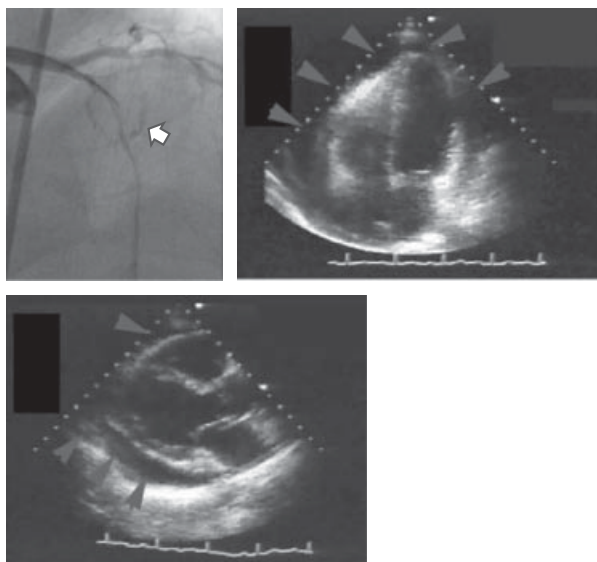


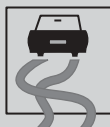Figure 15.8 After perforation in the middle of the left anterior descending artery, blood was seen in the pericardial space.

finding of a new septal shift on two-dimensional echocardiography, indicating ventricular interdependence (Figure 15.8). Pulse-wave Doppler interrogation of the mitral inflow velocity is also important to detect early subclinical stages of tamponade, with dissociation of intrathoracic and intracardiac pressures as well as enhancement of ventricular interaction. This will result in a decrease in the initial *E* velocity during inspiration on the transmitral flow–velocity curve. In typical tamponade, there is an overall decrease in the *E*:*A* ratio, due to a low early diastolic filling. However, the initial *E* velocity will decrease further with inspiration due to decreased filling in the left side, countered by increased filling of the right side during inspiration [22].

CAVEAT

Tamponade without echo-free space

Echocardiography initially universally documents a free space. However, as anticoagulation is stopped in a specific patient or if coagulation of the pericardial fluid starts, the free space may not be as easily visible. Careful analysis of the images and hemodynamic monitoring can identify and resolve this issue.



Management

The treatment of iatrogenic pericardial effusion (PE) varies. Typically, when a new effusion is documented, the procedure should be terminated and any anticoagulation reversed. In some patients, when only a small effusion is present, the two above maneuvers are sufficient to prevent hemodynamic deterioration. At the other end of the spectrum is tamponade requiring urgent resuscitation with pericardiocentesis and placement of an indwelling catheter for continued evacuation. If there has been a tear in a cardiac structure, percutaneous drainage may not successfully resolve the problem and surgery may be required, although infrequently. In these situations, maintaining the tamponade-related devices *in situ* is recommended to temporarily prevent bleeding while pericardiocentesis was performed and continuous pigtail drainage with negative pressure was established until the patient was transferred to the cardiac operating room [22].

TECHNIQUE Echo-guided pericardiocentesis Using ultrasound guidance, the optimal window for pericardiocentesis can be determined by the apical or subcostal approach. This is particularly true in acute tamponade, where most of the effusion is best visualized from an apical window on the posterior portion of the pericardium, necessitating an apical entry with the needle directed posteriorly. In some instances, a subcostal or lower parasternal approach is best if the effusion cannot be reached via an apical approach. In general, the specific route for needle placement should be that route that provides the shortest and easiest access to the pericardial space. If a subxyphoid approach is used, care should be taken to avoid trauma to the left lobe of the liver. For intercostal approaches, care must be taken to place the needle superior to the specific rib margin to avoid damage to the intercostal areas. Adequate local anesthesia is important. Some operators insert a long sheathed 16- to 18-gauge needle, whereas others prefer a micropuncture approach. Limited aspiration throughout the insertion of the needle with a 20-ml syringe is useful. Once blood is withdrawn through the needle, agitated saline should be injected under echocardiographic guidance to ensure that the entry point is within the pericardium and not within the ventricular chambers. Once the entry has been identified, the sheath is advanced into the pericardial space [22].

TECHNIQUE Blind pericardiocentesis Although echo-directed pericardiocentesis is optimal, the procedure should not be delayed if an echo machine is not available and hemodynamic collapse is imminent. Straightening and immobility of the left heart border, especially if mobility were confirmed to be normal before transeptal puncture, are usually pathognomonic for tamponade. If the patient is rapidly deteriorating, which usually relates to severe tamponade, a "blind" pericardiocentesis, which would usually be safe due to severe tamponade, from a subxyphoid or subcostal approach should be attempted rather than waiting for echocardiography during hemodynamic collapse. An ordinary

arterial puncture needle could be used for the subxyphoid approach in an acute setting. Through this puncture needle, a short wire is inserted into the pericardium under fluoroscopy to confirm the position of the wire, then an ordinary 6-Fr introducer sheath is inserted into the pericardial spaces (to ensure that there is free flotation of the wire and that the course is consistent with extracardiac insertion and position). After inserting a sheath, limited aspiration with a 20- or 50-ml syringe is required to immediately improve the hemodynamic status. Increase of blood pressure, decrease of heart rate, and a pulsation feeling of aspiration were reliable signs of right pericardiocentesis [22].

With either technique, a 6- or 5-Fr pigtail catheter is inserted and connected to continuous negative pressure. In certain situations, a "cell saver" can be used so that the blood drawn from the pericardial space can be reinfused back into the patient. However the patient can have severe pulmonary embolism if there are thrombi in the pericardial blood. This pigtail could be removed 1–2 days later when the drainage is not significant to avoid the pericarditis and reduce chest pain [22].

Intubation or at least hyperventilation should be avoided if at all possible, because the increased transthoracic pressure may lead to cardiac arrest [22]. Temporizing medical therapy is controversial: Rapid infusion of fluids is advocated by most operators; dopamine or dobutamine may also be of benefit in some patients while a pericardiocentesis can be performed [22].

Low pressure tamponade

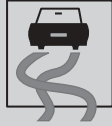Low-pressure tamponade may occur in a patient with hypovolemia during the setting of compressive pericardial effusion. Clinical findings may demonstrate a low-to-normal blood pressure with an absence of jugular venous distension or pulsus paradoxus. If a low-pressure tamponade is suspected, a fluid bolus before invasive hemodynamic measurement may help unmask occult tamponade or constrictive pericarditis hemodynamics [22].

Tamponade with RV and LV dysfunction

The clinical diagnosis of tamponade in a patient with pre-existing significant LV dysfunction can often be difficult. In such patients, the LV end-diastolic pressure may be elevated higher than the RV end-diastolic pressure and intrapericardial pressure. Similarly, in patients with isolated right heart failure (e.g. chronic obstructive pulmonary disease) and elevated right end-diastolic pressure, the intrapericardial pressure will increase to equal the LV end-diastolic pressure but remain lower than the RV filling pressures. Both RV and LV dysfunction may lead to absent pulsus paradoxus. The hemodynamic diagnosis of tamponade in patients with LV dysfunction can be made when the RA and intrapericardial pressures equilibrate and track each other throughout the respiratory cycle. Likewise, in a patient with predominantly right heart failure and high RV diastolic pressure, the pulmonary capillary wedge pressure (PCWP) and intrapericardial pressure track each other throughout the respiratory cycle [22].

CAVEAT**Pulmonary edema without tamponade**

In patients with poor LV function after pericardiocentesis, monitoring should focus on development of pulmonary edema mainly due to an abrupt increase in the pulmonary blood flow and left heart filling. If the PCWP remains elevated after complete drainage, the operator should consider pre-existing cardiomyopathy. Large-volume pericardiocentesis has been reported to cause transient LV systolic dysfunction and severe RV dysfunction, leading to cardiogenic shock [22]. In general, aspiration of 100-200 ml of blood tamponade in CVL is enough to restore the hemodynamics if anticoagulation is reversed and the perforation is not large.

**CASE STUDY: ATYPICAL PRESENTATION****Tamponade without pericardial effusion by isolated LA compression**

The diagnostic angiogram showed a patent LAD stent without significant restenosis and an occlusive in-stent restenosis of a small LCX artery and second obtuse marginal artery. The LCX and second obtuse marginal arteries were the site of a successful kissing balloon angioplasty. A contained type II mid-LCX artery perforation, located in the AV sulcus, and type II coronary perforation of a small atrial branch induced by wire position were noted. For the following 30 min, the angiogram showed contained pericoronary contrast staining without any leak. After the procedure, the patient remained asymptomatic with no hemodynamic compromise until 4 hours later, when he suddenly developed severe bradycardia and hypotension partially corrected with an IV administration of fluid, atropine, and catecholamines. A bedside transthoracic echocardiogram demonstrated a large hematoma adjacent to the left atrium without any pericardial effusion. Cardiac tamponade secondary to a localized compression of the left atrium was suspected. The patient remained unstable and was transferred immediately to the operating room. A second echocardiogram performed immediately before surgery showed a marked increase in the size of the hematoma. Surgery was performed via median sternotomy and revealed a *large hematoma located in the AV sulcus with compression of the left atrium*. Biological glue and patch were locally applied to repair the coronary perforation. The patient had a normal postoperative recovery.

LESSON TO LEARN

Tamponade with hemodynamic compromise occurs rarely in patients who have previously undergone cardiac surgical procedures due partly to partial pericardiectomy and

(Continued)

secondary pericardial adhesions. The partial pericardial adhesions probably favor migration of the hematoma with clinical presentation at a distance from the site of the perforation. So the lesson is that a hematoma can compress any cardiac chamber causing any symptom of tamponade without the presence of pericardial effusion [22].

CASE STUDY: ATYPICAL PRESENTATION

RV hematoma causing shock

Five hours after PCI of the RCA, a patient exhibited shock (BP 60/40 mmHg) and tachycardia. Coronary angiography and right heart catheterization were done for further diagnostic clarity. The RCA was patent and without evidence of extravasation of contrast. Passage of a Swan–Ganz catheter to the pulmonary artery (PA) was very difficult, unlike the previous right heart study. Right heart catheterization revealed a pressure gradient between the PA and the RV; PA pressure 23/15 mmHg; RV pressure 53/25 mmHg; low cardiac index (CI – 1.90 l/min per m², previously 2.93 l/min per m²), high mean RA pressure (26 mmHg), and cardiogenic shock with a systemic blood pressure of 48/36 mmHg. This hemodynamic collapse was treated with inotropic agents and adequate hydration, and a right ventriculogram was performed, which revealed compression of the right ventricular outflow tract (RVOT). Thus, this hypotension was found to be a result of compression of the RVOT caused by a hematoma. Pericardiocentesis was performed next to the left edge of the sternum into the hematoma. After inserting a 6-Fr sheath, contrast medium was injected through a pigtail catheter and identified a closed cavity. A total of 411 ml blood was aspirated. Following this procedure, the pressure gradient between the PA and RV became negligible (28/17 and 30/14 mmHg, respectively; pressure gradient 2 mmHg), RA pressure fell (26–12 mmHg), and CI increased (4.17 l/min per m²) with a rise in systemic blood pressure (104/68 mmHg) [12].

CASE STUDY: ATYPICAL PRESENTATION

Fatal dissecting subepicardial hematoma

Five months after stenting of the insertion site of an SVG to the LAD, a patient developed recurrent angina and repeat angiography showed diffuse in-stent restenosis. He was referred for angioplasty and vascular brachytherapy. The stenosis was crossed and dilated with a balloon at 8 atm. The stent appeared relatively underexpanded. Subsequent dilatations with another balloon at 16 atm and then a 3.0 × 10 mm cutting balloon at 14 atm resulted in complete expansion of the stent. Angiography after the final dilation revealed a large perforation at the vein graft anastomosis. The perforation was immediately sealed by inflating the cutting balloon inside the stent. A 2.5 × 20 mm Crossail RX balloon over a second wire was then introduced and rapidly exchanged with the cutting balloon to provide further sealing. Protamine 50 mg

was administrated to lower the ACT to 131 s. After a 15-min balloon inflation, the patient was hemodynamically stable and angiography showed that the perforation was sealed. Over the following 5–10 min, the patient developed chest pain and bradycardia. Angiography showed thrombosis in the body of the SVG with TIMI 1 flow distally. A temporary transvenous pacing wire was placed and thrombectomy was performed with a 4-Fr Angiojet device. Heparin 5000U was readministered to raise the ACT to 248 s. Despite the thrombectomy, there was still evidence of thrombus in the proximal portion of the SVG, which was then treated with a 3.0 × 23 mm stent. Final TIMI 2 flow was obtained after distal delivery of 100 µg sodium nitroprusside.

A transthoracic echocardiogram performed in the catheterization laboratory showed an echo-free space around the left lateral wall. Right heart catheterization did not reveal equalization of pressures. At this time, the patient was still experiencing chest discomfort and became hypotensive. The ECG showed diffuse ST elevation. Repeat angiography showed a patent SVG with persistent slow flow without evidence of perforation. An IABP was placed and the patient transferred to the coronary care unit (CCU). On transfer to the CCU, contrast echocardiography showed persistent localized collection with global severe hypokinesis. The patient was returned to the cardiac catheterization laboratory, and repeat coronary angiography was performed, showing that the LAD, which had had normal flow previously, now had markedly slow flow and did not fill distally to the apex. The SVG-D1 was patent with slow flow but no visible perforation. As a result of the patient's increasing hemodynamic instability and global ischemia, he was sent for cardiac surgery. Findings at surgery revealed neither fluid nor blood in the pericardial space. The heart was blue and distended. The epicardium was excised, showing a subepicardial hematoma cavity extending from the anterior wall to the posterior wall. Innumerable perforating branches from the epicardial vessels into the myocardium had been avulsed by the 2-cm hematoma.

The hematoma was evacuated but there was persistent oozing from the subepicardial surface without any accessible vessels to cauterize. The epicardium was glued back onto the raw exposed myocardium with Bioglue and the bleeding was brought under control. However, 3 days later the patient died. An autopsy was performed. There was a subepicardial hematoma extending from the anterior to the posterior aspect of the heart, compressing the native LAD. There was transmural LV AMI involving the anterior, lateral, and anterior septa, and partially the posterior septum and posterior wall. The cause of death was global AMI following a perforation of the SVG that caused a dissecting subepicardial hematoma. In the case described, the perforation was successfully controlled within seconds, but the patient continued to deteriorate until the diagnosis of the subepicardial hematoma was made in the operating room. It is believed that the risk of subepicardial hematoma is increased in patients after cardiac surgery as a result of adhesion of the epicardium to the pericardium [23].

CASE STUDY: ATYPICAL PRESENTATION

Localized tamponade causing a right-to-left shunt

Bedside echocardiogram revealed a small pericardial effusion posterior to the left atrium and ventricle and no significant fluid around the right ventricle, although the right atrium was not well visualized. Right heart catheterization showed normal right-sided pressures without equalization of diastolic pressures. However, the patient continued to require supplemental oxygen due to hypoxia with pulse oximetry of 85% on 4 liters of oxygen by nasal cannula. Physical examination did not reveal signs of fluid overload or congestive heart failure. A repeat echocardiogram demonstrated a large, localized pericardial effusion measuring 8 cm in diameter, surrounding and compressing the right atrium; hypermobile interatrial septum; and a right-to-left shunt through a patent foramen ovale by color flow Doppler and agitated saline injection. Repeat angiography confirmed TIMI 3 flow in the SVG and distal RCA with no angiographic evidence of persistent perforation. Serial bedside echocardiograms demonstrated no change in the size of pericardial effusion with persistent right-to-left interatrial shunting of blood. However, as the patient continued to exhibit significant hypoxia requiring moderate supplemental oxygen, he was ultimately referred for a pericardial window by a right-sided video-assisted thoracoscopic surgical approach evacuating approximately 150 ml of blood from the pericardial space and complete resolution of hypoxia. Repeat transthoracic echocardiogram demonstrated minimal pericardial fluid with no visible right-to-left interatrial shunt [24].

CORONARY ANEURYSM

A coronary artery aneurysm (CAA) is a rare disorder characterized by abnormal dilation of a localized portion of a coronary artery. Morphologically CAAs may be saccular or fusiform, single or multiple.

The introduction of PTFE-covered stents has facilitated the technique to treat CAAs percutaneously. The Jostent Graftmaster (and the self-expanding Symbiot stent system) are currently available to seal CAAs. However, important considerations associated with use of PTFE-covered stents need to be remembered. They include (1) decreased flexibility, making implantation in tortuous vessels complex and (2) that they are not suitable because of their lack of permeability (they block access to side branches when bifurcation lesions are treated).

To overcome these complexities, the use of non-covered bare metal stent (BMS) has been introduced alone or in combination with PTFE-covered stents. Orlic et al. reported a case with a large RCA aneurysm that was sealed with two PTFE-covered stents together with a BMS, using a sequential technique [25].

A custom-made bifurcation system was used to treat a large aneurysm of the proximal LAD involving bifurcation with a diagonal branch. A PTFE-covered stent was used for the main branch

and a BMS for the SB, with excellent clinical and angiographic results at the 5-month follow-up [26].

****Prevention of instent restenosis of covered stent**

However, as after any stenting procedure, the stent edges reveal a significant tendency for intimal renarrowing (in-stent restenosis) in contrast to the stent center. As drug-eluting PTFE stents are not available, the problem of restenosis can be solved by simultaneous implantation of a PTFE stent and a DES. Special care was taken to completely cover both ends of the stent graft to minimize the risk of edge stenosis due to intimal proliferation. High implantation pressures were used to obtain an optimal stent expansion. Both immediate and follow-up angiography showed excellent results without relevant late lumen loss [27].

NEW DEDICATED EQUIPMENT

Coiling a CAA with the help of a retrievable stent

A 58-year-old woman presented for percutaneous occlusion of an incidentally found aneurysm of the LM trunk bifurcation. Angiography and CT showed a dome of 11 mm and a neck of 6 mm communicating with the LAD and the LCX. Intravascular ultrasonography revealed a broad aneurysm neck. To prevent coils from dislocating into the lumen of the LAD, a retrievable self-expanding stent (Solitaire) was placed, reaching from the main trunk into the LAD, thus covering the neck and stabilizing the microcatheter. After coil embolization, the stent was removed. IVUS showed a patent lumen of the LAD and echogenic coils inside the aneurysm. This is the first reported use of a retrievable stent to support coiling of a CAA [28].



CEREBROVASCULAR ACCIDENT

During the interventional procedure, embolized material to the central nervous system can cause a transient ischemic attack (TIA) or disabling stroke. The lesser-known problems are transient or permanent blindness or seizure. The strongest independent predictors were use of thrombolytic before PCI, heparin before and after PCI, low creatinine clearance, past history of cerebrovascular accident (CVA), and diabetes [29].

Once an embolic stroke is confirmed, fibrinolytic drugs can be given intravenously: tPA 0.9 mg/kg to a maximum of 90 mg, 10% as a bolus and the rest to be infused in 1 h [30].

Transient and Permanent Blindness

Occipital blindness occurs rarely and usually disappears within a few hours. However, with emboli, the patient can develop permanent blindness. The MRI findings show contrast agent

extravasation, without cerebral ischemia or hemorrhage. These findings are also seen in posterior leukoencephalopathy syndrome. The mechanism is a transient vasculopathy with disruption of blood–brain barrier as a cause of transient cortical blindness after contrast angiography. The main treatment is aggressive hypertension control and symptomatic treatment of headache [31].

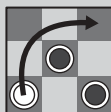
Ventricular Tachycardia and Fibrillation

Cardiac arrest can be caused by ventricular tachycardia (VT), ventricular fibrillation (VF), or asystole. While the patient is being resuscitated with intubation, external cardiac massage, IABP, or pacemaker insertion, usually the blood pressure is sustained at an unacceptable level of 50–60 mmHg during CPR in a patient with asystole who shows almost no flow to the coronary system.

TACTICAL MOVE

BEST maneuver for management of perforated vessel

- 1 **\$ FIRST BEST Maneuver:** Balloon tamponade; prolonged balloon tamponade at proximal segment if tolerated
- 2 **\$ SECOND BEST Maneuver:** If sealing is unsuccessful, then reverse anticoagulation with protamine
- 3 **\$ Add New Drug – Platelet Product:** If the distal end needs to be sealed off, then injection of 3–4 ml platelet infusate at the distal perforated end through the transit catheter or the lumen of an OTW balloon. Do not inject platelet infusate at the ostium of the main artery. The whole artery can clot. There is also risk of delayed bleeding
- 4 **\$\$ Add New Device:** Covered stent can be used to block the opening of the SB or closure with coil material any perforation at its distal end
- 5 **\$ Add New Drugs:** Injection of thrombin, gelatin sponge (Gelfoam), or PVA to distal segment to thrombose the distal vessel



The one and only maneuver – coronary perfusion during CPR

During CPR, the blood pressure is low, as evidenced by aortic pressure. If there is good LV function before cardiac arrest the chance of good recovery is high. The interventional cardiologist can help coronary perfusion by keeping the guide inside the LM, gently pulling it out, withdrawing oxygenated blood to a large syringe connected to the guide, and injecting this blood into the coronary system. Mix this blood with some contrast and inject to check the flow to the distal coronary vasculature and feeble movement of the LV. With good oxygenation from the ventilator (the patient is intubated), correction of electrolyte, acid–base

imbalance, and opening of the acute occluded artery (which causes the cardiac arrest), coupled with forced coronary perfusion by injection of oxygenated blood, the chance of recovery is higher. Try not to cause dissection of the LM with movement of the guide.

Technical Tip

*****How to differentiate between VT and supraventricular tachycardia by intracardiac ECG** To record an intracardiac ECG, a 0.014-inch Choice Floppy angioplasty wire is placed in the lumen of a 6-Fr multipurpose catheter with the wire tip minimally protruding. The proximal end of the wire is attached to a surface V1 ECG lead with a sterile alligator clamp. During continuous ECG and pressure monitoring, the catheter is manually withdrawn from the RV and rRA [32]. The RV ECG complex is wider and the RA ECG one smaller. VT is seen as an RV wide complex with AV dissociation. The RA ECG complex is seen in accordance with the RV complex in supraventricular VT (SVT).

BRADYCARDIA OR ASYSTOLE

Technical Tip

Pacing with a coronary wire Simply connect the wire hanging out of the patient to the cathode (negative pole) of the pacemaker device and the anode (positive pole) to some exterior part of the patient. A large skin electrode is ideal and the patient will feel no pinching even when high pacing output is used. In an emergency situation, one may just stick a needle into the anesthetized groin or even into the non-anesthetized chest wall to be ready for unipolar pacing.

First, it is important to know that the tip of the coronary wire has to be advanced deeply into a coronary SB feeding muscle (e.g. septum) rather than epicardium.

Second, as much of the wire length as possible should be insulated, up to the coronary orifice, by the guide. Within the coronary artery, advancement of monorail or OTW balloon catheter to the vicinity of the tip will help. Third, the pacing output should first be set at maximum and reduced only once pacing has been accomplished [33].

REFERENCES

1. Ellis S. Elective coronary angioplasty: Techniques and complications. In: Topol EJ (ed.), *Textbook of Interventional Cardiology*, 3rd edn. New York: Lippincott-Raven, 1998: 147–62.
2. Nayak K, White AA, Cavendish J, et al. Anaphylactoid reactions to radiocontrast agents: prevention and treatment in the cardiac catheterization laboratory. *J Invasive Cardiol* 2009;**21**:548–51.
3. Huber MS, Mooney JF, Madison J, et al. Use of a morphologic classification to predict clinical outcome after dissection from coronary angioplasty. *Am J Cardiol* 1991;**68**:467–71.
4. Sakurai H, Saburi Y, Matsubara K, et al. A pitfall in the diagnosis of LM coronary obstruction due to aortic dissection. *J Invasive Cardiol* 1998;**10**:545–6.

5. Bergelson BA, Fishman RF, Tommaso CL. Abrupt vessel closure: Changing importance, management, and consequence. *Am Heart J* 1997; **134**:362–81.
6. Abdou, SM, Wu, CJ. Treatment of aortocoronary dissection complicating anomalous origin right coronary artery and chronic total intervention with intravascular ultrasound guided stenting. *Catheter Cardiovasc Interv* 2011; **78**:914–19.
7. Adlakha S, Sheikh M, Wu J, et al. Stent fracture in the coronary and peripheral arteries. *J Interv Cardiol* 2010; **23**:411–19.
8. Kaplan BM, Benzuly KH, Kinn JW, et al. Treatment of no-reflow in degenerated SVG interventions: Comparison of intracoronary verapamil and nitroglycerin. *Catheter Cardiovasc Diagn* 1996; **39**:113–18.
9. Meerkink D, Balkin J, Shaheen J, et al. The twin-pass dual access catheter for assessment of the no-reflow phenomenon. *J Invasive Cardiol* 2010; **22**:125–9.
10. Hillegass W, Dean N, Laio L, et al. Treatment of no-reflow and impaired flow with the nitric oxide donor nitroprusside following PCI: Initial human clinical experience. *J Am Coll Cardiol* 2001; **37**:1335–43.
11. Haraphongse M, Rossall RE. Large air embolus complicating angioplasty. *Catheter Cardiovasc Diagn* 1989; **17**:244–8.
12. Kawase Y, Hayase M, Ito S. Compression of right ventricular out-flow due to localized hematoma after coronary perforation during PCI. *Catheter Cardiovasc Interv* 2003; **58**:202–6.
13. Flaherty M, Dawn B, Solankhi NK. Iatrogenic submedial coronary artery intramural hematoma presenting subacutely. *J Invasive Cardiol* 2009; **21**:e128–31.
14. Kashiwase K, Ueda Y, Ogasawara N, et al. A large dissecting sub-epicardial hematoma and cardiac tamponade following elective percutaneous coronary intervention. *J Cardiol* 2008; **52**:163–6.
15. Wedge D, Hauge M, von Birgelen C, et al. Treatment of coronary artery perforation with a new membrane covered stent. *Z Kardiol* 1998; **87**:948–53.
16. Pienvichit P, Waters J. Successful closure of a coronary artery perforation using makeshift stent sandwich. *Catheter Cardiovasc Interv* 2001; **54**:209–13.
17. Yeo KK, Rogers JH, Laird JR. Use of stent grafts and coils in vessel rupture and perforation. *J Interv Cardiol* 2008; **21**:86–99.
18. Patel T, Shah S, Kuladhipati I. Management of guidewire-induced coronary artery perforations through transradial route—a simple approach. *J Invasive Cardiol* 2009; **21**:E248–51.
19. Iakovou I, Colombo A. Management of right coronary artery perforation during percutaneous coronary intervention with polyvinyl alcohol foam embolization particles. *J Invasive Cardiol* 2004; **16**:727–8.
20. Hirotaka O, Masato O, Yashiro M, et al. Wire-induced coronary artery perforation treated with transcatheter delivery of subcutaneous tissue. *Catheter Cardiovasc Interv* 2005; **66**:369–74.
21. Silver K, Bauman W, Berkovitz K. Dual-catheter covered stenting: A novel approach to the treatment of large coronary artery perforations. *J Invasive Cardiol* 2003; **15**:348–50.
22. Holmes D, Nishimura R, Fountain R, et al. Iatrogenic pericardial effusion and tamponade in the percutaneous intracardiac intervention era. *J Am Coll Cardiol Interv* 2009; **2**:705–17.
23. Quan V, Stone J, Couper G, et al. Coronary artery perforation by cutting balloon resulting in dissecting subepicardial hematoma and avulsion of the vasculature. *Catheter Cardiovasc Interv* 2005; **64**:163–8.
24. Varghese V, Mogtader A, George JC. Regional cardiac tamponade resulting in hypoxia from acute right to left inter-atrial shunting. *J Invasive Cardiol* 2011; **23**:E96–8.

25. Orlic D, Vitrella G, Corvaja N, Colombo A. New technique to seal a long giant coronary aneurysm with PTFE-covered stents: A case report. *Catheter Cardiovasc Interv* 2006;**67**:41–5.
26. Iakovou I, Colombo A. Treatment of a coronary aneurysm involving bifurcation with the use of a custom-made polytetrafluoroethylene-covered bifurcation stent system. *Catheter Cardiovasc Interv* 2005;**64**:169–72.
27. Süsselbeck T, Haghi D, Borggrefe M, Kaden JJ. Percutaneous treatment of a coronary aneurysm by stent graft and drug-eluting stent implantation: A potential method to reduce stent graft restenosis. *J Interven Cardiol* 2008;**21**:325–8.
28. Schumm J, Ragoschke-Schumm A, Hansch A, et al. Embolization of a coronary aneurysm with support of a retrievable stent. *J Am Coll Cardiol Interv* 2011;**4**:361–2.
29. Dukkupati S, Deo D, Sadeghi M, et al. CVA after PCI: Incidence, predictors, outcomes. *J Am Coll Cardiol* 2003;**41**:6–2A.
30. The National Institute of Neurological Disorders and Stroke rt-PA Stroke Study Group. Tissue plasminogen activator for acute ischemic stroke. *N Engl J Med* 1995;**333**:1581–7.
31. Zwicker JC, Sila C. MRI findings of a case of transient cortical blindness after cardiac catheterization. *Catheter Cardiovasc Interv* 2002;**57**:47–9.
32. Holmes D, Kern M. Simplified intracardiac electrocardiography for Ebstein's anomaly. *Catheter Cardiovasc Interv* 2002;**57**:367–8.
33. Meier, B. Coronary or left ventricular pacing, the easy and obvious way out of asystole during cardiac catheterization. *Invasive Cardiol* 2011;**23**: 115–16.

CHAPTER 16**High-risk Patients**

Ramesh Daggubati, Rajasekhar Nekkanti, Vinh N. Pham,
 Nguyen Duc Cong, Phan D. Phong, Dan D. Le, Ali Oto,
 Vijay Dave, Thach N. Nguyen

Challenges 400

Modifying the Risk Factors 402

Left Ventricular Dysfunction 402

Right Heart Pressure Evaluation and Monitoring 402

Intra-aortic Balloon Pump 402

Options for Extremely High-risk Patients 403

Acute Coronary Syndromes 403

Multivessel Disease 404

Technical Tips 407

**The challenging first minute 407

How to identify the culprit lesion by ECG and angiographic findings 408

How to assess the lesion by history and ECG: Rationale for the dilation sequence 408

Non-invasive Evaluation of Lesions 409

Technical Tip 410

**Important meaning of ventricularization of pressure during diagnostic cannulation of the RCA 410

How to perform PCI in Patients with ACS or AMI 410

Left Ventricular Assist Devices 411

Advantages and Limitations 412

Technique 413

Advantages and Limitations 413

Discriminating Differences 413

IMPELLA in aortic stenosis 414

Technical Tips 414

Tips for impella insertion 414

Technical tips for TandemHeart 415

For both devices 415

Exotic Complex Interventions for the Weekend Urban Warriors 415

Hybrid MIDCAB and PCI 415

PCI and CABG for Patients with Aortic Stenosis 416

*Basic; **Advanced; ***Rare, exotic, or investigational

\$, <\$US100.00 extra; \$\$, >\$US100.00 extra

⌚, <10 min extra; ⌚⌚, >10 min extra

♣, low risk of complications; ♣♣, high risk of complications

CHALLENGES

High risk is defined as the probability and, more importantly, the consequence, of abrupt closure of the dilated site, occlusion of large side or distal branches, or widespread microvascular obstruction with spasm. Abrupt closure of a large epicardial artery or of a side or distal branch is recognized by standard angiogram whereas occlusion at the microvascular level is seen as slow flow or no reflow secondary to showers of material from ruptured plaques. Their immediate clinical presentation and long-term outcome is determined by the amount of myocardium in jeopardy and the degree of myocardial reserve. The treatment for abrupt closure at the epicardial artery is mainly by prompt stenting. However, the preventive measures of occlusion at the distal branches and at the microvascular level may require deployment of distal protection devices. The ultimate goals are to preserve the patency of the coronary arteries and the systolic function of both right and left ventricles, and to prevent negative localized or global ventricular remodeling. In general, as the patients undergoing percutaneous coronary interventions (PCIs) are older, and present to the hospital sicker, they are more vulnerable even with short episodes of ischemia or worse when there is irreversible acute closure due to extensive dissection or refractory thrombus. To facilitate short- and long-term success of PCI in complex lesions, the rationale that justifies the procedure and strategies to achieve clinical and procedural goals includes (1) identification of clinical and angiographic features of complex PCI, (2) determination of the appropriateness of complex PCI compared with alternative therapies such as open heart surgery (coronary artery bypass graft [CABG]), and (3) formulation of a strategy that maximizes immediate and long-term success [1].

The clinical risk factors predicting in-hospital mortality and morbidity are listed in Box 16.1 [2]. The most important factor is severe left ventricular (LV) dysfunction. However, the risk of acute periprocedural closure depends on the high complexity of lesion morphology (left main [LM] disease, angulation $<45^\circ$, lesions with thrombus, long lesion, bifurcation lesion, multiple vessel disease),

BOX 16.1 CLINICAL AND ANATOMICAL PREDICTORS OF MORTALITY AND MORBIDITY AFTER ACUTE CLOSURE

- 1 Left ventricular ejection fraction $<30\%$
- 2 Creatinine >1.5
- 3 Diabetes mellitus
- 4 Triple vessel disease
- 5 Age >70
- 6 Acute coronary syndrome
- 7 Female gender

and the suboptimal results of PCI. As a result of acute closure of the dilated artery, the most common presentation before fatality is profound cardiogenic shock. The predisposing risk factors for shock are listed in Box 16.2. The factors associated with abrupt closure are mostly lesion based. In contrast, the factors associated with shock and/or mortality are mostly clinically based, reflecting the poor ventricular function and greater extent of coronary artery disease (CAD). When performing interventions in complex lesions, more complications must be anticipated. Should disaster occur, the management approach should already be identified, and all the corrective mechanisms set in place can be put in motion as planned [3]. In the case of acute closure, a stable blood pressure is very important to secure survival. Lower blood pressure correlates with higher risk of death [4]. Thus, every attempt has to be made to keep a decent blood pressure while the patient undergoes cardiopulmonary resuscitation (CPR) or emergency measures to reopen the artery with a perfusion balloon or stent are taken. Strategies for PCI of complex lesions in high-risk patients are listed in Box 16.3 [4].

BOX 16.2 HIGH RISK OF SHOCK IF ACUTE OCCLUSION OF TARGET VESSEL

- 1 Left ventricular dysfunction (ejection fraction <30%)
- 2 Target vessel supplying more than 50% viable myocardium
- 3 Circulation to both papillary muscles compromised
- 4 High jeopardy score >3 [3]

BOX 16.3 STRATEGIES FOR COMPLEX AND HIGH-RISK LESION PCI

- 1 Over-prepare the possibility of a complication. Rehearse the scripted case strategy
- 2 Attention to the general factors: Control diabetes, enough hydration to optimize renal function, lower use of contrast, etc.
- 3 Early and appropriate use of anti-platelet agents
- 4 Hemodynamic support (IABP) for hypotension or left ventricular dysfunction
- 5 Meticulous access site management
- 6 Necessary and adequate sedation and anesthesia
- 7 Conservative equipment selection (larger guide, rotational atherectomy only if necessary)
- 8 Short procedure
- 9 Accept less than perfect results when benefit–risk unfavorable
- 10 Stop when appropriate before disaster; always favor safety over completion of procedure
- 11 Obsessive post-procedural care
- 12 Early follow-up angiography for selected group of patients (e.g. left main disease)

MODIFYING THE RISK FACTORS

Left Ventricular Dysfunction

LV dysfunction is the most important predictor of immediate and long-term survival in patients with CAD. Ejection fraction < 30% and a target vessel supplying >50% of the remaining viable myocardium are considered high-risk factors for mortality and severe morbidity if there is acute occlusion of the target vessel [5]. The mortality rate of these patients ranges between 12% and 33%. Therefore, optimal medical management and fluid status, stabilization of decompensated congestive heart failure (CHF), and unstable angina symptoms plus surgical consultation before PCI are needed. There is an absolute need to minimize the impact of periprocedural ischemia by using short inflation time. PCI in a lesion of an artery providing collaterals should be efficient, thus avoiding ischemia in distant areas. A cautious approach should be exercised in PCI of lesions that can cause slow flow or no reflow (lesion with thrombus, large bulky atheromatous lesion, degenerated vein graft, etc.). In patients with significant baseline LV dysfunction, liberal use of right heart pressure monitoring, inotropic support, and intra-aortic balloon pump (IABP) or left ventricular assist device (LVAD) is suggested. In cases of unplanned PCI, the LV end-diastolic pressure reflects the fluid status of the patient.

Right Heart Pressure Evaluation and Monitoring

While undergoing complex coronary interventions, every patient, especially patients with LV dysfunction and renal insufficiency, need adequate hydration to sustain a stable coronary and renal perfusion pressure. Monitoring the pulmonary capillary wedge pressure (PCWP) before intervention helps to optimize fluid management without provoking CHF and pulmonary edema, and is also a powerful adjunct for procedure planning. In some cases, with an elevated PCWP, the procedure may be deferred to allow time for clinical optimization by medical therapy. These patients may benefit from IABP support.

Those with low cardiac output should be treated with afterload reduction or inotropic support during intervention.

Intra-aortic Balloon Pump

The most common strategy to support LV dysfunction during complex coronary intervention is diastolic counterpulsation by IABP. Its mechanism is to increase the diastolic pressure and, by that, the diastolic coronary perfusion. With inflation of a 40-ml balloon to coincide with the closure of the aortic valve, IABP increases the cardiac output roughly 30%. The indications for insertion of IABP before PCI are listed in Box 16.4. In patients with LV ejection fraction (LVEF) <25%, stable BP <100mmHg, and PCWP >20mmHg, the IABP standby is suggested [6]. After patients have successfully undergone the complex procedures, the IABP can be removed. In some cases it is useful to continue IABP support on the day after the procedure. This strategy can be followed if the ventricular function is severely depressed, filling pressure is elevated, or PCI results are suboptimal. When the

BOX 16.4 INDICATIONS FOR INSERTION OF IABP BEFORE PCI: EJECTION FRACTION <25% PLUS

- 1 Target vessel supplying most of the viable myocardium
- 2 Jeopardy score >3
- 3 Abnormal resting hemodynamics (low BP <100 mmHg with high PCWP >24 mmHg)
- 4 Cardiogenic shock and multivessel disease

BOX 16.5 PCI SHOULD BE REFUSED: EJECTION FRACTION <20% PLUS

- 1 PCI to the only patent vessel (especially SVG)
- 2 PCI required deep engagement of guide
- 3 Use of rotational atherectomy
- 4 Complex lesion morphology (e.g. in no-option patients)
- 5 Unstable hemodynamics with decompensated CHF, severe pulmonary hypertension
- 6 Not an ideal anatomy for stenting

PCWPs are adequate after the procedure, and the PCI results are good, IABP may be discontinued before transfer out of the catheterization laboratory. Hemostasis can be achieved with a vascular closure device, making this approach very practical.

Options for Extremely High-risk Patients

In general, there are many patients with complex lesions on top of severe LV dysfunction, in whom the temptation for PCI should be resisted under normal circumstances (Box 16.5). However, as the LVAD is more available and refined, some patients could have PCI while under support of the LVAD and, with successful PCI, could be weaned off the LVAD [7].

Acute Coronary Syndromes

In general, the patients with acute coronary syndromes (ACSs) and continued, recurrent, or refractory angina should be referred for coronary angiography for subsequent PCI if needed. PCIs in these patients were laden with complications related to the presence of intracoronary thrombus and the hypercoagulable state triggered by a ruptured complex plaque. Effective antiplatelet drugs have had a dramatic effect in stabilizing these patients before intervention and diminishing periprocedural events. Glycoprotein (GP) IIb/IIIa inhibitors are most beneficial when given before the procedure in patients with positive troponin. They did not improve the outcomes in low-risk patients (type A lesions), or in procedures with mechanical difficulty (chronic total obstruction), or heavy atheromatous burden, with a high possibility of distal debris

BOX 16.6 STRATEGIES GUIDING THE PERFORMANCE OF PCI IN MVD

1 Pre-procedure evaluation

- a** Solid indications
- b** Comprehensive evaluation of risks
- c** Practical assessment for chance of success
- d** Thorough discussion with patient and family about risks and benefits

2 Strategy for SAFE procedure

- e** Stratify the significance of contribution of each artery in which the lesion is located in the maintenance of blood pressure
- f** PCI FIRST the artery that is not ESSENTIAL in maintaining a decent blood pressure

3 Procedural tactics for safety and success

- g** Set up with good rationale the sequential order of lesions to be dilated
- h** Constant monitoring of the progress and safety of the procedure
- i** Detecting early signs of hemodynamic instability
- j** Dilating the first lesion: The challenging first minute
- k** Transforming high-risk MVD PCI into single-vessel PCI

embolization (degenerated saphenous vein graft [SVG]) [8]. IABP can be inserted from the brachial approach if the patient has an abdominal aortic aneurysm (AAA) [9].

Multivessel Disease

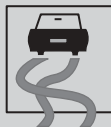Not every lesion needs revascularization because it is too distal, located in a small branch or in completed infarct areas. For patients with significant multivessel disease (MVD), there are safety concerns, rationale for indications, principles, and strategies guiding the performance of their PCI. They are listed in Box 16.6.

CAVEAT

Identify the lesions that bring catastrophe

During PCI, if there is acute occlusion of the target lesion, the highest risk of catastrophe is from persistent shock leading to mortality.

The cause of shock is refractory right and left heart failure, aggravated by ischemia of the papillary muscles triggering acute mitral regurgitation. Other problems include persistent complete heart block or right ventricular infarction. These complications can happen and are non-lethal in patients with good LV function. However, many high-risk patients



undergoing PCI have poor LV function. They are more vulnerable to any ischemic challenge and any mildly prolonged low diastolic blood pressure that decreases coronary perfusion. So during PCI of these lesions, the operators should be aware of these possible complications in order to prevent them, suspect their appearance at the earliest, and reverse their course before the situation becomes critical. The list of these lesions in strategic locations is in Box 16.7.

BOX 16.7 LESIONS IN STRATEGIC LOCATIONS WITH POSSIBLE CATASTROPHIC COMPLICATIONS

1 Proximal RCA

Large amount of myocardium in jeopardy
 Closure of sinus node artery causing complete heart block
 Closure of posterior descending artery (PDA) causing acute mitral regurgitation
 Occlusion of the right ventricular (RV) branch causing persistent RV infarction

2 Proximal LAD

Very large amount of myocardium in jeopardy
 Closure of diagonal causing acute mitral regurgitation

3 Sinus node artery

Complete heart block

4 First diagonal

Acute mitral regurgitation due to ischemia or infarction of the antero-lateral papillary muscle

5 First large OM

Acute mitral regurgitation due to ischemia or infarction of the anterolateral papillary muscle (right coronary dominance)

6 Right ventricular branch

Persistent hypotension due to RV infarction

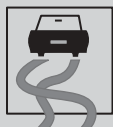7 PDA of RCA or PDA or posterolateral branch of the LCX

Acute mitral regurgitation due to ischemia or infarction of the posteromedial papillary muscle

CAVEAT

Lesions that are possibly safe to be dilated first

There are many situations where the master strategy of dilating first the lesions that are



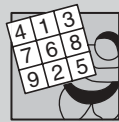
(Continued)

non-essential to maintain a decent blood pressure can be applied. In patients with arteries connected by collaterals, it is best to perform PCI on the lesion of the recipient artery, unless the collaterals are minimal. The reason is that acute occlusion of the artery that supplies the collateral can cause remote ischemia and infarction in the recipient artery. PCI of the stenosis on the supplying artery can be performed only if the first PCI was successful, with disappearance or reversal of collaterals.

In patients with ACS, it is rationally sound to perform PCI first on the culprit lesion. In patients with acute myocardial infarction (AMI), it is now accepted to dilate the infarct-related artery, without surgical standby. In patients with stable angina, performing PCI first on the lesion of the artery that is not vital in maintaining decent blood pressure is the best and safest strategy. In patients with subtotal ostial right coronary artery (RCA), if cannulation of the RCA by a diagnostic catheter causes ventricularization of the pressure, then PCI of the RCA seems to be safe because the RCA may not contribute much to the maintenance of systemic blood pressure. In patients with equally significant lesions in large arteries of equal size, without prior infarct, and no non-invasive imaging available, there is no convincing rationale on a clinical basis for which lesion should be dilated first, except that the type A lesion is easier to be opened and can be stented first (hit-and-run approach).

STRATEGIC MAPPING

The master strategy of performing high risk PCI in patients with MVD is to identify from all the arteries, with or without lesions, which one is essential or non-essential in preserving adequate LV contractility and decent blood pressure, or in other words, sustaining life. Then performing PCI first on the lesion of the artery that is not vital in maintaining decent blood pressure would offer a safe and BEST strategy. The reason is that during PCI of an artery with severe lesion which DOES NOT contribute to the maintenance of a decent blood pressure, in the case of acute occlusion and that being the dilated artery, a decent blood pressure is still maintained. Looking at the other side of this (coin) strategy, there are lesions that are located in strategic locations to watch for because occlusion of these lesions could bring persistent hypotension, shock and mortality. Another approach is to stent any type A lesion, if the chance of success is high. Different tactics in evaluation of lesions and patients by clinical, non-invasive and invasive methods are discussed below.



Technical Tips

****The challenging first minute** When the balloon is inflated for the first time, during balloon occlusion observe carefully the ECG and the symptomatic reaction of the patient. Marked ST-segment elevation, severe pain, malignant ectopy, hypotension, and marked decrease of wire tip movement (distal hypokinesis) all portend a major adverse clinical event in case of acute vessel closure [10]. This is why the first inflation should be short, of lower pressure and the speed of inflation slow and gradual. The second inflation may bring fewer symptomatic reactions because of collaterals recruitment and ischemic preconditioning. If the patient is symptomatic with the inflation, keep the inflation time short. The interval between the first and second inflation should be more than 2 minutes in order to achieve ischemic preconditioning [10].

CRITICAL THINKING

Why are these lesions possibly benign, whereas others are unpredictable?

In patients with an artery receiving collaterals, PCI of the recipient artery may cause no hemodynamic instability unless there is distal embolization cutting off the contralateral collateral flow. In patients with AMI, opening the acute occlusion may not cause any hemodynamic disturbance unless there is transient vasovagal symptom, no reflow, or large distal embolization. The reason is that, as the patient tolerated the acute occlusion and survived, the transient occlusion of a balloon should not cause hypotension of catastrophic extent. It is the same rationale for ACS patients with elevated level of troponin, for patients with previous MI, chronic total occlusion (CTO), or subtotal ostial RCA. In patients with stable angina (no previous MI) or unstable angina (without elevation of cardiac enzyme), these patients never experience any transient acute occlusion, then the clinical reaction to any acute occlusion has not been tested. These patients also do not have ischemic preconditioning so their reactions are unpredictable (Box 16.8).



BOX 16.8 THE POSSIBLE BENIGN LESIONS TO BE DILATED FIRST

- 1 The lesion of artery receiving collaterals
- 2 The culprit lesion of non-Q AMI
- 3 The infarct-related artery in AMI
- 4 The lesion of old MI
- 5 The chronic total occlusion
- 6 The subtotal ostial RCA
- 7 The lesions of small arteries

How to identify the culprit lesion by ECG and angiographic findings In any situation, a comprehensive evaluation should be carried out. The interventional cardiologists come to the bedside, examine the patient, review the history, assess the problems, and discuss the risks and benefits. Usually the ECG would show some hints on the location of the lesion and the angiogram would pinpoint the culprit lesion that is subtotal and has haziness due to thrombus. The following case report illustrates this strategy.

CASE REPORT

Assessment by history, ECG, and angiographic findings

A 73-year-old nurse with recurrent typical angina at rest had a coronary angiogram that showed severe lesion in the proximal, mid-LAD, and proximal RCA. Both arteries were large, not tortuous, nor too close to the ostium, and had no side branch involvement. Which one should be dilated first? There is a need to identify the culprit lesion and rationalize the sequential order of dilation. The ECG showed mild ST depression in 2, 3, and aVF so most likely the culprit lesion was in the RCA. The lesion in the RCA was subtotal, with haziness suggestive of thrombus, a hallmark of unstable fractured plaque. The lesion in the mid-LAD was severe and had sharp borders, so it was most likely a stable lesion. The patient underwent successful PCI of the RCA first by direct stenting, followed without complication by POBA and stenting of the two LAD lesions.

How to assess the lesion by history and ECG: Rationale for the dilation sequence One of the ways to guess the significance of the severity of two lesions is to reconstruct the historical sequence of symptoms that show the clinical stability of a significantly older lesion (while the patient had stable angina after an AMI) and the clinical destabilization by the appearance of a new lesion (patient now has unstable angina). If the first lesion was caused by an MI, then the artery containing the first lesion was not vital in maintaining a stable clinical condition and indirectly not responsible for the preservation of blood pressure. PCI of the first lesion is most likely safe. The subsequent case report illustrates this strategy.

CASE REPORT

Assessment of patient with a history of an old MI

An 80-year-old woman with unstable angina had a coronary angiogram that showed severe lesions in the proximal LAD and mid-RCA, both of which were type A. PCI should be technically easy and smooth for both lesions. Which one should be dilated first? To evaluate the contribution of each lesion to symptom and the maintenance of blood pressure, a resting ECG was ordered and a detailed history taken. The patient had had an AMI 7 years ago, which was confirmed by the Q wave in the V leads. She has had stable angina since then; this means that the LAD lesion caused only stable angina, without much interference to the

preservation of LV contraction or blood pressure. About 6 months ago, she began to have symptoms of unstable angina with chest pain on lower level activities, chest pain at rest, more shortness of breath, and more dizziness. Most likely the symptoms were caused by worsening of the lesion in the RCA which (without a lesion) most likely contributed the most to a stable clinical condition over the last 7 years and indirectly to the preservation of blood pressure. By this rationale, PCI was performed on the LAD lesion without causing any hypotension. Once it was successful, PCI of the RCA was done without technical difficulty. However, the patient developed chest pain, hypotension, and elevation of the ST segment in leads 2, 3, and aVF due to slow flow in the distal RCA. A coronary angiogram showed persistent patency of the newly stented segment with distal no reflow. The patient recovered later with intracoronary vasodilators. In this case, clearly the RCA was the one that maintained a decent blood pressure. The rationale for PCI first in the LAD lesion was justified. If PCI was performed in the RCA first, in the case of no reflow without adequate blood supply from the left system, then severe low blood pressure with cardiogenic shock could have happened with possible fatality.

Non-invasive Evaluation of Lesions

In general, besides a comprehensive history to identify the culprit lesion and its contribution in maintaining a decent blood pressure, non-invasive studies (ECG, stress echocardiography, nuclear stress testing) can be done to identify objectively the culprit lesion, its compromised area, and its extent of reversible ischemia, wall motion abnormality, or ST-segment change. A nuclear scan can also easily identify other areas with adequate perfusion at rest and under stress. By this, PCI should be performed FIRST in the area of ischemia, while an adequate blood supply at rest to the other areas that maintain a decent blood pressure is assured by the other patent arteries.

TACTICAL MOVE

BEST technique in identifying essential and non-essential lesions

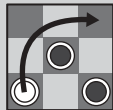
1 No added cost FIRST Best

option: Historical reconstruction of symptoms in order to identify the old lesion causing stable angina versus the new destabilizing lesion causing recent onset angina

2 \$ SECOND Best option: Resting ECG identifying location of Q wave or ST-T depression

3 \$\$ THIRD Best option: Nuclear scan for reversible ischemic change and extent of abnormal and normal areas

4 No added cost FOURTH Best option: Pressure tracing showing ventricularization during cannulation of the RCA ostial lesion by a diagnostic catheter



Technical Tip

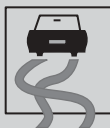****Important meaning of ventricularization of pressure during diagnostic cannulation of the RCA** The combination of a subtotal ostial lesion and ventricularization of pressure by a diagnostic catheter might suggest the irrelevant contribution of that artery in maintaining blood pressure. The case report below illustrates that notion and the safety of performing PCI in this kind of subtotal ostial lesion.

CASE REPORT**Tactics during PCI of patient with subtotal ostial RCA and LM disease**

A patient came to the emergency room with recurrent angina at rest. A coronary angiogram showed subtotal ostial lesions in the RCA and 50% lesions in the mid- and distal LM. Could the patient safely undergo PCI of the ostial RCA? The cardiac surgeon refused to do CABG surgery because the LM lesion did not seem severe enough to require it. During the diagnostic angiogram, cannulation of the RCA with severe ostial lesion by a 4-Fr Judkins right persistently caused a decrease in systolic and diastolic blood pressures without any symptom. As the patient was asymptomatic with occlusion of the RCA by a Judkins diagnostic right catheter, it seems that PCI of the RCA would not cause any major hemodynamic and symptomatic disturbance. Convinced by this rationale, one of the authors successfully carried out a long and complex PCI of the ostial lesion without any decrease of blood pressure. Following the same strategy, recently another patient with severe ostial RCA and proximal LAD successfully underwent PCI of two vessels. As the RCA seemed not to contribute much in maintaining blood pressure, the RCA lesion was first dilated successfully without a problem followed by an uneventful PCI of the LAD.

CAVEAT**Deceiving nuclear scan**

The main mechanism of a nuclear scan is to show a 7% difference of isotope uptake between territories. If there is dramatic change in one area, subtle change in other areas may be missed. If there is diffuse disease, there is not much difference between territories even if there are significant lesions. It is well known that a nuclear scan can look normal in patients with three-vessel disease because there is homogeneous, diffuse, and widespread decrease of blood flow at stress.

**How to perform PCI in Patients with ACS or AMI**

In patients with non-Q AMI, opening the subtotal occlusion may not cause any hemodynamic disturbance, unless there is a transient

vasovagal symptom, no reflow, or a large distal embolization. The reason is that the patient tolerated the acute transient occlusion and survived, so the transient occlusion of a balloon would not cause hypotension at a catastrophic level. It is the same rationale for PCI in ACS patients with elevated levels of troponin (non-Q MI). This rationale does not apply to ACS patients who do not have cardiac enzyme elevation (unstable angina). The case report below illustrates the rationale and tactic during PCI of these extremely high-risk patients.

CASE REPORT

PCI of the acutely transient total occlusion due to non-Q AMI

A patient came to the emergency room with chest pain, acute ST-segment elevation in V1–V4, and a blood pressure of 80–90 mmHg. When the patient arrived at the cardiac interventional laboratories, the pain subsided, and the ECG changes were less prominent; however, the blood pressure was still in the 80–90 mmHg region. The coronary angiogram showed an old total occlusion of the RCA and LAD. The LCX was acutely occluded with minimal collaterals to the distal segment. The left ventricular end-diastolic pressure (LVEDP) was 30 mmHg. After CABG was declined by the surgeon due to the extremely high risk, the patient successfully underwent PCI of the mid-LCX with an IABP, and a pacemaker on standby. The lesion was predilated with an undersized balloon, then a full-size stent was successfully deployed. The tactic was that the balloon should be undersized so that there was a lower chance for dissection and distal embolization. The first inflation was short (10s), at lower pressure, and the speed of inflation slow and gradual. The goal was to open a channel for stent position (Figure 16.1).

LEFT VENTRICULAR ASSIST DEVICES

Currently there are two percutaneous ventricular assist devices (pVADs) that can be placed in the cardiac catheterization laboratories, the TandemHeart pVAD and the Impella Recover LP 2.5 and 5.0 [11].

DEDICATED EQUIPMENT

Tandem Heart

The TandemHeart is a percutaneous left-atrial to-iliac artery bypass, powered by an external centrifugal pump that provides up to 3.5–4 l/min of forward flow using a standard implantation technique. To access the left atrium as well as the iliac artery, both arterial and venous access must be obtained at the femoral vessels. After venous access, transeptal puncture is performed, and a two-stage dilator (14 Fr then 21 Fr) is used to dilate the interatrial septum and implant the 21-Fr inflow cannula



(Continued)

into the left atrium. After this, a 15-Fr (maximal estimated flow, 3.5l/min) or 17-Fr (maximal estimated flow, 4.0 to 5.0l/min) outflow cannula is advanced into the iliac artery by way of the femoral artery, utilizing the standard Seldinger technique. Alternatively, two 12-Fr cannulas can be utilized in bilateral femoral arteries, with the potential for less vascular compromise at the expense of diminished maximal flow rates (about 2.5l/min). The cannulas are de-aired and connected to the external centrifugal pump, anticoagulation is provided, and flow is initiated.

Advantages and Limitations

As a result of the relatively complicated insertion technique, requiring transeptal puncture, insertion times on average exceed 30min in the non-emergency setting. Complications have included tamponade, major bleeding, critical limb ischemia, sepsis, arrhythmia, and residual atrial septal defect. Contraindications include aortic insufficiency, ventricular septal defect, and significant peripheral vascular disease. For these reasons, the device is implanted only by physicians experienced in transeptal puncture and distal aortography, with bilateral iliac runoff if required before implantation [11].

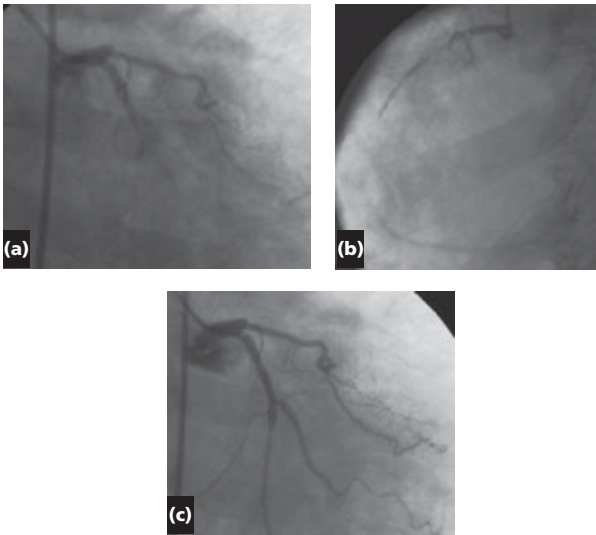


Figure 16.1 Strategy and tactics for PCI in patient with triple vessel disease and acute myocardial infarction. (a) The left anterior descending artery was occluded at its ostium. It was seen as a stump. The left circumflex artery (LCX) was acutely occluded. Only a ramus intermedius was patent. (b) The right coronary artery was severely and diffusely diseased. (c) The LCX was predilated with a balloon and successfully stented.

DEDICATED EQUIPMENT**The Impella recover 2.5L and 5.0L**

The Impella uses a miniaturized axial flow pump fitted on to a pigtail catheter to directly unload the left ventricle and deliver blood to the ascending aorta, simulating normal physiology. There are two available devices that provide either partial (Impella 2.5) or full (Impella 5.0) hemodynamic support, indicating maximal flow rates of about 2.5 and 5.0 l/min, respectively.

E

TECHNIQUE Anticoagulation is obtained, and the aortic valve is crossed in a retrograde fashion with the use of a multipurpose catheter and standard technique. An exchange-length 0.018-inch stiff wire is utilized to exchange for the 13-Fr Impella 2.5 catheter using the monorail technique (21-Fr Impella 5.0 catheter). Under fluoroscopic guidance the device is positioned with its elbow at the aortic valve, the wire is removed, and flow is initiated [12].

Advantages and Limitations

It is easy to use, has sole arterial access requirement, is of smaller catheter diameter, and avoids complicated techniques such as transeptal puncture, so implantation appears more rapid than TandemHeart (about 10 min), and complication rates appear lower.

Hemolysis has been reported more frequently in the first 24 hours, in about 5–10% of patients. Impella LP 5.0 needs a 21-Fr catheter and may need femoral vascular cutdown. Impella LD and RD 5.0, for the left and right ventricles, can only be done by cardiac surgeons under direct cannulation of the ascending aorta. Contraindications to device placement include significant peripheral vascular disease in <4 mm diameter of the common femoral artery, at least moderate (<1.5 cm²) aortic stenosis or insufficiency, ventricular septal defect, and left ventricular thrombus.

Discriminating Differences

In AMI with mild-to-moderate degrees of CHF and reduced cardiac output, the Impella 2.5 again seems superior on balance because the hemodynamic support would likely prove sufficient in such states to both rest the heart and normalize systemic perfusion and venous pressure, while its myocardial protective effects concomitantly limit infarct size.

As the degree of heart failure worsens, however, and especially in those with frank cardiogenic shock (due to AMI, acute-on-chronic heart failure, or fulminant myocarditis), hemodynamic support becomes the primary concern. In these patients, the Impella 2.5 device may prove insufficient, and the TandemHeart or Impella 5.0 device would seem to be indicated to increase the cardiac output to levels that would avoid end-organ dysfunction,

despite their longer time to implantation and associated higher complication rates (both cardiac and vascular). When both hemodynamic support and myocardial protection are taken into consideration, the Impella 5.0 appears to outperform the TandemHeart device.

In decompensated end-stage heart failure, the protocol for the selection of a percutaneous ventricular assist device depends on the cardiac index (CI). If the CI is >1.5 , an Impella 2.5 may be enough; however if the CI is <1.5 , a Tandem Heart is recommended.

For right ventricular support, the only percutaneous device currently available in the USA is the Tandem Heart. Impella RP is being developed. For LV support, in high-risk PCI, VT ablation, acute MI, cardiogenic shock, Impella 2.5 is easy to use and can be bridged to a 5.0-l device if needed. For patients with aortic stenosis or LV clot, TandemHeart is recommended and Impella is contraindicated [13].

IMPELLA in aortic stenosis The external diameter of the Impella catheter in the segment where it crosses the aortic valve is 12 Fr (4 mm). Using the formula, $\text{area} = 3.14 \times (\text{radius})^2$; the cross-sectional area of the catheter in this portion would be 0.13 cm^2 . Therefore, no difficulty is anticipated in placing the Impella catheter across an aortic valve with the aortic valve area estimated at $>0.9 \text{ cm}^2$. Serial transthoracic echocardiography during the intervention did not reveal significant aortic regurgitation [14].

Technical Tips

Tips for Impella insertion

- 1 Avoid trapping of the wire – exit the wire on the inner border of the aorta. Straighten the device cannula and the wire follows the inner border. Always pull the wire under fluoroscopic guidance.
- 2 Avoid any device in a calcified, tortuous, or diseased femoral or iliac artery. A distal aortography with runoff is advised.
- 3 Small femoral artery in AMI with severe cardiogenic shock patient on multiple pressors. The femoral artery size may appear to be smaller than a 7-Fr sheath due to peripheral vasoconstriction. Gradual dilation of the femoral arteriotomy will let the device be inserted.
- 4 Reposition the pump under fluoroscopic guidance once it has been checked at maximal performance (P9). At high rotational speeds, the pump has a tendency to suck itself into the left ventricle.
- 5 If you need to reposition the cannula without fluoroscopy, reduce the pump to the P2 level and follow the waveform on the console.
- 6 For removal of the Impella, set the console to PO.
- 7 Closure of the puncture site with Prostar, Preclose, or two Preclose devices is recommended. For larger devices, interventional cardiologists should learn the vascular cutdown and repair.
- 8 Indices of hemolysis should be measured every 6h after Impella insertion.

Technical tips for TandemHeart

- 1 Transeptal puncture is the most important. The more you do, the better you get at this procedure. The details of transeptal puncture are discussed under balloon mitral valvuloplasty in this book.
- 2 Transesophageal or intracardiac echocardiography (TEE or ICE) for both the transeptal procedure and initial positioning of the cannula is used in the USA.
- 3 Repositioning of the left atrial cannula can be done under TTE guidance at the bedside.
- 4 Similar techniques for vascular access and closure of the 17-Fr arteriotomy. Some have used ultrasound-guided vascular access to reduce complications and appropriate access site of the common femoral artery.
- 5 Fluid status: TandemHeart is highly dependent on preload and most flow problems are solved by increasing fluid administration.
- 6 Blood pressure control: Hypertension makes the pVAD work harder to eject blood, so maintain the patient normotensive.
- 7 Early insertion of TandemHeart for support of the right ventricle in RV infarction is important.

For both devices

- 1 Infection control: You cannot be TOO vigilant with these patients' infection control. Strict sterile dressings by trained staff, masks on patient and staff, close monitoring of the lines.
- 2 Good technical support from your perfusion/clinical engineering departments, especially if you see the devices infrequently – you need retraining.

EXOTIC COMPLEX INTERVENTIONS FOR THE WEEKEND URBAN WARRIORS

Hybrid MIDCAB and PCI

A patient with severe comorbidity had a severe lesion at the bifurcation of the LM–LAD, large ramus intermedius, and distal LM. The risk of mortality was too high for the patient to undergo conventional CABG, so the patient was scheduled for left internal mammary artery (LIMA) graft to LAD surgery, whereas the Ramus and LM lesion was to be dealt with by PCI. Under general anesthesia, a LIMA-to-LAD anastomosis was performed via a 2-inch left lateral intercostal incision (minimal invasive bypass surgery [MIDCAB]). Patency of the LIMA-to-LAD graft was confirmed. Then the patient was prepared for PCI of the LAD on the table in the operating room. With the LAD territory protected by the newly placed graft, the ostia ramus and circumflex disease were approached with a provisional bifurcation stent strategy. The patient had been pretreated with aspirin. Unfractionated heparin was used to maintain the activated clotting time (ACT) at >250s. The ramus branch was stented successfully. A follow-up angiogram revealed a widely patent stent with plaque shift to the LAD ostium which was protected by the LIMA graft. The appearance of the circumflex ostium was satisfactory and therefore not felt

to be in need of intervention. The patient was extubated in the operating room [15].

PCI and CABG for Patients with Aortic Stenosis

Many elderly patients present with concomitant CAD and various levels of severity of aortic stenosis (AS). In patients with mild or moderate AS, they can undergo PCI as can any other patient. The possible problem encountered during PCI is that the balloon inflation time should be short (10–15s) because the patient could develop significant hypotension. Once the balloon deflates, the blood pressure would return to the previous level. The patients with AS have a fixed cardiac output, which is why they already have difficulty maintaining a decent blood pressure during any myocardial dysfunction from transient ischemia. These patients would have much more difficulty maintaining a decent blood pressure during a short episode of acute occlusion of the index lesion. This is why extraordinary efforts should be made so that the balloon inflation time is short, and stenting should be prompt if there is acute occlusion. In general, PCI should be done before patients undergo percutaneous aortic valve replacement [16]. These patients also undergo PCI with a drug-eluting stent before minimally invasive aortic valve replacement because the perioperative mortality of a combined CABG and aortic valve replacement (AVR) is extremely high in elderly patients, whereas the mortality of minimally invasive atrioventricular regurgitation without CABG is low. The patient has PCI on clopidogrel and heparin. Right after the PCI, the patient goes directly from the cardiac catheterization laboratory to the operating room for a minimally invasive aortic valve replacement [16]. Recent studies are showing that simultaneous PCI and transcatheter AVR could be performed in low risk patients [17]. However in high risk patients, staged PCI is recommended.

REFERENCES

1. Davidson C, Ricciadi MJ. Complex angioplasty. In: *Cardiac Catheterization and Interventional Cardiology: Self Assessment Program*. Bethesda, MD: American College of Cardiology, 2001: 53–8.
2. Daniel WC, Lester SB, Jones P, et al. Risk factors predicting in-hospital mortality following balloon angioplasty versus stenting. *J Am Coll Cardiol* 1999;**33**(suppl A):24A.
3. Ellis SG, Myler RK, King SB, et al. Causes and correlates of death after unsupported coronary angioplasty: Implications for use of angioplasty and advanced support techniques in high risk settings. *Am J Cardiol* 1991;**68**:1447–51.
4. Mehran R, Ambrose JA, Bongu RM, et al. Angioplasty of complex lesions in ischemic rest angina: results of the Thrombolysis and Angioplasty in Unstable Angina (TAUSA) trial. *J Am Coll Cardiol* 1995;**26**:961–6.
5. Vogel RA, Shawl F, Tommaso C, et al. Initial report of the national registry of the elective cardiopulmonary bypass supported coronary angioplasty. *J Am Coll Cardiol* 1990;**15**:23–39.
6. Colombo A, Tobis J, eds. The high risk patients. In: *Techniques in Coronary Artery Stenting*. London: Martin Dunitz, 2000: 297–306.

7. Kollar A, Misra V, Pierson R III. Postoperative coronary revascularization on LVAD support for surgically inaccessible myocardial ischemia. *Catheter Cardiovasc Interv* 2002;**55**:381–4.
8. Ellis S. Elective coronary angioplasty: Techniques and complications. In: Topol E (ed.), *Textbook of Interventional Cardiology*, 3rd edn. Philadelphia, PA: WB Saunders, 1999: 466–74.
9. Takahashi A, Taniguchi N. Supported percutaneous coronary intervention using a novel 6-Fr intra-aortic balloon pump catheter via the brachial artery in a nonagenarian patient with an abdominal aortic aneurysm. *Catheter Cardiovasc Interv* 2011;**77**:1045–8.
10. Tanaka T, Oka Y, Tawara I, et al. Effect of time interval between two balloon inflations on ischemic preconditioning during coronary angioplasty. *Catheter Cardiovasc Diagn* 1997;**42**:263–7.
11. De Souza CF, De Souza Brito F, De Lima VC, De Camargo Carvalho AC. Percutaneous mechanical assistance for the failing heart. *J Interv Cardiol* 2010;**23**:195–202.
12. Kar B, Adkins LE, Civitello AB, et al. Clinical experience with the TandemHeart® percutaneous ventricular assist device. *J Tex Heart Inst* 2006;**33**:111–15.
13. Gregoric ID, Bruckner BA, Jacob L, et al. Techniques and complications of TandemHeart ventricular assist device insertion during cardiac procedures. *ASAIO J* 2009;**55**:251–4.
14. Harjai KJ, O'Neill WW. Hemodynamic support using the Impella 2.5 catheter system during high-risk percutaneous coronary intervention in a patient with severe aortic stenosis. *J Interv Cardiol* 2010;**23**:66–9.
15. Zimrin D, Reyes PA, Reicher B. A hybrid alternative for high risk left main disease. *Catheter Cardiovasc Interv* 2006;**69**:123–7.
16. Kuchulakanti P, Rha SW, Satler LF, et al. Safety of percutaneous coronary intervention alone in symptomatic patients with moderate and severe valvular aortic stenosis and coexisting coronary artery disease: Analysis of results in 56 patients. *J Invasive Cardiol* 2004;**16**:688–91.
17. Goel S, Agarwal S, Tuzcu M, Kapadia S, et al. Percutaneous Coronary Intervention in Patients with Severe Aortic Stenosis: Implications for Transcatheter Aortic Valve Replacement. *Circulation* 2012;**125**:1005–13.

CHAPTER 17**Removal of Embolized Material**

Thach N. Nguyen, Tung Mai, Quoc Nguyen, Katrina Nguyen,
Kirk Garrat

Challenges 420

Retrieval of an Embolized Coronary Stent 421**Risk of Stent Embolization 422****Clinical Scenarios 422****Technical Tip 422**

**How to withdraw a stent without embolizing it? 422

Removal of a Stent with a Snare 423**Standard Equipment 423****Retrieval of a Tubular Stent from the Coronary Artery 423****New Japanese Devices 423****Device Design 423****Removal Procedures 425****Advantages and Limitations 425****Trouble-shooting Tricks 425**

***Assembling an improvised snare from angioplasty wire
425

Discriminating Differences 426

The Art of Loop Snaring 426

Technical Tips 427

**Which end to loop? 427

**Critical positioning of the snare – perpendicular to the
object 427

**Securing the embolized wire fragment 427

***How to manipulate a pointed loop SAFELY 428

***Exotic Technique The “Hairpin-trap” Technique 428

Removal of a Stent with a balloon 428**Removal of a Stent with Two Wires 429****Technical Tip 429**

***Manipulation of Wires to remove an Embolized Stent 429

Deployment of an Embolized Stent 431**Damage Control 431****To Deploy or Remove an Embolized Stent 431****Removal of Fractured Wires 432****Withdrawal of an Uncoiling Ribbon of Wire 432****Technical Tip 432**

**Removal of wire fragments 432

*Basic; **Advanced; ***Rare, exotic, or investigational

\$, <\$US100.00 extra; \$\$, >\$US100.00 extra

⌚, <10 min extra; ⌚⌚, >10 min extra

♣, low risk of complications; ♣♣, high risk of complications

Removal of Embolized Material from the Iliac Artery 433
Biopsy or Alligator Forceps 434
Cook Retained Fragment Retrieval Tool 434
Technical Tips 434

**Retraction of a stent into a guide 434

***Stent removal from the iliac artery with a commercial snare 434

***How to upsize a larger sheath over two angioplasty wires and catheters 435

CHALLENGES

Percutaneous techniques for treatment of coronary artery disease (percutaneous coronary intervention or PCI) have evolved and diversified dramatically, but they all have at least one common feature: All involve technical manipulation of complex equipment in the confines of coronary arteries, and are operated from a significant distance. When traversing severely diseased coronary arteries and manipulating equipment, particularly devices with detachable components, the opportunity for loss or embolization of material in the coronary circulation presents itself. In this chapter we review and discuss the management strategies for embolized material.

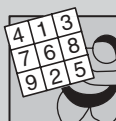
STRATEGIC MAPPING

When a problem with defective equipment (unexpandable stent, uncoiling wire, asymmetrically bulging balloon due to metal fatigue, twisted guide, etc.) arises inside the coronary artery or the ascending aorta, it is

ideal to remove the entire system below the level of the renal arteries so that the problem can be corrected without risk of embolization to the brain and any other vital organs.

In case of a stent that slips off the delivery balloon inside the coronary artery, the stent cannot be simply brought to the iliac artery by withdrawing the whole system, even as a unit. Pulling the indwelling angioplasty wire will leave a loose, free stent behind. So all efforts are concentrated on keeping the wire inside the stent and across the lesion for prompt access of rescue devices. As a stent slips off the delivery balloon, there are two options: To retrieve it or to deploy it in a safe, non-target location.

Once below the level of the renal arteries, the next important step is to remove the embolized stent from the femoral sheath without injury to the femoral artery or the need for arterial cutdown. Everything should be done within an acceptable time frame, with a wire still across the lesion. In the meantime, the patient has to be watched closely and



the clinical condition remains stable, so the scheduled PCI can be continued and finished.

Different options in the management of embolized material are listed in Box 17.1. All the techniques discussed in this chapter are used only as references. They range from standard methods with commercial snares to the improvised techniques, which become lifesaving if the procedure is successful. The selection of a particular method or equipment depends on the patient's clinical condition, familiarity with retrieval equipment by the operators, and availability of the equipment in the cardiac catheterization laboratories. The discussion focuses more on coronary stent, but the retrieval technique may be applied to any embolized device or fragments.

BOX 17.1 OPTIONS IN THE MANAGEMENT OF EMBOLIZED MATERIAL

- 1 No treatment for peripherally embolized small stents
- 2 Deploy the embolized stent in inconsequential location
- 3 Remove a tubular stent by a snare
- 4 Removal of a broken wire segment by a snare
- 5 Removal of embolized material by a snare made with a loop of angioplasty wire that has emerged from a transport catheter
- 6 Removal of a tubular stent with two twisted wires
- 7 Secure a stent by inflating a small balloon distal to it and remove the whole system
- 8 Remount the stent by a balloon through a transport catheter
- 9 Grasp a stent by a biopsy forceps at the ostium of a coronary artery

RETRIEVAL OF AN EMBOLIZED CORONARY STENT

Most stents currently in use are of balloon-expandable design. They differ from the self-expanding stents, which are generally constructed out of multiple interlacing strands of wire. As coronary stents represent a detachable component of a PCI system, stents are, by their nature, prone to accidental release from the overall apparatus. Significant coronary calcification, tortuosity, and suboptimal guide position can contribute to stent embolization. Sometimes, peripheral embolization of stents can be the best option. Systemic embolization does not cause any severe clinical sequelae, except to the cerebral circulation. Short wire fragments retained in a totally occluded artery do not pose any long-term side effects. There are many reports of embolized stents in the lower extremities and periphery, with no evidence of untoward long-term effects. Any foreign materials that are

retained more than 1 week should not be removed percutaneously because they may be covered and incorporated by fibrous tissue. Aggressive extraction of the embolized material may injure and perforate the vessel.

Risk of Stent Embolization

Coronary risk factors for stripped stents include higher degrees of calcification, tortuous vessels with proximal or moderate-to-severe angulation, prior coronary artery bypass graft (CABG) surgery, and passage through primary, recently placed, or non-endothelialized stents. Technical risk factors for stripped stents include manually crimped stents, poor support of the guide, increased rigidity of the stent, and direct stenting without complete predilation [1]. Previously described examples of complications during placement of stents include dislodgement of the stent within the catheter when negative pressure is applied, resulting in detachment from the balloon and allowing the stent to wedge into the distal tip of the guide. Stent migration can happen if a previously placed stent in the proximal portion of the coronary vessel strips the newer stent from its delivery balloon [1].

Clinical Scenarios

Typically stent embolization occurs in one of three scenarios. First, the stent may be successfully introduced into the coronary circulation, but it cannot be advanced into the target area. This is usually due to proximal tortuosity, rigid and calcified proximal segment, or insufficient predilation of the target lesion. Second, in an attempt to direct stenting without predilation, unexpected difficulty in advancing a stent may be encountered. In these cases, the stent should be gently retracted back into the guide, removed, and the lesion predilated. If the distal tip of the stent has engaged the lesion, it is possible that manipulation to advance the stent may strip the stent off the balloon, so that it remains embedded in the lesion when the balloon is retracted. In this case, the coronary wire is generally still in place, indwelling through the stent lumen and the lesion. Most frequently, stents also become dislodged from the deployment balloon when they are retracted from the coronary artery back into the guide. At that time, the tip of the guide (especially the 90° primary curve of the Judkins right) may catch the proximal edge of the stent, and strip it off the deployment balloon. The stent will be left dangling on the coronary wire at or near the ostium of the vessel under treatment [1].

Technical Tip

****How to withdraw a stent without embolizing it?** When a stent is unable to be delivered to the target area because of tortuous proximal segment or because it is unable to cross a tight lesion, it has to be withdrawn into the guide. Then the tip of the guide should be lined up well coaxially with the indwelling wire and its straddling stent. If the guide cannot provide an excellent coaxial relationship with the stent, then the guide should be retracted until a favorable alignment between the guide and stent can be achieved. Sometimes, removal may require retracting the

guide to the tip of the femoral sheath in order to straighten the tip of the guide [2].

REMOVAL OF A STENT WITH A SNARE

Standard Equipment

The GooseNeck Amplatz Microsnare catheter is a nitinol retrieval device that includes a transport end-hole catheter and loop snares. The wire, which moves freely in the catheter, extends from the proximal end of the catheter, out the distal end, and then it is folded, re-enters the distal lumen, and extends back to the proximal end. Retraction of one or both ends of the wire causes it to retract into the distal tip. The 4-French (Fr) catheter tapers to a 2.3-Fr tip. The snares are available in diameters 2, 4, and 7 mm. Once emerged from the catheter, the loop is at right angle to the tip, thus facilitating the grasping of target object. The 4-Fr transport catheter can easily fit inside a 6-Fr guide [3].

Retrieval of a Tubular Stent from the Coronary Artery

Once a stent slips off the delivery balloon, the indwelling wire is advanced as far as possible into the distal vasculature and the balloon removed. A 4-Fr transport catheter with a GooseNeck snare is assembled. The loop of the snare, emerging from the transport catheter is passed over the angioplasty wire, encircles it, and is advanced up to the coronary ostium. The snare is manipulated into the artery to loop around the unexpanded stent under fluoroscopic guidance. An effort should be made to grab the distal part of the stent (distal compared with the position with the heart or proximal compared with the position of the femoral artery entry). Once the loop is in the right position, the transport catheter is advanced to tighten the loop around the stent. Then the guide, with the stent secured by the snare, is withdrawn to the iliac artery as a unit. If extraction of a stent through the usual 6- or 7-Fr femoral sheath is difficult or impossible, the sheath is changed to a larger (9Fr) one through which the embolized stent can be removed. An embolized broken wire segment or any embolized device can be snatched by the snare with the same technique (Figure 17.1).

New Japanese Devices

Device Design

The device consists of four components: Ultra-low profile forceps with 2.0 mm in diameter, conducting shaft with 1.8 mm in diameter and 85 cm in length, control handle and button by which the forceps could be opened or closed, and a 7-Fr covering sheath (Figure 17.2). Two teeth are located at the tip and middle of each forceps to firmly catch the stents. As the forceps are connected with the button on the control handle by a coil within the shaft, forceps can be opened with the button at the neutral position and closed when the button is pulled back (Figure 17.2).

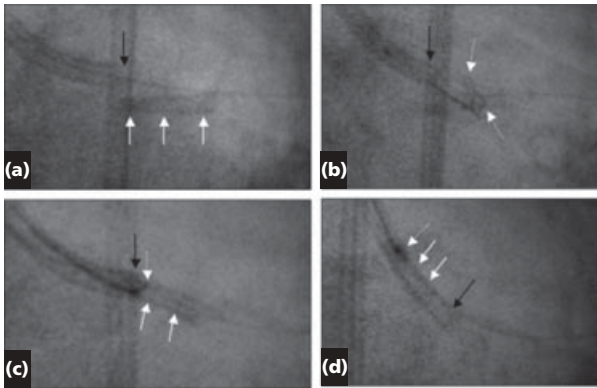


Figure 17.1 Serial angiographic images showing the use of a microsnares to entrap and remove an embolized stent from the left main coronary artery. (a) The non-deployed stent (white arrows) is seen inferior to the tip of the guiding catheter (black arrow). (b) The snare (white arrow with interrupted line) is opened and positioned around the stent (white solid arrows). (c) The snare (white arrow with interrupted line) has been tightened around the stent (white solid arrows) and is being pulled back into the guiding catheter (black arrow). (d) The stent has been fully retrieved into the guide [4].




Figure 17.2 Device for removal of vascular stents: (a) Overhead view; (b) blueprint of the tip and part of the shaft. The device has a lumen within it, through which a 0.014-inch coronary wire (arrow) can run. (c) Forceps with teeth can open with the button on the handle in the neutral position. (d) Forceps can be closed by pulling back the button (arrow). Note that the wire could be freely accessed through the center of forceps.

To safely advance the device into mid-sized arteries, the device has a lumen in the center of the shaft to allow a 0.014-inch wire to run through it (Figure 17.2). Thus, the device could be advanced into arteries by an over-the-wire (OTW) fashion. Importantly, even in a closed position, the tip of the forceps has sufficient space for the wire to freely pass through. This allowed us to keep the wire within the vessel even during or after manipulating the device to remove the foreign body. The 7-Fr cover sheath was used as guide and was used to cover not only the device itself, but also the foreign body that was caught by the forceps.

Removal Procedures

Intravascular foreign bodies such as stents were removed from the artery by a five-step procedure. First, the wire was manipulated to access the target stent. Second, the present device was inserted to advance along the wire and approach the stent. Third, the stent was firmly caught by the forceps by pulling back the button. Fourth, the cover sheath was carefully advanced to cover the forceps and stent. Under these conditions, it was important not to retract the forceps itself, because simple retraction of the captured stent by forceps could seriously damage vessel wall. Fifth, and finally, the whole system except the wire was removed from the artery [5].

Advantages and Limitations

The use of a sheath to cover the stent might also contribute to preventing the occurrence of severe vessel damage such as major dissection. While removing the stent, the minor dissection was frequently observed. The edge of the stent was crushed by the device, resulting in scratching of the vessel wall. Therefore, simply pulling a stent by our device without the sheath will injure the vessel wall more seriously than with the sheath. Thus, a sheath seems to be helpful and necessary to minimize the injury [5].

There are significant limitations of the device in its current iteration. First, this is a large device; in its current form, the device would require a 10- to 11-Fr-sheath and a 10- to 11-Fr guide to be used in the coronary arteries, which is the primary market for such a tool. This retrieval device would have to be made much more flexible and reduced in diameter by more than 50% to be practical and compete with existing technologies in the coronary arteries [5].

Trouble-shooting Tricks

*****Assembling an improvised snare from angioplasty wire** If there is no commercial snare available, a snare can be improvised by using regular angioplasty wire available in cardiac catheterization laboratories. The snare is formed by folding a 300-cm-long 0.014-inch wire and introducing it through a 4-Fr transport catheter. Once it arrives near the tip of the catheter, one end of the wire is pulled, whereas the other end is advanced slightly to position the sharp point of the tight fold within the catheter, so that it will not injure the vessels or cardiac wall during movement of the snare. By advancing one end of the wire, while

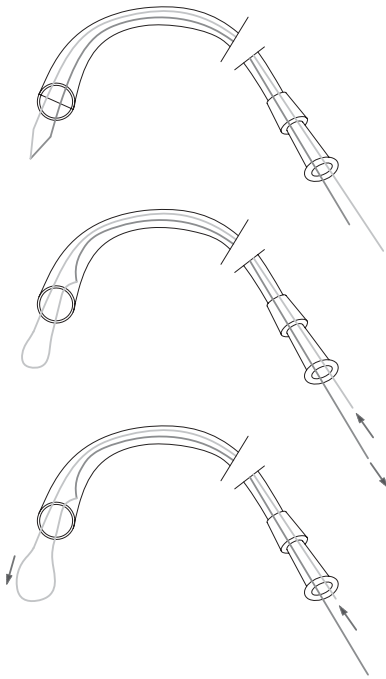


Figure 17.3 Making a snare from angioplasty wire. By advancing one end of the wire, while holding the other end until a desired diameter has been achieved, a workable loop snare emerges from the tip of the catheter. Illustrated by Quoc Nguyen.

holding the other end until a desired diameter has been achieved, a workable loop snare emerges from the tip of the catheter (Figure 17.3). The embolized material is trapped by the snare using the usual technique. After the loop is tightened successfully at the distal end, a hemostat is used to fix the wire in position at the proximal end and the entire system is pulled as a unit to the iliac artery.

Discriminating Differences

The Art of Loop Snaring [6] The important difference between the commercial and the improvised snare is the angle of the snare at the tip of the transport catheter. The GooseNeck loop is at a right angle to the catheter whereas the improvised snare loop is parallel to it. This difference is absolutely vital in positioning the loop and assessing its position in the technique of snaring. Once a stent slips off the delivery balloon, the wire should be kept indwelling inside the stent so that the free movement of the stent is limited to the longitudinal axis of the wire. That position of the wire would tremendously help the rescue effort by giving prompt access to the defective stent. The Goose-Neck Microsnare is inserted into the guide with its loop encircling

the angioplasty wire. It arrives at the right position as its loop is encircling the proximal end of the stent. Then the loop is tightened by advancing the transport catheter, and the whole stent–snare–wire complex is ready to be pulled out. The improvised snare can achieve the same result but requires more skilful manipulation because the loop is not at a right angle to the catheter. In the case of a broken wire segment or a free stent not on an angioplasty wire, their capture depends on correct alignment of the loop to the free end of these free fragments [6].

Technical Tips

****Which end to loop [6]?** The loop snare technique is effective if the embolized fragment (wire or stent) has a free end for ensnarement. The patient is positioned under the fluoroscope for locating both ends of the fragment and to identify its free end, which usually pulsates. The operator needs to encircle the free end with the loop [6].

****Critical positioning of the snare – perpendicular to the object [6]** The snare is held at right angles to the calculated plane of the embolized fragment. To do this, the patient must be positioned under the fluoroscope in such a way that the wire is seen in its full length. This implies that the wire or stent is vertical to the X-ray beam. Then the snare is held in such a way that it is shown under fluoroscopy as a straight line or a closed loop, confirming its vertical plane in relation to the wire or stent fragment. Then the free end of the wire can be captured. If the snare loop plane is parallel to the plane of the broken wire or stent, ensnarement is impossible (Figure 17.4).

****Securing the embolized wire fragment [6]** The next important step is to make sure that the snare has encircled the embolized wire or stent. The transport catheter is advanced, causing the broken wire fragment or stent to bend when the snare is engaged.

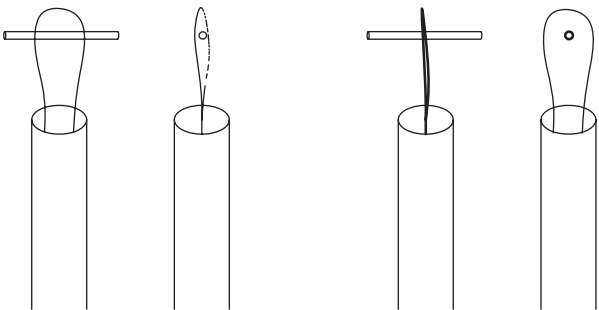


Figure 17.4 The significance of the plane of the snare loop in relation to the broken wire or embolized stent. The snare is held in such a way that it is shown under fluoroscopy as a straight line or a closed loop, confirming its vertical plane in relation to the wire or stent fragment. Illustrated by Quoc Nguyen.

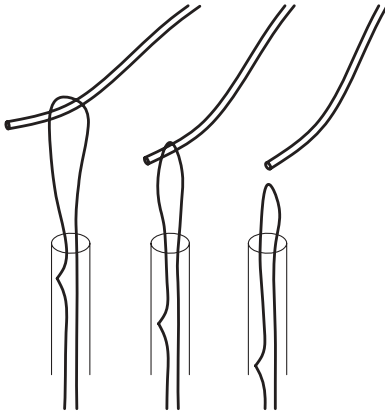


Figure 17.5 Improper technique of ensnarement: Withdrawal of the ends of the wire to capture the embolized wire or stent can cause disengagement. Illustrated by Quoc Nguyen.

Withdrawal of the ends of the wire to capture the embolized wire or stent is not suggested because it can cause disengagement (the stent or the wire fragment can get out of the encircling loop) (Figure 17.5). Remember to tighten the noose by advancing the transport catheter. Keep the wire immobile.

*****How to manipulate a pointed loop SAFELY** If the stiff folded end of the loop cannot be withdrawn in the catheter to make a round loop outside the tip of the catheter, then the pointed loop is kept inside the transport catheter during transit. When the tip of the catheter arrives near the embolized object, it is positioned with its tip cephalad to the object, and the wire loop, still well inside the catheter, is at the upper level of the object. While the wire loop remains in place, the catheter is withdrawn to expose the loop. This technique is helpful in preventing vascular injury from the stiff, folded end of the pointed loop [6] (Figure 17.6).

*****EXOTIC TECHNIQUE The “Hairpin-trap” Technique** A hydrophilic, polymer-jacket wire is bent approximately 5 cm from its distal tip (Figure 17.7a–c), the hairpin tip is inserted into the Touhy valve (Figure 17.7d) and exits through the distal tip of the guide (Figure 17.7e). The hairpin is advanced in the target vessel and then withdrawn, “hooking” the lost stent (Figure 17.7f). The wire tip is pulled back into the guide (Figure 17.7g), and a balloon is subsequently inflated inside the guide (Figure 17.7h,i) “trapping” the wire and securing the hairpin, hence preventing inadvertent release of the stent [6].

REMOVAL OF A STENT WITH A BALLOON

The technique is to advance a small 1.5- or 2.0-mm balloon, over the wire and through the stent, and inflate the balloon distal

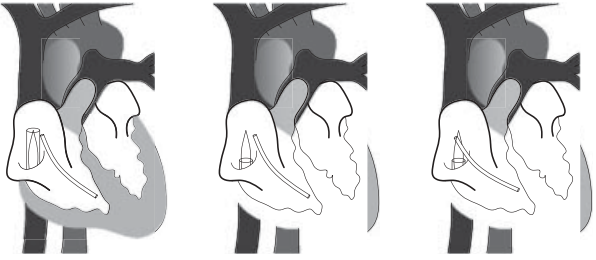


Figure 17.6 Technique of ensnarement with a pointed loop: When the tip of the catheter arrives near the embolized object, it is positioned with its tip cephalad to the object and the wire loop, still well inside the catheter, is at the upper level of the object. While the wire loop remains in place, the catheter is withdrawn to expose the loop. Illustrated by Quoc Nguyen.

to the stent. Retracting the balloon back will then bring the stent back into the guide. If the balloon cannot be advanced all the way through the stent, low-pressure inflation of the balloon, when it is at least partially within the stent, will suffice. In many cases, the system may be removed without loss of the coronary wire position or removal of the guide. This will be easiest if a 7- or 8-Fr guide has been used. In some cases, the stent may be contained within the distal tip of the guide, but the inflated balloon cannot be retracted into the guide. In this case, the guide and balloon should be removed as one unit over the wire. An extension wire will allow preservation of coronary access. The removal of an inflated balloon from a coronary artery is not without danger. The balloon should be of very low profile and the artery should be large enough to easily accommodate the movement of an inflated balloon.

REMOVAL OF A STENT WITH TWO WIRES

When a snare is not available to remove the embolized stent, there is a possibility of withdrawing the free stent with a second wire twisting around the stent to immobilize it to the first wire [7].

Technical Tip

*****Manipulation of Wires to remove an Embolized Stent** Once a stent slips off the delivery balloon, the wire should be kept indwelling inside the stent so that free movement of the stent is limited to the longitudinal axis of the wire. To remove this free-standing stent with wires, a second wire should be advanced and pass through the struts of that unexpanded stent and not through the central lumen. If the stent is half-expanded, the size of the cell is bigger to accommodate the tip of a second wire. Once the second wire has been advanced as far as possible, the two wires are twisted proximally with the stent straddling on their stiff segment. The stent is then trapped between the two entangled wires and removed. To be successful in entrapping the stent, both




Figure 17.7 The "hairpin" formed by the wire is advanced into the saphenous vein graft to the right posterior descending artery (b) and withdrawn "hooking" the lost stent (b). The wire tip is reinserted into the guiding catheter (c), where it is "trapped" by inflation of a balloon (d), and the entire "hairpin-trap-stent assembly" is withdrawn from the saphenous vein graft (e). The assembly could not be inserted in the ipsilateral femoral artery sheath (f) but was successfully snared via an 8-Fr contralateral femoral artery sheath (g). After inadvertent wire removal, the lost stent embolized to the right tibioperoneal trunk from where it was successfully snared (h,i).

wires should be advanced deeply so the stent is straddling their stiff part. A soft floppy distal tip is not strong enough to entrap a stent when twisted. As the wires are removed slowly, the guide engages deeper into the ostium. This is the sign that the stent has been properly snared. In theory, if the second wire goes through the central lumen of the stent, both wires can be easily pulled out, leaving the free stent behind. So the second wire should strategically go through the side struts and not the central lumen. With gentle and persistent pulling, the whole system (guide, stent entwisted between two wires) will be successfully withdrawn [7].

DEPLOYMENT OF AN EMBOLIZED STENT

Proper management of this situation is generally straightforward. The deployment balloon should be advanced back over the wire and fully into the stent. Even if the stent is not advanced completely through the lesion, it should be expanded where it is to its fullest possible dimension using the deployment balloon. If the deployment balloon cannot be advanced through the stent, a lower-profile, flexible-tipped balloon catheter should be inserted instead. Use of a very small diameter (1.5–2.0 mm) balloon will facilitate subsequent larger balloon entry, if a nominally sized balloon will not pass through. It is virtually always possible to advance a balloon at least part way through the stent, and open it partly. The remainder of the stent can be expanded sequentially. Occasionally, a new smaller balloon will need to be passed through the unopened portion of the lost stent. Predilation of the target lesion (usually possible with the balloon used to expand the initial stent) will assure success with additional stent implantation efforts.

Damage Control

To Deploy or Remove an Embolized Stent

It is important to make a decision whether to deploy or to remove an embolized stent right at the start, because, once a stent is partially deployed, it will have to be perfectly deployed with its struts well apposed to the arterial wall (as in any standard stenting procedure). A half-deployed stent that obstructs the flow will cause early or late acute vessel occlusion. So the stent is either perfectly deployed or removed. It is easier to remove an intact (not-yet-deployed) stent rather than remove one later with its struts sticking out or after being crushed or disfigured. It is also easier to deploy a stent at the time when the patient is still stable rather than later to recross an acutely occluded artery due to thrombus, obstructing a partially deployed stent in the setting of acute myocardial infarction. If the operator attempts to open the proximal half of a stent, try to open it as wide as possible because another balloon will have to be reinserted at the imperfect opening that has just been created. If the opening of the stent is small or crooked, the attempt to reinsert a larger balloon would

be difficult. Once the stent has been deployed, it will be recrossed by other interventional devices (including a new stent) to dilate and stent the distal index lesion. If the first (embolized) stent is not well deployed and the lumen is not large enough, PCI of the distal index lesion would be very hard, almost impossible. Contemplating all these challenges beforehand will help the operator to make a wise decision, whether to remove an embolized stent with a snare or to perfectly deploy it.

REMOVAL OF FRACTURED WIRES

Virtually every coronary angioplasty device is advanced into the coronary system over a wire. The soft, atraumatic tips of coronary wires have been known to fracture off, if being manipulated excessively, and embolize in the coronary circulation. This most frequently occurs when the shapeable wire tip becomes lodged in an atherosclerotic plaque and separates from the body of the wire when the wire is retracted. This occurred somewhat more frequently in the past, when nearly all wires were manufactured by bonding a flat-forming ribbon to the round end of a wire. Current coronary wires are constructed of a gradually tapering filament that is an extension of the shaft of the wire. So, solder points and other relatively weak junctions are minimized in contemporary wire design. Nevertheless, fracture of wire tips may still occur.

Withdrawal of an Uncoiling Ribbon of Wire

After excessive manipulation of a wire (more than a 180° turn), its distal segment can become uncoiled. This is detected as the distal tip shows a radiolucent segment. Instead of pulling the wire in an effort to remove it from the coronary system, the best technique involves proper seating of the guide, then advancing an OTW balloon or a transport catheter over the whole wire including the uncoiled segment, if it tracks easily. After the radiolucent segment has been advanced over by the balloon or a transport catheter, the whole system – guide, catheter, and wire – is removed as a unit. If the balloon catheter does not track easily over the floppy tip, it may dissect the artery. In this case, it may be better to simply pull the wire and all the devices as a unit. If the distal tip of a wire has been broken, this segment from a wire could be removed by tangling the broken tip with two more non-polymer wires advanced distally from the segment.

Technical Tip

****Removal of wire fragments** Recovery of wire fragments is generally accomplished relatively simply through insertion of two or more additional angioplasty wires into the coronary artery under treatment. The proximal ends of the wires are inserted together in a torque device, which is firmly screwed and rotated many times in a circular pattern. During this rotational motion, the broken segment is tangled within these rescue wires and all

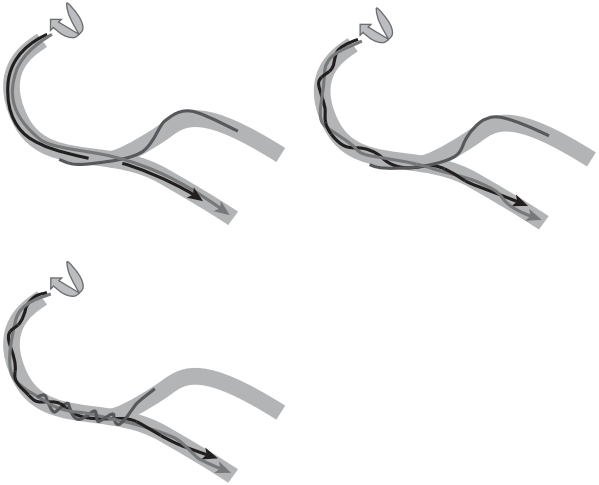


Figure 17.8 Tangling wires technique for broken wire segment removal. The two additional wires are inserted across the broken segment, turned together (40–50 rotations are a good number), and then all wires are removed together.

three wires are removed together. When this technique fails, a retrieval device such as a snare is needed for removal of these wire fragments (Figure 17.8).

REMOVAL OF EMBOLIZED MATERIAL FROM THE ILIAC ARTERY

Once the embolized object has been brought to the iliac artery, the main problem is to remove it through the vascular sheath without the need for arterial cutdown. If the 6- or 7-Fr sheath is too small the sheath should be changed for a 9-Fr sheath. Biliary forceps, alligator forceps, or a cardiac biopptome is suitable for retrieving the stent in the common iliac artery or at the tip of the arterial sheath. Coil stents have been successfully retrieved by using alligator forceps [8], and tubular stents have been successfully retrieved by using the biopptome [9]. The disadvantages of these instruments are:

- 1 the need to directly grasp the relatively small stent
- 2 the likelihood of damaging the stent itself
- 3 the possibility of endovascular trauma
- 4 the loss of wire position during stent retrieval.

Hence, innovative techniques have been developed for stent retrieval using easily available instruments. Most of the stents available today are radio-opaque and not difficult to locate under fluoroscopy. These removal devices are mainly used when the embolized material is brought to below the renal artery level. Familiarity with each removal device can be extremely useful in the rare event of stent misplacement.

Biopsy or Alligator Forceps

Alligator forceps are familiar to most cardiologists. The design of standard myocardial bioptomes follows the design principles of alligator forceps. This type of forceps is used widely throughout medicine and surgery. The “biting jaws” action makes them attractive for capturing embolized material. A variety of these devices is available in most hospital settings, but most are not suitable for use within the vascular tree because the catheter bodies have insufficient length, the shaft diameter is too large, or the devices are too rigid to be advanced safely into the coronary arterial system. Thinner, softer, disposable bioptomes are generally immediately available in catheterization laboratories and can be used, but they are still generally too rigid for use beyond the ostium of a vessel. Bioptome jaws are quite sharp, so gripping any device must be attempted with great care to avoid severing thin metallic structures [2].

Cook Retained Fragment Retrieval Tool

The Cook Retained Fragment Retrieval Tool produces a device that resembles a fixed-wire angioplasty balloon catheter with an articulating arm. The arm is operable from the proximal hub. Activating this arm opens the device in a “trap-door” fashion. Advancing this system alongside a retained fragment can be very useful for recovery of the lost material, but this device is too bulky and too rigid for safe use within the coronary tree. It is available in lengths of 80 and 145 cm [2].

Technical Tips

****Retraction of a stent into a guide** Once the stent is brought to the iliac artery, it is manipulated to be withdrawn into a guide, if there is a favorable alignment between the stent and guide. In these situations, the guide may be retracted into the arterial sheath to straighten its tip. If there is no excellent coaxial relationship, the stent can be stripped off the balloon [2].

*****Stent removal from the iliac artery with a commercial snare** Position the snare above the stent and tighten it at the distal end of the stent under fluoroscopic control (distal compared with the position of the heart and proximal compared with the position of the femoral artery). The stent can now be pulled into the guide and retrieved. The stent should be snared at the distal end, which is close to the operator. By pulling this end, the operator can manipulate it to enter the tip of the femoral sheath and be removed from the body. If the stent is snared at the proximal end (compared with the position of the heart), it is more difficult to manipulate the stent to enter the guide. If the stent is crushed from the proximal end, the whole stent will collapse and its large mass is difficult to pass through the femoral sheath. If the stent is crushed at the distal end, there is only a small area of damage, and it can still be manipulated to get into the sheath. Changing to a larger size (9-Fr) sheath will help to get the stent to enter the sheath [2].

*****How to upsize a larger sheath over two angioplasty wires and catheters** If a stent slipped off the balloon, advancing the snare and capturing the stent would be a straightforward procedure, but the combined stent and snare proved too bulky for retrieval through the 6-Fr sheath. The greatest challenge was to exchange the 6-Fr sheath for a larger 8-Fr model over the snare and coronary wire. So the 4-Fr snare catheter was removed and attempts made to keep the snare noose in place. The coronary wire had to remain advanced through the stent in the event the stent came loose from the snare. The inner lumen diameter of the 8-Fr sheath dilator could not accommodate both the snare shaft and the coronary wire. A 6-Fr dilator is advanced over the snare shaft within the 8-Fr femoral sheath, whereas the smaller dilator within the larger sheath allowed the coronary wire to remain between the sheath and dilator. After this successful maneuver, the snared stent was retrieved outside the patient's vasculature through the 8-Fr sheath with no damage to the vessel wall [10].

TAKE HOME MESSAGE

Embolization of equipment into the coronary tree is dominated by loss of stents in today's interventional practice. Loss of stents typically occurs because of inadequate predilation of the target lesion and/or improper guide alignment with the coronary ostium. Extreme tortuosity and extensive plaque calcification also contribute to the odds of coronary stent loss. The most important consideration in avoiding complications associated with stent embolization is to select appropriate tools and strategies for managing the planned intervention. Use of routine predilation of a target lesion, careful guide alignment with the ostium of the target vessel, and appropriately supportive wires will minimize opportunities for stent loss. Specific retrieval techniques to recover lost stents are described. The most consistent device, easiest to use and readily available, are the coronary loop snares, but all of the devices described above may have an important role to play in the event of embolized coronary equipment. Familiarity with, and immediate access to, these devices is important in contemporary practice.

REFERENCES

1. Wilke L, Divakaran VG, Mungee S. In-stent deployment of a stripped stent during percutaneous coronary intervention of a right coronary artery. *J Invasive Cardiol* 2009;**21**:E180–3.
2. Garratt K, Bachrach M. Stent retrieval: Devices and technique. In: Heuser R (ed.), *Peripheral Vascular Stenting for Cardiologists*. London: Martin Dunitz, 1999: 27–37.
3. Eisenhauer AC, Piemonte TC, Gossman DE, et al. Extraction of fully deployed stents. *Catheter Cardiovasc Diagn* 1996;**38**:393–401.

4. Paulus BM, Fischell TA. Retrieval devices and techniques for the extraction of intravascular foreign bodies in the coronary arteries. *J Intervent Cardiol* 2010;**23**:271–6.
5. Tsuchida M, Kawashiri MA, Uchiyama K, et al. An Enhanced device for transluminal retrieval of vascular Stents without surgical procedures: Experimental studies. *J Intervent Cardiol* 2010;**23**:264–70.
6. Brilakis ES, Abdel-karim AR, Banerjee S. Hairpin-trap: A novel stent retrieval technique. *Catheter Cardiovasc Interv* 2011;**77**:213–16.
7. Wong PHC. Retrieval of undeployed intracoronary Palmaz-Schatz stents. *Catheter Cardiovasc Diagn* 1995;**35**:218–23.
8. Eckhout E, Stauffer JC, Goy JJ. Retrieval of a migrated coronary stent by means of an alligator forceps. *Catheter Cardiovasc Diagn* 1993;**30**:166–8.
9. Berder V, Bedossa M, Gras D, et al. Retrieval of a lost coronary stent from descending aorta using a PTCA balloon and biopsy forceps. *Catheter Cardiovasc Diagn* 1993;**28**:351–3.
10. Larose E, Rogers C, Simon D. When size matters: Lessons learned from left main stent embolization and retrieval. *J Intervent Cardiol* 2006;**19**:350.

CHAPTER 18

Inoue Balloon Mitral Valvuloplasty

Jui-Sung Hung, Kean-Wah Lau

Challenges 439

Transeptal access 439**Instruments for Septal Puncture 440****Catheter/Needle Fitting Exercise 440****Landmarks for Optimal Puncture Site 440****Definition of the Vertical "Midline" 440**

Inoue's Angiographic Method 440

Hung's Modified Method 442

Technical Tips 443

**Variances of the "midline" 443

***Transeptal puncture in semi-recumbent position 443

Definition of the Horizontal "M-line" 443**Technical Tips 443**

**Appropriateness of Inoue's method – giant left atrium, kyphoscoliosis 443

***Transeptal puncture in semi-recumbent position 443

Septal Puncture 444**Placement of Transeptal Catheter/Needle 444****Catheter/Needle Manipulation 445****Technical Tips 445**

**Exact positioning of the catheter/needle tip 445

**Exact positioning of the catheter/needle tip in giant left atrium 447

**Repositioning the catheter/needle tip after failed first attempt 447

**Needle tip reshaping 447

The Technique of Septal Puncture 447**Technical Tips 448**

**How to puncture a thick septum 448

**How to avoid puncturing the aorta, tricuspid valve, and coronary sinus 449

**Avoid puncturing medial to the "midline" 449

***Inadvertent puncture of the aorta 449

**How to avoid puncturing the right atrium 449

Confirmation of left atrial entry 450

Heparinization 450

*Basic; **Advanced; ***Rare, exotic, or investigational

\$, <\$US100.00 extra; \$\$, >\$US100.00 extra

⌚, <10 min extra; ⌚⌚, >10 min extra

♣, low risk of complications; ♣♣, high risk of complications

Selection of Balloon Catheter 450

Technical Tip 451

**Pretesting for balloon–syringe mismatch 451

Advancement of the Balloon Catheter 451

Technical Tips 451

**Resistance at groin access site 451

**Septal resistance 452

**Deep catheter placement in left atrium 453

Crossing the Mitral Valve 453

Methods of Crossing 453

The vertical method 453

The direct method 456

Technical Tip 456

**Optimal position of the stylet 456

The Catheter-sliding Method 457

The Posterior Loop Method 457

Technical Tip 457

**Stylet reshaping 457

Balloon Inflation 458

Assuring Free Balloon Movement in the Left Ventricle 458

Technical Tip 459

**If the balloon strays among the chordae 459

Reassessment of Subvalvular Status 459

Technical Tips 459

**Severe subvalvular disease undetected by echocardiography 459

Difficulty in performing the accordion maneuver 459

Gross indentation of the inflated distal balloon (balloon compression sign) 460

“Balloon impasse” 461

Cogwheel resistance 461

Controlled Stepwise Dilations 461

Balloon Pressure–Volume Relationship 461

Balloon Sizing 461

Technical Tips 461

**Balloon sizing in patients with pliable, non-calcified valves 461

**Balloon sizing in patients with calcified valves and/or severe subvalvular disease 462

**Balloon sizing in cases of “balloon impasse” 463

Exchange for Different-sized Balloon Catheters 463

Technical Tips 464

**Balloon “popping” to the left atrium 464

**Subsequent valve crossings and dilations 464

**Catheter entrapment at atrial septum 464

**Avoiding the left atrial appendage 466

**Withdrawing the catheter from the ventricle 466

**Subsequent crossings 466

**Avoid entry into the left atrial appendage 466

**Minimizing atrial septal injury 466

**Bent balloon tip 467

Indications 468

Technical Tip 468

***Double-orifice mitral stenosis (incomplete bridge-type) 468

Contraindications 470

***Stenoses Mitral Bioprosthetic Valve 470

CHALLENGES

Percutaneous balloon mitral valvuloplasty (BMV), introduced in 1984 by Inoue et al. [1], has ushered in a new dimension in the treatment of patients with mitral stenosis. Extensive clinical studies have established this minimally invasive, non-surgical procedure to be a safe and effective therapeutic modality in selected patients with mitral stenosis [2–8] and is equivalent to or even better than surgical commissurotomy [9–13].

With successful balloon valve enlargement, there is generally a twofold increase in the mitral valve area [2–8] and an associated dramatic fall in transmitral valve gradient, left atrial pressure, and pulmonary artery pressure. These hemodynamic benefits are mirrored in post-procedural improvement in patients' symptoms and exercise tolerance [14]. The long-term results of BMV are excellent, especially when the acute results are optimal and in the presence of good valve morphology [14–19].

Besides the original Inoue technique using size-adjustable, self-positioning, balloon catheters, various other techniques using fixed-sized balloon catheters have been developed for performing BMV. These include the antegrade (transvenous) approaches with one or two balloon catheters through one or two interatrial septal punctures [20,21] or the retrograde (transarterial) approaches with or without transeptal access [22]. However, the Inoue-balloon catheter system via the transvenous approach has remained the principal BMV technique used today.

Our extensive experience in Inoue MVP has demonstrated that incremental operator experience and ongoing evolving technical refinements in BMV techniques have resulted in an almost 100% technical success rate and a significant diminution in complications despite the presence of a significant number of technically demanding scenarios and high-risk comorbid conditions [4,14,23–25]. This chapter focuses on the discussion of the pitfalls and tricks in Inoue BMV to ensure success and to minimize complications of the procedure. We hope that this chapter will be beneficial to all Inoue BMV operators at different levels of experience. The instrumentation of the Inoue-balloon catheter system has been extensively described previously [1,3] and is thus omitted in this chapter.

TRANSEPTAL ACCESS

Transeptal catheterization is a vital component of BMV. Transeptal puncture must be not only executed safely to avoid cardiac

perforation, but also made at an appropriate septal site to facilitate balloon crossing of the stenosed mitral valve. Inoue-balloon percutaneous transvenous mitral valvuloplasty (PTMV) is conventionally performed through the right femoral vein. Alternative routes, however, have been described in the past. Josef et al. [26], used right *jugular vein* access, and *left* femoral vein access has been utilized in two patients with right femoral vein thrombosis [27,28].

To avert cardiac perforation during transeptal catheterization, some operators have resorted to routine intraprocedural transesophageal echocardiography; however, even with the echocardiographic guidance, cardiac perforation may still occur [29]. Therefore, acquisition of basic transeptal skills is essential. To perform a transeptal procedure, biplane fluoroscopic equipment is preferable, but single-plane fluoroscopy is usually sufficient for experienced operators. Intracardiac echocardiography is useful in guiding transeptal catheterization in PTMV [30], but its use adds to the procedure cost.

Instruments for Septal Puncture

The essential instruments include (1) a Brockenbrough needle, (2) a 7- or 8-French (Fr) dilator catheter, and (3) an outer Mullins sheath. The use of the sheath is optional, but its utility is recommended, especially for inexperienced operators, for two reasons: To prevent inadvertent perforation of the dilator by the needle during its insertion, and left atrial perforation during insertion of the catheter/needle into the left atrium because the sheath tip works as a safety stopper at the septum.

Catheter/Needle Fitting Exercise

A catheter/needle fitting should be performed before its insertion into the patient. First, fully insert the transeptal needle until its tip extends beyond the catheter (Figure 18.1a). Then, withdraw the needle until its tip is concealed slightly (2–3 mm) within the tip of the catheter. The operator should fix his or her right index finger on the needle between the direction indicator and the catheter hub (Figure 18.1b) to prevent the needle from accidentally moving forward and protruding from the catheter tip. This is of vital importance during *in vivo* manipulation of the catheter/needle. The direction indicator on the needle is held between the thumb and the index finger (Figure 18.1c).

Landmarks for Optimal Puncture Site

To select an optimal transeptal puncture site, there are two imaginary reference lines that need to be defined first: (1) The vertical “midline” and (2) the horizontal “M-line.” The target site for septal puncture is, as a rule, located at the intersecting point of the vertical “midline” and the horizontal “M-line.”

Definition of the Vertical “Midline”

Inoue’s Angiographic Method Inoue has devised a specific transeptal puncture technique designed for the Inoue BMV, incorporating the concept of a vertical “midline,” a line assumed to

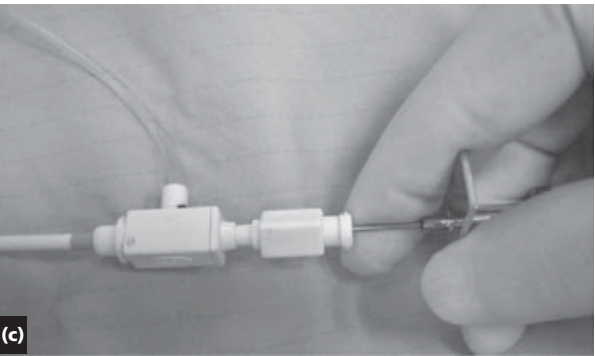
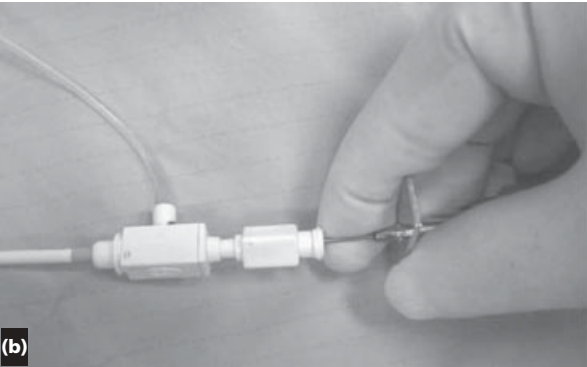
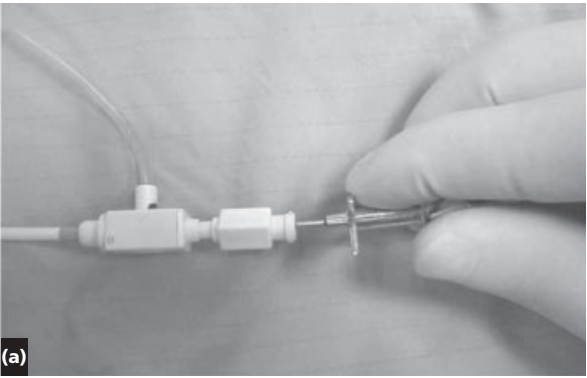


Figure 18.1 Catheter/needle fitting exercise: (a) First, fully insert the transeptal needle until its tip extends beyond the dilator tip. (b) The needle is then withdrawn until its tip is aligned with the dilator tip. (c) It is pulled back farther, so that the needle tip is concealed slightly (2–3 mm) from the dilator tip. The index finger is fixed as a stopper on the needle between the direction indicator and the catheter hub to prevent the needle from moving forward and protruding from the dilator tip. This is of vital importance during in vivo manipulation of the catheter/needle. The depth and the angle of the stopper finger (c) are adjusted according to the distance between the direction indicator and the catheter hub in each catheter/needle set. Each side of the direction indicator is held by the thumb and index finger, respectively. This makes rotation of the indicator easier, and also allows the blunt part of the direction indicator visible to the operator and the tutor, if any) (Courtesy of www.ptmv.org.)

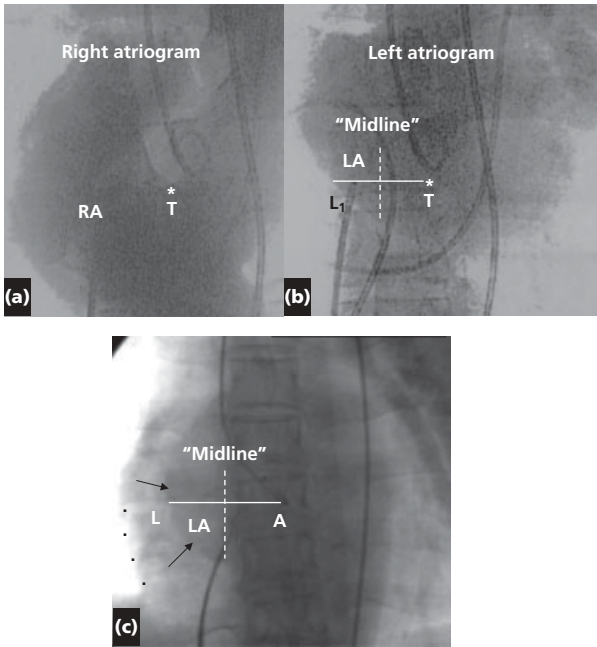


Figure 18.2 The "midline" – angiographic method: (a,b) The upper end of the tricuspid valve at systole (point T, marked as asterisk) is determined on a stop-frame frontal right atrial angiographic image (a) and translated to a stop-frame left atrial image (b). On the latter image, an imaginary horizontal line is drawn from point T to point L, where the line intersects the lateral border of the atrium encountered first (usually the left atrium, as in this case). Point L is assumed to be the posterior limit of the septum. The dotted vertical line crossing at the midpoint between T and L is the "midline." (c) Fluoroscopic method: A horizontal line is drawn from the tip of the pigtail catheter (point A) to L, the left atrial silhouette (black arrows), to define the "midline." The dotted line indicates the right atrial silhouette. (Courtesy of www.ptmv.org.)

divide the interatrial septum into anterior and posterior halves [31]. This line is defined based on the landmarks obtained from right atrial angiography during normal respiration in the frontal plane (Figure 18.2a,b).

Hung's Modified Method As in most cases of mitral stenosis, the left atrial silhouette is visible under fluoroscopy, one of us (JSH) has modified Inoue's method of defining the "midline." In this method, the aortic valve rather than the tricuspid valve is used as a landmark because of their proximity. Therefore, point T is substituted with the tip of a pigtail catheter (Figure 18.2c, point A) touching the aortic valve (usually the non-coronary sinus of Valsalva) in the frontal view. A horizontal line is drawn from point A to L, where the line intersects the right lateral edge of the left atrium. The "midline" thus derived is usually identical to that from Inoue's angiographic method.

Technical Tips

****Variances of the “midline”** The septum lies within the superimposed area between the two atria, and therefore there is no septum outside this area. The lateral (or posterior) limit of the septum is the lateral border of the medial atrium, usually the left atrium. Infrequently (such as in patients with giant left atria), the lateral border of the right atrium is medial to that of the left atrium, and thus point L should be on the right atrial border because there is no septum laterally beyond this point.

*****Transeptal puncture in semi-recumbent position** BMV can be performed with the patient in a semi-recumbent position such as when the patient is unable to assume a supine position because of severe pulmonary edema and needs to undergo BMV urgently. In this setting, the “midline” can be defined in frontal view with appropriate caudal tilting [32]. The frontal image intensifier needs to be tilted in a caudal angle corresponding to the degree of semi-recumbency to negate the patient’s tilt and “normalize” the positional relationship of the various intrathoracic structures, e.g. if the patient is lying at 30° to the horizontal, the frontal image intensifier should be rotated to 30° caudally.

Definition of the Horizontal “M-line”

The “M-line” is a horizontal line crossing the center of the mitral annulus (point M) as visualized in a left ventriculographic diastolic stop-frame obtained in 30° right anterior oblique (RAO) projection (Figure 18.3a). This line is memorized in relation to the vertebral body; there is no need to plot it on the image monitor screen. The stop-frame angiogram is also used as a road map during transeptal puncture and balloon catheter manipulation.

In individual cases, the puncture point in relation to this line may have to be adjusted, e.g. in patients with a more vertically oriented left ventricle, the puncture site is chosen slightly above the horizontal “M-line”. In patients with giant left atria, the operator is often forced to make the septal puncture more caudal to the “M-line.”

Technical Tips

****Appropriateness of Inoue’s method – giant left atrium, kyphoscoliosis** Inoue’s angiographic method is suited in following situations:

- 1 For operators inexperienced with the transeptal puncture technique
- 2 In cases in which atrial silhouettes are not well visualized under fluoroscopy
- 3 In extremely difficult cases of transeptal puncture, e.g. in the presence of a giant left atrium [31] or severe kyphoscoliosis [33]. In these cases, it may be necessary to perform biplane (frontal and lateral) right angiography to properly visualize the atrial septal orientation and relative anatomic relationships of both the atria, the tricuspid valve, and the aorta.

*****Transeptal puncture in semi-recumbent position** BMV can be performed with the patient in a semi-recumbent position

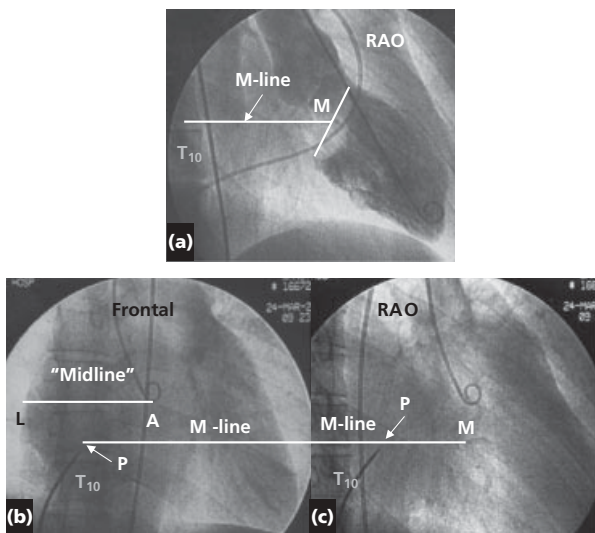


Figure 18.3 Defining horizontal M-line, vertical "midline," and target puncture site. (a) The M-line is obtained using the left ventriculogram with a stop frame RAO view. This line is memorized in relation to the vertebral body T10, and transcribed in the (b) frontal and (c) RAO views. The vertical "midline" is defined in fluoroscopic frontal view. The target site for septal puncture (point P) is located at the intersecting point of the vertical "midline" and the horizontal M-line (panel B). A, pigtail catheter tip; RAO, right anterior oblique; T10, tenth thoracic vertebra. (Courtesy of www.ptmv.org.)

in an emergency situation for the patient who is unable to assume a supine position because of severe pulmonary congestion. In this setting, the "midline" can be defined in frontal view with appropriate caudal tilting [32]. The frontal image intensifier needs to be tilted in a caudal angle corresponding to the degree of semi-recumbency to negate the patient's tilt and "normalize" the positional relationship of the various intrathoracic structures, e.g. if the patient is lying at 30° to the horizontal, the frontal image intensifier should be rotated to 30° caudally.

SEPTAL PUNCTURE

Placement of Transeptal Catheter/Needle

The catheter/sheath is inserted via the right femoral vein over a guidewire into the superior vena cava to the level of the carina. The catheter is aspirated and flushed after removal of the wire. Then, the Brockenbrough needle, attached with a 5-ml plastic syringe containing pure contrast medium, is inserted into the catheter and carefully advanced under fluoroscopic view until its tip reaches the predetermined position (refer to "Catheter/needle fitting exercise" in previous section). The needle is allowed to rotate freely during its passage. The right-hand stopper finger is

now firmly kept between the catheter hub and the direction indicator of the needle to prevent the needle from moving forward (see Figure 18.1). Extreme care should be taken not to let the needle slip forward during subsequent manipulation of the catheter/needle.

Catheter/Needle Manipulation

Under a frontal fluoroscopic view, the needle-fitted transeptal catheter with its direction indicator pointing at about 4 o'clock is slowly withdrawn downward (caudally) from the superior vena cava. A clockwise rotation is applied to the direction indicator to align the catheter/needle on the "midline." The catheter/needle is further withdrawn until its tip reaches the level of the pigtail tip, touching the aortic valve (see Figure 18.3b).

Under a lateral view, the catheter/needle is further withdrawn caudally while contrast medium is being injected (septal flush method) [31] by an assistant, or using the operator's right hand while fixing the catheter hub and the direction indicator using the left hand, to outline the right atrial margin of the septum (Figure 18.4c,d). The catheter tip is finally set at the curvilinear portion of the septum at the altitude of the "M-line" (Figure 18.4e).

Subsequently, the catheter needle/needle tip position is viewed under 30° RAO projection, contrasted with the left ventriculogram road map, to confirm optimal septal puncture site as well as to avoid puncture of other structures (Figure 18.4d). The catheter/needle tip is now seen on the "M-line," usually just anterior to the vertebra, and away from the ascending aorta, coronary sinus, and tricuspid valve. Although frontal and lateral views are sufficient for experienced operators, the RAO view is especially vital for inexperienced operators.

Technical Tips

****Exact positioning of the catheter/needle tip** In most cases of mitral stenosis, a sudden sharp movement of the catheter/needle toward the left is not observed when the tip of the transeptal assembly falls over the limbic ledge and enters the fossa ovalis. This is because the atrial septum bulges markedly toward the right atrium, making the fossa ovalis shallower. When the septal bulge starts in the upper septum, the catheter/needle being withdrawn from the superior vena cava takes a lateral course to the "midline." In this case, turning the needle to the 3 o'clock direction may lead the catheter/needle to a medial position. If not, the needle alone can be withdrawn slightly, and the floppy tip of the catheter should tend to flip medially. Then the needle is advanced slowly and carefully to bring its tip back to the original position, while keeping the catheter tip in the medial position. If the above means also fail to place the catheter/needle medially, the latter is withdrawn further downward and close to the lower edge of the left atrium (passing the caudal end of the bulge). With the needle pointing toward the left (about 3 o'clock), the catheter tip is allowed to shift medial to the "midline" and then carefully advanced cephalad.

A clockwise twist is made to the needle and the catheter tip is steered to, or near the target point.

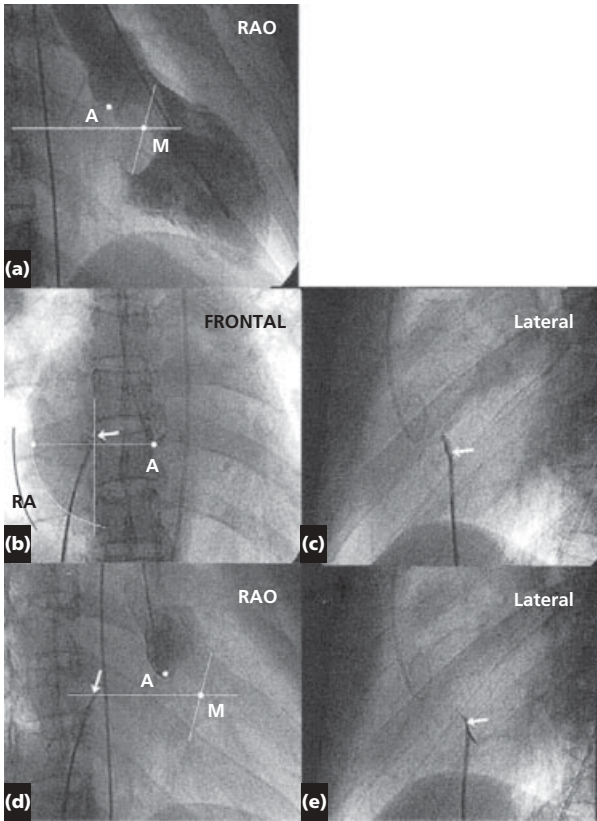


Figure 18.4 Catheter/needle manipulation: (a) Stop-frame left ventriculogram in 30° right anterior oblique (RAO) view shows a horizontal line, M-line, crossing the center of the mitral annulus. (b) Under frontal fluoroscopic view, the needle-fitted transeptal catheter is slowly withdrawn downward (caudally) from the superior vena cava to align the catheter/needle on the vertical midline. The catheter/needle is further withdrawn until its tip reaches the level of the pigtail tip touching the aortic valve (point A). (c) Under lateral view, the catheter/needle is further withdrawn caudally while contrast medium is being injected (septal flush method) to outline the right atrial margin of the septum. (d) The catheter/needle is further withdrawn to set its tip at the curvilinear portion of the septum at the altitude of the M-line. At this point, the catheter/needle is observed to be pointed dorsally. (e) Subsequently, the catheter/needle tip position is viewed under 30° RAO projection, contrasted with the left ventriculogram road map (A), to confirm optimal septal puncture site as well as to avoid puncture of other structures (the aorta, coronary sinus, and tricuspid valve). The catheter/needle tip is now seen on the M-line, usually just anterior to the vertebra.

****Exact positioning of the catheter/needle tip in giant left atrium** If the atrial septum bulges markedly toward the right atrium, especially in cases of a giant left atrium, it is difficult to align the catheter tip with the "midline" and perpendicular to the septum. The catheter tip faces a strong resistance at 4 o'clock when it touches the bulged septal surface. As the needle is being rotated clockwise, the catheter/needle will give way suddenly. In effect, the needle tip flips over the crest of the bulge and points toward the right side of the patient at 9 o'clock. To prevent this, the catheter should be pressed slightly against the septum as the needle is being rotated clockwise to 6–7 o'clock. At the same time, a slight counterclockwise twist is applied to the catheter with the left hand to counter any excessive clockwise rotation of the needle. If the crest of the bulge happens to be at the "midline," it is not possible to make a puncture on the line. In this case the puncture site is settled in the region slightly lateral to "the midline."

****Repositioning the catheter/needle tip after failed first attempt** If the initial pass of the transeptal catheter/needle is not successful in engaging it at an appropriate puncture site, the needle is removed from the catheter and the second attempt is started by repositioning the catheter in the superior vena cava over a guidewire. For experienced operators, the alternative is to reposition the catheter/needle high in the right atrium. This is done by setting the needle in the 12 o'clock direction (ventrally) and carefully moving the catheter/needle upward (cephalad) while slightly rotating the direction indicator of the needle clockwise and counterclockwise, to make certain that the catheter tip is free in the right atrium and not caught against the right atrial appendage or its free wall.

****Needle tip reshaping** Reshaping of the distal needle to make it more curved may be necessary in the following situations: (1) When the catheter/needle tip tends to take a more lateral course to the "midline" despite counterclockwise rotation of the direction indicator to 3 o'clock direction; and (2) at the intended puncture site, there is a sharp angle between the direction of the catheter/needle tip and the septum, therefore making septal penetration impossible or causing septal dissection when the needle is advanced forward.

The Technique of Septal Puncture

When the operator is satisfied with the intended puncture site, the catheter/needle is pressed firmly against the septum. Usually cardiac pulsations (so-called septal bounce) are felt by the right hand holding the catheter/needle. While keeping the catheter firmly against the septum to prevent it from slipping away from the puncture site, the operator releases the stopper finger and advances the needle forward. The needle is aspirated and contrast medium injected to confirm its entry into the left atrium. If no

blood is aspirated, the needle either has dissected the high septum or is caught in the thickened septum. Staining of the septum with injection of a small amount of contrast medium (septal stain method) [31] easily distinguishes between the two (Figure 18.4). This type of septal staining is of no consequence because contrast medium is absorbed rapidly. When the high septum is dissected, it is stained in more vertical fashion. In this situation the needle is withdrawn and septal puncture is made at a slightly more caudal site.

Technical Tips

****How to puncture a thick septum** When the needle is caught in the thick septum (usually in the muscular septum), the stain takes a more oblique orientation (Figure 18.5c,d). In this case the catheter/needle is carefully forced across the septum as described below or the puncture is attempted at another site. When the catheter/needle is being advanced, a “tenting” of the septum is observed before the septum is entirely pierced by the catheter/needle. With pressure monitoring, it is not possible to differentiate dissection of the high septum from entrapment of the needle in the thick septum. This is another reason why we perform the transeptal puncture without constant pressure monitoring.

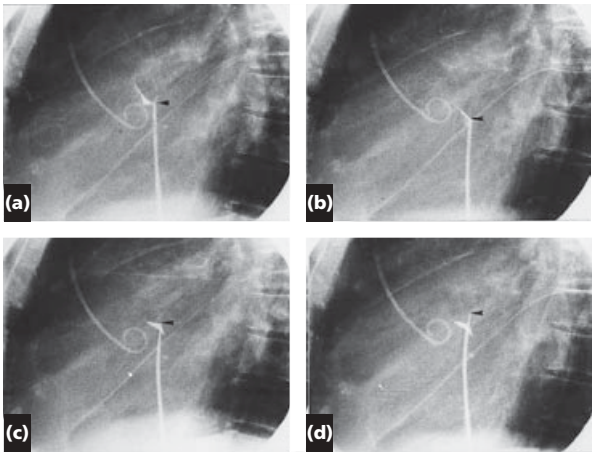


Figure 18.5 Septal flush/stain method illustrated in lateral views: (a) As the catheter/needle assembly is withdrawn caudally it is flushed with contrast medium, which outlines the right atrial margin of the septum. The tip of the catheter/needle (black arrow) is at the high anterior septum. (b) The catheter/needle is withdrawn to set its tip at the puncture target site, and the needle is advanced. (c) As the puncture is made in the thickened muscular septum, the needle is caught in the septum as demonstrated by oblique septal stain. When the catheter/needle is advanced, a “tenting” of the septum is observed. (d) The needle is carefully forced through the septum. (Reproduced from Hung et al. [30] with permission from Elsevier.)

When marked resistance is encountered during septal puncture, a sustained force is applied to the catheter/needle. After several cardiac beats, not infrequently a "give" is felt or seen under fluoroscopy when the catheter/needle finds its way into the left atrium. If this means failure to place the catheter/needle across the septum, a Bing stylet, which has a blunt tip, is inserted and extended beyond the needle. The catheter/needle is carefully forced through the tough septum by a forward push with the right hand while applying counter resistance with the left hand. During the process the operator must be prepared to withdraw the needle as soon as the catheter enters the left atrium, so that the excessive forward momentum does not carry the needle forward and perforate the left atrial wall, causing cardiac tamponade.

****How to avoid puncturing the aorta, tricuspid valve, and coronary sinus** When the catheter/needle is set on the "midline," puncture of these structures can be avoided. Being confirmed in the RAO projection, the intended puncture site is clearly separated from the aorta, tricuspid valve, and coronary sinus (see Figure 18.3c).

****Avoid puncturing medial to the "midline"** When a puncture is made medial to the line, there is a risk of puncturing the aorta, tricuspid valve, or coronary sinus. More importantly, the puncture site so made is too close to the mitral valve, and this makes balloon crossing of the mitral valve difficult or even impossible, unless the posterior-loop method (see "Crossing the mitral valve") is employed. Slight lateral deviation of the puncture site to the "midline" is permissible, especially in patients with relatively small left atria.

*****Inadvertent puncture of the aorta** When this rare event is confirmed by contrast injection or pressure recording, it is usually uneventful if the needle is withdrawn immediately; however, should the operator unknowingly advance the catheter into the aorta, it should not be withdrawn. The patient should be sent for emergency surgery with the catheter left in the aorta.

****How to avoid puncturing the right atrium** To avoid injury of the right atrium, the catheter/needle should be carefully manipulated and the needle tip always kept inside the catheter tip. When right atrial perforation is detected by contrast opacification of the pericardial space, do not advance the catheter and withdraw the needle/catheter immediately. Usually cardiac tamponade does not ensue, and the operator may proceed with puncture attempt at the optimal site. It is important to note that there may not be a septum in an area near the inferior (caudal) border of the left atrium caudal to the "M-line," because the atrium often bulges caudally beyond the true septal boundary. This is especially true in patients with a large left atrium. If this region is punctured, the catheter/needle may perforate through the right atrial wall and then enter the left atrium (the so-called

“stitching” phenomenon) [31]. After the guidewire is placed in the left atrium and the catheter withdrawn, cardiac tamponade ensues. To avoid puncturing the right atrium, setting of the catheter/needle tip at the septum can be confirmed by (1) observing the “septal bounce” and (2) the septal flush/stain method, as discussed above (see Figures 18.4 and 18.5).

Confirmation of left atrial entry After entry of the needle into the left atrium is confirmed, first by contrast medium injection followed by pressure recording, the needle direction is set toward 3 o’clock (left side of the patient). If there is no or little resistance, the catheter/needle is advanced forward about 2 cm into the left atrium. Then, the catheter alone is advanced another 2 cm (or until the tip of the sheath meets a resistance at the septum), while the needle is being withdrawn.

Heparinization Upon removal of the needle after the catheter is placed in the left atrium, heparin 100 U/kg body weight should be given immediately through the catheter. After baseline hemodynamic studies, BMV is performed. If the patient has been on warfarin before BMV, the drug is discontinued 2–3 days before the procedure and substituted with intravenous unfractionated or subcutaneous low-molecular-weight heparin until before the procedure.

SELECTION OF BALLOON CATHETER

Selection of an appropriate-sized balloon catheter for the controlled stepwise dilation technique is extremely important to avoid creating severe mitral regurgitation during BMV. Our balloon catheter selection methods have evolved from our continuing efforts to minimize this complication [4,14,23–25] (Table 18.1).

Selection guidelines are based on balloon reference size derived from patient height, transthoracic echocardiographic findings of the mitral valve, and fluoroscopic presence of valvular calcification.

Table 18.1 Catheter selection and balloon sizing based on patient height and valvular status

Reference size (RS) (mm)

Height (cm) (rounded to nearest 0) \times 1/10 + 10, e.g.
height = 147 cm

$$RS = 150 \times 1/10 + 10 = 25 \text{ mm}$$

Catheter selection

Valvular status	Balloon catheter
Pliable	RS matched (e.g. PTMC-26 for RS = 25 mm)
Calcified/SL	One-size < RS matched (e.g. PTMC-24 for RS = 25 mm)

The reference size (RS) is calculated according to a simple formula [24]: patient height (in centimeters) is rounded to the nearest zero and divided by 10, and 10 is added to the ratio to yield the RS (in millimeters), e.g. if height = 147 cm, then $RS = 150/10 + 10 = 25$ mm. In patients with pliable, non-calcified valves, and angiographic mitral regurgitation $\leq 1+$, a catheter with a nominal balloon size at least that of the RS (an RS-matched catheter) is used. In contrast, in patients at high risk for creating severe mitral regurgitation (valvular calcification and/or severe subvalvular lesions), a balloon catheter one size smaller than an RS match is selected. Therefore, in the above example with an RS of 25 mm, a PTMC-26 catheter would be selected for a pliable, non-calcified valve, and a PTMC-24 catheter for a calcified valve and/or a valve with severe subvalvular disease (SL).

Technical Tip

****Pretesting for balloon–syringe mismatch** Although the volume predefined by red marks on the syringe and its corresponding balloon size at full inflation have been tested by the manufacturer, balloon–syringe mismatch may occur. Although this mismatch is usually mild, gross mismatch may take place when the catheter and syringe are from different packaging or reused after sterilization. The mismatch, if undetected, may result in either underinflation or overinflation of the balloon. The former may result in suboptimal valvular dilation and the latter in severe mitral regurgitation. Therefore, before inserting the balloon catheter into each patient, the balloon diameters should be confirmed using a two-step test. First, the syringe should be filled with diluted contrast to the mark corresponding to the balloon diameter chosen for the first inflation (see “Balloon sizing” below). The balloon should then be fully inflated, and its diameter measured with a caliper. If there is a mismatch, the difference should be noted and adjusted during the second step of testing when the balloon is inflated to its nominal diameter.

After the pretesting exercise, the syringe is disconnected from the balloon catheter for two reasons. One is to purge the syringe of any remaining air, and the other to avoid any inadvertent overinflation of the balloon at its nominal size. After the catheter has been inserted into the left atrium, the air-free syringe, filled with diluted contrast corresponding to the predetermined initial balloon diameter, is reconnected to the catheter.

ADVANCEMENT OF THE BALLOON CATHETER

Insertion of the stretched Inoue balloon catheter over the 0.025-inch, stainless steel, coiled-tip guidewire into the right femoral vein is smooth in most patients. Occasionally, difficulties arise from resistance to the catheter at the femoral access site or the interatrial septum.

Technical Tips

****Resistance at groin access site** To avoid creating a long subcutaneous tunnel, which may pose some resistance during

insertion of the balloon catheter, the puncture needle is angled more vertically than usual during the initial vascular access (at about 60° to the skin surface). After transeptal puncture and insertion of the coiled-tip guidewire into the left atrium, the subcutaneous track is then well stretched with an artery forceps along the guidewire. This is followed by use of the 12-Fr dilator (enclosed in the Inoue balloon assembly set), which is also used to dilate the interatrial septum. Finally, when inserting the stretched balloon catheter, firm compression with the flat of the fingertips cephalad to the puncture site and over the subcutaneous track may be needed to aid catheter entry.

If significant resistance is encountered during insertion of the stretched balloon catheter, it is inserted into the vein at a more obtuse angle of about 90° until the catheter tip meets the posterior venous wall. The catheter is then tilted more horizontally and advanced over the wire. During the latter process, to facilitate catheter insertion and avoid bending the guide wire, firm compression should be applied cephalad to the puncture site and over the subcutaneous track (as described above), and the guidewire should be held taut by an assistant. If this technique fails, the subcutaneous track and the vein should be redilated with the 14-Fr dilator. If these precautionary measures are exercised, the need for a 14-Fr intravascular sheath for insertion of the balloon catheter is rare in our experience, even in patients with the right groin scarred from previous catheterization. However, one should not hesitate to use a 14-Fr vascular sheath to avoid bending the guidewire or metal tube, when a difficulty is encountered during the catheter insertion process.

It is also important to note that, during insertion of the catheter into the femoral vein, the catheter should never be twisted, lest the metal tube be bent. If the tube is inadvertently bent, it should be replaced with a new one. On the other hand, if the guide wire is bent, the 12F dilator is reinserted over the wire and carefully left into the left atrium.

It is also important to note that during insertion of the catheter into the femoral vein, the catheter should never be twisted, lest the metal tube be bent. If the tube is inadvertently bent, it should be replaced with a new one. On the other hand, if the guide wire is bent, the 12F dilator is reinserted over the wire and carefully left into the left atrium to permit guide wire exchange.

****Septal resistance** After atrial septal puncture and placement of the coiled-tip guidewire in the left atrium, occasionally there may be some difficulty in advancing the balloon catheter across the septum, particularly when the latter is markedly thickened at the puncture site. When this occurs, forceful action must be avoided because the catheter may curve excessively in the inferior vena cava, resulting in abdominal discomfort for the patient. Rather, the balloon catheter should be turned slightly, usually in a clockwise direction, as it is pushed forward (screwdriver maneuver) to overcome septal resistance. In the rare instances when this method also fails, the septum is redilated with the dilator. After passage across the septum, it is also important not to push the

catheter tip up against the left atrial roof, or the guidewire may be bent into an acute angle, making subsequent catheter manipulation difficult.

****Deep catheter placement in left atrium** The balloon catheter is introduced under frontal fluoroscopic view into the atrium over the coiled-tip guide wire to form a large loop with the tip medial to the mitral orifice, pointing in a 6–7 o'clock direction (Figure 18.6a). This placement has the following advantages: (1) The catheter thus positioned is less likely to flip to the left atrial appendage when the stylet is advanced to the catheter tip; (2) the catheter will not enter the pulmonary veins; and (3) in subsequent manipulations to cross the mitral valve, only the deep-seated catheter will need to be withdrawn. Thus, potential entrapment by a tough septum, which is only encountered during catheter advancement, is avoided (see "Catheter entrapment at atrial septum" below).

CROSSING THE MITRAL VALVE

After deep catheter placement in the left atrium, the fluoroscopic projection is changed from a frontal to a 30° RAO view (Figure 18.6b) that displays the left ventricular long axis in profile. In patients with giant left atria, additional use of lateral fluoroscopic view may be needed to facilitate crossing of the valve.

Methods of Crossing

With the stylet inserted to the catheter tip, the partially inflated distal balloon is directed toward the anteriorly located mitral orifice by applying a counterclockwise twist (usually 180°) to the stylet with the right hand (in a right-handed operator). The catheter is then withdrawn slowly, using the left hand, until a horizontal bobbing motion of the balloon is noted, indicating close proximity of the balloon to the mitral valve. Mitral valve crossing is then attempted using four methods in descending order of preference: (1) The vertical, (2) direct, (3) sliding, and (4) posterior loop method. The vertical method is the most frequently successful crossing method.

The vertical method Upon further slight retraction of the catheter, the balloon is observed to move in (during diastole) (Figure 18.7a,c) and out (during systole) of the left ventricle (Figure 18.7b,d) even though the catheter is not aligned with the orifice–apex axis. Coincident with diastole, only the stylet is withdrawn. To accomplish this, the operator must carefully watch the rhythmic motion of the heart. This allows the distal segment of the catheter to take on a more horizontal orientation to cross the valve and enter deep in the left ventricle (Figure 18.6e–g). If the distal portion of the catheter is still vertically oriented and points to the inferior wall of the left ventricle (Figure 18.7g), the catheter is carefully withdrawn to align it with the orifice–apex axis (Figure 18.7h). During the process, the distal balloon may need to be inflated further to prevent it from popping out of the ventricle.

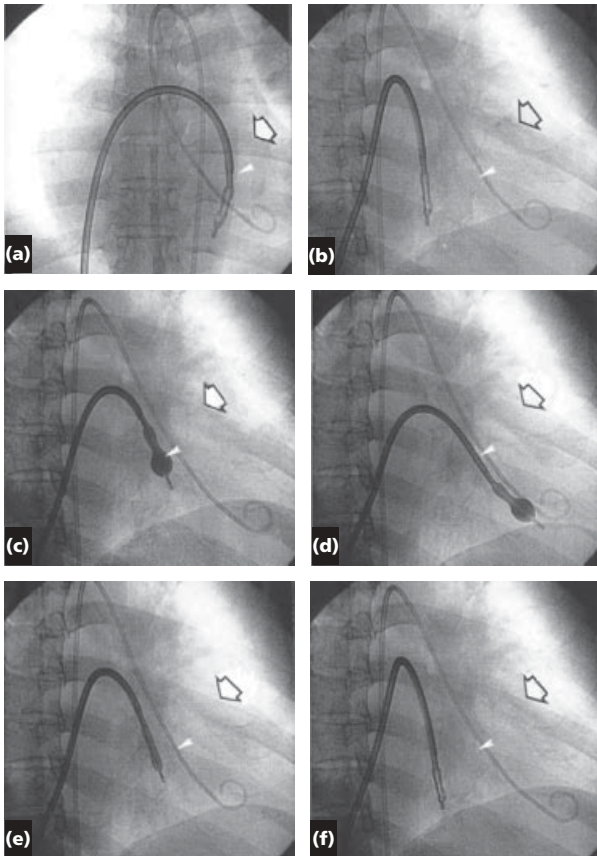


Figure 18.6 A balloon catheter is introduced under frontal fluoroscopic view into the left atrium over the coiled-tip guidewire to form a large loop with the tip medial to the mitral orifice, pointing to 6–7 o'clock direction (a). After the deep catheter placement, the projection is changed to a 30° right anterior oblique (RAO) view (b) and, with the stylet inserted into the catheter tip, the partially inflated distal balloon is directed toward the anteriorly located mitral orifice. The catheter is then withdrawn gradually, to direct the balloon to the mitral valve (white arrowhead) (c) and to cross the mitral valve (d). After balloon inflation procedure, the catheter balloon is then withdrawn to the left atrium. In subsequent crossing of the mitral valve with the stepwise dilation technique, the stylet is inserted on the catheter tip (e) and the catheter is advanced to deep seat the balloon (f). During balloon catheter manipulation under a 30° RAO fluoroscopic view, the catheter tip should always be kept to the left of the pigtail catheter pre-placed in the left ventricle to avoid trespassing on the left atrial appendage area (open arrowhead).

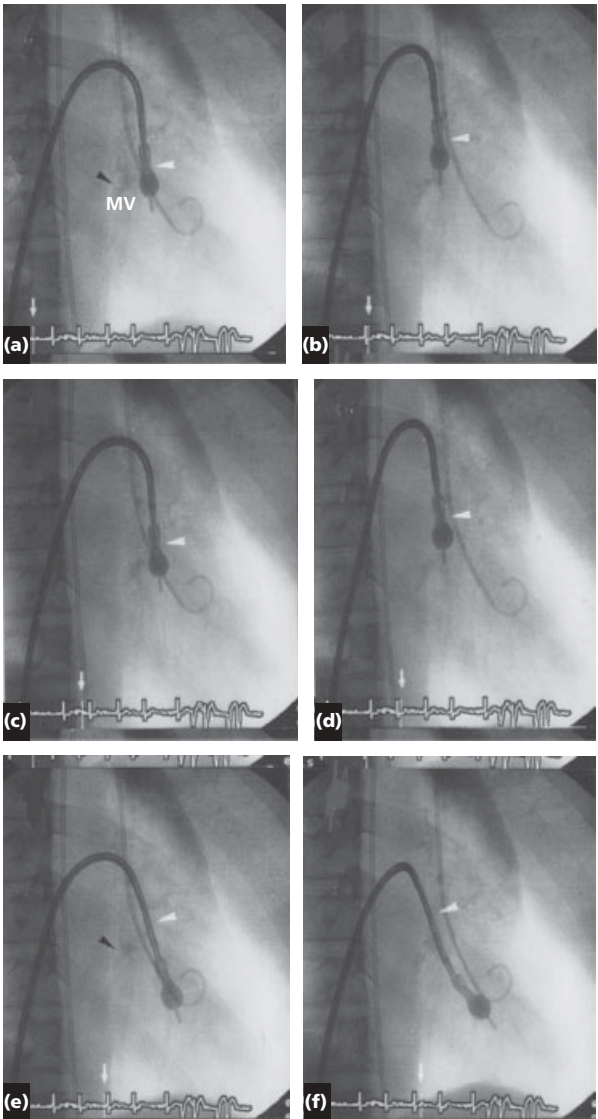


Figure 18.7 Vertical method: Fluoroscopic 30° right anterior oblique views during manipulations of Inoue-balloon catheter to cross the mitral valve. (a–d) During diastole (a,c) the catheter balloon crosses the calcified mitral valve (black arrowhead) into left ventricle whereas, during systole (b,d), it pops back into left atrium. (e) During diastole of the same cardiac cycle in (d), only the stylet is withdrawn and the distal catheter thus adopts a more horizontal orientation, permitting the balloon to enter the left ventricle. (f–h) The catheter is retracted to align along the left ventricular long axis. White arrowheads indicate stylet tip position. White arrows at the bottom of each frame depict timing of the cardiac cycle on the electrocardiogram. (See text for discussion.) (Reproduced from Hung and Lau [34] with permission from Journal of Invasive Cardiology.)

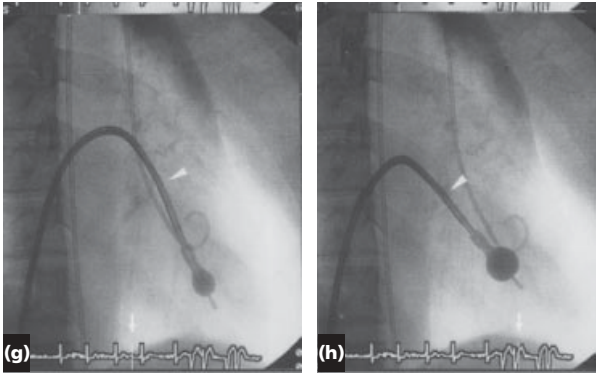


Figure 18.7 (Continued)

This vertical approach keeps the catheter from inadvertently flipping into the appendage, thus minimizing the risk of catheter encroachment into the left atrial appendage in cases with thrombi confined to the appendage [34].

The direct method When the vertical method fails, the balloon catheter is further withdrawn until the catheter balloon is near the valve and the catheter is well aligned with the orifice–apex axis. At this time a “woodpecking” sign is observed as the balloon moves away from the mitral orifice in systole, and toward it in diastole along the mitral–apex axis. Once this sign is evident, the balloon is in position to cross the mitral orifice. With careful attention to the rhythmic motion, the operator jerks the stylet back slightly (4–5 cm) as the balloon approaches the orifice, and simultaneously advances the catheter with the left hand to drive the balloon flow across the valve deep into the left ventricle. As timing is critical, in an operator’s early experiences with BMV, selection of patients with sinus rhythm is recommended, because it is then easier to make use of the regular cardiac cycle to advance the balloon across the mitral orifice.

Technical Tip

****Optimal position of the stylet** In the vertical and direct methods, it is important to insert the spring-wire stylet all the way to the balloon catheter tip to straighten the latter. Occasionally, however, the stylet may be too short to reach the catheter tip, thus making a slight bend in the catheter tip. If this occurs, the rubber grip at the proximal end of the stylet can be pulled further back to lengthen the exposed segment of the stylet or, failing this, the rubber grip is cut at 1–2 mm from its distal end and removed. To maintain the anterior orientation of the balloon (toward the mitral valve), the stylet must be kept twisted at all times. An extra counterclockwise twist is occasionally needed to

direct the catheter tip anteriorly, especially in cases with giant left atria. In these cases, the septum is markedly displaced anteriorly, and so the balloon catheter tends to point more posteriorly. An added lateral fluoroscopic view will facilitate manipulation of the catheter/stylet for balloon crossing of the mitral valve in these instances.

The Catheter-sliding Method

When the vertical or direct method fails, another technique that may be useful for crossing the mitral valve is the catheter-sliding method [23]. This method has proved to be effective in cases when the septal puncture is made too caudally and/or the left ventricle takes a more horizontal orientation (Figure 18.8a). The balloon is first directed toward the mitral valve by keeping the stylet twisted counterclockwise. The distal catheter segment is then made more flexible by withdrawing the stylet clear of the balloon segment (Figure 18.8b). Once the slightly inflated balloon is at the mitral orifice, cardiac contractions will cause the balloon segment to tilt upward during systole (Figure 18.8c). In diastole, the balloon segment aligns with the catheter shaft (Figure 18.8d). With the operator carefully watching the rhythmic motion of the cardiac cycle, only the catheter is advanced forward (with the stylet kept fixed) during diastole to cross the valve (Figure 18.8e). The stylet is then advanced to help align the catheter with the orifice–apex axis (Figure 18.8f).

The Posterior Loop Method

Crossing the valve with the balloon catheter may be difficult with the above-mentioned methods in patients with giant left atria, or when the atrial septal puncture has been made inappropriately either too cephalad or too anterior in relation to the mitral valve. In such circumstances, the loop approach may be used. This method, which has been well described previously [23], is infrequently used in our experience.

Technical Tip

****Stylet reshaping** The J-tipped stylet with its original curve will, in most instances, steer the balloon toward and across the mitral orifice. However, when it is difficult to direct the balloon toward the mitral orifice by aligning the catheter with the orifice–apex axis, the stylet should be reshaped according to the positional relationship between the septal puncture site and the valve orifice, e.g. in patients with a giant left atrium where the puncture site is often made more caudally and laterally in relation to the mitral orifice, the distal segment of the stylet can be shaped into a larger smooth curve to facilitate passage of the balloon across the mitral valve. Conversely, in those with a relatively small left atrium, when the puncture site is made suboptimally, either too medially or anteriorly (in relation to the mitral valve), the stylet can be reshaped into a tighter loop (or the posterior loop method described above can be employed).

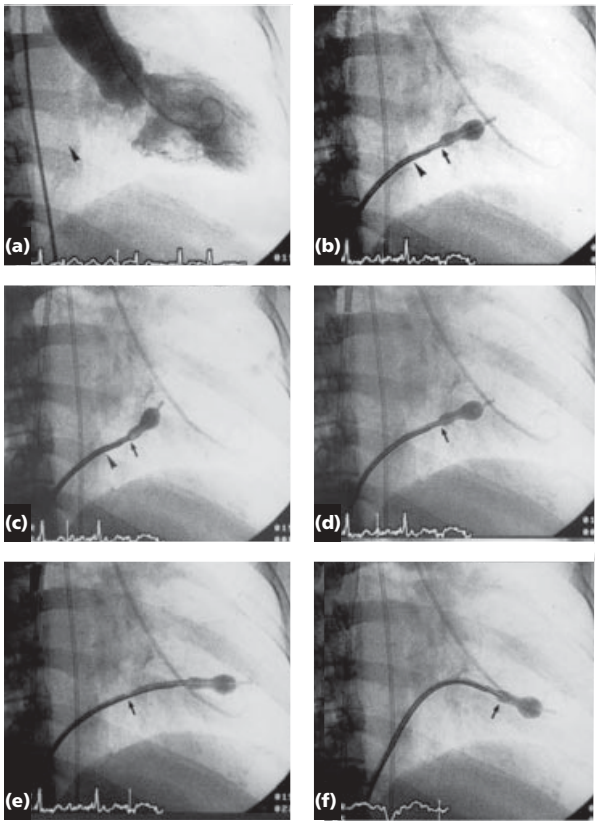


Figure 18.8 Catheter-sliding method. (a) Left ventriculogram in 30° right anterior oblique view, showing position of the transeptal puncture site (arrowhead), quite caudal to the mitral orifice; the left ventricle is more horizontally oriented. (b) The stylet (arrow) is slightly withdrawn from the balloon segment. (c,d) During a cardiac cycle, the balloon segment bobs up and down in systole and diastole, respectively, indicating proper positioning of the catheter tip at the mitral orifice. (e) During diastole, when the balloon bobs down and is aligned with the distal catheter (as in d), only the catheter is advanced forward (with the stylet kept fixed) to place the balloon in the left ventricle. (f) Thereafter, the stylet is carefully advanced to align the catheter with the mitral orifice/ventricular apex axis before initiating the balloon inflation procedure. (Reproduced from Hung and Lau [23] with permission from Wiley.)

BALLOON INFLATION

Assuring Free Balloon Movement in the Left Ventricle

One of the most dreaded complications of BMV is the development of severe mitral regurgitation requiring surgery. Once the mitral valve has been crossed, the free movements of the partially inflated distal balloon in the left ventricle should be ascertained to

prevent the disastrous consequences, i.e. rupture of chordae, papillary muscles, or leaflets, stemming from its subsequent full inflation between the chordae. This is done by simultaneously pushing the catheter and pulling the stylet slightly in opposite directions (“accordion” maneuver) [23] to ensure that the partially inflated distal balloon slides freely along the orifice–apex axis.

Technical Tip

****If the balloon strays among the chordae** After crossing the mitral valve, the catheter balloon may point more vertically and deviate away from the orifice–apex axis. This suggests that the catheter has strayed among the chordae. To correct this situation, the distal balloon is inflated larger to prevent the balloon from being inadvertently retracted into the atrium, and the catheter is carefully pulled back to assume a more horizontal orientation. After satisfactory alignment of the catheter with the orifice–apex axis, the catheter is advanced toward the apex, and the previously described accordion maneuver is performed before initiating the inflation procedure. Similarly, a twist in the balloon during the inflation process may also indicate that the catheter has become tethered among the chordae. In this case, the inflation should be promptly aborted and the balloon repositioned.

Reassessment of Subvalvular Status

Before BMV, mitral valvular status is determined by pre-procedural transthoracic echocardiography and fluoroscopy (for the presence of valvular calcification), and an appropriate balloon catheter is then chosen accordingly (see “Selection of balloon catheter” above). Extensive subvalvular disease has been found by various investigators to be a predictor for significant mitral regurgitation. As echocardiography (either transthoracic or transesophageal) often underestimates the severity of subvalvular disease [23], severe mitral regurgitation may be created during BMV despite the presence of an apparently favorable valve morphology. Therefore, during the actual balloon dilations, vigilance is required to identify the presence of previously undetected severe subvalvular disease. We and others have found other more reliable signs of significant subvalvular involvement [14,25,35]. Even in patients in whom no severe subvalvular disease is demonstrated by pre-procedural echocardiography, when any of the signs described below are observed, the balloon dilation protocol is altered accordingly as described below (see “Balloon sizing” below).

Technical Tips

****Severe subvalvular disease undetected by echocardiography** The following signs suggest or indicate the presence of severe subvalvular disease.

Difficulty in performing the accordion maneuver This occurs because of resistance at the subvalvular level. If this difficulty is not appreciated, subsequent full balloon inflation will be within the left ventricle because the balloon is not anchored at the mitral valve. Hence, it is the subvalvular apparatus and not the mitral

valve that is dilated. Although severe mitral regurgitation may result from such an accidental subvalvular dilatation [35], the inflation is usually harmless. However, it should be promptly recognized and the balloon quickly deflated. The size of the distal balloon is then reduced during subsequent attempts to anchor the balloon at the mitral valve.

Gross indentation of the inflated distal balloon (balloon compression sign) (Figure 18.9) This indicates severe subvalvular disease [14,25]. As soon as compression is observed on the distal balloon, the inflation procedure is aborted and the inflation strategy reassessed.

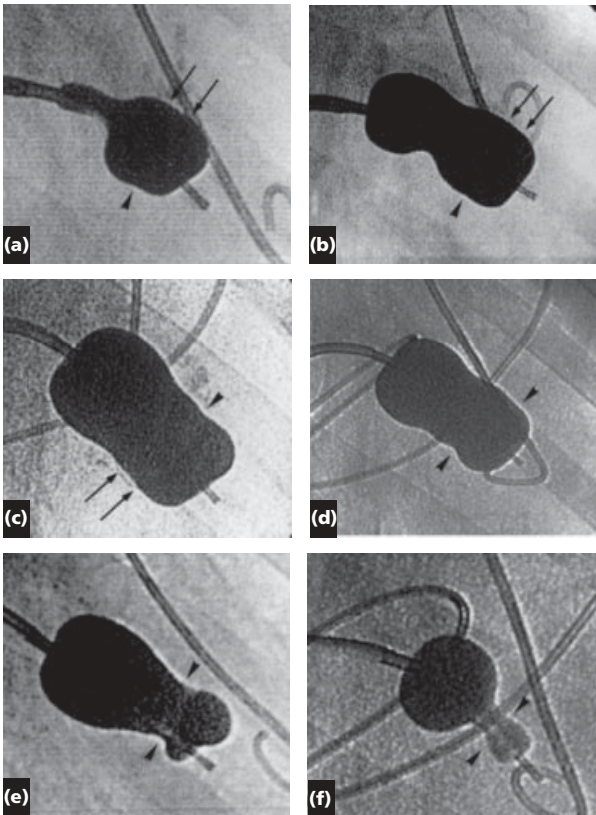


Figure 18.9 Various deformities of inflated balloon caused by severe subvalvular disease: (a–e) Indentation (arrowheads) and compression (arrows) are observed on the distal balloon segment. (f) During *in situ* test inflation of balloon at the mitral valve, the proximal but not the distal segment is inflated as the latter is compressed (arrowheads) by severe subvalvular disease (see text for discussion). (Reproduced from Lau and Hung [25] with permission.)

“Balloon impasse” (Figure 18.9f) In cases of tight mitral stenosis, valve crossing may be difficult even when the catheter, with its distal balloon partially inflated, is properly aligned with the long axis of the left ventricle. If this occurs, the balloon size is gradually reduced until it is accommodated by the mitral orifice. In rare and extreme instances, even when the balloon is not inflated, the catheter is checked (or entrapped) at the mitral valve. This finding, which we have termed “balloon impasse,” reflects resistance caused by severe obstructive subvalvular lesions [25]. In the presence of this sign, BMV performed with the usual catheter selection and balloon sizing is likely to tear the mitral leaflets and/or chordae, and thus create severe mitral regurgitation. Our experience in a limited number of patients suggests that, in addition to stepwise dilations previously emphasized, the use of smaller balloon catheters may prevent the complication of severe mitral regurgitation [25].

Cogwheel resistance Rarely, while withdrawing the partially inflated balloon to anchor it at the mitral valve, cogwheel resistance may be encountered. This suggests the presence of subvalvular disease.

CONTROLLED STEPWISE DILATIONS

In order to avoid or minimize the complication of severe mitral regurgitation, the selection of an appropriate balloon catheter (discussed above) and the controlled stepwise dilation technique are mandatory. In addition, one should be familiar with the pressure–volume relationship and inflation limit of the less compliant balloon of the second-generation catheter now in use [24].

Balloon Pressure–Volume Relationship

The intra-balloon pressure transits from the “low-pressure” to the “high-pressure” zone as the balloon is inflated to within 2 mm of its nominal size, e.g. the 24- to 26-mm zone in a 26-mm balloon catheter. Each catheter can be safely inflated to a maximal diameter of 1 mm above the nominal size because of the built-in safety margin. Initial balloon inflation should never be performed with a balloon diameter in the high-pressure zone regardless of the valvular morphology.

Balloon Sizing

Balloon sizing for the stepwise dilatation technique is crucial in avoiding the complication of severe mitral regurgitation (Table 18.2). Our balloon-sizing methods have evolved through our continuing efforts to minimize this complication. By adhering to the cautionary methods outlined below, especially in patients with severe subvalvular disease, creation of significant mitral regurgitation (increase of $\geq 2+$ angiographically) can be minimized [4].

Technical Tips

****Balloon sizing in patients with pliable, non-calcified valves** In patients with pliable, non-calcified valves and no severe subvalvular lesions, as determined by the subvalvular

Table 18.2 Balloon-sizing based on patient height and valvular status

Balloon sizing		
Valvular status	Initial	Increments
Pliable	(RS – 2) mm	1 mm, or 0.5 mm in high-pressure zone ^a (if MR or unilateral commissural split)
Calcified/SL	(RS – 4) mm	1 mm (low-pressure zone ^b) 0.5 mm (high-pressure zone ^a)

MR, mitral regurgitation, pre-existing or increased; RS matched, catheter with its nominal balloon size \geq RS; SL, severe subvalvular lesions.

^aHigh-pressure zone = balloon diameter within 2 mm of nominal balloon size.

^bLow-pressure zone = balloon diameter $<$ 2 mm of nominal balloon size.

reassessment outlined above, an RS-matched balloon catheter is selected as stated previously. The initial inflated balloon diameter is RS – 2 mm. In subsequent dilations, the balloon size is increased by 1 mm. When there is pre-existing mitral regurgitation or any question of increase in the degree of mitral regurgitation, the increment should be 0.5 mm in the high-pressure zone. This approach also applies when unilateral commissural splitting occurs during the previous dilation, as observed by an asymmetric balloon waist on fluoroscopy. The final diameter is best kept within 1 mm above the RS to avoid oversizing: a previous study [14] showed that oversizing of the balloon is a risk factor for creating severe mitral regurgitation in this group of patients.

****Balloon sizing in patients with calcified valves and/or severe subvalvular disease** In patients with either fluoroscopically visible valvular calcification or severe subvalvular lesions, as observed by transthoracic echocardiography, rather than an RS-match, a balloon catheter one size smaller than the RS-match is selected at the outset. For those whose subvalvular lesions are not detected by pre-procedural echocardiography, the RS-matched catheter already placed in the patient may still be used if the dilation procedures are carried out with extra care. Ideally, the catheter should be exchanged for a smaller one, but this is quite costly.

For the first dilation, a balloon diameter 4 mm less than the RS is used. For subsequent dilations, the balloon size is increased by 1 mm in the low-pressure zone and by 0.5 mm in the high-pressure zone until satisfactory results are obtained or mitral regurgitation develops. In cases where the gradient has already been reduced to half and several more dilation attempts have failed to reduce it further, the procedure is terminated to avoid creating severe mitral regurgitation [24]. Reducing the mitral valve gradient by half should result in a 41% increase in the mitral valve area, as calculated by the Gorlin formula, provided that the heart rate and cardiac output remain the same. A previous study [24]

suggests that a 40% improvement in the valve area is sufficient for symptomatic improvements in patients with a more sedentary lifestyle.

****Balloon sizing in cases of “balloon impasse”** If balloon impasse (see Figure 18.9f) is encountered, the initial catheter is exchanged for a smaller PTMC-18 or -20 catheter to predilate the valve and the subvalvular structures, regardless of the echocardiographic findings of the mitral valve [25]. We no longer force the usual-sized balloon through the valve to the left ventricle by slenderizing and stretching the deflated balloon segment, as previously recommended [2]; nor do we recommend advancing the balloon across the mitral valve over a guidewire pre-placed in the left ventricle. Both maneuvers may cause the catheter to stray among the chordae and, with larger-sized balloon catheters, it is difficult or impossible for the operator to execute the precautionary “accordion” maneuver to ensure that the catheter is not tethered among the chordae.

However, if a smaller PTMC-18 or -20 catheter also fails to cross the mitral valve with the catheter uninflated, the balloon segment of this small balloon catheter is slenderized and stretched for crossing the mitral valve. Before the balloon inflation procedure, it is mandatory to exercise the “accordion” maneuver with the distal balloon slightly inflated to ensure that the balloon catheter is free in the left ventricle. This maneuver would not have been possible with larger-sized catheters. The initial inflation is then performed with the balloon diameter at its nominal size. If further dilations are required, the catheter is exchanged for one size larger, and stepwise dilations are done according to the sizing method in patients with severe subvalvular lesions, as discussed above.

Exchange for Different-sized Balloon Catheters

Exchange of balloon catheters is carried out for two reasons. The first, as alluded to above, is to downsize the catheter because of the “impasse” posed by severe subvalvular distortions.

The second reason occurs in the rare instance when there is a need to upsize the balloon catheter to one that is one size larger because of inadequate hemodynamic improvement. In such a situation, before exchanging for a larger catheter, it is vital that the initial catheter’s final balloon diameter be re-measured and re-verified after its complete removal from the patient, particularly when it has been inflated beyond its nominal size. This precautionary exercise is essential because, not uncommonly, despite pre-testing, the balloon size is smaller than what it is supposed to be after *in vivo* usage. When this occurs, the original balloon catheter is retested to determine the actual volume of diluted contrast in the syringe necessary to achieve maximum balloon size (as mentioned above, the Inoue balloon tolerates about 1 mm in excess of its nominal size before rupturing), the original balloon catheter is reintroduced into the patient, and the dilation process is repeated. However, if the balloon matches its predefined size, an exchange for a larger-sized catheter is made and dilations with the larger balloon are performed. Failure to re-verify maximum

balloon size before inflating a much larger balloon creates the risk of severe mitral regurgitation.

Technical Tips

****Balloon “popping” to the left atrium** When the mitral valve has already been enlarged by dilations, the balloon may occasionally slip into the left atrium during subsequent inflations with larger balloon diameters. To prevent the latter from occurring, the stylet is advanced far into the balloon segment to stiffen the catheter and, before the catheter is retracted to anchor the balloon at the orifice, the distal balloon is inflated to a diameter slightly larger than the previous one. As soon as the balloon assumes an hour-glass configuration, the catheter is advanced slightly to prevent it from jerking out into the left atrium, and full balloon expansion is then executed. With this extra dilation, although the mitral gradient may be unchanged, further shortening of the A_2 -opening snap interval and enhanced splitting of the commissures, as assessed by echocardiography, are often observed.

The balloon “popping” signals enlargement of the mitral orifice with wide splitting of the commissures. It is usually encountered in patients with pliable, non-calcified valves, and foretells excellent BMV results. However, suboptimal hemodynamic results are occasionally observed despite the balloon “popping” sign, especially in the presence of atrial fibrillation. In these cases, although the mitral valve with split commissures can be forced to accommodate the fully inflated balloon, the effective mitral valve area is, in reality, limited by the thickened and stiff leaflets, and by ineffective atrial contractions in the beating heart.

****Subsequent valve crossings and dilations** After the initial balloon inflation procedure, the catheter balloon is then withdrawn to the left atrium, while keeping the catheter tip to the left of the pigtail catheter (see Figure 18.6e). The effects of the balloon dilation are assessed by observing the left atrial pressure waveforms and measuring the transmitral gradient, and also by auscultation. If mitral regurgitation is suspected by the advent of a large v-wave and a new or worsening systolic murmur, echocardiography or left ventriculography may be performed. In subsequent crossings of the mitral valve with the stepwise dilation technique, the stylet is inserted to the catheter tip and the catheter is advanced to deep seat the balloon (see Figure 18.6f). Thereafter, the above manipulations are repeated to cross the mitral valve for valve dilations.

****Catheter entrapment at atrial septum** When the septal puncture site is thick and tough, the catheter may be entrapped by the septum, thereby making manipulations difficult during subsequent attempts at crossing the mitral valve. The operator should be alert to the possibility of this entrapment when marked resistance is encountered at the septum during septal puncture. This vexing problem usually does not occur during the first crossing of the valve because, as alluded to earlier, the catheter is

already deeply placed and coiled in the left atrium. However, entrapment may occur during subsequent crossings, when it becomes necessary to advance the catheter, which has been inadvertently withdrawn too far back into the atrium after valvular dilation and caught at the thick septum. If the catheter cannot be advanced with the stylet inserted all the way to the catheter tip, a clockwise twist is applied to the stylet, directing the catheter tip posterolaterally to align it more or less perpendicular to the septal plane. The catheter may then be advanced forward together with the stylet (Figure 18.10c,d). If even this approach fails, the coiled-tip guide wire should be reinserted to facilitate deep placement of the catheter in the left atrium.

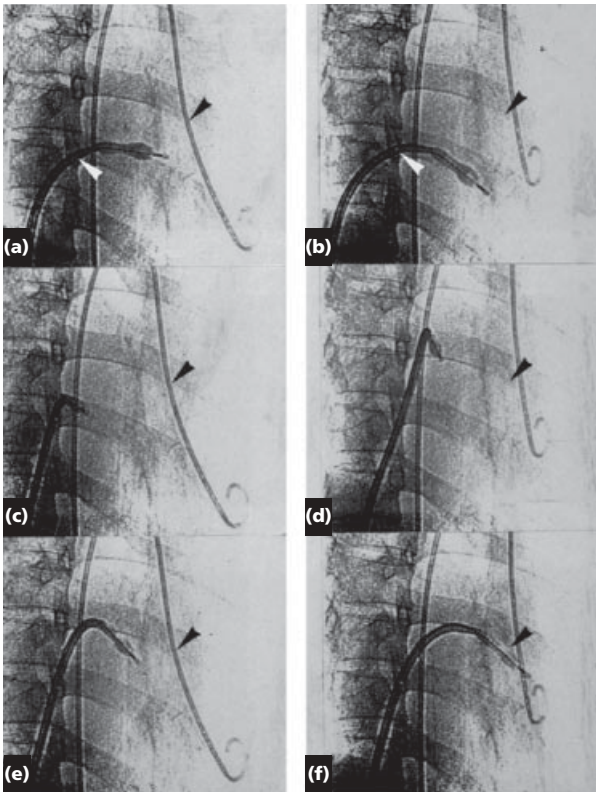


Figure 18.10 Sequence of steps to disengage a catheter entrapped in a thick septum: (a) Balloon catheter with stylet inserted to the tip is entrapped at the atrial septum (white arrowhead). (b) When the catheter is pushed, it does not advance forward, but rather turns downward. (c) Slight clockwise twist is made to the stylet to direct the catheter tip posteriorly. (d) The catheter, now aligned more or less perpendicular to the septal plane, can be effectively advanced farther into the left atrium. (e) Counterclockwise twist is now made to the stylet to direct the catheter tip anteriorly. (f) The catheter is carefully withdrawn to bring its tip toward the mitral orifice (black arrowhead).

****Avoiding the left atrial appendage** Left atrial appendage thrombus may be unsuspected when BMV candidates are screened with only insensitive transthoracic echocardiography. To minimize the risk of inadvertent thrombus dislodgement and systemic embolism, the anterolateral appendage region must be avoided. During balloon catheter manipulation performed under 30° RAO fluoroscopic view, the catheter tip should always be kept to the left of the pigtail catheter pre-placed in the left ventricle (see Figure 18.6). After the precautions detailed below have become rote, it may be possible to perform BMV safely even in the presence of left atrial appendage thrombi [36,37].

The alternatives are either to subject patients with appendage thrombi to mitral valve surgery, or to defer BMV for stable patients until resolution of the thrombi after warfarin treatment [37].

****Withdrawing the catheter from the ventricle** After each balloon inflation procedure, in order to exert better control over the catheter tip and prevent it from encroaching on the left atrial appendage, the stylet is advanced halfway into the balloon segment, and a slight clockwise twist to the stylet is applied as the catheter is withdrawn back to the left atrium. The balloon catheter, with its tip thus directed posteriorly, can then be safely pulled to the atrium by cautiously withdrawing the catheter and the stylet in steps. The catheter, however, should not be withdrawn too far during the process (see “Catheter entrapment at atrial septum” above). The stylet is then removed entirely from the catheter for left atrial pressure measurement, leaving the deflated balloon segment pointing vertically. Again, during hemodynamic measurements, care should be exercised to avoid accidentally pushing the catheter forward into the appendage.

****Subsequent crossings** The catheter, after having been withdrawn from the left ventricle, stands fairly straight up without looping. Thus, for the next crossings of the mitral valve, extra care is needed to keep the catheter to the left of the pigtail catheter. The stylet is carefully inserted to the catheter tip to bend the catheter downwards into a generous arch with the distal catheter segment oriented more vertically (see Figure 18.6f). Then a counterclockwise twist to the stylet is made, and the catheter is slowly withdrawn to direct the partially inflated balloon toward the mitral valve.

****Avoid entry into the left atrial appendage** It should be noted that the catheter has a propensity to enter the left atrial appendage if the catheter tip is more horizontally oriented, and the stylet is pulled back too vigorously during a failed crossing attempt. To avoid this, the stylet should not be withdrawn too much during any manipulation in the left atrium, particularly when the sliding or posterior loop method is used.

****Minimizing atrial septal injury** Inherent in the antegrade BMV approach is the creation of an atrial septal defect. Fortunately, most of these defects are small and of no clinical consequence and they tend to close spontaneously with time.

To minimize the occurrence of these defects and avoid septal avulsion, a number of precautionary steps should be adopted. First, before full balloon inflation, i.e. after the balloon has attained its hour-glass configuration and is securely anchored at the mitral valve, the distal segment of the catheter shaft (between the septal puncture site and the balloon) should be allowed to take on a gentle curve by releasing the tension exerted on the balloon catheter during its placement across the mitral valve. Second, it is mandatory to adhere to the standard practice of balloon slenderization during balloon passage across the septum (on both entry into and withdrawal from the left atrium). Third, before removing the stretched balloon catheter from the left atrium to the right atrium, the guidewire should be withdrawn, leaving only its soft distal floppy segment exposed. This may avoid "slicing" the septum by the stiff portion of the wire during withdrawal of the catheter/wire assembly.

****Bent balloon tip** Kinking of the stretched balloon occurs during placement of the catheter in the left atrium if the guidewire is withdrawn before releasing the inner tube from its locked position. The balloon segment, unsupported by either the metal tube or the guidewire, may also be inadvertently bent by advancing the inner tube alone. Once the tip is bent, subsequent attempts at crossing the mitral valve with the catheter may be extremely difficult, if not impossible. In addition, it may be impossible to reinsert the guide wire to retrieve the balloon catheter from the left atrium. This problem may be overcome by (1) pulling the inner tube to its limit to shorten the balloon segment, (2) carefully inflating the entire balloon in the left atrium to sufficiently straighten the kinked inner tube, and (3) passing the guidewire through the deflated balloon to re-establish its natural shape (Figure 18.11).

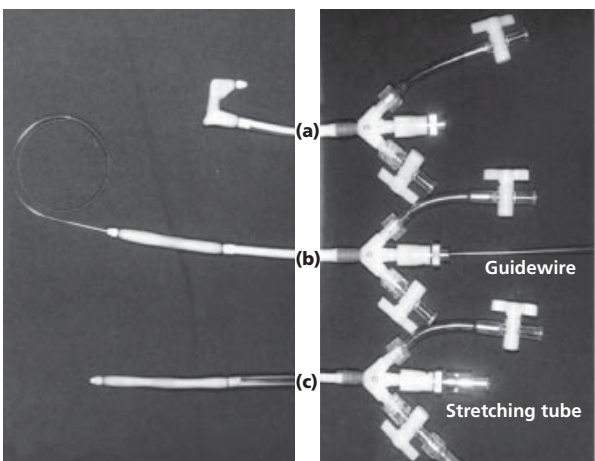


Figure 18.11 Kinked balloon: (a) Kinking of unsupported balloon segment occurs when inner tube is pushed to stretch the catheter balloon. (b) Balloon segment is supported by guide wire. (c) Balloon segment is supported by stretching tube.

INDICATIONS

The selection of patients for a BMV procedure is a complex decision involving consideration of multiple variables, including clinical profile, valve morphology, and operator skill.

The BMV procedure is best applied to patients with symptomatic moderate-to-severe mitral stenosis (mitral valve area $<1.5\text{cm}^2$) and favorable mitral valve morphology (pliable, non-calcified valve without significant subvalvular disease). In this subset of patients, BMV predictably yields excellent results and a low risk of resultant severe mitral regurgitation. BMV can be performed in asymptomatic patients with the favorable valve anatomy before non-cardiac surgery or planned pregnancy.

Inoue BMV is technically less demanding and clearly simpler to perform than the double-balloon approach, thereby engendering a shorter procedural and irradiation time [38]. This advantage is vital in pregnant patients for whom the hazards of irradiation to the fetus are of paramount importance, and for patients with pulmonary edema in whom swift and expeditious BMV is clearly desirable [32]. However, to minimize the hazards of fetal irradiation, it should be performed after the mid-second trimester, with adequate total abdominal and pelvic shielding, minimal use of fluoroscopy (by omitting diagnostic right heart catheterization and left ventriculography), and only by interventional cardiologists skilled in the transeptal and valvuloplasty techniques.

The utility of BMV in patients with adverse valve morphology (calcified mitral valves and/or with severe subvalvular disease) is unclear and controversial [38]. Most operators contend that these types of patients are better served with surgery which often means mitral valve replacement. Because BMV in this setting is associated with an increased risk of complications and inferior long-term results [14,39,40]. In patients who pose a prohibitively high risk for valve surgery, BMV may be a better option than surgery, and may occasionally be the only therapeutic modality available for some of them. On the other hand, some experienced operators [41,42] advocate more liberal use of the procedure because of a low risk of major complications, in particular resultant severe mitral regurgitation, and the procedure continues to offer sustained functional benefits in a substantial number of patients. Notwithstanding this, it cannot be overemphasized that BMV in these patients can be technically demanding, and does require a higher level of technical skill and extra caution in executing the procedure.

Technical Tip

*****Double-orifice mitral stenosis (incomplete bridge-type) (Figure 18.12)** Double-orifice mitral valve (DOMV) is a rare congenital anomaly characterized by the presence of two mitral orifices, each possessing an independent chordal attachment of a papillary muscle [43,44]. DOMV may occur as an isolated anomaly or, more often, in association with other congenital anomalies such as endocardial cushion defect, bicuspid aortic valve and coarctation of the aorta [44,45].

Echocardiographically, DOMV is classified into three types: Complete bridge, incomplete bridge, and hole type [46]. The complete bridge type is characterized by the presence of a fibrous tissue visible from the leaflet edge through the valve ring. In the incomplete form, however, the fibrous connection occurs only at the leaflet edge (Figure 18.12). In the hole type, the secondary orifice with its subvalvular apparatus occurs in the lateral commissure and is visible only at the mid-leaflet level.

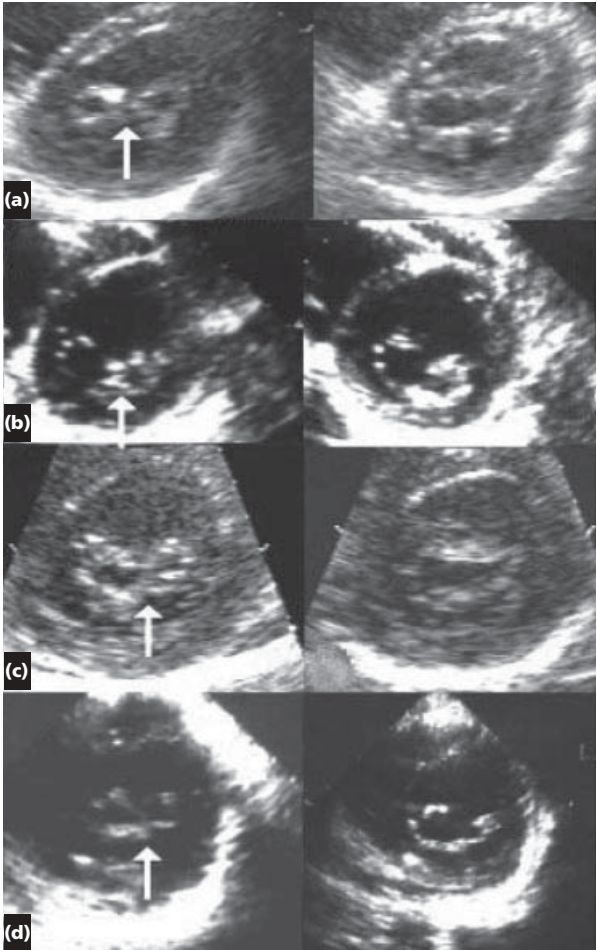


Figure 18.12 Transthoracic two-dimensional echocardiograms of mitral valves before (a–d) and after (e–g) balloon mitral valvuloplasty in eight cases. In each case, two stenotic orifices are separated by a fibrous bridge tissue (arrow in a–d). Balloon splitting of the fibrous septation results in a single, enlarged mitral orifice (e–g). (Reproduced from Lo et al. [48], with permission from Journal of Invasive Cardiology.)

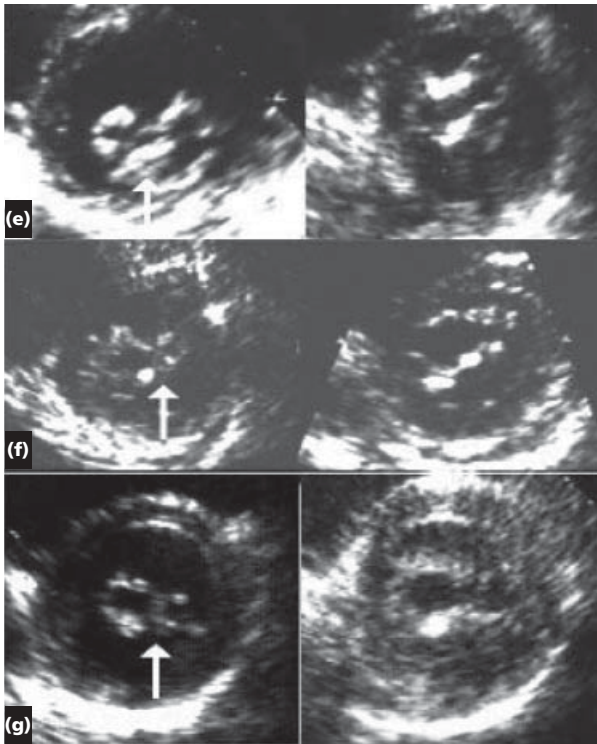


Figure 18.11 (Continued)

The isolated form of DOMV is more frequently observed in the bridge type. We have encountered 14 moderately symptomatic, middle-aged patients with stenotic DOMV of incomplete bridge-type. Their clinical presentations and physical findings were indistinguishable from those in rheumatic mitral stenosis. However, vigilance acquired from experience in the first case contributed to expeditious echocardiographic identification of the incomplete bridge-type DOMV in subsequent patients. All 14 patients successfully underwent Inoue BMV performed in the usual manner [47,48].

CONTRAINDICATIONS

There are two absolute contraindications in BMV: (1) Severe (\geq grade 3+) angiographic mitral regurgitation, and (2) the presence of left atrial cavity thrombus.

*****Stenoses Mitral Bioprosthetic Valve** In addition, we caution against the use of BMV in patients with stenotic mitral bioprosthesis given the hazards (resultant post-procedural severe mitral regurgitation from ruptured bioprosthetic leaflets and risk of embolism of friable leaflet debris) of BMV in such a scenario [49].

The treatment for patients with \geq grade 3+ mitral regurgitation is clearly that of mitral valve replacement. Patients with left atrial thrombus are subjected to open mitral commissurotomy or valve replacement, depending on the mitral valve status. Those patients with mobile thrombi in the left atrium are at a high risk of systemic embolism, and require urgent mitral valve surgery.

However, one may elect to administer long-term (3–12 months) warfarin therapy in patients with non-mobile thrombi in the left atrial cavity, if their clinical and hemodynamic status does not warrant immediate surgery, and the mitral valves are deemed suitable for BMV. Transesophageal echocardiography is deferred until thrombi resolution is observed by transthoracic echocardiography performed at 3-monthly intervals [37]. When transesophageal echocardiography confirms the absence of left atrial cavity thrombus, BMV can then be performed safely [23,36,37,50]. Based on our experience of 129 consecutive cases of Inoue BMV performed in the presence of left atrial appendage thrombus (without protrusion into the left atrial cavity), no thromboembolic complication was encountered. Hence, in our center, the presence of thrombi confined to the left atrial appendage are not a contraindication. BMV can be performed in this setting when executed with extra care using the Inoue balloon technique [23,36].

Patients with lytic-resistant thrombi after 12 months of warfarin treatment should be considered for open surgical commissurotomy with direct visual clot removal.

REFERENCES

1. Inoue K, Owaki T, Nakamura T, et al. Clinical application of transvenous mitral commissurotomy by a new balloon catheter. *J Thorac Cardiovasc Surg* 1984;**87**:394–402.
2. Inoue K, Hung JS. In: Percutaneous transvenous mitral commissurotomy: the Far East experience. In: Topol EJ (ed.), *Textbook of Interventional Cardiology*. Philadelphia: WB Saunders, 1990: 887–99.
3. Inoue K, Hung JS, Chen CR, et al. Mitral stenosis: Inoue balloon catheter technique. In: Cheng TO (ed.), *Percutaneous Balloon Valvuloplasty*. New York: Igaku-Shoin Medical Publishers, Inc., 1992: 237–79.
4. Hung JS, Lau KW, Lo PH, et al. Complications of Inoue-balloon mitral commissurotomy: Impact of operator experience and evolving technique. *Am Heart J* 1999;**138**:114–21.
5. Arora R, Kalra GS, Murty GSR, et al. Percutaneous transatrial mitral commissurotomy: Immediate and intermediate results. *J Am Coll Cardiol* 1994;**23**:1327–32.
6. Ruiz EC, Zhang HP, Macaya C, et al. Comparison of Inoue single-balloon versus double-balloon technique for percutaneous mitral valvotomy. *Am Heart J* 1992;**123**: 942–7.
7. lung B, Cormier B, Ducimetiere P, et al. Immediate results of percutaneous mitral commissurotomy. *Circulation* 1996;**94**:2124–30.
8. A report from the National Heart, Lung, and Blood Institute Balloon Valvuloplasty Registry. Complications and mortality of percutaneous balloon mitral commissurotomy. *Circulation* 1992;**85**:2014–24.
9. Turi ZG, Reyes VP, Raju S. Percutaneous balloon versus closed commissurotomy for mitral stenosis. A prospective, randomized trial. *Circulation* 1991;**83**:1179–85.
10. Patel JJ, Shama D, Mitha AS, et al. Balloon valvuloplasty versus closed commissurotomy for pliable mitral stenosis: A prospective hemodynamic study. *J Am Coll Cardiol* 1991;**125**:1318–22.

11. Arora R, Nair M, Kalra GS, et al. Immediate and long-term results of balloon and surgical closed mitral valvotomy: A randomized comparative study. *Am Heart J* 1993;**125**:1091–4.
12. Reyes VP, Raju BS, Wynne J. Percutaneous balloon valvuloplasty compared with open surgical commissurotomy for mitral stenosis. *N Engl J Med* 1994;**331**:961–7.
13. Farhat MB, Ayari M, Maatouk F, et al. Percutaneous balloon versus surgical closed and open mitral commissurotomy. Seven-year follow-up results of a randomized trial. *Circulation* 1998;**97**:245–50.
14. Hung JS, Chern MS, Wu JJ, et al. Short- and long-term results of catheter balloon percutaneous transvenous mitral commissurotomy. *Am J Cardiol* 1991;**67**:854–62.
15. Pan M, Medina A, de Lezo JS, et al. Factors determining late success after mitral balloon valvulotomy. *Am J Cardiol* 1993;**71**:1181–5.
16. lung B, Cormier B, Ducimetiere P, et al. Functional results 5 years after successful percutaneous mitral commissurotomy in a series of 528 patients and analysis of predictive factors. *J Am Coll Cardiol* 1996;**27**:407–14.
17. Dean LS, Mickel M, Bonan R, et al. Four-year follow-up of patients undergoing percutaneous balloon mitral commissurotomy. *J Am Coll Cardiol* 1996;**28**:1452–7.
18. Meneveau N, Schiele F, Seronde MF. Predictors of event-free survival after percutaneous mitral commissurotomy. *Heart* 1988;**4**:359–64.
19. Hernandez R, Banuelos C, Alfonso F, et al. Long-term clinical and echocardiographic follow-up after percutaneous mitral valvuloplasty with the Inoue balloon. *Circulation* 1999;**99**:1580–6.
20. Lock JE, Khalilullah M, Shrivastava S, et al. Percutaneous catheter commissurotomy in rheumatic mitral stenosis. *N Engl J Med* 1985;**313**:1515–18.
21. Al Zaibag M, Ribeiro PA, Al Kasab S, et al. Percutaneous double-balloon mitral valvotomy for rheumatic mitral valve stenosis. *Lancet* 1986;**i**:757–61.
22. Stefanadis C, Toutouzas P. Retrograde nontransseptal mitral valvuloplasty. In: Topol EJ (ed.), *Textbook of Interventional Cardiology*, 2nd edn. Philadelphia, PA: WB Saunders, 1994: 1253–67.
23. Hung JS, Lau KW. Pitfalls and tips in Inoue-balloon mitral commissurotomy. *Catheter Cardiovasc Diagn* 1996;**37**:188–99.
24. Lau KW, Hung JS. A simple balloon-sizing method in Inoue-balloon percutaneous transvenous mitral commissurotomy. *Catheter Cardiovasc Diagn* 1994;**33**:120–9.
25. Lau KW, Hung JS. “Balloon impasse”: A marker for severe mitral subvalvular disease and a predictor of mitral regurgitation in Inoue balloon percutaneous transvenous mitral commissurotomy. *Catheter Cardiovasc Diagn* 1995;**35**:310–19.
26. Josef G, Kurtukulam SV, Baruah DK, Chandy ST, Krishnaswami S. Transjugular approach to transseptal balloon mitral valvuloplasty. *Catheter Cardiovasc Diagn* 1997;**42**:227–8.
27. Patel TM, Dani SI, Rawal JR, Shah SC, Patel TK. Percutaneous transvenous mitral commissurotomy using Inoue balloon catheter: a left femoral vein approach. *Catheter Cardiovasc Diagn* 1995;**36**:186–7.
28. Vyas C, Shah S, Patel T. Percutaneous transvenous commissurotomy via left femoral vein approach – exploring an unusual approach for left atrial entry. *J Invasive Cardiol* 2011;**23**:E145–6.
29. Goldstein SA, Campbell A, Mintz GS, et al. Feasibility of on-line transesophageal echocardiography during balloon mitral valvulotomy: Experience with 93 patients. *J Heart Valve Dis* 1994;**3**:136–48.
30. Hung JS, Fu M, Yeh KH, Chua S, Wu JJ, Chen YC. Usefulness of intracardiac echocardiography in transseptal puncture during percutaneous transvenous mitral commissurotomy. *Am J Cardiol* 1993;**72**:853–4.

31. Hung JS. Atrial septal puncture technique in percutaneous transvenous mitral commissurotomy: Mitral valvuloplasty using the Inoue balloon catheter technique. *Catheter Cardiovasc Diagn* 1992;**26**:275–84.
32. Wu JJ, Chern MS, Yeh KH, et al. Urgent/emergent percutaneous transvenous mitral commissurotomy. *Catheter Cardiovasc Diagn* 1994;**31**: 18–22.
33. Ramasamy D, Zambahari R, Fu M, Yeh KH, Hung JS. Percutaneous transvenous mitral commissurotomy in patients with severe kyphoscoliosis. *Catheter Cardiovasc Diagn* 1993;**30**:40–4.
34. Hung JS, Lau KW. Vertical approach: A modified method in balloon crossing of mitral valve in Inoue balloon mitral valvuloplasty. *J Invasive Cardiol* 1998;**10**:548–50.
35. Hernandez R, Macaya C, Banuelos C, et al. Predictors, mechanisms and outcome of severe mitral regurgitation complicating percutaneous mitral valvotomy with the Inoue balloon. *Am J Cardiol* 1992;**70**:1169–74.
36. Yeh KH, Hung JS, Wu JJ, et al. Safety of Inoue balloon mitral commissurotomy in patients with left atrial appendage thrombi. *Am J Cardiol* 1995;**75**:302–4.
37. Hung JS. Mitral stenosis with left atrial thrombi: Inoue balloon catheter technique. In: Cheng TO (ed.), *Percutaneous Balloon Valvuloplasty*. New York: Igaku-Shoin Medical Publishers, Inc., 1992: 280–93.
38. Lau KW, Hung JS, Ding ZP, et al. Controversies in balloon mitral valvuloplasty: The when (timing for intervention), what (choice of valve), and how (selection of technique). *Catheter Cardiovasc Diagn* 1995;**35**: 91–100.
39. Dean LS, Mickel M, Bonan R, et al. Four-year follow-up of patients undergoing percutaneous balloon mitral commissurotomy. *J Am Coll Cardiol* 1996;**28**:1452–7.
40. Yoshida Y, Kubo S, Tamaki S, et al. Percutaneous transvenous mitral commissurotomy for mitral stenosis patients with markedly severe mitral valve deformity: Immediate results and long-term clinical outcome. *Am J Cardiol* 1995;**76**:406–8.
41. Hung JS, Lau KW. Percutaneous transvenous mitral commissurotomy is an acceptable therapeutic alternative in patients with calcified mitral valve. *J Invasive Cardiol* 1999;**11**:362–3.
42. Wahl A, Meier B. Percutaneous mitral balloon valvuloplasty in non-ideal patients: Go for it without expecting too much. *J Invasive Cardiol* 1999;**11**:359–61.
43. Rosenberg J, Roberts WC. Double orifice mitral valve: study of the anomaly in two calves and a summary of the literature in humans. *Arch Pathol* 1968;**86**:77–80.
44. Bano-Rodrigo A, Praagh SV, Trowitzsch E et al. Double orifice mitral valve: A study of 27 postmortem cases with developmental, diagnostic and surgical consideration. *Am J Cardiol* 1988;**61**:152–60.
45. Warnes C, Somerville J. Double mitral valve orifice in atrioventricular defects. *Br Heart J* 1983;**49**:59–64.
46. Trowitzsch E, Bano-Rodrigo A, Burger BM, et al. Two-dimensional echocardiographic findings in double orifice mitral valve. *J Am Coll Cardiol* 1985;**6**:383–7.
47. Kim MH, Cha KS, Kim JS, et al. Successful Inoue-balloon mitral commissurotomy in double-orifice mitral stenosis. *Catheter Cardiovasc Interv* 2000;**49**:200–3.
48. Lo PH, Hung JS, Lau KW, et al. Inoue balloon mitral valvuloplasty in double-orifice mitral stenosis. *J Invasive Cardiol* 2003;**5**:301–3.
49. Lin PJ, Chang JP, Hung JS, et al. Balloon valvuloplasty is contraindicated in stenotic mitral bioprostheses. *Am Heart J* 1994;**127**:724–6.
50. Hung JS, Lin FC, Chiang CW. Successful percutaneous transvenous catheter balloon mitral commissurotomy after warfarin therapy and resolution of left atrial thrombus. *Am J Cardiol* 1989;**64**:126–8.

CHAPTER 19

Retrograde Percutaneous Aortic Valvuloplasty

Ted Feldman, Thach N. Nguyen

Challenges 475

Technical Tips 477

- **Necessity of a temporary pacemaker 477
- **Vascular access 478
- **Preparatory installation of closure device suture 478
- **Local pain management with lidocaine 478
- **Dobutamine for low cardiac output 478

Crossing the Aortic Valve 479

Technical Tips 479

- **Manipulating the catheter 479
- **Wiring 480

Balloon Manipulation 480

Technical Tips 480

- **Balloon inflation 480
- **Balloon preparation 480
- **Set-up for balloon inflation 481
- **Balloon deflation 481

Management of Hypotension 482

Technical Tips 482

- **Differential diagnoses of hypotension 482
- **Hypotension caused by the wire 482

Diagnosis of Cusp Perforation 483

Sheath Removal 484

Post-procedure Management 484

CHALLENGES

Although not commonly performed in many catheterization laboratories, balloon aortic valvuloplasty (BAV) has an important role in the management of patients who do not have an option for surgery with aortic valve replacement.

(Continued)

*Basic; **Advanced; ***Rare, exotic, or investigational

\$, <\$US100.00 extra; \$\$, >\$US100.00 extra

☞, <10 min extra; ☞☞, >10 min extra

◆, low risk of complications; ◆◆, high risk of complications

BAV is a palliative procedure, and can be applied in appropriately selected patients with excellent relief from the symptoms of congestive heart failure associated with aortic valve stenosis. The American College of Cardiology/American Heart Association (ACC/AHA) guidelines [1] recognize BAV treatment for children and young adults with aortic stenosis under the age of 21 years (Tables 19.1 and 19.2) as class 1, and an indication among older patients with multiple comorbid conditions who are precluded from aortic valve replacement surgery as class 2B (Table 19.3). In our own practice, a third of these patients are nonagenarians and half octogenarians. Many have had prior coronary bypass or mitral valve replacement, or comorbid conditions such as chronic lung disease and multiorgan compromise. These patients typically obtain about 1 year of improved symptoms, with diminished need for re-hospitalization for their symptoms [2]. It is clear that no overall survival benefit is conferred by this procedure in studies of groups of patients, although for individual patients it seems likely that some may derive this benefit [3–5].

Table 19.1 Indications for diagnostic and therapeutic procedures

Definition	Class
General agreement procedure is useful/effective	I
Conflict evidence/divergent opinion	II
Weight of evidence/opinion in favor	Ila
Less well-established	Ilb
Evidence/agreement that procedure is not useful/harmful	III

Table 19.2 Balloon valvuloplasty in young adults (<21 years) with aortic stenosis and normal cardiac output

Indication	Class
Angina, syncope, dyspnea on exertion with peak gradient >50 mmHg	I
Catheter peak gradient >60 mmHg	I
New-onset ECG changes at rest or with exercise with gradient >50 mm	I
Gradient >50 mm, patient desires competitive sports or pregnancy	Ila
Catheter gradient >50 mm, no symptoms or ECG changes	III

Table 19.3 Balloon valvuloplasty in adults with aortic stenosis

Indication	Class
Bridge to surgery in hemodynamically unstable, high-risk patients for AVR	IIa
Palliation in patients with serious comorbid conditions	IIb
Before urgent non-cardiac surgery	IIb
Alternative to aortic valve replacement	III

STANDARD TECHNIQUE

The basic technique of retrograde BAV involves passing a catheter via the femoral arterial route retrogradely across the aortic valve, placing a wire in the left ventricular (LV) apex, and then via the femoral sheath passing a balloon into the aortic valve. Numerous special tips and tricks are critical to make this procedure successful.

Technical Tips

****Necessity of a temporary pacemaker** Rapid right ventricular (RV) pacing has been used to diminish LV stroke volume during balloon inflations, making ejection of the balloon by the left ventricle much less of a problem than it has been in the past. Burst pacing at rates of 160–220 beats/min are used just before balloon inflation to produce an aortic blood pressure (BP) of 50–60 mmHg. Pacing is terminated as soon as the balloon reaches peak inflation, at which point the balloon is either withdrawn or ejected from the LV. A coordinated approach among the operator, assistants and catheterization lab staff is needed to utilize this approach. The pre-procedural ECG has great bearing on planning for the procedure. Patients with pre-existing bundle-branch block or interventricular conduction delay (IVCD) should have a temporary pacemaker placed for the procedure, or at the very least have a venous sheath for pacemaker access. Complete heart block occurs infrequently but can be difficult to manage when it does occur in this group of patients. As a right heart catheter is used, and the left ventricle is instrumented significantly by the balloon, both sides of the septum may be abraded, with resultant loss of atrioventricular (AV) conduction. In addition, among patients with pre-existing conduction abnormalities, the displacement of aortic annular calcification by the balloon may impinge on the AV conducting system, with exacerbation of heart block or pre-existing conduction delays. When complete heart block does occur, it usually resolves within 12–24 h, but may be permanent. Infrequently, these patients need permanent pacemakers after the procedure, and we find it useful to warn most patients and families pre-procedure that permanent pacing is an occasional consequence of the effort.

****Vascular access** One of the most critical elements of the BAV procedure is assessment of the femoral artery. Fluoroscopic guidance of the initial puncture is critical, so that the common femoral artery is entered rather than the superficial femoral artery or the profunda femoris. Large sheaths needed for the balloons require the puncture to be above the femoral bifurcation. In between two-thirds and three-quarters of patients, the common femoral artery will be entered if the puncture is made at the level of the mid-femoral head. As the procedure is used principally in elderly patients, the location of the femoral crease is an unreliable landmark to guide the femoral puncture. Heavier patients may have two creases, and many thin elderly patients have lost the battle with gravity, with the crease having moved substantially caudal to the femoral head. Angiographic assessment of the femoral artery after the sheath is placed is also critical. We like to start with a 6-French (Fr) long sheath. If femoral angiography demonstrates too much atherosclerotic disease, a left internal mammary diagnostic catheter can be used to shoot over the top of the iliac bifurcation into the left iliac and femoral system, to see whether they are suitable for the large valvuloplasty sheath. In addition, if the puncture is below the femoral bifurcation, a sheath may be placed above the existing sheath on the right, or the left side might be used with angiographic guidance for the puncture.

****Preparatory installation of closure device suture** Preclosure of the puncture is important at this juncture within the order of the procedure [6,7]. The 6-Fr sheath can be exchanged for a 10-Fr Perclose device and sutures delivered into the artery. The sutures are of course not tied at this point. A wire is reintroduced into the Perclose delivery device, the delivery device backed out of the artery, and a 12- or 14-Fr sheath passed back over the wire. It is especially helpful to use an extra-stiff wire to allow passage of the large arterial sheath. It is our own preference to use a 30-cm-long sheath.

Sometimes this is not possible due to calcification or tortuosity of the iliac vessels, in which case a shorter sheath will suffice.

****Local pain management with lidocaine** The liberal use of lidocaine for local anesthesia is important to make passage of these large sheaths tolerable for the patient. At the same time, in very elderly people, especially among those with a history of prior stroke or seizure disorder, care must be taken not to create lidocaine toxicity. Changes in consciousness during the procedure may represent a variety of complications, but it is important to remember that lidocaine toxicity is among them and that lidocaine levels should be obtained any time that there is a change in consciousness during a valvuloplasty procedure [8].

****Dobutamine for low cardiac output** After right heart catheterization and baseline pressure measurements, special consideration should be given for the cardiac output. Among patients with cardiac output <3 l/min, and certainly <2.5 l/min, it is useful

to use dobutamine support. The decrease in blood pressure associated with balloon inflation may not be tolerated by patients with a low baseline cardiac output. It is our own practice to use a dobutamine infusion to improve cardiac output in those patients with a low baseline pre-procedure, and to reassess valve area after the dobutamine infusion has been started, for a new baseline measure [9].

CROSSING THE AORTIC VALVE

Crossing the aortic valve is an important challenge in this procedure. Our preference is to use a catheter designed specially for this purpose [10]. There are two catheter shapes: The first has an angled design (type B) and the second a curve design (type A). Each is constructed in small (A, B) and medium (A1, B2) curve lengths. The displacement from the shaft to the catheter tip, or the "reaching distance" of the catheter, measures 4, 5, and 6 cm for the small, medium, and large curves, respectively. A movable core straight wire can be used to change the angle of the catheter. When the aortic root is very small in diameter, the catheter can be straightened with the wire and formed into a shape similar to a Judkins right curve. The angled design catheter can reach the center of the aortic root in most patients unless the left ventricle and aortic meet at an extremely acute angle. The curve catheter is designed to reach a more acutely angled LV chamber but is slightly more difficult to maneuver into the left ventricle in some patients [10].

Technical Tips

****Manipulating the catheter** The catheter is selected based on the fluoroscopic appearance of the width of the aortic root. It is inserted into the aortic root with a straight wire and rotated clockwise to direct the tip of the catheter toward the center of the aortic root. A movable core straight wire can be used to change the angle of the catheter, allowing the operator to scan the surface of the aortic valve. Wires with a tapered movable core are not stiff enough for this purpose. The wire is initially made extremely soft by withdrawal of 7.5–10 cm of movable core, which allows the tip to assume its formed curve completely. The catheter tip is positioned over the center of the aortic valve as determined from the appearance of the heavily calcified leaflets on fluoroscopy. The straight wire is passed back and forth until it crosses into the aortic valve. Occasionally, a hand injection above the valve will help define the central area of the commissures. Of course, the wire may cross at some distance away from the commissures, but the central point represents the best chance for success. The catheter is advanced over the wire into the left ventricle and the wire withdrawn. In all patients, a small- or medium-length catheter is selected initially. Based on the direction of the wire, subsequent catheter choices are made. It should be noted that both catheters can be passed into the left ventricle with much greater ease than most coronary artery catheters.

****Wiring** After the left ventricle has been entered and hemodynamic measurements confirm the severity of aortic stenosis [11], a 260-cm-long, 0.038-inch exchange wire must be used to allow exchange or a valvuloplasty balloon. The wire must be as stiff as possible, but with the tip curled to make it less dangerous for LV apical perforation. It is helpful to grasp the wire over the end of a hemostat and “Christmas ribbon” the end into a ram’s horn shape with multiple concentric coils to protect the LV apex from wire trauma or perforations. The stiffest possible wire available is the best wire. It is critical to have a firm rail to allow the balloon to traverse tortuous anatomy in the aorta, and to have the support to keep the balloon in position in the aortic valve during balloon inflations. The assistant helping maintain wire position is as critical to the success of the procedure as the principal operator.

BALLOON MANIPULATION

Once a balloon has been passed into the aortic valve orifice, maintaining its position is challenging. In patients with poor LV function there is less of a tendency for the balloon to be ejected by the ventricle. When LV systolic performance is preserved, the balloon “watermelon seeds” back and forth during inflations.

Technical Tips

****Balloon inflation** It is useful to partially inflate the balloon in the ascending aorta above the valve before trying to engage the valve, so that less inflation is needed to achieve adequate inflation within the valve orifice. If the balloon is fully inflated in the valve orifice and continues to move back and forth, it may be undersized. The balloon “locks” in the valve when it is fully inflated and delivers adequate dilating force to displace the leaflets. If a first balloon is too small, it is often necessary to size up the sheath. A 20-mm-diameter balloon catheter will require a 12- or 13-Fr sheath. It is our practice to use a 12.5-Fr sheath for this purpose. A 23-mm balloon requires a 14-Fr sheath.

****Balloon preparation** Careful preparation of the balloon is necessary, because it is common for the balloon to rupture during inflations in the calcified aortic valve. Great care to remove all the air during the preparation process is essential. Preparation and balloon inflation are easiest if the contrast is diluted as much as possible. A ratio of 7:1 will allow the balloon to be visualized fluoroscopically, but inflated and deflated with the least difficulty. The contrast is ideally an old-fashioned ionic contrast, as these agents are less viscous than low-osmolarity contrast. It is our practice to use a 50-ml bottle of contrast, diluted with an additional 350 ml of saline to a total volume of 400 ml. Many of the basins used on the back table in cardiac catheterization labs are graduated. There is thus no need to use a syringe to top off the total volume, because the graduated basin allows one simply to pour saline into the 400 ml mark after the contrast has been placed in the bowl.

****Set-up for balloon inflation** The set-up for balloon preparation includes a short pressure tube to the inflate lumen, connected to a high-pressure stopcock. A 60-ml syringe is attached to one arm of the stopcock and a 10-ml to the other arm. If the 60-ml syringe is used to inflate the balloon, it is not possible to deliver adequate force to fully inflate the balloon [12]. Once the balloon has been inflated as much as possible with the 60-ml syringe, the stopcock can be switched to allow the 10 ml to finish the inflation, or “boost” the total inflation volume. If this is done on the back table, you will note that the balloon clearly increases in inflation volume when the booster syringe is used to fully inflate it. Thus, in vivo the balloon is passed across the valve and inflated as much as possible with the 60-ml syringe and then the stopcock is flipped and the 10 ml additional inflation used to maximize the balloon diameter. In all cases, BAV was performed using a PTA (percutaneous transluminal angioplast) balloon. BAV is typically performed by catheterizing the femoral artery above the bifurcation and passing a wire into the left ventricle. A balloon is delivered to the aortic valve opening through this wire, where it is inflated.

Typically, the balloon is inflated for 3–4 s and remains in the valve for a total of 5–7 s. With the technique that we used in this series of patients, the standard balloon was replaced with the Atlas PTA dilation balloon because it is made using a strong non-compliant composite material that permits delivery of higher pressure to the area requiring dilation, with rated burst pressures up to 18 atm. Most of the balloons traditionally used for BAV have a low-rated burst pressure (3–4 atm), which may be problematic in treating densely calcified, non-compliant valves. Furthermore, balloon rupture is not uncommon, e.g. in one large series, balloon ruptured occurred in 111 of 672 BAV cases (16.5%). The Atlas balloon is polyethylene terephthalate based and wrapped with a thin, strong matrix that allows attainment of high pressures. The matrix wrap also eliminated problems with “watermelon seeding” slippage. The Atlas 16 × 40 was utilized for small stature patients (body mass index [BMI] ≤24). For patients with a BMI >24, the balloon choice was arbitrarily based on the echocardiographic appearance of the annulus. Atlas balloons have a smaller profile than the standard BAV balloons, necessitating a smaller arterial access sheath and hopefully resulting in reduced risk for bleeding complications. Furthermore, the ability of these balloons to withstand high pressure was considered desirable to facilitate valve dilation. Balloons were inflated with ultradilute saline/contrast using power injection balloon inflation, allowing the balloon to inflate within 1 second and deflate immediately after delivering high pressure to the aortic valve. Consequently, the balloon would only remain in the valve space for 2–3 s, hopefully reducing the risk for complications due to valvular blockade [13].

****Balloon deflation** The strategy of balloon deflation is as important as the inflation. Once the balloon is fully inflated in the valve there is a precipitous decrease in systemic blood pressure, and usually significant ventricular ectopy. Rather than waiting for

the balloon to deflate to withdraw it from the valve, it can be pulled back from the valve orifice into the aortic root while it is still inflated, or just as the process of deflation starts. This allows a restoration of antegrade blood flow before balloon deflation is even initiated. It would be easier for patients to tolerate this very brief effective cross-clamping of the aorta than if the entire inflate–deflate cycle were performed within the valve orifice. When the balloon is withdrawn into the aortic root it is possible for the arch vessels to be obstructed, so care must be taken to avoid covering the carotid origins.

MANAGEMENT OF HYPOTENSION

The management of hypotension during the procedure is one of the greater challenges [14,15]. The BP inevitably falls during balloon inflations. In most cases there is a steady recovery of systolic pressure immediately after balloon deflation, and when the valve is successfully opened there is a rebound or increase in aortic peak systolic pressure above the baseline. Pressure can be monitored via the sidearm of the 12-Fr sheath. If the pressure does not recover rapidly after balloon inflation, it is unwise to proceed with further inflations. This represents LV depression that may require support with pressors, sometimes for as long as a day or two.

Technical Tips

****Differential diagnoses of hypotension** Other causes of hypotension must be considered. As the arterial sheath is large, femoral hematoma, retroperitoneal bleeding, or even venous bleeding from the venous access site must be considered. Patients with significant anemia before the procedure should be considered for transfusion so that they have a “full tank” before the procedure starts. If they are borderline, or there is some relative contraindication to transfusion consider obtaining a type and screen or type and crossmatch so that blood will be readily available if needed. Vagal reactions from insertion of the large sheath may occur although they are rare. This should be considered only after bleeding has been carefully evaluated and excluded. During the balloon inflations, the wire is forced into the LV apex, and the tip of the balloon may also impact on the apex with considerable force. Ventricular perforation is another important consideration for hypotension. Echocardiography should be used liberally in the catheterization lab to exclude this possibility when hypotension is persistent. In the worst cases, the aortic annulus may be ruptured, or a valve leaflet avulsed with catastrophic results. Hypotension associated with these latter complications is usually fatal, and cannot be reversed.

****Hypotension caused by the wire** In some cases, the ventricular ectopy produced by the wire in the ventricle for a prolonged period of time is not tolerated, and is another source of hypotension. Reshaping the wire, or repositioning the wire may give some relief from persistent ventricular ectopy. In some cases

the procedure cannot be performed due to ectopy. We have encountered a patient who had ventricular fibrillation requiring DC countershock each time the wire was introduced into the left ventricle. After two attempts it became clear that it was not feasible to perform aortic valvuloplasty for this patient. The possibility of cusp perforation (CP) should be kept in mind in all cases of distorted and difficult valve anatomy as described above. The use of a straight-tip hydrophilic wire to cross a stenotic valve is more likely to result in CP, particularly when sharp stabbing passes are made to cross the orifice. The risk of the wire tracking into coronary ostia and causing a dissection is also greater with a hydrophilic wire. In our experience, it is possible to cross severely stenosed, eccentric and calcified aortic orifices with a soft, steerable wire (e.g. 0.035 Cordis) very rapidly in all cases without the risk of a CP. We suggest the use of a soft-tip, non-hydrophilic steerable guidewire with gentle passes across the valve while probing the plane of the orifice.

Diagnosis of Cusp Perforation

There are important findings and signs at each step of the procedure that should alert the operator to the possibility of CP.

After initial crossing, one should suspect a CP if more than normal resistance is encountered in delivering and maneuvering the diagnostic Amplatz or pigtail catheter inside the left ventricle. The operator should abstain from using a smaller caliber catheter to cross into the left ventricle because it will only increase the dimension of the perforation. If a 6- to 7-Fr diagnostic catheter is not able to cross into the left ventricle with the usual maneuvers, a CP should be ruled out promptly. An abnormal course of the diagnostic catheter and an excessive acute angle of the catheter in the section between the valve plane and the ventricular base and body should also alert one to the possibility that the site of entry into the ventricle is not the aortic valve orifice and a CP should be suspected.

If the CP has been undetected till now, one can detect it at the time of BAV if one encounters more than usual resistance in deploying the valvuloplasty balloon, especially with low-profile balloons. A handy maneuver to rule out CP is to partially inflate the valvuloplasty balloon in the descending aorta to increase the profile to provide a greater degree of certainty that the site of entry is the true valve orifice.

Another important sign is an excessive "waisting" of the BAV balloon at the time of inflation and excessive recoil with deflation.

Finally if a CP has been undetected till now, one can suspect it by difficulty faced in tracking the delivery catheter across the aortic valve after BAV. Once the diagnosis of a CP is suspected, angiography should be performed in two orthogonal views (with the catheter still in the left ventricle through the CP) to delineate the site of entry of the catheter through the aortic valve and serve as a reference marker. Next, attempts should be made to recross the valve through the true orifice with the diagnostic catheter or Amplatz Superstiff wire in the left ventricle. Once the aortic valve has been recrossed through the true orifice, the different

course taken by the guidewires will be clear in the right anterior oblique view.

The wire can be removed from the site of a CP once the true orifice has been crossed and the operator can proceed to BAV and aortic valve deployment. An undetected CP can be associated with a poor procedural outcome and increased chances of complications such as leaflet avulsion, entrapment, and embolization after BAV. Deployment of a percutaneous aortic prosthesis through a CP will lead to vertical malalignment and underexpansion of the prosthesis which will fail to effectively address the underlying severe aortic stenosis. In the worst case scenario, the patient may need to undergo high-risk aortic root surgery for an iatrogenic complication that can be readily diagnosed and corrected in the cardiac catheterization laboratory [16].

SHEATH REMOVAL

Sheath removal is an important challenge in the management of these patients. The large-caliber femoral artery sheath has been associated with transfusion rates in about a quarter of patients in the past, and the need for vascular surgical repair in 5–10%. Recently, the use of percutaneous suture closure has been described as an adjunct to sheath removal. Preclosure using a 10-Fr Perclose device before insertion of the 12- or 14-Fr sheath has been successful in almost 90% of patients, with almost complete elimination of the need for blood transfusion after this procedure. For those patients in whom preclosure is unsuccessful, or in whom femoral anatomy does not allow its use, it is critical to use a pneumatic compression device such as the RADI FemoStop. Manual compression by itself is extremely difficult, because prolonged compression for this large sheath size is necessary. The rigid clamp devices cannot be monitored adequately and may result in either inadequate hemostasis, or overcompression of the vessel with the potential for thrombosis. The FemoStop device can be applied with a graded pressure, so that initially it is inflated to about the level of systolic pressure. As the device is transparent, hemostasis can be visualized directly. The pressure can be decreased 10–20 mm every 10–30 min depending on the activated clotting time, until hemostasis is achieved. Another benefit of the FemoStop device is that it helps keep the patient immobile during the period of vascular compression.

POST-PROCEDURE MANAGEMENT

Other than management of the punctures, the major issue is whether LV depression has been engendered by the balloon inflations. Patients who develop pulmonary congestion during the valvuloplasty procedure require special monitoring, and may need inotropic support and intensive heart failure management for 1–2 days post-procedure, until their LV performance recovers. Long-term follow-up requires no more than surveillance for recurrent symptoms, and periodic echocardiographic examinations to monitor the transaortic valve pressure gradient. An important

consideration in follow-up is the status of the other valve lesions. When the aortic valve is successfully opened, afterload reduction will often result in improvement in the associated mitral regurgitation that these late-stage aortic stenosis patients often have.

Among patients who have recurrence of the stenosis, repeat valvuloplasty may be accomplished with a high expectation for success [17].

We rarely offer repeat procedures to patients who re-stenose quickly, within 6–8 months of the initial procedure. For those who achieve a year or more of clinical benefit, repeat procedures can be performed even three or four times, although the resultant valve areas are usually no better than with the first procedure.

REFERENCES

1. Bonow O, Carabello B, Chatterjee K, et al. ACC/AHA 2006 Guidelines for the management of patients with valvular heart disease. Executive summary. *Circulation* 2006;**114**:450–527. Available at: www.americanheart.org (accessed August 10, 2007).
2. Levinson JR, Akins CW, Buckley MJ, et al. Octogenarians with aortic stenosis. Outcome after aortic valve replacement. *Circulation* 1989;**80**(3 Part 1):149–56.
3. Safian RD, Berman AD, Diver DJ, et al. Balloon aortic valvuloplasty in 170 consecutive patients. *N Engl J Med* 1988;**319**:125–30.
4. Otto CM, Mickel MC, Kennedy JW, et al. Three-year outcome after balloon aortic valvuloplasty. Insights into prognosis of valvular aortic stenosis. *Circulation* 1994;**89**:642–50.
5. Valvuloplasty Registry. Percutaneous balloon aortic valvuloplasty. Acute and 30-day follow-up results in 674 patients from the NHLB. *Circulation* 1991;**84**:2383–97.
6. Feldman T. Percutaneous suture closure for management of large French size arterial and venous puncture. *J Intervent Cardiol* 2000;**13**: 237–42.
7. Solomon LW, Fusman B, Jolly N, Kim A, Feldman T. Percutaneous suture closure for management of large French size arterial puncture in aortic valvuloplasty. *J Invasive Cardiol* 2001;**13**:592–6.
8. Guth A, Hennen B, Kramer T, Stoll HP, Bohm M. Plasma lidocaine concentrations after local anesthesia of the groin for cardiac catheterization. *Catheter Cardiovasc Interv* 2002;**57**:342–5.
9. Feldman T, Ford LE, Chiu YC, Carroll JC. Changes in valvular resistance, power dissipation, and myocardial reserve with aortic valvuloplasty. *J Heart Valve Dis* 1992;**1**:55–64.
10. Feldman T, Carroll JD, Chiu YC. An improved catheter for crossing stenosed aortic valves. *Catheter Cardiovasc Diag* 1989;**16** 279–83.
11. Fusman B, Faxon D, Feldman T. Hemodynamic rounds: Transvalvular pressure gradient measurement. *Catheter Cardiovasc Interv* 2001;**53**:553–61.
12. Feldman T, Chiu YC, Carroll JD. Single balloon aortic valvuloplasty: increased valve areas with improved technique. *J Invasive Cardiol* 1989;**1**:295–300.
13. Eles GR, Fisher DL, Khalil R, Dajani Z, Spotti JP, Lasorda D. Balloon aortic valvuloplasty for aortic stenosis using a novel percutaneous dilation catheter and Power injector. *J Intervent Cardiol* 2011;**24**:92–8.
14. Feldman TE. Balloon valvuloplasty. In: Nissen SE, Popma JJ, Kern MJ, Dehmer GJ, Carroll JD (eds), *CathSAP II*. Bethesda, MD: American College of Cardiology, 2001.

15. Feldman T. Percutaneous therapies for valvular heart disease. In: Baim DS, Grossman W (eds), *Grossman's Cardiac Catheterization, Angiography and Intervention*, 7th edn. Philadelphia, PA: Lippincott Williams & Wilkins, 2005: 543–61.
16. Ussia GP, Sarkar K, Tamburino C. Aortic valve perforation during aortic valvuloplasty: Identification and strategies for prevention. *Catheter Cardiovasc Interv* 2011;**77**:876–80.
17. Feldman T, Glagov S, Carroll JD. Restenosis following successful balloon valvuloplasty:bone formation in aortic valve leaflets. *Catheter Cardiovasc Diagn* 1993;**29**:1–7.

CHAPTER 20

Percutaneous Implantation of Aortic Valvular Prostheses

Stefan Toggweiler, John Webb

Challenges 487

Current Valves 488**Access 490****Patient Selection 491****Technical Tips 491**

*Role of echocardiography 491

*Measurement of the annulus 491

*Coronary angiography 492

**Assessment of the aortic root 492

**Assessment of the iliofemoral arteries 493

The Procedure 495**Technical Tips 495**

**Vascular access 495

**Pacing 496

*Crossing the valve 496

**Valvuloplasty 496

**Implantation of the valve 497

**Sheath removal 498

Complications 498**Technical Tips 498**

*Management of hypotension 498

**Management of arterial injury 499

**Aortic regurgitation 499

**Postprocedural atrioventricular block 499

CHALLENGES

Surgical valve replacement has a proven role in the management of severe aortic stenosis (AS), improving both symptoms and survival [1]. However, many patients with comorbidities are not good candidates for open heart surgery and do not undergo this procedure. In such “inoperable” patients, transcatheter aortic valve implantation (TAVI) has emerged as the therapy of choice. The recent PARTNER study demonstrated a marked absolute reduction in mortality at 1 year of 20%, as well as improvement in quality of life compared with medical therapy [2].

*Basic; **Advanced; ***Rare, exotic, or investigational

\$, <\$US100.00 extra; \$\$, >\$US100.00 extra

⌚, <10 min extra; ⌚⌚, >10 min extra

♣, low risk of complications; ♣♣, high risk of complications

Practical Handbook of Advanced Interventional Cardiology, Fourth Edition.
 Edited by Thach Nguyen, Dayi Hu, Shao Liang Chen, Moo-Hyun Kim,
 Shigeru Saito, Cindy Grines, C. Michael Gibson, and Steven R. Bailey.
 © 2013 John Wiley & Sons, Ltd. Published 2013 by John Wiley & Sons, Ltd.



Figure 20.1 The SAPIEN XT is a balloon-expandable transcatheter heart valve. The valve incorporates bovine pericardial leaflets and a fabric sealing cuff sewn to a cobalt chromium tubular frame.

Current Valves

Initial reports of long-term follow-up suggest good durability of first-generation transcatheter valves beyond 5 years, with preserved hemodynamic function and no reported structural failure to date [3].

Two balloon-expandable aortic valves are currently in use. The SAPIEN THV is a bovine pericardium prosthesis mounted on a balloon-expandable stainless steel stent. The valve is available as a 23- and 26-mm heart valve and requires a 22- and 24-French (Fr) sheath, respectively. The newer SAPIEN XT THV has improved bovine pericardial leaflets and a cobalt–chromium tubular frame with thinner struts and a more open cell design, which allows a lower crimped profile while maintaining radial strength (Figure 20.1). The bovine pericardial leaflets are processed with the same anti-calcification treatment commonly utilized in surgical valves. *In vitro* accelerated wear testing demonstrates durability out beyond 10 years, comparable to surgical valves. Limited experience with incorrectly positioned or undersized transcatheter heart valves (THVs) confirms that a second THV can be implanted within the first with a good functional result. Currently, the valve is available in sizes of 23, 26, and 29 mm diameter. The current SAPIEN XT valve is crimped on a low-profile NovaFlex catheter, which consists of a relatively stiff, deflectable catheter with a short tapered nosecone to facilitate passage through the aorta. Each size of the valve is supplied with a matched delivery system. The corresponding sheath size is listed in Table 20.1.

The CoreValve THV utilizes a self-expanding, rather than a balloon-expandable, frame. It consists of a nitinol alloy stent measuring 53–55 mm in axial length (Figure 20.2). The lower portion of the implant has a high radial force and anchors within

Table 20.1 Valve sizes and corresponding sheath diameter of the SAPIEN XT valves

Annulus (mm)	Valve	Delivery catheter	Internal sheath diameter (Fr)	External sheath diameter (mm)	Minimum recommended artery diameter (mm)
18–22	SAPIEN 23 mm	RetroFlex 3	22	8.4	7
22–25	SAPIEN 26 mm	RetroFlex 3	24	9.2	8
18–22	SAPIEN XT 23 mm	NovaFlex	18	7.2	6
22–25	SAPIEN XT 26 mm	NovaFlex	19	7.5	6.5
20–23	CoreValve 26 mm	CoreValve	18	6.5	6
24–27	CoreValve 29 mm	CoreValve	18	6.5	6

Additional sizes of valves including 20 and 29 mm SAPIEN XT and 29 mm CoreValve valves are anticipated.




Figure 20.2 The CoreValve is a self-expanding nitinol frame heart valve.

the native valve. The middle supra-annular portion is tapered and contains the valve leaflets. This portion is not in direct contact with the aorta or coronary sinuses allowing unobstructed blood flow to the coronaries through the stent struts. The upper portion of the frame is flared and anchors the prosthesis against the ascending aorta. There have been several device modifications since 2005 and required sheath size has been reduced from 24 Fr to the currently used 18-Fr third-generation device.

Several newer valves are currently in early clinical trials. These largely represent attempts to improve sheath size, deliverability, positioning, and the ability to reposition the valve if initial deployment is suboptimal.

Access

The transarterial femoral approach is most widely used today. Initial large profile systems severely limited the applicability of this approach, because vascular complications were frequent. Recent reductions in delivery system size to around 18 Fr now allow the femoral arterial percutaneous approach in most patients. In patients with small or diseased femoral arteries several other approaches are available. Options include transapical access through a mini-thoracotomy, transaortic access through a mini-sternotomy, iliac arterial access using a surgical retroperitoneal approach and subclavian/axillary arterial access through a local

cutdown. In this chapter we focus on tips and tricks relevant to the femoral transarterial procedure.

Patient Selection

As experience and clinical follow-up remain limited, TAVI is still generally restricted to patients who are considered to be in operable or at high risk with open surgery. On-line risk calculators developed from large surgical databases are often used to estimate surgical risk, e.g. a Society of Thoracic Surgeons (STS) predicted risk of mortality at 30 days (STS-PROM) >10% is often used to define high surgical risk (see www.sts.org/sections/stsnationaldatabase/riskcalculator). However, these risk calculators do not fully account for many surgical risk factors such as porcelain aorta, multivalve disease, frailty, chest deformity, or liver disease. Consequently the assessment of an experienced surgeon is often a more reliable estimate of high surgical mortality risk. Although mortality is important, increasingly increased risk of morbidity (e.g. functional recovery, mobility, non-fatal complications) with open surgery is being considered as an indication for a percutaneous procedure.

Technical Tips

***Role of echocardiography** Transthoracic echocardiography (TEE) is a cornerstone of the screening process. The diagnosis of severe aortic stenosis commonly made in the presence of an aortic mean gradient >40 mmHg, jet velocity >4 m/s, area <0.8 cm², or area index <0.5 cm². The bulk of experience to date has been with calcific tricuspid valves. The role of TAVI in the presence of bicuspid, rheumatic, non-calcified, or predominantly regurgitation valves is unknown because experience is limited and a calcified native valve is typically needed for a secure THV. The presence of a low gradient (<40 mmHg) in the presence of aortic stenosis should prompt consideration of moderate, rather than severe, stenosis or pseudo-stenosis due to low cardiac output. A more detailed hemodynamic evaluation at the time of catheterization with crossing may be indicated. Severe aortic stenosis is frequently associated with concomitant mitral or tricuspid regurgitation. After TAVI regurgitation of atrioventricular valves may be better tolerated or even improve (due to reduced afterload and ventricular remodeling). The choice between double-valve surgery or isolated aortic valve implantation needs to be individualized.

***Measurement of the annulus** Unlike open surgical valve replacement the required implant size cannot be determined directly and a non-invasive estimate is necessary. The commonly utilized annulus diameter is measured from the points of leaflet insertion as seen in the parasternal long axis view (Figure 20.3). This measurement is not equivalent to the more commonly reported left ventricular outflow tract diameter. Although the transthoracic measurement is often utilized we favor TEE measurements which are, on average, about 1–2 mm larger and more reproducible [4]. In general, an annulus as measured by TEE at 18–22, 22–25, or 25–28 mm would be considered appropriate for a 23-, 26-, or 29-mm SAPIEN prosthesis, respectively. An annulus

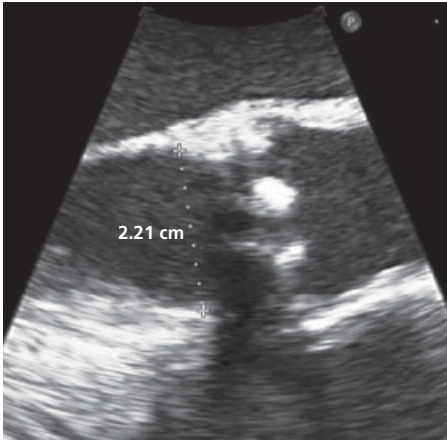


Figure 20.3 The diameter of the annulus is measured at the point of leaflet attachment. On average transesophageal echocardiography estimates exceed transthoracic estimates by 1–2 mm.

dimension of 20–24 or 24–27 mm may be appropriate for a 25- or 29-mm CoreValve respectively.

With limited data to date echocardiography remains the gold standard, although computed tomography (CT) measurements of the annulus are increasingly utilized [5]. An advantage of CT is that the aortic annulus is typically oval and both the long and the short axis can be measured. Typically dimensions are slightly larger than those reported by echocardiography.

***Coronary angiography** Coronary anatomy is routine to determine the potential for ischemia and the possible need for revascularization with angioplasty or surgery. In patients with renal dysfunction a couple views of the left and one of the right artery may be adequate. In many patients with angina and moderate coronary disease, TAVI may be all that is needed to improve symptoms. On occasion we perform angioplasty in patients with acute coronary syndromes or to reduce the potential for ischemic left ventricular dysfunction during valve implantation. Ventricular angiography is often omitted because echocardiographic assessment is routine. Right heart catheterization may be helpful to assess the presence of clinically important pulmonary hypertension and estimate the valve area. When echocardiography suggests a low gradient (<40 mmHg) or borderline valve area we usually cross the valve and obtain simultaneous pressure measurements.

****Assessment of the aortic root** An aortic root angiogram is routine in the assessment of patients for TAVI. Typically a pigtail is placed directly on the non-coronary cusp of the aortic valve and 20ml contrast is injected over 1 s. Ideally this is done in a fluoroscopic projection perpendicular to the aortic valve, so as to visualize all three cusps in a single plane. In most patients, the

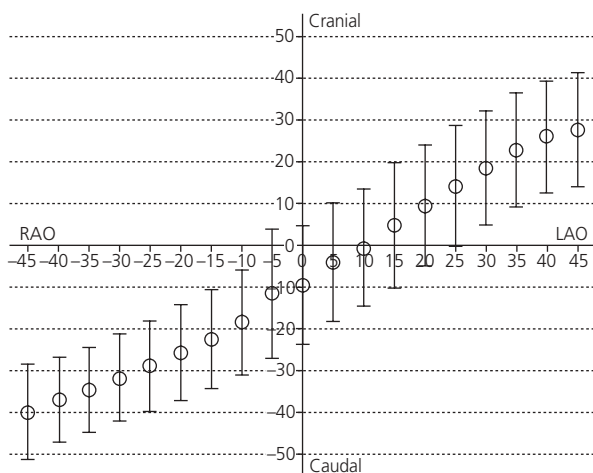


Figure 20.4 The “line of perpendicularity”: The graph represents the mean caudal or cranial angulation needed at the spectrum of a right or left anterior oblique projections to achieve valve perpendicularity to the X-ray beam for a large cohort of patients. Individual patients will vary.

plane of the aortic valve is tilted down anterior and to the right. Therefore, on average, a plane around 10–15° caudal in the anterior projection will result in a perpendicular view (Figure 20.4). In general, as the imaging plane moves more left anterior obliquely, more cranial angulation will be needed to remain perpendicular to the valve plane. Pre-procedural CT or intra-procedural three-dimensional reconstruction (e.g. DynaCT) can be used to determine the optimal projection for valve implantation (Figure 20.5) [6].

With the SAPIEN valves, the goal is primarily to assess the aortic valve and root, rather than the ascending aorta or arch. With the CoreValve device, greater attention must be paid to the ascending aorta because this valve is fixed above the coronaries as well as in the aortic valve itself. Consequently imaging of the ascending and transverse aorta may also be desirable. CT is becoming increasingly routine to assess aortic dimensions, particularly for CoreValve implantation.

****Assessment of the iliofemoral arteries** Descending aortography has been the mainstay of arterial access evaluation. We typically place a calibrated pigtail (e.g. Beacon Tip Royal Flush) in the abdominal aorta just above the bifurcation and inject 35 ml contrast dye over 2 s. Both iliac and femoral arteries can be visualized with rapid panning of the table (Figure 20.6). Using the catheter markers for calibration we measure the minimal lumen diameters of the iliac and femoral arteries on both sides. Shorter segments with a diameter of approximately 1 mm less than the external sheath diameter may be adequate in the absence of excess calcification or tortuosity. However, the likelihood of access

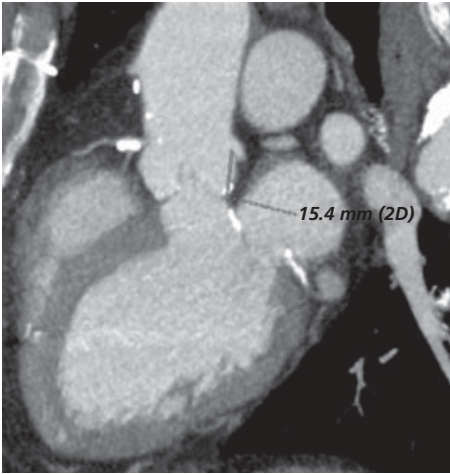


Figure 20.5 Computed tomography is most accurate in measuring the distance between the coronary ostia and the annulus, the length of the leaflets, and the distribution and bulkiness of calcium. A distance <12 mm from leaflet insertion to the left coronary ostium is often considered to be a marker of increased risk of coronary obstruction.

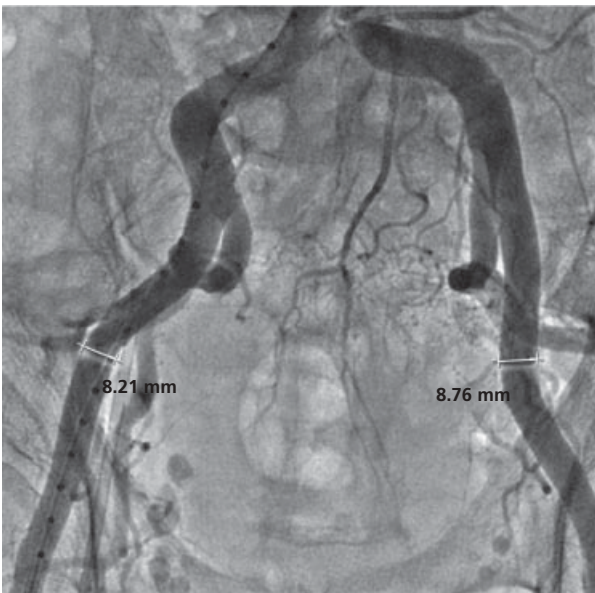


Figure 20.6 Both iliofemorals can be assessed with one injection of dye and rapid panning of the table. Minimal lumen diameter is measured on both sides.

complications increases rapidly as soon as the external sheath diameter is larger than the minimal lumen diameter of the artery. The degree of tortuosity and calcification must be considered in addition to the arterial diameter.

CT angiography of the iliofemoral arteries is very helpful in borderline cases and is becoming more routine in the assessment of patients for TAVI. Tortuosity can be assessed from two- or three-dimensional reconstructed images. However, the minimal lumen diameter of the iliofemoral arteries is generally determined from contrast-enhanced axial images. Non-contrast CT may be particularly helpful in assessing the degree and extent of calcification. Circumferential calcification suggests a non-dilatable artery.

THE PROCEDURE

Procedures can be performed in a cardiac catheterization laboratory or a hybrid operating room equipped with high-quality imaging. Operating room-like sterile precautions are desirable to minimize the risk of infection of the implanted prosthesis or femoral access site should operative closure be required. Optimal outcomes require full capabilities for anesthetic and cardiopulmonary support, coronary and peripheral vascular intervention, and pericardiocentesis, and thoracotomy should be available plus an interdisciplinary team involving interventional cardiologists, cardiac and vascular surgeons, cardiac anesthesiologists, perfusionists, and nurses.

We routinely check hemoglobin, electrolytes, creatinine, and coagulation status immediately before the procedure. Anesthetic pre-assessment a few days before the procedure is helpful in identifying any outstanding issues. Premedication includes aspirin, clopidogrel, and prophylactic antibiotics (1 g cefazolin or 1 g vancomycin in case of cephalosporin or penicillin allergy).

Procedures may be performed with conscious sedation. However, many groups prefer general anesthesia and endotracheal intubation to facilitate TEE, patient safety, and comfort. Intubated patients are usually extubated immediately after the procedure.

Technical Tips

****Vascular access** Ideally the femoral and iliac arteries should be larger than the sheath diameter. With current generation delivery systems this means above approximately 7 mm. In the absence of severe calcification, atherosclerosis or tortuosity diameters >6 mm may be acceptable. There is some controversy about the role of surgical femoral arterial cutdown. Surgical cutdown allows puncture of the femoral artery with control of the artery above and below the puncture site. We favor percutaneous puncture and percutaneous closure.

A common mistake is to underestimate the importance of visualization of the common femoral puncture site. The screening angiogram and CT scan should be reviewed and the side with the larger, less tortuous, less diseased femoral and iliac artery is selected for insertion of the large sheath. The ideal puncture site

is relatively free of disease, below the peritoneal space, as demarcated by the inferior hypogastric artery, and above the bifurcation into superficial and deep femoral arteries. Typically this is over the upper portion of the femoral head where it is compressible. Usually, we place a hemostat over the proposed puncture site and assess its position relative to the femoral head under fluoroscopy. When there are concerns related to a high femoral bifurcation, obesity, atheroma, or calcification, additional measures include use of a micropuncture sheath, ultrasound guidance, or a catheter passed from the contralateral artery to facilitate angiographic visualization of the puncture site.

“Preclosure” is usually performed using either two ProGlide devices (sutures implanted at 10 and 2 o’clock) or one Prostar device. Although vascular injury has been the most frequent complication associated with the transarterial procedure, it is possible to achieve much lower complication rates with careful screening and attention to procedural detail.

****Pacing** A temporary right ventricular pacemaker is routinely placed. It has two roles: Burst pacing and backup pacing.

Burst ventricular pacing at rates of 160–220/min is typically used during balloon valvuloplasty and/or balloon-expandable valve implantation. The idea is to reduce the left ventricular filling period, thereby reducing pulse pressure, transvalvular flow, and cardiac motion, and the likelihood of balloon ejection from the ventricle during inflation [7]. To reduce the risk of hemodynamic instability it is best to ensure that systolic blood pressure is >100 mmHg before the onset of burst pacing, to keep bursts <20s duration, and to allow periods of recovery between bursts.

A temporary pacing wire also provides backup pacing should new atrioventricular conduction block develop during the procedure. Pacing can be accomplished transfemorally and typically the wire can be removed on completion of the procedure. However, if a prolonged period with an indwelling pacemaker is likely, such as after CoreValve implantation or pre-existing block, a neck approach is preferred.

***Crossing the valve** We typically place an angled catheter such as an Amplatz left 1 (or Amplatz left 2 for a horizontal root) just above the valve. The valve is crossed with a straight 0.035-inch soft-tip or hydrophilic wire. The wire is gently advanced until it is deflected down the surface of one valve leaflet, at which point the wire is withdrawn and the catheter slightly repositioned. Forceful probing contributes nothing to the procedure and may risk atheroembolization. An Amplatz extra-stiff or super-stiff 0.035-inch guidewire, with a manually formed exaggerated J curve on the distal end, is advanced as far as possible into the ventricle, forming a gentle curve without entrapment in the mitral valve apparatus or ectopy (Figure 20.7). Caution must be exercised to ensure that the wire is not withdrawn until after the valve prosthesis has been implanted.

****Valvuloplasty** We typically use a 4- to 5-cm-long, 20- to 22-mm balloon. The diameter of the balloon should be slightly

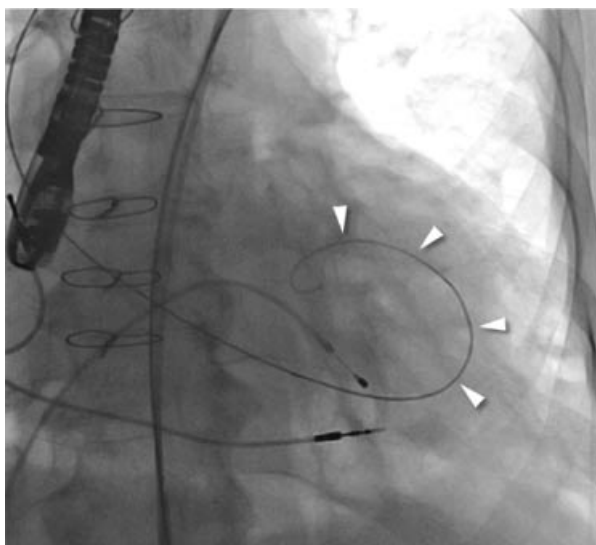


Figure 20.7 An Amplatz extra-stiff or super-stiff 0.035-inch guidewire with a manually formed exaggerated J curve on the distal end is advanced as far as possible into the ventricle forming a gentle curve.

smaller than the aortic annulus to avoid excessive dilation. Shorter balloons are often unstable and longer balloons take longer to inflate and deflate, resulting in longer periods of hypotension. Self-seating dumbbell-shaped balloons (e.g. Nucleus) may increase stability. We utilize diluted 10–20% contrast to reduce viscosity and inflation–deflation time. The balloon is positioned across the valve. Burst pacing is initiated, the balloon rapidly inflated and deflated, pacing terminated, and the balloon withdrawn from the valve to allow hemodynamic recovery. Motion of the valve leaflets during inflation should be observed to aid in later prosthesis positioning and assess the risk of coronary obstruction. Careful observation of the balloon during expansion is important. In the presence of septal hypertrophy, constriction at the level of the sinotubular junction, or a mitral prosthesis extending into the left ventricular outflow tract, the balloon may be displaced during inflation. This should raise concerns about possible interference with balloon expansion during valve deployment resulting in malposition of the prosthesis.

****Implantation of the valve** It is important that the physician personally examine the valve and delivery system before use, e.g. with the balloon-expandable SAPIEN-type valve the orientation of the prosthesis on the balloon catheter is opposite for the retrograde transarterial and antegrade transapical procedures. The prosthesis should be mounted so that the sealing cuff will be implanted in the ventricle and the open cells in the aorta.

Imaging is critical to accurate valve positioning. It is important for the operator to define the anatomic plane of the aortic

annulus and relevant landmarks. Pre-procedural aortography is routine. We routinely utilize pre-procedural CT or intraprocedure three-dimensional reconstructions to find the best fluoroscopic projections that demonstrate the valve cusps in a single plane. TEE is not routinely used but can be helpful in experienced hands. Repeated aortography during implantation is routine and remains the standard imaging modality during implantation. Immediately after implantation, aortography and/or TEE is utilized to evaluate positioning, function, and paravalvular leaks.

****Sheath removal** The large femoral sheath should be removed shortly after the valve is in place. As the sheath is removed the artery is manually compressed and the previously placed preclosure sutures are tightened to achieve hemostasis. Most operators leave a femoral wire in place or pass a wire from the contralateral leg to allow reintroduction of the sheath or balloon occlusion should preclosure fail. With attention to technique this should rarely be the case. As a last resort an endoluminal covered stent or controlled surgical repair remains an option.

Although a normal artery will dilate in the presence of an oversized sheath, rarely a diseased and undersized iliofemoral artery will rupture. This may become apparent only as a sudden drop in blood pressure at the time of removal of an oversized sheath. If perforation is suspected contrast injection through the sheath or a contralaterally placed catheter may be diagnostic. If a wire has been left in place, the sheath and/or dilator or an occlusion balloon can be quickly placed to tamponade any bleeding. Alternatively an occlusion balloon can also be advanced to, or above, the bleeding site from the contralateral femoral artery. With appropriate management conversion to a covered stent or surgery can be accomplished in a stable manner.

Regardless of the means or apparent success of vascular closure it is prudent to confirm a patent, non-leaking artery with a post-hemostasis antegrade angiogram from the contralateral artery.

COMPLICATIONS

Technical Tips

***Management of hypotension** Hypotension should prompt consideration of a variety of potential causes. Endotracheal intubation, internal jugular lines, etc. are not without risks of bleeding, airway obstruction, and pneumothorax. Blood loss due to arterial perforation may or may not be visible. Peritoneal tamponade may occur due to perforation of the right or left ventricle by a pacing wire, stiff guidewire, catheter, or valve delivery catheter. Left ventricular catheters may interfere with mitral valve function. Manipulation of the aorta may result in baroreceptor/vagal responses. Balloon valvuloplasty can avulse a native leaflet. A bulky native valve leaflet may be displaced by the newly implanted valve obstructing the left main artery. A newly implanted valve may be poorly positioned, sized, or underexpanded. The electrocardiogram can help with diagnosing coronary obstruction. TEE

may help in the differential diagnosis by assessing ventricular filling volumes, aortic and mitral valve function, changes in contractility, and left main coronary flow.

Perhaps the most common scenario leading to hypotension during valve implantation is the self-reinforcing spiral of reduced cardiac output and increased myocardial oxygen demand, leading to reductions in coronary perfusion pressure and contractility. Burst pacing, tachycardia, ventricular ectopy, radiographic contrast, balloon valvuloplasty, pre-existing left ventricular dysfunction, untreated coronary artery disease, and general anesthesia predispose to myocardial ischemia. Systemic arterial pressure should be continuously monitored because untreated hypotension can rapidly deteriorate into hemodynamic collapse in patients with severe aortic stenosis.

We aim for a systolic blood pressure of >100 mmHg or a mean aortic pressure >70 mmHg. Most patients receiving a general anesthetic will require intravenous vasopressor support (e.g. norepinephrine, phenylephrine). Inotropic and chronotropic agents (epinephrine, dopamine, or dobutamine) are less desirable because they may exacerbate myocardial ischemia. Most importantly the procedure must be judiciously paced, allowing appropriate time for recovery between pacing, angiography, and balloon valvuloplasty.

****Management of arterial injury** Dissection or vessel occlusion can usually be managed percutaneously, but perforation is of greater concern. A hematoma or unexplained hypotension may be the initial clue to vascular perforation. Aortic or iliac angiography with a pigtail inserted through the large sheath or contralateral sheath should be considered. We maintain contralateral arterial access until after large sheath removal has been successfully accomplished. Should pelvic arterial perforation occur, a compliant occlusion balloon is rapidly advanced into the aorta and inflated. Once this is done, the bleeding site is controlled with implantation of a covered stent or surgical repair.

****Aortic regurgitation** Significant valvular regurgitation after TAVI is unusual and most often due to interference with leaflet motion from a stiff guidewire. However, some degree of paravalvular regurgitation is very common. Generally this is mild to moderate and well tolerated. Clinically significant hemolysis has not been apparent. Rarely, severe paravalvular regurgitation resulting in heart failure or hemodynamic compromise may occur due to implantation of a prosthesis too aortic or too ventricular, allowing regurgitation through the open, uncovered cells of the prosthetic frame. If necessary a second valve can be implanted within the first, but slightly lower or higher as needed to extend the sealing cuff. Paravalvular regurgitation may also occur due to underexpansion or a prosthesis (in which case balloon dilation may be helpful) or an undersized prosthesis (where percutaneous options are limited).

****Postprocedural atrioventricular block** Compression of the atrioventricular (AV) conduction system as it travels through

the interventricular septum below the aortic valve may be associated with new AV block. Complete heart block is generally apparent immediately. Predisposing factors include pre-existing AV block, particularly right bundle-branch block, oversizing, and low implantation of the prosthesis in contact with the interventricular septum [8,9]. As the CoreValve prosthesis extends further into the left ventricular outflow tract than the SAPIEN valve, it is associated with a more frequent need for pacemaker implantation (15–40% versus 3–10%) and a greater risk of the late development of heart block. Consequently most centers remove pacing immediately following SAPIEN valve implantation in the absence of new conduction delay, while an indwelling jugular wire is typically left in place for some days following CoreValve implantation.

REFERENCES

1. Bonow RO, Carabello BA, Kanu C, et al. ACC/AHA 2006 guidelines for the management of patients with valvular heart disease: a report of the American College of Cardiology/American Heart Association Task Force on Practice Guidelines (writing committee to revise the 1998 Guidelines for the management of patients with valvular heart disease): developed in collaboration with the Society of Cardiovascular Anesthesiologists: endorsed by the Society for Cardiovascular Angiography and Interventions and the Society of Thoracic Surgeons. *Circulation* 2006;**114**: e84–231.
2. Leon MB, Smith CR, Mack M, et al. Transcatheter aortic-valve implantation for aortic stenosis in patients who cannot undergo surgery. *N Engl J Med* 2010;**363**:1597–607.
3. Gurvitch R, Wood DA, Tay EL, et al. Transcatheter aortic valve implantation. Durability of clinical and hemodynamic outcomes beyond 3 years in a large patient cohort. *Circulation* 2010;**122**:1319–27.
4. Moss RR, Ivens E, Pasupati S, et al. Role of echocardiography in percutaneous aortic valve implantation. *JACC Cardiovasc Imaging* 2008;**1**: 15–24.
5. Wood DA, Tops LF, Mayo JR, et al. Role of multislice computed tomography in transcatheter aortic valve replacement. *Am J Cardiol* 2009;**103**: 1295–301.
6. Gurvitch R, Wood DA, Leipsic J, et al. Multislice computed tomography for prediction of optimal angiographic deployment projections during transcatheter aortic valve implantation. *JACC Cardiovasc Interv* 2010;**3**: 1157–65.
7. Webb JG, Pasupati S, Achtem L, Thompson CT. Rapid pacing to facilitate endovascular prosthetic heart valve implantation. *Catheter Cardiovasc Interv* 2006;**68**:199–204.
8. Baan J, Jr., Yong ZY, Koch KT, et al. Factors associated with cardiac conduction disorders and permanent pacemaker implantation after percutaneous aortic valve implantation with the core valve prosthesis. *Am Heart J* 2010;**159**:497–503.
9. Godin M, Eltchaninoff H, Furuta A, et al. Frequency of conduction disturbances after transcatheter implantation of an Edwards Sapien aortic valve prosthesis. *Am J Cardiol* 2010;**106**:707–12.

CHAPTER 21**Subclavian Artery Interventions**

Gianluca Rigatelli, Paolo Cardaioli, Aravinda Nanjundappa

Challenges	502
Non-invasive Evaluation	503
Ultrasonography	503
CT and MRI	503
Invasive Evaluation	503
Angiography	503
Intravascular Ultrasonography	504
Stenting	504
Access	504
Guide	505
Wires	505
Technical Tips	506
*Crossing the lesion	506
**Sheath or guide	506
**Telescoping the guide or the sheath	506
Distal Protection	506
Balloons	507
Stents	507
Technical Tips	507
**Selection of stent	507
**Stent positioning	507
**Perfect stenting	508
Postdilation	508
Technical Tip	509
**Postdilation	509
Distal Subclavian Axillary Lesions	509
Innominate Artery Lesions	509
Associated Vertebral Disease	509
Subclavian Total Occlusion	509
Technical Tips	510
**Preferred vascular access	510
***Monitoring the intervention with contrast injection through the sheath	510
Injuries and pseudoaneurysm	511
***Stenting of subclavian traumatic injury	512
Complications	512
Advanced and Exotic Techniques	512

*Basic; **Advanced; ***Rare, exotic, or investigational

\$, <\$US100.00 extra; \$\$, >\$US100.00 extra

⌚, <10 min extra; ⌚⌚, >10 min extra

♣, low risk of complications; ♣♣, high risk of complications

- Occlusion of a subclavian artery causing acute myocardial infarction 512
- Aneurysmal exclusion of subclavian artery 513
- Coronary steal syndrome aggravated by arteriovenous fistula 513
- Open the total occlusion subclavian artery for central Percutaneous coronary intervention access 514

CHALLENGES

In recent years, percutaneous transluminal angioplasty (PTA) of the supraaortic vessels, especially the subclavian and innominate arteries, has become the treatment of choice for most patients with outcomes equal or superior to surgery [1,2]. To deploy a stent in the subclavian artery without any complications such as stroke or dissection is a great challenge.

As the subclavian and innominate arteries supply the blood to the brain and arms, in cases of proximal obstruction, both territories compete for blood flow and the clinical situations encountered may be very diverse [3].

The subclavian steal syndrome arises if there is flow reversal in the vertebral artery shunting blood away from the brain, and results in the symptoms of vertebrobasilar insufficiency, including dizziness, vertigo, ataxia, diplopia, nausea, vomiting, and syncope. Ipsilateral upper extremity ischemic symptoms include arm claudication, paresis, and atheroembolic digital ischemia. In patients with an internal mammary artery (IMA) graft to the coronary bed, ipsilateral critical subclavian artery stenosis might cause myocardial ischemia to the territory that it supplies, and this is clinically known as coronary–subclavian steal. The various clinical presentations are:

- 1** The subclavian–steal syndrome when blood is diverted from the vertebral arteries with symptoms involving the posterior cerebral circulation.
- 2** Acute or chronic ischemia of the upper extremity when a subclavian artery stenosis is the cause of thromboembolism or when it is obstructed with disabling exertional discomfort.
- 3** Coronary–steal syndrome when the blood is diverted from an arterial mammary graft which supplies the left coronary system in favor of the left upper extremity, in case of subclavian proximal stenosis.

Atherosclerosis is the main cause of subclavian stenosis but other etiologies include fibromuscular dysplasia, neurofibromatosis, arteritis, inflammation secondary to radiation, or compression syndromes. Traumatic injuries of the subclavian artery may lead to acute upper limb ischemia and be caused by shoulder dislocation, shoulder fracture, and injury. Dissection of the subclavian artery is very rare but it can occur after a car accident or associated

with dissection from the thoracic aorta. Pseudoaneurysm of the subclavian artery could be formed as a complication of venous line placement or a late complication of a chest blunt trauma [4].

NON-INVASIVE EVALUATION

Clinical evaluation of a suspected subclavian stenosis is very simple by measuring the blood pressure of both arms: A difference of >20 mmHg is highly suggestive. The standard work-up of a subclavian artery stenosis includes ultrasonography, computed tomography (CT), and magnetic resonance imaging (MRI).

Ultrasonography

Ultrasonography is more effective in detecting distal subclavian stenosis than proximal stenosis which is most often unrecognized. However, ultrasonography is important in assessing either the subclavian steal syndrome by detecting the flow inversion in the vertebral artery or the coronary–subclavian steal syndrome by evaluating the eventual inversion of blood flow in the IMA. Ultrasonography is also useful in analyzing the plaque composition as in carotid artery PTA and soft plaque prone to embolization, and should be managed with a distal protection device.

CT and MRI

A CT scan of the subclavian arteries is highly effective in detecting subclavian artery stenosis. A multidetector scan may be useful in planning endovascular treatment of subclavian stenosis, especially in complex cases, when the vertebral artery origin is not readily shown by ultrasonography. A CT scan is indicated in particular in cases of subclavian dissection, thoracic aorta dissection involving the subclavian artery, and subclavian artery pseudoaneurysm [5]. MRI is helpful in patients with impaired renal function but its utility is limited in cases of suspected occlusion of the subclavian artery.

INVASIVE EVALUATION

Angiography

Digital angiography of the subclavian artery remains the gold standard for assessing any significant stenosis. In patients undergoing angiography for coronary arteries, and venous and arterial grafts, subclavian artery angiography, even in the absence of clinical symptoms, should always be performed to detect possible subclavian artery stenosis [6]. The technique through the femoral approach includes the following:

- 1 Study of the thoracic aorta and subclavian artery takeoff by contrast injection through a pigtail catheter positioned in the ascending thoracic aorta in anteroposterior (AP) projection: A 5-French (Fr) catheter is preferable to a 4-Fr catheter due to the larger amount of injectable contrast (25 ml is usually enough).
- 2 Study of the subclavian artery itself by a 5-Fr Judkins right (JR) or multipurpose (MP) diagnostic catheter placed at the ostium of the subclavian artery (10 ml is usually enough).

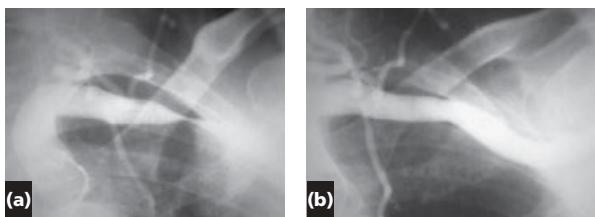


Figure 21.1 The angiographic appearance in thoracic outlet syndrome: (a) Subclavian stenosis during subclavian angioplasty in a patient scheduled for internal mammary graft for triple coronary vessels disease. (b) After having been asked to move the arms behind the head, there is a complete relief of the stenosis.

- 3** Use of multiple projections: First, the AP and then ipsilateral oblique projection to exactly assess the origin of the artery and its correlations with the vertebral and internal mammary arteries.
- 4** Manual pullback with a diagnostic 5-Fr catheter from distal to proximal subclavian artery to detect pressure gradient: 25–30 mmHg of gradient is usually recorded for significant stenosis. When a stenosis of the body of the subclavian artery is detected, be sure that it is not a case of thoracic outlet syndrome by asking the patient to move the arm up behind the head and then check the flow (Figure 21.1).

Intravascular Ultrasonography

When the length and severity of the stenosis could not be assessed accurately by angiography, intravascular ultrasonography (IVUS) may help to define the lesion severity, plaque composition, and lesion length to select the correct balloon–stent system.

STENTING

Access

Either the femoral or brachial access may be used. A 6- or 7-Fr sheath should be placed according to the location of the lesion in either the right or the left subclavian artery. Brachial access may be preferable in cases of total occlusion or in patients with coronary–subclavian steal syndrome. The brachial or radial approach is mandatory to cross the occlusion segment at the ostial or proximal part of the subclavian artery, because the guides and wires engaged in the aortic arch are usually unable to provide enough backup and penetrating force. If the takeoff of the subclavian or innominate artery is at such a steep angle to the aorta or when severe aortoiliac disease is present, brachial access is preferred. The low brachial approach near the olecranon fossa is better because of the difficulty in holding pressure to the brachial artery in the upper arm [7]. The axillary approach is not used because of possible brachial plexus injury from a hematoma: The main cause for recanalization failure is the creation of the subintimal false lumen with a wire. IVUS can play an important role in controlling the wire position during recanalization [8].

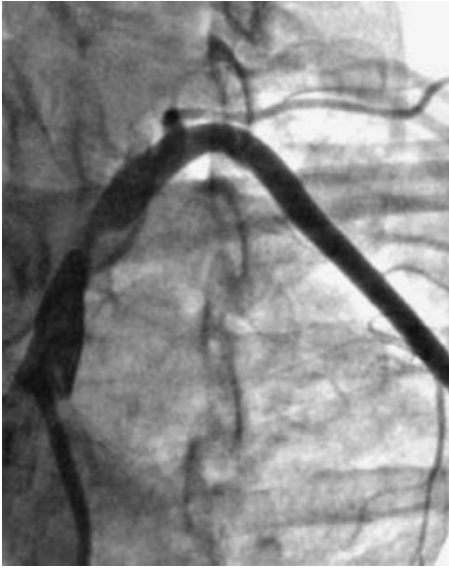

Figure 21.2 Catheterization of the left subclavian artery through a standard multipurpose guide.

Guide

Usually a 5-, 6-, or 7-Fr JR or MP guide offers good support and is quite atraumatic. Sometimes, in case of angled takeoff, a Sidewinder or Vitek guide is very helpful. Catheterize the subclavian artery by positioning the guide in the aortic arch. Slowly rotate the guide clockwise to lift its tip upward and to engage the subclavian ostium. In case the tip engages the right subclavian artery, do not pull the guide from the right subclavian to the left common artery because it may lead to dissection or embolization from the plaque (Figure 21.2). Just remove it from the right subclavian artery first, then reorient the guide to engage the left subclavian.

Once in place, check the position with an injection of 5–7 ml contrast and take a reference pictures. A roadmapping technique is quite useful to avoid excessive contrast injection and to ensure correct wire placement.

Wires

A 0.035-inch soft-tip performable wire such as the Storque can be used in cases of non-subocclusive stenosis; a 0.014-inch, high-support hydrophilic coronary wire may be selected in cases of subocclusive disease, when predilation is needed or a protection filter has to be placed [9,10]. Place the wire in a safe position, distal to the cervical and mammary artery; check the position with a small contrast injection or using a roadmapping technique. Protect the vertebral artery when the subclavian stenosis is closed to the origin of the vertebral artery: a non-hydrophilic 0.014-inch wire should be advanced into the vertebral artery.

Technical Tips

***Crossing the lesion** Pre-form the wire tip as a smooth J curve: avoid a too-angled wire shape that may lead to ostial dissection. Be gentle with wire manipulations to avoid causing the wire to dissect across the ostium. If a dissection occurs, stop and have the patient return at a later date [7].

****Sheath or guide** Whether with a guide or a sheath, it is important never to compromise the ability to inject contrast material for visualizing the lesion in relation to the balloon or stent catheter. Likewise, it is essential to obtain the best angle to see the takeoff of the vessel in relation to the aorta. It is also crucial to have the best angle to visualize the takeoff of key vessels (vertebral, common carotid, or internal mammary arteries). As a result of respiration, roadmap images are not often helpful [7].

****Telescoping the guide or the sheath** With the wire past the lesion, remove the diagnostic catheter and advance the long sheath (6–7 Fr) or the guide (7–8 Fr) just proximal to the lesion. If the diagnostic catheter is extra long (125–135 cm), telescope the sheath or guide over the diagnostic catheter and save a step. Never advance the sheath over and past the lesion [7].

Distal Protection

When a filter is needed, as in cases of previous embolic episodes or in the presence of a soft, ulcerated plaque (Figure 21.3a), an eccentric filter is preferred, at least when the subclavian artery diameter is about 5–7 mm. Select a concentric filter when the diameter of the vessel is about 7–9 mm. The indication for neuroprotected PTA is a tight stenosis (especially a soft plaque) involving the origin of the vertebral or right common carotid artery, with residual antegrade flow in the vertebral or right common carotid artery [8]. Patients with antegrade vertebral flow may be particularly vulnerable to cerebral embolization during vertebral and carotid angioplasty, indicating that retrograde flow in vertebral artery plays a protective role against brain embolization. Individuals with a large soft plaque involving the origin of the

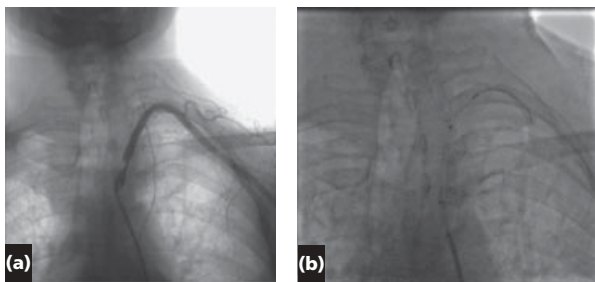


Figure 21.3 (a) A soft embolizing plaque is detected on subclavian artery angiography. (b) Filter wire has been selected and placed proximal to the internal mammary artery.

vertebral artery and no subclavian steal are at particularly high risk of brain embolization. In such patients the double-balloon kissing technique using a (preferably proximal) neuroprotection system should be considered [8].

Place the filter proximally to the origin of the vertebral artery if there is enough space or distally to the internal mammary artery if there is no bypass graft with the left internal mammary artery (Figure 21.3b). Placing a double filter for a vertebral and distal subclavian artery is very challenging and difficult. Most of the time, protect the vertebral artery with only a non-hydrophilic wire and the distal subclavian artery with a filter. However, in lesions involving the vertebral origin, the need to remove the protection device before subclavian stenting limits its application [8].

Balloons

Predilation may be needed when dealing with subocclusive disease, so the stent is not stripped during tight passage. Inflate the balloon slowly (1 atm/2–3s) and watch as the lesion is being modified. Avoid high pressure, especially in case of highly calcified lesions: 6–9 atm is usually enough. Unlike other major arteries, the origin of the subclavian artery is somewhat fragile, so always be cautious not to overdilate this vessel for fear of rupture, which can have catastrophic results [7].

Stents

Stent use has become the standard of care in subclavian stenosis endovascular repair, because simple angioplasty resulted in too much restenosis [10]. Stent types and sizes differ according to lesion diameter, length, and morphology. Focal, calcified, ostial stenosis can be simply managed with a stainless steel balloon-expandable stent: It can be simply expanded into the ostium and its placement is easy without excessive contrast injection, thanks to its excellent radioopacity and radial force. Long or soft lesions involving the ostium can be treated with a nitinol self-expandable stent: Their placement is more difficult because of the risk of missing complete coverage of the ostium, but the close design of the strut minimizes the risk of plaque shift and embolization.

Technical Tips

****Selection of stent** For lesions involving the proximal segments of the left subclavian, left common carotid, and especially the innominate artery, we always use a balloon-mounted stent. The chance of compression and deformation of the stent is low. Self-expandable stents are not chosen because of the inability to be exactly precise in a region where millimeters count. Furthermore, there is the possibility of stent migration with the self-expandable stents [7].

****Stent positioning** Another feature to be aware of is dramatic aortic pulsations when deploying a stent. If there is a large gap in diastolic and systolic blood pressures, there can be an excess of pulsations of the vessels. These pulsations can cause large motions (≥ 1 cm) in the position of the lesion relative to the

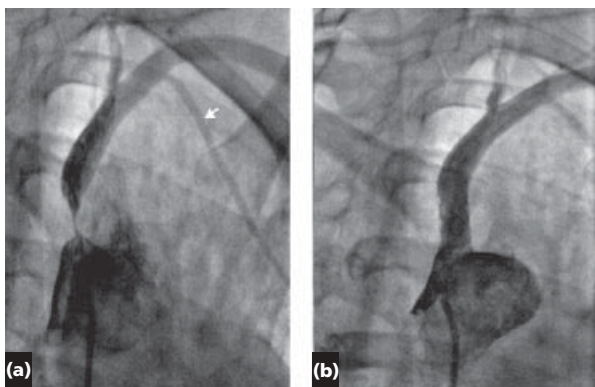


Figure 21.4 Stenting of an ostial subclavian artery stenosis: (a) Baseline and (b) final result using a balloon-expandable stent.

balloon catheter or self-expanding stent when trying to deploy. Blood pressure control is essential in these patients, as well as the need for slightly longer stents [7].

****Perfect stenting** For a stainless steel stent, be sure to maintain the stent 2–3 mm out of the ostium into the aorta (Figure 21.4). Be sure that important vessels such as the internal mammary and vertebral arteries are not compromised. When using a balloon-expandable stent, it is sufficient to have a diameter slightly inferior to the vessel size: Most balloon-expandable stents can be expanded to the correct size with postdilation balloons and minimal shortening. This ensures a safe procedure and minimizes the risk of vessel dissection or rupture. When using a self-expandable stent, select one with a diameter equal or slightly superior to that of the vessel. Maintain the stent 3–4 mm out to the ostium in the aorta to assure full coverage of the ostium. Check the position repeatedly with 4–5 ml contrast; avoid a roadmap technique during self-expandable stent deployment. If you have protected the vertebral artery, inflate the stent to nominal pressure, then place the subclavian wire into the vertebral artery and pass the vertebral wire into the subclavian artery. Hold the balloon tightly because of movement from the aortic arch pulsations and then deploy the stent quickly to approximately 8 atm [7]. Repeat the angiogram to assess the stent apposition to the vessel diameter. Perform a kissing balloon if needed (3.5 mm in diameter balloon is usually sufficient for the vertebral artery).

Postdilation

Postdilation is usually required, especially in cases of ostial stenosis. Monorail peripheral balloons 7–9 mm in diameter help to achieve good results. If a 0.035-inch system has been used, be sure that the length of the balloon catheter is at least 120 cm, because, normally, peripheral balloon catheters are 80 cm in length.

Technical Tip

****Postdilation** First inflate the stent, deflate and then withdraw the balloon until at least half outside the proximal end of the stent, and inflate to flare the ostial portion of the stent. Do not use high pressures: 8–10 atm is usually effective. Higher pressure can make the balloon slip out of the stent and damage the distal subclavian artery. Be happy with the results if the gradient across the lesion falls to almost 0, even if the angiographic result does not look satisfactory. Restenosis is unlikely for stents of diameter >6–7 mm.

Distal Subclavian Axillary Lesions

When there is indication for intervention, angioplasty is generally preferred at the crucial areas, such as between the first rib and clavicle, as well as at the subclavian/axillary junction where there is bending and compression. When the lesion does not respond to angioplasty, then self-expanding stents, such as Wallstents and nitinol stents, should be used. The stent should be oversized by 1–2 mm more than the vessel diameter, and delivered and deployed through a long 7- to 8-Fr sheath. Interestingly, there is a lot of slack that must be removed when deploying self-expandable nitinol stents. Furthermore, care must be taken to watch the proximal end of the stent, which tends to jump or shrink further distally than planned [7].

Innominate Artery Lesions

The technique for innominate artery lesions is similar to stenting the left subclavian and left common carotid arteries. Attention must be given to the bifurcation of the right common carotid and the right subclavian arteries. For disease that exists at the origin of the vessels, kissing stents may then be required. There has been some debate about the use of distal embolic protection in treating right subclavian artery disease, especially if the disease is close to the ostium of the subclavian artery. Distal protection should be used with a filter placed in either the internal carotid artery or the common carotid, depending on the carotid diameter and filter size available. The 7.5-mm Guidant AccUNET is often large enough to protect patients with small common carotid arteries [7].

Associated Vertebral Disease

Associated vertebral artery can be treated concurrently with subclavian artery stenosis using kissing balloon technique and T-stent technique if needed; however, it is very rarely required to treat the vertebral and subclavian arteries together. The double-balloon or stent procedure can be useful only in cases of very close proximity of a diseased vertebral artery and in the presence of clear clinical indications (e.g. contralateral vertebral occlusion) [9].

Subclavian Total Occlusion

Subclavian artery recanalization remains a debatable issue: The complication rate is higher than for subclavian artery stenosis and the results are somewhat inferior even in the stent era. In cases of chronic occlusion, the rules to be followed are the same with

regard to catheter, balloon, and stent selection, whereas approach and guide selection differ substantially.

Technical Tips

****Preferred vascular access** The presence of a nipple favors the femoral approach whereas the absence of a nipple makes the brachial approach the preferred one. The ideal wire is the hydrophilic 0.035-inch wire in almost all cases. Therefore, high-support, hydrophilic, 0.014-inch coronary wires may be selected in specific cases. In very difficult cases, a long wire between the brachial and femoral arteries, therefore creating a strong arterial loop, may help to advance the balloon–stent system through heavily calcified lesions. Be sure that the patients really need such procedure. It is better if you have a vascular surgical second opinion and stand-by. Be careful when advancing the wire: Check the position in two orthogonal planes. If the wire position is not certain, exchange the wire with a 4- or 5-Fr hydrophilic exchange catheter (Glidecath) and inject from the catheter itself. Use of a rheolytic thrombectomy catheter or manual aspiration catheter through a 7- to 8-Fr large lumen guide may be useful in recanalizing an acute or subacute occlusion, a very rare occurrence. Stent implantation is usually performed after recanalization to stabilize the plaque.

CASE REPORT

Coronary–Subclavian Steal Syndrome

A patient undergoing coronary bypass grafting with the left internal mammary artery (LIMA) may develop a coronary-subclavian steal syndrome because of a left subclavian artery (LSA) stenosis. Usually, stenting of the LSA is performed by the femoral route with a guide technique. This technique has clear drawbacks in cases of coronary–subclavian steal due to the poor opacification of the LIMA ostium, and difficult access to it in cases of plaque shifting, especially when the vertebral artery and the LIMA ostia are very close to the LSA stenosis. In this situation, subclavian angioplasty and stenting should be performed from the left brachial artery access [11,12].

*****Monitoring the intervention with contrast injection through the sheath** Use as a 6- or 7-Fr guide with a 45-cm-long, valved, anti-kinking sheath such as the Super Arrow Flex sheath or the Cook Shuttle Check Flow: Insertion of the long sheath should be monitored under fluoroscopy during the advancement to the subclavian artery ostium. It is preferable to use an hydrophilic anti-kinking sheath such as the Arrow or Cook to minimize the arterial damage (Figure 21.5a). Choose the diameter of the sheath to allow for injecting sufficient contrast volume through the sheath itself, even when the balloon catheter is inside during deployment of the stent. Place the sheath just before the LIMA graft ostium and engage the lesion with a 0.035

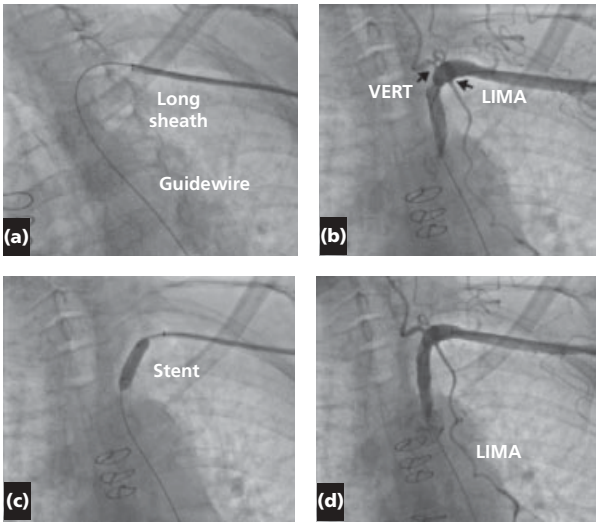


Figure 21.5 Subclavian artery tight stenosis in a 70-year-old woman. (a) Advancement of the long sheath to the lesion site. (b) Baseline angiography: The stenosis is very closed to the left internal mammary artery (LIMA) and vertebral artery origin (arrow). (c) Genesis stent deployment. (d) Final result after angioplasty and stenting: The LIMA and vertebral artery are perfectly patent.

inch \times 260 cm Storq wire and lead it to the descending aorta (Figure 21.5b). A balloon-expandable endovascular stent or a self-expandable stent can be implanted. It is important to check the correct position by direct contrast injection through the long sheath (Figure 21.5c).

This technique may be considered the optimal route to treat coronary–subclavian steal syndrome because of clear advantages: No manipulation of the catheter to cannulate the artery, perfect coaxial position of the catheter at the site of the LSA stenosis, clear visualization of the LIMA and vertebral ostia, and easy access to these vessel in cases of plaque shifting or embolic protection device deployment. Moreover, the procedure can be accomplished with a very little contrast and probably similar stenosis visualization to the standard femoral route.

Injuries and pseudoaneurysm Subclavian pseudoaneurysm can be approached by the femoral route through an 8-Fr guide due to the bigger size of the guide needed to advance the covered stent. The procedure can be performed easily as described above for standard subclavian artery stenosis. Rupture of the subclavian artery constitutes a life-threatening condition in which interventional techniques are sometimes useful in minimize operative stress and operation time, particularly in cases of complex multi-trauma settings.

*****Stenting of subclavian traumatic injury** Use the femoral route because the brachial route may be inaccessible due to pulse loss. Be sure to place the wire in the true lumen of the vessel by placing it in the descending aorta. Select stents of over-estimated length to be sure to cover the lesion. Obtain a venous access and then check the status of the subclavian vein: Often the rupture also involves the vein.

CASE REPORT

Stenting for injury-related subclavian–arterial venous fistula

A young man sustains a 1-cm stab wound in the supraclavicular fossa. An emergency aortic arch angiogram confirmed a large arterial venous fistula, but dilution of contrast made accurate definition of the anatomy very difficult. A catheter was then navigated into the innominate artery, and high-volume contrast angiograms were performed, further defining the fistula. Selective angiography of the thyrocervical trunk and ipsilateral internal mammary artery was performed without difficulty. This confirmed that the arterial venous fistula was distal to the origin of these vessels. Further manipulation of the catheter allowed advancement through the arterial venous fistula into the superior vena cava. The catheter was then gently retracted while injecting and ultimately returned into the subclavian artery. Over a 0.035-inch exchange length anchor wire, a 10-mm balloon was advanced into the origin of the subclavian artery based on anatomic landmarks, where it was inflated at a very low pressure. The patient hemodynamically stabilized within 2–3 min of balloon inflation. The stent graft was prepared, and immediately after balloon deflation via a 9-Fr sheath, a 9-mm self-expanding Wallgraft was positioned in the left subclavian artery, where it was deployed using meticulous fluoroscopic guidance and anatomic landmarks without difficulty. Finally, the 10-mm balloon was again inflated at low pressure in the stent-grafted segment and final angiography showed no evidence of an endoleak [13].

Complications

Complications may occur at different levels: Brain complications such as transient ischemic attacks or even strokes; acute upper extremities ischemia, of which the main causes are distal embolization, arterial dissection, or rupture; subacute stent thrombosis. Prevention of such complications can be obtained following clear rules, being careful at every procedural step, accurately planning the procedure, and being aware of any potential complications.

Advanced and Exotic Techniques

Occlusion of a subclavian artery causing acute myocardial infarction A 64-year-old man with history of coronary artery bypass graft (CABG) including a LIMA to the left anterior descending artery (LAD) presented with severe chest pain. The initial ECG demonstrated an acute anterior ST myocardial infarction. Angiography of the coronary vessels and aortic arch revealed an occlusion at the ostium of the left subclavian artery, with no

flow into the LIMA and LAD. There was normal flow identified in the left common carotid artery and innominate artery, with no retrograde filling identified in the left vertebral artery. An 8-Fr MP guide was inserted with a 035-inch guidewire used to cross the thrombotic occlusion of the ostium of the left subclavian artery. A balloon catheter was used to dilate the lesion and a stent deployed at the occlusion site. The angiographic result at the end of the procedure was excellent, re-establishing antegrade flow into the LIMA and LAD. On reperfusion the patient became pain free with significant resolution of his ECG changes [14].

Aneurysmal exclusion of subclavian artery A 72-year-old man presented to the emergency department with a possible mediastinal mass on chest radiograph. CT of the chest revealed a large, right-sided, subclavian artery aneurysm measuring 5.3 cm in diameter, arising just distal to the origin of the common carotid artery. The aneurysm was noted to encroach on the trachea and esophagus with significant associated tracheal compression. Selective angiography of the right subclavian artery confirmed that the aneurysm had a short proximal neck just distal to the takeoff of the right common carotid artery. The ipsilateral vertebral artery was occluded and selective angiography of the dominant left vertebral showed excellent crossover support to the right posterior cerebral circulation. The right femoral artery was cannulated and an exchange-length guidewire was advanced into the aneurysm through a diagnostic catheter and, with some difficulty, navigated into the distal portion of the aneurysm. A 12-Fr sheath was inserted into the right brachial artery and a 10-mm snare was introduced retrograde into the aneurysm to facilitate capture of the aforementioned guidewire. The distal end of the wire was cautiously extricated to avoid injuring the subclavian artery, and finally the wire was extended from the femoral artery to the brachial artery. A retrograde approach for insertion of the stent graft was used due to the short proximal neck of the aneurysm and concern about the accuracy of placement, including the potential risk of occluding the ipsilateral carotid artery. Embolization of the vertebral artery to avoid retrograde collateral endoleak was not necessary because the vessel was occluded at baseline. When the position was confirmed by fluoroscopy, the Wallgraft was partially deployed at the origin of the right subclavian artery. A soft-tip wire was then inserted in the proximal portion of the stent graft via the femoral approach and a 9-mm balloon was used to anchor the proximal portion of the device in place. After proximal fixation was assured, the stent was deployed completely. A bare metal stent was then placed in the proximal neck to prevent migration of the stent graft during subsequent manipulation. A final arteriogram was performed and showed no evidence of endoleak [15].

Coronary steal syndrome aggravated by arteriovenous fistula A patient with chronic renal failure treated with dialysis underwent CABG with a LIMA to the LAD. He was well and free of any angina until this presentation. Physical examination showed a systolic blood pressure difference between the right

(150/70 mmHg) and left (90/60 mmHg) arms of 60 mmHg. A Doppler study showed reversed flow in the left vertebral artery and normal cephalic flow in the right vertebral artery, suggestive of significant left subclavian artery stenosis. As the reverse flow in the left vertebral artery might be secondary to the high flow in the ipsilateral arteriovenous fistula (AVF), magnetic resonance angiography (MRA) was arranged to delineate the anatomy of the supra-aortic arteries. MRA documented severe stenosis at the origin of the left subclavian artery with subclavian steal syndrome. The critical left subclavian artery ostial stenosis resulted in significant pressure drop in the proximal part of the artery. This resulted in flow reversal in the ipsilateral vertebral artery as documented by Doppler, MRA, and contrast angiography. While hemodialysis was performed via an AVF in the ipsilateral forearm, blood was withdrawn from the left upper arm, which would cause reduction in flow in the LIMA and flow reversal in the left vertebral artery. This was clinically manifested as angina and dizziness during hemodialysis. Percutaneous recanalization and stenting of the left subclavian artery abolished the pressure drop in the proximal subclavian artery, and hence resulted in antegrade flow down both the left vertebral artery and the LIMA [16].

Open the total occlusion subclavian artery for central percutaneous coronary intervention access A patient with severe coronary artery disease was seen and an angiogram showed total occlusion of both iliac arteries and both subclavian and innominate arteries. Given the length of the right axillary artery occlusion and the unknown length of both iliac occlusions, the chance of short-term success in these regions was felt to be lower than that of the left subclavian artery, which showed the shortest occlusion length. PTA of the left subclavian artery was performed via left brachial arterial access. With the support of a guide, a 0.035-inch angled Glidewire (Terumo) was successfully used to cross most of the length of the totally occluded left subclavian artery. Despite multiple attempts, the angled tip of the Terumo wire failed to cross the final few millimeters of the occlusion. After confirming proper angulation of the headhunter catheter in multiple orthogonal views, final access into the aorta was achieved by advancing the stiff end of the Terumo wire through the occlusion. The headhunter catheter was advanced over the wire into the ascending aorta and the wire was removed. A 0.014 inch \times 300 cm Platinum Plus wire was advanced into the aorta through the headhunter, after which the headhunter was removed. PTA of the subclavian artery was then performed. Post-PTA angiogram revealed a 70% residual stenosis, creating a channel adequate enough to provide central access for subsequent successful coronary angiography and interventions [17].

REFERENCES

1. Rigatelli G, Rigatelli G. Vascular profile of patients with multivessel coronary artery disease. *Int J Cardiol* 2006;**106**:35–40.

2. Rigatelli G, Roncon L, Bedendo E, et al. Concomitant peripheral vascular and coronary artery disease: a new dimension for the global endovascular specialist? *Clin Cardiol* 2005;**28**:231–5.
3. Rigatelli G, Zanchetta M. Endovascular therapies for noncoronary atherosclerosis in the elderly: supra-aortic vessels and thoracoabdominal aorta lesions. *Am J Geriatr Cardiol* 2005;**14**:142–7.
4. Finlay DJ, Sanchez LA, Sicard GA. Subclavian artery injury, vertebral artery dissection, and arteriovenous fistulae following attempt at central line placement. *Ann Vasc Surg* 2002;**16**:774–8.
5. Prokesch RW, Coulam CH, Chow LC, Bammer R, Rubin GD. CT angiography of the subclavian artery: utility of curved planar reformations. *J Comput Assist Tomogr* 2002;**26**:199–201.
6. Rigatelli G, Rigatelli G. Screening angiography of supraaortic vessels performed by invasive cardiologists at the time of cardiac catheterization: indications and results. *Int J Cardiovasc Imaging* 2005;**21**:179–83.
7. Rigatelli G, Rigatelli G. Simultaneous preoperative brachiocephalic angiography and coronary angiography to prevent coronary-subclavian steal syndrome in coronary surgery candidates. *Heart Surg Forum* 2005;**8**:E175–7.
8. Przewlocki T, Kablak-Ziembicka A, Pieniazek P, et al. Determinants of immediate and long-term results of subclavian and innominate artery angioplasty. *Catheter Cardiovasc Interv* 2006;**67**:519–26.
9. Zaytsev AY, Stoyda AY, Smirnov VE, et al. Endovascular treatment of supra-aortic extracranial stenoses in patients with vertebrobasilar insufficiency symptoms. *Cardiovasc Intervent Radiol* 2006;**29**:731–8.
10. Criado FJ, Abul-Khoudoud O. Interventional techniques to facilitate supraaortic angioplasty and stenting. *Vasc Endovascular Surg* 2006;**40**:141–7.
11. Rigatelli G, Giordan M, Cardaioli P, et al. Subclavian artery angioplasty allows for implantation of the in situ internal thoracic artery graft in patients scheduled for surgical myocardial revascularization. *J Thorac Cardiovasc Surg* 2006;**131**:e9–10.
12. Rigatelli G, Cardaioli P, Giordan M, et al. Peripheral vascular disease endovascular management in patients scheduled for cardiac surgery: a clinical-angiographic approach. *Int J Cardiovasc Imaging* 2006;**22**:305–10.
13. Bates M, Campbell J. Emergent stent graft isolation of a knife-related subclavian arterial venous fistula: Lessons learned during long-term follow-up. *Catheter Cardiovasc Interv* 2005;**66**:483–6.
14. Barlis P, Brooks M, Hare DL, et al. Subclavian artery occlusion causing acute myocardial infarction in a patient with a left internal mammary artery graft. *Catheter Cardiovasc Interv* 2006;**68**:326–31.
15. Bates M, AbuRahma AF, Crotty B. Urgent endovascular surgery for symptomatic subclavian artery aneurysmal compression of the trachea. *Catheter Cardiovasc Interv* 2005;**64**:291–5.
16. Lee PY, Ng W, Chen WH. Concomitant coronary and subclavian steal caused by ipsilateral subclavian artery stenosis and arteriovenous fistula in a hemodialysis patient. *Catheter Cardiovasc Interv* 2004;**62**:244–8.
17. Yaneza LO, Sun LL, Bagsit NL, Baysa AN, Torres RN, Dy TC. Angioplasty of an asymptomatic total occlusion of the left subclavian artery to provide access for coronary angiography and intervention: A case report. *Catheter Cardiovasc Interv* 2004;**61**:310–13.

CHAPTER 22

Endovascular Repair of Abdominal Aortic Aneurysm

Aravinda Nanjundappa, Damras Tresukosol, Thach N. Nguyen

Challenges 518

Preoperative Imaging and Evaluation 519**Unfavorable Factors 519**

Proximal attachment site (aortic neck) 521

Distal attachment site 523

Anesthesia Preparations 523**Vascular Access 523****Technical Tip 523**

***The "preclose" technique 523

Equipment 523

The powerlink endograft 524

Advantages and Limitations 524

AneuRx 524

Excluder 524

Zenith 524

Technique Delivery of the Powerlink 525**Technical Tips 525**

**Difficulty in advancing the endocraft 525

Intraoperative imaging 525

Postoperative treatment 526

Complications 526**Endoleaks 526**

Type I endoleaks 526

Type II endoleaks 526

Type III endoleaks 527

Predictors of endoleaks 528

Graft migration 529

Predictors of migration 529

Endograft limb occlusion 529

Internal Iliac artery occlusion 529

Inadvertent renal artery exclusion 529

Technical Tips 530

**Correction of renal artery exclusion 530

Aortic side-branch ischemia 530

*Basic; **Advanced; ***Rare, exotic, or investigational

\$, <\$US100.00 extra; \$\$, >\$US100.00 extra

⌚, <10 min extra; ⌚⌚, >10 min extra

♣, low risk of complications; ♣♣, high risk of complications

Miscellaneous complications 530

Advanced and Exotic Techniques 531

Proximal fixation 531

Technical Tips 531

***Which side to introduce the delivery system to prevent angulation? 531

***How to bench test the endograft 531

***When to use the Palmaz stent 531

***The endowedge technique 532

***The kilt technique 532

Investigational Equipment 532

The Aorfix endovascular AAA repair system 532

The EndoRefix nitinol clips 532

The anaconda 533

Technical Tips 533

The aortic wrap technique 533

Advanced Technique 533

***Closure of endoleak with an Amplatzer 533

The aorta is the major vascular vessel between the left ventricle and the systemic arterial bed. The abdominal aorta starts below the diaphragm and ends by dividing into two iliac arteries. This part of the aorta is further divided based on the origin of renal arteries as suprarenal aorta and infrarenal aorta. The aorta is composed of three distinct layers: The intima, media, and adventitia. The intima is a smooth layer that lines the innermost surface of the blood vessel and prevents clot formation. It can be compared with a velvet lining. The media is a thick elastic layer intertwined with collagen and smooth muscle cells with sufficient elastic strength to withstand the pulsatile stress that occurs during the ejection of blood in systole. With aging, the elastic elements of the aorta degenerate, reducing elasticity and distensibility. This stiffness makes the aorta vulnerable to mechanical trauma and injury over time, and the endothelium disintegrates to expose the media. As a result, the aorta becomes enlarged. This enlargement is called an abdominal aortic aneurysm (AAA). The common causes of aneurysms include atherosclerosis, cystic medial fibrosis, syphilis, mycotic infection, rheumatic aortitis, and trauma.

CHALLENGES

The primary goal of endovascular repair of the AAA (EVAR) is the exclusion of the diseased aortic segment from the circulation without an abdominal incision. If the aneurysmal segment can be successfully excluded from arterial pressure blood flow, it is hoped that the risk of subsequent rupture will be significantly reduced.

PREOPERATIVE IMAGING AND EVALUATION

A contrast computed tomography (CT) scan using fine cuts (<3mm), in the axial, sagittal, coronal, and three-dimensional reconstructions is the imaging of choice for preoperative evaluation of the AAA before EVAR. In patients with severe renal insufficiency, contraindicating intravenous contrast, intravascular ultrasound (IVUS) can be used to size the aortic and iliac seal zones, evaluate potential eccentric thrombus in the aortic neck, and evaluate the external iliacs for occlusive disease.

The areas of consideration include (1) the diameter of the aneurysm neck, (2) the length of the normal aortic neck, (3) the location of the mesenteric arteries, particularly the celiac axis and the superior mesenteric artery, and (4) the proximal neck angulation. Distally, the anatomic concerns include (1) the size of the iliofemoral arteries, (2) the presence or absence of calcification, (3) the tortuosity of the iliofemoral arteries, and (4) the presence of aneurysmal change in the iliofemoral arteries. The selection criteria for EVAR are listed in Box 22.1.

Unfavorable Factors

Unfavorable neck anatomy is the primary factor for exclusion from endovascular repair. If the angle between the neck of the aneurysm and the aorta is too acute (>60° angle between the infrarenal aortic neck and the longitudinal axis of the aneurysm), the graft may be displaced from its intended position with a subsequent leak at the attachment site (Figure 22.1). Similarly, if the common iliac arteries are too large, the limb of the stent may not be well apposed to the wall of the artery, and a leak at the attachment site will result [1]. Most operators consider the relative contraindications for EVAR in Box 22.2.

BOX 22.1 SELECTION CRITERIA FOR ENDOVASCULAR REPAIR OF THE ABDOMINAL AORTIC ANEURYSM (EVAR)

- 1 Adequate iliac/femoral access
- 2 Infrarenal non-aneurysmal neck length of at least 1 cm at the proximal ends of the aneurysm, and a vessel diameter 10–20% smaller than labeled device diameter
- 3 Morphology suitable for endovascular repair:
 - (a) aortic diameter >5 cm
 - (b) a diameter of 4–5 cm and has increased in size by 0.5 cm in the last 6 months
 - (c) twice the diameter of the normal infrarenal aorta
 - (d) infrarenal neck >10 mm from the lowest renal artery
 - (e) proximal aortic neck angulations <60°
 - (f) iliac artery diameter sufficient for placing a 19-Fr sheath or >7 mm diameter
 - (g) iliac artery angulations <120°

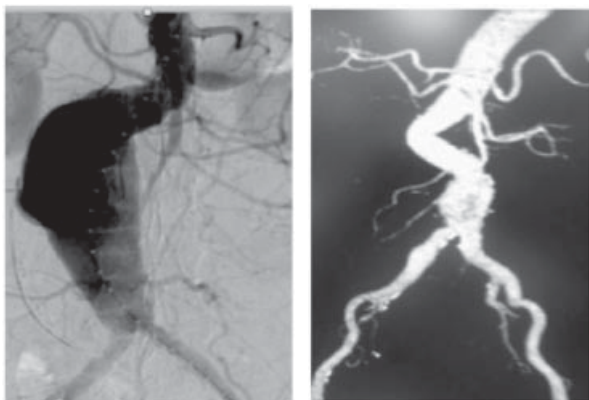


Figure 22.1 Angled necks.

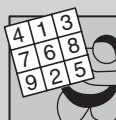
BOX 22.2 CONTRAINDICATION OF ENDOVASCULAR REPAIR OF THE ABDOMINAL AORTIC ANEURYSM (EVAR)

- 1 Proximal neck <15 mm
- 2 Infrarenal aortic diameter <26 mm
- 3 External iliac diameter <7 mm or >16 mm
- 4 Bilateral internal and external iliac aneurysms

STRATEGIC MAPPING

Anatomic considerations for selecting a patient for EVAR relate to: (1) Suitability of proximal and distal attachment sites, (2) adequacy of access arteries, and (3) the presence of side branches of aortoiliac circulation to be excluded from the systemic circulation.

When planning procedures, the operators should choose the side of access that facilitates the advancement of devices. The iliac arteries should cause the least degree of twists and crookedness of the device within the proximal neck to maintain the longitudinal and rotational ability with the delivery system. What appears to be an initially easy approach may cause the device to bend awkwardly. The operators should plan the full approach with this in mind. The operators should also be cautious about angulation within the target branch and should design grafts using centerline of flow analysis. Axial images, when incorporating branches, provide inadequate data for device design. When



considering branches or fenestrations to improve long-term results, devices that will not migrate should be used. Branch stents need to be strong enough to prevent migration because they will be crushed if the aortic device descends even only 3 mm. The operators should ensure that the proximal seal and fixation systems are within the healthy aorta. Significant overlap of modular systems can also improve long-term results. Overlap can serve as a stress relief mechanism to minimize migration risk [2].

Proximal attachment site (aortic neck)

The major anatomic factor in predicting suitability for EVAR is the character of the aortic neck. The most acceptable method of proximal endograft fixation is deployment at the level of the renal arteries, also known as infrarenal fixation. This is performed in the non-dilated portion of the infrarenal aorta proximal to the aneurysm sac, commonly known as the aortic neck. According to the instructions for use of endografts with infrarenal fixation, an infrarenal neck at least 15 mm in length and <32 mm in diameter with an angulation <60° is required for optimal sealing. The recommendations for Talent or Endurant stent graft system require a minimum 10 mm of infrarenal aorta neck for adequate proximal fixation [3]. As the aortic neck is the first place where the endograft excludes the aneurysm from systemic circulation, it is imperative to have a suitable aortic neck for effective device deployment. The considerations that may make a patient unsuitable for EVAR include an aortic neck that is too short, too tortuous, or too wide, or conditions such as the presence of excessive calcification or a thick layer of thrombus at the level of aortic neck [4] (Figure 22.2). A hostile neck is defined in Box 22.3.

Suprarenal fixation has been proposed as a more effective means of proximal fixation, especially when morphological features of aortic neck are unfavorable. Despite the potential advantages of suprarenal fixation, there have been concerns about short- and long-term risks of renal or mesenteric artery embolization and occlusion.

BOX 22.3 COMPONENTS OF A HOSTILE NECK

Length <10 mm
 Angle >60°
 Diameter >28 mm
 ≥50% circumferential thrombus
 ≥50% calcified neck
 Reverse tapering (Figure 22.3)

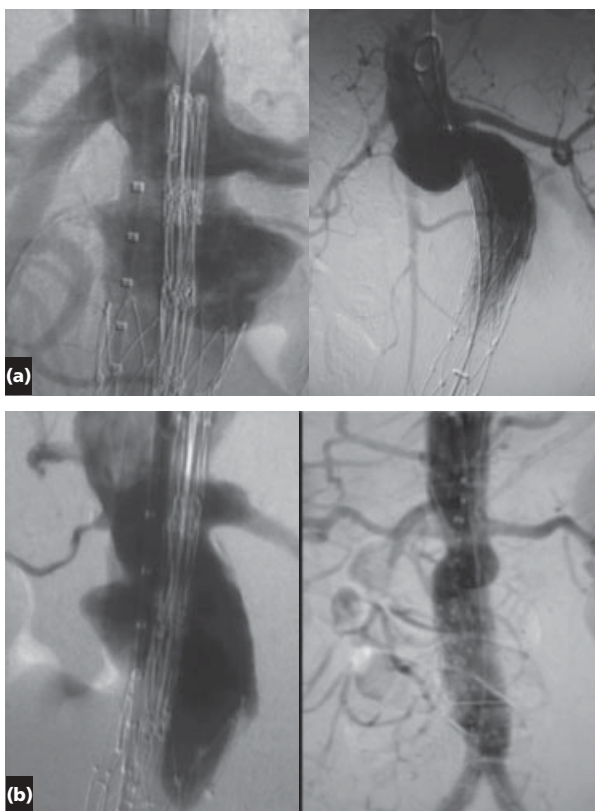


Figure 22.2 Short necks.

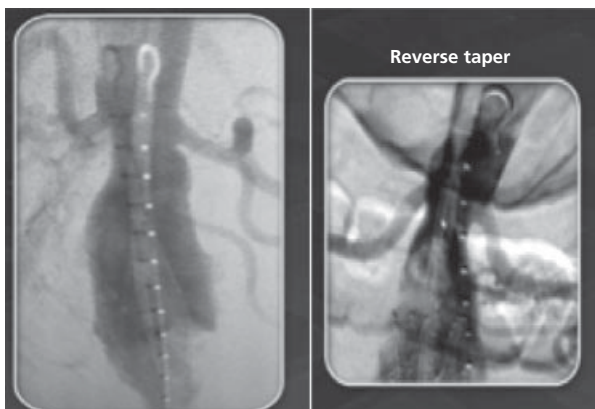


Figure 22.3 Reverse taper.

Distal attachment site

Bifurcated endografts are currently used in more than 95% of abdominal EVAR cases. In these the distal attachment, also known as the distal landing zone, is preferably in common iliac arteries, allowing antegrade perfusion of hypogastric vessels. However, in cases of too short or aneurysmal common iliac arteries, distal attachment can be at the level of external iliac vessels, in which case hypogastric coil embolization is recommended to decrease the chance of type II endoleak.

ANESTHESIA PREPARATIONS

An arterial line and a central venous line are placed. Palpable or Doppler pulses are noted on all four extremities. The preoperative creatinine/glomerular filtration rate (GFR) and the hematocrit are noted. The procedure has been done under local, regional, and general anesthesia based on the comorbidities of the patient.

VASCULAR ACCESS

Access to the femoral arteries can be obtained in an open or percutaneous fashion. Open access to bilateral femoral arteries using bilateral groin incision is a well-established and time-tested method. It also allows for the possibility of performing an endarterectomy or patch angioplasty to gain access in cases of femoral arterial occlusive disease. Delivery catheters of aortic endografts from most manufacturers have an outer diameter ranging from 18 Fr to 26 Fr, and easily traverse iliac segments as narrow as 5.5–7.5 mm in diameter.

With the advent of vascular access micro kit, percutaneous access to femoral arteries is increasingly being used with a low incidence of early and late access site complications.

Technical Tip

*****The “preclose” technique** Two Perclose ProGlide devices: The first device is deployed with a 30° medial rotation and the second with a 30° lateral rotation, while maintaining wire access. This technique places a single monofilament suture proximal and distal to the puncture site. The sutures are exteriorized and tagged for closure of the arteriotomy at the completion of EVAR. Anterior wall calcification and severe fibrosis of the access vessel are predictors of primary failure of this technique, whereas obesity and sheath size are not.

EQUIPMENT

There are many types of endovascular devices for AAAs. The endografts are composed of prosthetic grafts and vascular stents serve as fixation devices. Furthermore, the stents are divided into self-expanding versus balloon-expandable types. The advantages of the self-expanding stent are ease of deployment and ability to accommodate the aortic neck enlargement. The

disadvantages are risk of neck enlargement and stent migration. The balloon-expandable stent helps to deploy the endograft at an exact location which is needed if the proximal neck is short and angulated.

The two important types are straight grafts and bifurcated grafts. If the aneurysm ends >2cm above the bifurcation of the aorta to the iliacs, a straight graft can be placed. Otherwise a bifurcated graft is used. Bifurcated grafts have many subtypes. Some of them have three pieces to construct; however, most use the two-piece system.

Currently, five endovascular stent-grafts are approved for clinical use in the USA: Zenith, AneuRx AAAAdvantage, Gore Excluder AAA Endoprosthesis, Powerlink, and Talent.

The powerlink endograft This is a unique unibody endograft, which contains the main body and bilateral iliac grafts for fixation. The Powerlink device does not require bilateral femoral cutdown, because percutaneous 9-Fr access can be used on the contralateral side for stent positioning.

Advantages and limitations Some operators prefer the single-piece system – the Powerlink unibody bifurcated stent graft. Mimicking the shape of the natural anatomy of the abdominal aorta, the Powerlink unibody bifurcated stent graft is uniquely designed to allow it to be implanted sitting on the anatomical abdominal aortic bifurcation. This is a single piece bifurcated system that can be safely deployed with a small incision on one femoral artery. The device is accessed percutaneously on the contra-lateral femoral artery.

AneuRx The AneuRx consists of a main bifurcated segment and a contralateral iliac leg. The main bifurcated segment can be deployed through a 21-Fr catheter and the contralateral leg can be delivered through a 16-Fr catheter. The device is available in aortic diameters of 20–28mm and iliac diameters of 12–16mm. As a result of the concern over the relatively high rate of endoleaks, surveillance imaging should be performed at 1, 6, and 12 months after implantation and yearly thereafter [5].

Excluder The Excluder is constructed of a durable expanded polytetrafluoroethylene (ePTFE) bifurcated graft with an outer self-expanding nitinol support structure to combine both device flexibility and material durability. The device is wrapped around the delivery system and tied with dental-floss-like thread. With the pull of a string the device self-expands to the diameter of the aorta and iliac arteries, sealing off the aneurysm. The device is delivered through an 18-Fr access sheath and the contralateral extensions are introduced via a 12-Fr sheath (the smallest delivery system available in the US market) [5].

Zenith The Zenith is a supported, bifurcated, self-expandable stent graft with multiple stainless steel Z stents placed inside the graft. It attaches to the vessel wall via barbs. It is unique in having

proximal stent for suprarenal fixation to prevent migration and enhance graft-to-vessel sealing. The delivery system utilizes an 18- or 22-Fr introducer sheath for the main body and a 14- or 16-Fr introducer sheath for the iliac limbs. The graft is available with proximal neck diameters ranging from 22 mm to 32 mm and the iliac extensions come in diameters of 8–24 mm [5].

TECHNIQUE Delivery of the Powerlink After vascular access, with a graded pigtail catheter, a preliminary abdominal aortogram is obtained. External markers are avoided because they are frequently misguided by the angulation of the abdominal aorta. Using the graded intravascular catheter, the correct length of the aneurysm (based on the intracavitary catheter length) can be calculated. The Powerlink devices have only two diameters (25 or 28 mm) of the main body and proximal cuffs suitable for the abdominal aorta [6]. This process makes it easy to determine the size after aortography, and oversizing 10–20% of the aneurysm neck is recommended. As both these sizes fit most of the clinical cases, device management by the staff is greatly expedited. This is then followed by bilateral iliac artery balloon dilation.

Once the iliacs have been dilated and lifted of the retroperitoneum we place a purse-string suture (5/0 polypropylene) in the common femoral artery around the 9-Fr sheath on the side of the open cutdown. This helps to minimize blood loss during sheath exchange because the purse string can be tightened without any injury to the blood vessel. Our intention now is to pass a wire from one femoral artery crossover to the other femoral artery. This is done by using an intravascular snare from one femoral artery placed in the abdominal aorta. The wire fed through the contralateral limb is captured and delivered to the ipsilateral femoral artery.

Over the wire, the crossover catheter (DL-35-90 Dual Lumen Catheter Powerlink system) is advanced from one groin to the contralateral groin. The EVAR device is then attached to the crossover catheter and delivered through the cutdown site into the abdominal aorta. The contralateral limb is delivered to the contralateral groin using the crossover catheter.

Technical Tips

****Difficulty in advancing the endograft** If there is difficulty in advancing the endograft, the operator uses the push/pull technique: Pushing the device forward while pulling the wire back. Manual compression on the abdominal wall prevents kinking of the endograft and helps to advance the device.

Once positioned, the device is then deployed and the completion angiograms are done. The proximal and distal ends of the graft are dilated by a soft compliant balloon to further secure the graft to the wall of the arteries. The vascular access sites are closed in the standard manner.

Intraoperative imaging During the procedure, excellent fluoroscopy and angiography are needed to avoid inadvertent occlusion of the mesenteric and renal arteries, and to document

the proximal extent of the endograft. After deployment of the endograft, angiogram could be done simultaneously through both sheaths so enough flow can opacify both iliac arteries.

Postoperative treatment The patients recover in the recovery room and are frequently sent to a telemetry floor. They get out of bed and walk the same day, and they eat the same day. The Foley catheter is removed by midnight and the patients frequently go home the next day. Preoperative medications are resumed. A follow-up CT scan of the abdomen and pelvis is done at 6-monthly intervals.

COMPLICATIONS

Several morphological and structural changes of the endograft after delivery and leading to failure include: Suture breaks between the stent and the graft, fracture of the hooks used to anchor the proximal end of the endograft to the aortic wall, circular and longitudinal stent wire separation, separation of the connection between wire loops, graft fatigue, device migration, component separation, and endograft or vessel thrombosis. Most of these failures manifest with an endoleak. It can be avoided by selecting the common femoral artery or external iliac artery for the entry site of the device. If the vessel is diseased, it may be prudent to have a 7-mm graft cuff anastomosed end to side to minimize the trauma due to repeated movement at the vascular access sites.

Endoleaks

Different types of endoleaks are classified according to the site and origin of blood flow into the aneurysm sac.

Type I endoleaks

These occur due to imperfect sealing of the endograft at its proximal or distal landing zone. This leads to antegrade flow of blood at systemic pressure into the aneurysm sac, resulting in a high risk of rupture. Consequently, there is no role of conservative management in these types of endoleaks and most of these should be identified and treated at the time as stent graft implantation (Figure 22.4). Distal type I endoleaks can easily be repaired by placement of distal extension, leading to a seal at the level of the external iliac artery. Proximal type I endoleaks are mostly secondary to less than ideal aortic neck anatomy or poor patient selection. Studies have shown that a hostile neck anatomy (defined earlier) results in a higher incidence of early (intraoperative) proximal type I endoleak and intervention. Deployment of a proximal cuff or bare metal 'Palmaz'-type stent at the site of proximal landing zone can be used to correct these types of endoleaks, although failure of endovascular techniques would frequently result in an open repair.

Type II endoleaks

These result from retrograde perfusion of the aneurysm sac, frequently from the patent lumbar arteries or the patent inferior

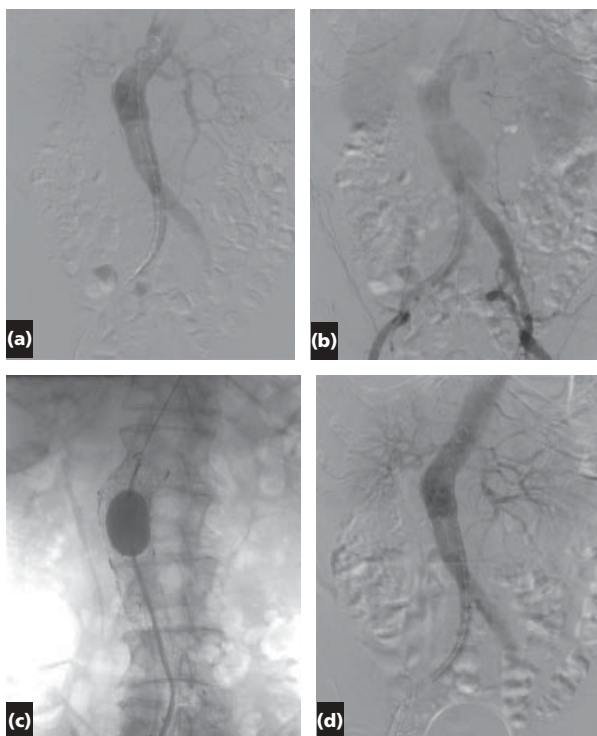


Figure 22.4 Endoleak type I.

mesenteric artery. Compared with the direct type I and type III endoleaks, type II endoleaks are indirect, and consequently low-pressure leaks are considered relatively benign with a low likelihood of sac expansion and rupture. Most of these type II endoleaks resolve spontaneously and can be followed up with serial surveillance CT scans. Aneurysm sac expansion and/or persistence of the endoleak is an indication for intervention for a type II endoleak (Figure 22.5). Transarterial coil embolization, open or laparoscopic suture ligation, and polymer embolization of the aneurysm cavity are the various treatment options.

Type III endoleaks

These are either secondary to tear in the fabric of the endograft or due to separation of its components, leading to a high-pressure leak into the aneurysm cavity with a high risk of rupture in the short term. As for type I leaks, these mandate an intraoperative correction, although progressive refinement of stent graft technology has made these leaks relatively rare. Imprecise sizing of the limbs leading to kinks is another cause of type III endoleaks (Figure 22.6). Treatment of type III endoleak requires deployment of an additional endograft at the site of component separation or fabric tear.

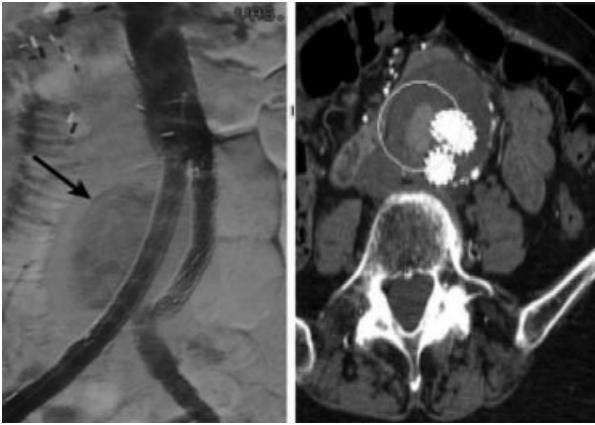


Figure 22.5 Endoleak type II.

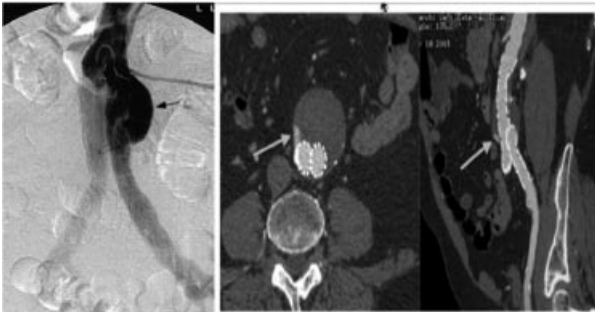


Figure 22.6 Endoleak type III.

Predictors of endoleaks

The most common predictors of endograft failure – resulting in type I endoleak and stent migration – are angulated and short infrarenal necks, large neck diameter, large maximal AAA diameter, neck thrombus, and complex iliac artery anatomy. The presence of extensive thrombus or excessive calcium deposition at the arterial implantation sites, specifically at the proximal aortic neck or common iliac artery interface, can prevent satisfactory anchoring of the stent graft and thereby increase the chance of migration and type I endoleak. Calcium or thrombus, or both, can compromise the fixation and sealing of the endograft at the implantation sites.

Postprocedural causes for the migration of stent grafts and for type I endoleak include aortic neck dilation, morphological changes of the aneurysmal sac enclosing the endograft (most notably longitudinal shrinkage), endograft shortening, and stent-

graft displacement secondary to proximal external compression. In addition to these postprocedural factors, the dimensions of the aneurysmal sac at the time of the procedure play an important role in endograft migration [7].

Graft migration

The stability of most of the EVAR grafts available is based on the ability of the hooks on the proximal part of the graft to cling to the aortic wall. Due to irregularities in the wall of the aorta and calcifications, the ability to secure the graft proximally can be inadequate. This is further exacerbated by the normal forward propulsion of blood flow and causes the graft to migrate distally. The Powerlink system uses a novel approach to minimize this problem. Apart from proximal fixation, the bifurcation of the graft is designed to seat at the normal aortic bifurcation. This gives additional fixation and prevents graft migration.

Predictors of migration

Similarly, an increased incidence of stent-graft migration has been associated with severe infrarenal neck angulation. Such severe neck angulation increases the incidence of type I endoleak by facilitating small leaks through the gaps between the stent and the neck. According to a bench-test study [8], stiffness of the stent also contributes substantially to stent migration in such patients. [7]

Endograft limb occlusion

Occlusion of the limb of the endograft can happen, usually 2 months after implantation. The patient presents with atypical leg discomfort, new-onset claudication, or acute limb ischemia. The treatment includes open or percutaneous thrombectomy to re-establish the flow to the lower extremities. Then the cause of the occlusion should be investigated and addressed such as limb kink, stenosis, distal dissection. The predisposing factors of limb occlusion are smaller limb diameter, limb stenosis, unsupported endografts, and the extension of the endograft into the external iliac arteries [9].

Internal Iliac artery occlusion

The internal iliac artery could be embolized as a staged procedure or it is excluded during the procedure. The complications are erectile dysfunction, and hip or buttock claudication. Other complications include scrotal skin sloughing, sacral decubitus ulcer, and intestinal ischemia. These complications happen more frequently if the profunda femoris artery is diseased, because the profunda is a major source of collaterals to these areas. So the decision of occlusion of the internal iliac artery should be evaluated well for risks and benefits [10].

Inadvertent renal artery exclusion

Right after deployment of the endograft, inadvertent renal artery exclusion could happen or be due to migration of the endograft.

If the endograft is not completely deployed, either resheathing or manually pulling the graft caudally may uncover the renal artery.

Technical Tips

****Correction of renal artery exclusion** Once the endograft has been fully deployed, the only option is to pass a wire across the aortoiliac bifurcation, from one femoral access, and externalize it through the contralateral access. Then pull the wire down to uncover the renal artery. A small catheter should be inserted over the wire before pulling the wire down, so that it does not damage the end-graft [10].

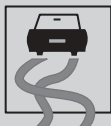Aortic side-branch ischemia Pelvic ischemia from obliteration of hypogastric vessels and type II endoleak, mainly from patent lumbar arteries, are two main issues related to obliteration of aortic side branches. As mentioned earlier, exclusion of the hypogastric artery (HA) is usually required during endovascular repair of aortoiliac aneurysms involving either the distal common iliac artery or the HA itself. Buttock claudication and erectile dysfunction are two complications most commonly associated with interruption of unilateral or bilateral hypogastric arteries during EVAR. The complications include persistent buttock claudication due to unilateral or bilateral hypogastric artery interruptions, impotence, ischemic colitis, colon necrosis in previously patent inferior mesenteric artery, previous colon surgery that has interrupted the collateral pathways from the superior mesenteric artery, or the superior mesenteric and celiac arteries are stenotic or occluded. In practice, colon ischemia is more likely to result from atheroembolism to the pelvic circulation than from proximal internal iliac artery occlusion [11].

Miscellaneous complications Contrast-induced nephropathy is a real risk in these patients, particularly because the volume of iodinated dye used in any given case can be highly variable. Furthermore, there is a risk of atheroemboli during deployment. The inadvertent obstruction of the renal arteries by the endograft is also a risk, particularly if there are accessory renal arteries that must be sacrificed. There have been rare case reports of graft migration cephalad with obstruction, which leads to acute renal failure.

Both mesenteric and pelvic/buttock ischemia can occur during EVAR. Although these can occur acutely, other than from embolization, this should be a fairly rare event. Careful imaging, localization, and even selective/staged embolization (when necessary) can help mitigate these complications. A few examples of anomalous mesenteric arteries and inadvertent endograft malposition have been described. This highlights the importance of personally reviewing and identifying all major arterial branches and accurately measuring lengths and diameters during the predeployment imaging studies.

CAVEAT

A major limitation of all endografts is the size of the deployment system required. Although there is a wide range of sizes, all potentially pose a risk. Patients with small, tortuous, and/or heavily diseased iliac arteries are at risk of iliac rupture or perforation. This complication can occur during any stage of the procedure but occurs most commonly during the insertion or removal of the deployment systems or sheaths. One should have ready access to an aortic occlusion balloon as a safety measure.

**Advanced and Exotic Techniques**

Proximal fixation To treat patients who have tortuous infrarenal neck anatomy, several manufacturers have modified their original designs to make the endograft more flexible. Some of the newer-generation endografts – the Zenith, the Excluder, and the Aorfix – also offer active fixation to the aortic wall with the use of barbs, clips, or hooks that are an integral part of the device [7].

Technical Tips

*****Which side to introduce the delivery system to prevent angulation?** As the anatomic causes of stent migration cannot be changed, success in preventing such migration lies in modifying the deployment technique and the design of the stent graft itself. Modifications in technique should begin with how the delivery system is introduced [12]. When the angulation, for example, is on one side of the coronal plane, introducing the delivery system from the side opposite the angle will facilitate passage at the top of the bend [7].

*****How to bench test the endograft** It is usually helpful to bench test the endograft to match the neck anatomy. Maneuvers such as bending the guidewire before introduction, to align it with the axes of the aneurysm and the neck, could be helpful [12]. Also of benefit is the use of a super-stiff wire, such as the 0.035-inch Lunderquist or the 0.035-inch Amplatz, in combination with slow and controlled deployment of the endograft [12]. It is not advisable to attempt to reposition the endoprosthesis after deployment has been initiated, because this increases the risk of migration. Several techniques have specifically applied the Excluder endograft to the prevention of distal migration and type I endoleak in patients who have severe infrarenal neck angulation, short infrarenal necks, or both [7,13].

*****When to use the Palmaz stent** In patients with complicated infrarenal neck anatomy, one of the techniques is the permanent deployment of the Palmaz XL stent in the infrarenal

neck before permanent deployment of the Excluder endograft. This technique has been shown to offer a reliable mode of Excluder fixation and prevention of distal migration. The combination of the use of the Palmaz XL stent after the deployment of the Excluder has also been successful in preventing type I endoleak and distal migration [7].

*****The endowedge technique** In patients who have short infrarenal neck anatomy, the “endowedge technique” also offers satisfactory juxtarenal sealing during Excluder endograft placement [13]. This technique enables the scalloped proximal 4mm of the Excluder endoprosthesis to be wedged against the renal angioplasty balloons, which are placed via the brachial approach. The first two to three rings of the endograft are slowly deployed (flowering technique), and then the device is advanced upward against the inflated renal balloons for the completion of deployment [7].

*****The kilt technique** In patients who have funnel-shaped or reverse-tapered aortic necks, an adjuvant procedure called the “kilt technique” is another possibility. In this technique, an aortic cuff is deployed in the distal infrarenal seal zone before the main body is deployed [13]. The proximal end of the Excluder contains barbs, which enable the device to remain above the aortic extension and thereby prevent distal migration. Careful inflation of an angioplasty balloon of the appropriate size then achieves the proximal seal of the prosthesis [7].

Investigational Equipment

The Aorfix endovascular AAA repair system

This is a newer-generation endograft that is designed to overcome problems with infrarenal neck anatomy. This device – currently undergoing clinical trials in the USA – is made of polyester material and is partially supported by nitinol frames. The proximal part of the Aorfix has incorporated nitinol clips for active fixation of the device to the aortic wall. The Aorfix has excellent procedural outcomes in terms of technical success, mortality rate, and avoidance of endoleak, migration, and stent-graft fracture [8,12]. This stent graft is very flexible and can conform to severely tortuous infrarenal necks. Due to its unique ring design, the Aorfix resists kinking, tolerates oversizing, and does not transfer strain to seal zones. The incidence of type I endoleak was very low with the use of this stent graft in patients who had severely angulated aortic necks [7].

The EndoRefix nitinol clips

These are clips that can be advanced through a delivery catheter and a 16-Fr sheath to staple the stent graft to the aortic wall in patients who experience distal migration of the previously placed endograft. The EndoRefix clips are currently undergoing clinical trial in the USA for use in patients who have previously placed stent grafts with distal migration or challenging infrarenal neck anatomy, which places them at risk of distal migration and type

I endoleak. Only patients with polyester stent grafts are candidates for the use of EndoReflex clips. The PTFE graft material is apparently at risk of damage from the use EndoReflex clips. Another innovation in the field of AAA repair is the Aptus stent graft, which incorporates an endostapling system with the endograft to prevent migration. [7]

The anaconda

This is another device, undergoing clinical trials in the USA, that represents the next generation of stent-graft systems for AAA repair. This is the only graft system that enables repositioning of the graft after deployment. The Anaconda's highly unusual flexibility and excellent torque control enable accurate deployment and optimal placement even in patients with challenging anatomy [7,14].

Technical Tips

The aortic wrap technique When EVAR fails to resolve type I endoleak, the aortic wrap technique can be an important surgical alternative. In using this technique, the infrarenal retroperitoneum is opened through a 5-cm left-flank incision, and the aneurysmal aorta is exposed. After both renal arteries have been exposed, the aorta is dissected circumferentially from the surrounding tissues below the renal arteries. A graft "passer" is then placed around the aorta, which enables a 12-mm Hemashield graft to be pulled around the aortic neck, encircling it just below both renal arteries. The graft is measured and tightened, and is then secured with 2/0 Ticron sutures. An abdominal aortic angiogram is then performed to check for type I endoleak. If the results are satisfactory, the omentum is placed between the duodenum and the aortic grafts to prevent any erosion of the graft into the intestine, and the abdominal incision is closed in a standard fashion [7,15].

Advanced Technique

*****Closure of endoleak with an Amplatzer** A 65-year-old man presented with a symptomatic, expanding abdominal infrarenal aortic aneurysm. The patient underwent surgery with a polyester graft (Sulzer Vasctek) implanted with an oblique proximal anastomosis just below the renal arteries and a distal anastomosis at the level of the aortic bifurcation. Two months later he returned with back pain, anemia, and collapse. CT angiography of the abdomen showed a high-flow proximal para-anastomotic leak with active extravasation into the aneurysm sac, which had expanded to a diameter of 9 cm. The communication was notable for the presence of a narrow neck bridging two larger lumina and was situated immediately adjacent to the origin of the left renal artery and in close proximity to the superior mesenteric artery. Consultation with interventional radiology and interventional cardiology led to an attempt at percutaneous closure utilizing an atrial septal defect occluder.

The patient was taken to the catheterization laboratory and under local anesthesia the aorta was cannulated utilizing a right femoral percutaneous approach. The leak was located utilizing a

Simmons 2 catheter, and hand injections of contrast. The communication appeared to have a large neck which tapered down to approximately 4mm in diameter before entry into a large aneurysmal sac. The leak was cannulated using a 6-Fr Judkins right catheter and a hydrophilic wire. The catheter was advanced into the aneurysm and the hydrophilic wire exchanged for a more supportive wire. Through the guide was advanced an oversized 8-mm waist diameter Amplatzer ASD occluder. Contrast injection through another catheter placed in the aorta from the femoral approach confirmed satisfactory placement. The device was deployed with the distal disk within the aneurysm and the proximal disk in the aortic neck, Aortography showed no visible contrast entering the aneurysm [16].

REFERENCES

1. Alzubaidi A, MacDonald S, Clement J, et al. Percutaneous closure of a paraanastomotic abdominal aortic graft leak. *Catheter Cardiovasc Interv* 2006;**68**:799–802.
2. Hallett JW Jr. Management of abdominal aortic aneurysms. *Mayo Clin Proc* 2000;**75**:395–9.
3. Tan JWC, Yeo KK, Laird JR. Food and drug administration–approved endovascular repair devices for abdominal aortic aneurysms: A review. *J Vasc Interv Radiol* 2008;**19**:S9–S17.
4. Dillavou ED, Mu luk SC, Rhee RY, et al. Does hostile neck anatomy preclude successful endovascular aortic aneurysm repair? *J Vasc Surg* 2003;**38**:657–63.
5. Chane M, Heuser R. Review of interventional repair for abdominal aortic aneurysm. *J Intervent Cardiol* 2006;**19**:530–8.
6. Carpenter JP. For the Endologix Investigators. Midterm results of the multicenter trial of the Powerlink bifurcated system for endovascular aortic aneurysm repair. *J Vasc Surg* 2004;**40**:849–59.
7. Ghouri M, Krajcer Z. Endoluminal abdominal aortic aneurysm repair the latest advances in prevention of distal endograft migration and type 1 endoleak. *Tex Heart Inst J* 2010;**37**:19–24.
8. Albertini JN, DeMasi MA, Macierewicz J, et al. Aorfix stent graft for abdominal aortic aneurysms reduces the risk of proximal type 1 endoleak in angulated necks: bench-test study. *Vascular* 2005;**13**:321–6.
9. Illig K, Green R, Ouriel K, et al. Fate of the proximal aortic cuff: implications for endovascular aneurysm repair. *J Vasc Surg* 1997;**26**:492–9.
10. Dieter R, Lair J. Endovascular abdominal aortic aneurysm repair. In: King S, Yeung A (eds), *Interventional Cardiology*. New York: McGraw Hill, 2007: 561–75.
11. Dadian N, Ohki T, Veith FJ, et al: Overt colon ischemia after endovascular aneurysm repair: the importance of microembolization as an etiology. *J Vasc Surg* 2001;**34**:986–96.
12. Albertini JN, Perdikides T, Soong CV, et al. Endovascular repair of abdominal aortic aneurysms in patients with severe angulation of the proximal neck using a flexible stent-graft: European Multicenter Experience. *J Cardiovasc Surg (Torino)* 2006;**47**:245–50.
13. Minion DJ, Yancey A, Patterson DE, Saha S, Endean ED. The endowedge and kilt techniques to achieve additional juxtarenal seal during deployment of the Gore Excluder endoprosthesis. *Ann Vasc Surg* 2006;**20**:472–7.

14. Saratzis N, Melas N, Saratzis A, et al. Anaconda aortic stent-graft: single-center experience of a new commercially available device for abdominal aortic aneurysms. *J Endovasc Ther* 2008;**15**:33–41.
15. Younis G, Messner G, Gregoric I, Krajcer Z. Aortic wrap as a novel technique of type I endoleak repair. *Ann Vasc Surg* 2006;**20**:690–5.
16. Alzubaidi A, MacDonald S, Clement J, et al. Percutaneous closure of a paraanastomotic abdominal aortic graft leak. *Catheter Cardiovasc Interv* 2006;**68**:799–802.

CHAPTER 23**Renal Artery Interventions**

Gianluca Rigatelli, Ho Thuong Dung, Paolo Cardaioli

Challenges 538

Non-invasive Evaluation 538**Ultrasonography 538****CT and MRI 538**

Nephro-photo-scintigraphy 538

Invasive Evaluation 538**Abdominal Aortogram 538****Technical Tips 538**

*Diagnostic aortogram 538

Diagnostic renal angiography 538

Technique Renal angiography 539**Technical Tips 539**

**Renal angiography from the radial approach 539

Fractional flow reserve 540

Technique pressure wire measurement 540

Intravascular ultrasound 541

Angiographic and hemodynamic criteria for RAS 541

Stenting 541**Access 541****Guides 541****Wires 542****Filter 542****Balloons 544****Stents 544****Technical Tips 545**

***Intervention in early renal bifurcation (short renal artery trunk) 545

***Sequential crushing technique for a renal bifurcation lesion 546

Complications 546**Arterial Rupture and Perforation 546****Restenosis 548****Renal Sympathetic Denervation 548****Advanced and Exotic Techniques 549**

Complex renal stenting in patient with renal artery compromised by aortic aneurysm dissection 549

Exclusion of renal artery aneurysm by covered stent 549

*Basic; **Advanced; ***Rare, exotic, or investigational

\$, <\$US100.00 extra; \$\$, >\$US100.00 extra

⌚, <10 min extra; ⌚⌚, >10 min extra

♣, low risk of complications; ♣♣, high risk of complications

CHALLENGES

Renal artery stenosis (RAS) is a relatively common problem, mainly in patients affected by hypertension and peripheral vascular disease. To stent successfully a severe renal artery lesion which was proved to cause refractory hypertension and early renal failure is a great challenge.

NON-INVASIVE EVALUATION**Ultrasonography**

Renal ultrasonography and Doppler are the most cost-effective methods for the evaluation of RAS, including functional assessment, such as translesional pressure gradient and parenchymal vascular resistance estimation. The specificity and sensibility are operator dependent and approach 90%.

CT and MRI

Magnetic resonance angiography (MRA) and CT angiography (CTA) have the same specificity (98–99%) and sensitivity (92–93%) for the detection of RAS. The choice depends on available equipment and characteristics of the patient (renal failure limits the use of iodinated contrast for CTA and ferromagnetic implants proscribe the use of MRA) [1].

Nephro-photo-scintigraphy Radionuclide angiography or captopril scintigraphy, which relies on differences in renal perfusion between the two kidneys, is not useful for diagnostic screening but is useful for functional evaluation before and after revascularization [2].

INVASIVE EVALUATION**Abdominal Aortogram**

At first an abdominal angiogram is done to locate the origin of the renal arteries and identify the accessory renal arteries and presence of significant renal stenosis, especially the ostial lesion, which is the most common lesion type of RAS. Also an abdominal aortogram is done to detect any coexistent aortic disease such as aneurysm, dissection, thrombus.

Technical Tips

***Diagnostic aortogram** A 4- to 6-French (Fr) diagnostic pigtail catheter should be placed just below the diaphragm in the left anterior oblique (LAO) 20° projection to depict correctly both right and left renal arteries. The injector should be set in order to deliver 20–25 ml contrast medium at 8–10 ml/s. Digital subtraction is preferable but not strictly necessary, in particular in elderly patients who can have problems in holding their breath and movement even for a few seconds.

Diagnostic renal angiography Digital subtraction angiography (DSA) of the renal arteries is the “gold standard” for defining both normal vascular anatomy and vascular pathology. It remains

the most readily available and widely used imaging technique. RAS more often involves the ostium (ostial RAS) and less frequently the renal artery itself (true RAS), or both (mixed RAS) [3].

TECHNIQUE Renal angiography The usual technique includes the placement of a 4- or 5-Fr pigtail catheter level of L1–2 above the renal artery in an LAO 30° projection. Injection of 25–30 ml contrast at rate of 10–12 ml/s is usually sufficient with a digital subtraction technique to depict both the renal arteries (Figure 23.1). The smallest contrast volume possible should be used when renal angiography is performed together with cardiac angiography. Selective injection by a Judkins right diagnostic catheter should be done when lesion severity is not known or when renal artery angiography is carried out after cardiac angiography. In these situations, especially in patients with borderline or impaired renal function, injection of 5–8 ml for each renal artery is usually sufficient to define any stenosis (Figure 23.2).

In patients with multivessel coronary artery disease undergoing coronary angiography, renal angiography may be useful as a part of the global cardiovascular investigation to rule out renal artery disease, which may sometimes be present in patients with normal creatinine (Box 23.1) [4].

Technical Tips

****Renal angiography from the radial approach** With regard to the renal arteries, it is easier to cannulate most renals using the transradial approach rather than the femoral approach

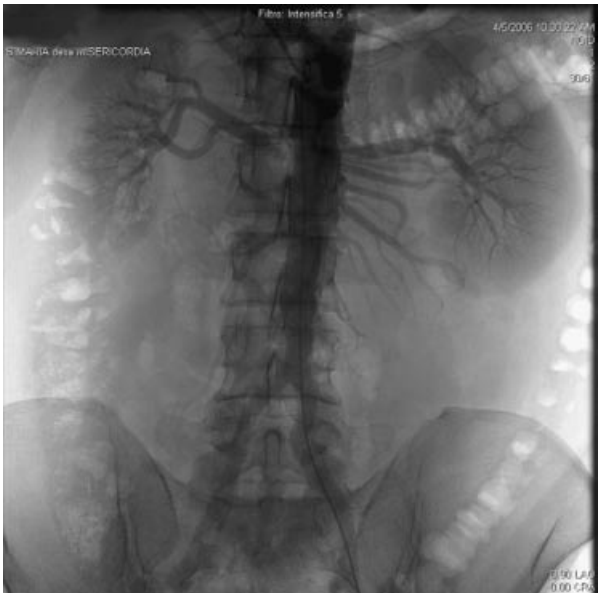

Figure 23.1 An abdominal aortography in a patient with three-vessel coronary artery disease and mild renal insufficiency revealed a tight stenosis of the right renal artery.

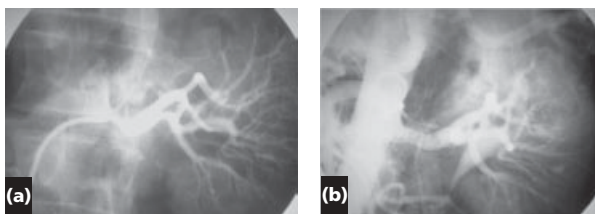


Figure 23.2 Renal artery stenosis is slightly different in patients with coronary artery disease: (a) The normal ostial pattern can be switched to a mixed pattern. (b) A mixed renal artery stenosis needs a longer stent to be adequately treated.

BOX 23.1 INDICATIONS FOR RENAL ANGIOGRAPHY DURING CORONARY ANGIOGRAPHY

Onset of hypertension <30 years or >55 years
 Malignant, accelerated, or resistant hypertension
 Unexplained renal dysfunction
 Development of azotemia with an angiotensin-converting enzyme inhibitor or angiotensin receptor blocker medication

because they originate typically in a caudal fashion from the aorta. The catheters of choice for renal angiography are the Judkins right (JR), multipurpose (MP), or internal mammary in their longer versions (125 cm). The transradial approach for renal artery stenting is feasible with a “coronary technique.” Furthermore, it allows better guide alignment with the renal artery. Longer balloon catheters (150 cm) and stents are needed in patients of larger stature [6]. The advantages of the radial approach are the same as for transradial coronary interventions: No access site complications, early ambulation, outpatient procedures, and reduced cost.

Fractional flow reserve In unclear cases, lesion gradient assessment with fractional flow reserve (FFR) may be useful. A value >0.90 can be considered a threshold value below which the stenosis is likely responsible for an upregulation of renin production and, thus, for renovascular hypertension [5].

TECHNIQUE Pressure wire measurement Intravascular pressures measurements are performed with the Pressurewire XT, a high-fidelity micromanometer-tipped wire (0.014 inch diameter). Pressure measurements are recorded 60 s after selective intrarenal papaverine injection. The pressure measurements are averaged over 15–20 beats. The measured pressures are analyzed with SmartFlow systems and the baseline mean pressure gradient, hyperemic mean pressure gradient, and renal FFR are calculated. Papaverine is administered selectively into the renal artery distal

to the stenosis to minimize systemic vasodilation. A small catheter (4Fr or less) is used to cross the stenosis. Papaverine is diluted in non-heparinized saline at a concentration of 8mg/ml and is then administered by bolus infusion into the renal artery. The infusion catheter is then withdrawn into the guide and translesional pressure measurements are calculated. The results are calculated from the formula below:

$$\text{Renal FFR} = Q_{\max,s} / Q_{\max,n} = (P_d - P_v) / (P_a - P_v)$$

where $Q_{\max,s}$ is the maximal flow in the stenosed artery, $Q_{\max,n}$ the maximal flow in the normal unstenosed area, and P_d is the pressure distal to the stenosis, P_v the venous pressure, and P_a the aortic pressure. Assuming the central venous pressure to be zero, this equation can be simplified to renal FFR = P_d/P_a . This equation suggests that, in a renal artery without stenosis, the renal FFR will be equal to 1 [7].

Intravascular ultrasound Intravascular ultrasound (IVUS) may be needed intraoperatively when severity of lesion and length are not measured accurately or when ostial disease cannot be fully excluded.

Angiographic and hemodynamic criteria for RAS Pull-back gradient pressures are unreliable. The translesional pressure should be taken by the two-catheter method which involves placement and simultaneous pressure measurement through a catheter (4Fr) distal to the lesion and a catheter (6Fr) proximal to the lesion. The pressure measured by the pressure wire distal to the stenosis is also acceptable. The criteria for RAS are either:

- 1 80% stenosis by quantitative coronary analysis
- 2 between 50 and 80% with >20mmHg peak gradient.

STENTING

For angioplasty of the RAS, three techniques have been proposed: The guide (direct) technique; the two-catheter coaxial (indirect) technique (a diagnostic catheter is inserted into a larger guide); and the wire (indirect) technique in which two femoral punctures are made, one for the wire and one for a pigtail catheter.

Access

Access is usually obtained from the contralateral femoral artery through a 5- to 6-Fr (renal artery diameter 4–6mm) or 7-Fr (renal artery diameter 6–8mm) sheath. Use the contralateral approach whenever possible which allows easy engagement of the renal ostium and optimal guide support (Figure 23.3). In cases of severe kinking of femoroiliac arteries or acute angulation of the renal arteries, a brachial or radial approach should be used.

Guides

Recommended guides are the renal double curve (RDC) JR for the femoral approach and the JR or MP for the brachial or radial approach. In cases of severely calcified aorta, use a hydrophilic

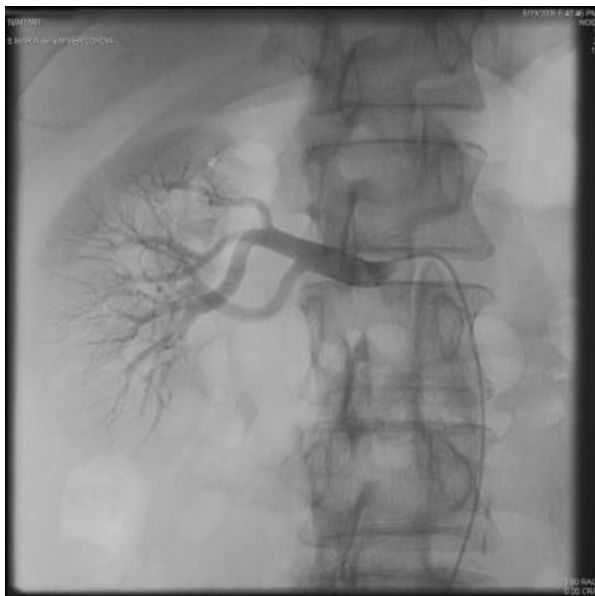

Figure 23.3 Renal artery stenosis is better engaged from a contralateral approach: This allows more support from the guide during percutaneous revascularization.

wire with a tip 2 cm outside the guide to ensure safe catheterization of the renal artery, especially when a 7-Fr guide is selected (no-touch technique). This technique helps to avoid dissection of the aorta or the renal trunk.

Wires

Wire selection is a quite important step: 0.14-inch coronary, soft-tip, pre-formable wire may be preferable in most cases. Alternatively, a 0.18-inch wire can be selected but careful manipulation is suggested due to increased stiffness. Don't use a hydrophilic wire because of the higher risk of perforating the distal renal arterioles. Place the wire at the end of a main branch of the renal artery far from the renal cortex (Figure 23.4).

Filter

Distal embolic protection is believed to be helpful in avoiding distal embolization and worsening renal function, but definitive data are still lacking. The balloon occlusion (Percusurge) or eccentric (Filter-Wire) or concentric filter (Angioguard) may be selected according to the renal artery size. The eccentric or concentric filters are recommended because they are easy to deploy and less prone to renal perforation, in cases of soft, opalescent, and ulcerated stenosis (Figure 23.5), when the main renal trunk is long at least 15–16 mm (Figures 23.6 and 23.7). Early bifurcation of the

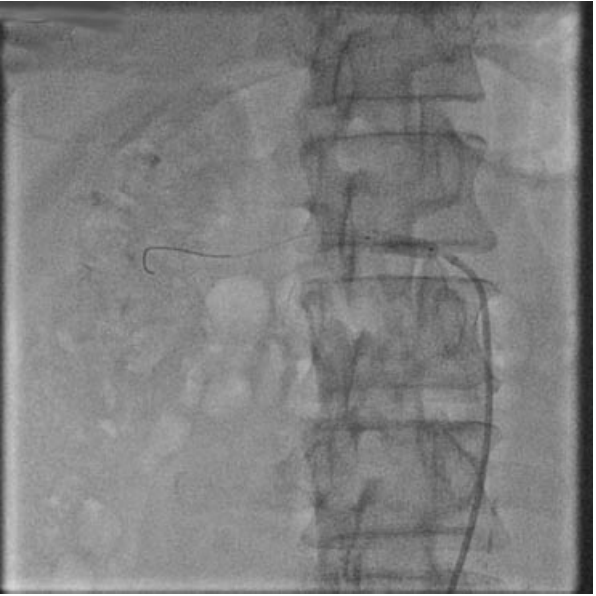


Figure 23.4 The wire should be placed not too deeply into the renal arterioles to avoid iatrogenic perforation. A non-hydrophilic wire should be used.

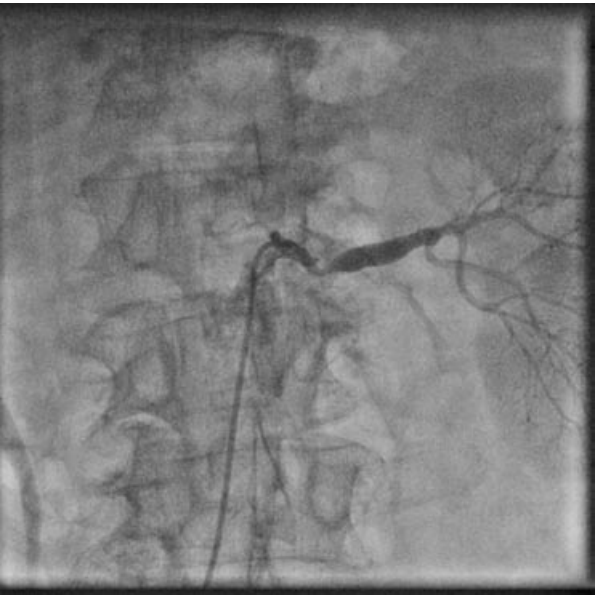

Figure 23.5 A typical renal artery stenosis, which should benefit from a filter-assisted percutaneous revascularization; the bifurcation is far from the stenosis and the renal artery length is <15mm.

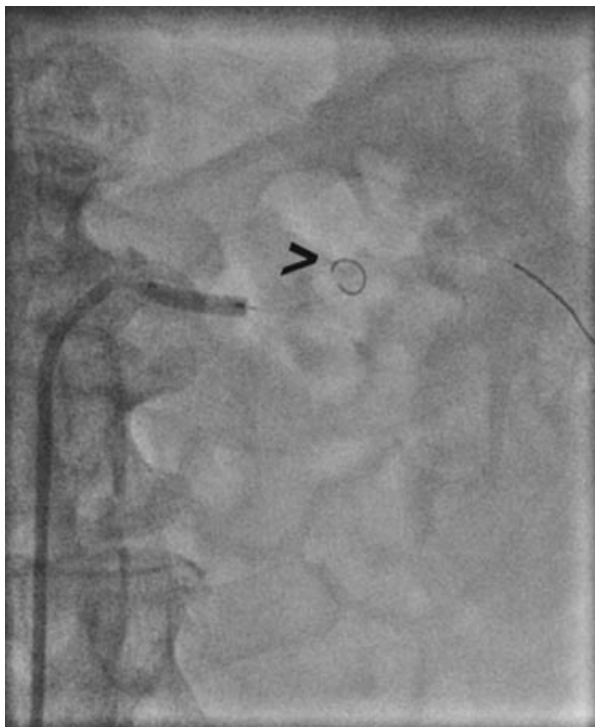

Figure 23.6 A filter wire 3.5–5.5 mm (arrow) has been placed over a 0.014-inch non-hydrophilic guidewire.

renal artery remains a contraindication to the use of distal protection [8,9].

Balloons

Usually direct stenting is the technique of choice for most lesions but sometimes predilation is needed. Low-profile, 0.014-inch monorail, coronary balloon 1.5–2.5 × 15–20 mm inflated to nominal pressure is usually sufficient for advancement of the stent in cases of very tight stenosis. For inflation, use a manometer to inflate the balloons, especially when facing severe calcified stenosis. Inflate slowly 1 atm/3–4 s, and watch as the lesion is being modified at a maximum pressure of 8–10 atm. Hold the wire and balloon catheter firmly in your hand during inflation to avoid guide or balloon distal migration. Stop inflation as the patient feels pain and check for any dissection or renal artery rupture.

Stents

Proper stent selection is mandatory to achieve excellent immediate and long-term results [10,11]. High radial force stents – 4–6 × 12–18 mm stainless-steel balloon-expandable – are the best option for focal calcified stenosis in the ostium or main vessel. They allow precise implantation thanks to their excellent

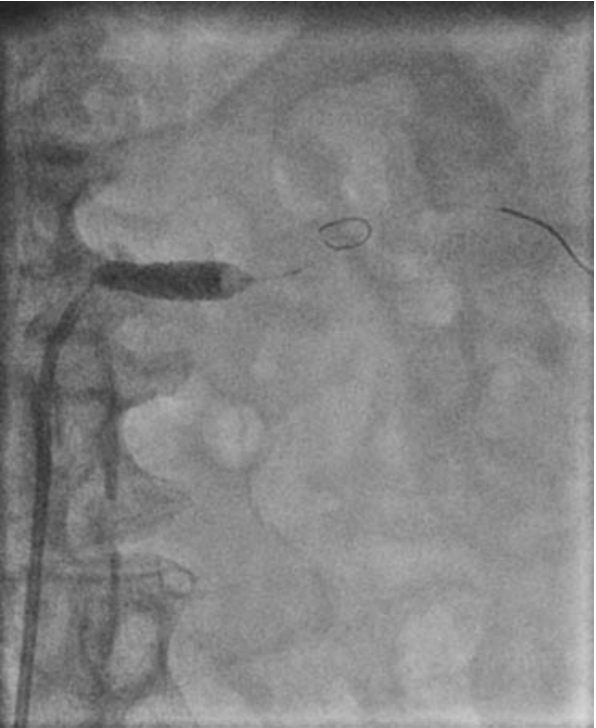


Figure 23.7 Stent deployment: Note the incisure at the ostium due to a heavy calcified ostium.

radio-opacity and can be overexpanded if needed with only minimal shortening. Long diffuse soft stenosis is better treated with 4–6 × 15–18 mm stainless-steel balloon-expandable stents. Drug-eluting stents have been proposed and are currently under investigation. For RAS, coronary chromo-cobalt stents are preferred compared with stainless steel stents in cases of ostial stenosis and renal artery size 4–5 mm; their high radial force protects the ostium better. Keep the balloon-expandable stent 2–3 mm beyond the ostium in the abdominal aorta to be sure that the ostium is covered. A pressure of 12–16 atm is usually enough to deploy the stent. After deployment, withdraw the balloon 2–3 mm outside the ostium while gently pushing the guide until perfect coaxiality is achieved. Then quickly inflate the balloon at high pressure to flare the ostial portion of the stent. Carefully check the final results with a generous injection from the guide to assess all segments of the renal parenchyma. Change the guide at the end of the procedure for a diagnostic pigtail catheter in the abdominal aorta. Perform DSA to assess any aortic damage.

Technical Tips

*****Intervention in early renal bifurcation (short renal artery trunk)** In cases of short renal trunk, a kissing balloon

technique may be necessary. A 7- or 8-Fr guide should be selected. We strongly suggest stenting the main vessel and dilating the secondary branches through the stent strut as in coronary interventions. Wire both the renal branches. Select the balloons size to match the renal artery size (e.g. 3 × 2 mm balloons for 5-mm renal artery trunk). After performing a kissing balloon, deploy the balloons simultaneously with two deflators at the same pressure (10–12 atm), deflate and withdraw both balloons beyond the proximal end of the stent in the abdominal aorta, then overdilate with high pressure (12–14 atm) to flare the ostial parts of the stent.

*****Sequential crushing technique for a renal bifurcation lesion** In cases of renal artery with proximal bifurcations, stenting can be performed in the same fashion as bifurcation coronary stenting. If the guide is a 7-Fr guide, the usual technique is used. In cases of a 6-Fr guide, sequential crushing technique can be used. A coronary balloon should have been inflated to nominal pressure. First, a non-compliant balloon is advanced into the main vessel, beyond the bifurcation, and then a stent is positioned so that it covers the lesion in the secondary branch while protruding around 4 mm into the main vessel proximal to the bifurcation. The balloon in the main vessel is then retracted so that its midpoint is positioned at the level of the proximal marker of the stent. The stent is deployed at standard pressure. Then the stent balloon and the corresponding wire are removed. At this point, the balloon in the main branch is inflated to 20 atm to crush the proximal portion of the stent. The balloon is then withdrawn and a second stent deployed in the main branch across the bifurcation. Sequential postdilation inflation and kissing technique is performed as usual [12,13].

COMPLICATIONS

Although rarely, complications may occur, some of which are potentially lethal. Complications may include distal embolization, aortic dissection, renal artery rupture, renal perforation (Table 23.1). Renal artery dissection can frequently be observed and in itself is not a major problem, being managed with stent implantation. Aortic dissection is a life-threatening condition and requires surgery.

Arterial Rupture and Perforation

Renal artery rupture can be managed with covered stents, the availability of which in the cardiac catheterization laboratories is a prerequisite for renal artery stenting (Figure 23.8). Renal perforation needs to be assessed with angiography and possibly with a CT scan, and can be managed with occlusion coils. The availability of microcatheters is a prerequisite for renal angioplasty. Small coil size should be selected depending on the perforated vessel size: usually 0.014- to 0.07-inch platinum microcoils are used through 3-Fr microcatheters. Alternatively, if a microcatheter is not available, an over-the-wire small balloon (1.5 mm) can be used

Table 23.1 Management of complications

Complications	Management
Main renal artery rupture	Prolonged inflation of the balloon at low pressure – graft stents
Renal perforation	Immediate embolization
Distal dissection	Ballooning or stenting
Acute and subacute stent thrombosis	Local thrombolysis and redilation
Cholesterol embolization	Antiaggregants, corticosteroids Cardiac and renal failure treatment

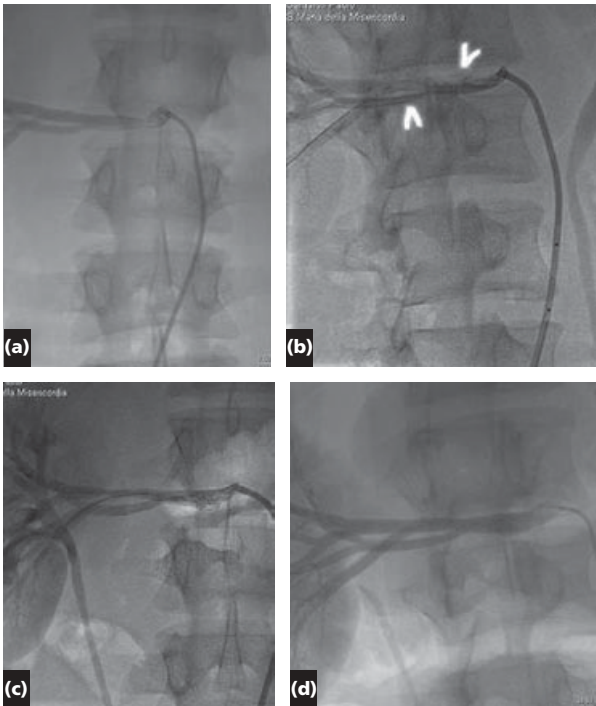


Figure 23.8 Renal artery rupture and dissection in a patient with fibromuscular dysplasia: (a) Diagnostic renal angiography demonstrating stenosis just beyond the ostium; (b) after balloon dilation, proximal artery rupture (arrow), and dissection of one of the main branches (arrow) appeared; (c) prolonged balloon dilation results; (d) result on post-stenting angiography.

to release the microcoils. If the condition remains uncontrolled, surgical management is needed.

Restenosis

Renal artery stenting appears to be durable, with only 10% of stented arteries requiring target vessel revascularization (TVR) during clinically based long-term follow-up. Arteries with a final stent diameter <5.0mm were more than twice as likely to need TVR as patients with a solitary kidney. Recent reports suggest restenosis rates vary from 36% for small renal arteries (vessel diameter <4.5 mm) to only 6.5% for larger renal arteries (>6 mm) [13]. A recurrence rate of 22–43% has been reported at 6 months after balloon angioplasty for renal in-stent restenosis (ISR). Surveillance of implanted stents is warranted by Doppler ultrasonography and in particular CTA. Follow-up of renal function should be warranted by nephro-scintigraphy and creatinine clearance.

The treatment of in-stent restenosis in renal arteries remains a challenge with restenting and angioplasty, especially in patients who have aggressive disease. Recurrent ISR was successfully treated with paclitaxel-eluting stent implantation, using IVUS guidance, with maintained stent patency at 6 months.

Renal Sympathetic Denervation

Renal sympathetic hyperactivity is seminal in the maintenance and progression of hypertension. Sympathetic nervous activation via efferent nerve fibers lying in the adventitia of the renal arteries leads to increased Na^+ reabsorption, increased renin secretion, and a reduction in renal plasma flow. Via afferent sympathetic fibers in the dorsal root of the spinal cord, the kidneys induce a further augmentation of central sympathetic nervous activity [14,15]. Renal sympathetic denervation by means of an ablation catheter, with an electrode in the tip connected with a radiofrequency generator, is able to precisely ablate the afferent and efferent sympathetic nervous fibers surrounding the renal arteries. Four to six ablation sites are usually administered in both arteries, leading the denervation of the nerves through an arterial femoral or radial approach. Recent studies showed a significant reduction of blood pressure of 25–30mmHg systolic and 10–15mmHg diastolic for at least 2 years [16,17].

CASE REPORT

Aortic hematoma after stenting

A patient was found to have a 70–80% diameter stenosis in the ostium of the right renal artery. The patient underwent renal artery stenting. After predilation with a 6 × 20 mm balloon and deployment of a stent in the stenotic lesion, the patient complained of severe back pain. The systolic blood pressure immediately dropped from 170mmHg to 80mmHg. The urgent aortogram showed localized aortic dissection with intimal flap from the right renal artery. There were DeBakey type I acute intramural hematoma (AIH – crescentic thickening of aortic wall without contrast enhancement from the ascending aorta to the

abdominal aorta), and about a 5-cm localized aortic dissection arising from the right renal artery ostium. In patients with hypertension, high blood pressure may injure the arterial wall, which can be dissected with these additional stresses after the balloon injury. There was a possibility that underlying medial degeneration predisposed the vasa vasorum to hemorrhage and AIH. The aorta, with more calcified atherosclerotic components, may prevent progression of the dissection. Surgery is the treatment of choice for patients with AIH involving ascending aorta. However, in some selected cases, the intensive medical treatment can stabilize the patient [18].

Advanced and Exotic Techniques

Complex renal stenting in patient with renal artery compromised by aortic aneurysm dissection

A 60-year-old white man with history of a thoracic aortic aneurysm, moderate aortic stenosis, and a dissection flap in the descending aorta successfully underwent an aortic valve replacement, with an aortic root graft. Two months later, the patient developed persistent refractory hypertension. MRA of the abdominal aorta demonstrated a sizable dissection plane involving much of the abdominal aorta. The origin of the left renal artery appeared to be significantly stenotic, with impairment of blood flow to the left kidney. The dissection extended to involve the distal aorta. The combined lumina measured 2.2 cm in diameter. The patient underwent a thoracic and abdominal angiography, as well as selective right and left renal arteriography. Aortic root injection demonstrated no abnormalities of the previously placed graft. An abdominal aortogram showed the right main and accessory renal arteries to be arising from this lumen, and both appeared normal. No other major branches were seen arising from this lumen. A Storz wire was advanced under fluoroscopic guidance through the left femoral access and the lumen of the pigtail catheter, and advanced to the aortic root to ensure continued access to the ascending aorta. The pigtail catheter was then introduced via the left femoral artery retrogradely into what appeared to be the false lumen and another abdominal aortogram was performed. This second abdominal angiogram demonstrated that the celiac, superior mesenteric, and left renal arteries arose from the false lumen. There was significant ostial compromise of the left renal artery. A 7-Fr short renal guide was used to engage the left renal artery. Selective angiography demonstrated a proximal critical stenosis (90%) of the left renal artery. The lesion in the left renal artery was predilated with a balloon and stented. There was prompt resolution of the patient's hypertension [19].

Exclusion of renal artery aneurysm by covered stent

A 63-year-old woman with escalating hypertension, referred for workup of renovascular hypertension, was incidentally noted to have an aneurysm of the left renal artery. The berry-shaped aneurysm measured 12–13 mm and was located just proximal to the origin of two interlobar arteries supplying the lower pole of a

normal-sized kidney. Renal function was normal and no evidence of atherosclerotic RAS was noted. An 8-Fr left internal mammary artery guide was manipulated to cannulate the renal artery. A hand-crimped stent graft was successfully delivered to the aneurysm site [20].

REFERENCES

1. Jurgen J, Wildermuth S, Pfammatter T, et al. Aortoiliac and renal arteries: prospective intraindividual comparison of contrast-enhanced three-dimensional MR angiography and multi-detector row CT angiography. *Radiology* 2003;**226**:798–811.
2. Rigatelli G, Rigatelli G. Malpractice in invasive cardiology: is angiography of abdominal aorta or subclavian artery appropriate in patients undergoing coronary angiography? A meta analysis. *Int J Cardiovasc Imaging* 2005;**21**:591–8.
3. Rigatelli G, Roncon L, Rinuncini M, et al. Angiographic characteristics of renal arterial disease over the spectrum of coronary artery disease. *Am J Nephrol* 2005;**25**:116–20.
4. Rigatelli G, Rigatelli G. Predictors of renal artery stenosis in patients with normal renal function undergoing coronary angiography. *Minerva Cardioangiol* 2006;**54**:145–9.
5. De Bruyne B, Manoharan G, Pijls NH, et al. Assessment of renal artery stenosis severity by pressure gradient measurements. *J Am Coll Cardiol* 2006;**48**:751–5.
6. Blum U, Krumme B, Flugel P, et al. Treatment of ostial renal-artery stenoses with vascular endoprostheses after unsuccessful balloon angioplasty. *N Engl J Med* 1997;**336**:459–65.
7. Subramanian R, White CJ, Rosenfield K, et al. Renal fractional flow reserve: A hemodynamic evaluation of moderate renal artery stenoses. *Catheter Cardiovasc Interv* 2005;**64**:480–6.
8. Edwards MS, Craven BL, Stafford J, et al. Distal embolic protection during renal artery angioplasty and stenting. *J Vasc Surg* 2006;**44**:128–35.
9. Henry M, Henry I, Klonaris C, et al. Renal angioplasty and stenting under protection: the way for the future? *Catheter Cardiovasc Interv* 2003;**60**:299–312.
10. van de Ven PJ, Kaatee R, Beutler JJ, et al. Arterial stenting and balloon angioplasty in ostial atherosclerotic renovascular disease: a randomised trial. *Lancet* 1999;**353**:282–6.
11. Lederman R, Mendelsohn F, Santos R, Phillips H, Stack R, Crowley J. Primary renal artery stenting: characteristics and outcomes after 363 procedure. *Am Heart J* 2001;**142**:314–23.
12. Granillo G, van Dijk LC, McFadde EP, et al. Percutaneous radial intervention for complex bilateral renal artery stenosis using paclitaxel eluting stents. *Catheter Cardiovasc Interv* 2004;**64**:23–7.
13. Bates MC, Rashid M, Campbell JE, Stone PA, Broce M, Lavigne PS. Factors influencing the need for target vessel revascularization after renal artery stenting. *J Endovasc Ther* 2006;**13**:569–77.
14. Symplicity HTN-1 Investigators. Catheter-based renal sympathetic denervation for resistant hypertension: durability of blood pressure reduction out to 24 months. *Hypertension* 2011;**57**:911–17.
15. Brandt MC, Mahfoud F, Böhm M, Hoppe UC. Renal sympathetic denervation. [A novel interventional treatment option for therapy-resistant arterial hypertension.] *Herz* 2011;**36**:8–11.
16. O'Brien E. Renal sympathetic denervation for resistant hypertension. *Lancet* 2009;**373**:96–81.

17. Krum H, Schlaich M, Whitbourn R, et al. Catheter-based renal sympathetic denervation for resistant hypertension: a multicentre safety and proof-of-principle cohort study *Lancet* 2009;**373**:1275–81.
18. Park JH, Rhee YS, Ko JK. A case report of type I acute aortic intramural hematoma with localized dissection as a complication of renal artery stenting. *Catheter Cardiovasc Interv* 2005;**65**:552–5.
19. Awadalla HM, Salloum JG, Smalling RW. Renal artery compromise treated percutaneously in a patient with chronic aortic dissection: A case report. *Catheter Cardiovasc Interv* 2004;**61**:445–4.
20. Pershad A, Heuser R. Renal artery aneurysm: Successful exclusion with a stent graft. *Catheter Cardiovasc Interv* 2004;**61**:314–16.

CHAPTER 24**Carotid Artery Occlusive Disease**

Gianluca Rigatelli, Paolo Cardaioli, Horst Sievert

Challenges 554

Fibromuscular Dysplasia 554**Spontaneous Cervical Dissection 554****Acute Aortic Dissection extended to the Carotid Arteries 555****Management 555****Procedures 555****General Measures 558****Vascular Access 559****Transbrachial and Radial Approach 559****Cervical Approach Via Direct Puncture 559****Technique 559****Transapical Approach 560****Technique 560****Guides 560****Technical Tips 560**

*Cannulation of the brachiocephalic arteries 560

**Technique of engagement of right carotid artery 561

**Why a guide fails to advance through tortuous artery 561

***Multiwire technique for a hostile neck 564

***Carotid access in the presence of occluded ECA, CCA lesion below bifurcation, or ostial CCA lesion 564

Angiography 566**Protection Devices 566****Filter Devices 566****Occlusion Devices 568**

Gore Neuro Protection System 568

Advantages and Limitations 570

MO.MA (Invatec) 571

Selection of the protection system 571

Balloon Angioplasty 571**Stents 571****Discriminating Differences 572****Post-stent Dilation 574****Advanced Techniques 574**

**Aortic dissection extended to carotid artery 574

*Basic; **Advanced; ***Rare, exotic, or investigational

\$, <\$US100.00 extra; \$\$, >\$US100.00 extra

⌚, <10 min extra; ⌚⌚, >10 min extra

♦, low risk of complications; ♦♦, high risk of complications

***Association between severe kinking and occlusive disease of the carotid artery 574

Complications 576

Thrombotic and Embolic Complications 576

Carotid Artery Spasm 576

Stent Restenosis 576

Carotid Perforation and Dissection 577

Cerebral Hyperperfusion Syndrome 577

Cerebral Protection Devices-related Complications 577

****Difficult Retrieval of Filter Devices 578**

CHALLENGES

Most carotid artery disease is due to atherosclerosis from hypercholesterolemia. However, other rare pathologies can also cause symptomatic carotid artery disease. They are fibromuscular dysplasia, spontaneous cervical dissection, and acute aortic dissection extended to the carotid arteries. To stent a carotid lesion without causing major and minor stroke is a great daily challenge.

Fibromuscular Dysplasia

Fibromuscular dysplasia (FMD) is a non-atherosclerotic, non-inflammatory vascular disease characterized by stenosis due to thickening of the arterial wall [1]. Carotid FMD is most commonly encountered in middle-aged women, who may be symptomatic or asymptomatic. Clinical manifestations may include stroke, transient ischemic attack (TIA), carotid dissection, Horner syndrome, cranial nerve palsies, or subarachnoid hemorrhage. The pathophysiology and natural history are unknown. Gross pathological manifestations include elongation, kinking, and coiling of the carotid artery, spontaneous dissection, and aneurysmal degeneration. Antiplatelet therapy is generally recommended even for asymptomatic patients. Both surgical revascularization and endovascular approaches have been successful in alleviating ischemic symptoms in patients with FMD of the carotid arteries.

Spontaneous Cervical Dissection

Spontaneous carotid artery dissection is a non-traumatic tear in the wall of the internal carotid arteries or the vertebral arteries, not a rare event in young patients of both genders (25% of strokes in patients aged <45 years) [2]. Dissection results from an intimal tear that initiates an intramural hematoma. Subintimal dissection tends to cause stenosis, whereas subadventitial dissection can result in aneurysmal degeneration. A number of pathological associations have been described, most of which involve connective tissue disorders. In 90% of cases it causes local signs and symptoms of carotid territory ischemia on the side of dissection, but in 10% of patients it is asymptomatic. Head, facial, or

neck pain and pulsatile tinnitus are the most frequent symptoms. Urgent magnetic resonance imaging (MRI) and computed tomography angiography (CTA) is warranted to define diagnosis when an ischemic stroke is preceded by these symptoms and signs.

Acute Aortic Dissection extended to the Carotid Arteries

This occurrence usually causes sudden onset of excruciating, ripping pain. The ascending aortic dissections tend to manifest with pain in the midline of the anterior chest whereas descending aortic dissections manifest with pain in the back. Aortic dissections usually occur in the presence of risk factors including hypertension, pregnancy, atherosclerosis, and other conditions that lead to degeneration of the aortic media, such as Marfan syndrome and/or Ehler–Danlos syndrome. In cases of retrograde extension of the dissection flap to the common carotid arteries, these symptoms precede the cerebral ischemic syndrome. In a known aortic dissection involving the ascending aorta, new cerebral ischemic events mean extension of the dissection with a need for surgical interventions [3].

Management

The current treatment includes smoking cessation, inhibition of platelets by aspirin, lowering cholesterol levels with a statin, and a pharmacological treatment of hypertension and diabetes, if present. Variation in this treatment includes the additional use of ticlopidin, clopidogrel, or warfarin [4]. The contraindications to carotid stenting are listed in Box 24.1.

PROCEDURES

The pre- and postprocedural checklist for carotid procedures is listed in Box 24.2. Especially for a center starting a carotid program, it is recommended that all these evaluations should be performed before doing the procedure. Of course it is essential that the diagnostic tests listed in Box 24.2 are repeated after the procedure.

BOX 24.1 CONTRAINDICATIONS TO CAROTID STENTING

Anatomical contraindications

- Severely tortuous, calcified, and atheromatous aortic arch vessels (type III aortic arch)
- Severe kinking and tortuosity of the femoroiliac arteries and no viable brachia/radial arteries
- Pedunculated thrombus at the lesion site

Clinical contraindications

- Severe renal impairment precluding safe use of contrast agents
- Patient contraindications to antiplatelet agents

BOX 24.2 PRE- AND POSTPROCEDURAL CHECKLIST FOR CAROTID PROCEDURES

- Adequate medical and neurological evaluation
- CT scan or MRI of the brain to document pre-procedural anatomic deficits
- A formal neurological assessment and completion of a National Institutes of Health (NIH) stroke scale pre- and post-procedure
- Some operators still recommend a complete cerebral angiography in a separate examination or immediately before carotid angioplasty and stenting. However, with the availability of MRI, angiography seems to be less important. In our center a four-vessel angiography is rarely performed
- Duplex ultrasonography pre- and post-stenting to exclude fresh thrombus and as a baseline for follow-up
- Aspirin 300 or 325 mg and clopidogrel (Plavix) 75 mg once a day. Different from coronary interventions, the goal is not so much to avoid thrombus formation after stent implantation as to avoid fresh thrombus before stent implantation. This fresh thrombus may embolize during the procedure, so the treatment with aspirin and clopidogrel should start at least 1 week before

PROCEDURE

Step 1: Vascular Access

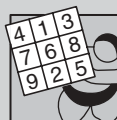
The femoral access approach is the most commonly used with a 4 or 5-French (Fr) sheath. In complex anatomy or when it is planned to choose a proximal cerebral protection system, a standard 5- to 9-Fr, 12-cm arterial sheath is used. In cases of diseased iliac arteries a 23-cm sheath may be used and in cases of an abdominal aortic aneurysm a 40-cm sheath may be preferred. The patient is given heparin to obtain an activated clotting time (ACT) of 200–250s.

Step 2: Aortogram

A 5-Fr pigtail is advanced into the ascending aorta over a standard 0.035-inch wire. After angiography of the aortic arch and recognition of the anatomy, a road map can be obtained to facilitate a 5-Fr internal mammary artery or Judkins right catheter is advanced into the common carotid artery (CCA). Before cannulation of the CCA, a careful aspiration and flush of saline should be performed to clear any debris or thrombus.

Step 3a: Cannulation of the carotid artery and selective angiography (long-sheath technique)

Cannulate the CCA with a 5-Fr diagnostic catheter, usually with a right coronary or a Headhunter catheter. Access the external carotid artery (ECA) with an angled hydrophilic wire



and advance the diagnostic catheter into the ECA. Perform a digital angiogram (road mapping) to display the origin of the ECA. Replace the current wire with an exchange-length 0.035-inch wire. Generally, a stiff Amplatz-type wire should be used. The diagnostic catheter is then exchanged over the wire for a 6-Fr 90-cm sheath, which is then advanced into the CCA below the bifurcation. Gently manipulate the sheath during engagement because it can cause a tear at the ostium of the CCA or dislodge atherosclerotic debris. Aspirate and flush meticulously so that there is no air inside.

Step 3b: Cannulation of the carotid artery and selective angiography (guide technique)

We prefer to use the no-touch technique to minimize the risk of embolism or dissection of the common carotid artery: Over a standard 0.035-inch wire a 8-Fr multipurpose (MP) guide is carefully advanced into the aortic arch over the previously obtained road map. Then a 0.035-inch hydrophilic wire is advanced into the guide till its proximal tip exits from the guide. Manipulate the guide with gentle rotation to engage the common carotid artery: "Back bleed" and flush carefully and take a "guiding" image lesion by injecting through sheath. An arteriography is performed in an angulation that shows the most opening of the bifurcation and pinpoints the severity of the stenosis. Then, during the intervention, the most useful projection is not only the one showing the maximum stenosis, but also projections separating the internal carotid artery (ICA) and ECA, and those showing the bony landmarks.

Step 4: Angiography of Intracranial Vessels

Perform angiography of the intracranial vessels in two projections, lateral and anteroposterior 30° cranial. These angiograms will be very important for comparison and further intracranial rescue procedures in cases of cerebral embolization during intervention.

Step 5: Cerebral Protection

Distal embolization is the major cause of complications during carotid stenting. Therefore, we use cerebral protection devices in all patients. They are described in more detail later in this chapter. Generally, the device has to be introduced and placed distal (filter or occlusion balloon) or proximal (occlusion balloon) to the lesion.

Step 6: Predilation

This is to facilitate introduction of the stent delivery system in cases of very tight or calcified carotid artery stenosis. A 2- or 3 mm monorail or coaxial angioplasty balloon is advanced to the lesion over the 0.014-inch wire which is attached to the filter or distal occlusion balloon or over a

(Continued)

separate 0.014-inch wire in case a proximal occlusion balloon is used for cerebral protection. For predilation, the angioplasty balloon is inflated at low pressures. In very rare occasions (very tight and calcified lesions) predilation has to be performed even before introduction of a cerebral protection device. Give atropine (1 mg intravenously) 2–3 min before balloon inflation to prevent bradycardia.

Step 7: Self-expandable Stent Deployment

Exchange the balloon system for a stent system. The diameter of the stent should be 1–2 mm larger than the largest carotid segment to be covered. Most often stents with a diameter between 6 (if the stent is implanted into the ICA only) or 8 and 10 mm are used. Although the ICA is 2–3 mm smaller than the CCA, oversizing the stent in the ICA does not cause problems. Covering the ECA is safe and rarely causes occlusion of the ECA. The stent should be long enough to cover the lesion completely, usually 3 or 4 cm long.

Step 8: Post-stenting Management

Post-stent deployment a balloon dilation should be done at nominal pressure, watching carefully for bradycardia and hypotension: Give atropine (1 mg intravenously) 1–2 min before balloon inflation to prevent bradycardia. The balloon diameter should be equal to the diameter of the ICA distal to the stent. Post-stent dilation of the stent segment in the CCA is not necessary and not recommended. If the ECA becomes significantly stenosed or occluded, this does not cause symptoms and does not need treatment. Perform angiography to identify further lesions, dissections, and embolic complications.

Step 9: Removal of the Cerebral Protection Device

Almost all currently available filter devices are removed with a retrieval catheter. In cases of an occlusion balloon, the debris in the internal carotid artery has to be aspirated before occlusion balloon deflation and retrieval (at least two 20-ml syringes using MO.MA device). Perform carotid angiography including intracranial branches to document the final result and to exclude distal embolization.

General Measures

Continuous monitoring of the heart rate, blood pressure, and neurological status throughout and post-intervention is mandatory. Good hydration and maintenance of an appropriate blood pressure are important in the recovery period. At the time of balloon inflation the blood pressure always goes down, so there is no need to lower the blood pressure before, even if the patient is severely hypertensive. After the procedure the systolic blood pressure should be <140 mmHg. A lower pressure is preferable,

especially in case of a very tight lesion before stenting and/or in case of a contralateral occlusion. because these patients have a higher risk of intracranial bleeding. The sheath is removed when the ACT is <180s.

VASCULAR ACCESS

The standard approach is through femoral approach; however, when there is problem with accessing or because of a hostile neck, other approaches can be used.

Transbrachial and Radial Approach

Puncture (radial artery and brachial artery) or cutdown (brachial artery) is performed according to standard techniques. We prefer the right arm for both carotid arteries (right and left side). A 5- or 6-Fr sheath is introduced. Cannulation of the CCA is usually possible with a Judkins right (JR) catheter or a left mammary artery catheter. If this turns out to be difficult, a Sidewinder catheter can be used. After entering the ostium of the right or left CCA with the catheter, a wire with hydrophilic coating (Terumo) is advanced. Over this wire, a 6-Fr long sheath is introduced. In a patient without elongation of the aortic arch, the angle between the right brachial artery and the right CCA is not suitable for the transbrachial approach, whereas in a patient with aortic arch elongation the angle is often more favorable (Figure 24.1).

Cervical Approach Via Direct Puncture

TECHNIQUE The patient is placed on the table with a cushion under the shoulders. The head is turned away from the side that has to be punctured. Duplex ultrasonography should be used to locate and mark the carotid bifurcation. The best puncture side is located approximately 1.5–2 cm above the clavicle. The position of the needle tip in relation to the carotid bifurcation has to be checked with a contrast injection before any further steps are taken. If the position is correct, the needle is exchanged for a 5- or 6-Fr sheath over a 0.035-inch wire. After the procedure the sheath is withdrawn and gentle pressure has to be applied for 10–15 min. Protamine should not be given.

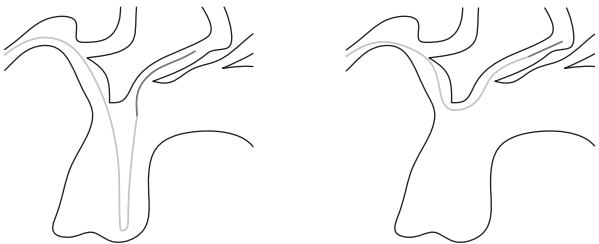

Figure 24.1 Entering the left common carotid artery from the right brachial approach: The left common carotid artery can be entered via the right brachial artery using a Sidewinder catheter [5].

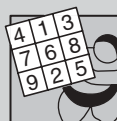
Transapical Approach

TECHNIQUE A patient came with a “hostile” aortic arch, manifesting as unfolding of the thoracic aorta, an inferior angulation of the arch, and origin of the innominate artery at an acute angle from the ascending aorta. These factors precluded the advancement of a 10-Fr sheath into the innominate artery, despite several attempts. Neither a right brachial approach nor an open surgical approach was deemed an acceptable alternative. A transapical approach was considered a possibility in this case based on the reported experience of other centers with transapical aortic valve replacement. The angle of origin of the innominate artery from the ascending aorta made passage of the 10-Fr sheath into the right CCA fairly straightforward. Deployment of the covered stent was accomplished expediently and without difficulty over a 0.035-inch J-wire [6].

GUIDES

STRATEGIC MAPPING

The key is to advance the guide slowly over the wire while maintaining the wire deep inside the carotid artery. The left wall of the upper thoracic aorta can be used to support advancement of the guide into the carotid artery. One has to recognize “bad” and “good” curves of the guide within the aortic arch while advancing it. The guide is pushed over the wire slowly, also taking advantage of the pulsating blood flow. This maneuver, advancement of the guide, and withdrawal of the wire are made several times until the guide is securely placed in the artery. If there is tortuosity of the proximal segment, the artery can be straightened with a wire. The guide can also be rotated while being advanced, clockwise or counterclockwise, depending on the curve formation in the aortic arch. Asking the patient to take a deep breath would help to elongate and thus straighten the great vessels. During that short window of opportunity, the guide is moved farther. Another important aspect is to gently “ease back” on the guide curve in the arch as successive wires are advanced. This reduces the curve in the arch and prevents the successively stiffer wires from prolapsing the guide down into the ascending aorta. Excessive manipulation of the guide in the arch may predispose to distal embolization.



Technical Tips

***Cannulation of the brachiocephalic arteries** A 5-Fr JR or left mammary artery guide is usually preferred. Guides with a similar shape are the Headhunter H1 and the Bentson/Hannafee JB1 guides. This type of guide is advanced over the aortic arch using a hydrophilic 0.035-inch wire. This avoids trauma to the intima of the aortic arch and prevents the guide tip from becoming

trapped by vessel ostia. In the ascending aorta the guide is turned around 180° which places the tip in a vertical upright position. Thereafter, the guide is gently pulled back. Usually this motion will bring the guide tip into the brachiocephalic artery. If the left CCA is the target, the guide should be pulled further distally very slowly. During this period, the guide should be turned 20° counterclockwise to make the tip point slightly anteriorly. This helps to engage the left CCA. To stabilize the guide in the left CCA, it is necessary to rotate the guide 20° clockwise to make the tip of the guide point vertically or slightly posteriorly again.

If we are not successful with one of these guides, we usually switch to a Simmons/Sidewinder guide. This guide forms a loop in the ascending aorta. By pulling back this type of guide, the tip engages the vessels of the aortic arch (brachiocephalic trunk first). In contrast, with the Vitek guide a loop is formed in the descending aorta. A catheter with a similar shape is the Mani guide. By pushing the guide toward the ascending aorta, the tip engages the left subclavian artery, the left CCA, and finally the brachiocephalic trunk.

****Technique of engagement of right carotid artery** Usually engagement of the right carotid artery is accomplished by advancing the guide in the right subclavian artery and rotating the guide counterclockwise to engage the ostium of the right common artery.

If catheterization of the internal carotid artery is desired, the head is again turned to the contralateral side; however, the neck is flexed to align the internal carotid artery with the CCA. The tip of the guide is now pointed posteriorly and the wire is inserted. The guide is advanced over the wire, and its tip is placed at the level of C2. It is important not to advance the catheter farther, because this may cause spasm. In cases of a cervical carotid loop, the guide is placed below the loop (Figure 24.2) [7].

****Why a guide fails to advance through tortuous artery** One major problem is the failure of advancing the guide into the carotid artery. Persistent forward movement of the guide will cause a loop to form in the aorta or the tip of the guide flips back into the aorta (Figure 24.3). The physical and mechanical mechanisms of the above problems are discussed in Table 24.1. These mechanisms and their solutions can be applied universally during instrumentation of any vascular bed, including the coronary, carotid, or renal arteries or their anomalies. The example illustrations are based on the anomaly of the left CCA.

To solve the problem of a weak platform created by a floppy wire, the wire has to be advanced further so that the stiff segment is in the proper area. If the wire is not strong enough, it has to be exchanged for a stiffer one [5].

To solve the problem of acute angle at the origin of the artery, a stiff wire will straighten out the angle and help to advance the guide.

To solve the problem due to excessive friction between the wire and the internal surface of the catheter, the catheter should be advanced and the wire withdrawn simultaneously (Figure 24.4). This maneuver reduces significantly the friction between the wire

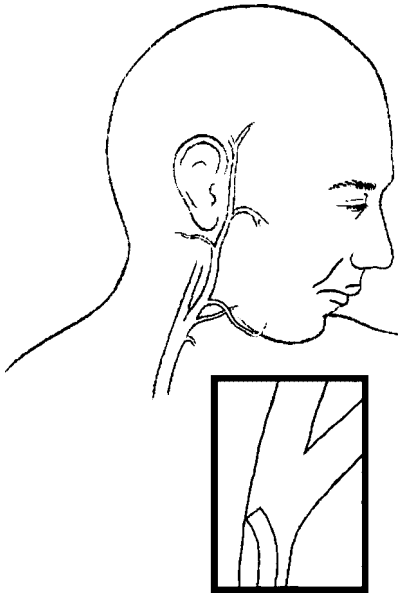


Figure 24.2 Catheterization of the internal carotid artery: The neck is flexed. This maneuver brings the internal carotid artery in line with the common carotid artery. Note the position of the tip of the catheter, which is pointed posteriorly (inset). (Adapted from Gerlock and Mirfakhræe [5] with permission.)

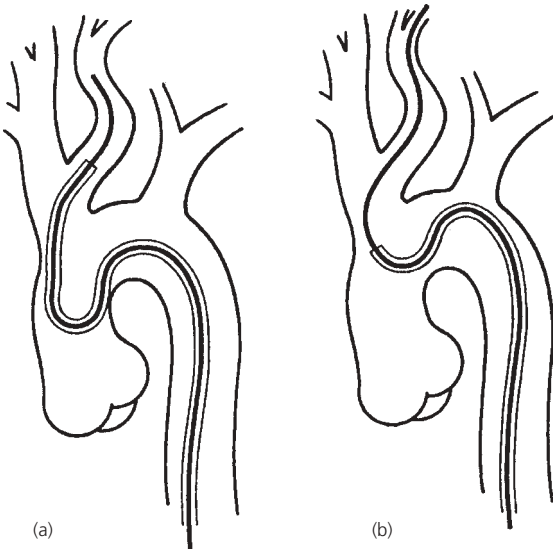


Figure 24.3 Difficulty in advancing the catheter over the guidewire: (a) The catheter forms a loop in the aorta. (b) The tip of the catheter flips back into the aorta. (Adapted from Gerlock and Mirfakhræe [5] with permission.)

Table 24.1 Strategies for advancing a guide

Mechanism	Strategies
Lack of support by the wire	To use stiffer wire (Terumo stiff, Supracor, Amplatz, etc.)
Excessively angled carotid origin	To use stiffer wire or multiwire technique
Friction of the wire within the catheter	To advance the catheter while withdrawing the wire
Excessive distal curve of the catheter	To rotate while advancing the catheter

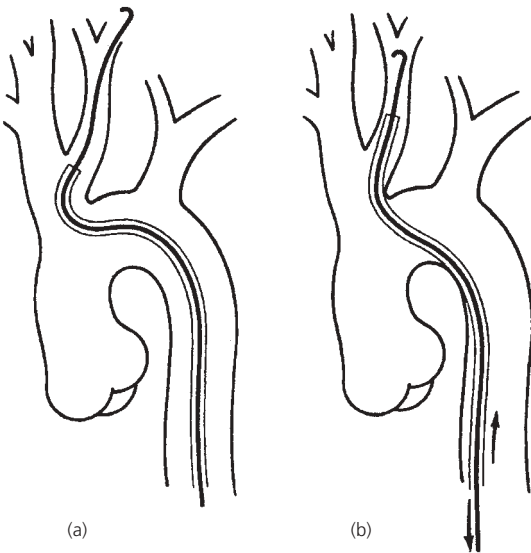


Figure 24.4 Diagram showing how to reduce the friction between the wire and the internal surface of the catheter: (a) The catheter tip is at the orifice of the left common carotid artery and the tip of the wire is in the left internal carotid artery. (b) The catheter is advanced while the wire is withdrawn. (Adapted from Gerlock and Mirfakhraee [5] with permission.)

and the internal surface of the catheter. Another way is to change the size of the wire to a smaller one, although this wire would not provide the same support as the previous wire; however, it would help to advance the catheter if the problem were related primarily to friction rather than support [5].

To solve the problem of a sharp angle at the end of the catheter, while the wire is fixed, the catheter is advanced over it while rotating the catheter gently. The goal is to straighten the distal segment of the catheter by the wall of the artery so the catheter can adopt itself more to the angle and be advanced further (Figure 24.5). In difficult situations, two or three of the above-mentioned

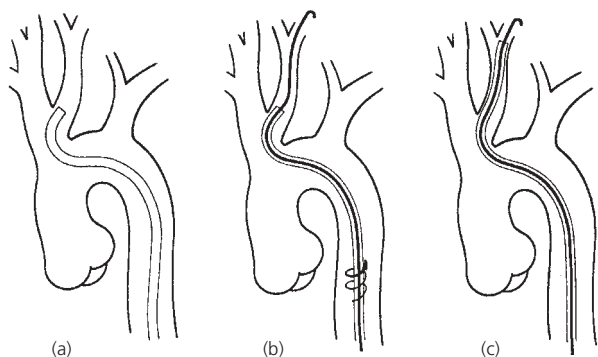


Figure 24.5 Straightening of the tip of the catheter by the wall of the artery: (a) The tip of the catheter is at the orifice of the left common carotid artery. (b) While the wire is fixed, the catheter is advanced over it using rotating forward movement. (c) The catheter has advanced over the wire into the vessel. (Adapted from Gerlock and Mirfakhraee [5] with permission from Elsevier.)

maneuvers may be required before the tip of the catheter can be advanced to the desired level.

The failure to advance the guide catheter usually includes different mechanisms related to angulation, excessive friction, or tortuosity. Table 24.1 describes the main mechanisms and the relative corrective strategies.

*****Multiwire technique for a hostile neck** Sometimes, especially on old patients with aortic arch type III or anomalous origin of the carotid arteries (bovine arch), it may be difficult to access severely tortuous, calcified arteries using the standard approach. In those arteries in which the wire will not advance without “kicking” the guide back, alternative strategies have to be considered.

In such cases we prefer to use the so-called multiwire technique. A hostile neck is approached with multiwire technique that includes, as a first step after aortic arch angiography, the cannulation of the CCA with a 5-Fr diagnostic left mammary artery catheter. With the aid of the roadmap technique and injection of 6 ml contrast medium, the operator attempts to advance a 0.035-inch soft Terumo wire into the ECA. Then, the catheter was exchanged with an 8-Fr MP guide. If the first attempt to advance an 8-Fr MP guide to the distal CCA fails, a second and even up to a third Terumo soft wire were advanced into the ECA in order to obtain advancement of the guide to the ICA (Figure 24.6).

*****Carotid access in the presence of occluded ECA, CCA lesion below bifurcation, or ostial CCA lesion** Placing a 7-Fr 90-cm access sheath into the CCA may present special challenges when the ECA is occluded, a critical lesion is situated below the bifurcation, or there is a critical ostial common carotid

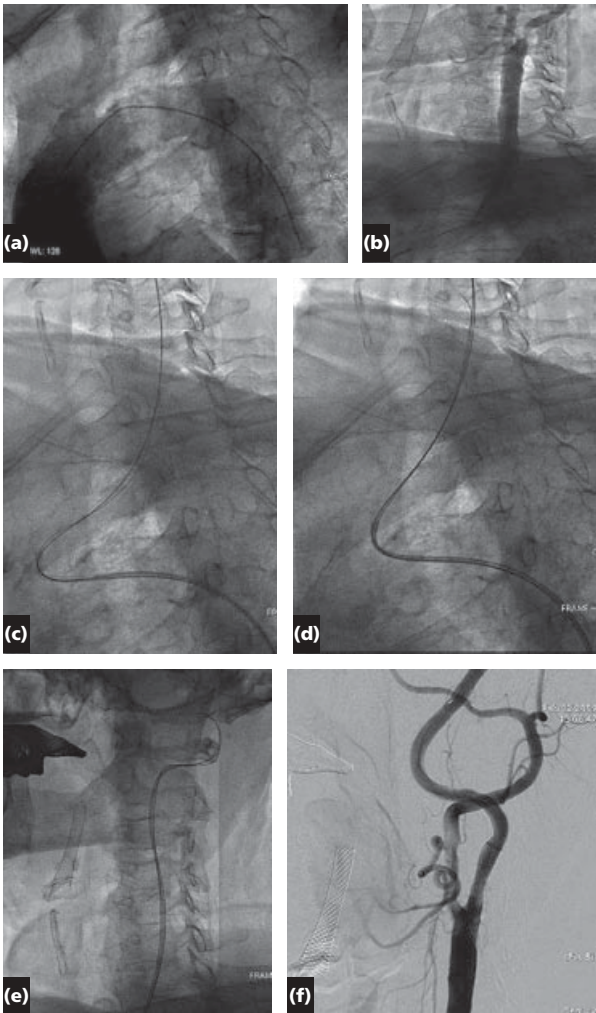


Figure 24.6 Multi-wire techniques: (a) Aortic arch type III on aortography. (b) Carotid artery angiography with a 5-Fr diagnostic catheter. (c) Change of the diagnostic catheter for an 8-Fr MP guide and subsequent advancement of three hydrophilic 0.035-inch wires in the external carotid artery. (d,e) Advancement of the guide over the three wires. (f) Success of carotid stenting and final result on angiography.

lesion. If possible, avoid crossing the lesion with a stiff 0.038-inch wire because this is more likely to disrupt the necrotic plaque material and cause distal embolization. When possible, advance the 5-Fr diagnostic catheter over the 0.038-inch guidewire to be placed more distally. In this situation, the guidewire and 5-Fr catheter are first advanced through the lesion. This maneuver should be done only in patients considered at high risk for carotid

surgery if the risk:benefit ratio still favors stenting. In the presence of a carotid ostial lesion, the origin of the CCA should be first dilated to allow sheath access. The bifurcation should be stented first, and the ostium stented on the “way out.”

ANGIOGRAPHY

After the guide enters the artery, slow hand injection is done to confirm the position of the guide, to make sure that good blood flow is maintained and there is no subintimal entry of the contrast agent. Injections of contrast agent into all brachiocephalic arteries should be done with small amounts of contrast (no more than 6 ml per injection, hand injection, or 3–6 ml/s). Larger volumes create a mixture of arterial, intermediate, and venous phases, thus obscuring early filling veins and other pathologies.

Some operators always perform a four-vessel angiography to check collaterals for interventions and rescue when needed. We usually do not do this in order to avoid the additional risk, especially if we use magnetic resonance angiography (MRA). Of course, MRA does not provide information about the functional capacity of the intracranial collaterals. If the ICA provides collaterals to the contralateral system, balloon inflation with transient occlusion of the ICA can cause seizure. On the other hand, stenting still would be possible.

PROTECTION DEVICES

A major limitation of carotid artery stenting is distal embolization. Balloon dilation, stent implantation, and manipulation of the guide and wires release embolic debris, which can cause cerebral ischemic events. To prevent this usually catastrophic event and to improve the overall results, two different kinds of systems are used: the distal filter and the proximal occlusion devices.

Filter Devices

Different filter devices usually have a similar mechanism of protection. Generally a filter basket made by various membrane materials is attached at a fixed distance to the distal tip of a standard 0.014-inch wire. The undeployed filter device is manipulated to cross the lesion and opened distally at the carotid siphon. The commonly used devices are listed in Table 24.2 and shown in Figures 24.7–24.9.

Equipment

Angioguard XP/Angioguard RX The Angioguard filter (see Figure 24.7) consists of a parachute type filter, which is mounted on a 300- or 180-cm long, 0.014-inch wire, a delivery catheter, and a retrieval catheter. The monorail version using the short wire is preferred by most interventionalists. The filter comes in diameters between 4 and 8 mm and is compatible with vessels between 3.5 and 7.5 mm. The filter membrane is made of polyurethane. The pores in the filter have a diameter of 100 μm . The filter has eight nitinol struts. Four of these struts have a radio-opaque

Table 24.2 Common filter devices

Name	Membrane material	Vessel range (mm)	Need for retrieval catheter	Guide size (Fr)
Angioguard XP/RX	Polyurethane	3.5–7.5	Yes	8
Filterwire EX/EZ	Polyurethane	3.5–55	Yes, angled	8
Emboshield RX	–	3–6	Yes, 5.5 Fr	–
SpiderRX	Windsack-type of nitinol wire mesh	3–7	Yes	6
RX Accunet	Polyurethane	4.5–7.5 mm	No	6/8

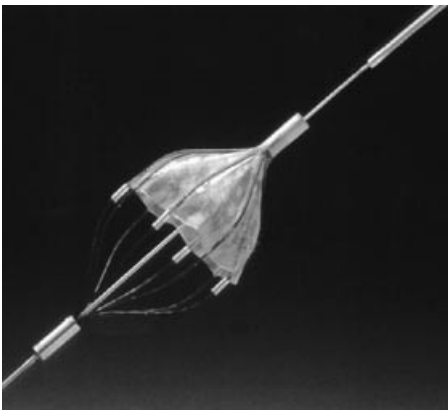
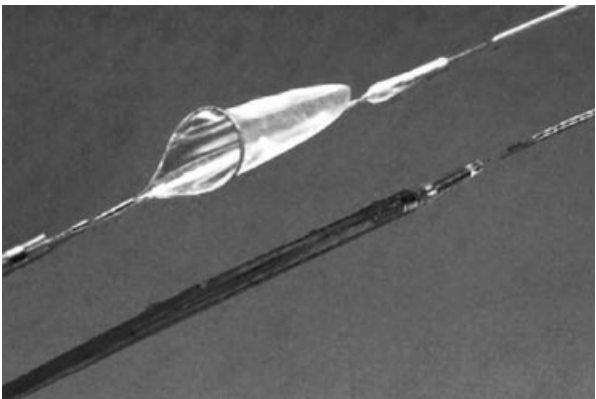
**Figure 24.7** Angioguard filter device.**Figure 24.8** Filter wire device.



Figure 24.9 SpiderX device.

marker. The deployment sheath is a rapid exchange system and has a crossing profile of 3.2–3.9Fr.

FilterWire EX/EZ This filter (see Figure 24.8) is mounted on a 0.014-inch wire by means of an eccentric nitinol wire loop. Due to this design, the entry of the particles into the filter is not impeded by filter struts. The new version of this device (FilterWire EZ) has a better vessel wall apposition than the former device. The membrane of the filter is made of polyurethane and has pores with a diameter of 110 μ m. The delivery catheter has an outer diameter of 3.2Fr. The filter comes in one size and adapts to vessel diameters between 3.5 and 5.5 mm in diameter. It can be withdrawn with a retrieval catheter of 4.3 Fr or with any 0.018-inch-compatible balloon catheter.

SpiderRX (ev3) The SpiderRX Vascular Filtration System (see Figure 24.9) consists of a windsock-type filter basket made of a nitinol wire mesh. The design of this filter has some similarities with the EPI filter. However, it comes in different sizes between 3 and 7 mm. At the entrance of this filter there is a clasp to ensure a better vessel wall apposition of the opening of the filter. After crossing the lesion with the wire the delivery catheter of the system is introduced. The crossing profile of the delivery catheter is 3.2 Fr. The wire is removed and the filter advanced through the delivery catheter and placed distal to the stenosis.

Occlusion Devices

The occlusion devices are based on the closure by means a compliant balloon of the CCA and the ECA to establish a retrograde flow in the ICA (Figure 24.10). Recently the most commonly used system, the MO.MA device, has proved to be very effective with a 30-day major stroke rate of 0.9% [7,8]. The features of the commonly used system are described in Table 24.3.

Gore Neuro Protection System This device prevents distal embolization by establishing a retrograde flow in the ICA (Figure 24.10). It consists of a 9-Fr guide with a balloon at its distal tip. This balloon is inflated in the CCA. To avoid blood flow from the ECA to the ICA the former is occluded with a separate balloon mounted on a wire which is introduced through the lumen of the guide. The proximal hub of the guide is connected with a venous sheath. Due to the pressure difference between the distal ICA and the venous system a retrograde blood flow is established. A filter

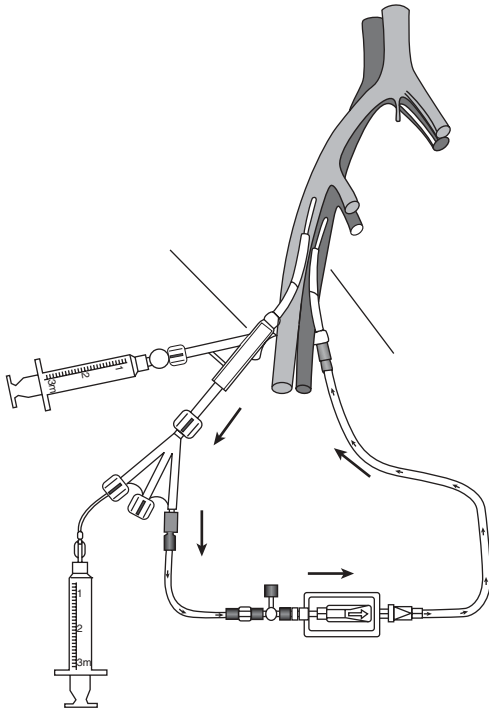


Figure 24.10 Gore Neuro Protection device.

Table 24.3 Common occlusion system devices

Name	Guide catheter size (Fr)	Separated balloons	Venous sheath	Mechanism of action
Gore Neuro Protection System	9	Yes	Yes	Occlusion on both external and common carotids; no need of aspiration; retrograde flow due to difference in pressure between vein and artery
MO.MA	9	No	No	Occlusion of both carotids; aspiration through the guide

located in the arteriovenous shunt prevents embolisation of the debris into the venous system.

Advantages and Limitations

The major advantage of this technique is that during the procedure emboli cannot move toward the brain. This protection starts already before crossing the lesion. This is of special importance in lesions that contain fresh thrombus (Figure 24.11). The operator may use the wire of his or her choice which helps to cross difficult lesions. There is no risk of distal problems in elongated vessels (Figure 24.12). Disadvantages of this technique are the need for a 9-Fr sheath and intolerance of balloon occlusion in some patients. In contrast to the distal balloon occlusion technique (PercuSurge), angiography during the procedure is possible. To perform the procedure in a stepwise fashion is easier and faster than with the PercuSurge technique, because there is no need for an aspiration catheter before deflating the balloon.

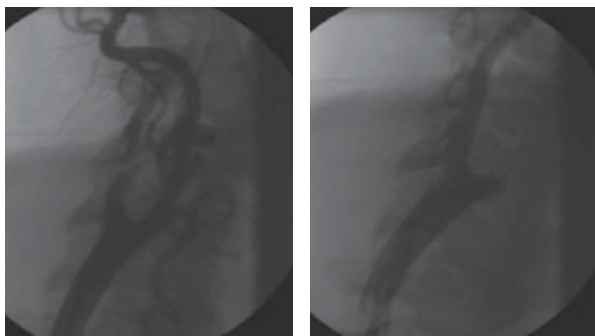


Figure 24.11 Angioplasty of a lesion with a fresh thrombus: In this situation a proximal occlusion system as embolic protection device should be used.

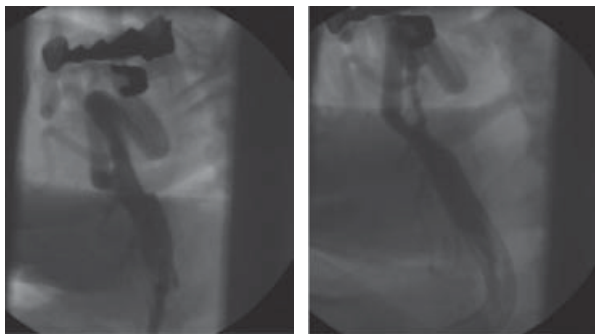


Figure 24.12 Angiogram of severely elongated vessel: As it might be difficult to place a distal protection system in the internal carotid artery, we would suggest the use of a proximal occlusion system.

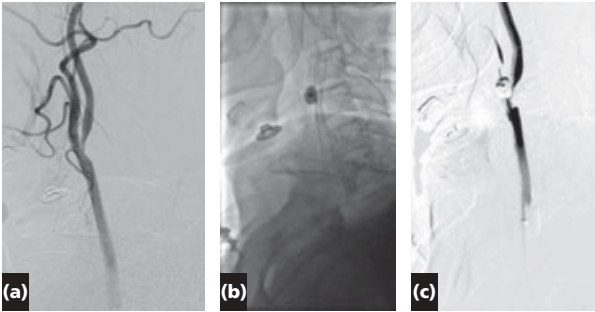


Figure 24.13 Carotid lesion containing fresh thrombus (a) treated with MO.MA-assisted stenting. (b) Note the two inflated balloon in the common and external carotid arteries (c).

MO.MA (Invatec) This device has some similarities with the Gore Neuro Protection System. The occlusion balloon for the ECA is fixed to the guide (9Fr) which allows faster and more reliable placement. This implies that the fixed distance between the balloon at the tip of the guide and the external occlusion balloon is suitable for the individual anatomy of the patient, which is the case in most. The distal balloon is capable to occlude vessels up to 6mm (ECA) and the proximal up to 13mm (CCA) (Figure 24.13). Instead of a continuous retrograde flow to the venous system, aspiration with a syringe is used to remove the debris between the different steps of the procedure or at the end of the procedure. As with the Gore Neuro Protection System, device angiography during the procedure is possible. The operator may use any kind of wire to cross the lesion and in case of intolerance the procedure can be performed stepwise.

Selection of the protection system Neuroprotection systems should be selected on anatomic and clinical criteria: Fresh thrombus containing lesions and absence of contralateral disease can probably be better managed by the use of occlusion system, whereas, in the presence of contralateral disease or occlusion, filter devices are probably preferable.

BALLOON ANGIOPLASTY

Very tight or subocclusive carotid disease can be approached with gentle predilation using coronary 2.0, 2.5, or 3.0 × 20 or 30mm balloon at nominal pressure, even in the presence of thrombus-containing lesion. In such cases, a filter wire not fixed over a wire such as the SpiderX, or for very unstable lesions proximal occlusion systems, should be used if predilation is necessary.

STENTS

Within the last few years the number of available carotid stents increased considerable as well as major improvements have been

Table 24.4 Features of commonly used stents

Name	Stent material	Stent size (mm)	Foreshortening	Open cell	Flexibility
Carotid Wallstent	Stainless steel	6–10	Yes	No	Yes
Xact	Stainless steel	7–10	Yes	No	No
RX Acculink	Nitinol	5–10 ^a	No	Yes	Yes
Sinus–carotid	Nitinol	7–9 ^a	No	Yes	Yes
Protege RX	Nitinol	6–10 ^a	No	Yes	Yes
Cristallo ideale	Nitinol	7–11 ^a	No	Yes	Yes
Precise RX	Nitinol	5–10	No	Yes	Yes

^aTapered.

made to meet the specific requirements of carotid stenting. During the first years of carotid stent implantation mainly balloon expandable stents were used. This technique had to be abandoned due to stent crushing which lead to cerebral flow impairment. Since then the interventionalists can choose between self-expanding nitinol stents and stainless steel stents. Which stent to select depends on the arterial anatomy and the specific characteristics of the lesion. All nitinol stents are constructed from a nitinol tube that is laser-cut. Depending on the number of the bridges between the different rings, the nitinol stents can be classified into stents with a closed-cell or an open-cell configuration. The main features of commonly used stents are described in Table 24.4.

Discriminating Differences

In very tortuous access vessels, a low crossing profile of the delivery catheter is important. At present the crossing profile does not differ significantly between the different stents.

In tortuous lesions a flexible stent is required to avoid straightening of the vessel and kinking of the artery at the end of the stent. Stents with a high flexibility are open-cell nitinol stents. The Wallstent delivery system currently has the highest flexibility.

To accomplish an even smoother transition between the ICA and CCA, tapered stents have been developed, which are characterized by a smaller stent diameter at the distal end of the stent. All currently available stents provide these features.

To treat severely calcified lesions, a stent with a high radial force is recommended. In general, closed-cell design stents have a higher radial force. Closed-cell stents provide better scaffolding to treat lesions with high emboligenic potential.

Equipment

Carotid Wallstent The Carotid Wallstent comes in a diameter of 6–10 mm and a length of 22–37 mm when fully opened. If the stent is implanted in a vessel, the length varies depending on the degree of compression. This also means that the stent is much longer as long as it is fixed in the delivery system. During deployment, it foreshortens according to the diameter of the vessel, e.g. a 31-mm-long stent with a diameter of 10 mm (fully open) is approximately 60–70 mm long as long as it is compressed in the delivery system. Implanted in a 9-mm vessel it has a length of 40 mm. If it is implanted in an 8-mm vessel it is 49 mm long.

It is a rapid exchange system and 0.014-inch wire compatible. The outer diameter of the delivery system is 5 or 5.9 Fr depending on the diameter of the stent. The stent mesh design provides high plaque coverage. A disadvantage is that the stent straightens the vessel more than open cell Nitinol stents do.

Xact carotid stent The Xact stent is a nitinol stent that comes in two different shapes. The straight stent is available in a diameter of 7–10 mm and a length of 20–30 mm, and the tapered stent has a diameter of 6–8 mm, 7–9 mm, and 8–10 mm, and a length of 30 and 40 mm. It has a crossing profile of 5.7 Fr and a rapid exchange delivery system. The Xact stent has a closed cell design so it is stiffer than other nitinol stents. It should be deployed only in straight vessel segment.

RX Acculink This open-cell nitinol stent is also available in two different shapes. The straight stent comes in a diameter of 5–10 mm and has a length of 20–40 mm and the tapered stent has a diameter of 6–8 mm and 7–10 mm (length of 30 and 40 mm). The rapid exchange system is compatible to a 0.014-inch wire and a 6-Fr sheath.

Sinus–Carotid-RX/Conical RX This nitinol stent is another stent that is available in two configurations. The straight stent has a diameter of 6–9 mm and a length of 20–40 mm. The tapered stent comes in a diameter of 6–9 and 7–10 mm and has a length of 30 or 40 mm. It has an open-cell design. The distal ends of the stent have higher radial force than in the middle. A special feature is that the stent is attached to the 5-Fr delivery system until the very end of the release process, which prevents the stent from “jumping distally” during deployment.

Precise RX nitinol stent system The Precise stent has a rapid exchange system with an outer diameter of 5–6 Fr. It is 0.014- and 0.018-inch wire compatible. The open-cell nitinol stent has a diameter of 5–10 mm and a length of 20–40 mm. This stent has a high conturability and flexibility.

Protégé RX (ev3) This nitinol stent is available in a straight and a tapered design. The straight stent has a diameter of 6–10 mm and a length of 20–60 mm. The tapered stent has a diameter of 8–6 mm or 10–7 mm and a length of 30 or 40 mm. The stent does

not shorten during the implantation. The Exact Placement Release Technology avoids premature stent deployment.

Cristallo ideale This is a 5-Fr rapid exchange system. The straight stent has a diameter of 7, 9, or 11 mm and a length of 20–40 mm. The tapered stent comes in sizes of 7–10 and 6–9 mm with a length of 30 or 40 mm. It has a small cell size in the middle and a larger cell size (with more flexibility) at the proximal and distal ends.

Post-stent Dilation

It is safer to underdilate than overdilate the oversized self-expanding stents. Overdilation squeezes the atherosclerotic material through the stent mesh, causing emboli. A 10–15% remaining stenosis does not cause clinical problems. Importantly, it is not necessary to dilate the stent to obliterate segments of contrast-filled ulcerations external to the stent. This angiographic appearance is of no prognostic significance and follow-up angiography has documented complete fibrotic healing of these lesions over time. Importantly, it is not necessary to overexpand the stent to produce a 0% residual diameter narrowing. Covering the ECA with a stent does not cause problems. If the ECA becomes occluded after dilation of the stent, this vessel can be approached through the stent mesh, and reopened using coronary balloon techniques.

Advanced Techniques

****Aortic dissection extended to carotid artery** Acute aortic dissection is one of the most common catastrophes affecting the aorta. Aortic branch occlusion occurs in up to a third of patients with aortic dissection, and is associated with increased risk of early death and serious complications. Surgery is the first-line therapy but has a high mortality and morbidity. Postoperative stroke is known to be an independent predictor of late mortality and the best management for this complication is still debated. Carotid artery stenting before complete repair by means of surgery or stent-graft implantation can be a viable option in such cases. The use of protection devices may be problematic because of the difficulty defining the true and false lumen, whereas probably they are not very useful because of the different nature and pathophysiology of the dissection with respect to atherosclerotic plaque. The clue is to advance the wire into the true lumen: To do this, careful evaluation of an aortogram and engagement of the carotid artery with a soft guidewire and small amount of contrast injection are undertaken to check the correct position within the true lumen, whereas advancing the guidewire is mandatory for success (Figures 24.14 and 24.15).

*****Association between severe kinking and occlusive disease of the carotid artery** Even if in the past the distal internal carotid coiling or kinking was considered a contraindication to carotid artery stenting because it was thought to interfere with adequate distal embolic protection, recent studies showed

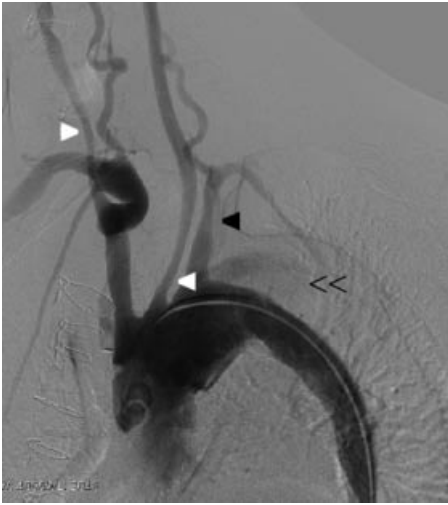


Figure 24.14 Aortic dissection extended to both the carotid arteries (arrows).

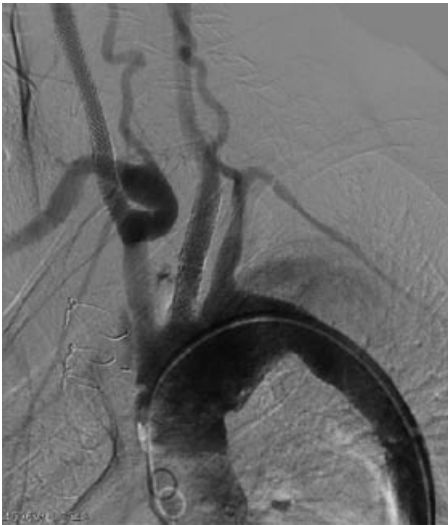


Figure 24.15 Successful stenting of the right internal and left common carotid arteries

that this finding does not influence the carotid artery stenting outcome and should not be considered as a contraindication to carotid artery stenting. Moreover, sometimes new kinking or an increase in previously moderate kinking can occur after successful stenting of the ICA. If severe flow limitation develops, implantation of a second stent may be considered an option: Segmented nitinol stents improved the conformity between the prosthesis

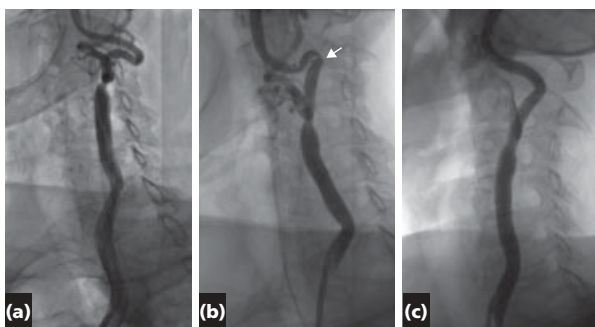


Figure 24.16 (a) Severe kinking and disease of the internal carotid artery. (b) After the first stent implantation, worsening of the previous kinking is noted with flow impairment. (c) A second nitinol stent re-establishes a good flow fitting the vessel curve well.

and vascular anatomy should be considered the stent of choice in such cases (Figure 24.16).

COMPLICATIONS

Thrombotic and Embolic Complications

Advantages of the endovascular approach over endarterectomy include the ability to immediately diagnose and treat these complications, and the patient can be awake, allowing close neurological monitoring. For acute thrombosis, local intra-arterial thrombolysis can be carried out using mechanical as well as chemical disruption of the clot. Extreme care must be exercised to avoid vessel perforation. Only very flexible microcatheters and soft wires may be used in the intracerebral circulation. Today cerebral protection devices are widely used and recommended by current guidelines, although a clear benefit has not been fully proved.

Carotid Artery Spasm

Wire-induced phenomena are minimized by the use of 0.014- to 0.018-inch wires. Carotid artery spasm can be successfully treated with nitroglycerin but usually it disappears spontaneously.

Stent Restenosis

The restenosis rate for carotid stenting is less than 10% in most series [9]. Careful Doppler ultrasonography evaluation should be performed in the follow-up, keeping in mind that velocity measurements are altered from the previous stent and the correlation between velocity and stenosis cannot be calculated exactly as for native stenosis. In doubtful cases CTA or MRA can be performed. Rarely there are clinical indications to perform a re-do percutaneous transluminal angioplasty. In such cases balloon dilation or an additional stent is required for treating a stenosis at the end of a stiff stent.

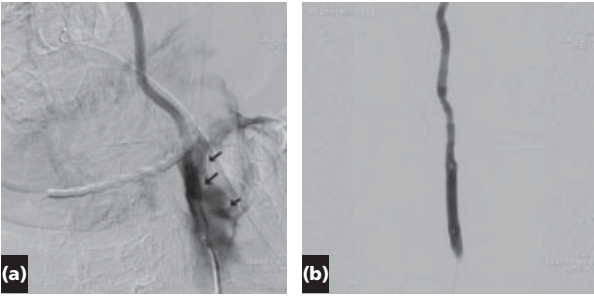


Figure 24.17 (a) Common carotid artery rupture during carotid artery stenting. (b) Result after stent-graft implantation.

Carotid Perforation and Dissection

These complications are very rare and can occur after excessive balloon sizing before or after stent placement, especially in very tortuous or calcified arteries. If encountered, prolonged balloon inflation or even covered stents can be used if there is no compromise of major side branches in cases of rupture, whereas additional stenting may be necessary to avoid flow disruption in cases of dissection (Figure 24.17).

Cerebral Hyperperfusion Syndrome

Hyperperfusion syndrome may be fatal once an intracranial hemorrhage occurs. Impaired cerebral autoregulation and post-revascularization changes in cerebral hemodynamics are the main mechanisms involved in the development of the syndrome. These are associated with a combination of excessive anticoagulation, uncontrolled hypertension, intracranial vessel manipulation, and stenting after a recent stroke (3 weeks) [10]. Terminate the procedure, reverse the anticoagulation, and control the hypertension. An emergency brain CT scan should be performed. Operators should be familiar with the angiographic features of an intracranial mass effect. Sudden loss of consciousness preceded by a severe headache in the absence of intracranial vessel occlusion should alert the operator to this devastating event. Fortunately, with careful patient selection and compulsive attention to the above technical and anticoagulation issues, cerebral hemorrhage remains a very rare occurrence.

Cerebral Protection Devices-related Complications

Cerebral protection devices may also cause problems. All devices placed distally in the ICA may cause spasm or dissection. Rarely additional balloon inflations and/or stent implantations have been necessary to solve the problem. It may be difficult to retrieve these devices through the implanted stent. It may occur that the filter is not fully apposed to the vessel wall. In contrast, the major disadvantage of the occlusion devices is intolerance in patients with occlusion or high-grade stenosis of the contralateral internal carotid artery or patients with poorly developed intracranial

collaterals. A specific disadvantage of the occlusion devices is the need for a larger sheath which may cause vascular access problems.

****Difficult Retrieval of Filter Devices**

Occasionally because of vessel tortuosity and kinking and the angle created by the relative position of the stent within the vessel, retrieval of the filter device can be difficult. When the ICA above the stenosis appears tortuous and worsening of the pre-existing kinking is likely, guide-catheter technique and filters with angled retrieval catheter, such as the Filter wire, or an occlusion device should be selected in order to retrieve the filter successfully with gentle manipulation of the guide or filter retrieval guide. Alternatively, when withdrawing the filter with the given guide is not possible due to the appearance of new kinking after stent placement, manipulating a diagnostic 4- or 5-Fr 135-cm JR or MP catheter inserted through the guide, or the long sheath may change the angle between stent and the filter and enable filter retrieval.

REFERENCES

1. Zhou W, Bush RL, Lin PL, et al. Fibromuscular dysplasia of the carotid artery. *J Am Coll Surg* 2005;**200**:807.
2. Biondi A, Katz JM, Vallabh J, Segal AZ, Gobin YP. Progressive symptomatic carotid dissection treated with multiple stents. *Stroke* 2005;**36**: e80–2.
3. Trimarchi S, Nienaber CA, Rampoldi V, et al. International Registry of Acute Aortic Dissection Investigators. Contemporary results of surgery in acute type A aortic dissection: The International Registry of Acute Aortic Dissection experience. *J Thorac Cardiovasc Surg.* 2005 **129**:112–22.
4. Goldstein LB, Adams R, Becker K, et al. Primary prevention of ischemic stroke: a statement for healthcare professionals from the Stroke Council of the American Heart Association. *Circulation* 2001;**103**: 163–82.
5. Gerlock A, Mirfakhraee M. Difficulty in catheterization of the left common carotid arteries. In: Gerlock A, Mirfakhraee M (eds), *Essentials of Diagnostic and Interventional Angiographic Techniques*. Philadelphia: WB Saunders, 1985: 106–19.
6. Harjai KJ, Anderson J. Repair of right carotid artery pseudoaneurysm in a patient with hostile aortic Arch through left ventricular approach. *J Interven Cardiol* 2008;**21**:239–41.
7. Reimers B, Sievert H, Schuler GC, et al. Proximal endovascular flow blockage for cerebral protection during carotid artery stenting: results from a prospective multicenter registry. *J Endovasc Ther* 2005;**12**: 156–65.
8. Ansel GM, Hopkins LN, Jaff MR, et al Investigators for the ARMOUR pivotal trial. safety and effectiveness of the INVATEC MO.MA proximal cerebral protection device during carotid artery stenting: results from the ARMOUR pivotal trial. *Catheter Cardiovasc Interv* 2010;**76**:1–8.
9. Chakhtoura EY, Hobson RW, Goldstein J, et al. In-stent restenosis after carotid angioplasty-stenting: incidence and management. *J Vasc Surg* 2001;**33**:220–5.
10. Moulakakis KG, Mylonas SN, Sfyroeras GS, Andrikopoulos V. Hyperperfusion syndrome after carotid revascularization. *J Vasc Surg* 2009; **49**:1060–8.

CHAPTER 25**Iliac Artery Stenosis**

Timothy C. Dy, Gianluca Rigatelli, Paolo Cardaioli, Rosli Mohd Ali, Aravinda Nanjundappa

Challenges 580

Non-invasive Evaluation 580**Ankle/Brachial Index 580****Treadmill Exercise Test with and without ABI 580****Ultrasonography 580****Computed Tomography Angiography 580****Magnetic Resonance Angiography 581****Invasive Evaluation 581*****Diagnostic Aortoiliac Angiography 581****Technique 581****Intravascular Ultrasound 581****Stenting Technique 582****Access 582****Wires 582****Balloons 583****Stent 584****Technical Tip 584******Recommended stent positioning 584****Brachial Access 588****Zigzag Wire Technique 589****Chronic Total Occlusions 589****Diagnostic Angiography 590****The Challenge 591****Technical Tips 593******The "body floss" technique 593*******Use the stiff end of the wire 593****Complications 599****Perforations 599****Acute or Subacute Occlusion 599****Iliac Artery Rupture 600****Technical Tips 600**

Damage control 600

Case selection 600

*Basic; **Advanced; ***Rare, exotic, or investigational

\$, <\$US100.00 extra; \$\$, >\$US100.00 extra

⌚, <10 min extra; ⌚⌚, >10 min extra

♣, low risk of complications; ♣♣, high risk of complications

CHALLENGES

Aortoiliac artery disease is a common presentation of atherosclerotic cardiovascular disease. As a result of the high correlation between coronary artery disease and aortoiliac atherosclerosis, a global workup including coronary artery disease screening should be performed whenever possible [1]. With excellent results of angioplasty and stenting of the aortoiliac vessels, the endovascular approach has become the first-line therapy in most of these patients.

NON-INVASIVE EVALUATION**Ankle/Brachial Index**

The new guidelines of peripheral artery disease (PAD) management divided patients into asymptomatic and symptomatic groups. For both groups measurement of the ankle/brachial index (ABI) is of paramount importance. An ABI <0.90 is abnormal and highly suggestive of significant PAD. An exercise ABI might be helpful in asymptomatic patients with a high suspicion for PAD and a normal resting ABI (0.9–1.3) [2].

Treadmill Exercise Test with and without ABI

Exercise testing may be extremely useful (1) in establishing the diagnosis of lower extremity PAD when resting measures of the ABI are normal, (2) to objectively document the magnitude of symptom limitation in patients with lower extremity PAD and claudication, (3) to objectively measure the functional improvement obtained in response to claudication interventions, (4) to differentiate claudication from pseudo-claudication in individuals with exertional leg symptoms, and (5) to provide objective data that can demonstrate the safety of exercise and to individualize exercise prescriptions in patients with claudication before initiation of a formal program of exercise training. Dedicated personnel and equipment are needed.

Ultrasonography

Doppler ultrasonography is useful to provide an accurate assessment of lower extremity PAD location and severity, to follow lower extremity PAD progression, and to provide quantitative follow-up after revascularization procedures. Unfortunately in the aortoiliac segment, the efficacy of ultrasonography is limited by the poor acoustic window of obese patients and the deep localization of the vessel in the abdomen.

Computed Tomography Angiography

Computed tomography angiography (CTA) requires intravenous injection of iodinated contrast, which opacifies the arteries. The angiographic image is constructed from multiple cross-sectional images and then presented as a maximum-intensity projection, similar to the appearance of standard arteriography. The image can be rotated three dimensionally in space and be viewed in any

projection. This is particularly useful in the aortoiliac segment, where Doppler ultrasonography is often suboptimal because of technical difficulty.

Magnetic Resonance Angiography

Magnetic resonance angiography (MRA) of the extremities can be used to diagnose the anatomic location and degree of stenosis of PAD. MRA evaluation is based on imaging the arteries, similar to standard arteriography. Assessment of the accuracy of MRA depends on the MRA technique used and the standard against which it is compared. MRA techniques continue to evolve and improve. The techniques include two-dimensional time of flight, three-dimensional imaging, and contrast enhancement with gadolinium, subtraction, cardiac gating, and bolus chase. These techniques may be used in combination, because each has its advantages and disadvantages. The technique is particularly useful in elderly patients with poor renal function but is limited by presence of metallic prosthesis and cardiac implants [2].

INVASIVE EVALUATION

***Diagnostic Aortoiliac Angiography**

Digital subtraction angiography (DSA) is the “gold standard” for defining both normal vascular anatomy and vascular pathology. It remains the most readily available and widely used imaging technique. As a result of possible distal embolization or the effect of below-knee distal runoff on short- and long-term iliac stent patency, pre- and postprocedural lower extremity angiograms should be done and compared against each other to assess for either of these complications [3].

TECHNIQUE The usual technique includes the use of 4- or 5-French (Fr) pigtail catheter placed above the renal artery if flat panel radiological equipment is available, or infrarenal if cardiac equipment is used [3]. Injection of 25–30ml contrast at 10–12 ml/s is usually sufficient with digital subtraction technique to delineate the aortoiliac bifurcation and the external iliac arteries. An ipsilateral 20–30° oblique view can be selected in case of eccentric lesions. Pressure gradient measurement should be obtained with manual pullback to detect any significant stenosis: >30 mmHg. Place a side-hole catheter at level of L1–2. Use the smallest contrast volume possible especially when aortoiliac angiography is performed together with cardiac angiography and/or angiography of other vascular beds. Use 20° contralateral angulation with 20° caudal angulation injection when a detailed relationship between the internal/external iliac arteries is needed (Figure 25.1).

Intravascular Ultrasound

Intravascular ultrasound (IVUS) may be needed intraprocedurally when the severity of lesion and length is not easily measured or when ostial disease cannot be fully excluded: 6-Fr peripheral intravascular catheter and sometimes, in cases of severely ectatic iliac arteries, a 9-Fr intracardiac ultrasound probe can be used [4,5].

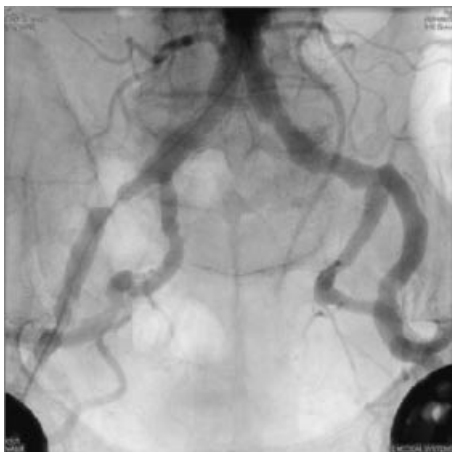

Figure 25.1 Aortoiliac angiography during coronary angiography in a 70-year-old patient with multivessel coronary artery disease.

STENTING TECHNIQUE

Access

Access is usually obtained from the ipsilateral femoral artery [6,7]. Sometimes the contralateral approach is preferable especially in cases of total occlusion without a nipple or when the ipsilateral femoral artery itself is diseased. Use whenever possible the ipsilateral approach. Select a 6- or 7-Fr sheath (at least 23 cm long). The longer sheath allows for sufficient contrast opacification and optimal visualization of the lesion through the sheath itself, even if injection is done retrogradely against systemic pressure. This often obviates the need for use of a contralateral pigtail catheter for positioning of balloons and stents (Figures 25.2 and 25.3).

Wires

Wire selection is quite an important step. A 0.35-inch soft-tip performable wire may be used in most cases. Occasionally, an extremely tight stenosis will not allow passage of a 0.035-inch wire. In these cases, a 0.014-inch, coronary high-support, hydrophilic wire may be used to facilitate predilation with small coronary balloons before proceeding with a 0.035-inch system. Stiffer wires such as the 0.035-inch Supracor or Super Stiff Amplatz wires may be considered in cases where there is severe tortuosity, calcium, or stenosis that makes balloon passage difficult. In such cases it is useful to exchange the workhorse 0.035-inch wire to a stiff wire over a hydrophilic exchange catheter such as the 4-Fr Glidecath.

When using a hydrophilic wire, one must pay careful attention to the tip. Follow the advancement of the tip under fluoroscopy to avoid access to an aberrant renal artery (with potentially severe renal damage). The wire tip is curved as a large C rather than a J.

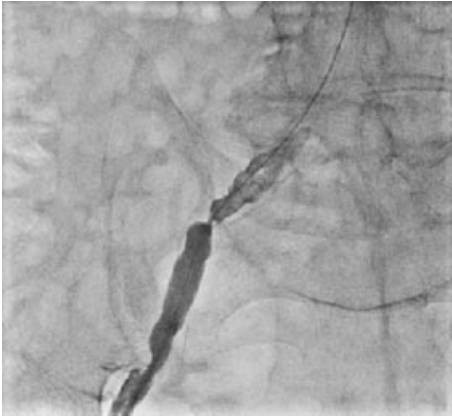


Figure 25.2 A 23-cm 7-Fr sheath has been placed through the femoral artery into the external iliac artery and a pre-formable 0.035-inch soft-tip wire has been advanced through a external iliac artery tight stenosis.

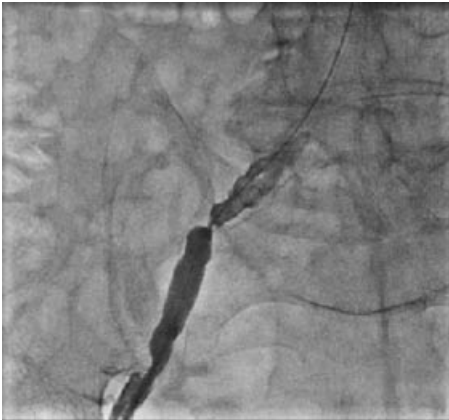

Figure 25.3 A small contrast injection through the 23-cm 7-Fr sheath visualized the tight stenosis; thus, a roadmap is created to allow for correct placement of a stent.

This shape is usually sufficient to cross the lesion without vessel damage, but is also shaped in a way that it can inadvertently enter other aortic branches. Place the wire into the thoracic descending aorta where there are fewer branches to decrease the chance of the wire accidentally entering and damaging the arterial trees of other organs.

Balloons

For non-critically narrowed lesions, primary stenting is the usual technique of choice. However, sometimes predilation is needed.

In rare cases of a very tight stenosis, a low-profile, 0.014-inch monorail coronary balloon, 2.5–3.5 × 20–30 mm inflated to nominal pressure, would help to advance the stent. In all the other cases, a normal peripheral 0.035-inch balloon, 4–6 mm × 20 or 30 mm, depending on the lesion length can be used. Use of an inflator to inflate balloons is recommended. Inflate slowly 1 atm for 3–4 s and watch as the lesion is modified. Stop inflation if the patient complains of pain because this could signify impending arterial injury or rupture. In general, undersizing the balloon by 1–2 mm will allow for adequate plaque modification even in calcified lesions because the balloon can be inflated to over nominal pressure. This will not only facilitate stent passage across the lesion but also stent expansion during stent deployment.

Stent

Stent implantation is probably the current standard practice in iliac artery interventions. Proper stent selection is mandatory to achieve good immediate and long-term results. Focal calcified stenosis should be managed with high radial force stent: 8–10 mm × 20–30 mm stainless-steel balloon expandable is the best option as well as for focal and ostial stenosis (Figure 25.4). The balloon-expandable stents allow precise implantation thanks to their excellent radio-opacity. They can be overexpanded with only minimal shortening. Long diffuse soft stenoses are better treated with an 8–10 × 40–80 mm self-expandable nitinol stents: Its open-cell design is preferred because of the low risk of distal embolization and optimal conformation to vessel anatomy (Figure 25.5).

Technical Tip

****Recommended stent positioning** Use a roadmapping technique when possible if balloon-expandable stenting is planned. Inject 5–8 ml contrast ensuring that the iliac ostium is

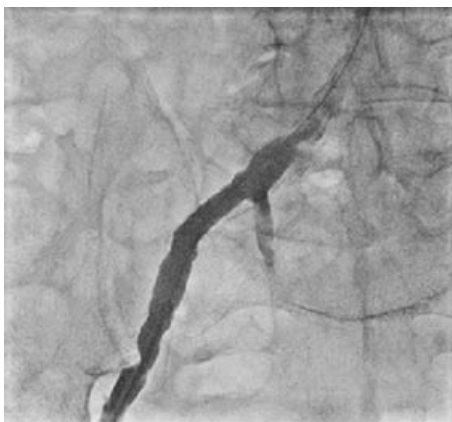


Figure 25.4 A 8 × 30 mm balloon-expandable stainless-steel stent has been correctly placed with a good angiographic result.

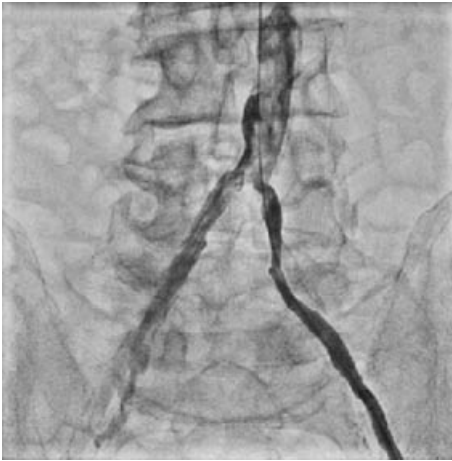

Figure 25.5 An aortogram during coronary angioplasty showed a long, diffuse stenosis of the left common iliac artery in a patient with multivessel coronary artery disease and 50 m claudication. The pressure gradient through the lesion was about 35 mmHg.

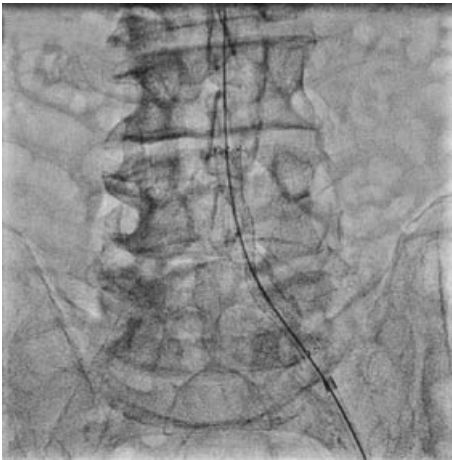


Figure 25.6 A self-expandable stent was deployed to cover the ostium and the entire lesion through a 7-Fr 23-cm sheath.

visualized particularly if the ostium is to be covered. Position the balloon-expandable stent 2–3 mm beyond the iliac ostium in the abdominal aorta to assure full ostial coverage. Deploy the stent very slowly under fluoroscopy: if the stent moves during deployment, gently withdraw/advance the stent system as necessary, check the position, and continue to deploy the stent slowly (Figures 25.6–25.8). An alternative technique is to advance the sheath over its dilator through the lesion within the distal

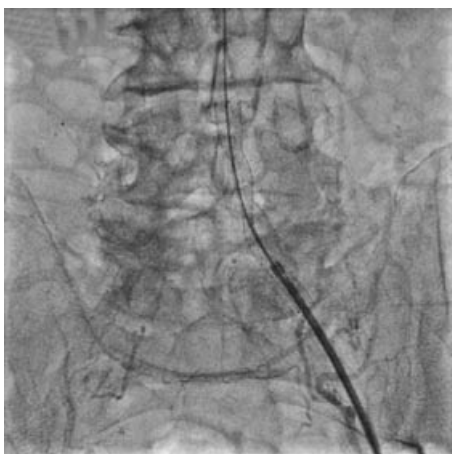

Figure 25.7 The sheath is gently advanced over its dilator into the stent to allow safe advancement of the balloon into the stent.

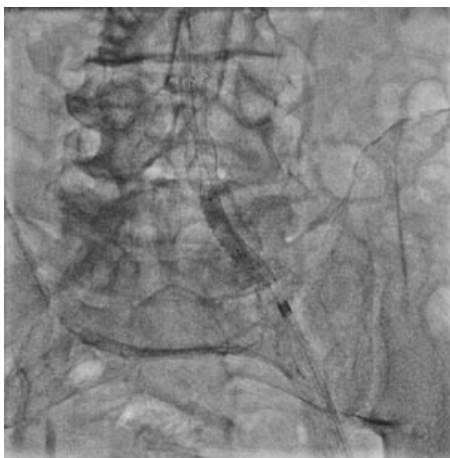


Figure 25.8 The balloon is slowly inflated at nominal pressure until the patient feels pain.

abdominal aorta, take a picture with the roadmap technique, position the stent within the sheath, then withdraw the sheath while keeping the stent in place and deploy it. If possible, avoid kissing stents with self-expandable stents: They can potentially be more difficult, cumbersome, and often the results are not satisfying [8].

When performing a kissing stent technique, deploy the stents simultaneously with two indeflators at the same pressure (8–9 atm for most stents). Deflate the balloons then advance both balloons beyond the distal end of the stent in the abdominal aorta, and

overdilate with high pressure (10–12 atm) to flare the ostial segments of the stents. This last maneuver should be done with care if there is a distal aortic lesion. For these cases, consideration should be made to position the kissing stents above the distal aortic lesion and include the lesion in the stenting. There should be little concern if 4–6 mm of the proximal end of the stent lies in the aorta: Usually it is uneventful and some operators even prefer it (Figures 25.9–25.11) [9]. This simply recreates the carina of the aortoiliac bifurcation cephalad to the original bifurcation point and should be of no clinical consequence. Check the final

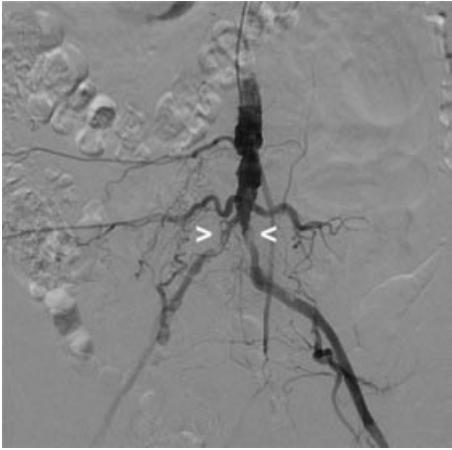


Figure 25.9 Aortoiliac angiogram in 20° left anterior oblique projection showing severe aortoiliac occlusive disease (arrows).

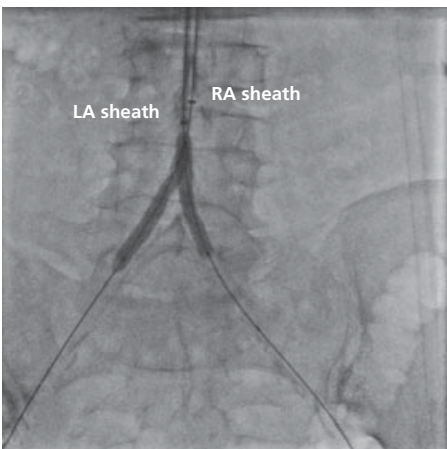


Figure 25.10 Kissing stenting with two 6.0 × 39mm balloon-expandable stent through the long 6-Fr brachial sheaths.

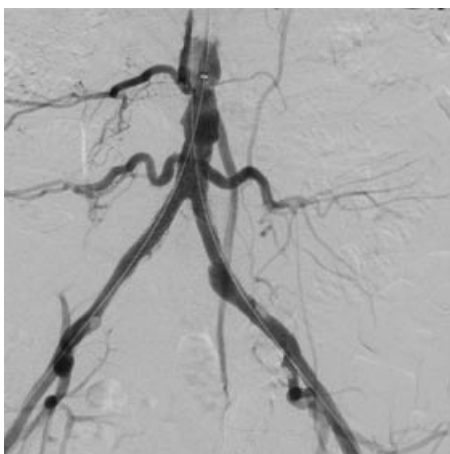


Figure 25.11 Final angiographic results after kissing stenting.

results carefully with an aortogram using a diagnostic pigtail catheter (with digital subtraction) technique to assess the results and any aortic damage. Alternatively, in bilateral kissing stents, simultaneous bilateral sheath injections would suffice.

Brachial Access

In rare cases the procedure cannot be accomplished through the femoral approach. New alternative access sites have been proposed for a wide spectrum of endovascular interventions, such as the radial approach for renal and carotid interventions, and the axillary approach for subclavian and aortic aneurysmal repair. Unfortunately, the axillary route often requires surgical cutdown and the diameter of the radial artery should be carefully measured before the procedure to minimize arterial complications when large sheaths are to be used. Recently, a case of radial access for ipsilateral iliac stenting has been reported [10,11]. Brachial access may have the advantage of being able to accommodate larger sheaths and is more likely to be effective in reaching the aortoiliac segment in most patients. In cases of a severely calcified or tortuous aorta, passage of devices from the brachial artery all the way down to the aortoiliac bifurcation could be facilitated by the use of stiff wires. Damage to the aorta can be avoided by passing the wire through a 4-Fr catheter and replacing the catheter with a long sheath (approximately 85 cm). In addition to added safety, this technique offers more support than using two different guides, reduces the stress on the arterial vessel at the subclavian site, and enables a stiff balloon or stent catheter to be advanced, even through the tortuous and calcified aorta, without the risk of dislodging the stent.

In the absence of a long sheath, a coronary guide catheter (Judkins right or multipurpose 6-Fr guide) can be used with a 90-cm-long sheath (Figures 25.9–25.11). In cases of kissing

stenting through a brachial approach, a 6-Fr Brite tip sheath is inserted into both brachial arteries and a standard 4- or 5-Fr Judkins right diagnostic catheter is inserted over a 260-cm 0.038-inch Terumo Stiff wire through both the sheaths. Appropriate, alternative, long-exchange wires can be used. The catheters from both sides are navigated up to the aortic bifurcation and, after selecting the common iliac artery ostia, the wires are navigated through the lesions and advanced into the ipsilateral superficial femoral arteries. The catheters can then be advanced over the wires beyond the occlusions and the Terumo wires replaced by two 0.038-inch 260-cm Supracor wires. Alternative long-exchange stiff wires can also be used. To facilitate the forward movement of the stents without the risk of dislodging them, consider two 6-Fr 90-cm Shuttle Flexor introducer long sheaths. These can be advanced over the stiff wires until they reach the common iliac artery ostia. A roadmap technique can be used to check the ostia position in order to properly deploy the selected stent (Figures 25.12–25.14).

Zigzag Wire Technique

On rare occasions, wire bias will prevent a postdilation balloon or a sheath from advancing into a previously deployed stent. A technique that can easily be used to overcome wire bias is the “zigzag” wire technique. Bends are intentionally placed on the wire so, while the balloon or sheath is being advanced, the leading edge of the device being advanced can be lifted off the stent struts and easily advanced into the stent (Figure 25.15).

CHRONIC TOTAL OCCLUSIONS

Due to increased restenosis and reocclusion rates, chronic total occlusions (CTOs) of the iliac arteries are usually best treated

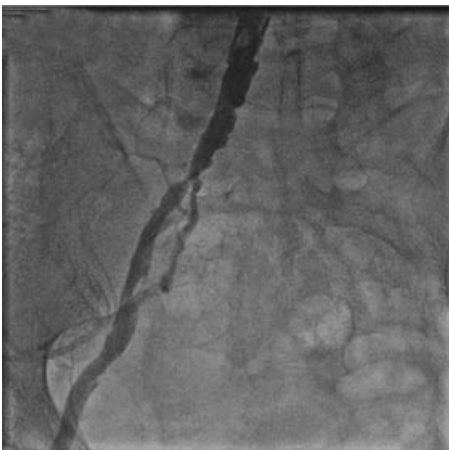


Figure 25.12 Iliac angiography through a diagnostic catheter advanced from the brachial artery.

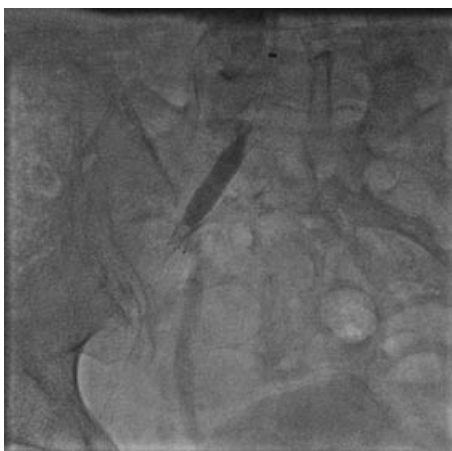


Figure 25.13 After changing the catheter with a long 6-Fr 90-cm sheath, a soft-tip 260-cm wire is advanced through the lesion and the stent is correctly deployed using a roadmap technique.

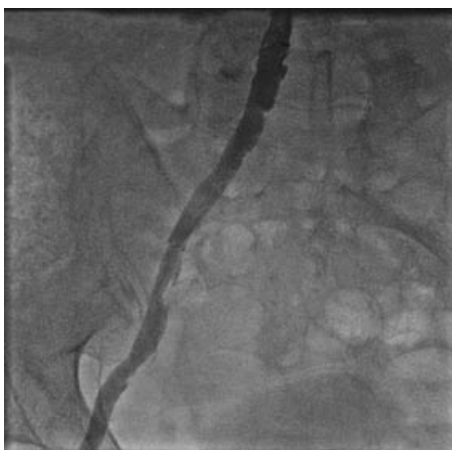


Figure 25.14 Final result by direct injection through the 6-Fr 90-cm sheath.

surgically. However, in patients who are poor surgical candidates or for those who refuse surgery, percutaneous revascularization can still be considered.

Diagnostic Angiography

Adequate lesion assessment is key in planning a strategy for treatment. The full extent of the occlusion should be documented in the diagnostic study. Often, a CT or MR angiogram is extremely helpful in approaching CTOs. In the absence of a non-invasive study, the diagnostic angiogram might need to include more than

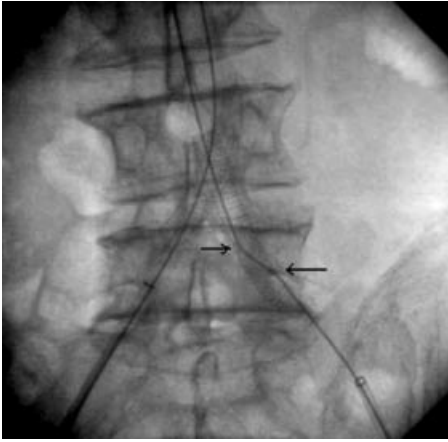


Figure 25.15 Zigzag wire technique in a patient post-kissing iliac stents wherein postdilation of the left iliac stent was hampered by inability to pass the balloon and sheath through the more distal portion of the stent strut because of wire bias. Arrows show the angles intentionally formed and positioned within the stent to lift off the leading edge of the balloon from the stent struts.

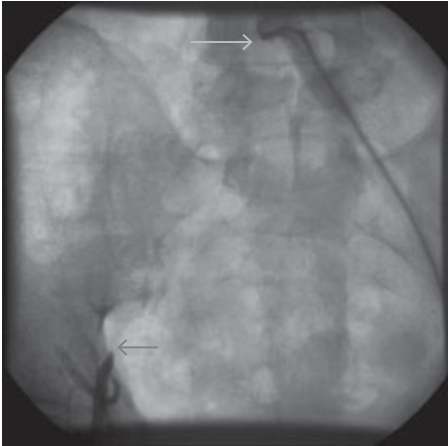


Figure 25.16 Diagnostic iliac angiography fully delineating the proximal and distal extent (in arrows) of a CTO using a left internal mammary artery catheter via a left contralateral femoral approach and a sheath injection from the right femoral artery.

one vascular access route in order to document the proximal and distal ends (length) of the CTO (Figure 25.16).

The Challenge

The main obstacle in successful percutaneous treatment of an iliac CTO is the thick fibrotic cap on either side of the occlusion. Using

a hydrophilic 0.035-inch wire such as the Terumo Glidewire will often allow passage into one end of the fibrous cap because it often has a nipple. If the entire length of the CTO is successfully crossed, the rest of the procedure is done using a standard angioplasty and stenting technique. However, crossing the fibrous cap on the opposite end of the CTO is often cumbersome because the nipple is directed toward the opposite direction and has a tendency to deflect the wire away from the lumen and into a dissection plane (Figures 25.17 and 25.18).

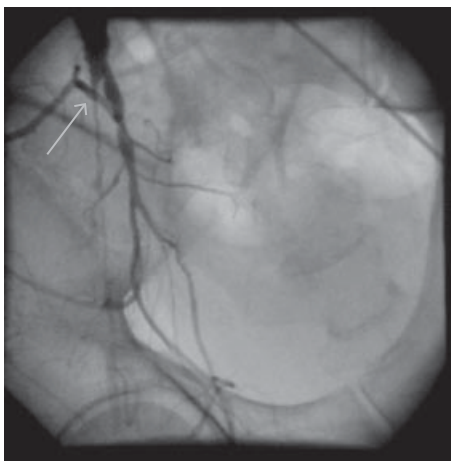


Figure 25.17 Angiogram of the right iliac artery via a left contralateral approach revealing total occlusion (arrow) of the external iliac artery with bridging collaterals.

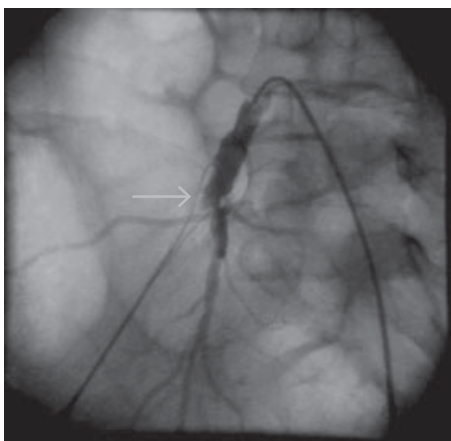


Figure 25.18 Full length of CTO traversed through an ipsilateral approach only to encounter resistance at vessel entry to the fibrous cap in the proximal portion of the CTO (arrow). The hydrophilic wire is being directed away from the central lumen and deflected back, essentially doubling up on itself.

Technical Tips

****The “body floss” technique** In these cases, approaching the CTO from two access sites, one from above and another from below, could be the only way to successfully revascularize the iliac artery. Ipsilateral access is established through the femoral artery and access to the superior portion of the CTO can be through contralateral femoral or brachial access. The choice will depend on the anticipated support that can be gained versus the support that will be needed. In general, brachial access with the use of a 6- or 7-Fr multipurpose guide or long sheath might offer more support because it allows entry of equipment into the iliac artery coaxially with minimal angulation.

A hydrophilic wire such as a 0.035-inch Terumo Glidewire is preloaded on to a hydrophilic catheter such as a Terumo Glidecath. The system is advanced through the ipsilateral femoral artery until it reaches the point of occlusion. The occlusion is probed for a soft spot by pushing the wire against the lesion, even if it doubles up. Once a J is formed by pushing the wire against the lesion, the J-shaped portion of the wire will enter the lesion only by having the J-shaped or looped portion enter the CTO. If the J-shaped portion does not advance and only deflects the tip of the wire away from the occlusion, another area of the fibrous cap can be probed until a soft spot is found and the wire loop advanced into the lesion.

Once in the lesion, usually the Glidecath can easily be advanced over the wire into the center of the lesion. Oftentimes when attempts are made to cross the superior end of the occlusion, however, one will end up in a dissection plane in the common internal iliac (Figure 25-18) or distal abdominal aorta. This is the rationale for now approaching the superior portion of the occlusion with a similar system, entering the plaque by looping the wire and advancing the loop into the middle of the occlusion followed by the catheter.

The midportion of the occlusion is almost always softer than the ends because it is usually composed of semi-organized thrombotic material. Within the lesion the catheters can actually be manipulated and twisted in such a way that they align and are essentially abutting each other. When this occurs, the wire in the catheter inserted through the brachial or contralateral femoral artery can be withdrawn and the wire of the catheter inserted through the ipsilateral femoral artery can be advanced into the tip of the other catheter and the distal aorta, thus establishing a true lumen to true lumen tract. The wire can then be externalized, essentially creating a “body floss.” Once this is achieved, standard angioplasty and stenting technique can easily be performed (Figures 25.19–25.29).

*****Use the stiff end of the wire** On rare occasions, and only under strict fluoroscopic guidance and confirmation in multiple orthogonal views, the stiff end of a hydrophilic wire can be used to traverse the final portion of a CTO. (See Figure 25.17 for baseline angiography and Figure 25.28.) This should be used only as a last resort and only after careful consideration of the possible consequences such as arterial perforation and rupture.

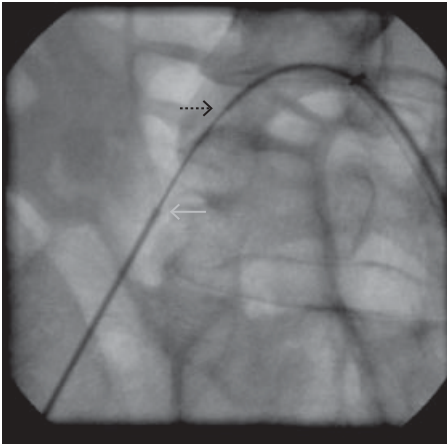


Figure 25.19 “Body floss” technique performed by advancing a hydrophilic wire through one catheter (arrow), into the CTO, then into a second catheter inserted into the CTO via a contralateral approach (dotted arrow) and eventually externalizing the wire through the contralateral sheath.

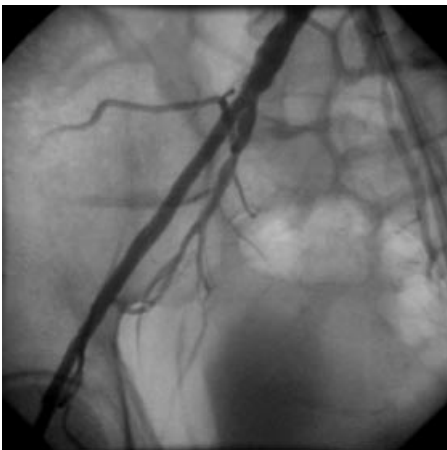


Figure 25.20 Completed procedure from Figure 25.19 after deployment and postdilation of a long self-expanding nitinol stent.

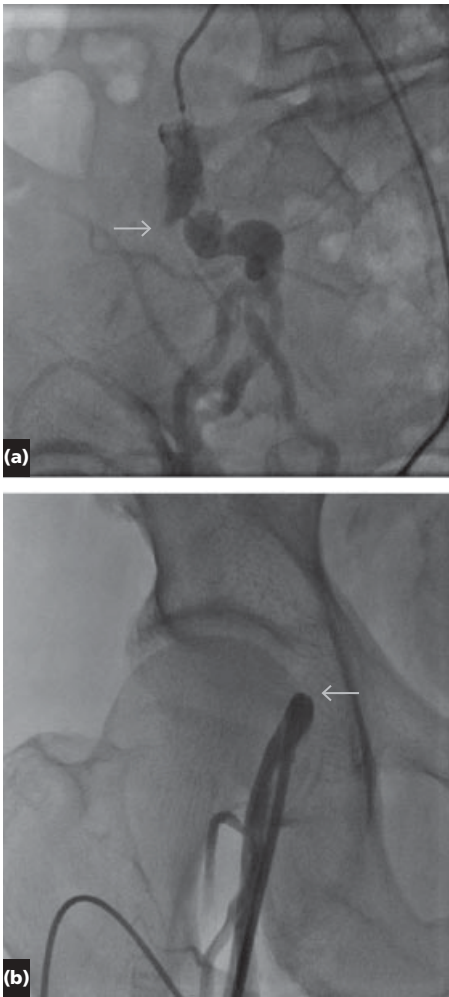


Figure 25.21 (a) Another case of CTO with angiography performed via a left contralateral approach. (b) Sheath injection showing the distal extent of the CTO.

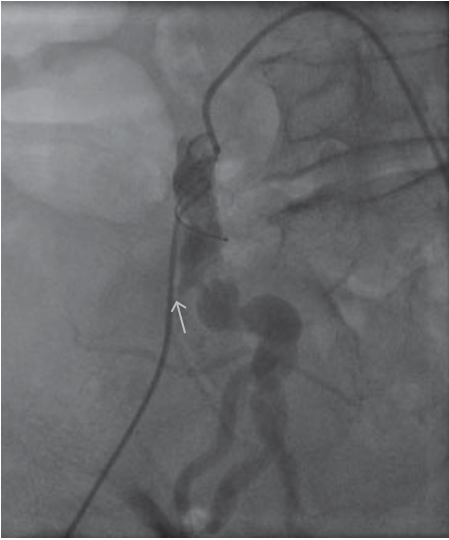


Figure 25.22 Arrow showing entry of the hydrophilic wire and catheter into a dissection plane proximally.

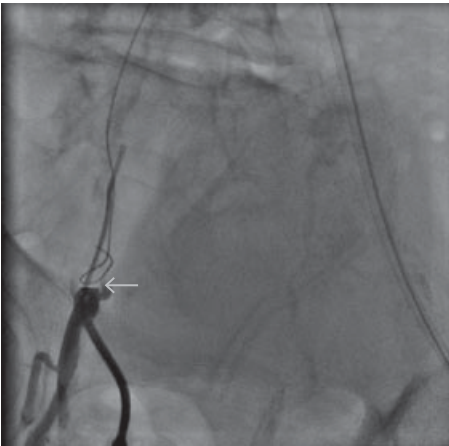


Figure 25.23 Arrow showing inability of the hydrophilic wire to cross the distal extent of the lesion from above. Note presence of initial catheter within the CTO from femoral access.

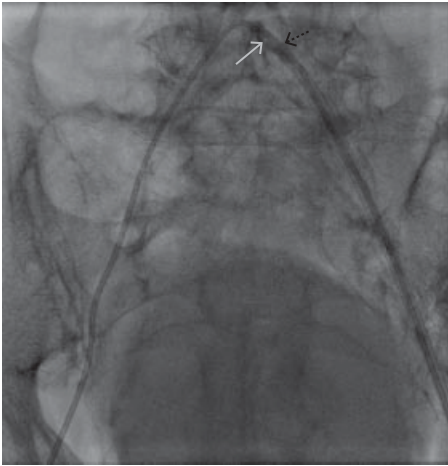

Figure 25.24 Still frame showing successful crossing of the ipsilateral catheter not only into the proximal portion of the left internal iliac but also into the tip of the crossover sheath (arrow) using a “body floss” technique where the hydrophilic wire exited the ipsilateral catheter and entered the contralateral catheter within the CTO. The dotted arrow shows the tip of the contralateral catheter within the crossover sheath.

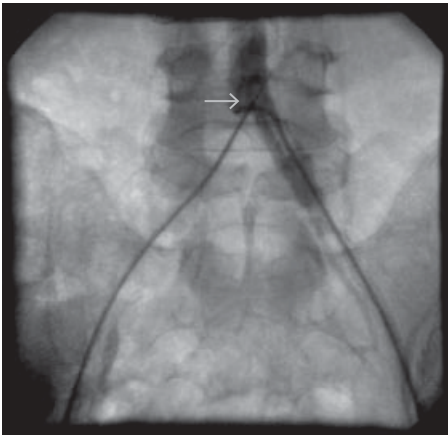


Figure 25.25 The terminal portion of the CTO traversed via retrograde access using the stiff end of the wire.

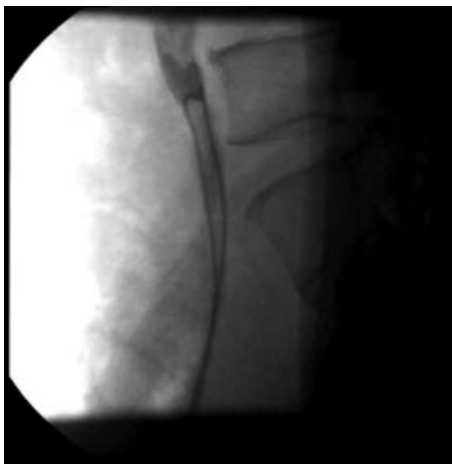

Figure 25.26 Intraluminal position of the wire confirmed first by injection of contrast through the contralateral catheter.

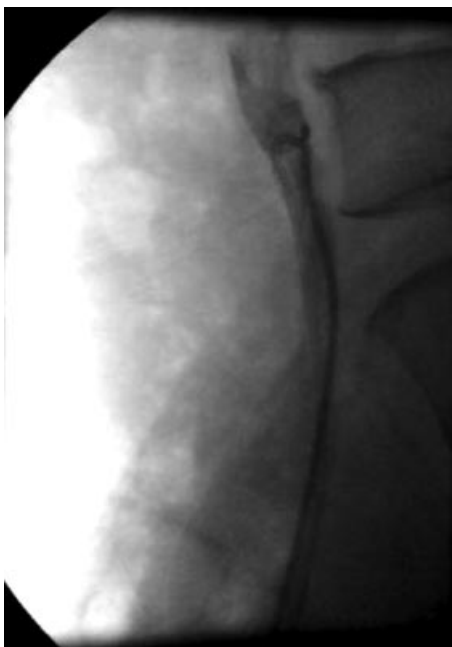

Figure 25.27 After removal of the wire from the ipsilateral catheter, blood is successfully aspirated, pressure documented, and intraluminal location confirmed by injection of contrast into the ipsilateral catheter.

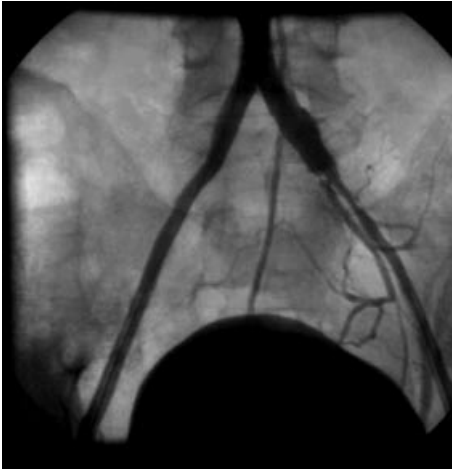

Figure 25.28 Completed procedure after routine balloon angioplasty and deployment of overlapping stents from the common iliac artery down to the external iliac artery.

COMPLICATIONS

Although rare, complications may occur, some of which are potentially lethal [12,13]. Complications may include distal embolization, stent migration, iliac artery dissection, and iliac artery rupture.

Perforations

Covered stent availability in cardiac catheterization laboratories is a prerequisite for iliac artery stenting as well as large occlusion balloons which may often keep the patient stable until reaching the operating room. Surveillance of an implanted stent should be warranted by Doppler ultrasonography and particularly by CTA and MRA.

Acute or Subacute Occlusion

Despite its rare occurrence, acute or subacute occlusion of the common or external iliac artery may occur, especially due to iliac artery dissection during diagnostic femoral procedures or long-term aortic counterpulsation [9]. In cases of acute occlusion, local thrombolytic therapy should be used whenever possible, perfused through a 5- to 6-Fr infusion catheter from the retrograde contralateral or brachial access. In cases of subacute occlusion, declotting with manual or rheolytic thrombectomy could be successfully performed. Protection with distal filter should be used whenever possible by placing a large 6- to 8- mm filter from the contralateral approach in the femoral artery. Infusion of antiplatelet agents such as glycoprotein IIb/IIIa antiplatelet agents may be helpful and suggested if there is significant residual thrombotic burden after mechanical thrombectomy.

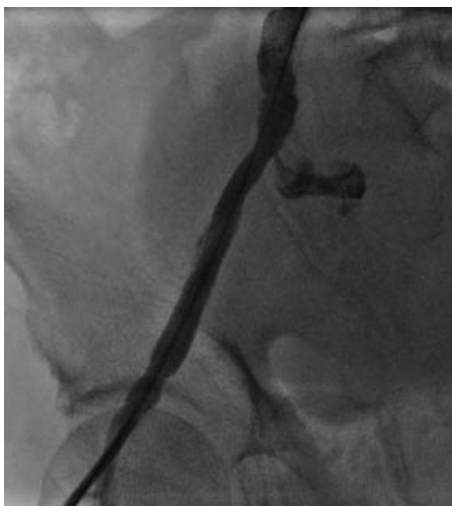

Figure 25.29 Right iliac artery perforation with extravasation of contrast.

Iliac Artery Rupture

When faced with an iliac artery rupture or perforation, we recommend immediate balloon tamponade, aggressive reversal of anti-coagulants, including the use of protamine to reverse heparin, and transfusions of fresh frozen plasma or platelets as appropriate. Balloon tamponade of the injured vessel may be undertaken with prolonged balloon inflations for up to 15–20 min. However, this may be unsuccessful and a covered stent should be made available to treat the injured vessel. In the event of significant blood loss, blood transfusions should be given. As a last resort, surgical repair may be required, but this may be associated with significant risk (Figure 25.29).

Technical Tips

Damage control Use the brachial access to place an infusion catheter whenever possible to minimize the risk of bleeding. In cases of subacute thrombosis, first perform a manual aspiration thrombectomy with a 6-Fr large lumen guide and then use any thrombectomy catheter available: This strategy may help to obtain maximal declotting (Figure 25.30). When using rheolytic catheter (usually a 6-Fr peripheral device), be sure not to aspirate more than 200–250 ml each time because hemolysis can occur.

Case selection Poor infrainguinal runoff is the main risk factor for decreased primary patency stenting to treat TASC (TransAtlantic Inter-Society Consensus) type B and type C iliac lesions. The presence of poor runoff, external iliac artery disease, and female gender are independent predictors of poor outcome after iliac stenting, and therefore the risk for post-procedural embolization and poor flow should be assessed to determine the need for surgical reconstruction: careful patient selection is recommended.

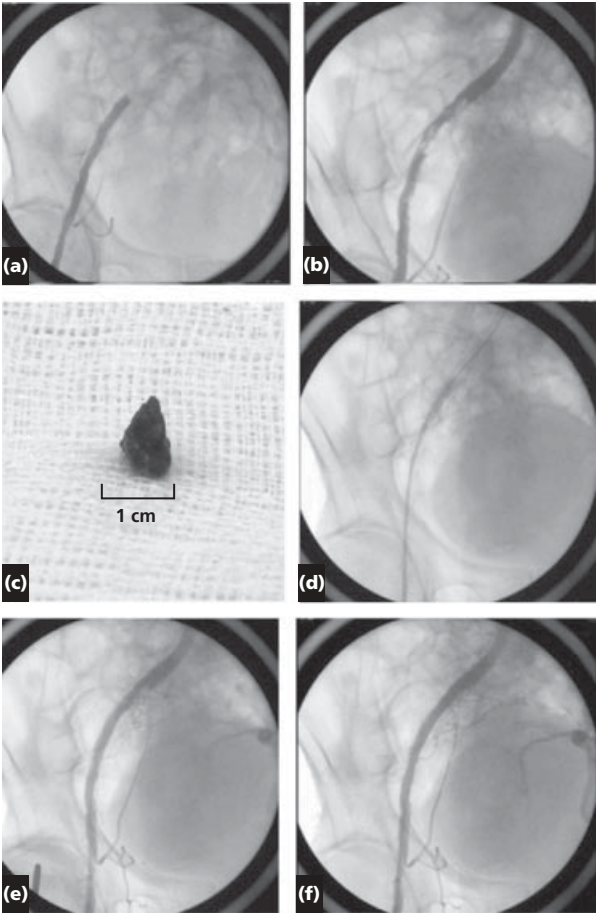


Figure 25.30 (a) Subacute occlusion of the right common iliac artery after prolonged counterpulsation in patients who underwent coronary surgery. (b) Result of 12-h infusion of tirofiban. (c) Manual aspiration and (d) balloon inflation. (e) The residual dissection has been covered with (f) a balloon-expandable stent.

REFERENCES

1. Rigatelli G, Rigatelli G. Vascular profile of patients with multivessel coronary artery disease. *Int J Cardiol* 2006;**106**:5–40.
2. Hirsch AT, Haskal ZJ, Hertzner NR, et al. ACC/AHA Task Force on practice guidelines (Writing Committee to develop guidelines for the management of patients with peripheral arterial disease): endorsed by the American Association of Cardiovascular and Pulmonary Rehabilitation. National Heart, Lung, and Blood Institute; Society for Vascular Nursing; TransAtlantic Inter-Society Consensus; and Vascular Disease Foundation. *Circulation* 2006;**113**:e463–654.
3. Rigatelli G, Rigatelli G. Malpractice in invasive cardiology: Is angiography of abdominal aorta or subclavian artery appropriate in patients

- undergoing coronary angiography? A meta analysis. *Int J Cardiovasc Imaging* 2005;**21**:591–8.
4. Buckley CJ, Arko FR, Lee S, et al. Intravascular ultrasound scanning improves long-term patency of iliac lesions treated with balloon angioplasty and primary stenting. *J Vasc Surg* 2002;**35**:316–23.
 5. Navarro F, Sullivan TM, Bacharach JM. Intravascular ultrasound assessment of iliac stent procedures. *J Endovasc Ther* 2000;**7**:315–9.
 6. Krajcer Z, Howell MH. Update on endovascular treatment of peripheral vascular disease: new tools, techniques, and indications. *Tex Heart Inst J* 2000;**27**:369–85.
 7. Rigatelli G, Cardaioli P, Giordan M, et al. Peripheral vascular disease endovascular management in patients scheduled for cardiac surgery: a clinical-angiographic approach. *Int J Cardiovasc Imaging* 2006;**22**:305–10.
 8. Mouanoutoua M, Maddikunta R, Allaqaband S, et al. Endovascular intervention of aortoiliac occlusive disease in high-risk patients using the kissing stents technique: long-term results. *Catheter Cardiovasc Interv* 2003;**60**:320–6.
 9. Rigatelli G, Giordan M, Cardaioli P, et al. Iliac artery thrombosis after aortic balloon counterpulsation: treatment with intraarterial tirofiban, manual thrombectomy and stenting. *Int J Cardiol* 2006;**112**:387–8.
 10. Rigatelli G, Magro B, Maronati L, et al. An improved technique for gaining radial artery access in endovascular interventions. *Cardiovasc Revasc Med* 2006;**7**:46–7.
 11. Flachskampf FA, Wolf T, Daniel WG, Ludwig J. Transradial stenting of the iliac artery: a case report. *Catheter Cardiovasc Interv* 2005;**65**:193–5.
 12. Kudo T, Chandra FA, Ahn SS. Long-term outcomes and predictors of iliac angioplasty with selective stenting. *J Vasc Surg* 2005;**42**:466–75.
 13. Timaran CH, Prault TL, Stevens SL, Freeman MB, Goldman MH. Iliac artery stenting versus surgical reconstruction for TASC (TransAtlantic Inter-Society Consensus) type B and type C iliac lesions. *J Vasc Surg* 2003;**38**:272–8.

CHAPTER 26

Infrainguinal and Infragenicular Interventions

Jasrai Gill, Robert Dieter, John Lopez, Gianluca Rigatelli,
Thach N. Nguyen, Paolo Cardaioli, Prakash Makham,
Aravinda Nanjundappa

Challenges 604

Non-Invasive Evaluation 605

Ankle/Brachial Index 605

Invasive Evaluation 606

Vascular Access 606

Retrograde Puncture and Crossover Technique 606

Antegrade Technique 607

Brachial and Radial Access 609

Angioplasty and Stenting 610

Subintimal Angioplasty 610

Atherectomy 611

Excisional atherectomy 611

Excimer laser plaque debulking 611

Endovascular cryoplasty 611

Stent or balloon for femoral disease 612

Chronic Total Occlusion of the SFA 612

Piercing the hard proximal cap 612

Technique The SafeCross wire 612

Crossing a long CTO segment of the SFA 613

Distal re-entry 613

Technical Tips 613

**Special technique for re-entry in femoral artery occlusion 613

Recanalization of acute femoral occlusion 615

Placement of emboli protection device 617

Discriminating Differences 617

Technical Tips 617

**Filter sizing 617

**Infrapopliteal EPD 617

**Minimize EPD migration 617

**Postprocedural filter angiogram 617

**FilterWire support 617

**The "full basket" 618

**Adequate landing zone 618

*Basic; **Advanced; ***Rare, exotic, or investigational

\$, <\$US100.00 extra; \$\$, >\$US100.00 extra

⌚, <10 min extra; ⌚⌚, >10 min extra

◆, low risk of complications; ◆◆, high risk of complications

Endovascular Treatment for Disease of the Infrapopliteal Arteries 618**Conventional Angioplasty and Primary Stenting of Below-the-knee Vessels 619****Atherectomy 619****Technical Tips 619**

***Popliteal and pedal access 619

**Puncture of the popliteal artery 619

***The "transcollateral" access 619

**Pedal puncture 620

***Combining coronary and peripheral equipment for tibial and pedal occlusion 622

***Pedal loop technique 622

***Use of Rotablator in the pedal artery 623

Management of Deep Vein Thrombosis in the Lower Extremities 624**Technique 625****Complications 625****Access Complications 625****Technical Tips 626**

***Avoiding plaque excision complications 626

***Avoiding laser atherectomy complications 626

**Avoiding angioplasty complications 626

Perforations 626**Arterial Spasm 626****Acute Thrombosis 627****Distal Embolization 627****Compartment Syndrome 627****CHALLENGES**

At the level of the inguinal ligament, the external iliac artery becomes the common femoral artery (CFA) just distal to the lateral circumflex and inferior epigastric arteries. At the lower edge of the femoral head, the CFA subsequently divides into the deep profunda femoral artery (PFA) and superficial femoral artery (SFA). The laterally situated PFA is an important source of collateral flow to the distal vessels. Significant occlusive disease of the PFA, together with severe SFA disease, can lead to critical limb ischemia (CLI). This fact must be recognized and patency of the PFA preserved when working on the SFA. The tibial or infrapopliteal arteries provide blood flow to the gastrocnemius and soleus muscles of the calf, as well as to the arterial arcade of the foot. Although these vessels are common sites of PAD, single or multiple stenosis of one crural vessel rarely provokes claudication. Rather, significant disease of all three infrapopliteal arteries (anterior tibial, peroneal, and posterior tibial) is usually required to provoke symptoms in the absence of proximal flow-limiting lesions of the iliofemoral system. In the setting of limb salvage, most patients will present with multilevel and multilesion disease [1,2].

NON-INVASIVE EVALUATION

Ankle/Brachial Index

Ankle/brachial indices (ABIs): Values <0.3 – 0.4 are associated with severe claudication. Non-healing ulcerations or gangrene occurs in the presence of ankle pressures <50 mmHg. Toe systolic pressures are particularly useful in patients with diabetes where the ABI may be falsely elevated due to arterial calcification. Values <30 mmHg suggest CLI and portend poor tissue viability. Other modalities of testing include Doppler ultrasonography, CT angiography (CTA) and MR angiography (MRA) [3].

Color-assisted duplex imaging has been proposed as an attractive alternative to scanning and, in expert hands, can provide most of the essential anatomic information plus some functional information (e.g. velocity gradients across stenoses). The lower extremity arterial tree can be visualized, with the extent and degree of lesions accurately assessed and arterial velocities measured. Disadvantages include the length of the examinations and variability of skill of the technologist. In addition, crural arteries are challenging to image in their entirety [3].

Multidetector CTA (MDCTA) is being widely adopted for the initial diagnostic evaluation and treatment planning of PAD. Multislice MDCTA enables fast imaging of the entire lower extremity and abdomen in one breathhold at submillimeter resolution. Although prospectively designed studies with MDCTA are currently lacking, there are emerging data that the sensitivity, specificity, and accuracy of this technique may rival invasive angiography. Major limitations of MDCTA include the usage of iodinated contrast (>120 ml/exam), radiation exposure, and presence of calcium. The last can cause a “blooming artifact” and preclude assessment of segments with substantive calcium. Stented segments can also cause significant artifact and may preclude adequate evaluation [3].

In many centers, MRA has become the preferred imaging technique for the diagnosis and treatment planning of patients with PAD. The advantages of MRA include its safety and ability to provide rapid high-resolution three-dimensional imaging of the entire abdomen, pelvis, and lower extremities in one setting. The three-dimensional nature of MRI implies that image volumes can be rotated and assessed in an infinite number of planes. MRA is useful for treatment planning before intervention and in assessing suitability of lesions for endovascular approaches. Pre-procedure MRA may minimize use of iodinated contrast material and exposure to radiation. Stents within segments of peripheral vessels may produce a susceptibility artifact that can render evaluation of these segments difficult. However, the signal loss with stents is extremely dependent on the metallic alloy, with nitinol stents producing minimal artifact. In contrast to CTA the presence of calcium in vessels does not cause artifacts on MRA, and this may represent a potential advantage in examining diffusely calcified vessels in patients with diabetes and chronic kidney disease. Contrast-enhanced MRA has a sensitivity and specificity $>93\%$ for the diagnosis of PAD. A number of studies have demonstrated

that contrast-enhanced-MRA has better discriminatory power than color-guided duplex ultrasonography for the diagnosis of PAD [3].

INVASIVE EVALUATION

Currently, contrast angiography remains the dominant diagnostic tool used to stratify patients before intervention. When used for this purpose, complete imaging of the affected territory is usually recommended. Digital subtraction angiography (DSA) is recommended for contrast angiographic studies because this technique allows for enhanced imaging capabilities compared with conventional unsubtracted contrast angiography. Knowledge of inflow and outflow patterns, as well as characterization of the lesion, may affect decisions about therapy. From a technical standpoint, the closer the catheter is to the target vessel to be imaged, the better the image definition and the smaller the volume of contrast required. Accordingly, selective and superselective catheter placements are useful in optimizing image quality. This is particularly recommended in the setting of renal insufficiency or when occlusive distal vessels may not be visualized by a more proximal bolus injection of contrast. The acquisition of views from orthogonal angles, which has been the rule in coronary angiography, is less prevalent in peripheral imaging, largely because of the extensive territory to be covered in a complete diagnostic peripheral runoff angiogram (as opposed to a coronary angiogram). Nevertheless, for areas where there is doubt or uncertainty about the presence or absence of a significant lesion, angulated views can be useful to better delineate and define the severity of the lesion and clarify its potential contribution to the clinical syndrome [3].

Complications of angiography include arterial dissection, atheroemboli, contrast-induced renal failure, and access site complications (i.e. pseudoaneurysm, arteriovenous fistula, and hematoma). These problems have been greatly mitigated by technological improvements in the procedure, including the use of non-ionic contrast agents, DSA, intra-arterial pressure measurements across a stenosis with and without vasodilator (significance peak systolic difference 5–10 mmHg pre-vasodilation and 10–15 mmHg post-vasodilation), and more sophisticated image projection and retention [3].

VASCULAR ACCESS

Retrograde Puncture and Crossover Technique

The common femoral artery is accessed by standard puncture and 4-French (Fr) sheath. After abdominal aortoiliac angiography, a diagnostic 4-Fr Judkins right or, better, a 4 Fr diagnostic mammary artery catheter should be advanced over a Terumo 0.035-inch wire to the aortic bifurcation and gently torqued to gain access to the contralateral iliac arteries. Once the wire has been advanced in the CFA, the catheter should be gently advanced over the wire: Selective angiography of the contralateral artery can be performed. In cases of percutaneous interventions, a moderately stiff

BOX 26.1 LIMITATIONS OF THE FEMORAL RETROGRADE ACCESS

- Weak support to cross TASC D femoral, popliteal, and tibioperoneal lesions
- Limited guide, wire, and balloon catheter length
- Limited access in those with steep femoral bifurcation, bilateral common iliac artery stents, aortofemoral grafts, and aortic aneurysm modular stent grafts

BOX 26.2 THE ADVANTAGES AND LIMITATIONS OF THE ANTEGRADE APPROACH

- Higher success to reach and cross lesions
- Can reach pedal lesions
- Long learning curve and high radiation exposure for novice operator
- Cumbersome in obese patients and higher risk of hematoma
- Best with duplex ultrasound-guided puncture with micropuncture needle

standard 0.035-inch wire should advance over the diagnostic catheter and the catheter itself, together with the femoral sheath, can be exchanged for a crossover straight or preformed 5- or 6-Fr long sheath. The limitations of femoral retrograde access are shown in Box 26.1.

Antegrade Technique

Antegrade access is the most direct access to the target vessel when the site of disease is well known and monolateral. After local anesthesia, puncture should be performed under fluoroscopy guide in exactly the same site as retrograde access, which is the CFA at the medial third portion of the femoral head. Fluoroscopy guide is the preferred tool, because palpation of the pulse can very often lead only to low puncture of the PFA. Once a backflow is observed from the needle, the standard wire of a 4- or 5-Fr sheath can be advanced within the vessel on fluoroscopy guide. If resistance is felt, the back of the wire should be pre-curved with a smooth J tip, and can be navigated within even mildly diseased or calcified artery. Alternatively, a very small volume of contrast for obtaining a roadmap can be injected through the needle, not directly but by means of a short connection tube, to avoid movement causing dislodgement of the needle from the arterial lumen. On the roadmap, the wire can be navigated into the SFA (Figure 26.1).

The advantages and limitations of the antegrade approach are listed in Box 26.2, the indications for direct SFA puncture and

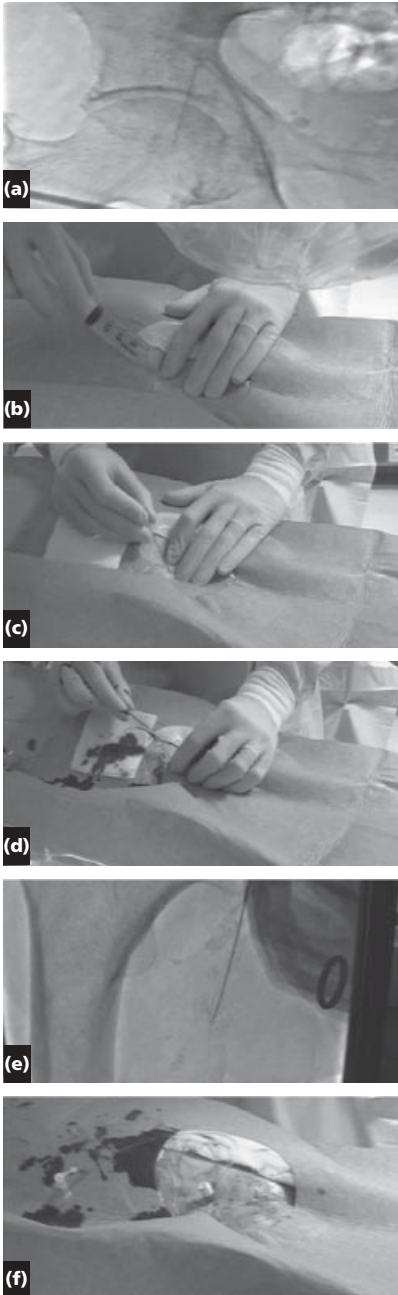


Figure 26.1 Antegrade puncture step-by-step: (a) Fluoroscopy guide to visualize relative position of the needle in respect to the femoral head, (b) local anesthesia, (c) standard needle puncture, (d,e) wire insertion and advancement, (f) Sheath advanced over the wire.

BOX 26.3 INDICATIONS FOR DIRECT MID-SUPERFICIAL FEMORAL PUNCTURE AND ACCESS

- Short calcified proximal or ostial SFA occlusion
- Failed retrograde or antegrade femoral access
- Need for common femoral angioplasty in patients with bilateral iliac stents
- Complication of proximal-to-superficial femoral artery closure device
- Iatrogenic injury to circumflex iliac or inferior epigastric; needs embolization

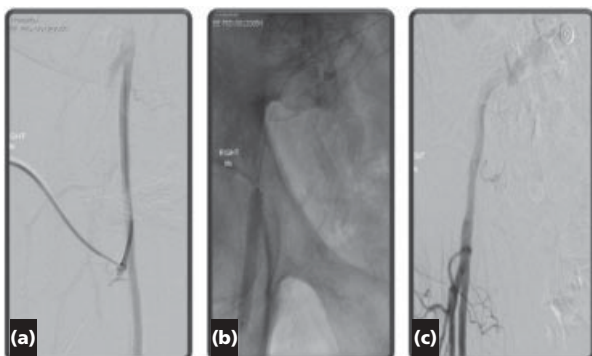


Figure 26.2 An 82-year-old woman underwent attempted transcatheter aortic valve replacement from the right femoral artery approach. Two days later she presented with right leg acute limb ischemia, stage IIa. The ankle–brachial index of the right leg was 0.22. A common femoral angiogram showed acute occlusion at the puncture site. Retrograde crossover access was unsuccessful, so the patient underwent (a) puncture at the midsegment of the right superficial femoral approach, (b) successful balloon angioplasty of the proximal common femoral artery, and (c) revascularization of the right iliofemoral artery.

access are listed in Box 26.3, and a case report is presented in Figure 26.2.

Brachial and Radial Access

In selected cases, especially when an iliac disease is combined with a proximal stenosis of the SFA, brachial or even radial access, depending on the patient's size, could be an option. After gaining artery access as usually for coronary artery catheterization, after having advanced a standard 0.035-inch guidewire into the descending aorta with the help of a diagnostic 4-Fr Judkins right or even Amplatz left or right 1.0, a 5- or 6-Fr 90-cm-long hydrophilic sheath should be advanced over the wire to reach the

selected iliac and femoral artery. Equipment for interventions in such cases should include balloon and stent with at least a 120-cm shaft.

ANGIOPLASTY AND STENTING

The traditional endovascular approach to femoropopliteal lesions includes use of balloon angioplasty and/or balloon-expandable or self-expanding bare metal stents made of stainless steel or, more recently, nitinol. Balloon dilation and stent implantation for claudication and stenosis have yielded comparable long-term patency rates in the treatment of femoropopliteal arterial disease [4]. Conventional balloon angioplasty is considered the treatment of choice for non-calcified focal stenosis with two- to three-vessel runoff. It has been well documented in TASC (TransAtlantic Inter-Society Consensus) type A and B lesions with high procedural success rates. Its main disadvantages are elastic recoil, dissection, and restenosis. It has limited application in ostial lesions, calcified lesions, and diffuse disease with poor runoff [5].

The use of balloon-expandable stainless steel stents in the SFA and popliteal artery was associated with favorable initial results, but only small increments in late patency compared with conventional balloon angioplasty. Stenting can be applied for significant residual stenosis of flow-limiting dissection post-PTA, and for long, complex disease. Balloon-expandable stents (particularly in the distal SFA) are associated with late stent deformation, mechanical compression, and restenosis with resultant late clinical failure. Newer nitinol self-expanding stents have shown improved 1- and 3-year patency rates and can possibly be placed in flexion areas such as the distal SFA or popliteal artery. They have, however, been limited by late mechanical fatigue and associated restenosis. Currently, no long-term comparative data exist about the role of these new technologies [4].

Subintimal Angioplasty

The technique consists of passage and often prolapsing of a flexible, directional wire (usually nitinol) through long, diffusely diseased, arterial segments. The wire is intentionally directed subintimally but is ultimately redirected within the true lumen. By means of subintimal angioplasty, very complex anatomical subsets, including long occlusions, highly calcified occlusions, diffuse tandem lesions, and flush SFA occlusions can be effectively crossed with the wire and treated. Technical failures associated with subintimal angioplasty are generally due to the inability to re-enter the true lumen from the subintimal space. To improve the success of subintimal recanalization, several new devices are developed and now available. One new catheter, the Pioneer, uses intravascular ultrasound (IVUS) to help locate the distal true lumen by identifying pulsatile blood flow and thus guide re-entry with a puncture needle. With the catheter oriented in the direction of the true lumen, a 0.014-inch wire is passed into the true lumen to complete the recanalization process. The Outback catheter, used for re-entry, is a 6-Fr-compatible catheter with a hollow

22-gauge cannula for distal vessel entry using fluoroscopic imaging [6].

Atherectomy

Excisional atherectomy This ablative technique avoids the barotrauma and plaque displacement that often occur during balloon angioplasty. Historically, excisional atherectomy has been associated with prohibitively high restenosis rates; however, newer technical improvements may achieve better early and late results.

Severely calcified SFA lesions are still difficult to treat with atherectomy devices; it is difficult to cut away the calcium, and there is an increased risk of embolization.

The SilverHawk atherectomy catheter is the most recent atherectomy device designed for the treatment of new and restenotic atherosclerotic lesions. There are several models depending on the size of the vessel and length of lesion. The device tracks over a 0.014-inch wire and can be introduced via antegrade or retrograde access depending on the location of the lesion(s). A 7- or 8-Fr sheath is recommended depending on the size of the device, but we have found that we can safely go one size smaller than that recommended for each device. With the blade spinning at 8000 rev/min, the catheter is slowly and smoothly advanced across the lesion, shaving the plaque from the vessel wall. When performing atherectomy, it is recommended that the device be advanced only the length of the nosecone during each pass. This is to reduce the risk of distal embolization. When the cutting process is complete, the lever is advanced, closing the reservoir and covering the cutting blade. The device is then repositioned for the next pass. This is achieved by withdrawing the device and then rotating the cutting blade housing approximately 30°, to engage another portion of the plaque. This sequence can be repeated as many times as necessary. After two to six passes, depending on the length of the lesion, the device must be removed and cleaned. The atheroma must be removed from the nosecone. Once cleaned, the device may be reinserted and atherectomy continued [7].

Excimer laser plaque debulking The technique of excimer laser-assisted angioplasty uses intense bursts of ultraviolet (UV) light in short pulse durations to achieve a penetration depth of 50 mm per pulse. The advantage of excimer laser-assisted angioplasty lies in the ability to break molecular bonds directly by photochemical rather than thermal means, negating the risk for thermal injury that historically limited the use of continuous wave hot-tip lasers in the treatment of peripheral vessel occlusions. Small laser size (the largest probe creates a 2.5-mm lumen) limits the procedure to use in the SFA with adjunctive angioplasty or other intervention required to achieve adequate luminal diameter [8].

Endovascular cryoplasty Endovascular cryoplasty combines the dilation force of angioplasty with the simultaneous delivery of cold thermal energy to the arterial wall. Both effects are

achieved by filling the catheter with nitrous oxide instead of the usual mixture of contrast medium and saline. This approach has been experimentally shown to induce apoptosis in smooth muscle cells and other cell lines that participate in the restenosis process [4,6].

Stent or balloon for femoral disease Focal stenosis or occlusion can be often easily treated with high pressure (>16 atm) balloon dilation with a balloon:artery ratio slightly less than 1.0 and short 30- or 40-mm long balloons. In case of flow-limiting dissection or suboptimal result, short balloon-expandable or self-expandable stents can be used to gain success. Very long occlusion (>80 mm) after recanalization with endoluminal or subintimal technique can be approached as a first step with high pressure (>16 atm) balloon dilation with 120- to 150-mm or 200-mm-long balloons. It is important to keep the balloon inflated for at least 4–5 min and to treat eventual leg pain with morphine or a combination of analgesic drugs. Again in case of suboptimal results or flow-limiting dissection long flexible self-expanding stent can be used [9].

Chronic Total Occlusion of the SFA

Most long SFA occlusions begin with a proximal stump followed by varying degrees of distal vessel reconstitution by way of collaterals from the PFA. Angiographic assessment of the proximal stump requires a 35–40° ipsilateral lateral angiogram. In this view, one can determine the length of the proximal stump and the possible access options, including antegrade, contralateral, or even brachial approaches. If the proximal stump or cap is <3–5 cm long, management of the ostial SFA segment must be factored into device selection [10].

Piercing the hard proximal cap The initial cap of chronic total occlusion (CTO) is usually crossed with support catheter such as a Glide or Quickcross catheter, and an angled or straight stiff guidewire. In rare cases, an operator may choose to use a stiffer wire, such as the Confianza or the back end of a guidewire, or the Frontrunner Catheter. Do not perform angiograms through the support catheters that have not re-entered the true lumen because this will stain the subintimal space and impair distal visualization. In patients with a difficult proximal cap, an operator might attempt recanalization through the popliteal access (retrograde popliteal stick) [11].

TECHNIQUE The SafeCross wire The SafeCross wire has the unique property of an optical coherence reflectometer. This wire is coupled with radiofrequency energy that is delivered from the tip if the reflective signal obtained by the near infrared sensor identifies a luminal position, signified by a green indicator. Radiofrequency is not deliverable if the reflective signal is red, suggesting wire proximity to the endoluminal wall. The benefit of this technology is the theoretical advantage of remaining in the intraluminal space, thus reducing the dissection plane of a long

occlusive lesion. Certain anatomical situations favor its use. The following are three clinical scenarios in which intraluminal passage with the SafeCross wire may produce greater success [4,6].

- 1 A flush occlusion of the SFA with no visible nub
- 2 Occlusions across the knee joint
- 3 Occlusions at the site of a prominent collateral channel.

Crossing a long CTO segment of the SFA Many long occlusions of the SFA are composed of a focal proximal cap followed by a long segment of debris culminating in a distal fibrous cap. Some operators use a stiff angled guidewire and create a small loop, supported by straight glide or Quickcross catheter. Make sure that the loop is not larger than 5–6 mm (the diameter of most SFAs). If the loop increases in size, it often means significant dissection into the subintimal space. The success of reliable re-entry into the true lumen diminishes as the diameter of the wire loop increases. When the wire loop size increases, the operator should stop advancing, retract the wire into the support catheter, then probe with the wire and re-engage the occlusion at this point with a smaller wire loop with catheter support [4,6].

Distal re-entry When the wire tip is near the distal cap, the operator should retract the wire, and probe again without the wire loop, if possible first before attempting to re-enter with a loop. Do not continue to create a more distal subintimal channel with more dissection if the wire does not appear to be in the true lumen at this point. This is where re-entry devices are utilized. Further dissection with the Glidewire would lead to progressive subintimal channel creation, reducing the likelihood of successful true lumen re-entry. Upon re-entry into the true lumen, the operator should be able to remove the wire and aspirate blood through the support catheter. If this occurs, the operator can then take an angiogram through the catheter with diluted contrast to evaluate the distal anatomy [4].

Technical Tips

****Special technique for re-entry in femoral artery occlusion** Sometimes, re-entry in the true lumen during subintimal recanalization can be very challenging because of gross calcification and very long occlusion. Re-entry before the popliteal artery is mandatory in preserving the chance of surgical revascularization if the percutaneous attempt goes wrong. Techniques for gaining the true lumen may include:

- 1 Use of re-entry device, which can be helpful but is cumbersome and costly (Figure 26.3)
- 2 Use of a stiff coronary wire inside a 4-Fr Bernstein catheter to perforate the intimal flap and gaining the true lumen (Cross-it 200–300, Figure 26.4)
- 3 Use of the back portion, J custom-made preformed, of a Terumo wire
- 4 Use of the proximal end of a V18 wire, after exposing the central core of the wire, cutting the proximal floppy hydrophilic portion with a Klemmer forceps.

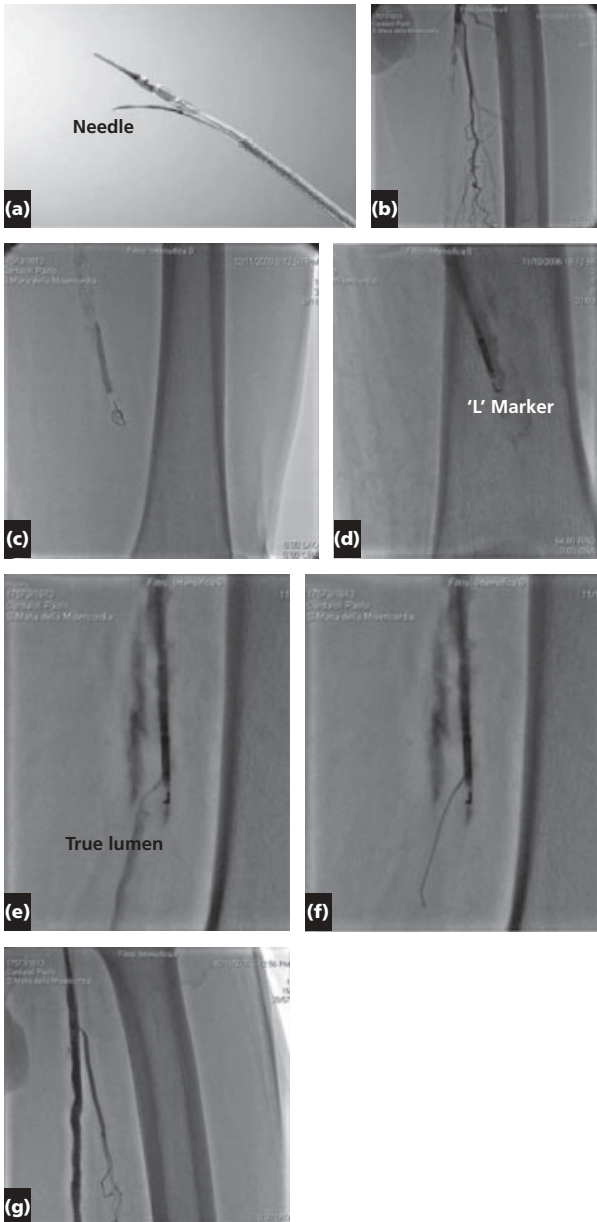


Figure 26.3 (a) Outback catheter: The needle comes out from the side of the catheter that can be easily oriented. (b) Baseline angiography showing heavily calcified occlusion of the superficial femoral artery. (c) Inflation of the balloon inside the subintimal space. (d) Needle orientation procedure: The “L” marker pointed toward the SFA. (e) Injection of contrast from the hole of the needle confirmed the correct position within the true lumen of the vessel. (f) Wire passage through the needle. (g) Final results after stent implantation and balloon postdilation.

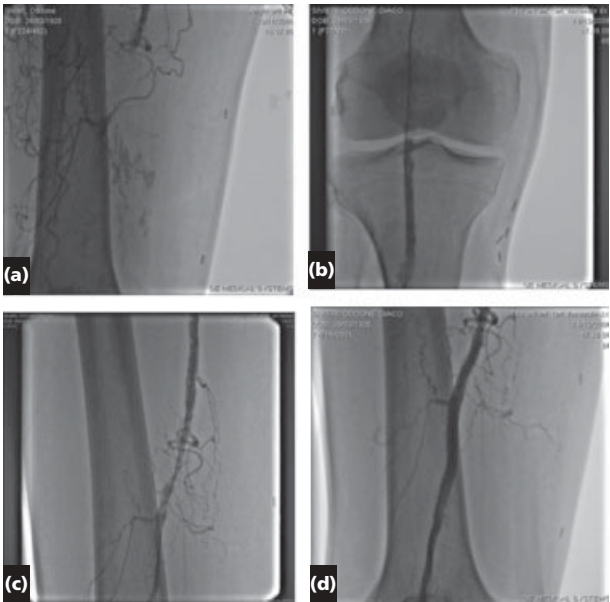


Figure 26.4 (a) Long occlusion in a patient with diabetes and coronary artery disease. (b) Subintimal recanalization with a Bernstein catheter and a Cross-it 300 wire. (c) Result after balloon angioplasty. (d) Final result after 6 × 150 mm self-expandable stent implantation.

These last two techniques should be carefully used only when other option does not work and there are no surgical options.

Recanalization of acute femoral occlusion The spectrum of femoropopliteal disease includes not only the chronic occlusive disease, but also less often the occurrence of acute ischemia, due to plaque embolism or iatrogenic maneuvers, such as a compressive bandage after invasive catheterization. This phenomenon occurs through a mechanism mediated by chronic arterial lesions. Intra-arterial thrombolysis is an alternative to balloon embolectomy in the treatment of acute lower limb ischemia. The percutaneous treatment includes thrombus aspiration catheter or rheolytic thromboembolectomy [12,13].

The technique includes the contralateral retrograde or ipsilateral antegrade femoral approach and the passage of a soft 0.035-inch wire through the occlusion. In case of acute thrombosis, intra-arterial thrombolysis or antiplatelet drugs (tirofiban, eptifibatide, etc.) should be infused through a side-hole catheter. In case of subacute thrombosis, a large-lumen 6-Fr guide connected with a 50-ml syringe should pass over the wire aspirating fresh thrombus. To optimize the result, rheolytic thrombectomy with a peripheral 6-Fr device such as the AngioJet can be used for three to six passages (maximal blood volume 200–300 ml to avoid hemolysis in elderly patients) to completely restore the flow. Angioplasty balloon may be also used in case of resistant thrombus (Figure 26.5).

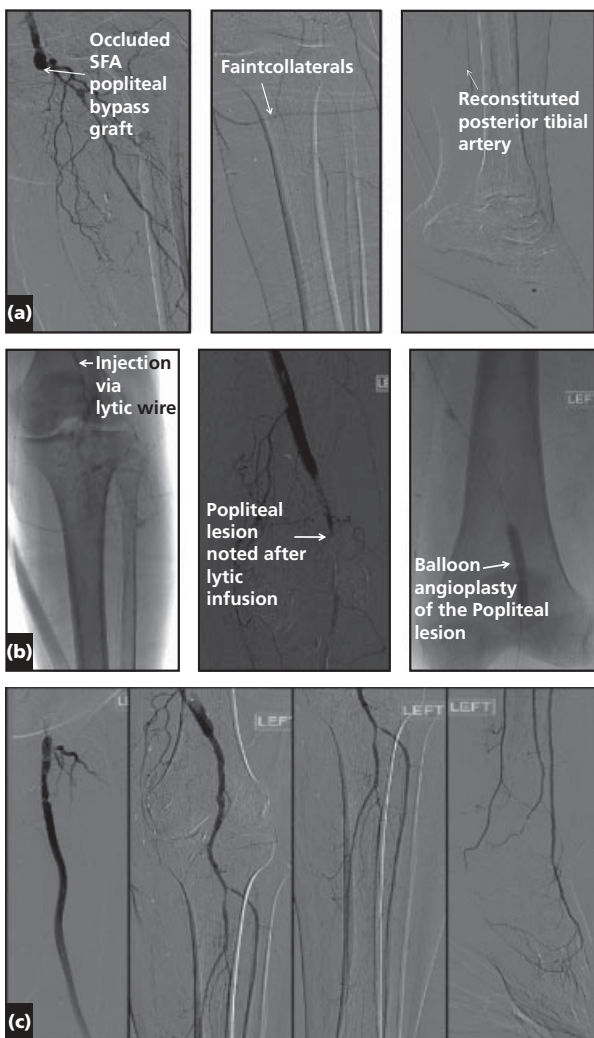


Figure 26.5 A 59-year-old woman with hypertension, diabetes, obesity, hypercholesterolemia, tobacco use, and history of left leg femoropopliteal bypass in 1999 for left toe gangrene. There was subsequent bypass failure and a redo femoropopliteal bypass with a prosthetic graft. She presents with left leg rest pain of 1 week. Baseline ankle/brachial index was 0.10. (a) The baseline angiogram with occluded superficial femoral bypass graft and faint distal reconstituted posterior tibial artery. (b) The patient underwent thrombolytic therapy for 12 hours and angioplasty of the popliteal lesion. (c) The final angiogram showed three-vessel flow to the foot.

Placement of emboli protection device Cross all SFA and bypass graft lesions, thrombosis, and CTOs with a 0.035-inch tapered hydrophilic Quick-Cross catheter, the CROSSER high ultrasonic energy CTO crossing device, followed by the wire – Quick-Cross exchange.

Discriminating Differences

We believe that this central luminal crossing of the vessel will minimize the embolization risk of crossing the CTO in a non-central luminal or subadventitial plane utilizing traditional J-wire techniques. This central luminal crossing would then facilitate emboli protection device (EPD) delivery and maximize whatever definitive peripheral vascular intervention (PVI) option the operator selects. The filter EPD can be delivered through the Quick-Cross catheter delivering the filter >10–15 mm distal to the most distal lesion. The Spider filter system is user friendly and easily delivered by this method saving two to three steps and exchanges.

Technical Tips

****Filter sizing** Never oversize the filter to the vessel. Match the filter to the exact vessel size or 1.0 mm less. This will minimize vessel injury and vasospasm.

****Infrapopliteal EPD** These vessels are prone to spasm so liberal use of intra-arterial nitroglycerin, verapamil, and antispasmodic agents is recommended with an infrapopliteal EPD. The Spider EPD sizes range from 3 mm to 7 mm. Filter oversizing and movement must be avoided during infrapopliteal EPD to decrease complications.

****Minimize EPD migration** It is mandatory to minimize EPD filter movement after deployment to avoid complications. Keep the filter in full fluoroscopy view during all PVI exchanges and manipulation. Failure to minimize EPD wire movement may increase the incidence of vasospasm and intimal injury.

****Postprocedural filter angiogram** Obtain a detailed final magnified angiogram of the filter to identify any debris to strategize EPD capture. Partial filter capture is now recommended with the 0.035-inch Quick-Cross catheter on all cases when debris is identified on angiography. The horseshoe-shaped opaque marker on the proximal filter “mouth” facilitates partial capture by capturing only the marker within the Quick-Cross catheter during filter retrieval. The inner Quick-Cross catheter edge is hydrophilic and the diameter of the Quick-Cross catheter is larger than the existing Spider capture system, which facilitates partial filter capture so there is less likelihood of extrusion or debris through the filter pores during capture with a “full basket.”

****FilterWire support** The Spider filter wire is easily delivered and supportive enough to allow most PVIs, including laser atherectomy, plaque excisional atherectomy, and stenting. You must keep the filter-wire wet with each exchange to minimize

migration and facilitate the PVI. The Spider device is not compatible for use with the CSI orbital atherectomy system.

****The “full basket”** If a filter becomes occluded (“full basket”) before the final angiogram, partially capture the filter and reposition a second new filter because it is difficult to “clean” a “full basket.” This is not uncommon when performing complex PVIs on a long SFA in-stent thrombosis or thrombosed bypass grafts. If sluggish flow is encountered any time during a contrast injection, visualize the filter and suspect embolization. We use glycoprotein (GP) IIb/IIIa inhibition in all PVI cases in which we suspect a large plaque–thrombus burden and the case is at high risk for distal embolization.

****Adequate landing zone** A relatively disease-free vessel of appropriate size must be identified. The mid-distal popliteal artery, at least 5–10 mm above the infrapopliteal trifurcation, is our ideal landing zone in most cases.

Technical indications for EPD use in the following “high risk for embolization” clinical scenarios:

- 1 All bypass graft occlusions, thrombosis, and any graft stenosis with a large plaque or thrombotic burden with an adequate landing zone
- 2 All SFA stent occlusions, thrombosis, and most cases of long SFA in-stent restenosis with an adequate landing zone
- 3 Patients with acute (<2 weeks) worsening of symptoms because these patients often have a larger amount of “fresh” thrombus, and so are at a higher risk for embolization
- 4 Most complex long SFA TASC type C and D lesions with an adequate popliteal segment with single vessel runoff
- 5 Any iliac, CFA, SFA, or popliteal artery lesion, with an adequate distal filter target vessel and a lesion determined to be highly ulcerative on CTA or during angiography. We have found pre-procedure CTA lesion morphology to be helpful in identifying lesions at high risk for distal embolization
- 6 CLI patients with a ≥ 3.0 mm infrapopliteal vessel feeding a jeopardized distal vascular segment or angiosome
- 7 CLI patients with severe proximal SFA disease and single-vessel runoff with an adequate popliteal segment [14].

Endovascular Treatment for Disease of the Infrapopliteal Arteries

The most severe manifestation of lower extremity arterial disease is CLI, a progressive multilevel atherosclerotic condition frequently involving multiple stenoses and occlusions of any or all of the three tibial arteries. Clinical manifestations include rest pain and non-healing ulcers. Unless a straight-line flow to the foot is restored, the tissue will not heal; the sequelae often include amputation. The TASC II report asserts that there is increasing evidence supporting percutaneous transluminal angioplasty (PTA) for patients with CLI and infrapopliteal occlusion, when inline flow to the foot can be re-established and where there is medical comorbidity, with predictors of successful outcome including shorter occlusion length and fewer vessels treated [3,5].

Conventional Angioplasty and Primary Stenting of Below-the-knee Vessels

CLI was defined as (1) persistent recurring rest pain requiring analgesia and an ankle systolic pressure <50mmHg and/or toe systolic pressure <30mmHg, and/or (2) ulceration, gangrene, or non-healing wounds of the foot [15].

Atherectomy

The authors suggest that stenoses in the calf arteries can be treated by atherectomy without predilation, whereas occlusions should be predilated with an undersized balloon to ensure that the wire crosses the occlusion intraluminally. They strongly advised against the use of atherectomy in cases in which the occlusion was crossed subintimally because of the potential for perforation. They noted that the device may not be usable below the knee in patients (such as those with diabetes or on chronic hemodialysis), with the reference vessel diameter severely restricted by medial sclerosis. They also cautioned about the potential for dissection and perforation when using the device to treat bifurcation lesions, especially at the branches of the anterior tibial artery [16].

It must be emphasized that endovascular interventions do not preclude either subsequent bypass surgery or repeat or additional endovascular interventions. Thus, the failure of an endovascular intervention for treatment of CLI is clearly amenable to subsequent reintervention for limb salvage with limited morbidity and mortality.

Technical Tips

*****Popliteal and pedal access** Although rarely used, popliteal and pedal artery access can be a viable option to gain retrograde revascularization of the superficial femoral and tibial arteries revascularization in cases in whom the antegrade revascularization results impossible and there is no surgical option, especially in treatment of the diabetic foot syndrome. Concomitant ipsilateral antegrade puncture is needed to obtain complete revascularization obtaining an arterial loop.

****Puncture of the popliteal artery** This should be performed under Doppler ultrasonography guide in order to avoid puncture of the popliteal vein. Patients should be prepared in supine position. The needle entry can be marked with a pen during or after Doppler ultrasound examination at the point where the popliteal artery can be visualized without interference of the popliteal vein. Hemostasis should be done directly with compression but very often an antegrade 5–7 min long balloon inflation at the puncture site through a femoral access with patients reverted in prone position, ensured complete recanalization and vessel hemostasis. The tips and tricks for popliteal access are given in Box 26.4.

*****The “transcollateral” access** This access is based on the creation of a loop with the wire from one artery to another through collaterals. This loop can be used to directly open the artery from a retrograde approach or as a “roadmap” for further

BOX 26.4 TIPS AND TRICKS OF POPLITEAL ACCESS

- Indicated for difficult calcified SFA and CFA segments
- Need prone position: Difficult puncture in morbidly obese patients
- Best with ultrasound guidance and micropuncture
- Avoid puncture below the knee joint
- Watch for popliteal hematoma, nerve entrapment
- No clear indications for use of closure device because of potential failure of device with distal embolization, acute limb ischemia, and vein entrapment
- Monitor vitals, especially saturation; avoid excess sedation

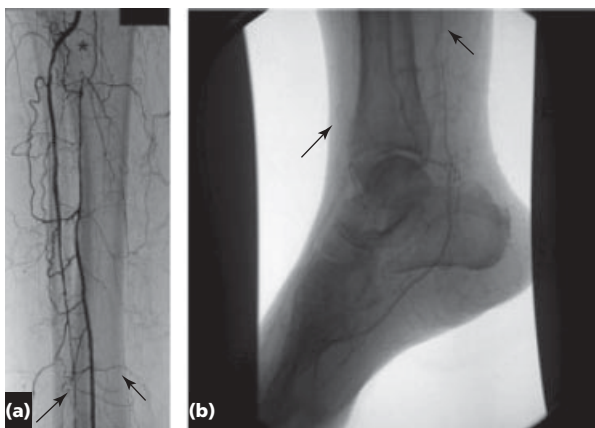


Figure 26.6 The baseline angiogram shows an occlusion of the anterior and posterior tibial arteries (arrows), with an occlusion of the tibioperoneal trunk (*).

attempts to reopen antegradely the vessel. This technique may be of value specifically when a proximal occlusion stump is not evident, when a dissection flap or a perforation in the proximal tract of the target vessel impairs wire advancement, or when distal disease makes retrograde percutaneous puncture impossible (Figures 26.6–26.8) [17].

****Pedal puncture** The patient can be prepared as usually, puncturing the anterior pedal artery with a short catheter and advancing a 0.014-inch coronary guide wire directly through the needle, proceeding with balloon inflation without a sheath, directly through the skin. Hemostasis should be done by manual compression of 5- to 7-min balloon inflation with a coronary 3- to 3.5-mm balloon through the ipsilateral antegrade femoral access when the procedure has been completed.

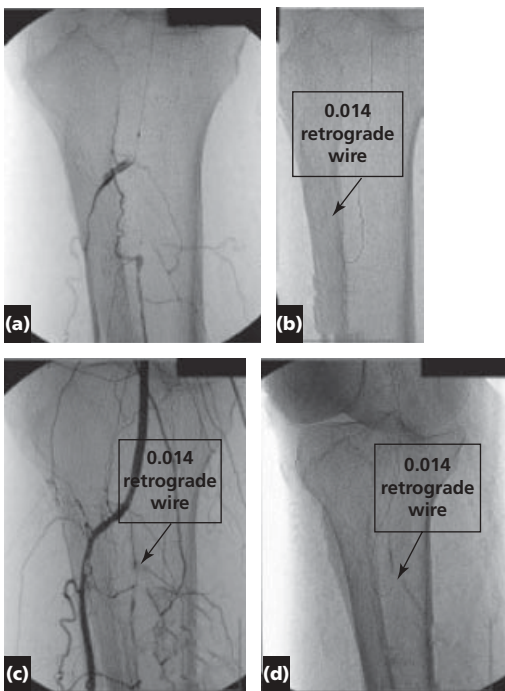


Figure 26.7 Selective angiography of distal popliteal artery performed through an OTW 2.0-mm balloon showed an absence of visible proximal stump of the occlusion of the tibioperoneal trunk and a well-developed collateral for the peroneal artery (a). (b) The retrograde transcollateral approach at the occlusion of the tibioperoneal trunk by means of a hydrophilic 0.014-inch wire and a 2.0-mm OTW balloon. The wire first engaged and crossed the collateral with balloon support (arrows). (c,d) The wire crossed the occlusion of the tibioperoneal trunk in a retrograde fashion (arrows).

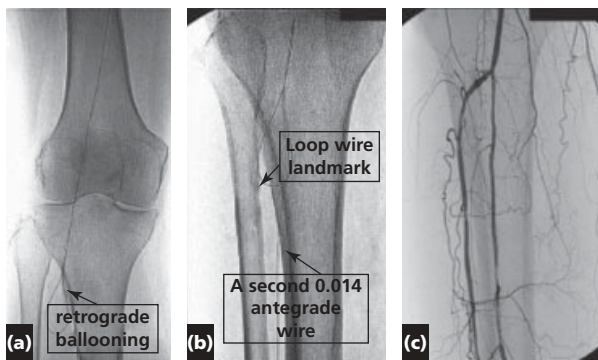


Figure 26.8 (a) The retrograde ballooning of the tibioperoneal trunk with a 2.0-mm OTW balloon. (b) Leaving the loop wire in place as a marker, another 0.014-inch hydrophilic wire was inserted in an antegrade manner, through the pathway created with retrograde angioplasty (arrows). (c) The result of angioplasty of the tibioperoneal trunk performed with a 3.0-mm OTW balloon (arrow).

Table 26.1 Equipment for the below-the-knee revascularizations

Wire	Company	Use
Pilot 150	Abbot Vascular International	Endoluminal recanalization
Whisper MS/ES		Endoluminal recanalization/re-entry ^a
Cross-it 100–200		Re-entry ^a
Balloon		
Sprinter 1.5–3.5 × 15–20–30mm	Medtronic Inc.	Dilation in calcified lesions
Sprinter NC		Dilation in very calcified–fibrotic lesions
Quantum	Boston Scientific	Dilation in tight lesions
Stent		
Integrity 2.5–3.5 × 23–30mm	Medtronic Inc.	Tibioperoneal stenting
Falcon 2.5–3.5 × 20–26mm	Invatech-Abbot	Tibioperoneal stenting

^aAfter subintimal angioplasty.

*****Combining coronary and peripheral equipment for tibial and pedal occlusion** Tibial and pedal arteries are very similar, although not identical, to coronary artery. Coronary wires and balloons work very well in such arterial segments allowing for complete recanalization when peripheral standard or even dedicated wires (Terumo, V18, etc.) and balloons fail to pass. Similarly coronary stent, in particular the cobalto-chromium stents can be successfully used in the tibioperoneal vessels for flow-limiting dissection. A complete list of coronary wire, balloons, and stents useful in the below-the-knee revascularization is shown in Table 26.1.

*****Pedal loop technique** Especially in patients with diabetes and a foot ulcer, the plantar arch should be recanalized from the anterior or posterior tibial artery with the aid of a V18 or coronary wire, advancing the wire in a retrograde fashion within the contralateral vessel (pedal plantar loop technique [5] – Figure 26.9); dilation is usually performed with long dedicated balloons and in very tight, uncrossable lesions with coronary 2.0- to 3.0-mm diameter balloons. The dedicated balloons included long 100- to 200-mm Sterling or Amphirion peripheral balloons for below the knee and for the plantar or malleolar arteries, and 1.5, 2.0, 3.0, × 20-, 30-, 40-mm-long Sprinter coronary balloon.

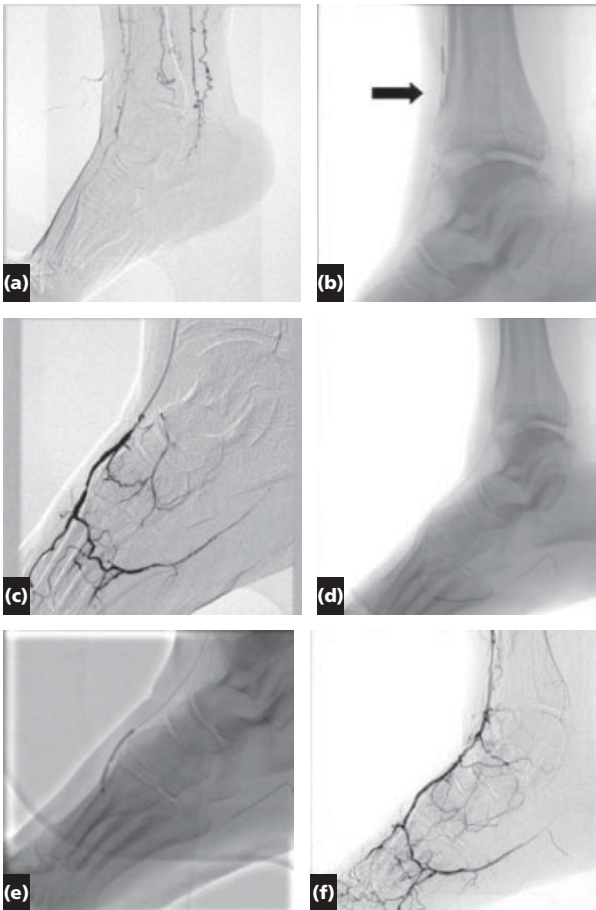

Figure 26.9 Pedal plantar loop technique: (a) Occlusion of anterior and posterior tibial arteries with minimal refilling of pedal artery. (b) Subintimal recanalization of anterior tibial artery with looped hydrophilic 0.018-inch wire (arrow). (c) Selective angiography of pedal artery and arch via injection of contrast medium through an over-the-wire 1.5 × 20 mm coronary balloon to confirm successful re-entry. (d) Arterial loop through the plantar arch. (e) Balloon inflation. (f) Final result.

*****Use of Rotablator in the pedal artery** Rotablator with a 1.25–1.5 burr at maximum can be successfully used in pedal and malleolar recanalization when dedicated and even coronary balloons fail to pass (Figure 26.10). Attention should be paid to exchanging the coronary wire for the standard Rotablator wire through a neuroradiology microcatheter or an over-the-wire, coronary, 1.25-mm balloon to avoid losing the wire and position.

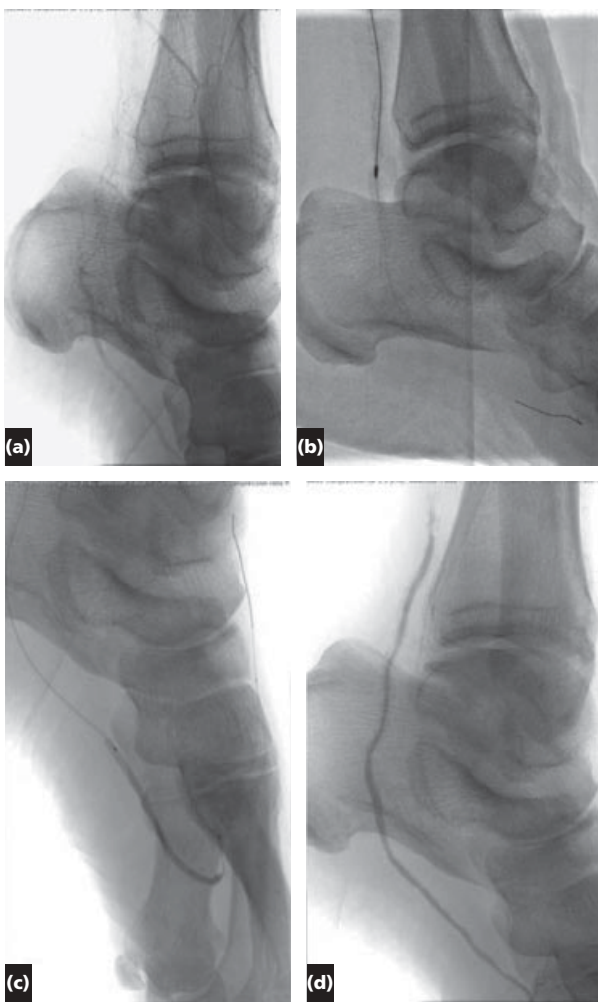

Figure 26.10 (a) Very calcified and long occlusion of the malleolar artery approached with mixed equipment; (b) after unsuccessful attempt with a coronary balloon, passage of a coronary 1.5-mm burr Rotablator, dilation with a coronary 2.0 × 30 balloon, and then (c) a peripheral long 2.0 × 100 balloon, with (d) good final results.

Management of Deep Vein Thrombosis in the Lower Extremities

For treatment of deep vein thrombosis (DVT) the venous access sites include the right or left internal jugular vein, the common femoral vein, the popliteal vein, and a pedal vein. Over time, the ipsilateral popliteal venous approach became the access site of choice. Thrombolytic drugs are given locally through an indwelling catheter and a stent can be deployed to correct the underlying lesion that triggers DVT (Figure 26.11).

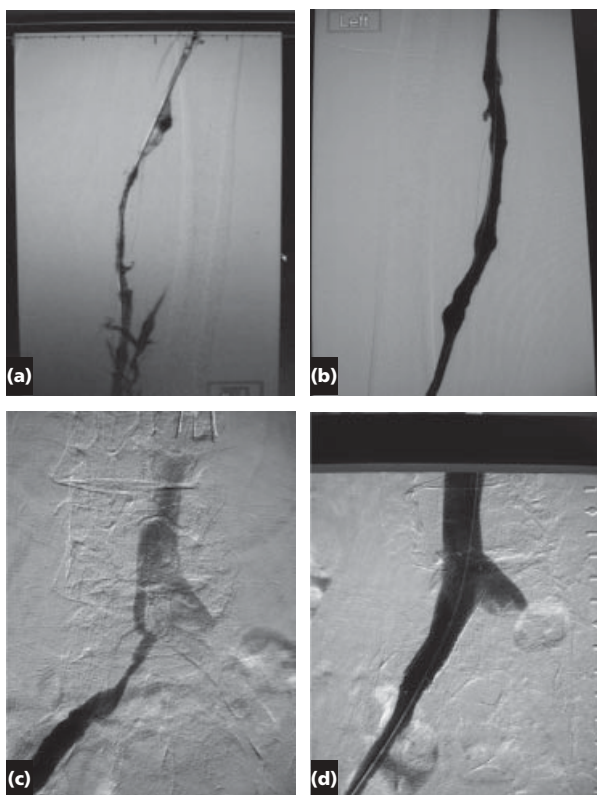


Figure 26.11 Management of deep vein thrombosis: (a) Baseline left femoral venogram with extensive thrombi. (b) Left femoral vein after pharmacomechanical thrombectomy. Left iliac vein (c) before stenting and (d) after stenting (courtesy of Dr Anas Safadi, Merrillville IN).

TECHNIQUE With the patient prone on the table, the popliteal vein was accessed, under ultrasound guidance, with a small-gauge echogenic needle to avoid inadvertent puncture of the adjacent popliteal artery. The needle should be angled from medial to lateral and the entry should be made 1–2 cm medial to the midline in order to minimize the risk of an arterial puncture. A 5-F sheath commonly was inserted through which all subsequent catheter and wire exchanges were performed. Patient is given thrombolytic agent through a coaxial catheter and infusion wire and/or a multiple-side-hole system [18].

COMPLICATIONS

Access Complications

When using a contralateral approach, operators should avoid excessive sheath manipulation to avoid distal embolization. When performing antegrade puncture, insert the needle at a 45° angle

and coaxially to avoid intraoperative sheath kinking. Operators should be sure to use fluoroscopy to identify the femoral head and avoid a high or low stick. High sticks can lead to retroperitoneal bleeds and low sticks to intraoperative thrombosis [5].

Technical Tips

*****Avoiding plaque excision complications** When performing plaque excision in the SFA, operators should always take a picture after cutting into four quadrants to avoid a deep wall cut or a perforation. One should always take care not to overcut around artery bends and heavily calcified vessels. When encountering resistance, operators should not force the device distally. Instead, apply slight forward pressure and slowly rotate the catheter to find a plane with less resistance. Then return to the resistant area and try again. One should always pack the larger devices after cutting the length of the nosecone (e.g. if the nosecone is 4 cm, pack every 4 cm). Some operators choose to use distal protection when performing atherectomy in heavily calcified vessels with single vessel run-off [5].

*****Avoiding laser atherectomy complications** One should never push the laser catheter if there is any resistance. When operators encounter resistance, they should pull the catheter back and let the laser work at the point of resistance for a few seconds, or downsize to a smaller catheter [5].

****Avoiding angioplasty complications** Operators should always choose the proper balloon size for the size of the artery. Operators should never overinflate the balloon. One should always be sensitive to patient feedback while performing an angioplasty. If the patient complains of anything but minor pain the operator should use lower pressures when inflating the balloon, or in postdilating a stent [5].

Perforations

For minor perforations (particularly wire perforations) in the SFA many operators elect to continue the procedure and reduce or reverse anticoagulation. For minor perforations below the knee, one should reverse the anticoagulation and compress externally with an Ace wrap to avoid compartment syndrome. For perforations from atherectomy, operators can often manage the situation with long, low-pressure balloon inflations for a few minutes and a reversal of anticoagulation. If this does not work after a few attempts, one can use a covered stent, such as the Viabahn [5].

Arterial Spasm

Operators often see spasm in the tibial/peroneal arteries, which can be relieved with intra-arterial nitroglycerin. If this does not resolve on the first attempt, one should deliver several 100 μ m through a catheter directly into the artery in spasm. One may also try a combination of nitroglycerin and a calcium channel blocker for greater efficacy. Some operators elect to use papaverine to treat spasm due to its longer half-life [5].

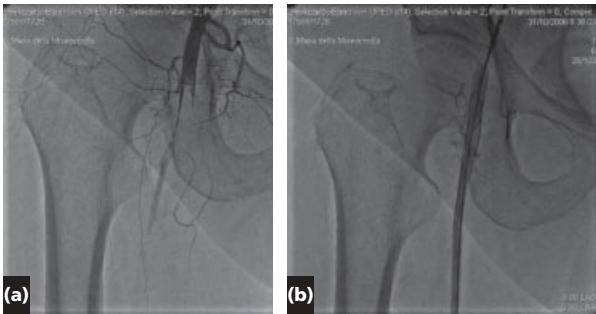


Figure 26.12 (a) Acute occlusion of the superficial femoral artery after compressive bandage following cardiac catheterization. (b) Restored flow after manual aspiration and rheolytic thrombectomy and balloon angioplasty.

Acute Thrombosis

Operators can manage peroperative thrombosis with the use of mechanical thrombectomy catheters such as the Export catheter or rheolytic catheters such as the AngioJet. Operators can also choose to deliver lytics locally through an infusion catheter for a few minutes or overnight (Figure 26.12). Laser is also another option in these patients [5].

Distal Embolization

Operators can use manual aspiration catheters such as the Diver, Pronto, and Quick Cat. If this is unsuccessful one can attempt to tackle the embolus using a low-profile angioplasty balloon. If there is residual embolization, one can consider using anticoagulation for a longer period of time and/or a bolus of a GP IIb/IIIa inhibitor [5].

Compartment Syndrome

This syndrome refers to the situation in which the pressure in a closed space, usually one of the enclosed myofascial compartments of an extremity, becomes high enough to restrict tissue perfusion and oxygen delivery. It usually follows prolonged ischemia and often results from both the original ischemic insult and reperfusion [5].

REFERENCES

1. Makam P, Nguyen P. Infringuinal and infragenicular interventions. In: *Practical Handbook of Advanced Interventional Cardiology: Tips and tricks*, 3rd edn. Oxford: Blackwell, 2008: 438–52.
2. Lumsden AB, Davies MG, Peden EK. Medical and endovascular management of critical limb ischemia. *J Endovasc Ther* 2009;**16**(suppl II):31–62.
3. Norgren L, Hiatt WR, Dormandy JA, et al. Inter-society consensus for the management of peripheral arterial disease (TASC II). *J Vasc Surg* 2007;**45**(1 suppl):S5–67.

4. Lyden S, Shimshak T. Contemporary endovascular treatment of the superficial femoral and popliteal arteries: An integrated device-based strategy. *J Endovasc Ther* 2006;**13**(suppl II):41–51.
5. Hirsch AT, Haskal ZJ, Hertzler NR, et al. ACC/AHA 2005 guidelines for the management of patients with lower extremity PAD executive summary, a collaborative report from the American Association for Vascular Surgery/Society for Vascular Surgery, Society for Cardiovascular Angiography and Interventions, Society for Vascular Medicine and Biology, Society of Interventional Radiology, and the ACC/AHA Task Force on Practice Guidelines. *J Am Coll Cardiol* 2006;**47**:1239–312.
6. Das T. Crossing peripheral CTOs: A look at today's options, from guidewires to re-entry devices. *Endovasc Today* 2006;**9**:50–6.
7. Radvany M, Kiesz RS. Plaque excision in management of lower extremity peripheral arterial disease with the SilverHawk atherectomy catheter. *Semin Interven Radiol* 2008;**25**:11–18.
8. Laird J, Zeller T, Gray BH, et al. Limb salvage following laser-assisted angioplasty for critical limb ischemia: Results of the LACI multicenter trial. *J Endovasc Ther* 2006;**13**:1–11.
9. Rigatelli G, Cardaioli P. Endovascular treatment of femoro-popliteal obstructive disease. *Minerva Cardioangiol* 2007;**55**:125–32.
10. Weaver FA, Comerota AJ, Youngblood M, Froehlich J, Hosking JD, Papanicolaou G. Surgical revascularization versus thrombolysis for nonembolic lower extremity native arterial occlusions: results of a prospective randomized trial. The STILE investigators. Surgery versus thrombolysis for ischemia of the lower extremity. *J Vasc Surg* 1996;**24**:513–21.
11. Korn P, Khilnani NM, Fellers JC, et al. Thrombolysis for native arterial occlusions of the lower extremities: clinical outcome and cost. *J Vasc Surg* 2001;**33**:1148–57.
12. Berczi V, Deutschmann HA, Schedlbauer P, Tauss J, Hausegger KA. Early experience and midterm follow-up results with a new rotational thrombectomy catheter. *Cardiovasc Interven Radiol* 2002;**25**:275–81.
13. Kasirajan K, Gray B, Beavers FP, et al. Rheolytic thrombectomy in the management of acute and subacute limb-threatening ischemia. *J Vasc Interven Radiol* 2000;**12**:413–21.
14. Allie C, Ingraldi A, Patlola R, et al. Clinical insights into the use of embolic protection devices during lower extremity peripheral vascular interventions *J Invasive Cardiol* 2009;**21**:418–22.
15. Dorros G, Jaff MR, Dorros AM, Mathiak LM, He T. Tibioperoneal (outflow lesion) angioplasty can be used as primary treatment in 235 patients with critical limb ischemia: five-year follow-up. *Circulation* 2001;**104**:2057–62.
16. Feiring AJ, Krahn M, Nelson L, et al. Preventing leg amputations in critical limb ischemia with below-the-knee drug-eluting stents: the PaRADISE (PREventing Amputations using drug eluting StEnts) trial. *J Am Coll Cardiol* 2010;**55**:1580–9.
17. Fusaro M, Agostoni P, Biondi-Zoccai G. "Trans-collateral" angioplasty for a challenging chronic total occlusion of the tibial vessels: A novel approach to percutaneous revascularization in critical lower limb ischemia. *Catheter Cardiovasc Interv* 2008;**71**:268–72.
18. Mewissen M, Seabrook G, Meissner M et al. Catheter-directed thrombolysis for lower extremity deep venous thrombosis: report of a national multicenter registry. *Radiology* 1999;**211**:39–49.

CHAPTER 27

Percutaneous Intervention of Cardiac Congenital Anomalies

Gianluca Rigatelli, Zhang Shuang Chuan, Nguyen Thuong Nghia, Nguyen Lan Hieu, Do Huan Quang

Challenges 631

Atrial Septal Defect 631

Indications 631

Contraindications 632

The Procedure 632

Preprocedure Evaluation/Management 633

Technical Tips 633

**Identification of different types of ASD 633

Technique Defining the Anatomy 633

Technical Tips 633

**Reshaping the tip of the catheter to enter the ASD 633

**Detecting additional defects 635

Technique Selecting the size of device 636

Technical Tips 636

**Selecting the type of device 636

**Selecting the size of the device 637

***ICE-guided device closure procedure 637

Technique Sheath placement 638

Technical Tips 638

**Sheath placement in fenestrated ASDs 638

Technique Device positioning 638

Technical Tips 638

**How to position the sheath perpendicular to the atrial septum 638

**Final check of device position 639

Technique Post-placement assessment 639

Technical Tips 640

***Device closure in patients with severe pulmonary artery pressure 640

Patent Ductus Arteriosus 640

Contraindications 641

The Procedure 641

Preprocedure Evaluation/Management 642

*Basic; **Advanced; ***Rare, exotic, or investigational

\$, <\$US100.00 extra; \$\$, >\$US100.00 extra

⌚, <10 min extra; ⌚⌚, >10 min extra

♣, low risk of complications; ♣♣, high risk of complications

Technical Tips 642

**Misleading systolic flow mimicking PDA 642

Technique Defining the Anatomy 642

Technical Tips 643

**Locating the point of minimal diameter of the PDA 643

***Preoperative definition of the anatomy by MRI 643

***Preoperative definition of the anatomy by three-dimensional rotational angiography 643

**Crossing the PDA from the aorta 645

Technique Selecting device Size 645

Technical Tips 645

**Use fewer coils in PDA closure 645

Technique Sheath placement 646

Technical Tips 646

**Inserting the sheath into the RVOT 646

Technique Device positioning 646

Technical Tips 646

**Avoiding first coil embolism while deploying the second coil 646

**Avoiding entangling the already deployed coil by directional wire 647

**Checking the position of device before deployment 647

**Closing the PDA with the occluder 648

Technique Post-placement assessment 648

Coarctation 649

Contraindications 649

The Procedure 649

Preprocedure Evaluation/Management 650

Technique Defining the anatomy 650

Technical Tips 651

**Measuring the gradient across the coarctation 651

***Defining the anatomy with three-dimensional rotational angiography 651

Technique Selecting balloon and stent size 651

Technical Tips 652

**Sequential dilation of the coarctation 652

**Advantage of MRI-compatible stents 652

Technique Sheath and wire placement 652

Technical Tips 653

**Optimal wire position 653

Technique Balloon and stent positioning 653

Technical Tips 653

**No problem with subclavian jailing 653

**Postdilation with a high-pressure balloon 654

Technique Post-placement assessment 654

Technical Tips 654

**Accurate pressure gradient measurement 654

Coarctation and Aneurysm Implantation Technique with Covered Stent 654

CHALLENGES

Adult patients with congenital heart disease are an exponentially increasing population due to improved treatment strategies for children resulting in excellent long-term survival. Newer interventional techniques and tools developed over the last 20 years are now able to treat most common congenital lesions in the catheterization laboratory instead of the operating suite. This chapter details percutaneous interventional techniques for treating the most common congenital cardiac lesions seen in adults including atrial septal defect (ASD), patent ducts arteriosus (PDA), and coarctation of the aorta.

ATRIAL SEPTAL DEFECT

Secundum ASDs are one of the more common congenital heart defects making up 6–10% of all congenital anomalies, occurring in 1/1500 live births [1]. Anatomically secundum ASDs are due to absence, perforation, or deficiency of the septum primum. This defect typically occurs sporadically but has been linked to genetic abnormalities such as Holt–Oram syndrome and mutations on chromosome 5p.

Technology and technique have been modified and refined over the years; however, the procedure remains conceptually identical. A collapsible double-sided disk device with a metal frame and fabric patches is positioned antegrade through a long femoral sheath across the secundum ASD. Upon extrusion from the sheath, the device expands creating a patch on both sides of the septum, clamping the surrounding ASD tissue rim. The endocardium grows in to cover the device and create a permanent seal. As a result of the need for surrounding rim tissue, device closure is limited to secundum-type defects, not applicable to either primum (no inferior posterior rim) or venosus (no superior rim) ASDs. With recent technological device closure has rapidly become the treatment of choice for secundum ASDs.

Early complications have been minor occurring in <9% of patients consisting primarily of transient arrhythmias, vascular injury, or asymptomatic device embolization. Serious complications have been quite rare but include thrombus formation on the device, heart block requiring pacing, and cardiac perforation [2].

Indications

Indications for ASD device closure include any size secundum ASD with evidence on echocardiogram of right ventricular (RV) volume overload. Patients with ASD and symptoms of exercise intolerance or history of cryptogenic stroke should also be closed. There is mounting evidence that ASD closure, even in elderly people, can improve maximal oxygen consumption [3]. ASDs can and have been closed by devices in small children including infants; however, the optimal timing for elective closure appears to be between 2 and 4 years of age.







Contraindications

There are no absolute contraindications for device ASD closure except for patients with active thrombus in the left atrium (LA) and those with a defect >40 mm, the risk being of aortic erosion increased for devices >30 mm. Known allergy to the device implant materials, particularly the nickel in nitinol, an extremely rare condition, is not an absolute contraindication: A sort of device syndrome has been described [4] but no case of true allergy requiring device removal has been described in the literature to date. Patients who are hypercoagulable, particularly those with disorders that predispose to arterial clots, should be considered very carefully because the post-placement risk of clot formation during the fibrotic process may be significantly increased. Patients with significant left ventricular (LV) dysfunction also must be monitored closely after the procedure due to the potential for the development of acute LA hypertension and resultant pulmonary edema. Diuretics immediately post-closure may be very helpful in this subgroup of patients. Patients with pulmonary hypertension must be considered carefully but may benefit as long as there is a baseline left-to-right shunt [5].

The Procedure

There are currently four devices used recently for ASD closure including the Amplatzer septal occluder, the Button device, the CardioSEAL, and STARFlex Helix (Table 27.1). By far the most commonly used device and the one capable of closing the largest ASDs is the Amplatzer septal occluder. Unlike the others, this device has a central stenting mechanism that expands to the

Table 27.1 Comparison of patent foramen ovale (PFO) and atrial septal defect (ASD) closure devices

Device		Frame	Material	Sizes	Delivery sheath
Amplatzer PFO		Nitinol wire	Polyester fabric	18, 25, 35	9
<input type="checkbox"/> ASD				4–40	6–12
Button PFO		Teflon coated stainless steel wire	Polyurethane foam	25–30	7–9
<input type="checkbox"/> ASD				25–60	9
CarioSEAL		MPN35	Polyester fabric	17–40	10
Guardian Angel		Nitinol wire	Polyester fabric	18–30	10
Helix		Nitinol wire	PTFE	15–35	9
PFO Star		Nitinol wire	Ivalon plug	15–35	10

edges of the defect, filling it with frame and patch material, improving stability and complete closure rates in large ASDs. It is available in sizes up to 4 cm capable of closing a 3.8-cm defect.

Preprocedure Evaluation/Management

Complete omniplane transesophageal echocardiography (TEE), if the patient is an older adolescent or adult, is necessary to define the atrial septal anatomy before the procedure. Secundum ASDs are rarely round, so attention to defect dimensions in multiple planes is essential for a complete anatomic understanding. Documentation of an adequate atrial septal rim circumferentially (>3 mm, especially at the posteroinferior inlet portion), and evaluation for additional defects, tissue strands, or septal aneurysms with perforations is essential (Figure 27.1).

Technical Tips

****Identification of different types of ASD** Identification of all pulmonary veins, particularly the right upper, is essential due to the association of partial anomalous pulmonary venous return with sinus venosus ASD. However, nowadays the presence of secundum ASD and associated pulmonary venous return is not a contraindication to device closure, with the total surgical time being reduced when the defect has already been closed with a device. Sinus venosus defects cannot and should not be closed by device because this will only complicate surgical repair of the anomalously draining vein.

As a result of a small incidence of atrial arrhythmias after device placement, a baseline ECG should also be obtained. Usual protocols for anticoagulant, antiplatelet, anesthesia, and antibiotic prophylaxis are suggested.

TECHNIQUE Defining the Anatomy An 8- or 10-French (Fr) sheath is placed in the femoral vein and right heart catheterization is performed using a Berman balloon-tipped or multipurpose catheter, with measurement of pressures and saturations in the superior vena cava (SVC), right atrium, right ventricle, and pulmonary arteries, to assess the degree of left-to-right intracardiac shunt, exclude pulmonary hypertension and additional pathology, especially anomalous pulmonary veins. An angiogram is then performed in the RUPV (this promotes contrast flow along the atrial septum to define the ASD optimally) with the anteroposterior (AP) camera angled 20° right anterior oblique (RAO) and 20° cranial, and the lateral camera 70° left anterior oblique (LAO) and 10° caudal. Contrast 24 ml is injected at a rate of 24 ml/s. The lateral projection will profile the ASD nicely, whereas the AP camera will define LA free wall landmarks so that both can be used as roadmaps for device delivery (Figure 27.2). Echocardiographic evaluation of the ASD is performed using either TEE or ICE and will be used for device placement guidance as well as post placement evaluation.

Technical Tips

****Reshaping the tip of the catheter to enter the ASD** Standard technique includes the use of a multipurpose (MP)

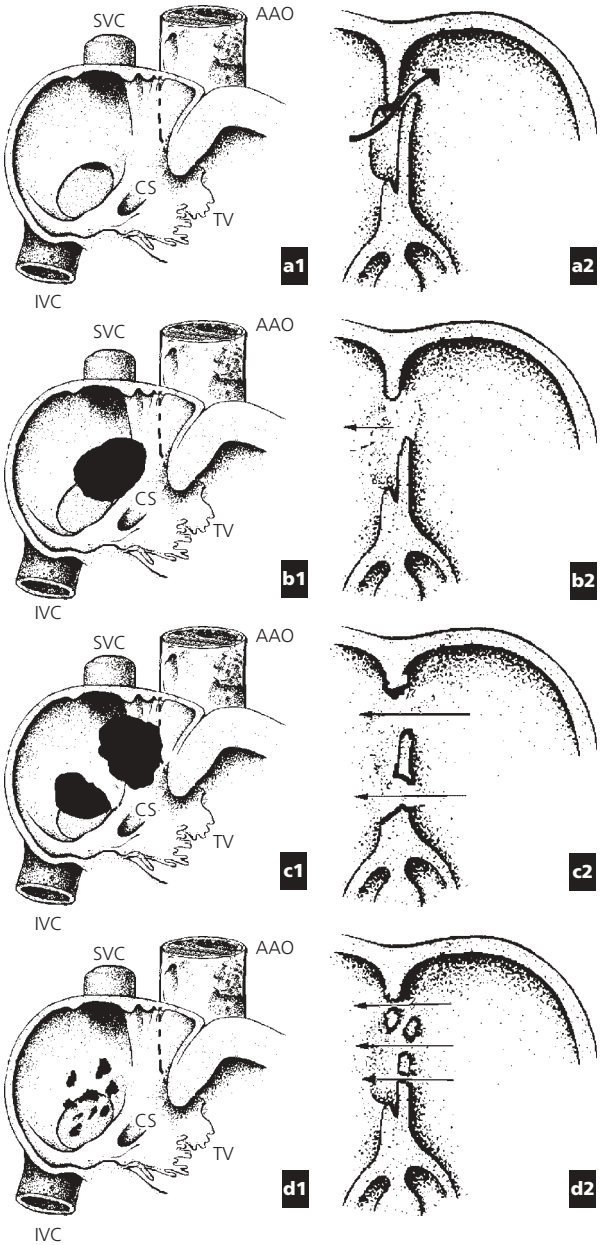


Figure 27.1 Schematic drawing of the different types of secundum atrial septal defects – isolated, multiple, fenestrated.

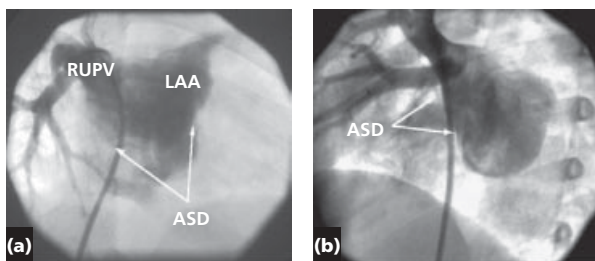


Figure 27.2 Antero-posterior and lateral angiogram of a secundum atrial septal defect.

1- to 5-Fr diagnostic catheter and a standard J-tip 0.035-inch guidewire to enter the LA. Alternatively it is possible to cross the ASD with the Berman catheter by inserting the stiff end of a 0.035-inch straight wire shaped with a 45° angle at the distal 3 cm. This will give the end of the Berman catheter a “hockey-stick” shape that can be easily directed slightly leftward and posterior, to slip through the ASD. Clockwise rotation then turns the tip into the right upper pulmonary vein.

Balloon sizing of the defect is then performed. Exchange the Berman catheter for a directional, Judkins right (JR)-4 or Bentson tip to direct a 0.035-inch wire through the ASD into the left upper pulmonary vein. Position a compliant sizing balloon (both AGA Medical Corporation and Nitinol Medical Technologies make ASD sizing balloons up to 3.5 cm in diameter) with reference markers across the defect and inflate until a discrete waist is detected. Measure the stretch diameter on AP and lateral angiograms because the echocardiographic measurement may not be as accurate or reliable.

Nowadays the use of an ice probe, in particular the mechanical 360° scan probe or the 90° electronic probe, allows for correctly sizing the defect without the use of balloon sizing (Figure 27.3) [6].

****Detecting additional defects** It is essential to evaluate the defect with echocardiography while the defect is occluded with the balloon. This allows careful assessment of the septum for additional defects and assures accurate stretch diameter measurement by confirming complete occlusion of the defect with the balloon. We prefer intracardiac echocardiography (ICE) assessment due to improved patient comfort, reduced need for deep sedation, and reduced need for echo personnel support. In general ICE has been equivalent to transesophageal echocardiography (TEE) for assessing the atrial septum in experienced hands and has been suggested as superior in the presence of complex ASDs [7], including defect >25–30 mm, multiple defects, multi-perforated ASD, insufficiency or absence of two rims, embryonic remnant of incomplete floor of the fossa ovalis, and floppy or aneurysmal rims.

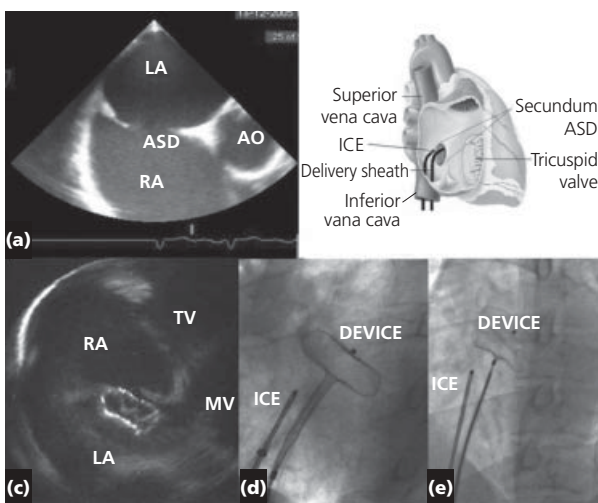


Figure 27.3 The delivery catheter and mechanical intracardiac echocardiography (ICE) probe were advanced up to the right atrium: (a) Transesophageal echocardiography revealed a defect located within the region of the fossa ovalis. (b) ICE appearance of the ASD as absence of tissue in the fossa ovalis region surrounded by its rims. (c) The delivery catheter is moved forward across the ASD, whereas the intracardiac echocardiography probe is placed in front of the defect. (d) Opening of the left atrial disk. (e) Complete opening of the device. LA, left atrium; MV, mitral valve; RA, right atrium; TV, tricuspid valve.

TECHNIQUE Selecting the size of device In general, the smallest device that effectively covers the defect should be used to minimize foreign body mass, and interference with intracardiac structures such as the atrioventricular (AV) valves or pulmonary vein/SVC inflow. Total septal length should be measured both angiographically and by echo to determine the largest device that can safely fit in the patient's atrium. Specific sizing depends on the type of device being used. In general, for the CardioSEAL STARFlex, Button, and Helix devices the size should be selected roughly twice the stretch diameter of the defect. The Amplatzer device, which is sized by the central stent diameter, should be 2–4 mm larger than the stretch diameter.

Technical Tips

****Selecting the type of device** TEE or ICE measurement of rim length and thickness is important for selecting the device type. A short aortic rim is not a contraindication for device closure with the Amplatzer device family but it poses an increased risk of aortic erosion, so selecting a different type of device, softer and less metallic, such as the Helex, may be safer. Similarly, hypertrophic or lipomatous rims (rim thickness >11 mm), particularly common in hypertensive or older patients, remain relative contraindications for the use of the Amplatzer device, due to the

fixed length of the waist. In these situations, selecting a softer device may be a physiologically better option.

****Selecting the size of the device** The smaller the defect stretch diameter the less you need to oversize devices, especially the Amplatzer device. For defects <16mm we often use devices equal to the stretch diameter, for defects 17–32mm we use the stretch diameter + 2 mm and for very large defects >32mm we will oversize by 4mm. If there is limited rim, particularly in the inferior, posterior, or anterosuperior portion (aortic region on echo short axis) of the defect, we will oversize by 3 or 4 mm from the stretch diameter. For the other devices the same concept holds; if there is a limited rim in a region, choose a device closer to 2.5 times the stretch diameter if the total atrial chamber size will allow.

*****ICE-guided device closure procedure** In most laboratories ICE is replacing TEE, so avoiding general anesthesia with its related morbidity and increasing patient comfort. The electronic device with color-Doppler capability (AcuNav) and the mechanical device with a 360° scan can measure the fossa ovalis or ASD surrounding rims to select the proper device size. In particular, the measurement of the aortic rim and the entire atrial septum length is of paramount importance, due to the risk of device impingement on the aortic wall when the aortic rim is too short or the device is oversized. Two orthogonal views are selected to measure the diameters of the fossa ovalis or the ASD due to the elliptical shape of some defects (Figure 27.4). ICE has been shown to be equivalent to TEE in resolution and precision [8].

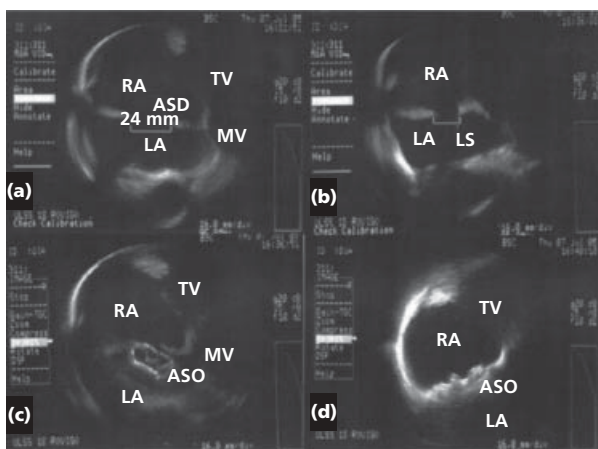


Figure 27.4 (a) ASD closure monitoring on ICE in the four-chamber plane; (b) aortic valve plane views; (c) device deployment; and (d) release. ASD, atrial septal defect; ASO, Amplatzer septal occluder; LA, left atrium; MV, mitral valve orifice; RA, right atrium, TV, tricuspid valve orifice.

TECHNIQUE Sheath placement The sheaths required for device closure range in size from 6 Fr to 12 Fr depending on device type and size. As air embolus remains one of the major concerns and causes of significant complications, proper flushing of the sheath is imperative. Use of a curved-tip sheath that can be manipulated directly from the right atrium (RA) to the left atrium (LA) without the use of a guidewire is preferred. The long sheath is placed in the RA over a wire, the wire and dilator removed, and the sheath cleared of air and flushed. The sheath is then manipulated across the defect into the LA for placement of the device. For small defects the tip of the sheath can be positioned in the center of the LA; for large defects the tip should be positioned in the opening of the right or left upper pulmonary vein.

Technical Tips

****Sheath placement in fenestrated ASDs** Sheath placement should be modified for fenestrated or multiple defect closure. In these cases proper placement of the sheath across the exact defect of interest is crucial to the success of the procedure. To ensure that the sheath crosses the same defect that was balloon sized, a long 0.035-inch wire should be left across the defect of interest in the left upper pulmonary vein, and the long sheath exchanged over the wire for the balloon-sizing catheter. Flush the sheath continuously when advancing into the LA and during removal of the dilator and wire. Refrain from negative suction on these large sheaths. Allow passive bleed back and keep the end of the sheath significantly below the level of the patient's heart to facilitate this. Be aware of the patient's breathing and be sure to time clearance of the sheath with exhalation to minimize the risk of air embolism. Give supplemental nasal cannula O₂ during sheath and device placement to minimize the effects if air embolism occurs. ICE is particularly useful in cases of multiperforated ASDs. Crossing the holes with different wires under ICE monitoring allows selection of the most central wire in respect of the fossa ovalis, permitting the use of a single device rather than multiple devices (Figure 27.5) [9].

TECHNIQUE Device positioning The device is soaked in heparinized saline and inspected for defects. It is compressed into the loader with constant flushing to remove any residual air and loaded into the sheath. The tip of the sheath is positioned in the mid-LA and the distal disk of the device opened. Use angiographic and echocardiographic landmarks to ensure that the device is not opened in a pulmonary vein or pressed against the LA roof.

Technical Tips

****How to position the sheath perpendicular to the atrial septum** Often the angle of the sheath with the atrial septum is quite acute, making the approach of the device to the septum difficult and often resulting in device edge prolapse, particularly in the anterosuperior region (especially if there is a limited aortic knob rim) or superior SVC region (especially if defect superiorly

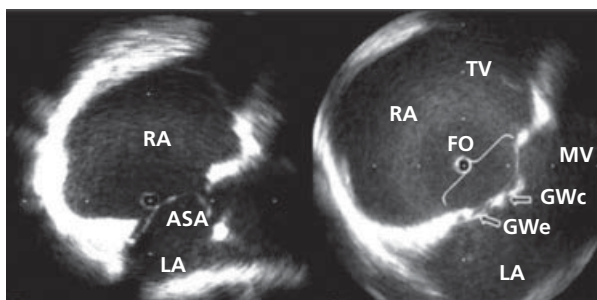


Figure 27.5 Intracardiac echo-aided closure of a multiperforated aneurysmal secundum ASD in the right panel; the left panel shows crossing the most central holes with different guidewire to enable selection of the best one for use as a single device. ASA, atrial septal aneurysm; FO, fossa ovalis; LA, left atrium; RA, right atrium; MV, mitral valve; TV, tricuspid valve; GWc and GWe, different guidewire in different holes.

located). To improve the angle and bring the device more perpendicular to the atrial septum, rotate the sheath clockwise to drive the tip of the sheath posterior and superior. The sheath can be shaped with a posterosuperior curve to improve device alignment (Cook Inc. currently has a commercial sheath available with this bend on the tip called a Lock–Hausdorf sheath).

The LA side of the device is brought back toward the atrial septum, but not snug as with patent foramen ovale (PFO) closure because this will promote device prolapse into the RA. For the CardioSEAL STARFlex type device, the centerpin of the device should be kept slightly into the LA side of the septum for RA disk delivery. Both the Amplatzer and Helix devices can be kept centered on the atrial septum during RA disk delivery.

****Final check of device position** The larger the defect the further the device center should be kept into the LA during RA disk delivery to prevent LA disk prolapse into the RA. After RA disk delivery, but before device release, complete echocardiographic assessment of the device and the relationship to surrounding structures must be completed. Evaluation for new-onset tricuspid or mitral valve regurgitation, residual left-to-right ASD flow, and obstruction of SVC or right upper pulmonary vein flow must all be carefully assessed. For the STARFlex device all frame arms must be identified on the appropriate side of the septum. For the Amplatzer device, the atrial septum must be identified between the two disks circumferentially. Pulling and pushing slightly on the delivery cable to separate the two disks will facilitate this process and confirms device stability. Once in an appropriate position the device is released and the delivery cable removed.

TECHNIQUE Post-placement assessment Repeat pressure and saturation measurements throughout the right heart should

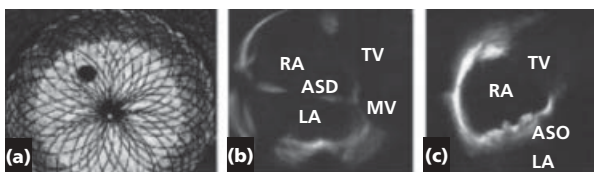


Figure 27.6 Procedural steps: (a) Fenestrated Amplatzer ASD occluder before implantation; (b) ICE guide showing the secundum ASD; (c) appearance on ICA of the released fenestrated device. ASD, atrial septal defect; LA, left atrium; MV, mitral valve; RA, right atrium; TV, tricuspid valve.

be performed to assure hemodynamic stability post-device and check for residual shunt. An angiogram at the MPA or RPA consisting of 24 ml contrast injected at 24 ml/s should be performed to confirm device position and evaluate for residual left-to-right shunting. The cameras can be positioned to evaluate the device on faux in the AP plane (usually 15° RAO and 10° caudal) and on profile in the lateral plane (75° LAO and 5° caudal). Echocardiographic assessment should be repeated after device release to assess final device position and residual shunt.

Technical Tips

*****Device closure in patients with severe pulmonary artery pressure** Transcatheter repair of secundum ASD is generally contraindicated in patients with associated severe pulmonary hypertension. In older patients, decompensated right heart failure may develop and is often associated with pulmonary hypertension, which is caused by excessive pulmonary flow over a long period of time. A homemade fenestrated device has been recently suggested in the management of such patients, reporting favorable results in the short term, with a significant decrease in pulmonary artery pressure. Fenestration can be made inflating a 4- to 6-mm non-compliant coronary balloon throughout the waist of the ASO in order to make a 4- to 6-mm fenestration (Figure 27.6). Moreover, it can be fixed by means of a surgical ligature of the nitinol meshes forming the border of the fenestration, or it may be possible to leave the newly formed hole free for eventual spontaneous closure by the fibrotic process, allowing for a slow and further decrease of pulmonary pressure, expected when the device and the fenestration are closed and completely covered by the fibrotic process [10].

PATENT DUCTUS ARTERIOSUS

Patent ductus arteriosus (PDA) is the persistence of a normal fetal connection between the proximal descending aorta and proximal left pulmonary artery, which allows the right ventricle to bypass the lungs and pump deoxygenated blood via the descending aorta to the placenta for oxygenation. Normal ductal closure occurs within the first 12 hours after birth, by contraction and

cellular migration of the medial smooth muscle in the wall of the ductus, resulting in protrusion of the thickened intima into the lumen and causing functional closure. Final closure and creation of the ligamentum arteriosum is completed by 3 weeks of age, with permanent sealing of the duct by infolding of the endothelium, disruption of the internal elastic lamina, and hemorrhage and necrosis in the subintimal region; this leads to replacement of muscle fibers with fibrosis. This process of closure is incomplete in 1/2000 live births and accounts for up to 10% of all congenital heart disease [11].

The technique is simple, consisting of placement of a device or vascular occlusion coil in the PDA either antegrade from the femoral vein or retrograde from the femoral artery. Once implanted the device physically occludes the ductal flow. Over the first 6–8 weeks after implant, endothelial overgrowth covers the device or coil from both the pulmonary artery and the aorta, permanently sealing the PDA.

Contraindications

Patients with systemic pulmonary hypertension (HTN) and right-to-left ductal shunting should not have their PDA closed. If pulmonary HTN is noted during catheterization then an accurate assessment of the degree of HTN and the reactivity of the pulmonary bed must be made during temporary occlusion of the ductus. A second venous sheath should be placed so that simultaneous pulmonary artery (PA) pressure measurement and pulmonary vascular resistance calculations can be made while balloon occlusion of the PDA is performed. If there is baseline left-to-right shunt and a decrease in PA pressures with balloon occlusion, then ductal closure is indicated.

The Procedure

Several different closure devices are currently used due to the significant variability of ductal anatomy. The most common anatomic shape is conical with a large aortic ampulla that narrows at the pulmonary artery end; however, other distinct anatomic forms exist, including “tubular” without a narrowing at the pulmonary artery end, “complex” with narrowing at both the aortic and pulmonary end, and a short “window” that is an anatomy commonly found in adults [12]. Different closure tools and techniques may be needed to effectively address these less common PDA anatomic subtypes; however, this section focuses on the two most common closure techniques for the conically shaped ductus. The most commonly used technique for closure of PDAs <4mm is retrograde placement of embolization coils. For large ducts, antegrade placement of an Amplatzer duct occlude device is the preferred method. These two techniques are described below.

Transcatheter ductal closure procedural success has been extremely high with rates of complete closure >96% [13]. The procedure takes approximately 2 h with discharge within 6 h. Full activity may resume within 48 h of the procedure. No anticoagulation or antiplatelet therapy is recommended post-coil closure procedure, although most centers recommend daily aspirin for

4–6 months after Amplatzer duct occlusion or device closure. Procedural complications are uncommon, occurring in <5% [14]. Hemolysis causing anemia may occur if a residual shunt is present after closure with either coils or a device, and requires repeat catheterization with placement of additional embolization coils. The major complication associated with coil closure of the PDA is coil embolization to the lungs; however, this is a technical issue that occurs at or immediately after implant, the incidence of which significantly decreases with operator experience. It is related to either undersizing of the coil or malposition on placement. In all but a very few patients the coils can be snared from their embolized position in the pulmonary artery and removed from the body without sequelae. Device embolization, thrombus, and ductal aneurysm have been reported in <1%.

Preprocedure Evaluation/Management

A complete physical examination and transthoracic echocardiogram is necessary before catheterization to make the diagnosis. Large PDAs will have a continuous murmur at the left infraclavicular region, prominent pulses, and a widened pulse pressure. Small PDAs may have only a systolic ejection murmur with normal pulses and pulse pressure. Echo will show an abnormal systolic left-to-right color flow jet into the main PA (MPA) or proximal left PA directed inferiorly and anteriorly. A complete blood count (CBC) and type and screen are obtained for the procedure. The usual protocols for anticoagulant, antiplatelet, anesthesia, and antibiotic prophylaxis are suggested.

Technical Tips

****Misleading systolic flow mimicking PDA** Be wary of a color flow jet seen on echo directed posteriorly from the anterior wall of the MPA associated with a systolic or continuous murmur. This most often represents a small coronary to PA fistula but can easily be mistaken for a PDA.

TECHNIQUE Defining the Anatomy The procedure should be adjusted based on the size of the PDA and technique used for closure. Small PDAs can be addressed solely through a 5- or 6-Fr femoral artery sheath with only retrograde catheterization. Larger PDAs require both femoral and venous access. The anatomy of the PDA is evaluated with a proximal descending thoracic aortic angiogram in a straight lateral plane using a pigtail catheter to inject 35 ml contrast at 35 ml/s (Figure 27.7). For small PDAs the pigtail catheter is then exchanged for a 5- or 6-Fr directional catheter, either Bentson or JR-4 shape, with a 0.038-inch lumen. The catheter is advanced to the proximal descending thoracic aorta and directed anteriorly and leftward. Often the catheter itself can be advanced across the PDA into the MPA, particularly if the catheter tip has been shaped by hand with an exaggerated anterior curve. If the catheter itself will not advance through the PDA, then the soft end of a straight 0.035-inch wire can be advanced into the MPA and the catheter advanced over the wire. Pressure and saturation measurements should be obtained in the

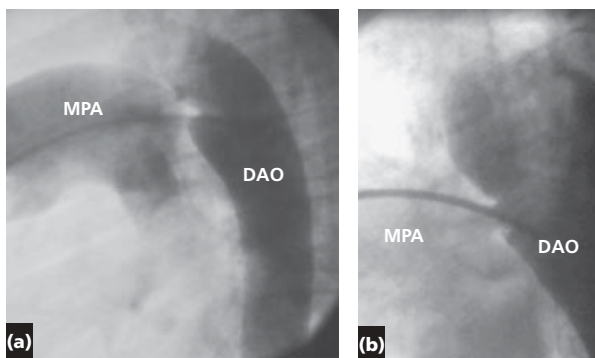


Figure 27.7 Lateral DAO angiogram showing a typical conically shaped PDA and a window-type PDA (patent Ductus Arteriosus).

MPA and descending aorta (DAO) to confirm catheter location and document left-to-right ductal shunting.

Technical Tips

****Locating the point of minimal diameter of the PDA** If the point of minimal diameter of the PDA is not well defined angiographically, it can be located by correlating catheter tip position relationship to bony and tracheal air column landmarks during pressure pullback from the MPA to the DAO through the PDA. The point of acute pressure change from the low MPA pressure to systemic DAO pressure will correspond to the minimal PDA diameter. This typically occurs at or just anterior to the anterior edge of the tracheal air column on straight lateral projection.

For larger PDAs a 7-Fr balloon wedge or multipurpose catheter can be manipulated through the right heart to the branch PAs with measurement of pressures and saturations to determine the degree of ductal shunting. The catheter can be manipulated antegrade through the PDA by advancing with clockwise rotation in the distal MPA. If this does not track easily a floppy directional wire such as a 0.035-inch Terumo can be advanced across the PDA and the catheter advanced over the wire.

*****Preoperative definition of the anatomy by MRI** MRI is becoming an indispensable imaging tool in planning cardiovascular interventions, in particular in the field of congenital and structural heart disease. MRI is able to depict correctly the shape and dimensions of the duct, in particular in cases of tiny or serpiginous ducts, and to reveal other potential congenital malformations that can usually be associated with a Botallo duct. Moreover it is able to give a three-dimensional reconstruction of the rapport of the duct with respect to the PA (Figure 27.8).

*****Preoperative definition of the anatomy by three-dimensional rotational angiography** Three-dimensional digital angiography was developed as a useful tool for assessing

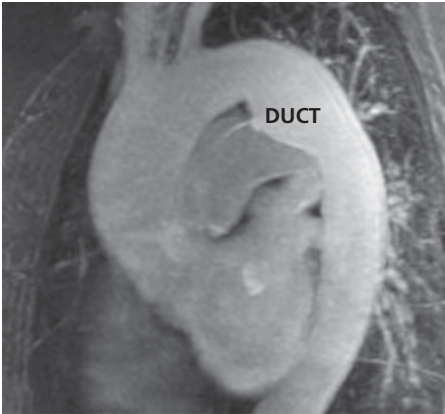


Figure 27.8 Magnetic resonance imaging of a tiny symptomatic Botallo duct.

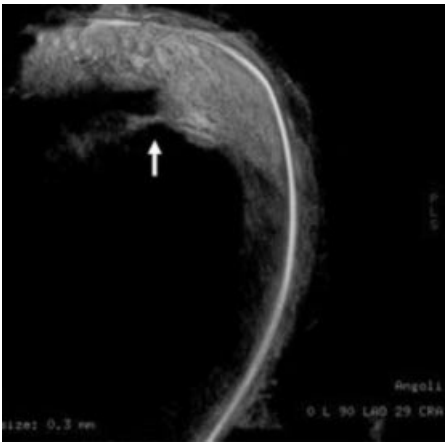


Figure 27.9 Three-dimensional reconstruction of rotational digital angiography of the aorta (arrow).

cerebral vascularization and is now a well-accepted technique for guiding cerebral aneurysm endovascular repair and other cerebral interventions. In a congenital heart disease setting it can be useful to select the best angiographic view, avoiding excess contrast. Aortography is performed using the three-dimensional rotational digital subtraction technique (RDSA) and 40 ml contrast at a flow of 10 ml/s (80 frames to complete a rotation of 180°). This enabled the operator to select the best projection for measuring the duct (Figure 27.9). The exact oblique and craniocaudal degree of projection selected by rotational three-dimensional reconstruction can be replicated to obtain the best standard DSA view of the duct to guide the intervention [15].

****Crossing the PDA from the aorta** If you are having difficulty crossing the PDA from the MPA, cross retrograde from the DAO with a directional catheter. Place a 10-mm snare through the retrograde catheter that is now in the MPA and snare the soft end of a 0.035-inch straight wire protruding from the antegrade catheter in the MPA. The retrograde catheter can then be used to pull the antegrade catheter across the PDA for proper positioning.

TECHNIQUE Selecting device size For small PDAs <4 mm in diameter, Gianturco embolization coils can be used for closure. They are available in a variety of wire diameters (0.018, 0.025, 0.035, 0.038, or 0.052 inch), loop diameters (3–15 mm), and total wire lengths (3–15 cm). For the most part 0.038-inch wire diameter coils are used although 0.052-inch coils can be used for larger PDAs and 0.035-inch ones for very small ducts. Initial coil size is chosen based on minimal PDA diameter with the loop diameter two or more times the minimal PDA diameter. Coil length should allow for at least four loops of coil (one loop on the PA side of the PDA and the remainder in the aortic ampulla), so length $\geq 4 \times \pi \times$ loop diameter, e.g. a 2.5-mm minimum diameter PDA can be closed with an 0.038-inch, 7-cm-long, 5-mm loop diameter coil which will provide a total of 4.4 loops.

For ducts ≥ 4 mm the Amplatzer duct occlude device can be used. This nitinol wire mesh self-expanding device has a wider aortic flange measuring 2 mm larger than the central ductal plug which ranges in length from 5 mm to 8 mm (Figure 27.10). Central ductal plug diameters range from 4 mm to 14 mm. The diameter of the ductal portion of the device should be 2 mm larger than the minimal diameter of the PDA, so this device can close ducts up to 14 or 15 mm in diameter, e.g. a 5.7-mm minimal diameter ductus can be closed with a 10- to 8-mm diameter, 8-cm long Amplatzer ductal occluder.

Technical Tips

****Use fewer coils in PDA closure** You can reduce the ratio of the minimal PDA diameter to coil loop diameter to 1.7 if you use the thicker, stiffer, 0.052-inch-diameter embolization coils. In fact larger ducts, up to 7 mm in diameter, can be effectively closed with these 0.052-inch coils, particularly if simultaneous deployment of two 0.052-inch coils is performed antegrade through a long 7-Fr sheath.




Figure 27.10 Patent Ductus Arteriosus device and coils.

TECHNIQUE Sheath placement For retrograde coil closure of the PDA a short 5- or 6-Fr sheath in the femoral artery is all that is needed. For antegrade Amplatzer duct occluder PDA closure, an appropriate 6- or 7-Fr long sheath with a curved tip (180° transeptal shape) placed across the PDA into the DAO is needed. Once an end-hole catheter has been advanced antegrade across the PDA, advance it to the proximal abdominal aorta and place a 0.035-inch J-tipped exchange wire through the catheter. Remove both the catheter and short sheath, and advance a long sheath from the femoral vein over the wire through the right heart into the DAO.

Technical Tips

****Inserting the sheath into the RVOT** To ease passage of the sheath through the right ventricular outflow tract (RVOT) and minimize ectopy, rotate the sheath clockwise as it moves into the RVOT to avoid being caught on the moderator band. If there is difficulty in passing the sheath, this maneuver can be facilitated by either using a more stiff wire (such as an 0.038-inch or Amplatzer super stiff) or by snaring the tip of the wire in the DAO with the retrograde directional catheter and a 10-mm nitinol snare loop.

TECHNIQUE Device positioning For coil closure of the PDA from a retrograde approach, the tip of the directional Bentson or JR-4 with a 0.038-inch lumen is positioned across the PDA in the MPA. Lateral fluoroscopy is used to guide the procedure with a roadmap image from the lateral angiogram available to define ductal anatomy. A straight 0.035-inch wire is used to load the embolization coil into the catheter and advance or “push” the coil to the tip. One loop of coil is extruded from the tip of the catheter by advancing the 0.035-inch pushing wire, and the entire catheter/coil/pushing wire is then brought back slowly together to position this extruded loop of coil against the PA end of the PDA. As the extruded end of the coil makes contact with blood, it will change shape by either rotating or opening slightly. The pushing wire is now held in position and the catheter is retracted over it. This uncovers the proximal end of the coil in the aortic ampulla while maintaining the distal loop of coil on the PA side of the ductus. The catheter is brought back, completely uncovering the proximal end of the coil, which will then spring from the tip of the catheter and coil up in the aortic ductal ampulla. Controlled-release coils are available, allowing the pushing wire to be advanced once a secondary loop starts to form in the descending aorta for a more controlled release of the proximal end of the coil near the aortic ampulla.

Technical Tips

****Avoiding first coil embolism while deploying the second coil** Watch the PA loop of coil carefully while delivering the proximal portion of the coil. If an additional coil loop is advancing forward into the PA as you deliver the proximal portion of the coil, the catheter and pushing wire must be pulled back

more aggressively to avoid embolization of the entire coil into the PA. If the PA loop of coil is getting smaller and pulling into the aorta during delivery, the pushing wire must be held more stable or advanced to keep the distal loop in the PA and prevent embolization of the coil into the DAO.

Approximately 10–15 min after coil placement, an angiogram should be performed by hand through the directional catheter, with the tip positioned at the inferior margin of the aortic ductal ampulla pointing anteriorly and leftward. If there is a significant residual leak through the initial coil, additional coil placement is needed. A significant leak is evidenced by contrast passing through the coil as a jet or contrast filling into the MPA 5 mm or more past the PA end of the existing coil. The second coil should be 2 mm smaller in loop coil diameter and have a length providing three or four loops. To cross the PDA with an existing coil in position, the directional catheter is positioned at the inferior edge of the aortic ductal ampulla, pointing toward the PA. The soft end of a 0.035-inch straight wire is advanced gently through the existing coil into the PA. This may take several attempts with slight angulation of the directional catheter on each attempt to find the residual defect.

****Avoiding entangling the already deployed coil by directional wire** Be careful to use a non-steerable wire when you cross the initial coil. Directional wires with floppy ends can inadvertently have the tip spin in the existing coil. This will wrap fibers of the implanted coil around the directional wire, entangling the two and causing the implanted coil to dislodge.

Once the straight wire goes through the PA, advance the directional catheter over the wire. Delivery of the second smaller coil is performed in a similar fashion to delivery of the first coil. Occasionally, a third coil may be necessary for complete closure.

For the Amplatzer PDA duct occluder device, the long sheath should be positioned antegradely in the mid-thoracic DAO and kept there until the device has been advanced to the tip of the sheath. This prevents the sheath from inadvertently being withdrawn through the duct into the MPA as the device advances. The entire system is then brought back until the tip of the sheath is just off the posterior wall of the DAO at the level of the ductal ampulla. The device is held in position and the sheath retracted to open only the distal flange of the device. The entire system is withdrawn together and the aortic flange pulled firmly against the aortic ampulla. A pigtail catheter is positioned from the femoral artery in the thoracic DAO for a lateral angiogram to confirm the appropriate position of the aortic end of the device. Once the position has been confirmed the device cable is held in position and the sheath retracted while opening the ductal plug within the PDA.

****Checking the position of device before deployment** A hand angiogram through the delivery sheath can be performed to assess the PA side of the device. If the PA end protrudes >3 mm or there is evidence of LPA obstruction, the device should be

recaptured and repositioned. A repeat angiogram is performed in the DAO to confirm appropriate device position and the cable is then unscrewed for device release, keeping slight tension on the cable to maintain position.

****Closing the PDA with the occluder** A window-shaped ductus may be more effectively closed with an Amplatzer septal occluder or CardioSEAL STARFlex device. The technique is similar to that described above for the Amplatzer PDA duct occluder device.

TECHNIQUE Post-placement assessment Repeat hemodynamic measurements are then performed with particular attention to pressure measurements in the LPA, MPA, transverse arch, and DAO to ensure that no obstruction to the proximal LPA or DAO has occurred. A final angiogram through the pigtail catheter in the proximal thoracic DAO is performed in the lateral projection (35 ml at 35 ml/s) to assess final positioning and closure. Some leaks through the Amplatzer duct occluder device is expected as fibrin deposition on the fabric for complete closure occurs over a few hours (Figure 27.11).

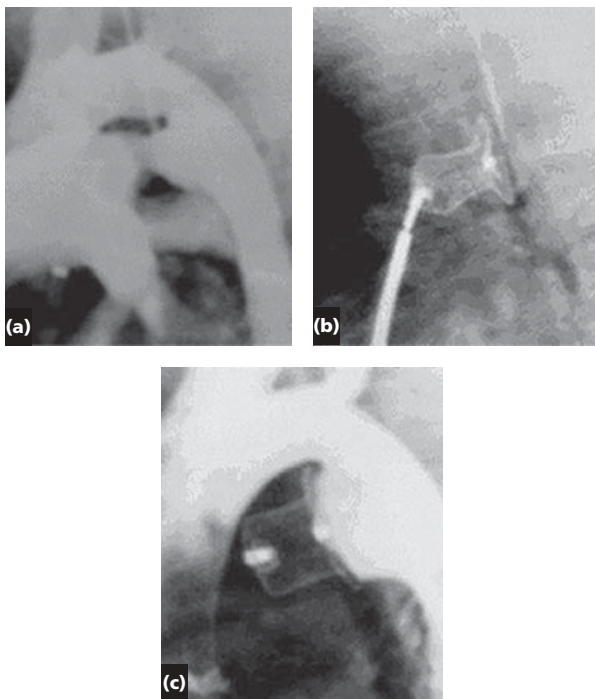


Figure 27.11 Lateral angiograms of Patent Ductus Arteriosus before, during, and after Amplatzer duct occluder.

COARCTATION

Coarctation is most often a discrete narrowing of the proximal descending thoracic aorta just distal to the origin of the left subclavian artery at the site of the ductus ligamentum. It makes up 7% of all patients with congenital heart disease and results in upper extremity hypertension, LV hypertrophy, and eventually ventricular failure if left untreated. It should be considered during the initial evaluation of systemic hypertension and can easily be diagnosed on physical examination by decreased femoral pulses, with a delay compared with radial pulses and blood pressure differential between the arms and leg. Often a 2/6 systolic ejection murmur can be heard at the left upper sternal border and over the left back. The narrowing is due to thick intimal and medial ridges that protrude posteriorly and laterally into the aortic lumen [16]. Intimal proliferation and elastic lamina disruption occur distal to the ridges due to the high-velocity jet impact on the distal aortic wall. Cystic medial necrosis with disarray and loss of medial elastic tissue occurs commonly in the adjacent aorta and may extend to the ascending aorta as well. It is this abnormality that may lead to late aneurysm formation. The body's compensatory response to coarctation is the development of vessels that bypass the obstruction, collateral vessels from the innominate, carotid, and subclavian arteries that connect to the thoracic aorta below the level of the coarctation, often connecting through the intercostal arteries. Enlargement of the intercostals arteries due to this collateral flow is the mechanism for rib notching seen on chest radiograph in adult patients with severe native coarctation.

Contraindications

Patients with coarctation gradients <20 mmHg with no evidence of collateral flow, hypertension, LV hypertrophy, or abnormal blood pressure response to exercise do not need treatment. Patients with significant hypoplasia and obstruction of the transverse aortic arch in the area of the origin of the carotids should be excluded. Stent repair with jailing of the carotids may be appropriate in the rare patient at extremely high surgical risk; however, for most patients with this lesion, surgical repair should be performed. Any patient with an existing aneurysm should also be cautiously considered. The use of covered thoracic stents may have a role in this setting, although there are currently limited data.

The Procedure

The equipment available for angioplasty and stent repair of coarctation has improved significantly over the last 20 years. Balloons that are specifically designed for large sent implantation and stents that have adequate radial strength at sizes appropriate for an adult thoracic aorta are only recently available. Currently there are three large stents designs, two stainless steel and one platinum, that can reach diameters of 18–25 mm with adequate coverage and radial strength appropriate for treatment of coarctation.

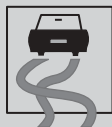Preprocedure Evaluation/Management

A complete physical examination including upper and lower extremity blood pressure measurements is essential. Echocardiography may be helpful in confirming the diagnosis if the physical examination is unclear; however, echo often poorly defines the anatomic detail of the obstruction and frequently overestimates the degree of obstruction. Anatomic definition of the coarctation before catheterization is critical to determine the best approach for treatment. Patients with a hypoplastic transverse arch or a “kinked” high third arch may respond poorly to stent repair and may best be treated surgically. MRI with MR angiography (MRA) is currently the best technique for defining the arch anatomy and can give functional data, including estimation of degree of obstruction based on blood velocity at the site and percentage collateral flow, an excellent indication of the physiological significance of the coarctation. In addition MRI gives accurate anatomic detail of the size, location, and length of coarctation so that appropriate equipment including dilation balloon and stent sizes can be planned in advance. A CBC and type and cross are obtained for the procedure. Blood is kept available in the cath lab during balloon dilation and stent implantation. Usual protocols for antiplatelet, anticoagulant, anesthesia and antibiotic prophylaxis are suggested. An additional intravenous opiate, fentanyl, is given immediately before balloon dilation or stent implantation because aortic stretch caused acute moderate pain. Patients who are taking antihypertensive medications continue these on the morning of the procedure. A short-acting intravenous β blocker is given immediately after balloon dilation or stent implantation if significant acute hypertension develops.

CAVEAT

**A note of caution

This procedure can have relatively high rates of significant complications that can be reduced by careful patient selection and operator experience; however, in hospital, cardiothoracic surgical availability to address emergencies is mandatory.



TECHNIQUE Defining the anatomy Right and left heart catheterization is performed in routine fashion. As a result of the large sheath size required in the artery for this procedure, suture closure of the femoral artery is recommended, so be sure that the sheath insertion site is appropriately located. The cardiac index should be measured with either saturation or thermodilution techniques. This is essential both before and after balloon dilation or stenting in order to properly interpret the degree of stenosis measured across the coarctation. Pressure pullback across the area of coarctation is recorded.

Technical Tips

****Measuring the gradient across the coarctation** Remember that the pressure gradient across the coarctation depends primarily on the cross-sectional area of the lesion, its length, and the amount of flow crossing the lesion. Severe coarctations may have very little pressure gradient from ascending aorta (AAO) to DAO if there are substantial collateral vessels limiting the flow through the lesion. Despite collateral vessels, this obstruction remains a significant increased workload for the left ventricle and stimulates upper body hypertension.

An angiogram is performed in the distal transverse arch using a marker pigtail catheter to allow accurate measurements. The camera should be angled 15° LAO and 10° caudal, combined with a straight lateral projection with an injection of 35 ml at 35 ml/s. Careful measurements are then made of the distal transverse arch diameter, coarctation diameter, coarctation length, distal normal vessel diameter, distance from the left subclavian artery origin to the coarctation, and diameter of the left subclavian artery (Figure 27.12).

*****Defining the anatomy with three-dimensional rotational angiography** Thanks to its ability in three-dimensional reconstruction, RDSA can be useful in depicting the point of maximum narrowing of the aorta and in defining correctly the ostium of the subclavian artery, in particular in cases of aberrant vessel. Aortography is performed using 40 ml contrast at a flow of 10 ml/s (80 frames to complete a rotation of 180°).

TECHNIQUE Selecting balloon and stent size Balloon diameter should never exceed the smallest diameter of the normal aorta surrounding the coarctation that the balloon may contact. In other words, the goal is to enlarge the coarctation to the size of the smallest contiguous normal aorta, not to stretch it to larger than the normal diameter. Preferably the balloon should be at least 2.5 times larger than the coarctation diameter but not more than 3.5 times larger. Remember that, if the wire and balloon tip are in the innominate or left subclavian artery for stabilization, the balloon diameter must not exceed the normal vessel diameter

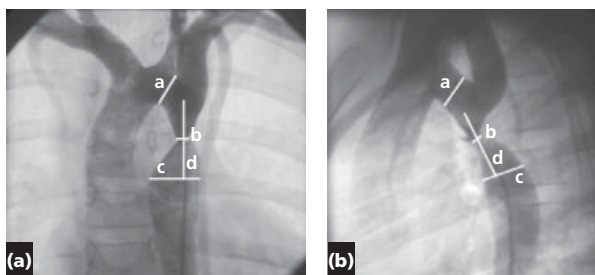


Figure 27.12 Lateral and antero-posterior angiogram of native coarctation with key measurements shown.

of the proximal innominate or subclavian. These guidelines minimize the risk of aneurysm or rupture.

Technical Tips

****Sequential dilation of the coarctation** If the coarctation is severe with a diameter less than a quarter of the normal aortic diameter (for a normal sized adult with a 20-mm distal transverse arch this would be a coarctation diameter ≤ 5 mm), complete repair should be performed in two or three stages at 3-monthly intervals to allow adequate healing of the aorta between the procedures. The first procedure should be balloon dilation with stent implant and enlargement to 2.5 times the coarctation diameter (in the example given a stent would be implanted and dilated to 12 mm). Three months later the patient should have dilation of the implanted stent to the size of the surrounding normal aorta (in the example the stent would then be dilated to 20 mm).

Care must be taken to select a balloon that is long enough to remain stable in the lesion but not extend around the arch or substantially into the head and neck vessels. Generally a 3- or 4-cm balloon length is optimal. The balloon should be of scratch-resistant material, preferably designed for use with stents. Remember that the stent will need to be mounted during the procedure, so care must be taken not to damage the balloon during the mounting process. Some operators have advocated the use of a double balloon delivery catheter. This has an inner balloon half the diameter of the final outer balloon. The concept is that the inner balloon allows a more uniform enlargement of the stent with minimal stent tip flaring and the ability to adjust stent position before final implant with the larger balloon in a more controlled manner. We have not found that the balloon in a balloon technique offers any significant advantage over careful delivery with a single lumen balloon; however, it did add complexity to coordinate sequential inflation of both balloons.

The stent used should be able to reach a diameter appropriate for the normal aorta and the patient's size, which for most adults will range between 18 and 22 mm. The stent length should be kept as short as possible while maintaining adequate length after foreshortening with dilation to completely cover the length of the lesion for degree of shortening. Unnecessary stent length may be a disadvantage due to increased length of non-compliant aorta after implant, which may influence blood pressure, particularly in response to exercise.

****Advantage of MRI-compatible stents** Although not readily available at present, platinum or nitinol stents may be preferred over stainless steel stents due to their MRI compatibility, allowing follow-up MRI assessment of these patients' coarctation sites, which is not possible after stainless steel stent placement.

TECHNIQUE Sheath and wire placement Wire position is important to optimize balloon and stent positioning as well as to minimize risk of complications. A relatively stiff exchange length wire should be used; we prefer an Amplatz wire with a short soft

tip. The first choice for wire position is the left subclavian artery if there is adequate distance (1.5 cm) from its origin to the site of coarctation. This position is easy to obtain and allows for a straight balloon/stent course while minimizing wire/sheath/balloon exposure to the carotid arteries, thereby minimizing the risk of a neurological complication. If the distance between the site of coarctation and the origin of the left subclavian is too short or the diameter of the proximal left subclavian too small to accept the tip of the dilating/implanting balloon, the wire should be placed in the right innominate and subclavian arteries. This will usually allow for a reasonably straight balloon/stent course, although it does mandate a wire and balloon immediately below the origin of the carotid arteries. If the right innominate cannot be used due to its small size or tortuous origin, an apex wire should be used and positioned in the LV apex.

Technical Tips

****Optimal wire position** Some operators have advocated positioning the wire in the ascending aorta; however, we have found that this can lead to inadvertent cannulation of the coronaries or prolapse through the aortic valve, resulting in significant ectopy. If wire placement in the left ventricle is necessary, choose the shortest balloon possible to minimize the straightening of the aortic arch that will occur during dilation or stent implantation.

The sheath should be straight and long enough to reach the coarctation from the femoral artery. For stent implantation increase the French size of the sheath 1 or 2 above that recommended for the balloon alone (this will generally be 10- to 12-Fr sheath size). To minimize the risk of a neurological complication we prefer to keep the sheath at or below the area of coarctation, particularly if the wire is positioned in the right innominate or left ventricle. The sheath is continuously flushed with heparinized saline to minimize risk of clot formation.

TECHNIQUE Balloon and stent positioning The stent is flared open on the table using an appropriate dilator to allow it to easily slip on to the delivery balloon (which is under negative pressure) without contacting the balloon material. The stent is hand crimped on to the balloon and the negative balloon pressure released. The long sheath is positioned in the abdominal aorta and the stent balloon combination advanced to the tip of the sheath, allowing only the balloon tip to protrude. The sheath and balloon/stent system are advanced across the lesion and the sheath pulled back just below the coarctation. A hand-injected angiogram through the sheath is then performed in the lateral projection, to define the coarctation and origin of the subclavian artery relative to the position of the stent. The stent should be centered on the coarctation, with care taken so that the proximal edge of the stent is distal to the origin of the subclavian artery.

Technical Tips

****No problem with subclavian jailing** The subclavian artery can be crossed and jailed if absolutely necessary to effectively

stent the coarctation. As the subclavian originates at approximately 90° to the aortic arch and the interspaces of these large stents are quite sizable, no obstruction will occur. There have been no late reports of either stenosis or distal thrombus after subclavian “jailing.” However, daily aspirin is recommended for at least 12 months after implant if the subclavian is “jailed.”

The sheath is retracted over the balloon catheter just to the proximal edge of the balloon. In this way the sheath can help maintain balloon position during inflation and help prevent distal movement due to the force of the ejecting blood. This fact should be considered when positioning the balloon and stent before delivery by having the stent centered just proximal to the center of the coarctation. Inflation of the stent should initially proceed slowly until both ends of the stent are partially flared. The balloon position can still be adjusted at this point if necessary. Full inflation is then performed taking care not to exceed the burst pressure of the balloon.

****Postdilation with a high-pressure balloon** It is much better to postdilute a stent with a residual waist by placing a high-pressure balloon after initial implant than to attempt resolution of a residual waist by excessive pressure with the initial implanting balloon. Removal of a ruptured balloon from a freshly implanted stent can be problematic and the effectiveness of a post-implant high-pressure dilation is usually significantly greater than the initial implant dilation.

TECHNIQUE Post-placement assessment After balloon dilation or stent implantation, repeat hemodynamic assessment should be performed including measurement of the cardiac index by saturation or thermodilution techniques. Pressure pullback across the dilated and/or stented coarctation should be performed with a “Y” adaptor over a wire to maintain distal wire position.

Technical Tips

****Accurate pressure gradient measurement** To get an accurate pressure measurement and optimal picture the wire used with the pigtail catheter should be downsized to an 0.025-inch Rosen or Amplatz wire once the pigtail catheter has been advanced well past the site of coarctation.

The pigtail catheter should then be advanced just proximal to the coarctation for an angiogram. Cameras should be kept with the camera angled 15° LAO and 10° caudal and a straight lateral projection with an injection of 25 ml at 25 ml/s (rate and volume need to be reduced from initial picture to safely use the power injector with a wire and the “Y” adaptor). Additional views with different camera angles may be necessary if an aneurysm or extravasation of contrast is suspected on the initial post-implant angiogram.

Coarctation and Aneurysm Implantation Technique with Covered Stent

Informed consent was obtained from all patients or their parents before the procedure. All patients underwent general anesthesia.

Intravenous heparin (100IU/kg to a maximum of 5000IU) was given after femoral artery cannulation with an 8-Fr sheath. The access was percutaneous in seven cases and surgical in the other four. The stenotic segment was crossed with a 6-Fr multipurpose catheter on a floppy guide wire (0.035-inch Terumo guidewire). This catheter was then exchanged with a standard 0.035-inch 260-cm exchange guidewire for a pigtail catheter, and the peak-to-peak pressure gradient between the 8-Fr femoral sheath and the pigtail catheter in the ascending aorta was measured. Aortic arch angiograms were performed in three different projections (anteroposterior, laterolateral, and LAO views) with the holes of the pigtail catheter adjacent to the stenotic area. The following measurements were noted: (1) Diameter and length of the stenotic area, (2) diameter of the descending aorta at the level of the diaphragm, (3) diameter of the aorta at the level of the subclavian artery, and (4) diameter of the transverse arch. The diameter of the balloon was selected to equal that of the distal arch at the level of the origin of the subclavian artery. If distal arch hypoplasia was present, the diameter of the transverse arch was chosen as the balloon size. When a near atretic aortic coarctation was found, predilation of the aortic segment was performed using coronary balloons. In these cases, dilation up to a maximum of six to eight times the diameter of the stenotic area was performed, and the balloon catheter was chosen to be longer than the intended stent length. Stent length was determined by the distance from just beyond the left subclavian artery, or the left common carotid if the left subclavian artery had been sacrificed in previous surgery, to about 10–15 mm beyond the site of the coarctation. BIB or Crystal balloons were used. Mullins transeptal long sheaths 3–4 Fr larger than the sheath needed for the balloons alone were used as long sheaths, ranging from 10 Fr to 13 Fr in size. The Mullins sheaths were exchanged over a 0.035-inch stiff guidewire positioned in the ascending aorta or right subclavian artery.

CP stents are covered along their length with expanded polytetrafluoroethylene, as previously well described [5–8], and available in lengths from 22 mm to 45 mm. Only 8-Zig-covered CP stents were used, manually crimped onto the appropriate balloon. The crimped stents were inflated at the coarctation site up to the balloon pressure recommended by the manufacturer, usually up to 4–6 atm. Angiography was performed during and after stent placement through the sheath side arm or by using a pigtail catheter to assess the result and investigate any dissection or aortic rupture. Pressures were recorded after the procedure. The femoral arterial access was surgically sutured in four patients, and manual pressure was used to achieve hemostasis in seven patients [17].

REFERENCES

1. Sam'aneek M. Children with congenital heart disease: probability of natural survival. *Pediatr Cardiol* 1992;**13**:152–8.

2. Chessa MM, Carminati M, Butera G, et al. Early and late complications associated with transcatheter occlusion of secundum atrial septal defect. *J Am Coll Cardiol* 2002;**39**:1061–5.
3. Suchoń E, Podolec P, Tomkiewicz-Pajak L, et al. Cardiopulmonary exercise capacity in adults with atrial septal defect. *Acta Cardiol* 2002;**57**:75–6.
4. Rigatelli G, Cardaioli P, Giordan M, et al. Nickel allergy in interatrial shunt device-based closure patients. *Congenit Heart Dis* 2007;**2**:416–20.
5. de Lezo JS, Medina A, Romero M, et al. Effectiveness of percutaneous device occlusion for atrial septal defect in adult patients with pulmonary hypertension. *Am Heart J* 2002;**144**:877–80.
6. Rigatelli G, Cardaioli P, Braggion G, et al. Transesophageal echocardiography and intracardiac echocardiography differently predict potential technical challenges or failures of interatrial shunts catheter-based closure. *J Intervent Cardiol* 2007;**20**:77–81.
7. Rigatelli G, Dell'avvocata F, Cardaioli P, et al. Five-year follow-up of transcatheter intracardiac echocardiography-assisted closure of interatrial shunts. *Cardiovasc Revasc Med* 2011;**12**:355–61.
8. Rigatelli G, Cardaioli P, Giordan M, et al. Transcatheter intracardiac echocardiography-assisted closure of interatrial shunts: complications and midterm follow-up. *Echocardiography* 2009;**26**:196–202.
9. Zanchetta M, Rigatelli G, Pedon L, Zennaro M, Carrozza A, Onorato E. Catheter closure of perforated secundum atrial septal defect under intracardiac echocardiographic guidance using a single amplatzer device: feasibility of a new method. *J Invasive Cardiol* 2005;**17**:262–5.
10. Dell'avvocata F, Rigatelli G, Cardaioli P, Giordan M. Home-made fenestrated amplatzer occluder for atrial septal defect and pulmonary arterial hypertension. *J Geriatr Cardiol* 2011;**8**:127–9.
11. Mitchell SC, Korones SB, Berendes HW. Congenital heart disease in 56,109 births: incidence, and natural history. *Circulation* 1971;**43**:323–32.
12. Krichenko AL, Benson N, et al. Angiographic classification of the isolated, persistently patent ductus arteriosus and implications for percutaneous catheter occlusion. *Am J Cardiol* 1989;**63**:877–80.
13. Wang JK, Liau CS, Huang JJ, et al. Transcatheter closure of patent ductus arteriosus using Gianturco coils in adolescents and adults. *Catheter Cardiovasc Interv* 2002;**55**:513–18.
14. Rigatelli G, Zamboni A, Cardaioli P. Three-dimensional rotational digital angiography in a complicated case of patent ductus arteriosus transcatheter closure. *Catheter Cardiovasc Interv* 2007;**70**:900–3.
15. Faella HJ, Hijazi ZM. Closure of the patent ductus arteriosus with the amplatzer PDA device: immediate results of the international clinical trial. *Catheter Cardiovasc Interv* 2002;**51**:50–4.
16. Edwards JE, Christensen NA, Clagett OT, et al. Pathologic considerations in coarctation of the aorta. *Mayo Clin Proc* 1948;**23**:324–32.
17. Butera G, Heles M, MacDonald ST, Carminati M. Aortic coarctation complicated by wall aneurysm. *Catheter Cardiovasc Interv* 2011;**78**:926–32.

Index

Note: page numbers in *italics* refer to figures; those in **bold** to tables.

- abdominal aortic aneurysms (AAA)
 - 518
 - dissecting, renal artery stenting 549
 - endovascular repair *see*
 - endovascular (aortic) aneurysm repair
 - preoperative evaluation 519–23, 520, 522
- accordion maneuver 459–60, 463
- N-acetylcysteine (NAC) 350, **351**
- acute coronary artery closure, during PCI 353–62
 - causes 353, 362
 - dissection 353–61
 - precautions 356
 - predictors of poor outcome 400, 401
 - risk factors 400–1
 - thrombotic 361–2
 - see also* no reflow
- acute coronary syndromes (ACS) 403–4
 - lesions safe to dilate first 406, 407
 - performing PCI 410–11
- acute myocardial infarction (AMI)
 - acute simultaneous occlusion of two major coronary arteries 289
 - concurrent stroke 286
 - large coronary aneurysms 288–9
 - left main compression by aortic dissection 286–7
 - left ventricular assist devices 413
 - non-Q wave 410–11
 - recent stroke 286
 - spontaneous coronary dissection 287–8, 288
 - subclavian artery occlusion 512–13
 - with triple vessel disease 411, 412
 - ventricular septal defects complicating 290–1
- acute ST-segment elevation myocardial infarction (STEMI) 269–91
 - with bleeding, PCI 285–6
 - high-risk patients 270–1, 272
 - post-CABG surgery 308–9
 - primary PCI 272–90
 - rescue PCI, after thrombolysis 278
 - urgent coronary angiography 270, 271
- adenosine 306, 366–7
- air embolism 367–8
- Allen test, reverse 143
- allergy
 - ASD closure device 632
 - contrast 352
 - vascular entry site 165
- alligator forceps 434
- All Right catheter 162
- AMI *see* acute myocardial infarction
- Amplatzer PDA duct occluder 645, 645
 - deployment 647–8
 - post-placement assessment 648, 648
 - sheath placement 646
- Amplatzer PFO occluder **632**
- Amplatzer septal occluder **632**
 - atrial septal defects 632–3, 639, 640
 - endoleaks 533–4
- Amplatz guides 54, 63–6, 65
 - aortic aneurysms/dissections 73–4
 - coronary anomalies 74, 75, **76**
 - optimal position 64–5
 - selection 68, 70
 - size 63–4
 - transcatheter aortic valve implantation 496, 497
 - withdrawal 65–6

- Amplatz left (AL) guides 54, 64
 - aortic aneurysms/dissections 73
 - backup force 77
 - chronic total occlusion 215
 - coronary anomalies 75, 76
 - right coronary artery lesions 70
 - saphenous vein grafts 299
 - transradial approach 153, 153, 158, 162
 - backup force 178, 179, 180
- Amplatz maneuver, rotational 69, 71
- Amplatz right (AR) guides 64, 70
 - coronary anomalies 75
 - saphenous vein grafts 299
- Anaconda device 533
- anchoring techniques *see*
 - balloon-anchoring techniques; wire-anchoring techniques
- AneuRx endograft 524
- angiographic views 27–49
 - coronary artery anomalies 43–9
 - deceptive and suboptimal 39, **40**, 216
 - internal mammary artery 39
 - left anterior descending artery 34–6, 36
 - left circumflex artery 36, 36–7
 - left main artery 32–4, **34**, 186
 - magnification and balloon or stent sizing 40–1, **42**, 42
 - moving image intensifier 28–32, **29**
 - radiation exposure 41–3
 - right coronary artery 37–8, 38
 - saphenous vein graft 38
 - selecting camera angle **40**
 - sequencing 29–30
 - technical tips 30–2
- angiography
 - abdominal aortic aneurysm repair 525–6
 - acute limb ischemia 15–16
 - atrial septal defects 633–5, 634, 635
 - carotid artery 556–7, 566
 - chronic total occlusion 210–11, 590–1, 591
 - coarctation 651, 651
 - contrast-related complications 349–52
 - coronary *see* coronary angiography
 - femoral access checks 3, 4
 - intracranial vessels 557
 - minimum contrast (MINICON) technique 183
 - patent ductus arteriosus 642, 643
 - peripheral artery disease 581, 582, 606
 - renal artery stenosis 538–40, 539
 - subclavian artery disease 503–4, 504
 - three-dimensional rotational 643–4, 644, 651
 - transcatheter aortic valve implantation 492–5, 493, 494
 - see also* aortography
- Angioguard filter devices 542, 566–8, **567**
- AngioJet device 284, 308
- angioplasty
 - balloon *see* balloon angioplasty
 - force-focused 111–12
 - laser, unexpanded stents 134
 - subintimal, femoropopliteal disease 610–11
- Angio-Seal device 12, 13, 14, 291
- angiotensin-converting enzyme (ACE) inhibitors 350
- angle, guide with aortic wall (θ) 77, 171–2, 172, 173–5
- ankle/brachial index (ABI) 580, 605–6
- anterior tibial artery 604
- anteroposterior (AP) view
 - caudal 30, 31
 - cranial 34, 35
 - first neutral 29–30, **33**
- anticoagulants
 - chronic total occlusions 213–14
 - reversal, coronary perforation 370, 373–4
 - transradial approach 168
 - see also* heparin; warfarin
- antiplatelet drugs 285, 286, 362, 403, 556
- antithrombotic agents 213–14
- Aorfix endovascular AAA repair system 531, 532
- aorta 518
 - avoiding, septal puncture 449
 - coarctation *see* coarctation
 - crossing PDA from 645
 - dampened pressure 56, 67–8
 - inadvertent puncture 449
 - intramural hematoma 548–9
 - side-branch ischemia, after EVAR 530

- aortic aneurysms
 - abdominal *see* abdominal aortic aneurysms
 - ascending, catheters for PCI 72–4
 - coarctation with, covered stents 654–5
- aortic arch, type III 564, 565
- aortic dissection
 - ascending, PCI catheters 72–4
 - complex renal artery stenting 549
 - extending to carotid artery 555, 574, 575
 - iatrogenic
 - from coronary artery 359, 359–61
 - from iliac artery 24
 - from renal artery 548–9
 - left main compression, AMI with 286–7
 - spontaneous 360
- aortic regurgitation 215, 499
- aortic root, angiography 492–3, 493, 494
- aortic stenosis
 - balloon aortic valvuloplasty 476, **476–7**
 - CABG and PCI 416
 - recurrent 485
 - transcatheter aortic valve implantation 491–2
 - ventricular assist devices 414
- aortic valve
 - crossing 479–80, 496, 497
 - cuspid perforation (CP) 483–4
 - measuring annulus 491–2, 492
- aortic valve implantation, transcatheter (TAVI) 416, 487–500
 - complications 498–500
 - left main occlusion after 203–4
 - patient selection 491
 - pre-procedure evaluation 491–5, 492, 493, 494
 - procedure 495–8, 497
 - prostheses 488, 488–90, **489**, 490
 - vascular access 490–1, 495–6
- aortic valvuloplasty *see* balloon aortic valvuloplasty
- aortic wrap technique 533
- aortography
 - abdominal 493–5, 494, 525, 538–9, 539
 - ascending 72–3, 556
 - coarctation 651, 651
 - aortoiliac disease 579–600
 - evaluation 580–1, 582
 - interventions 582–93
 - see also* iliac artery
 - aorto-ostial lesions
 - saphenous vein grafts 297
 - stenting 260, 260–3
 - watermelon-seeding effect 259
 - see also* ostial lesions
 - aorto-subclavian tortuosity, transradial approach 154–5, 155
 - arterial grafts, coronary, PCI 300–3
 - arterial injuries, iatrogenic
 - femoral approach 14–24
 - transcatheter aortic valve implantation 498, 499
 - transradial approach 164, 164–5, 166
 - see also* coronary artery dissection; coronary artery perforation
 - arterial pressure, dampening 56, 67–8
 - arteria lusoria 155–6, 156
 - arteriovenous fistulas (AVFs)
 - coronary steal syndrome with 513–14
 - femoral 15
 - subclavian 512
 - ASD *see* atrial septal defects
 - aspiration thrombectomy devices
 - acute STEMI 278, 281, 281–2
 - saphenous vein graft thrombus 307–8
 - aspirin 307, 362, 556
 - asystole 395
 - atherectomy
 - complications 626
 - directional coronary (DCA) 321–2
 - excisional 611
 - femoropopliteal disease 611–12
 - infrapopliteal disease 619
 - rotational *see* rotational atherectomy
 - atherotomes *see* cutting balloons
 - Atlas PTA dilation balloon 481
 - atrial fibrillation, STEMI and 286
 - atrial septal defects (ASD)
 - 631–40
 - closure devices 631, **632**, 632–3
 - selecting size 636, 637
 - selecting type 636–7

- atrial septal defects (ASD) (*Contd.*)
 - device closure 631–40
 - contraindications 632
 - ICE-guided procedure 637, 637–40, 639, 640
 - indications 631
 - pulmonary hypertension 640
 - post-procedure assessment 639–40
 - preprocedure evaluation 633–5, 634, 635, 636
 - secundum 631, 633, 634, 635
 - atrial septum
 - catheter entrapment at 464–5, 465
 - minimizing injury, mitral valvuloplasty 466–7
 - puncture *see under* transeptal access
 - atrioventricular (AV) block, postprocedural 499–500
 - atropine 274–5, 558
 - axillary artery
 - anatomy 8–9, 9
 - cannulation 8–9, 10
 - balanced force transmission 88
 - Balanced middle weight (BMW) wires 92, 93
 - balloon(s) 106–15
 - advancement 108–9
 - aortic valvuloplasty 481
 - buddy *see* buddy balloon technique
 - coarctation 651–2
 - compliant 107
 - cutting *see* cutting balloons
 - embolic protection *see* occlusive embolic protection devices
 - entrapment during withdrawal 113–14
 - failure to cross lesion 108
 - failure to deflate 112–13
 - fixed wire 106
 - guide stabilization 78, 216, 218
 - hand crimped, covered stents 138
 - inflation 109–10
 - aortic valvuloplasty 480, 481
 - checking adequacy 110, 110
 - checking for collaterals 110
 - cutting balloons 114–15
 - kissing *see* kissing balloon inflation
 - mitral valvuloplasty 458–67
 - post-stent *see* stent(s), balloon expansion
 - pre-stent *see* balloon angioplasty, pre-stent speed 110
 - infrapopliteal interventions **622**
 - length 107–8
 - lubrication 341
 - markers 107
 - monorail 106, 108
 - non-compliant 107
 - positioning 109, 109
 - predilation *see* balloon angioplasty, pre-stent
 - pressure–volume relationship 461
 - proximal deflecting, stent advancement 124
 - pushability 106
 - removal of embolized stents 428–9
 - rupture
 - damage control 114
 - due to material fatigue 113
 - repeated 114
 - in stented area 137
 - sizing 106–7
 - angiographic views 40–1, **42, 42**
 - mitral valvuloplasty **450, 450–1, 461–3, 462**
 - tamponade
 - bleeding peripheral artery 18–19, 600
 - coronary perforations 369–70, 372, 381–2
 - trackability 106
 - wire immobilization 100, 101
 - wire tip deflection 96–9
 - see also* balloon angioplasty; balloon catheters; over-the-wire (OTW) balloons
- balloon-anchoring techniques
 - acute left main occlusion 204
 - advancing balloon into side branch 340–1
 - chronic total occlusion 243
 - guide stabilization 78, 216, 218
 - stenting distal left main 202–3
 - balloon angioplasty 105–16
 - advancing, positioning and inflating balloon 108–11
 - balloon entrapment 113–14
 - balloon rupture 113, 114
 - balloon selection 107–8
 - bifurcation lesions 320–1, 342

- calcified lesions 112
- carotid artery 571
- chronic total occlusions 238–9
- coarctation 649–55
- coronary perforation 372
- cutting *see* cutting balloon angioplasty
- failure to deflate balloon 112–13
- failure to dilate lesion 111–12
- femoropopliteal disease 610–11, 612
- force-focused 111–12
- large vessels 112
- post-stent *see* stent(s), balloon expansion
- pre-stent (predilation) 126
 - aortic coarctation 655
 - bifurcation lesions 320–1
 - carotid artery disease 557–8, 571
 - coronary ostial lesions 259
 - iliac artery stenosis 583–4
 - preventing dissection 357
 - renal artery stenosis 544
 - subclavian artery 507
- saphenous vein grafts 299
- subclavian artery 507, 508–9
- without stenting *see* plain old balloon angioplasty
- balloon aortic valvuloplasty (BAV) 475–85
 - balloon manipulation 480–2
 - deflation 481–2
 - inflation 480, 481
 - preparation 480
 - catheter manipulation 479
 - crossing aortic valve 479–80
 - indications 476, **476–7**
 - low cardiac output 478–9
 - management of hypotension 482–4
 - post-procedure management 484–5
 - sheath removal 484
 - standard technique 477
 - temporary pacemaker 477
 - transcatheter aortic valve implantation 496–7
 - vascular access 478
 - wiring 480
- balloon : artery ratio 106–7, 369
- balloon catheters
 - exchanging, over regular-length wire 100–1, 110–11
 - mitral valvuloplasty 450–3
 - advancement 451–3, 454
 - bent tip 467, 467
 - controlled stepwise dilations 461–7
 - crossing the mitral valve 453–7, 455–6, 458
 - entrapment in septum 464–5, 465
 - exchanging different sized 463–4
 - pretesting for balloon–syringe mismatch 451
 - selection **450**, 450–1
 - sizing **450**, 450–1, 461–3, **462**
 - see also* balloon(s)
 - balloon compression sign, mitral valvuloplasty 460, 460
 - balloon impasse, mitral valvuloplasty 460, 461, 463
 - balloon mitral valvuloplasty (BMV)
 - see* Inoue balloon mitral valvuloplasty
 - balloon popping sign, mitral valvuloplasty 464
- Barbeau catheter 153, 153, **154**
- Barbeau test 143
- below-the-knee interventions *see* infrainguinal/infragenicular interventions
- Bentali procedure 289
- bifurcation angles 189, 317, 322–3, 323
- bifurcation lesions 313–44
 - balloon angioplasty 320–1, 342
 - carina shift 315, 316
 - directional atherectomy 321–2
 - distal protection devices 305–6
 - guides 318
 - intervention strategies 315–16, 317–18
 - kissing balloon formulae 321, 321
 - kissing balloon inflation (KBI) 327, 328, 342–3
 - left main 189–204
 - lesion preparation 319–22
 - renal artery 546
 - side branches *see* side branches (SB), coronary
 - stenting 322–36, 327
 - crush technique 193–5, 330
 - culotte technique 200, 201, 327, 335–6
 - double-kiss crush technique 195, 196, 197, 330–2, 332
 - flower petal technique 343

- bifurcation lesions (*Contd.*)
 - mini-crush technique 193–5, 194–5, 330, 331
 - provisional left main 191, 191–2
 - provisional side branch 324–5
 - proximal optimization technique 324, 324
 - reverse crush technique 332–3
 - simultaneous kissing technique 196–200, 199, 333–5
 - stent selection 323, 323–4
 - step-crush stenting 195–6
 - strategies 189–91, 190
 - T stenting 192, 192–3, 325–30
 - V stenting 196–8, 197, 327, 333, 334
- T-angle 189, 190, 323
- transradial approach 163
- wires 318–19, 336–40
- Y-angle 189, 190, 323
- biopsy forceps 434
- bivalirudin 285, 286, 374
- bleeding, PCI for STEMI patients with 285–6
- blindness, transient and permanent 393–4
- body floss technique, iliac artery 593, 594–9
- both hands maneuver, chronic total occlusion 228
- brachial artery (BA), transradial approach 152, 152, 154
- brachial artery access 8
 - carotid procedures 559, 559
 - iliac artery disease 588–9, 589–90, 593
 - infrainguinal/infragenicular interventions 609–10
 - subclavian artery stenting 504, 510
- brachiocephalic arteries, cannulation 560–1
- bradyarrhythmias/bradycardia 274–5, 395
- Brockenbrough needle 440, 444
- buddy balloon technique 116, 125
 - distal 124
- buddy wire technique 78, 123–4
 - chronic total occlusion 216, 217
- buttock claudication 530
- Button occluder devices 632, **632**
- CABG see coronary artery bypass graft
- calcified lesions
 - balloon angioplasty 112
 - direct stenting 126
 - in-stent balloon rupture 137
- calcium channel blockers see verapamil
- cardiac arrest
 - complicating PCI 394–5
 - primary PCI after resuscitation 288
- cardiac output, low 478–9
- cardiac tamponade
 - aggravating factors 383
 - attenuating factors 383–4
 - atypical presentations 389–92
 - clinical presentation 384–6, 386
 - coronary artery perforation **369**
 - iatrogenic 383–92
 - isolated left atrial compression causing 389–90
 - localized, causing right-to-left shunt 392
 - low pressure 388
 - management 387–8
 - post-infarction 290, 291
 - septal perforation 251, 252
 - with ventricular dysfunction 388
- cardiogenic shock
 - acute occlusion of unprotected left main 277, 277
 - acute periprocedural occlusion 401
 - infarct-related ventricular septal rupture 290–1
 - left ventricular assist devices 413–14
- cardiopulmonary resuscitation (CPR)
 - air embolism 368
 - during PCI 394–5
 - primary PCI after 288
- CardioSEAL device 632, **632**, 639
- carotid artery
 - angiography 556–7, 566
 - anomalous origin 564
 - aortic dissection extending to 555, 574, 575
 - direct puncture 559
 - fibromuscular dysplasia 554
 - iatrogenic perforation and dissection 577, 577
 - occlusive disease 553–77
 - severe kinking 574–6, 576

- spasm 576
- spontaneous dissection 554–5
- see *also* common carotid artery;
 - external carotid artery;
 - internal carotid artery
- carotid procedures 555–77
 - advanced techniques 574–6
 - angiography 566
 - balloon angioplasty 571
 - cerebral protection 566–71
 - checklist 556
 - complications 576–8
 - contraindications 555
 - general measures 558–9
 - guides 560–6, 562, **563**, 563, 564
 - multiwire techniques 564, 565
 - post-stent dilation 574
 - stents 571–4, **572**
 - step-by-step outline 556–8
 - vascular access 556, 559, 559–60
- Carotid Wallstent **572**, 573
- CART technique 245, 245–6
- catheters
 - aortic aneurysms and dissections 72–4
 - aortic valvuloplasty 479–80
 - guide strengthening 79–83, 80, 81
 - thrombectomy 283–4
 - transradial access 152–6, **154**
 - see *also* balloon catheters; guides; microcatheters
- cephalic vein access 162
- cerebral angiography 556, 557
- cerebral hyperperfusion syndrome 577
- cerebral protection devices see distal embolic protection devices
- cerebrovascular accident (CVA) see stroke
- cervical approach, direct carotid puncture 559
- cervical dissection, spontaneous 554–5
- chest radiography, cardiac tamponade 385
- Choice wires 88, **222–3**
- chordae tendinae, mitral valvuloplasty balloon position 459
- chronic total occlusion (CTO) 207–52
 - antithrombotic and anticoagulant 213–14
 - balloon angioplasty 238–9
 - connecting antegrade to retrograde channel 244–50, 245
 - CART technique 245–6
 - double balloon inflation 248–9
 - IVUS-guided re-entry 247
 - knuckle wire technique 248
 - retrograde wire crossing 244–5
 - reverse CART technique 246–7
 - trapping wire technique 248
 - wire crossing technique 247–50
- contralateral injection 210–11
- criteria for terminating intervention 214
- factors influencing success **209**
- guides 215–19
 - selection 215
 - strengthening techniques 216–19, 217, 218
- iliac artery 589–93
- piercing distal cap 232–4
 - retrograde approach 243–4, 244
 - shaping wire tip 231, 232
 - wire selection 232
- piercing proximal cap 220–4
 - drilling strategy 221
 - IVUS guidance 224, 225–6
 - penetrating strategy 221
 - sliding strategy 221–4
 - strengthening/stiffening wire tip 224
- preprocedure evaluation 210–11, 212–13
- re-entering distal true lumen 234–8
 - antegrade subintimal approach 238
 - confirming wire position 236
 - dedicated equipment 237–8
 - IVUS-guided wire re-entry 233, 236
 - minimizing subintimal wiring 235
 - shaping wire tip 235
- retrograde approach 239–52
 - angiography of collaterals 239–40
 - complications 250–2
 - connecting to antegrade channel 244–50, 245
 - crossing the collateral 242, 242–4

- chronic total occlusion (CTO)
 (*Contd.*)
 dedicated equipment 241–2
 factors influencing success
 243–4, 244
 retrograde wire crossing
 244–5
 selection of collateral 240,
 240–1
 wire externalization 249–50
 wire manipulation 241
 strategy for PCI 211–12, 214
 superficial femoral artery
 612–15, 614–15
 transradial approach 163
 using 5-fr guide 182
 traversing length 226–31
 avoiding entry to intima 229
 determining wire location
 228–9
 manipulation of wires 228
 optimal projection angle
 231, 231
 parallel wire method
 229–30, 230
 tracking loose tissue 227
 wire going wrong way 231
 wire selection 228
 vascular access 214–15
 wires 220–38, 221, **222–3**
 clips, vascular closure 10–11
 clopidogrel 307, 362, 556
 coarctation 649–55
 and aneurysm, covered stent
 implantation 654–5
 angioplasty and stenting
 649–55
 balloon and stent positioning
 653
 balloon and stent selection
 651–2
 contraindications 649
 postdilation 654
 post-placement assessment
 654
 sequential dilation 652
 sheath and wire placement
 652–3
 subclavian jailing 653–4
 preprocedure evaluation
 650–1, 651
 pressure gradient measurement
 651, 651, 654
 cogwheel resistance, mitral
 valvuloplasty 461
 coil embolization
 coronary aneurysms 393
 coronary perforation 374–6
 equipment 375
 lacerated small artery 19, 21
 patent ductus arteriosus
 641–2, 645–8
 renal artery perforation 546–8
 collagen plugs
 intra-arterial deployment 13,
 13, 14
 vascular closure 10, 12
 collateral channels 210
 checking for, balloon
 angioplasty 110
 epicardial 240, 240
 retrograde approach via
 239–44
 septal 240, 240
 common carotid artery (CCA)
 cannulation 559, 559, 561
 lesions, carotid access 564–6
 common femoral artery (CFA)
 604
 acute occlusion 15, 16
 antegrade puncture 7–8, 607
 bifurcation 3, 3, 8
 dissection 23
 in vivo bypass 16
 pulseless, puncture technique
 5–6
 see also femoral arterial
 approach
 compartment syndrome
 forearm (CSF) 167–8
 lower limb 627
 volar 165, 167
 complications of PCI 347–95
 computed tomography (CT)
 abdominal aortic aneurysms
 519
 chronic total occlusion (CTO)
 211, 212–13
 subclavian artery disease 503
 transcatheter aortic valve
 implantation 492, 493,
 494, 495
 computed tomography
 angiography (CTA)
 chronic total occlusion 211,
 212–13
 peripheral artery disease
 580–1, 605
 renal artery stenosis 538
 transcatheter aortic valve
 implantation 495
 cone crush-modified T stenting
 193
 Confianza (Conquest) Pro wire
 221, **223**, 228, 231, 231,
 232
 Confianza (Conquest) wire **223**,
 227, 228, 236

- congenital cardiac anomalies 629–55
- Contour Emboli 376
- contrast-induced nephropathy (CIN) 349–52, 530
 - prevention 349–52, **351**
 - risk factors **350**
- contrast media
 - allergic reactions 352
 - MINICON technique 183
 - minimizing volume 350–2
- conus branch (CB), inadvertent cannulation 160–1
- Cook Retained Fragment Retrieval Tool 434
- CoreValve transcatheter heart valve 488–90, **489**, 490, 493, 500
- coronary angiography
 - acute STEMI 270, 271
 - identifying culprit lesion 270, 271, 274, 408
 - missing lesions 41
 - radiation exposure 41–3
 - renal angiography with 539, 539, 540
 - sequences 29–30
 - stenting without 127
 - transcatheter aortic valve implantation 492
 - transradial 143, 145, 152–6
 - views *see* angiographic views
- coronary artery(ies)
 - acute iatrogenic closure *see* acute coronary artery closure, during PCI
 - acute simultaneous proximal occlusion of two major (ASOMC) 289
 - air embolism 367–8
 - infarct-related *see* infarct-related artery
 - intramural hematoma 368
 - no reflow *see* no reflow
 - pseudolesions 92–3
 - side branches *see* side branches (SB), coronary
 - single (SCA) 43
 - threatened closure, during PCI 353–62
 - tortuous 93, 126
 - see also specific arteries*
- coronary artery aneurysms (CAA) 392–3
 - AMI 288–9
 - coil embolization 393
 - covered stents 138–9, 392–3
 - with bare metal stents 392–3
 - preventing in-stent restenosis 393
 - with stenosis, wiring 92
- coronary artery anomalies 43–9
 - angiography 43–9
 - anterior course 43, 44, 46–7
 - guides 74–7, **76**
 - interarterial course 43, 44, 47, 48
 - mechanism of ischemia 48
 - retroaortic course 43, 44, 44–5, 46, 47
 - septal course 43, 44, 46, 47
- coronary artery bypass graft (CABG) surgery
 - acute STEMI shortly after 308–9
 - aortic stenosis, PCI with 416
 - early postoperative ischemia 295
 - emergency
 - acute STEMI 272
 - coronary perforation 382
 - spontaneous coronary artery dissection 288
 - trapped cutting balloons 116
 - indications for reoperation 295–6
 - interventions after 293–310
 - arterial grafts 300–3
 - coronary perforation 372, 373
 - distal embolization treatment and prevention 303–6
 - indications 295–6
 - native coronary arteries 296
 - safety 295
 - vein grafts *see* saphenous vein grafts
 - late postoperative ischemia 295
 - minimally invasive (MIDCAB), with PCI 415–16
- coronary artery disease (CAD)
 - aortoiliac disease and 580, 582, 585
 - bifurcation lesions *see* bifurcation lesions
 - chronic total occlusion *see* chronic total occlusion
 - multivessel *see* multivessel coronary artery disease
 - ostial lesions *see* ostial lesions, coronary
 - percutaneous intervention *see* percutaneous coronary intervention

- coronary artery disease (CAD)
 - (*Contd.*)
 - renal artery stenosis and 539, 539, 540
 - see also acute coronary syndromes; acute myocardial infarction
- coronary artery dissection
 - 353–61
 - antegrade propagation 353, 354
 - classification 355, 355
 - differential diagnosis 356, **356**
 - left main 353, 354, 358–9
 - management 356–61, **358**
 - no-reflow phenomenon 366
 - prevention 357, 361
 - retrograde aortic dissection 359, 359–61
 - retrograde propagation 353
 - spontaneous (SCAD) 287–8, 288
- coronary artery perforation
 - 368–82
 - classification **369**, 370
 - differential diagnosis 290
 - management 372–82, 394
 - balloon inflation 369–70, 372, 381–2
 - CABG surgery 382
 - coil embolization 374–6
 - covered stents 370, 372–3, 374, 375, 377, 378–81, 381–2
 - distal end 381
 - proximal and mid-segment 372–7
 - reversal of anticoagulation 370, 373–4
 - strategies 369–70, 371
 - switching balloon technique 377, 378–81
 - prevention 371–2, 382
 - risk factors 369
- coronary artery thrombosis
 - acute closure, during PCI 361–2
 - no reflow 365
 - primary PCI 280–5
 - avoiding embolization 282, 282–3, 283
 - catheter aspiration 281, 281–2
 - stent-related 128, 130, 362, 363
 - see also acute myocardial infarction
- coronary sinus, avoiding, septal puncture 449
- coronary stenting
 - acute occlusion after 362
 - acute STEMI 272–3
 - bifurcation lesions see bifurcation lesions, stenting
 - left main bifurcation lesions 189–203
 - ostial lesions 259–66
 - preventing dissection 356
 - preventing perforation 372
 - see also stenting
- coronary stents
 - bifurcation lesions 200, 323, 323–4
 - crossing, to enter side branches 201–2, 337–9, 338, 339
 - distortion, bifurcation lesions 324, 342–3
 - embolized 421–32
 - damage control 431–2
 - deployment 431–2
 - hairpin-trap technique 428, 430
 - loop snaring technique 426–8, 427, 428, 429
 - no treatment option 421–2
 - prevention 422–3
 - removal with balloon 428–9
 - removal with snares 423–8, 424, 426
 - removal with two wires 429–31
 - risk factors 422
 - extraction by cutting balloon 266
 - fractures 363, 363
 - lubrication 341
 - luxation, during SVG aneurysm exclusion 309
 - ostial lesions 262–3
 - stent: artery ratio 263, 273
 - see also stent(s)
- coronary–subclavian steal syndrome 502, 503
 - with arteriovenous fistula 513–14
 - intervention 510–11, 511
- corrected TIMI frame count (CTFC) 275, 275–6
- Corsair microcatheter 239, 241–3, 249, 250
- coumadin 286
- covered stents 137–9
 - aortic coarctation with aneurysm 654–5
 - balloon expanded 375
 - coronary aneurysms 138–9, 392–3

- coronary perforations 370, 372–3, 374, 375, 377, 378–81, 381–2
- hand crimping 138
- improvised 373
- perforated small artery 22
- renal artery aneurysm 549–50
- renal artery rupture 546
- CP stents 655
- Cristallo ideale stent **572**, 574
- critical limb ischemia (CLI) 604, 605, 618–19
- Cross-It wires **222**, 227, 613, 615, **622**
- Crosswire EX **223**
- Crusade microcatheter 94–6, 97, 339
- crush technique, bifurcation stenting 193–5, 330
 - reverse 332–3
 - see *also* double-kiss crush technique; mini-crush technique
- cryoplasty, endovascular 611–12
- CT see computed tomography
- CTO see chronic total occlusion
- culotte stenting 327, 335–6
 - left main bifurcation lesions 200, 201
- cuspl perforation (CP), aortic valve 483–4
- cutting balloon angioplasty 114–15
 - jailed side branch ostial lesion 265
 - ostial lesions 259
- cutting balloons (CB) 114–16
 - blade entrapment 115–16
 - inadvertent stent extraction 115, 266
- daughter-in-mother technique see mother-and-child techniques
- deep circumflex iliac artery 20
- deep-seating maneuver see guides, deep seating
- deep vein thrombosis, lower extremity 624–5, 625
- dextrocardia 74
- diagonal arteries
 - angiography 32, 32, **33**, 35
 - high-risk PCI 405
- digital subtraction angiography (DSA)
 - peripheral artery disease 581, 606
 - renal artery stenosis 538–9
- directional coronary atherectomy (DCA) 321–2
- distal buddy balloon technique 124
- distal embolic protection devices
 - in a 5-fr guide 182
 - carotid procedures 557, 558, 566–71
 - complications 577–8
 - removal 558
- femoropopliteal interventions 617–18
- post-CABG interventions 279, 279, 303, 304–6
 - bifurcating 305–6
 - improvised 304, 305
 - no flow 304–5
 - pros and cons 297–8
 - selection 304
 - technical problems 305
- renal artery stenting 542–4, 543, 544
- subclavian stenting 506, 506–7, 509
- distal embolization
 - carotid procedures 566, 576
 - infringuinal/infragenicular interventions 627
 - PCI 282, 282, 393–4
 - post-CABG interventions 303–6
 - renal artery stenting **547**
- distal vascular bed dysfunction 366
- dobutamine 478–9
- dottering technique
 - primary PCI 280, 282
 - recrossing a stented area 129–30
- double balloon inflation technique 248–9
- double-kiss crush technique 330–2, 332
 - left main bifurcation lesions 195, 196, 197
- double-lumen catheters, wiring side-branches 94
- dual-guide technique
 - coronary perforation 377
 - IMA grafts 302
 - ostial lesions 258
- Eaucath guide catheter system, sheathless 146
- EBU guides see extra backup (EBU) guides

- ECG
 intracardiac 395
 multivessel disease 408
- echocardiography
 cardiac tamponade 385–6,
 386
 coarctation 650
 guided pericardiocentesis 387
 intracardiac *see* intracardiac
 echocardiography
 mitral valve disease 459
 patent ductus arteriosus 642
 transcatheter aortic valve
 implantation 491–2, 492
 transesophageal *see*
 transesophageal
 echocardiography
- Ehlers–Danlos syndrome 555
- embolic protection devices (EPDs)
 distal *see* distal embolic
 protection devices
 femoropopliteal interventions
 617–18
 proximal, post-CABG
 interventions 303–4
- embolization
 coil *see* coil embolization
 distal *see* distal embolization
 with particle agents, coronary
 perforations 376–7
 retrograde, during primary PCI
 283, 283
 stent *see* stent(s), embolized
- embolized materials 419–35
 coronary stents *see* coronary
 stents, embolized
 fractured wires 432–3
 hairpin-trap technique 428,
 430
 loop snaring technique 426–8,
 427, 428, 429
 management options 421
 removal from iliac artery
 433–5
- Emboshield RX device **567**
- endografts *see* endovascular
 (EVAR) stent-grafts
- endoleaks 526–9
 management 533–4
 predictors 528–9
 type I 526, 527
 type II 526–7, 528
 type III 527, 528
- EndoReflex nitinol clips 532–3
- endovascular (aortic) aneurysm
 repair (EVAR) 517–34
 anesthesia preparation 523
 complications 526–31
 contraindications 520
 equipment 523–5, 531, 532–3
 patient selection 519, 520
 postoperative treatment 526
 preoperative evaluation
 519–23
 techniques 525–6, 531–2
 vascular access 523
see also abdominal aortic
 aneurysms
- endovascular cryoplasty 611–12
- endovascular (EVAR) stent-grafts
 (endografts) 523–5, 531
 bench testing 531
 distal attachment site 523
 investigational 532–3
 limb occlusion 529
 migration 529
 proximal attachment site 521,
 522, 531
- endowedge technique 532
- Endurant stent graft system 521
- epicardial arteries, iatrogenic
 perforation 369
- epicardial collaterals 240, 240
 retrograde approach via 241
- epinephrine 352, 366
- EVAR *see* endovascular (aortic)
 aneurysm repair
- excimer laser plaque debulking
 611
- Excluder AAA endoprosthesis
 524, 531, 532
- exercise testing 580
- Export catheter 284
- external carotid artery (ECA)
 catheterization 556–7, 564
 occlusion, carotid access
 564–6
 stenting 574
- extra backup (EBU) guides 55,
 66, 67
 chronic total occlusion 215
 coronary anomalies 75, 76
 selection 68–9, 69, 70
 strength 77
 transradial approach 158, 162
- false lumen technique, chronic
 total occlusion 233, 236
- femoral arterial approach 2–8
 abdominal aortic aneurysms
 523
 antegrade puncture 7–8,
 607–9, 608
 aortic dissection 72
 aortic valve interventions 478,
 490, 495–6
 carotid procedures 556
 chronic total occlusion 214–15

- complications 14–24, 143, 625–6
- IABP insertion in iliac artery disease 6–7
- ideal puncture location 2, 3
- iliac artery disease 582, 583, 593
- infrainguinal/infragenicular interventions 606–9
- internal mammary artery grafts 300
- micropuncture technique 3–6
 - angiographic checks 3, 4
 - directing the needle 4–5
 - kinked wire 5
 - pulseless femoral artery 5–6
 - venous puncture before/after 5
 - wire insertion problems 5
- obese patients 4, 7
- renal artery stenting 541, 542
- subclavian artery interventions 510
- two catheters via one puncture 7
- femoral artery
 - acute thrombosis/occlusion 15–16, 16, 615, 616
 - angiography 4, 493–5, 494
 - dissection 23–4
 - in vivo bypass 16
 - pseudoaneurysms 22–3
 - see also common femoral artery; superficial femoral artery
- femoral bypass graft, puncture 6
- femoral neuropathy, retroperitoneal hematoma 17–18, 166
- femoral vein access
 - before/after arterial puncture 5
 - Inoue balloon mitral valvuloplasty 440, 451–2
 - preclosure with Perclose device 11–12
 - transeptal approach 10, 444
- femoropopliteal bypass graft, acute occlusion 616
- femoropopliteal disease
 - acute occlusions 615
 - atherectomy 611–12
 - balloon angioplasty 610, 612
 - chronic total occlusion 612–15, 614–15
 - complications of interventions 625–7
 - embolic protection devices 617–18
 - evaluation 605–6
 - stenting 610, 612
 - subintimal angioplasty 610–11
 - vascular access 606–10
- FemoStop device 14, 22, 484
- fibromuscular dysplasia (FMD) 547, 554
- Fielder wires 94, 221, 242
- filter devices, distal embolic **567**
 - carotid interventions 566–8, 567, 568
 - difficult retrieval 578
 - femoropopliteal interventions 617–18
 - full basket 618
 - post-CABG interventions 298, 303, 304–5
 - renal artery stenting 542–4, 543, 544
 - subclavian artery stenting 506, 506–7
- Filterwire devices 279, 542, **567**, 567, 568, 617–18
- final kissing inflation (FKI) 193, 197, 198
- Finnet formula, kissing balloons 321
- five-in-six guide strengthening techniques 79–82, 80, 217–19
- flower petal stenting technique 343
- fluoroscopy
 - abdominal aortic aneurysm repair 525–6
 - femoral arterial micropuncture 3–6
- force-focused angioplasty 111–12
- forearm, compartment syndrome in (CSF) 167–8
- fractional flow reserve (FFR), renal 540–1
- frictional force (λ) 172, 172, 173, 176
- gastrointestinal bleeding, AMI with 285
- Glidecath 510, 582, 593
- Glidewire 513, 514, 565, 592, 593, 613
- glycoprotein IIb/IIIa inhibitors (GPIs)
 - acute coronary syndromes 285, 403
 - chronic total occlusions 213–14
 - no-reflow phenomenon 366

- glycoprotein IIb/IIIa inhibitors (GPIs) (*Contd.*)
 - reversal, coronary perforation 373
 - saphenous vein graft thrombus 307
 - transradial approach 168
- GooseNeck Amplatz Microsnare catheter 423, 426–7
- Gore Neuro Protection System 568–70, **569**, 569
- grandma–mother-and-daughter technique 82
- Guardian Angle device **632**
- GuidLiner catheter 79–82, 80, 81, 146
- guides 51–84
 - active support maneuvers 70–2
 - angle with aortic wall (θ) 77, 171–2, 172, 173–5
 - aortic aneurysms and dissections 72–4
 - arterial pressure dampening 56, 67–8
 - backup mechanics 77, 171–7
 - bifurcation lesions 318
 - carotid procedures 560–6, 562, **563**, 563, 564
 - changing, with wire across lesion 83–4
 - chronic total occlusion 215–19
 - coaxial alignment 56
 - contact area with opposite aortic wall 77, 173, 176
 - coronary anomalies 74–7, **76**
 - coronary ostial lesions 256–8
 - deep seating
 - chronic total occlusion 216–17, 217
 - mechanics 172, 175
 - technique 68, 77–8
 - design 54–5
 - difficult engagement 77
 - double 61–2
 - entrapped cutting balloons 116
 - external diameter and ostial obstruction 56, 57
 - frictional force (λ) 172, 172, 173, 176
 - internal diameters 57–60, **60**
 - internal mammary artery (IMA) 300–1
 - LAD lesions 68
 - large, safe use 61
 - LCX lesions 68
 - left main lesions 66–8
 - left main ostium entry 55–6
 - manipulations 55–62
 - during PCI 77–84
 - safety measures 55
 - ostial stented lesions 61
 - RCA lesions 70–2
 - renal artery stenting 541–2
 - saphenous vein grafts 299
 - selection 62–72
 - shaping 61
 - shortening 57, 58–9
 - side holes 60–1
 - size, and backup force 77, 173–4
 - stent advancement 122
 - stent retraction into 434
 - strength, factors influencing 77, 171–4
 - strengthening/stabilizing techniques 77–83, 80, 81
 - chronic total occlusion 216–19
 - ostial lesions 260–1, 261
 - subclavian artery stenting 505, 505, 506
 - suctioning embolic material 304
 - support 62
 - tip extension 79
 - too long 56–7
 - tortuous iliac artery 55
 - transradial intervention 157–9
 - backup mechanics 171–9
 - twisted, untwisting method 84
 - wide ascending aorta 61
 - see also specific types*
- Guidewire GT **223**
- hand ischemia, acute 167
- heart block, complete 405, 477, 500
- heart failure
 - left ventricular assist devices 413–14
 - see also* left ventricular (LV) dysfunction
- Heartrail catheters 79, 80, 82, 217–18, 284
- Helix device 632, **632**, 639
- hematomas
 - aortic intramural 548–9
 - arterial access site 14–15, 164
 - compressive, causing tamponade 389, 390
 - coronary intramural 368
 - distant 165
 - septal 241
 - subepicardial, fatal dissecting 390–1
 - under tension 165
 - see also* retroperitoneal hematoma

- heparin
 - acute femoral artery thrombosis 15
 - acute STEMI 285, 286, 308
 - chronic total occlusions 214
 - coarctation repair 655
 - Inoue balloon mitral valvuloplasty 450
 - reversal, coronary perforation 370, 371
 - saphenous vein graft thrombus 307
 - transradial approach 145
- high-risk and complex PCI 399–416
 - acute coronary syndromes 403–4, 410–11
 - AMI 270–1, 272, 410–11
 - exotic complex interventions 415–16
 - left ventricular assist devices 403, 411–15
 - left ventricular dysfunction 402–3
 - modifying the risk factors 402–15
 - multivessel disease 404–10
 - precautionary strategies 401
 - risk factors 400, 401
- High Torque wires **222**
- hockey-stick guides 299
- horizontal M-line, transeptal puncture 440, 443, 444
- hydration, peri-procedure 349–50, **351**
- hydrocortisone sodium succinate 352
- hydrophilic wires 88–9
- hypertension, renovascular 538, 540
- hypogastric artery (HA) exclusion 530
- hypotension
 - acute guide-induced 215
 - balloon aortic valvuloplasty 482–4
 - cardiac tamponade 384
 - perforated saphenous vein graft 309
 - transcatheter aortic valve implantation 498–9
 - transient, primary PCI 274–5
- IABP *see* intra-aortic balloon pump
- iCAST covered stent 375
- ICE *see* intracardiac echocardiography
- Ikari F-type guide 174, 176
- Ikari left (IL) guide 174–7, 179–81
 - backup mechanics 174–5, 176–7
 - engagement 177
 - power position 181, 181
 - right coronary artery 178–9, 180, 181
- Ikari right (IR) guide 177–9, 180, 181
- iliac artery
 - acute or subacute occlusion 599, 600, 601
 - chronic total occlusions (CTO) 589–93
 - body floss technique 593, 594–9
 - the challenge 591–2, 592
 - diagnostic angiography 590–1, 591
 - using stiff end of wire 593, 597
 - dissection 23–4, 599
 - perforation/rupture 599, 600, 600
 - removal of embolized material from 433–5
 - stenosis 579–600
 - evaluation 580–1, 582
 - IABP insertion 6–7
 - interventions 582–9
 - stenting 582–9
 - balloons 583–4
 - brachial access 588–9, 589–90
 - complications 594–600
 - kissing stent 586–8, 587–8
 - stent positioning 584–6, 584–8
 - vascular access 582, 583
 - wires 582–3
 - zigzag wire technique 589, 591
 - tortuous, guide advancement 55
- iliofemoral angiography 493–5, 494
- image intensifier, guidelines for moving 28–32, **29, 40**
- Impella Recover devices 413–14
- infarct-related artery (IRA) 270, 271
 - crossing the lesion 280
 - identifying 274
 - thrombus management 280–3
 - unprotected left main as 277, 277
 - verifying wire position in true lumen 280–3

- infections, vascular entry site
165
- inferior epigastric artery 2, 3
balloon closure 18–19
coil embolization 21
laceration 18–19, 20
- Infiniti Diagnostic Catheter
146
- infringuinal/infragenicular
interventions 603–27
complications 625–7
embolic protection devices
617–18
evaluation 605–6
vascular access 606–10
see *also* femoropopliteal
disease; infrapopliteal
disease
- infrapopliteal disease 604,
618–23
angioplasty and stenting
619–23
atherectomy 619
complications of interventions
625–7
equipment 622, **622**
pedal plantar loop technique
622, 623
popliteal and pedal access
619–20, 620–1
rotational atherectomy 623,
624
- innominate artery
stenting 509
tortuosities, transradial
approach 151, 154–5,
155
- Inoue balloon mitral valvuloplasty
(BMV) 437–71
alternative techniques 439
avoiding left atrial appendage
466
balloon catheter advancement
451–3, 454
balloon catheter selection **450**,
450–1
balloon impasse 460, 461,
463
balloon inflation 458–67
accordion maneuver
459–60, 463
balloon popping sign 464
balloon pressure–volume
relationship 461
bent balloon tip 467, 467
catheter withdrawal from
ventricle 466
checking balloon position
458–9
controlled stepwise technique
461–7
exchanging different-sized
balloons 463–4
minimizing septal injury
466–7
signs of subvalvular disease
459–61, 460
subsequent valve crossings
464, 466
balloon sizing **450**, 450–1,
461–3, **462**
catheter entrapment in septum
464–5, 465
contraindications 470–1
crossing mitral valve 453–7
catheter-sliding method
457, 458
direct method 456
optimal stylet position
456–7
posterior loop method 457
stylet reshaping 457
vertical method 453–6,
455–6
indications 468–70
transeptal access see transeptal
access
- in-stent restenosis (ISR)
carotid artery 576
coronary 363
coronary ostial lesions 261,
265
covered stents, prevention 393
renal 548
repeated balloon rupture
114
- interatrial septum see atrial
septum
- Interceptor PLUS 304
- internal carotid artery (ICA)
catheterization 561, 562
severe kinking 574–6, 576
see *also* carotid artery; carotid
procedures
- internal iliac artery, post-EVAR
occlusion 529
- internal mammary artery (IMA)
grafts
angiography 39
challenges for PCI 301–2
dual-guide technique 302
guides 300–1
PCI 300–3
subclavian artery interventions
309, 510–11, 511
subclavian artery stenosis see
coronary–subclavian steal
syndrome

- see *also* left internal mammary artery (LIMA) grafts; right internal mammary artery (RIMA) grafts
- intra-aortic balloon pump (IABP)
 - acute iatrogenic coronary artery closure 356
 - acute STEMI 271
 - indications for use with PCI 191, 402–3
 - insertion via diseased iliac artery 6–7
- intracardiac echocardiography (ICE)
 - atrial septal defect closure 635, 636–7, 637–40, 639–40
 - balloon mitral valvuloplasty 440
- intramural hematoma
 - aortic 548–9
 - coronary 368
- intravascular ultrasound (IVUS)
 - abdominal aortic aneurysms 519
 - aortoiliac disease 581
 - catheters, wire entanglement 101–2
 - chronic total occlusions 224, 225–6, 233, 236, 247
 - left main disease 186
 - renal artery stenosis 541
 - spontaneous coronary artery dissection 287
 - subclavian artery stenosis 504
 - transradial intervention with 5-fr guide 182
 - wiring across stents 100
- ischemia
 - acute hand 167
 - aortic side-branch 530
 - upper extremity 502
 - see *also* lower limb ischemia; myocardial ischemia
- ischemic preconditioning 407
- ISR see in-stent restenosis
- JoStent coronary stent graft system 137
 - coronary aneurysms 138–9, 392
 - coronary perforations 370, 375
- Judkins guide catheters 54, 62–3, 63
 - ostial lesions 256–7
 - transradial approach 152–3, **154**
- Judkins left (JL) guides 54, 67
- aortic aneurysms/dissections 73
- backup force 77, 172, 173–4
 - deep engagement 172, 174
- coronary anomalies 74, 75, **76**
- LAD lesions 68
- LCX lesions 68–9, 69
- rotational Amplatz maneuver 69
- size selection 62–3, 63
- transradial approach 153, 157–8, 162
- Judkins right (JR) guides 70
 - aortic aneurysms/dissections 73
 - coronary anomalies 75
 - engagement 63, 64
 - LIMA grafts 300
 - rotational Amplatz maneuver 71
 - saphenous vein grafts 299
 - transradial approach 158, 162, 177–8, 178, 181
 - wire insertion problems 5
- jugular vein access, balloon mitral valvuloplasty 440
- Kawasaki disease 288–9
- keep it open (KIO) concept, side branches 320, 336
- kilt technique 532
- Kimny catheter 153, 153, **154**, 162
- kissing balloon inflation (KBI) 327, 328, 342–3
 - 5-Fr guides 181–2
 - formulae for balloon sizes 321, 321
 - main vessel and side-branch stent distortion 342–3
 - unsatisfactory results 343
- kissing stent technique
 - aortoiliac disease 586–8, 587–8
 - see *also* simultaneous kissing stent (SKS) technique
- knuckle wire technique (KWT) 248
- kyphoscoliosis 443
- LAD see left anterior descending artery
- laser angioplasty, unexpanded stents 134
- laser atherectomy, femoropopliteal disease 611, 626
- lateral view 35
- Launcher **60**, 162
- LCA see left main coronary artery

- LCX *see* left circumflex artery
- left anterior descending artery (LAD)
- angiography 29, 31–2, 32, **33**, 34–6
 - anomalies 43, 45–6
 - balloon or stent sizing 41, **42**
 - chronic total occlusion 215, 225
 - guide selection 68
 - ostial lesions 255, 261
 - proximal lesions 405
 - stenting
 - at bifurcation 189, 190, 191–202
 - with high flow LIMA 127
 - transradial approach 158
 - wiring 90–1
 - see also* bifurcation lesions
- left anterior oblique (LAO) view
- caudal (spider) 31, 33, 35–6, 36, 37
 - cranial 31, 32, 32, 33, 34–5
 - right coronary artery 37–8
 - steep cranial 35, 41–3
- left atrial appendage thrombus 466, 471
- left atrium (LA)
- balloon catheter placement 453, 454
 - balloon popping sign, mitral valvuloplasty 464
 - compression, causing tamponade 389
 - confirming entry into 450
 - giant, transeptal access 443, 447
 - perforation 383
 - thrombus 471
- left circumflex artery (LCX)
- anchoring balloon in, distal LM stenting 202–3
 - angiography 28–9, 30, 30–1, **31**, 36–7
 - anomalies
 - angiography 43, 44–5, 45
 - guides 75, 76, **76**
 - balloon or stent sizing 41, **42**, 42
 - bifurcation stenting 189, 190, 191–202
 - chronic total occlusion 215
 - dissection, iatrogenic 353, 354
 - guide selection 68
 - ostial lesions 255, 261
 - transradial approach 158
 - wiring 90, 91
 - see also* bifurcation lesions
- left internal mammary artery (LIMA) grafts 300–3
- angiography 39, 127
 - cannulation 300
 - challenges for PCI 301–2
 - dissection 353, 357
 - dual-guide technique 302
 - guide 301
 - LAD stenting 127
 - pseudo-lesions in tortuous 302–3
 - subclavian artery interventions 510–11, 511
 - transradial approach 162, 300
- left main coronary artery (LM or LCA) 185–204
- acute occlusion
- aspiration thrombectomy causing 284
 - transcatheter aortic valve replacement 203–4
 - unprotected disease, primary PCI 277, 277
- angiography 31, 32–4, **34**, 36, 67, 186
- anomalies
- angiography 43, 46–8, 47, 48
 - guides 74, **76**
- bifurcation stenting 189–203
- anchoring balloon in LCX 202–3
 - crossing stent to enter side branch 201–2
 - crush and mini-crush
 - technique 193–5, 194–5
 - culotte technique 200, 201
 - debulking before 202
 - double-kiss crush technique 195, 196, 197
 - modified T stenting 193
 - provisional 191, 191–2
 - proximal optimization technique 200
 - removal of jailed wire 200
 - simultaneous kissing
 - technique 196–200, 199
 - stent selection 200
 - step-crush technique 195–6
 - strategies 189–91, 190
 - T stenting 192, 192–3
 - V stenting 196–8, 197
 - which branch to stent first 202
- disease/lesions 186
- assessing risk 186–7
 - catheter position 67
 - catheter selection 66–8
 - dampening pressure 67–8

- dissection, iatrogenic 353, 354, 358–9
- guide entry technique 55–6
- guide mechanism 171–7
- IABP indications 191
- left ventricular assist device for PCI 203
- mid-shaft lesions 187
- ostial lesions, stenting 187–8, 188
- reconstructed prosthetic, PCI 289–90
- thrombectomy, primary PCI 278
- transradial approach
 - catheters 153, **154**
 - guides 157, 157–8, 171–7, 172–7
 - ostial cannulation 160, 161–2
- left radial approach (LRA) 145
- left ventricle (LV), perforation 383
- left ventricular assist devices (LVAD) 356, 411–15
 - infarct-related ventricular septal defects 291
 - left main PCI 203
 - technical tips 414–15
- left ventricular (LV) dysfunction
 - after balloon aortic valvuloplasty 484
 - after pericardiocentesis 389
 - ASD device closure 632
 - contraindicating PCI 403
 - high-risk PCI 400, 401, 402–3
 - tamponade with 388
- leg fracture, bleeding, AMI with 285
- lidocaine 478
- LIMA grafts *see* left internal mammary artery (LIMA) grafts
- LIMA guide 300, 302
- LM *see* left main coronary artery
- local anesthesia 478
- loop snaring technique 426–8, 427, 428, 429
- lower limb
 - compartment syndrome 627
 - deep vein thrombosis 624–5, 625
- lower limb ischemia
 - acute 15–17, 615, 616
 - critical (CLI) 604, 605, 618–19
- Mach 1 guide **60**, 161
- magnetic resonance angiography (MRA)
 - carotid artery disease 566
 - coarctation 650
 - peripheral artery disease 581, 605–6
 - renal artery stenosis 538
- magnetic resonance imaging (MRI)
 - compatible aortic stents 652
 - patent ductus arteriosus 643, 644
 - subclavian artery disease 503
- magnification artifacts, coronary angiography 40–1, **42**, 42
- Magnum wire **223**
- Marfan syndrome 289–90, 555
- mesenteric ischemia 530
- microcatheters
 - aiding wire advancement 93
 - embolization of coronary perforations 376, 377
 - side-branch entry across stents 338
- microcoil embolization
 - coronary perforations 376
 - lacerated small artery 19, 21
 - see also* coil embolization
- MIDCAB (minimally invasive coronary artery bypass), with PCI 415–16
- mini-crush technique 330, 331
 - left main bifurcation lesions 193–5, 194–5
- minimum contrast (MINICON) technique 183
- Miracle Brothers wires 221, **223**, 224, 228, 232, 235, 236
- mitral regurgitation
 - postprocedural 458–9, 460, 461, 462, 464
 - preexisting 451, 462, **462**, 471
- mitral stenosis 468–71
 - bioprosthetic valves 470
 - double-orifice (DOMV) 468–70, 469–70
- mitral valve
 - calcified **462**, 462–3, 468
 - crossing, with balloon catheter 453–7, 455–6, 458
 - subvalvular disease 459–61, 460, 462–3, 468
- mitral valvuloplasty *see* Inoue balloon mitral valvuloplasty
- Mitsudo formula, kissing balloons 321, 321
- MO.MA device 568, **569**, 571, 571
- monorail balloons 106, 108
- mother-and-child techniques 79–82, 80, 217–19

- MRI see magnetic resonance imaging
- Mullins sheaths 440, 655
- multipurpose (MP) guides 54–5, 66
- coronary anomalies 74, 75, 76
 - saphenous vein grafts 299
 - selection 68
 - subclavian artery stenting 505, 505
 - transradial approach 153, 153, **154**, 158
- multivessel coronary artery disease (MVD) 404–10
- AMI with 411, 412
 - evaluation of lesions 408–10
 - lesions safe to dilate first 405–7
 - lesions with highest risk 404–5
 - renal angiography 539, 539
- multiwire techniques, carotid procedures 564, 565
- Murray formula, kissing balloons 321
- Mynx vascular closure device 10, 12
- myocardial infarction (MI)
- acute (AMI) see acute myocardial infarction
 - previous, unstable angina with 408–9
- myocardial ischemia
- complicating PCI 353
 - coronary artery anomalies 48
 - post-CABG 295
 - retrograde PCI 252
- myocardial perforation 383–4
- N*-acetylcysteine (NAC) 350, **351**
- nephro-photo-scintigraphy 538
- nephrotoxic drugs, concomitant 350
- neuroprotection systems see distal embolic protection devices
- nicardipine 367
- nitinol wires 88
- nitroglycerin 272, 306, 366
- nitroprusside 306, 366, 367
- no flow, with distal filter devices 304–5
- no reflow 363–7
- after stenting 284
 - classification 365–6
 - dedicated equipment 364–5
 - improvised equipment 364
 - treatment 306, 366–7
 - see also acute coronary artery closure, during PCI
- nuclear scan 409, 410
- obesity, femoral access 4, 7
- obtuse marginal (OM) arteries
- angiography 31, 36, 38, 42
 - first, high-risk PCI 405
 - wiring 91, 96–9
- occlusive embolic protection devices **569**
- carotid interventions 568–71, 570
 - post-CABG interventions 297, 303–4
- optical coherence tomography (OCT)
- assessing PCI results 128, 129, 130
 - spontaneous coronary artery dissection 287, 288
- ostial lesions, coronary 255–66
- guides 256–8
 - disengagement 257, 257–8
 - positioning 257
 - re-engagement 257, 258
 - selection 256–7
 - stented lesions 61
 - two-guide technique 258
- in-stent restenosis (ISR)
- double wire technique 261
 - PCI through side strut 265
- stent extraction by cutting
- balloon 266
- stenting 259–66
- preparation 259
 - side branches 263–5
 - stent deployment 262–3
 - stent positioning 260, 260–1, 262, 263
 - strategic concerns 256
 - wire selection 258–9
 - see also aorto-ostial lesions
- Ostial Pro device 257, 261
- Outback catheter 610–11, 614
- over-the-wire (OTW) balloons 106, 108
- advancing over regular-length wire 100
 - aiding stent advancement 124
 - chronic total occlusions 238
 - crossing stent to enter side branch 338, 339, 340
 - deep seating of guides 217, 217
 - distal embolic protection 305
 - embolization of coronary perforations 376, 377
 - exchanging, over regular-length wire 110–11

- freeing trapped balloons
 - 113–14
- puncture of undeformed balloons
 - 112–13
- pacing, temporary
 - with angioplasty wire 102–3
 - balloon aortic valvuloplasty 477
 - with coronary wire 395
 - primary PCI 275
 - transcatheter aortic valve implantation 496
- Palmaz XL stent 531–2
- papaverine 540–1
- parallel wire method 229–30, 230, 235, 236
- particle embolization materials, coronary perforations 376, 377
- patent ductus arteriosus (PDA)
 - 640–8
 - coil closure technique 641–2, 645–8
 - coil deployment 646–7
 - coil selection 645, 645
 - crossing from aorta 645
 - occluder device closure 641, 642
 - device selection 645, 645
 - procedure 646, 647–8
 - preprocedure evaluation 642–5
 - transcatheter closure 641–8
 - complications 642
 - contraindications 641
 - device positioning 646–8
 - post-procedure assessment 648, 648
 - sheath placement 646
- patent foramen ovale (PFO), closure devices **632**
- PCI *see* percutaneous coronary intervention
- PDA *see* patent ductus arteriosus; posterior descending artery
- pedal artery
 - equipment 622, **622**
 - puncture 619, 620
 - rotational atherectomy 623, 624
- pedal plantar loop technique 622, 623
- pelvic ischemia 530
- Perclose (ProGlide) devices
 - 11–12, 23
 - abdominal aortic aneurysms 523
 - aortic valve interventions 478, 484, 496
 - see also* preclosure/preclose technique
- PercuSurge 182, 570
- percutaneous coronary intervention (PCI)
 - acute STEMI 269–91
 - balloon angioplasty 105–16
 - bifurcation lesions 313–44
 - chronic total occlusion 207–52
 - complications 347–95
 - contraindications 403
 - guide manipulation 77–84
 - high-risk and complex *see* high-risk and complex PCI
 - left main 185–204
 - ostial lesions 255–66
 - post-CABG surgery 293–310
 - primary *see* primary percutaneous coronary intervention
 - rescue, after thrombolysis 278
 - spontaneous coronary artery dissection 287–8, 288
 - stenting 119–39
 - subclavian artery intervention before 514
 - transradial *see* transradial intervention
 - wires 87–103
 - without radial sheath 146, 147
- percutaneous transluminal angioplasty (PTA), occluded femoral artery 15, 16
- pericardial effusion (PE), iatrogenic 383–92
 - clinical presentation 384–6
 - management 387–8
 - see also* cardiac tamponade
- pericardiocentesis
 - blind 387–8
 - echo-guided 387
 - pulmonary edema after 389
- peripheral artery disease (PAD)
 - 604
 - evaluation 580–1, 605–6
 - iliac artery interventions 582–93
 - infringuinal and infragenicular interventions 606–27
 - see also* femoropopliteal disease; infrapopliteal disease
- peroneal artery
 - 604
 - spasm 626
 - see also* infrapopliteal disease
- PFO Star device **632**

- pigtail catheter, RIMA graft
engagement 301
- Pilot wires **222**, 242, 249, **622**
- Pioneer catheter 610
- plain old balloon angioplasty
(POBA) 106
- acute STEMI 273–4
- bifurcation lesions 320–1
- femoropopliteal disease 610
- no reflow after 363
- polyvinyl alcohol (PVA) particles
376
- popliteal artery
puncture 619, 620
- stenting 610
- transcollateral access 619–20,
620–1
- see *also* femoropopliteal
disease
- popliteal vein access 624, 625
- posterior descending artery (PDA)
angiography 38, **40**
- embolic protection devices
305, 306
- high-risk PCI 405
- posterior tibial artery 604
- Powerlink endograft 524, 525
- Precise RX stent **572**, 573
- preclosure/preclose technique
11–12
- abdominal aortic aneurysms
523
- aortic valve interventions 478,
484, 496, 498
- large arterial access 11
- large venous access 11–12
- prednisone 352
- pregnancy, balloon mitral
valvuloplasty 468
- pressure–volume relationship,
balloon 461
- primary percutaneous coronary
intervention (PCI)
272–90
- acute simultaneous occlusion of
two major coronary arteries
(ASOMC) 289
- after resuscitated cardiac arrest
288
- after thrombolysis 278
- angiographic exclusions 272
- avoiding vasovagal reaction
274–5, 280
- balloon angioplasty without
stenting 273–4
- bleeding patients 285–6
- complex 277–83
- contrast leakage into ventricle
290
- crossing the lesion 280
- evaluation of results 275,
275–6, 276
- identifying infarct-related artery
274
- large coronary aneurysm
288–9
- left main compression by aortic
dissection 286–7
- lesions with thrombi 280–5
- aspiration thrombectomy
281, 281–2
- avoiding antegrade
embolization 282, 282
- avoiding retrograde
embolization 283, 283
- complications of
thrombectomy 284
- persistent thrombotic burden
284–5
- thrombectomy catheters
283–4
- reconstructed prosthetic left
main 289–90
- right ventricular infarction
278
- saphenous vein graft 278–80,
279
- slow or no reflow 284
- spontaneous coronary dissection
287–8, 288
- unprotected left main 277,
277
- verifying wire position 280
- without on-site surgical backup
273
- profunda femoral artery (PFA)
7–8, 604
- ProGlide devices see Perclose
devices
- Pronto device 284, 307
- Prostar device 496
- protamine 370, 371
- Protégé RX stent **572**, 573–4
- provisional T-stenting technique
191, 191–2, 324–5
- Prowater wire 88, 92, 93
- proximal deflecting balloon
technique 124
- proximal optimization technique
(POT) 200, 324, 324
- proximal (embolic) protection
devices 303–4
- Proxis device 80, 304
- pseudoaneurysms (PA)
femoral artery 22–3
- radial artery 165
- subclavian artery 503, 511
- ventricular 291

- pulmonary capillary wedge
 - pressure (PCWP) monitoring 402
- pulmonary edema
 - after pericardiocentesis 389
 - balloon mitral valvuloplasty 468
- pulmonary hypertension
 - atrial septal defects with 632, 640
 - patent ductus arteriosus with 641
- pulmonary trunk, right coronary artery origin from 48–9
- pulse infusion thrombolysis (PIT) catheter 289
- pulseless disease 10
- pulse pressure, cardiac tamponade 384–5
- pulsus paradoxus 384, 385
- pushability 106
- push-and-turn maneuver 65
- push/pull technique, endograft advancement 525

- Q guides 161
- Quickcross catheter 612, 613, 617

- radial approach *see* transradial approach
- radial artery (RA)
 - anatomic variations 151, 151
 - diameter 158–9, 159
 - external side compression 152, 152
 - grafts, PCI 300
 - hemostasis 150, 150, 163
 - iatrogenic perforation 164, 164–5, 166
 - knotted coronary catheter 166–7
 - loops 153–4, 154
 - missing 145
 - occlusion
 - after transradial access 163
 - distal entry technique 147–8, 150
 - proximal entry technique 148–50, 149
 - pseudoaneurysms 165
 - puncture 143–50, 144
 - spasm 163, 164, 168
- radial sheaths 145
- radiation exposure, coronary angiography 41–3
- RCA *see* right coronary artery
- renal angiography 538–40, 539
- renal artery
 - aneurysm 549–50
 - dissection 546, **547**, 547
 - inadvertent exclusion 529–30
 - interventions 537–50
 - perforation 546–8, **547**
 - restenosis 548
 - rupture 546–8, **547**, 547
 - stent thrombosis **547**
- renal artery stenosis (RAS)
 - 537–50
 - coronary artery disease and 539, 539, 540
 - evaluation 538–41
 - fractional flow reserve (FFR) 540–1
 - stenting 541–6
 - aortic dissection and 549
 - balloons 544
 - bifurcation lesions 546
 - complications 546–50, **547**
 - distal embolic protection 542–4, 543, 544
 - guides 541–2
 - short renal trunk 545–6
 - stent deployment 545, 545
 - stent selection 544–5
 - vascular access 541, 542
 - wires 542, 543
- renal sympathetic denervation 548
- rendez-vous technique 249
- retrograde wire crossing 244–5, 245
- retroperitoneal hematoma (RPH)
 - 17, 17–22
 - bladder indentation 18, 19
 - percutaneous management 18–22, 20, 21
 - radial approach 165–6
- reverse CART technique 245, 246–7
- reverse crush technique 332–3
- reversed-wire technique 94–6, 95, 97–8
- reverse wire-trapping technique 249
- rheolytic thrombectomy 308
- right anterior oblique (RAO) view
 - 32, **33**
 - caudal 30, 31, 37
 - cranial 31
 - right coronary artery 38, 38
- right aortic arch, guides for 74
- right atrium (RA)
 - perforation 383, 384, 449–50
 - pressure waveform, tamponade 384

- right coronary artery (RCA)
 - acute occlusion 271
 - angiography 37–8, 38, 216
 - anomalies
 - angiography 43, 45, 46, 48–9
 - guides 74, 75, **76**, 76–7
 - balloon or stent sizing 40, **42**
 - chronic total occlusion 215, 226, 233
 - dissection, iatrogenic 353
 - guides 70–2
 - proximal lesions 405
 - rotational Amplatz maneuver 71
 - transradial approach
 - catheters 153, **154**
 - guides 158, 177–9, 178–81
 - ostial cannulation 160–2
 - ventricularization of pressure 410
 - wiring 90
- right-hand maneuver, chronic total occlusion 228
- right heart catheterization, venous access at elbow 162
- right heart pressure evaluation 402
- right internal mammary artery (RIMA) grafts
 - engaging guide with a wire 300–1
 - engaging with a pigtail catheter 301
 - transradial approach 162, 300
- right radial approach (RRA) 145
- right-to-left shunt, localized tamponade causing 392
- right ventricle (RV)
 - branch artery lesions 405
 - hematoma, causing shock 390
 - perforation 383
- right ventricular (RV) dysfunction
 - after pericardiocentesis 389
 - percutaneous assist devices 414
 - tamponade with 388
- right ventricular infarction (RVI), primary PCI 278
- RIMA grafts *see* right internal mammary artery (RIMA) grafts
- roadmapping technique
 - carotid artery stenting 557
 - iliac artery stenting 583, 584–5, 589, 590
 - infrainguinal/infragenicular interventions 607
 - transeptal puncture 443, 445, 446
- Rotablator wire 249
- Rotaglide 341
- rotational Amplatz maneuver 69, 71
- rotational angiography, three-dimensional 643–4, 644, 651
- rotational atherectomy (rotablation)
 - after stenting 134–6, 135
 - bifurcation lesions 322, 336
 - coronary ostial lesions 259
 - pedal artery 623, 624
 - stent-jailed side branch stenoses 265–6
- Runthrough wires 88, 92, 93
- RX Acculink **572**, 573
- RX Accunet device **567**
- SafeCross wire 612–13
- saphenous vein grafts (SVGs) 296–300
 - acute occlusion 278–80, 279
 - angiography 38
 - aorto-ostial lesions 297
 - balloon angioplasty 299
 - clinical and technical problems **294**
 - complex interventions 297
 - complications of degenerated 297–8, 310
 - dissection 353, 358
 - distal embolization 298
 - distal protection devices 297–8
 - guides 299
 - iatrogenic perforation 309, 390–1
 - stenting 298, 299–300
 - stent luxation during aneurysm exclusion 309
 - thrombus in 306–8
 - mechanical thrombectomy 283–4, 307–8
 - medical treatment 307
 - transradial approach 162
- SAPIEN heart valves 488, 488, **489**, 493, 500
- seesaw wiring *see* parallel wire method
- septal arteries
 - angiography 32, 35
 - rupture, management 252
- septal bounce 447
- septal collateral channels 240, 240
- perforations 250–2, 251
- wiring 241, 242–3

- septal flush/stain method 448, 448
- septal hematoma 241
- septal puncture *see under* transeptal access
- sheathless Eucath guide catheter system 146
- sheathless guide catheter system using 5fr (virtual 3fr) 182
- sheaths
 - atrial septal defect closure 638–9
 - coarctation repair 652–3
 - guide stabilization 78–9, 218
 - patent ductus arteriosus closure 646
 - radial 145
 - removal, aortic valve procedures 484, 498
 - septal puncture 440
 - subclavian artery stenting 506
- Shinobi wires **223**
- shock
 - acute periprocedural occlusion 401
 - early signs 352
 - see also* cardiogenic shock; hypotension
- Shuttle Select diagnostic catheter 146, 147
- side branches (SB), coronary
 - bifurcation lesions 336–43
 - balloon advancement 340–2
 - balloon angioplasty 320–1, 342
 - crossing stent side cell to access 337–9, 338, 339
 - flower petal stenting 343
 - intervention strategies 315–16, 317–18
 - kissing balloon inflation 342–3
 - lesion preparation 319–22
 - provisional stenting 324–5
 - rotational atherectomy 322, 336
 - wiring 318–19, 336–40, 338, 339
 - withdrawing jailed wire 319, 341–2
 - crossing a stent to access 99–100, 201–2
 - cutting balloon angioplasty of jailed lesion 265
 - IVUS-guided wiring of chronic total occlusions 224, 226
 - keep it open (KIO) concept 320, 336
 - ostial lesions, stenting 263–5, 264
 - stent pull-back technique 264
 - wire-twisting problem 264, 264
 - reverse-wire technique 94–6, 95, 97–8
 - rotablation for stent-jailed stenoses 265–6
 - stenting, acute STEMI 273
 - wiring 93–100
- Silverhawk atherectomy catheter 611
- simultaneous kissing stent (SKS) technique 333–5
 - left main bifurcation lesions 196–200, 199
 - see also* kissing stent technique
- single coronary artery (SCA) 43
- Sinus–Carotid stent **572**, 573
- sinus node artery 405
- SION wire 241, 242
- slow reflow phenomenon 284, 365–7
- snares
 - improvised loop 425–6, 426
 - loop snaring techniques 426–8, 427, 428, 429
 - new Japanese devices 423–5, 424
 - removal of cutting balloons 116
 - removal of embolized stents 423–8
 - removal of trapped balloons 114
 - standard 423, 424
 - stent removal from iliac artery 434–5
- sodium bicarbonate 350, **351**
- Spider RX device 304, **567**, 568, 568, 617–18
- stainless steel wires 88
- Starclose device 10–11
- STARFlex device 632, **632**
- STAR (subintimal tracking and re-entry) technique 238
- Steer-it wire 89, 94, 131
- STEMI *see* acute ST-segment elevation myocardial infarction
- stent(s) 119–39
 - advancing 122–5
 - buddy wire technique 123–4
 - distal buddy balloon technique 124

- stent(s) (*Contd.*)
- proximal deflecting balloon
 - technique 124
 - testing the road 123
 - balloon expansion 127–8
 - acute STEMI 273
 - carotid artery 558, 574
 - coarctation 652, 654
 - coronary ostial lesions 263
 - failure 134–6, 135
 - left main ostial lesions 188
 - renal artery 545
 - subclavian artery 508–9
 - see also kissing balloon inflation
 - carotid 571–4, **572**
 - clinical evaluation 121–2
 - coarctation 651–2
 - covered see covered stents
 - crushed 133, 133–4
 - curve conformity 120–1
 - deploying 125–8
 - balloon inflation after 127–8
 - tapering artery 126–7
 - tortuous artery 126
 - without angiogram 127
 - easy delivery 120
 - edge dissection 128, 129
 - embolized
 - deployment 136–7, 431–2
 - management options 421
 - retrieval 421–35
 - extraction by cutting balloon 115, 266
 - flexibility 120, 121
 - iliac artery 584
 - infrapopliteal disease **622**
 - low profile 120
 - malapposition 128, 129
 - MRI-compatible 652
 - perfect deployment 120–1
 - radial strength 120–1
 - re-crossing 128–32
 - to access side-branches 99–100, 201–2
 - with a bent stiff wire 131
 - dottering technique 129–30
 - with a movable tip wire 131
 - steer wire to new branch 130–1
 - using two balloons 131
 - redeploying 132–7
 - after balloon rupture 137
 - after failed expansion 134–6, 135
 - crushed stents 133, 133–4
 - embolized stents 136–7, 431–2
 - renal artery stenosis 544–5
 - restenosis see in-stent restenosis
 - size
 - angiographic views 40–1, **42, 42**
 - checking adequacy 110, 110
 - strut network strength 121–2
 - subclavian artery 507
 - subclavian/axillary junction 509
 - thrombosis
 - coronary 362, 363
 - imaging 128, 130
 - renal **547**
 - tissue prolapse 128, 129
 - user friendliness 122
 - wire exit through struts 128
 - see also coronary stents
- StentBoost 260
- stenting 119–39
 - assessing results 128, 129, 130
 - carotid artery 558
 - coarctation 649–55
 - coronary see coronary stenting
 - direct 125–6
 - femoropopliteal disease 610, 612
 - iliac artery 582–9
 - innominate artery 509
 - lesion predilation 126, 259
 - renal artery 541–6
 - saphenous vein grafts 298, 299–300
 - subclavian artery 504–12
- stent pull-back technique, side branch ostial lesions 264
- step-crush technique, left main bifurcation lesions 195–6
- Stingray system 237
- stroke
 - complicating PCI 393–4
 - concurrent, AMI 286
 - recent, AMI 286
 - see also distal embolization
- ST-segment elevation myocardial infarction (STEMI) see acute ST-segment elevation myocardial infarction
- subclavian artery
 - aneurysm 513
 - arterial venous fistula 512
 - dissection 502–3
 - distal/axillary artery lesions 509
 - evaluation of disease 503–4, 504
 - internal mammary artery graft interventions 300, 301, 303

- interventions 501–14
- jailing, coarctation stenting
 - 653–4
- occlusion causing AMI 512–13
- pseudoaneurysm 503, 511
- retroesophageal (arteria lusoria)
 - 155–6, 156
- stenosis 502
 - imaging 503–4, 504
 - interventions 309, 504–9, 510–11
- stenting 504–12
 - balloon predilation 507
 - complications 512
 - crossing the lesion 506
 - distal protection 506–7
 - guides 505, 505, 506
 - perfect 508, 508
 - postdilation 508–9
 - stent positioning 507–8
 - stent selection 507
 - vascular access 504
 - wires 505
- tortuosities, transradial
 - approach 151, 154–5, 155, 159–60
- total occlusion 509–10, 514
- traumatic injuries 502, 511–12
- subclavian steal syndrome 502, 503, 514
- subcutaneous tissue, embolization
 - of coronary perforations 377
- subepicardial hematoma, fatal
 - dissecting 390–1
- subintimal angioplasty, femoropopliteal disease
 - 610–11
- subintimal tracking and re-entry (STAR) technique 238
- superficial femoral artery (SFA)
 - 604
 - acute thrombosis 627, 627
 - antegrade puncture 7–8, 607–9, 609
 - atherectomy 611, 626
 - balloon angioplasty 612
 - chronic total occlusion 612–15, 614–15
 - perforation 626
 - stenting 610, 612
- surgery, AMI after recent
 - 285–6
- switching balloon technique, coronary perforations
 - 377, 378–81
- Symbiot covered stent 137, 392
- sympathetic denervation, renal
 - 548
- tachycardia, guide-induced 215
- Takayasu's arteritis 10
- Talent stent graft system 521
- TandemHeart device 411–12, 413–14, 415
- tangled wires technique, removal
 - of broken wires 432–3, 433
- TAP stenting technique 193, 328–30, 329
- thoracic outlet syndrome 504, 504
- thrombectomy, mechanical
 - acute femoral occlusion 15, 615
 - acute STEMI 278, 281–5
 - avoiding antegrade embolization 282, 282
 - avoiding retrograde embolization 283, 283
 - catheter selection 283–4
 - complications 284
 - persistent thrombotic burden 284–5
 - technique 281, 281–2
- saphenous vein graft thrombus
 - 307–8
- subacute iliac artery occlusion
 - 599, 600, 601
- thrombin injection 19, 22–3
- thrombolysis
 - acute femoral occlusion 615
 - acute iliac artery occlusion 599
 - carotid artery thrombosis 576
 - cerebrovascular accident 393
 - coronary aneurysm 289
 - deep vein thrombosis 624, 625
 - rescue PCI after 278
 - saphenous vein graft thrombus 307
- thrombolysis in myocardial infarction see TIMI
- thrombus/thrombosis
 - acute, lower limb arteries 627, 627
 - acute femoral 15–16, 16, 615, 616
 - during carotid procedures 576
 - coronary see coronary artery thrombosis
 - deep vein, lower extremity 624–5, 625
 - iliac artery 599, 600, 601
 - left atrial cavity/appendage 466, 471
 - saphenous vein grafts 306–8
 - stent see stent(s), thrombosis

- ThromCat 284
- tibial arteries 604
 equipment 622, **622**
 spasm 626
 vascular access 619–20, 620–1
see also infrapopliteal disease
- Tiger catheter 153, **154**, 160–1, 162
- TIMI flow 270, 271
- TIMI frame count, corrected (CTFC) 275, 275–6
- TIMI myocardial perfusion grading (TMPF) system 276, 276
- tissue plasminogen activator (tPA) 15, 285, 307, 393
- Tornus catheter 234
- trackability 106, 120
- transapical approach, carotid procedures 560
- transcatheter aortic valve replacement (TAVR) *see* aortic valve implantation, transcatheter
- transcatheter heart valves (THV) 488–90
- transcollateral access, infrapopliteal arteries 619–20, 620–1
- transeptal access 10, 439–50
 catheter/needle fitting exercise 440, 441
 instruments for septal puncture 440
 puncture site landmarks 440–4
 giant left atrium, kyphoscoliosis 443
 horizontal M-line 440, 443, 444
 Hung's modified method 442, 442
 Inoue's angiographic method 440–2, 442, 443
 semi-recumbent position 443–4
 variances of midline 443
 vertical midline 440–3, 442, 444
- septal puncture 444–50
 after failed first attempt 447
 catheter/needle manipulation 445–7, 446
 catheter/needle placement 444–5
 confirming left atrial entry 450
 heparinization 450
 needle tip reshaping 447
 technique 447–50, 448
- TandemHeart device 415
see also Inoue balloon mitral valvuloplasty
- transesophageal echocardiography (TEE)
 atrial septal defect 633, 635, 636, 637
 transcatheter aortic valve implantation 491–2, 498–9
 transeptal access 440
- transfemoral approach *see* femoral arterial approach
- transient ischemic attack (TIA) 393
- Transit catheter 302–3
- transradial approach (TRA) 141–68
 alternative access sites 156
 aortic aneurysms/dissections 72
 aorto-subclavian tortuosity 154–5
 arterial puncture 143–50
 bifurcation lesions 163
 carotid procedures 559
 catheter advancement 153–6, 154, 155
 catheters 152–6, 153, **154**
 chronic total occlusion 163
 complications 163–8
 contraindications 143
 coronary cannulation 160–2
 hemostasis 150, 150
 iliac artery stenting 588
 infrainguinal/infragenicular interventions 609–10
 internal mammary artery grafts 162, 300
 learning curve 156
 left vs. right 145
 patient selection 143
 renal angiography 539–40
 right heart catheterization 162
 subclavian artery stenting 504
 wires 151–2
- transradial intervention (TRI)
 guides 157–9
 backup mechanics 157–8, 171–9
 crossing tortuous subclavian artery 159–60
 left coronary arteries 157, 157–8, 171–7, 172–7
 right coronary artery 158, 177–9, 178–81
 radial artery diameter 158–9, 159
 slender (5-fr guide) 171–83

- backup force 179–81
- chronic total occlusion 182
- distal protection devices 182
- intravascular ultrasound 182
- kissing balloon technique 181–2
- limitations 179–82
- minimum contrast technique 183
- power position 181, 181
- sheathless system (virtual 3fr) 182
- trapping wire technique 248
- TR Band 165
- treadmill exercise testing 580
- tricuspid valve, avoiding, septal puncture 449
- trouser stenting, bifurcation lesions 327
- T-stenting 325–30, 326, 327
 - cone crush-modified 193
 - left main bifurcation lesions 192, 192
 - modified 193, 325–8, 328
 - and protrusion (TAP) technique, provisional 193, 328–30, 329
 - provisional 191, 191–2, 324–5
- Twin-Pass catheter 88, 237, 364–5
- two-guide technique *see* dual-guide technique
- ulnar artery approach 156
- ultrasonography
 - intravascular *see* intravascular ultrasound
 - peripheral artery disease 580, 605
 - renal artery stenosis 538
 - subclavian artery disease 503
 - see also* echocardiography
- unstable angina 408–9, 411
- upper extremity ischemia, subclavian artery disease 502
- vascular access 1–24
 - abdominal aortic aneurysms 523
 - aortic valve interventions 478, 490–1, 495–6
 - carotid procedures 556, 559, 559–60
 - chronic total occlusion 214–15
 - complications 14–24
 - femoropopliteal disease 606–10
 - iliac artery stenosis 582, 583, 588–9
 - infrapopliteal disease 619–20
 - renal artery stenting 541, 542
 - subclavian artery interventions 504, 510
 - vascular bed dysfunction, distal 366
 - vascular closure devices (VCDs) 10–14
 - intra-arterial deployment 13, 13, 14
 - selection 12–13
 - see also* preclosure/preclose technique
 - vasovagal reaction, primary PCI 274–5, 280
- VB-1 catheter 301
- venous access
 - at elbow, right heart catheterization 162
 - Inoue balloon mitral valvuloplasty 440, 444, 451–2
 - lower limb deep venous thrombosis 624–5
 - preclosure with Perclose device 11–12
 - see also* femoral vein access
- ventricular assist devices *see* left ventricular assist devices
- ventricular ectopy, wire-induced 482–3
- ventricular fibrillation (VF) 275, 394–5, 483
- ventricular free wall rupture, post-infarction 291
- ventricularization of pressure 56, 60, 410
- ventricular pseudoaneurysm 291
- ventricular septal defects (VSD), post-infarction 290–1
- ventricular tachycardia (VT) 275, 394–5
- Venture catheter 88–9
 - chronic total occlusions 237–8
 - side branch entry 96, 99, 339
- verapamil 145, 306, 366, 367
- vertebral artery disease 509
- vertebrobasilar insufficiency 502
- vertical midline, transeptal puncture 440–3, 442
- ViperWire Advance guidewire 249
- virtual 3fr method 182
- Vista Brite Tip **60**
- volar compartment syndrome 165, 167
- Volkman's contracture 167

- V-stenting technique 327, 333, 334
 left main bifurcation lesions 196–8, 197
- warfarin 450, 471
- watermelon-seeding effects 259, 480, 481
- Whisper wires 88, **622**
 chronic total occlusion 221, **222**, 228
 coronary aneurysm with stenosis 92, 92
- wire(s) 87–103
 advancement 89, 90, 90–3
 avoiding prolapse 91
 coronary aneurysm with stenosis 92
 pseudolesion formation 92–3
 tortuous arteries 93
 balloon aortic valvuloplasty 479, 480, 482–3
 bias 89, 322, 589
 bifurcation lesions 318–19, 336–40, 338, 339
 buddy see buddy wire technique
 chronic total occlusion 220–38, 221, **222–3**
 coarctation repair 652–3
 coronary perforation 290, 368–9, 371
 entanglement with IVUS catheters 101–2
 entering side branches (SB) 93–100
 exchanging balloon catheters over 100–1
 exit through stent struts 128
 failure to cross a lesion 101–3
 fractured embolized 432–3
 loop snaring 427, 427–8, 428
 removal using wires 432–3, 433
 guide stabilization, chronic total occlusion 216, 217
 hydrophilic (flexible) 88–9, 220, 228
 iliac artery stenting 582–3
 improvised loop snare from 425–6, 426
 inadvertent jailing 102
 jailed, removal 200
 kinking, at vascular entry point 5
 measuring lesion length 92
 nitinol 88
 ostial lesions 258–9
 pacing with 102–3, 395
 removal of embolized stents 429–31
 renal artery stenting 542, 543
 reversed-wire technique 94–6, 95, 97–8
 second, ostial lesions 260, 260, 261
 spring type 220, 228
 stainless steel 88
 stent advancement 122–3
 stiff 89, 89
 subclavian artery stenting 505
 tip deflection using distal balloon 96–9
 transradial approach 151–2
 twisting, side branch ostial lesions 264, 264
 uncoiling, withdrawal 432
 vascular insertion problems 5
 ventricular, hypotension due to 482–3
- wire-anchoring techniques
 guide stabilization 216, 217
 stenting ostial lesions 261, 262, 263
- woodpecking sign 456
- Xact carotid stent **572**, 573
 X-sizer 284
- Y-stenting technique 327
- Zenith endograft 524–5, 531
 zigzag wire technique, iliac artery 589, 591