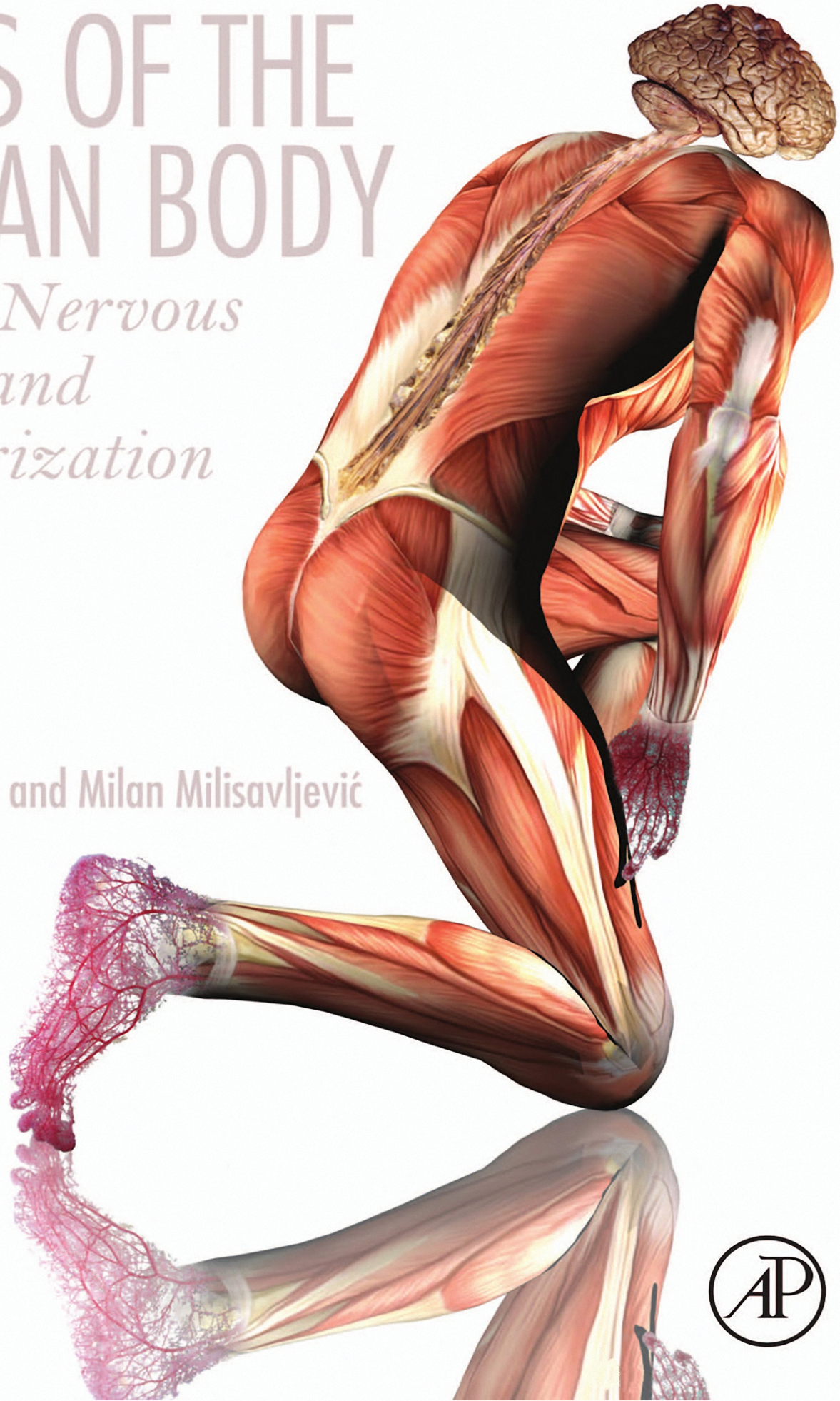


ATLAS OF THE HUMAN BODY

*Central Nervous
System and
Vascularization*

Branislav Vidić and Milan Milisavljević



Atlas of the Human Body

Central Nervous System and Vascularization

BRANISLAV VIDIĆ, DS

Professor, Texas Tech University Health
Science Center, Lubbock, TX,
United States

MILAN MILISAVLJEVIĆ, MD, DS, DSc

Professor, Institute of Anatomy,
University of Belgrade, Belgrade, Serbia

in collaboration with

ALEKSANDAR MALIKOVIĆ, MD, DSc

Professor, Institute of Anatomy,
University of Belgrade, Belgrade, Serbia



ACADEMIC PRESS

An imprint of Elsevier

Academic Press is an imprint of Elsevier
125 London Wall, London EC2Y 5AS, United Kingdom
525 B Street, Suite 1800, San Diego, CA 92101-4495, United States
50 Hampshire Street, 5th Floor, Cambridge, MA 02139, United States
The Boulevard, Langford Lane, Kidlington, Oxford OX5 1GB, United Kingdom

Copyright © 2017 Elsevier Inc. All rights reserved.

No part of this publication may be reproduced or transmitted in any form or by any means, electronic or mechanical, including photocopying, recording, or any information storage and retrieval system, without permission in writing from the publisher. Details on how to seek permission, further information about the Publisher's permissions policies and our arrangements with organizations such as the Copyright Clearance Center and the Copyright Licensing Agency, can be found at our website: www.elsevier.com/permissions.

This book and the individual contributions contained in it are protected under copyright by the Publisher (other than as may be noted herein).

Notices

Knowledge and best practice in this field are constantly changing. As new research and experience broaden our understanding, changes in research methods, professional practices, or medical treatment may become necessary.

Practitioners and researchers must always rely on their own experience and knowledge in evaluating and using any information, methods, compounds, or experiments described herein. In using such information or methods they should be mindful of their own safety and the safety of others, including parties for whom they have a professional responsibility.

To the fullest extent of the law, neither the Publisher nor the authors, contributors, or editors, assume any liability for any injury and/or damage to persons or property as a matter of products liability, negligence or otherwise, or from any use or operation of any methods, products, instructions, or ideas contained in the material herein.

Library of Congress Cataloging-in-Publication Data

A catalog record for this book is available from the Library of Congress

British Library Cataloguing-in-Publication Data

A catalogue record for this book is available from the British Library

ISBN: 978-0-12-809410-5

For information on all Academic Press publications visit our website at
<https://www.elsevier.com/books-and-journals>



Publisher: Mica Haley
Acquisition Editor: Stacy Masucci
Editorial Project Manager: Sam Young
Production Project Manager: Edward Taylor
Designer: Matthew Limbert

Typeset by Thomson Digital

Contents

Preface	vii		
1. Upper Limb and Vascularization	1	7. Cranial Central Nervous System and Spinal Cord	173
2. Lower Limb and Vascularization	25	8. Vascularization of Head and Neck and the Cranial Central Nervous System	229
3. Thorax and Vascularization	55	References	259
4. Abdomen and Vascularization	89	Index	261
5. Pelvis and Perineum with 5–6-Month-Old Fetal Specimens	117		
6. Head and Neck Regions and Vascularization	129		

Preface

Anatomy is one of the oldest medical sciences that still continues today, and is the foundation for the study and practice of the medical arts. It provides, first of all, the basic vocabulary of the medical world and the necessary skills required in solving health–disease problems in three-dimensional space. By sequentially dissecting a region, the anatomical analysis leads to a gradually expanding appreciation of the entire makeup of the human body. This process is fundamental in providing biophysical data for subsequent conceptual elaboration and integration of morphological data into a meaningful functional complex. Dissection, considered the most ancient method of studying an anatomical subject, survived scrutiny and the test of time throughout the history of medicine. However, it still remains a reliable method of scientific and pedagogical analysis of fundamental human structure and function, which is important for minute differential assessment between normal and abnormal conditions, as well as for the optimal treatment of abnormal (diseased) conditions.

Atlas of the Human Body, Central Nervous System and Vascularization has been written with several goals in mind. The most important one was to establish a detailed coverage of anatomical structures/relationships throughout topographic regions, as completely as it was technically possible. To avoid overcrowding of photographs by labels and to provide better visibility of images, two, three, or even more similar regional views, in some instances, have been utilized. In addition to adult specimens, a few prenatal examples were utilized to enable a better understanding of structure/relation specificity of corporal differentiation (conduits, organs, somatic, and branchial derivatives) at various developmental intervals. Another quest of this Atlas was to systematically present arterial distribution, up to the precapillary level, using the “methyl methacrylate injection and subsequent digestion of tissue” method. The resulting photographic presentation of the arterial distribution throughout topographic regions, organs, and special subregions makes this Atlas a unique and invaluable published document in the arsenal of the existing academic literature. The present Atlas, furthermore, contains a very rich collection of: surface and three-dimensional dissection images, native and colored cross-sectional views made in different plans (whenever appropriate these views were compared, side by side, with dissection images), and the distribution of blood vessels throughout body regions and central nervous system. A separate segment of Atlas is devoted to the central nervous system and its specific regions: brain, brainstem, cerebellum, and spinal cord. Each region is presented by a detailed collection of surface (dissection) and cross-sectional views, native blood vessels, and blood vessel casts. The latter collection could adequately subserve as a complete educational–visual aid for the requirements of a Neuroscience course.

Terminology used in the *Atlas of the Human Body, Central Nervous System, and Vascularization* is according to the Terminologia Anatomica (1998).

Authors express their sincere gratitude to Stacy Masucci, Senior Acquisition Editor, Elsevier Inc. and Samuel Young, Editorial Project Manager, Elsevier Inc. for unlimited assistance and help during the course of preparation of *Atlas of the Human Body, Central Nervous System and Vascularization*. Administrative help and encouragement from the Faculty of Medicine, University of Belgrade, Belgrade, Serbia, and Texas Tech University Health Science Center, Texas Tech University, Lubbock, Texas, USA are well appreciated.

We are also deeply grateful for essential scientific contributions by:

Dr. Mila Petković Milisavljević, from the Institute of Histology and Embryology, Faculty of Medicine, University of Belgrade, Serbia, for her quality, beautiful drawings and histological specimens used in this Atlas.

Dr. Zdravko Vitošević, University Professor and 2011 year Laureate of the “Brothers Karic Foundation” in Belgrade, Serbia, was wholly committed to this project and helped in the organization of scientific material throughout.

Dr. Bojan Štimec, from the Faculty of Medicine, Department of Cellular Physiology and Metabolism, Anatomy Sector, University of Geneva, Geneva, Switzerland, who provided numerous helpful suggestions and assisted in updating the lower limb and abdomen parts of our Atlas.

Chapter 1

Upper Limb and Vascularization

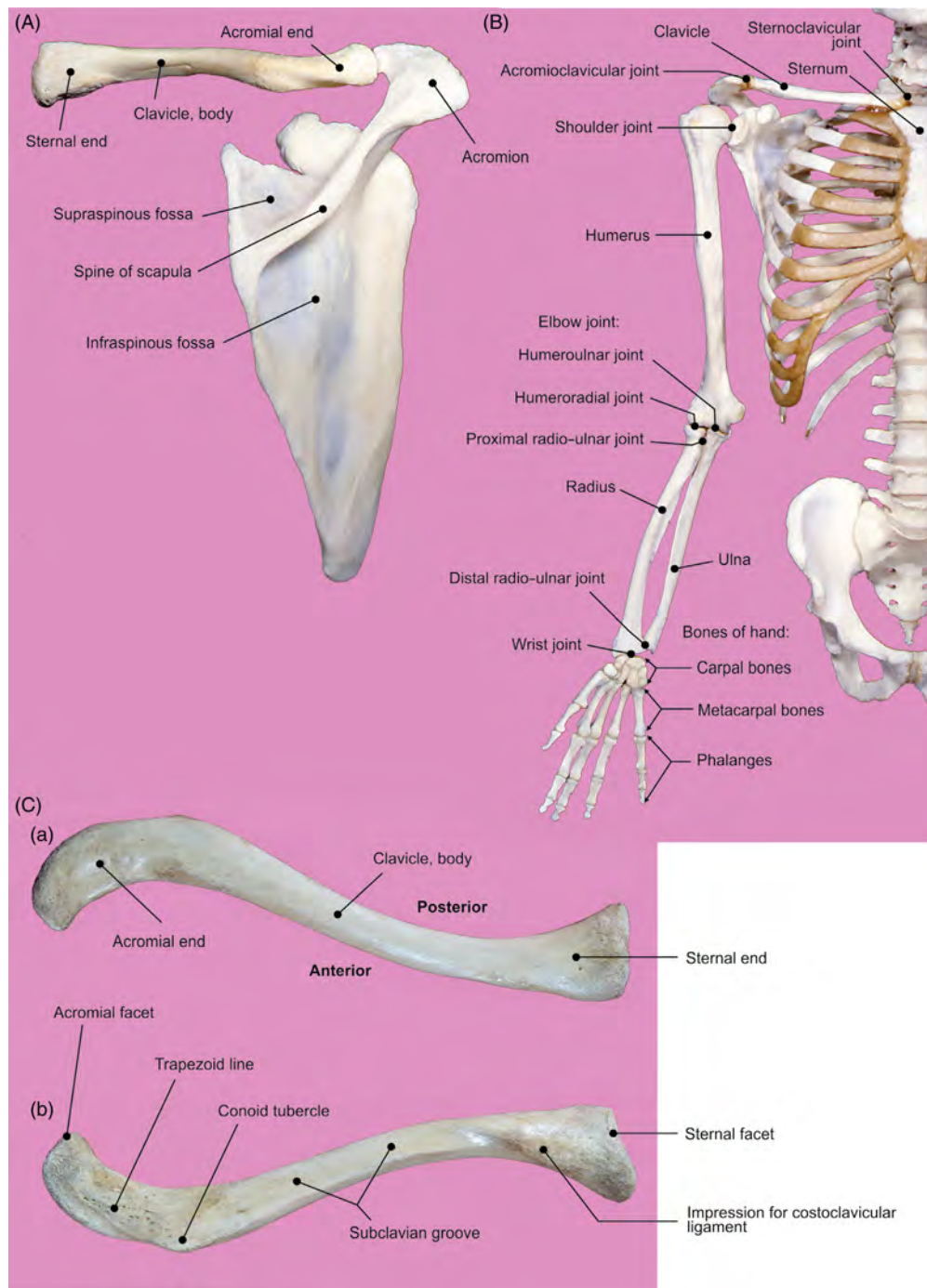


FIGURE 1.1 Skeleton of the upper limb. (A) Posterior view of the right clavicle and scapula. (B) Bones of the shoulder region. (C) Right clavicle: (a) superior and (b) inferior views.

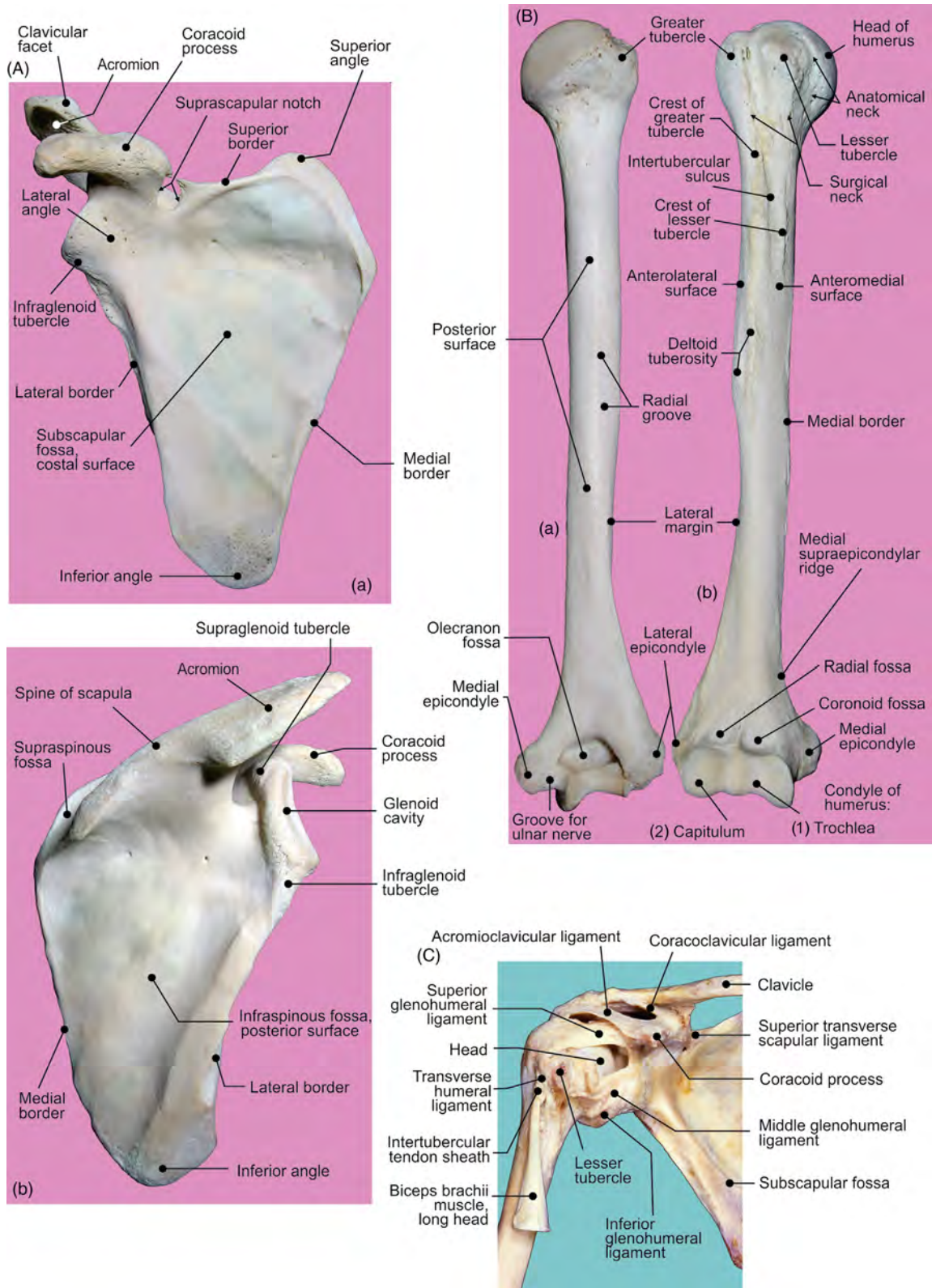


FIGURE 1.2 (A) Right scapula: (a) anterior and (b) posterior views. (B) Right humerus: (a) posterior and (b) anterior views. (C) Anterior view of the shoulder joint.

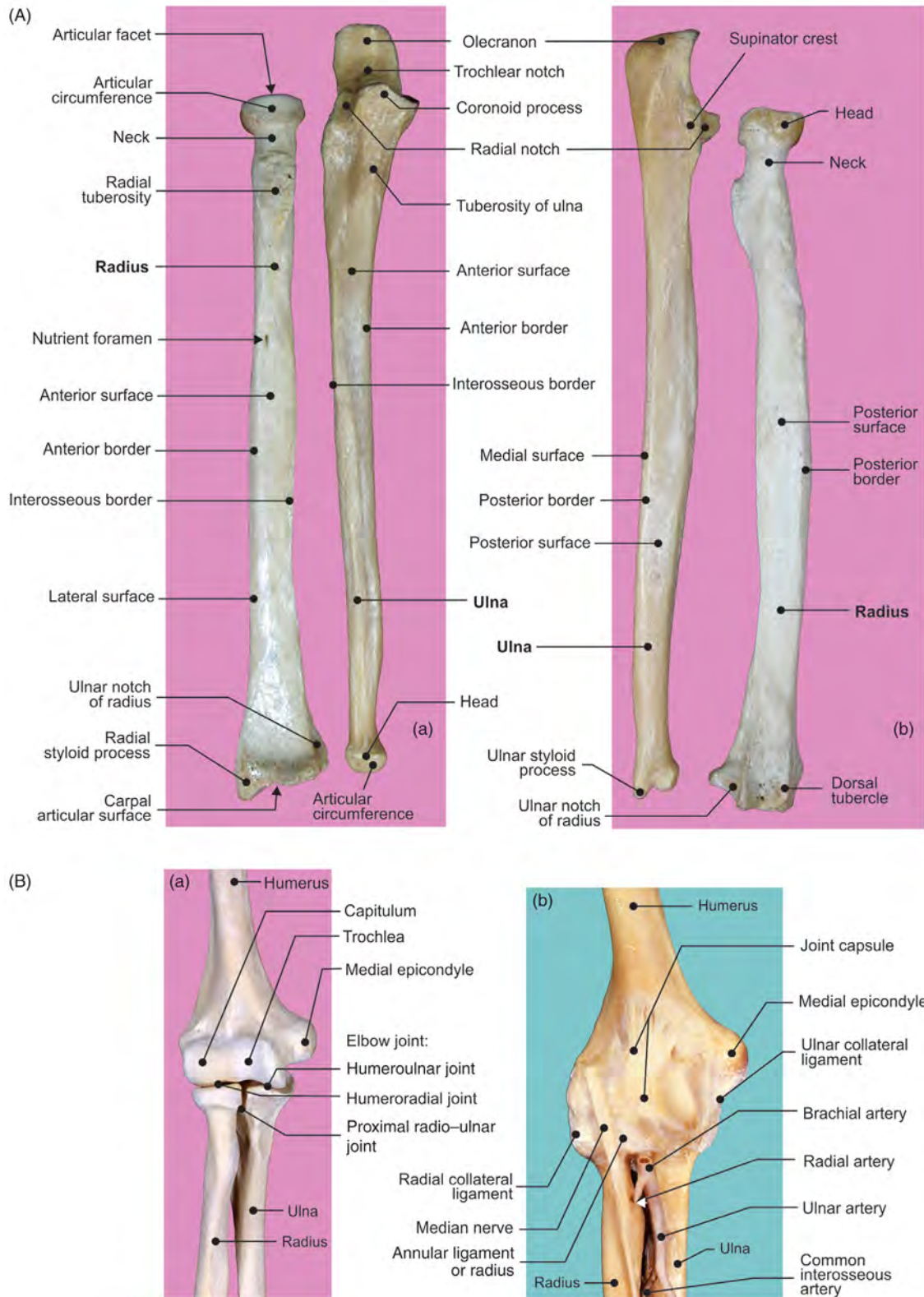


FIGURE 1.3 (A) Right forearm: (a) anterior and (b) posterior views of radius and ulna. (B) Elbow joint: anterior view (a) bones and (b) ligaments.

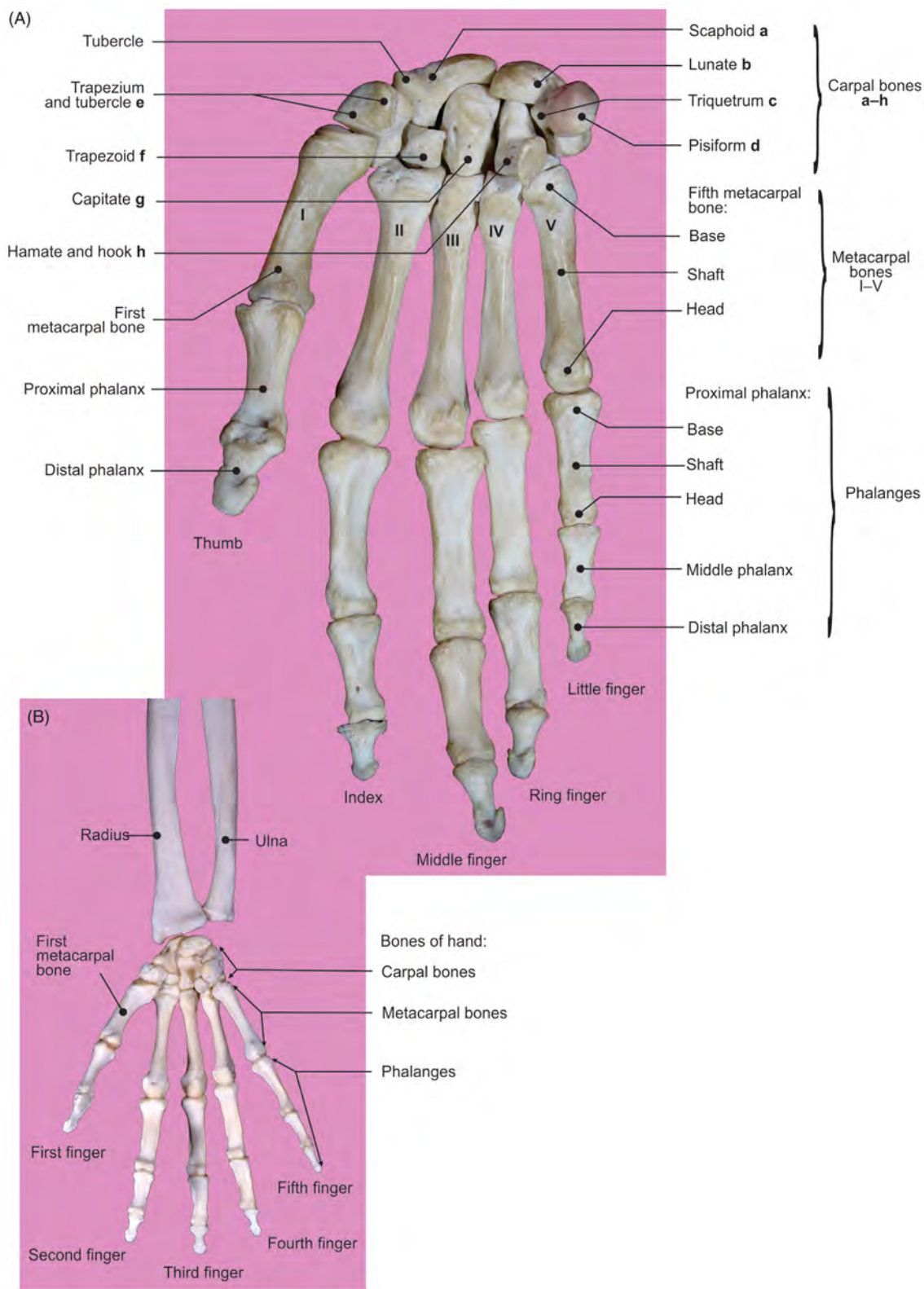


FIGURE 1.4 Palmar surfaces of hand skeleton. (A) Bones of the hand. (B) Wrist joint.

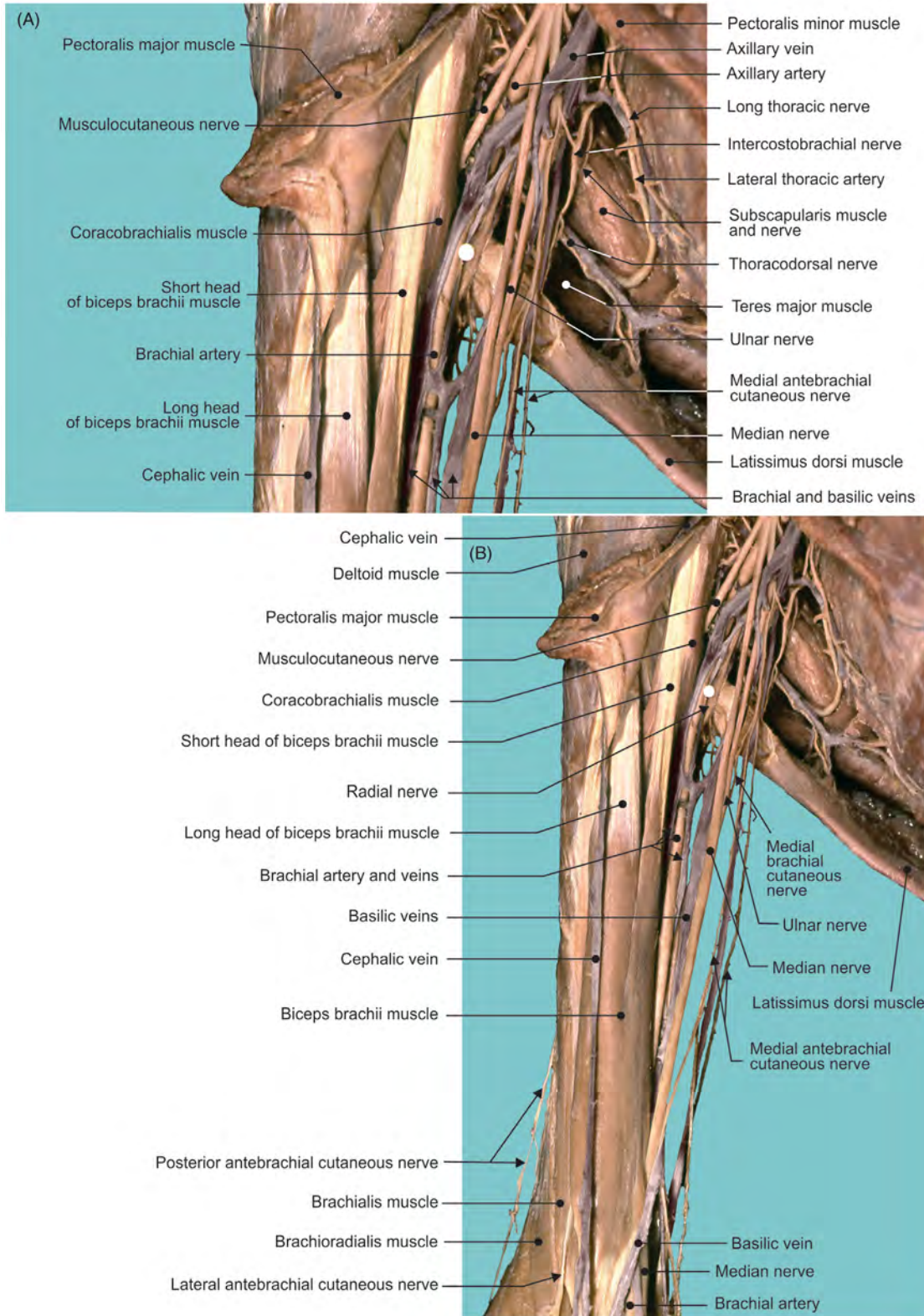


FIGURE 1.5 Anterior views of the (A) axillary and (B) brachial regions.

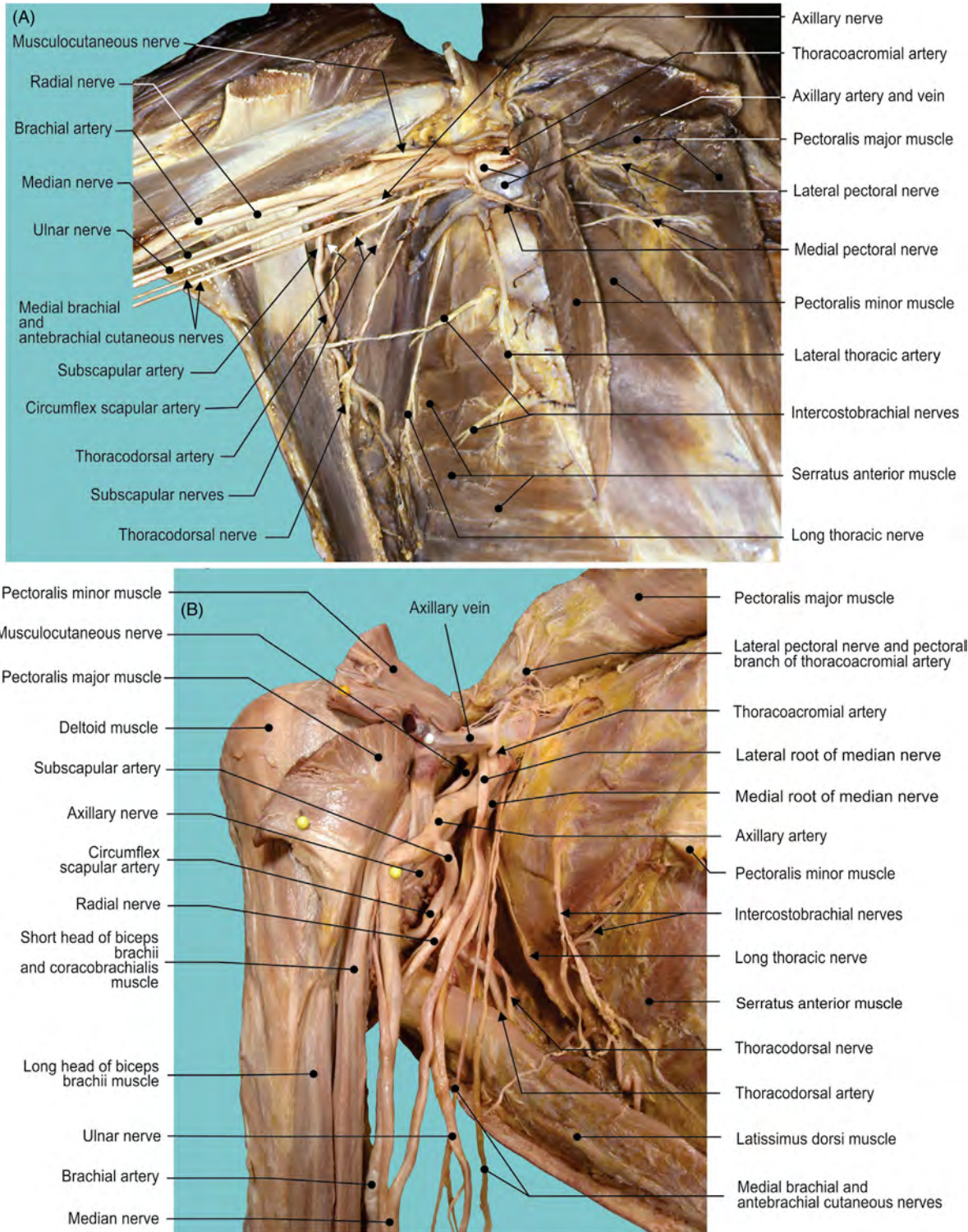
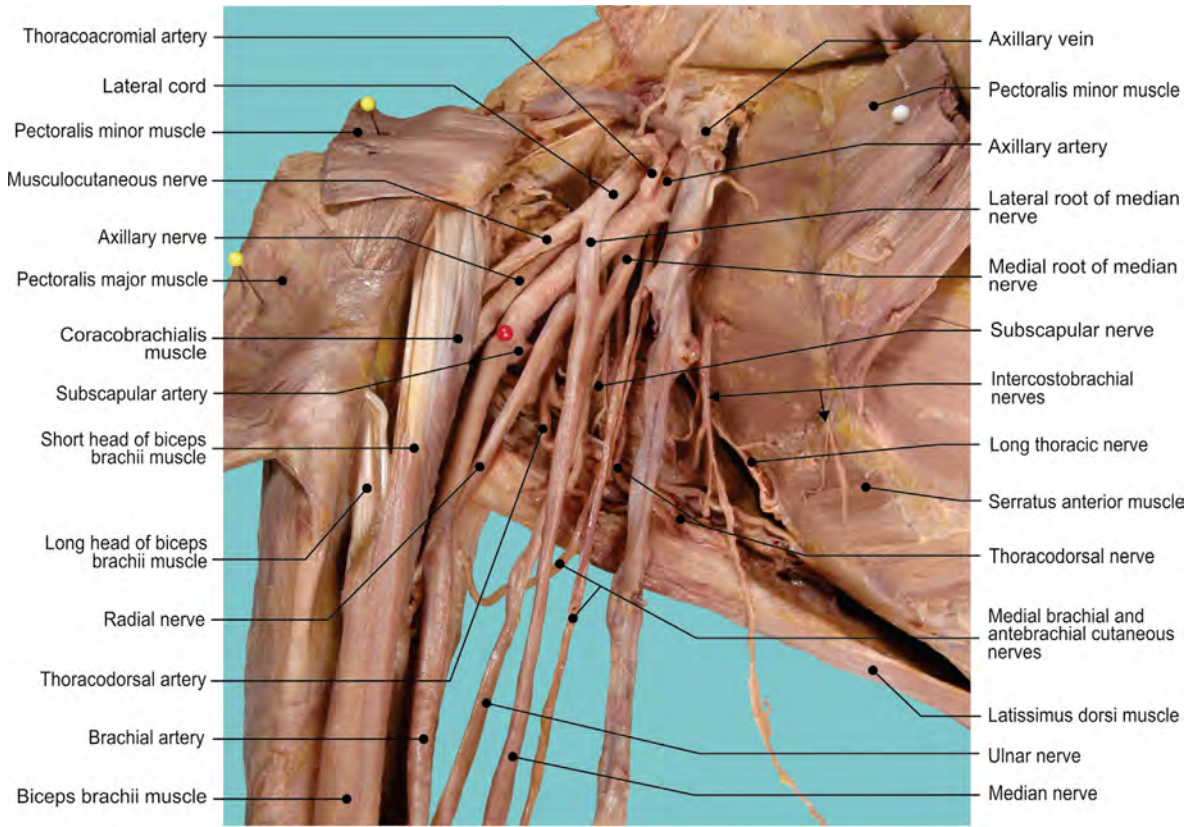
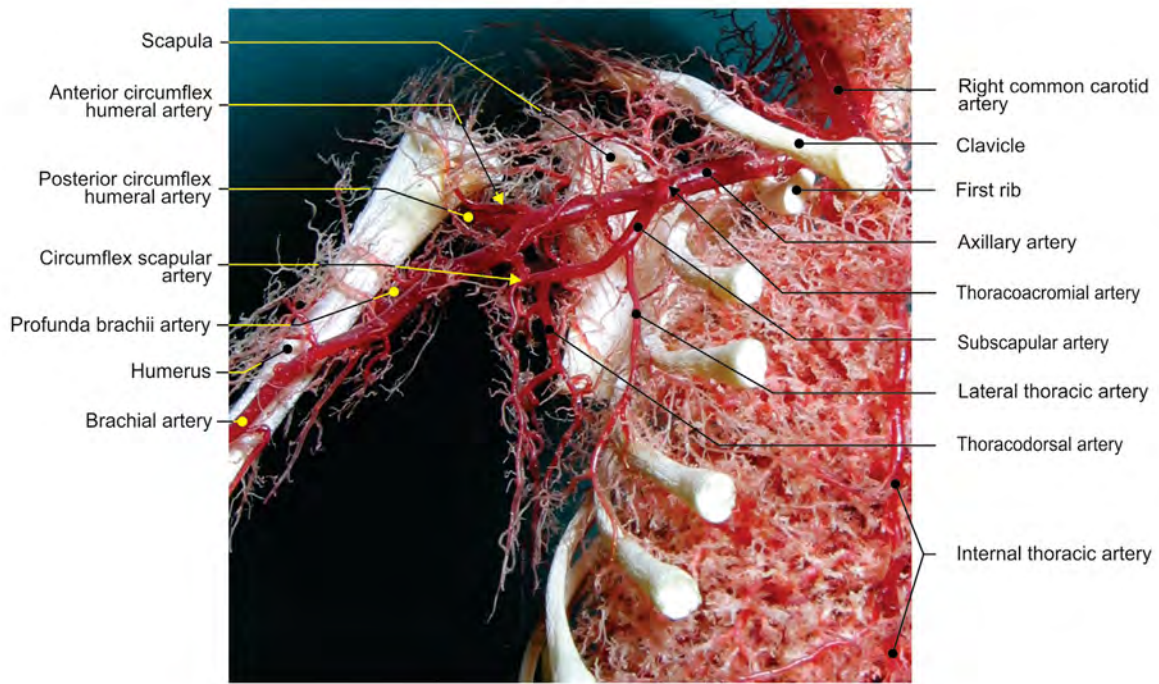


FIGURE 1.6 Anterior views of the (A) axillary and (B) brachial regions.



(A)



(B)

FIGURE 1.7 (A) Anterior view of the axillary fossa. (B) Anterior view of the fetal arterial distribution over rib cage and arm (corrosion cast).

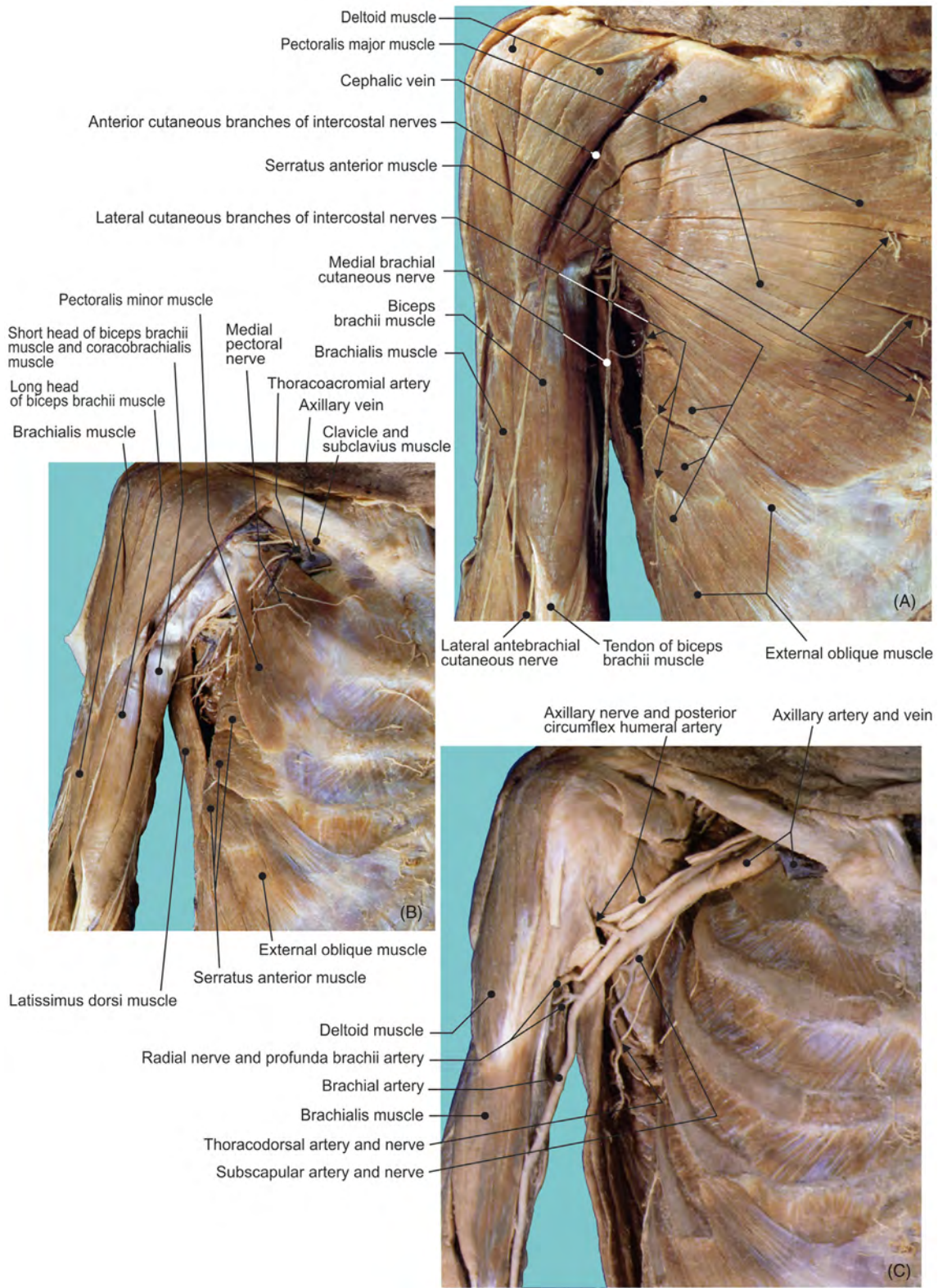


FIGURE 1.8 The pectoral region. (A) Superficial layer. (B) Deep layer. (C) Axillary fossa after the removal of medial and lateral cords of the brachial plexus.

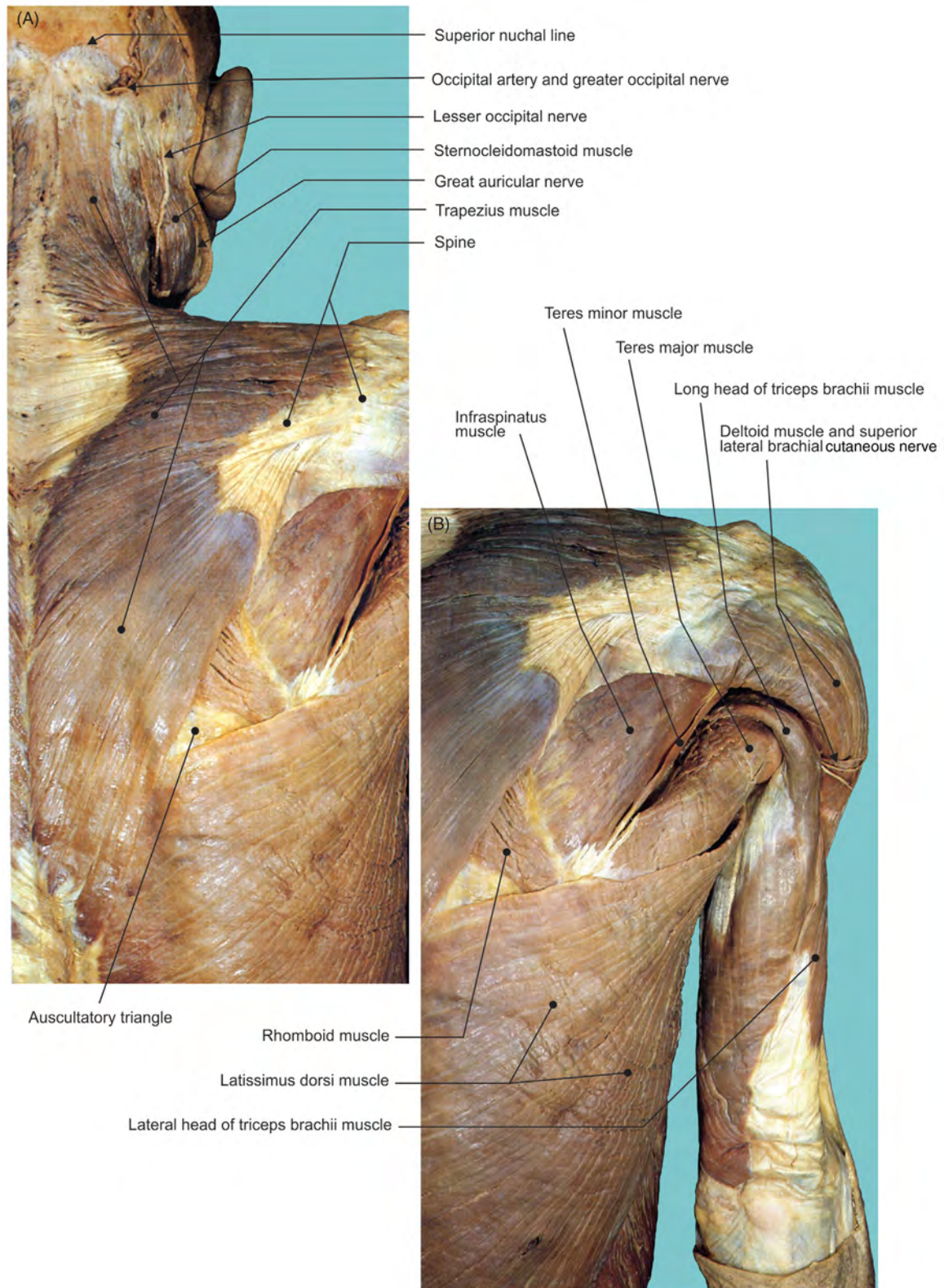


FIGURE 1.9 Superficial layer of the scapular region. (A) Scapular and (B) posterior brachial regions.

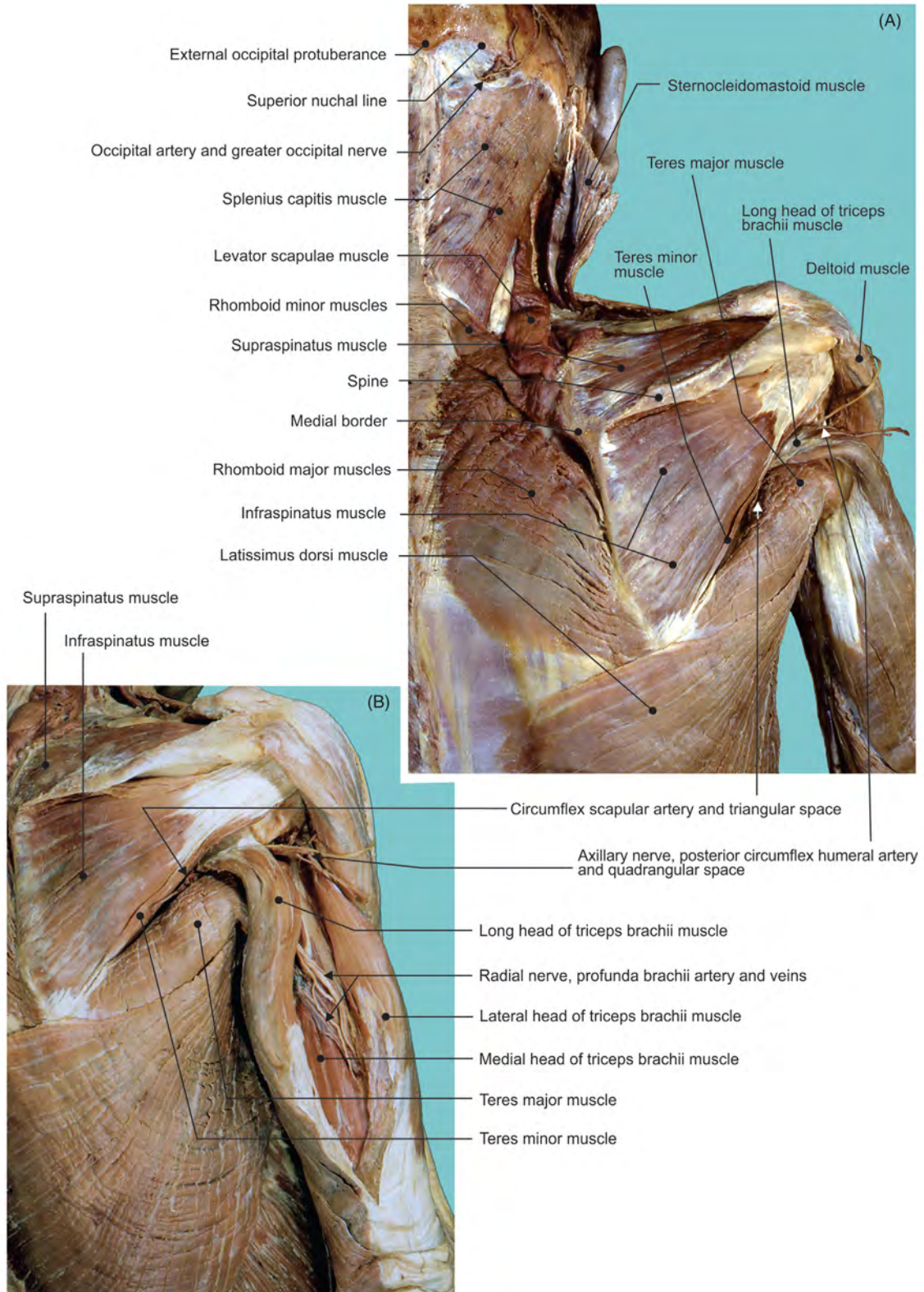


FIGURE 1.10 (A) Middle layer of the scapular region and (B) the posterior brachial region.

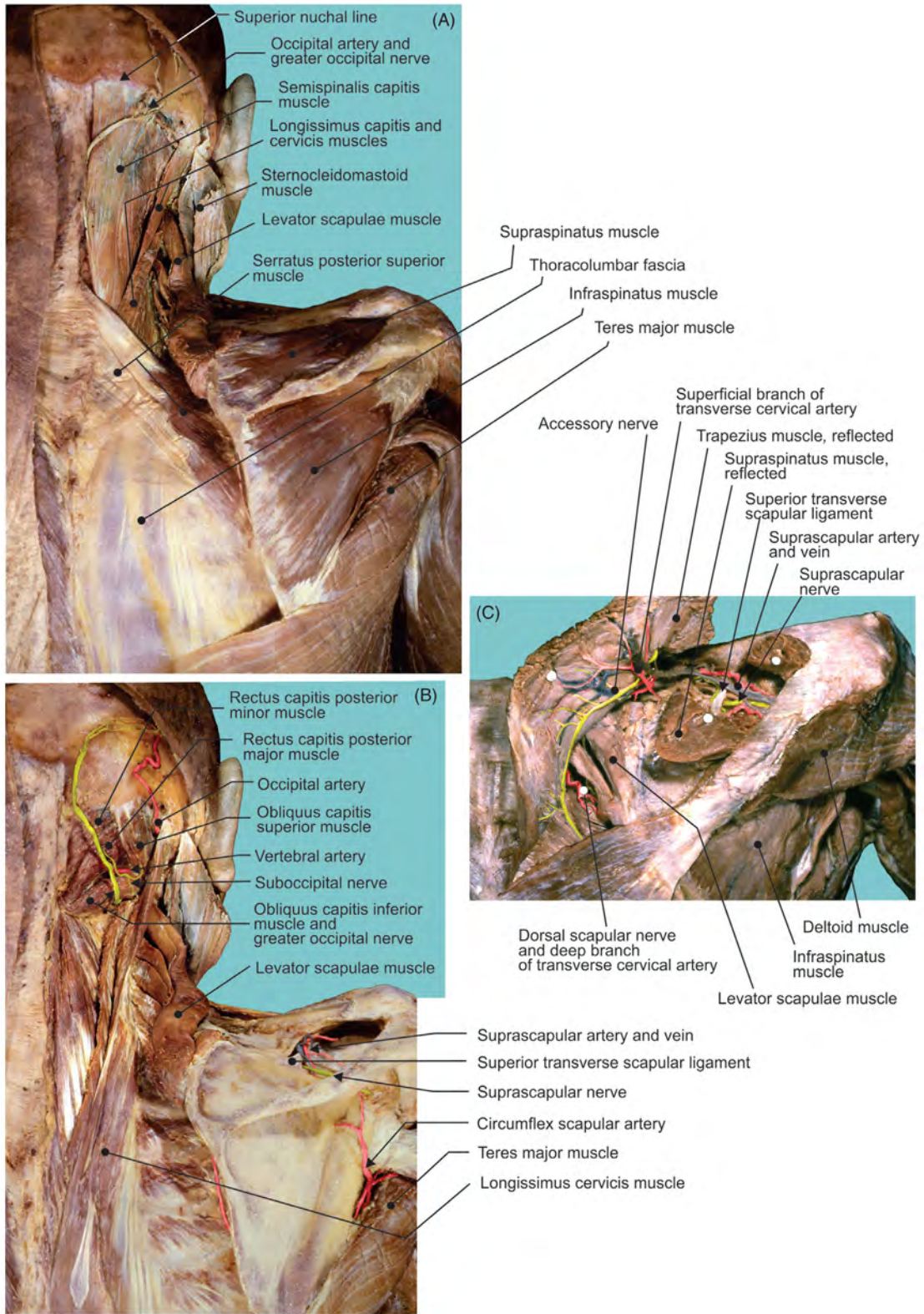


FIGURE 1.11 Deep layer of the scapular region. Illustrations of structures: (A) muscles, (B) vascularization, (C) and details.

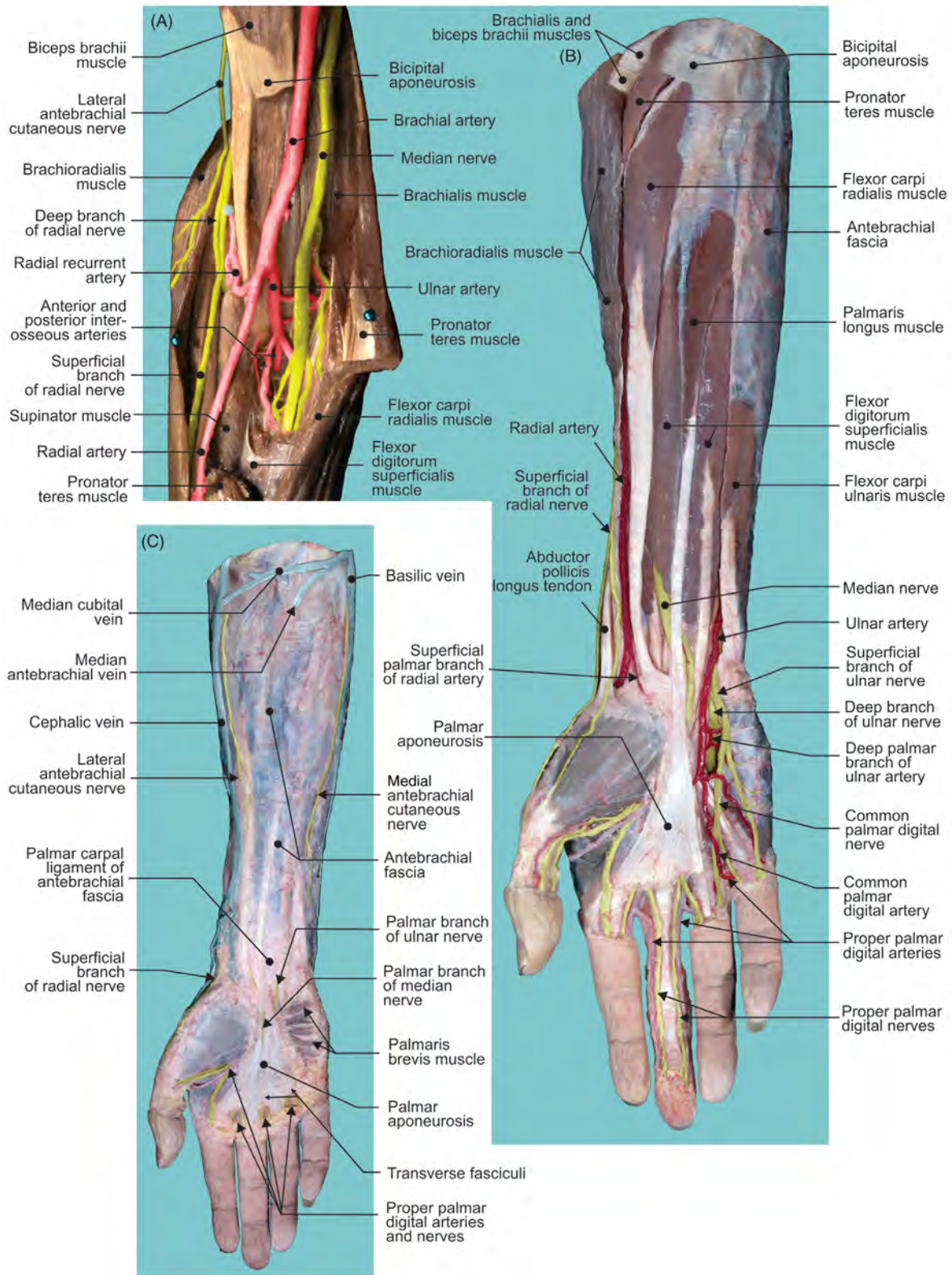


FIGURE 1.12 (A) Anterior cubital region. (B–C) Superficial layer of the anterior antebrachial region.

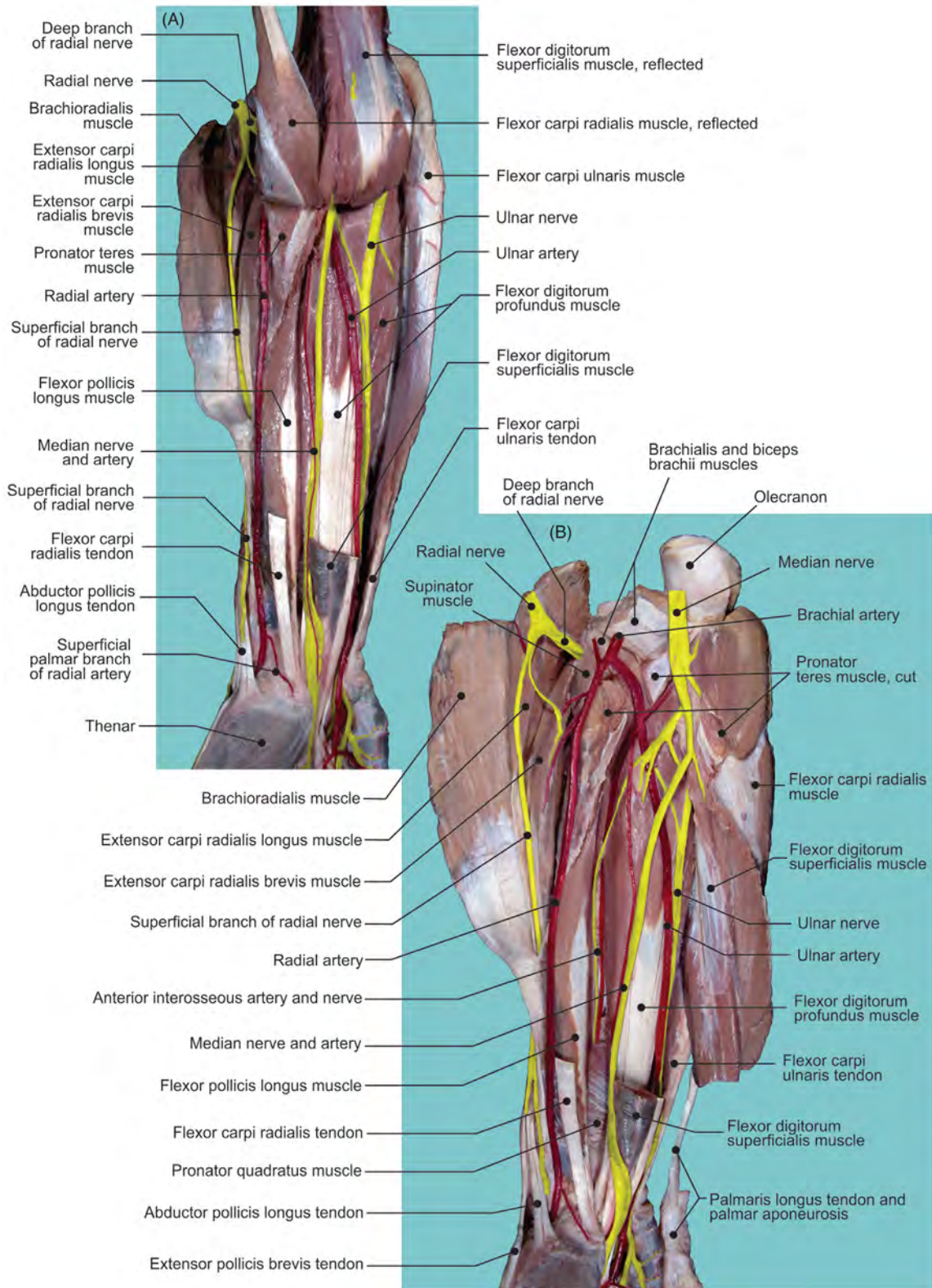


FIGURE 1.13 Deep layer (A–B) of the anterior antebrachial region.

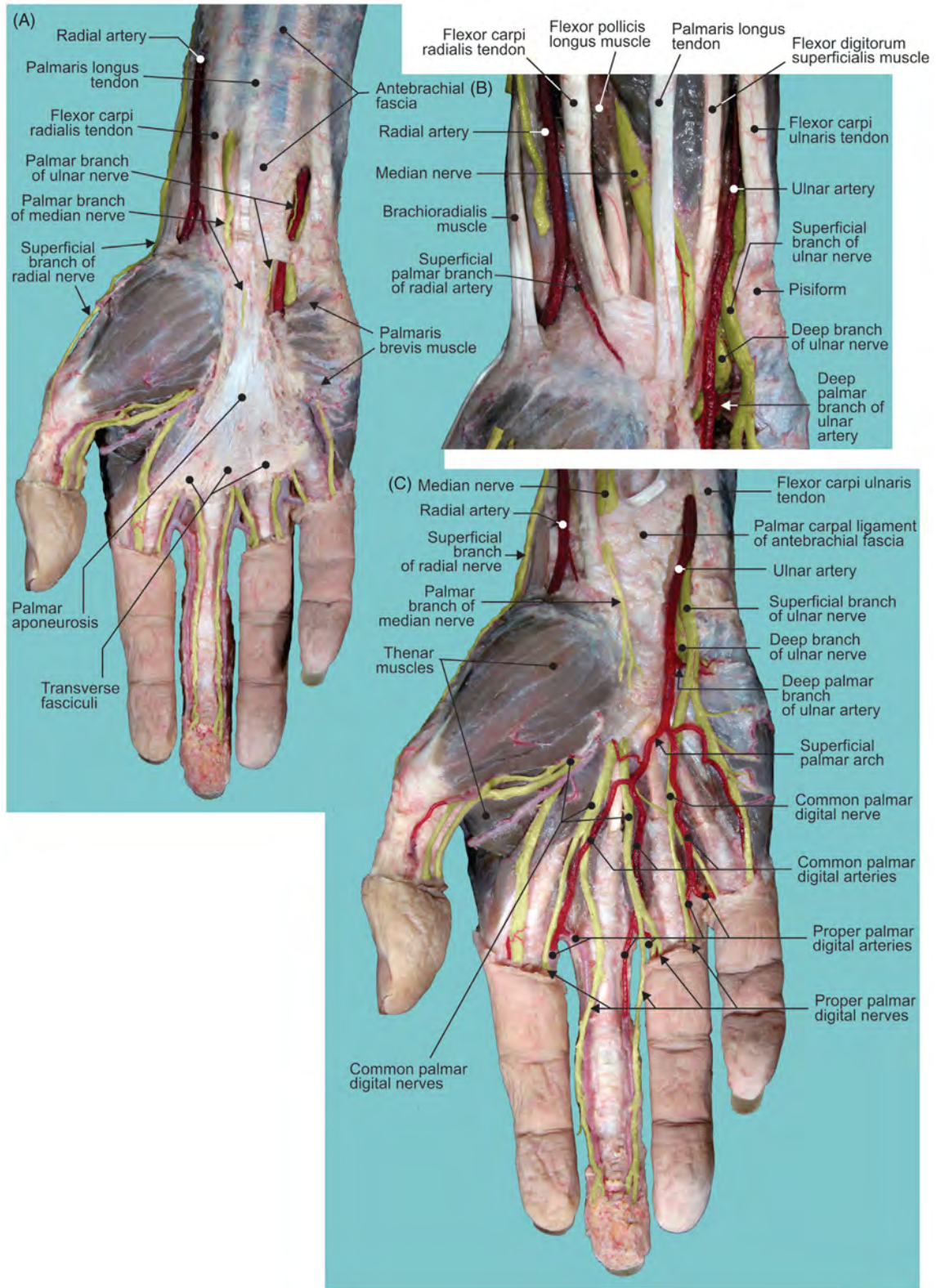


FIGURE 1.14 Superficial structures in the palmar region. (A–C) Different layers offering structural details.

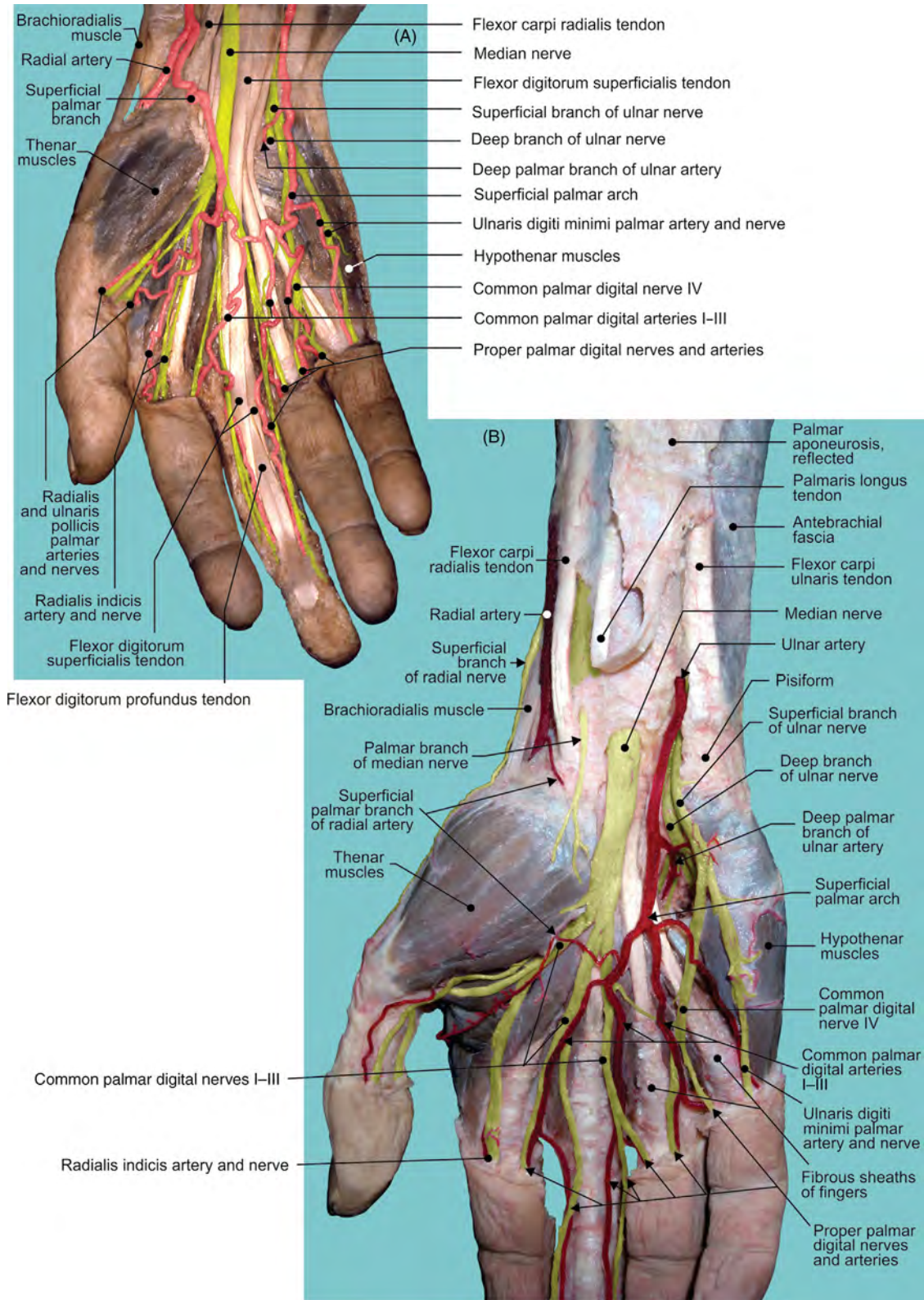


FIGURE 1.15 Structures in the palmar region deep to palmar aponeurosis. (A–B) Different specimens offering structural details.

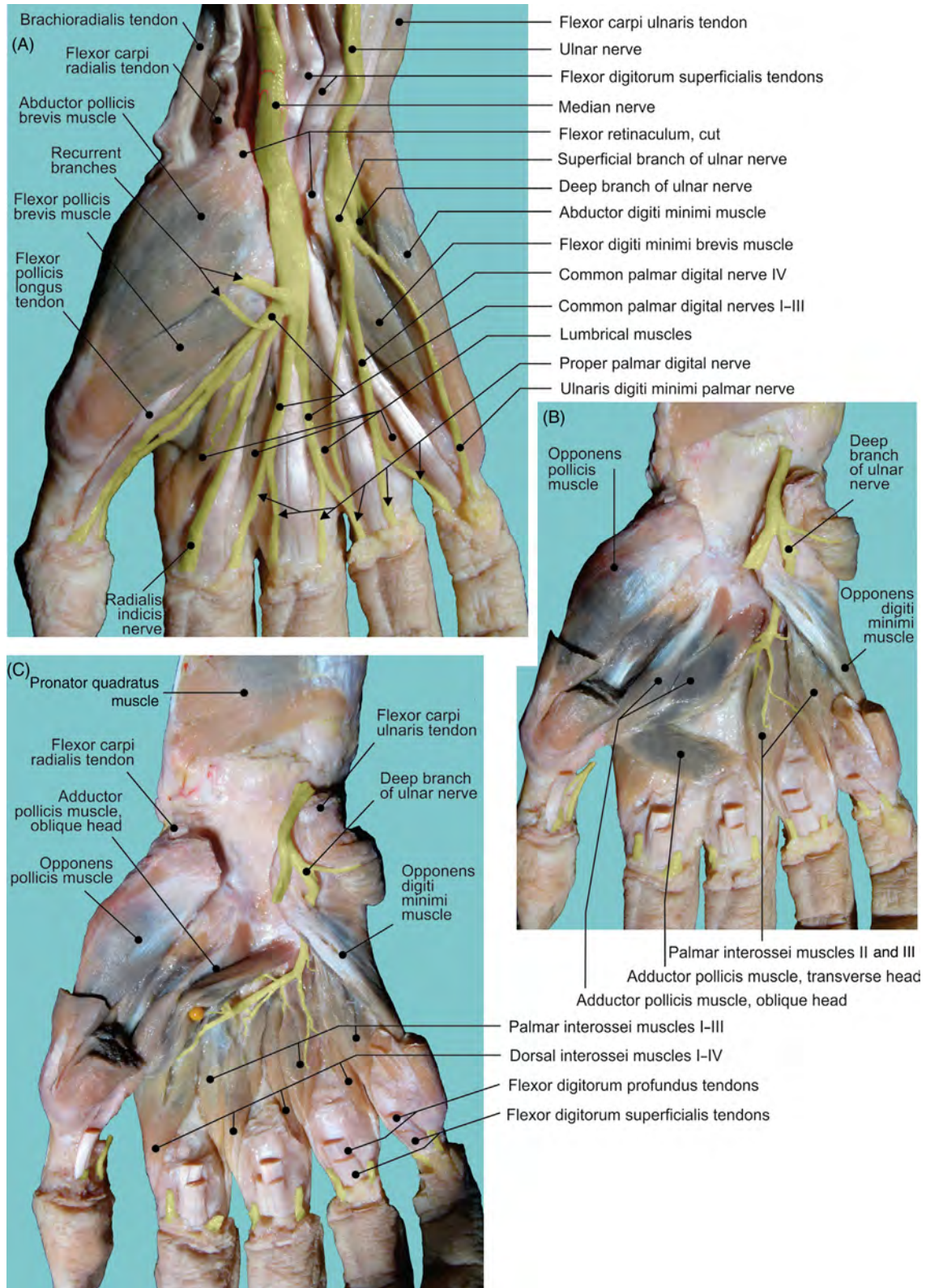


FIGURE 1.16 Structures in the deep layer of the palmar region. (A–C) Different layers offering structural details.

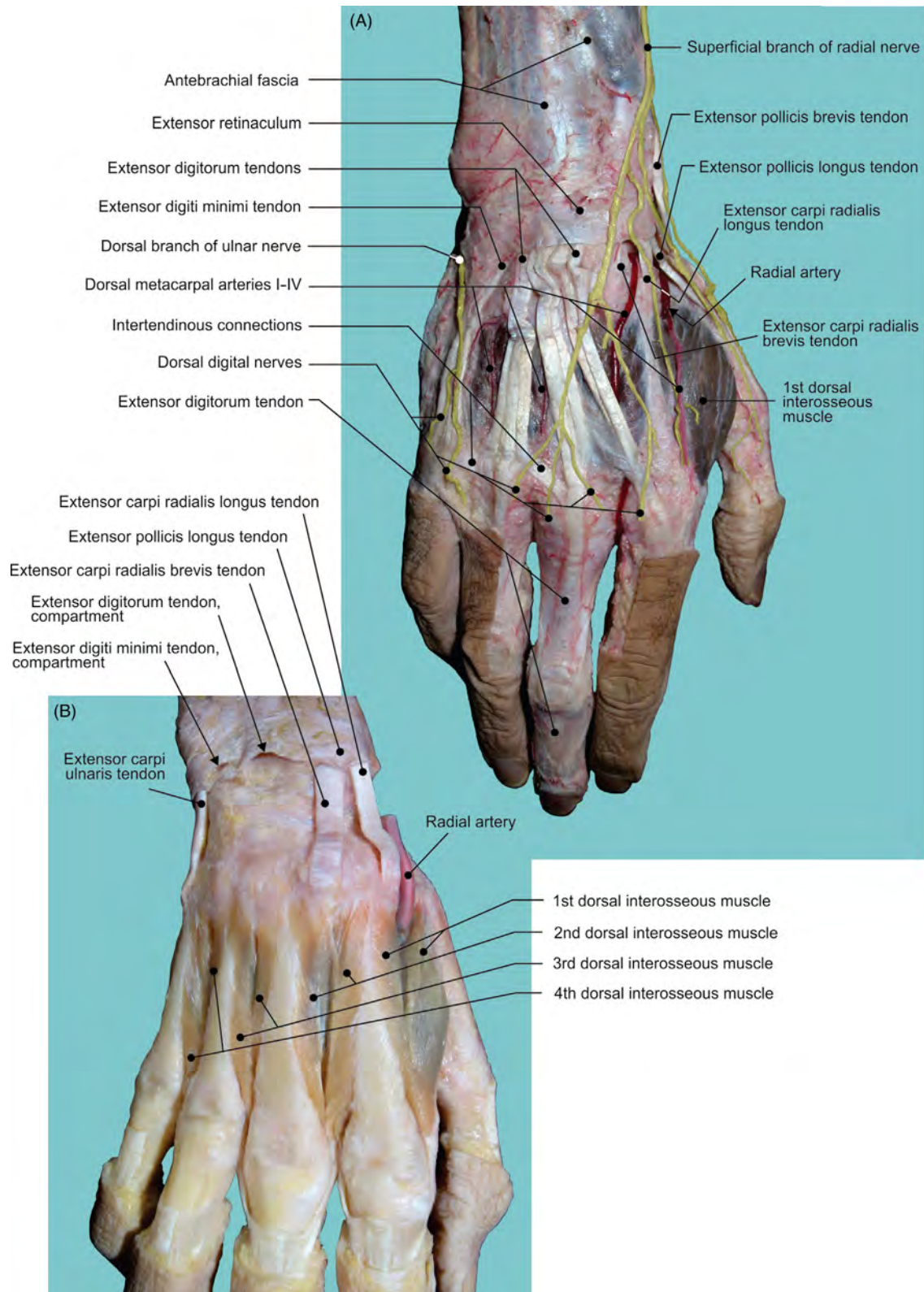


FIGURE 1.17 Structures in the posterior region of the hand. (A–B) Different layers offering structural details.

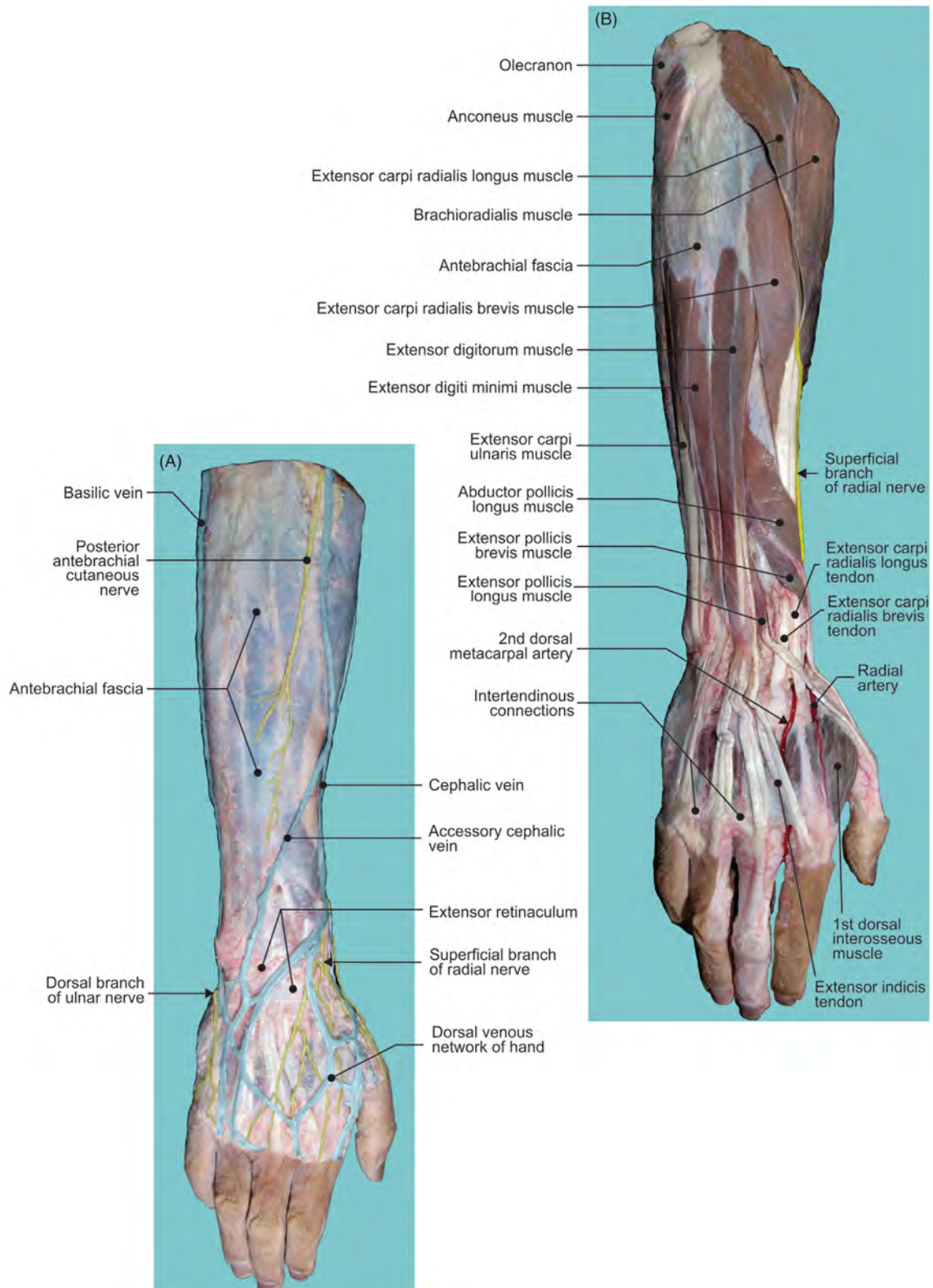


FIGURE 1.18 (A) Structures in the subcutaneous and (B) superficial layers of the posterior antebrachial and hand regions.

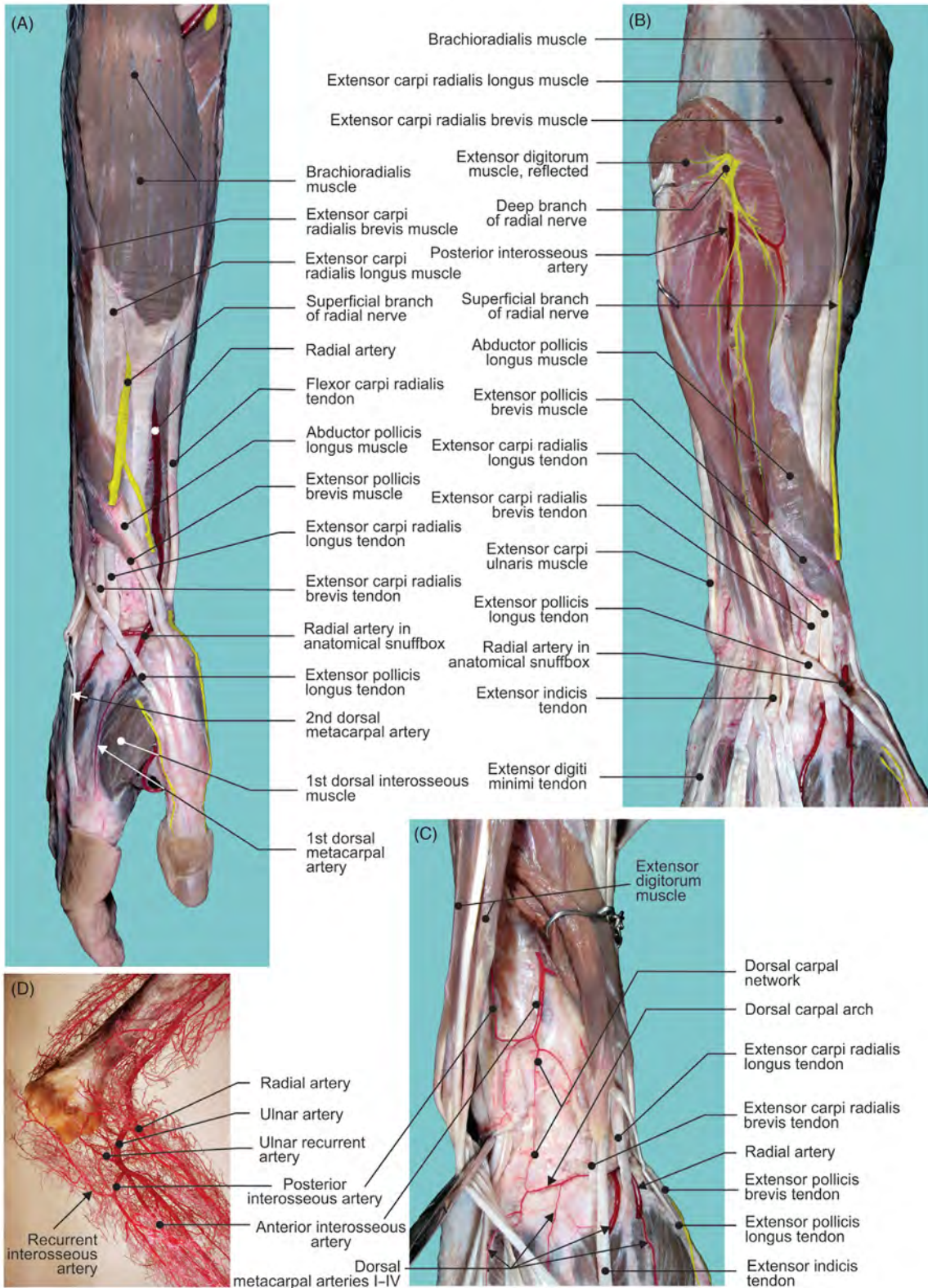


FIGURE 1.19 (A) Superficial and (B–C) deep structures of the posterior antebrachial and carpal regions. (D) Corrosion cast of arterial network around the elbow joint.

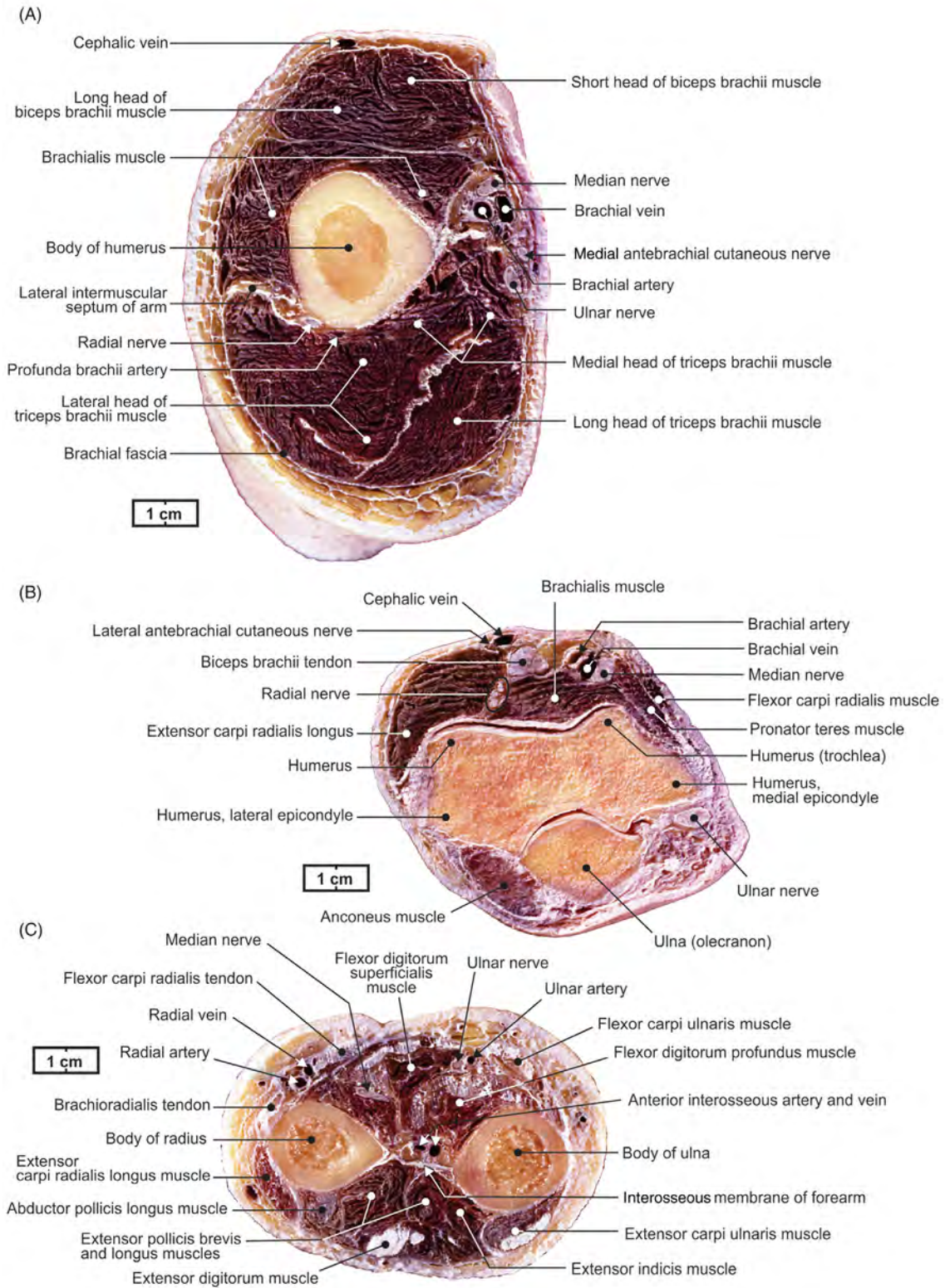


FIGURE 1.20 Transverse cross-sectional views of the right (A) arm, (B) elbow joint, and (C) forearm.

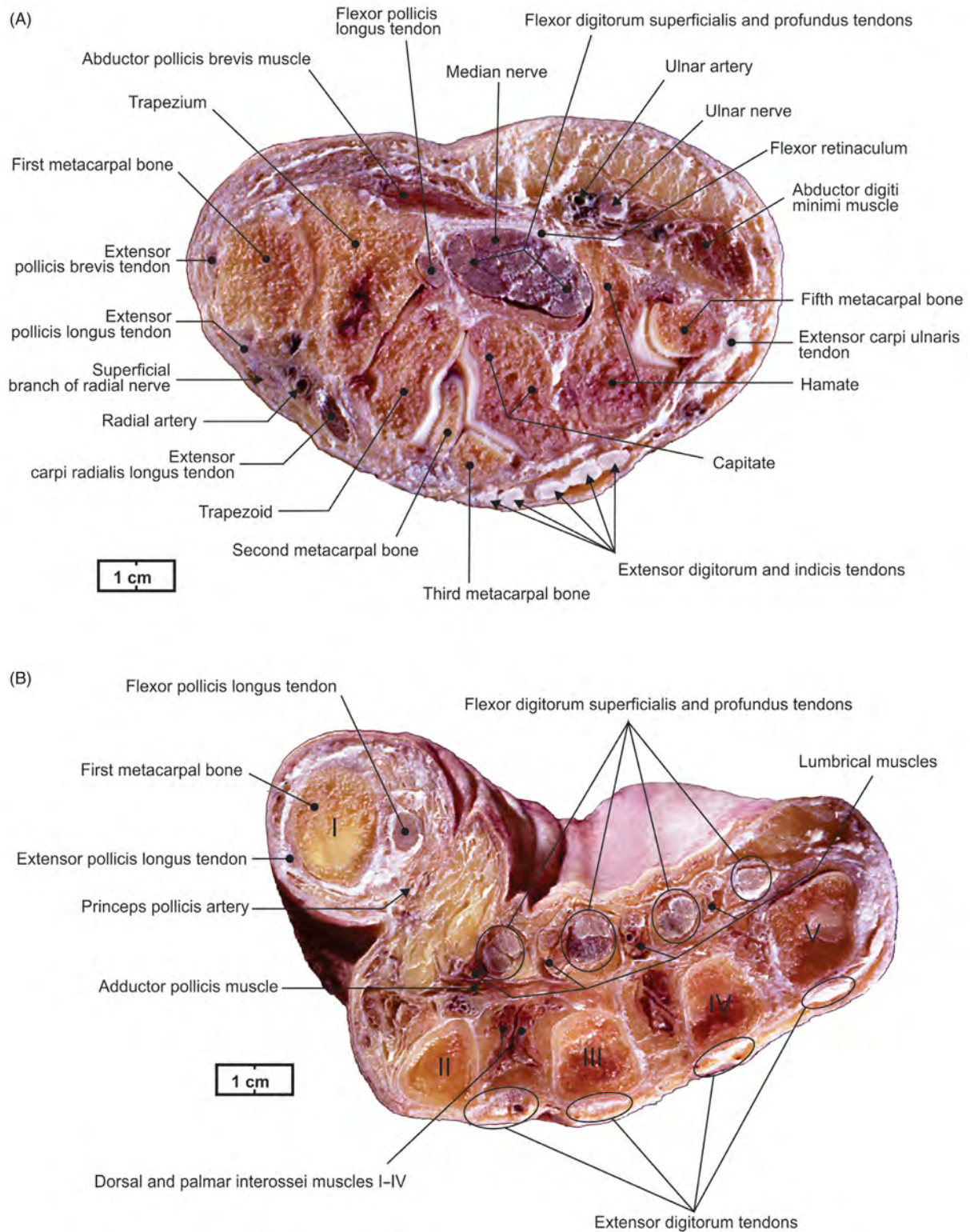


FIGURE 1.21 Transverse cross-sectional views of the right (A) carpal and (B) metacarpal regions.

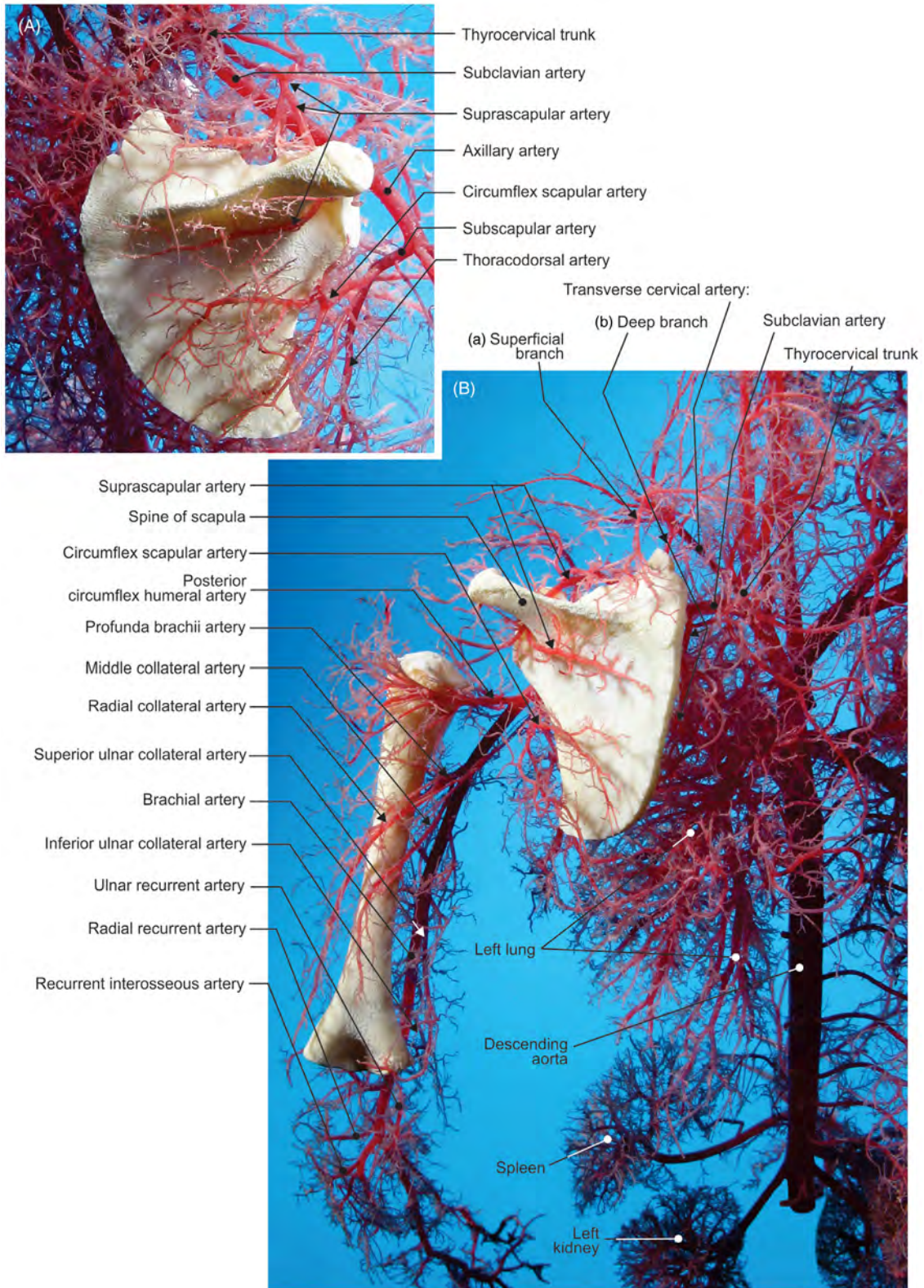


FIGURE 1.22 Fetal arterial corrosion casts on the posterior aspects of (A) scapula and (B) scapula, brachium, and elbow.

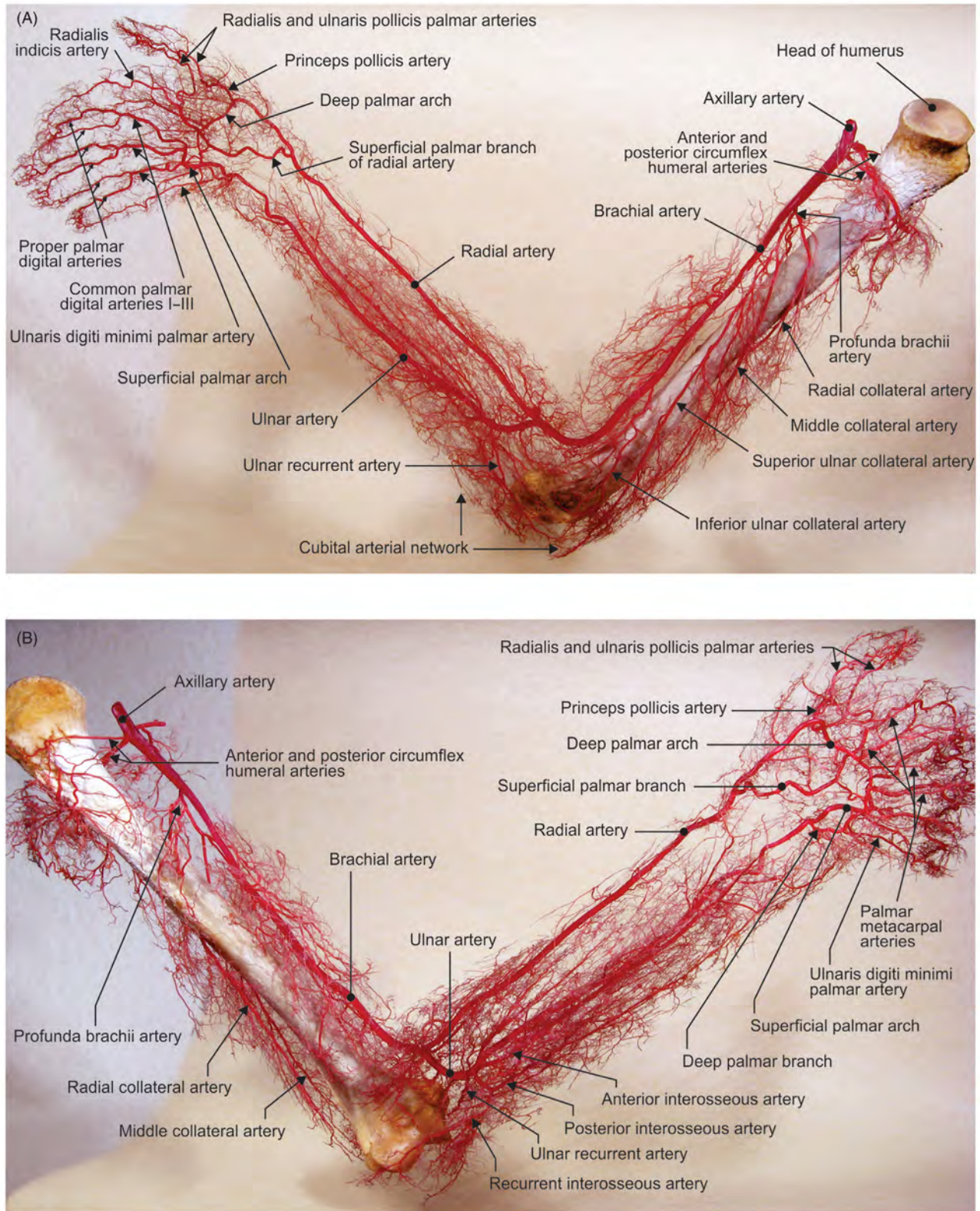


FIGURE 1.23 Arterial corrosion cast of the right upper limb. (A) Medial and (B) lateral views.

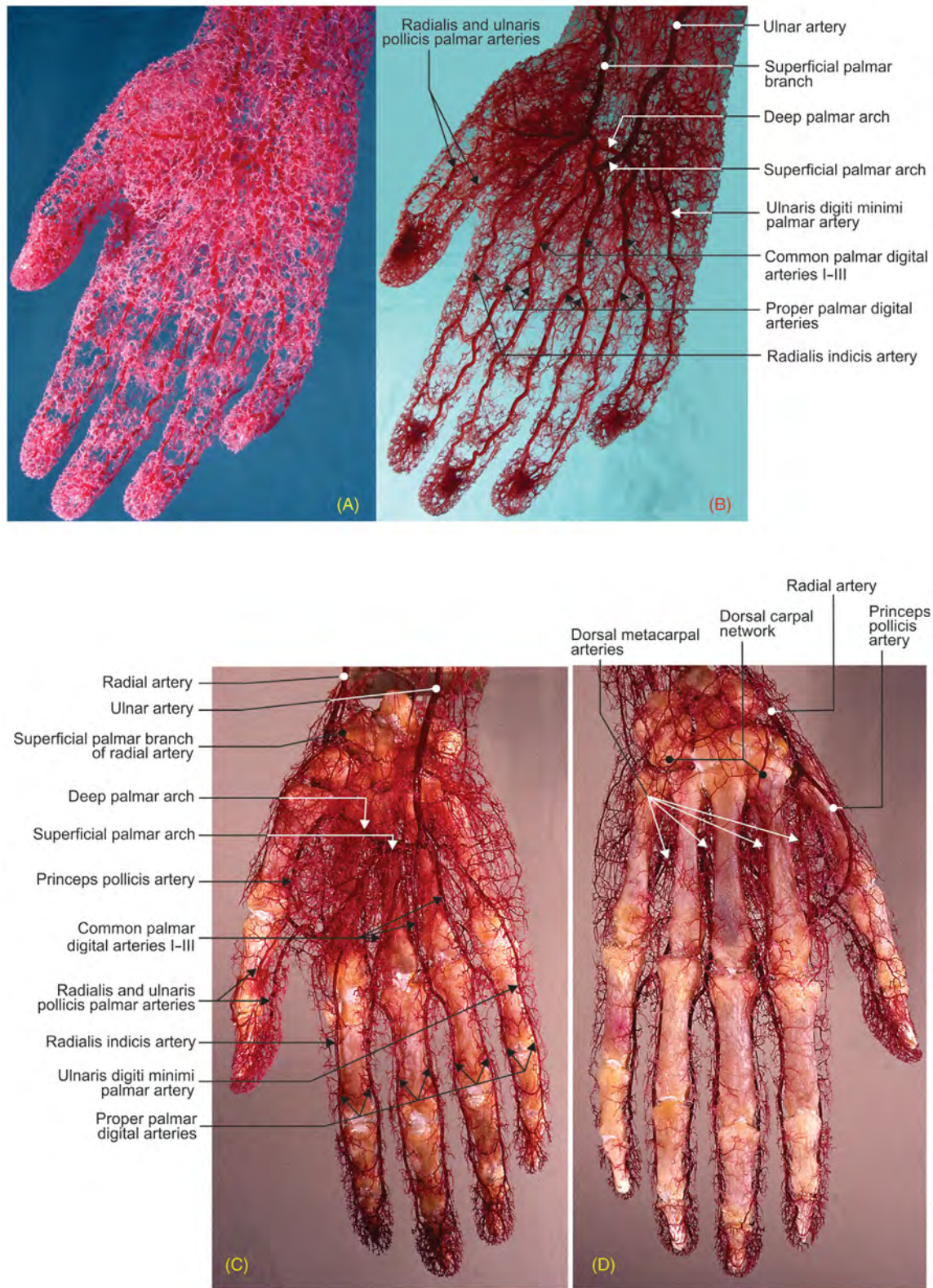


FIGURE 1.24 Arterial networks (corrosion casts) of right hand. (A) Superficial vessels, (B) major vessels, (C) palmar side, and (D) dorsal side.

Chapter 2

Lower Limb and Vascularization

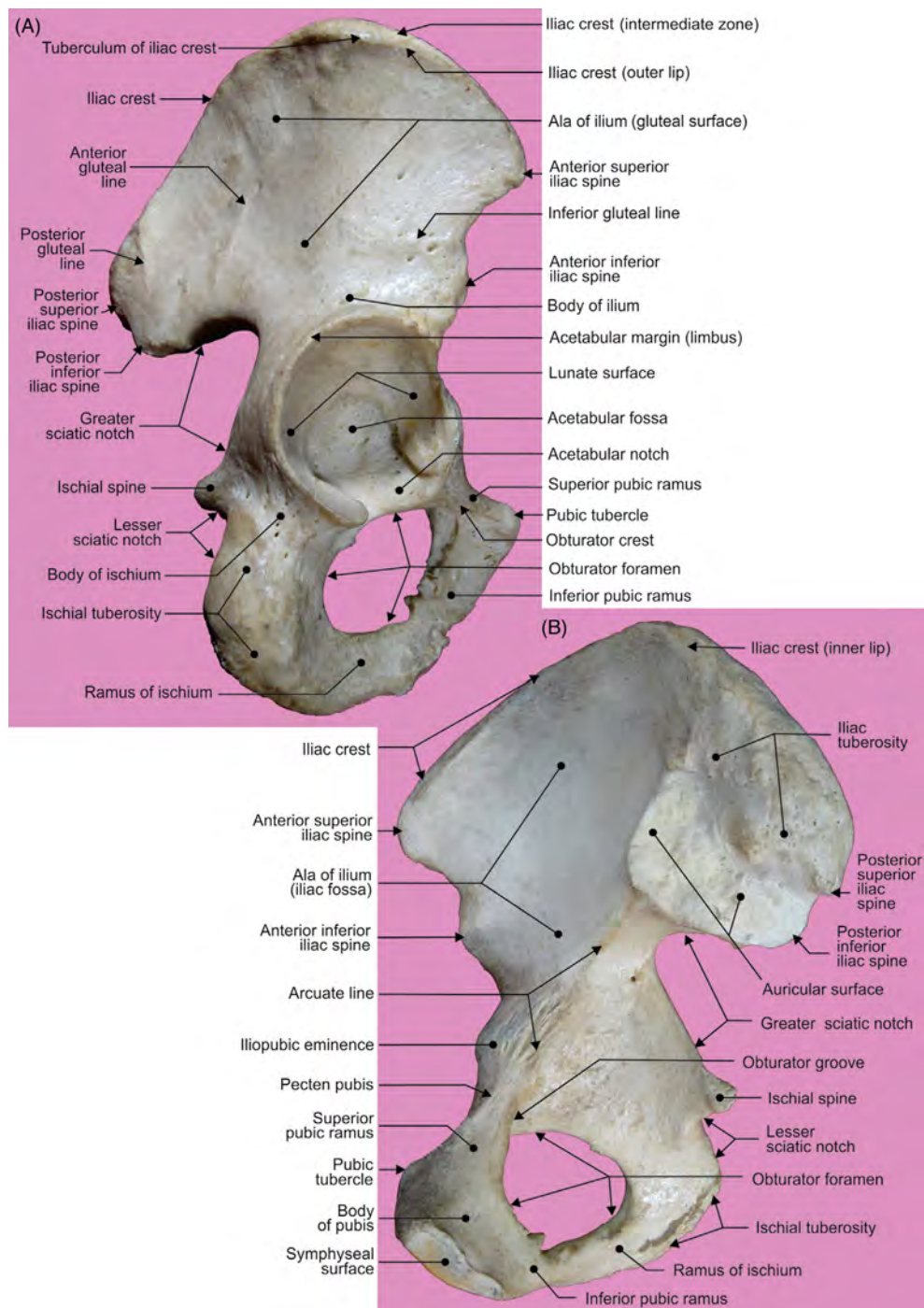


FIGURE 2.1 The hip bone. (A) Lateral and (B) medial views.

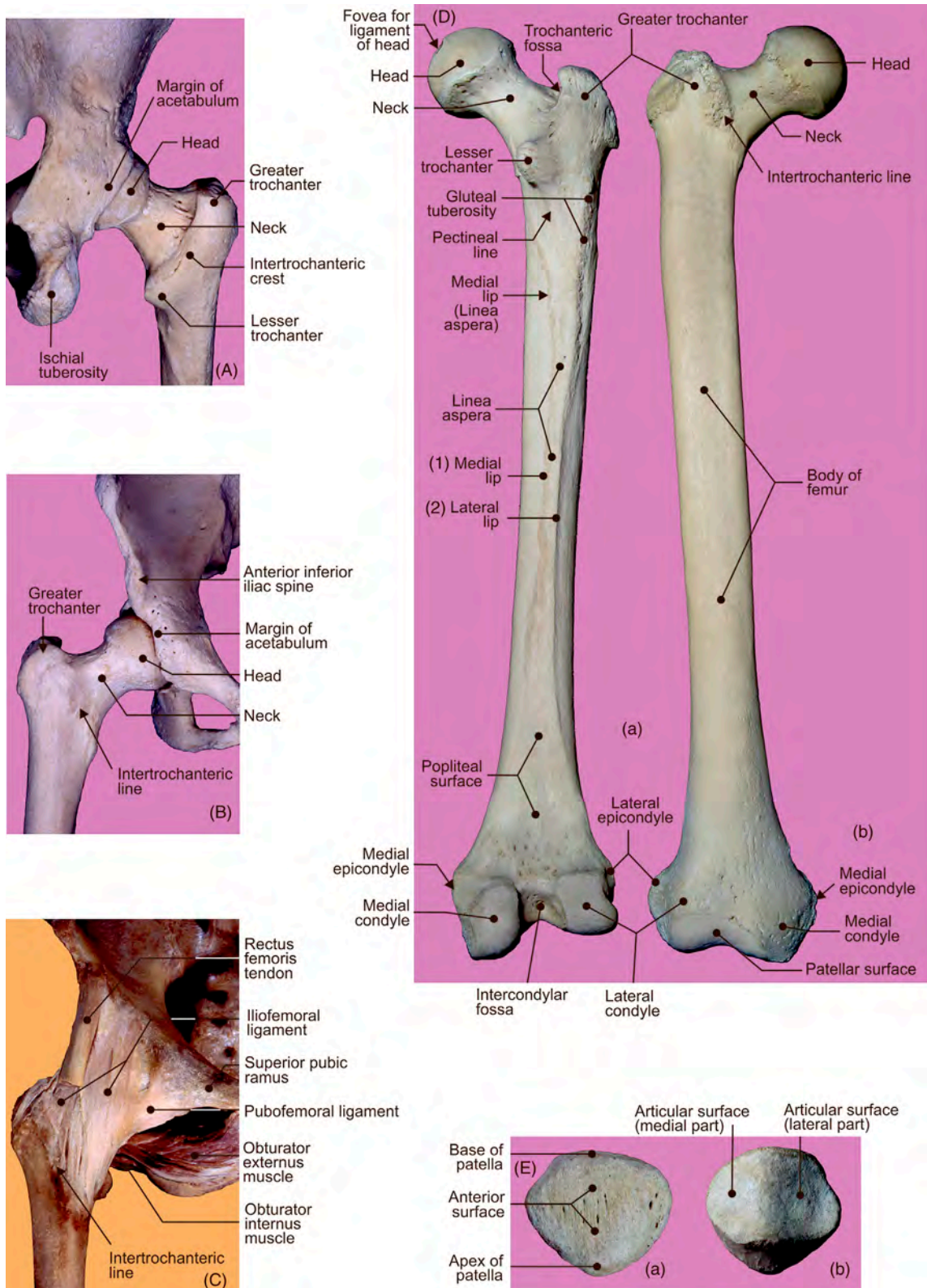


FIGURE 2.2 The hip joint: (A) posterior and anterior (B) views of the bones; (C) anterior view of the ligaments. (D) Right femur: (a) posterior and (b) anterior views. (E) Patella: (a) anterior and (b) posterior views.

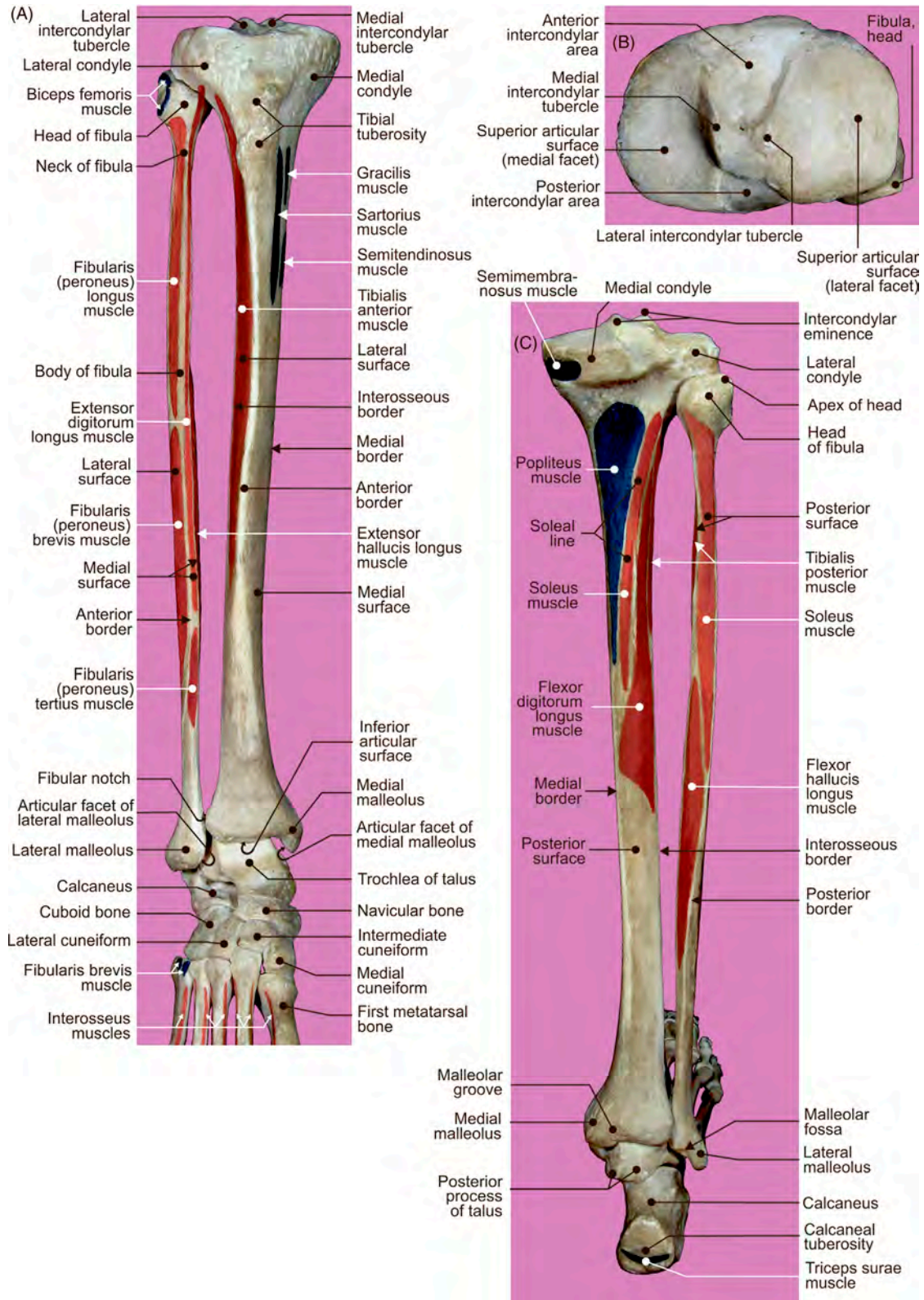


FIGURE 2.3 Right tibia and fibula. (A) Anterior, (B) superior, and (C) posterior views.

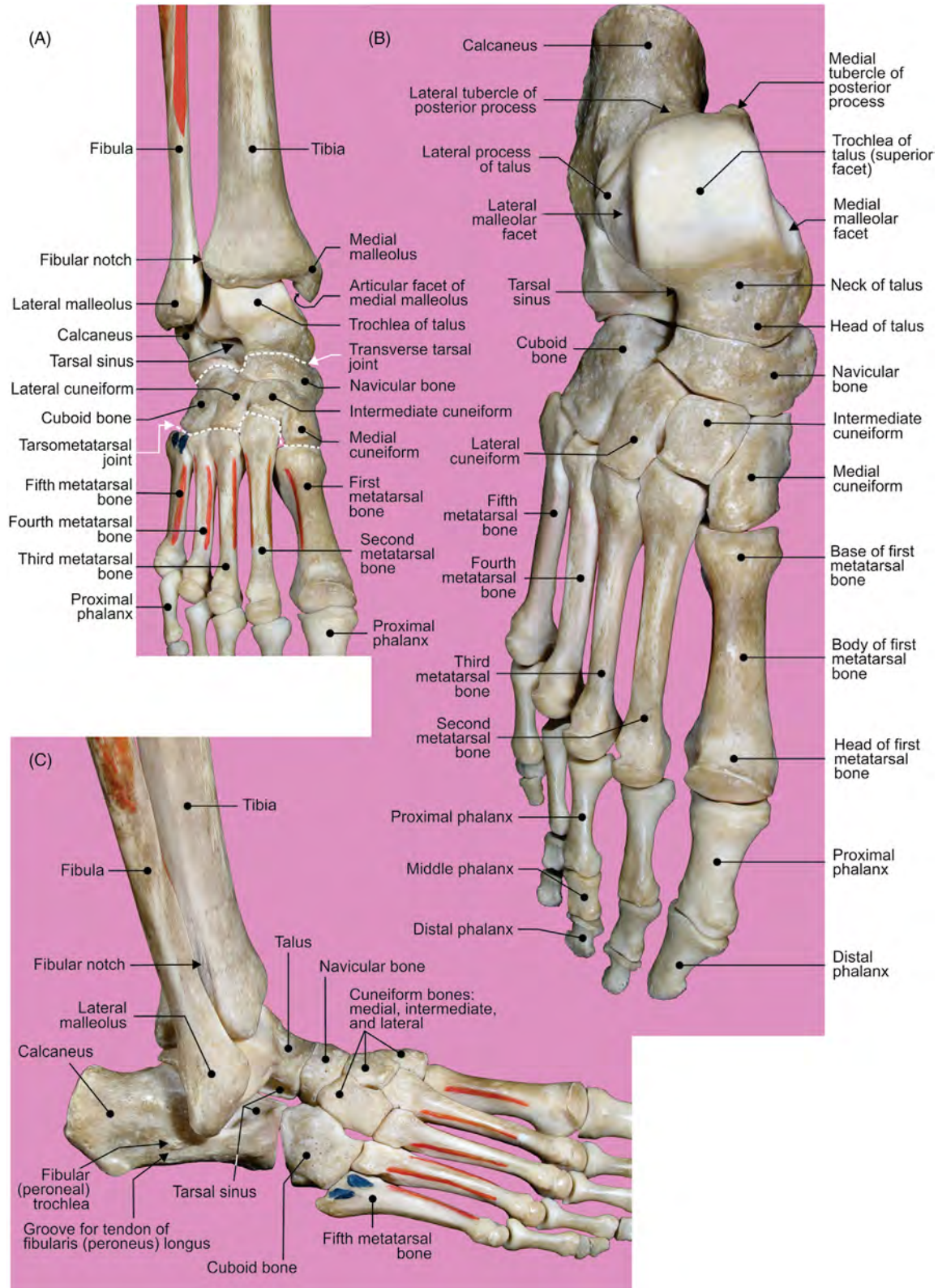


FIGURE 2.4 Skeleton of the foot. (A–C) Different views of the dorsal aspect.

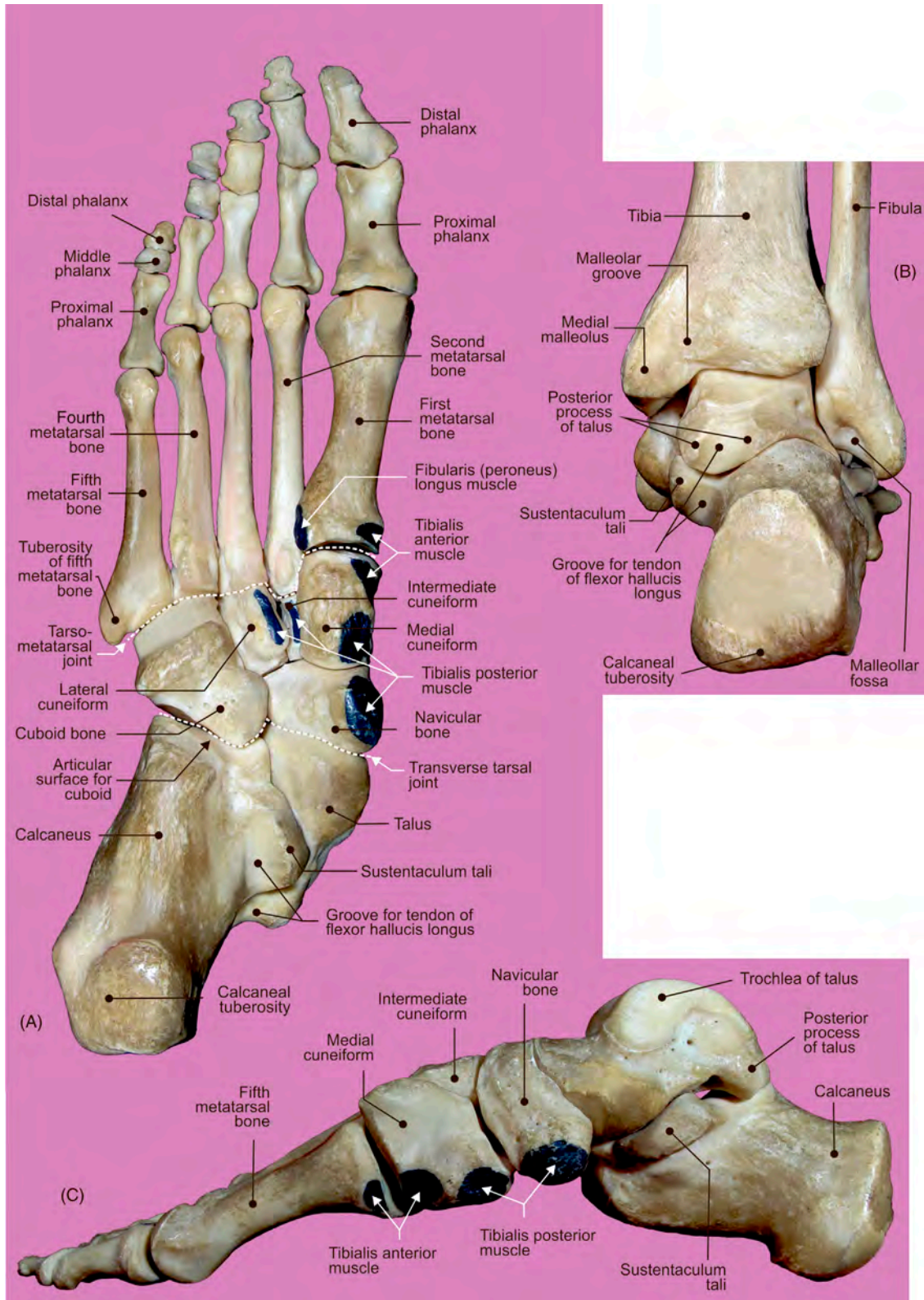


FIGURE 2.5 Skeleton of the right foot. (A) Inferior, (B) posterior, and (C) medial aspects.

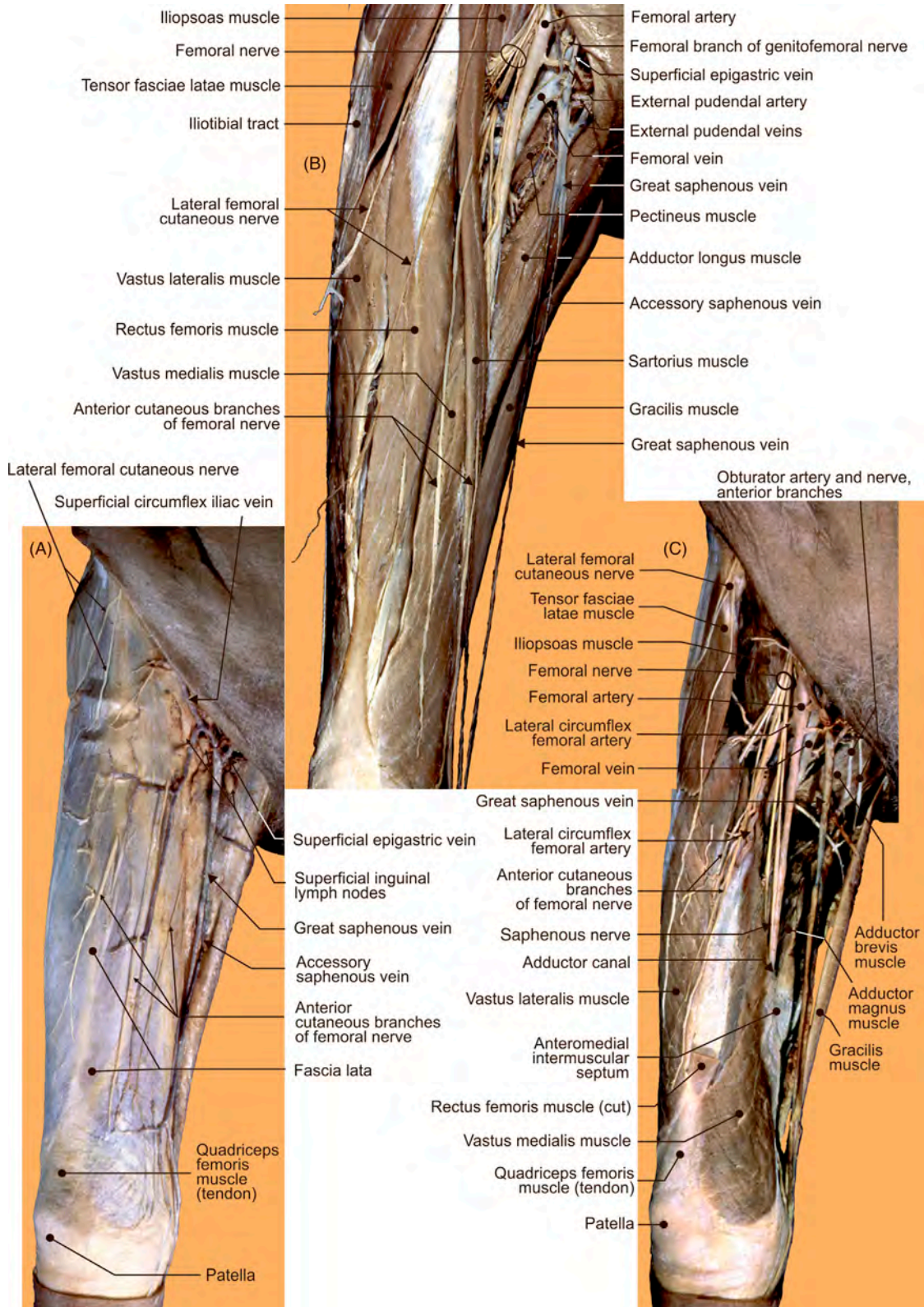


FIGURE 2.6 Frontal view of the anterior femoral region. (A–C) Different layers offering structural details.

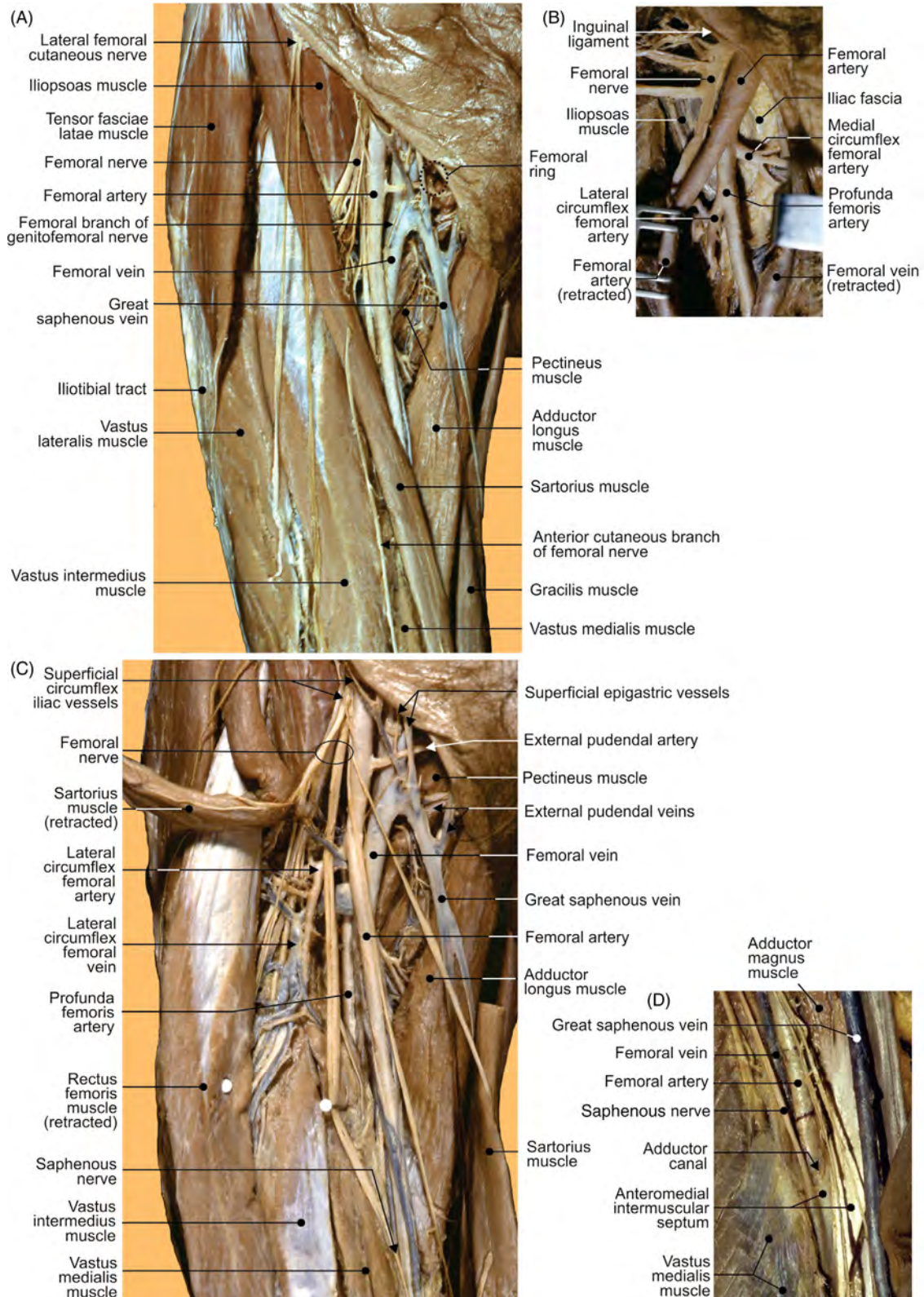


FIGURE 2.7 Frontal view of the right anterior femoral region. (A,C) Frontal view of the right anterior femoral region, (B) femoral artery, and (D) detail of the lower medial femoral subregion.

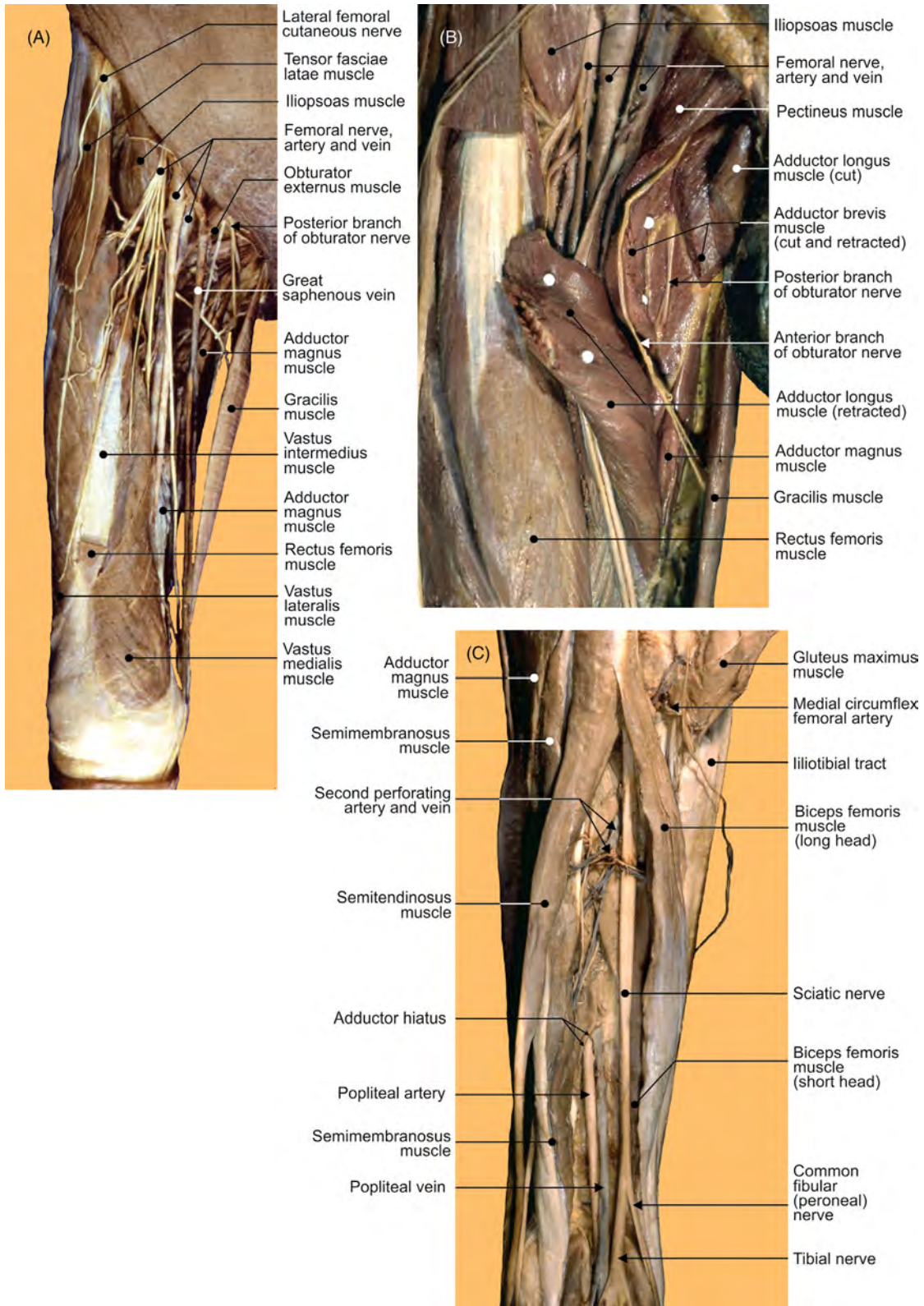


FIGURE 2.8 The right lower limb. Frontal views of the (A–B) anterior femoral regions and (C) posterior femoral region.

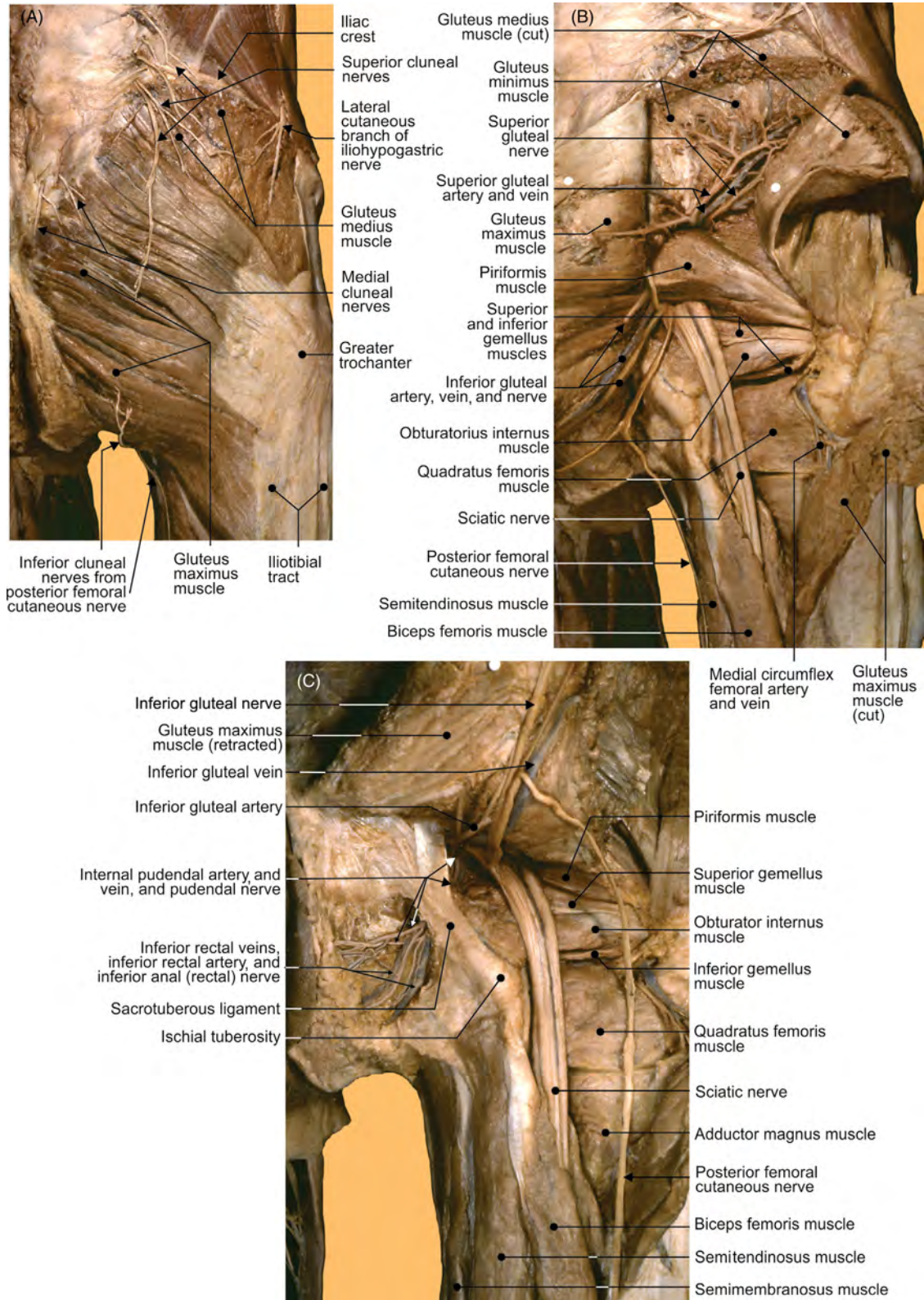


FIGURE 2.9 The right gluteal region. (A–C) Different views offering structural details of the superficial and deeper layers.

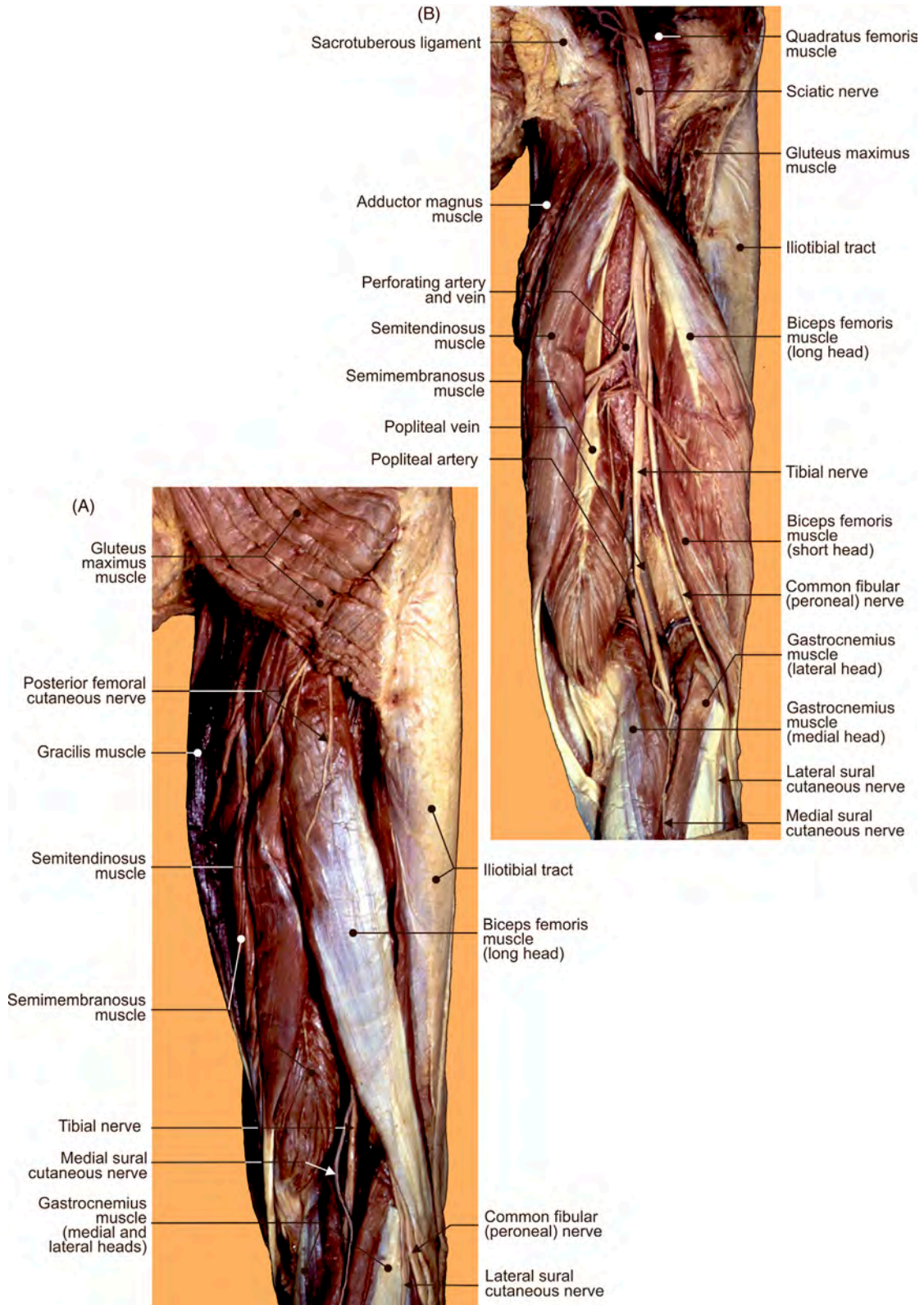


FIGURE 2.10 The right posterior femoral regions and popliteal fossa. (A) Superficial and (B) deep layers.

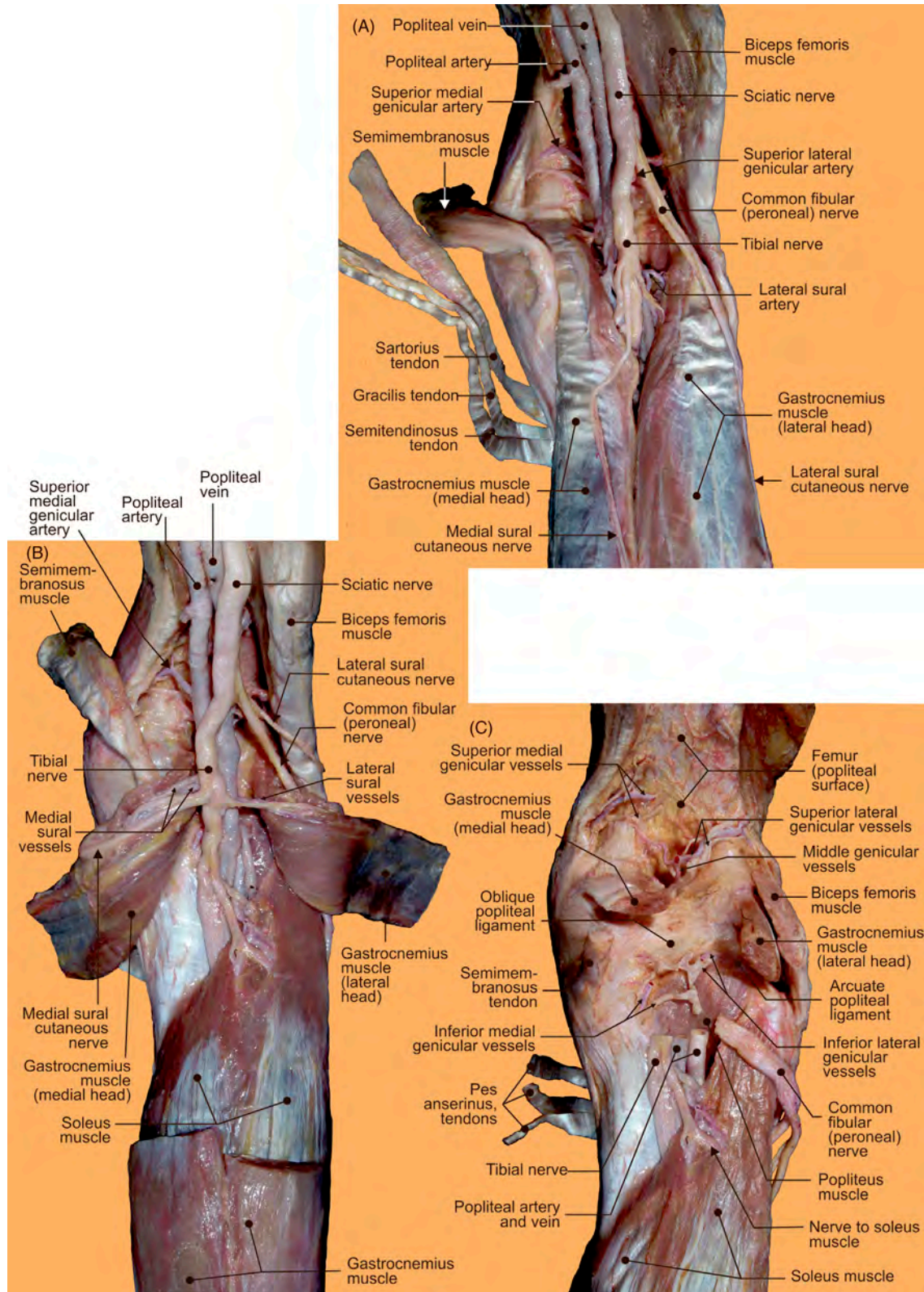


FIGURE 2.11 The right posterior view of the knee region and popliteal fossa. (A–C) Different views offering structural details of the walls and content.

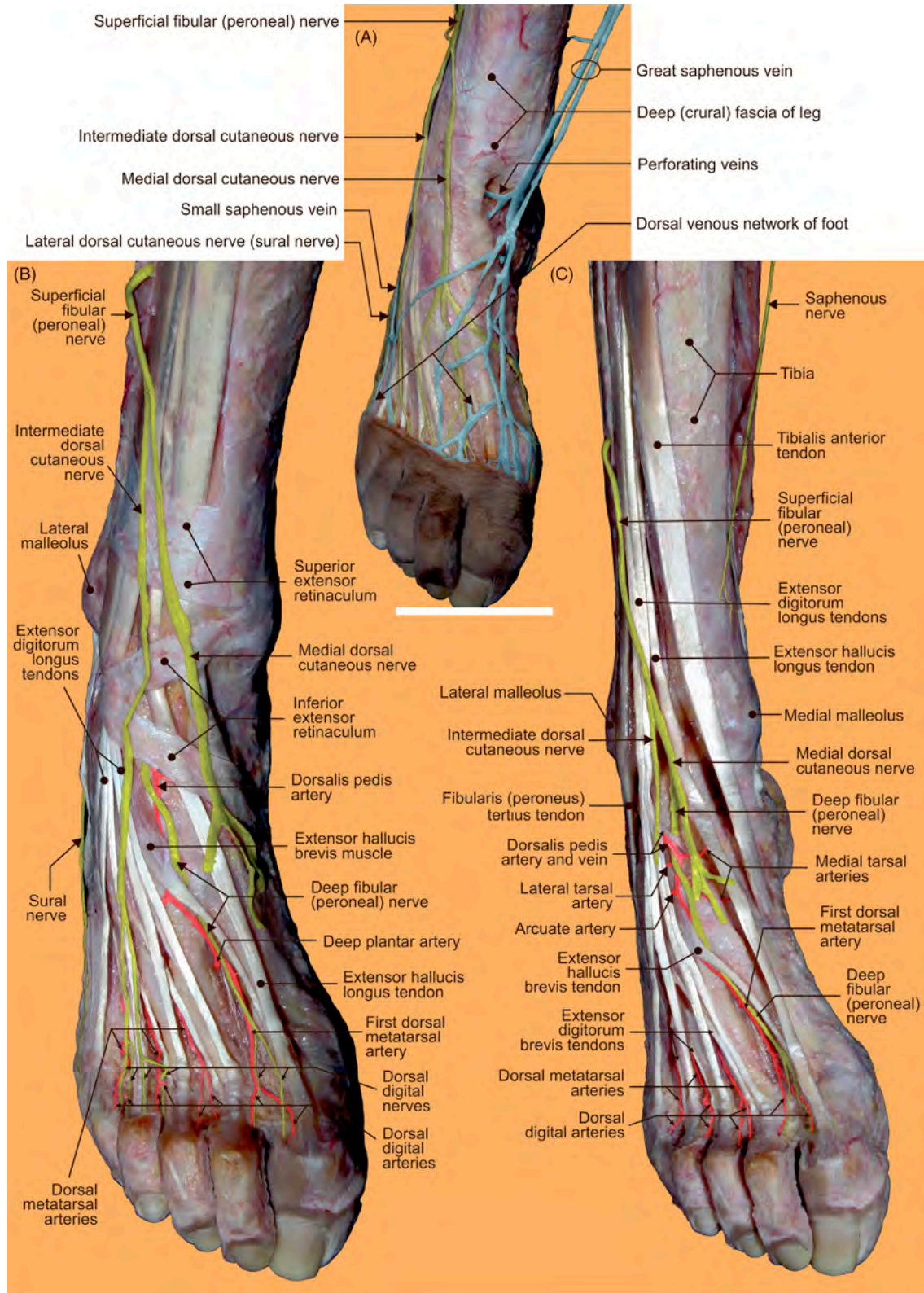


FIGURE 2.12 Nerves, blood vessels, and tendons of the right foot. (A) Superficial and (B–C) deep layers.

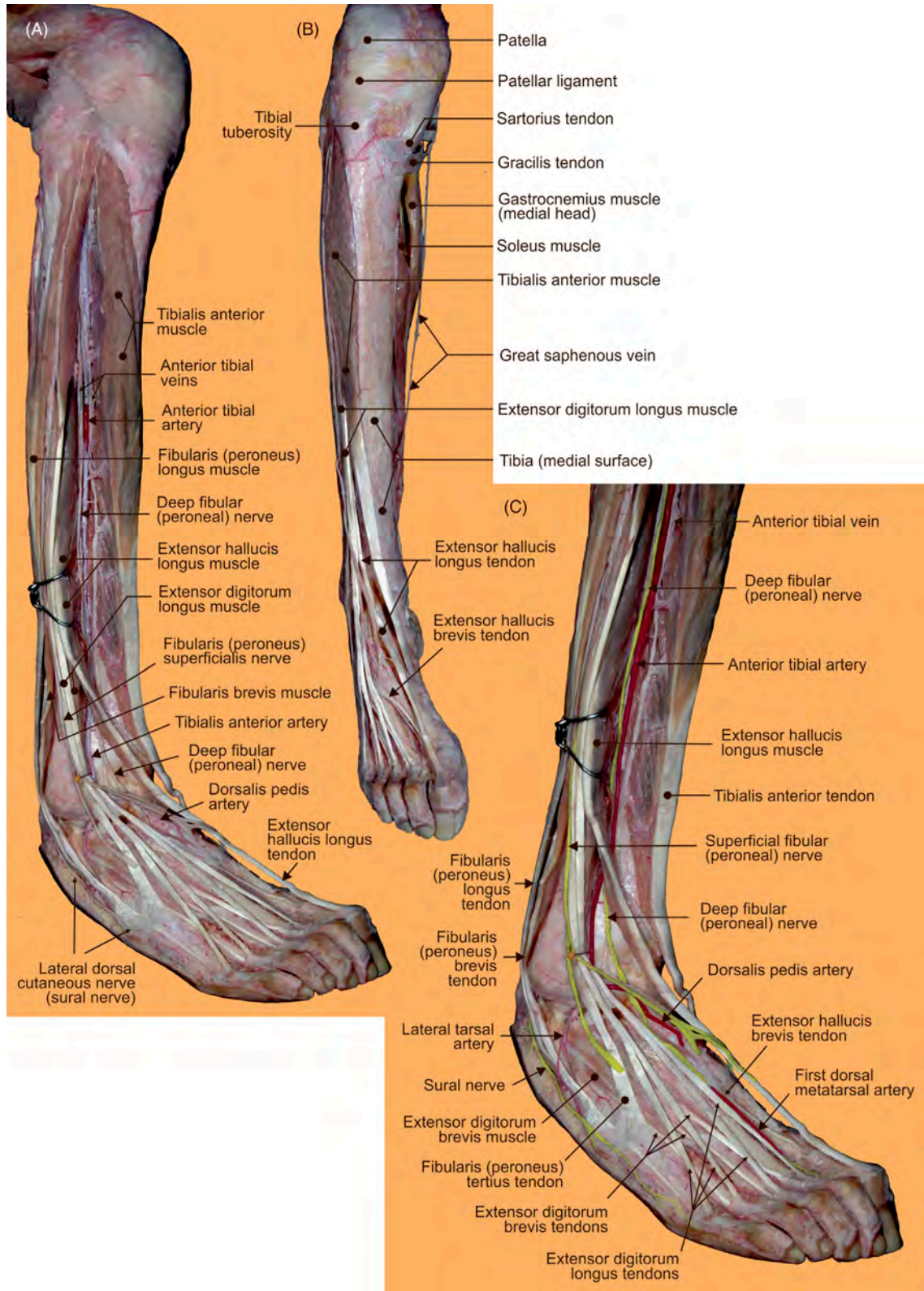


FIGURE 2.13 The right lower limb. (A–C) Different views offering structural details of the anterior region of the leg and the dorsum of the foot.

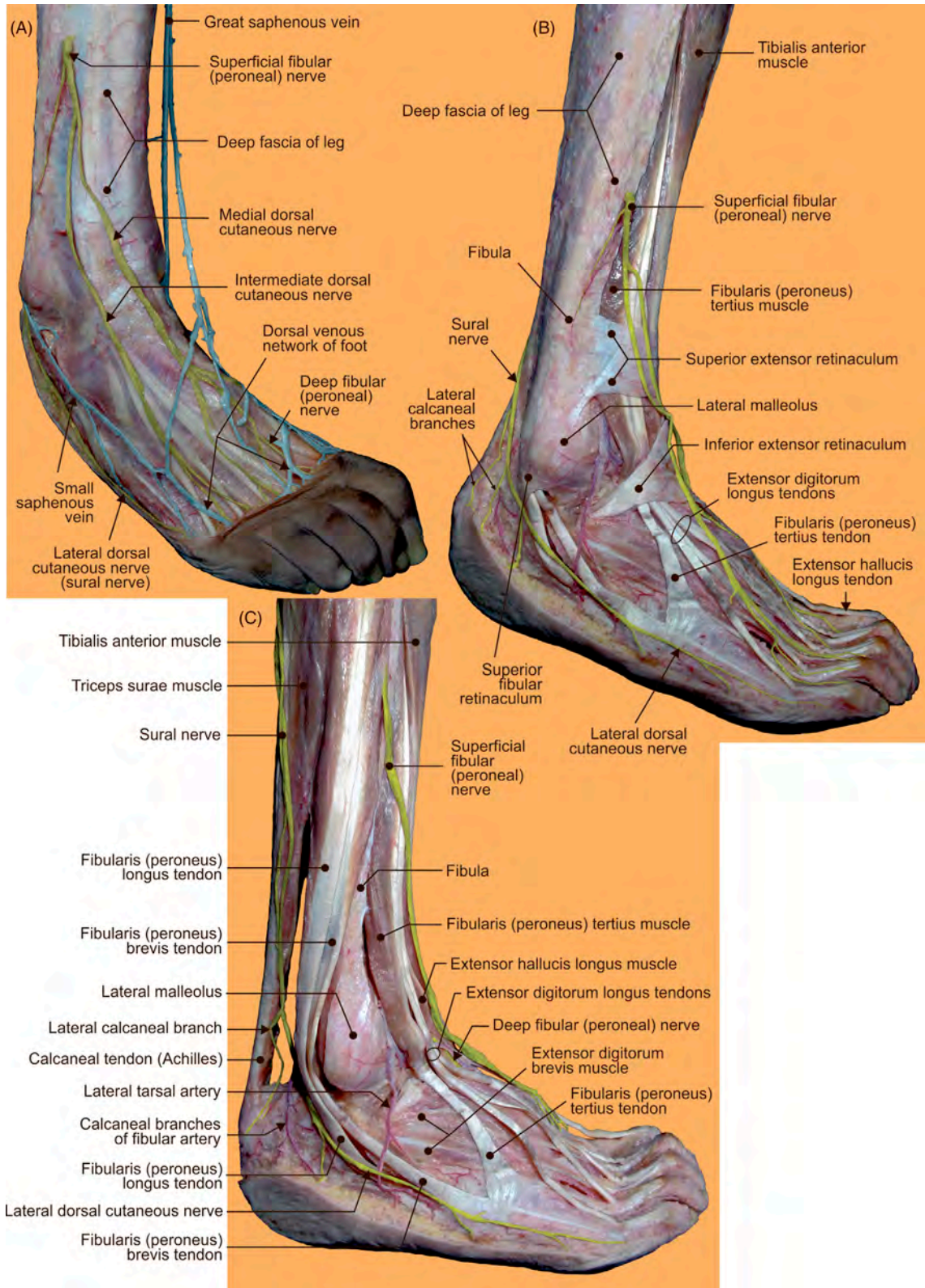


FIGURE 2.14 The right foot. (A–C) Different layers offering the lateral aspect of nerves, blood vessels, and muscles on the dorsal surface.

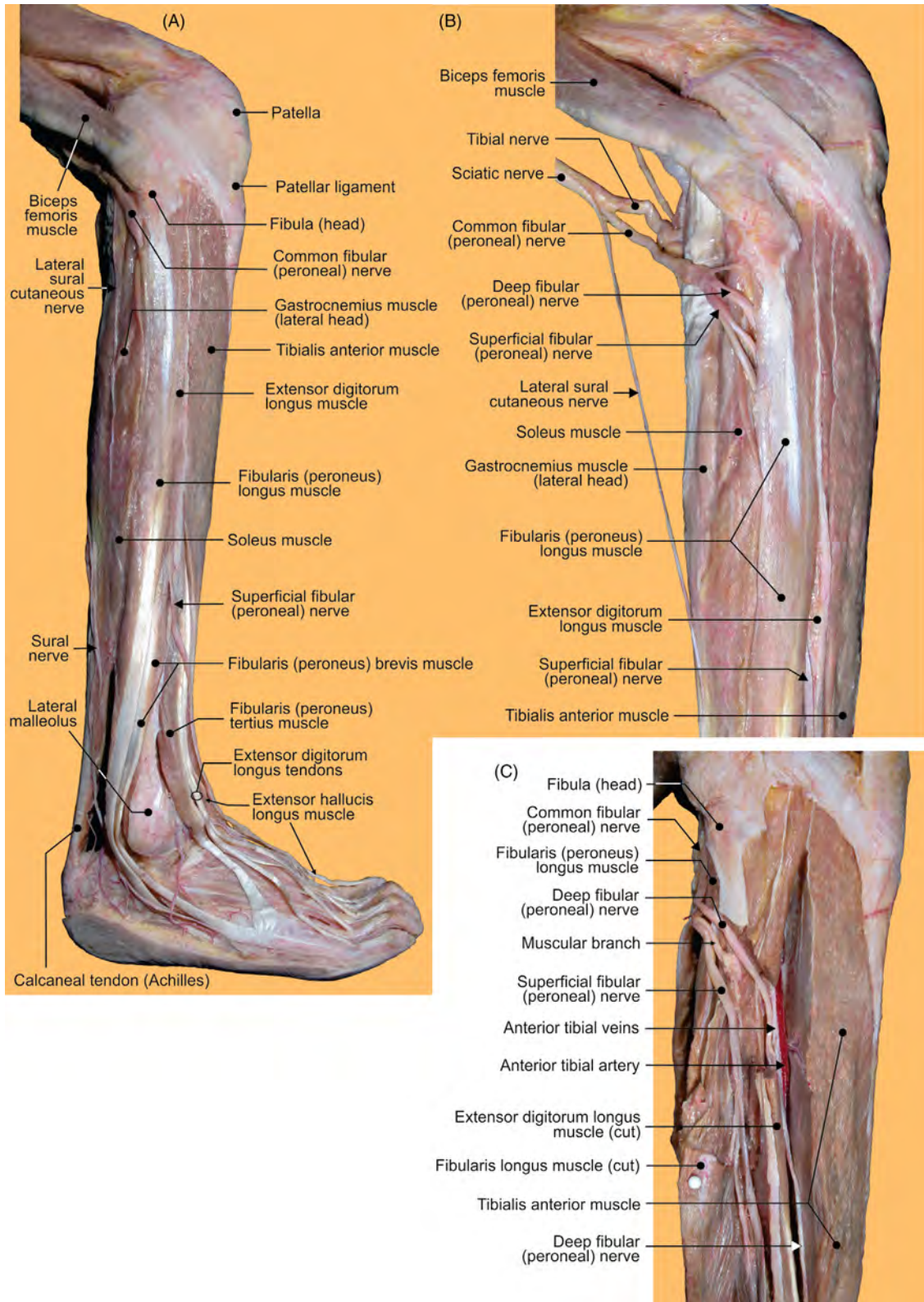


FIGURE 2.15 The right limb. (A) Anterior region of leg with dorsum of foot and (B) without foot. (C) Removed upper part of the fibularis (peroneus) longus muscle.

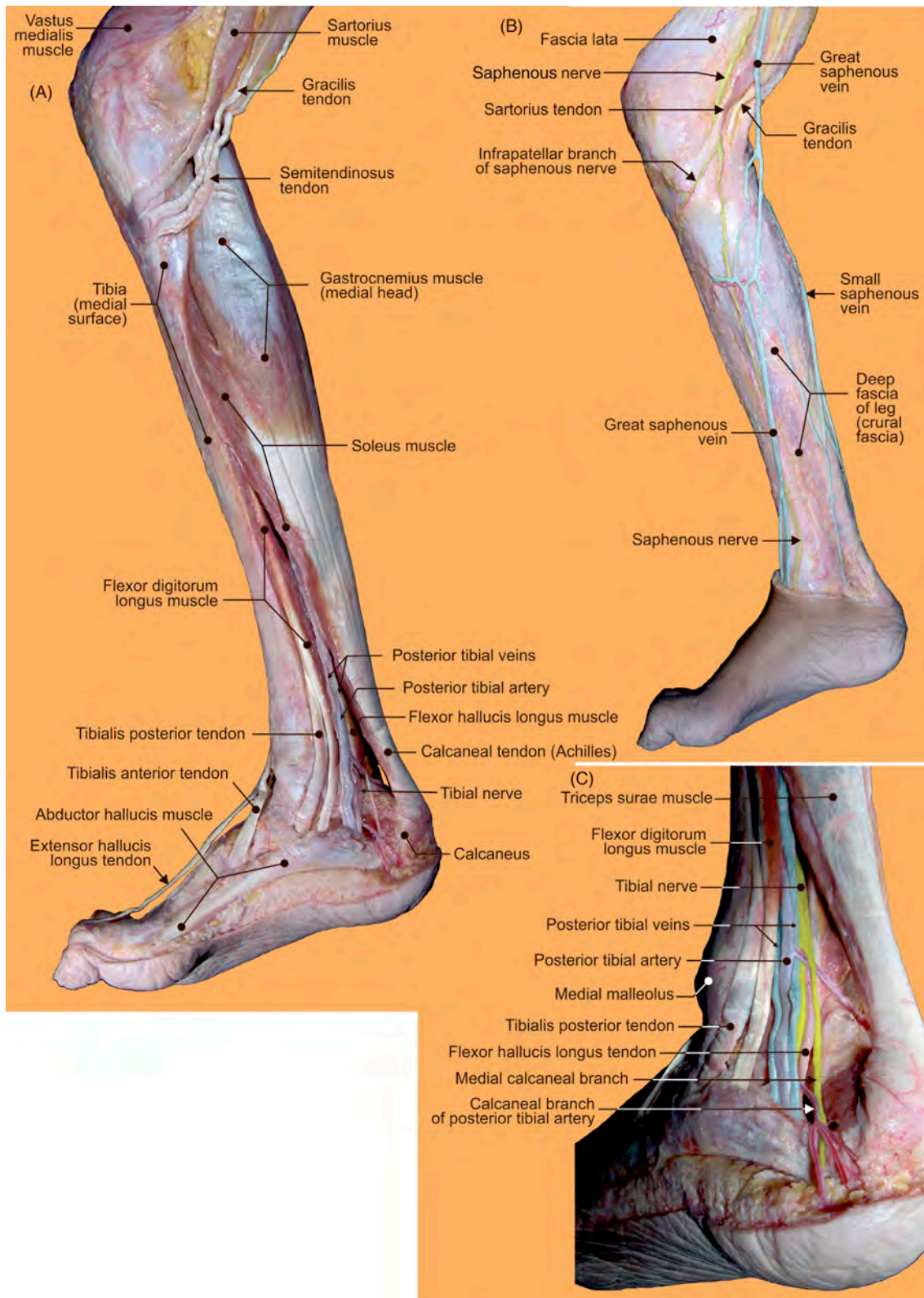


FIGURE 2.16 The medial aspects of the right leg and foot. (A) Deep and (B) superficial dissected layers. (C) The medial retromalleolar region.

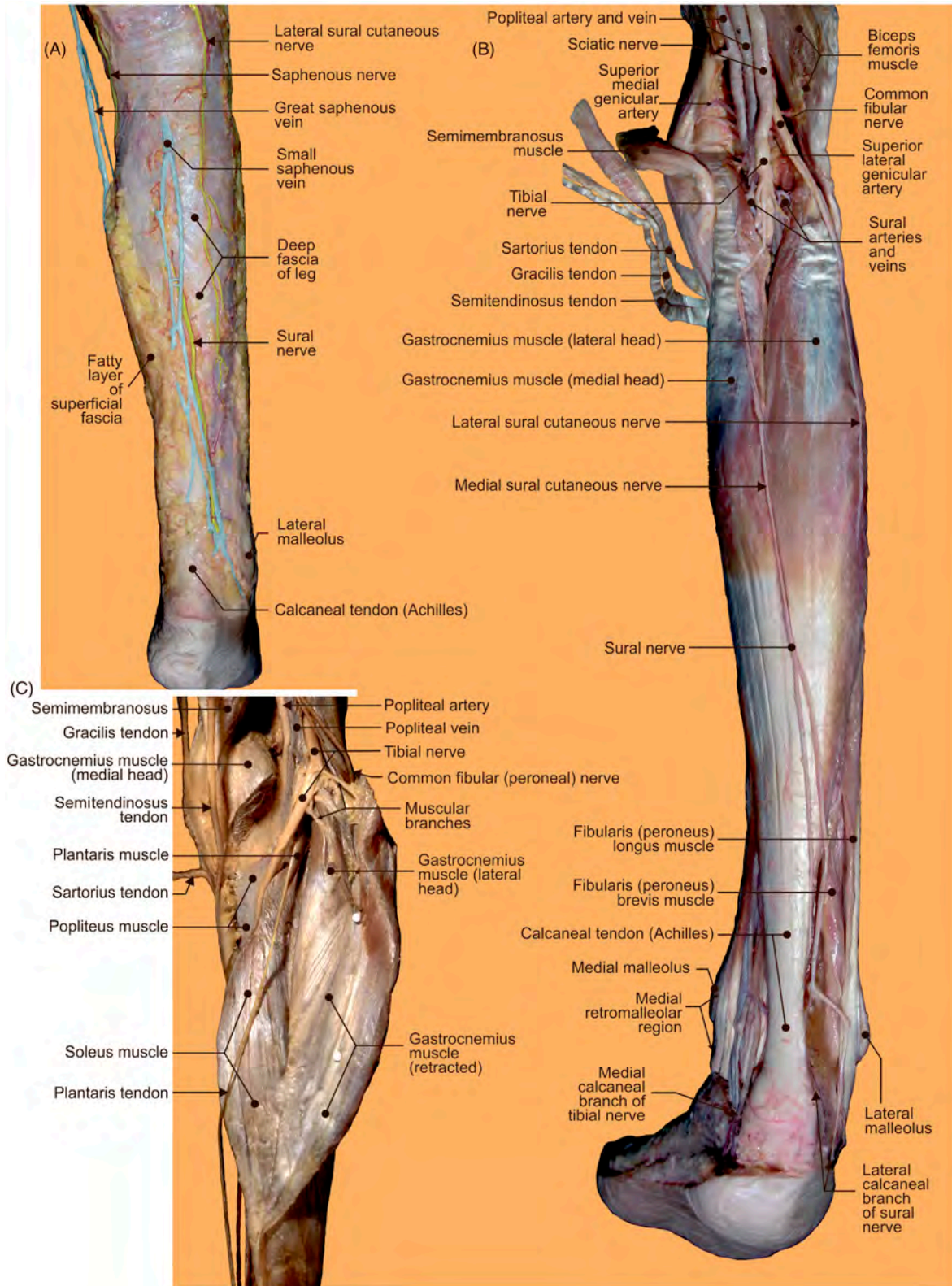


FIGURE 2.17 The popliteal and posterior crural regions of right limb. (A–B) Superficial and (C) deep layers.

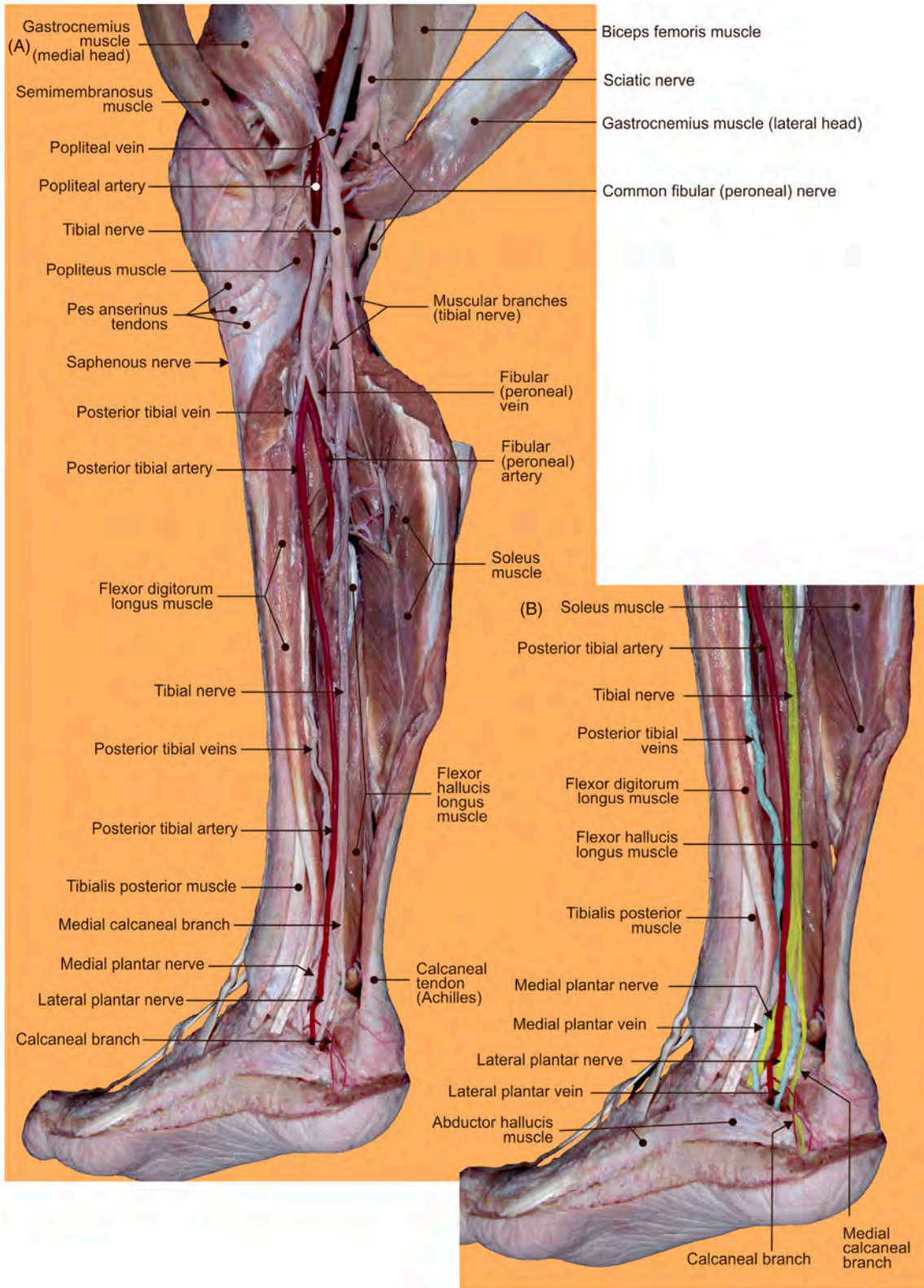


FIGURE 2.18 (A–B) Structural details of the deep layers of the popliteal, posterior crural, and medial retromalleolar regions.

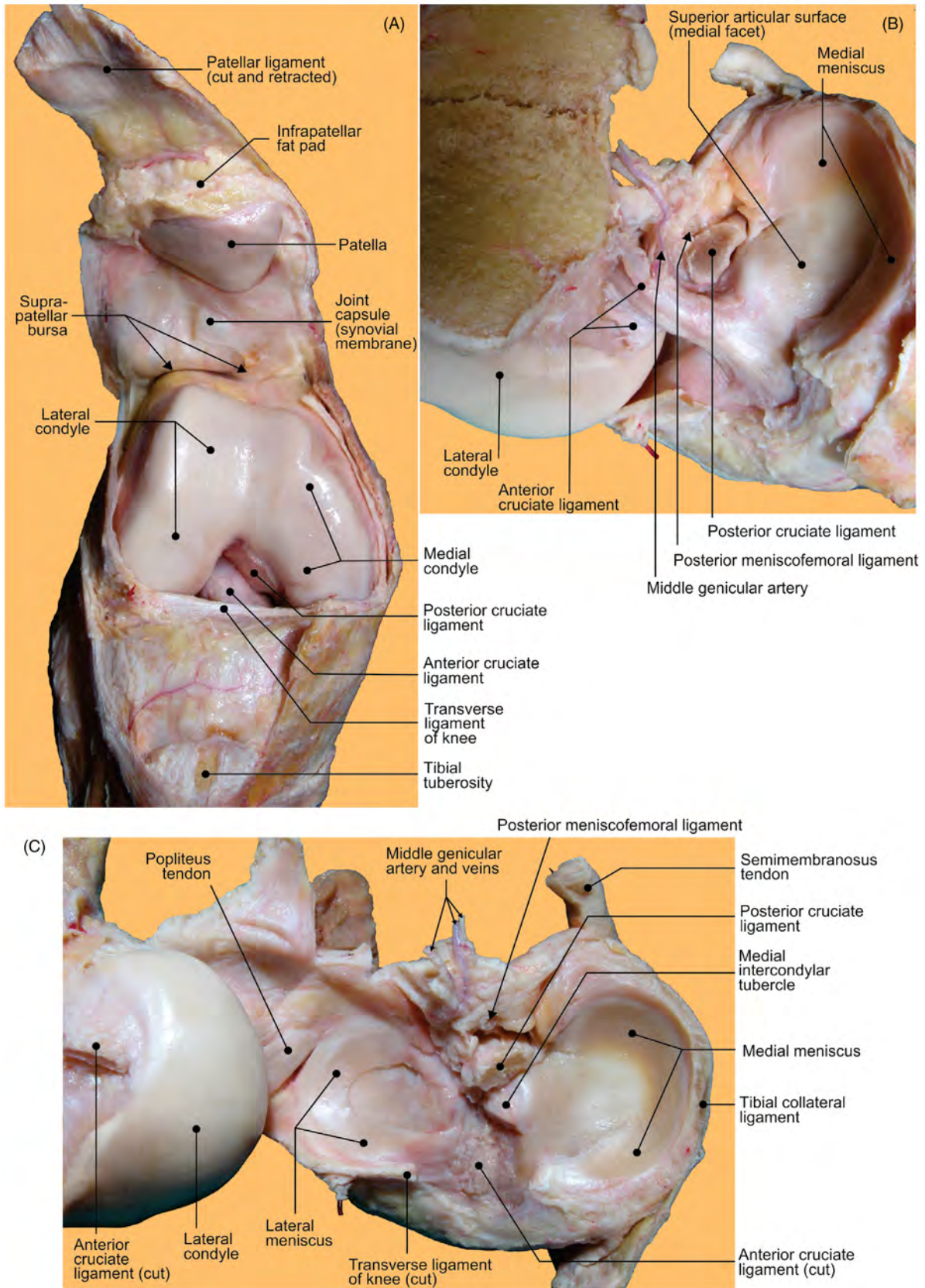


FIGURE 2.19 The right knee joint. (A) Anterior view of open joint. (B) Removed medial condyle and transected posterior cruciate ligament. (C) Superior view of the tibial articular surface after transection of both cruciate ligaments.

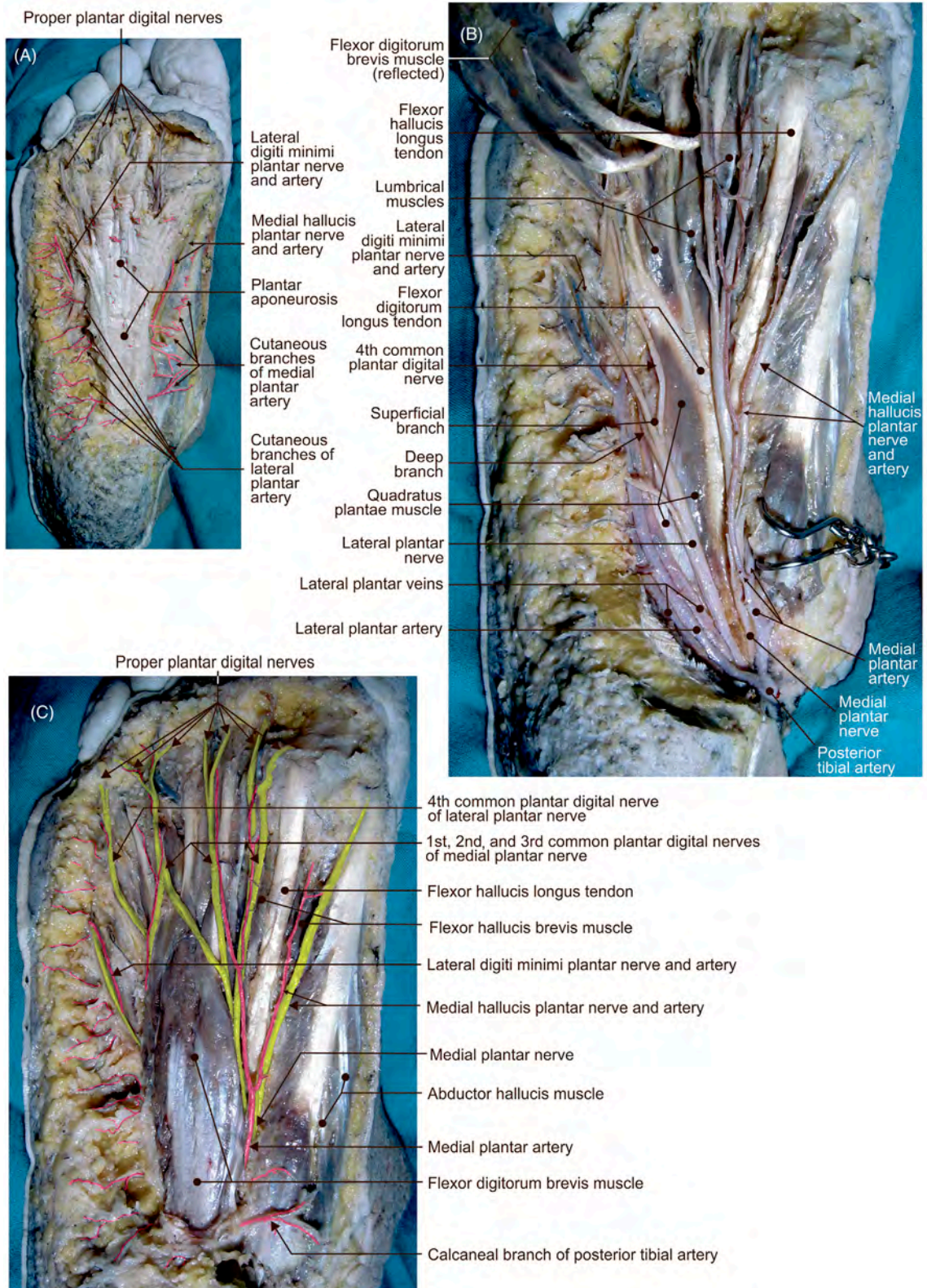


FIGURE 2.20 Plantar aspect of the right foot. Structures in the (A) superficial and (B–C) middle layers.

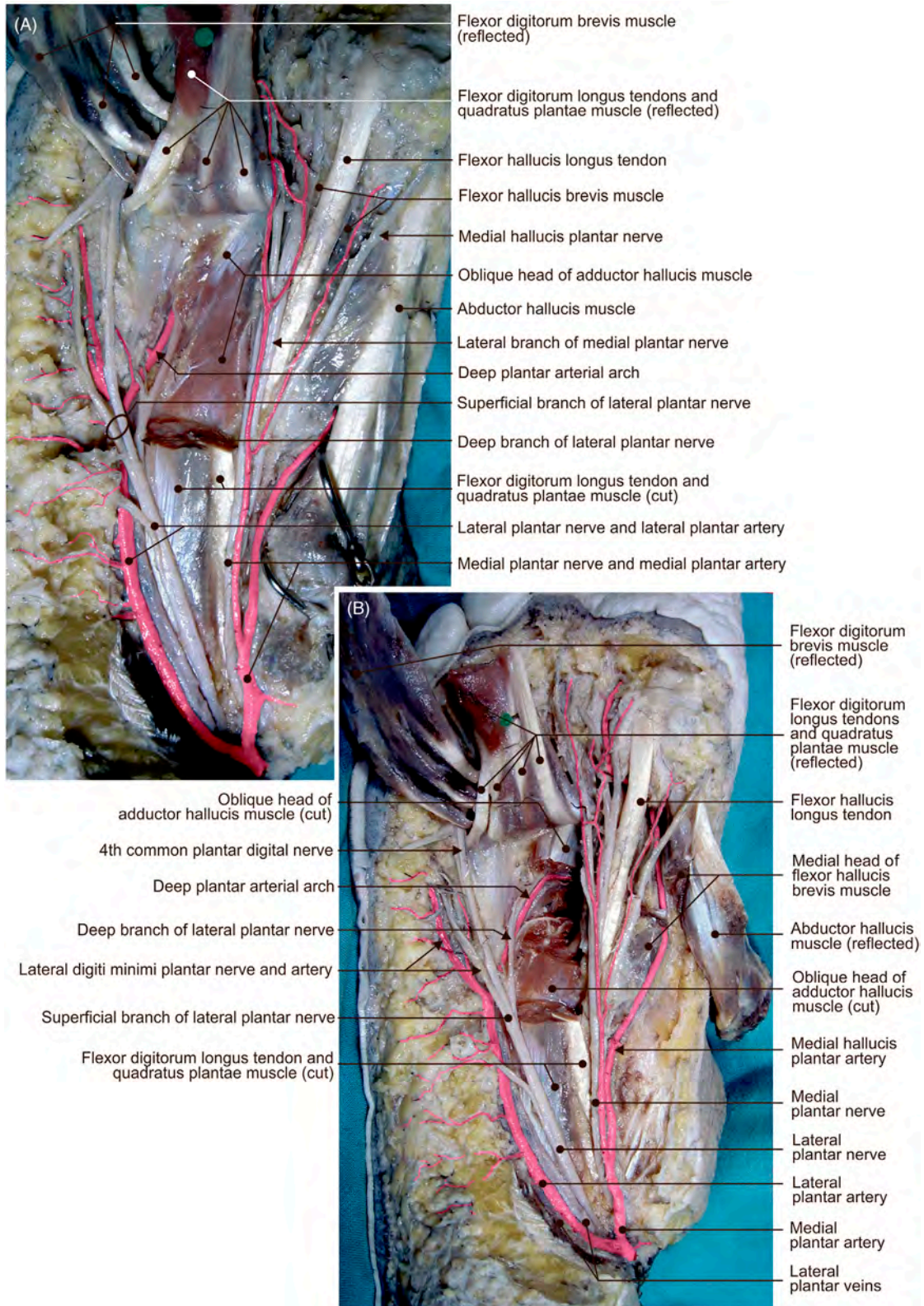


FIGURE 2.21 Plantar aspect of the right foot. (A–B) Different views offering structural details in the deep layer.

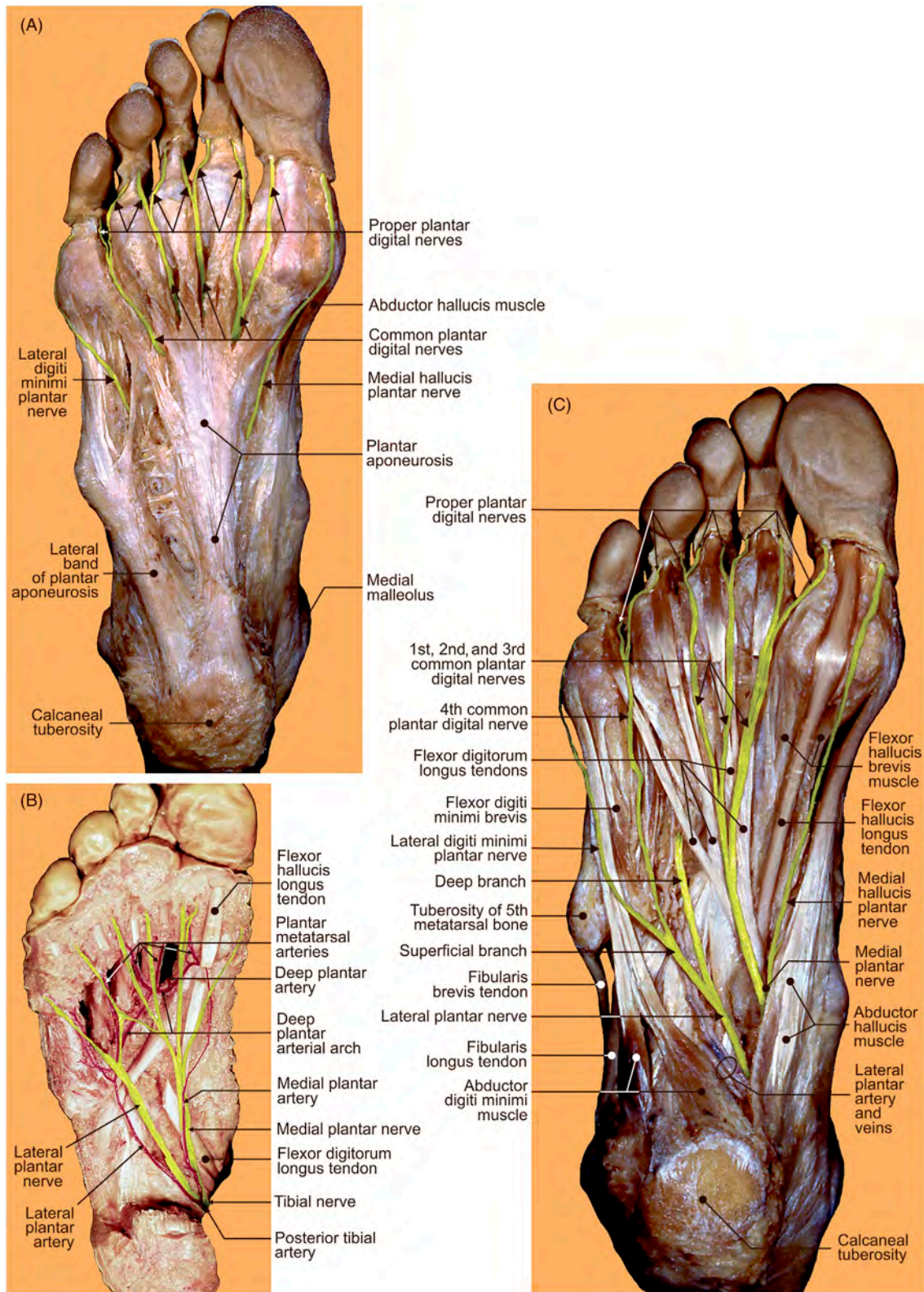


FIGURE 2.22 Plantar region of the right foot. (A–C) Different views displaying arteries, nerves, and tendons.

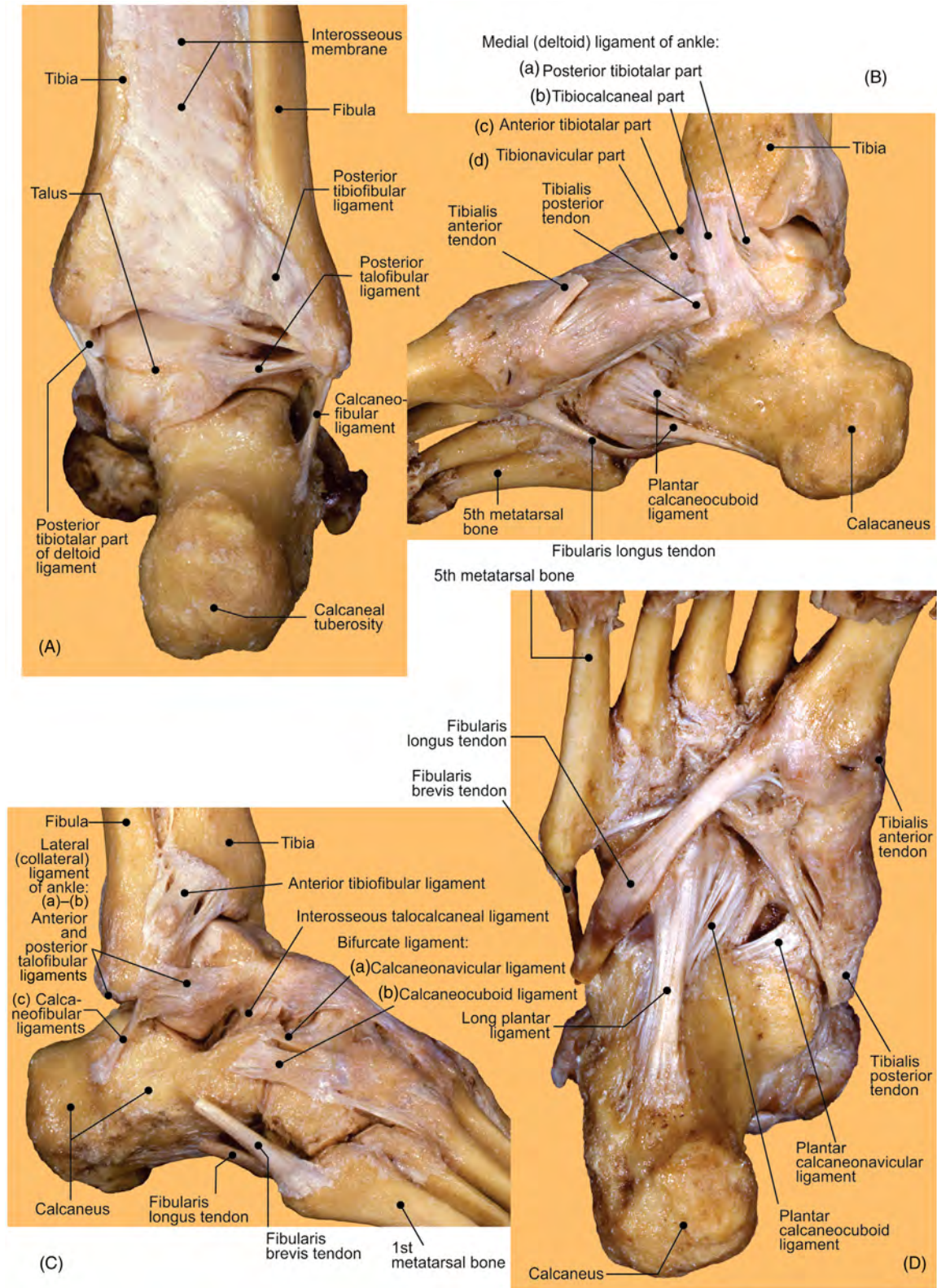


FIGURE 2.23 Ligaments and tendons of the right foot. (A) Posterior, (B) medial, (C) lateral, and (D) inferior views.

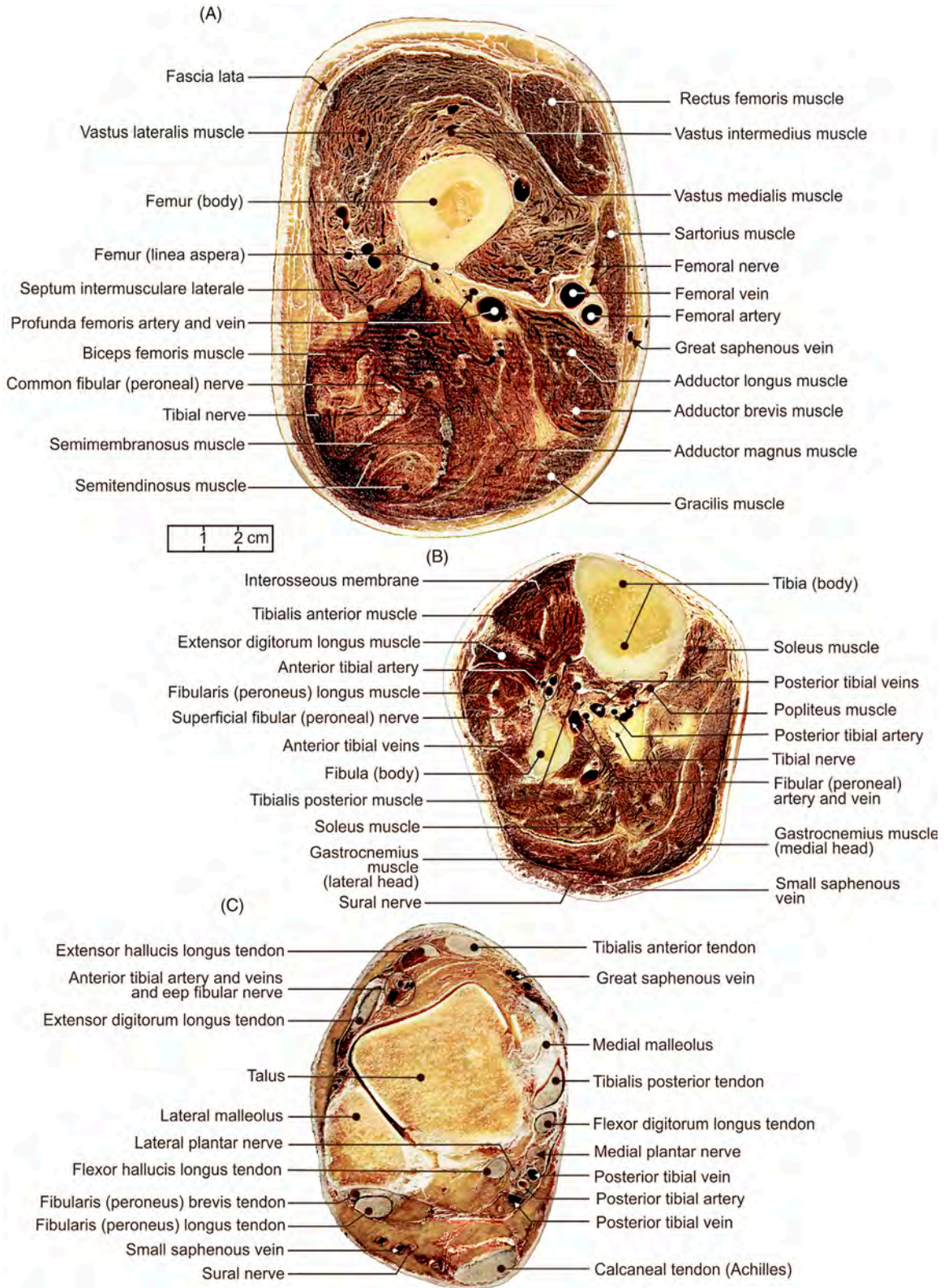


FIGURE 2.24 The right limb. Cross-sectional views of the (A) thigh, (B) leg, and (C) proximal segment of foot.

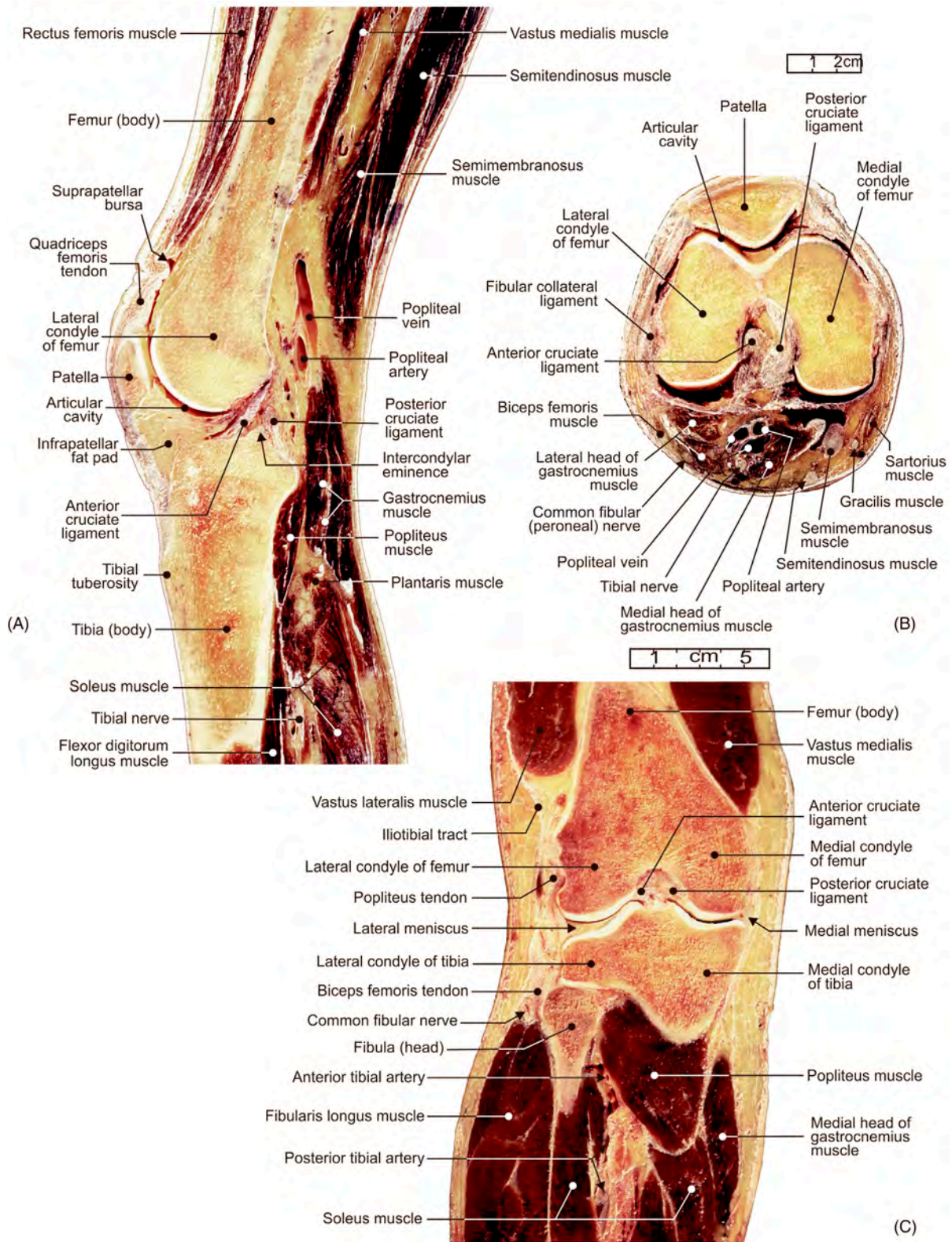


FIGURE 2.25 The right limb knee region. (A) Sagittal, (B) transverse, and (C) coronal sections.

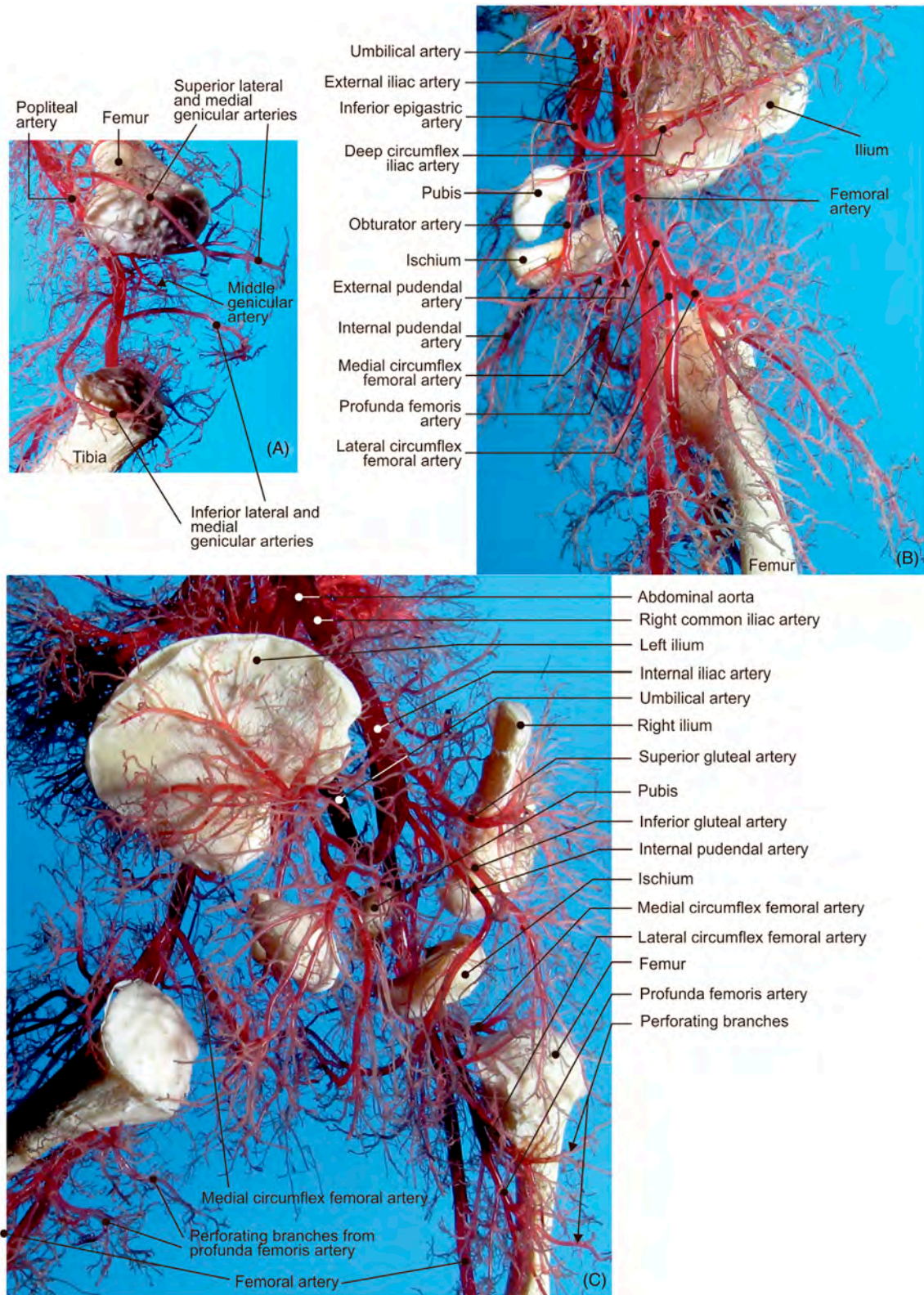


FIGURE 2.26 The fetal left limb. Arterial distribution (corrosion casts) around the (A) knee region, (B) anterior aspect of thigh, and (C) gluteal region.

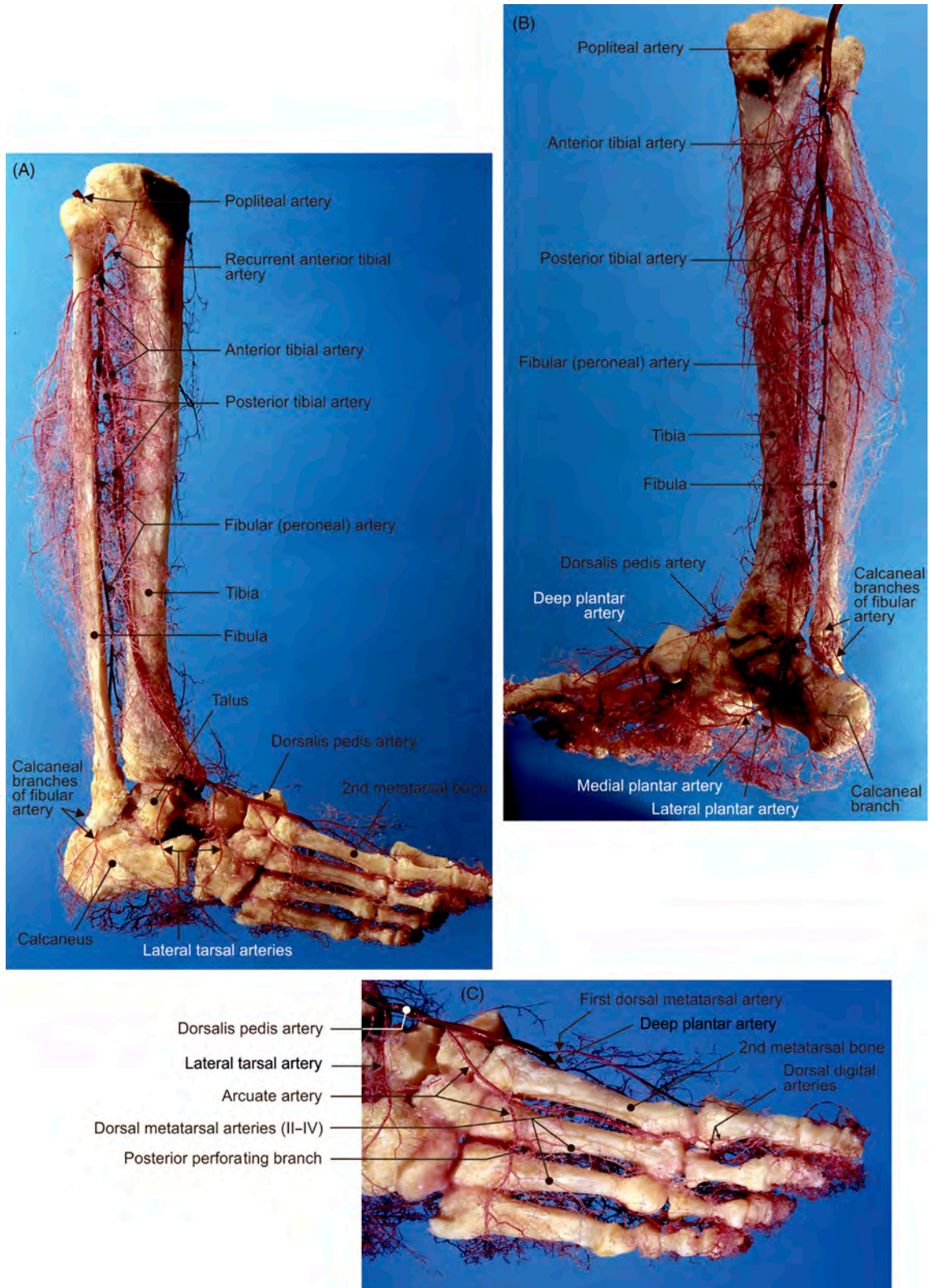


FIGURE 2.27 Arterial distributions (corrosion cast) along the (A) lateral and (B) medial aspects of the right leg and (C) dorsal aspect of the right foot.

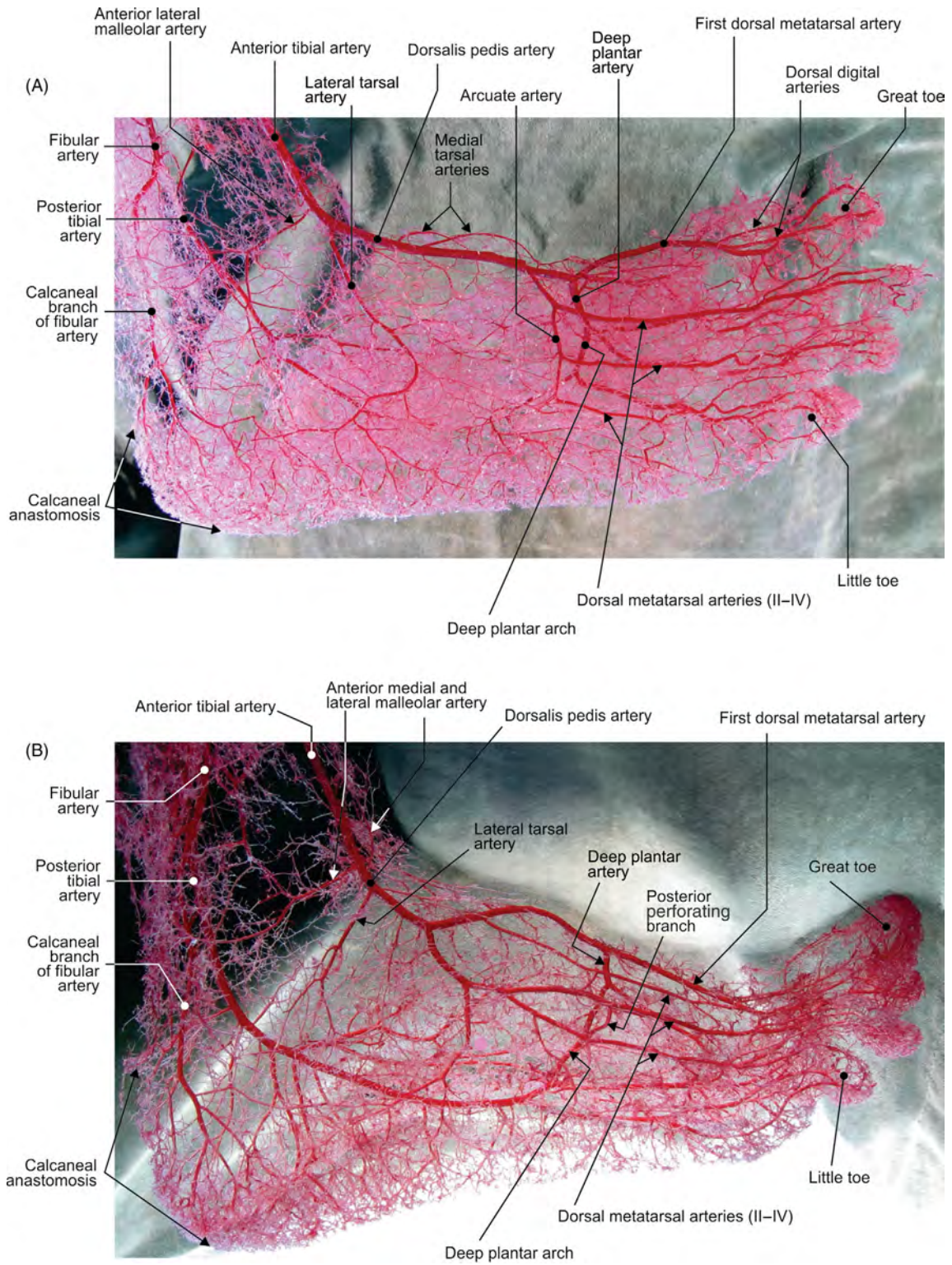


FIGURE 2.28 (A–B) Different specimens depicting arterial distributions (corrosion casts) along the dorsal aspect of the right foot.

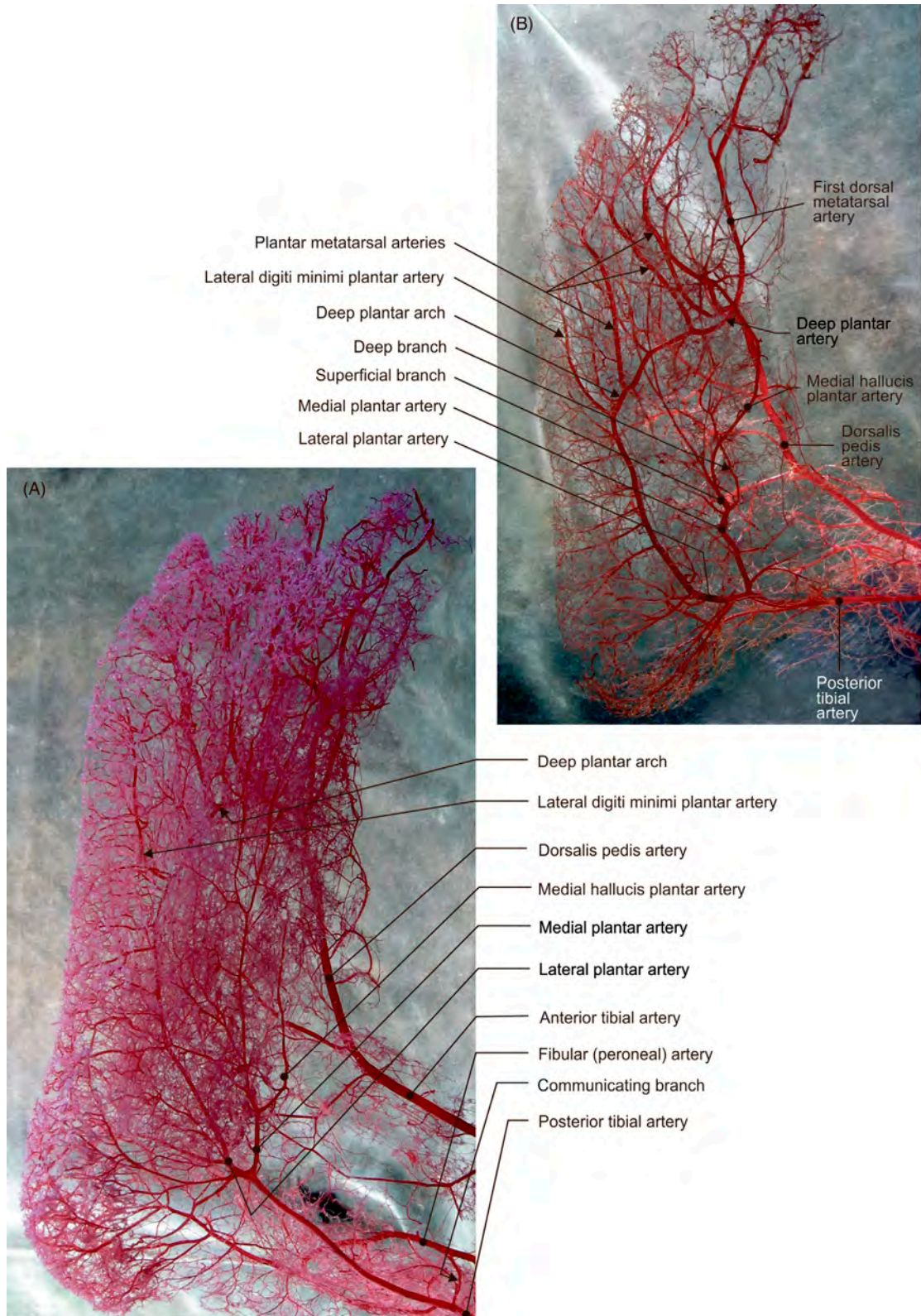


FIGURE 2.29 (A–B) Different specimens depicting arterial distributions (corrosion casts) along the plantar aspect of the right foot.

Chapter 3

Thorax and Vascularization

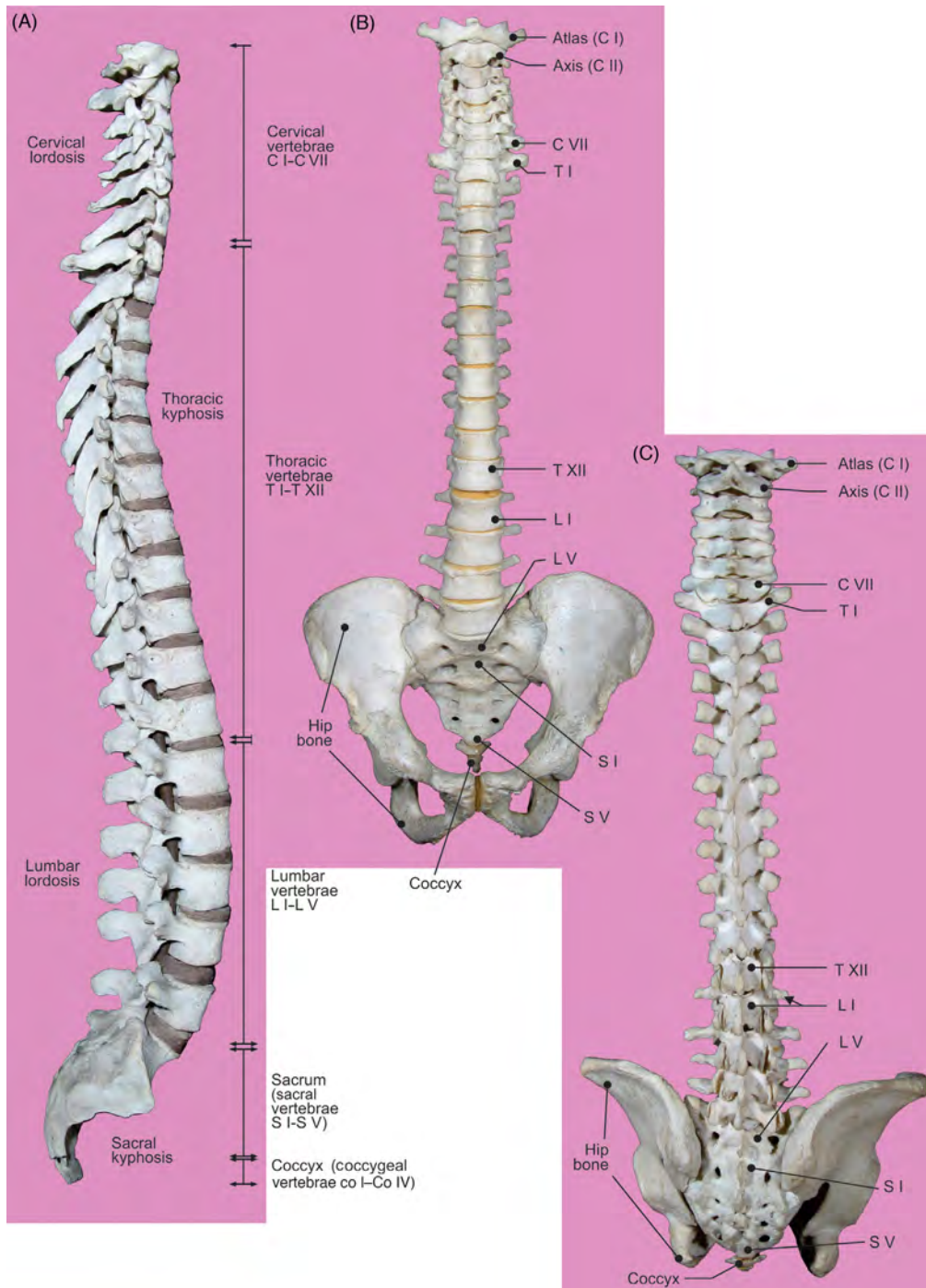


FIGURE 3.1 The vertebral column and bony pelvis. (A) Right, (B) anterior, and (C) posterior aspects.

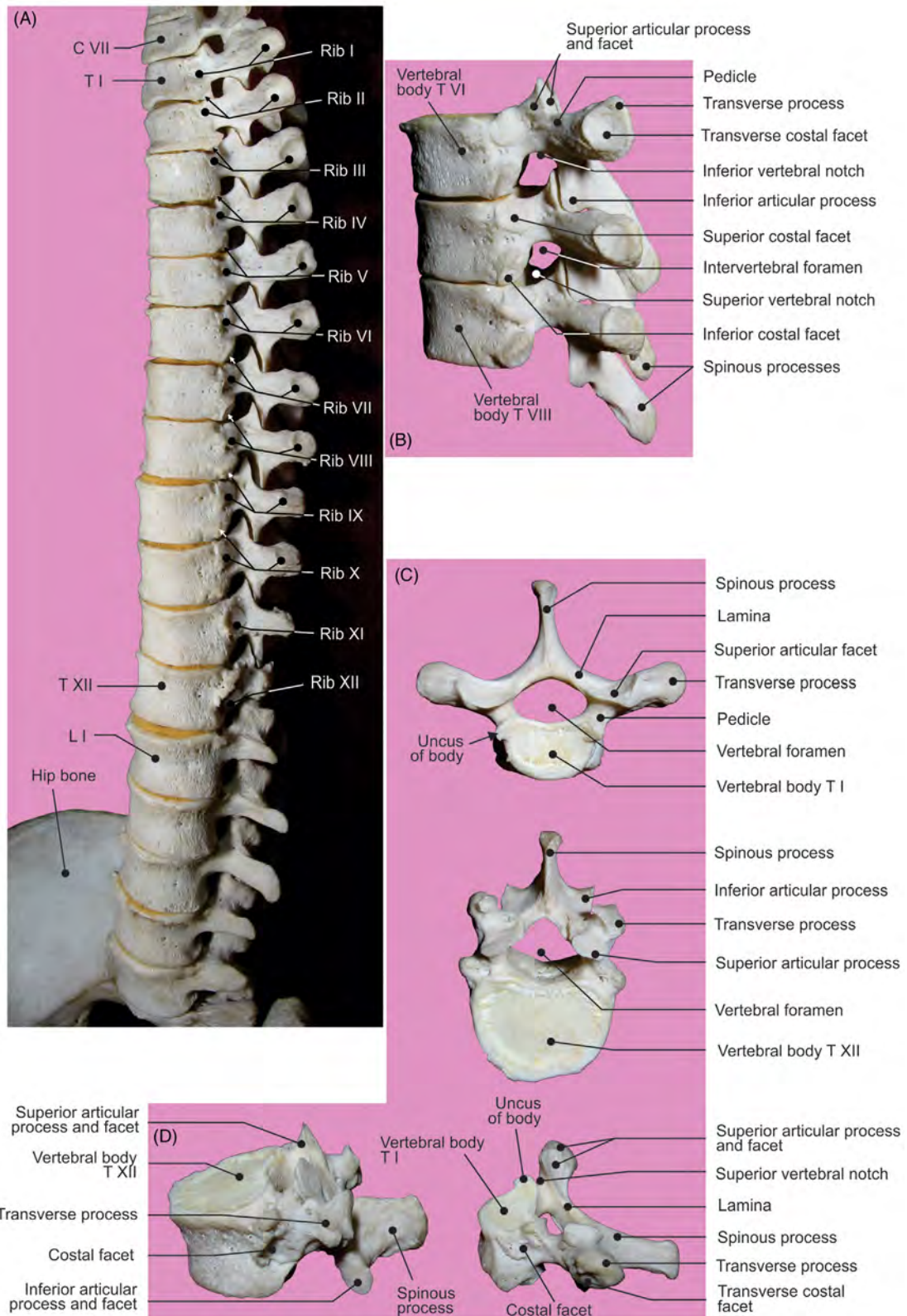


FIGURE 3.2 Thoracic segment of the (A) vertebral column and (B) lateral view of T6–T8 vertebrae. T1 and T12 vertebrae: (C) superior and (D) lateral views.

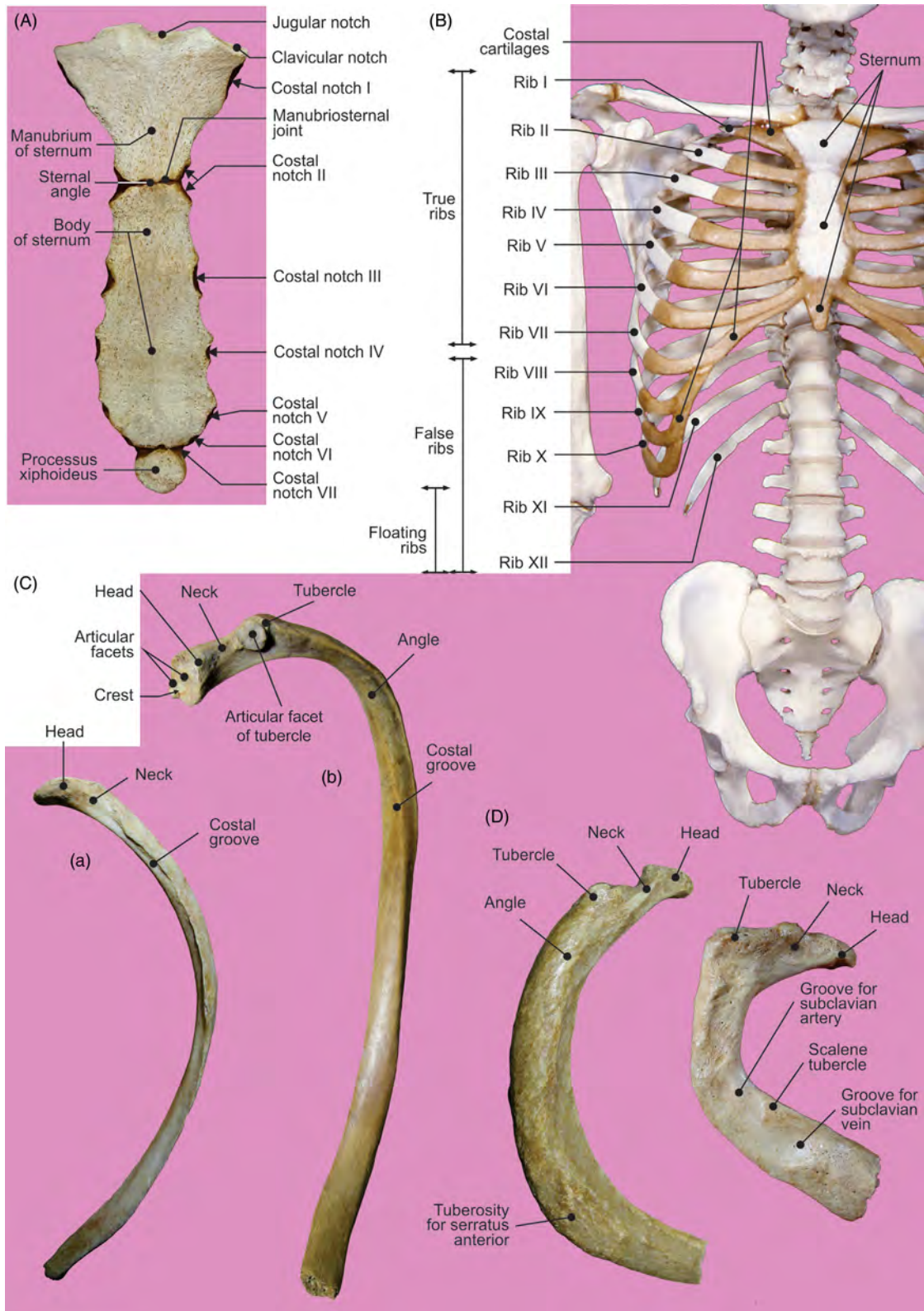


FIGURE 3.3 (A) Sternum: anterior view. (B) Rib cage: anterior view. (C) (a) 11th rib: inferior view and (b) typical rib (3rd–10th): inferior view. (D) 1st and 2nd right ribs: superior view.

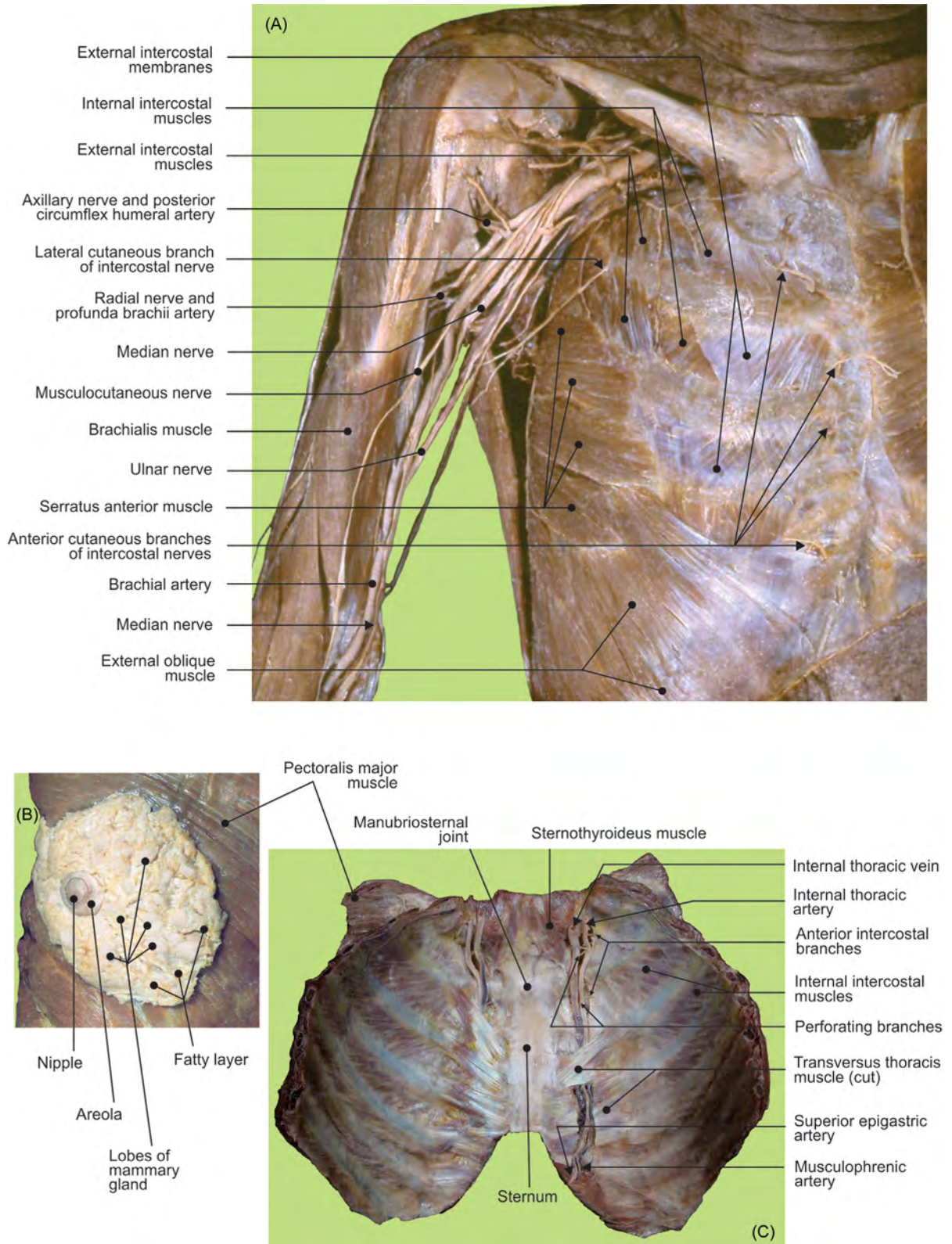


FIGURE 3.4 (A) Pectoral and axillary regions. (B) Dissected mammary gland. (C) Thoracic cage: posterior aspect of the anterior segment.

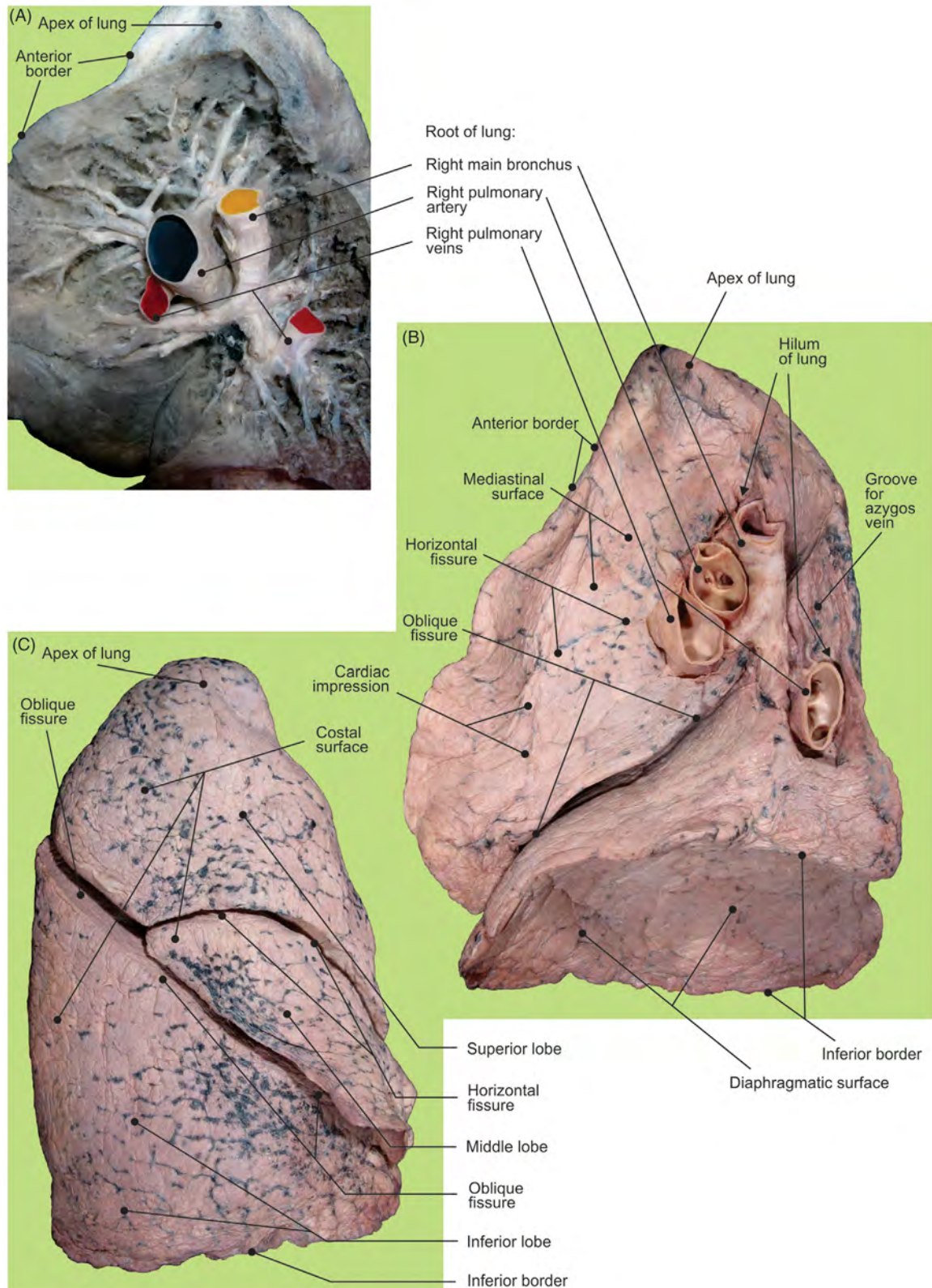


FIGURE 3.5 The right lung. (A) Dissected structures of the pulmonary root inside the pulmonary tissue. (B–C) Superficial elements and (C) structures of the pulmonary root.

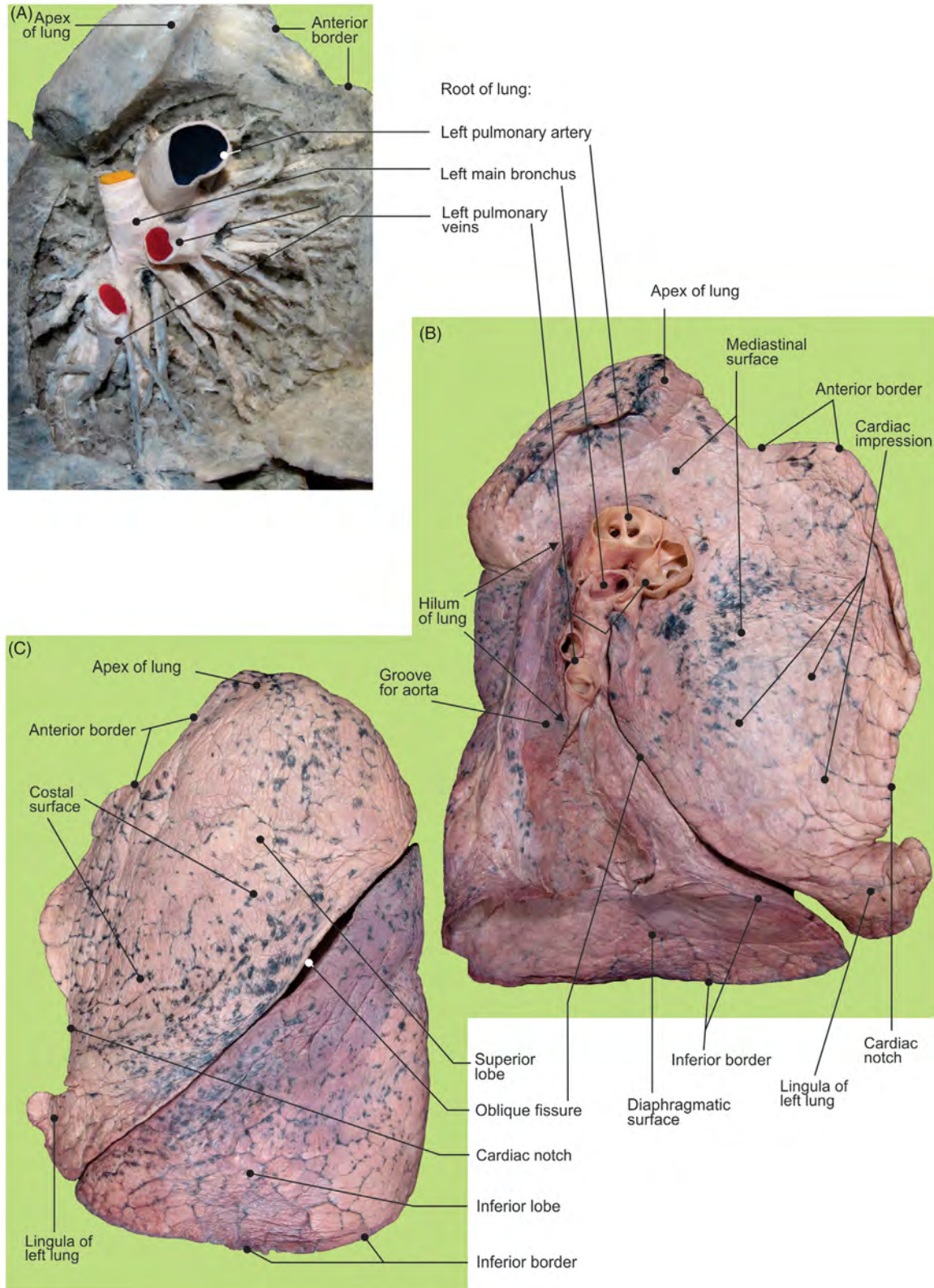


FIGURE 3.6 The left lung. (A) Dissected structures of the pulmonary root inside the pulmonary tissue. (B–C) Superficial elements and (C) structures of the pulmonary root.

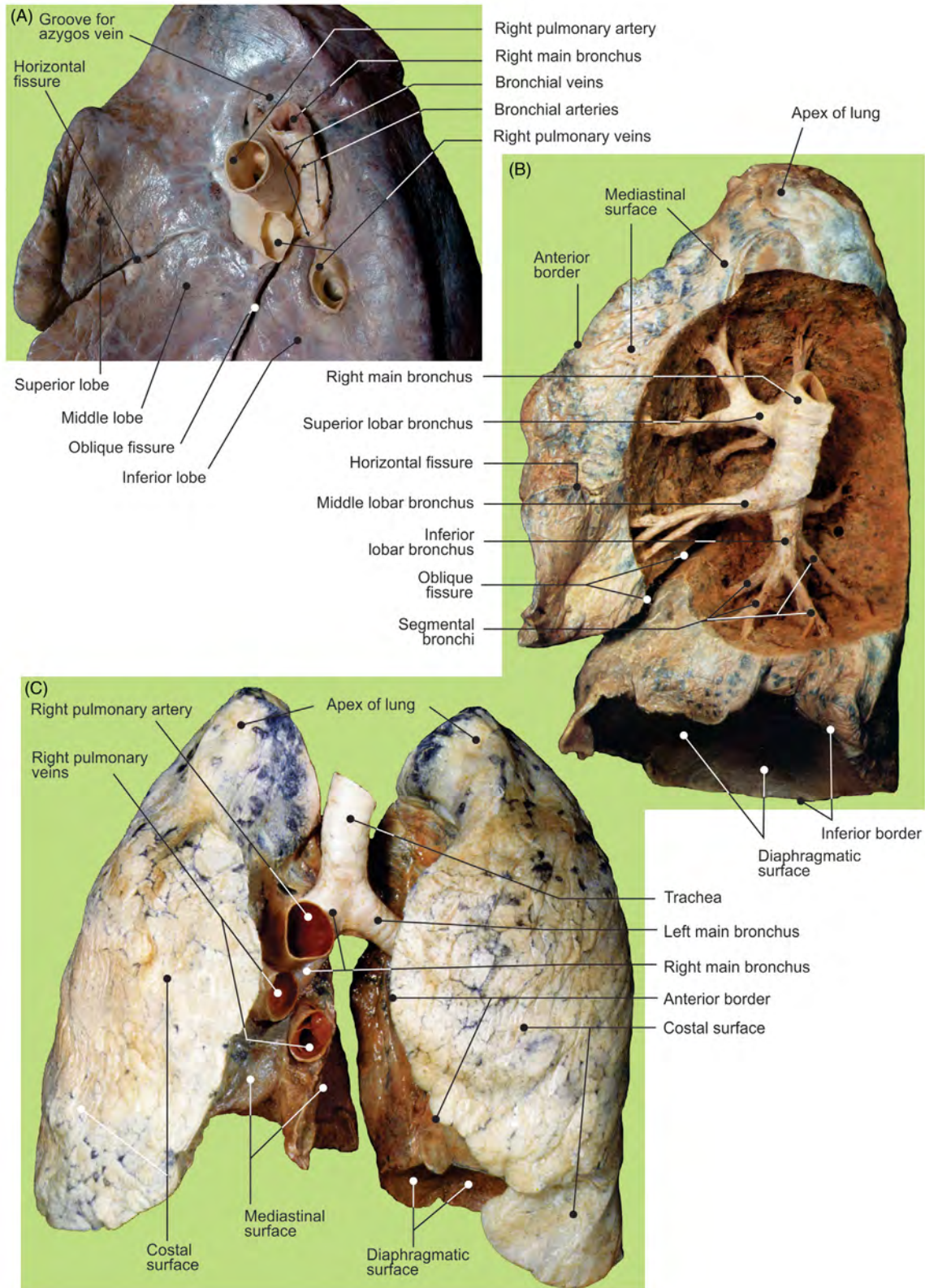


FIGURE 3.7 The right lung. (A) Mediastinal surface and tracheobronchial trunk. (B) Primary, secondary, and tertiary bronchi inside the pulmonary tissue. (C) The anterior aspect of lungs, trachea, and bronchi.

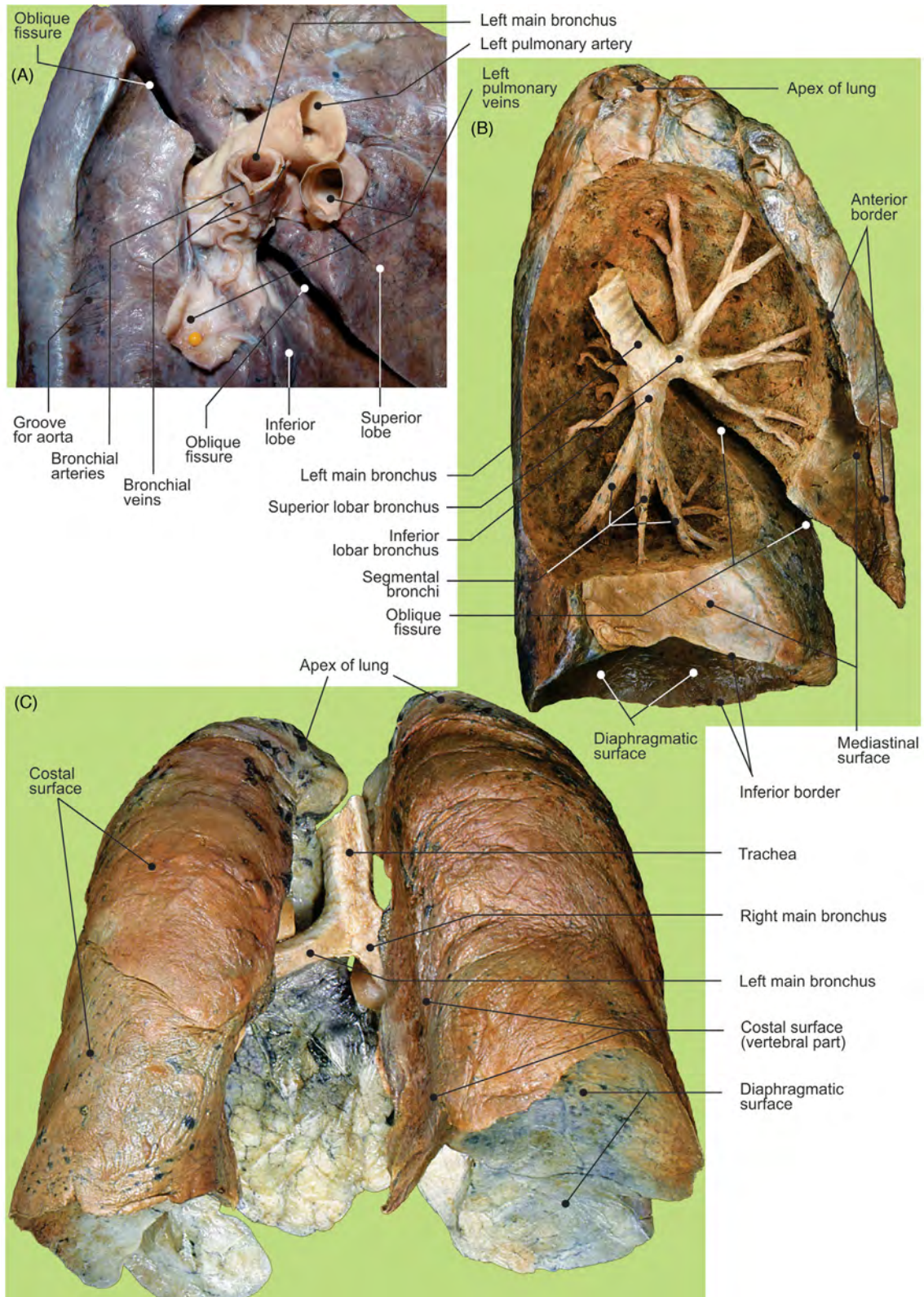


FIGURE 3.8 The left lung. (A) Mediastinal surface and tracheobronchial trunk. (B) Primary, secondary, and tertiary bronchi inside the pulmonary tissue. (C) Posterior aspect of lungs, trachea, and bronchi.

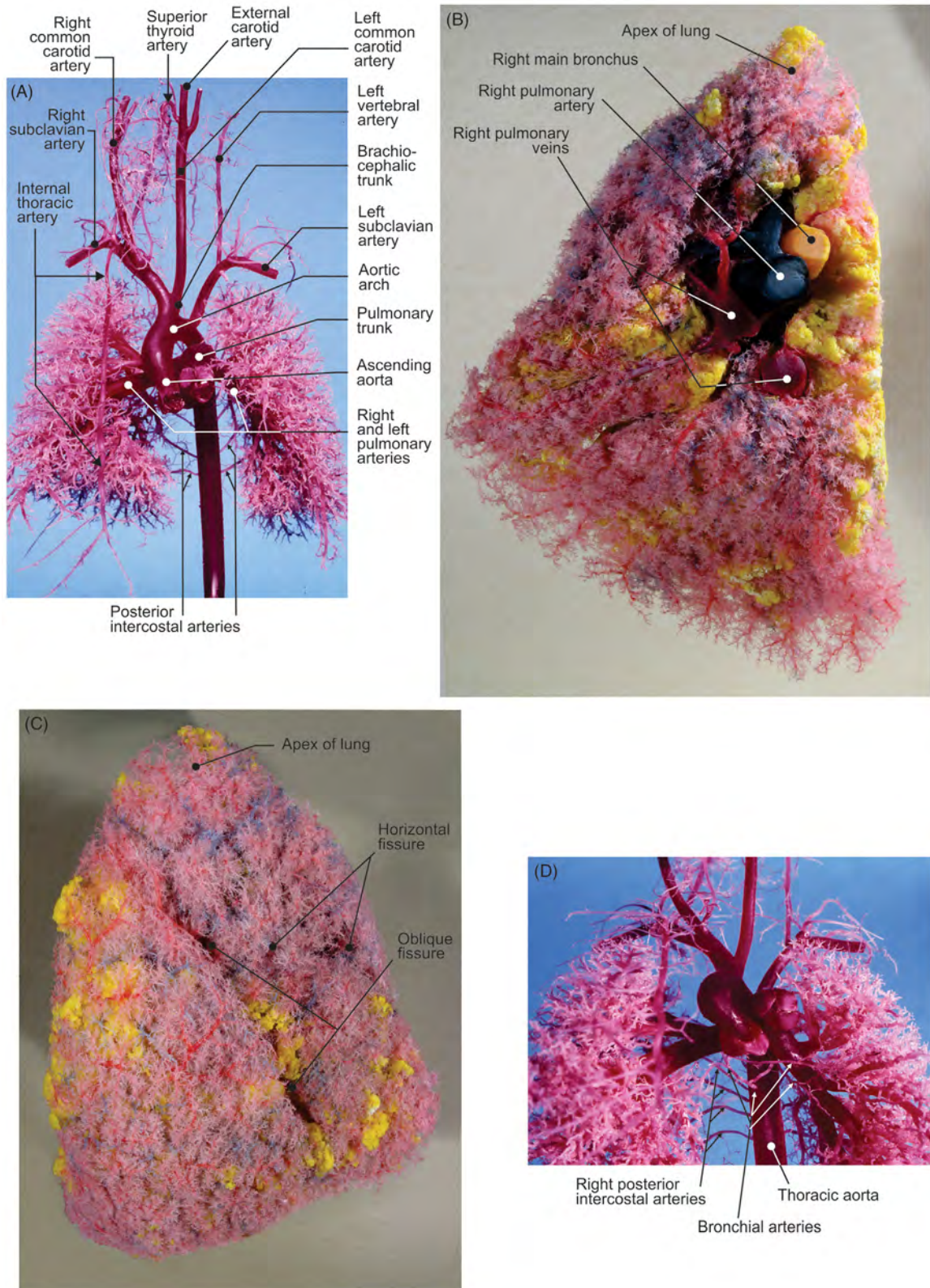


FIGURE 3.9 (A) Branching of pulmonary arteries and aorta (corrosion cast, fetus). (B–C) Right lung, corrosion cast: branching of the pulmonary artery (blue), pulmonary veins (red), and bronchial trunk (yellow); (B) mediastinal surface and (C) costal surface. (D) Bronchial arteries (corrosion cast, fetus).




FIGURE 3.10 (A–C) Branching of the pulmonary artery (*blue*) follows bronchial stem (*yellow*), while tributaries of pulmonary veins (*red*) are peripheral (corrosion cast). (D) Terminal bronchiole continues as respiratory bronchiole, alveolar sac, and, eventually, pulmonary alveoli (corrosion cast).

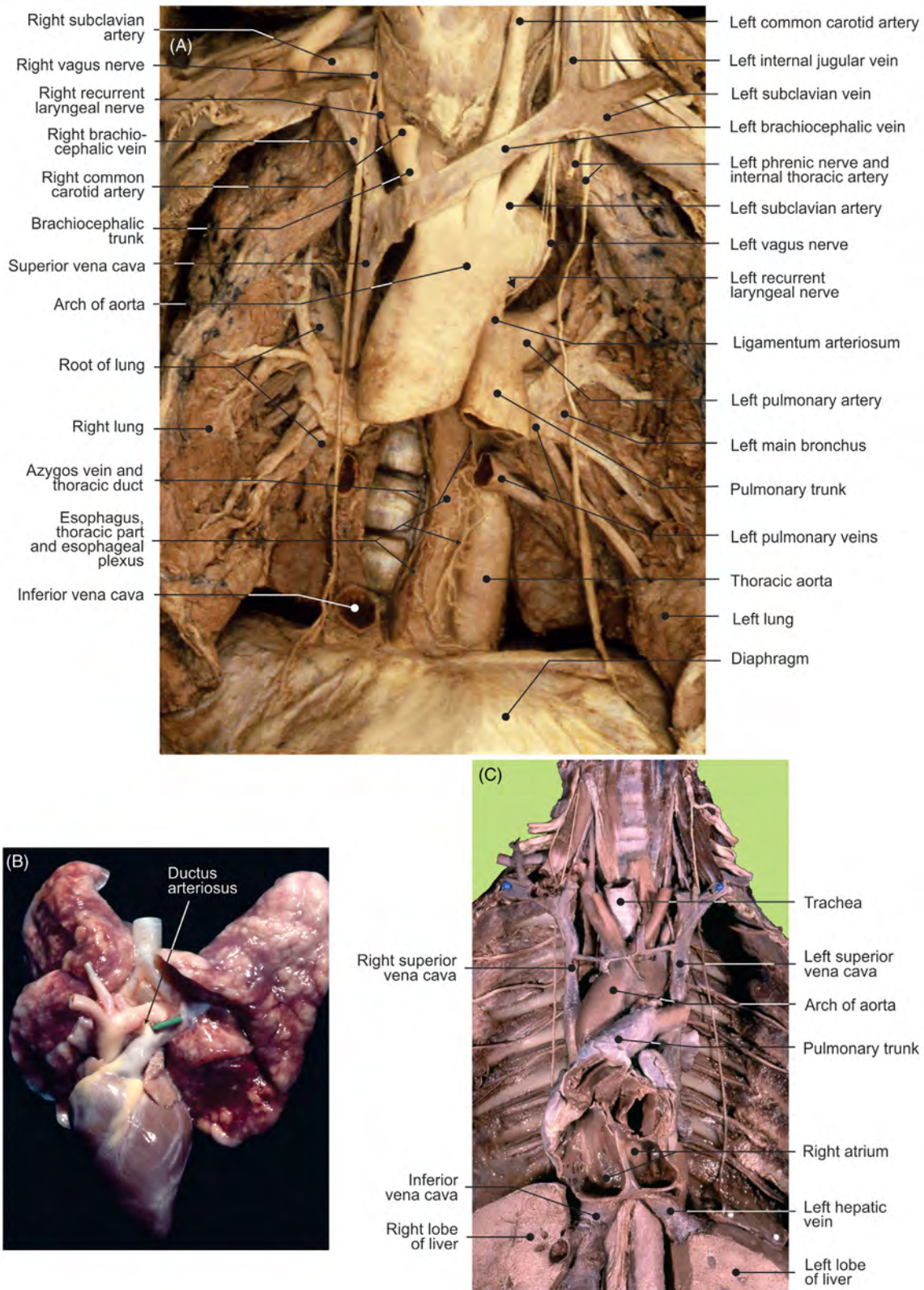


FIGURE 3.11 (A) The anterior aspect of lungs and mediastinum in situ after the heart has been removed (layer of blood vessels). (B) The anterior aspect of fetal lungs and heart. (C) Double superior caval vein.

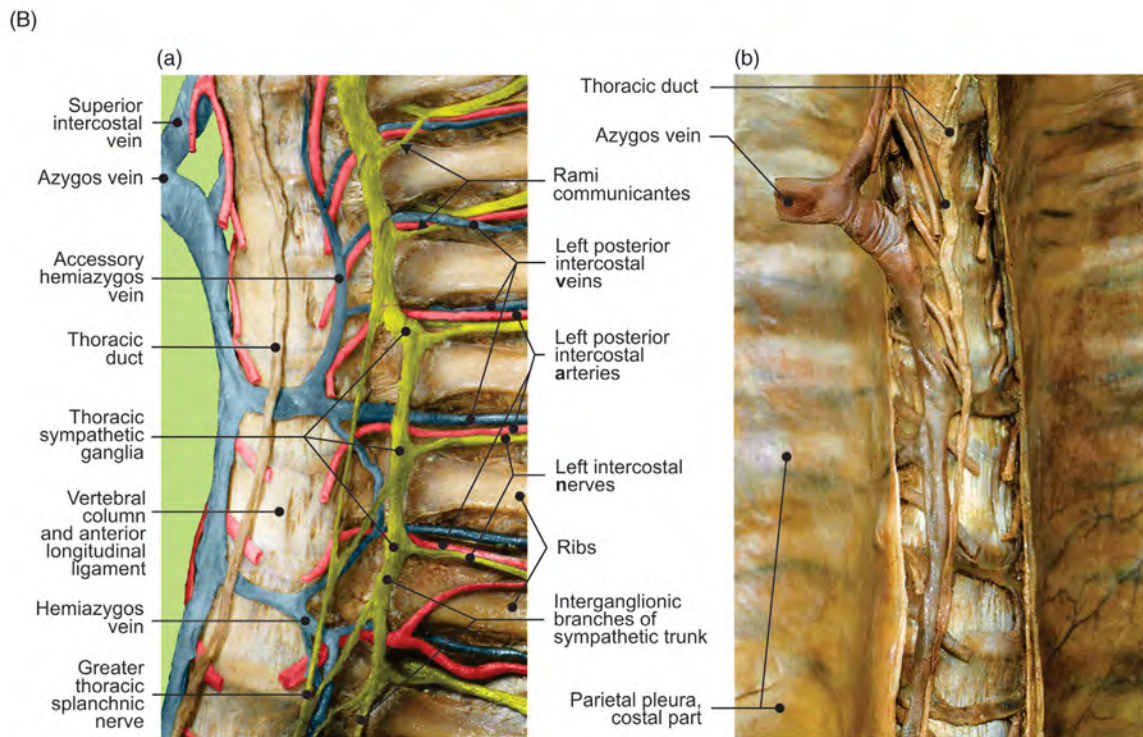
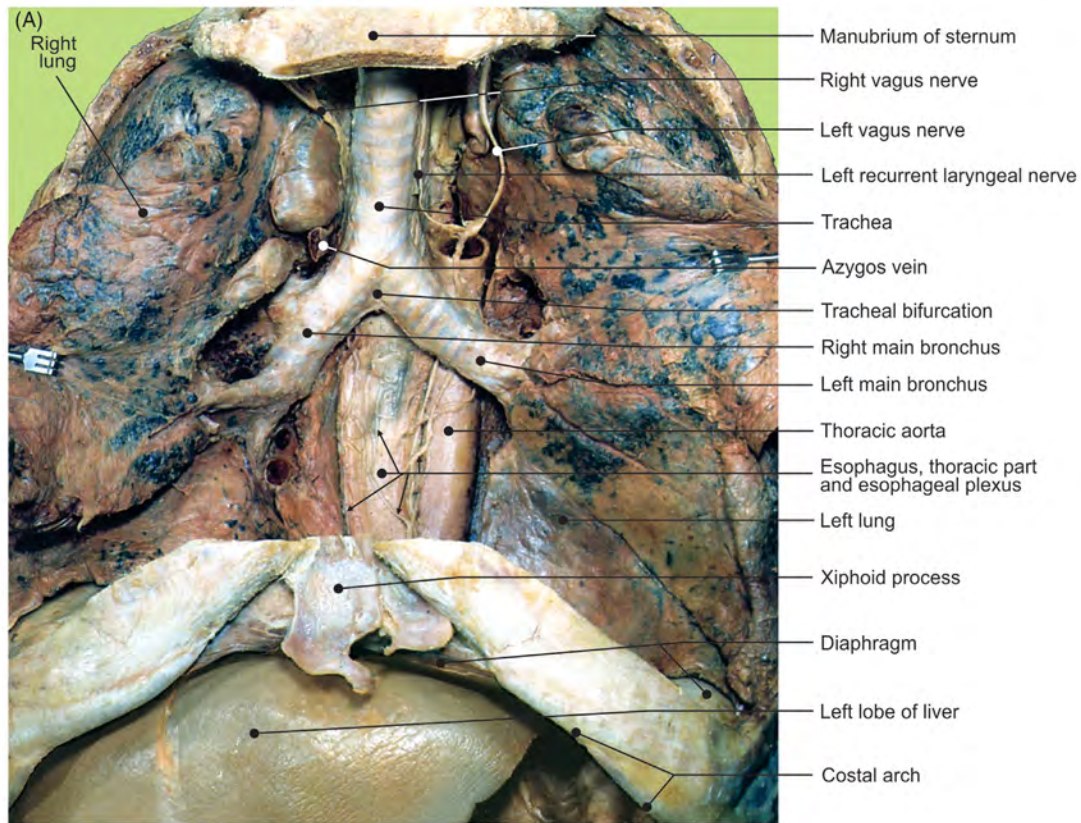


FIGURE 3.12 (A) The anterior aspect of lungs and mediastinum in situ. The major blood vessels and heart have been removed. (B) Posterior mediastinum (a) with blood vessels and nerves and (b) after removal of costal pleura.

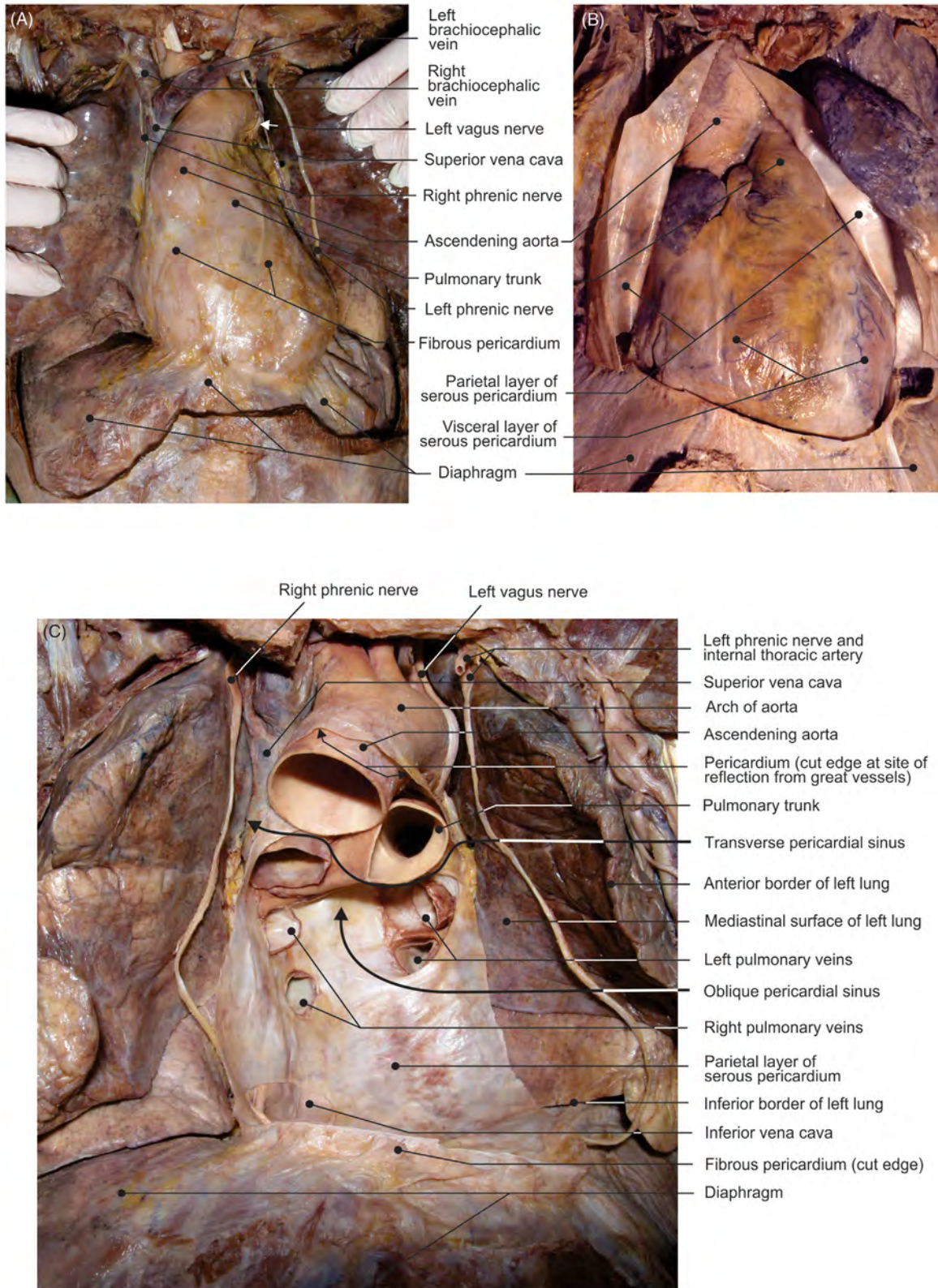


FIGURE 3.13 (A) Heart and pericardium in situ. (B) The anterior aspect of the heart. (C) The pericardial cavity after the heart has been removed.

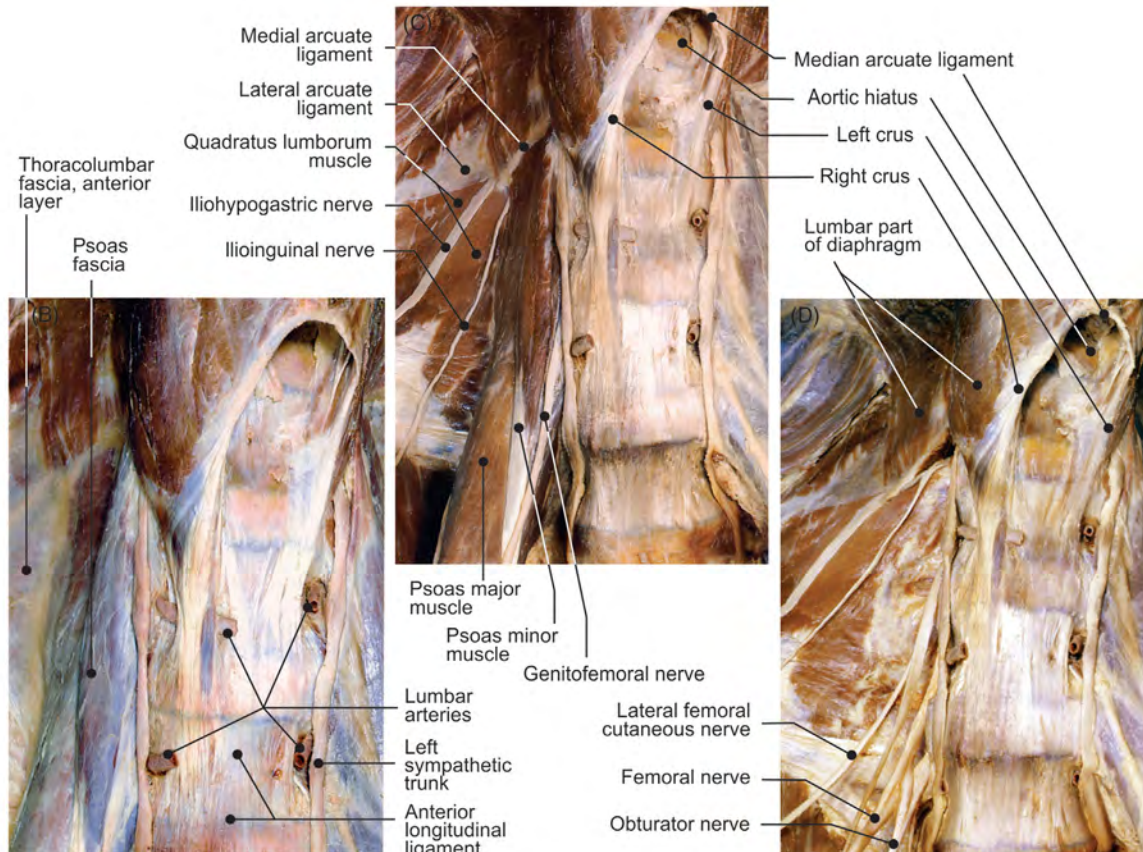
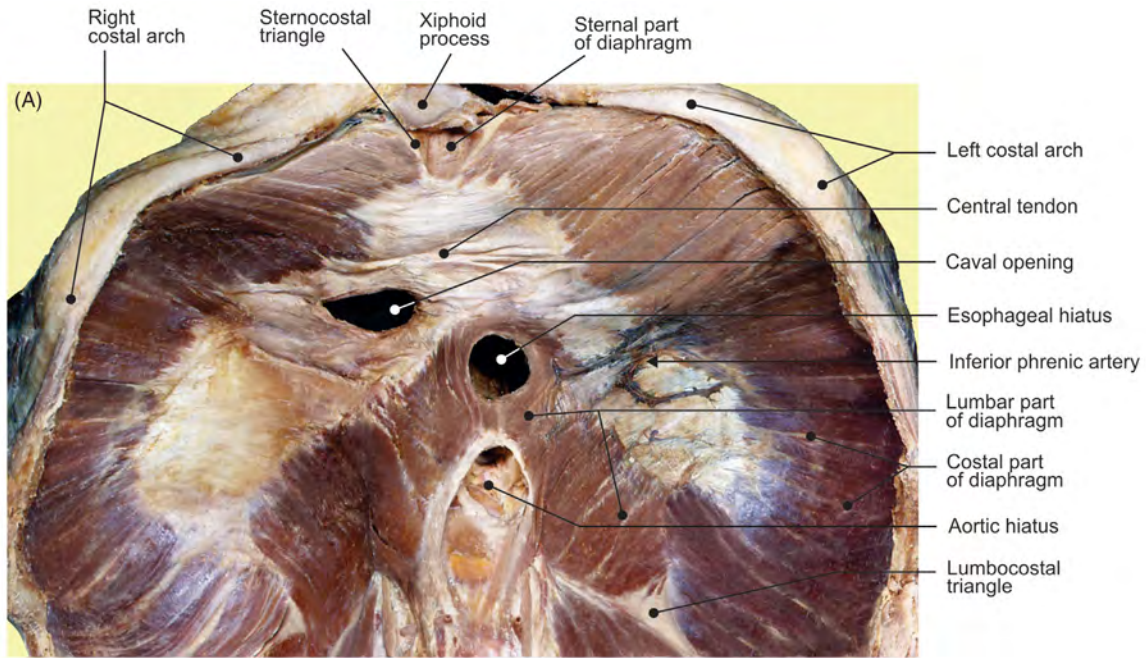


FIGURE 3.14 (A) The abdominal surface of the diaphragm. (B–D) Different layers of the anterior aspect of the lumbar part of diaphragm and parts of the posterior abdominal wall.

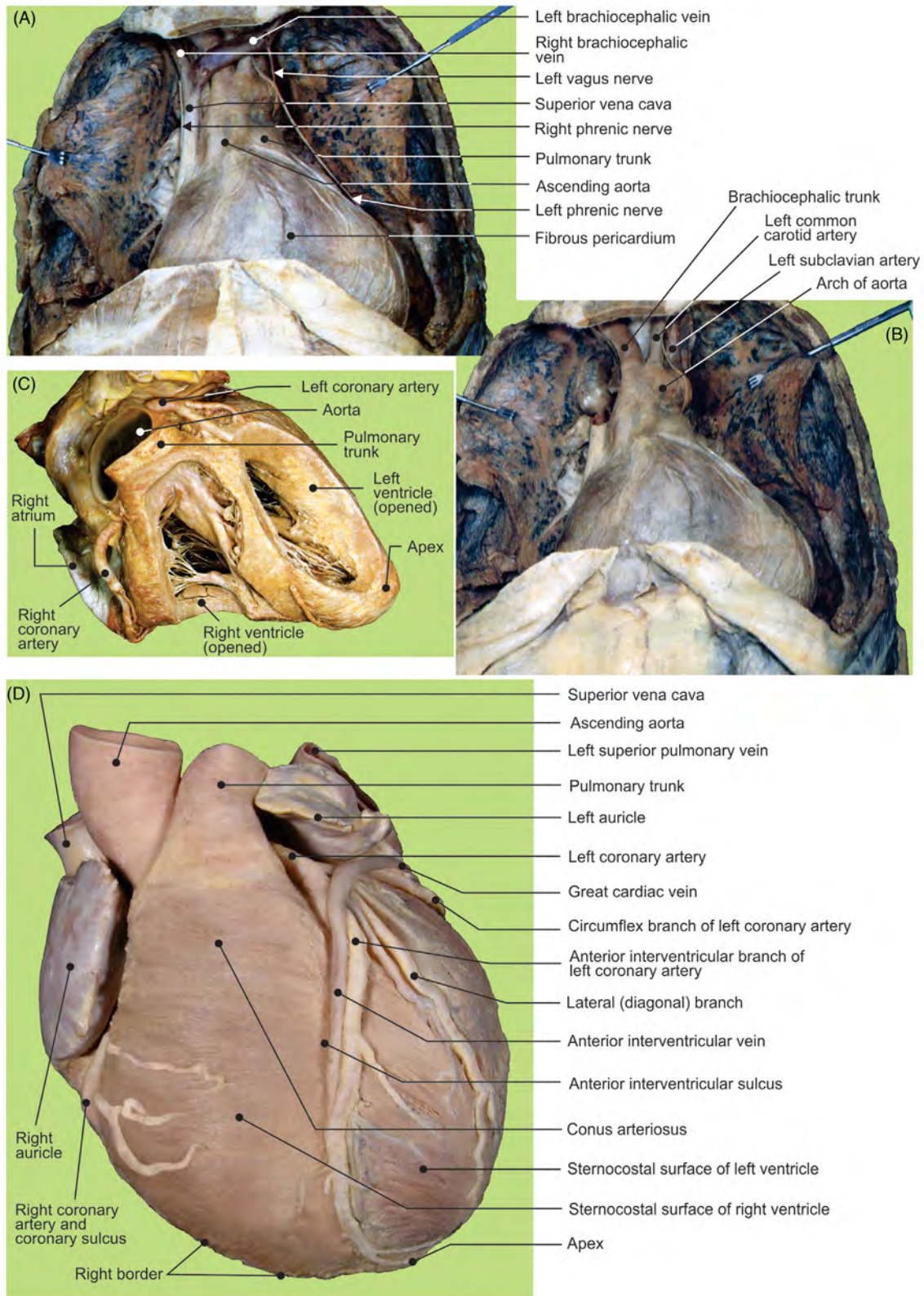


FIGURE 3.15 Superior mediastinum and heart in pericardium in situ: (A) venous and (B) arterial layers. (C) Anterior view of heart with opened ventricles. (D) Anterior view of heart.

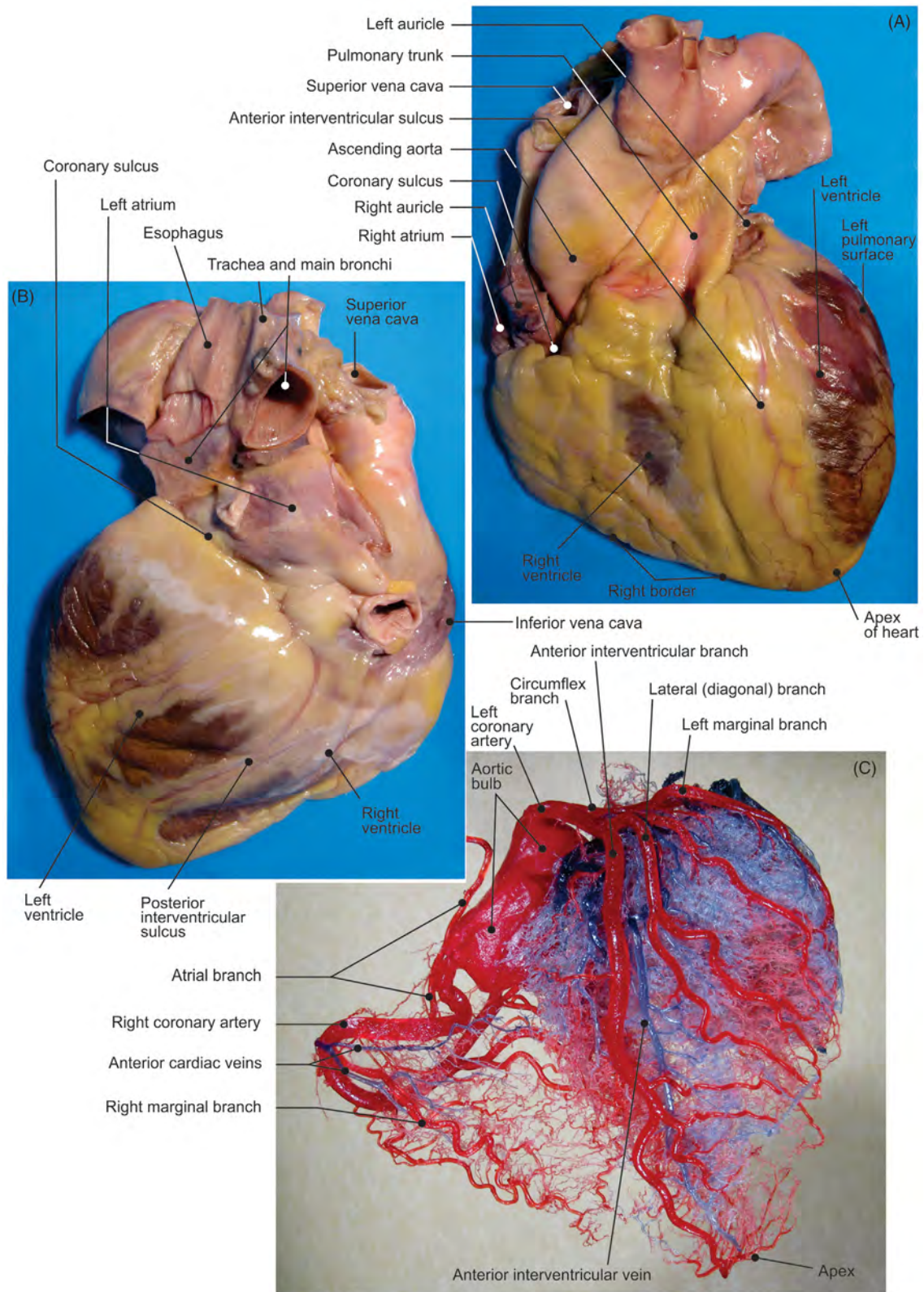


FIGURE 3.16 The native heart: (A) sternocostal surface and (B) diaphragmatic surface. (C) Anterior view: corrosion cast of cardiac arteries (red) and veins (blue).

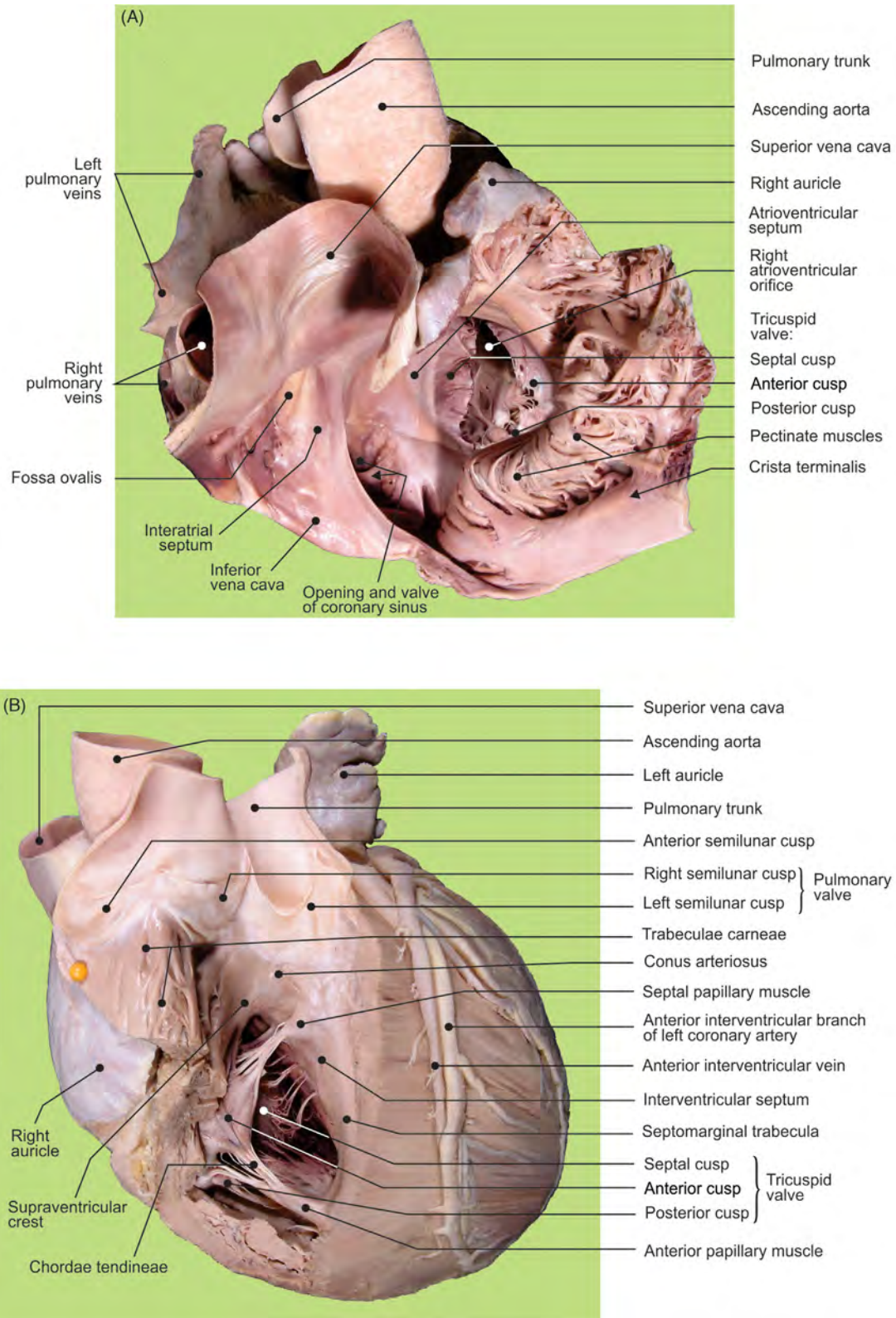


FIGURE 3.17 (A) The right atrium: view from above. (B) The right ventricle: view from the front.

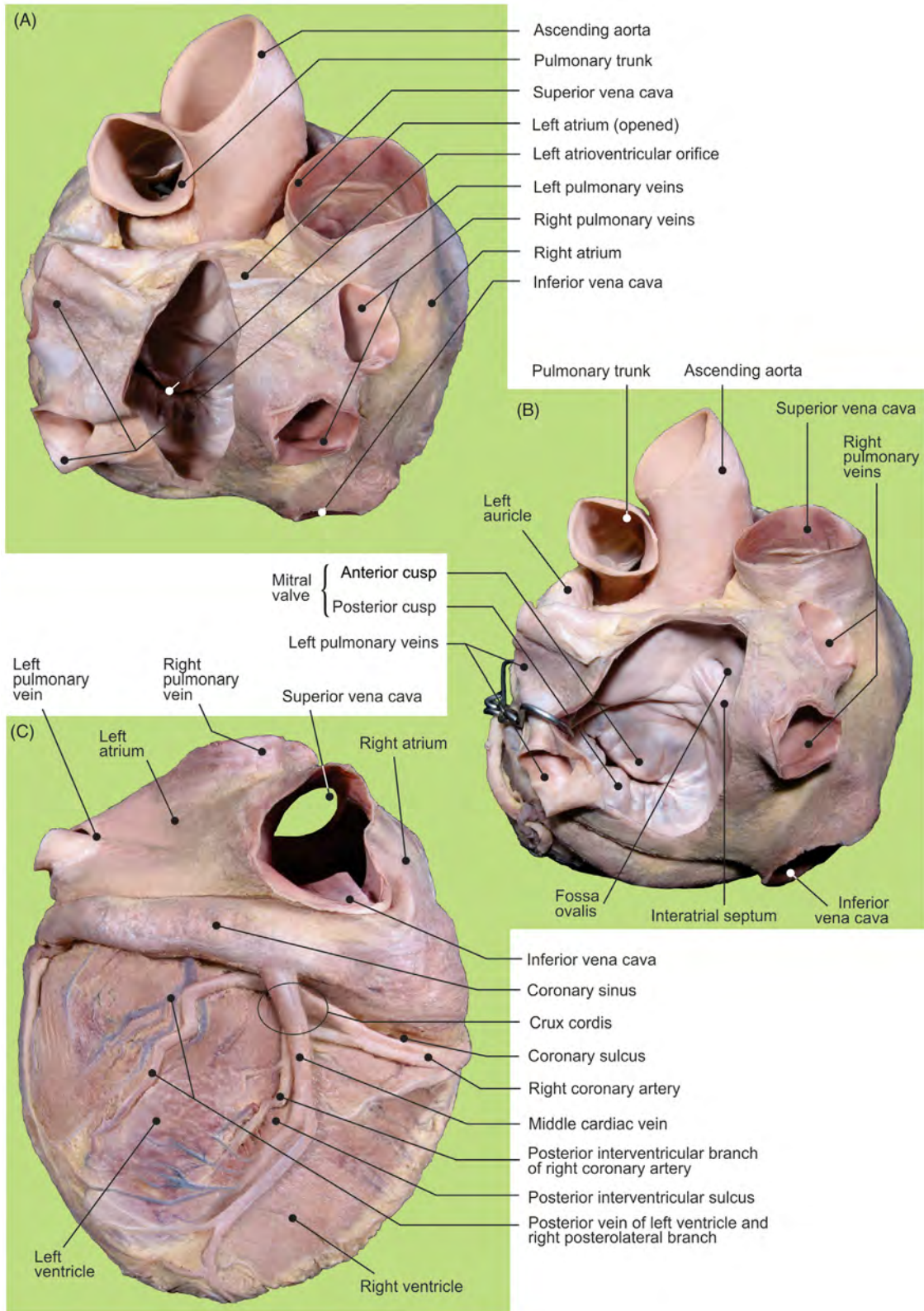


FIGURE 3.18 Cardiac base: (A) view from behind and (B) with open posterior wall. (C) Diaphragmatic surface of the heart.

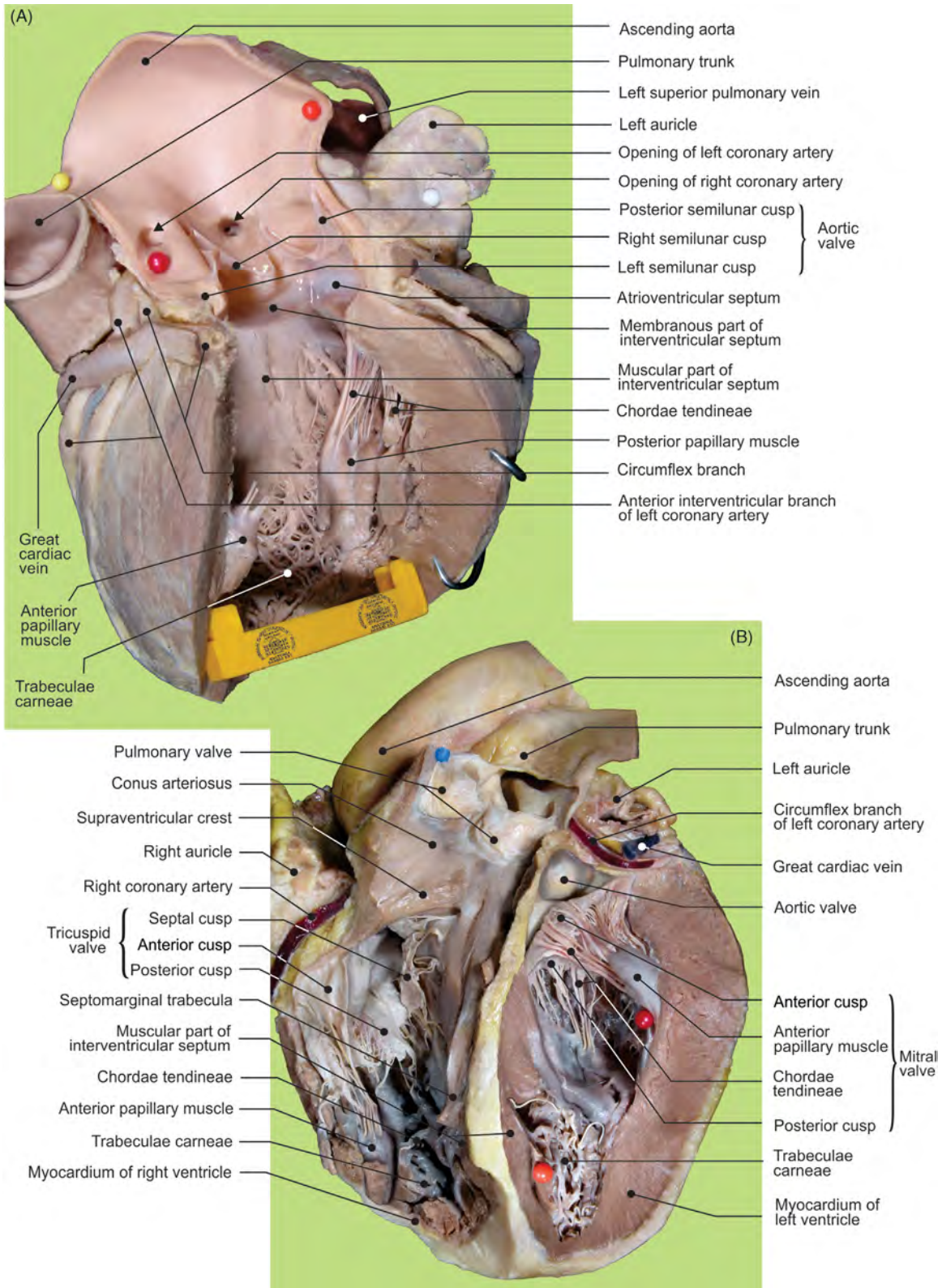


FIGURE 3.19 (A) Left ventricle: open longitudinally. (B) Right and left ventricles: removed anterior wall.

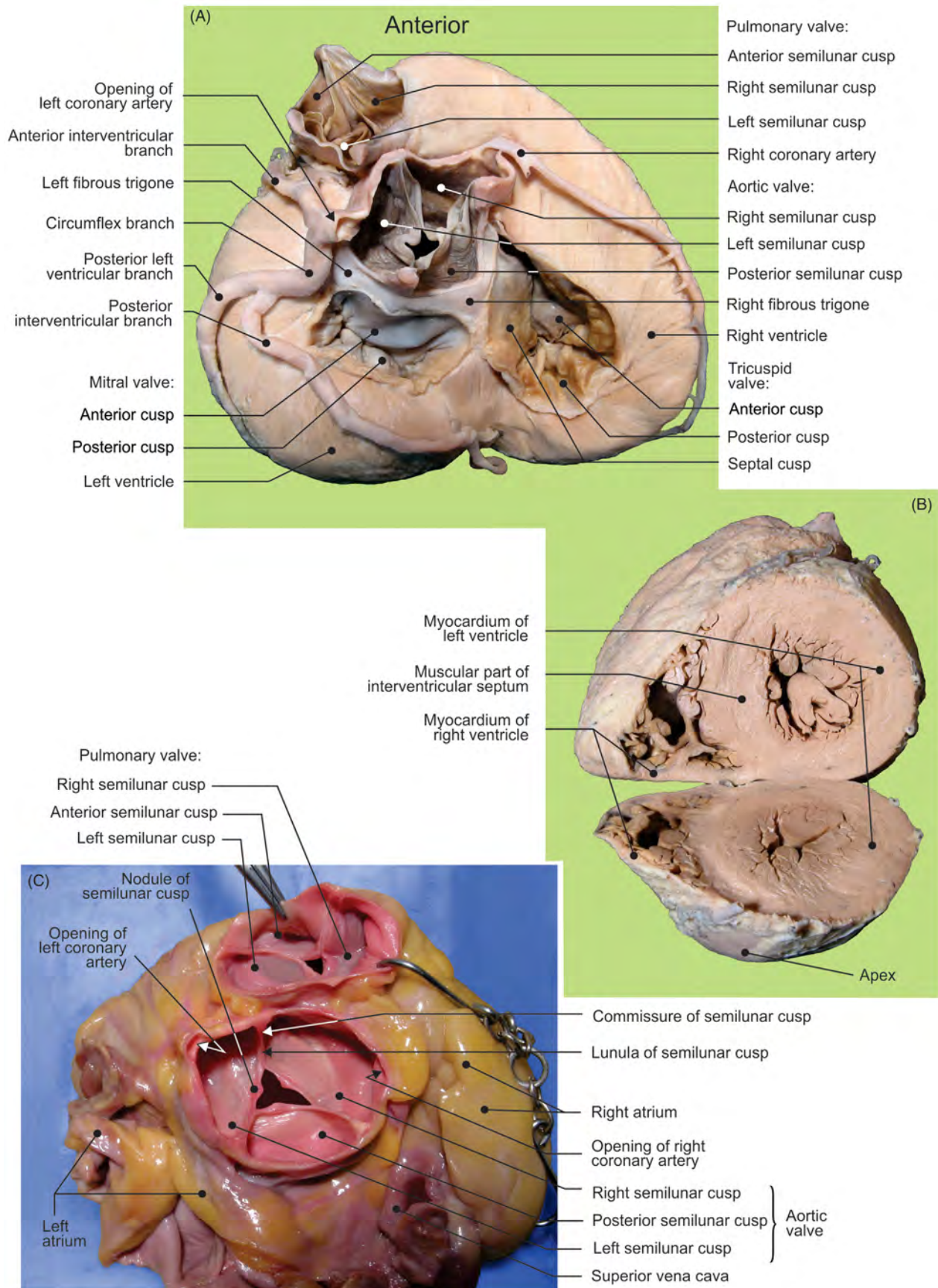


FIGURE 3.20 (A) Cardiac base with removed atria. (B) Transverse section of heart at level of apex. (C) Native specimen: semilunar valves.

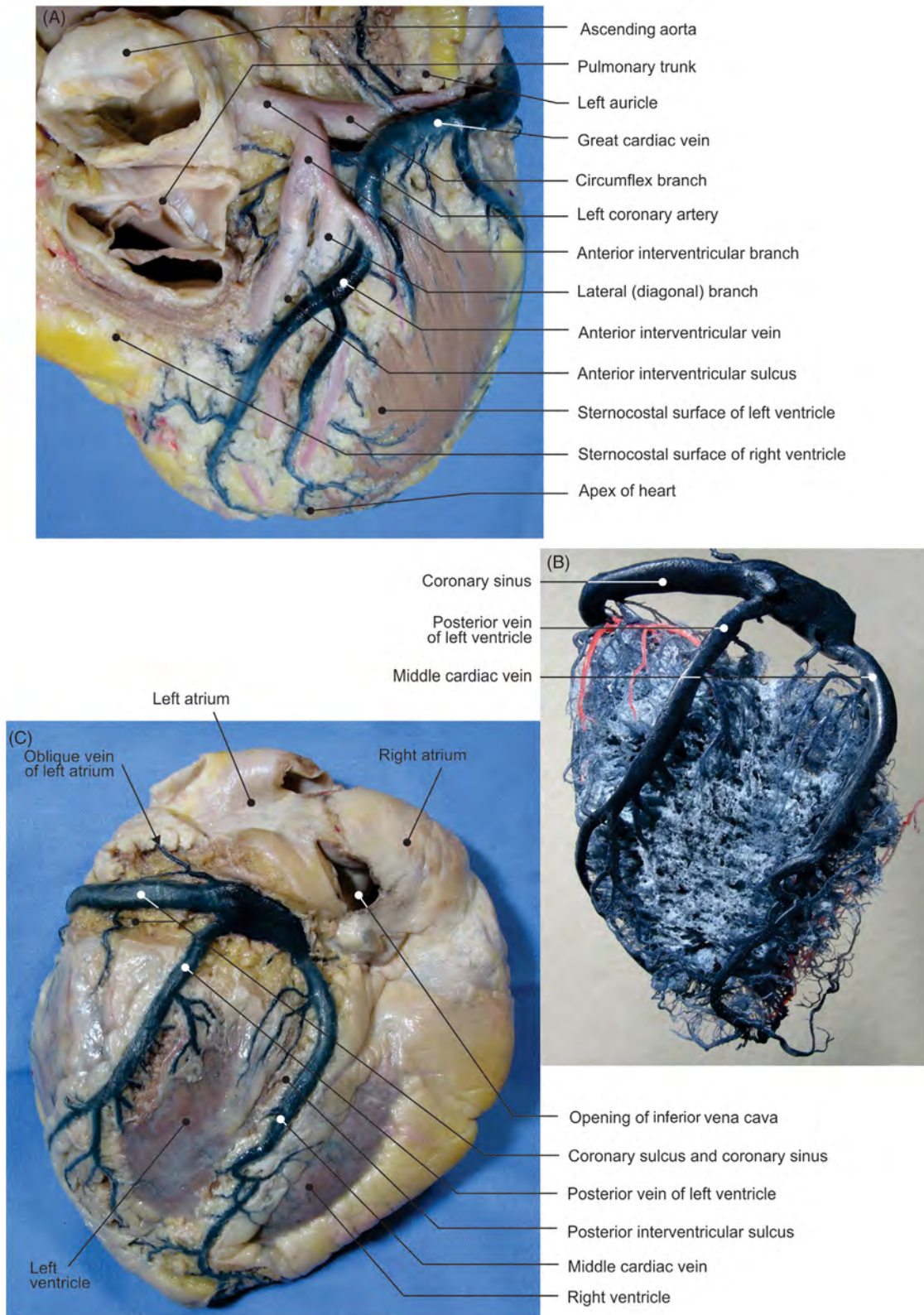


FIGURE 3.21 (A) The heart: anterosuperior aspect. Diaphragmatic surface of heart: (B) corrosion cast and (C) dissection.

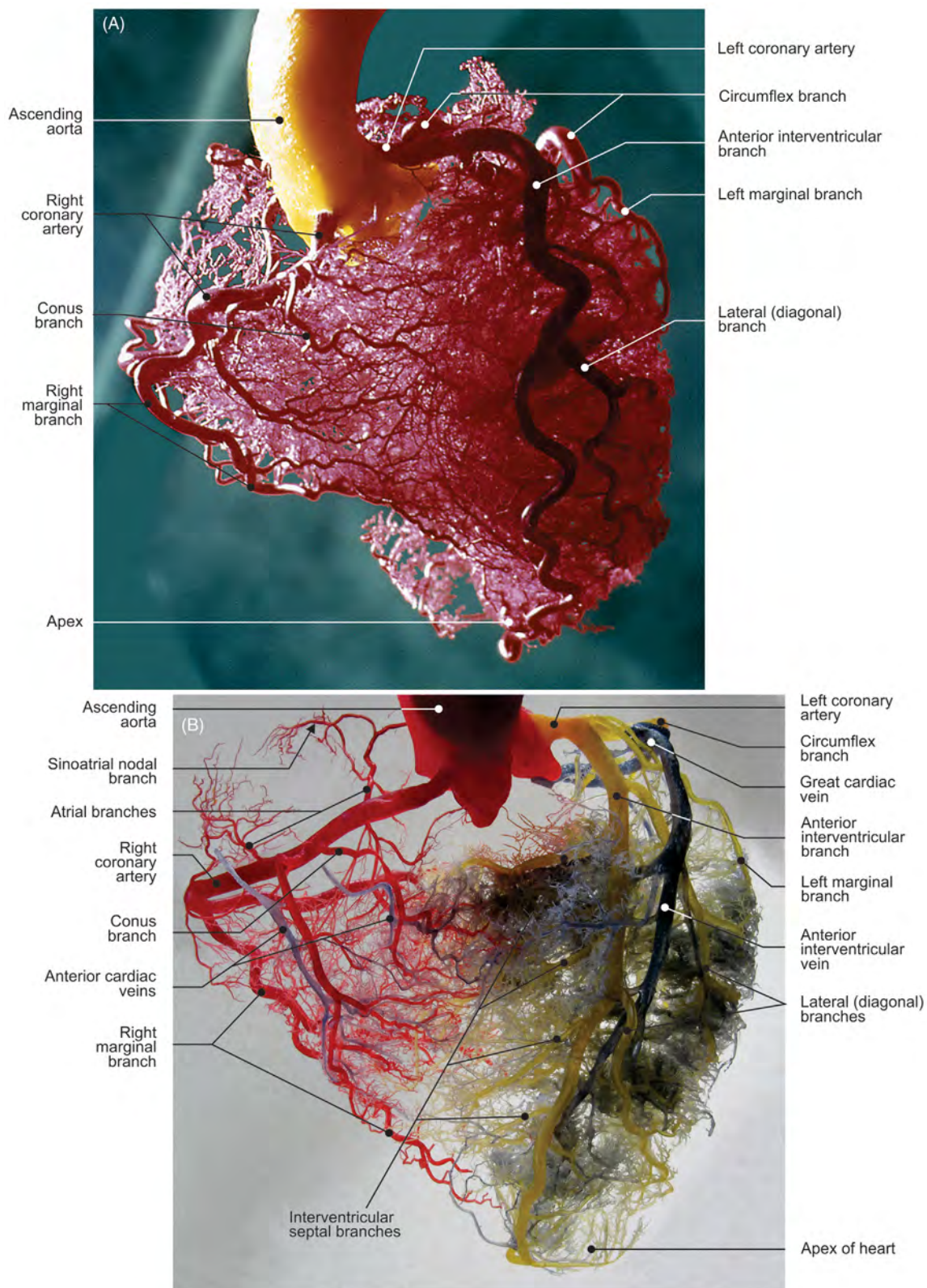


FIGURE 3.22 Sternocostal surface of the heart. (A–B) Different specimens of the arterial and venous distributions (corrosion casts).

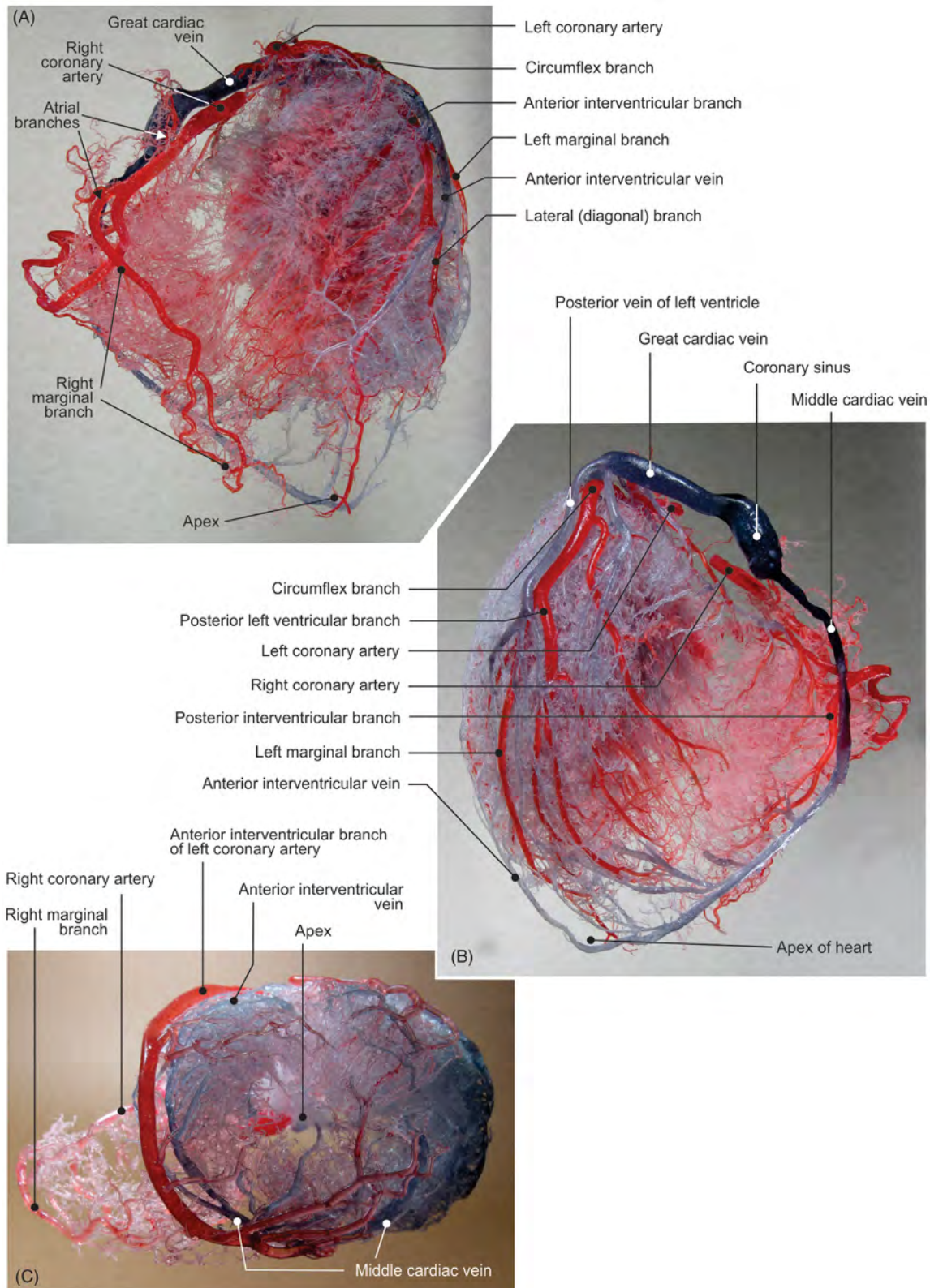


FIGURE 3.23 Cardiac arterial and venous distributions (corrosion cast). (A) Sternocostal surface. (B) Diaphragmatic surface (adjusted tip of circulation). (C) Inferior view of the cardiac apex.

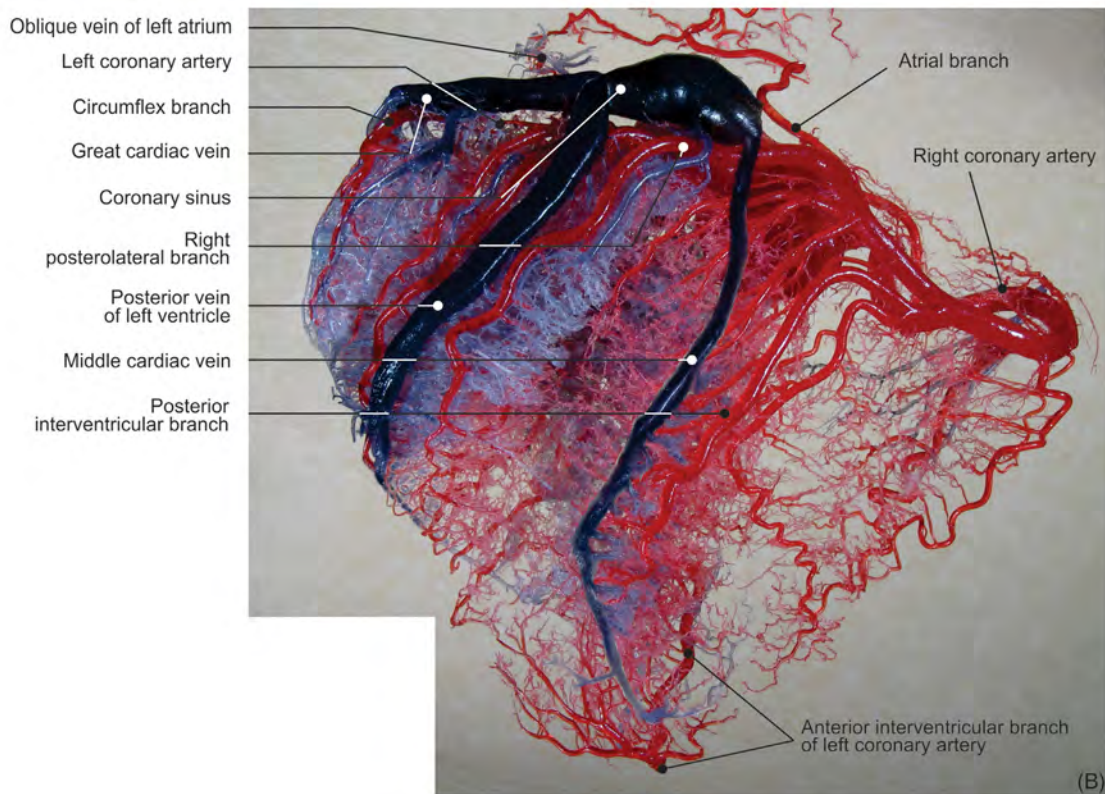
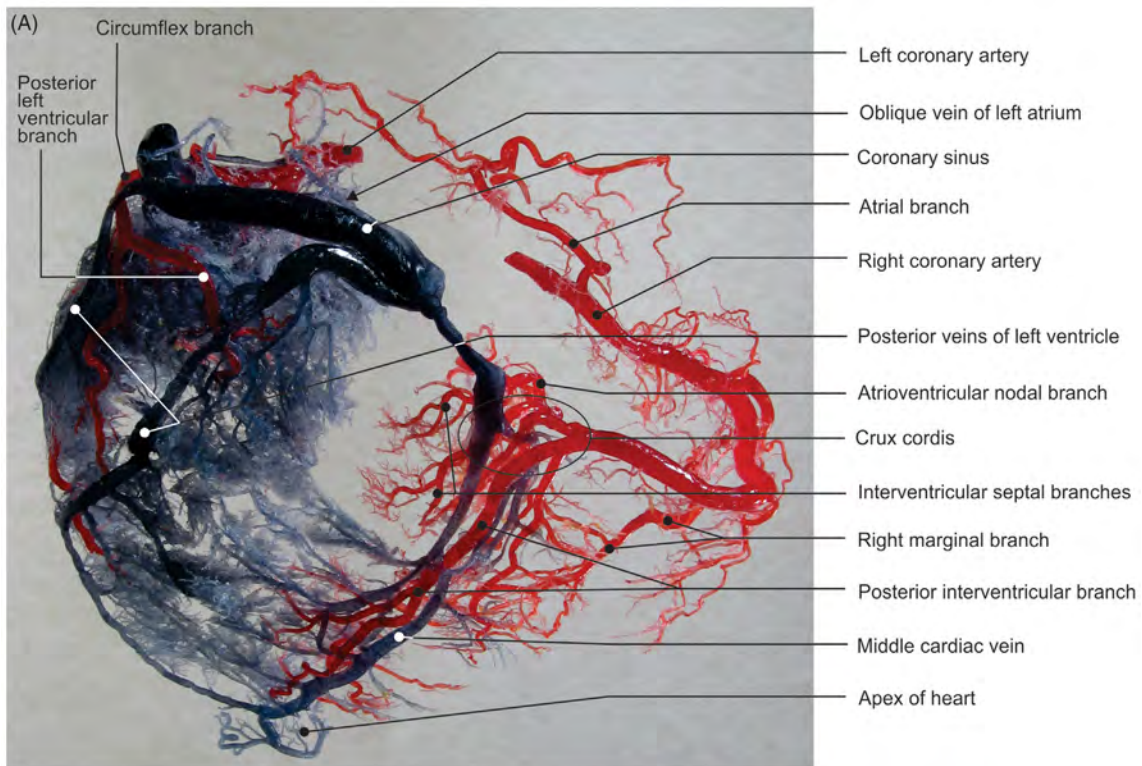


FIGURE 3.24 Cardiac arterial and venous distributions (diaphragmatic surfaces of corrosion casts). (A) Adjusted tip of circulation and (B) dominant right coronary artery (specimen from Fig. 3.16).

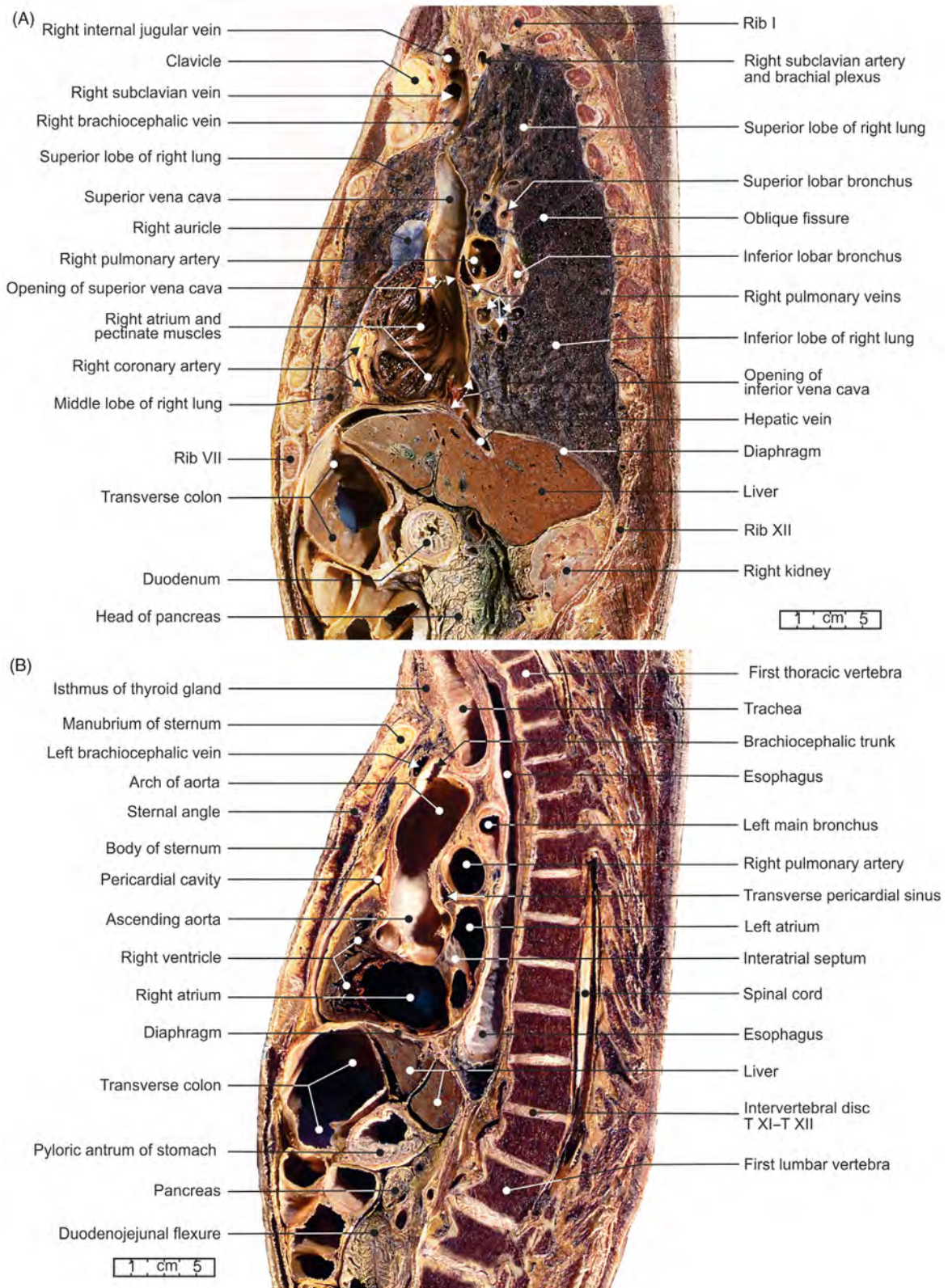


FIGURE 3.25 Sagittal sections of the thorax. Right (A) atrium and (B) ventricle of the heart.

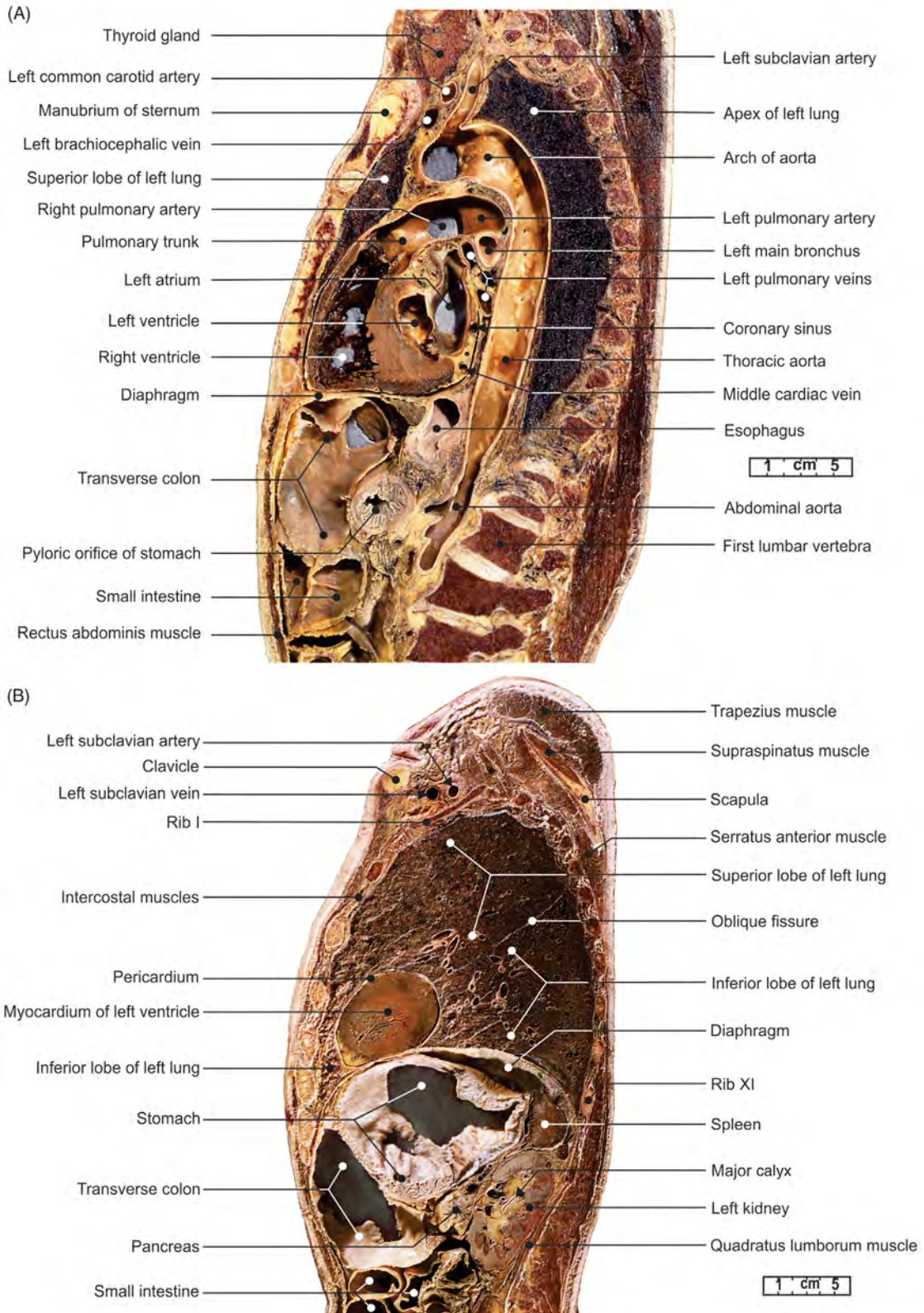


FIGURE 3.26 Sagittal sections of the thorax. (A) Both ventricles and (B) apex of the heart.

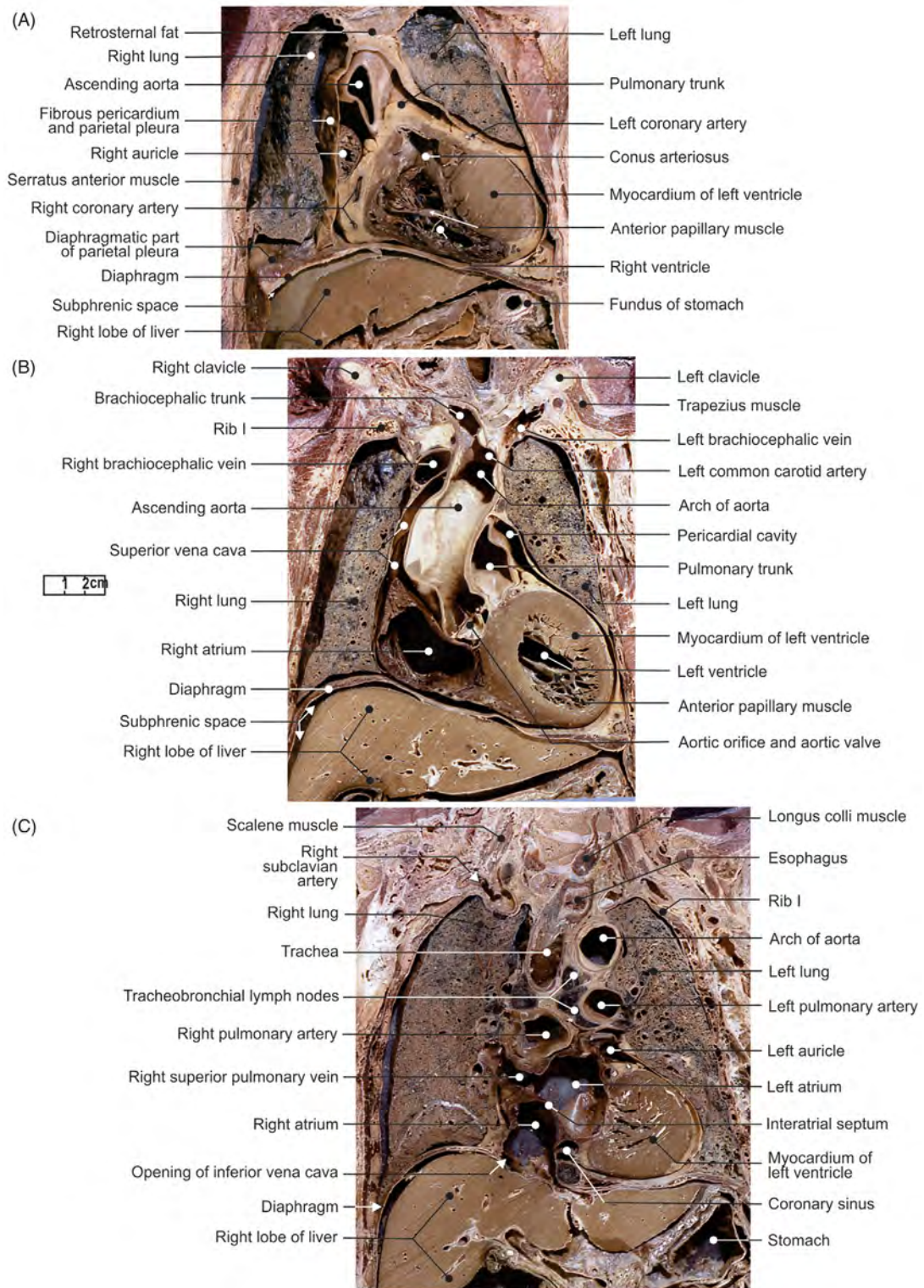
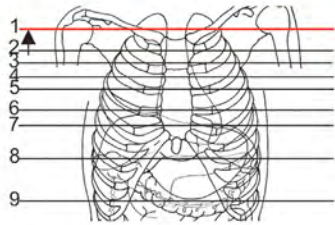
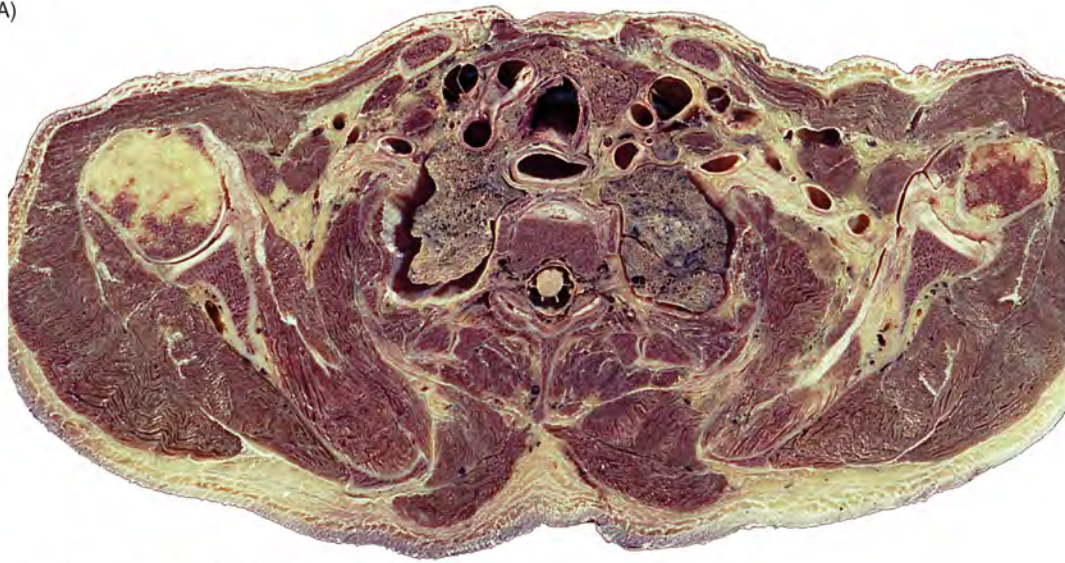

FIGURE 3.27 Coronal sections of the thorax. (A) Right ventricle, (B) left ventricle, and (C) left atrium.

(A)



(B)

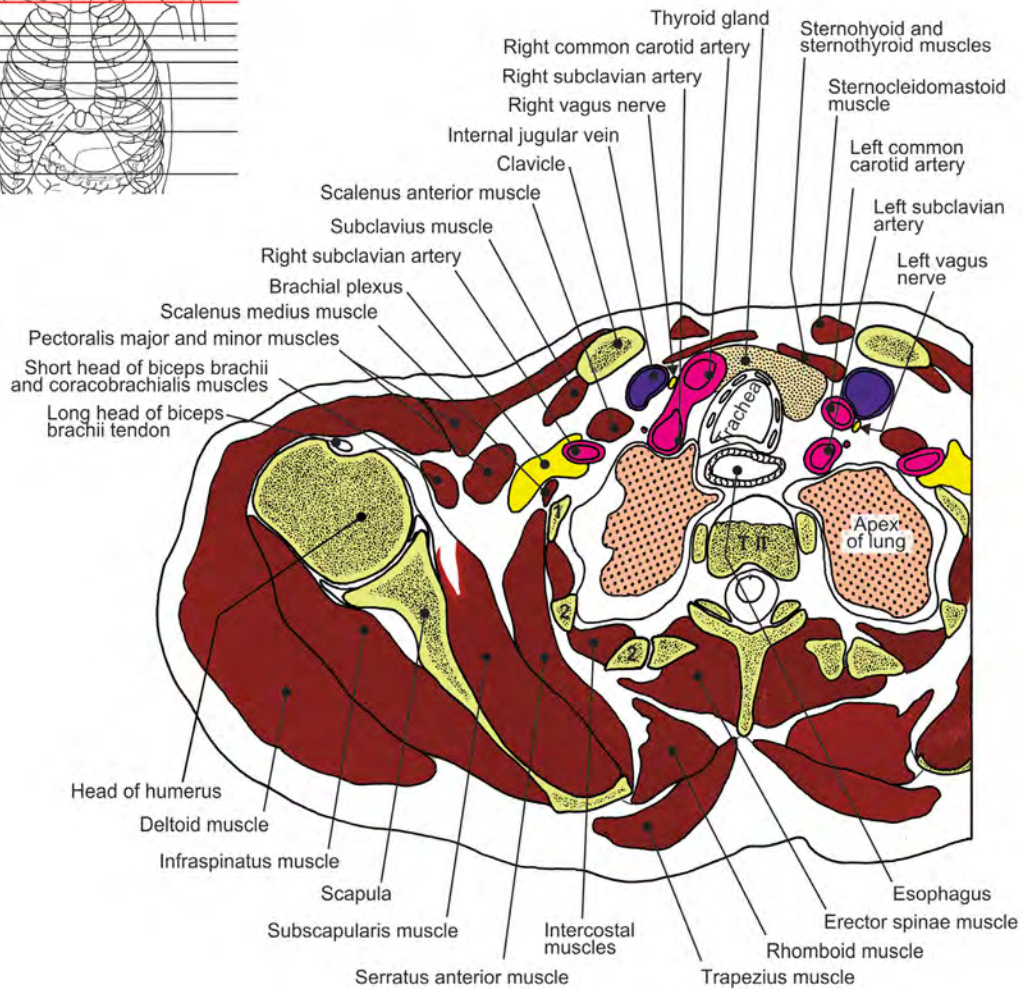


FIGURE 3.28 Cross-section of the thorax at the T2 vertebral level. (A) Section and (B) illustration.

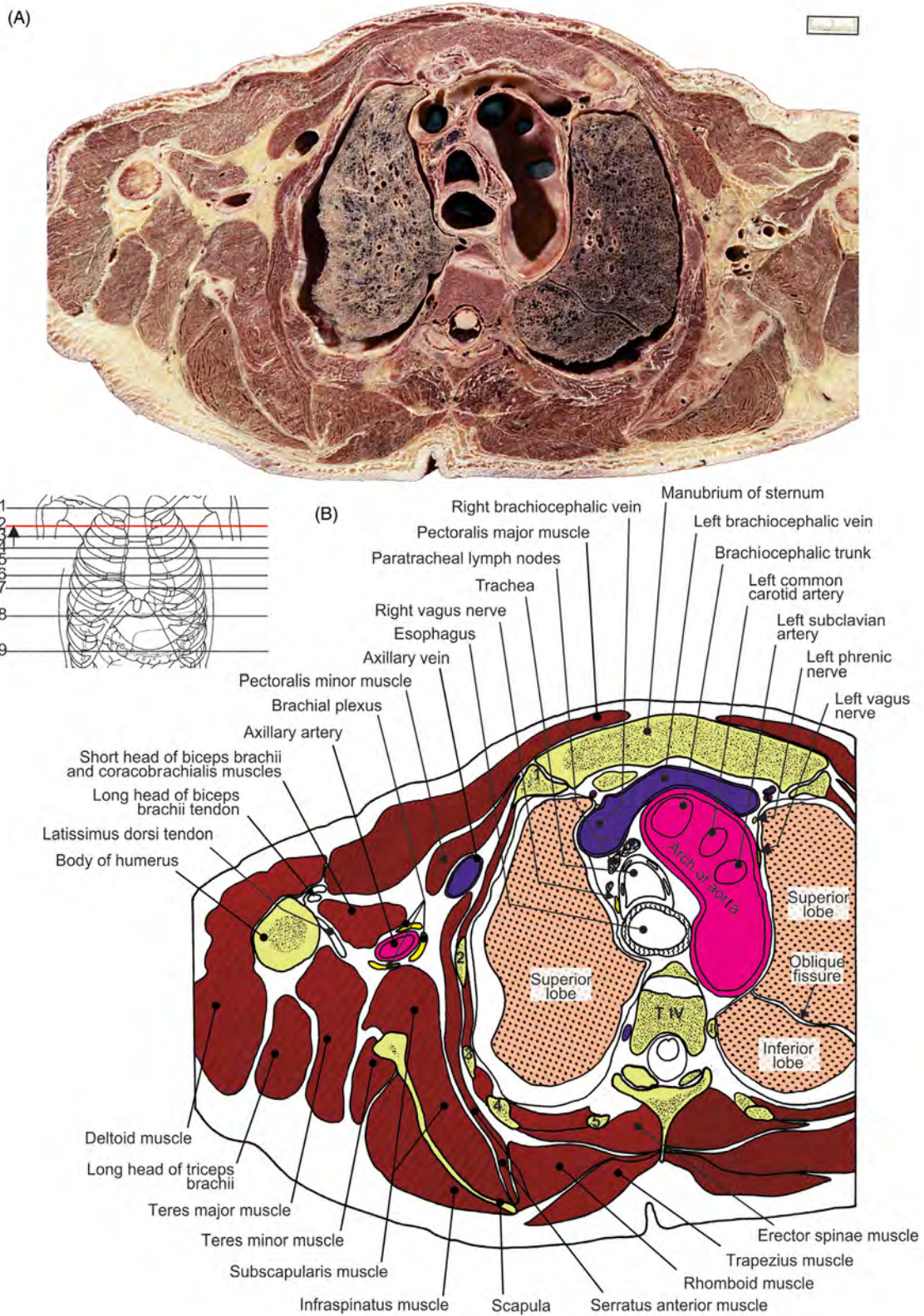


FIGURE 3.29 Cross-section of the thorax at the T4 vertebral level. (A) Section and (B) illustration.

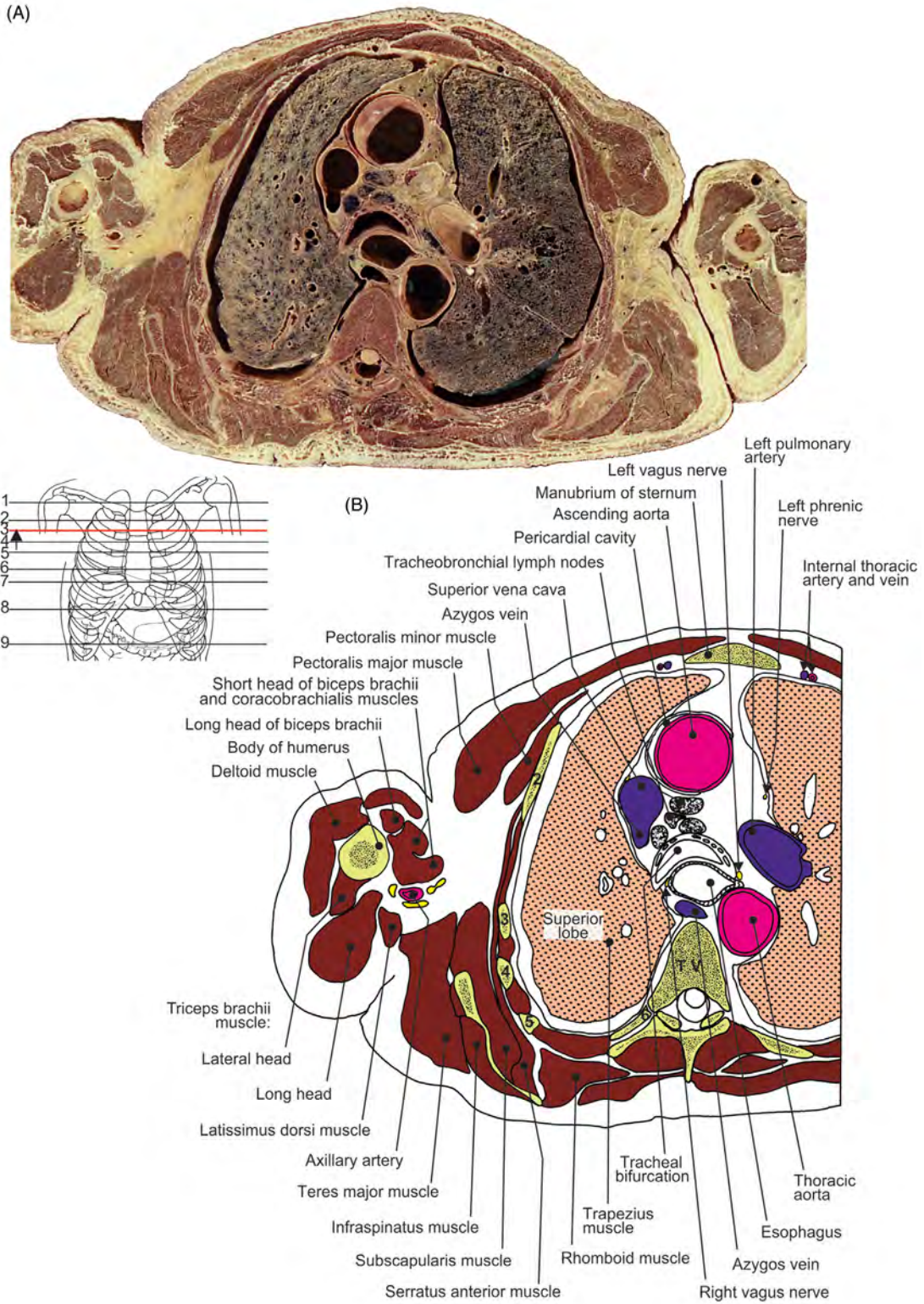


FIGURE 3.30 Cross-section of the thorax at the T5 vertebral level. (A) Section and (B) illustration.

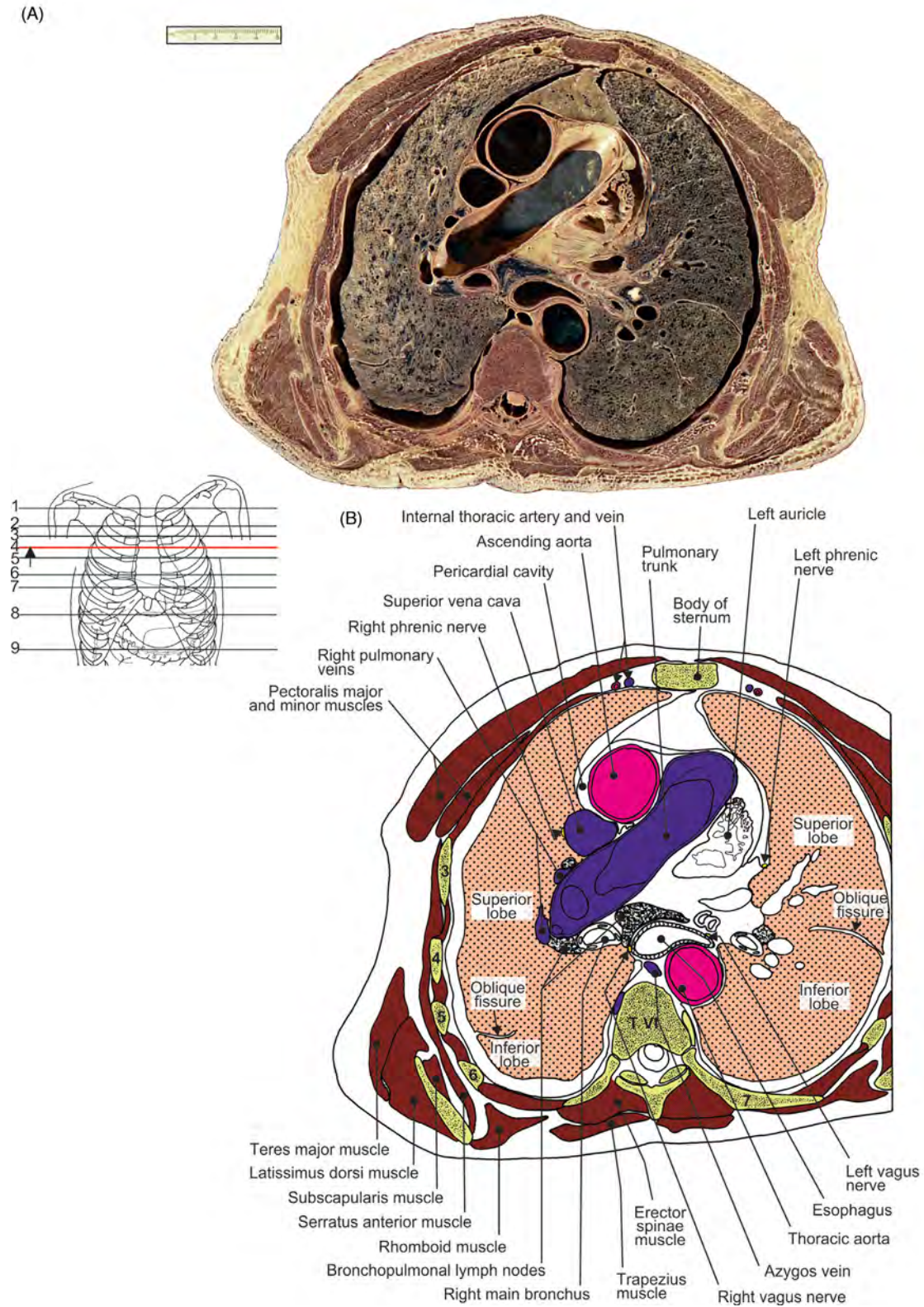


FIGURE 3.31 Cross-section of the thorax at the T6 vertebral level. (A) Section and (B) illustration.

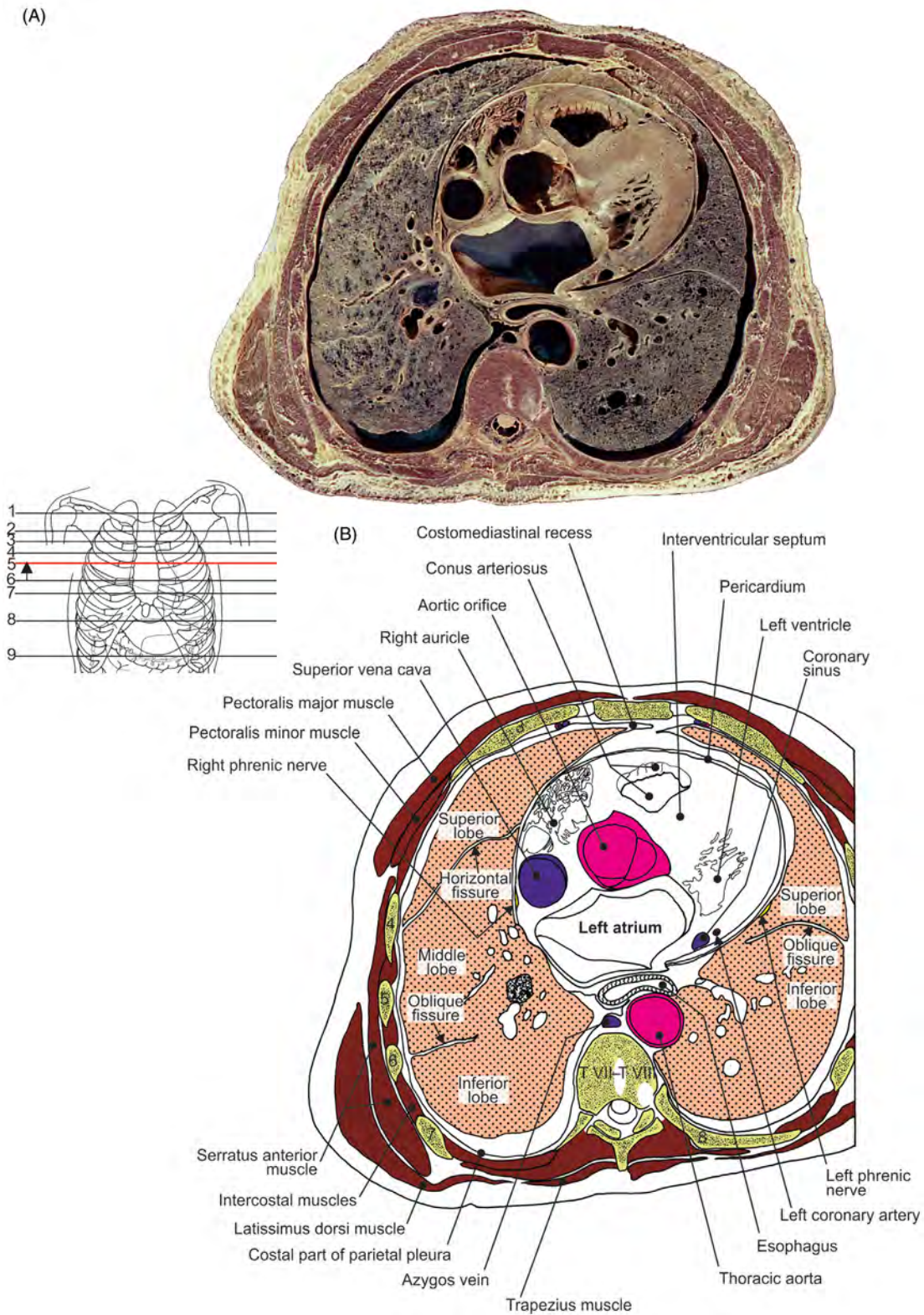


FIGURE 3.32 Cross-section of the thorax at the T7–T8 vertebral level. (A) Section and (B) illustration.

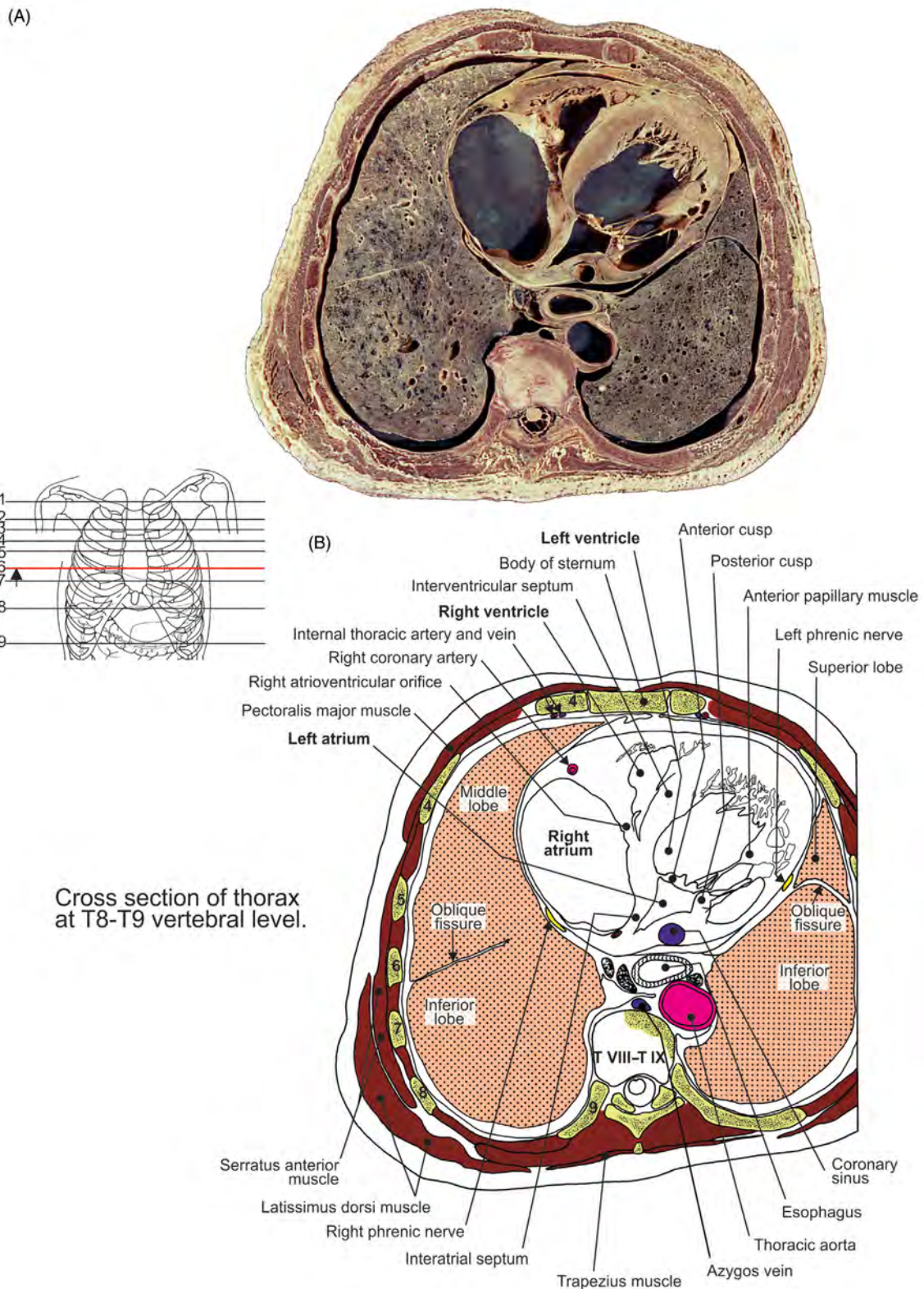


FIGURE 3.33 Cross-section of the thorax at the T8–T9 vertebral level. (A) Section and (B) illustration.

(A)

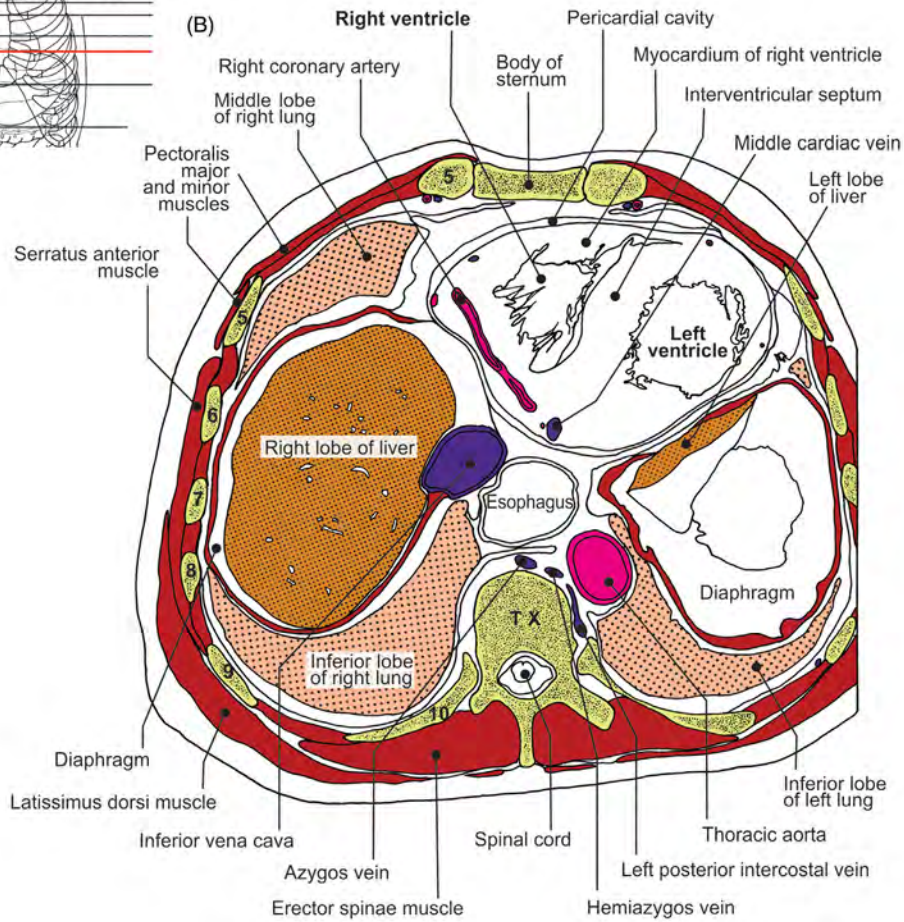
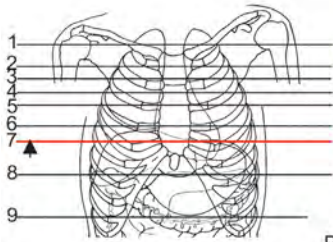
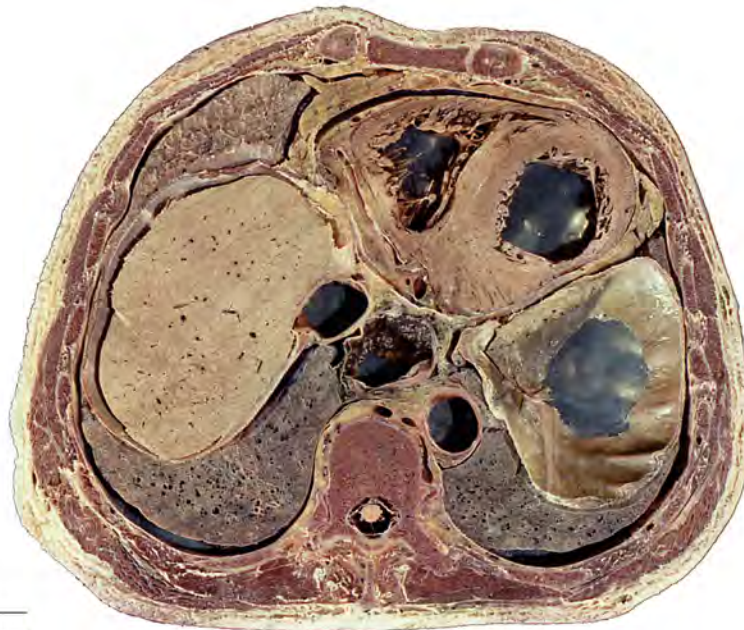


FIGURE 3.34 Cross-section of the thorax at the T10 vertebral level. (A) Section and (B) illustration.

Abdomen and Vascularization

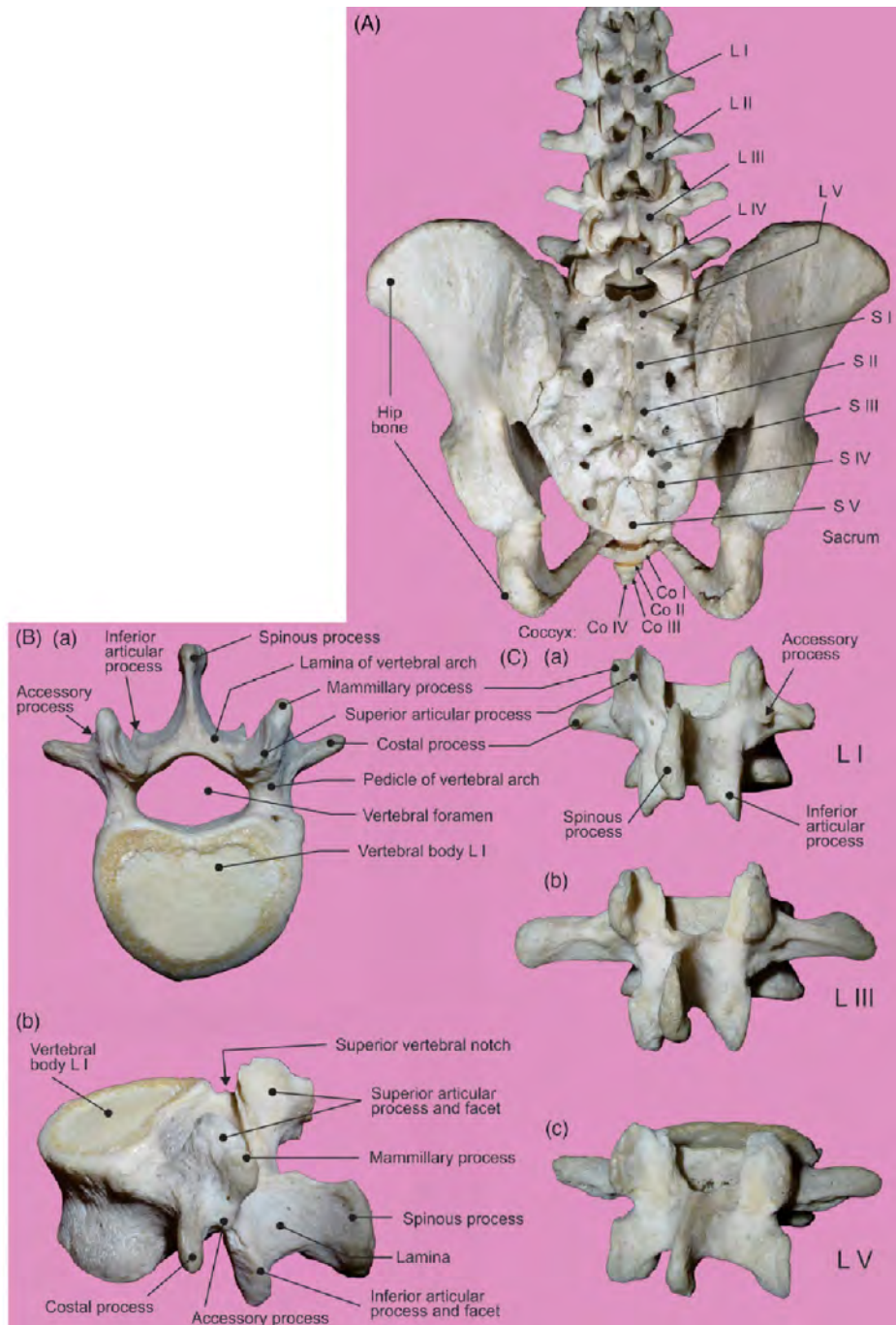


FIGURE 4.1 (A) Lumbar and sacral segments of the vertebral column: posterior view; total fusion of L5 vertebra with sacrum. (B) Vertebra L1: (a) superior and (b) lateral views. (C) Vertebrae posterior view: (a) L1, (b) L3, and (c) L5.

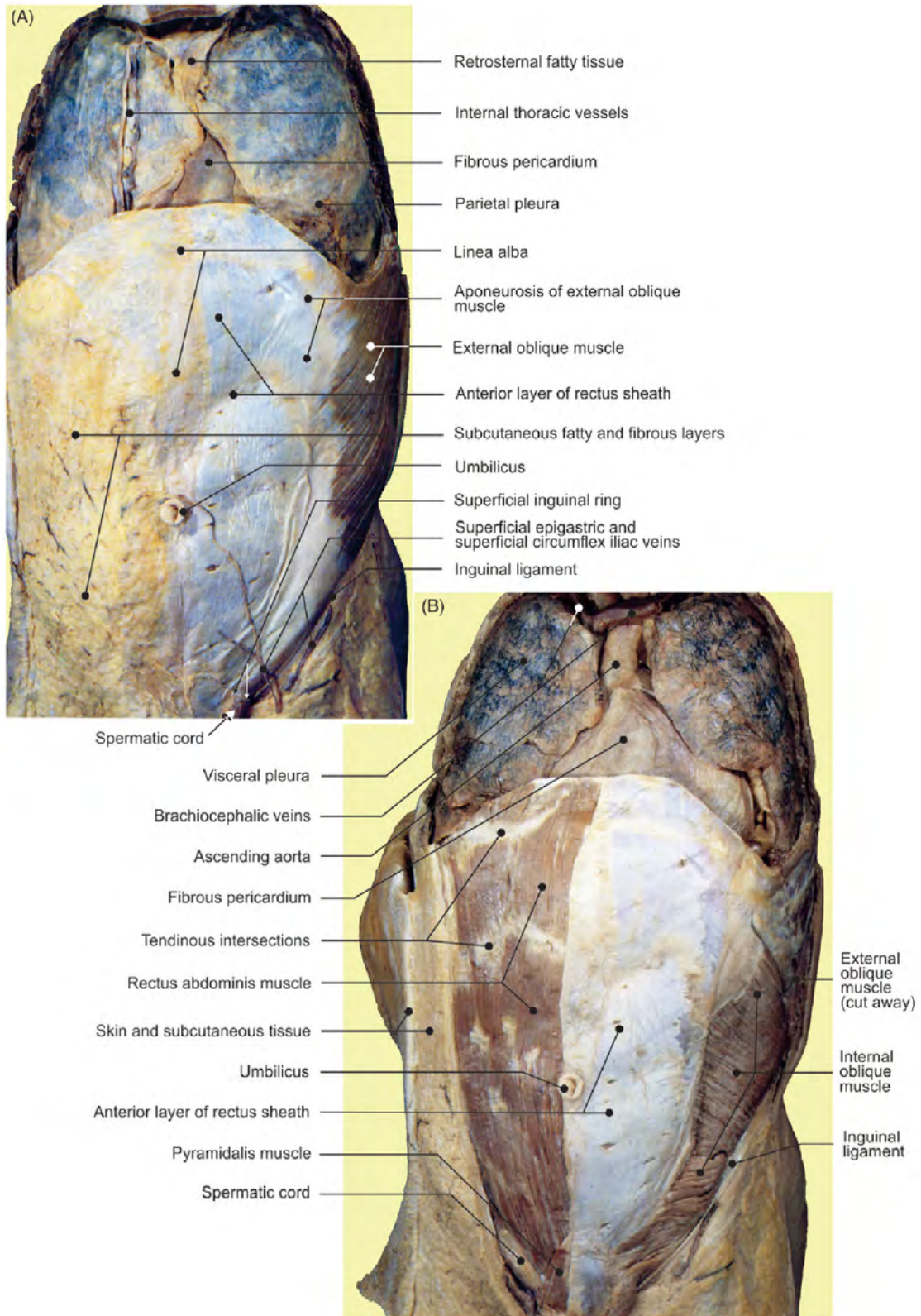


FIGURE 4.2 The anterolateral abdominal wall. (A) Superficial and (B) middle layers.

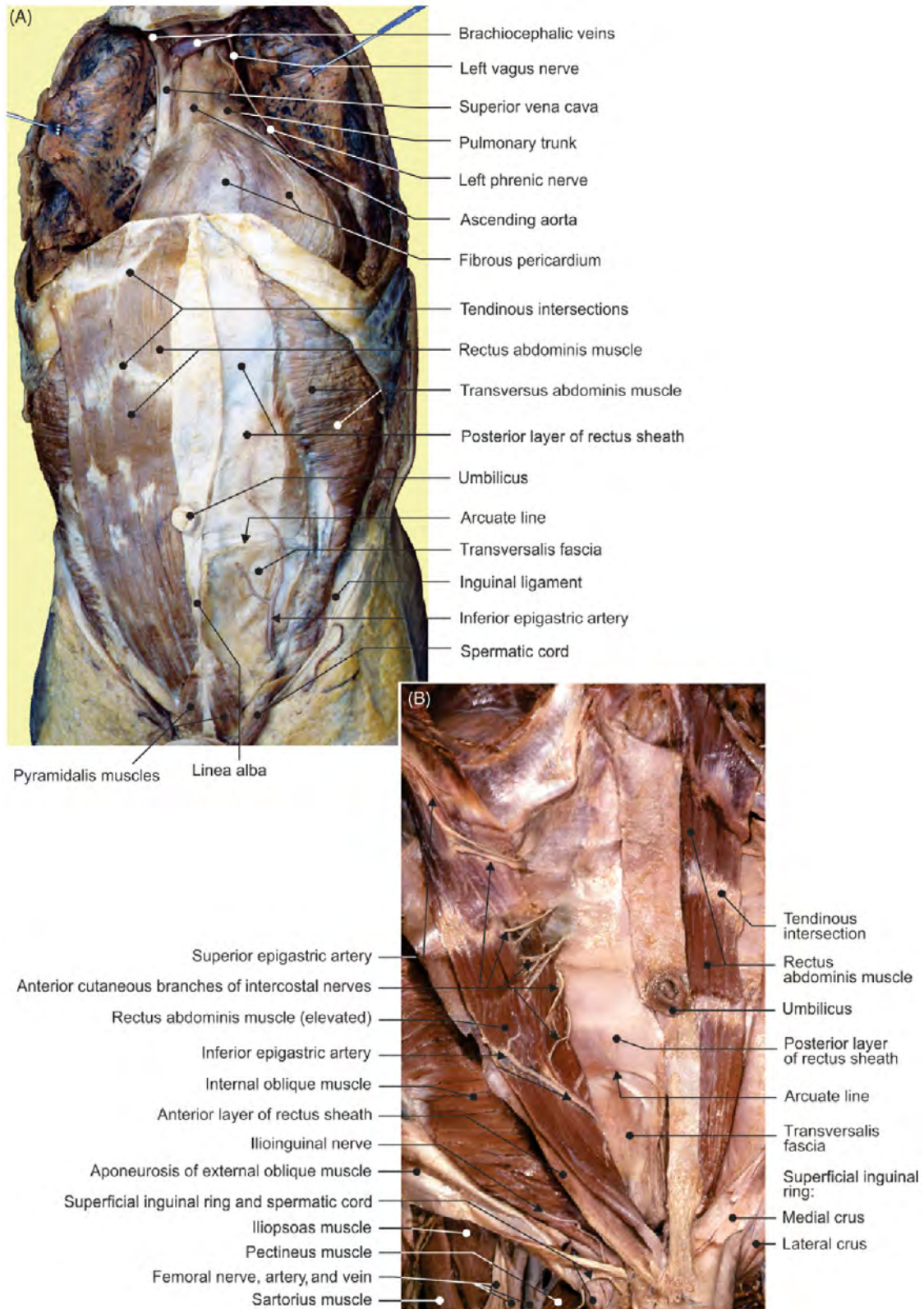


FIGURE 4.3 The anterolateral abdominal wall. (A) Deep layer and (B) structural details.

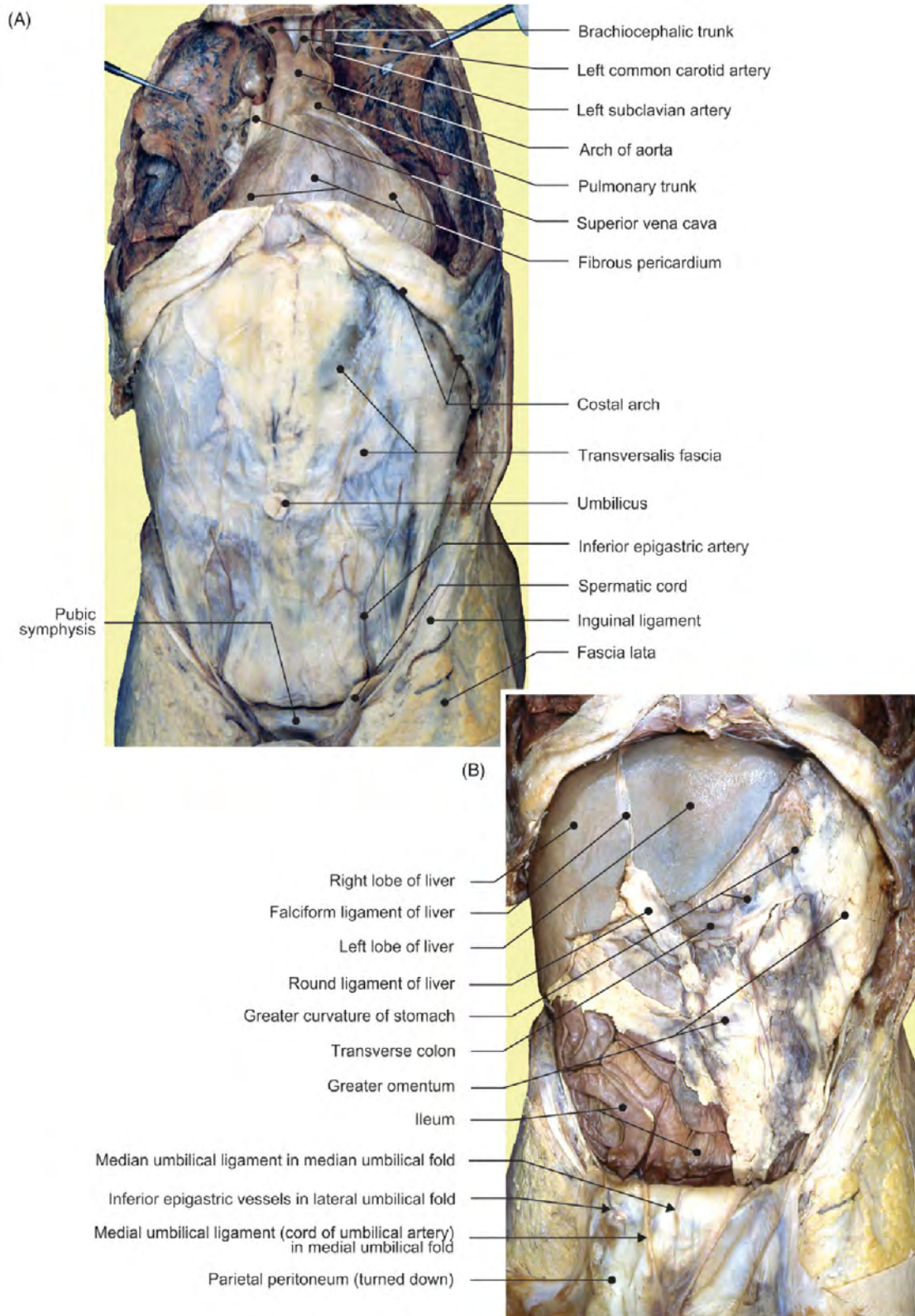


FIGURE 4.4 The anterolateral abdominal wall. (A) Transversalis fascia and (B) exposed anterior aspect of the abdominal content in situ.

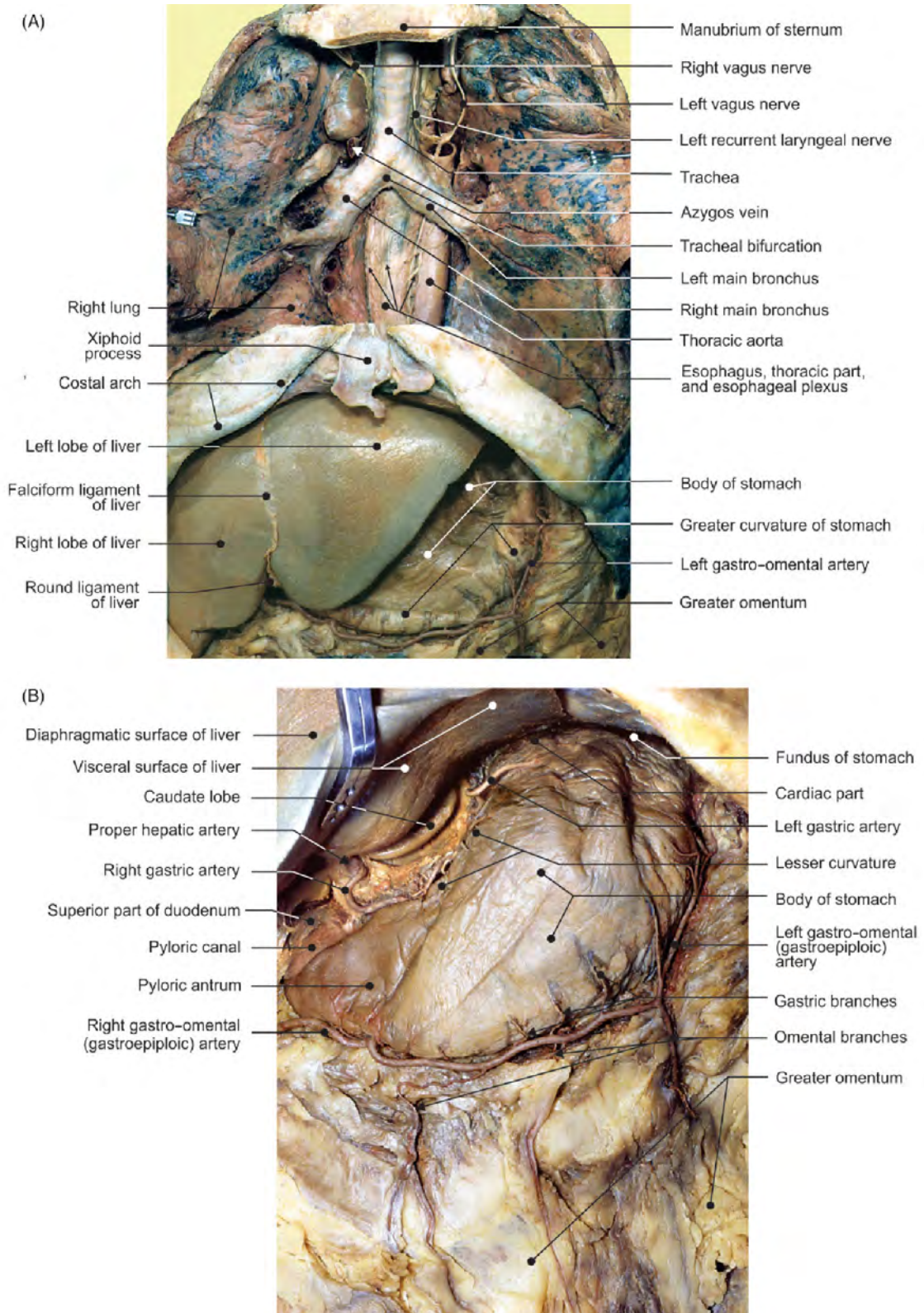


FIGURE 4.5 The stomach in situ. (A–B) Different views displaying relationships and blood vessels.

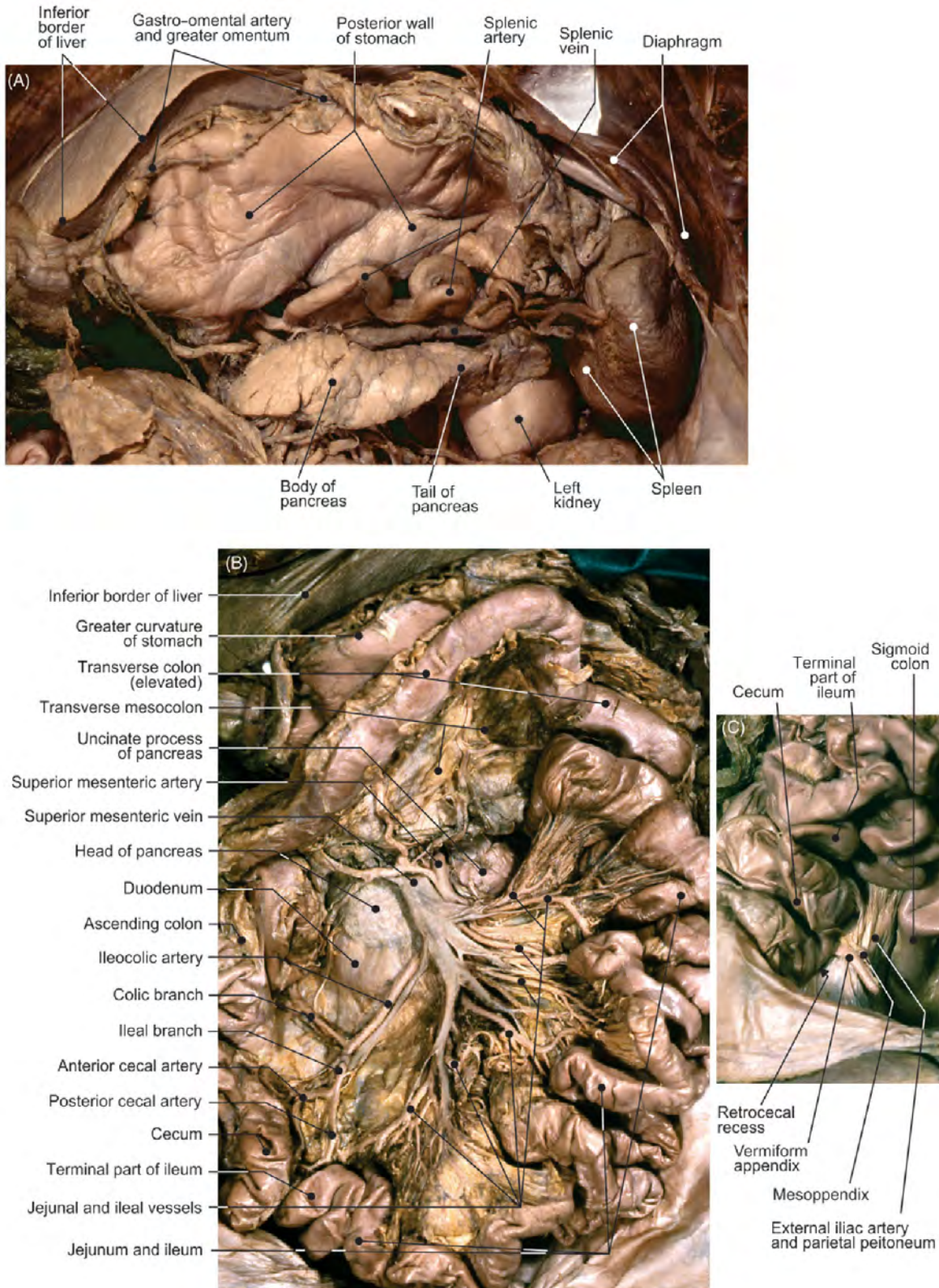


FIGURE 4.6 Abdominal viscera and vascularization. (A) Stomach reflected superiorly: exposed omental bursa. (B) Superior mesenteric artery and vein. (C) Appendix: relationships.

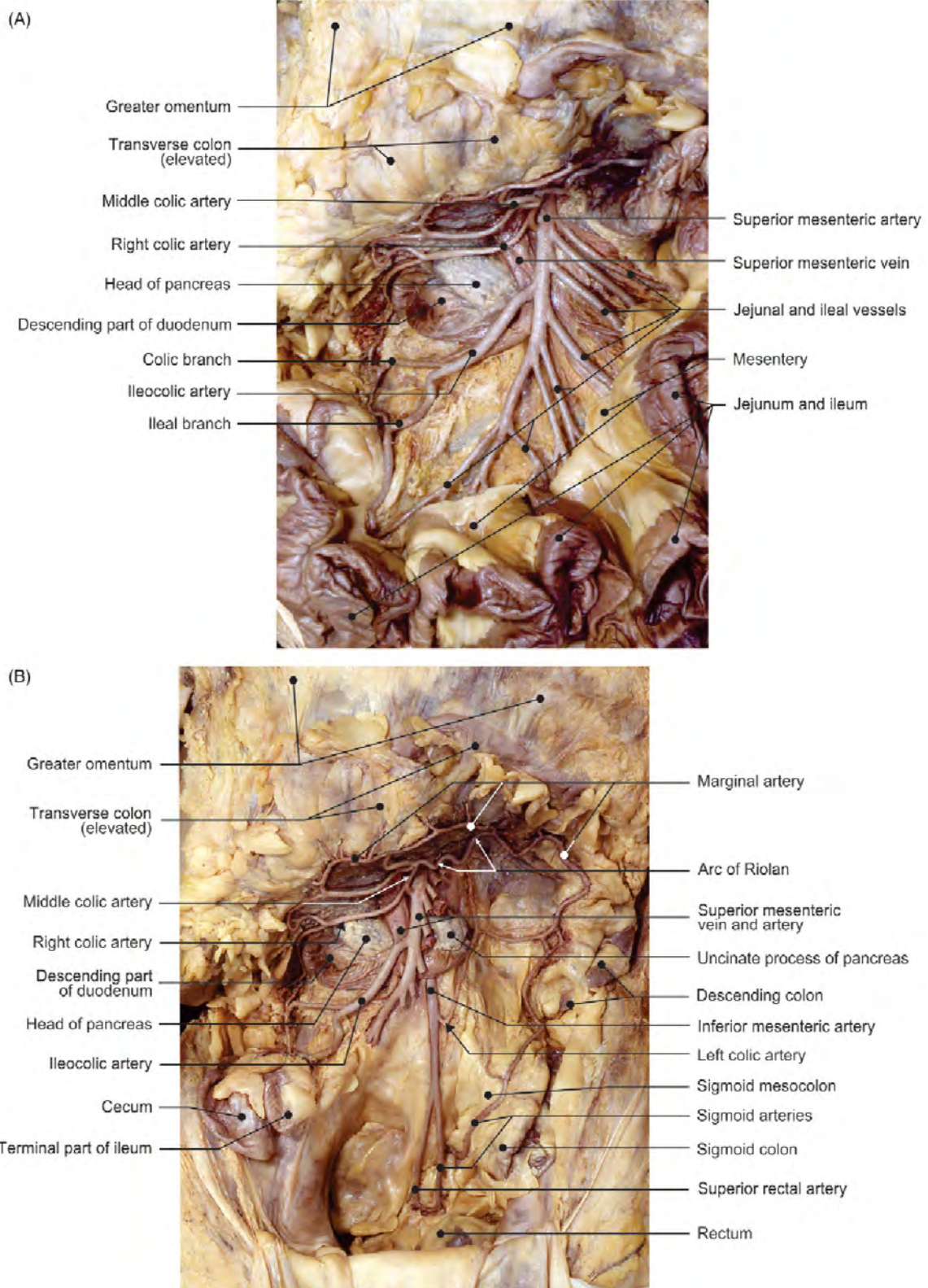


FIGURE 4.7 (A–B) Different views depicting the arterial supply of the small and large intestines.

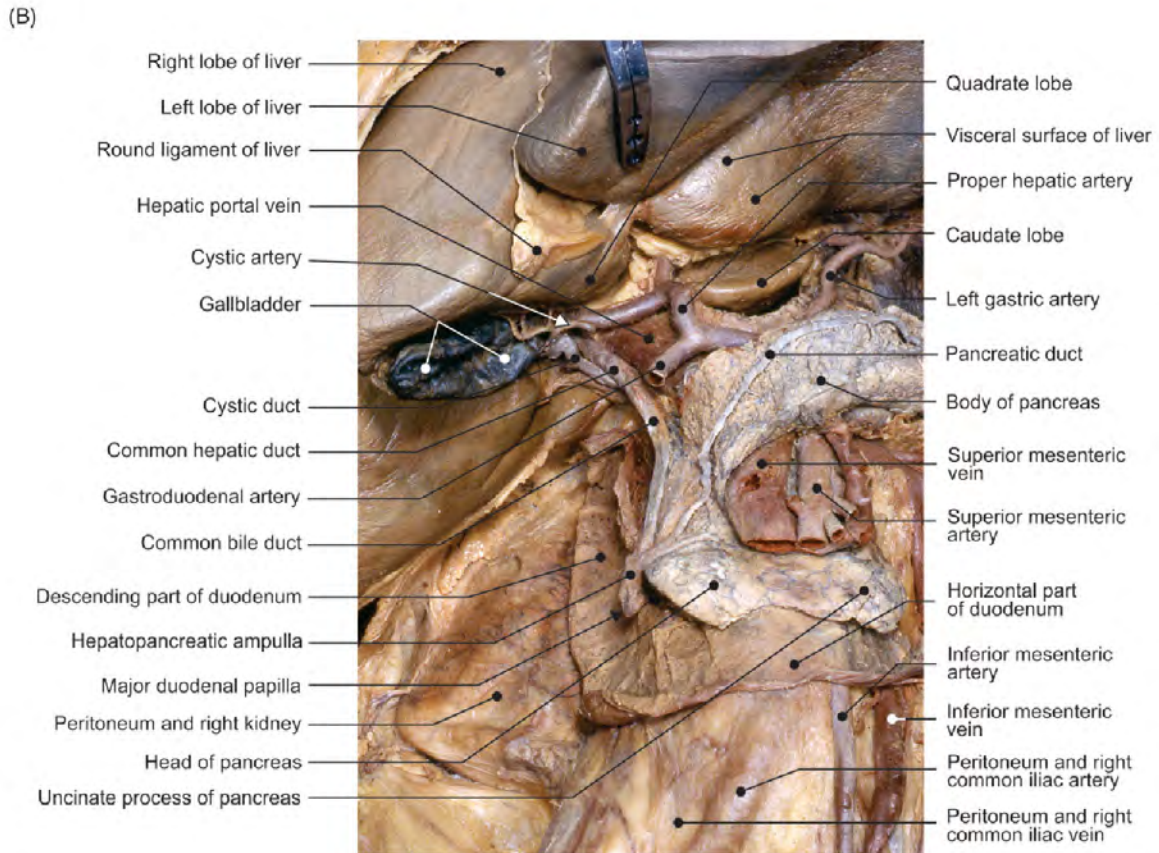
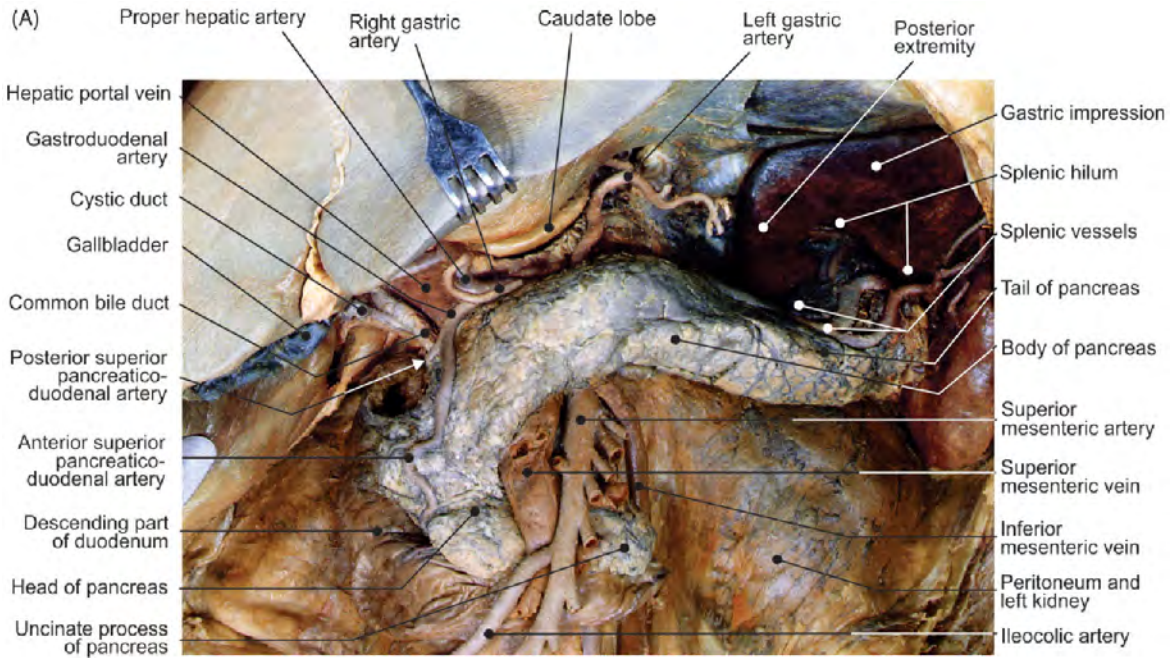


FIGURE 4.8 (A–B) Different views displaying the liver, pancreas, duodenum, and biliary structures in situ.

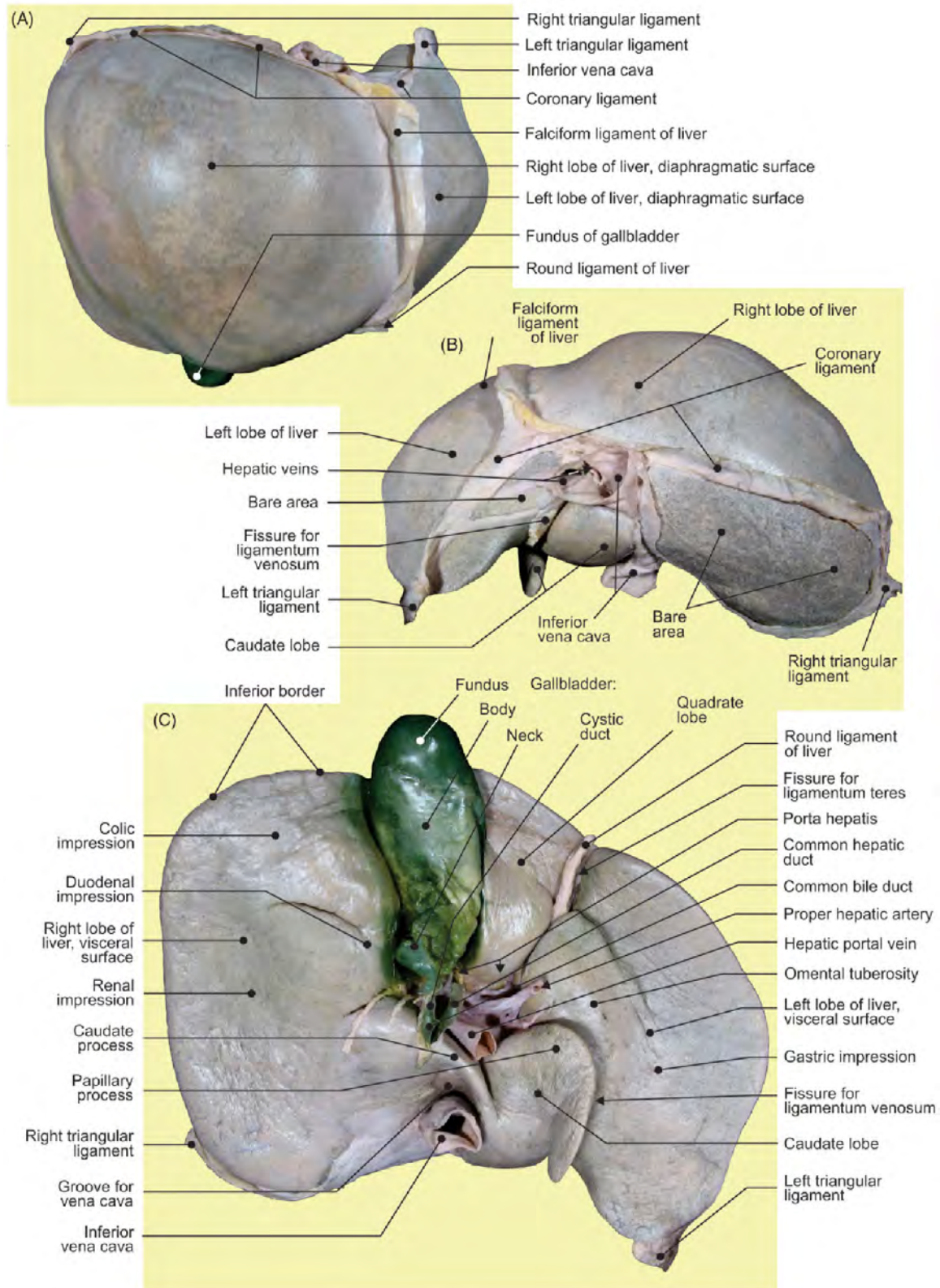


FIGURE 4.9 The liver. (A) Superior, (B) posterior, and (C) inferior aspects.

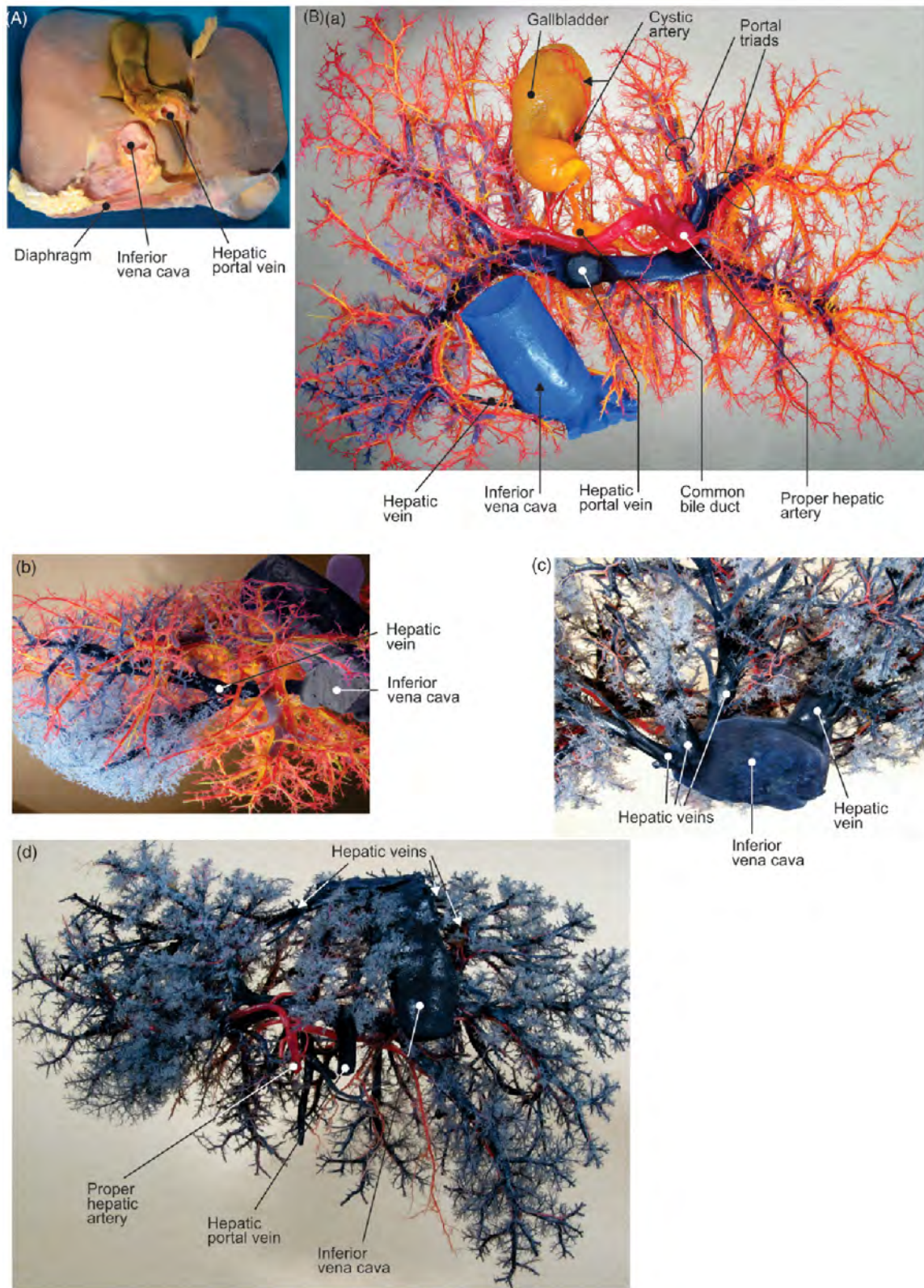


FIGURE 4.10 The liver. (A) Visceral surface of the native liver. (B) Blood circulation (corrosion casts): arborization of hepatic artery proper (*red*) following bile ducts (*yellow*), and branches of the portal vein (*blue*). (a) Inferior, (b) superior, (c) detailed superior, and (d) posterior views of the cast.

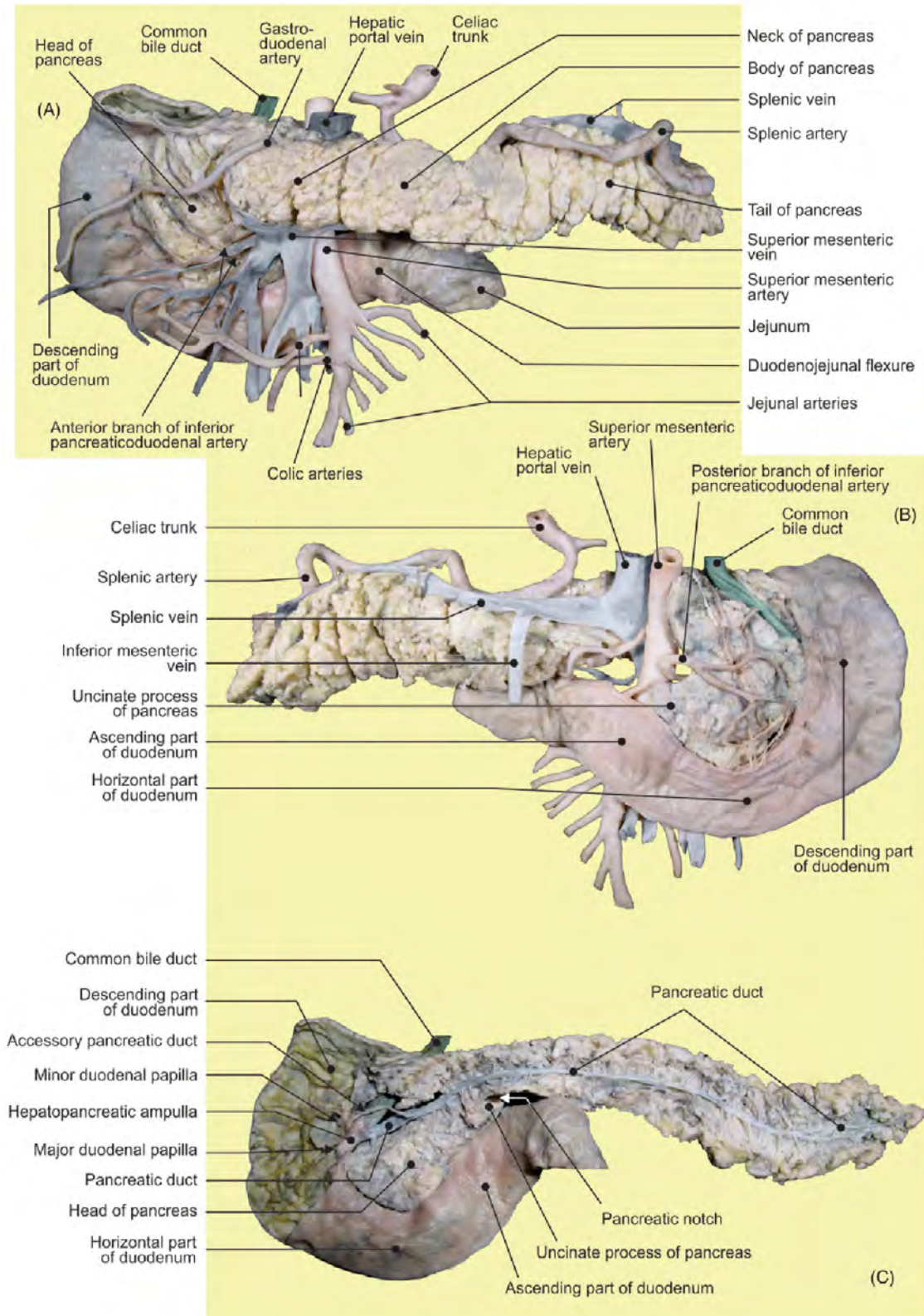


FIGURE 4.11 The duodenum and pancreas. (A) Anterior, (B) posterior views, and (C) dissection of the pancreatic duct.

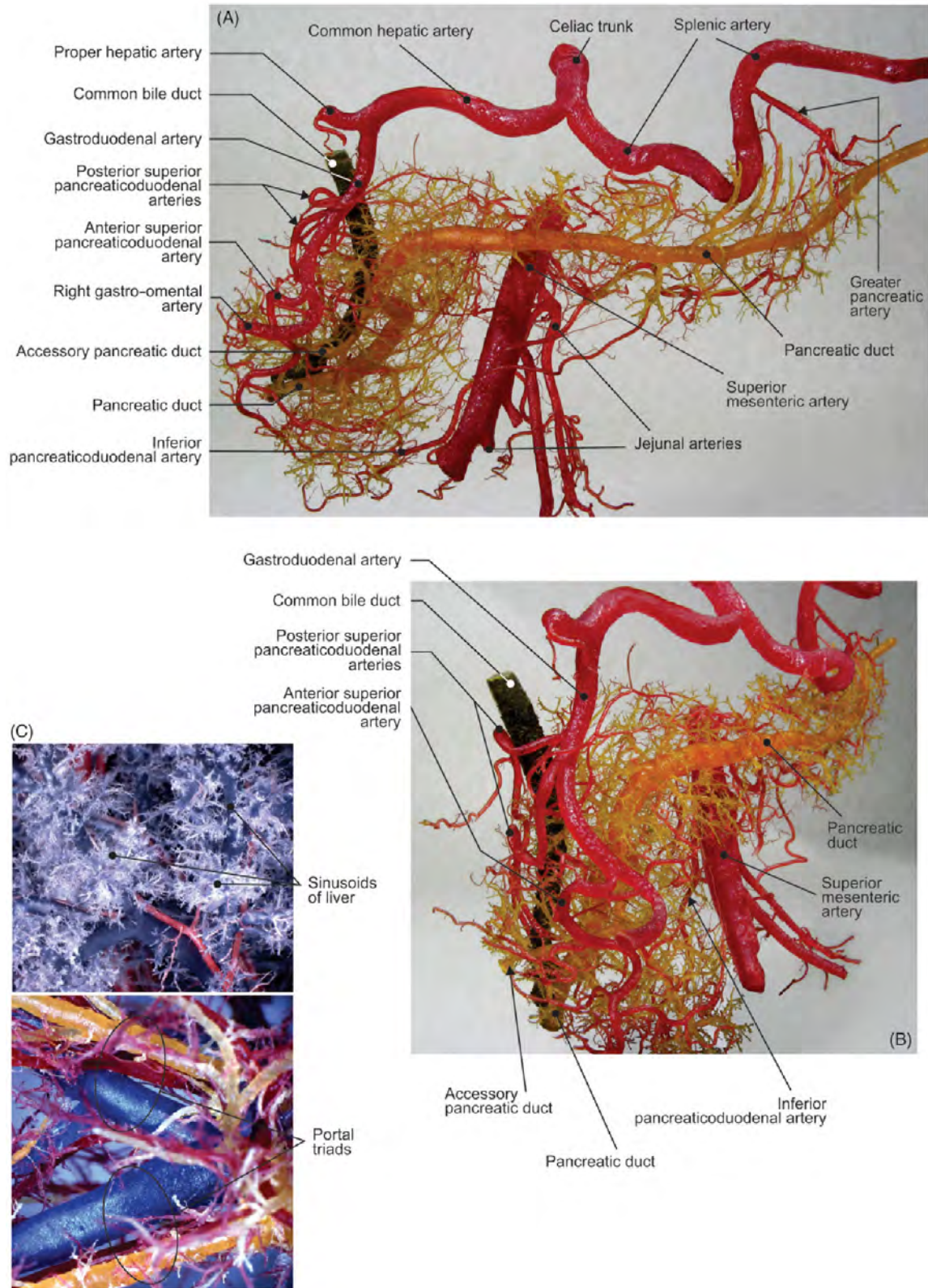


FIGURE 4.12 Corrosion casts of arteries and excretory pancreatic ducts. (A) Anterior view and (B) view from the right side. (C) Corrosion casts of the liver.

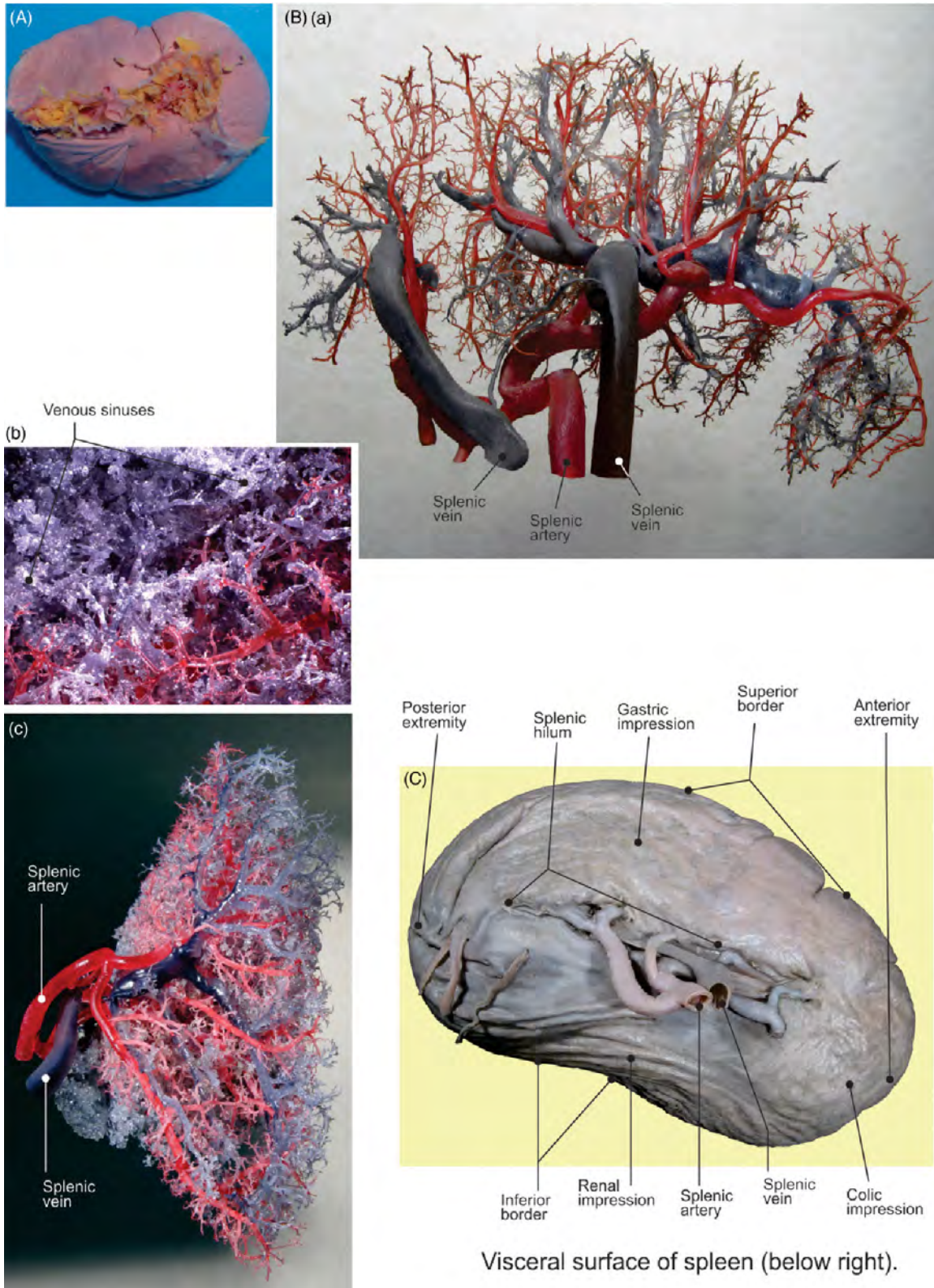


FIGURE 4.13 (A) The native spleen: visceral surface. (B) (a–c) Corrosion casts of the splenic artery and vein branches inside of the spleen. (C) Visceral surface of the spleen.

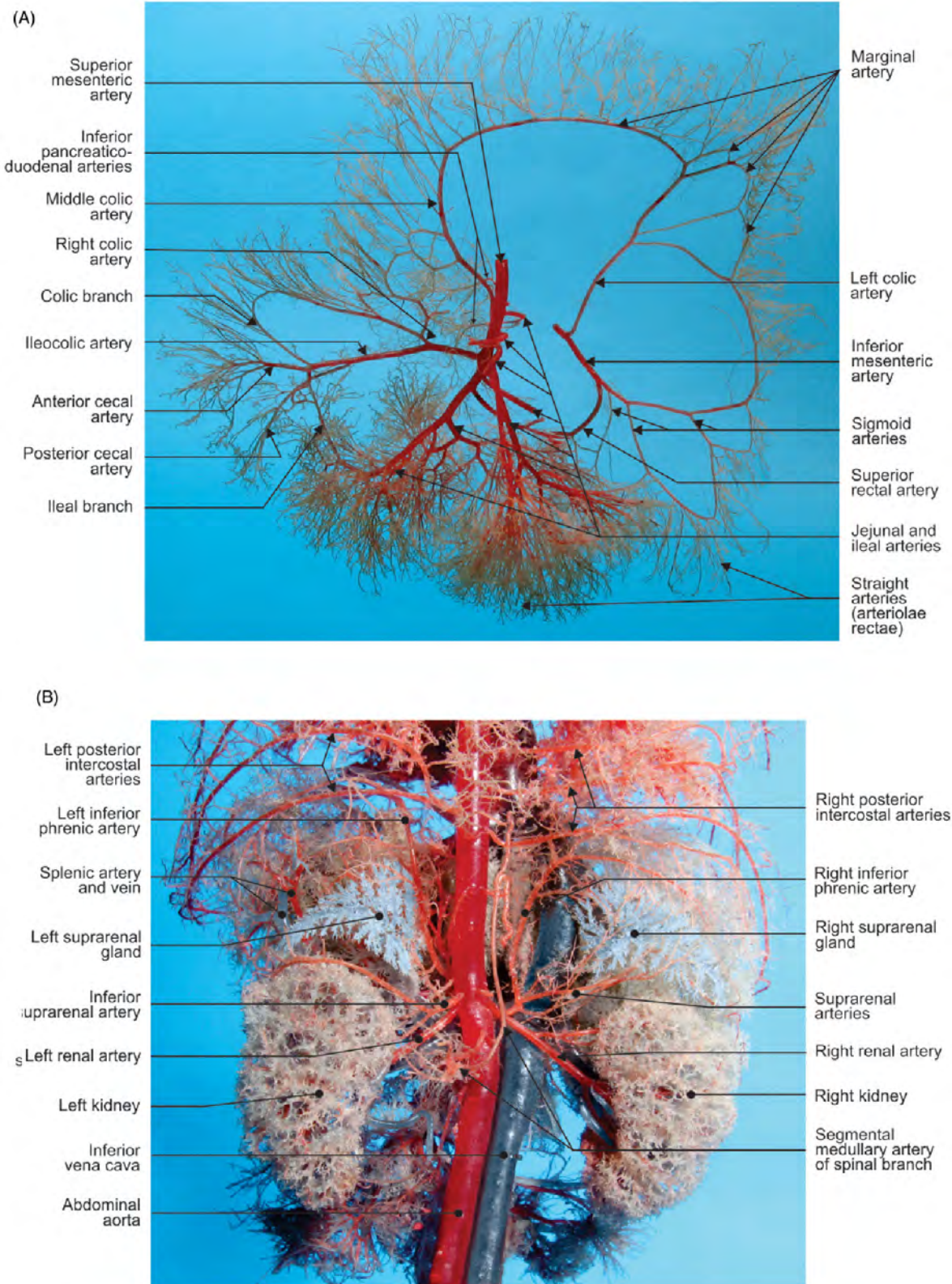


FIGURE 4.14 Corrosion casts of the fetus. (A) Anterior aspect of the intestinal arteries and (B) posterior aspect of the visceral abdominal blood vessels.

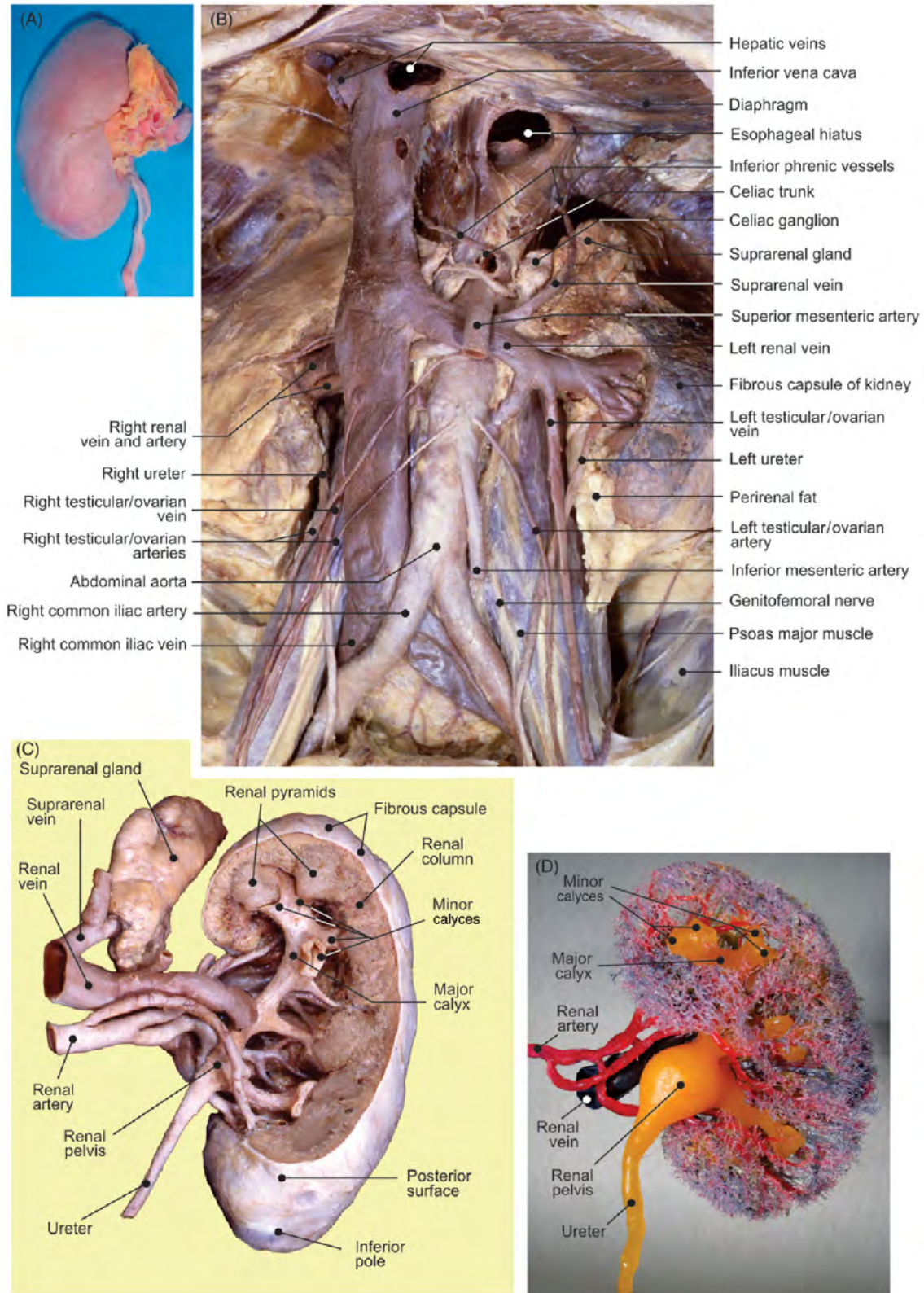


FIGURE 4.15 (A) The native kidney: anterior surface. (B) Kidneys in situ: anterior aspect. Posterior aspect of the right kidney: (C) dissection and (D) corrosion cast.

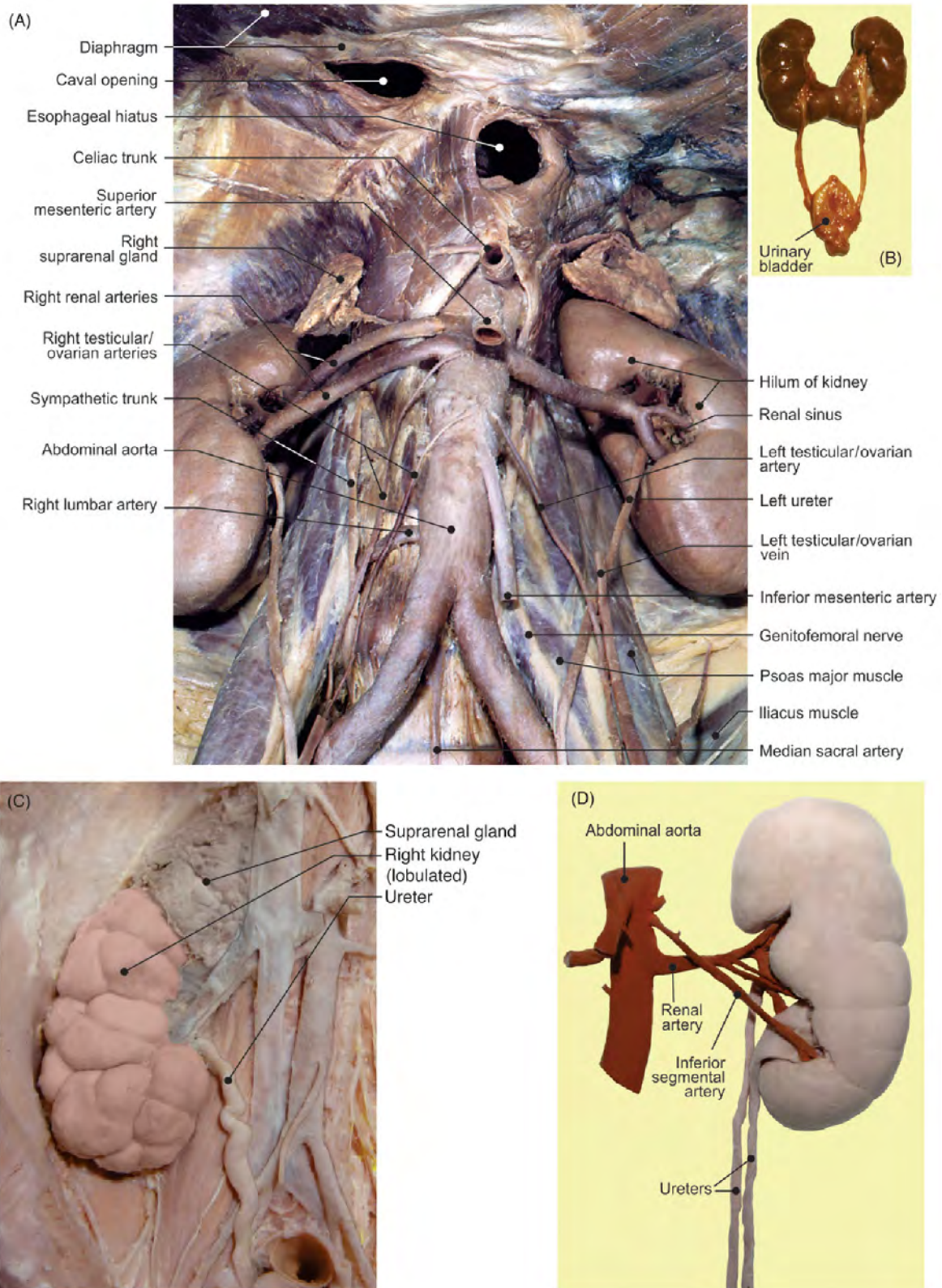


FIGURE 4.16 (A) Anterior aspect of the kidneys after the removal of veins. Newborn: (B) arcuate kidney and (C) right suprarenal gland, lobulated kidney, and ureter in situ. (D) Double ureter and accessory inferior segmental artery.

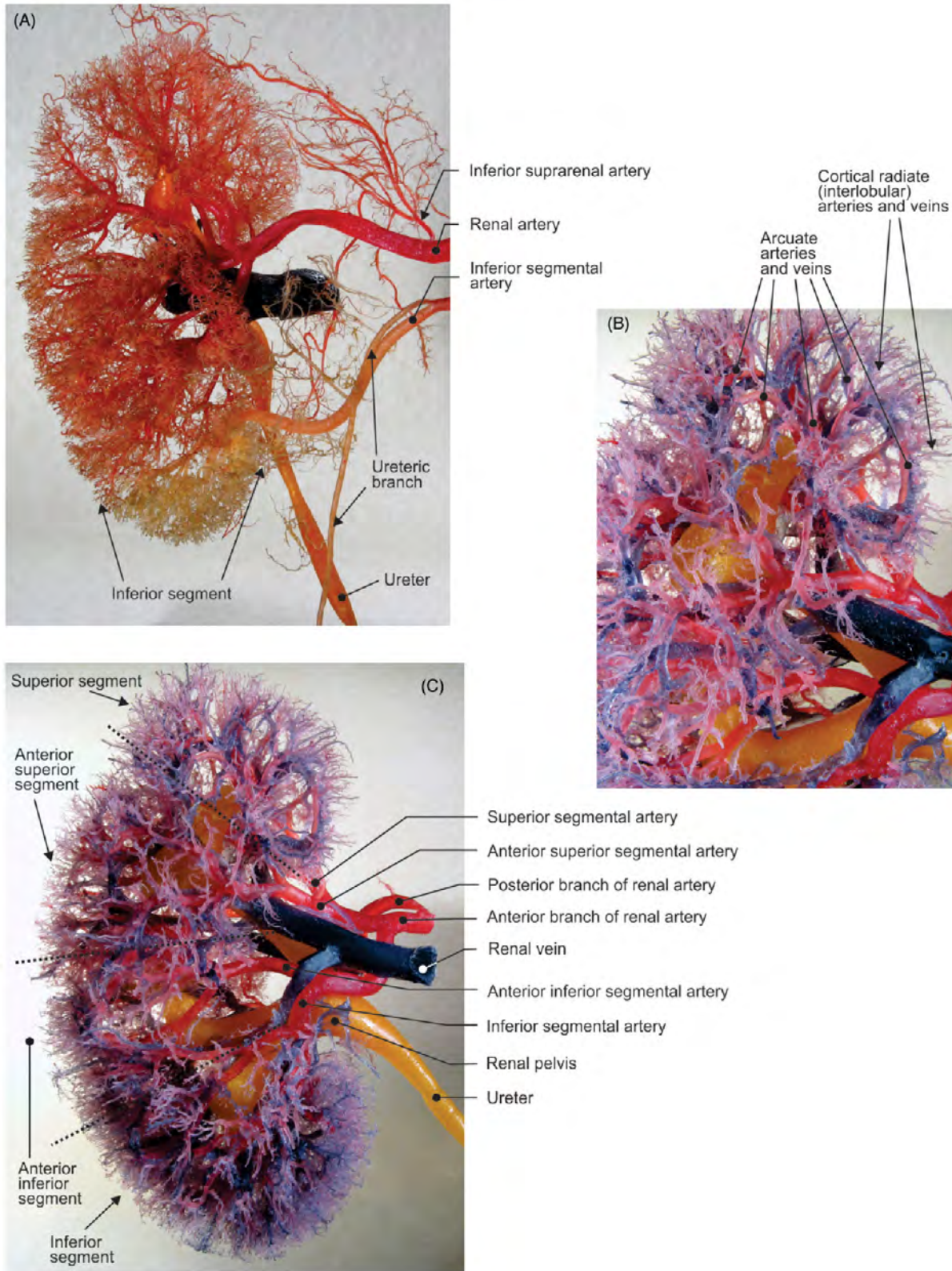


FIGURE 4.17 (A–C) Different views of the anterior aspect of the right kidney (corrosion casts).

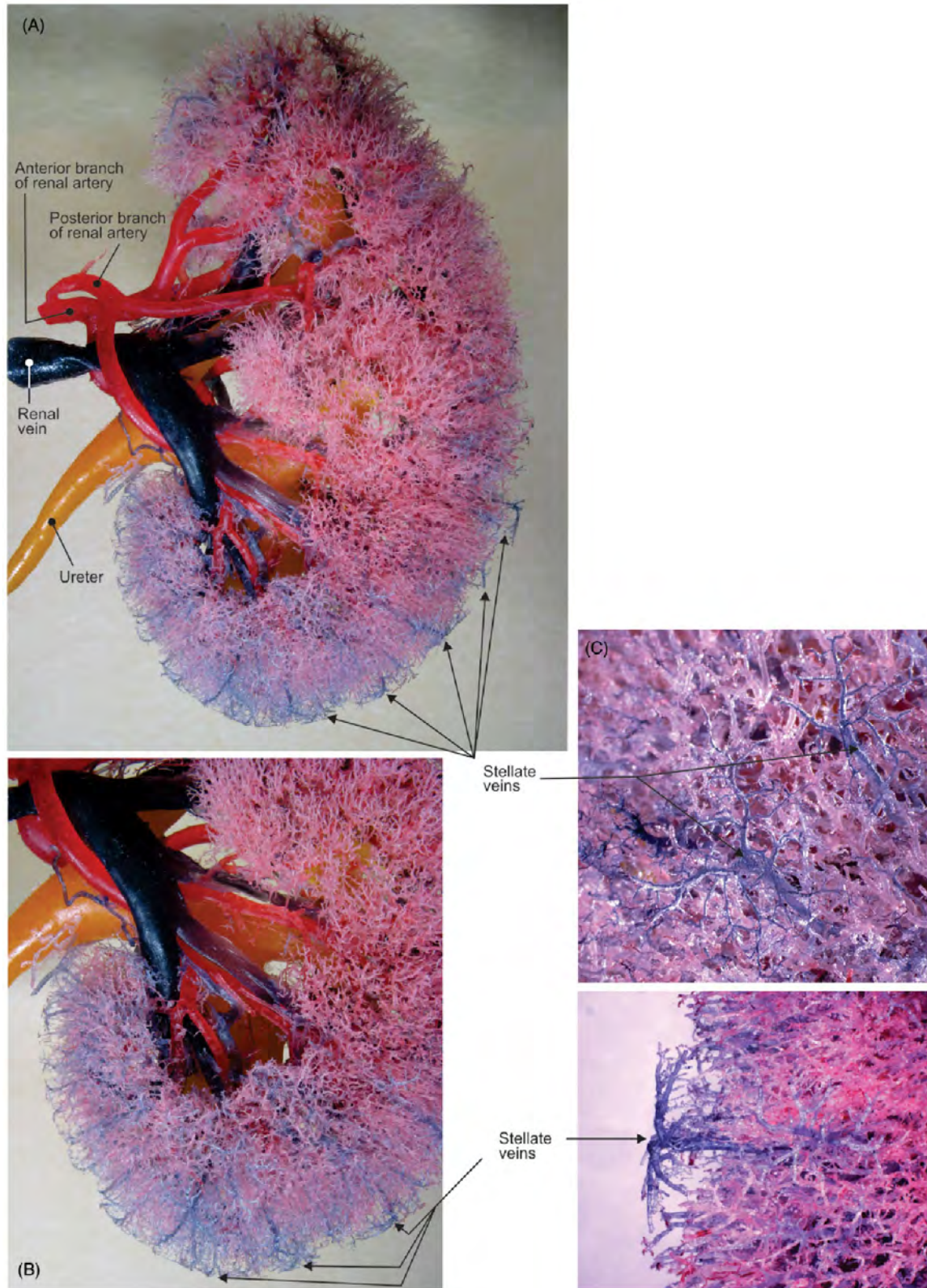


FIGURE 4.18 (A–C) Different views of the posterior aspect of the right kidney (corrosion casts).

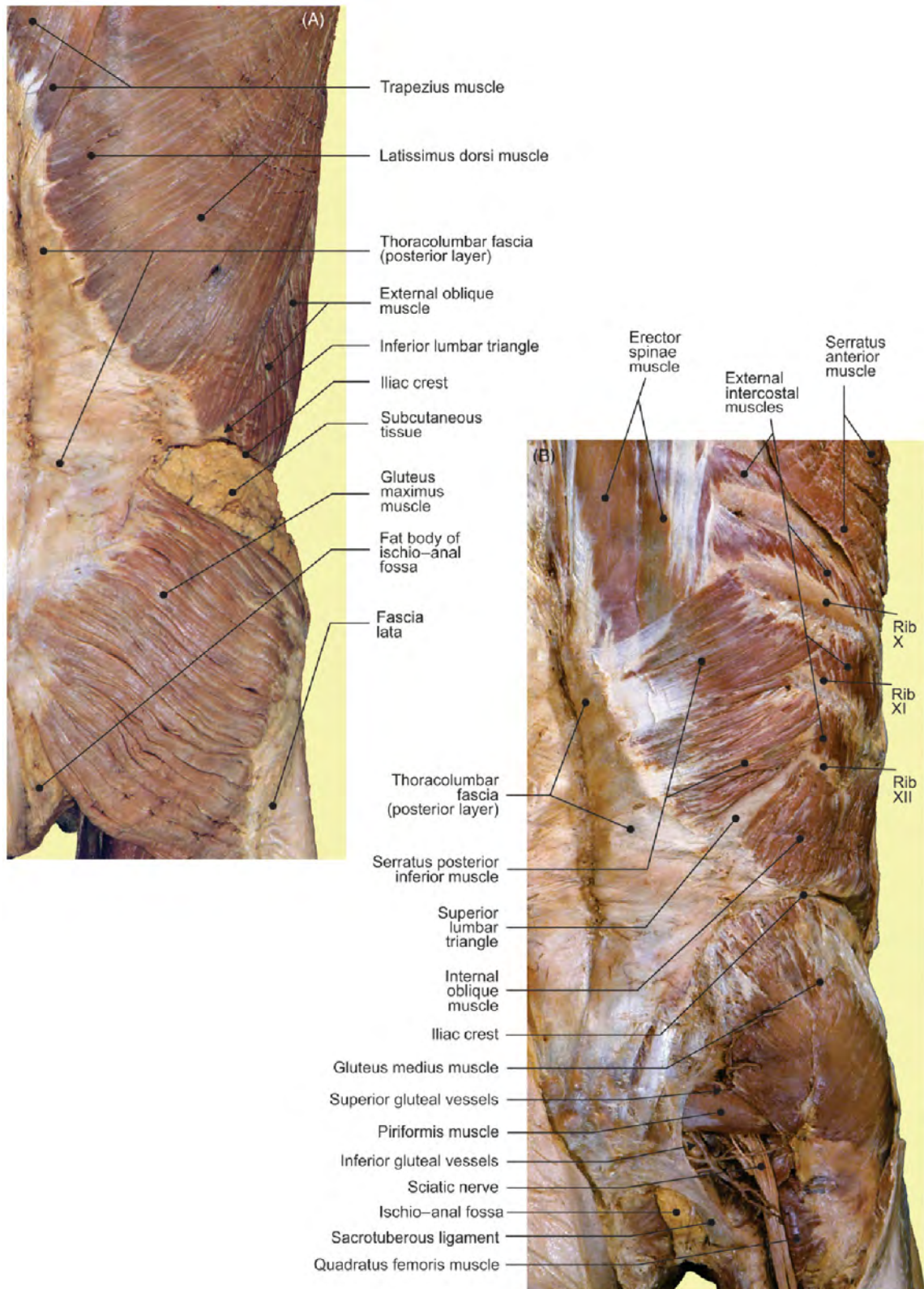


FIGURE 4.19 The posterior aspect of the abdominal wall and gluteal region. (A) Superficial and (B) middle layers.

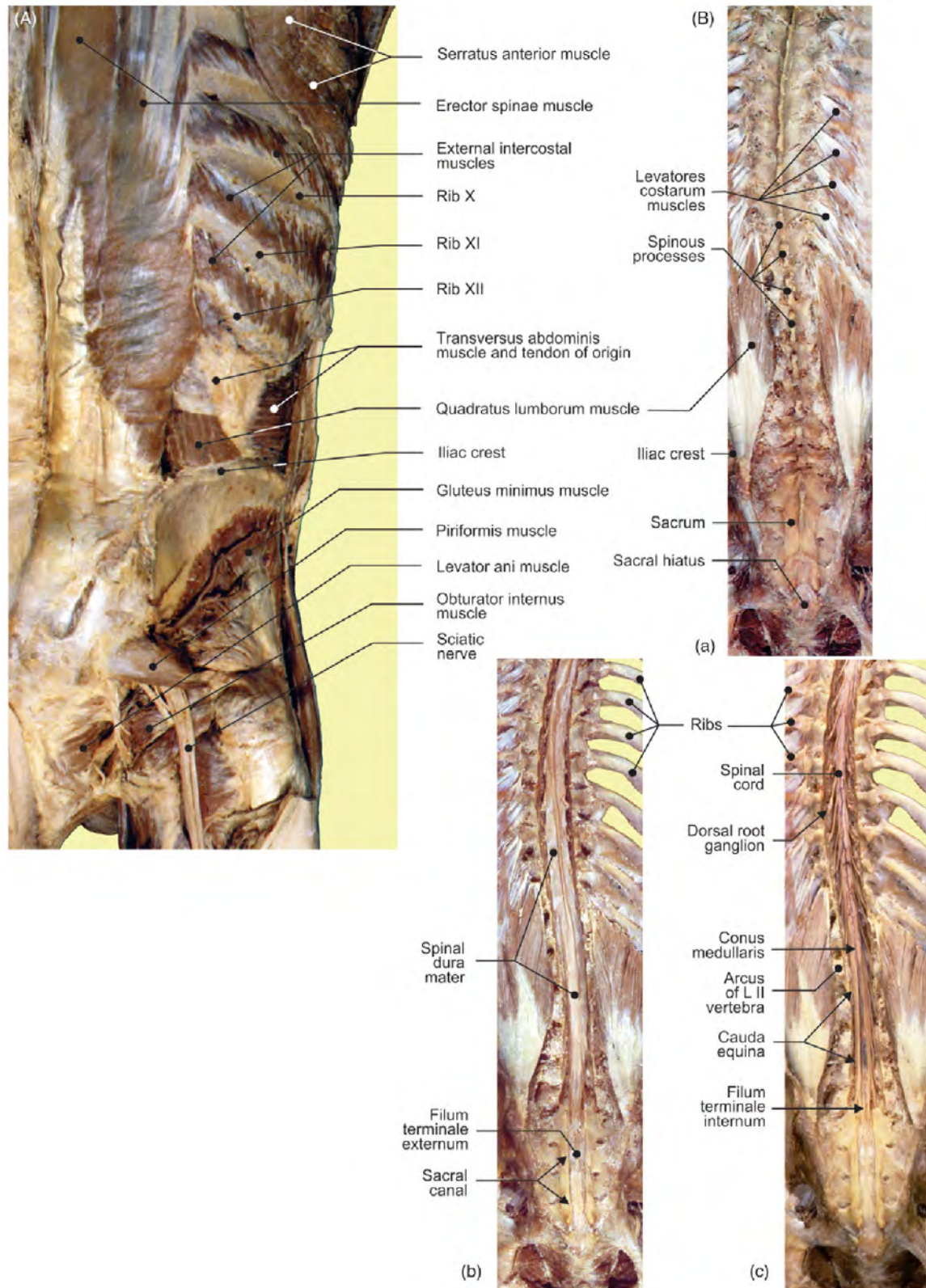


FIGURE 4.20 (A) Posterior aspect of the abdominal wall and gluteal region: deep layer. (B) Posterior views of the vertebral column: (a) spinal processes; (b) dura mater, after the spinal processes were removed; and (c) spinal cord, after dura mater was removed.

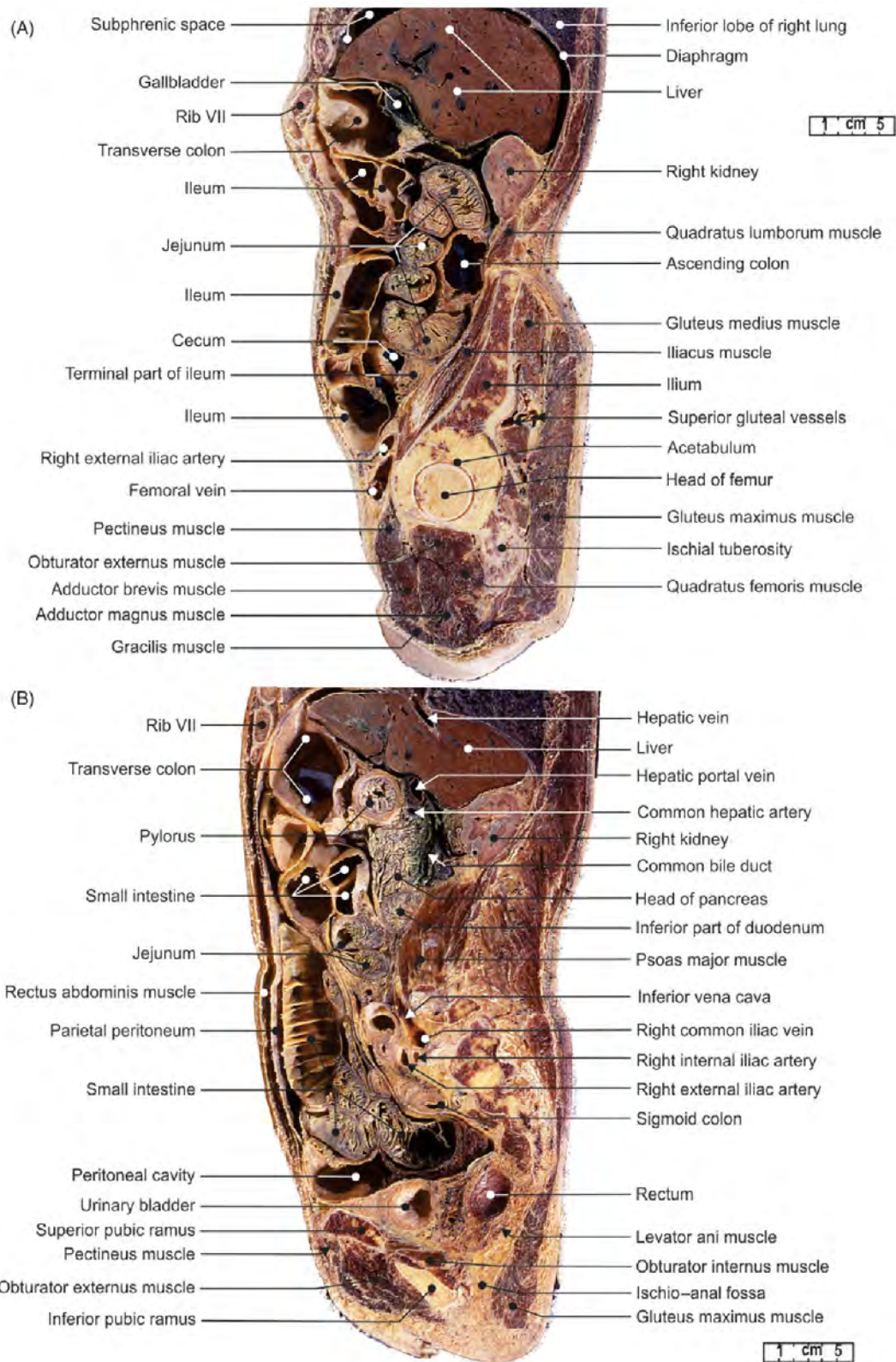


FIGURE 4.21 The abdomen and pelvis. (A) Sagittal sections of the gallbladder and (B) pancreatic head.

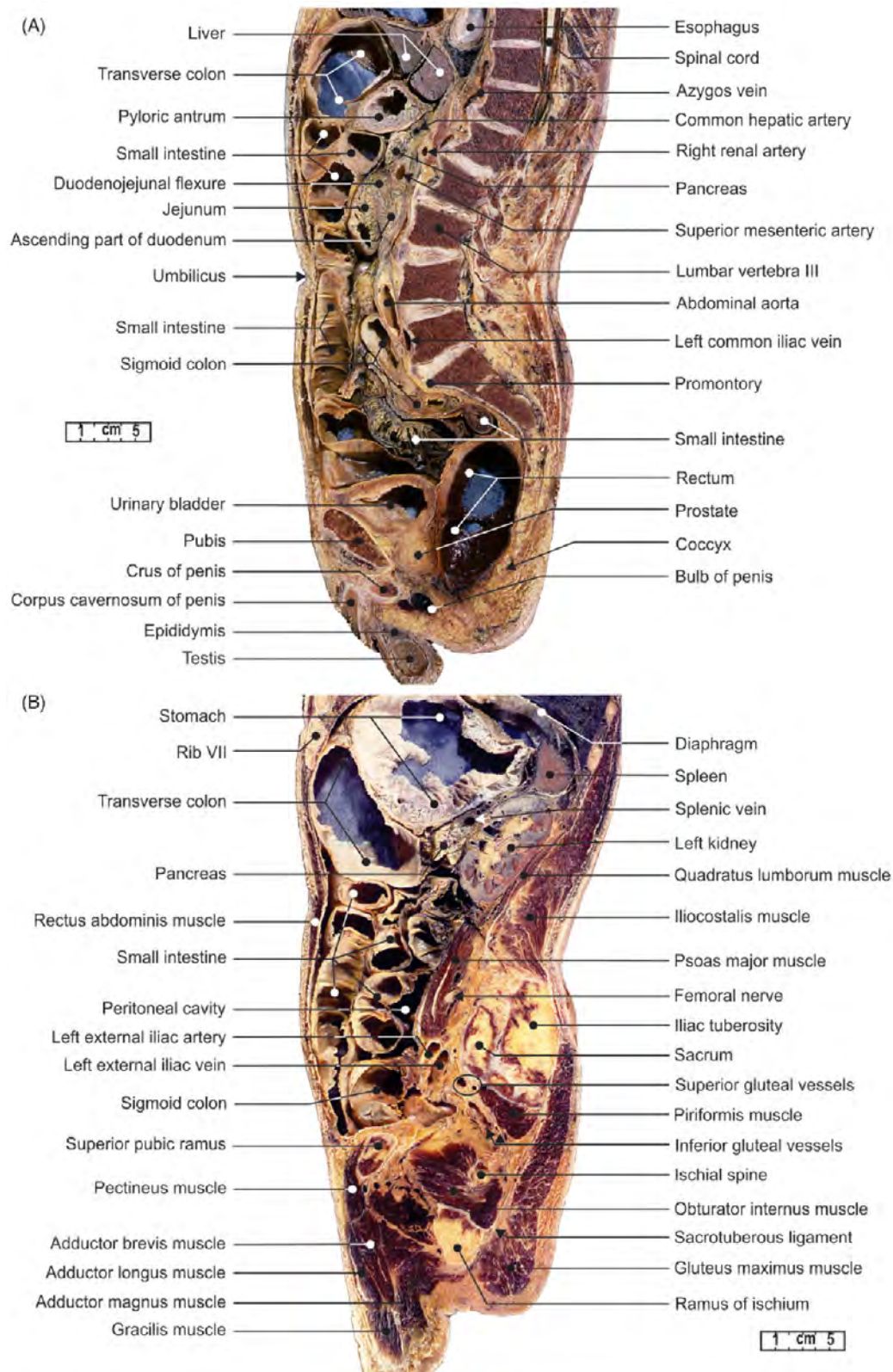


FIGURE 4.22 The abdomen and pelvis. (A) Sagittal sections of the spinal canal and cord and (B) the left kidney.

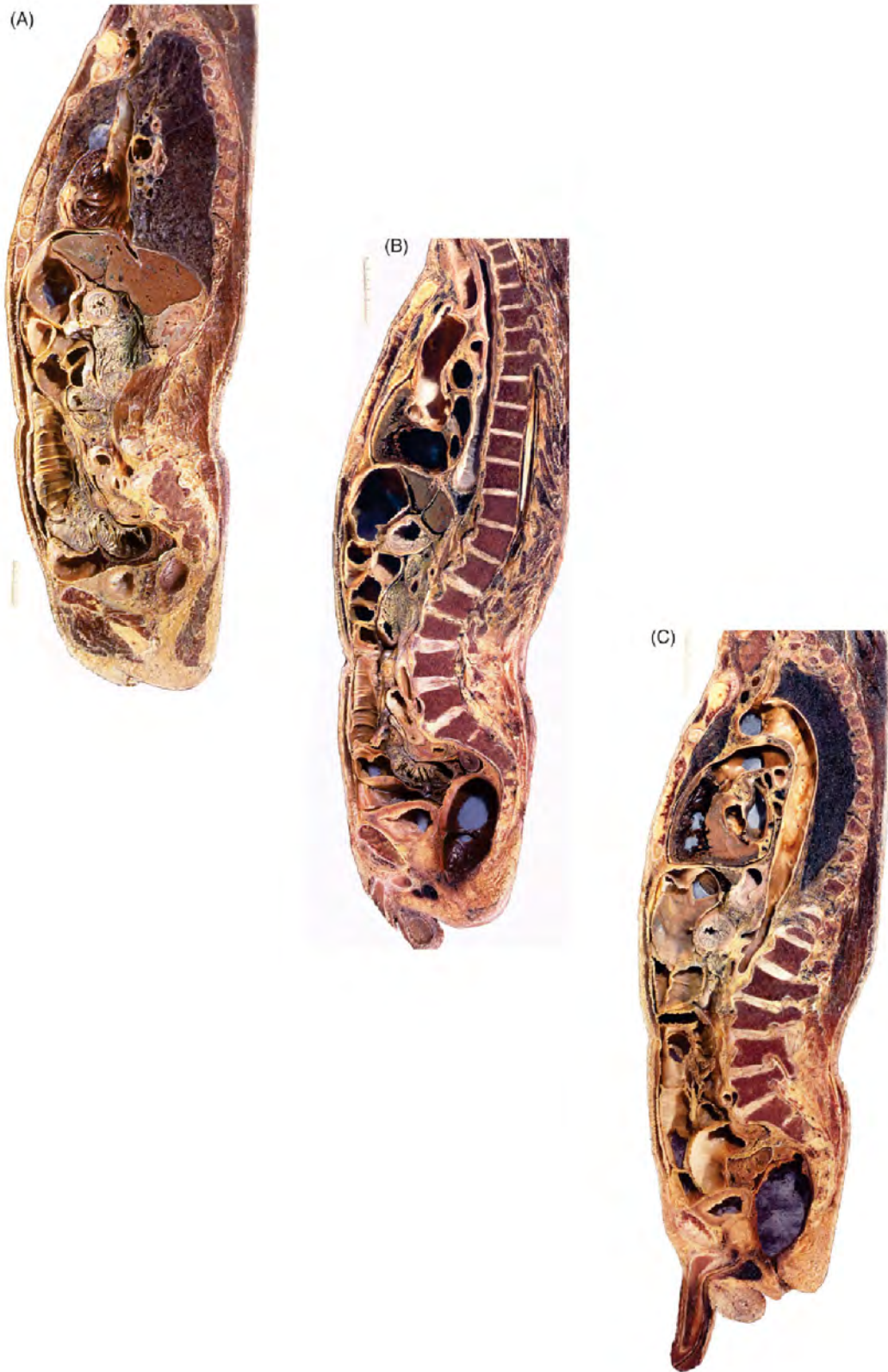

FIGURE 4.23 Sections of the human body (refer to Figs. 3.25A,B, 3.26A, 4.21B, and 4.22A). (A) Right sagittal section of the pancreatic head and right kidney. (B) Midsagittal and (C) left sagittal sections of the descending aorta.

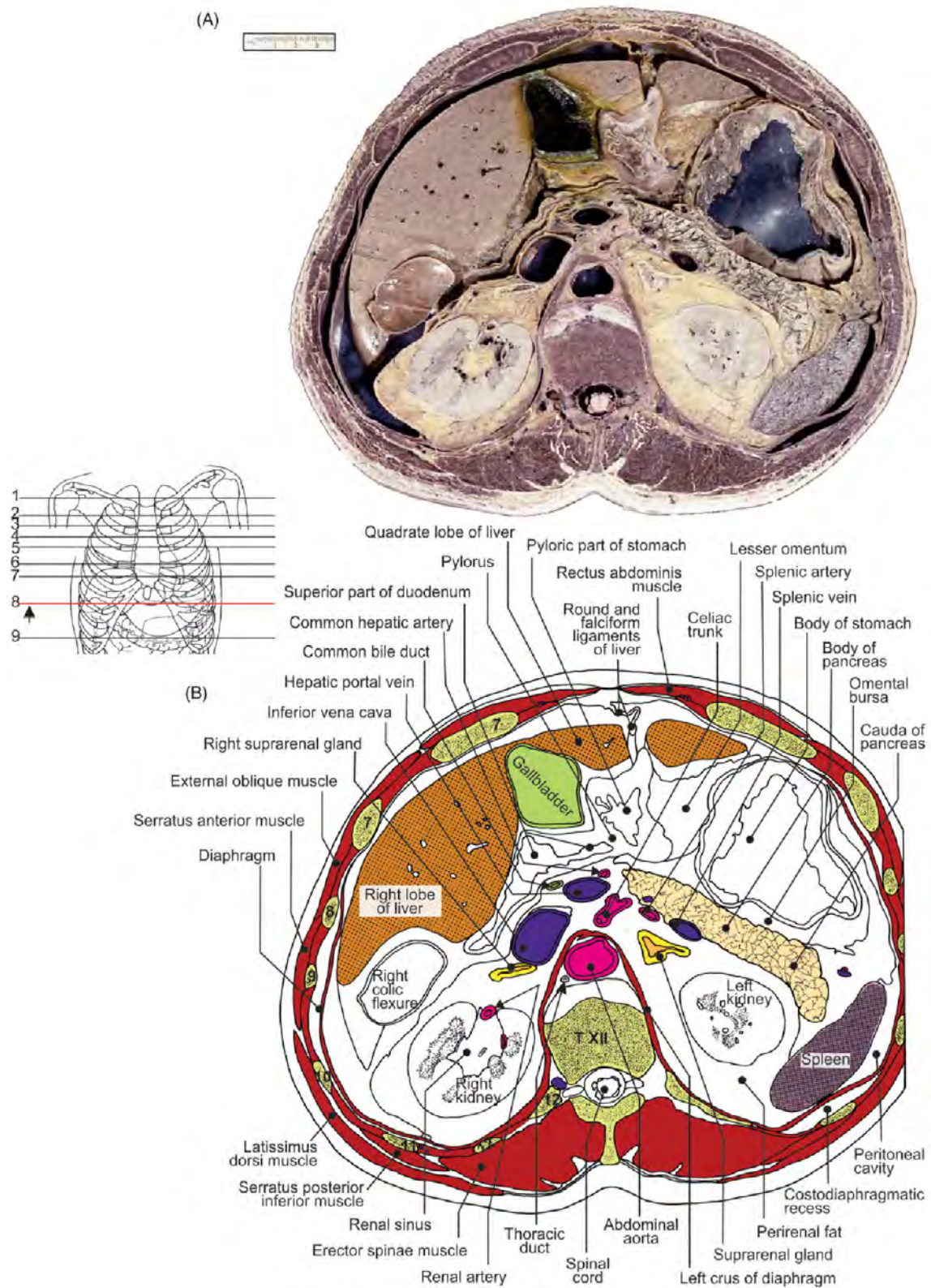


FIGURE 4.24 Transverse section of the abdomen at the T12 vertebral level. (A) Section and (B) illustration.

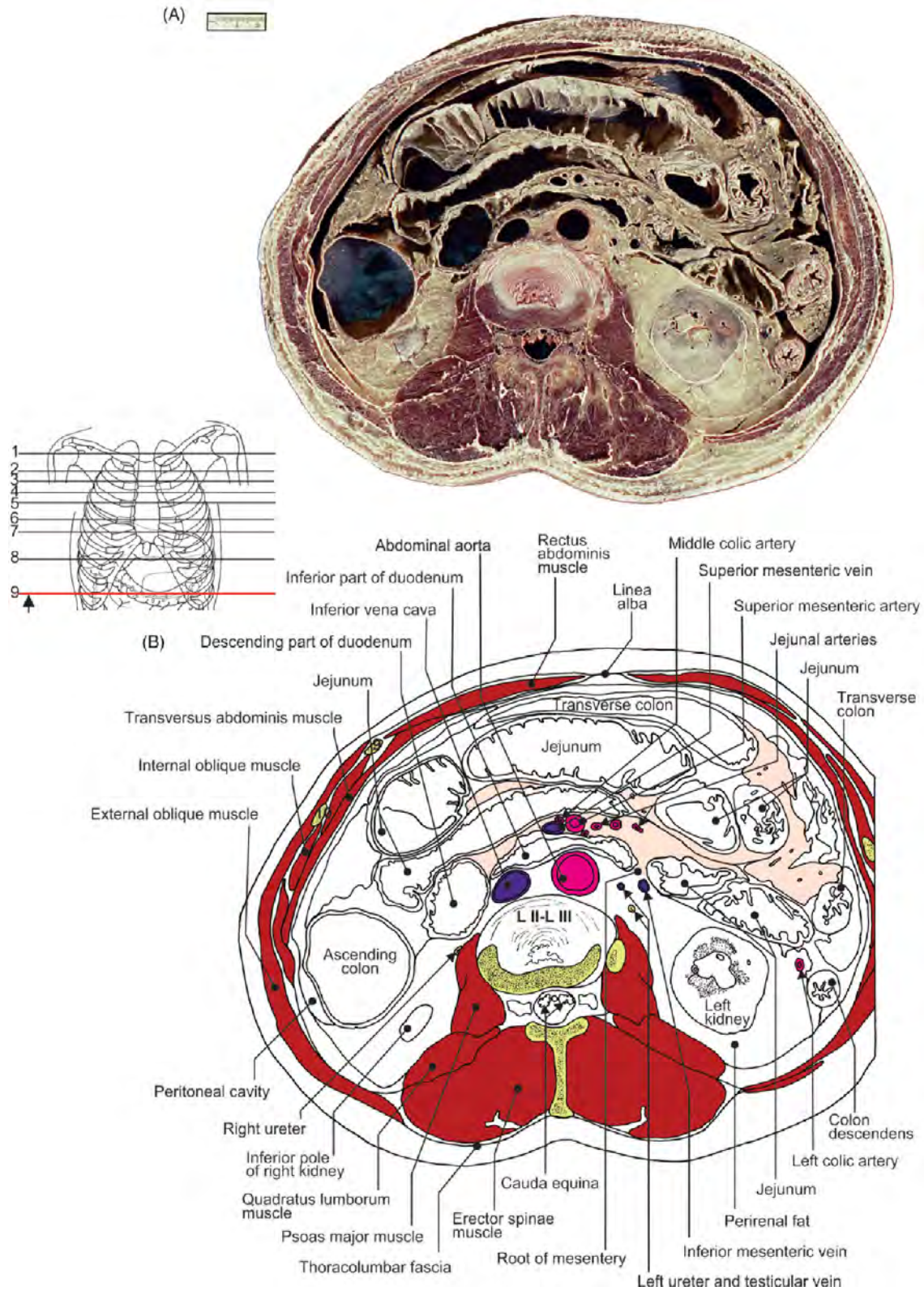


FIGURE 4.25 Transverse section of the abdomen at the L2-L3 vertebral level. (A) Section and (B) illustration.

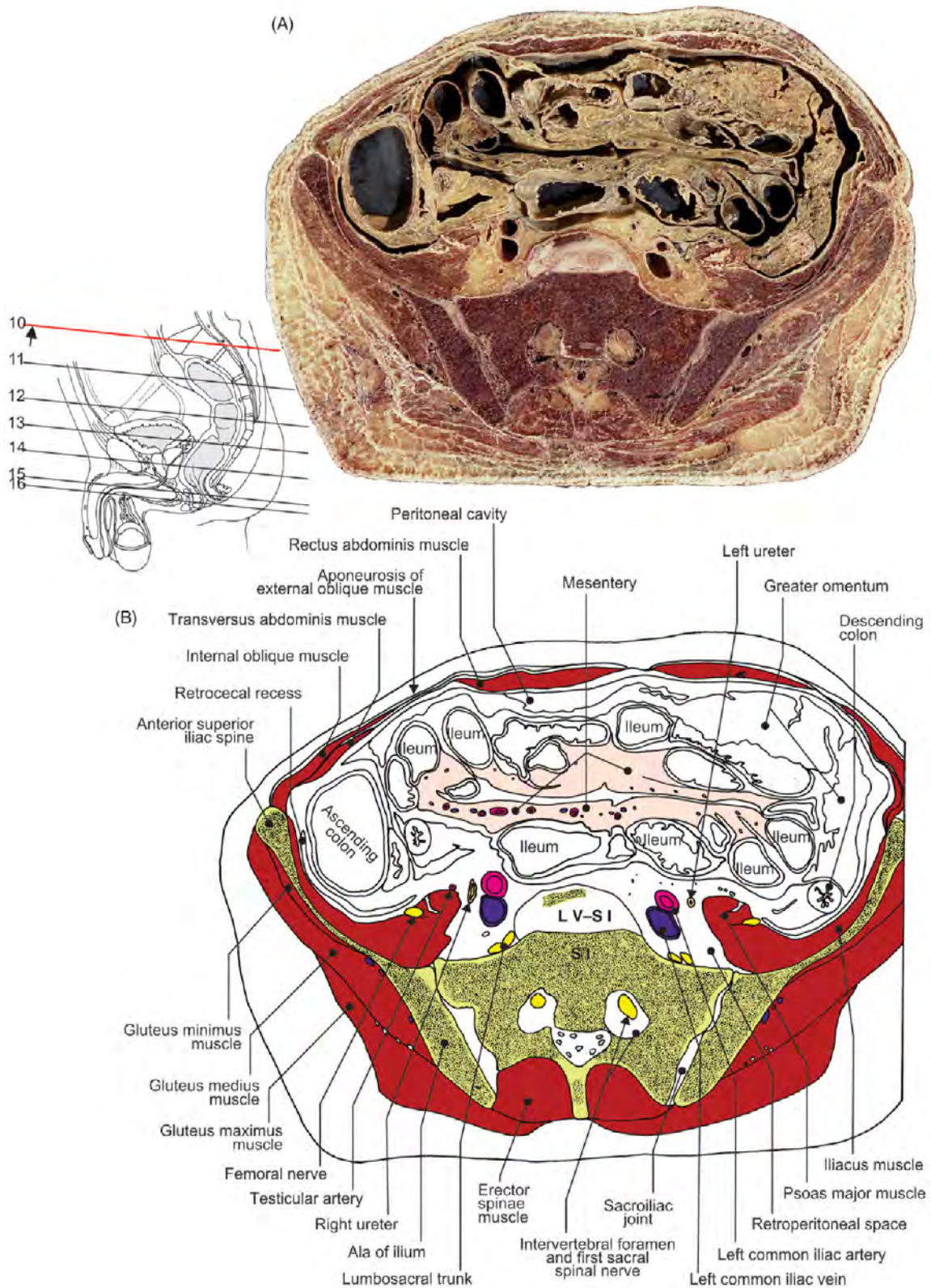


FIGURE 4.26 Transverse section of the abdomen at the L5-S1 vertebral level. (A) Section and (B) illustration.

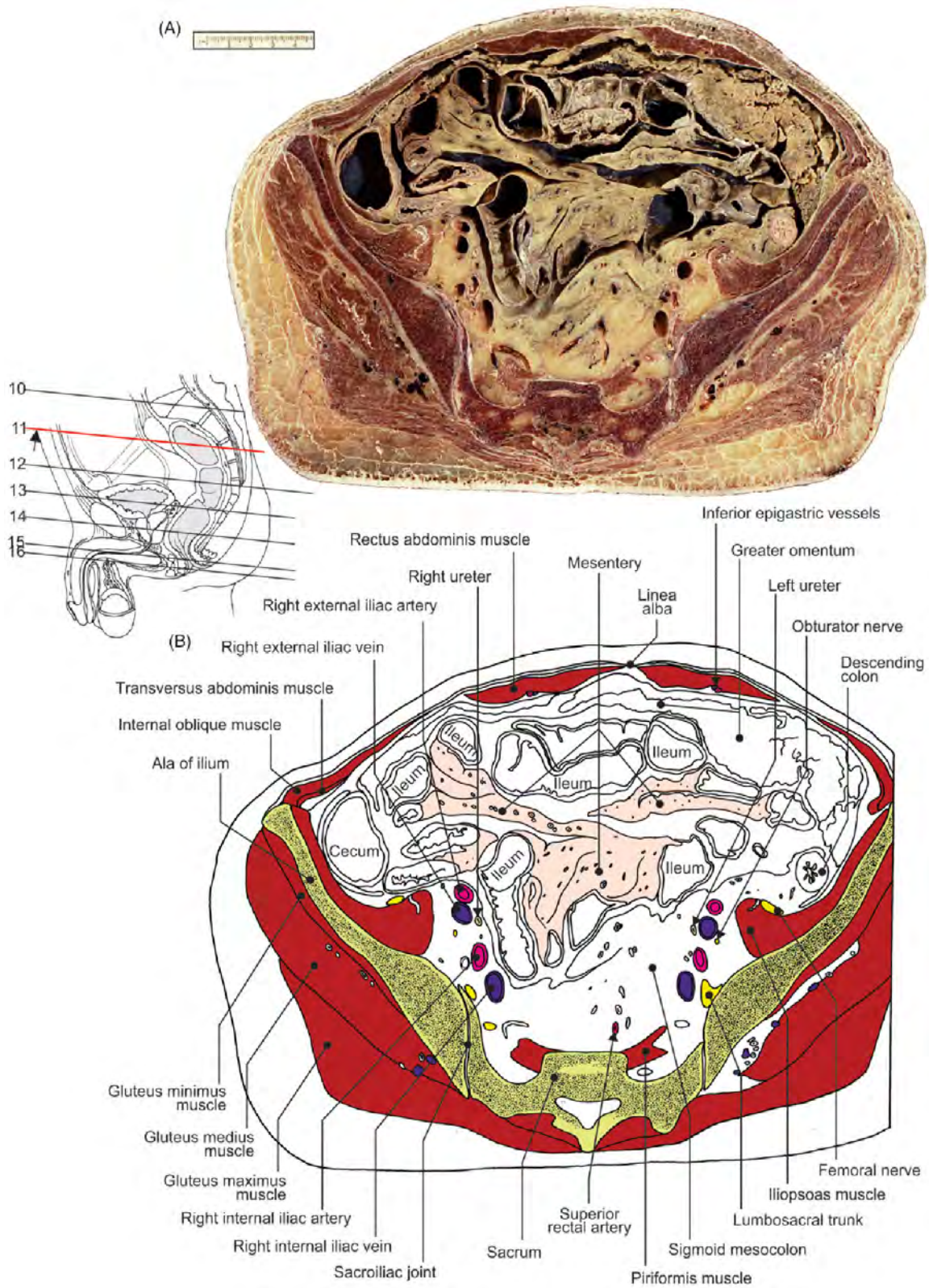


FIGURE 4.27 Transverse section of the abdomen and pelvis at the midpelvic level. (A) Section and (B) illustration.

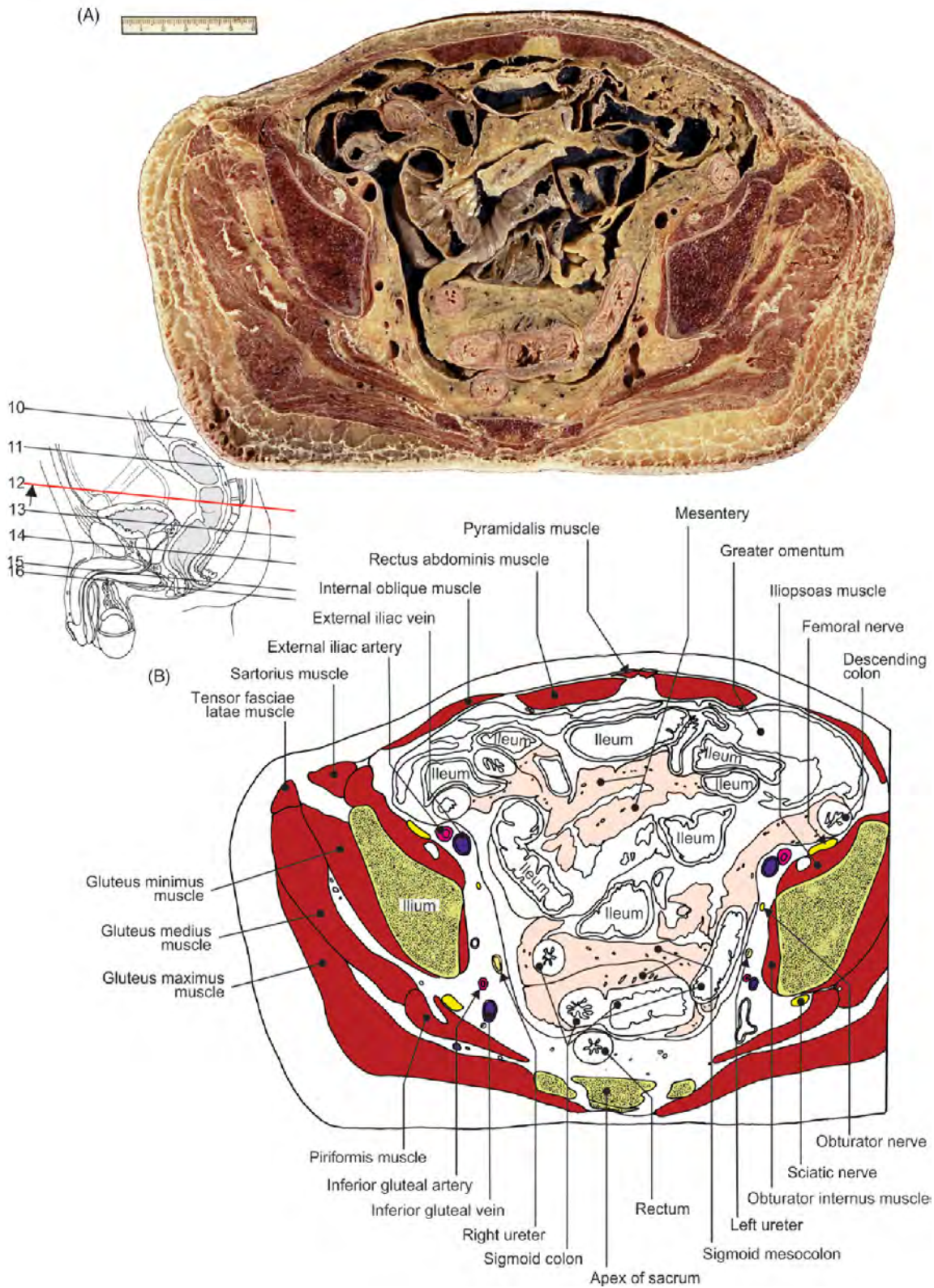


FIGURE 4.28 Transverse section of the abdomen and pelvis at the sacral tip level. (A) Section and (B) illustration.

Chapter 5

Pelvis and Perineum with 5–6-Month-Old Fetal Specimens

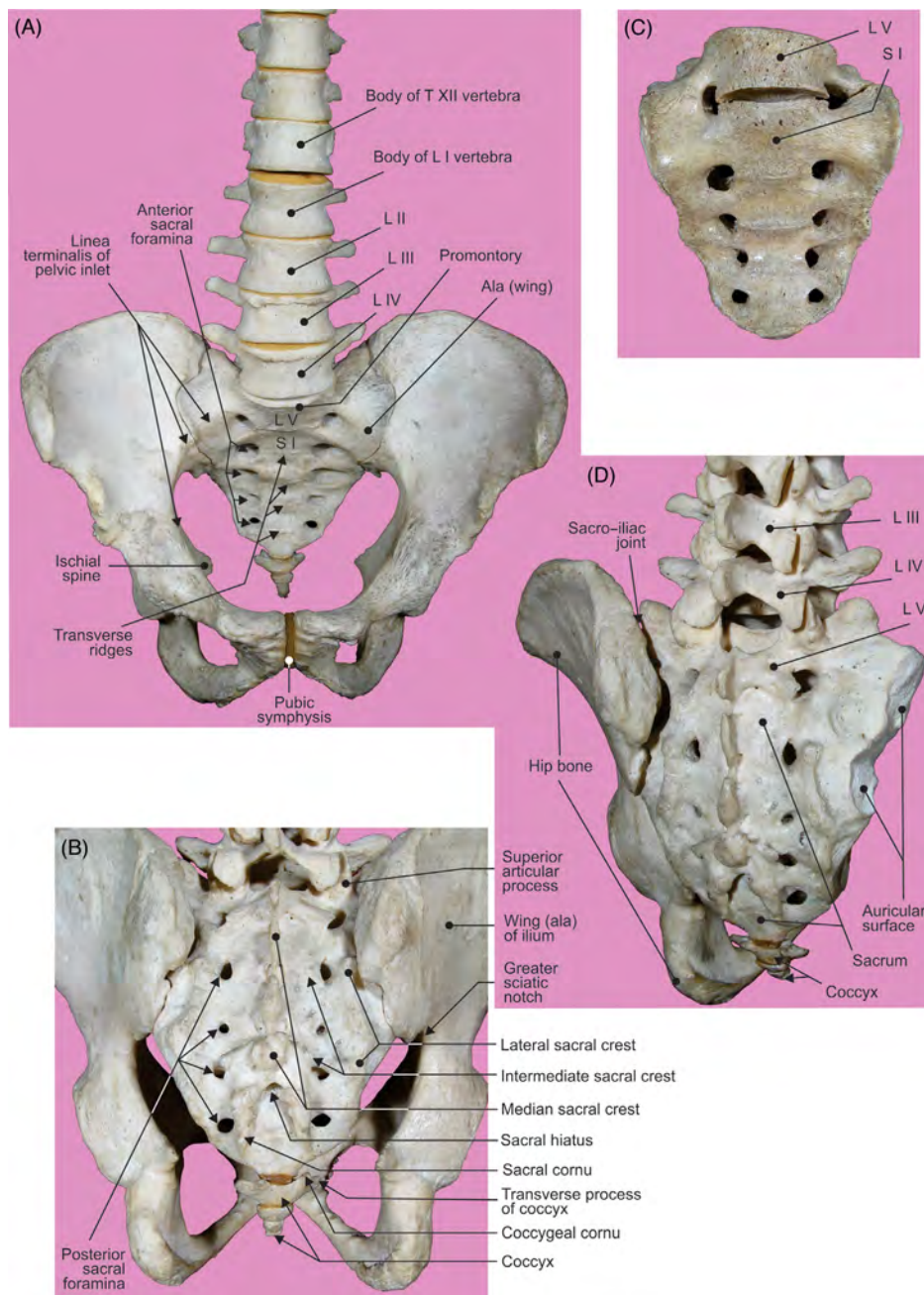


FIGURE 5.1 The sacrum and coccyx. L5 vertebra: (A) Anterior and (B–D) posterior views. Incomplete fusion of L5 vertebra with sacrum: anterior view and total sacralization of L5 vertebra.

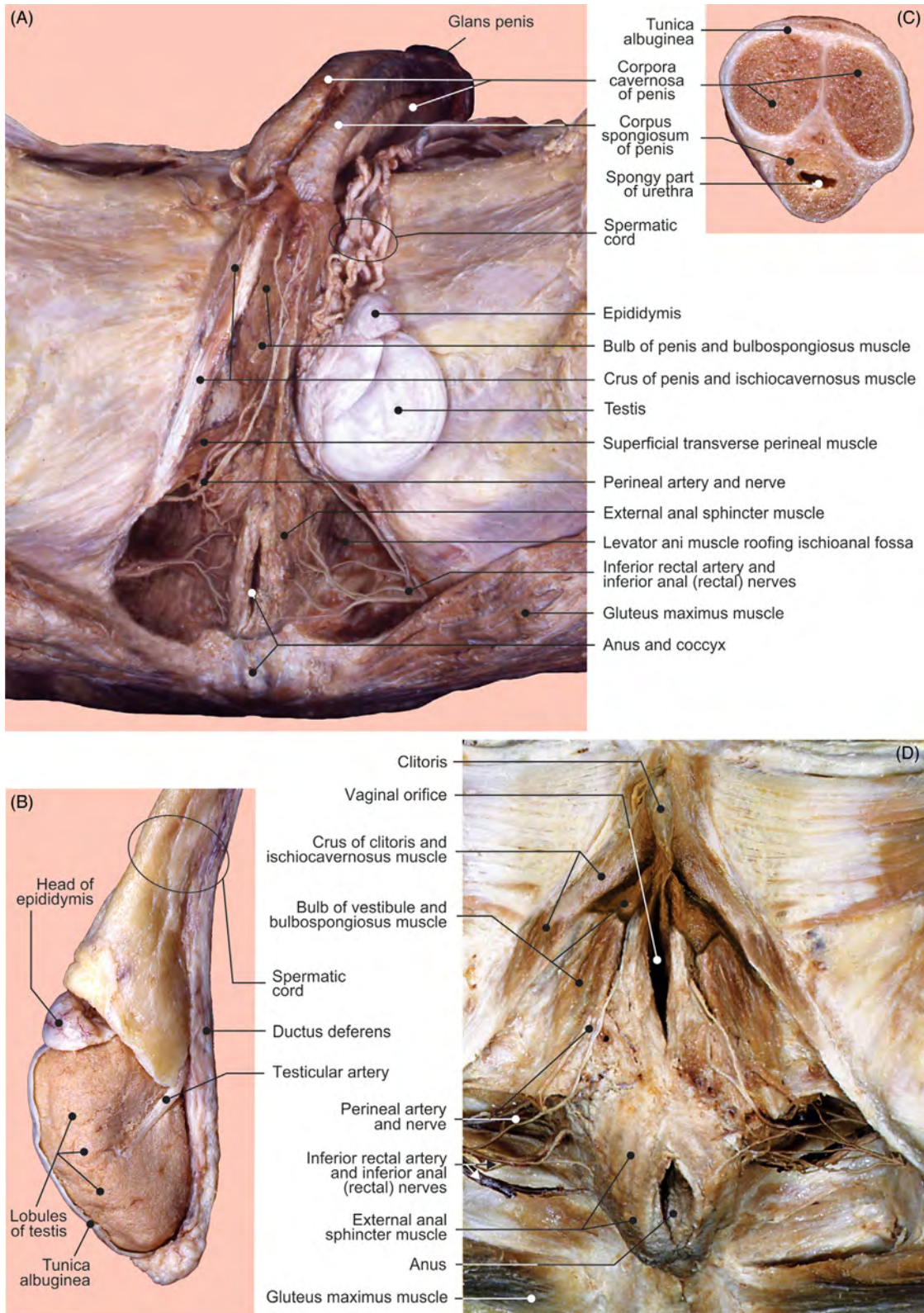


FIGURE 5.2 Perineum: (A) male. Testis: (B) dissection. Penis: (C) transverse section of shaft. Perineum: (D) female.

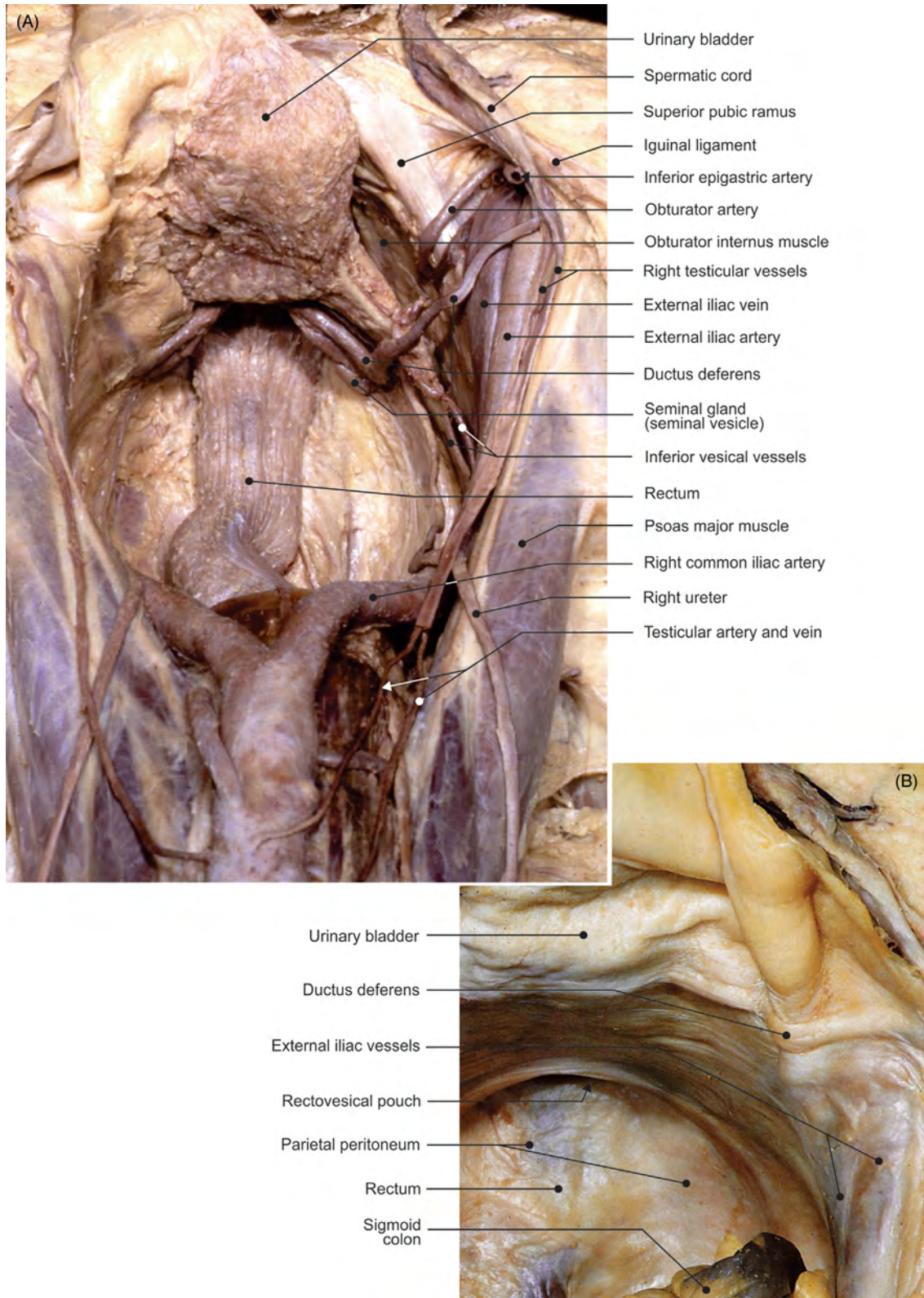


FIGURE 5.3 The male pelvis. View from above: (A) organs with peritoneum removed and (B) organs covered by peritoneum.

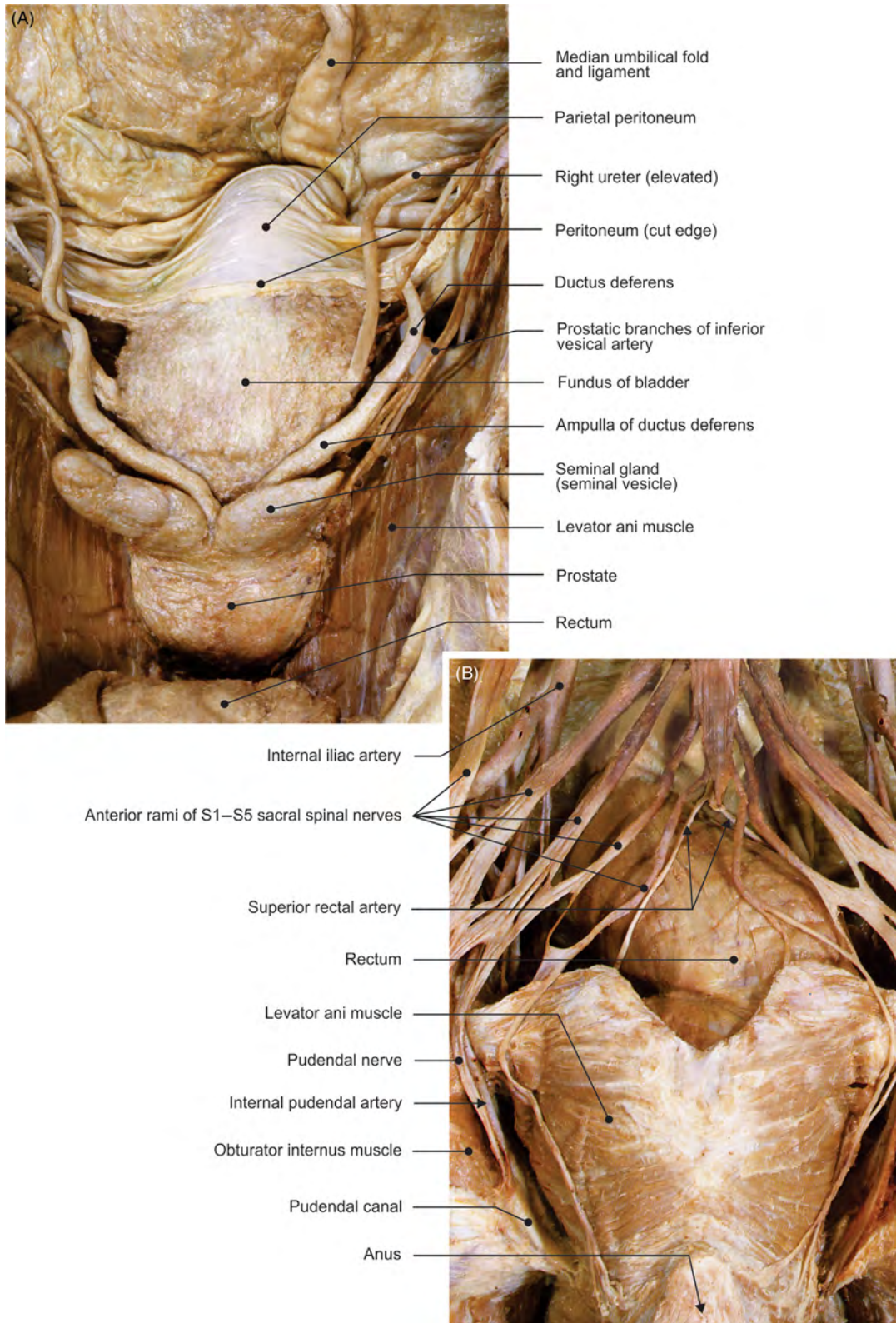


FIGURE 5.4 The prostate and urinary bladder. (A) View from behind. Levator ani muscle and branches of sacral plexus: (B) view from behind.

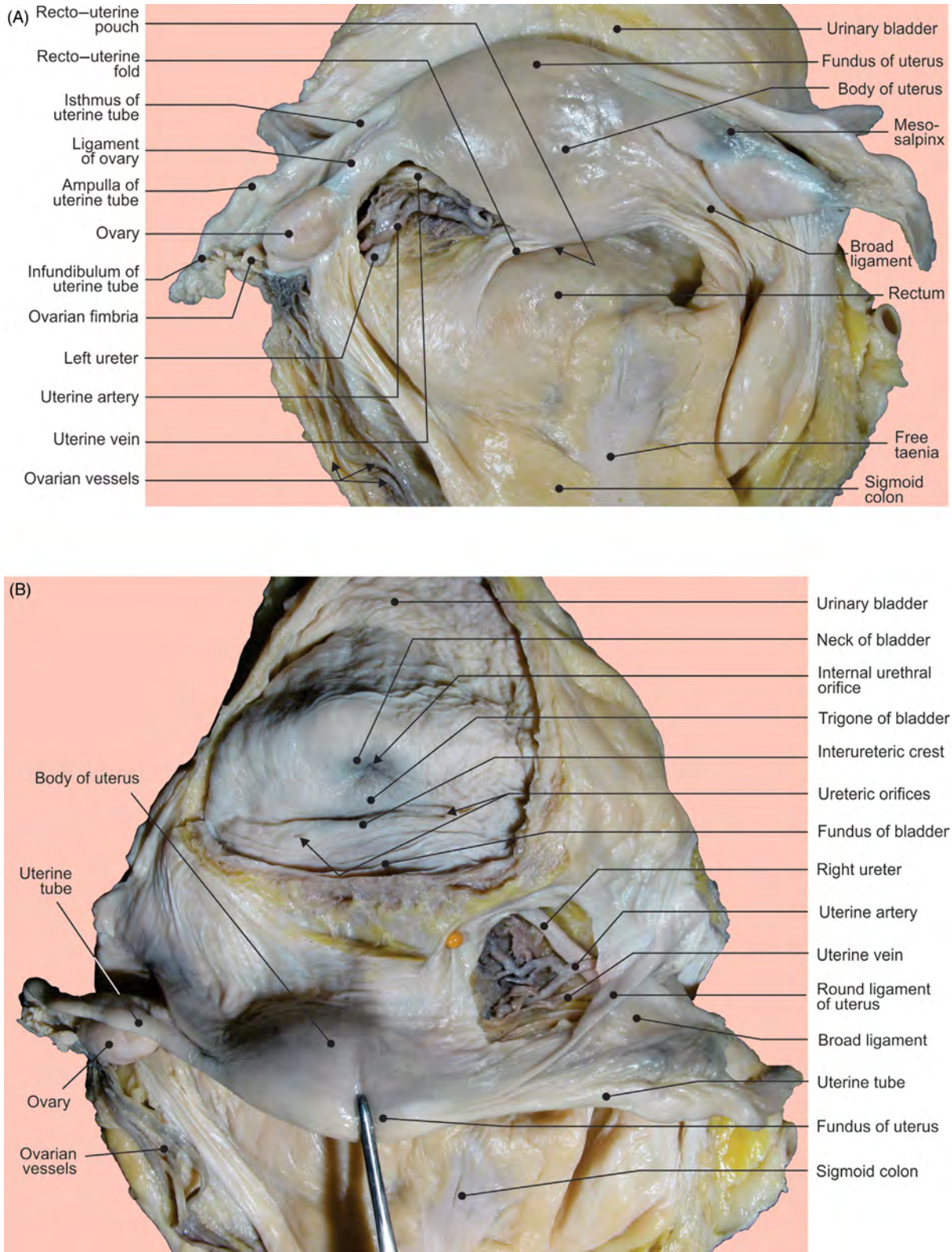


FIGURE 5.5 The female internal genital organs viewed from above. (A) Open broad ligament. Female internal genital organs viewed from above: (B) uterus is reflected and broad ligament and urinary bladder opened.

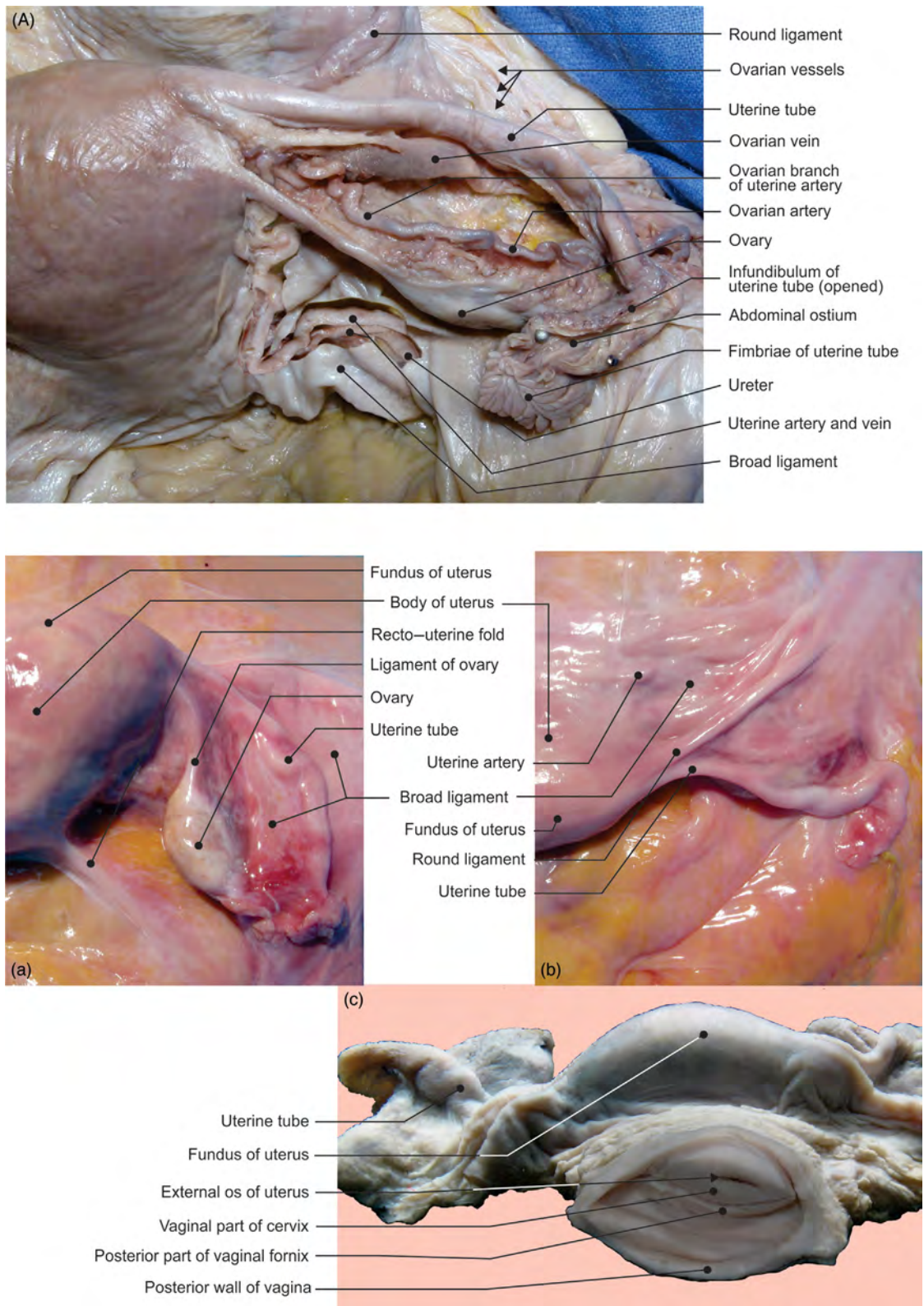


FIGURE 5.6 The female internal genital organs viewed from above. (A) Open broad ligament. Uterus and associated structures in situ: view from above on (a) posterior and (b) anterior surfaces of native samples, and (c) view from the front.

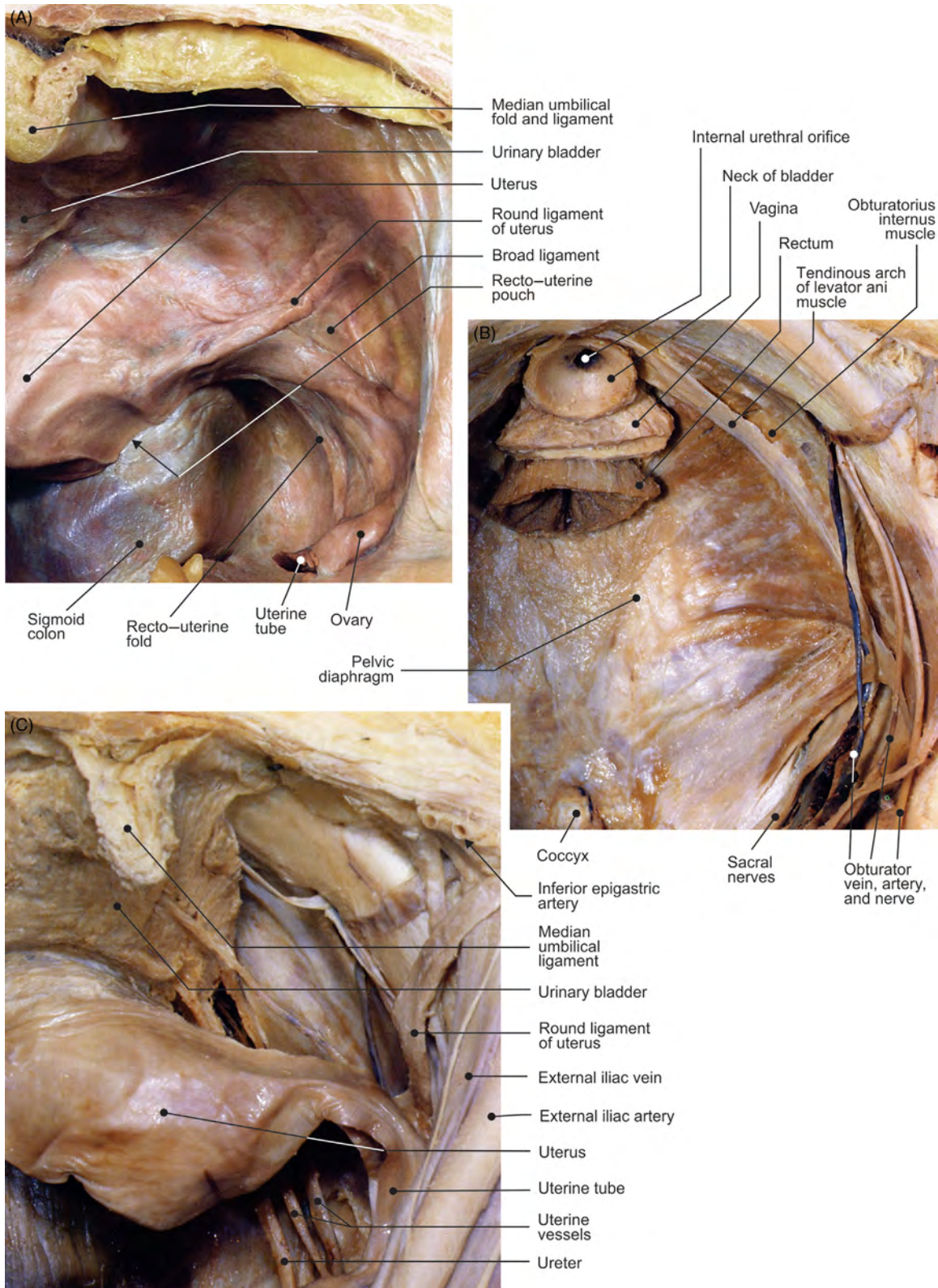


FIGURE 5.7 The female pelvic organs covered by peritoneum. (A) View from above. Female pelvic diaphragm: (B) view from above. Female pelvic organs with peritoneum removed: (C) view from above.

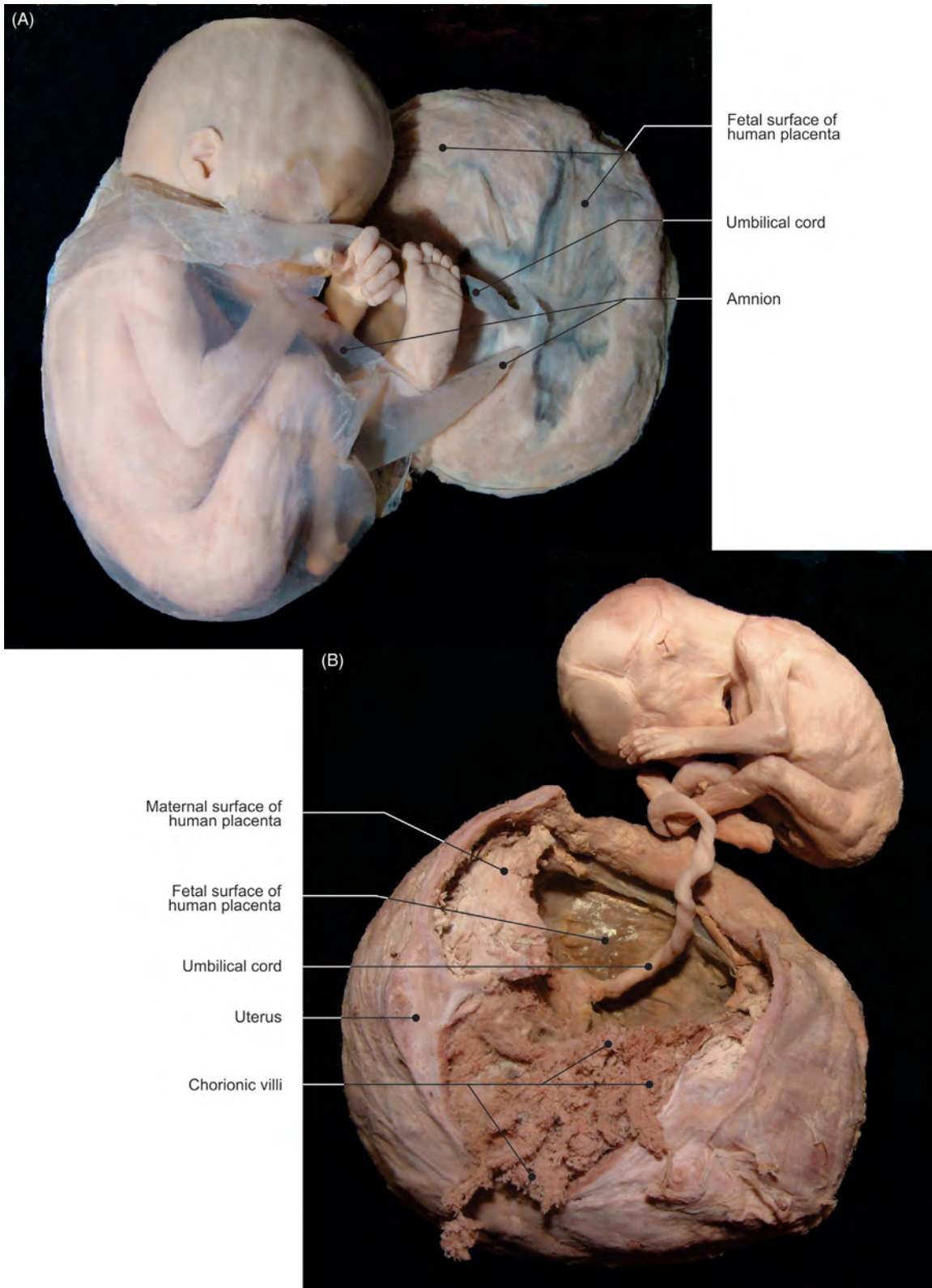


FIGURE 5.8 Five- to six-month-old fetal specimens. (A–B) Different specimens demonstrating the fetus–uterus relationship.

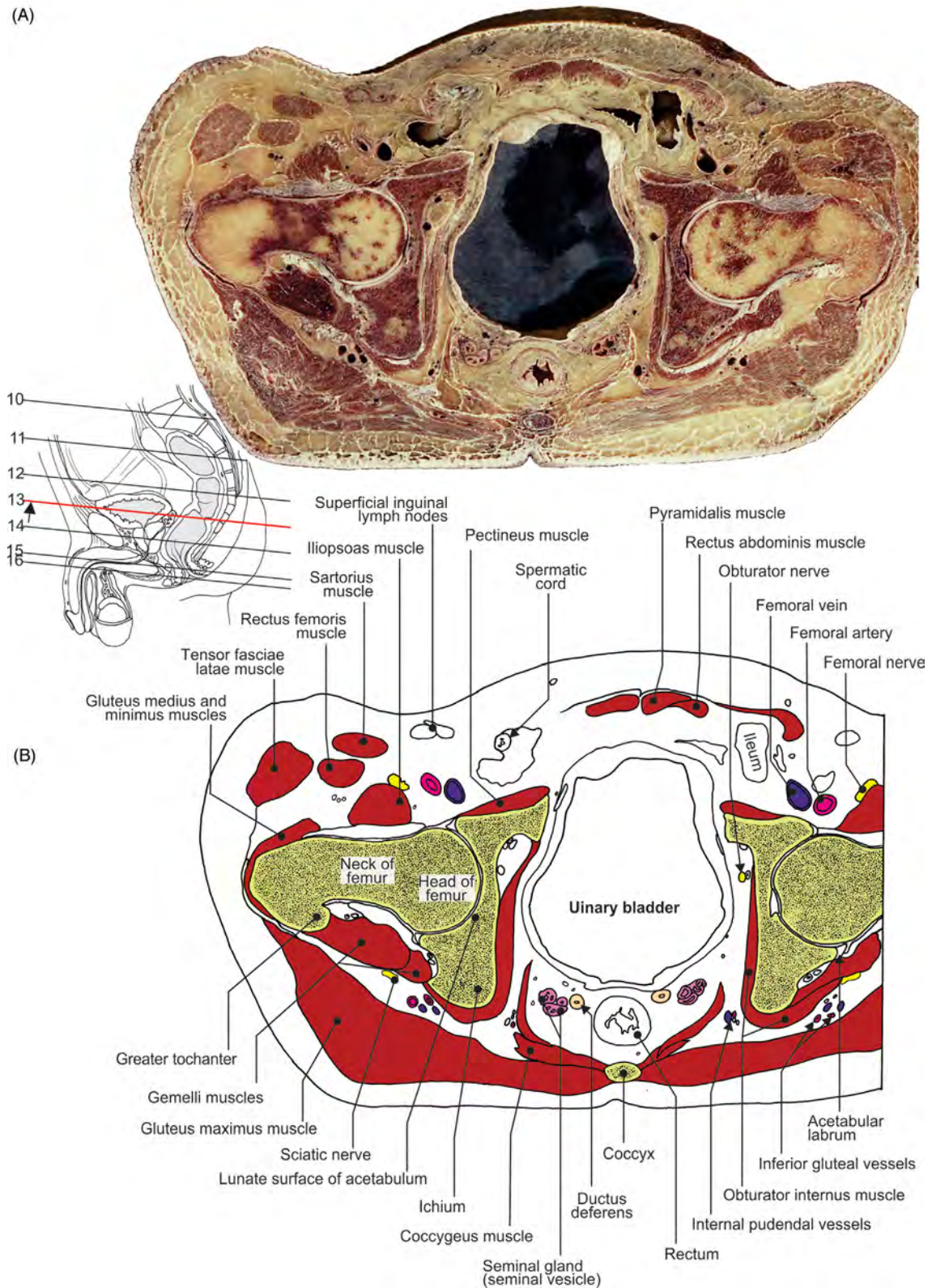


FIGURE 5.9 The male pelvis and hip joint. Transverse section at the coccygeal level. (A) Section and (B) illustration.

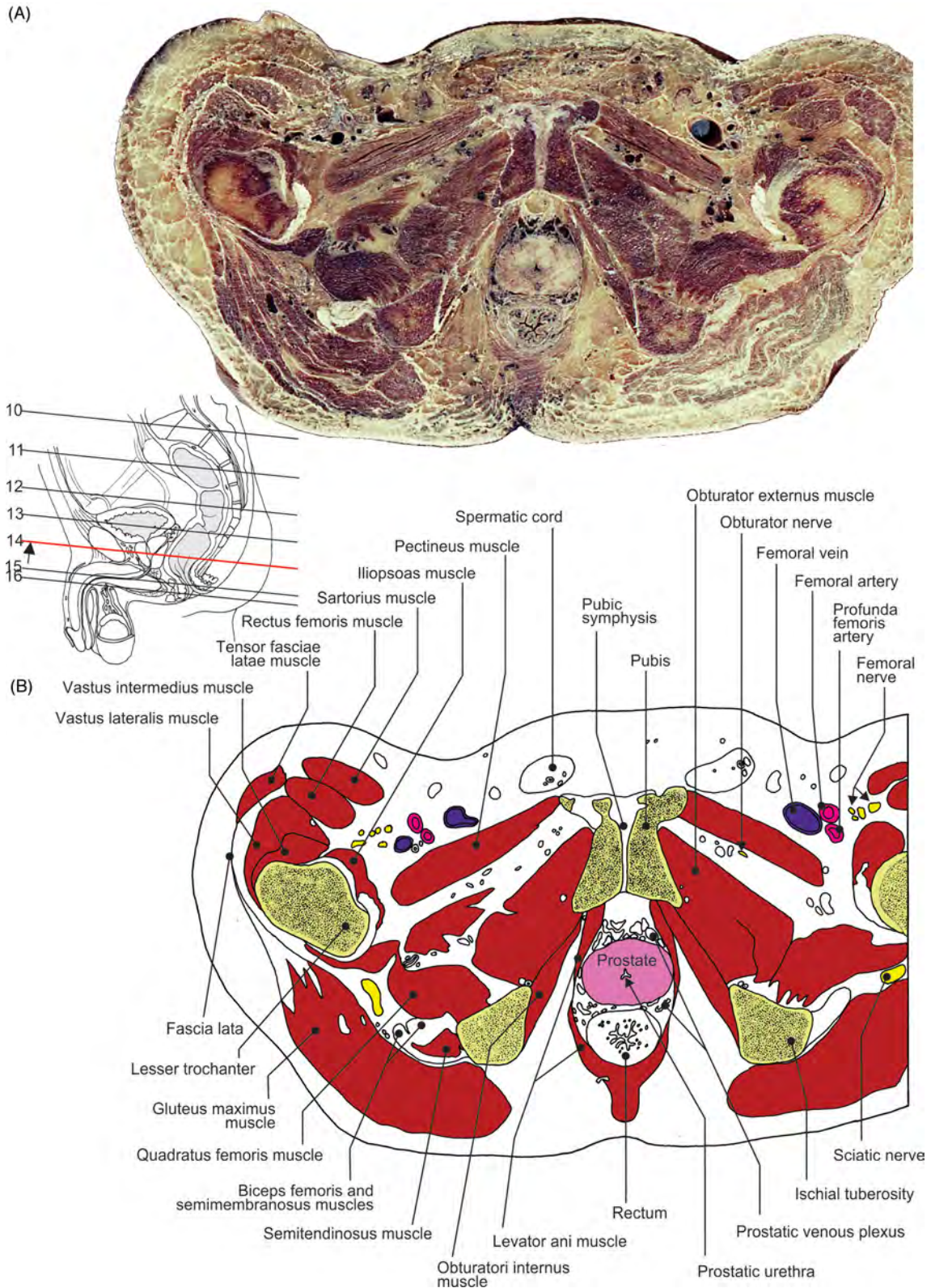


FIGURE 5.10 The male pelvis and hip region. Transverse section at the prostatic level. (A) Section and (B) illustration.

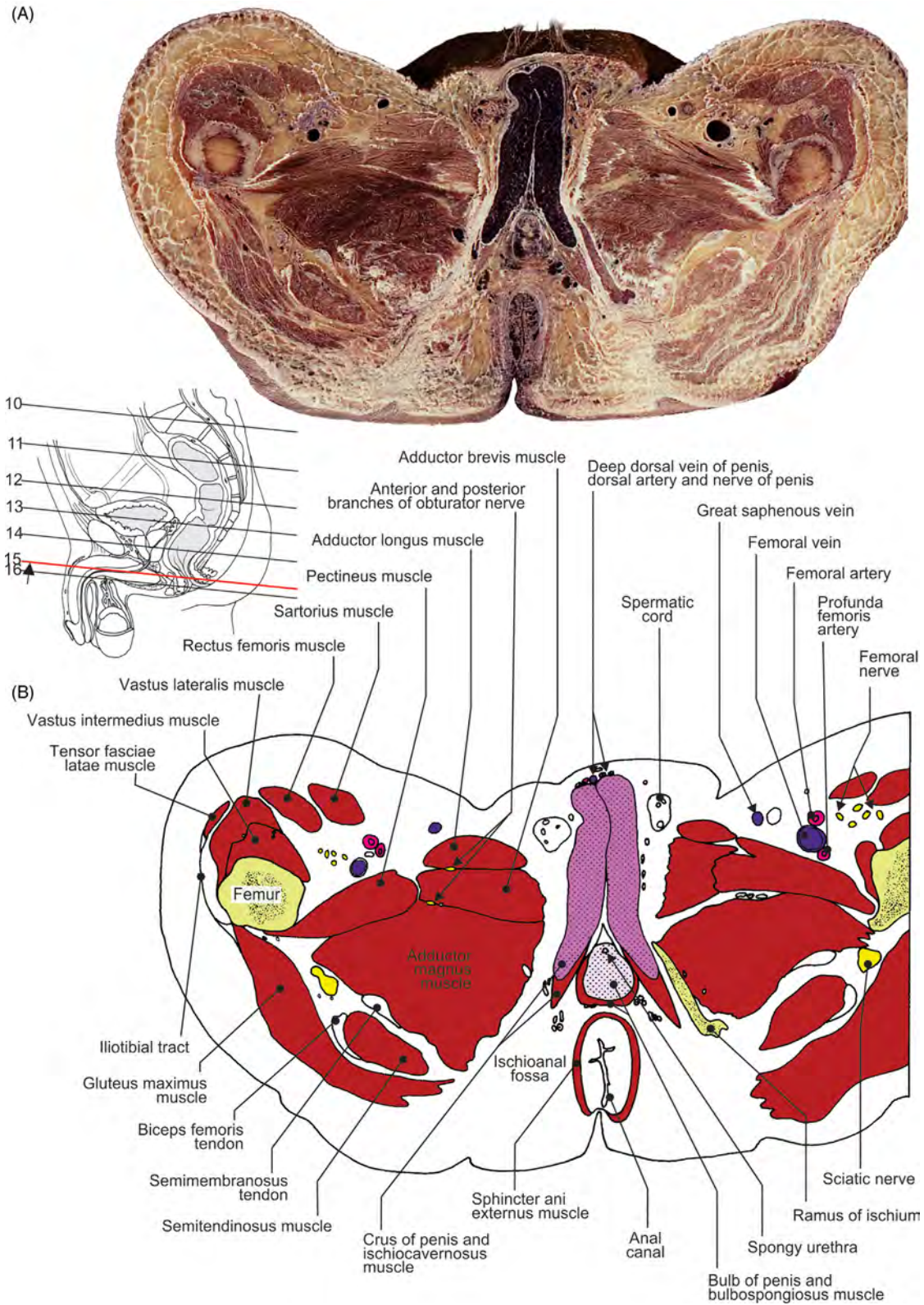


FIGURE 5.11 Male perineum. Transverse section at the level of root of penis. (A) Section and (B) illustration.

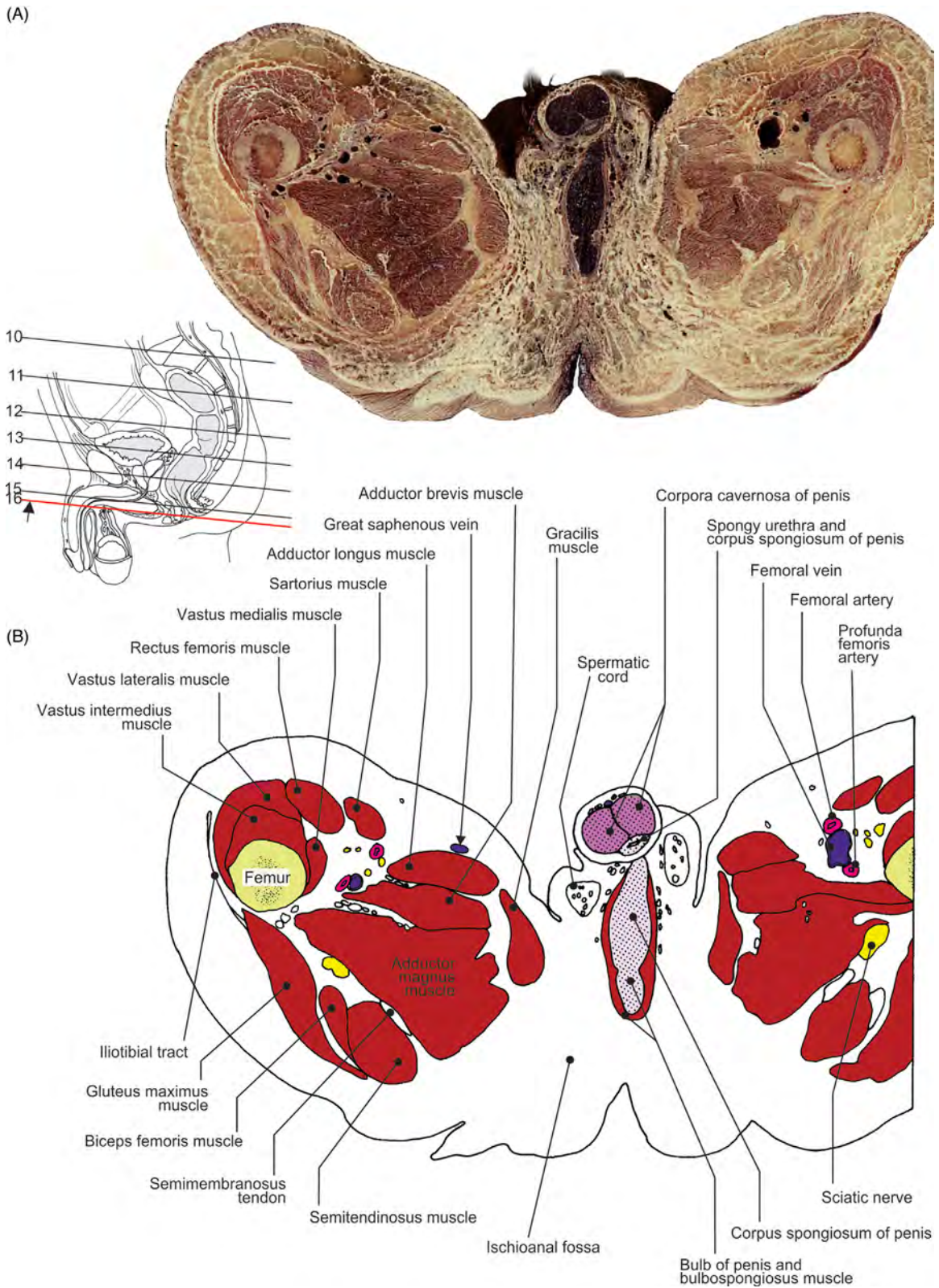


FIGURE 5.12 The transverse section of the perineum and upper region of thigh. (A) Section and (B) illustration.

Chapter 6

Head and Neck Regions and Vascularization

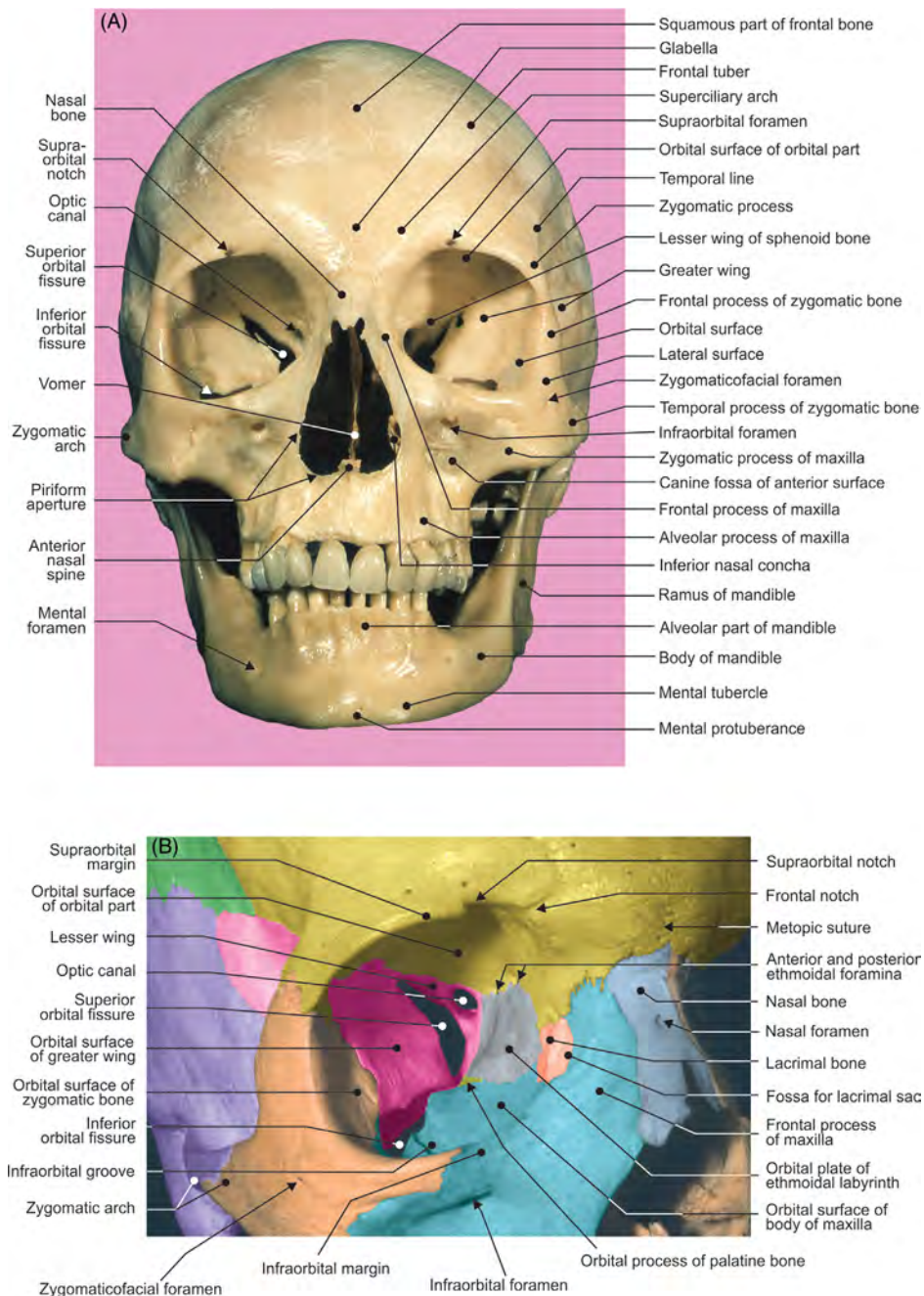


FIGURE 6.1 (A) The anterior surface of skull and mandible. (B) Right orbit: view from the front.

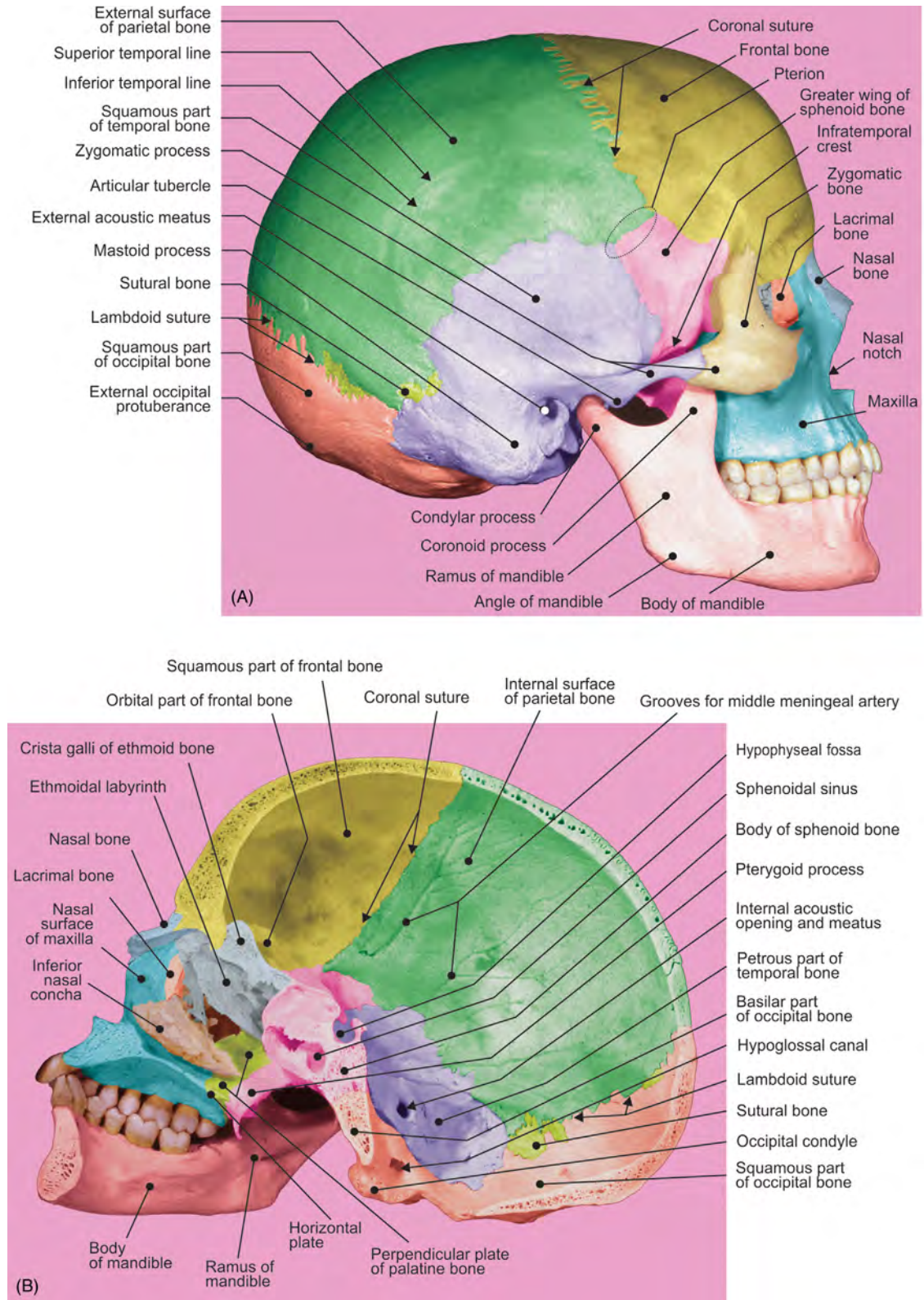


FIGURE 6.2 (A) The lateral surface of cranium and mandible. (B) Midsagittal section of cranium and mandible, right half: inside view.

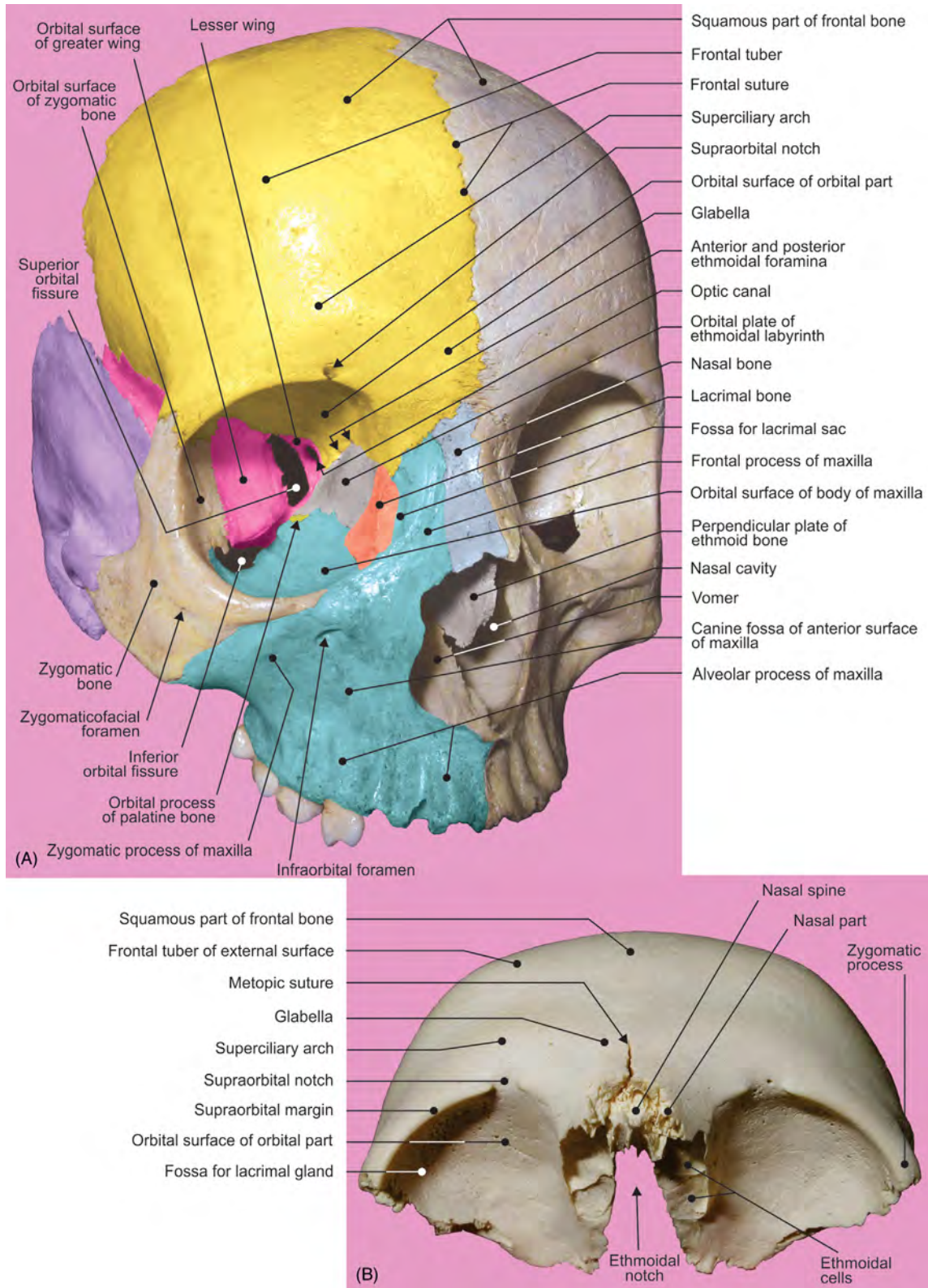


FIGURE 6.3 (A) The anterior aspect of cranial segment: frontal bone divided by persistent frontal suture. (B) The inferior aspect of the isolated frontal bone.

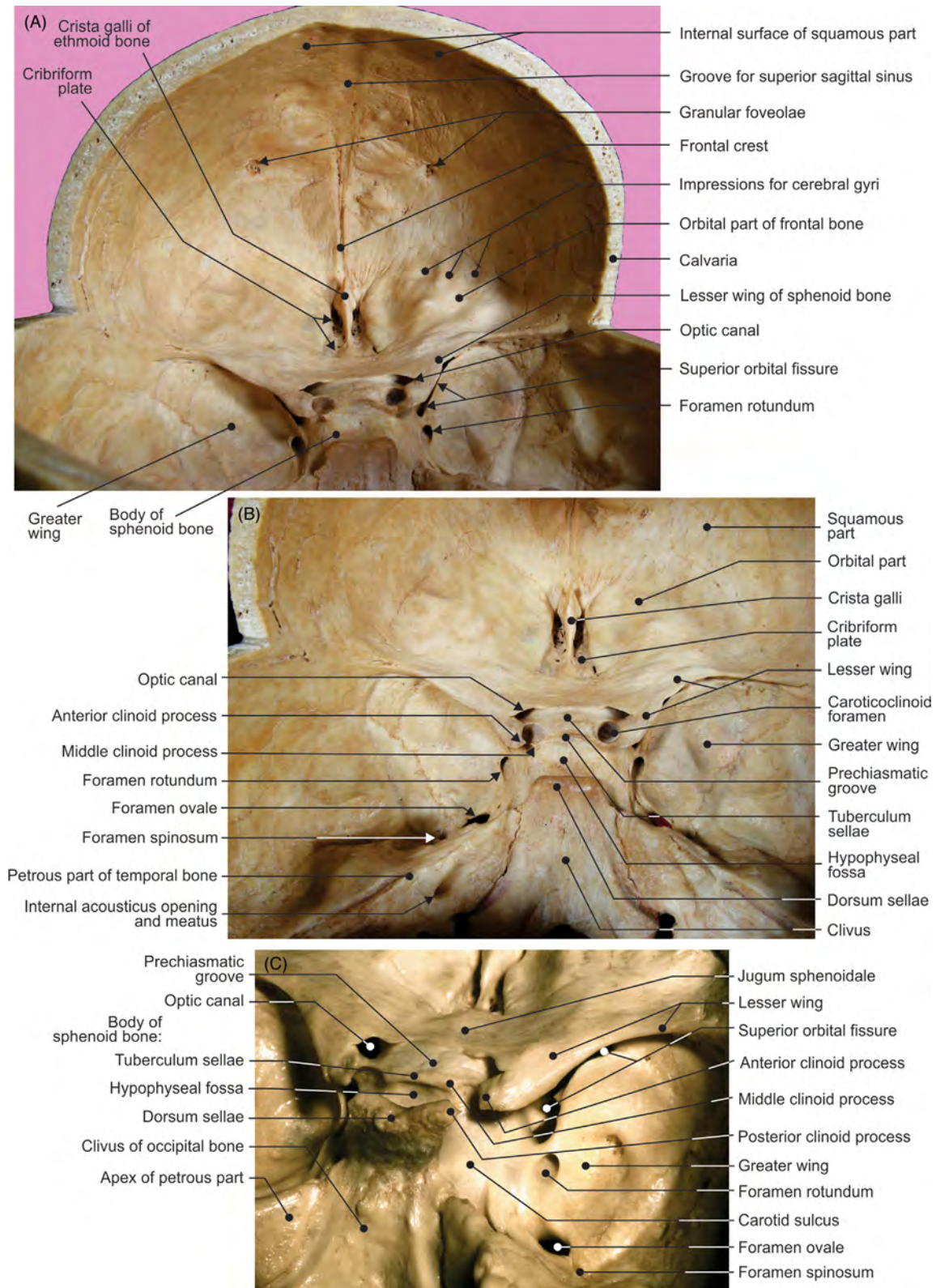


FIGURE 6.4 (A) The internal surface of the frontal bone. (B) The anterior cranial fossa and (C) middle cranial fossa.

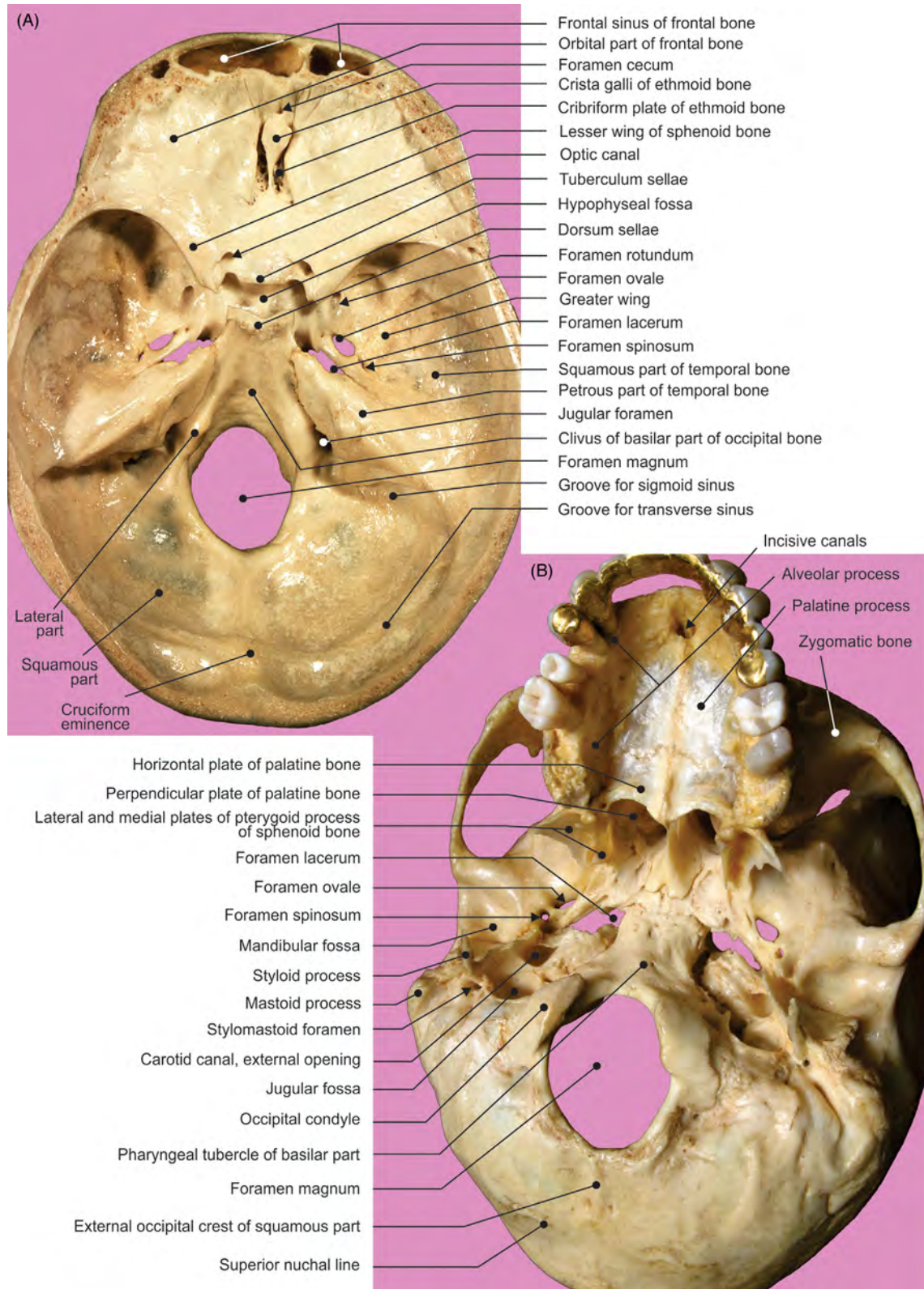


FIGURE 6.5 The cranial base. The (A) internal, superior view and (B) external, inferior view.

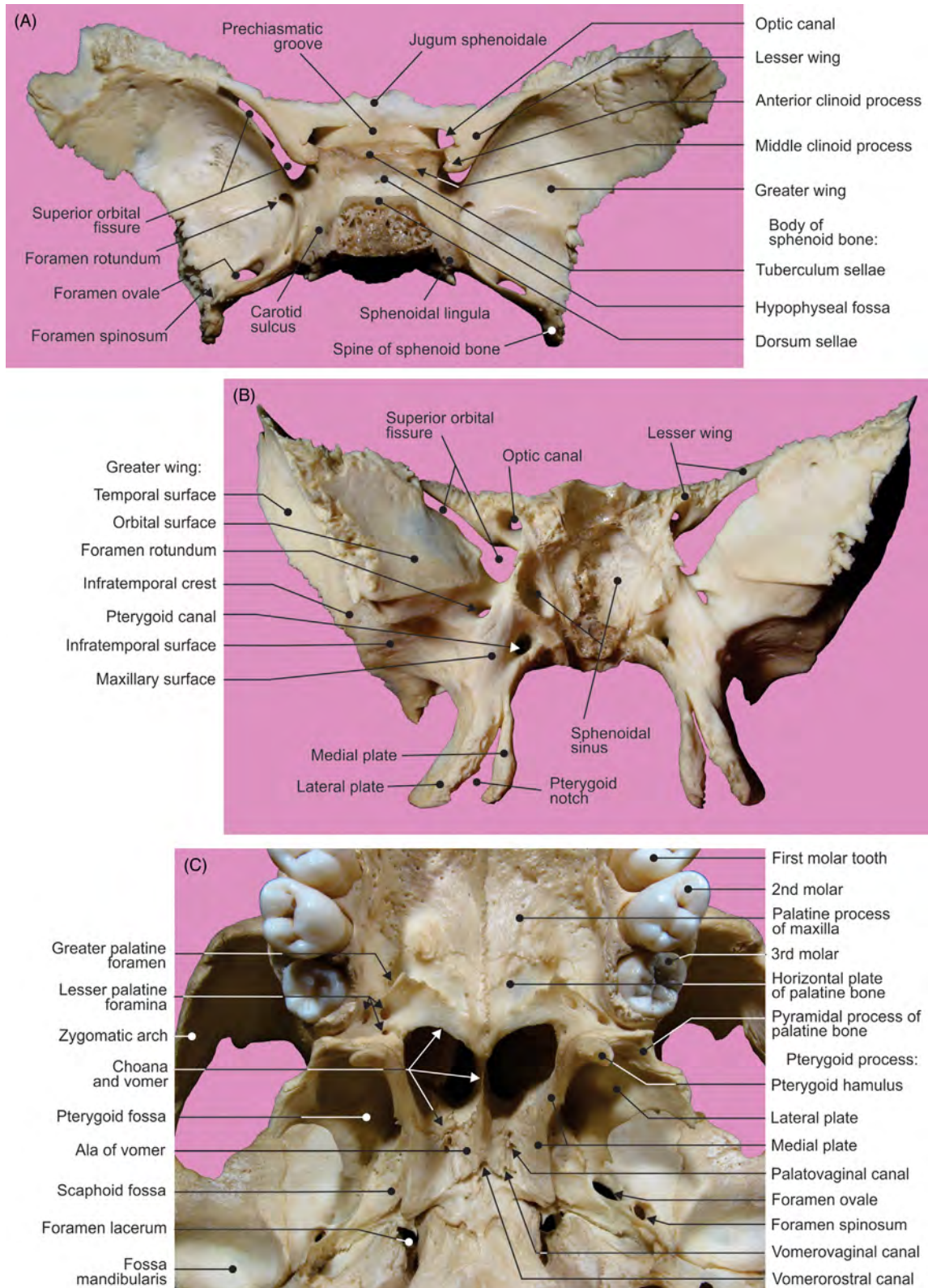


FIGURE 6.6 The isolated sphenoid bone: (A) view from above and (B) view from the front. (C) External, inferior aspect of the cranial base.

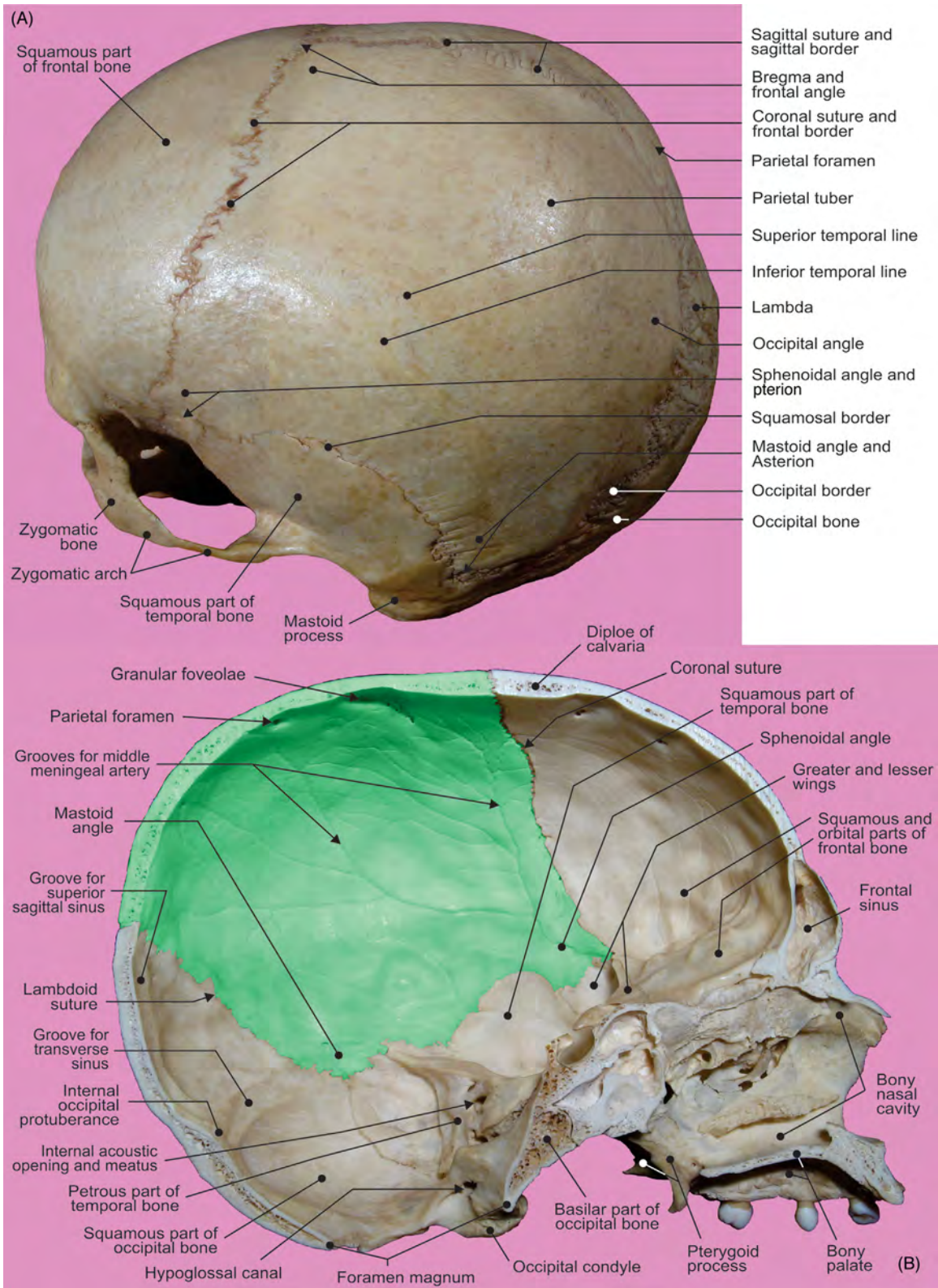


FIGURE 6.7 The (A) external and (B) internal aspects of the parietal bone.

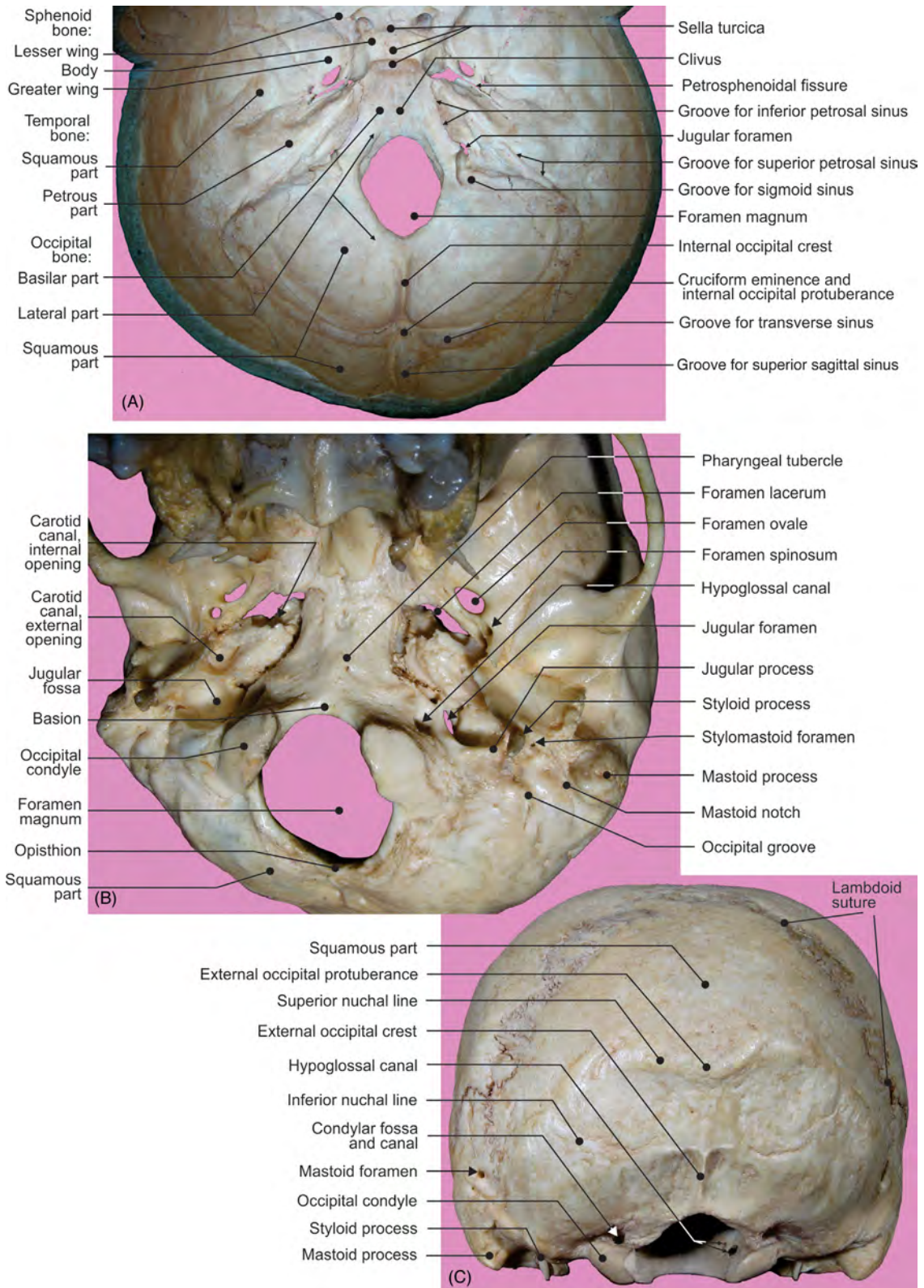


FIGURE 6.8 The occipital bone. (A) Internal aspect, view from above; (B) external aspect, view from below; and (C) external aspect, view from behind.

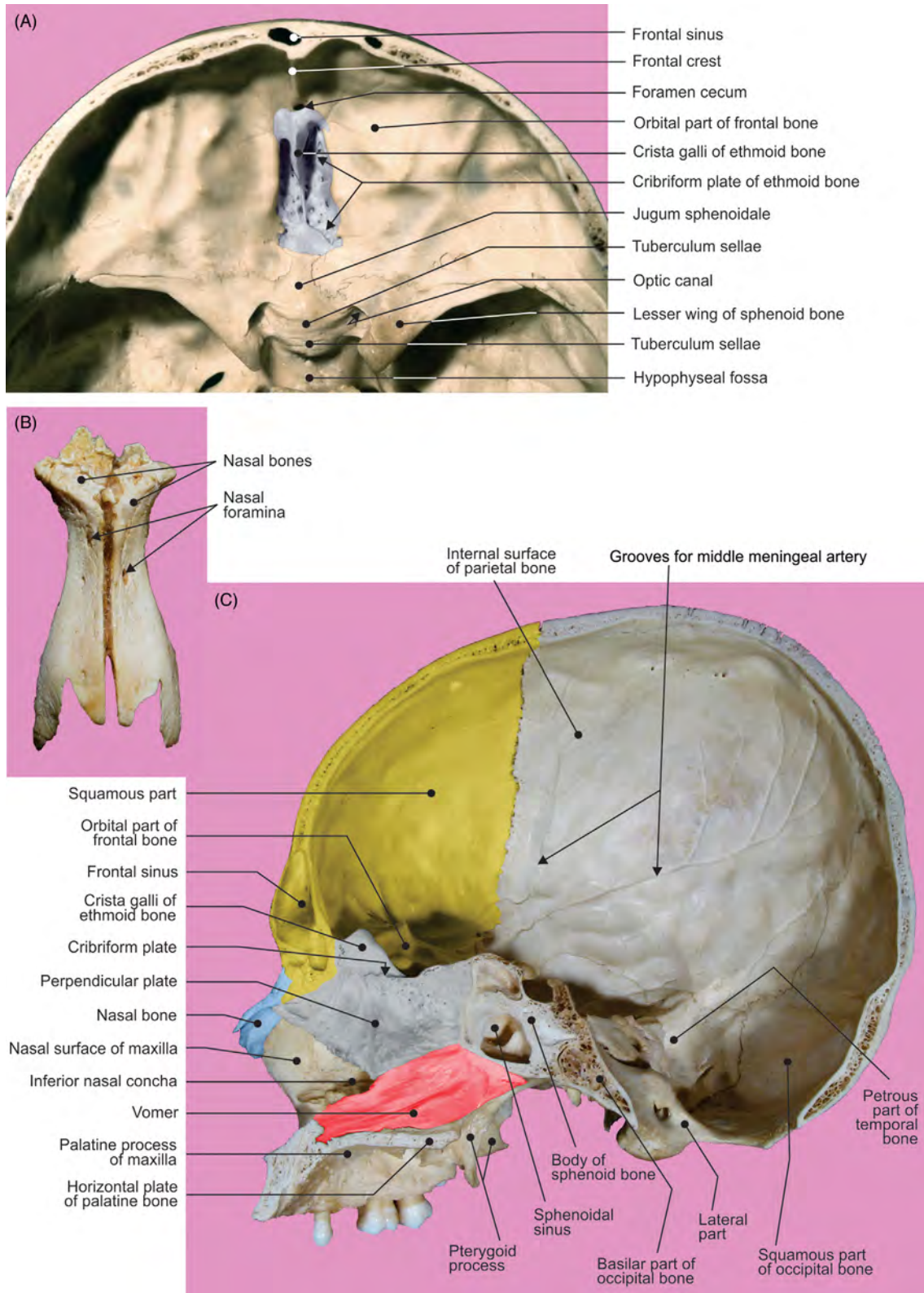


FIGURE 6.9 (A) The anterior cranial fossa. (B) Nasal bones. (C) Bony nasal septum on sagittally sectioned cranium.

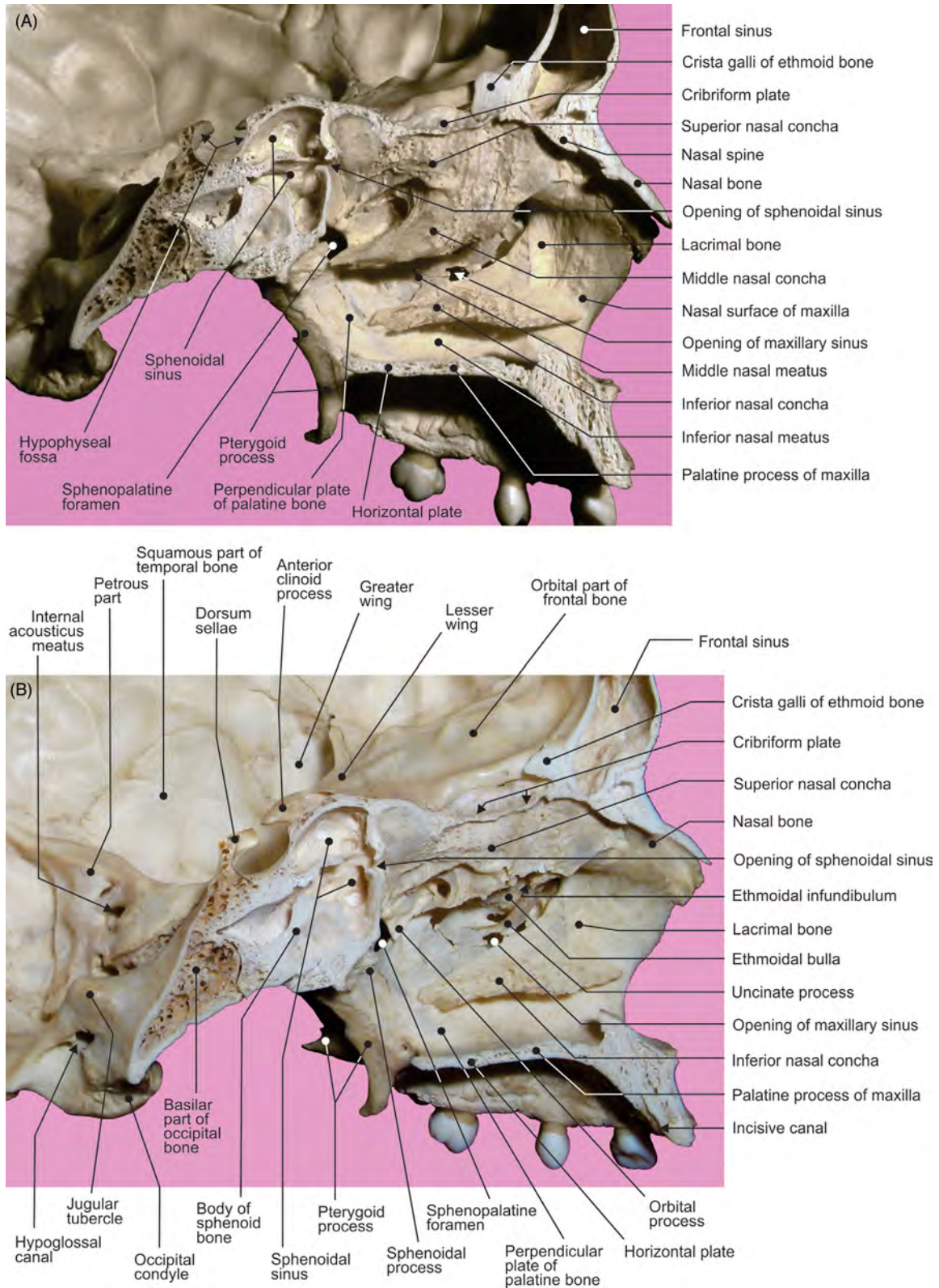


FIGURE 6.10 (A–B) Different views displaying the midsagittal sections of the bony nasal cavity.

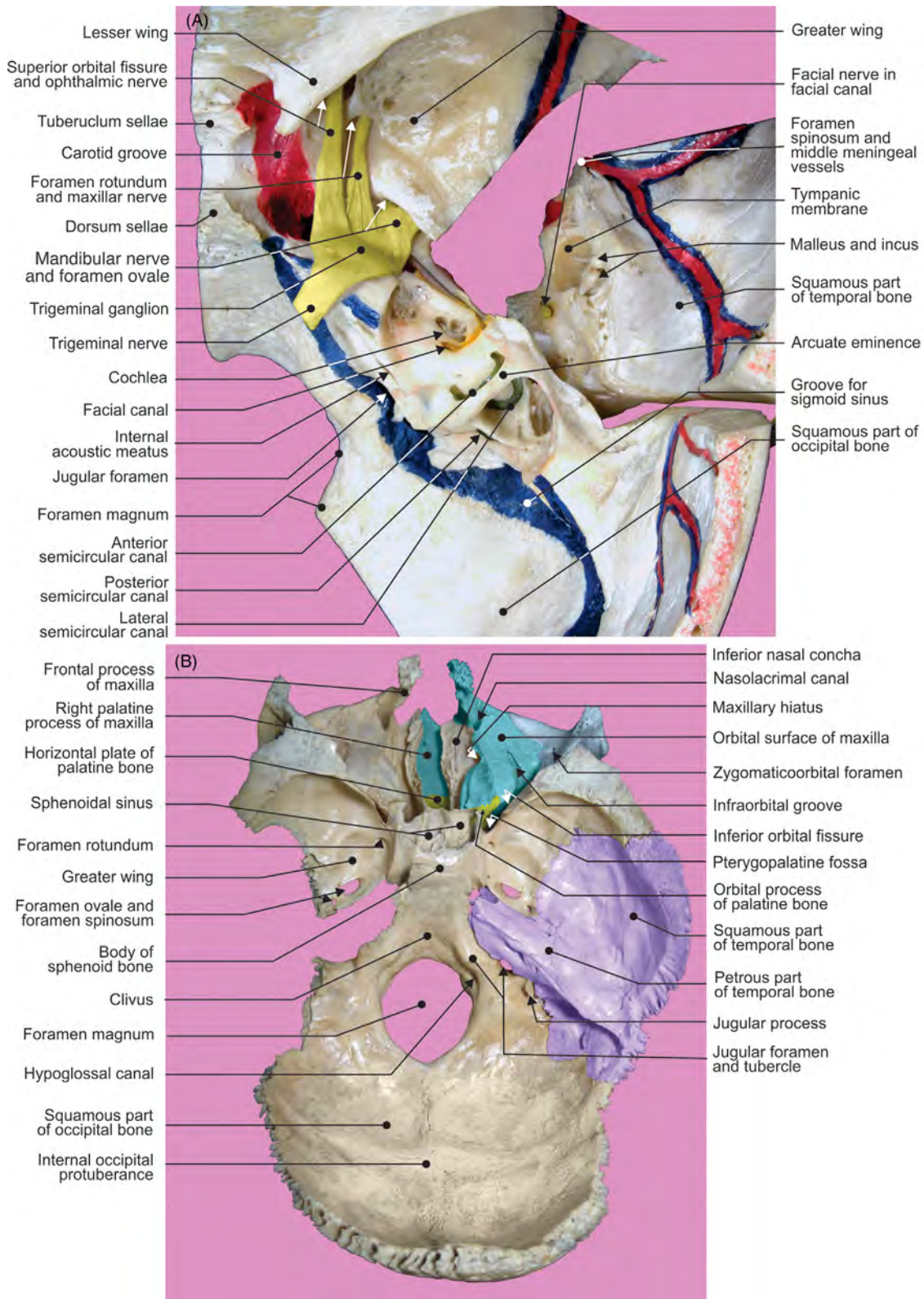


FIGURE 6.11 (A) View from the above of section and dissection of the temporal bone. (B) The internal aspect of the cranial base. Following bones were removed: frontal, ethmoid, part of sphenoid, left temporal, parietal, and small facial.

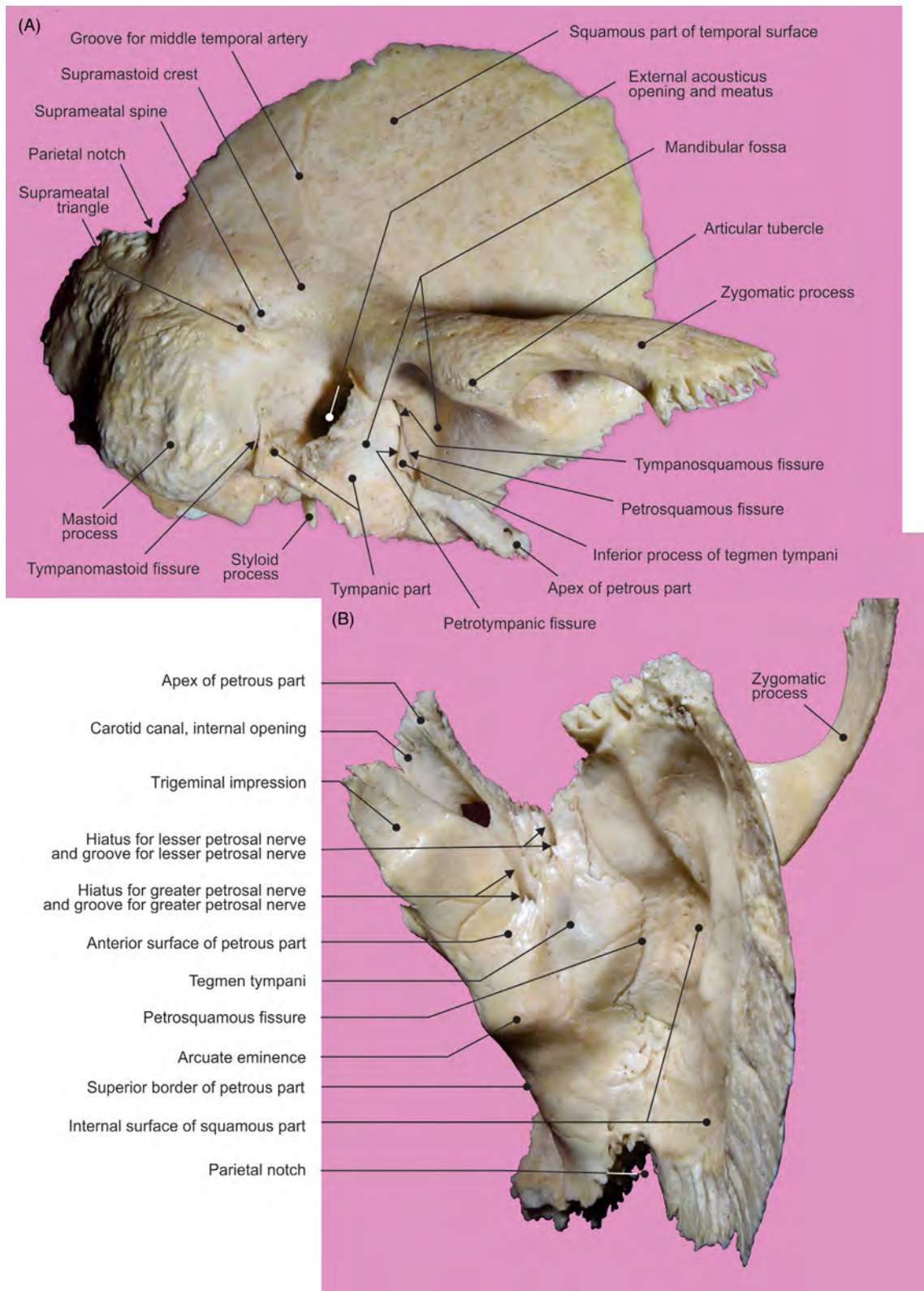


FIGURE 6.12 The isolated right temporal bone. (A) View from lateral side and (B) from above.

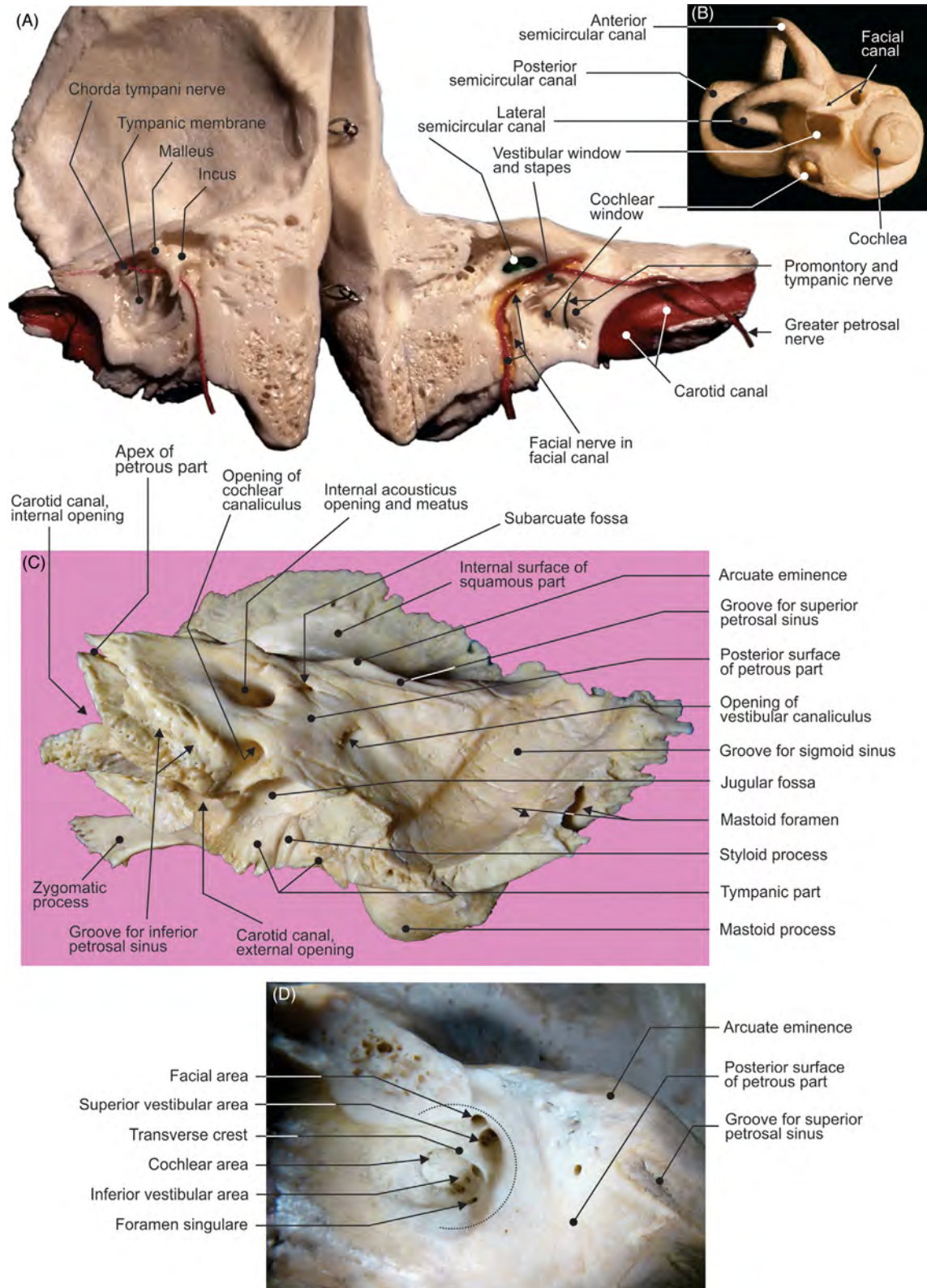


FIGURE 6.13 (A) The longitudinal section of temporal bone and (B) isolated bony labyrinth. (C) Internal, cranial aspect of isolated right temporal bone. (D) Dissection of fundus of the right internal acoustic meatus.

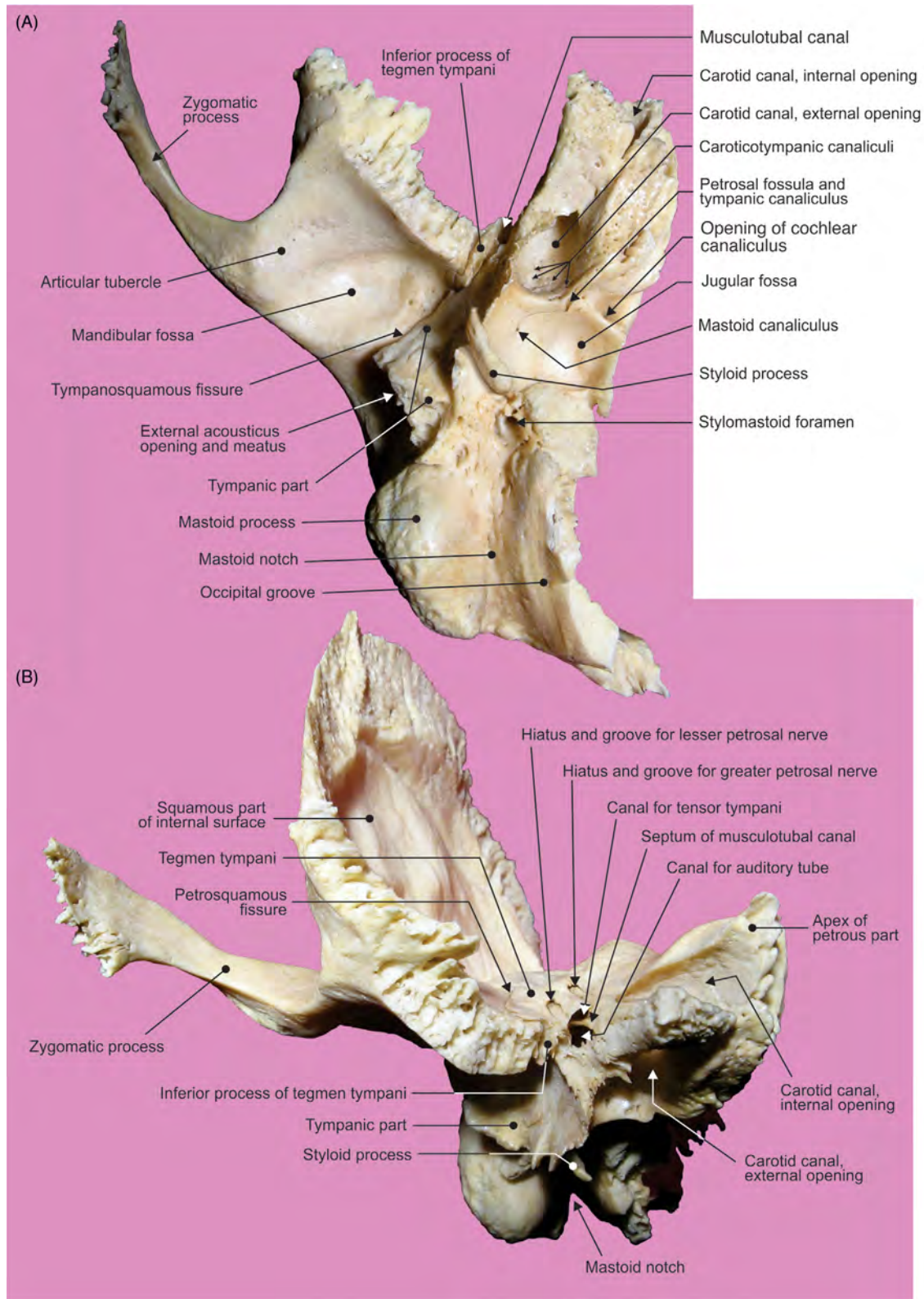


FIGURE 6.14 The right temporal bone. (A) View from below and (B) from the front.

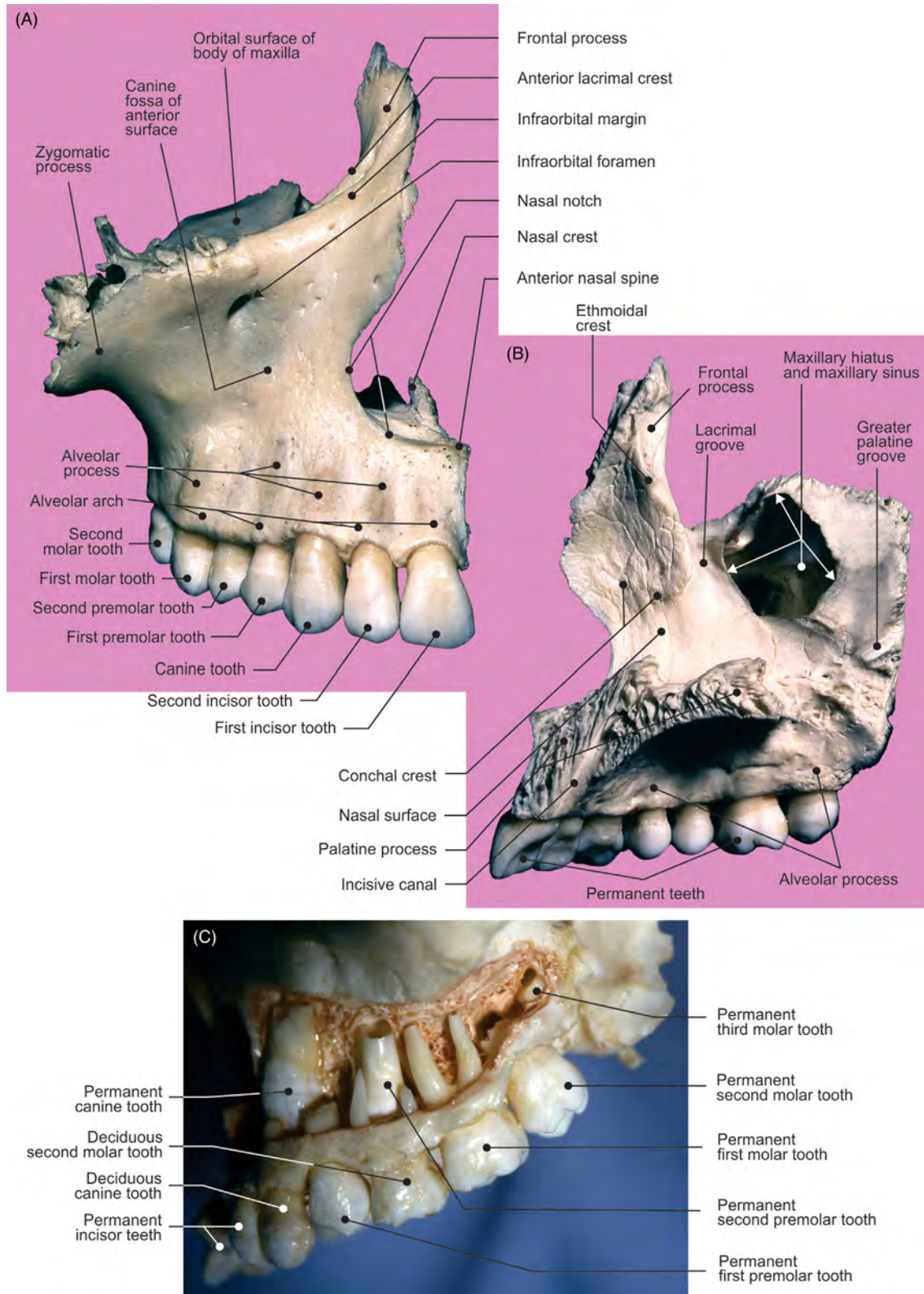


FIGURE 6.15 The maxilla. (A) View from the front and (B) from the internal side. (C) Maxillary dental arch.

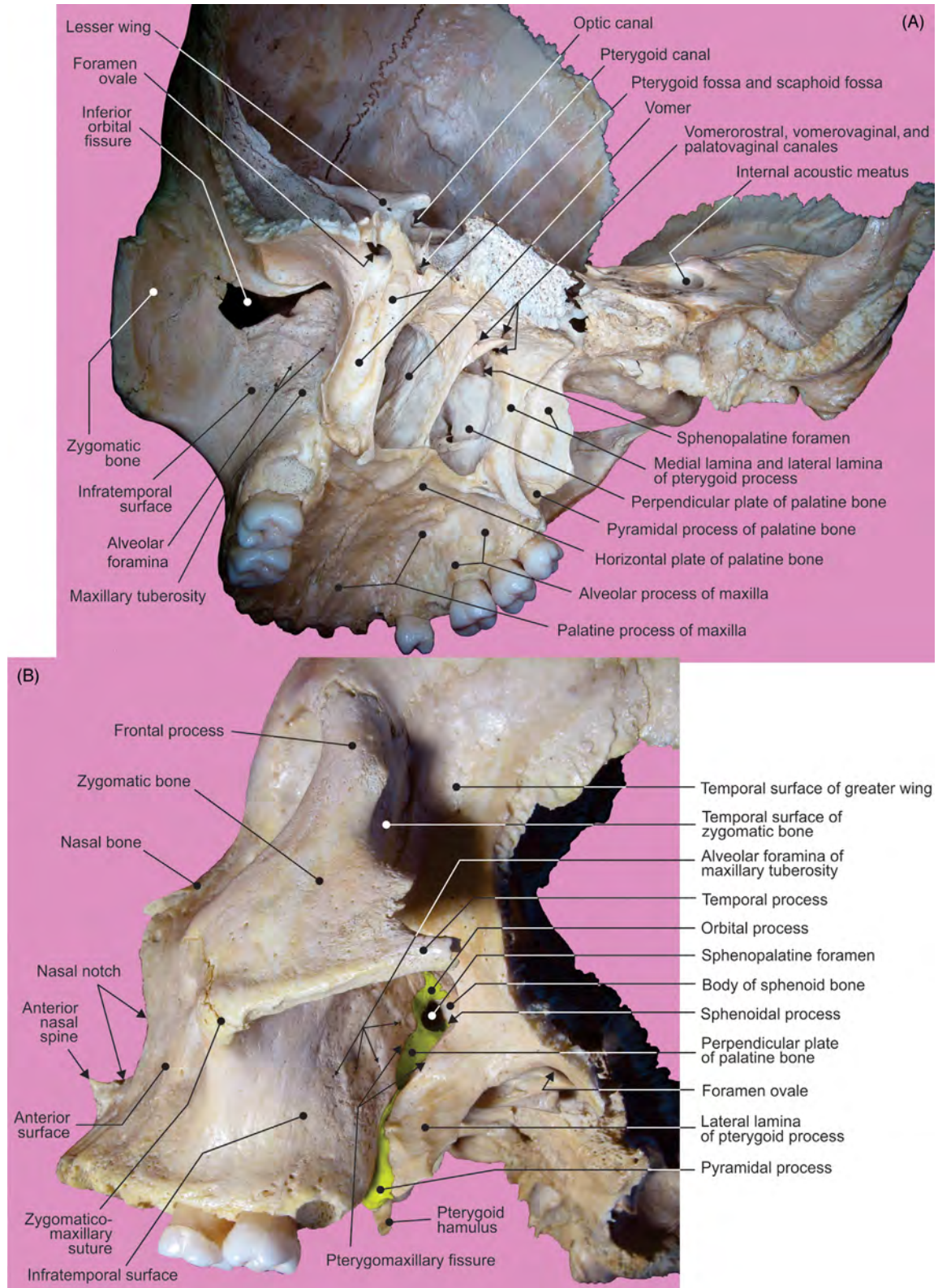


FIGURE 6.16 The palatine bone. (A) View from behind. (B) Pterygopalatine, or sphenopalatine fossa.

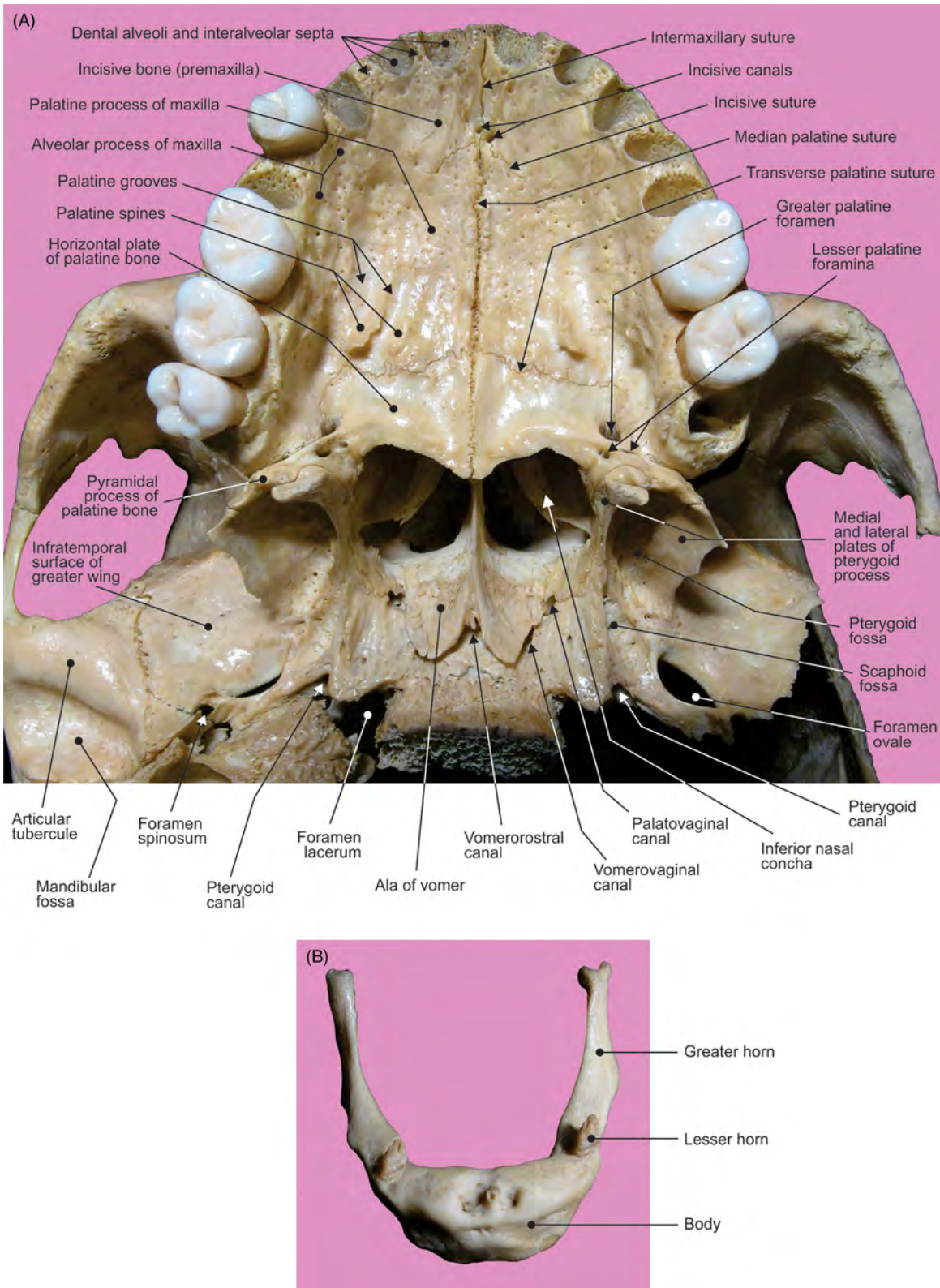


FIGURE 6.17 (A) Inferior view of the bony, hard palate. (B) Superior view of the hyoid bone.

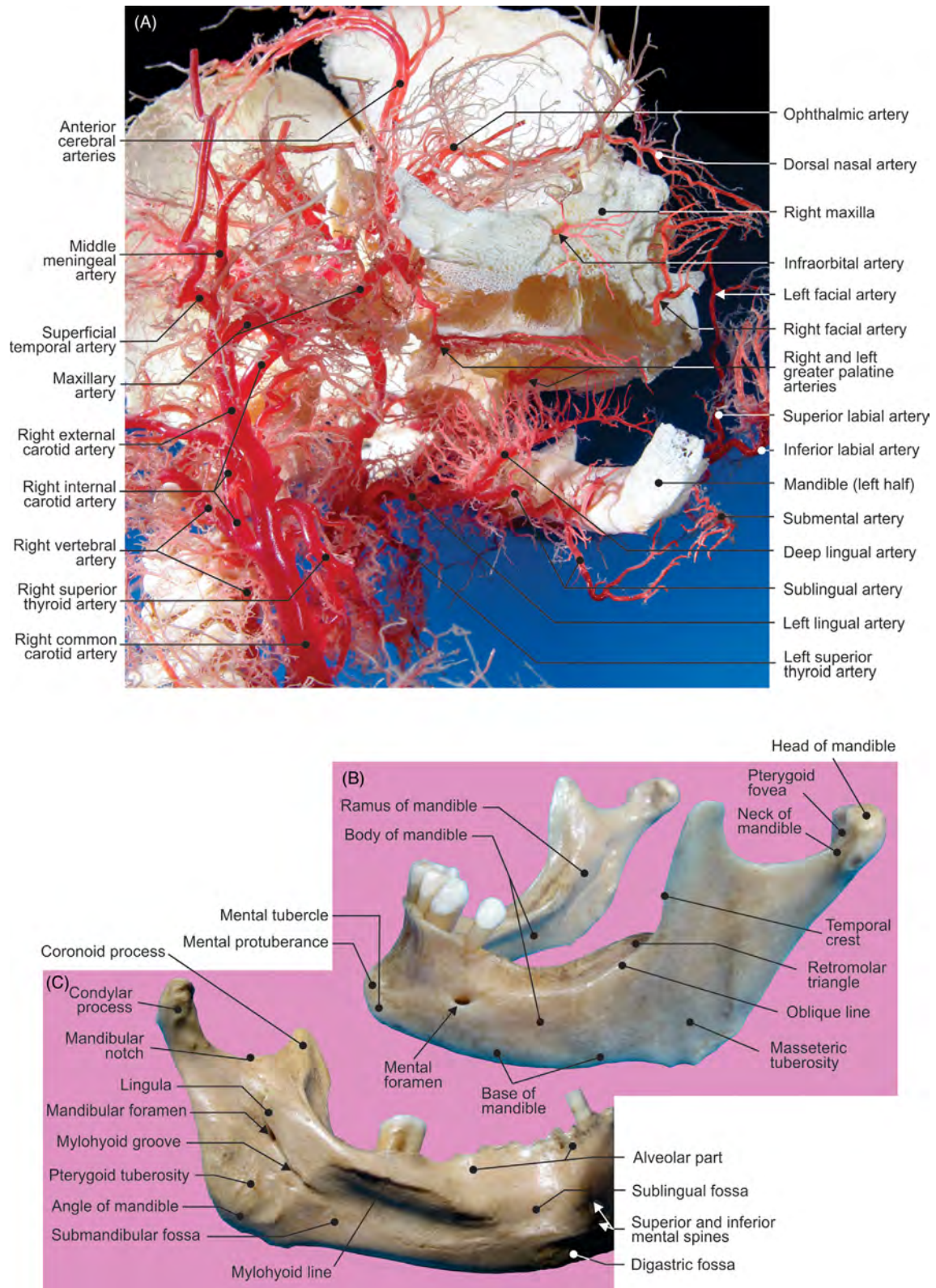


FIGURE 6.18 (A) The fetal arteries of the head and neck: inferior view from the right side. (B–C) Mandible: view of the external and internal side.

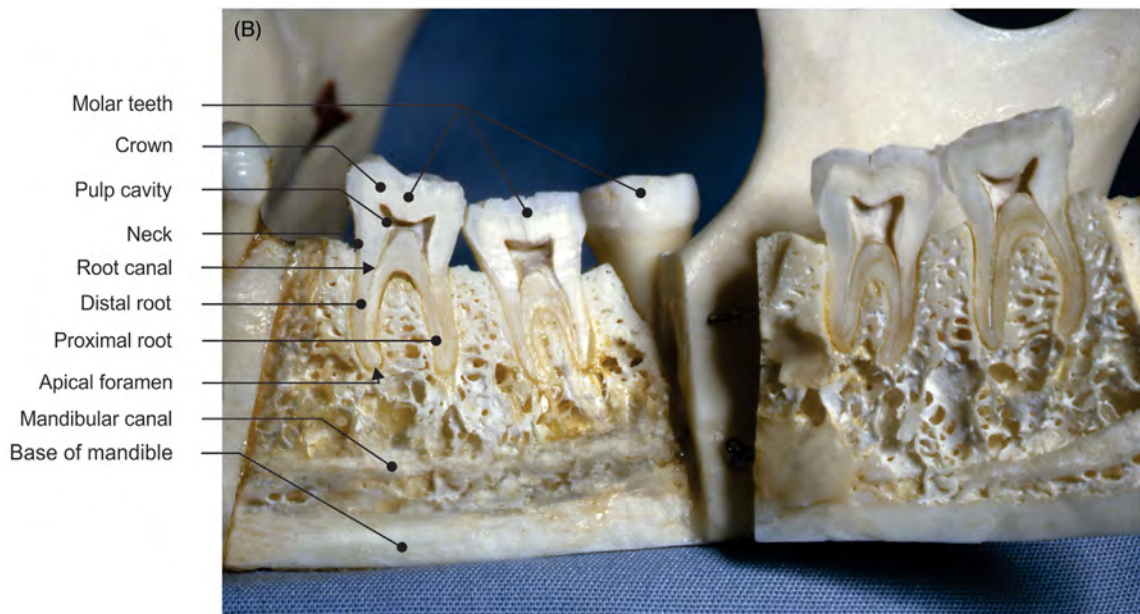
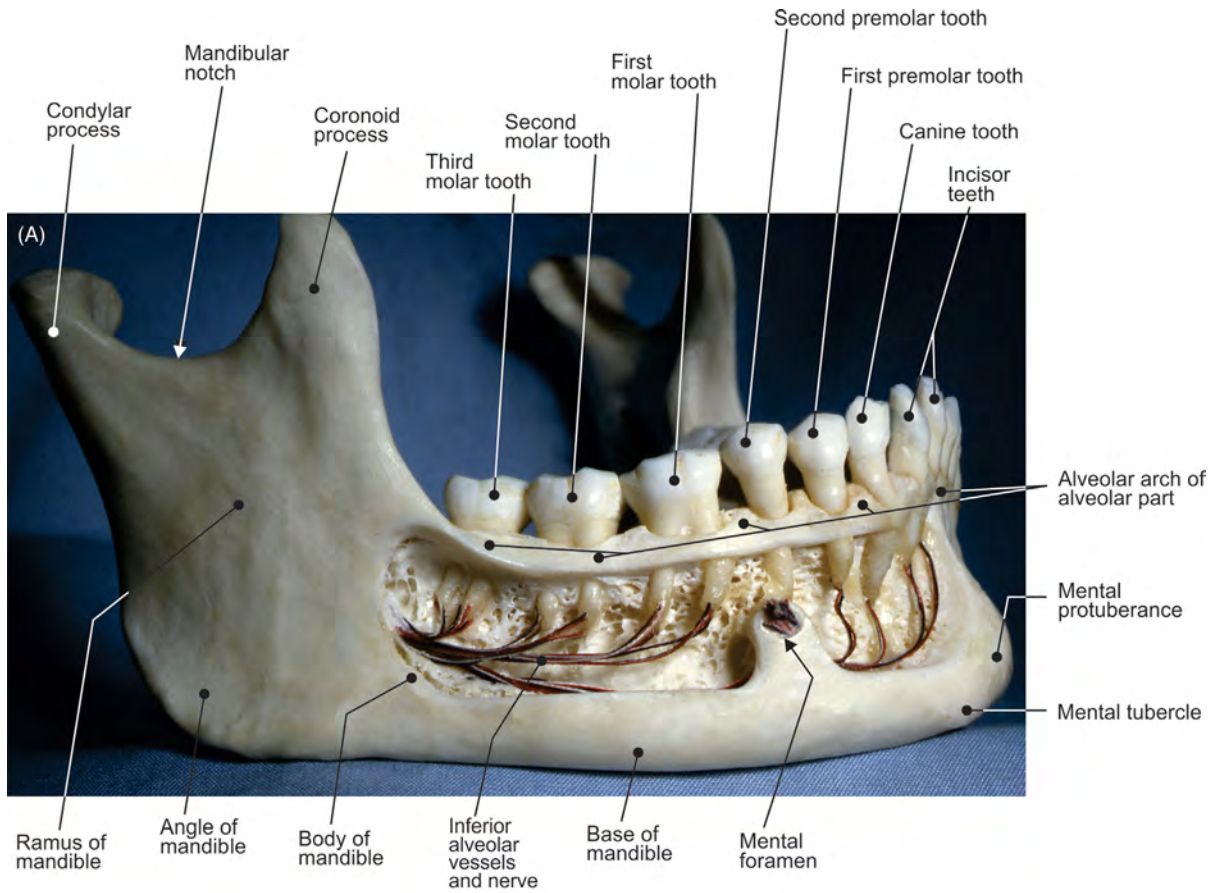


FIGURE 6.19 The mandible. (A) Dental arch and (B) sagittal section of the molar region.

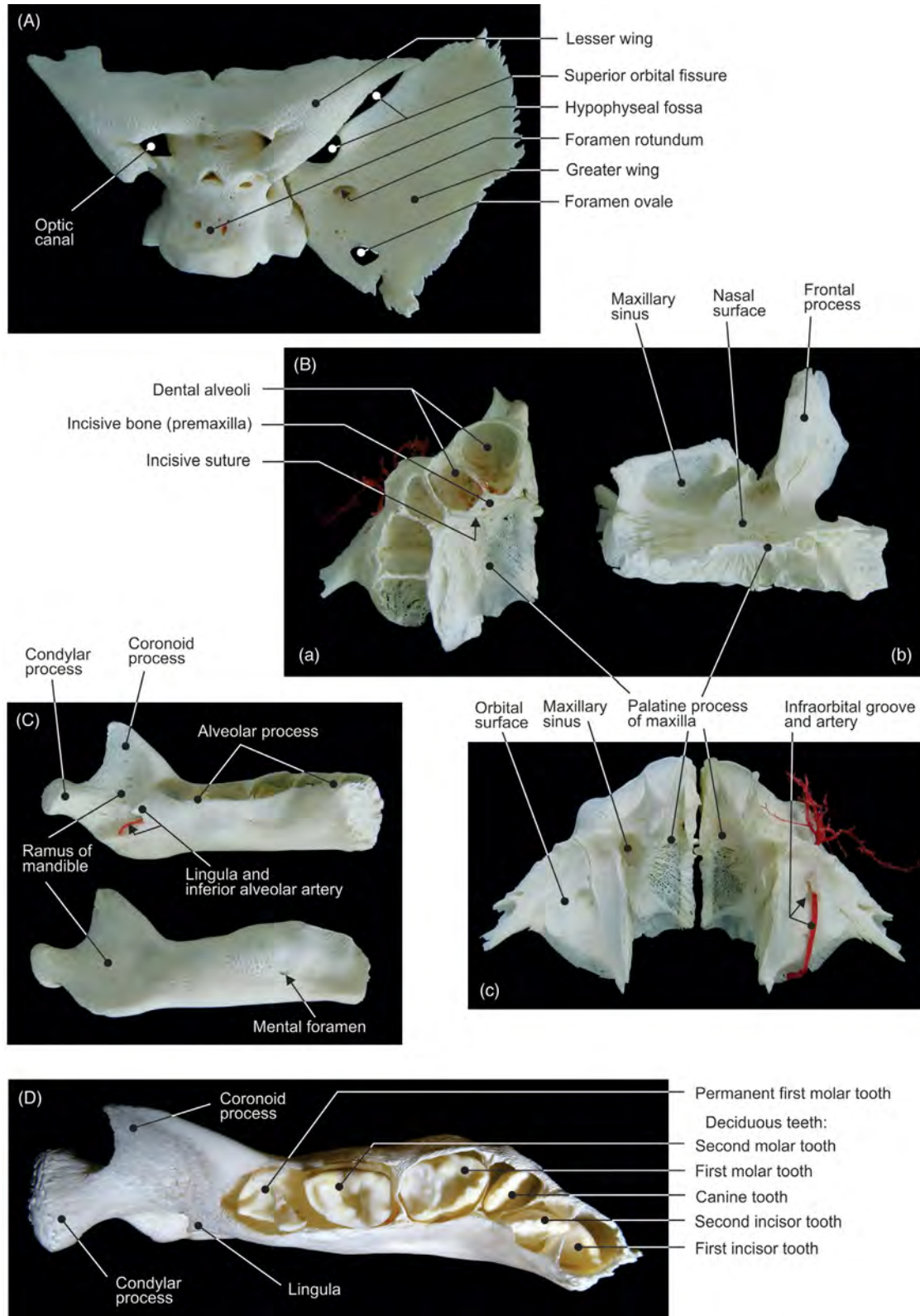


FIGURE 6.20 (A) Fetal sphenoid bone: superior view. (B) Fetal maxilla: (a) inferior, (b) internal, and (c) superior views. (C–D) Different views of the fetal mandible.

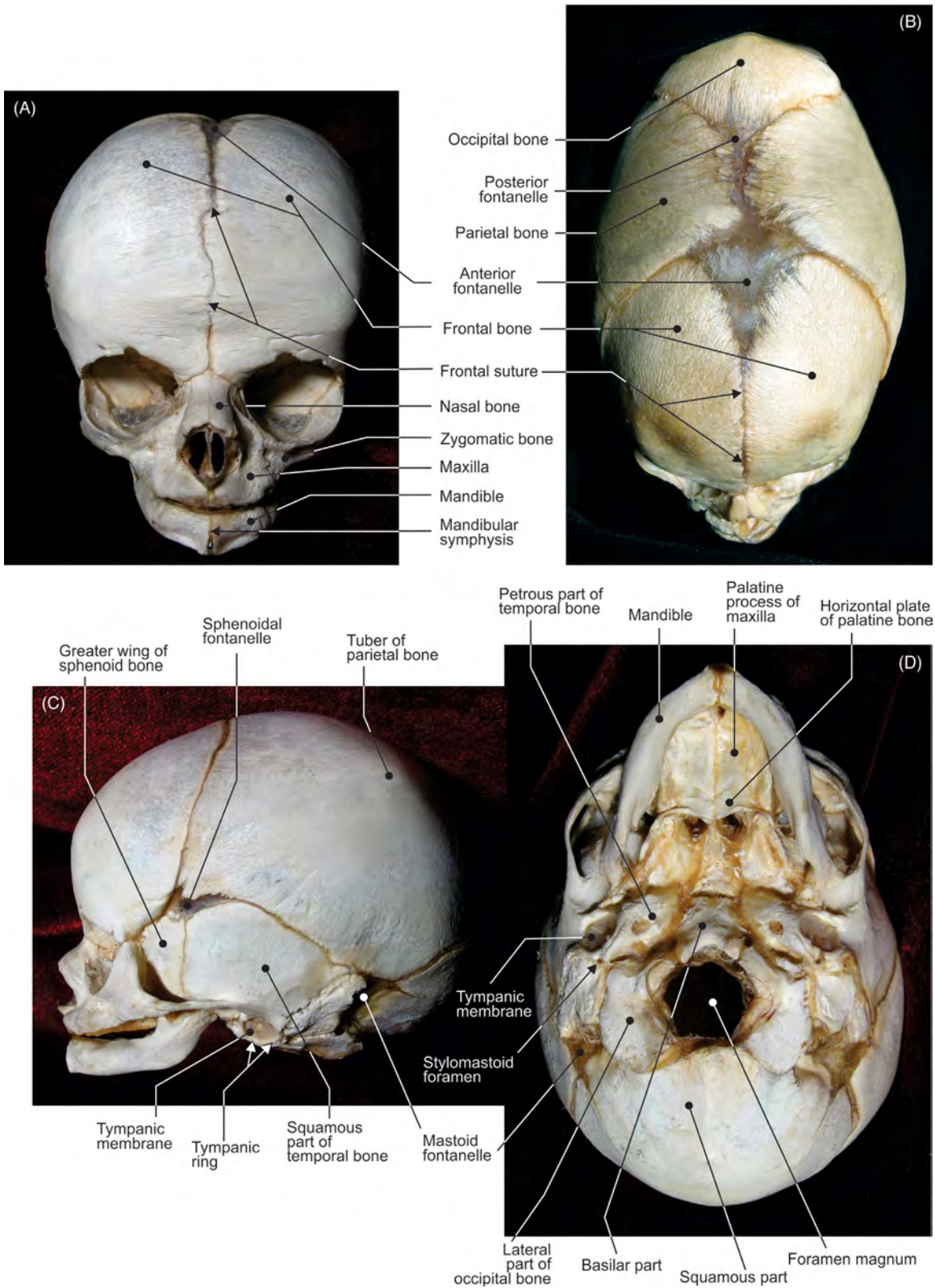


FIGURE 6.21 The fetal skull with mandible. (A) View from the front, (B) from above, (C) from the left lateral side, and (D) from below.

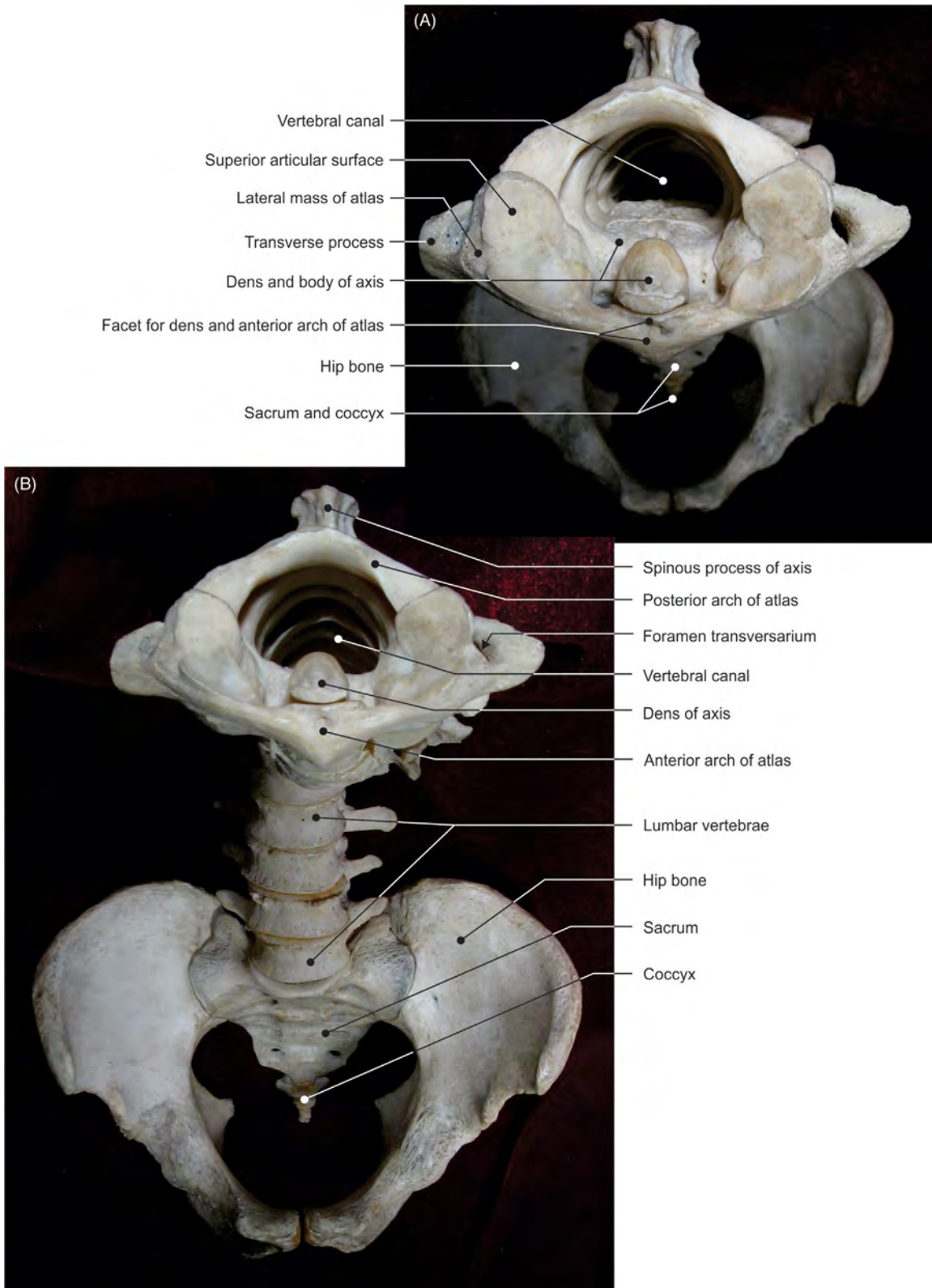


FIGURE 6.22 The vertebral column. (A) View from above and (B) from the front.

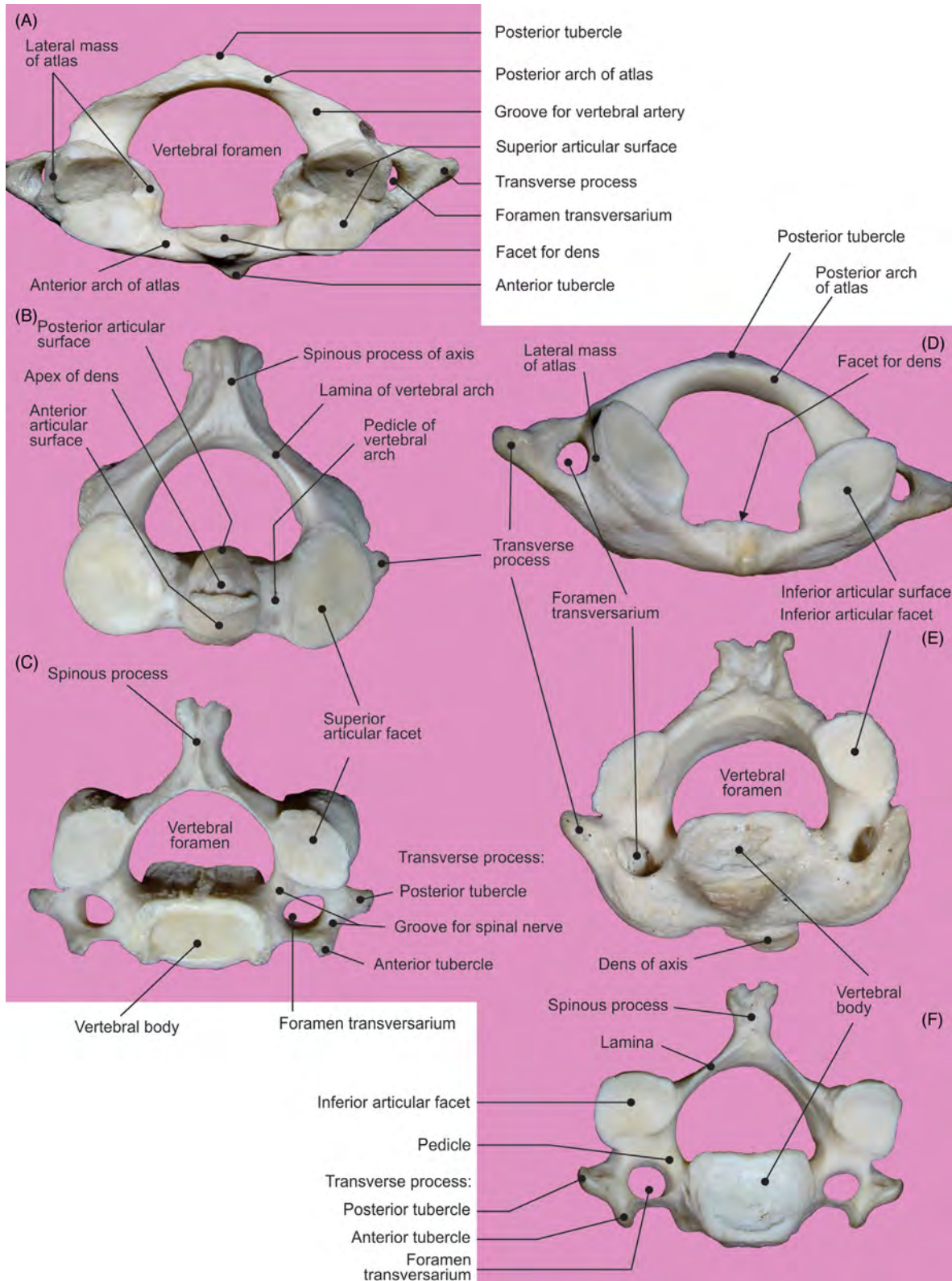


FIGURE 6.23 Atlas, axis, and C3 vertebra. (A–C) Views from above and (D–F) from below.

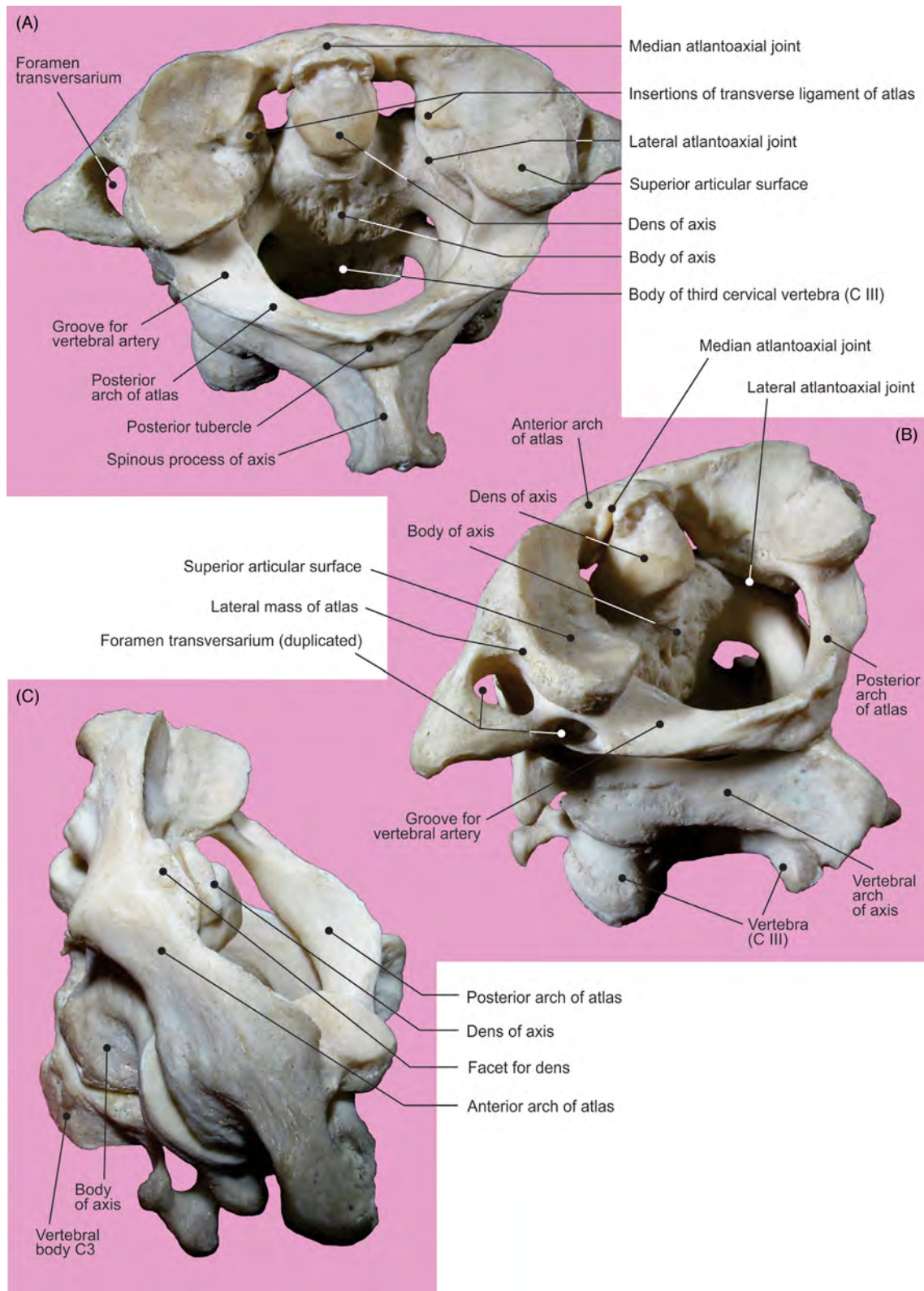


FIGURE 6.24 Atlas, axis, and vertebra C3. (A) View from behind and (B–C) from the left lateral side.

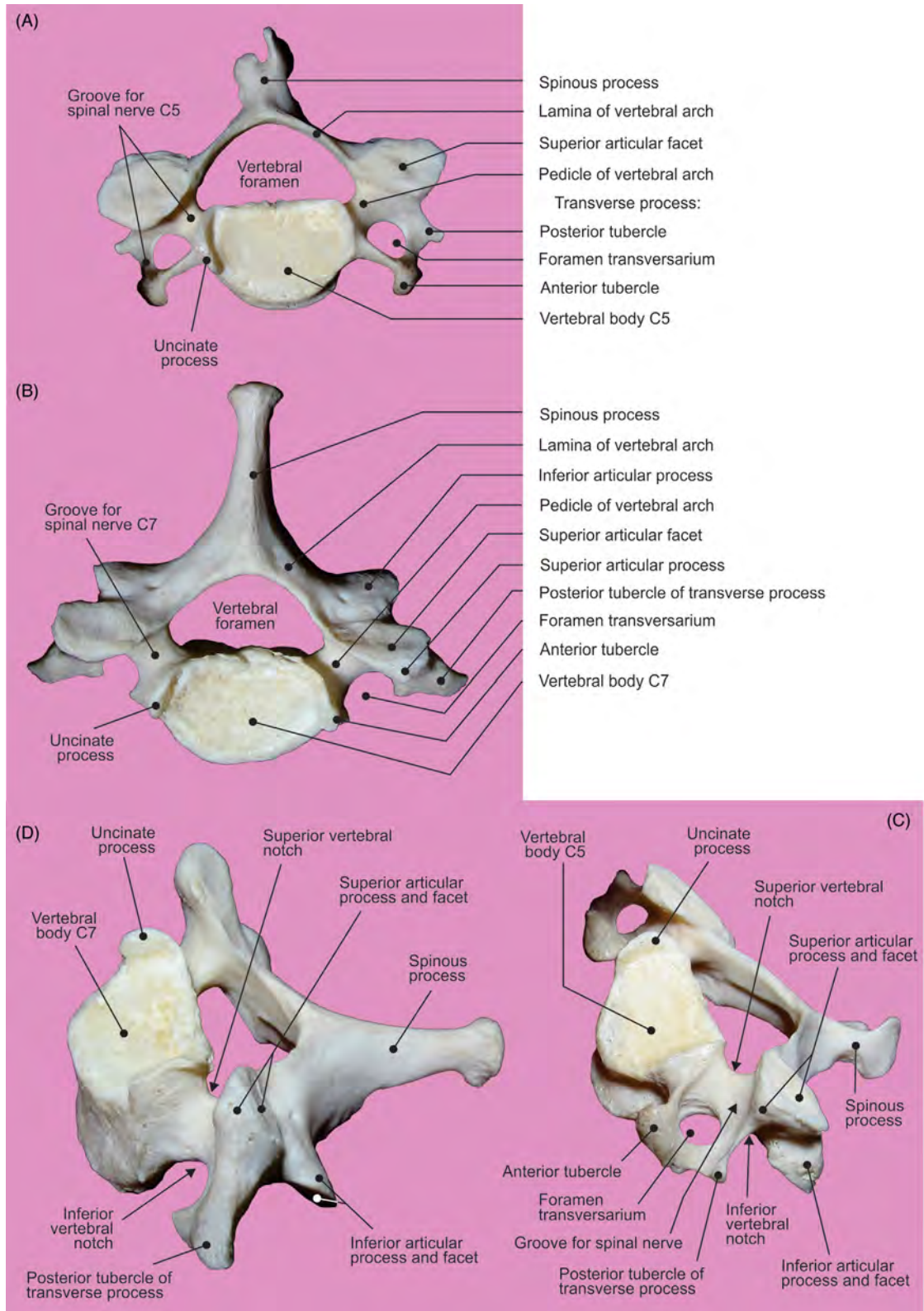


FIGURE 6.25 Vertebrae C5 and C7. (A–B) View from above and (C–D) from the left lateral side.

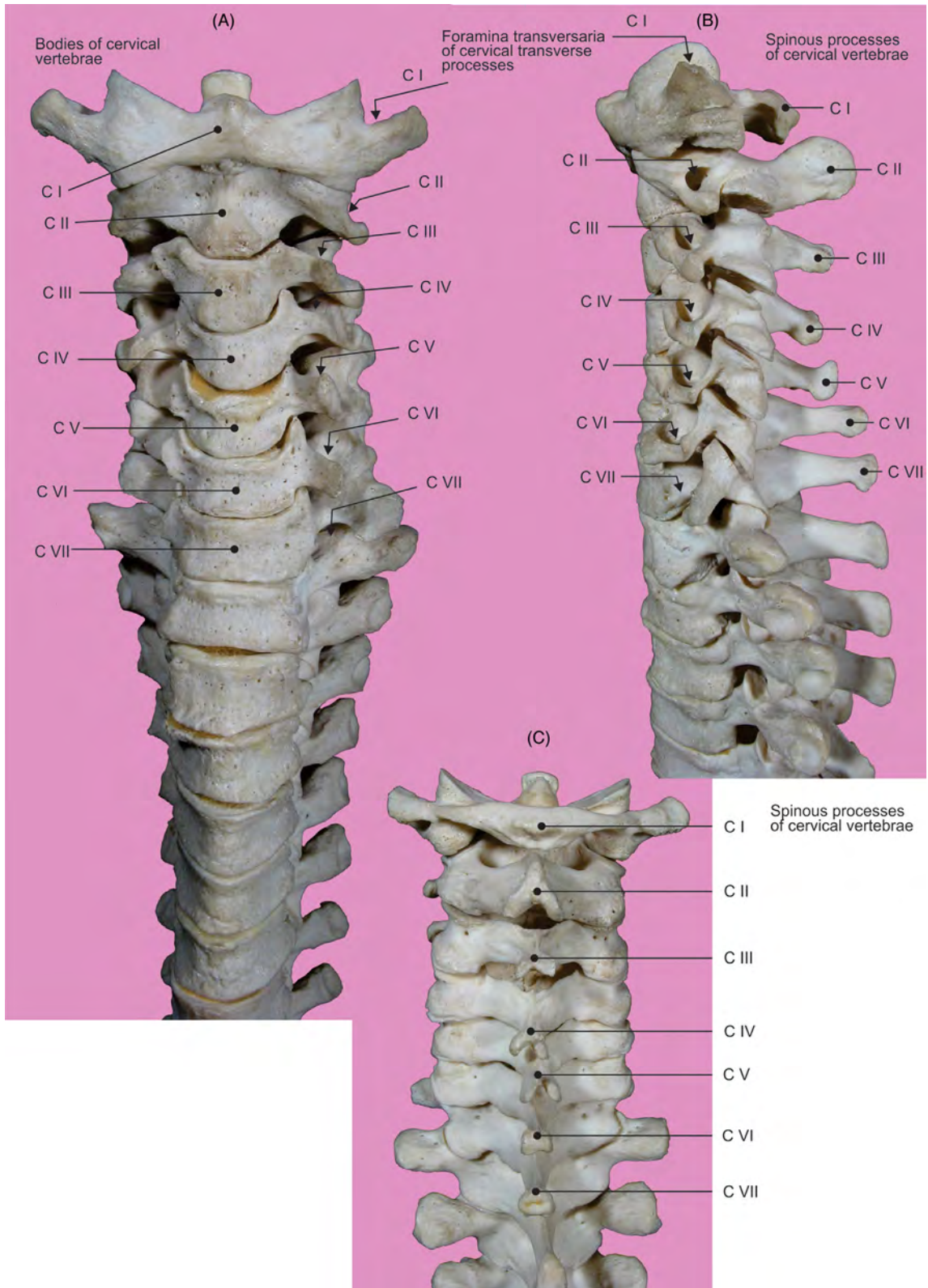


FIGURE 6.26 The cervical vertebral column. (A) View from the front, (B) from the left lateral side, and (C) from behind.

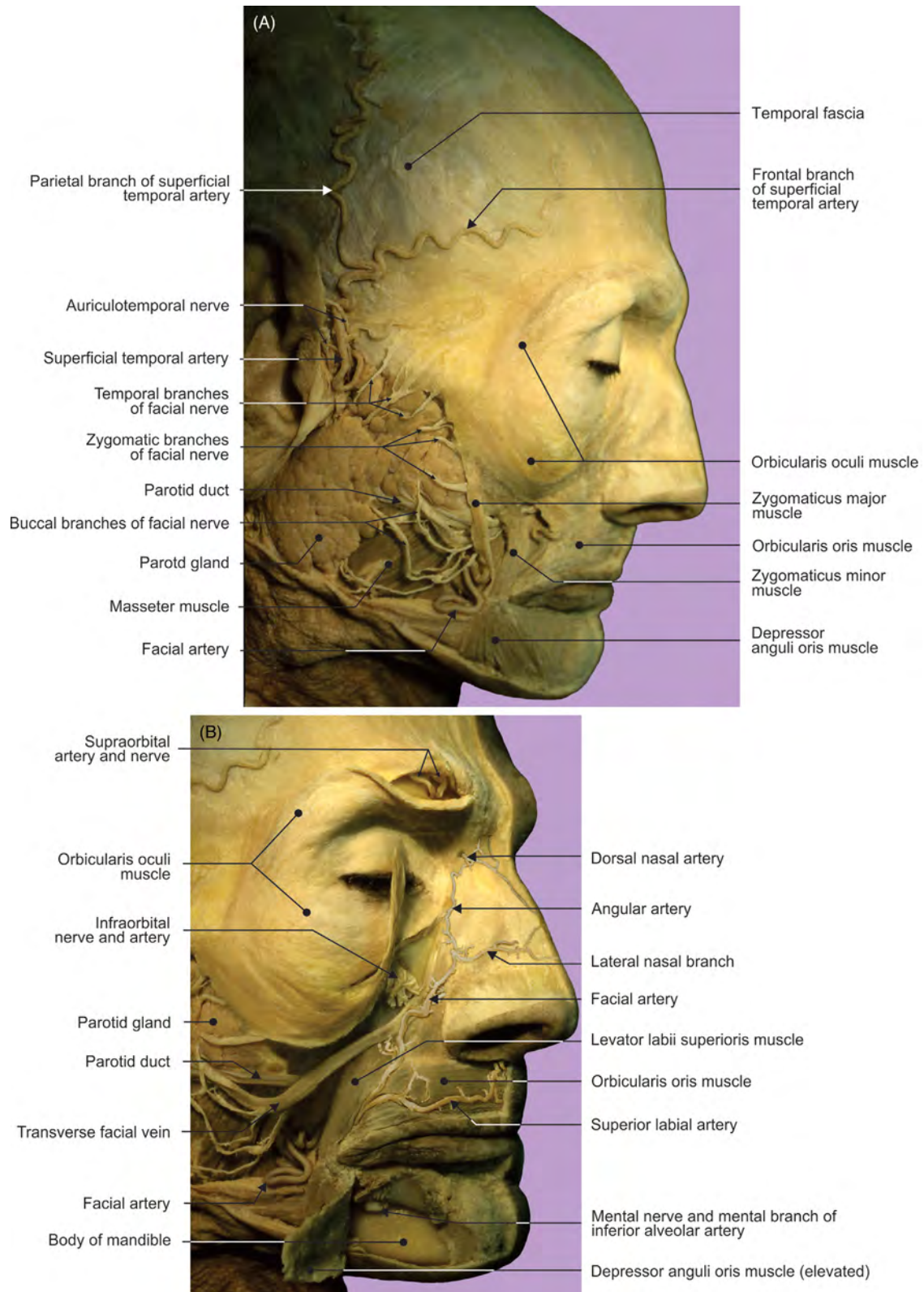


FIGURE 6.27 The facial and parotid regions. (A) Superficial muscular layer and (A–B) nerves and blood vessels.

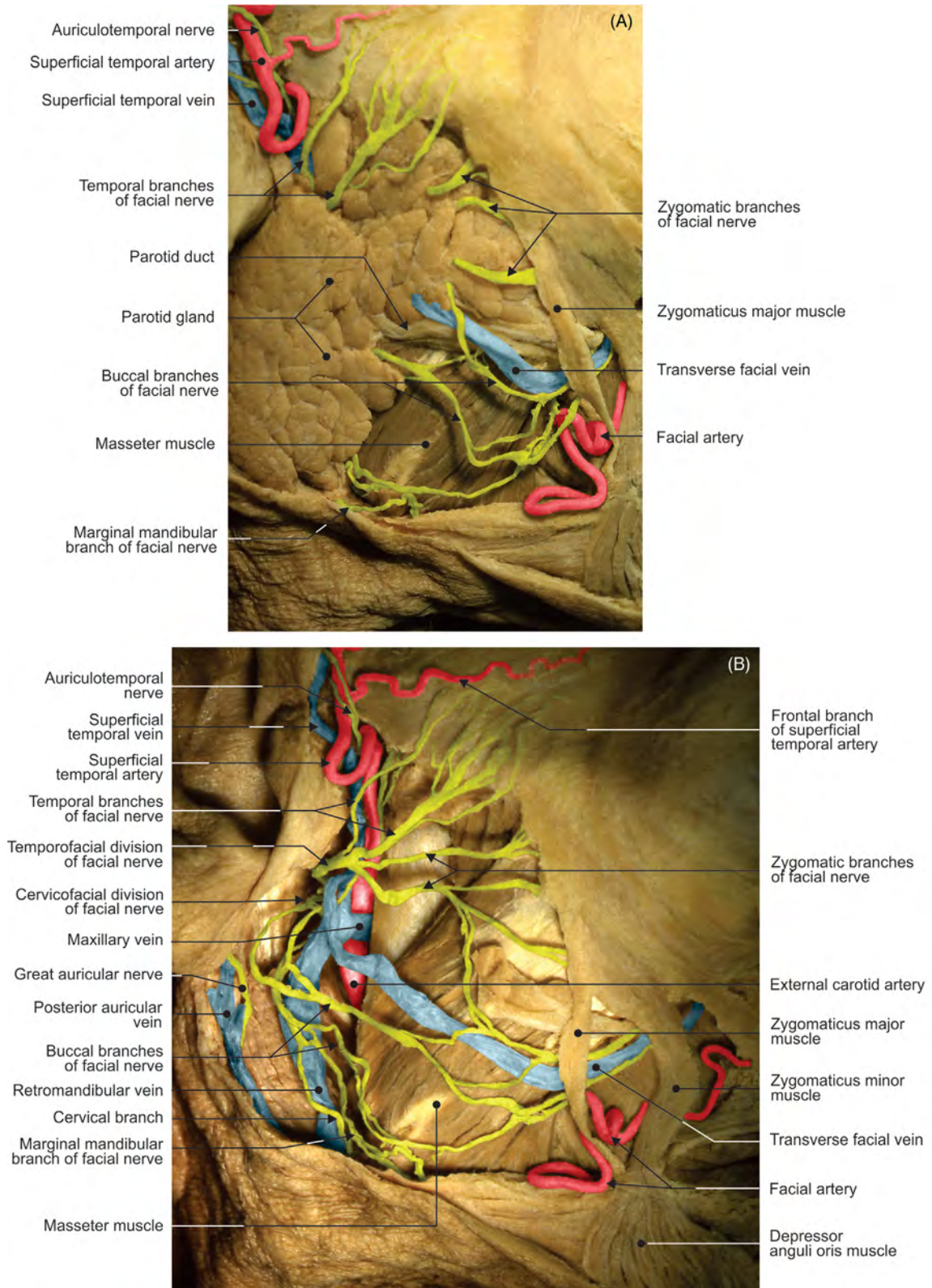


FIGURE 6.28 The parotidomasseteric region. (A) With parotid gland and (B) after the gland has been removed.

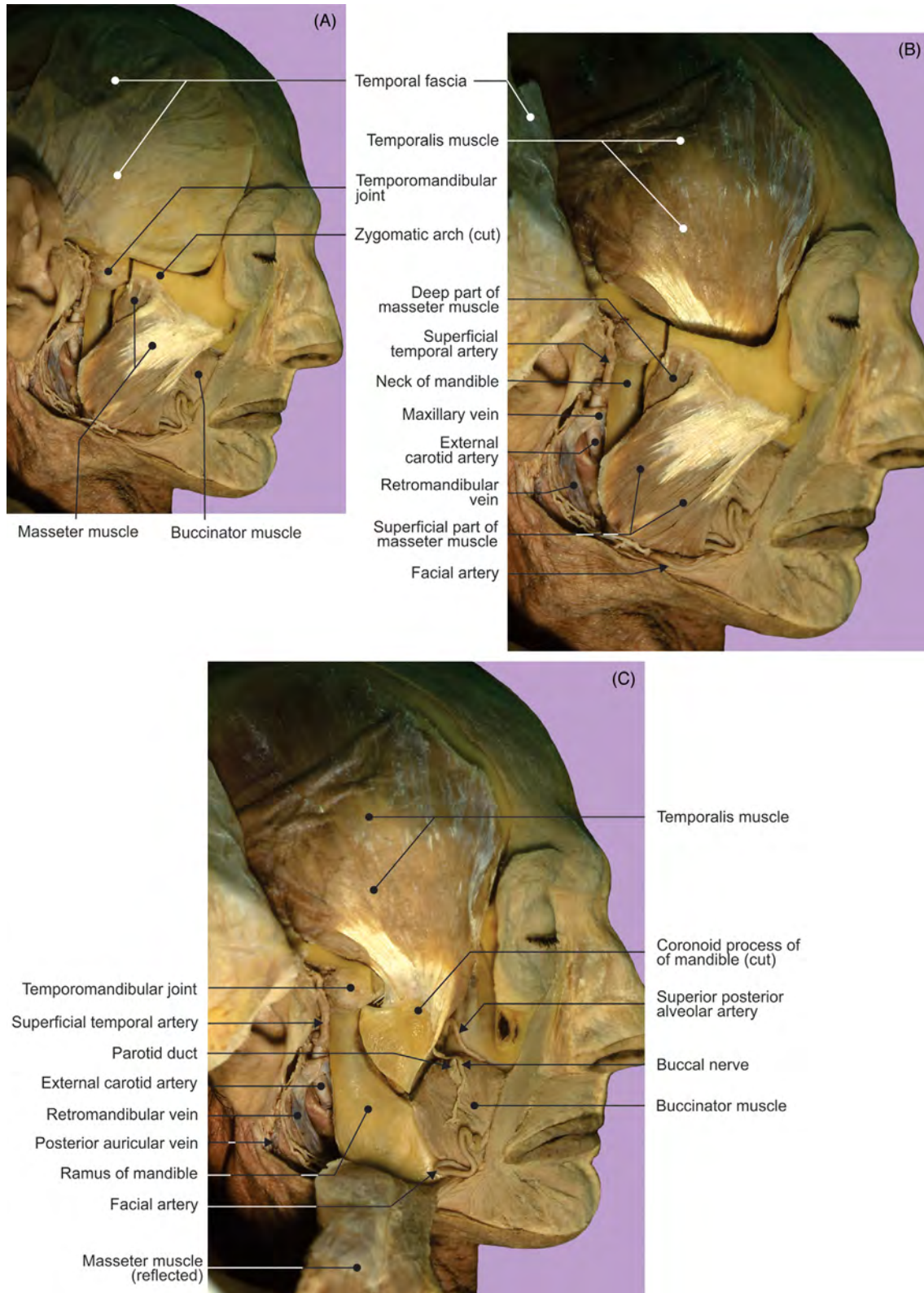


FIGURE 6.29 The muscles of mastication. (A) Masseter and (B–C) temporalis.

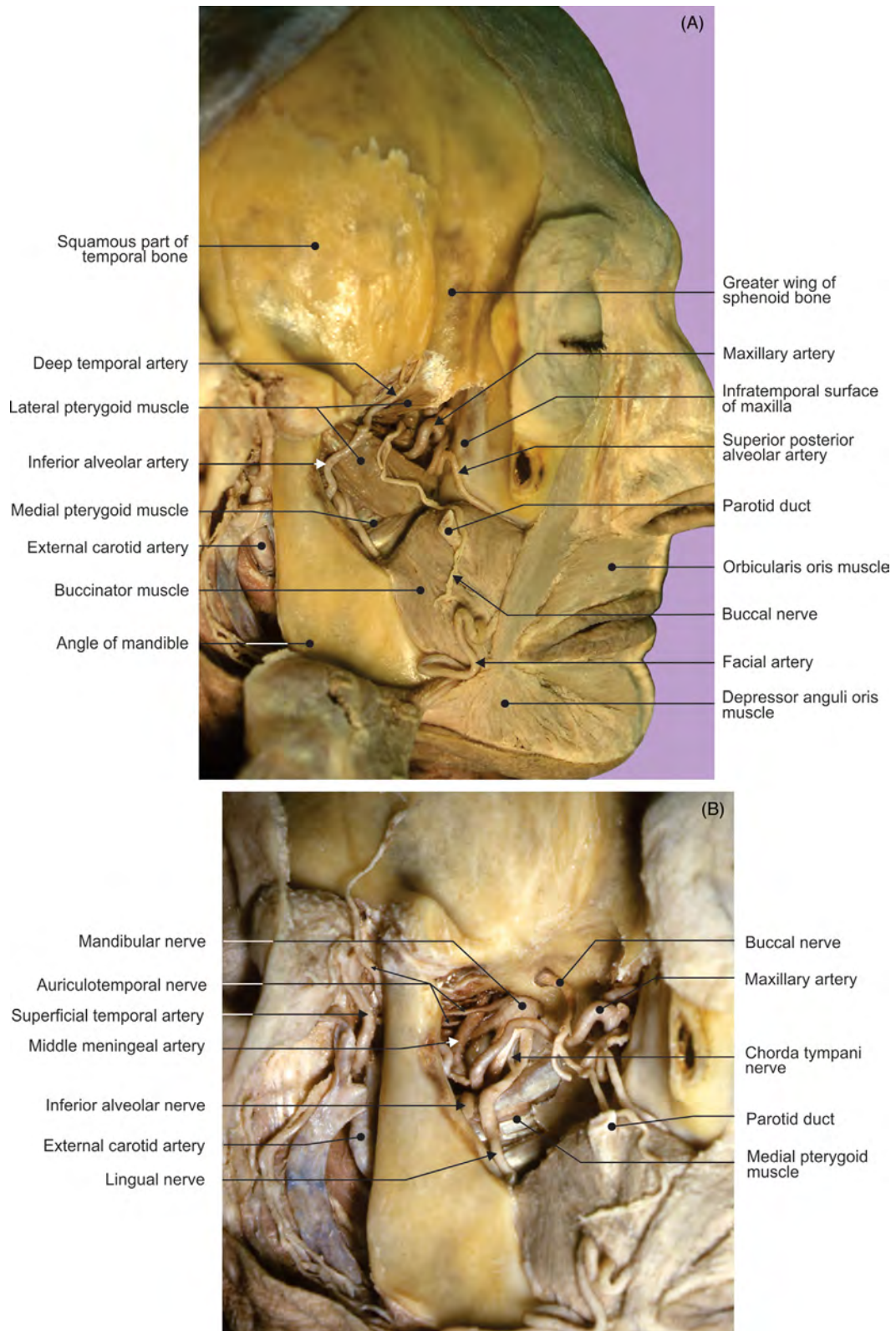


FIGURE 6.30 The infratemporal fossa. (A) Structures in superficial and (B) deep layers.

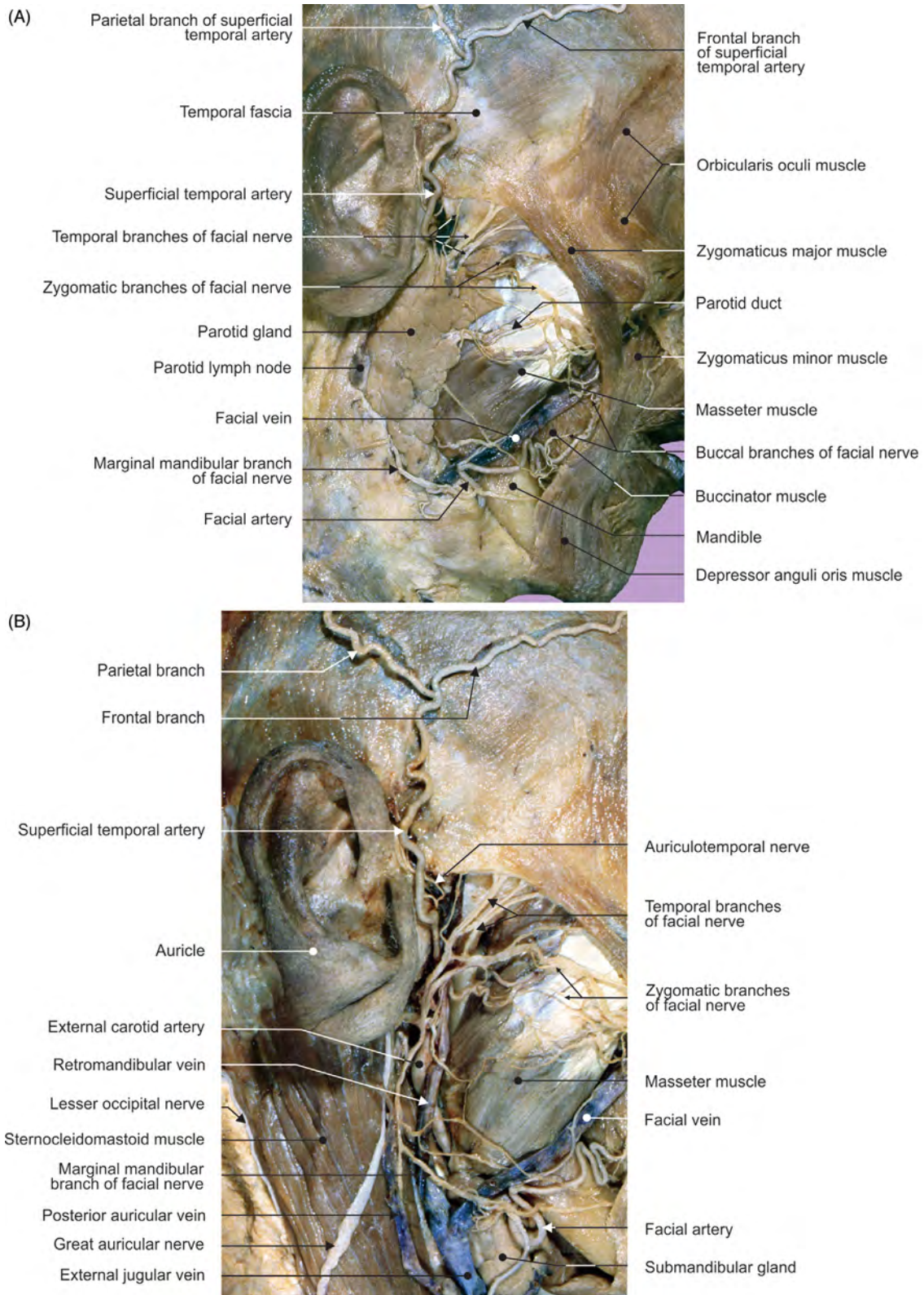


FIGURE 6.31 The parotidomasseteric region. (A) With parotid gland and (B) after the gland has been removed.

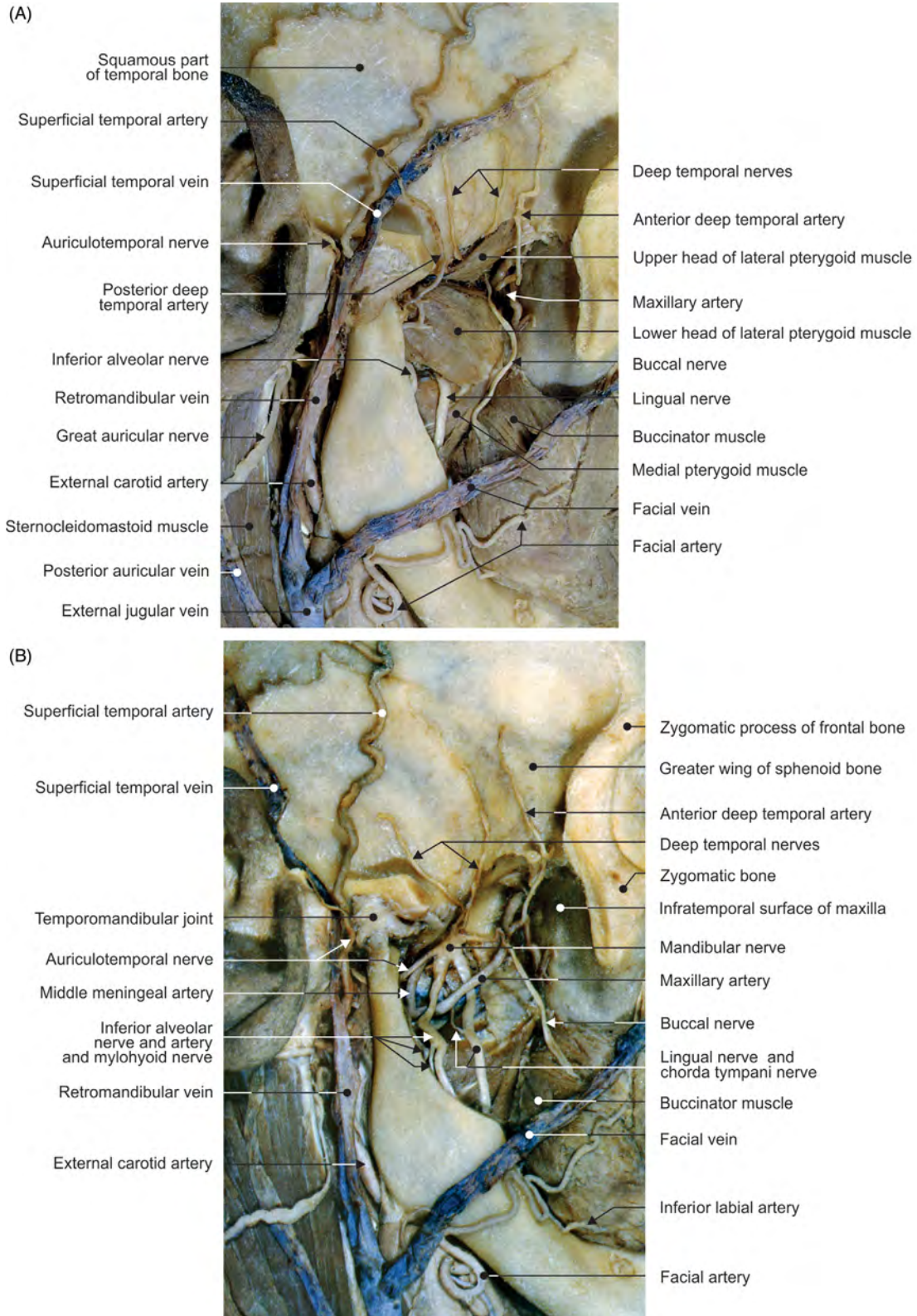


FIGURE 6.32 The infratemporal fossa. Structures in the (A) superficial and (B) deep layers.

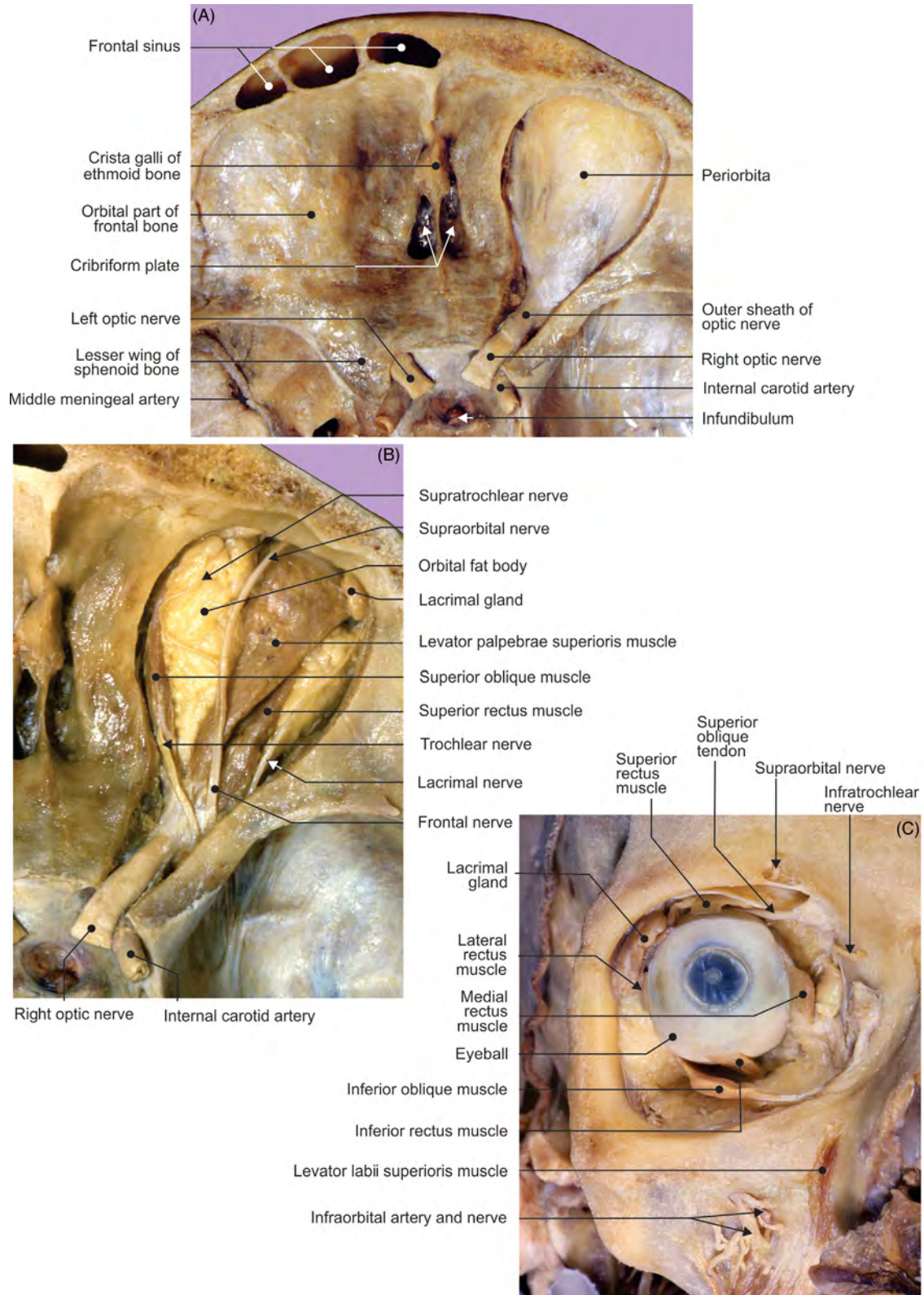


FIGURE 6.33 Dissection of the orbit. (A–B) View from above and (C) from the front.

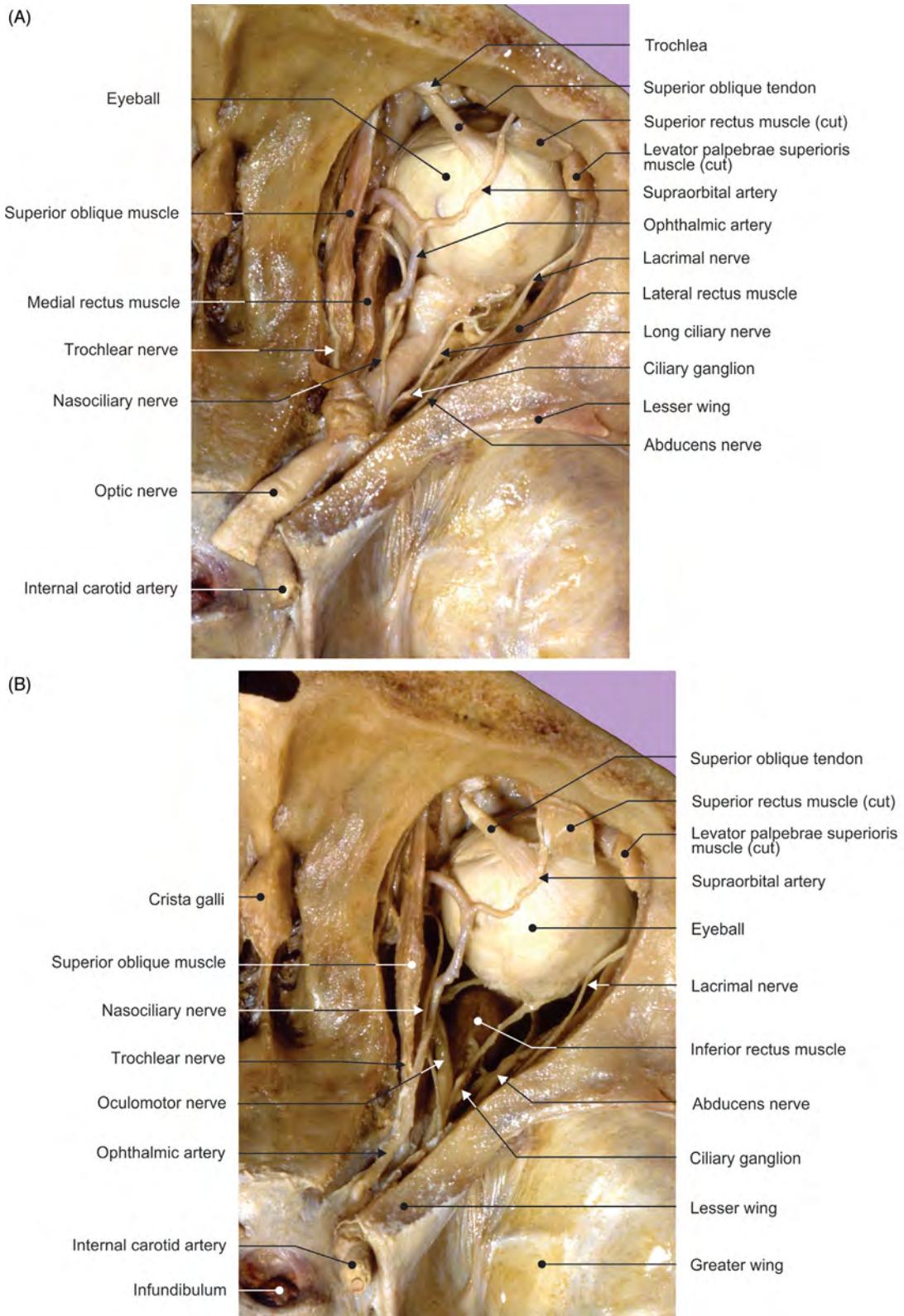


FIGURE 6.34 Dissection of the orbit. (A–B) Different views from above.

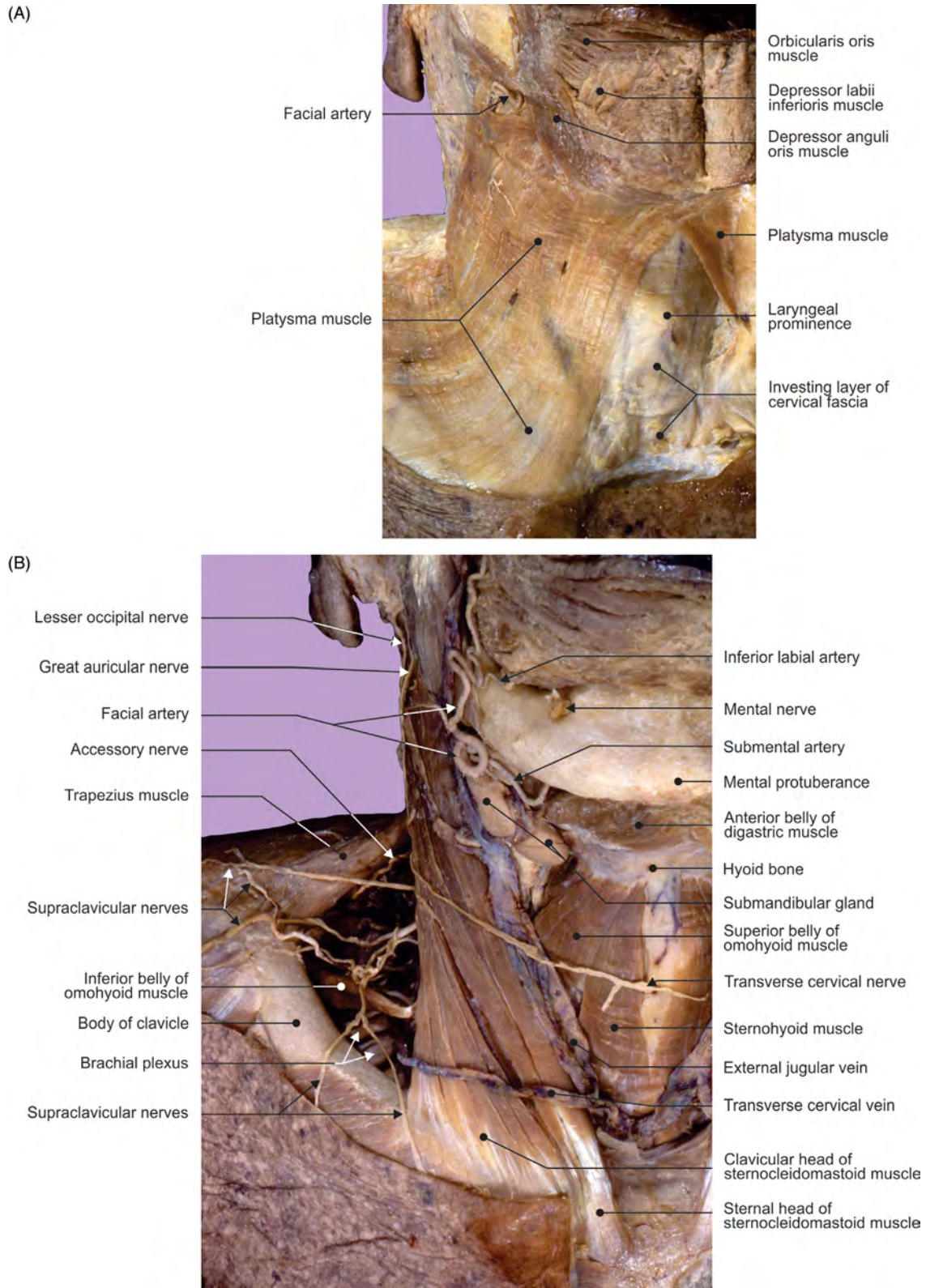


FIGURE 6.35 The anterior and lateral cervical regions. (A–B) Different views of the superficial, first layer.

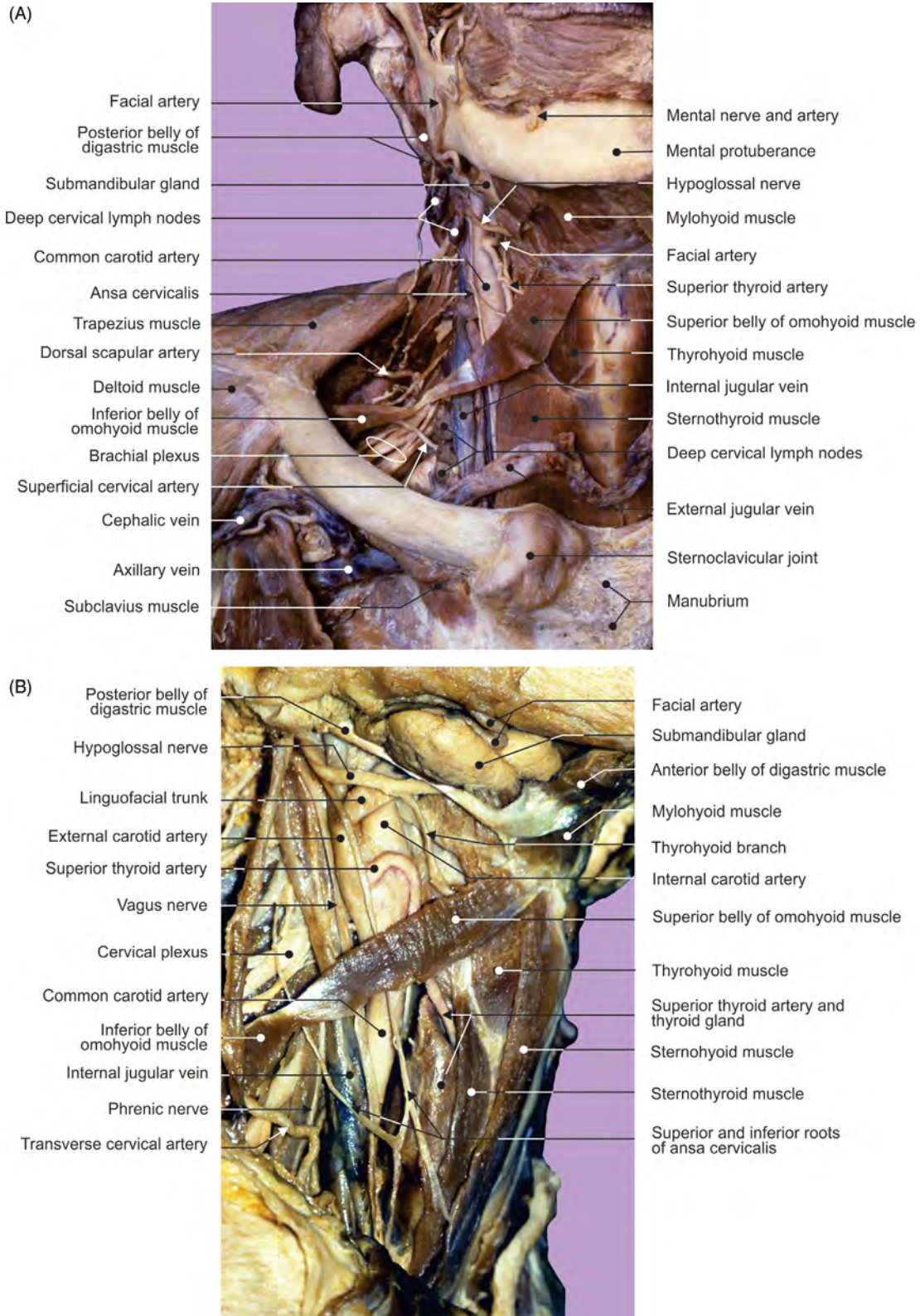


FIGURE 6.36 The anterior and lateral cervical regions. (A–B) Different views of the middle, second layer.

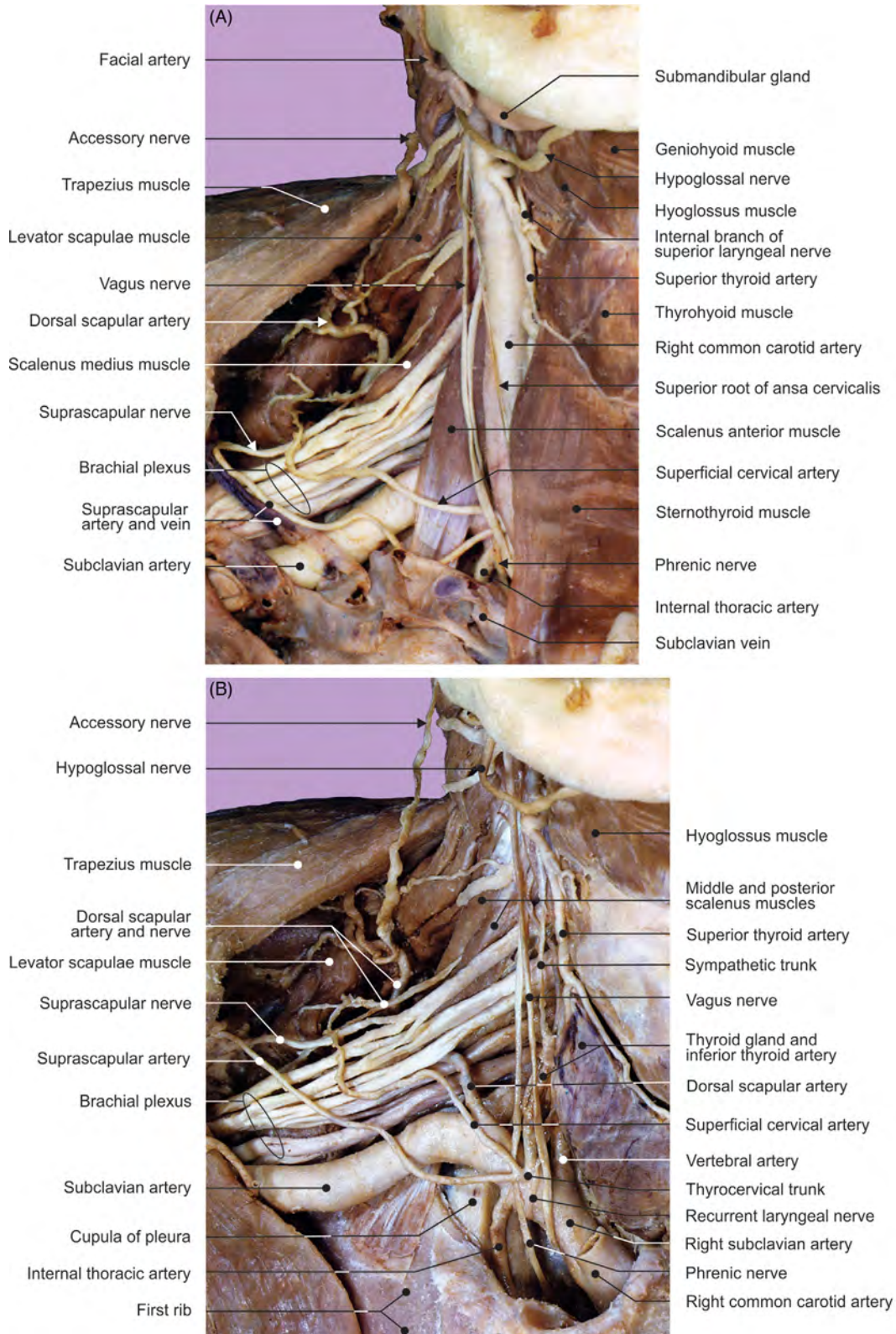


FIGURE 6.37 The anterior and lateral cervical regions. (A–B) Different views of the deep, third layer.

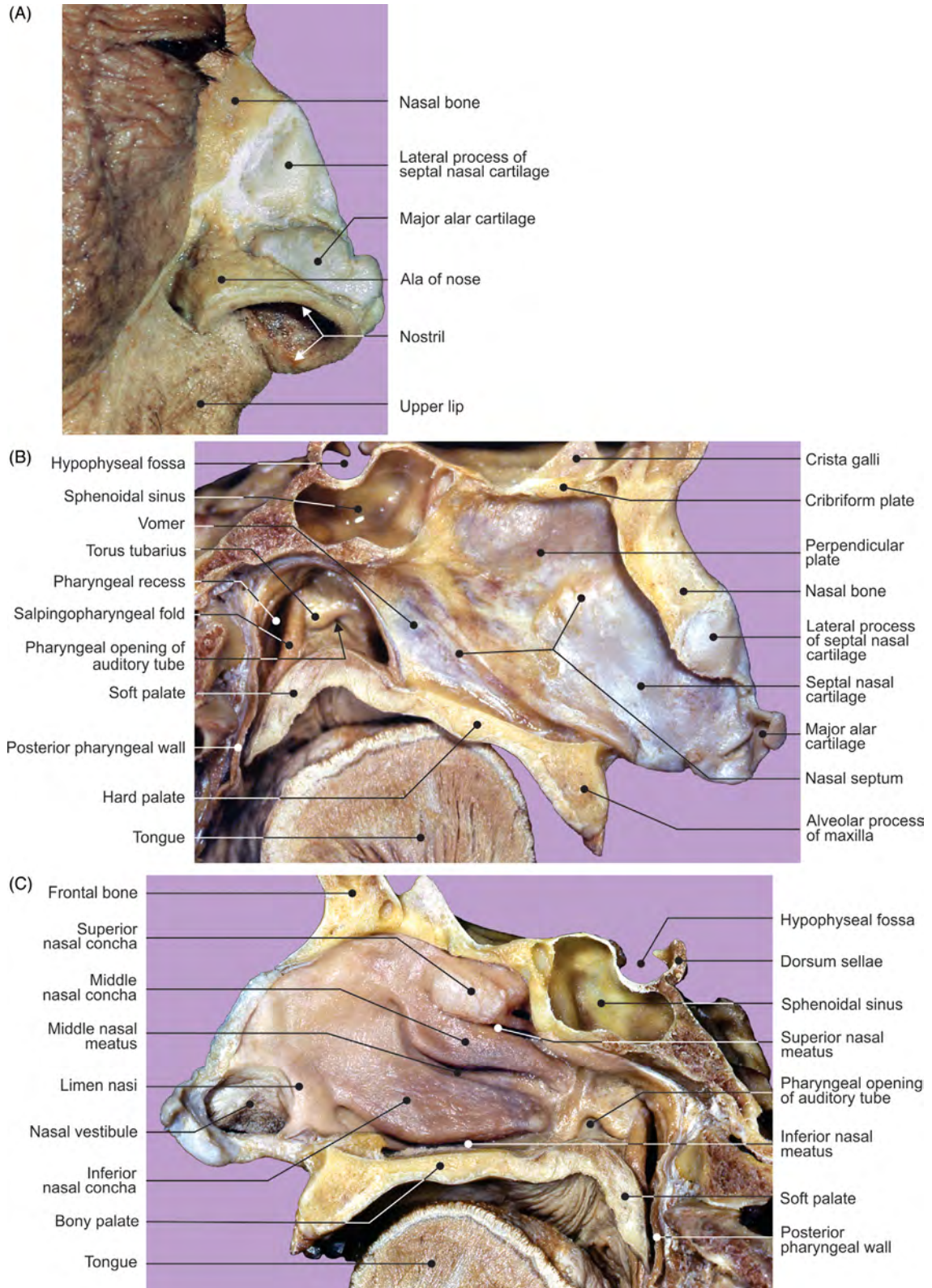


FIGURE 6.38 The nasal and nasopharyngeal regions. (A) External nasal cartilages, (B) nasal septum, and (C) lateral nasal wall and nasopharynx.

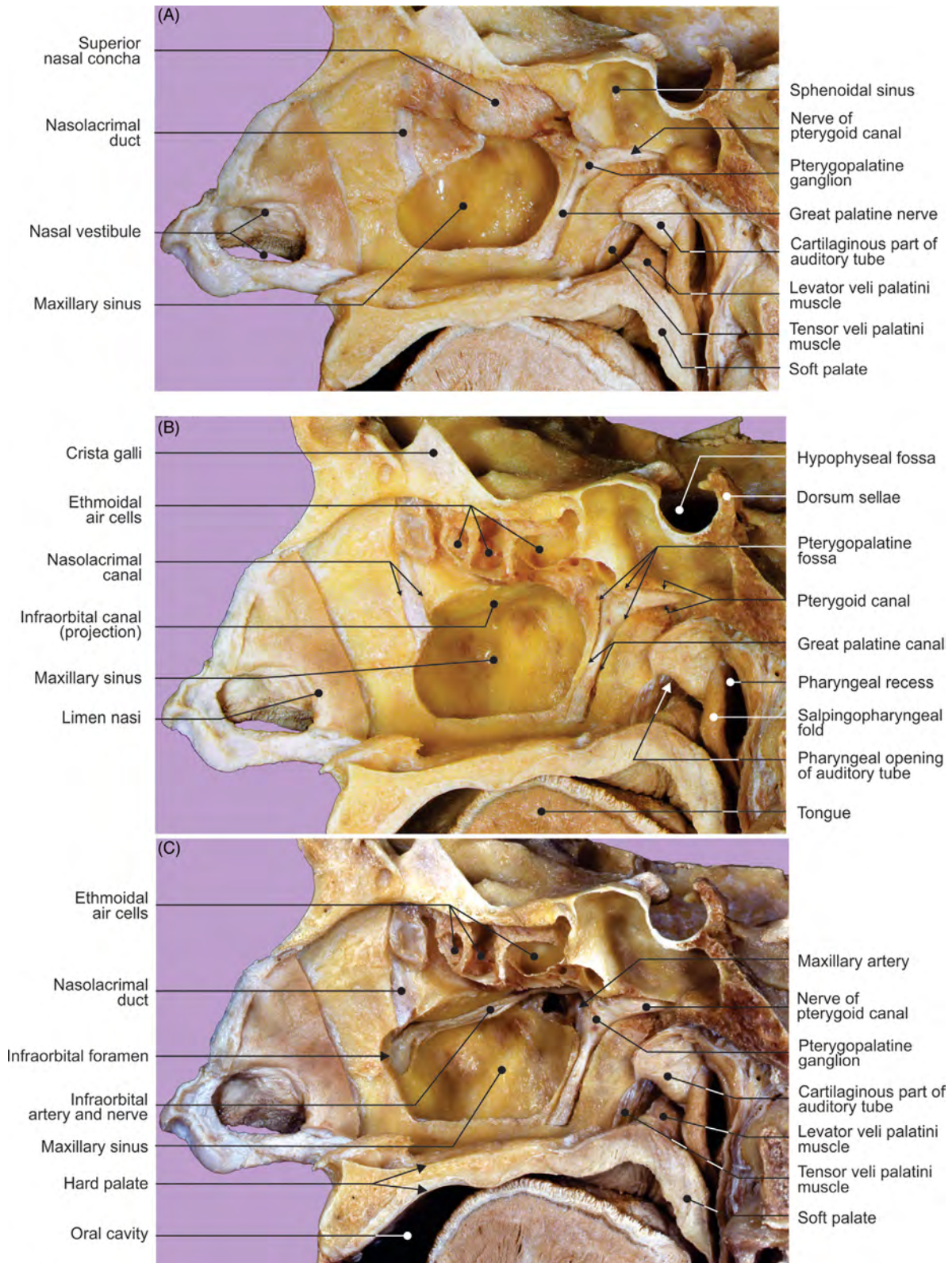


FIGURE 6.39 Dissection from the nasal cavity of the lateral nasal and nasopharyngeal walls. (A) First, (B) second, and (C) third layers.

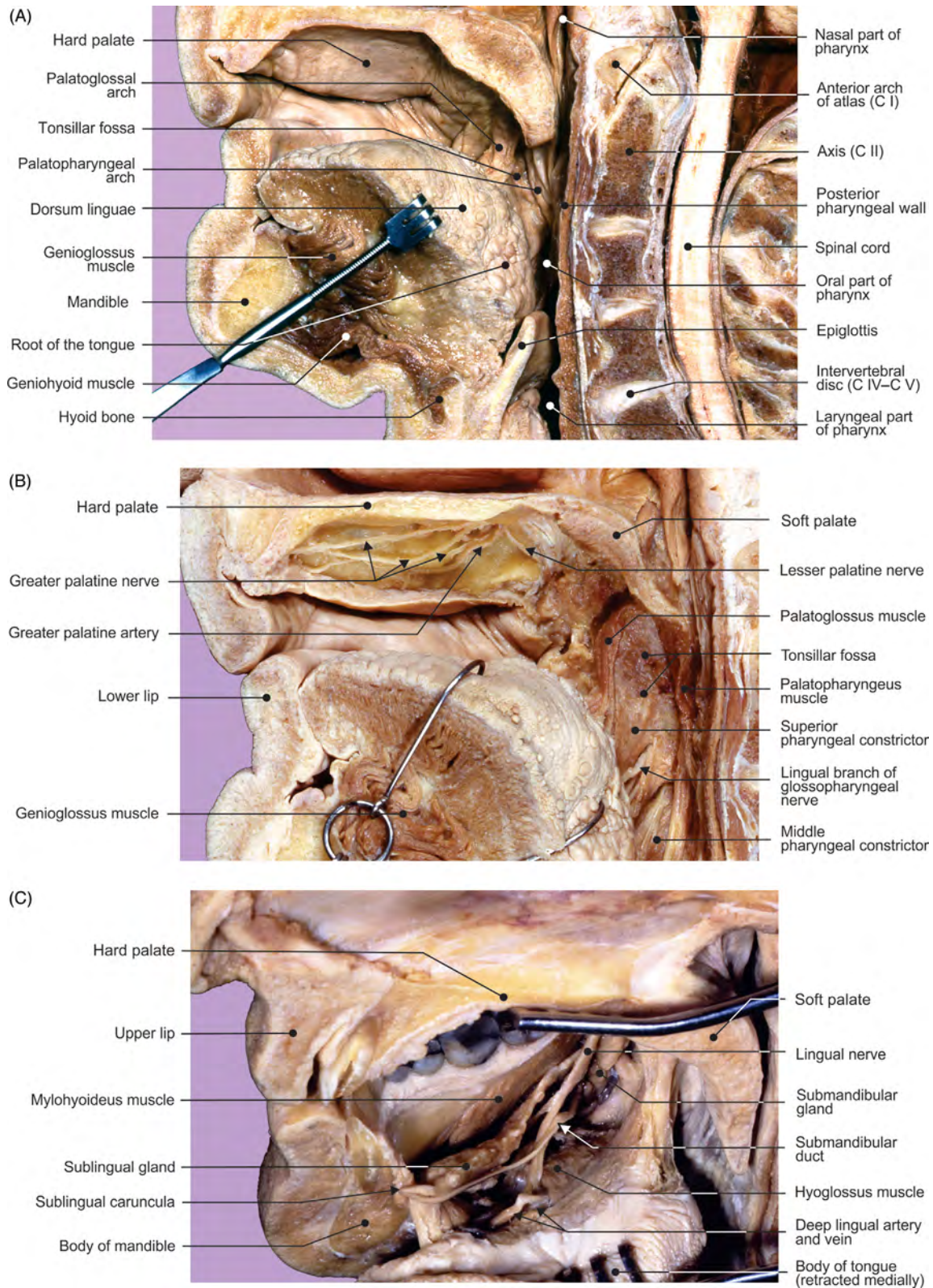


FIGURE 6.40 The midsagittal section of the oral cavity. Dissections of the (A) lateral wall, (B) roof, and (C) floor.

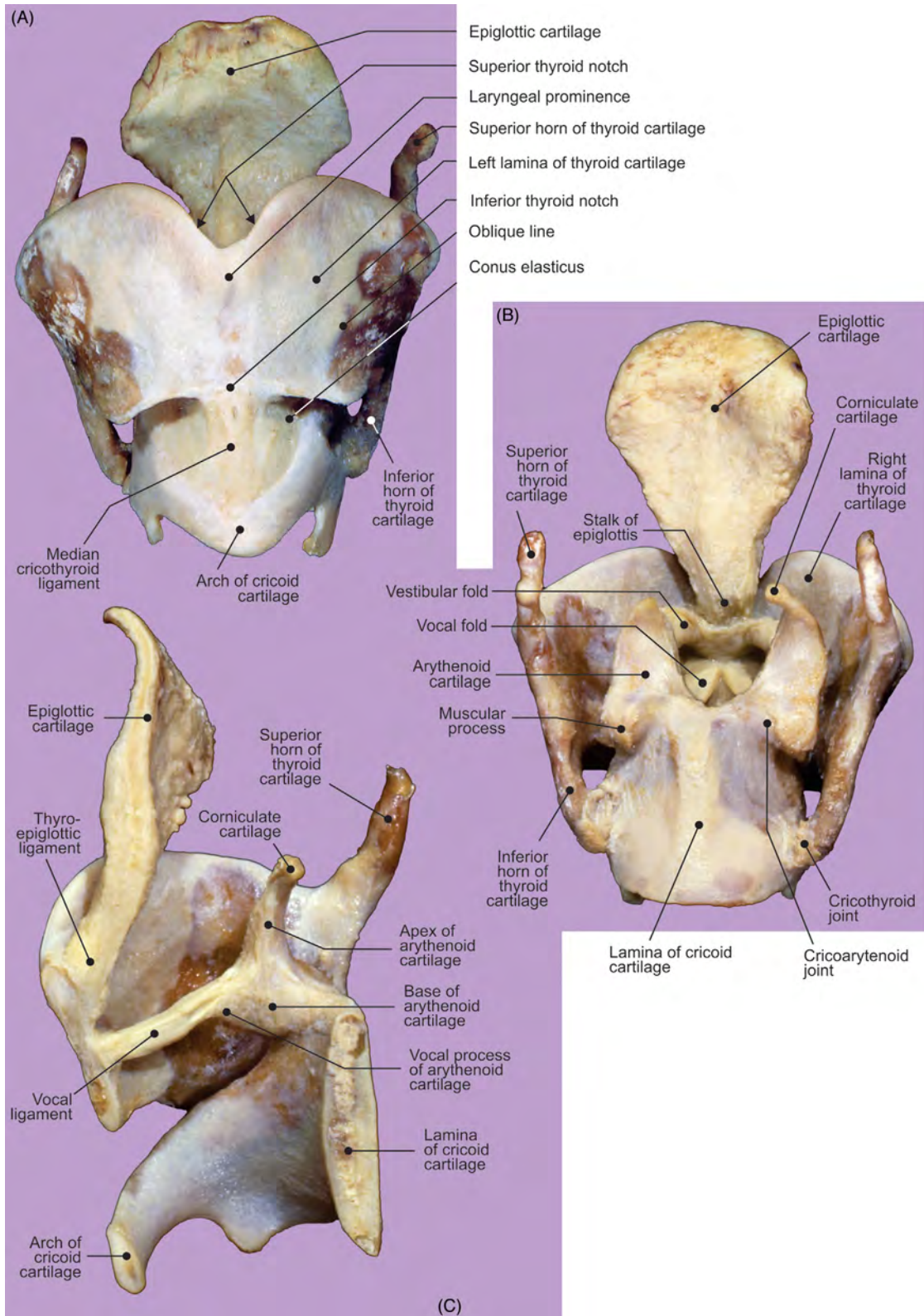


FIGURE 6.41 The laryngeal cartilages. (A) Anterior, (B) posterior, and (C) right half of laryngeal cartilages viewed from inside (midsagittal section of laryngeal cartilages).

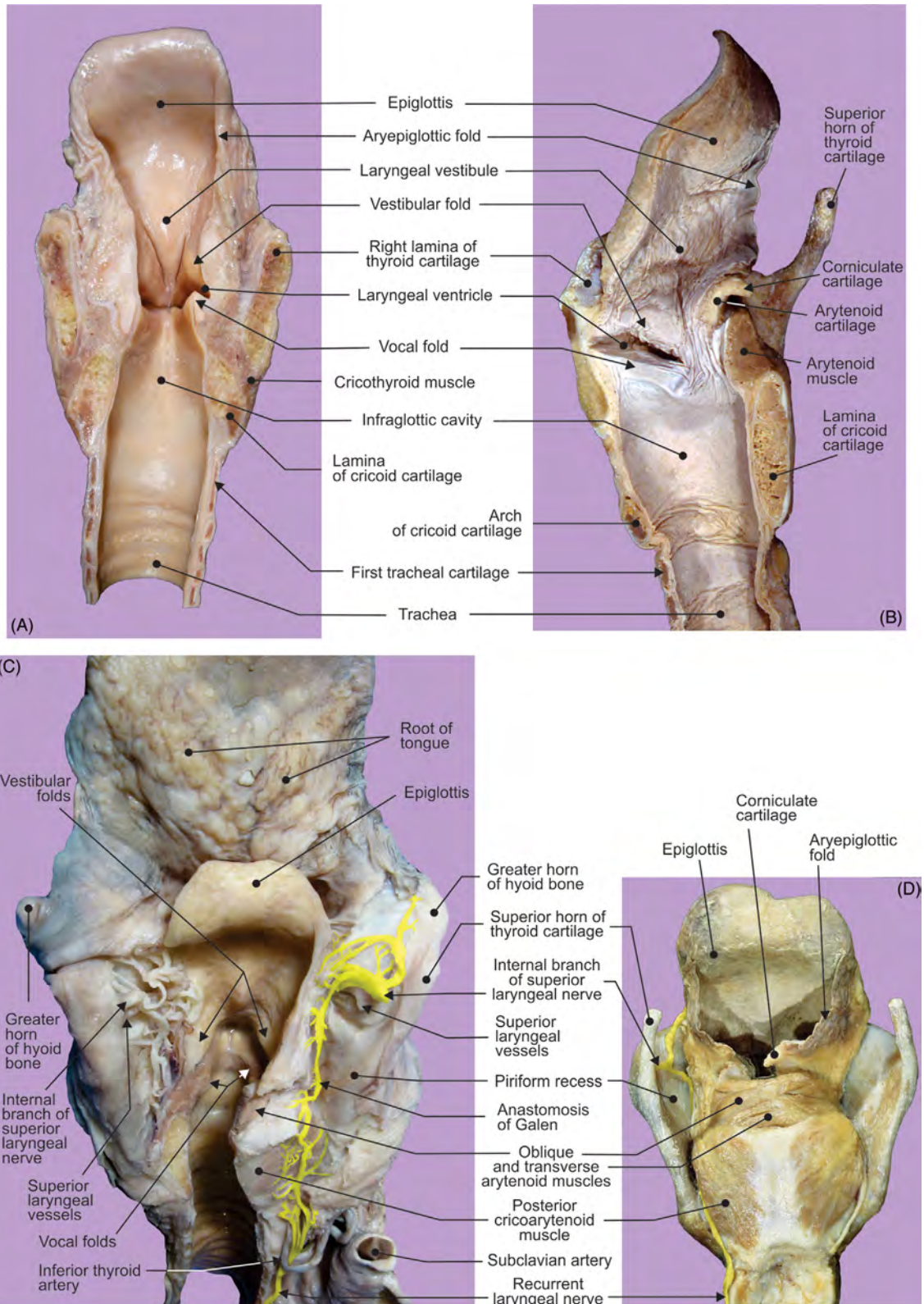


FIGURE 6.42 The internal laryngeal features. (A) Frontal section, view from behind; (B) right half of the midsagittal section, view from inside; (C) dissection of the piriform recess; and (D) dissection of the posterior laryngeal muscles.

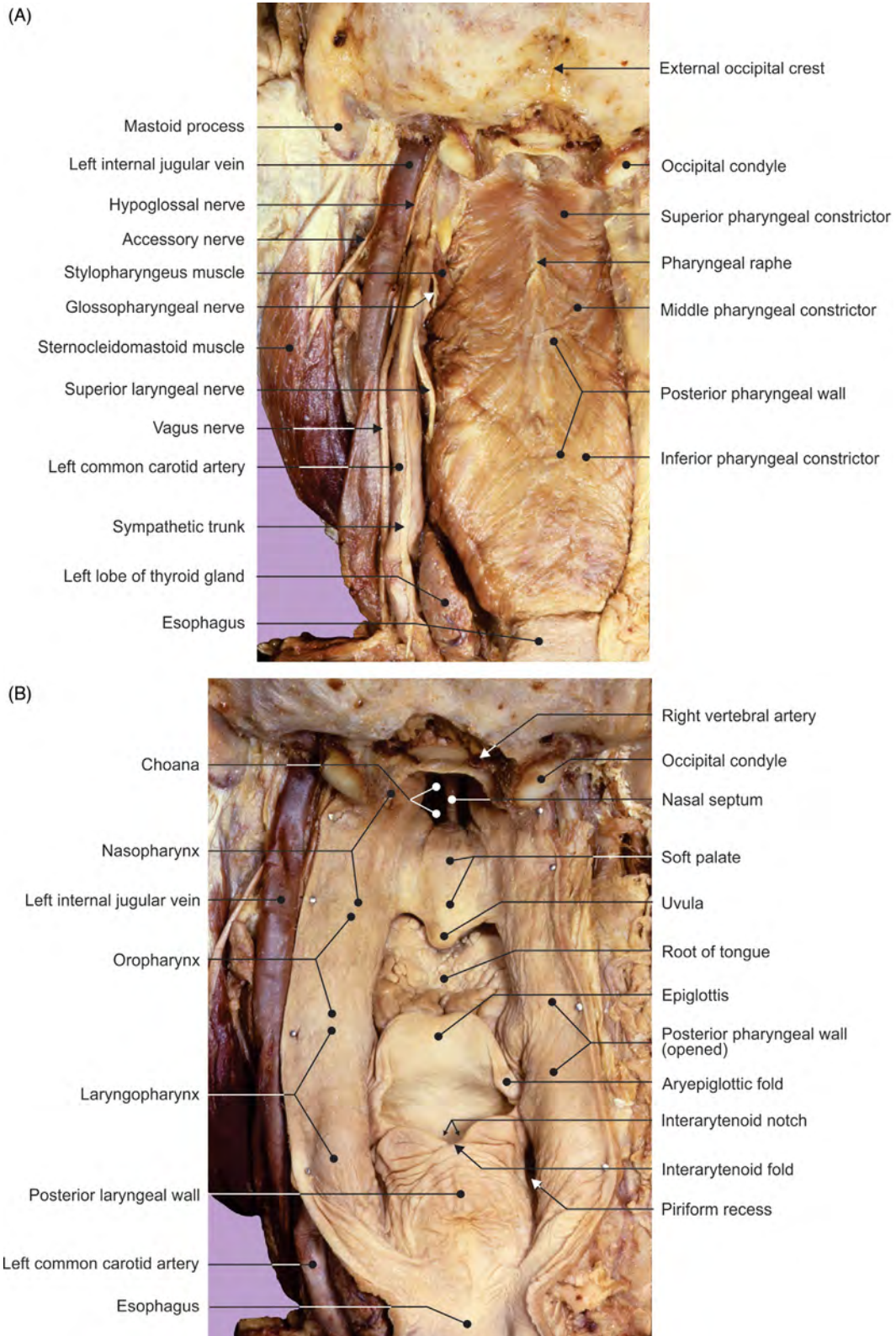


FIGURE 6.43 (A) The posterior aspect of the pharyngeal constrictor muscles and content of the parapharyngeal space. (B) Reflection of the posterior pharyngeal wall, internal pharyngeal structures.

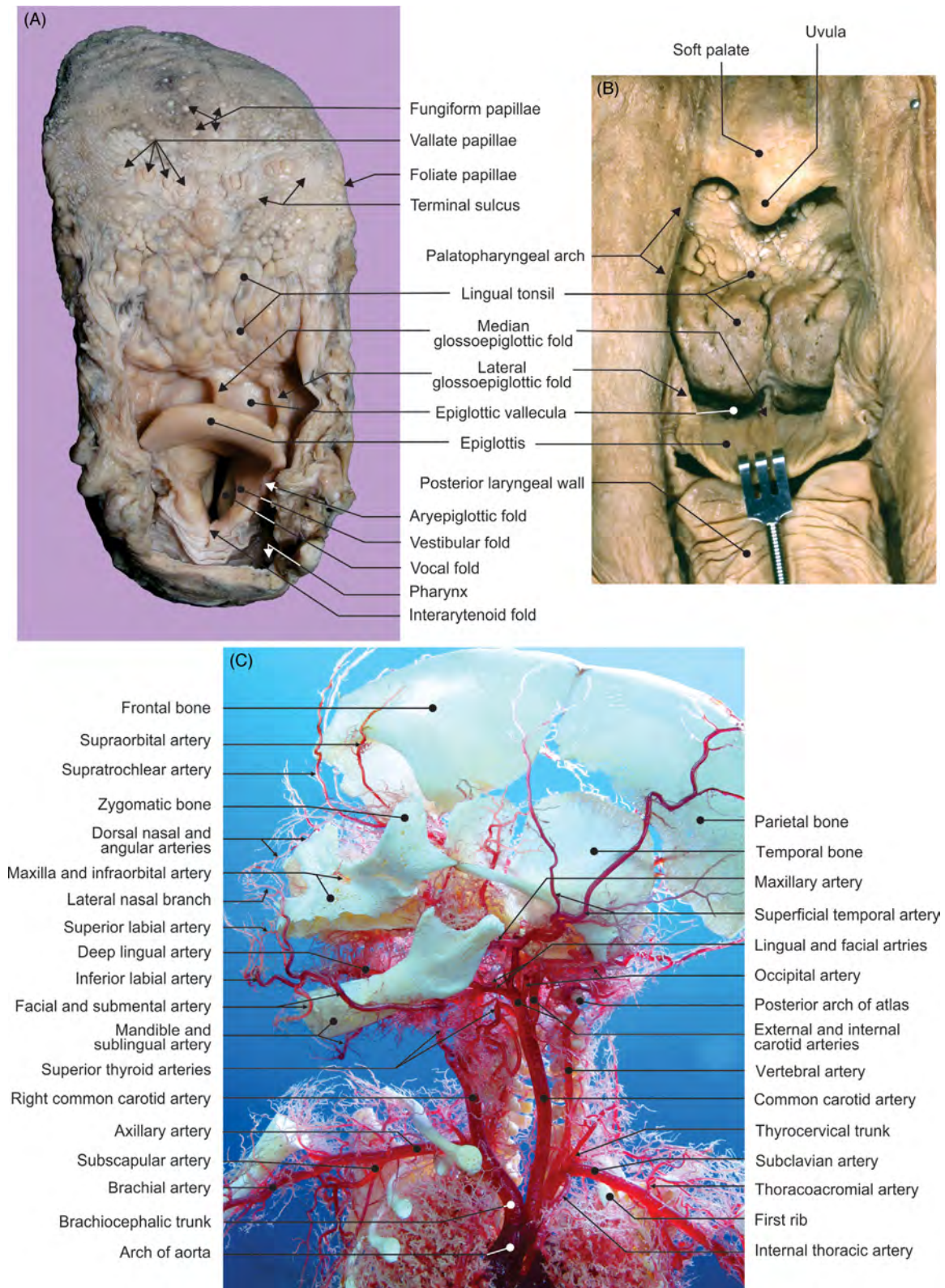


FIGURE 6.44 (A) Superior view of the tongue and larynx. (B) Root of tongue viewed from behind. (C) Fetal arterial corrosion cast of head and neck.

Chapter 7

Cranial Central Nervous System and Spinal Cord

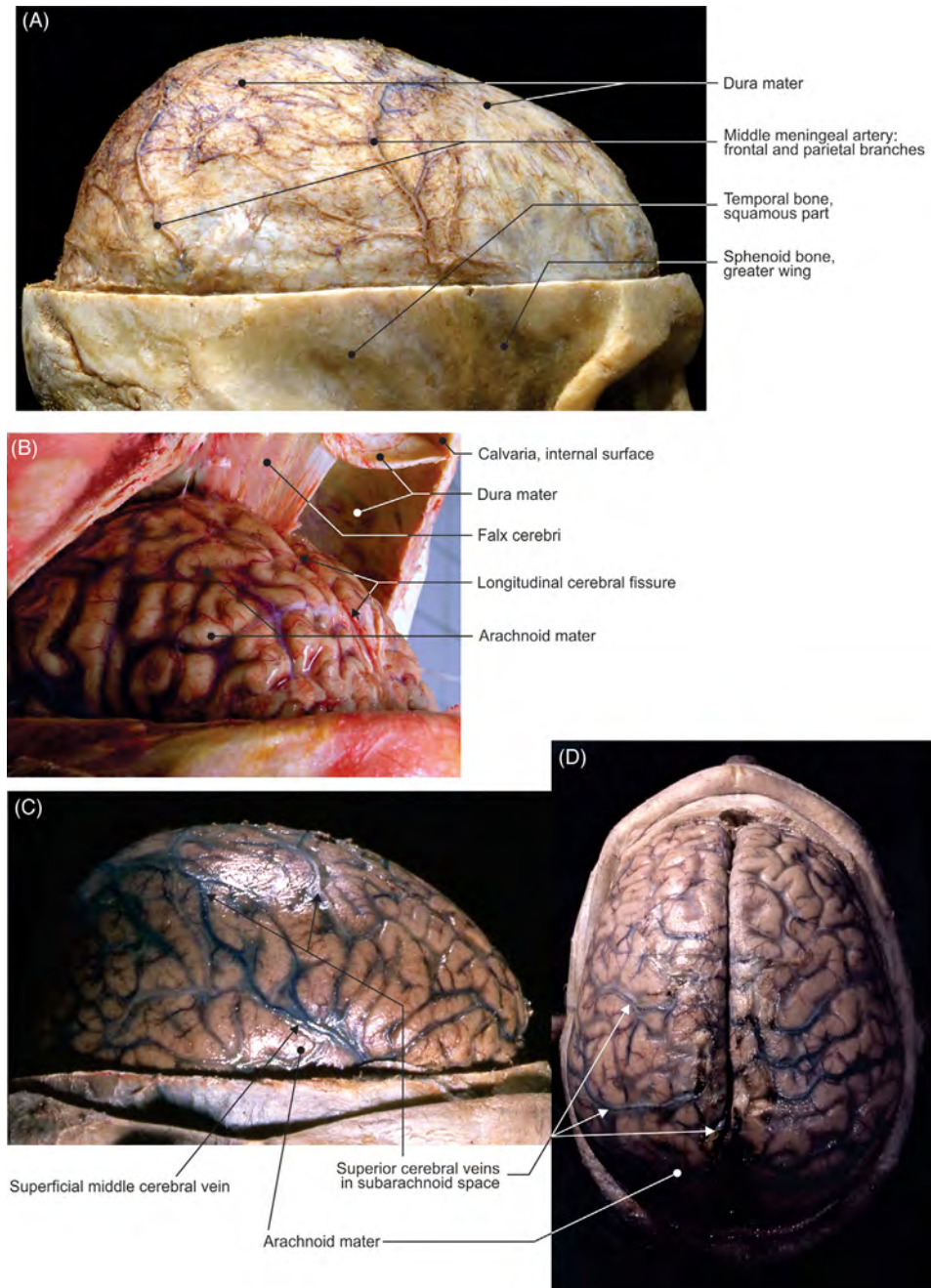


FIGURE 7.1 Meninges. (A, C–D) Formalin-fixed and (B) native specimens.

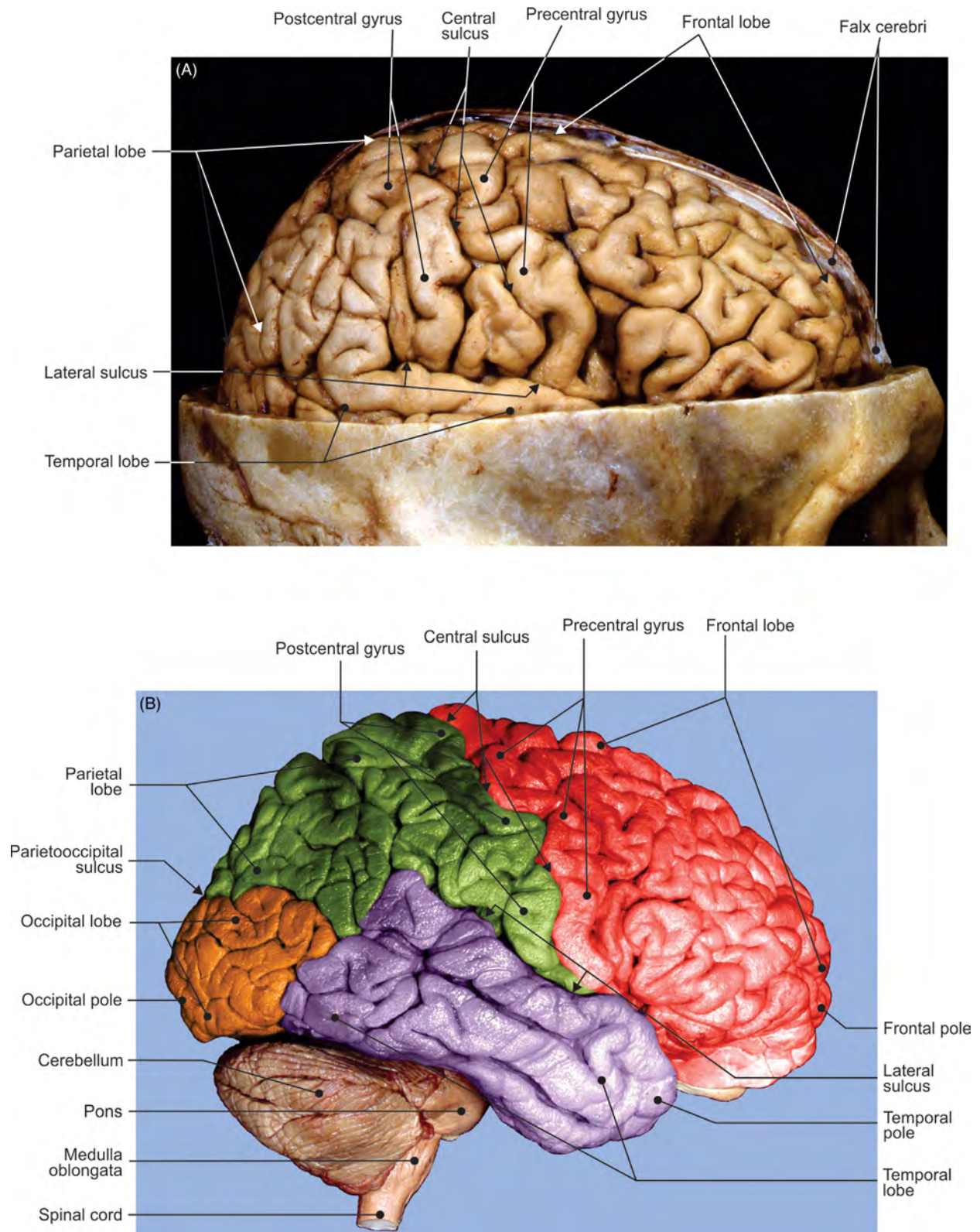


FIGURE 7.2 The right cerebral hemisphere. (A–B) Different views of the superolateral aspect.

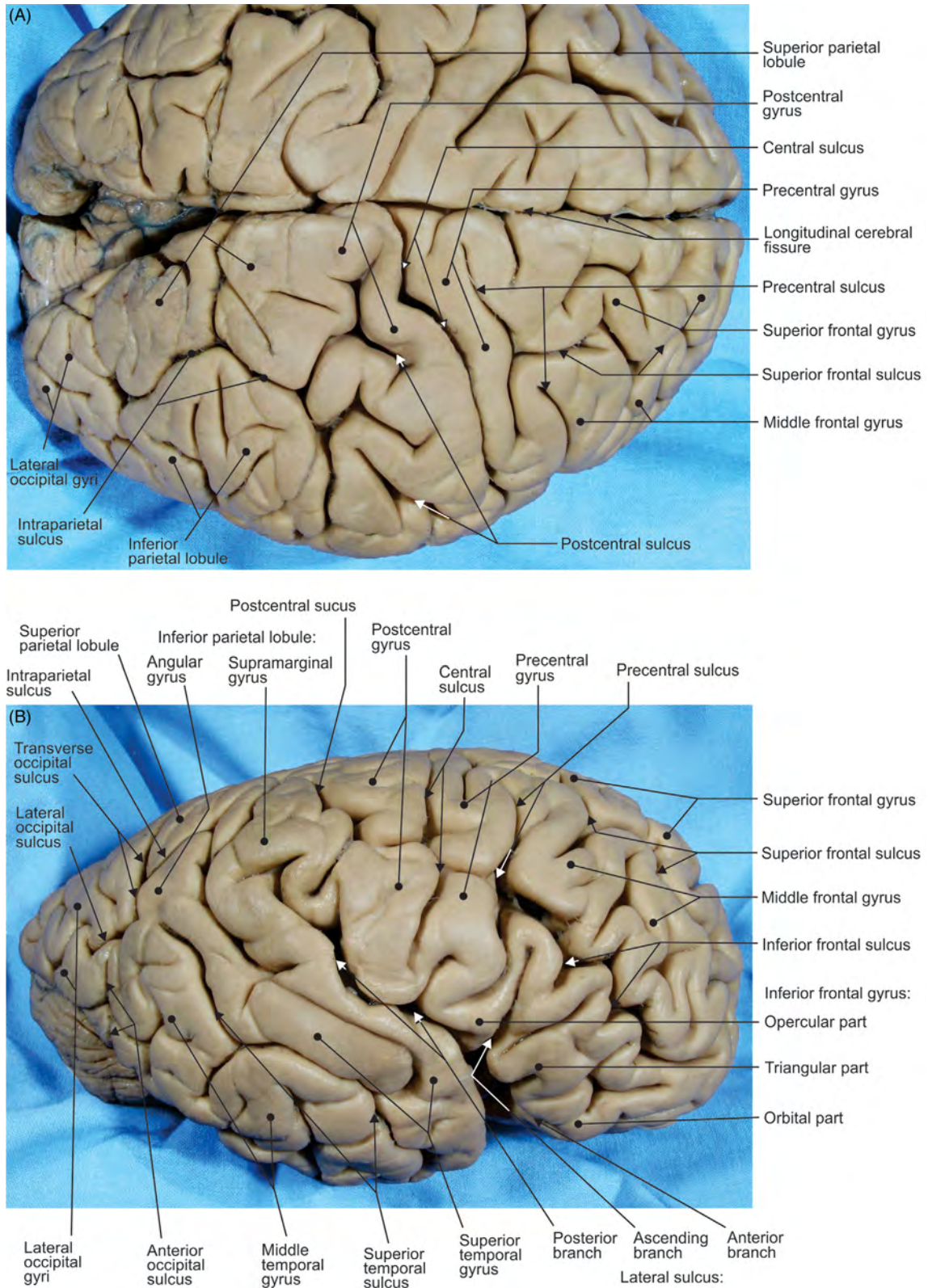


FIGURE 7.3 Superior aspect of (A) both hemispheres and (B) of the right hemisphere.

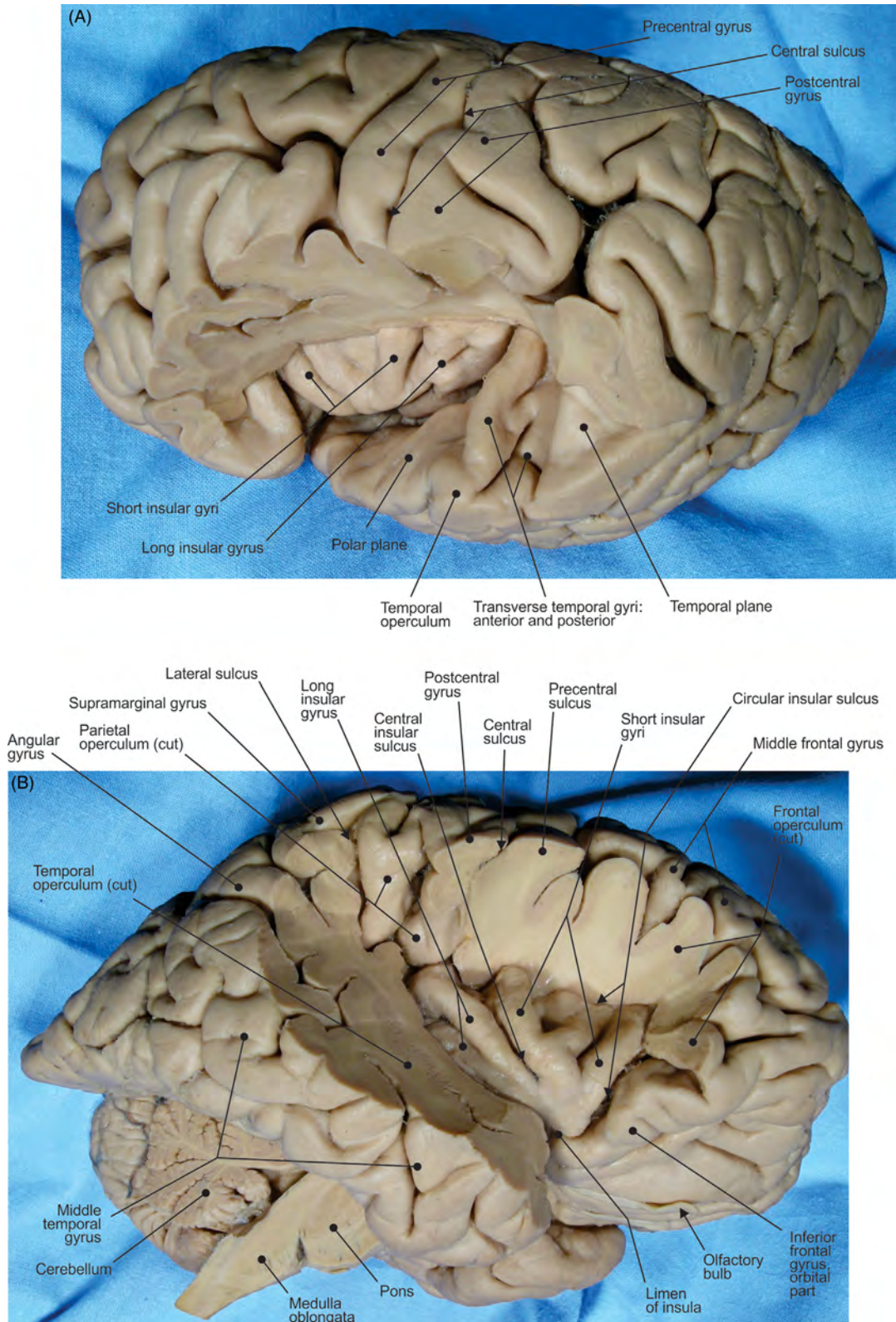


FIGURE 7.4 (A–B) Different views of the superolateral aspect of a hemisphere.

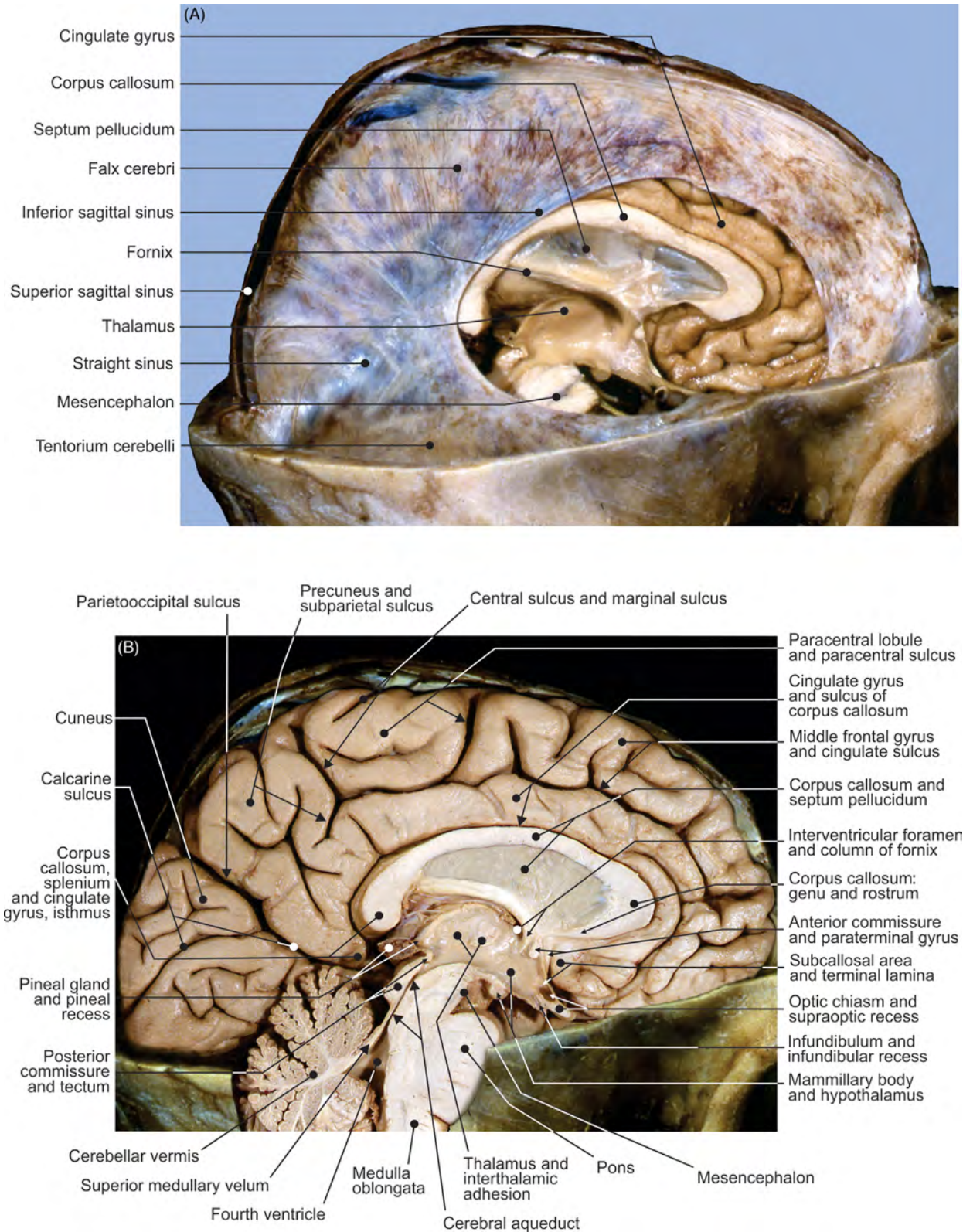
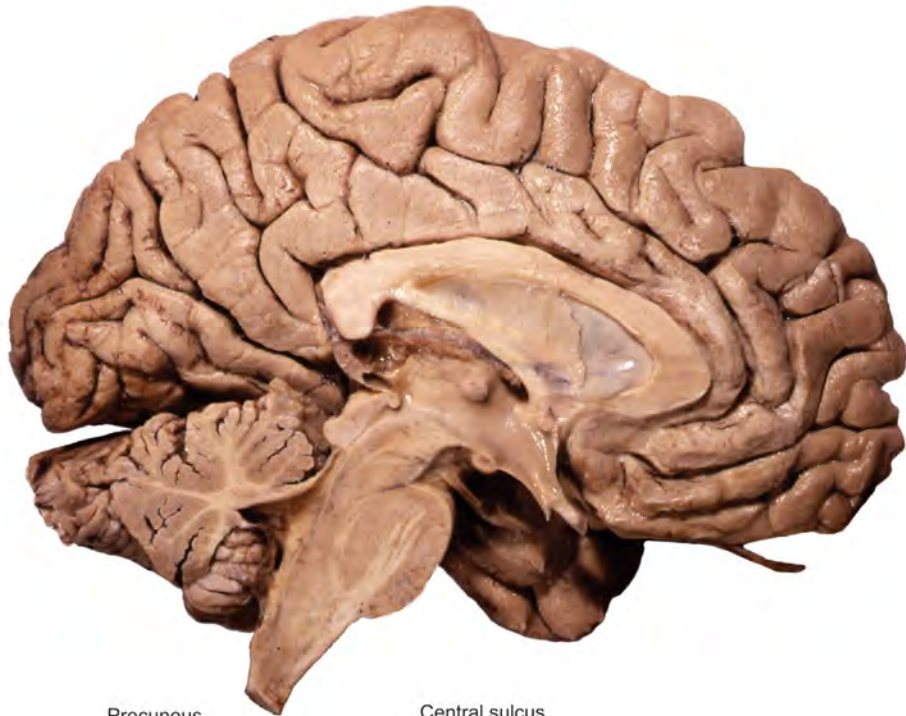

FIGURE 7.5 (A) Falx cerebri and (B) the medial aspect of the left hemisphere.

(A)



(B)

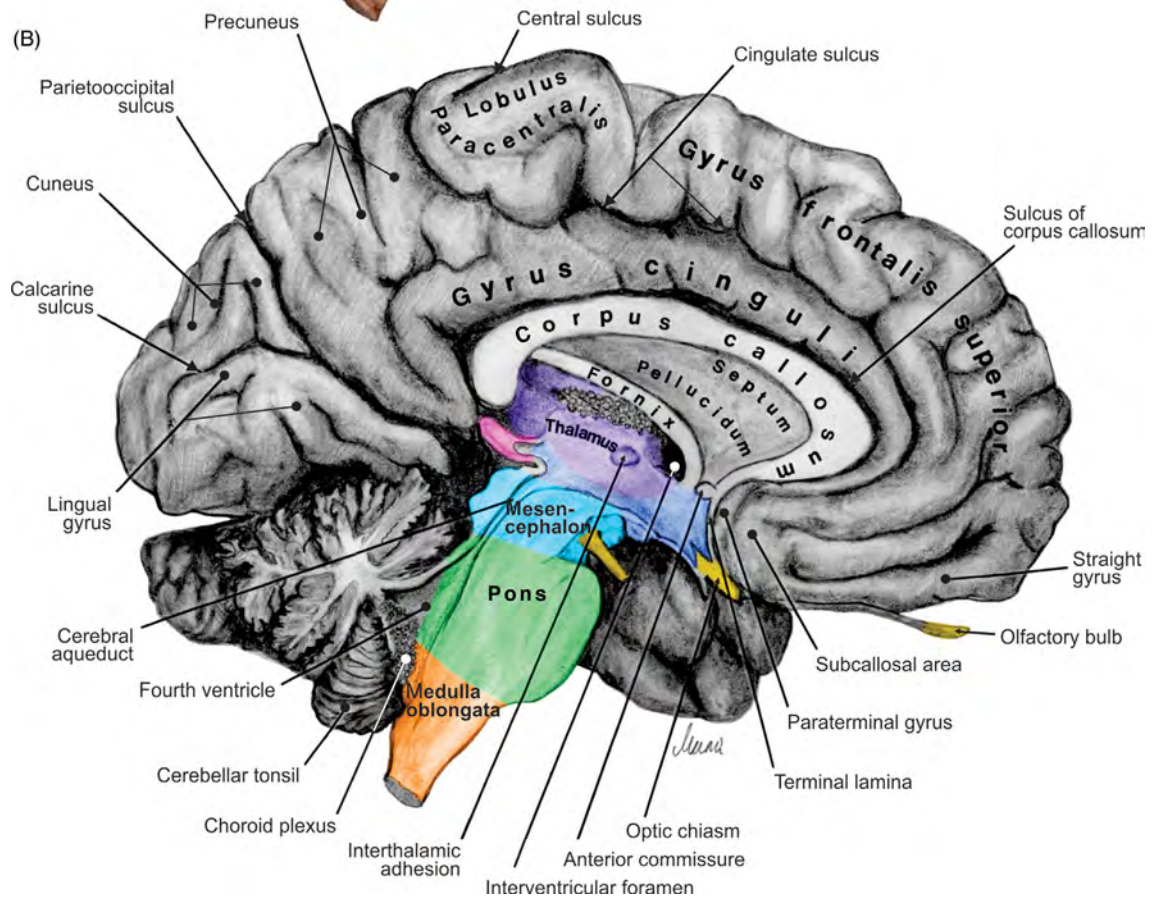


FIGURE 7.6 Midsagittal section of the brain. (A) The medial aspect of the left hemisphere and (B) illustration.

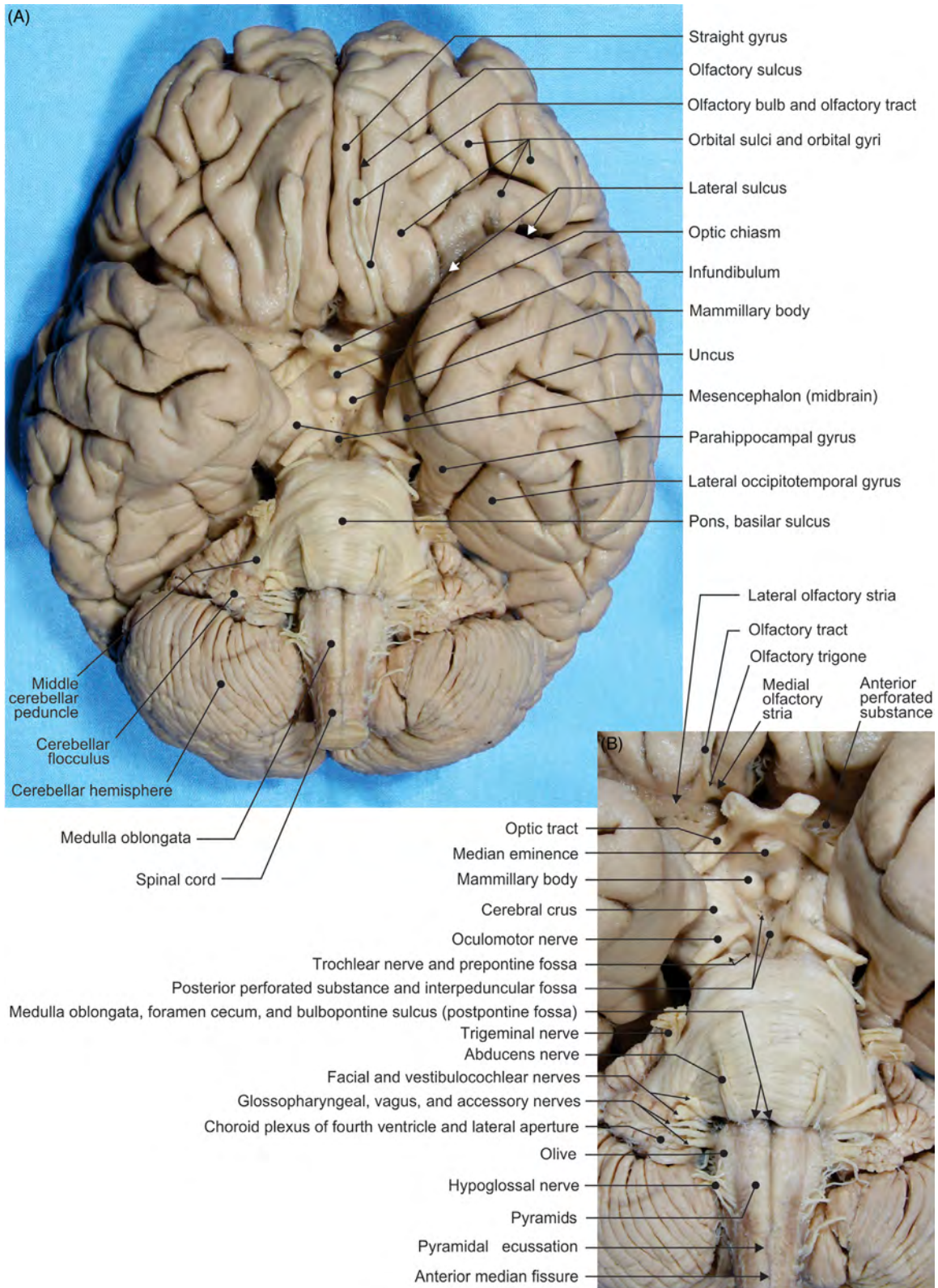


FIGURE 7.7 Cerebrum, cerebellum, and brainstem. (A) Inferior aspect and (B) details.

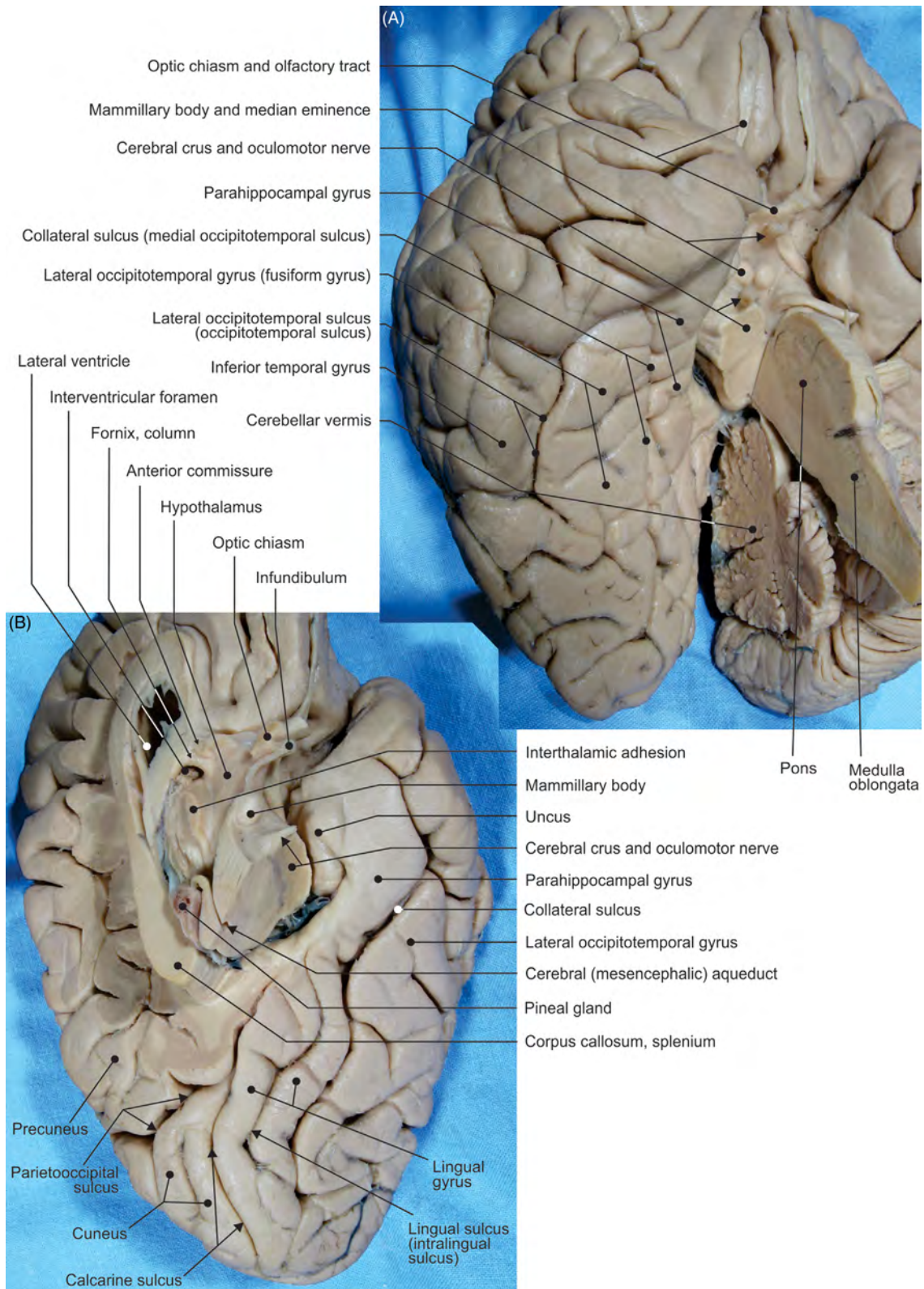


FIGURE 7.8 (A–B) Different views of the inferior aspects of the cerebral hemispheres.

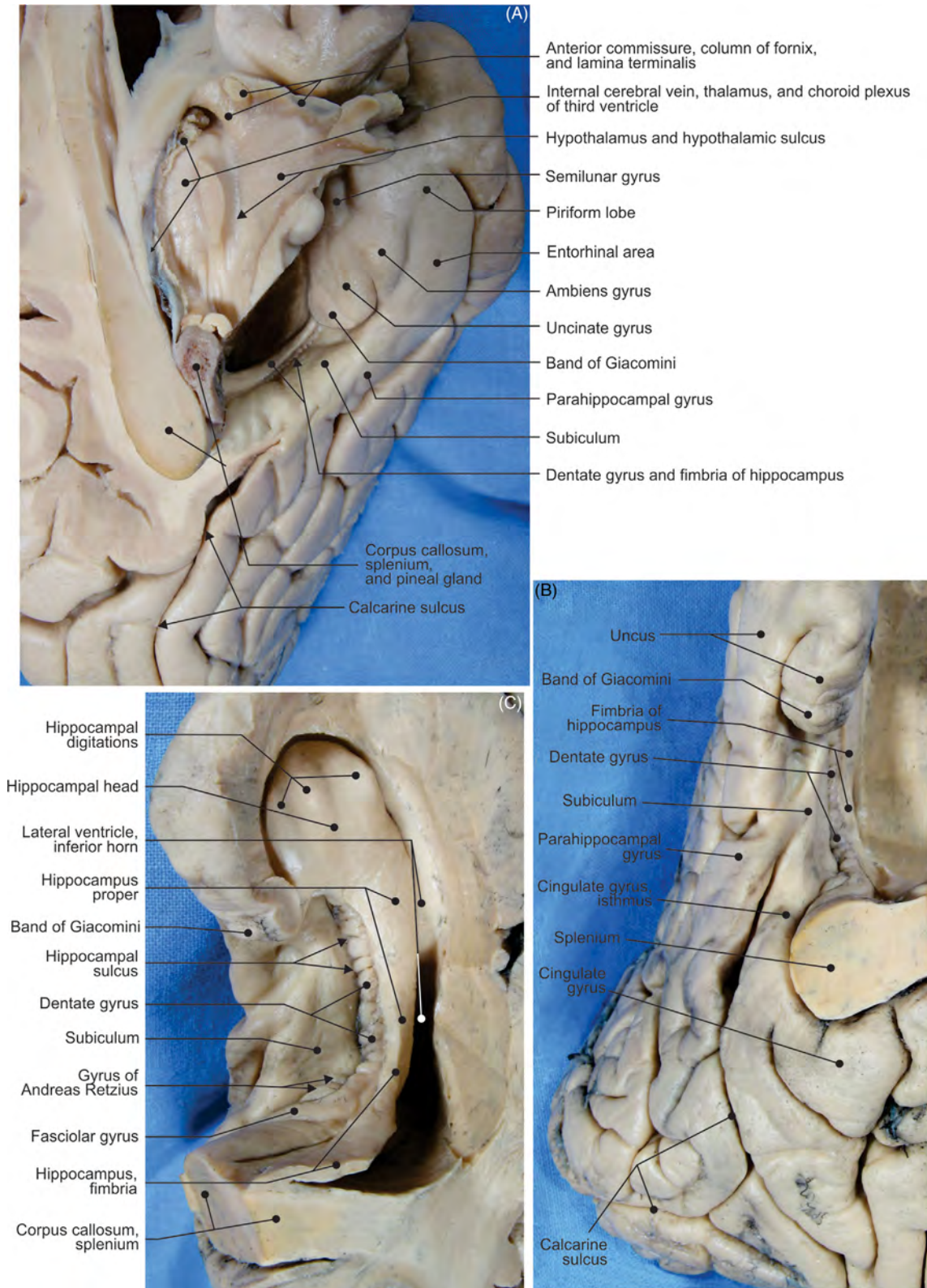


FIGURE 7.9 The hippocampus. (A) Inferomedial view, (B) medial view, and (C) view from the lateral ventricle.

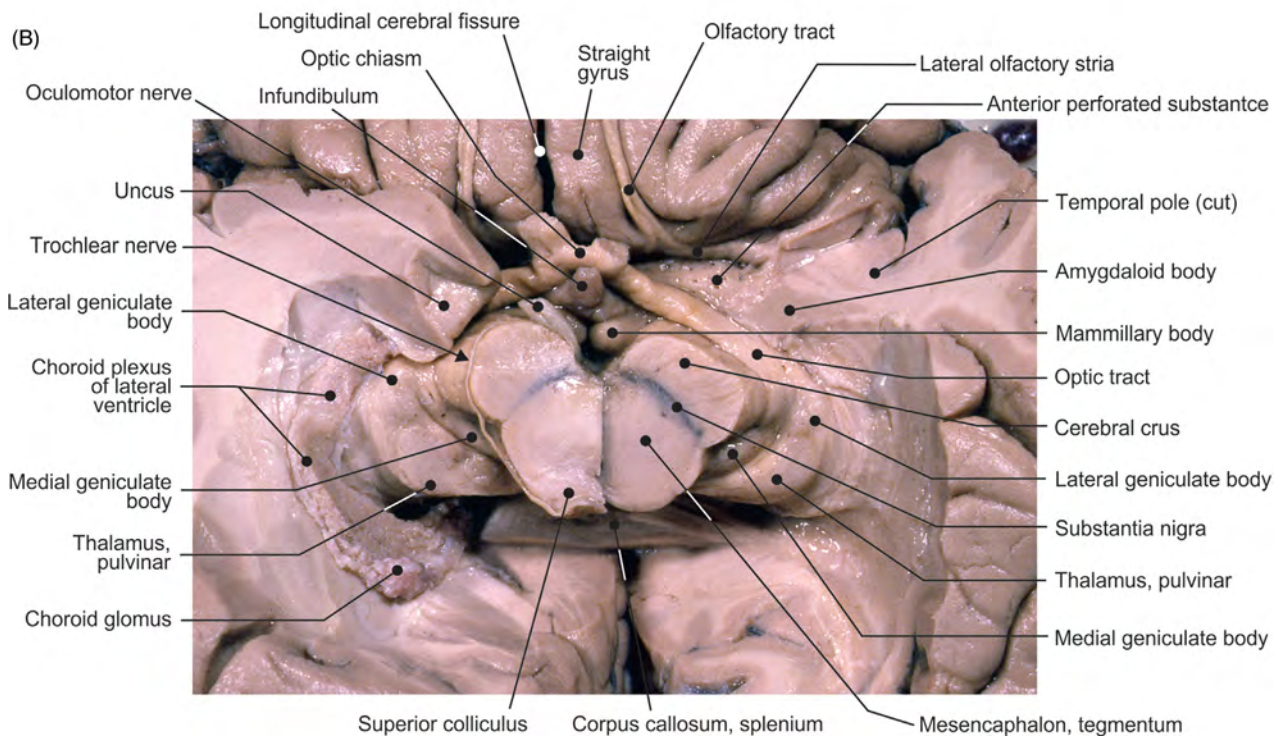
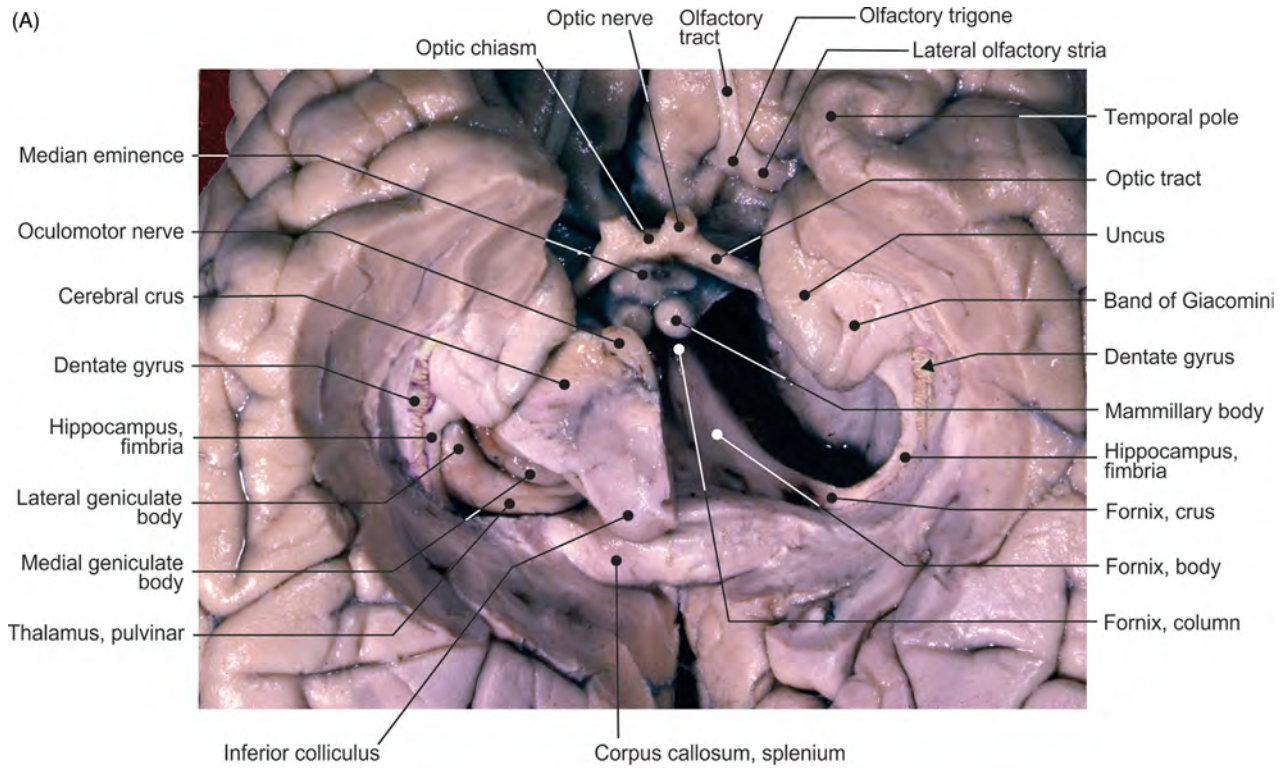


FIGURE 7.10 The inferior aspect of encephalon. (A) Removed: both parahippocampal fimbriae, caudal segment of the brainstem, and thalamus of the left side. (B) Removed: both parahippocampal fimbriae and caudal segment of the brainstem.

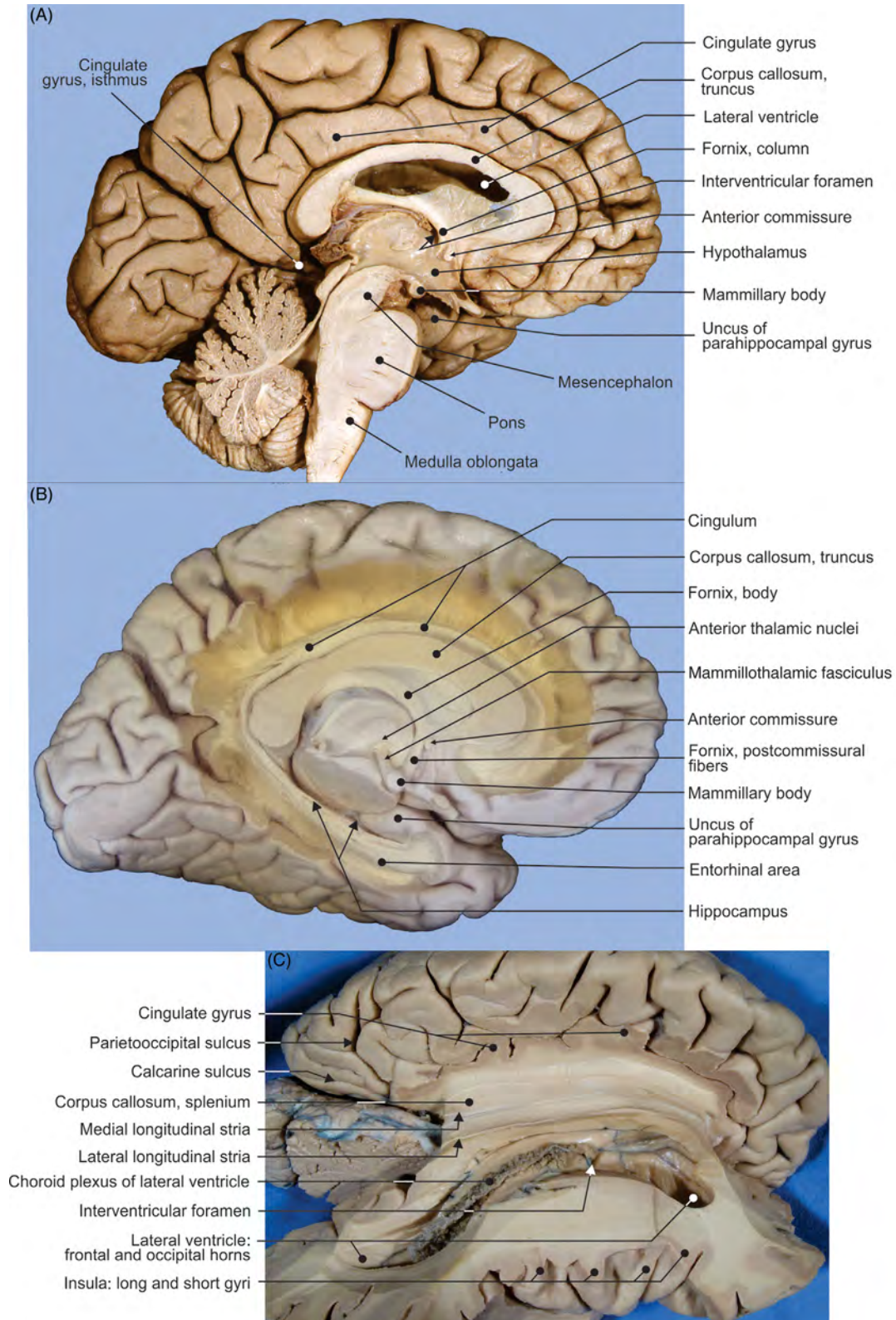


FIGURE 7.11 The limbic lobe. (A) Medial aspect, (B) dissection, and (C) corpus callosum, view from above.

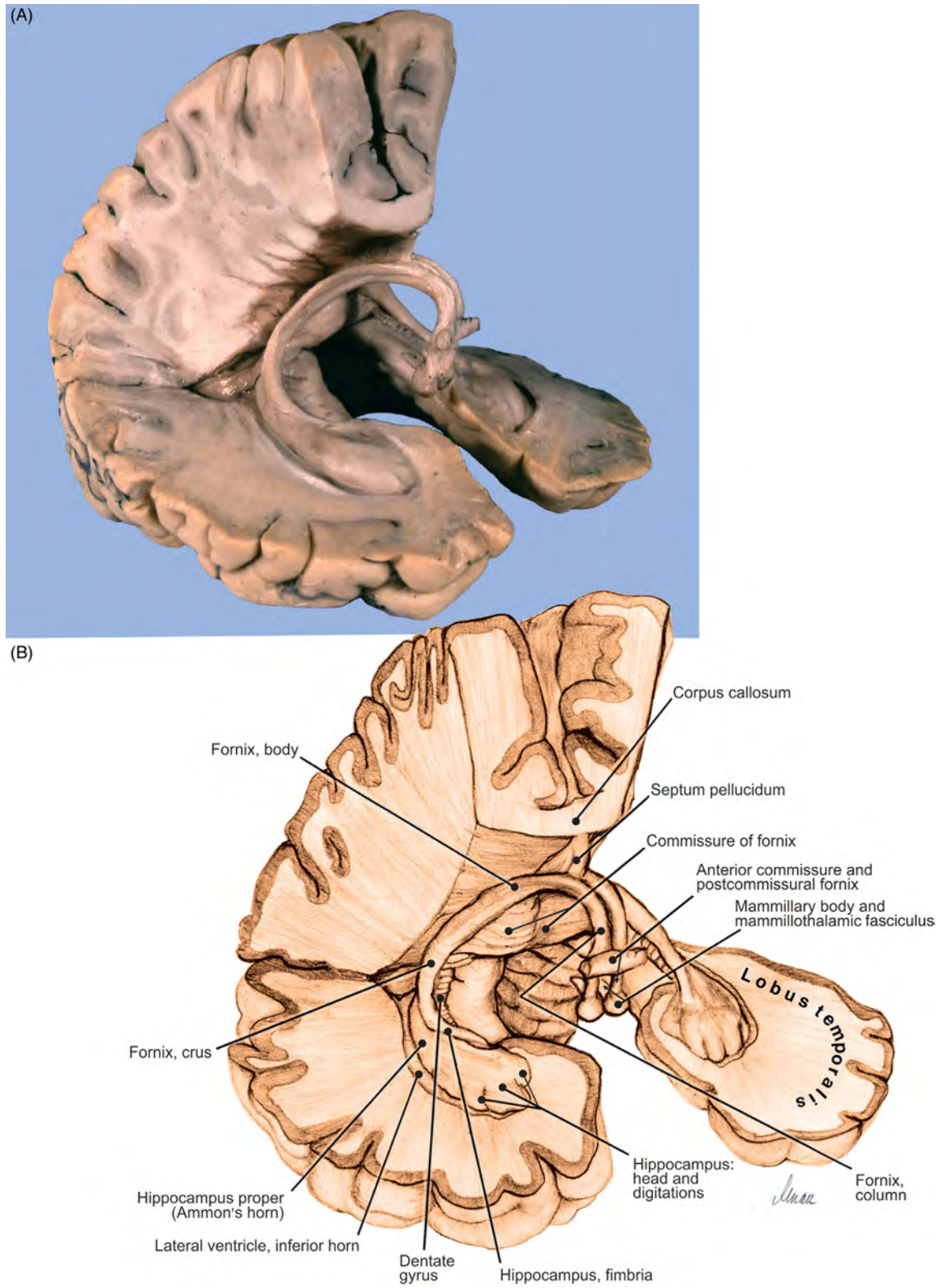


FIGURE 7.12 The fornix and hippocampus. (A) Dissection and (B) illustration.

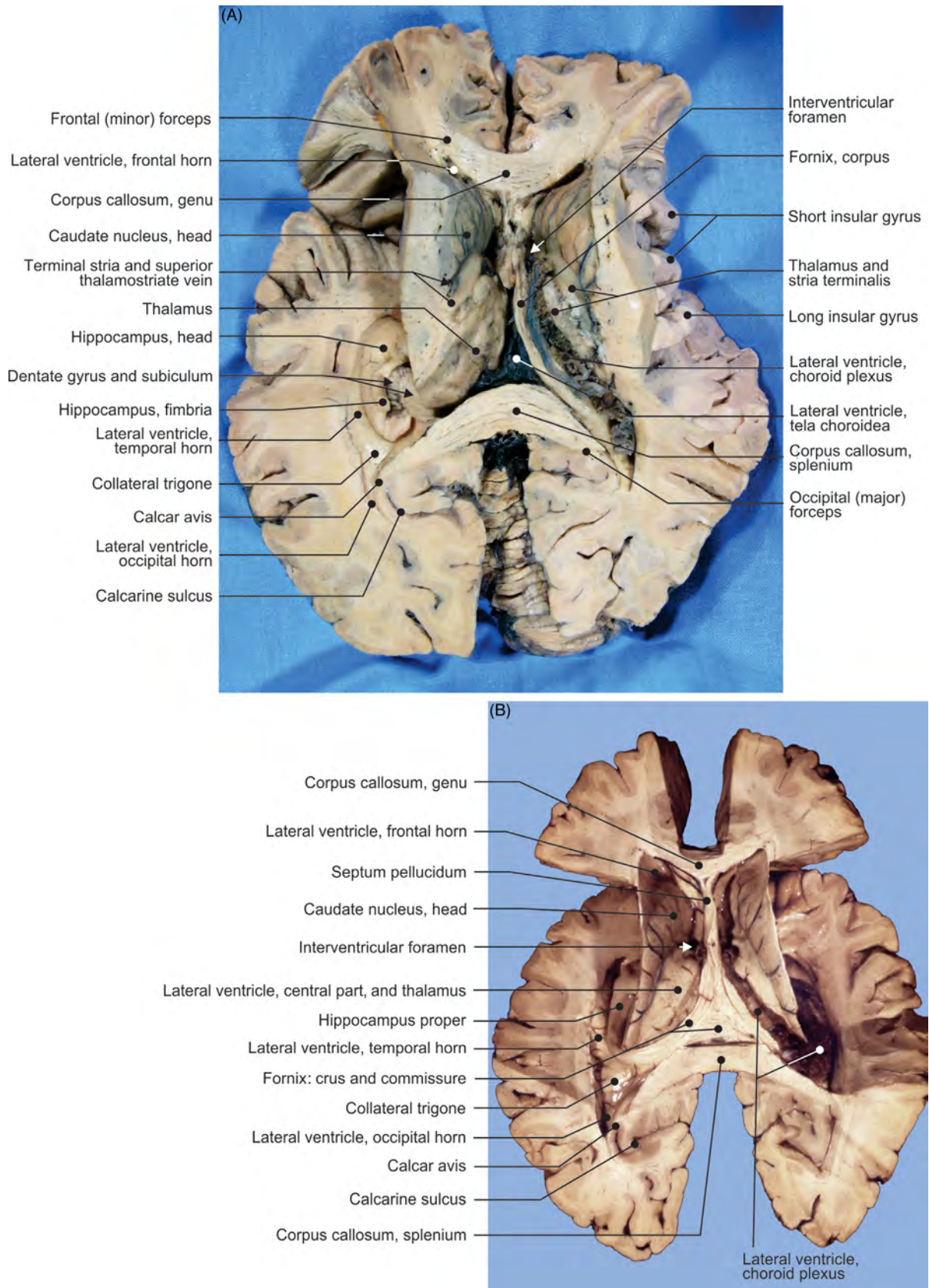


FIGURE 7.13 Lateral ventricles. (A–B) Different views from above.

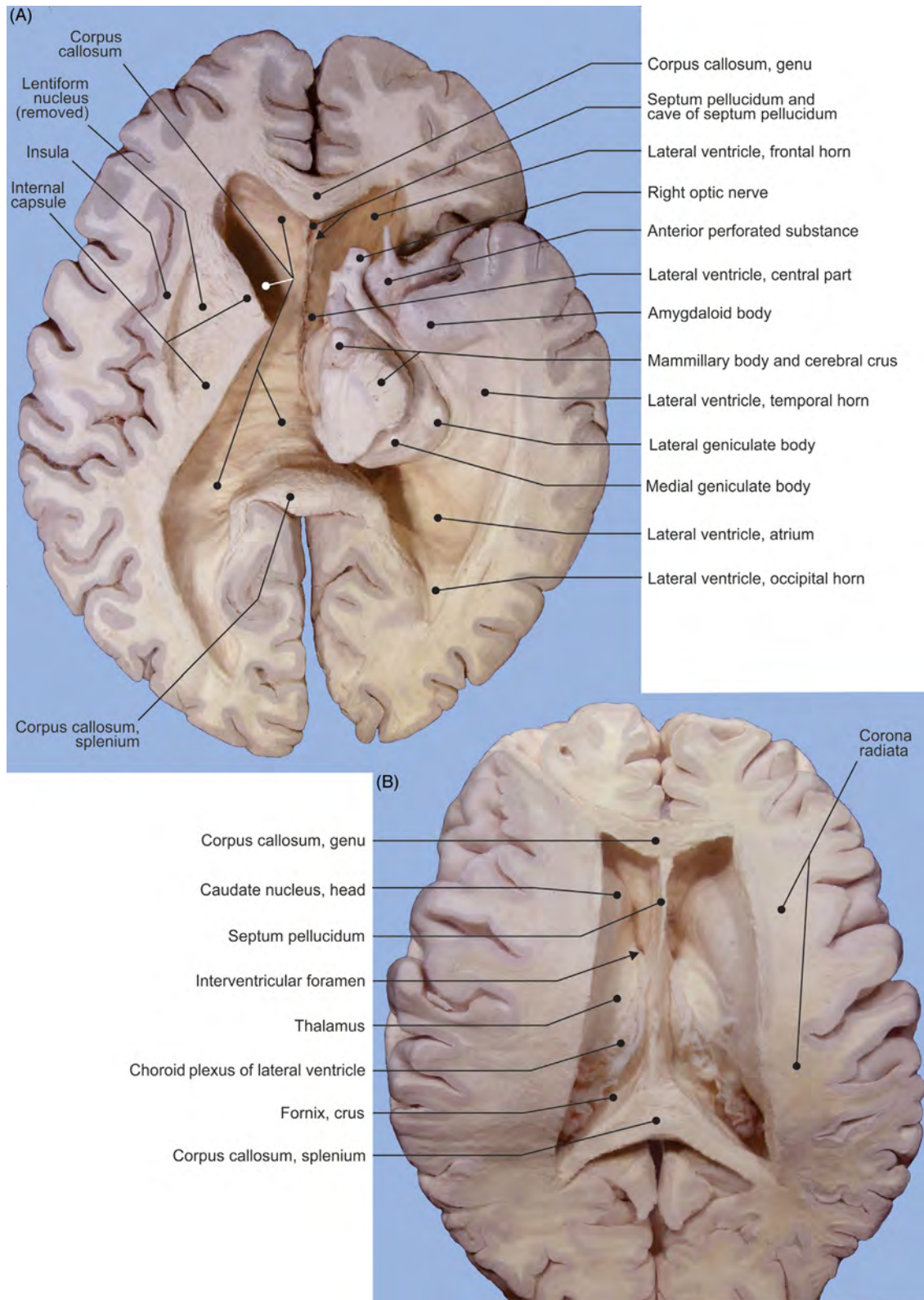


FIGURE 7.14 Dissected lateral ventricles. Views from (A) below and (B) from above.

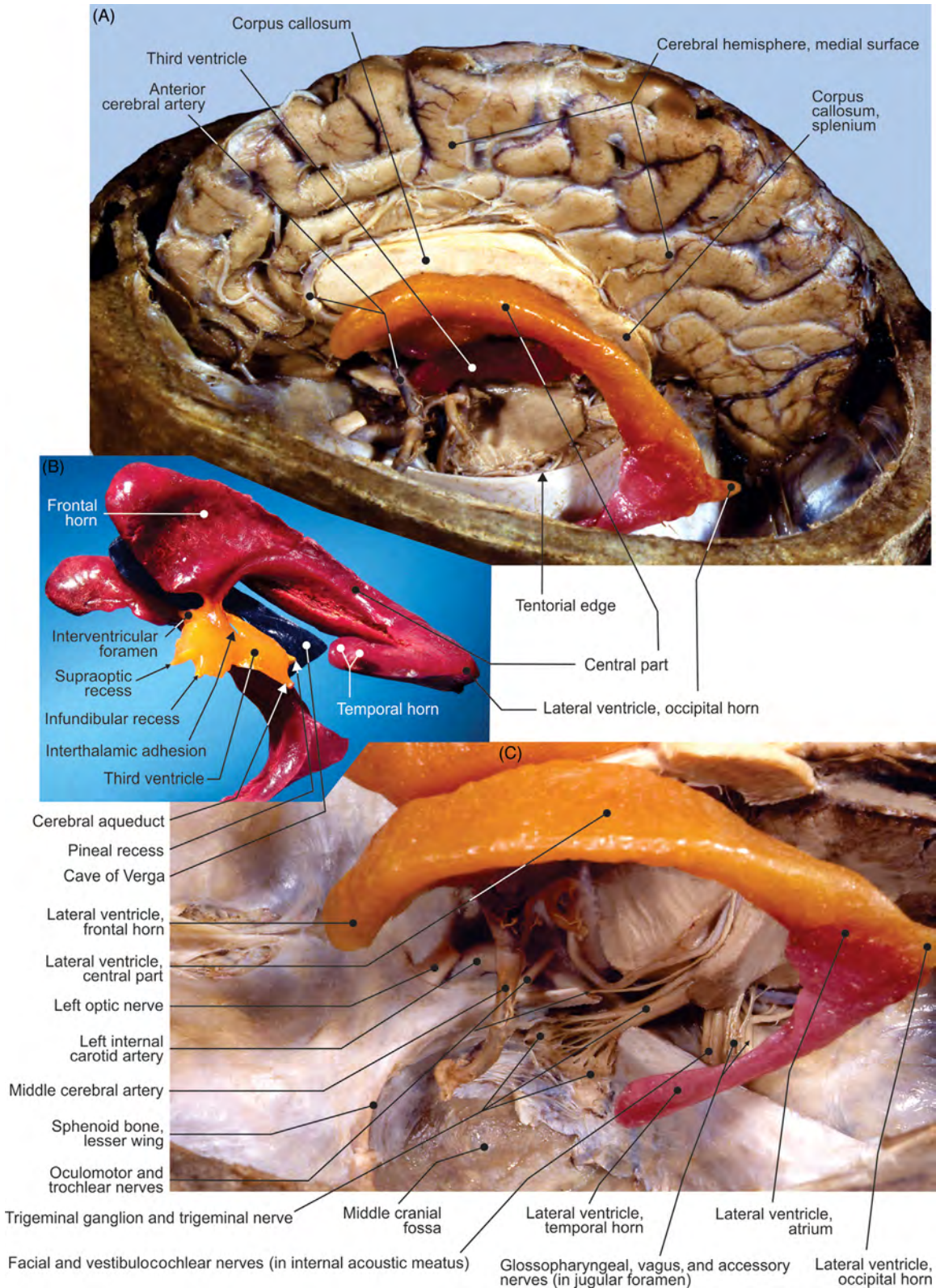


FIGURE 7.15 (A–C) Different views of the lateral ventricle dissected and filled with acrylic cast.

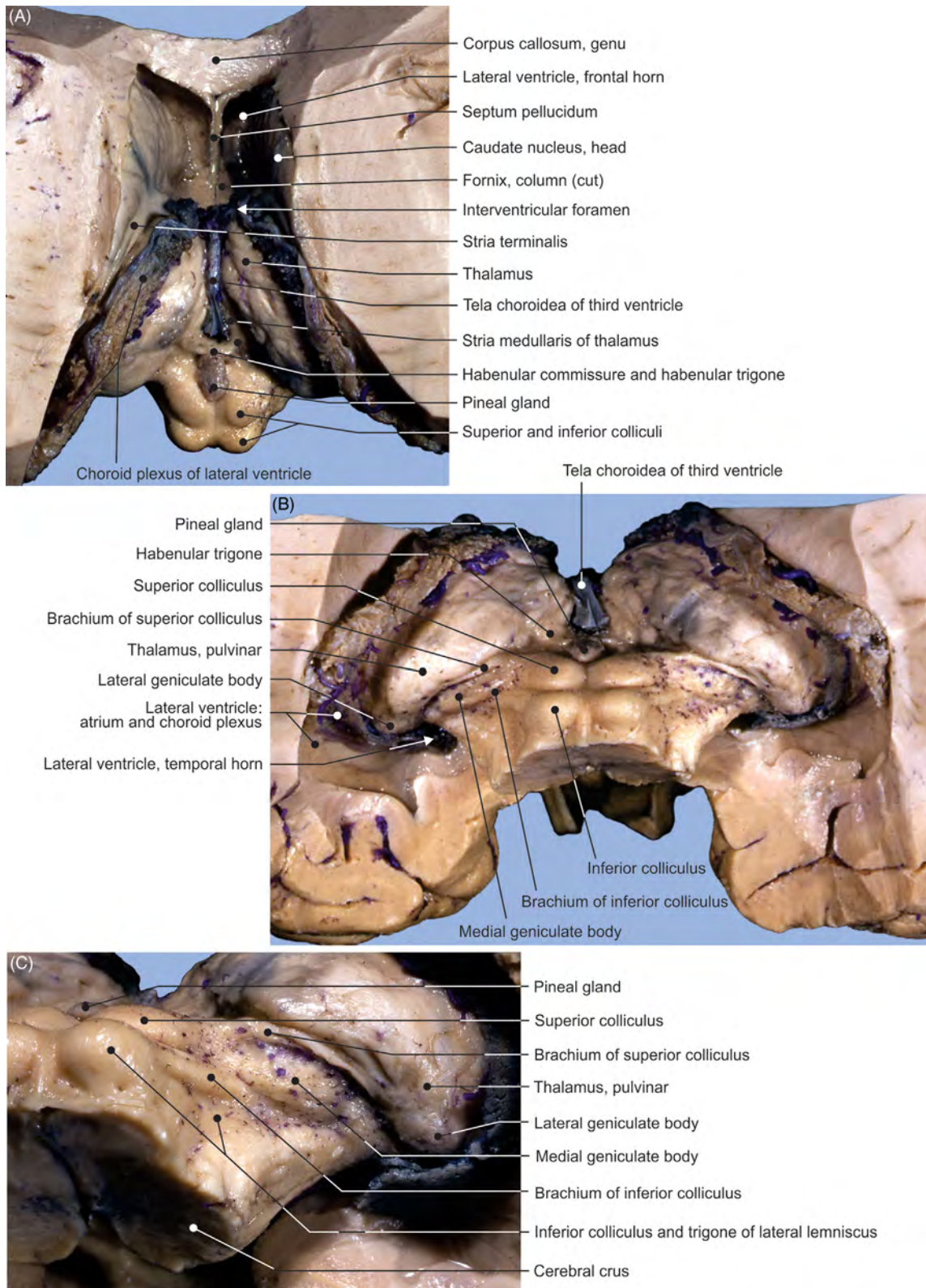


FIGURE 7.16 Dissection of the thalamus and mesencephalon. View from (A) above, (B) behind, and (C) the lateral side.

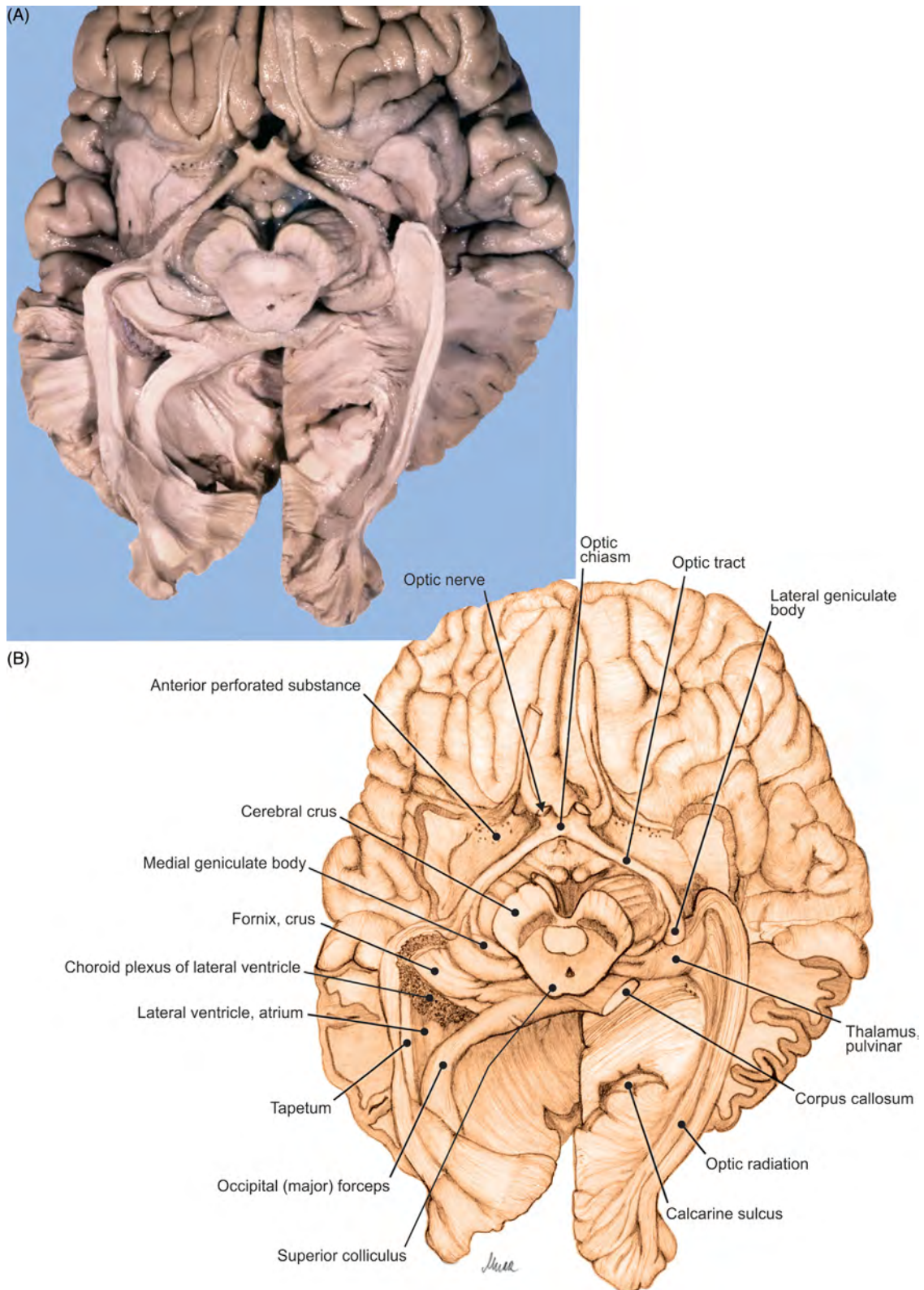


FIGURE 7.17 The encephalon, optic pathway. (A) Dissection of the inferior aspect and (B) illustration.

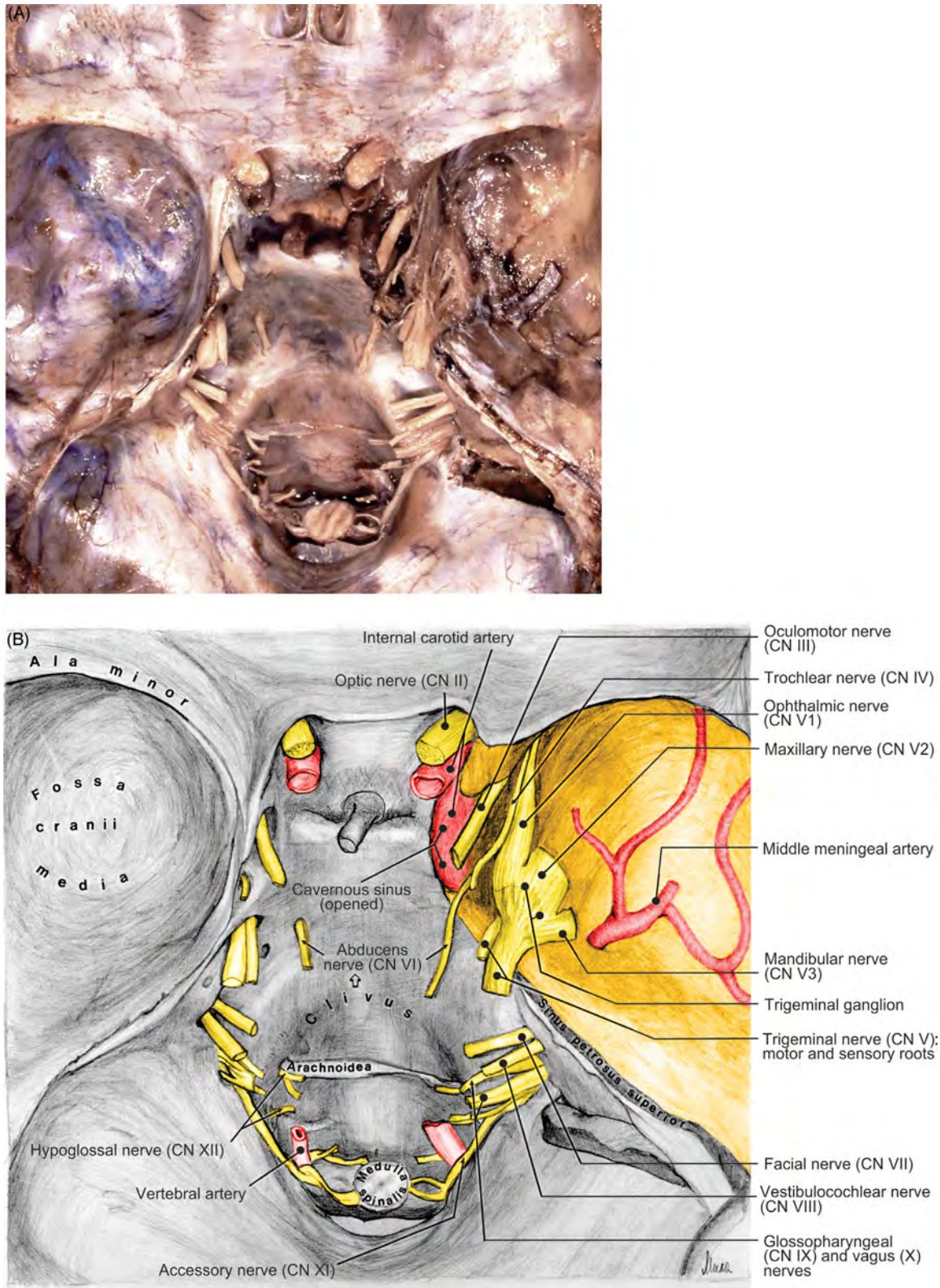


FIGURE 7.18 The base of the skull with passage of cranial nerves. (A) Dura mater removed from the right half of the cranial base and (B) illustration.

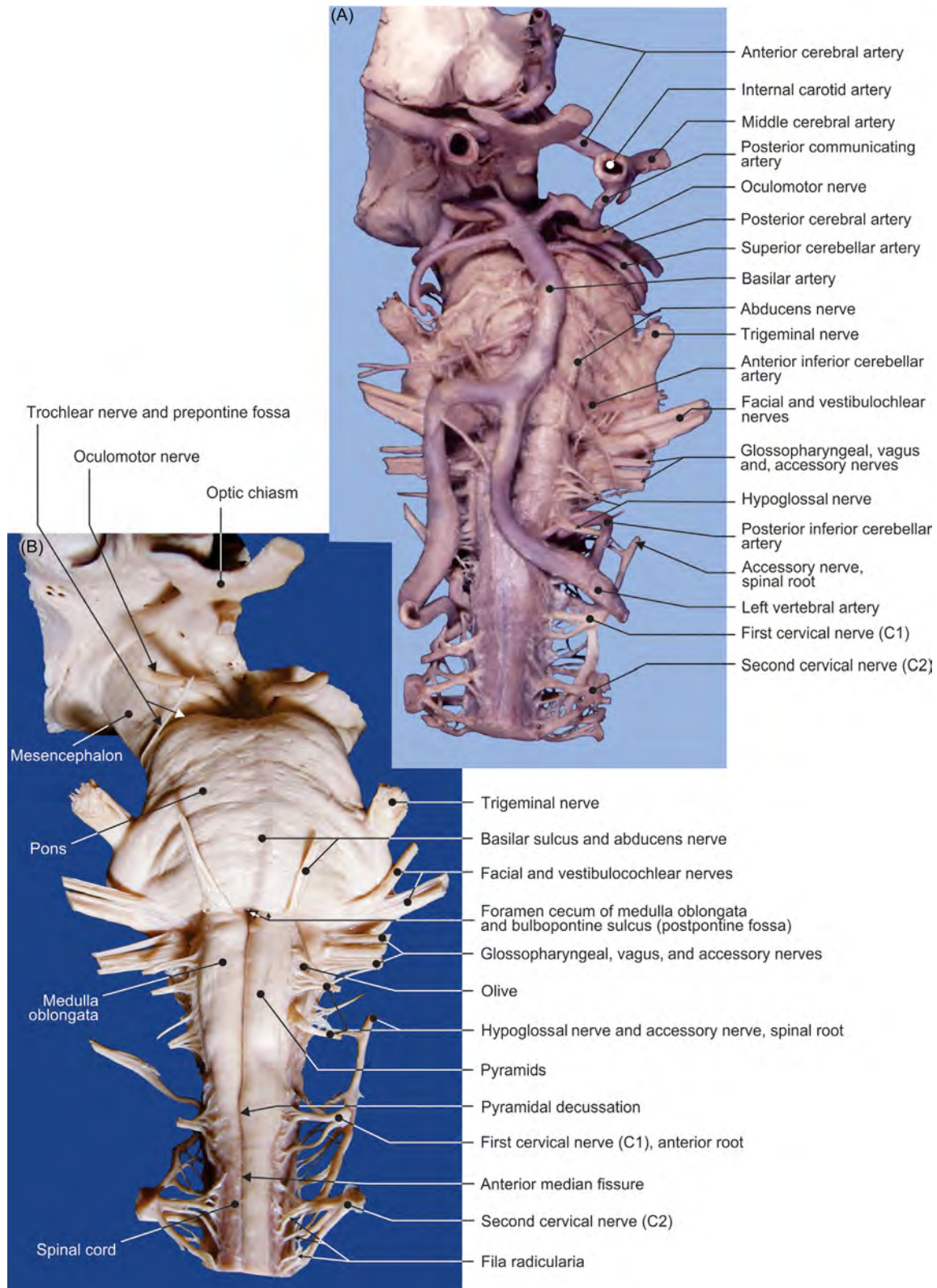


FIGURE 7.19 The brainstem. (A–B) Different views of the ventral aspect.

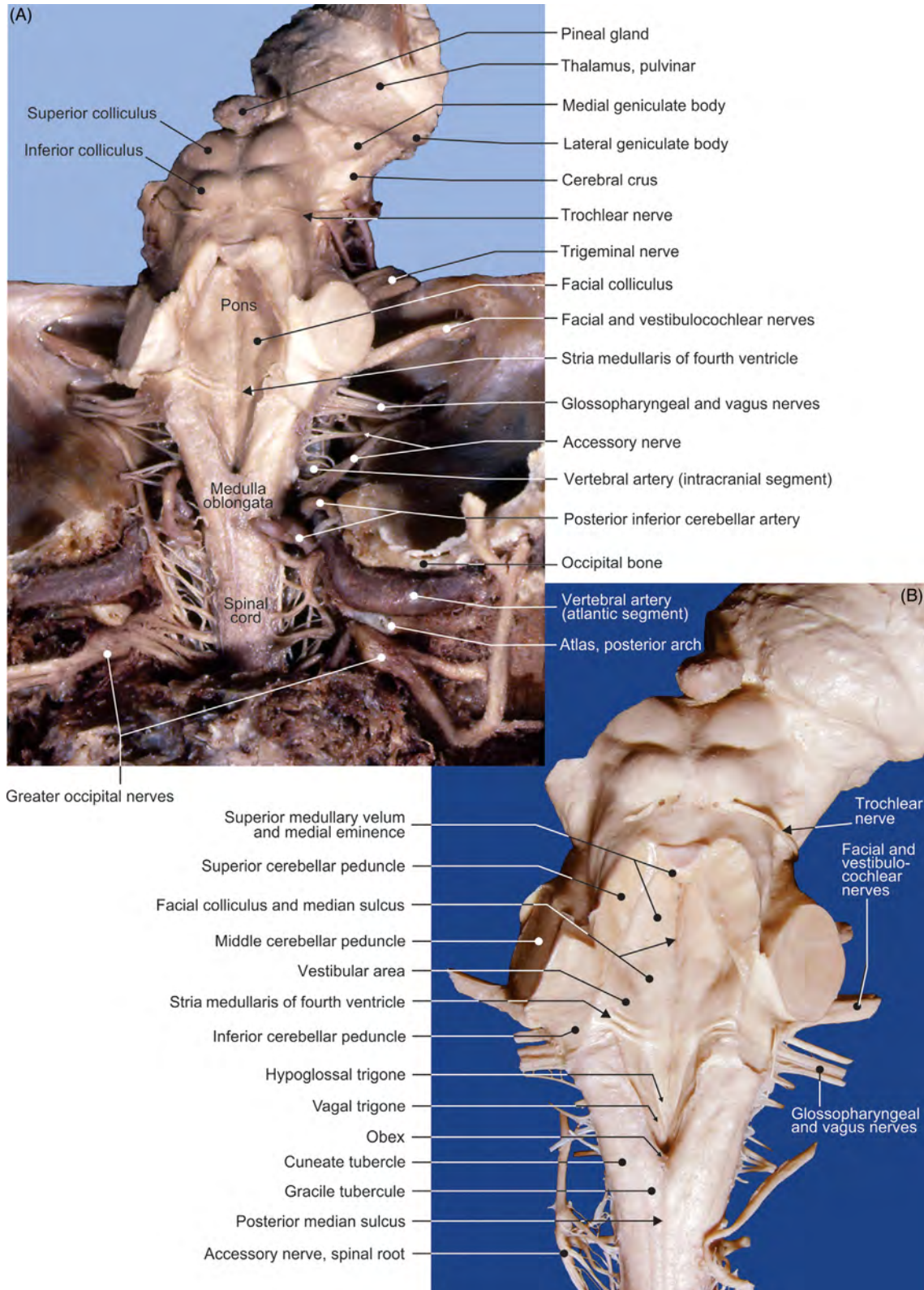


FIGURE 7.20 The brainstem. (A–B) Different views of the dorsal aspect.

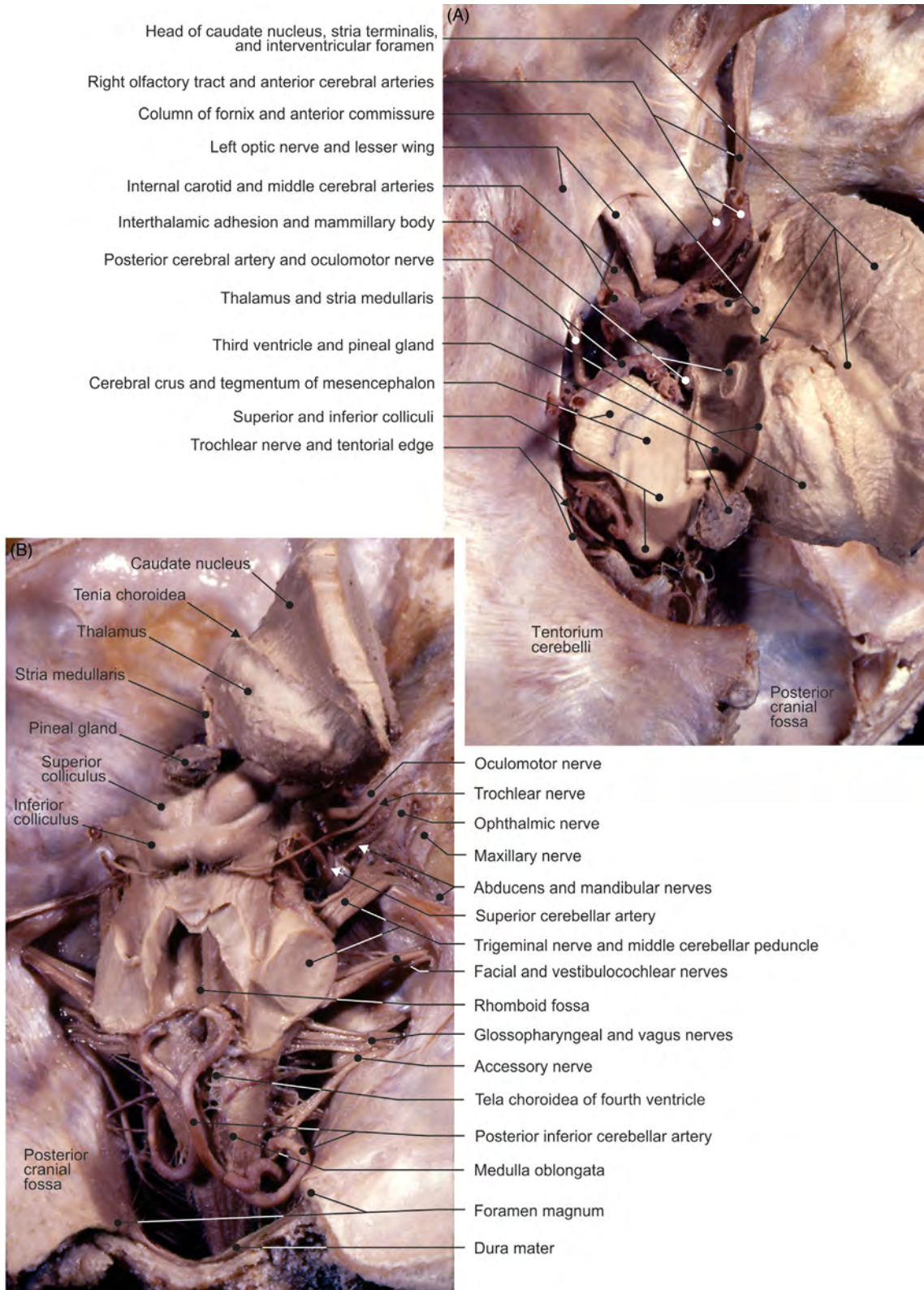


FIGURE 7.21 Dissection of the mesencephalon and right thalamus in situ. (A) View from above and (B) view from behind.

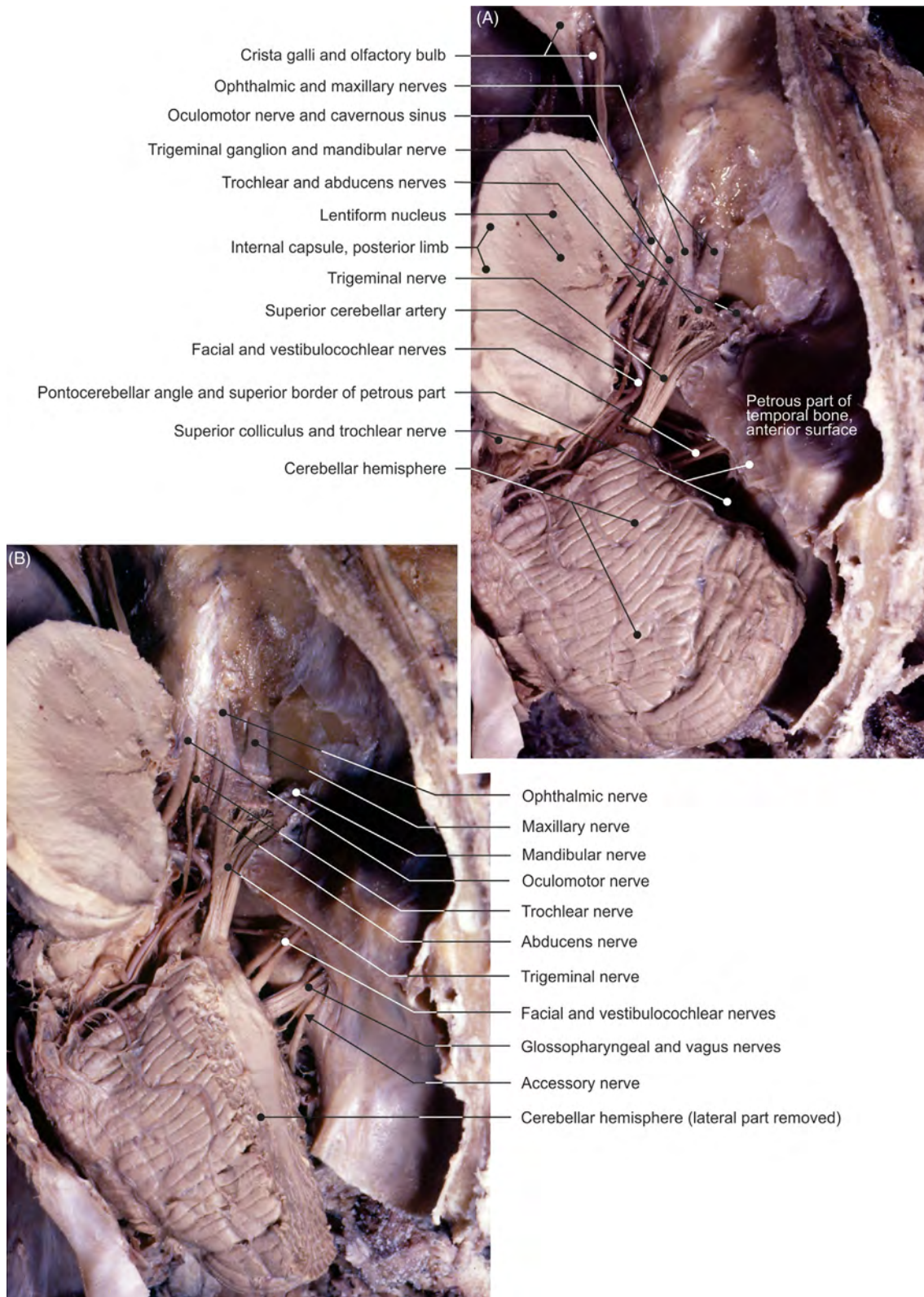


FIGURE 7.22 (A–B) Different views of the dissection of the cavernous sinus and pontocerebellar angle.

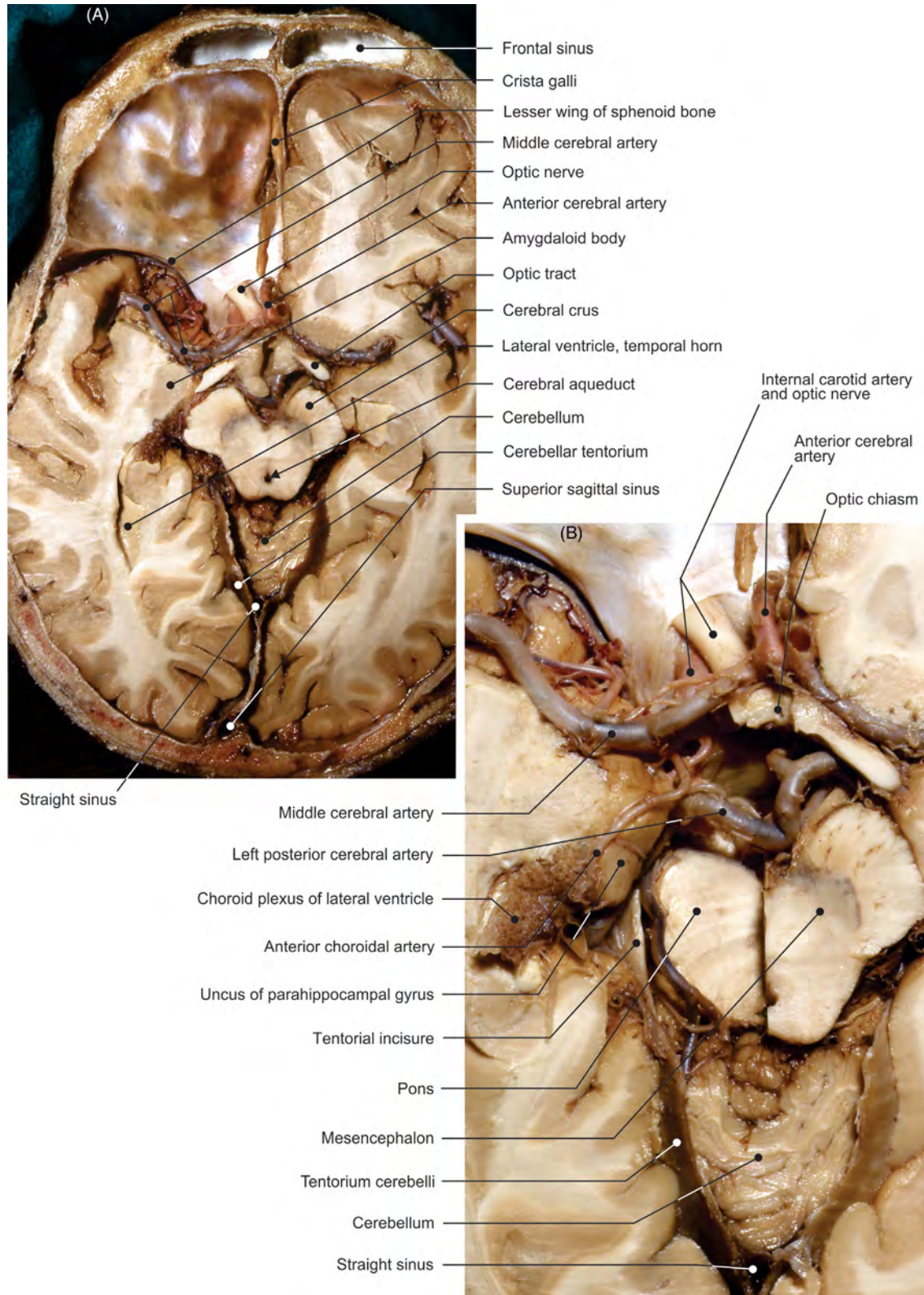


FIGURE 7.23 (A–B) Transverse sections of the head: dissections.

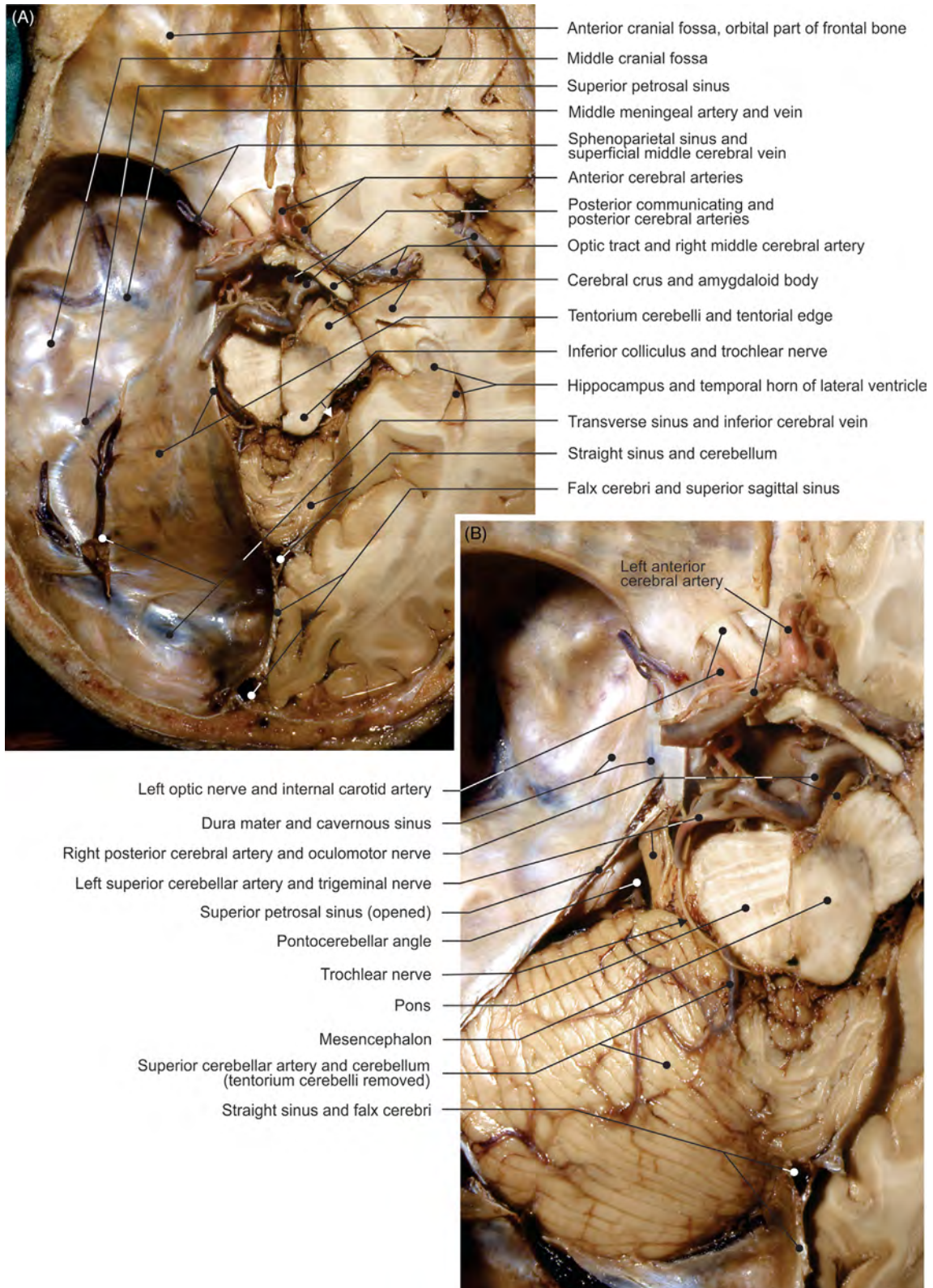


FIGURE 7.24 (A–B) Transverse sections of the head: dissections.

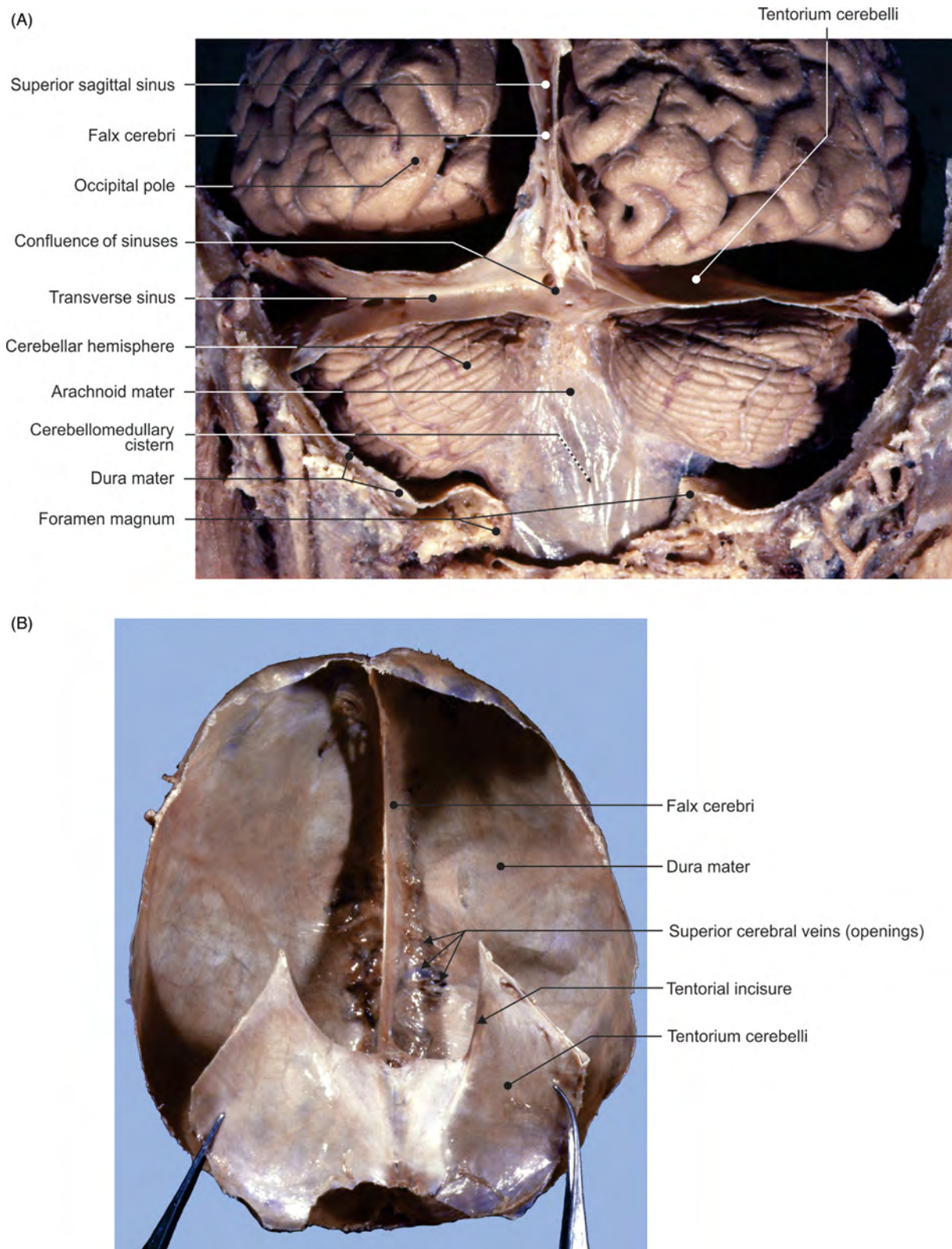


FIGURE 7.25 (A) The telencephalon and cerebellum in situ: view from behind. (B) Isolated cranial dura mater: view from below.

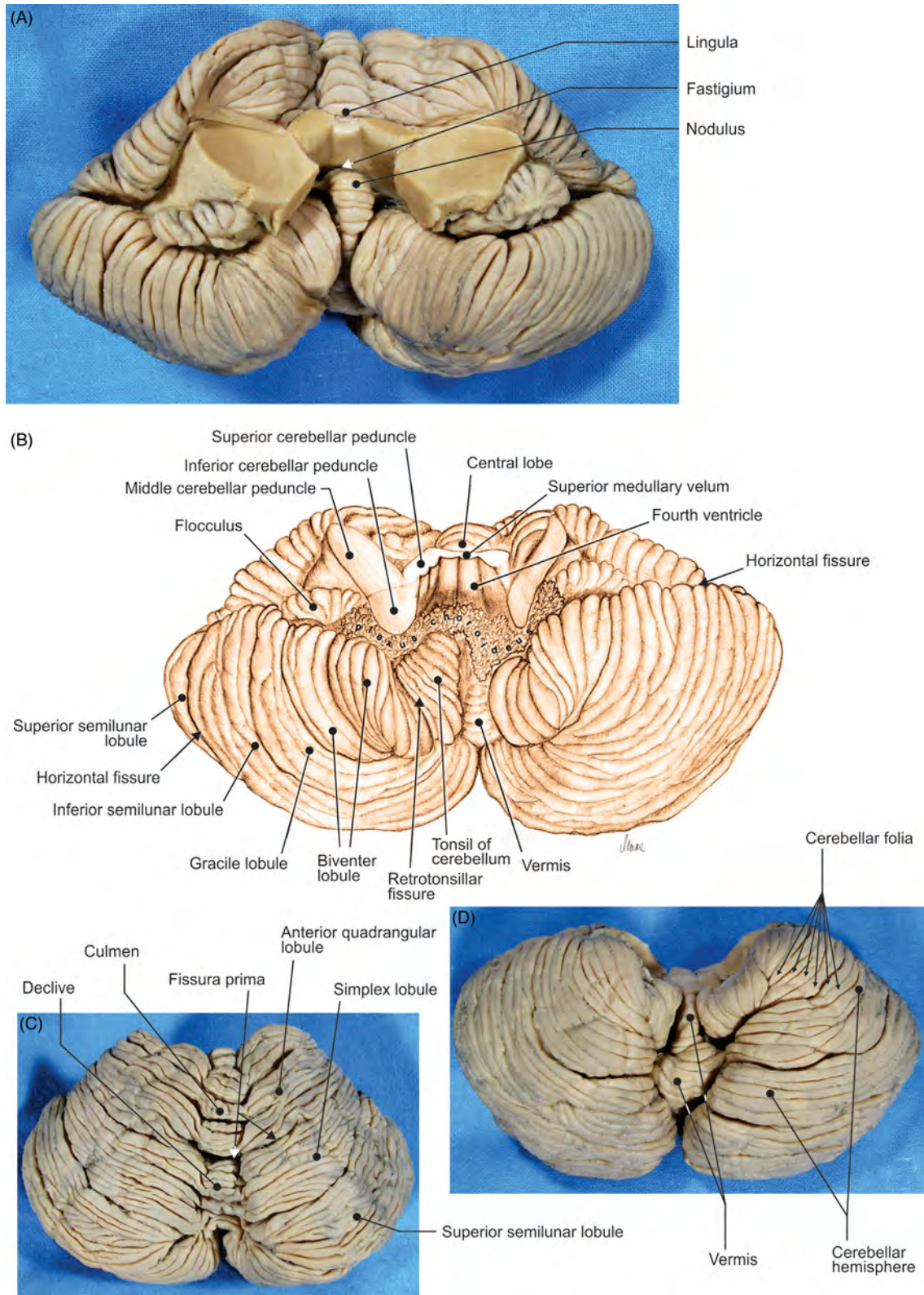


FIGURE 7.26 The cerebellum. (A) View from the front, (C) view from above, and (D) view from below. (B) Illustration of the cerebellum.

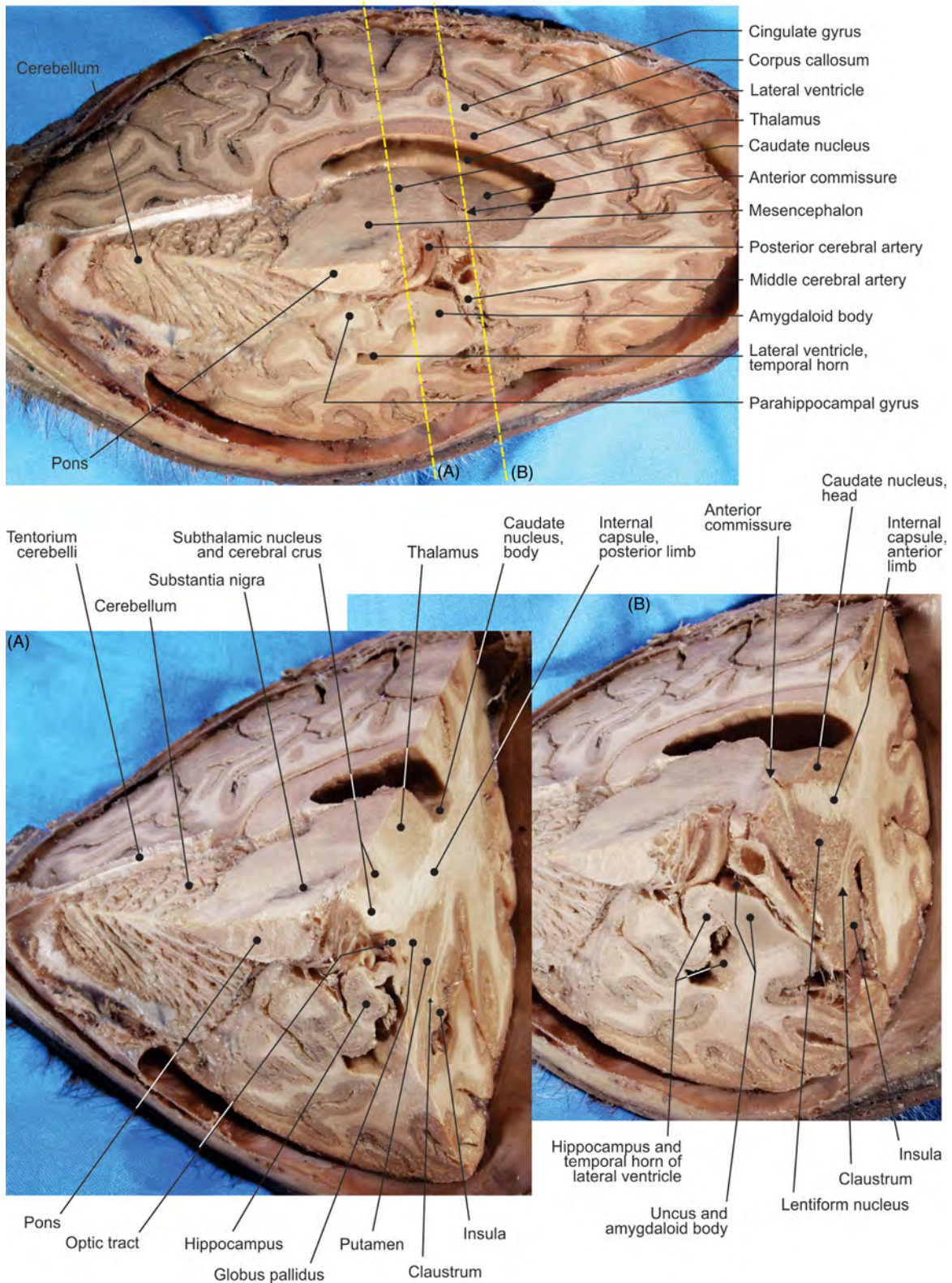


FIGURE 7.27 Different views of the sections of the cerebral hemisphere. (A) and (B) are the frontal sections.

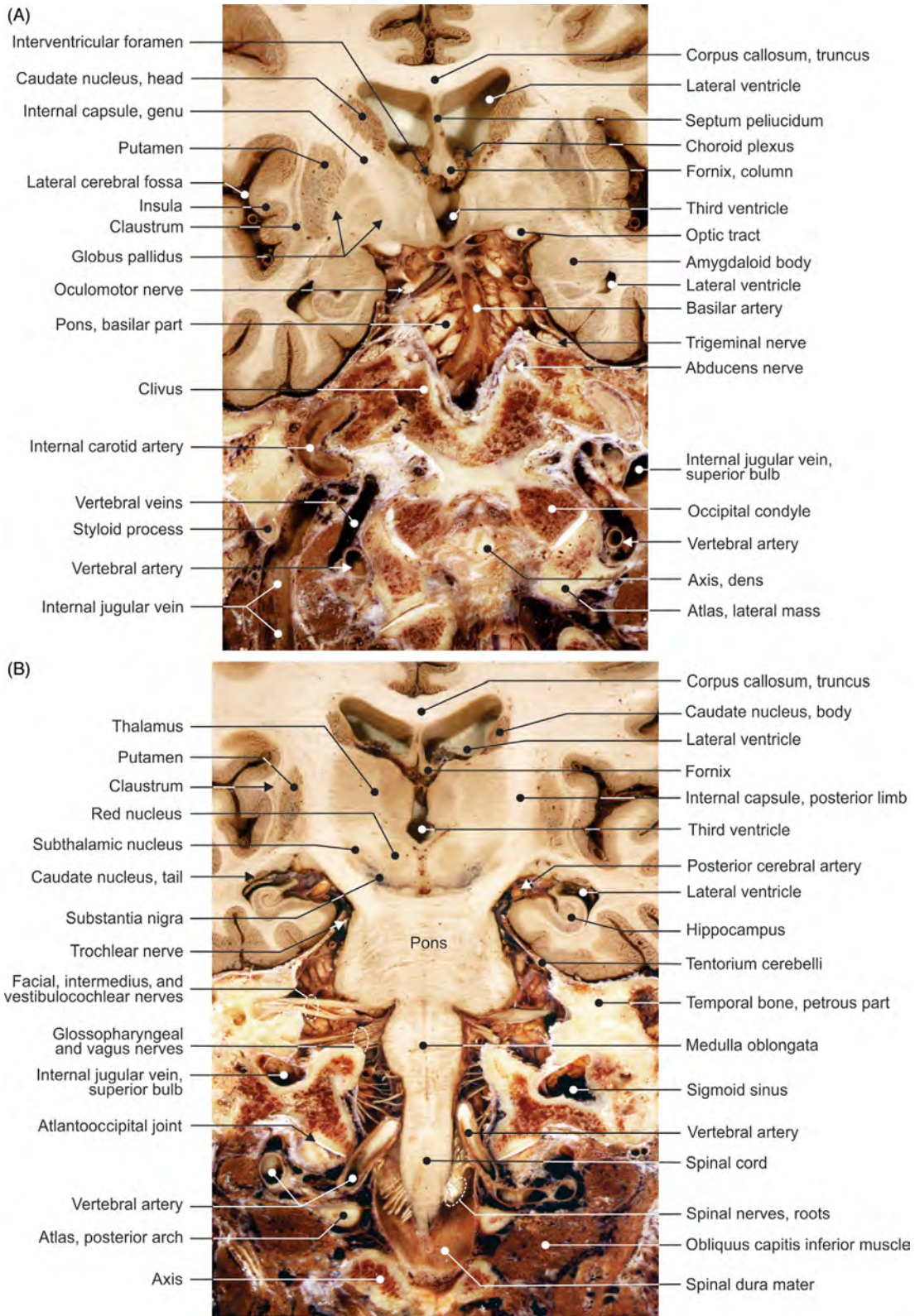


FIGURE 7.28 (A–B) Different views of the frontal sections of the third ventricle.

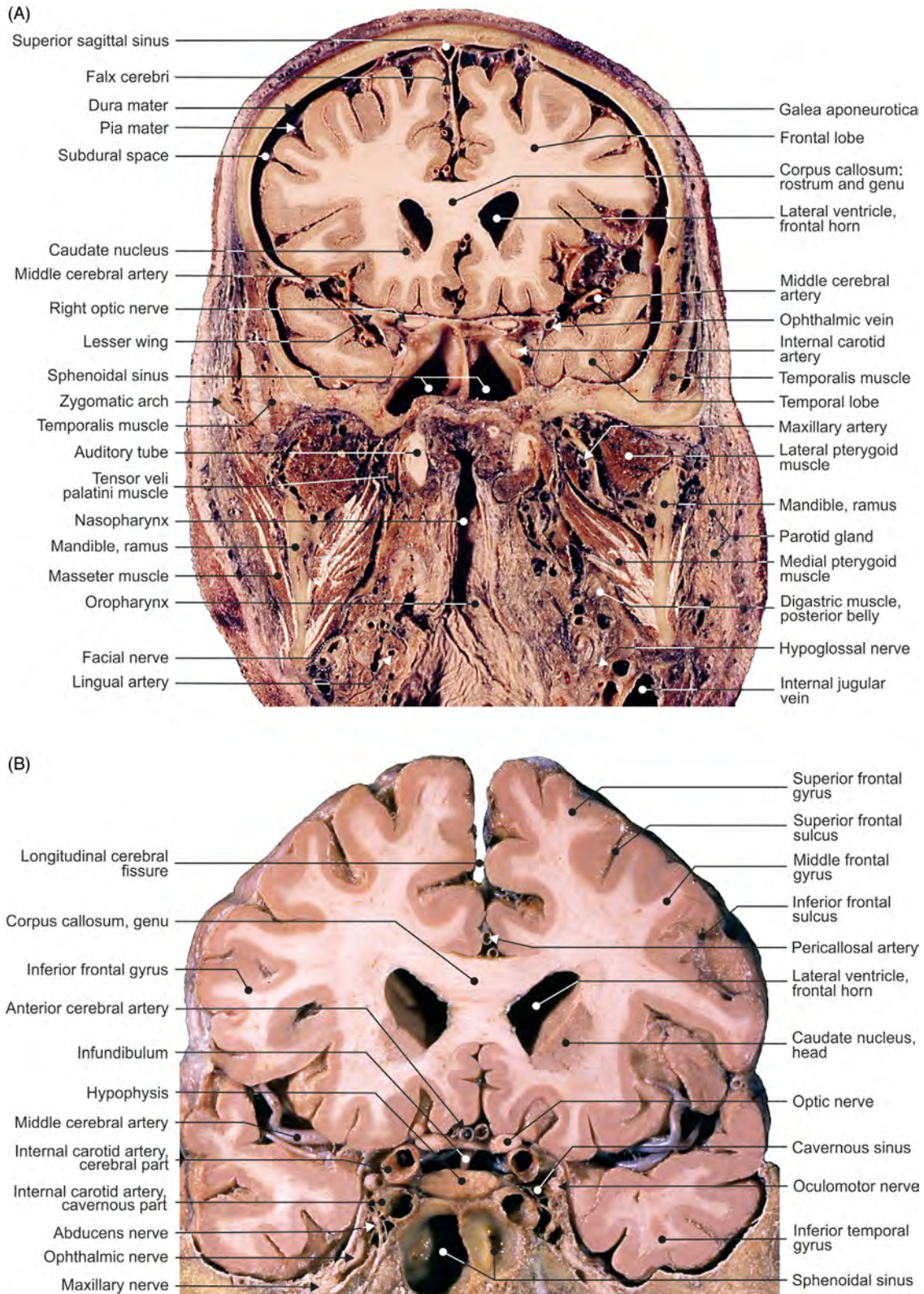


FIGURE 7.29 (A–B) Different views of the frontal sections of the anterior horn of the lateral ventricle.

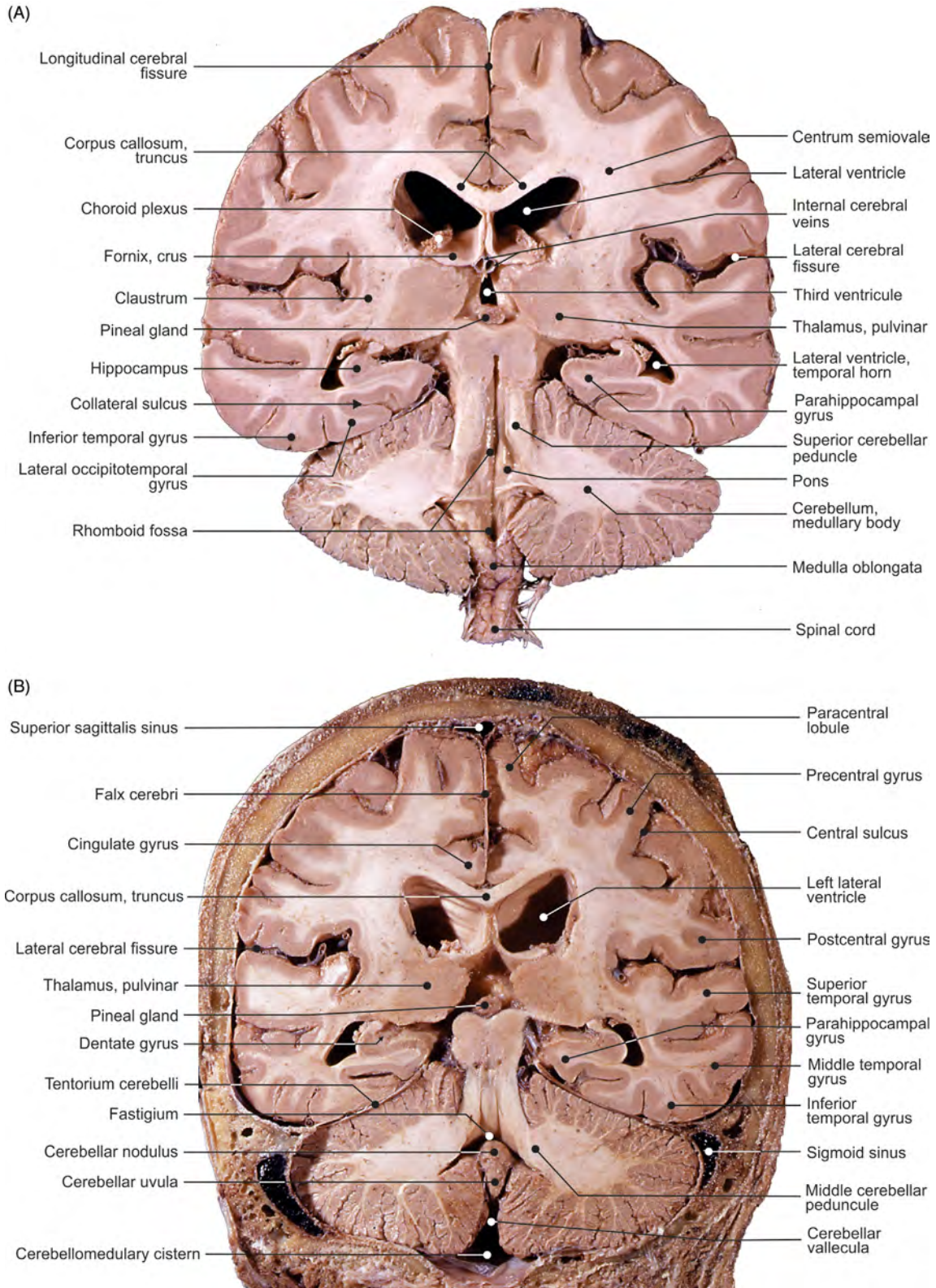


FIGURE 7.30 The (A) anterior and (B) posterior frontal sections of the fourth ventricle and epithalamus.

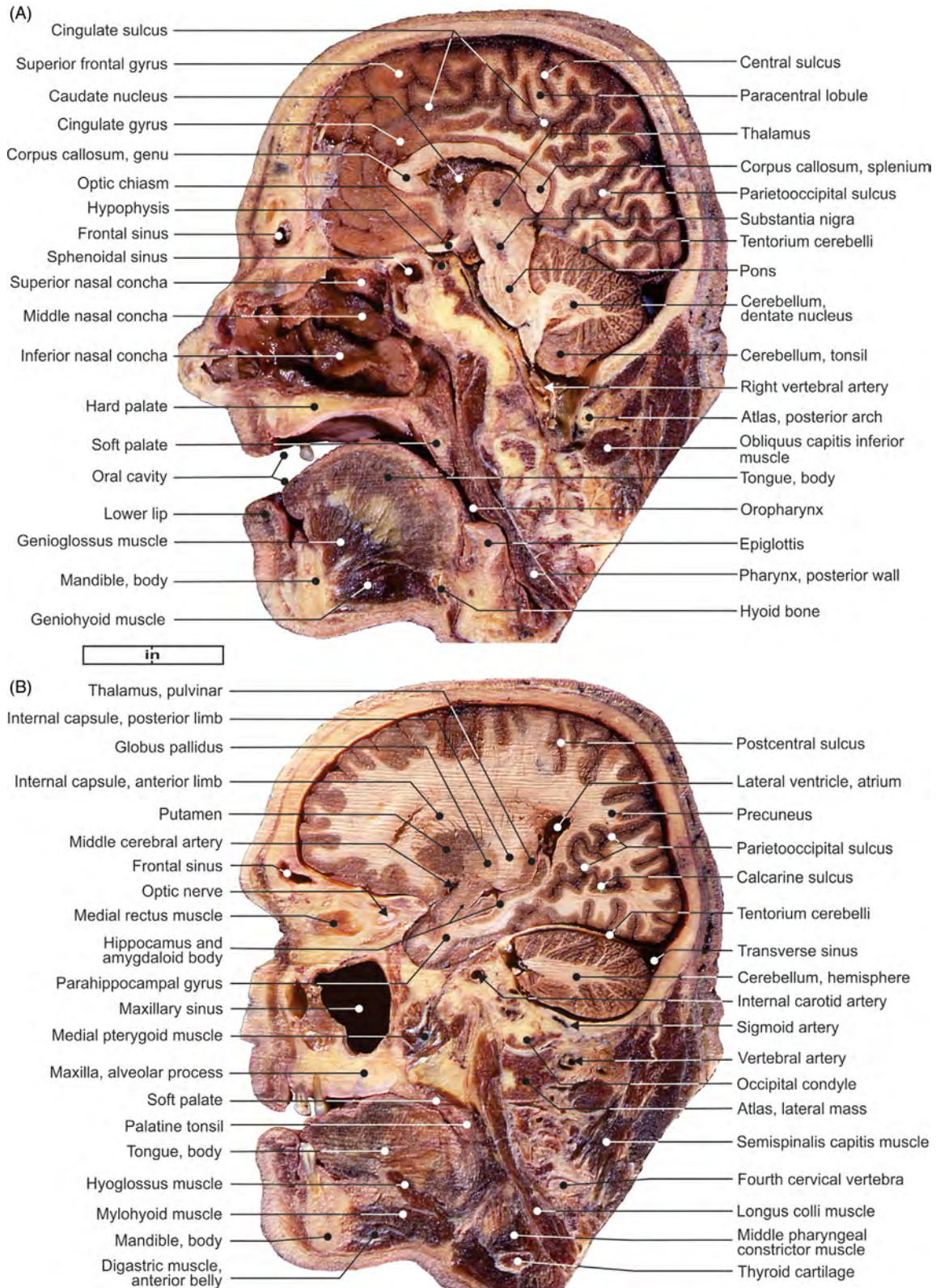


FIGURE 7.31 The sagittal sections of the (A) nasal cavity and (B) maxillary sinus.

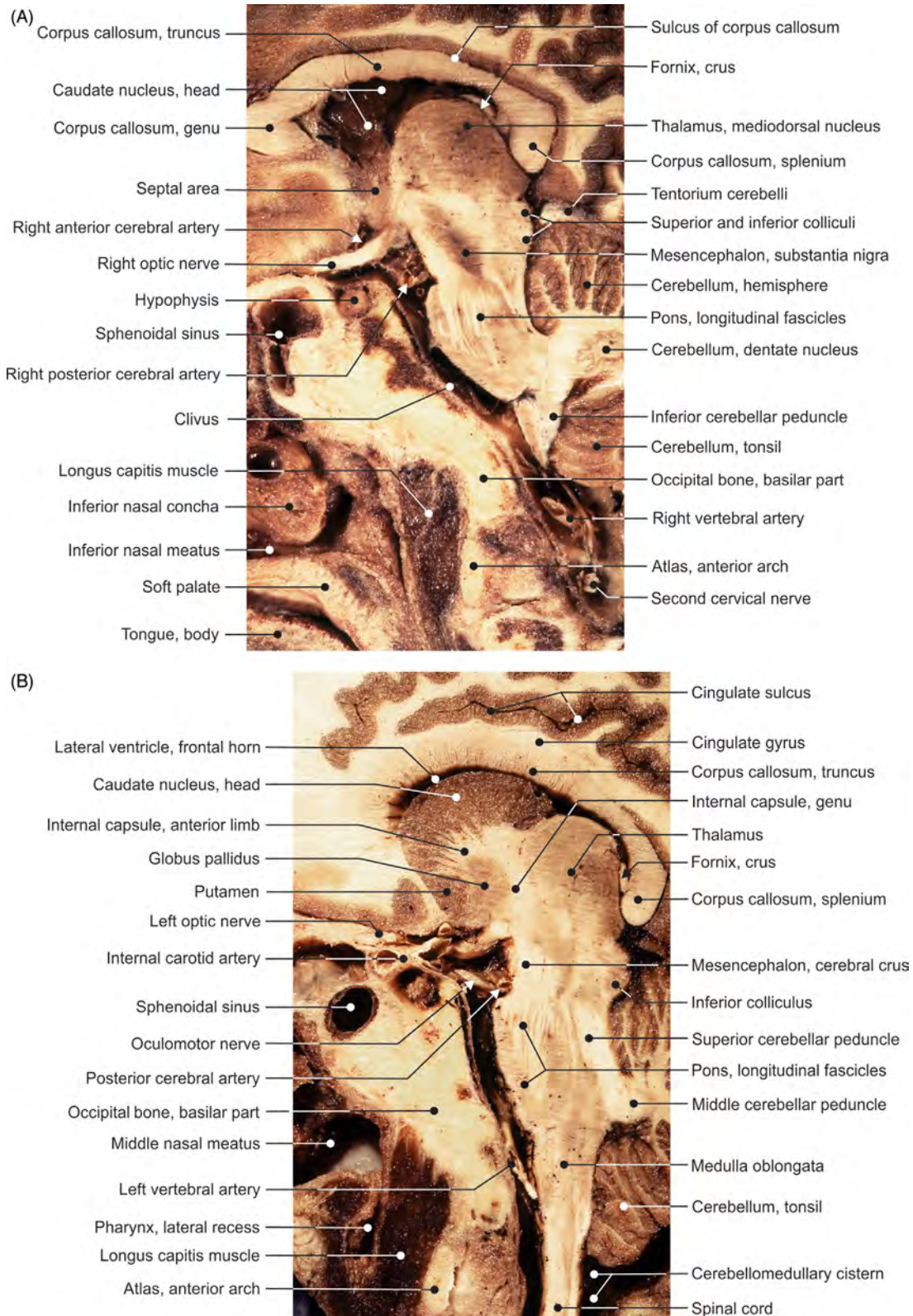


FIGURE 7.32 (A–B) Different views of the sagittal sections of the cerebral hypophysis.

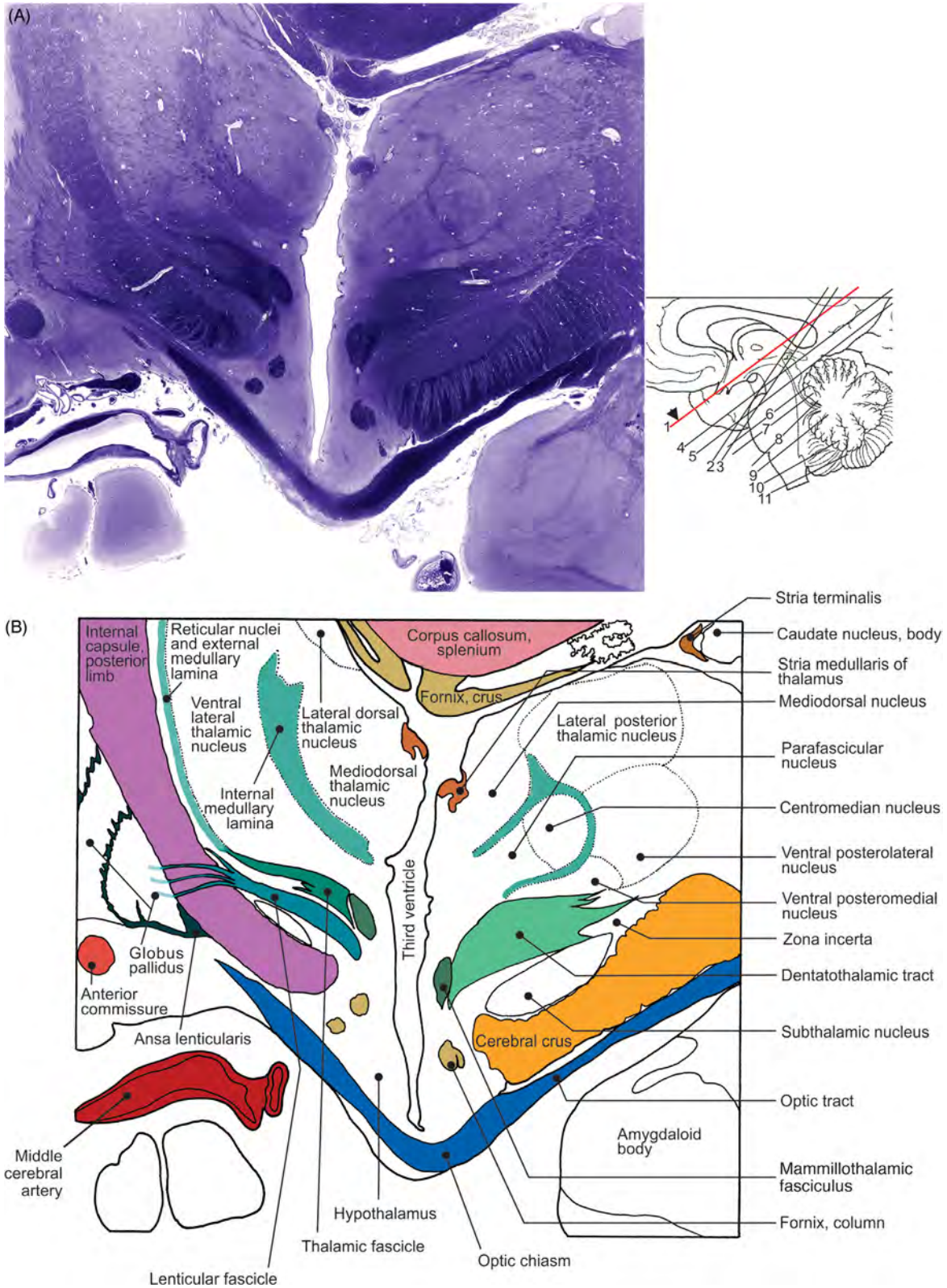


FIGURE 7.33 Transverse section of the brain at the level of optic chiasm and optic tract. (A) Histology and (B) illustration.

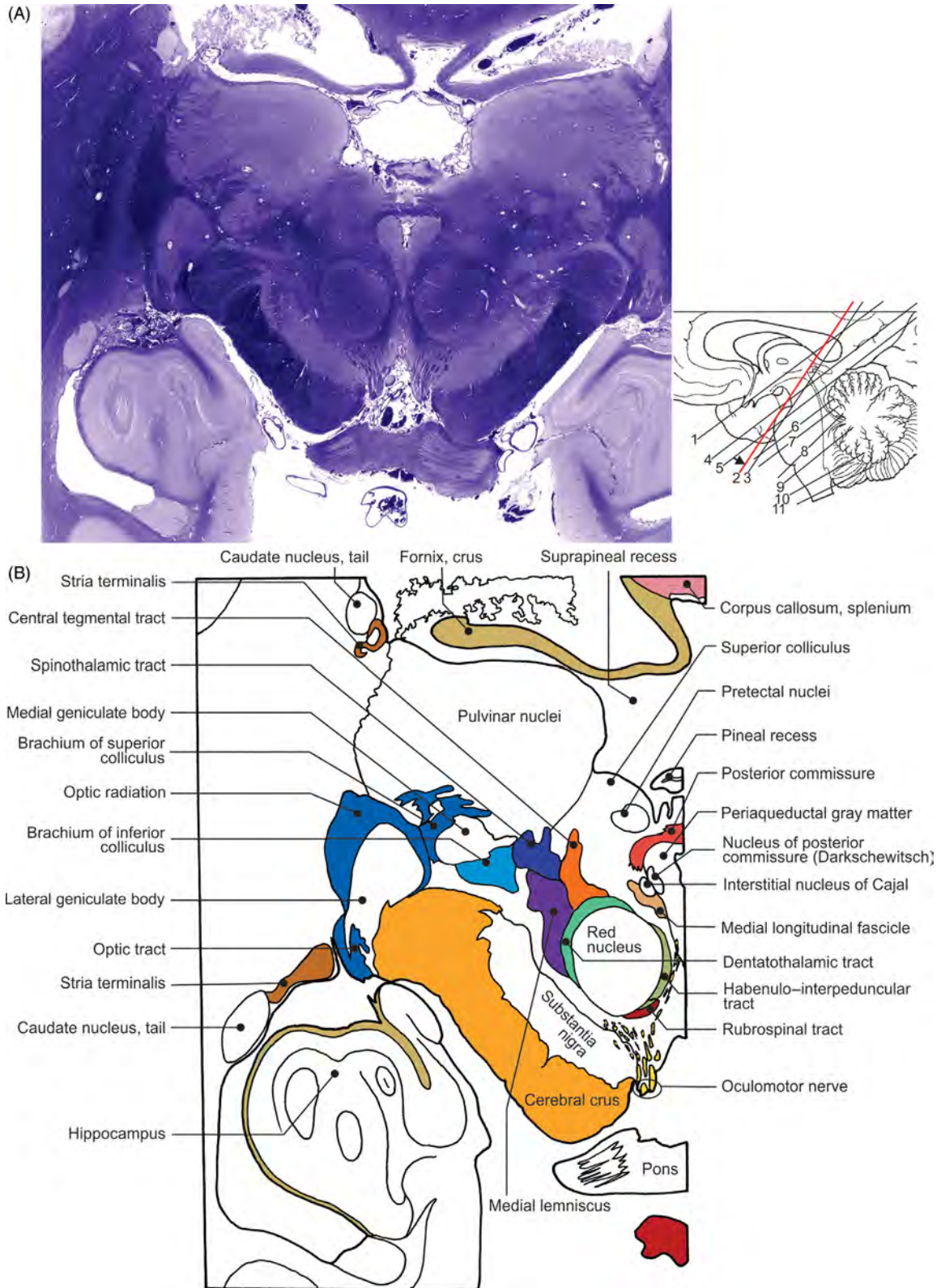


FIGURE 7.34 Transverse section of the brain at the level of red nucleus. (A) Histology and (B) illustration.

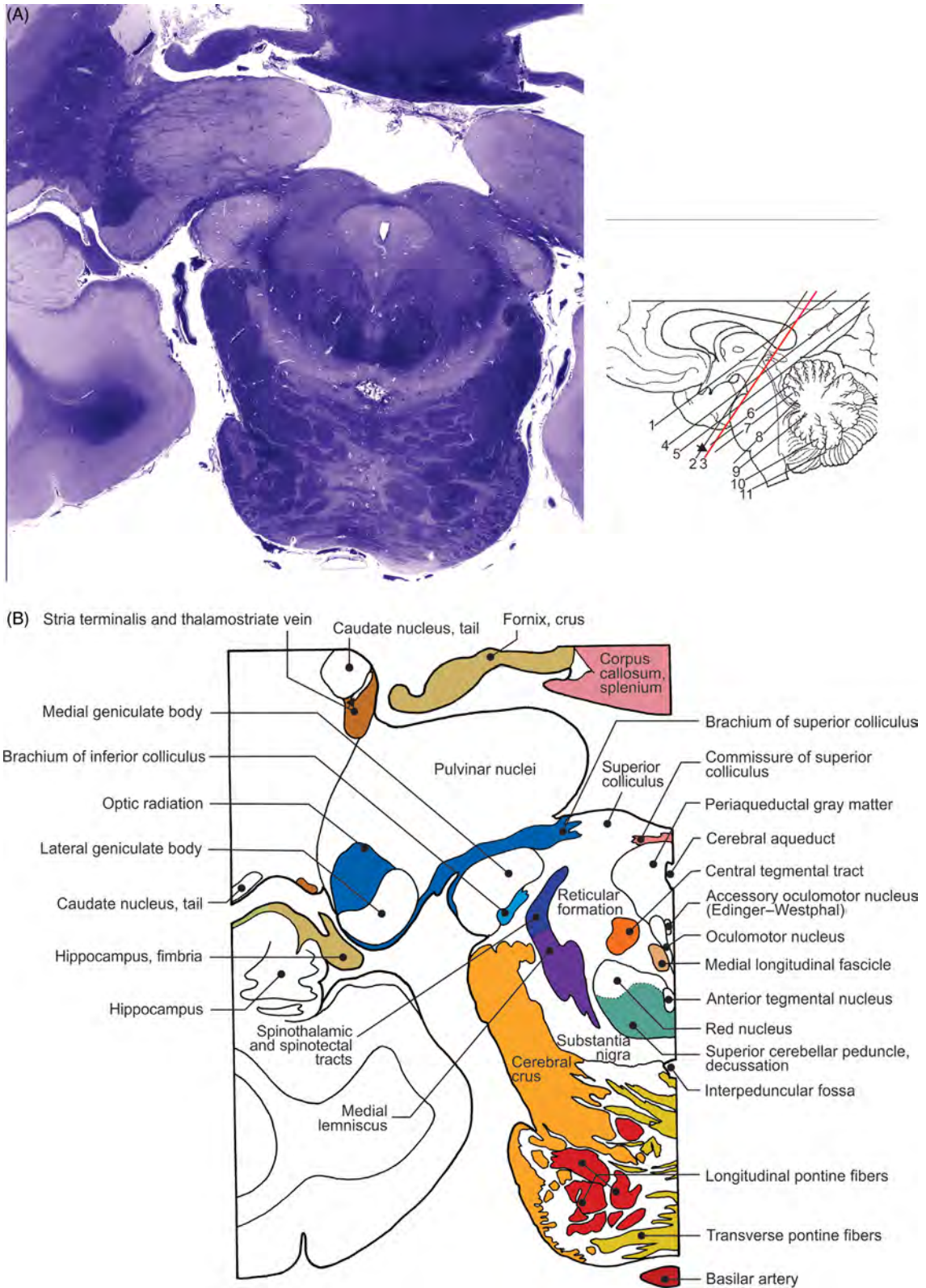


FIGURE 7.35 Transverse section of the brain at the level of lateral and medial geniculate bodies. (A) Histology and (B) illustration.

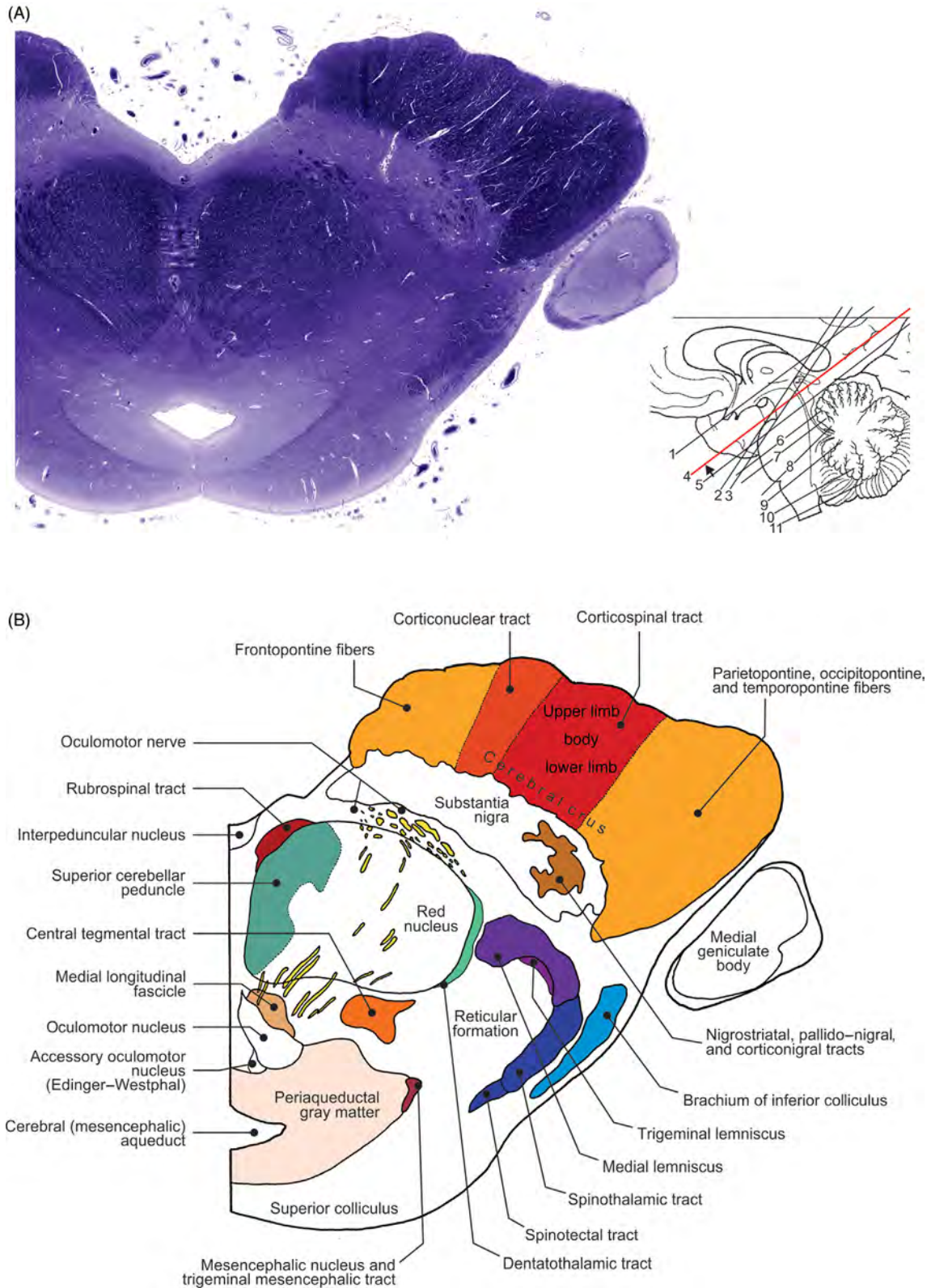


FIGURE 7.36 Transverse section of the mesencephalon at the level of the superior colliculus. (A) Histology and (B) illustration.

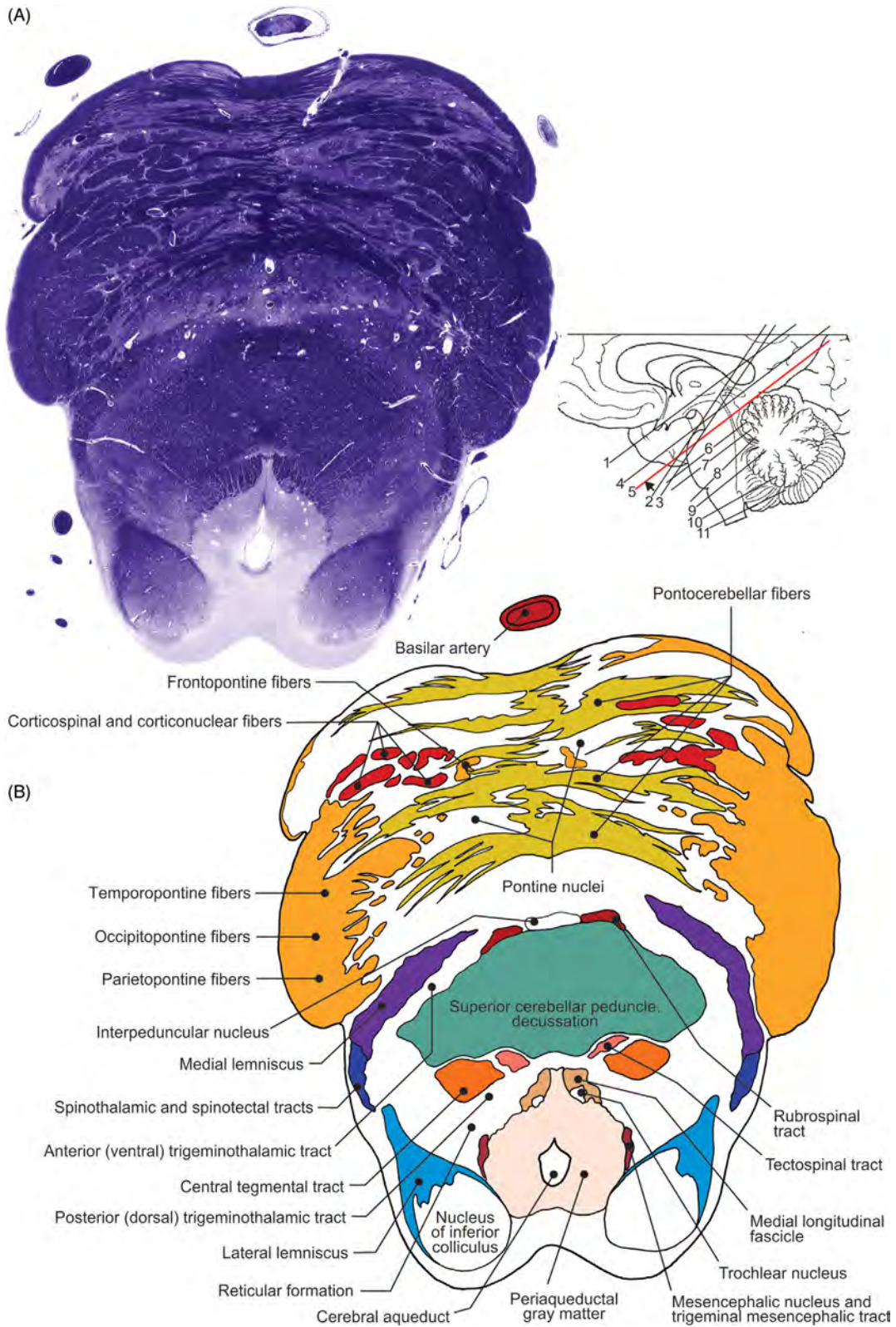


FIGURE 7.37 Transverse section of the pons and mesencephalon at the level of the inferior colliculus. (A) Histology and (B) illustration.

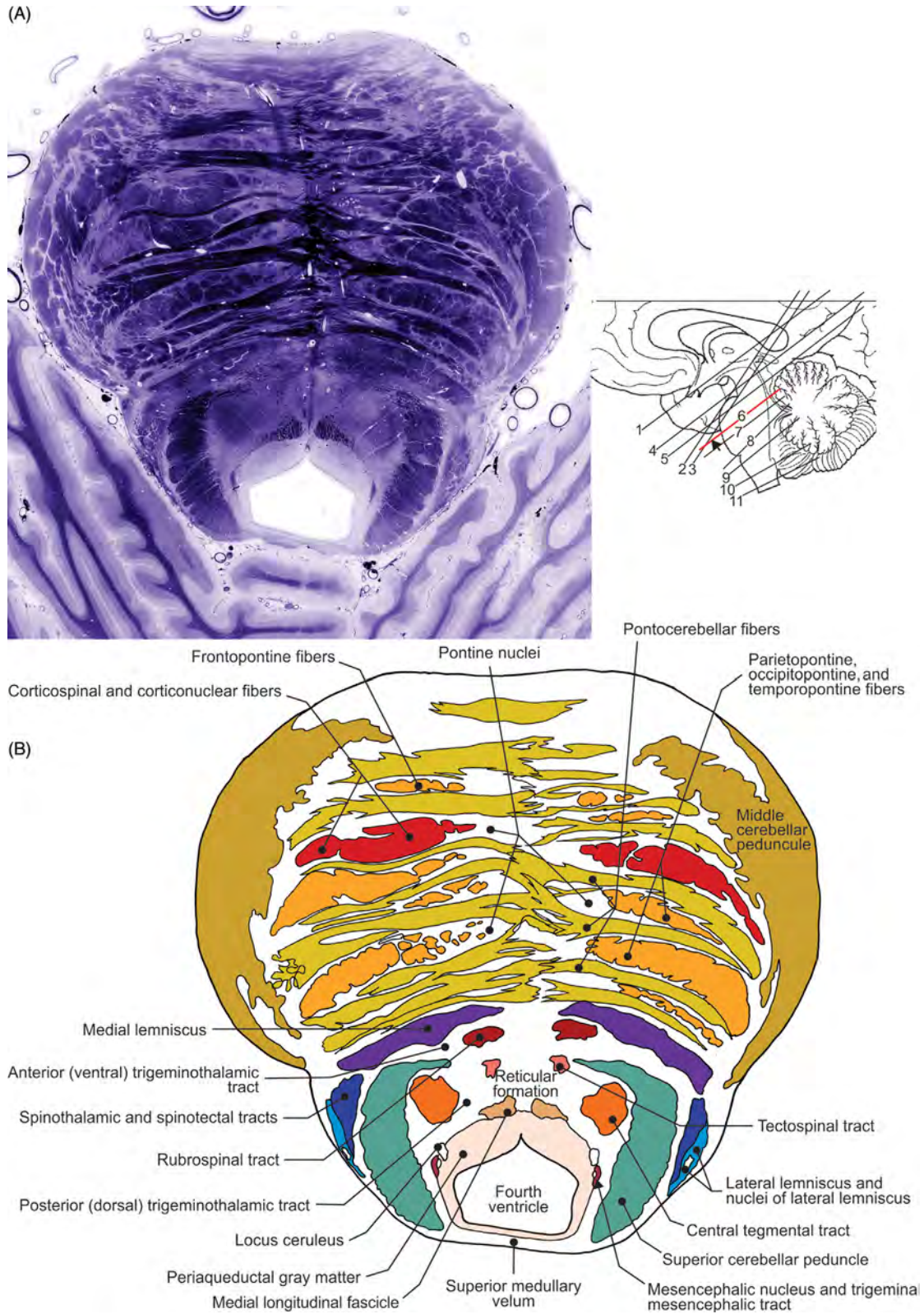


FIGURE 7.38 Transverse section of the upper segment of pons. (A) Histology and (B) illustration.

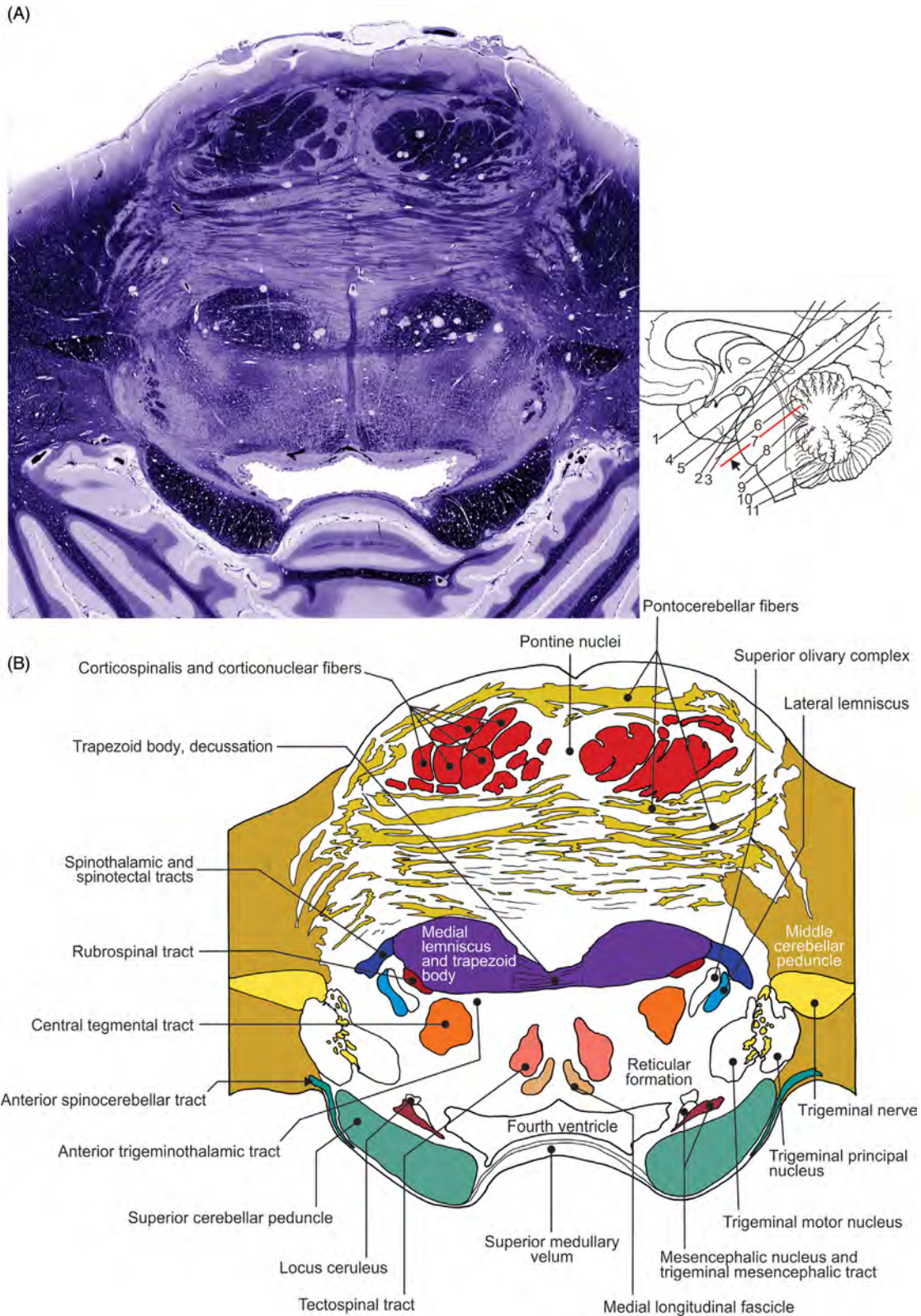


FIGURE 7.39 Transverse section of the middle third of pons. (A) Histology and (B) illustration.

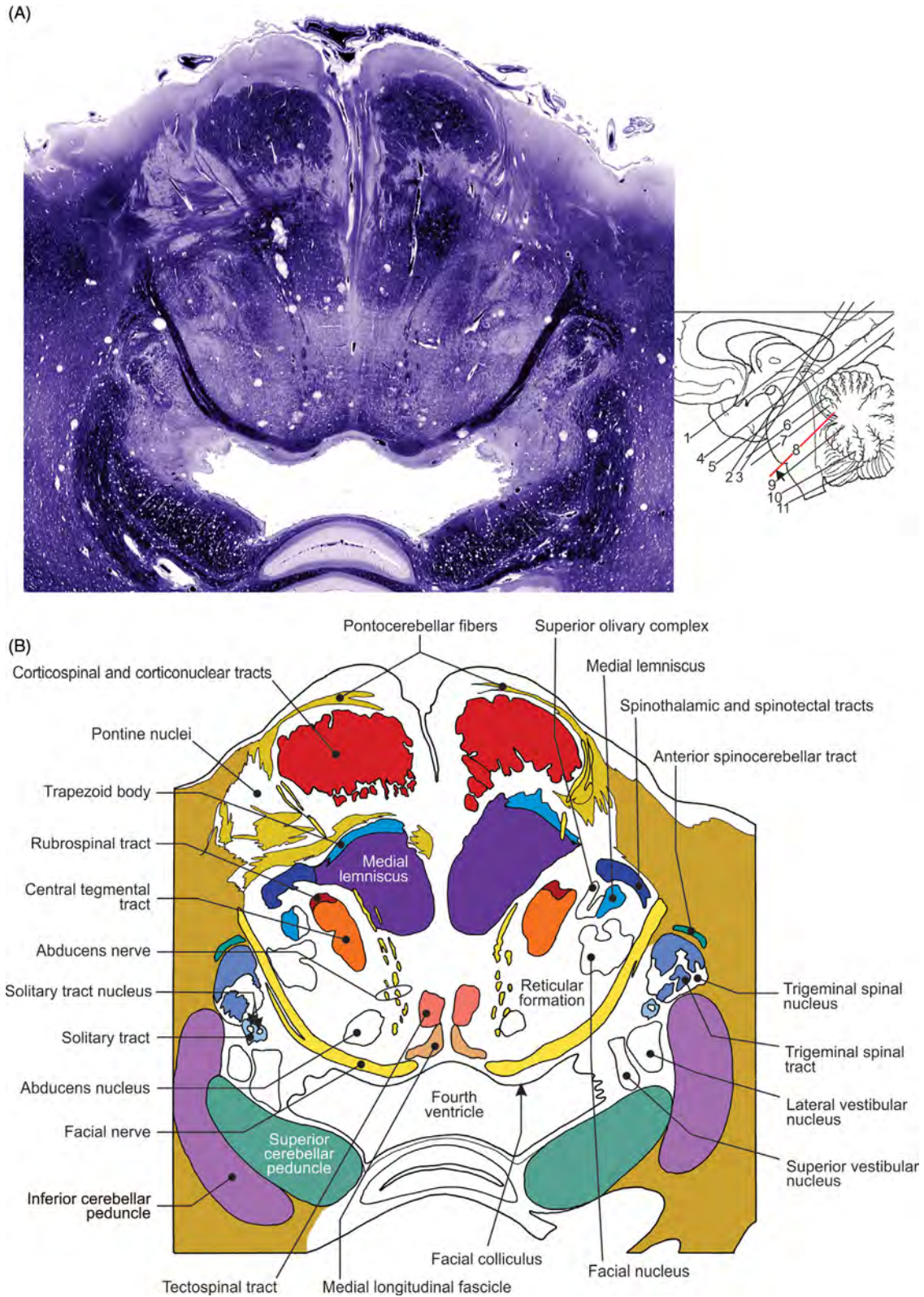


FIGURE 7.40 Transverse section of pons at the level of the facial nerve nucleus. (A) Histology and (B) illustration.

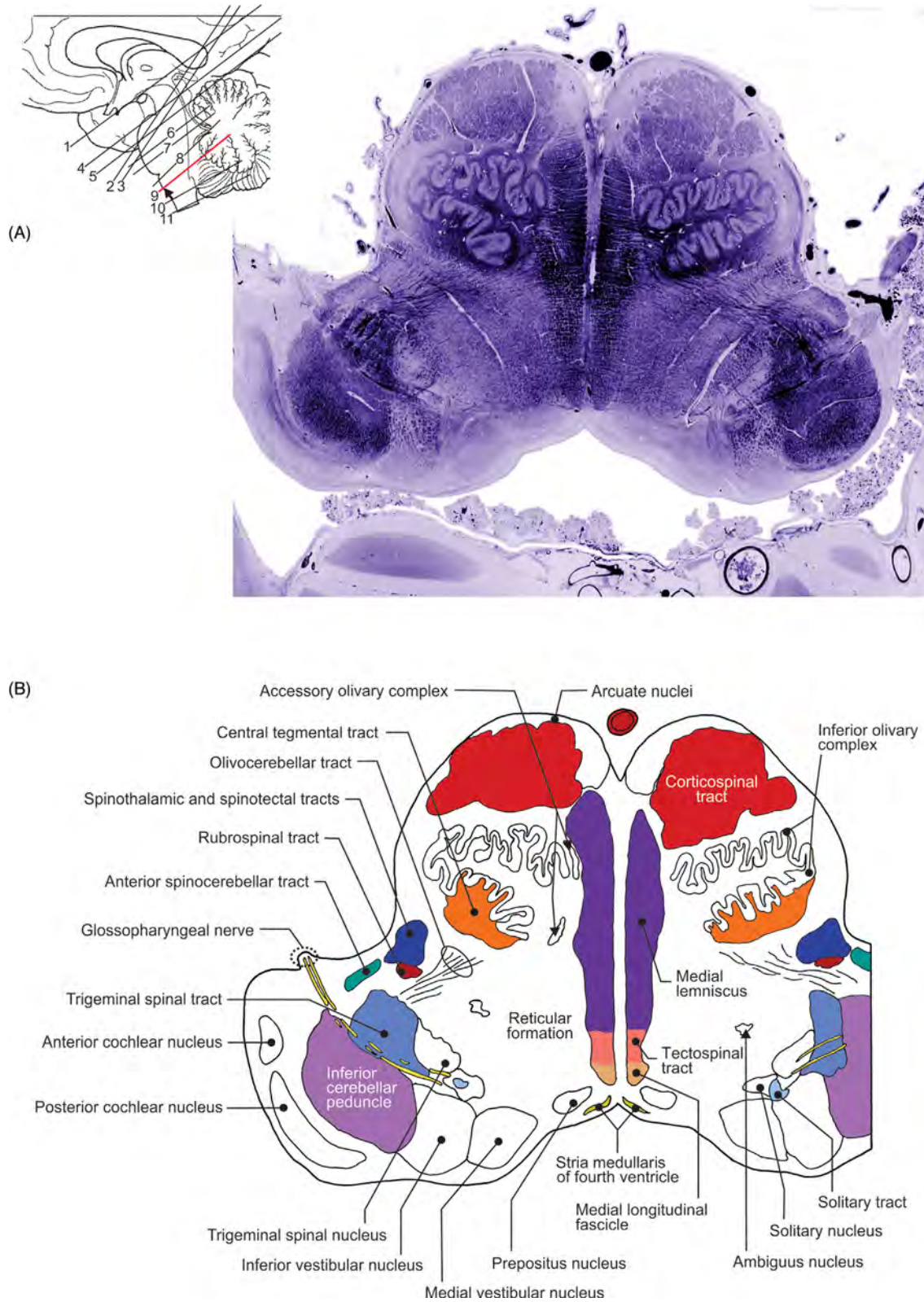


FIGURE 7.41 Transverse section of the uppermost segment of medulla oblongata. (A) Histology and (B) illustration.

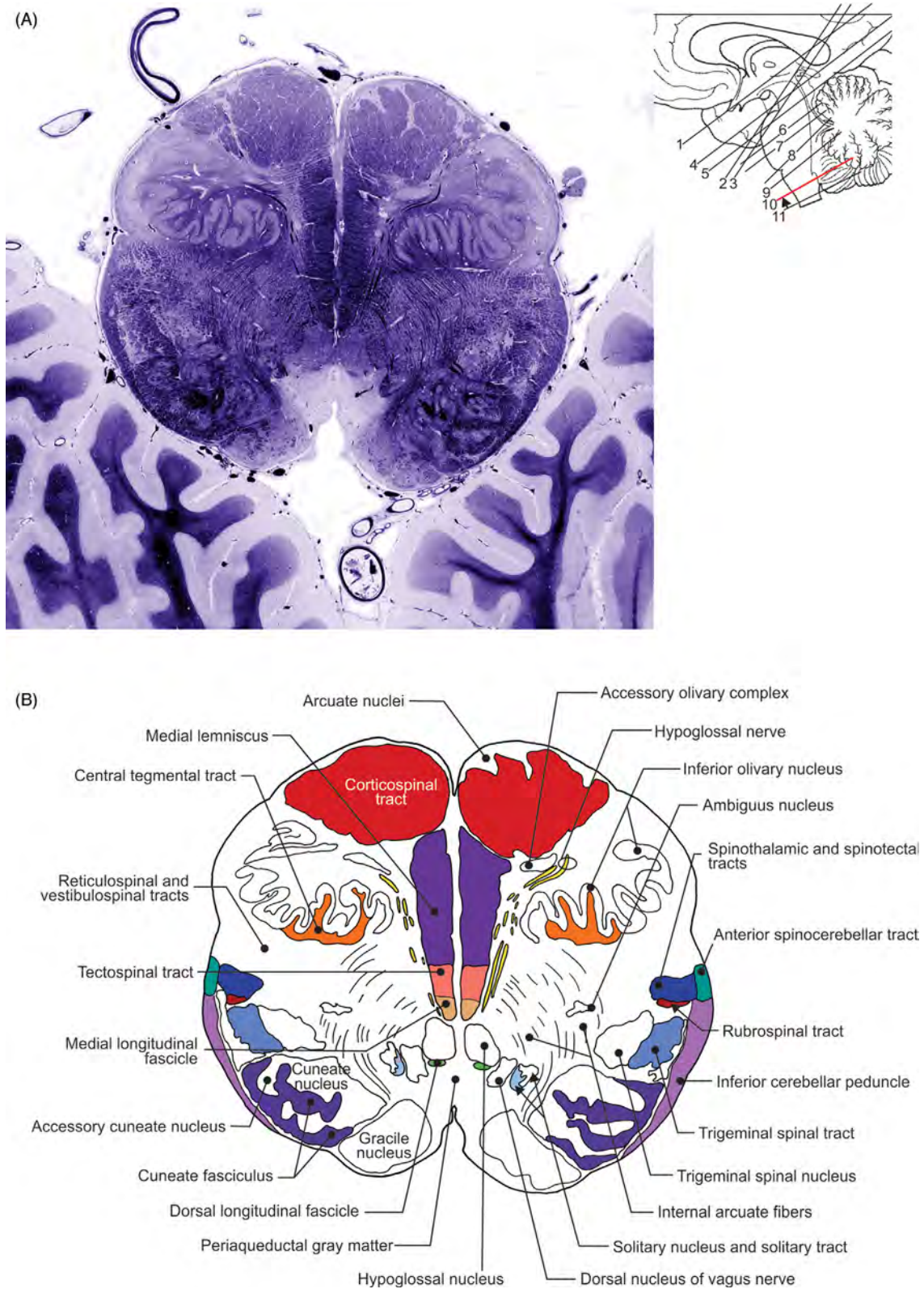


FIGURE 7.42 Transverse section through the middle segment of medulla oblongata. (A) Histology and (B) illustration.

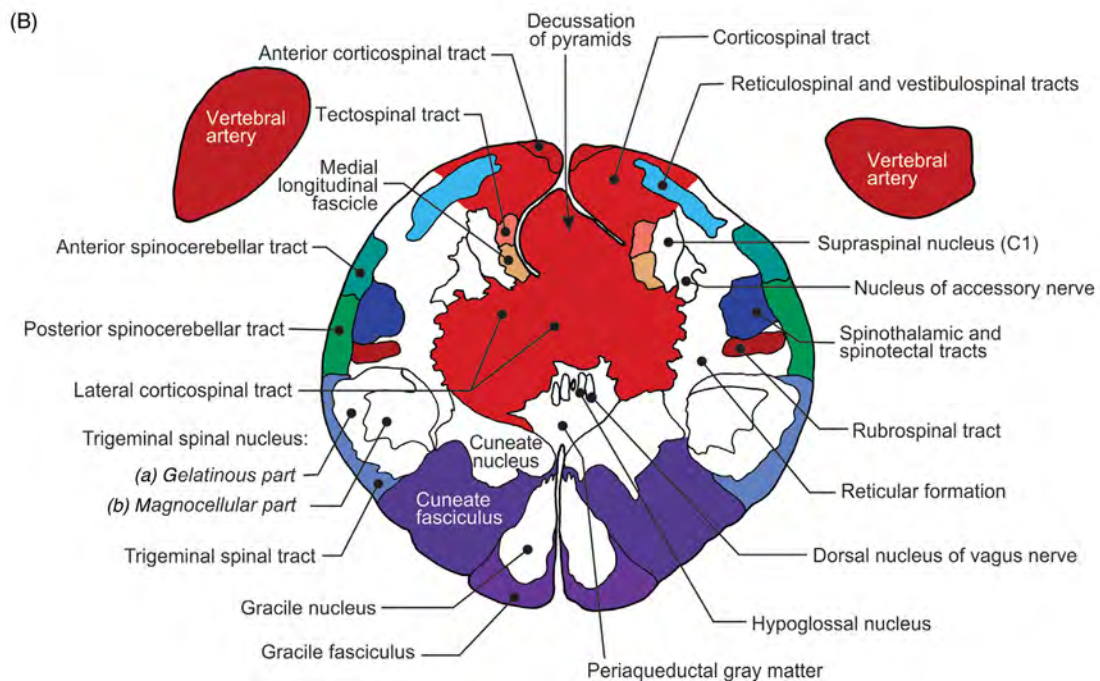
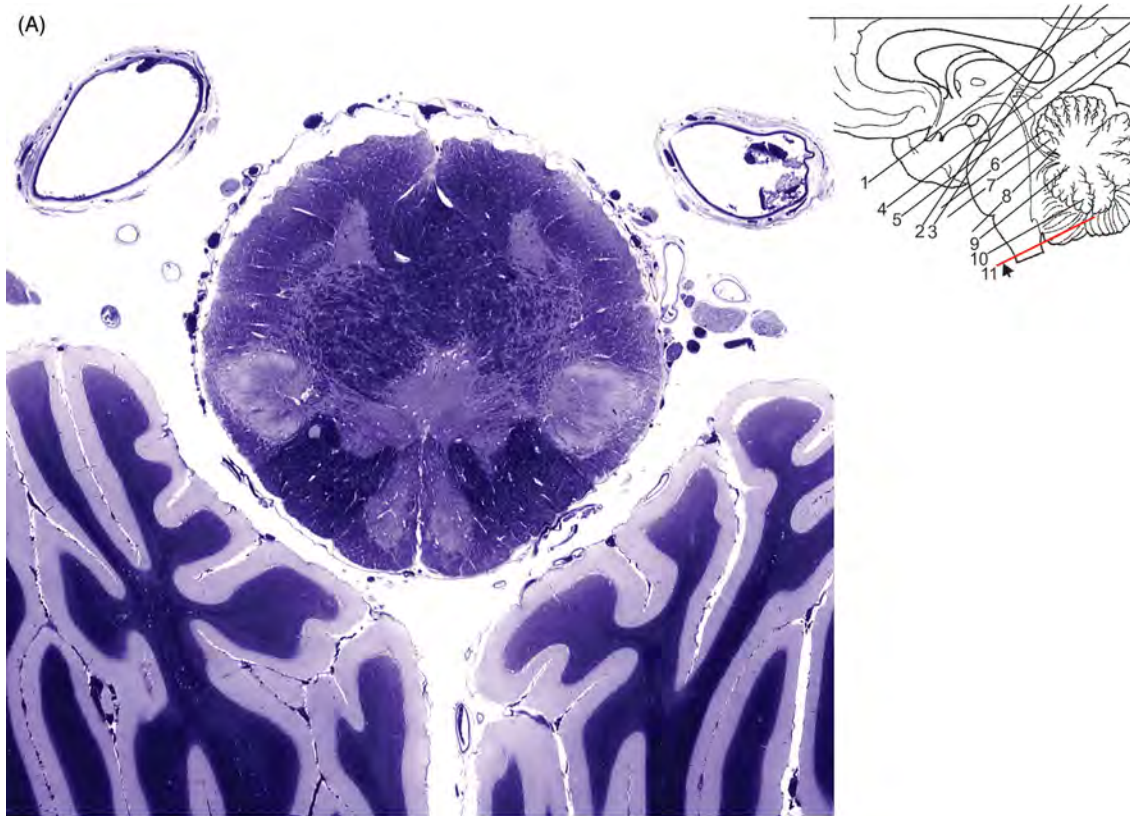


FIGURE 7.43 Transverse section of medulla oblongata through the decussation of pyramids. (A) Histology and (B) illustration.

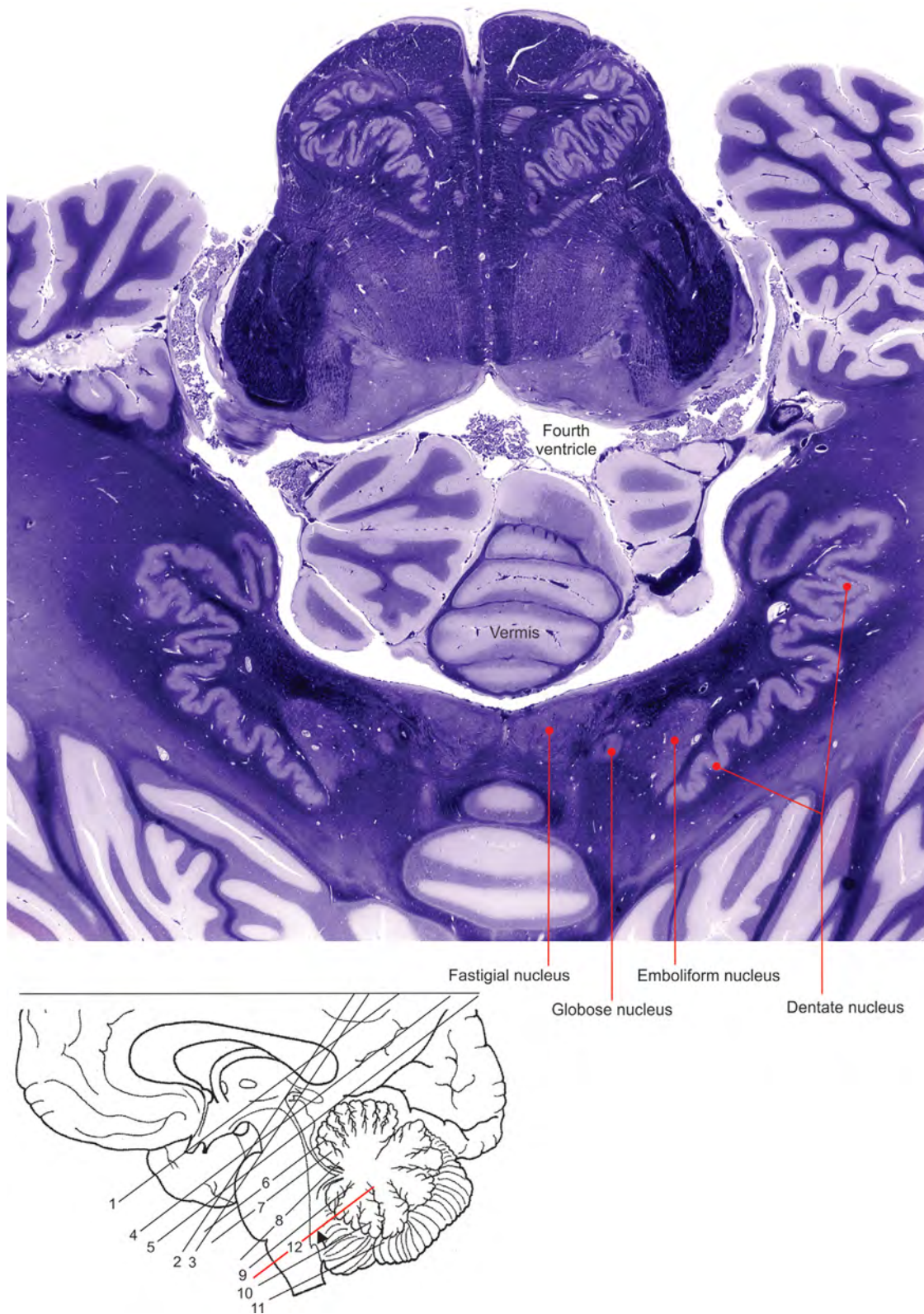


FIGURE 7.44 Transverse section of cerebellar nuclei.

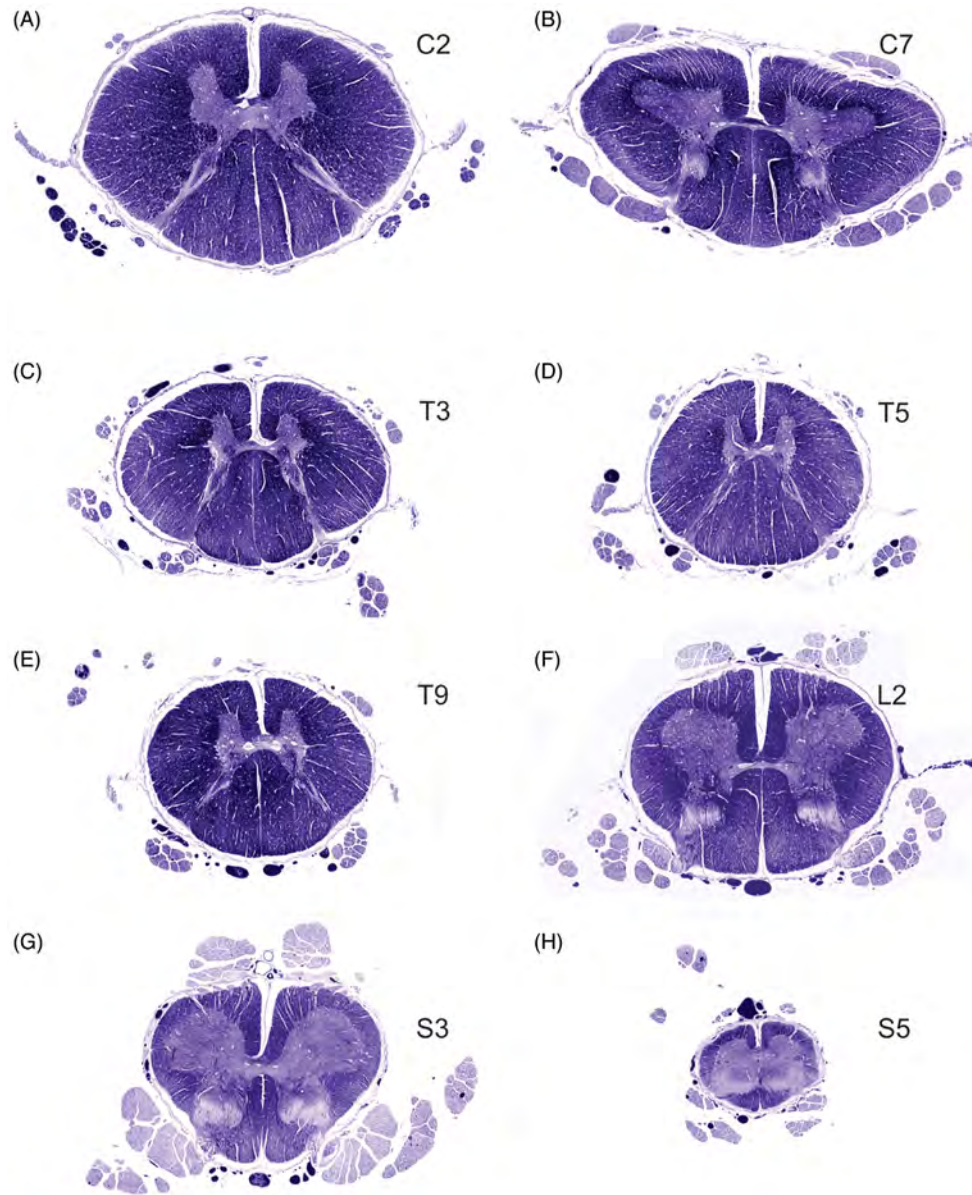


FIGURE 7.45 (A–H) Sequential transverse sections of the spinal cord.

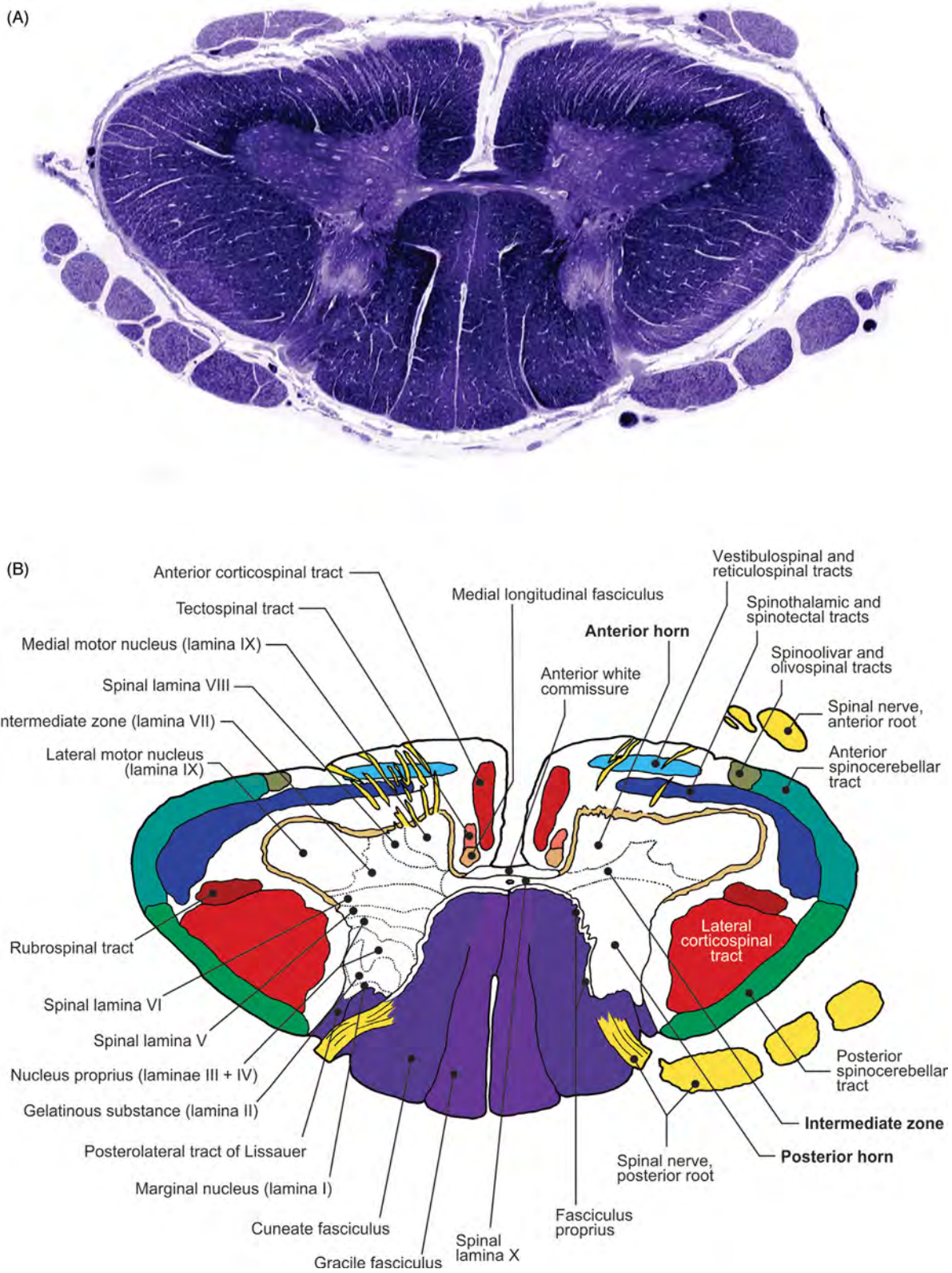
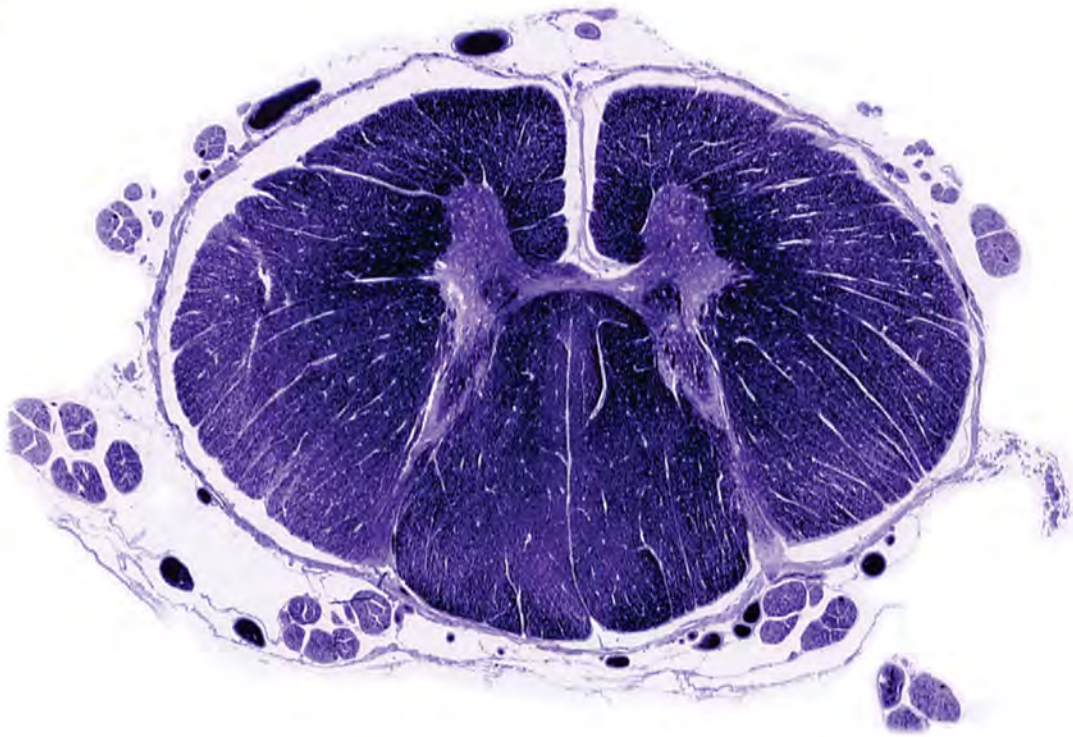

FIGURE 7.46 Transverse section of C7 segment of the spinal cord. (A) Histology and (B) illustration.

(A)



(B)

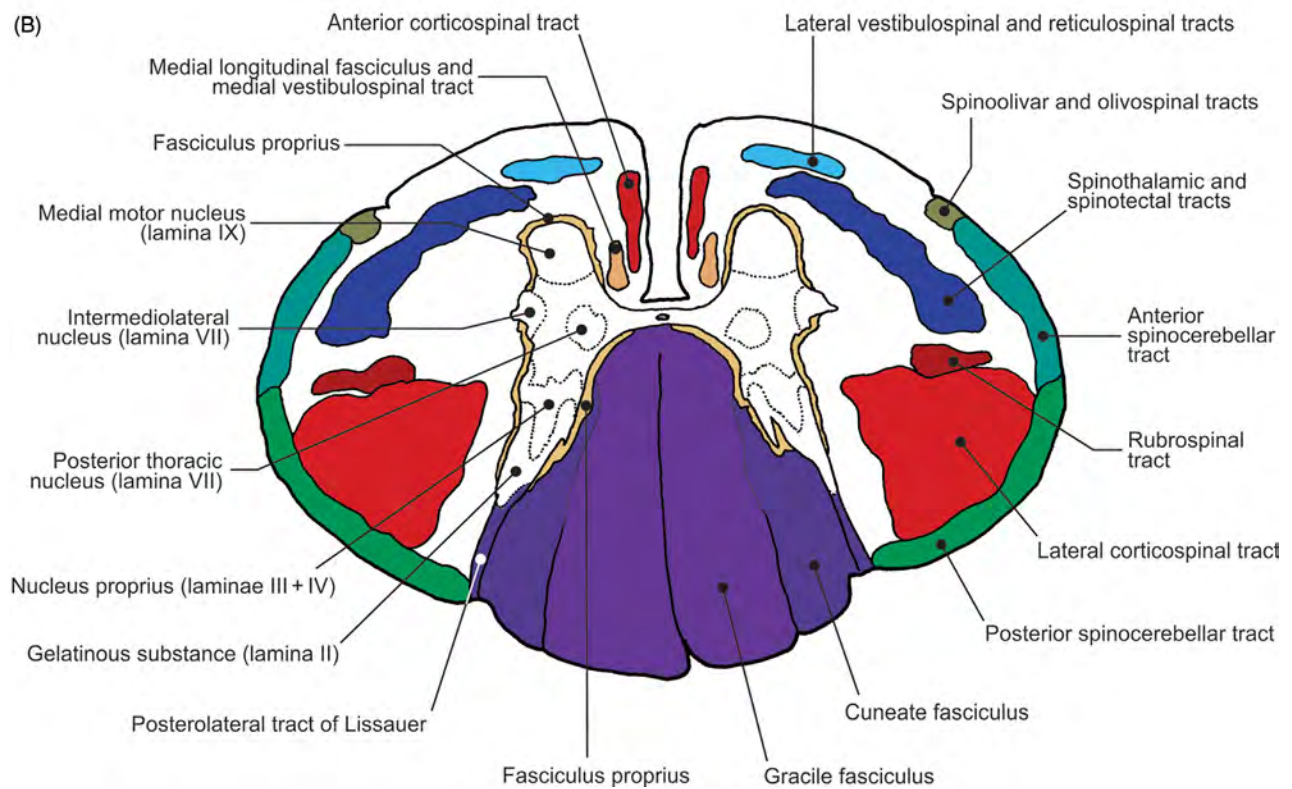


FIGURE 7.47 Transverse section of T3 segment of the spinal cord. (A) Histology and (B) illustration.

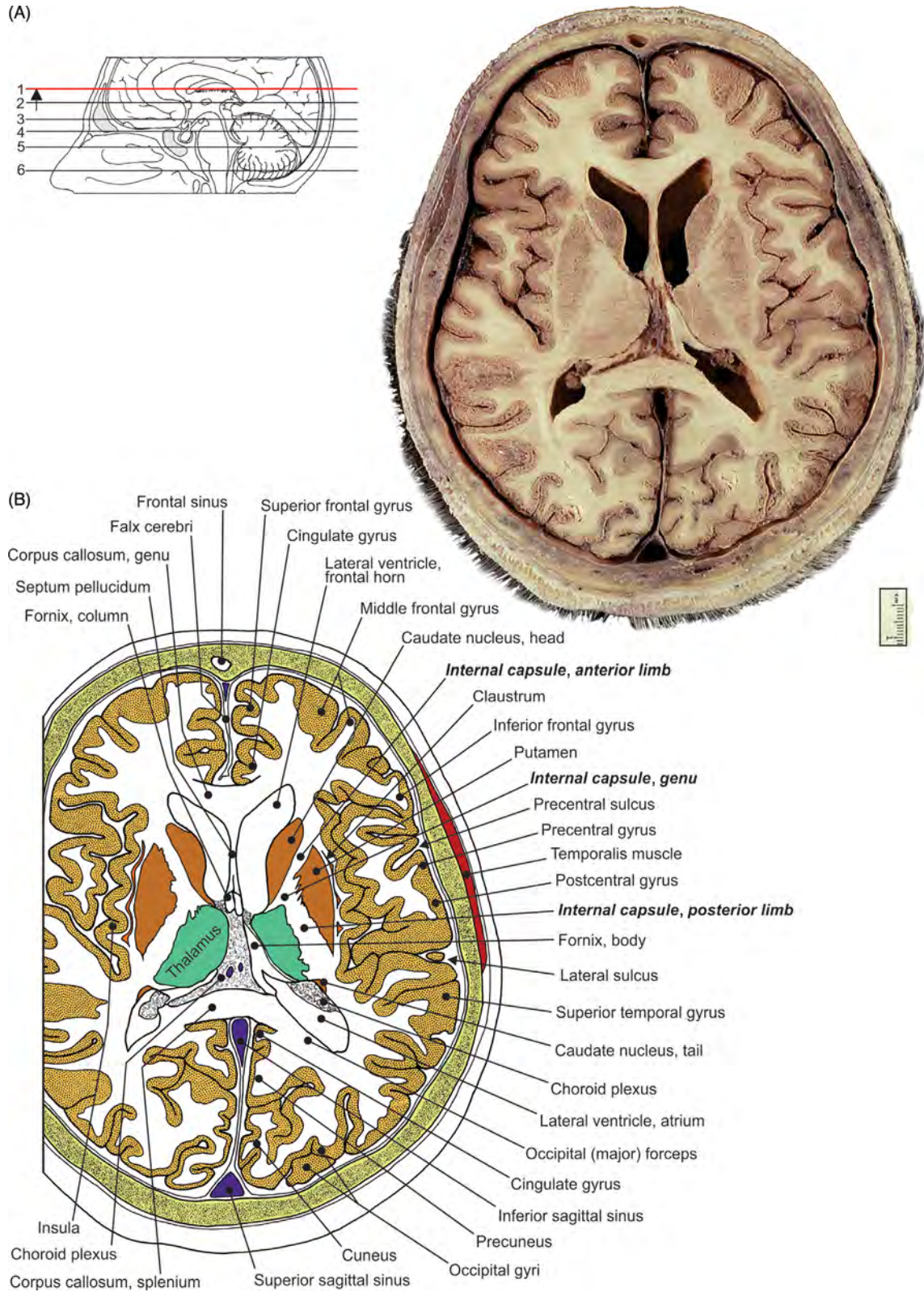


FIGURE 7.48 Transverse section of the genu and splenium of corpus callosum. (A) Section and (B) illustration.

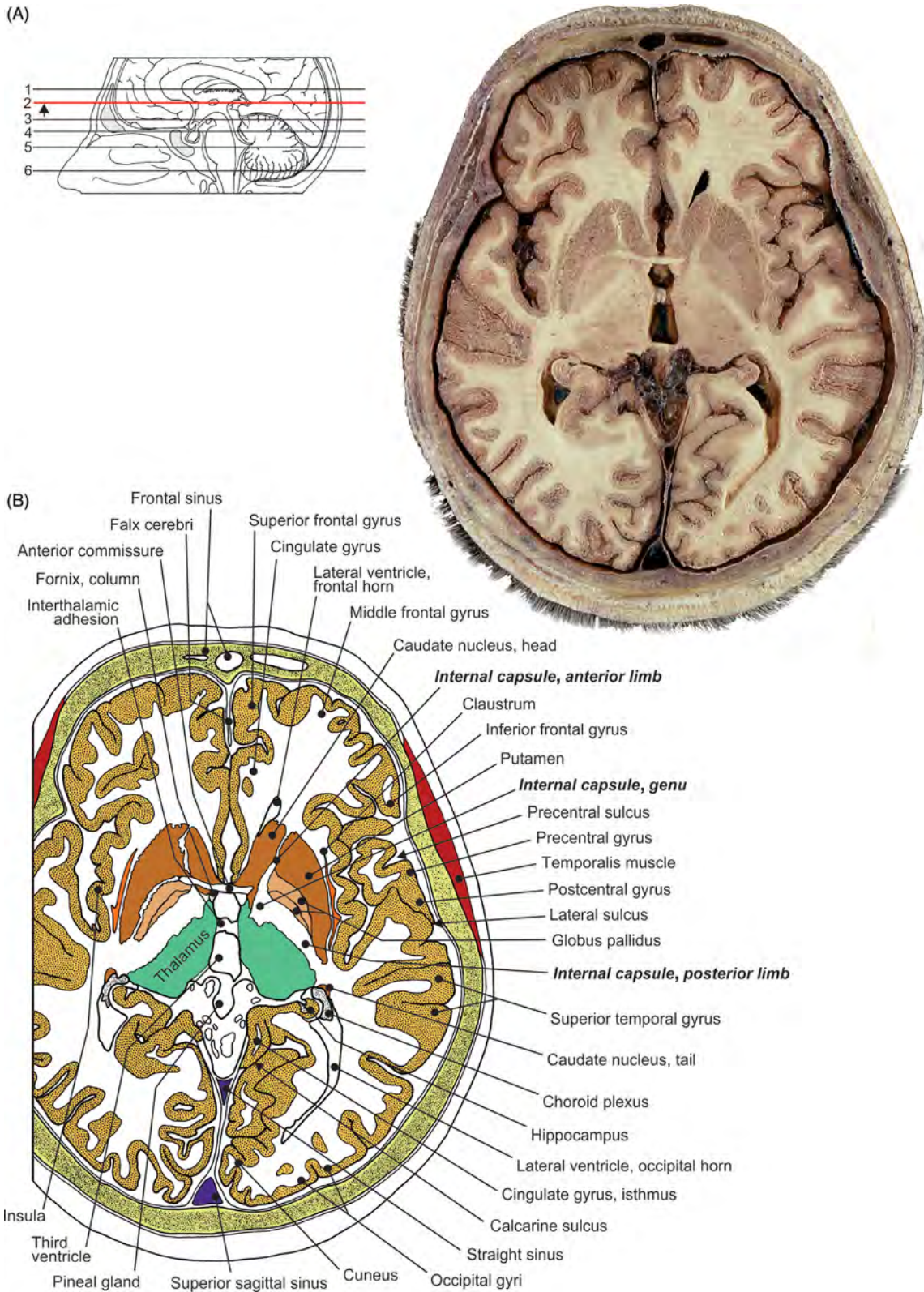


FIGURE 7.49 Transverse section of the pineal gland. (A) Section and (B) illustration.

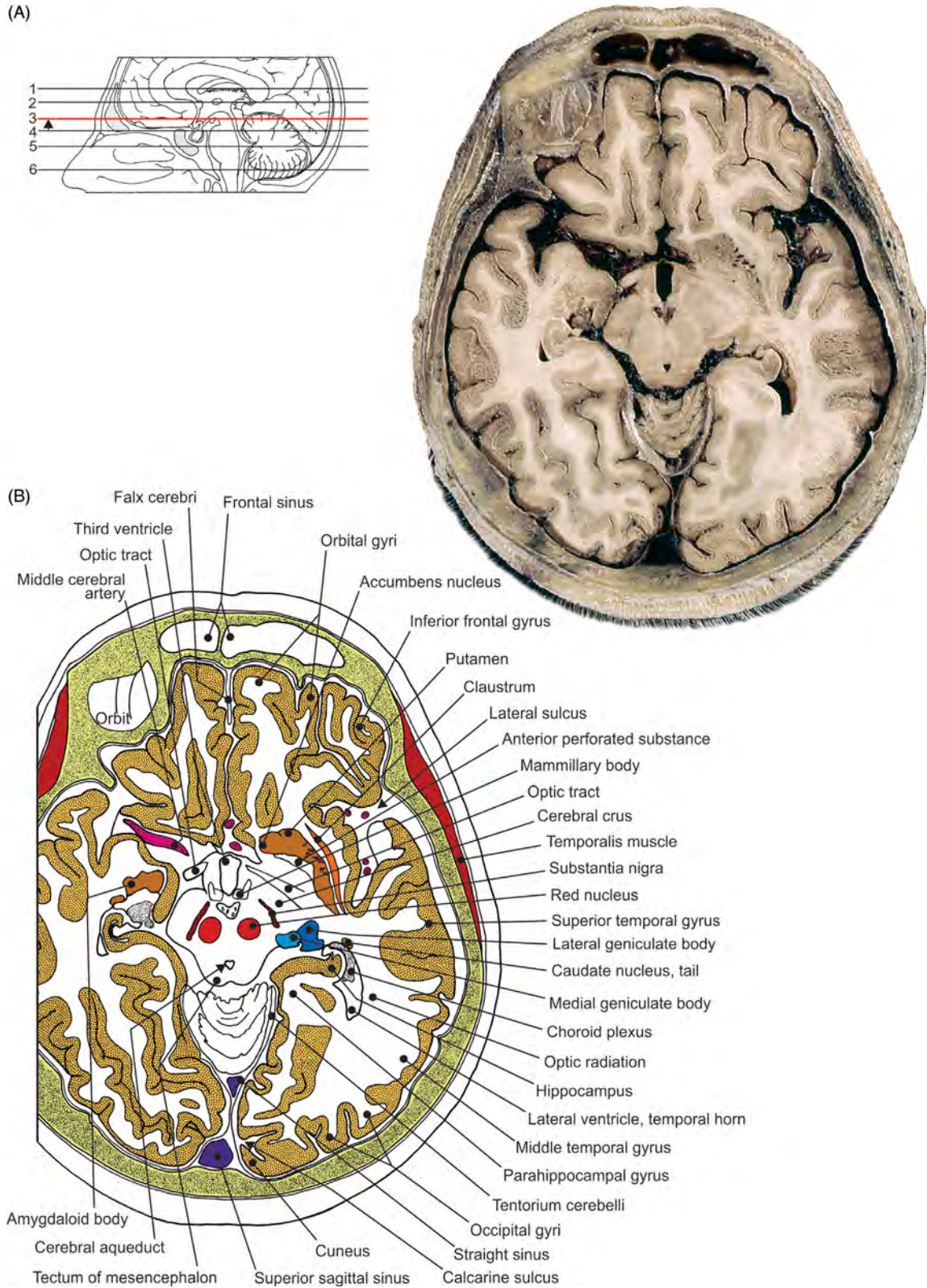


FIGURE 7.50 Transverse section of the mesencephalon. (A) Section and (B) illustration.

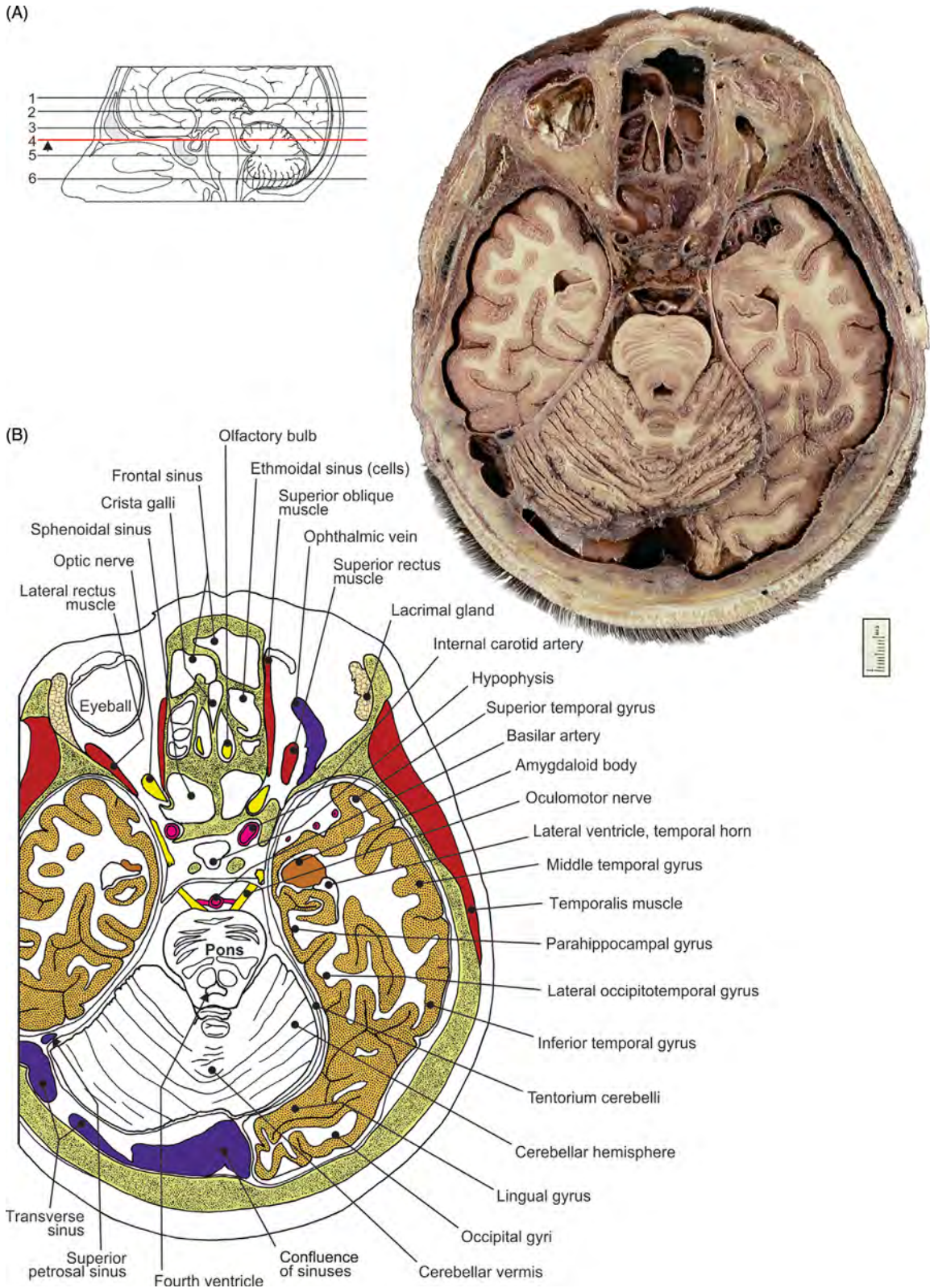
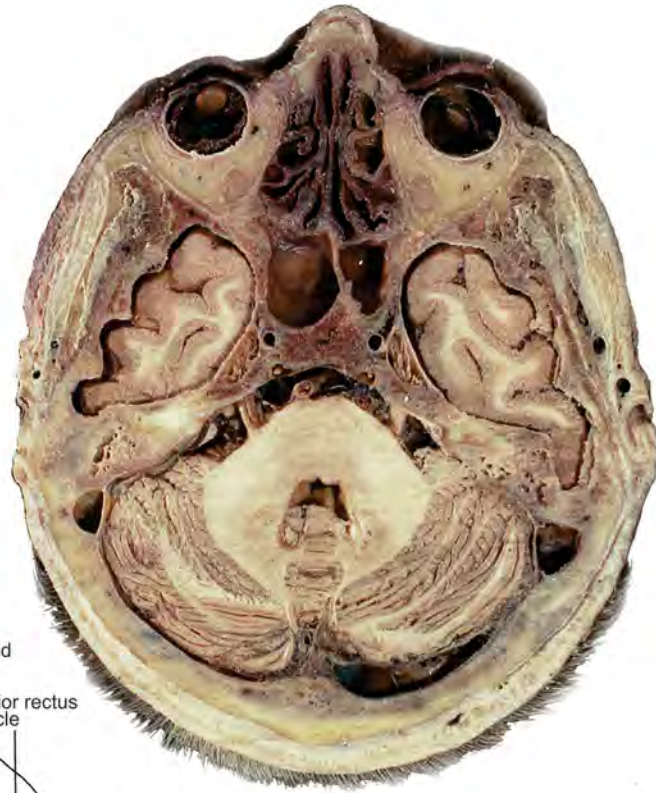
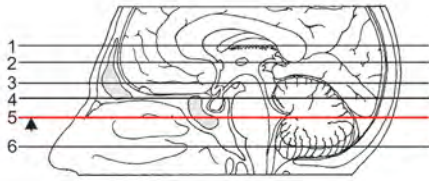


FIGURE 7.51 Transverse section of the uppermost segment of pons. (A) Section and (B) illustration.

(A)



(B)

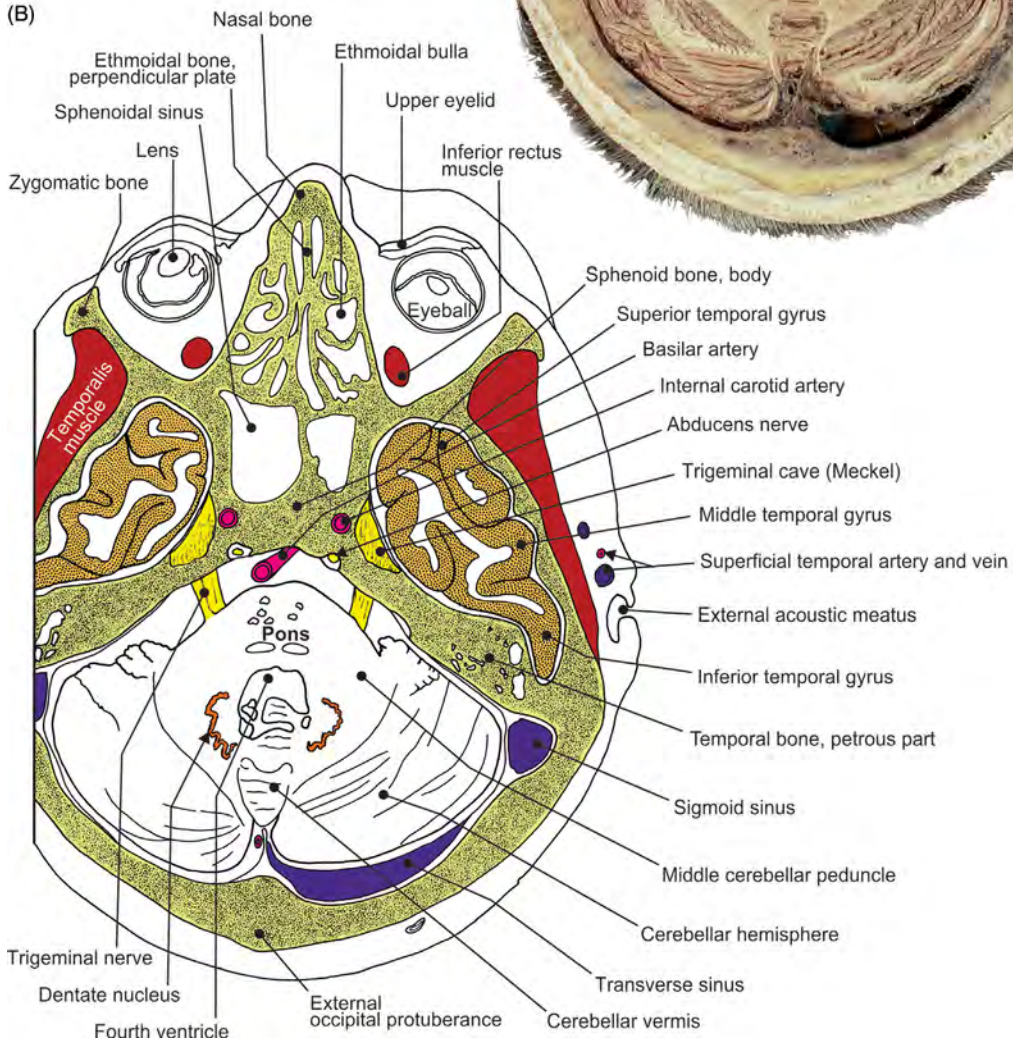


FIGURE 7.52 Transverse section of the lowermost segment of pons. (A) Section and (B) illustration.

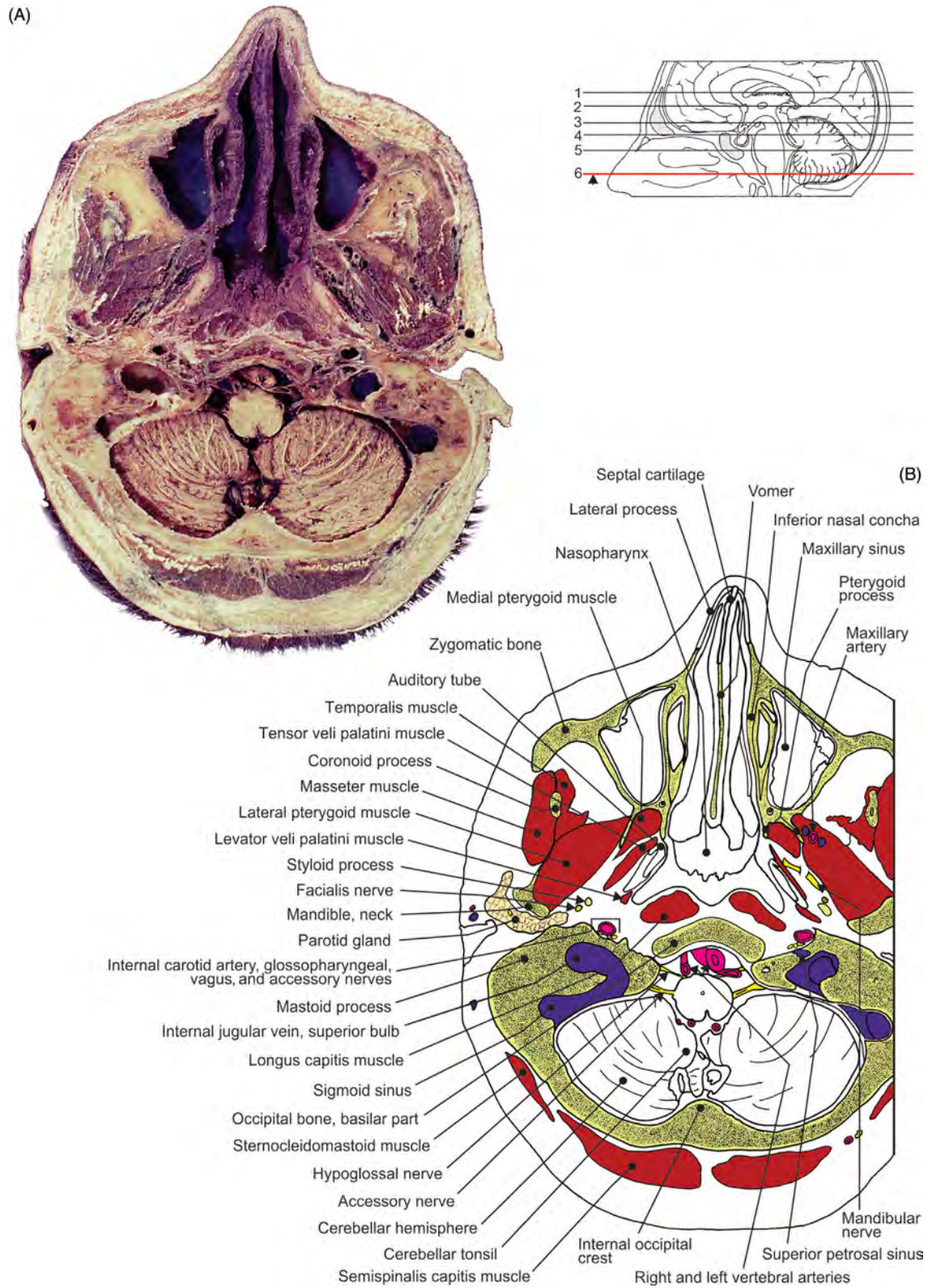


FIGURE 7.53 Transverse section of medulla oblongata. (A) Section and (B) illustration.

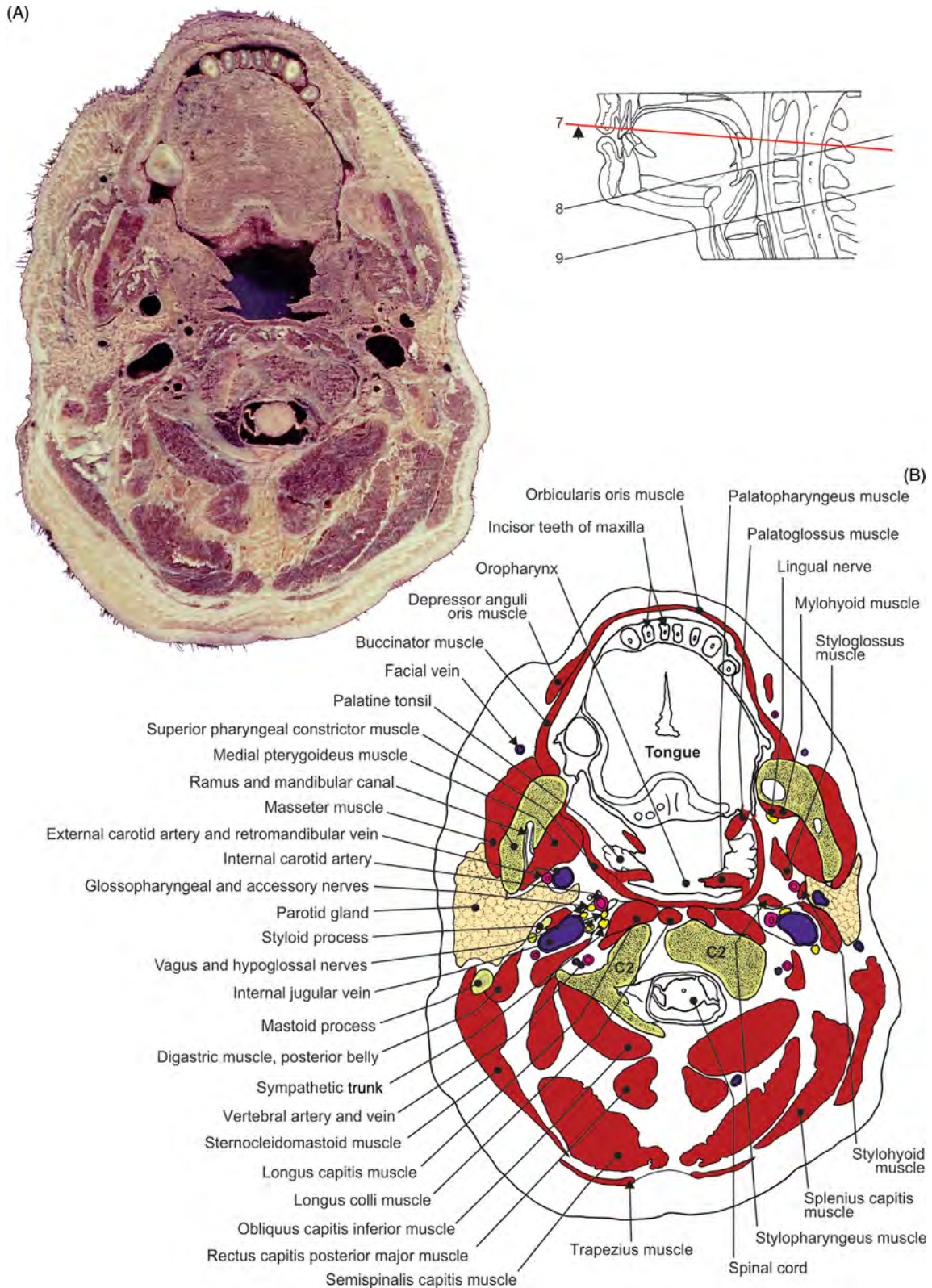


FIGURE 7.54 Transverse section of the oral cavity at the level of C2 vertebra. (A) Section and (B) illustration.

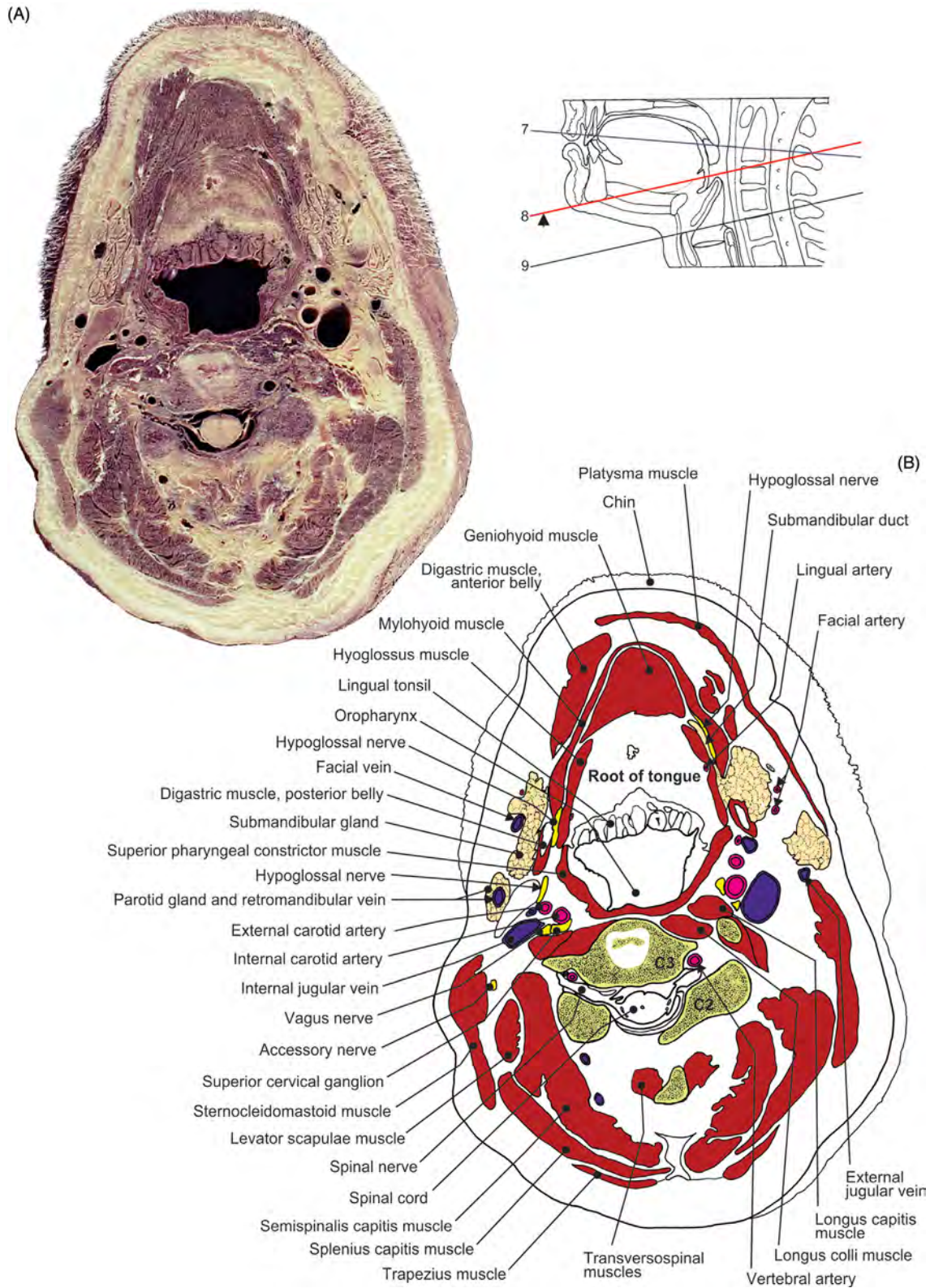


FIGURE 7.55 Transverse section of the neck at the level of C3 vertebra. (A) Section and (B) illustration.

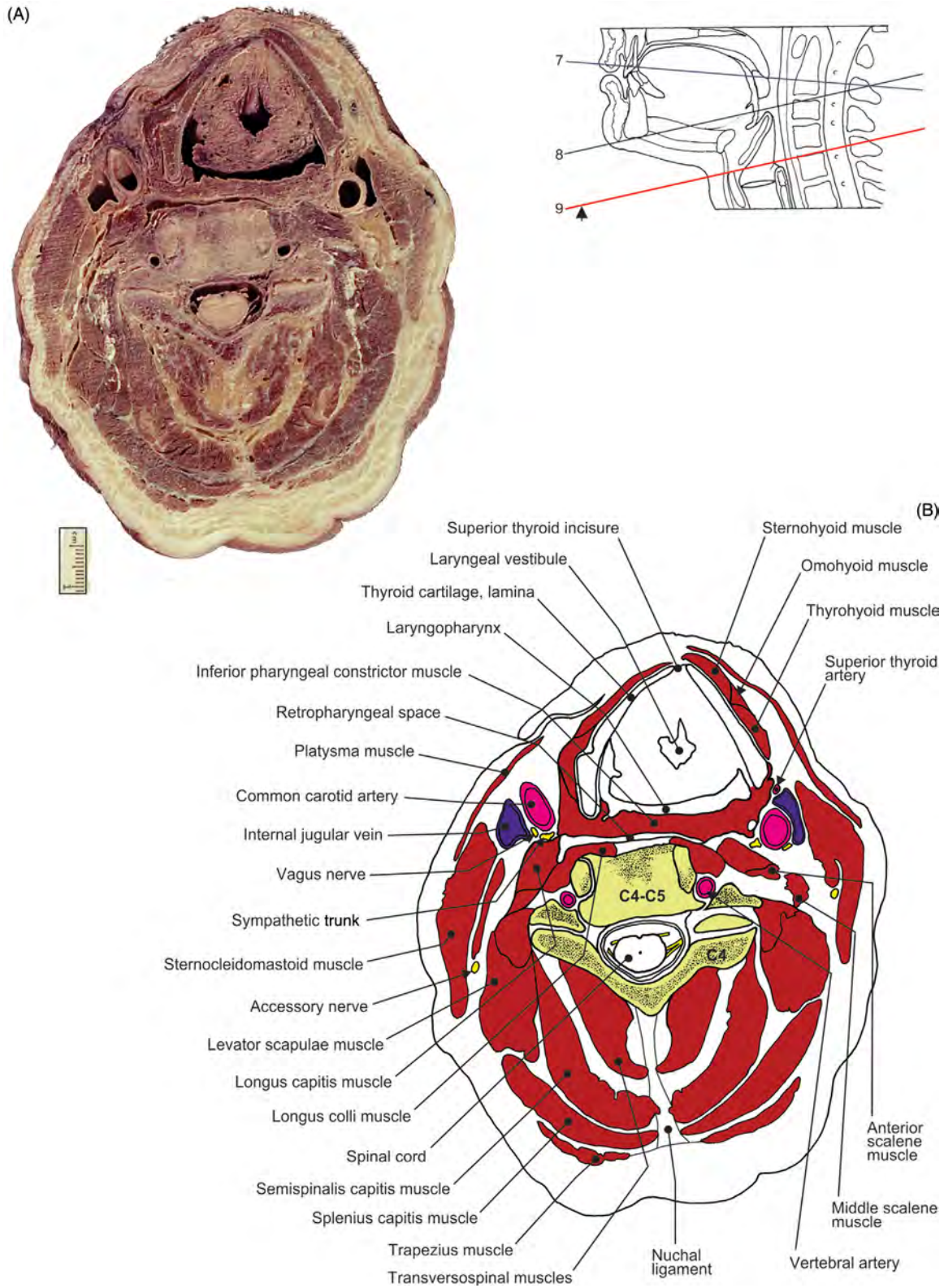


FIGURE 7.56 Transverse section of the neck at the level of C4–C5 vertebrae. (A) Section and (B) illustration.

Vascularization of Head and Neck and the Cranial Central Nervous System

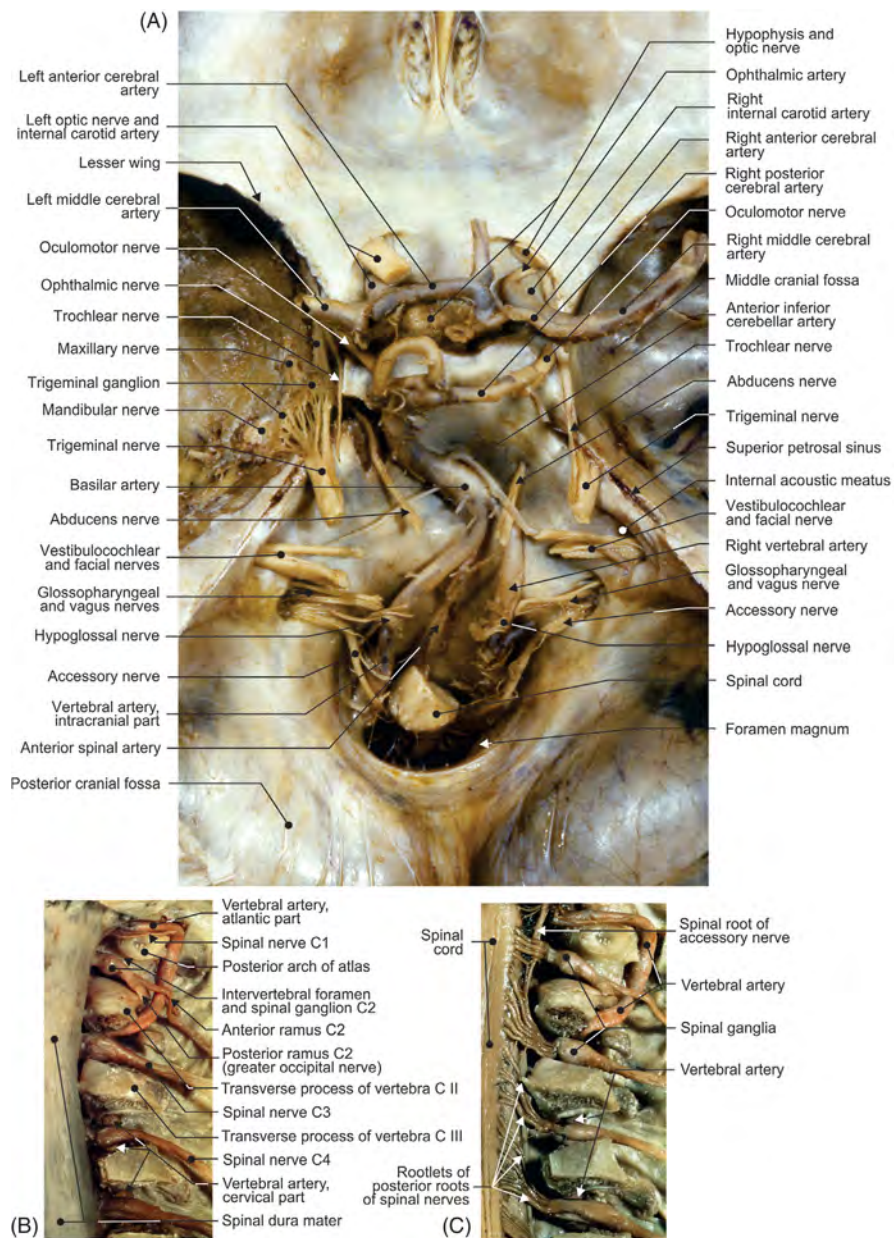

FIGURE 8.1 (A) Cranial base with cranial nerves and arteries. Posterior views of vertebral artery and spinal cord: (B) view with vertebral segments removed and (C) view with dura mater removed.

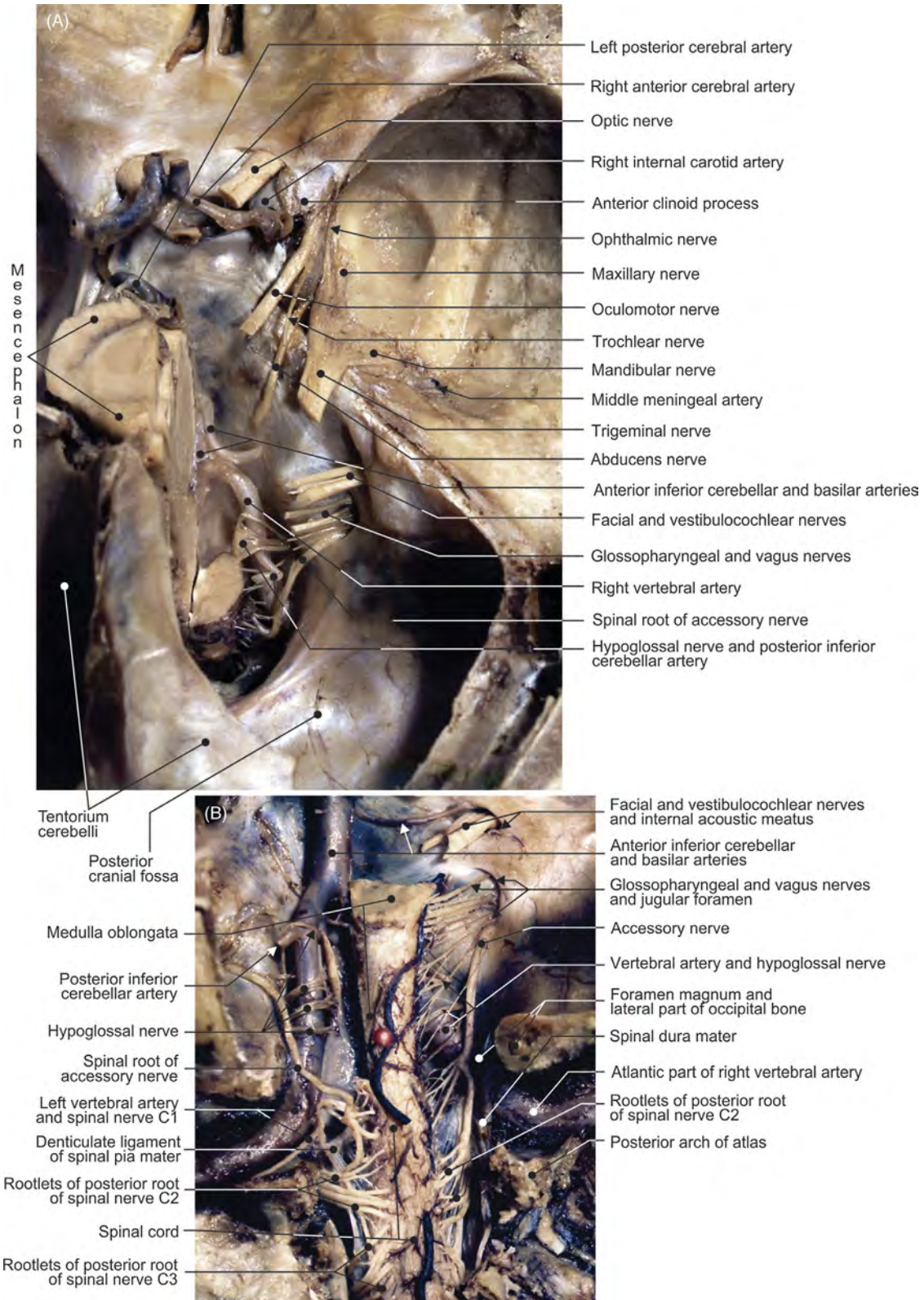


FIGURE 8.2 (A) Right half of the cranial base: cranial nerves and arteries. (B) Posterior view of the terminal segment of the vertebral artery: dissection.




FIGURE 8.3 (A) Right and (B) both hemispheres removed, view from the right side. (C) Relationships of structures on the cranial base.

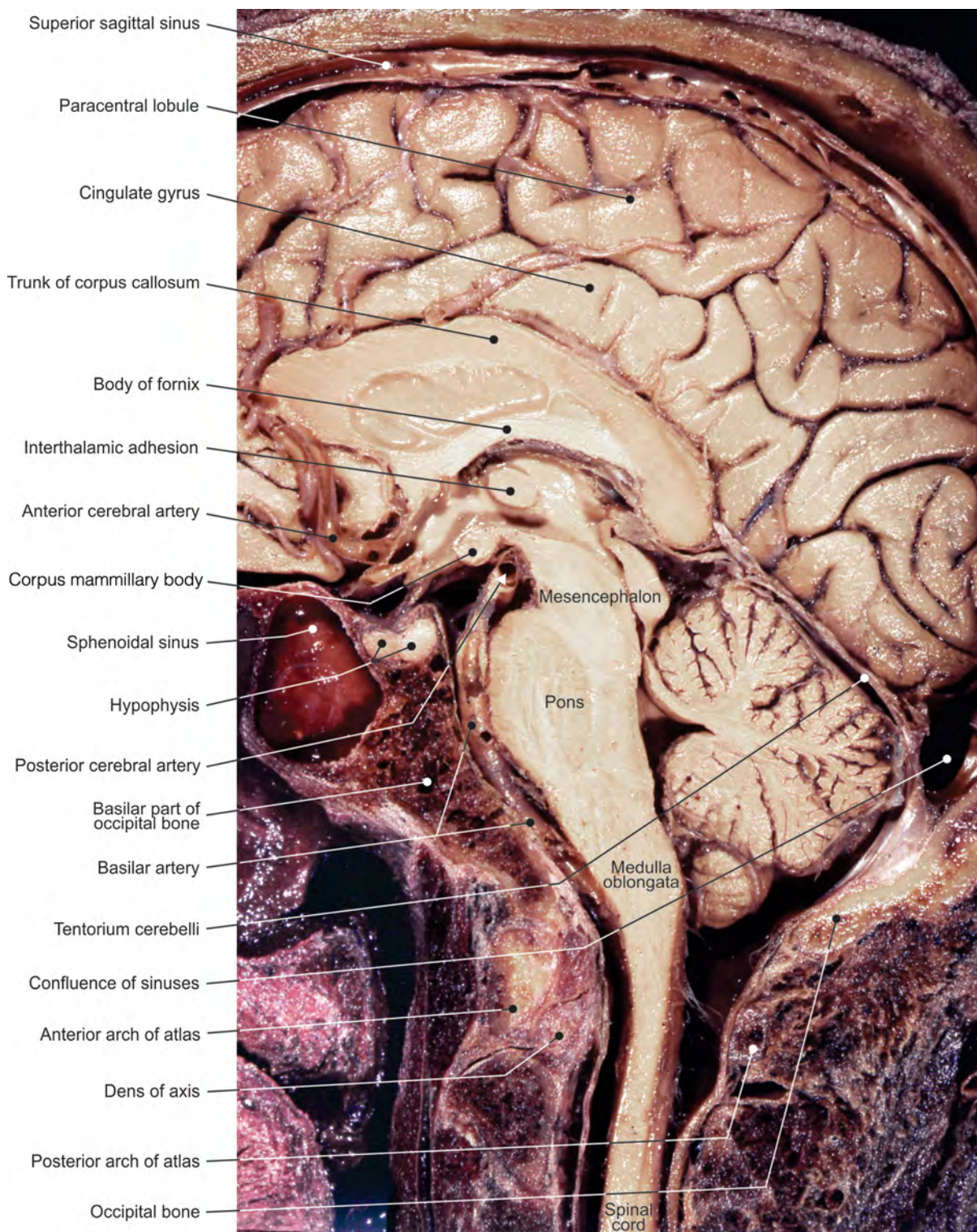


FIGURE 8.4 The midsagittal section of the head. Internal aspect of the right hemisphere.

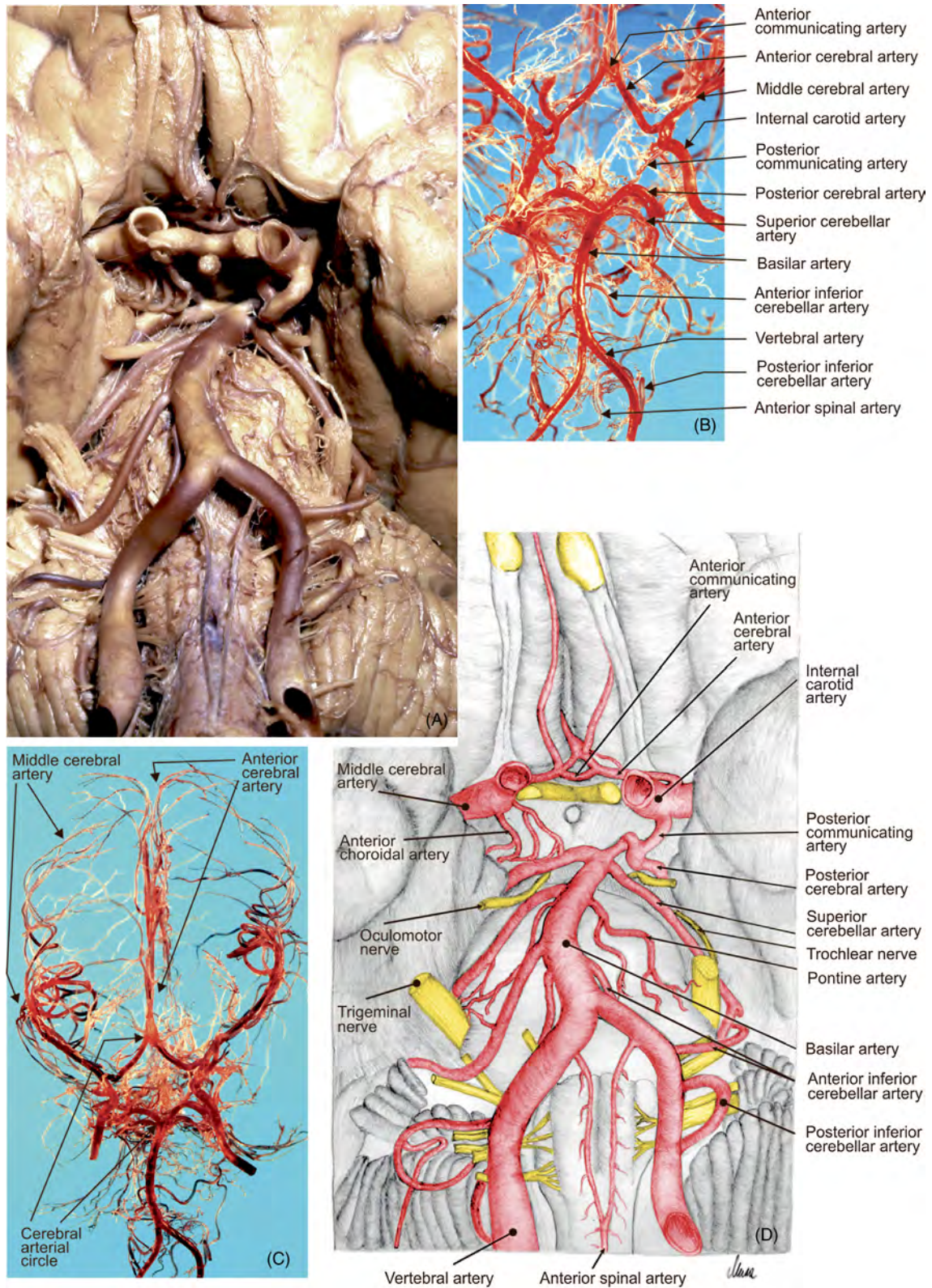


FIGURE 8.5 Arterial distribution on the base of the cranial central nervous system. (A) Formalin preparation, (B–C) corrosion casts, and (D) illustration.

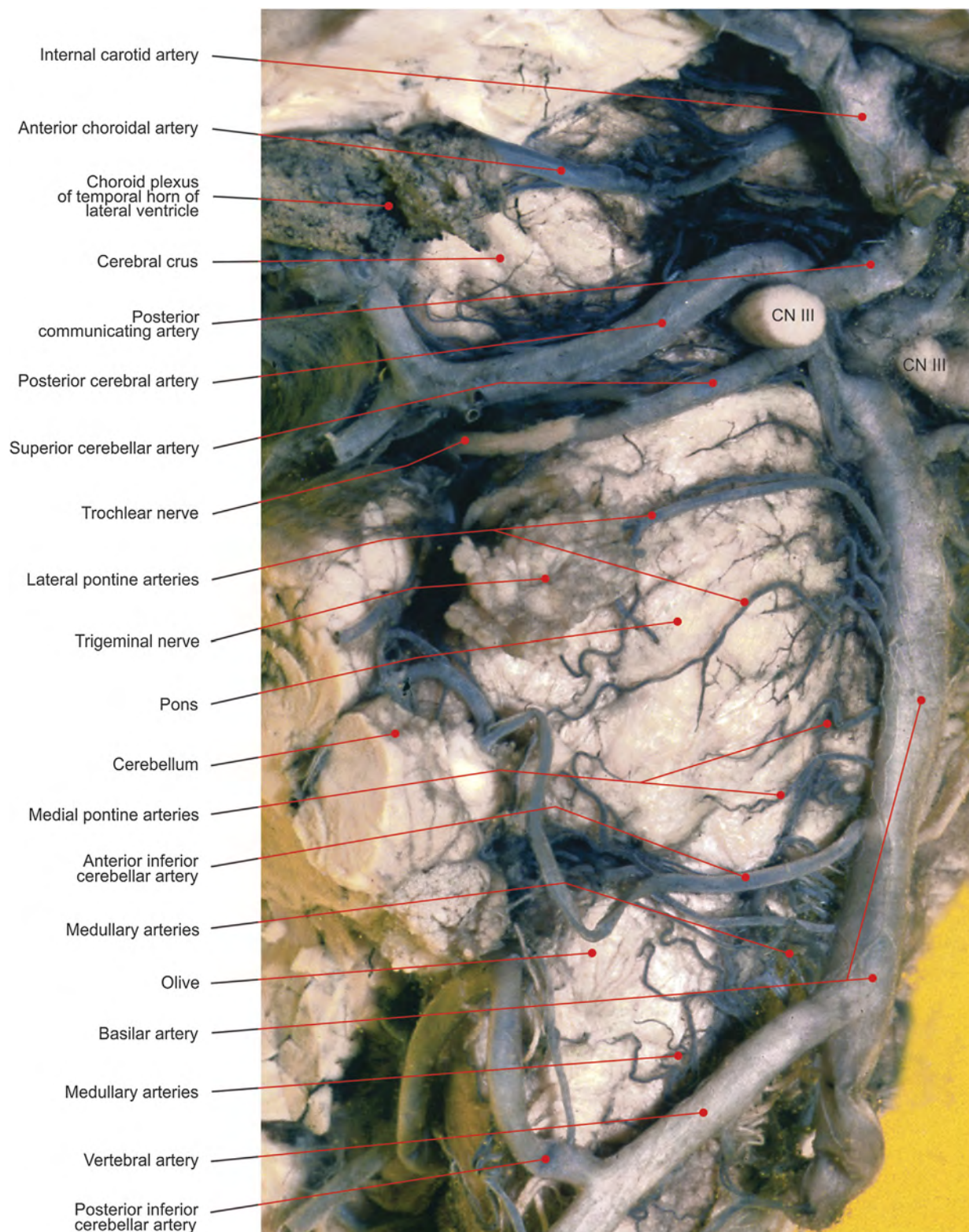


FIGURE 8.6 Arteries on the anterolateral side of the brainstem (India ink–gelatin).

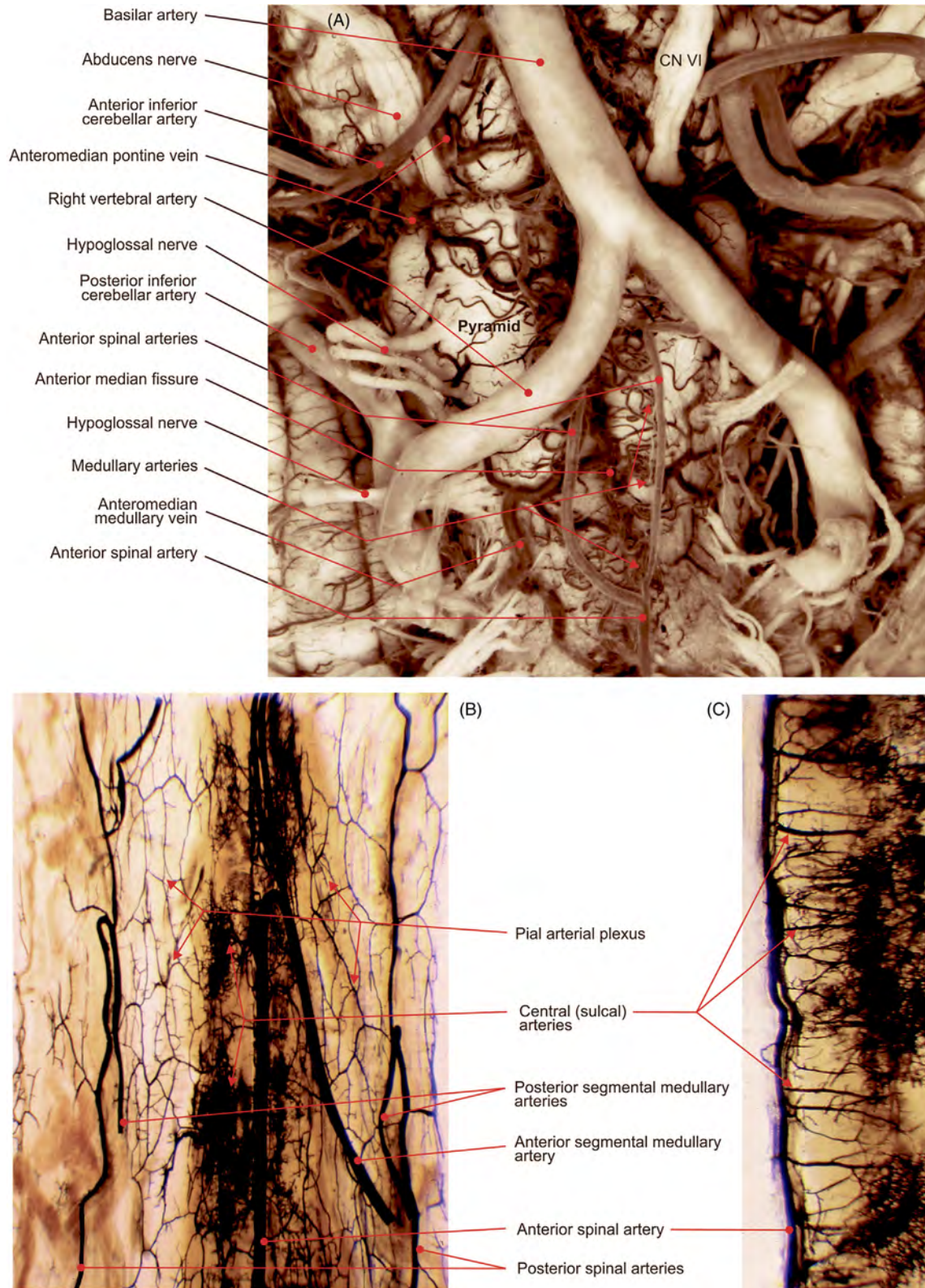


FIGURE 8.7 (A) Arteries, prepared with India ink–gelatin, on the anterior surface of the medulla. (B–C) Cleared specimens of arteries, injected with India ink–gelatin, in relation to the (B) thoracic segment of the spinal cord, and (C) midsagittal section of the spinal cord.

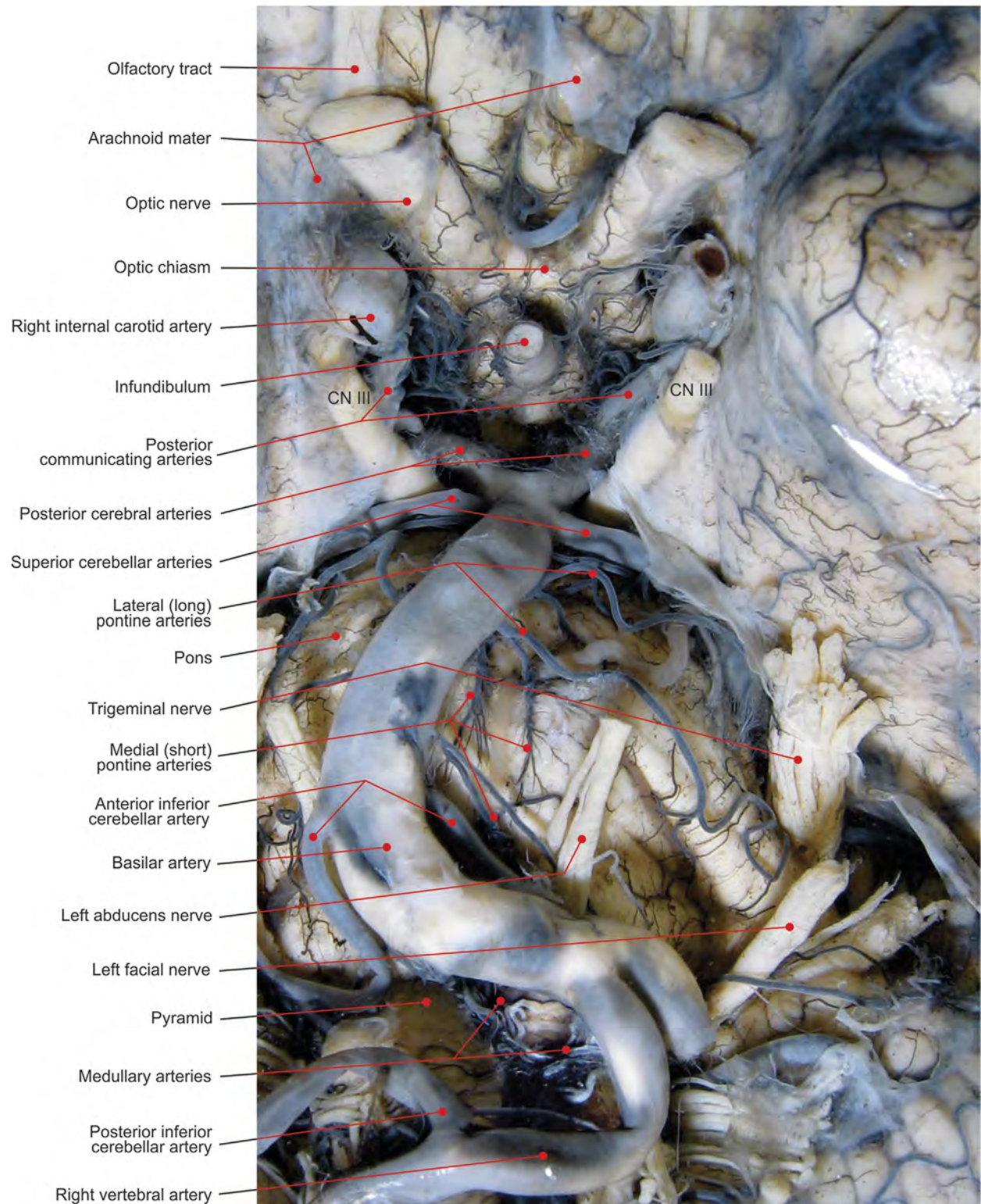


FIGURE 8.8 Arteries on the anterolateral side of the brainstem (India ink–gelatin).

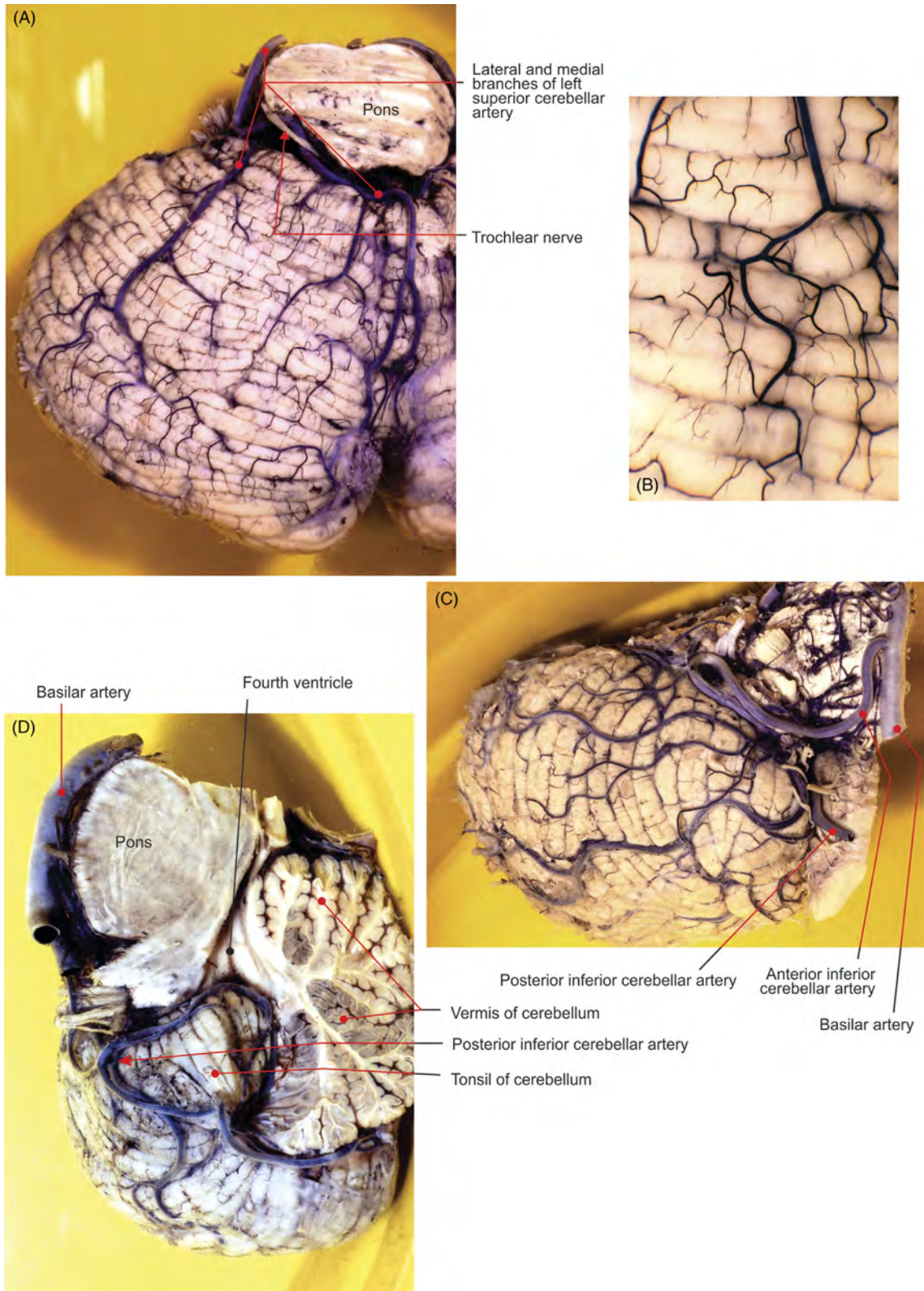


FIGURE 8.9 The cerebellum. (A) Vascularization of the superior aspect; (B) detail. (C) The anterior segment and (D) inferior aspect.

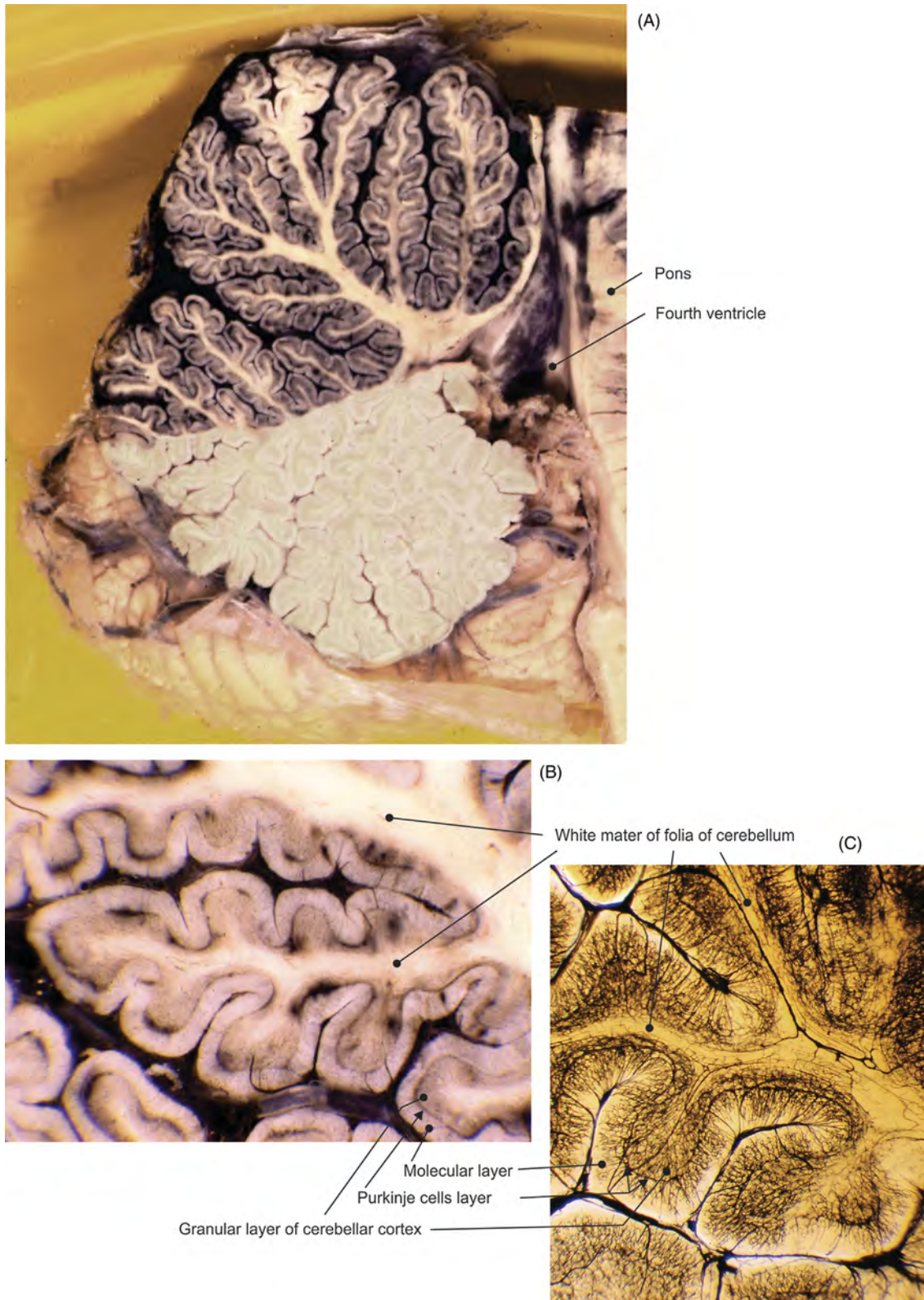


FIGURE 8.10 Selective injection of India ink–gelatin mixture in the superior cerebellar artery. (A) Midsagittal section of the cerebellum, (B) detail, and (C) cleared specimen.

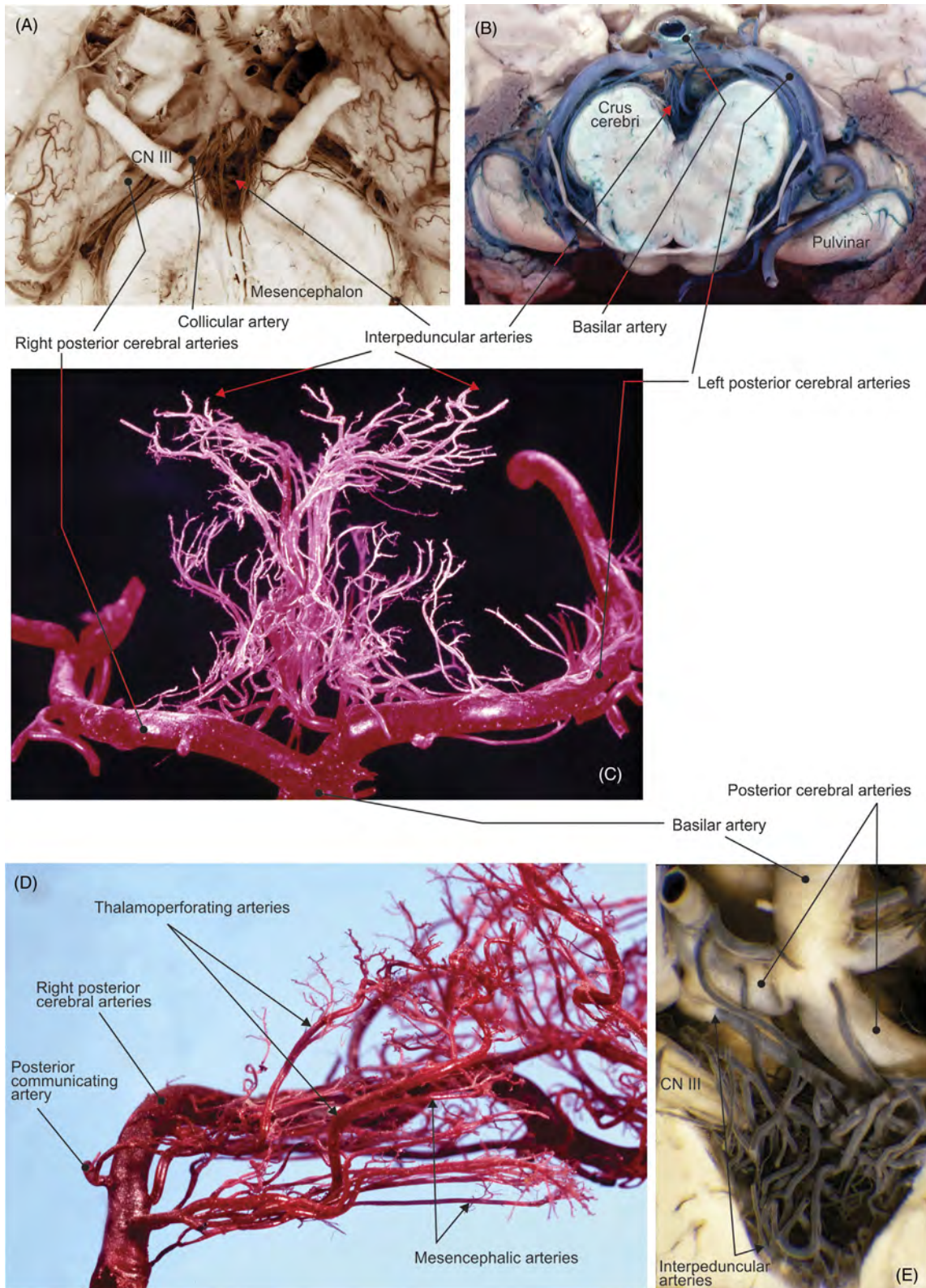


FIGURE 8.11 Interpeduncular branches of the posterior cerebral artery. (A, B, E) Basilar artery lifted from brainstem (India ink–gelatin). (C) Anterior view (corrosion cast) and (D) view from the medial side (corrosion cast).

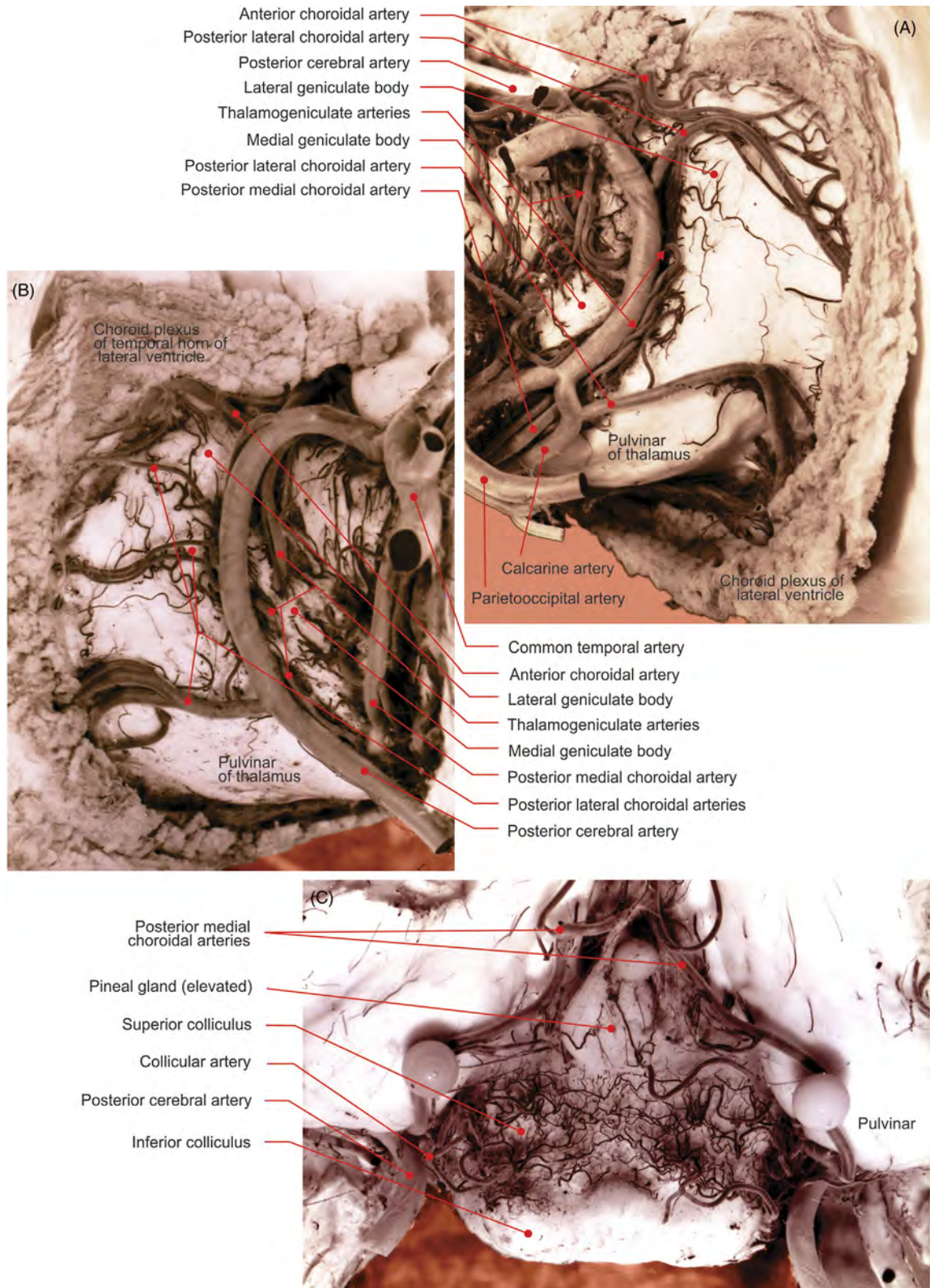


FIGURE 8.12 (A) Left and (B) right posterior cerebral arteries and branches (India ink-gelatin). (C) Mesencephalon: arterial network around the superior colliculi (India ink-gelatin preparation).

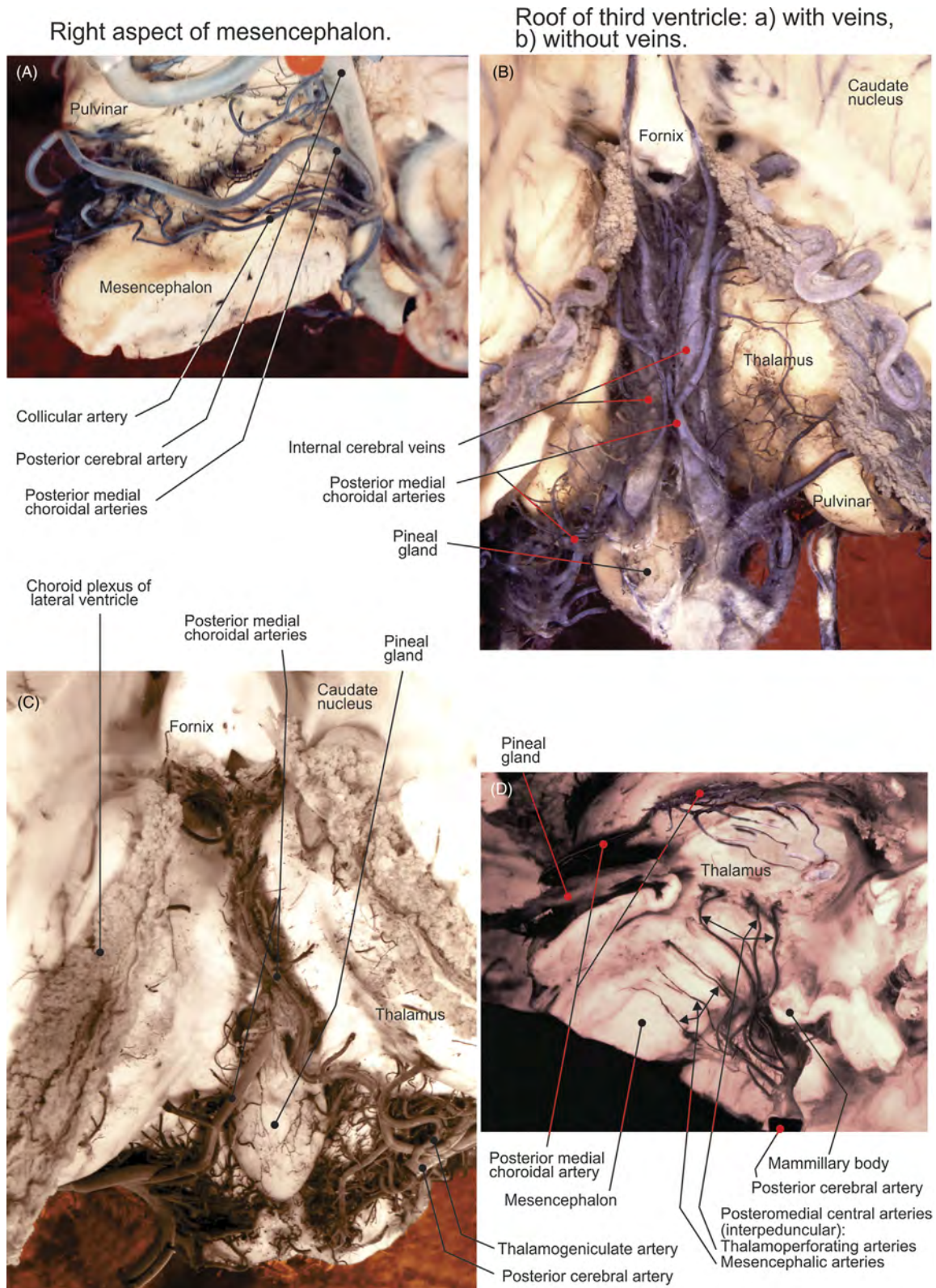


FIGURE 8.13 (A) Right aspect of the mesencephalon. (B–C) Roof of the third ventricle: (B) with veins and (C) without veins. (D) Midsagittal section of the brainstem.

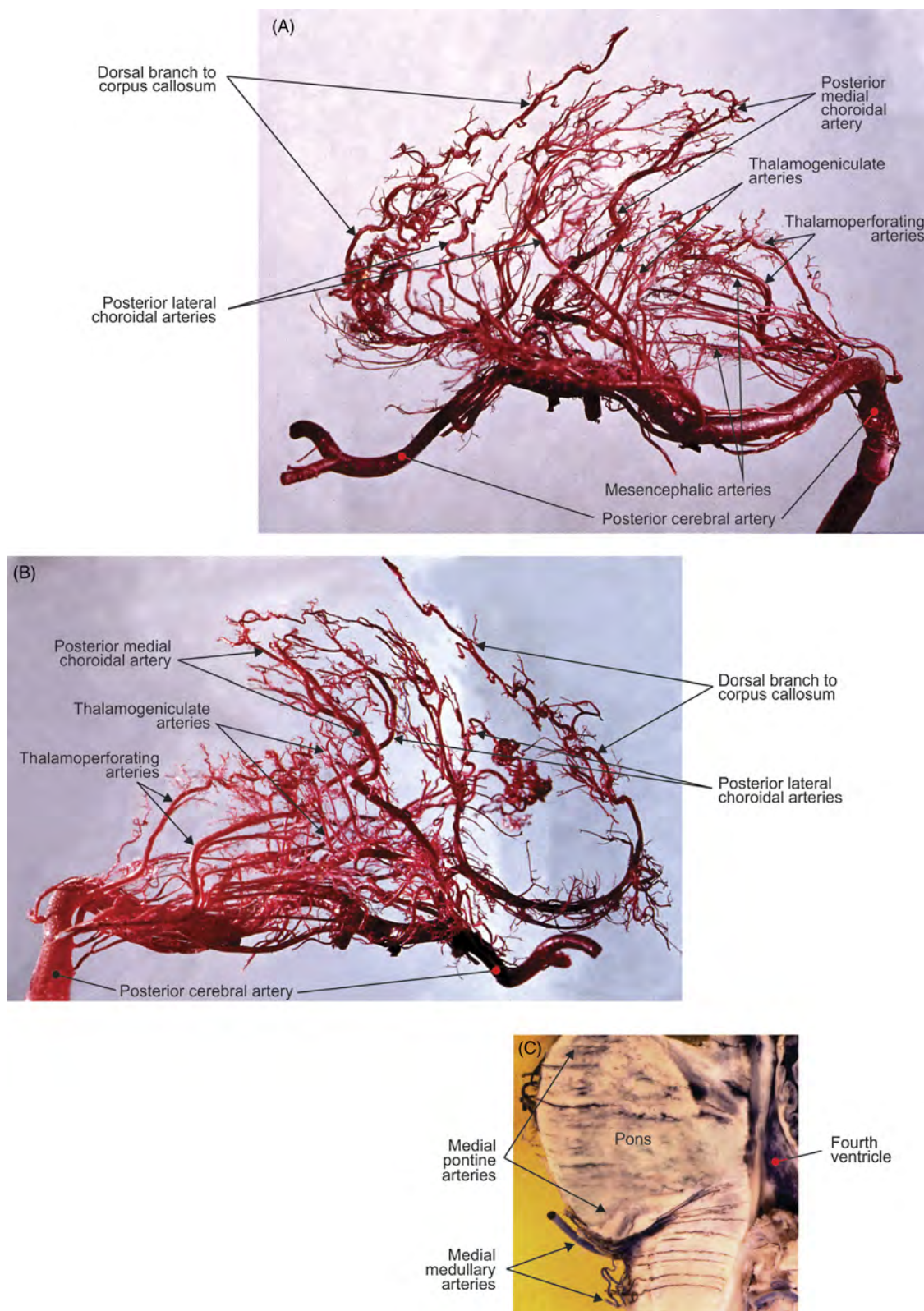


FIGURE 8.14 Deep branches of the posterior cerebral artery: view of the right artery from (A) outside and (B) inside (corrosion casts). (C) Mediosagittal section of brainstem (India ink–gelatin preparation).

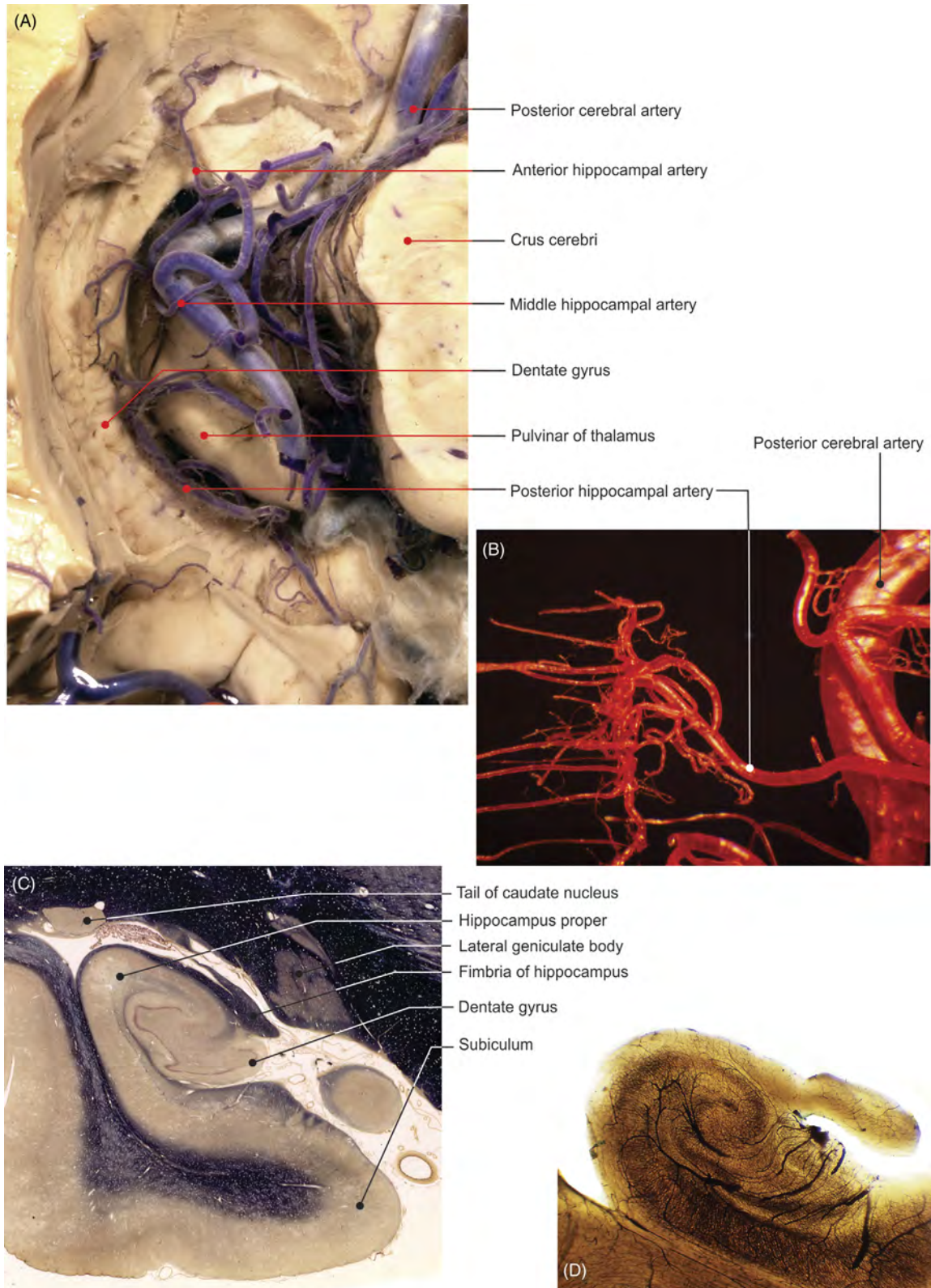


FIGURE 8.15 Hippocampal vascularization. (A) Dissection, (B) corrosion cast, (C) histologic slide, and (D) view of blood vessels of cleared transverse section.

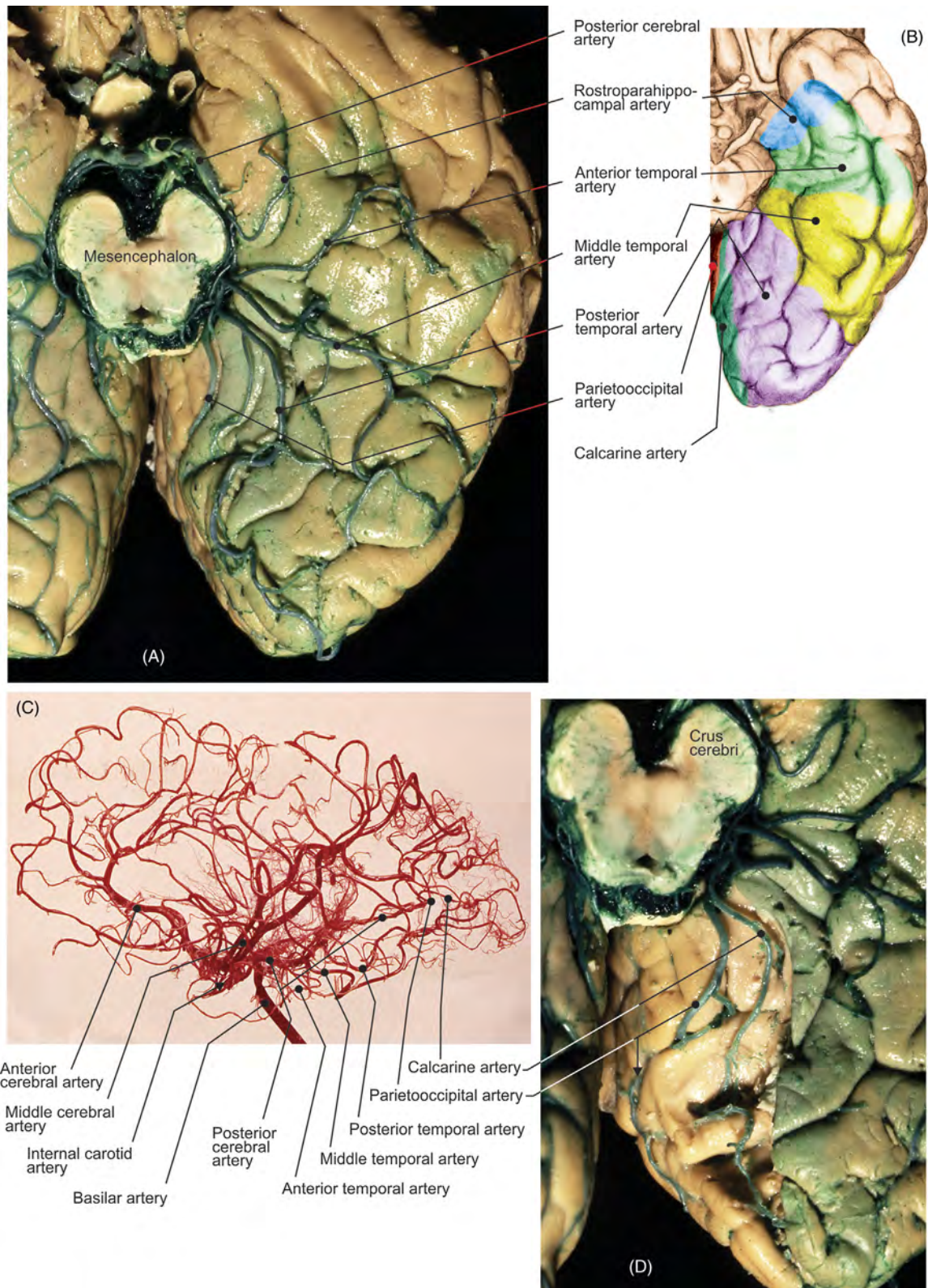


FIGURE 8.16 Cortical branches of the posterior cerebral artery: (A) India ink-gelatin preparation and (B) illustration. (C) Cortical branches of the cerebral arteries, view from outside (corrosion cast). (D) Calcarine sulcus open.

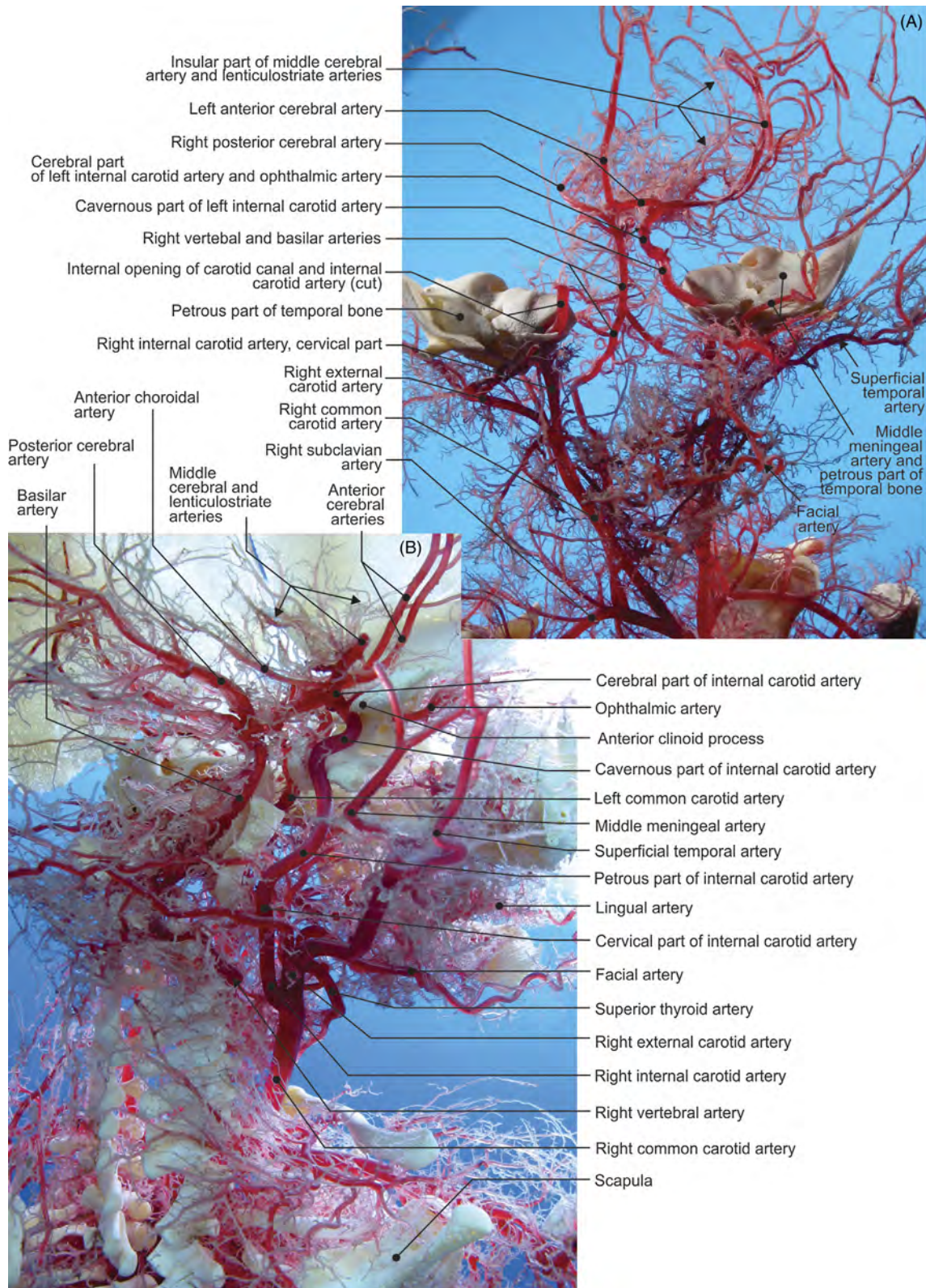


FIGURE 8.17 Fetal internal carotid artery (corrosion casts). (A) View from the front and (b) from the right.

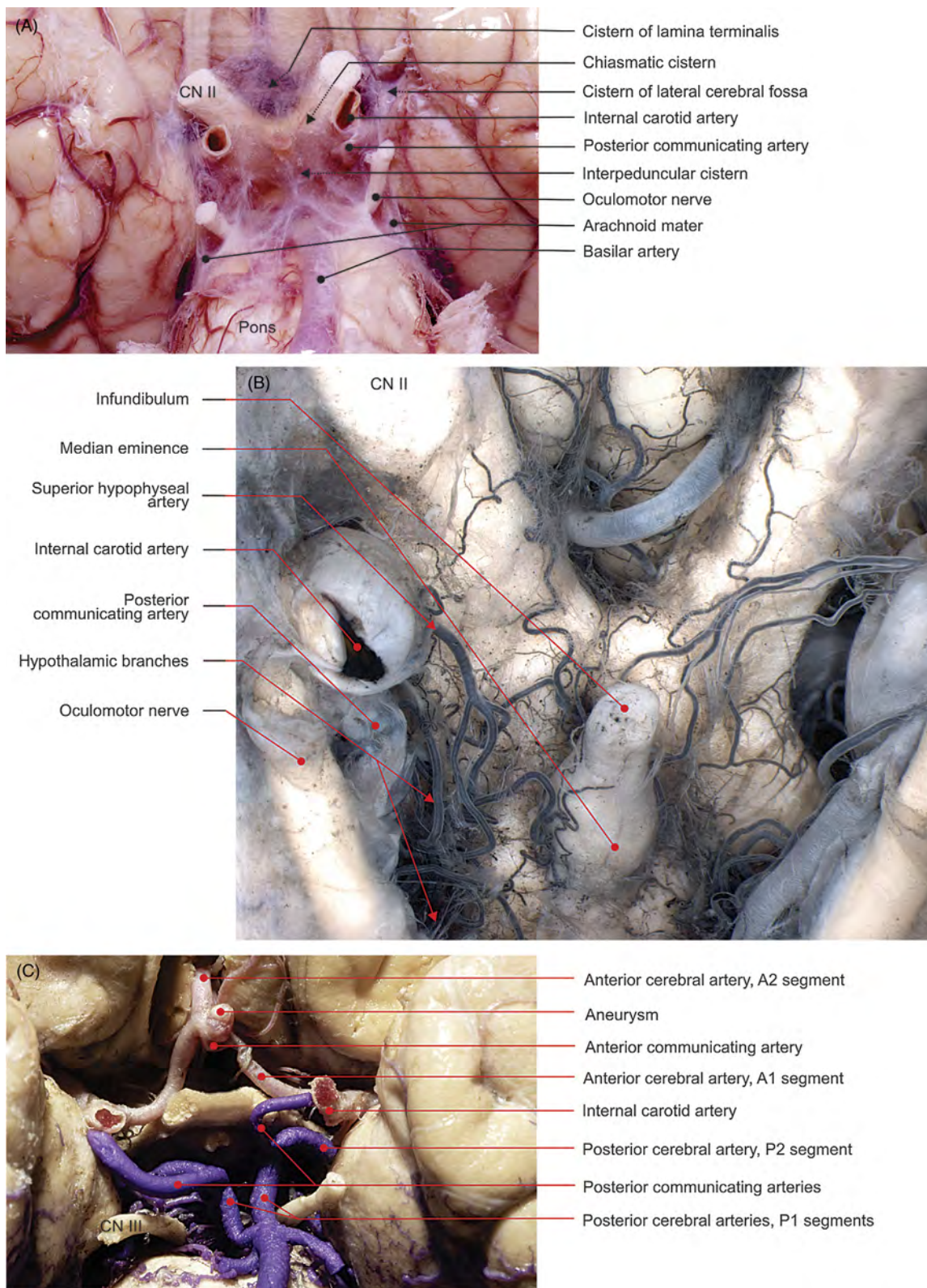


FIGURE 8.18 (A) Optic chiasm, native preparation. (B) Arteries of the optic chiasm and hypothalamus, India ink–gelatin preparation. (C) Cerebral arterial circle of Willis, silicone.

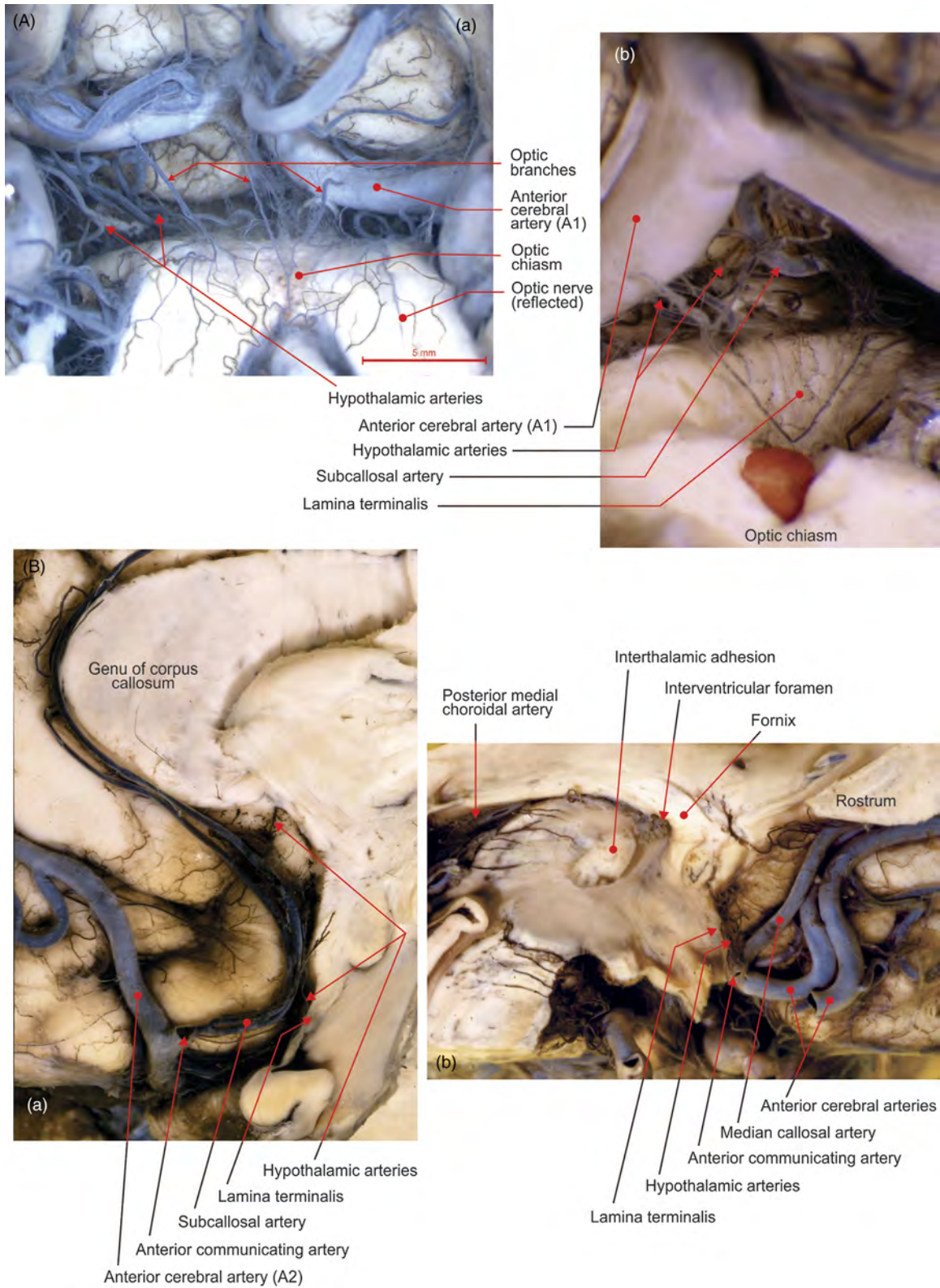


FIGURE 8.19 (A) (a) Lamina terminalis and (b) optic chiasm viewed from below (India ink–gelatin preparations). (B) (a–b) Midsagittal sections of the lamina terminalis (India ink–gelatin injection).

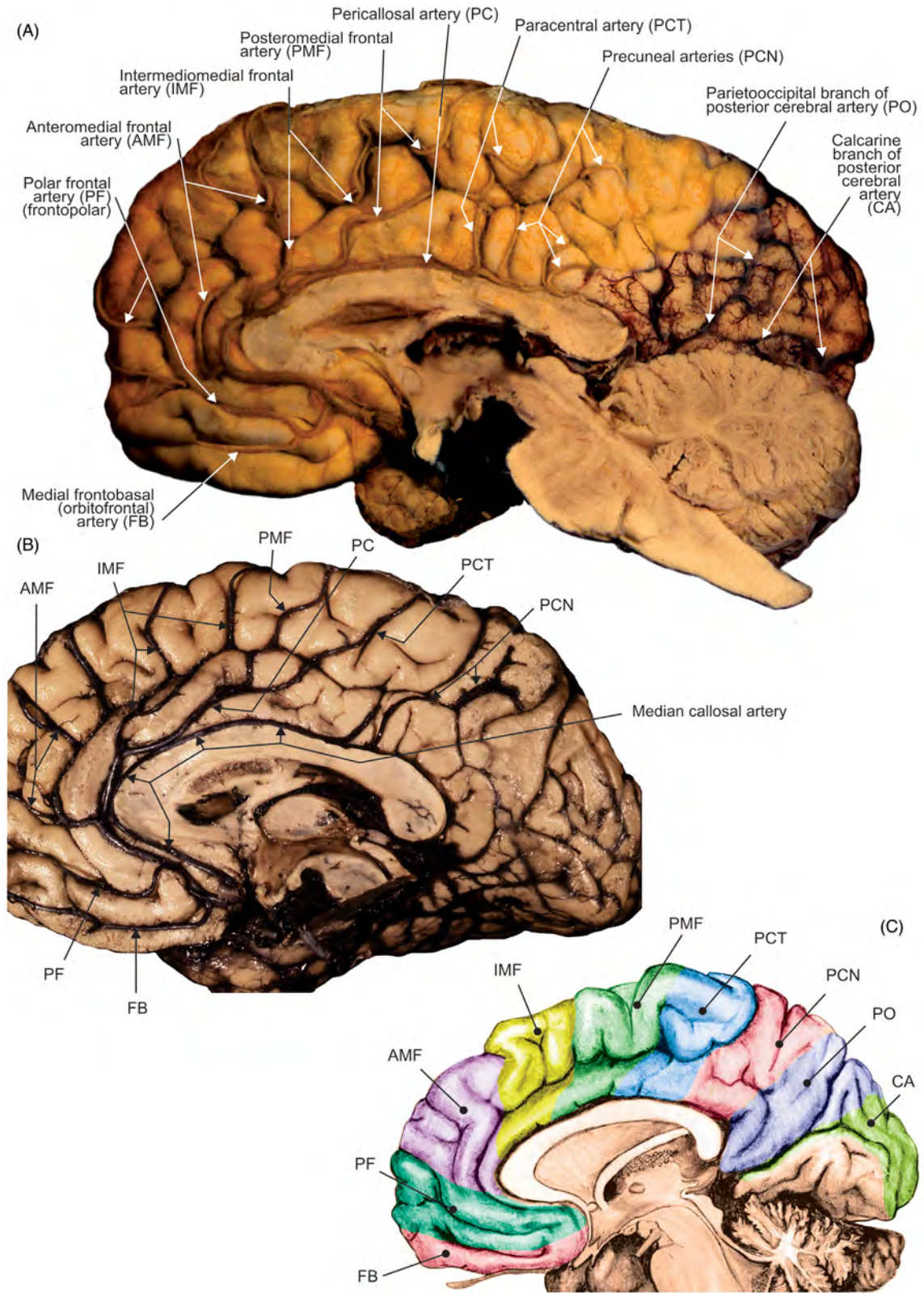


FIGURE 8.20 Cortical branches of the anterior cerebral artery on the medial aspect of the right cerebral hemispheres (India ink–gelatin preparations). (A–B) Dissections and (C) illustration.

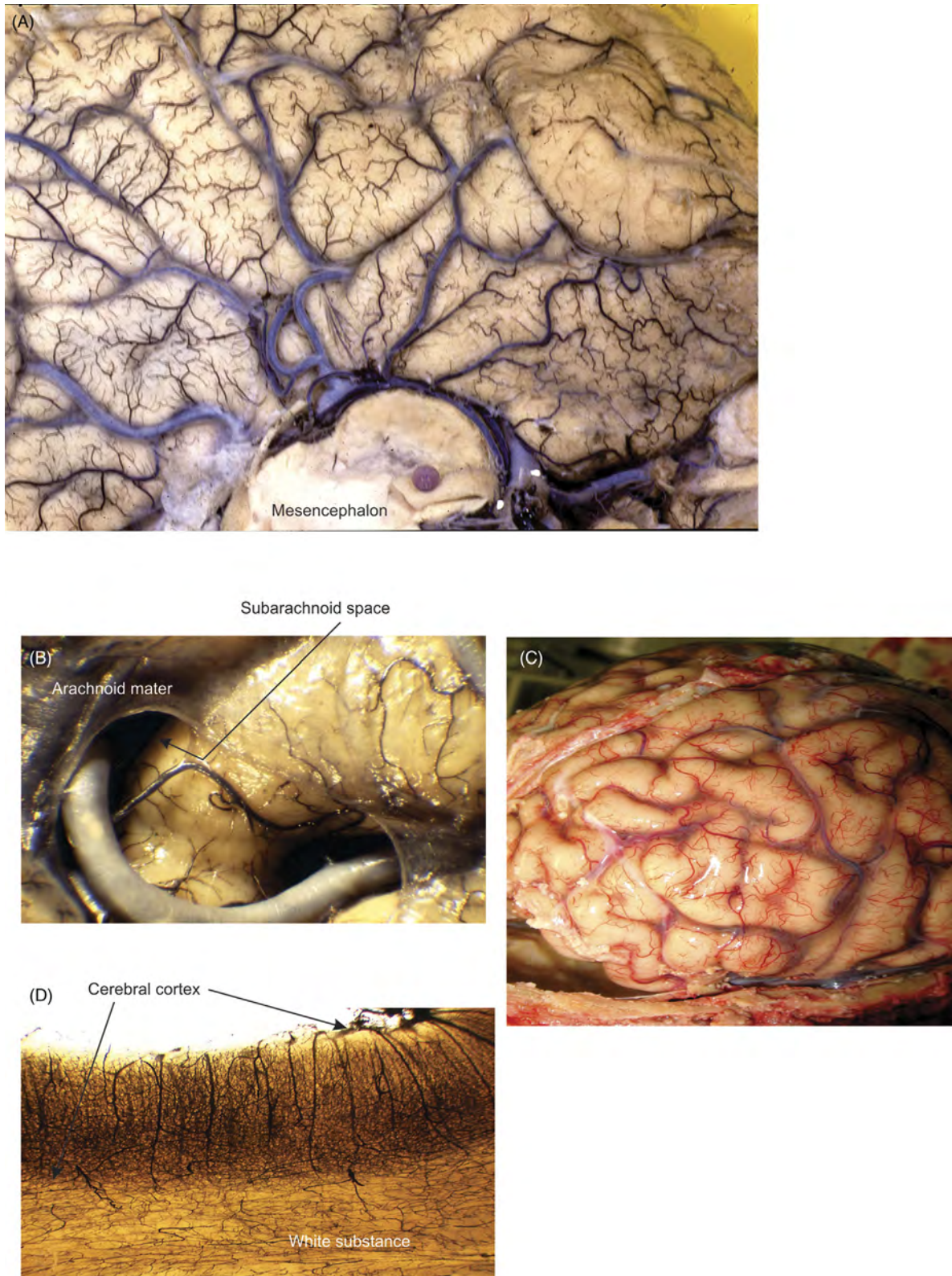


FIGURE 8.21 Vascularization of the cerebral cortical layer (India ink-gelatin). (A) Inferior view, (B) detail, (C) native sample, and (D) view of the cleared cortical arteries.

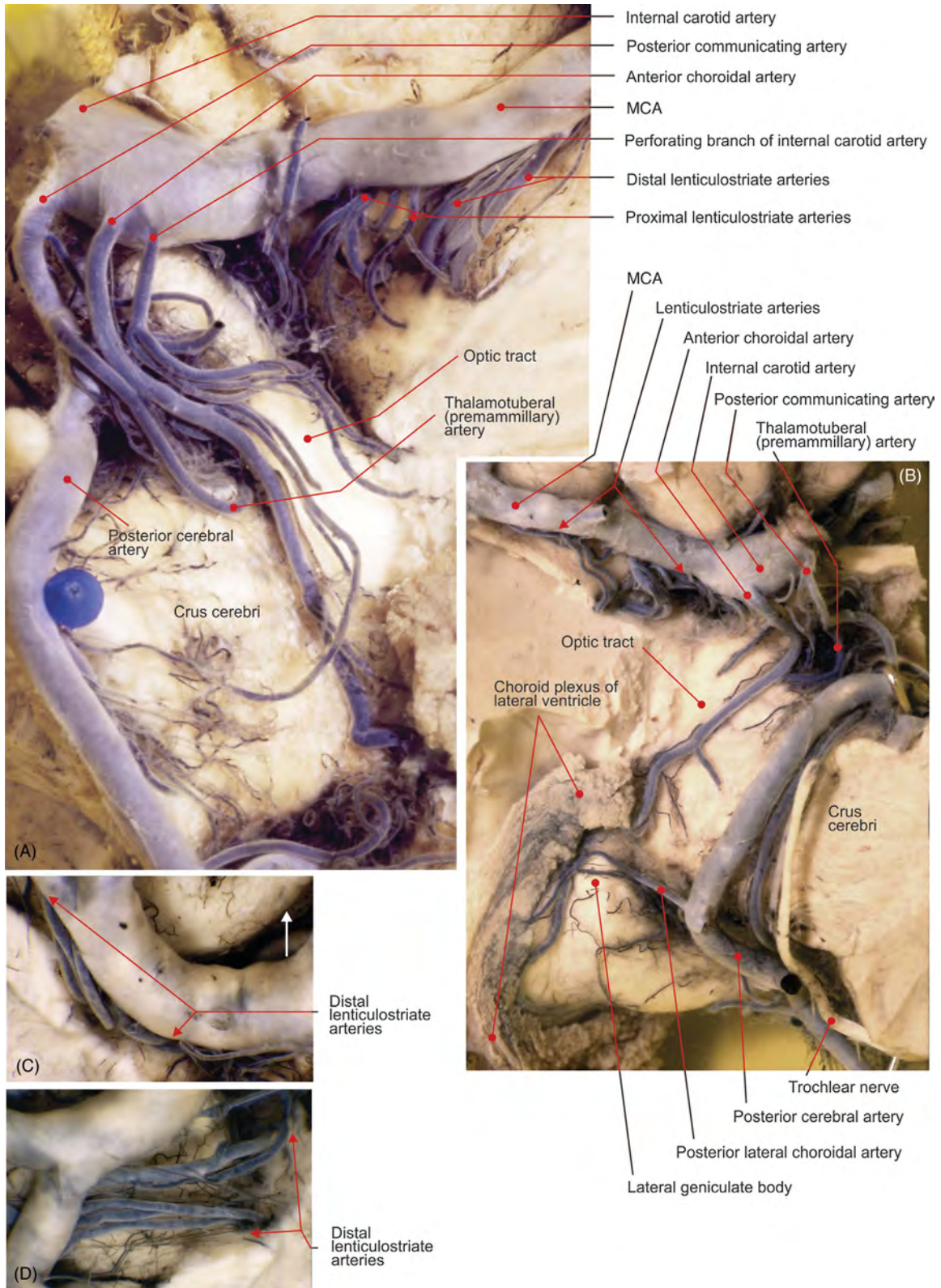


FIGURE 8.22 (A–B) Deep part of the (A) left and (B) right hemispheres after the removal of the temporal lobe. (C–D) Trunk of the middle cerebral artery (MCA) (M1 segment), view from below: (C) before and (D) after reflection of the artery.

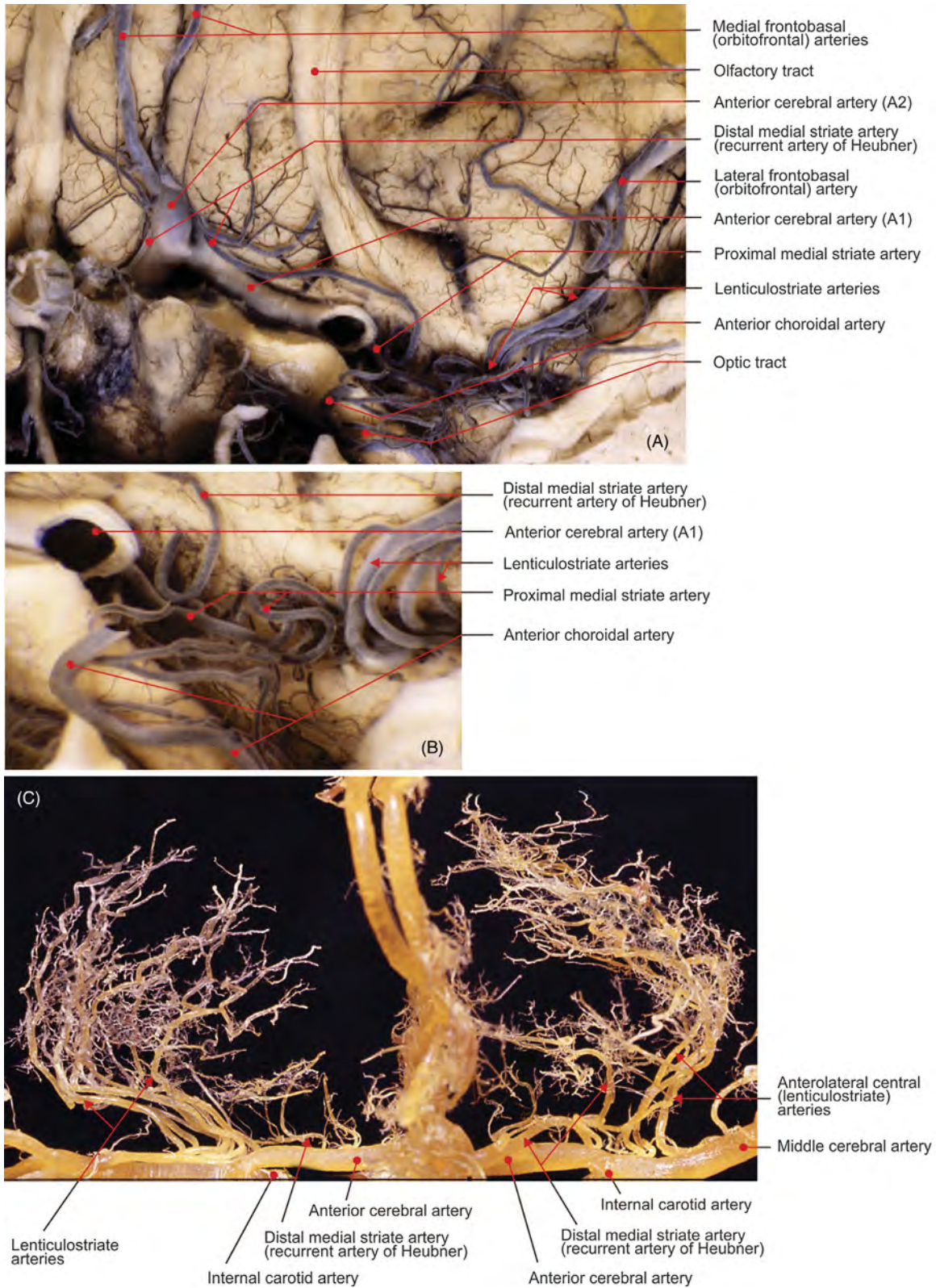


FIGURE 8.23 (A) Anterior perforated substance and (B) details, after the removal of the temporal lobe. (C) Corrosion cast of the anterior perforating arteries, view from the front.

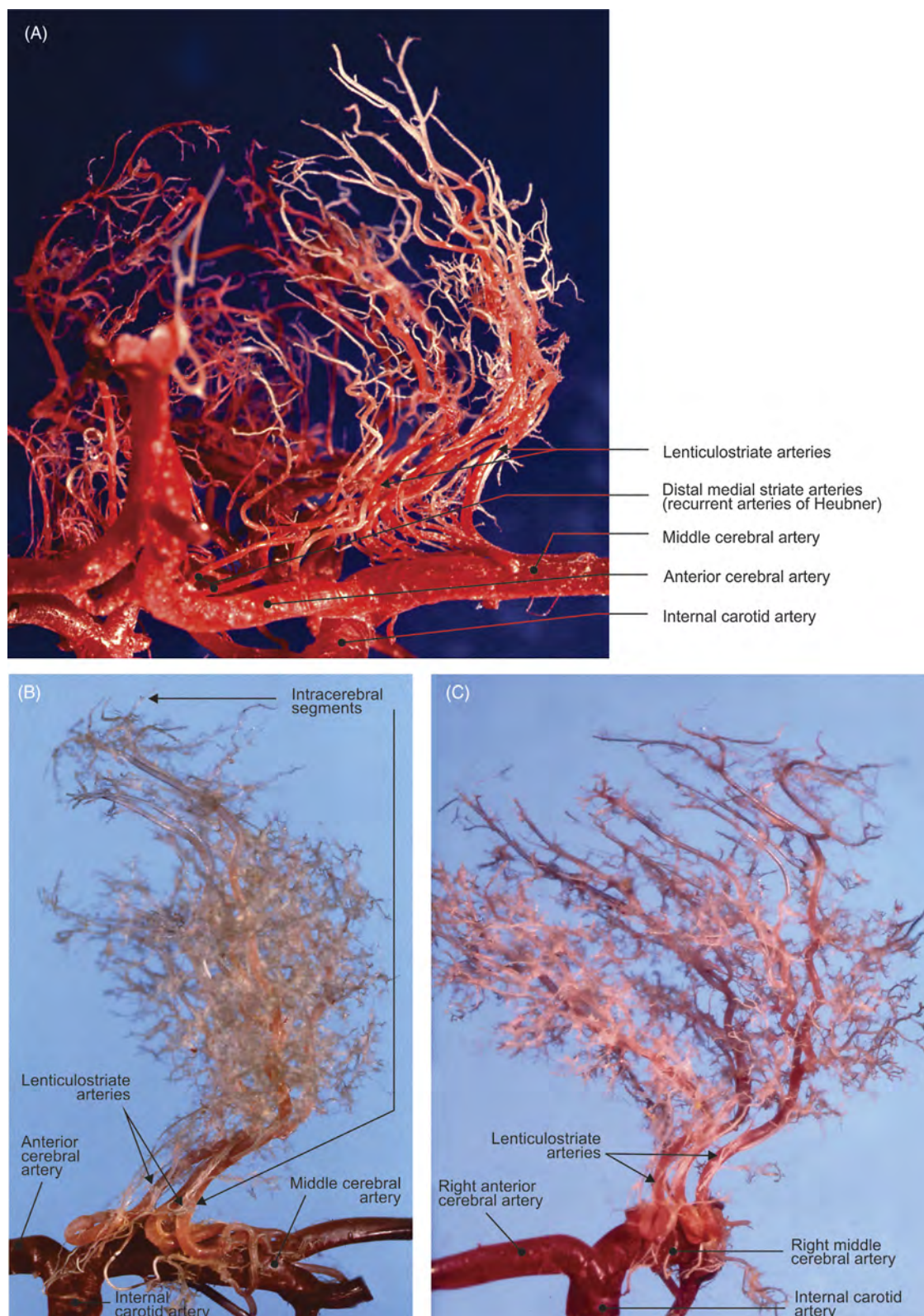


FIGURE 8.24 (A) Corrosion cast of the anterior perforating arteries, view from the front. (B–C) Corrosion cast of the lenticulostriate arteries viewed from (B) behind and (C) medial side.

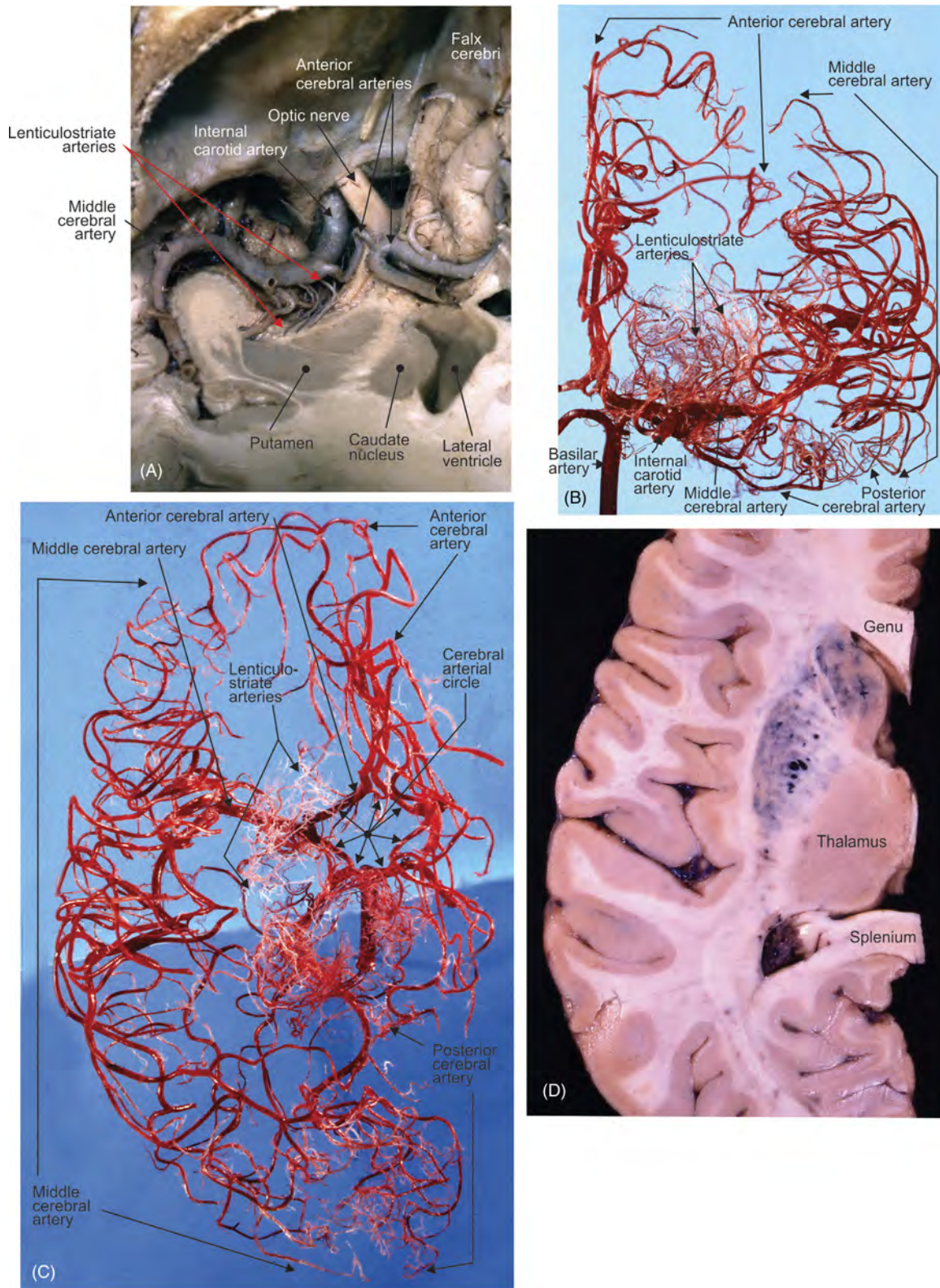


FIGURE 8.25 Left lenticulostriate arteries. (A) View from above after the removal of the frontal lobe (corrosion cast), (B) view from the front, (C) from above (corrosion cast), and (D) the transverse section of hemisphere after selective injection of arteries with India ink–gelatin mixture.

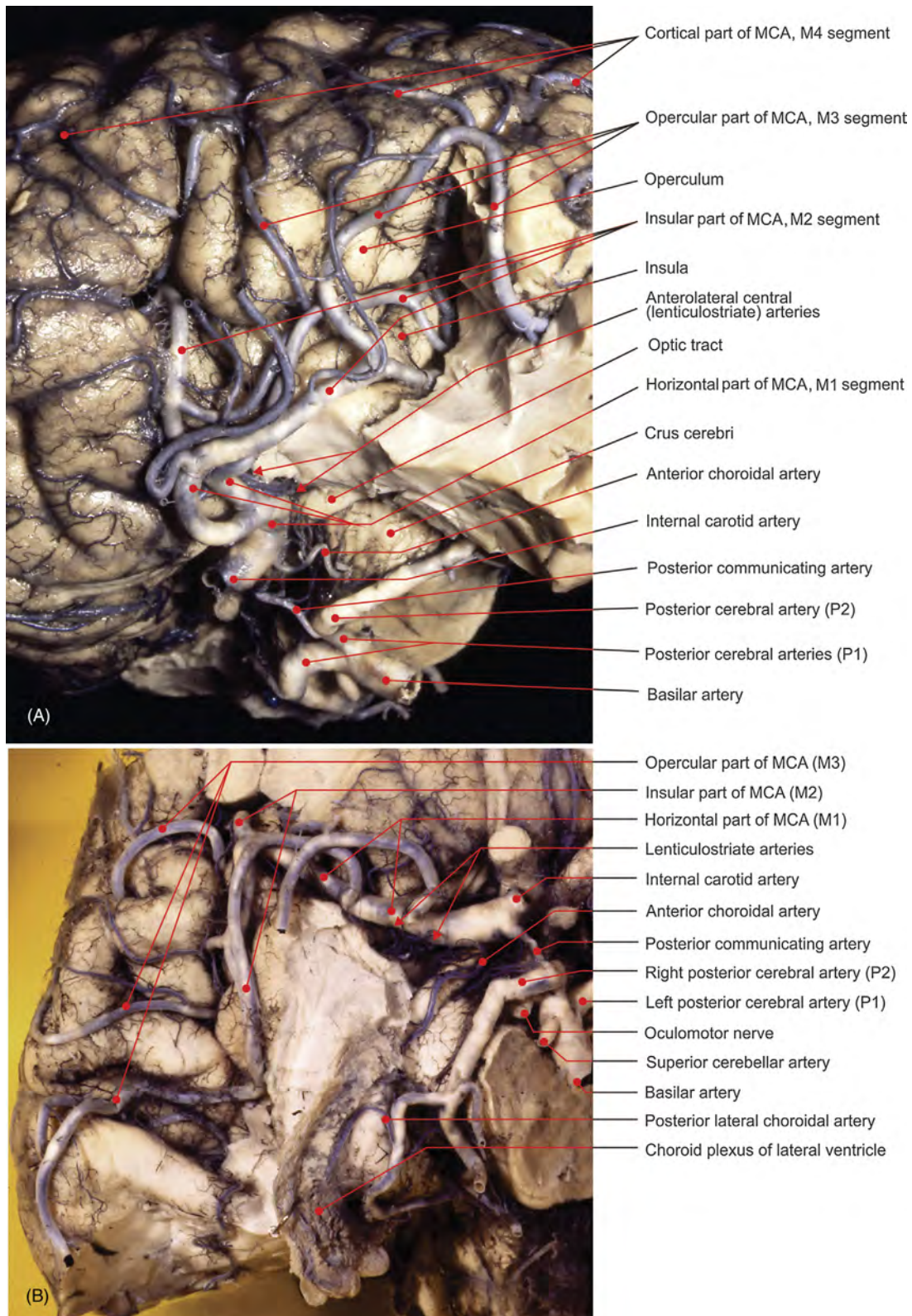


FIGURE 8.26 Pathway and branching of the (A) left and (B) right middle cerebral arteries (MCA) after the removal of the temporal lobes (India ink–gelatin).

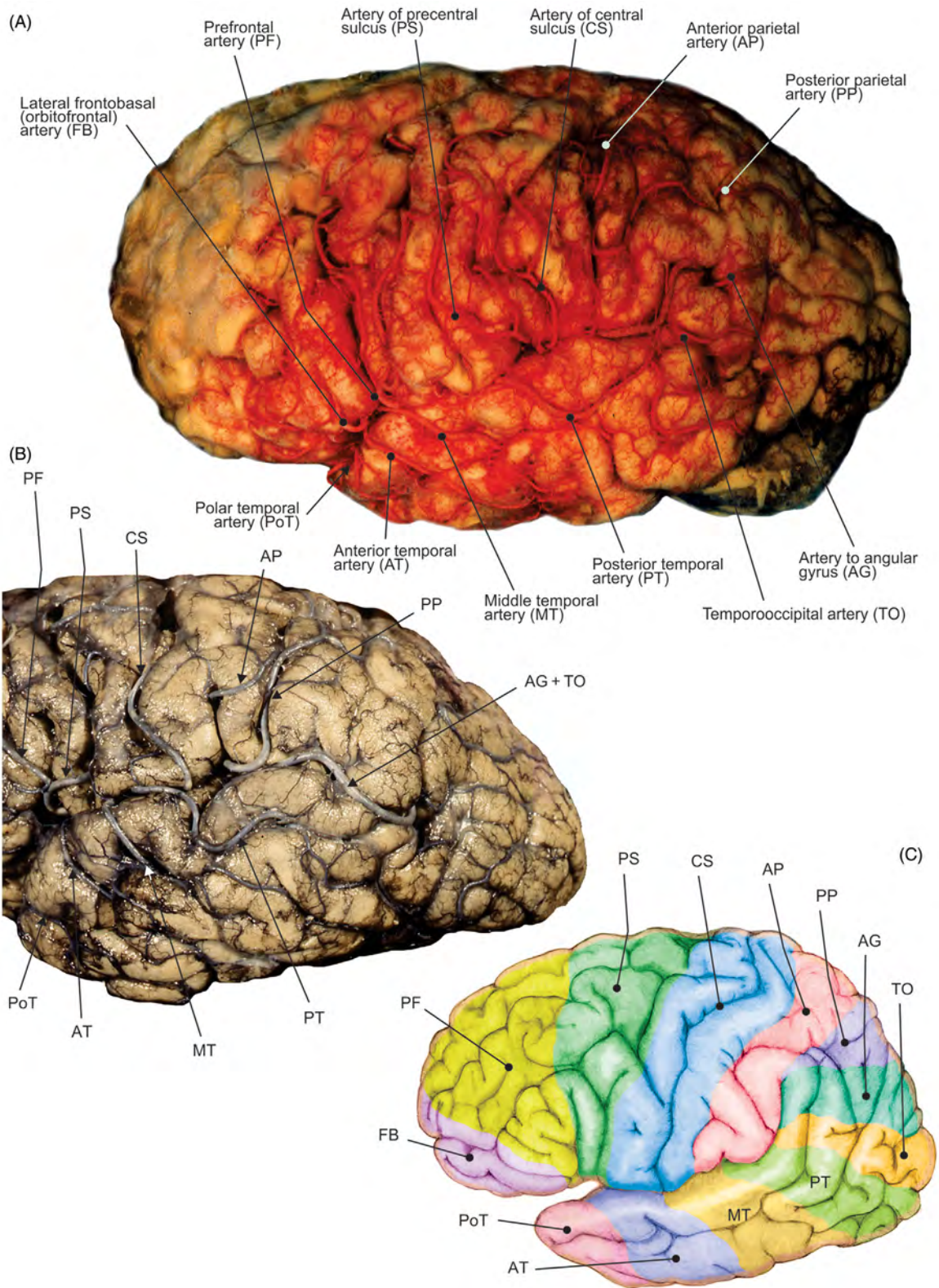


FIGURE 8.27 Cortical branches of the middle cerebral artery (India ink-gelatin): view of the superolateral aspect of the left hemisphere. (A–B) Dissections and (C) illustration.

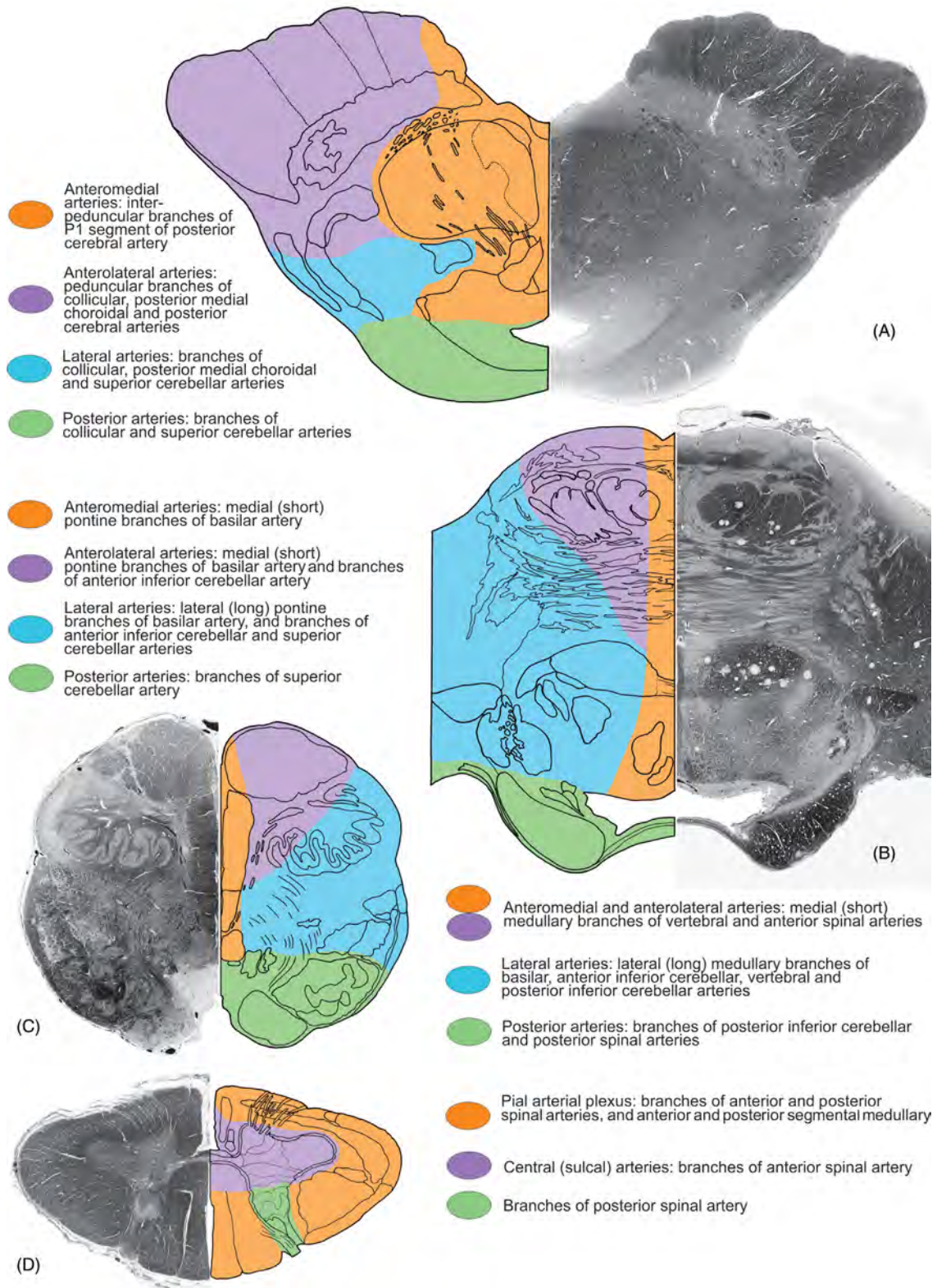


FIGURE 8.28 Vascular territories. (A) Mesencephalon. (B) Pons. (C) Medulla oblongata. (D) Spinal cord.

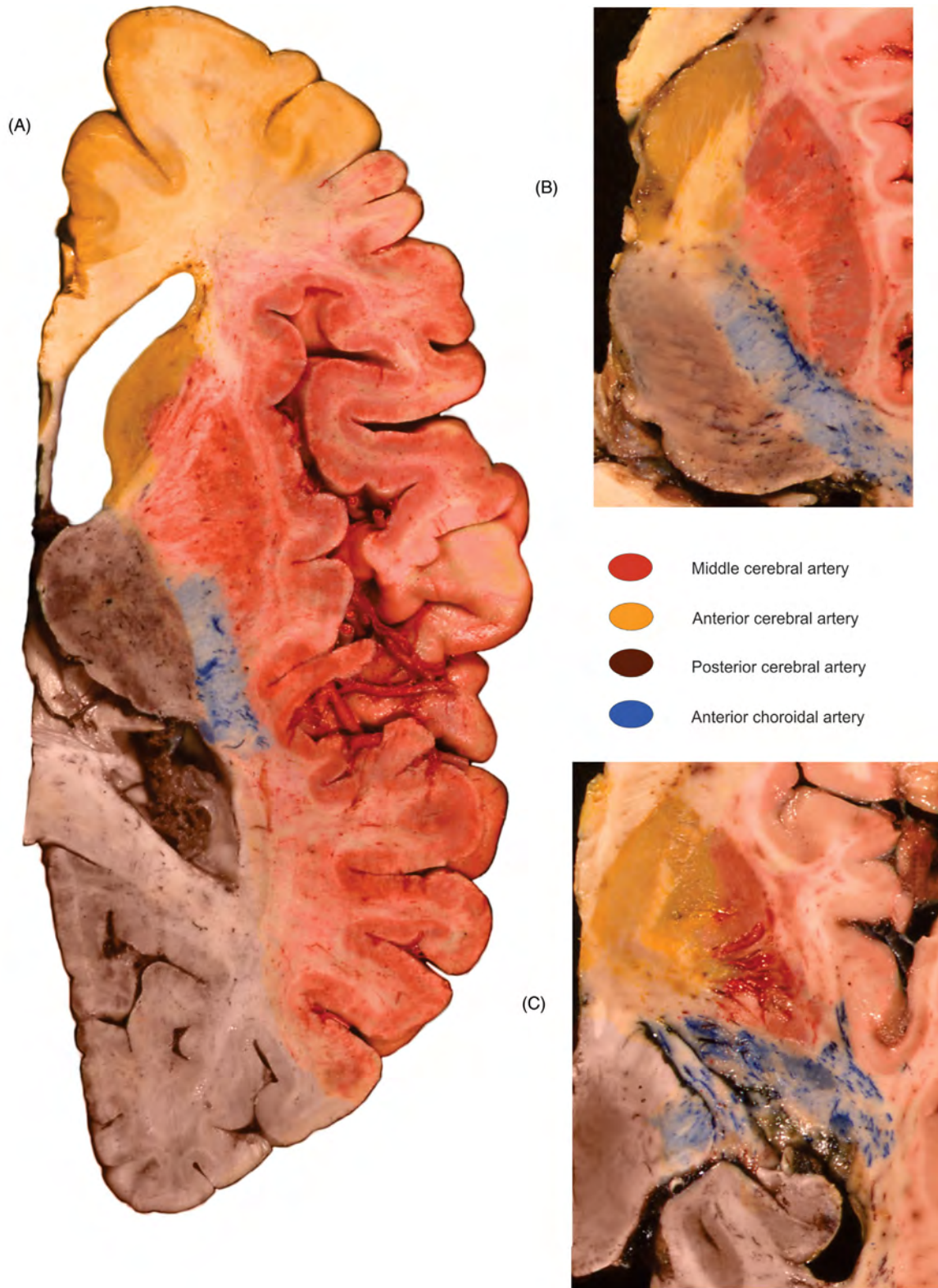


FIGURE 8.29 Vascular territories on the transverse sections of the cerebral hemisphere. (A) The level of dorsal thalamus, (B) midlevel of thalamus, and (C) level ventral of thalamus.

References

- Abrahams, P., Spratt, J., Loukas, M., van Schoor, A.-N., 2013. *McMinn & Abrahams' Clinical Atlas of Human Anatomy*. Elsevier Mosby; London.
- Carpenter, M., 1991. *Core Text of Neuroanatomy*. Williams & Wilkins, Baltimore; Tokyo.
- etkovi , M., Antunovi , V., et al., 2011. Vasculature and neurovascular relationships of the trigeminal nerve root. *Acta Neurochir.* 153 (5), 1051–1057.
- DeArmond, S., Fusco, M., Dewey, M., 1976. *Structure of the Human Brain*. University Press, New York; Oxford.
- Drake, R., Wayne Vogl, A., Mitchell, A., 2015. *Gray's Anatomy*. Churchill Livingstone Elsevier, Philadelphia.
- Duvernoy, H., 1978. *Human Brainstem Vessels*. Springer Verlag, Berlin; Heidelberg; New York.
- Duvernoy, H., 1985. *The Human Hippocampus*. JF Bergmann Verlag, Munchen.
- Ellis, H., Logan, B., Dixon, A., 1999. *Human Sectional Anatomy. Atlas of Body Sections, CT and MRI Images*. Butterworth–Heinemann, Oxford; New Delhi.
- Gambarelli, J., Guerinel, G., Chevrot, L., Mattei, M., 1977. *Computerized Axial Tomography. An Anatomic Atlas of Sections of the Human Body*. Springer Verlag, Berlin; New York.
- Gerhardt, P., 1988. *Atlas of Anatomic Correlations in CT and MRI*. Thieme Verlag, Stuttgart; New York.
- Gilroy, A., MacPherson, B., Schuenke, M., Schulte, E., Schumacher, U., 2016. *Atlas of Anatomy*. Thieme, New York; Stuttgart; Delhi; Rio de Janeiro.
- Hagens, G., Romrell, L., Ross, M., Tiedemann, K., 1990. *Visible Human Body*. Lea & Febiger, Philadelphia; London.
- Haines, D., 2011. *Neuroanatomy: An Atlas of Structures, Sections, and Systems*. Lippincott Williams & Wilkins, Baltimore.
- Hanaway, J., Woolsey, T., Gado, M., Roberts, M., 1998. *The Brain Atlas*. Fitzgerald Science Press, Inc., Bethesda.
- Koritke, J., Sick, H., 1983. *Atlas of Sectional Human Anatomy*. Urban & Schwarzenberg, Baltimore; Munich.
- Mai, J., Assheuer, J., Paxinos, G., 1997. *Atlas of the Human Brain*. Academic Press, San Diego; Toronto.
- Marinkovi , S., Gibo, H., Milisavljevi , M., et al., 2001. Anatomic and clinical correlations of the lenticulostriate arteries. *Clin. Anat.* 14 (3), 190–195.
- Marinkovi , S., Gibo, H., Milisavljevi , M., et al., 2005. Microanatomy of the intrachoroidal vasculature of the lateral ventricle. *Neurosurgery* 57 (Suppl. 1), 22–36.
- Marinkovi , S., Milisavljevi , M., et al., 1985. Perforating branches of the middle cerebral artery. Microanatomy and clinical significance of their intracerebral segments. *Stroke* 16, 1022–1029.
- Marinkovi , S., Milisavljevi , M., et al., 1986a. Anastomoses among the thalamoperforating branches of the posterior cerebral artery. *Arch. Neurol.* 43, 811–814.
- Marinkovi , S., Milisavljevi , M., et al., 1986b. Anatomical bases for surgical approach to the initial segment of the anterior cerebral artery. Microanatomy of Heubner's artery and perforating branches of the anterior cerebral artery. *Surg. Radiol. Anat.* 8, 7–18.
- Marinkovi , S., Milisavljevi , M., et al., 1986c. Interpeduncular perforating branches of the posterior cerebral artery. Microsurgical anatomy of their extracerebral and intracerebral segments. *Surg. Neurol.* 26, 349–359.
- Marinkovi , S., Milisavljevi , M., et al., 1987. Distribution of the occipital branches of the posterior cerebral artery. Correlation with occipital lobe infarcts. *Stroke* 18, 728–732.
- Marinkovi , S., Milisavljevi , M., et al., 1990a. Branches of the anterior communicating artery. Microsurgical anatomy. *Acta. Neurochir.* 106 (1–2), 78–85.
- Marinkovi , S., Milisavljevi , M., et al., 1990b. The perforating branches of the internal carotid artery: the microsurgical anatomy of their extracerebral segments. *Neurosurgery* 26 (3), 472–478.
- Marinkovi , S., Milisavljevi , M., et al., 1992. Microvascular anatomy of the hippocampal formation. *Surg. Neurol.* 37, 339–349.
- Marinkovi , S., Milisavljevi , M., et al., 2004. Microsurgical anatomy of the perforating branches of the vertebral artery. *Surg. Neurol.* 61 (2), 190–197.
- Marinkovi , S., Schellinger, D., Milisavljevi , M., Antunovi , V., Petrovi , P., Vidi , B., Gibo, H., Štimec, B., Malikovi , A., 2000. *Sectional and MRI Anatomy of the Human Body*. CIC Edizioni Internazionali; Roma.
- Malikovi , A., Vučeti , B., Milisavljevi , M., et al., 2012. Occipital sulci of the human brain: variability and morphometry. *Anat. Sci. Int.* 87 (2), 61–70.
- Martin, J., 1989. *Neuroanatomy, Text and Atlas*. Elsevier, New York; London.
- Milisavljevi , M., Marinkovi , S., et al., 1986. Anastomoses in territory of the posterior cerebral artery. *Acta Anat.* 127, 221–225.
- Milisavljevi , M., Marinkovi , S., et al., 1988. Anatomic basis for surgical approach to the distal segment of the posterior cerebral artery. *Surg. Radiol. Anat.* 10, 259–266.
- Milisavljevi , M., Marinkovi , S., et al., 2013. Duplication of the superior vena cava associated with atrial termination of the left hepatic vein. *Phlebology* 28 (7), 369–374.
- Milisavljevi , M., Marinkovi , S., et al., 1986b. Oculomotor, trochlear and abducens nerves penetrated by cerebral vessels. *Arch. Neurol.* 43, 58–61.

- Milislavljević, M., Marinković, S., et al., 1991. The thalamogeniculate perforators of the posterior cerebral artery—the microsurgical anatomy. *Neurosurgery* 28 (4), 523–530.
- Milislavljević, M., Vitošević, Z., Vidić, B., Malinković, A., 2011. Atlas Disekcije Čoveka. Data Status, Beograd.
- Mtui, E., Gruener, G., Dockery, P., 2016. *Fitzgerald's Clinical Neuroanatomy and Neuroscience*. Elsevier, Philadelphia.
- Netter, F., 2014. *Atlas of Human Anatomy*. Saunders & Elsevier, Philadelphia.
- Nolte, J., Angevine, J., 1995. *The Human Brain. In Photographs and Diagrams*. Mosby, St. Louis; Wiesbaden.
- Paulsen, F., Waschke, J., 2013. *Sobotta Atlas of Human Anatomy*. Elsevier, Munich.
- Roberts, M., Hanaway, J., Morest, K., 1987. *Atlas of the Human Brain in Sections*. Lea & Febiger, Philadelphia.
- Rohen, J., Yokochi, C., Lutjen-Drecoll, 1998. *Color Atlas of Anatomy*. Williams & Wilkins, Baltimore.
- Whitmore, I., Federative Committee on Anatomical Terminology, 1998. *Terminologia Anatomica*. Thieme, Stuttgart; New York.
- Toldt, C., Dalla Rosa, A., 1948. *An Atlas of Human Anatomy*. Macmillan Company, New York.
- Vidić, B., Suarez, F., 1984. *Photographic Atlas of the Human Body*. Mosby, St Louis; Toronto.
- Vitošević, Z., etković, M., et al., 2005. Vaskularizacija kapsule interne i bazalnih jedara. *Srp. Arh. Celok. Lek.* 133 (1–2), 41–45.
- Vitošević, Z., Marinković, S., etković, M., Štimec, B., et al., 2013. Intramesencephalic course of the oculomotor nerve fibers: microanatomy and possible clinical significance. *Anat. Sci. Int.* 88 (2), 70–82.
- Watson, C., 1985. *Basic Human Neuroanatomy: An Introductory Atlas*. Little, Brown and Company, Boston; Toronto.
- Yasargil, M., 1984. *Microneurosurgery*. Georg Thieme Verlag, Stuttgart; New York.
- Zuleger, S., Staubesand, J., 1977. *Atlas of the Central Nervous System in Sectional Planes*. Urban & Schwarzenberg, Baltimore; Munich.

Index

A

- Abdomen
 - cross sections of
 - at L2-L3 level, 113
 - at L5, S1 level, 114
 - at S3 level, 115
 - at S5 level, 116
 - at T12 level, 112
 - sagittal section of, 109–111
- Abdominal wall
 - anterior, 90–92
 - posterior, 107–108
- Abducens nerve (CN VI), 162, 190, 191, 194
- Abducens nucleus, 202
- Abductor digiti minimi muscle, 16, 21
- Abductor hallucis muscle, 44–45
- Abductor pollicis brevis muscle, 16, 21
- Abductor pollicis longus muscle, 18–19
- Accessory hemiazygos vein, 66
- Accessory nerve (CN XI), 163, 165
- Accessory oculomotor nucleus, 207–208
- Accessory pancreatic duct, 99
- Accessory process, lumbar, 89
- Acetabular fossa, 25
- Acetabulum, 25
- Acinus, 64
- Acoustic meatus
 - external, 140, 142
 - internal, 141
- Acromial facet, of clavicle, 1
- Acromioclavicular joint, 1
- Acromion, 1–2
- Adductor brevis muscle, 32, 127–128
- Adductor canal, 30–31
- Adductor hallucis muscle, 45
- Adductor hiatus, 32
- Adductor longus muscle, 30–32, 127–128
- Adductor magnus muscle, 30, 32, 127–128
- Adductor pollicis brevis muscle, 16, 21
- Adductor pollicis muscle, 45
- Alveolar artery
 - inferior, 147, 158, 160
- Alveolar foramina, 144
- Alveolar arch, 143, 147
- Alveolar nerve
 - inferior, 147, 158, 160
- Alveolar process, 143–145
- Alveolus, 64
- Ambiens gyrus, 181
- Ambiguus nucleus, 213–214
- Ampulla
 - of ductus deferens, 120
 - hepatopancreatic, 96, 99
 - of rectum, 119, 123, 126
 - of uterine tube, 121
- Amygdaloid body, 195–196, 199–200, 203, 205, 223
- Anal canal, 127
- Anal sphincter muscle
 - external, 127
- Anatomical snuffbox, 19
- Anconeus muscle, 18, 20
- Angular gyrus, 175
- Ankle
 - ligaments of, 47
- Ansa cervicalis, 164
- Ansa lenticularis, 205
- Anus, 118, 120
- Aorta
 - abdominal, 80, 103–104, 112–113
 - arch of, 65, 83
 - ascending, 67–68, 71–72, 76, 84
 - thoracic, 65–66, 80, 84–88
- Aortic arch, 65, 79–80, 83
- Aortic hiatus, 68
- Aortic sinus, 74
- Aortic sulcus, 60, 62
- Aortic valve, 73–74, 81
- Aponeurosis
 - bicipital, 12
 - of external oblique muscle, 90
 - palmar, 12, 14
 - plantar, 44
- Appendix
 - vermiform, 94
- Arachnoid mater
 - cranial, 173, 197, 236
- Arcades, of small intestine, 94
- Arcuate artery, 105
- Arcuate line, 91
- Arcuate vein, 105
- Arcuate eminence, 141
- Arcuate ligament, of diaphragm, 68
- Arcuate line, of hip bone, 25
- Arcuate popliteal ligament, 35
- Areola, 58
- Arteriae rectae, 102
- Artery of Adamkiewicz, 235
- Artery of Heubner, 247, 251
- Articular process, 56, 89, 153
- Aryepiglottic fold, 170, 172
- Arytenoid muscle
 - oblique, 170
 - transverse, 170
- Atlas (C1), 55, 150–153
- Atlanto-axial joint
 - lateral, 152
 - middle, 152
- Atlanto-occipital joint, 200
- Atrioventricular nodal artery, 78
- Atrioventricular septum, 71
- Atrium, 69, 71–72, 79–80, 86–87
 - left, 69, 72, 80, 86
 - right, 65, 71, 79, 87
- Auditory tube, 142, 166–167, 201
 - cartilaginous part of, 167
 - osseous part of, 142
 - pharyngeal opening of, 166–167
- Auricle, 159
- Auricular nerve
 - great, 156, 159–160, 163
- Auriculotemporal nerve, 158–160
- Axilla, 5–8, 83–84
- Axillary artery, 5–8, 22–23, 83–84
- Axillary fossa, 5–8, 83–84
- Axillary nerve, 6–7, 10
- Axillary vein, 5–6, 8, 83
- Axis (C2), 55, 150, 200, 226
- Azygos vein, 66, 84–88
 - groove for, 61
 - transverse section of, 84–88

B

- Back
 - muscles of
 - deep layers of, 82–83, 85, 108, 110, 112–114
 - intermediate layers of, 107
 - superficial layers of, 9, 82–83, 85, 107
- Basilar artery, 191, 200, 223–224, 229, 232–236
- Basilic vein, 5, 12, 18
- Biceps brachii muscle, 5–8, 12, 20
- Biceps femoris muscle, 32–35, 39, 41, 48–49
- Bicipital aponeurosis, 12
- Bicuspid valve, 72–74
- Bifurcate ligament, 47
- Bile duct, 96–99, 109
 - common, 96–99, 109, 112
- Brachial artery, 5–8, 22–23
- Brachial cutaneous nerve
 - medial, 6, 8
 - superior lateral, 9

Brachialis muscle, 8, 12, 18–20
 Brachial plexus, 6–7, 83
 Brachiocephalic trunk, 65, 69, 79, 83
 Brachiocephalic vein, 65, 67, 69, 80, 83
 left, 65, 67, 69, 80, 83
 right, 65, 67, 69, 79, 83
 Brachioradialis muscle, 5, 12–15, 20
 Brain
 coronal sections of, 200–202
 sagittal section of, 203–204
 transverse sections of, 205–225
 Brainstem
 anterior view of, 200–202
 posterior view of, 203–204
 sections, 205–225
 Bregma, 135
 Broad ligament, 121–123
 Bronchial artery, 61–62
 Bronchial vein, 61–62
 Bronchiole
 respiratory, 64
 terminal, 64
 Bronchus, 59–63, 66
 left main, 60, 62, 66, 79–80
 right main, 59, 61, 63, 66, 85
 Buccal nerve, 157–160
 Buccinator muscle, 157–158, 160
 Bulb of penis, 118, 127
 Bulb of vestibule, 118
 Bulbospongiosus muscle, 118, 127–128

C

Calcaneal tendon, 38–42
 Calcaneal arteries, 42, 44, 51–52
 Calcaneal nerves, 38, 41
 Calcaneal tuberosity, 29, 47
 Calcaneocuboid ligament, 47
 Calcaneofibular ligament, 47
 Calcaneonavicular ligament, 47
 plantar, 47
 Calcaneus, 40
 Calcar avis, 185
 Calcarine artery, 240, 244, 248
 Calcarine sulcus, 178, 180–181, 185, 203, 221–222
 Callosomarginal artery, 248
 Calvaria, 129, 131, 135
 anterior view of, 129, 131
 inferior view of, 130, 135
 lateral view of, 130
 posterior view of, 136
 superior view of, 135
 Calyx
 major, 103
 minor, 103
 Canine teeth, 143, 147
 Capitate, 4, 21
 Capitulum, 2–3
 Cardia, 93
 Cardiac notch, 60
 Cardiac vein
 anterior, 76
 great, 69, 73, 75–76, 78
 middle, 75, 77–78, 88

Carotid artery
 common, 65, 82, 164–165, 171–172, 228
 external, 156–157, 159–160, 164, 172, 226–227, 245
 internal, 161–162, 164, 172, 223–227, 244–246, 252–254
 Carotid canal, 133, 136, 141–142
 Carpal bones, 4, 21
 Carpal tunnel, section, 21
 Cartilage
 arytenoid, 169
 of auditory tube, 167
 costal, 57
 cricoid, 169–170
 thyroid, 169
 tracheal, 170
 Cauda equina, 108, 113
 Caudate nucleus, 185, 201, 203–204, 206, 220–221
 Caudate process, 97
 Caval opening, 68
 Cavernous sinus, 190, 196
 Cecal artery, 94, 102
 Cecum, 94–95, 115
 Celiac ganglion, 103
 Celiac trunk, 99–100, 103–104, 112
 Central sulcus, 174–176, 202–203
 Cantral tegmental tract, 206–214
 Central tendon, 68
 Centrum semiovale, 202
 Cephalic vein, 5, 12, 18, 20
 Cerebellar artery
 anterior inferior, 229–230, 233–234, 236–237
 posterior inferior, 191–193, 233–234, 236–237
 superior, 191–196, 233–234, 236–237
 Cerebellar flocculus, 198
 Cerebellar nodulus, 198
 Cerebellar nuclei, 216
 Cerebellar peduncles, 179, 192–193, 202, 210, 224
 Cerebellum, 176, 196, 198, 203–204, 223–225
 anterior lobe of, 198
 posterior lobe of, 198
 Cerebral aqueduct, 180, 195, 208–209, 222
 Cerebral arterial circle of Willis, 229, 233, 246, 253
 Cerebral artery
 anterior, 195–196, 229–233, 244–247, 251–254
 middle, 195, 229, 231, 244–246, 250–254
 posterior, 192–196, 230, 231–234, 239–240, 242, 244–246, 251–254
 Cerebral crus, 179–180, 182, 188–189, 193, 195–196, 206–208
 Cerebral fissure, longitudinal, 175, 201–202
 Cerebral hemisphere
 inferior surface of, 179–181, 189
 medial surface of, 177–178, 180, 183, 187
 superolateral surface of, 174–176
 Cerebral vein
 great, 231
 internal, 241
 superior, 173, 197

Cerebrum
 frontal lobe of, 174–176, 178
 gyri of, 174–184
 cross section through, 205–206, 220–224
 inferior view of, 179–182, 189
 lateral view of, 174–176
 medial view of, 177–178, 183
 occipital lobe of, 174–175, 177–178, 180
 parietal lobe of, 174–178
 sulci of, 174–184
 superior view of, 175–176
 temporal lobe of, 174–176, 180–182
 Cervical artery
 superficial, 164–165
 transverse, 164
 Cervical nerves
 transverse, 163
 Cervical plexus, 164–165
 Cervical vertebrae, 150–154
 C1, 150–152, 154, 203, 232
 C2, 150–152, 154, 226, 232
 C3, 154, 227
 C4, 154, 203, 228
 C5, 153–154
 C6, 154
 C7, 153–154
 Cervix of uterus, 122
 Choana, 171
 Chordae tendineae, 71, 73
 Choroidal artery
 anterior, 233–234, 240, 250–251, 254
 posterior, 240, 242
 posterior lateral, 240, 242
 posterior medial, 240, 242
 Choroid plexus
 of lateral ventricle, 183, 185–186, 188, 198, 202, 234, 240
 of third ventricle, 181
 of fourth ventricle, 198
 Cingulate gyrus, 177–178, 183, 199, 202–203
 isthmus of, 183
 Cingulate sulcus, 177–178, 203–204
 Cingulum, 183
 Circle of Willis
 inferior view of, 233, 246
 in situ, 229, 233
 Cistern
 cerebellomedullary, 197, 202, 204
 chiasmatic, 246
 lateral cerebral fossa of, 246
 terminal lamina of, 246
 Claustrum, 199–200, 202, 220–222
 Clavicle, 1–2, 79–80, 82
 Clitoris, 118
 Clivus, 200, 204
 Clunial nerves, 33
 Coccygeal cornu, 117
 Coccygeus muscle, 125
 Coccyx, 4, 55, 110, 117, 123, 125
 Cochlea, 139, 141
 Cochlear nuclei, 213
 Cochlear (round) window, 141
 Colic artery, 95, 102, 113
 Colic flexure
 right, 112

- Collateral artery
middle, 22–23
radial, 22–23
ulnar, 22–23
- Collateral ligament
fibular, 49
radial, 3
tibial, 43
ulnar, 3
- Collateral sulcus, 180, 202
- Collateral trigone, 185
- Collicular artery, 239, 241
- Colliculus
facial, 192
inferior, 182, 188, 192–193, 204, 209
brachium of, 188, 204, 206–207
superior, 182, 188–189, 192–193, 206, 208
brachium of, 188, 204
- Colon, 94–95, 109–110, 113–114
- Commissure
anterior, 177–178, 180, 183, 205, 221
habenular, 188
posterior, 177, 206
of semilunar valve cusps, 74
- Communicating artery
anterior, 233, 246–247, 250
posterior, 231, 233–234, 236, 239, 246, 250, 254
- Condyle
lateral, 26, 43, 49
medial, 26, 43, 49
occipital, 130, 133, 135–136, 200, 203
- Conus arteriosus, 69, 71, 73, 81
- Coracoacromial ligament, 2
- Coracobrachialis muscle, 6–7
- Coracoclavicular ligament, 2
- Coracoid process, 2
- Coronary artery
left, 69–70, 74–78
right, 69–70, 72–78, 88
- Coronary ligament
of liver, 97
- Coronary sinus, 72, 75, 77–78, 80, 86–87
- Coronary sulcus, 70, 72
- Coronoid fossa, 2
- Coronoid process, 146–147
- Corpora cavernosa, 118
- Corpora quadrigemina, 188, 192
- Corpus callosum, 177–178, 183–187, 189, 199, 201–205, 220
- Corpus cavernosum, 128
- Corpus spongiosum, 118, 128
- Corpus striatum, 199, 221
- Corticonuclear tract, 208–212
- Corticospinal tract, 208–215
- Costal facet, 56
- Costal pleura, 66, 86
- Costoclavicular ligament
impression for, 1
- Costodiaphragmatic recess, 112
- Costomediastinal recess, 86
- Cranial fossa
anterior, 132–133, 137
middle, 132–133, 190
posterior, 133, 136, 190
- Cribriform plate, 132–133, 137–138, 161, 166
- Cricothyroid muscle, 170
- Crista galli, 130, 132–133, 137–138, 167, 195
- Crista terminalis, 71
- Crista supraventricularis, 71
- Cross section
of abdomen, 112–116
at L2–L3 level, 113
at L5–S1 level, 114
at middle T12 level, 112
at T10 levels, 88
of arm, 20
of elbow, 20
of forearm, 20
of leg, 48
of thorax, 82–87
at T2 level, 82
at T4 level, 83
at T5 level, 84
at T6 level, 85
at T7–T8 level, 86
at T8–T9 level, 87
of wrist, 21
- Cruciate ligament, 43, 49
- Cubital fossa, 12, 20
- Cubital vein, median, 12
- Cuboid bone, 28–29
- Culmen, 198
- Cuneate tubercle, 192
- Cuneate fasciculus, 214–215, 218–219
- Cuneiform bone
intermediate, 28–29
lateral, 28–29
medial, 28–29
- Cuneus, 177–178, 180, 220–222
- Curvature
greater, 94
lesser, 92–93
- Cutaneous nerves
antebrachial
lateral, 5, 8, 12, 20
medial, 5–7, 12, 20
posterior, 5, 18
brachial
medial, 5–8
superior lateral, 9
dorsal
intermediate, 38
lateral, 38
medial, 38
femoral
lateral, 30–32, 68
posterior, 30–31
of forearm, 5–8, 12, 18, 20
of hand, 12, 14–18
of head and neck, 159–160, 163
sural, 37–38, 41, 48
- Cystic duct, 96–97
- D**
- Declive, 198
- Deltoid ligament, 47
- Deltoid muscle, 5–6, 8–11, 82–84
- Deltoid tuberosity, 2
- Dens
of axis, 150–152
- Dentate gyrus, 181–182, 184–185, 243
- Dentate nucleus, 216
- Dentatothalamic tract, 205–206
- Denticulate ligament, 230
- Depressor anguli oris muscle, 155–156, 158–159, 163
- Depressor labii inferioris muscle, 163
- Diaphragm, 67–68, 103–104
- Digastric fossa, 146
- Digastric muscle, 163–164, 203
- Digital artery
palmar, 14–15
common, 14–15
plantar, 44
common, 44
- Digital nerve
dorsal, 17
palmar, 14–16
plantar, 44–46
- Diploe, 135
- Distal medial striate artery (recurrent artery of Heubner), 247, 251
- Dorsal interosseous muscle, 17–19, 21
- Dorsal longitudinal fascicle, 214
- Dorsalis nasi artery, 155
- Dorsalis pedis artery, 36–37, 51–53
- Dorsal root ganglion, 229
- Ductus arteriosus
obliterated, 65
prenatal, 65
- Ductus choledochus, 96–99, 109, 112
- Ductus deferens, 118–120, 125
- Duodenal flexure, 99
- Duodenal papillae, 96, 99
- Duodenojejunal junction, 99
- Duodenum, 96, 99, 109–110, 112–113
- Dura mater, 173, 196, 201
meningeal, 173
spinal, 108, 200, 230
- E**
- Ear
external, 130, 140, 159, 224
internal, 139, 141
middle, coronal oblique section
of, 139, 141
tympanic cavity of, 139, 141
- Edinger-Westphal nucleus, 207–208
- Elbow
arteries, 12–13, 20
bones of, 1, 3
cross section of, 20
joint capsule of, 3
joints, 1, 3
ligaments of, 3
- Emboliform nucleus, 216
- Entorhinal area, 181
- Epicondyle
lateral, 26
medial, 26

Epididymis, 118
 Epigastric artery
 inferior, 91–92, 115
 superficial, 90
 superior, 58, 91
 Epiglottis, 168, 170–172, 203
 Erector spinae muscle, 107–108
 cross section of, 82–83, 85, 88, 112–114
 Esophageal hiatus, 68, 103–104
 Esophageal plexus, 65–66, 93
 Esophagus, 65–66, 79, 82–88, 93
 Ethmoidal bone, 130–131, 133, 138
 Ethmoidal incisure, 131
 Extensor carpi radialis brevis muscle,
 13, 18–19
 Extensor carpi radialis longus muscle, 13,
 18–21
 Extensor carpi ulnaris muscle, 18–21
 Extensor digiti minimi muscle, 18–19
 Extensor digitorum brevis muscle, 36–37
 Extensor digitorum longus muscle, 36–39, 48
 Extensor digitorum muscle, 18–21
 Extensor hallucis brevis muscle, 36–37
 Extensor hallucis longus muscle, 36–39
 Extensor hallucis longus tendon
 sheath, 36–37, 48
 Extensor indicis muscle, 18–21
 Extensor pollicis brevis muscle, 18–21
 Extensor pollicis longus muscle, 18–21
 External occipital protuberance, 130, 136
 Extrinsic eye muscles, 161–162, 223–224
 Eyeball, 161–162, 223–224

F

Face
 arterial supply sources of, 155–160,
 163–164
 muscles of, 155–160, 163
 sensory nerves of, 155
 superficial arteries and veins of, 155–160
 superficial view of, 155
 Facets
 articular, 56
 costal, 56
 Facial artery, 155–157, 163–165, 227
 Facial vein, 159–160, 226
 Facial colliculus, 192
 Facial nerve (CN VII), 139, 141, 155–156, 159,
 200
 Facial nucleus, 212
 Falciiform ligament, 92–93, 97, 112
 Falx cerebri, 174, 177, 201–202
 Fascia
 antebrachial, 12, 14, 18
 crural, 38, 40–41
 lata, 30, 48, 92
 renal, 112–113
 thoracolumbar, 107
 transversalis, 92
 Fascicle
 cuneate, 215, 218–219
 gracile, 215, 218–219
 Fastigial nucleus, 216
 Fastigium, 198, 202

Fat
 of mammary gland, 58
 pararenal, 79
 perirenal, 103, 112–113
 Fat pad
 infrapatellar, 43
 Fauces, 168, 172
 Femoral artery, 30–32, 48, 50, 91, 126–127
 Femoral nerve, 30–32, 48, 68, 91, 126–127
 Femoral ring, 31
 Femoral vein, 30–32, 48, 91, 126–127
 Femur, 26, 48–49
 Fetus
 corrosion cast, 22, 50, 146, 172, 245
 Fibula, 27–28, 47–48, 51
 Fibular artery, 42, 48–49, 51
 Fibular collateral ligament, 49
 Fibularis brevis muscle, 37–39, 41, 48
 Fibularis longus muscle, 37–39, 41, 48–49
 Fibularis tertius tendon, 37–39
 Fibular nerve
 common, 32, 34–35, 39, 41, 49
 deep, 36–39
 superficial, 36–39, 48
 Fibular vein, 48
 Filum terminale, 108
 Finger(s), 4, 14–15, 18, 21
 extensor tendons of, 17–19, 21
 flexor tendons of, 15–16, 21
 Flexor carpi radialis muscle, 12–15, 20
 Flexor carpi ulnaris muscle, 12–15, 20
 Flexor digiti minimi brevis muscle, 16
 Flexor digitorum brevis muscle, 44–45
 Flexor digitorum longus muscle, 44–45
 Flexor digitorum profundus muscle, 13, 16, 20
 Flexor digitorum superficialis muscle, 12–13,
 15–16, 20
 Flexor hallucis brevis muscle, 45–46
 Flexor hallucis longus muscle, 44–46
 Flexor pollicis brevis muscle, 16
 Flexor pollicis longus muscle, 13–14, 16, 21
 Flexor retinaculum, 21
 Fontanelle, 149
 Foot
 arteries of, 36–38, 44–46, 51–53
 bones of, 28–29
 ligaments of, 47
 muscles, 36, 44–46
 Foramen
 interventricular, 177–179, 183, 187
 Foramen cecum, 133, 137
 Foramen lacerum, 133–134
 Foramen magnum, 133, 136, 139
 Foramen ovale, 132–133, 136, 144–145
 Foramen rotundum, 132–133
 Foramen spinosum, 132–133, 136
 Foramen transversarium, 151–153
 Forceps
 major (occipital), 185
 minor (frontal), 185
 Forearm
 bones of, 1, 3, 20
 corrosion cast of, 23
 cross section of, 20
 cutaneous nerves of, 12, 18

 muscles of, 12–13, 18–20
 Fornix, 178, 182–185, 204–205, 220
 Frontal bone, 129–133, 137, 149
 Frontal gyrus
 inferior, 175–176, 201, 222
 medial, 177–179
 middle, 175–176, 201, 220–221
 superior, 175, 201, 203
 Frontal horn, 183
 Frontal lobe, 174, 201
 Frontal nerve, 161
 Frontal operculum, 175–176
 Frontal pole, 174
 Frontal sinus, 133, 137–138, 195, 220–222
 Frontal suture, 131, 149

G

Galea aponeurotica, 201
 Galen
 anastomosis of, 170
 great cerebral vein of, 231
 Gallbladder, 96–98, 109, 112
 Gastric artery, 93, 96
 Gastric impression, 97
 Gastrocnemius muscle, 35, 41, 48–49
 Gastrocolic ligament, 95
 Gastroduodenal artery, 96, 100
 Gastro-omental artery, 93–94, 100
 Gemellus muscle, 33
 Genicular artery, 35, 41, 43, 50
 Genicular vein, 43
 Geniculate body
 lateral, 182, 188, 192, 206
 medial, 182, 188, 192, 206, 208
 Genioglossus muscle, 168
 Geniohyoid muscle, 168, 227
 Genitofemoral nerve, 68, 103–104
 Genu, of corpus callosum, 177, 188, 201,
 203–204, 220
 Giacomini, tract of, 181
 Glabella, 129, 131
 Glans penis, 118
 Glenohumeral joint, 2
 Glenohumeral ligament, 2
 Glenoid cavity, 2
 Globose nucleus, 216
 Globus pallidus, 203–205, 221
 Glossoepiglottic fold, 172
 Glossopharyngeal nerve (CN IX), 171,
 190–194, 226
 Gluteal artery, 33, 107, 125
 Gluteal nerve, 33
 Gluteal tuberosity, 26
 Gluteal vein, 33, 107, 125
 Gluteus maximus muscle, 32–34, 107,
 109–110, 114–116
 Gluteus medius muscle, 33, 107, 114–116
 Gluteus minimus muscle, 33, 108, 114–116
 Gracile fasciculus, 215, 218–219
 Gracile tubercle, 192
 Gracilis muscle, 30–32, 34–35, 48–49
 Great auricular nerve, 156, 159–160, 163
 Greater occipital nerve, 192
 Great toe, 28, 36, 46, 52

H

Habenular commissure, 188
 Habenular trigone, 188
 Habenulo-interpeduncular tract, 206
 Hamate, 4, 21
 Heart, 67, 69, 86–88
 apex of, 69–70, 74–78
 base of, 70, 72
 corrosion casts of, 70, 75–78
 diaphragmatic surface of, 70, 72, 75, 78
 fibrous skeleton of, 71, 73–74
 in situ, 67, 90–92
 in pericardium, 67, 90–92
 sternocostal surface, 69–71, 76–77
 valves of, 72–74
 Hemizygos vein, 66, 88
 Hepatic artery, 97–98
 Hepatic duct
 common, 96–97
 left, 98
 right, 98
 Hepatic triade, 100
 Hepatic portal vein, 96–99, 109, 112
 Hepatic vein, 97–98, 103
 Hepatopancreatic ampulla, 96, 99
 Hilum, of kidney, 103–104
 Hip bone, 25–26, 109–110, 114–116, 125
 Hip joint, 26, 125
 Hippocampus, 181–182, 184–185, 196,
 199–200, 202, 206, 221, 243
 arteries of, 243
 fimbria of, 181–182, 185, 207
 foot (pes) of, 181–182, 184
 Hippocampus proper, 181, 184–185
 Horizontal fissure, 59, 61
 Humerus, 1–3, 20, 23, 82–84
 Hyoglossus muscle, 165, 168, 203
 Hyoid bone, 145, 163, 168
 Hypoglossal canal, 130, 135–136, 138–139
 Hypoglossal nerve (CN XII), 164–165, 171,
 179, 190–191, 226–227, 230
 Hypoglossal nucleus, 214–215
 Hypoglossal trigone, 192
 Hypophyseal artery, 246
 Hypophyseal fossa, 130, 131, 137–138,
 166–167
 Hypophysis, 203–204, 223, 232
 Hypothalamus, 181, 183, 205
 Hypothalamic sulcus, 181
 Hypothenar eminence, 15–16
 Hypothenar muscles, 15–16, 21

I

Ileal artery, 94–95, 102
 Ileocecal junction, 94–95
 Ileocolic artery, 94–96, 102
 Ileum, 92, 94–95
 Iliac artery
 circumflex, 30–31, 50, 90
 common, 50, 96, 103, 114, 119
 external, 50, 115–116
 internal, 50, 115, 119–120
 Iliac crest, 25, 108
 Iliac fascia, 31

Iliac fossa, 25
 Iliac spine, 25–26, 114–115
 Iliac tuberosity, 25
 Iliacus muscle, 103–104, 109, 114
 Iliac vein, 103, 114–116, 119
 Iliocostalis muscle, 110
 Ilioinguinal nerve, 68, 91
 Iliohypogastric nerve, 68
 Iliopsoas muscle, 30–32
 Iliopubic eminence, 25
 Iliotibial tract, 31, 33–34, 49
 Ilium, 25, 50, 114–115, 117
 Incisive canal, 133, 143, 145
 Incisor teeth, 143, 147–148
 Incus, 139, 141
 Infrahyoid muscles, 163–165, 228
 Infraorbital artery, 148, 155, 161
 Infraorbital foramen, 129, 143
 Infraorbital groove, 129
 Infraorbital nerve (branch of CNV₂), 155,
 161, 167
 Infraorbital vein, 155, 167
 Infrapinatus muscle, 9–11, 82–84
 Infratrochlear nerve, 161
 Infundibulum, 161–162, 179–180, 182, 246
 Inguinal canal, 91
 Inguinal ligament, 90, 92
 Inguinal lymph nodes, 30
 Inguinal region, 90–92
 Inguinal ring
 deep, 91
 superficial, 91
 Insula (island of Reil), 176, 183,
 186, 220
 Interarytenoid notch, 171
 Interarytenoid fold, 171–172
 Interatrial septum, 72, 81
 Intercondylar eminence, 27
 Intercondylar fossa, 26
 Intercondylar tubercle, 27
 Intercostal artery
 anterior, 58
 posterior, 66
 Intercostal membrane, 58
 Intercostal muscle, 58, 80, 86
 Intercostal nerve, 58, 66, 91
 Intercostal vein, 66
 Intercostobrachial nerve, 5–7
 Interganglionic rami, 66
 Intermediolateral nucleus
 of gray matter, 219
 Internal capsule, 186, 199–200, 204–205,
 220–221
 Interosseous artery, 12–13, 19
 Interosseous muscles
 of hand, 16–19, 21
 Interpeduncular artery, 239, 241
 Interpeduncular fossa, 179, 207
 Interpeduncular nucleus, 208–209
 Interstitial nucleus of Cajal, 206
 Interthalamic adhesion, 178, 180, 221,
 232, 247
 Intertrochanteric fossa, 26
 Interventricular foramen, 178, 180, 183, 185,
 193, 200

Interventricular sulcus

 anterior, 69–70
 posterior, 70, 72

Interventricular septum, 71, 73–74

Intervertebral disc, 79, 113

Intervertebral foramen, 56

Intraparietal sulcus, 175

Ischial spine, 25

Ischial tuberosity, 25–26, 109

Ischioanal fossa, 109, 118, 127–128

Ischiocavernosus muscle, 127

Ischiococcygeus (coccygeus) muscle, 125

Ischium, 25, 125

J

Jejunal artery, 94–95, 99–100, 102

Jejunum, 94–95, 99

Jugular foramen, 133, 136, 139

Jugular fossa, 133, 136, 141–142

Jugular vein

 external, 159–160, 163, 227

 internal, 79, 82, 164, 171, 226–228

K

Kidney, 103–106, 109–110, 112–113

Knee, 43, 49

L

Labial artery, 146, 155

Labyrinth

 bony, 139, 141

Lacrimal bone, 129–131, 138

Lacrimal gland, 161, 223

Lacrimal nerve, 161–162

Lambda, 135

Lambdoid suture, 130, 135–136

Lamina cribrosa, 132–133, 137–138, 161, 166

Lamina terminalis, 177–178, 247

Large intestine, 94–95, 109–110, 112–116,

 119–120, 125–127

Laryngeal nerve (CN X)

 recurrent, 170

 superior, 170

Laryngopharynx, 168, 171

Larynx

 cartilage of, 169

 intrinsic muscles of, 170

 nerves of, 170

Lateral cerebral fissure, 202

Lateral lemniscus, 209–212

 nuclei of, 210

Latissimus dorsi muscle, 9–10, 86–88, 107

Lenticular fascicle, 205

Lenticulostriate artery, 250–254

Lentiform nucleus

 globus pallidus of, 203–205, 221

 putamen of, 203, 220–222

Lesser occipital nerve, 159, 163

Levator ani muscle, 118–120, 126

Levator costarum muscle, 108

Levator labi superioris muscle, 155, 161

Levator palpebrae superioris muscle, 162

Levator scapulae muscle, 10, 165, 227–228

Ligament of ovary, 121–122
 Linea alba, 91
 Linea aspera, 26, 48
 Linea terminalis, 117
 Lingual artery, 172, 201
 Lingual gyrus, 178, 180, 223
 Lingual nerve, 158, 160, 168
 Lingula
 cerebellar, 198
 pulmonary, 60
 Lip
 lower, 168
 upper, 168
 Liver, 79, 93, 97–98, 109, 112
 Locus ceruleus, 210
 Longitudinal cerebral fissure, 175, 201–202
 Longus capitis muscle, 11, 204, 226–228
 Longus coli muscle, 11, 226–228
 Lumbar artery, 68
 Lumbar triangle, 107
 Lumbar vertebrae, 55–56
 Lumbrical muscles, 16, 21, 44
 Lunate, 4
 Lung, 59–64, 66, 81–88

M

Malleolus
 lateral, 27–28, 36, 38–39, 41, 48
 medial, 27–29, 36
 Malleus, 139, 141
 Mammary gland, 58
 Mammillary body, 179–180, 182–184, 186, 232
 Mammillary process, 89
 Mammillothalamic fascicle, 205
 Mammillothalamic tract, 184, 187, 205
 Mandible, 129–130, 146–148, 155, 158, 168
 Mandibular canal, 147
 Mandibular foramen, 146
 Mandibular fossa, 133–134, 136, 142
 Mandibular nerve, 139, 155, 160, 190, 194, 230–231
 Manubriosternal synchondrosis, 57
 Manubrium, 57, 79–80, 83–84
 Marginal artery, 95, 102
 Marginal collecting vessels, 95, 102
 Masseter muscle, 155–157, 159
 Mastication, muscles of, 155–160, 225–226
 Mastoid foramen, 141
 Mastoid incisure, 142
 Mastoid process, 130, 135, 140–142, 171
 Maxilla, 129–131, 138, 143–144, 149, 167
 Maxillary artery, 158, 160
 Maxillary nerve, 139, 190, 194, 230–231
 branches of, 168
 Maxillary sinus, 143, 148, 167, 225
 Medial lemniscus, 207–214
 Medial longitudinal fasciculus, 208–213
 Median eminence, 179–180, 182, 246
 Median nerve, 5–7, 13–16, 20–21
 Mediastinum
 anterior, 67, 80, 82–83
 posterior, 65–66, 80, 86–88
 superior, 69, 80, 82–83

Medulla oblongata, 174, 176–180, 183, 191–192, 200, 202, 204, 230, 232, 235
 cross section of, 213–215
 Medullary artery, 234–236
 anterior segmental, 102, 234–235
 posterior segmental, 235
 Membranous septum
 atrioventricular part of, 71
 interventricular part of, 73
 Meningeal artery, middle, 139, 158, 160, 190, 230
 Meninges, 173, 177, 196–197, 236
 Menisofemoral ligament, posterior, 43
 Meniscus, 43
 coronal section, 49
 sagittal section, 49
 Menta, 227
 Mental foramen, 129, 146–148
 Mental nerve, 163–164
 Mental protuberance, 163–164
 Mental ramus (artery), 164
 Mesencephalic artery, 239, 242
 Mesencephalic nucleus, 208–210
 Mesencephalon, 177–178, 182–183, 188, 193, 195–196, 199, 204, 208–209
 Mesenteric artery
 inferior, 95–96, 102
 superior, 94–96, 99–100, 102–103, 113
 Mesenteric vein
 inferior, 96
 superior, 94, 96, 99
 Mesentery, 94–95, 115–116
 Mesoappendix, 94
 Mesocolon
 sigmoid, 95
 transverse, 94
 Mesometrium, of broad ligament, 121–123
 Mesosalpinx, of broad ligament, 121
 Mesovarium, 122
 Metacarpal artery
 dorsal, 17–19, 24
 palmar, 23
 Metacarpal bone, 1, 4, 21
 Metatarsal artery
 dorsal, 36–37, 51–53
 plantar, 46, 53
 Metatarsal bones, 27–29
 Metopic suture, 129, 131, 149
 Mitral valve, 72–74
 Moderator band (septomarginal trabecula), 71–73
 Musculocutaneous nerve, 5–7
 Musculophrenic artery, 58
 Myocardium, 73–74, 80, 81, 88
 Mylohyoid line, 146
 Mylohyoid muscle, 164, 168, 203, 226–227
 Mylohyoid nerve, 160

N

Nares, 166
 Nasal bone, 129–131, 137–138, 144, 166
 Nasal cartilages, 166
 Nasal cavity, 135, 138, 166–167

Nasal concha
 inferior, 130, 138, 145, 166, 203, 225
 middle, 138, 166, 203
 superior, 138, 166–167, 203
 Nasal limen, 167
 Nasal meatus, 138, 166
 Nasal septum, 137, 166, 171, 225
 Nasal spine, 131, 138
 Nasal vestibule, 166–167
 Nasociliary nerve, 162
 Nasopharynx, 167–168, 171, 225
 Nasolacrimal duct, 167
 Navicular bone, 27–29
 Newborn, skull of, 148–149
 Nostrils, 166
 Nuchal ligament, 228
 Nucleus ambiguus, 213
 Nucleus of accessory nerve, 215
 Nucleus of posterior commissure (Darkschewitsch), 206

O

Obex, 192
 Oblique aponeurosis
 external, 90–91, 107
 internal, 90, 107
 transverse, 108
 Oblique fissure, 59–63, 83, 85–87
 Oblique muscle
 external, 90, 107, 112–113
 internal, 90–91, 107, 113
 Oblique pericardial sinus, 67
 Oblique popliteal ligament, 35
 Oblique vein of left atrium, 75, 78
 Obliquus capitis inferior muscle, 200
 Obliquus capitis superior muscle, 11
 Obturator artery, 50, 119, 123
 Obturator externus muscle, 26, 32, 109, 126
 Obturator foramen, 25
 Obturator internus muscle, 33, 110, 119–120, 123, 126
 Obturator nerve, 32, 68, 123
 Obturator vein, 123
 Occipital artery, 10–11, 172
 Occipital bone, 130, 133, 135–136, 139, 149, 232
 Occipital condyle, 130, 133, 135–136, 138
 Occipital gyrus
 lateral, 175
 Occipital horn, 183, 185–187, 221–222
 Occipital nerve
 greater, 10–11, 192
 lesser, 159, 163
 Occipital protuberance
 external, 10, 130, 136, 224
 internal, 135–136, 225
 Occipital sulci
 anterior, 175
 lateral, 175
 transverse, 175
 Oculomotor nerve (CN III), 162, 182, 187, 190–191, 194, 231, 254
 Oculomotor nucleus, 207–208
 accessory, 207–208

Olecranon, 3, 20
 Olfactory bulb, 176, 178–179
 Olfactory stria
 lateral, 179, 182
 medial, 179
 Olfactory sulcus, 179
 Olfactory tract, 179–180, 182
 Olfactory trigone, 179, 182
 Ovary complex
 accessory, 213–214
 inferior, 213–214
 superior, 213–214
 Olive, 179, 191
 Omental bursa, 94, 112
 Omentum
 greater, 93, 95, 114–116
 lesser, 93, 112
 Omohyoid muscle, 163–164, 228
 Operculum, 176, 254
 Ophthalmic artery, 146, 162, 229, 245
 Ophthalmic nerve, 139, 190, 229–231
 Opponens digiti minimi muscle, 16
 Opponens pollicis muscle, 16
 Optic canal, 129, 131–132, 134, 137
 Optic chiasm, 177–180, 182, 189, 191, 195, 203, 236
 Optic nerve (CN II), 161–162, 182, 189–190, 195–196, 204, 223, 229–230, 253
 Optic radiation, 189, 206–207
 Optic tract, 179, 182, 189, 195–196, 205, 250
 Oral cavity, 167–168, 172, 203, 226
 Orbicularis oculi muscle, 155, 159
 Orbicularis oris muscle, 155, 158, 163, 226
 Orbit, 131, 161–162, 224
 Orbital fissure
 inferior, 129, 131, 144
 superior, 129, 131–132, 134
 Orbital gyri, 179, 222
 Orbital sulci, 179
 Oropharynx, 168, 171, 203, 226
 Osseous cochlea, 139, 141
 Ossicles, 139, 141
 Oval (vestibular) window, 141
 Ovarian vessels, 121–123
 Ovary, 121–122

P

Palate
 bony, 133–135, 137–138
 hard, 167–168
 soft, 167–168
 Palatine bone, 130, 133–134, 137–138, 144–145
 Palatine foramen
 greater, 134, 145
 lesser, 134, 145
 Palatine nerve
 greater, 168
 lesser, 168
 Palatoglossal arch, 168
 Palatoglossus muscle, 168, 226
 Palatopharyngeal arch, 168, 172
 Palatopharyngeus muscle, 168, 226
 Palatovaginal canal, 134, 144–145
 Palmar aponeurosis, 12, 14
 Palmar arterial arch
 deep, 23–24
 superficial, 14–15, 23–24
 Palmar digital artery, 12, 14–15, 23–24
 Palmar digital nerve, 12, 14–15
 Palmar interosseous muscle, 16, 21
 Palmaris brevis muscle, 14
 Palmaris longus muscle, 12–15
 Pancreas, 94, 96, 99, 109–110, 112
 Pancreatic duct, 96, 99–100
 Pancreatic notch, 99
 Pancreaticoduodenal artery, 96, 100, 102
 Papilla
 duodenal
 major, 96, 99
 minor, 99
 foliate, 172
 fungiform, 172
 vallate, 172
 Papillary muscle, 71, 73
 Paracentral artery, 248
 Paracentral sulcus, 177
 Paracentral lobule, 177–178, 203, 232
 Parahippocampal gyrus, 180–181, 202–203, 222–223
 Paraterminal gyrus, 178
 Parietal bone, 130, 135, 137, 149
 Parietal foramen, 135
 Parietal lobe, 174–175
 Parietal lobule
 inferior, 175
 superior, 175
 Parietal operculum, 176
 Parietal pleura, 66, 81, 86, 90
 Parietooccipital sulcus, 180, 183, 203
 Parotid duct, 158–159
 Parotid gland, 159, 225–226
 Patella, 26, 30, 37, 39, 43, 49
 Patellar ligament, 37, 39, 43
 Pectinate muscles, 71, 79
 Pectineus muscle, 30–32
 Pectoralis major muscle, 5–8, 82–87
 Pectoralis minor muscle, 5–8, 82–86
 Pectoral nerve, 6, 8
 Peduncle
 cerebellar
 decussation of, 209
 inferior, 192, 198, 204, 212–214
 middle, 179, 192–193, 198, 202, 204, 210–211
 superior, 192, 198, 202, 208, 210–212
 Pelvic diaphragm, 123
 Penis, 118, 127–128
 Perforated substance
 anterior, 179, 186
 posterior, 179
 Periaqueductal gray matter, 206–210
 Pericallosal artery, 201, 248
 Pericardial cavity, 67, 88
 Pericardial reflection, 67
 Pericardial sac, 67, 79, 88, 113
 Pericardial sinus
 oblique, 67
 transverse, 67

Pericardium, 67, 69, 80–81, 86, 90–92
 Perineal artery, 118
 Perineal nerve, 118
 Peritoneum, 92, 96, 109
 Peritoneal space, 93–96, 109–110, 112–115
 Perpendicular plate, 137, 224
 Pes anserinus, 27, 35
 Pes hippocampus, 181, 184–185
 Petrosquamous fissure, 140
 Petrotympenic fissure, 140
 Phalanx, 4, 28–29
 Pharynx, 166–168, 171–172, 226–228
 Phrenic artery, 102–103
 Phrenic nerve, 65, 67, 84–87
 Phrenic vein, 103
 Pial arterial plexus, 235, 256
 Pia mater, 201, 230
 Pineal gland, 177, 180–181, 188, 192–193, 202, 221, 240–241
 Pineal recess, 177, 187, 206
 Piriform lobe, 181
 Piriform recess, 170–171
 Piriformis muscle, 33, 108, 110, 116
 Pisiform bone, 4
 Placenta, 124
 Plantar aponeurosis, 44, 46
 Plantar arterial arch, deep, 52–53
 Plantar artery
 deep, 51–53
 lateral, 42, 44–46, 51–53
 medial, 44–46, 51–53
 Plantar digital nerve
 common, 44, 46
 proper, 44, 46
 dorsal branches of, 36–38
 Plantaris muscle, 41–42
 Plantar ligament
 long, 47
 short, 47
 Plantar metatarsal artery, 46, 53
 Plantar nerve
 lateral, 44–46, 48
 medial, 44–46, 48
 Platysma muscle, 163, 227
 Pleura
 parietal, 66, 81, 86, 90
 visceral, 90
 Pleural cavity
 costodiaphragmatic recess of, 112
 costomediastinal recess of, 86
 Polar frontal artery, 248
 Polar temporal artery, 255
 Pons, 174, 176–180, 183, 191–193, 200, 203–204, 210–213, 223–224, 232
 Pontine artery, 233–236
 Pontine nuclei, 209–212
 Pontocerebellar fibers, 209–211
 Popliteal artery, 34–35, 41–42, 49, 51
 Popliteal fossa, 34–35, 41
 Popliteal vein, 34–35, 41–42, 49
 Popliteal vessels, 34–35, 41–42, 49
 Popliteus muscle, 35, 41–42, 49
 Porta hepatis, 97–98
 Portal triad, 97–98
 Portal vein, 96–99, 112

Postcentral gyrus, 174–176, 220–221
 Posterior lateral choroidal artery, 240, 242, 250
 Posterior medial choroidal artery, 240–242
 Precentral artery, 255
 Precentral gyrus, 174–176, 202, 220–221
 Prechiasmatic groove, 132
 Precuneal artery, 248
 Precuneus, 178, 180, 203, 220
 Prefrontal artery, 255
 Pretectal nuclei, 206
 Princeps pollicis artery, 23–24
 Profunda brachii artery, 7, 10, 20, 22–23
 Profunda femoris artery, 31
 Promontory, 110, 118
 Pronator quadratus muscle, 13
 Pronator teres muscle, 12–13, 20
 Prostate, 110, 120, 126
 Psoas major muscle, 103–104, 109–110, 113–114
 Pterion, 130, 135
 Pterygoid canal, 134
 Pterygoid fossa, 134, 144–145
 Pterygoid incisure, 134
 Pterygoid muscle, 201
 Pterygoid plate, 133–134, 144–145
 Pterygoid process, 130, 133–134, 138, 144–145
 Pterygomaxillary fissure, 144
 Pterygopalatine fossa, 144
 Pubic symphysis, 92, 117
 Pubic tubercle, 25
 Pubis, 109–110, 126
 Pudendal artery
 external, 30–31
 internal, 33, 120
 Pudendal canal, 120
 Pudendal nerve, 33
 Pudendal vein
 internal, 33
 external, 30–31
 Pulmonary artery, 59–64
 Pulmonary trunk, 65, 67, 69–73, 80, 81, 85
 Pulmonary valve, 71, 74
 Pulmonary vein, 59–63, 65, 67, 71–72, 79–80, 85
 Pulvinar, 188, 192, 202, 240, 243
 Pulvinar nuclei, 206–207
 Putamen, 203, 220–222
 Pyloric antrum, 93
 Pyloric canal, 93
 Pylorus, 93
 Pyramidal eminence, 191
 Pyramidal muscle, 91, 125
 Pyramis, 191

Q

Quadrangular space, 10
 Quadratus femoris muscle, 33, 108, 126
 Quadratus lumborum muscle, 80, 108, 113
 Quadratus plantae muscle, 44
 Quadriceps femoris muscle, 30–32, 48, 127

R

Radial artery, 12–15, 17–21, 23–24
 Radial collateral ligament, 3

Radial fossa, 2
 Radial nerve, 5–8
 deep branch of, 12–13, 19
 superficial branch of, 12–15, 18–19
 Radial notch, of ulna, 3
 Radial styloid process, 3
 Radial tuberosity, 3
 Radioulnar joint
 distal, 1
 proximal, 1, 3
 Radius, 1, 3, 20
 Rami communicantes, 66
 Recess
 costodiaphragmatic, 112
 costomediastinal, 86
 rectovesical, 119
 retrocecal, 114
 subphrenic, 81
 Rectal artery
 inferior, 118
 superior, 95, 102, 120
 Rectouterine pouch, 121, 123
 Rectovesical pouch, 119
 Rectum, 109–110, 119–121, 123, 125–126
 Rectus abdominis muscle, 90–91, 109–110, 112–116
 Rectus capitis major muscle,
 posterior, 11, 226
 Rectus capitis minor muscle,
 posterior, 11
 Rectus femoris muscle, 30–32, 48–49
 Rectus sheath, 90–91
 Recurrent artery
 of Heubner, 247, 251
 interosseous, 19, 22–23
 radial, 12, 22
 ulnar, 19, 22–23
 Recurrent laryngeal nerve, 65–66, 170
 Red nucleus, 200, 206–208, 222
 Renal artery, 102–106, 112
 Renal capsule, 103
 Renal column, 103
 Renal hilum, 103–104
 Renal impression, 97
 Renal pelvis, 103, 105
 Renal segments
 arteries of, 105–106
 Renal sinus, 104
 Renal vein, 103, 105–106
 Reticular formation, 207–212
 Reticular nucleus, of thalamus, 205
 Retrocecal recess, 114
 Retromandibular vein, 15–160, 226
 Retroperitoneal space, 103–104, 110, 112–114
 Rhomboid fossa, 192–193, 202
 Rhomboid muscle, 9–10, 82–85
 major, 10
 minor, 10
 Ribs, 57, 80, 83–88, 107–108
 Rostroparhippocampal artery, 244
 Rostrum, of corporis callosum, 201
 Round ligament
 of liver, 92–93, 96–97
 of uterus, 121–123

Round (cochlear) window, 141
 Rubrospinal tract, 206, 208–213

S

Sacral canal, 108
 Sacral cornu, 117
 Sacral crest, 117
 Sacral foramen, 117
 Sacral hiatus, 117
 Sacral promontory, 117
 Sacral tuberosity, 89, 108, 117
 Sacroiliac joint, 119–115
 Sacrotuberous ligament, 33–34, 107
 Sacrum, 89, 115, 117
 Sagittal sinus
 inferior, 220
 superior, 197, 201–202, 221–222, 232
 Sagittal suture, 135
 Salpingopharyngeal fold, 167
 Saphenous nerve, 31, 36, 40
 Saphenous vein
 accessory, 30
 great, 30–32, 36, 40–41, 48
 small, 36, 38, 40–41, 48
 Sartorius muscle, 30–31, 41, 48
 Scalene muscles, 165, 228
 Scaphoid bone, 4
 Scaphoid fossa, 134, 144–145
 Scapula, 1–2, 7, 9, 11, 82–83
 Scapular artery
 circumflex, 6–7, 10, 22
 Scapular ligament
 superior transverse, 11
 Sciatic foramen
 greater, 33, 107–108
 lesser, 33, 108
 Sciatic nerve, 32–35, 107–108, 116, 125–126
 Sciatic notch
 greater, 25
 lesser, 25
 Scrotum
 contents of, 110, 118
 skin of, 110
 Segmental renal artery, 105–106
 Semicircular canal, 139–141
 Semilunar cusp, 71, 73–74
 Semilunar gyrus, 181
 Semilunar valve, 71, 73–74
 Semimembranous muscle, 32–34, 41–42, 48–49
 Seminal vesicle, 119–120, 125
 Semispinalis capitis muscle, 11, 203, 225–228
 Semitendinosus muscle, 32–34, 41, 48–49
 Septal area, 204
 Septal papillary muscle, 71
 Septomarginal trabecula, 71, 73
 Septum pellucidum, 120, 178, 220
 Serratus anterior muscle, 6–8, 58, 83–87
 Serratus posterior inferior muscle, 107
 Serratus posterior superior muscle, 11
 Sigmoid arteries, 95, 102
 Sinuatrial nodal artery, 76

- Sinuses
 cavernous, 190, 195
 confluens of, 223, 232
 ethmoidal, 167, 223–224
 frontal, 135, 220–223
 maxillary, 143, 148, 203
 petrosal, 196, 223
 sagittal, 197, 201–202, 220–222, 232
 sigmoid, 224–225
 sphenoidal, 137–138, 204, 223–224
 straight, 221–222
 transverse, 197, 203, 223–224
- Skull
 anterior view of, 129, 131
 base of, 132–134, 137, 139, 145
 lateral view of, 130, 144
 midsagittal section of, 130, 135, 137–138
 posterior view of, 136
 superior view of, 135
 of fetus, 149
- Small intestine, 92, 94–95, 99, 109–110, 113–116
- Soleal line, 27
- Sole (foot)
 ligaments of, 47
 superficial, middle and deep dissection of, 44–46
- Soleus muscle, 35, 39–42, 48–49
- Solitary tract nucleus, 212–214
- Solitary tract, 212
- Spermatic cord, 90–92, 118–119, 127–128
- Sphenoidal sinus, 137–138, 204, 223–224
- Sphenoid bone, 129–130, 132–136, 138–139, 224
- Sphenopalatine foramen, 138, 144
- Spinal artery
 anterior, 229, 233, 235
 posterior, 235
- Spinal cord, 108, 110, 229–230, 232, 235
 arteries, 229, 233, 235
 cross-section of, 217–219, 226–228
 dissection, 108
- Spinal dura mater, 108, 200, 230
- Spinal ganglion, dorsal root, 108, 229
- Spinal nerves, 229–230
- Spinocerebellar tract, 211, 213–214
- Spinotectal tract, 208–213
- Spinothalamic tract, 206, 208–215
- Spinous process, 56, 89, 108
- Splanchnic nerves, 66
- Spleen, 94, 96, 101, 110
 cross section of, 112
- Splenic artery, 96, 99–101
- Splenic vein, 96, 99, 101
- Splenium, of corpus callosum, 177, 180, 183, 185–187, 203–205, 220
- Splenius capitis muscle, 10, 227–228
- Stapes, 141
- Stellate artery, 106
- Stellate vein, 106
- Sternoclavicular joint, 1
- Sternocleidomastoid muscle, 9–11, 82, 159–160, 163, 180, 226–228
- Sternocostal triangle, 68
- Sternohyoid muscle, 163–165, 228
- Sternothyroid muscle, 164–165
- Sternum, 1, 57–58, 79, 83–88
- Stomach, 93–94, 110, 112
- Straight gyrus, 178–179
- Straight sinus, 221–222
- Stria medullaris
 of fourth ventricle, 192
 of thalamus, 205
- Striate artery, distal medial (of Heubner), 247, 251
- Stria terminalis, 193, 205–207
- Striatum, 185, 201, 203–206, 220–222
- Styloglossus muscle, 226
- Stylohyoid muscle, 226
- Styloid process
 of temporal bone, 133, 136, 140, 142, 226
 radial, 3
 ulnar, 3
- Stylomastoid foramen, 133, 142
- Stylopharyngeus muscle, 171, 226
- Subcallosal area, 177–178
- Subclavian artery, 22, 63, 65, 80, 82–83, 165
- Subclavian vein, 65, 79–80
- Subclavius muscle, 8, 82
- Subdural space, 201
- Subiculum, 181
- Sublingual fossa, 146
- Sublingual gland, 168
- Submandibular duct, 168
- Submandibular fossa, 146
- Submandibular gland, 159, 163–165
- Suboccipital nerve, 11
- Suboccipital triangle, 11
- Subphrenic recess, 81
- Subscapular artery, 6–8, 22
- Subscapular fossa, 2
- Subscapularis muscle, 6, 82–85
- Subscapular nerve, 6–7
- Substantia nigra, 199–200, 203, 206–208, 222
- Subthalamic nucleus, 199–200, 205
- Sulcus
 calcarine, 178, 180–181, 185, 203, 221–222
 central, 174–176, 203
 lateral, 174–175, 179, 220–222
- Supinator muscle, 13
- Supraclavicular nerve, 163
- Supramarginal gyrus, 175
- Supraoptic recess, 187
- Supraorbital artery, 172
- Supraorbital nerve, 155, 161–162
- Suprapineal recess, 206
- Suprarenal gland, 103–104
- Suprarenal artery, 102, 105
- Suprarenal vein, 103
- Suprascapular artery, 22, 165
- Suprascapular nerve, 165
- Suprascapular vein, 165
- Supraspinatus muscle, 165
- Supratrochlear artery, 172
- Supratrochlear nerve, 161
- Supraventricular crest, 71, 73
- Sural nerve, 36–38, 41
- Sustentaculum tali, 29
- Suture
 coronal, 130, 135
 frontal (metopic), 129, 131, 149
 lambdoid, 130, 135–136
 sagittal, 135
- Sympathetic trunk, 68, 104
- T**
- Talocalcaneal ligament, 47
- Talofibular ligament, 47
- Talus, 27–29, 47
- Tectospinal tract, 209–210
- Teeth, 143, 147–148
- Tegmen tympani, 140
- Tela choroidea, 188
- Temporal artery
 deep, 158, 160
 superficial, 156–160, 172, 245
- Temporal bone, 132–133, 135–136, 139–142, 224–235
- Temporal fascia, 159
- Temporal fossa, 130, 135
- Temporal gyrus, 175–176, 179–181
- Temporalis muscle, 157, 220–224
- Temporal lobe, 174–176, 179–181, 184–185
- Temporal operculum, 176
- Tensor fasciae latae muscle, 30–32
- Tensor veli palatini muscle, 167, 201
- Tentorial incisure, 196–197, 231
- Tentorium cerebelli, 177, 197–198, 202–203, 221, 223, 230–232
- Teres major muscle, 9–11, 83–84
- Teres minor muscle, 9–10, 83
- Terminal filum, 108
- Terminal lamina, 177–178, 247
- Testicular artery, 103–104, 114, 119
- Testicular vein, 119
- Testis, 107, 118
- Thalamic fascicle, 205
- Thalamogeniculate artery, 240–242
- Thalamoperforating artery, 239–242
- Thalamus, 177–178, 181, 185–186, 193, 200, 202–206, 220–221, 253
- Thenar, 13
- Thenar muscle, 14–16
- Third ventricle, 187, 200
- Thoracic artery
 internal, 58, 165, 172
- Thoracic duct, 66, 112
- Thoracic vertebrae, 55–56, 82–88
- Thoracic wall
 anterior, 57–58
 internal view of, 58, 66
- Thoracis muscle, transverse, 58
- Thoracoacromial artery, 6–8
- Thoracodorsal artery, 6–8, 22
- Thoracodorsal nerve, 6, 8
- Thoracolumbar fascia, 11, 107
- Thyrocervical trunk, 22, 165, 172
- Thyrohyoid muscle, 164–165
- Thyroid artery
 inferior, 170
 superior, 164–165, 172, 245
- Thyroid gland, 82, 165, 171

Tibia, 27–29, 36, 47–49, 51
 Tibial artery
 anterior, 37, 39, 48, 51–53
 posterior, 40, 42, 44, 46, 48–49, 51–53
 Tibialis anterior muscle, 36–39, 48
 Tibialis posterior muscle, 40, 42, 48
 Tibial nerve, 34–35, 39–42, 46, 48
 Tibial vein
 anterior, 37, 39
 posterior, 40, 42, 48
 Tibial tuberosity, 27, 37, 49
 Tibiofibular ligament, 47
 Toes, 28–29, 36, 46
 Tongue, 166–168, 171–172, 203, 226–227
 Tonsil
 cerebellar, 178, 198, 204, 225
 lingual, 172
 palatine, 226
 Torus tubarius, 166
 Trabeculae carneaе, 71, 73
 Trachea, 66, 79, 82–84, 170
 Tract of Giacomini, 181
 Transverse abdominal muscle, 91, 108, 113
 Transverse pericardial sinus, 67
 Transverse process, 56, 150–151, 153–154
 Trapezium, 4, 21
 Trapezius muscle, 9, 11, 80, 82–87, 163–165, 226–228
 Trapezoid, 4, 21
 Trapezoid body, 211–212
 Triceps brachii muscle, 9–10, 20
 Tricuspid valve, 71, 73–74
 Trigeminal ganglion, 187, 190, 194
 Trigeminal lemniscus, 208
 Trigeminal nuclei, 211–214
 Trigeminal nerve (CN V), 179, 187, 190–194, 196, 224, 229–230, 236
 Trigeminothalamic tract, 209–210
 Triquetrum bone, 4
 Trochanter
 greater, 26, 125
 lesser, 26, 126
 Trochanteric fossa, 26
 Trochlear nerve (CNIV), 161–162, 182, 187, 190–192, 194
 Trochlear nucleus, 209

Truncus of corpus callosum, 178, 200, 202
 Tympanic ring (anulus), 149
 Tympanic cavity, 139, 141–142
 Tympanic membrane, 149
 Tympanosquamous fissure, 140, 142

U

Ulna, 1, 3, 20
 Ulnar artery, 12–15, 19–20, 23–24
 Ulnar collateral ligament, 3
 Ulnar nerve, 5–7, 12–16, 20
 Ulnar notch, 3
 Ulnar styloid process, 3
 Ulnar tuberosity, 3
 Umbilical artery, 92
 Umbilical cord, 124
 Umbilical fold, 92
 Umbilical ligament, 92
 Umbilicus, 91–92, 110
 Uncinate process, 96
 Uncovertebral joint, 154
 Uncus, 180, 182–183
 Ureter, 103–106, 113–116, 119–120, 123
 Urethra, 126, 128
 Urinary bladder, 119–121, 123, 125
 Uterine artery, 121–123
 Uterine vein, 121–123
 Uterine tube, 121–123
 Uterus, 121–124

V

Vagal trigone, 192
 Vagina, 118, 122–123
 Vagus nerve (CN X), 65–67, 82–84, 93, 164–135, 171, 190–193, 200, 226–230
 Vallate papillae, 172
 Vallecula, 202
 Vastus intermedius muscle, 31–32, 48
 Vastus lateralis muscle, 30–32, 48–49
 Vastus medialis muscle, 30–32, 48–49
 Vena cava
 inferior, 70, 72, 75, 79, 88, 97–98, 103, 112–113
 superior, 65, 67, 69–72, 79, 84–86
 Ventricle
 cerebral
 fourth, 210–212, 223–224

 lateral, 181, 183–189, 199–202, 220–222
 third, 185, 200, 202, 205, 221–222

heart

 left, 69, 73–74, 79–81, 86–88
 right, 69, 71, 74, 79–81, 86–88

Vermis, 177, 180, 198, 202, 216
 Vertebrae, 55–56, 89, 150–154
 Vertebral artery, 11, 191–192, 200, 204, 225–230, 233–236
 Vertebral body
 cervical, 150–154
 lumbar, 80, 89, 110, 117
 thoracic, 56, 82–88
 Vertebral canal, 150
 Vertebral column, 55, 89, 110, 150–154
 Vertebral foramen, 56, 89, 151, 153
 Vesical artery, 119–120
 Vesical vein, 119–120
 Vestibular area, 192
 Vestibular fold, 169–170, 172
 Vestibular nuclei, 212–213
 Vestibule, 141
 Vestibulocochlear nerve (CN VIII), 179, 190–194, 200
 Visceral pleura, 90
 Vocal fold, 169–170, 172
 Vocal ligament, 109
 Vomer, 129, 134, 137, 144
 Vomerovaginal canal, 134, 144–145
 Vomerorostral canal, 134, 144–145

W

Willis, cerebral arterial circle of, 229, 233, 246

X

Xiphoid process, 57, 66

Z

Zona incerta, 205
 Zona intermedia, 218
 Zygomatic arch, 130, 133, 135
 Zygomatic bone, 129–131, 135, 160, 224
 Zygomatic muscle
 major, 155–156
 minor, 155–156
 Zygomatic process, 129, 140, 142

ATLAS OF THE HUMAN BODY

Central Nervous System and Vascularization

Branislav Vidić, S.D. Professor, Department of Cell Biology and Biochemistry, Texas Tech University Health Sciences Center School of Medicine, Lubbock, Texas, United States.

Milan Milisavljević, M.D., S.D., D.Sc., Professor, Laboratory for Vascular Anatomy (Head), Institute of Anatomy, Faculty of Medicine, Belgrade, Serbia

The *Atlas of the Human Body, Central Nervous System and Vascularization* is a multidisciplinary approach to the technical coverage of anatomical structures and relationships. It contains surface and 3D dissection images, native and colored cross-sectional views made in different planes, demonstrations of cranial nerve origins, distribution of blood vessels by dissection, and systematic presentation of arterial distribution using the “methyl metacrylate injection and subsequent tissue digestion” method. Included throughout are late prenatal (fetal) images to contribute to better understanding of structure/relationship specificity. Each chapter features Cross Sectional Correlations providing a unique perspective of side-by-side comparisons of dissection images and sections. Created after many years of professional and scientific cooperation between the authors and their parent institutions, this important resource will serve researchers, students, and doctors in their professional work.

Key Features

- Contains over 700 color photos of ideal anatomical preparations and sections of each part of the body that have been prepared, recorded and processed by the authors.
- Covers existing gaps including Prenatal Periods, detailed Vascular Anatomy, and Neuro Anatomy.
- Features a comprehensive alphabetical index of structures for ease of use.
- Features a Companion Website which contains access to all images within the book.

Related Titles

- Cole, *Human Physiology, Biochemistry and Basic Medicine*, 1e, NYP 2015, 9780128036990
- Patton, Thibodeau, Douglas, *Essentials of Anatomy and Physiology*, 1e, 2012, 9780323053822
- Koepfen & Stanton, *Berne and Levy Physiology*, 6e, 2010, 9780323073622
- Arroyo & Schweickert, *Back to Basics in Physiology*, 1e, 2015, 9780128017685
- Mai & Majtanik & Paxinos, *Atlas of the Human Brain*, 4e, NYP Oct 2015, 978012828001
- Drake, Vogl, Mitchell, Tibbitts and Richardson, *Gray's Atlas of Anatomy*, 2e, 2015, 9781455748020
- Gosling, Harris, Humpherson, Whitmore, & Wilan, *Human Anatomy*, 5e, Mosby, 2009, 9780723434511



ACADEMIC PRESS

An imprint of Elsevier
elsevier.com/books-and-journals

ISBN 978-0-12-809410-5



9 780128 094105