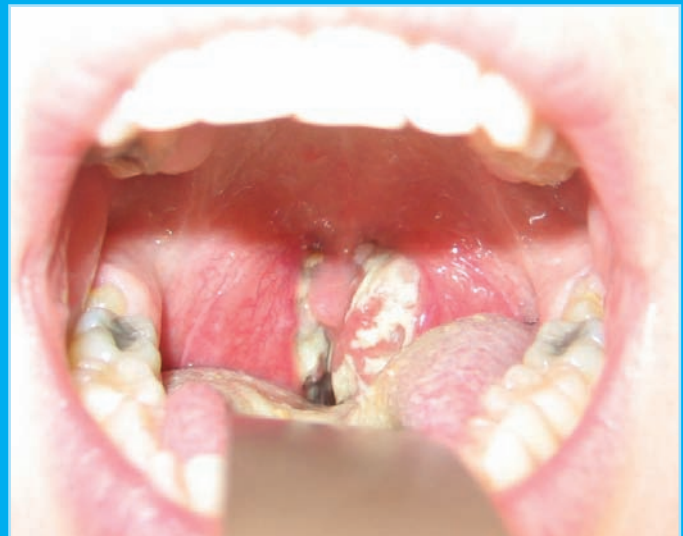
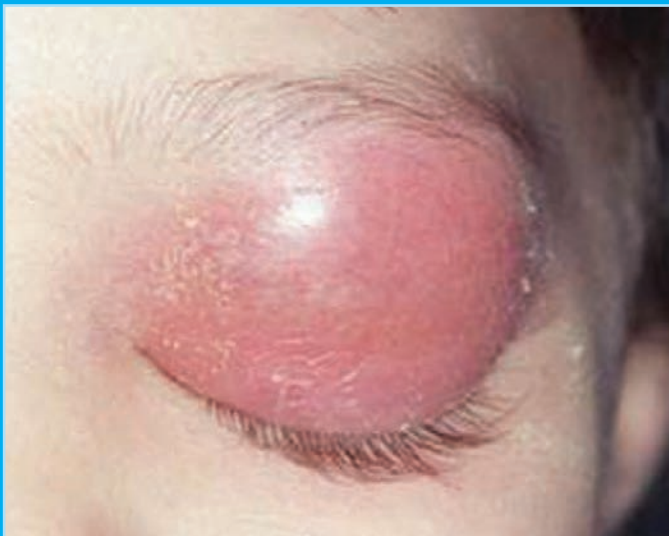
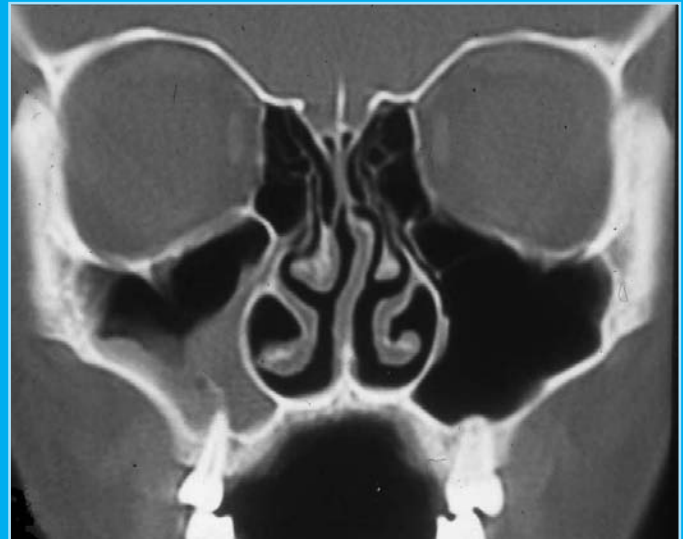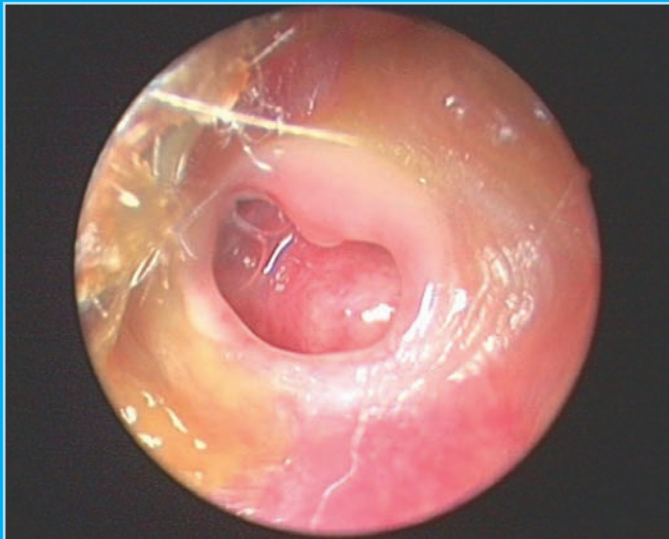**An Atlas of Investigation and Management**

# **ENT INFECTIONS**

**Vinidh Paleri • John Hill**



**CLINICAL PUBLISHING**

---

# Dedication

This book is dedicated to the memory of both our fathers.  
They inspired us, believed in us, and were our heroes.

**An Atlas of Investigation and Management**

---

# **ENT INFECTIONS**

**Vinidh Paleri**

Consultant Surgeon and Honorary Senior Lecturer  
Department of Otolaryngology – Head and Neck Surgery  
Newcastle-upon-Tyne Hospitals  
Newcastle-upon-Tyne, UK

**John Hill**

Consultant Surgeon and Honorary Senior Lecturer  
Department of Otolaryngology – Head and Neck Surgery  
Newcastle-upon-Tyne Hospitals  
Newcastle-upon-Tyne, UK

**CLINICAL PUBLISHING**

OXFORD

**Clinical Publishing**

an imprint of Atlas Medical Publishing Ltd  
Oxford Centre for Innovation  
Mill Street, Oxford OX2 0JX, UK  
Tel: +44 1865 811116  
Fax: +44 1865 251550  
Email: [info@clinicalpublishing.co.uk](mailto:info@clinicalpublishing.co.uk)  
Web: [www.clinicalpublishing.co.uk](http://www.clinicalpublishing.co.uk)

**Distributed in USA and Canada by:**

Clinical Publishing  
30 Amberwood Parkway  
Ashland OH 44805 USA  
Tel: 800-247-6553 (toll free within US and Canada)  
Fax: 419-281-6883  
Email: [order@bookmasters.com](mailto:order@bookmasters.com)

**Distributed in UK and Rest of World by:**

Marston Book Services Ltd  
PO Box 269  
Abingdon  
Oxon OX14 4YN, UK  
Tel: +44 1235 465500  
Fax: +44 1235 465555  
Email: [trade.orders@marston.co.uk](mailto:trade.orders@marston.co.uk)

© Atlas Medical Publishing Ltd 2010

First published 2010

All rights reserved. No part of this publication may be reproduced, stored in a retrieval system, or transmitted, in any form or by any means, without the prior permission in writing of Clinical Publishing or Atlas Medical Publishing Ltd.

Although every effort has been made to ensure that all owners of copyright material have been acknowledged in this publication, we would be glad to acknowledge in subsequent reprints or editions any omissions brought to our attention.

A catalogue record of this book is available from the British Library

ISBN print 978 1 84692 006 6  
ISBN e-book 978 1 84692 607 5

**The publisher makes no representation, express or implied, that the dosages in this book are correct. Readers must therefore always check the product information and clinical procedures with the most up-to-date published product information and data sheets provided by the manufacturers and the most recent codes of conduct and safety regulations. The authors and the publisher do not accept any liability for any errors in the text or for the misuse or misapplication of material in this work.**

Printed by Marston Digital Ltd, Didcot, Oxon, UK



# Contents

Foreword	vii		
Preface	viii		
Acknowledgements	viii		
Contributors	xi		
Abbreviations	x		
<b>1 Clinical examination</b>	<b>1</b>	<b>4 Infections of the ear</b>	<b>25</b>
<i>Ear</i>	<i>1</i>	JOHN HILL	
JOHN HILL		Introduction	25
Examination of the ear	1	Infections of the pinna	25
 		Infections of the external ear canal	25
<i>Nose</i>	<i>3</i>	Furunculosis	26
WOLFGANG ISSING		Acute otitis externa	26
Examination of the nose	3	Chronic otitis externa	28
Radiological examination	3	Fungal otitis externa	30
 		Sequelae of chronic otitis externa	30
<i>Oral cavity, oropharynx, larynx and hypopharynx, and neck</i>	<i>5</i>	Viral infections	31
VINIDH PALERI		Bullous myringitis	31
Examination of the oral cavity	5	Herpes zoster	31
Examination of the oropharynx	7	Infections of the middle ear	32
Examination of the larynx and hypopharynx	7	Viral acute otitis media	32
Examination of the neck	8	Acute otitis media	32
 		Acute mastoiditis	33
<b>2 Microbiology of ENT infections</b>	<b>11</b>	Infected perforated tympanic membrane	34
MANJUSHA NARAYANAN		Infected grommets or ventilation tubes	34
Microorganisms that cause human infections	11	Cholesteatoma	36
Commensals	13	Infected mastoid cavity	39
Principles of microbiological diagnosis	13	Aural polyp	39
Causative organisms	18	Ototoxicity	41
Upper aerodigestive tract and sinus infections	19	Infections of the inner ear	41
Ear infections	19	Osteomyelitis of the skull base	41
 		Pyogenic infection of the inner ear	42
<b>3 Principles and practice of anti-infective therapy in ENT infections</b>	<b>21</b>	Bell's palsy	42
VINIDH PALERI AND JOHN HILL		Vestibular neuronitis or labyrinthitis	42
Introduction	21	<b>5 Infections of the nose and paranasal sinuses</b>	<b>43</b>
Resistance	21	WOLFGANG ISSING AND ANDREAS LEUNIG	
Parenteral therapy	22	Introduction	43
Frequently used antibiotics in ENT practice	22	Infections of the external nose	43
Choice of antibacterial therapy	24	Erysipelas	43
		Herpes simplex	43
		Fistula of the nasal dorsum	44
		Foreign bodies	44
		Infections of the nasal cavity	45
		Vestibulitis	45
		Viral papilloma	45
		Septal haematoma and septal abscess	45
		Nasal polyposis	47

Nasal foreign bodies	47	Acute suppurative sialadenitis	74
Adenoiditis	47	Submandibular salivary gland infections	76
Infections of the paranasal sinuses	48	Chronic recurrent parotitis of childhood	77
Rhinitis, sinusitis, and rhinosinusitis	48	Granulomatous infections	77
Viral rhinosinusitis	48	Tuberculosis	77
Acute and chronic bacterial rhinosinusitis	48		
Fungal sinusitis	50	9 <i>Infections of the larynx</i>	79
Complications of paranasal sinus infections	50	VINIDH PALERI	
Orbital cellulitis	50	Introduction	79
Pott's puffy tumour (osteomyelitis of the frontal bone)	52	Laryngeal infections	80
Frontal sinus mucocoele and pyocoele	50	Supraglottitis in children	80
		Supraglottitis in the adult	81
6 <i>Infections of the oral cavity</i>	55	Laryngotracheobronchitis (croup)	81
VINIDH PALERI AND KONRAD STAINES		Bacterial tracheitis	82
Introduction	55	Chronic infective laryngitis	82
Viral infections	55	Laryngeal papillomatosis	84
Primary herpetic gingivostomatitis	55	Laryngopyocoele	84
Recurrent herpetic infections (cold sores)	57	Chondronecrosis	84
Chickenpox (varicella)	57		
Shingles (zoster)	57	10 <i>Infections of the neck</i>	87
Hairy leukoplakia	58	VINIDH PALERI	
Papillomatosis	58	Introduction	87
Bacterial infections	58	Neck infections	87
Acute ulcerative gingivitis	58	Cervical lymphadenitis	87
Fungal infections	61	Monomicrobial infections	88
Candidiasis	61	Cat scratch disease	88
		Toxoplasmosis	89
7 <i>Infections of the oropharynx</i>	65	Mycobacterial infections	89
VINIDH PALERI		Actinomycosis	90
Introduction	65	Polymicrobial infections	90
Viral infections	67	Cellulitis of the neck	90
Infectious mononucleosis	67	Necrotizing cervical fasciitis	91
Herpes simplex	68	Infection of branchial and thyroglossal cysts	91
Human papilloma virus	68	Deep neck space infections	93
Bacterial infections	69	Post-operative infection	97
Group A beta haemolytic streptococci (GABHS)	69	Infective thyroiditis	98
Diphtheria	69	Atlanto-axial subluxation (Grisel syndrome)	98
Peritonsillar abscess	70		
Candida	71	11 <i>Tropical ENT infections</i>	101
		SURIANARAYANAN GOPALAKRISHNAN AND	
8 <i>Infections of the salivary glands</i>	73	VINIDH PALERI	
VINIDH PALERI		Common infections	101
Introduction	73	Rhinoscleroma	101
Viral infections	73	Leishmaniasis	102
Mumps	73	Rhinosporidiosis	103
Human immunodeficiency virus	74	Leprosy of the nose	103
Bacterial infections	74	Anthrax	104
		Index	105

# Foreword

It is indeed a great honour and pleasure to be asked to write a Foreword to accompany this publication. *ENT Infections: an Atlas of Investigation and Management* is a quality publication which brings together clinical scenarios that present to a diversity of clinicians on a daily basis. By dividing the ear, nose, and throat into its appropriate anatomic sites, the consulting clinician can refer to the Atlas and confirm with a greater degree of accuracy what the diagnosis is or likely to be. As well as covering the principles of microbiology and anti-infective therapy, this Atlas highlights the need for an appropriate physical examination of each anatomic area. Each chapter is lavishly illustrated with pictures of pathologies and clinical scenarios and includes algorithms and tables where needed. The addition of a chapter on tropical infections will be welcomed by many who will purchase this publication.

The authors, both Consultants in Otolaryngology – Head and Neck Surgery, at Newcastle-upon-Tyne Hospitals, are professionally aware that lack of knowledge among clinicians, general practitioners, and hospital consultants about the conditions and diseases that affect the ear, nose, and throat may result in inappropriate treatment. For example, the majority of acute symptoms that develop in ENT are labelled as caused by ‘an infection’ with the result

that each such clinical scenario is treated by a course of ‘an antibiotic’. While the result of such intervention would seem appropriate as the condition, in the acute phase, seems to abate with the easing of ‘pain’ symptoms, often the infection lingers with the result that it returns with a vengeance within a short period of time. The symptom of ‘sore throat’, depending on the age of the patient, maybe called tonsillitis or pharyngitis, but is usually treated the in the same way; and in the older or elderly patient when such symptoms persists for weeks and, perhaps, months, the incorrect diagnosis of a ‘throat cancer’ is not infrequently made. Sometimes, what appears to be a ‘simple sore throat’ may become a life-threatening condition, such as a parapharyngeal abscess or epiglottitis, which if not treated correctly may result, tragically, in death.

I would recommend this publication to all professionals who are exposed to acute clinical scenarios, from paediatrics to care of the elderly. This book will also be invaluable to medical, dental, and nursing students, providing a foundation for future clinical experiences and expertise.

Patrick J Bradley, MBA, FRCS  
Professor of Head and Neck Oncologic Surgery  
The University of Nottingham

# Preface

Medicine is an ever changing speciality, as is medical education. Recent changes in medical education have meant less exposure to some clinical specialities, with Otorhinolaryngology being one of them. Infections form a significant proportion of ENT diseases, more so in primary practice and emergency care. The aim of this book is to provide a richly illustrated overview of ENT infections, taking the reader through clinical presentation, diagnosis and management, along with supporting chapters on microbiology and pharmacology. The illustrations have been carefully chosen to represent common findings,

eschewing exotic disease presentations. This book is a source of concise and easily accessible information on all common infections of the ear, nose, mouth, throat, and neck. It is suitable for clinicians working in primary care, junior hospital doctors, and nurses who routinely or occasionally care for patients with these infections. We also hope that this book will satisfy its aim of being a reference manual for other senior clinicians who may occasionally deal with these diseases.

Vinidh Paleri  
John Hill

# Acknowledgements

The authors are very grateful to all medical and nursing staff, past and present, in the Department of Otolaryngology-Head and Neck Surgery in Newcastle upon Tyne Hospitals. We thank them for their help in procuring

the vast majority of illustrations in this book. We are indebted to Professor Janet Wilson for her valuable advice and help during the preparation of this book.

# Contributors

**Surianarayanan Gopalakrishnan, MS, DLO**

Professor and Head  
Otolaryngology – Head and Neck Surgery  
Jawaharlal Institute of Postgraduate Medical Education  
and Research  
Pondicherry, India

**John Hill, FRCS Eng, FRCS Ed, FCS HK**

Consultant Surgeon and Honary Senior Lecturer  
Otolaryngology – Head and Neck Surgery  
Newcastle-upon-Tyne Hospitals NHS Foundation Trust  
Newcastle-upon-Tyne, UK

**Wolfgang Issing, MD**

Consultant Surgeon  
Otolaryngology – Head and Neck Surgery  
Newcastle-upon-Tyne Hospitals NHS Foundation Trust  
Newcastle-upon-Tyne, UK

**Andreas Leunig, MD**

Consultant Surgeon  
Otolaryngology – Head and Neck Surgery  
Klinikum Großhadern  
Ludwig-Maximilians University  
Munich, Germany

**Manjusha Narayanan, MD, FRCPath**

Consultant Microbiologist  
Department of Microbiology  
Newcastle-upon-Tyne Hospitals NHS Foundation Trust  
Newcastle-upon-Tyne, UK

**Vinidh Paleri, MS, FRCS Eng (ORL-HNS)**

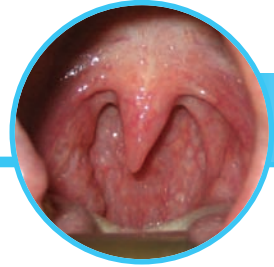Consultant Surgeon and Honorary Senior Lecturer  
Otolaryngology – Head and Neck Surgery  
Newcastle-upon-Tyne Hospitals NHS Foundation Trust  
Newcastle-upon-Tyne, UK

**Konrad S Staines, BChD, FDSRCS (Eng), MOMed  
RCS (Edin)**

Consultant in Oral Medicine  
Newcastle Dental Hospital & School  
Newcastle-upon-Tyne Hospitals NHS Foundation Trust  
Newcastle-upon-Tyne, UK

# Abbreviations

AIDS	acquired immunodeficiency syndrome	HSV	herpes simplex virus
BIPP	bismuth iodoform paraffin paste	IFA	immunofluorescent assay
CLED	cystine lactose electrolyte deficient (medium)	Ig(M)	immunoglobulin(M)
CMV	cytomegalovirus	MIC	minimum inhibitory concentration
CT	computed tomography	MMR	mumps, measles, and rubella
DNA	deoxyribonucleic acid	MR(I)	magnetic resonance (imaging)
EBV	Epstein–Barr virus	MRSA	methicillin-resistant <i>Staphylococcus aureus</i>
ENT	ear, nose, and throat	OME	otitis media with effusion
ESR	erythrocyte sedimentation rate	PCR	polymerase chain reaction
GABHS	group A beta haemolytic streptococci	RBC	red blood cell
GAS	group A streptococci	RNA	ribonucleic acid
HHV	human herpes virus	RSV	respiratory syncytial virus
HIV	human immunodeficiency virus	TEM	transmission electron micrograph
HL	hairy leukoplakia	VZV	Varicella-zoster virus
HPV	human papilloma virus		



# Clinical examination

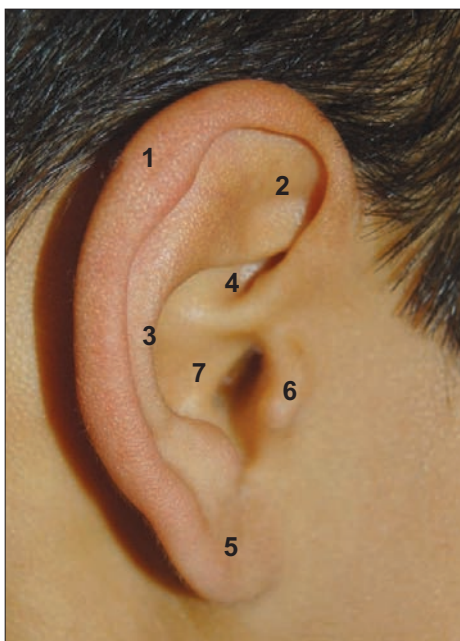
## Ear

*John Hill*

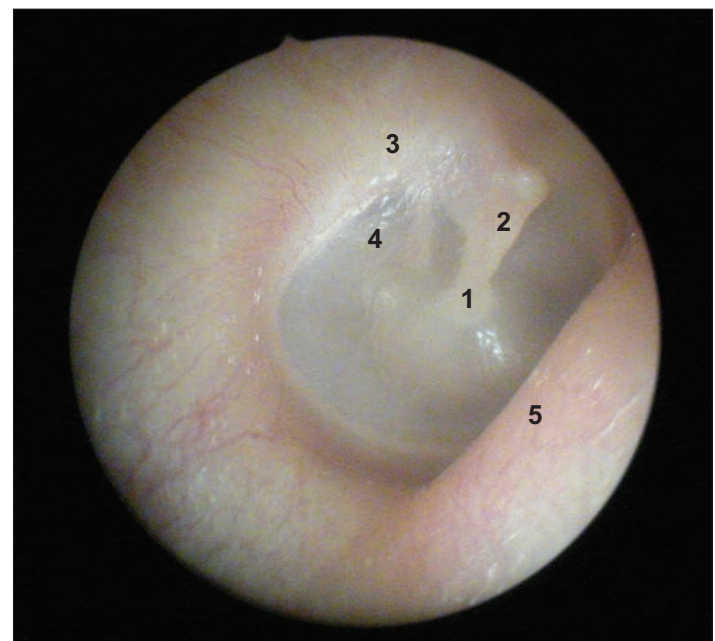
### Examination of the ear

In infective cases it is worth checking behind the ear to see if there is any swelling of the post-auricular lymph nodes or a subperiosteal abscess (1.1; see acute mastoiditis, 4.32–4.34). The best view of the drum is obtained by using an auriscope which is inserted into the lateral third of the ear canal only (1.2). Avoid putting the tip of the speculum into the medial two-thirds of the canal as it is much more sensitive. The view is improved by elevating the pinna upwards and backwards in an adult or straight backwards in

a child. Holding the auriscope horizontally, rather than vertically, means the patient's shoulder is less likely to get in the way. Holding the little finger out extended towards the cheek is a useful technique in children because if the child turns towards the examiner unexpectedly it reduces the chance of twisting the speculum of the auriscope in the ear canal, which can be painful. If the drum is difficult to see it is often worth looking more superiorly by tilting the patient's head away from the examiner (1.3).



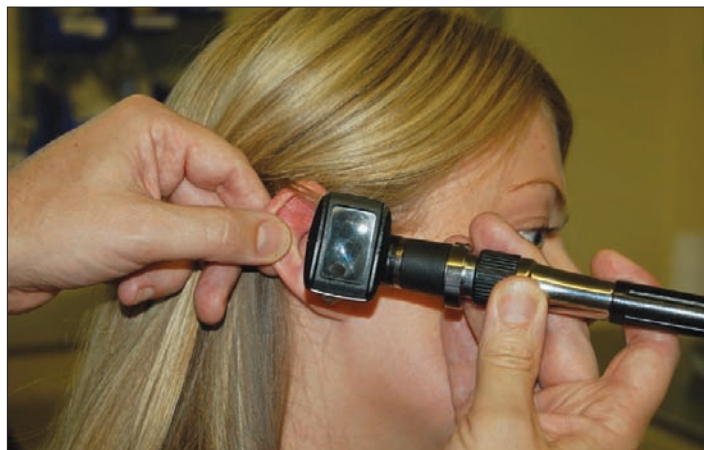**1.1** Normal pinna showing the main anatomical features: helical fold (1), triangular fossa (2), antihelical fold (3), scaphoid fossa (4), lobule (5), tragus (6), and conchal bowl (7).



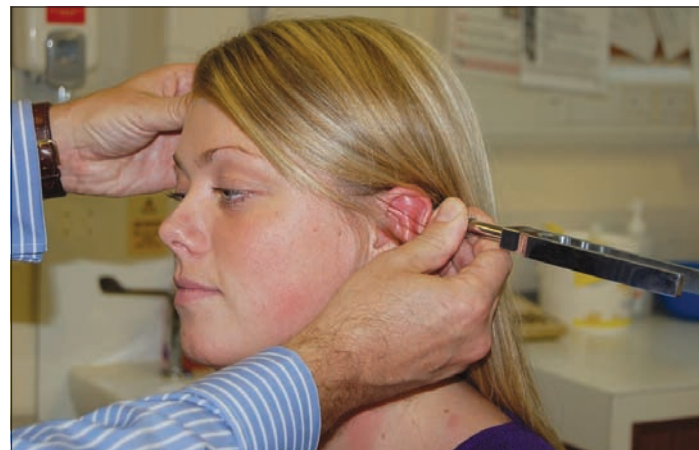**1.2** Normal right tympanic membrane showing the main features: umbo (1), handle of the malleus (2), pars flaccida (3), long process of the incus visible through the pars tensa (4), and bulge of the anterior wall of the ear canal (5).



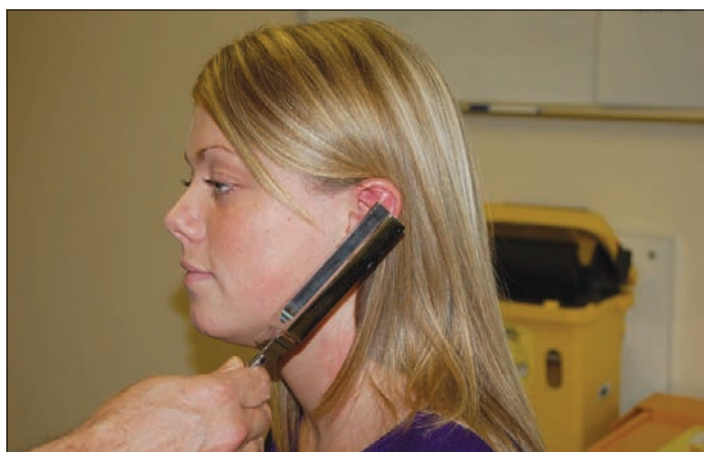## 2 Clinical examination



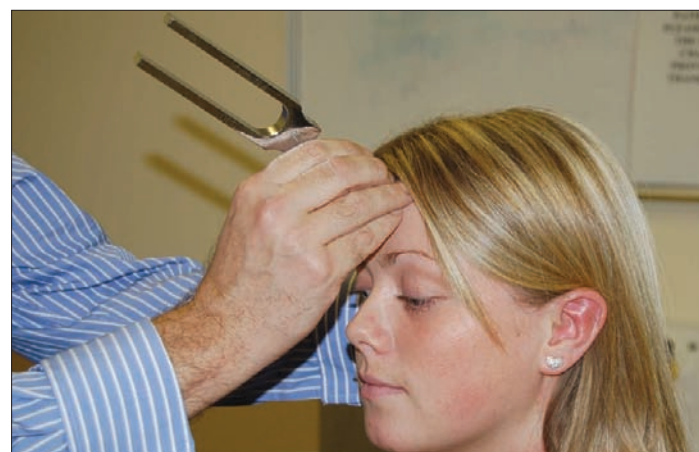1.3 Position of auriscope during otoscopy.



1.4 Rinne test 1. 'Can you hear this?'



1.5 Rinne test 2. 'Is this louder or quieter?'



1.6 Weber test. 'Does this sound as if the sound is in the middle or coming from the side? Which side?'

### ***Tuning fork tests***

The traditional Rinne and Weber tuning fork tests using a 512 Hz tuning fork are still of value in establishing whether hearing loss is conductive or sensorineural in nature. Hearing loss due to disease in the external ear canal or middle ear will give a conductive loss. Diseases affecting the inner ear cause a sensorineural loss.

### ***Rinne test***

The tuning fork is placed on the mastoid process behind the ear and counter pressure applied to the side of the head to make sure of good contact. The patient is asked: (1) Can you hear the tuning fork? The tuning fork is then held alongside the ear approximately 2–3 cm from the meatus and the patient is asked: (2) Is this louder or quieter (1.4, 1.5)? A positive Rinne response means that the tuning fork was heard louder beside the ear rather than placed on the mastoid behind. A negative Rinne response is the converse.

### ***Weber test***

The tuning fork is placed in the centre of the patient's forehead. The patient is asked: (1) Can you hear the tuning fork? (2) Is it louder in one ear or is it equally heard in both ears (1.6)?

### ***Interpretation***

A Rinne positive response is present if the hearing is either normal or the hearing loss is sensorineural in nature. If the Rinne test is negative, hearing loss will be due to a conductive loss. If a conductive hearing loss is present, a Weber test should be loudest in the affected ear. If sensorineural hearing loss is present a Weber test should be heard loudest in the unaffected ear.



# Nose

*Wolfgang Issing*

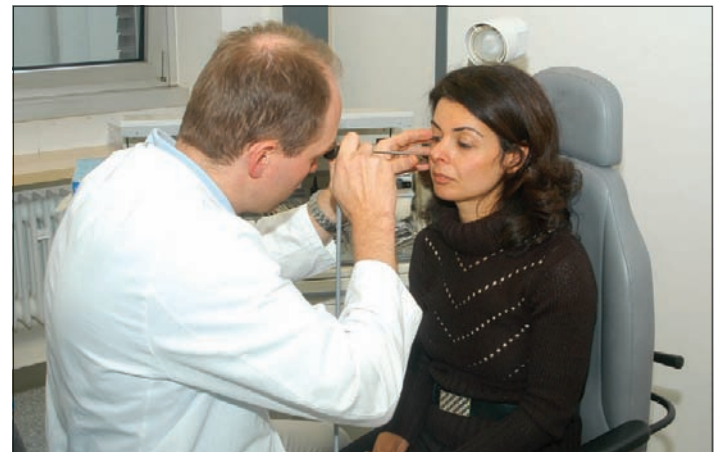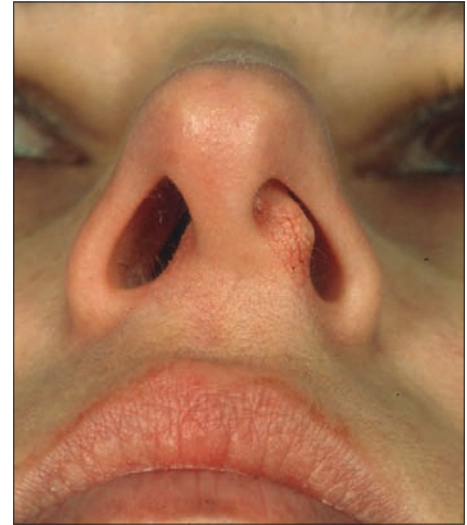## Examination of the nose

Traditional anterior rhinoscopy using Thudicum's speculum and a headlight or head mirror is helpful in detecting gross anatomical variations such as septal deviation, dislocation of the columella (1.7) and hypertrophic inferior turbinates. With the help of a rigid (1.8) or flexible endoscope, the whole of the nasal cavity and the postnasal space can be examined. The middle meatus, into which most of the sinuses drain, can be thoroughly examined (1.9) and bony crests, spurs (1.10) and other abnormalities farther back in the nasal cavity can be identified. Rigid endoscopes give the clearest view but flexible endoscopes help if the nasal anatomy does not allow passage of the rigid endoscope. Decongestion of the nose, using sprays containing pseudo-ephedrine or pseudo-ephedrine plus lignocaine may be necessary to achieve optimum results and improve tolerance. The examination should be done to document findings systematically in the inferior and the middle meatus and the sphenoid recess. Several anatomic variations exist in the nasal cavity that may contribute to an infection (1.11, 1.12). Possible findings include the presence of mucus or mucopus, polyps, and other mass lesions. Except for the posterior ethmoid and the sphenoid sinuses, all the sinuses drain into the middle meatus. Thus, the majority of sinus infections present with signs in the middle meatus.

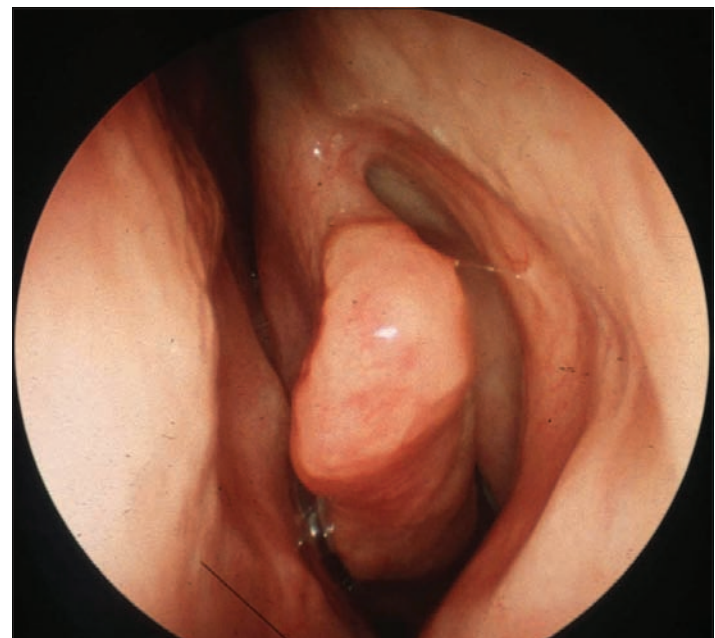
## Radiological examination

If indicated, a CT scan of the paranasal sinuses in a coronal sequence is the most appropriate examination technique (1.13). Plain X-rays do not have a role in managing sinus infections.

1.7 Dislocation of the columella into the left nostril.

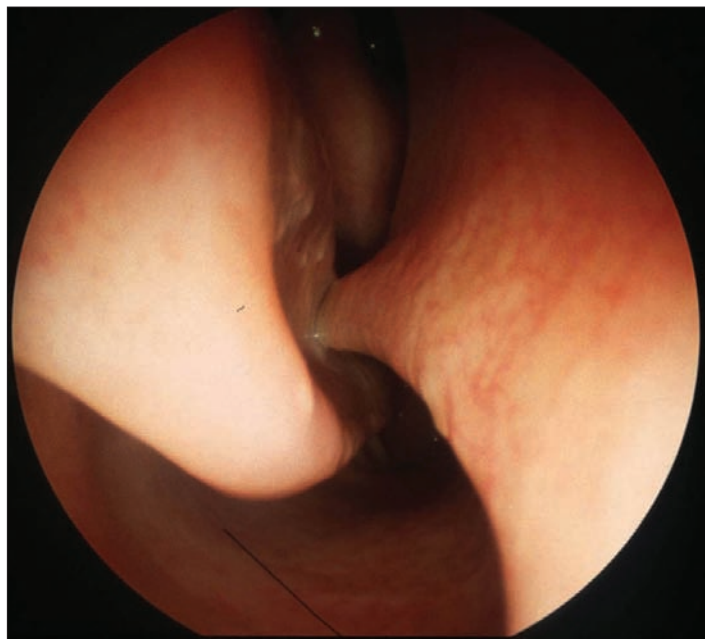

1.8 Rigid nasal endoscopy can be easily performed under local anaesthesia.

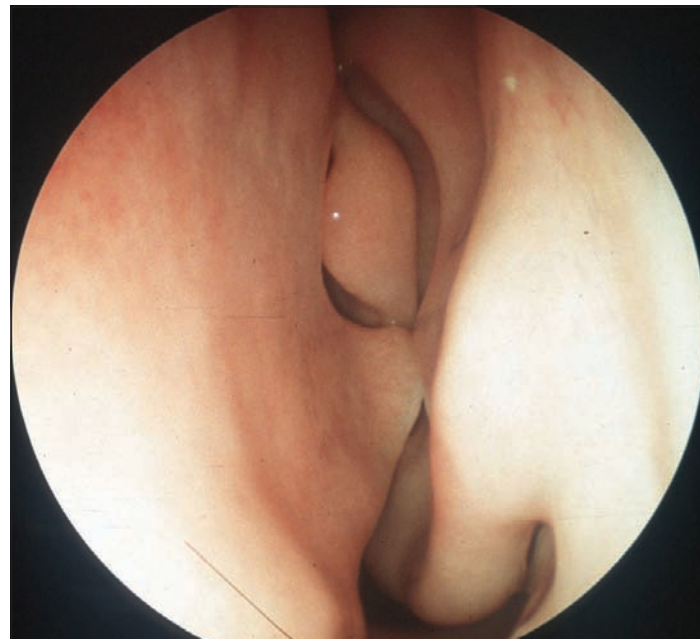


1.9 Left middle meatus.

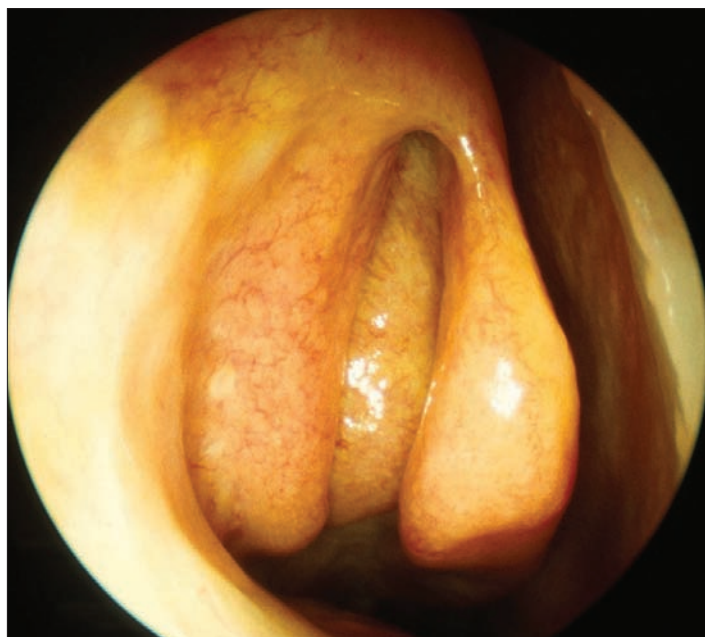#### 4 Clinical examination



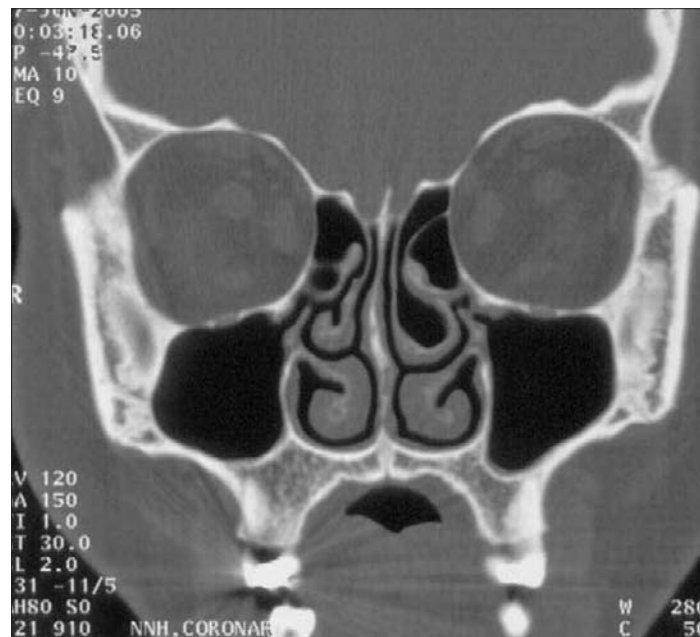
1.10 Septal spur in contact with the right inferior turbinate.



1.11 Septal spur protruding into the left middle meatus which impairs drainage of the sinuses.



1.12 Right middle meatus with uncinete process and bulla ethmoidalis. The latter can impair sinus drainage.



1.13 Coronal CT scan of paranasal sinuses demonstrating well aerated sinuses and a pneumatized middle turbinate.

# Oral cavity, oropharynx, larynx, hypopharynx, and neck

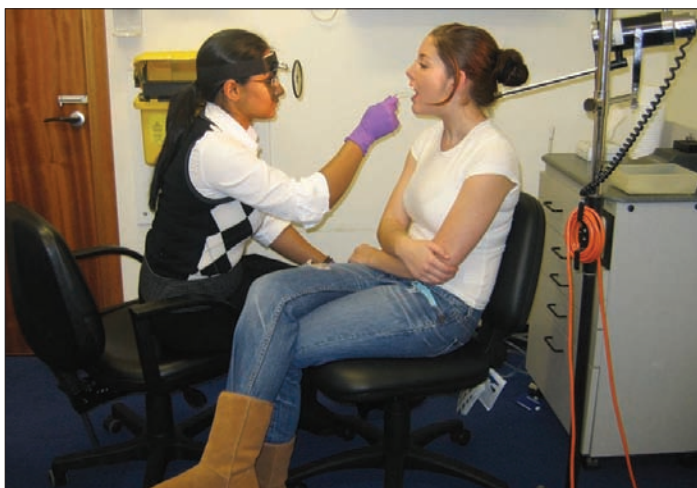*Vinidh Paleri*

## Examination of the oral cavity

A good headlight and proper positioning is essential to examine the oral cavity and the oropharynx. The examiner and the patient sit with their legs close together, but facing opposite directions. This is demonstrated in figure 1.14. The oral cavity starts at the lips and is separated from the oropharynx behind by an imaginary plane that runs from the junction of the hard and soft palate above to the circumvallate line on the tongue below. It comprises of seven regions: these include the vermillion margin of the lips, the buccal mucosa, the gingiva and the teeth of the upper and lower jaws, the floor of the mouth, the hard palate, the oral tongue and the retromolar trigone (1.15–1.17). The retromolar trigone is that part of the mucosa that lies over

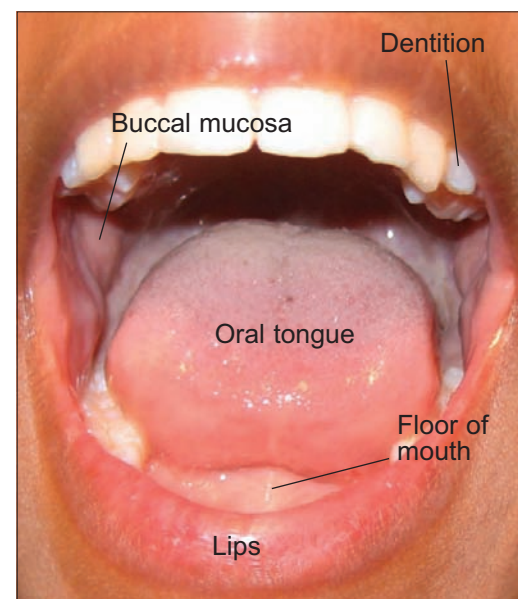
the ascending ramus of the mandible behind the last molar and heads up to the maxillary tuberosity (1.18).

Systematically counting off all these regions will ensure that that all the mucosal lining is inspected during examination, especially the recesses where findings can be missed. Oral cavity examination is best achieved with a good headlight and a pair of angled tongue depressors. These can be used to sweep the buccal mucosa gently away from the gingiva so as to inspect the gingivo-buccal sulci comprehensively. The parotid duct orifice (Stenson's duct) is also inspected during this phase of the examination, seen opposite the crown of the second molar (1.19). This manoeuvre is once again useful to inspect the posterior most

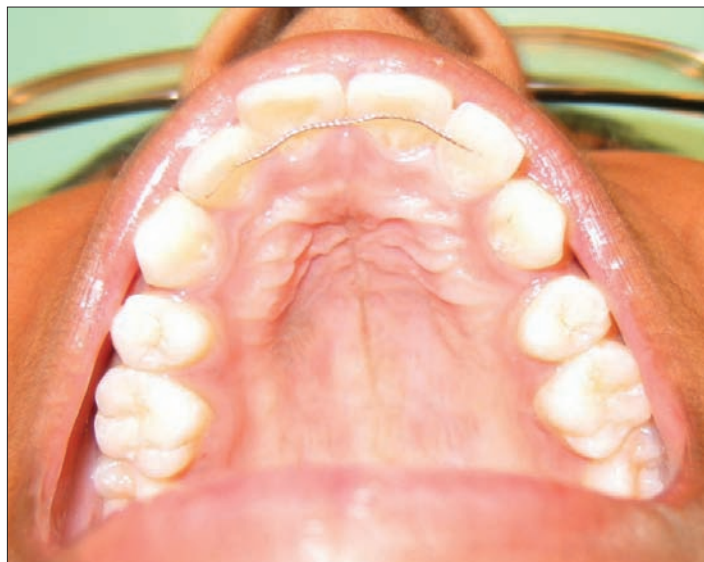

**1.14** Optimal positioning for ENT examination. Note how the examiner's and the patient's legs face opposite directions.

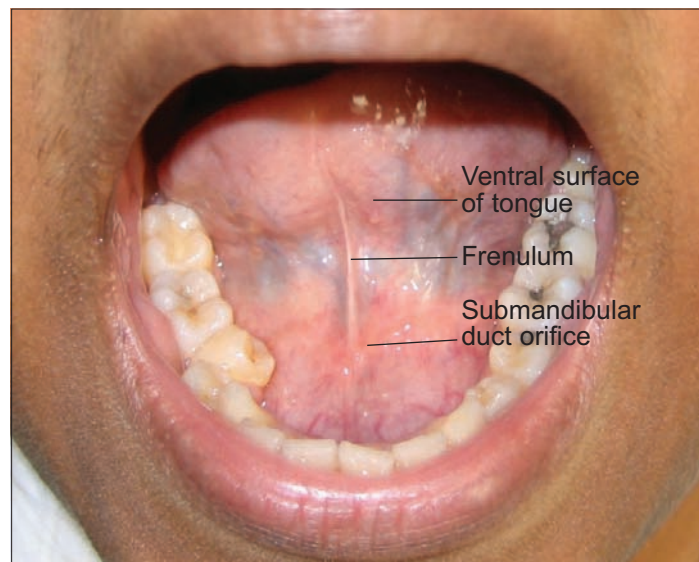
**1.15** Inspection of the oral cavity with a good headlight is essential to identify subtle mucosal lesions.



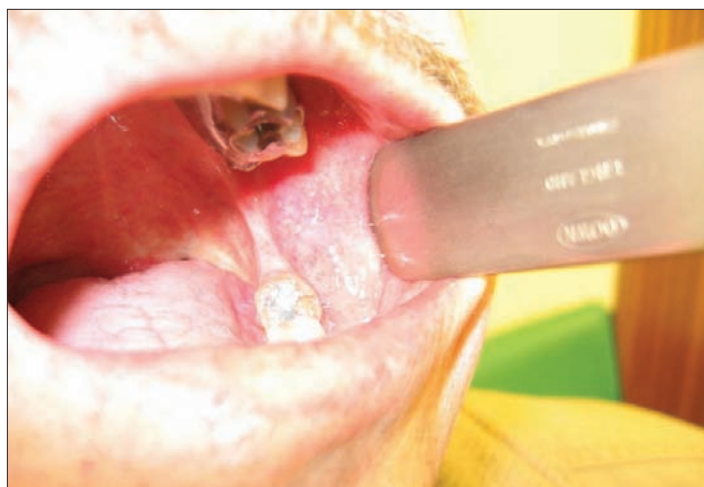



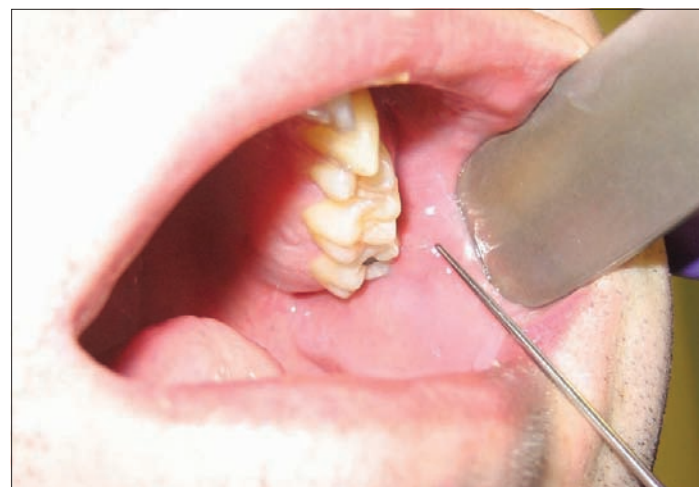1.16 The hard palate.



1.17 The floor of the mouth.



1.18 Left retromolar trigone seen just behind the last molar. This region overlies the ascending ramus of the mandible.



1.19 The parotid duct orifice (Stenson's) opposite the crown of the second molar tooth is being demonstrated by the pointer.

corner of the floor of the mouth where findings can be missed. The status of the submandibular duct orifice (Wharton's duct) is noted while inspecting the floor of the mouth (1.17). Examination findings should note the colour of the oral mucosa and the presence of discrete lesions. If present, their site, number, size, and colour (usually white or red) are noted. If white patches are seen one should assess if they can be gently rubbed off with a tongue blade. If they do rub off, the base underneath the patches should be inspected for erythema and bleeding. Patches caused by pseudo membranous type of *Candida* infection tend to rub off

without any underlying bleeding. Leukoplakic patches caused due to an inciting factor do not rub off. Lesions may also be vesicular or ulcerated, and flat or proliferative, sometimes with surface bleeding.

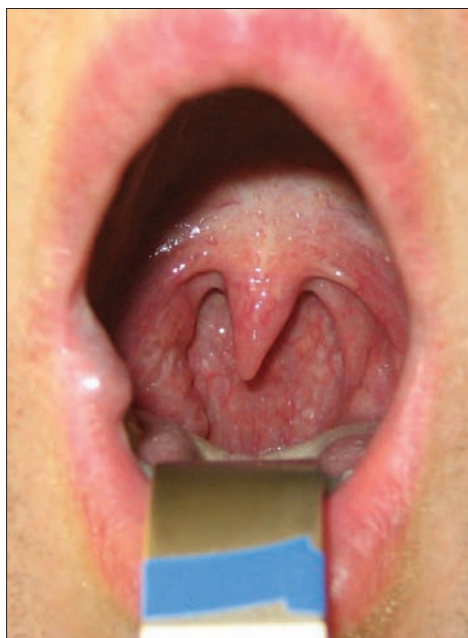The salivary gland ducts should be assessed for the nature of the secretions and for redness around the ducts. Documentation should also include the dentition and the presence of carious teeth if any. Where appropriate, dental percussion should be performed to identify tenderness or lack of sensation in teeth.

## Examination of the oropharynx

The oropharynx comprises of four regions and five walls, akin to a box lying open on its side, facing the examiner. The tonsils and the lateral pharyngeal walls on either side form the lateral walls. The posterior pharyngeal wall lying between the level of the soft palate and the hyoid bone forms the posterior wall, the soft palate forms the roof, and the posterior one-third of the tongue behind the circumvallate line forms the floor. Except for the base of the tongue, all the other regions can be quite easily assessed on a simple inspection by gently depressing the tongue using a tongue depressor (1.20). When performing this manoeuvre care should be taken not to insert the tongue depressor beyond the anterior two-thirds of the tongue as this can trigger a gag reflex.

Findings on the mucosa are inspected as above. Infections of the oropharynx can also cause tonsillar hypertrophy and exudates on the surface. The tongue base is visualized better on a flexible nasendoscopy or an indirect laryngoscopy using a mirror. It must be noted that apart from mucosal lesions, many tongue base neoplasms tend to start submucosally and these are better felt than seen. Therefore, a complete oropharyngeal examination must include tongue base palpation. However, this may not be appropriate in most clinical scenarios where an infection is suspected, especially in the child presenting with an acute sore throat.

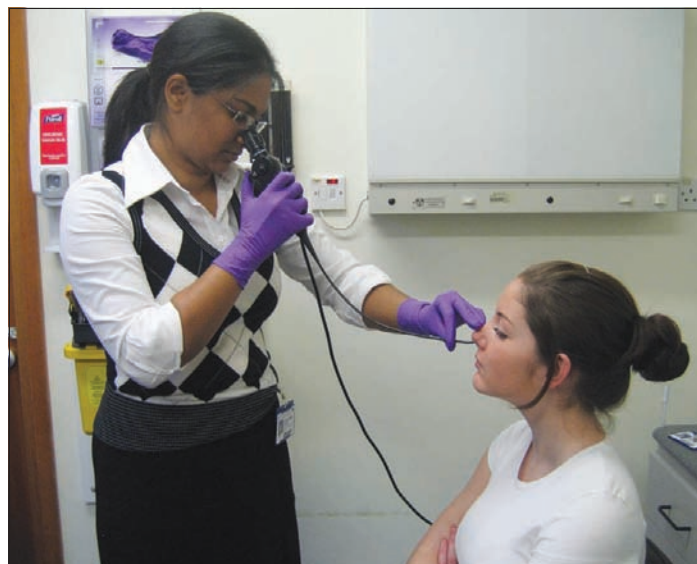**1.20** Oropharynx can be examined easily by gently depressing the tongue. Note that the tongue base cannot be examined by mere inspection alone.



## Examination of the larynx and hypopharynx

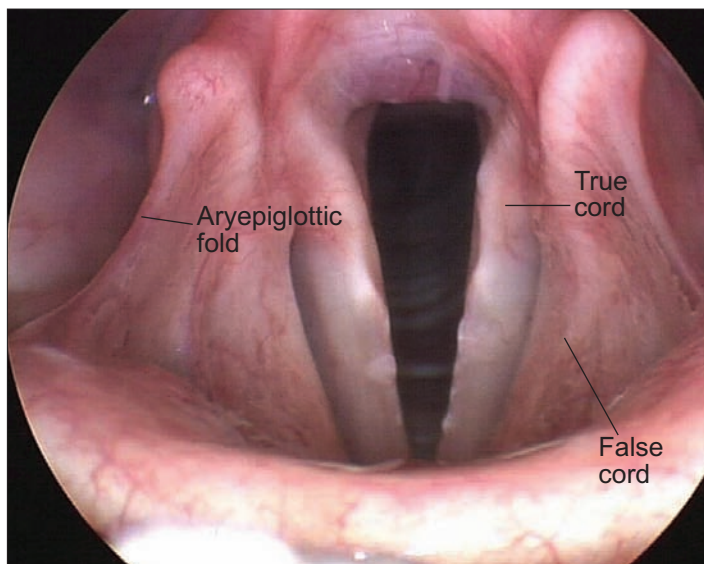
Examination of larynx and hypopharynx is best performed using a flexible nasolaryngoscope (1.21). In the past, examination was commonly performed using a mirror and this can be a useful technique especially in patients who are unable to tolerate a nasolaryngoscopic examination. The technique of nasolaryngoscopy is discussed elsewhere in this book. Following introduction of the flexible nasolaryngoscope and the examination of the nasopharynx, the patient is asked to breathe through the nose. This enables the soft palate to fall forwards. At the same time the tip of the scope is turned downwards. This gives a panoramic view of the posterior oropharynx, the hypopharynx, and the larynx.

The endoscope is advanced further and inspection of the tongue base and vallecula is performed by asking the patient to open his or her mouth wide and protrude the tongue. Following this manoeuvre the regions of the larynx are systematically inspected: the epiglottis, aryepiglottic folds, the arytenoids, the false cords, and the true cords (1.22). The true cord mobility is also assessed. Hypopharyngeal regions are the posterior pharyngeal wall below the level of the hyoid bone to the cricopharynx, the pyriform fossae on both sides, and the postcricoid region. The pyriform fossae are best inspected during phonation, as medial movement of the cords causes the fossae to open (1.23). Instructing the patient to perform a Valsalva manoeuvre during flexible



**1.21** Flexible nasolaryngoscope being used to assess the larynx and the hypopharynx.





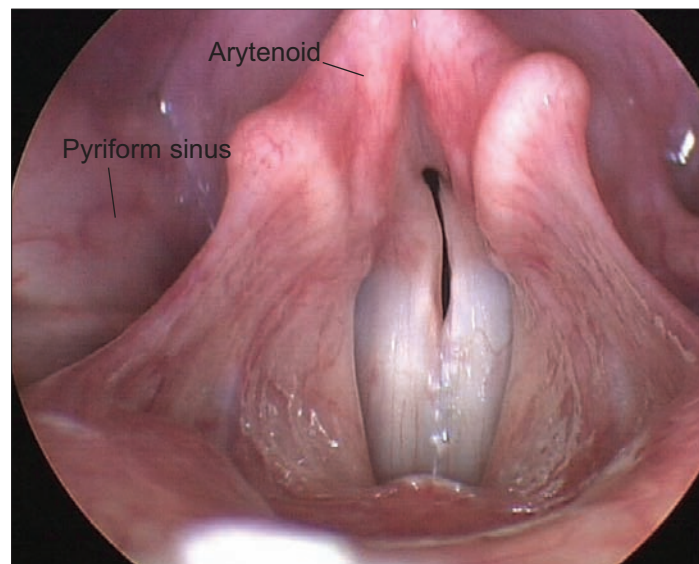
**1.22** View of the larynx during inspiration using a 70° rigid endoscope, showing abducted cords.

endoscopy also opens the pyriform fossae. Findings to look for include a redness or erythema of the mucosa, the colour of the vocal cords, the presence of oedema, swelling or ulceration or growths anywhere in the larynx or the hypopharynx. It must be noted that the post cricoid region is not so easy to see and lesions in this part of the hypopharynx can be missed with this examination.

### Examination of the neck

The examination is primarily directed at detecting lymphadenopathy and will pick up other lumps in the neck during the course of the examination if systematically performed. The neck nodes can be divided into a superficial and deep group. The superficial nodes are placed like a ring between the junction of the head and neck and include the submental, facial, pre-auricular, post-auricular, and the occipital nodes. The deep nodes are distributed around the major structures and are located as follows: submandibular, upper, middle and lower jugular, supraclavicular, and the posterior triangle.

Examination of the neck is best done with the examiner standing behind the patient. The author prefers to examine one side at a time. This enables one to document findings

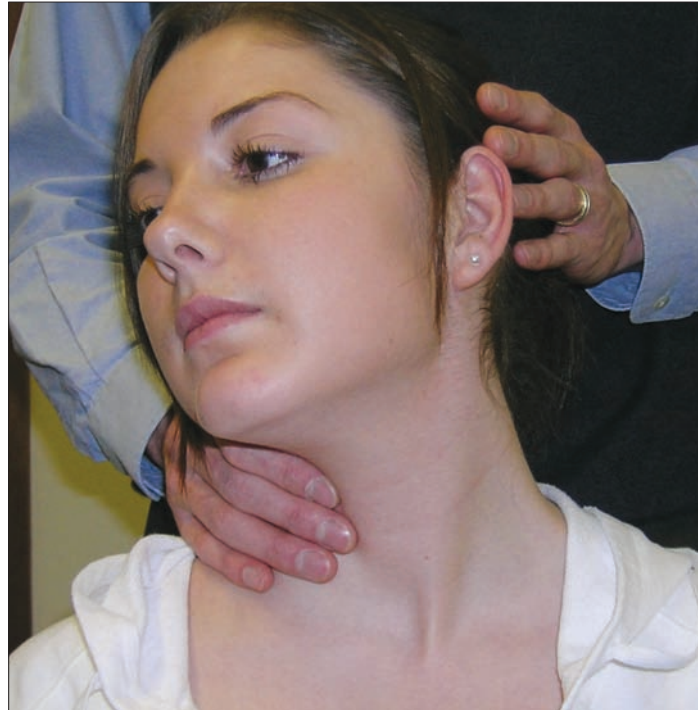

**1.23** View of the larynx during phonation using a 70° rigid endoscope, showing adducted cords.

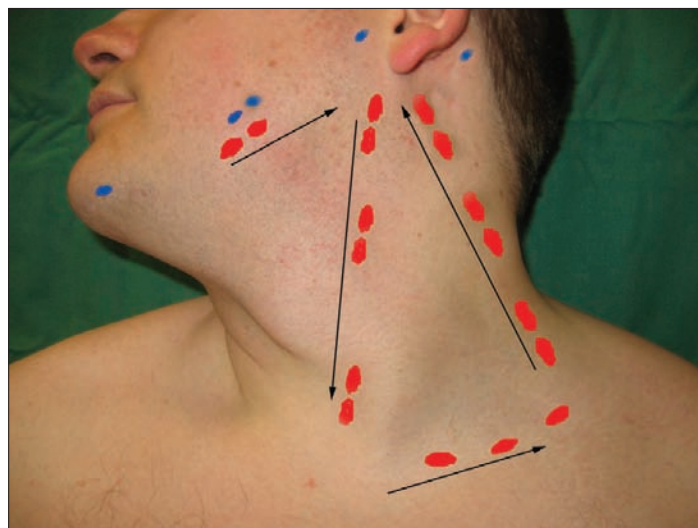
accurately, which include the site, size, consistency, and mobility of any lumps. The patient's neck is tilted and turned to the side where the examination is to be performed (1.24). This will relax the sternomastoid muscle and enable good palpation of the jugular chain of nodes. Subtle enlargement of the jugular nodes can be missed if the muscle is not relaxed.

The examination starts in the submandibular region from the front to the angle of the mandible. The soft tissues are rolled against the mandible to feel for nodes. The jugular chain is examined by gently pinching up the sternomastoid muscle from superior to inferior and feeling for nodes underneath the muscle. Once the clavicle is reached, the supraclavicular region is examined, heading towards the acromion. This naturally leads to the inferior part of the trapezius muscle. Climbing up the trapezius will take one back to the mastoid and the upper end of the sternomastoid muscle (1.25). The thyroid gland is then palpated in the midline, asking the patient to swallow. Any enlargement will be felt to move under the finger tips.

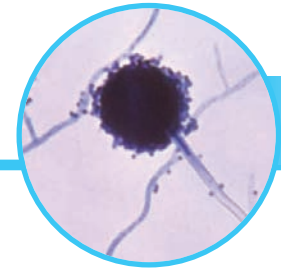
The superficial nodes are then assessed. The submental nodes are palpated by pressing the soft tissues against the mandible. The facial and the pre-auricular nodes lie on the mandible and the post-auricular nodes on the mastoid. The occipital nodes are to be found in the nape of the neck.



**1.24** The neck is turned and tilted to the same side that is being examined to relax the sternomastoid muscle.



**1.25** A suggested method to examine systematically the deep lymph nodal chains in the neck.



# Microbiology of ENT infections

*Manjusha Narayanan*

## Microorganisms that cause human infections

Infections in the human body can be caused by microorganisms present in the endogenous environment (e.g. microorganisms colonizing the host's skin, respiratory tract, and the gut, considered to be normal flora) or in the exogenous environment (e.g. fomites, food, water, cross infection from humans or animals). They can be broadly classified as shown in *Table 2.1*, but infections relevant to

ENT are mostly bacterial, fungal, or viral in nature.

In the laboratory, for simple preliminary identification, bacteria are classified into gram-positives and gram-negatives microscopically, based on the staining characteristics of their cell walls (2.1, 2.2). Cell walls of gram-positive bacteria are thicker and retain the colour of the blue dye crystal violet, whereas gram-negative bacteria

**Table 2.1 Classification of microorganisms**

### 1 Eukaryotes

Higher forms with complex subcellular organization (e.g. having mitochondria for aerobic respiration)

- Protozoa and helminths
- Fungi

### 2 Prokaryotes

Simpler form of cellular organization

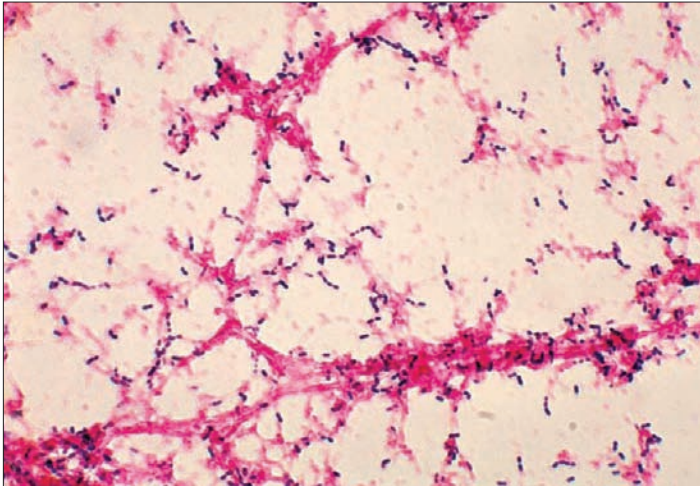
- Filamentous bacteria: *Actinomyces*, *Nocardia*, *Streptomyces*, mycobacteria
- True bacteria: gram-positive and gram-negative cocci and bacilli, e.g. streptococci, staphylococci, coliforms, *Pseudomonas*

- Spirochaetes: treponemes, *Borrelia*, *Leptospira*
- Mollicutes: *Mycoplasma*, *Ureaplasma*
- *Chlamydia*
- *Rickettsia*

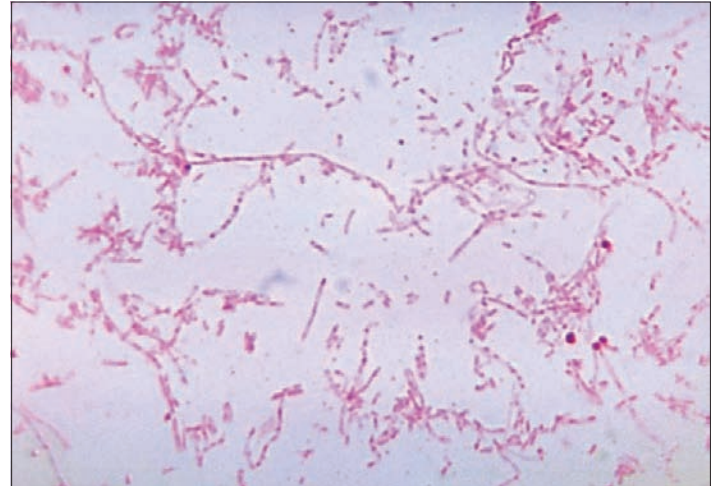
### 3 Viruses

- RNA viruses
- DNA viruses

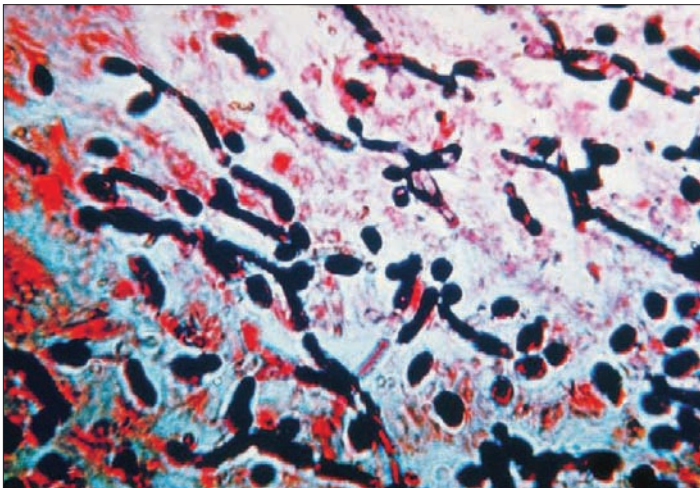




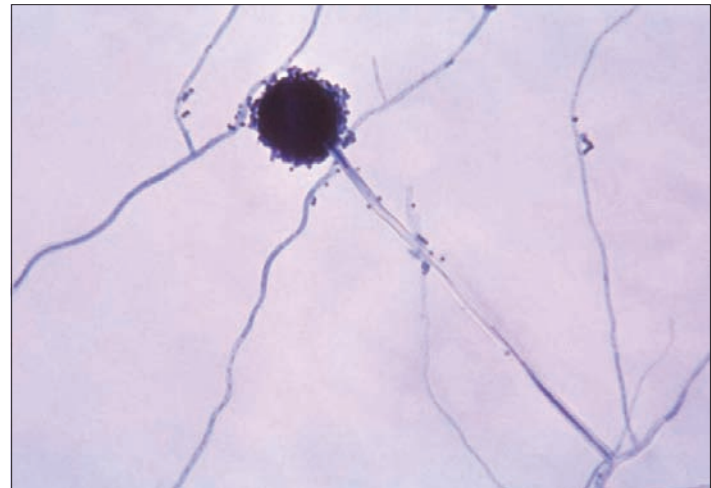
**2.1** Gram stain shows gram-positive (blue) lanceolate diplococci belonging to *Streptococcus pneumoniae*. Gram-positive cocci in chains are usually streptococci.



**2.2** Gram stain showing *Fusobacterium necrophorum*, an anaerobic gram-negative bacillus. (Courtesy of CDC, Dr VR Dowell, Jr.)



**2.3** Photomicrograph showing yeast cells and pseudohyphae of *Candida species*. (Courtesy of CDC, Sherry Brinkman.)

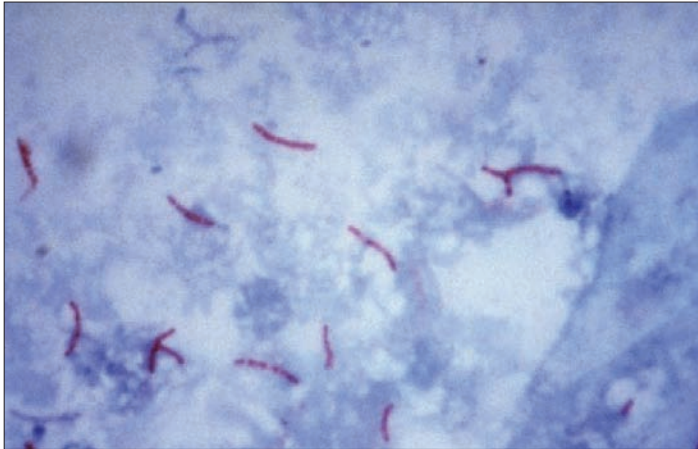


**2.4** Microscopic appearance of *Aspergillus niger* showing a globose conidial head containing fungal spores. (Courtesy of CDC, Dr Lucille K Georg.)

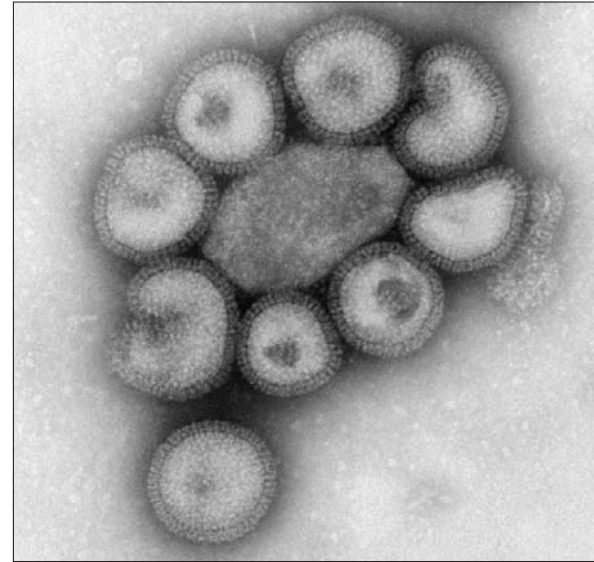
with a thinner but more complex cell wall lose the blue dye and take the colour of red or pink counterstain (e.g. safranin). Yeasts and moulds are gram-positive on gram stain (2.3, 2.4) and can also be identified by various other stains microscopically.

Mycobacteria are identified on slide smears by Carbol

fuchsin stain (e.g. Ziehl Nielsen, 2.5) or fluorochrome stains (e.g. auramine, rhodamine). Viruses (2.6) are the smallest of infective agents visible under electron microscope and are taxonomically classified according to viral structure (e.g. presence/absence of envelope, shape, symmetry) and antigenic composition.



**2.5** Ziehl Nielsen stain to identify acid-fastness of organisms such as *Mycobacteria* and *Nocardia*. Shown here are red staining acid-fast bacilli of *Mycobacterium tuberculosis*. Fluorochrome (auramine, rhodamine) stains are used in many laboratories these days. (Courtesy of CDC, Dr George P Kubica.)



**2.6** Negative stained transmission electron micrograph (TEM) depicting a number of influenza virus particles or 'virions'.

## Commensals

The upper respiratory tract harbours various microorganisms, mostly bacteria, which form part of normal local flora. The bacteria are gram-positive and gram-negative aerobes and anaerobes and most of these are of low pathogenicity. Significant pathogens like  $\beta$ -haemolytic streptococci and *Staphylococcus aureus* can also be part of the normal flora in some individuals.

Saliva and gingival crevices from healthy adults yield heavy growths of coliforms and anaerobic bacteria such as *Prevotella*, *Porphyromonas*, *Bacteroides*, and *Fusobacterium* which together with other commensal mouth flora can cause Ludwig's angina and submandibular abscesses. Commensals of the mouth such as *Actinomyces israelii* and other *Actinomyces* spp. can cause chronic suppurative infection.

The naso- and oropharynx can harbour *Streptococcus pneumoniae*, *Neisseria meningitidis*, and *Haemophilus influenzae*, usually without evidence of disease process, but occasionally can be a cause of pharyngitis. The nares are also usually colonized with *Staphylococcus aureus*, *Streptococcus pneumoniae* and, in a small percentage, with *Neisseria meningitidis*. In hospitalized premature infants, the nasopharynx may be found to grow members of the *Enterobacteriaceae* (coliforms like *Escherichia coli*, *Klebsiella oxytoca*, and *Enterobacter cloacae*) and *Pseudomonas* spp., usually representing a more generalized disease process.

The external auditory canal is colonized with skin flora


such as staphylococci and diphtheroids but may also carry *S. pneumoniae*, *Pseudomonas aeruginosa*, and anaerobic bacteria such as *Propionibacterium acnes*. Colonization with *Aspergillus niger* and *Candida albicans* can be a precursor of fungal otitis externa in children or diabetics. The middle and inner ear are usually sterile.

## Principles of microbiological diagnosis

It is imperative to take appropriate specimens for culture and sensitivity to guide treatment and its duration. Based on the kind of specimen, appropriate specimen transport media should be used (2.7–2.11). Microbiological diagnosis in most laboratories is based on microscopy and culture for bacteria and fungi. Blood culture bottles (2.12) inoculated with blood from patients with suspected sepsis are incubated in semi-automated blood culture cabinets. Some hazardous specimens and growing microorganisms are processed in biological safety cabinets (2.13) to prevent dangerous infections in laboratory personnel. Bacteria and fungi have characteristic appearance on a variety of culture medium (2.14–2.23). The final identification is based on biochemical tests (by recognition of metabolic end-products or enzymes). In the microbiology laboratory, differentiating normal from pathogenic flora depends on information provided about clinical presentation, findings, and also on local epidemiological knowledge.



## 14 Microbiology of ENT infections



**2.7** Sterile universal container for sending urine, fluid, and pus specimen for culture.



**2.8** Small-tipped nasopharyngeal swab to reach the posterior nasopharynx through each nostril for *Bordetella pertussis* culture.



**2.9** Culture swab for bacteria and fungi in charcoal transport medium.



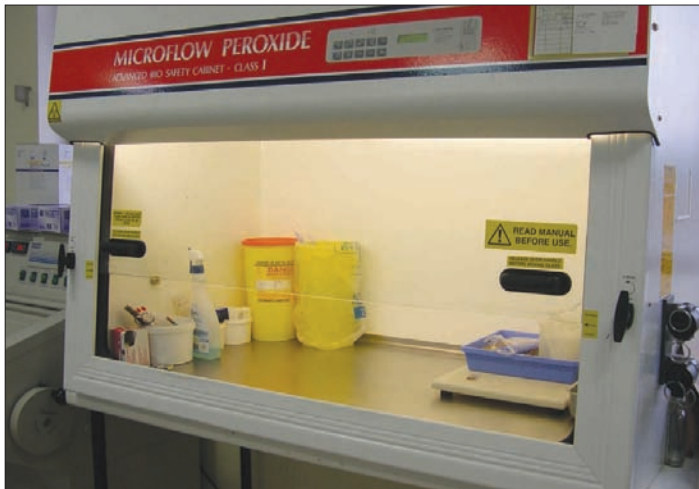**2.10** Viral swab needs to be transported in liquid viral transport medium (not shown) for viral cell cultures and immunofluorescent staining.




**2.11** Blood culture bottle. The medium used is nutritionally enriched and requires at least 10 mL of patient's blood (adult).



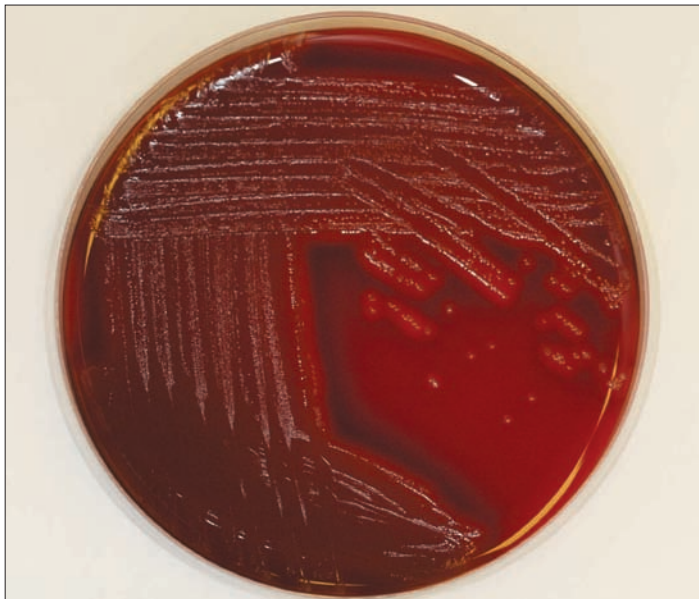
**2.12** Blood culture system. This consists of cabinets with receiving wells for blood culture bottles. As microorganisms grow, liberated carbon dioxide is detected by a colour changing sensor that sets off an alarm alert. Gram stain and culture of the blood is performed on the positive culture bottles.



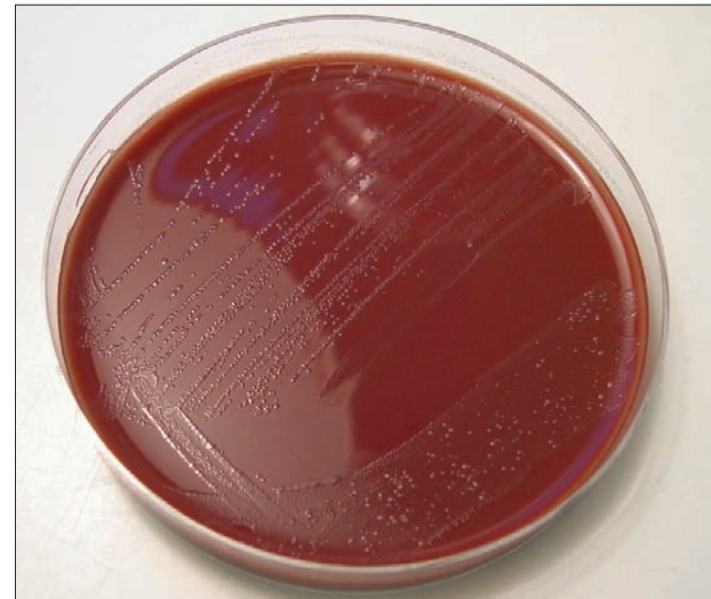
**2.13** Biological safety cabinet (BSL1 or 2) in a routine diagnostic microbiology laboratory for containment of aerosols produced while processing a specimen. A higher biosafety level is applied for stringent conditions depending on the degree of biohazard of the suspected microorganism.



**2.14** Bacterial culture plates for culture from routine specimens. **A:** Blood agar; **B:** cystine lactose electrolyte deficient medium (CLED); **C:** chocolate agar.

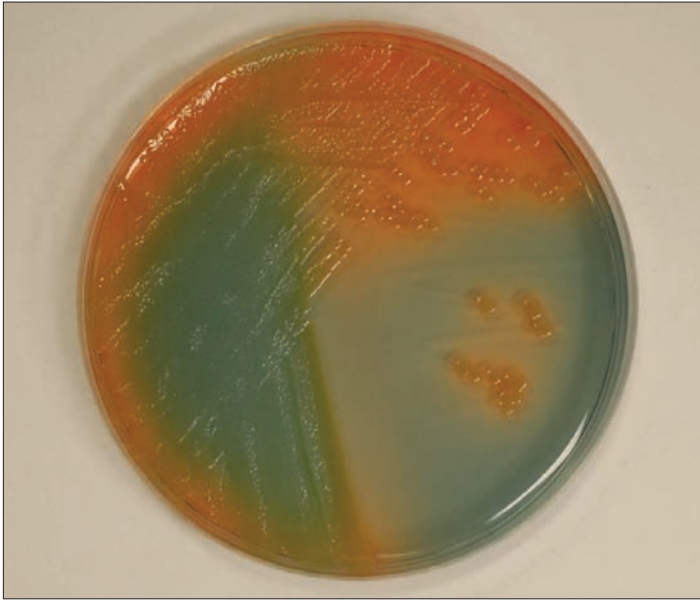

**2.15** Group A streptococci (*Streptococcus pyogenes*) colonies on blood agar. These are 1–2 mm round pale colonies surrounded by a zone of haemolysis (halo).

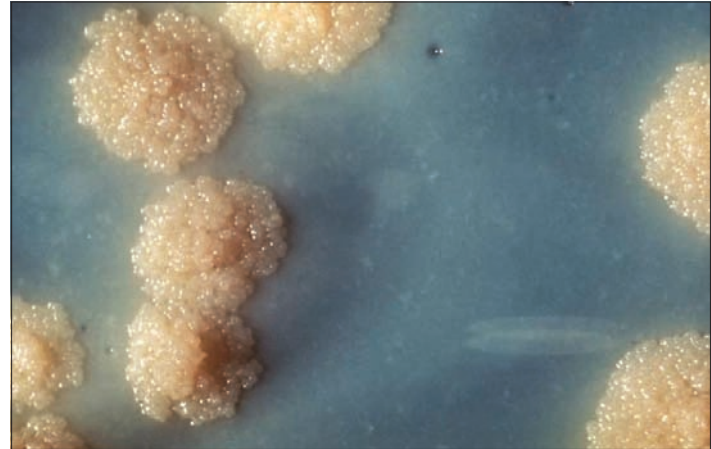


**2.16** Colonies of *Haemophilus influenzae* on chocolate agar. Blood is heated (hence chocolate colour) before pouring in culture plates to release essential nutrients for bacterial growth from lysed red blood cells.





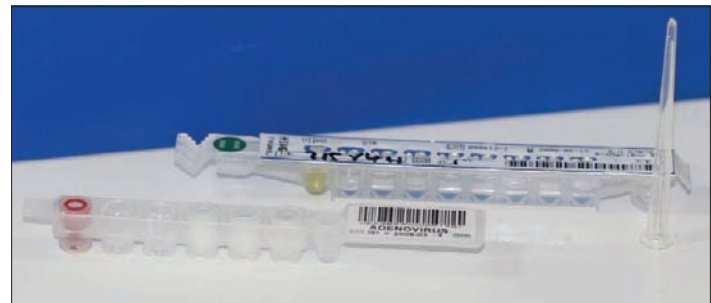**2.17** Coliforms (*Escherichia coli*, *Klebsiella* spp. and other species from the Enterobacteriaceae family) on CLED medium. On gram stain these are gram-negative (red/pink) bacilli, typical of coliform appearance.



**2.18** *Mycobacterium tuberculosis* colonies growing on solid medium. (Courtesy of CDC, Dr George Kubica.)



**2.19** Serodiagnosis (looking for microbial antigens or antibodies) by immunoassay is carried out by automated analysers in batches with a rapid turnover time for results.

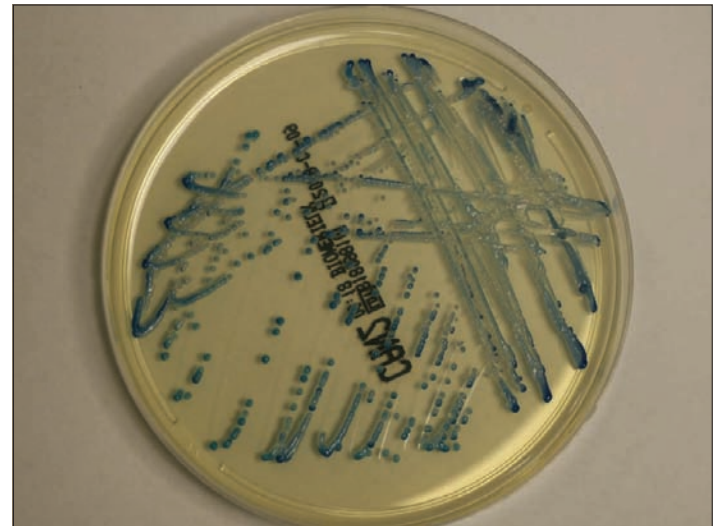


**2.20** Immunoassay strip for adenovirus and HIV with wells for the various reaction steps that are carried out by the analysers.

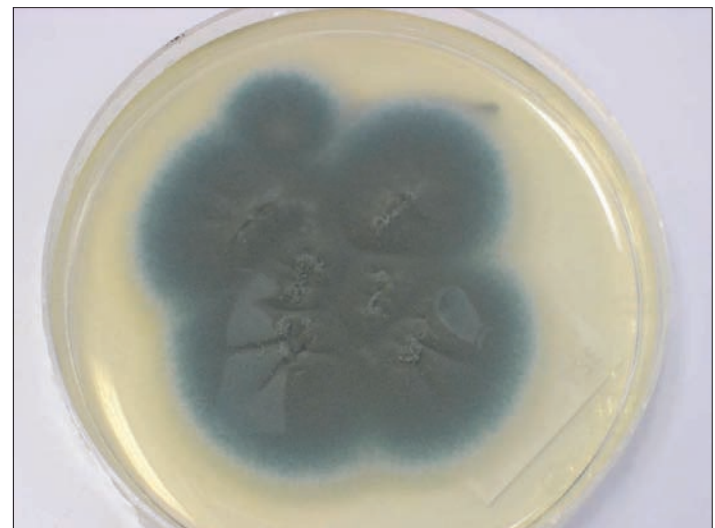
Processing of specimens for viral or tuberculosis microscopy and culture may be limited to specialist laboratories (2.18). Serological tests for direct detection of antigen as well as antibodies formed in response to infection is useful in certain cases (2.19, 2.20) and may serve as an adjunct to positive cultures. It can be helpful in culture-negative cases (e.g. throat swab taken after starting antibiotics), in infections with microorganisms that are

difficult to culture (e.g. *Mycoplasma pneumoniae*), or in cases where routine culture is not possible, as with viruses, e.g. heterophil antibody test (monospot test) in EBV infection or IgM in CMV infection. Molecular-based techniques like DNA probes (bacterial 16SrRNA) or polymerase chain reaction (PCR) for genetic analysis are being constantly improved, but in most places these are not yet widely available for clinical diagnostic purposes.


**2.21** *Candida* on chromogenic Sabouraud's medium. Various species of *Candida* can be identified by the colour of their colonies.



**2.22** *Aspergillus fumigatus* isolated from maxillary sinus aspirate.



**2.23** Grey-white 'cottony' colony of *Mucor* spp., rapidly grows to lift the lid of the culture plate.



## Causative organisms

Tables 2.2–2.4 summarize the bacterial, viral, and fungal pathogens usually implicated in ENT infections.

**Table 2.2 Examples of bacteria causing infections**

### Gram-positive (blue on gram stain)

#### Cocci

Group A streptococci (GAS) ( <i>Streptococcus pyogenes</i> )	Pharyngitis Quinsy, sinusitis
Group C, G streptococci <i>Streptococcus pneumoniae</i>	Pharyngitis, sinusitis, otitis media

#### Bacilli

<i>Corynebacterium diphtheriae</i>	Pharyngitis, pseudomembranes, and toxin-mediated symptoms
<i>Arcanobacterium haemolyticum</i>	Pharyngitis

#### Other bacteria causing upper respiratory tract infections

*Mycoplasma pneumoniae*  
*Chlamydia pneumoniae*  
*Mycobacterium tuberculosis*  
*Treponema pallidum*

### Gram-negative (pink/red on gram stain)

<i>Neisseria gonorrhoea</i>	Pharyngitis
<i>Neisseria meningitides</i>	Pharyngitis
<i>Pseudomonas aeruginosa</i>	Otitis externa, malignant otitis externa
<i>Fusobacterium necrophorum</i> (anaerobe )	Pharyngitis, Lemierre's disease

**Table 2.3 Common viruses causing ENT infections**

Rhinovirus  
Adenovirus  
Coronavirus  
Influenza A & B viruses  
Parainfluenza virus  
Respiratory syncytial virus (RSV)  
Cytomegalovirus (CMV)  
Epstein–Barr virus (EBV)  
Herpes simplex virus (HSV) 1 & 2  
Coxsackie virus

**Table 2.4 Fungi causing ENT infections**

#### Yeasts

*Candida albicans*  
*C. tropicalis*, *C. krusei*, *C. glabrata*, *C. parapsilosis*

#### Moulds

*Aspergillus*  
*Mucor*  
*Fusarium*

## UPPER AERODIGESTIVE TRACT AND SINUS INFECTIONS

Most upper respiratory tract infections are viral in origin and will be self-limiting in a couple of weeks, except in immunocompromised patients. Some of these may be complicated by secondary bacterial infections, which may necessitate antibiotic therapy and/or drainage of pyogenic collections.

Group A streptococci (GAS, *Streptococcus pyogenes*) cause pharyngitis and tonsillitis. Pharyngeal exudates seen in this condition can also be present in infections caused by adenovirus, herpes simplex virus (HSV) and infectious mononucleosis. There has been an epidemic increase in *Corynebacterium diphtheriae* infection (which is also known to produce a characteristic grey membrane across the posterior pharynx) more recently in the former Soviet Union. Group C and G streptococci can also cause pharyngitis but not rheumatic fever as is sometimes the case in GAS infection. HSV and coxsackie viruses often cause ulcers in the mouth and pharynx.

Acute laryngitis, more common in winter months, is due to rhinoviruses (nearly 100 immunotypes and cause of 50% colds in adults), influenza, parainfluenza, adenovirus and coronavirus. Enteroviral upper respiratory infections are more common in summer months. Acute laryngotracheobronchitis (croup) is age specific (3 months–3 years) and is caused by parainfluenza, influenza A & B, adenovirus, and respiratory syncytial virus (RSV). Epiglottitis in children

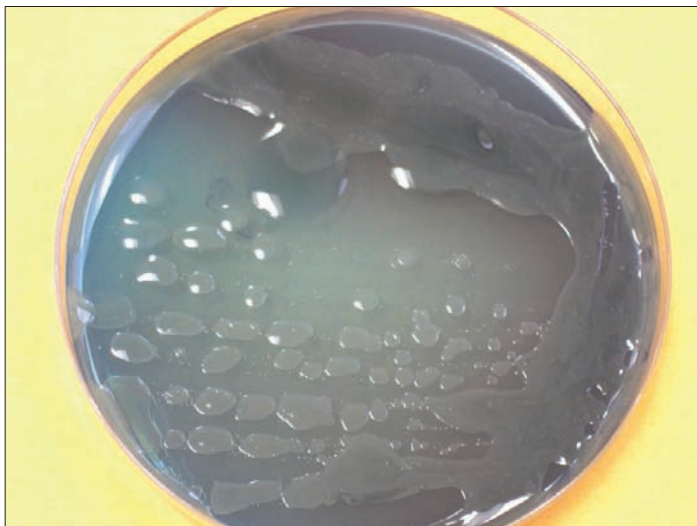
with *Haemophilus influenzae* type B is now uncommon (95% fall) due to HiB immunization. In adults with epiglottitis, blood culture taken prior to starting antibiotics can yield *H. influenzae*.

The microbiological aetiology of sinusitis reflects upper respiratory commensals. Fungal sinusitis with moulds (Table 2.4) occurs in immunocompromised individuals and can be very difficult to treat as the infection can rapidly spread to adjoining structures.

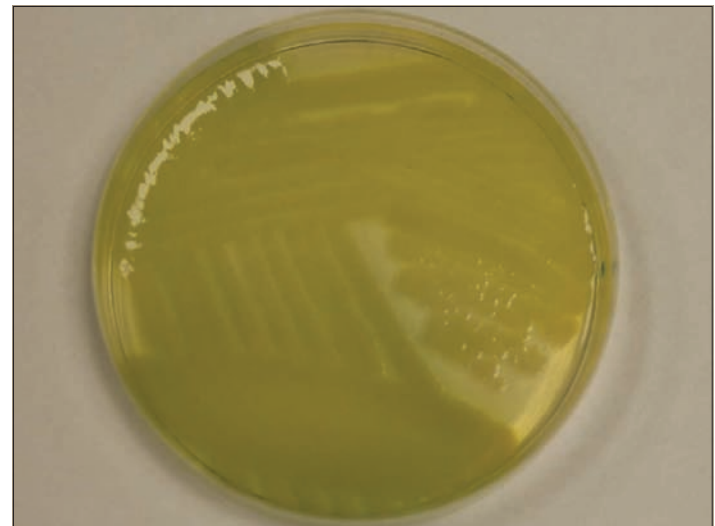
## EAR INFECTIONS

Otitis externa is usually caused by *S. aureus*, haemolytic streptococci, *Pseudomonas aeruginosa*, *Candida*, and *Aspergillus*. In its simple form it responds to topical antibiotics but treatment of aggressive infection with Group A streptococci and *Staphylococcus aureus* or the malignant form with *Pseudomonas aeruginosa* will require systemic antibiotics (2.24, 2.25).

The use of 7-valent pneumococcal conjugate polysaccharide vaccine and HiB has reduced the incidence of otitis media caused by *S. pneumoniae* and *H. influenzae*. Nontypable strains of *H. influenzae* are a significant cause of otitis media in older children, adolescents, and adults, the other being *Moraxella catarrhalis* and *S. pyogenes*. Viruses, mostly RSV and adenovirus, cause the majority of acute otitis media. *Mycoplasma pneumoniae* and *Chlamydia*



**2.24** Mucoid strain of *Pseudomonas aeruginosa* isolated from sputum of a patient with cystic fibrosis.



**2.25** Pigmented *Pseudomonas aeruginosa* on production of pyoverdinin (fluorescein) which appears as a yellow diffusible pigment on agar.

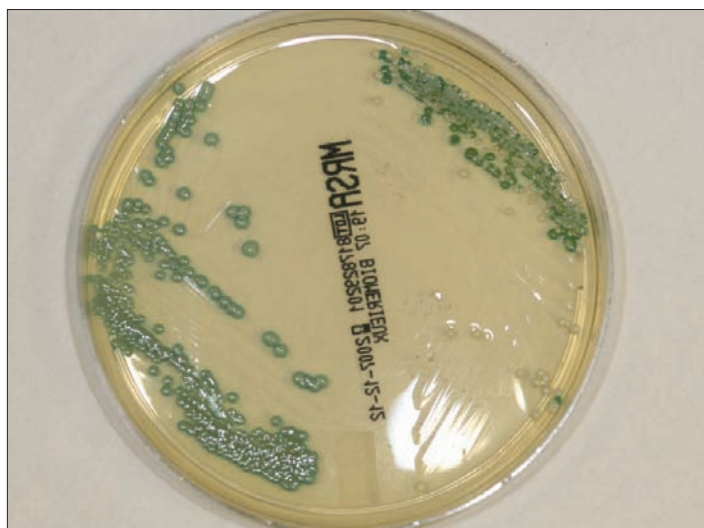


## 20 Microbiology of ENT infections

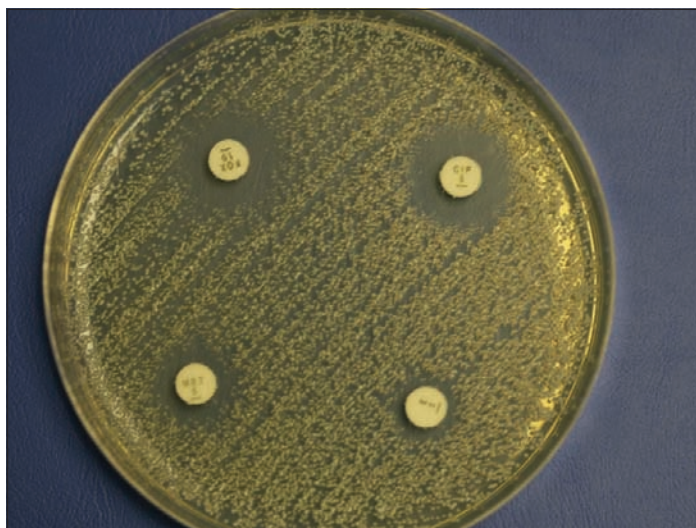
*trachomatis* (in infants <6 months) have been reported as unusual causes and so is tuberculous otitis.

The microbiological aetiology of mastoiditis (*S. pneumoniae*, *H. influenzae*, *M. catarrhalis*, *S. pyogenes*, *S. aureus*) is dependent on the age of the patient and whether it is an acute or chronic presentation, and reflects the flora involved in the middle ear infections. Periosteal abscess and spread to the temporal bone in the form of abscess or

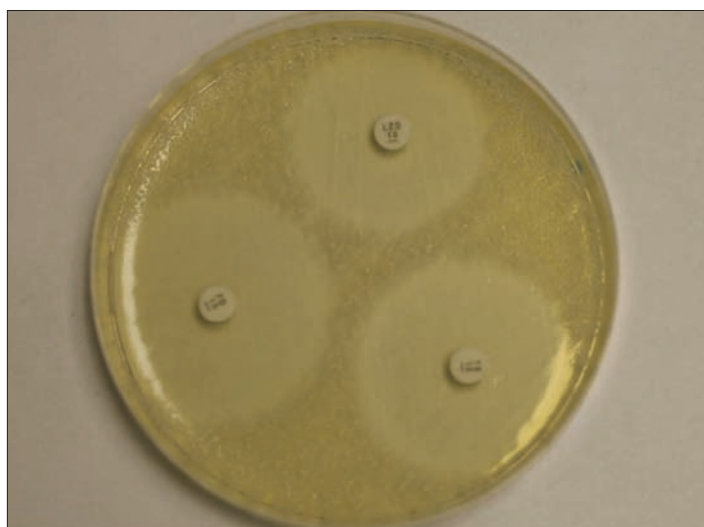
osteomyelitis will require aggressive debridement and long-term antibiotics based on culture results or empirical, best guess antibiotics in culture-negative ones. Nosocomial infection of the sinuses or postoperative wound infections of the ear, nose, throat, head, and neck is usually due to resistant gram-negative bacilli (coliforms and *Pseudomonas* species) and MRSA (methicillin-resistant *Staphylococcus aureus*) depending on local prevalence in hospitals (2.26–2.29).




**2.26** Greenish-blue MRSA colonies on chromogenic agar medium.




**2.27** Antibiotic susceptibility testing for MRSA. Resistance demonstrated by no zones, or smaller zones around the antibiotic disc, to (clockwise, from top right) ciprofloxacin (Cip), erythromycin (E), metronidazole (MZ), and cefoxitin (Fox).



**2.28** Antibiotic susceptibility testing for MRSA. Susceptibility, demonstrated by a clear zone around the antibiotic disc, to (clockwise from top) linezolid (LZD), tetracycline (TE), and fucidic acid (FD).



**2.29** Automated system for antimicrobial susceptibility testing and biochemical identification tests, is faster and less labour intensive than manual methods.



# Principles and practice of anti-infective therapy in ENT infections

*Vinidh Paleri and John Hill*

## Introduction

This section will outline some of the principles of antibiotic therapy and discuss the commonly used agents in ENT practice. The suggested treatment regimes are not exhaustive and prescribing antibiotics should always take into consideration the local sensitivity profiles for the infecting organisms.

The choice of an antibacterial compound for a particular patient and a specific infection is based on several factors: the pharmacokinetic profile of the antibiotic, the adverse effect profile, the site of infection, the sensitivity profile of the infecting organism, the patient's immune status, evidence of efficacy from well conducted trials, the cost of the regime, and the patient's history of allergy to antibiotics. The local sensitivity profile, where available, is useful when empiric treatment is being considered.

Minimum inhibitory concentration (MIC) is the lowest concentration of an antimicrobial that will inhibit the visible growth of a microorganism after overnight incubation. An adequate antibiotic dose should aim to achieve a concentration of antibiotic in the infected tissue that exceeds the MIC by three to four times for at least 75% of the time between successive doses. However, when the infection is located in a site where penetration is poor, such as an abscess cavity in the neck or in complicated sinusitis, drainage of pus collection is paramount. Sometimes, despite adequate MIC at the site of infection, activity may be reduced due to the local environment, such as an unfavourable pH.

Antibiotics inhibit or abolish the growth of microorganisms (bacteria and fungi) through a number of

mechanisms, as shown in *Table 3.1*. Antibacterials are broadly classified into bactericidals, that kill bacteria directly, and bacteriostatics, which prevent them from dividing. However, these classifications are based on laboratory behaviour and, in practice, both classes are capable of ending a bacterial infection. In the treatment of most ENT infections acquired in the community, the choice of either a bacteriostatic or bactericidal antibiotic is of limited importance. However, in patients with severe infection, especially in immunocompromised states, a bactericidal agent must be used.

## Resistance

Acquired resistance commonly occurs through one of the following mechanisms: production of drug-inactivating enzymes (e.g.  $\beta$ -lactamase production by *Haemophilus influenzae*), alteration of the target site (e.g. penicillin binding protein in methicillin-resistant *Staphylococcus aureus* [MRSA]; 2.27, 2.28), and mechanisms which prevent access of the drug to the target site (e.g. drug efflux pumps and poor cell wall permeability seen in *Pseudomonas aeruginosa*). Resistance can be passed on horizontally (e.g. by plasmid transfer) or vertically (by mutation). Knowledge of resistance patterns in the local environment is important and multi-disciplinary working with microbiologists is important in planning the treatment regime for serious infections. Clinical vigilance is necessary to reduce the emergence of resistant strains (*Table 3.2*).

### Parenteral therapy

While parenteral administration improves the bioavailability of a drug, it is associated with an increased risk of adverse effects. Thus, parenteral administration should be reserved for patients who are severely ill (e.g. acute mastoiditis) or in situations where oral intake is not possible (e.g. quinsy). Oral treatment can be commenced once the patient shows clinical improvement.

### Frequently used antibiotics in ENT practice

#### ***β-lactams***

These are the most widely used group of antibiotics and include penicillins, cephalosporins, monobactams, and carbapenems. All these drugs fall into this category as they contain a β-lactam nucleus in their chemical structure. β-lactams are bactericidal. They act by binding to penicillin-binding proteins and inhibit the final step in the synthesis of the peptidoglycan layer of the cell wall.

**Table 3.1 Mechanism of action of antibiotics**

Mechanism of action	Antibacterial drugs	Antifungal drugs
Inhibition of synthesis or damage to cell wall	Penicillins, cephalosporins and other β-lactams; vancomycin	Fungi do not have a cell wall
Inhibition of synthesis or damage to cytoplasmic membrane	Polymyxin	Amphotericin, nystatin; clotrimazole; fluconazole
Inhibition of synthesis or metabolism or function of nucleic acids	Ciprofloxacin; rifampicin; nitrofurantoin; metronidazole	Griseofulvin
Inhibition of protein synthesis	Gentamicin; tetracycline; chloramphenicol; erythromycin; fusidic acid	Flucytosine
Modification of energy metabolism	Sulphonamides; trimethoprim; isoniazid	None

**Table 3.2 Measures to reduce emergence of resistant strains**

- 1 Ask yourself if an antibiotic is indicated for the infection
- 2 Ensure that correct dosage for the appropriate duration is being prescribed
- 3 Educate the patient regarding the importance of completing the antibiotic regime
- 4 Use a single agent with a narrow spectrum of activity where possible to avoid reduction in natural flora, that paves the way for nosocomial infection
- 5 Use combination chemotherapy in scenarios where monotherapy is known to promote emergence of resistant mutants

Penicillin is the drug of choice for gram-positive organisms, such as group A and B streptococcal infections, actinomyces, and most bacteria involved in oral and periodontal infections. Resistance to penicillin is widespread in staphylococci and in pneumococci in some geographic areas. Ampicillin and amoxicillin extend the activity of penicillin among gram-negative organisms such as *H. influenzae*, but as mentioned below,  $\beta$ -lactamase producing variants exist. The addition of  $\beta$ -lactamase inhibitors (clavulanic acid, sulbactam) has extended their spectrum to include these resistant gram-negative organisms. Penicillinase-resistant penicillins (e.g. flucloxacillin) are used primarily to treat staphylococcal infections. Carboxypenicillins and ureidopenicillins are especially active against pseudomonas infections.

Cephalosporins are categorized into four generations based on their activity profile. As a rule of the thumb, the activity of cephalosporins against gram-negative bacteria is greater with the newer generations. The fourth generation cephalosporins, however, have true broad spectrum activity. First generation cephalosporins act well against gram-positive bacteria, including penicillinase-producing staphylococci. Second and third generation cephalosporins are active against the bacterial agents causing sinusitis and otitis media and against resistant *H. influenzae*, thus being useful in epiglottitis. Third generation cephalosporins are primarily used against multi-drug-resistant gram-negative agents such as *Pseudomonas* spp. and when intracranial complications supervene, as they penetrate the blood–brain barrier well. Carbapenems are primarily used against gram-negative bacteria resistant to third generation cephalosporins.

### **Aminoglycosides**

This class of antibiotics is not used as frequently in ENT infections. They are bactericidal and prevent protein synthesis by binding irreversibly to the 30S subunit of the bacterial ribosome. Their primary indication is in managing gram-negative infections, especially of nosocomial origin, but they are active against staphylococci and *Pseudomonas* spp. They exhibit poor penetration into abscess cavities and renal and otic toxicity is one of the major reasons for reduced use. However, topical aminoglycosides are very effective in controlling bacterial otitis media.

### **Macrolides**

Erythromycin, clarithromycin, and azithromycin are very commonly used for community acquired ENT infections. These are bacteriostatic antibiotics, and act by interfering with protein biosynthesis and binding to the 50S subunit of the ribosome. The spectrum includes gram-positive bacteria with limited activity against gram-negative organisms. It must be noted that bacteria that are resistant to erythromycin are also resistant to clarithromycin and azithromycin, owing to a similar mechanism of action. The latter two have fewer gastrointestinal side-effects compared to erythromycin. These are primarily used in streptococcal pharyngotonsillitis, acute sinusitis, and in patients allergic to penicillin. Unlike penicillin, it must be recognized that *Streptococcus pyogenes* resistance to macrolides exists. Clarithromycin and azithromycin are also used in treating nontuberculous mycobacterial infection.

### **Lincosamides**

Clindamycin is the only lincosamide that is widely used. This class of agents is bacteriostatic with a mechanism of action similar to the macrolides. It is active against gram-positive aerobes (streptococci and staphylococci) and all strict anaerobes. Antibiotic associated diarrhoea and pseudomembranous colitis is a well-documented complication that is also associated with most of the other antibiotics.

### **Fluoroquinolones**

This group of antibiotics is bactericidal, acting by inhibiting DNA replication and transcription. These antibiotics have excellent activity against gram-negative organisms, including *Pseudomonas* spp. The newer quinolones are also active against gram-positive bacteria. Major indications in ENT practice include second-line therapy for sinusitis (after treatment failure) and pseudomonal skull base osteomyelitis (malignant external otitis). Ophthalmic preparations can be used topically in chronic otitis media to eradicate *Pseudomonas* spp.

### **Tetracyclines**

These are bacteriostatic drugs that act by binding reversibly to the 30S ribosomal subunit and blocking translation. They have a wide spectrum of gram-positive and gram-negative activity, but resistance is common of late. MRSA is susceptible to tetracyclines but treatment should be advised based on susceptibility tests.



**Metronidazole**

This agent is active solely against anaerobes, especially the gram-negative species. It disrupts the DNA structure after being actively transported into anaerobic bacteria to be converted into its active form. It penetrates into abscess cavities very well, but has no activity against aerobic organisms. Topical metronidazole is used on malodorous wounds to reduce anaerobic growth.

**Choice of antibacterial therapy****Acute otitis media and acute sinusitis**

The organisms causing acute otitis media and acute sinusitis have a similar distribution in children and adults. Apart from viruses, *Streptococcus pneumoniae*, *Haemophilus influenzae*, *Moraxella catarrhalis*, and *Streptococcus pyogenes* are implicated. Cultures are difficult to obtain in both scenarios without invasive means and therapy is generally empirical. Given the above spectrum, amoxicillin is recommended as the first-line agent and success with this agent is well documented. Resistance to penicillin and amoxicillin is seen in *S. pneumoniae*, *H. influenzae*, and *M. catarrhalis*, with geographic variation. Lack of response within 72 hours may indicate a  $\beta$ -lactamase-producing strain of *H. influenzae* or *M. catarrhalis* or a strain of penicillin-resistant *S. pneumoniae*. In these instances, a change in antibiotic is needed. The choice is best made taking into account local sensitivities and directed by culture results if appropriate.

Therapy is typically administered for 5–7 days for uncomplicated acute otitis media and 10–14 days for acute sinusitis. Treatment failures can occur with acute sinusitis with inadequate doses or resistant organisms. In such instances, longer courses of culture directed antibiotics for 4–6 weeks may be required to eradicate the infection.

**Chronic otitis media and topical antibiotics**

*Pseudomonas aeruginosa* and *Staphylococcus aureus* are the common pathogens seen in this setting. Oral and parenteral antibiotics usually achieve concentrations in the middle ear that is slightly above the MIC for most pathogens (4–6  $\mu\text{g/mL}$ ). However, a 0.3% topical antibiotic solution (the most common formulation) contains 3000  $\mu\text{g/mL}$ , a concentration that is several hundred times higher than that achieved by other routes of administration. Moreover, this concentration greatly exceeds the laboratory reported MIC

for any organism, which are designed for tissue concentrations achieved by systemic administration. For this reason, sensitivity reports have no clinical implication. Thus, topical therapy has very high success rates in controlling the infection and resistance is not an issue. Topical antibiotic preparations include aminoglycosides (gentamicin and framycetin), fluoroquinolones, gramicidin, and polymixin, often in combination.

**Pharyngotonsillitis**

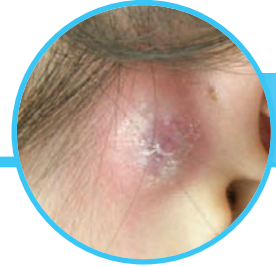GAS pharyngitis must be treated with a full 10-day course of oral penicillin, with erythromycin being used in penicillin-allergic individuals. Penicillin resistance has not been reported so far and newer antibiotics do not offer any advantage. No treatment is required for pharyngitis caused by viruses, *Mycoplasma* or *Chlamydia* as these are self limiting.

**Epiglottitis**

Antibiotic therapy should target *H. influenzae* and should be guided by recent local sensitivity profiles if available. Several studies have shown increasing resistance of this organism to  $\beta$ -lactam antibiotics and thus therapy with a  $\beta$ -lactam/ $\beta$ -lactamase inhibitor combination (amoxicillin/clavulanic acid) or a second- or third generation cephalosporin (cefotaxime, ceftriaxone) is recommended. Clindamycin is reserved for patients allergic to  $\beta$ -lactams. Antibiotic therapy should be continued for 7–10 days and should be tailored, if necessary, to the organism recovered in culture. Unvaccinated children exposed to patients should receive prophylaxis with rifampicin.

**Neck space abscesses**

These are life-threatening infections and empirical therapy should be started soon after a clinical diagnosis is made. This should cover streptococci, oral anaerobes, and *S. aureus*. Amoxicillin/clavulanic acid or clindamycin alone is usually effective. Once cultures are obtained, the antibiotics can be changed to reflect sensitivity. Drainage of abscess is essential, as antibiotics do not reach bacteria in the presence of pus.



# Infections of the ear

*John Hill*

## Introduction

Infections of the external and middle ear have similar presentations. A good history, coupled with examination of the ear under magnification after cleaning out the ear canal, is necessary to achieve the diagnosis. Significant vital structures crowded in a small area, proximity to the intracranial compartment and the variety of infectious syndromes makes this a challenging aspect of ENT practice.

## Infections of the pinna

Pre-auricular sinuses are commonly asymptomatic and require no treatment. They appear as small pits or dimples anterior to the root of the antihelix. More extensive sinuses will collect squamous debris and can become infected. Incision and drainage will be needed if an acute abscess develops but formal excision of the tract is necessary to prevent recurrence (4.1).

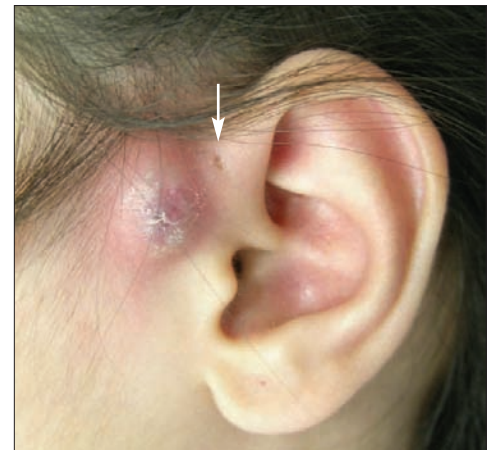Sebaceous cysts occur in the lobule of the ear and can become infected, but most infections in this area are secondary to ear piercing. Abscesses will require incision and drainage (4.2).

Infection of the perichondrium of the pinna can be secondary to an infected wound on the pinna or an otitis externa. The pinna becomes thickened, erythematous, and tender (4.3). Treatment should be prompt with broad-spectrum intravenous antibiotics initially. If untreated, the infection leads to a loss of cartilage and a cauliflower ear appearance.

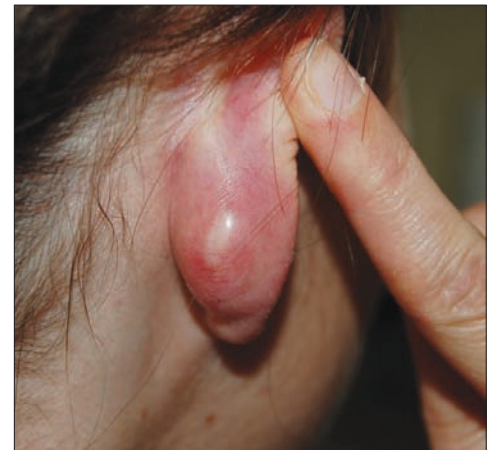## Infections of the external ear canal

The squamous epithelium of the tympanic membrane and ear canal is migratory in nature. The squamous epithelium over the drum is very thin and is only one cell thick. The skin

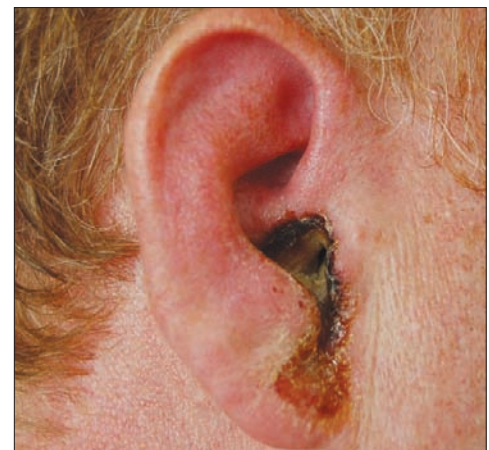**4.1** Pre-auricular abscess in front of the pre-auricular pit (arrowed).



**4.2** Infected sebaceous cyst.



**4.3** Perichondritis secondary to otitis externa.



becomes progressively more stratified towards the meatus of the ear canal but remains thin throughout the external ear. The confined space of the ear canal means that it is not possible to have a desquamating stratified squamous epithelium on the drum or the ear canal. If this were the case the desquamated cells would collect in the ear canal and lead to a build up of debris. The migratory nature of the epithelium avoids this problem. The squamous epithelium grows out radially across the surface of the drum until it reaches the annulus and then grows out laterally along the ear canal. The ceruminous glands, which produce the wax, are only located in the outer third of the ear canal. As a result, in a normal ear, the skin gradually migrates out towards the meatus taking excess wax with it. The normal ear is self-cleansing and the antiseptic, hydrophobic nature of wax keeps the medial end of the external ear canal relatively clean with only scanty growths of commensals present. Typically these are *Staphylococcus epidermidis*, *Corynebacterium* spp., *Staphylococcus aureus*, and *Streptococcus viridans*.

### FURUNCULOSIS

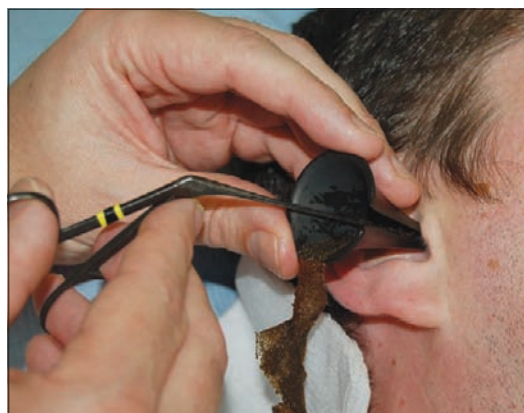The outer third of the ear canal contains hair bearing skin and furunculosis is an infection of a hair follicle. It gives rise to a very tender localized swelling. Oedema in a confined area gives rise to severe pain. There may be little in the way of pus present. Infections are usually caused by *Staphylococcus aureus*. The principle of treatment is to reduce the swelling in the ear canal using impregnated wicks. These are strips of ribbon gauze that can be soaked in topical agents. They need to be replaced or removed after 24–48 hours. For furunculosis, a wick soaked in ichthammol glycerin is the treatment of choice (4.4, 4.5). Wicks soaked with creams containing steroid and antibiotic may also be effective. Additional oral anti-staphylococcal antibiotics are of value if there is erythema visible on the pinna. The swelling is caused by local oedema and very little pus and so surgical drainage is rarely effective.

### ACUTE OTITIS EXTERNA

Acute infection of the ear canal presents as a painful ear which may be accompanied by a blocked feeling. Even gentle traction on the patient's pinna exacerbates pain. In mild cases the ear canal will appear red and in more severe cases there will be acute oedema of the ear canal with narrowing of the meatus and a variable amount of debris in the canal. The aetiology of acute otitis externa may be idiopathic, traumatic due to scratching of the ear canal or injudicious use of cotton buds or related to water with an accompanying history of water getting into the ear as a result of swimming or syringing.

Treatment will vary depending on the degree of oedema. If the canal is inflamed and there is no evidence of debris, topical antibiotic drops or sprays containing broad-spectrum antibiotics and steroids may be all that is required (4.6). Cases where there is significant oedema will be very tender and will require gentle microsuction of any debris (4.7, 4.8). This is followed by the introduction of wicks to remove the oedema of the ear canal. These can be ribbon gauze wicks impregnated with ichthammol glycerin or steroid and antibiotic creams (4.9). Inserting a dessicated expandable ear wick followed by addition of a topical antibiotic drop preparation can also be effective (4.10–4.12). If the patient is toxic or there is associated erythema of the pinna or face then additional systemic antibiotics are required. In early acute otitis externa the infecting organisms are likely to be staphylococcal or streptococcal in nature, but with time the organisms soon change to those seen in chronic otitis externa.

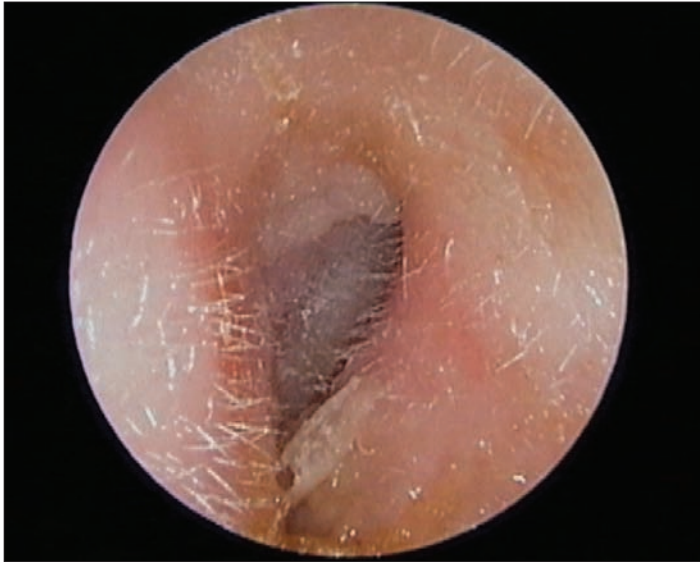As the ear responds to treatment, further suction clearance to clear the build up of any further debris may be necessary. Frequency of microsuction is highly variable. Wicks tend to dry out in 24–48 hours and therefore need to be changed every 24–48 hours. As the oedema settles, the ear canal widens and progressively longer/larger wicks can be inserted.



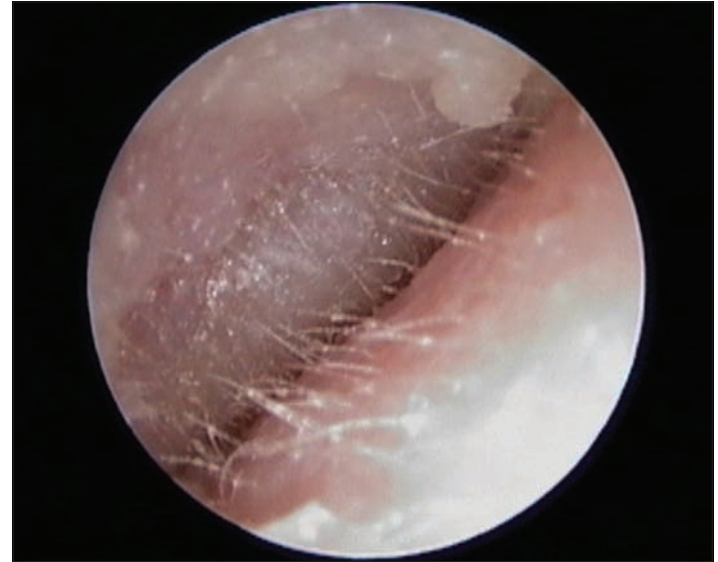4.4 Glycerine and ichthammol ribbon gauze wick.

4.5 Insertion of a wick.

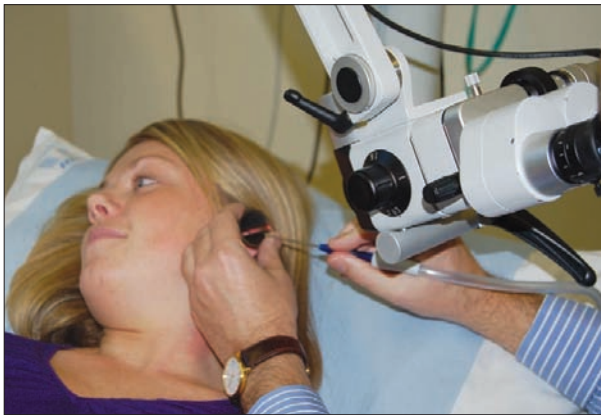




4.6 Otitis externa with mild oedema and erythema but no debris.



4.7 Otitis externa with severe oedema and slit-like meatus.



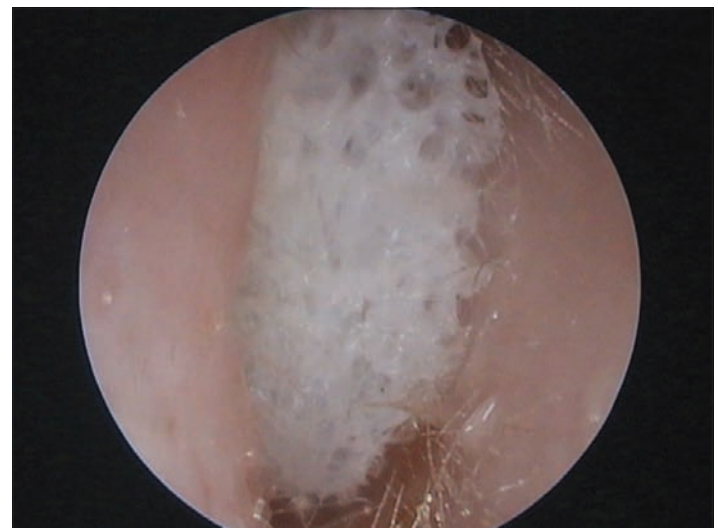
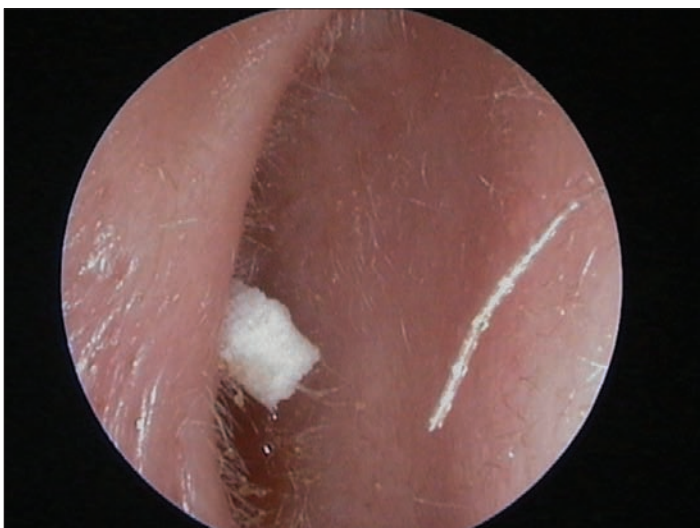4.8 Microsuction to remove debris in otitis externa.



4.9 Ribbon gauze soaked in combination steroid and antibiotic cream.



4.10 Desiccated expandable ear wick.



4.11, 4.12 Desiccated expandable ear wick *in situ* (4.11), and after addition of antibiotic drops (4.12).



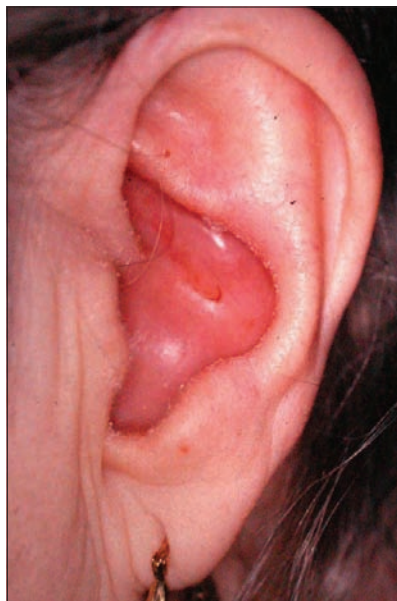### CHRONIC OTITIS EXTERNA

Chronic otitis externa is as much an inflammatory as an infective process. The common reasons for persistence of the condition are:

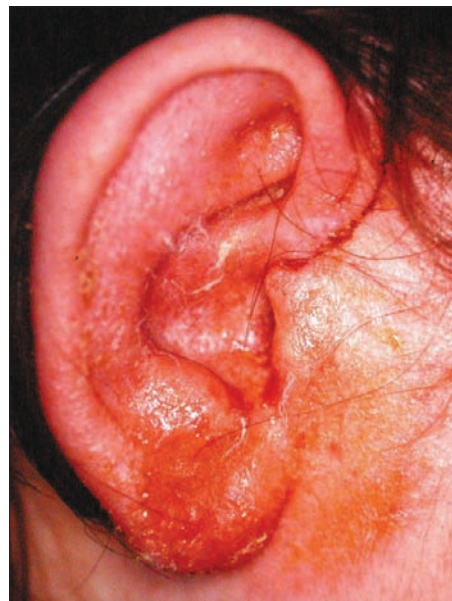- Continuing trauma.
- Secondary bacterial overgrowth: swabs taken from ears with chronic otitis externa will produce cultures of a large variety of pathogens. *Pseudomonas* spp. are the commonest, but *Proteus* spp., coliforms, and *Staphylococcus aureus* are frequently found in mixed growths.
- Underlying skin conditions: eczema, seborrhoeic dermatitis, and psoriasis.
- Chemical irritation: hair preparations and agents in antibiotic drops can become irritative.
- Allergic reaction: the antibiotics in drops such as neomycin, gentamicin, and framycetin can induce a contact dermatitis with prolonged use. Hearing aid moulds and antiseptic dressing used after ear surgery can also cause allergic reactions (4.13, 4.14).
- Environmental exposure to water or humid conditions.

Although it may simply be a result of an acute otitis externa that is slow to resolve, in the majority of cases the failure of resolution is due to direct or indirect trauma (4.15–4.17). This condition is common in patients who have a tendency to eczema. The patient complains of an itching in the ear accompanied by variable amounts of discomfort and pain. The ear will tend to discharge and there will be a blocked feeling in the ear. In mild cases, the eczematous inflammation of the ear canal may be the only disease process (4.13). The inflamed skin loses its natural migratory ability and there is decreased wax production. There is a tendency for dry desquamated cells to collect in the ear canal. Treatment at this stage is gentle microsuction of any debris and use of steroid drops to settle the eczema and stop the itching.


Itching of the ear canal tempts the patient to use cotton buds, hair grips, pen tops, finger nails, and so on to rub or scratch the ear canal. A scratch inside the ear canal breaks the integumental layer of the skin and allows for infection to spread subcutaneously, giving rise to the classic appearance of a chronic infective otitis externa (4.18–4.21). The ear



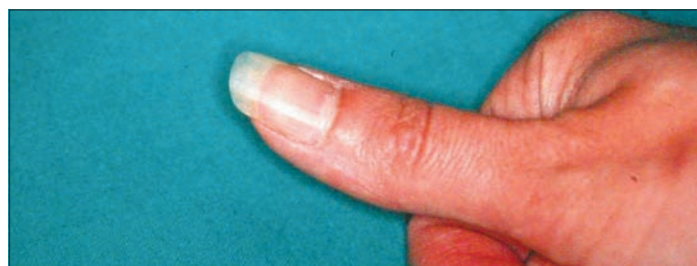4.13 Erythema in the conchal bowl due to allergy to a hearing aid mould.



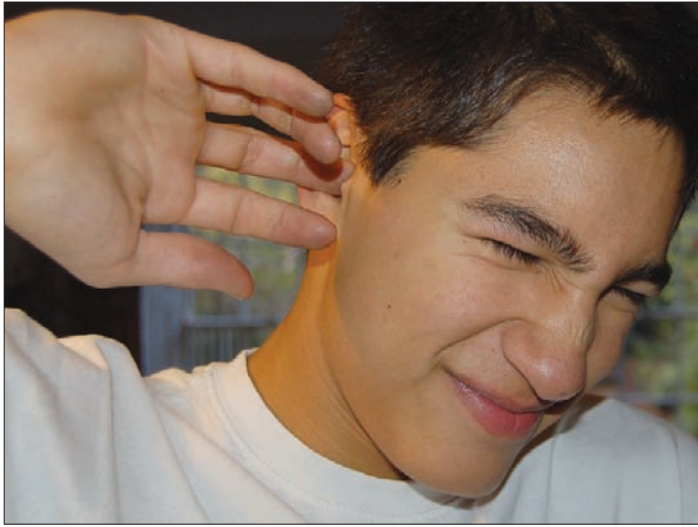4.14 Weeping erythema due to allergy to bismuth iodoform paraffin paste (BIPP) dressing used after middle ear surgery.



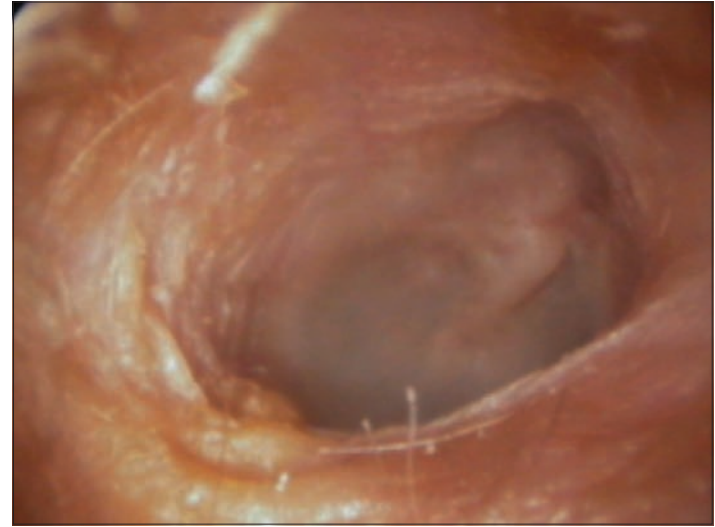4.15 Trauma to ear canal: cotton buds.



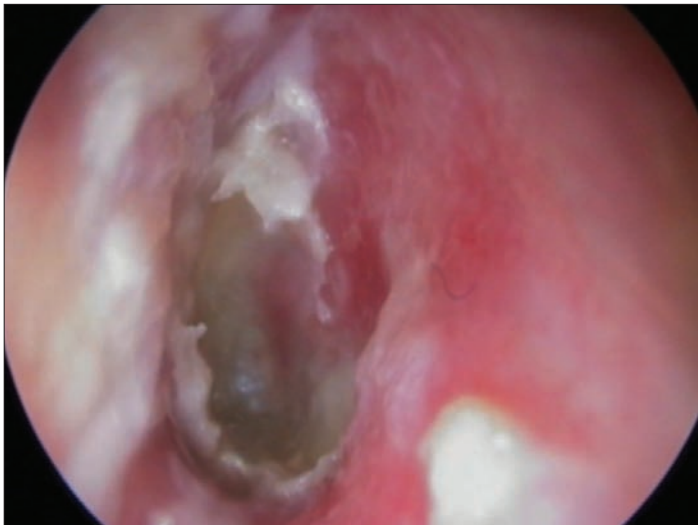4.16 Trauma to ear canal: finger nails.



4.17 Trauma to ear canal: rubbing.



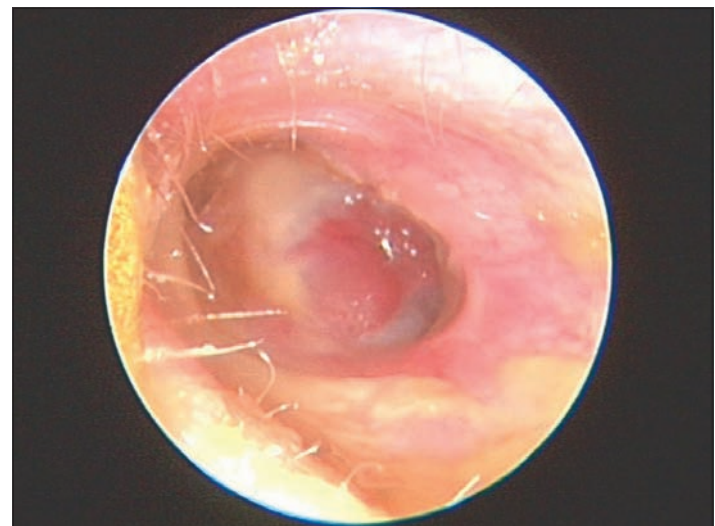
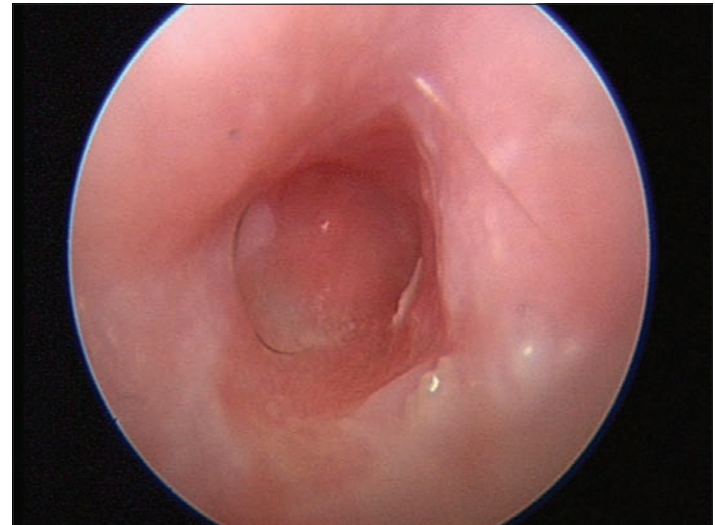
4.18 Dry mildly eczematous ear canal with no wax.



4.19 Chronic otitis externa: erythema, oedema, and debris.

4.20 Chronic otitis externa: erythema and oedema.

4.21 Chronic otitis externa: erythema, oedema and associated inflammation of the tympanic membrane (myringitis).

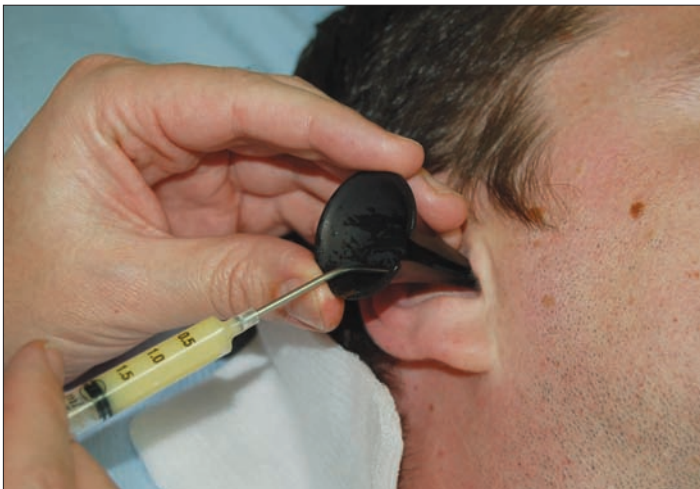



canal appears red with variable degrees of oedema and debris. The treatment is a 'triple therapy' approach as follows:

- 1 Stop the patient rubbing, scratching, and poking the ear and keep the ear dry until the infection has settled.
- 2 Microsuction to remove the debris, which is a collection of desquamated skin cells, bacteria, and wax. This is likely to be required to be done repeatedly depending on the response to treatment.
- 3 Topical treatment using combinations of steroids and antibiotics. Milder cases will respond to simple drops and sprays, more severe cases benefit from insertion of steroid and antibiotic cream or ointment in the ear canal. Wicks can be used if there is significant oedema, but when the ear canal is reasonably open, insertion of cream or ointment into the ear canal using a 2 ml syringe with a plastic intravenous cannula attached is often easier (4.22). These treatments will often require to be repeated. Appearance of a normal ear canal with normal wax usually indicates that the problem has been solved. Oral antibiotics are rarely needed or helpful.

Patients will often complain of recurrent problems over many years. This is usually due to incomplete eradication of the initial infection. In chronic low-grade otitis externa it may be possible to gain control by using topical antiseptic solutions such as aluminium acetate or alcohol and acetic acid mixtures. These work by inhibiting bacterial growth by acidifying the ear canal.



**4.22** Filling the ear canal with combination steroid and antibiotic cream without a wick as treatment for chronic otitis externa.

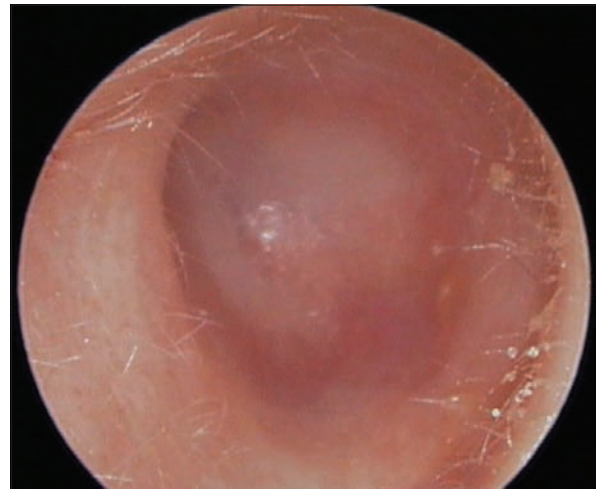### FUNGAL OTITIS EXTERNA

Continued or overuse of antibiotics can result in an otitis externa in which the inflammation is accompanied by a fungal infection. Clinically, the appearance may be the same as that of chronic bacterial otitis externa and the diagnosis is only made by fungal growth on aural swabs. Alternatively, the clinical appearance may be that of an obvious fungal growth with visible hyphae and on otoscopy a dry or wet mould can be seen. *Aspergillus* species are most commonly isolated. The treatment is similar to that of the triple therapy of the chronic otitis externa with:

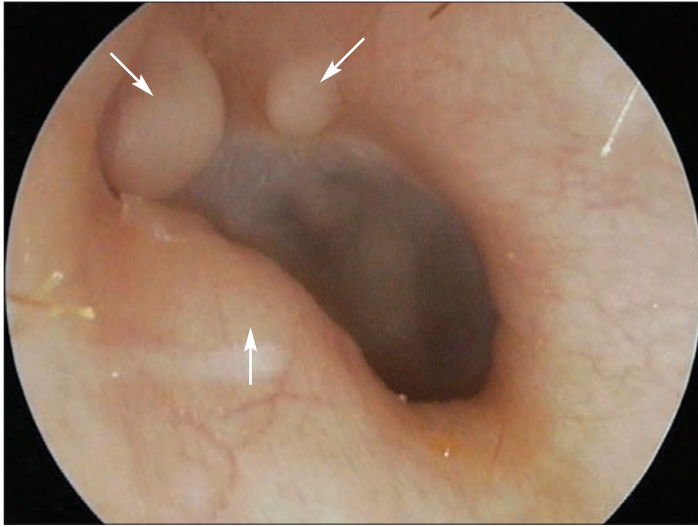
- 1 Stopping the patients traumatizing the ear canal and keeping it dry.
- 2 Repeated careful microsuction.
- 3 The use of antifungal agents. As the topical antibiotic and steroid creams often contain nystatin, these agents may be suitable but specific treatment with antifungal creams and drops such as econazole or clotrimazole may be required. Fungal infections have a reputation for reoccurring which is due to reactivation of persisting spores. Therefore, antifungal topical agents are recommended for 4–6 weeks.

### SEQUELAE OF CHRONIC OTITIS EXTERNA

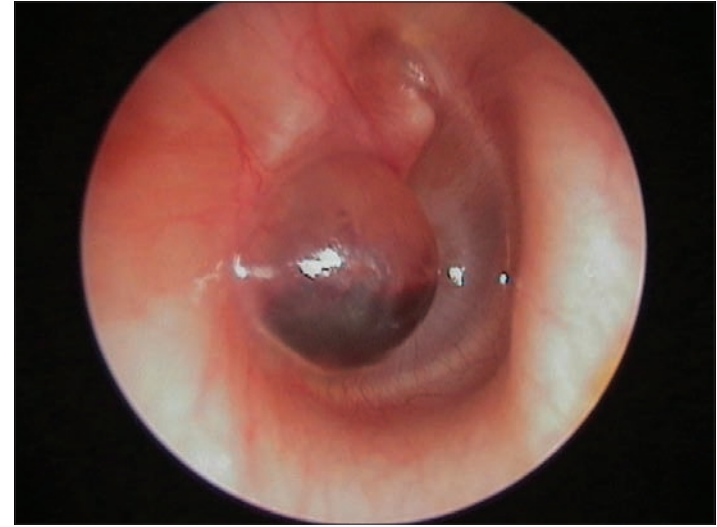
False fundus: a chronic otitis externa, particularly if it involves the drum, can result in an adhesive fibrosis whereby the canal stenoses and a fibrous layer grows over the tympanic membrane. This can be quite thick so that the canal appears shorter than normal. The infective process has resolved but a conductive hearing loss results (4.23).



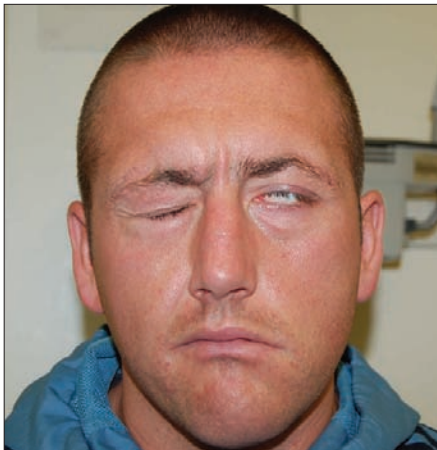**4.23** False fundus secondary to chronic otitis externa.



**4.24** Multiple exostosis (arrowed) secondary to swimming in cold water or otitis externa (left ear).

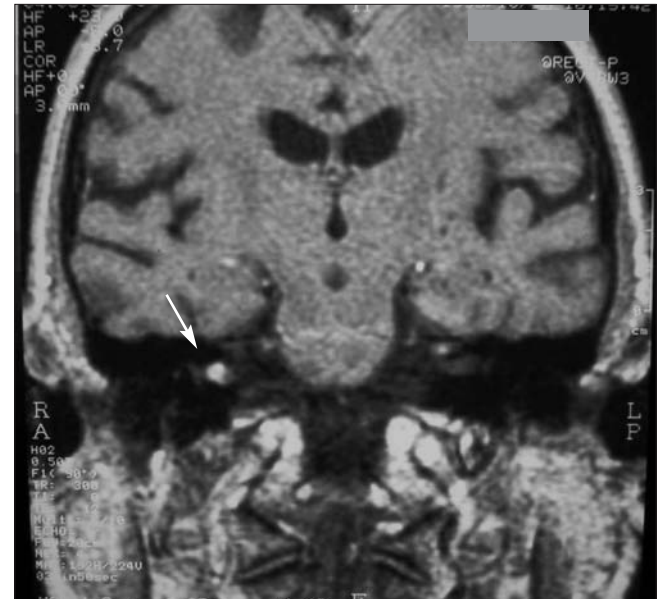


**4.25** Vesicle on the posterior part of the tympanic membrane caused by bullous myringitis.



**4.26** Left facial palsy seen in Ramsay-Hunt syndrome (herpes zoster infection of the geniculate ganglion of the facial nerve).

**4.27** MR scan showing temporary enhancement (arrowed) in the facial nerve in a case of Ramsay-Hunt syndrome.



Bony exostosis: these are usually multiple hard bony overgrowths that appear deep in the ear canal and are common in those that swim regularly in cold water. They are thought to be secondary to periosteal inflammation induced by the cold water or otitis externa. Treatment is usually unnecessary (4.24).

### **VIRAL INFECTIONS** **BULLOUS MYRINGITIS**

Influenza and Coxsackie viruses have been implicated in this condition. It presents with a painful ear often accompanied

by reduced hearing. On otoscopy there is blistering of the ear canal or drum. It is usually a single blister and has a characteristic appearance. It may be accompanied by a middle ear effusion. The condition is self-limiting but is painful and topical steroid drops can be used to try to ease the discomfort (4.25).

### **HERPES ZOSTER**

A herpes zoster infection based on the geniculate ganglion of the facial nerve is given the eponym Ramsay-Hunt syndrome (4.26, 4.27). The patient presents with pain



followed within 24–28 hours by a facial palsy. There may be an associated sensorineural hearing loss and tinnitus. On examination, as well as a facial palsy, there will be vesicles evident in the external ear. The commonest site is the conchal bowl but the canal wall or drum can also be involved.

Treatment with antiherpetic medications, such as acyclovir, accompanied by a week's course of prednisolone (30–60 mg) to attempt to improve the prognosis of the facial palsy is often used, but there is no evidence to support their efficacy. If there is a discomfort from the vesicles and crusting in the ear canal this may be alleviated by using topical steroid and antibiotic drops.

## Infections of the middle ear

### VIRAL ACUTE OTITIS MEDIA

Viral acute otitis media is associated with an upper respiratory tract infection and is caused by the usual viruses that cause coryza, e.g. rhinoviruses, influenza viruses, parainfluenza viruses, and adenoviruses. It is usually self-limiting and any treatment required is analgesia. The tympanic membrane will be hyperaemic but otherwise normal.

### ACUTE OTITIS MEDIA

Classical otitis media is a pyogenic infection of the middle ear cleft. It is most common in childhood, particularly in the first 2 years of life. The first phase of an infection will start with a viral upper respiratory tract infection. At this stage there would be slight hyperaemia of the tympanic membrane with no middle ear effusion. Over the next 24–48 hours blockage of the eustachian tube is followed by a bacterial infection of the middle ear cleft. The bacteria migrate up the eustachian tube from the nasopharynx. The commonest infecting organisms are  $\beta$ -haemolytic streptococcus, *Streptococcus pneumoniae*, *Staphylococcus aureus*, *Moraxella catarrhalis*, and *Haemophilus influenzae*. By the time the bacterial pyogenic infection has become established the drum will appear red with a middle ear effusion and the yellowish appearance of pus visible through the drum. The pus will fill the middle ear and mastoid air cell system.

The classical presentation is therefore initially with the symptoms of a coryza which is followed by otalgia and a conductive hearing loss. There is an accompanying pyrexia,

but no otorrhoea. The otalgia may persist for a further 24–48 hours. If the infection resolves by bursting through the drum, there will be a sudden discharge of pus which is usually mixed with fresh blood and a decrease in the otalgia and the accompanying pyrexia. In young children, particularly those under 2, it can be easy to miss a diagnosis of acute otitis media. At this age children may not localize pain to the ear and just complain of ill defined ache or falsely localize the pain to the abdomen. It is therefore necessary to examine the ears of all pyrexial children to exclude the diagnosis.

Once a pyogenic infection of the middle ear space is established there are several possible outcomes:

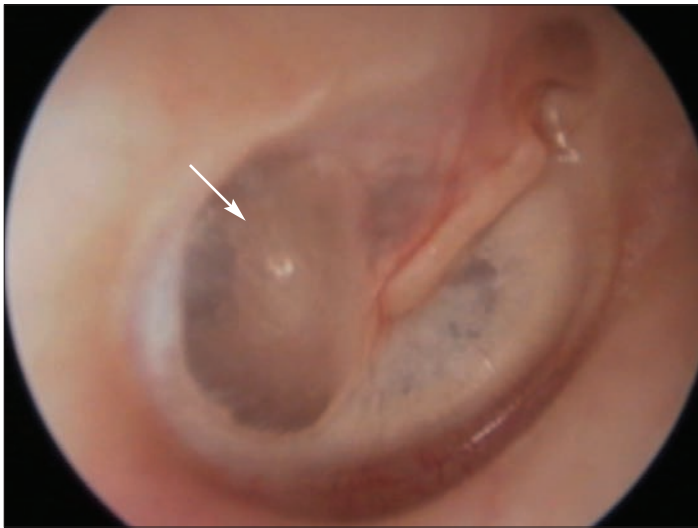- 1 The condition may resolve spontaneously (4.28).
- 2 Acute perforation. It is usually the posterior part of the tympanic membrane that thins and then bulges laterally before perforating. There is then a discharge of pus which is associated with bleeding from vessels on the surface of the drum. The bleeding can be more obvious than the pus. The commonest outcome is resolution of the infection with drying of the otorrhoea and healing of the tympanic membrane.
- 3 Persistent perforation (4.29). The majority of acute perforations will heal spontaneously as above, but a persisting perforation may persist particularly if the acute otitis media becomes a recurrent problem.
- 4 Glue ear or otitis media with effusion (OME) (4.30). The infection may resolve spontaneously, but if the eustachian tube remains blocked a sterile effusion will persist in the middle ear cleft. The inter-relationship between glue ear and acute otitis media is two-fold. Glue ear can occur as a result of an episode of acute otitis media and equally the presence of glue ear makes some children more prone to recurrent episodes of acute otitis media.
5. Recurrent episodes of acute otitis media. Treatment of acute otitis media in the primary care setting remains contentious. There are several large studies which indicate that the use of antibiotics is unwarranted and that the outcome of acute otitis media is not affected by prescribing oral antibiotics. The consensus view in primary care is that there is no need for antibiotics in the first 48 hours and children with a putative diagnosis of acute otitis media can be treated with analgesia alone. However, in order to include large numbers of subjects, these studies have had relatively lax entry criteria and may have inadvertently included a significant number of patients with viral acute otitis media rather than those

with a true pyogenic infection. This would tend to mask any benefit achieved by using antibiotics in bacterial cases. There therefore remains a case for use of oral antibiotics in acute otitis media of more than 48 hours duration, particularly if the patient is pyrexial.

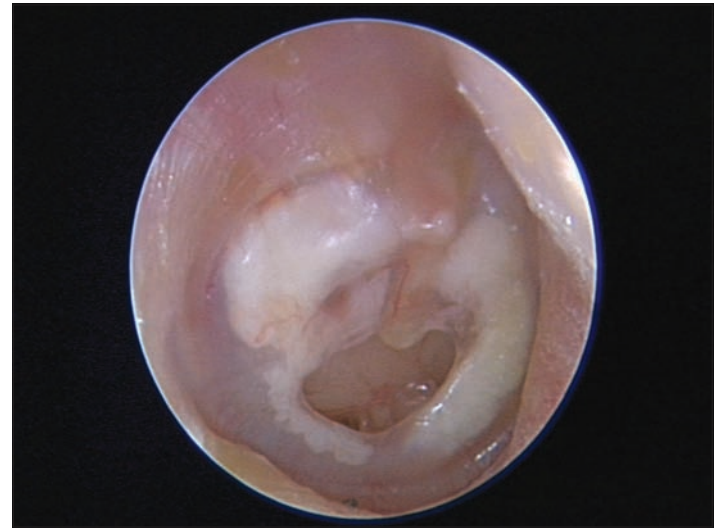
6 Acute mastoiditis. See below.

### ACUTE MASTOIDITIS

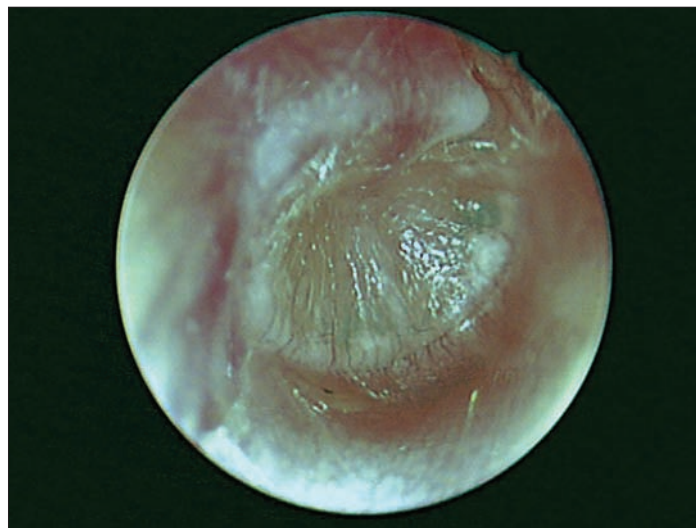Acute mastoiditis was one of the commonest causes of surgical intervention in children in the early twentieth century. The advent of antibiotics has greatly reduced the instance of this disease and it is now uncommon, but cases still occur and the condition has the risk of serious



**4.28** Site of perforation that has healed spontaneously (arrowed).



**4.29** Central perforation with areas of tympanosclerosis.



**4.30** Glue ear.

complications. In acute mastoiditis there is an osteitis, i.e. an infection of bone. In acute otitis media the middle ear cleft will contain pus but the surrounding bone is not infected. In acute mastoiditis the bone of the mastoid and middle ear is infected. Classically the osteitis will only develop 7–10 days after the onset of an acute pyogenic otitis media.

The symptoms and signs of acute otitis media will be compounded by increasing pain and a swinging pyrexia. Young children become increasingly lethargic and systemically unwell. The pus spreads through eroded areas of the cortical bone lateral to the mastoid cell system or through thrombosed mastoid emissary veins and then lies subcutaneously over the mastoid process behind the ear. Initially this will just cause erythema behind the ear, but progresses to form a red tender swelling behind the ear. The post-aural sulcus disappears and the pinna is pushed forwards (4.31–4.33). In early cases where there is just erythema behind the ear, there will be tenderness over the antrum of the mastoid. This lies deep to the triangular fossa of the pinna and pressure in the fossa will elicit the tenderness. On examination of the ear canal it is often difficult to see the drum as the posterior-superior segment of the ear canal is oedematous and the canal is narrowed. When the drum is seen it will be erythematous and pus may be visible in the middle ear. Acute mastoiditis has significant associated morbidity and potential mortality. The spreading osteitis leads to bone erosion and further spread of infection. Posterior spread into the sigmoid sinus causes a lateral sinus thrombosis and potential septicaemia. Superior spread through the tegmen or roof of the middle ear cleft into the middle cranial fossa results in meningitis or temporal lobe abscess (see 4.45).

If the infection is advanced to the extent that there is a swelling behind the pinna, pus is present and surgical drainage is necessary. At operation the subcutaneous pus is drained and the mastoid antrum is opened and also drained. Further exploration of the mastoid air cell system and the sigmoid sinus may be necessary (4.34). In earlier cases where there is just erythema and tenderness over the mastoid with no clinical or radiological evidence of intracranial infection, then it is reasonable to treat with intravenous antibiotics for the first 24 hours. If there is improvement then antibiotics may be continued and surgery may not be necessary. If there is no clinical improvement after 24 hours, cortical mastoidectomy is required. The

bacteria that cause acute mastoiditis are the same as those that cause acute otitis media, i.e. *Streptococcus pyogenes*, *S. pneumoniae*, *Staphylococcus aureus*, *Moraxella catarrhalis*, and *Haemophilus influenzae*.

### INFECTED PERFORATED TYMPANIC MEMBRANE

An ear with a tympanic membrane perforation is more prone to infection. The infection may come from externally as a result of swimming or showering, or it may spread up the eustachian tube as is seen in acute otitis media. The larger the perforation the more prone it will be to recurrent infections.

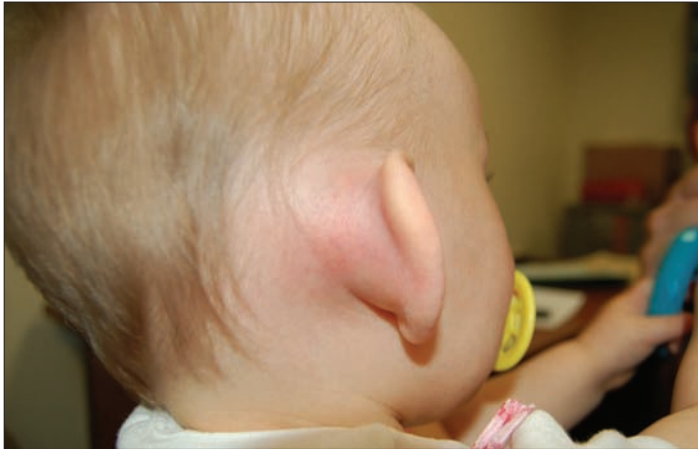An infected perforation may be slightly uncomfortable but pain is not usually a significant feature. There is no confined space and the otorrhoea will discharge through the perforation and the patient will complain of an unpleasant odour associated with the discharge. Hearing may feel slightly reduced (4.35). Swabs can be taken to identify the bacterial pathogen, but in long-standing cases mixed growth with coliforms and *Pseudomonas* species are common. More acute infections are caused by the usual upper respiratory tract commensals but are seen less frequently. Prompt resolution is usually achieved by use of topical broad-spectrum antibiotic drops or sprays. Additional use of oral antibiotics may be helpful in refractory cases. Recurrent infections can be treated by careful avoidance of the precipitating causes, i.e. by refraining from swimming or using well fitting ear plugs when doing so and keeping ears dry when showering or bathing. The best long-term solution to a recurrent infection is surgical repair of the perforation (tympanoplasty or myringoplasty).

### INFECTED GROMMETS OR VENTILATION TUBES

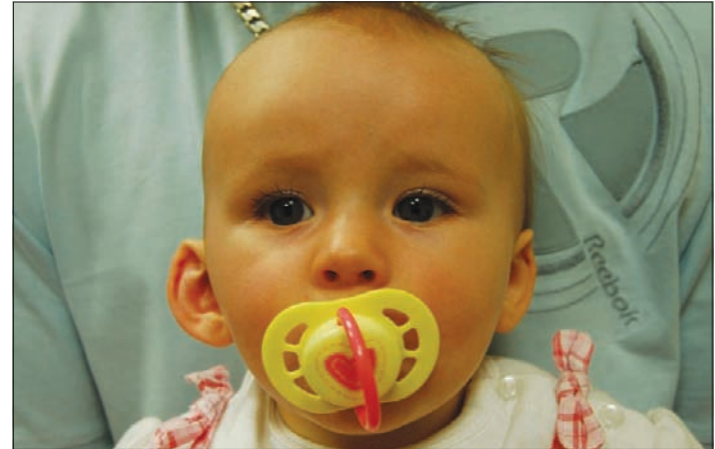Infections in the ears with ventilation tubes *in situ* are relatively common (4.36, 4.37). A patient with grommets *in situ* will present with slightly smelly discharge from the affected ear. Pain is not usually a significant feature but the hearing is usually reduced. The source of the infection may be external from dirty water or via the eustachian tube when it is associated with an upper respiratory tract infection. However, contrary to popular belief, there is no evidence that children that swim with grommets *in situ* are any more prone to infections than those who do not.

On examination the otorrhoea may make visualization of the grommet difficult. In an older child suction clearance will help, but most children tolerate this poorly. Swabs can

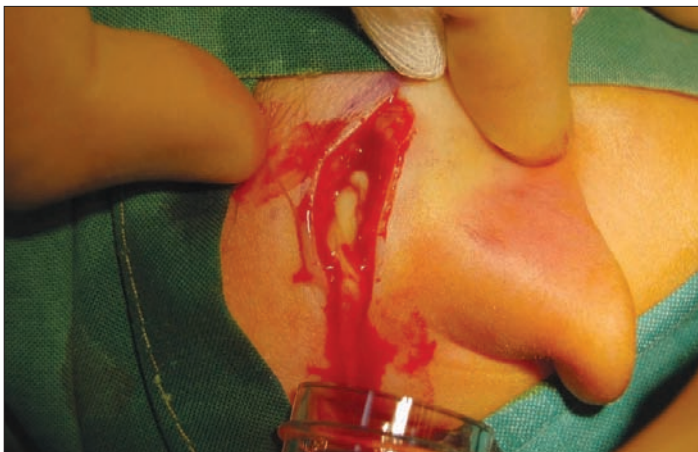



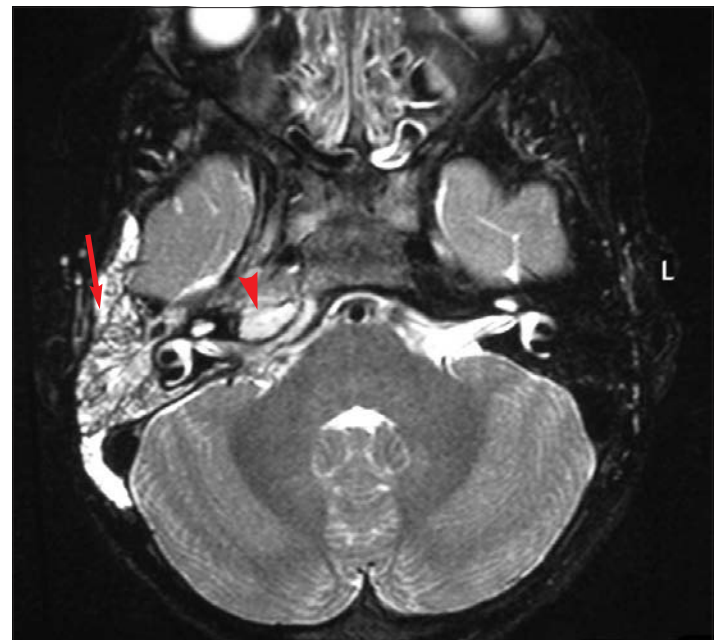
4.31 Acute mastoiditis: loss of the post-aural sulcus.



4.32 Acute mastoiditis: the right pinna is displaced forwards by post-aural swelling.

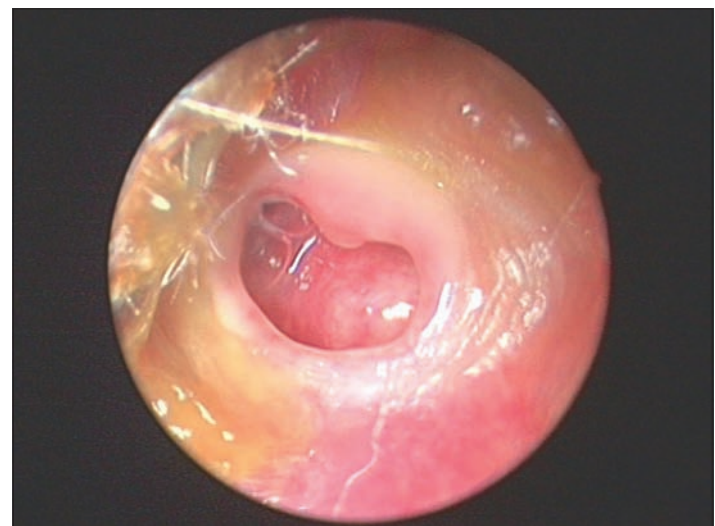

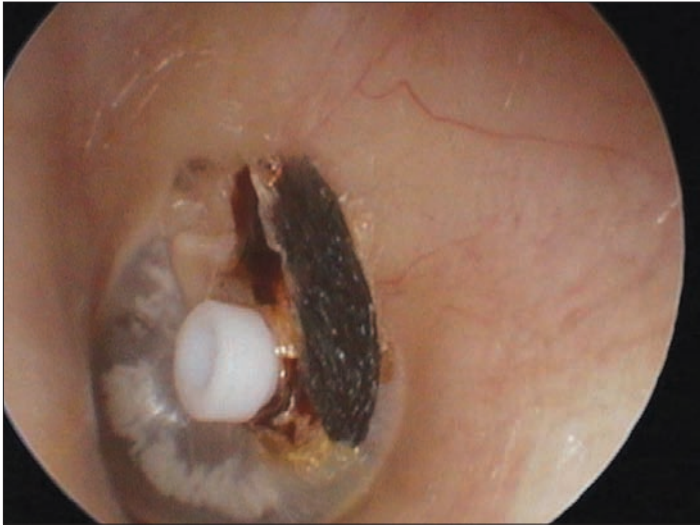
4.33 Acute mastoiditis: pus draining after an incision for cortical mastoidectomy.



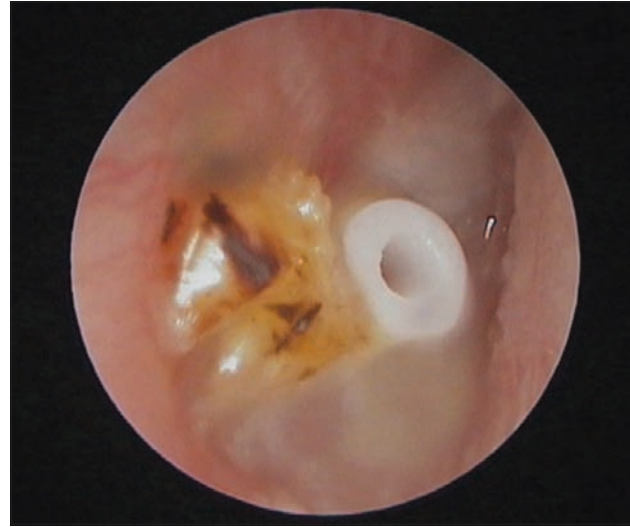
4.34 Acute mastoiditis: enhancement on MR scan in mastoid air cells (arrow) and petrous apex (arrowhead).

4.35 Infected central perforation with scanty otorrhoea.

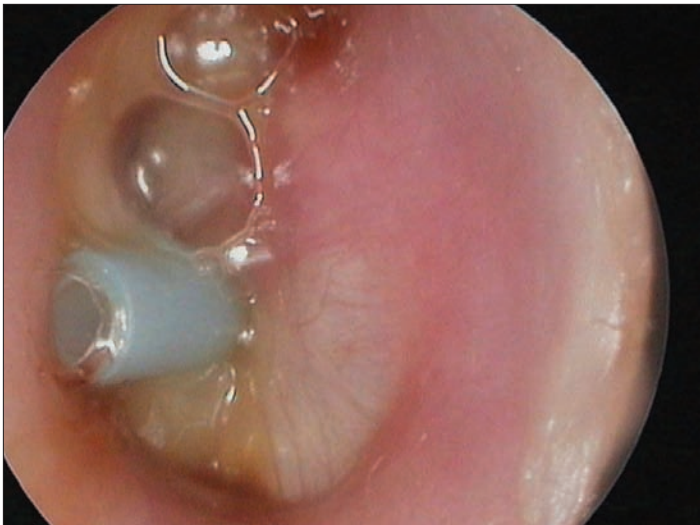



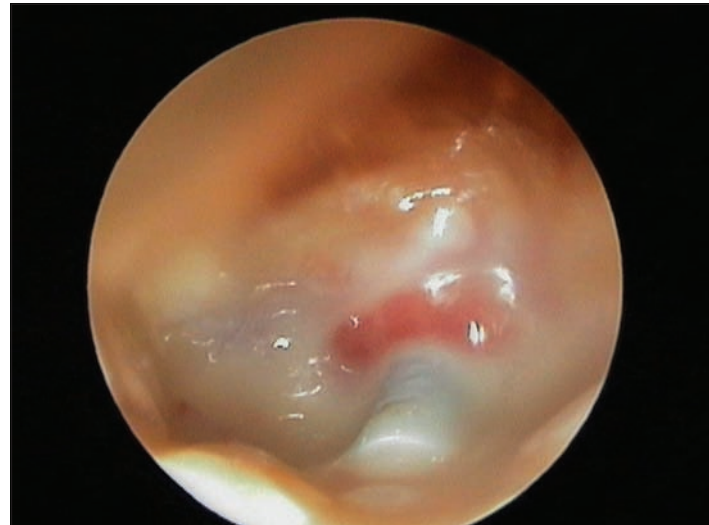
4.36 Dry uninfected grommet.



4.37 Infected grommet with scanty otorrhoea.



4.38 Infected long-term grommet with scanty otorrhoea.



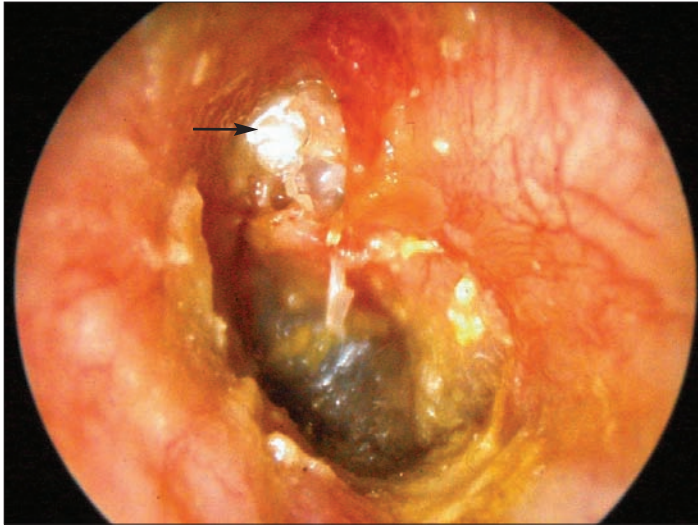
4.39 Infected long-term grommet with copious otorrhoea.

be taken to identify the bacterial pathogen but in most cases there is a mixed growth of coliforms and *Pseudomonas* species. The mainstay of treatment is topical antibiotic drops and sprays with a broad spectrum of activity. The addition of broad-spectrum oral antibiotics with antianaerobic activity may be necessary in refractory cases. Long-term grommets are more prone to infections than short-term grommets. When infections become recurrent or persistent removing the grommet usually solves the problem (4.38, 4.39).

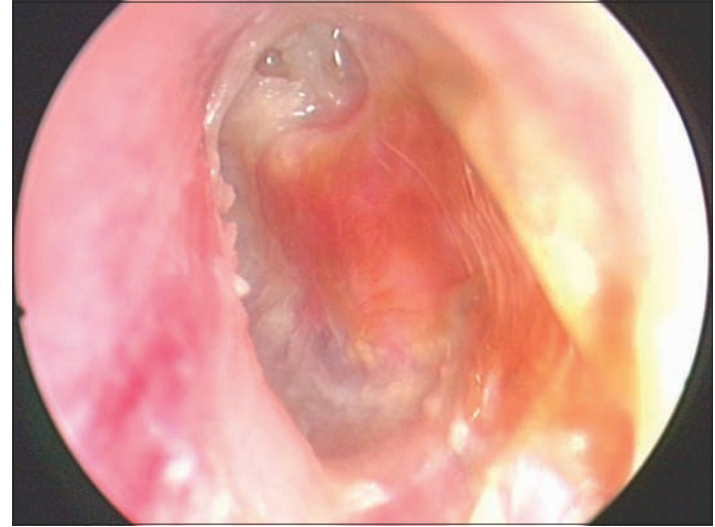
### CHOLESTEATOMA

Cholesteatoma is caused by the ingrowth of a pocket of squamous epithelium from the outer surface of the tympanic membrane into the middle ear cleft. The squamous epithelium of the outer surface of the tympanic membrane would normally migrate away from the drum. However, when a retraction pocket has been formed (usually in the pars flaccida or postero-superior segment of the pars tensa), the migratory nature of the squamous epithelium is not able to function. The epithelium then desquamates dead

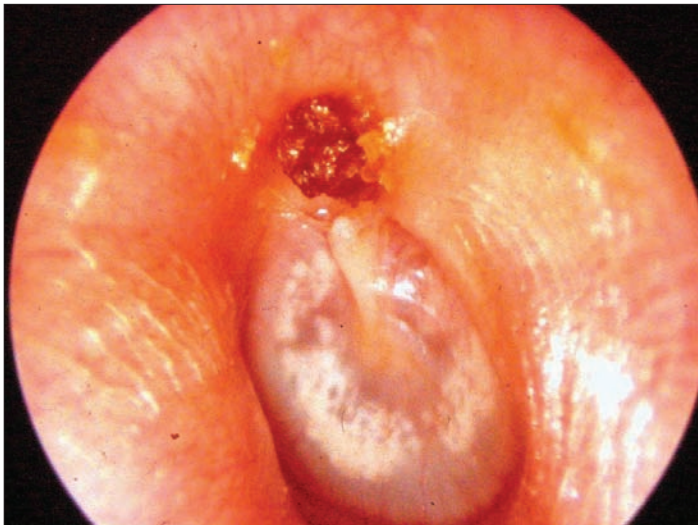



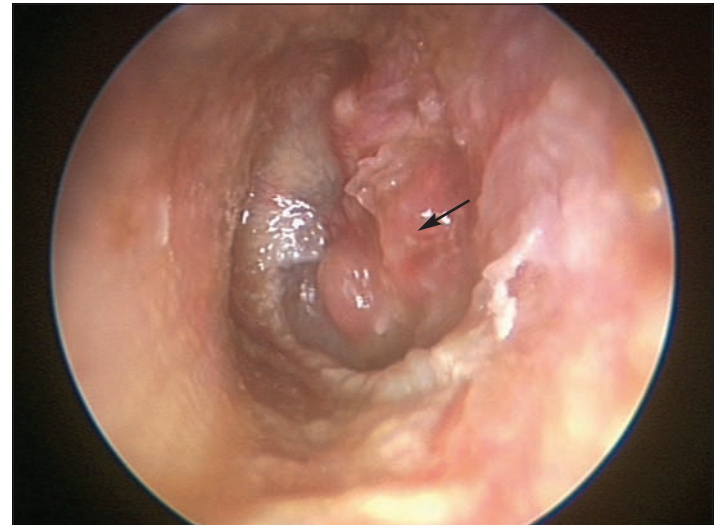
**4.40** Cholesteatoma: attic defect containing white keratin (arrowed), mildly infected.



**4.41** Cholesteatoma: attic defect with otorrhoea.



**4.42** Cholesteatoma: oxidised dry keratin collecting in an attic defect.



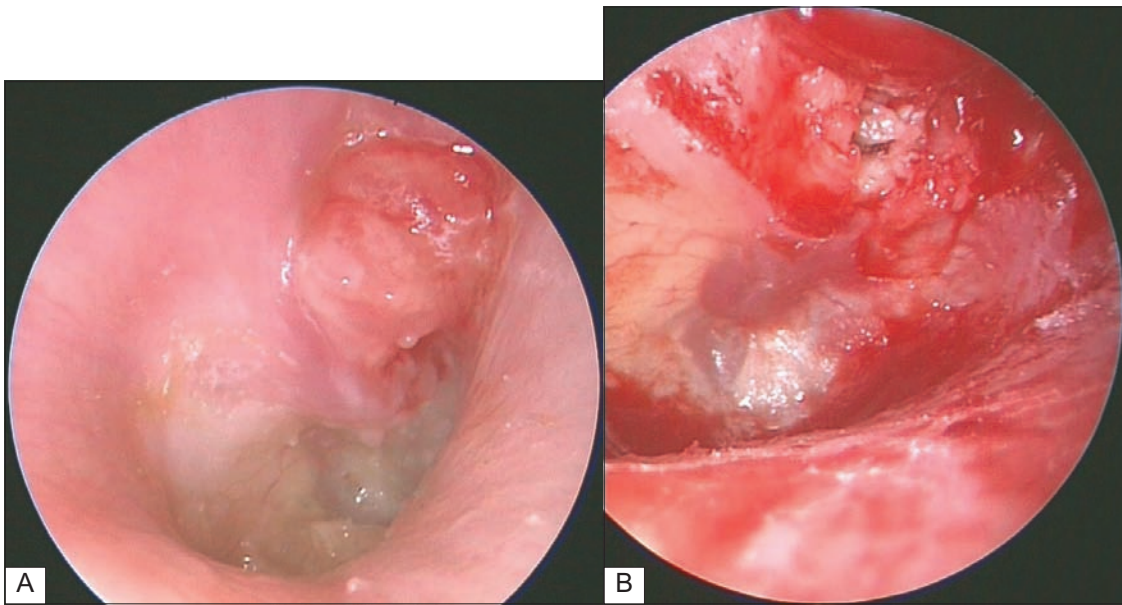
**4.43** Cholesteatoma: granulations (arrowed) in posterior-superior segment of the left tympanic membrane obscuring underlying an early cholesteatoma.

squamous cells and the retraction pocket fills with trapped desquamated cells and keratin. This pocket of dead skin constitutes a cholesteatoma. More dead epithelial cells are continually added and so the cholesteatoma enlarges. Proteolytic and osteolytic enzymes are released by the dying epithelial cells and this adds to the slow local destructive nature of the condition. As the lesion enlarges it causes further damage by local erosion, but this process accelerates when the lesion becomes secondarily infected.

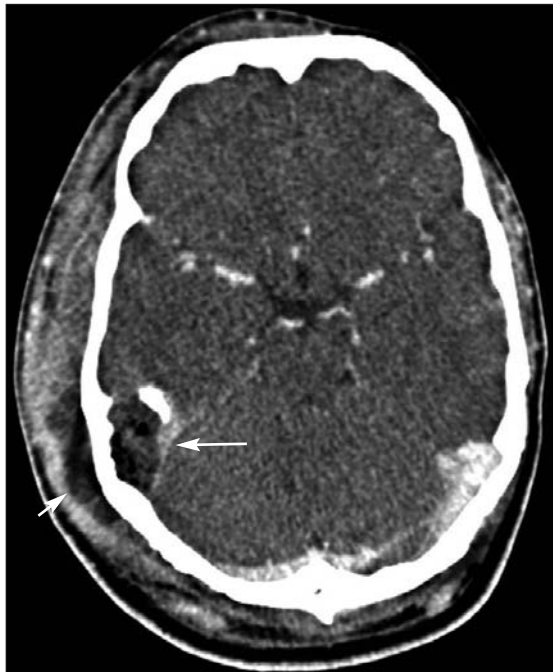On examination it may be possible to see the classical

appearances of cholesteatoma with white keratin collecting in a retraction pocket in the attic region or in the postero-superior part of the tympanic membrane (4.40, 4.41). Uninfected, dry keratin oxidises slowly forming a firm brown crust (4.42). Once infection is present the view is often obscured by otorrhoea and granulation or polyp formation (4.43, 4.44). Infected cholesteatomas are also associated with acute damage to the facial nerve causing a facial nerve palsy. Erosion of the roof of the middle ear allows intracranial complications such as temporal lobe

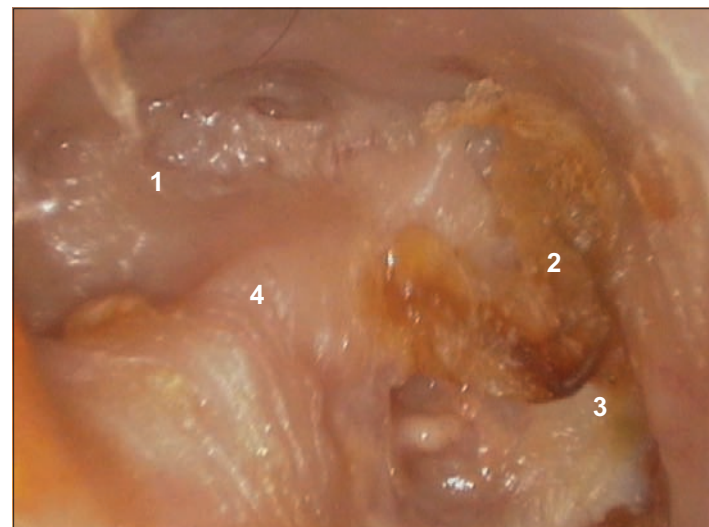




**4.44** (A) Cholesteatoma: granulations in the attic region of the tympanic membrane obscuring an underlying cholesteatoma. (B) The same ear immediately following surgical removal of the granulations revealing the underlying cholesteatoma.



**4.45** Axial CT showing intracranial collection of pus in the middle cranial fossa (long arrow) and corresponding collection extracranially (short arrow), secondary to acute mastoiditis with an underlying cholesteatoma.



**4.46** Dry healthy mastoid cavity showing: mastoid bowl (1), normal wax (2) on a reconstructed tympanic membrane (3), and facial ridge (4).

abscess and meningitis (4.45).

In a discharging ear when cholesteatoma is suspected, initial treatment is with topical broad-spectrum antibiotic and steroid containing drops. These agents may dry up the

otorrhoea and decrease the size of any granulations or polyps and make the cholesteatoma more evident. If an aural polyp persists or the attic region does not become clearly visible, then a formal examination under anaesthesia

is required to exclude the diagnosis of cholesteatoma. The definitive treatment for a cholesteatoma is surgical excision.

Once cholesteatoma has become infected there is a risk of developing a secondary mastoiditis with osteitis, which gives a clinical appearance very similar to that of acute mastoiditis. In this situation the patient will present a history of slow progressive hearing loss which is now accompanied by an offensive otorrhoea, pain, and post-aural swelling.

### INFECTED MASTOID CAVITY

Open cavity mastoid surgery is performed to remove cholesteatoma or chronic mucosal disease of the mastoid air cell system. The result is a variably sized cavity which is in continuity with the external ear canal. To the examiner's eye on otoscopy there is air filled space lying posteriorly and superiorly to the normal ear canal (4.46). In a well designed and maintained cavity there may be the occasional collection of wax but the cavity remains infection free. However, infections in a mastoid cavity are relatively common and common aetiologies include:

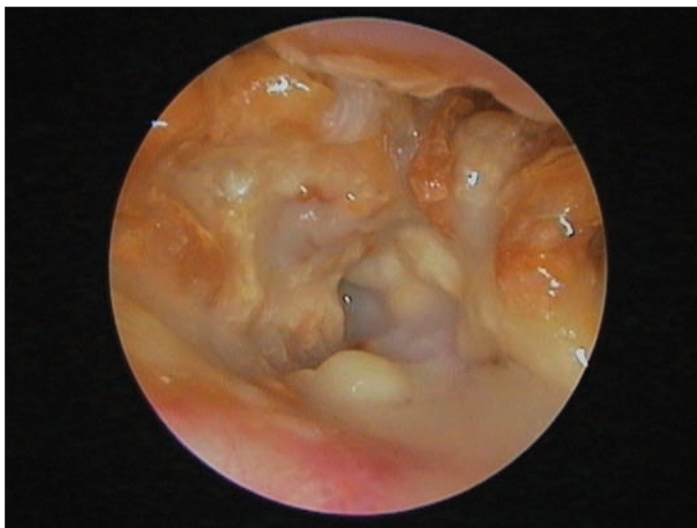- A build up of wax leading to an underlying infection (4.47).
- A poorly designed cavity with overhangs and ridges which prevent the normal function of the migratory epithelium (4.48).
- A narrow meatus which prevents adequate cleaning of the cavity or adequate ventilation.

These all cause infections that are analogous to an otitis externa, i.e. infections occur following irritation of the lining by cotton buds or other foreign bodies, or by the ingress of dirty water.

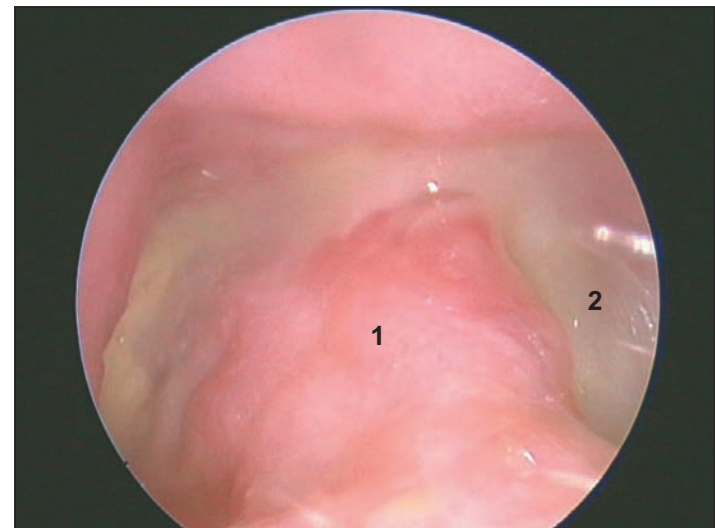
- A perforation in the tympanic membrane remnant or failure to close off the eustachian tube orifice at the time of the original surgery. This tends to lead to mastoid cavity infections when the patient develops an upper respiratory tract infection. The bacteria gain access to the mastoid cavity via the eustachian tube (4.49, 4.50).

Treatment is the same as that used to combat chronic otitis externa. The principles are:

- Suction clearance of all wax, debris, and infected material.
- Topical application of antibiotic and steroid medication in the forms of drops or sprays.
- More resistant cases may require the use of antibiotic and steroid creams or ointments applied either directly to the cavity or on wicks.
- In persistent or recurrent cases a revision mastoid surgery with redesigning or obliteration of the mastoid cavity or closure of defects in the tympanic remnant. A variety of techniques may be needed.

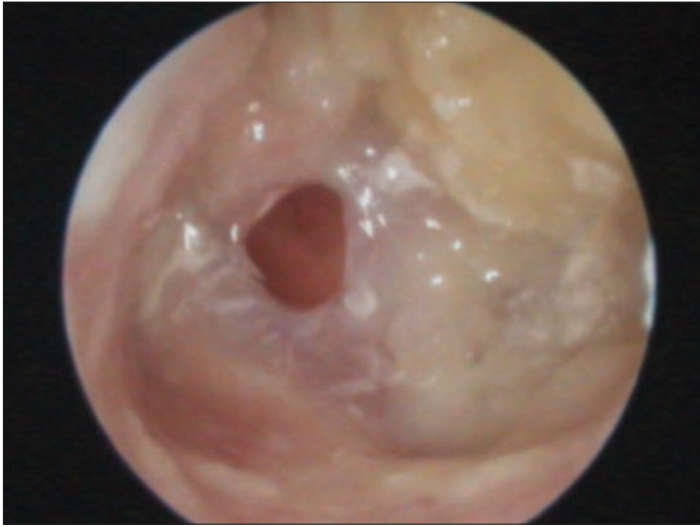


4.47 Infected mastoid cavity full of wax and debris.

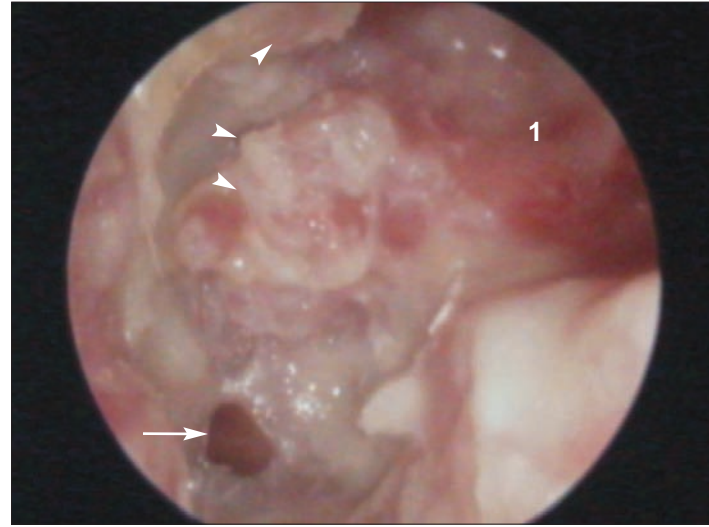


4.48 High facial ridge (1) in a mastoid cavity limiting access to, and ventilation of, the mastoid segment (2).

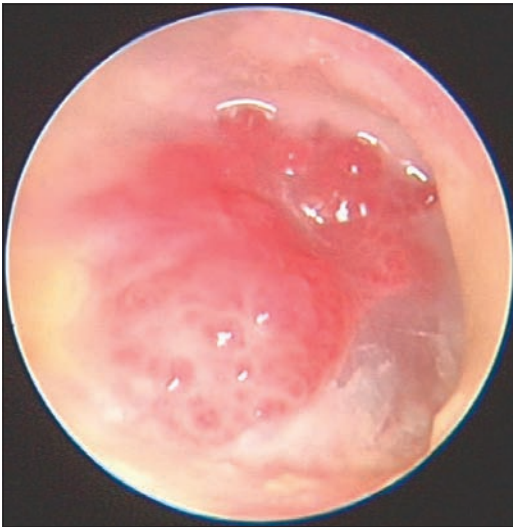



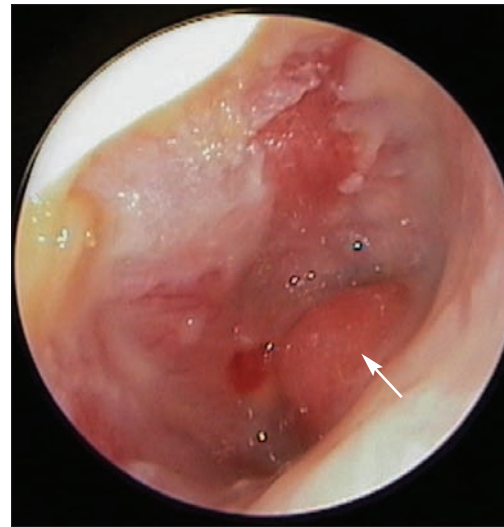
**4.49** Infected perforation in the tympanic remnant of a mastoid cavity.



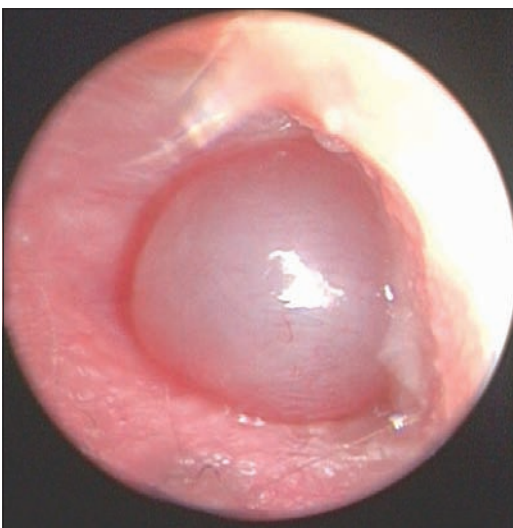**4.50** Infected mastoid cavity (1) after suction clearance showing perforation (arrow) and irregular bony contours (arrowheads). Both features contribute to a tendency to recurrent infection.



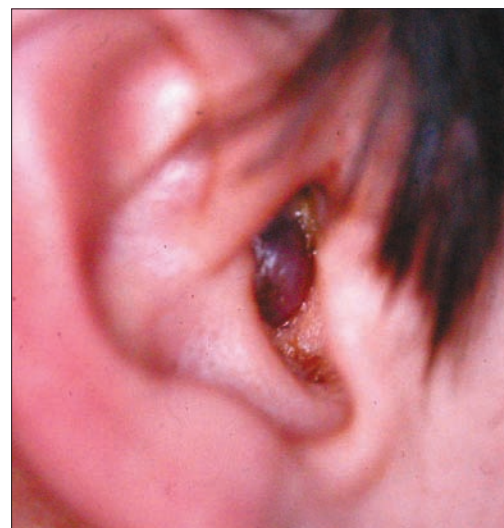**4.51** Granulations in the posterior aspect on the right tympanic membrane.



**4.52** Aural polyp (arrowed) in antero-inferior segment of the tympanic membrane associated with an underlying infected perforation.



**4.53** Large aural polyp filling the external auditory meatus secondary to an infected central perforation.



**4.54** Large aural polyp filling the external auditory meatus secondary to cholesteatoma.



### AURAL POLYP

An aural polyp results when there is a chronic infection of the ear which results in an area of osteitis or infected bone. Polyps are essentially localized areas of granulation tissue (4.51). They may be small or fill the ear canal (4.52–4.54). The most common cause of an aural polyp is an underlying cholesteatoma, but they are also seen protruding through central tympanic membrane perforations and occasionally with chronic otitis externa.

Small polyps may respond to topical treatment with antibiotic and steroid creams or drops or sprays. These are used for 7–14 days; on review of the patient it is then necessary to establish whether there is an underlying perforation or cholesteatoma. If the polyps persist and the drum is not fully visible or if the polyp is large on presentation, an aural polypectomy and examination of the underlying tympanic membrane under general anaesthesia will be necessary.

### OTOTOXICITY

Topical antibiotics are very useful in the treatment of middle ear infections. However, the common antibiotics used, such as gentamicin and neomycin, have the potential to be ototoxic. Ototoxicity can take the form of sensorineural hearing loss or vestibular toxicity. There is no perceived risk to patients with an intact tympanic membrane, but when the middle ear is open, i.e. perforations, ventilations tubes, cholesteatoma, or mastoid cavities there is a theoretical risk of ototoxic antibiotics getting into the middle ear cleft. Once in the middle ear, it is possible that they could soak through the oval or round windows and into the labyrinth and hence cause sensorineural hearing loss or vestibular loss. In practice there are case reports of sensorineural hearing loss associated with gentamicin. The risk appears to be greater with long-term use of these agents and particularly if they are being used when there is no evidence of infection being present. The thickened middle ear mucosa that is found in infected ears is probably protective and less permeable to the ototoxic agents than normal thin middle ear mucosa. Gentamicin-based drops are very effective, particularly against the commonly found *Pseudomonas* infections. Most of the alternative preparations are less effective against *Pseudomonas* except for ciprofloxacin-based drops, but as yet these are not licensed for otological use in the UK.

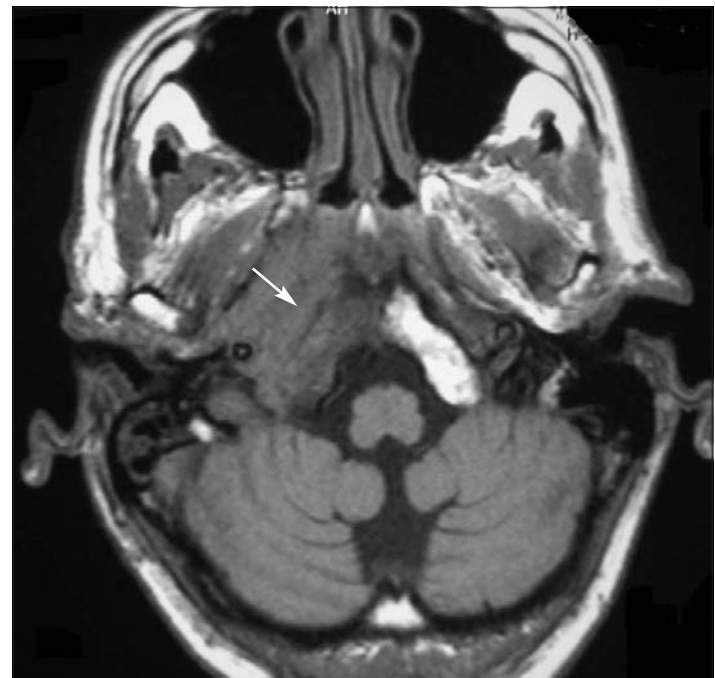
Persisting middle ear infections are ototoxic in their own right and long-standing infections will release toxins which have a significant risk of sensorineural hearing loss. The risk of ototoxicity from an infective otitis is thought to be higher

than the risk of ototoxicity from the judicious use of gentamicin-containing antibiotic drops. It is for this reason the British Association of Otolaryngologists, Head and Neck Surgeons in the UK gives the following advice on the use of topical agents in the presence of an open middle ear: ‘Topical medication should be used for a maximum of 2 weeks and treatment should cease earlier if infection settles’.

### Infections of the inner ear

#### OSTEOMYELITIS OF THE SKULL BASE

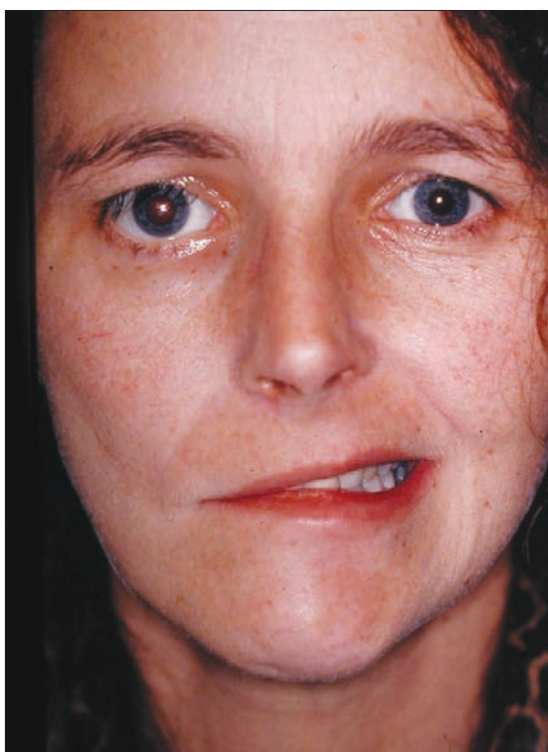Osteomyelitis of the skull base is alternatively known as malignant otitis externa. This is a reflection of the relentless destructive nature of this infection but it is an infective rather than a neoplastic process. It is caused by a *Pseudomonas aeruginosa* infection of the skull base. This may start in the ear canal, mastoid, or middle ear. Once the osteitis is established the infection spreads across the skull base (4.55). Clinically, the patient is usually elderly, diabetic, or otherwise immunocompromised. In the early stages the symptoms will be of discomfort or pain and possible otorrhoea. On examination, granulations may be evident in the ear canal or in the middle ear segment. As the infection spreads into the temporal bone, facial nerve palsies



4.55 Enhancement on MR scan seen in pseudomonal osteitis of the skull base (arrowed).

are common and may be the mode of presentation. Infections spreading through into the labyrinth will be associated with sensorineural hearing loss and vertigo. Infection then spreads medially towards the petrous apex and jugular bulb where it can cause ninth, tenth, and eleventh nerve palsies, or more posteriorly where it causes twelfth nerve palsy.

Diagnosis can be difficult as it is sometimes difficult to distinguish between the infective process and a malignant destruction of the skull base. Biopsies of the granulations will show an inflammatory process. There will be systemic markers of an infective process and *Pseudomonas* is usually grown from culture of the otorrhoea. MR scanning will show a destructive enhancing lesion and CT will show demineralization of the skull base. Prompt aggressive treatment is required as this condition is associated with a high mortality as well as morbidity. Long-term antibiotic treatment with antipseudomonal agents such as ciprofloxacin is required.



4.56 Right sided Bell's palsy.

### PYOGENIC INFECTION OF THE INNER EAR

This can occur secondary to an erosive process such as cholesteatoma. The otic capsule of the inner ear is made of very dense bone and is resistant to erosion, but once erosion has occurred (usually in the region of the lateral semicircular canal or oval window), an acute inflammatory reaction takes place within the inner ear. This is associated with sensorineural hearing loss accompanied by acute vertigo, nausea, and vomiting.

### BELL'S PALSY

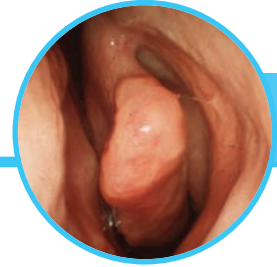
The aetiology of this condition is still debated, but acute oedema of the facial nerve with constriction in the region of the geniculate ganglion where the facial nerve canal is at its most narrow is the mechanism of injury. Viral infections, particularly those caused by herpes simplex, have been implicated most frequently. A classic history is of a slight discomfort in the region of the ear followed by an acute onset of a complete facial palsy which usually comes on overnight (4.56). Clinically complete resolution occurs spontaneously in 98% of the cases and some improvement is usually evident in the first 6 weeks after onset.

Treatment with the use of high-dose steroids to reduce the oedema in the canal has long been advocated and recent studies have demonstrated benefit, but there is no good evidence to prove that the use of antitherpetic medication improves the outcome.

### VESTIBULAR NEURONITIS OR LABYRINTHITIS

The exact aetiology of this condition is debated but a viral aetiology is suspected.

The classic history is of a patient who develops an acute rotatory vertigo that is associated with severe nausea and vomiting that persists for up to 1 week. A history of preceding upper respiratory tract infection is usually present. There is then usually a steady resolution of symptoms, although more minor recurrent attacks may occur which become gradually less severe and less frequent. This condition is self-limiting and apart from symptomatic support with labyrinthine sedatives no treatment is necessary.



# Infections of the nose and paranasal sinuses

*Wolfgang Issing and Andreas Leunig*

## Introduction

Infections of the nasal cavity and the paranasal sinuses present with similar symptoms. A comprehensive history and examination, including nasendoscopy, is necessary to arrive at a differential diagnosis. Viral infections are ubiquitous. Despite a similar spectrum of bacterial infective organisms, there is geographical variation to antibiotic sensitivity and some infections (rhinoscleroma, fungal rhinosinusitis) are endemic.

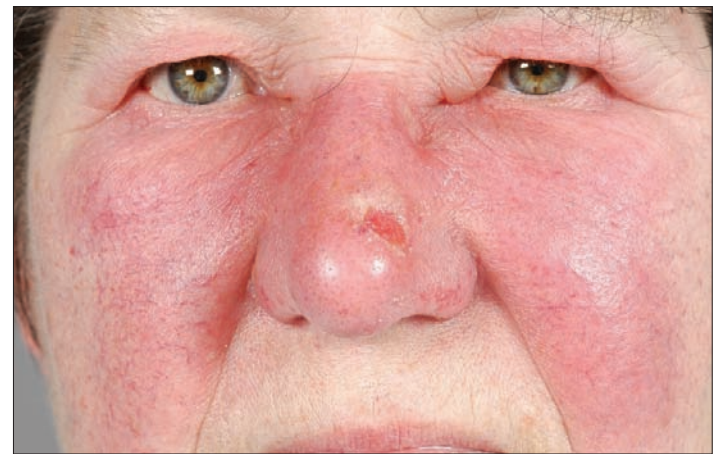## Infections of the external nose

### ERYSIPELAS

This is a cellulitic infection of the skin of the face. There is an erythematous area of skin with well demarcated edges (5.1). It is caused by a streptococcal (group A) infection, which usually starts in a small laceration of the skin. The laceration may not be visible but often starts in the nasal vestibule or outer ear canal, i.e. is secondary to a vestibulitis or otitis externa. The disease is associated with pain and high temperature. In rare cases blisters and necrotic areas can appear. The first-line treatment is intravenous penicillin.

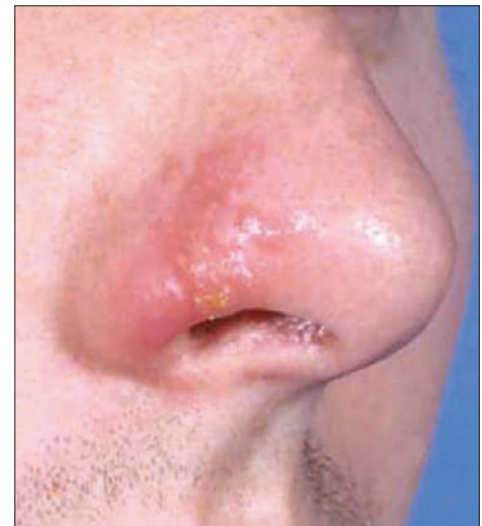### HERPES SIMPLEX

This infection is caused by herpes simplex virus 1. Following a primary infection, recurrent infections can occur after activation of the dormant virus. Sun exposure and stress are common triggers. The typical lesions are found around the lips and the nose. The first symptoms are paraesthesia and a burning sensation. Later, small blisters develop which burst and leave the typical crusted, herpetic lesion (5.2). The herpes simplex infection disappears without scarring after a couple of days. There is no evidence



5.1 Erysipelas with lesions on the nasal dorsum.

5.2 Herpes simplex of the right nasal ala.

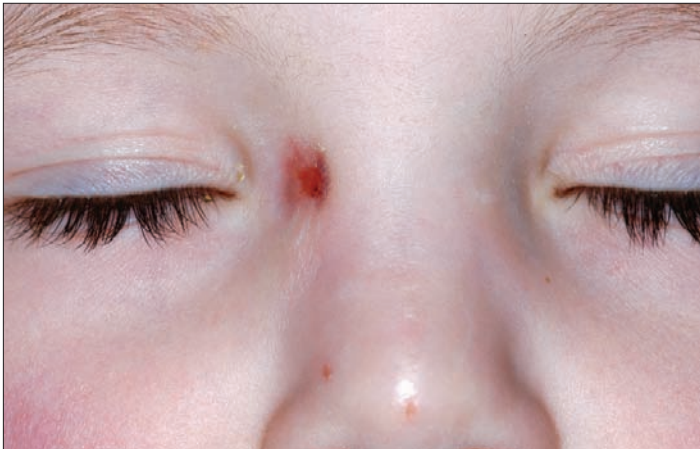

to support the use of topical antiviral agents, but in severe cases, especially in immunocompromised patients, systemic antivirals (acyclovir and famciclovir) may reduce the duration of symptoms if taken early in an attack. Prevention is possible in the presence of clear-cut triggers.



### FISTULA OF THE NASAL DORSUM

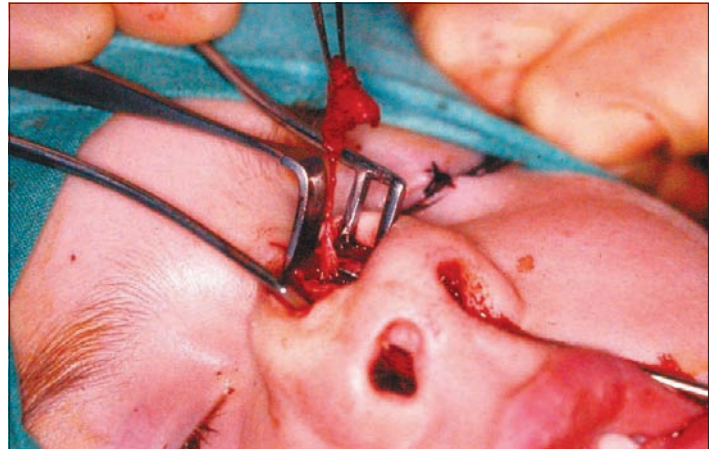
Rarely, incomplete separation of the superficial ectoderm from the neuroectoderm during the embryological development results in the development of a dermoid or a fistula of the nasal dorsum (5.3). The fistula comprises a duct of squamous cell epithelium and can extend from the glabella to the tip of the nose. In rare cases there can be an extension intracranially. Intermittent secretions from the opening of the fistula can occur and secondary infections are common. A complete excision of the fistula and the duct is the therapy of choice in order to avoid recurrence (5.4).



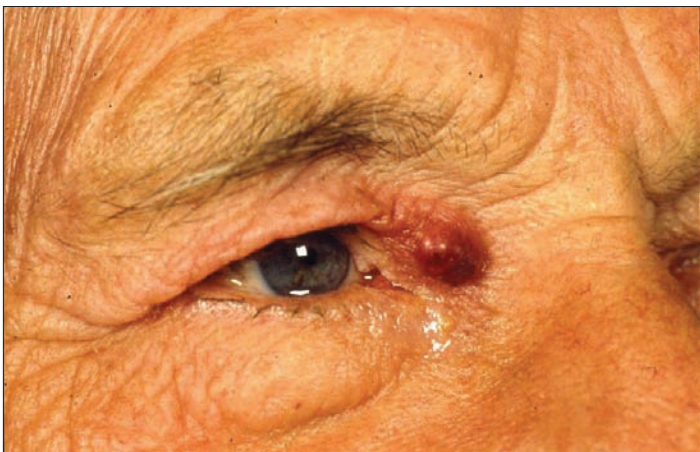5.3 Congenital fistula of the nasal dorsum.

### FOREIGN BODIES

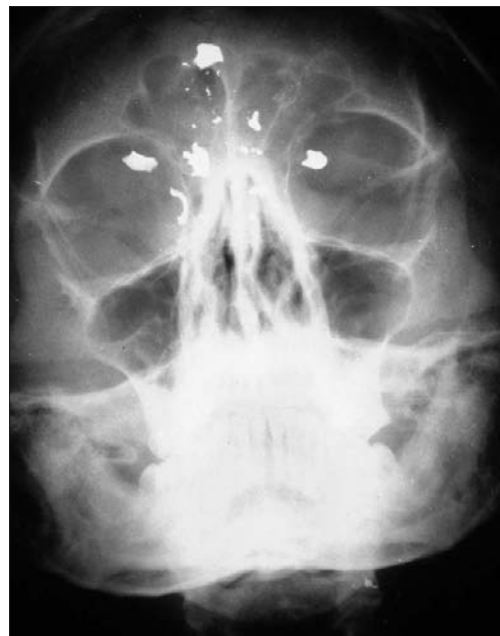Foreign bodies (e.g. shrapnel) which are implanted in the soft tissue of the external nose and face due to trauma or explosions can migrate, even decades after the original injury and cause fistulas (5.5, 5.6). Treatment is the complete removal of the foreign body. Piercings and studs around the nasal vestibule can be the focus of a *Staphylococcus aureus* infection or a localized cellulitis (streptococcal). Removal of the foreign body and appropriate antibiotic therapy is required.



5.4 Excision of a nasal dorsal fistula.



5.5 Infected shrapnel close to the medial canthus.



5.6 Plain X-ray showing multiple pieces of embedded shrapnel.

## Infections of the nasal cavity

### VESTIBULITIS

Infections of the nasal vestibule are usually caused by *Staphylococcus aureus*. In children, digital trauma leads to a chronic inflammation of the vestibule which becomes secondarily infected. Recurrent epistaxis is common and topical antiseptic creams will often eradicate the bacterial overgrowth and allow resolution of the vestibulitis and the recurrent epistaxis. In adults, infection in the hair follicles of the nasal vestibule causes a folliculitis (5.7).

### VIRAL PAPILLOMA

The human papilloma viruses cause warts or benign epithelial proliferations both on the skin of the nose and on the mucosal surfaces around the nasal vestibule. Inside the nose the proliferations are much more filliform and treatment is surgical removal as topical agents and cryotherapy are difficult to administer in this region (5.8).

### SEPTAL HAEMATOMA AND SEPTAL ABSCESS

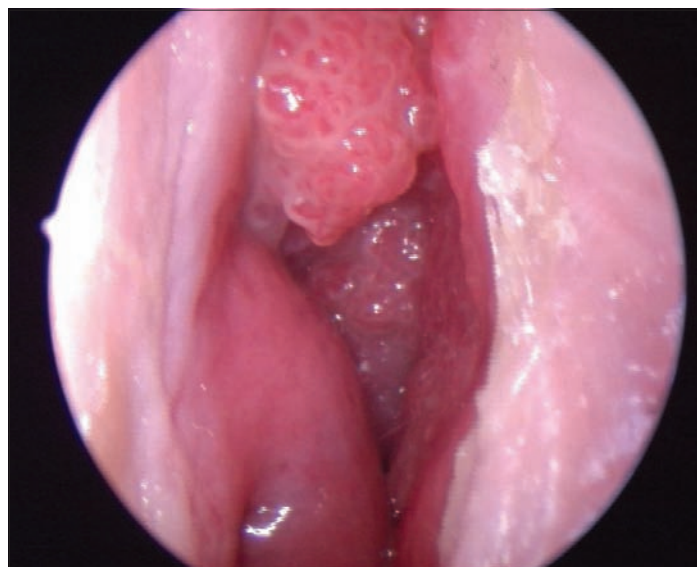
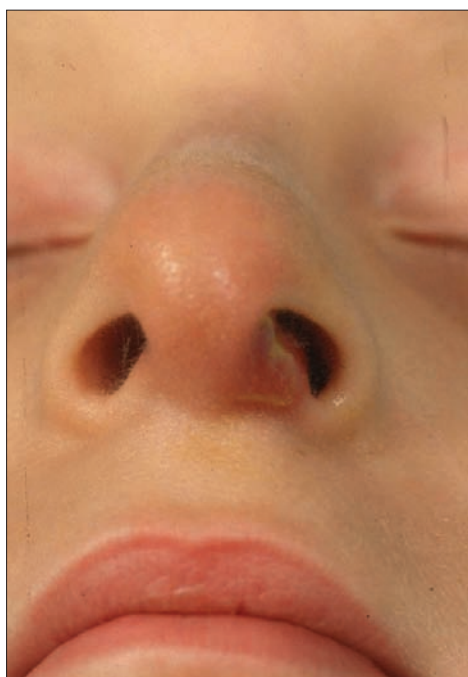Trauma to the cartilaginous part of the nose can lead to a septal haematoma. A direct blow on the nasal tip is the commonest mechanism of injury, and there may or may not be an associated nasal fracture. The haematoma detaches septal perichondrium from the septal cartilage. If this occurs bilaterally the septal cartilage becomes detached from its

blood supply, which comes via the perichondrium, and undergoes necrosis. Septal haematoma is a less common result of nasal trauma than a fractured nose. It can occur with relatively minor injuries, particularly in children, where an associated fracture is unusual. In adults an associated nasal fracture is more common and it can also occur as an early complication following septal surgery.

Haematomas will therefore present with a history of nasal obstruction following on from an episode of trauma. Anterior rhinoscopy reveals obliteration of the nasal cavity bilaterally by a soft swelling arising from the septum. They need early surgical drainage as left untreated the haematoma becomes secondarily infected and by 7 days the haematoma has become a septal abscess.

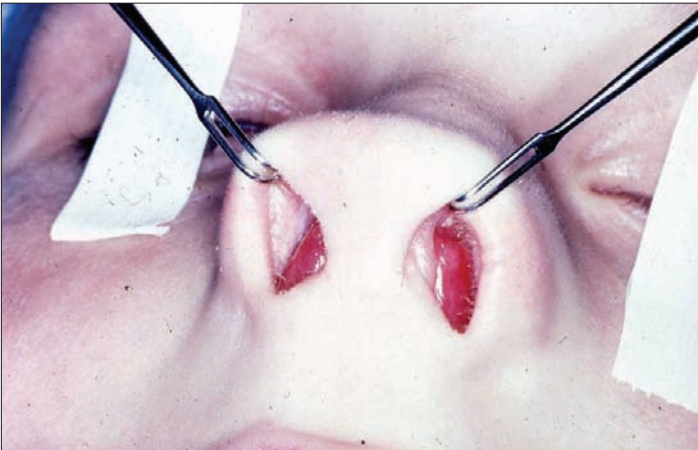A septal abscess will present 5 or more days after the trauma and the patient will have developed toxæmia, pyrexia, and increasing pain (5.9). Acutely, this condition has a significant associated morbidity with cavernous sinus thrombosis, orbital cellulitis, and meningitis all described as possible complications. Prompt surgical drainage is required but by this stage there is always a loss of septal cartilage, leading to a septal perforation (5.10). If this is excessive, or if it occurs in a child, this will often lead to a saddle nose deformity in the long term (5.11).

5.7 Folliculitis of the nasal vestibule.

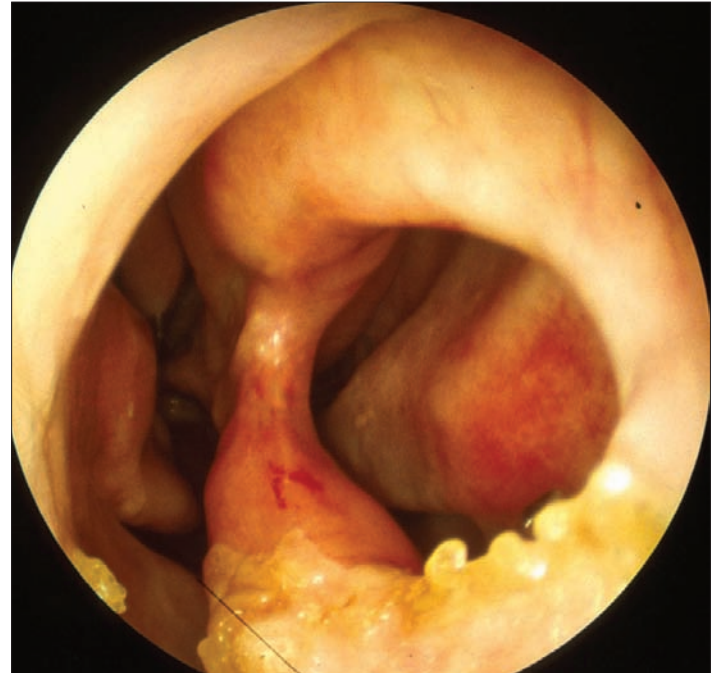


5.8 Viral papillomatosis of the nasal cavity.



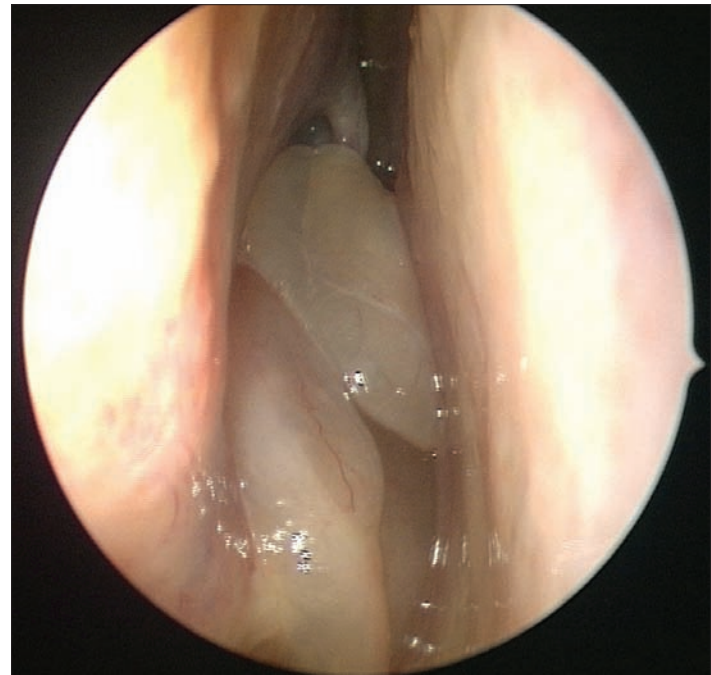
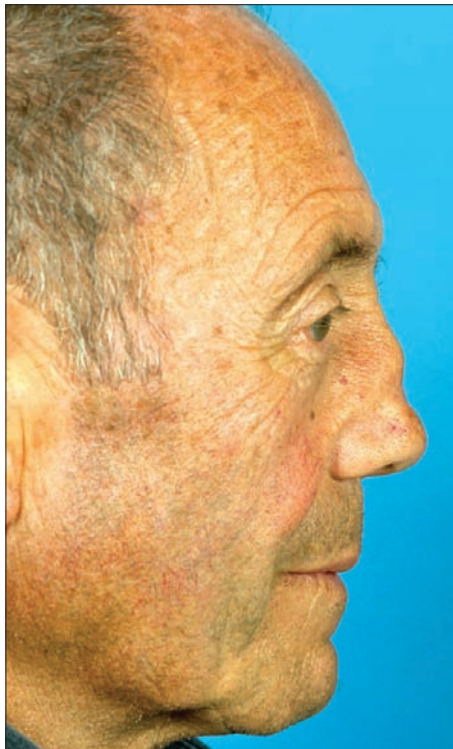

5.9 Septal abscess showing the collection bulging into both nasal cavities.



5.10 Nasal septal perforation following a septal abscess.

5.11 Saddle nose following a septal abscess.



5.12 Endoscopic view of right nasal polyposis.



### NASAL POLYPOSIS

The origin of this disease is still unknown. Infection is not normally thought to be part of the aetiology in the majority of cases, but patients with nasal polyps are more prone to problems with chronic infective rhino-sinusitis (see below). In addition, some patients with chronic sinusitis can develop an inflammatory hyperplasia of the nasal mucosa. This leads to the development of localized nasal polyps, which will originate in the area of the uncinate process and the middle meatus (5.12). Simple inflammatory nasal polyps present with nasal obstruction and hyposmia as the main symptoms, with little accompanying pain. Treatment is predominantly surgical although steroids used both topically or systemically may have a role. Polyps associated with underlying infected chronic sinusitis are more likely to have associated sinus pain.

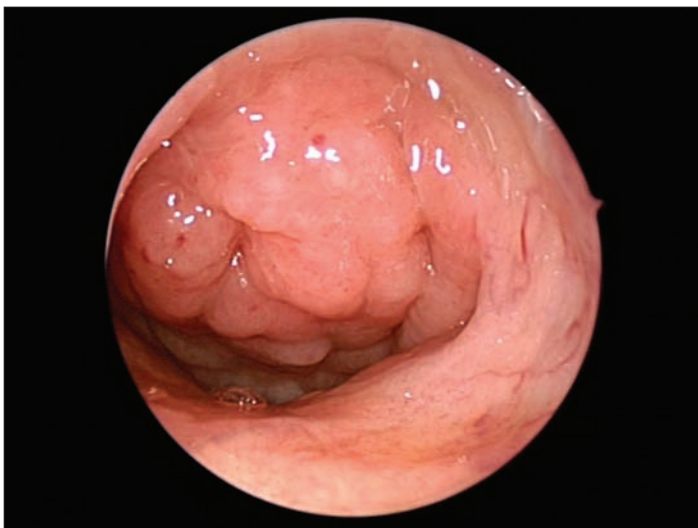### NASAL FOREIGN BODIES

Children between 2 and 4 years of age have a tendency to insert foreign bodies into their noses. Round objects such as plastic beads are common and tend to become stuck just anterior to the inferior turbinate, where they are visible and cause nasal obstruction. Foreign bodies such as sponge,

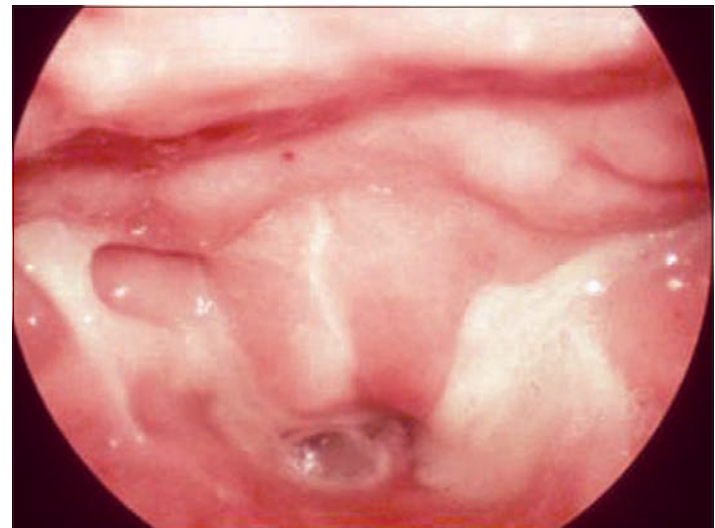
paper, and vegetable matter become secondarily infected after 24–48 hours and the child will present with a foul smelling unilateral nasal discharge. The foreign body may not be visible, so all children presenting with a unilateral foul smelling nasal discharge need an examination under anaesthesia to exclude the presence of a foreign body.

### ADENOIDITIS

In childhood, upper respiratory tract infections are often accompanied by local infection of the adenoid tissue. This will be initially viral but there may be a secondary bacterial infection (see below). Adenoiditis will often coexist with tonsillitis. Adenoid tissue is at its most prominent between the ages of 3 and 7 years (5.13). Hyperplasia of the tissue will lead to increased nasal obstruction, hyponasal voice, rhinorrhoea (5.14), and snoring. The local inflammation reduces eustachian tube function and makes the child more prone to otitis media with effusion or 'glue ear'. Treatment is essentially that of an upper respiratory tract infection in the acute phase and adenoidectomy with or without grommet insertion or tonsillectomy in recurrent cases.



5.13 Endoscopic view of adenoidal hypertrophy causing choanal obstruction.



5.14 Infected adenoids with mucopus on the surface.

## Infections of the paranasal sinuses

### RHINITIS, SINUSITIS, AND RHINOSINUSITIS

These are the most common infections of the nasal cavity and paranasal sinuses. The term rhinitis implies an infection predominantly in the nasal mucosa. Sinusitis predominantly affects the sinus mucosa but in reality most infective conditions affect both areas and are best described as rhinosinusitis. A distinction is made between acute and chronic sinusitis. The acute form can last up to 2 weeks but is frequently recurrent in nature. Chronic rhinosinusitis implies persistence of the inflammation and symptoms for 12 weeks or longer.

### VIRAL RHINOSINUSITIS

Viral rhinosinusitis or coryza is the common cold. It is caused by rhinoviruses (there are up to 100 different subtypes) in 50%, coronaviruses 20%, influenza, parainfluenza, respiratory syncytial virus, adenoviruses and enteroviruses. Spread is by aerosol droplets and contact. There are four stages of infection:

- 1 Prodrome: dry, hot sensation. 2–4 hours.
- 2 Irritation: dry, sore throat with sneezing and watery rhinorrhoea. Mild toxæmia. 48 hours.
- 3 Venous stasis: bluish tinge to mucosa. Rhinorrhoea become thicker, secondarily infected and discoloured (5.15). 2–5 days.
- 4 Resolution: 5–10 days.

Treatment is supportive. Anti-inflammatory and decongestant medication may ameliorate symptoms. Antibiotics are not indicated.

### ACUTE AND CHRONIC BACTERIAL RHINOSINUSITIS

The tendency to suffer from rhinosinusitis is increased by a variety of anatomical and physiological abnormalities. The sinuses are normally kept infection free by continuous movement of a mucus blanket over the respiratory epithelium of the sinuses, through the sinus ostia, and into the nasal cavity. Therefore, any factor that interrupts this process increases the chances of infection.

The following anatomical features have all been implicated in sinus disease, but their relative importance is the subject of debate: septal deviation (1.11), bulla ethmoidalis (1.12), concha bullosa (5.16), a prominent uncinatè process, and a narrow frontal recess. Nasal polyps and other nasal disease processes may also block the sinus

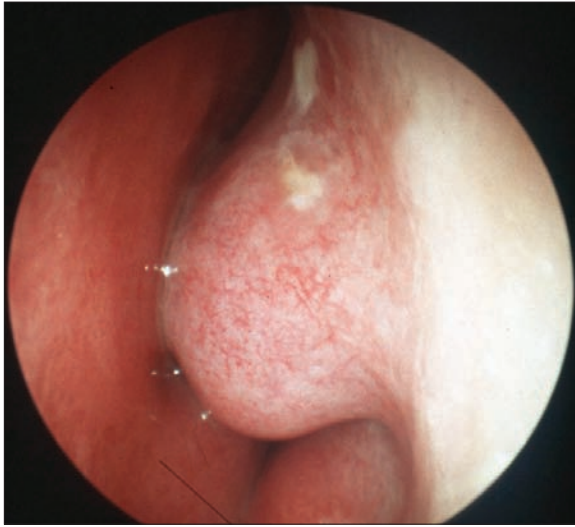
ostia. Conditions which affect the mucociliary transport mechanism such as allergic rhinitis, nasal polyposis, cystic fibrosis, primary ciliary dyskinesia, and Kartagener's or Young's syndromes will also be detrimental. Failure of the mucociliary clearance from the sinuses through the ostia leads to stasis and the formation of pus in the sinus.

In about 60% of cases, an acute bacterial rhinosinusitis is caused by *Streptococcus pneumoniae* and *Haemophilus influenzae*. The rest are caused by *Streptococcus* group A, *Streptococcus milleri*, *Staphylococcus aureus*, *Neisseria* spp., gram-negative bacilli, *Klebsiella* sp., *Moraxella catarrhalis*, and *Pseudomonas* sp. Anaerobic pathogens such as *Peptostreptococcus*, *Bacteroides* spp., and *Fusobacteria* are found in cases of maxillary sinusitis when the infection is secondary to dental disease (5.17).

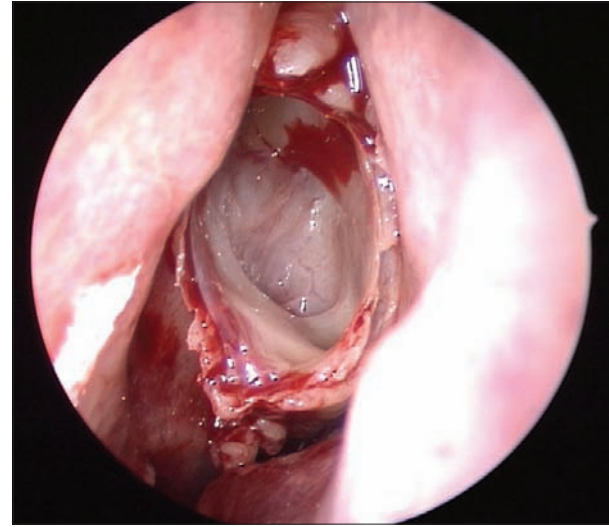
In principle, a bacterial sinusitis is a secondary infection of a primary viral sinusitis. The symptoms will, therefore, initially be those of a coryza but the patient will then develop facial pain. The pain is characteristically dull, throbbing, and worse on bending forward. Maxillary sinus pain tends to be felt in the cheek but radiates down into the teeth. Fronto-ethmoid disease gives pain around, behind, and between the eyes. Isolated sphenoid sinusitis is rare but the pain may be retro-orbital or felt on the vertex.

On examination there may be tenderness medially over the maxillary sinus or above the inner canthus of the eye over the fronto-nasal duct region. Swelling of the face is not seen in uncomplicated sinusitis. Swelling over the cheek is usually indicative of an underlying dental infection. The maxillary sinus may be clear of infection or may be secondarily infected. The typical endoscopic finding is pus in the middle meatus (5.18). The diagnosis is made from the history and examination findings but a CT scan of the paranasal sinuses in coronal sequence will show partial or total opacification of the affected sinuses.

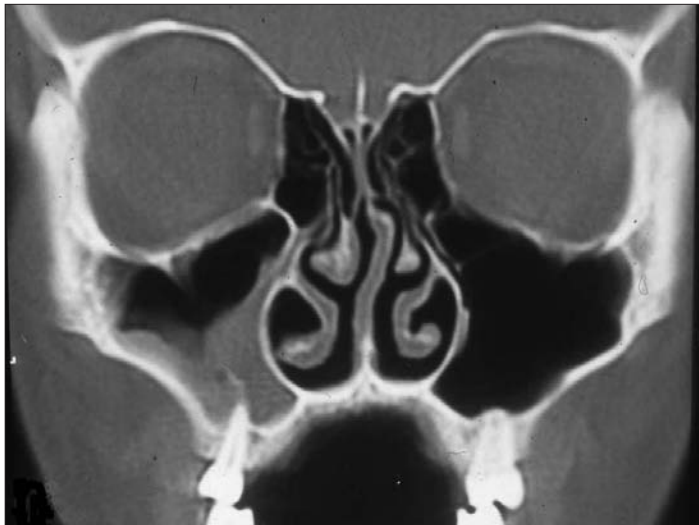Treatment of acute sinusitis is the subject of much debate in the primary care setting. Supportive treatments with analgesia and decongestants such as pseudo-ephedrine and xylometazoline are logical. The role of antibiotics is disputed, and there are understandable concerns about the over-prescription of these agents. Several large studies conducted in the primary care setting suggest that they are of no value, but the entry criteria for some of these studies were lax and it may be that many cases of viral coryza were included, thus diluting any positive benefit for those subjects



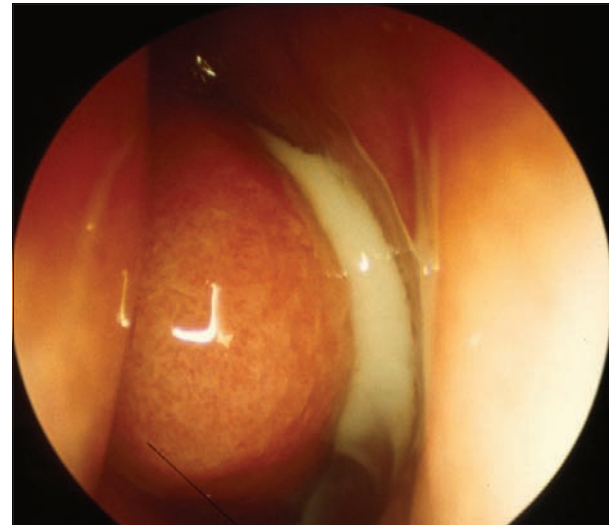
**5.15** Viral rhinitis demonstrating congested hyperaemic mucosa with mucopus.



**5.16** A concha bullosa (pneumatized middle turbinate) can impair sinus ventilation. (Courtesy of Mr Salil Nair, Winchester, UK.)



**5.17** CT scan showing right maxillary sinusitis secondary to dental disease.



**5.18** Acute left maxillary sinusitis showing mucopus coming from the middle meatus.

with true bacterial sinusitis. Studies conducted in the secondary care setting tend to be more supportive of the value of antibiotics. These studies tend to have the advantage of radiological confirmation of the diagnosis and, therefore, have slightly different entry criteria. Most otolaryngologists would recommend the use of antibiotics in clear cases of bacterial sinusitis with toxaemia. In community acquired sinusitis, a 2 week course of amoxycillin should control the infection. Erythromycin or one of the other macrolide antibiotics is useful in penicillin allergic individuals.

Chronic rhinosinusitis may have an underlying degree of inflammatory rhinitis that is helped by the addition of topical steroid preparations. In addition, recent studies suggest that prolonged courses of low-dose or full-dose clarithromycin (which has an anti-inflammatory as well as antimicrobial action) may be of benefit. Refractory cases will need endoscopic sinus surgery to enlarge the natural sinus ostia to enhance drainage and restore normal mucociliary clearance.



### FUNGAL SINUSITIS

Fungal infections of the sinuses can take distinct forms and the type of infection depends on the immune status of the host. The classification is still in evolution, but the major categories are identified in *Table 5.1*. Although uncommon in the UK, this condition is a relatively frequent occurrence in the USA, the Far East, and Asia. There is a possible link with the use of air conditioning units which are easily colonized with fungal overgrowths.

A high index of suspicion should be maintained to diagnose these infections as, apart from the acute fulminant variant, the others have similar presenting symptoms. The diagnosis is established by meticulous endoscopic examination and characteristic imaging findings. On the CT scan the fungal ball can appear like a metallic foreign body or have areas of microcalcification (5.19).

### COMPLICATIONS OF PARANASAL SINUS INFECTIONS

Infections of the nose and the paranasal sinuses, especially incompletely treated, can lead to extension of infection into the adjacent anatomical structures.

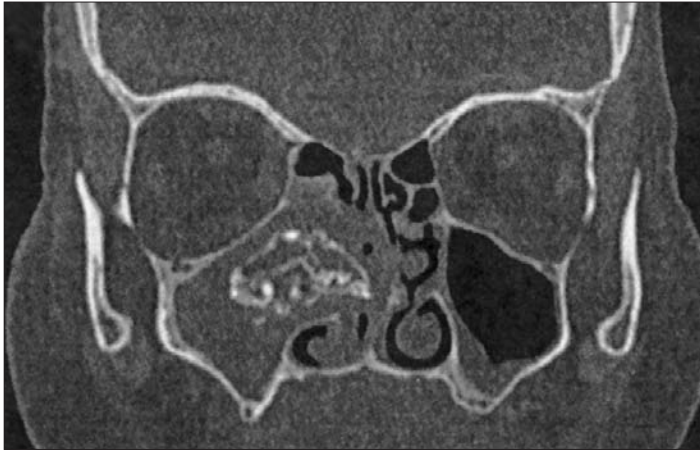
### ORBITAL CELLULITIS

The majority of the cases occur in children and the focus of the infection is predominantly in the ethmoid sinuses. Infection spreads through the lamina papyracea into the orbit by passing through bony dehiscences or through thrombosed communicating vessels. Initially there may just be a mild cellulitis with an inflamed upper eyelid, no restriction of eye movement, and no proptosis (5.23). It may be difficult to differentiate the diagnosis at this stage from causes of pre-septal infection such as infections of the lacrimal glands (5.24), abscesses of the upper lid (5.25), and infections of the nasolacrimal duct.

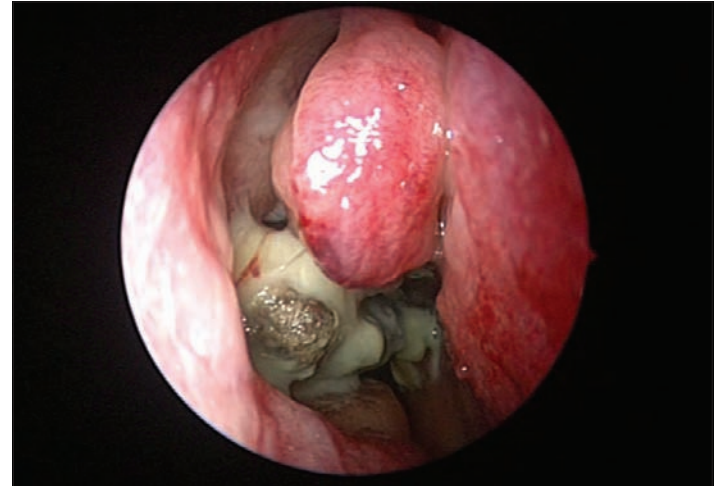
Subsequently, a peri-orbital cellulitis may develop in the post-septal part of the orbit. At this point the oedema of the lid is worse, it is difficult to open the eye, and there is proptosis with possible restriction of eye movement and diplopia. If a subperiosteal abscess develops there is a significant risk to the vision. (Colour vision tends to be lost before black and white). Diagnosis is mainly clinical but imaging studies help identify the presence of an abscess or cellulitis and may help differentiate between pre- and septal infections (5.26). In rare cases an intraorbital abscess can be found.

**Table 5.1 Fungal infections of the sinuses**

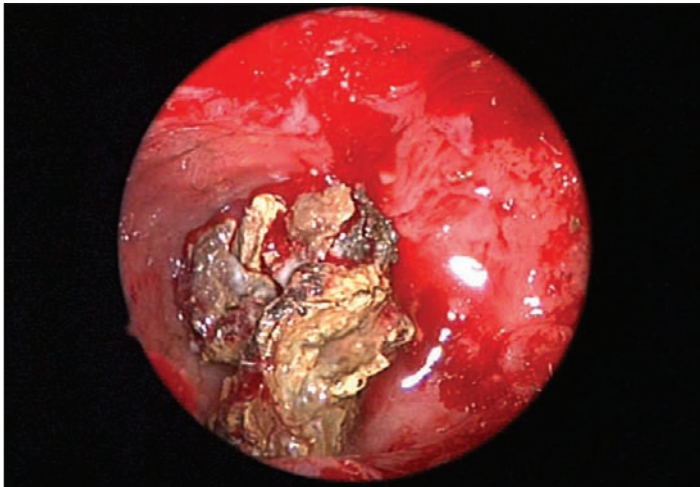
Type of infection	Host status	Causative agent	Symptoms and signs	Treatment
Invasive fungal sinusitis	Immunocompromised	<i>Aspergillus</i> spp., <i>Mucor</i> spp.	Pain, fever, facial swelling, cheek anaesthesia, nasal mucosal necrosis. Rapid progression	Control underlying immunosuppression, surgical debridement and antifungal therapy
Chronic invasive	Immunocompetent	<i>Aspergillus</i> spp., <i>Alternaria</i> spp.	Chronic sinusitis symptoms, slower progression with variable course	Surgical debridement and antifungal therapy
Fungus ball	Immunocompetent	<i>Aspergillus</i> spp., <i>Alternaria</i> spp., <i>Mucor</i> spp.	Chronic sinusitis-like symptoms, grey clay-like or rubbery mass (fungal ball) seen on endoscopy (5.20, 5.21)	Surgical removal
Allergic fungal sinusitis	Atopic	<i>Curvularia</i> spp., <i>Aspergillus</i> spp., <i>Bipolaris</i> spp.	Recurrent nasal polyposis, allergic fungal mucin (5.22)	Surgical removal, steroids



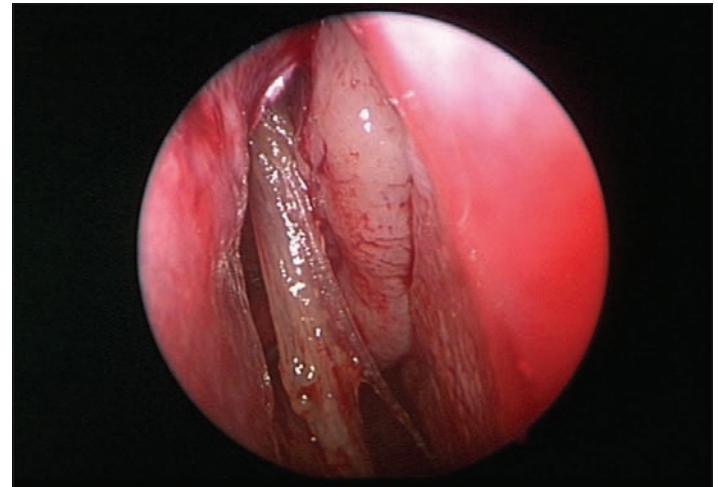
**5.19** CT scan showing a fungal ball (aspergilloma) in the right maxillary sinus.



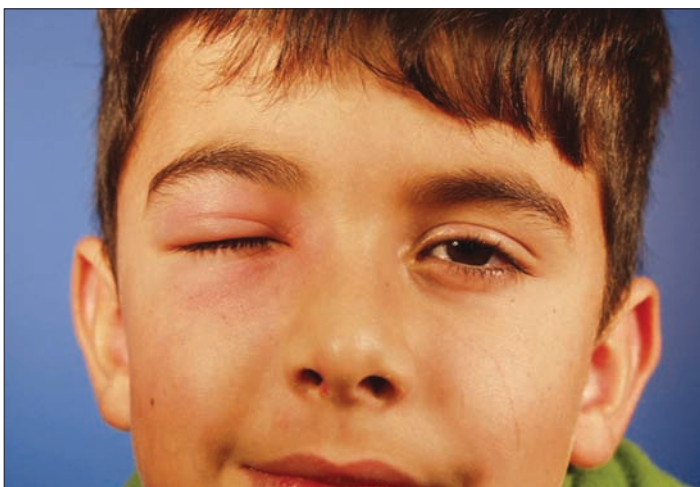**5.20** Endoscopic view of an aspergilloma extending into the nasal cavity.



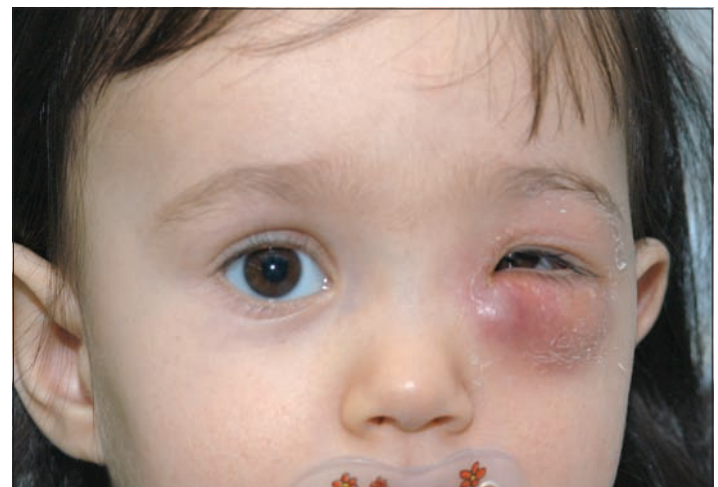**5.21** Aspergilloma visualized within the maxillary sinus.



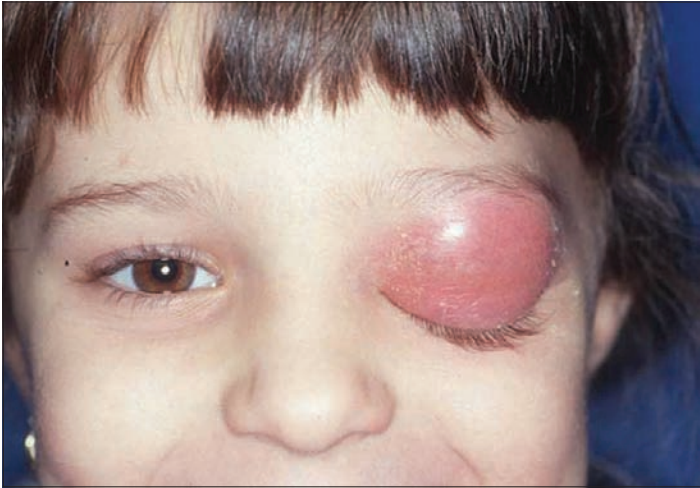**5.22** Thick inspissated mucin characteristic of allergic fungal sinusitis.



**5.23** Early right orbital cellulitis.

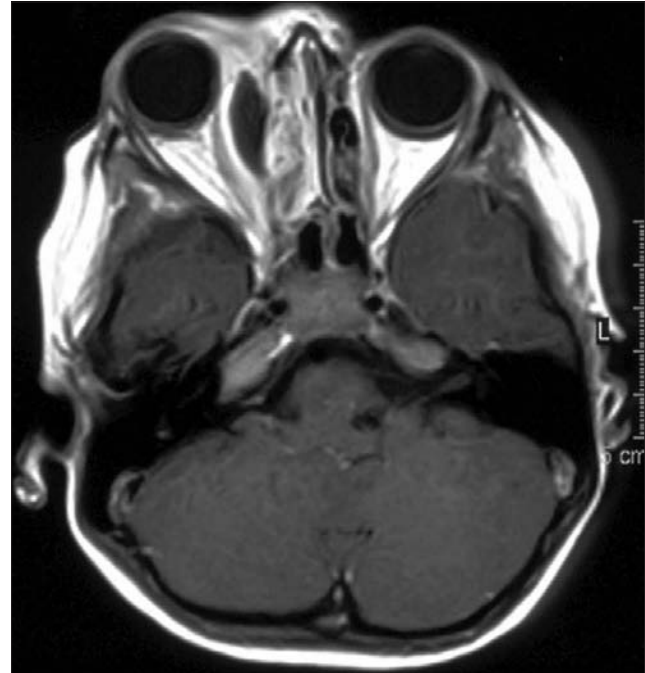


**5.24** Empyema of the left lacrimal duct.



5.25 Abscess of the left upper lid.

5.26 MRI scan showing right orbital cellulitis with subperiosteal abscess. Note opacified ethmoids on the same side.



Therapy depends on the state of infection. In early cases in which there is no significant proptosis, restriction of eye movement, or threat to vision systemic intravenous antibiotics and decongestant nasal sprays for the first 24 hours may be effective. In more advanced cases a surgical approach with external or endoscopic opening of the opacified paranasal sinuses is required.

#### **POTT'S PUFFY TUMOUR (OSTEOMYELITIS OF THE FRONTAL BONE)**

An insufficiently treated acute frontal sinusitis can, especially in adolescent patients, lead to a subperiosteal abscess over the frontal bone and to an underlying osteomyelitis. In children and adolescents there is a relatively large cancellous layer in the frontal bone which allows easier spread of infection. An intracranial extension through the posterior wall of the frontal sinus can lead to meningitis or an extradural, subdural, or frontal brain abscess. The infection is transmitted by the small veins in the diploic bone which have no valves.

The patient will complain of headache and clinical examination shows a soft swelling over the forehead (5.27). The clinical diagnosis is confirmed by imaging studies (5.28). Treatment usually requires surgical debridement which may have to be done as a joint neurosurgical

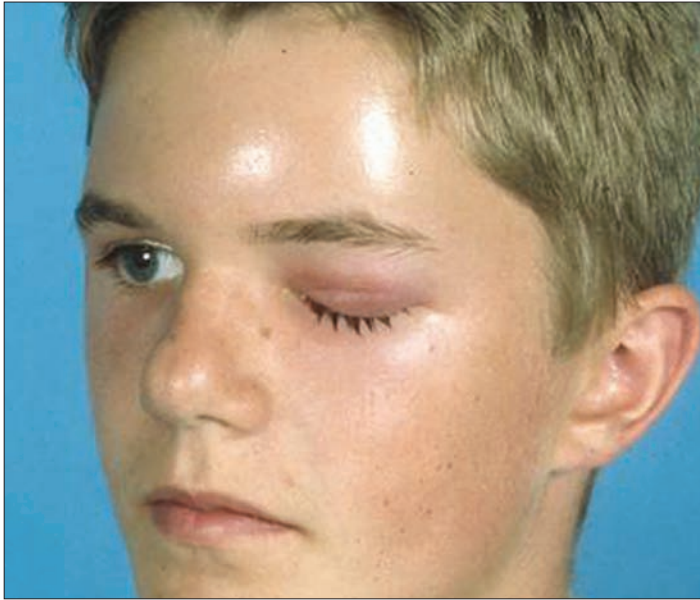procedure if there is an intracranial extension of the infection (5.29). In cases where a significant section of the frontal bone has been eroded or resected and a cosmetic impairment results, delayed reconstruction can be undertaken as a secondary procedure.

#### **FRONTAL SINUS MUCOCOELE AND PYOCOELE**

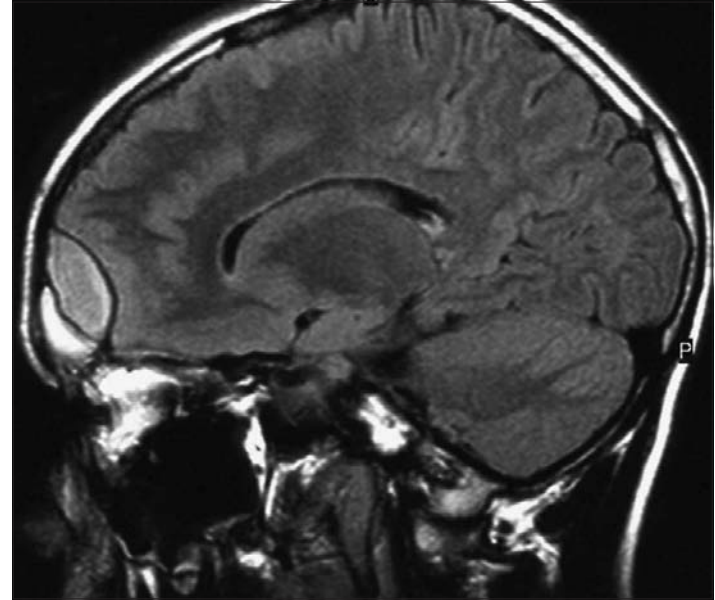
Obliteration of the sinus ostium by trauma, surgery, or infection can result in mucus entrapment in the frontal sinus. This is a mucocoele. Slow expansion and remodelling of the sinus takes place leading to destruction of the surrounding bone. Mucocoeles are prone to infections and can become a pyocoele.

The commonest site is the frontal sinus where there is expansion of the frontal sinus and displacement of the globe of the eye infero-laterally causing diplopia (5.30). Maxillary sinus mucocoeles present with swelling on the cheek (5.31). Ethmoid sinus mucocoele will similarly cause displacement of the globe and sphenoid sinus mucocoeles can lead to optic and oculomotor palsies (5.32). Any of these mucocoeles can get infected leading to a pyocoele. The clinical diagnosis is confirmed by a CT scan which shows soft tissue opacification and expansion of the sinus (5.33–5.35). Treatment is surgical and drainage of the mucus or mucopus is usually possible endoscopically.



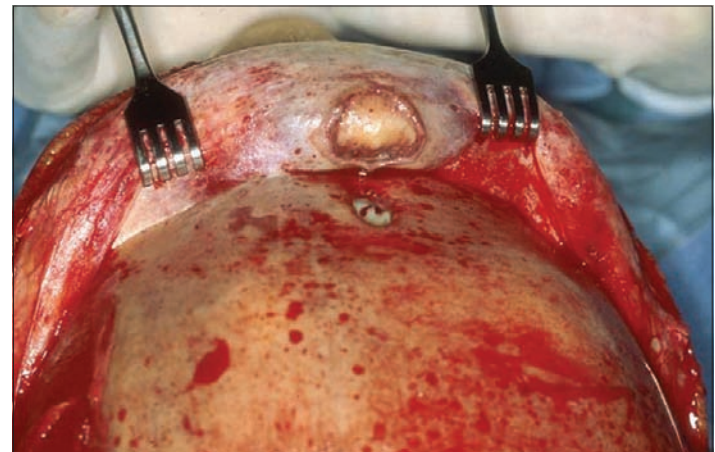


**5.27** Pott's puffy tumour caused by left frontal sinusitis. Note eyelid oedema.

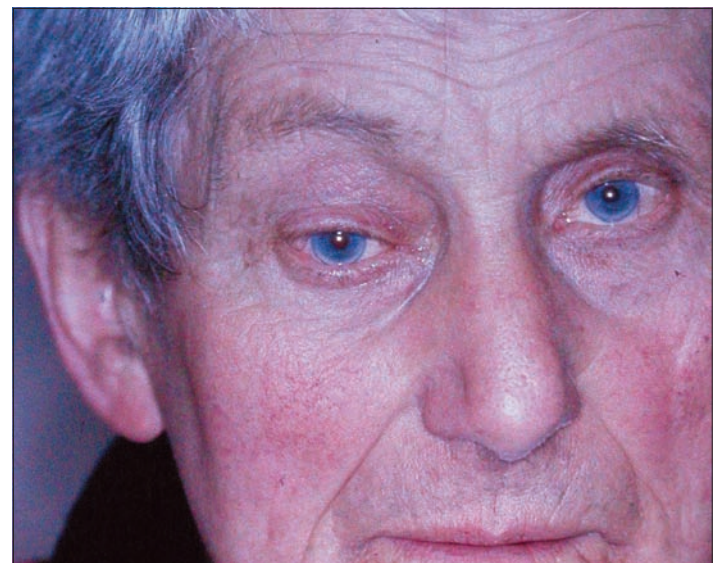

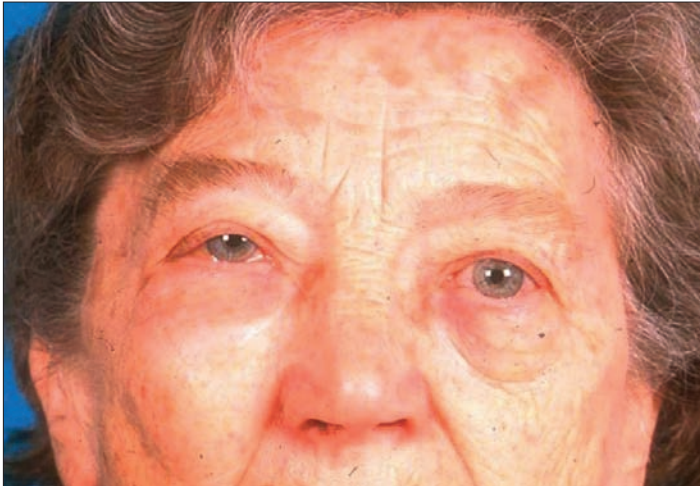**5.28** MRI scan showing frontal sinusitis with extradural abscess.

**5.29** Bicoronal flap to drain an abscess shows the site of erosion through frontal bone.

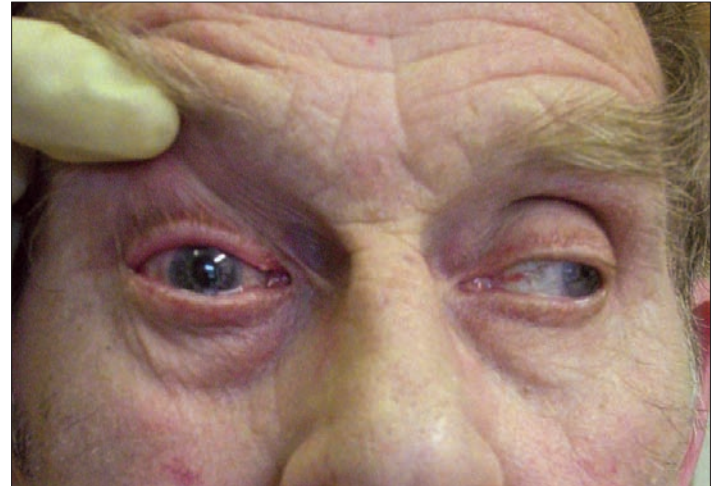

**5.30** Proptosis caused by a mucocoele in the right frontal sinus.

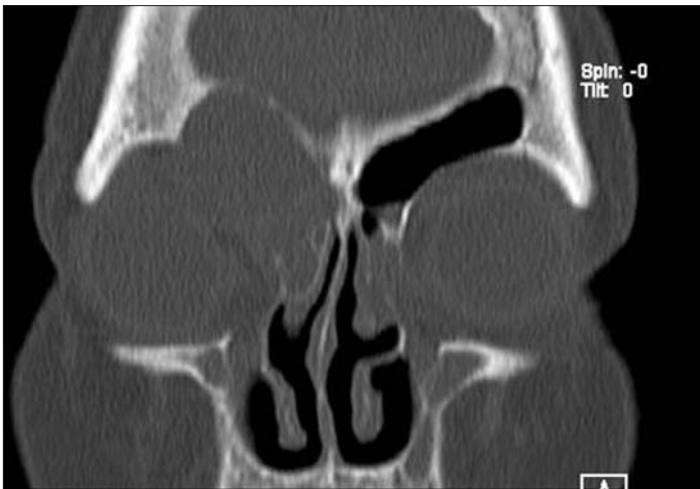



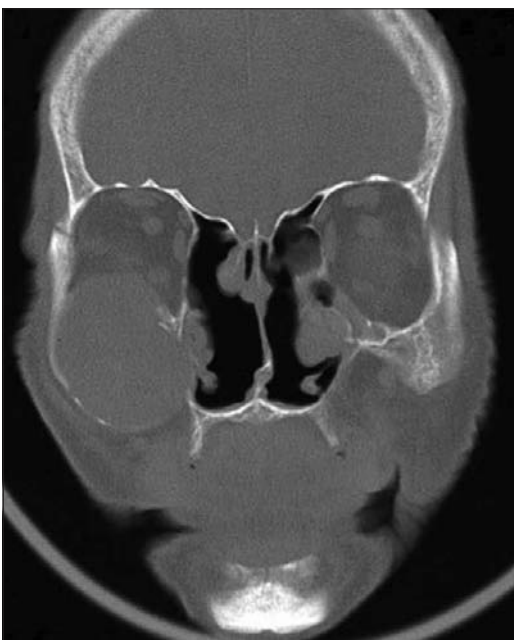5.31 Mucocoele in the right maxillary sinus.



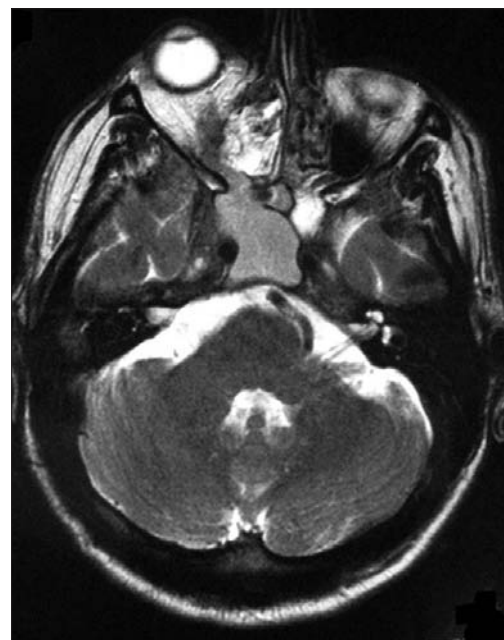
5.32 Oculomotor palsy caused by a sphenoid mucocoele.



5.33 CT scan showing a mucocoele in the right frontal sinus.

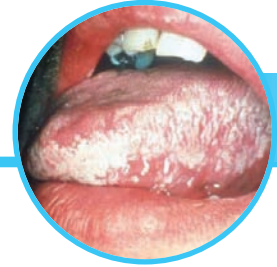

5.34 CT scan in the coronal plane showing a mucocoele in the right maxillary sinus.



5.35 MR scan showing a sphenoid mucocoele.





# Infections of the oral cavity

*Vinidh Paleri and Konrad Staines*

## Introduction

Infections in this region are most commonly of dental origin, consequent to dental caries or periodontal disease. Rarely, underlying odontogenic cysts may become infected and produce a similar clinical picture. While dental infections are outside of the scope of this book, they can spread to the neck spaces and present with serious life threatening illnesses. These are dealt with in Chapter 8 Infections of the oropharynx. This chapter deals with the oral mucosal infections seen in ENT practice.

## Viral infections

Viral infections of the oral mucosa may have a varied clinical presentation. The most common viral infections of the oral mucosa are listed in *Table 6.1*. Other rarer viral conditions with oral manifestations are outlined in *Table 6.2*.

### PRIMARY HERPETIC GINGIVOSTOMATITIS

Human herpes virus (HHV-1) infections of the oral cavity are very common. These are DNA viruses that spread through direct contact. Primary infection most often occurs in infancy or childhood. It typically follows viral entry into the oral mucosa, and may be symptomatic, unnoticed, unrecognized, or asymptomatic. Primary herpetic gingivostomatitis occurs in individuals who lack primary immunity 5–7 days following contact with a source. A vesicular eruption can be preceded by a prodrome of local tenderness. The vesicles are thin walled and short-lived, leaving behind shallow, painful ulcers. A characteristic and diagnostic feature of this infection is the involvement of keratinized mucosa, especially the marginal gingiva (6.1, 6.2). The lesions last 1–2 weeks and settle spontaneously

**Table 6.1 Common viral infections of the oral mucosa**

<b>Virus</b>	<b>Oral mucosal disease</b>
HSV 1 and 2	Primary herpetic stomatitis Recurrent herpetic stomatitis: labialis or intra-oral
Varicella-zoster virus	Chickenpox Intraoral herpes zoster
Epstein–Barr virus	Hairy leukoplakia Infectious mononucleosis

but, despite clinical resolution, viral shedding takes place and these individuals can be a source of infection.

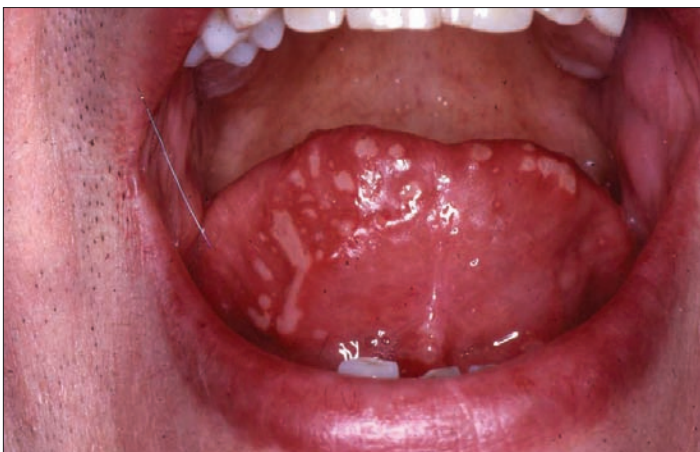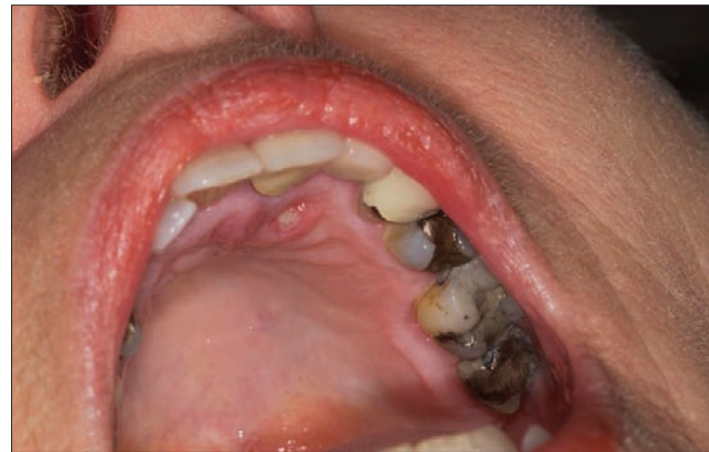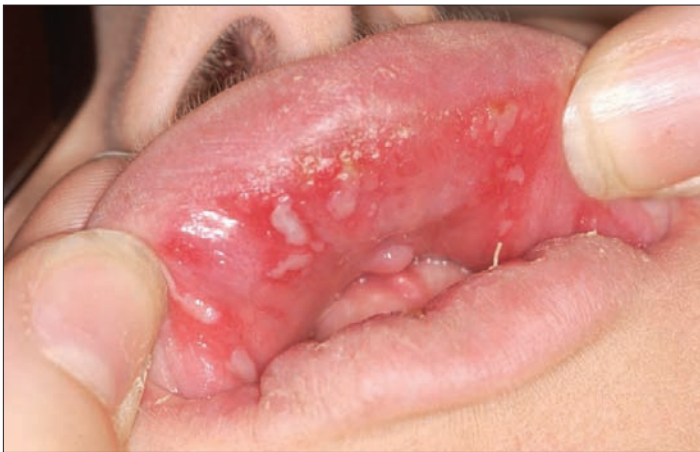Differential diagnosis mainly consists of noninfective conditions such as herpetiform aphthous stomatitis (6.3), erythema multiforme, and Stevens-Johnson syndrome. Infective conditions include acute necrotizing gingivostomatitis, herpes zoster, measles, and other rarer viral infections listed in *Table 6.2*.

Treatment is usually symptomatic to relieve the pain and maintain oral hygiene. Paracetamol and ibuprofen are effective in relieving pain and pyrexia. Local analgesics such as benzydamine hydrochloride mouthwash or lidocaine (lignocaine) ointment can be used, but their duration of action is short-lived. Chlorhexidine mouthwash or gel helps prevent bacterial superinfection of the ulcerated areas and is therefore indicated. There is no evidence to support the use



Table 6.2 Other viral infections causing oral mucosal lesions

Virus	Infection	Systemic features caused	Oral mucosal	Location features
Paramyxovirus	Measles	Malaise, fever, anorexia, conjunctivitis, and respiratory symptoms	Koplik spots (bluish-grey specks on an erythematous background)	Buccal mucosa in the premolar and/or molar area
Coxsackie A1–6, 8, 10, 22	Herpangina	Fever, headache, anorexia, vomiting, and abdominal pain	Punctate macules that evolve into erythematous papules, vesicles, and ulcers	Soft palate, tonsil, posterior pharyngeal wall
Coxsackie A10	Acute lymphonodular pharyngitis	Fever, headache, anorexia, vomiting, and abdominal pain	Papules that do not progress to vesicles and ulcers	Soft palate, tonsil, posterior pharyngeal wall
Coxsackie A16	Hand–foot–mouth disease	Mild fever, malaise, anorexia, and a sore mouth	Oral vesicles, leading to shallow ulcers	Anterior buccal mucosa, the tongue, and the soft palate
HHV-8	Kaposi's sarcoma (KS)	Malignant vascular tumour found predominantly in HIV positive patients; characterized by blue-red nodules on the skin and/or visceral tissues	Lesions (blue-red nodules) may be asymptomatic; however, progression may result in complications, e.g. pain, bleeding, difficulties in talking or eating	Palate (majority of cases), tongue and gingivae



6.1 (Above left) Primary herpetic stomatitis.

6.2 (Above) Herpetic stomatitis of the premaxilla.

6.3 (Left) Herpetiform aphthous stomatitis.

of topical antiviral agents for the first attack of oral herpes simplex. In severe cases, especially in adults or immunocompromised patients, systemic antivirals (acyclovir and famciclovir) may reduce the duration of symptoms if taken early in an attack and can be used in severe infections. Owing to the high risk of infecting others, appropriate advice on hand washing and limiting contact must be given.

### **RECURRENT HERPETIC INFECTIONS (COLD SORES)**

During the primary infection, the virus also gains entry into the neurones and becomes latent in the trigeminal, vagal, and sympathetic ganglia. At times when the host immunity is compromised or following certain triggers like stress, illness, and sunlight, viral reactivation may occur. Generally this results in a clinical picture of recurrent herpes labialis (6.4) with the vermillion of the lip and adjacent skin characteristically involved. The prodrome is characterized by tingling, itching, or pain, followed by vesicular eruption. These crust over 48 hours and heal without scarring over a week. However, reactivation may also involve oral mucosa (recurrent intraoral herpes) with vesicles developing which burst to leave a cluster of oral ulcers (6.5). Their distribution tends to be localized and unilateral.

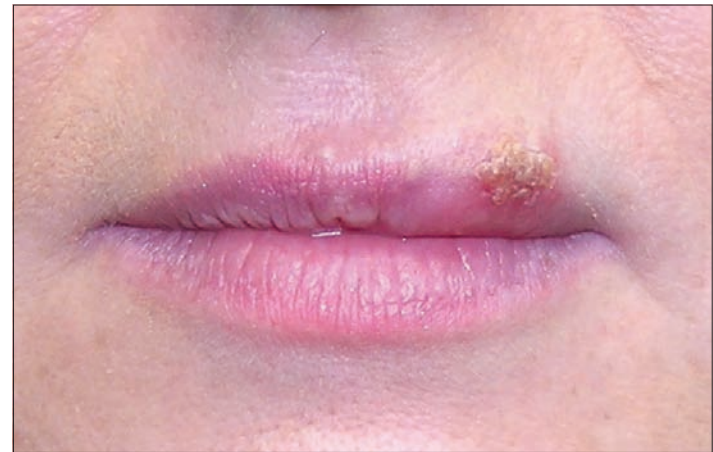While there is no consensus on the use of topical antivirals, best evidence suggests that topical penciclovir 1% or acyclovir 5% must be started as soon as symptoms begin, to be of any benefit. Oral antivirals may be of benefit in severe cases. Prevention is possible in the presence of well-defined triggers, e.g sunscreens when sunlight can trigger an episode. For most patients there is no role for prophylactic antivirals to prevent cold sores.

### **CHICKENPOX (VARICELLA)**

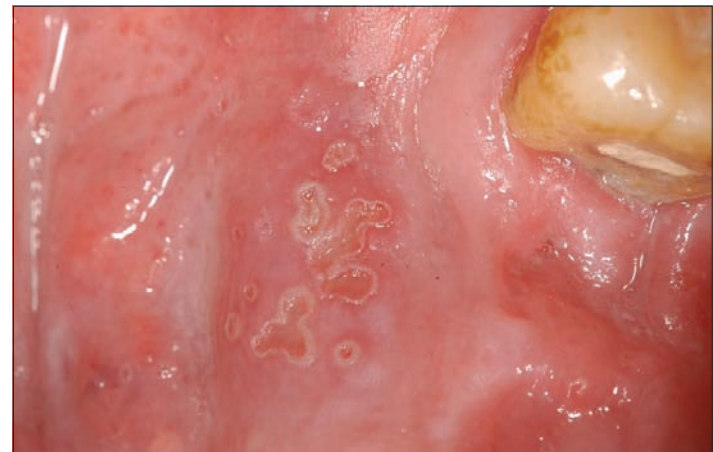Oral manifestations may include generalized superficial ulceration. The clinical picture may be similar to primary herpetic gingivostomatitis although there tends to be less gingival involvement. Treatment is only supportive.

### **SHINGLES (ZOSTER)**

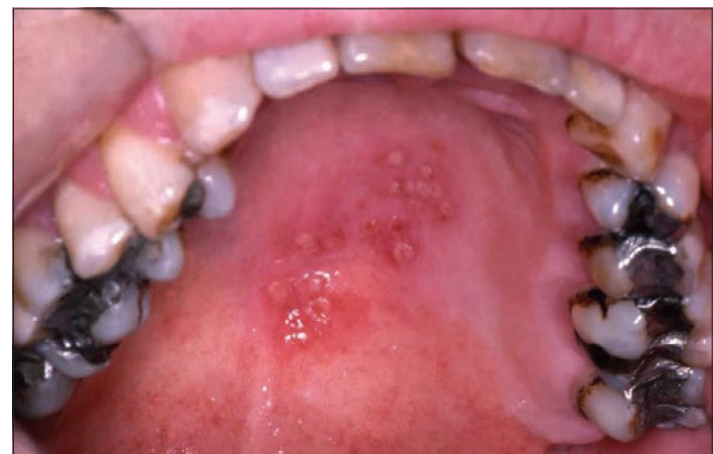Reactivation of VZV may involve the trigeminal region in a quarter of cases. Oral mucosal involvement can occur and generally this can be seen in an unilateral distribution on the hard palate (6.6). Pain usually accompanies this rash. Systemic antiviral therapy can decrease the likelihood of post-herpetic neuralgia and is therefore warranted.



6.4 Recurrent herpes labialis.



6.5 Recurrent intraoral herpes simplex occurring on the hard palate.



6.6 Herpes zoster of the hard palate.



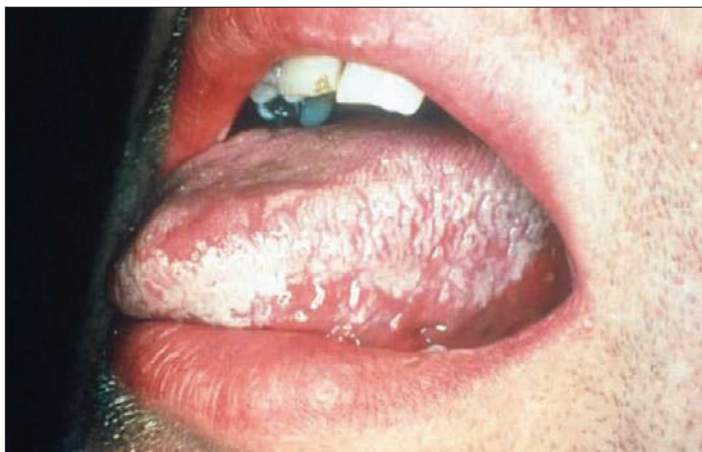### HAIRY LEUKOPLAKIA

Hairy leukoplakia (HL) occurs almost exclusively in the immunosuppressed individual, typically in HIV-positive patients. The aetiologic agent is the Epstein–Barr virus. Examination will reveal whitish lesions generally, but not exclusively, on the lateral borders of the tongue, with prominent projections, giving a hairy appearance (6.7). Bilateral lesions are common. HL is not to be confused with ‘hairy tongue’, which is caused by hypertrophy of the filiform papillae on the tongue (Table 6.3). The lesions are generally asymptomatic unless there is concomitant candidal superinfection. HL in HIV is a poor prognostic marker.

If the lesion is asymptomatic, there is no need to treat it actively as many resolve spontaneously if the underlying local or systemic immunosuppression is corrected. They usually settle with antiretroviral treatment. Treatment options for aggressive lesions include systemic antivirals, topical podophyllin or retinoic acid, and ablation with laser or cryotherapy.

### PAPILLOMATOSIS

Human papilloma viruses (commonly HPV-2 and -4) can cause warts on the lips, palate, and gingiva (6.8). These are sessile with well-defined borders. Excision biopsy usually suffices. Condyloma acuminata, although typically involving the genital region, may be seen in the oral cavity (HPV-6 and -10).



6.7 Hairy leukoplakia on the lateral surface of the tongue in a patient with HIV infection. (Courtesy of Prof. D. Wray, Glasgow, UK.)

### Bacterial infections

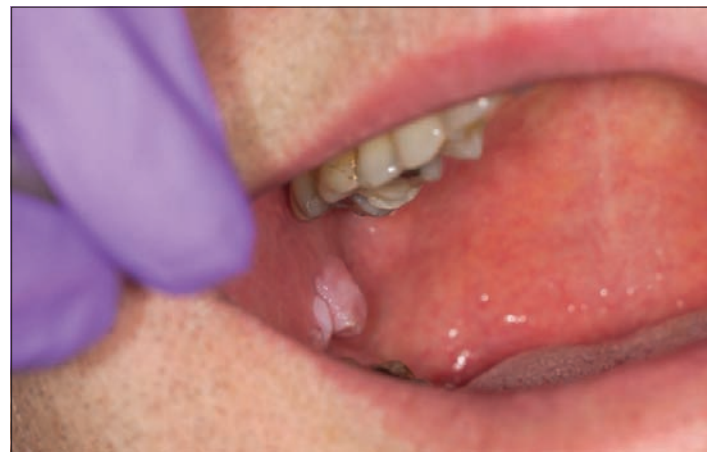The most common manifestation of intraoral bacterial infections is a periodontal abscess or indeed a draining dental sinus, further description of which is outwith the scope of this chapter.

### ACUTE ULCERATIVE GINGIVITIS

This is an acute gingivitis associated with the proliferation of mainly anaerobic fusospirochaetal bacteria, generally in the presence of predisposing factors such as smoking and stress. An acute gingivitis with typically punched out necrotic ulceration of the interdental gingival papillae with overlying fibrinous necrotic slough and gingival bleeding is classically observed (6.9). It is extremely painful, associated

Table 6.3 Differential diagnosis for hairy leukoplakia

Frictional keratosis
Foliate papillitis (hypertrophy of foliate papillae secondary to irritation)
Lichen planus
Leukoplakia
Squamous cell carcinoma



6.8 Papillomas on the oral mucosa in a patient treated for lymphoma.

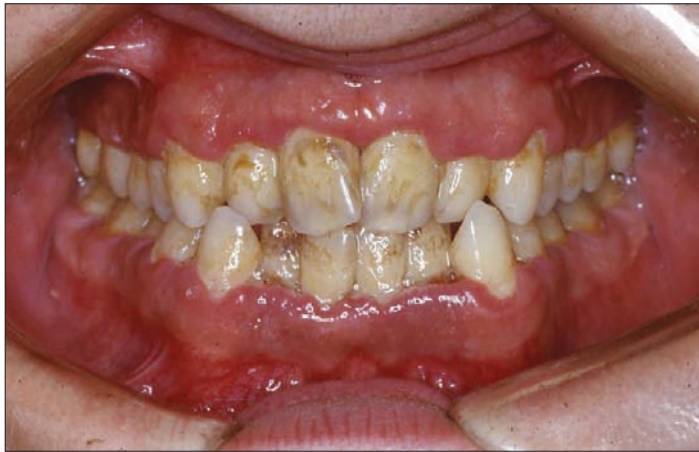

lymphadenopathy and pyrexia may be present and, invariably, foul smelling halitosis is present. The differential diagnoses are presented in *Table 6.4*.

Local debridement in combination with hydrogen peroxide and chlorhexidine mouthwash and systemic

antimicrobial therapy (metronidazole being the drug of choice) is recommended. Correction of predisposing factors is essential to prevent recurrence.

Oral manifestations of other rarer bacterial infections are outlined in *Table 6.5 (6.10–6.14)*.



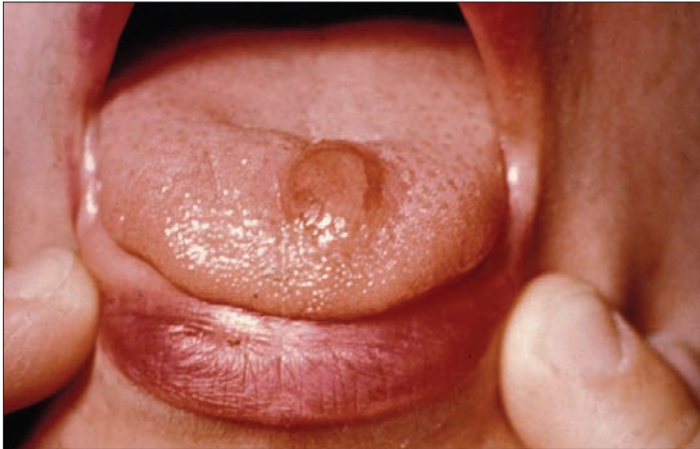**6.9** Acute ulcerative gingivitis. Note the ulceration of the interdental papillae.

**Table 6.4 Differential diagnosis of acute ulcerative gingivitis**

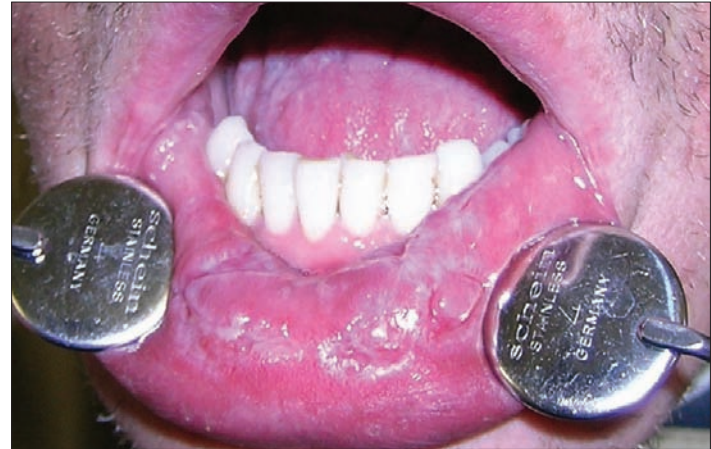- Primary herpetic gingivostomatitis
- Herpetiform aphthous stomatitis
- Erythema multiforme
- Stevens–Johnson syndrome
- HIV gingivitis and periodontitis
- Oral manifestations of haematological dyscrasias
- Oral manifestations of vesiculobullous disorders, e.g. mucous membrane pemphigoid

**Table 6.5 Rare bacterial infections with oral manifestations**

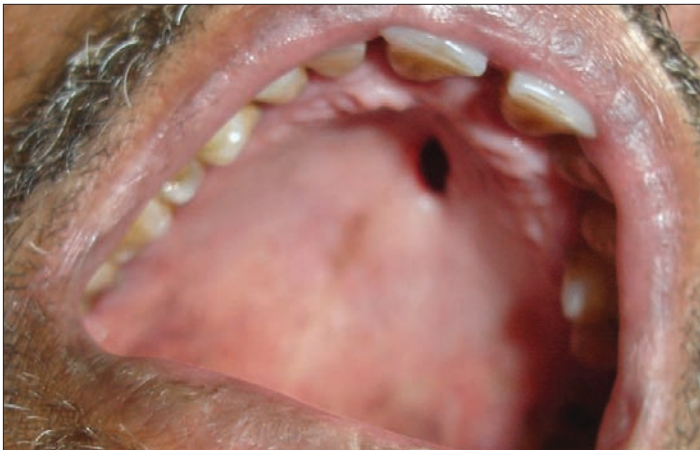<b>Disease</b>	<b>Characteristic lesion</b>	<b>Clinical features</b>
Primary syphilis	Chancre	Indurated swelling which breaks down to form an indurated ulcer within a few days ( <b>6.10</b> )
Secondary syphilis	Mucous patches Snail track ulcers	Painless greyish ulcers ( <b>6.11</b> )
Tertiary syphilis	Gumma Syphilitic leukoplakia	Tissue mass of a granulomatous nature which breaks down to leave a defect classically in the hard palate ( <b>6.12</b> ) Nonremoveable white patch
Tuberculosis	Tuberculous ulcer	Ulcer which has a grey sloughy surface which may mimic a squamous cell carcinoma ( <b>6.13</b> )
Gonorrhoea	Stomatitis	Erythematous stomatitis with superficial ulceration ( <b>6.14</b> )
Staphylococcal stomatitis and Crohn's disease	Stomatitis	Erythematous stomatitis can occur in coexistence with other oral manifestations of Crohn's disease



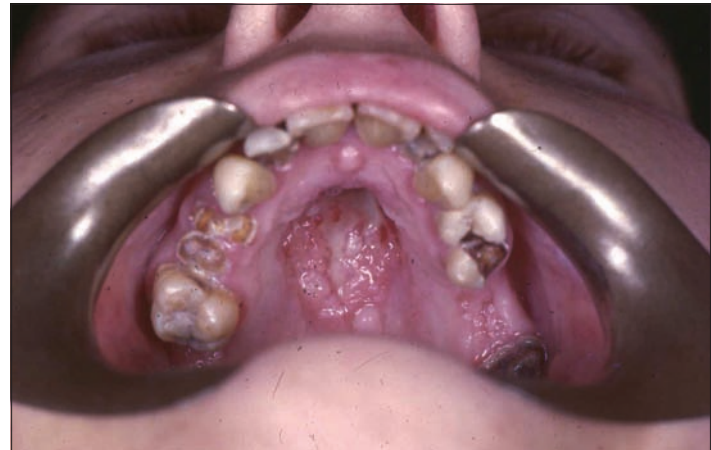**6.10** Primary syphilitic chancre on the tongue.  
(Reproduced with permission from Quintessence Publishing; *Practical Oral Medicine: Oral Surgery and Oral Medicine* -3, 2006, I. Macleod, A Crighton.)



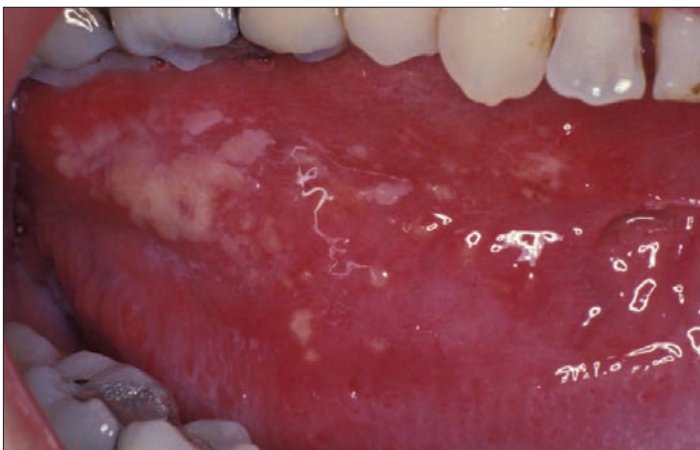**6.11** Snail track ulcers of the oral mucosa in secondary syphilis.



**6.12** Perforation of the hard palate caused by a syphilitic gumma. (Courtesy Prof. S. Gopalakrishnan, Pondicherry, India.)



**6.13** Tuberculous ulcer of the palate.



**6.14** Superficial stomatitis caused by gonorrhoea. (Courtesy of Dr. I. Macleod, Newcastle, UK.)

## Fungal infections

### CANDIDIASIS

Oral candidiasis is caused by *Candida* species, a saprophytic yeast that is a commensal in the oral cavity. *Candida albicans* is the most common agent, with others such as *C. krusei* and *C. tropicalis* also being implicated. The presence of oral candidosis should prompt a search for local or systemic predisposing factors (Table 6.6).

Clinical presentation of oral candidiasis can take distinct forms:

- Pseudomembranous oral candidiasis (thrush). Patches of curd-like white pseudomembrane occur on the cheek, gums, and the palatal mucosa. These are easily removed and reveal an erythematous base. It may involve the tongue in immunocompromised patients (6.15).
- Acute erythematous oral candidiasis usually occurs following antibiotic treatment and in immunosuppression, marked by erythema on the dorsum of the tongue (6.16).

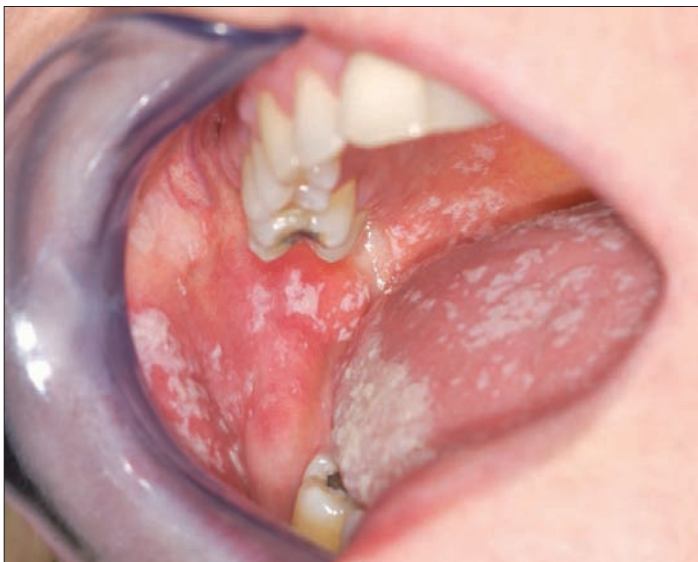**Table 6.6 Predisposing factors for oral candidiasis**

#### Local factors

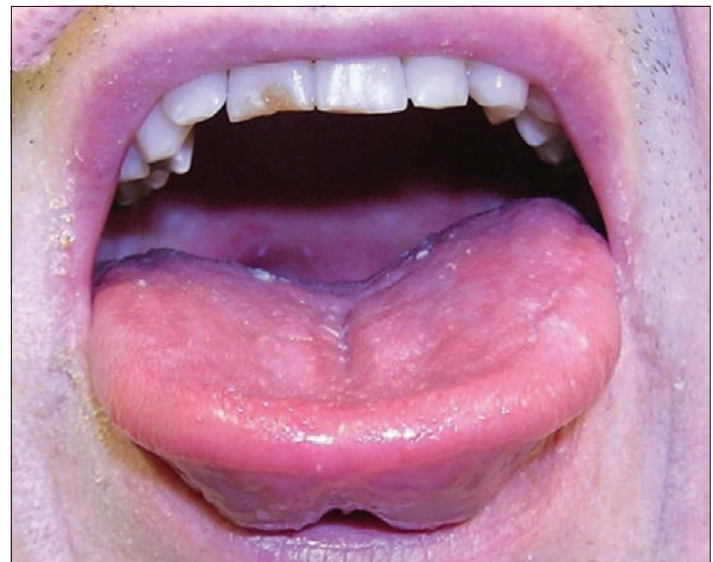- 1 Diet rich in carbohydrates
- 2 Tobacco smoking
- 3 Denture hygiene and wearing
- 4 Xerostomia
- 5 Topical steroid use (most commonly steroid inhalers in asthmatics)

#### Systemic factors

- 1 Physiological factors: infancy, old age, pregnancy
- 2 Drug therapy: antibiotics
- 3 Endocrine disease
  - a Diabetes mellitus
  - b Autoimmune polyendocrinopathy
- 4 Immunosuppression:
  - a Primary immune deficiency
  - b Steroids, cancer chemotherapy
  - c Radiation therapy
  - d HIV infection
  - e Leukemia



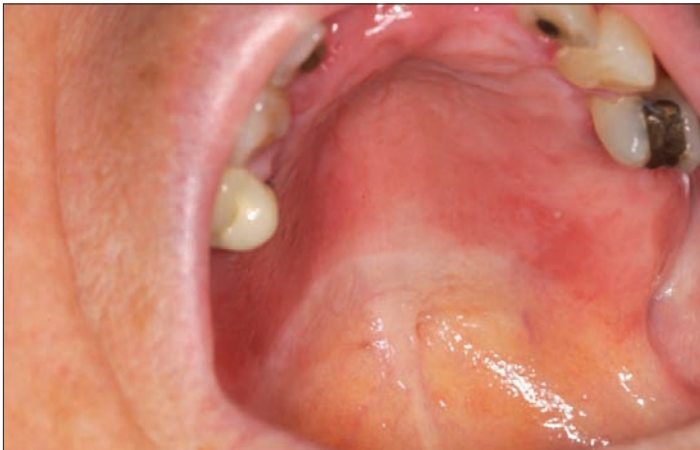**6.15** Pseudomembranous oral candidiasis.



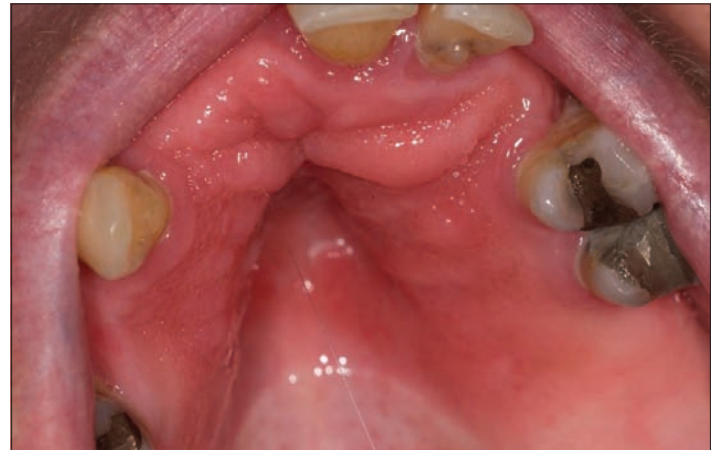**6.16** Acute erythematous candidiasis in an immunosuppressed patient.



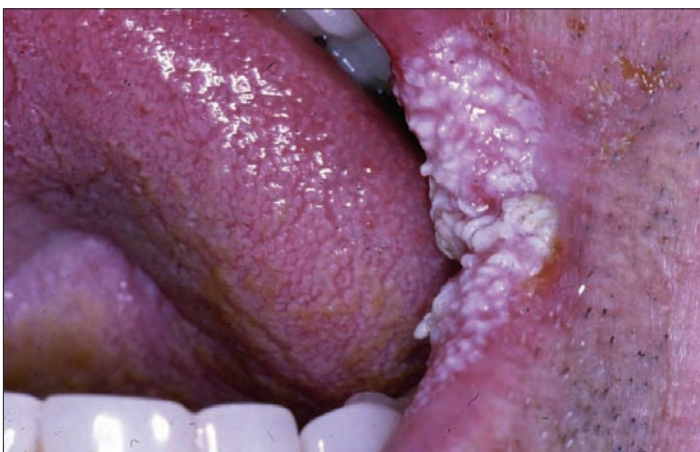- Chronic erythematous stomatitis (denture stomatitis) is characterized by redness in the denture bearing area in the palate (6.17, 6.18). Soreness is not a prominent feature.
- Chronic hyperplastic oral candidiasis (candidal leukoplakia) presents with white plaques on the cheek or tongue that are not easily removed, with little or no symptoms (6.19). It is nearly always seen in smokers and regression may follow smoking cessation. An incisional biopsy is indicated to determine the presence of dysplasia. This lesion can be classed as a premalignant one.
- Median rhomboid glossitis shows an erythematous area devoid of papilla of the tongue in the midline just anterior to the circumvallate papillae (6.20).
- Angular stomatitis presents as erythema and fissuring of the angles of the mouth (6.21). These lesions may also be caused by a staphylococcal infection or may also be an indicator of underlying vitamin deficiency, anaemia, or even diabetes, hence appropriate screening is warranted.



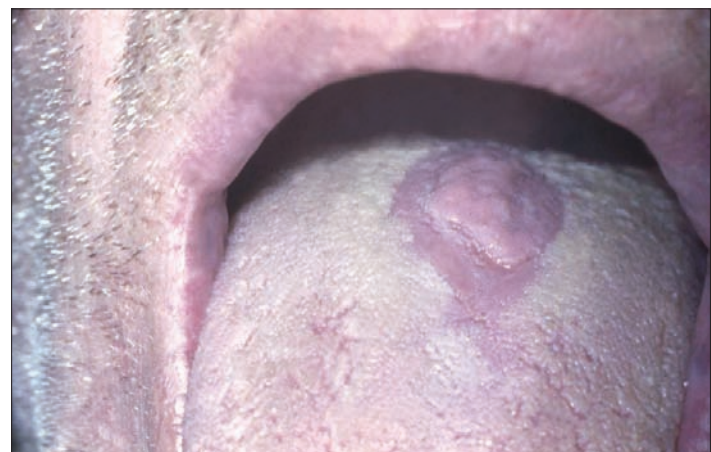6.17 Denture stomatitis, showing erythema of the palatal mucosa that is covered by the upper denture.



6.18 Denture stomatitis with hyperplastic tissue reaction.



6.19 Chronic hyperplastic candidiasis.

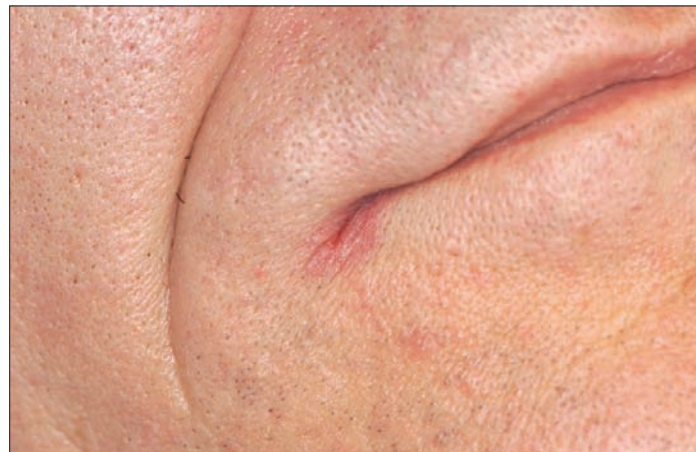

6.20 Median rhomboid glossitis.

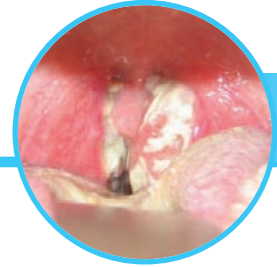The varied presentation of oral candidiasis permits many differentials. All keratotic lesions can be ruled out easily as they do not rub off on examination. Chemical burns, superficial bacterial infections, lichen planus, white sponge nevus syndrome, and necrotic ulcers from systemic disease should be considered.

As a first-line drug, topical miconazole or nystatin is recommended; if a response does not occur with one of them, the other can be tried. Oral imidazoles (fluconazole and itraconazole) are licensed for use in oral candidiasis

where first-line measures have been unsuccessful. Identification and removal of predisposing factors is essential. Avoiding sleeping with dentures in place, tobacco cessation and rinsing of the mouth following steroid inhaler use are examples of simple advice that may be given when indicated. In the absence of obvious predisposing factors, screening for systemic risk factors may be warranted. Recurrent infections in the immunocompromised patient may warrant prophylaxis.



**6.21** Angular cheilitis in a diabetic patient.



# Infections of the oropharynx

*Vinidh Paleri*

## Introduction

Oropharyngeal infections are commonly caused by viruses, and the frequent pathogens are identified in *Table 7.1*. In adults, viral infection accounts for 80–90% of pharyngitis, with this figure reducing to 60% in children.

**Table 7.1 Organisms causing oropharyngeal infections**

### Viruses

Epstein–Barr virus  
 Herpes simplex virus (HHV-1)  
 Rhinovirus  
 Roseolavirus (HHV-6)  
 Coronavirus  
 Influenza  
 Cytomegalovirus  
 Adenovirus  
 Measles virus

### Bacteria

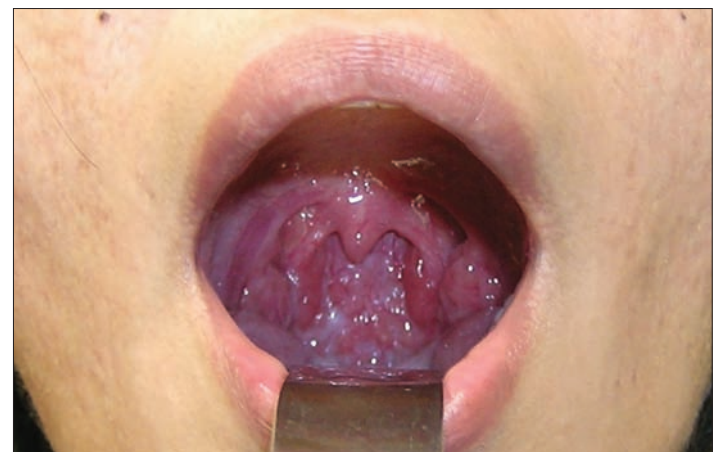Group A beta-haemolytic streptococcus  
*Staphylococcus aureus*  
*Haemophilus influenzae*  
*Neisseria gonorrhoeae*  
*Mycoplasma pneumoniae*  
*Chlamydia pneumoniae*  
*Corynebacterium diphtheriae*

### Fungi

*Candida* sp.

It is difficult to differentiate clinically viral infections from bacterial infections of the oropharynx, but the latter are more likely to present with severe local and systemic symptoms such as high-grade fever. Viral infections are more likely to be associated with nasal blockage and discharge. Throat swab cultures will identify bacterial pathogens, but this should be interpreted in the clinical context, as bacterial contaminants are common. Anaerobes such as *Bacteroides* species may have a greater role to play in peritonsillar abscesses but can be cultured from infected tonsils. Most uncomplicated infections of the oropharynx need symptomatic treatment only, and antibiotics are indicated in less than 20% of patients.

In acute pharyngitis (7.1) clinical symptoms include sore throat, halitosis, odynophagia, and tender cervical lymph nodes. The adenoid and tonsil hypertrophy associated with



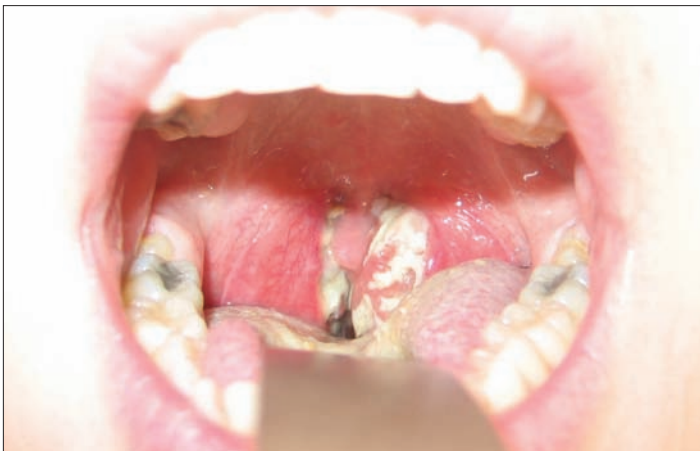**7.1** Acute pharyngitis showing diffuse erythema with prominent lymphoid follicles.



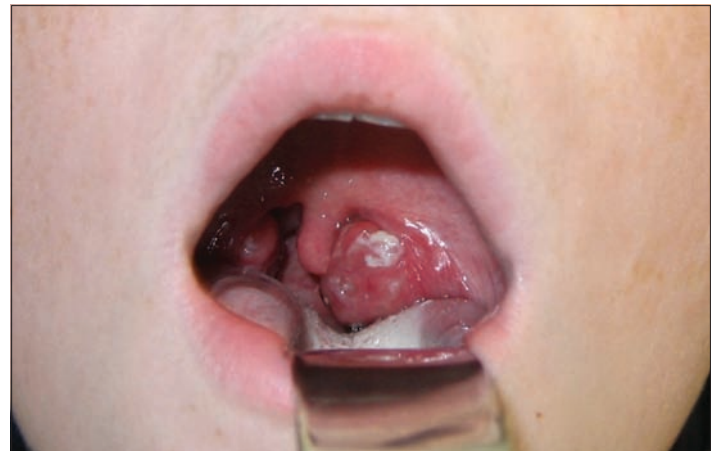the infection can cause mouth breathing, snoring, or even sleep apnoea. Systemic symptoms such as low-grade fever, lethargy, and malaise are common. Examination will reveal an inflamed pharynx with exudate or mucopurulent discharge running down from the pharynx. The tonsils may show mild inflammation.

When tonsillitis is present, the predominant findings can include all of the above with spots of exudates, or perhaps even a membrane covering the whole of the tonsils (7.2). Palatal petechiae can be present in both bacterial (typically Group A streptococci) and viral infections (typically with

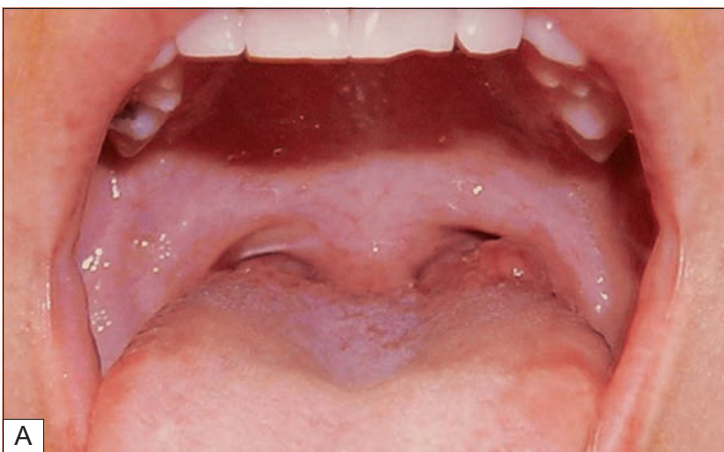
Epstein–Barr virus). Systemic examination is largely unproductive in the majority in identifying the pathogen. Presence of mucocutaneous ulceration, in the anus and genitalia, occurs during the acute seroconversion illness in HIV infection. Sometimes, the tonsillar hypertrophy is asymmetrical during an infectious episode (7.3). Follow-up is needed to ensure that the asymmetry settles down. Persistent enlargement of one tonsil should be investigated further to exclude neoplasm, and commonly tonsillectomy and histological examination is recommended. Lingual tonsillitis is a rare presentation (7.4A, B).



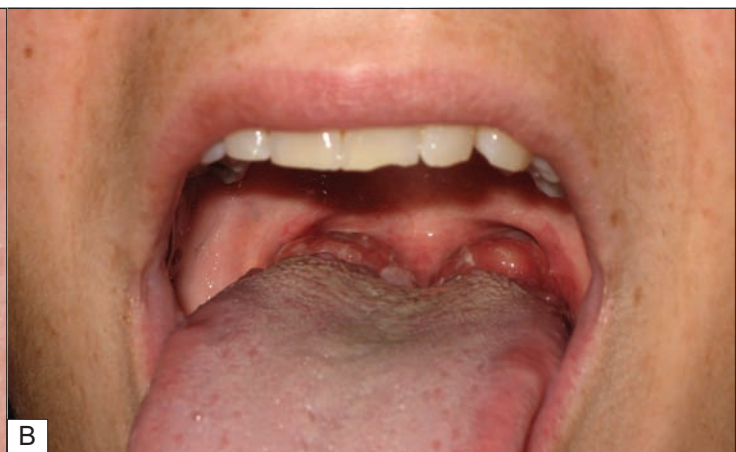**7.2** Tonsillitis showing tonsillar hypertrophy with greyish exudate on the surface. This patient had infectious mononucleosis.



**7.3** Asymmetrical hypertrophy of the left tonsil during acute tonsillitis.



**A**



**B**

**7.4 (A)** Prominent lingual tonsils in the noninflamed state. **(B)** Lingual tonsillitis in the same patient showing multiple follicular exudates.

## Viral infections

### INFECTIOUS MONONUCLEOSIS

Infectious mononucleosis is caused by the Epstein–Barr virus (EBV), a double stranded DNA virus. This is one of the most common causes of viral pharyngotonsillitis in clinical practice. Transmission usually occurs through the saliva of infectious persons and subsequently the virus infects through lymphoid tissue in the pharynx.

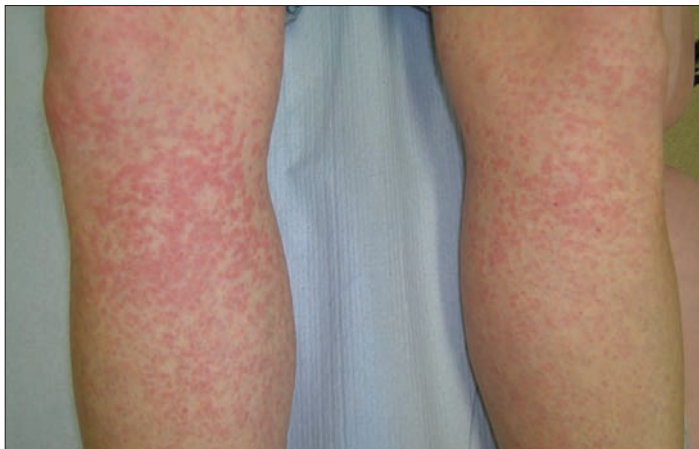Following a variable incubation period between 2–7 weeks, a prodrome of generalized myalgia, fever, and malaise occurs followed by the acute symptoms. These are constituted by fever, sore throat, loss of appetite, and cervical lymphadenopathy. Examination reveals any of the combination of symptoms and signs described above. Periorbital oedema, especially of the upper eyelids (Hoagland’s sign), can be found in nearly 30% of patients in the early days of the infection. Systemic examination will reveal splenomegaly in 60% of patients.

Blood tests are usually helpful in the diagnosis. The presence of atypical lymphocytes with a background picture of lymphocytosis usually suggests an EBV infection. It must be noted that other viral infections such as cytomegalovirus and HIV can also cause a similar atypical lymphocytosis. Other blood count abnormalities include thrombocytopenia and neutropenia. EBV infection also generates heterophile antibodies in the blood. The EBV shares similar epitopes with the cells of other animals. For example, treating the

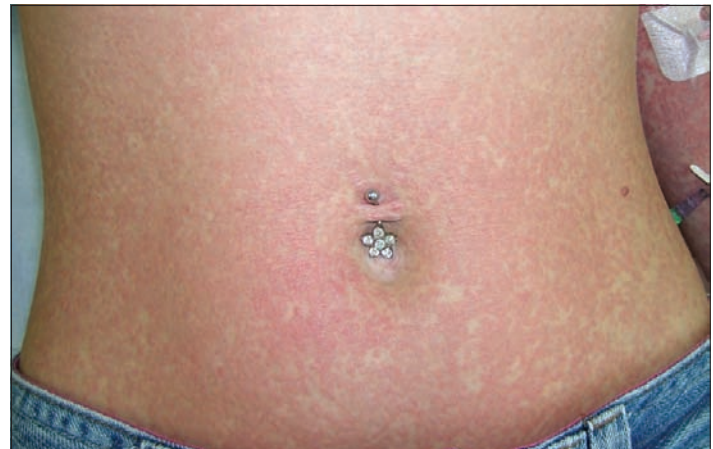serum of affected humans with sheep red blood cells (RBC) causes an agglutination reaction. Using sheep RBC forms the basis for the Paul–Bunnell test and using horse RBCs forms the basis for the Monospot test. Other specific tests include looking for EBV-specific antibodies, like the viral capsid antigen.

Based on the severity of the infection, admission and nursing in an inpatient setting may be needed. Supportive treatment includes analgesics, antipyretics, and intravenous fluids. The severity of the infection can be quite variable, with uncomplicated infections usually resolving within 2 weeks. More than one-third of patients can have a secondary bacterial infection and antibiotics are usually given. The use of ampicillin or amoxycillin in these patients can cause a maculopapular skin rash in 90% of patients (7.5, 7.6), and thus should be avoided if infectious mononucleosis is suspected.

Infectious mononucleosis is a systemic infection and other symptoms involving the gastrointestinal and the central nervous system can occur. The presence of worsening abdominal symptoms or an acute abdomen should raise suspicion of a splenic rupture. Central nervous complications occur in about 3% of patients presenting as aseptic meningitis, cranial neuropathy, and transverse myelitis. Thrombocytopenia and haemolytic anemia are rarely seen.



**7.5** Maculopapular rash on the lower limbs caused by use of amoxycillin in a patient with infectious mononucleosis.

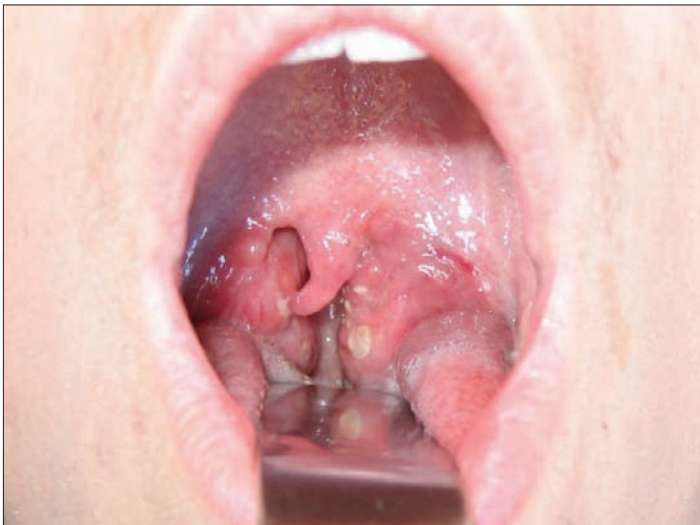

**7.6** Maculopapular rash on the trunk caused by use of amoxycillin in a patient with infectious mononucleosis.



### HERPES SIMPLEX

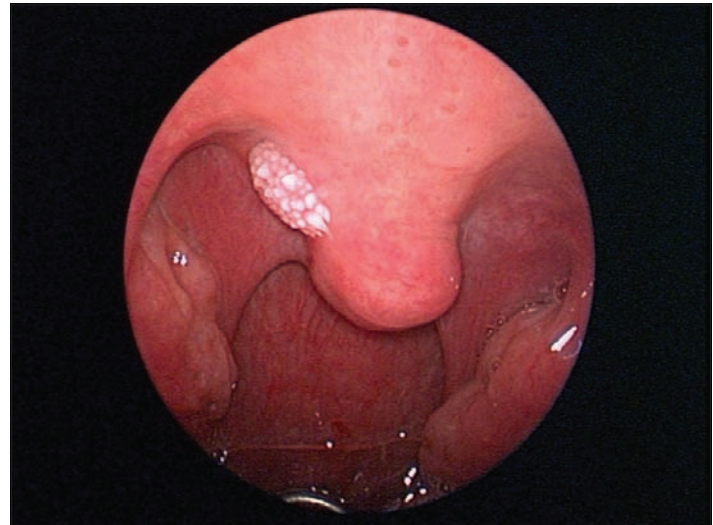
Herpes simplex tonsillopharyngitis (7.7) can present with multiple ulcers on the surface of the tonsil and other sites of the oral cavity or oropharynx in one-third of patients. Unless directed cultures are performed or multinucleated giant cells are seen in a Tzanck smear, it may be difficult to distinguish this from other causes of tonsillitis. Serological tests are usually not helpful.



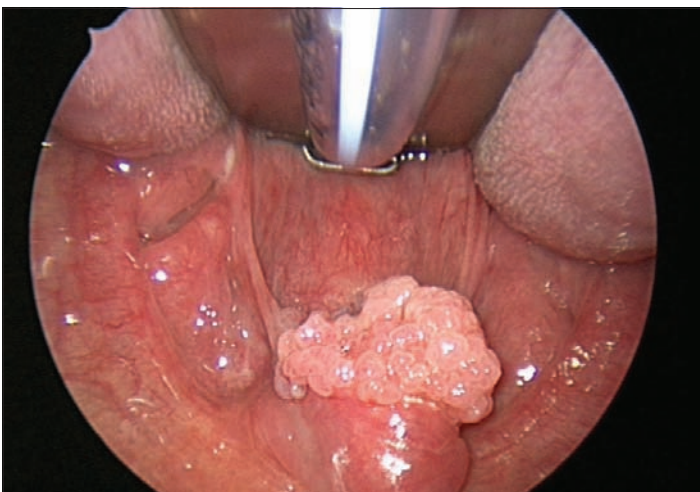
7.7 Tonsillopharyngitis caused by herpesvirus with multiple discrete ulcers on the surface.

### HUMAN PAPILLOMA VIRUS

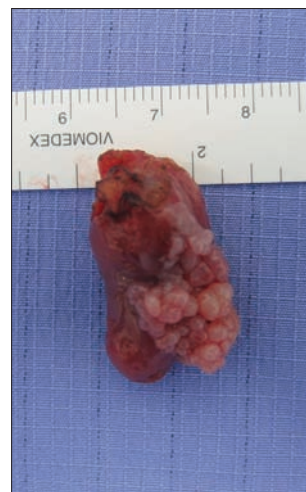Human papilloma virus infections can present as well delineated, warty lesions usually on the palate, which may be flat or pedunculated (7.8, 7.9). The characteristic appearance of the mass is diagnostic. Treatment is surgical excision (7.10).



7.8 Flat papilloma on the uvula.



7.9 Pedunculated papilloma hanging from the uvula.



7.10 Uvula excised along with papillomatous mass to ensure complete removal of the lesion.



## Bacterial infections

### GROUP A BETA HAEMOLYTIC STREPTOCOCCI (GABHS)

GABHS are responsible for the majority of bacterial pharyngitis. The profile of pharyngeal disease these organisms can cause ranges from asymptomatic colonization of the pharynx to a severe pharyngotonsillitis. The symptoms and signs are as discussed above. A scarlatiniform rash can accompany the throat and systemic symptoms. GABHS infections need systemic antibiotics as serious complications can ensue from the infection. These include rheumatic fever, scarlet fever, toxic shock syndrome, necrotizing fasciitis, and septicaemia. Antibiotics do not prevent poststreptococcal glomerulonephritis.

Scarlet fever is a very uncommon presentation these days, and most cases are less severe than in the past. There are characteristic findings in the oral cavity and oropharynx that may be encountered in otolaryngological practice. These include palatal petechiae and a strawberry tongue (white fur on the surface through which red papillae appear) initially. The white fur on the tongue later peels off leaving red papillae (raspberry tongue). The skin shows symmetrical, punctate, diffuse, blanching rash in the neck, axillae, and groin, usually on the second day of the infection. This rash resolves over 3 weeks and skin peeling occurs over the extremities.

Several clinical scoring systems have been developed to help diagnose GABHS infection to start prompt antibiotic treatment. None have demonstrated high diagnostic efficacy. The streptococcal rapid antigen test is a rapid immunoassay that looks for specific group A streptococcal carbohydrate antigen from a throat swab, with the results being available in a few minutes. This has been demonstrated to have a high specificity and negative predictive value.

The indications for antibiotic use are set out in *Table 7.2*. The antibiotic of choice is penicillin, with erythromycin for individuals allergic to penicillin. Analgesia and supportive care are essential. However, aspirin should be avoided in children under 16 years due to the risk of Reye's syndrome.

### DIPHTHERIA

Diphtheria is caused by *Corynebacterium diphtheriae*, a gram-positive rod. With excellent immunization coverage, this infection is virtually extinct in children in the developed nations. However, the epidemiology is changing with nearly 75% of elderly individuals lacking the protective antitoxin. Approximately 70% of patients in the 1990–1995 outbreak in the states of the former Soviet Union were above 15 years of age.

This organism resides exclusively in humans. Spread occurs via airborne droplets from carriers. While infection in the pharynx incites a mild local inflammatory reaction, the virulence of the organism is caused by the production of an exotoxin by toxigenic strains. Diphtheriae toxin causes local tissue necrosis and enters the systemic circulation, primarily affecting the myocardium and peripheral nerves. In the pharynx, a pseudomembrane composed of fibrin, leucocytes, erythrocytes, necrotic cells, and organisms forms. This cannot be differentiated easily from the exudates seen in bacterial and viral tonsillitis. Tissue oedema and cervical adenitis lead to the typical 'bull neck' appearance, which may be accompanied by severe respiratory embarrassment. Systemic signs are curiously less prominent as evidenced by lack of fever and malaise.

**Table 7.2 Indications for antibiotic treatment in acute sore throat**

- Features of marked systemic upset secondary to the acute sore throat
- Unilateral peritonsillitis
- History of rheumatic fever
- Immunosuppressed individuals

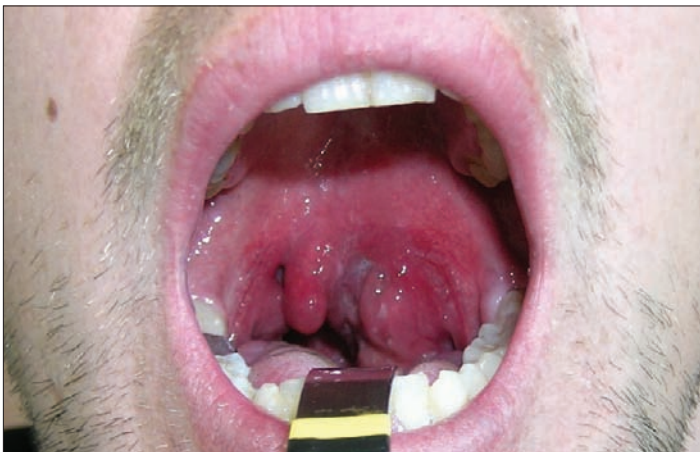(National Institute for Health and Clinical Excellence 2001)

**PERITONSILLAR ABSCESS**

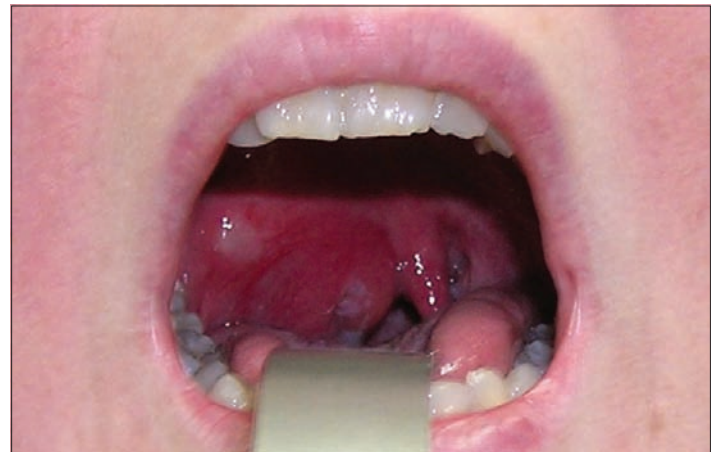Peritonsillar abscess is one of the commonly seen complications from tonsillitis. This occurs due to spread of infection from the superior pole to the peritonsillar space, which lies between the tonsil and its bed. The abscesses are usually polymicrobial, with anaerobes playing a significant role. Symptoms typically include a unilateral sore throat, with referred otalgia and trismus. Examination reveals the tonsil to be inflamed and pushed medially by the peritonsillar collection (7.11, 7.12). The adjacent anterior pillar and soft palate can be inflamed and swollen, with the uvula pushed across the midline. In early cases, a cellulitis alone may exist without an abscess. Diagnosis is clinical and if a collection is suspected, it should be drained. This can be done using a wide bore needle aspiration under local

anaesthesia in the majority of cases (7.13). The site of aspiration is usually the most prominent point of the peritonsillar swelling. Reaspiration may be needed in many cases. Incision and drainage is an alternative strategy, but has no proven advantage over simple aspiration. In children with recurrent quinsy where aspiration is not possible without a general anaesthetic, a quinsy tonsillectomy will serve as definitive management. Hospital admission and intravenous antibiotics are needed.

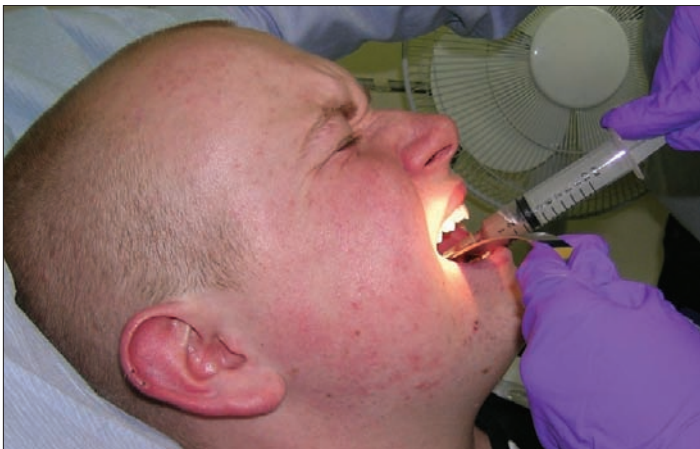Following tonsillectomy, a membrane of slough that gradually separates over 10–14 days covers the post-tonsillectomy fossa (7.14). This appearance can be mistaken for an infection. No antibiotics are needed in this situation.



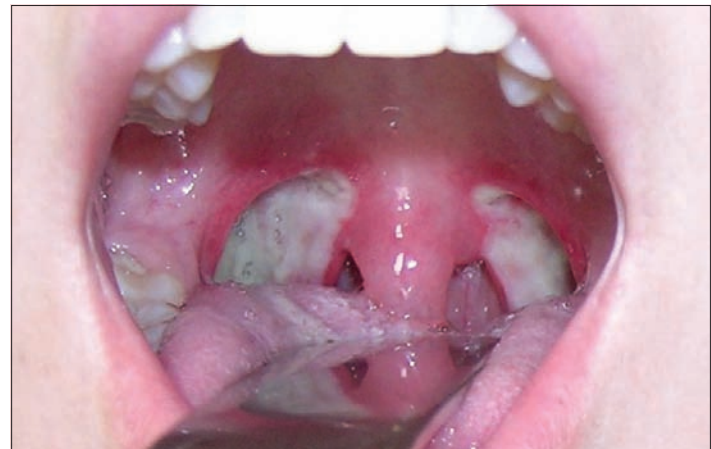7.11 Early left peritonsillitis showing the tonsil and uvula pushed medially with minimal soft palate swelling.



7.12 Large right peritonsillar space abscess, displacing the uvula and tonsil, pointing through the soft palate.



7.13 Needle aspiration of peritonsillar abscess being performed under local anaesthesia.

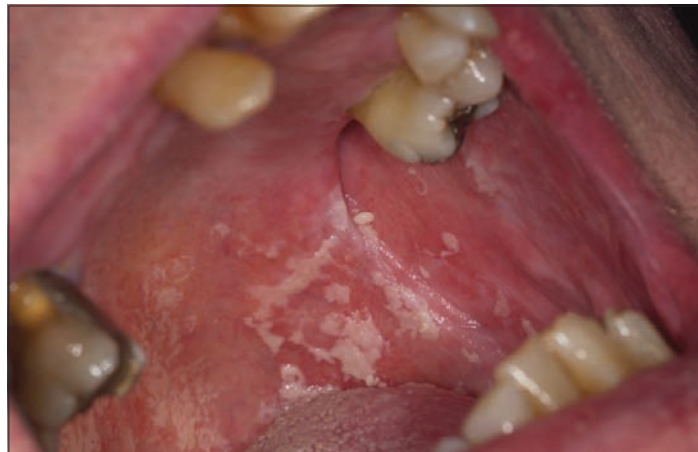

7.14 Post-tonsillectomy fossa as seen on day 4. Note the uniformly sloughy exudate limited to both fossae.

**CANDIDA**

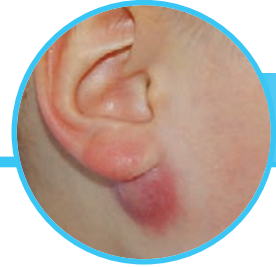*Candida* species are normal commensals in the oral cavity and oropharynx. Infections are thus opportunistic, occurring in the background of predisposing conditions. Radiation, Sjögren's syndrome, immunosuppressant, and diabetes mellitus are some of the predisposing factors. Altered taste, burning sensation, and dysphagia are the usual presenting complaints. The pseudomembranous variant is the most common presentation (7.15), with

whitish patches on the oropharyngeal mucosa that rub off easily, leaving an erythematous base. Treatment involves optimal management of the predisposing factor and antifungals. Topical nystatin is used as a first-line agent. For refractory disease, systemic antifungals like fluconazole or itraconazole are helpful. In patients where there is a high risk of relapse, prophylactic therapy with weekly fluconazole may be warranted.



**7.15** Pseudomembranous variant of *Candida* infection in the oropharynx in a patient who uses steroid inhalers. (Reproduced with permission from Quintessence Publishing; *Practical Oral Medicine: Oral Surgery and Oral Medicine* -3, 2006, I. Macleod, A Crighton.)





# Infections of the salivary glands

*Vinidh Paleri*

## Introduction

Both bacteriae and viruses are involved in salivary gland infections. The clinical setting and clinical features do permit differentiation with a reasonable degree of certainty.

## Viral infections

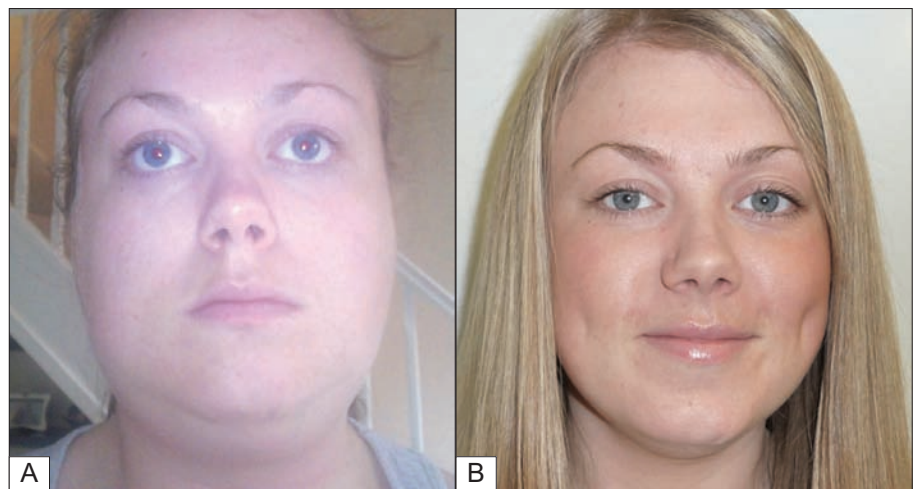Viral pathogens cause salivary gland infections more often than bacteria. The parotid gland is more susceptible compared to the submandibular gland as the salivary secretion is more serous. Serous saliva lacks lysosomes, IgA, and glycoproteins, which have anti-infective properties. These infections occur when pathogens enter the gland through the salivary duct. Reduction in the salivary flow, caused by dehydration, medications, radiation, and Sjögren's syndrome, are predisposing factors. *Table 8.1* lists the viral pathogens that can cause salivary gland infections.

## MUMPS

Mumps caused by paramyxovirus is the most common viral infection, usually involving the parotid gland. This is a RNA virus transmitted by airborne droplets. After an incubation period of 2–3 weeks, low-grade fever, malaise, and anorexia occur. This is then followed by parotitis, which is usually bilateral. Enlargement of the gland can be differentiated from cervical lymphadenopathy by outward displacement of the lobule of the pinna (**8.1**). Spontaneous resolution is the norm, but this can take a few weeks. Mumps can be associated with other serious complications such as sensorineural hearing loss, aseptic meningitis, orchitis, and pancreatitis. The clinical presentation should suggest the diagnosis. Serological tests to identify antibody to mumps-specific IgM will confirm a recent infection. Treatment involves supportive care and recognizing the possible complications, which often need medical input. Use of the live attenuated MMR (mumps, measles, and rubella) vaccine has led to a decrease in the incidence of this disease.

**Table 8.1** Viral causes of parotitis

Paramyxovirus
Parainfluenza 3
Coxsackie virus
Influenza A virus
Cytomegalovirus
Epstein–Barr virus
Human immunodeficiency virus



**8.1 (A)** Patient with mumps depicting parotid gland enlargement with cervical lymphadenopathy. **(B)** The same patient after she fully recovered.

### HUMAN IMMUNODEFICIENCY VIRUS

Human immunodeficiency virus (HIV) causes a chronic infective process in the salivary glands. Enlargement of intra- or periparotid nodes and lymphatic infiltration of the glandular structure causes bilateral, noninflammatory, diffuse hypertrophy of the salivary glands (8.2). Lymphoepithelial cysts can also result from duct obstruction. The diagnosis is suspected from the clinical picture in persons known to be HIV positive. Rarely is the diagnosis made retrospectively from tissue biopsy from the salivary gland. Imaging (CT or MR scans) will differentiate parenchymal hypertrophy from lymphoepithelial cysts. The presence of multiple cysts may require a parotidectomy for cosmetic reasons. Parenchymal hypertrophy may settle with antiretroviral treatment.

### Bacterial infections

#### ACUTE SUPPURATIVE SIALADENITIS

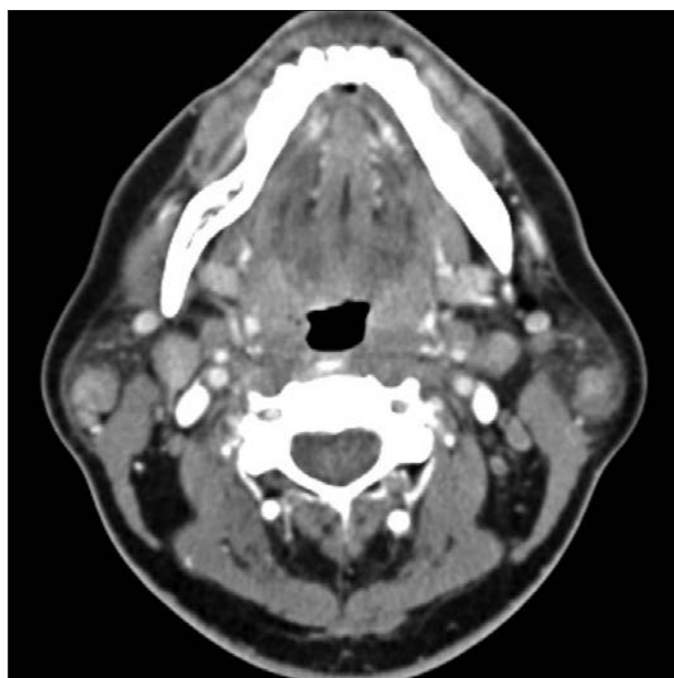
Acute suppurative sialadenitis is commonly seen in the post-operative setting following major surgery and in patients with chronic illnesses such as diabetes mellitus and renal failure.

Calculus obstruction of the duct, more frequent in the submandibular salivary gland, can lead to secondary infection of the gland (8.3, 8.4). A similar syndrome of neonatal parotitis, often bilateral, is seen in pre-term neonates.

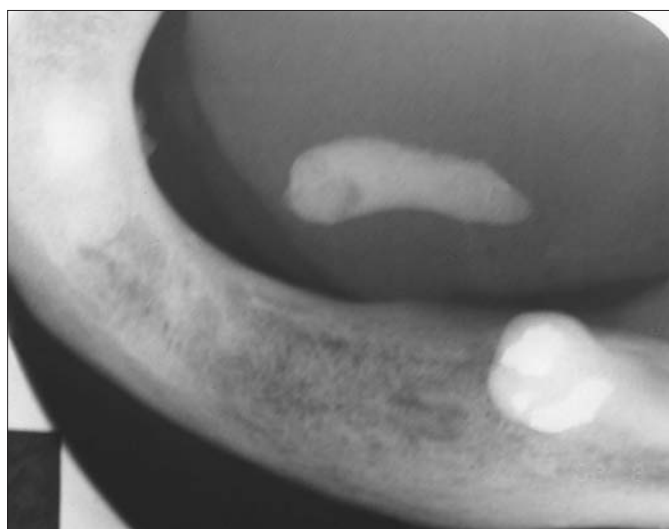The offending pathogens are often the oral commensals, with *Staphylococcus aureus* being the most common, with some contribution from anaerobes. Gram-negative bacteria also play a role in neonatal parotitis. These are identified in Table 8.2. Bacterial parotitis can progress to a parotid abscess. The presenting symptoms and signs of parotid abscess include (8.5):

- Pain and tenderness.
- Swelling.
- Erythema over the parotid region.
- Purulent discharge at duct orifice.

It must be noted that fluctuation may not be clinically evident until the abscess is quite advanced owing to the overlying tense parotid fascia. Purulent discharge may be seen flowing through the duct orifice (8.6). Facial weakness is an uncommon finding.



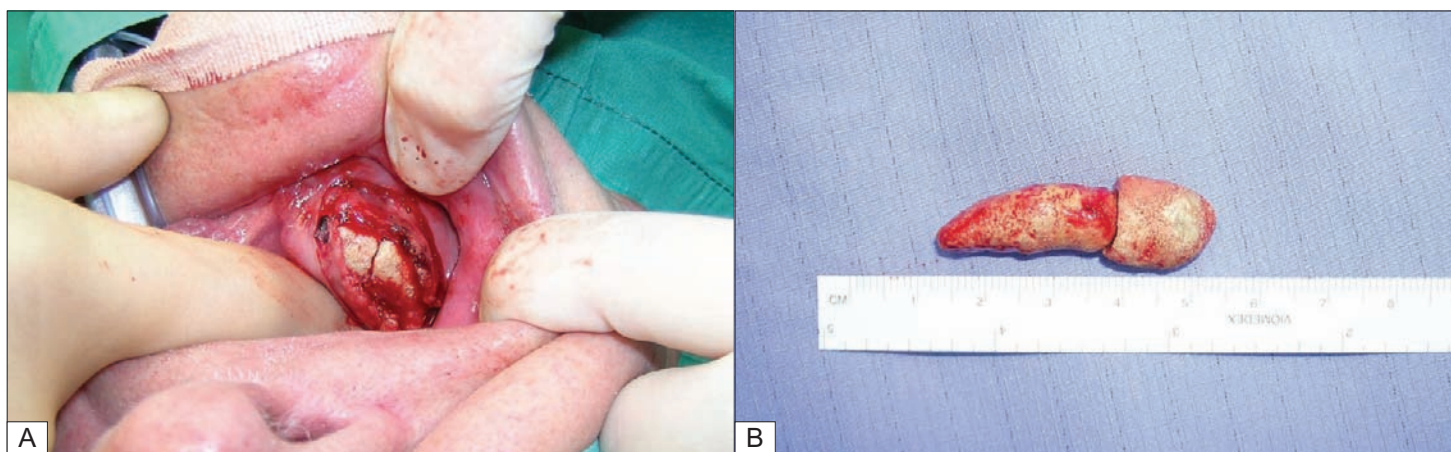
8.2 Bilateral intraparotid nodes causing parotid enlargement in HIV infection.



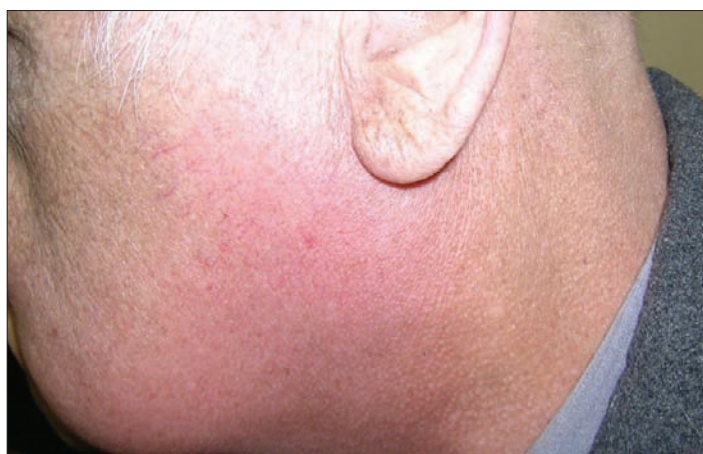8.3 Plain radiograph demonstrating a calculus within the submandibular duct.

**Table 8.2 Bacterial causes of parotitis**

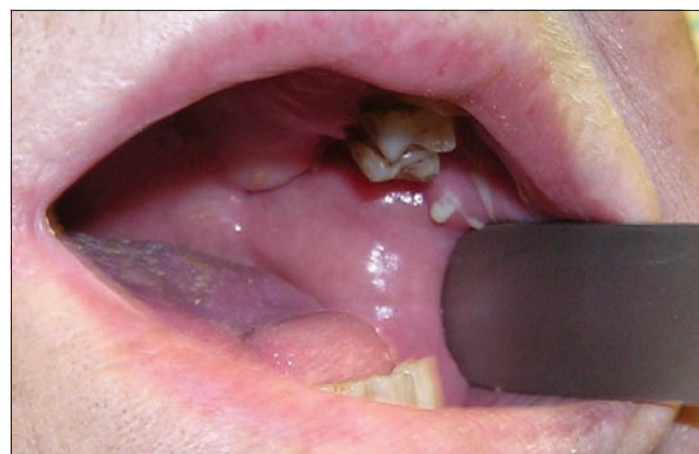<i>Streptococcus pyogenes</i>
<i>Streptococcus viridans</i>
<i>Streptococcus pneumoniae</i>
<i>Haemophilus influenzae</i>
<i>Peptostreptococcus</i>
<i>Bacteroides</i>
<i>Fusobacterium</i>



**8.4 (A)** Intraoperative picture demonstrating large submandibular salivary gland calculus in the duct. **(B)** Submandibular gland calculus removed through the floor of the mouth.



**8.5** Erythema and inflammation seen over the parotid region in acute bacterial parotitis.



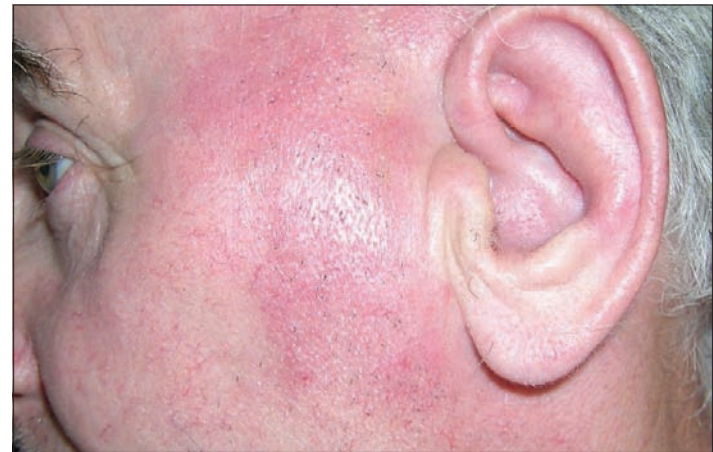**8.6** Pus draining from the parotid duct of the patient shown in **8.4**.



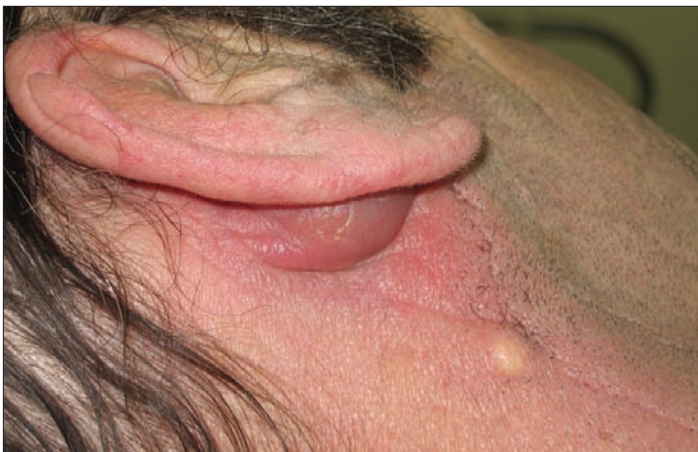Differential diagnosis includes facial cellulitis (8.7), pre-auricular (see 4.1) and infra-auricular abscesses (8.8) and infections of skin cysts over the parotid region (8.9) can present with symptoms and signs that can be mistaken for parotid abscesses. Careful examination will reveal the superficial nature of these lesions.

### SUBMANDIBULAR SALIVARY GLAND INFECTIONS

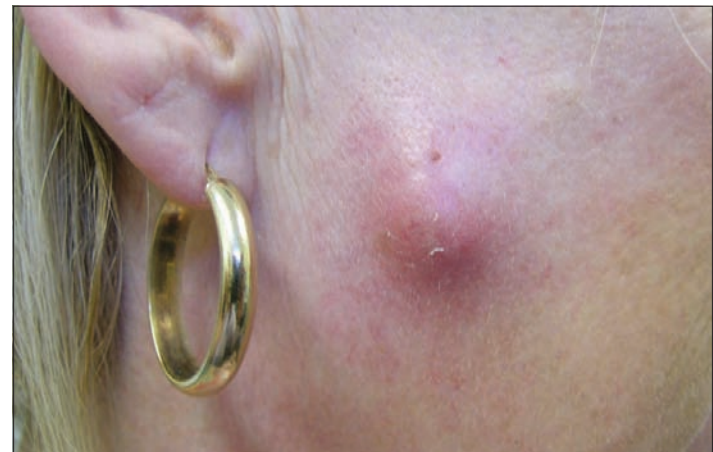Submandibular salivary gland infections present with similar symptoms and signs under the lower jaw (8.10, 8.11). Fluctuation will be evident earlier than in parotid abscesses. An ultrasound scan is useful to confirm the presence of a collection if clinical examination is not confirmatory.



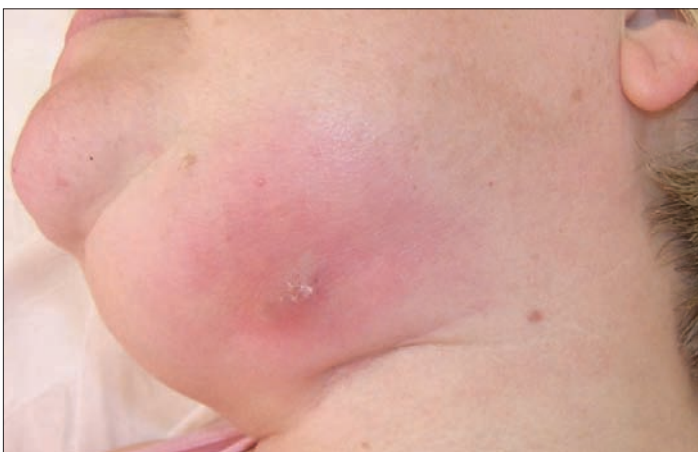8.7 Cellulitis of the face.



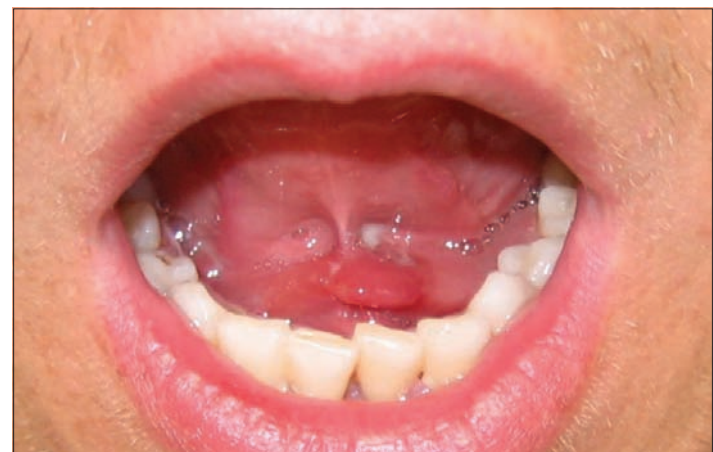8.8 Infra-auricular abscess from a sebaceous cyst. Note another cyst lower down on the neck.



8.9 Infected sebaceous cyst of the face.



8.10 Abscess evolving from acute bacterial submandibular sialadenitis.

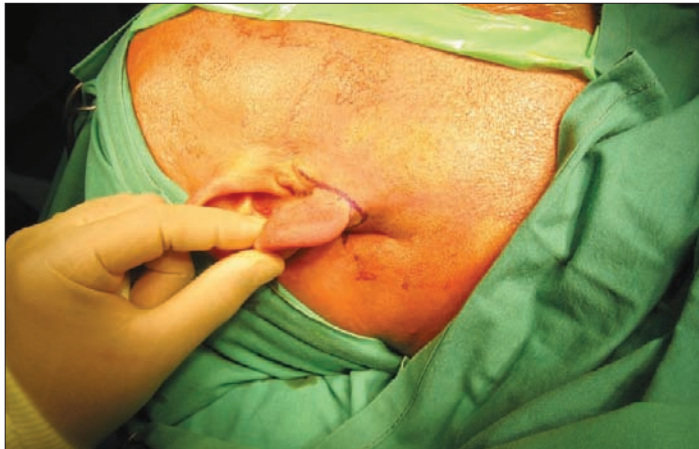


8.11 Pus being expressed through the submandibular duct orifice with inflammation of the adjacent frenulum and floor of mouth.

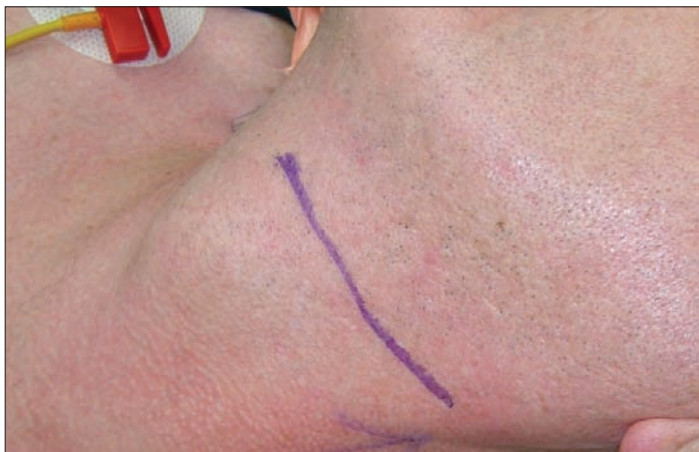Rehydration and systemic antibiotics are indicated and the presence of a collection requires surgical drainage. This can be performed through a parotidectomy type incision (8.12). An incision over the cheek should be avoided as cosmetic results can be unsatisfactory (8.13). In submandibular collections, care should be taken to place the incision at least an inch (2 cm) below the lower border of the mandible to avoid injury to the marginal mandibular nerve (8.14).

### CHRONIC RECURRENT PAROTITIS OF CHILDHOOD

Chronic recurrent parotitis of childhood is the second most common inflammatory disease in children after mumps.



8.12 A limited parotidectomy incision provides good access and will blend in the pre-auricular crease.



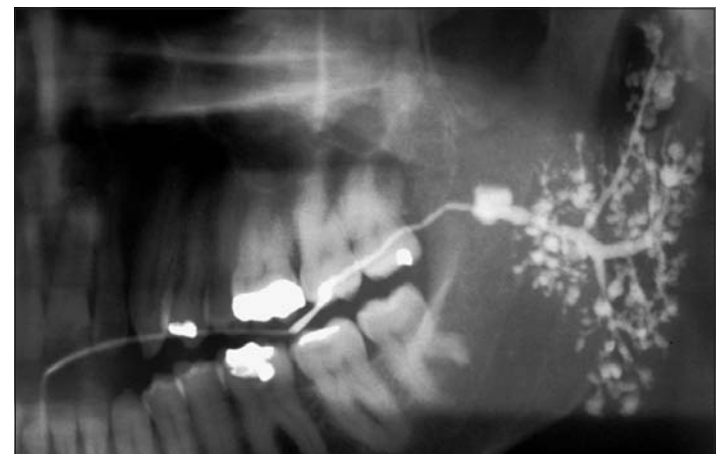
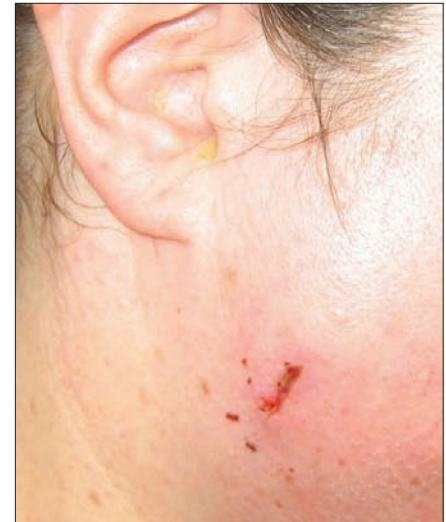8.14 Incision for submandibular region surgery should be placed an inch (2 cm) below the lower border of the mandible.

This is characterized by recurrent mild inflammatory episodes of the parotid gland. Several organisms have been implicated, including *Staphylococcus aureus*, *Streptococcus viridans*, and viruses. The episodes usually settle down by puberty. Sialography characteristically shows punctate sialectasis (8.15). Treatment involves symptom control, rehydration, and antibiotics.

### GRANULOMATOUS INFECTIONS

Mycobacterium tuberculosis and nontuberculous mycobacteria are responsible for all granulomatous infections of the salivary glands. The incidence of atypical mycobacterial

8.13 Incision over the site of the abscess on the cheek can lead to an unsatisfactory cosmetic result.



8.15 Sialography demonstrating numerous punctate globular pools of contrast medium that correspond to peripheral intralobular ducts. (Courtesy of Dr. I. Macleod, Newcastle, UK.)

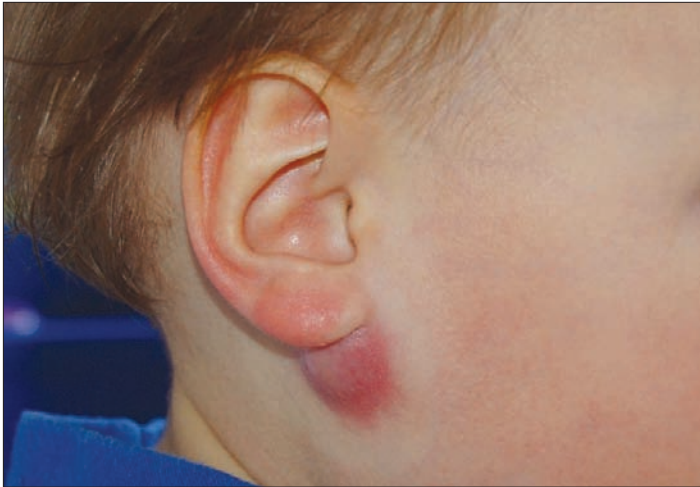

(*M. avium-intracellulare*, *M. scrofulaceum*, *M. kansasii*) infections has increased over the years. This typically occurs in children under 5 years of age and presents as an enlarging, nontender, inflamed mass with a violaceous hue over the involved salivary gland, which gradually suppurates into the subcutaneous tissues (8.16, 8.17). Systemic symptoms may be marked by their absence. If left untreated, this can lead to a discharging fistula. The clinical picture can be quite suggestive and diagnosis is achieved by confirming growth of the organism in the discharge or in the aspirate of the gland. An open biopsy may be needed if aspiration is unsuccessful. Treatment for this condition continues to

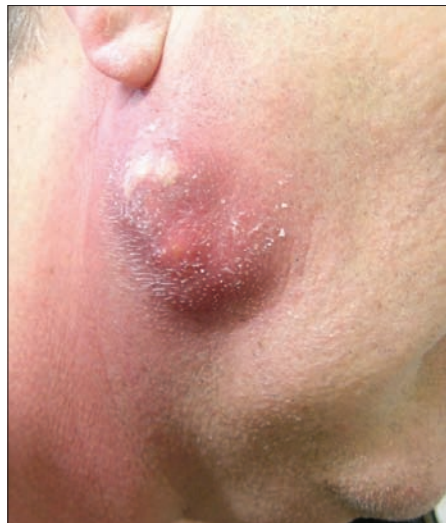evolve. Current options include antibiotics if medically responsive, complete surgical excision if possible, or a combination of both.

### TUBERCULOSIS

Tuberculosis of the salivary glands is a rare disease in the developed world and presents in the young adult or in immunocompromised individuals. There is diffuse enlargement of the gland parenchyma or intra- and/or periparotid lymphadenopathy. Antituberculous therapy is needed to cure the infection.

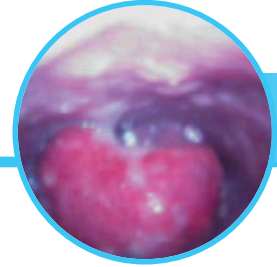


**8.16** Atypical mycobacterial infection in a child presenting as a chronic abscess.



**8.17** Atypical mycobacterial infection of the parotid presenting as a chronic abscess.





# Infections of the larynx

*Vinidh Paleri*

## Introduction

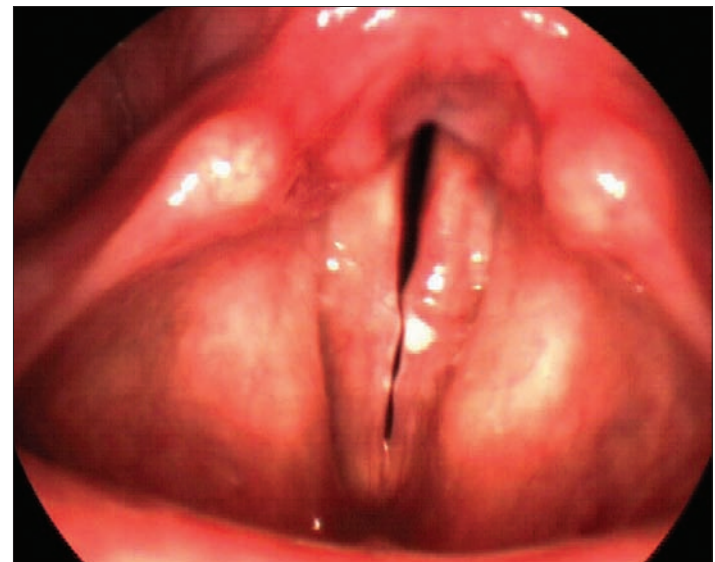
Laryngeal infections are classified into acute and chronic infections based on the duration of symptoms. Most acute laryngeal infections are caused by viruses and resolve spontaneously within 2 weeks. These occur usually as one of the manifestations of an upper respiratory tract infection. It variably involves the nose and nasopharynx, the oropharynx, and the larynx. The pathogens commonly involved are identified in *Table 9.1*.

Following a variable prodrome of low-grade fever and malaise, the primary symptoms include sore throat, cough, and a change in voice. The nature of the change in voice can vary from a breathy voice, usually due to the patient protectively splinting the larynx, to a raspy hoarse voice

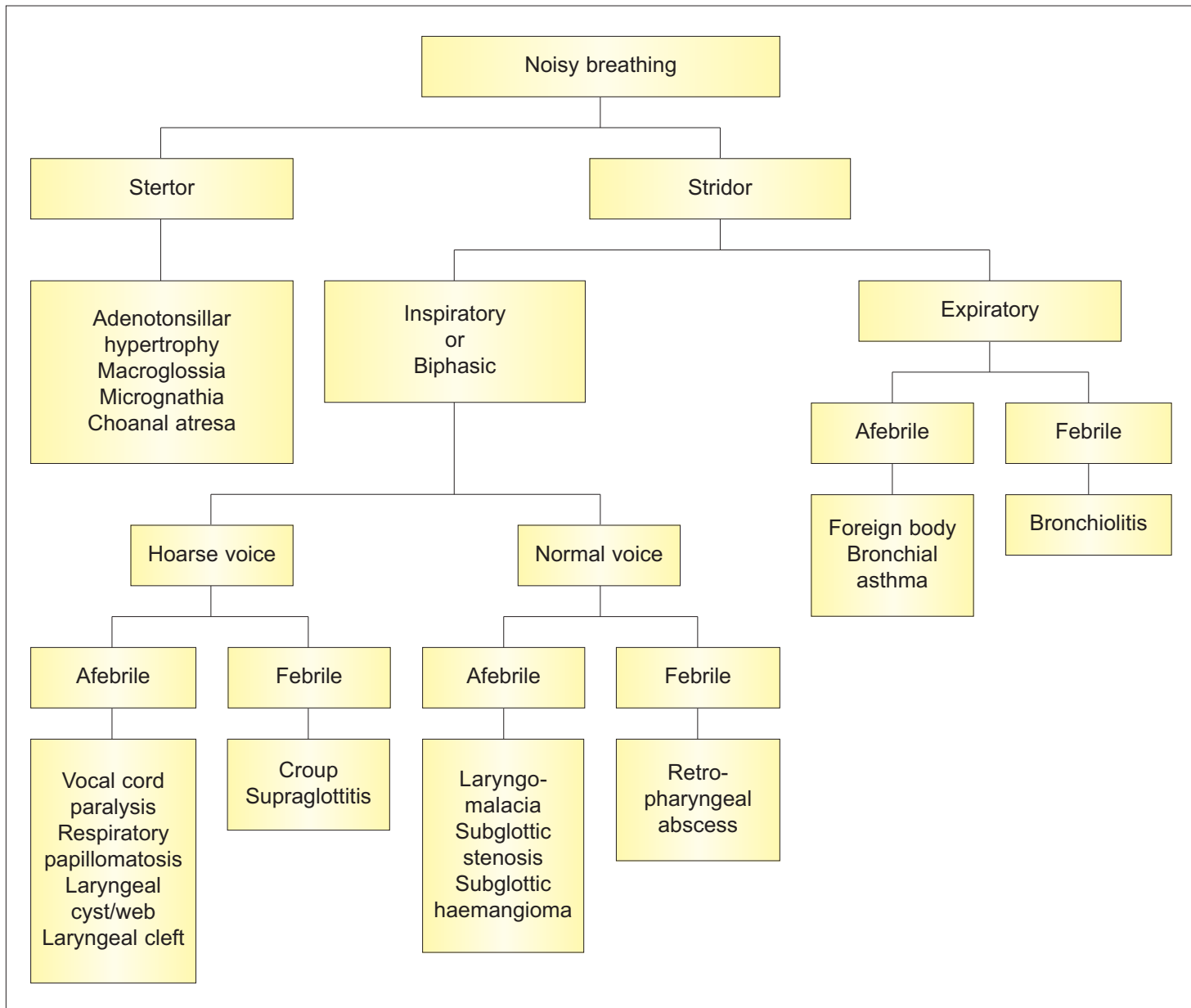
secondary to a haemorrhagic lesion on the cords. The diagnosis is made on the basis of history, general examination, and listening to the voice. Laryngeal inspection is not necessary to confirm the diagnosis. Laryngoscopy will reveal congested vocal cords with prominent vessels and oedema (9.1). Excessive mucus may be evident. Treatment is symptomatic, with advice to rest the voice for at least 48 hours, followed by gentle voicing. However, several infections of the upper aerodigestive tract can present with stridor and airway compromise. A systematic approach is required to achieve the diagnosis and the algorithm shown helps this process (9.2).

**Table 9.1 Organisms commonly implicated in acute laryngitis**

- Rhinovirus
- Coronavirus
- Influenza virus
- Parainfluenza virus
- Paramyxovirus
- Respiratory syncytial virus
- Enterovirus
- Adenovirus
- *Bordetella pertussis*



**9.1** Acute viral laryngitis as seen through a 70° rigid endoscope, showing congested, oedematous vocal cords.



9.2 Algorithm to show the differential diagnosis of stridor in children. (Adapted from Paleri V and Bradley PJ [2007]. Breathing disorders. In: Ludman H and Bradley PJ [eds], *ABC of ENT*. Blackwell Publishing Ltd, Oxford.)

## Laryngeal infections

### SUPRAGLOTTITIS IN CHILDREN

*Haemophilus influenzae* type B is the usual infective agent, although the incidence has significantly decreased with HiB vaccination. Children between the ages of 2 and 7 years of age are affected, with a peak incidence in 3-year-olds. The disease typically presents with a rapid onset of high fever, toxicity, agitation, stridor, dyspnea, muffled voice, and

painful swallowing. Examination will reveal a child in distress, seated, and leaning forward with the mouth open and drooling. If supraglottitis is suspected, no further examination is recommended outside of a controlled setting. In acute supraglottitis, the risk of complete obstruction is high and the airway has to be secured. Endotracheal

intubation is the method of choice as the supraglottic swelling is usually reversible in a few days, unless complications occur. Senior anaesthetic help, with experience in managing the compromised airway, must be sought. An oedematous, cherry red epiglottitis with inflammation of the surrounding supraglottis is seen on direct laryngoscopy. Intravenous antibiotics are required.

### SUPRAGLOTTITIS IN THE ADULT

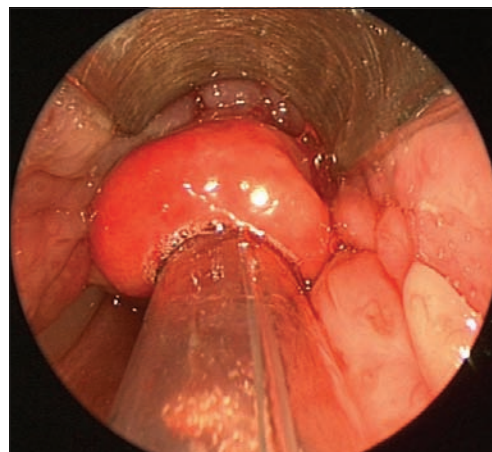
Although caused by the same infective agent, adult supraglottitis less commonly causes airway distress. Presenting symptoms include fever and acute onset odynophagia, similar to tonsillitis and quinsy. Examination of the oropharynx will be normal or slightly inflamed. Flexible nasendoscopy will clinch the diagnosis when an inflamed supraglottis is evident (9.3). The diagnosis can be missed if laryngeal examination is not performed in adults with acute odynophagia and a normal oropharynx. Management is primarily medical with antibiotics and close observation of the airway. Adult epiglottitis can rarely lead

to an epiglottic abscess (9.4). Only 10% of patients will need intubation and intensive care monitoring.

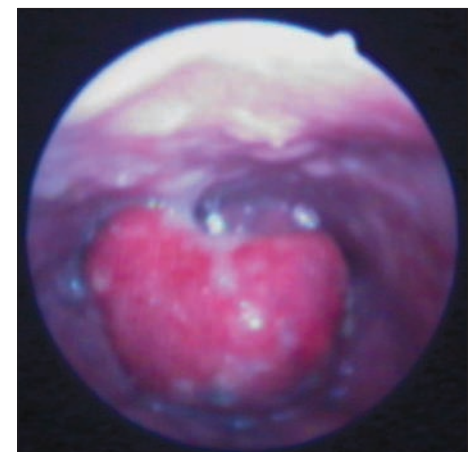
### LARYNGOTRACHEOBRONCHITIS (CROUP)

The most common cause of acute stridor in childhood is laryngotracheobronchitis or croup. Parainfluenza virus is the most common causative agent, with influenza virus types A or B, respiratory syncytial virus, and rhinoviruses also being implicated. Children between the ages of 6 months and 3 years are affected, with a peak incidence in the second year of life. A history of preceding upper respiratory tract infection is usually present. Symptoms include low-grade fever, barking cough, inspiratory stridor, and hoarseness. These are characteristically worse at night and are aggravated by agitation and crying. If the diagnosis is clear, no endoscopy is needed. Humidification, oxygen, nebulized steroids, and nebulized adrenaline with systemic steroids are recommended in croup (9.5). Severe cases may need intubation and ventilation for a few days. Recurrent croup should raise the suspicion of congenital subglottic stenosis.

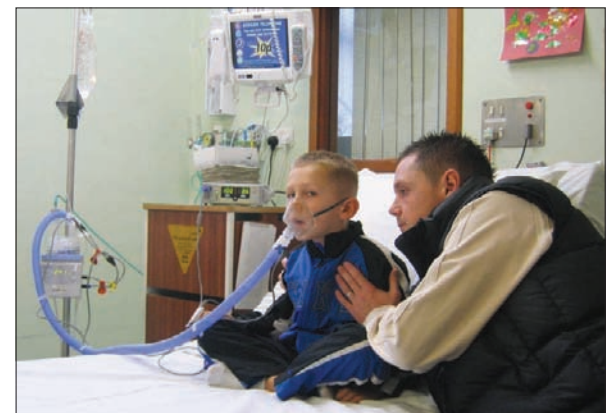**9.3** A rigid endoscopic view of an inflamed and oedematous epiglottis in an adult with supraglottitis.



**9.4** Flexible endoscopic view of a grossly swollen epiglottis caused by an epiglottic abscess.



**9.5** The treatment set-up for managing a child with croup. The picture demonstrates a mask in place delivering humidified oxygen and nebulized steroids. Note the saturation monitor and parental presence to calm the child.





**BACTERIAL TRACHEITIS**

This is a complication of croup, caused by bacterial superinfection of the trachea. The usual pathogen is *Staphylococcus aureus*, with others being implicated as well. The presentation is usually that of a croup that does not improve with nebulized epinephrine. High fever, with worsening respiratory distress and chest signs, should alert one to the diagnosis. Treatment involves systemic antibiotics, with tracheobronchoscopy and suctioning of the secretions under general anaesthesia. The majority of patients need intubation and ventilation.

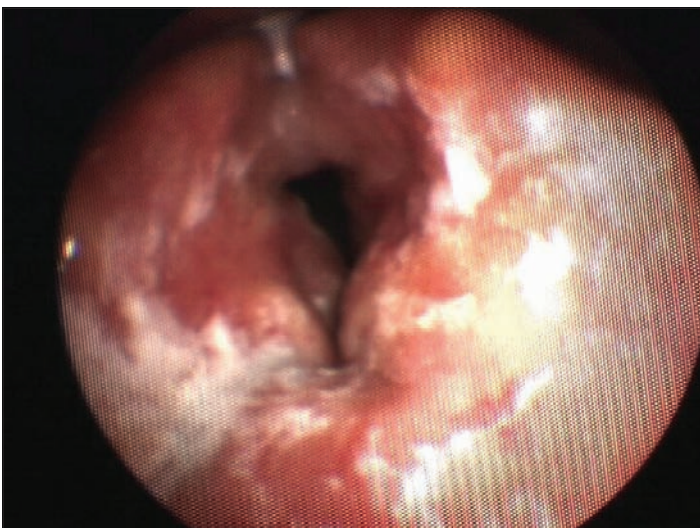
Epiglottitis and laryngotracheobronchitis are the two infective conditions that can present with stridor in children and the differences are set out in *Table 9.2*. Differentiating between them is important as the management differs.

**CHRONIC INFECTIVE LARYNGITIS**

Common causes of chronic infective laryngitis are *Mycobacterium tuberculosis* and *Candida* sp. Patients present with longer duration of symptoms such as hoarseness, cough, pain, and weight loss. Candidal infections of the larynx usually accompany similar lesions in the pharynx and oesophagus and can present with odynophagia (9.6). This condition is common in immunosuppressed hosts and is also frequently seen after radiation for head and neck cancer. Symptomatic infections need systemic antifungals to effect a cure. Other rare fungal infections, such as histoplasmosis and blastomycosis, are usually endemic to certain areas in the United States. The latter infection can be mistaken for a malignancy in clinical presentation and histology.

**Table 9.2 Characteristics differentiating between epiglottitis and croup**

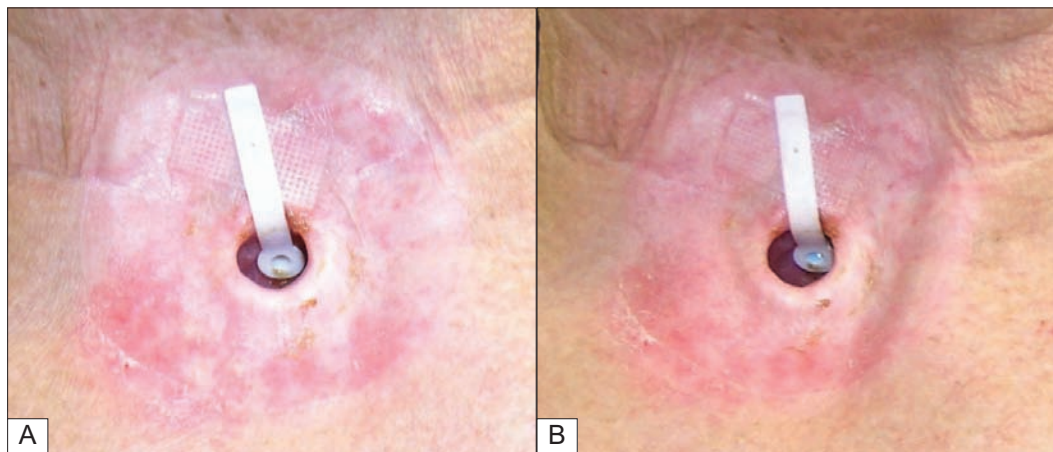
<b>Characteristic</b>	<b>Epiglottitis</b>	<b>Croup</b>
Peak age (range)	3 years (2–7 years)	2 years (0.5–3 years)
Preceding URTI	No	Yes
General examination	High fever, toxic	Mild fever
Onset	Few hours	1–3 days
Cough	No	Yes
Stridor	Inspiratory	Inspiratory/biphasic
Drooling	Yes	No
Neck tenderness	Yes	No
Voice	Muffled, hoarse	Hoarse



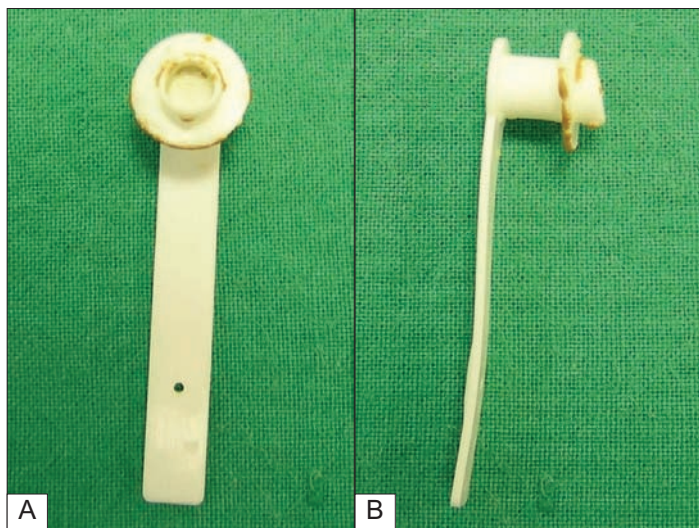
**9.6** Flexible endoscopic view of the larynx showing candidal pseudomembranes on the supraglottic mucosa.

Rehabilitation after laryngectomy involves insertion of a speech valve through a primary tracheoesophageal puncture. The speech valve is prone to be colonized by fungi, leading to deterioration in the life of the speech valve. This presents as leakage of liquids through the valve (9.7A, B). Signs of *Candida* colonization include evidence of colonies on the flanges (9.8A, B) with brittle and stiff retention collars. Patients with previous radiation treatment are at greater risk for colonization, probably because of mucosal changes and decreased salivary flow. Treatment involves replacing the valve and prophylaxis against fungal infection.

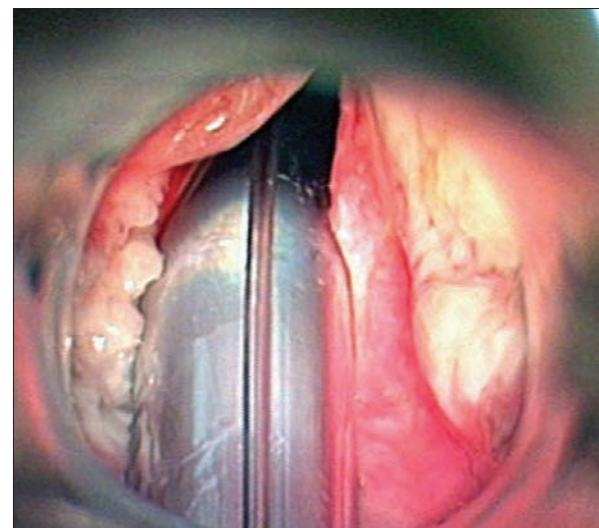
Tuberculosis rarely presents with primary lesions in the larynx. The combination of symptoms and signs mimic laryngeal cancer and certain diagnosis cannot be made unless a biopsy is done. The lesions tend to occur on the epiglottis or the posterior glottis (9.9), the latter being an unlikely site for primary glottic cancer. These patients usually have concurrent pulmonary disease (9.10). Antituberculous chemotherapy leads to these patients becoming rapidly noninfective (9.11).



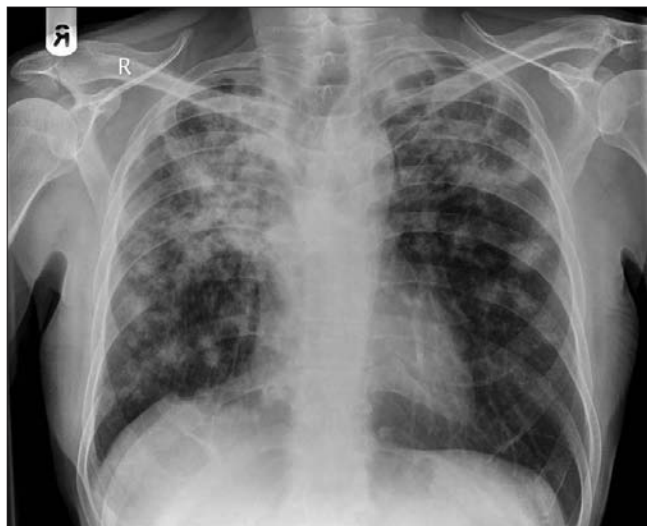9.7 (A) View of a speaking valve *in situ* prior to swallowing blue dyed liquid. (B) The speaking valve *in situ* with a leak of blue dyed liquid through the valve.



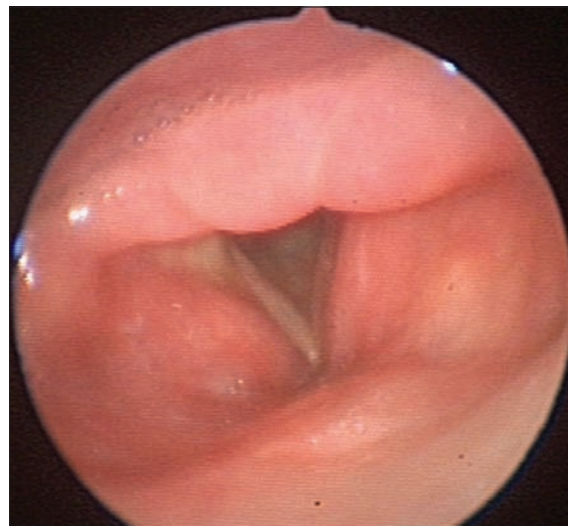
9.8 (A, B) Colonies of *Candida* on a Blom-Singer speaking valve.



9.9 Microlaryngoscopic picture depicting tuberculous infection of the larynx showing the lesion sited in the posterior part of the left vocal cord.



**9.10** Chest X-ray of the patient with laryngeal tuberculosis showing multiple infiltrates in both lung fields.



**9.11** Flexible endoscopic view of the larynx of the patient shown in **9.9**, 2 weeks after being started on chemotherapy.

### LARYNGEAL PAPILOMATOSIS

Laryngeal papillomas are one of the clinical manifestations of respiratory papillomatosis in children, which can involve mucosa of the nose, mouth, and oropharynx. Human papilloma virus types 6 and 11 usually cause the infection. This is essentially a disease process that involves all respiratory mucosa, as evidenced by the finding of viral genome in normal mucosa. Symptoms do not start earlier than 6 months of age. Children present with a hoarse, weak voice in the early stages. With progressive disease, chronic cough and mild inspiratory stridor become evident. With higher load of papillomas, severe airway compromise occurs with stridor, use of accessory muscles, and features of carbon dioxide retention, which is a vanishingly rare presentation these days. The characteristic finding of solitary or often multiple warty lesions with an irregular surface on flexible nasolaryngoscopy establishes the diagnosis (**9.12**, **9.13**). Histological confirmation should be obtained prior to treatment.

Spontaneous resolution may occur as the patient grows older. Repeated intervention, based on the growth of the papillomas, is needed to control symptoms and maintain the airway. Tracheostomy is to be avoided as it can enhance spread to the lower airways. Treatment involves debulking the papilloma by mechanical means (laser or microdebrider)

to remove the obvious lesions (**9.14**). Care must be taken to avoid damage to normal adjacent tissue to minimize disruption of the voice. Systemic treatment with antivirals has fallen out of favour due to side-effects. There is resurgence for medical treatment using local antivirals like cidofovir, but this is used in a controlled setting.

### LARYNGOPYOCOELE

At the anterior end of the laryngeal ventricle lies a pouch called the saccule. Dilatation of the saccule or the ventricle can lead to an internal or a combined (internal-external) laryngocoele (**9.15**). These dilations can become obstructed and the contents subsequently get infected leading to a laryngopyocoele. These are rare entities. Presentation will include sore throat, odynophagia, altered voice and, if large, a compromised airway. Treatment involves drainage of the collection initially and interval excision of the laryngocoele.

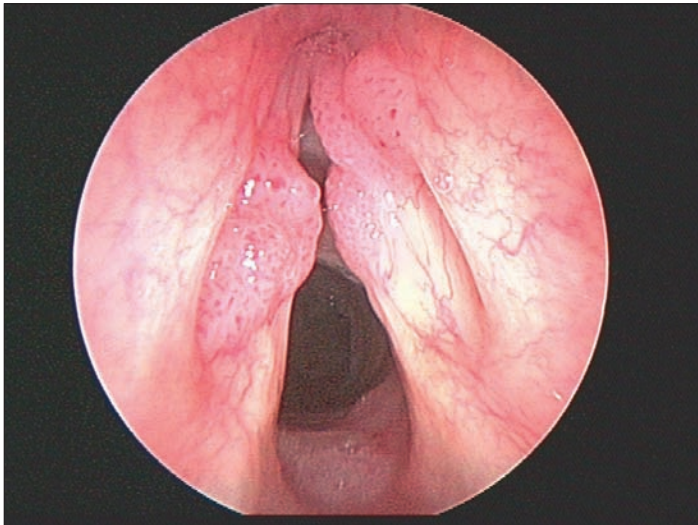
### CHONDRONECROSIS

This is a rare complication that usually occurs following radiation therapy to the larynx. It can occur a few months to many years after radiation. Usually, a minor traumatic event sets off the process, although it has been known to start

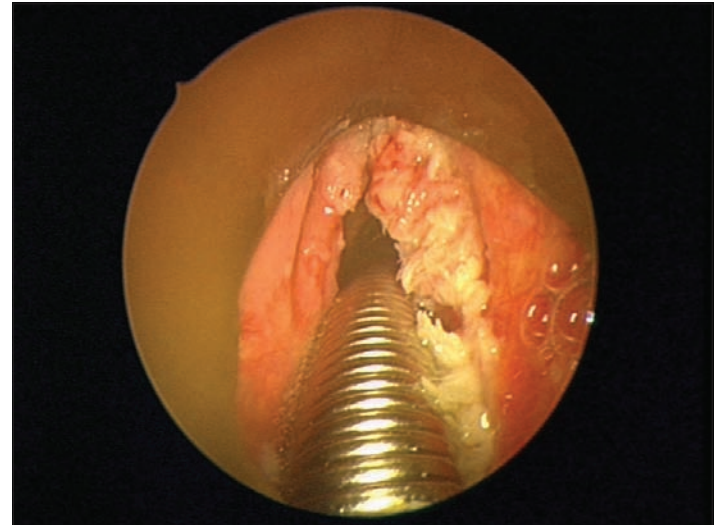


spontaneously. The patient complains of poorly controlled pain, dysphagia, and aspiration. Clinical examination may be unrewarding, although rarely a discharging sinus may be present (9.16). Usually, diffuse laryngeal oedema is all that is seen. In severe cases, endoscopic examination may reveal

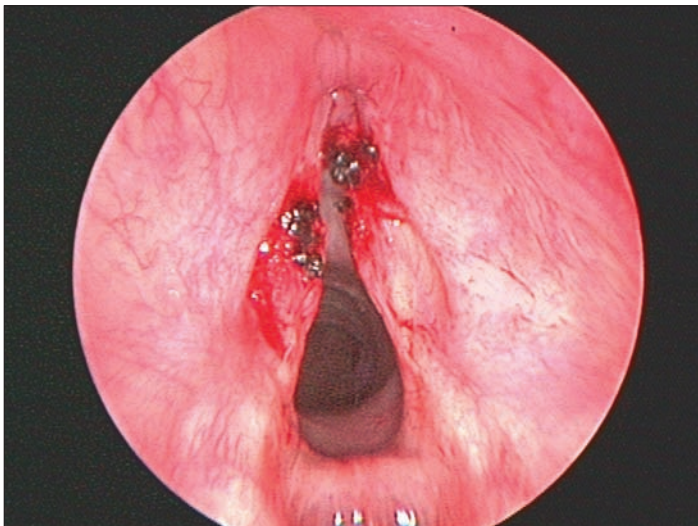
necrotic cartilage sequestering into the laryngopharynx (9.17). A high index of suspicion should be maintained to arrive at the diagnosis. A CT scan will reveal evidence of chondronecrosis (9.18).



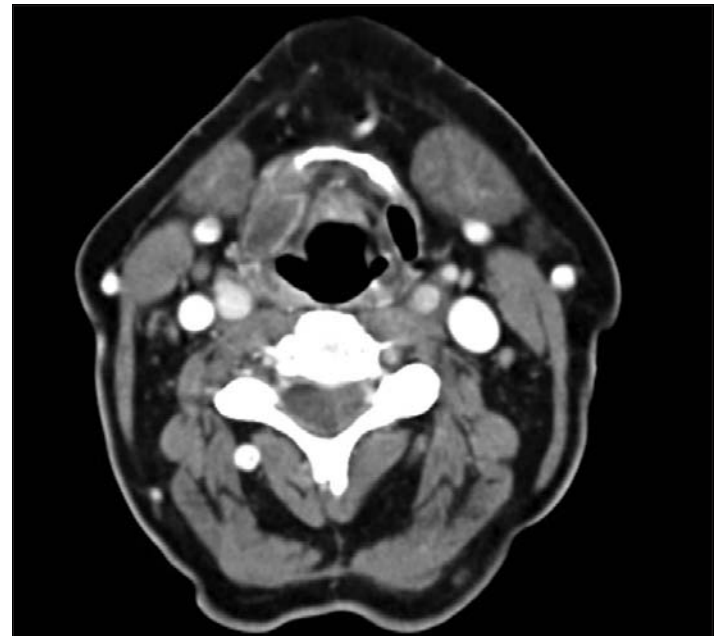
**9.12** Rigid endoscopic view of the larynx showing multiple papillomatous masses on the vocal cords bilaterally and the right false cord.



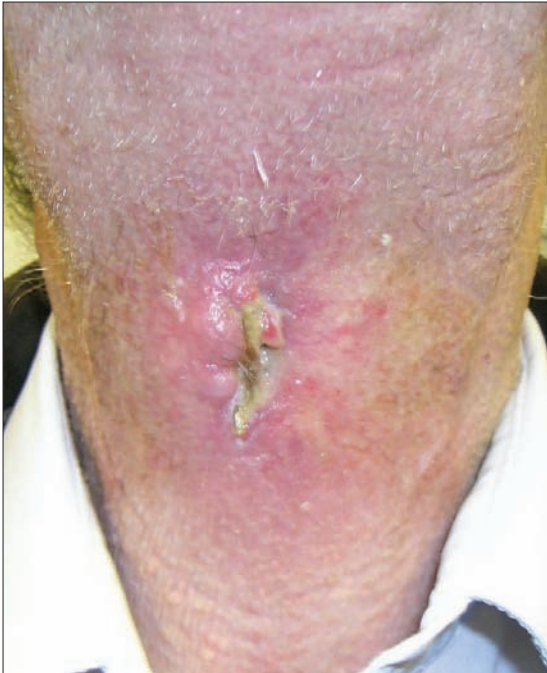**9.13** Rigid endoscopic view of florid papillomatosis involving both vocal cords.



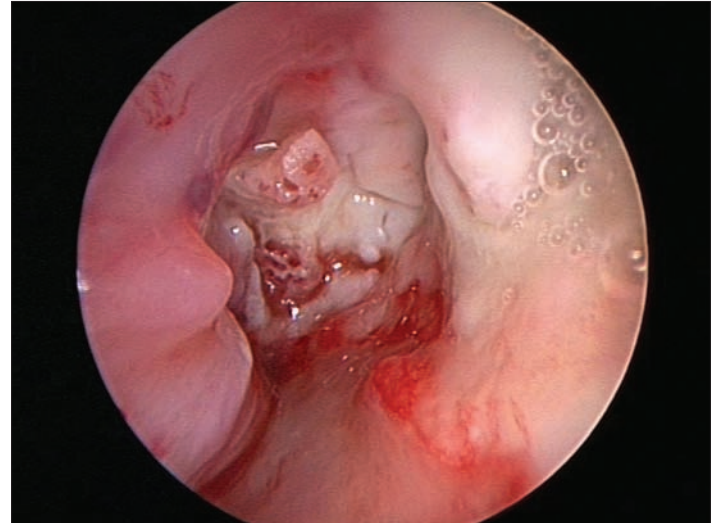
**9.14** Rigid endoscopic view of the larynx shown in 9.12 after laser ablation of the papillomas.



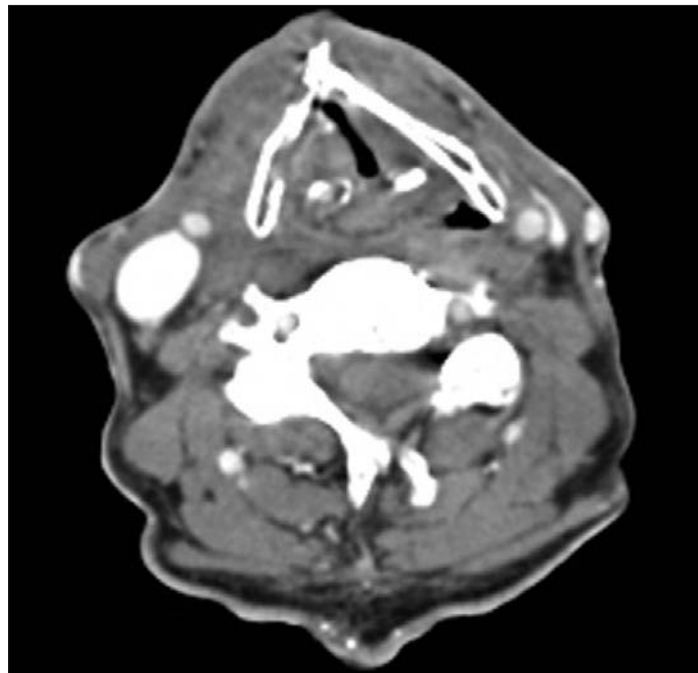
**9.15** Axial CT scan showing bilateral laryngocoele with an infected collection on the right side.



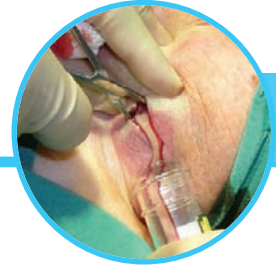**9.16** Chondronecrosis of the thyroid cartilage as a late complication following radiation therapy for cancer. Note the necrotic fragment of cartilage in the wound.



**9.17** Endoscopic view of necrotic cartilage extruding into the right pyriform fossa.



**9.18** Axial CT scan of the patient in 9.16 showing destruction of the thyroid cartilage.

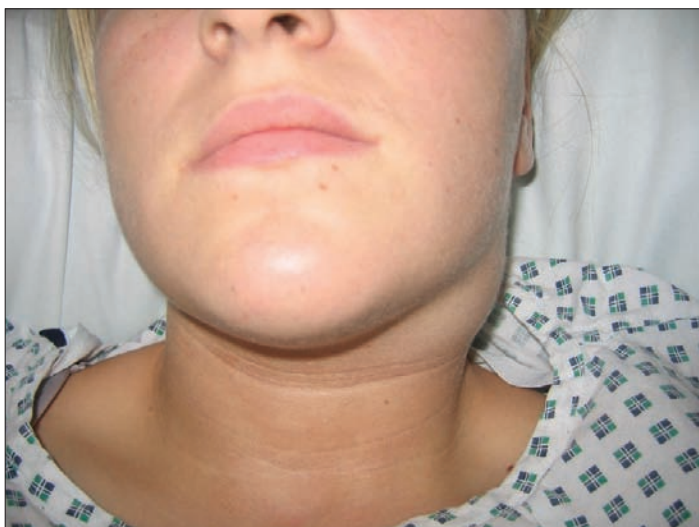

# Infections of the neck

*Vinidh Paleri*

## Introduction

Each side of the neck houses approximately 200 lymph nodes, which drain the whole of the upper aerodigestive tract. The supraclavicular nodes on the left hand side also receive lymphatics from the abdominal viscera. These nodes are involved in any infectious or inflammatory process that may affect the aerodigestive tract and also in many systemic illnesses. In addition, there are many potential spaces in the neck through which infection can spread to other areas of the neck and outside the neck. Abscesses in these spaces can lead to serious and life-threatening complications if not recognized and treated expeditiously. Neck infections form a significant proportion of infectious problems seen in otolaryngologic practice.



**10.1** Reactive cervical lymphadenopathy in a patient with viral pharyngitis.

## Neck infections

### CERVICAL LYMPHADENITIS

Reactive cervical lymphadenopathy is a common occurrence in children, presenting as neck lumps (**10.1**). These are usually secondary to a primary infection in the upper aerodigestive tract or a systemic illness. There are many organisms that can cause cervical lymphadenopathy and these are listed in *Table 10.1*. The history usually is of short duration, from a few days to 2 weeks. Clinical examination should include all relevant drainage sites, including the ears, nose, oral cavity, larynx, and pharynx. *Table 10.2* sets out

**Table 10.1** Infections presenting with cervical lymphadenopathy

#### Viruses

Epstein–Barr virus	HIV
Cytomegalovirus	HHV-6
Adenovirus	

#### Bacteriae

<i>Streptococcus pyogenes</i>
<i>Staphylococcus aureus</i>
Mixed oral bacteria, including anaerobes
<i>Mycobacterium tuberculosis</i>
Nontuberculous mycobacteria
<i>Bartonella henselae</i>
<i>Treponema pallidum</i>

#### Protozoans

<i>Toxoplasma gondii</i>
--------------------------



the drainage areas for different lymphatic groups in the neck. Cervical examination usually reveals small, soft cervical nodes, commonly in the jugulo-digastric region.

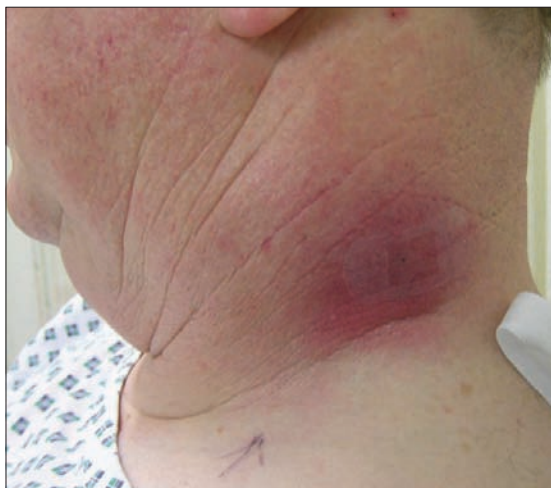The majority of these patients need no intervention and the lymphadenopathy settles down, although this can take 8–10 weeks. The challenge is to differentiate these reactive lumps from infections such as tuberculosis and neoplastic conditions. Symptoms and sign that should instigate further work-up are shown in *Table 10.3*.

Investigation for persistent lymphadenopathy should include a chest radiograph, serology for infectious agents (e.g. cytomegalovirus, Epstein–Barr virus, HIV, *Toxoplasma*, and *Bartonella*) and imaging of the neck. Rarely, pyogenic lymphadenitis can occur (10.2) and needs drainage (10.3). Fine needle cytology is not of great benefit in this setting. Inflammatory cervical lymphadenopathy is uncommon in adults and should always be investigated to rule out malignancy (see branchial cysts, below).

## Monomicrobial infections

### CAT SCRATCH DISEASE

Cat scratch disease is caused by a gram-negative bacillus, *Bartonella henselae*, and is so called as kittens are typically the vectors. It is a self-limiting illness characterized by papules or pustules at the inoculation site following an incubation period of 3–10 days. Regional painful lymphadenopathy then occurs, and can last up to 2 months. Suppuration occurs in 30% of patients. Systemic symptoms



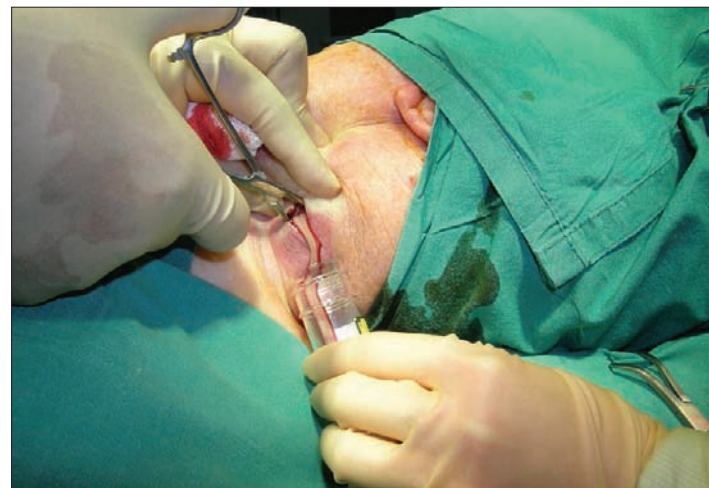**10.2** Suppurative bacterial cervical lymphadenitis in an otherwise well patient.

**Table 10.2** Cervical lymph nodal groups and their drainage areas

Submaxillary and submental:	teeth, tongue, gums, and buccal mucosa
Upper cervical:	tonsil, tongue, larynx
Lower cervical:	larynx, hypopharynx
Posterior triangle:	scalp, nasopharynx
Pre-tracheal:	larynx, thyroid
Pre-auricular:	skin of cheek, eyelids, temporal scalp
Occipital:	Posterior scalp

**Table 10.3** ‘Red-flag’ symptoms in patients with cervical lymphadenopathy that should instigate further work-up

Supraclavicular nodes
Nodes larger than 3 cm
Unexplained weight loss
Dysphagia
Dysphonia
Hepatosplenomegaly
Night sweats



**10.3** Incision and drainage of the pus from the neck of the patient in 10.2. Note loculi being opened with blunt forceps.

like low-grade fever and malaise can be present. Rarely, serious neurological (transverse myelitis, encephalitis) and haematological (thrombocytopaenic purpura) complications ensue. Diagnosis is achieved by serological testing or PCR assay of lymph nodal tissue. For mild disease, symptomatic treatment is sufficient. Incision and drainage of suppurative lymphadenitis does not hasten recovery. In the immunosuppressed host, prolonged antibiotic treatment is needed.

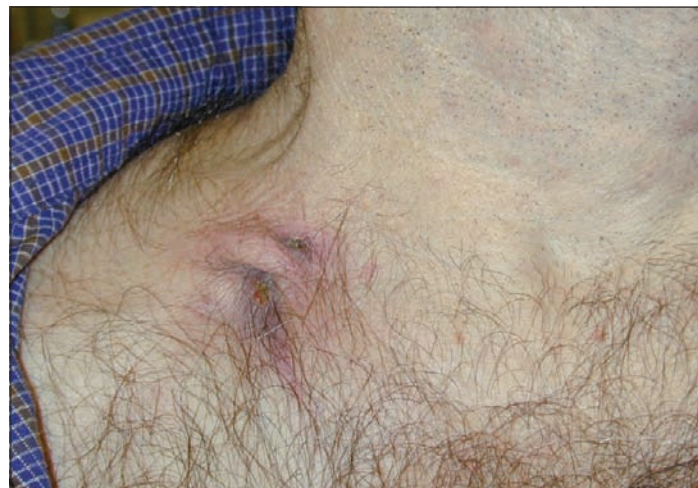### TOXOPLASMOSIS

Toxoplasmosis, caused by the protozoan *Toxoplasma gondii*, is an intracellular parasite. Cats are the definitive hosts for the organism and excrete oocysts. Infection is acquired by ingesting oocysts from faecal contamination or from tissue cysts in uncooked meat. Immunocompetent hosts present with sore throat, malaise, fever, and cervical lymphadenopathy, which is clinically indistinguishable from other viral infections, such as infectious mononucleosis. The lymphadenopathy can last several months. Immunofluorescent assay (IFA) for IgM antibody confirms acute infection. No treatment is required in the immunocompetent host. The infection can involve multiple systems in the presence of immunocompromise such as AIDS, manifesting as necrotizing encephalitis, pneumonitis, and myocarditis.

### MYCOBACTERIAL INFECTIONS

Tuberculous and nontuberculous mycobacterial infections present with persistent cervical lymphadenopathy, with or without suppuration (10.4). This may be the sole presentation of nonrespiratory tuberculosis. Slow insidious growth and the examination findings of matted groups of nodes that feel rubbery on palpation should lead one to suspect the diagnosis of tuberculosis. In contrast, atypical mycobacterial infections involve a single nodal group and are characterized by relatively rapid growth and suppuration, usually in the submandibular or parotid region. Systemic symptoms such as fever, loss of weight, and malaise may not be present in the immunocompetent host. Diagnosis is established by identifying the organism on culture or on PCR assays.

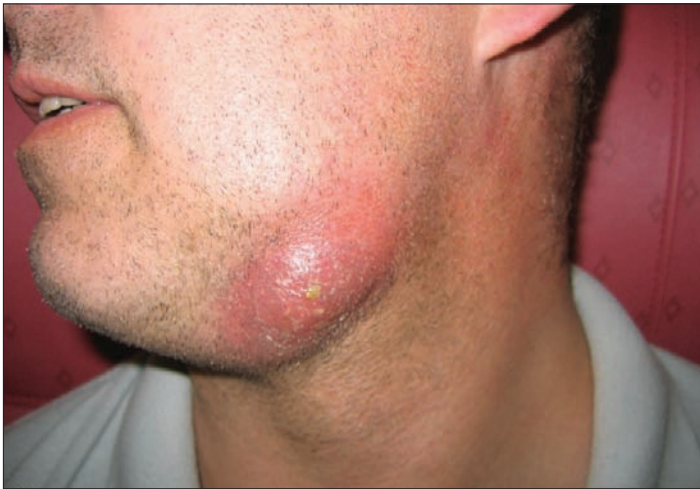Therapy for tuberculosis is medical and triple therapy has a high success rate in controlling the disease. Atypical mycobacterial infections, if localized, can be excised, which is curative. Disseminated disease in immunocompromised hosts will need chemotherapy.



10.4 Draining sinus from a tuberculous infection of a neck node.

### ACTINOMYCOSIS

This infection is uncommon but important to recognize as it can mimic other diseases. Despite their fungal sounding name, these are gram-positive bacilli. Most members of the *Actinomyces* species are commensals in the oral cavity. The infection usually presents as a mass adjacent to the mandible, with surrounding induration, erythema, and abscess formation (10.5). The mass is caused by the organisms proliferating in the soft tissue rather than lymph node inflammation. The classical description is that of draining sinuses with bright yellow granules in the pus (sulphur granules) caused by the filaments of the organism. Diagnosis can be made only after microbiological confirmation. Prolonged antibiotic therapy is essential to effect a cure (10.6).

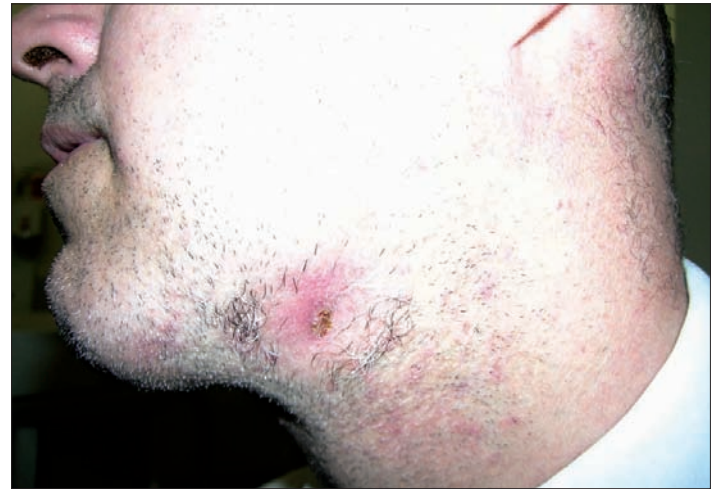

10.5 Actinomycosis of the neck depicting a discharging sinus overlying a mass in the submandibular region.

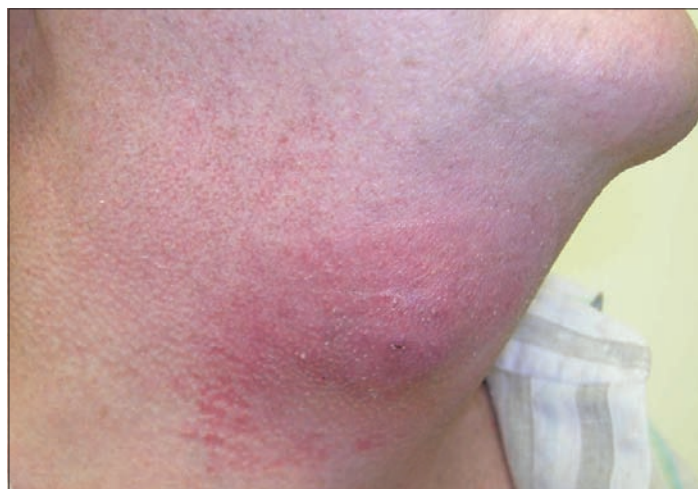### Polymicrobial infections

#### CELLULITIS OF THE NECK

Superficial cellulitis of the neck occurs after minor trauma or spontaneously. *Staphylococcus aureus* and *Streptococcus pyogenes* are commonly implicated. Rarely, this can be the presentation of serious underlying disease in the upper aerodigestive tract. Clinical examination reveals superficial inflammation, with no symptoms of dysphagia or general systemic upset (10.7). Treatment with systemic antibiotics usually clears the vast majority of infections.



10.6 Resolving actinomycosis 1 month after commencing treatment.



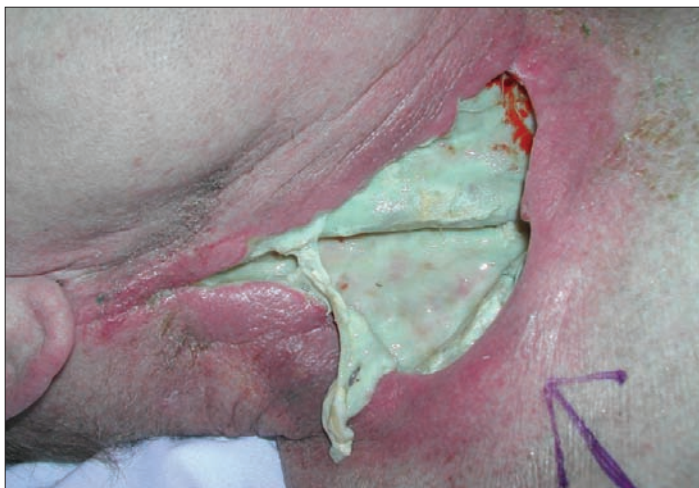10.7 Cellulitis of the neck.



### NECROTIZING CERVICAL FASCIITIS

This is a rapidly progressive infection of the soft tissues usually caused by group A haemolytic streptococci or *Staphylococcus aureus*. Other pathogens, including gram-negative organisms and anaerobes, have also been implicated. Minor trauma or surgery can trigger this, although it can begin spontaneously. Clinical signs are characterized by pain, rapidly increasing erythema, and crepitation in the affected area. The skin and subcutaneous tissue becomes necrotic, demonstrated by dark areas, which may not be contiguous. Blisters form over the affected skin, which soon sloughs off (10.8). Systemic symptoms of fever, hypotension, and respiratory failure indicating septicaemia are evident. Early intervention is essential as the condition can rapidly become fatal.

CT scans are required to assess the extent of the process. Systemic broad-spectrum antibiotics and aggressive, repeated surgical debridement of necrotic tissues should be performed. Given the severity of the systemic problems and the risk of multi-organ failure, monitoring in an intensive care setting is usually needed. Hyperbaric oxygen therapy has been shown to be beneficial. Reconstructive surgery may be needed to replace lost skin (10.9).

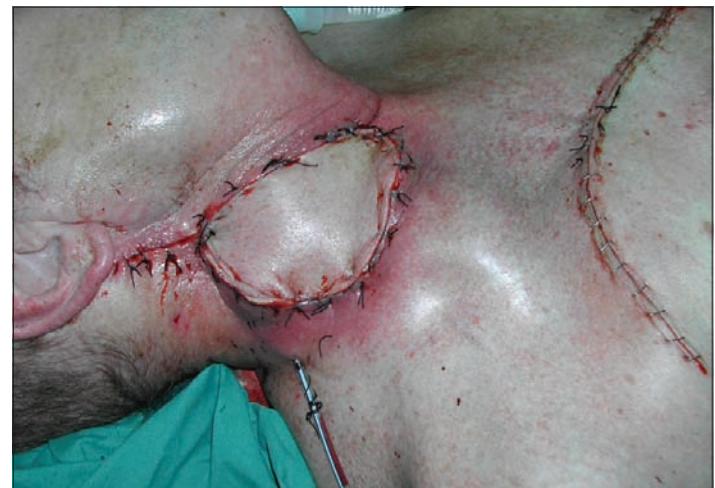

**10.8** Necrotizing fasciitis after surgery and leading to significant skin loss.

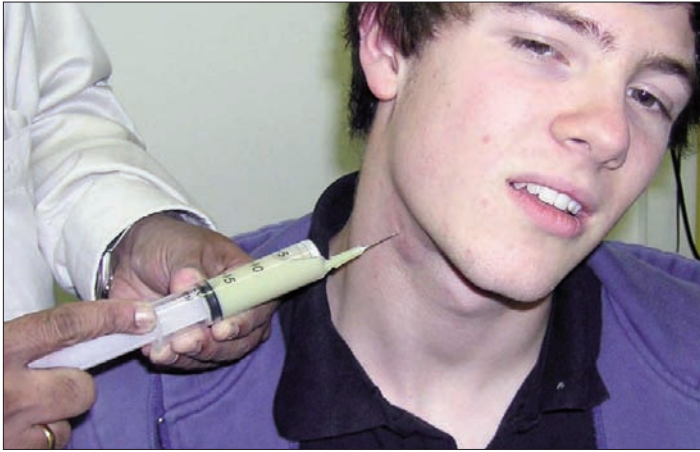
### INFECTION OF BRANCHIAL AND THYROGLOSSAL CYSTS

Branchial cysts develop from trapped squamous elements in the cervical lymph nodes during embryonic development. Usually, these present as tensely fluctuant neck lumps in the high lateral neck in the 2<sup>nd</sup> to 3<sup>rd</sup> decade. Sometimes, these cysts can get infected and present as tender neck abscesses. Being a single cavity, the abscess can be aspirated and systemic antibiotics are required (10.10). Neck imaging is recommended to assess the size of the cyst and its relation to the vital structures in the neck (10.11). Recurrent infections can occur (10.12), and sometimes repeated drainage may be required. Interval cyst excision is curative (10.13). Similar infective lumps presenting later in life, after the 5<sup>th</sup> decade, should be considered to be neoplastic unless proven otherwise. An exhaustive search should be carried out to look for primary malignancies in the upper aerodigestive tract. This should include fine needle cytology, panendoscopy, and CT scans.

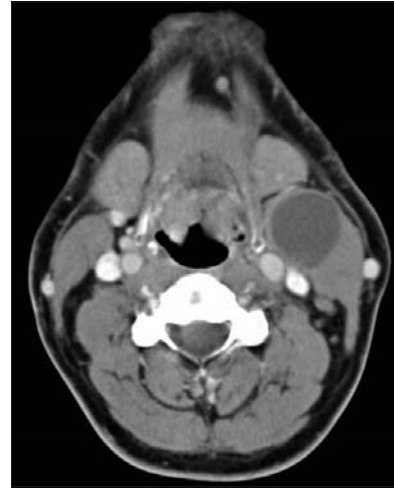Thyroglossal fistulas are the result of persistence of the thyroglossal duct after the descent of the thyroid gland from the tongue base. They usually present as cysts in the midline, below the hyoid bone (10.14). When they get infected, an abscess (10.15) or a fistula results (10.16). Intermittent or chronic discharge of purulent fluid occurs accompanied by pain and swelling. Treatment is with systemic antibiotics and excision of the tract up to the tongue base, including a segment of the body of the hyoid (Sistrunk's procedure; 10.17), is usually curative.



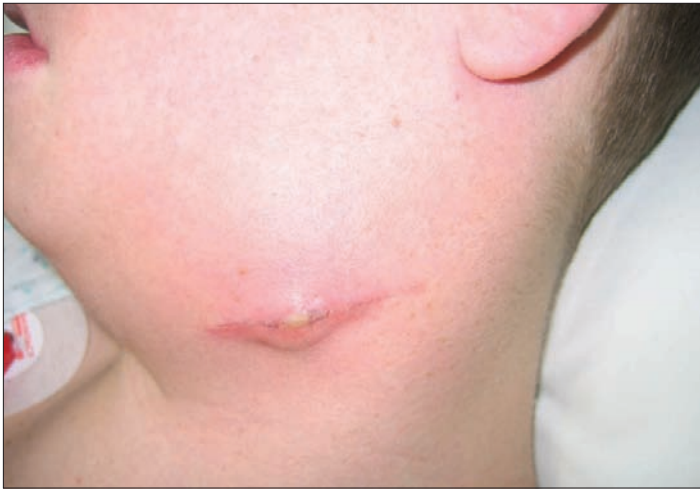**10.9** Pectoralis major myocutaneous flap used to reconstruct the skin defect of the patient shown in 10.8.



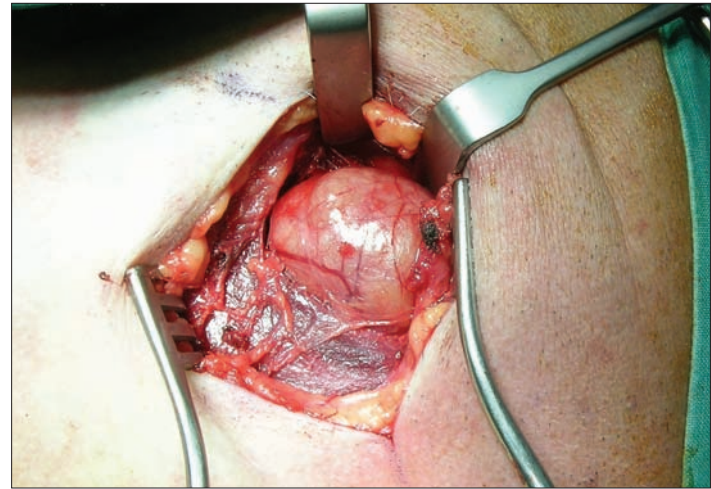
10.10 Needle aspiration of an infected branchial cyst.



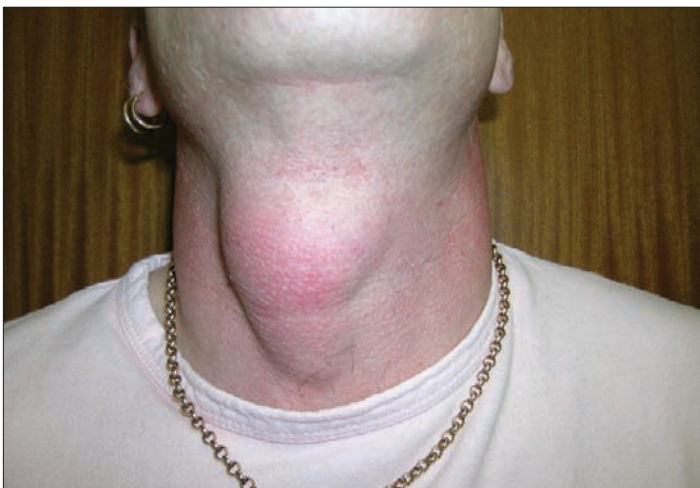10.11 Axial CT scan showing a left branchial cyst.



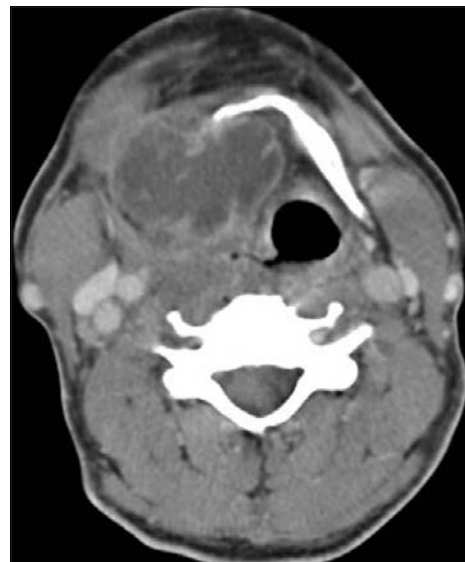10.12 Recurrent infection of a left branchial cyst. Note scar from a previous incision to drain the abscess.



10.13 Left branchial cyst exposed in the left neck prior to excision.



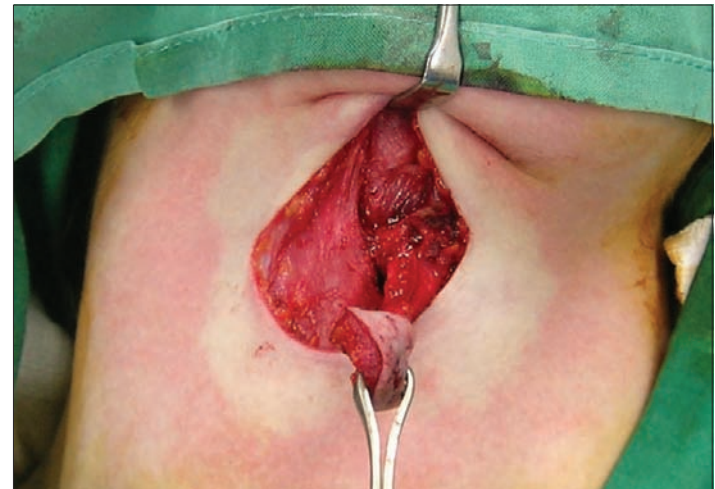
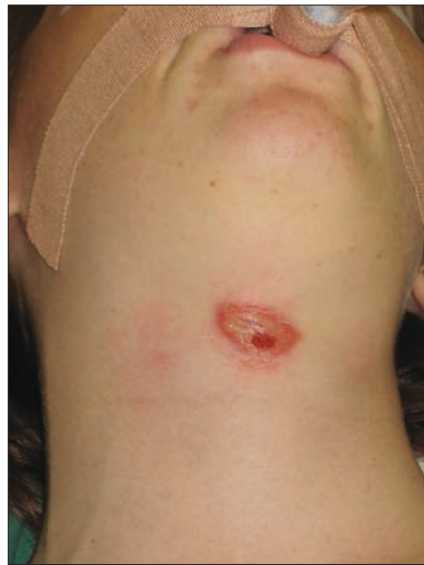10.14 Large thyroglossal cyst. Note the high position of the cyst compared to thyroid lumps.



10.15 Axial CT scan showing a large infected thyroglossal cyst causing airway compromise.



**10.16** Infected thyroglossal tract sinus.



**10.17** Sistrunk's procedure to excise a thyroglossal fistula. Note the tract being dissected up to the hyoid bone.

### DEEP NECK SPACE INFECTIONS

Many potential spaces exist in the neck where infection can easily spread unchecked owing to loose areolar tissue and fascial planes. Neck space infections are serious illnesses and potentially fatal if not treated early, due to the complications such as airway compromise and septicaemia. Often, an infectious source is evident in the head and neck. (This could be from the teeth, tonsils, ears, salivary glands and, rarely, foreign bodies.) Neck spaces can be classified according to their anatomical site in the neck and are shown in *Table 10.4*. These divisions are helpful in diagnosis and planning treatment as these spaces can present with unique clinical features. It must be noted that many of these spaces lie in close proximity and it is not uncommon for multiple neck spaces to be involved in the same patient. The diagnosis is straightforward in buccal and canine space infections, but imaging is usually required to assess the involvement of the deeper neck spaces. Many of these infections, especially of the retropharyngeal space, can present with or lead to airway complications. If surgical drainage is planned, anaesthetists with expertise in managing the compromised airway will be needed. For odontogenic infections, management should include dental assessment and treatment of the affected teeth after the acute infection has settled down.

#### **Facial spaces**

Spread of infection to the spaces around the face occurs from odontogenic sources and is more commonly seen in maxillofacial practice. Buccal and canine space infections

**Table 10.4 Neck spaces**

#### **Face**

Buccal, canine, masticator, and parotid spaces

#### **Suprahyoid neck**

Peritonsillar, submandibular, sublingual, and parapharyngeal spaces

#### **Infrahyoid neck**

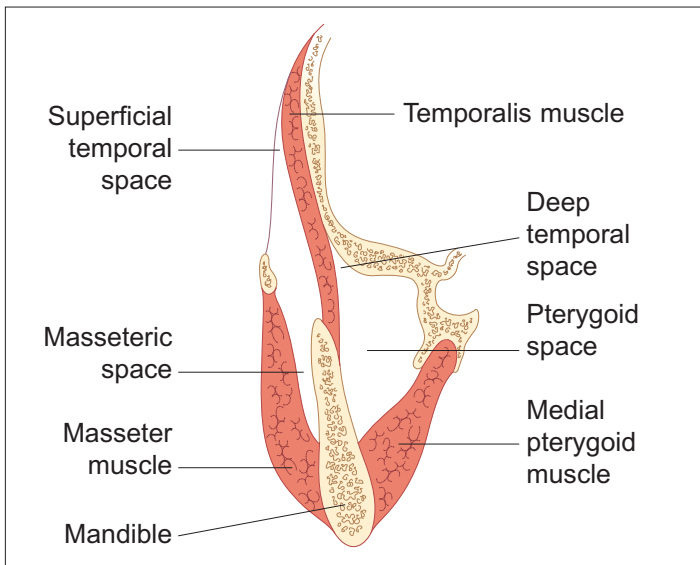
Anterior visceral space

#### **Whole neck**

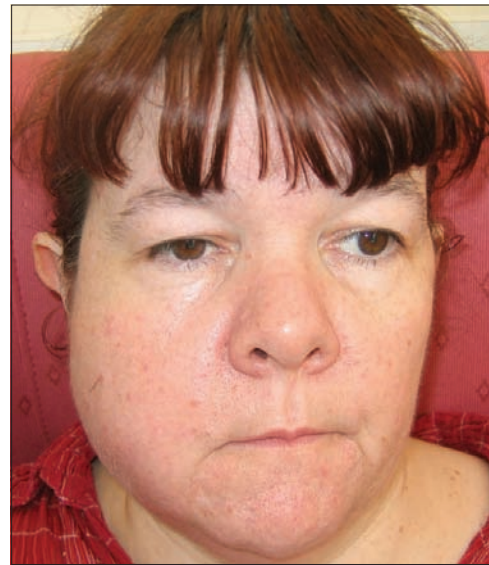Retropharyngeal and carotid sheath spaces

present with swelling on the cheek and the upper lip respectively. No trismus is seen with either of these space infections. Antibiotics usually suffice to control the infection. The space medial to the masseter (masseteric space), around the temporalis (temporal space), and lateral to the medial pterygoid (pterygoid space) make up the masticator spaces (**10.18**). Infection in the masticator spaces are characterized by trismus and swelling of the area around the involved space (**10.19**). CT scans are needed to assess the extent of the collections (**10.20**, **10.21**). Surgical drainage is needed. Except for temporal space collections, the rest can be drained transorally.

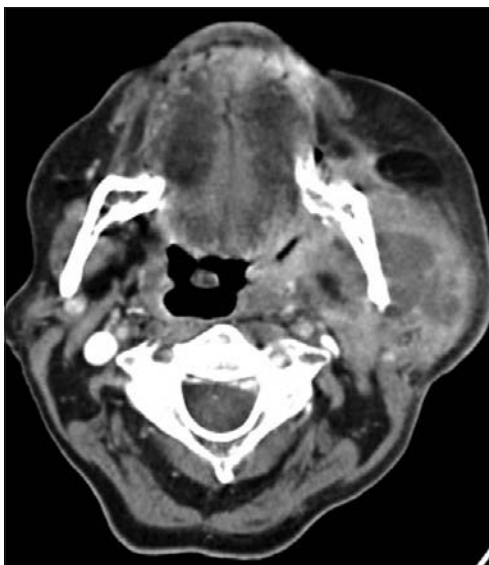



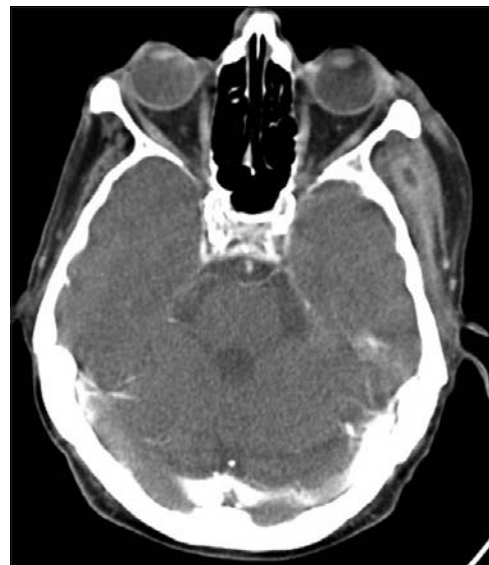**10.18** The four masticator spaces distributed around the masticatory muscles.



**10.19** Masticator space infection involving primarily the masseteric space.



**10.20** Axial CT scan showing a collection in the masseteric and pterygoid spaces on either side of the mandible.



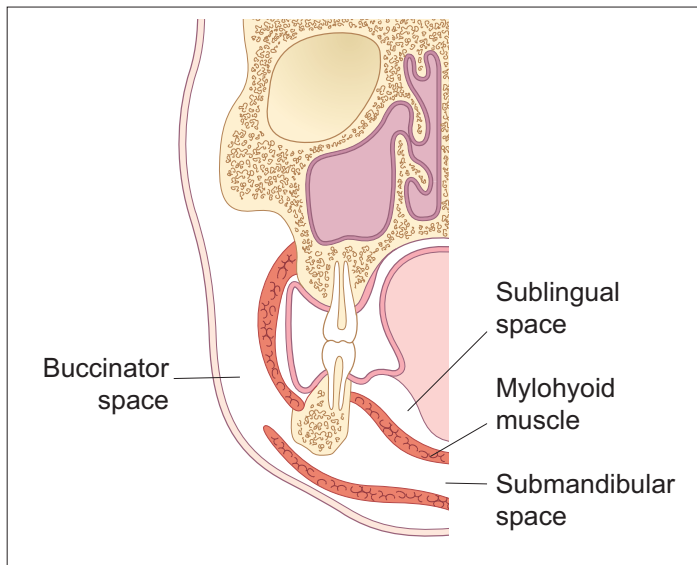
**10.21** Axial CT scan showing an abscess collection in the temporal space, between the temporalis muscle and the skull.

### **Suprahyoid neck spaces**

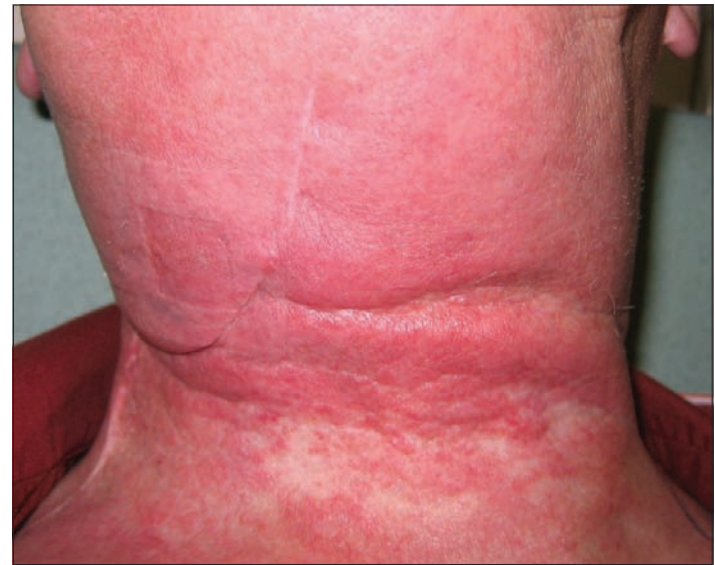Peritonsillar infections are frequently seen in ENT practice and this is discussed in Chapter 8 Oropharyngeal infections. The mylohyoid muscle partitions the fascial spaces in the floor of the mouth into the sublingual space above and the submandibular space below. In sublingual space infections, the floor of the mouth mucosa is very inflamed, pushing the tongue upwards. Submandibular space infections arise from the second and third molars, whose roots lie below the mylohyoid line (10.22). Brawny swelling in the neck and tenderness is evident. Both these infections will need surgical

drainage. Ludwig's angina is a rare presentation these days where the sublingual and submandibular spaces are involved bilaterally (10.23). The infection is characterized by the lack of fluctuation or suppuration and its tendency to cause tongue base swelling and airway compromise. Imaging will reveal a collection if present (10.24). Surgical drainage and antibiotics are required to control the infection.

The parapharyngeal space is like an inverted pyramid, with its base superiorly at the skull and the apex at the hyoid bone. It communicates postero-medially with the

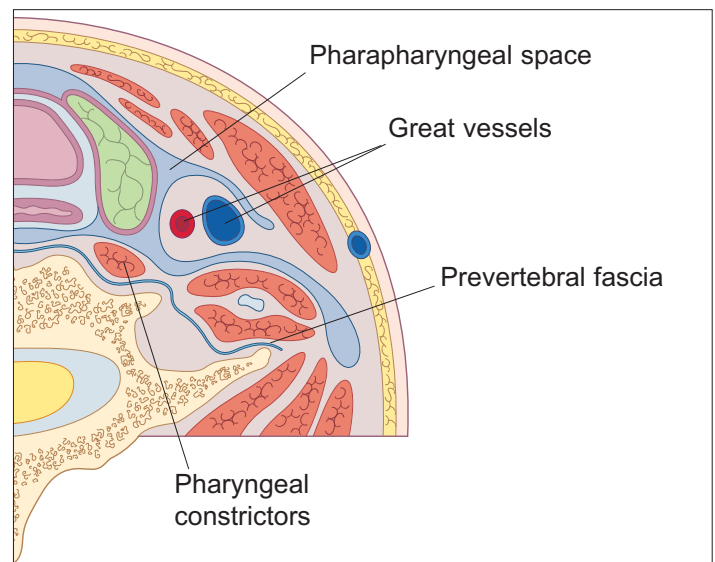
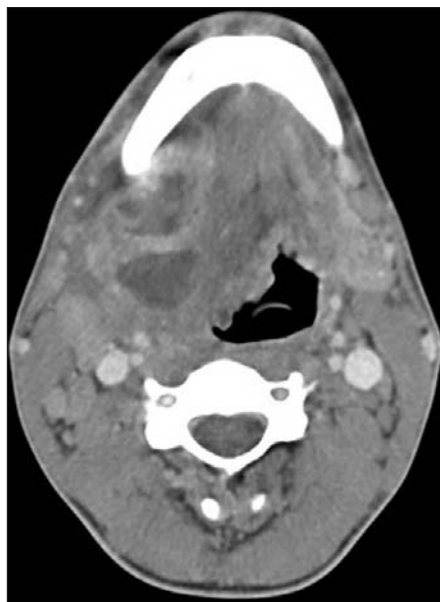

10.22 Submandibular and submental spaces.



10.23 Brawny swelling and oedema of the submental and submandibular regions in Ludwig's angina.

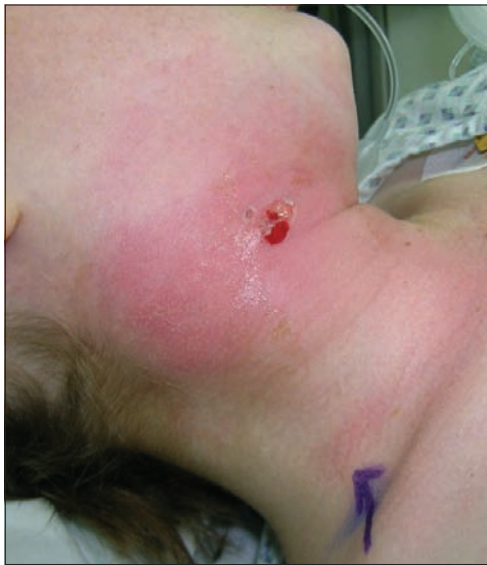10.24 Submandibular space infection with an abscess collection.



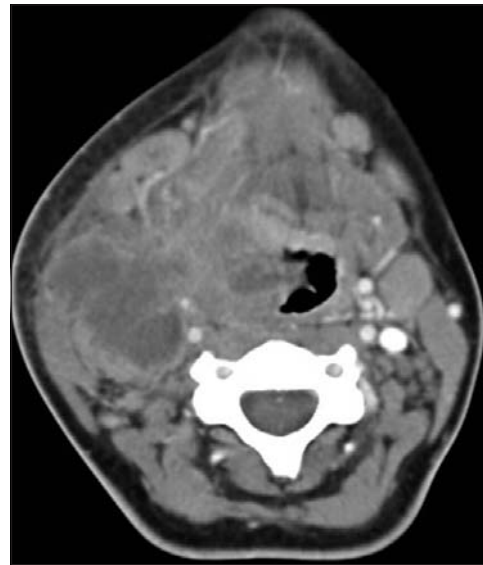
10.25 Parapharyngeal space.

retropharyngeal space, facilitating easy spread of infections to the lower neck. It is bound medially by the superior constrictor muscle and laterally by the pterygoids, mandible, and the deep lobe of the parotid gland (10.25). Its contents include the internal carotid artery, the internal jugular vein, and the vagus nerve, along with lymph nodes. Primary sources of infections are usually the tonsils, teeth, mastoid, and the parotid gland. Suppurative lymphadenitis may also cause an abscess in this region. Presenting symptoms include fever, chills, trismus, and odynophagia. Examination may

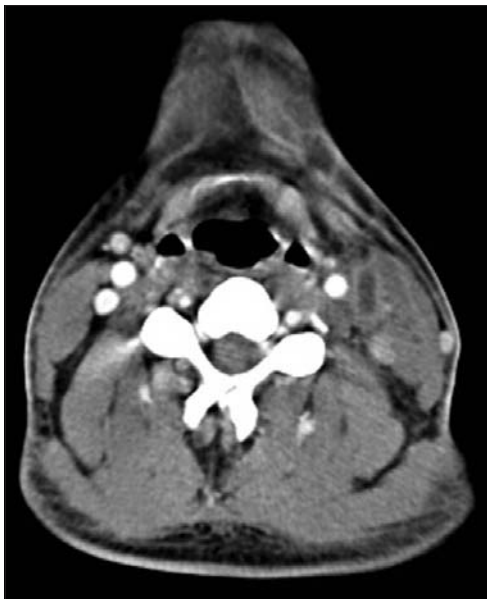reveal a tender neck with erythema and diffuse swelling (10.26). Sometimes, little or no swelling is seen if the abscess is deep seated. In the oropharynx, the tonsil and lateral pharyngeal wall may be pushed medially with mild overlying inflammation. A CT scan is required to confirm the diagnosis, to assess the presence and size of an abscess (10.27), and to look for complications such as thrombosis of the internal jugular vein (10.28). In the early inflammatory stage, systemic antibiotics will suffice. A collection, however, requires surgical drainage through the cervical route.



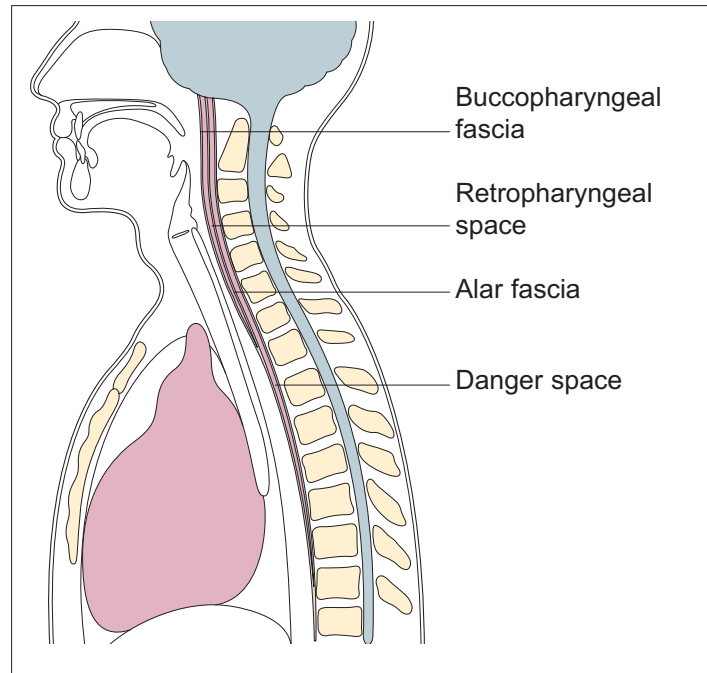
**10.26** Parapharyngeal abscess presenting with neck swelling and swallowing problems in a patient with resolving tonsillitis.



**10.27** Right parapharyngeal abscess pushing the lateral pharyngeal wall of the pharynx.



**10.28** Axial contrast enhanced CT scan showing a thrombosed left internal jugular vein with an enhancing abscess within.



**10.29** The retropharyngeal, 'danger', and prevertebral spaces.

**Whole neck spaces**

The retropharyngeal, prevertebral, and the 'danger' space run the length of the neck behind the visceral structures (10.29). As the name suggests, the prevertebral space lies most posteriorly and inbetween the vertebrae and the prevertebral fascia, and runs down to the coccyx. This space is infected by trauma or primary infections of the spine. In front of the prevertebral fascia lies the alar fascia, running from the skull base to the level of the diaphragm. Together, these bound the 'danger' space, so called as infections here can easily spread into the thorax. The source of infection is usually the parapharyngeal space or the retropharyngeal space anterior to it. Infections in this space are difficult to

differentiate from retropharyngeal space infections clinically, with similar presentation and treatment. The latter lies behind the buccopharyngeal fascia, which tightly envelops the viscera, and in front of the alar fascia.

Typically, infections in the retropharyngeal and 'danger' spaces occur in childhood, with half of these occurring between 6 and 12 months of age. Presentation includes fever, irritability, dysphagia, sore throat, drooling and, in



advanced cases, airway compromise. Examination reveals the posterior pharyngeal wall to be pushed anteriorly, with only limited view of the larynx (10.30). In many cases, the child has had antibiotics for suspected infection and the source is identified only on imaging (10.31). In the adult, examination may reveal a bulging posterior pharyngeal wall. Transoral drainage of a collection usually leads to rapid improvement.

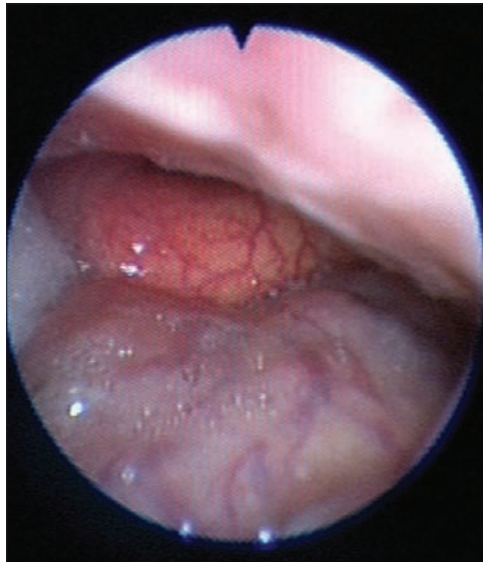### POST-OPERATIVE INFECTION

The incidence of post-operative wound infection following neck surgery tends to vary based on whether the upper aerodigestive tract has been entered or not. During clean-contaminated procedures (e.g. laryngectomy), contamina-

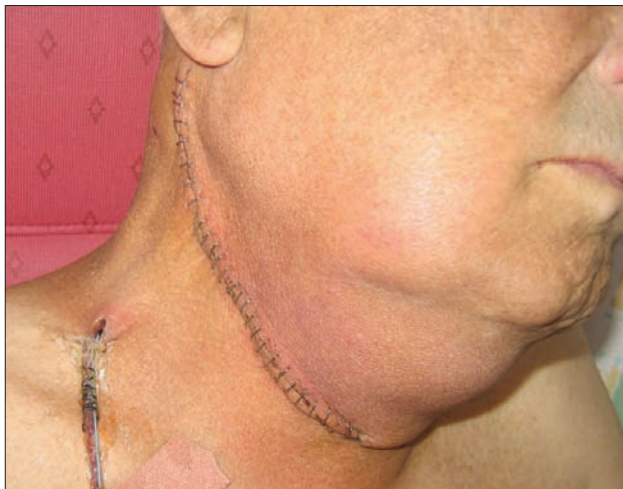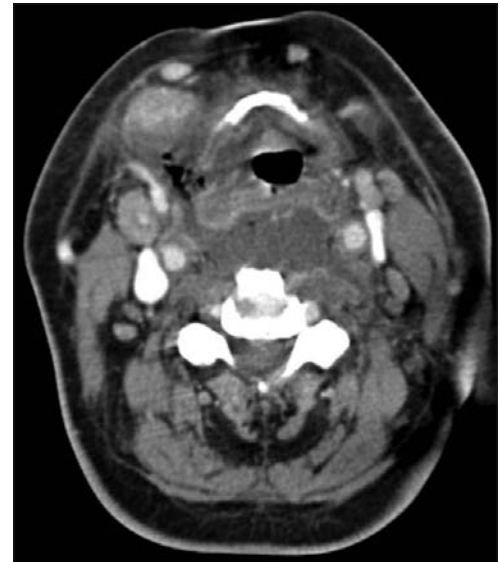
tion of the surgical field by pharyngeal contents occurs. Prophylactic antibiotics are not indicated in the former category, but recommended in the latter. There is no consensus on the timing and duration of antibiotic therapy, but there is no evidence that prolonged courses are more effective than shorter regimes of 3 days or less.

The appearance of a healthy neck wound at 72 hours is shown in figure 10.32. A wound infection is characterized by erythema, increasing tenderness, and weeping around the incision site, beginning about 72 hours post-operatively (10.33). Systemic antibiotics may suffice in the early stages. If clinical examination indicates the presence of a collection, demonstrated by fluctuation of the neck wound, the incision will have to be laid open and the collection drained.

**10.30** Flexible nasendoscopic view just below the level of the soft palate showing the pharynx almost in contact with the tongue base and limiting the view of the larynx.

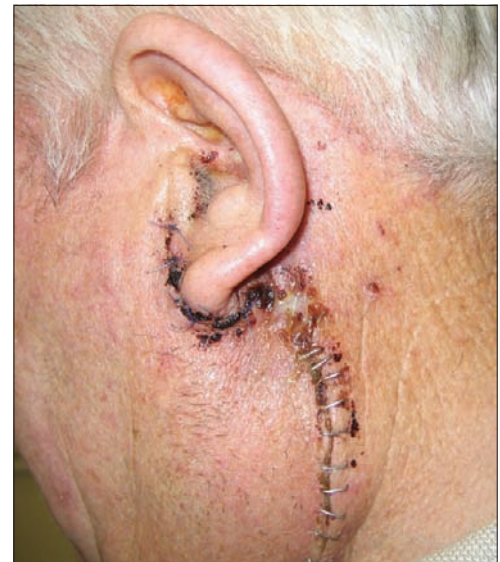

**10.31** Axial CT scan showing a retropharyngeal abscess with air pockets within.



**10.32** Appearance of the neck 72 hours after right neck dissection. Note the neck drain that is still in place.

**10.33** Post-operative wound infection after parotidectomy showing an erythematous, weeping suture line.



### INFECTIVE THYROIDITIS

Both bacteria and viruses can infect the thyroid gland, but they present with two distinct syndromes. Bacterial infections are very rare. *Staphylococcus aureus* and the haemolytic streptococci usually cause acute suppurative thyroiditis. Patients present with acute symptoms including fever, neck pain, sore throat, and odynophagia. Examination reveals tenderness over the thyroid gland, worsened by extension of the neck. Imaging studies (ultrasonography or CT scan) are required to confirm the diagnosis. If a collection is present, surgical drainage is required.

Viral infections of the thyroid gland are usually a manifestation of a systemic infection and cause subacute thyroiditis (de Quervain's thyroiditis), a self-limiting condition. These commonly occur following an upper respiratory tract infection or another defined viral syndrome (see *Table 10.5*). Patients who carry HLA-Bw35 are more susceptible to this syndrome. The clinical findings in the thyroid gland region can vary from mild pain and discomfort to severe pain and tenderness, mimicking acute suppurative thyroiditis. However, the systemic findings present in three phases and should clinch the diagnosis. The infection initially causes release of stored thyroxine into the circulation leading to a hyperthyroid phase. This manifests as anxiety, nervousness, palpitation, tremor, and weight loss. The hyperthyroid state lasts about 6–8 weeks and leads into a hypothyroid phase of similar duration, with more than

90% of patients returning to normal function. The diagnosis is established on clinical grounds, the finding of very high ESR levels, and poor uptake of radio-iodine on uptake scans despite the patient being hyperthyroid (**10.34**). Supportive treatment is required for the pain, and beta-blockers are given to suppress the symptoms of hyperthyroidism.

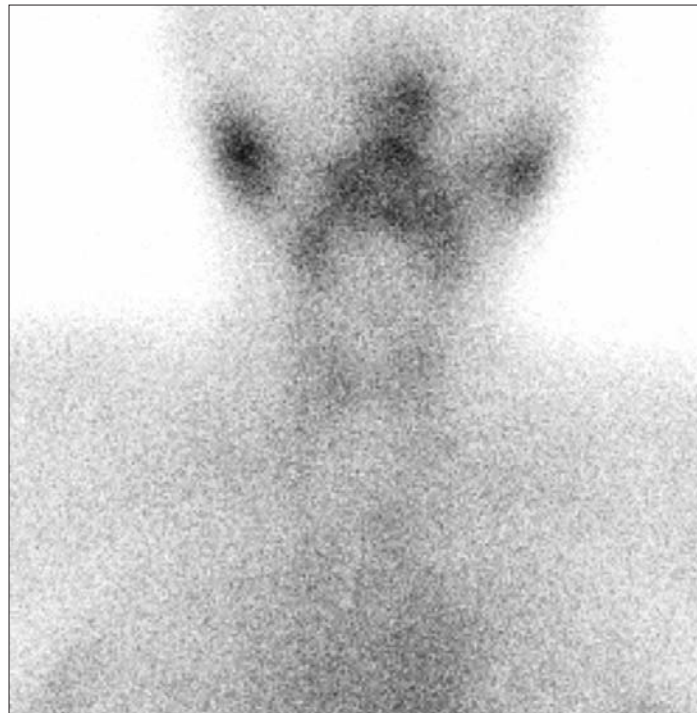### ATLANTO-AXIAL SUBLUXATION (GRISEL SYNDROME)

This is a rare complication that follows an inflammatory process in the head and neck region. It involves disruption of the ligamentous support of the atlanto-axial joint, probably due to oedema of the atlanto-axial ligaments and a consequent increase in laxity. The clinical findings include neck tenderness and torticollis opposite to the side of subluxation. The spinous process of the axis opposite to the side of the subluxation may be palpable (Sudek's sign). The presence of neurological sequelae depends upon the severity of the subluxation.

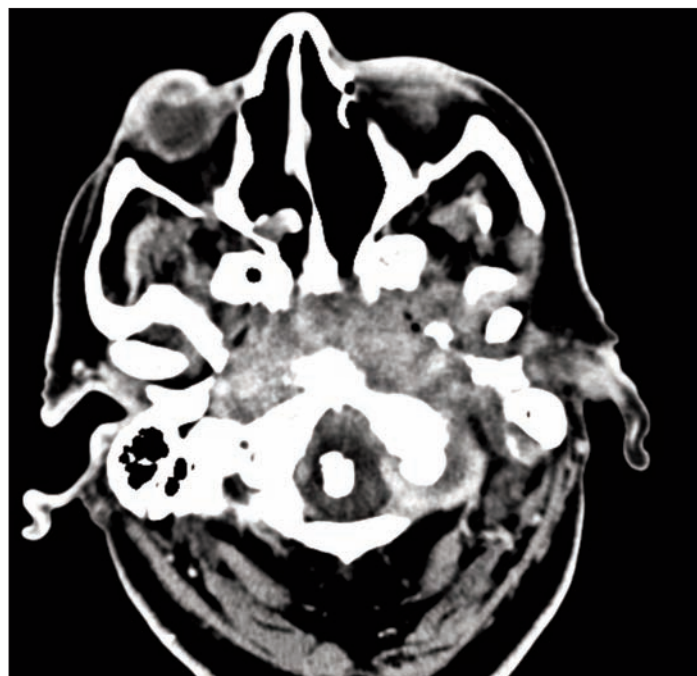
The investigation of choice is either a high resolution CT scan to demonstrate bony subluxation (**10.35**) or an MRI scan to demonstrate inflammation of the atlanto-axial ligaments. Neurosurgical advice must be sought as soon as the diagnosis is made as it can have devastating consequences if not detected and treated early.

**Table 10.5 Infectious diseases causing subacute thyroiditis**

Infectious mononucleosis (Epstein–Barr virus)
Mumps (paramyxovirus)
Common cold (Coxsackie virus, adenovirus)
Influenza (influenza virus)
Measles (paramyxovirus)
Malaria ( <i>Plasmodium</i> sp.)
Cat scratch fever ( <i>Bartonella henselae</i> )
Q fever ( <i>Coxiella burnetii</i> )

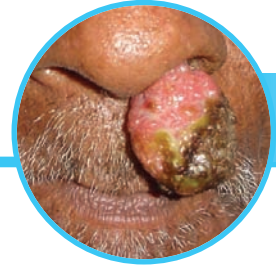

**10.34** Radio-iodine uptake scan showing no uptake in the thyroid gland in subacute thyroiditis.



**10.35** Axial CT scan showing subluxation of the odontoid peg posteriorly.





# Tropical ENT infections

*Surianarayanan Gopalakrishnan and Vinidh Paleri*

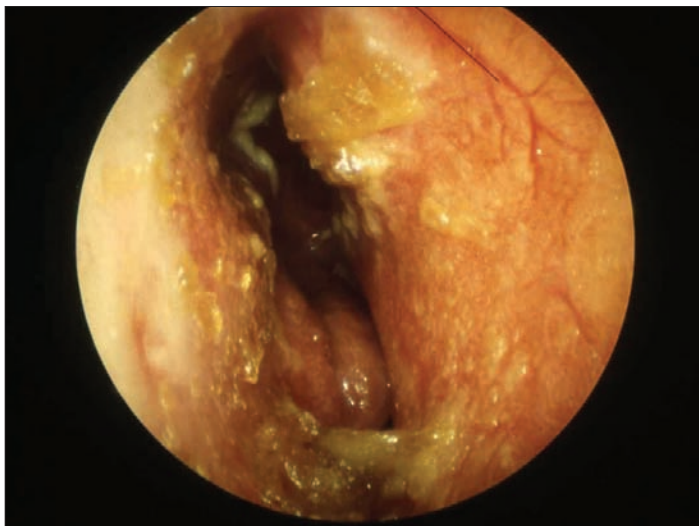
## Common infections

Several tropical infections can cause ENT manifestations and some of the common ones are discussed below.

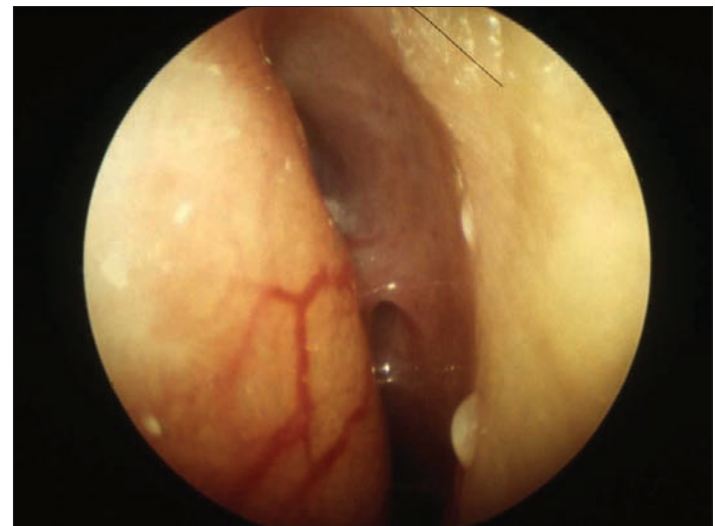
### RHINOSCLEROMA

Rhinoscleroma is a rare infectious disease of the upper respiratory tract caused by *Klebsiella rhinoscleromatis*. There are five endemic regions including Eastern Europe, South America, Africa, India, and Indonesia. The infection usually starts in the nasal mucosa as transmission is thought to be by airborne droplet spread. The disease can be subdivided into three different stages. The first stage is associated with rhinorrhoea and crusting in the nasal cavity lasting months (11.1). The second stage is characterized by

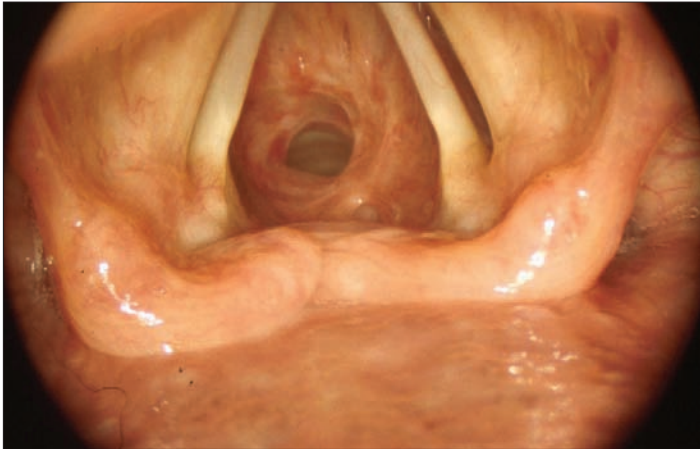
nodular granulomatous masses appearing within the nasal cavity, and these may extend to sinuses, nasopharynx, oropharynx, larynx, and tracheobronchial tree. The third sclerotic stage is characterized by healing that occurs with extensive scarring and adhesions around the nose, palate, and larynx (11.2). Subglottic stenosis can occur as a life-threatening late manifestation requiring immediate surgical intervention (11.3). The diagnosis has to be confirmed with biopsy and histopathological examination. Medical treatment primarily consists of a long-term course of antibiotics. Tetracycline and ciprofloxacin have proved to be the most effective drugs.



**11.1** Crusts seen in the right nasal cavity in early rhinoscleroma. (Courtesy of Dr. Andreas Leunig, Munchen, Germany.)

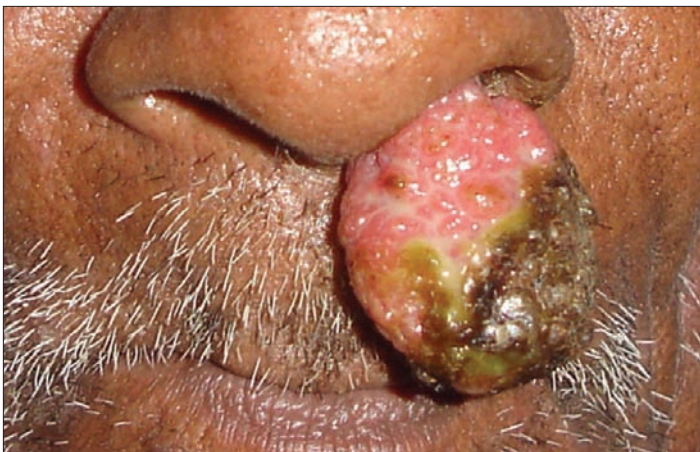
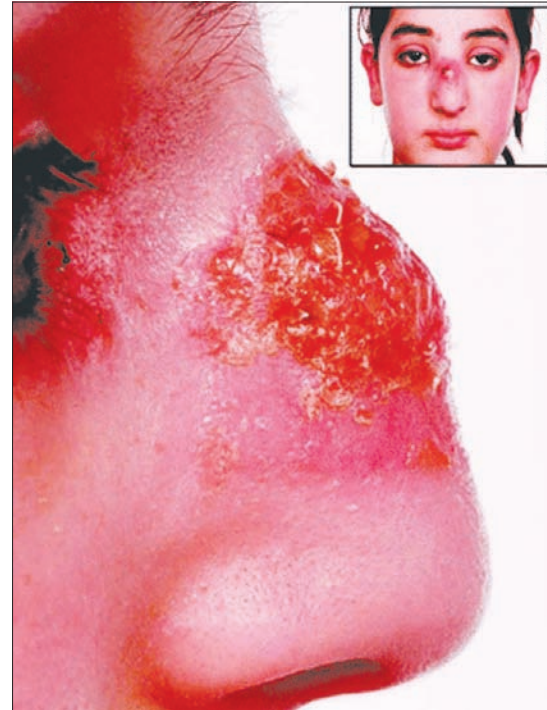
**11.2** Synechiae in the right nasal cavity in late rhinoscleroma. (Courtesy of Dr. Andreas Leunig, Munchen, Germany.)

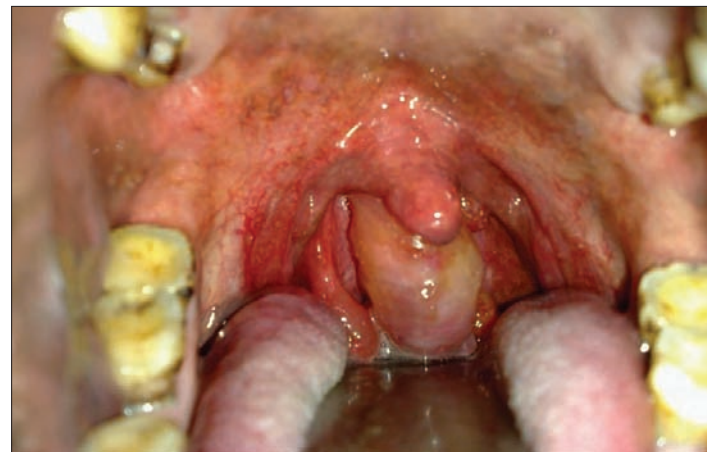

11.3 Subglottic stenosis in late rhinoscleroma. (Courtesy of Dr. Andreas Leunig, Munchen, Germany.)

11.4 Cutaneous leishmaniasis on the nasal dorsum. (Reproduced with permission from *BMJ*, 2007;335:354, Ariff MH.)



11.5 Rhinosporidiosis protruding out of the nasal cavity.



11.5 Rhinosporidiosis presenting as a nasopharyngeal mass.

### LEISHMANIASIS

This disease is caused by protozoan parasites of the genus *Leishmania*, transmitted from animal reservoirs in many tropical and subtropical countries. It is transmitted to humans by the bite of the sandfly, of the genus *Lutzomyia* and *Phlebotomus*. The nose can be involved in the cutaneous and the mucocutaneous forms of the infection. Findings include skin papules at the site of the bite that gradually ulcerate over a period of months (11.4). The

ulcers heal leaving unsightly scars behind. Mucosal lesions usually occur after the skin lesions heal. These are ulcerative lesions involving the nose and the mouth causing eventual destruction of the nasal septum and the hard palate. The clinical picture in endemic areas and the demonstration of the parasite on microscopy is diagnostic. Treatment is with pentavalent antimonials (e.g. sodium stibogluconate).



### RHINOSPORIDIOSIS

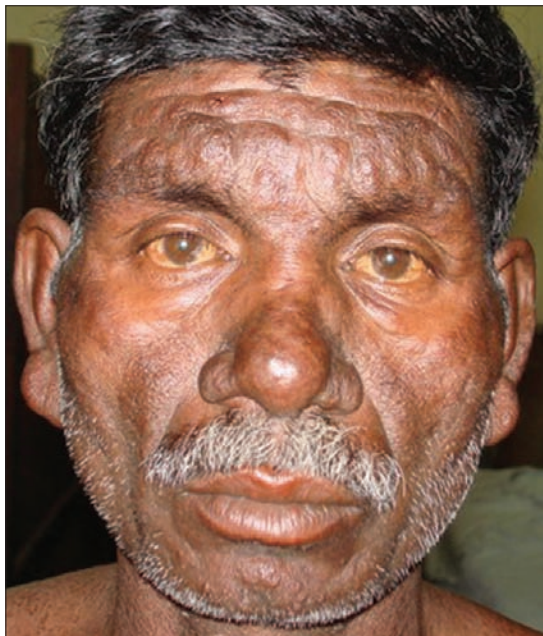Rhinosporidiosis is caused by *Rhinosporidium seeberi*, initially thought to be a fungus. This organism is currently classified under the class Mesomycetozoa, a heterogeneous group of microorganisms at the animal–fungal boundary. These include aquatic protist parasites that infect fish and other amphibians. It has been reported worldwide, but is endemic in south Asia. Although the clinical lesions are associated with the organism, no transmission has been documented between hosts.

The anterior nasal cavity is the most common site of infection, involving the inferior turbinates, nasal septum, and floor of the nose. The clinical picture is diagnostic in endemic areas: a granular, vascular polypoidal lesion, with yellowish spots on the surface that represent underlying mature sporangia (11.5, 11.6). Treatment is surgical excision with electrocautery to the base. Recurrences may occur and are treated by resection. There are case reports that suggest dapsone may be of use in controlling the growth of the organism.

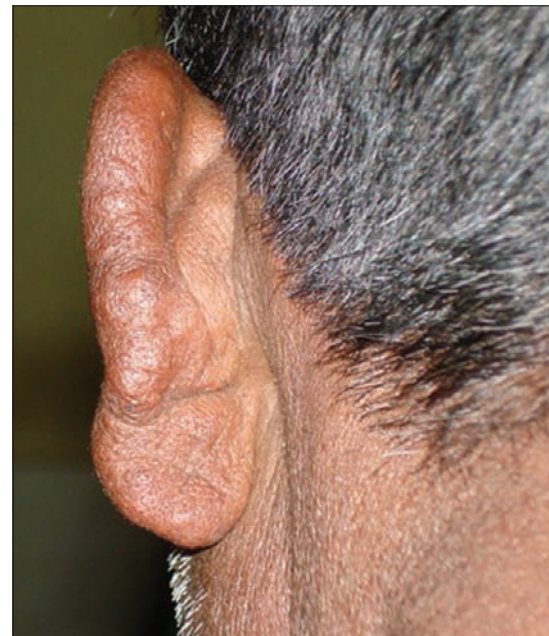### LEPROSY OF THE NOSE

Leprosy is a chronic granulomatous disease caused by *Mycobacterium leprae*, an acid-fast nonalcohol-fast bacillus. The organism cannot be cultured in artificial media, but can be inoculated in experimental animals. Leprosy is almost exclusively a disease of developing countries affecting areas of Asia, Africa, Latin America, and the Pacific. The route of transmission is uncertain and may be multiple.

The clinical presentation depends on the host immunity. In the tuberculoid variety, a good immune defence is mounted and the major finding is a hypopigmented, anaesthetic patch. The mucosa is not involved. In the lepromatous variant, nasal mucosal involvement occurs early in the disease and is present in 97% of cases. The nasal mucosa appears pale and nodular, especially over the inferior turbinate. There is crust formation in nose, nasal obstruction, and blood stained discharge. Nasal discharge in these cases contains millions of infectious bacilli and is the primary route of spread. In due course, destruction of the cartilaginous nasal septum leads to a saddle nose. Associated facial features include loss of eyebrows and eyelashes, pendulous earlobes, and scaling of skin (11.7, 11.8). Nasal scraping and staining for acid-fast bacilli confirms the diagnosis. Long-term mono- or multi-drug therapy is needed to cure the disease.



11.7 Skin nodules and plaques, alopecia of the lateral eyebrows seen in the lepromatous variant.



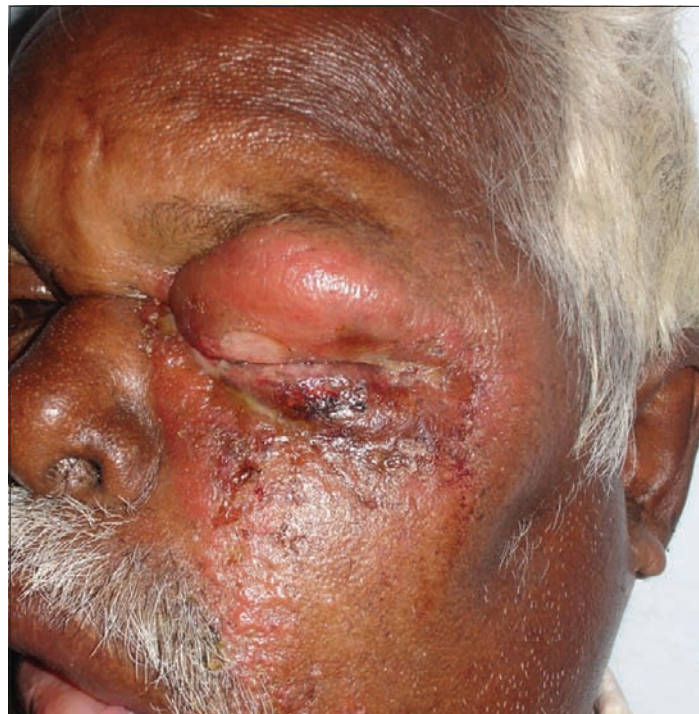11.8 Pendulous ear lobule and scaly skin seen in the lepromatous variant.



### ANTHRAX

Caused by *Bacillus anthracis*, a gram-positive bacillus, the cutaneous and oropharyngeal variants of anthrax can present with ENT manifestations. Humans are usually infected through occupational exposure to infected animals or their products. The organisms gain access through small breaks in the skin. The clinical signs occur 1–7 days after exposure. A pruritic, painless ulcer surrounded by vesicles initially forms at the site, and weeps clear or bloody fluid. A black eschar subsequently covers the ulcer. Extensive oedema is evident from an early stage (11.9). Oropharyngeal

anthrax presents with an ulcer covered by a membrane, usually unilaterally and accompanied by cervical lymphadenopathy. A high index of suspicion is required to make a diagnosis. Staining and culture of the exudates readily reveals the organism. If suspected, the lab must be informed of the possibility of anthrax as appropriate biohazard precautions need to be taken. Intravenous penicillin (doxycycline in penicillin allergic individuals) is curative, but morbidity and mortality are higher in the inhalational and septicemic variants.



11.9 Cutaneous anthrax presenting with eschar and severe facial oedema.

# Index

Note: Page numbers in *italic* refer to tables or boxes in the text

- abscess
- actinomycosis 90
  - frontal sinus 52–3
  - infra-auricular 76
  - intracranial 34, 38
  - neck spaces 24, 95–6
  - parotid gland 74, 75, 78
  - peritonsillary 70
  - pre-auricular 25
  - septal 45–6
  - submandibular 13
  - subperiosteal 50, 52
  - thyroglossal 91, 92, 93
- acid-fast bacilli 12, 13
- Actinomyces* spp. 13
- actinomycosis 90
- acyclovir 57
- adenoiditis 47
- adenovirus 48, 79
- airway compromise
- laryngeal papillomatosis 84
  - supraglottitis 80–1
- allergic reactions 28
- Alternaria* spp. 50
- aminoglycosides 23
- amoxicillin 23, 24, 67
- ampicillin 23
- analgesics 55
- angular cheilitis 62, 63
- anthrax 104
- antibiotics
- acute pharyngitis 69, 69
- antibiotics (*continued*)
- aminoglycosides 23
  - β-lactams 22–3
  - choice in ENT infections 21, 24
  - classification 21
  - infectious mononucleosis 67
  - lincosamides 23
  - macrolides 23, 49
  - mechanisms of action 22
  - metronidazole 24
  - oral infections 59
  - ototoxicity 41
  - parenteral therapy 22
  - resistance 21, 22, 23
  - sinusitis 48–9
  - skin rash 67
  - tetracyclines 23
  - topical 24, 26
- antifungal agents 30, 63, 71
- antimicrobial sensitivity testing 20
- antiseptics, ear canal 30
- antiviral agents 57, 84
- apthous stomatitis 55, 56
- Arcanobacterium haemolyticum* 18
- aspergilloma 50, 51
- Aspergillus* spp. 30, 50, 51
- identification 12, 13, 17
- aspirin 69
- atlanto-axial subluxation (Grisel syndrome) 98–9
- aural polyp 40–1
- auriscope 1, 2
- azithromycin 23
- Bacillus anthracis* 104
- bacteria
- anaerobic 13, 48
  - causing infections 18
  - classification 11–12, 11
  - commensal 13
  - gram-negative 11–12, 18, 48
  - gram-positive 11, 18
  - identification 11–12
- bacterial culture plates 15
- bacterial infections
- oral cavity 58–60
  - oropharynx 65
  - salivary glands 74–8
  - sinuses 48–9
- Bacteroides* spp. 65
- Bartonella henselae* 88
- Bell's palsy 42
- benzylamine hydrochloride 55
- β-lactam antibiotics 22–3
  - β-lactamase inhibitors 23, 24
- biological safety cabinet 15
- Bipolaris* spp. 50
- blastomycosis 82
- blood culture system 14
- bony exostoses, ear canal 31
- Bordetella pertussis* 79
- branchial cysts 91–2
- bulla ethmoidalis 4, 48
- calculus, salivary glands 74, 75
- Candida albicans* 13, 61
- Candida krusei* 61
- Candida tropicalis* 61
- candidiasis
- diagnosis 12, 17

- candidiasis (*continued*)  
 differential diagnosis 63  
 larynx 82  
 oral cavity 61–3  
 oropharynx 71  
 predisposing factors 61, 63, 71  
 pseudomembranous 6, 61, 71  
 speaking valves 83
- carbapenems 23
- Carbol fuchsin stain 12, 13
- carboxypenicillins 23
- cat scratch disease 88–9
- cats, toxoplasmosis transmission 89
- cellulitis  
 face 76  
 neck 90  
 orbital 50, 51, 52
- cephalosporins 23
- ceruminous glands 26
- cervical lymph nodes, groups and  
 drainage areas 88
- cervical lymphadenitis 87–9  
 causative organisms 87  
 mycobacterial infections 89  
 ‘red-flag’ symptoms 88
- chancre, syphilitic 59, 60
- chickenpox 57
- children  
 adenoiditis 47  
 croup 19, 81–2  
 diagnosis of stridor 80  
 ear examination 1  
 nasal foreign bodies 47  
 recurrent parotitis 77  
 supraglottitis (epiglottitis) 80–1
- chlorhexidine mouthwash/gel 55, 59
- cholesteatoma 36–9
- chondronecrosis 84–6
- clarithromycin 23, 49
- clindamycin 23, 24
- clotrimazole 30
- cold sores 57
- coliforms 13, 16, 36
- columella, dislocation 3
- commensal organisms 13, 26
- concha bullosa 48, 49
- condyloma acuminata 58
- congenital fistula of nasal dorsum 44
- coronaviruses 48, 79
- Corynebacterium diphtheriae* 18, 19, 26, 69
- coryza (viral rhinosinusitis/common cold) 48, 49
- cotton buds 28
- Coxsackie viruses 31, 56, 73
- Crohn’s disease 59
- croup 19, 81–2  
 differentiation from epiglottitis 82
- culture swab 14
- Curvularia* spp. 50
- cystic fibrosis 19
- cytomegalovirus 73
- ‘danger space’ infection 96–7
- decongestants 3, 48
- dental disease  
 causing maxillary sinusitis 48, 49  
 causing neck space infections 94
- denture stomatitis 62
- dessicated expandable ear wick 26, 27
- diabetes mellitus 62, 63
- diphtheria 69
- diplopia 52
- ear  
 commensal flora 13, 26  
 disease-causing organisms 18, 19–20  
 examination 1–2  
 inner ear infections 41–2  
 middle ear infections 19–20, 24, 32–3  
*see also* external ear canal
- EBV, *see* Epstein–Barr virus
- econazole 30
- empyema, lacrimal duct 51
- enterovirus 48, 79
- epiglottitis, *see* supraglottitis
- epistaxis 45
- Epstein–Barr virus (EBV) 55, 58, 65, 66, 73  
 diagnosis of infection 67
- erysipelas 43
- erythema, ear canal 27, 28, 29
- erythromycin 23, 49, 69
- Escherichia coli* 13, 16
- ethmoid sinus  
 infection 50  
 mucocoele 52, 53
- eukaryotes 11
- examination  
 ear 1–2  
 larynx 7–8  
 neck 8–9  
 nose 3–4  
 oral cavity 5–6  
 oropharynx 7  
 patient positioning 5
- external ear canal 25–6  
 acute otitis externa 26–7  
 bony exostoses 31  
 chronic otitis externa 28–31  
 commensal flora 13, 26  
 fungal infection 30  
 furunculosis 26  
 normal cleansing 26  
 trauma 26, 28, 29  
 viral infections 31–2
- eye disorders, sinus infections 50, 51, 52, 53, 54
- eye lid  
 cellulitis 50–2  
 oedema 53, 67
- facial nerve 31–2, 37, 42
- facial palsy 31–2, 42
- false fundus 30
- famciclovir 57
- fasciitis, necrotizing cervical 91
- fistula  
 nasal dorsum 44  
 thyroglossal 91, 93
- fluconazole 63, 71
- fluorochrome stains 12
- fluoroquinolones 23
- folliculitis, nasal vestibule 45
- foreign bodies  
 external ear canal 28  
 face/external nose 44  
 nasal cavity 47
- fractures, nose 45
- frontal sinus infections 52, 53
- fungal infections  
 causative organisms 18



- fungal infections (*continued*)  
   ear canal 13, 30  
   oral cavity 61–3  
   sinuses 50–1, 50  
   *see also Candida* infections  
 fungus ball 50, 51  
 furunculosis, ear canal 26  
*Fusobacterium necrophorum* 12, 18
- gentamicin-based drops 41  
 gingivitis, acute ulcerative 58–60  
 gingivostomatitis, primary herpetic 55–7  
 glossitis, median rhomboid 62  
 glue ear 32, 33, 47  
 gonorrhoea 59, 60  
 Gram staining 11–12  
 Grisel syndrome 98–9  
 grommets, infection 34, 36  
 gumma 59, 60
- haematoma, septal 45  
*Haemophilus influenzae* 13, 15, 19, 24, 48  
   culture plate 15  
   type B (HiB) 19, 80–1  
 hairy leukoplakia 58  
 hand–foot–mouth disease 56  
 hard palate  
   examination 6  
   herpes infection 57  
 hearing aid, causing otitis externa 28  
 hearing loss  
   assessment 2  
   conductive 30  
   sensorineural 32, 42  
 herpangina 56  
 herpes labialis 57  
 herpes simplex infections  
   nose 42, 43  
   oral 57  
   tonsillopharyngitis 68  
 herpes zoster infections  
   facial nerve (Ramsey–Hunt syndrome) 31–2  
   oral 57  
 HIV infection, *see* human immunodeficiency virus
- Hoagland's sign 67  
 human herpes virus (HHV-1) infections 55–7, 55  
 human immunodeficiency virus (HIV) 58, 66, 67, 74  
 human papilloma viruses 58, 68, 84  
 hydrogen peroxide 59  
 hyperbaric oxygen therapy 91  
 hyperthyroidism 98  
 hypopharynx, examination 7, 8
- ibuprofen 55  
 ichthammol glycerin wicks 26  
 imidazoles 63  
 immunoassay strip 16  
 immunosuppression 50, 61, 61, 63, 82  
 infectious mononucleosis 66, 67  
 influenza viruses 31, 48, 79  
 inner ear infections 41–2  
 itraconazole 63, 71
- Klebsiella* spp. 16, 48, 101  
 Koplik spots 56
- labyrinthitis 42  
 lacrimal gland infections 50, 51  
 laryngectomy, speaking valve infection 83  
 laryngitis  
   acute viral 19, 79, 79  
   chronic 82–3  
 laryngopyocoele 84–5  
 laryngoscopy 7–8, 79, 82  
 laryngotracheobronchitis (croup) 19, 81–2  
   differentiation from epiglottitis 82  
 larynx  
   examination 7–8  
   papillomas 84–5  
 leishmaniasis 102  
 Lemierre's disease 18  
 leprosy 103  
 leukoplakia 6  
   candidal 62  
   hairy 58  
 local analgesics 55  
 Ludwig's angina 13, 94, 95
- lymph nodes, neck 8–9, 88  
 lymphadenitis, cervical 87–8
- macrolide antibiotics 23, 49  
 masticator space infection 93, 94  
 mastoid cavity infection 39–40  
 mastoidectomy, cortical 34, 35  
 mastoiditis  
   acute 33–4, 35, 39  
   causative organisms 20  
   secondary 39  
 maxillary sinus  
   infections 48, 49  
   mucocoele 52, 54  
 measles 56  
 meningitis 34, 38  
 metronidazole 24  
 miconazole 63  
 micro-organisms  
   causing ENT infections 18, 19–20  
   classification 11, 11  
   commensal 13, 26  
   *see also named micro-organisms*  
 microbiological diagnosis 13–17  
 microsuction 26, 27, 30  
 middle ear infections 32  
 middle meatus, examination 3, 4  
 minimum inhibitory concentration (MIC) 21  
 Monospot test 67  
*Moraxella catarrhalis* 19, 24, 48  
 mouth  
   floor 6  
   *see also* oral cavity  
 mouthwashes 55, 59  
 MRSA 20, 21  
 mucillary transport 48  
 mucocoele 52–4  
 mucopus 47, 49  
*Mucor* spp. 17, 50  
 mumps 73  
 mycobacterial infections  
   atypical 77–8, 89  
   cervical lymphadenopathy 89  
   diagnosis 12, 13  
   salivary glands 77–8  
*Mycobacterium leprae* 103

- Mycobacterium tuberculosis* 12, 13, 16, 82
- mylohyoid muscle 94
- myringitis, bullous 31
- nasal cavity
- anatomic variations 3, 4
  - commensal bacteria 13
  - examination 3–4
  - infections 45–7
  - polyps 46, 47, 48
  - viral papilloma 45
- nasal dorsal fistula 44
- nasoendoscopy 3, 7, 81
- nasolaryngoscopy 7–8
- nasopharyngeal swab 14
- nasopharynx, commensal organisms 13
- neck
- examination 8–9
  - lymphadenopathy 87–9, 87
- neck dissection, post-operative infection 97
- neck space infections 24, 87, 93–7
- ‘danger’ space 96–7
- necrotizing cervical fasciitis 91
- Neisseria* spp. 48
- Neisseria gonorrhoea* 18
- Neisseria meningitidis* 13, 18
- nose (external)
- erysipelas 43
  - foreign bodies 44
  - herpes simplex infection 43
  - leprosy 103
  - saddle deformity 45, 46
  - see also* nasal cavity
- nystatin 30, 63, 71
- oculomotor palsy 52, 54
- oedema
- ear canal 26, 27, 29
  - facial nerve 42
  - periorbital 53, 67
- oral cavity
- bacterial infections 58–60
  - examination 5–6
  - fungal infections 61–3
  - viral infections 55–8
- oral mucosa
- examination 6
  - papillomatosis 58
  - white patches 6, 58, 62
- orbital cellulitis 50, 51, 52
- oropharynx
- anthrax 104
  - bacterial infections 65, 69–70
  - candidal infections 71
  - commensal organisms 13
  - examination 7
  - infectious organisms 65
  - viral infections 65, 67–8
- osteitis, mastoid bone 34
- osteomyelitis
- frontal bone (Pott’s puffy tumour) 52–3
  - skull base 41–2
- otic capsule, erosion 42
- otitis externa
- acute 26–7
  - causative organisms 13, 18, 19
  - chronic 28–30
  - fungal 13, 30
  - sequelae of chronic 30–1
- otitis media
- acute 24, 32–3
  - antibiotic therapy 24
  - causative organisms 18, 19–20
  - chronic 24
  - with effusion (OME/glue ear) 32, 33, 47
- otorrhoea 34, 35, 36, 37
- ototoxicity 41
- papillomatosis
- larynx 84–5
  - nasal cavity 45
  - oral mucosa 58
  - oropharynx 68
- paracetamol 55
- parainfluenza virus 48, 73, 79
- paramyxovirus 56, 73, 79
- paranasal sinuses
- bacterial infections 24, 48–9
  - complications of infections 50–4
  - fungal infections 50–1, 50
- paranasal sinuses (*continued*)
- radiology 3–4
- parapharyngeal space 94–6
- parotid gland
- duct orifice (Stenson’s duct) 5, 6
  - enlargement 73, 74
  - see also* parotitis
- parotidectomy, post-operative infection 97
- parotidectomy-type incision 77
- parotitis
- bacterial 74–6, 75
  - chronic recurrent of childhood 77
  - viral 73, 73
- patient positioning 5
- Paul–Bunnell test 67
- penciclovir 57
- penicillin 23, 69
- intravenous 104
  - penicillinase-resistant 23
- perichondritis 25
- peritonsillar abscess 70
- pharyngitis
- acute 56, 65–6, 69
  - causative organisms 18, 19
  - lymphadenopathy 87
- pharyngotonsillitis 24, 68
- pinna
- examination 1
  - infections 25
- polyps
- aural 40–1
  - nasal 46, 47, 48
- post-aural sulcus, loss 34, 35
- post-operative infections 97
- Pott’s puffy tumour 52–3
- premature infant, hospitalized 13
- prevertebral space infection 96
- prokaryotes 11
- Propionibacterium acnes* 13
- proptosis 50, 51, 53
- Proteus* spp. 28
- pseudo-ephedrine 48
- Pseudomonas* spp. 28, 36, 41, 48
- Pseudomonas aeruginosa* 13, 18, 19, 41
- pyocoele, frontal sinus 52
- pyriform fossae, examination 7, 8

- radiation therapy, complications 82, 84–6
- Ramsey–Hunt syndrome 31–2
- reconstructive surgery, necrotizing cervical fasciitis 91
- respiratory syncytial virus 48, 79
- retromolar trigone 5, 6
- retropharyngeal space infections 96–7
- rhinitis, viral 48, 49
- rhinorrhoea 47, 48, 49
- rhinoscleroma 101–2
- rhinoscopy 3
- rhinosinusitis  
bacterial 48–9  
viral (coryza/common cold) 48, 49
- rhinosporidiosis 102, 103
- Rhinosporidium seeberi* 103
- rhinoviruses 19, 79
- Rinne test 2
- saddle nose deformity 45, 46
- salivary glands  
bacterial infections 74–8  
calculus 74, 75  
duct orifices 5, 6  
examination 5–6  
granulomatous infections 77–8  
viral infections 73–4
- scarlet fever 69
- sebaceous cyst  
face 76  
pinna 25
- septal abscess 45–6
- septal haematoma 45
- septal perforation 45, 46
- septal spur 3, 4
- serological tests 16
- shingles (zoster) 57
- sialadenitis, acute suppurative 74–6
- sialectasis, punctate 77
- sialography 77
- sinus, pre-auricular 25
- sinuses, *see* paranasal sinuses
- Sistrunk's procedure 91, 93
- skin rash, amoxicillin use 67
- skull base, osteomyelitis 41–2
- snail track ulcers 59, 60
- sore throat, acute 69
- speaking valves, *Candida* colonization 83
- specimen container 14
- sphenoid sinus, mucocoele 52, 54
- squamous epithelium, ear  
canal/tympanic membrane 25–6, 36–7
- Staphylococcus aureus* 13, 19, 26, 28, 44, 45, 48, 74, 82, 90  
methicillin-resistant (MRSA) 20, 21
- Stenson's duct 5, 6
- sternomastoid muscle 8, 9
- steroids 30, 32, 42
- stomatitis  
angular 62, 63  
denture 62  
primary herpetic 55–7  
staphylococcal 59
- strawberry tongue 69
- streptococcal rapid antigen test 69
- streptococci  
group A (GAS) 15, 19, 24, 43, 48  
group A beta haemolytic (GABHS) 69  
groups C and G 18, 19
- Streptococcus epidermidis* 26
- Streptococcus milleri* 48
- Streptococcus pneumoniae* 12, 13, 18, 20, 24, 48
- Streptococcus pyogenes* 15, 18, 19, 24, 90  
antibiotic resistance 23
- Streptococcus viridans* 26
- stridor 79, 84  
diagnostic algorithm 80  
laryngeal papillomas 84
- sublingual space infections 94
- submandibular gland  
duct orifice (Wharton's duct) 6  
infections 76–7
- submandibular space infection 94, 95
- supraglottitis 80–1  
adult 81  
antibacterial therapy 24  
causative organisms 19  
child 80–1  
differentiation from croup 82
- suprahyoid neck spaces 94–5
- swimming 26, 31
- syphilis 59, 60
- tetracyclines 23
- throat swab 65
- thrush 61
- Thudicum's speculum 3
- thyroglossal fistula 91–2
- thyroid cartilage, chondronecrosis 86
- thyroid gland, examination 8
- thyroiditis, infective 98–9
- tinnitus 32
- tongue  
hairy leukoplakia 58  
median rhomboid glossitis 62  
strawberry 69  
syphilitic chancre 60
- tongue base, examination 7
- tongue depressor 5, 7
- tonsillectomy 70
- tonsillitis 66, 70
- Toxoplasma gondii* 87, 89
- toxoplasmosis 89
- tracheitis, bacterial 82
- 'triple therapy' 30
- tuberculosis  
larynx 83  
oral ulcers 59, 60  
salivary glands 78
- tuning fork tests 2
- tympanic membrane  
cholesteatoma 36–9  
examination 1  
false fundus 30  
perforation 32, 33, 34–5  
squamous epithelium 25–6, 36–7
- Tzanck smear 68
- ulcers, oral 57, 59, 60
- uvula, papilloma 68
- Valsalva manoeuvre 7–8
- varicella-zoster virus (VZV) 55, 57
- ventilation tubes, infection 34, 36
- vertigo 42
- vestibular neuronitis 42
- vestibulitis 45



- viral infections
  - common ENT pathogens 18
  - diagnosis 12, 13
  - external ear 31–2
  - inner ear 42
  - laryngitis 19, 79, 79
  - middle ear 32
  - oral mucosa 55–8
  - oropharynx 65, 67–8
  - salivary glands 73–4
  - sinuses 48, 49
- viral papillomatosis 45, 58, 68, 84–5
- viral swab 14
- vocal cords
  - congestion 79
  - examination 7, 8
  - papillomatosis 84–5
- VZV, *see* varicella-zoster virus
- wax
  - ear canal 26
  - mastoid cavity 39
- Weber test 2
- Wharton's duct 6
- wicks, impregnated ear canal 26, 30
- xylometazoline 48
- yeasts, identification 12
  - see also* *Candida* spp.
- Ziehl Nielsen stain 12, 13