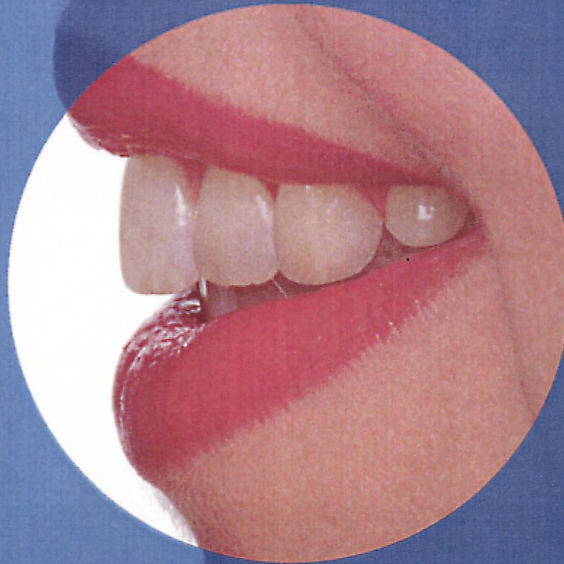

ESTHETICS IN DENTISTRY

SECOND EDITION

VOLUME 1
PRINCIPLES,
COMMUNICATIONS,
TREATMENT METHODS



RONALD E. GOLDSTEIN, D.D.S.

ESTHETICS IN DENTISTRY

SECOND EDITION

VOLUME 1

PRINCIPLES

COMMUNICATIONS

TREATMENT METHODS

VOLUME 2

INDIVIDUAL TEETH

MISSING TEETH

MALOCCLUSION

FACIAL APPEARANCE

VOLUME 3

SUPPORTING STRUCTURES

EMERGENCIES

TREATMENT FAILURES

SPECIAL POPULATIONS

TECHNICAL PROBLEMS

ESTHETICS IN DENTISTRY

SECOND EDITION

VOLUME 1

PRINCIPLES

COMMUNICATIONS

TREATMENT METHODS

Ronald E. Goldstein, D.D.S.

Clinical Professor of Oral Rehabilitation
Medical College of Georgia School of Dentistry
Augusta, Georgia

Adjunct Clinical Professor of Prosthodontics
Boston University Henry M. Goldman School of Dental Medicine

Adjunct Professor of Restorative Dentistry
The University of Texas Health Science Center at San Antonio

Visiting Professor of Oral and Maxillofacial Imaging
and Continuing Education
University of Southern California School of Dentistry,
Los Angeles, California

1998
B.C. Decker Inc.
Hamilton • London

B.C. Decker Inc.
4 Hughson Street South
P.O. Box 620, L.C.D. 1
Hamilton, Ontario L8N 3K7
Tel: 905-522-7017
Fax: 905-522-7839
e-mail: info@bcdecker.com
website: <http://www.bcdecker.com>



© 1998 Ronald E. Goldstein

All rights reserved. No part of this publication may be reproduced, stored in a retrieval system, or transmitted, in any form or by any means, electronic, mechanical, photocopying, recording, or otherwise, without prior written permission from the publisher.

98 99 00 01 / BP / 9 8 7 6 5 4 3 2 1
ISBN 1-55009-047-X
Printed in Canada

SALES AND DISTRIBUTION

United States

B.C. Decker Inc.
P.O. Box 785
Lewiston, NY 14092-0785

U.K., Europe, Scandinavia, Middle East

Harcourt-Brace & Company Ltd.
24-28 Oval Road
London, NW1 7DX
United Kingdom
Tel: 71-267-4466
Fax: 71-482-2291

Canada

B.C. Decker Inc.
4 Hughson Street South
P.O. Box 620, L.C.D. 1
Hamilton, Ontario L8N 3K7
Tel: 905-522-7017
Fax: 905-522-7839

Korea

Jee Sung Publishing Company
236-15, Neung-Dong
Seung Dong-Ku, Seoul
Korea
Tel: 02 424-5463
Fax: 02 456-5058

Japan

Ishiyaku Publishers Inc.
7-10, Honkomagome 1-Chome
Bunkyo-ku, Tokyo 113
Japan
Tel: 03 5395-7604
Fax: 03 5395-7606

India

Jaypee Brothers Medical Publishers Ltd.
B-3, EMCA House,
23/23B Ansari Road, Daryaganj,
P.B. 7193, New Delhi-110002, India
Tel: 11 3272143
Fax: 11 3276490

Notice: The authors and publisher have made every effort to ensure that the patient care recommended herein, including choice of drugs and drug dosages, is in accord with the accepted standard and practice at the time of publication. However, since research and regulation constantly change clinical standards, the reader is urged to check the product information sheet included in the package of each drug, which includes recommended doses, warnings, and contraindications. This is particularly important with new or infrequently used drugs.

Contributors

Jack D. Preston, DDS

Don and Sybil Harrington Foundation
Professor of Esthetic Dentistry
Chairman, Department of Oral and
Maxillofacial Imaging
University of Southern California
California

Robert M. Ricketts, DDS, MS

Professor of Orthodontics
University of California
Los Angeles, California
Professor of Orthodontics
University of Illinois
Illinois

Sidney I. Silverman, BA, DDS

Professor Emeritus and Clinical Professor
of Prosthodontics
New York University College of Dentistry
Clinical Professor of Neurology
New York University School of Medicine

Robert C. Sproull, DDS

Cofounder and Past President
American College of Prosthodontics
Past President
American Academy of History of Dentistry
American Academy of Esthetic Dentistry

Edwin J. Zinman, DDS, JD

Law Practice, specializing in dental
jurisprudence and personal injury
San Francisco, California
Consultant
American Academy of Periodontology

Contributors At Large

Pinhas Adar, MDT, CDT

Oral Design Center, Inc.
Atlanta, Georgia

David A. Garber, DMD

Clinical Professor, Department of Periodontics
Clinical Professor, Department of Oral Rehabilitation
School of Dentistry
Medical College of Georgia
Augusta, Georgia

Cary E. Goldstein, DMD

Clinical Instructor
Department of Oral Rehabilitation
School of Dentistry
Medical College of Georgia
Augusta, Georgia

Cathy Goldstein Schwartz, DDS

Private Practice
Atlanta, Georgia

Van B. Haywood, DMD

Professor
Department of Oral Rehabilitation
School of Dentistry
Medical College of Georgia
Augusta, Georgia

Angela Gribble Hedlund, DMD

Private Practice
Atlanta, Georgia

Maurice A. Salama, DMD

Clinical Assistant Professor
Department of Periodontics
School of Dentistry
Medical College of Georgia
Augusta, Georgia

Contents

Preface	ix
Acknowledgments	x
PART 1 Principles of Esthetics	
1. Concepts of Dental Esthetics	3
2. Esthetic Treatment Planning	17
3. Marketing	51
4. Legal Considerations	65
5. Photography	83
6. Biology of Esthetics	101
7. Pincus Principles	123
8. Creating Esthetic Restorations through Special Effects	133
9. Divine Proportion	187
10. Understanding Color	207
PART 2 Esthetic Treatments	
11. Cosmetic Contouring	223
12. Bleaching Discolored Teeth	245
13. Composite Resin Bonding	277
14. Etched Porcelain Restorations: Veneers and Inlays/Onlays	339
15. Crown Restoration	395
Appendix A	453
Appendix B	457
Appendix C: Manufacturer Index	461
Appendix D: Product Index	463
Index	464

Preface

I was first drawn to the study of esthetics a number of years before my 1969 article “The study of the need for esthetic dentistry” was published in the *Journal of Prosthetic Dentistry*. That article identified dentistry’s general lack of understanding of and appreciation for the natural link between a patient’s appearance and his or her self-perception.

During the first half of the 1970s, I avidly pursued my study of esthetics, investigating every known aspect of dentofacial appearance. I became convinced of the huge untapped potential the field offered for improving patient outcomes and enhancing dental practice. Eventually, I was inspired to dedicate my professional career to promoting a comprehensive interdisciplinary approach to dentistry that united function and esthetics in the service of total dentofacial harmony.

When the first edition of this text was published in 1976, the United States was in the midst of a celebration marking the 200th anniversary of our birth as a nation. It was an unprecedented national observance of the highly successful American Revolution. At the time, I considered the two events—both of considerable importance to me—distinct from one another. Since that time, however, I have come to recognize that, although the publishing of any textbook could never be considered in the same breath with the emergence of a nation, both events were indeed revolutionary.

Two decades ago or longer, esthetics was considered, at best, a fortuitous byproduct of a dental procedure—a bridesmaid, but certainly not a bride. In the years that have ensued, esthetics has taken its rightful place, along with functionality, as a bona fide objective of dental treatment. The revolution that has transpired has been not only in our knowledge of the field but also in methodology and technology. Today’s patients are highly informed about the possibilities of esthetic dental restorations and fully expect that expert esthetics will be considered, from the inception of treatment to the final result.

Consumers know that dental esthetics play a key role in their sense of well-being, their acceptance by others, their success at work and in relationships, and their emotional stability. Informed by books and ongoing media coverage, bolstered by increased means, and driven by the desire to live better lives, patients seek out dentists who can deliver superior esthetic services.

The ongoing effort to meet these demands with state-of-the-science treatment represents the continuation of that revolution. Little did I know, at the time this book first appeared, that esthetics would eventually hold a preeminent position in our profession. That it is recognized today as a basic principle of virtually all dental treatment is a gratifying and exciting state of affairs.

As with the original text, the three volumes of this edition have been organized into two basic categories: patient problems and technical problems. This first volume deals specifically with problems of communication, esthetic principles, and the basic esthetic treatments such as cosmetic contouring, bleaching, bonding, porcelain laminates, and the full crown restoration.

Joining me to help complete volumes two and three will be a respected colleague and highly knowledgeable academician Van Haywood. Volume Two will feature problems of individual teeth, missing teeth, malocclusion, and facial appearance. Volume Three will feature problems of the supporting structures, emergencies, esthetic failure, and issues associated with the elderly and the youth. Finally, technical problems such as chairside procedures, and specific problems dealing with various restorative materials will be covered.

It is my hope that, in some small way, this updated volume will serve to advance all aspects of the esthetic dental revolution and, in so doing, help patients and practitioners achieve ever greater, more satisfying esthetic outcomes.

Ronald E. Goldstein
May 1998

Acknowledgments

So many people have worked on various aspects of this book that it would take far too much space to mention all of them. However, there were those who gave significant time to the project, and it is those people who I will attempt to thank at this time.

To begin with, I must acknowledge the excellent chapter contributions of the contributors, Dr. Edwin J. Zinman, Dr. Sidney I. Silverman, Dr. Robert M. Ricketts, Dr. Robert C. Sproull, and Dr. Jack D. Preston. They were patient in enduring a number of delays, including the time I needed to find a publisher who would invest the appropriate time, talent, and money to produce the quality I wanted in this second edition. B.C. Decker made that commitment and followed through with excellent color separations, improved illustrations, and many other quality-enhancing areas to significantly improve on the first edition. I would like to thank the production staff at Decker Inc., and Andy Rideout who created the high-quality illustrations for all the dedication and hard work they put into the making of this book. A special thanks to Lewis Hinely, who also created several of the illustrations.

Most helpful in every way was the extraordinary effort of my personal executive assistant, Susan Hodgson. Susan's attention to detail and meticulous follow-through helped me to complete this first volume. Others who assisted me on various aspects of the book were Cindy Sullivan, Kelly Sadowski, Mary Jane King, and Sylvia Wrobel.

My clinical office staff has always been generous with their help over the years. Those assistants who have been most helpful with this volume were Regina Baird, Charlene Bennett, Pat Jones, Silvia Rodriguez, and Carlyn Kalmar.

It also takes a talented group of professionals for the day-to-day support necessary to sustain a lengthy project such as this text. My most sustaining support is derived from my long-time partner, David Garber. No one could ask for a more understanding and gifted friend than David. Maurice and Henry Salama have always been ready to lend a hand or help solve a dilemma as only they can. Angie Gribble Hedlund was particularly helpful during the final edits and contributing material, especially in Chapter 15. Thanks also to Pinhas Adar, who has always been willing and available to help with technical or illustrative assistance.

We have been blessed with competent and especially remarkable administrative assistants over the years: Cynthia Clement, Candace Paetzhold, Elaine Swyers, and for many years Margie Smith. They are always willing to help me despite their workload. Final peer reviews of certain chapters were efficiently and expertly done by Van Haywood, Howard Strassler, and Bill Glassgold.

Last but not least, I must thank my busy but devoted family: first and foremost my wife, Judy, who has continued to support and advise me throughout my career; our eldest son, Cary, a prosthodontist, who was with our group before opening his own practice, his wife Jody, and son Maxwell; our daughter, Cathy, a general dentist, her husband Steve, daughters Katie and Jennie, and son Brett; our son Rick, a physician, and his wife Amy; and our son Ken, an endodontist. They are all a source of great pride and joy for me.

PART 1

PRINCIPLES OF ESTHETICS

CHAPTER 1

CONCEPTS OF DENTAL ESTHETICS

Beauty is in the eye of the beholder.

Margaret Hungerford

WHAT IS ESTHETICS?

Webster's Third New International Dictionary defines "esthetic" as "appreciative of, responsive to, or zealous about the beautiful; having a sense ... of beauty or fine culture." Each of us has a general sense of beauty. However, our own individual expression, interpretation, and experience make it unique, however much it is influenced by culture and self-image.

What one culture perceives as disfigured may be beautiful to another. Chinese women once bound their feet, and Ubangis distend their lips. Individuals' sense of what is beautiful influences how they present themselves to others. Esthetics is not absolute, but extremely subjective.

HISTORICAL PERSPECTIVE OF DENTAL ESTHETICS

Recognizably cosmetic dental treatment dates back more than four millennia. Throughout history, civilizations recognized that their accomplishments in the field of restorative and cosmetic dentistry were a measure of their level of competence in science, art, commerce, and trade. There are repeated references in history to the value of replacing missing teeth. In the El Gigel cemetery located in the vicinity of the great Egyptian pyramids, two molars encircled with gold wire were found. This was apparently a prosthetic device.⁴ In the Talmudic Law of the Hebrews, tooth replacement is permitted for women. The Etruscans were well-versed in the use of human teeth or teeth carved from animal's teeth to restore missing dentition.¹¹

Other historical evidence that ancient cultures were concerned with cosmetic alteration of the teeth include reference to the Japanese custom of decorative tooth-staining called "ohaguro" in 4000-year-old documents. Described as a purely cosmetic treatment, the procedure had its own set of implements, kept as a cosmetic kit. The chief result of the process was a dark brown or black stain on the teeth. Studies suggest that it might also have had a caries-preventive effect.²

Smiles are evidenced as early as 3000 BPE.¹ A smile on the face of a statue of an early king of Abab is noted in the art of Sumer. Aboucaya noted in his thesis that the smile was absent or not very marked in early works of art and, when present, was almost always labial. The dentolabial smile, where the teeth are seen behind the lips, starts to emerge in the first decades of the 20th century. This is attributed to an increased emphasis of awareness of the body and art of cosmetics due to the evolution of social life and the change in habits



Figure 1-1: This 2000-year-old Mayan skull provides some of the best evidence that jadeite inlays were used for cosmetic, rather than functional, purposes.

4 Esthetics in Dentistry

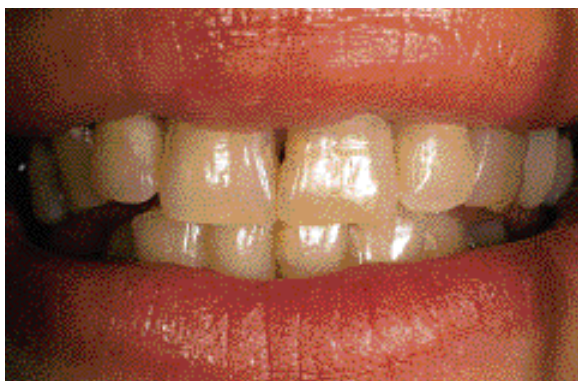

Figure 1-2A: Discolored teeth and leaking and discolored fillings marred the smile of this 24-year-old internationally known ice skating performer. (Note also the slight crowding of the front teeth, with the right lateral incisor overlapping the cuspid.)

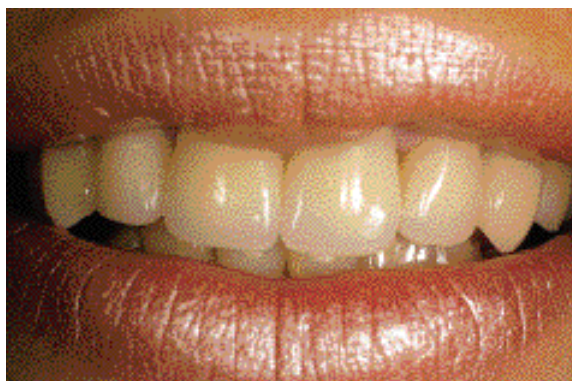

Figure 1-2B: A new sense of self-confidence and a much more appealing smile was the result of six full porcelain crowns. The teeth appear much straighter and the lighter color brightens the smile and enhances the beauty of her face and lips.

and manners. Teeth began to play an increasingly important role as more attention was paid to the face, which exhibited more open and unrestricted expressions. The resulting emphasis on dental treatment and care also created an interest in the improvement of the esthetics of the smile.

At the height of the Mayan civilization, a system of dental decoration evolved in which some teeth were filed into complicated shapes (see Figure 1-1), and others were decorated with jadeite inlays. These dental procedures were purely cosmetic and not restorative. That ancient Japanese proudly displayed black teeth and the Mayans flashed a jadeite-studded smile testify to an apparently deep-seated urge to decorate the body.

Although the intent of these ancient attempts at cosmetic dentistry was strictly ornamental, there were sometimes beneficial side effects, such as the possible caries-preventive consequence of ohaguro. More often, however, the side effects were harmful. Some Mayans, seeking to brighten their smiles with jadeite, developed periapical abscesses because of careless or overenergetic “filers of the teeth,” as their dentists were called.

Today, dental esthetics is founded on a more ethically sound basis: the general improvement of dental health. But the same desires of those ancient men and women to submit to dental decoration as an outward portrayal of the inner self, motivate today's adults to seek esthetic treatment. Although

esthetic dentistry can help achieve self-assurance, it must always be predicated on sound dental practice and keyed to total dental health. The limitations of esthetic treatment must be communicated to the patient by dentists who are fully conversant with the procedures, methods, and materials available.

THE SOCIAL CONTEXT OF DENTAL ESTHETICS

A desire to look attractive is no longer taken as a sign of vanity. In an economically, socially, and sexually competitive world, a pleasing appearance is a necessity. Since the face is the most exposed part of the body, and the mouth a prominent feature, teeth are getting a greater share of attention. “Teeth are sexy” announced a leading fashion magazine and it then went on to elaborate in nearly 500 words (Figures 1-2A and B). The headline was just the capstone of a string of magazine articles that drew new attention to teeth. Gradually, the public has been made more aware of the “aids to nature” that Hollywood stars have been using since movies began. They discovered that their favorite actors, models, and singers used techniques of dental esthetics to make themselves more presentable and attractive. Some followed the Hollywood lead and asked their dentists to give them teeth like those of some celebrities and thus learned of methods and materials that could improve their appearance.

In the United States today, we place a premium on health and vitality. In fact, these two words are

now intertwined with images of beauty. Goleman and Goleman¹⁰ reported that researchers found that attractive people win more prestigious and higher-paying jobs. At West Point, cadets with Clint Eastwood-style good looks—strong jaws and chiseled features—rise to higher military ranks before graduation than their classmates. They also found that good-looking criminals were less likely to be caught; if they did go to court, they were treated more leniently. Teachers were found to go easier when disciplining attractive children; both teachers and pupils consider attractive children as smarter, nicer, and more apt to succeed at all things. Many studies on self-esteem have illustrated that body image was one of the primary elements in self-rejection.^{11,12} Television reinforces in us an extraordinarily high standard of physical attractiveness, and Hollywood has long rewarded beauty and given us standards that are probably higher than most of us will ever achieve.

Society chooses leaders to set unspecified but pervasive standards of acceptable dress, behavior, and recreation. The swings of fashion filter down from the posh salons of couturiers patronized by

the wealthy, or up from department store racks from which the majority buy their clothing. A catch-phrase repeated on radio or television instantly becomes part of the national language, and songs that began as commercials wind up topping the popular music charts.

Uninfluenced by the esthetic standards set by society, many individuals want to change their appearance to emulate their chosen leaders. General social attitudes profoundly influence an individual's idea of what is attractive; "natural," "beautiful," and "goodlooking" hold different things within the population. The female shown in Figure 1–3C was happy with her diastema, thinking it was "cute" and part of her personality. Occasionally, patients take extreme measures to call attention to the mouth in an attempt to achieve an attractive image (Figure 1–3 and Figure 1–4). Therefore, it is the responsibility of the dentist to understand what the patient means when using a particular term, and to decide to what degree the patient's ideal may be realized. The patient's own feeling of esthetics and concept of self-image is what is most important.

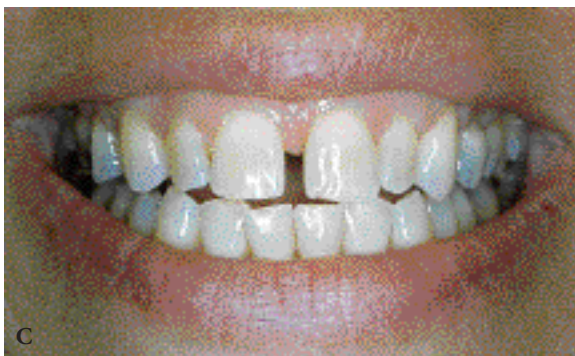
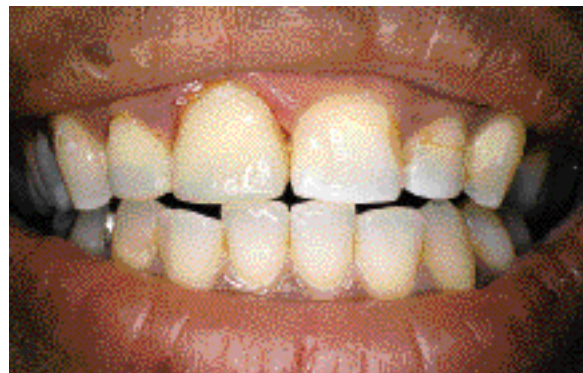
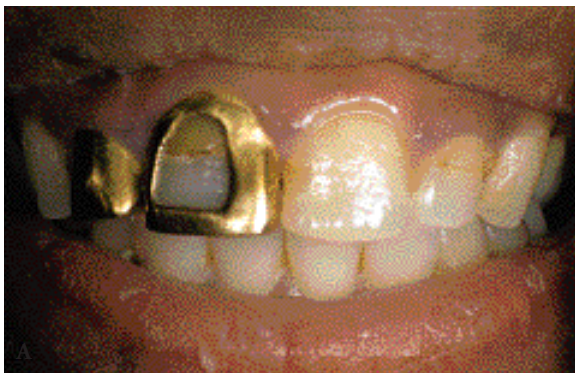Figure 1–3: Esthetic values change with social attitudes. (A) This patient once thought that showing gold was desirable, and it was accepted in her socioeconomic peer group. (B) When her status changed 10 years later, so did her attitude, and the gold crowns were removed. It is important to "wear" these temporary acrylic crowns for 1 to 3 months to make certain the patient will continue to like his or her new look. (C) This lady was happy with her diastema, thinking it was "cute" and part of her personality.

6 Esthetics in Dentistry

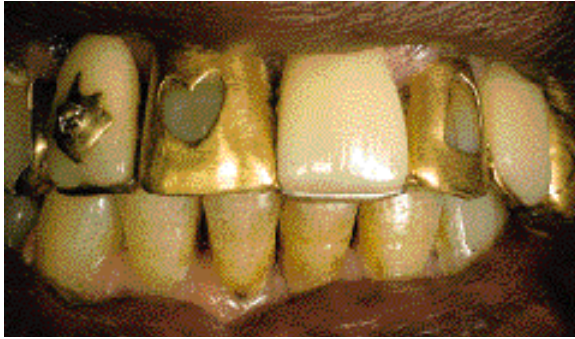

Figure 1–4: An attractive person convinced a dentist to construct these open-faced crowns, depicting a heart in the right central incisor and an inlaid diamond in the right lateral incisor. The patient's own feeling of esthetics and concept of self-image is most important.

Esthetic dentistry demands attention to the patient's desires and treatment of the patient's individual problems. Esthetic dentistry is the art of dentistry in its purest form. The purpose is not to sacrifice function but to use it as the foundation of esthetics.

The excellence of every art is its intensity, capable of making all disagreeables evaporate, from their being in close relationship with beauty and truth.

John Keats

ESTHETICS: A HEALTH SCIENCE AND SERVICE

Is esthetic dentistry a health science and a health service?⁹ Or is it the epitome of vanity working its way into a superficial society?

The answer to these questions lies in the scientific facts gleaned from over a thousand studies proving the direct and indirect relationship of how looking one's best is a key ingredient to a positive self-image, which, in turn, relates to good mental health.

The authors of a recent survey of nearly 30,000 people point to a relationship between psychosocial well-being and body image.⁷ They found that feeling attractive, fit, and healthy results in fewer feelings of depression, loneliness, and worthlessness. This study also found that the earlier in life appearance is improved, the more likely it is that the person goes through life with a positive self-image.

Sheets states that, "An impaired self-image may be more disabling developmentally than the pertinent physical defect."²³ For instance, adults who reported having been teased as children were more likely to have a negative self-evaluation than those who were not teased (Figure 1–5A).

According to Paetzer, the face is the most important part of the body when determining physical attractiveness.²⁰ Specifically, "the hierarchy of importance for facial components appears to be mouth, eyes, facial structure, hair, and nose." Therefore, it becomes apparent that not only should esthetic dentistry be performed, it should also be performed as early as possible (Figures 1–5A and B). It is not necessary for every dentist to master all of the treatments available. However, the advantages, disadvantages, possible results of treatment, maintenance required, and life expectancy of each treatment modality should be thoroughly understood by all dentists. A willingness to refer to another dentist when he or she is more capable of satisfying the patient's desires is both ethical and necessary for good patient relations. Your patient will likely return to you with trust and loyalty for your good judgment in referring for the specific esthetic treatment. The alternative is that your previously satisfied patient may leave you for another dentist if you do not offer the requested treatments or belittle their effectiveness without offering an alternative. The fact is, all esthetic treatment modalities work on indicated patients. A good example would be a patient with teeth yellowed due to aging. If you do not provide vital tooth bleaching as one of your routine esthetic dentistry treatments, refer to a colleague who does provide this service. Most likely, the patient will return to your office for routine treatment. Patients may actually appreciate you more, realizing that you are more concerned with their well-being than your own.

Two questions seem in order. Are we as dentists doing all we should to motivate our existing patients to improve their smiles? Are we as a profession doing all we should to motivate the 50% of the population who do not normally visit the dentist to have their smiles esthetically improved?

Based on the enormous amount of research showing the advantages of an attractive smile, the answer to both questions would seem to be "No." We can and should do much more to inform the public about why a great smile is an important asset

and that we as a profession are the logical group to help accomplish this goal. Furthermore, we need to show how easy and painless it can be to achieve.

Most dentists want to see greater effort on the part of organized dentistry to promote the value of dentistry to the public through radio, television, or printed educational messages. In a recent survey, Wilson²⁴ reported that 83% of surveyed dentists would like to see more effort in this area.

UNDERSTANDING THE PATIENT'S ESTHETIC NEEDS

A practicing dentist must be acquainted with certain generalities concerning the psychological significance of the patient's mouth. He or she must be familiar with certain basic considerations that apply to esthetic treatment and must be aware of problems that such treatment may elicit or aggravate in the patient.

The Importance of Facial Appearance

Gordon Allport observes, "Most modern research has been devoted not to what the face reveals, but what people think it reveals."³ He describes tendencies to perceive smiling faces as more intelli-

gent and to see faces that are average in size of nose, hair, grooming, set of jaw, and so on, as having more favorable traits than those that deviate from the average. Summarizing an experiment by Brinswick and Reiter, Allport notes, "One finding ... is that in general the mouth is the most decisive facial feature in shaping our judgments."² Meerloo observes, "Through the face, one feels exposed and vulnerable. One's facial expression can become a subject of anxiety."¹⁹

Studies suggest that even infants can tell an attractive face when they see one, long before they learn a society's standards for beauty. Results of experiments with two groups of infants were reported by psychologist Judith Langlois and five colleagues at the University of Texas at Austin. One group consisted of infants from 10 to 14 weeks old with an average age of 2 months and 21 days. Sixty-three percent of the infants looked longer at attractive faces than at unattractive faces when shown pairs of slides of Caucasian women. The second group consisted of 34 infants whose ages ranged from 6 months to 8 months. Seventy-one percent of the infants looked longer at attractive faces than at unattractive faces.¹³⁻¹⁷



Figure 1-5A: This beautiful 13-year-old girl reported that boys "called her names," referring to her tetracycline-stained teeth.



Figure 1-5B: Although bleaching was attempted, bonding the four maxillary incisors was required to properly mask the tetracycline stains. Unless attention is paid to esthetics in young people, severe personality problems may develop. Improving one's self-confidence through esthetic dentistry can make all the difference in having a positive outlook on life.

8 Esthetics in Dentistry

Any dentist dealing with appearance changes in the face must consider the psychological as well as the physical implications of the treatment. The consideration must involve not only results and attitudes following treatment but also causes, motivations, and desires that compel the patient to seek esthetic treatment (Figures 1–6A and B).

“The psychological concept of self- and body-image is totally involved in esthetics,”⁶ notes Burns, continuing with the observation that dentofacial deformities have been largely regarded in terms of diagnosis and treatment, rather than in terms of their psychological ramifications. Burns’ consideration of the psychological aspects of esthetic treatment stems from his initial observation that the mouth is the focal point of many emotional conflicts. For example, it is the first source of human contact—a means of alleviating or expressing discomfort or expressing pleasure or displeasure.

Patient Response to Abnormality

The smile is the baby’s most regularly evoked response and eventually signifies pleasure. Thus, any aberration it reveals can naturally be a point of anxiety. Frequently the response to a deformity or aberration can be out of proportion to its severity.

Abnormality implies difference, a characteristic undesirable to most people. To diminish differences, they may resort to overt or subtle means of hiding their mouths (Figures 1–7A and B). However, as Rottersman notes, “The response may not be out of all proportion to the stimulus. This is a signal for the doctor to exercise caution, and to attempt to discern what truly underlies the patient’s response.”²²

Understanding the patient’s motives requires acute perception on the dentist’s part, informed by a thorough examination and history that reveal the patient’s actual dental problems.¹⁸ The patient’s own assessment of his problems and his reaction to them are of equal importance. The dentist should be alert for a displacement syndrome, in which an anxiety aroused by real and major emotional problems may be transferred to a minor oral deformity.

When a patient with a longstanding complaint finally presents for treatment, the dentist must determine what prevented him or her from coming for treatment sooner. A patient who criticizes a former dentist is apt to be hostile, and the dentist should not present a treatment plan before determining what the patient believes treatment can accomplish.

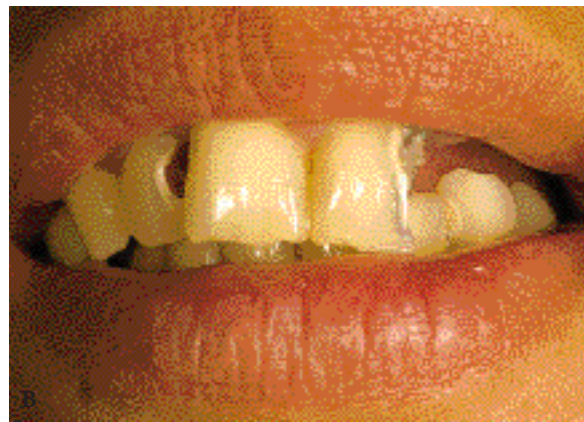
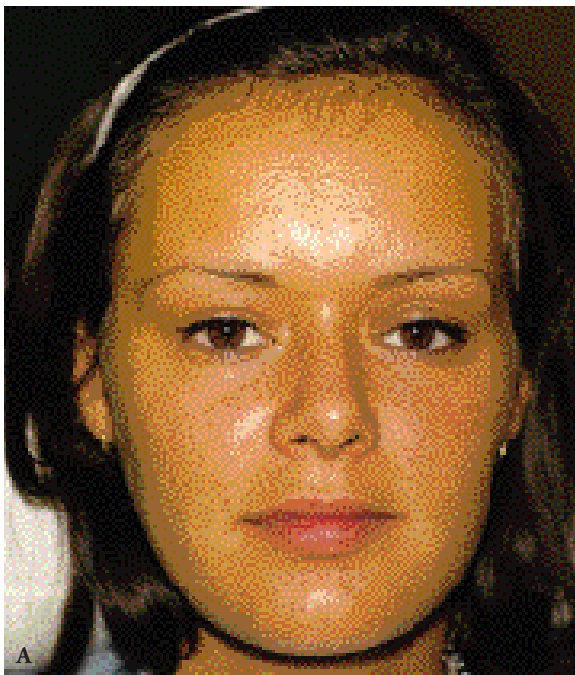
Figure 1–6A and B: This pretty girl shows why she chose not to smile. Despite the total breakdown of the oral cavity, her motive in seeking dental treatment was esthetic.

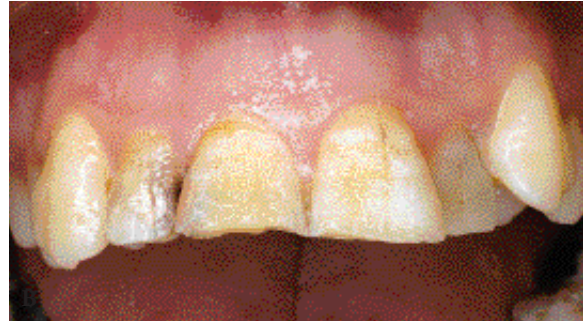
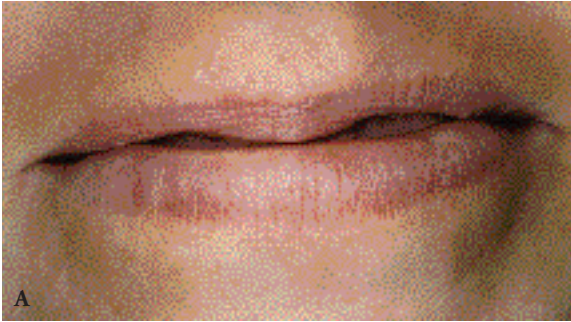
Figure 1–7A and B: This attractive female developed a habit of smiling with her lips together to avoid showing her unsightly maxillary incisors.

ADVANTAGES OF ESTHETIC TREATMENT

Esthetic dental treatment can enhance a patient's own intensely personal image of how he or she looks and how he or she would like to look. As Frush observes, "A smile can be attractive, a prime asset to a person's appearance, and it can be a powerful factor in the ego and desirable life experiences of a human being. It cannot be treated with indifference because of its deep emotional significance." Frush notes that in any esthetic treatment, there is the need for consideration of a patient's satisfaction with the natural appearance and function of the result. Artificial appearance or failure to satisfy the patient's expectations may damage his or her ego. Frush terms such damage a negative emotional syndrome.⁸

Frush continues, "The severe emotional trauma resulting from the loss of teeth is well recognized, and dentists, being the closest to this emotional disturbance, normally have a deep desire to help the patient through the experience as best they can. It is of prime importance to understand that a productive and satisfying social experience after treatment depends upon the acceptance of the changed body structure and the eventual establishment of a new body image by the patient as it is. The acceptance of treatment by the patient is made considerably easier when the prosthesis accomplishes two basic esthetic needs: the portrayal of a physiologic norm, and an actual improvement in the attractiveness of the smile and thus all related facial expressions." Facilitating such acceptance requires several things from the dentist: (1) constructive optimism, never exceeding the bounds of fact and candor; (2) specific demonstration of the means

and methods to be employed in treatment; and (3) an open discussion of all patient anxieties and the proposed treatment options.

Healthy teeth are taken for granted; when they are painful they become a point of exclusive attention. However, such overt stimulus is not necessary for a patient to become obsessively concerned about the appearance or health of the teeth. As an integral component of the body image, teeth can be the focus of feelings ranging from embarrassment to acute anxiety. As noted earlier, teeth may not be the actual cause of the disturbance, but instead, the object of displaced anxieties.

All of these anxieties related to dental deformities are influenced by the patient's own view of the dental deformity and the reaction of other people to that deformity. Root notes that, "The first and foremost psychological effect of dentofacial deformity manifests itself in a sense of inferiority. This sense of inferiority is a complex, painful, emotional state characterized by feelings of incompetence, inadequacy, and depression in varying degrees."²¹ These feelings of inferiority are a significant part of a patient's self-image, desire for treatment, and expectations of what the treatment can accomplish. Every patient is an individual and requires individual treatment. Generalities almost never apply; they are more useful as guidelines and suggestions than as prescribed courses or methods of treatment.

WHY PATIENTS SEEK ESTHETIC TREATMENT

The reasons why patients seek esthetic treatment are as varied and intricate as the reasons they avoid

10 Esthetics in Dentistry

it. How adults feel about and care for their mouths often reflects past, current, and future oral developmental experiences. Adults in their mid-20s may not have developed a sense of the meaning of time in the life cycle. Lack of oral healthcare may reflect a denial of mortality and normal body degeneration. Between the ages of 35 and 40 adults become reconciled to the fact they are aging and a renewed interest in self-preservation emerges. This interest is often directed toward various types of self-improvement such as orthodontic, cosmetic restorative, cosmetic periodontal, plastic or orthognathic surgery, or any combination of these.

Our teeth and mouths are critical to psychological development throughout life. Often, the way we treat our mouths and teeth indicates how we feel about ourselves. If we like ourselves, we work toward good oral health. Once we have reached this goal, our sense of well-being is increased.

Burns, in his discussion of motivations for orthodontic treatment, cites the results of a study by Jarabak that determined five stimuli that may move a patient toward orthodontia. The motives, also applicable to esthetic dentistry, are: (1) social acceptance, (2) fear, (3) intellectual acceptance, (4) personal pride, and (5) biological benefits. (It should be noted that these stimuli pertain only to patients who cooperate in treatment.)^{6,12}

A spirit of cooperation and understanding between you and your patient is paramount to successful esthetic treatment. This relationship is a kind of symbiosis in which each contributes to the attitude of the other. The necessity for close observation and response on your part, particularly to nonverbal cues offered by the patient, cannot be overemphasized. The confidence generated by a careful and observant dentist will be perceived by the patient; so, unfortunately, will a lack of confidence. A competent, confident, professional dentist can reinforce the positive side of the ambivalence that patients feel toward persons who can help them but who they fear may hurt them.

Much psychological theory in dental esthetics must be formulated through analogy because of the comparatively recent recognition of the importance of dental esthetics and the consequent lack of a comprehensive database. The most obvious parallel field is plastic surgery. In a pioneering paper pub-

lished in 1939, Baker and Smith⁵ posited a system that categorized 312 patients into three groups based on personality traits as they related to a desire for corrective surgery, the motives for requesting it, and the prognosis for successful treatment.

Patients who were placed in Group I consisted of well-adjusted individuals. Group II included people with unassertive or inadequate personalities who used their disfigurements as a shield and an unconscious defense. Group III included those of a prepsychotic or psychotic nature for whom the facial abnormality was the focal point of a deviant personality.

In your own practice, patients who fall into the first group are moderately successful people who want repair of their disfigurements for cosmetic reasons or comfort, not as an answer to all their problems. They do not expect too much from the improvement and they have a realistic visual concept of the outcome. They are ideal subjects for successful treatment.

Group II patients are the most exasperating for the practitioner who has already obtained excellent technical results. Patients in this group have come to depend upon their disfigurement as an escape and a protection from social responsibility. Once it is corrected, these patients often find that life is not as easy for those with pleasing faces as they had expected and they may be unprepared to cope with their new situation without this excuse. Thus, they may develop other neurotic defense mechanisms. Such cases emphasize the importance of treating the entire person rather than the oral cavity alone. But not every person in Group II adopts this attitude. A subset of this group consists of passive, apologetic persons who are grateful for any interest or aid given or offered. Their attitude is good and causes little problem for the practitioner, even if the surgical results are unsatisfactory.

Patients who fall into Group III should raise a red flag with the practitioner. With these people, any esthetic correction serves only to disrupt the rationalization process. Soon, some other defect is seized upon as the focus for their continuing psychotic delusions.

Predicting Patient Response

When certain patients appear for treatment, it is wise to proceed with extreme caution, and it is sug-

gested that function alone be used as the criterion for operative intervention. Regardless of the technical success of the procedure, it would only serve to exacerbate, rather than remove, expression of their incipient psychosis. Many times, the restorations look good to you, but the patient still expresses dissatisfaction. This dissatisfaction may be a manifestation of some underlying fear or insecurity rather than a desire for artistic perfection in the restoration. Desire for artistic perfection may be indicative of a patient's underlying problems and may make it impossible for you to treat that person successfully. If we can know enough about the patient's personality to determine the various factors influencing his or her desire for esthetic correction, we would then be better equipped to predict the degree of psychological acceptance of that correction.

How can these patients be recognized by the busy dentist? Although experience may be the best teacher, the cardinal requirement is to show an interest in the patient's complete makeup. Look at the patient as an integrated human being, not just as another oral cavity. Baker and Smith offer the following questions to help evaluate patients:⁵

1. What was the personality prior to the disfigurement?
2. What was the patient's emotional status when first conscious of his or her disfigurement?
3. What part has the disfigurement played in forming the present personality? In other words, is there some limitation in personality development because, for instance, the patient does not smile? What habit patterns have developed?
4. What will probably be the emotional effect of the esthetic correction of the defect?

Obviously it will take some time to arrive at the answers. The conclusion should reveal to which group this patient belongs, and in this way you can better predict the patient's acceptance of the esthetic results. Consideration of the emotional status of any patient who seeks esthetic treatment is important. It can help preclude unpleasant reactions toward either the treatment or you in those cases where treatment, though functionally and artistically successful, is unsatisfactory to the patient. Therefore, the patient's entire personal, familial,

and social environment must be considered in relation to esthetics.

References

1. Aboucaya WA. The dento-labial smile and the beauty of the face, (Thesis) 1973; No. 50. Academy of Paris, University of Paris VI.
2. Ai S, Ishikawa T. "Ohaguro" traditional tooth staining custom in Japan. *Int Dent J* 1965;15:426.
3. Allport GW. *Pattern and growth in personality*. New York: Holt and Rinehart, 1961:479.
4. Anderson JN. The value of teeth. *Br Dent J* 1965; 119:98.
5. Baker WY, Smith LH. Facial disfigurement and personality. *JAMA* 1939;112:301.
6. Burns MH. Use of a personality rating scale in identifying cooperative and non-cooperative orthodontic patients. *Am J Orthod* 1970;57:418.
7. Cash TF, Winstead BA, Janda LH. The great American shape up. *Psychol Today* 1986; April:30-7.
8. Frush JP. Personal communication.
9. Goldstein RE. Esthetic dentistry—a health service. *J Dent Res* 1993;641-2.
10. Goleman D, Goleman TB. Beauty's hidden equation. *American Health* 1987; March.
11. Guerini V. *A history of dentistry from the most ancient times until the end of the eighteenth century*. New York: Milford House, 1969.
12. Jarabak JR. *Management of an orthodontic practice*. St. Louis: CV Mosby, 1956.
13. Langlois JH. Attractive faces get attention of infants. *Atlanta Journal*, 1987; May 6.
14. Langlois JH. From the eye of the beholder to behavioral reality: the development of social behaviors and social relations as a function of physical attractiveness. In: Herman CP, Zanna MP, Higgins ET, eds. *Physical appearance, stigma, and social behavior: the Ontario symposium*. Hillsdale, NJ: Erlbaum, 1986:23-51.
15. Langlois JH, Roggman LA. Attractive faces are only average. *Am Psychol Soc* 1990;1(2):115-21.
16. Langlois JH, Roggman LS, Casey RJ, et al. Infant

12 Esthetics in Dentistry

preferences for attractive faces: rudiments of a stereotype? *Dev Psychol* 1987;23:363–9.

17. Langlois JH, Roggman LA, Rieser-Danner LA. Infant's differential social responses to attractive and unattractive faces. *Dev Psychol* [In press].

18. Levinson N. Psychological facets of esthetic dentistry: a developmental perspective. *J Prosthet Dent* 1990;64:486–91.

19. Meerloo JAM. *Communication and conversation*. New York: International Universities Press, 1958.

20. Patzer GL. *The physical attractiveness phenomena*. New York: Plenum Publishing, 1985.

21. Root WR. Face value. *Am J Orthod* 1949;35:697.

22. Rottersman W. Personal communication.

23. Sheets CG. Modern dentistry and the esthetically aware patient. *J Am Dent Assoc* 1987;103E–105E.

24. Wilson PR. Perceptual distortion of height as a function of ascribed academic status. *J Soc Psychol* 1968;74:97–102.

Additional Resources

Ament P, Ament A. Body image in dentistry. *J Prosthet Dent* 1970;24:362.

American Dental Association News, Feb 3, 1986:1011.

Antonoff SJ. Esthetics for the indigent. *Quintessence Int* 1979;3:33–9.

Ayer WA, Hirschman RD. *Psychology and dentistry*. Springfield: Charles C Thomas, 1972.

Barkley RF. *Successful preventive dental practices*. Macomb, IL: Preventive Dentistry Press, 1972.

Berscheid E. America's obsession with beautiful people. *US News & World Report*, Inc. 1982; Jan:60–1.

Berscheid E, Walster E, Bohrnstedt G. The happy American body, a survey report. *Psychol Today* 1973; 7:119.

Blass JL. *Motivating patients for more effective dental service*. Philadelphia: JB Lippincott, 1958.

Bonner P. Smiles and success. *SKY* 1981;24–8.

Brehm TW. Diagnosis and treatment planning for fixed prosthodontics. *J Prosthet Dent* 1973;30:876.

Brisman AS. Esthetics: a comparison of dentists' and patients' concepts. *J Am Dent Assoc* 1980;3:345–52.

Buffington P. *In the eye of the beholder*. SKY 1990; 109–12.

Christensen GJ. *A consumer guide to dentistry*. St. Louis: CV Mosby, 1995.

Cinotti WR, Grieder A, Springob HK. Psychological aspects of orthodontics. In: *Applied psychology in dentistry*. St. Louis: CV Mosby, 1972.

Cinotti WR, Grieder A, Springob HK. *Applied psychology in dentistry*. St. Louis: CV Mosby, 1972.

Culpepper WD, Mitchell PS, Blass MS. Esthetic factors in anterior tooth restoration. *J Prosthet Dent* 1973;30:576–82.

Cunningham MR. Measuring the physical in physical attractiveness: quasiexperiments on the sociobiology of female facial beauty. *J Pers Soc Psychol* 1986;50:925–35.

Dunn WJ, Murchison DF, Broome JC. Esthetics: patients' perceptions of dental attractiveness. *J Prosthodont* 1996;5(3):166–71.

Espeland LE, Stenvik A. Perception of personal dental appearance in young adults: relationship between occlusion, awareness and satisfaction. *Am J Orthod Dentofacial Orthop* 1991;100:234–41.

Ettinger RL. An evaluation of the attitudes of a group of elderly edentulous patients to dentists, dentures, and dentistry. *Dent Pract* 1971;22:85.

Fastlicht S. Tooth mutilations in pre-Columbian Mexico. *J Am Dent Assoc* 1948;36:315.

Fastlichts S. Dental inlays and fillings among the ancient Mayas. *J Hist Med Allied Sci* 1962;17:393.

Fastlichts S. La odontologia en el Mexico prehispanico. *J Clin Orthod* 1970;14:588.

Fitz-Patrick CP. Is dental appearance important in business? *Oral Hygiene* 1963;53:52.

Furst G. Collecting examples of dental mutilation. *Dent Survey* 1980; August:16–7.

Gibson R. Smile's power means more than just lip service. *Albuquerque Journal* 1, sect B, 1977; June 15.

Gibson RM. *The miracle of smile power*. Honolulu: Smile Power Institute, 1977.

- Giddon DB. The mouth and the quality of life. *N Y J Dent* 1978;48(1):3-10.
- Gilbert J. Ethics and esthetics. *J Am Diet Assoc* 1988;117:490.
- Goldstein RE. Change your smile. Chicago; Quintessence 1997.
- Goldstein RE. Communicating esthetics. *N Y State Dent J* 1985;51:477-9.
- Goldstein RE. Current concepts in esthetic treatment. *Proceedings of the Second International Prosthodontic Congress* 1979:310-2.
- Goldstein RE. Study of need for esthetics in dentistry. *J Prosthet Dent* 1969;21:589.
- Goldstein RE. The difficult patient stress syndrome: Part 1. *J Esthet Dent* 1993;5:86-7.
- Goldstein RE, Garber DA, Goldstein CE, et al. The changing esthetic dental practice. *J Am Dent Assoc* 1994;125:1447-57.
- Goldstein RE, Lancaster JS. Survey of patient attitudes toward current esthetic procedures. *J Prosthet Dent* 1984;52:775-80.
- Goodman RM, Gorlin RJ. The face in genetic disorders. St. Louis: CV Mosby, 1970.
- Grieder A, Cinotti WR. Periodontal prosthesis. St. Louis: CV Mosby, 1968.
- Grieder A, Cinotti WR. Teeth are sexy. *Harper's Bazaar* 1968; July:112-3.
- Hatfield E, Perlmutter MS. Social psychological issues in bias: physical attractiveness. In: Murry J, Abramson P, eds. *Handbook of bias in psychology*. New York: Praeger, 1979.
- Hatfield E, Sprecher S. *Mirror, mirror*. Albany: State University of NY Press, 1986.
- Henderson D, Steffel VL. McCracken's removable partial prosthodontics. St. Louis: CV Mosby, 1973.
- Heymann HO. Esthetic dentistry: ethics and excellence. *J Am Dent Assoc* 1988; September.
- Hoffmann-Axthelm W. *History of dentistry*. Chicago: Quintessence, 1981.
- Kanner L. *Folklore of the teeth*. New York: Macmillan, 19 .
- Kerns LL, Silveira AM, Dernas DG, Regennitter FJ. Esthetic preference of the frontal and profile views of the same smile. *J Esthet Dent* 1997;9:76-85.
- Kim M. In the eye of the beholder. *Savvy* 1988; August: 76-7.
- Koper A. The initial interview with complete-denture patient: its structure and strategy. *J Prosth Dent* 1970;23:590.
- Kranz PH. *Dentistry shows its biblical roots*. Atlanta: Alpha Omegan 30, 1985.
- Land M. Management of emotional illness in dental practice. *J Am Dent Assoc* 1966;73:63.
- Lavine BH. Elizabethan toothache: a case history. *J Am Dent Assoc* 1967;74:1286.
- Lee JH. *Dental aesthetics*. Bristol: John Wright and Son, 1962.
- Leinbach MD, Fagot BI. Pretty babies. *Allure* 52, November 1992.
- Lenchner NH, Lenchner M. Biologic contours of teeth: therapeutic contours of restorations, Part 1. *Prac Perio Aesth* 1989;1(4):18-23.
- Levin RP. Esthetic dentistry in the next decade. *Dent Econ* 1990; 80(7):53-9.
- Levinson N. Anorexia and bulimia: eating function gone awry. *J Calif Dent Assoc* 1985;18-22.
- Levinson N. Oral manifestations of eating disorders: indications for a collaborative treatment approach. In: *Textbook of eating disorders*. New York: Plenum Press, 1987.
- Levinson N. The psychology of dental health. *Am Dent Assoc Children's Dental Health Month*, 1986.
- Levinson NA. Our smiles, ourselves: the psychology of dental health. *American Dental Association News*, February 3, 1986.
- Linn L, Goldman IB. Psychiatric observations concerning rhinoplasty. *J Psychosom Med* 1949;11:307.
- Lombardi RE. Factors mediating against excellence in dental esthetics. *J Prosthet Dent* 1977;38:243-8.

14 Esthetics in Dentistry

- Lucker GW. Esthetics and a quantitative analysis of facial appearance. In: Lucker GW, Ribbens KA, McNamara JA, eds. *Psychological aspects of facial form*. Ann Arbor, MI: The Center for Growth and Development, University of Michigan, 1981.
- Mack MR. Perspective of facial esthetics in dental treatment planning. *J Prosthet Dent* 1996;75:169–76.
- Maret SM. Attractiveness ratings of photographs of Blacks by Cruzans and Americans. *J Psychol* 1983;115:113–6.
- Maury F. *Treatise on the dental art*. In: *Founded on actual experience*. Boston: Milford House, 1972.
- McLean JW. Aesthetics in restorative dentistry: the challenge for the future. *Br Dent J* 1980;149:368–73.
- Miller MB. Options: the key to satisfied patients [editorial]. *Pract Periodontics Aesthet Dent* 1996;8:402.
- Moller, et al. The psychological effect of restorative dentistry. *Ala J Med Sci* 1976;13:17–20.
- Morris AL, Bohannon HM. *The dental specialties in general practice*. Philadelphia: WB Saunders, 1969.
- Moskowitz M, Nayyar A. Determinants of dental esthetics: a rationale for smile analysis and treatment. *Compend Contin Educ Dent* 1995;16:1164–6.
- Nash DA. Professional ethics and esthetic dentistry. *J Am Dent Assoc* 1988;7E–9E.
- O'Regan JK, Dewey ME, Slade PD, Lovius, BBJ. Self-esteem and aesthetics. *Br J Orthod* 1991;18:111–8.
- Ouellette PL. Psychological ramifications of facial change in relation to orthodontic treatment and orthognathic surgery. *J Oral Surg* 1978;36:787–90.
- Patzer GL. Measurement of physical attractiveness: truth-of-consensus. *J Esthet Dent* 1994;6:185–8.
- Patzer GL. Reality of physical attractiveness. *J Esthet Dent* 1994;6:35–8.
- Patzer GL. Self-esteem and physical attractiveness. 1995;7(6):274–7.
- Patzer GL. Understanding the casual relationship between physical attractiveness and self-esteem. *J Esthet Dent* 1996;8:144–7.
- Peck S, Peck L, Kataja M. The gingiva smile. *Angle Orthod* 1992;62:90–100.
- Pollock WJ. An expanded approach to the patient seeking rhinoplasty. *South Med J* 1970;63:96.
- Prinz H. *Dental chronology*. Philadelphia: Lea & Febiger, 1945.
- Qualtrough AJE, Burke FJT. A look at dental esthetics. *Quintessence Int* 1994;25:7–14.
- Rigsbee OH, Sperry TP, BeGole EA. The influence of facial animation on smile characteristics. *Int J Adult Orthodon Orthognath Surg* 1988;3:233–9.
- Ring ME. *Dentistry: an illustrated history*. St. Louis: Mosby, 1985.
- Ring ME. Dentistry in Ancient Egypt. *Compend Contin Educ Dent* 1986;VIII:386.
- Romero J. *Multilaciones dentarias Prehispanicas de Mexico y America en General*. Mexico: Instituto Nacional de Antropologia de Historia, 1958.
- Rosenthal LE, Pleasure MA, Lefer L. Patient reaction to denture esthetics. *J Dent Med* 1964;19(3):103–10.
- Samson E. Odontoaesthetics. *Br Dent J* 1976;140.
- Schweitzer JM. *Oral rehabilitation problem cases*. Vol. 1. St. Louis: CV Mosby, 1964.
- Sendax VI. An approach to the psychology of dento-facial esthetics. *Dent Clin North Am* 1967; Mar:7.
- Shelby DS. Cosmetic restorative problems: initial study with television. *J Prosthet Dent* 1964;14:107.
- Silverman S. The psychology of aesthetics. *J Dent Assoc S Afr* 1975;30(1):159–62.
- Slavkin HC. What's in a tooth? *J Am Dent Assoc* 1997; 128:366–9.
- Stella L. *The archaeology of teeth*. UNIDI Press 1979;5(19):20–3.
- Strauss R, Slome B, Block M, et al. Self-perceived social and functional effects of teeth: dental impact profile. *J Dent Res* 1989;68:384.
- Tulchin L. *The photography of women*. New York: AS Barnes and Co., 1964.
- Tylman SD. *Theory and practice of crown and fixed partial prosthodontics (bridge)*. St. Louis: CV Mosby, 1970.

Valenry D. Stardom via dentistry. Tic 1960.

Vallittu PK, Ballittu AS, Lassila VP. Dental aesthetics—a survey of attitudes in different groups of patients. *J Dent* 1996;24:335–8.

Voss R. Problem of treatment according to the patient's wishes. *ZWR* 1971;80:557.

Wagner IV, Carlsson GE, Ekstrand, et al. A comparative

study of assessment of dental appearances by dentists, dental technicians, and laymen using computer aided image manipulation. *J Esthet Dent* 1996;8:199–205.

Wood JT. Aesthetics and orthodontics. *Dent Pract* 1969;19:247.

Woodforde J. *The strange story of false teeth*. London: Routledge and Kegan Paul, 1968.

CHAPTER 2

ESTHETIC TREATMENT PLANNING

Most esthetically motivated patients who first appear for consultation are eager to begin corrective treatment. Nevertheless, their enthusiasm and, at times, their self-diagnosis should not influence the dentist's esthetic diagnosis. Failure to attend to this caution could lead to treatment failure.

Although the functional aspect of every case should be the dentist's primary consideration, esthetics may well be the patient's main concern. Therefore, assurance must be given that success in esthetics is based on careful diagnosis. In fact, ethically and legally, the dentist is obliged to inform the patient of various treatment alternatives. The authoritarian concept that there is only one way to treat a problem, and the old maxim "the doctor knows best" are both outdated. Once the treatment alternatives have been explained, the patient has the ultimate responsibility for making the decision to accept treatment. However, unless the patient's final decision for treatment is within the dentist's ethical and legal bounds, he or she should not be accepted into that particular practice.

It is essential that the patient make an informed decision, after receiving from the dentist or staff a thorough explanation of his or her condition and the ramifications of treatment, including the advantages and disadvantages of each treatment alternative. Since this may take a considerable amount of time, much of it can and should be provided by a competent staff member. At the same time, the patient should be given printed material for further study at home.

Printed information, whether copies of various popular magazine articles or handouts especially prepared in the dental office, should support and give credibility to the treatment plan proposed. Presenting the patient with alternative treatment plans will also allow the patient to choose (usually with your advice) among alternative plans rather

than alternative doctors. The dentist who gives the patient a one-choice solution to a difficult esthetic problem may also be telling the patient, "Choose between me and my one plan, or find yourself another dentist." The wise dental consumer may elect to obtain a second opinion, to see whether other alternatives are available.

BEFORE THE INITIAL VISIT

A patient's education begins even before his or her first visit. It begins with the telephone call to schedule an appointment. The manner in which the potential new patient is handled by the receptionist, what is said and done over the telephone, helps to establish the desired image.

PERSONALITY IN TREATMENT PLANNING

Successful esthetic dentistry requires skills that involve more than the ability to diagnose and correct functional and pathologic irregularities. Each patient is an individual with an individual problem or concern and should be evaluated as a personality while considering the problem/solution diagnosis. The dentist who is able to master the art of understanding personalities and how to relate to each type will achieve greater treatment planning acceptance. Levin¹ identifies four personality types and suggests the proper response to each of these types. These are:

Driven. Bottom-line person, focuses on results, decides quickly, time-conservation oriented, highly organized, likes details in condensed form, businesslike person, assertive, dislikes small talk. Respond to this personality in a quick, efficient manner, and maximize use of appointment time.

Expressive. Loves to have a good time, cheerleader type, wants to feel good, highly emotional, makes decisions quickly, dislikes details or paperwork, often

18 Esthetics in Dentistry

disorganized and irresponsible, likes to share personal life. Respond to this personality by discussing the benefits of treatment through photographs and stories, engage in small talk, and sound excited.

Amiable. Attracted by people with similar interests, reacts poorly to pressure or motivation, emotional, slow in making decisions, fears consequences, slow to change, a follower more than a leader. Manage this personality type by presenting information over a period of several visits.

Analytical. Requires endless detail and information, technologic mind, highly exacting and emotional. Hardest of the four to reach a decision. Handle this personality type by providing additional information in the form of written, objective materials when suggesting a form of treatment.

The dentist and staff should master the identification of these four personality types. Understanding them and how to relate to each will enhance the doctor-patient relationship as well as the doctor-staff relationship. Interpersonal skills are just as important as technical skills. As Levin says, "After all, we are not just technicians; we are doctors to people."¹⁵ Basically, a personal, communicative relationship between dentist and patient is required.

Esthetic treatment entails attention to pathology and function; it also requires attention to the

patient's attitudes. These attitudes reflect the patient's self-image, which is the sum of appearance, personality, and position in the social milieu, as well as interrelationships with family, friends, business associates, and casual acquaintances.

Educational Materials

The dentist's first priority should be to start educating the patient about the techniques and philosophy of the esthetic dental practice. The more understanding that patients have regarding their dental problems and potential solutions, the easier and more effective the first and future meetings with them will be.

Thus, a consumer book like "Change Your Smile" can be of immense value. It is important to have copies of the book (Figure 2-1A) in the reception area for the edification of current patients. It can also be a major benefit for the new patients prior to their first visit. In addition to broadening their understanding of esthetic dentistry, such materials prepare them to anticipate realistic fee scales for the various esthetic procedures, each of which is discussed in detail including fee range, advantages, disadvantages, results of treatment, maintenance required by the patient, and realistic esthetic results. Furthermore, this particular publication establishes esthetics as a different sort of treatment. For example, treatment to obtain an esthetic correction usually requires payment in advance. Having one's patient read this in "Change




Figure 2-1A: Although it is best for new patients to receive and read "Change Your Smile" before their first appointment, it is important to have copies in your reception room to re-educate your existing patients.

Your Smile” helps to establish this method of practice management. The book will also tell the patient not to expect insurance to pay for esthetic dentistry since it is rarely a covered benefit.

There are several ways in which this book can be made available to a patient before his or her first visit. The patient might be asked to pick up a copy at a designated book store with the understanding that he or she will be reimbursed after the first visit. As an alternative, the bookstore might mail a copy to a prospective new patient if a trip to the bookstore would be inconvenient.

THE SMILE ANALYSIS

A self-smile-analysis, or comparable index, should be explained and made available to the patient

before the first visit (Figure 2–1B). The importance of such a self-evaluation cannot be overstated. Through this self-analysis, you can begin to recognize and understand the problems uppermost in the patient’s mind concerning his or her appearance, particularly as he or she is affected by the mouth and smile. It also serves as a documented and convenient starting point for a specific discussion of esthetic treatment that will be workable for the dentist and satisfying to the patient. The smile analysis provides a means by which the dentist can avoid two common errors: the belief that patients care little about their smiles and that they are willing to accept any recommended course of treatment. Experience indicates that if you accept at face value a patient’s remarks such as “If it’s good and it lasts, I really do not care what it looks like”

SMILE ANALYSIS		
Yes	No	Teeth
<input type="checkbox"/>	<input type="checkbox"/>	1. In a slight smile, with teeth parted, do the tips of your teeth show?
<input type="checkbox"/>	<input type="checkbox"/>	2. Are your two upper front teeth slightly longer than the adjacent teeth?
<input type="checkbox"/>	<input type="checkbox"/>	3. Are your two upper front teeth too long?
<input type="checkbox"/>	<input type="checkbox"/>	4. Are your two upper front teeth too wide?
<input type="checkbox"/>	<input type="checkbox"/>	5. Are your upper six front teeth even in length?
<input type="checkbox"/>	<input type="checkbox"/>	6. Do you have a space between your front teeth?
<input type="checkbox"/>	<input type="checkbox"/>	7. Do your front teeth protrude or stick out?
<input type="checkbox"/>	<input type="checkbox"/>	8. Are your front teeth crowded or overlapping?
<input type="checkbox"/>	<input type="checkbox"/>	9. When you smile broadly, are your teeth all one color?
<input type="checkbox"/>	<input type="checkbox"/>	10. Do your teeth have white or brown stains?
<input type="checkbox"/>	<input type="checkbox"/>	11. If your front teeth contain tooth-colored fillings, do they match the shade of your teeth?
<input type="checkbox"/>	<input type="checkbox"/>	12. Is one of your front teeth darker than the others?
<input type="checkbox"/>	<input type="checkbox"/>	13. Are your lower six front teeth straight?
<input type="checkbox"/>	<input type="checkbox"/>	14. Are your lower six front teeth even in appearance?
<input type="checkbox"/>	<input type="checkbox"/>	15. In a full smile, the back teeth normally show. Are your back teeth free of stains and discolorations from unsightly restorations?
<input type="checkbox"/>	<input type="checkbox"/>	16. Do the necks of your teeth indicate erosion, a ditched-in “V,” that either can be seen or felt with your fingernail?
<input type="checkbox"/>	<input type="checkbox"/>	17. When you smile broadly, does your top lip rise above the necks of your teeth so that your gums show?
<input type="checkbox"/>	<input type="checkbox"/>	18. Do your restorations—fillings, laminates and crowns—look natural?
Gums		
<input type="checkbox"/>	<input type="checkbox"/>	19. Are your gums pink and “knife-edged,” or are they red and swollen?
<input type="checkbox"/>	<input type="checkbox"/>	20. Have your gums receded from the necks of the teeth?
<input type="checkbox"/>	<input type="checkbox"/>	21. Does the curvature of your gum around each tooth create a half-moon shape?
Breath		
<input type="checkbox"/>	<input type="checkbox"/>	22. Is your mouth free from decay or gum disease that can cause bad breath?
If you could alter your smile, what would you most like to change? _____		

Figure 2–1B: The advantage of having your patients complete a smile analysis like this one is to help them visualize and communicate to you all potential problems before treatment planning is initiated. (Reprinted from Change Your Smile, 3rd edition, Quintessence Books, 1997.)

20 Esthetics in Dentistry

or “You are the doctor,” you may soon have a dissatisfied patient. Memories can be short, and patients may easily forget the condition of their mouth before treatment, choosing instead to concentrate on anything, however trivial, that they regard as an imperfection. Such reactions illustrate again the depth and breadth of consideration, somatic and psychological, involved in esthetic treatment, and they point to the practical and esthetic value of the smile analysis.

There are several ways to get a smile analysis form accessible to your patients:

1. Fax a copy of your selected version to each new patient.
2. Include it in an information package you mail to new patients.
3. Provide “Change Your Smile” (Quintessence Publishing, Carol Stream, IL) and have them use the smile analysis form (Figure 2–1B).

The advantage of this last method is that “Change Your Smile” contains more additional information. It will provide your new patient with treatment alternative summary sheets that will give them more insight into their esthetic problem.

THE INITIAL VISIT

The dentist-patient relationship is the necessary foundation for any satisfactory course of treatment. It must be encouraged and developed from the beginning and is most important in esthetic dentistry. The patient must feel at ease. To this end, a neat, well-ordered, attractive, and comfortable reception area is an obvious prerequisite (see Chapter 3). The first visit, which may or may not involve a functional procedure, is the best time to intensify the communication process. The patient’s first impression, if positive, will serve as a reinforcement for subsequent treatment. If negative, it can be harmful to the atmosphere of candor and trust essential to successful esthetic treatment.

Why Are They Here?

There is no more important information than why the patient came to see you. This is not to be confused with your patient’s major complaint. Rather, why are they at your office instead of another? And why did they leave another office (or offices) for yours?

Frequently, this information can reveal valuable insight into your patient, his or her fears, needs, desires, and expectations. These may not necessarily be related to a specific dental condition.

Who Referred Your New Patient?

This information can be quite helpful in determining what concerns your new patient has regarding his or her dental needs. One basic problem is that many individuals choose not to disclose the information, not wanting to prejudice you in rendering your opinion. The fear is that you may “slant” your treatment plan one way or another based upon the referring patient rather than offer completely objective analysis.

Other reasons why certain patients do not disclose their referral source are:

1. There will be less chance for the dentist to determine their financial status (the referring source may or may not be at an entirely different economic level).
2. Many people do not want you to prejudge them.
3. Some individuals are so secretive that they are afraid of listing a referral source fearing you will disclose their condition or treatment to them.

Therefore, always respect your new patient’s right of privacy, especially at first. Often, the referral source will later become known, usually through casual conversation.

Who Should See the Patient First?

There is always the question of who should see the patient first—you or your hygienist. There are advantages and disadvantages to each being the first contact. (See Figure 2–1C for a typical flow of patient contacts in a practice for comprehensive dental treatment.)

Even if the patient wishes an appointment only for a prophylaxis, it may be important for you to see and meet the patient first. Not only is it valuable for you to identify your new patient’s primary concerns, it is also quite helpful for you to examine the patient before your hygienist alters the appearance of the mouth (Figure 2–2A). One definite advantage of this is to be able, if necessary, to place the patient in a soft tissue management program before a prophylaxis.

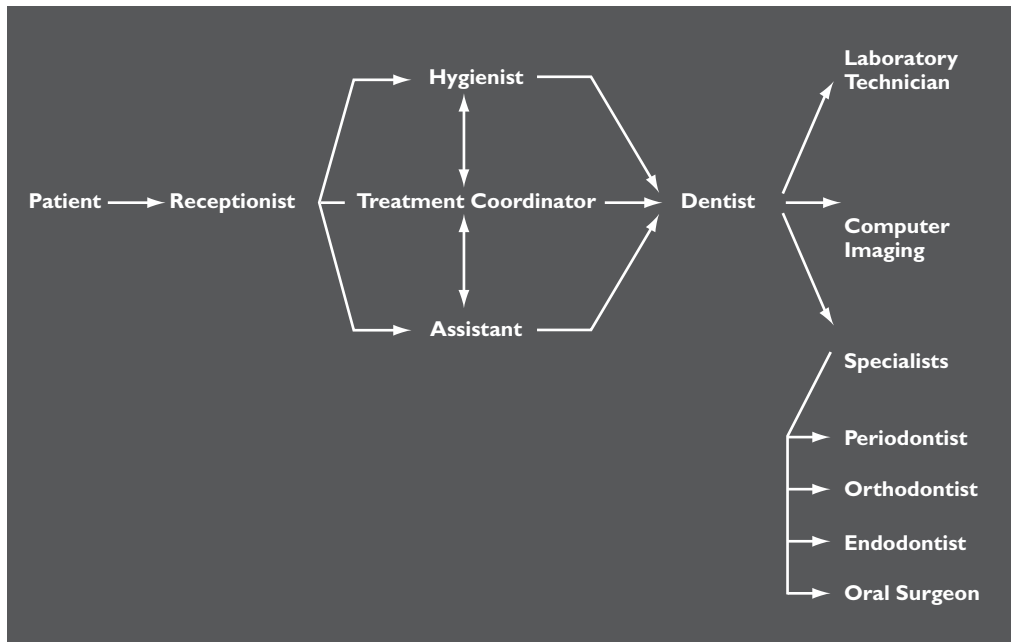


Figure 2–1C: Sequence of patient office contacts.

laxis is scheduled. This can also emphasize to the patient just how essential it is to have healthy tissue before any esthetic treatment is planned.

Observe calculus, stains, and baseline oral disease in order to be of maximum help to your patient. Also be sure to take photographic records before a prophylaxis removes stains or other visible evidence of just how your patient performs oral care.

What to Look For

Prehygiene: Look at the patient and observe the following:

1. **Stains**
What types and severity.
2. **Calculus**
How much and the length of time since the last prophylaxis.
3. **Plaque**
Most patients attempt to brush their teeth as well as possible before a dental appointment, so if your patient has a great deal of plaque present, this should give you a good idea of how the patient's oral hygiene is lacking.
4. **Habits**
A hygiene appointment could erase valuable

evidence left by any harmful habits the patients may have. Examples are heavy smokers or coffee drinkers whose stains would be eliminated after prophylaxis (see *Esthetics in Dentistry* 1st ed., Vol. II, Chapter 20: Personal Habits; or Vol. II, Chapter 16: Stains and Discoloration.) Therefore, make sure you examine any new patient before a hygiene appointment.

5. Attitude

Another reason to meet the patient before the hygiene appointment is to get a better idea of the patient's personality. After a 30- to 50-minute hygiene appointment, the patient may be stressed, out of time, or even non-communicative.

Remember, you can uncover important information during this initial interview, and it is imperative to ascertain that you have sufficient information to develop a comprehensive treatment plan. The more difficult the esthetic problem, the more time is required for patient information gathering. Failure to obtain even one critical piece of patient information can make the difference between esthetic success and failure. Sources of this essential information may include the receptionist, dental assistant, hygienist, dental laboratory technician, and treat-

22 Esthetics in Dentistry

ment coordinator. Although we assume that all of the above individuals have contact with the patient, valuable information can also be gained by involving your laboratory technician with the patient's esthetic concerns. In most cases, the laboratory technician will be able to tell you whether the technical problems involved can be easily overcome. This information is also essential before finalizing your patient's treatment because, for example, your fee and that of the technician can vary considerably based on the technical requirements involved (Figures 2-2B to D).

THE ROLE OF THE HYGIENIST

The hygienist may be either the second, third, or fourth member of the treatment team the patient meets. However, the hygienist usually is the first who

actually performs treatment and therefore must be fully proficient in hygienic techniques and subtle investigation while maintaining a reassuring manner. Many times the hygienist will develop a special relationship with your patient (Figure 2-3). This rapport can result in learning crucial information that can make your treatment a success or warn you of possible failure. The hygienist must be both inquisitive and observant enough to help discover potentially harmful habits and bring them to the attention of both the patient and you. Such habits include lip, cheek, or nail biting, chewing ice or other foreign objects, or grinding of teeth (see *Esthetics in Dentistry* 1st ed., Vol. II. Chapter 20: Personal Habits). As the teeth are being cleaned, the patient's desires in regard to esthetic treatment can and should be deter-

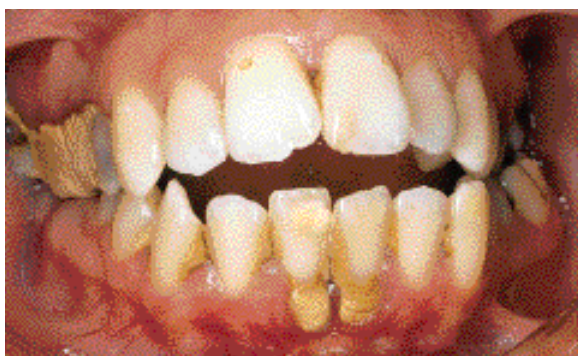

Figure 2-2A: A sense of inferiority can create a depression that occasionally causes patients to become desperate about their self-image. In this case, the 28-year-old woman was so ashamed of her appearance that she balked at even opening her mouth.

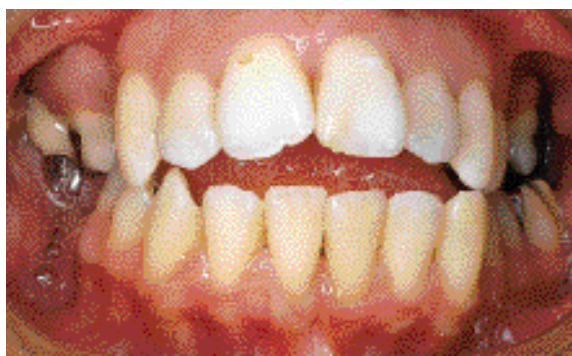

Figure 2-2B: The first step was soft tissue management to eliminate inflammation.

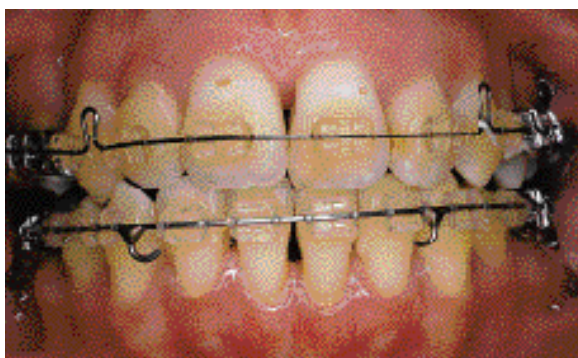

Figure 2-2C: Orthodontic treatment corrected the open bite.

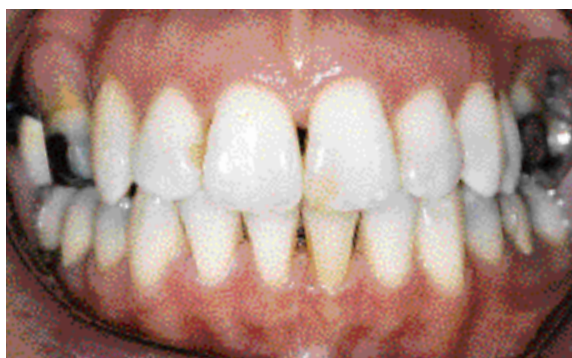

Figure 2-2D: The reward of an extended consultation period to help overcome a fear of dentistry is the acceptance of combined therapy to achieve an esthetic result.

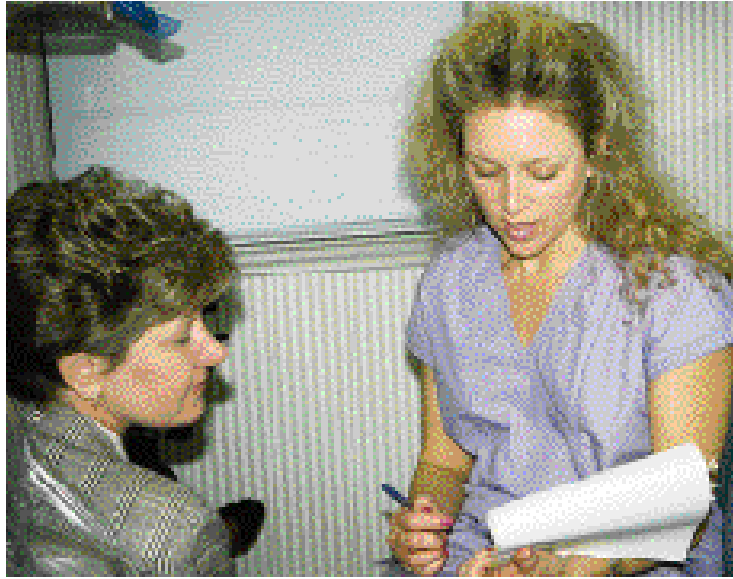

Figure 2-3: The rapport between the hygienist and the patient often can help to uncover a patient's interest in esthetic dentistry.

mined. Preliminary observations can be made concerning obvious discolorations, necessary restoration, ill-fitting crowns, etc. The approach can be in the form of a question, such as, "Does this concern you? If so, the doctor may be able to correct it." The possibility and applicability of esthetic treatment should be of central concern, but the concern should not manifest itself at this time as direct recommendations or specific advice to the patient. The hygienist must be alert to cues that indicate a patient's interest in esthetic dentistry. A patient who covers his or her mouth when laughing is making a wordless, vitally important statement. Lips pulled tightly over the teeth, constricted cheeks, or a tongue pressed against a diastema are subconscious signals from the patient. Directly or indirectly, they express a patient's concern for his or her appearance. The hygienist should communicate these observations to the dentist in private.

At the initial visit, the patient may see the dentist for a comparatively brief time. This depends upon the patient's ability and desire to spend up to several more hours for the "second visit" at the same appointment. If the patient is from out of town, it is usually advisable to plan both first and second visits at the same appointment to reduce the patient's travel time and costs.

Good rapport must be established while convincing the patient that only after a thorough study of radiographs and other diagnostic aids will treatment alternatives be suggested. In addition to a medical and dental history, thorough charting of both periodontal and general tooth conditions, diagnostic models, occlusal analysis, computer imaging, and color photographs or slides are taken at this visit. Normally, specific suggestions should be postponed until the second visit. At that time, you should examine and discuss treatment alternatives as well as the patient's own esthetic evaluation as it is revealed in the smile analysis unless the patient has previously completed this self-examination.

THE CLINICAL EXAMINATION

Every new patient receives a clinical examination. For the patient who is primarily interested in cosmetic dentistry, an esthetic clinical evaluation is mandated. This patient may have already received a prophylaxis, radiographs, examinations, and treatment plans from several other offices. Therefore, the initial appointment with you may be specifically for an esthetic evaluation, and more time should be reserved to listen to the patient's problem and desires. The remainder of the appointment is focused on the nonesthetic but functional clinical analysis.

Examining the Patient

Although the entire stomatognathic system should be evaluated, there are three main components of any clinical examination:

1. Evaluation of the teeth and arch
2. Determination of the periodontal status
3. Facial analysis

The order in which you perform these specific functions is not important, just as long as you spend sufficient time on each one.

1. Teeth and Arch Examination

Regardless of which chart you use, a tooth-by-tooth examination is essential to verify functional as well as esthetic limitations for the desired treatment. As basic as it may sound, there is no substitute for an extremely sharp explorer.

It is impossible to visually determine the soundness of each individual tooth. Saliva, plaque, and food deposits can too easily fill a defective margin and make it appear “perfect.” The absence of stain around a leaking or defective margin may make it easy to overlook the necessity of including that tooth in your treatment plan. Therefore, each surface of each tooth should receive a thorough evaluation. Magnifying lenses of 2.5 diopter or greater (available through Designs For Vision, Inc.) are extremely valuable tools in being able to properly detect defective restorations as well as other defects. In addition, the use of an intraoral camera (see page 29) will not only support your findings but also may reveal to you other deformities not seen by either the naked eye or with the aid of magnifying loops. The intraoral camera also has the ability to easily transilluminate and photographically record hidden microcracks that could easily alter your treatment plan. This photographic or video examination of the mouth can also make you aware of potential pit and fissure problems or hidden surface caries that could be overlooked in your visual examination or even missed with the explorer. Finally, an intraoral camera provides for easier and more accurate communication with your patient so that he or she can more readily understand the reasons for your treatment recommendations. Pay particular attention to facial and incisal erosion as well as large, defective amalgam restorations. At what point do you suggest crowning versus the more

conservative treatment of bonding or laminates or 2 to 3 surface porcelain inlays? Esthetically and functionally, it may be much better to conserve the labial (or lingual) enamel rather than reduce it to place a crown. This is one instance where patients should be given a choice after being informed of the advantages and disadvantages of each treatment option. Frequently, informed patients will opt for the most costly but more conservative procedure.

Arch alignment. Arch integrity should be evaluated both vertically and horizontally. Although orthodontics can correct most arch deformities, restorative treatment frequently can provide an acceptable esthetic and functional compromise.

Determine the plane of occlusion and analyze just how discrepancies will affect the ability of your ceramist to create occlusal harmony. Slight irregularities in tooth-to-tooth position can make such a difference in the final arrangement that it always pays to take adequate study casts and then double-check your initial visual analysis to ensure that you can achieve the occlusal and incisal plane you wish.

2. Periodontal Evaluation

Evaluation of bone support, tissue recession, tooth mobility, bleeding points, and periodontal pockets all have tremendous influence on your ability to achieve an esthetic as well as functional result. Presence or absence of appropriate ridge tissue also can change the treatment approach. A major reason for predestined esthetic failure is a failure to realize the negative factors involved.

If your patient has periodontal disease that you feel will not heal with routine prophylaxis treatment, you may first wish to institute soft tissue management procedures. This is especially important if the final treatment plan could vary, depending on how successful the soft tissue management therapy will be. In fact, spending extensive time establishing your patient's entire treatment plan at this time could be counter-productive. What may appear to be the best plan of action now could be considerably altered depending on not only your therapy, but also on how well the patient follows your homecare program.

3. Facial Analysis

The first step in facial evaluation is to make sure you are viewing your patient at an appropriate angle. Have your patient stand or sit up in the chair

with his or her gaze parallel to the floor. Then you can evaluate if a part of the face is out of proportion. Later, computer imaging can confirm this for you. Note any facial deformities or parts of the face that stand out disproportionately.

Visualize your intended changes, such as increasing the interincisal distance, or shortening, widening, or narrowing the teeth. Then confirm your ideas via computer imaging. Try to see how your patient's appearance could be improved. To do this you need to visualize an ideal facial form and identify what is lacking to make that face ideal. You may not be able to accomplish this—nor does every patient wish to be “perfect”—but for those that do, your careful evaluation can be

extremely helpful. The more you do this the better you will become at helping your patients see what is needed to improve their appearance (see Esthetics in Dentistry 1st ed., Vol. II, Chapter 28: Facial Considerations).

A video camera and monitor also allow both you and your patient to see the face in two-dimensional silhouette form. By recording your patient while speaking, various facial positions can be seen, thus making it easier to identify the extent of the esthetic problems.

Esthetic Evaluation Chart

To accurately diagnose a patient's problems and then create the best esthetic treatment plan, an

ESTHETIC EVALUATION CHART	
Clinical Examination of Conditions Present	
A Color	Discoloration _____ Unsightly restorations _____ De-calcification _____ Hypercalcification _____ Caries _____ Stains _____ Other _____
B Size and shape	Large teeth _____ Small teeth _____ Faulty restorations _____ Attrition _____ Abrasion _____ Erosion _____ Other anomalies of tooth form, size or number _____
C Arrangement	Missing teeth _____ Crossbite _____ Chipped or fractured teeth _____ Open bite _____ Uneven incisors _____ Excessive overbite _____ Excessive uniformity _____ Spaced incisors _____ Protrusion maxillary teeth _____ Crowded incisors _____ Protrusion mandibular teeth _____ Closed vertical dimension _____ Smile line _____ Undererupted and extruded teeth _____
D Periodontal	High lip line _____ Low lip line _____ Inflamed gingiva _____ Receding gingiva _____ Hypertrophic gingiva _____ Calculus _____ Plaque _____ Cleft _____ Advanced bone loss _____ Gingivitis _____ Periodontitis _____ Other _____
E Other abnormalities	_____
Treatment Indicated for Esthetic Improvement	
Subject needs some _____ no _____ elective _____	
Cosmetic contouring _____	
Orthodontia _____ major _____ minor _____	
Operative _____	
Prosthodontia _____	
Bridgework _____	
Periodontia _____ SGC _____ GPY _____ GTY _____	
Other _____	

Figure 2-4A: Esthetic evaluation chart. (Reprinted from Esthetics in Dentistry, 1st edition, 1976.)

esthetic evaluation chart is helpful. It can be a simple one-page form as developed by Goldstein (Figure 2-4A) or a more elaborate version. The comprehensive charts developed by Abrams (Figure 2-4B) and Dawson (Figure 2-5) incorporate both esthetics and function in their evaluation criteria. All critical areas of the teeth, mouth, and face are nicely displayed in an easy-to-understand diagrammatic fashion. Whether you use one of these charts or develop one of your own, they can be valuable diagnostic tools in your treatment planning.

TRANSILLUMINATION

Large tooth fractures can usually be observed clinically, but enamel microcracks are usually not seen

unless the affected teeth are either transilluminated (Figure 2-6A) or viewed with an intraoral camera. Therefore, you should allow sufficient examination time to transilluminate or view each tooth and record whether there are vertical, horizontal, diagonal, or no microcracks present. This will help you predict the probability of future problems (Figure 2-6B).

The presence of microcracks does not mean it is necessary to bond, laminate, or otherwise restore the tooth. The greatest percentage of teeth with vertical microcracks are not restored and rarely offer problems. However, teeth with horizontal or diagonal microcracks, usually the result of substantial or unusual trauma, may warrant repair. At the very least, bonding over the microcrack, if sensi-

The form is divided into several main sections:

- I. MEET THE PATIENT (Patient History):** Includes fields for patient name, date, and a section for 'Past or Present History' with checkboxes for various dental conditions like caries, periodontitis, etc.
- II. MEET THE FACE (Facial Examination):** Features a facial diagram with labels for forehead, eyes, nose, lips, chin, and jawline, and a list of characteristics to evaluate such as symmetry, proportion, and skin texture.
- III. MEET THE MOUTH (Intraoral Examination):** Includes a 'Smile Line' diagram and checkboxes for various dental features like gingival margin, tooth color, and alignment.
- IV. TOOTH CHARACTERISTICS (tooth):** A table with columns for 'YES' and 'NO' evaluating various tooth attributes like shape, size, and color.
- V. INCISAL GUIDANCE — OCCLUSION:** A table evaluating the relationship between upper and lower teeth during different jaw movements.
- VI. DISEASE SECONDARY (periodontal, soft tissue):** A table evaluating conditions like gingivitis, periodontitis, and oral lesions.
- VII. HABITS:** A table evaluating habits like bruxism, nail biting, and lip sucking.
- VIII. PROGNOSIS (F.V. Position):** A table for recording the position of various teeth (I-VI) and their prognosis.
- IX. Summary Table:** A large table at the bottom summarizing the findings for each tooth (I-VI) across various categories like 'Diagnosis & Treatment' and 'Esthetic'.

Figure 2-4B: An example of an excellent detailed esthetic diagnostic analysis form is pictured here. A full-size form is provided in Appendix A. (Courtesy of Abrams)

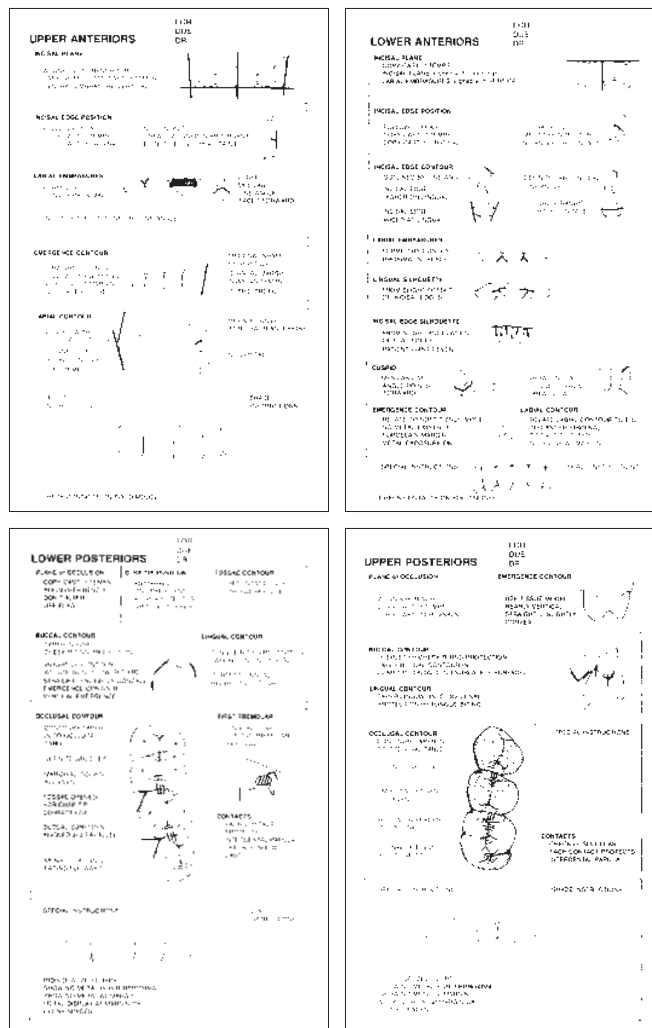


Figure 2-5: An example of an excellent, detailed esthetic diagnostic analysis form is pictured here. A full-size form is provided in Appendix B. (Courtesy of Dawson)

tive, can be useful in reducing discomfort and help to seal the defect and hold the tooth together.

Intraoral Camera

The more high-tech method of documenting the presence of microcracks is the use of an intraoral camera (Figures 2-7A to C). It allows you to show patients their microcracks enlarged on a TV monitor, and also to record the finding on either a photograph or videotape. Thus, the patient involved in an accident claim has tangible evidence to provide insurance companies with proof of damaged teeth.

An intraoral camera provides instant visualization of the patient’s teeth in real time. It is a pow-

erful communication tool that helps you and your patient focus on “how to treat” instead of “why treat?” In today’s high-tech society, patients relate to live video images in a way they seldom do to a sketch or x-ray. Since an intraoral camera also has the ability to store the images it records, the pictures are available later to both you and your patient, to demonstrate the before- and after-treatment images.

With the ability to see and record conditions such as the presence of enamel cracks, the intraoral camera has become one of the most valuable diagnostic aids in the dental operator. It is the best

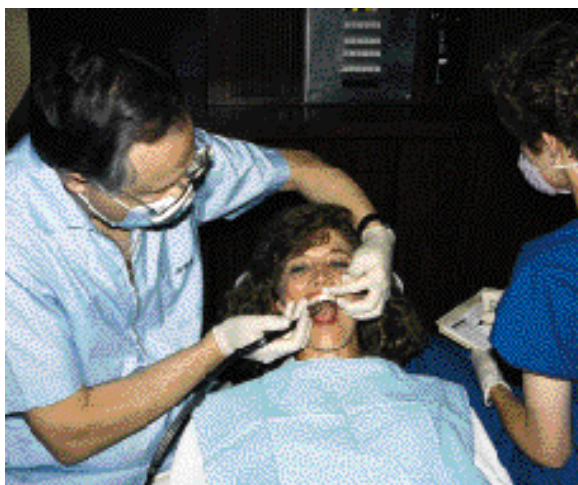

Figure 2–6A: Using an intraoral transilluminator is an excellent method of diagnosing microcracks. The intraoral camera can also record these microcracks.

tool to allow you to reveal which teeth and/or restorations are defective. In addition to showing your patient exactly why you are suggesting restorative therapy during the treatment planning stage, you can use the camera as a continuous communicator and educator during treatment. For example, you can point out actual caries under an old filling you are replacing. Since very few patients have ever seen real “decay,” you are also reinforcing your credibility as an honest practitioner performing necessary procedures.

A major use of the intraoral camera in esthetic dentistry is in showing patients defective restorations. This is especially useful when discussing how defective Class II restorations might affect the color of the proposed porcelain laminates. To achieve ideal esthetics when making porcelain laminates, the teeth should be uniform in color. Thus, an old amalgam restoration that is darkly staining a part of the tooth can influence the color of the final laminate. The intraoral camera will provide convincing evidence that the offending restoration should be changed prior to laminate construction.

The Extraoral Camera

This dual form of recording information will capture simultaneously the pretreatment full face and smile of the patient as well as the conversation relative to his or her perceived condition or problem. Both an audio and video recording are extremely

helpful if there is any future question about the exact condition with which the patient originally presented. The camera is mounted on a track above the patient and is remotely controlled to show and record all desired aspects of the patient’s face and mouth (Figure 2–8). A monitor in the room shows the recording in real time, or you may record without the monitor for future viewing only. Viewing the two-dimensional full-face aspect on a television screen makes it easier for both you and your patient to accurately see the silhouette form. This is also true when recording the patient’s right and left profile, and close-up smiling and speaking. Most patients are amazed by what is revealed in these views. They become acutely aware that this is what everyone else sees and they want to make sure these views eventually present them in the most flattering way possible. The result is a greater potential for a more comprehensive treatment plan.

X-Rays. Although the typical full-mouth radiographic series is indispensable to patient examination, there are times when some patients will object to the extent of the radiation or to x-rays, period. In these cases, it is extremely valuable to have technology like radiovisiography (RVG) (Figures 2–9A and B). Because it accomplishes the same service at 80 to 90% less radiation, it can effectively overcome patient objections to traditional x-rays. Computerized radiographs are also used to take multiple different-angle views of problem areas, and the fact that it is instantaneous can save time in diagnostic procedures.

This technology is also helpful when fitting inlays, onlays, crowns, posts, and virtually all other fixed prostheses where try-in adjustments are usu-

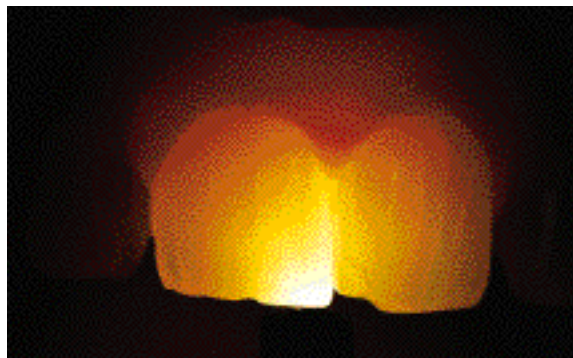


Figure 2–6B: Transillumination vividly reveals vertical microcracks in both central incisors.

ally necessary to obtain perfection in fit. Patients will not object to further radiographs when they realize how little radiation the process involves. This means you can continue to fit your prosthesis and repeatedly check the margin with additional x-rays until it is perfect.

T-Scan Occlusal Analysis. Although there are innumerable methods of evaluating your patient's occlusal problems relating to esthetics, one device

(T-Scan) is of particular help in both diagnosing and demonstrating occlusal difficulties to your patient (Figure 2-10). The T-Scan is a computerized system that uses sensor technology to identify the location, timing, and relative force of occlusal contacts. You will also find it indispensable when treating patients who have a difficult time explaining their problem to you. While it may be difficult for you to see occlusal articulating marks on a tooth, it is easy for

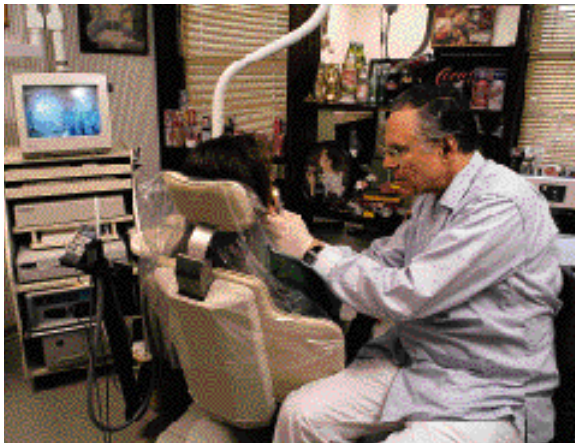

Figure 2-7A: An intraoral camera showing an enlarged view of a restored tooth includes a radiograph on the monitor for comparison.




Figure 2-7B: This intraoral camera system is equipped with a 20-inch monitor for better patient viewing.

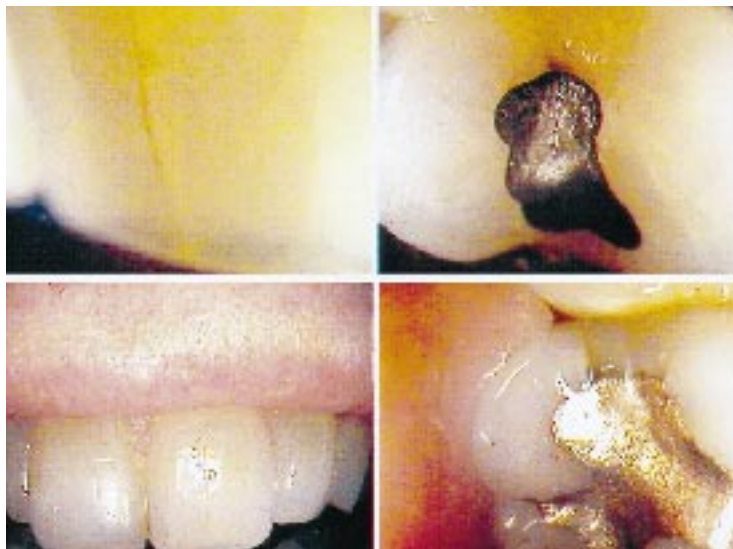

Figure 2-7C: This printout consists of four different camera views that can be sent to an insurance company for more effective communication to maximize patient benefits.

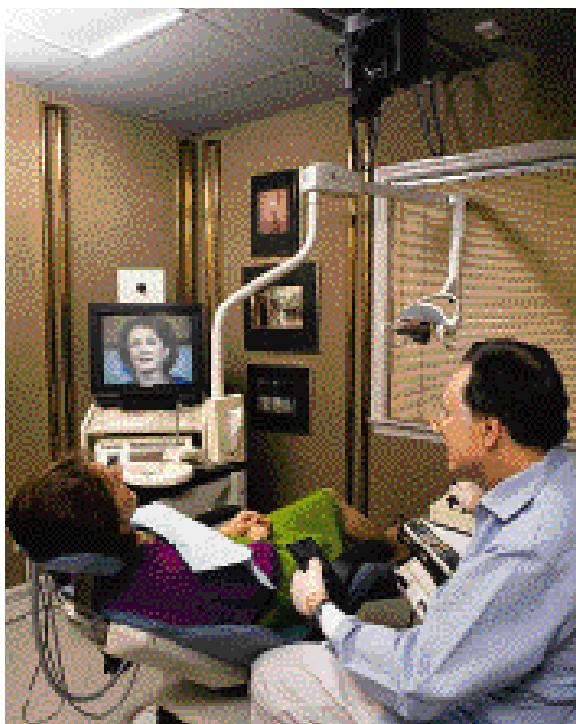

Figure 2-8: An extraoral camera (Panasonic D5100) is remotely controlled (Telemetrics, Inc.) to obtain a full face recording of the patient. Two intraoral cameras are also connected to the system.

both you and your patient to visualize and understand occlusal trauma areas when displayed three-dimensionally by the T-Scan on your monitor.

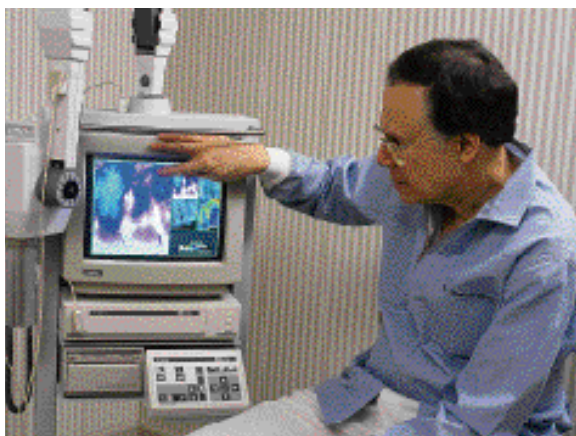

Figure 2-9A: The color format of the computerized radiovisiographs (RVG, Trophy) makes it easier for patients to better understand their problem and potential treatment.

Periodontal Charting. No part of the esthetic examination is more important than ascertaining the condition of your patient's supporting bone structure.

The most perfect restoration in the world will fail if placed in a tooth with a weak supporting structure. Therefore, functionally, esthetically, and legally you are required to thoroughly examine full-mouth radiographs as well as probe teeth in six locations. This can be done with a traditional periodontal probe or by an electronic device (Figure 2-11), where the data can be recorded electronically using a voice-activated system.

One major advantage in producing a color, 8 × 10 easy-to-comprehend chart (Victor, Prodentec) to give to the patient is to make him or her feel more responsible for any diagnosed periodontal problems. It is far better to give your patients tangible evidence of their periodontal problems rather than merely orally informing them of your findings. Voice activation makes it easy and quick for your hygienist to perform this periodontal charting on virtually every patient and also enables you to provide periodic progress charts when necessary.

Computer Imaging. One of the most exciting new diagnostic and treatment planning aids in esthetic dentistry is computer imaging. Used first in 1986 by plastic surgeons and beauty companies, the computer makes it possible to digitally alter the pictures of a patient's teeth and face, and to pro-

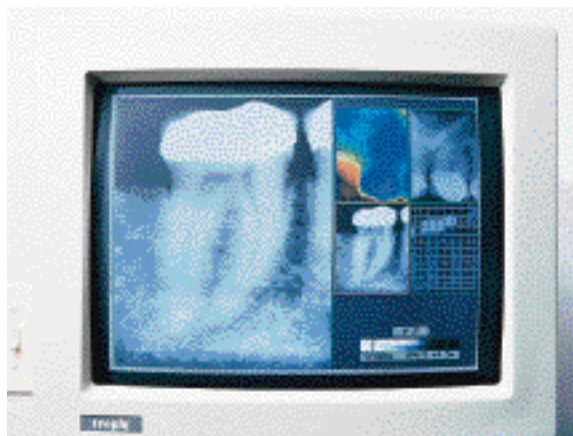

Figure 2-9B: The greatly reduced amount of radiation with computerized radiovisiography (RVG, Trophy) eases patient concern when verifying the marginal fit of fixed restorations prior to cementation.

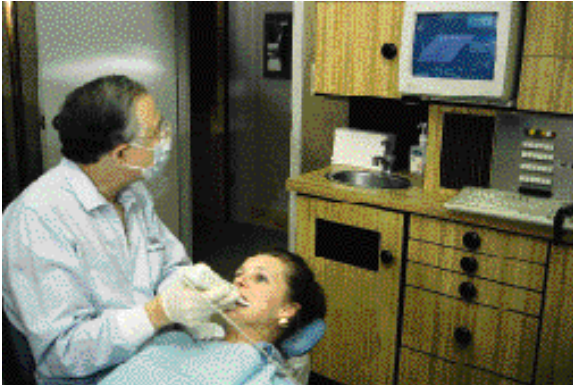

Figure 2-10: The T-Scan (Tek-Scan) helps identify subtle occlusal discrepancies that are difficult to detect with only articulating marking paper.

duce a picture of how they might look after cosmetic treatment (Figure 2-12A). This visual prediction of potential treatment solutions to esthetic problems offers an unparalleled method of letting you and the patient look at how your intended esthetic correction will not only change your patient's smile, but also in many cases, his or her entire face. It also accomplishes the following:

1. It allows you to do a better job of treatment planning by allowing you to visualize a possible result, which can then be studied to determine its esthetic effect.

2. The patient is able to view your intended correction and make suggestions on how he or she would like to see it modified.
3. Based on feedback from the patient, further computer imaging allows you to show the patient how they can look with any number of additional or different esthetic changes and improvements. You, therefore, are limited only by your creative ability.
4. It increases patient motivation by demonstrating the positive aspects of an improved appearance and enhanced self-image, and reducing patient uncertainty and anxiety.
5. It helps to establish the fact that your office employs state-of-the-art diagnostic and communicative tools and techniques, making a positive statement about the type of dentistry you practice. The real value in enabling a patient to see proposed changes is ensuring that both dentist and patient envision the same result. If, for any reason, they do not have the same expectations, this is the proper time to make any changes regarding results. Certainly, unmet expectations after your treatment can require either redoing or altering the correction; or even worse, they may establish a defensive position with the patient, which frequently causes a wider communication gap.

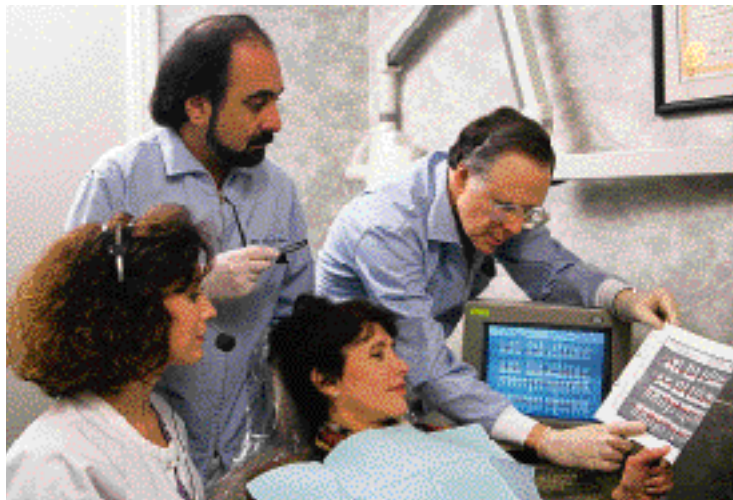

Figure 2-11: Voice-activated charting (Victor, Pro-Dentec), followed by a detailed 8-by-10-inch color printout is of immense help in gaining patient compliance in home care and acceptance of appropriate treatment plans.



Figure 2-12A: Computer imaging is essential to help plan treatment for almost every esthetic problem.

At the very least, one can avoid discovery after the fact, which is expensive. Retreatment of the patient is usually done at a loss for the dental office. It does not take too many losses of this type to realize that computer imaging can be a valuable asset when a major esthetic correction is being planned.

There is a legitimate question raised when turning to the decision of who is to perform the imaging. Obviously, many dentists like to make their own computer changes while others prefer to have a computer imaging therapist assist in providing this service. Unfortunately, time, or lack of it, may help make the decision. In our office, this certainly is a major reason why we chose to not only have a computer imaging therapist on staff but also one who is a practicing hygienist. This fact makes her more capable of understanding our intended changes, plus she is artistically qualified and has excellent ability to communicate with the patient. This last fact also saves the doctors considerable “explanation” time. However, the imaging therapist can be a hygienist, assistant, or another person knowledgeable about dental procedures. When you state what your intended correction will encompass, the computer imaging therapist must understand sufficiently to make the proposed changes in the computer. The patient must be made to clearly understand that the image produced by the computer is only an approximation of intended results the dentist feels he or she can reasonably attain. If you plan to give a copy of the computerized image to the patient,

remember to always print, in color, a disclaimer clause on the copy. This clause may read as follows: “*This picture is for purposes of illustration only. It does not represent a guarantee of any kind.*” Figure 2-12B shows an example of the type of statement that should be included on any computer printout given to the patient.

The following is a good example of just how important computer imaging can be:

A 26-year-old professional athlete was concerned about his crowded teeth (Figure 2-13A). Clinical examination revealed a high lip line with gingival tissue covering the cervical third of the teeth. This combination resulted in a disproportional smile/tooth relationship to the full face.

The patient’s previous dentist stressed the ideal solution of orthodontics but did not give him any alternative. The patient felt there must be an alternative, such as crowning. When orally discussing the various options for improving his appearance, the patient could visualize how straight the teeth would look, but he had difficulty understanding the need for cosmetic periodontal therapy.

Computer imaging was used to show the patient what could be expected of cosmetic periodontal surgery plus ten porcelain laminates (Figure 2-13B). When he saw the intended result through computer imaging, his immediate question was, “How fast can the treatment be accomplished?” Following cosmetic periodontal surgery, ten porcelain laminates were




Figure 2-12B: If you give your patient a copy of his or her computer image, be sure to include a disclaimer similar to the one shown on this printout.

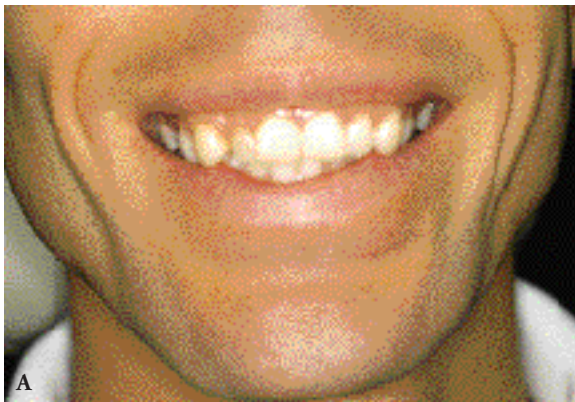inserted to achieve the look in Figure 2–13C. Computer imaging played a major role in convincing this patient of the importance of both procedures to obtain maximum esthetic results.

Other major uses of computer imaging are as follows:

1. You can show the patients views of their teeth and smile that they would not normally see (Figure 2–14A).
2. You can provide full-face frontal and profile views that can help you and your patient visualize what effect proposed changes to the teeth and gingival tissues can have on the face.
3. Imaging may reveal to you and to your patient what not to do. Not infrequently, certain intraoral changes can have a detrimental effect, instead of the desired one, by being too perfect or too imperfect. Equally damaging is

making teeth too light or too dark. Although not guaranteeing a perfect shade, the computer can help illustrate to the patient an acceptable, approximate shade range. A critical consideration for imaging occurs when orthodontic treatment achieves occlusal success only to destroy facial balance. For example, moving anterior teeth lingually either with orthodontics or through prosthetic means may make for occlusal success, but it may cause more prominence to the patient’s nose. Your patient may like his or her nose as it is. Making the proposed change could produce an esthetic disaster from the patient’s point of view.

4. When restorative treatment consists of bonding, laminates, or crowns, imaging can be invaluable during the try-in phase when the patient or dentist is not absolutely certain of the optimal length or width of the new



Figures 2–13A to C: Although crowded teeth caused this patient to seek esthetic treatment, computer imaging indicated the need for cosmetic periodontal-gingival raising therapy for improved facial proportion. Imaging also gave him a much desired alternative to orthodontic therapy by demonstrating the proposed results using porcelain laminate restorations. The final smile would not have been possible had this patient not been motivated to undergo both periodontal and restorative therapy after seeing the potential results via computer imaging.

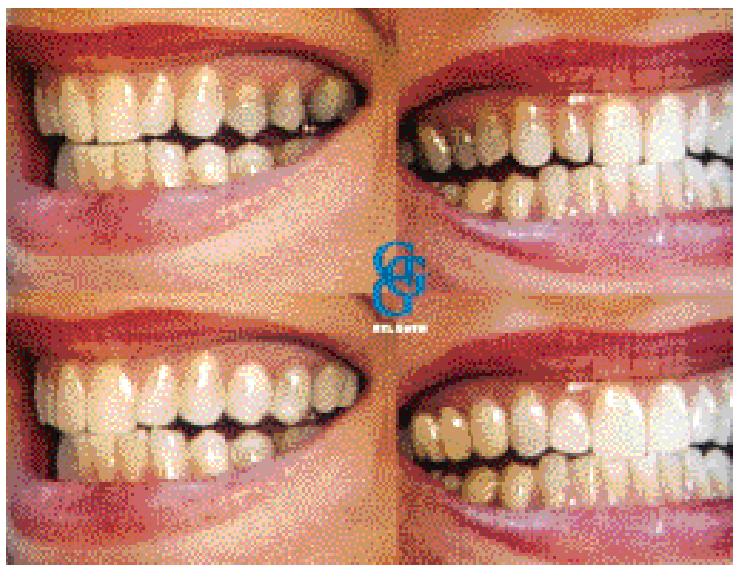


Figure 2-14A: This computer imaging printout shows the importance of taking a lateral view since this aspect as seen by others is seldom observed by the patient.

restoration. Rather than blindly removing existing porcelain incisal edges on the restoration, which could ruin your esthetic result, it is easier to image your patient and make the changes on the screen. You and your patient can then come to a mutual agreement on what looks best.

5. Another critical area where computer imaging can make a significant difference is in the communication between the dentist and the off-site laboratory technician. That communication is most often in the form of models, impressions, and written notes. If an actual picture reflecting what you and your patient expect is given to the laboratory technician, the probability of a successful result is greatly improved.

HIGH TECH IN ESTHETIC DENTISTRY

Dentistry is fast heading toward a paperless office where every conceivable record can and will be computerized. The patient's file, including all diagnostic and treatment records can already be stored, displayed, printed, and transported electronically. One of the major advantages of this trend is that it enables you to accumulate vast amounts of knowledge about your patients and retrieve the information faster than by looking through pages of

records to find, for instance, what cement you used many years ago to seat a particular crown.

The Integrated System

Currently, most high-tech diagnostic systems consist of independent units, one to do each job, resulting in higher purchase costs and the need for more storage and usage space. State-of-the-art diagnostic procedures in the future will be controlled by an integrated workstation. The advantage of this clinical and management-oriented system is the ability to add and retrieve information quickly and easily from multiple, flexible locations within the office. Records, x-rays, and reports will not be misplaced. A patient's last x-ray and the next day's schedule will be at your fingertips while you are on the phone determining how and when to treat him or her. You may even have workstations at home for on-call situations involving any patient in your practice. This will be especially valuable for multidocor and multi-location practices. Fast and comprehensive specialty and referral consultations are easily made using modems. Third-party reimbursement is certainly faster if claims are submitted electronically, and procedure approvals can be higher with the ability to submit more in-depth documentation.

The various components of such a typical integrated system are:

1. Practice/business management system
2. Extraoral camera and video, with memory and printer
3. Intraoral camera
4. Computerized radiography
5. Occlusal analysis
6. Voice-activated periodontal and general oral diagnostics
7. Patient education and interactive video system
8. Computerized imaging system

The voice-activated charting component is actually the core of the system from a clinical perspective because it generates the basic information of the electronic chart. In addition, temporomandibular joint analysis and esthetic evaluation can be incorporated into this integrated system. The video recordings become a form of informed consent. While recording face and smile, you also capture the patient's voice stating that he/she understands what a particular procedure is and why it is being done. For the esthetic practice, this can prove to be a definite advantage, especially if a patient presents a problem after treatment. Photographic records will be the rule rather than the exception. Recreating the circumstances of a restorative procedure will take only seconds if they are stored in the system. Eventually, three-dimensional diagnostic models and even their occlusion will be possible when the principles of CAD/CAM are integrated into the system.

The first visit frequently ends with the recording of the patient's images. The actual computer imaging correction often occurs after the patient leaves, either by or in consultation with the dentist.

PREPARATION FOR THE SECOND VISIT

Review of Radiographs

Preliminary reading of radiographs will reveal obvious caries, periodontal disease, and evidence of abscess or other pathology. Any teeth to be considered for crowning should be examined on the radiograph to see if the pulps are large or receded, because their condition can alter treatment expectations. Teeth that have deep caries or thickened apices may sometimes require root canal therapy. It is better to determine any necessary endodontic treatment before inserting esthetic crowns. Perform-

ing an endodontic procedure on a newly cemented porcelain crown is not a pleasant task, especially given the possibility of lingual surface fracture. Therefore, interim treatment crowning for an extended period may be indicated before you insert the final restorations.

Evaluation of Diagnostic Models

Diagnostic models are an essential part of the treatment planning procedure. However, they must be accurate, well-made, and contain as much detail as possible. Arch relationships and tooth form, size, and arrangement should be studied. It may be necessary to consult a specialist with the diagnostic models before the patient's second visit. Several questions should be asked when reviewing the models:

1. Is repositioning needed for a proper esthetic result?
2. Can restorative dentistry alone achieve esthetic balance?
3. Are periodontal or other surgical procedures necessary for a successful restorative result?
4. Do wear facets indicate a loss of vertical dimension or any other occlusal problem? It might be necessary to wax-up an intended restoration as well as various alternatives to help the patient choose the best one. A wax-up is an important visual aid and enhances communication between the patient and dentist.

Review of Medical and Dental Histories

The dentist should be aware of any systemic physical or mental disease. Using a history chart similar to that in Figure 2-14B, the dentist can learn if a patient has any of the various medical ailments that could compromise a successful esthetic result. It is important to know, for example, if the patient can tolerate sitting for extended periods during try-ins or difficult staining procedures.

It is obvious that not every patient can undergo cosmetic restorative treatment. The patient's history can show if there are systemic diseases that can cause problems, particularly in combined therapy cases where orthodontics, periodontics, and full-mouth reconstruction are performed. An esthetic result that will last for any length of time is difficult to achieve if there is continual periodontal breakdown due to pre-existing disease.

MEDICAL HISTORY FORM

Date _____

Name _____ Home Phone _____ Business Phone _____

Address _____ City _____ State _____ Zip Code _____

Occupation _____ Social Security No. _____

Date of Birth _____ Sex M / F Height _____ Weight _____ Single / Married

Name of spouse _____ Closest relative _____ Phone _____

If you are completing this form for another person, what is your relationship to that person? _____

Referred by _____

For the following questions, circle yes or no, whichever applies. Your answers are for our records only and will be considered confidential. Please note that during your initial visit, you will be asked some questions about your responses to this questionnaire and there may be additional questions concerning your health.

1. Are you in good health? Yes No
2. Has there been any change in your general health within the past year? Yes No
3. My last physical examination was on Yes No
4. Are you now under the care of a physician? Yes No

If so, what is the condition being treated? _____

5. The name and address of my physician(s) is _____
6. Have you had any serious illness, operation, or been hospitalized in the past 5 years? Yes No

If so, what was the illness or problem? _____

7. Are you taking any medicine(s) including non-prescription medicine? Yes No

If so, what medicine(s) are you taking? _____

8. Do you have or have you had any of the following diseases or problems?
 - a. Damaged heart valves, artificial heart valves, heart murmur or rheumatic heart disease Yes No
 - b. Cardiovascular disease (heart trouble, heart attack, angina, coronary insufficiency, Yes No
 coronary occlusion, high blood pressure, arteriosclerosis, stroke)
 1. Do you have chest pain upon exertion? Yes No
 2. Are you ever short of breath after mild exercise or when lying down? Yes No
 3. Do your ankles swell? Yes No
 4. Do you have inborn heart defects? Yes No
 5. Do you have a cardiac pacemaker? Yes No
 - c. Allergy Yes No
 - d. Sinus trouble Yes No
 - e. Asthma or hay fever Yes No
 - f. Fainting spells or seizures Yes No
 - g. Persistent diarrhea or recent weight loss Yes No
 - h. Diabetes Yes No
 - i. Hepatitis, jaundice or liver disease Yes No
 - j. AIDS or HIV infection Yes No
 - k. Thyroid problems Yes No
 - l. Respiratory problems, emphysema, bronchitis, etc. Yes No
 - m. Arthritis or painful swollen joints Yes No
 - n. Stomach ulcer or hyperacidity Yes No
 - o. Kidney trouble. Yes No
 - p. Tuberculosis. Yes No
 - q. Persistent cough or cough that produces blood Yes No
 - r. Yes No
 - s. Yes No
 - t. Sexually transmitted disease Yes No
 - u. Epilepsy or other neurological disease. Yes No
 - v. Problems with mental health Yes No

Figure 2-14B: Medical history form (side 1).

w. Cancer	Yes	No
x. Problems of the immune system	Yes	No
y. Have you had abnormal bleeding?	Yes	No
a. Have you ever required a blood transfusion?	Yes	No
10. Do you have any blood disorder such as anemia?	Yes	No
11. Have you ever had any treatment for a tumor or growth?	Yes	No
12. Are you allergic or have you had a reaction to:		
a. Local anesthetics	Yes	No
b. Penicillin or other antibiotics	Yes	No
c. Sulfa drugs	Yes	No
d. Barbiturates, sedatives, or sleeping pills	Yes	No
e. Aspirin	Yes	No
f. Iodine	Yes	No
g. Codeine or other narcotics	Yes	No
h. Other _____		
13. Have you had any serious trouble associated with any previous dental treatment?	Yes	No
If so, explain _____		
14. Do you have a disease, condition or problem not listed above that you think I should know about?	Yes	No
If so, explain _____		
15. Are you wearing contact lenses?	Yes	No
16. Are you wearing removable dental appliances?	Yes	No
Women		
17. Are you pregnant?	Yes	No
18. Do you have any problems associated with your menstrual period?	Yes	No
19. Are you nursing?	Yes	No
20. Are you taking birth control pills?	Yes	No
Chief dental complaint _____		

I certify that I have read and understand the above. I acknowledge that my questions, if any, about the inquiries set forth above have been answered to my satisfaction. I will not hold my dentist, or any other member of his/her staff, responsible for any errors or omissions that I may have made in the completion of this form.		
Signature of Patient _____		
.....		
For completion by the dentist:		
Comments on patient interview concerning medical history _____		

Significant findings from questionnaire or oral interviews _____		

Dental management considerations _____		

Date _____	Signature of Dentist _____	
Medical history update		
Comments _____		

Date _____	Signature _____	

Figure 2-14B: Medical history form (side 2).

The dental history can indicate the patient's familiarity with dentistry. From this, the dentist can judge how much time should be allowed for the second visit or if subsequent visits will be necessary before the final presentation. Frequently, the patient with little knowledge of dentistry will require several visits before a successful case presentation can be made. The patient's "dental IQ" indicates his or her opinion of dentists and dentistry. The patient who is extremely critical of previous dentists may soon be critical of the current dentist.

Preparation of a Preliminary Treatment Plan

A preliminary treatment plan should definitely be formulated and it is also prudent to use an organized form on which to place these clinical recommendations (Figure 2-14C). Although it may be revised considerably, different alternatives should be considered before the second appointment. A quadrant-by-quadrant outline of functional necessities with a separate list of esthetic options will suffice.

The diagnosis and treatment planning phase for the treatment of esthetic dental problems can occupy a considerable amount of time. However, the presentation of the findings can often be better handled by a treatment coordinator skilled in the art of patient communication than by the dentist.

THE ROLE OF THE TREATMENT COORDINATOR

The ideal dental treatment coordinator is skilled in all the phases of dental practice including insurance, patient accounts, and has a good rapport with people. The treatment coordinator's job begins either when the patient telephones for information as a new patient or upon the patient's initial meeting with the dentist. During examination and initial diagnosis, the treatment coordinator records the findings. The treatment coordinator needs a full and clear understanding of all phases of treatment to enable him or her to present the treatment plan to the patient in an easy-to-understand format (Figures 2-15A to C). After the treatment coordinator has presented a plan that is mutually acceptable to the doctor and the patient, he or she then proceeds to schedule the treatment and make the financial arrangements.

With the increasing use of auxiliary personnel, a dental treatment coordinator can be the backbone of the treatment team's communication process,

providing support to the dentist, dental assistants, hygienist, receptionist, bookkeeper, and office manager alike. Your dental treatment coordinator should spend about half of the average workday dealing with treatment planning. Another third of the day will be devoted to necessary paperwork including insurance and accident cases. That leaves the balance of the day for patient problems—fees, miscommunications, and explanations of complicated dental procedures that the patient may not completely understand.

The dental treatment coordinator is responsible for office public relations as well as problem solving. All lines of professional communication help to provide a smooth and effective treatment process for the patient. The treatment coordinator should maintain the credibility of the dentist and staff and reinforce the entire staff's dedication to ensuring the patient's faith in treatment already begun. It involves organizing and streamlining all aspects associated with patient treatment. This also requires checking the insurance and personal information that the patient provides.

Although payment for esthetic dentistry is always arranged in advance, if the treatment plan extends over considerable time a payment plan may need to be developed and explained fully to the patient. Some dentists do not want to talk about money with patients while others are perfectly comfortable doing so. If you are uncomfortable discussing fees with patients, you may too often end up giving away a good portion of your time, or working for a lower fee than you would normally charge. Therefore, for the financial health of your practice, make sure the treatment coordinator discusses fees and methods of payment with the patient.

In many instances, one appointment is all that is needed to diagnose, image, plan treatment, and make financial arrangements with your patient. However, more complex patient problems will usually require a second appointment.

THE SECOND APPOINTMENT

A completed Smile Analysis form (see Figure 2-1B) should be discussed after the patient has reviewed the radiographs with the dentist and understands the preferred course of treatment. With a thorough analysis, useful conclusions can be made about the patient's attitude toward his or her esthetic problems.

PROPOSED PATIENT TREATMENT FORM

Patient _____ Date _____

Doctor _____ Treatment Coordinator _____

The diagram shows two dental arches. The upper arch is labeled 'RIGHT' on the left side and 'LEFT' on the right side. Teeth are numbered 1 through 16. The lower arch is also labeled 'RIGHT' on the left and 'LEFT' on the right, with teeth numbered 17 through 32. Each tooth is represented by a rectangular box with its number inside.

Cosmetic Contouring Nightguard Bleaching H O C

Periodontal Case Type _____

Other Treatment _____

Referrals _____

Remarks _____

Figure 2-14C: Proposed patient treatment form.



Figure 2–15A: Final treatment presentation consists of three phases. The first part is a brief meeting between the dentist and the treatment coordinator.

The Smile Analysis provides information essential to the thorough knowledge and understanding of the patients' attitudes, which should never be ignored. Patients may ask the impossible or make statements that point to more profound wishes and attitudes. Hear not only what a patient says but also what he or she means. If the planned esthetic

treatment is simple, present the final treatment plan soon after the Smile Analysis has been discussed. For the patient with a difficult tooth problem (repositioning or periodontal involvement), consultation with a specialist should be arranged.

Consulting a Specialist

Too often a dentist, impatient to begin treatment, fails to stress the importance of the patient consulting a specialist. For instance, dentists often do not emphasize the functional objectives of tooth repositioning, and consequently may not motivate patients to seek orthodontic treatment that might prevent bone loss later in life.

In most instances when there are difficult spaces to restore, even a minor orthodontic intervention can make a tremendous difference in the final result. It is important to let the patient know what options he or she has and the degree of excellence that could be obtained with or without orthodontic treatment.

The next most important specialty to consider is periodontics. The control and correction of bone loss that could complicate the diagnosis or compromise the treatment results are obvious reasons to refer to a periodontist. In addition, the patient's soft tissue needs to be observed during maximum smiling. Could tissue repositioning help create a more favorable tooth size relative to the patient's face or smile? Would ridge augmentation help

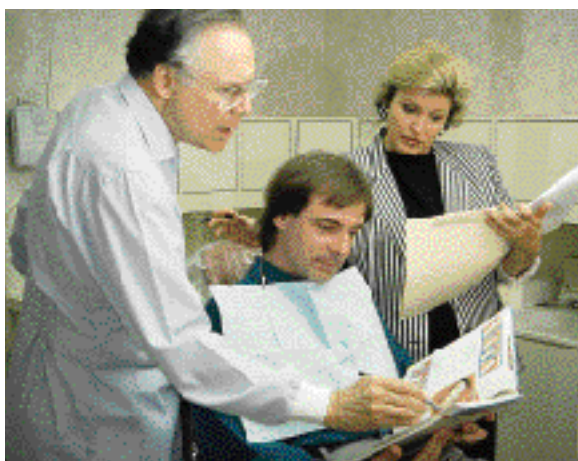

Figure 2–15B: Next, the dentist reviews treatment options with the patient with the treatment coordinator present.



Figure 2–15C: The final, and perhaps most important, phase consists of the treatment coordinator reviewing the treatment plan with the patient and answering all questions relating to the treatment and financial arrangements.

make a more realistic result? These, plus other questions regarding where and what type of margins to create are typical problems that could be more successfully solved with the aid of a periodontist skilled in cosmetic surgical techniques.

When there are questionable areas regarding periapical pathology, such as in teeth with deep, old restorations or periapical thickening, an endodontic consultation is in order. Previously placed ill-fitting crowns or endodontically questionable teeth could also seriously compromise the esthetic results unless you treat these areas, if necessary, before you begin.

Finally, oral surgery must be considered when facial deformities could also complicate maximum esthetic results. This may mean scheduling a consultation with a plastic surgeon as well.

The best way to communicate the advantages of obtaining specialty consultations is to let your patient know that you work with an excellent team consisting of orthodontists, periodontists, plastic surgeons, endodontists, and oral surgeons, and that your interest is in obtaining the best possible result based on their desires or preconceived images. You also need to stress that you are treating him or her as a whole person, not just treating the teeth. Finally, make sure you help your patient visualize the various options available.

The Final Case Presentation

The final case presentation should be a carefully prepared, easily understood treatment plan. Visual aids, before and after photographs, slides, models, intra- and extraoral video and computer imaging, and examples of the procedures to be used assist in communicating the possibilities and limitations of esthetic treatment.

These are three basic methods for helping patients visualize your suggested solutions for their individual esthetic problems:

1. Soft, Tooth-Colored Wax or Composite Resin Applied Directly in the Mouth

The advantages to this technique (Figures 2-16A to C) are:

- it is the least costly for the patient;
- it is the quickest method;
- it is especially useful in space or diastema problems.

2. A Waxed Study Model

When the potential solution to an esthetic problem requires extensive tooth preparation, this method can be effective for those patients who are used to visualizing plans, such as an architectural blueprint (Figure 2-17). The

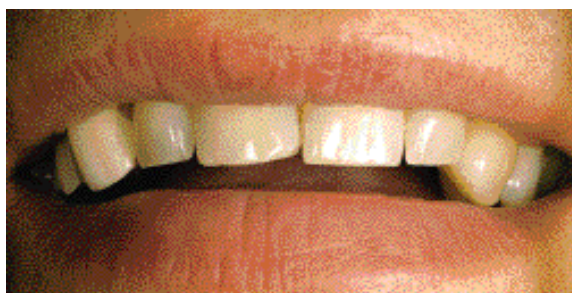

Figure 2-16A: Even with computer imaging it is helpful for patients to be able to see how changes will affect their speaking ability and the appearance of their lip line. This patient was unhappy with his smile and wanted longer teeth.

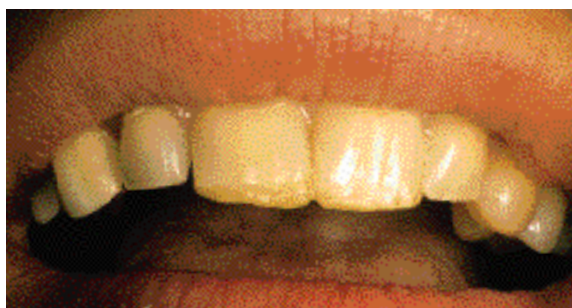

Figure 2-16B: Tooth-colored wax applied to the central incisors showed the patient how the final restorations would correct his problem.

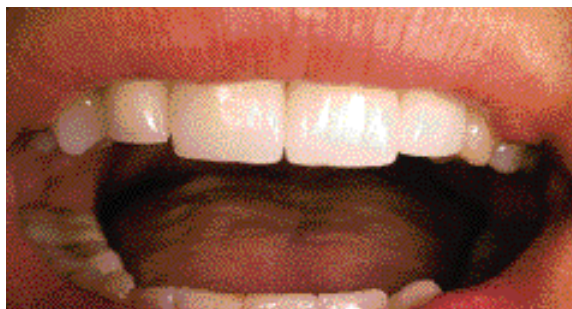

Figure 2-16C: Visualizing the esthetic improvement motivated this patient to obtain esthetic correction with fixed ceramic restorations.

waxed model is also important from a diagnostic standpoint when your patient has a space problem. By preparing the teeth, then waxing them, you can determine if there is too much or too little space for normal-sized tooth replacement. This allows you to adjust the treatment plan as necessary to make certain you can create an adequate esthetic restoration.

3. Computer Imaging

By far, esthetic imaging is the best method to help your patient visualize your intended corrections (see Figure 2–12). The printouts and the image on the monitor can be effective communication tools. This method also allows you to easily alter your treatment plan to reflect various compromises. Rarely will it be necessary for your patient to return for further imaging if you have thought of possible options in advance. It is also extremely effective to show your patient the various choices, since most people will opt for the best look, provided they can find a way to afford the correction.

For patients with complex problems, the combination of computer imaging and waxed diagnostic models will be the best choice for complete visualization.

WHEN NOT TO TREAT... BUT TO REFER

It is impossible for any one dentist, regardless of how capable he or she is, to satisfy every patient's esthetic needs. Most new patients are on their best behavior during the initial interview session. That is why it takes a skilful dentist and staff, as well as extra time, to ascertain what kind of patient is presenting to your office. Your goal is to determine who should be the patient you refer. To help with the decision, the following patient-type categories can be incorporated into your treatment philosophy.

The Perfectionist

This patient has the highest standard of esthetic excellence. Unless you are willing to spend an inordinate amount of diagnostic and treatment time with this patient, you are much better off, emotionally and financially, making an early decision to refer this patient. Deciding to treat this type of patient may mean charging two, three, or even four

times your normal fee in order to cover the extra time, stress, laboratory and office costs, and extended warranty for this patient. Offices that elect to do this should also consider the probability of having to redo the treatment several times in an attempt to satisfy this patient's esthetic and functional demands. Will it be worth it and can your office afford this type of expense? Too often, dentists find that treating these patients costs them so much they would have paid another dentist double the amount after they have failed in their attempts to satisfy the patient. Although many of us may enjoy a challenge, the question is, can your office afford the risk of taking on such a challenge?

Poor Communicator

These are the patients who cannot communicate what they want because they do not themselves know what they want. They may show you a picture of exactly what they want, but when they eventually see it in their mouth, they may be terribly disappointed. Even study models with wax-ups may look good to these patients, but that approval may be of no benefit when the final restoration is in their mouth. What can be most frustrating is to show this type of patient a computer image of his or her enhanced smile, which may be enthusiastically received but, amazingly, not appreciated when tried in. The problem is, these people really do not know what they want when it comes to their own appearance. Typically, they have difficulty making up their minds in other areas of their lives as well.

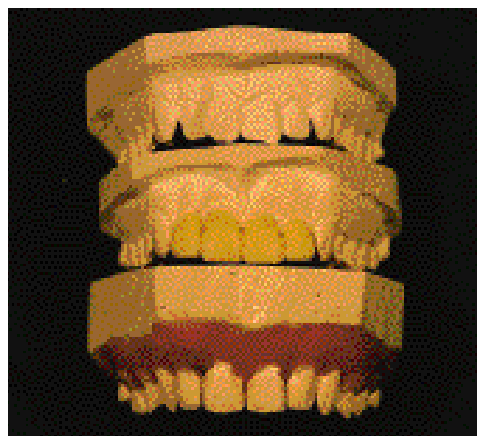


Figure 2–17: Creating waxed models of the available choices helps the patient understand the treatment options and enhances the dentist's diagnostic ability.

They may be constantly redecorating their homes, apartments, or offices. They may be frequently frustrated with their hairstyles and constantly changing their barber or hairstylist in an attempt to find that “perfect” style. The real problem here is identifying this type of patient before agreeing to treat them. This is one of the hardest categories to identify because, at first glance, these people seem so easy to please. You may be tempted to proceed with treatment too hastily only to find that you, in fact, are now treating the type of patient you may have wished you had referred. One important clue to help you recognize this patient type is that he or she presents to you in the middle of treatment from another office. Frequently, that dentist may have redone their treatment many times before the patient sought another opinion. If this is the situation, carefully analyze the treatment with which the patient presents. Has it been done poorly? Is it esthetically inferior? Frequently, the patient will state “I hear you’re the best.” Although we all like to think we can do something better, “better” may, however, be just another failure to this problem patient. And the sad situation is that few, if any, practitioners may be able to satisfy this patient. Frequently, the root of the problem is psychological. The patient may not truly know what he or she wants. Other times he or she is looking for your esthetic dentistry to solve a problem that only a psychologist or psychiatrist can solve.

High Expectations/Limited Budget

There is nothing wrong with patients who are limited in the amount of money they can invest in their dental treatment. In fact, this may make up the majority of your patients. However, proceed cautiously with the budget-conscious patient who has extremely high esthetic expectations. Rather than having a dissatisfied patient, you are much better off explaining that because they may not be able to afford the ideal or recommended treatment due to the great amount of time, cost, etc. involved, they need to compromise.

“Wrinkle Patient”

These patients are afraid of looking old. They expect esthetic dentistry to make them look young again, expecting you to get rid of their wrinkles by “plumping out” the restorations. Unfortunately, your dentistry may not be able to accomplish this esthetically, which can make for patient dissatisfaction.

The other type of patient in this category is the reverse—the one who claims that after your esthetic treatment, wrinkles appeared. This is one of the situations where the before full-face photograph is essential. It is advised that these photographs be taken with and without makeup. Ask the patient to remove all makeup, thus allowing you to more accurately see facial characteristics, which will help you in your diagnosis and treatment. Then point out every wrinkle and/or other facial deformities that are not likely to change. However, be quick to point out to this type patient that you work with an excellent team which includes a plastic surgeon, and that, following your dental treatment, the plastic surgeon may be able to improve that condition. Follow this suggestion with a recommendation for a consultation with a plastic or oral surgeon during your diagnostic stage—never after your treatment is complete. Make sure to document the recommendation so that you will not be taking responsibility for something you cannot control.

Uncooperative Patient

This is another potential problem patient that can be overlooked if your diagnostic time is too short. Frequently, this patient presents with poor dentistry or no restorative dentistry at all. Hygiene is either nonexistent or inadequate at best. They will vociferously complain about a previous dentist and staff. The major problem with these patients is they will not accept responsibility for any of their problems or faults. A typical response of a patient with extremely worn teeth may be, “I never grind my teeth,” and he or she may become agitated at you for even suggesting it. Or, “I brush my teeth six times a day,” despite the extensive presence of plaque indicating less than adequate homecare. These patients are frequently so abusive to everyone in your office, including you, that your staff will agree that no fee you may charge is worth the aggravation of treating this type of patient. This is certainly one time when a consultation with your staff about accepting this patient for treatment in your practice would be extremely beneficial. If you do decide to accept this patient, you should consider substantially increasing your fee. A doubling, tripling, or more might be appropriate.

The purpose of classifying potential problem patients here is not to dissuade you from treating them. Rather, it is to make you and your staff more

aware of the potential consequences of treating certain types of patients. You and your staff should now be able to recognize better a potential problem before it happens. The treatment sequence outlined in Figure 2-1C is extremely important in this regard. The chain of people who can give you information as to the patient's personality is the receptionist, the assistant/hygienist, and then the treatment coordinator. Be sure to use the input from these key staff members before you elect to take up a patient's esthetic treatment. Should you decide to treat a problem patient, be sure to adjust your fees accordingly.

Remember, it is not enough to just cover the cost of treatment of such patients. If you elect to dedicate the extra time, effort, and above all, stress (not only yours but also that of your staff and perhaps even your family), you are entitled to a reasonable profit for doing so. Your staff and family expect and deserve it as well. The greater is the difficulty, time, and effort required, the greater is the multiple of one's routine fee. In the past 40 years many of the perceived "difficult" patients who elected not to proceed with my proposed treatment due to the increased fee have gone elsewhere for treatment—only to come back years later, still not happy. Now they will have to spend even more money to have their treatment redone. Incidentally, if you misjudged the patient the first time by referring when, perhaps, they might have been a perfectly acceptable patient, do not make the mistake of underestimating the amount of time, stress, and costs involved in redoing that patient's case.

HOW TO TREAT PROBLEM PATIENTS ... AND KEEP YOUR STAFF SANE

There are several precautions to take if you elect to treat problem patients. One, be prepared to spend much more time in diagnosis. The best way to handle patients who have difficulty communicating what they want is to schedule several diagnostic sessions. Use different approaches to attempt to understand what your patient visualizes as a final result. It is essential for you to help your patient understand that the problem is with himself or herself, not with you. The only time you can accomplish this is during the diagnostic stage. This diagnostic time must be considered as a period of discovery not only of the intraoral condition but also

of the patient's psychological and visual concept of self-image. Only when the patient realizes that it is his or her own problem can there be a solution. If your patient refuses to admit that he or she has or is a problem, it would be wise for you to avoid accepting any treatment liability. This means that if you still wish to treat the patient, you must have a signed, limited-treatment liability agreement. This agreement should specify that you will provide a specific treatment to this patient for a specific period of time, including post-treatment care.

The second consideration is that you should never proceed with your treatment plan until both you and your patient have a thorough understanding of what your treatment will be. Make sure your treatment coordinator has your patient sign a form, following an oral presentation of recommended treatment, that all options were presented and that the patient understands the options and agrees with the treatment. Next, follow up with a detailed treatment letter listing any exceptions or potential problems that could be encountered.

The third precaution to take when treating problem patients is to consider treatment phases. The advantage of treating problem patients in phases is that you never proceed to the next phase until the patient is pleased with the current phase of treatment. The following is an example of how this may occur:

First Phase. Diagnosis and treatment planning. This may consist of soft tissue management, all diagnostic tests and records, specialist referrals, and appropriate endodontic and periodontic therapy.

Second Phase. Treatment splinting and/or bleaching. This is the time to redo and alter, as necessary, treatment crowns or bridges until your patient is esthetically pleased and signs your release to proceed to Phase Three. If a problem patient says, "I like them just the way they are except I want this tooth built out a little more," you should not proceed to the next phase of treatment. Make the necessary changes and let the patient live with the changed restoration for at least another week to make sure no other exceptions arise. The patient must be pleased with the appearance of the treatment splints, otherwise he or she may well be dissatisfied with the final restoration, stating, "I thought it would be different!" It also means using

a capable laboratory to make well-shaded and proportioned acrylic temporaries.

Third Phase. Placement of final restorations. Your treatment should virtually duplicate the temporaries. Take either a very good alginate or even better, a vinyl polysiloxane impression to accurately record just how your patient wishes to look. When all is done, the patient should be satisfied with the esthetic treatment you have painstakingly performed.

The fourth precaution is to make sure your fee is adjusted appropriately. You should apportion your fee to the various phases after determining your expenses and desired profit in each phase of treatment. The fact that your increased fee may be considerably higher than that of your colleague across the hall or down the street also should play no role in setting your fee. Your attitude should be, if the patient does not understand your special abilities and the extra effort you will expend in helping to solve his or her problem, you are better off letting another dentist suffer the consequences, including the financial loss, in dealing with this type of problem patient.

In the final analysis, you should thoroughly consider all of the problems associated with each patient, whether a difficult clinical or emotional issue, or both. In some cases an astute staff member may sense that you cannot satisfy a particular patient. In all cases, be upfront and honest about your decision that a particular patient may be better treated by another dentist. Issues of patient abandonment do not apply if you decide to not treat during the diagnostic phase and before any treatment has begun.

The fifth and last precaution in treating problem patients is to pay particular attention to your treatment warranty. Make sure your patient knows exactly what you are guaranteeing so there is no misunderstanding about what is explicitly stated and what is implied.

CONTINUOUS COMMUNICATION

Treatment planning is not complete until the patient makes a final decision about accepting treatment. However, follow-through by the treatment coordinator is necessary throughout your patient's treatment. Any proposed changes to your treatment plan must involve your treatment coordinator. In

fact, if your proposed changes affect your fee, then be certain to have the new case fee verified with the patient by the treatment coordinator prior to your beginning the altered treatment procedures.

How esthetic procedures differ from ordinary dental procedures should be explained. The patient must understand that esthetic dentistry may be time-consuming and, unlike routine procedures, does not always produce immediate results. Differences such as time involved for extra try-ins, treatment plans that require chairside carving and shaping of temporaries, staining of porcelain at chairside, and the dentist's time and expertise should all be discussed. The patient must be convinced and satisfied that any additional time necessary for better esthetic results is worth the investment.

Dentists should be aware that patients are often completely unfamiliar with esthetic dentistry and are reluctant or unable to ask the important and relevant questions about the procedures. The limitations of esthetic dentistry should also be explained to the patient. While esthetic treatment can produce dramatic improvements, it cannot do everything. If compromise is necessary, say so. It becomes the dentist's responsibility, therefore, to see that all doubts and questions are cleared away during the final case presentation. You must be careful not to impose your own esthetic notions on the patient. Superior knowledge and training make dentists the arbiter of what is practical and workable; they do not give him or her any precedence in matters of esthetic preference.

Esthetic treatment demands personal communication between patient and dentist that must continue throughout treatment. Be an acute observer, a precise listener, and an understanding interpreter. Always remember that good communication can make it possible to change an insecure frown into an assured smile.

FEES

One of the biggest stumbling blocks to offering quality esthetic dentistry is the mistaken belief that your patients will not pay for it. I once had a patient who was a bricklayer and who was dissatisfied with his smile. I spent a considerable amount of time trying to educate him as to why the best esthetic dentistry might cost more. I gave him three alternative choices for different qualities of esthetic

treatment and thoroughly explained the differences among the three. Although he was dressed poorly and not well-groomed, the gentleman eventually chose the best quality dental service. My father had pointed out to me that he thought I might have spent too much time with someone who did not appear to be interested in such a high-quality procedure. However, this taught me (and my father) never to judge someone by first appearance.

This is not to say you should spend the same amount of time with every patient. It becomes obvious that not everyone will be receptive to learning the differences between quality and average treatment. In the final analysis, it will be up to you to determine if the patient who is not interested in understanding the differences will be the patient you wish to treat. Generally, these patients are shoppers who will base their decision on price only.

The different classifications of patients will have different motivations and expectations for esthetic dentistry (see page 17). Some are influenced more by the life expectancy of the restoration while others care more about the esthetic result.

Almost every patient wants to know, “How much is it going to cost?,” even before visiting the dental office. In fact, some patients, the price shoppers, will call to request prices before deciding to make an appointment. These people are usually driven primarily by price, and yet still may have a high esthetic dental need. Probably the most difficult task most dentists face is answering the fee question. Your fee should reflect the quality of care your office provides and should not be presented with apology. If the patient views the treatment as a need and is aware of the benefits of that treatment, he or she will usually consent to the proposed treatment plan, provided finances are not a problem.

The patient will usually feel more at ease with a third party, the treatment coordinator, and thus more comfortable voicing questions about fees at this time. If necessary, a compromise or a different treatment alternative can be introduced when there is genuine dissatisfaction or a problem with a patient’s ability to pay. If this situation occurs, it is often helpful for the treatment coordinator to suggest, “Let me speak with the doctor and see if some compromise treatment can be arranged.” You may then choose to alter the terms, the total fee, or suggest alternative treatment plans.

Although there may be no question about the best method for solving a particular esthetic problem, we must always be aware that alternative treatment plans can be given in most instances.

The amount of a fee is not as important as how your patient perceives it. A company president may reject even moderately priced dentistry, whereas the president’s secretary may accept the same treatment plan and fee if he or she realizes the need and finds a way to prioritize the expense. One of the most important components of any case presentation is showing your patients the difference between ordinary and exceptional esthetic dentistry. For instance, show the difference between a regular porcelain crown and one of inlaid porcelain. Show the difference in an extracted tooth that has routine bonding versus one with characterized bonding. Always have two types of laminates: one with opaque monochromatic porcelain and one with color and artifacts built in. And, remember, not every patient wants or appreciates the difference. Patient feedback helps you know who your patient is and how to approach your esthetic dentistry treatment plan to gain acceptance.

Many dentists have little awareness of the factors upon which they should base their fees for esthetic dentistry. Therefore, they feel inadequate or unable to properly define and, unfortunately, even defend their fees. One thing should be made clear from the outset. Most patient insurance policies do NOT appropriately cover fees for esthetic dentistry. So how should fees be determined? The following are key factors that should be considered when you establish your fees for esthetic dentistry:

1. Training

This consists not only of your educational background but also the amount of time and money you invest in brief and/or extensive courses and educational videos, reading books, magazines, and newsletters (including the volumes of information you receive from dental suppliers and manufacturers). Do not forget all those dental meetings you have attended—not only the cost of the meeting but the cost of lost income and the time away from your family and personal life.

2. Procedure

Is a crown just a crown? Is it just as difficult to do a crown on a right central incisor as it is to

do one on a bicuspid? Or how about a “hidden” second molar? Laminating or crowning a single tooth to match an adjacent tooth is many times more difficult a procedure to accomplish than if you crown or laminate two or four teeth. More advanced clinical and laboratory skills are needed for the former. Is it not considerably easier to match a maxillary first or second molar to another one than to perfectly match one central incisor to another? In fact, if you are treating a single tooth, your cost per tooth is considerably more than that for doing six or eight teeth. Consequently, there is a significant difference in your cost, depending upon which procedure you are doing.

3. Technical Skill

Those of you who have been practicing 5, 10, 15, or 20 years and have reached a high level of skill and are teaching other people should be charging more because your technical skill level is higher than someone just coming out of school. And it is also higher than someone who does not take the time for additional training to improve skills.

4. Time

The amount of time necessary for a procedure is just part of the formula. Consider the extra time it will take to answer your patients’ questions. How much extra time will you allow for patients who ask a lot of questions? Time should cover diagnosing, planning, accomplishing the procedure, redoing, repairs, and postoperative visits.

5. Artistic Skill/Patient Requirements

Patients vary. Some truly do not care what your result looks like, just as long as it fits. Others may not seem to care—until he or she goes home and looks closely in the mirror. Always give a patient a mirror and have him or her hold it at arm’s length because that is the perspective from which other people will observe. The patient who holds the mirror very close requires something different of us; he or she is usually the perfectionist and you may need to adjust your fee accordingly. Another important consideration is your artistic ability. It is accepted, often expected, in every profession and culture to pay more for

the best. We pay more for the best sculptures, artwork, photographs, ceramics, jewelry, and all types of other things that require artistic skill. We refer to our profession as “the art and science of dentistry.” The science is well-understood, but the art has been ignored for too long. You deserve to be compensated based in part on your artistic skill.

6. Overhead

Your overhead is based on many factors, including where you are geographically. It is also based on OSHA requirements. It can cost as much as \$25 or more per patient in some offices just for sterilization procedures. Laboratory fees, if any, must be considered, as well as the quality of the laboratory, the materials, and the equipment that you use. Does your office employ the latest in high-tech equipment? All of these things benefit the patient but cost money. If your office is a state-of-the-art facility, then it should be differentiated from the offices that appear outdated and are, in fact, furnished with antiquated equipment.

7. Warranty

What do you guarantee? Are you giving a minimal or extended warranty? Is it 3 months, 6 months, or 1 year? For how many months will you render free aftercare and for how many years will you provide service at a reduced fee and at what percent discount? Are your patients told to wear a protective appliance? Do they? They may have accidents, caries, periodontal conditions, tooth loss, or root fracture; are you guaranteeing your treatment against all those things? You prescribe home care; are they going to do all that you expect? Your warranty must point out the circumstances under which you will guarantee your dental treatment. Are you guaranteeing that if your patient bites into a candied apple your laminate will not break? If eating habits are expected to change after you insert your ceramic crowns or laminates, then this, too, must be stressed and put into your warranty. The best car manufacturer may not honor its warranty if the owner does not fulfill the agreement—changing oil and allowing the dealer to perform necessary mainte-

nance. Are you prepared to honor your warranty for patients who do not come in for routine prophylaxis and clinical examination? Certainly, damage caused by neglect can be costly. A well-constructed warranty and fee structure can help to protect you against patient-neglect situations.

Reference

1. Levin RP. Patient personality assessment improves case presentation. *Dent Econ* 1988;78(9):49–50,52,54–55.

Additional Resources

Annusavice KS. Treatment regimens in preventive and restorative dentistry. *J Am Dent Assoc* 1995;126:727–43.

Bakland LK, Andreasen JO. Examination of the dentally traumatized patient. *J Calif Dent Assoc* 1996;24(2):35–7, 40–4.

Blatchford WA. Patient-driven care presentation. *J Calif Dent Assoc* 1996;24(4):71–6.

Brehm TW. Diagnosis and treatment planning for fixed prosthodontics. *J Prosthet Dent* 1973;30:876.

Burket W. Oral medicine: diagnosis and treatment. Philadelphia: J.B. Lippincott, 1971.

Chalifaux PR. Perception esthetics: factors that affect smile design. *J Esthet Dent* 1996;8:189–92.

Chiche G, Pinault A. Esthetics of anterior fixed prosthodontics. Chicago: Quintessence, 1994.

Chiodo GT, Tolle WE. Referrals to specialists: ethical issues. *Gen Dent* 1995;43:226–32.

Christensen GJ. A consumer's guide to dentistry. St. Louis: Mosby, 1995.

Craig RG. Restorative dental materials. St. Louis: Mosby, 1995.

Crispin BJ. Contemporary esthetic dentistry: practice fundamentals. Tokyo: Quintessence, 1994.

de Kloet HJ, Steneker C. Cosmetics aspects of dental treatment (Dut). *Ned Tijdschr Tandheelk* 1991;98(6): 198–202.

Dietschi D, Spreafico R. Adhesive metal-free restorations: current concepts for the esthetic treatment of posterior teeth. Chicago: Quintessence, 1997.

Dzierzak J. Computer imaging. Its practical application. *J Am Dent Assoc* 1991;122(3):41–4.

Friedman MJ. Polaroid photography: an important tool for esthetic dentistry. *J Calif Dent Assoc* 1991;19(3): 23–7.

Goldman HM, Burket LW. Treatment planning in the practice of dentistry. *J Am Dent Assoc* 1973;87:878.

Goldstein CE, Goldstein RE, Garber DA. Computer imaging: an aid to treatment planning. *J Calif Dent Assoc* 1991;19(3):47–51.

Goldstein CE, Goldstein RE, Garber DA. Esthetic imaging in dentistry. Chicago: Quintessence, 1997.

Goldstein RE. Change your smile. Carol Stream: Quintessence, 1997.

Goldstein RE, Ronald E. Goldstein talks about esthetic care (interview). *J Am Dent Assoc* 1991;122(4):32–6.

Goldstein RE, Ronald E. Goldstein talks about esthetic care (interview). *J Am Dent Assoc* 1991;122(3):34–7.

Goldstein RE, Ronald E. Goldstein talks about esthetic care (interview by Lawrence Meskin). *J Am Dent Assoc* 1991;122(2):36–41.

Goldstein RE, Miller MC. High technology in esthetic dentistry. *Curr Opin Cosmet Dent* 1993;5–11.

Hall SS. Rounds: the case of the woman with bad taste. *In Health* 1991;42.

Hall WB, Roberts WE, LaBarre EE. Decision making in dental treatment planning. St. Louis: Mosby, 1994.

Hardin JF. Clark's clinical dentistry, 1997 update. St. Louis: Mosby, 1996.

Jameson C. Enhanced esthetics: networking with the plastic surgeon. *J Esthet Dent* 1996;8:241–3.

Jameson C. Financing esthetic dentistry: overcoming the barrier of cost. *J Esthet Dent* 1996;8:93–5.

Kay EJ, Blinkhorn AS. A qualitative investigation of factors governing dentists' treatment philosophies. *Br Dent J* 1996;180(5):171–6.

Kuhlberg AJ, Glynn E. Treatment planning considerations for adult patients. *Dent Clin North Am* 1997; 41(1):17–27.

- Mack MR. Perspective of facial esthetics in dental treatment planning. *J Prosthet Dent* 1996;75(2):169–76.
- McDaniel TF, Miller D, Jones R, Davis M. Accessing patient willingness to reveal health history information. *J Am Dent Assoc* 1995;126:375–9.
- Meskin LH, et al. *The 1996 year book of dentistry*. St. Louis: Mosby, 1996.
- Meskin LH, et al. *The 1997 year book of dentistry*. St. Louis: Mosby, 1997.
- Mills EJ, Dunson BC, Koch JP. Evaluation, diagnosis, and treatment planning of complex implant cases. *J Oral Implantol* 1996;22(1):12–6.
- Naert IE. Patient evaluation and treatment planning. *J Dent* 1997;25 Suppl 1:S5–S11.
- Neuman K. Cosmetic imaging: the new wave of co-diagnosis. *J Can Dent Assoc* 1991;57:843–4.
- O'Brien WJ. *Dental materials and their selection*. 2nd edn. Chicago: Quintessence, 1997.
- Preiskel HW. *Overdentures made easy*. London: Quintessence, 1997.
- Redford M, Gift HC. Dentist-patient interactions in treatment decision-making: a qualitative study. *J Dent Educ* 1997;61(1):16–21.
- Roblee R. *Interdisciplinary dentofacial therapy: a comprehensive approach to optimal patient care*. Chicago: Quintessence, 1994.
- Rule J, Veatch RM. *Ethical questions in dentistry*. Chicago: Quintessence, 1995.
- Salama H, Salama M, Te-Fu L, et al. Treatment planning 2000: an esthetically oriented revision of the original implant protocol. *J Esthet Dent* 1997;9:55–67.
- Sarver DM. Video cephalometric diagnosis (VCD): a new concept in treatment planning? *Am J Orthod Dentofacial Orthop* 1996;110(2):128–36.
- Schwartz R, Summitt J, Robbins JW, dos Santos J. *Fundamentals of operative dentistry: a contemporary approach*. Chicago: Quintessence, 1996.
- Shillingburg Jr HT, Hobo S, Whitsett LD, et al. *Fundamentals of fixed prosthodontics*. Chicago: Quintessence, 1997.
- Strassler HE. Esthetic diagnosis. *J Esthet Dent* 1992;4:64–6.
- Ter Horst G, Molendijk B, Brouwer E, Verhey HG. Differences in dental treatment plan and planning for drug-addicted and non-drug addicted patients. *Community Dent Oral Epidemiol* 1996;24(2):120–3.
- Tickle M, Worthington HV. Factors influencing perceived treatment need and the dental attendance patterns of older adults. *Br Dent J* 1997;182(3):96–100.
- Voss R. Problem of treatment according to the patient's wishes. *ZWR* 1971;80:557.
- White SC. Decision-support systems in dentistry. *J Dent Educ* 1996;60(1):47–63.
- Whitehead SA, Wilson NHF. Restorative decision-making behavior with magnification. *Quintessence Int* 1992;23:667–71.
- Wise MD, Laurie A. *Failure in the restored dentition: management and treatment*. London: Quintessence, 1995.
- Zarb GA, Bolender, CL, Carlsson GE. *Boucher's prosthodontic treatment for edentulous patients*. St Louis: Mosby, 1997.

CHAPTER 3


MARKETING

WHAT IS MARKETING?

Marketing is identifying the needs of the community and seeing that the practice's clinical and personal services meet those needs. Some of us tend to think that as professionals we should not become involved with marketing because it is frequently misunderstood and is often equated with media advertising. In reality, all of us market ourselves and our practice in one way or another every day of our lives. The location and appearance (Figures 3–1A and B) of your office is marketing. The way you and your staff dress is marketing. The quality of care and the level of service you provide is marketing. Thus, marketing is everything you do to attract patients and keep them coming back to you for their dental care. Your major goal in marketing is to equate quality and success with your own abilities—no more, no less. In other words, try to develop congruity between what you promise in your marketing efforts and your ability to deliver on that promise.

Marketing your dental practice can be divided into two parts: first, internal marketing, which refers to everything you do to inform your existing patients about you and your practice; and second, external marketing, which notifies people outside your practice as to who and where you are, and the specific care you provide.

Both internal and external marketing can actually be beneficial and less costly than media advertising. One of the reasons you might feel that you want to advertise your practice is peer pressure. If five out of six dentists are advertising, can you build or maintain a successful practice without doing the same? The answer is, yes! In fact, you can create a more elite image by not advertising, which can indicate to the public that you do not find it necessary to advertise. Often, the people you want as patients are those who feel that discount coupons imply discount quality and, since “you get what you pay for,” they will look elsewhere for



Figures 3–1A and B: Esthetically pleasing decor enhances the patient's perception of the dentist's level of esthetic awareness and judgment.

quality dentistry. According to the American Dental Association and Federal Trade Commission there is nothing illegal, unethical, or immoral about advertising, provided you stay within their published guidelines. However, you had better be as good as your advertisements indicate that you are.

External marketing is not inexpensive. We are beginning to see more highly visible dentists using all the promotional skills used by some gourmet restaurants, superior hotels, and other highly competitive businesses. You should also consider the quality of patients you will attract when your message is aimed at the price-conscious segment of the market. The patient who is looking only for price can frequently cost you and your practice more than any gain you might realize. The type of marketing you choose should be related to the type of esthetic identity you wish to market. Assuming you wish to practice the best of esthetic dentistry, you must be careful of both the content and methods you choose to market your practice.

Naturally, you need patients to be able to practice. However, you also need the type of patients who will both accept and appreciate your services. The fact that you place an advertisement in one or more media outlets will signify to certain patients that you need to advertise. They may well be turned off by this form of marketing and turn to another practice which they perceive does not need to advertise, assuming that it may be better, when the opposite may in fact be true.

BEFORE YOU MARKET YOUR ESTHETIC PRACTICE

An important prerequisite to letting others know that you would like to increase the portion of your practice devoted to esthetic dentistry is solid knowledge and accomplishment of the related procedures. All dentists are trained to treat both functional and esthetic problems. However, the esthetic skills often taught in dental schools are less than adequate to solve difficult and complex esthetic problems. Improving your skills involves taking as many courses, lectures, hands-on workshops, and video courses as possible. Video is especially helpful because it allows you to conveniently repeat any part that is not easily understood. We tend to forget much of what we see and hear, yet retain much of what we see and do. Just as it is helpful to watch a

tennis pro repeat a particular stroke over and over, so it will help you to watch a dental expert repeat a procedure again and again. Textbooks and audiotapes also are extremely helpful in expanding your knowledge.

GENERAL TIPS ON MARKETING

This list should be kept in mind as you read the following detailed sections on external and internal marketing.

- Prepare yourself by developing a comprehensive marketing plan so that you have a clear idea of what you want to accomplish and how you are going to do it.
- Make sure your techniques are the best they can be. Take courses, attend lectures, read every journal concerning esthetic dentistry, and do not forget video! There are excellent videotapes that will help improve your skills.
- Be sure your marketing plan will not offend or alienate your colleagues.
- Make sure your colleagues are aware of your demonstrated expertise in what you are promising and develop an active referral relationship with them.
- Emphasize to your colleagues that you are offering special services that not many have cared to do (for instance, hospital dentistry). Conversely, if there are services you would rather not do or do not feel competent enough to do, make sure they know that, too.
- Invest in the appearance of your office, and complete all desired changes before launching any marketing activities.
- “Making the sale” is not worth it if you cannot deliver the result. Remember, patient visions are not always the same as yours.
- Always keep in mind—“Truth in Advertising.” Avoid guaranteeing the impossible or promising the improbable. This is especially important now the 1997 Readers’ Digest article³ has done so much to question the honesty of dentists.
- Surveys have consistently shown that dentistry has enjoyed the confidence, respect, and trust of the public. Never do anything to destroy that.

- Advertising presents a danger in that we may overstep the boundaries of professionalism, good taste, and our own ability to deliver the service. If you fail, it may cost the patient more to find someone else to correct your mistake.
- When promoting yourself in a marketing campaign, be aware that you have never seen the particular, individual problem of that next patient you attract through your marketing.
- You may wish to contract for the services of an outside consultant, if only to fine-tune your marketing plan.
- Everything you have done up to now will be in vain if you have an unprepared, untrained staff. It is essential that they know and understand your emerging marketing plan, and that they are well trained to augment rather than detract from your endeavors.

EXTERNAL MARKETING

This segment of marketing lets people know who you are, where you are, and the specific care you provide. This is the marketing area that can become controversial. External marketing can be conservative, yet effective, as has been done throughout history by physicians and dentists. It can also be aggressive and highly visible. Altshuler¹ says that ethical marketing techniques are as varied as the imagination can create. As more dentists come into practice, there will be more competition for patients. Dentists will increasingly seek visibility and recognition through publishing, politics, and personal public relations programs.

If you choose the conservative path, you will find that you probably have already been doing external marketing. Keeping in touch with colleagues for referrals has been a tried and true method for a long time. A broader base for referrals can be accomplished by contacting physicians and general dentists who are not yet referring to you. A member of your staff can be delegated the responsibility of watching the local newspapers and magazines and sending copies of articles printed about your colleagues to them along with a note of congratulations.

Although esthetic procedure brochures can be sent to referring colleagues, a more effective approach would be sending a reception room copy

of “Change Your Smile.”⁴ Not only will this educate your referring doctors but also their patients. Above all, promptly acknowledge all referrals.

Develop speaking skills and do not overlook opportunities to speak to civic clubs, garden clubs, schools, or local medical and dental societies. Write to these groups, provide your credentials, and volunteer to speak. Also, include a list of other places where you have spoken. Arrange press releases in cooperation with the group for mutually beneficial recognition after the presentation. Your own patients should be your best referral source and probably your best target. Let your patients know you are available to speak to groups. Put a notice in your newsletter, list topics and features of your presentations, and always include information about a previous or upcoming speaking engagement.

Newsletters are the external marketing choice of many practices today (see Figures 3–4A and B). This can be a positive method of retaining your present patients but unless you distribute widely outside your practice, it does not reach many new prospective patients. However, unlike other marketing projects, newsletters regularly require substantial investment of time, work, and money. Sachs⁸ suggests they should only be attempted after you have a strong image, firm policies, a good staff, and an identifying logo, stationery, and practice brochure.

Contribute articles to professional journals on innovations in techniques or new solutions for old problems. Professional journals reach a large audience that can be a source of referral. Even a technique variance can be an important contribution to the literature and help you get your name in print in a positive way. Many universities have an unwritten rule, “publish or perish.” They know the effectiveness of perceived image and how important continuous publishing by its faculty members is to the reputation of the university. Let your staff’s creativity help you identify interesting ideas, techniques, or procedures about which to write. It may just be about how successful your special management techniques are in motivating patients to accept esthetic dentistry. Remember, helping patients improve their self-image is what esthetic dentistry is all about.

If you choose the aggressive path and wish to develop an advertising program, work with a firm

that has some background in medical or dental promotion. There are many excellent firms but also many others with incredibly poor taste. Keep in mind that increasing the number of your patients alone is not the answer to a successful practice. Target marketing with a quality program can provide the quality patient base you want.

INTERNAL MARKETING

Internal marketing for esthetics begins as soon as the patient calls your office. Your immediate objectives should be to find out the patient's major needs and desires, and to begin educating the patient to the various treatments in esthetic dentistry that you will offer.

Accurate notes taken by your receptionist are important. They allow you and your staff to begin identifying why the patient is motivated to change to your practice and what his or her expectations are. Then your internal marketing program continues the process by educating patients about esthetic dentistry and advising them of your expertise and abilities in that area.

Silverstein⁹ states that the purpose of internal marketing is to motivate existing patients to:

1. seek regular dental care
2. accept needed treatment
3. refer others to the practice.

This should begin with a carefully prepared plan that consists of the following four basic categories:

1. Patient education
2. Office atmosphere
3. Appearance and attitude
4. Staff training program

Patient Education

Internal marketing for esthetic dentistry begins the moment a prospective patient phones your office. The wording used by your staff sets the tone for the remainder of your professional relationship. How he or she speaks, what is said, the tone of voice, and the responses given should be orchestrated to achieve a positive result. You can follow up the telephone call with a properly written letter or, better yet, a package of material to help acquaint the prospective

patient with your practice. Since many esthetic failures are caused by a lack of understanding and communication among the patient, dentist, and staff, it is absolutely essential to establish a standardized routine at this stage so that all patients receive the same initial information and thus have the same basic grasp of who you are and what you do.

Brochures can be an effective way to attract and hold new patients. An informative brochure that tells about the philosophy of your practice, who is involved in the practice, office hours, emergency procedures, insurance claim handling, and payment procedures, etc. helps answer many questions and should be mailed to the new patient before the first office visit.^{7,8}

In order to help patients better understand dental terminology, potential esthetic treatments, alternatives, and procedures, it is extremely helpful to provide them with the opportunity to read appropriate sections in "Change Your Smile," (as discussed in Chapter 2, Esthetic Treatment Planning).

Illustrations help to reinforce the practice in the mind of the patient and can reduce some of the anxiety associated with the first visit. An effective use of before-and-after photographs as part of the office decor can initiate questions and heighten interest in esthetic treatments (Figure 3-2). Another excellent method of patient education is through the use of short videos describing various esthetic treatments (Figure 3-3). Typical subjects are bleaching, bonding, and porcelain laminates. These videos can be quite effective to both educate and



Figure 3-2: Before-and-after photographs help educate patients and increase your esthetic practice.



Figure 3-3: This patient is using a portable small screen VCR (Panasonic) to learn about available esthetic treatments while her x-ray films are being developed.

motivate your patients in a short time period. While professionally done patient-education tapes are usually the most effective, you can also make your own tapes. Using a good color video camera (Panasonic AG-3 or similar model) and a tripod, let your assistant film you telling an imaginary patient what you want him or her to know. A TV/VCR can be placed in the reception room to allow patients to view these tapes while they are waiting. We will discuss this topic in more detail later.

A “family album” in the reception room is another effective educational tool. Include some biographical data of each practitioner and staff member as well as before-and-after photographs of patients who have received esthetic treatment. Ideally, the photographs you use should be from your own practice with your patients’ identities carefully masked. If not, truth in advertising requires that you or your staff make sure your patients understand that the photographs are not yours and that they are only for purposes of illustration of the possibilities of treatment in situations like theirs.

The danger of presenting someone else’s results and implying that they are your own can come back to haunt you if later your patient is not satisfied with your results and wants to cause problems for you. He or she can say that the photographs you showed were

considerably better than the quality received. Then, if your patient (or their attorney) discovers that the photographs you presented do not represent your own treatment but that of someone else, you may be liable to be questioned. This is far different than showing them a book written by another dentist, with illustrated photographs that demonstrate certain principles of esthetic correction. As an alternative, or in addition, a professional or self-made video can be played on a continuous basis in your reception room using a TV and VCR. Informational brochures on topics such as bonding, laminates, cosmetic contouring, etc., can be displayed as well. These brochures may be the same ones you use in your external marketing.

There are also many small touches you can add to personalize your practice, such as recipe cards marked “From Dr. Jones’ office” on which to copy out recipes. This may keep your current reception room magazines from being torn and will also remind the patient of your practice when the recipe is used. Notepaper with the practice name and phone number is also appreciated.

For many practices, one of the simplest and most effective ways of letting patients know about ongoing activities is through a newsletter. By communicating patient events (with permission) such as marriages, births, vacations, achievements, etc., you can help your patients feel like members of an extended family. In addition to your office news, try to relate longevity and proper oral maintenance to healthy eating, and other tips for better living. The newsletter can be a simple one-page typed sheet up to a more elaborate four-color, multipage, professionally done newsletter (Figure 3-4). Several companies provide complete newsletters including an open column or two that you can use to personalize your practice. However, as previously mentioned, this can be an expensive project. Alternatively, if you or one of your talented staff members feels creative, why not consider desktop publishing? Have fun, and at the same time, save money!

Office Atmosphere

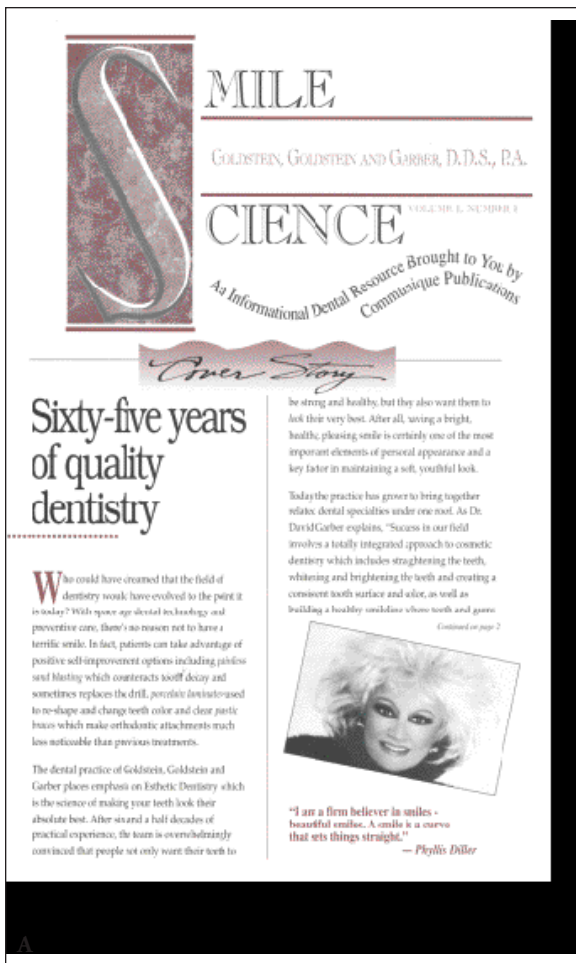The image you want to project should be reflected by your surroundings. A building that is well maintained, attractively landscaped (Figure 3-5), has convenient parking facilities, and is clearly marked with professional signage says a lot about the practice to the new patient. Once the patient enters the

reception area, does a receptionist greet the patient (Figure 3-6) and see that all necessary information is completed and made part of the chart? Or does the patient have to ring a bell and wait for someone to appear from behind a closed window or door? There are other considerations in making the patient immediately feel comfortable. The reception room itself must extend a warm greeting (Figure 3-7). Sit in your own reception area for 15 minutes. Do you feel comfortable? Could you sit there for a lengthy period? Are materials available to occupy your time? Is the area clean? Does it contain current magazines that are not torn or carelessly stacked? Are there fresh flowers or green plants? Does the room give a favorable professional and esthetic impression to the patient?

A TV and VCR can make the reception room come alive with positive ambience: we live in a TV-addicted culture where the presence of the monitor is normal, even comforting (Figure 3-8). Waiting time can pass much faster, especially for impatient spouses or companions.

The videotapes provide a patient education “hot spot”; people tend to absorb and retain more information from videos than from printed material or verbal presentation. Establish a video library and keep it updated; most people like to choose from a selection of videos. You may also want to make certain videos available for your patients to borrow, especially because of the low cost of video duplication. Consider videotaping public or health channel programs for reception-room viewing. Programs relating to critical healthcare issues and Occupational Safety and Health Administration (OSHA) requirements will convey to your patients your concern for them and their health and safety. I suggest the use of earphones to avoid disturbing nonviewers.

Take a quick tour of the rest of the office. Are treatment and consultation rooms esthetically pleasing and not too “clinical” (Figure 3-9)? Are the counters clean with items neatly arranged? Are the color and decor consistent throughout the office? Is the business office cluttered? Is privacy possible for discussing financial matters? Take a close look; if you would not feel comfortable as a patient in your office, take steps to improve the things that bother you. Remember, esthetic details such as color and art influence the patient’s perception of your artistic ability.



Figures 3-4A and B: Professionally done newsletters are a choice of many practices today, wisely used only after higher priority marketing programs are in place. (Figure 3-4B courtesy of Dr. Arlen Lackey)



Figure 3–5: A new patient entering your office should be favorably impressed with your building and entryway.

Appearance and Attitude

Next, take a close look at your staff. Are their uniforms attractive, clean, and professional-looking? Are members of the staff well groomed or do you see excessive use of makeup and jewelry (Figure 3–10)? Do they project the image of the practice you want? Remember that your staff may have more interaction with your patients than you have!

Now, take a look at yourself. Are you presenting a well-groomed and up-to-date professional image (Figure 3–11)? Hippocrates wrote that a physician should “be clean in person, well dressed and anointed with sweet-smelling unguents.” Since that time, we have seen trends in dress from starched white jackets to tie-dyed T-shirts. Studies by researchers conclude that, for the sake of maintaining the confidence of their patients, dentists should dress well, but not too well. The issue of dress and appearance turns out to be more important than it might seem, because patients make decisions about how much confidence to place in a dentist partly based on his or her appearance. Patients judge everything from the length and style of your hair, your nails, weight, posture, and especially your breath. There is no single way to look or dress that will appeal to every potential patient. Thus, you need to decide which type of patient you wish to cultivate and establish your look and dress accordingly.

Our opinions are influenced by what we see. The office that is tastefully done from the reception room

to the treatment rooms with esthetically pleasing decor enhances the patient’s perception of the dentist’s ability in esthetic judgement. Just as the surroundings influence the opinion, so does the appearance of the dentist and staff. This especially applies to the esthetic appearance of the smiles of the dentists and staff. Miles⁶ says, “Projecting the best image is a matter of caring how the patient feels.” Every opportunity to display an appreciation of esthetics is an opportunity to inspire confidence in your patients. So look in the mirror at your own smile and make sure it represents your own concept of esthetics. You may also wish to go a step further and make sure all of your staff, and even your spouse, take advantage of the best that esthetic dentistry has to offer.



Figure 3–6: Patients should be greeted in a cordial manner and assisted with all necessary information.



Figure 3-7: The reception area should be neat, interesting, and attractive.

Concern for the patient's well-being and comfort can be demonstrated in many ways. Requests for information should always be accompanied by "please" and "thank you." Good manners are never out of style. Unless they request otherwise, always refer to patients as "Mr.," "Mrs.," or "Dr."

Seating throughout the patient's stay should be comfortable and provide ease of sitting and rising, particularly if you have elderly patients. During the first few visits, when the patients move from the reception area to other rooms in the office they should be introduced to your staff. Make sure one

of your staff members escorts patients when they need to walk through your office. Privacy should be provided for confidential conversations such as financial arrangements, treatment planning, and any time that your patient feels it necessary to discuss something with you without others present.

Staff Training Programs

Develop a cohesive, standardized training philosophy and program for your staff, by first inculcating in them your individual approach to dentistry, patient care, office management, and interpersonal relationships. Once they understand your philosophy, you



Figure 3-8: A reception room TV monitor can provide educational information as well as entertainment for patients and their companions.



Figure 3-9: Treatment rooms should be esthetically inviting to help offset possible fear of dental procedures.

and your staff can work better together to develop a more effective training program. You will be ahead of the attitude game if you involve them in the decision making and development process of the training program. They will have psychologically “bought into” the program by helping design it. Training can be done by hiring an outside professional, having yourself or a staff member conduct training sessions or workshops, or producing video training tapes.

VIDEO TRAINING TAPES—WHY?

What better way to efficiently project your image than with self-made video training tapes. This can give you an excellent opportunity to personalize your office with your concepts. Do not delegate this important responsibility. However, you can share it. And you can make it fun for both you and your staff by injecting your own brand of in-office humor when you make your own videotapes. A readily accessible library of training tapes for current and future staff members can accomplish many things. It can:

- Standardize training with one consistent, comprehensive source of information, eliminating misinterpretations from being passed on from one person to another.
- Allow staggered training schedules in a busy office, including less stressful “at home” training.
- Allow new employees to learn something in a logical order, from the beginning of a tape to

the end, at any time, rather than having to jump into the middle of an ongoing, live training session.

- Guarantee 100% attendance, with no excuses for having missed something.
- Lessen frustration, increase understanding and retention, and generally enhance the credibility of the topic.
- Reduce training time and costs. Trainers will be freed from repetitive teaching tasks and can devote more time to individual problem solving.
- Allow the concise presentation of separate but related tasks in a procedure, reducing the time and effort normally required to learn the complete procedure.
- Allow new employees to “meet” former employees on tape, also helping to retain continuity for staff who usually will remember (fondly or otherwise) those who are “long gone.”
- Allow the use of vignettes to simulate positive or negative behavior or emphasize key points.
- Keep the techniques and procedures current because the tapes can be easily modified as necessary.

Remember, if you do it right once, you do not have to do it again, and again, and again....

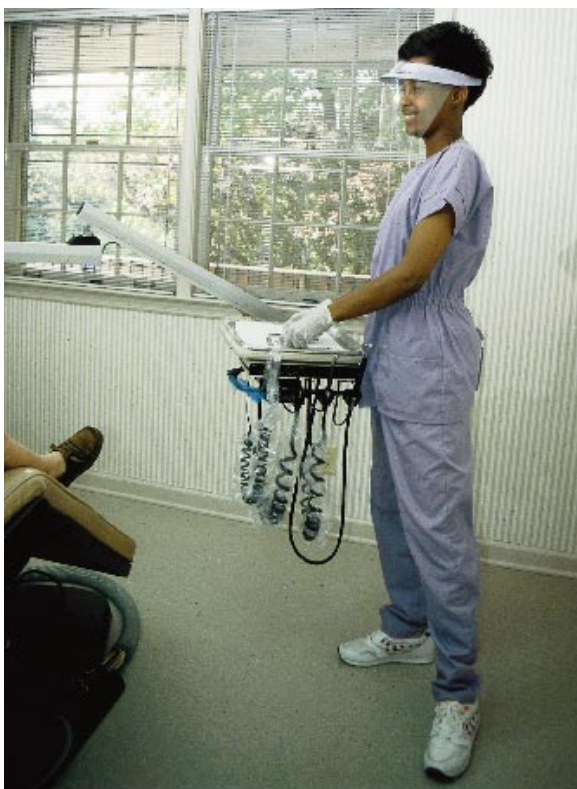

Figure 3–10: The appearance of your staff should reflect the image of your practice, especially since they usually have extensive contact with the patients.

What Do You Need?

Good training tapes can be made with basic equipment, such as a video camera with a good zoom lens and external microphone. However, the better the equipment, the better the quality and effectiveness of the training film. A good example of appropriate equipment used in making a training film can be seen in Figure 3–12.

Always purchase the highest quality of videotape available because you will be using your original tape as a master, making edits, and then duplicating it to produce copies. The better the tape, the better the quality of the end product.

Once your basic film is completed, you will need to edit it. You can either invest in your own equipment (Figure 3–13), or purchase editing time at one of the editing studios that are located in most major cities. Many of these studios also have a manager or professional present who will instruct you in using the equipment, allowing you to do it

yourself, or will do it for you. Naturally, the fee varies, depending upon the service rendered.

Doing It the Easy Way

Unless you are trying to win an Academy Award for your efforts, try to make the process simple and fun for everyone involved. First, decide how many different training tapes you want to make. It is better to produce a series of tapes, each concerning a specific part of a large topic, than one tape that tries to cover it all.

For example, although you can produce one long tape for dental assistants that discusses everything they need to know of your procedures, you may be wiser producing a series of tapes, each one of which covers a single procedure or job. Then they can watch a specific segment as they wish or need to. It is much easier for someone to watch a 5- or 10-minute tape, than a one-hour tape; the shorter tape can be digested, understood, and remembered much more thoroughly. Keep this in mind when you make the tape; and so make your points quickly and concisely.

Making the Videotape

List the topics you wish to teach. Once this is done, make a series of “storyboards” for each topic. This is actually a sequential working script that you will use to keep your subject matter in proper order. A sample beginning storyboard may look like this:

Subject	View	Persons
1. Dr. talking to patient	wide angle	Dr. Jones and Sally
2. Assistant enters with study models	wide angle	Molly

Although your videotapes can be as simple as doing a no-rehearsal-one-time-“take” (after all, mistakes can be fun, too!), a few practice sessions can help make your production much better.

An external microphone is quite important for good sound, since the internal, attached mikes on most video cameras pick up too much extraneous noise, and the oral instruction part is so important in esthetic training tapes.

Although most video cameras can record in dim, interior lighting, the benefit of adding extra photo-floods will result in a greater depth of field, sharper pictures, and improved color.

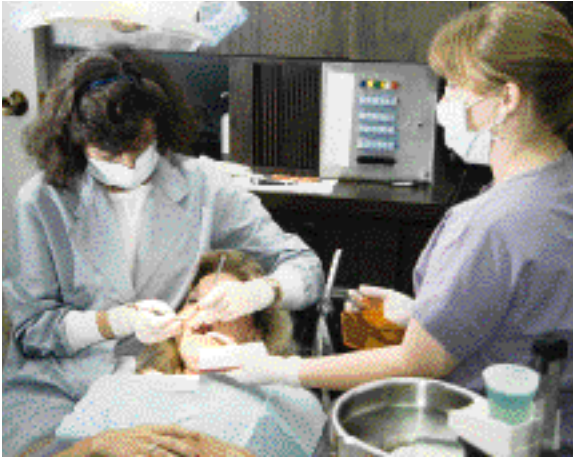

Figure 3–11: Your professional appearance can positively influence the amount of confidence that patients place in your treatment recommendations.

If you desire to really make your training film more professional, consider doing second shots of the same scene but close up. Professionals call this “B-role.” It is easy to edit-in additional shots showing the reaction of a second person’s face or a close-up of the item being described. As you are talking, the video of a close-up can be edited in, making it easier for the viewer to understand exactly what is being described in the audio part.

Cole² says he feels that in 10 years or less, dentists will be using all the tools of marketing with the

same freedom and effectiveness as other businessmen and women, and possibly more than in other professions. One reason for this increase in marketing is that a large part of dentistry is becoming elective. Today’s dentist offers a greater range of services than in the past, and there is greater competition among dentists to provide those services.

If you want to develop a marketing plan, you will find many excellent resources. They offer services ranging from generalized marketing guidelines, profiles, and analyses to developing and implementing customized marketing programs. There are many local, regional, and national professional healthcare marketing consultants and advisors. Even if you feel comfortable with planning your own marketing campaign, it can certainly be beneficial to have professional marketers review it for you.

Professional marketers are the best conduits to advise patients of your personal ability and achievements in both the community and the profession. Therefore, do not forget to inform them of your lectures, awards, community involvement, and any new dental techniques you have mastered and courses you have taken. This information can be communicated to your patients by your staff, by posting it on an office bulletin board, or even through a one-page newsletter. If you are the shy type, and some dentists are, all you have to do is list this information along with other interesting facts about your staff, their accomplishments, items of personal interest,

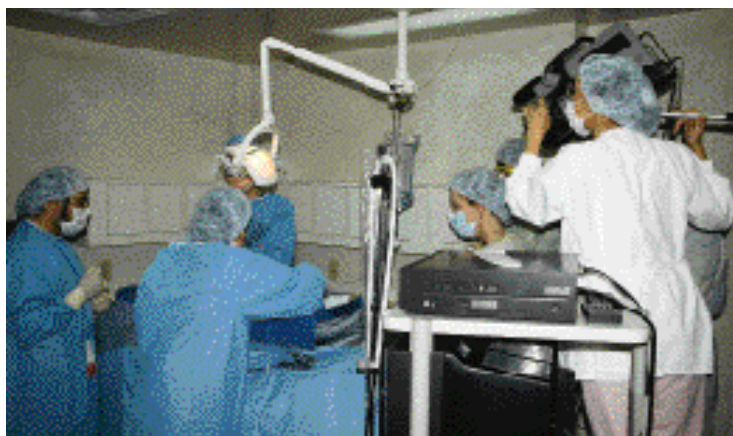

Figure 3–12: Economically produced by you and your staff, in-office training films can provide consistency to your marketing message while emphasizing your practice goals and specifying how your staff should personalize their interactions with your patients.



Figure 3-13: This professional, but easy-to-operate, editing system (Panasonic) can make the in-office editing task both fun and rewarding. While this system shown here was designed for editing audiovisual material for professional presentations, less costly and more simplified systems are available for in-office use.

office goals, and planned office changes. Then distribute it, post it, or publish it as you wish.

Hankin⁵ says that it is important how we represent ourselves to the public. If it is done poorly, it will contribute to a decline in the profession's image, and your practice will suffer. If it is done well, it will help correct years of misconceptions about dentistry, and your practice will be the beneficiary.

References

1. Altshuler JL. Marketing cosmetic dentistry. *J Calif Dent Assoc* 1989;17(8):26-31.
2. Cole BH. The future of dental advertising. *Dent Econ* 1986; :72-9.
3. Ecenbarger W. How honest are dentists? *Readers' Digest* 1997; Feb:50-6.
4. Goldstein RE. *Change your smile*. Carol Stream: Quintessence Pub. Inc., 1997.
5. Hankin RA. Marketing workshop. *Dent Manage* 1988;28.
6. Miles LL. Modern marketing. *J Dent Practice Admin* 1987;4(1):39.
7. Milone CL. Practice building with brochures. *J Dent Pract Adm* 1989;6(4):152-6.
8. Sachs L. *Do-it-yourself marketing for the professional practice*. Englewood Cliffs, NJ: Prentice Hall, Inc., 1986.

9. Silverstein J. For better practice relations. *Int Dent J* 1987;37:123-6.

Additional Resources

- Ball R. Practical marketing for dentistry. 5. Buyer behavior. *Br Dent J* 1996;181:66-71.
- Ball R. Practical marketing for dentistry. 8. Communication strategies, identifying audiences and developing messages. *Br Dent J* 1996;181:180-5.
- Ball R. Practical marketing for dentistry. 9. Marketing communication tools. *Br Dent J* 1996;181:214-6, 217-9.
- Ball R. Practical marketing for dentistry. 4. Marketing strategy and planning for dental organization. *Br Dent J* 1996;181:105-10.
- Ball R. Practical marketing for dentistry. 3. Relationship marketing and patient/customer satisfaction. *Br Dent J* 1996;180:467-72.
- Ball R. Practical marketing for dentistry. 2. The core concepts of marketing. *Br Dent J* 1996;180:427-32.
- Ball R. Practical marketing for dentistry. 1. What is marketing? *Br Dent J* 1996;180:385-8.
- Blatchford WA. Patient-driven care presentation. *J Calif Dent Assoc* 1996;24(4):71-6.
- Boswell S. *Suiting the customer*. New York: Prentice-Hall, 1993.

- Boswell S. The mystery patient's guide to gaining and retaining patients. Tulsa: PennWell, 1997.
- Brahe NB. Executive dynamics in dental practice. Appleton, Wisconsin: Project D, 1969.
- Chambers DW. The first P—product. *J Am Coll Dent* 1996;63(4):55–7.
- Chan SD. Logos: the emblem in the marketing wars. *Quintessence Int* 1994;25:509–15.
- Chiodo GT, Tolle SW. Ethics and advertising. *Gen Dent* 1996;44(2):106,108,110.
- Deneen LJ. Effective interpersonal and management skills in dentistry. *J Am Dent Assoc* 1973;87:878.
- De St Georges JM. The future is now...five steps to make it happen. *J Esthet Dent* 1996;8:290–3.
- Farran H. Location and logo: impressions are everything. *J Am Dent Assoc* 1994;125:316–20.
- Garrison J. Purchasers and payers: who's driving the market !? *J Dent Educ* 1996;60:365–9.
- Gerbert B, Bleecker T, Saub B. Dentists and the patients who love them; professional and patient views of dentistry. *J Am Dent Assoc* 1994;265–72.
- Goldstein RE. Communicating esthetics. *NY State Dent J* 1985;51(8):77–9.
- Goldstein RE, Garber DA. A “gap” in our understanding...why those who can don't seek esthetic treatment. *J Esthet Dent* 1996;8:99.
- Goldstein RE, Garber DA, Goldstein CE, Schwarz CG, et al. The changing esthetic dental practice. *J Am Dent Assoc* 1994;125:1447–57.
- Grace M. Should we give them what they want? [editorial] *Br Dent J* 1997;182:79.
- Hartley MS. Staff members help promote patient acceptance of esthetics. *Dent Off* 1989.
- Heiert CL. Computer use by dentists and dental team members. *J Am Dent Assoc* 1997;128:91–5.
- Jameson C. Cosmetic dentistry: a practice-building videotape for dentists. New York: Mayfair Communications, Inc., 1991.
- Jameson C. The team approach to marketing cosmetic dentistry. New Jersey: Plain Talk Productions, 1991.
- Jameson C, Sachs L. Cosmetic dentistry workbook: a step-by-step program for the dental office team. New York: J.F. Jelenko and Co., 1991.
- Jupp A. Senior patients in the dental practice. *J Can Dent Assoc* 1997;63:25–6.
- Kublich RG. Building relationships with general dentists. *J Clin Orthod* 1996;30(2):99–105.
- Levin RP. Building value in a changing world. *J Esthet Dent* 1997;9:100–1.
- Levoy RP. The successful professional practice. Englewood Cliffs, NJ: Prentice Hall, 1970.
- Mann RP. The successful professional practice. Englewood Cliffs, NJ: Prentice Hall, 1970.
- Mann WR. Practice administration for the dentist. St. Louis: C.V. Mosby, 1955.
- Marchack BW. Market segmentation and service: a strategy for success. *J Prosthet Dent* 1995;73:311–5.
- Maxon NT. Marketing: a necessary tool. *CDS Rev* 1992;10.
- McCann D. Dentistry in the headlines. *J Am Dent Assoc* 1990;120:483–90.
- Meerlo JAM. Communication and conversation. New York: International Universities Press, 1958.
- Mills PB. Tiptoeing through the yellow pages. *Georgia Dental Assoc Action* 1991:5.
- Ozar DT. Professional ethics and dental advertising. *J Calif Dent Assoc* 1994;22(10):27–9.
- Roth KJ. Marketing infection control. *Dent Econ* 1996;86(6):60–2.
- Rubin MS. The changing marketplace: informed choices; safe action. *J Am Coll Dent* 1996;63(1):14–8.
- Shore NA, Shore MF. How to test and hire for the professional office. Philadelphia: J.B. Lippincott, 1967.
- Simon M. From r&d to the mouth—a viable roadmap for the technology era. *Technol Health Care* 1996;4:283–9.
- Stein RM. Lessons from medicine: an economist's perspective. *J Dent Educ* 1996;60:368–72.
- Stella PJ. Harness the power of video for training. *AVC Presentation*, 19–22, Jan, 1993.
- Wilde JA. Subtleties of contemporary dental marketing. *Dent Econ* 1996;86(3):43–7.
- Wilde JA. We like these ideas. Appleton, Wisconsin: Project D, 1970.

CHAPTER 4

LEGAL CONSIDERATIONS

Edwin J. Zinman, DDS, JD

MALPRACTICE PROPHYLAXIS

The threat of a malpractice suit is no longer an illusive nightmare but a practical reality. One out of every ten dentists can expect to be sued during his or her professional career.²⁴

The U.S. is home to 70% of the world's lawyers even though the nation accounts for just 5% of the world's population. In all, there are 777,000 attorneys in the U.S., about 312 per 100,000 citizens. Since 1980, the number of U.S. lawyers has increased by 43%.

Canada has just half the U.S. lawyer population on a per capita basis. Germany has only 111 lawyers per 100,000 citizens. Japan's 14,000 lawyers represent 11 per 100,000 citizens. Lawyer population increases reflect changes in both technology and public sensibilities during the 1960s and 1970s, which spawned the creation and expansion of areas of law that either never existed before or were relatively insignificant. These laws include civil rights and antidiscrimination laws; environmental law, including toxic waste regulation; and intellectual property laws. Americans enjoy an enormous number of rights, and lawyers act as champions and protectors of those rights. The prominence of the law and its protection is evident in that the United States is the only country in the world where the court system is an equal branch of the government, along with the legislative and executive branches.

Dental negligence settlements had risen from an average payout of \$6,000 in 1981 to \$26,000 by 1989. Premiums more than tripled in the same time period. Fortunately, by the 1990s, professional liability premiums leveled off or even declined from their prior heights in the 1980s. Then, unwise insurance company investments caused rising pre-

miums, beginning in 1992. Thus, professional liability premiums follow the cyclical trends of the economy.

Dentistry is not unique among professions with increasing premiums. Among healthcare professions, medicine was the first to see its premiums climb in the 1970s. Currently, lawyers are leading the professional pack for professional liability premium increases due to rising jury awards. As an example, a \$26-million legal malpractice verdict against the former attorneys of a screen actress was affirmed on appeal.⁹

Although it would be tempting to be able to identify a suit-prone patient and refuse treatment, such a patient is mythical. It is this author's experience that virtually all plaintiffs in dental negligence litigation have not previously sued a healthcare professional or anyone else. Consequently, the best means of avoiding malpractice suits is to adhere to the basic principles of quality care and to communicate realistic expectations to the patient.

Consumer products are involved in approximately 33,000,000 injuries and 29,000 deaths each year. Punitive damages may be awarded to punish serious misconduct and deter a defendant from engaging in fraud, deceit, or reckless conduct pursued in conscious disregard of safety and health.

The U.S. Council on Competitiveness, first chaired by former Vice President Dan Quayle, proposed placing caps on punitive damage awards. In the largest retrospective study of punitive damage awards over the past 25 years, only 355 product liability awards included punitive damages.² Of these, more than one-third of plaintiffs collected no punitive damages due to postverdict settlements or appellate court reversals. The median of the remainder

was \$250,000. The study concluded that punitive damage awards are "far too rare and too insignificant to impact national competitiveness." On the other hand, the study also found that 82% of corporations that had punitive damages awarded against them implemented safety-related actions, such as product recalls or improved warnings or instructions.

ESTHETIC ADVANCEMENTS

Dentists have a legal obligation to remain current through continuing education and to update their armamentarium with currently accepted technological advances. It might be said that a practicing dentist who graduated 10 years ago but failed to take continuing education courses possesses one year's experience repeated ten times.

Advances in adhesive chemistry and resin technology have expanded esthetic dentistry capabilities. Composite restorations have become an accepted material for Class III, IV, and V restorations in anterior teeth but remain questionable as a standard restoration for occlusal and proximal areas of posterior teeth with strong occlusal loading.¹⁷ Conservative restorations decrease marginal degradation and fracture associated with composites. A major exception to this conservative approach is when posterior composites are indicated for esthetics. In this situation, the patient should be advised in the informed consent disclosure that function and longevity will be compromised for improved esthetics.

Composite restorations are not recommended for molar teeth in which the cavity preparation exceeds two-thirds of the distance between the buccal and lingual cusps.¹⁵ A patient should not be asked to consent to negligent care where the esthetic compromise exceeds the reasonable functional capabilities of restorative materials.

Bleaching or bonding vital teeth is an accepted treatment for stained teeth.¹⁸ The esthetic utilizations of porcelain laminates include correcting tetracycline staining and recreating physiological contours of teeth.

Failure to offer the alternatives of bonding, bleaching, or porcelain laminates instead of full coverage crowning, if feasible, violates the doctrine of informed consent. This is because complete crowning can result in greater potential endodontic or periodontal complications. Informed consent

requires disclosure of reasonable alternatives, which necessarily includes lesser-risk procedures.

NEGLIGENT CUSTOMARY PRACTICE

A negligent custom is not consonant with reasonable and prudent care, which the standard of practice requires. Many negligent customs, although widely practiced, are nonetheless unreasonable and therefore substandard. In other words, average customary care is below the average of reasonable care if it is not reasonable and prudent. Examples include the use of contraindicated cold sterilizing solutions to disinfect instruments,¹⁰ unnecessary exposure of the patient to a higher dose of x-rays because newer types of x-ray film is not used,^{16,20} and pulpal irritation from microleakage of poorly cured resins because a dentin bonding agent was not used.⁴

A majority of dentists do not practice impression disinfection,¹¹ even though they should. Guidelines from OSHA, effective March 6, 1992, are designed to protect employees from the risk of infection transmissions by instituting controls that prevent contact with bloodborne pathogens.

Effective May 30, 1992, OSHA mandated sterilization rather than merely the attempted disinfection of handpieces. Apparently, the majority of dentists were not following previously suggested voluntary recommendation by the Centers for Disease Control (CDC) to autoclave handpieces.

Comparison of Kodak Ektaspeed with Kodak Ultraspeed film demonstrates that the imaging characteristics and diagnostic quality of each film are comparable, and the Ektaspeed offers the additional benefit of significant reduction in patient radiation exposure. Nonetheless, the majority of practitioners have not yet changed to the lower dosage Ektaspeed film.¹⁶ Meanwhile, technology marches on with the development of radiovisiography, a major advancement that lessens radiation exposure to the patient by approximately 90%.

Composite restorations can potentially cause pulpal irritation with the acid-etch technique if the acid reaches dentin when the dentinal tubules become exposed during the procedure. Children or adults with extremely large pulp canals are prime candidates for pulpitis. Therefore, in these instances, exposed dentin may require protection before the etchant is applied. Not all practitioners

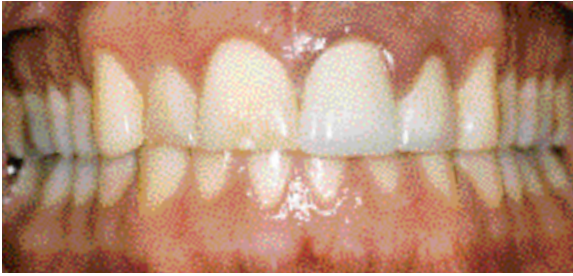

Figure 4-1A: This 29-year-old man wanted esthetic treatment to lighten his natural tooth structure to match the two previously crowned left central and lateral incisors.

recognize or appreciate the risk of pulpal irritation resulting from microleakage or chemical irritation from poorly cured resins.^{4,5}

The philosophy of “extension for prevention,” originally advocated by G.V. Black, is still widely practiced. Nonetheless, no current credible evidence exists that subgingival margins prevent decay. Although subgingival margins are used in high and medium lipline patients for esthetic purposes, subgingival margins cause inflammation by shifting plaque subgingivally. However, many dentists continue to place porcelain laminates up to 0.5 mm subgingivally, although esthetics can be accomplished with porcelain margins ending at, rather than below, the free margin of the labial gingiva.¹³ This practice, however, must be balanced against the risk of ending a margin at or just beneath the gingival margin where potential gingival shrinkage may allow a dark margin to show.

Another example of negligent customary substandard practice is prophylactic amalgam removal to prevent or treat systemic diseases. The mercury used in properly constructed dental amalgam restorations has not been established as a cause of any systemic diseases except in the few rare cases of mercury allergy confirmed by dermatological testing. The amalgam contains elemental mercury rather than the more toxic methyl (organic) mercury. Nine grams of mercury would have to be swallowed before the patient would suffer an acute toxic reaction. The amount of mercury vapor released from amalgam fillings in released air is far less than the accepted medically permissible dosage. The threshold limit value (TLV) is 0.05 mg per cubic meter of air for 8 hours a day for a total of 40 hours per week. Removal of existing amalgams contributes temporarily, but sig-

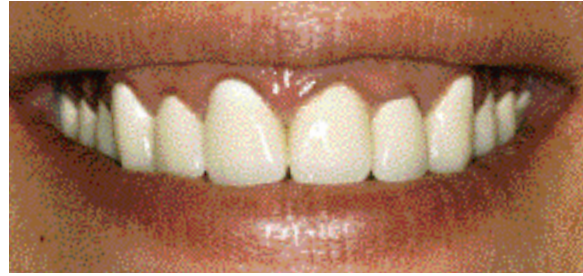

Figure 4-1B: After several more conservative consultations, including bonding, bleaching, and periodontal therapy, he chose a dentist who elected to crown all of his teeth. Note the extended, overall presence of periodontal disease.

nificantly, to mercury vapor in expired air; consequently, the possible exposure effects of amalgam removal, if any, prior to unnecessary replacement, mitigates against its prophylactic removal. Background mercury exposure also occurs daily from the environment and from ingested fluids.

The incidence of mercury allergy is rare as evidenced by a Swedish study that identified only 82 cases in Sweden’s entire health insurance program during a 12-year period for an incidence of 0.0012%.^{4,23} If suspected, a dermatologist can verify allergy to common dental metals and also conduct blood and urine mercury testing. The ADA Mercury Testing Service recommends a thorough review of mercury hygiene habits if testing reveals levels above 50 mcg of mercury per liter of urine.

Prophylactic amalgam removal and replacement with composites or other restorative materials is not scientifically justifiable. Amalgam replacement is indicated only if an existing restoration is dentally

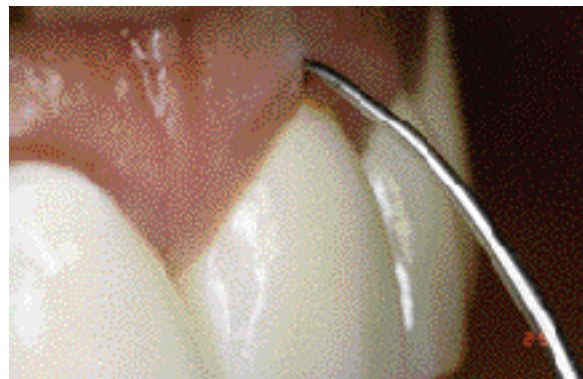


Figure 4-1C: Unesthetic crowning. Note open margin.

unsound or the patient requests replacement for esthetic reasons and preparations remain conservative without excessive stress-bearing occlusion. See Form 4-1 for a sample consent form.

GUARANTEE OR WARRANTY

Esthetic dentistry is particularly vulnerable to claims of broken promises since patient expectation may not equate with dental realization, particularly if the dentist promises more than can reasonably be delivered. Statements such as “You will be as beautiful as a star,” are tantamount to a guarantee or warranty that the esthetic result will match the beauty of, for example, Julia Roberts.

The law does not require that the esthetic result match or meet the subjective and capricious esthetic standard of an unreasonable patient. The law measures an objective standard of satisfactory esthetics as judged by a reasonable person regardless of a patient’s particular whim or perfectionistic desire. *Nevertheless, a dentist who foolishly guarantees a particular cosmetic result must satisfy the subjective esthetic whim of the patient.* Warranty, if proven, voids the usual rule of law that a dentist is not a guarantor of a particular cosmetic result, such as a perfectly pleased patient.⁷

To avoid a claim of warranty, a dentist should promise only to do his or her best, even if that best may not ultimately satisfy the patient’s arbitrary esthetic desire. No one using man-made materials can exactly duplicate a natural tooth or make it esthetically age in the same way as the adjacent unrestored teeth.

PROGNOSIS

Prognostications on crown longevity should be based on average crown life expectancy rather than wishful optimism. Crown studies indicate a useful, functional life of 10 years.¹⁹ However, esthetic longevity is less than functional longevity due to yellowing or darkening of adjacent and opposing teeth due to age and/or gingival recession over time. Esthetic crown life can range from 5 to 15 years.¹⁴ Accordingly, the patient should be advised of this risk.

Porcelain fractures occur for many reasons, ranging from inadequate restorative preparation to extreme bruxism. If a fracture occurs, bonding repairs may be considered. Composites have a useful life of 3 to 8 years¹⁴ and the patient should be

so advised.¹³ Otherwise, the disappointed patient may sue, claiming a lack of informed consent. It may be fraudulent misinformation to represent that bonded restorations will esthetically last as long as the relatively more durable cast porcelain-fused-to-metal restorations.

TRY-IN APPOINTMENT

Consent should be obtained not only initially but also at the try-in appointment. Inquire if the patient is trying to esthetically please someone else. Request that this person also be present at the try-in. Otherwise, the patient may leave appearing satisfied but quickly change his or her mind after a trusted friend or spouse criticizes the esthetics.

At completion of the try-in, record in the patient’s chart the patient’s approval of fit, comfort, and esthetics. Although not legally required, for difficult patients, the chart entry may be initialled and witnessed on the chart itself or on a separate form (Form 4-2).

With the availability of newer materials, temporaries need not be esthetically inferior restorations. Although not as critical as the try-in approval, the patient should see and approve the temporaries before leaving the office to avoid surprise or embarrassment when they are seen at home by the patient and his or her family.

RECORD KEEPING

Records “remember” but patients and dentists may forget. The treatment plan as approved by the patient should be documented on the chart (Form 4-3). A follow-up letter to the patient constitutes additional documentation verifying the patient’s consent (Form 4-4). Such a letter is a permanent addendum to the patient’s record and may be introduced into evidence at trial. Juries trust written documentary evidence more than oral testimony since a short pencil is more credible than a long memory, particularly if the record was made before any threat of litigation occurred. Therefore, avoid statements in the confirming letter to the patient that may be equated with an esthetic guarantee. Rather, commit only to do your best. For example, do not write a letter to the patient that states, “Following treatment, you will look 100% better and undoubtedly will get the sales position for which

you recently interviewed.” Instead, write “I will try my best to improve your smile and hope that you obtain the employment position you are seeking.” The latter is a safe statement since the law obligates a dentist to always use his or her best clinical judgment in diagnosis and treatment.

Written records documenting clinical findings, diagnosis, treatment plan, and prognosis are the minimum that a dentist is obligated to maintain. Informed consent does not absolutely require verification on the chart. However, the following statement documents that informed consent was pro-

ESTHETIC CONSENT TO SILVER FILLING AMALGAM REPLACEMENT WITH COMPOSITE RESIN

I consent to the removal and replacement of my existing silver amalgam fillings in teeth number _____, _____, and _____, with new restorations consisting of _____
restoration name

Doctor _____
name has informed me of the following:

1. My existing amalgam fillings are sound and well functioning. If not replaced, my present amalgams will likely last a number of years.
2. Current scientific evidence has established the biologic safety of amalgams. Therefore, there is no necessity to replace my present amalgams for any medical or dental health reasons. I have been provided and read American Dental Association literature concerning amalgam safety.
3. Proposed new restorations are designed to esthetically resemble adjacent natural tooth structures. An ideal or perfect match is not guaranteed nor likely. Natural aging of adjacent tooth structure can darken or yellow over the years compared to the newly placed ceramic restorations, which may necessitate periodic replacement.
4. Replacement restorations are durable but not permanent. Plastic composite fillings may last approximately three to five years. Crowns or caps last on average between 10 and 15 years. Durability predictions represent statistical averages. Each individual’s restorative longevity may vary depending upon a variety of factors, including, but not limited to each patient’s intake of coffee, tobacco, and tea; oral hygiene, and frequency of professional maintenance visits.
- *5. Replacement risks include, but are not limited to, root canal therapy in a small percentage of cases, pulp (nerve) exposure, cusp or enamel fracture and presence of deep stains from the older amalgam restoration being replaced.
6. Doctor has personally explained the risks and esthetic benefits of amalgam replacement, as well as the reasonable alternative of doing nothing with my present amalgams. Doctor has answered any of my questions concerning amalgam replacement.
7. I understand the above and consent to amalgam replacement solely for esthetic reasons.

Date _____ Patient _____ Witness _____

Form 4-1: Treatment consent form.

vided if later disputed by the patient: “Patient advised on usual bonding risks including chipping and staining, and preventive maintenance measures.”

Video informed consent is admissible in court as part of the dentist’s records (Form 4–5).^{25,28}

The appearance of dental records may vary from office to office, but all should have similar characteristics.

A. Function

The dental records should:

1. Document the course of the patient’s dental disease and treatment by recording the diagnosis, treatment plan, and treatment provided.
2. Contain all communication among the treating dentist and other healthcare providers,

consultants, subsequent treating practitioners, and third-party carriers.

3. Be an official document in dental/legal matters (lawsuits) which, if properly maintained, will imply a sound plan of dental management.
4. Conform to peer review evaluation standards.

B. Entries

If patients forget, a dental record remembers; if the dentist forgets, the dentist’s records remember.

Erroneous entries should have a line drawn through the error and a corrected entry written above or below, indicating a later entry. Never block out or white out an entry so that it cannot be read, in order to avoid suspicion of falsified records. Entries can be made in ink, or pencil. If a

Date	Service
3/31/93	HX: NCR-pt has had a cold DX: Try-in lower partial TX: Tried in lower framework w/ wax bite rims. Bite adjusted in wax. Wax-up of teeth adjusted. Pt. approves shape and color of teeth and stated, “These look great. I really like them.” Pt. advised teeth will be processed as he approved. AX: None CX: None RX: None FX: Rel /L partial; photos made of try-in
I accept the cosmetics, contour and position of the teeth as they appear today at the try-in visit.	
Date _____	Patient _____ Witness _____ Patient signature _____
<p>HX: Health history DX: Disposition—reason for this appointment TX: Treatment narrative AX: Anesthetic used CX: Complications, problems, etc. RX: Prescriptions given FX: Follow-up—next appointment</p>	

Form 4–2: Try-in approval form.

pencil is used, avoid erasures which suggest record changes.

C. Content

Dental records should include:

1. Dental history (updated)
2. Medical history
 - a. Name and phone number of the patient's physician(s) and date of last physical examination
 - b. Systemic diseases such as bleeding disorders, diabetes, hepatitis, rheumatic fever, and HIV
 - c. Current drugs and dosages, length of time taken, and recent changes
 - d. Allergies and drug sensitivities
 - e. Cardiac abnormalities, current blood pressure, and pulse rate
3. Chief complaints

Proposed		Deferred		Accepted		Schedule		Complete		Patient Treatment Plan Report (Doctor Copy)				Time:	
Date	Date	Date	Date	Date	Date	Prov #	Type	Description	Tooth	Surface	Phase	Case	TP#	Amount	Ins Amount
02/09/98		02/09/98	02/13/98	02/13/98	02/13/98	17	274	Four Bitewing X-rays			0	0	0	\$44.00	\$0.00
02/09/98		02/09/98	02/13/98	02/13/98	02/13/98	17	1110	Adult Prophylaxis			0	0	0	\$62.00	\$0.00
Total for Phase 0														\$106.00	\$0.00
02/13/98						6	2387	Resin-Posterior 3 SURF	4	MOD	1	0	0	\$470.00	\$0.00
02/13/98						6	2386	Resin-Posterior 2 surf	12	OD	1	0	0	\$385.00	\$0.00
02/13/98						6	2386	Resin-Posterior 2 surf	13	OD	1	0	0	\$385.00	\$0.00
02/13/98						6	2386	Resin-Posterior 2 surf	14	MO	1	0	0	\$385.00	\$0.00
Total for Phase 1														\$1625.00	\$0.00
03/19/98						6	2752	Porcelain/noble metal	31	MODFL	2	0	0	\$1485.00	\$0.00
02/13/98						6	4320	Provisional Splinting-intr	31		2	0	0	\$250.00	\$0.00
02/13/98						6	2952	Cast Post_Core	31		2	0	0	\$385.00	\$0.00
Total for Phase 2														\$2120.00	\$0.00
02/13/98						6	2385	Resin Filling 1 Surface P	30	O	3	0	0	\$200.00	\$0.00
02/13/98						6	2385	Resin Filling 1 Surface P	30	F	3	0	0	\$200.00	\$0.00
02/13/98						6	2385	Resin Filling 1 Surface P	32	O	3	0	0	\$200.00	\$0.00
Total for Phase 3														\$600.00	\$0.00
02/13/98						6	9940	Occlusal Guards/report		Upper	4	0	0	\$585.00	\$0.00
Total for Phase 4														\$585.00	\$0.00
Total														\$5036.00	\$0.00

Total Proposed	\$4930.00
Total Deferred	\$0.00
Total Accepted	\$0.00
Total Scheduled	\$0.00
Total Completed	\$106.00

Comments:

I understand and accept the treatment plan as proposed herein. I have had my questions answered and wish to begin treatment. I understand I am responsible to make full payment for the treatment outlined herein at least 2 weeks prior to the first appointment.

_____ Signature	_____ Date
_____ Witness	_____ Date

Form 4-3: Treatment plan approval form. Note the box in which the patient signs to acknowledge the cost of treatment and how it will be paid for.

- | | |
|---|---|
| 4. Clinical examination findings | 9. Completion notes |
| 5. Diagnosis (including differential, if uncertain) | 10. Cancelled or missed appointments and stated reasons |
| 6. Treatment plan | 11. Emergency treatment |
| 7. Referral information | 12. Patient concerns and dissatisfactions and planned follow-up |
| 8. Progress notes | |

Date

Dear Patient:

It was a pleasure meeting you last week. As a follow-up to your initial consultation, I am enclosing a copy of the "Estimated Dental Treatment," which Dr. Ronald Goldstein recommended. Listed below is your treatment schedule.

First Appointment: The bleaching technician will perform an office bleach in your lower anteriors. A custom follow-up home bleaching appliance will be fabricated and instructions provided for further bleaching at home. During the first visit, which lasts approximately two hours, Dr. Goldstein will check the bleaching color achieved.

Second Appointment: All the upper teeth will be prepared for crowns (#2 through #15). A set of new temporaries or treatment splint will be constructed during this all-day visit, which includes initial cosmetic contouring or reshaping of the new crowns. Should endodontics (root canals) be required, the referred specialist or endodontist will advise you of such additional endodontic fee.

Third Appointment: Approximately two weeks later, a metal try-in appointment lasts about 2 1/2 hours in which the crowns' metal substructure are fit checked and then returned to the dental laboratory for porcelain baking. Final seating (cementing) visit is scheduled in two weeks.

Fourth Appointment: Final crowns are seated with an interim cement. Cosmetic contouring on the lower anteriors is finalized and impressions for a nightguard taken. Please allow a full day for this appointment.

Follow-up Visit: Following the initial completion of your dental treatment, additional short visits are scheduled for any minor adjustments and to finalize the occlusion (bite) and check health of surrounding gum tissue.

If I can be of further assistance, please do not hesitate to call me.

Sincerely,

Form 4-4: Example of patient follow-up letter.

INFORMED CONSENT

Any unconsented procedure performed on a patient constitutes battery, which may subject the dentist to punitive damages for unauthorized touching.

Consent may be explicit, i.e., the patient stating “I accept,” or it may be implied by the patient’s tacit approval of the dentist’s treatment plan following an explanation by the dentist of proposed therapy.

Informed consent, a legal doctrine, requires the dentist to provide adequate disclosure of benefits versus risks of procedures as well as reasonable alternative therapies.³ This is so the patient is fully

advised of the nature of the suggested treatment and inherent non-negligent potential complications. Although the procedure may be performed non-negligently with the highest degree of dental care, the dentist may still be found negligent for inadequate disclosure of inherently unavoidable potential risks of treatment, which are known to the dentist but unsuspected by the lay patient.

Although the patient may have consented to the treatment, that consent is voidable if the patient did not make an intelligent and informed decision after first receiving proper advice from the dentist regarding which course of treatment should be pur-

Goldstein, Garber, & Salama, LLC
 1218 W Paces Ferry Road, Suite 200
 Atlanta, GA 30327

PERIODONTAL VIDEO INFORMED CONSENT

CERTIFICATION: I have viewed the video entitled “Periodontal Diagnosis and Treatment, Version 4.1.” This video has aided my understanding of periodontal diagnosis and periodontal therapy.

Ronald Goldstein, DDS, has encouraged me to ask any questions before proceeding, which I have done. Dr. Goldstein has answered any and all of my questions.

I agree to periodontal treatment with full and complete understanding of my options of nonsurgical, surgical care, and/or referral to a periodontist and elect;

_____ Non-surgical periodontal therapy only with Dr. Goldstein and staff

_____ Periodontal surgery by Dr. _____

_____ Non-surgical periodontal therapy, and after reevaluation, surgery as necessary by Dr. Goldstein

Date _____ Patient _____ Witness _____

Form 4–5: Video consent form.

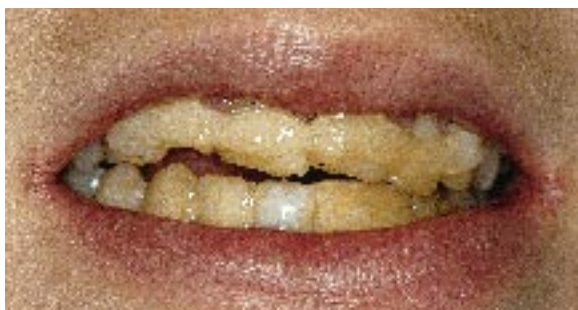

Figure 4-2A: This 19-year-old accident victim presented with emergency splinting material, which had been applied by her attending oral surgeon.

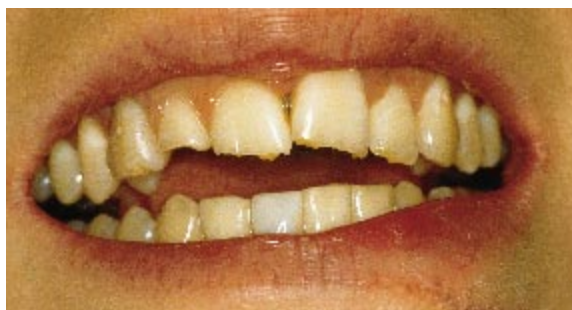

Figure 4-2B: Displaced teeth and incisal fractures are seen after the splinting material was removed.

sued if that procedure bears a reasonable risk of serious injury.

State laws vary regarding the duty of informed consent. Although each state requires that the patient be advised of the material risks of treatment, the variations among the states concern whether adequate disclosure pertains to what a reasonable patient may justifiably want to know, or to what a reasonable dentist would disclose in accordance with standard practice.

In a lawsuit in those states that rely upon what a reasonable dentist should disclose, the duty of disclosure requires expert dentist testimony regarding the standard of practice concerning such material

disclosures. On the other hand, in those states that determine informed consent from the perspective of the reasonable patient standard, it is for the jury to determine what a reasonable patient would wish to know irrespective of the customary practice of disclosure.²⁷

For instance, internal bleaching of nonvital teeth occasionally results in external root resorption. In the states requiring expert testimony, the patient would lose the suit unless an expert witness testified that the standard of practice among reasonable dentists is to advise the patient of the statistically small, recognized risk of external root resorption. Conversely, in states such as California, where no expert testimony is mandated, the state would permit the jury to determine what a reasonable patient would expect the dentist to advise.⁶

In another example (Figures 4-1A to C), a patient alleged unnecessary crowning since he was not offered the alternative of bonding or bleaching.²² These options should have been provided since treatment was done purely for esthetic rather

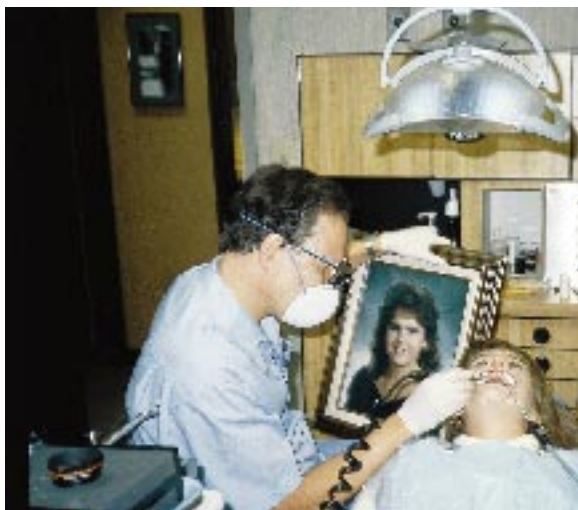

Figure 4-2C: A recent photograph was used as a model to mold and carve the patient's teeth when rebuilding her teeth during first direct bonding stage.

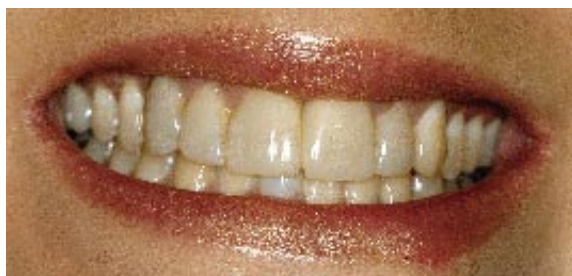

Figure 4-2D: Result following the first the stage of direct bonding.

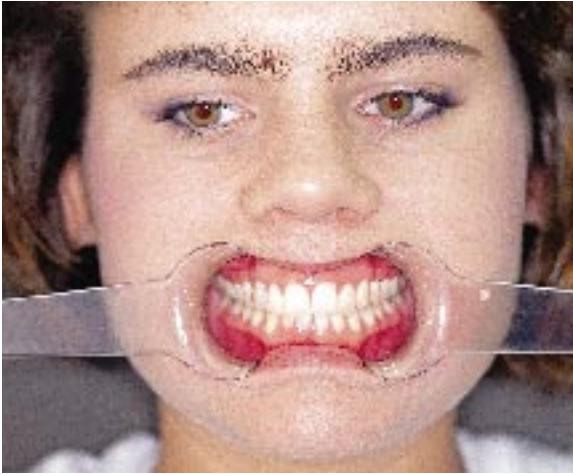

Figure 4-2E: The patient's orthodontist provided a photograph of the patient following his successful orthodontic treatment only 10 months prior to the accident.

than restorative reasons. Thus, even if the crowns were well constructed, the patient in such a case could still claim that he already suffered and would likely suffer future repetitive trauma from necessary crown removal, reparation, and replacement. Such replacement may be necessitated once every 10 to 15 years due to material wear but also every 5 to 15 years due to esthetic changes. Simple bonding or laminating with little or no tooth reduction represents a reasonable and preferred alternative in this case (Figures 4-1A to C). This case eventually settled for \$80,000, an expensive lesson for the dentist involved.

Informed consent may be oral or written, but a written consent form is more credible to a jury. Written documentation of informed consent also avoids the perils of a conflict between dentist and patient regarding who said what and when.

Product liability suits require that the injured patient prove a product defect. Once proven, the product manufacturer is strictly liable even in the absence of any proven negligent design or manufacturing process. Product design defect includes failure of the manufacturer to warn of likely injury risks associated with product usage.

Informed consent does not require the dentist to advise the patient of a rare or remote risk. Thus, if the risk is one in a million, no legal duty of disclosure is required.

Although a non-negligent risk may occur despite the best of care, a dentist is nonetheless legally obligated to reduce or minimize the risk once it becomes clinically apparent. Because external root resorption is known to be an associated risk of bleaching, the dentist should take periodic diagnostic-quality periapical radiographs to check for early root resorption, and take appropriate action to arrest the condition if and when it first appears (see Figure 4-5). Calcium hydroxide therapy may remineralize external root resorption or arrest its progress if treated early.⁸

Another example of a non-negligent risk of treatment being changed from merely a duty of informed consent disclosure to that of active intervention is root resorption resulting from orthodontic treatment. Root shortening and its associated risk of premature loosening or loss of teeth occurs predictably with teeth that have already undergone some degree of root resorption prior to orthodontic therapy or in teeth with existing blunted roots. In such instances, the dentist should monitor the patient for recurring root resorption. Once discovered, orthodontic treatment can either be halted or the degree of attempted correction of the occlusion compromised in order to prevent or minimize any additional root resorption.

To avoid any misunderstanding, the dentist should orally describe to the patient the pros and cons of bonding. Written consent forms are strong evidence that the patient was fully advised and understood the benefits as well as the risks of bonding compared to alternative restorative procedures. In addition to a chart entry that the patient was fully advised by the dentist concerning bonding, Form 4-6 is offered as a suggested guideline for the

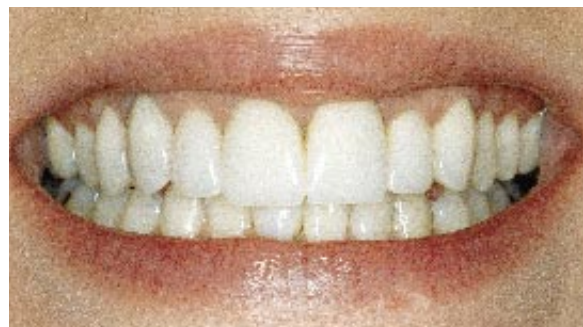

Figure 4-2F: Final picture of the patient's smile following second stage treatment with porcelain laminate veneers.

dentist interested in developing an office informed consent form for bonding.

Documentation of informed consent in the chart is illustrated by the following typical entry concerning bonding:

Date: Patient has read pages ___ and ___ of “Change Your Smile.”¹⁴ Patient fully understands pros and cons of bonding and alternative of crowning. Patient told doctor “You have answered all of my questions about bonding and I agree to bonding my upper six front teeth.”

(Signature by patient or witness is ideal and optional but not mandatory.)

REFUSAL TO TREAT

A demanding patient may attempt to convince you to treat him or her, despite your misgivings, by stroking your vanity. Having one’s ego momentarily inflated is not worth the predictable crash after joining the patient’s list of alleged incompetents who promised dental salvation and, instead, became the dental devil in the patient’s mind.

Accordingly, be leery of the patient whose dental history includes complaints that other well-qualified dentists failed to satisfy the patient’s esthetic needs. Notwithstanding your exceptional reputation, skills, and experience, you will likely not succeed where other competent dentists have failed.

A dentist has the legal right to refuse to treat anyone, except for reasons of race, religion, or handicap.²¹ Despite the patient’s praise, his or her needs may be so unique, special, or demanding that the patient would be better served by a dentist who can spare the additional time necessary to satisfy the patient’s excessive esthetic demands.

ABANDONMENT

Collective dental wisdom teaches that a patient may not be satisfied with esthetic dentistry if a payment balance is still owing. Therefore, it is sound practice management and legally permissible to demand payment in full initially or before completion. However, a dentist cannot avoid completion, once begun, even though a balance is due, without risking a lawsuit for patient abandonment.

Reasonable temporization and periodic restorative maintenance until the balance is paid may be a prudent measure to prevent a lawsuit for abandonment.

RIGHT OF PATIENT TO SELECT BEST DENTIST

A patient has the right to decide on a dentist of his or her own choice. This right usually involves selecting the very best available dentist skilled in cosmetic procedures. However, insurance companies and managed care plans will generally attempt to provide, instead, the most economical choice.

The following case demonstrates that courts allow patients to exercise their right to select a dentist.

A 19-year-old woman was a front-seat passenger in a vehicle that was struck broadside when it turned in front of another vehicle (Figures 4–2A to F). The jury found both drivers responsible for the collision and compensated the passenger victim for her pain, suffering, and hospital and medical expenses associated with her injuries. The jury’s verdict of \$90,000 also compensated her for future costs associated with maintenance of her restored teeth, including periodic replacement of laminate veneers over her lifetime.

This case

1. had admitted into evidence the plaintiff’s orthodontic post-treatment photographs to prove the virtually ideal esthetic condition of the patient’s teeth pre-accident
2. recognized the value of conservative dental treatment such as the use of porcelain laminates
3. confirmed the right of the accident victim to choose a dentist with greater expertise and higher fees than those in her insurance plan
4. awarded a sufficient amount of compensation to periodically re-treat or maintain restored teeth for the victim’s life.

REFUNDS—SETTLEMENT OR ADMISSION?

Maloccurrence does not alone prove malpractice. Unless an untoward complication or bad result was caused by a negligent error or omission by the dentist, an unsatisfactory result can occur despite the best of care.¹

**INFORMED CONSENT TO BONDING:
BENEFITS AND LIMITATIONS FOR PATIENT INFORMATION**

A. Introduction

Bonding pros and cons are discussed in this form, so you may understand and appreciate the benefits as well as the limitations of bonding.

Bonding is a dental procedure which bonds plastic dental restorative materials to your teeth. Plastic bonding may last for several years but is less strong than the more durable or longer lasting restorations such as porcelain laminates or crowns (caps).

Bonding may be accomplished in one or more visits. It requires more patient care to prevent staining or future chipping. Breakage of the bonding material occurs more readily with bonding than with silver filling restorations or the porcelain in crowns or caps.

Most patient are gratified by the immediate improvement in their smile and appearance, which bonding accomplishes without local anesthesia. Initially, tooth surfaces which are to be "bonded" to the plastic material are prepared by etching or roughening the surfaces with a chemical. This is similar to wallpapering by first applying a chemical to prepare the wall before application of the wallpaper.

Bonding materials are applied in layers to the teeth until the desired esthetic result occurs. In certain instances, the bonding material is hardened by a curing process with high intensity light shielded from the patient's eyes. If the patient is esthetically displeased, bonding material may be added, removed or recontoured to improve esthetics.

B. Alternatives

1. Crowning of teeth.

Crowns or caps usually last longer than bonding materials. Although individual experiences may differ markedly from statistical averages, the average bonding life expectancy before repair or replacement is required is approximately 3 to 8 years. Porcelain crowns, which require the grinding of natural tooth structure, local anesthesia, and impressions, last on the average 10 years, but may last up to 15 years. Esthetic life ranges between 5 to 15 years. Chipping or fracturing can occur with any dental material at any time after placement but bonding materials are more prone to fracture than porcelain crowns. However, bonding can be repaired more easily by the application of additional bonding material to the fracture site whereas crowns may require total replacement to achieve a comparable esthetic result.

2. Other Dental Materials.

Silver alloy amalgam fillings may be as durable as crowns but lack esthetics due to their heavy metal appearance rather than natural tooth color. Bonding is ordinarily not applied over silver fillings. Porcelain laminates are porcelain shells, which, after some minor tooth reduction, are cemented to the outside surface of teeth. esthetic life ranges between 4 to 12 years.

3. Nontreatment.

Bonding is designed primarily for esthetic reconstruction in selected areas of the patient's mouth. Patients may also elect treatment for tooth fracture or replacement of existing restorations that are decaying or breaking down and likely to cause future decay problems. Many patients choose bonding for psychological reasons since an improved appearance may benefit the patient socially or aid career advancement.

C. Risks of Bonding

1. Staining can occur with smoking and excessive amounts of coffee and tea.
2. Durability varies but is approximately three to five years before replacement is required.
3. Chipping or fracturing may necessitate repair or replacement.

D. Consent

I have read the above informed consent document, which has legal significance. All of my questions concerning bonding have been answered by the doctor or I have no questions. I hereby consent to bonding for esthetic reasons and/or for treatment of dental decay, if any exists.

Date _____ Patient _____ Witness _____

Form 4-6: An example of an informed consent form for a specific treatment.

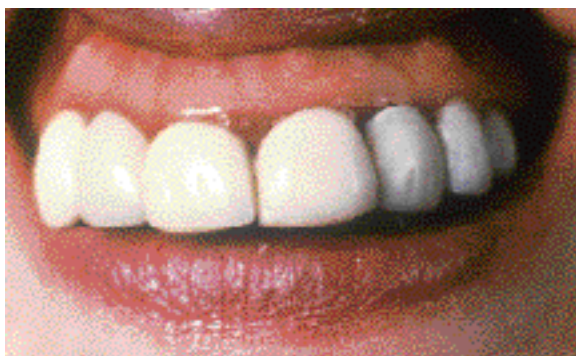

Figure 4-3A: Crowns prior to periodontal surgery.

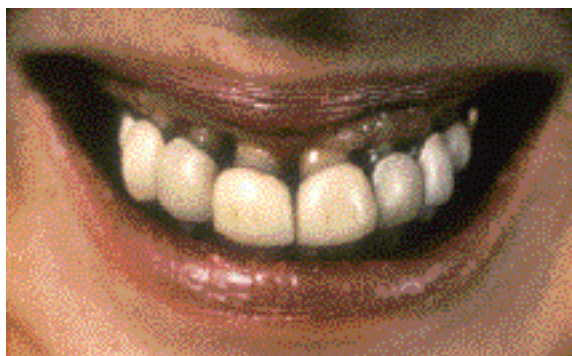

Figure 4-3B: Postperiodontal surgery. Note grossly open margins.

Nevertheless, it is good patient relations to redo or correct unesthetic restorations without additional charge to a patient. For instance, chipping, or fractures occurring within the first year after completion should be considered for remake without charge.

If the dentist concludes that a patient likely will not be satisfied esthetically or otherwise, a refund is not an admission of fault. Rather, it is an admission of mutual frustration. Both dentist and patient would be better served with selection of a new dentist. A dentist is entitled to a fee for reasonable esthetic attempts to satisfy a patient. Notwithstanding, a refund may be less expensive than a constantly reappearing patient who wreaks havoc with both your patient schedule and your gastrointestinal tract.

Settlement offers are usually inadmissible in court¹² whereas admissions of fault are admissible. To avoid the appearance of an admission of guilty negli-

gence, the dentist may write on the refund check "Refund Settlement" or draft a release (Form 4-7), which the patient should sign at the time of refund.

BLEACHING

Bleaching precautions include:

1. Use of rubber dam when using high-concentration bleaching solution to reduce gingival and pulpal irritation.
2. Minimum necessary bleaching times and temperatures to preserve pulpal vitality.
3. Avoidance of abrasive bleaching techniques that expose dentin, particularly in cervical areas where the enamel is thinnest. Be aware that the enamel does not actually meet the cementum in 10% of teeth.
4. Avoidance of cervical area bleaching of non-vital teeth. If bleaching is required, place a

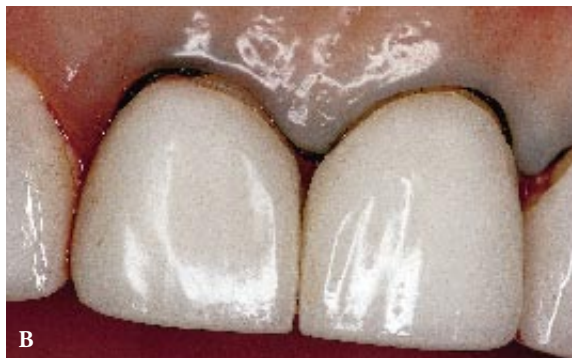
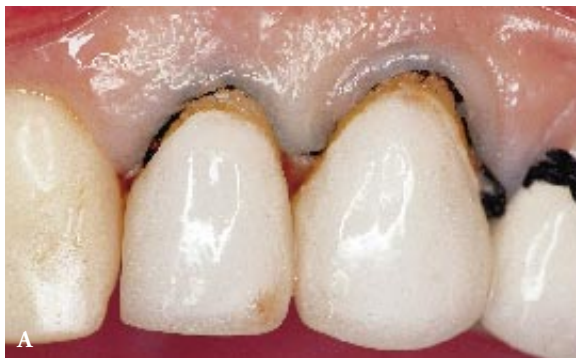
Figure 4-4: A and B, Cotton displacement cord has been packed into the gingival sulcus to better illustrate the defective margins. Even if the porcelain was not fitted to the margin, resin cement could have helped by properly filling in the voids.

RELEASE OF ALL CLAIMS

_____, in consideration of \$_____, hereby acknowledges as received, does release _____, DDS, his agents, and/or employees, and all other persons or corporations of and from any and every claim, right, liability, and/or causes of action of whatever kind or nature the undersigned has, or may hereafter have, whether known or unknown, arising out of, or in any way connected with, the dental care and treatment of _____, including any act or omission of _____, DDS, his agents and/or employees.

It is likely that future harm or injury may occur. This release is intended to cover and does cover all present and any and all further claims against _____, DDS, his agents, corporations, and/or employees, who are finally and forever compromised, settled, and discharged.

The undersigned acknowledges that _____, DDS, denies any liability but has agreed to the terms of the release to buy peace and resolve all differences between dentist and the undersigned patient.

Date _____

Patient' signature _____

Witness _____

REVIEW OF IMPORTANT MALPRACTICE PROPHYLAXIS MEASURES

1. Suggest that your patient read your cosmetic dentistry literature, which provides a list of the limitations as well as advantages of the proposed esthetic treatment. An excellent example of this would be a specific chapter in "Change Your Smile" that the patient acknowledged having read, and had all his or her questions answered. The note might read as follows:
 "Patient read and discussed Chapter in 'Change Your Smile' with the doctor. All patient questions answered and patient consented to treatment of teeth #_____ and _____ with _____" (restoration).
2. Educate your patients about their esthetic problems as well as any potential complications that may occur during treatment. Give alternatives or choices of treatment for each problem explaining risks and benefits of each alternative. Communicate verbally the limitations of each proposed treatment. Consider supplementing this verbal consent with a written consent form.
3. Forecast an accurate range of restoration life expectancy, both esthetically and functionally.
4. Following the consultation, write a treatment plan letter to the patient confirming your findings and plans.
5. Do not promise to satisfy the patient's esthetic demands. Rather, state you will work hard to do your best in an attempt to please the patient, although there are no guarantees of success.
6. Provide good-looking and well-fitting temporaries to fulfil your patient's esthetic desires. Make sure the color, form, fit, and tissue compatibility are acceptable.
7. Obtain and record the patient's approval at the try-in appointment before placing any final restoration. Ask questions at the try-in stage, such as "Do you see anything else you wish to be changed before we place the final glaze or polish?"
8. Determine if there is anyone else whose opinion the patient values, and if so, include that person at the try-in appointment. It is most helpful and a valuable source of psychological reinforcement to have the patient's spouse, family member, or friend present at this appointment to offer suggestions and aid the dentist in obtaining the final approval.
9. Observe gingival healing following your treatment. At the postoperative examination verify removal of all cement, absence of overhangs, and that all surrounding gingival tissues are healthy. If not, continue to see the patient until tissue health is restored. Correct all deficiencies. Re-emphasize oral hygiene measures necessary to maintain the esthetic restorations. Record your recommendations legibly in the patient's chart.
10. If the patient fails to return, telephone to make sure there is no problem. Most patient dissatisfaction can be eliminated or eased with good communication between the dentist and the patient, even in instances of evident dental negligence. Patients are more likely to sue an uncaring dentist than a perceived friend.
11. If the patient expresses dissatisfaction, suggest that he or she return to the office to attempt to solve the problem. If the patient refuses, again be helpful in letting the patient know that you have done your best, would be happy to refer him or her to another dentist for further treatment or consultation, and would be willing to discuss the matter with any other dentist of the patient's choice, or consider paying for another dentist's corrective care upon receipt of a treatment estimate. Your general liability policy, usually included with the professional liability policy, typically pays \$1000 or more for any "accident" under the medical benefits portion of the policy. This can be applied to the corrective care fee of another healthcare provider.
12. Plan a potentially difficult patient's treatment plan in stages. For example, the first stage is the temporization phase, and you should quote a fee for just this service. This fee will take into consideration approximately how many hours it may take to satisfy your patient's reasonable esthetic demands for temporaries. If initial esthetic success is unattainable, the patient has the option of being referred elsewhere. The patient's only obligation is the fee charged for performing stage one, already paid in advance.

Legal abandonment does not result if the patient is notified of the termination of the dentist-patient relationship, is given ample opportunity to find another dentist, and the termination will not jeopardize the patient's dental health. Thus if both the dentist and patient agree that the final restorations will be completed with another dentist, no legal abandonment occurs. Offer to transfer patient models and records to the new dentist and to care for the patient's emergencies for 30 days until the transfer is complete.

base over the endodontic fill to the level of the epithelial attachment, followed by placement of a calcium hydroxide paste into the canal for several days after bleaching.¹⁸

EXAMPLES OF ESTHETIC MALPRACTICE CASES

Case One (Figures 4–3A and B)

This is a 45-year-old woman who wanted to improve her smile. Neither bonding nor orthodontics were offered as alternatives to crowning. Overcontoured crowns contributed to periodontal disease, and her appearance after the necessary periodontal surgery was very unesthetic due to the continued existence of the original crowns and the newly exposed margins and roots.

Case Two

An attractive young model sought to improve her smile, and the dentist suggested porcelain laminates to improve the shape and color of her teeth (Figure 4–4A). Unfortunately, the dentist overbuilt the laminates with a resulting bulky look that destroyed her original smile's attractiveness (Figure 4–4B). A new dentist reconstructed porcelain laminates that provided the esthetics that the model sought. Dentists have an obligation to provide esthetic enhancement to their patients upon request if reasonably attainable. At the very least, patients should not be restored in an esthetically inferior way or appear worse than when first presented.

Case Three

Figure 4–5 is a California case in which the dentist was unaware of the risk of external root resorption associated with bleaching endodontically treated teeth and failed to disclose such a risk to the patient despite the literature discussing such risks.

The manufacturer of the bleaching agent was also a defendant in the lawsuit for inadequately disclosing root resorption risks in the product information provided with its product. Root resorption is avoidable by retaining endodontic root fill to the cementoenamel junction.

OSHA

Under federal law, OSHA requires manufacturers to supply material safety data sheets concerning



Figure 4–5: Post-bleaching external root resorption.

their products. If not given with the product at the time of sale, it must be available from the manufacturer upon request.

References

1. Am.Jur2d, Physicians Surgeons. 208.
2. ATLA Advocate. Citing Reistad M. Demystifying punitive damages in product and injury cases: A survey of a quarter-century of trial verdicts. 1992;18:1.
3. Bailey B. Informed consent in dentistry. JADA 1985;110:709.
4. Bowen R, Mitchen J. Biocompatibility of materials. JADA 1985;111:925.
5. Bowen R. Restorative dentistry. JADA 1985;111:925.
6. California book of approved jury instructions. 6.10.
7. Cirofici v. Goffen. 1980;407 N.E.2d 633.
8. Cohen S, Burns R. Pathways of the pulp. 5th ed. St. Louis: CV Mosby, p. 510.
9. Day v. Rosenthal. 217 Cal.Rptr. 89 1985;170 CA3 1125.
10. Dental products report (December 1985). U.S. government halts sporicidin sales. ADA News 1992; 23:1.
11. Dental products report. April 1992.
12. Federal rule of evidence 408.
13. Goldstein R, Garber D, Schwartz C, Goldstein C. Patient management of esthetic restorations. 123 JADA 61 (1992).

82 Esthetics in Dentistry

14. Goldstein R. Change your smile. Chicago, IL: Quintessence 1997.
15. Jordon R, Suzuki M. Posterior composite restorations. JADA 1991;122:31.
16. Kantor M, Reiskin A, Lurie A. Clinical comparison of x-ray films for detection of proximal surface caries. JADA 1985;111:96.
17. Mazer R, Leinfelder K. Evaluating a microfill-posterior composite resin—a five-year study. JADA 1992;123:33.
18. Powell L, Bales D. Tooth bleaching: its effect on oral tissues. JADA 1991;122:(50)18–43.
19. Schwartz N, Whitsett L, Berry T, Stewart J. Unserviceable crowns and fixed partial denture: lifespan and causes for loss of service ability. JADA 1970;81:1395.
20. Silha R. Methods for reducing patient exposure involved with Kodak Ektaspeed dental x-ray film. Dental Radiogr Photogr 1980;54:80.
21. The Americans with Disabilities Act, Public Law 101-336; Americans with Disabilities Act Title III Regulations, 28 CFR Part 36, “Nondiscrimination on the basis of disability by public accommodations and in commercial facilities,” U.S. Department of Justice, Office of the Attorney General; and Americans with Disabilities Act Title I Regulations, 29 CFR part 1630, “Equal Employment Opportunity for Individuals with Disabilities,” U.S. Equal Employment Opportunity Commission.
22. *Tillery v. Lynn*. Docket #83 CIV 2624 U.S. Dist Ct., So. Dist. of New York.
23. Wilson R. Restorative dentistry. JADA 1985; 111:551.
24. Winer H, D’Antony J. Malpractice litigation—a practice management dilemma. Calif Dent Assoc 1985; 13:(11)38–40.
25. Zinman EJ, Masters D. Implant informed consent, an animated video.
26. Zinman EJ. Periodontal diagnosis and treatment, version 4.1, and animated video.
27. Zinman EJ. Advise before you incise. Western Society of Periodontology, Fall 1976.

Additional Resources

Burris S. Legal considerations in infectious diseases and dentistry. Dent Clin North Am 1996;40(2):425–35.

Chiodo GT, Tolle SW. Self-effacement in dental practice. Gen Dent 1996;44(4):290–5.

Handley DA. Dental malpractice claims: causes and cures. Dent Econ 1996;86(4):46–51,53–4.

Jones GA, Behrents RG, Bailey GP. Legal considerations for digitized images. Gen Dent 1996;44(3):242–4.

Milgram P, Fiset L, Whitney C, et al. Malpractice claims during 1988–1992: a national survey of dentists. JADA 1994;125:462–9.

Morris W. This dentist’s legal advisor. St Louis: Mosby, 1995.

Plunkett LR. Statute of limitations. Key to understanding dental malpractice cases. NY State Dent J 1996; 62(9):12–7.

Recker FR. Preventive dentistry—a legal check-up. J Oral Implantol 1996;22(1):24.

Sfukas PM. Guarding the files: your role in maintaining the confidentiality of patient records. J Am Dent Assoc 1996;127(8):1248–52.

Sfukas PM. Hold-harmless agreements. What every dentist needs to know. J Am Dent Assoc 1996;127(6): 804–5.

Szekely DG, Milam S, Khademi JA. Legal issues of the electronic dental record: security and confidentiality. J Dent Educ 1996;60(1):19–23.

Trombly RM. Taming the paper tiger. Record keeping in the dental office. Dent Teamwork 1996;9(4):18–21.

CHAPTER 5

PHOTOGRAPHY

This chapter provides, first, a guideline for obtaining the necessary photographic views and then a basic foundation of the technical aspects of photography that are specifically related to dental photography.

Why a chapter on the technical aspects of photography? With today's "idiot-proof" cameras, why do you need to know so many details? The answer is as simple as some of the cameras on the market—no one camera or technique can do it all. Rather, it takes a good understanding of what you wish to accomplish with photography and what limitations will be imposed on whatever choices you make. The more you know, the better able you will be to make the kind of photographic records you require.

With the current emphasis on computer imaging, one might think that photographs have become less important. The answer is "not yet." When high-definition television becomes commonplace, print-outs of the video screen could make current dental photography obsolete. However, for the present, dental photographs are an integral part of diagnostic record-keeping procedures in esthetic dentistry.

DIAGNOSTIC PHOTOGRAPHS

The two-dimensional perspective of a photograph provides a different view, and therefore, sometimes a different interpretation, from the usual three-dimensional perspective that you see at chairside. Tooth silhouette form becomes much easier to observe. Obtaining esthetic perfection requires close scrutiny of tooth shape as well as arch form and color. Thus, it becomes considerably easier to improve your final result by using two-dimensional photographs. Photographs have also become an essential part of dental records as a result of increased dental litigation.

Before you begin your correction of any esthetic problem, approach each patient as if you are prepar-

ing for a court case. Make the kind of records you would want to have if you were on the witness stand to defend not only what you did but why you did it. This recommendation means you should not just take random photographs; you need to take specific pictures from specific angles. The camera angles must show why you are making your correction as well as how you are doing it. Then, following your final result, take additional diagnostic photographs to illustrate the exact amount of change created by your treatment. Few, if any, patients can recall their exact appearance before therapy.

There is no amount of insurance that can take the place of accurate photographic records that cover the pretreatment, treatment, and post-treatment conditions. These records are essential for any patient for whom an esthetic change might take place. Take duplicate pictures of important views if you plan to send one to the insurance company, referring or consulting dentists, or to the patient. This saves the time and expense of having to duplicate the print or slide later. Furthermore, for potentially difficult esthetic problem patients, either use Polaroid prints, or do not begin your therapy before you have evidence that your photographs or slides have adequately recorded your "before" treatment condition. What can go wrong? Anything!!

For example, once the numbness wears off, it is not uncommon for patients to feel like they have "buck teeth" after crown or laminate placement. The first thing they feel is their front teeth touching their lip, and even if you have not built the teeth out labially, it may still feel to the patient that you have. If you have taken the time to photograph the pretreatment labiolingual dimension of the anterior teeth, you could prove to the patient, with diagnostic casts, a dental caliper, and post-treatment photographs that you have not altered the labial-lingual dimension.

TECHNICAL PROBLEM AREAS

Basically, four problems can occur: problems with the camera, the film, the developing, or in getting the pictures back. First, you may have failed to notice that the camera settings had inadvertently been changed. Someone else may have taken the previous photographs, and altered the standard settings. So to avoid the inconvenience of retakes, check the settings every time.

There could be a problem with the film. Sometimes, certain batches of film are damaged by heat, especially if stored for a long time without being refrigerated. As a result, the color balance can be significantly altered. Both tooth and tissue colors must be accurate so you can eventually compare the pretreatment color to the final result.

Film processing is another area for possible damage to occur, again affecting the photograph's color integrity. Chemical imbalance or incorrect temperatures in the processing of the film is not uncommon, especially with inexpensive local photo-finishers. Always examine the finished pictures carefully and look for the telltale sign of an overall color shift.

The last concern, but certainly not the least, is in having your photographs lost in the mail or at the developer. Sometimes the developed film goes to someone else who may not realize the importance of getting the films back to their rightful owner.

Unfortunately, there is no second chance if any of this happens after you have begun your treatment. Therefore, the only sure way to prevent these occurrences from ruining your essential record keeping is to make certain you see the pretreatment pictures before ever starting treatment. Most cities have a same-day or one-hour service available that may well be worth any extra cost involved.

Practical Considerations

Although one photograph can certainly tell a story, take a sufficient number of photographs to record not only the full face from the front and side, but also the smile line and the mouth with the lips retracted. Rigorous attention to standardization of important photographic variables—such as patient position, camera position and angle, background, lighting, lens length, and camera-to-patient distance—will ensure that you achieve the objective of focusing the viewer's attention on the “before” and “after” differences resulting from the treatment.

In many situations, it is both timesaving and less obtrusive to the dental procedure for your assistant to take the photographs. Preoperative photographic records can often be obtained before you enter the treatment room during the treatment planning stage, or at a separate appointment by the assistant. However, if you delegate this job to an auxiliary staff member, make sure that the person is well trained in basic photography.

An album showing the difference between good and bad photographs is helpful when training new staff members. Before entrusting responsibility to your assistant, evaluate several rolls of film photographed by that individual.

Also, patients do not like to wait in the chair while you are taking photographs. They may feel it is a waste of time unless they understand the advantage of making adequate photographic records. Train your assistants or hygienists to take accurate, but also speedy, photographs.

RECORDING THE PATIENT'S PREOPERATIVE CONDITION

The following series of patient photographs provides a thorough record not only for the purposes of esthetic treatment verification and liability protection but also for the purposes of staff training, professional publications, and presentations.

1. Full Face—Front and Profile

A main purpose of taking before and after full-face photographs (Figures 5–1A and B) is to record the effects of your dental treatment on the entire face. For this reason, it is necessary to have a camera that makes it easy to sharply focus in order to record any wrinkles or other facial defects prior to treatment.

Although you need to record the patient's full-face smile, it is also valuable to have a record of the nonsmiling patient with the face relaxed, lips closed. If there is muscle tension when the patient closes, this will be recorded as well. It is also valuable to photographically record any skin conditions or facial wrinkles; this may require asking your patient to remove makeup. Facial makeup can conceal valuable information necessary for preoperative clinical records; therefore, first take your normal facial pictures, smiling and nonsmiling, frontal and profile, with makeup on. Then ask your patient to remove all the makeup, especially around the lower third of



Figure 5-1A: Full-face photography becomes easier when there is a standard setup with proper lighting. The patient is holding a reflector to help balance light, while the assistant uses a “slave” flash, which provides light in addition to the standard camera flash.

their face, so you can also view the natural skin tones and properly record it. In this way, you are also collecting valuable information about muscle tone as well by recording any wrinkles present but previously camouflaged.

Full-face records are especially important when your patient has a protrusion that he or she wants corrected. Any correction, orthodontic or restorative, can have a profound effect on a prominent nose. Your patient’s nose may look proportionate when the jaw or jaws are protruded, but after orthodontic or surgical correction, the previously proportioned prominent nose may now stand out so much that it is disproportionate with the new face. This could lead to your patient’s dissatisfaction with his or her new appearance. This possibility should be discussed with the patient before treatment, aided by computer imaging (see Chapter 2). Rhinoplasty can then be considered for inclusion in the cosmetic treatment plan.

Since correcting a protruded arch can also result in greater facial muscle relaxation, there is the distinct possibility of the patient assuming there are more post-treatment facial wrinkles present. This is

another reason why it is mandatory for you to include at least one nonsmiling facial picture without makeup that will reveal any wrinkles present before any treatment. Many dentists would have given anything to have this full-face photographic record after they have been falsely accused of creating a facial wrinkle.

You may wish to have a separate camera set up for full-face records (see Figure 5-1A). The advantages are in always having a camera ready (mounted on a fixed tripod) to take pictures, the same colored background (medium blue works well), for all of your pictures (see Figure 5-1B), a special lens (usually 100mm) that takes the full face with no perceptible distortion, and most of all, complete consistency in before, during, and after facial views.

If possible, a separate room, part of a room, or designated area can be used for this purpose. All you have to do then is seat the patient in a pre-marked place in the room and take your pictures.

2. Smiling (Figures 5-2A to D)

Take natural smiles, but make sure the incisal edges show in at least one shot.



Figure 5-1B: This is an example of a good full-face photo with contrasting background, which makes it easier to see facial silhouette form. A second view of the profile is a useful view when changes to the profile will be made by either restorative or orthodontic therapy.

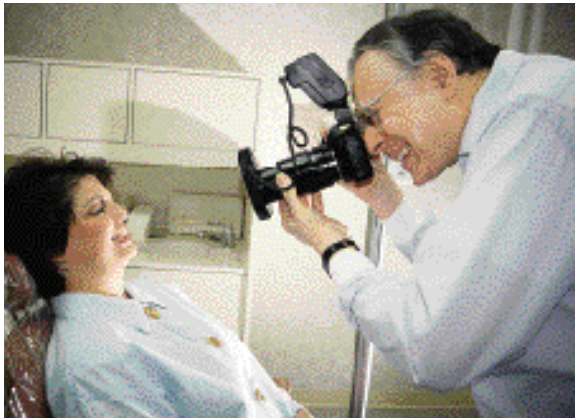

Figure 5-2A: The normal position for recording the patient's smile.

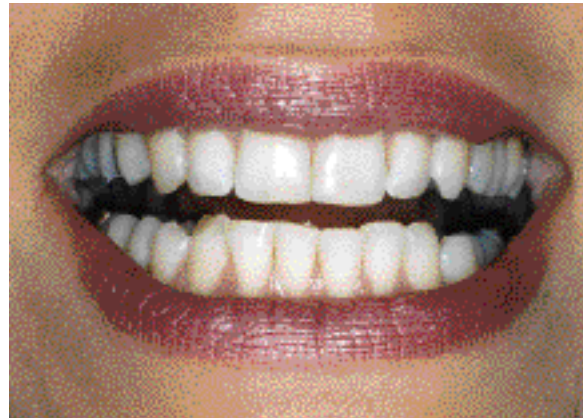

Figure 5-2B: When photographing the full smile, try to record both maxillary and mandibular incisal edges.



Figure 5-2C: This lateral view shows the smile with teeth parted, taken at an angle approximately perpendicular to the cuspid.

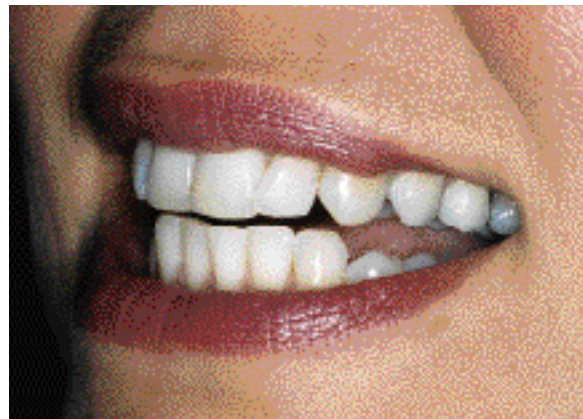

Figure 5-2D: The opposite lateral smile view.

3. Lips Retracted/Teeth in Centric Occlusion
Right, center, and left (Figures 5-3A to E).
Alternative shot with mirror with a special front surface shown in Figures 5-4A and B.

4. Lips Retracted/Teeth Slightly Open
(Approximate the thickness of finger separating the posterior teeth (Figures 5-5A to C). These views can also be done with a mirror.

5. Close-Up Retracted
Right, center, and left (Figures 5-6A to C). Doctor and assistant position same as in Figures 5-4A and B.

6. Occlusal
Taken with mirrors—maxillary (Figures 5-7A to D). With dentist in front of the patient (Figure

5-8A), or behind the patient (Figure 5-7B).
Mandibular (Figure 5-8A).

7. Special Views
These can include close-up views such as the lingual of the lower anteriors (Figure 5-8B), or specific quadrants (Figures 5-9A to C).

8. Extra Views
These can include photographs of the diagnostic study casts, especially how they articulate if the patient will be involved with extensive restorative dentistry. If diagnostic wax-ups are to be used, record them as well.

9. Parafunctional
These habits may have caused a problem that will

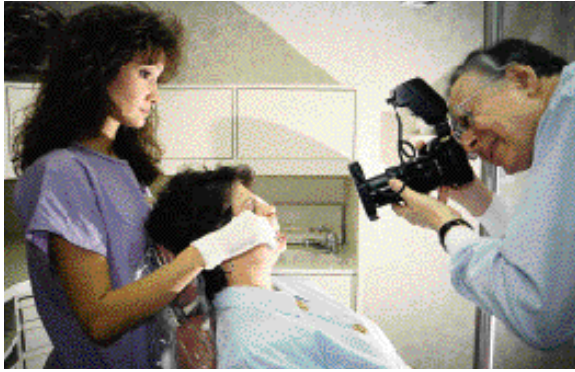

Figure 5-3A: This shows the appropriate stance of the assistant when he or she evenly retracts the lips for full arch pictures in centric or with slight spacing to show incisal edges.

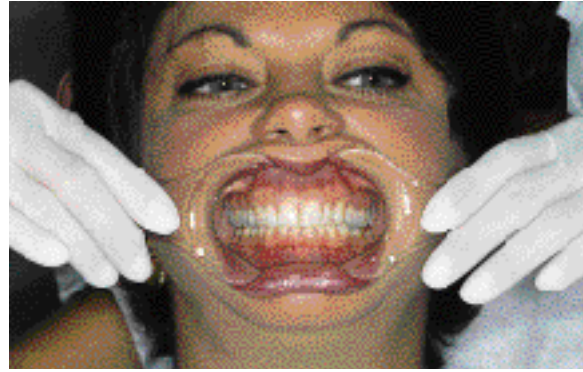
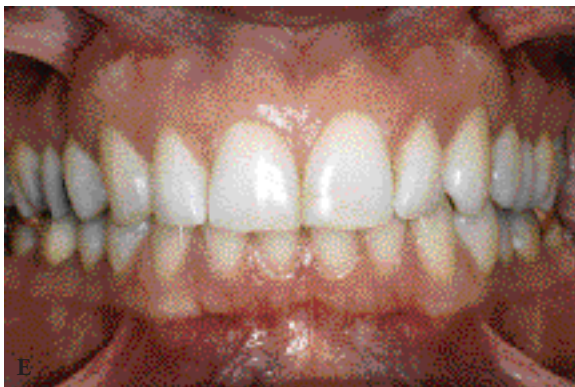
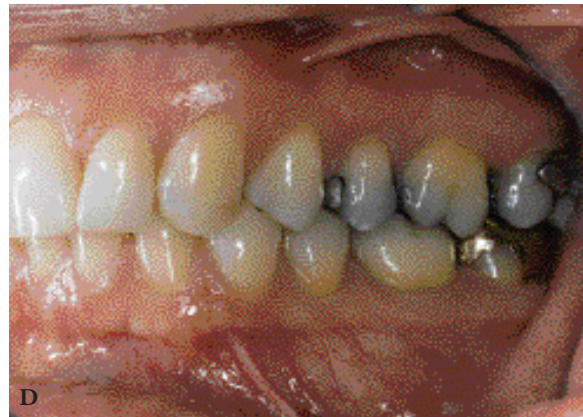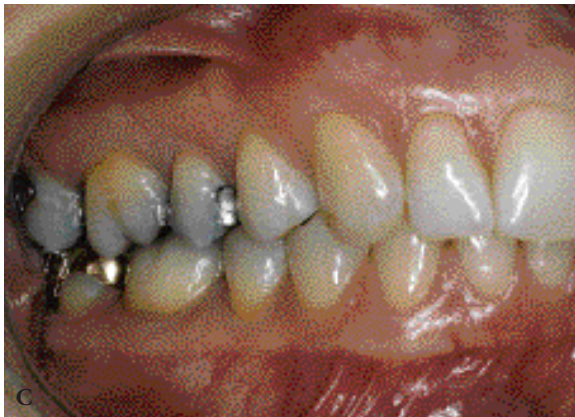Figure 5-3B: Try to match the size of the patient's cheek opening to the retractor size, using the largest retractor the patient can comfortably tolerate while keeping the lips fully retracted.

influence your treatment plan. For example, if your patient bruxes, show the wear facets, how the patient clenches the teeth, and how they interdigitate in lateral and protrusive excursions.

10. Photographs for Television

If you intend to use some of your before or after photographs for television viewing, make sure you allow for TV "cropping." This refers to the



Figures 5-3C to E: The right, left, and center views in centric, lip retracted position. Note that the teeth are parallel to the horizontal and centered in the picture. On the center view, focus on the lateral incisors. On the lateral views, focus between the cuspid and first bicuspid.

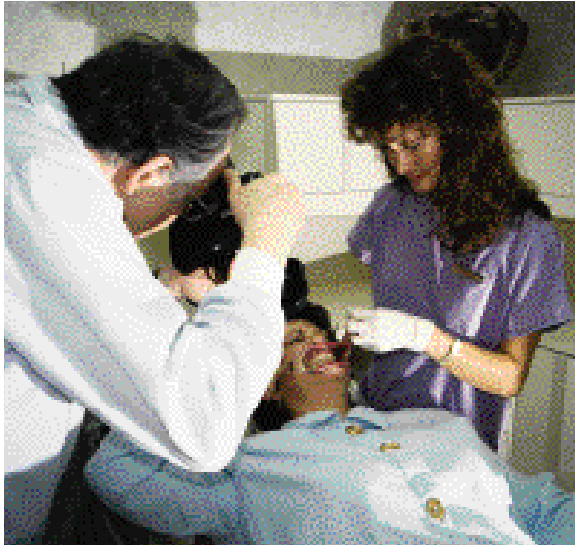

Figure 5-4A: An alternate technique for taking the lateral views with teeth either in centric position or slightly apart has the assistant standing to the side.

decreased image extent that occurs when a 35-mm slide is transmitted via TV. To offset this loss, take wider views of all the pictures than you actually need (Figure 5-10).

“Why So Many Pictures?”

If your patients ask, inform them that these photographs are the best records you can make. They are for their benefit. Although photographs increase your overhead, and therefore a charge must be made for them, they are necessary. In addition to allowing you to formulate a comprehensive, excellent treatment plan, you can remind them that:

- A picture is worth a thousand words.
- There is no accurate way to describe everything you see in words.
- If there are insurance questions, especially regarding benefits, the patient profits by your recording exactly why the tooth or teeth need treatment.

Useful Tips

1. Wet retractor, place over the lower lip at corner of mouth, then roll up.
2. Be careful not to inadvertently press the tip of the retractor on the patient's gingivae.

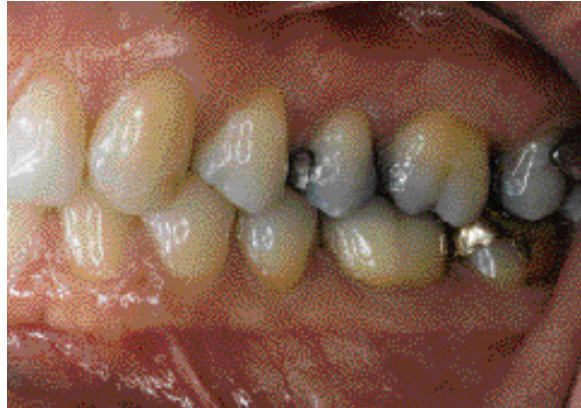

Figure 5-4B: The advantage of using a mirror to take this close-up lateral view is that more of the teeth are in sharper focus than can be achieved by the direct view shown in Figures 5-3C to E.

- If there is a question with the treatment later on, you can recreate the exact way the restoration was done via slides or photographs.

Postoperative Views

Record your patient's tissue after it has returned to normal. This will show how your restorative treatment fits and, perhaps, would not be the cause of a later inflammation.

CAMERAS

Cameras come in two basic types—still and action. The still varieties include cameras that use film and those that record the image electronically on a disc. Of the film types, the choices are instant print (Polaroid), and the more common type where film is removed for processing. Of this latter type, there are many different formats. Format refers to the size of the film used and each size requires the use of a different kind of camera. Typical formats are 4×5 , $2\frac{1}{4}$ square, 35 mm, and 126 and the new Advanced Photo System cassette is a modified 35 mm. The 35-mm format is the most popular for dental photography because of the compact equipment size,

accessories available, ease of use, image quality, and ease of storage. The other basic option, action, uses the color video cameras that have become so popular for consumer use.

Of all of these possibilities, four have appropriate uses in the field of esthetic dentistry:

- Instant print
- 35 mm
- Electronic still
- Video action

Each of these will be covered in detail.

Instant Print Still Photography

The main advantage for taking instant photographic prints is the knowledge that you have a certified legal pretreatment record on hand before you make any alterations. Often, 35-mm film sent to an outside laboratory for processing has been lost. Having the instant photograph assures at least some type of record of the patient prior to treatment.

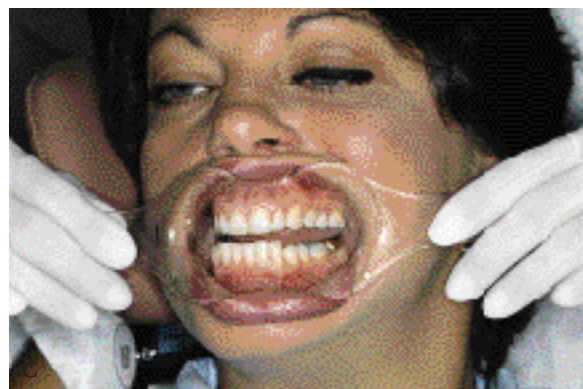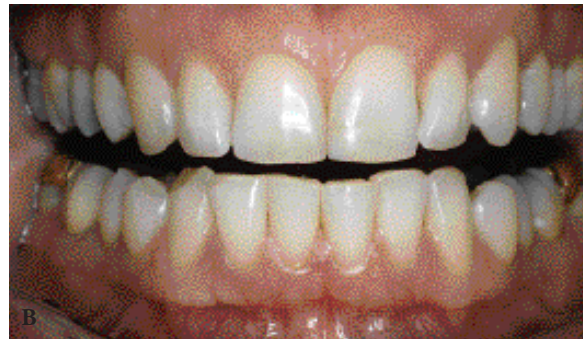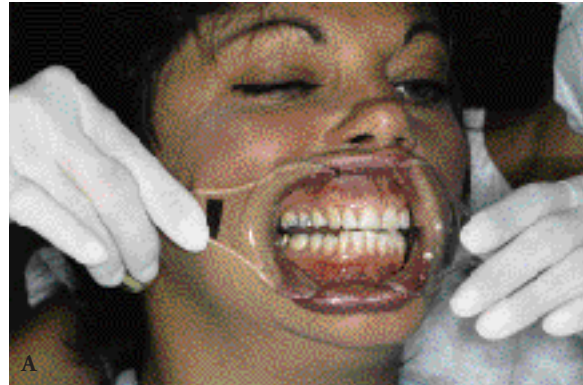A second important use is the ability of the instant camera to quickly record the patient's full face while smiling. This photograph should be attached to the patient record for easy patient identification by your staff.

By far, the best instant print photographic set-up is that developed by Lester A. Dine, Inc. (Macro 5). A full-face photograph from most other instant cameras is not sharp enough to clearly see incisal edges or other identifying tooth characteristics. The Dine set-up is an exception; this easy-to-use camera system takes the sharpest instant photograph of any camera we have ever tested. Adapted from Polaroid's Macro 5 camera, this new version also streamlines picture-taking with a unique focusing mechanism based on the convergence of two circles of light into one circle.

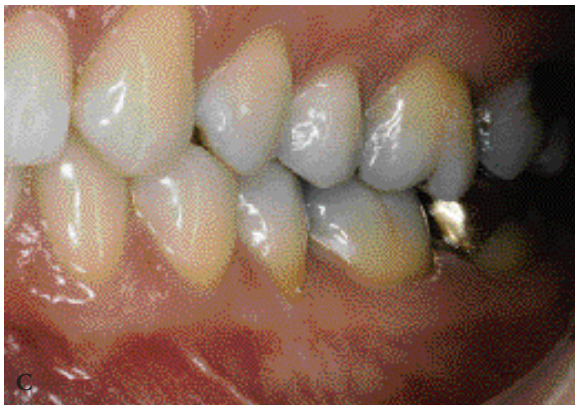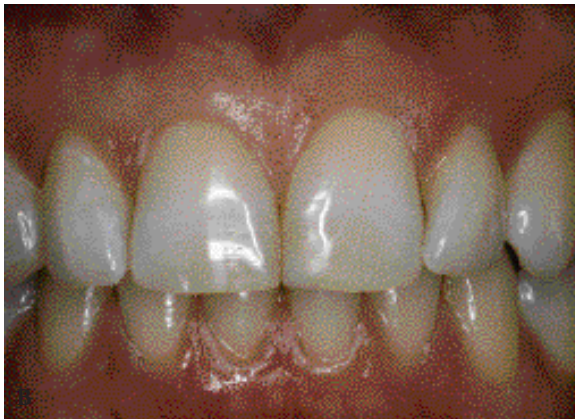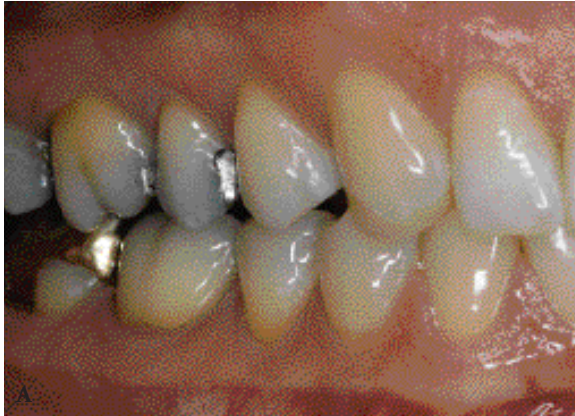35-mm Cameras

The 35-mm cameras are classified into two major categories: rangefinder and single lens reflex (SLR). There are key functional differences between these types of cameras, of which the most important to the dental photographer is the focus mechanism. The SLR is preferable for close-up work because the photographer sees almost exactly what the final picture will look like when he or she looks through the viewfinder. This is because the viewfinder is designed to "look" through the picture-taking lens.

In a rangefinder camera, on the other hand, the viewfinder is separate from the lens. In typical photography in which pictures are taken from distances of several feet or more, the rangefinder works fine. In close-up photography, however, the offset of the



Figures 5-5A and C: When taking direct, lip-retracted views of the right and left sides, the arches can be best seen by relaxing the retractor on the opposite side and pulling outward and harder on the retractor on the side being viewed. Figure 5-5B shows the center position with the lips retracted and teeth slightly apart to show the incisal edges.



Figures 5–6A to C: These close-ups, right, center, and left views are taken with the patient in centric occlusion. It is a direct view of both right and left arches but taken usually at $f/22$ or $f/32$ increasing the depth to produce extremely sharp images. Focusing should be done on the bicuspid area in both lateral incisors in the center view.

viewfinder from the lens makes it difficult to accurately compose the picture.

In summary, the SLR is recommended because “what you see is what you get,” as compared to the rangefinder where what you see is not quite what you get.

There is an almost unlimited number of camera brands. It is fair to say that any brand name camera body (Minolta, Olympus, Nikon, Canon, Yashica, Leica, etc.) will serve the basic requirements of dental photography. If you are considering purchasing a camera specifically for clinical use, there are a few features which, while not necessary, are worth considering. These features include interchangeable focusing screens, high-synchronization speed, through-the-lens (TTL) flash metering, autofocus, and autoadvance.

Focusing Screens

Most cameras are equipped with a split-image focusing screen, which makes it easier for you to focus your picture by lining up the middle section of your subject. While this is acceptable, a grid focusing screen may be a more convenient choice. The grid allows for accurate and repeatable placement of the subject on the film. This is critically important for “before-and-after” photographs. A grid screen can be used only in cameras that allow for interchangeable focusing screens. This type of screen is also helpful if you are making titles or close-up art photographs.

Synchronization Speed

The synchronization speed is the highest shutter speed with which a flash may be used with a camera. A camera with a synchronization speed of $1/60$ th second or less should be avoided, as this relatively slow shutter speed can result in blurred images due to camera movement during flash photography. Many cameras now come with speeds of $1/100$ th to $1/250$ th second, producing sharper images and allowing more versatile use of the camera and flash, both in and out of the office.

Through-the-Lens (TTL) Flash Metering

TTL flash metering is an option that makes dental photography much easier (see the section on Illumination for a detailed explanation). The TTL flash technology has placed complex lighting techniques into the hands of all photographers. Furthermore, if you also plan to use your dental camera as your personal camera, TTL metering is almost essential.

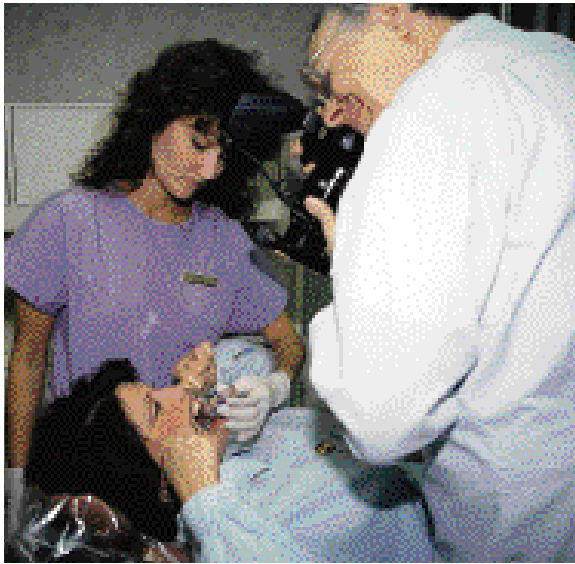

Figure 5-7A: The first of two alternative positions for taking the occlusal view of the full-arch photographs. Anytime mirror photographs are taken, be certain to rinse the mirror with hot water first, wiping it clean with tissue, to keep it from fogging in the mouth.

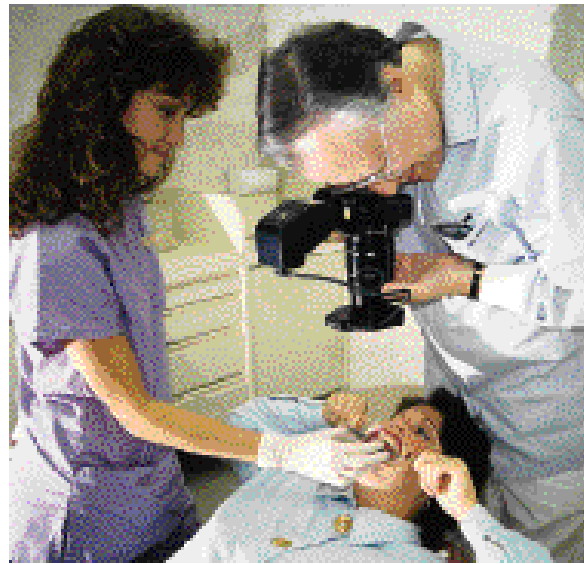

Figure 5-7B: The second position taken from over the patient's face can usually be more effective but also requires the patient to open the mouth extremely wide to get the last molars.

Automatic Focus

The relative lack of subject contrast makes teeth difficult subjects for some autofocus cameras. While it is also possible to use most sophisticated

cameras in a manual mode for dental photography, the inability to accurately and consistently photograph at specific magnification ratios with autofocus cameras makes them unsuitable for most den-

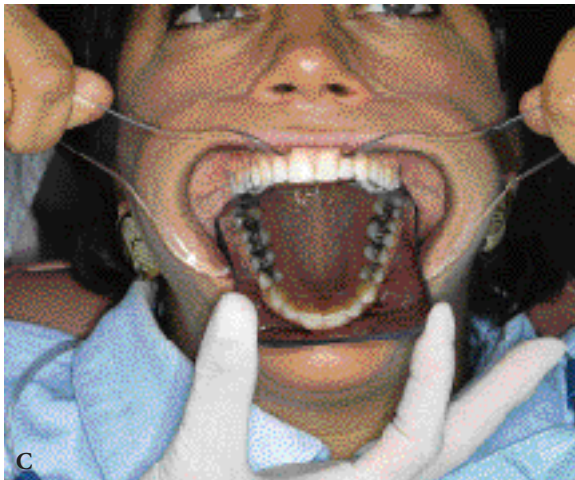
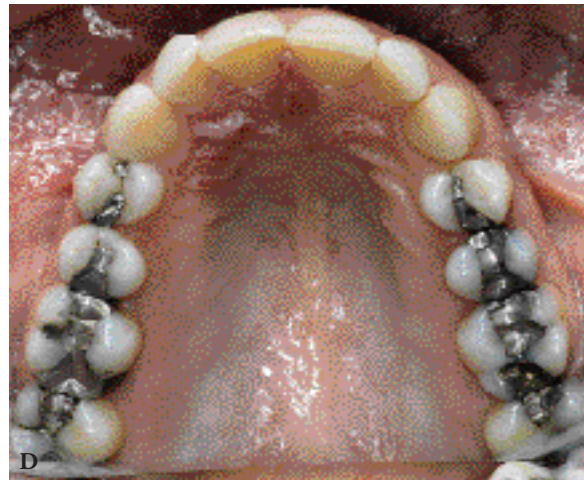
Figure 5-7C: After the assistant correctly places either medium or small retractors, the patient then holds them in place while the assistant places the heated mirror behind the last molar, asking the patient to open the mouth extremely wide. Figure 5-8D was made from the frontal position (Figure 5-8A) and shows that the posterior tooth has been cut off as well as some slight fogging on the back of the mirror.



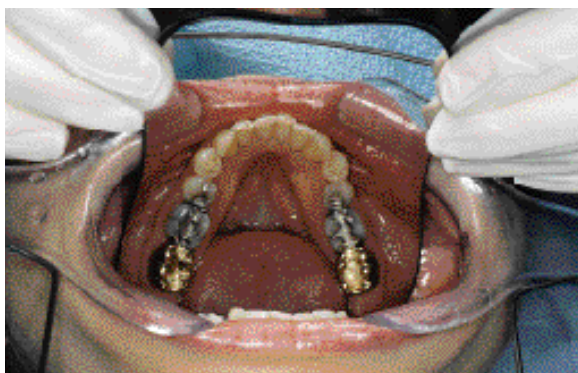

Figure 5-8A: This reverse picture shows the lower arch clearly.

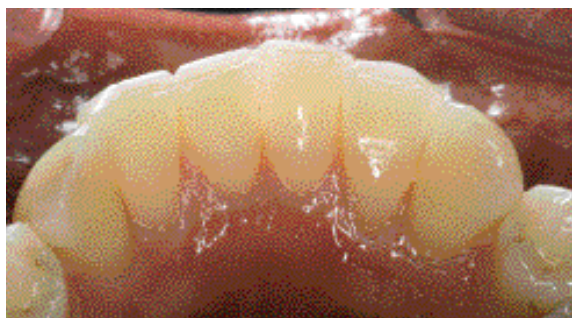

Figure 5-8B: A close-up view of the lingual surface is also possible from this mirror position by changing the angle of the photograph.

tal photography. However, autofocus cameras may be useful in surgery or at other times when you may wish to use only one hand to take a quick picture. Also, if you intend to routinely use your camera outside of office, this is another option well worth considering.

Automatic Advance

It is nearly impossible to manually wind a 35-mm camera without taking your eye away from the viewfinder. An autowinder advances the film and cocks the shutter after an exposure is made. The

winder permits you to make multiple photographs without removing your eye from the camera. This ability allows for sequential photographs with the same composition. Autowinders may either actually be built into the camera body or added on as an accessory. Motor drives do exactly the same thing as winders, only much more quickly. They are usually much heavier than winders and are, therefore, not recommended for this type of photography.

In conclusion, a 35-mm single lens reflex camera is the single best choice for dental photogra-

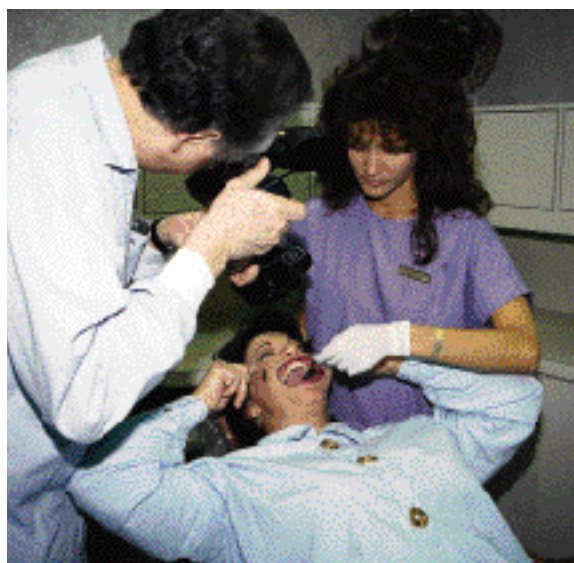

Figure 5-9A: A close-up quadrant or lingual view can be taken by having the patient hold the retractors and the assistant hold a narrow front-surface heated mirror over one of the quadrants.

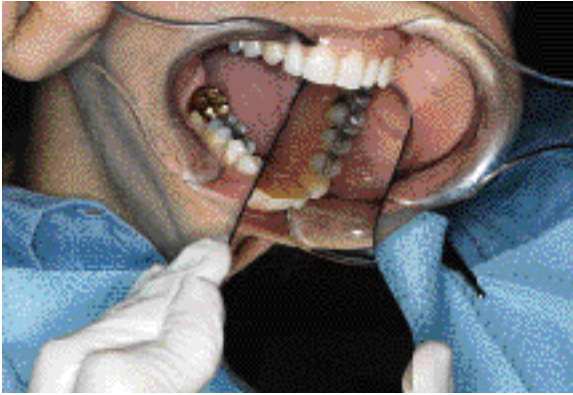

Figure 5-9B: The same mirror position can be angled easily to achieve a one-to-one view of just four or five teeth.

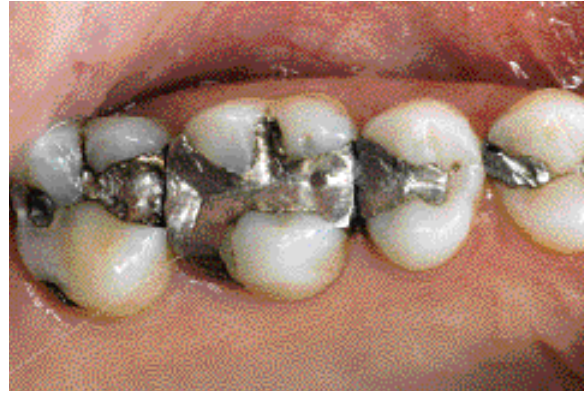

Figure 5-9C: From this close-up view, technique changes can easily be seen. Any abnormalities would be best photographed from this view, especially if individual teeth will be dramatically changed.

phy. A camera with interchangeable focusing screens, a high synchronization speed, TTL flash metering capability, autofocus, and autowinder capabilities is an ideal choice. You will also need to understand the following options, characteristics, and techniques of 35-mm photography as they relate to dentistry to consistently produce good quality photographs.

Lenses

A wide choice of lenses is available for 35-mm cameras. It is possible, however, to limit the number of lenses we choose from if we consider some additional factors.

Focal Length

The focal length (FL) of a lens determines its picture-taking characteristics and is the distance (in millimeters) between the film plane and the lens when the lens is sharply focused on an object at infinity. Generally, lenses are divided into three broad classifications based on their focal lengths: wide angle or short focal length (FL < 35 mm); normal (FL = 50 mm); and telephoto or long focal length (FL > 100 mm).

We usually think of lenses and focal lengths in terms of angle of view. We see a lot of the scene with a wide angle lens. As we change to a normal

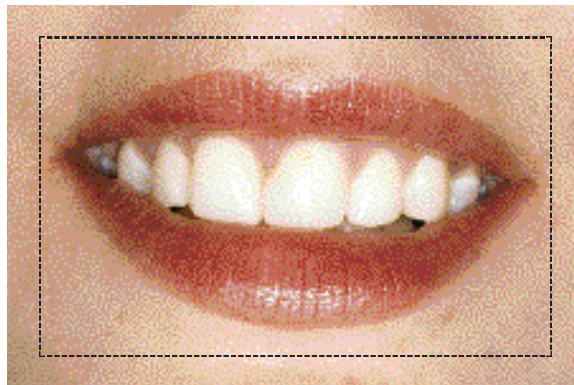


Figure 5-10: If you are taking a photograph which will eventually be shown on television, be sure to incorporate extra area in your photograph since it will be cropped in the final television view.

and then a telephoto lens, the scene in the viewfinder narrows and also appears foreshortened.

In order to choose among the various focal lengths, we need to consider attributes other than just angle of view. Let us briefly consider working distance, image magnification, and perspective.

Working Distance. Working distance, the distance between the lens and the subject, is another characteristic of focal length. The greater the focal length of the lens, the greater its working distance. Suppose you intended to photograph a patient's full face; you could find yourself 40 inches away from the patient with a 100-mm lens, 20 inches away with a 50-mm lens, or about 10 inches away with a 24-mm lens. The face in each of these photographs would be the same size, although they would all look slightly different. A longer focal length lens will diminish the apparent differences between the "hills and valleys" of the face, making it appear flatter. A shorter focal length lens will accentuate the differences, for example, making the nose appear much more prominent than it really is (the "fish eye" look). These considerations are important for dental photography. Therefore, to avoid having to work at uncomfortably close distances to the patient's face and to minimize unflattering distortions, the 100-mm lens should work best.

Magnification Ratios. Image magnification refers to the size of the subject on the film or in the

viewfinder of the camera. There are several factors that influence image magnification; focal length and working distance are two of the most important. At a given camera-to-subject distance, image magnification increases with increasing focal length or decreasing working distance. In other words, the closer you get to the subject, the larger it appears.

Magnification ratio is defined as the ratio of image to object size (image/object).

A magnification ratio of 1 to 1 (1:1) indicates the object and its image on the film are the same size. A frame of 35-mm film is 1×1.5 inches. If you are photographing at a magnification of 1:1, you are photographing an area 1×1.5 inches in dimension. The upper central incisors might be photographed at this magnification.

A magnification ratio of 1 to 2 (1:2) indicates the object is twice the size of its image on film. At a magnification ratio of 1:2 on 35-mm film, you are focused on an area 2×3 inches. The mandibular occlusal views can be photographed at this magnification.

Perspective. Perspective refers to the relative spatial relationship between objects in space. Strictly speaking, photography depends mainly on the camera-to-subject distance. It is important to remember that focal length has no effect on perspective.

During normal conversation, people are usually at a distance of about $3\frac{1}{2}$ feet (40 inches) from

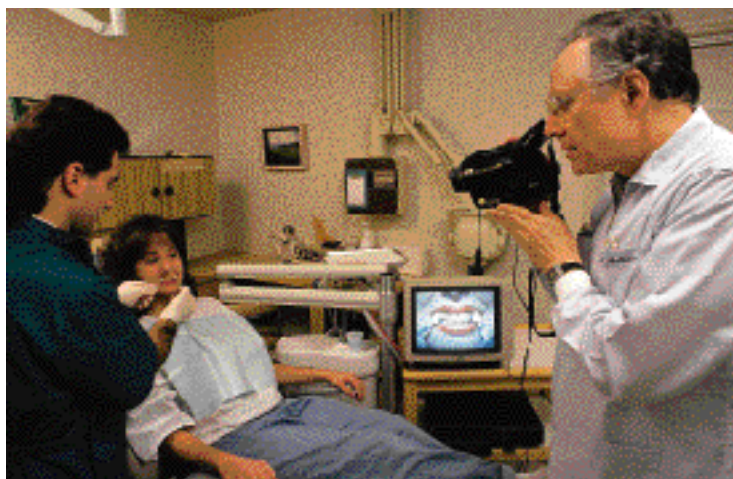

Figure 5-11: An extraoral video camera is another excellent way to communicate to your laboratory technician shade, lipline, and facial form with the patient speaking and smiling.

each other. At this distance we see primarily the head and shoulders of the person with whom we are speaking. This interpersonal distance is approximated by the 100-mm lens. Therefore, the 100-mm lens provides what appears to be a true perspective in full-face photographs.

Close-Up Photography Lenses

Since most standard lenses will not allow for close-up photography at high magnification ratios, special lenses are required.

A discussion of the differences between standard lenses and macro (or close-up) lenses is most appropriate at this point. These differences are best illustrated with the following exercise. If you focus each lens (the standard and macro) at something far away and slowly begin walking toward the subject, refocusing as you get closer, as you approach the subject the object distance decreases. You will find that you will be able to get within two or three feet of the subject with the “standard” lens. It is impossible to get closer and keep the subject in focus. The macro lens, however, will allow you to get within inches of the subject. Image magnification will be greater with the macro lens because the camera is closer to the subject. Thus, a single tooth or even a part of a tooth can be made to fill the viewfinder and, thus, the eventual picture.

Alternatives to Macro Lenses

There are other ways of obtaining photographs at the high magnification ratios required by dental photographs. Inexpensive “diopter” lenses attach over a standard lens, allowing it to photograph at higher than its normal magnification ratios. It is also possible to increase image distance, the distance between the rear of the lens and the film, which also increases magnification by using either extension tubes or bellows that are accordion-like, movable extenders. These are really compromise alternatives, each with its own set of problems.

Summary of Lenses

It is possible to summarize the discussion of lenses by recommending the purchase of a macro lens with a focal length of about 100 mm. This lens should, at a minimum, focus from several inches to infinity and up to a magnification ratio of 1:1 without the addition of supplementary lenses or extension tubes.

The 35-mm lens and camera body need not be made by the same manufacturer. Many fine lenses

are made by companies that do not make camera bodies. However, unless you are determined to use one of your existing cameras, you will find most manufacturers have created customized dental photography set-ups that make it much easier for you to take the type of photographs you need.

Once you have chosen from among the options previously discussed, you can then buy a specific 35-mm camera body and lens. Other variables now need to be considered before you can take your first picture.

Cameras and lenses have dials on them that you manually adjust to set various parameters according to the conditions present and what you are trying to achieve. The next sections discuss these variables and how to decide on the appropriate settings.

EXPOSURE CONTROL AND DEPTH OF FIELD

The shutter speed on the camera body and the *f*/stop on the lens work together to control exposure. The shutter is a device inside the camera that opens to allow light to expose the film and then closes. The exposure time is referred to as shutter speed and is selected on the shutter speed knob (1, 2, 4, 8, 15, 30, 60, 125, etc.) or with the newer electronic cameras from the LCD display on the top of the camera. These numbers indicate shutter speed as reciprocal seconds. Thus, a setting of 30 means the shutter is open (and the film is exposed) for a 1/30th of a second. Notice each number is either approximately double or half of the adjacent number. Changing from 125 to 60, therefore, doubles the amount of light reaching the film. Higher shutter speeds yield less exposure. When photographing with flash illumination, the shutter speed must be set at the synchronization speed of the camera (usually 1/60, 1/100, 1/125, or 1/250). This speed synchronizes the time the shutter is open with the length of time the flash operates.

The *f*/stop or aperture numbers appear on the barrel of the lens and typically range from 2 or 2.8 to 32. The aperture number is a measure of the size of the opening at the back of the lens through which the light passes. Higher aperture numbers indicate a smaller opening, allowing less light to pass through and strike the film. Although the pattern is not as obvious as that of the shutter speeds,

changing between adjacent *f*/stops also either doubles or halves the amount of light striking the film. As with shutter speed, changing to the next *f*/stop number increases or decreases the exposure by half.

Depth of Field

The range in front of and behind a sharply focused subject in which details also look sharp is called depth of field. Depth of field is influenced by two factors: focal length and working distance. At a given *f*/stop and camera-to-subject distance, longer lenses will have less depth of field. Depth of field also decreases as camera-to-subject distance decreases. Stated differently, depth of field decreases with increasing image magnification. After all these factors are fixed for a given photograph, the *f*/stop will determine the depth of field; as the *f*/stop increases, so does the depth of field.

Depth of field is an important issue for the dental photographer. The longer lens (100 mm) and short work distances required for most intraoral photography take their toll on depth of field. It is extremely important to be photographing at the highest possible *f*/stop numbers in order to obtain adequate depth of field. *F*/stops of 22 or 32 are suggested.

ILLUMINATION

Theoretically, almost any source of light could be used for dental photography. In practical terms, the choice is between continuously radiating sources, such as floodlights, and relatively brief emitting sources, such as flashes. The quantity of light, quality of light, and the heat produced are important factors in choosing between these types.

The use of floodlights should be avoided because, while they produce sufficient light, they also generate too much heat, creating discomfort for the patient. Flashes, by comparison, provide high-intensity, low-heat, short-duration bursts of light. The illumination is daylight quality. Some flashes may have an abnormally high UV component; if so, you should use a skylight or UV filter on the lens to compensate. Also, because of the fast speed of flash photography, camera/subject movement during close focus photography is generally not a problem. It is recommended that all dental photographs be made with flash illumination. Be sure to shoot several test rolls to make certain your light source looks balanced in your developed slides.

Flash Photography

All flashes work in basically the same manner. When the flash is fired, electrical energy stored in capacitors is rapidly discharged through a flash tube, creating a burst of light. Immediately after firing, there is a short period of time when the power capacitors are recharging and the flash will not fire. This is referred to as recycle time.

Recycle time is influenced by the type of power source. Battery operated flashes typically recharge more slowly than those operated with AC power. As the batteries discharge, the recycle time becomes longer. This can significantly extend your chairside time. Batteries can also be a large expense. As an alternative, you may wish to purchase a recharger with rechargeable batteries. Although shorter lasting than conventional batteries, in most practices one set should last for a day and can then be recharged in the evening. In view of the limitations of batteries, you may wish to obtain an AC power adapter for your flash system, which will shorten recycle time to several seconds or less.

Important considerations with the use of flashes include the intensity of the flash, the ability to control the amount of light reaching the film (exposure control), and the ability to position the flash.

The amount of usable light in flash photography is determined by the intensity of illumination of the flash and the distance between the flash and the subject. It is imperative that the flash allows you to use an *f*/stop of 22 or 32 when photographing at magnifications of 1:2 or 1:1. Almost all flash units provide enough illumination for intraoral photography because of the short working distances involved (less than twelve inches) when photographing at these magnification ratios. In fact, you are much more likely to have a problem with too much light.

In general photography, three variables can be manipulated to control the light exposure of a subject: (1) the distance between the flash and the subject; (2) the *f*/stop of the lens; and (3) the actual output of the flash. In dental photography, the first variable cannot be manipulated because to achieve standardized magnification ratios, you must maintain specific working distances, usually short ones. Likewise, the *f*/stop variable cannot be changed from 22 or 32 without excessively reducing the depth of field. Thus, if you want to keep the *f*/stop high, the ability to vary the output of the flash is

the only effective way of controlling exposure during dental flash photography. Flashes with TTL (through-the-lens) metering capabilities electronically adjust the duration of the flash by metering the amount of light that eventually strikes the film. When the camera senses that the right amount of light has reached the film, it stops the flash. A common feature among many camera models, TTL metering enables even novices to achieve excellent results in close-up photography.

Ring Flash versus Point Source Flash

Flashes are manufactured with two distinctly different design styles, ring and point source. The ring flash is a circular flash tube that fits around the lens barrel. The point source flash is the more typical of the two. It consists of a linear flash tube within a rectangular reflector housing that is mounted near and even to the front of the lens. It can be rotated around the barrel to different positions in order to ensure that the flash properly illuminates the subject.

The ring flash is the easier of the two to use. Its major advantage is that by surrounding the lens it is always pointed directly at what the lens is focused on. Because the flash surrounds the lens, it projects shadowless illumination. However, shadows are very useful in establishing form, particularly in two-dimensional representations of three-dimensional objects. Thus, photographs taken with ring lights may appear somewhat unnatural because of a lack of shadow modeling.

Point source flashes sometimes are awkward or less effective when trying to illuminate the same area that the lens is viewing, such as with subjects deep within the mouth. Because the point source creates shadowing, however, it creates photographs that have a more natural appearance.

Although the point source is more difficult to use, it can yield superior results. If untrained office personnel will be taking photographs, you may have better results with a ring flash. The Lester Dine Company manufactures a combination ring and point light source flash. Minolta cameras use a ring flash divided into four quadrants. You can use one, two, three, or all four to get the effect you want.

FILM

Film is a multilayered medium consisting of four layers: antiscratch, emulsion, support, and antihala-

tion. Photographically, the emulsion is the most important layer.

The black and white emulsion is a suspension of silver halide crystals in a gelatin-binding medium. The gelatin is much like jello, minus the sugar and food coloring. The silver halide crystals provide the film's light-capturing abilities. Color films use different processes.

Film Speed

Generally speaking, slow films require a lot of light for proper exposure. These films have very small silver halide grains and are capable of recording the finest details. High speed films require less light for proper exposure, but these films have large silver halide grains and are incapable of recording fine detail.

The amount of light a particular film needs for proper exposure is expressed by its ISO/ASA speed rating. The ISO/ASA scale is linear and inversely proportional to the amount of light required for proper exposure. In other words, a film with an ISO of 400 requires half the amount of light for proper exposure than does a film with an ISO of 200. Changing the ISO rating by a factor of two either doubles or halves the required amount of illumination. A practical demonstration of the principle of ISO film speed might involve using a weak flash that allows you to photograph at no smaller an aperture than $f/16$ with a 100-speed film. You could photograph at $f/22$ achieving greater depth of field, using the same flash, by switching to a 200-speed film.

Speed versus Image Quality

The trade-off in choosing films is between speed and the ability to render fine detail. Faster films (those with higher ISOs) allow for photography at high f /stop (or shutter speed) numbers with little illumination. Slower films allow for the recording of fine detail and require more illumination. The best speed/detail compromise for dental photography is to use film in the ISO/ASA range of about 64–200.

Film Categories

The four broad categories of film include black and white negative, black and white positive, color negative, and color positive (or slide). Dental photography almost always is done using color positive transparency (slide) films. It is possible to make a print, either black and white or color, from slide

film, but you will lose quality in the extra processing step. It is best to choose the most appropriate film category for a specific need. In other words, do not shoot color positive slide film if your images are all to be made into prints.

There is an industry-wide convention of naming slide films with the suffix "chrome." Kodachrome, Ektachrome, Fujichrome, and Agfachrome are examples. A good choice for dental photography is Ektachrome 200.

Economics may also play a role in the selection of your film type. Slide films are usually less expensive to shoot and also generally easier to store.

Film Storage

If you are taking photographs primarily for your own patient education, albums, and to give copies of their before and after pictures to your patients, color prints may be preferable over slides. However, adequate patient photographic records generally require taking a large number of photographs and, therefore, it would be better to use 35-mm slides. This could also avoid a serious storage problem. The slides can be stored in plastic sheets of 24 or 36 slides per sheet. You can set up horizontal files that permit the sheets to be hung from storage racks or placed in albums and arranged in alphabetical order.

The plastic sheets come in either polypropylene or archival quality plastic (from 20th Century Plastics) for longer lasting storage.

For extended storage, keep unexposed film in a cool, preferably dark, location. You may also wish to purchase film in lots of 20 (called a "brick") with the same emulsion number in order to ensure color matching from roll to roll. Film should also be processed as soon as possible after it is exposed.

Color Quality

Accurate color reproduction is assured only if there is a match between the spectral sensitivity of the film and the spectral distribution of the light source. Manufacturers have designed films for use under tungsten light, fluorescent light, and daylight.

Tungsten light (regular light bulbs) has a spectral distribution with proportionally more red than blue or green. Fluorescent light has more green and daylight illumination has a fairly even spectral distribution. If there is a mismatch between the film type and light, the photographs will be off-color.

For example, color photographs made with daylight balanced films under tungsten illumination will appear too red, while those made with tungsten balanced film under daylight illumination will appear too blue. Because flashes emit a daylight quality illumination, which will also generally counteract your room light, you should use daylight balanced film when you do flash photography.

USEFUL ACCESSORIES

Lip and cheek retractors are necessary to display the teeth and internal structures of the mouth. Retractors are made of plastic, metal, and wire. Although metal retractors are more durable and more easily sterilized, they can create light reflection problems. Plastic retractors must be cold sterilized and are less durable, but they present no reflection problems. Retractors are available in various sizes in both adult and child versions and in a combination style which is adult-sized on one end and child-sized on the other. It is useful to use the child (smaller) retractors when photographing the upper or lower arch view to allow you to expose more of the cheek.

Mirrors are necessary to take pictures of some of the teeth or to get a particular view of the teeth and oral cavity. Mirrors are made in a variety of sizes and shapes and may be made of metal or glass. Metal mirrors are less expensive than glass and are sturdier. However, they are not as reflective or as optically pure as glass, and they degrade photographic images somewhat. Glass mirrors may be either front or rear surfaced. Rear-surfaced mirrors have two reflecting surfaces (the front and rear surfaces of the glass) and should be avoided. Front-surfaced glass mirrors provide the best photographic surface. Unfortunately, they are also the most expensive and fragile. As previously mentioned, in order to avoid fogging of the mirror, run hot water over its surface before placing it in the mouth. Also, handle the mirror carefully because it scratches easily and, therefore, may need frequent replacement.

A Point-and-Shoot Camera

The cameras discussed so far in this chapter are capable of taking the range of full-face to magnified intraoral views. Unfortunately, they cannot take wide angle or group photographs showing an event or a patient in a particular setting. For these types of pictures, you need to use a conventional camera lens or a separate "point-and-shoot" camera. Your

best bet is to purchase a 35-mm or Advanced Photo System "point-and-shoot" camera and keep it ready to take nonintraoral pictures. Maybe the process of making a decision needs to be recorded. For instance, if a patient's spouse or friend is helping you select a shade, you should photograph this event. Include also all persons present during the selection process: you, your assistant, the treatment coordinator, and the laboratory technician.

ELECTRONIC STILL PHOTOGRAPHY

This method of photography can be useful especially in offices that perform only a moderate amount of esthetic dentistry. Consisting of a video disc camera, playback unit, and possibly a printer, these images are produced instantly, eliminating costly developing procedures.

The images are preserved on an optical or floppy magnetic disc, and it is possible to have 50 images on a single disc. The discs can be reused by erasing the images you do not wish to save. Almost everything you can do with conventional 35-mm photography, you can do with the video disc camera.

The single biggest advantage of this type of system is the instant access you have to the pictures you have taken. You will immediately know you have your "befores" before you begin changing anything intraorally.

One special use for this system is that it allows you and your technician to have the obvious benefit of viewing the patient on a monitor in the lab. This can also be useful during shade determination. Another advantage is in being able to transmit the images via modem, making it possible to have an immediate consultation with people in different locations.

The major disadvantage is that this technique is relatively new and the technology is still evolving. Customer support and equipment repairs are problematic. Also, the electronic pictures are more grainy than slides. Hard copies made with a printer lack fine detail and accurate color. However, this technology is probably the wave of the future.

VIDEO ACTION PHOTOGRAPHY

Video is becoming an important adjunct to patient records. The diagnostic interview for most patients

is routine, but for the patient with a difficult esthetic problem, recording his or her concerns, desires, and needs along with your clinical evaluation and resultant prognosis can be indispensable. Patients tend to forget what they say, especially during the initial appointment, so this method of record keeping presents the patients with an accurate and indisputable account of his or her statements as well as your prognosis and any "guarantees" you may offer.

If you have a potentially difficult patient who complains that loss of teeth or any other condition is collapsing his or her face and "producing wrinkles," it is essential to record that patient's facial details. In fact, perfectionist-type patients who are concerned with looking younger may eventually, as mentioned earlier, blame you for causing them to have more wrinkles than they had before. The best evidence that your treatment was not the cause is a good "before" videotape of the patient speaking, laughing, and smiling. Try to obtain this video of your patient without makeup.

After recording the doctor/patient interview, zoom in on the patient in right, left, and center close-up views, while the patient smiles and speaks. Make sure you get the patient relaxed sufficiently to record the maximum smile line. These views will provide further documentation of details such as facial shape, hair, and makeup, and any wrinkling or scars. Next, focus on the patient's mouth, at first smiling, then with lips retracted. Do not forget to use a good front surface palatal mirror for inside views as well.¹

Video is much more effective in the recording of facial irregularities or deformities than conventional photography, and it is still possible to make a print of any single frame if you wish. Do not try to use these prints as a substitute for good slides, however, because printouts from a video freeze frame lack details, have poor color accuracy, and lack longevity.

It is indeed unfortunate that we need to even consider the legal scenario, but the realities of today's litigious climate are inescapable. In the event of litigation, such video documentation could prove invaluable. Remember, in the absence of adequate documentation of a pre-existing causal condition you must bear responsibility for patient problems that appear to result from treatment.¹

To put your patient's mind at ease, assure him or her that the video allows you to confer better with others not present, such as the technician or specialists and, by reviewing the tape during treatment planning, you will not miss any of their concerns. Additionally, the videotaping provides you with the most accurate facial recording, which can augment the diagnostic process so that you arrive at the best possible treatment plan.

These video images can help both you and your treatment coordinator. They will improve communication with your patient about both diagnostic problems and treatment options. A reluctant patient may be far more motivated to pursue treatment after seeing what the camera sees. You can also transfer the images to the computer imaging system so different treatment options can be considered (see Chapter 2). Remember, printouts can be produced at any time during the recording, especially if you see something that is a key point in the discussion. You can give a copy of the print to your patient while keeping one for yourself in the patient's chart.

Another good use of the video camera is recording information to share with your laboratory technician (Figure 5-11). Video gives you the opportunity to show your ceramist exactly how your patient will look while speaking, smiling, and laughing. Shade comparison with multiple camera angles and videos can be more helpful than a single 35-mm slide or instant photograph.

The Color Video Camera

Any of the color video cameras available today is adequate, especially if it has a remote control focus and zoom capability.

The camera should be mounted above the chair and to the patient's right shoulder if you are right-handed or to the patient's left shoulder if you are left-handed. This way the wide angle view will include both you and your patient during the diagnostic interview.

For ease of use, it is best to suspend the camera from a ceiling-mounted motorized track (Telemetrics). This system allows for pan/tilt, zoom, and focus capability by remote control. With the remote

control, it is easy for you to move and guide the camera unobtrusively. When the camera is not in use or is being used for the diagnostic interview, it is out of the way and, in fact, is hardly noticed by the patient. It runs quietly so as to not intrude on the interview, and patients do not object when you tell them you are video recording the session for their benefit (see Chapter 2, Figure 2-10).¹

Reference

1. Goldstein RE, Miller M. High technology in esthetic dentistry. *Curr Opin Cosmet Dent* 1993;5-11.

Additional Resources

Chuman TA, Hummel SK. Teaching photography in dental schools. *J Dent Educ* 1992;56:696-7.

Freedman G. Advanced instant photography. *J Can Dent Assoc* 1996;62:856-8, 861.

Freehe CL. *Dental Photography*. Dental Clinics of North America. Philadelphia: W.B. Saunders. 1983; 27:1.

Goldsmith A. Composition: are there any rules? *Popular Photography* 1992; July:34-42.

Goldstein CE, Goldstein RE, Garber DA. *Esthetic imaging in dentistry*. Chicago; Quintessence, 1997.

Levin RP. High tech has arrived in dentistry. *Dent Econ* 1996;86(3):84.

Manji I. Beyond the bells and whistles: hi-tech/high care dentistry. *J Can Dent Assoc* 1996;62:658-61.

Nash R. Dental photography: an integral part of modern dentistry. *Compend Contin Educ Dent* 1996;17:724-7.

Seino H, Masuda J, Igawa S, et al. Clinical records in dentistry. *Dental Imagination*, Tokyo: Quintessence, 1988:9-44.

Singer BA. Special report: 35 mm intra-oral camera systems. *J Am Acad Cosmet Dent* 1992;7:1-6.

Weathers AK. Photo expert discusses clinical tips for success. *Dent Today* 1987; April:20-2.

Clinical cameras, 35 mm single lens reflex. *Clinical Research Associates Newsletter* 1992;16(9):.

CHAPTER 6

BIOLOGY OF ESTHETICS

Sidney I. Silverman, DDS

Esthetics is a major focus of contemporary dentistry. Heavily promoted by manufacturers' publications and continuing education courses in dental schools and professional associations, most instruction relies on anecdotal reports and some experimental research.²⁹ The most prevalent research efforts relate to color control and duplication, the physical properties of materials, and processing procedures.

It is particularly because of the recent, blind elation about achievement in dental esthetics that this chapter is written, because there appear to be, under this umbrella of outstanding success, many instances of failure. These failures become more apparent as the years pass after completion of the cosmetic treatment. These failures appear early or late, despite the excellent marginal fit, true color rendition, and precise duplication of tooth form. Patients may complain, "It's not me," or that their new teeth are too large, too white, or too dark. Others say, "too much gum shows," or that their lips are too full, too small, or too thin. Still others complain, "all I wanted was to eat and now look at me."²⁷ This may be related to the notable paucity of research in the biology, the psychology, and the sociocultural aspects of esthetics.

These failures are usually the result of violating or at least not heeding some biological phenomenon related to the morphogenesis, growth, development, and degeneration of the dentofacial hard and soft structures, and their related orofacial spaces, the airway, and the esophagus and related tissues. The failures may also be related to the distortions of the static and dynamic activity states of oral function, i.e., mastication, swallowing, respiration, and speech. It is significant to note that these activities have psychosocial correlates.

As the structures of these four interdependent functions move within their envelope of motion, they must always be able to return to their rest positions in any given state or head posture (Figure 6-1). This illustration of the hemisection of the head and neck of a cadaver shows two tubes passing through the head representing the passage of air and food through the facial structures. Any disturbances, such as emphysema in adults or asthma in children, will affect the facial esthetics. Both of these respiratory disorders usually result in an open

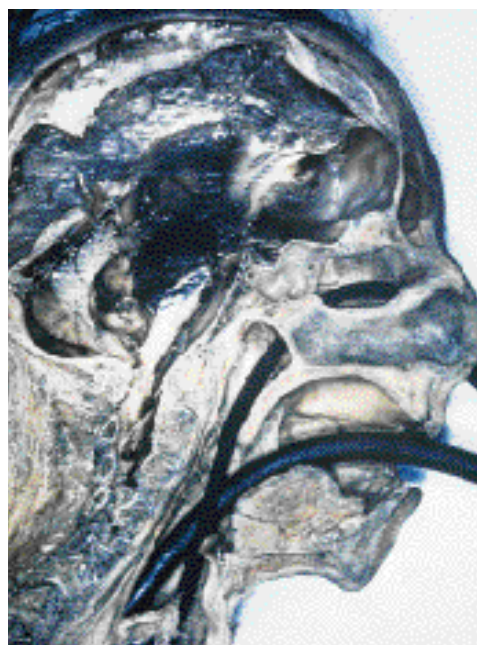


Figure 6-1: Esthetics of the face depends essentially on the static and dynamic state of the structures and activities of the face. The respiratory and masticatory passages are denoted by tubes.

anterior bite, dry mouth with serious diminution of saliva, and debris and plaque accumulations, which can increase the incidence of caries and periodontal disease. Degenerative neuropathies affecting jaw closure during swallowing, and mastication cause alterations in lip form, and asynchronous jaw closing forces, which also affect the esthetic results.

Body posture in part dictates the position of the mandible during swallowing, mastication, respiration, and speech. Since the mandible is suspended in space in a sling of musculature and a highly displaceable two-chambered temporomandibular joint, it is vulnerable to displacement by gravity as the body parts are altered in relation to each other. This must be taken into account when you rehabilitate a dental occlusion. For example, tongue and lip thrusting during speech and swallowing are related to misalignments in the dental arch form and individual tooth positions.

These derangements in form and position have adverse effects on esthetic outcomes in treatment. When patients suffer degenerative neuropathies or musculoskeletal problems affecting the neck, spine, or general body posture, they may develop aberrant jaw closure and posture during respiration. Obviously, the ideal head and neck position is the erect posture during which occlusal records are taken. The erect head posture is also the ideal posture for

effective chewing, swallowing, speaking, and respiration (Figure 6-2). It is also the ideal position for optimal vision, hearing, and vestibular responses.³³ Patients with spinal vertebra changes from arthritis or work habits develop exaggerated head flexion at rest (Figure 6-3). However, when they walk, sit at a table, or speak to someone, they extend their necks to establish eye contact. This adjustive movement from the flexed rest position induces a posterior premature occlusion, resulting in an anterior open bite (Figure 6-4). When the head and neck are flexed by gravity, disease, habit, or trauma, the patient may develop an unsteady gait or altered senses. They may be required to visually observe their footsteps to avoid stumbling. Such chronic postural habituation may eventually create a mandibular protrusion and anterior premature closing contacts. Accordingly, an exaggerated horizontal overjet may be required to create a good esthetic appearance during speech and respiration.

It appears then that any esthetic treatment would need to include the stabilization of the head and neck and thus improve the sitting or standing posture with the head erect at rest. Neglect may result in treatment failure. Other major reasons for unsuccessful esthetic outcomes are the significant psychophysiological and the sociocultural aspects of dental therapeutics.³⁵

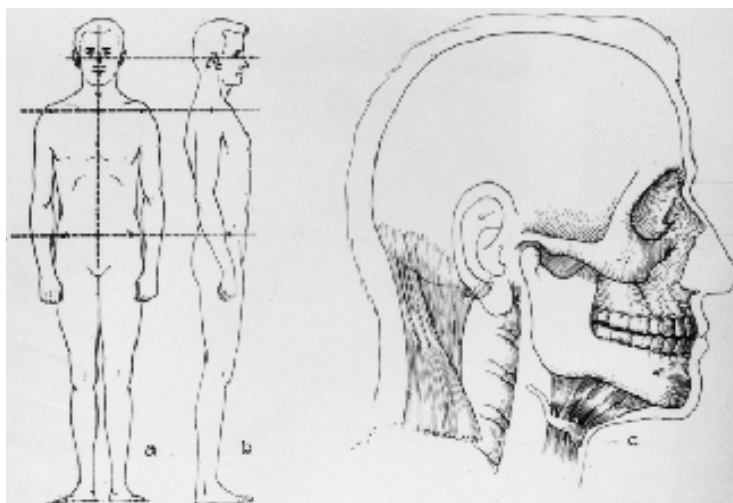


Figure 6-2: This illustration demonstrates how in the erect posture, the hip axis, shoulder axis, and eye axis are all parallel to the ground. The occlusion is stable in the centric relation position, the maximal intercuspal position, and the free way position (the vertical dimension of rest when the teeth are not in contact).

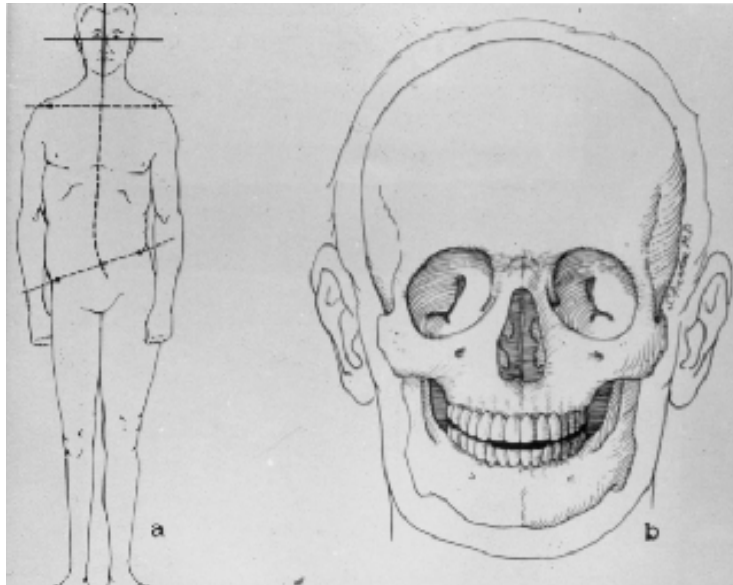


Figure 6-3: This illustration indicates how a disturbance in the hip axis alone may be compensated for by maintaining the shoulder axis parallel to the ground, thus maintaining fairly stable occlusion positions.

In summary, esthetic outcomes of treatment are influenced and perceived by patients and dentists in specific ways due to a wide range of factors, including physical, biologic, and cultural. Patients frequently express their reactions to esthetic treatment through verbal or nonverbal behaviors, or through a

spectrum of symptoms from digestive and metabolic reflexes, allergic, respiratory, and circulatory manifestations to antisocial and maladaptive behaviors.³ Verbal responses are often expressions of joy and confidence, smiling, laughter, and increased eye contact, high head posture, and firm, confident

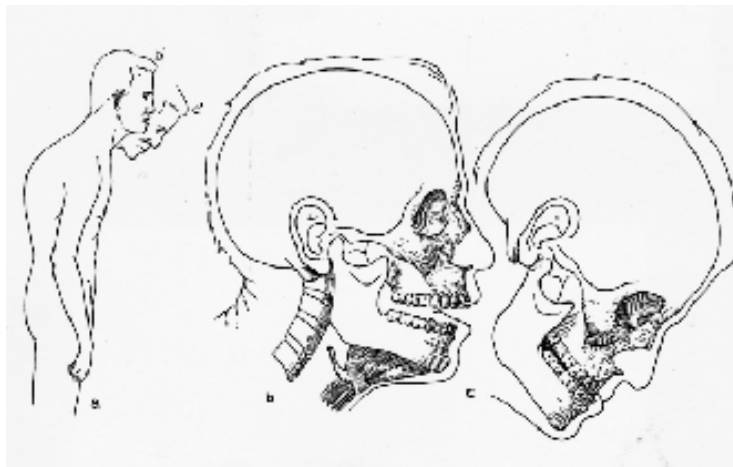


Figure 6-4: As patients age, disease of the spine may develop because of changes in head and neck posture. This postural problem may lead to a Class III pseudoprognathic occlusion with premature contacts.

body posture and gait. On the other hand, low self-esteem, associated with dissatisfaction, is accompanied by negative comments about appearance in general.¹⁵ The most serious expression of dissatisfaction with esthetics is the nonverbal grimace, jaw clenching pulsations, cold sweating, and tension in the facial, temporalis, and mentalis musculature—often observed as lip pursing and facial tics.²⁴

Visual and acoustic stimuli, for instance, are subject to enhancement and modification by external events, equipment, and/or technologic interceptions. Just as harmonics and overtones, pitch, and decibel perception can be augmented by electronic or mechanical or other factors,³⁹ you can create an esthetic effect in dental treatment by using artificial materials to create an illusion. This illusion can be enhanced further by both the artifice and reality to satisfy a patient's own, sometimes distorted, perception of his or her image.⁴⁰

The psychological implications of a cosmetic dental treatment are infinitely more complex than the perception of an auditory stimulus. The whole range of a patient's self-image and self-concept should play an essential role in the dentist's clinical judgment relative to esthetics. Personality disorders, psychosomatic, and emotional dysfunctions are critical factors in decision making.² The adolescent who wants to wear orthodontic braces for very minor tooth irregularities, the young adult who wants white porcelain veneers, and the mature single woman who wants large, long, white teeth arranged without irregularities, all present challenges to you. These patients are not generally capable of reconciling their desired appearance with their real life appearance. They keep them apart, repeatedly changing the desired appearance as you rearrange the shape, color, and position of the already perfect teeth. These cases are often failures and the patients may not allow final cementation.² Ultimately, they seek another dentist and repeat the treatment behavior. The classification of relevant personality disorders and the availability of professional resources for helping these patients is necessary to satisfactorily treat these patients. Ultimately, the dentist may need to protect himself from verbal abuse, office disruption, and malpractice suits from these patients.¹⁸

A recent development in esthetic management has been the computer modeling technology.⁷ This tech-

nology provides imaging techniques to modify the existing full-face, profile, and intraoral appearance of the patient. The anticipated outcomes of treatment with respect to the soft and hard tissue changes can thus be viewed before treatment. The arch form, face height, jaw relations, tooth form, position of the lips, facial contours, and position in the static and the dynamic states may be recorded during mastication, swallowing, speech, and respiration.

A computer can also assist you in the collection of data over a lifetime. It allows data to be retrieved and analyzed for a variety of tissue responses to treatment. It can be helpful in maxillofacial surgery and prosthodontics associated with tumor, trauma, or agenesis and is especially important in reconstructive and plastic surgery.¹ This imaging technology is now available for use to plan esthetic modification relating to tooth form modification or tooth movement. (See Chapter 2)

From this brief introductory discussion of reality and illusion, it is apparent that you must orchestrate multiple phenomena to create a satisfactory esthetic illusion with artificial materials introduced into biologic structures. This range of phenomena includes numerous anatomic, physiologic, psychological, sociocultural, and artistic factors to satisfy not only the patient but also you, the dentist, while adhering to professional and ethical guidelines, the civil law, and malpractice-avoidance requirements.

Central to this complex array of requirements are the morphologic and physiologic characteristics of the orofacial structures and environment within which your treatment will occur. Some of these biologic concepts are variable and give the dentist wide latitude in manipulating esthetic events, such as the specific placement in the dental arch of the anterior teeth which support lip form.³⁴ The anterior teeth are contained within this arch by the labial muscles which have only one bony attachment into the craniofacial skeleton, except for the orbicularis oris, which has no bony attachment. The intrinsic muscles of the tongue tip also have no bony attachment. Since the reciprocal action of the tongue and lips are so variable, you have a wide latitude in placement of the incisor teeth with respect to lip support, speech, and overbite.²² When placing the posterior teeth, the dentist has less latitude in their exact location over the ridge areas because the masticatory muscles, the internal pterygoid,

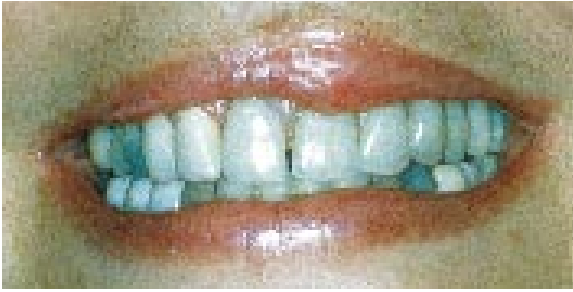

Figure 6-5A: The patient is wearing a provisional removable upper partial denture after the initial surgical wound healing. Also note how the lower lip has a vermilion surface almost twice the height of the upper.

and the masseter muscles have limited lateral traverse when contracting or relaxing. The limits are very narrow because these muscles have bony attachments at both their origins and insertions.²⁸

In addition to normal tissue and structure variations, the other biologic variables affecting esthetics are those where tissue spaces are distorted by acute disease, trauma, surgery, agenesis, and degenerative processes associated with aging and senescence. These numerous disorders overtly modify the oral tissue form, position, and activity.

The interrelationships among tissue variability, function, and healing in the presence of cosmetic dental treatment can be demonstrated in the following trauma case involving a gunshot wound to the upper left face and jaw (Figures 6-5A to G).

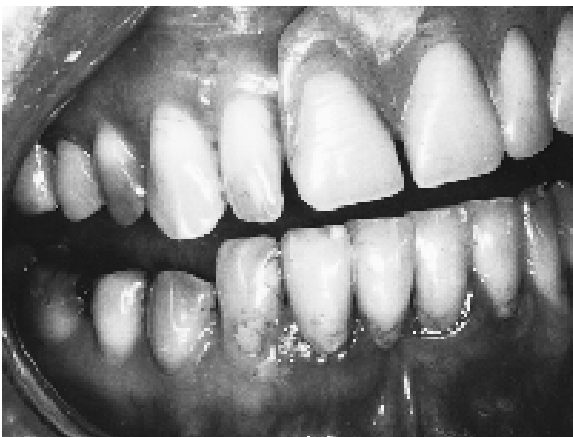

Figure 6-5B: The two planes of occlusion on the lower dental arch complicated the restoration of the occlusion. Note the diastemas, which were corrected in incremental stages.

After the initial surgical intervention, the patient wore a provisional removable maxillary partial denture during healing (Figure 6-5A). Correction of the redundant vermilion lip tissue over the left central incisor was postponed until after the additional healing and correction of the occlusion. The presence of a two-plane occlusion, maintained and unchanged by the provisional restoration, complicated the occlusal rehabilitation (Figure 6-5B). A severe wear facet, seen here on the mesiobuccal of the lower first bicuspid, is typical of this type of occlusal problem, caused by the passive eruption of the opposing tooth at the junction of the two planes. In older patients, this situation would normally be associated with periodontal pockets and excessive tooth mobility. The tooth and bone loss in the anterior segment (Figure 6-5C) necessitated a complex treatment plan that would restore not only proper function but also appearance.

Following the principles espoused by Silverman and Hayashi,³⁴ the upper arch should be expanded by an incremental program of treatment to conform to the catenary curve generated by gravity (Figure 6-5D). In this patient modifying the provisional restorations incrementally, working within the bounds of this individual's healing rate and functional recovery, the arch form, tooth length and contours, vertical dimension, plane of occlusion, and centric relation positions were returned to near-normal. As a consequence of these structural and functional corrections, her esthetic appearance also improved considerably (Figure 6-5E), notwithstanding the marked increase in the vertical dimension of occlusion and the expansion of the

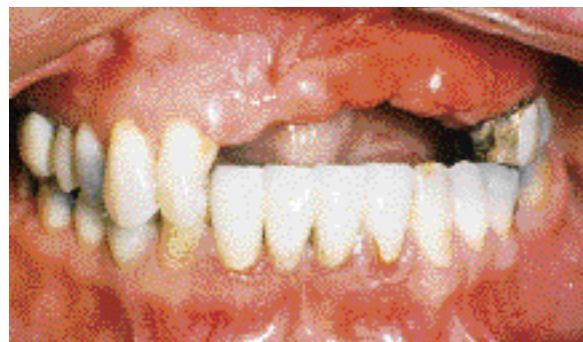

Figure 6-5C: Note the loss of teeth and marked loss of maxillary alveolar bone.

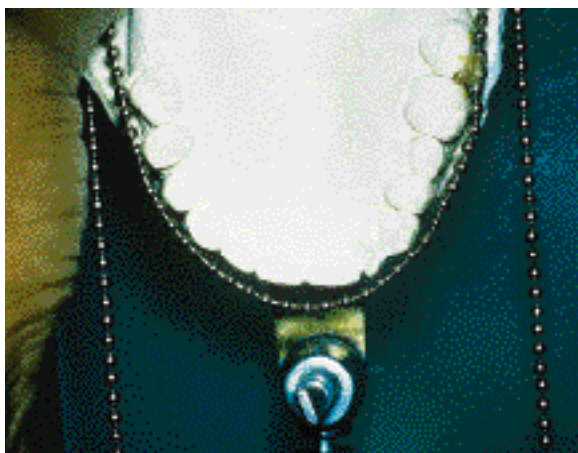

Figure 6-5D: The catenary curve form generated by gravity on her diagnostic casts is used as a guide for her provisional fixed prosthesis. Note how wax was placed on the labial surface of several teeth to model the proposed expansion of the arch.

upper arch. Corrective lip surgery was then performed, resulting in improved lip contour and absence of redundant tissue on upper lip. Especially, note the normal contour and position of the tubercle of the upper lip, the recovery of the diamond shape and form of the philtrum of the upper lip, and the clear and definite border between the vermillion and skin around the lips (Figure 6-5F). The recovery of these facial and lip anatomic landmarks is a clear indication of the recovery of the neural and functional activity of the musculoskeletal tis-

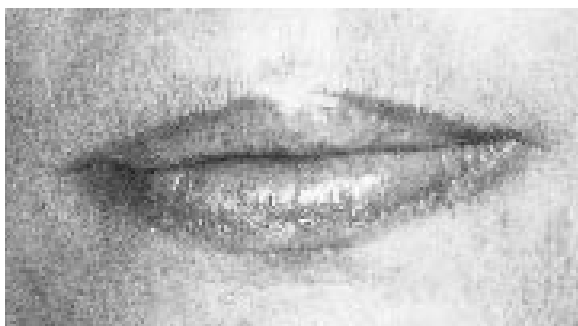


Figure 6-5F: After opening the vertical dimension of occlusion, expanding the arch form to conform to the catenary curve, and modifying the two planes of occlusion to one coherent plane, the patient was referred to a plastic surgeon for corrective lip surgery.

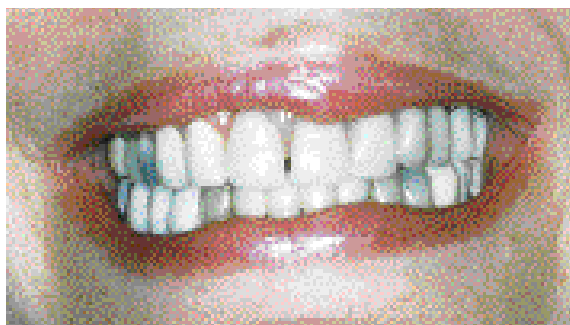

Figure 6-5E: The incremental therapy program not only advanced the health and function but also mediated the improving esthetics.

sues of the oral and facial structure. The patient's post-treatment smile (Figure 6-5G) reveals normal lip position and function, and pleasing esthetics of the restored dentition. Her smile also attests to her renewed positive self-image. Processes for which cosmetic treatment may be sought may be classified into five groups, each of which is discussed briefly:

1. Disorders of morphogenesis
2. Disorders of childhood and adolescence
3. Disorders of adulthood
4. Positional disorders of function
5. Disruption of the dental-alveolar elements

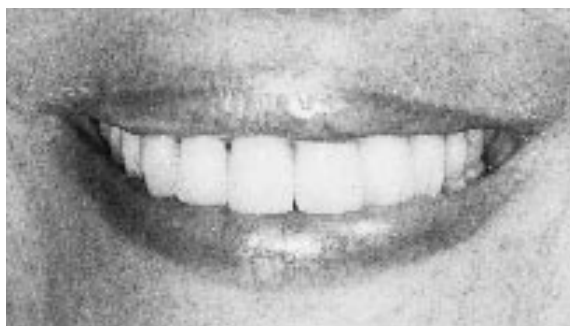


Figure 6-5G: Note normal lip function, improved smile-line contours, and full arch form to support the lips.

1. Disorders of Morphogenesis. The maxillo-mandibular complex in the 12- to 14-week-old embryo may show a wide variety of facial deformities caused by teratogenic agents, stress, or the life style of the mother. In addition, the genetic history of the family may predispose the fetus to inherit facial anomalies. The clinical manifestations of these genetic, congenital, and neonatal manifestations are cleft palate, micrognathia, pseudoprog-nathism, and prognathism. In addition to these common esthetic management problems are the more serious teratologic problems²¹ such as mongolism, Tay-Sachs disease and approximately forty more congenital disorders.²⁶ The period of neonatal concern is from birth to one year of age.

2. Disorders of Childhood and Adolescence. The cranial and facial skeletons have changing growth ratios from ages 1 to 6; 6 to puberty; puberty through adolescence (ages 13 to 18); and finally from late adolescence to young adulthood (ages 19 to 24). The ratio of facial height to cranial height changes, respectively, from 3:1, to 3:2, to 1:1 in adulthood. However, within facial height, the mandible or maxilla or both may have accelerated or retruded growth in any of eight possible combinations, e.g., both jaws may be retruded or expanded; the upper or lower jaw may be retruded with a normal opposing jaw; or both upper and lower jaws may be retruded with an expanded opposing jaw. These aberrations may be caused by dental disease and loss of teeth, myofunctional disorders of lips and tongue, improper orthodontic and/or restorative (i.e., iatrogenic dentistry), pulmonary, metabolic, or hormonal disorders. For example, in childhood asthma, impaired respiration can result in mouth breathing and an open anterior bite, or, large tonsils and adenoid tissue may cause mouth breathing and mandibular displacement. These relatively minor childhood problems, with more significant problems such as a poorly repaired or unrepaired cleft lip and palate, may have substantial effects on any attempt to restore esthetics.

A minor adolescent parafunctional habit of fist-thrusting into the mouth, associated with a maladaptive psychological disorder, caused the extreme anterior open bite seen in Figure 6-6A. Rather than follow the previous dentist's recommendation to resect the jaw to realign the teeth, this 20-year-old woman's current dentist, the author, ground

down the contacting areas of the posterior teeth (Figure 6-6B) until the bite was closed to near-contact on the cuspids (Figure 6-6C). This 30-minute treatment clearly indicated that dramatic orthognathic surgery was not indicated. Most tooth height was removed from the lower molars and minimal cusp height was reduced on the upper molars. With further reduction, the usual restorative procedures of crowns and inlays made a remarkable and dramatic change in facial profile and bite relationships, and no pulp treatment was needed. This vignette demonstrates a major treatment concept that is similar to the surgical diagnostic/therapeutic practice of excisional biopsy. The excision removes the suspect lesion therapeutically, but it also provides and/or confirms a diagnostic judgment. Similarly, in this patient, the tooth reduction accomplished by grinding the cusp heights down confirmed the judgment that a rotational (flexed) movement of the jaws could restore a reasonably normal jaw relationship at rest, maintain proper occlusal function, and provide a major esthetic improvement.

It is, however, the premature loss of teeth during the developmental stages of childhood and adolescence that results in the widest discrepancies in jaw relationships, especially in the Class II (retrusive) mandibular cases. These cases give rise to problems of reconstructing facial height, and horizontal and vertical overbites. It is therefore imperative during diagnostic planning for esthetic procedures to make accurate records of jaw relationships, use photographs, take an oral history, and, when possible, do an examination of the patient's parents or siblings.

3. Disorders of Adulthood. The early adulthood period covers ages 24 to 50 when few esthetic changes take place that are not easily remedied by simple restorative and prosthetic procedures accompanied by continuing periodontal care. The problems of esthetics are relatively simple to solve, even with progressive loss of teeth, migrations and rotations of teeth, diastemas, tooth wear and abrasions, and tooth color changes originating from food and chemical stains. The ease of restoration or maintenance of esthetics rests essentially on the basis that the jaw relationships of face height, arch form, and height and inclination of the plane of occlusion remained relatively stable during this stage. There are also few skin, muscle tone, lip

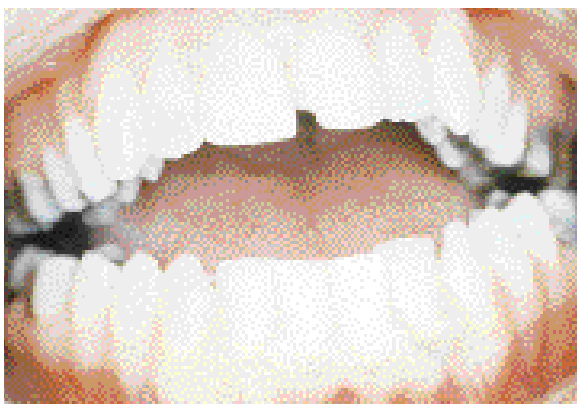

Figure 6-6A: Open-mouth view demonstrating that the only occlusal contacts in the open bite position were on the cusp tips of the opposing second molars.

form, and head posture changes. However, beyond age 45 to 50, patients begin to reveal many of numerous chronic disorders affecting the cardiorespiratory systems, the musculoskeletal system, the neurologic systems, the dermatologic tissues, and the general metabolic and endocrine systems.¹² In addition, negative behavioral characteristics related to esthetics emerge and intensify, especially distorted personality traits, emotional lability, and acute and chronic psychopathology. The incidence of these behavioral and systemic disorders gradually increases to 90% in the 85-year-old-and-up patient group.¹¹ In this fastest-growing age group, the incidence of chronic illness is almost 100%.³⁸ The use of pharmacologic agents and psychoactive drugs

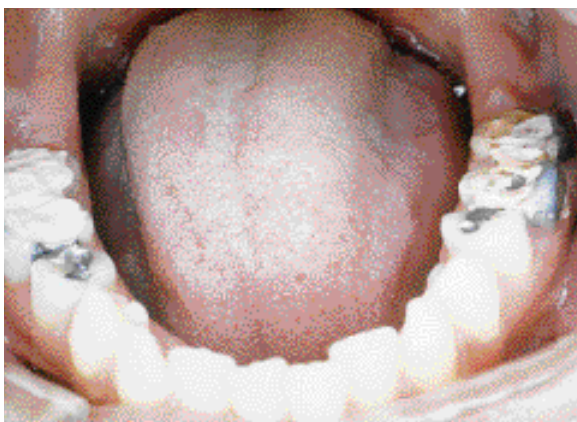


Figure 6-6B: The four lower molar teeth were reduced in occlusal height and filled with a cement base.

reaches such a high incidence that few patients do not require a physician, psychiatrist, or dentist.

4. Positional Disorders of Function. The mobility patterns of the jaw and the stability and posture of the head and neck are critical determinants of esthetics. Obviously, the jaws and head and neck must move to facilitate the functions of speech, respiration, mastication, and deglutition, and to increase the field of vision and the range of hearing. For example, the envelope of motion of speech is generally contained within the envelope of motion of mastication, except for the pronunciation of the “e” sound.^{19,23,25} If the mandible is protruded and the lower incisors are always anterior to the upper incisal edges, the result is usually unesthetic. Furthermore, if the tooth arrangement contributes to production of an acoustically intrusive sibilance or lisp, the esthetic effect is considered unfavorable. Pound¹⁹ proposes an excellent method of using discrete speech sounds as a guide for restoring anterior occlusal relationships of the incisor teeth. Silverman²³ similarly describes the incisal “speaking space” as a therapeutic guide for restoring the vertical dimension of occlusion.

Head posture often becomes an esthetic problem as patients get older. They often develop arthritic spinal vertebrae with a resting state scoliosis, which causes the mandible to be suspended in a protrusive position. Since occlusal records are usually produced in the dental chair with head held firmly erect or in the recumbent position, there is often disparity between the treatment position (an

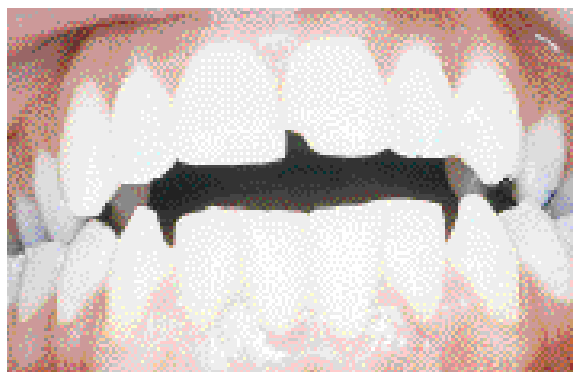

Figure 6-6C: The anterior teeth after a simple half hour of treatment time.

artificial position with the mandible guided posteriorly) and the patient's resting respiratory position where the head and neck are relatively flexed. In these patients the mandible is usually protruded and the lower lip and jaw look prognathic. Thus, wide variations in jaw motion patterns during function must be reconciled for esthetic reasons.

The transition from functions such as breathing to speech, speech to mastication, mastication to swallowing, and swallowing to respiratory rest, must be achieved with a coherence between their respective envelopes of motion that always provides a positive esthetic effect. The center of the constellation of these several functional motion envelopes is the respiratory rest position to which all jaw and head motion must return after any activity, be it crying, sobbing, screaming, jaw clenching, normal speaking, biting, kissing, chewing, or swallowing. The overbite, arch form arrangement, height and inclination of the plane of occlusion, the inclinations of the coronal and root portions of teeth, and the form and position of denture base material are each critical in the formulation of a motion pattern of the lips and jaws that is esthetically appropriate by current professional standards.

It is also essential for patients requiring plastic and reconstructive surgery to be able to accommodate a wide range of jaw displacement associated with any given tooth position and arrangement and to then be able to return to a rest state of quiet respiration.

5. Disruption of the Dental-Alveolar Elements.

The structural and spatial elements of significance in the diagnosis, treatment planning, and reconstruction of esthetics are multiple. They are:

1. The height and inclination of the plane of occlusion
2. The arch form contours of the maxilla and mandible and their relationships in the static and dynamic state
3. The overjet and overbite in the static and dynamic states
4. The individual tooth position in the arch with respect to the coronal and root inclinations relative to the vertical plane
5. The intercuspal relationships with respect to centric relation, centric occlusion, protrusive and other excursive positions

6. The restorative procedures and their esthetic sequelae:
 - a. intracoronary restorations
 - b. extracoronary restorations
 - c. fixed prostheses
 - d. removable prostheses
 - e. fixed-removable prostheses
 - f. implant prostheses
 - g. maxillofacial prostheses
7. Measurements of treatment outcomes
8. Psychological factors
9. Artistic factors
10. Synthesis of artistic and biologic factors into a dynamic state where rhythm, speed, and strength of oral-facial tissue activity are coordinated

A full discussion of these factors in relation to esthetics requires a text that is devoted solely to these issues. Accordingly, this chapter will select only the following important elements, adapted from the preceding list, for further discussion. They are:

1. The biology of lip and face contours and profile
2. The dental arch form
3. The inclination of the labial surface of tooth contours
4. The vertical dimension of facial height
5. The esthetics of adult development and aging
6. Recent diagnostic procedures based on physiologic behavior of tissues

1. The Biology of Lip and Face Contours and Profile. Lieb, Silverman, and Garfinkel studied lip form and position in dentulous and edentulous subjects.¹³ They found that from ages 25 to 95 the lower lip moved progressively anteriorly with increased head flexion and with the loss of vertical face height associated with occlusal changes (Figures 6-7A and B). The Lieb et al. study also demonstrates the anterior/posterior relationship of the lower lip to upper lip in sagittal plane view when comparing 150 young dentulous subjects between 20 to 30 years of age, 54 dentulous subjects 45 years

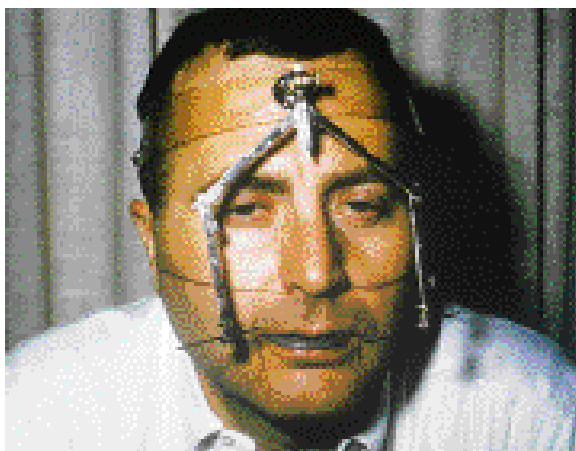

Figure 6-7A: Full-face view of experimental head gear to study position of lip and face structures relative to dental occlusion landmarks.

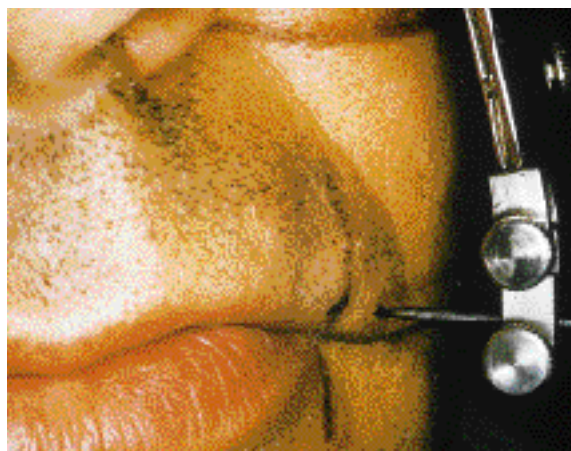


Figure 6-7B: Close view of lip position measuring instrument showing movable pointer that locates soft tissue positions relative to dental arch landmarks.

old and older, and 50 edentulous subjects wearing old dentures (Figure 6-8). The age-related shift in the relative anterior positions of the lips was quite definite and dramatic. The causes may be shifts in the vertical body axis around the center of gravity (see Figures 6-2, 6-3, 6-4), loss of tooth cusp height, or dental arch and tooth position shifts in centric occlusion. When posterior teeth are lost, the

resting jaw posture and the habitual closing position move progressively anteriorly. This change causes protrusion of the lower jaw and lower lip profile. One very significant observation was that the normal arches had cuspids which geometrically intersected the anterior arch form curve with the posterior arch form curve when measured at the height of the contour of the teeth on the labial surfaces.

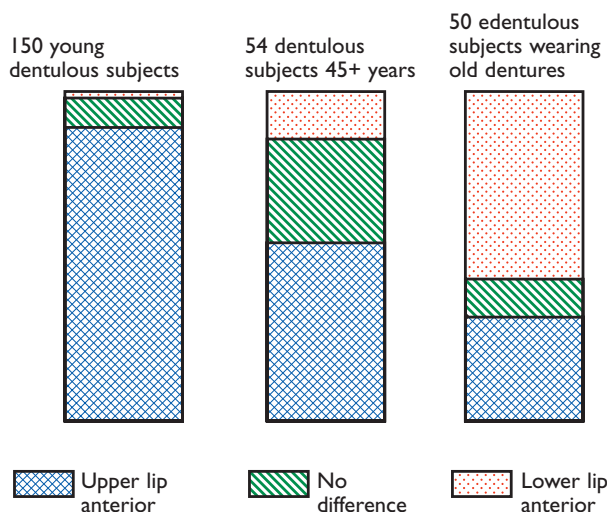


Figure 6-8: The Lieb et al. study also demonstrates the relationships of lower lip to upper lip in the sagittal plane view.¹³ Note the age-related shift in the anterior position of the lower lip to the upper lip among the three groups.

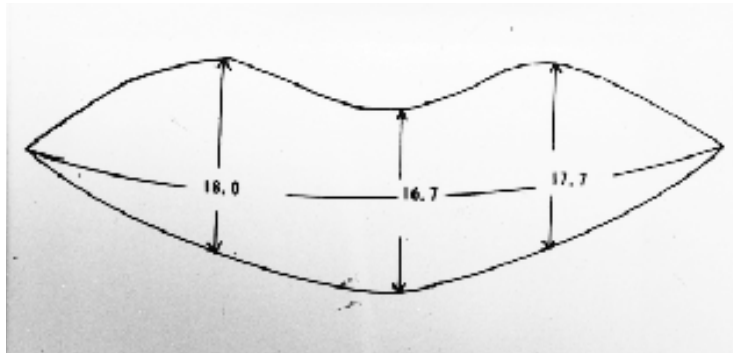


Figure 6-9A: Demonstrates the average vertical height of the three areas of the lips that dominate their appearance in a fully dentulous mouth. Average variation is ± 2 mm, depending on the state of the arch forms and the overlap and overjet.

The study also measured lip length and dimensions relating to vermilion border positions. The study suggests that occlusal reconstruction procedures should include pre- and post-treatment measurements of lip position and profile, height and width of the vermilion aspects of the lips (Figures 6-9A to C), and the position and contour of the tubercle of the upper lip and the dimension of the philtrum. The study measurements reveal the possibility of recovery after physiologic loss of muscle tone, strength, and speed of motion of the oral and facial musculature. It is significant that the orbicularis oris muscle, which circumscribes the oral opening, has no bony attachments and that the upper and lower facial muscles and the buccinator

muscle all have one bony attachment on the facial skeleton and anterior tendinous attachments to the orbicularis oris. The obvious conclusion is that any change in the position and form of the dental arch, in the height and inclination of the plane of occlusion, in the vertical height of occlusion, or in the extent of the overlap or overjet of the anterior teeth would cause a change in the tone, form, and position of the lips.

In treatments, measurements are taken and usually maintained in addition to photographs. The photographs and measurements are especially useful for psychologically anxious, depressed, or demanding patients. The change in lip form must be done incrementally for anxious and neurotic

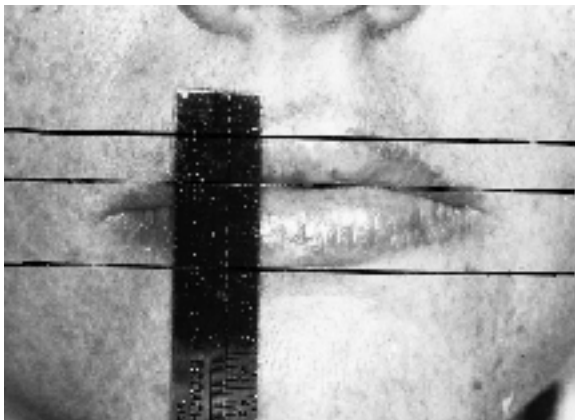


Figure 6-9B: Demonstrates the marked differences between the height of the upper and lower lips before treatment. Note the lower lip is more than twice as high as the upper lip.

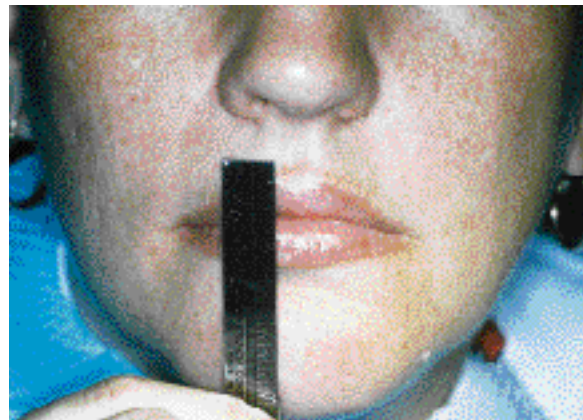


Figure 6-9C: Demonstrates the same surface areas of the lips after treatment. The upper lip is equal to the lower lip surface, 7 mm each for a total of 14 mm for both lips.

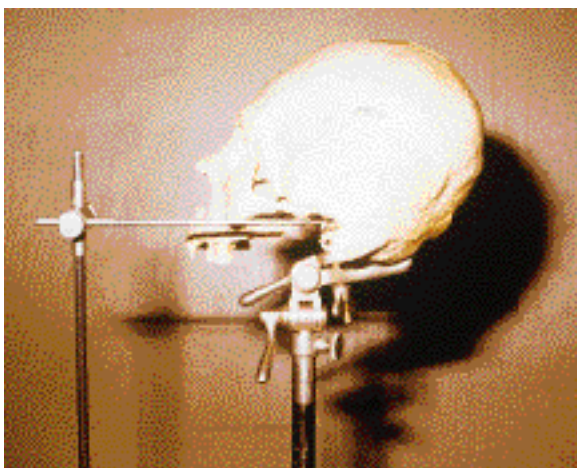


Figure 6-10A: This illustration demonstrates the tracing of arch form and selected tooth positions with a craniophore, an instrument that transfers observations on skulls or casts to graph paper. Tracings are of the buccal height of contour of the teeth, which best conform to the catenary curve.

patients. These vulnerable patients require psychological support and repeated reassurance during this treatment.

2. The Dental Arch Form. Genetic characteristics and perinatal problems of growth can significantly determine the facial esthetics with respect to the developing arch form. The growth chart of a facial skeleton shows that disease and deformity during several specific periods of childhood and adolescence can alter the normal cranial to facial height ratio. More significantly, disturbances in the ratio of mandibular growth to maxillary and premaxillary growth creates lifetime effects on facial esthetics. These disturbances can be a result of disease, trauma, or disorders of the teeth. Reconstructive efforts in adults must take into account that treatment objectives, in relation to arch form and height of occlusion and tooth inclinations, must not only conform to and be coherent with physiologic muscle tone and form of the musculature but also to the genetic and developmental characteristics of the anomalous occlusion.

One of the more significant aspects of the fetal and neonatal periods is the arch arrangement of the tooth buds in a catenary curve, which predicts the arch form in the adult (Figure 6-10A). The catenary curve is one of several generated by natural

forces. It is the form taken by a beaded chain or other memory-free, string-like material when it is fixed at each end and gravity pulls the center down.

In a 1970 study of Indian skulls, Silverman and Hayashi³⁴ demonstrated that this curve can be used as a guide to reconstructing a dental arch. To match the curve to teeth on a cast or a skeleton of the jaws, the ends of the chain are suspended on an axis horizontal to the ground and the chain ends are moved laterally or medially to accommodate the position of buccal heights of contour of the mesial cusp of the second molar. The chain's apex is made more acute when the ends are closer; when the ends are more widely separated, the apex becomes more obtuse.

The findings in the study demonstrated that the catenary curve of the chain almost always coincides with the buccal contours of the cuspid, the first and second bicuspids, the first molar, and the mesio-buccal cusp of the second molar (Figure 6-10B).




Figure 6-10B: The photograph demonstrates matching the chain to the readout of the tracings.

This uniformity between skulls may be explained by muscle and skeletal morphology of the “sling” effect of the masseter and internal pterygoid muscles, which have superior and inferior bony attachments to the craniofacial skeleton. Their restricted traverse of motion during elevation of the mandible restrains the emerging eruption of these posterior teeth in a form coherent with the catenary curve. After the experience of measuring numerous curves a clinician can intuitively measure the relationship of each tooth in the arch to the catenary curve of that arch. You can sense, with a measured glance at the arch form curvature, whether any given rehabilitative dental procedure is appropriate (Figure 6–10C).

However, the anterior arch varies significantly as follows: 60% of the anterior arches were aligned with the beaded chain, 30% of the anterior arches were external to the catenary arch, and 10% were contracted within the catenary curve. These variations may result from the more flexible and widely variable position the lips assume during speech and swallowing. Accordingly, the tongue or lips may dominate the functional activity, either expanding or contracting the dental arch to cause these variations of the anterior arch form.

In the previously discussed clinical case (Figures 6–5A to G), the healed wound contracted the left alveolar arch form. Several options for rehabilitation of the maxilla were considered. They included a hip graft to restore the ridge form, osseointegrated implants, and various removable and fixed prostheses. The choice was made by both patient and dentist to construct a fixed prosthesis on both the upper and lower arches because that option would allow the restoration of an arch form that would conform to a catenary curve.

3. The Inclination of Labial Surfaces of Tooth Contours. These studies of the catenary curve led Roizin to see if the labial vestibules of completely edentulous patients could be used as a guide for the arrangement of artificial teeth rather than the then generally used alveolar ridge crest. Roizin²⁰ measured the inclination of a line drawn from a point from the height of the vestibule at the apex of a tooth to the height of contour on the labial surface of the tooth (Figure 6–11B).

In a study of casts, lines going medially from the vertical were given negative (–) values and lines

going buccally or labially, a positive (+) value. The findings are as follows:

Molars	–15°
Bicuspid	–4°
Cuspid	0°
Lateral	+ 7°
Central	+15°

It is these same buccal heights of contour in the vestibule that Silverman and Hayashi had found were most coherent with the catenary curve. Thus, the two studies demonstrate how the catenary curve model can be used in construction of fixed or removable prostheses.

The clinical examples demonstrated in the trial base plates were reinforced by a study by Darvang,⁶ who asked for dentists’ and patients’ preferences on the arrangement of the anterior teeth. They nearly all agreed on the +15 degree inclination of the incisors as the most preferred tooth position (Figure 6–12).

4. The Vertical Dimension of Face Height. The effects of genetically-induced Class I, II, and III occlusions on patients generally persist throughout life. Even if the arches are distorted by caries, periodontal disease, or trauma, the underlying jaw relationships persist.

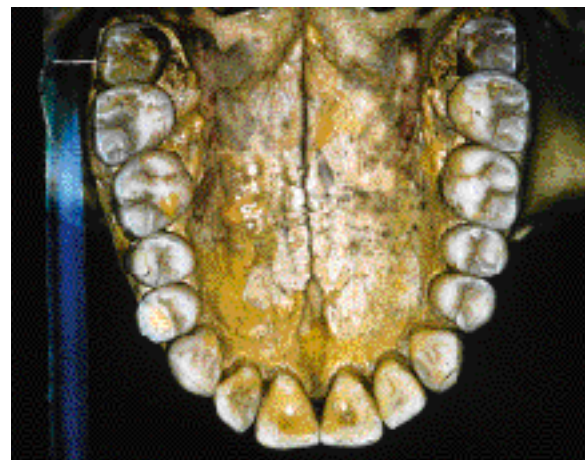


Figure 6–10C: Natural skull held in the catenary arch position. Note slight collapse medially of the right second bicuspid and first molar and expansion away from catenary of the right first bicuspid and second molar. On tracing the height of contour, the teeth would lie, respectively, medially and buccally of the chain position.

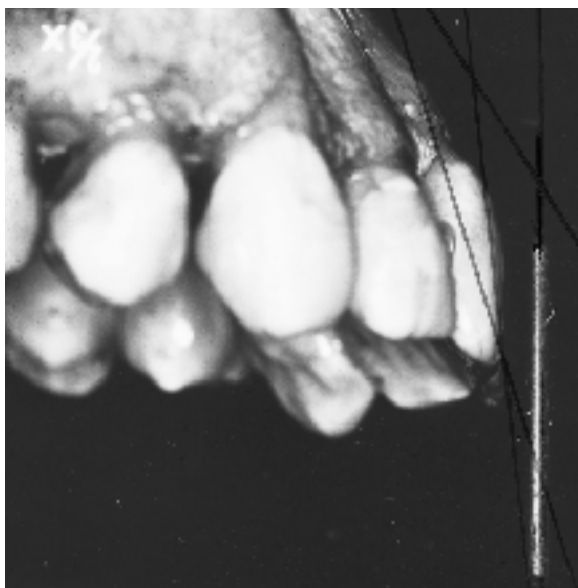

Figure 6-11A: Note the relative vertical inclination of the labial face of the central incisor to the vertical inclination of the alveolar buccal plate of bone. The catenary curve procedure requires the labial surfaces of teeth to be placed on the curve to be in a relatively normal contour. Teeth placed, especially anterior teeth, far too medially will collapse the face; far too labially will distort and tense the lip and cause arch form disorganization when the lips must approximate during swallowing or speaking. Note the angular displacement of the flat labial profile of the central incisor is about 5° from the vertical plane. However, the displacement of the buccal plate of alveolar bone is about 20° . When the bone is covered with soft tissue, muscle, and the contour surface of the clinical vestibular fornix, the angle measured from the fornix to the incisal edge is about 15° , according to Roizin.²⁰

Restorative and prosthodontic procedures which use preformed artificial teeth or rigid gnathologic concepts should be modified to accommodate these genetic influences as well as to conform to the respiratory, deglutitive, speech, posture, and body habits of a patient. A change of a severe Class III prognathism to a desired Class I or Class II without orthognathic surgery may be doomed to failure and subsequent remakes. However, it is possible to modify the jaw relationship as measured in a horizontal plane by increasing the vertical height, which allows expansion of the upper arch and retraction of the lower arch. A study of vertical height as a three-dimensional phenomenon by Silverman³² suggests that the oral space in the steady respiratory state has a constant volume at the vertical dimension of rest. This constant vol-

ume, the oral dead space component when gas exchange takes place in the lungs, is an essential element in the respiratory cycle. It is hypothesized that if all a patient's teeth were extracted at one sitting, the volume of space added to the oral cavity by the loss of teeth and their investing alveolar bone would be eliminated to restore the original volume of oral air existing before the surgery. The mouth must collapse to restore the constant oral volume, and this is accomplished by elevating the mandible and the tongue and collapsing the lips and cheeks.

To test this hypothesis, the ball bearings were placed on selected points at the midline of the face of edentulous patients (Figure 6-13A). The ball bearing locations were charted with and without dentures in place (Figures 6-13B and C). The data generally showed that the upper lip moved through a range of from a 3-mm collapse to a 20-mm anterior advance and the lower lip moved from a 3-mm collapse (flexion) to a 10-mm opening (extension) in an anterior-superior direction. Hence, there are many options for manipulating the vertical dimension and the arch form to get a constant air volume in the mouth and yet obtain good face profile and other esthetic outcomes. For example, increasing the vertical height is tolerated when the arch forms are contracted. The steady state of respiratory rest continues under investigation by Silverman, and it appears the hypothesis is correct according to preliminary studies by observing displaced water vol-

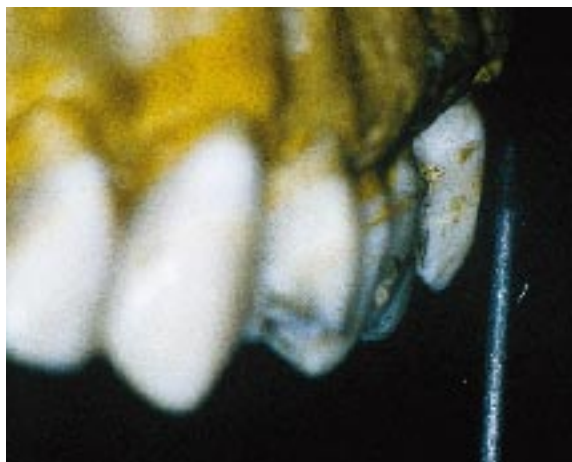

Figure 6-11B: The molar facial inclination is -15° from the vertical plane. The alveolar bone inclination is about $+20^\circ$ and the clinical vestibule is about $+10^\circ$.

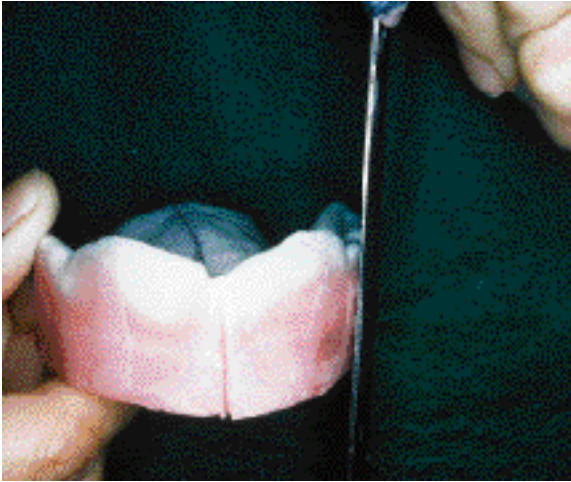


Figure 6-12: This illustration demonstrates the clinical preparation of a denture base wax rim prepared for labial inclination prior to taking occlusion records of vertical dimension and centric relation record. The hot spatula is held in a generally vertical position from the buccal surface of the fornix of the trial base. It is then, while still hot enough to melt wax, swept around the trial base to simulate the inclinations suggested by Roizin and Darvang's⁶ studies. The inclinations from the vertical are: molars, -15° ; bicuspid, -40° ; cuspids, 0° ; lateral incisors, $+7^{\circ}$; and the central incisors, $+15^{\circ}$. These inclinations are only provisional in the trial bases. They usually require modification $\pm 2^{\circ}$ to accommodate the vertical dimension of occlusion, the inclination of the plane of occlusion, the overjets, and the required arch forms.

ume in edentulous patients with and without dentures in the mouth.

A rectangle is a useful two-dimensional representation of the oral structures (Figure 6-14A) because the total area can be held constant when the height is increased and the width is decreased. The hypothesis states that after tooth extraction and the loss of the alveolar bone, the total space reconstitutes itself to become identical to the volume with the teeth present (Figure 6-14B). The return to the presurgical state occurs by elevating the mandible and the tongue, and collapsing the lips and cheeks at respiratory rest position. This hypothesis, if proven correct by three-dimensional air volume studies, has major implications in the restoration of facial esthetics when face contour has been lost or deformed by disease, trauma, surgery, or iatrogenically induced through faulty restorative or prosthetic dental care. When the volume is too great, as

where the teeth are extracted, the patient elevates the tongue to recreate the constant volume and the patient assumes the typical edentulous collapsed cheeks. Conversely, if the volume is too small the patient pushes the teeth anteriorly off the ridges and keeps displacing the dentures or suffers mucosal irritations. This constant volume concept provides a physiologic measure for growth and development, maintenance, and recovery of orofacial esthetics.

Figures 6-15A to F demonstrate a three-dimensional treatment for a patient requiring the recovery of face contour. This 50-year-old male physician had experienced less than adequate dental care throughout his adult years. Despite his posterior tooth loss, he had never worn a removable prosthesis and would not consider any implant possibilities. He felt compelled to seek dental care because he became aware that his appearance prejudiced his patients about his personality. A front view at rest (Figure 6-15A) shows that his jaw is deviated and lips are distorted. His profile (Figure 6-15B) shows

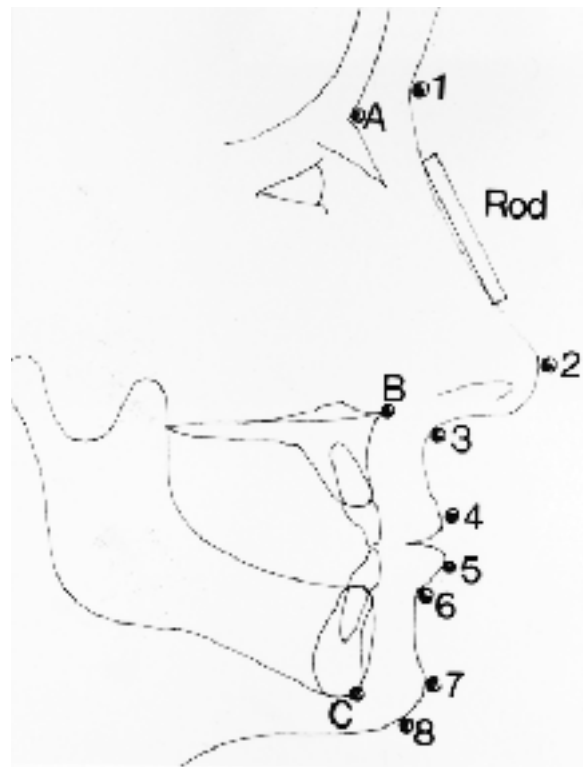


Figure 6-13A: Schema for placement of ball bearings on selected points on the midsagittal profile of the face to study the change in face contour, height, and displacement patterns.

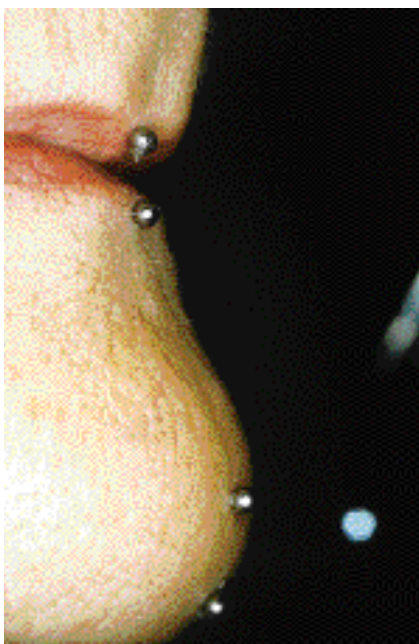

Figure 6-13B: Placement of the ball bearings on the face without dentures. Note how the lips are generally collapsed.

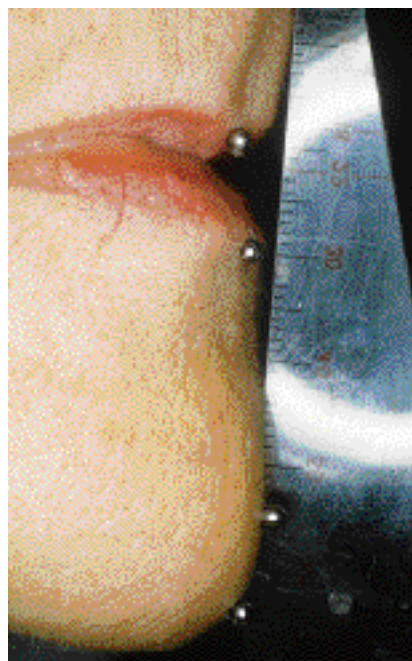


Figure 6-13C: With dentures in the mouth, the lower lip moved forward and downward.

protruded lower lip, slight prognathism of lower jaw, and markedly thin upper lip and thick lower lip. The lower lip on the right side is from three to four times the height of the upper lip. Intraorally, his missing upper posterior teeth deny him any posterior tooth contacts (Figure 6-15C). Accordingly, he moves his jaw habitually to a protruded lateral position where available tooth contacts exist. Treatment for this habitual closing position will require wearing a provisional prosthesis to recover (increase) lost vertical, facial, and occlusal height. The provisional prosthesis will also recover (retrude) the mandible to approximate the occlusion position before he lost his posterior teeth. Note how in this untreated state the incisal edges of the upper right incisors are lingual to the lower right incisors and cuspid. At the heart of attempts to improve his facial appearance is the correction of the distorted vertical height and maladaptive jaw posture by increasing the facial height and retruding the condylar position.

Two provisional removable partial dentures and acrylic onlays supported by metal were constructed to restore the centric relation position and recover

the vertical height of occlusion (Figure 6-15D). The onlays created the desired tooth lengthening and a new plane of occlusion. And, in the centric relation position, the midline of the lower anterior teeth has moved to the left and the upper right anterior teeth are now slightly labial to the lower anterior teeth. The patient's profile is improved due to an increase in vertical height, retrusion of the lower jaw, and the change of lip form—especially in the increase of the vermilion portion of the upper lip (Figure 6-15E). Note also the retrusion of the lower lip, placing it posterior to the upper lip in the sagittal plane. Measurements of the frontal and profile view of the exposed vermilion portions of the lips reveal them to be generally equal in vertical height dimensions. Compare this to Figure 6-15B. A front view (Figure 6-15E) shows a reduction of the lateral displacement of the lower jaw and the recovery of normal lip form, especially in the upper lip, which now has almost the same vertical height as the lower lip.

Using the concept of constant intraoral volume, changes were made to the patient's teeth, altering his occlusion and dramatically improving his outward appearance. Further research needs to be done

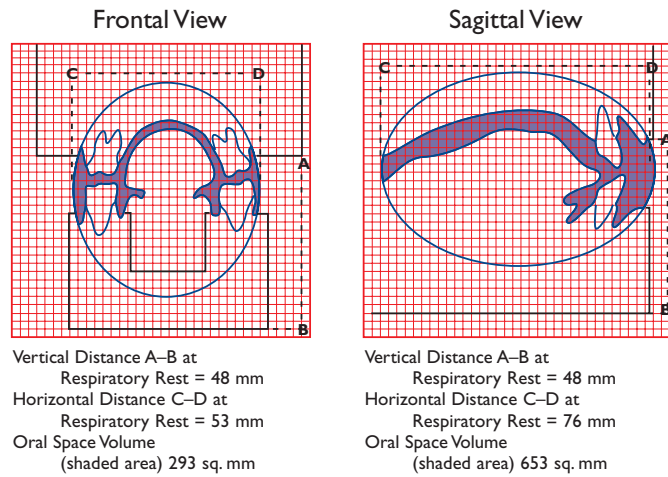


Figure 6-14A: A schema demonstrating dentulous oral and facial structures in the sagittal and frontal views at a given measure of the Space of Donders (the intraoral space above the tongue and below the hard and soft palates, the labial and buccal vestibular spaces labial to the lips and cheeks, and the sublingual spaces). The schema defines the volume in square millimeters.

on respiration as a function not only of esthetics but also of swallowing and mastication functions.

5. The Esthetics of Adult Development and Aging. During the period of adult development, from age 24 to 65 when chronic acute diseases may arise, the soft tissue contours, occlusal relationships and maladaptive behaviour considerations require careful and insightful diagnostic and treatment procedures. These procedures include orthodontic,

periodontic, orthognathic surgery, and options for alloplastic implant treatment.

The period of aging and senescence is from 65 to 95 years of age, when marked changes in body posture, neuromuscular control of orofacial muscles may occur, and intellectual functions may decline. During this age period, visual and acoustic perception may change, causing severe alterations in awareness. Replacement teeth may appear to be too dark

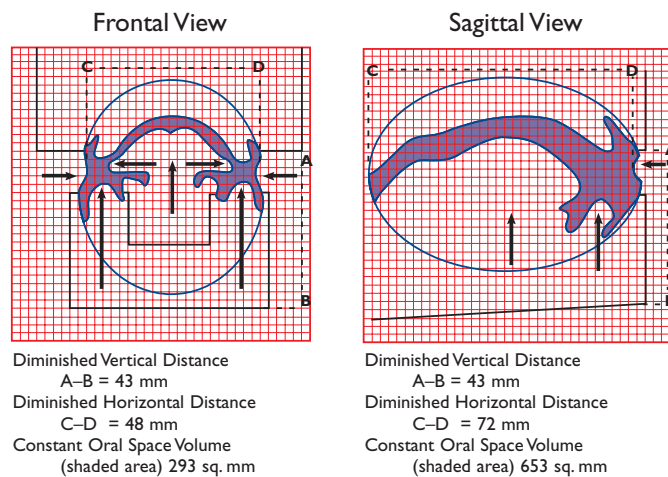


Figure 6-14B: The schema of the Space of Donders and other oral spaces after the teeth with their investing alveolar bone are lost.

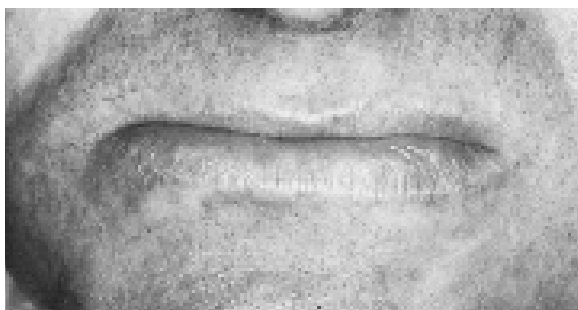


Figure 6-15A: Front view of patient demonstrating marked distortion of lip contour at his habitual occlusal relationship.

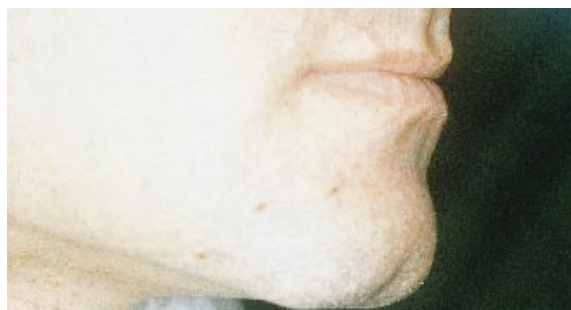

Figure 6-15B: Pretreatment profile view highlights his lip distortion.

or too light, the slightest tooth contact may sound like an explosive irritating noise, the opposing contact of normal tooth contours may feel rough to the tongue. A speech sound may be distorted by restored overbite deemed necessary by the dentist for both esthetics and for incision. Accordingly, patients will need time for speech retraining. The patient's coping skills and personality behavior as studied by Silverman et al. in 1975³⁵ show how field-independent and field-dependent patients cope with esthetics and need for adjustment. This study cites numerous case examples where esthetic considerations dominate the diagnostic and treatment recommendations.

There are some neurologic changes that affect esthetics in patients in all age groups, although they are more prevalent in the older patient. Wanatabe et al.⁴¹ in 1985 reported that 5% of his 887 patients had neurologic or drug-related dyskinesia. These patients also had marked deviations from guidelines for tooth arrangement. Stepwise tooth replacement is often required to accommodate

existing lip deformities to achieve a reasonable, acceptable esthetic result.

Finally, older patients with burning mouth syndrome (BMS) or Verkrumpte Kopf syndrome (VKS) (in which patients feel the head is "crooked" with the new teeth) often present very severe and difficult problems.³⁰ Silverman³¹ demonstrated that conflict over unsolved personal problems and systemic symptoms often focused on the esthetics of the mouth, sometimes expressed as the "not me" syndrome. These patients require from two to four times the length of treatment as normal patients with equivalent problems. Ten percent of these difficult patients require up to 10 times the normal treatment time, usually ending in hostility, law suits, or with the death of the patient. In a series of articles on burning mouth syndrome, Selye and his group at the University of Toronto describe how personality and sensory peripheral disorders create problems of localization, tactile, and taste distortions, which may be experienced as esthetic problems.^{8,9}

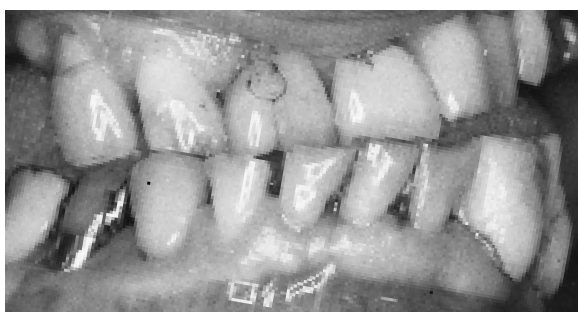

Figure 6-15C: The patient is illustrated with teeth closed in contact in habitual closure.

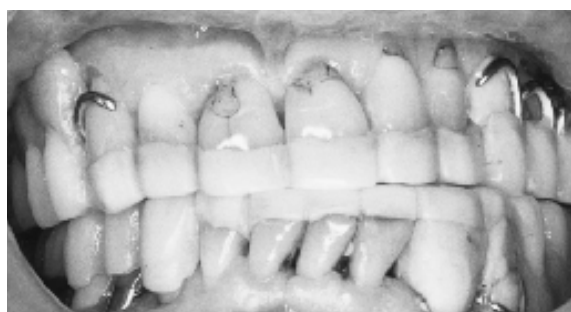

Figure 6-15D: The patient wears these onlays and provisional removable dentures until psychologically prepared to wear fixed prostheses and/or a removable prosthesis.

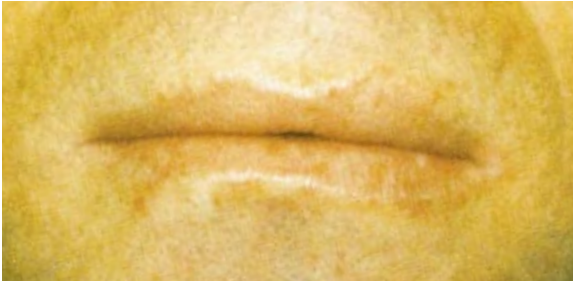

Figure 6-15E: The frontal view of the patient with the provisionally restored dentition.

6. Recent Diagnostic Procedures Based on Physiologic Behavior of Tissues. A study by Sonies et al.³⁷ from the intramural program at the National Institute of Dental Research (NIDR) recommends including in a clinical examination the following oral and motor sensory examinations: the symmetry of the orofacial region, the physiologic properties of the swallow, oral sensation, tongue and lip measurement and strength, speech fluency, and vocal and articulation functions. Deviations from normal are often expressed by patients as complaints about esthetics. Patients thus express morphologic and physiologic variances based in genetics, growth, development, aging, or senescence as “esthetic problems.”

Swallowing and esthetics are generally confined to concepts of tongue and/or lip thrusting. However, a new horizon for study has been suggested by Coster and Swaze, engineers from Johns Hopkins University.⁵ In their article “Rheology and the Safe Swallow Bolus” they suggest that the application of the principles of rheology is an appropriate element in the study and care of patients with diaphragm disorders that affect swallowing. They say that normally a patient can prepare a bolus so that it can pass unimpeded through the food pathway without aspiration, choking, retention in the pharynx, or regurgitation into the nasal spaces. Such a bolus is “swallow-safe.” New prostheses often require a period of retraining for a patient to consistently produce a swallow-safe bolus.

Esthetic rearrangement of tooth positions and arch form is often accompanied by sensory, perceptual, and personality distortions which require resetting teeth, closing vertical dimensions, reducing overlap and overjet, and then restoring them

again as the patient learns his or her new swallow-safe bolus size. The most effective way to treat these special patients may be to construct a provisional prosthesis within an incremental program of altering tooth position, arch form arrangement, vertical height, and centric occlusion. When these positions are recovered, the definitive prosthesis may be a duplication or a further modification of the provisional prosthesis.

Christianson, Lufkin, and Hanafee⁴ demonstrate a new technology for esthetic decision programs in arch form, plane of occlusion, and tooth position in reconstructive prosthodontics, surgery, and orthodontics. They demonstrate the ability to measure denture space with a reasonable degree of accuracy and, since denture space is the basis for facial height restoration, such a method of measurement can be useful in esthetic decision-making processes.

The maxilla varies in size more than other bones in the human body, and this is due to more than just the genetic characteristics of an individual. Some investigators suggest that part of the variation is due to neonatal and developmental problems associated with physiologic functions, traumas, and disease. The induction time for these changes is up to 24 years of age, during which period the maxilla is most plastic. Studies have shown that the intermaxillary width between the first molars is gradually decreasing and that, in addition to these morphologic and physiologic adaptations to biologic forces, it may be civilization itself that is responsible for the reduction. Studies by Lundstrom and Lysell,¹⁴ More et al.,¹⁶ and Heer¹⁰ show how much intermaxillary width has decreased over

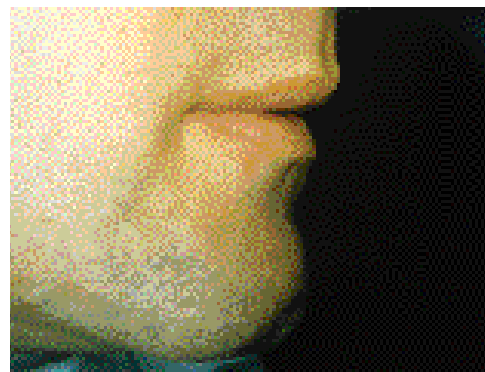


Figure 6-15F: The improved profile view is shown.

the centuries. In a study comparing skulls from 350 AD to skulls from 1350 AD, they demonstrated that the average width only decreased from 36.5 to 36 mm. However, when compared to modern skulls the width diminishes dramatically to 33.4 mm. The evolutionary period of only 1600 years is too short to decrease the width by 3.1 mm. Only environmental and experiential factors could reduce the maxillary width by 10% in such a short period of time. The factors, suggested by Solomon³⁶ and Pepys et al.,¹⁷ which stimulate normal growth differentiation are atrophy or allergic reactions to dust, food, and milk, and other asthmatic and psychogenic conditions. In adults, the problems of emphysema and chronic restrictive or obstructive pulmonary disorders alter the position of respiratory rest. Other possible systemic factors are venous congestion of the pharynx, chemical irritation, lymphoid growth, deviated septum and, of course, mouth breathing.

The normal relationship between maxillary size and airway restriction are further disrupted by abnormal tongue position, size, tonus, or distorted sensory-motor integrity during the functional activity of swallowing, breathing, or mastication. Additional factors in respiratory function relate to the head, neck, and/or body posture. Esthetic considerations are thus rooted primarily in the patency of the airway for both genetic and environmental factors.

SUMMARY

The principal hypothesis of this chapter is that the essential factors in restoring or creating an esthetic outcome of treatment are based on fundamental biologic principles that underlie tissue modification. Thus, before artificial materials like porcelain, metals, composites, and other plastic materials are used *in vivo*, the issues of biological stability of tissue function and the compatibility of these artificial materials must be resolved.

References

1. Armstrong P, Wilson AG, Dee P. Imaging of diseases of the chest. Year Book Medical Publishers, Inc., 1989:5-14.
2. Bergman K. Neurosis and personality disorders in old age. In: Isaacs AD, Post F, eds. Studies in geriatric dentistry. New York: Wiley, 1978:41-78.
3. Chamberlain BB, Chamberlain KR. Depression: a psychological consideration in complete denture prosthodontics. *J Prosthet Dent* 1985;53:235-675.
4. Christianson R, Lufkin R, Hanafee. Normal magnetic resonance imaging anatomy of the tongue, oropharynx, hypopharynx and larynx. *Dysphagia* 1987; 1:119-27.
5. Coster ET, Swaze WH. Rheology and the safe swallow bolus. *Dysphagia* 1987;1:113-8.
6. Darvang L. MSD research: labial arch form preferences. NYU College of Dentistry, 1979.
7. Downer NW. The evaluation of dysphagia by radiography and other methods of imaging. *Dysarthria* 1986; 1:49-50.
8. Gorsky M, Silverman JS, Chinn H. Burning mouth syndrome: a review of 98 cases. *J Oral Med* 1987;42: 7-9.
9. Grushka M, Sessle BJ, Miller R. Pain and personality profiles in burning mouth syndrome. *Pain* 1987;28: 155-67.
10. Heer F. The medieval world. London: Collins, 1957.
11. Johnson ES, Kelly JE, Van Kirk LE. Selected dental findings in adults by age, race & sex. Division of Health Examination & Statistics, Department of Health, Education & Welfare, Series 11, #7, 1965.
12. Kelly J. Basic data on dental examination findings of persons 1-74 years. National Health Survey, Department of Health, Education & Welfare, Series 11, #214, 1974.
13. Lieb N, Silverman SI. An analysis of soft tissue contours of the lips in relation to the maxillary cuspids. *J Prosthet Dent* 1967;18:292-303.
14. Lundstrom A, Lysell L. An anthropological examination of a group of medieval Danish skulls with particular regard to the jaws and occlusal condition. *Acta Odontol Scand* 1953;III:111-28.
15. Milgrom P, Weinstein P, Getz T. Fear and anxiety reduction in the geriatric dental patient. *Gerodontics* 1987;1:14-9.
16. More WJ, Cavelle CLB, Spence TF. Changes in size and shape of the human mandible in Britain. *Br Dent J* 1968;125:163.

17. Pepys J, Chan M, Hargreave FE. Mites and house dust allergy. *Lancet* 1968;1270-2.
 18. Pollack BR. The essential components of dental/medical health history form. *Perspectives, Block Drug Co.*, Vol. 5, N. 2, Oct. 1989.
 19. Pound E. Personalized denture procedures. 2nd edn. Kansas City: Kay See Dental Mfg. Co., 1973.
 20. Roizin A. MSD research thesis: vestibular arch form & catenary curve. NYU College of Dentistry, 1975.
 21. Silverman ET. Profile of speech and language disorders relevant to dental therapeutics. *Scientific Proceedings, Second International Congress of Gerontology, Singapore Dental Association, Singapore, 1986.*
 22. Silverman ET. Speech rehabilitation: habits and myofunctional therapy. In Seide L, ed. *Restorative procedures in dynamic approach to restorative dentistry.* Philadelphia, London, Toronto: W.B. Saunders, 1980.
 23. Silverman MM. Occlusion in prosthodontics and in the natural dentition. Washington: Mutual Pub. Co., 1962.
 24. Silverman SI. Correlation of biologic, psychologic and clinical aspects of dental care for the aging. In: Toga CJ, Mandy K, Chauncey HN, eds. *Geriatric dentistry: clinical application of selected topics.* Lexington, Mass: Lexington Books, 1979:195-214.
 25. Silverman SI. Dental care for rehabilitation of the aging. T.F. Williams E. New York: Raven Press, 1984:255.
 26. Silverman SI. Dental care for the aging and communication disorders. *Scientific Proceedings, Second International Congress of Gerontology, Singapore Dental Association, Singapore, 1986.*
 27. Silverman SI. *Esthetics.* New York: Medcom Learning Systems, 1973.
 28. Silverman SI. *Oral physiology.* St. Louis: C.V. Mosby, 1961:304-430.
 29. Silverman SI. Research in the biology of esthetics. Presented as the Distinguished Lecturer Award lecture at the annual meeting of the Greater New York Academy of Prosthodontics, December 4, 1989, New York, New York.
 30. Silverman SI. The burning mouth syndrome. *J Dent Assoc S Afr* 1975;30:163-76.
 31. Silverman SI. The burning mouth syndrome—restorative and prosthodontic treatment. *J Am Dent Assoc* 1967;33:459-66.
 32. Silverman SI. Vertical dimension: a three dimensional phenomenon, Part II. *J Prosthet Dent* 1985;53:573-7.
 33. Silverman SI, Block M. Visual motor function, dental occlusion, proprioception & inter-sensory function. *IADR Abstract, 1970.*
 34. Silverman SI, Hayashi T. Dental arch form, alveolar bone contours and the catenary curve. *IADR Abstract, 1975.*
 35. Silverman S, Silverman SI, Silverman B, Garfunkel L. Self image and its relation to denture acceptance. *J Prosthet Dent* 1976;35:131-42.
 36. Solomon W. Allergic responses in upper respiratory function. *Symposium on Naso-Respiratory Function and Cranio-Facial Growth, University of Michigan, Ann Arbor, 1979.*
 37. Sonies BC, Weffenbach J, Atkinson JC, et al. Clinical examination of motor and sensory functions of the adult oral cavity. *Dysphagia* 1987;1:178-86.
 38. Steinberg BJ, Brown S. Dental treatment of the health compromised elderly: medical and psychological considerations. *Alpha Omegan* 1986;79:34-41.
 39. Suzuki J, Yamane H. The choice of stimulus in the auditory brainstem response test for neurological and audiologic examinations: evoked potentials. *Ann N Y Acad Sci* 388:731-6.
 40. Tao S, Lowenthal U. Some personality determinants of denture preference. *J Prosthet Dent* 1980;44:10-2.
 41. Wanatabe J, Sato M, Yamani H, Nakawaza K. Oral dyskinesia of the aged: clinical aspects. *Gerodontology* 1985;1:39-43.
- Additional Resources**
- Begg . The dentition of the stone age man. *Am J Orthod* 1954;40:28.
- Berg E, Johnson TB, Ingebretsen R. Patient motivation to fulfillment of motives in renewal of complete dentures. 1985;42:235-40.
- Hermel J, Schonwetter S, Samueloff S. Taste sensation and age in man. *J Oral Med* 1970;25:39-42.



Charles L. Pincus
1904–1986

CHAPTER 7

PINCUS PRINCIPLES

Dedication

Dr. Charles L. Pincus and I met for the first time in 1959 at the International Symposium in Knokke-Sur-Mer, Belgium, where we were the only Americans lecturing. From the beginning, a rapport was established and a friendship began that was to grow and endure until the day of Charlie's death on September 4, 1986.

As mentor as well as friend, Charlie nurtured my interest in esthetic dentistry in the early years of our friendship. In fact, had it not been for my strong family ties in Atlanta, I might have accepted his early invitation to enter practice with him in Beverly Hills. I did manage, however, to attend every course he taught and received much personal instruction.

Some ten years later, I suggested to Charlie the need for a multidisciplinary organization comprising people who shared an interest in esthetic dentistry and who envisioned the important role it would play in the future of the profession. Together, we identified a group of approximately fifty leading dental educators and founded the American Academy of Esthetic Dentistry. That academy became the inspiration and stimulus for a worldwide expansion in esthetic dentistry, including the establishment of numerous other academies focusing on the same discipline as well as the International Federation of Esthetic Dentistry.

In view of the pioneering contributions of this leader in the field, it is appropriate that we include some of the important principles that Charles Pincus taught the profession over the years. At the end of this chapter, Dr. Pincus's autobiographical history, "The Development of Dental Esthetics in the Motion Picture Industry," appears. Thus, it is with a great deal of pride, nostalgia, and fond memories that I present this chapter.

EARLY CONTRIBUTIONS

Although his first published article appeared in a 1938 issue of the *Journal of the California Dental Association*,¹ Dr. Charles Pincus actually began pioneering esthetic dentistry techniques some 10 years earlier when he was asked to solve a threefold problem presented to him by the heads of the makeup departments at Twentieth Century Fox and Warner Brothers Motion Picture Studios (see end of this chapter).

The problem stemmed from the emerging technology of talking movies, a technology that focused the camera and thus, the audience's attention, on the actors' mouths to a much greater extent than in silent movies. The makeup executives needed procedures for: (1) improving the photographic appearance of the actor's mouth; (2) developing appliances that would change the visual appearance

of the performer, such as when playing Count Dracula or Frankenstein; and (3) creating esthetic restorations that would not degrade the quality of speech or be a hindrance to the actor. Although some work had been done in the area, it was altogether useless in the new "talkies."

Thus, Charles Pincus began the work that would consume much of his career and launch the field of esthetic dentistry. One of Dr. Pincus's major contributions was to recognize the important principles of how teeth play a role in mouth personality. He also realized the vital role played by light reflection, surface texture, and tooth contour. He taught the basics of these theories throughout his career, constantly reminding us of how important they are in preventing esthetic failure. The remainder of this chapter is a distillation of the legacy he bequeathed to us.

CREATION OF MOUTH PERSONALITY

Typically, dentists emphasize patient treatment outcomes related to function, articulation, and the like, with significantly lesser regard for the esthetic outcomes that affect the patient's visual personality. Said another way, many in our profession perceive the role of dentistry as functioning in three dimensions to achieve rehabilitation of the mouth. Factors associated with the dimensions of physiologic, biologic, and mechanical functions are the traditional concerns. The fourth dimension of effective mouth rehabilitation includes those psychologic factors that can be critically important to the self-concept of the patient.

Although their devotion to technical perfection is commendable, most dentists need to develop a greater sensitivity to the value of an attractive smile and the benefits it may hold for the patient. The opposite of the positive personality resulting from a smile that shows an even row of natural, white teeth is the inferiority felt by those with crooked, unattractive teeth. They tend to cover their mouths during speech or move their lips unnaturally to cover their teeth. This lack of confidence frequently accounts for the difference between success and failure in the lives of many people.

The importance of mouth personality is exemplified by the movie industry. Stars are provided with state-of-the-art makeup and costumes to maximize their attractive faces and figures. Writers and directors develop scripts for them that enable them to achieve precisely the desired dramatic effect. Yet, the entire illusion can be lost when those perfect lines proceed from a mouth full of crooked, protruding, or ill-spaced teeth. In realizing this, motion picture executives require that every prospective star have his or her mouth personality brought up to a level comparable to the actor's dramatic ability. Thus, while the need for attractive dental features among movie stars is obvious, the less obvious fact is that the same benefits are appreciated by the public. The effective dentist is the one who combines sensitive understanding of patient needs with knowledge of the principles of esthetic technique.

THE IMPORTANCE OF LIGHT

Basic to the practice of successful esthetic dentistry is a working knowledge of the properties of light.

Unfortunately, there seems to be too little consideration given to this critically important factor. We must consider three characteristics of light if we expect to achieve superlative results with porcelain:

1. Direction of light
2. Movement of light
3. Color of light

The direction and movement of light cast shadows and are the basic factors in the creation of cosmetic illusions. By varying the contour and facets on tooth surfaces we alter and affect the direction of light reflection. Shadows are created that are the basis of tooth illusion, as they affect porcelain restorations. As an example of the character of direction in light reflection, the shadows created are varied by the silhouette form of the teeth and the concavities and convexities of the enamel surface. Variation in the silhouette form can alter the color of the background by variation in the angle of lighting. The concavities and convexities of the enamel surface determine, partly, the surface texture, which influences the intensity and character of the reflected light by the way the surface absorbs or reflects the light. Shadows are used to dramatize a lighted area. The general lighting in one area may be deliberately played down by a darker shade of tooth or by darkening the interproximal areas as they curve into the contact areas. As an illustration, for an anterior fixed partial denture restoration, where insufficient depth can be attained interproximally to create the desired depth of shadow, the porcelain shade should be darkened interproximally to simulate the shadow, and thus create an illusion of depth.

Surface Texture

Porcelain crowns and bridges should be fabricated so that the surface texture, including the convexities and concavities, matches the enamel surfaces of the adjacent natural teeth. This reproduces the characteristics of light reflection inherent in the patient's natural dentition (Figures 7–1A and B). One of the very important things accomplished is lowering the value of the shade to the correct value for those teeth.

The Character of Color in Light Reflections

Tissue color—the color of the lips, cheeks, tongue, palate, and gingiva reflects against and affects the

color of the teeth. This causes variations in the appearance of the color and shade of the teeth. A high palatal vault will increase the translucency of a tooth with a thin incisal edge. With anterior porcelain restorations we grind away the linguoincisor and replace it with a translucent porcelain to simulate this very natural appearance when appropriate. When taking the shade, hue, value (brilliance or amount of gray), and chroma (saturation) should be differentiated and matched. Concentrate on the tooth for only 5-second intervals, so as not to allow the phenomenon of adaptation of the retina of the eye to induce fatigue wherein all the shades tend to gray into one another. A florid (reddish) complexion will induce your judgment toward a green cast, while the patient with a sallow (yellowish-green) complexion will influence you toward a red cast. Also remember that the gingival color will influence your selection as well. With a dark gingiva you are apt to pick a shade that is too light. A light gingiva will usually result in a darker shade by contrast. The gingival tooth shade must be adapted to the influence of the gingival color. Pure north light or color-corrected fluorescent lighting is believed to reproduce shades and colors more accurately (Figure 7-2). The final shade in the mouth should be checked with the patient in dynamic action. This is because a speaking patient affects the light reflections from the tooth surfaces differently (see Chapter 10).

The Character of Movement in Light Reflection
The movement of the lips, cheek, and tongue strongly influence light reflection. It varies with the

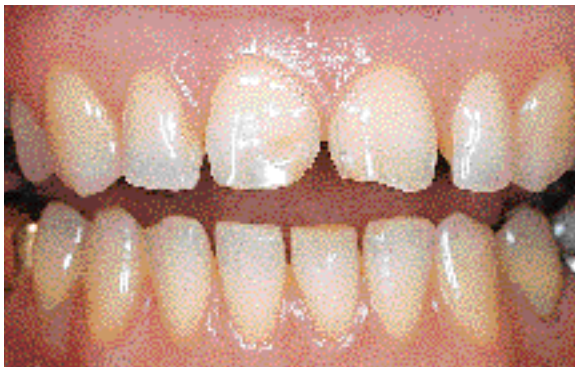

Figure 7-1A: This patient with occlusal problems and broken teeth needed a metal framework to reinforce the porcelain.

differences in the width of the arch form of the teeth and the width of the vestibule. The narrower the arch form, as a rule, the wider the vestibule of the cheek; and the light reflections will create more shadows posteriorly, so that the shade of the posterior porcelain teeth should be lightened. The wider the arch form, the narrower is the vestibule, so that very little or no shadows are produced by the light reflections on the teeth. As an example, a decalcified, whitish area added to a bicuspid crown in a narrow arch with a wide vestibule should be boldly placed, as otherwise it will not be visible in the mouth. The same addition in a mouth with a wide arch and a narrow vestibule requires a delicate placement to preclude it standing out like a headlight. This explains why so often the insert, which looked so good on the model, defeats its purpose in the mouth. All of these factors must be communicated to the knowledgeable technician to ensure a superlative porcelain result.

Influence of Contours on Esthetic Results

A. The Contours Affecting Appearance

We create illusions to obtain the appearance of larger, smaller, longer, or shorter teeth in the same place. This is achieved in part by varying the outline or silhouette form, thus changing the character of light as the result of the direction and movement of light. To illustrate what is meant by the outline or silhouette form, consider that the mesial and distal highlights or marginal ridges of a maxillary central incisor tooth curve lingually from the ridges to the contact areas, reflecting light mesially or distally to the sides. The cervical one-fifth of the tooth

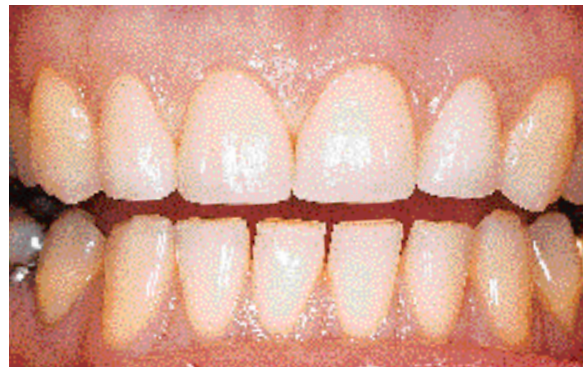

Figure 7-1B: Four ceramometal crowns were constructed by Dr. Pincus for this patient. Note how the delicate texture breaks up the light reflection for a more natural light.

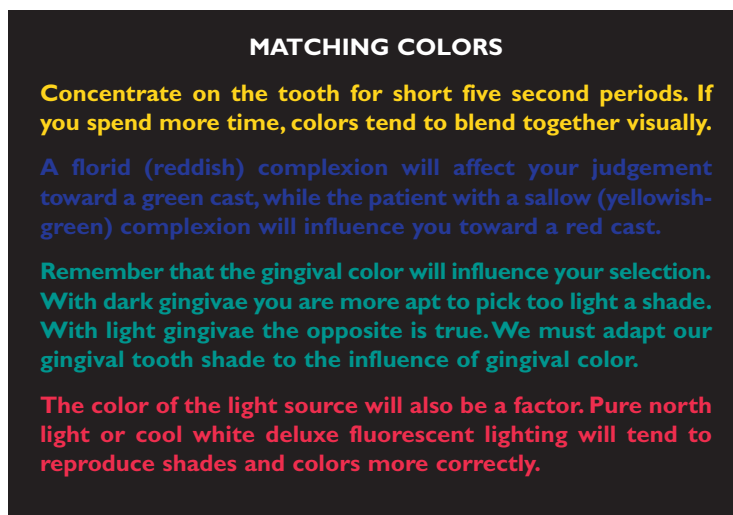

Figure 7-2: Dr. Pincus used bright colors in his teaching slides to illustrate his principles. Here four tips were offered about matching colors.

curves lingually into the gingival sulcus, reflecting light upward. The incisal one-fourth curves lingually, reflecting and shadowing the light downward. When we speak of the outline or silhouette form of a tooth we describe that portion of a central incisor that reflects light forward or anteriorly. By reducing the portion of the tooth reflecting light forward, the silhouette form, we create the illusion of a smaller or shorter tooth in the same space. By enlarging the portion of the tooth reflecting light forward, the silhouette form, the illusion of a larger or longer tooth results (Figure 7-3).

Incisal edge contour should conform to the dynamic action of the lips. This is checked in the mouth with the wax try-in. If one side of the lip raises more in speaking and smiling, the incisal line should also be raised on that side to make certain the teeth do not appear longer. Also check the median line. At the initial appointment, well before the restoration is started, it should be observed and noted whether the patient has a low, medium, or high lip line to determine how much gingiva is revealed. Covering the exposed roots of the teeth can transform a simple case to one so difficult as to tax to the utmost the ability of the most skilled cosmetic dentist to obtain a superlative result.

B. The Surface Texture of the Enamel

The convexities and concavities of the porcelain break up the surface and vary the reflection of light

to a brilliance (value) that can be compared to the facets on a diamond. An actress with protrusive teeth, for example, photographed normally on screen because in dynamic action the lower anterior teeth did not allow the lower lip to fall under the upper teeth during speaking and smiling. Another actress with the same amount of protrusion photographed on screen with teeth extremely protrusive due to the lower anterior teeth being retrusive; this allowed the lower lip to hook under the upper teeth, thus exaggerating the defect. Contours have much effect on not only esthetic results but also on biologic and physiologic results, making it important not to overlook this area.

BASIC COSMETIC PRINCIPLES TO ACHIEVE ULTIMATE BEAUTY IN PORCELAIN

A. Do not build on quicksand. Treat and resolve all inflammatory reactions and unstable periodontal conditions and allow healing before preparations are started. Sometimes it may require only a prophylaxis, other times several periodontal treatments.

B. Create models. In the parlance of the theatre, full-mouth casts should act as a “dress rehearsal” for the exact mouth preparations. Prepare the teeth on plaster or stone models as though you are working on a vital tooth, keeping in mind the relationship of the pulp to the preparation so as to retain vitality.

After preparing, wax-up the correction on the study model. Very often it will be found that too much tooth structure was eliminated where it was not necessary, and not enough where it was important for the correction. In this way, we will know in advance each step in the preparation in the mouth to conservatively achieve the ideal porcelain correction.

C. Avoid tissue insults. In other words, do not injure the gingival tissues or periodontal fibres in preparation, impression taking, or treatment with chemicals before cementing. Otherwise, you may start a pattern of tissue recession that, once started, is difficult to stop. There are, of course, times when the preparation will include removing the epithelial lining of a periodontal pocket as part of the treatment plan. In most cases there should be “bloodless cutting”; no hemorrhaging during preparation.

D. Adapt the movement, color, and direction of light reflections to achieve the necessary illusions through varying the outline or silhouette form. Achieve the correct surface texture of the enamel for value in color. Adapt the placement and intensity of characteristic inserts to the presence of a wide or narrow vestibule of the cheeks.

E. Use a cast of soft resilient plastic to enable you to reproduce the gingival tissue and thus achieve the correct contour that will be biologically compatible with the soft tissues.

F. Have a wax try-in in the mouth to verify the fit of the pontics, the contact points, the length of the teeth, and arch form in relation to the dynamic action of the lips and illusions created.

G. The margins of the restoration should fit perfectly with appropriate contours to adequately deflect food and to provide support, not pressure, to the sulcular tissues (pressure would initiate a pathologic reaction). All of the margins and contours should be biologically compatible with the surrounding tissues.

H. The articulation should be free of prematurities, with the correct centric relation, and should not produce trauma to either the hard or soft tissues. To avoid additional stress on the investing tissues of the teeth by ceramometal restorations, create narrow occlusal tables with occlusal markings parabolic in form for minimal surface contact.

I. Proper maintenance, including a balanced

diet (low in refined carbohydrates, high in protein), proper brushing, plaque control, vitamin and mineral supplements, and regular check-ups are vital to long-term success. The objective is good resistance and reparative ability, which is the greatest preventive factor of all.

J. The proximal surfaces should be properly contoured to allow a sufficient gingival papilla to regenerate or to be maintained (Figure 7-4A). As much as possible, the crown contours should simulate the ideal physiologic pattern that existed, hopefully, before tooth preparation (Figure 7-4B).

Three faults that can commonly occur during tooth preparation are illustrated in Figure 7-4C:

1. Insufficient reduction of finish line
2. Insufficient reduction on gingival half
3. Insufficient rounding of buccal surface and linguo-occlusal line angle.

Interdisciplinary Communication

Dentistry in general, and esthetic dentistry in particular, can greatly benefit from assuming an interdisciplinary perspective. There are many benefits that could result from a knowledgeable dialogue between the various disciplines. Some examples are:

1. Where a short lip would expose the entire gingival area in speech and smile, a know-

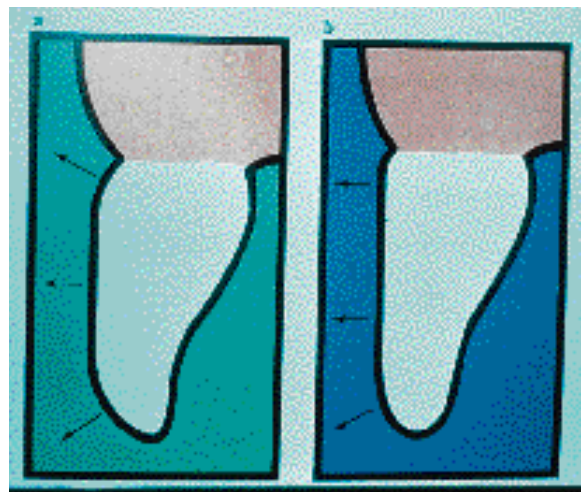


Figure 7-3: This illustration shows how changing the contour of the labial surface alters the light reflection to make the tooth appear longer.

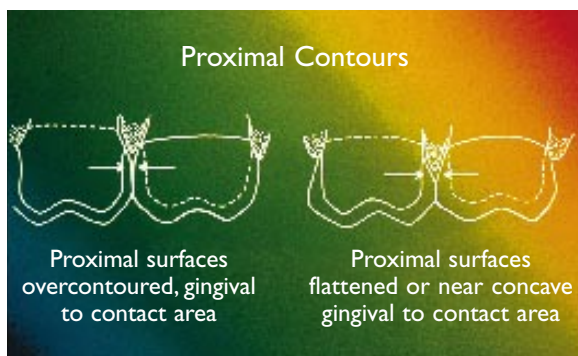


Figure 7-4A: The proximal surface must be carefully planed and contoured to avoid impinging upon the gingival papilla.

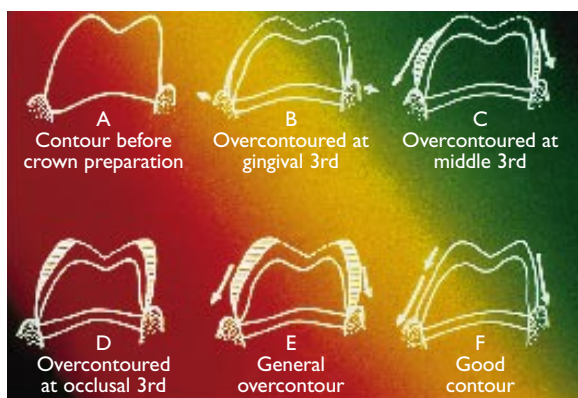


Figure 7-4B: One of the most difficult tasks is to properly contour a full-crown replacement. This illustration shows proper contouring and the four common types of overcontouring.

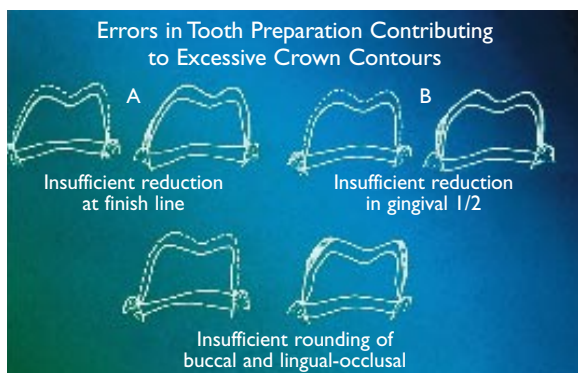


Figure 7-4C: Errors in tooth preparation are a major factor in excessive crown contours.

ledgeable dentist can try to prevent a future gingivectomy by recommending a conservative subgingival curettage or a conservative flap operation first.

2. When you have a short upper lip and maxillary anterior protrusion, correct the protrusion rather than extract the teeth. This will avoid the loss of the maxillary anterior ridge and prevent the creation of another dental cripple. Many of us have sweated blood and tears trying to arrive at an esthetic result on a similar case that had been irreparably ruined.

We must stress cooperation and discussion among the various disciplines in advance of work being done! Intelligent discussion between experts from various disciplines could result in several additional choices for the cases described above; for example:

- a. If the patient has sufficient time, adult orthodontics would be a good choice.
- b. If the patient does not have the time for adult orthodontics and there is enough pulp recession to sufficiently shorten the teeth so that proper preparation can restore a cosmetic arch form, then crowning the teeth would be the restoration of choice.
- c. In extreme cases, it would be good dentistry to treat the teeth endodontically, building the dowels lingually, so that the crowns may be placed in an esthetically pleasing arch form.

In these ways, a cosmetic result is achieved while retaining all the alveolar bone to keep normal lip support and actions.

Porcelain or Plastic?

The use of porcelain crowns has been criticized by some dentists because of the frailty of the material. The reason for such frailty is that most dentists resort to porcelain only when the tooth has been badly broken down. By failing to build-up the tooth with a casting in order to achieve a normal preparation to support the porcelain against stress, these dentists encounter breakage. Porcelain is only as strong as its underlying support. In contrast, acrylic crowns are much stronger and more resistant to breakage. When used on broken teeth, the preparation should be built up with a platinized gold casting.

Attention to Detail

The single most important consideration when building mouth personality is attention to detail. The superior dentist, whose work stands apart from that of his average peers, is one who pays particular attention to every small detail and it is this that explains why two dentists using exactly the same procedure will produce outcomes that are perfect in one case and marginal or unacceptable in the other. Although in the latter case we may believe we are following the procedure exactly, we may actually miss several tiny items, the sum of which results in a product that is less than we could have achieved had we painstakingly addressed each one.

Procedures for Building Mouth Personality

Building mouth personality includes using one or more of the following five procedures:

1. Porcelain or acrylic veneers
2. Fixed porcelain or acrylic crown and bridge restorations (full-mouth reconstruction)
3. Improving arch appearance
4. Orthodontia
5. Full or partial denture restorations

1. Porcelain or acrylic veneers are thin facings that improve the appearance of incorrectly spaced, short, rotated, protruded, or retruded teeth. They were used exclusively in motion picture work, as they have very little strength to withstand the stresses induced by eating and other functions of daily living. In addition to improving the appearance of the actor's teeth, veneers are also used to build up teeth for the purpose of filling out narrow, sunken cheeks.

2. Although dentists may use the word "permanent" to describe porcelain or acrylic crown and bridge restorations, its use is misleading. Experienced clinicians understand that there are simply too many uncontrolled variables that can break down these esthetic restorations, such as a sudden and sustained craving for sweets that results in widespread caries in a patient who had been heretofore relatively free of caries, or psychosomatically induced breakdowns in healthy mouths brought on by anxiety and stress. Although these variables

and others like them are the patient's responsibility, it is only ethical for the dentist to inform the patient when such a situation exists that might tend to break down esthetic restorations. They may prefer choosing a stronger, albeit less esthetic, material.

3. Improving arch appearance is achieved through a combination of restorative procedures and cosmetic reshaping of the natural teeth (rounding cusp angles, shortening tooth lengths, etc.).
4. Orthodontia may be easily accomplished with good results in children and adolescents in whom alveolar bone tissue is quick to regenerate. In general, adults do not respond as well, due in part to faulty bone regeneration that creates a predisposition to periodontosis. It is imperative for dentists, therefore, to identify the need for orthodontia during childhood. Patients who experienced previous root resorption secondary to orthodontia, hypothyroidism, or unknown causes usually can be esthetically corrected with porcelain crowns.
5. Full and partial denture restorations constitute the final category of esthetic procedures that can be employed to build mouth personality. The emphasis in this chapter is on crown and bridge restorations and improving arch appearance, so if you want to study the various techniques included in this category, they are described in detail elsewhere in the dental literature.

The Use of Study Models in Treatment Planning

The recommended starting point for patients needing esthetic treatment is to make a thorough diagnosis and treatment plan. The next step is taking an impression from which casts of both upper and lower jaws are poured and mounted for study. As mentioned earlier, the involved teeth are prepared and then correctly built up in wax in order to study the results that might be achieved and to ascertain the need for additional preparation. In this way, you can avoid excessive and unnecessary destruction of tooth structure. Full-mouth x-rays are always obtained at the start of the process, and in more extreme cases, additional radiographs are obtained at intervals in order to note the ever-closer proximity to the pulp as tooth structure is removed.

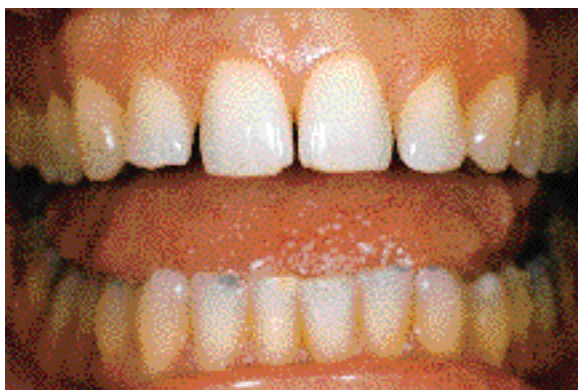

Figure 7-5A: Dr. Pincus taught that spaced teeth need to each be proportionally restored rather than create teeth that are too wide by treating only one or two of the teeth. Here, a patient with multiple spaces is shown.

Frequently, 2 to 3 mm or more of tooth structure may be removed, especially in cases of excessive overbite with a short lip and recessive pulp. In contrast, patients with abnormally high and wide pulps may require shallow preparation in order to prevent death of the pulp. In these cases, the temporary crowns may be worn for as long as 2 years, during which time the pulp has time to safely recede, before making the final preparations.

A common mistake when treating widely spaced teeth with porcelain or acrylic crowns is to fill the entire space with only one crown, which typically results in a more unsightly outcome than the original problem. To create the best mouth personality, we must strive for a perfect, natural appearance that defies detection (Figures 7-5A to C). Thus, just as abnormal spaces should be corrected by working with the teeth on either side of the space, protrusion should be corrected by bringing the protruded tooth in lingually and the adjacent retruded tooth (or teeth) out labially. Multiple tooth correction requires careful advance planning. One tooth may require more reduction on the distal surface to make room for a normal-sized tooth adjacent to it. Often the central incisor on one side is normally positioned with respect to the median line, and the other is responsible for most of the space. Again, with advanced planning and common sense, these situations can easily be corrected.

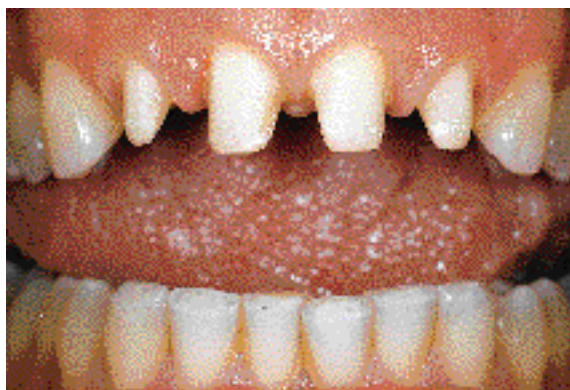

Figure 7-5B: Four teeth were ideally prepared for full crowns. This patient was treated years before more conservative restorations (such as bonding with composite resin or porcelain/laminates) were available.

CONCLUSION

In addition to the benefits that accrue to the patient through the use of esthetic procedures, the benefit of an enhanced practice accrues to the dentist. Even simple procedures, such as rounding off long, sharp cusps to create a “softer” effect, will generate much enthusiasm in the patient. Such enthusiasm cannot help but result in loyalty and referrals. Thus, the clinician can enjoy expanded financial rewards and derive the personal satisfaction that comes from knowing that a patient’s deep concern for his or her appearance has been met.

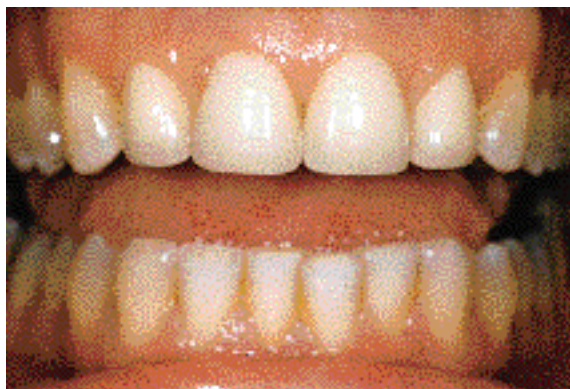

Figure 7-5C: The final result shows four symmetrically placed, full porcelain crowns. Note how good the tissue response was to well-performed esthetic dentistry.

“THE DEVELOPMENT OF DENTAL ESTHETICS IN THE MOTION PICTURE INDUSTRY”*

Charles L. Pincus, DDS

Esthetic or cosmetic dentistry is actually the fourth dimension in addition to the biologic, physiologic, and mechanical factors—all of which must be achieved for the successful result. As one of the individuals responsible for the initial concepts and growth of esthetics, it might not be amiss for me to detail how it came about. Cosmetic Dentistry was first brought to my attention around 1928 by Ern and Perc Westmore, who were then the executive heads of the makeup departments of Twentieth Century Fox and Warner Brothers Motion Picture Studios, respectively. They were referred to me with their problems by the top executives of the Max Factor makeup company who were patients of mine. Talking pictures were being born. Great dramatic stars were being imported from the legitimate stage and later from Europe. Quality in every phase of motion picture production was being stressed. Their requests were threefold:

1. They needed to know how to improve the photographic appearance of the mouth.
2. They wanted some form of appliance to change the visual appearance of the performer where a characterization (Dracula or Frankenstein) or dual role was required.
3. Most important was the fact that restorations could not interfere with speech or make the performer conscious of something foreign in the mouth, thereby affecting his dramatic ability.

Some crude work had been done in the past. However, this was completely unacceptable with the advent of sound and the emergence, as from a chrysalis, of motion pictures as a true art form. To solve their dilemma I pioneered and refined the “false front” we called veneers, now known as “Hollywood facings.” These were very thin porcelain facings that were baked in a contour to cover the spaced, turned, or twisted teeth, so as to give

the appearance of well-rounded arch form with normally positioned teeth, thus preventing the teeth from photographing black on screen. They were placed upon the teeth before the actor appeared on camera, for interviews, or for personal appearances and were removed afterward. Ern and Perc Westmore were joined in their problems with me by a number of executive makeup heads (Jack Pierce of Universal Pictures, Jack Dawn of Metro-Goldwyn-Mayer, Clay Campbell of Columbia Pictures, and Mel Burns of RKO Studios). These men were the creative giants among the pioneers whose basic techniques formed the cornerstones that are responsible for so many of the makeup advances to date. We were called upon to look at screen tests at the studios and to recommend and produce the necessary changes. These improvements allowed the audience to focus on the beautiful performance presented by the actor or actress instead of being distracted by the defects in the mouth. Knowledge and techniques advanced with each challenge. For example, we learned that it was a simple matter to correct the arch form by placing facings on the two maxillary central incisors where they were in extreme lingual retrusion. Unfortunately, in covering the teeth to the incisal edge they would appear unduly long because the entire surface reflected light forward instead of only the gingival half, as before. Hence, it became necessary to bevel the incisal portion of the veneer from about 4 mm gingivally to the incisal edge of the natural central, so that a portion of the light would be reflected downward thus creating the needed shorter appearance. This was the basis for all our subsequent work on illusions, varying tooth contours to change the light reflections and silhouette form, thereby making teeth appear longer, shorter, wider, or narrower in the same approximate space. It was also found that it was possible to cover short protrusive maxillary teeth from the lingual, lengthening the teeth without additional protrusion, and sometimes the correction of sibilation when it was present. Techniques were also evolved for shortening, evening, and recontouring teeth through judicious grinding with Carborundum stones and Joe Dandy discs followed by polishing with fine sandpaper and crocus discs. In many instances this allowed mandibular buckled teeth to photograph normally on screen. Because of the time factor for performers, and the fact that “adult orthodontics” was not a technique

*Originally written as an appendix for *Esthetics in Dentistry*, First Edition, this section is reprinted here for its historical value.

of orthodontists in those days, a need arose for replacing long-term orthodontic therapy with simple and rapid techniques of illusion, hence, techniques for contouring turned or twisted anterior teeth or correcting diastemas were developed. The sum of all these experiences led to improved jacket crown restorative contours.

In Warner Brothers' "Man of Two Faces" Edward G. Robinson played a dual role. In order to maintain suspense, a Frenchman had to be unrecognizable until the final scene. This posed quite a problem because of the short, square jaw, and thick lips that showed no teeth during speech or smile that were so unmistakably Robinson. Maxillary and mandibular removable castings were fabricated, opening the vertical dimension to create an elliptical face and longer teeth. Porcelain facings were placed so that teeth would show when he spoke and smiled. The makeup artist took over from there. Metro-Goldwyn-Mayer was in much the same difficulty with Lionel Barrymore in "Devil Doll." He was to be disguised as a woman in a portion of the picture. The difficulty lay in the fact that the Barrymore characteristics were so strong that, in the screen test in his female disguise, he looked exactly like his sister, Ethel Barrymore. (As a matter of fact, as he was walking from the makeup department to the sound stage in female costume a mutual acquaintance who had just arrived from New York, rushed across the street calling him Ethel!) Impressions had to be taken on the set at the studio, as the picture was in production. A denture was constructed that modified the appearance of the lower third of his face. Much of the knowledge of what to avoid during contouring for natural looking teeth was gleaned from these radical departures.

We were under contract to Twentieth Century Fox to ensure that Shirley Temple's mouth personality photographed the same in every film while she was a child star, regardless of the stage of primary tooth loss or eruption of the permanent teeth. It was vital that no picture production time be lost, as this would cost many thousands of dollars. The replacements varied from temporary dentures or very thin gold castings for retention with porcelain facings replacing missing teeth, to porcelain facings completely covering the partially erupted dentition. The latter were changed to labial facings as the teeth finally erupted.

Some motion pictures required character restorations to lend authority. A Twentieth-Century-Fox production "This Is My Affair" was about Theodore Roosevelt and his era. To create Roosevelt's protrusive and toothy appearance, and so create character authenticity, an appliance was constructed to overlay Sydney Blackmer's perfect arch of teeth. Thus, the teeth were lengthened and the arch widened without making him look too grotesque or stagey on camera and without interfering with his speech. Another character was built for Henry Hull in Universal Studios "Great Expectations," from the Charles Dickens classic. In this instance it was vital that there be a protrusive, bulldog effect of the lower jaw. For Paramount Studios "The Years Are So Long," starring Beulah Bondi and Victor Moore, we created a typical mouth-breather type of tooth protrusion for a brother and sister who were supposed to possess the same family characteristics. We were called upon to make the teeth for Frankenstein, Dracula, and the Wolf Man, and from the grotesque learned what not to do for the beautiful. Out of this motion picture proving ground emerged so many of the principles that contribute to the many beautiful results achieved today by the competent esthetic dentist.

Reference

1. Pincus CL. Building mouth personality. *J Calif Dent Assoc* 1938; July-Aug:125-9.

Additional Resources

- Blancheri RL. Optical illusions. *J Calif Dent Assoc* 1950;17, 29.
- Clark EB. An analysis of tooth color. *J Am Dent Assoc* 1931;18:2093.
- Gill JR. Color selection—its distribution and interpretation. *J Am Dent Assoc* 1950;40:539.
- Pincus CL. Cosmetics—the psychological fourth dimension in full mouth rehabilitation. *Dent Clin North Am* 1967; March:71-88.
- Pincus CL. New concepts in model techniques and high temperature processing of acrylic resins for maximum esthetics. *J S Calif Dent Assoc* 1956;24:26-31.
- Pincus CL. The role of jacket crown and fixed bridge restorations in the prevention and treatment of periodontal lesions. *J S Calif Dent Assoc* 1956;2:19-25.

CREATING ESTHETIC RESTORATIONS THROUGH SPECIAL EFFECTS

ILLUSIONS

Creating illusions is one of the most important objectives of esthetic dentistry. The ability to make a tooth look wider or thinner, smaller or larger, is an invaluable aid when solving difficult esthetic problems.

Esthetic effects of dental restorations are controlled by factors such as form, size, alignment, contour, surface texture, and color of the original teeth. When using restorative or prosthetic techniques on one or more teeth, duplicating the conditions and esthetics of the remaining natural dentition should be the ultimate goal. When patients request a “natural appearance” it does not necessarily mean that they want an exact copy of the adjacent or opposite tooth as the goal; the dentist frequently must alter tooth form by illusion to accomplish the desired esthetic results. The presence of space limitations—too much or too little—or other problems may make it impossible to duplicate the original tooth. Nevertheless, in many esthetic situations, the desired objective is to duplicate the natural teeth in order to attain symmetry in the smile. Dentists such as Blancheri, Frush, Fisher, Goldstein, Pound, and Pincus have been instrumental in developing esthetic dentistry’s illusions.

This chapter presents many of the problems encountered in esthetic restoration, and offers techniques of illusion that help overcome these barriers to a desired appearance.

Principles of Illusion

Several basic principles of illusion, such as those used to describe form, light, shadow, and line, may be applied specifically to dentistry. In the presence of excess light or in the absence of light, form cannot be distinguished since shadows are necessary to help make perceptible the contour or curvature of

a surface and depth. The edge of any form is described as a line; therefore, an object with many edges can be drawn “linearly” with little difficulty in visual interpretation (Figure 8–1A). If the object has smooth curved surfaces rather than edges, the form may not be easily comprehended (Figure 8–1B), unless one brings light and shadow into play (Figure 8–1C).

Light has the ability to change the appearance of a surface by its relation to that form. This ability relies on an observer’s learned, intellectual approach to perception. For example, we learn that sunlight comes from above; therefore, when we view geometric designs drawn with another light source, an illusion is created. The classic example of this is where three cubes are seen when one side of a figure is up, but five appear when the figure is turned around (Figure 8–1D). This manipulation of light and perception is used in esthetic dentistry to create the ideal dentition: by staining to simulate shadow, creating appropriate shadows through the arrangement of teeth, and by shaping or changing the contours of a tooth.

The relationship of lines plays an important role in creating illusion. To anyone who is not perceptually sophisticated, the vertical line seen in Figure 8–1E appears longer than the horizontal line because horizontal movements of the eyes are executed more easily than vertical movements. More time is spent “seeing” the vertical line, so the brain interprets the longer time spent as being due to a longer line. Figure 8–1F illustrates the effect of convergent and divergent lines. One’s attention is directed outward on the right and inward on the left, altering perception, even though both lines are the same length.

The application of light, shadow, and linear elements to illusion and their relationship to each

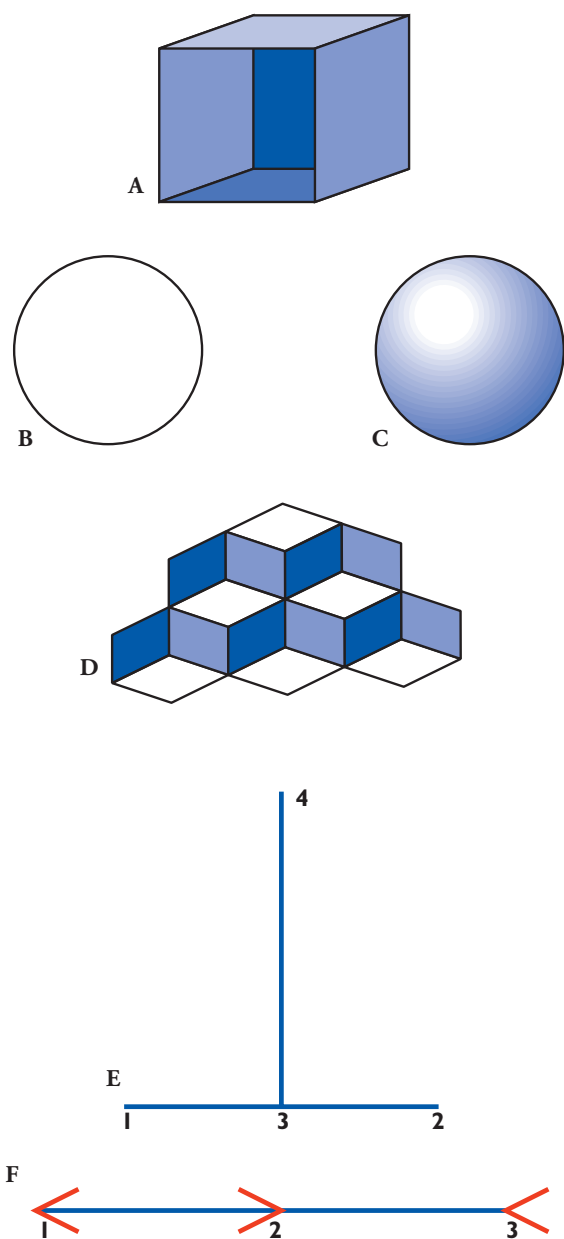


Figure 8-1: *A*, Visual interpretation is relatively simple for a linear drawing with many edges. *B*, Form is not so easily understood in an object with smooth curved edges. *C*, Added light and shadow helps to clarify form interpretation. *D*, Like the illusion created in this drawing, the perception and manipulation of light is used in cosmetic dentistry by staining, shaping, and contouring the dentition. *E*, Although the lines are of equal length, the vertical line appears longer because the brain spends more time “seeing” the vertical and interprets longer time as longer length. *F*, Illusion is created by the angled direction of the arrows. The outward position of the arrows of line 1–2 gives the illusion that it is shorter in length than is line 3–4.

other is seen in Figure 8-1G1. The folded piece of paper in this line drawing may be interpreted as being folded forward or backward. When shade is applied to this linear image (Figures 8-1G2 and 3), form is more easily understood (arrows indicate direction of light). This illusion is aided by the fact that white “comes forward” while dark recedes. We are accustomed to seeing distant objects as darker and receding objects as darker or shaded from light.

Given two teeth possessing identical shading, the presence of vertical and horizontal accent lines can create the illusion of length or width, respectively (Figure 8-1H). Although one figure may seem wider or longer than the other, both are identical in size, illustrating that combinations of light, shadow, and emphasizing lines are essential in creating effective illusions.

Illusions in dentistry are created using three techniques:

1. Shaping and contouring
2. Arrangement of teeth
3. Staining

Shaping and Contouring

The most frequent illusion is the creation of a different outline by shaping or carving the tooth. The eye is quite sensitive to silhouette form, so the incisal edges of a relatively white tooth will be easily seen silhouetted against the shadows of the oral cavity. The slight alteration of tooth structure done by shaping can alter this silhouette form to create a desired illusion.

The basic principles of illusion concerning shape and outline form are:

1. Vertical lines accentuate height and de-emphasize width.
2. Horizontal lines accentuate width and de-emphasize height.
3. Shadows add depth.
4. Angles influence the perception of intersecting lines.
5. Curved lines and surfaces are softer, more pleasing, and perceived as more feminine than sharp angles.
6. The relationship of objects helps determine appearances.

The creation of successful illusions is an art that requires advance planning. If the patient has a size, space, or arrangement problem that will need to be solved through illusion or other special effects, the following actions should be considered:

1. Look for problems during the clinical examination and when reviewing the study casts.
2. Consider whether repositioning through orthodontics, periodontics, preprosthetic surgery, or any other means will lessen or eliminate the problem. If so, the patient should be encouraged to undergo such treatment since the best illusion is none at all.
3. If it is necessary to create illusions, begin planning by determining how much tooth reduction is necessary, allowing for any increase or decrease in the size of the intended restoration. Computer imaging may help you see which possibilities will have the best potential solution to the problem. Use the images, incorporating the illusion you have created, to show your patient all the possibilities and how his or her new smile can look.

Once this determination has been made, make detailed notes on the shade chart. The teeth are then prepared and the temporary restoration is constructed.

It is essential to make the temporary restoration after tooth preparation and before the final impression is made. The temporary restoration provides a preview of the illusions that are planned for the final restoration and also gives the dentist a working model on which any necessary alterations in the treatment plan may be made. The temporary restoration therefore acts as the blueprint for a successful esthetic illusion. Since the final impression will be made at a subsequent appointment, the patient has time to adjust to and to voice any criticism of the temporary restoration. The dentist also has the additional opportunity to alter the tooth preparation, the surrounding tissue, and the shape, size, or arrangement of the temporary restoration.

During this appointment make an impression and study cast of the finished temporary restoration. (This can be done while waiting for the anesthetic to take effect for the final impression.) Send this impression, along with the final impression, to

the laboratory. This will eliminate any guesswork by the laboratory technician as to the illusion desired.

The next step, shaping and contouring, is done at the try-in appointment. This is the time when any necessary correction through illusion is performed (see Chapter 42). After fitting the restoration to the teeth, examine it for size-of-space defor-

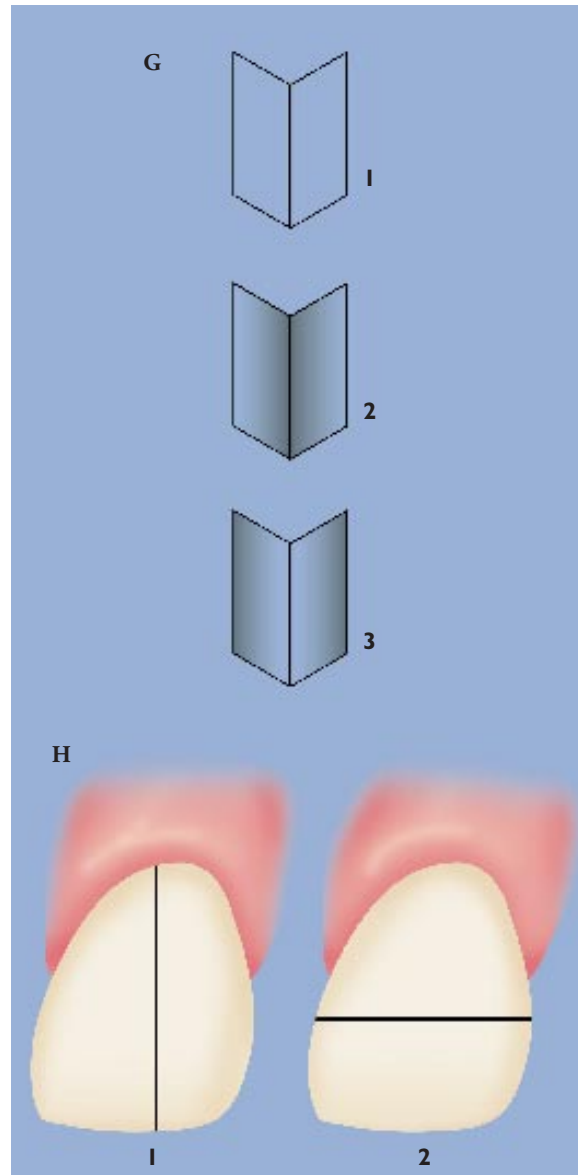


Figure 8-1: G, The interpretation of whether this folded paper is outward or inward can be more accurate when shading is added. H, Although teeth 1 and 2 are equal in size, the accent lines make tooth 1 appear longer and tooth 2 appear wider.

mities. Before correcting with a disc or porcelain stone, outline the intended correction with a black alcohol marker to provide greater perspective. Then proceed with the necessary shaping and contouring.

Although the eye is more sensitive to outline than to surface form, it is surface contour, a basic part of good illusion, that controls light reflection. Application of surface characterizations should be done with this in mind.

When planning surface characterizations, these procedures should be followed:

1. Study the teeth being restored prior to tooth preparation.
2. Study adjacent teeth before and during treatment.
3. Make notes on the texture desired. Include convexities and concavities, grooves, fissures, stains, shadows, and highlights. Determine whether the lines are vertical, horizontal, or a mixture of both.
4. Take an accurate study model and pour it in yellow or green stone to best show the texture (Figure 8–2). Use Jelenko model spray (J.F. Jelenko and Co., Kuzler Lab Products, Armonk, NY) to bring out the highlights.
5. Then take a 35-mm slide or photograph of the adjacent or opposite teeth. This can be

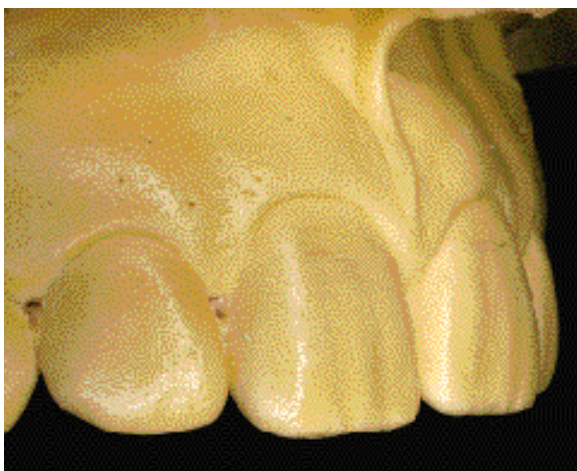

Figure 8–2: A study cast in yellow or green stone is sprayed with Jelenko model spray to show texture and highlights. (Adapted from Lombardi)

helpful in observing texture and its influence on light reflection.

6. Match the degree of smoothness or roughness of adjacent teeth.

When there are no guidelines and the anterior teeth have faulty or unesthetic restorations that must be replaced, it is important to remember that in older patients the enamel is usually worn on the incisal edges and is generally smoother in overall surface texture; younger patients have more textured teeth. If you observe the opposite arch there may be indications of the type of texture required. Characterized or textured surfaces produce shadows, and shadow position can determine how the mind will interpret contour. A tooth with a shadow or shading on the incisal portion will cause the gingiva to appear more prominent. Shadows or shading can also cause a two-dimensional object to appear three-dimensional and can change the apparent length, width, or height.

Arrangement of Teeth

The second most frequently used technique for creating illusions involves the arrangement of the teeth being restored. Alterations of the axial inclination of labial/lingual and mesial/distal surfaces can dramatically change appearance. This is accomplished by placing or building one tooth in front of, behind, overlapping, or rotated with respect to another. Planning must be done at the outset.

Lombardi offers good, simple advice for those taking the first steps in altering tooth arrangement. His *One, Two, Three Guide* includes incisal modifications (Figure 8–3). *One* refers to the central incisor, which expresses age; *Two* to the lateral incisor, which expresses sex characteristics; and *Three* to the cuspid, which denotes vigor. This guide shows how to use the “negative” or dark space behind the teeth. Alteration of incisal edges, which are then silhouetted against the dark intraoral background, helps to create a nearly limitless variety of illusions.²

To predict what type of arrangement will be necessary, construct the temporary before taking the final impression. The effect can then be seen in the temporary restoration or fixed partial denture and, if necessary, the preparation can be refined before taking the final impression. The patient is allowed time to live with the newly constructed restoration, eval-

uate acceptability, and express any desires for change. This is especially important in cases where a non-ideal arrangement such as overlapping or crowding is to be included. Unless patients have a chance to visualize the arrangement conceived by the dentist, they may react unfavorably when the final restoration is inserted. This can be avoided by allowing the patient to try the restoration and to understand the reasons and space limitations that caused you to elect this type of illusion. For example, a patient who had overlapping centrals may not realize that overlapping laterals can be much more attractive when combined with straight centrals. By creating the new appearance in the temporary, the patient can gain the necessary confidence that will make the final restoration acceptable. It is difficult for most dentists to look at a particular patient and tell what type of tooth arrangement will be best suited for that type of face.

Although there is no convincing research to show that certain types of faces should have certain types of teeth, there are principles that can aid you in selecting the appropriate appearance. These include understanding the patient's personality, age, and esthetic wishes. It is only through trial and error that the delicate balance that creates harmony can be achieved. This takes time and the willingness on your part to experiment and re-experiment in the temporary stage. It is a mistake to wait until the try-in appointment to create or recreate arrangement possibilities. The try-in appointment already takes a great amount of your time and skill to make a properly chosen restoration appear as natural and esthetic as possible.

Staining

Previously, no dental material had the same ability as enamel to absorb or reflect light under all conditions. However, the development of a new generation of ceramic materials for both ceramic and ceramometal restorations makes it much easier to mimic the natural dentition. Staining is the final opportunity to enhance the original shade, and to correct or improve restorations. Even though illusions through contouring may have been attempted, a combination of contouring and staining may be necessary to accomplish the desired results. Figure 8-4A illustrates a successful mandibular reconstruction made necessary by periodontal disease. The patient wished to maintain a natural appearance through crowning; effective shading, shaping,

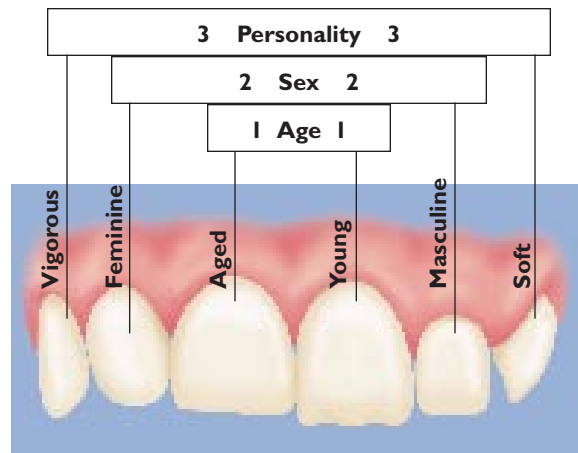


Figure 8-3: Lombardi's guide for altering tooth arrangement illustrates incisal edge modifications that affect personality, sex, and age characteristics.

arrangement, and staining accomplished this goal (Figure 8-4B).

Staining may be used not only to duplicate the natural variations in tooth color (see Chapter 10 for a full discussion) but also to create and enhance illusions through manipulation of shape and surface characterization. There are two basic aspects of color that you can use to create and enhance illusion. First, by increasing the value of the color (increasing whiteness) you will make the area to which it is applied appear closer. Second, by decreasing the value of the color (increasing grayness) you will make the area to which it is applied appear less prominent and farther away.

Although most dentists leave staining to the laboratory technician, it is desirable to have a small porcelain oven in the office where this type of correction can be done. Staining in the office saves time, and it allows experimentation with different stains until the desired effect is achieved. To rely entirely on the laboratory technician to create the desired stain may require several visits by the patient before the effect is successfully achieved. Unfortunately, after a few visits, the patient or dentist may become impatient and insert a restoration that could have been further improved with additional staining.

If the dentist does not employ a laboratory technician, an interested dental assistant who likes

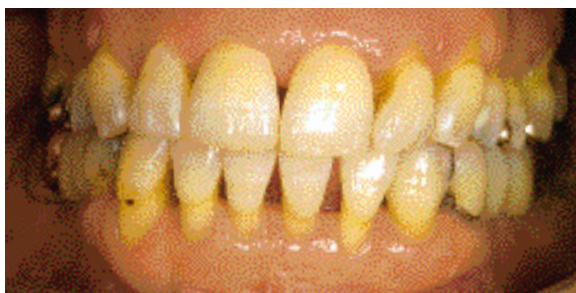

Figure 8-4A: This patient required anterior splinting to correct the effects of mandibular periodontal disease and therapy which left her with large interdental spaces.

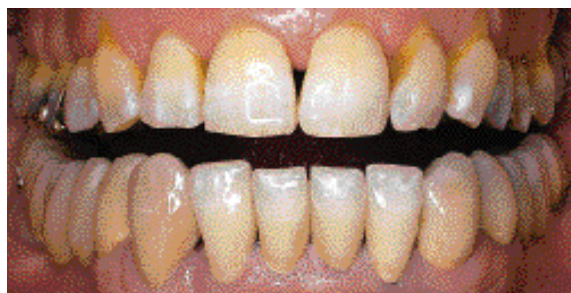

Figure 8-4B: A combination of staining, contouring, and effective arrangement of the mandibular anterior crowns gave this patient a natural-appearing result.

to paint is a good candidate to learn the art of staining porcelain or acrylic and may become quite proficient.

An important consideration is to refer to a natural tooth while staining. A model constructed from extracted teeth is also an excellent aid when attempting to achieve a more natural result.

Whenever possible, staining should be incorporated into the body of the restoration. The closer to the final shade the opaque and body layers are, the more lifelike will be the result. Opaquing material of various colors can influence the appearance of porcelain and add depth to the color. Seven basic modifying colors can be used for certain effects (Figure 8-5). Figures 8-6A to F illustrate the staining technique and what can be accomplished using

subsurface or internal staining. Ideally, surface stains should be used only to add the final touch of realism and exactness to the restoration.

Figure 8-6A shows a molar metal coping with two base tone opaque modifiers. The cervical orange/brown helps to modify the gingival, interproximal and occlusal surfaces. The use of darker opaque modifiers creates depth, especially in the thinner aspects of the tooth.

Figure 8-6B shows opacious dentin (yellow) that has been applied to the cervical, interproximal, and occlusal surfaces. This is followed by application of the dentin color (green) on top of the opacious dentin.

Figure 8-6C shows the incisal (blue) layer being applied after the dentin layer was cut back.




Figure 8-5: Basic opaque modifiers that can be used to create the background for certain effects.

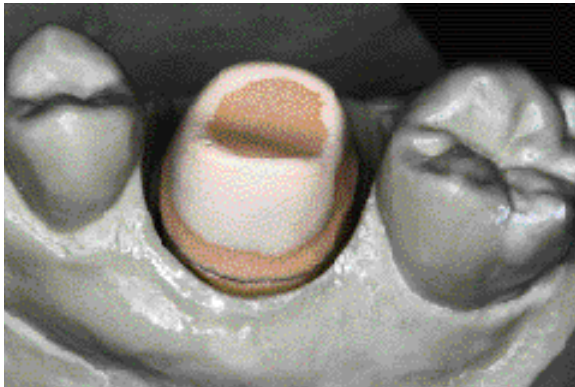


Figure 8-6A: This metal coping has been opaqued with cervical and occlusal modifiers to create the illusion of depth.

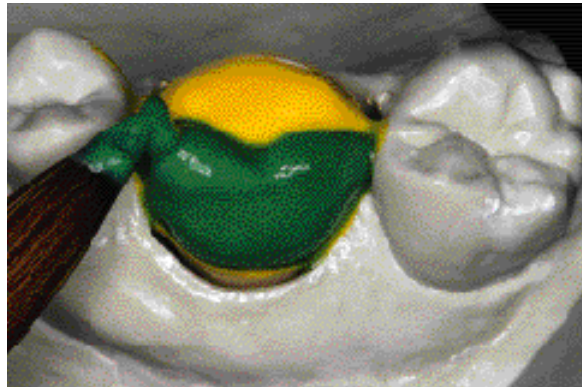


Figure 8-6B: Food coloring has been added to help distinguish between the layers. The yellow is opacous dentin overlaid with the green "dentin" porcelain.

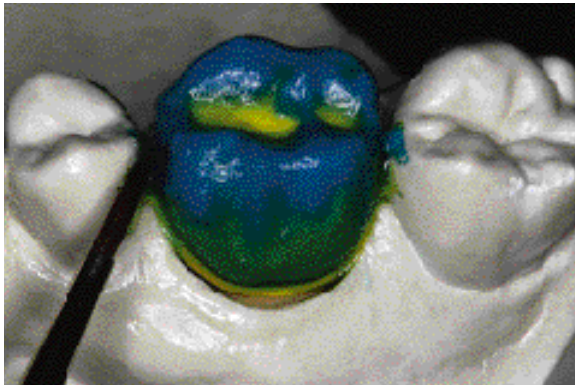


Figure 8-6C: The blue, or incisal, layer is overlaid on the dentin layer.

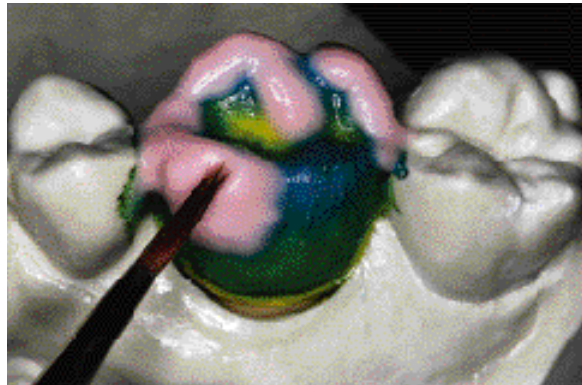


Figure 8-6D: A final layer of pink, "milky opalescence" porcelain is placed over the incisal layer.

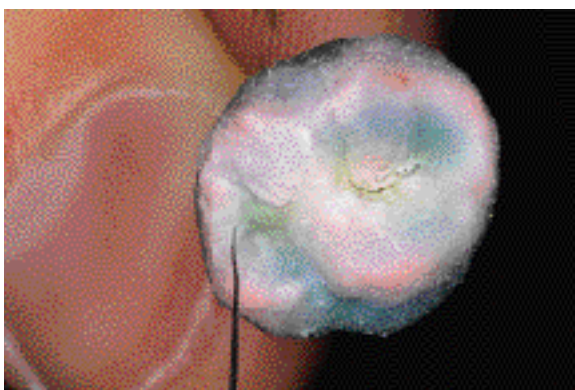


Figure 8-6E: The final morphology is enhanced with a thin endodontic file to help create more realistic occlusal anatomy.

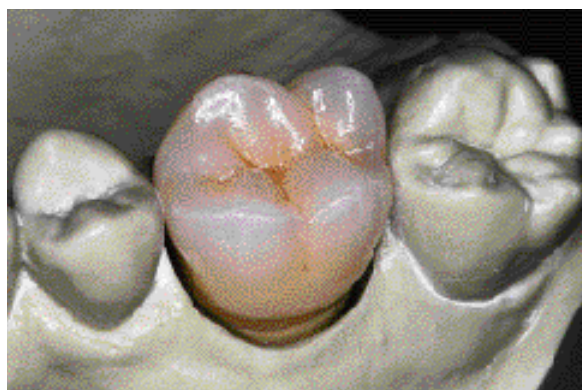

Figure 8-6F: The completed crown after firing, glazing and polishing. Note how the deep orange-brown modifier provides a more realistic crown.

To complete the buildup, a “milky opalescence” layer (pink) is applied on top of the incisal layer (Figure 8–6D). In ceramic layering, it is important to realize that the incisal layer has several different tones, from gray to off-white, which help simulate interproximal enamel color.

Figure 8–6E shows the full contour shape and final occlusal anatomy being carved with a thin endodontic file.

Finally, Figure 8–6F shows the crown after glazing. Note the many colors used to create a more realistic and natural looking tooth.

There are three techniques that may be used with surface stains:

Glaze the Crown First. This allows surface stains to be applied over the glaze in a separate operation. However, Aker et al.⁴ state that unless a second glaze is applied over the surface stain, the resultant wear will be accelerated approximately 50%, wearing through the stain in 10 to 12 years.

Cut into the Porcelain. The porcelain may be slightly cut back and fluorescence stains placed on the surface. An incisal or translucent opalescent porcelain is then added and the crown is reglazed (Figures 8–7A and B).

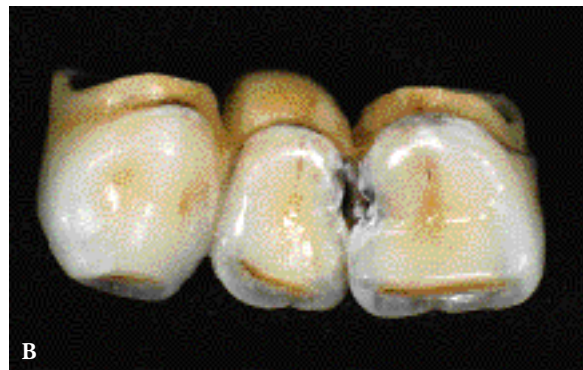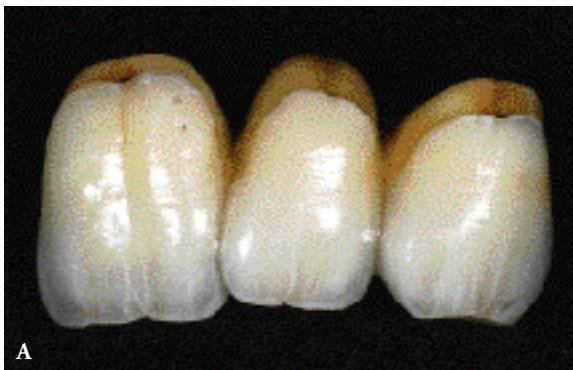Combine Glaze with Stains. Apply the glaze first, using the technique described below:

1. Mix the glaze to the consistency of thick cream.

2. Moisten a dry glaze brush in a small pool of liquid medium, and squeeze any excess medium from the brush.
3. Load the brush with glaze mix.
4. Cover the surfaces to be glazed with a thin, even coat.
5. Vibrate the tooth using a serrated instrument to make the glaze flow evenly.
6. Rebrush only where necessary to assure a smooth, even coat with no pooling.
7. Stain as desired.

Figures 8–8A to D illustrate this technique at the try-in appointment. After the restoration has been thoroughly checked for fit, shape, and occlusion, it is removed and cleaned (Figure 8–8A). The preselected stain is mixed as instructed in Step 1 (Figure 8–8B). The stain and glaze combination is applied to the restoration (Figure 8–8C), and fired at 1760°F. The result after firing is seen in Figure 8–8D. When selecting a particular shade of stain, mix enough powder into the liquid medium to achieve a creamy mix. Refer to a color wheel to observe the effects of combining hues.

The decision of which type of stain to use will be based on the degree of shade alteration required, and observation of the type of stains in the natural tooth under fluorescence (Figures 8–9A to C). If an intense effect is desired, use a thin brush, pick up a



Figures 8–7A and B: This is a good example of internal characterization to mimic the natural effects sometimes seen in the naturally aged dentition.

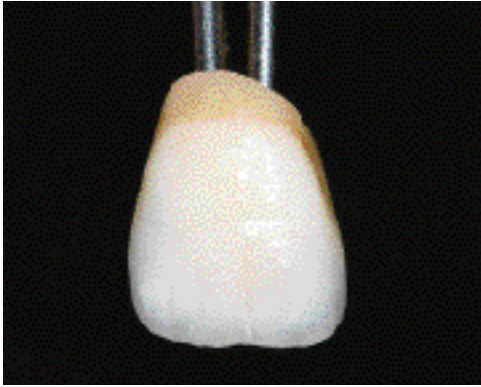


Figure 8-8A: A combined glaze and stain technique is shown here at the try-in appointment. The restoration has been checked for fit, shape, and occlusion.

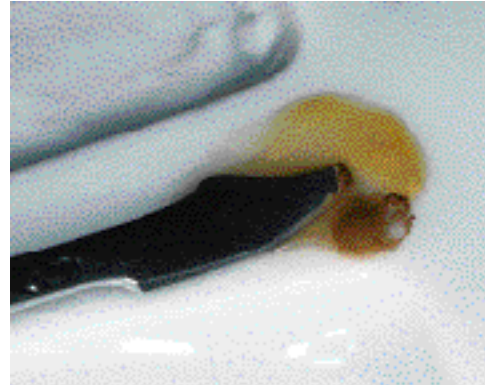


Figure 8-8B: The appropriate shade of stain is mixed to a thick, creamy consistency.

small amount of stain powder, and apply it directly to the area of desired effect. Since the porcelain is already wet, the stain will intensify in the small area, and it may be shaped as desired using the brush. This technique is also good for applying white stain to achieve effects. Figure 8-9D is a duplicate of the color wheel made with the two basic kinds of stains. Note that although the stains appear similar in conventional light, they change their behavior under black light (Figure 8-9E). Lack of fluorescence is evident in the conventional stains. The final crowns should look natural both in normal light (Figure 8-9F) and black light situations (Figure 8-9G).

When first building the porcelain it is important to select the proper shade from the guide. If a guide tooth selection cannot be made, it becomes necessary to establish a basic shade with stains. Select a guide tooth that is lighter than the desired one and free from undesirable underlying hues.

Tips on Technique

1. Keep stain colors pure. Constantly check the porcelain for dirt specks. If you find any, cut back the porcelain and repair. Keep colors far apart to avoid contamination. Wearing magnifying loupes, lenses, or telescopes (Designs for Vision, Long Island, NY) can be helpful.

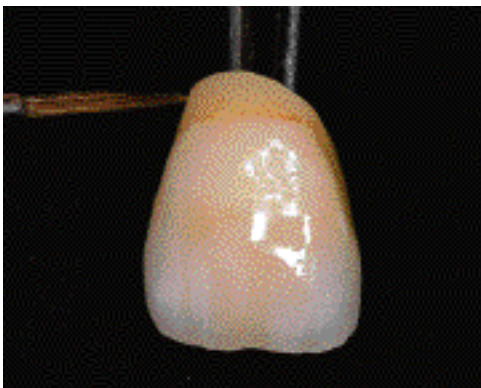


Figure 8-8C: The stain and glaze mixture is applied to the restoration.

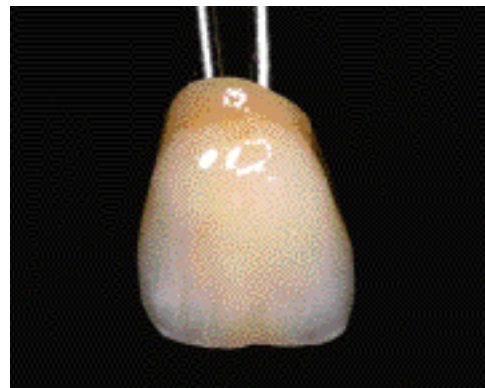

Figure 8-8D: The final result after firing. Note how the contrast between orange, brown, and blue can help create a more natural look.

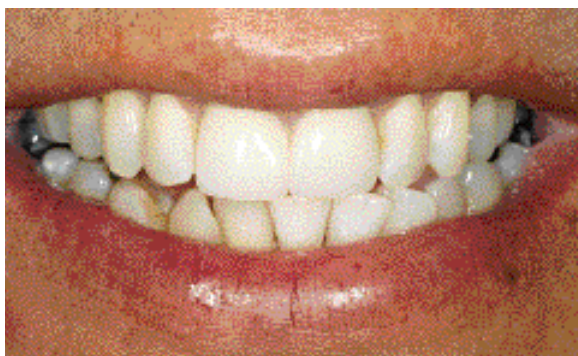

Figure 8-9A: This patient's two central incisors were restored with ceramometal crowns showing a reasonable color match to the adjacent teeth.

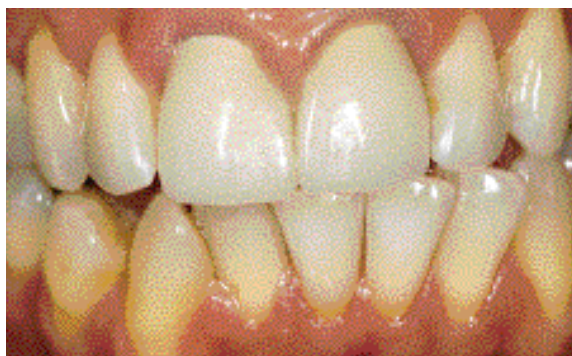

Figure 8-9B: A lip-retracted view of the two central crowns. The patient complained that the crowns were "too gray" even though it is evident that they do not appear too gray in natural light.

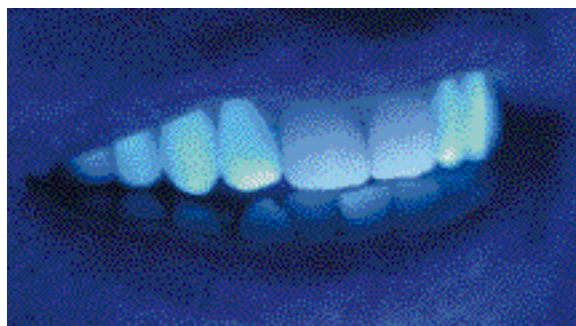


Figure 8-9C: This photograph of the central crowns taken under black light demonstrates that they did not fluoresce like the adjacent natural enamel, causing the crowns to appear different under various light conditions.




Figure 8-9D: There are two basic types of stains that are used: (1) a new generation of fluorescing stain (In Nova—Creation, Jensen Industries, North Haven, CT), and (2) a conventional nonfluorescing stain.




Figure 8-9E: The best way to determine the type of stain to use is to observe the natural tooth in a dark room under black light. If the stains on the natural tooth do not fluoresce, then you can use nonfluorescing stains on the crown.

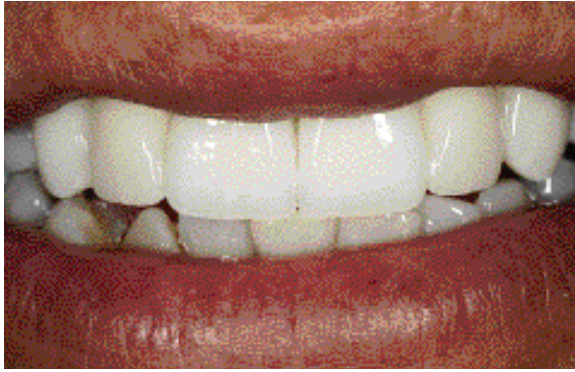

Figure 8-9F: The final close-up smile shows the two new ceramometal crowns combined with porcelain veneers.

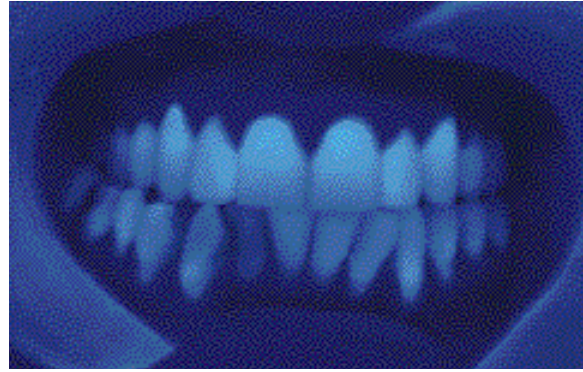

Figure 8-9G: Black light helps to show how naturally the new crowns and porcelain laminate veneers fluoresce.

2. If your experience in the art of staining is limited, do not overstain.
3. Staining should be done on a smooth surface. The tooth can be textured, but the surface should be free of pits and stone marks. Diamonds may scar the surface and puddles can form. An even, all-over texture is best. Avoid using any stones that could leave a residue that could be incorporated into the porcelain. (Use Dedeco [Dedeco International Inc., Long Eddy, NY], Shofu [Shofu Dental, Lab Division, Portland, OR], or Busch [Pfungst and Co., South Plainfield, NJ] chipless porcelain stones.)
4. Opaque white can be applied better when a small amount of glaze is mixed with it.
5. Stains, while wet, have essentially the same color value as when fixed.
6. Stains should be dried carefully in front of the furnace door so they do not run or bleed.
7. When simulating a “check line” or micro-crack with surface stains, apply a broad line first with the chosen shade of stain (Figure 8-10A). Using a flat edge of the brush, carefully wipe away each side of the line until the desired thinness is achieved (Figure 8-10B). After inserting additional characterization as needed, fire the crown according to instructions (Figure 8-10C). Similar effects can be created with white microcracks instead of brown (Figure 8-10D). This can be helpful in younger patients.

8. The guides for staining to alter shades and add characterization (Tables 8-1 and 8-2) should serve as a reference to help solve esthetic problems or to improve results. Some of the techniques can make the difference between unenthusiastic patient acceptance and complete satisfaction.

Too many firings may cause the restoration to lose its original vitality and alter shading. However, Barghi⁵ states that repeated firings (up to nine) do not normally affect the porcelain shade but that repeated firings could cause reduction and loss of autoglaze in porcelain. Nevertheless, try to incorporate as much staining as possible into the original bake and glaze.

Place stains on the tooth and fire the restoration at a temperature slightly less than for glazing until all the desired effects are achieved. Then glaze at the proper temperature. Multiple staining effects are better achieved in this fashion.

Proper communication with your laboratory is essential if you expect to receive an accurate rendition of your esthetic concept. One of the most frequent complaints dentists have is that their laboratory did not return a finished product that had the anticipated esthetic qualities.

There are six basic ways to achieve proper communication:

1. Computer imaging can provide a good idea of what the final result should look like. This is especially true if the images are taken by an

intraoral camera, which allows occlusal and labial views to be included. Thus, the correction can be visualized on two or more planes. Eventually, computer-aided design–computer-aided manufacture (CAD-CAM) will provide the most useful information to the technician. If your technician does not have a direct link to your computer but has a similar system, you can send a disk with your intended results; otherwise, send a printout.

2. A waxed model may be sufficient to illustrate to you, your technician, and your patient the suggested changes.
3. Another effective way to let patients visualize just how their esthetic correction will appear

is to apply ivory wax directly to the teeth. Use cotton rolls or plastic retractors to keep the teeth dry, and place a 2 × 2 gauze over the lower lip to protect it in case the hot wax accidentally drips. Flow tooth-colored or ivory type wax onto the incisal edges of the teeth, shape with a wax carver, and then show your patient the anticipated result. Be sure to remind the patient to hold the mirror at arm's length to get the proper illusion.

4. The same effect can also be achieved by using the vacuform matrix/composite resin technique. Take a diagnostic cast and wax up the intended correction. Make a plaster model of the corrected waxup and then make a vacu-

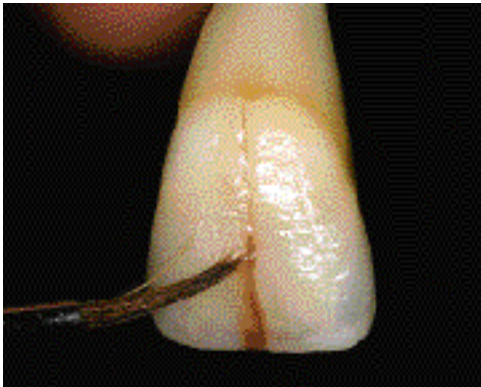

Figure 8-10A: A “natural-looking” microcrack is added by first applying a broad band of the selected shade of stain.

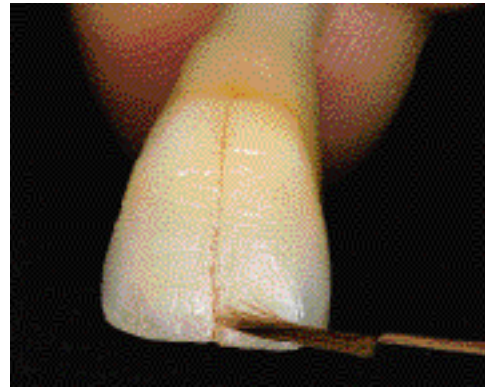

Figure 8-10B: The flat edge of the brush is used to achieve the desired thinness.

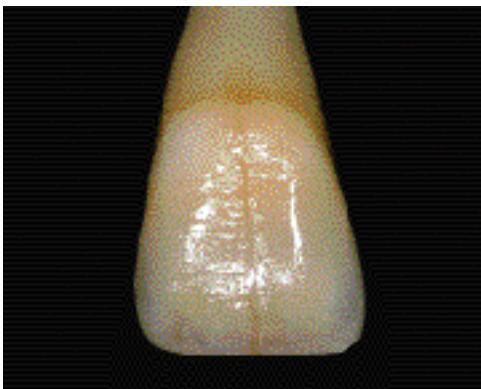


Figure 8-10C: The final result including additional “characterizations” after firing gives the appearance of realism.

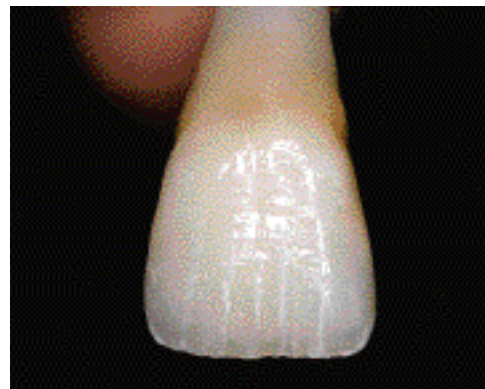


Figure 8-10D: These white “microcracks” may be more esthetically pleasing, especially for a younger patient.

Table 8–1. Guide for Staining to Alter Shade

OBJECTIVE	COLOR OF STAIN	FORMULA	APPLICATION	RATIONALE
Reduce real translucency	White	White as a base		
Make coping invisible	Gray, black or blue	Match value level with gray, black and blue	Match value level of incisal area	Method maintains value, chroma, hue, and blend
Masking small flaws and dirt specks	Orange	Gingival effect with orange		
Control apparent translucency				Complementary hue lowers value (grays) and reduces chroma (weakens)
Incisal edge				
To intensify translucency	Blue Blue-violet Blue-green Orange Orange-brown Brown	Use complementary color to neutralize orange, yellow, or pink	Brush lightly over labioincisal or linguoincisal area .5 mm, from edge in an irregular pattern Apply orange adjacent to incisal area and feather lightly into proximal contact areas. Applying thin area to incisal edge helps increase translucency and makes tooth appear more natural	Complementary hue lowers value (grays) and reduces chroma (weakens) (Same as above) and Complementary hues applied adjacent to one another enhance each other. Also helps to create third dimension
To decrease translucency	Orange Red Yellow Gray White	Add complementary color to compensate for the increased value due to the white	Add white <i>sparingly</i> ; adjust value with orange, red, yellow If necessary to lower value further, use gray	Complementary hue can alter value or chroma
Incisal-gingival blend				
To increase incisal translucency	Violet Blue	If yellow body shade, use a violet stain If brownish-orange body shade, use a blue stain (other hues similar procedure)	Add small increments brushing lightly	Use a hue that complements the body shade
To eliminate green	Pink		Add to body color as stain	A yellow body color with a gray opaquer results in a green cast. Red complements green
Control chroma (strength)				
Thin areas (gingival third)	Yellow or orange	Use opaquer of the same hue desired in thin areas		Color of thin area greatly influenced by the color of opaquer
Between abutment and pontic	Select desired hue		The final buildup and opaquer of the abutments and pontic should be of equal thickness	Thickness of area will influence chroma
Increase chroma (strength)	Red Yellow Blue	Add all three primary colors in equal amounts with emphasis on the hue to be strengthened		Addition of the three primary colors will not change the shade (extremely difficult procedure)
Decrease chroma	Clear		Add clear material sparingly	Do not use white; it will increase the value (brilliance) of the shade
Reduce value (brilliance)				
Match a too light, (too bright) crown with the natural dentition	Complementary hue of desired shade		Add sparingly	Graying the shade by using a complementary hue reduces value
Example: yellow shade	Violet			
Increase value				
(This is practically impossible to do with stains.)				Choose a shade of higher value, if necessary

Table 8–2. Guide for Staining to Add Characterization

EFFECT SOUGHT	COLOR OF STAIN	FORMULA	APPLICATION	RATIONALE
Random discoloration	White Orange Brown, Blue Yellow	Combine small amount of white with body shade	Randomly intensify the chroma over the labial surface (adds dimension)	Cervical and interproximal discoloration can tolerate some opacity
Labial mottling	Same		Same as above	
Fissures and apertures				Depends on age and habit of patient
Sulci and proximal apertures	Orange to brown	Use lighter yellow-orange in young people; deeper burnt orange as aging progresses	Apply thin lines asymmetrical	
Worn enamel and exposed dentin (incisal edge lower anteriors of the aged)	Orange to brown		May take 2 bakes	
Exposed dentin of smoker	Orange-brown or brown, blue		Vary shading, reduce incisal surface in center of teeth; increase incisal translucency at interproximals	
Incisal wear/erosion	Yellow-brown	1 part yellow 1 part brown 2 parts diluent (medium)	Stain center area of incisal edge. Undiluted or slightly diluted brown may be placed centrally to depict exposed and heavily stained dentin. Mix with orange to radiate from center	Adds depth and feeling of naturalness to incisal edge if worn
Enamel cracks (young patients)	Gray (distal) White (mesial) Yellow	Use thick consistency	Stain runs 3–5 mm. (1/3 length of crown) (gray-white) to the incisal edge	Add depth to surface (3rd dimension)
	Black		Place brush tip in the center of the crown, with a fast light stroke bring to incisal edge Apply thicker line with correct shade Wipe away mesially and distally until desired thickness is achieved. Create shadow effect by abutting the (gray/white) stain with black. Apply only a faint line	
Check-lines	Brown Black Yellow Orange	Brown with a small amount of black or yellow 4 parts stain 1 part diluent (medium)	A wide strip of stain is applied, this is brushed until a very fine sometimes not continuous line remains. These lines can slant mesial or distally towards the embrasure terminating at the incisal edge	
Grooves and pits (on the occlusal of posterior teeth and lingual surface of anteriors)	Brown Black Orange Blue	Brown with a small quantity of black or orange for a young person	Stain as fine lines, except in occlusal pitting. Combine pitting and grooves with bluish enamel staining of adjacent ridges	Creates a lifelike appearance to the tooth
Decalcification/hypocalcification	Opaque white Yellow Brown Gray	Opaque white alone or with a trace of yellow, brown, gray	Use a thick layer of opaque applied irregularly in various areas. Effective if used on several teeth evenly in gingival area. Otherwise, vary	Used to match adjacent teeth. Note area and intensify
Cervical stain/gingival erosion	Brown Yellow Gray or lime-green	3 parts brown 1 part yellow or gray 4 parts diluent (medium) or lime-green	Blend with body shading where it begins. Occasionally dark brown spots may be placed using the feathered edge of a brush	Ditching possible to actually create an eroded area
Existing silicate or composite Stained outline	Orange Brown Gray	Limit diluent added to stain.	Paint the outline form using brown/gray/orange. It should fade out irregularly. Place the inside portion with opaque white	
Restoration itself	Opaque white Gray Yellow Brown	Opaque white with small amounts of any combination using gray, yellow or brown		
Amalgam stain	Gray Black Blue	Match adjacent teeth	Gray or bluish stain on the proximal angle over a distance of 2 mm on the labial surface	
Gold inlay	Gold pottery stain		Superglaze surface to be stained. Paint a thin layer of gold stain over super glaze. Fire the layer and then coat with two thin layers of white glaze	

form matrix of this. Fill the inside with old or outdated composite resin and place in the mouth without polymerizing. An alternative is to line the inside of the vacuform matrix and polymerize only after eliminating undercuts by trying in the matrix several times.

5. To assure that a restoration will have the desired shape, contour, and size when it is returned from the laboratory, detailed instructions must be written. For example, in the case of a diastema, the technician should be instructed to carve the contact areas to the lingual surface in order to diminish the apparent width of the crowns. This kind of communication makes it more likely that you can achieve the desired results before the restoration is even tried in the mouth.

Written communication can be the only source of information or be an additional or secondary aid. However, it leaves the greatest chance for miscommunication unless it is carefully written and leaves no room for misinterpretation.

In cases of illusion through arrangement, a diagram on the prescription blank is most helpful. If you want a tooth either overlapped, rotated in labio- or linguoversion, or in any other position not commonly used by the laboratory, planning must be done at the outset. If you desire the ultimate in esthetics, then spend the necessary time to write a detailed, graphic laboratory prescription.

Another method that can also be quite helpful is to furnish your technician with slides or photographs. Even good Polaroid® (Polaroid Corporation, Cambridge, MA) instant close-up photographs of whatever you need to communicate can help the technician better understand both your patient's esthetic problem and what you want to accomplish in the restoration. Try taking a close-up photograph holding the chosen shade tab against the area to be restored. Often, even slight differences in chroma and value can be seen. The more pictures you take, the better the technician will be able to visualize what he or she must do to help achieve the desired esthetic result.

An alternative photographic technique is using a good intraoral camera with color-balanced film and lighting. Do not use any overexposed slides or prints, because the washed-out color will be inaccurate.

TECHNIQUES FOR VARIOUS PROBLEMS

The most commonly encountered problems that can be corrected through illusions are discussed below.

Space Available is Wider than the Ideal Replacement Tooth

This problem is typically encountered either when space was present between the teeth prior to extraction or when drifting has occurred to widen the space. If the space is to be restored with the correct number of teeth and tooth contact is to be re-established, avoid horizontal lines, edges, and characterizations, and incorporate as many vertical ones as possible into the restoration.

Shaping

The width of the replacement tooth or teeth will have to be wider than ideal; therefore, various illusions achieved through shaping and contouring should be used. The width needed to close the space is gained in the areas of contact.

Illusions for Incisors

The extra width can be disguised by placing the contact areas more lingually and cervically. In Figure 8–11, the diameter of tooth “a” is larger than that of tooth “b,” but by carving the mesial and distal line angles to the lingual, the tooth appears thinner. One reason for this illusion is the reflection created by shaping and contouring the tooth.

Light usually reflects from the flat labial surface. Line angles “e” and “f” usually reflect light and give the appearance of width to the tooth. The corresponding lines on the right central would be “g” and “h.” By moving the mesial and distal line angles slightly to the middle of the tooth, new line angles “c” and “d” are created and thus less flat labial surface remains. This reduction in the reflective surface makes the tooth appear narrower than it really is. Although these should be subtle carvings, at times, labial prominences can be created to actually catch light rays. In this manner, more precise distance can be interpreted by the observer.

Summary. The mesial and distal line angles in Figure 8–11 are moved toward the center of the labial surface (c and d). The mesial and distal surfaces are then made more convex, curving from the line angles into the areas of contact.

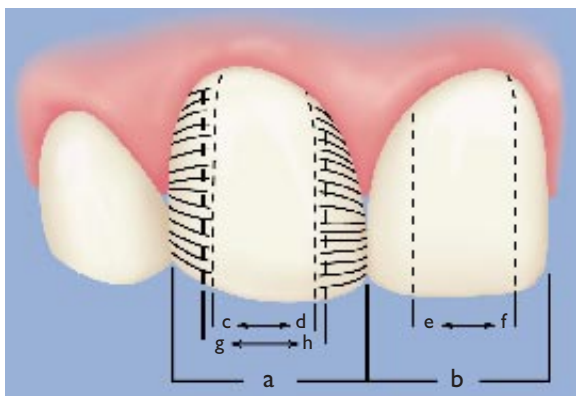


Figure 8-11: Tooth a is made to appear thinner than it actually is by carving the mesial and distal line angles to the lingual, thus presenting less labial surface.

The shape of the incisal edge can abet the illusion of decreased width. The mesioincisal corner is rounded, and a gentle curve is created from the middle third of the incisal edge to the distal contact (Figure 8-12).

The incisal edge can be notched slightly to break up the horizontal line. Even a slightly curved indentation, a wave result, will alter visual perception and create a more pleasing effect. The eye tends to wander away from a horizontal line, and the curves provide relief.

Only a limited amount of mesioincisal rounding permitted, mainly due to the possibility of creating asymmetry in the restoration by overdoing it. It is possible, however, to create the illusion of a slight incisal diastema by moving the mesial contact of the larger tooth gingivally. This produces an entirely different effect than a complete diastema. The open incisal diastema can be natural in appearance and quite effective in balancing space variations. More incisal shaping is possible from the distal side. Since the observer sees the patient mainly from straight ahead, it is possible to achieve much of the space illusion by opening the disto-incisal embrasure. The distance (Figure 8-12) c-d is also re-emphasized by carving mainly from this point, both mesially and distally.

At times, it may even appear as if a diastema is placed distally, depending on how much the contact is placed gingivally. This is still a much better esthetic choice than having an oversized contralateral central incisor.

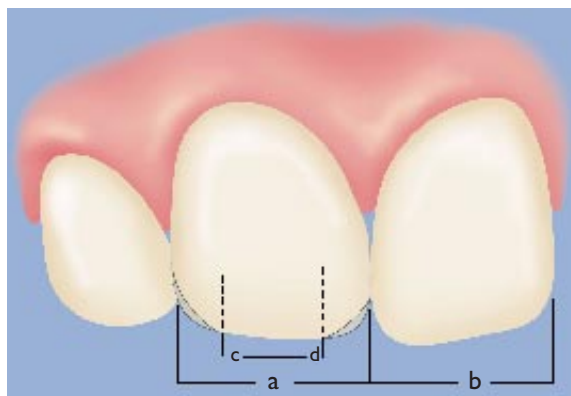


Figure 8-12: Gentle curving of the mesioincisal and disto-incisal edges, as well as a slight indentation at the midincisal edge, alters visual perception.

Illusions for Cuspid

Extra width can be disguised by moving the visual center of the labial or buccal surface more to the mesial by carving the buccal ridge to the mesial (Figure 8-13). The cusp tip should then be moved mesially if this is compatible with functional requirements. Contact areas should also be moved lingually and cervically.

Illusions for Anterior or Posterior Teeth

The developmental grooves are moved closer together (Figure 8-14). These grooves do not have to be deep to be effective. Shallow grooves will give the desired shadows. To further this illusion, any

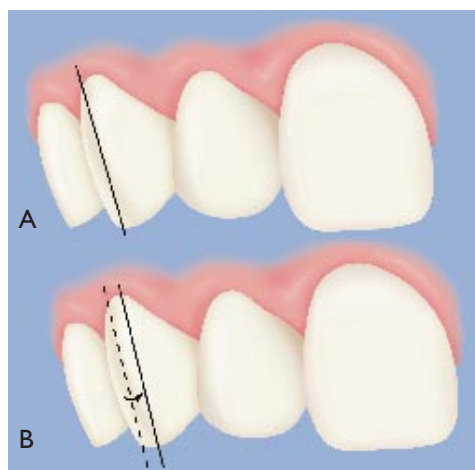


Figure 8-13: *A*, This figure illustrates a too-wide cuspid. *B*, The buccal ridge is carved to the mesial to disguise the excess width in the cuspid.

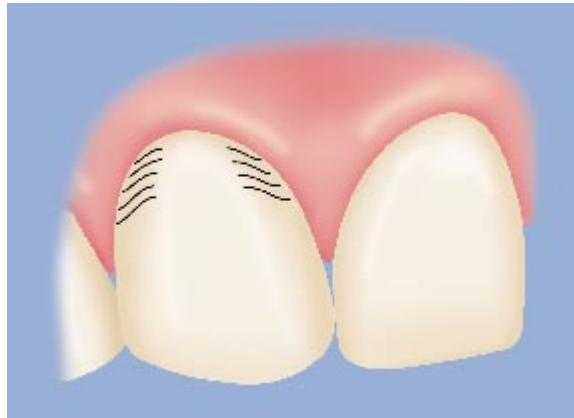


Figure 8-14: Shallow developmental grooves which break up the smooth labial reflecting surface make the tooth appear less wide.

characterizations ground into the labial or buccal surface should be vertically oriented. By breaking up the smooth unbroken labial or buccal reflecting surface with characterizations, you make the tooth appear less wide.

The curve of the cemento enamel junction carved into the restoration can be made more pronounced and brought into a more incisal or occlusal position in the interproximal gingival embrasure areas (Figure 8-15). When shaping the restoration, the opposite tooth should be kept in mind as the ideal.

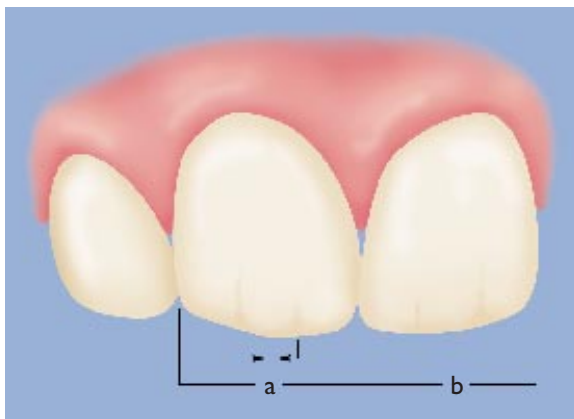


Figure 8-15: A more pronounced curve carved into the cemento enamel junction which is in a more incisal or occlusal position is another technique used to make the tooth appear thinner.

Slight concavities in the gingival third also give the illusion of a narrower tooth. Special attention should be paid to duplicating ridges and depressions that reflect light (Figure 8-15). One should remember that it is the individual pattern of light and color reflection that determines tooth character. Figure 8-16 shows all the shaping effects combined to produce the illusion of a thinner tooth.

Staining

For masking a large tooth, color can be used to advantage in one of several ways.

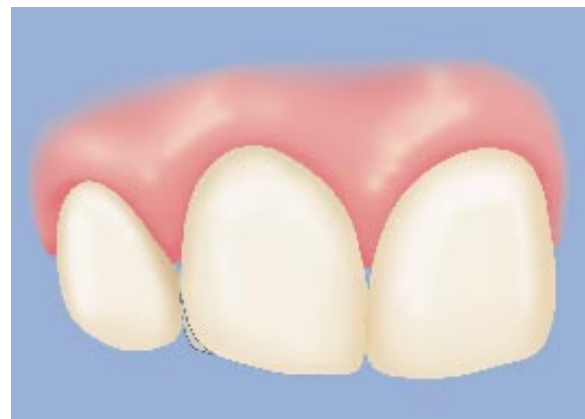

Figure 8-16: All three shaping special effects are combined on this restoration to produce the illusion of a thinner tooth.

By selecting a body color barely darker than that of the approximating teeth, the larger tooth appears less prominent. The mesial and distal thirds of the labial or buccal surface can be stained grayer (Figures 8–17A and B) than the middle third. The gray color disappears in the mouth and the appearance of size is transmitted to the glancing eye by the normally colored area. Note how much thinner the teeth appear in Figure 8–17B after using the above technique. The developmental grooves and characterizations ground into the surface can also be emphasized with gray stain. Indefinite, barely perceptible, vertical lines can be incorporated to accent the vertical aspects of the tooth. This is done by using a stain slightly lighter than the body color and by running it from the tooth body to the incisal or occlusal edge. To further highlight the lighter lines suggested above, an opaque white, yellow, orange, or brown stain can be used to create vertical check or microcrack lines (see Figure 8–10C).

Arrangement

The position or arrangement of the teeth can create the illusion of decreased width. When a tooth is placed in linguoversion, not only is its real width masked by the more prominent approximating teeth but the effect of the increased shadowing also masks its size (Figure 8–18). Rotation of a tooth from its normal labiolingual position will accomplish several illusions. Through rotation, the normal perception of the tooth is changed, and the tooth loses some of its identity. Depending upon the degree of rotation, the tooth can be made to appear less wide. In Figure 8–19A, the right central

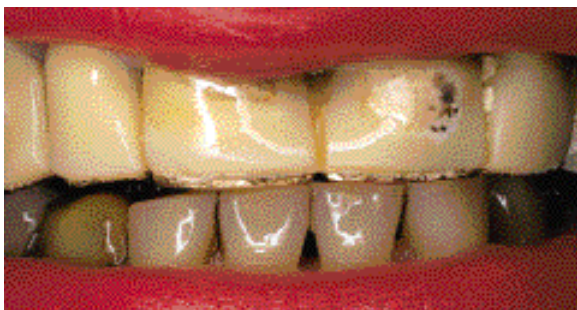

Figure 8–17A: These two central incisors appear too wide with respect to the other teeth in the patient's dentition.

appears wider than the left central; actually the left central is rotated distally, so it looks thinner (Figure 8–19B). When the mouth is viewed from midway between the rotated and nonrotated teeth, the teeth look much the same width (Figure 8–19C). When two central incisors are replaced, the distal aspects of the wide crowns are rotated lingually, thereby narrowing the area that reflects light forward and decreasing the apparent width (Figure 8–20). You can create a diastema to avoid widening the replacement teeth. Position the teeth so that the space left on the distal aspect of the restoration is not prominent (Figure 8–21).

If the space to be filled is much wider than the replacement teeth, the only reasonably esthetic solution may ultimately be the addition of an extra tooth. This method of handling the extra space works especially well when replacing the lower anteriors. (You may refer to Esthetics in Dentistry Vol. II, Chapter 24: Restorative Treatment of Diastema.)

Space Available is Narrower than the Ideal Replacement Tooth

This problem is usually encountered when extraction was not immediately followed by replacement and the adjacent teeth drifted or tilted to encroach upon the space. If the space is to be restored with the correct number of narrower teeth, avoid vertical lines, edges, and characteristics, and incorporate as many horizontal lines as possible.

Shaping

Before the replacement crowns are shaped, the proximal surfaces of the adjacent teeth should be

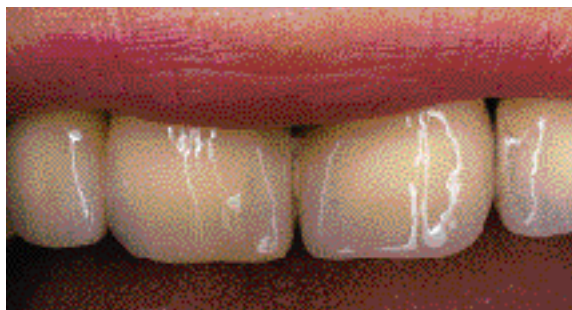

Figure 8–17B: The mesial and distal thirds of the labial surface are contoured and stained a darker gray to give the appearance of thinner teeth. In addition, the incisal was slightly curved to break up the “straight across” and wider appearing line angle.

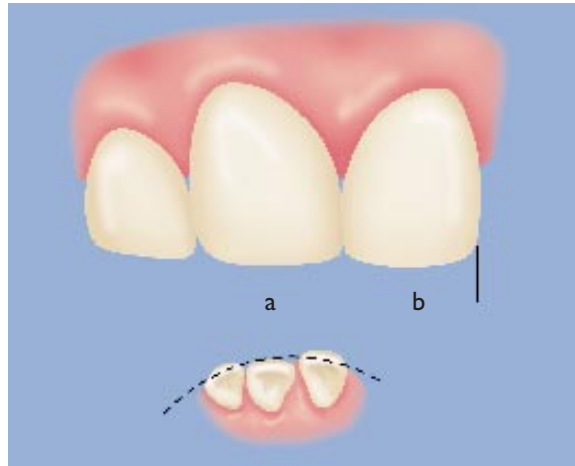


Figure 8-18: Placing the wider tooth in linguoversion masks its real width by diminishing its prominence with the adjacent teeth and adding shadowing.

reduced slightly to increase as much as possible the space available. Most or all of the needed space can be obtained in this fashion. If this procedure is used, the reduced enamel surfaces must then be refinished

(see Chapter 11). By altering the contour of the labial or buccal surface and the incisal or occlusal edge, an illusion of width can be achieved, even when the actual tooth is narrowed.

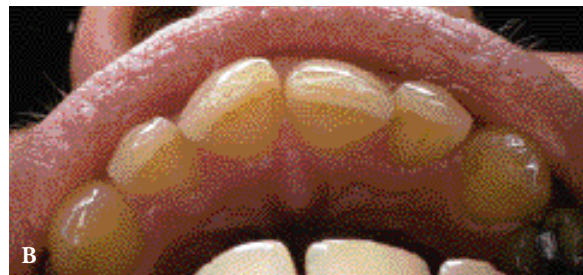
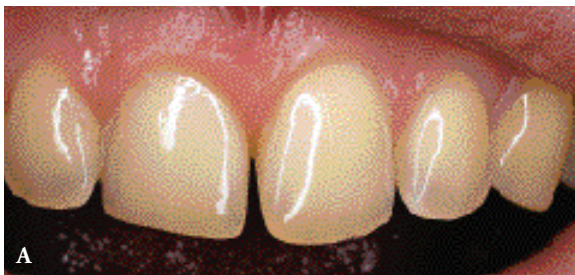
Figure 8-19A and B: Although the right central appears wider than the left central, the left central is actually rotated distally which causes it to look thinner.

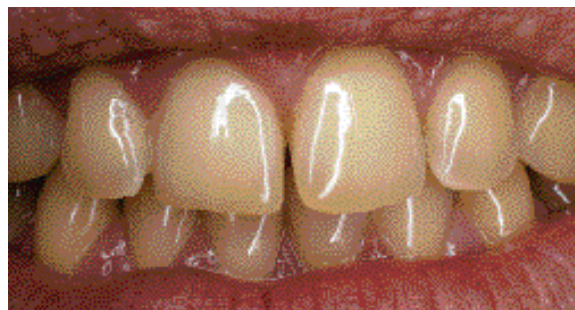

Figure 8-19C: When the patient is viewed from a different angle (halfway between the rotated and nonrotated teeth) the teeth look proportional.

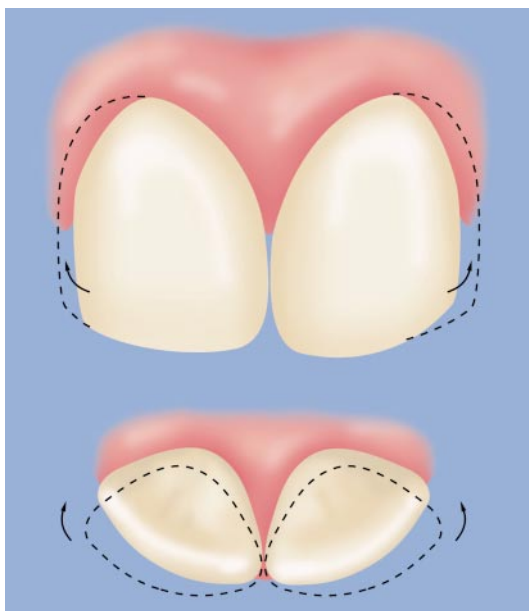


Figure 8-20: The distal aspects of both the replaced central incisors are rotated which narrows the light reflecting surface and decreases width perception.

Illusion for Incisors

The contact areas are moved labially and incisally, as illustrated in Figure 8-22. In this case, the right central is narrower than the left central and needs to be made to appear wider. By extending the contact areas both labially and incisally, the apparent width of line angle X is increased and helps make the right central look wider than it really is.

If the previous technique is used in conjunction with flattening the entire labial surface and the proximal line angles, the overall effect will be lengthening of the incisal edge and development of a broad labial surface for light reflection. Both of these effects heighten the illusion of width (see Figure 8-22).

Another technique is to leave the incisal edge as flat and as horizontal as is compatible with adjacent teeth (see Figure 8-22). It may also help to reshape the incisal edge of the adjacent teeth slightly to help make the entire effect more esthetically harmonious. The adjacent central incisor can be shaped to look narrower by carving its distoincisor edge gingivally.

Illusions for Cuspids

The narrowness of the crown can be disguised by moving the visual center of the labial or buccal surface (Figure 8-23) more distally. This is accom-

plished by carving the buccal ridge to the distal. The cusp tip should be moved distally if this is compatible with functional requirements, and the contact areas should be moved labially and incisally to accent the horizontal aspects of the narrow tooth.

Illusions for Anterior or Posterior Teeth

The curve of the cemento-enamel junction can be influential. It should be at the same level as the curve on the adjacent natural teeth but should have a flatter appearance (Figure 8-24A). To further accentuate the horizontal, additional grooves can be carved gingivally on the original one (see Figure 8-24A). However, if the adjacent natural teeth have strong vertical lines, this cannot be done effectively; therefore, the effort should be directed toward de-emphasizing as much as possible any vertical lines or edges. If there are only a few vertical lines on the adjacent natural tooth, it may be possible to cosmetically contour the labial surface on that tooth to diminish their effect.

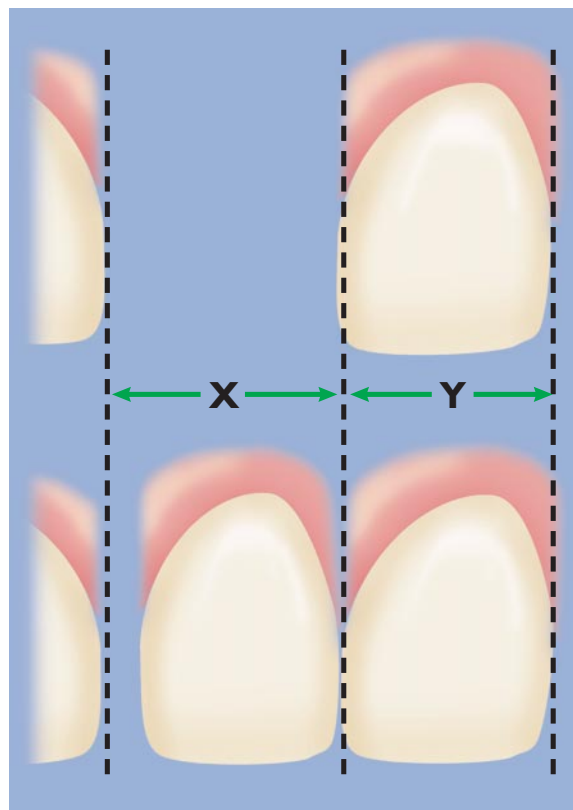


Figure 8-21: When a space is too wide, a diastema is preferable to making the replacement tooth too wide.

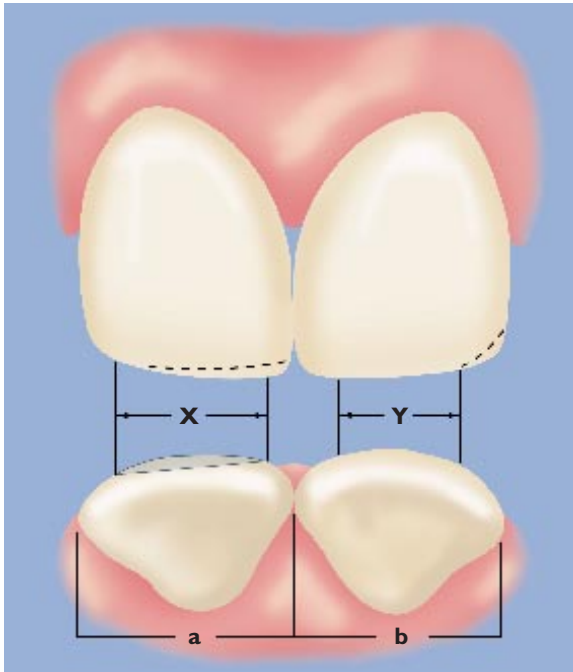


Figure 8-22: The narrow right central incisor needs to appear as wide as the left central incisor. The line angle X is extended labially and incisally, making the right central appear wider. If necessary, the distoincisor angle of the wide incisor can be reshaped, making it appear slightly narrower.

By eliminating developmental grooves and lobes, the labial surface can be carved to develop a broad, flat surface to provide an area for unbroken light reflection. This area will appear broader than the same area that has the surface broken with grooves and characterizations that scatter the reflections (see Figure 8-24A).

Staining

Color can also be used to increase the illusion of width. For instance, when a body color is selected that is slightly lighter than that of the adjacent teeth, the narrow tooth will appear more prominent and therefore wider. The mesial and distal thirds can be stained a shade lighter than the middle third, to highlight the proximal aspects and the width of the tooth. Any horizontal grooves or lines that have been carved into the labial surface can be accentuated with a light stain. Definite, barely perceptible, horizontal lines can be created to accentuate width. This is done by choosing a stain slightly lighter than body color and running it from mesial

to distal. To further accentuate these lines, a light, thin orange, yellow, brown, or white opaque line can be placed on the labial surface (Figure 8-24B).

Another way to accentuate width is to simulate multiple decalcification spots running horizontally across the middle third of the tooth (Figure 8-24C). Other horizontal lines can be created by using staining to indicate one or two anterior restorations that have been carried out onto the labial surface. If adjacent teeth show cervical erosion, this erosion should either be restored or reproduced in the replacement tooth. Staining can be used to create an illusion of erosion, and if it is horizontal and flat, it will emphasize width (Figure 8-24D).

Arrangement

The most simple and direct solution for inadequate space is to rotate and overlap the replacement crowns or teeth without reducing their ideal widths. If rotation and overlapping is unacceptable or impossible, and if the encroachment upon the space has been severe, it may be possible to eliminate one tooth entirely with good results, especially in cases involving lower anteriors. In cases where the maxillary central incisors are involved, the distal aspects can be rotated labially, making these teeth appear more prominent and wider (Figure

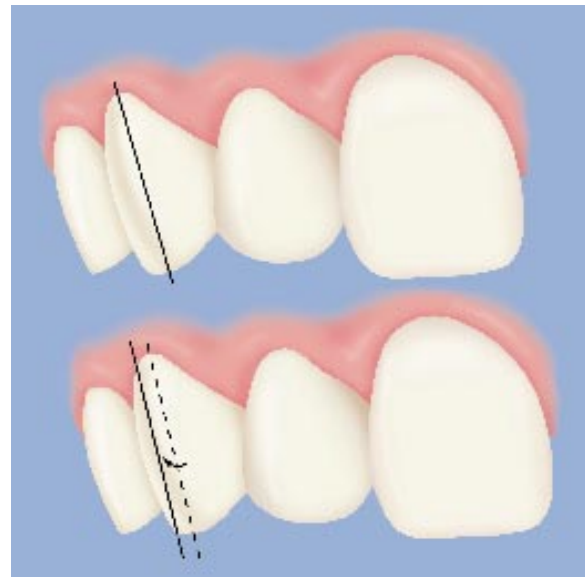

Figure 8-23: When the crown of the cuspid is too narrow, move the visual center of the labial surface distally by carving the buccal ridge distal to the usual position if this remains compatible with functional requirements.

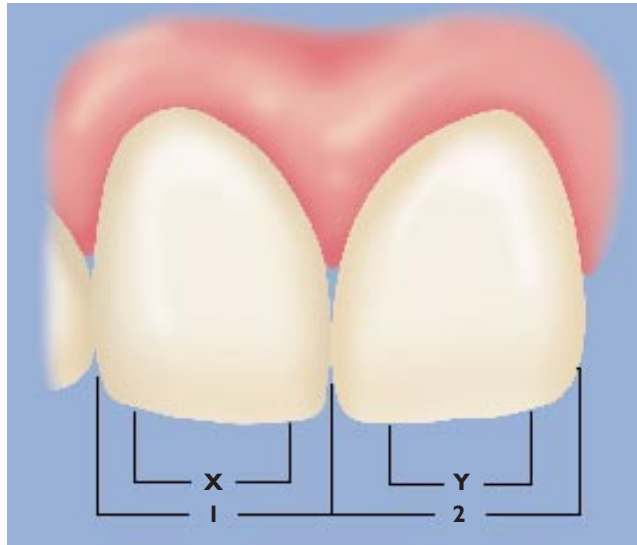


Figure 8-24A: Horizontal grooves were carved into the right central (1) to give it a wider appearance.

8-25). The principle involved here is to create prominent distolabial line angles to create more horizontal reflections.

When the problem involves both maxillary central and lateral incisors, the centrals can be placed normally and the laterals can be rotated. In the case of a male, the mesial aspects of the laterals are rotated and lapped lingually behind the centrals increasing the overall appearance of width and boldness

and decreasing the amount of space needed (Figure 8-26A). In the case of a female, the mesial aspects of the laterals are rotated labially and lapped in front of the centrals, increasing the feminine appearance (Figure 8-26B).

The Too-Short Tooth

If a tooth appears too short, as is likely if it is wider than normal, several techniques can be used to create the illusion of length.

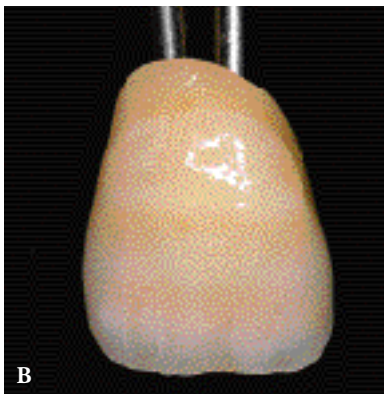


Figure 8-24B: Light, thin, orange and yellow opaque lines were placed on the surface to further enhance the carved horizontal lines.

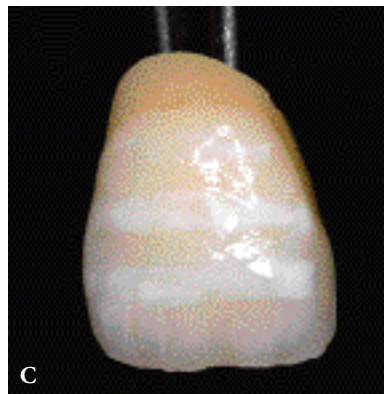


Figure 8-24C: White calcification spots running horizontally across the middle third of the tooth further accentuate width.

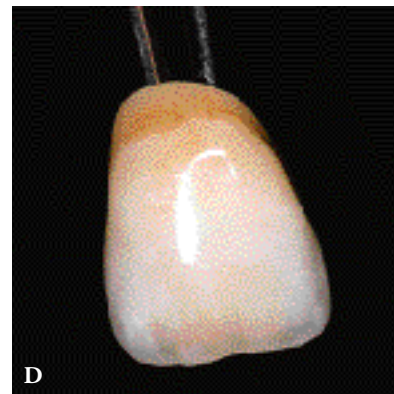


Figure 8-24D: Staining used to create the illusion of cervical erosion to match adjacent teeth also emphasizes width if the crown is horizontal and flat.

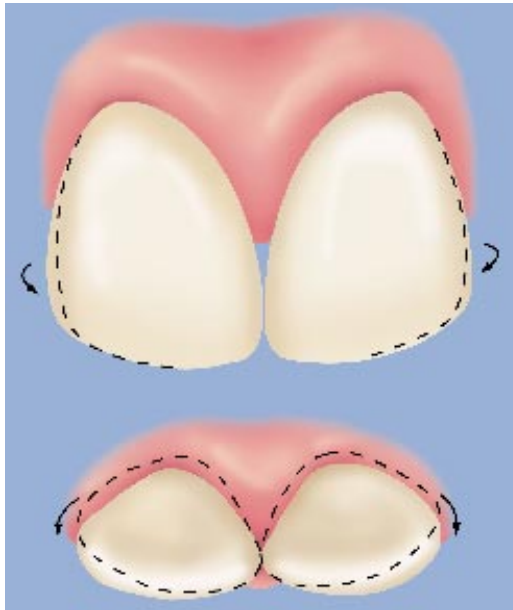


Figure 8-25: For an inadequate space involving central incisors, the teeth can be slightly rotated labially and lapped rather than reducing their ideal width, making them appear wider and more prominent.

Shaping

If the gingival third is narrowed mesiodistally (Figures 8-27A to C), the tooth will appear more tapered and longer (a). This illusion can be further enhanced by having a vertically flat labial middle third to increase the vertical reflecting surface (b,c).

The shape of the incisal edge can be altered to create an illusion of greater length in the anterior region. For each involved tooth, the mesial and distal halves can be sloped gently toward the gingiva from the midline to the contacts (Figure 8-28A). In the specific case of the central incisors, each incisal edge can be made to slope gingivally away from the approximating common incisal angles, lending the illusion of length (Figure 8-28B).

Staining

The main principle to remember when using staining to increase height is that stains of higher value (whiter) make the area to which they are applied more noticeable. A fine, opaque, white check-line running from the body of the tooth to the incisal edge accentuates the height. A white decalcification spot placed close to the incisal edge also increases the height illusion. Staining can be

used to duplicate the appearance of a long, vertical interproximal anterior restoration, which increases the illusion of length (Figure 8-29A).

Arrangement

If the maxillary six anterior teeth have worn unnaturally, producing noticeably shorter teeth, consider cosmetic contouring, to create the illusion of longer teeth, by shortening the laterals slightly and reopening the incisal embrasures (Figures 8-29B and C).

The Too-Long Tooth

When alveolar or gingival recession has been severe, the length of the pontics or crowns must be made to appear shorter. Basically, vertical grooves or lines should be diminished and horizontal lines emphasized. This can be accomplished by several methods.

Shaping

The areas of contact can be lengthened as much as is physiologically acceptable while the gingival embrasures are kept as narrow as possible (Figure 8-30). The cervical portion and the incisal one-fifth

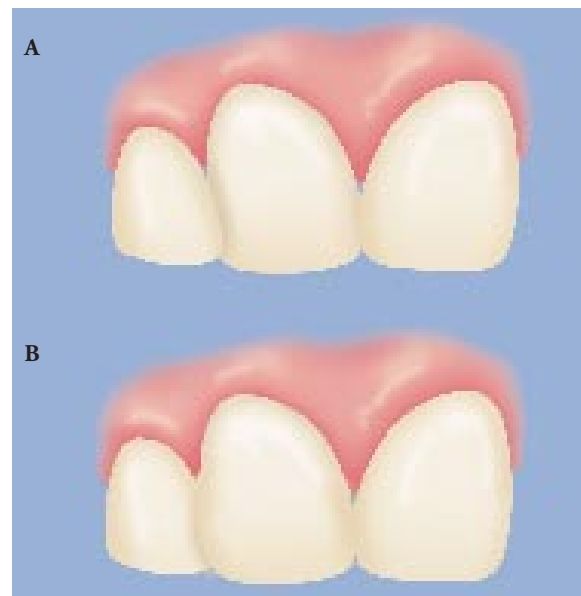


Figure 8-26: *A*, The mesial aspect of the lateral incisor of this male patient is rotated and lapped lingually behind the central to project width and boldness without requiring additional space. *B*, For a female, the mesial aspect of the lateral incisor is rotated labially and lapped in front of the centrals to increase a soft, feminine appearance without increasing the space needed for the replacement teeth.

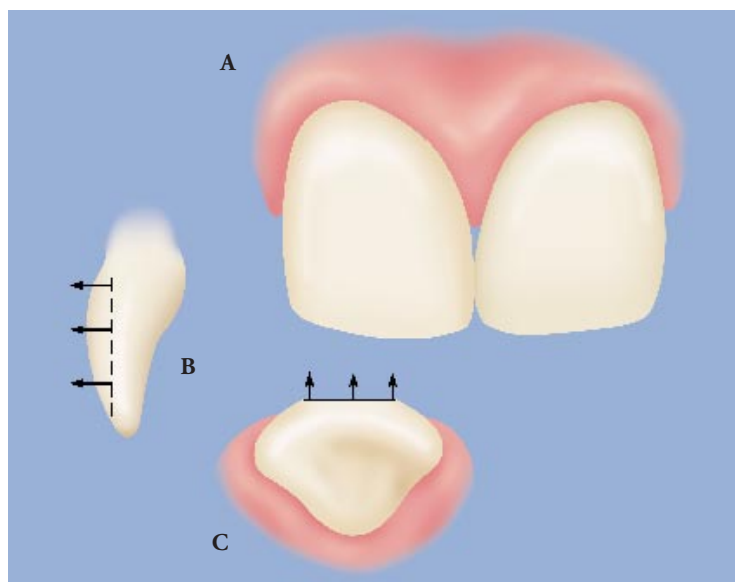


Figure 8-27: Narrowing a too-short tooth mesiodistally at the gingival one-third creates the illusion of length (a). To further this illusion, vertically flatten the labial middle third (b,c).

of the pontic or crown should be inclined lingually (Figures 8-30 and 8-31). By changing the inclination of these surfaces, the effective reflecting surface is shortened, decreasing the appearance of length. The incisal edge may be shaped to seemingly decrease length by notching the center (Figure 8-32B). If there are two adjacent teeth that need to appear shorter, grind the incisal edges to converge gingivally at the proximal contact (Figure 8-32A).

Staining

A definite demarcation at the cemento-enamel junction decreases the apparent length, and this can be carved into the restoration and further accentuated with stain. The color of the cervical portion should be deepened by staining it either a deeper body or cervical shade (see Figure 8-8D).

To mask the height of extremely long teeth, either stain the gingival portion of the crown or

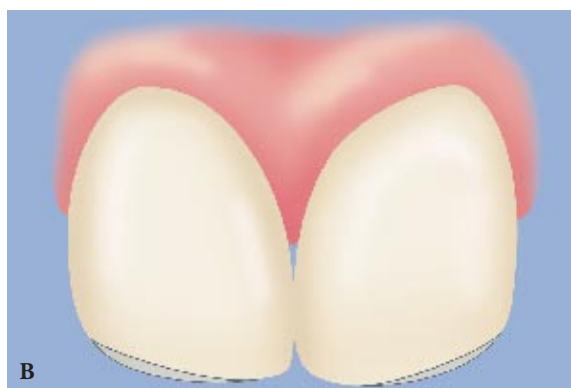
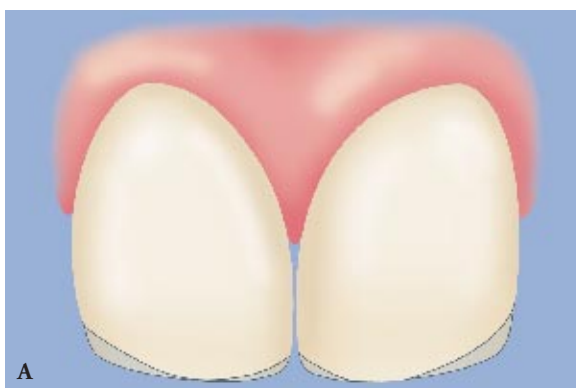


Figure 8-28: A, An illusion of length can be created by gently sloping the mesial and distal halves of the incisal edge toward the gingiva from the midline to the contact areas. B, If two adjacent anterior teeth need to appear longer, each incisal edge should be made to slope gingivally away from the approximating common incisal angles, lending the illusion of length.

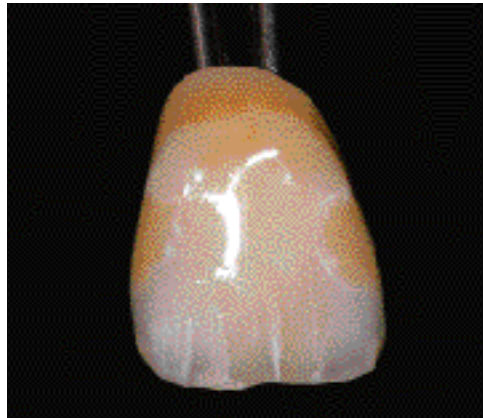

Figure 8–29A: Check-lines, decalcification, and interproximal restoration staining has produced the illusion of length.

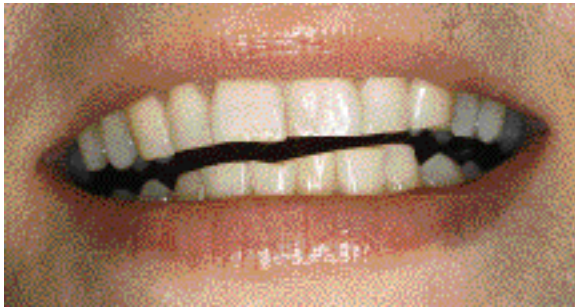

Figure 8–29B: This 31-year-old patient had an extreme case of bruxism resulting in an older looking smile.

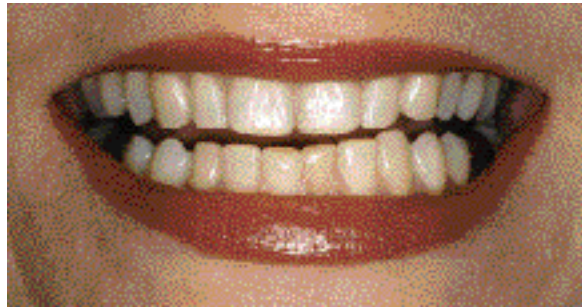

Figure 8–29C: A more youthful look was attained with cosmetic contouring consisting mainly of reopening the incisal embrasures and shortening the lateral incisors.

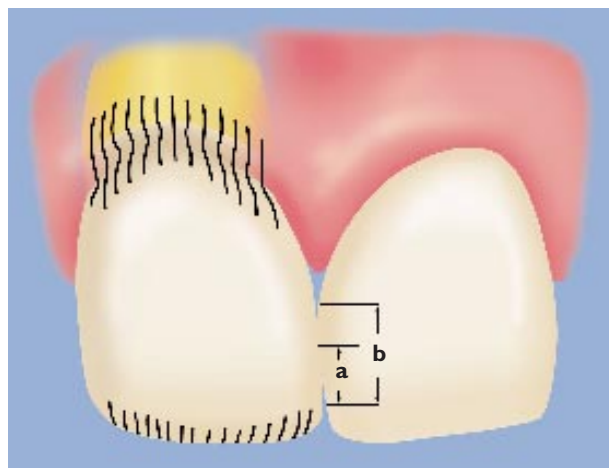


Figure 8–30: For the too-long tooth, increase the vertical contact area (from a to b), keep the embrasures as narrow as possible, and lingually incline the cervical and incisal one-fifth areas.

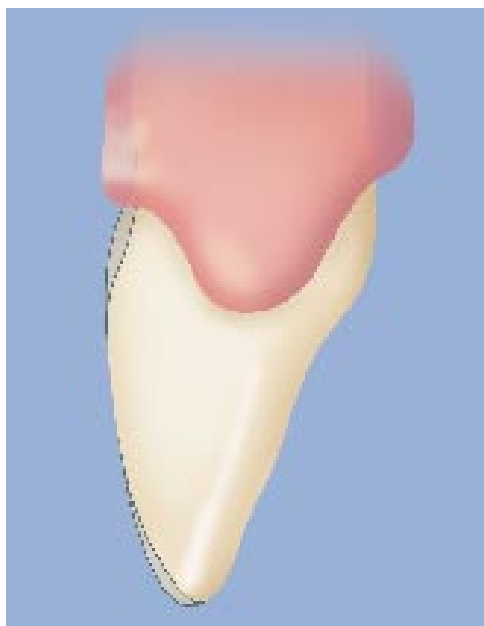

Figure 8-31: A lateral view demonstrating the lingual inclination of the cervical and incisal one-fifth areas which decreases the appearance of length.

pontic pink (to simulate gingival tissue) or use a combination of tissue-colored porcelain stains when baking the crown. Figure 8-33 shows how unattractively long a tooth can look without staining. The effect of staining to mask the long expanse of porcelain can be seen in the following case.



PROBLEM: A male, age 35, presented with unattractive crowns with coverage of the left central incisor root area (Figure 8-34A). When these crowns were placed, no attempt was made at contouring or staining to mask the difference in gingival height. In addition, the existing gold veneer crowns and fixed partial dentures had worn, and gold was exposed. Finally, there were missing teeth in the right quadrant, requiring another fixed partial denture.

TREATMENT: Porcelain-fused-to-metal crowns and fixed partial dentures were used to replace the faulty and unsightly restorations. The gingival aspect of the maxillary left central incisor was carved as thin as possible in the root area. In addition, the porcelain was stained cervically with a gingival color and a pink or gingival tone adjacent

to the gingival area (Figure 8-34B). (Optionally, a gingiva-colored composite resin could have been used to mask the exposed root surface.)

RESULT: The techniques of shaping and staining were combined to produce new anterior crowns with the illusion of proper relative sizes. The patient's smile was improved and he was very happy with his new appearance.



Often, when recession has been severe, the areas that would normally be occupied by the gingival papillae appear empty and black. To improve esthetics, add porcelain and stain to the linguo-proximal surfaces to help fill in these spaces and help improve this unsightly condition (see Figures 8-51A and B).

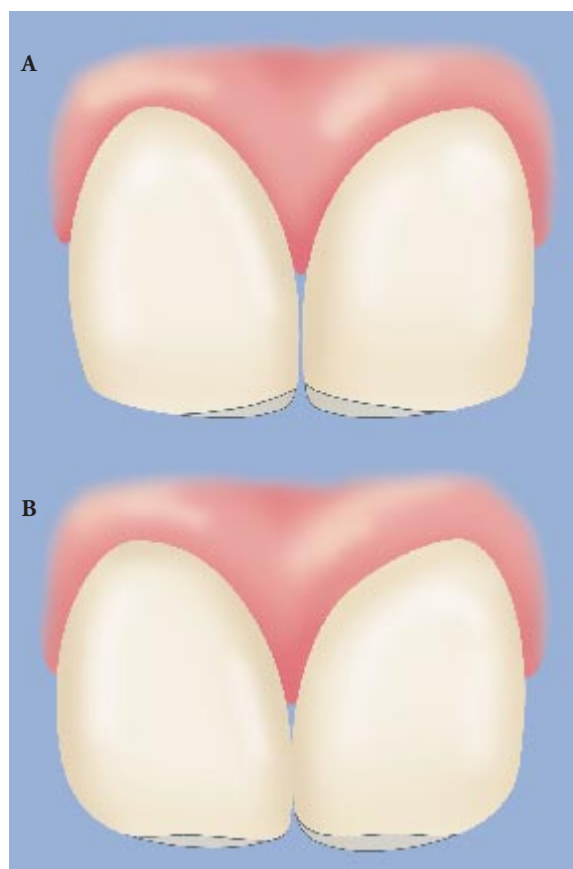


Figure 8-32: When the two teeth are involved, reduce the incisal edges to converge gingivally at the proximal common contact (A). The length of the tooth will appear to decrease by the notching of the center of the incisal edge (B).

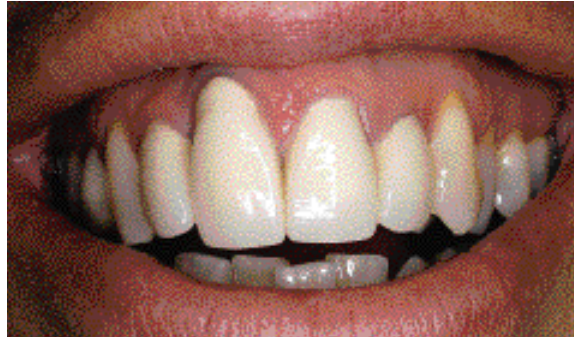

Figure 8-33: Lack of cervical staining made this patient's crown on the right central incisor appear much too long.

Need to Disguise Long Axis Inclinations

When restoring a severely tipped tooth, it may be impossible to achieve correct alignment simply by altering the preparation. In these cases the use of illusions can confer the appearance of good alignment.

Increasing Mesial Inclination

In an anterior tooth (Figure 8-35), the distal contact is moved cervically and the mesial contact is moved incisally. The distal line angle is carved toward the center of the incisal edge. To help com-

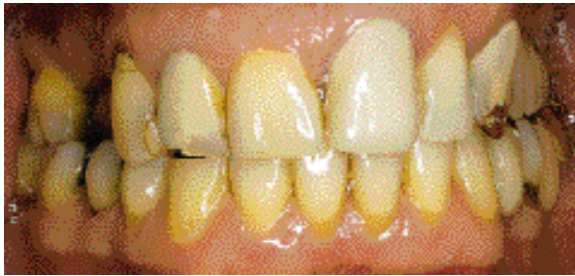

Figure 8-34A: The gingival recession evident in this patient was not masked with the placement of the restorations; staining and contouring should have been considered.

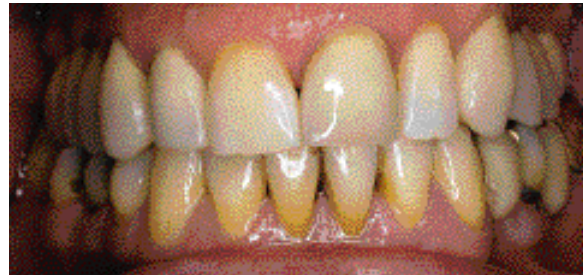

Figure 8-34B: In addition to treating the faulty and unsightly restorations, the recessed gingival area was contoured and stained to make the tooth appear a more esthetic length.

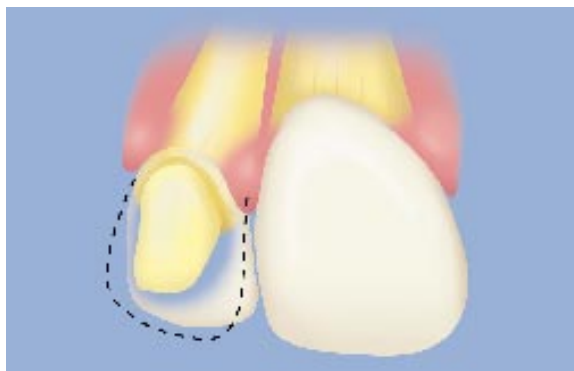


Figure 8-35: Increasing the mesial inclination on a severely tipped tooth is an illusion that increases the appearance of good alignment.

plete this illusion, the incisal edge is pointed on the mesial and notched toward the distal. In a posterior tooth, the distal contact is moved cervically and the mesial contact is moved occlusally. The buccal ridge is carved to curve from the distolingival to the mesio-occlusal. The cusp tip can be moved mesially if this is compatible with functional requirements.

In both anterior and posterior teeth, the illusion of mesial inclination can be increased by incorporating light lines, by staining, that follow the distal line angle, or buccal ridge, or that run approximately parallel to them.

Increasing Distal Inclination

To increase the perception of a distal inclination, reverse the preceding instructions on mesial inclination.

In an anterior tooth, the mesial contact is moved cervically and the distal contact is moved incisally. The mesial line angle is carved toward the center of the incisal edge. The incisal edge is pointed on the distal and notched toward the mesial. In a posterior tooth, the mesial contact is moved cervically, and the distal contact is moved occlusally. The buccal ridge is carved to curve from the mesiogingival to the disto-occlusal. The cusp tip can be moved distally if this is compatible with functional requirements.

In both anterior and posterior teeth, the illusion of distal inclination can be increased by incorporating lightly stained lines that follow the mesial line angle or buccal ridge or that run approximately parallel to them.

Insufficient Differentiation between Teeth

Special problems occur in the attempt to achieve a natural appearance in the multiple unit anterior ceramometal restoration. The major objective is to give the illusion that the teeth are actually separate and not a connected series. This can be accomplished by placing the proximal connector as lingual as possible to allow for maximum interdental separation between the teeth. Staining should be used to give the teeth the appearance of individual units. Most restorations appear artificial because of stains that are too light or the absence of stains between the teeth. By the use of darker stains, the interproximal areas can be shaded where they curve into the embrasures. This will add an illusion of interproximal depth and separateness. Use an

orange-brown or gray-green combination, whichever approximates the color of the adjacent or opposing teeth.

Sometimes, it is still difficult to obtain the desired illusion of separation in crowded lower anterior units. An alternative technique is post-soldering when multiple crowns are involved. The actual separation between the crowns, even though minimal, may create an individual, natural-looking restoration. Make certain not to create too much space between the crowns. Complete visualization of the result should occur before the final soldering. It is advisable to examine the framework and try to picture the degree of separation before the porcelain buildup. A slight depression in the framework strut in the contact area will also increase the illusion of separation by allowing a deeper depth-cut in the porcelain veneer.

The incisal edge (ie) can also be curved into the interproximals, heightening the illusion (Figure 8-36).

Arch Irregularity

Upon smiling, an arch irregularity can cause exposure of more crowns, or more of the crowns on one side of the mouth than on the other (Figure 8-37). You need to discuss this problem with the patient before treatment, explaining that the crowns will not be bilaterally symmetrical in the final restoration. All other unusual conditions should be noted at the second appointment during the esthetic diagnosis. Prerestorative photographs should be taken to

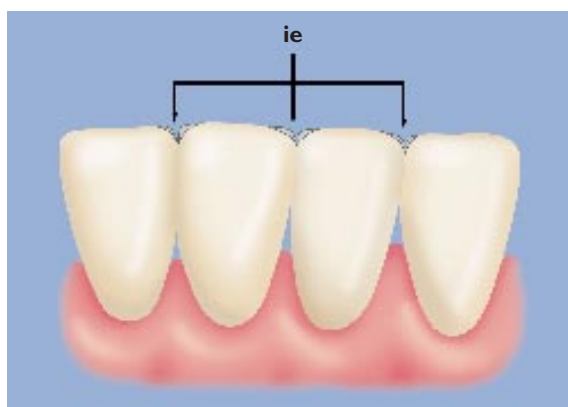


Figure 8-36: In addition to staining the interproximal areas where they curve into the embrasures, the incisal edges (ie) are slightly curved to create differentiation between teeth.

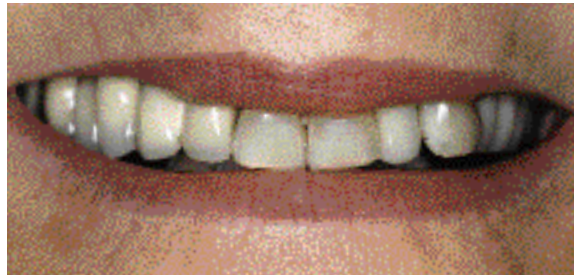

Figure 8-37A: When this patient smiles she reveals more tooth length on the maxillary right side than the remainder of the arch.

preserve a good record of both smiling and lip-retracted positions. It is a good idea to give a copy of these photographs to the laboratory as well.

Treatment for arch irregularity usually involves gingival raising, tooth shortening or lengthening, or a combination to help achieve the illusion of a more balanced arch (see Figure 8-37).

Influencing Facial Shape

In general, the oval is considered the ideal facial shape. If the face is too long, shortening long teeth will help to add width. Reduce the interincisal distance (the vertical height between the central incisal edges and the lateral incisal edges) if the central incisors are extra-long or extended. Also, horizontal lines and characterizations can be added or emphasized. The reverse procedure can be used on the round face by emphasizing tooth length, and using vertical lines and characterizations.

Incorporating Age Characteristics

Once the correct form and function have been

achieved in a crown or pontic, the wear and stains that normally accumulate with age should be incorporated into the new restorations to blend with the appearance of the remaining natural teeth. Foods and various filling materials leave stains and discoloration. A clean, new, perfect tooth would be quite noticeable if set among others with worn incisal edges, multiple restorations, and tobacco stains. Overall, teeth are generally lighter in young people than in the aged, and rarely are all of the teeth uniform in shade in the older dentition.

Nature incorporates in each tooth many colors that usually become more pronounced with age, e.g., the gray and yellow tones. A prosthesis prepared for an older individual should be stained to simulate the color variations found in the remaining natural teeth. For example, the presence of Class III restorations can be simulated with stains (see Figure 8-29A). If the patient desires, actual gold restorations may be placed in artificial replacement teeth to increase the illusion of age and realism.

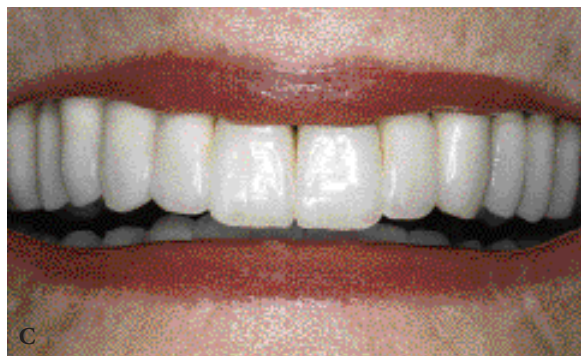
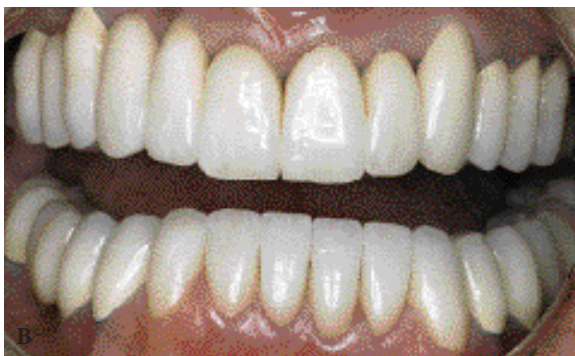
Figure 8-37B and C: After periodontal surgery and full ceramometal crown restoration, the maxillary crowns are extremely long.

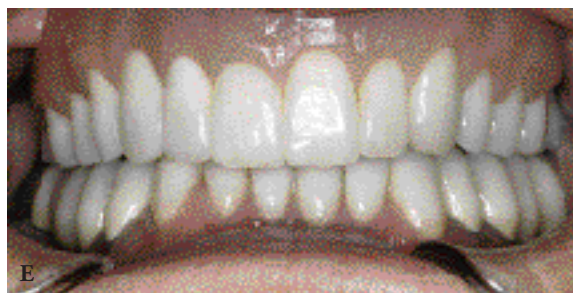

Figure 8-37D and E: An artificial tissue insert was made to mask the extra tooth length.

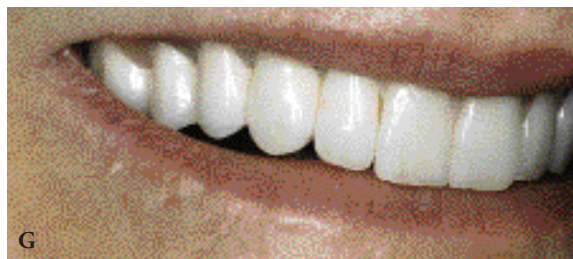
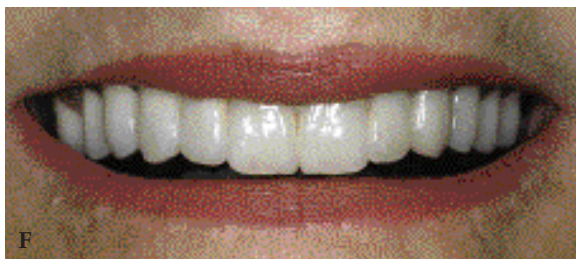
Figure 8-37F and G: The final result shows how wearing the artificial tissue insert enhances this woman's smile.

Careful shaping and polishing can effectively mimic abrasion and imply advancing age. Wear on the incisal edge accumulates with increasing age, shortening the anatomic crown by abrading its translucent edge. This aging is simulated by carving

the incisal edges and cusp tips to simulate accumulated abrasion. The grinding should not be a flat reduction in height but should simulate natural, angled wear facets produced by opposing teeth. Note in Figure 8-38A how incisal wear can occur



Figure 8-37H: This lady has a maxillary arch that drops down on the right side.

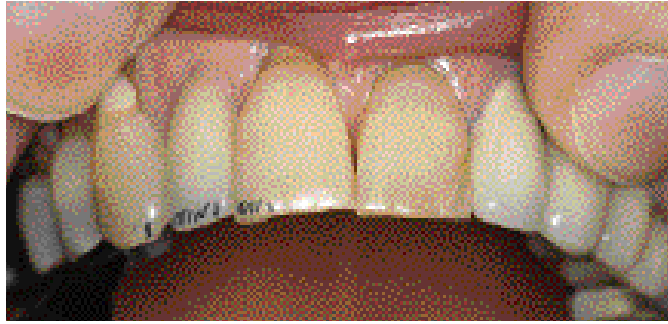


Figure 8-37I: The teeth are outlined with an alcohol marker to show where they will be contoured.

in natural teeth, and in Figures 8-38B and C how cuspids can wear. To maintain harmony of appearance, if there is cemental erosion or erosion on the gingival one-third of the remaining teeth, carving and staining a similar pattern into the replacement tooth is indicated.

Observe the incisal wear in a vigorous, 60-year-old man (Figure 8-39A). A six-unit porcelain-fused-to-metal fixed prosthesis was shaped and stained to duplicate the natural teeth (Figure 8-39B), and its natural appearance can be seen in Figure 8-39C.

Tooth migration, shifting, or rotation may also occur with aging. If the long axes of the remaining

teeth are variable and if some of the teeth are rotated, a row of straight, perfectly-aligned pontics or crowns will stand out. A slight rotation or shift of the long axis can mean the difference between an artificial appearance and a natural one (Figure 8-40).

Although most patients request a younger look, never assume that this is what all patients prefer.

Reducing Age Effects on the Smile

Many patients are motivated to seek esthetic dental treatment to make them look younger. They want to eliminate the aging effects just described. This is usually possible by the use of various restorative techniques.



Figure 8-37J: After contouring, the patient's smile shows a balanced arch.

A too-light shade will look false, so avoid the temptation to follow the patient's wishes for "white teeth." When patients look at a single tooth tab from a shade guide, their inclination may be to choose the lightest color. What they usually fail to understand is that multiple teeth of a lighter shade will appear even whiter in the mouth when they are all together. The shade can be lighter, but vary the intensity of body color when staining the tooth. Use a deeper gingival shade that blends to the incisal edge. Avoid too much incisal shading. To make the tooth appear natural, the incisal edge should be mostly body colors, with bluish translucency appearing on the mesial and distal edges where the enamel may have worn thin. A bluish incisal surrounded by light opaque orange on the incisal edge intensifies the color, creating a halo effect, and helps give a much younger look (Figures 8-41A and B). Figure 8-41C shows a three-unit bridge incorporating these younger-looking incisal effects.

Aging wears down the incisal edges, usually drastically shortening the central incisors. Increasing the interincisal distance by making the centrals again longer than the laterals can help make the individual appear younger.

Most aged individuals show either too little tooth structure or none at all. If occlusion permits, make the entire anterior segment of teeth longer. Consider bevelling or cosmetic contouring on the lower anterior teeth to permit lengthening the upper incisors. In certain patients, it may even be possible to restore lost vertical dimension after which you can lengthen the upper anteriors. If this is attempted, begin with a removable or fixed interim appliance for several months to make sure your patient is comfortable with the new occlusal position. Then temporarily restore the teeth with laminates, crowns, or bonding that incorporate the new length. It is best to keep the patient in these tem-

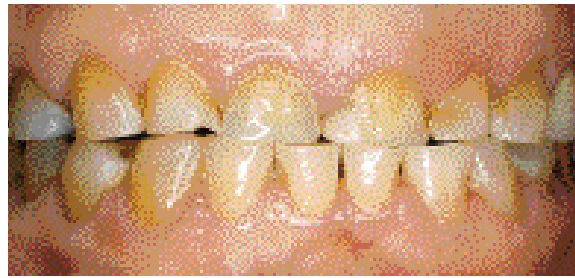

Figure 8-38A: This patient has uniform incisal and occlusal wear on all of the teeth due to bruxism.

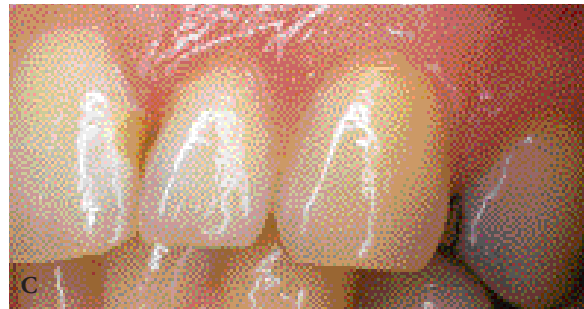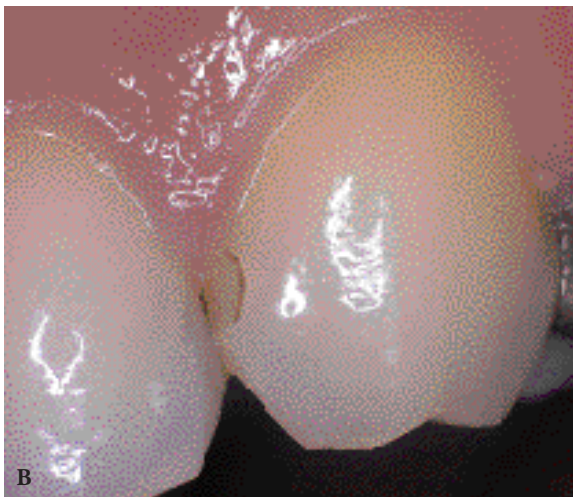


Figure 8-38B and C: These are examples of individual incisal tooth wear that often occurs in cuspids.

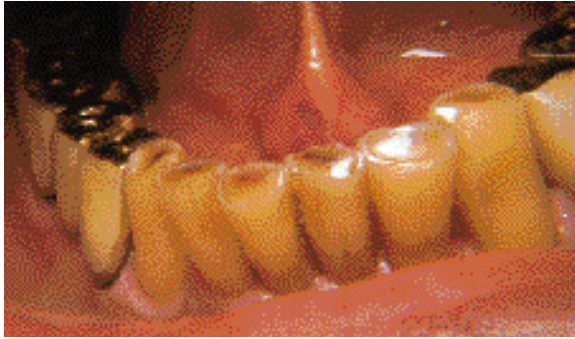

Figure 8-39A: An example of incisal wear in a vigorous 60-year-old man.

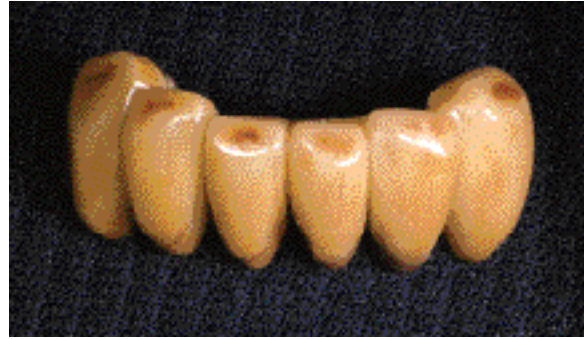

Figure 8-39B: This six-unit prosthesis was contoured and stained to match the surrounding natural teeth.

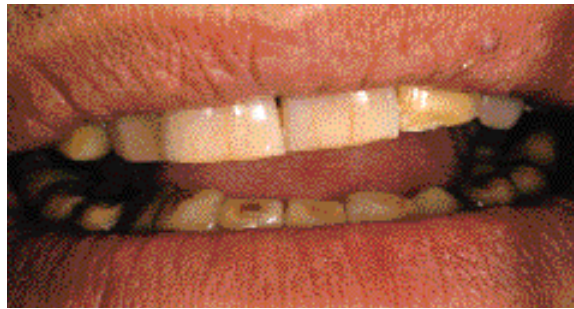

Figure 8-39C: A post-treatment photograph reveals a natural-looking result that is appropriate for the age of the patient.

porary restorations for an additional three months before constructing the final restorations to allow for any occlusal adjustments, should your patient develop any TMJ discomfort.

Incisal edge wear can eliminate the incisal embrasures, a characteristic identified with the elderly. Carving the embrasures into the restoration helps create a younger look.



PROBLEM: This case shows the effect of discolored irregular teeth on a 67-year-old female (Figure 8-42A). Unfortunately, the teeth did nothing but create an even older appearance. No amount of makeup or any other cosmetic improvement could disguise the feeling of old age one got from her

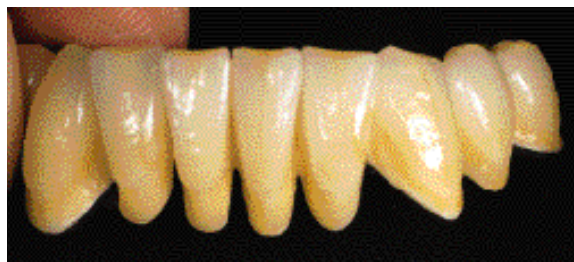

Figure 8-40: The slight rotation of the long axis of some teeth in a prosthesis can result in a more natural look. (Photograph courtesy of Magna Laboratories)

smile. Lipstick only helped to call attention to this unattractive mouth.

TREATMENT: Treatment consisted of full-mouth reconstruction with a fixed porcelain fused-to-metal prosthesis.

RESULT: For purposes of this chapter, the patient illustrates the importance of the final esthetic result, particularly its effect on the lip line. With proper restoration, a more youthful look has been created by lengthening the central incisors and producing a more feminine (rounded) appearance in the anterior teeth. Note the overall improvement achieved by the use of a harmonious shade (Figure 8-42B).



Incorporating Sex Characteristics

Wear of incisal edges eliminates certain sex charac-

teristics. When teeth are contoured or crowns carved, you may need to incorporate either feminine or masculine characteristics. The remaining teeth should be observed to see if the replacement tooth is in harmony. We tend to interpret a female mouth as one where the contours and lines are more rounded and curved than those in the male, which are usually flatter, sharper, and more angular. By rounding angles and edges, a more feminine appearance can be achieved (see Figure 8-38B). By squaring angles and edges, a more masculine feeling is created (Figure 8-43). The idea of masculinity can be further enhanced by slightly abrading the incisal surface.

Staining the prosthesis to simulate tobacco, coffee, or tea stains can also aid this masculine illusion, as will the incorporation of light microcrack lines.

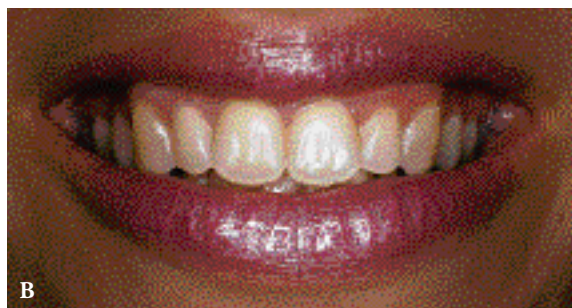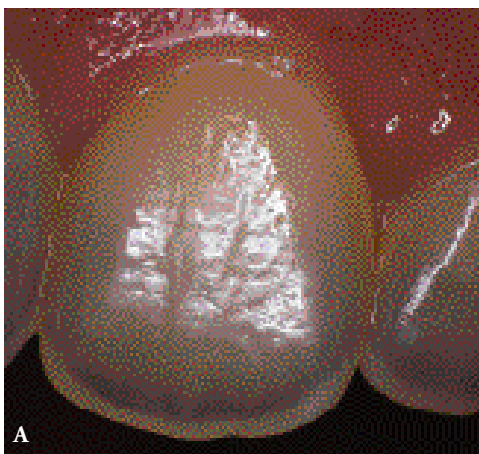


Figure 8-41A and B: The bluish tint at the incisal edge surrounded by light opaque orange is applied to an anterior crown, producing a halo effect and giving a younger-looking appearance to the teeth.

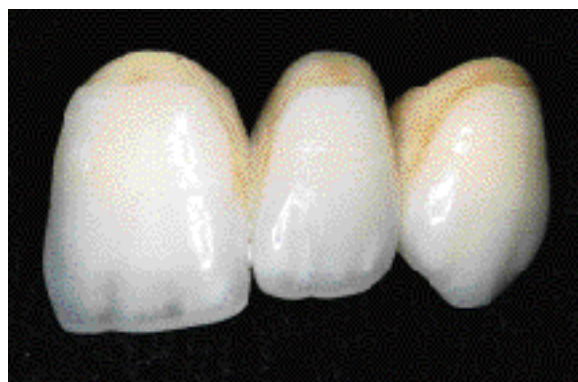

Figure 8-41C: A mild incisal halo effect combined with darker cervical staining helps produce a younger look in an older person.

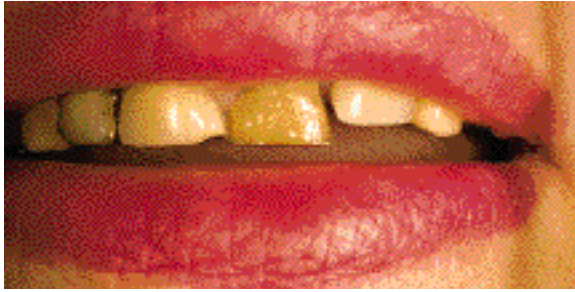

Figure 8-42A: Irregular and discolored teeth contribute to an older-appearing smile.

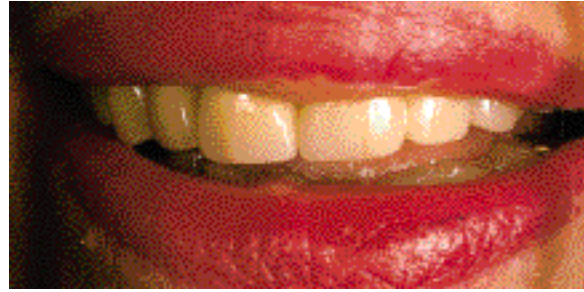

Figure 8-42B: A younger-looking and more attractive appearance achieved by restoring the teeth with rounded, even, more feminine lines and a more uniform and harmonious shade.

Figures 8-44A and B show the technique used to obtain the masculine, stained characteristics accomplished in Figure 8-29A. Note the simulated restorations and hypocalcified areas.

Staining of women's teeth should consist of adding a touch of blue to the incisal edge (Figures 8-38A and B).

It is not always necessary to match adjacent, natural, untouched teeth. In fact, many times the opposite should be the case. During the planning stage, a decision should be made about the type of esthetic result desired by the patient. Since it is possible to alter the patient's masculine or feminine appearance through conservative procedures such as cosmetic contouring, bonding, or laminating on the adjacent teeth, determination should first be made about the extent of the masculine or feminine character that is desired before creating the final restorations. For example, for a female

who has worn her incisal edges until they now appear angular and masculine, you may elect to recontour her natural dentition before carving the new restoration.

This is not to say every female should have a soft, curvaceous look to her mouth, or every male should look sharp and angular. The degree of femininity or masculinity is dependent on the patient's personality, habits, and (most of all) desire. Patients have an unquestionable right to help choose what type of appearance they will eventually have. The dentist must be sensitive enough to go beyond the patient's apprehensions about being considered vain and find out their true desires.

Incorporating the Personality of the Patient

A delicate personality can be differentiated from the vigorous one by the degree of characterization, coloring, and arrangement of teeth. Overaccentuation of color, bold characterization, and nonuniform

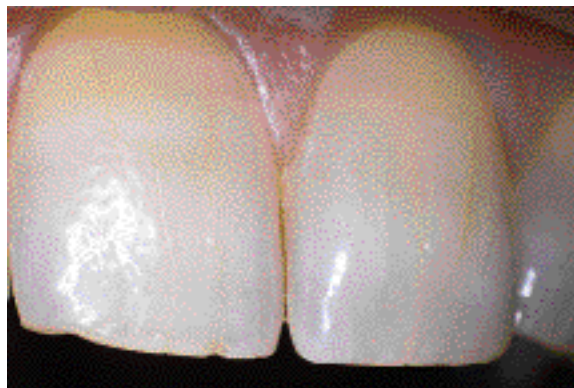


Figure 8-43: Squared angles and edges create a more masculine look.

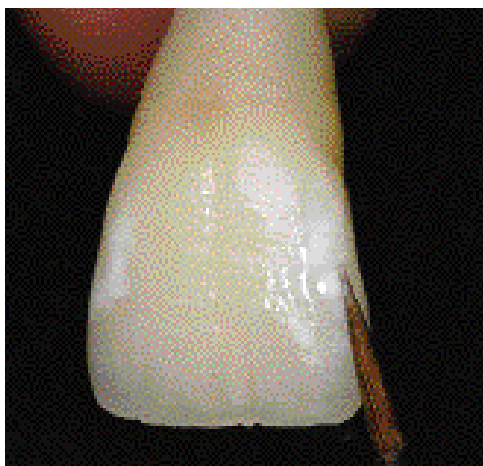


Figure 8-44A: Light microcracks, simulated restorations, and hypocalcified areas can help create a more natural and youthful look.

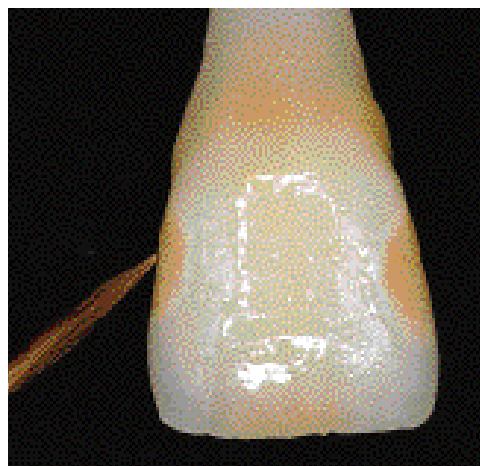


Figure 8-44B: Orange staining is a natural characteristic of the older dentition.

arrangement are compatible with an aggressive personality. The mild, demure personality is associated with less starkness and less color differentiation. The patient and his or her teeth should be evaluated carefully to achieve the desired final effect.

Some patients wish to improve the appearance of their teeth but fear a too-perfect look might alter their image. They want a natural appearance that retains their personality. An example was seen in a 32-year-old female patient (Figure 8-45A). Three different sets of porcelain crowns had to be constructed to obtain a result that pleased both the patient and the dentist. One set of teeth were intricately stained, but the shapes and incisal length were incorrect (Figure 8-45B). Another set of teeth were too perfect for the patient (Figure 8-45C), even though they made an attractive smile. Figure 8-45D shows the patient's choice for a natural, youthful appearance.

A vigorous 39-year-old male wanted slightly larger teeth to partially close his diastemas, without losing his natural appearance. This was accomplished by retaining the form, incisal length, shade, and texture of the original teeth. Figures 8-46A and B show the before and after smiles.

A method of incorporating personality into overdentures is to use characterized teeth in an arrangement that approximates the patient's original appearance (Figure 8-47A).

Overlapping and wide incisal diastemas are carved into the restoration with an extra-thin steel or diamond disc (Figure 8-47B). Incisal abrasion is simulated by first notching the incisal edges with a fissure bur (Figure 8-47C) and then smoothing with a small rubber wheel (Figure 8-47D). Using a resin stain kit, concentrated but thin stain is applied in the concave incisal edge areas (Figure 8-47E) until the desired appearance is achieved. The stain is allowed to dry for half a minute before adding additional layers. After the stain is set, three thin coats of glaze are applied. Figure 8-47F shows the final result.

Check-lines or microcracks can be placed into acrylic teeth by using a straight Bard-Parker scalpel to create a defect in the surface, as in Figure 8-48A. Resin stain is then repeatedly placed into the defect with the excess immediately wiped off each time until the desired chroma is reached. Gingival tinting can be accomplished in the same manner and the results of both techniques are seen in Figure 8-48B. Another technique for staining the acrylic resin is used to personalize an acrylic saddle (Figures 8-49A and B).

In completing any restoration, whether it is one crown or several, the patient must be observed from different perspectives in order to be able to properly characterize his or her teeth in the restoration. Turning the patient's head to different positions as well as observing the patient speaking, laughing, and

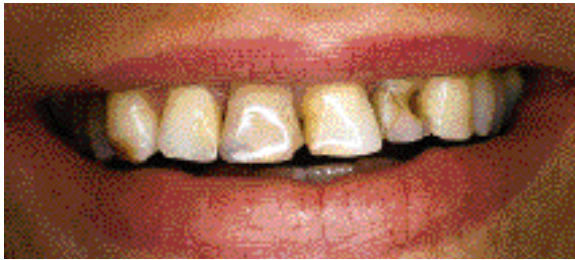

Figure 8-45A: This patient wanted to restore her teeth and have a more attractive smile without creating a “too-perfect,” unnatural look.

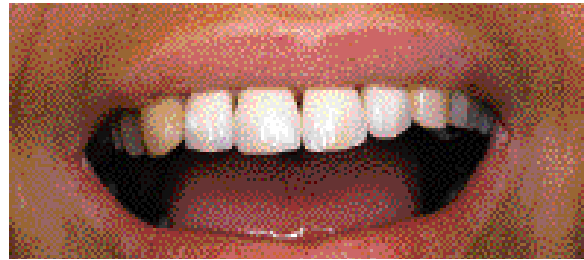

Figure 8-45B: The shape and incisal length were incorrect in the first crowns fabricated for this patient.

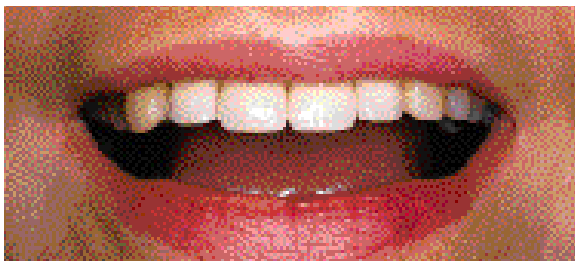


Figure 8-45C: The patient thought the second set of crowns looked “too perfect” and generic.

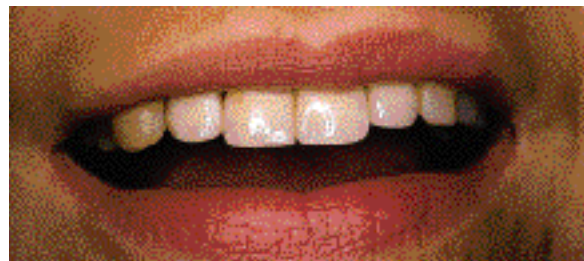

Figure 8-45D: The patient selected these crowns for her new “natural” smile. She preferred the more interesting proportion offered by the larger central incisors.

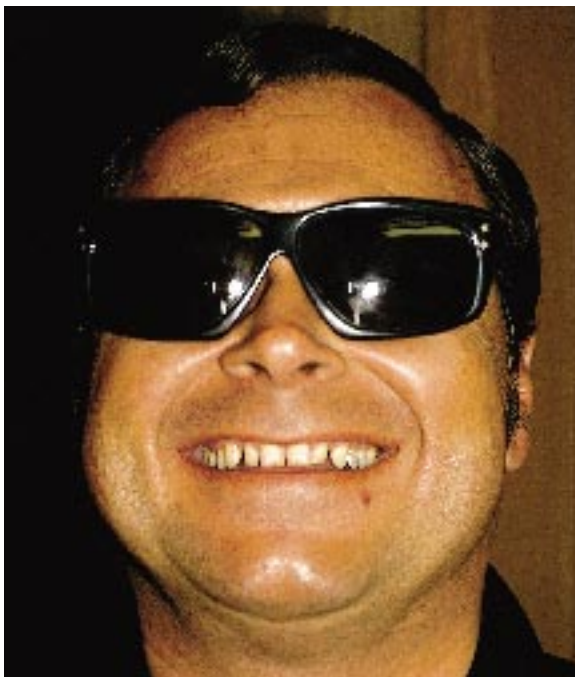

Figure 8-46A: This patient wanted to partially close his diastema with slightly larger teeth while retaining his overall natural appearance.



Figure 8-46B: The natural-looking result was achieved by not entirely closing the central diastema and by using the form, incisal length, shade, and texture of the original teeth.

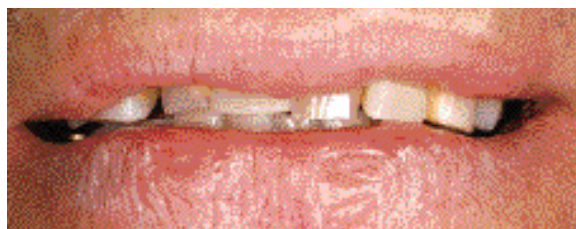

Figure 8-47A: This 70-year-old man had advanced periodontal disease requiring extractions, periodontal surgery, and restoration with a telescopic overdenture.

smiling can also influence how you may want to change an observer's visual perception. Video can create unnatural shadowing, so there is really no better way than by taking the time to carefully study your patient's expressions and teeth yourself. Relevant factors can be noted from this careful observation that photographs just cannot duplicate.

Loss of Interdental Tissue

Minimizing the loss of interdental tissue and concealing the fact that it is missing are problems that intrigue both the periodontist and the general practitioner, as well as the prosthodontist. Patients who have had periodontal surgery resulting in the loss of interdental tissue that then created holes or spaces

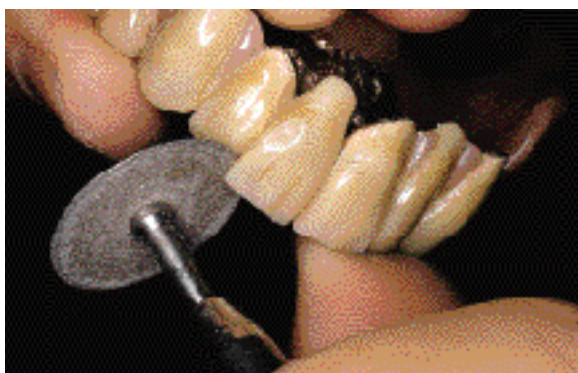

Figure 8-47B: An extra-thin steel or diamond disc helps to carve overlaps and incisal diastemas into the prosthesis.

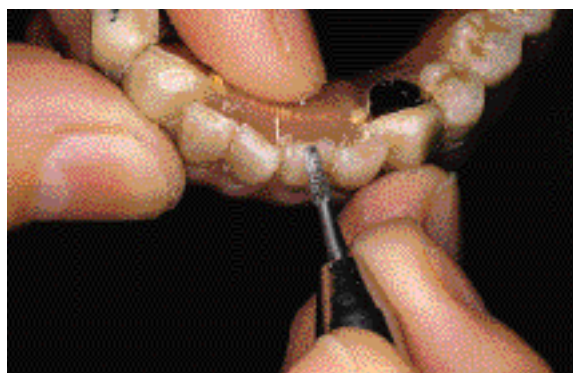

Figure 8-47C: A fissure bur notches the incisal edges to produce incisal erosion.

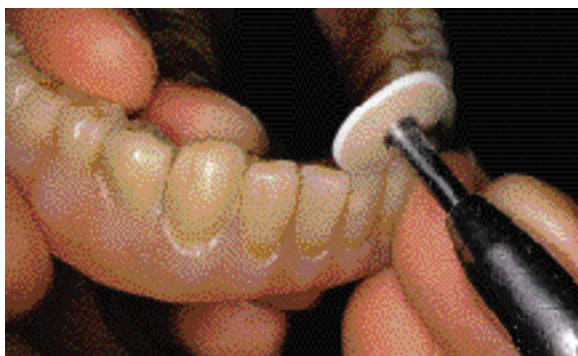

Figure 8-47D: A small rubber wheel smooths the incisal erosion.

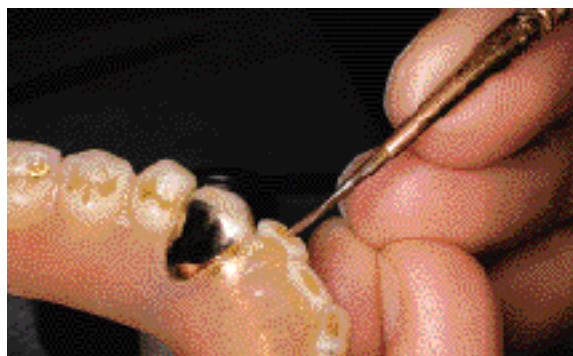

Figure 8-47E: Stain is applied in the concave incisal edge areas with a resin stain kit.

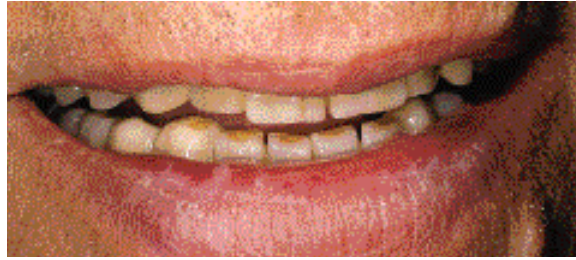

Figure 8-47F: The final result retains much of the characteristics of the natural teeth while improving the general esthetic appearance.

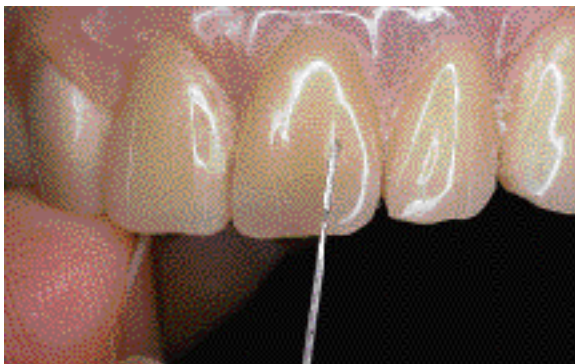

Figure 8-48A: Microcracks are added to acrylic teeth with a straight Bard-Parker scalpel.

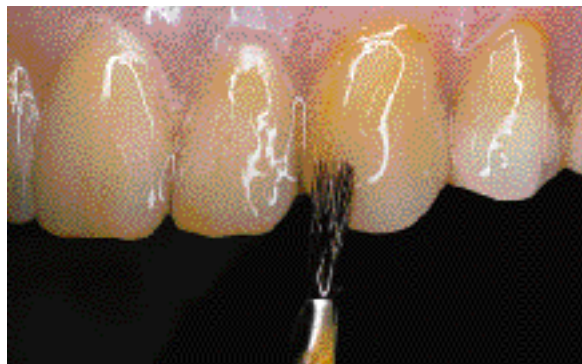


Figure 8-48B: Resin stain is then added until the correct color is achieved.

between the teeth can be miserable about their appearance. Occasionally, surgical techniques can be altered to include either a lingual approach or other procedure that does not expose as much root surface.

Both the restorative dentist and the periodontist should always examine the patient's smile line to see exactly how much tissue would be exposed by each

of several different procedures. If no compromise is possible, then a special effect may have to be created after the tissue has healed. There are generally four solutions to this problem: (1) a removable artificial interdental tissue appliance, (2) composite resin bonding or porcelain laminates, (3) full crowning, or (4) fixed porcelain interdental addition.

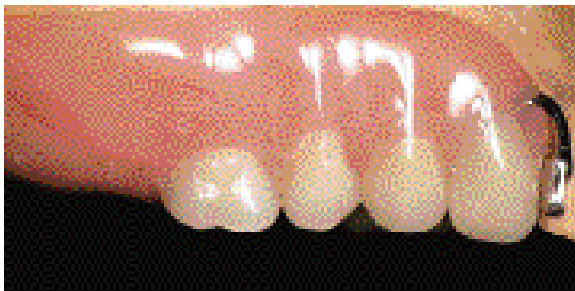

Figure 8-49A: Note the generic look of this acrylic prosthesis before staining.

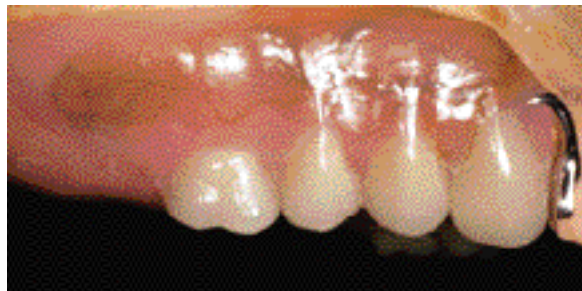

Figure 8-49B: Acrylic stain was added to personalize the look of the prosthesis.

Removable Artificial Interdental Tissue Appliance

This appliance is primarily for individuals who have lost a great deal of tissue and need the visible root portion lessened to hide the open interdental spaces. The patient with a high lip line who would normally show such tissue loss (Figures 8–50A to J) is a good candidate for this procedure. A removable appliance can be fabricated quite easily and it can be esthetically color-matched to the patient’s gingival tissue (Figures 8–50D to F). Make sure all of the visible areas are covered during the widest smile. This usually means extending the appliance to either the first or second molars. Patients wear the appliance by locking it into the interdental space (Figures 8–50E and F) and they usually have no problem wearing it as often and as long as they wish.

Schweitzer³ makes the following recommendations relating to the final impression technique and appliance construction:

1. Pour a preliminary stone cast that includes the teeth and buccal and labial gingivae.
2. Adapt modeling compound to the palate, extending the compound into the lingual embrasure areas. This prevents the final impression material from running into these areas.
3. Construct a cold-cure custom acrylic tray for the final impression of the buccal and labial gingivae and tooth surfaces.
4. Take the final impression of the buccal and labial gingivae and tooth surfaces with the palatal modeling compound insert in place. Use alginate or, preferably, rubber base or vinyl polysiloxane impression material. Since you are less concerned with the lingual aspect of the teeth, one good method is to first syringe the impression material into the buccal interdental spaces and then insert the tray from the anterior direction. Pour the impression in stone.

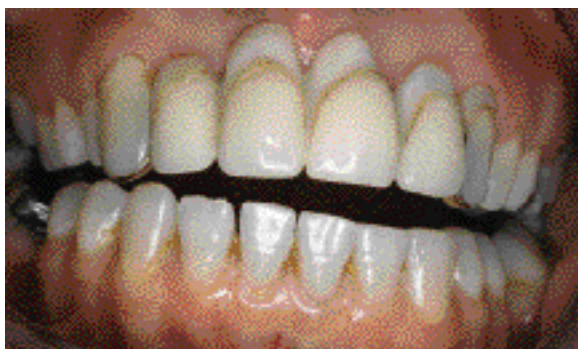

Figure 8–50A: Stains, poor contour, exposed metal, wear, tooth loss, and tissue recession ruined this beautiful model’s smile.

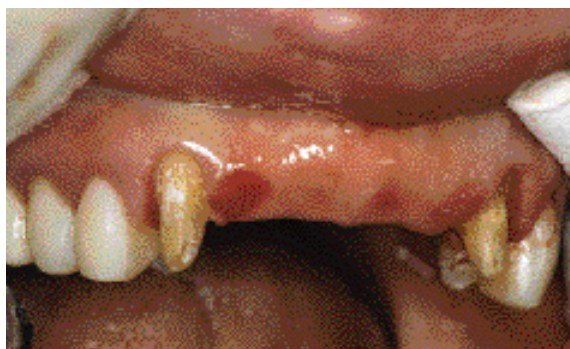

Figure 8–50B: A ceramic fixed bridge will be constructed to replace the missing teeth.

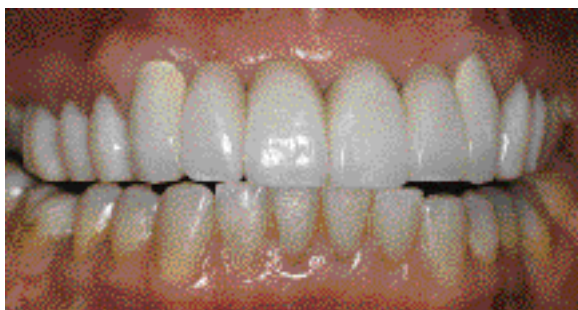

Figure 8–50C: Esthetic periodontal surgery plus a new fixed bridge created an improved appearance.

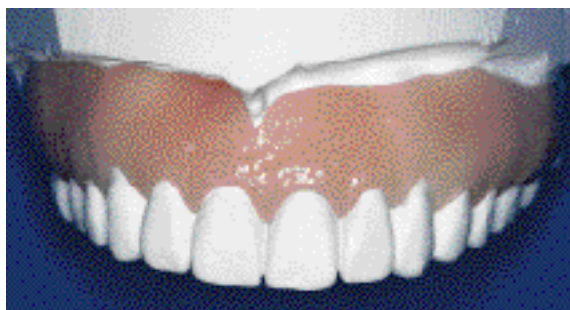


Figure 8–50D: Artificial tissue insert on the working cast.

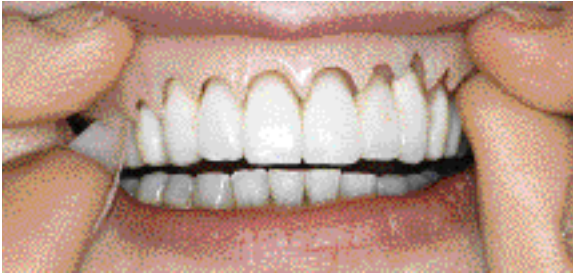

Figure 8-50E: The patient slips the appliance into the mouth. Friction holds the appliance in place.

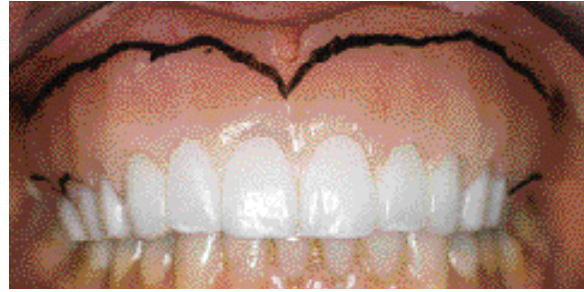

Figure 8-50F: Shows the effectiveness of the artificial tissue insert. Note the squareness of the final ceramic fixed bridge before the appliance was made (Figure 8-50C). Incorporating the appliance completely changes the smile to a more feminine tooth form due to the improved silhouetting.

5. Wax, carve, and process the insert in slow-cured acrylic resin. Do not return the finished insert to a duplicate impression because the undercut that is usually present may cause breakage. This undercut provides sufficient retention for the appliance. The extensions that fill the interproximal embrasures may need a little trimming (Figure 8-50G) in

order to allow the appliance to seat properly. These extensions provide additional retention. One patient whose appliance was so constructed has worn it for 15 years (Figure 8-50J).

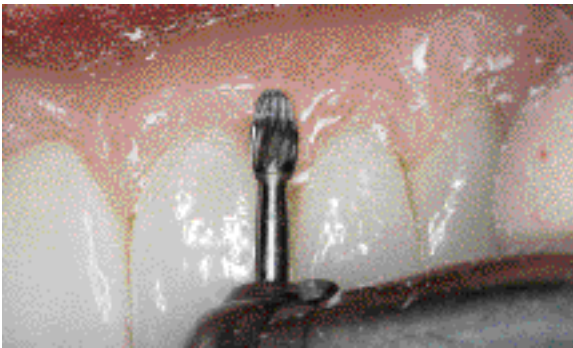


Figure 8-50G: An ET OS1 (Brasseler, Savannah, GA) is used to make final adjustments in the acrylic.

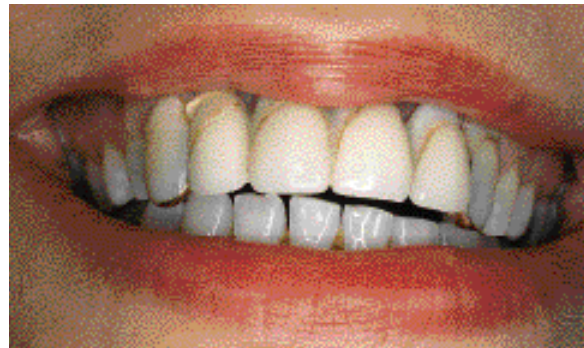

Figure 8-50H: The smile before treatment.

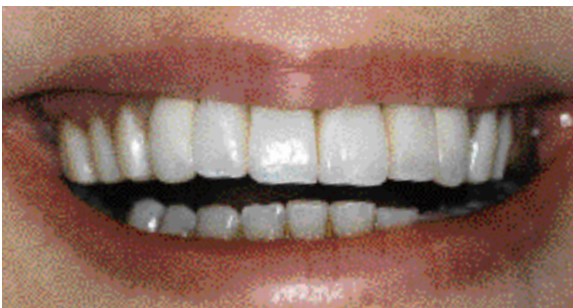

Figure 8-50I: The smile after insertion of the fixed prosthesis and no removable tissue insert.

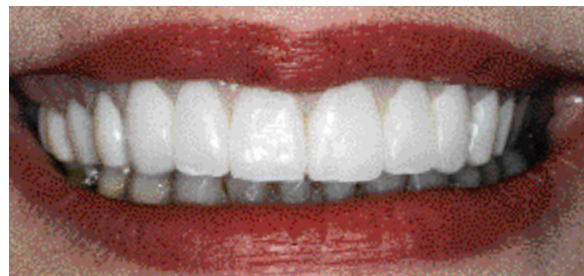

Figure 8-50J: The smile with the patient wearing her removable acrylic tissue insert. After fifteen years this treatment functions well and is still esthetically pleasing.

Composite Resin Bonding or Porcelain Laminates

It is possible, by use of an acid-etch composite resin technique, to proportionally bond composite resins to each tooth so that the space is closed. This method is perhaps the easiest, and certainly the quickest, to perform. When doing so, it is important to add the material mainly from the linguo-proximal surface, so that the size of the tooth is not changed appreciably (Figure 8–51A). The lingual, proximal and mesiolabial surfaces of both central incisors were etched and the composite resin was placed. The final attractive result was achieved by not overbuilding the tooth and yet hiding the unsightly spaces left by the missing interdental tissue (Figure 8–51B).

When using this technique, it is important to take as much time as necessary for shaping and forming the composite resin. For this reason, a light-polymerized composite resin is best. Adequate time is then available to fully carve each tooth to obtain a good esthetic result.

An alternative to this technique is to use porcelain laminates to mask the spaces. If this is done, make sure the proximal surfaces of the teeth are prepared deeply into the embrasure space.

Full Crowning

Full crowning can also be used to mask the loss of interdental tissue; however, it is generally not advised unless the teeth also need to be restored. In Figures 8–52A and B, we see a patient after periodontal surgery left him with unsightly interdental

spaces. Since individual gold telescopes plus full-arch splinting was necessary, closure of these spaces could be adequately handled with the fixed prosthesis. By raising the contact areas gingivally and by adding additional porcelain lingually to close the interdental spaces, an improved smile line is created (Figure 8–52C). Figure 8–52D shows graphically where the porcelain is added to hide the spaces and keep the crowns from looking too bulky. Note that the visible gold bands at the gingival margins are concealed by the patient's medium lip line.

Fixed Porcelain Interdental Addition

An alternative solution to the interdental space problem is adding a gingiva-colored porcelain insert attached to the fixed partial denture. This method works well when there are missing anterior teeth and extreme ridge resorption. The following case illustrates the technique for construction.



PROBLEM: A male patient, age 45, presented with a missing right lateral incisor (Figure 8–53A). The patient was conscious of his unattractive smile and tried to hide it by keeping his upper lip as far down as possible (Figure 8–53B). His main problem was loss of interdental tissue at the distal of the central and a loss of the alveolar ridge in the pontic area. The treatment options included a bridge with an extra-long pontic, a ridge augmentation, a fixed or removable interdental insert, or an implant. He chose a fixed bridge with a fixed interdental insert.

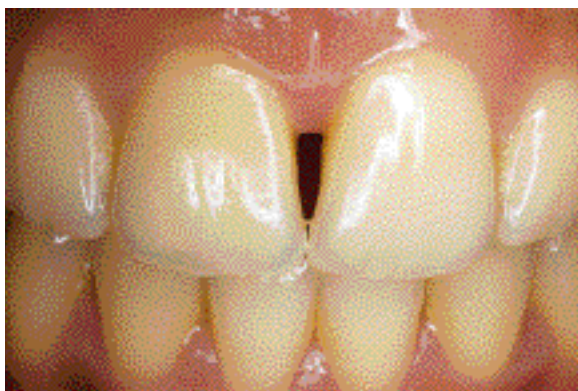

Figure 8–51A: The loss of interdental tissue has resulted in a dark, unattractive space between the two central incisors.

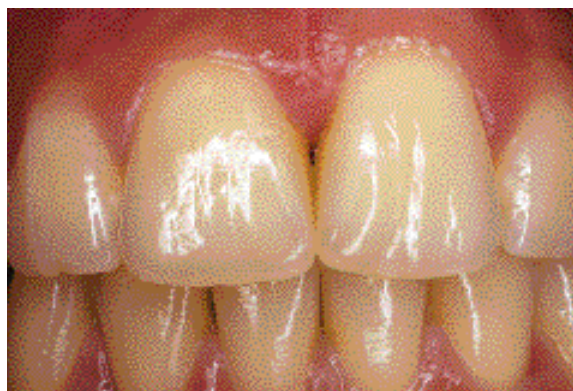

Figure 8–51B: Conservative composite resin bonding of the lingual, mesial, and labial surfaces of both central incisors hides the space while not overbuilding the teeth.

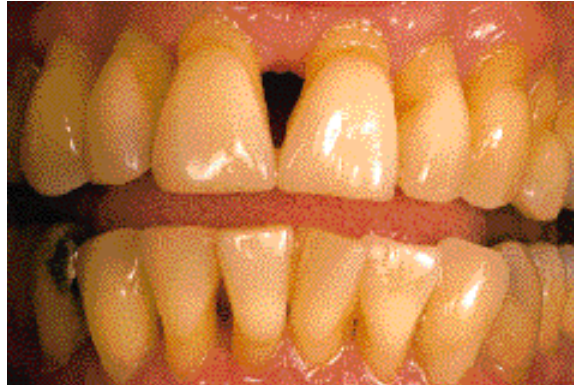

Figure 8-52A: Interstitial spaces from periodontal surgery plus severe cervical erosion may require more than the usual conservative treatments of bonding or laminating.

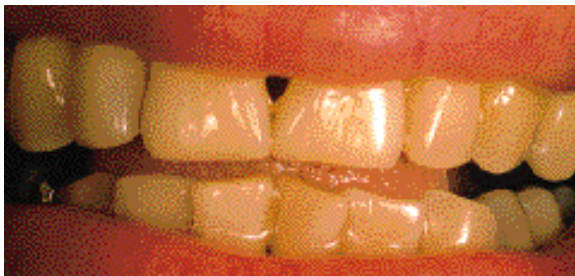

Figure 8-52B: An unsightly dark space was clearly visible between the central incisors in the before-treatment smile.

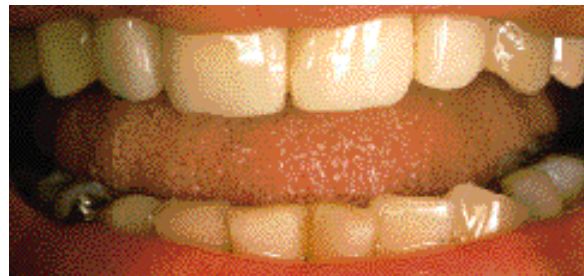

Figure 8-52C: Full arch splinting with a telescopic prosthesis allowed for both raising the contact area gingivally and the addition of material lingually to lessen the space. After treatment, the interstitial space is not evident, and the patient now has a more attractive smile line.

TREATMENT: The teeth were prepared and the impression was made for a three-unit fixed partial denture to be constructed of ceramometal. The

restoration was fitted at the try-in appointment, and final shaping was done (Figure 8-53C). The normal gingival height was marked in red (Figure

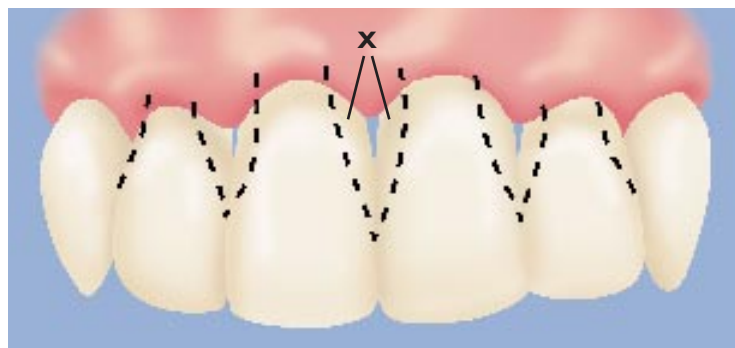


Figure 8-52D: This illustrates where to add porcelain so that the spaces are masked and the restorations do not appear too bulky.

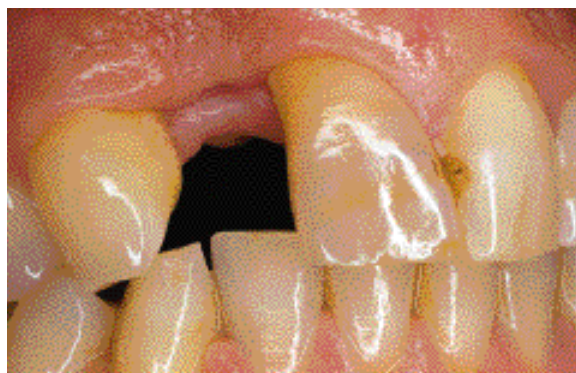

Figure 8-53A: This man's missing right lateral incisor was further complicated by the loss of interdental tissue at the distal of the right central incisor and loss of bone in the pontic area.

8-53D). At this point, an alginate impression was taken of the area, being careful to include the interdental spaces. A model was made by first pouring tooth-colored quick-cure acrylic into the area occupied by the teeth, and followed by pink gingiva-colored quick-cure acrylic into the tissue area. This enabled the exact effect of the tissue in relation to the fixed partial denture to be seen (Figures 8-53E and F). The tissue portion can be poured in a semi-hard acrylic if a more realistic finish is desired.

This model enables the technician to accurately build an interdental tissue area using tissue-colored pink porcelain (Vita Shade 571, Vident, Brea, CA) (Figure 8-53G). It is carved and stained (Figure 8-53H) and taken back to the mouth for another try-in. Figures 8-53I and J show the finished fixed partial denture with the gingival insert added. Tissue responds quite well to these types of appliances if the patient brushes and flosses as instructed (Figures 8-53K and L).

RESULT: Lost interdental tissue can be effectively and esthetically treated with the above technique. The patient no longer has to control his lip line, and his smile is considerably improved (Figure 8-53M).



Another type of porcelain addition has been suggested by Cronin and Wardle.¹ They describe a cantilevered porcelain papilla that features a convex gingival form, which can be easily cleaned with dental floss. Treatment could also consist of a combined therapy including orthodontics to erupt the central and cuspid bringing the tissue level down to balance the opposite side, followed by ridge augmentation as necessary, and completed with a single tooth implant replacement or a conventional three-unit bridge.

Another alternative to the fixed porcelain interdental tissue is to use a fixed composite resin addi-

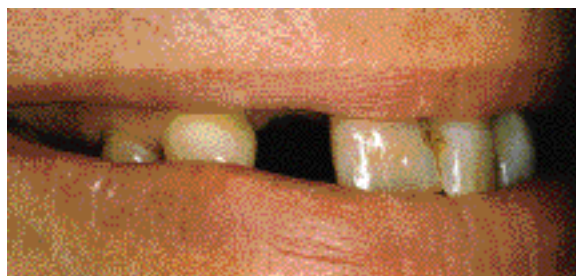

Figure 8-53B: The patient minimized his smile so that his lip would cover the space as much as possible.

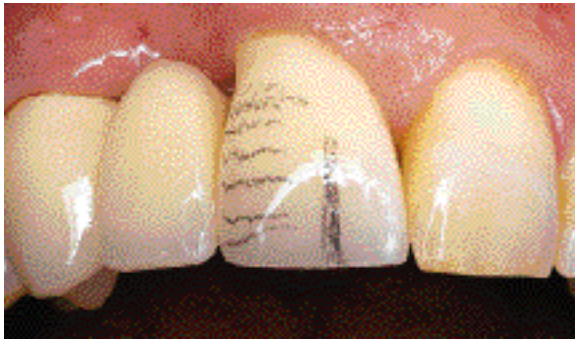

Figure 8-53C: At try-in, the three-unit ceramometal fixed bridge is marked for final shaping.

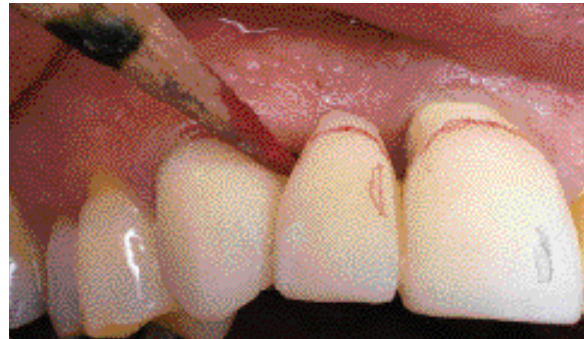

Figure 8-53D: Next, the desired tissue height is marked in red.

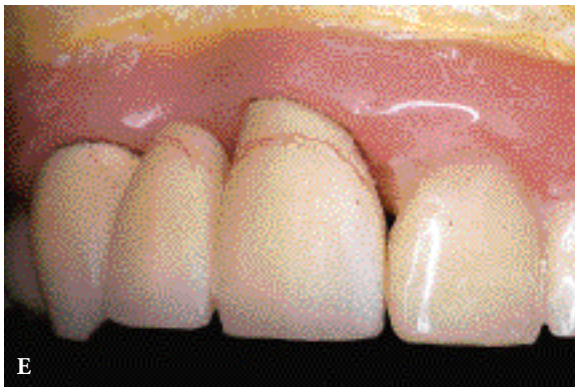

Figure 8-53E and F: A living tissue model consisting of tooth-colored acrylic and pink gingiva-toned acrylic is fabricated.

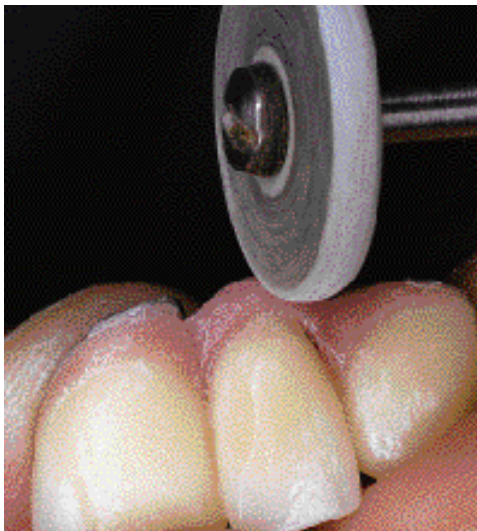
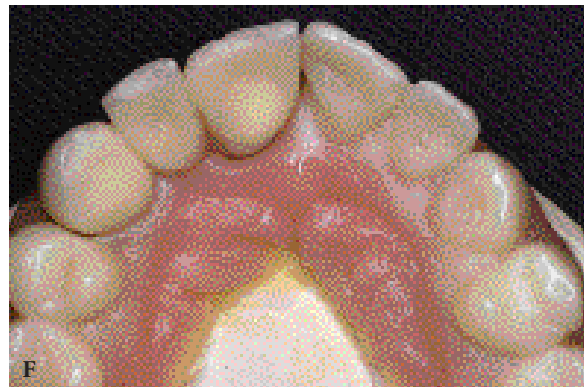


Figure 8-53G: Pink tissue-colored porcelain is added to replace the missing interdental tissue. Here a porcelain wheel refines the pontic area.

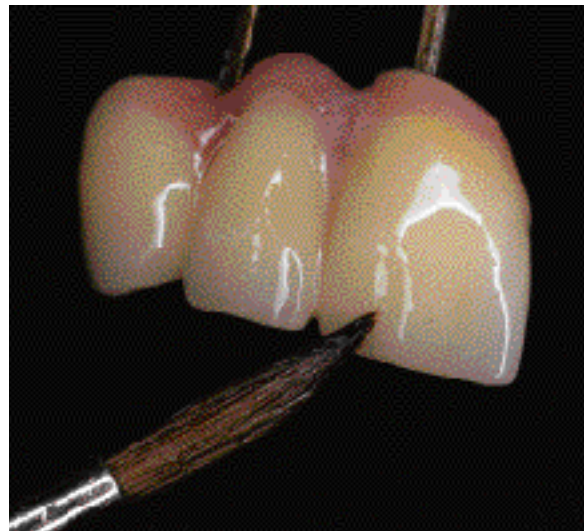


Figure 8-53H: After contouring, the porcelain is stained and glazed.

tion. A major advantage to composite resin is the ease of masking the add-on and the ability to repair it in the mouth. The following example describes this treatment.



PROBLEM: This secretary shows her lower teeth when she talks (Figure 8-54A). It is especially noticeable

since most people view her from above when she is seated at her desk. Therefore, in replacing the existing four-unit mandibular fixed bridge with a six-unit ceramometal bridge, it was essential to mask the interdental spaces with proportional crown forms.

TREATMENT: A fixed composite resin interdental tissue addition was selected as one of the best solutions

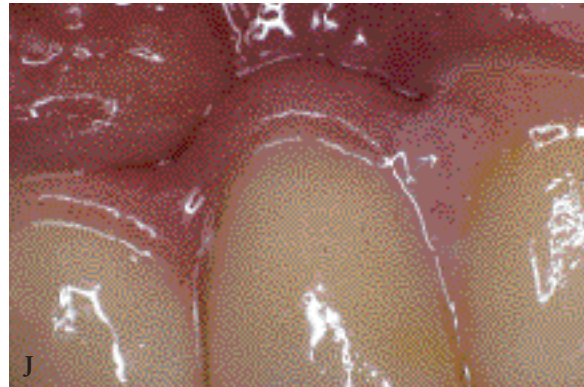
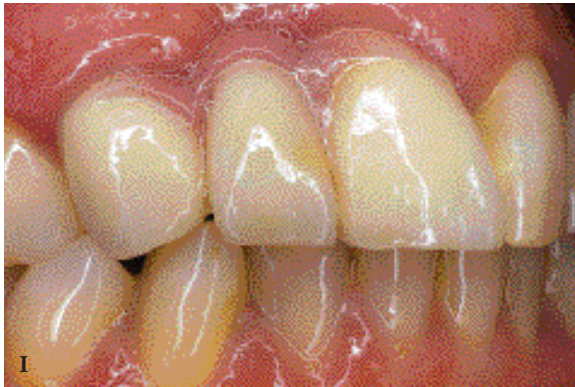

Figure 8-53I and J: A fixed partial denture with a tissue insert replaced both the missing tooth and interdental tissue.

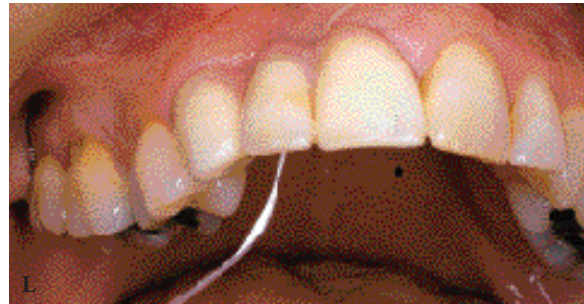
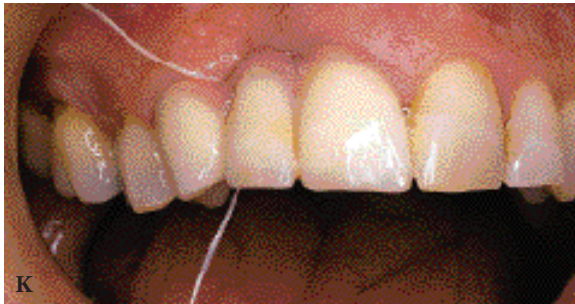
Figure 8-53K and L: The patient must be able to easily insert floss for gentle cleaning under the pontic.

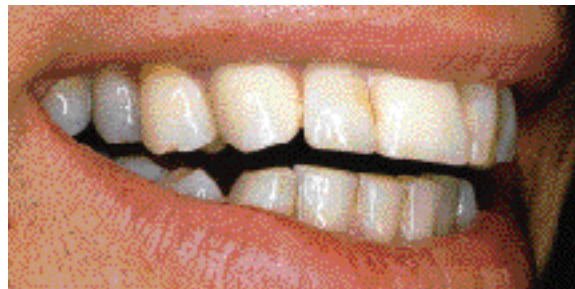

Figure 8-53M: With his new prosthesis in place, the patient now allows himself a wide, full, exuberant smile.

to the problem of keeping the crown shapes proportional (Figure 8-54B). Although the fixed tissue addition fits snugly to the natural tissue, the bridge was designed to allow the patient to easily floss under the addition (Figure 8-54C) and to use a site-specific rotary brush (Rotadent, Pro-Dentec) (Figure 8-54D) to clean the area. Proper home care is essential to maintain healthy tissue and, thus, to ensure the success of the treatment.

RESULT: The speaking position reveals a normal

interdental tissue relationship (Figure 8-54E). The patient is now less self-conscious about her appearance and more comfortable in her conversations at the office.



SUMMARY

This chapter has presented a variety of methods to help make artificial teeth look more realistic. Selecting material with optical properties closest to

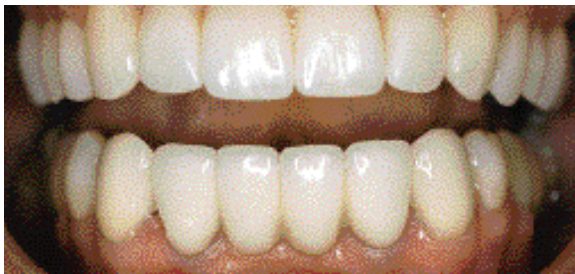

Figure 8-54A: A retracted view of a patient's four-unit mandibular fixed bridge.

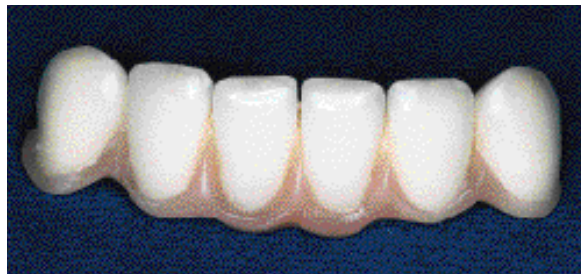

Figure 8-54B: View of the fixed composite resin interdental tissue addition. Note the proportional crown shapes.

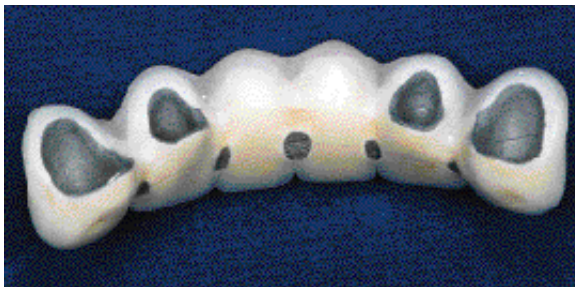

Figure 8-54C: The internal view shows the relative space occupied by the tissue-colored porcelain.

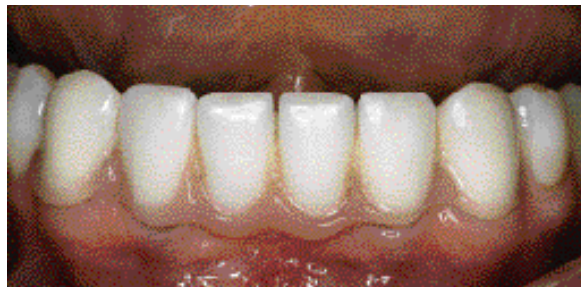

Figure 8-54D: Design allowed for proper daily maintenance to ensure success with dental floss and a site-specific rotary brush (Rotadent, Pro-Dentec).

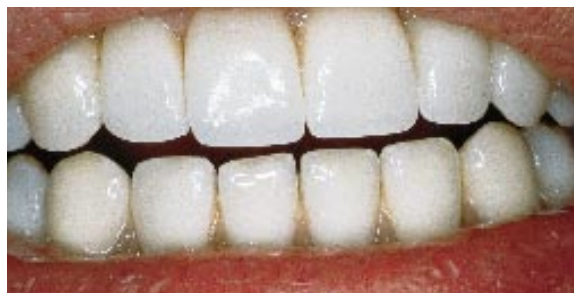

Figure 8-54E: The speaking position reveals a normal interdental tissue relationship.

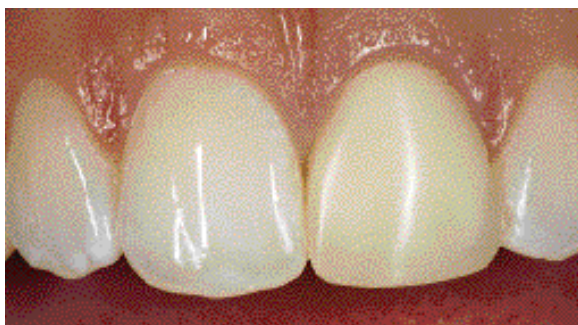

Figure 8-55A: A preoperative view of the patient's existing left central incisor crown shows a lack of (1) color match, (2) proper tooth form, (3) luster, and (4) texture.

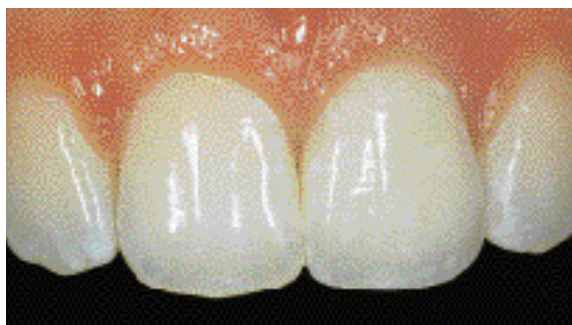

Figure 8-55B: A new Inceram (Vident) crown was fabricated to better mimic the natural dentition. Note the type of shade characterization, the density of calcified spots, and the finishing texture and luster which give the illusion of a natural tooth.

the natural dentition in all light conditions is a good start. The ceramometal crown can be just as realistic as the all-ceramic crown. Splinted teeth can look just as individual as single units. However, in

the final analysis, the quality of the result is directly proportional to good communication and the ability and artistry of the dental ceramist (Figures 8-55A and B, and 8-56A to C).

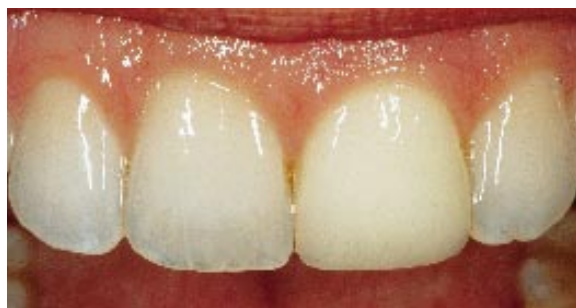

Figure 8-56A: This patient presented with a crown that was fabricated without consideration of the inherent natural qualities of the patient's adjacent tooth structure.

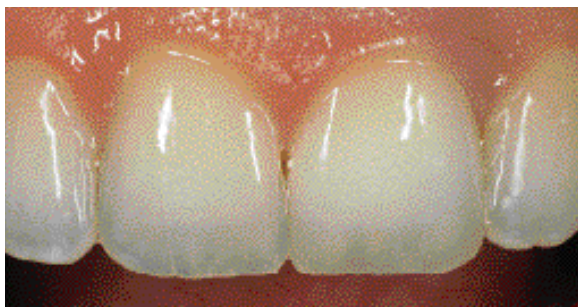

Figure 8-56B: The crown was replaced with a new Inceram-Spinell single unit restoration. Observe the internal detail of the mammellons, the bluish translucence, and the halo effect incorporated to duplicate the qualities of the adjacent teeth.

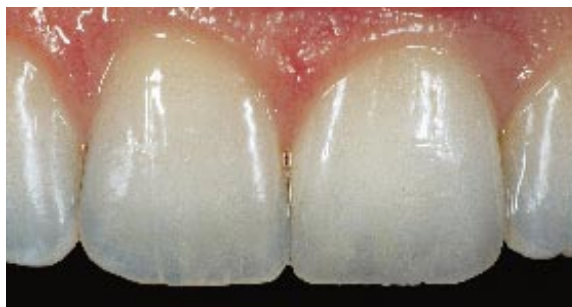


Figure 8-56C: The same restoration was photographed close-up with a black background to further contrast the internal detail incorporated into the incisal one-third of the crown.

Natural tooth positions, contours, surface characterizations, and blemishes can be quite esthetic. Asymmetry is a normal occurrence. Neither dentist nor patient may wish to reproduce that which is grotesque, but the classic ideal may be just as unesthetic. All or some of these factors must be analyzed and resolved before an esthetic result can be achieved. There is an obligation to the patient to restore not merely healthy function but the esthetics that are so important to a healthy personality. Through the use of illusion, this end can often be achieved, despite seemingly impossible esthetic problems.

Figures 8-5; 8-6A to F; 8-7A and B; 8-8A to D; 8-9A to C; 8-10A to D; 8-24B, C, and D; 8-29A; 8-41C; 8-44A and B; 8-55A and B; 8-56A to C courtesy of Pinhas Adar, M.D.T. Oral Design Center, Atlanta, GA.

References

1. Cronin RJ, Wardle WL. Loss of anterior interdental tissue: periodontal and prosthodontic solutions. *J Prosthet Dent* 1983;50:505-9.
2. Lombardi RE. The principles of visual perception and their clinical application to denture esthetics. *J Prosthet Dent* 1973;9:358.
3. Schweitzer JM. Oral rehabilitation problem cases: treatment and evaluation. St. Louis: C.V. Mosby, 1964.
4. Aker DA, Aker JR, Sorensen SE. Toothbrush abrasion of color-corrected porcelain stains applied to porcelain fused-to-metal restorations. *J Prosthet Dent* 1980;44(2):161-3.
5. Barghi N. A study of various factors influencing shade of bonded porcelain. *J Prosthet Dent* 1978;39(3):282-4.

Additional Resources

- Adisman IK. Management of esthetic problems in unconventional denture prosthesis. *Dent Clin North Am* 1967;Mar:101-14.
- Aeziman HT. Use of surface stains for ceramic restorations. *Northwest Dent* 1971;50:215.
- Anusavice KJ. Stress distribution in atypical crown designs. In: Preston J, ed. *Perspectives in dental ceramics*. Chicago: Quintessence, 1988:175.
- Aoshima H. A collection of ceramic works: a communi-

cation tool for the dental office and laboratory. Tokyo: Quintessence, 1992.

Arnheim R. *Visual art and perception*. Berkeley: University of California Press, 1966.

Baumhammers A. Prosthetic gingiva for restoring esthetics following periodontal surgery. *Dent Digest* 1969;75:58.

Baumhammers A. *Temporary and semipermanent splinting*. Springfield, IL: Charles C. Thomas, 1971.

Bazola FN, Maldne WF. A customized shade guide for vacuum-fired porcelain-gold combination crown. *J Am Dent Assoc* 1967;74:114.

Beagle JR. Surgical reconstruction of the interdental papilla: case report. *Int J Periodontics Restorative Dent* 1992;12(2):145-51.

Beder OE. Esthetics and enigma. *J Prosthet Dent* 1971;25:588.

Berger RP. Esthetic considerations in framework design. In: Preston J, ed. *Perspectives in dental ceramics*. Chicago: Quintessence, 1988:237.

Blancheri RL. Optical illusions. *J S Calif Dent Assoc* 1950;17:24.

Blancheri RL. Optical illusions and cosmetic grinding. *Rev Assoc Dent Mex* 1950;8:103.

Borenstein S. Effects of the age factor on the layering technique. In: Preston J, ed. *Perspectives in dental ceramics*. Chicago: Quintessence, 1988:257.

Boucher CD, ed. *Swenson's complete dentures*. 6th ed. St. Louis: C.V. Mosby, 1970.

Boucher CD. Esthetics and occlusion. In: *Esthetics*. New York: Medcom, 1973.

Bourelly G, Pruden JN. Influence of firing parameters on the optical properties of dental porcelains (FRE). *Rev Fr Prothes Dent* 1991;27:33-40.

Brecker SC. *The porcelain jacket crown*. St. Louis: C.V. Mosby, 1951.

Brecker SC. *Clinical procedures in occlusal rehabilitation*. Philadelphia: W.B. Saunders, 1966.

Bronstein BR. Problems in porcelain rehabilitation. *J Prosthet Dent* 1967;17:79.

- Buckner RC. Cosmetics in denture prostheses. *J Am Dent Assoc* 1963;66:787.
- Bulanov VI, Strelnikov VN. The planning of the design of combined crowns with regard to tooth display during conversation and smiling (RUS). *Stomatologïa* 1991;4:60-2.
- Butterworth ML. Their smile. Esthetics in dentistry. [Lecture] 5th Dist Dent Soc, Atlanta, September 17, 1973.
- Calamia JR. Dental restorations of firmly bonded porcelain in anterior and posterior regions (GER). *Quintessenz Zahntech* 1991;17:821-38.
- Cappello N, et al. Anthropometric assessments in dental esthetics (ITA). *Minerva Stomatol* 1991;40:613-7.
- Carlson C, Krueger KR. Full coverage cosmetic dentistry and gingival health. *J Esthet Dent* 1991;3:43-5.
- Celenza FV, et al. Occlusal management of metal ceramic restorations. In: Preston J, ed. *Perspectives in dental ceramics*. Chicago: Quintessence, 1988:457.
- Ceramco Color System. Long Island City, New York, Ceramco Equipment Corporation, 1956.
- Chase RF. Sex and the upper central incisor. *Tex Dent J* 1972;90:39.
- Chiche G, Pinault A. Esthetics of anterior fixed prosthodontics. Chicago: Quintessence, 1993.
- Crispin B. Contemporary esthetic dentistry: practice fundamentals. Tokyo: Quintessence, 1994.
- Crispin BJ, Hewlett E, Seghi R. Relative color stability of ceramic stains subjected to glazing temperatures. *J Prosthet Dent* 1991;66:20-3.
- Cross TP. Creating the appearance of white enamel dysmineralization with bonded resins. *J Esthet Dent* 1991;3:30-3.
- Culpepper WD. Esthetic factors in anterior tooth restoration. *J Prosthet Dent* 1973;30:576.
- DeFabianis E, Preti G. The esthetic factor in total prosthesis. *Minerva Stomatol* 1968;17:51.
- de Kloet JJ, Steneker C. Cosmetic aspects of dental treatment (DUT). *Ned Tijdschr Tandheelk* 1991;98(6):198-202.
- Dickerman MJ. Esthetics and optical illusions. *Certified Dent Technol* 1964;2:4.
- Dunn W. Staining artificial teeth to match exceptional natural ones. *Am J Dent Sci* 1983;17:302-7.
- Dwork HR. The godfather takes his family to the dentist. *Dent Survey* 1972;48:26.
- Fabelis N. The four harmonies of esthetics. *J Ky Dent Assoc* 1964;16:71.
- Feigenbaum NL. Aspects of aesthetic smile design. *Pract Periodontics Asthet Dent* 1991;3(3):9-13.
- Feigenbaum NL. Reshaping tooth contours with direct resins. *J Esthet Dent* 1991;3:57-61.
- Feinberg E. Full mouth restoration in daily practice. Philadelphia: J.B. Lippincott, 1971.
- Ferreia D, Monard LA. Measurement of spectral reflectance and colorimetric properties of Vita shade guides. *Tydskr Tandheelk Ver S Afr* 1991.
- Frisch J, Jones RA, Bhaskar SN. Conservation of maxillary anterior esthetics: a modified approach. *J Periodontol* 1967;33:11.
- Frush JP, Fisher RD. Introduction to dentogenic restorations. *J Prosthet Dent* 1955;5:586.
- Frush JP, Fisher RD. How dentogenic restorations interpret the sex factor. *J Prosthet Dent* 1956;6:160.
- Frush JP, Fisher RD. How dentogenics interprets the personality factor. *J Prosthet Dent* 1956;6:441.
- Frush JP, Fisher RD. The age factor in dentogenics. *J Prosthet Dent* 1957;7:5.
- Frush JP, Fisher RD. The dynesthetic interpretation of the dentogenic concept. *J Prosthet Dent* 1958;8:558.
- Frush JP. Dentogenics: its practical application. *J Prosthet Dent* 1959;9:914.
- Glickman I. *Clinical periodontology*. 4th edn. Philadelphia: W.B. Saunders, 1972.
- Gmur O. News about the metal porcelain technique. *Zahntechnik* 1970;28:450.
- Goldman HM. Management of the esthetic problems of gingivectomy in the maxillary anterior teeth. [Lecture] Univ of Penna School of Dentistry. April 27, 1963.

- Goldstein CE, et al. Computer imaging: an aid to treatment planning. *J Calif Dent Assoc* 1991;19(3):47-51.
- Goldstein RE. Diagnostic dilemma: to bond, laminate, or crown? *Int J Periodontics Restorative Dent* 1987; 87(5):9-30.
- Goldstein RE. Esthetics in dentistry. *J Am Dent Assoc* 1982;104:301-2.
- Goldstein RE. Solving tooth color problems in esthetic dentistry. Presented at Hinman Dental Meeting. Clinical Topics in Dentistry. Univ of Nebraska Medical Center. #81, 1992.
- Goldstein RE. Study of need for esthetics in dentistry. *J Prosthet Dent* 1969;21:589.
- Goldstein RE, Adar P. Special effects and internal characterization. *J Dent Technol* 1989;17(11).
- Goldstein RE, et al. Esthetic considerations in the selection and use of restorative materials. *Dent Clin North Am Philadelphia: W.B. Saunders.* 1983;27(4):723-31.
- Goldstein RE, et al. Immediate conservative corrections of esthetic problems. *J Dent Technol (Jpn)*, 1990;75(3): 50-9.
- Goodsir L. Creating illusions of tooth size by varying tooth form. *The Thermotrol Technician*. New Rochelle, New York: JF Jelenko and Co., Vol. 25, March-April 1971.
- Goodsir L. Creating illusions of tooth size by shading and characterizing. *The Thermotrol Technician*. New Rochelle, New York: JF Jelenko and Co., Vol. 25, Sept.-Oct., 1971.
- Grant D, Stern IB, Everett FG. *Organ's periodontics*. 2nd edn. St. Louis: C.V. Mosby, 1963.
- Hallarman E. A statistical survey of the shape and arrangement of human male and female teeth. Master's thesis. NY Univ College of Dentistry, 1971.
- Hardy IR. Problem-solving in denture esthetics. *Dent Clin North Am* 1960:305.
- Hawkins CH, et al. Ridge contour related to esthetics and function. *J Prosthet Dent* 1991;66:165-8.
- Henderson D. The dentist, the technician, and work authorizations. In: *Esthetics*. New York: Medcom, 1973.
- Henderson D, Frazier Q. Communicating with dental laboratory technicians. *Dent Clin North Am* 1970; 14:603.
- Hickey JC. *The esthetics of anatomy*. In: *Esthetics*. New York: Medcom, 1973.
- Hickey JC, Boucher C, Woelfel J. Responsibility of the dentist in complete dentures. *J Prosthet Dent* 1962;12: 637.
- House MM. *Form and color harmony in denture art*. Whittier, CA: House & Loop, 1939.
- Hubbard JR. Natural texture and lustre in ceramics. In: Preston J, ed. *Perspectives in dental ceramics*. Chicago: Quintessence, 1988:263.
- Hulten P, Dudek RP. The importance of translucency and fluorescence in dental ceramics. In: Preston J, ed. *Perspectives in dental ceramics*. Chicago: Quintessence, 1988:273.
- Jinoian B. The importance of proper light sources in metal ceramics. In: Preston J, ed. *Perspectives in dental ceramics*. Chicago: Quintessence, 1988:229.
- Johnston JF, Dykema RW, Mumford G, Phillips R. Construction and assembly of porcelain veneer gold crowns and pontics. *J Prosthet Dent* 1962;12:1125.
- Johnston JF, Mumford G, Dykema RW. Porcelain veneers bonded to metal castings. *Pract Dent Monogr* 1963:2.
- Johnston JF, Phillips RW, Dykema RW. *Modern practice in crown and bridge prosthodontics*. 3rd edn. Philadelphia: W.B. Saunders, 1971.
- Jones D. *Ceramics in dentistry*. *Dent Technol* 1971; 24:64.
- Jordan RE. *Esthetic composite bonding: techniques and materials*. 2nd edn. St. Louis: Mosby 1993.
- Kataoka S, et al. Layering technique with opal ceramic for natural color in front teeth (GER). *Quintessence Int* 1991;17(2):189-200.
- Katz SR. Aesthetics in ceramics. *J Can Dent Assoc* 1966;32:224.
- Klaffenbach AO. Dental porcelains, glazes, stains and their application to dental restorations. *Dent Cosmos* 1928;19:1185.
- Kohler FD. Personalizing the teeth. In: *Esthetics*. New York: Medcom, 1973.
- Koper A, Gordon DC. *Esthetics in oral restorations*

- [Course] Univ. of Calif. School of Dentistry. December 3, 1971.
- Kornfeld M. Mouth rehabilitation: clinical and laboratory procedures. St. Louis: C.V. Mosby, 1967.
- Korson D. Aesthetic design for ceramic restorations. London: Quintessence, 1994.
- Krajicek DD. Dental art in prosthodontics. *J Prosthet Dent* 1969;21:122.
- Krajicek DD. Anatomy of esthetics. In: *Esthetics*. New York: Medcom, 1973.
- Kurzeja R. Translucency and esthetics. In: Preston J, ed. *Perspectives in dental ceramics*. Chicago: Quintessence, 1988:267.
- Landa LS. Anterior tooth selection. In: *Esthetics*. New York: Medcom, 1973.
- LaVere AM, et al. Denture tooth selection: an analysis of the natural maxillary central incisor compared to the length and width of the face: Part 1. *J Prosthet Dent* 1992;67:661–3.
- Lee JH. Dental aesthetics: the pleasing appearance of artificial dentures. Bristol: John Wright and Sons, 1962.
- Lee JH. Immediate full upper denture. *Dent Pract* 1952; 2:336.
- L'Estrange PR, Strahan JD. The wearing of acrylic periodontal veneers. *Br Dent J* 1970;128:193.
- Levin EI. Dental esthetics and the gold proportion. *J Prosthet Dent* 1978;40:244.
- Lombardi RE. A method for the classification of errors in dental esthetics. *J Prosthet Dent* 1974;32:501.
- Luckiesh M. Visual illusions. New York: Dover Publications, 1965.
- Marquis PM. Optimizing the strength of all-ceramic jacket crowns. In: Preston J, ed. *Perspectives in dental ceramics*. Chicago: Quintessence, 1988:15.
- Martinelli N. Dental laboratory technology. St. Louis: C.V. Mosby, 1970.
- Martone AL. Complete denture esthetics and its relation to facial esthetics. *Dent Clin North Am* 1967;Mar:89–100.
- McLean JW. The alumina reinforced porcelain jacket crown. *J Am Dent Assoc* 1967;65:621.
- McLean JW. The science and art of dental ceramics. Vol 2. London: Quintessence, 1980.
- McLean JW, Kedge M. High-strength ceramics. In: Preston J, ed. *Perspectives in dental ceramics*. Chicago: Quintessence, 1988:153.
- Miller CJ. Inlays, crowns and bridges. Philadelphia: W.B. Saunders, 1962.
- Miller IF. Complete restorative dentistry. *J Prosthet Dent* 1973;30:675.
- Miller IF, Belsky MW. Cosmetics in restorative dentistry. *Dent Clin North Am* 1967;Mar:11–8.
- Miller L. A clinician's interpretation of tooth preparation and the design of metal substructures for metal-ceramic restorations. In: McLean JW, ed. *Dental ceramics*. Chicago: Quintessence, 1983:153.
- Mitchell RG. Method used to obtain optimum esthetics in the porcelain gold crown. *Tex Dent J* 1968;85:7.
- Morali M. Esthetics. *Rev Belge Med Dent* 1970;25:421.
- Morley J. Smile designer's workshop. *Dent Today* 1991; 10(1):42.
- Morrison K, Warnick M. Staining porcelain-bonded-to-metal restorations. *J Prosthet Dent* 1967;15:713.
- Muia P. Esthetic restorations: improved dentist-laboratory communication. Chicago: Quintessence, 1993.
- Myers GE. Textbook of crown and bridge prosthodontics. St. Louis: C.V. Mosby, 1969.
- Nelson AA. The aesthetic triangle in the arrangement of teeth: face form, tooth form, alignment form, harmonious or grotesque. *Natl Dent Assoc J* 1922;9:392.
- Newman A. Dental porcelains and furnaces. *Dent Technol* 1968;2:14.
- Nixon RL. Smile showcase—redesigning the narrow smile. *Pract Periodontics Aesthet Dent* 1991;3(4):45–50.
- Owall B, Kayser AF, Carlsson GE. Prosthodontics: principles and management strategies. St. Louis: Mosby, 1996.
- Owen EB. A study of the human complexion and a means of determining hues and shades in edentulous cases. *J Am Dent Assoc* 1925;12:944.
- Palmieri CJ, Platzer KM. Orthodontic-plastic surgical

- collaboration in aesthetic facial remodeling. *N Y State Dent J* 1991;57(4):32–3.
- Pameijer JH. Esthetic aspects of crowns and bridges (DUT). *Ned Tijdschr Tandheelk* 98(6):236–41.
- Patur B, Glickman I. Gingival pedicle flaps for covering root surfaces denuded by chronic destructive periodontal disease: a clinical experiment. *J Periodontol* 1968;29:50.
- Payne AGL. Factors influencing the position of artificial upper anterior teeth. *J Prosthet Dent* 1971;26:26.
- Payne SH. Contouring and positioning. In: *Esthetics*. New York: Medcom, 1973.
- Pensler AV. Shade selection: problems and solutions. *Compendium Cont Educ Dent* 1998;19:387–96.
- Philippe J. Esthetics of the face and teeth (FRE). *Orthod Fr* 1991;62:423–32.
- Pilkington EL. Esthetics and optical illusions in dentistry. *J Am Dent Assoc* 1936;23:641.
- Pincus CL. Building mouth personality. *J Calif Dent Assoc* 1938;14:125.
- Pincus CL. The role of jacket crown and fixed bridge restorations in the prevention and treatment of periodontal lesions. *J S Calif Dent Assoc* 1956;24:19.
- Pincus CL. New concepts in model techniques and high temperature processing of acrylic resins for maximum esthetics. *J S Calif Dent Assoc* 1956;24:26.
- Pincus CL. Functional esthetic restorative procedures. [Course] *Univ of Alabama School of Dentistry*, Feb. 1962.
- Pincus CL. Cosmetics—the psychologic fourth dimension in full mouth rehabilitation. *Dent Clin North Am* 1967;Mar:71–88.
- Pincus CL. Light reflections. In: *Esthetics*. New York: Medcom, 1973.
- Potter RB. Impressionism in denture esthetics. *J Tenn Dent Assoc* 1970;50:16.
- Potter RB. Dentoesthetics through visual aids. *J Tenn Dent Assoc* 1970;50:19.
- Pound E. Esthetics and phonetics in full denture construction. *J Calif Dent Assoc* 1950;26:179.
- Pound E. Recapturing esthetic tooth position in the edentulous patient. *J Am Dent Assoc* 1957;55:181.
- Pound E. Applying harmony in selecting and arranging teeth. *Dent Clin North Am* 1962;3:241.
- Pound E. Modern American concepts in esthetics. *Int Dent J* 1960;10:154–72.
- Pound E. Lost—fine arts in the fallacy of the ridges. *J Prosthet Dent* 1964;4:6.
- Preston J. The elements of esthetics—application of color science. In: McLean JW, ed. *Dental ceramics*. Chicago: Quintessence, 1983:491.
- Prichard JF. *Advanced periodontal disease*. 2nd edn. Philadelphia: W.B. Saunders, 1972.
- Prinz R. An error and its correction. *Quintessence Int* 1971;2:47.
- Renner RP. An introduction to dental anatomy and esthetics. Chicago: Quintessence, 1985:241–73.
- Risch JR, White JG, Swanson HM. The esthetic labial gingival prosthesis. *J Indiana Dent Assoc* 1977;56:15.
- Roach RR, Mujia PJ. Communication between dentist and technician: an esthetic checklist. In: Preston J, ed. *Perspectives in dental ceramics*. Chicago: Quintessence, 1988:445.
- Rosenstiel SF, Land ME, Fujimoto J. *Contemporary fixed prosthodontics*. 2nd edn. St. Louis: Mosby, 1994.
- Rufenacht CR. *Fundamentals of esthetics*. Chicago: Quintessence, 1990.
- Saklad MJ. Achieving esthetics with the porcelain jacket. *Dent Clin North Am* 1967;Mar:41–55.
- Saleski CG. Color, light shade matching. *J Prosthet Dent* 1972;25:589.
- Scharer P. A clinician's view of porcelain reconstructions. In: McLean JW, ed. *Dental ceramics*. Chicago: Quintessence, 1983:293.
- Schweitzer JM. Esthetics and hygiene after extensive periodontal treatment. *J Prosthet Dent* 1960;10:284.
- Sharry JJ. *Complete denture prosthodontics*. New York: McGraw-Hill, 1968.
- Shavell HM. Dentist-laboratory relationships in fixed prosthodontics. In: Preston J, ed. *Perspectives in dental ceramics*. Chicago: Quintessence, 1988:429.

- Shelby DS. Esthetics and fixed restorations. *Dent Clin North Am* 1967;Mar:57–70.
- Shelby DS. Practical considerations and design of porcelain fused to metal. *J Prosthet Dent* 1962;12:542.
- Shelby DS. Cosmetic restorative problems: initial study with television. *J Prosthet Dent* 1964;14:107.
- Shelby DS. Esthetic needs in anterior tooth restoration. *N Y J Dent* 1967;37:108.
- Sieber C. *Voyage: visions in color and form*. Chicago: Quintessence, 1995.
- Silver M, Howard M, Klein G. Porcelain bonded to a cost metal understructure. *J Prosthet Dent* 1961;11:132.
- Silverman HN, Wolf ROL. Posterior restorations. *Dent Manage* 1991;31(8):41–3.
- Staffileno H. Management of gingival recession and root exposure problems associated with periodontal disease. *Dent Clin North Am* 1964:11.
- Stein RS. Ceramometal and aluminous porcelain restorations. [Course] College of Dental Medicine, Charleston, S.C. Dec. 11–12, 1971.
- Stoloff CI. The fashionable tooth. *J Oreg Dent Assoc* 1972;42:6.
- Sturdevant CM, Roberson TM, Heymann HO, Sturdevant JR. *The art and science of operative dentistry*. 3rd edn. St. Louis: Mosby, 1994.
- Swenson HM, Hanson NM. The periodontist and cosmetic dentistry. *J Periodontol* 1961;32:82.
- Tanaka A. Successful technologist-dentist teamwork. In: Preston J, ed. *Perspectives in dental ceramics*. Chicago: Quintessence, 1988:439.
- Tashma J. Coloring somatoprostheses. *J Prosthet Dent* 1967;17:303.
- Tillman EJ. Modeling and staining acrylic-resin anterior teeth. *J Prosthet Dent* 1955;5:497.
- Tylman SD. *Theory and practice of crown and fixed partial prosthodontics (bridge)*. St. Louis: C.V. Mosby, 1970.
- Valderhaug J. A 15-year clinical evaluation of fixed prosthodontics. *Acta Odontol Scand* 1991;49(1):35–40.
- Vig RG. The denture look. *J Prosthet Dent* 1961;11:9.
- Vryonis P. Aesthetics in ceramics: perceiving the problem. In: Preston J, ed. *Perspectives in dental ceramics*. Chicago: Quintessence, 1988:209.
- Wehner PJ, Hickey JC, Boucher CO. Selection of artificial teeth. *J Prosthet Dent* 1967;18:222.
- Weller R. Updated esthetics. [Course] First District Dent Society of New York, May 9, 1969.
- Williams DL. Prosthesis for a lost gingival papilla. *Dental Survey* 1977; Nov:36.
- Williams Gold Refining Co. *Basic colormanship*. Buffalo, New York: H.D. Justi Co., 1968.
- Woon KC, Thong YL. A multidisciplinary approach in achieving aesthetics and function. *J Ir Dent Assoc* 1991; 37(1):15–7.
- Zarb GA, Bolender CL, Carlsson GE. *Boucher's prosthodontic treatment for edentulous patients*. 11th edn. St. Louis: Mosby, 1997.
- Zena RB, Abbott LJ. Light harmony of crowns and roots: understanding and managing the black line phenomenon. *Pract Periodontics Aesthet Dent* 1991;3(4):27–31.

CHAPTER 9

DIVINE PROPORTION

Robert M. Ricketts, DDS, MS

A natural law, “The Divine Proportion,” has been recognized, at least subliminally, since the beginning of recorded history. Given its name by Pacioli, a mentor of Leonardo DaVinci, this phenomenon has unique properties, and it seems so mystical in its qualities that it baffles the imagination and eludes understanding. The proportion is 1.0 to 1.618. This relationship links geometry to mathematics, hence it has also been called the “sacred geometry,” “the magic numbers,” and “the golden cut.” It is found in art, architecture, and in anatomy. Parts organized in this proportion seem to display maximum beauty and ultimate efficiency in function.

A lay person might view this relationship as a simple “given” but the mathematician sees it as a challenge for deep exploration. The metaphysician accepts it as a matter of divine order, and the biologist considers it a basic phenomenon of nature. The clinician may employ the principle as a diagnostic or reconstructive guide.

This relationship attracted the earliest artisans, who created beautiful objects to please the senses. It is recognized as one path to reaching contentment in the beauty of nature. In recognition of Phidias, a Greek sculptor who employed the proportion in his work, it has been labelled “phi,” using the Greek symbol ϕ . Multiples are expressed as ϕ^2 , ϕ^3 , etc., and smaller proportions are designated as ϕ^{-2} , ϕ^{-3} , etc.

The Rediscovery

The basis for the rediscovery was a series of investigations over a period of 15 years. In 1966, a major study of human facial morphology was conducted with the use of the computer on 40 children. A polar center was discovered in the sagittal perspective. This polar center was located at the base of the sphenoid bone at the foramen rotundum, a neural

point for the maxillary nerve. From this point, growth seemed to occur radially, like the rays of the sun (Figure 9–1A).

It was evident from this polar phenomenon that some underlying principle was being expressed. Structures located in close proximity to the center grew less while parts more distant grew more in order to maintain proper facial proportion in a three-dimensional context. Thus, a size-gain relationship was immediately demonstrable in growth.

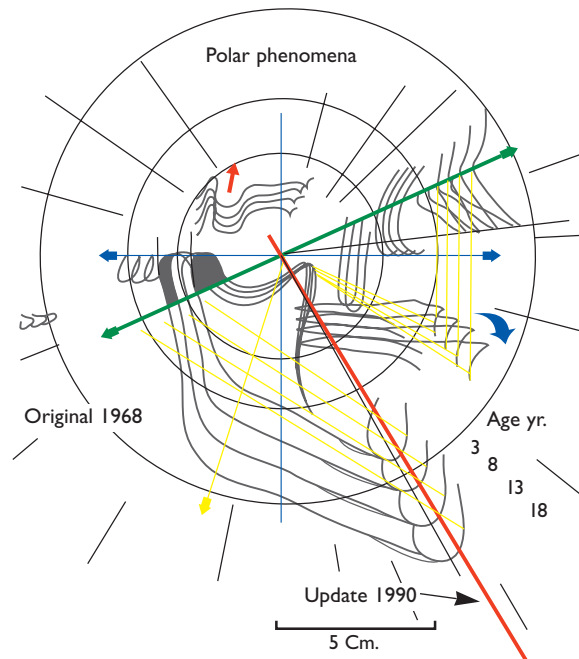


Figure 9–1A: Composite studied with a polar grid revealed the center at the base of the sphenoid bone at foramen rotundum. Parts more distant to the center increased correspondingly more, suggesting a law of growth.

In that study, gnomons (an addition to a figure to enlarge it without changing its shape) were discovered for all the facial cavities. This even included the buccal occlusal plane (Figure 9–1B). As a result of the growth bend of the mandible, an arc for function of a logarithmic spiral reflects the golden cut proportion of 1.0 to 1.618.

Computer-generated composites of an average face as seen from a frontal view showed that the nasal cavity, the upper jaw, and the mandible were also related in a “one-two-three” developmental order. Growth behaviour, from this view, was bipolar in nature, due allegedly to the neurotrophic supply to the two halves of the face. These are

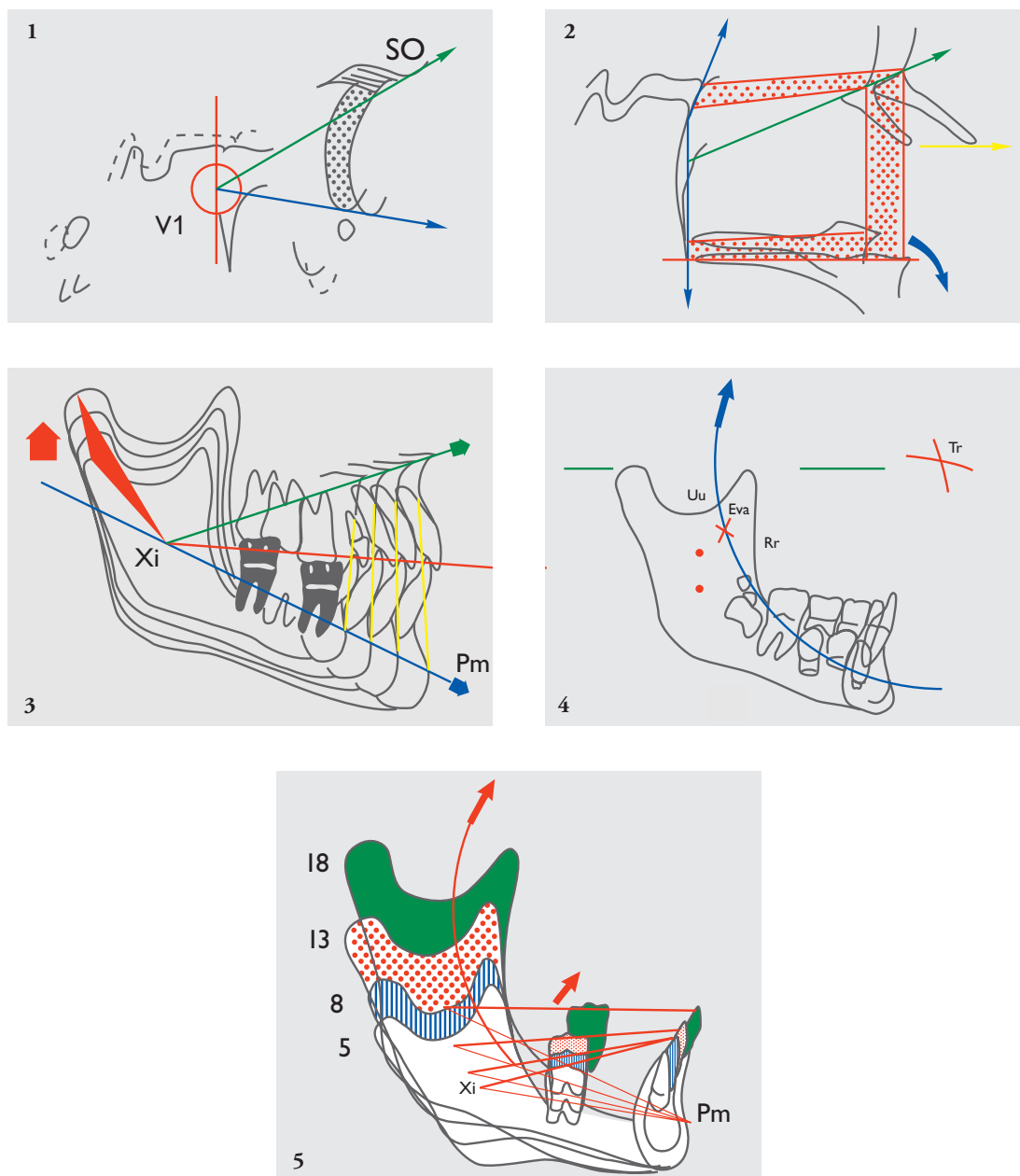


Figure 9–1B: Gnomons were found as based at the entrance of the 5th nerve into facial cavities. 1, orbit; 2, nasal. 3, (at Xi)—oral cavity. An arc of growth was found, as shown in 4. 5 shows occlusal plane movement with the Xi Point.

melded at the midline at Nasion to yield a single gnomon for mandibular growth in the downward and transverse directions (Figure 9–2).

In discussion with Dr. Melvin Moss of Columbia University, the phenomena of polar and bipolar growth, gnomonic growth, spiral growth, and the progressive units of growth were shown to be common in nature. Such growth had been described by D’Arcy Wentworth Thompson as early as the 1920s. Subsequent inquiry by others led to the discovery of these proportions throughout the entire human body. But our current interest for the general dentist, orthodontist, and oral surgeon as well as practitioners in the field of cosmetology is in the golden cut proportions present in the face, jaw, and teeth.

Historical Significance

Geometry was discovered thousands of years before mathematics.¹ Art forms were designed in relation to the human body and nature. The cubit (length of the forearm) was used together with the foot, thigh, and dimensions of the hand and fingers, as units of measurement. The pyramids, the Parthenon and other constructions, including art objects, were built using the proportion 1.0 to 1.618, which in whole numbers can be expressed as 5 to 8. Even Pythagoras formed organizations to study the meaning of this proportion during the sixth century BC.

The basis of the phenomenon is the “golden section”; a straight line can be cut so that the proportional length of the smaller part compared to the larger part is the same as that of the larger part to the sum of both parts (the original line) (Figure 9–3A).

Geometrically, as viewed in Figure 9–3B, the golden cut can be obtained with a compass and a ruler by 1) bisecting a line; 2) erecting a perpendicular to the bisection on one end of the line; 3) connecting the ends to form a triangle; 4) marking off the distance of the original bisection on the hypotenuse; and 5) swinging a new arc from that point to the original line.

Such a relationship between any two parts, when observed to be in this proportional length, is referred to as “golden.”

When the smaller unit (CB) is considered 1.0, the larger (AC) is 1.618 times its length. When the larger is considered 1.0, the smaller is 0.618. This length relationship is referred to as “golden.”

The Harmonic Equation

The golden proportion not only symbolizes beauty and comfort at a primitive level but it is also the key to much of normal morphology. It constitutes a natural law of growth for both plants and animals.

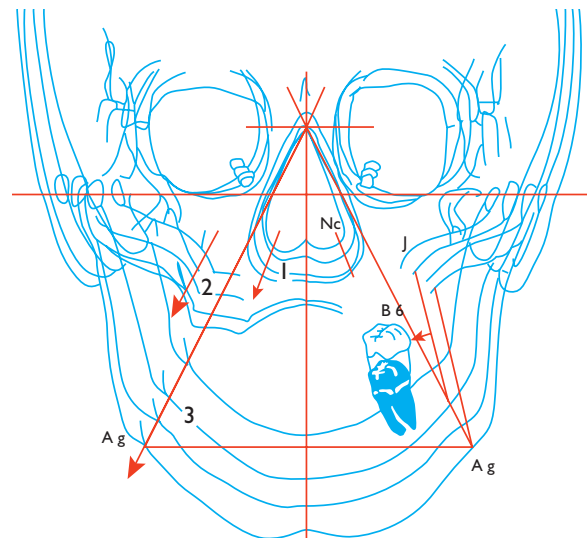
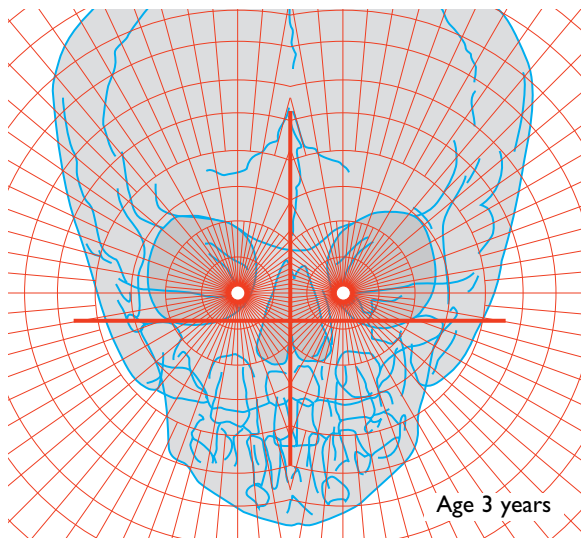


Figure 9–2: A bipolar behaviour was found in the frontal region due to two nerve and blood supplies. The nasal cavity, maxilla, and mandible displayed a 1-2-3 growth unit phenomenon. Rectified as one center for a grid at the Frankfort plane, the mandible (at Ag) showed gnomonic-like behavior from frontal nasion.

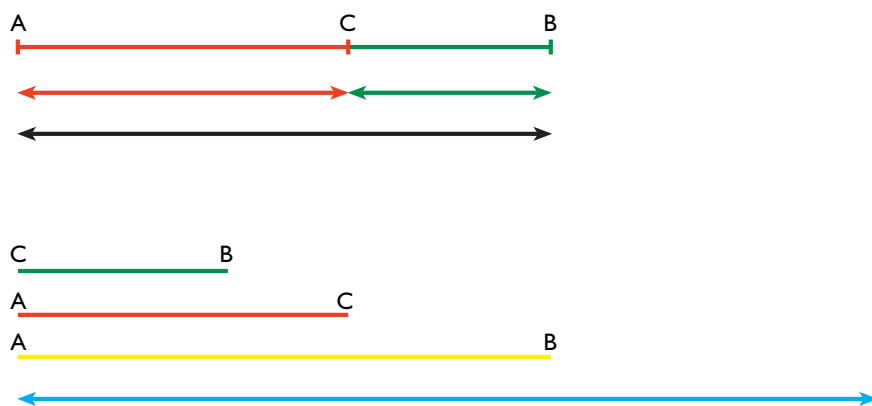


Figure 9-3A: The golden cut and the golden progression. It is called phi and is 1.618. The total line AB is sectioned at C. The length of AC is 1.618 the length of CB. The length of AC is 0.618 the length of AB. CB is 0.382 the length of AB. The proportions CB, AC, AB form a new progression.

Also, two independent lines or parts can be related in this proportion. Parts can contribute to other relations in congruence. The relative parts can also be even with each other, hence a harmonic equation.

How the Proportion Works Clinically

In the case of the teeth, the lower central incisor (the smallest tooth in the mouth) may be used as a starting reference. Interestingly, the upper central incisor has a golden, phi or 1.618 proportion to the lower incisor, and the total width of both lower centrals are golden to that of the upper incisors (Figure 9-4).

Single teeth or groups of teeth can be accurately measured using a golden link caliper, developed by Shumaker. This device allows us to find golden proportions throughout the mouth.

From data for mean tooth dimensions, the typical maxillary central incisor crown length is 8.9 mm, and the maxillary lateral incisor length is 6.4 mm. This makes the central 1.375 times the size of the lateral or the lateral 0.727 times the central. But from the direct frontal perspective, as seen in a photograph, the curve of the arch makes the lateral appear narrower. Thus, instead of the total width of the upper four teeth measuring 3 to 4 mm if laid out on a straight line, the width appears about 1 mm less on each side and, therefore, almost golden to the total width of the two central incisors alone.

In normal arch form, the next progression is at the premolar area. A divine progression occurs

when one distance is golden to another which, in turn, is golden to another. An example of this is

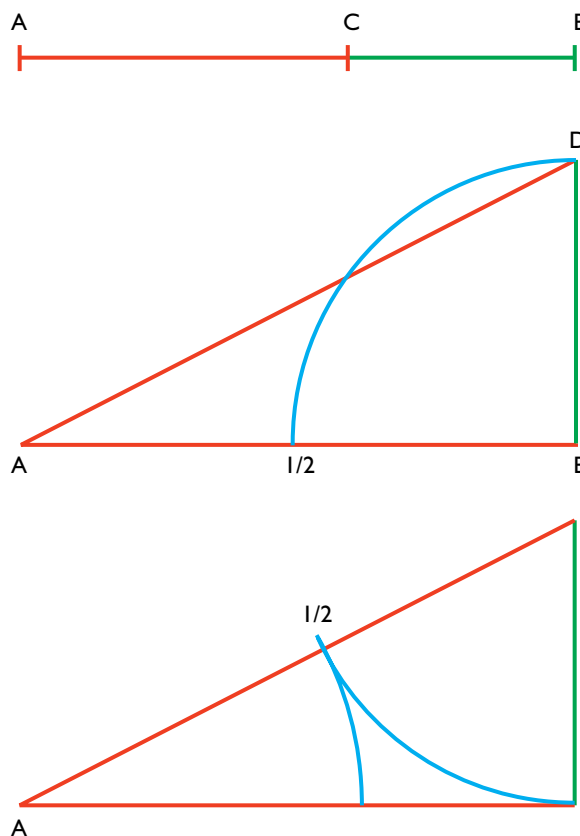


Figure 9-3B: Technique for determining the golden section ACB with a ruler and a compass.

shown in Figure 9–5. The lower incisor width (across the arch) is golden to the upper intercanine widths, and that is golden to the width between the second molars. Also, as a matter of interest, the width of the lower canines tends to be golden to the width of the maxillary first molars, from the mesial to the buccal groove.

These divine relationships are found in people with the most pleasing smiles, the most beautiful or handsome faces, and the most graceful bodies. Nature is seldom absolute or exact but this relationship, as a fundamental phenomenon of development, seems to be a component of a major biologic plan. It is present without doubt. Persons without these proportions are not as beautiful as those with “divine” values but may still be attractive because of a stimulated interest in their variation. The face with the medley of these proportions never becomes boring to observe.

The Magic Numbers

It was not until the 13th century, when the Western world adopted Arabic numbers, that this divine relationship was translated into mathematical terms by Filius Bonaccio, which in fact helped lay the foundation for the Renaissance. The numerical relationship became known as the Fibonacci series.

This mathematical phenomenon is also called the “magic numbers.” To create the series, you begin with the simple addition equation of 0+1=1. The second number to be added in that equation, 1, and the sum of that equation, also 1, are added together, in that order, to create the next line (1+1=2). The sums of each line—1,2,3,5,8,13, etc., are the Fibonacci series.

$$\begin{aligned}
 0 + 1 &= 1 \\
 1 + 1 &= 2 \\
 1 + 2 &= 3 \\
 2 + 3 &= 5 \\
 3 + 5 &= 8 \\
 5 + 8 &= 13 \\
 &\text{etc.}
 \end{aligned}$$

This pattern is not a simple arithmetic progression; it follows an exponential law that can be applied to esthetic dentistry. This progression is most pleasing to the senses and provides a unique relationship. The Fibonacci numbers, after the thirteenth in the series, increase in an unchanging pro-

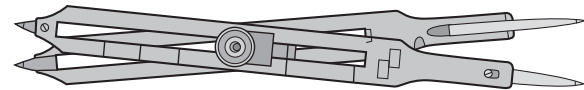
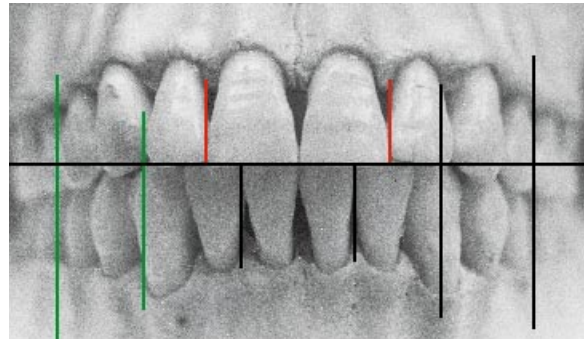


Figure 9–4: Above: A skull with normal occlusion, showing a “golden” proportion of the two lower incisors to the upper incisors, thence to the distal of the upper laterals (on the arc of the arch and at the gingival margin), and also proceeding to the first premolars. Below: The Nestor-Shumaker golden link caliper (GLC) for precise measurement of the teeth in the mouth.

portion of 1.0 to 1.61803. Therefore, in that part of the series, the Fibonacci numbers are golden to their neighbors.

Divide:

$0 / 1 = 0$	$34 / 21 = 1.61904$
$1 / 1 = 1$	$55 / 34 = 1.6176$
$2 / 1 = 2$	$89 / 55 = 1.61818$
$3 / 2 = 1.5$	$144 / 89 = 1.61797$
$5 / 3 = 1.666$	$233 / 144 = 1.61805$
$8 / 5 = 1.6$	$377 / 233 = 1.61802$
$13 / 8 = 1.625$	$610 / 377 = 1.61803$
$21 / 13 = 1.615$	$987 / 610 = 1.61803$

THE GOLDEN FORMS

The Golden Rectangle

In the golden cut, the larger section (AC) related to the whole unit is 0.618 and the smaller is 0.382 (see Figure 9–3 A,B). When the golden cut segments (see Figure 9–3 A-I) are used to construct a rectangle with a base of 1.618 (AC) and a height of 1.0 (CB), it forms a “golden rectangle” (Figure 9–6).

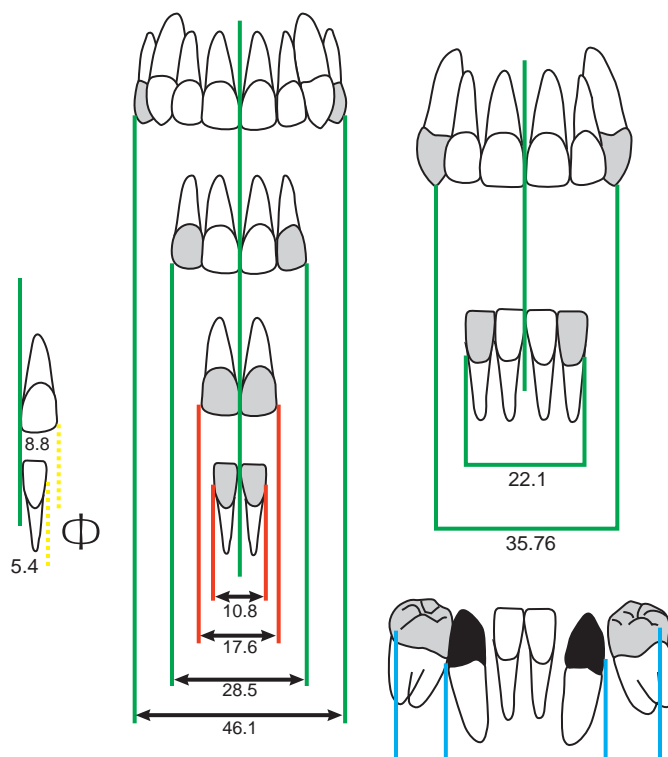


Figure 9-5: A series of proportions starts with the lower central incisors, to the upper centrals, to the width of all four upper incisors (on the arch), and to the premolar area. A second relationship is seen for the width of the lower incisor segment to the upper canine width. A third tends to be present from the distal of the lower canines to the buccal groove on the molar.

This rectangle is found in playing cards, credit cards, windows, picture frames, architectural patterns, and in many art forms. Most objects in daily use may become monotonous if not formed in this

proportional relationship, also known as “dynamic symmetry.” “Dynamic” means that this proportion seems to display some sort of action to the mind rather than being static or dead. In other words,

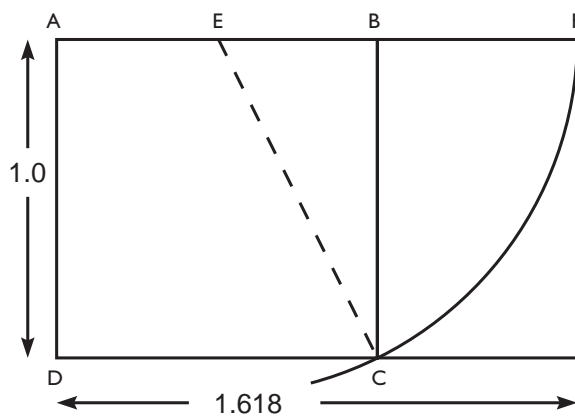


Figure 9-6: Method of constructing a golden rectangle from a square.

this relationship seems to have life, animation, and stimulation, and many plants and animals display its beauty. A series of such rectangles characterizes the human face (Figure 9-7).

The Golden Triangle

If an isosceles triangle is formed with its base as 1.0 and its sides as 1.618, it is called a “golden triangle” (Figure 9-8). Bisecting one of the 72-degree base angles separates that angle into two 36-degree angles

and sections the opposite sides of the triangle in golden sections (Figure 9-8).

If a series of these bisections is made and the vertices of each progressively smaller golden triangle are connected, a logarithmic spiral is produced. This spiral describes the growth of seashells, of horns, and the development of incisors in the rodent. It is found in the cochlea of the inner ear and is the basis upon which the human mandible grows (Figure 9-9).

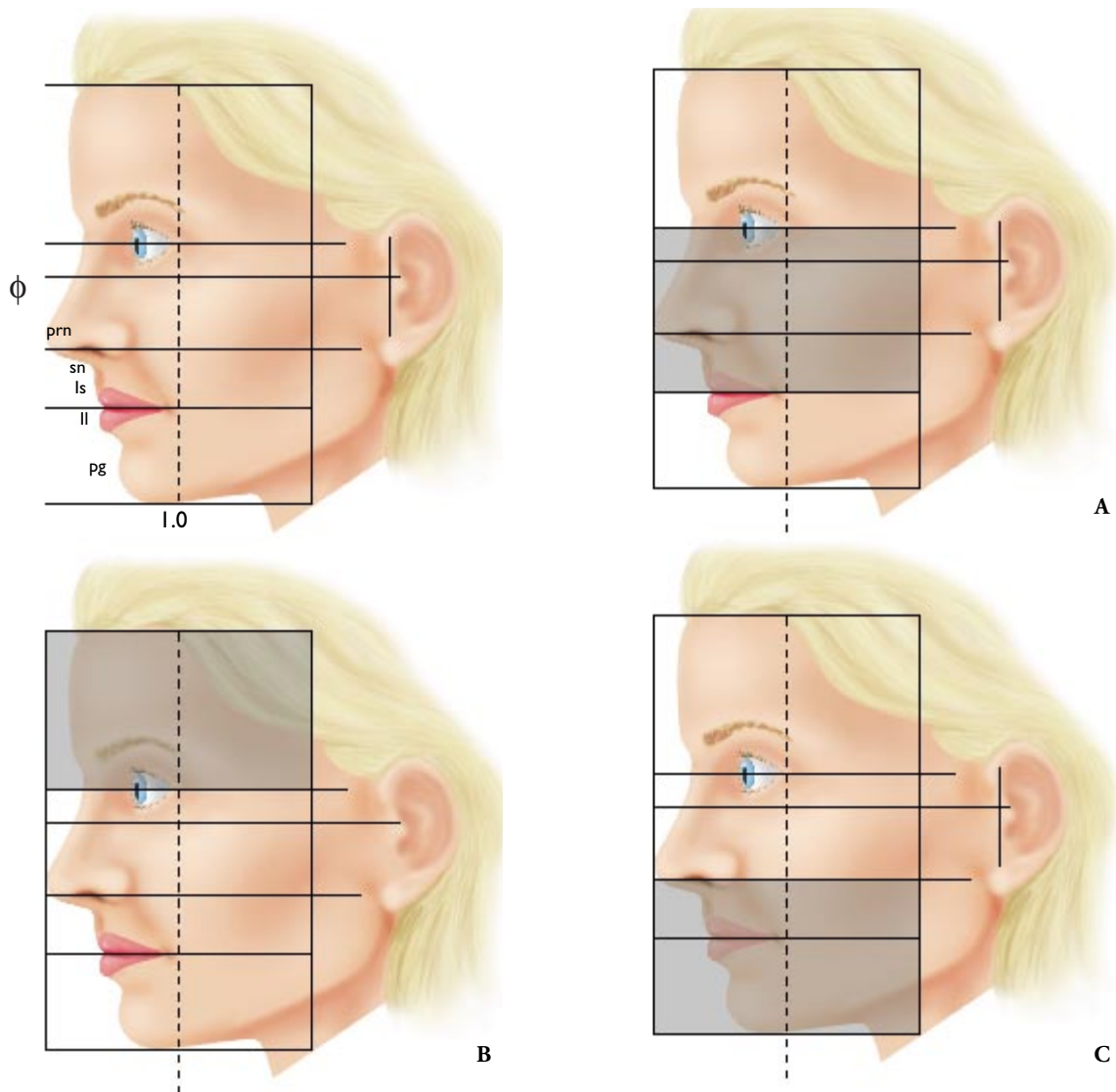


Figure 9-7: If a golden rectangle is formed from facial height and from the end of the nose, a bisection will be noted at the lateral canthus of the eye. Notice the divine proportion of the lip position relative to the nose tip and lateral canthus of the eye. Note the middle face rectangle (A), the upper face rectangle (B), and lower face rectangle (C) are all equal in height.

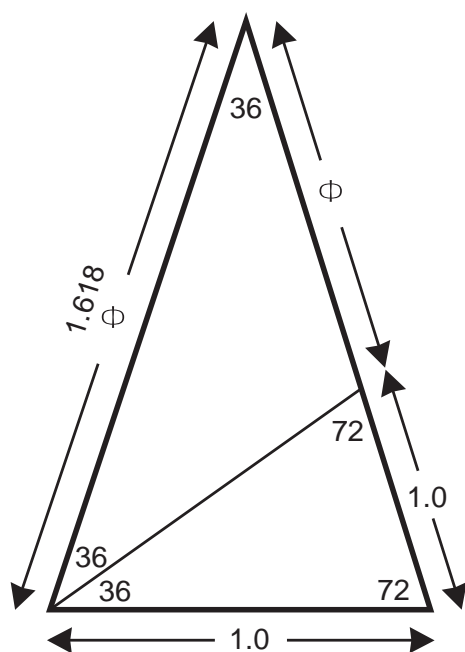


Figure 9-8: The golden triangle. When one of the lower angles is bisected, it forms a new 36°–72°–72° triangle and sections the opposite side into the golden section.

The Pentagon

A golden pentagon is the result of connecting the points of a five-pointed star where all five sides are of equal length. In nature, a five-pointed star is seen in the core of an apple. By connecting one vertex to the two opposite corners of a golden pentagon, a golden triangle (BED) is formed (Figure 9-10). Crossing that triangle with a line connecting the two other corners (AC) will divide the sides of the golden triangle into golden sections, and the line itself will be divided into golden sections at P and Q. It will be noted that the center portion (PQ) is golden to both sides, which makes it reciprocal. It will be seen later that the nose and upper lip length are such reciprocal parts for the human face.

DENTAL AND FACIAL BEAUTY AND HARMONY

Research studies on tooth size and arch form reveal that the beauty of the smile can be enhanced with straight and properly oriented teeth. Imperfections may be accepted, especially when irregularities are used by prosthodontists to conceal the use of artifi-

cial teeth but these efforts are often unappreciated. Before orthodontics became so popular, deliberate misalignment was perhaps appropriate. Today, however, orthodontists making the slightest transgressions are criticized by patients who desire really “straight teeth.” This public viewpoint suggests that ideal tooth mass and size, in keeping with the tenets of divine proportions, are most acceptable, desirable, and expected. The old artificial irregularity for denture work is therefore outmoded on a contemporary cultural basis.

Arch Forms

Research led to the discovery of five distinctive variations in natural human arch form. In the lower arch you can fit a straight line connecting the buccal surfaces of the first premolar to the first molar. The extension of these lines to their intersection in the average arch forms a 36-degree angle and allows the construction of a golden triangle (Figure 9-11). The ovoid and tapered arches still fit, but not as well.

When arches are constructed in the proportions as shown in Figure 9-4, they are pleasing to the senses. It can be understood now why a missing

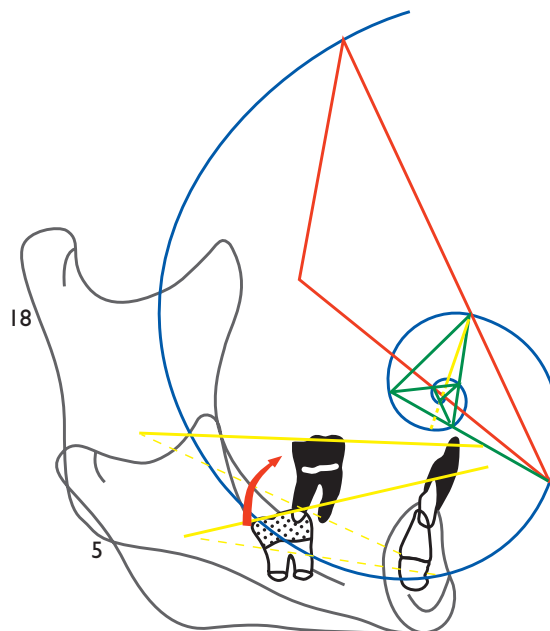


Figure 9-9: The connection of the ends of progressive golden triangles forms a logarithmic spiral. This is the pattern of the growth of the human mandible. Notice the eruption of teeth to explain space for the second and third molars.

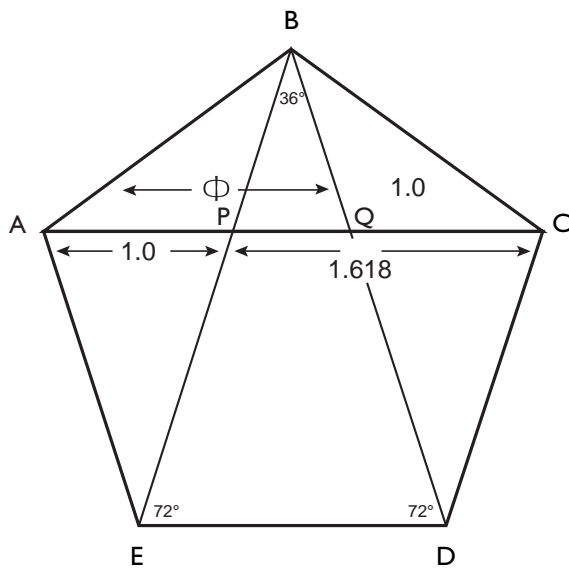


Figure 9-10: The analysis of a pentagon. Notice that the pentagon when connected at its top and bottom corners forms the golden triangle. Note that line A-B also sections the triangle into divine proportion and that P-Q is reciprocal.

tooth, a misplaced tooth, an undersized tooth, a collapsed arch, or an excessive spacing in the arch may be so displeasing. A divine proportion also extends to the details of the individual tooth form in certain instances. This proportion may be a part of the general consideration for esthetics, which together with form, color, hue, and chroma are of interest to the esthetic dentist.

The Golden Divider

An ordinary divider is used to measure a span but if separate short arms with the divine measurements, 1.0 to 1.618, are constructed between the two legs of a simple divider, a third point is established between the two end points. The intersection would also remain at a point of the golden section as such dividers are spread (Figure 9-12). By use of this golden divider, relationships can easily be identified for the teeth, the mouth, the jaws, the face, and indeed the entire body.

Divine Proportion Expressed in the Face

It is well known in orthodontics that it is most difficult to permanently maintain an overexpanded lower intercanine width. This is no doubt associated with muscles that are attached to the lips and to the nasal cavity. The soft tissue integument is the limiting muscular structure on the outside of the

human dentition. The golden proportions seem to be connected from the nose and mouth and to the teeth through the smile.

The relationship between the width of the nose at the level of the ala to the maxillary intercanine width at the cusp tips in the smiles of fashion models in magazine advertisements was studied. The relative proportions established a clinical working hypothesis for nasal width and upper intercanine width in the smile of the adult face. Smiling widens the nostrils slightly. Thus, we see an esthetic connection between arch form and facial form and structure.

Facial soft-tissue relations were studied from patients directly and from photographs. The points employed are depicted in Figure 9-13. These studies were conducted allegedly with the jaws and lips at physiologic rest.

A photograph of a beautiful woman will serve as the model for a discussion of these facial findings; however, men considered to be handsome also display the same proportions.

Starting with the nostrils (Figure 9-14A), a golden proportion is observed in comparing the width of one nostril and alar rim to the columella and nostril of the opposite side. Most beautiful faces also express a divine progression as you compare the width of the nose at the interdacyron (the

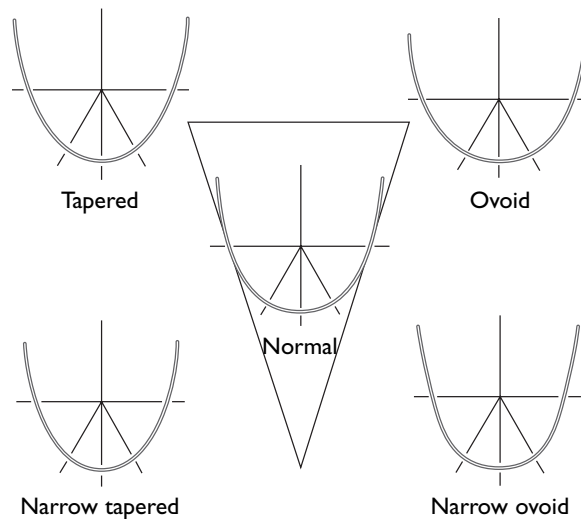


Figure 9-11: Detail work on arch form revealed five arch shapes that characterized the human population. Notice the golden triangle laid on the most typical arch.

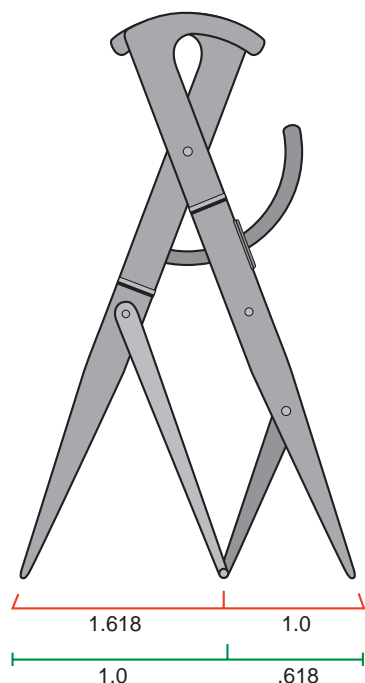


Figure 9-12: The plan for construction of the golden divider, which maintains its proportions during expansion. This was designed for analysis of the face and to be used at the operating table by surgeons.

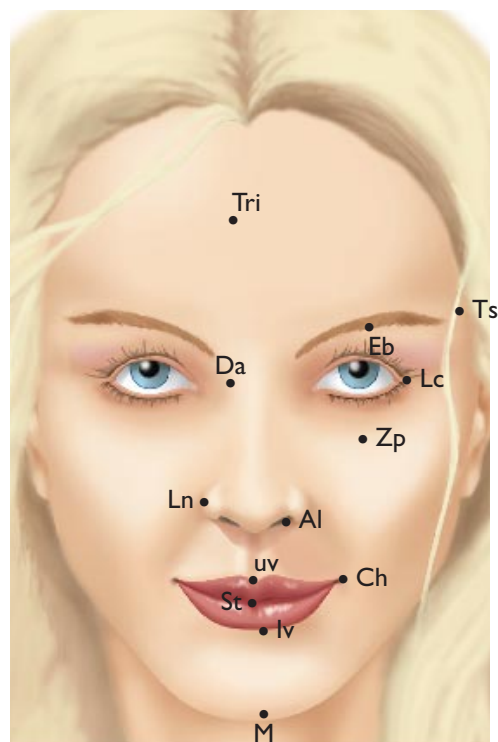


Figure 9-13: Facial soft tissue relation points.

bony bridge between the eyes) (Figure 9-14B), to the width of the nose at the ala (Figure 9-14C). This progression continues to the mouth width (Figures 9-14D and E), to the width of the eyes at the lateral canthus, and finally to the width of the head at the level of the eyebrows (see Figure 9-13). Figure 9-15 summarizes four divine progressions just described. Ten randomly selected fashion mod-

els all bore out these relationships to within the 90th percentile.²

Vertical Divine Relations

Of greater significance to facial balance are the vertical proportions. These relationships start with the proportion of the upper lip to the lower lip (Figure 9-16A). In the most beautiful lips, when a unit of

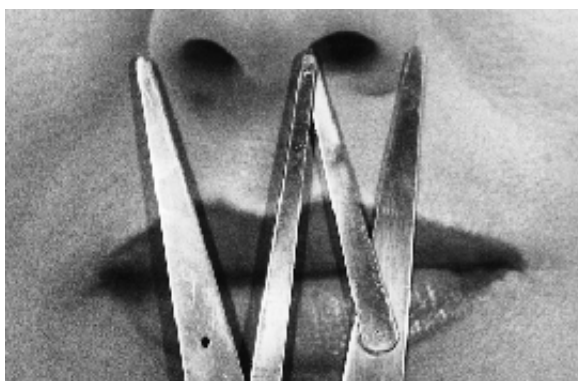

Figure 9-14A: Shows that one nostril compared to the central columella and the nostril on the other side follows the golden proportion.



Figure 14B: Shows the Ricketts golden divider at the interdacryon (medial border of orbit). The width of the nasal bridge is found golden to the width of the lateral nares seen in C.

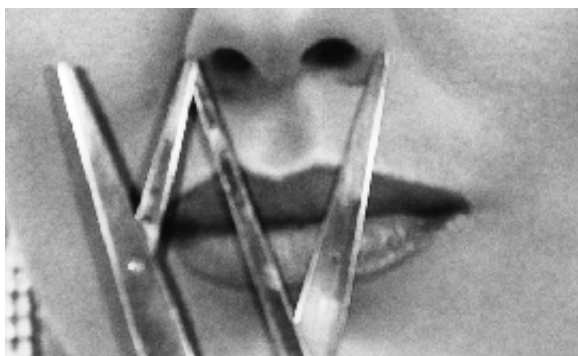

Figure 9-14C: The divider is not changed, and shows that the small portion of the interdacyron is golden to the nose width, as seen in B.



Figure 9-14D: The small portion is set at the nose width at the alar width (Lm) (see Figure 9-13).



Figure 9-14E: Without alteration of the divider, the large portion equals the width of the mouth at cheilion (corner of the mouth).




Figure 9-15: The lines summarize the proportions seen in Figure 9-14 as a four-step progression.

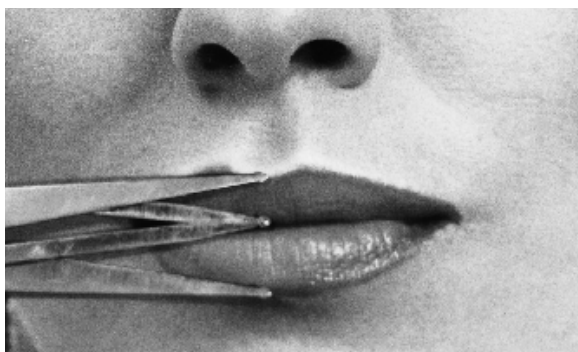


Figure 9-16A: The vertical golden proportion of the upper to the lower lip in one model.

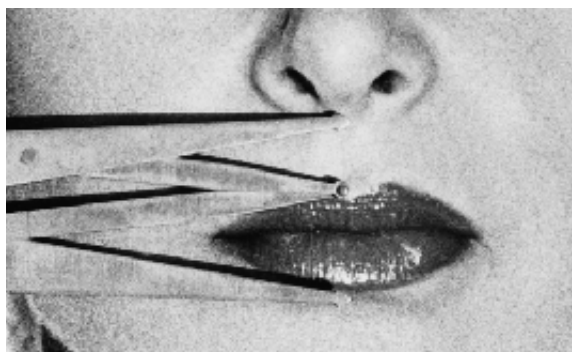


Figure 9-16B: The total lip height is golden to the philtrum as shown in another model.

one is taken from a point midway on the cupid's bow to Stomion (the point of contact of the lips), the lower lip height is greater and in divine proportion to the upper.

Another vertical golden relationship is observed when the length of the philtrum (from cupid's bow to the base of the nose columella) is defined as 1.0,

then the vertical height of the upper and lower lips combined is 1.618 (Figure 9-16B).

The distance from Stomion to ala, taken as a unit of one, yields the distance from Stomion to menton to be 1.618 (Figure 9-17). (The nose tip may be upward or downward and does not affect this result.)



Figure 9-17: The golden divider reveals a golden proportion from the chin (menton) to the lip embrasure (stomion) to the alar rim (al) of the nose in a model from a cosmetics advertisement (Milopa/Mila d'Opiz Cosmetics, Switzerland).



Figure 9-18: The relationship of the eye (medial canthus) to the nose to the chin is found to be golden in beautiful faces. This has been called "dynamic symmetry" or "dynamic balance."



Figure 9-19: The inverse proportion seen in Figure 9-18, showing the eye to the mouth to the chin. The length of the upper lip is the reciprocal area, or the area of congruency, which should fit both the middle and lower face.

Similarly, from Stomion to ala was also found to be golden to the distance from the level of the center of the eyes to the ala. Thus, in the ideal face, the distance from the eyes to the ala of the nose is equal to the distance from the mouth to the chin (a harmonic equation). Other relationships in the analysis of the eye, nose, mouth, and chin positions can be seen in Figures 9-18 and 9-19.

A divine relationship is seen in beautiful faces from trichion (located at the top of the forehead at the beginning of the aponeurosis of the skull), to the level of the eyes, and from there to menton. If the divider is then reversed without changing its width, it will be observed that an identical golden relationship exists from menton to ala and from ala to trichion (Figure 9-20).

These findings indicate that three vertical heights in the ideal face are essentially equal, again the harmonic equation, as shown in Figure 9-21. These are: (1) from trichion to the eye (Figure 9-21C), (2) from the eye to Stomion (Figure

9-21B), and (3) from the ala of the nose to the chin (Figure 9-21D). (Interestingly, even the length of the ear bears a close relationship to this same dimension in the beautiful head.) These should be reviewed together with Figure 9-7.

The Facial Medley

A medley of golden relationships is observed in the beautiful face. Dental clinicians and maxillofacial surgeons can employ these values for orthodontics, facial orthopedics, or for prosthetic construction. In orthognathic surgical reconstruction, these values are quite superior to older methods, such as the rule of thirds for vertical proportions or the rule of fifths for transverse proportions. Using these golden relationships leads to greater enhancement of facial beauty, which is the underlying clinical objective.

Divine Proportions Cephalometrically

Orthodontists have used cephalometrics for many decades to establish their treatment plans. Adding the concept of golden relationships to cephalometrics will allow the lips, the tongue, and tooth rela-



Figure 9-20: The golden proportion is seen from trichion to the eye and from the eye to the chin. Inversely, this should be trichion to the ala of the nose (Al) to the chin (M).

tionships to be recorded, evaluated, and planned in a more reproducible and sophisticated manner. The result will be that the practice of cosmetic dentistry will begin to permeate all of the dental specialties with an inevitable consequence of greater patient satisfaction.

The Skeletal Framework

Research with computer composites of ideal occlusions in different racial populations all tend to bear out certain underlying skeletal golden relation-

ships. A computer composite of 30 Peruvian males, each with 32 teeth, was used in this study (Figure 9-22). The cranial base golden proportions will be seen between S-Ba and S-N, and also from Ar-Cc to CC-N.

As shown in Figure 9-23C, there is a golden relationship linking the lower incisal edge (I), the anterior nasal spine (A), and the mental protuberance (Pm). This is present throughout normal growth from age three to maturity.

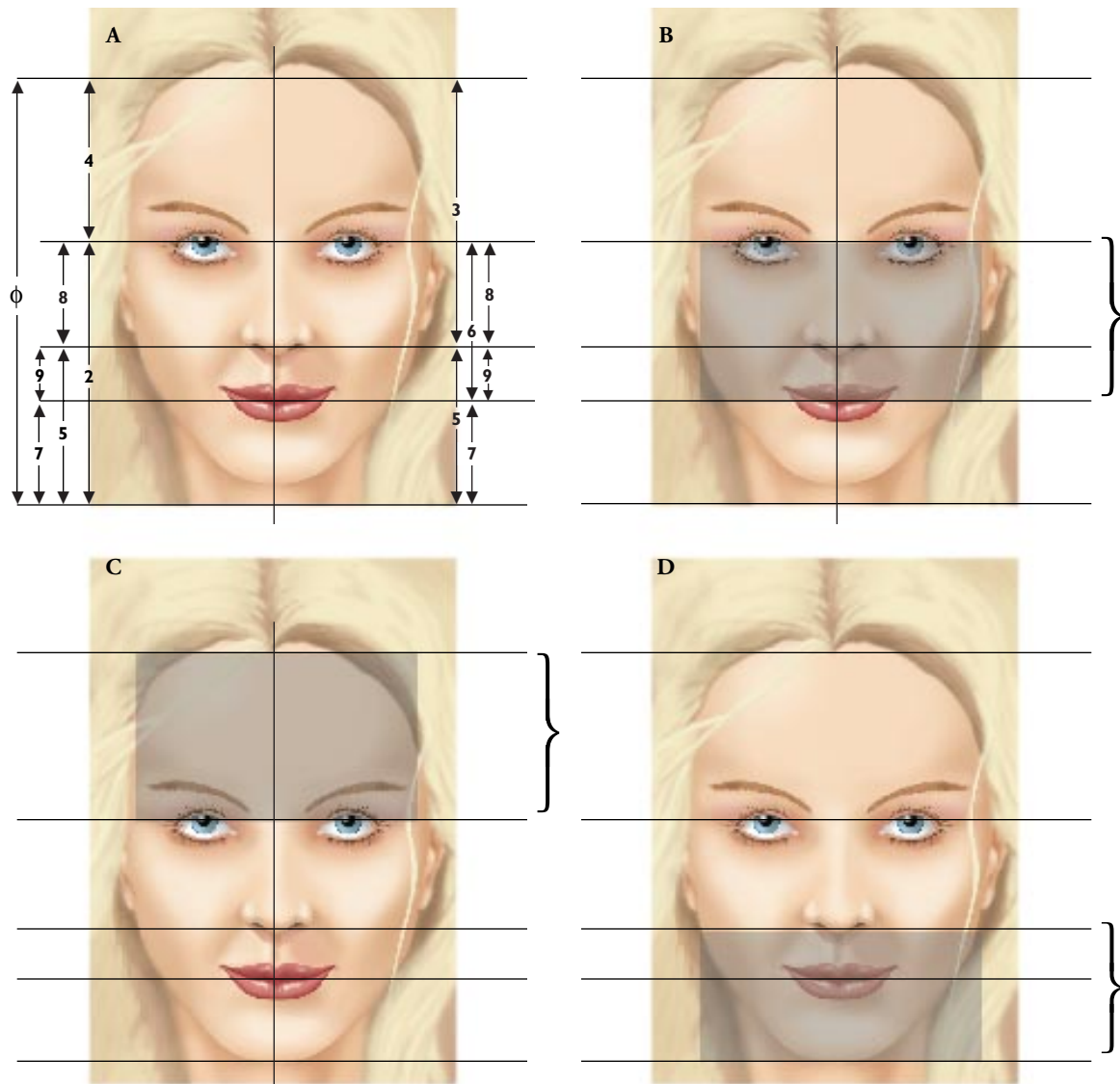
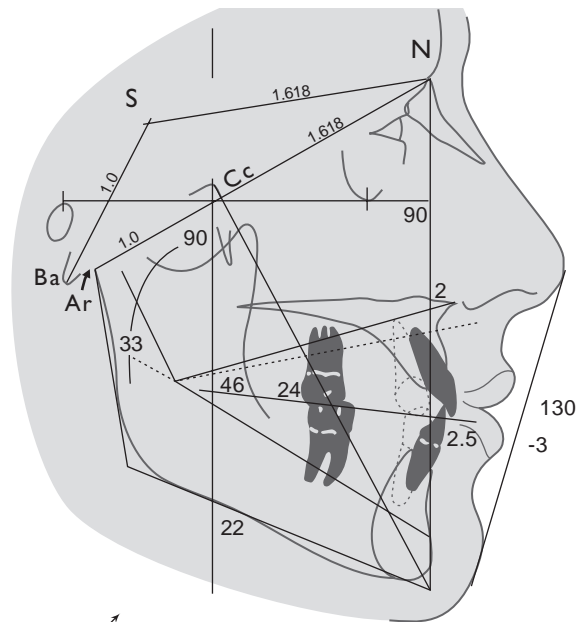


Figure 9-21: *A*, The vertical proportions are summarized. Note the inverse proportions and the nose length and the upper lip length as key congruent structures to total face height and lower face height respectively. *B*, The center golden rectangle is at nose tip. *C*, The upper golden rectangle is at center of forehead. *D*, The lower rectangle is at lower lip border. Note the equal dimensions are trichion to eye (*C*), ala of nose to chin (*D*), and eye to mouth (*B*).



N = 30 ♂

Figure 9-22: Golden proportions in the composite of a sample of normal occlusions with 32 teeth present are shown. Notice the proportions at the base of the skull (S-N-Ba and Ar-Cc-N).

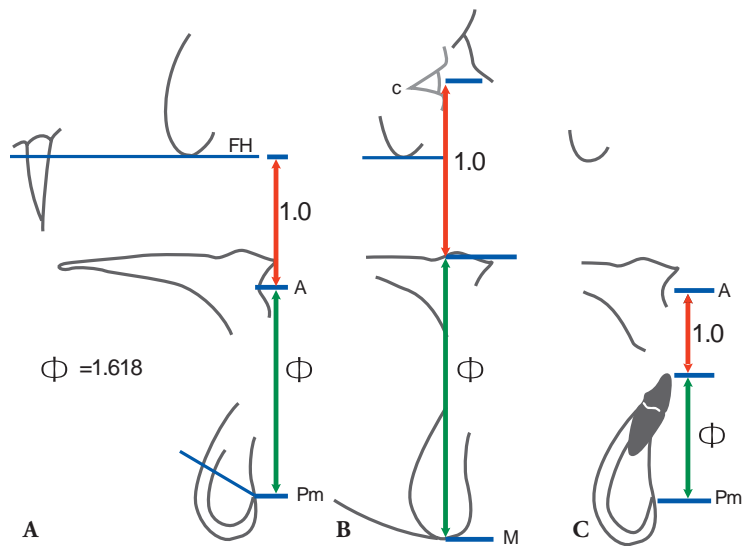


Figure 9-23: *A*, A golden proportion from the Frankfort plane (ear canal to lower border of the orbit) to the base of the anterior nasal spine (point A) and thence to the mental protuberance (Pm) is shown. FH to point A is 0.382 the height of the distance FH to Pm, and Pm to point A is 0.618. This is most useful for setting up orthodontics, orthognathic surgery, and for setting vertical dimension in prosthetic patients. *B*, The lateral canthus of the eye (c) to the nasal floor (nf) to menton (M) is shown. *C*, The edge of the lower incisor is seen to be in a golden proportion from A and Pm and is remarkably uniform in beautiful normal faces.

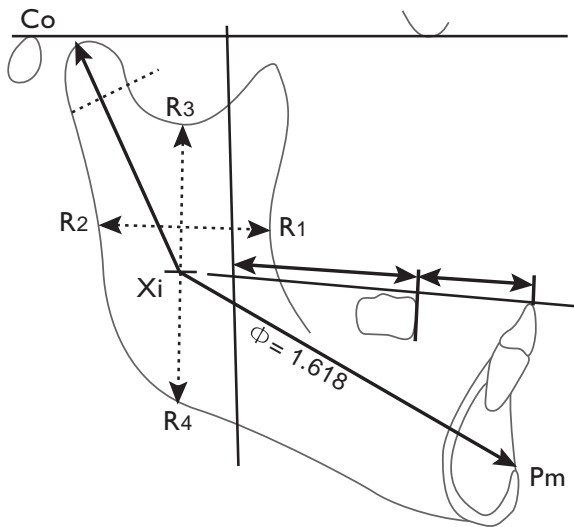


Figure 9-24A: Xi is a measured point at the centroid of the ramus (R1– R4) but lies directly over the mandibular foramen. Condylion (Co) is the most upward and backward point on the condyle. Pm is protuberance menti at top of symphysis. A divine proportion was found from Pm to Xi to Co.

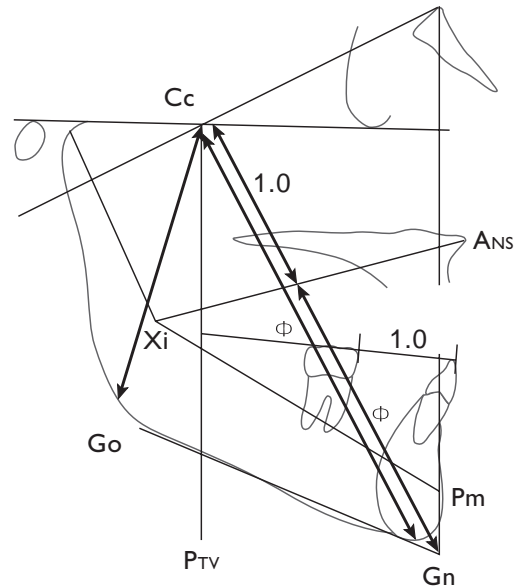


Figure 9-24B: Notice that the length from the Cc (cranial center) to Go (gonion) is a golden proportion to the distance from Cc to Gn (gnathion).

The next divine relationship (Figure 9-23B) is from the Frankfort horizontal plane (FH) (the level of the lower border of the orbit) to Point A and from A to Pm. This is the most useful measurement for planning the vertical in orthodontics and orthognathic surgery because it can be used to determine optimal denture height.

A further golden relationship is the lateral canthus of the eye (C) (as seen on a radiograph) to the nasal floor (nf) to menton (M) (Figure 9-23B).

Because, FH to A is golden to A to Pm, and, I to Pm is golden to A to Pm. Therefore, FH to A is equal to I to Pm. All of these golden relationships help the clinician to establish ideal vertical skeletal and dental relationships.

Other golden relationships exist in the mandible, as shown in Figures 9-24A and B. These are the condyle axis (Co-Xi) to the corpus axis Co-Xi-Pm. In addition the “balance” of the mandible is seen in gonion and gnathion relative to Cc point (Go-Cc-Gn).

In order to summarize these pertinent vertical relations, Figures 9-24C and D are offered. A harmonic progression can be established so that, given one measurement, the others can be predicted.

Starting with the arbitrary height from A to I as 1.0, ϕ is present to both a superior point (FH) and an inferior point, (Pm). Likewise, a ϕ^2 distance is

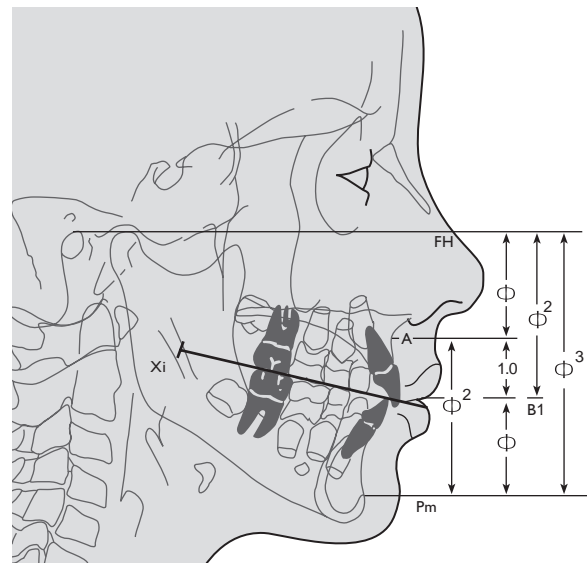


Figure 9-24C: Tracing of 9 year old: vertical divine relationships are shown for the lower face height (FH to Pm), point A position, and lower incisor location (B1). Please see text for this useful phenomenon.

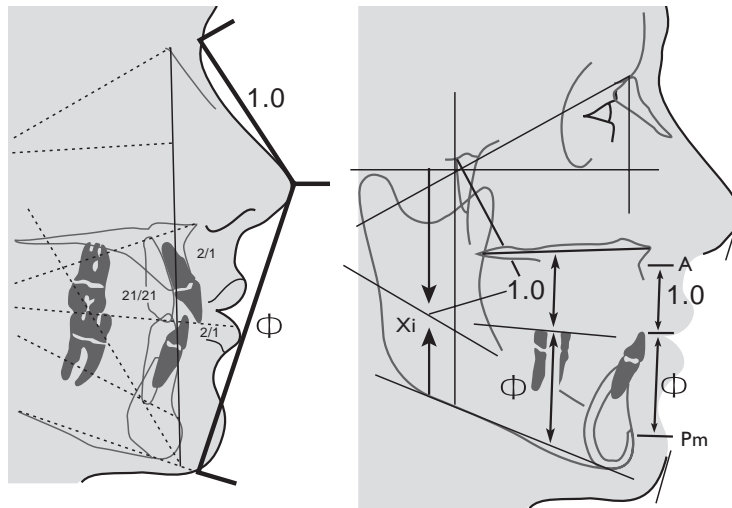


Figure 9-24D: A second composite of 73 untreated subjects at age 18 years. Note height of occlusal plane and position of Xi point.

present vertically in both directions (A-Pm and I-FH). A ϕ^3 relation is seen in the total height from FH to Pm.

These illustrations should be studied and memorized by all clinicians. If the distance FH to Pm is defined as 1.0, then the previous ϕ^2 measures

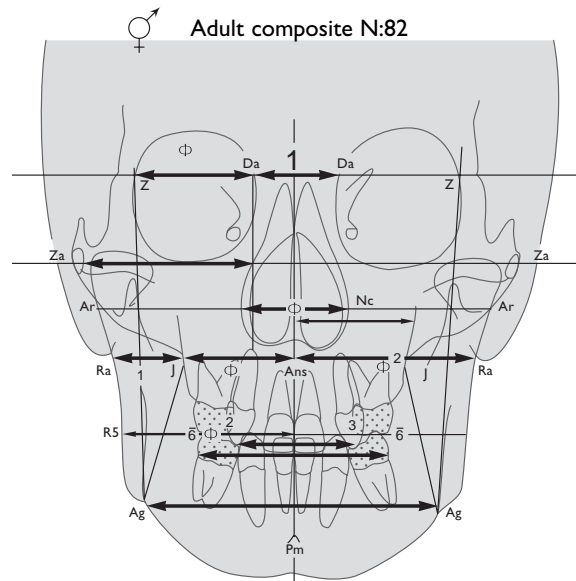


Figure 9-25: Frontal, a golden proportion exists between the nasal bridge and the width of the eye socket. At the piriform aperture a golden proportion, a ϕ^2 relationship, exists to the width of the maxilla at the tuberosity, and a ϕ^3 relationship at articulare. Note width of maxilla at J point is golden to mandibular width at Ra from the midline. Note upper intercanine width to first molar width. Note Ans to Ra is golden to Ag-Ag.

would be 0.618, ϕ would be 0.382, and the distance from A to I would be 0.236. Thus, a 1.0, ϕ , ϕ^2 , and ϕ^3 is present so that, given the height from the Frankfort horizontal plane to Pm, both the A and I points can be calculated.

TRANSVERSE SKELETAL PROPORTIONS

Frontally, a sample of adult normal occlusions suggest that certain relationships do exist. The width of the nose at the piriform aperture (29 mm) was seen in a golden progression to the width of the maxilla ($\phi^2 = 73.3$ mm) at the tuberosity and to the width of the mandible at lateral articulare (118.6 mm) ϕ^3 (Figure 9–25). The width of the maxilla at point J (jugal point) to the midline is golden to the ramus point (Ra) at that level. Interdacryon width was golden to each orbit. Upper intercanine width was golden to half the width of the ramus at Ra.

Perhaps the most useful application of the golden proportion is found in the lateral photograph where dental protrusion has been a point of debate throughout the history of orthodontics. Limited work on ideal faces suggests that the protrusion of the lips is also related to the nose in the golden proportion as projected in Figure 9–7.

Body Proportions

Other aspects can be related to the body in terms of proportions. These are proportions of the fingers and hands because each phalanx on each finger is related in a golden proportion (Figure 9–26A). Total body height is related to the crest of the ilium and inversely from the tip of the fingers to the floor (Figure 9–26B). It has been thought that the total facial height is one-eighth the height of the whole body. The umbilicus at the level of the hip point is located at a 5 to 8 proportion to the total height.

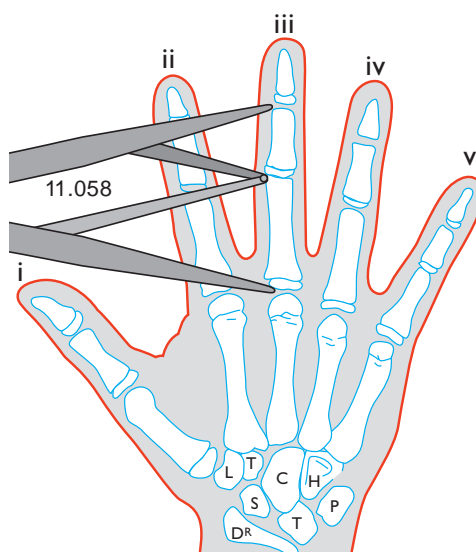
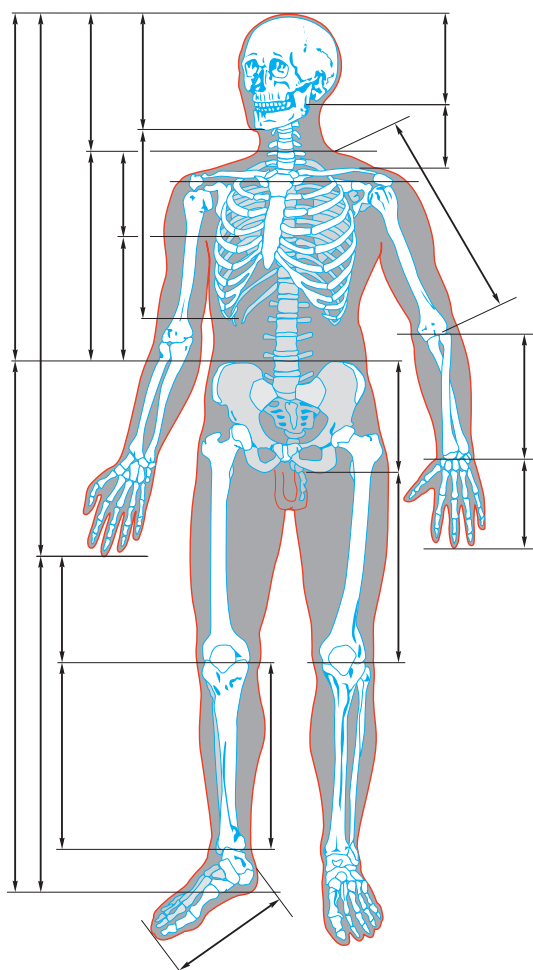


Figure 9–26: Hand proportions: note the golden progression of each phalanx. Body proportions: note the foot to the foreleg, the foreleg to the hip. Note the hand to the forearm and upper arm to scapula. Note top of head to the hip to the heel.

SUMMARY—WHY THE DIVINE PROPORTION WORKS

There is a proportion that the mind registers at the subconscious level that provides beauty, comfort, and pleasure to the senses. This mathematical relation is 1.0 to 1.618, and is called the golden section. Because the teeth, jaws, and face are geometric structures, the more closely they are allied to this proportion the more pleasing are the sensations conveyed to the beholder esthetically. It is therefore preferable to call it the divine proportion, and when two parts are so related they are said to be golden to each other.

Golden relationships are not new; they have been present for the entire span of human history. Many of these proportions no doubt have been used by clinicians intuitively because they “look good.”

With the recognition of the divine proportion principle, these relationships can be employed by the clinician on a practical basis. This brings esthetics from the subliminal, subjective level to an objective potential where it can be analyzed and communicated among clinicians on an open basis. Thus, with the use of the Fibonacci numbers and the divine proportion, objective relationships can be assessed and planned in clinical dentistry.

As an underlying concept, these values—so often expressed in nature—seem to display a basic plan of perfection. This phenomenon is often referred to as a part of “sacred geometry.” The more familiar clinicians are with these relationships, the more beautiful will be their results!

Esthetic dentistry will continue its golden years with the golden section application. It is a matter of becoming sophisticated enough to apply it routinely in a clinical setting. Esthetics has become a driving force in the “science of occlusion,” which is itself the profound basis of dentistry and allied disciplines.

Reference

1. Ardrey R. *The social contract*. New York: Atheneum, 1970.
2. Ricketts RM. The biologic significance of the divine proportion and Fibonacci Series. *Am J Orthod* 1982;81: 351–70.

Additional Resources

- Angle E. *Treatment of malocclusions of the teeth*. 7th edn. Philadelphia: S.S. White Company, 1907.
- Baumrind S, et al. Changes in facial dimensions associated with forces to retract the maxilla. *Am J Orthod* 1981;80:17–30.
- Boyko R. Use of the activator in mixed dentition treatment. *Proc Foundation Orthod Res* 1971:77.
- Chataney TH. *Chirurgie maxillo-faciale et orthodontie*. Paris: Masson, 1978.
- Clements B. Nasal imbalance and the orthodontic patient. *Am J Orthod* 1969;55:3,244–64,329–52, 477–98.
- Clements B. Lecture to Great Lakes Orthodontic Society, 1981.
- Ghyka M. *The geometry of art and life*. New York: Dover Publications, Inc. 1977.
- Henri R. *The art spirit*. Philadelphia: J.B. Lippincott, 1960.
- Huntley HE. *The divine proportion: a study in mathematical beauty*. New York: Dover Publications, Inc., 1970.
- LeCorbusier CEJ. *The modulator*. London: Faber and Faber, Ltd., 1951.
- Lejoyeux J, ed. *Prothese complete. Tome 2. Diagnostie et traitement*. 2nd edn. Paris: Librairie Maloine, 1971.
- Levin EI. *Prosthet Dent* 1978;40:3.
- Lombardi RE. The principles of visual perception and their clinical application to denture esthetics. *J Prosthet Dent* 1973;29:4.
- Maltz M. *Psycho-cybernetics*. New York: Simon & Schuster, 1960.
- McNamara J. The Frankel Appliance, five years later. *Proc Foundation Orthod Res* 1981.
- Moss ML. Functional analysis of human mandibular growth. *J Prosthet Dent* 1960;10:1149–59.
- Moss ML. Personal communication, 1978.

- Ricketts RM. Planning treatment on the basis of the facial pattern and an estimate of its growth. *Angle Orthod* 1957;27:14–37.
- Ricketts RM. The influence of orthodontic treatment on facial growth and development. *Angle Orthod* 1960;30:103–33.
- Ricketts RM. Cephalometric synthesis. *Am J Orthod* 1960;46:647–73.
- Ricketts RM. Esthetics, environment, and the law of lip relation. *Am J Orthod* 1968;54:272–89.
- Ricketts RM. Introducing computerized cephalometrics. Denver: Rocky Mountain Communicators, 1969.
- Ricketts RM. The discovery of a law of arcial growth of the mandible. *Proc Foundation Orthod Res* 1971:31–52.
- Ricketts RM. New perspectives on orientation and their benefit to clinical orthodontics. Parts I and II. *Angle Orthod* 1975;45:238–48, 1976;46:26–36.
- Ricketts RM. Possibilities of change in the oral environment. *Foundation Orthod Res Newsletter* 1979;10:3.
- Ricketts RM. Is there a science to esthetics? Presentation to the American Academy of Esthetic Dentistry, 1980.
- Ricketts RM. The golden section. *Proc Foundation Orthod Res* 1980.
- Ricketts RM. Perspectives in the clinical application of cephalometrics. *Angle Orthod* 1981;51:115–50.
- Ricketts RM. Five-year analysis of 12 patients following mandibular advancement. Unpublished observations, 1981.
- Ricketts RM. Divine proportion in facial esthetics. *Clin Plast Surg* 1982;9(4):401–22.
- Runion GE. The golden section and related curiosa. Glenview, Illinois: Scott, Foresman & Company, 1972.
- Thompson D. On growth and form. London: Cambridge University Press, 1977.
- Wilson EO. An introduction to scientific research. New York: McGraw Hill Book Company, 1952.

CHAPTER 10

UNDERSTANDING COLOR

Robert C. Sproull, DDS, Jack D. Preston, DDS

The contents of this text amply document the many areas that must be coordinated to achieve that intangible result called “esthetic.” Color must take its place as merely another building stone, a part of the total perceptual impression. However, just as the disharmony is created by a discordant note in a symphony, the wrong color can destroy a result so painstakingly sought.

To the untrained eye, all teeth are white. To the dentist, who must match the natural teeth using a restorative material, the wide and subtle gamut of color is a real, perceptual challenge. Although the need to know accepted color matching procedures is a basic requirement, it is often ignored in dental education. It is also usually poorly understood by the dentist, the technician, and manufacturers of dental materials.

The science of color matching involves physics, psychophysics, psychology, and even philosophy. A knowledge of advanced algebra and calculus is helpful. The nature of light, color vision theories, spectrophotometric studies, tristimulus values, color order systems, and other equally confusing matters are all part of the color engineer’s world.^{1,7} These advanced concepts are not required for perceiving and equating colors, but if one is to truly understand what is occurring in color perception and matching, they are essential.

This chapter is intended to provide practical guidelines for shade selection and color “matching.” In a text that emphasizes the clinical approach to esthetics, the reader has the right to expect clinical guidelines on color matching instead of a technical discourse. Only that technical information essential to accomplish these goals is presented.

Clinical shade selection involves more than picking a tab from a shade guide and having a restoration of the same color processed. One often wishes it were that simple; unfortunately, that is the extent of understanding that usually accompanies the shade selection procedure. Because of current problems in concept and development, there is a difference between “shade selection” and “color matching.” To understand this difference and to develop an ability to select a shade that will ultimately result in a restoration matching the adjacent natural dentition, it is essential to have an appreciation of the role of the three-dimensional nature of color. There must also be a realization of the limitations of existing guides and materials.

In keeping with the above philosophy, the following subjects will be explored:

1. The three dimensions of color
2. Evaluating color differences
3. Dental shade guides
4. Shade selection
5. Shade modification and communication
6. A look to the future

THE THREE DIMENSIONS OF COLOR

E. Bruce Clark,² an early leader in color matching in dentistry, succinctly stated the need for learning the three-dimensional nature of color: “In the study of color not only is an intimate acquaintance with its three dimensions the first requisite that should be acquired, but it is, without exception, the most important.” Complete familiarity with the three-dimensional nature of color is the key to successful clinical color matching.

A mental image of a box can be conveyed to another person by describing its length, width, and depth. It is easy to give instructions on modifying its dimensions, or to make comparisons of its size and shape to those of another box. This is possible because other people know what a “box” is, they understand the concept of three dimensions, and the scales, inches, feet, millimeters, by which those dimensions can be expressed. A color can also be accurately and meaningfully described if the dimensions, and the scales of their measurement, are understood. The dimensions of color—hue, value, and chroma—enable the same type of communication regarding color. Even more importantly, color can be analyzed, and the color differences between objects (for example, a tooth and a shade guide) can be specified.

Colors differ in many ways: they may be red, orange, yellow, blue, etc., or they may be light or dark, weak or strong. The description of these differences is the basis for the clinical approach to color matching. Perceiving and analyzing color is a skill that can be taught, and one that can be improved with practice. However, it is not enough to see, the viewer must understand what is being seen; that is, seeing must be accompanied by perception. Shade selection is both a visual and a cerebral process. Color matching and color modification consist of looking at and analyzing color differences, and then taking appropriate action. Scientists and artists have devised many ways to describe the three dimensions of color and many systems that relate these dimensions have been developed. Some of these systems are best suited for complex instruments, others are psychological, serving the needs of a viewer—not a device. The Munsell Color Order System¹¹ is the system that best serves the needs of the dental profession in its attempt to visualize and organize color.

Many approaches have been used to describe Munsell’s Color Order System. One of these is the “desert island” analogy as presented by Judd.⁷ In it a mythical sailor is shipwrecked on a desert island. To fight the loneliness and occupy his time he decides to logically arrange the multicolored pebbles on the beach. Figure 10–1A represents the random arrangement of the pebbles as he begins.

He notes that, in addition to stones that are colored (having a hue), there are those without any

color—black, gray, and white. He first sorts these colorless (achromatic) stones into a separate pile. He next arranges the colored stones into piles according to the sequence of colors as he sees them in a rainbow (Figure 10–1B). The quality of color that allows him to separate the stones into piles is synonymous with Munsell Hue.[†] As he strolls from one pile of hues to another he notes additional differences and realizes that his task is far from finished.


He next tackles the achromatic pile and arranges the pebbles into a column according to how dark or light they appear. The blacker ones he places at the bottom, the whiter ones, at the top, and a series of grays blending from near-black to near-white in the appropriate intervals in between. This dimension of lightness/darkness is synonymous with Munsell Value (see the first column in Figure 10–1C).

Using this single quality of lightness/darkness he then further rearranges each of the hue piles into a column with the darkest colors at the bottom, the lightest at the top, with gradations in between, just as in the achromatic column (Figure 10–1C). He has now arranged color by hue and relative lightness, but differences in purity or strength of the hues still exist.

The castaway next considers each hue pile at the various value (lightness) levels and makes his final adjustments according to the differences he observes in the concentration or purity of the hues. Figure 10–2 shows his final achievement. Those stones with colors of the least intensity at each value level are nearest the achromatic value axis, to the left. The colors become more saturated (concentrated or purer) to the right. This dimension is synonymous with Munsell Chroma.

The sailor has arranged all the colored pebbles in conformity with the previous statement that color may be red, orange, yellow, green, blue, etc.; it may be whiter or blacker, and the hue may be weak or strong. He has inadvertently simulated the Munsell Color Order System—a system ideally suited to the problems in dentistry. It is widely understood, logical, consistent, flexible, and it attempts to achieve equal visual (perceptual) spacing between the samples.

[†]Whereas the color dimensions are usually not capitalized, when referring to them in Munsell specification, they are written as Hue, Value, and Chroma.



Figures 10–1A to C: Arrangement of pebbles: (A) random arrangement (B) by hue (C) by value.

The only step necessary to convert this arrangement of pebbles into a more easily visualized three-dimensional color system would be to allow the castaway to have camera equipment. He could then make pictures of the final arrangement of the ten hues plus the value column and construct a three-dimensional representation of the Munsell System, known as a Color Tree (Figure 10–3). The tree depicted has 20 hues.

The Munsell color tree consists of a trunk (the Value column) with the Hues arranged vertically in sequence around this trunk in the manner of the pages in an opened book. This tree demonstrates how colors differ and how they relate to one another.

Hue differences are arranged around the Value axis: blacker colors toward the base, whiter colors toward the top. The colors become increasingly concentrated (saturated) toward the tree’s periphery and progressively less intense (lower Chroma) as they approach the central trunk.

Anyone who grasps this relationship between the sailor’s pebble arrangement and the Munsell system (Figure 10–4) should have a clearer understanding of the definitions of hue, value, and chroma. Since clinical color matching depends upon the ability of the operator to perceive which dimension(s) of the tooth/shade guide comparison differ, complete understanding of the color dimensions is



Figure 10–2: Judd has organized the Munsell System further to produce an arrangement based on intensity.




Figure 10-3: The Munsell Color Tree is a three-dimensional representation of the Munsell System.

critical. If there is confusion concerning whether a difference is one of value or chroma, color matching can be an exercise in futility.

Hue

The dimension of hue is most easily understood. It is, in Munsell's words, "that quality by which we distinguish one color family from another, as red from yellow from blue or purple."¹¹ This dimension is exemplified by the pile of stones seen in Figure 10-1B. It is important to realize that the hues are the result of the wavelength of the stimulus—light. Color is light and light is color. Light is merely one small portion of the electromagnetic spectrum (Figure 10-5A). All the common forms of energy are in this system, from those having short wavelengths and thus greater frequency (such as cosmic rays) to those having very long wavelengths and lower frequency, such as electrical energy. Between these extremes are found such familiar energy sources as television rays, radio waves, X-rays.

The energy source, termed the visible spectrum, lies in a narrow band from 380 to 760 nanometers (or millimicrometers). These light rays have the ability to stimulate the cells in the retina that, when interpreted by the brain, allow the sense of sight. The sensation evoked by those rays having the shortest lengths is termed violet, and that created by the longest rays, red. Ultraviolet rays are shorter than the visible spectrum and are familiar to those

who have seen "black light" demonstrations. Infrared rays are those just longer than 760 nm—immediately above the visible spectrum. These are the rays that are associated with heat. The order of visible spectral hues is: violet, blue, green, yellow, orange, and red (Figure 10-5B). It is important to understand that these hue names are descriptive of a family of sensations and there is no clear distinction between where one hue terminates and another begins. The spectrum is a continuum of sensations to which we have given convenient (if sometimes meaningless) names. That thousands of auxiliary names have been devised is indicative of the confusion that accompanies the naming of the visual response we call hue.

Value

Value relates a color brightness to the specific area on the black-white scale. The value of a color is determined by that quality of gray with which its brightness can be matched. The arrangement of the hue piles in Figure 10-1C was based on this dimension. Each hue pile matches the brightness of the achromatic value pile at the left. Value relates to the quality (not quantity) of a color's grayness. A black and white photograph of a colored object is a value picture. It is a one dimensional (value) rendition of a three-dimensional (colored) object. Value is the only one of the three color dimensions that can exist independently.

Chroma

Chroma, the third dimension, was described by Munsell as "that quality by which we distinguish a strong color from a weak one; the departure of a

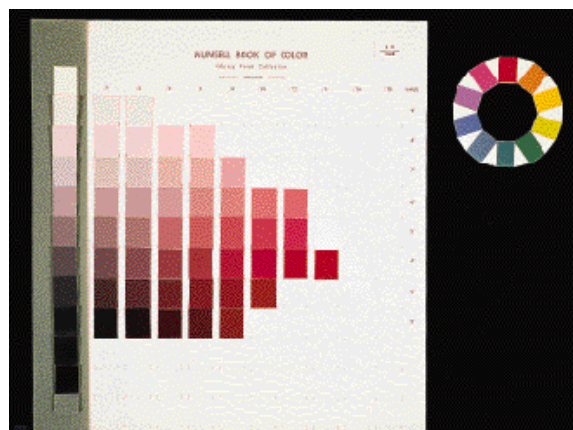


Figure 10-4: The Munsell System.




Figure 10-5A: A collimated beam of white light passed through a prism is dispersed into hues from violet to red.

color sensation from that of white or gray; the intensity of a distinctive hue; color intensity.”¹¹ This dimension was the final discrimination the sailor made when he arranged the hue piles at each value level. The final arrangement reflected a gradual transition in the strength of colors at each value level from near gray to increasing purity (Figure 10-2).

The qualities of Munsell Hue, Value, and Chroma allow definition of the location in the “color space” of any color by using a numbering system referred to as a Munsell Notation.¹¹ The format of designation is Hue Value/Chroma or H V/C. In Figure 10-4 the Hue page illustrated is 5 Red. Each Hue in the Munsell System is divided into 10 parts; 5 Red is the central red, midway between purple red and yellow red. To designate Tab “a” in Figure 10-4, the Munsell notation would read 5R 7/8; Tab “b,” 5R 2/8; Tab “c,” 5R 4/14; and Tab “d,” 5R 4/8. For interpolation of colors between tabs, the decimal system is used. By using Munsell notations colors can be communicated anywhere to anyone who is knowledgeable about the system.

Figure 10-6 is a graphic idealized representation of the Munsell System as a stack of wheels. The ten Hues are arranged around the central Value axis and are labeled by initials at the periphery of the wheel at Value level 9. Chroma is represented by the spokes of the wheels. The purest colors are at the periphery. Colors become progressively weaker as they approach the central, achromatic Value axis. The nine Value levels are represented by the nine wheels. The dots illustrate the distortion of the system from a true cylinder to reflect the outline form of the color solid for the yellow and purple-blue Hues. The pie-shaped wedge of color within the upper left corner of the solid roughly delineates the

volume of color in which the colors of natural teeth are found. A representation of the Hayashi³ Shade Guide and how it relates to this wedge is seen outside and to the left of the cylinder. In the Munsell System, each color tab is, in effect, the center of a sphere of color, and it is this arrangement that so ideally suits the system to visual color matching procedures.¹⁷ Differences in Value are seen in color tabs above or below a given tab, differences in Chroma are to the right or left, and differences in Hue are in the set ahead or behind the one in which the given tab lies.

A large portion of this chapter has been devoted to defining Munsell System Hue, Value, and Chroma ordering because it is basic to comprehending a logical basis for dental shade selection and color matching. This will become more apparent when shade guides and their use are discussed. However, before familiarity with the three-dimensional nature of color can be a practical aid, one must know how to identify color differences and attribute them to hue, value, or chroma.

EVALUATING DIMENSIONAL DIFFERENCES

Hue differences are, perhaps, the only dimensional differences that most individuals have been accustomed to making with any degree of accuracy. Differences of value and chroma are many times vaguely lumped together and used interchangeably. The ceramist who receives a note that a restoration is “too gray” knows only too well how inadequate such a description is. Depending on the dentist, the note may mean that the restoration is too low in value, or that the color is not sufficiently saturated and therefore appears more “gray” than “colored.” (The attentive reader may note that the first situa-

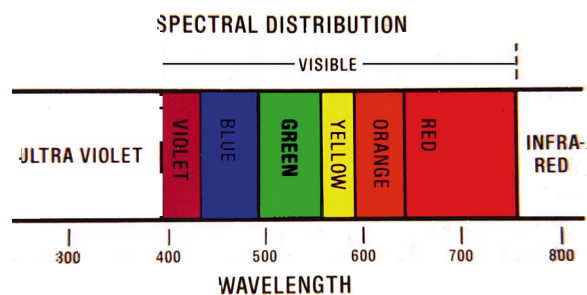


Figure 10-5B: The spectral distribution of visible light.

tion defines a quality of gray, the second relates to the quantity of gray.) The ceramist is left to interpret, and has no indication of the extent to which either or both situations might be correct.

Figure 10-1B shows the pebbles separated according to hue only. Differences in value and chroma exist in each pile, but the sailor successfully separated the different colored stones in spite of these differences. His accomplishment closely reflects the fact that hue is the dimension most likely to be successfully identified. In the evaluation of value and chroma differences, education and training are needed. The danger in confusing a value (degree of brightness) difference with chroma (color purity or saturation) difference is clear. If the value of a restoration is changed when the difference is one of chroma, the restoration cannot possibly match the natural tooth. What is needed is a sorting mechanism to establish a starting point in color difference evaluations. Such a mechanism does exist, and artists

have used it for years. To test for value differences, squint. This eliminates detail and reduces the field of vision to a more achromatic (colorless) condition. When two objects being compared look more different during squinting than with normal viewing, a value difference is certain. This does not preclude the existence of a chroma difference, however. Squinting helps eliminate the confusion introduced by hue and chroma differences, and allows one to concentrate on value differences. Black and white television does this automatically. The original scene is one filled with a wide range of hues, values, and chromas, but all that is viewed on the set is value. Squinting is, in effect, an attempt to emulate the black and white television image.

It may be difficult to believe that Tab c in Figure 10-4 would appear exactly the same in a black and white photograph as the gray at value 4, but this is true. In fact, every horizontal line of the color chart is exactly the same value, and each tab would

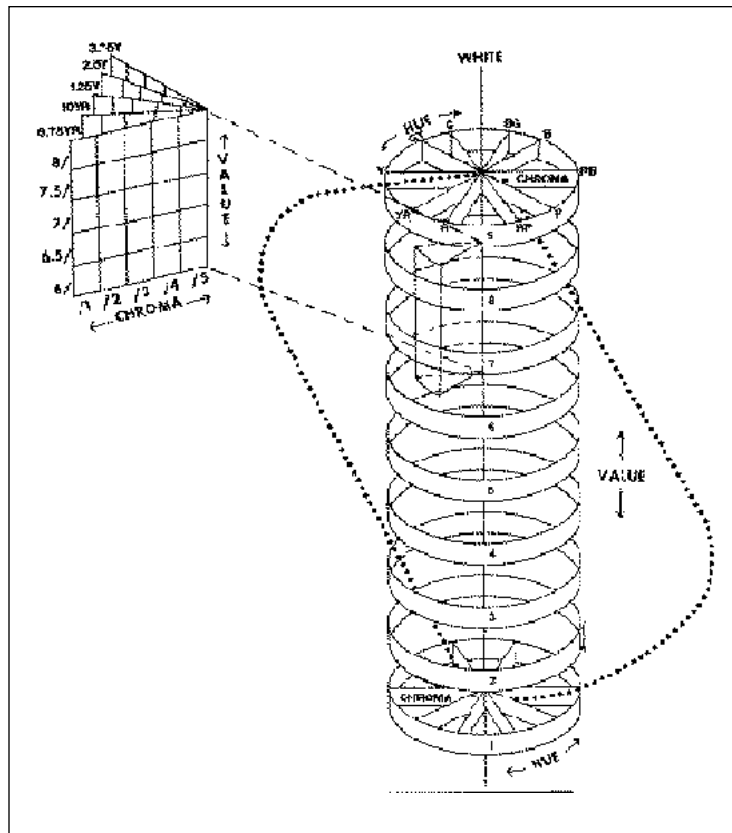


Figure 10-6: A graphic representation of the Munsell System as a stack of wheels.

appear to be identical if viewed on a black and white monitor, or seen in a black and white photograph. Figure 10–7, a black-and-white print of the 5R page from the Munsell Book of Color, demonstrates this effect.

It is evident that even with a correct value level, difference in the hue and chroma may still prevent a color match. Squinting is not a panacea for matching problems, but it provides a starting point that can be applied to clinical practice.

The colors in Figure 10–8 are arranged according to the Munsell System. One can expect difficulty when there is also a difference in value. In any vertical column, all chromas are the same. Squinting helps make possible the elimination or inclusion of value differences as part of the color matching equation.

There is some question concerning the relative clinical importance of a difference in hue as opposed to a difference in value or chroma. However, since value perception is a rod function and hue and chroma a cone function, it is not surprising that the human observer is more aware of value differences, since rods greatly outnumber cones. Since color judgment has a subjective element, differences of opinion about the relative importance of hue, value, and chroma are to be expected.¹⁹

Color matching authorities state that hue differences are easiest to detect and value differences the most difficult. The authors have approached clinical color matching of teeth with the opinion that value differences are most important, and hue differences the least. Bruce Clark,² in his pioneering work, thought likewise. He felt that hue differences played a minor role in the color of teeth when compared with the dimension of value (termed “brilliance” by Clark) and saturation (chroma). Clark’s modified shade guide was fabricated in one hue, with ten value steps and six chroma increments.

Perhaps it is a question of semantics. Hue differences may well be recognized most easily, but a slight mismatch in hue may not be as objectionable as a slight value mismatch. Sproull¹⁸ determined the volume of Munsell color space that encompasses natural tooth shades as extending roughly from 7.5 YR to 2.7 Y in Hue, 5.8–8.5 in Value, and 1.5–5.6 in Chroma (Figure 10–6). Hayashi³ defined the color space for human teeth in the

Japanese population using paper shade tabs based on the Munsell notation. Lemire and Burk⁸ explored the range of extracted human teeth for a study upon which the JM Ney Corporation based their porcelain formulation. The Sproull, Hayashi, and Lemire and Burk studies have been combined by Miller^{9,10} to represent a composite of the color space (Figures 10–9 and 10). Although undocumented by intraoral color evaluation of a significant population sample, this composite represents the best estimate of the human tooth color space. An adequately designed shade guide would have an orderly and equal distribution of tabs throughout this space. Spectrophotometric studies of commonly available shade guides have shown that these guides do not meet this basic specification.¹⁸ Unlike the arrangement in the Munsell System, where the position in space indicates the relationship of one color to another, most guides have an illogical haphazard relationship of one tab to another, and all current shade guides have an inadequate distribution.

DENTAL SHADE GUIDES

The clinical significance of the shortcomings of current guides is the difficulty that arises in attempting to determine, in an accurate and logical manner, which tab most closely emulates the appearance of the teeth being “matched.” The illogical structure of shade guides does not obviate the need for greater familiarity with the dimensions of color but rather makes such understanding even more critical.¹² In the absence of a logically ordered shade guide, the user must supply the logic.




Figure 10–7: A black-and-white print of the 5R page from the Munsell Book of Color.




Figure 10–8: A representation of the five hues in the shade guide designed by Hayashi.

Figure 10–8 is important to the understanding of shade guides. Although it is not a commercial guide, it is a concept that can serve as a guideline for future guides. It will also be important in the following section relating to the proper method of choosing shades. This illustration is a representation of the five hues in the shade guide designed by Hayashi³ and printed on paper. A similar guide was developed in porcelain by Clark² 60 years ago. The illustrated Hayashi guide is based on the Munsell Color Order System with Hue steps of 1.25 intervals, Value steps of 0.5 intervals, and Chroma steps in unit intervals. All that would be needed to make this concept into a usable shade guide would be to convert the tabs to porcelain and have the product made available commercially. A paper guide is not suitable for clinical use because of the difference in the specular characteristics between paper and natural tooth enamel, and because of other factors such as translucency and metamerism (defined later).

There were 125 tabs in the Hayashi guide and 60 in the Clark guide. Experience with available shade guides and the difficulty in arriving at an acceptable color match with even this limited number of tabs naturally creates doubts about the practicality of a guide having such an abundance of

tabs. In reality, the shade selection would be facilitated, rather than complicated, by having an adequate range and a logical distribution.¹⁶ The following procedure can be used:

1. Determine the value level (squant). The number of tabs is reduced from 125 to 25 when the value is decided.
2. Determine the chroma. This reduces the number of tabs to be considered to 5 (one for each of the five hues).
3. Determine the correct hue.
4. Analyze any difference that may remain between the tooth and the tab, and move in the appropriate direction to determine if a more exact match exists.

The Hayashi guide was offered as a theoretical approach to shade selection and color matching. Logically ordered guides have been developed. One such system, Spectatone, used 12 hues, but the shade guide had only every other hue represented. The missing hues could be selected by interpolation. Once the closest hue was selected, the viewer had 36 value and chroma variations of this hue. Since there were 6 hues, a total of 256 selection

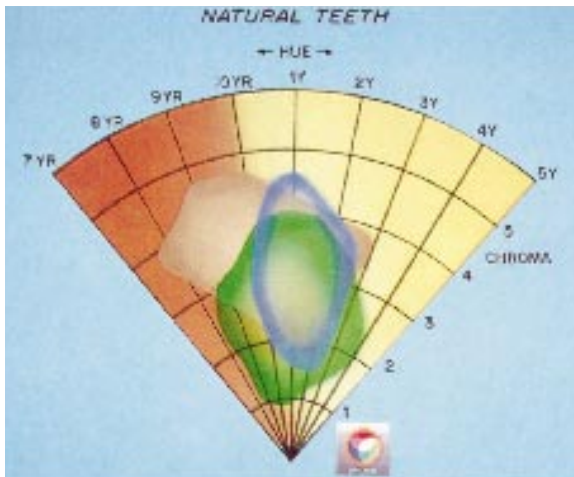


Figure 10-9: Consolidation of natural teeth studies (Hue/Chroma overlap). Brown = Sproull, green = Ney, blue = Hayashi.

tabs were available, and an additional 256 tabs could be created by interpolation. The system enabled the viewer to move about in the color space to every hue, value, and chroma needed to achieve the closest match to the tooth being replicated. Even though the initial consideration of 256 tabs seemed overwhelming, the guide was simpler and more effective than the illogically ordered systems having fewer tabs.

SHADE SELECTION

When using currently available guides, it must be accepted that it is unlikely that an exact match will be found. In the past it was taught that when there is a choice between a shade that is somewhat lower in value and one slightly too light, the lower value tab was the better choice if no further modification were to be done.¹³ While it is true that a completed restoration having slightly lower value is less noticeable than one that is brighter than the adjacent teeth, it is possible to modify a shade that is too bright and reduce the value. Such modifications may be either intrinsic (at the time of fabrication) or extrinsic (surface coloration). Without unnecessarily complicating this explanation, suffice it to say that the principles of modifying a restoration, either intrinsically or extrinsically, follow the rules of subtractive color.¹³ For example, when modifying a completed restoration using surface colorants, the surface color blocks some bands of the spectrum (hues) and the resulting appearance is usually lower in value (less bright).

While it is relatively easy to increase chroma using porcelain modifiers intrinsically or surface colorants that are more intensely colored (more saturated), it is much more difficult to lower chroma.

Whenever adequate instructions can be given to the ceramist to modify the shade, or if surface modifications may be made prior to placement, the rule for shade selection is, therefore, to select a shade that is as close to matching as possible, but higher in value and lower in chroma. If, however, no modifications of the shade are to be attempted, a shade that is lower in value is less noticeable in the finished restoration.

If the middle tab in the second row is the shade of the tooth to be matched, any of the tabs to the right, whether above, below, or on the same line, should be discarded in favor of any of the tabs to the left on the same line. Refer again to Figure 10-8. It is comparatively easy to modify the extreme left tab in the top row to match the middle tab in the second row, while it may be nearly impossible to modify the extreme right tab in the second row and assuredly impossible to modify the extreme right tab in the third row. Even the tab directly below the “tooth” tab may prove to be

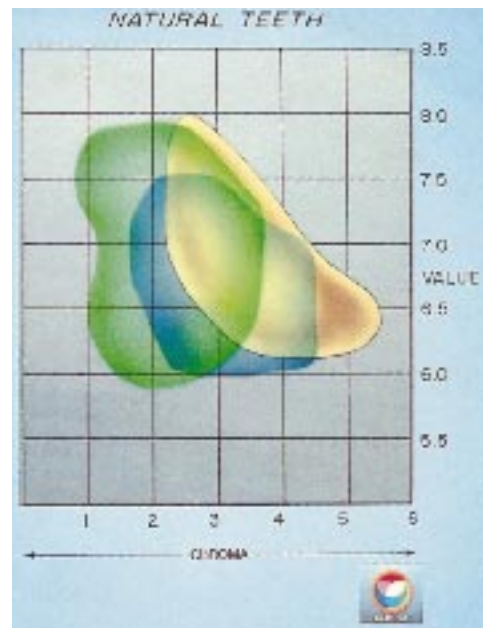


Figure 10-10: Value/Chroma overlays of natural teeth studies for comparison. Brown = Sproull, green = Ney, blue = Hayashi.

impossible to successfully alter. Again, select a shade so that modifications involve lowering value and increasing chroma.

If the ceramist fabricating the restoration is familiar with the dimensions of color, some of the modifications may be accomplished during fabrication. If not, choosing a shade that is higher in value and lower in chroma will keep the restoration in the proper volume of color space that permits successful modification at chairside when the patient arrives. Of course, the dentist must have the proper materials and equipment (ceramic colorants and porcelain oven) to make such modifications, as well as the time and desire to do so.

COMMUNICATING COLOR

If the principles of color are understood by both the technician and the dentist, communicating color is much simpler. Until improved shade guides that adequately represent the color range of natural teeth are developed, the dentist must rely on several aids in shade selection to adequately communicate. Of course, if the fabricating technician is on site, a consultation visit with the patient is of inestimable value. When the technician is at a remote site, most state laws currently prohibit consultation in the absence of the dentist, and other methods must be used.

Modified Shade Guides

When a tooth closely approximates a specific shade selection tab, but has characterizations or deviations, those variations may be defined and communicated using a shade guide with the glaze removed and a set of dental surface colorants ("stains"). Airborne particle abrading using aluminum oxide is recommended to remove the glaze although this may also be done using emery discs. The colorant may be applied, and removed or modified until the proper effect is achieved. Once the guide closely resembles the tooth to be matched, it should be placed in a vial to avoid smearing, and sent to the laboratory along with a description of the colorants used and the effects desired.

Custom Shade Guides

The fabrication of a custom shade guide, especially one having an expanded shade range, can be very helpful. Although fabrication of such a guide is time consuming it provides a more realistic representation

of what is achievable. Unlike most shade guides, a custom guide is made of the same material as the final restoration, thus reducing metamerism. Miller⁹ has recommended the addition of red (pink) modifiers to supplement the conventional guide in this area of the color space where such guides are lacking. Fabrication of a custom guide should include a metal backing for metal ceramic restorations, and should be of realistic thickness, achievable with clinical restorations. Guides having varying textures and gloss may also be helpful.

Color Sketches

A set of colored pencils or fine-line markers can be very helpful in sketching the color zones and variations in translucency. Such sketches do not have to be artistic renderings but should adequately define areas of transition between shades, relative translucency and transparency, and characterizing colors. Such sketches require a narrative describing the meaning of each part of the drawing. Often just making oneself look closely enough at tooth color to attempt to minutely describe it in sketches improves perception of the actual color components.

Photographs for Communication

One of the best methods of communicating color to a remote location is through the use of color photographs. The truest colors will come from color transparencies (slides). However, there are definite color distortions with the film emulsion and only relative color can be communicated. To be more effective, the shade guide(s) most closely approximating the desired color should be held adjacent to the tooth and photographed. The field of view must include the shade tab designation (Figure 10–11).

The photograph gives a vivid description of the relative translucency, opacity, color zones, and incisal variation. Color slides can usually be developed within 1 day. Although the technique requires photographic equipment and film, the cost of improved shade selection is rapidly offset by avoiding remakes and disappointment. This method has proven to be the most effective of all.

The intraoral video camera can also be a great help with shade communication. It can be used in the manner described for the conventional 35-mm intraoral camera and, if a printer is available, a print made of the image. If the technician has a

computer, the images may be stored on a removable medium (depending on the file size) and displayed on the laboratory computer. Images may also be sent by telephone using a modem and downloaded directly to the laboratory. Eventually, videoconferencing may well be part of the dental and laboratory environment to truly enhance both verbal and visual communication.

In all events, the technician and dentist must form a team that desires improved quality, and is willing to communicate and to learn from one another. Until shade guides and porcelain selections improve, the dentist and technician will be forced to use compensatory mechanisms, such as those described.

SHADE MODIFICATION

A few simple and relatively inexpensive supplies and pieces of equipment are needed including a selection of colorants for porcelain (usually termed “stains”), high quality sable brushes (a #4-0 and #1 are a good beginning), a ceramic or glass mixing surface, and a glazing oven in which to fire the restorations.

Any porcelain furnace will suffice. Vacuum or sophisticated circuitry are not needed for glazing, but the unit should have automatic (and accurate) temperature control that will signal to the operator when the desired temperature has been reached.

Porcelain fusing is a result of time and temperature, so a restoration can be taken more rapidly to a higher temperature, or to a lower temperature and held at that temperature longer. Since porcelain is also a product of its thermal history, the type of porcelain and the number of times it has been fired as well as the temperatures used in fabrication will determine the temperature at which the desired maturation will occur. The smoothness and surface gloss must be visually inspected to evaluate the proper glazing temperature. With the recent advent of low-fusing materials, it is essential that the dentist knows what materials were used in the ceramic restoration.

The choice of materials is optional, but it should evolve through a cooperative effort of the technician and dentist. Once the dimensions of the color to be modified have been identified and the concepts of modification understood, the process becomes one of logic as much as art. “Stains” are metallic oxides in a modified porcelain base. Even though most

stain kits use the same color names, the actual colors vary widely. The authors use colorants from a number of kits to supply the desired colors. The brand of the porcelain or the stain to be used is of no great significance. Most kits of colorants have a wider range of colors than is necessary. The most useful colors are orange, yellow, violet, gray, browns of different hues and concentrations, and whites having different translucencies. Violet is useful for neutralizing the basic hue, reducing chroma, and giving the appearance of a more gray (lower value) and translucent appearance of the incisal one-third. Brown plus the dominant hue will lower value, and increase chroma in the cervical portion. Yellow and orange are helpful in hue changes. White, gray, orange, and brown may all be used in characterizing.

This chapter is not intended as an extensive treatise on the technique of surface coloring but rather to point out the principles involved. Once the concept of hue, value, and chroma is grasped and the interrelationships understood, all that remains is practice and improved technique. There is no question that intrinsically building color in a tooth produces a superior restoration and is the preferred technique. Surface modifications should be reserved for minor changes to improve initial results. The dentist-ceramist team must comprehend the concepts of hue, value, and chroma to communicate and cooperate to achieve excellence.

Translucency is a significant factor in successfully replicating the human dentition. The dentist should have understanding of ceramic fabrication procedures to successfully communicate translucency and

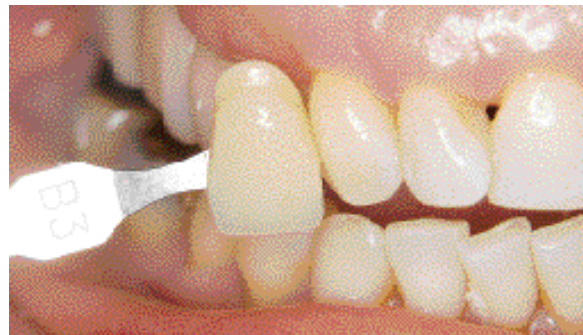

Figure 10–11: A photograph of both adjacent tooth and the most appropriate color guide is one of the best methods for communicating to a remote laboratory. Be sure to include the shade tab designation.

incisal blending. Iridescence is also a consideration, and most porcelain manufacturers have developed iridescent incisal porcelains. Drawings depicting the desired layering of incisal shades and effects are helpful to the technician. These should include not only the facial view, but a labiolingual cross-section to indicate the relative thickness of each layer. It is often necessary to select a cervical shade from one guide and the middle one-third or incisal from another. Such custom fabrication requires more time, is more demanding of both the ceramist and the dentist, and yields greater satisfaction for everyone. Magnification is helpful to discern nuances of shading, and teeth must be viewed while moist. When teeth are allowed to dry out, they appear whiter and more opaque. For this reason, shade selection is best done at the beginning of an appointment rather than at the end. The success of shade selection can also be enhanced by noting the color of dentin after enamel is removed as well as the presence of any hyperchromatic areas.

THE SHADE SELECTION ENVIRONMENT

There are many elements that preclude the successful matching of natural teeth with ceramics or other restorative materials. Shade guides are usually made of different materials than those used in the actual restoration. Different porcelains that have the same shade designation will vary in their actual color.¹⁵ The guides themselves may vary from one batch to another, further confusing the issue. Shade guides are frequently thicker than the amount of material that can be used in a crown or veneer. All of these elements add to the complexity of the problem because color is the result of the various light wavelengths being absorbed and reflected.

Since the dentist and technician are dealing with appearance, not physical measurement, it is important to recognize that the same appearance may result from different spectral formulas. For example, green may be generated by wavelengths of light that are in the green range of the spectrum, or by blue and yellow light being reflected. The perceived color may be the same in both situations. However, lighting environments vary. Natural daylight is very different from incandescent or fluorescent lighting. Fluorescent lighting itself may be one of several colors. When a wavelength of light is lack-

ing in the light source, it cannot be reflected from the object (tooth) being viewed. In the previous example, if blue wavelengths were not available to mix with the yellow, or were available in inadequate quantities to effect the blue + yellow = green equation, the “green” object would no longer match the object that was reflecting green wavelengths. This phenomenon is termed “metamerism” and is technically described as “pairs of objects having the same appearance in a given environment but having different spectral curves.”

The impact of metamerism in shade selection is apparent. Shade guides, teeth, and the restorative materials all are composed of different materials, and have different spectral curves. Therefore, the lighting environment in which a shade selection is made is very important and the chain of metamerism of tooth-guide-restorative material must be recognized. This is another good reason to have custom shade guides made of the same material (and thus having the same spectral makeup) as the finished restoration. Patients must also be made to understand that although a restoration, a single central incisor, in particular, may look good in one lighting environment, it may not in another. For this reason, the dentist may wish to select a shade in a specific critical environment. The authors have found patients quite understanding of the result when the limitations are explained before treatment is initiated. Of course, the greater the number of teeth restored, the smaller the problem becomes.

The importance of lighting for a shade selection environment becomes apparent once the factor of metamerism is recognized.¹⁴ A full-spectrum light is needed to elicit all the color a tooth is capable of reflecting. The “standard” is summer’s noon, clear sky daylight. This is an impossibility. Daylight varies from morning to evening, with the cloud cover, the air pollution, and from any color surfaces from which it is reflected. The authors recommend color corrected fluorescent lighting. The key factor is termed the “color rendering index” that is a standard for lighting. Any light source that has a color rendering index greater than 90 is ideal. The color of the light should resemble standard daylight, which has a “color temperature” of 5500 K. Therefore, independent of any brand name or advertised quality, these two standards will ensure a good color matching source.

Teeth also fluoresce a blue color when seen in light source that includes ultraviolet energy (such as daylight). This blue fluorescence acts as a whitening agent, through the principles of additive color. Without getting into the technicalities, the blue light emitted by fluorescence neutralizes some of the yellow light and makes the tooth appear whiter. Therefore, the light source should have a near-ultraviolet component.

It should be clear that shade selection and color matching are complex procedures that can only be simplified by an understanding of the factors involved, and better controls at each step. In the absence of industry standards, the onus is on the dentist and technician to work together to understand the basic principles, learn effective communication, and invoke the controls needed to optimize results. The rewards outweigh the efforts, and the patient benefits as a result.

A LOOK TO THE FUTURE

It is risky to predict the future, and the authors have expected greater progress in the past than has actually been accomplished. The hope is that electronic technology for dental applications will provide solutions for many of the current problems in shade selection and color matching.

Spectrophotometry

Inasmuch as tooth color depends on the spectral qualities of the material from which the restoration is fabricated, and the tooth that is to be matched, it would be of interest to know those spectral qualities. A spectrophotometer is a device that measures the spectral reflectance of a body. If the spectral quality of a tooth were known and a restorative material could be fabricated to replicate or approach that quality, then shade selection and color matching could be made much more objective. At the time of this writing several dental spectrophotometric projects are making substantial advancements. Ishikawa-Nagai⁴⁻⁶ and coworkers at Iwate University have developed not only a shade detection system but have also formulated porcelain to coordinate with the spectrophotometric readings. Such devices must provide a cost/benefit ratio that makes them attractive. Color science is the key to solving the shade selection-color matching problem and electronic adjuncts will assist in objectifying observations. Still, it is the human observer who is most

able to discern what is and what is not esthetic and who must ultimately be satisfied.

Communication

The development of networks has facilitated data transmission, and it is certainly conceivable that image transmission, spectrophotometric data, and even optical impressions for CAD/CAM can alter the practice of dentistry. It is hoped that the potential to solve current problems is used by manufacturers to supply materials that make esthetic restorations easier to fabricate. Improved, standardized shade selection systems and coordinated restorative materials are greatly needed.

Education

As the equipment and methods for dental practice change, the dental schools training tomorrow's practitioners must introduce this technology and information into their curricula. Cooperation between educators, practitioners, technicians, and manufacturers can lead to solutions to the color problem in dentistry. Should this cooperation occur, patients will be the ultimate benefactors. The authors hope that the combination of science and education will allow objective shade selection and color matching to become a routine part of dental education and practice.

SUMMARY

It is hoped that the information contained in this brief chapter will help initiate further study to expand the scientific basis for clinical practice. The current use of shade guides is illogical and counterproductive, and improved materials will only be made available if consumers create the demand and recognize the potential from improved products and techniques. The art of shade selection and color matching is practiced by a devoted few. The science and art must be made available to all, and should facilitate not only improved results but the enjoyment of accomplishing the difficult task of replicating natural beauty with dental materials.

References

1. Billmeyer FW Jr, Saltzman M. Principles of color technology. New York: John Wiley & Sons, 1966.
2. Clark EB. The color problem in dentistry. Dent Digest 1931;37:3.
3. Hayashi T. Medical color standard V. Tooth crown. Tokyo: Japan Color Research Institute, 1967.

4. Ishikawa-Nagai S, Sato R, Ishibashi K. Using a computer color matching system in color reproduction of porcelain restorations. Part 1, Application of CCM to the opaque layer. *Int J Prosthodont* 1992;6:495–502.
 5. Ishikawa-Nagai S, Sato R, Shiraishi A, Ishibashi K. Using a computer color matching system in color reproduction of porcelain restorations. Part 3, A newly developed spectrophotometer designed for clinical application. *Int J Prosthodont* 1994;7:50–5.
 6. Ishikawa-Nagai S, Sawafuji F, Tuchitōi H, Ishibashi K. Using a computer color matching system in color reproduction of porcelain restorations. Part 2, Color reproduction of stratiform layer porcelain samples using CCM. *Int J Prosthodont* 1993;6:522–7.
 7. Judd DB. Ideal color space. *Color Eng.*, 1970;8:38.
 8. Lemire PA, Burk B. *Color in dentistry*. Hartford, CT: JM Ney Co., 1975.
 9. Miller L. A scientific approach to shade matching. In Preston JD, ed. *Perspectives in dental ceramics*. Chicago: Quintessence Publ. Co., 1988.
 10. Miller L. Organizing color in dentistry. *J Am Dent Assoc* 1987; (Special issue):26E–40E.
 11. Munsell AH. *A color notation*. 11th edn. Baltimore: Munsell Color Co., Inc. 1961.
 12. Preston JD. Current status of shade selection and color matching. *Quintessence Int* 1985;16:47–58.
 13. Preston JD, Bergen S. *Color science and dental art*. St. Louis: CV Mosby.
 14. Preston JD, Ward L, Bobrick M. Light and lighting in the dental office. *Dent Clin North Am* 1978;22: 431–51.
 15. Seghi RR, Johnston WM, O'Brien WJ. Spectrophotometric analysis of color differences between porcelain systems. *J Prosthet Dent* 1986;46:35–40.
 16. Sproull RC. Color matching in dentistry. Part III, Color control. *J Prosthet Dent* 1974;31:146.
 17. Sproull RC. Color matching in dentistry. Part II. Practical applications of the organization of color. *J Prosthet Dent* 1973;29:560.
 18. Sproull RC. Color matching in dentistry. Part I. The three-dimensional nature of color. *J Prosthet Dent* 1973;29:416.
 19. Wright WD. *The Measurement of colour*. 3rd edn. London: Hilgar & Watts, Ltd. 1964.
- Additional Resources**
- Comfortes I. Porcelain veneer color blending. *J Calif Dent Assoc* 1995;24(10)45–150.
- Goldstein GR, Schmitt GW. Repeatability of a specially designed intraoral colorimeter. *J Prosthet Dent* 1993; 69:616–9.
- Hersek NE, Canay SR, Yuksel G, Ersin A. Color stability of provisional bridge resins. *J Esth Dent* 1996;8(6): 284–9.
- Wagner IU, Carlsson GE, Ekstrand K, et al. A comparative study of assessment of dental appearance by dentists, dental technicians and laymen using computer-aided image manipulation. *J Esth Dent* 1996; 8950: 199–205.
- Zarb GA, Anderson JD, Fenton AH. Decision-making in prosthodontics. In: Owall B, Kayser, Carlsson GE, eds. *Prosthodontics, Principles and management strategies*. London: Mosby-Wolfe, 1996:125–34.

PART 2

ESTHETIC TREATMENTS

CHAPTER 11

COSMETIC CONTOURING

Cosmetic contouring is the reshaping of the natural teeth for esthetic purposes. Such reshaping does not merely consist of filing and leveling the incisal edges—it involves shaping the mesial, distal, labial, and lingual surfaces as well. It is necessary to have a good concept of the original tooth anatomy and how that structure can be recarved into the teeth.

EARLY TECHNIQUES

Cosmetic contouring is one of the oldest of all the esthetic procedures known to man because as long as humans have had teeth, we have had tooth fractures. Since the file was an instrument known to early man, it is easy to understand that the sharp edges on fractured teeth would be filed to a smoother surface and that people in some cultures filed teeth merely to beautify them. A 2000-year-old Mayan skull shows teeth contoured into points for cosmetic purposes (Figure 11–1A). In fact, the ornamental use of jadeite inlays in anterior teeth and other decorative treatments is further evidence of ancient cosmetic tooth contouring. In Bali, it has been a custom for young women to undergo filing of the labioincisal enamel at puberty to make the

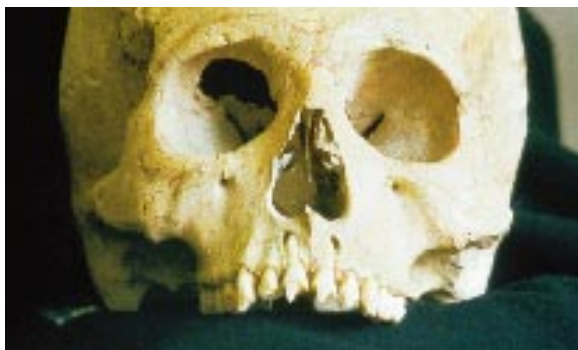

Figure 11–1A: This 2000-year-old Mayan skull bears evidence of how early civilizations used cosmetic contouring for cosmetic and possibly functional purposes.

edges of the teeth appear even (Figure 11–1B). This shortening of the anterior teeth is said to be necessary for eventual cremation and was thought to be a factor in assuring the normal growth and development of the child. Central African Wawira men point their teeth for esthetic reasons only. A man who does not do so may be unable to find a woman in the tribe who would want to marry him.

In our society, cosmetic contouring is increasingly popular and is also one of the most economical esthetic procedures. In a two-year study performed on 60 beauty contestants, cosmetic contouring was strongly indicated in 40 percent of cases and almost all the rest of the contestants could have been helped through contouring as a compromise to more extensive treatment.⁷

Cosmetic reshaping provides an excellent compromise in many situations when other procedures

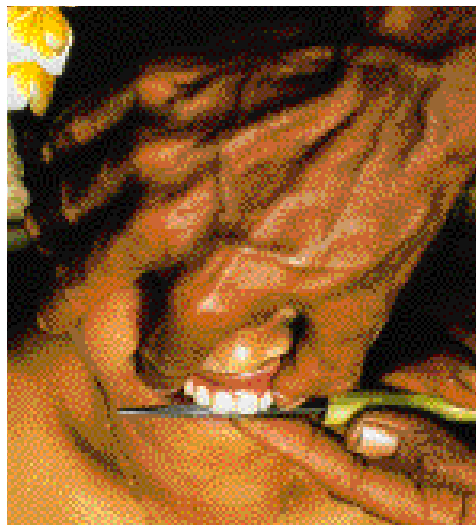

Figure 11–1B: In Bali, it is the custom for young women to undergo filing of their labioincisal enamel at puberty to make the edges appear even.

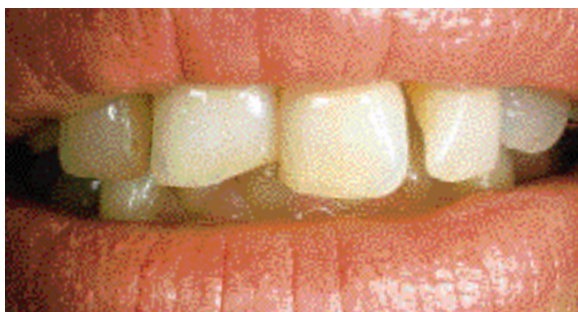

Figure 11-2A: This 45-year-old politician was concerned about her chipped and extruded anterior teeth.

are prohibitively expensive. It is always better to offer a suggested treatment for less-than-ideal esthetic improvement than to tell the patient nothing can be done except crowning or treatment that is considered ideal. If crowning is the ultimate answer but cosmetic reshaping could improve the appearance somewhat, there is no reason why crowning cannot be done later if the patient so decides.

Finally, cosmetic contouring is one of the most valuable of all esthetic procedures because, in addition to esthetic benefits, function frequently is improved. Reshaping and polishing malposed teeth make them more self-cleansing and reduce the likelihood of fracture.

Perhaps most importantly, cosmetic contouring is one of the dental treatments most appreciated by patients. As Pincus declared, "One must always keep in mind that one is dealing with organs which can change an individual's entire visual personality. Few things will cause a patient to enthuse as much as the results which may be obtained by a little rounding of very long sharp cusps, creating a 'softer' more rounded effect instead of the harsh angular appearance."⁸ And as Shelby said, "In every restoration, contouring the teeth may lend that esthetic extra that creates life and character."⁹

INDICATIONS

Cosmetic contouring has a number of other advantages over other more involved esthetic procedures. It is perhaps the most inexpensive cosmetic treatment. It is a rapid procedure that gives immediate and long lasting results and it is nearly painless and therefore requires no anesthetic. Cosmetic contouring is indicated for the following purposes:

Alterations of Tooth Structure

The most frequent use of cosmetic contouring is in the reshaping of fractured, chipped, extruded (Figure 11-2A), or overlapped teeth to give them a more pleasing appearance. Reshaping and repolishing chipped incisal edges also decreases the chance of additional fracturing (Figure 11-2B).

Correction of Developmental Abnormalities

Often teeth that are malformed can be reshaped to correct unattractive areas at the incisal edges, such as nonfused mamelons (Figures 11-3A to C).

Substitute for Crowning

Cosmetic contouring can often be a substitute for crowning anterior teeth. Too often the dentist, in an attempt to improve the patient's appearance, will think only of crowning, sacrificing tooth structure that might have been merely recontoured.

Minor Orthodontic Problems

Cosmetic contouring is a recommended treatment in patients with slightly crowded anterior teeth that are not sufficiently maloccluded to warrant orthodontic intervention. These teeth usually can be reshaped to create an illusion of straightness. Extruded teeth in Class II cases can be reshaped to appear more esthetic. Cosmetic contouring may be used after orthodontic treatment to obtain an even better esthetic result.

Removal of Stains and Other Discolorations

Reshaping can cause light to be deflected at different angles and effectively "remove" a superficial hypocal-

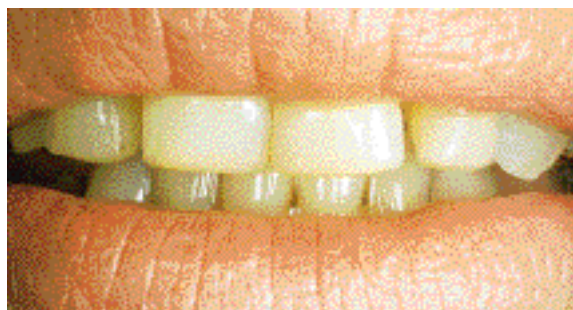

Figure 11-2B: Cosmetic contouring of both maxillary and mandibular arches not only provides more pleasing esthetics but also reduces the possibility of further fractures. Note the location of the small dark spot on the mesial of the right lateral incisor before and after contouring that illustrates how much can be reduced in certain cases to provide both esthetic and functional harmony.

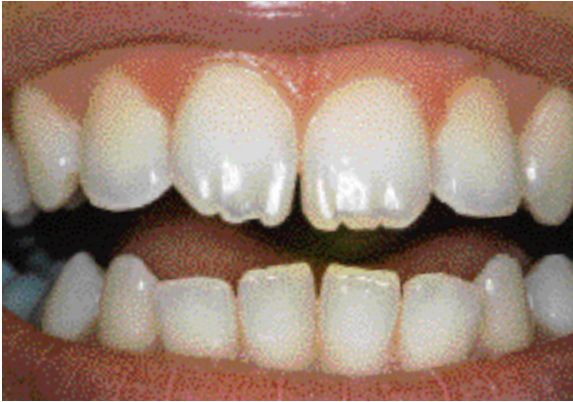

Figure 11-3A: This 33-year-old female had complained about the jagged appearance of her front teeth. Clinical examination revealed maxillary central incisors with non-fused mamelons. The mandibular incisors were slightly overlapped and distolingually inclined.

cified area or make a stain appear lighter in certain cases (Figures 11-4A and B). If contouring and polishing are not successful, microabrasion may remove, or a composite resin bonding can effectively mask, the stain.

Periodontal Problems

Coronal recontouring is definitely indicated in cases where destructive occlusal forces have injured the periodontium. If significant evidence of injury such as tooth mobility, migration, or bone loss exists, the specific interferences should be found

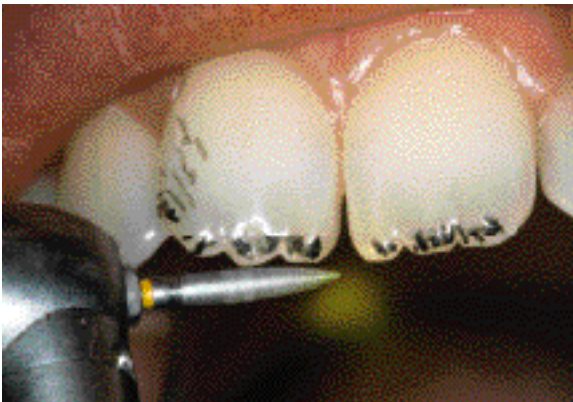

Figure 11-3B: The maxillary central incisors were cosmetically contoured to eliminate the spaces caused by the prominent mamelons and to reduce the amount of distal-labial overlap of the mandibular central incisors.

and eliminated. The usual specific problems that can be addressed by contouring include uneven incisal levels, overlapping, rotation, supraeruption, and insufficient horizontal overlap.

Bruxism

Bruxism makes the anterior teeth wear evenly across the front, producing sharp angular edges, which may be considered masculine. In women the teeth can be reshaped by rounding the corners to make the lateral and central incisors look more feminine, especially where the incisal embrasures have been obliterated by wear. The following case illustrates how cosmetic contouring can improve the appearance of a patient with excessively uniform teeth caused by bruxism:



Excessive Uniformity of the Maxillary Incisors

PROBLEM: An extremely attractive female model presented with excessive uniformity of the maxillary incisors and extrusion and crowding of the left lower anterior, which caused the lip to be shifted slightly to the right (Figure 11-5A).

TREATMENT: Cosmetic contouring of the maxillary and mandibular incisors was performed by reopening the incisal embrasures and varying the length of the incisal edges. The importance of feminine or masculine reshaping of the anterior teeth should be remembered when contouring in these cases.

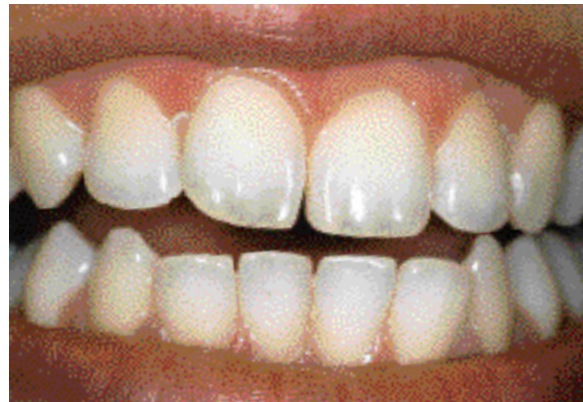

Figure 11-3C: The post-treatment smile reveals more symmetrically-balanced maxillary and mandibular incisal edges.

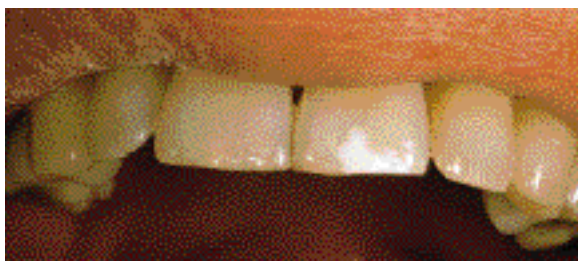

Figure 11-4A: This 50-year-old executive objected to the hypocalcified area on the labioincisal of the maxillary left central incisor.

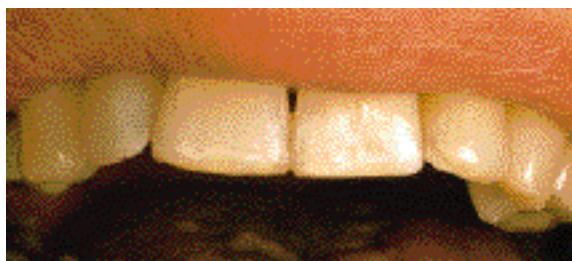

Figure 11-4B: Cosmetic contouring consisted of removing most of the offending chalky white defect and changing the angle of light reflection to minimize the appearance of that which remained.

RESULT: A more attractive smile was created with minimal effort (Figure 11-5B). To prevent additional, future damage, it is often necessary to correct the underlying problem of bruxism, and a night guard may be indicated.



CONTRAINDICATIONS

Cosmetic contouring cannot change the position of the teeth and the position of the teeth may limit the amount of tooth structure that can be removed. Furthermore the patient's bite may limit the amount of cosmetic treatment achievable. Contraindications to cosmetic contouring include:

Hypersensitive Teeth

If a patient, usually a child or adolescent, complains that the tooth is sensitive, it is better to defer cosmetic contouring until the tooth becomes or can be made less sensitive. The patient should be

encouraged to have orthodontic treatment to correct even minor crowding since there is a chance the tooth may remain sensitive for most of the patient's life.

Large Pulp Canals

Young people with extremely large pulp chambers and pulp canals are poor candidates for cosmetic contouring (Figure 11-6) because of possible discomfort during the procedure and sensitivity afterward. If contouring is absolutely necessary, the teeth can be desensitized but it is advisable to do as little contouring as possible in such cases. It may even be necessary to administer a local anesthetic. If crowding is the problem, orthodontic treatment may be the best option.

Thin Enamel

Cosmetic contouring should be avoided in patients with overlapping incisors where proximal reduction might create translucency or expose dentin. Excessive removal of enamel from the labial surface

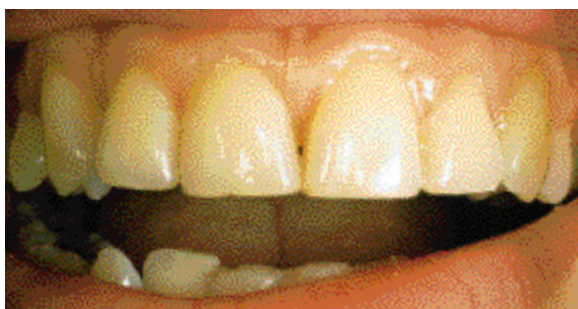

Figure 11-5A: This 23-year-old female presented anterior edges worn flat due to bruxism.

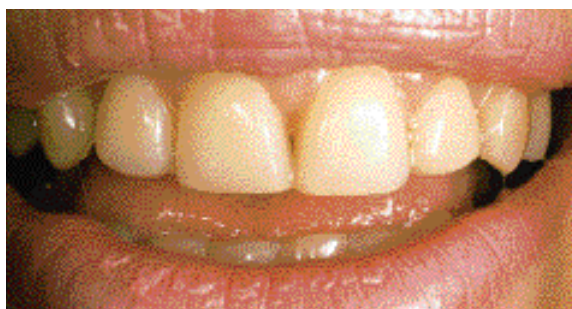

Figure 11-5B: A younger, more feminine, and attractive smile was accomplished with cosmetic contouring of the maxillary and mandibular incisors.

of the incisors may result in the darker yellow dentin beneath showing through, creating an iatrogenic problem. Excessive thinning at the mesio- and distoincisor corners of teeth that already have thin enamel may lead to future fracture. Teeth with thin enamel on the mesiolabial, distolabial, or incisolabial surfaces as the result of erosion, attrition, or abrasion should not usually be considered for cosmetic contouring. If, however, these teeth are in bucco- or linguoversion, it is sometimes possible to contour the linguoincisor or labioincisor to make them blend in and look straighter. However, it is important to preserve all possible enamel on the labioincisor and linguoincisor so that the tooth can resist further wear. In the final analysis, it is a value judgment based on experience and the patient's goals for the esthetic treatment. A combination of conservative cosmetic contouring and bonding or veneering may be indicated.

Deeply Pigmented Stains

Hypocalcifications or stains that would require extensive reduction to eliminate or lighten should be treated by restorative procedures. Otherwise, the enamel may be too thin and the dentin may become more visible. In this situation minor cosmetic contouring may be tried and, if it is unsatisfactory, microabrasion, bonding, or veneering should be considered. If there are doubts as to the thickness of the stain, be sure to let your patient know in advance that additional treatment may be necessary to completely eliminate the stain.

Occlusal Interferences

Centric occlusion and lateral and protrusive excursions should always be checked before the treatment. If contouring might create an occlusal disharmony, e.g., eliminating a cuspid rise, thus changing the occlusal relationships, cosmetic contouring is contraindicated.

Periodontal Involvement

In many cases the teeth need to be orthodontically repositioned to make them easier to clean. There should never be any doubt that orthodontics would be the ideal treatment to achieve the best functional and esthetic result. In fact, by reshaping the incisal edges, cosmetic contouring might only postpone ideal treatment. For the most part, cosmetic contouring is usually a compromise treatment and should be explained as such to the patient and documented as such in the chart. Nevertheless, for the

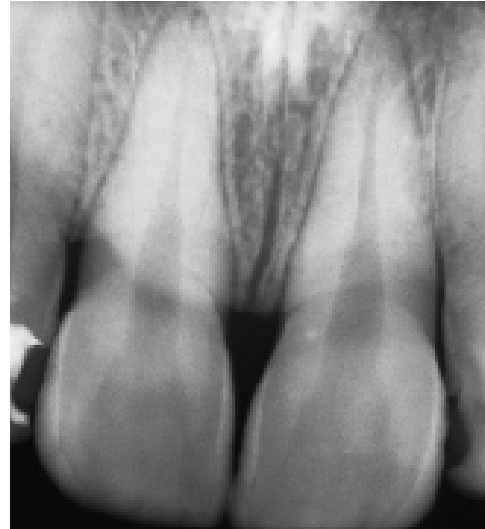

Figure 11-6: Due to the large pulp canals, sensitivity could be a problem for this 24-year-old student if cosmetic contouring were performed.

patient who will not consider orthodontic treatment, there may be considerable benefit to a compromise treatment of cosmetic contouring. Certainly, by making the teeth easier to clean and eliminating some food traps, the teeth will look better and the patient will feel better about his or her appearance. Thus, the patient will be more apt to take better care of the teeth and gums.

Susceptibility to Caries

As the enamel is made thinner a tooth could be more susceptible to caries. In situations of crowded teeth, however, this is partially offset because the now less-crowded teeth are easier to clean. In all cases the tooth must be repolished and treated with fluoride postoperatively.

Negative Psychological Reactions

The patient may be subconsciously afraid to look better. Cosmetic contouring will alter a person's smile, so the patient should be forewarned of the change in appearance. Occasionally, the spouse may be the concerned individual. Therefore, show the patient and spouse, if necessary, how his or her appearance will change by first doing computer imaging.

Large Anterior Restorations

Large composite or other anterior restorations may limit the amount of contouring that can be done.

If too much enamel is reduced, the remaining tooth structure may be so weakened that it will eventually fracture.

Extensive Anterior Crowding or Occlusal Disharmony

Although cosmetic contouring can usually help improve the appearance of crowded anterior teeth, if there is severe crowding it may accomplish so little that it should not be attempted. In these situations, the patient should be strongly advised to undergo corrective orthodontic treatment. This also applies to those instances when there is extreme functional impairment in the dentition. Cosmetic contouring is never a substitute for definitive or complete occlusal adjustment or functional repositioning of malaligned teeth.

PRINCIPLES OF COSMETIC CONTOURING

Golden Proportion

Dentists who perform cosmetic contouring must give foremost attention to the golden proportion (see Chapter 9). Whether or not a tooth or other structure conforms to the golden proportion is best evaluated by visualizing the silhouette form of a tooth or an arch. The silhouette form is the shape of a tooth as defined by the outline of the tooth, and it, even more than color, governs what most people perceive as either attractive or unattractive. The outline of the tooth is usually determined by the portion of the tooth within the mesiolabial and distolabial line angles. This area defines the perception of how big, long, or short a tooth is. Total perception is gained not only by looking at the tooth but also by looking at the smile and at the entire face. It involves first focusing on the tooth and how the teeth relate to each other and then stepping back and visualizing the smile and its relation to the face and seeing what, if anything, can be done to improve the overall appearance. Opening or closing an incisal embrasure may make a difference. The silhouette form of a tooth that is out of proportion can be altered by adjusting the location and curvature of the mesiolabial or distolabial line angles. But a distoincisor line angle that is needed to preserve the golden proportion should not be curved. Care must be taken to also understand the effect on the illusion created by light reflection (see Chapter 8).

Gender Differences

The assumption of gender differences in tooth form was introduced in the 1950s by Frush and Fisher in their series on full denture esthetics.¹⁻⁶ They said that the feminine tooth has more curves while the masculine tooth is more angular and boldly textured. However, according to Abrams, there is no anthropologic basis for this claim. In 1981, Abrams conducted a survey at the American Academy of Esthetic Dentistry's annual meeting. He showed images of teeth from 60 patients from right, left, and center views with the lips blocked out so that the audience could not see whether the person was male or female. The 150 dentists who participated in the test were given five seconds to determine whether each person was a male or female and their degree of certainty. Only one participant guessed correctly more than 50% of the time. This study showed that dentists have prejudices about what is masculine and feminine but these prejudices are not substantiated by the facts. In your clinical practice, however, you should be aware that rounding teeth does soften the appearance and making the mesioincisor and distoincisor line angles more angular gives a harder, more aggressive look. You should consider these appearances as descriptive rather than gender specific.

Occlusion

Cosmetic contouring must always be done with the principles of good occlusion in mind. Nothing should be added or eliminated that will produce occlusal disharmonies. Occasionally, the factors that produce poor esthetics are also responsible for the malocclusion, and an esthetic improvement may correct both.

Simring et al. reviewed a series of occlusal considerations for anterior teeth.^{10,11} Ideally, in mandibular anterior teeth a series of thin, symmetrical incisal edge contacts exist that produce vertical forces that are contained within the area of periodontal support.

When establishing a new incisal level for mandibular anterior teeth through contouring, consideration should be given to the following:

1. Establish an incisal level that permits optimum contact without producing occlusal trauma. An uneven incisal level and a labiolingual curve produced by crowded teeth not

only create problems in esthetics but can also create occlusal trauma.

2. Establish symmetrical incisal edge contacts, and when that is not possible, labial contacts should be created that are positioned as far incisally as possible.

In maxillary anterior teeth, the objectives for centric and protrusive positions and excursions are:

1. To reduce destructive forces occurring in these positions.
2. To produce optimum contact and to eliminate deflecting contacts. Optimum contact is contact of the greatest possible number of teeth without poor esthetics or undesirable occlusion. Since the optimum mandibular incisal level should be established first, all additional grinding to obtain these objectives should be done on the maxillary teeth.

Sometimes there will be a conflict between the amount of reduction that gives optimal function and the amount that gives optimal esthetics. The decision will have to be based on the degree of occlusal dysfunction that will remain, the importance of the esthetics and the ultimate health of the dental organ.

TREATMENT PLANNING

Cosmetic contouring is one treatment that can be included in almost every patient's overall treatment plan. When deciding whether to bond, veneer, or

crown, ask yourself the question: "Can cosmetic contouring help me to achieve a more successful esthetic result?" Four methods are useful to aid you in answering this question:

1. Computer imaging
2. Diagnostic study casts
3. Intraoral marking
4. Radiographs

Computer Imaging

The best way to show your patient how cosmetic contouring can improve his or her smile is with computer imaging (Figures 11–7A and B). The technique accomplishes two purposes: first, it serves as the best method for patient communication and second, it can be invaluable in letting you know exactly how much tooth alteration is necessary to achieve the best result. Even if patients can appreciate basic principles of tooth alteration, it is almost impossible for the average patient to visualize the tooth changes you plan through cosmetic contouring, or how the new tooth shapes will affect the smile and the face. This can also be the quickest method of determining if cosmetic contouring will suffice or if an alternative treatment should be chosen (Figures 11–8A to C).

Diagnostic Study Casts

Take impressions of both arches and pour a duplicate set of models. Analyze where and how tooth structure will have to be altered and perform the proposed treatment on the patient's duplicate study

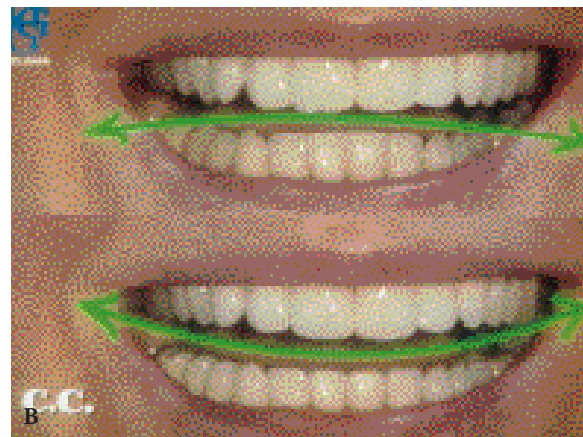
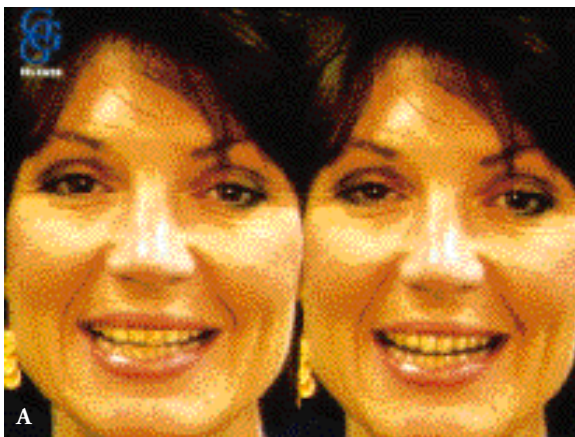

Figure 11–7A and B: Computer imaging is the best method to show your patients how cosmetic contouring can improve their smile. It can also show you just how much tooth alteration you will need to do to achieve the best result.

models (Figure 11–9). By practicing this way, the end result will be more predictable. In addition, the patient also can more easily visualize what the final result will be, and it gives you an exact record of what the teeth were like before they were reshaped.

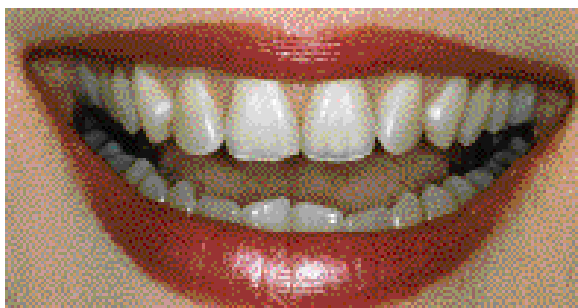

Figure 11–8A: This 30-year-old wanted straighter teeth without orthodontic treatment. Note the uneven appearance of the mandibular incisors.



Figure 11–8B: By selecting an imaginary lower arc which mimics the lower lip line, it is possible to create an illusion of straightness especially in the lower anterior area.

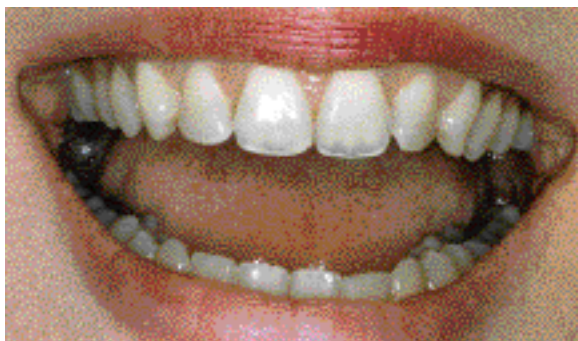

Figure 11–8C: Cosmetic contouring provides the illusion of straightness the patient desires.

Intraoral Marking

A third method of predetermining the effect of cosmetic contouring is to block out the tooth surfaces that will be contoured with a black alcohol marker. Dry the teeth with your air syringe and mark the visible overlapping tooth surfaces. Have your patient hold a mirror at arm's length to see the effect of the new silhouette form. If the patient wears glasses ask him or her to remove them for a more realistic view of the proposed silhouette form.

Radiographs

Radiographs, particularly of the anterior teeth, should be examined for thickness of the enamel as well as for the size and shape of the pulp. This is the best way to predict potential sensitivity and to give an indication of how much enamel you will safely be able to remove.

TECHNIQUES OF COSMETIC CONTOURING

Achievement of Illusions

The purpose of planning is to determine how to achieve an illusion of straightness. This process must include different views and perspectives (Fig-

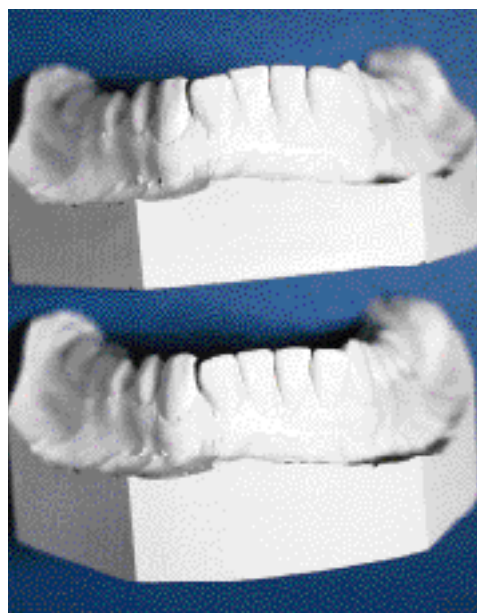

Figure 11–9: Before and after study models aid in treatment planning of cosmetic contouring. This helps both the dentist and the patient to better visualize the anticipated result.

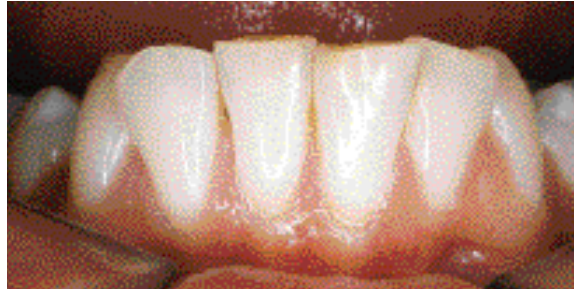

Figure 11-10A: This patient desired straighter looking lower teeth. Although the teeth appeared to be even from a horizontal aspect, a more normal speaking position revealed lingually locked right central and left lateral incisors.

ure 11-10A to C). An optical illusion should work most effectively in the position from which most people will be viewing the patient. For example, if your patient is a secretary or receptionist, he or she will probably be seen most often sitting down (see Figure 11-10C). The easiest way to determine if cosmetic contouring can obtain the result you want is to use computer imaging to record the way more people will view the patient. Draw an imaginary line to simulate the arc you wish to create by contouring (see Figure 11-10C). Most contour planning should be done by marking the teeth with a black marker when the patient is sitting. However, the patient should also stand with the dentist sitting, and then both the patient and dentist should stand. Each time, the areas to be contoured should be dried and marked with a black alcohol marker. Areas to avoid cutting, such as a holding cusp in the cuspid areas, may be distinguished with a red alcohol marker. The patient should have an opportunity to visualize the planned reshaping or contouring with a mirror. Many times the patient will see something the dentist has not observed.

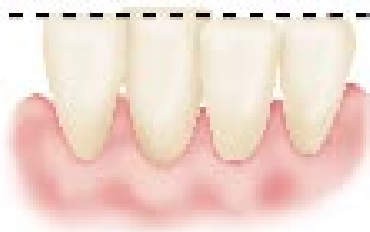


Figure 11-10B: This is the view of the lower arch as seen by a person at eye level.

Angle of Correction

A lower incisor that actually or apparently extends above the lower incisal plane is quite noticeable. The angle of view is important, especially in shaping a lower tooth. Owing to the relative positions of the eyes and mouth, most people look down at the lower arch. This is why, because of the angle of view, an anterior tooth that is in linguoversion appears to be much more prominent than the one in labioversion. To contour the tooth in linguoversion, its incisal edge should be beveled lingually (Figure 11-10D). Figure 11-10E shows the position of the diamond stone used to reduce the unsightly tooth. Correction must be done with this lingual aspect in mind. Using these principles helped create a much more attractive smile with straighter-looking teeth when this patient smiled or spoke (Figure 11-10F).

Reduction

Before doing even preliminary contouring, the dentist must be profoundly aware of the fact that reshaping of the natural dentition must always be in relationship to the lip positions in both speaking

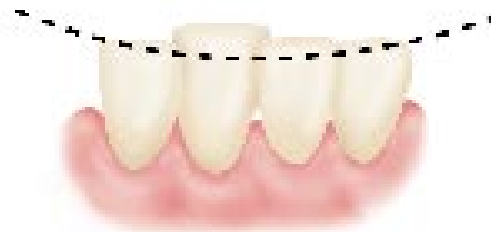


Figure 11-10C: Shows the same individual as viewed when speaking. A line is drawn to simulate the desired arc.

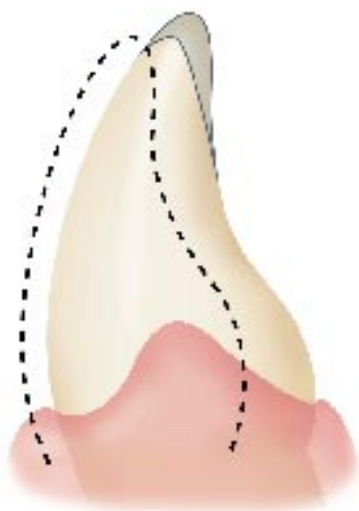


Figure 11-10D: Shows the relative amount of linguoincisal enamel necessary to alter to achieve a straighter look.

and smiling. Failure to do this may lead to over-reduction in areas not actually needed for esthetics. In addition, the lips should be retracted as little as possible during the recontouring procedure so that their influence and natural relationship toward the dentition will always be apparent.

The entire process of contouring should usually be scheduled in two appointments instead of a single appointment simply because after prolonged observation, the teeth tend to be seen as the dentist wants them to be rather than as they actually are. In rare cases it may be necessary to desensitize the teeth. The teeth can be desensitized using a paint-on agent, either a 0.717 stannous fluoride (Dentin Bloc, Colgate Oral Pharmaceuticals, Canton, MA) or a dentin sealer (Gluma Desensitizer, Heraeus Kulzer, South Bend, IN, or Pain-Free, Parkell, Farmingdale, NY). A dentin bonding agent (All-Bond 2, Bisco Dental Products, Itasca, IL) can also be used to desensitize. These patients should be advised to use a desensitizing toothpaste as necessary after treatment.

It is important during all cutting operations to use a water spray as a coolant. Furthermore, with the use of water, it is often possible to see a slight color shift before the enamel is completely penetrated. The last few layers of enamel are more translucent, so that the yellow dentin becomes more visible. Enamel removal should be stopped as soon as a color

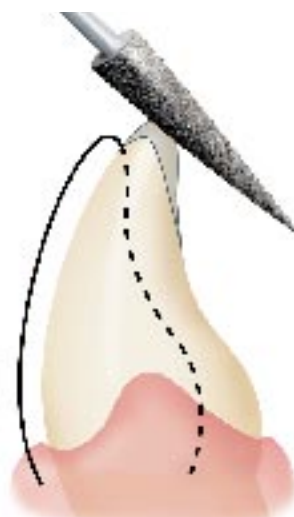

Figure 11-10E: Notice the correct angle to hold the bur.

shift is observed and hopefully before. When such a tooth is dried and polished, it will look fine.

As the teeth are contoured, it is important to move from one tooth to another frequently. Not only will this minimize frictional heat build-up but it will help maintain a proper perspective toward the overall goal.

If a tooth is being shortened, it will need to be reduced labiolingually as well. If this is not done, the patient may be able to feel the difference in the widths of the incisal edges and the difference may also be visible.

Anterior teeth in the lower arch should be shortened only to the level where they still occlude in protrusive movements. Simring et al. state, “Lower

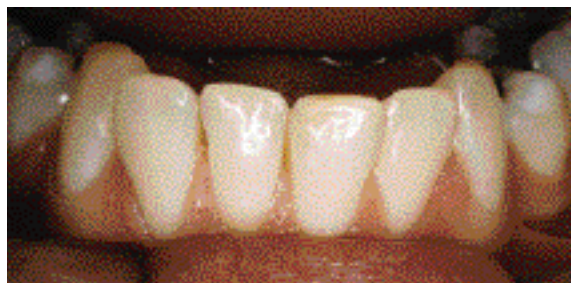

Figure 11-10F: The final photo shows how much straighter the lower teeth appear following cosmetic contouring. Both mesial and distal aspects of the adjacent labial surfaces were also contoured.



Figure 11–11: The Shofu Cosmetic Contouring Kit, which contains impregnated wheels, is used to polish the enamel after cosmetic contouring.

anterior teeth that are ground out of occlusal contact in the intercuspal position will not overerupt if they have occlusal contact in protrusive excursion.¹¹ Wear facets can detract from the esthetic shape of the teeth. These teeth can be esthetically contoured by rounding away from the flat planes of wear, thereby distributing the occlusal forces more evenly and creating a more pleasing appearance.

The Cosmetic Contouring Kit (Shofu, Shofu Dental Corp., Menlo Park, CA) contains nearly all of the instruments necessary to perform the enamel contouring and finishing procedure (Figure 11–11). There are times when initial shaping of the teeth is done with fine and ultrafine diamonds on a high speed handpiece with water spray. Excellent shapes of these diamonds are the needle-shaped DET6 (F and UF) and the DET3 (F and UF) (Brasseler, Savannah, GA).

Reduction is accomplished by carefully shaping the marked areas with the bulk reduction diamonds except for the lower anterior teeth. Bulk reduction in these teeth should be done with fine finishing diamonds at high speed rather than with the bulk reduction diamonds. Because of the thinness of the enamel on these small teeth, if enamel is cut with a fine grit, little will be lost at one time. Therefore, there is less danger of cutting away too much tooth structure. After the initial reduction, the patient should be viewed again in all relevant positions and the teeth remarked.

Final shaping on the mesial, distal, incisal, and embrasure is done with the thin and extra-thin diamond points, because their shapes allow for better access to these areas. This is followed by the white or green finishing stone.

After facial shaping is complete, finishing is begun by using an extra-coarse sandpaper disc (3M or Cosmedent). Finishing is continued by using the impregnated polishing wheels of varying grits in the following order: plain shank, single yellow band, and double yellow band. This will restore the enamel to its original luster; this procedure can also be used to refinish porcelain.

The following case is a good step-by-step example of a patient who chose cosmetic contouring as an esthetic treatment.



Contouring Crowded and Superior Erupted Teeth

PROBLEM: An attractive female graphic illustrator, aged 40, presented with malposed, supererupted, and chipped anterior teeth for cosmetic analysis (Figure 11–12A). Orthodontics was ruled out because the patient wanted an immediate esthetic result. She also was reluctant to have her teeth reduced for crowning or veneering.

TREATMENT: Cosmetic contouring was the treatment of choice for an economical and quick esthetic solution. The first step in the procedure is to analyze the occlusion. The patient is asked to chew on articulat-

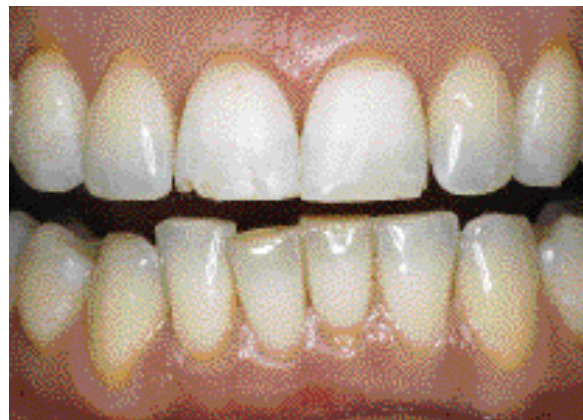

Figure 11–12A: Malposed, supererupted, and chipped anterior teeth are evident in this before photograph.

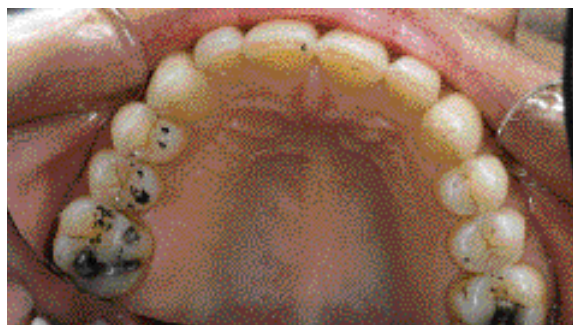
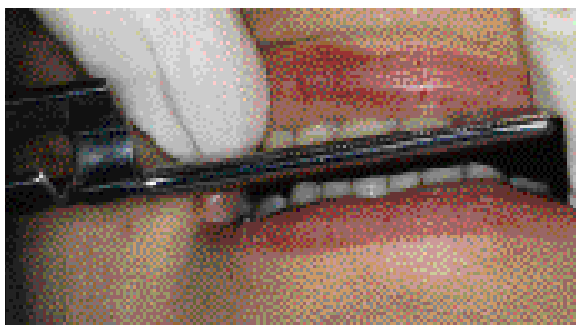
Figure 11-12B and C: Articulating paper is used to record the existing centric holding cusps and lateral inclined planes.



Figure 11-12D: Examples of alcohol marking pens (Masel, Inc., Bristol, PA).

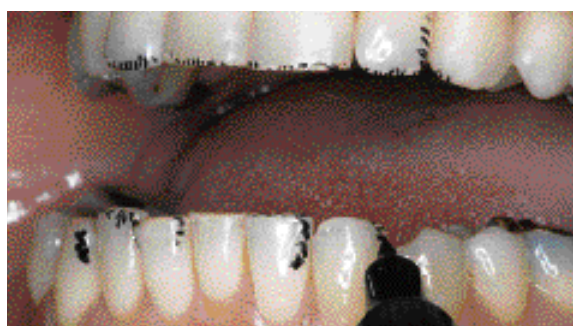


Figure 11-12E: After thoroughly drying the teeth, a black alcohol marker is used to outline the areas to be contoured.

ing paper in various directions to determine existing centric holding cusps and lateral inclined planes (Figures 11-12B and C). It is necessary to determine how much the tooth structure can be altered without sacrificing functional occlusion. The angle from which most people see the patient determines the angle of view for which an illusion of straightness will be created. The areas where the initial reduction will be done are drawn on the teeth with a black alcohol marker, which creates marks that are removed by cutting with the diamonds and carbides (Figures 11-12D and E). Looking in a mirror, the patient can get some idea of how the teeth will look.

The vertical correction was made first by reducing the incisal edges slightly to achieve an esthetic balance (Figure 11-12F). The distal edges of the overlapping laterals (Figure 11-12G) were then recontoured. The incisal symmetry is refined with a Soflex disc (Figure 11-12H). The incisal embrasure is then reopened for a more natural esthetic appearance (Figure 11-12I).

The patient's chin drops down during normal conversation, and this, combined with the typical labial angulation of the lower incisors, presents an oblique view of these teeth to most viewers. So, in order to achieve a more natural look when the patient is speaking, an approximate 45-degree correction angle is used for lingual shaping (Figure 11-12J). Next, any horizontal overlap created by overly wide or poorly aligned incisors is reduced (Figure 11-12K). The mandibular teeth are then finished from the lingual surface to make them appear even (Figure 11-12L). After the original reshaping, the patient is viewed again in the given position to see if there is any further contouring required. It is a good idea to vary both your and the patient's position, e.g., sit up, stand up, lean back, and don't forget lateral views. All of these views are helpful to make sure the illusion of straightness is as complete as possible. If necessary, remark and repeat the above steps.

Figure 11-12M demonstrates using the same green stone or the white stone to begin smoothing

any marks created by the diamond. As an alternative the DET UF6 may be used. Enamel finishing is done with the Shofu gray mounted point found

in the Cosmetic Contouring Kit. The wheel shape, with no yellow band, (Figure 11–12N) is used to polish incisal edges and labial and lingual surfaces.

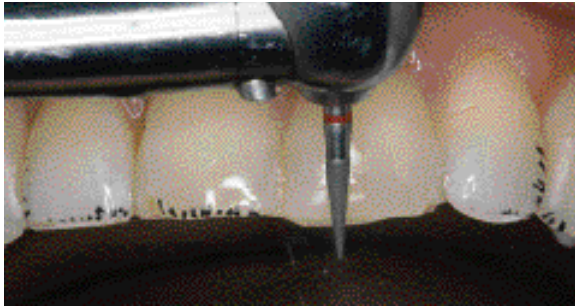


Figure 11–12F: Vertical correction was accomplished by leveling the incisal edges of the central incisors and slightly shortening the incisal edges of the laterals.

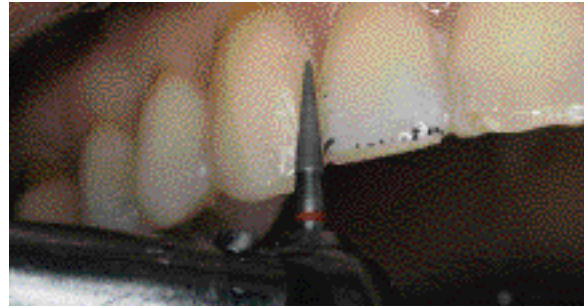


Figure 11–12G: Recontouring of the distolabial edges and line angles of the overlapping laterals helps to create better distolabial proportion and exposes more of the mesial surface of adjacent cuspids.

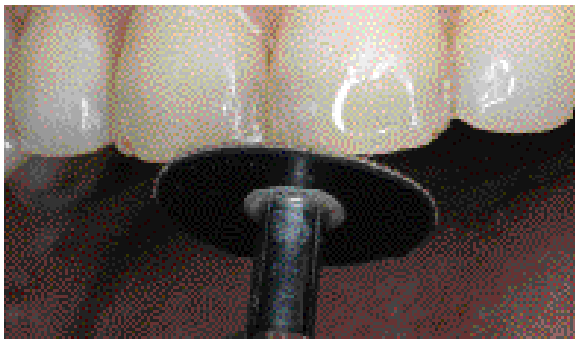

Figure 11–12H: The final incisal symmetry is created with an extra-coarse Soflex sandpaper disc (3M, St. Paul, MN).

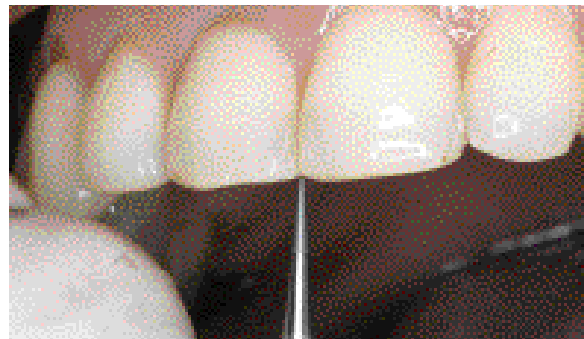

Figure 11–12I: An ET 3UF 8-micron grit diamond (Braseler) is used to reopen and carve the incisal embrasure for a more natural esthetic appearance.

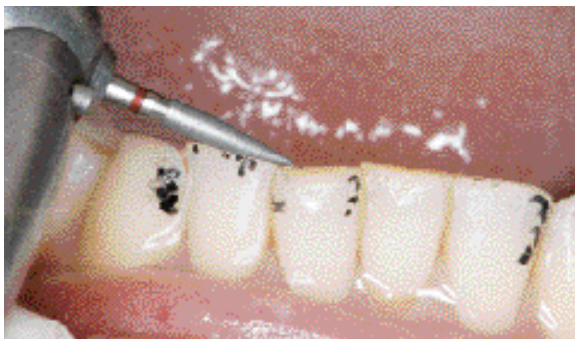

Figure 11–12J: Lingual shaping is done using an approximate 45-degree angle. This helps achieve a more natural look when the patient is speaking.

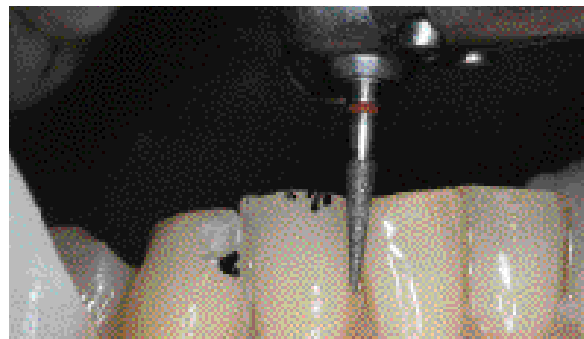


Figure 11–12K: Horizontal overlap, which is created by too-wide or poorly aligned incisors, is narrowed.

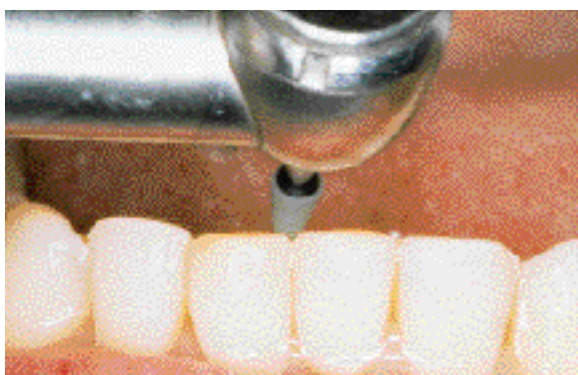

Figure 11-12L: Mandibular teeth are finished with the green stone from the lingual surface to create an even appearance.

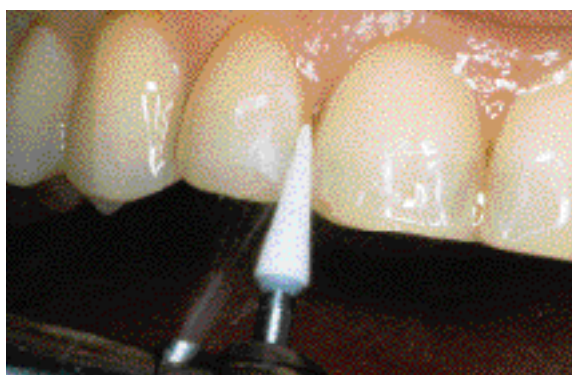

Figure 11-12M: Smoothing the marks created by the diamond during contouring can be done using the white or green stone.

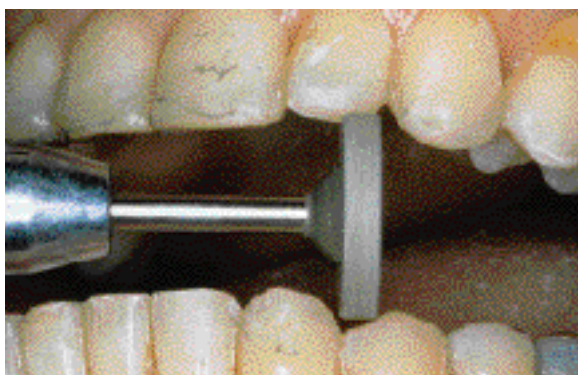

Figure 11-12N: The no-band wheel shape is used to finish the incisal edges of the maxillary incisors.

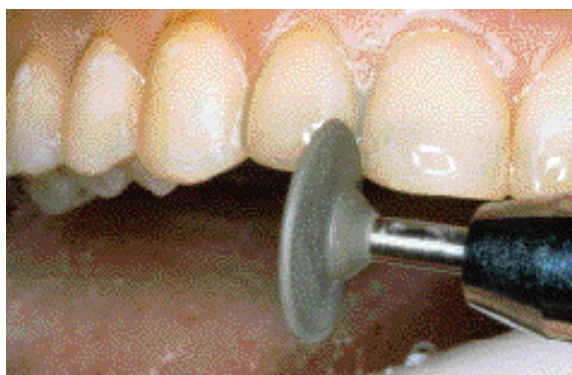

Figure 11-12O: Interproximal surfaces and incisal embrasures of maxillary central and lateral incisors are polished using the disc shape.

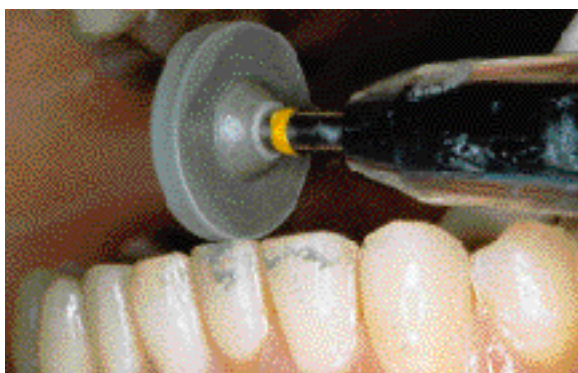

Figure 11-12P: Switch to the one yellow-banded wheel for further incisal edge and labial finishing.

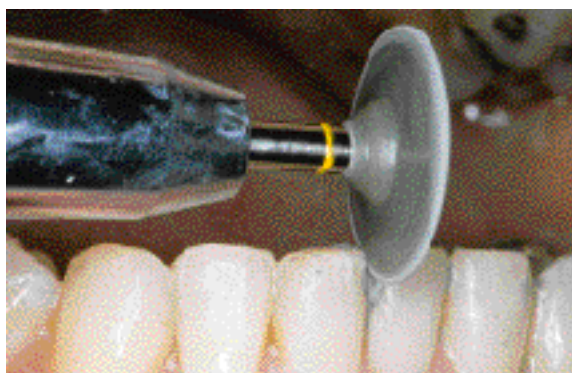


Figure 11-12Q: The one yellow-banded disc shape further smooths the incisal embrasures and proximal surfaces.

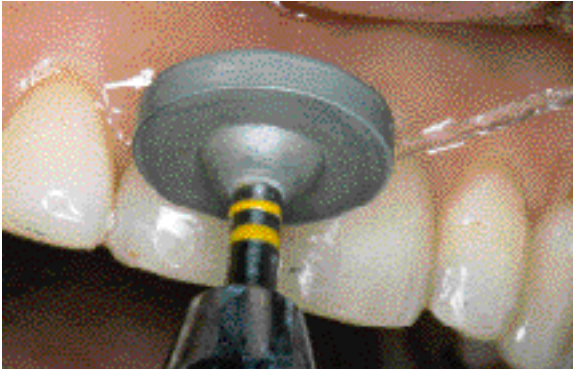

Figure 11-12R: The final finishing is done with the two yellow-banded wheel. Note how water is used to cleanse the tooth surface while reducing heat.

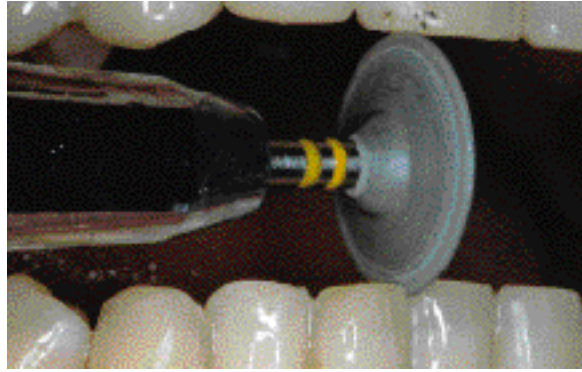


Figure 11-12S: The two yellow-banded disc shape places the final finish on incisal embrasures.

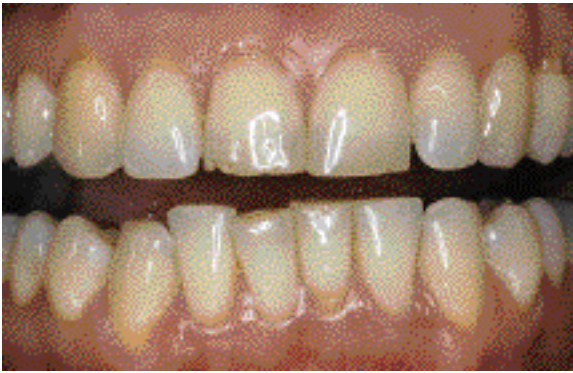

Figure 11-12T: Retracted view before cosmetic contouring.

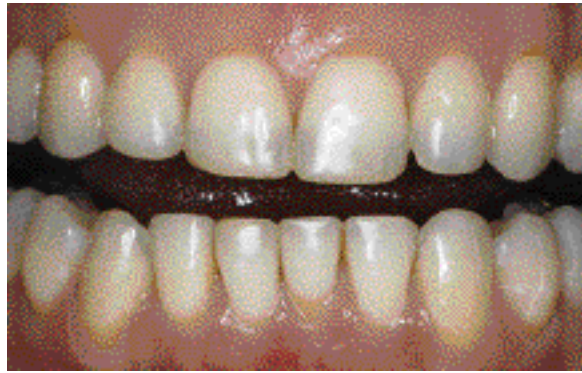

Figure 11-12U: Retracted view after cosmetic contouring shows the improved lower and upper incisal planes.

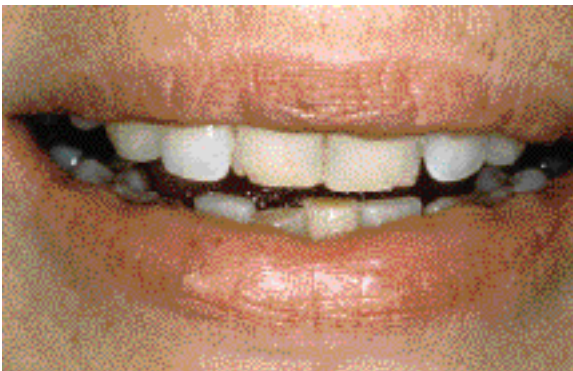

Figure 11-12V: Note how the supererupted maxillary right lateral and the lower crowding called unfavorable attention to the smile.

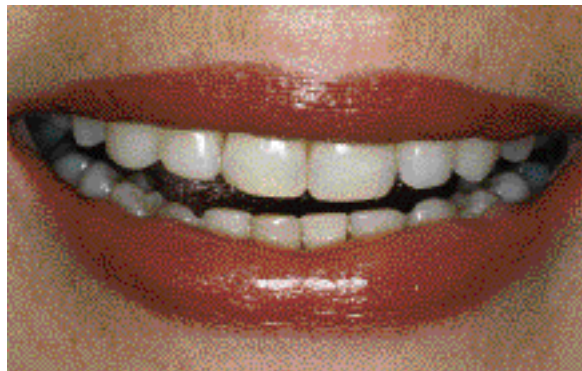

Figure 11-12W: This after smile shows how the lower incisal plane was improved. Shortening of the lateral incisors also helped to create a younger-appearing smile line.



Figure 11-12X: This full-face before photograph shows the unesthetic teeth and uneven smile line.

The disc shape is well suited for interproximal and incisal surfaces (Figure 11-12O). Remember to always use these in sequence: no band (see Figures 11-12N and O), then one yellow band (Figures 11-12P and Q), then two yellow bands (Figures 11-12R and S).

RESULT: Before and after views can be seen in Figures 11-12T and U. In studying the before and after retracted views, you can see how the lower incisal plane was improved by cosmetic contouring. Also, note how shortening the lateral incisors makes the central incisors appear longer, thereby creating a younger-appearing smile line. If occlusion is a limiting factor, then consider restoring the opposing teeth to allow for your esthetic contouring. For instance, if you feel it is necessary to shorten a mandibular cuspid, it may be possible to bond or veneer the opposing maxillary cuspid to close the resulting interocclusal space so that your occlusion will not be altered.

When looking at the before smile (Figure 11-12V) one's attention is subconsciously drawn to the supererupted maxillary lateral incisor which has a fang-like appearance. This preoccupation with the mouth tends to compete with the eye-to-eye contact that most individuals strive for in speaking with others.

The dramatic effect that cosmetic contouring can have on the facial appearance is shown in Fig-

ures 11-12 V, W, X, and Y. An illusion of straightness has been created.



Altering Tooth Form

Often the anatomic form of one tooth is altered to resemble another. A canine that has drifted or been repositioned into the space of an extracted or congenitally missing lateral incisor can sometimes be reshaped to resemble the missing tooth. Another example is the removal of part of the lingual cusp and reshaping of the labial surface of a first bicuspid so that it resembles a cuspid. Frequently, however, attempts to alter anatomic form do not produce the results that were hoped for. Nevertheless, in these cases, cosmetic contouring is still the most economical and least time-consuming method available, and the appearance may be quite acceptable.

The next two cases are examples of how alteration of tooth form can create improved esthetics.



Esthetic Shaping of Incisal Edges

PROBLEM: A female, aged 24, presented with a worn cuspid (Figure 11-13A). She expressed a desire to have her anterior teeth "capped" to produce a more attractive smile but was willing to try cosmetic contouring first.



Figure 11-12Y: The full-face after photograph shows the dramatic effect cosmetic contouring had on facial appearance by helping to achieve an illusion of straighter-looking teeth.

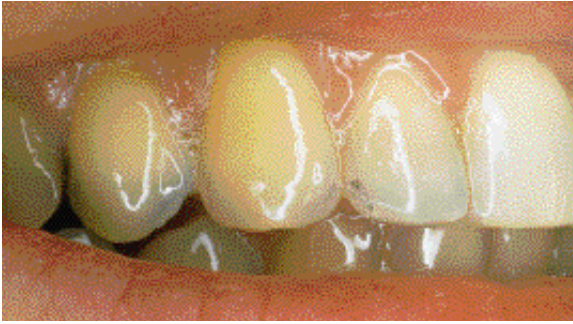

Figure 11-13A: This patient requested anterior crowns to produce a more attractive smile.

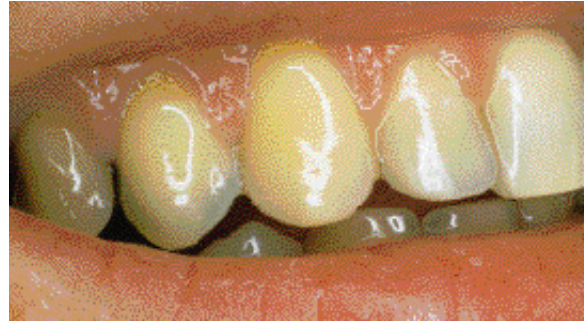

Figure 11-13B: The mesioincisal and distoincisal surfaces of the maxillary right cuspid were contoured instead.

TREATMENT: Cosmetic contouring of the maxillary right cuspid is done by contouring the mesioincisal and distoincisal surfaces to open the incisal embrasures. New contours are created which give a softer look (Figure 11-13B).

RESULT: The patient was so pleased with the result that she no longer desired to have her teeth crowned. Most patients who want anterior esthetic improvement will usually ask to have their teeth crowned, laminated, or bonded. However, cosmetic contouring should always be considered as an alternative ideal or compromise solution.



Reducing Cuspid Protrusion

PROBLEM: An attractive female, age 38, presented with fanned and distorted maxillary cuspids. She stated that when she smiled her cuspids were so

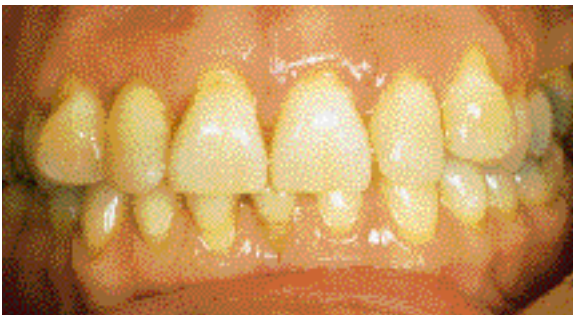

Figure 11-14A: Unesthetic maxillary cuspids detracted from this attractive female's smile.

prominent that they detracted from her appearance, and she wanted them crowned (Figure 11-14A).

TREATMENT: The patient was told that although crowning could be done later, another, more conservative procedure should first be performed that might be more satisfactory. Cosmetic contouring of the labial surface of the cuspids was then done without exposing sensitive dentin (Figure 11-14B).

RESULT: The patient was extremely pleased at the dramatic improvement of her appearance that was accomplished without crowning her teeth.



Overlapping Central Incisors

The main objective in correcting overlapping incisors is to remove as much as possible of the tooth structure that overlaps the adjacent tooth by contouring the labial aspect of the labially malposed

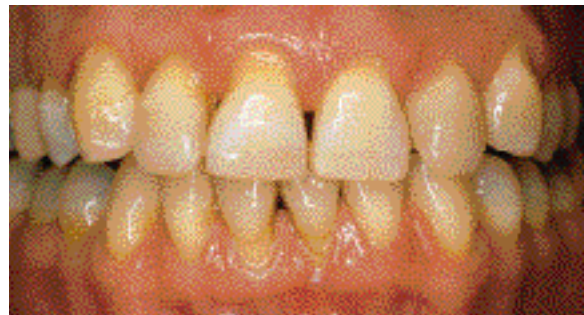

Figure 11-14B: Cosmetic contouring of the labial surface of the cuspids created an improved smile. This conservative treatment was sufficient to esthetically please the patient and avoid the more invasive, full-crown treatment.

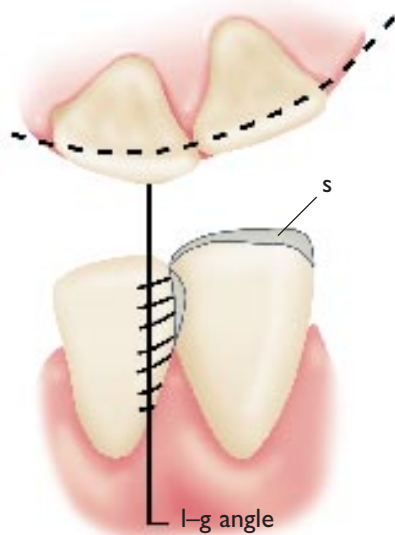


Figure 11-15A: These are the areas to contour to reduce the horizontal overlap and make the teeth appear straight.

tooth and the lingual aspect of a lingually malposed tooth. This straightens the portion that overlaps the adjacent tooth and makes the long axis of the teeth more parallel to each other (Figure 11-15A).

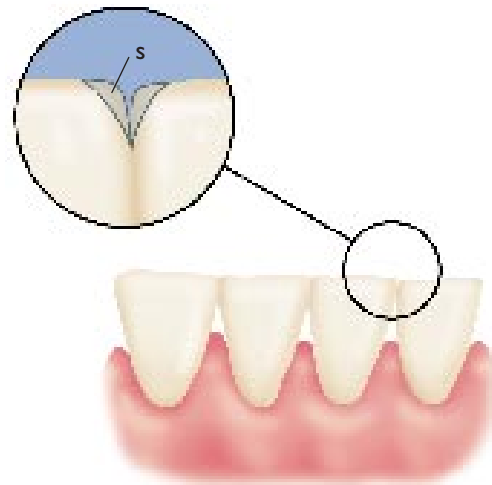


Figure 11-15B: An incisal embrasure can break up a too-even, worn look at the incisal edge.

An important consideration is the amount of tooth structure that will show when the patient speaks and smiles. This can be determined by having the patient repeat words that emphasize different lip positions. Also ask the patient to smile slightly and then to smile as widely as possible. If a compromise has to be reached, then make that

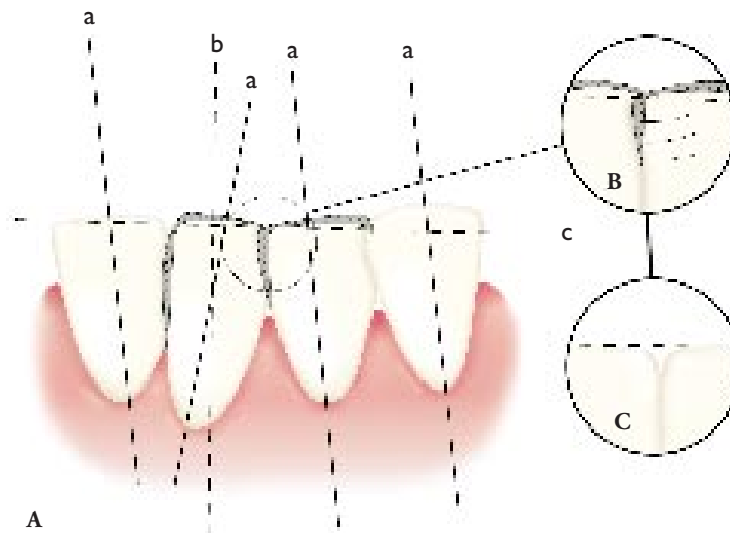


Figure 11-16: *A*, The gingivoincisor angle of straightness between all the teeth must be determined as it will be used to correct the overlapping tooth. The long axes of overlapping teeth will usually vary when the lower anterior teeth are crowded, therefore choose a parallel line (*B*) when doing your mesial and distal correction. *B* and *C*, Reopen the incisal embrasure after removing the incisal and vertical overlaps.

determination during conversation so that the incisal one-third of the dentition—the part that shows most of the time—can be contoured to achieve the desired illusion of straightness.

One important point in reshaping is to make sure that the incisal embrasure between the teeth is reopened to at least 0.25 to 0.50 mm length. This is accomplished by using an extra-thin needle-shaped diamond (DET 3, Brasseler) or abrasive disc (Figure 11–15B). This helps achieve an illusion of straightness. In the labiogingival area, the extension of an overlapping tooth is de-emphasized by blending the shape into the newly created contour.

Care must be taken in reducing the extended portion (circle) of an overlapping tooth (Figure 11–16B). One of the most common pitfalls in reshaping is to thin the tooth so much that the dentin shows through. If that happens, the tooth may appear discolored.

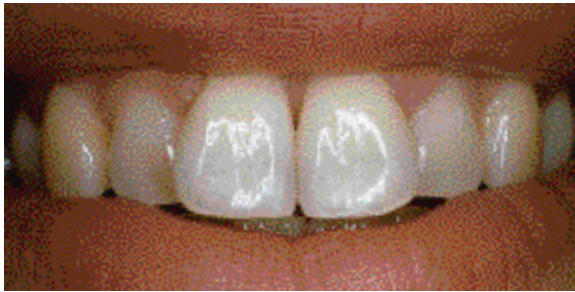

Figure 11–17A: Unesthetic central incisors can benefit from contouring.

The long axis of each of the teeth must be determined, as it will be used to correct the overlapping tooth. Usually the long axes of the teeth (a) will vary from tooth-to-tooth when the lower anterior teeth are crowded (Figure 11–16A). Therefore, choose a parallel line (b) and do all of the mesial and distal reshaping with this line as the guide. Then reopen the incisal embrasure (Figures 11–16B and C).

The following two cases are examples of two solutions to this problem—the first is solved with cosmetic contouring by itself and the second with cosmetic contouring and bonding.



Reducing Large Teeth

PROBLEM: A female, age 25, presented with extremely large, overlapping, and flaring central incisors (Figures 11–17A and B). Because of the

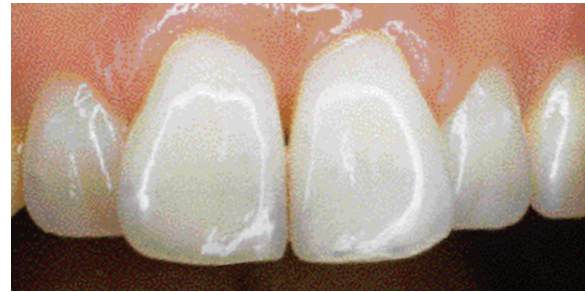


Figure 11–17B: A high lipline made it impossible to conceal the unesthetic appearance.



Figure 11–17C: The diagnostic study casts were shaped with a sandpaper disc, so that the patient could visualize the final result.

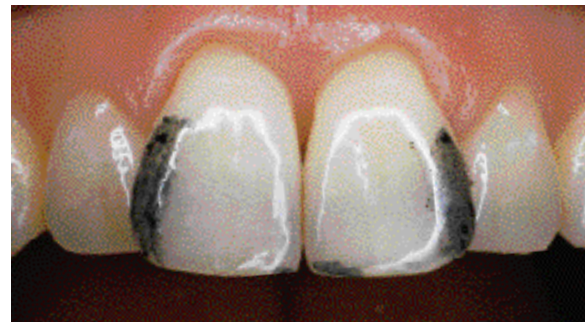

Figure 11–17D: Areas to be reduced were marked with an alcohol marking pen.

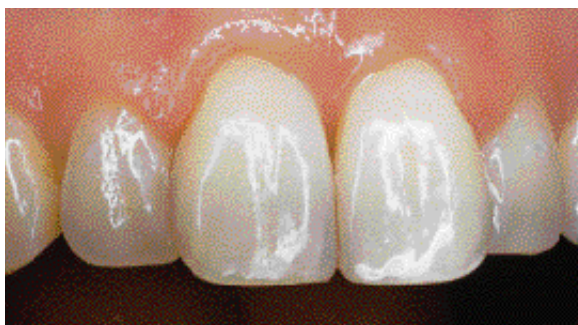


Figure 11-17E: Note the more proportional appearance created by cosmetic contouring and polishing the central incisors.

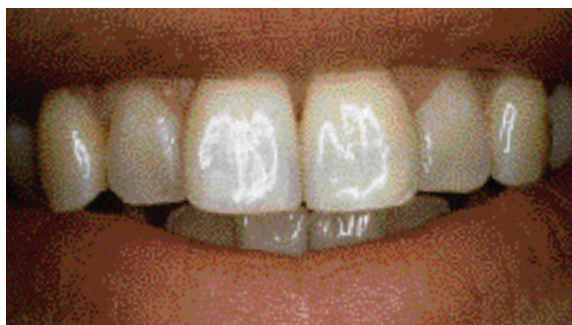

Figure 11-17F: Cosmetic contouring improved this patient's smile. The teeth are now in better proportion.

arch alignment, the labioversion of the centrals called attention to their size. The patient's high lipline made it impossible to conceal the unesthetic appearance.

TREATMENT: Cosmetic contouring was selected as a compromise to orthodontics or crowns. The teeth on the diagnostic study casts were reshaped with a sandpaper disc, so that the patient could then visualize the anticipated result (Figure 11-17C). The areas to be reduced were marked in the mouth (Figure 11-17D). The procedure for reduction and polishing was followed, and the results can be seen in Figure 11-17E.

RESULT: A definite improvement is seen in the patient's smile, since the teeth are now in better proportion (Figures 11-17E and F).



Cosmetic contouring is an important adjunct to bleaching, bonding, veneering, crowning, or any

other treatment designed to make the teeth look better. In fact, the procedure is indicated to some degree in almost every patient who wants to achieve the best smile possible. This is a case that illustrates the combined therapy of cosmetic contouring and composite resin bonding.



Crowded Teeth Featuring Overlapping Large Central Incisors

PROBLEM: This female wanted to improve her smile which was marred by two protruding, wide central incisors (Figures 11-18A and B).

SOLUTION: Cosmetic contouring narrowed the central incisors and composite resin was added to the labial surfaces of the lateral incisors. Figure 11-18C shows the occlusal view of this newly improved arch relationship.

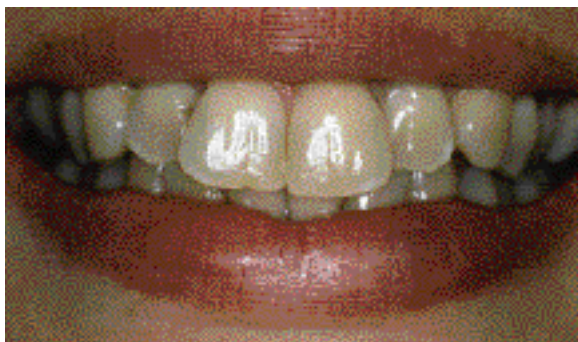

Figure 11-18A: This otherwise attractive 35-year-old female's smile was marred by two extremely wide protruding central incisors.

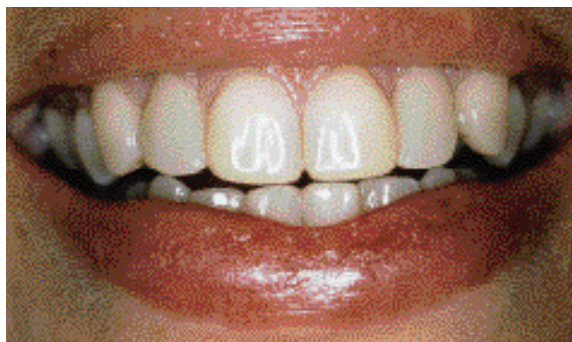

Figure 11-18B: The after smile photo reveals a more symmetrical smile produced in part by the balanced light reflection made possible by building out the lateral incisors.

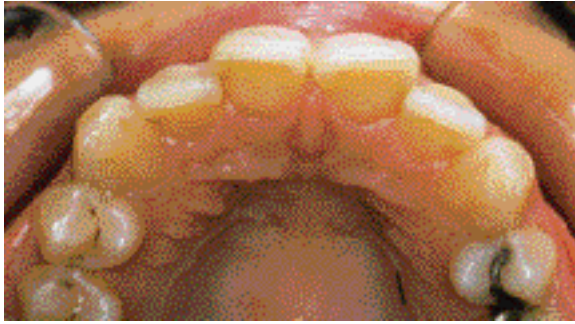

Figure 11-18C: The lingually-tipped lateral incisors seen in this occlusal view needed to be built out labially with bonding.

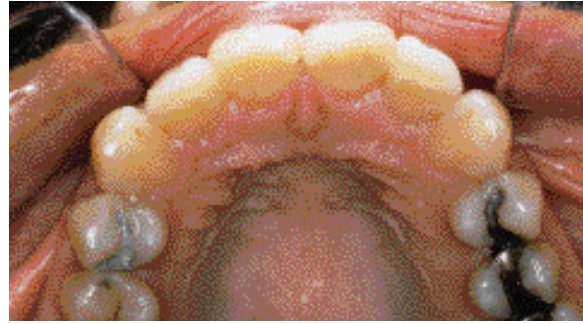

Figure 11-18D: After bonding the lateral incisors with composite resin, there is an improved arch relationship.

RESULT: Better tooth alignment and a balanced light reflection produced a more symmetrical smile (Figure 11-18D). Anterior teeth that are in linguoversion typically can benefit from bonding or veneering to improve the alignment and arch form.



References

1. Frush JP, Fisher RD. Dentogenics: its practical application. *J Prosthet Dent* 1959;9:914.
2. Frush JP, Fisher RD. How dentogenic restorations interpret the sex factor. *J Prosthet Dent* 1956;6:160.
3. Frush JP, Fisher RD. How dentogenics interprets the personality factor. *J Prosthet Dent* 1956;6:441.
4. Frush JP, Fisher RD. Introduction to dentogenic restorations. *J Prosthet Dent* 1955;5:586.
5. Frush JP, Fisher RD. The age factor in dentogenics. *J Prosthet Dent* 1957;7:5.
6. Frush JP, Fisher RD. The dynesthetic interpretation of the dentogenic concept. *J Prosthet Dent* 1958;8:558.
7. Goldstein RE. Study of need for esthetics in dentistry. *J Prosthet Dent* 1969;21:589.
8. Pincus CL. Cosmetics—the psychologic fourth dimension in full mouth rehabilitation. *Dent Clin North Am* 1967;March:71.
9. Shelby DS. Anterior restoration, fixed bridgework, and esthetics. Postgraduate course. First District Dent Soc. of N.Y., October 1967.
10. Simring M. Practical periodontal techniques for esthetics. Postgraduate course. First District Dent. Soc. of N.Y. November 1966.
11. Simring M, Koteen SM, Simon SL. Occlusal equilibration. In: Ward HL, Simring M. *Manual of clinical periodontics*. St. Louis: C.V. Mosby, 1973.

Additional Resources

Abrahams LJ, Simon EE III: Esthetic recontouring and bonding. *Gen Dent* 1987;35:47.

Abrams L. Presentation at American Academy of Esthetic Dentistry (City) (State), 1981.

Antonoff SJ. Esthetics without prosthetics. *J Am Dent Assoc* 1974;88:833.

Appleby DL, Craig C. Subtleties of contour: a system for recognition and correction. *Compend Contin Educ Dent* 1986;7:109.

Brecker SC. Procedures to improve esthetics in restorative dentistry. *J North Carolina Dent Soc* 1957;4:33.

Brecker SC. *Clinical procedures in occlusal rehabilitation*. Philadelphia: W.B. Saunders, 1966.

Brehm TW. Improving esthetics by recontouring natural teeth. *J Prosthet Dent* 1971;26:497.

Chalifoux PR. Perception esthetics: factors that effect smile design. *J Esthet Dent* 1996;8:189-92.

Croll TP. Enamel microabrasion for removal of superficial discoloration. *J Esthet Dent* 1989;1:14-20.

Croll TP. Enamel microabrasion for removal of superficial dysmineralization and decalcification defects. *J Amer Dent Assoc* 1990;120:411-5.

- Glickman I. *Clinical periodontology*. 4th edn. Philadelphia: W.B. Saunders, 1972.
- Goldstein RE. *Change your smile*. Chicago: Quintessence, 1997.
- Goldstein RE, Garber DA, Goldstein CE, Schwartz CG, et al. The changing esthetic dental practice. *J Am Dent Assoc* 1994;125(11):1447-57.
- Goldstein RE. Current concepts in esthetic treatment. *Proc Second Int Prosthodont Congress* 1979.
- Goldstein RE. Diagnostic dilemma: to bond, laminate, or crown. *Int J Periodontics Restorative Dent* 1987; 87(5):9-30.
- Goldstein RE. Esthetics in dentistry. *J Am Dent Assoc* 1982;104:301-2.
- Goldstein RE. Special report: cosmetic contouring. *Cosmet Dent GPs*. 1990;3.
- Goldstein RE, Goldstein CE. Is your case really finished? *J Clin Ortho* 1988;Nov:702-13.
- Goldstein RE. *Esthetics in Dentistry*. Philadelphia: JB Lippincott 1976:162-74.
- Goldstein RE, et al. Immediate conservative corrections of esthetic problems. *J Dent Technol (Jpn)* 1990;75(3): .
- Hak R. Dental tribal marks and habits in the southern provinces of Sudan. *Egypt Dent J* 1961;7:21.
- Heymann HO. The artistry of conservative esthetic dentistry. *J Am Dent Assoc* 1987;Dec(Special Issue):14E-23E.
- Johnston JF, Phillips RW, Dykema RW. *Modern practice in crown and bridge prosthodontics*. 3rd edn. Philadelphia: W.B. Saunders, 1971.
- Kanner L. *Folklore of the teeth*. New York: The Macmillan Company, 1928.
- Koper A, Gordon D. Esthetics in oral restorations. Postgraduate course. University of California, School of Dentistry, December 1971.
- Lenchner NH, Lenchner M. Biological contours of teeth: therapeutic contours of restorations, Part I. *Pract Periodontics Aesthet Dent* 1989;1:18.
- Lombardi RE. The principles of visual perception and their clinical application to denture esthetics. *J Prosthet Dent* 1973;29:358.
- Pincus CL. Functional esthetic restorative procedures. Postgraduate course, University of Alabama, School of Dentistry, February 1962.
- Posselt U, Nilson E. Occlusal rehabilitation in periodontal therapy. *Dent Clin North Am* 1964; March: 183.
- Ramfjord SP, Ash MM. *Occlusion*. 2nd edn. Philadelphia: W.B. Saunders, 1971:271.
- Ross IF. *Occlusion; a concept for the clinician*. St. Louis: C.V. Mosby, 1970.
- Ross IF. Treatment of malposed anterior teeth in adults. *J Prosthet Dent* 1973;30:43.
- Ross IF. Incisal guidance of natural teeth in adults. *J Prosthet Dent* 1974;31:155.
- Ross IF. Tooth movement and repositioning of the mandible without appliances. *J Prosthet Dent* 1974;31: 290.
- Rushton JB. Cosmetic reshaping of the natural teeth [film]. *J Am Dent Assoc* 1958;56:588.
- Saklad MJ. Achieving esthetics with the porcelain jacket. *Dent Clin North Am* 1967;March:41.
- Schaffer BS. Mutilation of the teeth. *Dent Stud Magazine* 1947;25:23.
- Shelby DS. Esthetics and fixed restorations. *Dent Clin North Am* 1967;March:62.
- Stoner C. Types of esthetic corrections. *Dent Digest* 1956;62:403.
- Tylman SD. *Theory and practice of crown and fixed partial prosthodontics*. 6th edn. St. Louis: C.V. Mosby, 1970.
- Ward HL, Rosov H. Tooth mutilations—old and new. *Bull Hist Dent* 1971;19:44.
- Weiller R. Updated esthetics. Postgraduate course. First Dist. Dent. Soc. of N.Y., May 1969.
- Williams HA, Caughman WF. Principles of esthetic dentistry: practical guidelines for the practitioner. In: Hardin J, ed. *Clinical dentistry, IV*. New York: Harper & Row, 1990:Chapter 15.
- Zachrisson BU, Mjor IA. Remodeling of teeth by grinding. *Am J Orthod* 1975;68:545-53.

BLEACHING DISCOLORED TEETH

Ask the average person how they would most like to improve their smile and the answer would most often be “with whiter and brighter teeth.” It is commonly known that people are responded to in a more positive manner when they have a dazzling, healthy smile. This chapter is about how dentistry can fulfill our patients’ requests for a brighter smile through bleaching.

Most newly formed teeth have thick, even enamel. This enamel layer modifies the base color of the underlying dentin, creating a milky white appearance.¹² For many of your patients, that bright, white look can typify youth, health, and physical attractiveness. It is the look against which they measure the appearance of their own teeth.

For some, unfortunately, their teeth will seem dingy and discolored in comparison. Teeth become stained and discolored, sometimes before they even erupt, almost always as they age, for one or more genetic, environmental, medical, or dental reasons. The most common problems are the superficial color changes that result from tobacco, coffee or tea, or highly colored foods. Teeth that contain microcracks are particularly susceptible to these stains. Discoloration also occurs through the penetration of the tooth structure by a discoloring agent, such as a medication given systemically, excessive fluoride ingested during the development of tooth enamel, byproducts of the body such as bilirubin released into the dentinal tubules during illness, trauma (primarily the breakdown of hemoglobin), or pigmentation escaped from the medications and materials used in dental repair. Wear and thinning of the enamel caused by aging, too abrasive cleaning materials and aggressive brushing, and acidic food and drink also can diminish the covering power of the white enamel, letting more of the darker-hued dentin show through.¹²

Severe discoloration of a tooth or teeth can be a major esthetic problem. If left untreated, this discol-

orization may produce social and psychological difficulties. Other chapters have described some of the ways in which dentistry has responded to patients’ desire for whiter teeth, from full crowns to bonding and laminating with various veneers and inlays and onlays. For the appropriate patient, with careful diagnosis, case selection, treatment planning, and attention to technique, bleaching can be the simplest, least invasive and least expensive approach to brighter teeth. Sometimes one office session is sufficient to change a patient’s appearance dramatically. If considered as an adjunct to other procedures for correcting discoloration and other esthetic problems, bleaching extends promise to an even larger group of patients who seek more attractive teeth.

Bleaching Vital Teeth

The earliest efforts to bleach teeth go back more than a century and focused on the search for an effective bleaching agent to paint on discolored teeth. As described in a detailed history by Zaragoza,³⁸ Abbot had introduced by 1918 the forerunner of the combination used to bleach vital teeth today: hydrogen peroxide and an accelerated reaction caused by devices delivering heat to the teeth.

The recent history of this procedure comprises the bleaching of stained vital teeth that became increasingly popular in the 1970s when a growing number of dentists saw how well it worked on the stains caused by tetracycline ingestion at critical developmental stages of the teeth.

Although many of the mechanisms by which bleaching removes discoloration may not be fully understood, the basic process almost certainly involves oxidation, during which the molecules causing the discoloration are released. The use of heat and light devices appears to accelerate the oxidation reaction.

For the next 20 years, in-office bleaching or power bleaching by dentists proved helpful for this

and other problems. More recently, dentists began combining in-office bleaching with further treatments that the patient continues at home. This combination is increasingly popular among dentists and patients alike, particularly because of the ease and lower costs of night guard vital bleaching.

In the early 1990s, bleaching gained a new prominence in the public eye with the introduction and aggressive marketing of bleaching materials intended to be used without dental evaluation and monitoring.²⁰ The widespread acceptance of these products can also be seen as a disturbing trend due to the potential for misdiagnosis, use of bleaching for inappropriate conditions, poorly fitting mouthguards, and unesthetic or painful results. Bleaching materials applied inappropriately may make the existing situation worse, creating uneven color change or deleteriously affecting restorations. The availability of such products places additional responsibility on the dental profession to make people aware how well professionally applied bleaching works, or whether it works at all, depends on the discoloration itself, its cause, the length of time the discoloring agent has permeated the structure of the tooth, and other factors about which a dentist's advice and monitoring is critical.

A good visual examination usually will suggest the etiology of discoloration and consequently the appropriateness of bleaching as a treatment. The diagnostic workup should include pretreatment photographs, x-ray films, and an intensive prophylaxis to remove superficial staining that may be compounding more intrinsic discoloration. The presence and condition of all restorations must be noted, and special attention paid to the materials of which these are made. The medical history should focus on diagnosis of any systemic problems or medications that might have affected or be affecting tooth coloration. A behavior inventory should determine the possible contributions of tobacco, beverage, and foods. The workup should establish color baselines, note the condition of the teeth and mouth in general, and note the patient's tooth sensitivity in particular.

Etiology of Discoloration

Extrinsic Stains. The most commonly seen staining of vital teeth is the result of highly colored drink or food. Tobacco produces a yellowish brown to black discoloration, usually in the cervical portion of the teeth and primarily on the lingual sur-

faces. Chewing tobacco frequently penetrates the enamel to produce an even darker stain, and marijuana may produce sharply delineated rings around the cervical portion of the teeth next to the gingival margins. Coffee and tea can cause severe, tenacious brown to black discolorations. Those stains, like the ones caused by brightly colored foods, are most difficult to remove from pits, fissures, grooves, or enamel defects. You can try bleaching if the enamel seems slightly stained, once you have attempted conventional surface removal procedures.

Intrinsic Stains. The most difficult discoloration to remove by bleaching is an endogenous stain such as the intrinsic stains that occur when the tooth structure itself is penetrated by some discoloring agent, usually during the formation of the tooth. Since enamel and dentin are porous tissues, the scientific basis for bleaching vital teeth is sound, however. How the stain occurs is a significant factor in understanding and evaluating bleaching techniques.

Tetracycline Stain. The success of bleaching for the yellow, or brown stains caused by tetracycline discoloration was key to its place in the emerging field of dental esthetics. The devastating effect on tooth formation of as little as one gram of tetracycline was recognized in the late 1950s,¹ with the first certain identification reported by a study of cystic fibrosis patients by Swachman et al.³⁵ In 1970, Cohen and Parkins published a method for bleaching the discolored dentin of young adults with cystic fibrosis who had undergone tetracycline treatment.¹⁰ The results were promising, and dentists concerned with esthetics began applying bleaching procedures to other stains and discolorations.

Teeth are most susceptible to tetracycline discoloration during their formation, that is, during the second trimester in utero to roughly 8 years of age. It is believed that the tetracycline particles are incorporated into the dentin during calcification of the teeth. Mello²⁹ reports that the probable mechanism by which tetracycline molecules bind to dentin involves chelation with calcium, which forms tetracycline orthophosphate, the cause of tooth discolorations. When tetracycline-stained teeth are exposed to sunlight, they gradually turn to shades of dark gray or brown. Cohen and Parkins¹⁰ suggest that the reason the labial surfaces of the incisors darken while the molars remain yellow for a longer period of time is because of the different exposure to light.

Although the Food and Drug Administration issued a warning about the use of such antibiotics for treating pregnant women and children more than a quarter of a century ago, unfortunately, tetracycline cases are still seen.

The severity of the stains depends on the time and duration of the drug administration and the type of tetracycline administered (more than 2000 variants have been patented). Because of these factors, tetracycline staining is extremely variable in its extent, coloration, depth, and location. Fluorescence is necessary for precise diagnosis and description but most cases fall into the three major categories of tetracycline involvement first proposed by Jordan and Boksman in 1984.²⁷ Each category has a different prognosis for successful bleaching.

- First-degree tetracycline staining is a light yellow or light gray staining, slight but uniformly distributed throughout the crown without

banding, or concentrated in local areas. It is highly amenable to vital bleaching, with good results usually in fewer than four sessions of office bleaching or one series of dentist-monitored home bleaching (Figures 12–1A and B).

- Second-degree tetracycline staining is a darker or more extensive yellow or gray staining without banding. Although this type is responsive to vital bleaching, it may take five or more in-office treatments to obtain a satisfactory result. A combination of in-office/home matrix bleaching is the preferable technique (Figures 12–2A and B). Home bleaching alone may take 2 to 6 months.
- Third-degree tetracycline staining produces severe staining, characterized by dark gray or blue coloration, usually with banding. Although bleaching may lighten these teeth to some degree, the bands may remain evident follow-

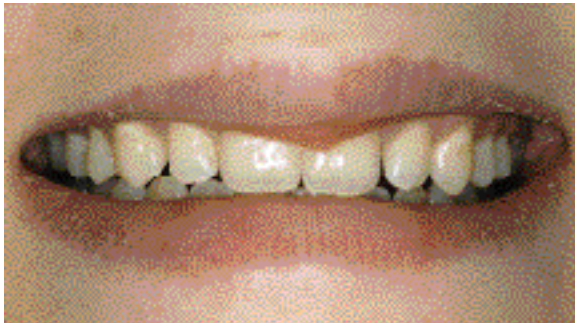

Figure 12–1A: This is a good example of first-degree tetracycline stain, which is usually light yellow or grey, and slight and uniformly distributed throughout the crown with no banding or localized heavy concentration.

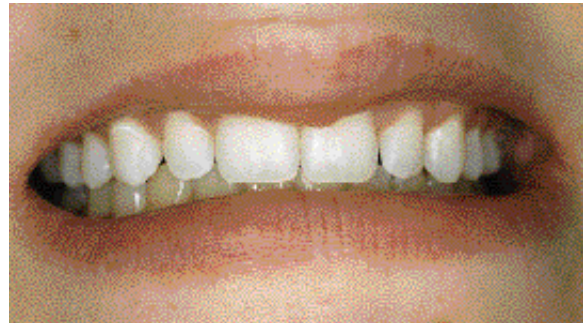

Figure 12–1B: Bleaching a first-degree tetracycline stain usually produces a good result like the one shown here, which is a combination of one in-office treatment plus home bleaching for 3 weeks.

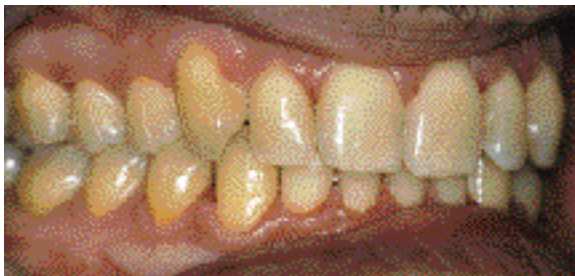

Figure 12–2A: The darker and more extensive yellow stain seen here is typical of second-degree tetracycline stain.

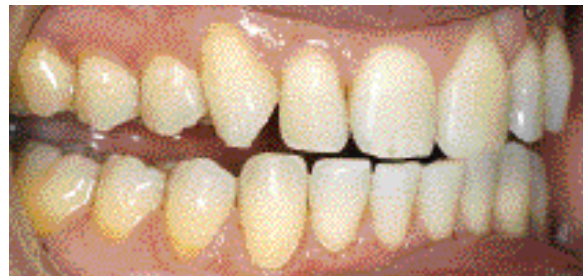

Figure 12–2B: Although responsive to vital bleaching, second-degree tetracycline stain generally takes five or more in-office treatments, as this one did, to obtain a good result.

ing even extensive treatment. Veneering techniques with opaquers are often necessary to achieve satisfactory esthetic results (Figures 12–3A and B).

- Fourth-degree tetracycline, while not one of the original categories proposed by Jordan and Boksmann,²⁷ includes those stains that some dentists believe are too dark to attempt vital bleaching¹⁷ (Figure 12–4). However, these stains may not be too dark to try bleaching unless there is blue-gray stain at the gingivae.

Minocycline Stain. Because tetracycline is incorporated in the dentin during calcification of the teeth, adults whose teeth have already formed appear to be able to use the antibiotic without risk of discoloration. However, recently a semisynthetic derivative of tetracycline has been found to cause staining on the teeth of adolescents who were being given the drug for severe acne.⁸ Unlike tetracycline, minocycline is absorbed from the gastrointestinal tract and combines poorly with calcium. Researchers believe the tooth pigmentation occurs because of minocycline's ability to chelate with iron and form insoluble complexes. A study by Dodson and Bowles¹¹ suggests the minocycline pigment produced in tissues is the same or very similar to that produced by UV radiation. Since minocycline is used for a variety of infections as well as for acne, you should expect to see rising numbers of cases of this discoloration and questions regarding its use should be included in the medical history of patients. Although these stains may be responsive

to bleaching, severe banding of the stains may suggest laminating for a satisfactory result. In each situation, the treatment depends on the degree of lightening desired by your patient.

Several adult patients have presented with stained teeth similar to the patient seen in Figure 12–5A. In each instance, the patients stated that the teeth had severely discolored after they began taking minocycline. Although the stain is somewhat amenable to bleaching, there is no guarantee that the final result will match the patient's previous tooth color. As a case in point, the patient in Figure 12–5B did achieve a light shade. Nevertheless, she ultimately decided to have her teeth laminated so she could obtain a much lighter color.

Fluorosis Stain. Black and McKay⁷ gave the first clinical description of fluorosis in 1916, although the role of fluoride in causing these defects was not discovered for another 15 years. In areas where drinking water has a fluoride content in excess of 1 to 2 ppm, children may ingest excessive fluoride during the development of enamel and calcification. The high concentration of fluoride is believed to cause a metabolic alteration in the ameloblasts, which results in a defective matrix and improper calcification. Histologic examination of the affected teeth will show a hypomineralized, porous subsurface enamel below a well-mineralized surface layer. This enamel hypoplasia is called endemic enamel fluorosis or mottled enamel. In general, there are two types of damage: discoloration and surface defects. The affected teeth are

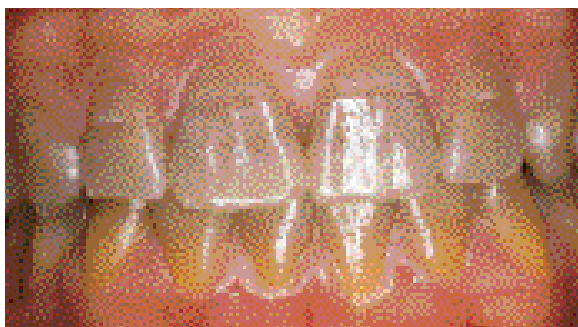

Figure 12–3A: Third-degree tetracycline stain generally does not respond well to bleaching. Depending on the patient's needs, a better result would be achieved with porcelain laminates.

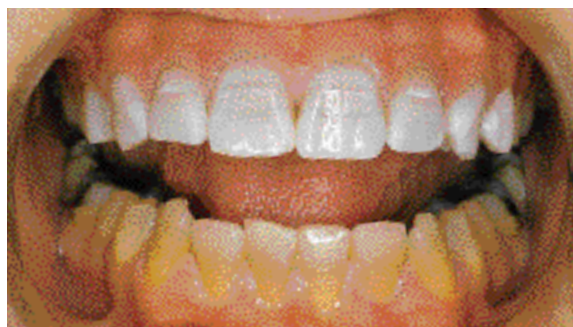

Figure 12–3B: This is an example of what can be achieved with multiple in-office visits. Although bleaching did lighten these teeth to some degree, the bands are still evident and the overall color would not be satisfactory to most patients. Nevertheless, there will be some patients who will prefer their own teeth lightened as much as possible rather than veneering.

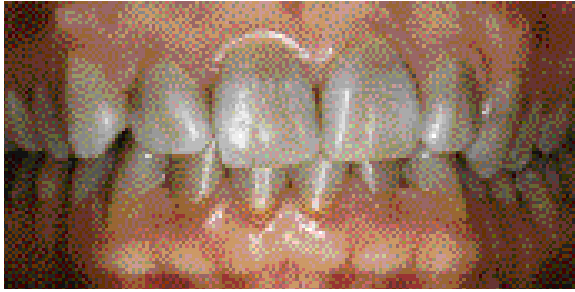

Figure 12-4: This is a good example of what has been termed fourth-degree tetracycline stain, which is so dark that bleaching may not respond enough to please the patient. Patients can be persuaded to seek one of the veneering methods to accomplish tooth lightening.

usually glazed on the surface and may be paper white with areas of yellow or brown (and sometimes black) shades. Shading does not take a definite pattern and may be located on any area of the teeth. In some cases, as Arens reports,¹ the labial surfaces are pitted. If the mottling is serious enough, the enamel may be chalky, without the glaze and luster of a normal tooth. As Bailey and Christen note,² the condition becomes more severe with increased concentration of the fluoride ion.

Bleaching can be an effective modality for the discoloration associated with fluorosis. It works best for simple fluorosis staining, i.e., brown pigmentation on a smooth enamel surface. It is less successful with opaque fluorosis, in which flat gray or white flecks are visible on the enamel surface, or when there are

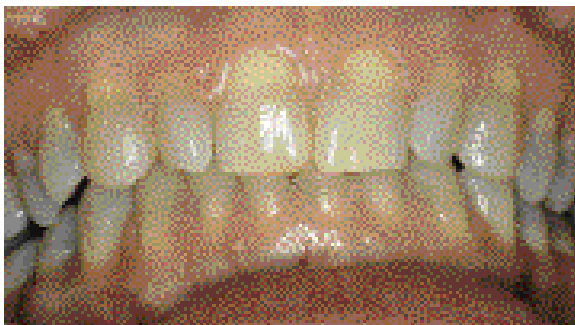

Figure 12-5A: This female took several doses of the antibiotic minocycline for her facial complexion. Shortly after, she began to notice some darkening of the teeth, which continued until they reached the above color. She states that she had “white” teeth up until that time.

white or opaque spots or multicolored staining (Figures 12-6A and B). Although bleaching will lighten the white spots, it will also lighten the surrounding tooth color, which may make the white spots less noticeable. In such cases, and in cases in which staining is accompanied by pitting and other surface defects, bleaching is best viewed as a useful adjunctive treatment preceding bonding or veneering. Bleaching should never be used for sensitive teeth in which fluorosis has caused severe loss of enamel. A restorative masking procedure is a better alternative.

Stain from Dental Conditions or Treatments.

Dental caries are a primary cause of pigmentation and may be seen as an opaque, white halo, or a gray discoloration. An even deeper brown to black discoloration can result from bacterial degradation of food debris in areas of tooth decay or decomposing filling. Such problems should be corrected before bleaching is attempted. In some cases, repair and proper cleaning may negate the need for bleaching.

Restorations also frequently cause discolorations. Degraded tooth-colored restorations such as acrylics, glass ionomers, or composites can cause teeth to look grayer and discolored. Metal restorations, such as amalgams, even silver and gold, can reflect discoloration through the enamel and should be replaced with less visible materials such as composite resin before bleaching.³ Again, in some cases, bleaching may then not be necessary once such changes are made. If amalgams cannot be replaced, however, bonding or laminating may be preferable alternatives.

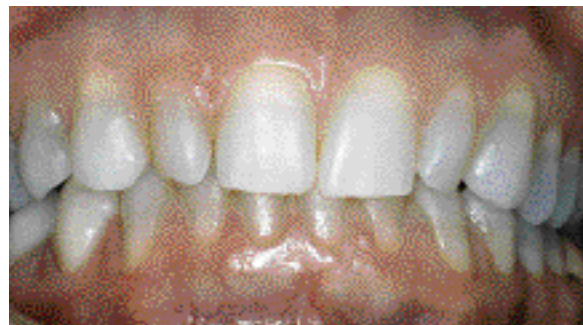

Figure 12-5B: Six in-office treatments plus 1 month of home matrix treatments were used to obtain this result.

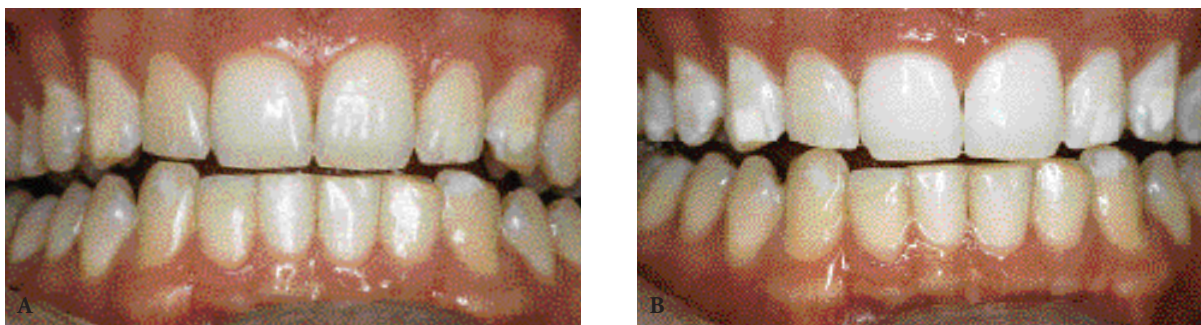


Figure 12-6A and B: When hypocalcified spots (A) are bleached the teeth become lighter. Note how the hypocalcified areas can also become lighter and in some instances stand out even more (B).

Oils, iodines, nitrates, root canal sealers, pins, and other materials used in dental restorations can cause discoloration. The length of time these substances have been allowed to penetrate the dentinal tubules will determine the amount of residual discoloration and will, consequently, affect the success of bleaching. Metallic stains are the most difficult to remove.

Stain from Systemic Conditions. Although there are a large number of genetic conditions or childhood illnesses that cause discoloration of the teeth, most are rare and infrequently seen. Bleaching can be quite effective for the discoloration caused by infusion of the dentin during development. Some examples are:

- the bluish-green or brown primary teeth seen in children who suffered severe jaundice as infants. The stains are the result of postnatal staining of the dentin by bilirubin or biliverdin.
- the characteristically brownish teeth caused by destruction of an excessive number of erythrocytes in the blood cells that occurs in erythroblastosis fetalis, a result of RH factor incompatibility between mother and fetus.
- the purplish-brown teeth color of persons with porphyria, an extremely rare condition that causes an excess production of pigment.

Other illnesses cause discoloration of the teeth by interfering with the normal matrix formation or calcification of the enamel. Hypoplasia or hypocalcification can occur with genetic conditions like amelogenesis imperfecta and clefting of the lip and palate or with acquired illnesses such as cerebral

palsy, serious renal damage, and severe allergies. Brain, neurological, and other traumatic injuries also can interfere with the normal development of the enamel. Deficiencies of vitamins C and D, and calcium and phosphorus can cause enamel hypoplasia if they take place during the formative period. Bleaching is usually a less appropriate treatment than bonding, laminating, or crowning for these problems involving the structure of enamel.

Discoloration Due to Aging. With the aging population of America, an increasing number of your patients will be older. We no longer expect to lose our teeth as we age as our great-grandparents expected, nor do most persons in our youth-oriented society easily accept the changes in color, form, and texture of teeth that almost inevitably accompany aging. The type and degree of such changes will depend on a mixture of genetics, use and abuse, and habits. Years of smoking and coffee drinking have a cumulative staining effect, and these and other stains become even more visible because of the inevitable cracking and other changes on the surface of the tooth, within its crystalline structure, and in the underlying dentin and pulp. In addition to wear and trauma on the teeth, amalgams and other restorations placed years ago may begin to degrade.

Even with the most careful avoidance of or attention to such problems, our teeth are likely to become more discolored as we age, both from natural wear and exposure to normal environmental insults. The first change to occur is usually a thinning of the enamel. This may cause the facial surface of the tooth to appear flat with a progressive shift in color due to a loss of the translucent enam-

el layer. At the same time the enamel begins to thin, secondary dentin formation begins through a natural tooth protective mechanism in the dentin and pulp. This larger mass of dentin also begins to darken. The combination of thinned enamel and darkened dentin creates an older-looking tooth. If these types of problems occur in a young individual, laminating will produce a better long-term result.

For many of the discolorations seen in older patients, home matrix bleaching can be a safe, effective treatment option. Additionally, unless the enamel is too badly worn, in-office or combined bleaching can be an effective treatment. For many geriatric patients, the short time required in the dental chair, the relatively low cost, and lack of trauma involved make bleaching an especially appealing treatment. Another reason why bleaching can be such an effective treatment for older patients is that in most instances the pulp has shrunk back, making it possible to use higher bleaching temperatures.

Contraindications to Bleaching of Vital Teeth Using In-Office Techniques

The following problems may suggest the use of other methods of esthetic improvement or may be more appropriate for dentist-monitored home bleaching:

- Extremely large pulps, which may increase sensitivity.
- Other causes of hypersensitivity, such as exposed root surfaces or the transient hyperemia associated with orthodontic tooth movement.
- Severe loss of enamel.
- Teeth exhibiting gross or microscopic enamel cracking.
- Extremely dark teeth, especially those with banding.
- Teeth with white or opaque spots. Although bleaching will not eradicate these spots, the process can lighten the surrounding tooth structure and then the white spots can be eliminated with microabrasion or with bonding.
- Teeth in which there are restorations that must be matched or, especially, teeth that have been bonded or laminated.
- Extensive restorations. Koa et al.²⁸ suggest strongly that bleaching materials never come in contact with restorative materials. Their

study of bleaching chemicals found some roughening on contact with all tooth-colored restorative materials, the greatest damage done to glass ionomer, the least to porcelain. (See also various studies referenced in the section on matrix bleaching in which the teeth have a longer exposure to the chemicals, although the chemicals are less invasive.)

- Patients who are perfectionists. Bleaching is not perfect, in the way veneers can be. This is especially true for severe stains. With darker tetracycline stains, for example, the majority of the bleaching will occur on the incisal one-half of the teeth. The remaining surfaces can only be partially helped by a selective bleaching solution and heat application.

For these patients, and others, you may find that a combined bleaching approach and restorative procedures like bonding, veneering, or crowning are indicated. For example, patients with Class V lesions which are eroded and sensitive may find there is too much discomfort with the bleaching process, either in the office or at home. In these instances, an alternative is to cover the sensitive areas with a rubber dam or dam substitute (Den-Mat or Ultradent) while bleaching, and to bond the cervical areas with slightly lighter composite, hoping that the remainder of the tooth will “catch up” in color.

Level of Expectation

The “perfectionist” type of patient may not be happy unless the teeth resemble the concept of the “Hollywood starlet.” However, others may enjoy and appreciate only a slight lightening of tooth shade (Figures 12–7A and B). It is essential that you thoroughly understand the color level your patient expects. The imaging computer can be of considerable help in this regard.

SEQUENCE OF TREATMENT

Simple discoloration generally can be effectively treated with in-office bleaching. An individual tooth discoloration would usually require an in-office individual bleaching instrument whereas generalized discoloration would need a comprehensive in and/or out-of-office treatment. Classification should be based on the type of discoloration and whether it is generalized or individualized.

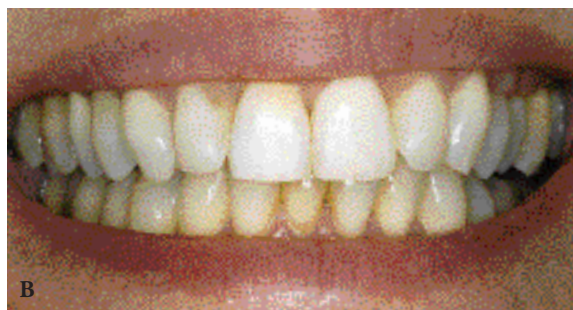
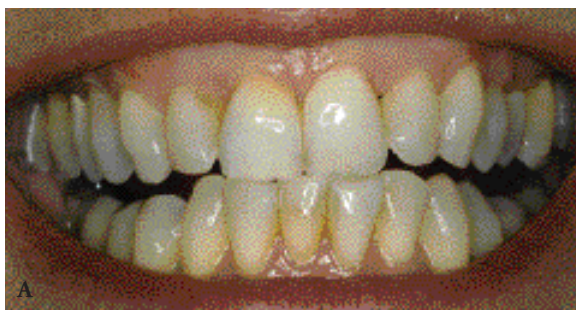
Figure 12–7A and B: Many patients are satisfied with only a minimal result (A). The patient was happy after two in-office bleaching treatments (B).

Individual Stains. Teeth that have staining in one or more areas are usually treated differently than generalized staining. Although tooth contouring can sometimes make stains disappear if they are only in the first cell layers of enamel, bleaching the darker stain with repeated short treatments is generally the treatment of choice. Selective tooth isolation with the rubber dam is the best method for treating this problem (Figure 12–8). Teeth that have had traumatic injury can sometimes be bleached by in-office, by itself or combined with matrix, bleaching or matrix bleaching alone. Selective placement can also be effective with traumatically involved teeth (Figures 12–9A to C).

Generalized and Yellow Stains. Teeth that are yellowing due to heredity or age can usually be improved with both in-office and matrix bleaching. In most instances, bleaching teeth should be attempted before any other treatment is undertaken, with the exception of soft tissue management.

Sequence of Therapy

1. Soft tissue management (prophylaxis).
2. Bleaching teeth.
3. Re-evaluation/restorative considerations.
4. Restorative treatment.

In general, treat one arch at a time. This provides a good comparison of just how effective your treatment is. However, certain patients have limited time or want to maximize their dental appearance, so consider bleaching both arches simultaneously (Figures 12–10A to C).

COMBINED BLEACHING

When combining bleaching with restorative dentistry, estimate the number of bleaching treatments in the office or at home before an acceptable result will be affected in order to calculate how long afterwards the restorative treatment could begin. Generally, this occurs 2 to 3 weeks after the last bleaching treatment. For in-office bleaching alone, this is about 2 weeks but if at-home treatments are included, then add an additional 4 weeks. Eight weeks from the onset of this combined bleaching approach is usual. Some patients are happy with the bleaching regimen alone but others will desire bonding or laminates as the total treatment.

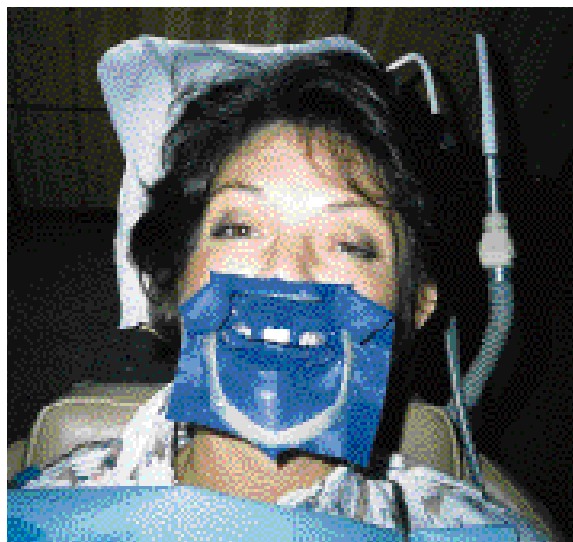

Figure 12–8: Rubber dam placement: in-office selective bleaching can be accomplished by carefully applying the rubber dam to expose only the teeth that require bleaching.

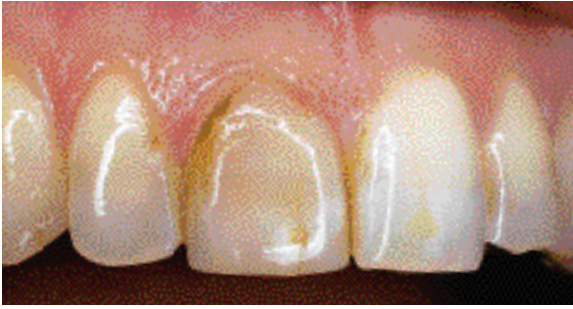

Figure 12-9A: This female patient presented with a cervical stain on this previously traumatized yet still vital tooth.

Bleaching Combined with Crowning

When crowns are anticipated but adjacent teeth are to be corrected with bleaching first, wait at least 2 to 3 weeks before taking the shade for the final crowns. In the event you must take a shade prior to seeing the final bleaching result, choose a lighter shade and be prepared to darken the crown if necessary to match the final color. The patient should be warned that additional matrix or in-office bleaching may be necessary from year to year or after several years in order to keep the adjacent teeth matched to the new crown or crowns.

Bleaching Combined with Orthodontics

It is generally preferred to bleach teeth before orthodontia is initiated if ceramic or metal brackets will be bonded to the teeth because the bonding impregnates the enamel and thus makes it more difficult to bleach. However, it is acceptable to straighten the teeth first, remove the brackets, and clean the teeth of all bonding materials before bleaching. In this case, a Prophy-Jet (Dentsply, Int.) should be used, followed by a mild etching before the first bleaching treatment to make sure there is no bonding material remaining on the teeth.

It is also possible to do a combined technique when a removable orthodontic positioner is being used to move the teeth (Figure 12-10D). The bleaching solution can be added to one or both arches in the clear orthodontic positioner. A breathing space can also be created in the splint between the arches (Figure 12-10E).

Bleaching Combined with Periodontics

Patients with soft tissue problems must first be treated to control and reverse the inflammation before bleaching is attempted. However, if




Figure 12-9B: The tooth is isolated with a rubber dam and treated with 35% hydrogen peroxide combined with a heat wand.

advanced bone loss is present and surgery will mean raising the tissue well onto the root surface, it may be advisable to perform an in-office power-bleach with adequate rubber dam protection before periodontal therapy is undertaken. This would make it easier for the tissue to hold the dam in place at the CE junction, rather than having the cervical root surfaces being exposed to the bleaching solution.

In the event that the patient already has root exposure, you may need to mask those areas with artificial dam material (Ultradent or Den-Mat) and seal the defects with composite resin to prevent any leakage of the bleaching solution from damaging these areas.

Bleaching Combined with Bonding

Patients who have a considerable amount of bonded restorations should be advised that any leaking or defective restoration should be replaced prior to in-office power bleaching. However, this could mean

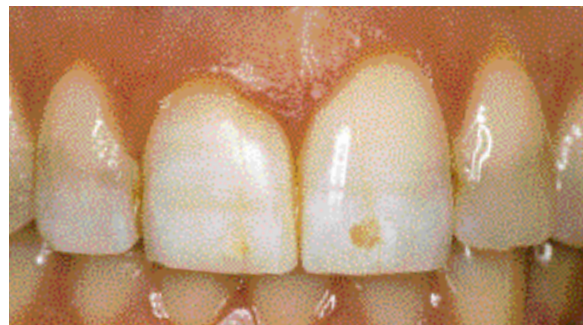

Figure 12-9C: Polishing with coarse pumice and external surface bleaching with heat successfully restored the patient's tooth color.

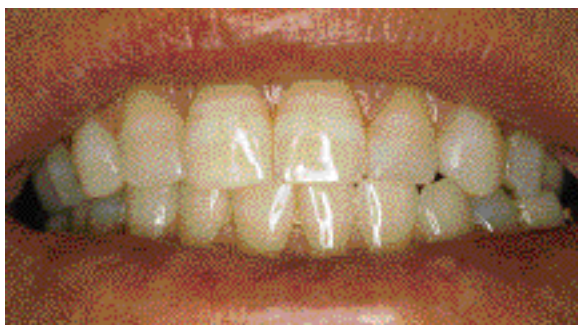

Figure 12-10A: This busy executive wanted to lighten his teeth as quickly as possible.

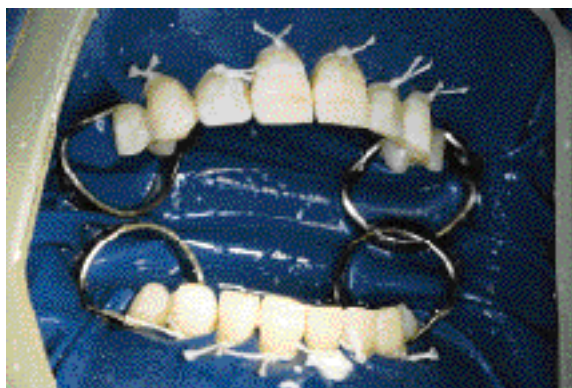

Figure 12-10B: A rubber dam was applied to both arches to save treatment time.

double replacement or, at the very least, partial veneering to match the final shade several weeks after the last bleaching treatment. An alternative plan would be to etch the defective margins and seal the defects with composite resin to prevent leakage of the concentrated bleaching solution into the compromised teeth. (Because of the lower concentration of bleaching solution, this would not be a problem with dentist-monitored home bleaching.)

- For dark, irregularly marked or spotted teeth, bleaching can be a useful adjunctive treatment, improving the results of bonding or veneering. But one study by Torneck et al.³⁷ reported that bleaching bovine teeth with peroxide reduced the adhesion of light-cured resin, regardless of whether it was applied before or after etching. It was suggested that residual peroxide in the dentinal tubules interfered with bonding and even 1 minute of washing with water did not

eliminate this residual peroxide. However, as cited in Torneck et al.,³⁶ several studies have shown that roughening the enamel or waiting 1 day to 2 weeks will eliminate this reduction of adhesion. Torneck recommends waiting longer than 7 days after bleaching before attempting bonding restorations. Nevertheless, Barghi⁴ found that using a water displacement solution and a dentin bonding agent containing acetone could result in immediate successful bonding. A partial veneering using the overlay techniques (as described on page 296) is oftentimes the esthetic treatment of choice to blend in the old restoration with the newly bleached result.

Bleaching for Children

Children with discolored teeth can be good candidates for bleaching but there are several caveats. The

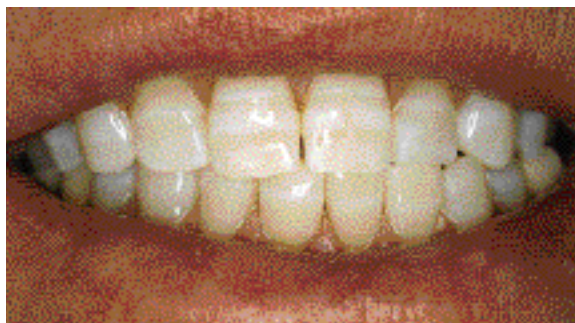

Figure 12-10C: Three in-office bleaching appointments produced this lightened result.

larger pulps of children can lead to greater sensitivity when office bleaching is performed and you should be especially careful to avoid irritation of the pulp, including not using heat. If a child has an adequate number of teeth to hold a matrix in place, dentist-monitored home bleaching may be preferable. However, you will need to make the child understand that less than perfect home care will tend to leave plaque on teeth, diminishing the effect of bleaching. It is imperative that the teeth be clean before bleaching at home. Disclosing tablets or solutions may be effective tools in helping less than meticulous brushers see what they are missing. And you must forewarn the child and parents that bleaching will need to be repeated as new teeth erupt.

Bleaching for Elderly Patients

Older patients are excellent candidates for bleaching, especially to improve the yellowing that can occur with age, but their teeth must be basically free of defects and restorations. In fact, since the pulps often have receded, there usually will be little or no sensitivity present during the bleaching process. This means you will be able to use photo-oxidation or heat as a method of choice. Older patients can withstand higher heat when the Illuminator (Union Broach) or bleaching light or even laser is used, which should permit faster results.

Office bleaching will most often be the technique chosen by the elderly who wish to have lighter teeth. Although they may have more time for home or matrix bleaching, their patience with

all the ramifications of matrix bleaching may not be sufficient. In addition, if there is any problem with the intraoral tissues, matrix bleaching could be contraindicated. Dry mouth syndrome, periodontal disease, or advanced bone loss are all conditions that may influence the choice of bleaching technique. If you find that your patient's soft tissues become irritated with matrix bleaching, switch to rubber dam protected office bleaching.

Techniques for In-Office Bleaching of Vital Teeth

The etiology of the discoloration makes a difference in the techniques selected for bleaching vital teeth but the procedures for preparing and protecting the mouth are identical. No matter which form of concentrated hydrogen peroxide or bleaching apparatus is used, it is essential to protect the tissue.

Preparation

1. Record the staining, with an instant and/or 35-mm camera, possibly using a constant such as a shade tab in the photograph. This provides an excellent data baseline and record of pretreatment that will be useful in determining needed follow-up. Because bleaching can be an incremental, gradual change, patients often forget what their teeth looked like before and are surprised to see how discolored their teeth actually were.
2. Verify the vitality of the teeth, their sensitivity, and the repair and replacement you deter-

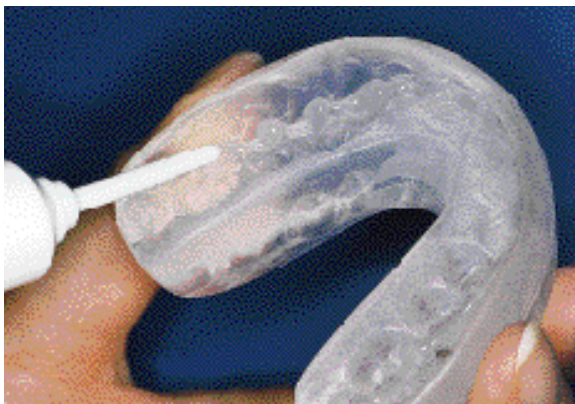

Figure 12-10D: Bleaching solution is added to this removable orthodontic positioner.

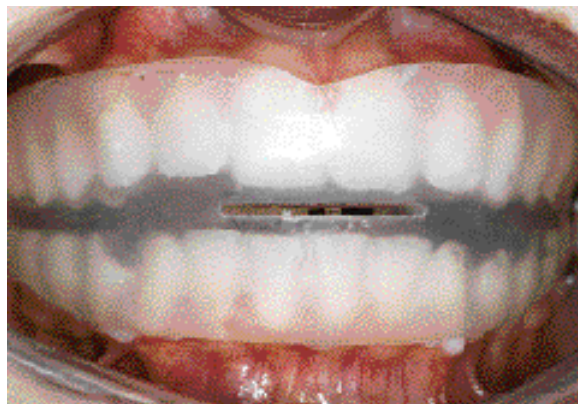

Figure 12-10E: If both arches are being straightened and bleached, a breathing space can be created in the combined matrix/retainer. This special dual-therapy appliance represents a real time saver for the patient.

mined were necessary during the diagnostic workup. This should have concentrated on any possible periapical or other pathology, caries, defective restorations, and any enlargement of the pulp that might indicate that the teeth could be unusually sensitive to temperature changes involved with office bleaching. Radiographs and thermal and electric pulp tests are the only means of answering questions of pulp size and vitality that, in turn, will help determine the procedures to be used in bleaching. Ultraviolet light is the only definitive method for diagnosing tetracycline staining; the tetracycline depositions will fluoresce. Transillumination techniques will enable you to look at the teeth from different angles and observe the opacity, depth, and layers of any stains. Transillumination also can reveal microcracks, decalcified or hypocalcified areas, and areas of excess calcification, all of which may affect coloration and/or supply information essential for diagnosis of causative factors.

3. Free the teeth of all surface stains and plaque with a Prophy-Jet (Dentsply) or similar cleaning device. Normal prophylaxis pastes, even the very good ones, are simply not strong enough to take off deeply ingrained stain.
4. Isolate and protect the teeth and mouth (Figures 12–11A to H). Apply plain Oraseal (Ultradent) to gingiva, labially, buccally, lingually, and interproximally, to protect the soft tissue.




Figure 12–11A: An alcohol marker (Masel) is used to score the rubber dam for exact spacing between the teeth so that no leakage will occur.

The teeth to be bleached should be isolated with a rubber dam and all teeth ligated with waxed dental floss. Form a protective pocket with the corners of the rubber dam by placing Oraseal on the interproximal surfaces only at the gingival areas to act as an additional seal to prevent leakage. Also put Oraseal on any amalgams present to seal and help block out some of the heat that will be generated by the bleaching instrument (see Figure 12–11B). If the dam tears, try repairing the defect with a rubber dam substitute (Den-Mat, Ultradent) (Figures 12–12A to C).

5. Take steps to protect the patient from bleaching materials, light, and or heat used. Explain in detail the necessity of the patient's wearing safety glasses until told they can be removed. Protect the patient's hands and clothes with a plastic wrap. To protect the patient's upper lip and adjacent tissue, place a piece of gauze saturated with cold water under the rubber dam (see Figure 12–11G). Also place gauze saturated with cold water over any metal clamps and the lower lip on top of the dam when bleaching maxillary teeth (see Figure 12–11H). Keep these gauze squares wet throughout the bleaching procedure, in order to protect the lips from the increased temperatures generated by the bleaching light. *Because you want to count on the patient's reflexes being fully intact so he or she can provide feedback if there is leakage on tissue or if the heat becomes too intense, you*

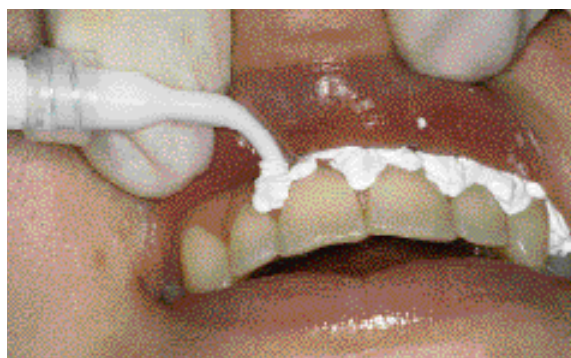

Figure 12–11B: Oraseal (Ultradent) caulking material is placed both labially and lingually to protect the tissue from potential leakage around the rubber dam.

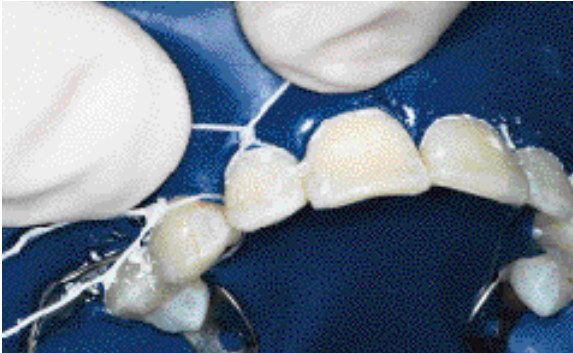


Figure 12-11C: Light waxed dental floss is used to make certain the dam is placed in an optimal position. It is best to use white floss so that the color pigment does not flow onto the tooth.

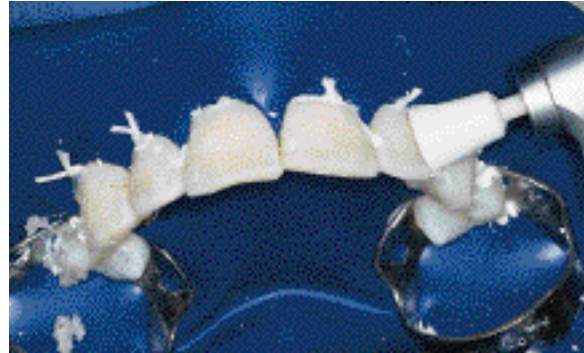


Figure 12-11D: The teeth are pumiced to remove all evidence of any residue especially from surface stain and excess Oraseal.

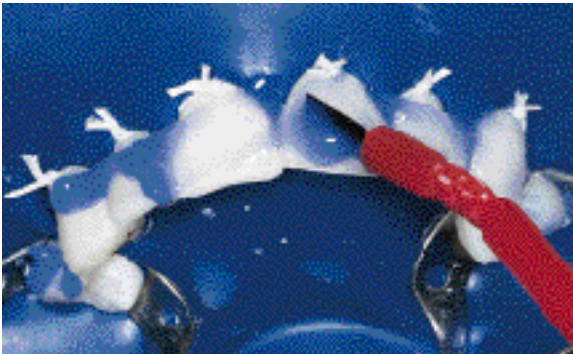

Figure 12-11E: As an optional procedure, the teeth can be etched with 32% phosphoric acid for 5 to 10 seconds. If the teeth are sensitive, 10% phosphoric acid can be used, or skip this step.

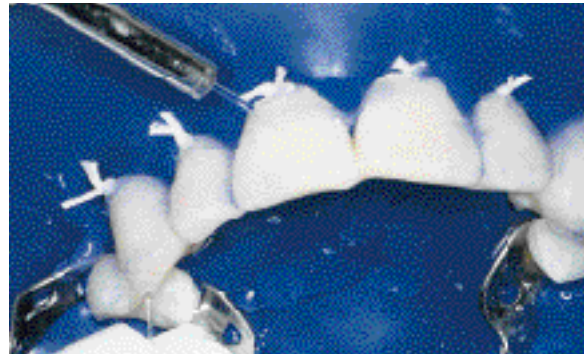


Figure 12-11F: The acid is thoroughly rinsed from the teeth.

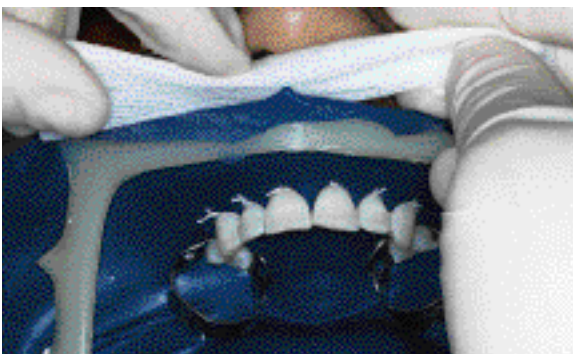

Figure 12-11G: Cool, wet gauze is folded and placed underneath the dam in order to protect the lip from excess heat.

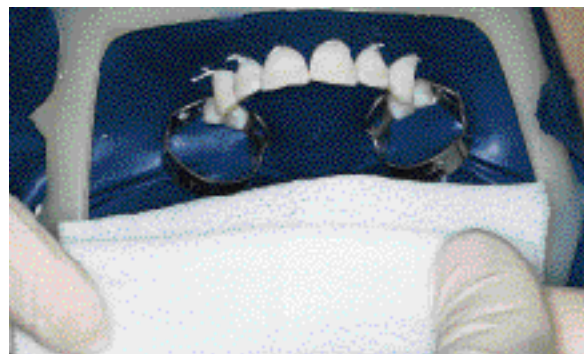

Figure 12-11H: Cool gauze is also placed on top of the lower dam to catch any solution that may leak as it is being applied to the upper teeth and to also protect the lower lip from excess heat.

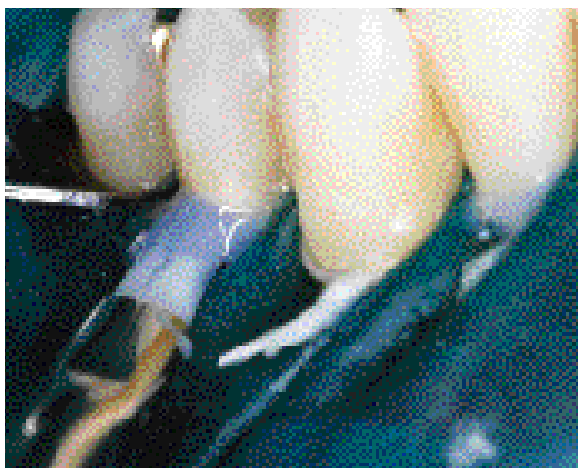

Figure 12-12A: If you have a slight tear or do not feel the rubber dam is fitting as closely as possible, consider use of rubber dam substitute (Den-Mat, Ultradent).

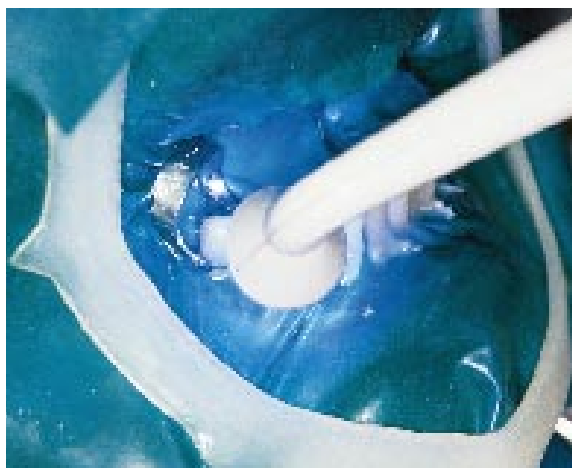

Figure 12-12B: Polymerize each tooth as if it were for a standard composite resin restoration (60 seconds).

must not use any local anesthesia during bleaching. In the rare patient for whom sensitivity is a major problem, it is best to resort entirely to the matrix or home technique (see pages 264 to 268) or use a bleaching compound that will not injure tissue if the dam should leak. You also may consider using nonmetallic clamps to secure the rubber dam. These products will reduce any possible sensitivity caused by heat buildup in the metal clamps. They can also be helpful to prevent fracture if your patient has a ceramic crown that must be clamped (Wed-jets, Hygienic Corp.).

6. Protect the dental team by insisting on surgical rubber gloves and safety glasses for all participants in all in-office bleaching procedures.
7. Prepare the teeth by pumicing each tooth to remove any dam sealant or stain. Rinse thoroughly.

Application of Bleaching Materials

The actual application of bleaching material varies depending on the etiology and severity of the stain. In general, all methods of application rely on the combination of some form of a hydrogen peroxide bleaching agent applied to the teeth and an initiating device or catalyst, either an indirect heating lamp, intense light, or a direct solid state heating unit or enzymatic catalyst to speed the chemical reaction.

Friedman¹³ advocates the use of a photoflood lamp that focuses its rays on the labial surface of the tooth because he believes the light is useful as well as the heat. Hodosh and colleagues²⁵ recommend the rheostat-controlled solid state heating device because it requires less time—they suggest that no more than 10 minutes is normally required to improve the color noticeably—and the fine control of the heating temperature, administered through specially designed tips, allows bleaching and heating in grooves, depressions, and smaller areas in a pinpoint manner. When an individual metal tip is the desired bleaching tool, it is helpful to use one with predictable temperatures (Figure 12-13).

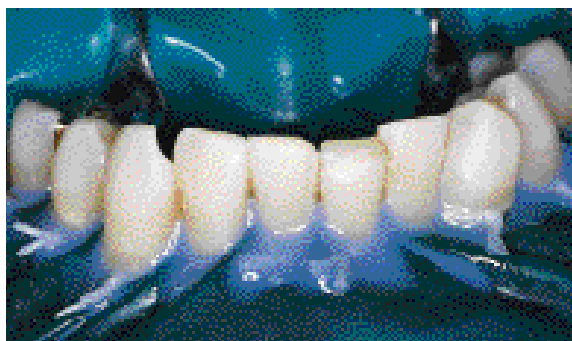

Figure 12-12C: Finished result shows rubber dam substitute snugly around cervical portions of teeth, which are now ready to bleach.



Figure 12-13: The Illuminator (Union Broach) bleaching instrument with activation light and wand is used for both vital and nonvital tooth bleaching procedures.

The Illuminator (Union Broach, see Figure 12-13) is a state-of-the-art bleaching instrument combining an activation light and activation wand for bleaching procedures on both vital and nonvital teeth. A built-in sensor allows precise temperature of the light, elevating or lowering it as needed to maintain predetermined temperatures. However, its greatest asset is the convenience of having both bleaching light and individual tooth wand within easy reach. This means the color of any darker tooth or teeth can be blended with extra heat by the bleaching wand following the overall in-office bleaching procedure. Safety features are built into the light, including monitory beeps and automatic shut-off.

Certain manufacturers suggest using a polymerization light to accelerate the bleaching process (Shofu) (Figures 12-14A to I). Other in-office techniques use a laser as the accelerator. However, these techniques require someone to hold it on each single tooth to be bleached. A dedicated bleaching lamp can simplify this procedure by allowing the assistant (in most cases) to monitor the result.

Alternative procedures include use of laser light combined with different bleaching solutions. The instructions will vary depending on which laser company's apparatus is being used. Whether laser or conventional in-office bleaching, there is a definite market for the patient who does not want "home-

work" or refuses to wear a matrix for multiple hours at home. The ability to have these treatments in the office is a definite attraction for busy executives and others who share this philosophy.

No matter which method you choose, care must be taken to prevent pulp damage from thermal irritation. The patient's comfort can be used as a guide for increasing or decreasing the temperature administered. A general rule of thumb is to adjust the temperature several degrees below the temperature at which the patient experiences discomfort (although you should know your patient since some patients will stoically and silently suffer in their desire to have bright teeth.)

Apart from the dentist's decision to use a heating or light catalyst device, which is a matter of preference, there are several differences in the actual bleaching procedure to consider, depending on the etiology and severity of the discoloration:

- a. The number of treatments required will differ. For teeth stained by coffee, tea, or other substances, a dramatic difference can appear in only one or two visits. This is also true for many cases of fluorosis-stained teeth. For tetracycline-stained teeth, three or more visits are generally required even if combined with an out-of-office matrix technique. We believe

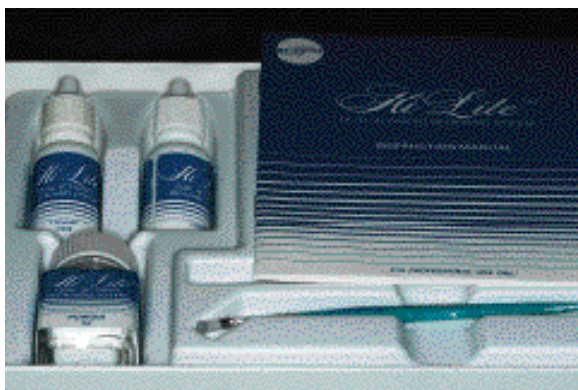

Figure 12-14A: The Shofu Kit presents a slightly alternative bleaching method from the previous one.

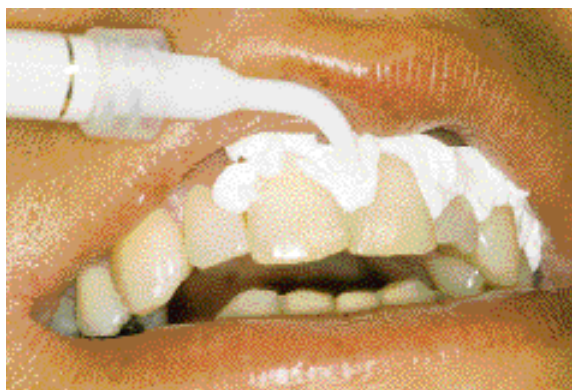

Figure 12-14B: Oraseal is placed to protect the tissue from chemical leakage.

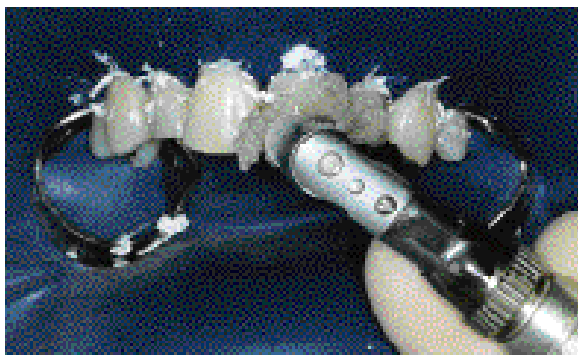


Figure 12-14C: The teeth are pumiced to remove any residue of Oraseal.




Figure 12-14D: Mix 3 drops of liquid to 1 level scoop of powder.

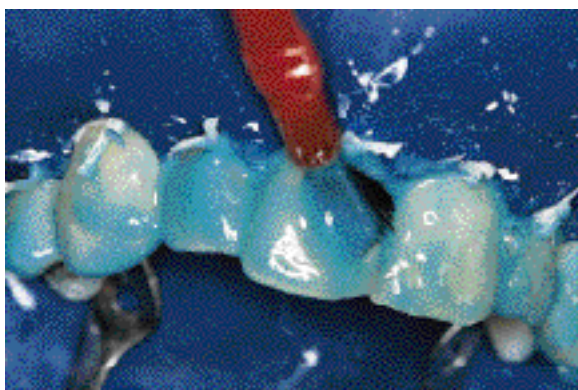

Figure 12-14E: The combined gel is applied for 7 to 9 minutes.




Figure 12-14F: An optional procedure is to use a curing light for 2 to 4 minutes per tooth (see product instructions).

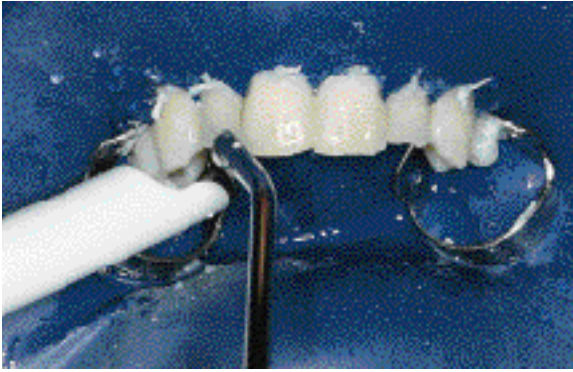


Figure 12-14G: The gel is rinsed following oxidation.

it is psychologically advantageous to prepare the patient for a longer sequence and to check carefully as the treatment proceeds, treating every 2 to 4 weeks.

- b. The solution itself will vary, depending on the severity of the stain. For most bleaching, a 30 to 35% concentration of hydrogen peroxide is used.

A conservative approach is to first try bleaching with or without light/heat, but no etch. If the desired results are not achieved, then etch with a five-second application on both labial and lingual surfaces with 35% phosphoric acid and proceed with the bleaching agent as described.

Microabrasion. In cases of severe enamel stains on isolated teeth, you can use Prema (Premier), a combination of hydrochloric acid (muriatic acid) and pumice with mechanical

abrasement, which will etch the enamel slightly to facilitate stain removal. Another alternative is to use air abrasive technology (American Dental Technologies, Sunrise or Kreativ Inc.). Although several seconds with air abrasive can remove certain stains, you must be prepared to bond the enamel surface if the technique is not successful. You can also use “Macro-Abrasion” as per Heywood, with friction grip diamonds or carbides with Soflex disk polishing.^{31B}

- c. The way in which the bleaching solution is applied to the teeth will differ. For the more even distribution of extrinsic stains or tetracycline stains, the bleaching solution usually is applied by infusing gauze over the teeth. For the more heterogeneous stains of fluorosis, paint the bleach on the tooth directly in order to concentrate on the pattern of staining. In most procedures, all involved teeth should not be bleached simultaneously. In order to determine the effect of the treatment, some teeth should be left untreated as controls. Treatment should begin on the most discolored teeth, proceeding to the less discolored, using the minimally discolored teeth as a control. Yellow or yellow-brown stains are easier to remove than gray, and the incisal halves of teeth are bleached more quickly than cervical halves due to thinner dentin. For fluorosis-stained teeth, there may be unaffected teeth that can be used as controls. For tetracycline-stained teeth and other problems, the mandibular teeth can be used as a control.

The application of the bleaching solution is identical for extrinsic staining, tetracycline, minocycline,

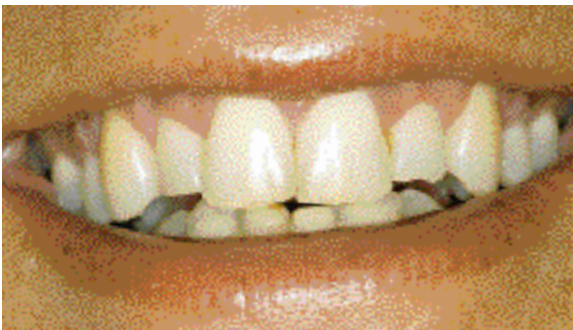

Figure 12-14H: Before bleaching.

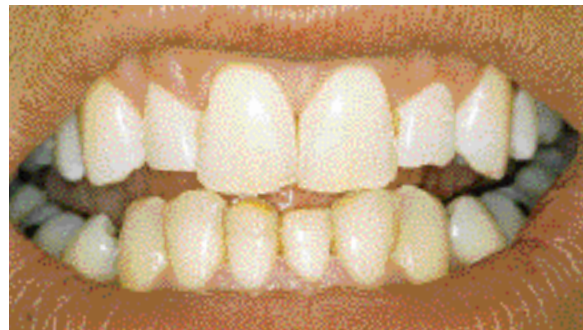

Figure 12-14I: Results after one bleaching treatment.

or other systemic causes of a consistent, homogeneous discoloration. There are three basic steps.

1. After rinsing and drying the teeth as in the preparatory steps above, place on the dried teeth a piece of cotton gauze that has been cut to size and saturated with 35% hydrogen peroxide bleaching solution (Figures 12–15A and B). If you are using a thick paste, you will not need to use the gauze.
2. Position a bleaching light approximately 13 inches from the teeth to be bleached, and shine the light directly on the teeth. Begin with 115°F (rheostat setting 5) and increase

the temperature as long as the patient feels no sensitivity. The bleaching temperature recommended for vital teeth ranges from 115° up to a maximum of 140°; however, temperatures slightly less than 115° also will bleach teeth at a slower rate (Figures 12–15C and D).

3. If using a liquid hydrogen peroxide, keep the gauze over the teeth being bleached continually wet with the bleaching agent by dispensing fresh bleaching solution from an eyedropper or cotton swab, and maintain contact of teeth to be bleached with a bleaching agent and heat/light for 30 minutes. Then remove the gauze and flush the teeth with copious

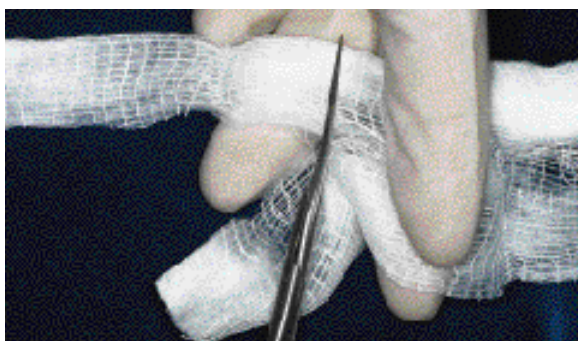


Figure 12–15A: Single thickness 2 × 2 gauze is cut and applied to the teeth to hold the solution in place.

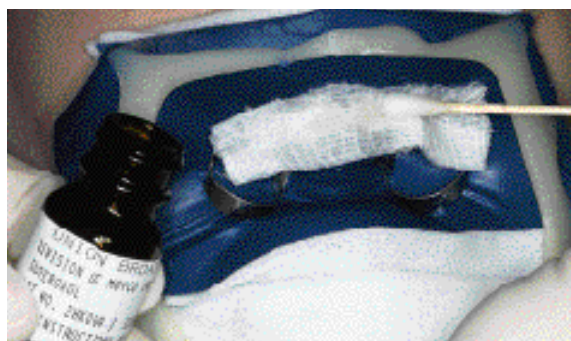

Figure 12–15B: Thirty-five percent hydrogen peroxide (Union Broach) or concentrated bleaching gel is applied to the teeth approximately every 5 minutes to keep the teeth well saturated during the entire treatment.

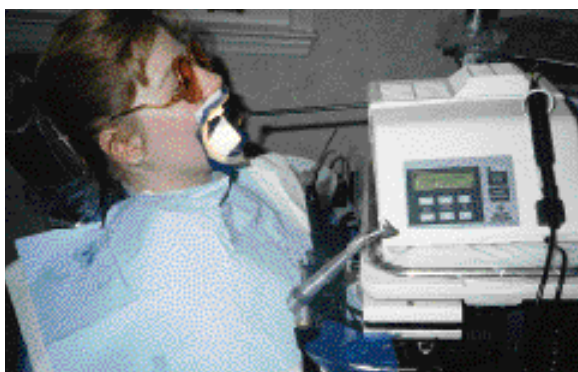

Figure 12–15C: The bleaching illuminator is turned on for 30 minutes with a sensor placed just under and in front of the arch being bleached. The LED readout is programmed for the correct temperature beginning at 110–115°F, increasing gradually to as warm as possible while still comfortable for the patient.




Figure 12–15D: The bleaching wand is attached also to the illuminator and is controlled by LED readout. Temperatures beginning at 140 degrees F can provide extra heat to a darker tooth when necessary.

amounts of warm water before carefully removing the gauze and rubber dam (Figure 12–15E). Next, have your patient brush and rinse the teeth thoroughly (Figure 12–15F).

For uneven discoloration such as fluorosis and other conditions in which only selected teeth are affected or parts of teeth are more severely affected, the application of liquid bleaching solution requires extra effort in dealing with the more concentrated stained areas. The same three basic steps apply.

1. After rinsing and drying as in the preparatory steps listed above, use a cotton-tipped applicator to apply a fresh solution of 35% hydrogen peroxide to the stained area or enamel of the teeth which have been exposed through the rubber dam. Allow to remain for 5 to 10 minutes.
2. Reapply the mixture, and this time use the bleaching wand for extra heat intermittently for up to 5 minutes.
3. Repeat this sequence of bleach and heating with light until the desired shade is obtained, then neutralize by swabbing with 5.25% sodium hypochloride and flushing with copious amounts of warm water before removing the rubber dam and any excess Oraseal.

Finishing

If you have etched the teeth, then polish them with yellow-banded Shofu finishing wheels. In treat-

ments that extend over several weeks, you may want to apply a protective interim seal between appointments for follow-up to exclude new extrinsic stains. Berman⁶ uses 30% NaF (removable with subsequent H₂O₂ applications) or a varnish (removable with chloroform). He also suggests veneering the tooth with a thin coat of transparent sealant at the end of the bleaching sequence. After the last treatment, polish with an impregnated rotary polishing wheel to achieve a high enamel luster (Shofu) (Figure 12–15G).

The patient needs to be told that the teeth may appear chalky because of dehydration and that they will darken over the next few days after treatment, although to a shade lighter than the previous one. Some patients experience heightened sensitivity to cold for 1 or 2 days and should avoid cold weather and cold drinks or food. Most patients are able to alleviate any discomfort in this period by taking two ASA, acetaminophen, or ibuprofen tablets every 4 to 6 hours. Caution patients that an annual “touch-up” bleach usually will be recommended for the removal of any new accumulated stain.

The longevity of tooth color change has been found to vary widely between patients. This may be in part because of the inability of patients to remember change. Rosenstiel et al.³² report only 1 of 10 young adults who received one vital bleaching treatment were able to see the effects of the

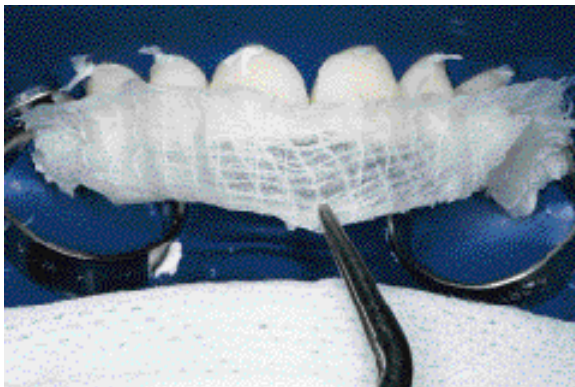


Figure 12–15E: After 30 minutes or following completion of individual tooth bleaching, the gauze and rubber dam are removed.



Figure 12–15F: The patient is requested to brush the teeth, removing any excess Oraseal following rubber dam removal.

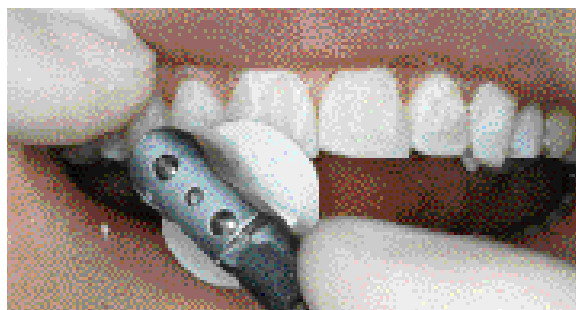

Figure 12–15G: If the teeth are etched, they can be gently buffed with a Shofu polishing wheel.

treatment past one month, although colorimetry could still detect change. The best clinical evidence that color change is taking place is to check the upper to lower cuspid areas. Before-treatment photographs are especially important so these areas can be compared for both the patient's and your use in determining color change (Figures 12–15H and I).

MATRIX BLEACHING (NIGHTGUARD VITAL BLEACHING)

Matrix bleaching refers to bleaching procedures that the patient uses outside the dental office. Wearing a matrix fabricated by the dentist, the patient is able to apply bleaching material to the affected teeth while at his or her office, exercise facility, driving a car, or almost any place in daily life.

Nightguard vital bleaching has proven to be quite successful, with 9 out of 10 patients experiencing a lightening of their teeth in 2 to 6 weeks

application time.²⁴ There are three basic forms of matrix bleaching, involving different levels of dentist participation and supervision. Many patients who desire a rapid and effective result prefer a combined approach in which in-office bleaching is bolstered and continued by matrix bleaching sessions, enabling close monitoring of the process by the dentist. However, some patients prefer to use matrix bleaching only, still relying on the dentist's diagnostic and monitoring abilities. And finally, there is a growing trend toward whiteners sold over the counter (OTC) that are intended for home use by unsupervised individuals. These three forms of matrix bleaching are discussed below:

Power Matrix Bleaching. Dentist-monitored nightguard vital bleaching combined with in-office bleaching.

The combination approach of one in-office bleaching session, using the stronger bleaching solu-

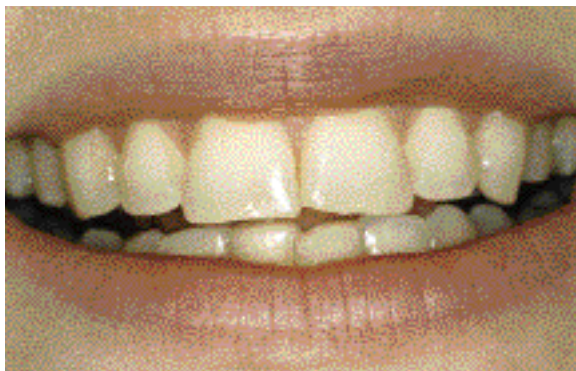

Figure 12–15H: Before in-office bleaching.

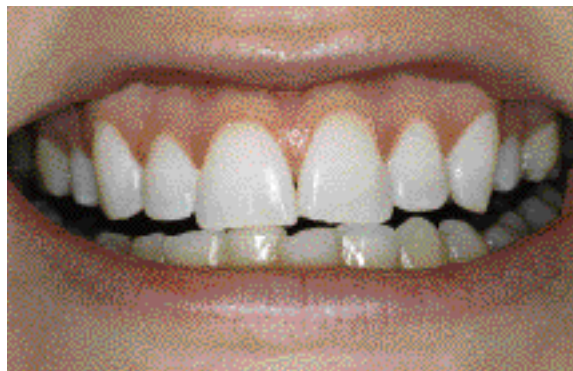

Figure 12–15I: Following one in-office bleaching treatment.

tions with a heat/light device to speed the chemical reaction, and a sequence of matrix treatments controlled by the patient provides the most effective result seen to date.¹⁵ With optimal patient selection, treatment, and compliance, the results of the dentist-monitored power/matrix bleaching provides the most predictable of all the bleaching techniques. The power bleach achieves immediate results. The creation of a matrix to fit the patient's own mouth increases the efficiency and safety of the home bleach sessions. The continuous nature of the matrix bleaching sessions with a milder solution permits refreshing of the bleaching when the brightening effect begins to regress, as occurs in all bleaching processes.

Indications for Power/Matrix Bleaching of Vital Teeth

Many of the conditions for which in-office bleaching has been appropriate are also appropriate for the power/matrix bleaching, although the patient must recognize that the matrix bleaching segment of the treatment depends on a milder bleaching solution. Compliance with the prescribed regimen is essential for success. The indications for which matrix bleaching is most often suggested are:

- Yellowed or discolored teeth in First degree and moderate Second degree.
- Moderate yellow and/or brown tetracycline stains, intrinsic stains (brown and yellow, as well as light to moderate gray), although the success depends on the severity and the ability of the teeth to absorb rebleaching as well as patient compliance.
- Patients who are not candidates for in-office bleaching because of hypersensitive teeth, time restrictions, financial considerations, or psychological objection to rubber dam placement.

Contraindications for Power/Home Bleaching of Vital Teeth

- Extremely hypersensitive teeth as described in contraindications for bleaching, but also transient hypersensitivity that may occur with prolonged application. For example, in certain patients a potentiated 15% urea peroxide or a 10% hydrogen peroxide can lead to tooth sensitivity if worn more than 1 to 3 hours per day. Instead, substitute with a lower concentration of carbamide peroxide (5 to 10%).

- Other hypersensitivity reactions, such as burning sensations, sore throat, nausea, irritation, or edema. These may indicate allergic reactions.
- Lack of compliance, whether through inability or simple unwillingness to wear the appliance the necessary 1 to 3 hours per day.
- Severe discoloration, including cases for which all bleaching is assumed to be ineffective except as an adjunctive therapy.
- Teeth with extensive restorations may be contraindicated as well. Several studies have suggested in-office and matrix bleaching products cause degradation of resin composite surfaces^{4,5,9,28} although others disagree.¹⁴ The costs of replacement may be an additional factor.

Preparing the Patient for Matrix-Monitored Bleaching

First use the appropriate procedure above for diagnosis, and preparation, for bleaching of the discolored teeth.

1. Take color photographs to provide a standard for comparison against the initial session. This will be especially useful since the patient has more control over deciding when renewal is needed.
2. An impression of the arch to be treated is made with an alginate or other accurate material, and a cast of durable stone is poured and trimmed. With the appropriate trimming of the cast, the vacuum-formed matrix will adapt completely over the cast with minimal creasing. Modeling clay or block-out compound may be used to block out significant undercuts. In addition, you may wish to incorporate a die spacer to create a reservoir.
3. A plastic nightguard-like matrix is used to completely cover all teeth to be treated and minimize the exposure of the gums to bleaching solution. It is constructed on a vacuum-formed machine. According to Haywood,²¹ the best prosthetic material is a 0.035 inch clear soft material (Soft-Tray, Ultradent Products, Inc.). Thin materials also diminish chances for a temporomandibular joint or occlusal problem. Selective bleaching can also be accomplished by carefully trimming the matrix to include only the teeth to be bleached (Figures 12–16A and B).

4. Again, appropriate trimming is necessary to minimize injury to the soft tissue. In particular, the palatal portion and the majority of the matrix covering the gingival tissue must be removed with a scalpel or hot knife while the material is still on the model and with scissors, diamond disc, or a carbide acrylic trimming bur once it is removed from the model. Further adjustments must be made at the time of patient try-in. Trim the gingival margins as close as possible to the cervical margin of the teeth. The objective is to keep bleaching material in contact with the tooth surface and away from the tissue.
5. Instruct the patient to place a drop of solution in the appropriate space around each tooth corresponding to the areas to be lightened, as in the written instructions given the patient. The most common regimen is between 1 to 4 hours daily use from 4 weeks to 6 months (for tetracycline stain). Some companies recommend wearing the matrix up to 20 hours per day with the bleaching gel changed every 2 to 4 hours, but such long-term exposure of the soft tissue to bleaching materials has not yet been researched adequately. For that reason, some dentists recommend sessions lasting only 45 minutes to 1 hour per day. Most dentists, however, suggest 1 to 3 hours daily with one application or changing the solution once during that time. One suggested regime is to arrange the first session on the same evening as the power bleaching, with subsequent sessions every

night for 3 weeks. Another is to have the gel worn every other night for 6 weeks.

Most matrix bleaching uses 10 to 15% carbamide peroxide rather than the 35% hydrogen peroxide used in in-office procedures. However, several companies manufacture a three-tier bleaching approach beginning with a 5 or 6% solution and followed a week or so later with a solution percentage increased to 10 or 12%, and finally to a 15 to 17% solution. The advantage is to reduce possible patient sensitivity by beginning with lesser concentrations of hydrogen peroxide. The greater the concentration of urea peroxide and the thicker the material, the quicker the results will be and the less wearing time will be necessary. In our experience, more viscous solutions work best; they stay in the tray better and appear to provide the necessary time for the H_2O_2 to diffuse into the tooth, since the viscosity seems to prevent the saliva from breaking down the H_2O_2 . The total diffusion into the enamel may allow for the tooth to be bleached more effectively from deeper within this enamel layer. In summary, 15% solutions work faster than a 5% solution, thicker gels generally work better than thinner ones, and dispersants with pigment are superior to those without.

The combination of power bleach and continued home treatment by the patient means there is little or none of the usual degradation of the lightening effect usually observed after the first in-office bleach since the home bleaching begins immediately and continues over the next 2 weeks. The costs of in-office bleaching with multiple appointments are lowered, the patient has control over

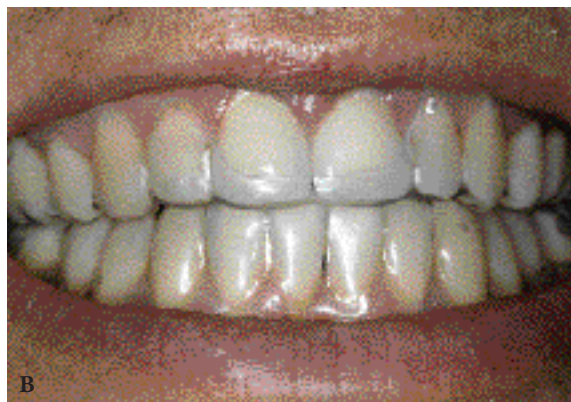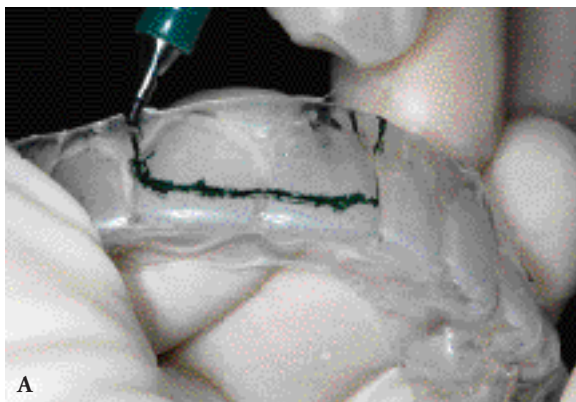


Figure 12-16A and B: Selective bleaching can also be achieved with matrix bleaching by removing specific areas in the matrix.

when the bleaching is to be enhanced, and there is minimal exposure of the tissue to the bleaching agent (Figures 12–17A to D).

Dentist Monitoring of Completely Home-Based Bleaching

Certain patients either prefer or are especially appropriate for the home treatment as an entity unto itself. In many cases, the primary concern is cost. While recognizing the need for professional diagnosis and monitoring, the patient nonetheless wants to avoid as much as possible the costs of office treatment. Other patients may have an aversion to the rubber dam or do not want to spend the necessary 60 to 90 minutes in the dental chair.

In providing a patient completely home-based bleaching, you should focus on three important features: (1) diagnosis and evaluation of the appro-

priateness of bleaching, determining if bleaching will be effective for the patient's particular discoloration; (2) that there are no contraindications to the use of bleaching because of lack of soundness of the teeth or health of the oral cavity; (3) precise fitting of a matrix to minimize exposure of tissue to the bleaching agent, which is a concern with the generic matrices supplied by kits; and (4) monitoring of the potential adverse changes in soft tissues, teeth, and restorations.

Home Bleaching without Dental Supervision (OTC Systems)

When the mouthguard vital bleaching technique burst upon the scene in the late 1980s, product claims often exceeded the proof of research or clinical experience. As Haywood outlines in a detailed history of the Food and Drug Administration's

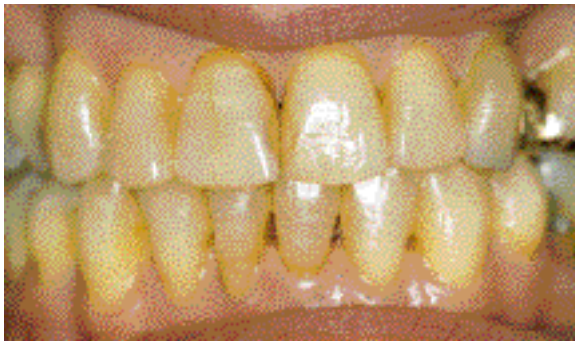

Figure 12–17A: This female patient presented with maxillary and mandibular yellow stained teeth.

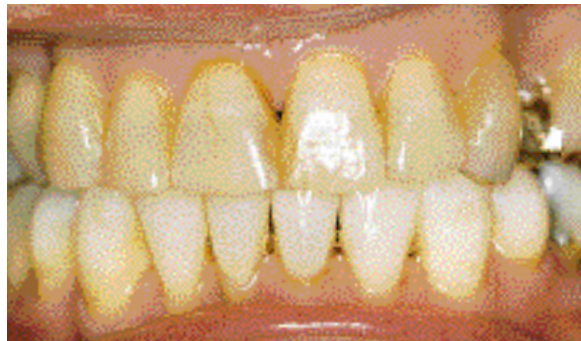

Figure 12–17B: First an in-office bleach of the lower teeth was performed, followed by matrix bleaching for 3 weeks.




Figure 12–17C: Three weeks later the first in-office bleach was performed on the maxillary arch using 35% hydrogen peroxide with the bleaching illuminator. Note the position of the temperature gauge.

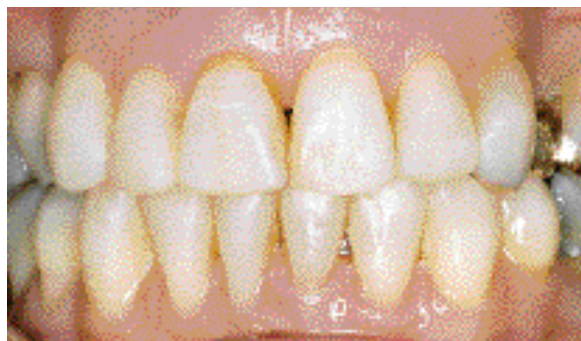

Figure 12–17D: Two more in-office bleaches were done for the upper arch resulting in uniform lightening of the upper and lower teeth.

influence on home bleaching,²² before the FDA stepped in to attempt to control home bleaching products intended for over-the-counter sales, there was virtually no control on ethical advertising to the public. People were buying all sorts of kits and products that in many cases, were contraindicated for the very problem they were trying to solve. Although some people asked the advice of their dentists before embarking on their purchased treatment package plan, most did not.

The controversy over home bleaching has been an interesting, and in many ways helpful, time for dentistry. In 1991, the FDA ruled that the use of carbamide peroxide in the form advocated for home bleaching constituted a new drug use and hence was subject to new drug approval process. The agency did not make a distinction between the home bleaching provided by dentists and the home bleaching kits the consumer could pick up in a department store. (Thirty-five percent hydrogen peroxide used for in-office bleaching was considered to be “grandfathered” because of its long time use for this purpose.) Because of this ruling, manufacturers were forced to submit evidence to back up their claims of the efficacy of bleaching materials, or to demonstrate these materials’ safety. Consequently, many small manufacturers faced closure because they lacked the resources to do so, and inferior products were more likely to be taken off the market. The ruling also forced manufacturers of materials sold directly to dentists to examine whether their products could meet the new drug standards.

The FDA appears to have reconsidered its position, especially concerning distinctions between home-bleaching agents meant for use under dental supervision and those meant for sale to the general public. Possible negative effects would include a restricted supply market to the dentist, with the removal of adequate but less costly materials. However, there have been many positive effects already, including a public made more aware of the risks of unsupervised home bleaching, increased funding for research in this area, a recognition by many general dentists that they must stay current with laboratory and clinical research literature for the good of their patients, and a greater involvement by the dental organizations in the federal and public arenas.

The sections above have described the advantage of having a dentist involved in home bleaching—

the correct diagnosis and decision on appropriate treatment, the recognition and management of side effects, and the use of more potent or highly viscous materials. Other reasons, as outlined by Haywood,²² include:

- a thinner, softer, better fitting mouthguard can be constructed, increasing patient comfort and minimizing side effects due to tissue or tooth irritation.
- not subjecting the person to the dangers of using boiling water in the self-fabrication of the mouthguard.
- adjustment of the occlusion on the mouthguard to minimize any potential temporomandibular joint problems.

MAINTAINING BLEACHING RESULTS

Although both in-office and matrix techniques can produce effective results, the advantage of the latter technique is that it will allow for touch-ups or retreatment as necessary. As long as the matrix continues to fit properly, new solution can be given to the patient for an additional series of bleaching treatments every few years or as needed. Haywood estimates that it may be 3 years before retreatment is desirable.²³

IN-OFFICE BLEACHING OF NONVITAL TEETH

The pulpless tooth is frequently an excellent candidate for bleaching. The fact that the pulp is already nonvital immediately removes one of the major concerns of in-office bleaching, that is, that the intense heat will cause damage to the pulp. While you should remain within the upper limits of the normal range of heat due to possible internal or external resorption, the ability to use higher temperatures without causing the patient discomfort will enable you to increase the rate at which the bleaching agent is effective. However, for many patients, custom designed matrix bleaching trays may be used.

Garretson¹⁶ first bleached nonvital teeth at the turn of the century. The presence of a pulpless chamber inspired dentists such as Pearson³¹ to use chemicals with both bleaching capability and oxygen-releasing capability to provide the same activation of

bleaching as heat does in bleaching for nonvital teeth. He left his bleaching agent, Superoxol, in the pulp chamber for three days. Nutting and Poe's "walking bleach" technique³⁰ went another step: Superoxol and sodium perborate are sealed in the pulp chamber for as long as a week. A range of choices is important in treating nonvital teeth since the discoloration can range from mild to extreme.

Etiology of Discoloration. Although nonvital teeth are subject to external and other stains, the primary discoloration of the nonvital tooth is likely to come from within the pulp chamber itself, resulting from pulp degeneration, with or without hemorrhage. Pulp hemorrhage is more likely to cause pronounced discoloration than pulp degeneration not accompanied by hemorrhage. In fact, according to Ingle,²⁶ the greatest amount of discoloration seen is in the traumatized anterior tooth. Nutting and Poe³⁰ also list necrotic pulp tissue with pulp hemorrhage as the factor most frequently responsible for tooth discoloration. Trauma severe enough to cause pulp death also causes the rupture of blood vessels into the pulp chamber. The blood from the ruptured vessels is driven into the dentinal chamber where the red blood cells undergo hemolysis, exuding hemoglobin. This released hemoglobin is further degraded, releasing iron, which forms a black compound by combining with hydrogen sulfide to become iron sulfide. The resultant necrotic tissue contains various protein degradation products that create the familiar grayish-black discoloration of the tooth.

After pulp necrosis, the most frequent cause of discoloration is an incomplete root canal in which pulpal debris is left in the tooth. Pulp remnants, residual tissue in the pulp horns, filling material, and medicaments all can lead to discoloration. Spasser³⁴ has noted that color changes also may be caused by a root canal sealer containing eugenol, Canada balsam, or precipitated silver. Since nonvital teeth are deprived of tissue fluid, fluid may penetrate them more easily than vital teeth.

Whatever the cause, the degree of discoloration is directly related to the length of time between pulp death and treatment. The longer the discoloring compounds are in the chamber, the deeper the penetration into the dentinal tubules and the greater the discoloration. Discoloration of long duration presents the greatest challenge to successful treatment.

Contraindications to Bleaching of Pulpless Teeth with Concentrated Hydrogen Peroxide (35%)

It remains as true as when Nutting and Poe first stated it 20 years ago:³⁰ prudent case selection is vital to a successful esthetic result. The primary requirement for bleaching is the existence of an adequate root canal filling. Contraindications include:

- small amount of remaining dentin.
- extensive restorations. There may not be sufficient tooth structure to make bleaching worthwhile.
- restorations with composite or acrylic resins, since as Cohen and Parkins point out,¹⁰ the bleaching technique probably causes temporary dehydration. However, this may only be a problem if your patient does not want or need to replace his or her restorations following bleaching.
- cracks and hypoplastic or severely undermined enamel.
- discoloration by metallic salts, particularly silver amalgam. The dentinal tubules of the teeth are virtually saturated with the alloys and no amount of bleaching with available products will significantly improve the esthetic quality of these teeth.

Techniques for Bleaching Pulpless Teeth

The choice of in-office or walking bleach technique and thus of bleaching solution will depend on the degree of discoloration. In either procedure, the object is to allow the bleaching agent to release oxygen in a concentration high enough to penetrate the stained dentinal tubules and neutralize the discoloration (Figure 12–18A).

Preparation. Preparatory procedures are similar whether in-office or walking techniques are to be used.

1. Isolate the tooth or teeth. To protect the patient's tissues from the caustic bleaching solution, use a well-fitted rubber dam of heavy material. The size of the hole punched is also important; too small a hole will cause the dam to tear. Since tears can allow leakage, a torn dam should be removed and the cause for the tear found and corrected. Rubber dam substitutes (Den-Mat, Ultradent) may also be

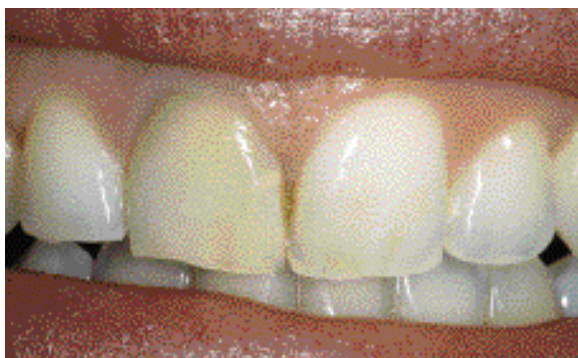

Figure 12-18A: This young woman was self-conscious of her discolored central incisor.

applied to the outside of the dam around the neck of the tooth for further seal especially if cementum is exposed as in severe tissue recession. A ligature may be placed around the tooth if desired but this is not usually necessary. Before placing the dam, the gingivae should be coated with Oraseal (Ultradent) as a precaution against damaging the periodontal tissue if some of the bleaching material should seep through the dam. After the dam is sealed, the lubricant may be applied with a cotton applicator on the labial and lingual surfaces. Meticulous care must be taken to ensure the tissue is completely protected. When the dam is in place, additional lubricant can be used in the interdental spaces by using a small plastic instrument. Extreme caution also must be used to ensure that the solution does not come in contact with the lip, which could result in an unsightly disfiguring lesion with extensive edema. (However, these lesions generally heal without scarring.)

2. After isolation, the tooth is meticulously cleaned. Any caries in the crown should be excavated and any leaky or washed out restorations replaced.
3. Establish a lingual opening of sufficient size to secure proper access to the entire pulp chamber and orifice of the root canal. Seidler³³ suggests using a #8 round bur for initial entry into the chamber and for removal of the necrotic tissue. A smaller bur should be used in lower anteriors and in those teeth in which pulp recession would be evident radiographically.

4. Remove all debris and the surface layer of dentin within the pulp chamber with a slow rotation bur. The freshened dentin permits easier penetration of the bleaching material. Since the dentin will be bleached as well as the enamel, the more mature the tooth and the greater the amount of dentin present, the longer the effect will be retained following bleaching. For this reason, preserve as much dentin as possible.
5. In endodontically treated teeth, the root canal filling material should be removed to a depth of 2 to 3 mm apical to the cervical line. This distance may be extended if the gingival recession has been severe. Ingle²⁶ recommends that the root canal filling be removed to a level well below the height of the labial gingivae, although Grossman¹⁸ recommends that the root canal filling extend only to the gingival margin (Figure 12-18B).
6. Remove any surface stains visible on the inside of the preparation with a bur. The apical seal should be checked and secured at this time.
7. The entire preparation should be swabbed with acetone, or xylol to dissolve any fatty material and facilitate the penetration of the bleaching agent into the tubules. The chamber should then be blown dry.
8. Cover the root canal filling with zinc phosphate cement, polycarboxylate cement, glass ionomer, or Cavit, 2 mm thick, since bleaching agents may affect the root canal sealer. Bleaching should never be attempted on any tooth without a complete seal in the root canal since the agent could escape through a porous root canal filling and cause the patient extreme discomfort. If this should occur, heavy sedation will be required to mask the pain, and removal of the bleaching agent and the root canal filling may be required to restore comfort.

In-Office Nonvital Bleaching Technique (Figure 12-18C)

9. Fill the pulp chamber loosely with cotton fibers and cover the labial surface with a few strands of cotton fibers in order to hold the bleaching solution.

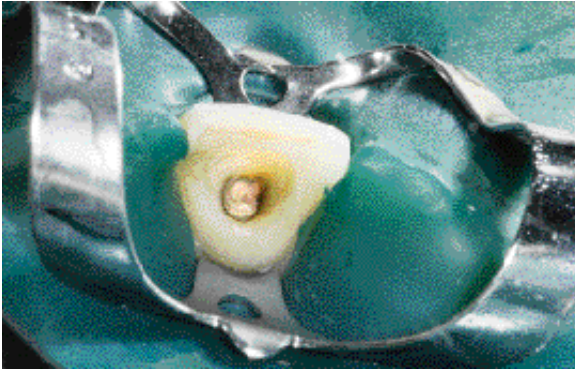


Figure 12-18B: After an adequately-sized access opening was made, gutta percha is removed to slightly below the gingival line.

10. Place 35% H_2O_2 into the preparation with a syringe fitted with a stainless steel needle. Discharge the solution slowly, thoroughly saturating the cotton inside the pulp chamber and on the labial surface; wipe away any excess immediately. Since hydrogen peroxide tends to decompose rapidly, the best way to ensure that the solution is as potent as possible is to use fresh solution with each treatment. Always refer to the expiry date on the label, discarding the solution when this date is reached.
11. In order to activate the bleaching action of the drug to diffuse the bleaching agent into the dentinal tubules, expose the tooth to heat using either a modified photoflood lamp or a special bleaching tool (Union Broach) (Figure 12-18D). The lamp unit should be approximately 13 inches away from the patient's face, which has been thoroughly protected by safety glasses, mask, and gauze over the lips that is continuously saturated with cold water.
12. After 5 minutes of heat and light exposure, remove the cotton and dry the chamber. Once again, build a matrix of cotton within the pulp chamber, covering the labial surface with a few strands of cotton fiber. Saturate this matrix with the bleach. And again apply the light from the bleaching instrument to the saturated cotton gauze for 5 minutes. Remove the light, and remove the cotton.

13. Repeat this process of 5-minute treatment four to six times, or a total of 20 to 30 minutes, using new cotton saturated with fresh bleach for each treatment.

Some improvements can be obtained in difficult cases by sealing H_2O_2 or sodium perborate wetted with H_2O_2 on a cotton pellet inside the pulp chamber between bleaching appointments. Bleach the teeth a little higher than the final shade desired to compensate for anticipated slight darkening (Figure 12-18E).

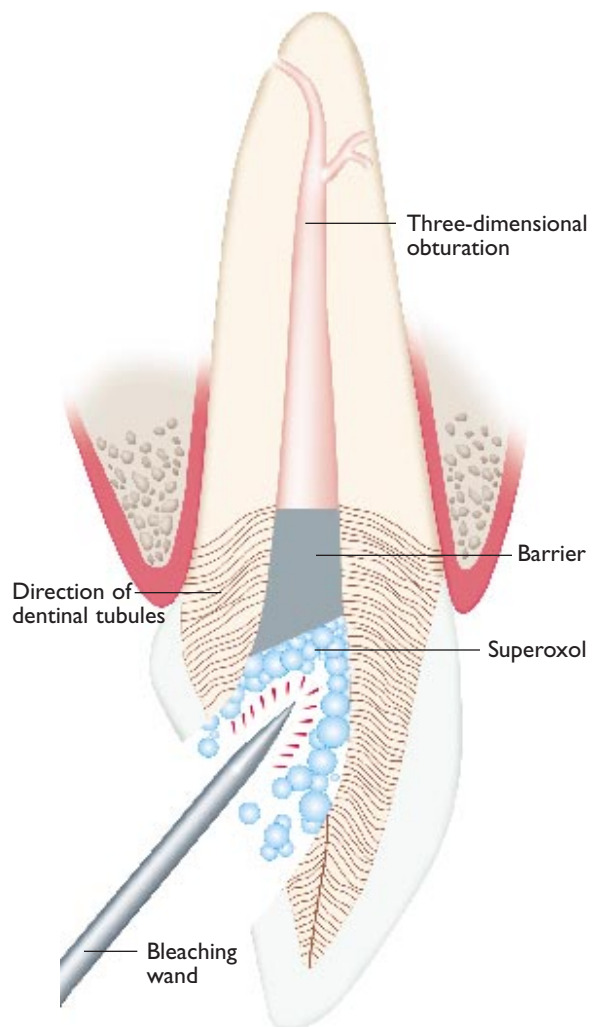


Figure 12-18C: A heated bleaching wand activates the hydrogen peroxide bleaching solution in a prepared pulpless tooth. (From Cohen S, Burns R [eds]. *Pathways of the Pulp*, 6th edn, St. Louis: Mosby, 1994)



Figure 12-18D: The Union Broach bleaching wand heats the tooth in order to accelerate the bleaching process. A sequence of 1 minute on and 10 seconds off at 140° was repeated eight times.

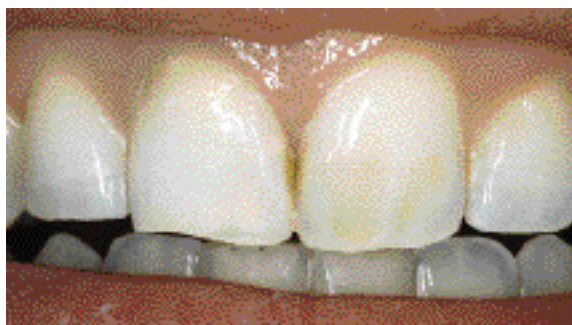

Figure 12-18E: After bleaching, the patient's nonvital tooth blends in nicely with her other teeth.

Out-of-Office Bleaching Technique (or Walking Bleach) (Figure 12-19)

Follow the same preparation techniques given earlier.

1. On a glass mixing slab, prepare a bleaching paste of peroxyborate monohydrate (Amosan) or sodium perborate and enough 35% hydrogen peroxide to form a thick white paste.
2. Fill the entire preparation with the bleaching paste, leaving adequate space to place a temporary restoration and sealer. Make certain that the seal is effective as moist paste can damage tissue if it leaks into the pulp chamber. One method is to carefully apply a solvent (Prep Dry) around the enamel margin and flow a medium-stiff mix of Cavit to close the area. If the patient experiences a burning on the tongue, rinse until the sensation is gone.
3. Have the patient return in 5 days. If the degree of bleaching is not sufficient, repeat the entire procedure. Again, a slight overbleaching is desirable since teeth tend to darken slightly after the final bleach.

Finishing

Finishing is identical after bleaching by either technique.

1. Remove the cotton or bleaching paste and swab the preparation throughout with acetone or xylol.
2. Air dry internally and throughout the bleached crown to penetrate and seal the dentinal tubules and to maintain the tooth's translucency.

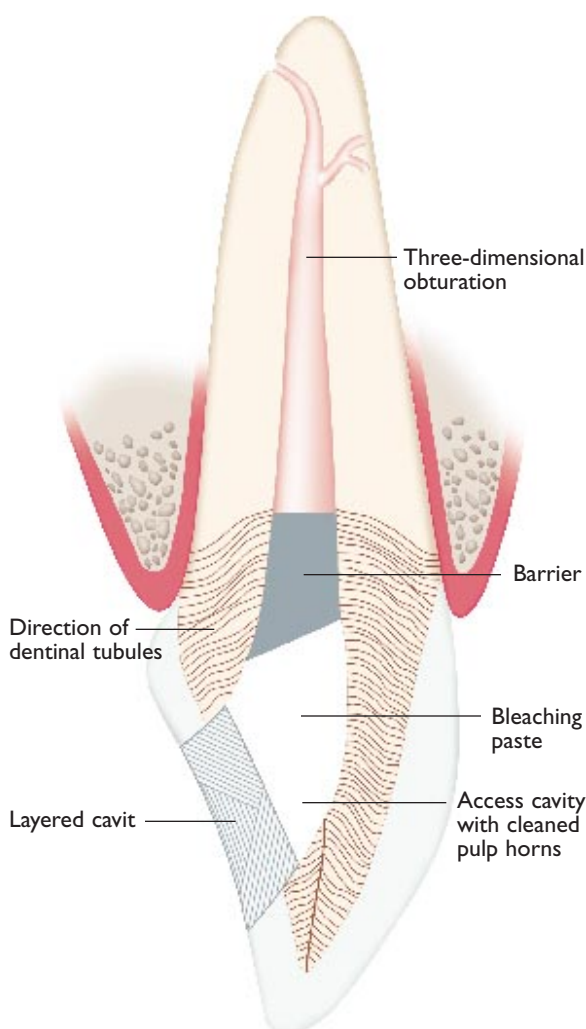


Figure 12-19: The walking bleach requires an effective seal for the bleaching paste to remain active. (From Cohen S, Burns R [eds]. *Pathways of the Pulp*, 6th edn, St. Louis: Mosby, 1994)

gency. Use several coats of a clear dentin bonding agent to prevent recurrent coronal stain.

3. Etch the marginal walls with 35% phosphoric acid to assure good mechanical bonding. The entire restoration is placed at one time and finished properly to assure good marginal adaptation.
4. Apply a dental bonding agent and cure before filling the cavity with composite resin restorative materials of the lightest shade esthetically compatible with the tooth. Use a composite with a good dentin bonding agent, being careful to etch the enamel walls before restoring the final area. A microfill or polishable hybrid is the best material to use because it allows a polished surface to blend with the adjacent enamel surface. A typical result is seen in Figures 12–20A and B.

Planning for Continued Treatment

You must use your clinical judgment to decide if rebleaching would effect greater improvement. If the tooth shows significant improvement, then the solution chosen obviously contained the solvent for the stain and rebleaching is likely to continue improvement. Conversely, if results are not obtained, bleaching out the discoloration may not be possible. It may be advantageous to employ 1 or 2 parts of HCl in such instances as an added solvent before abandoning the procedure as ineffective. Try at least three to four visits.

You also must use your clinical judgment about the length of time a tooth is likely to remain

bleached. Spasser³⁴ notes that the determining factors include the amount and depth of the external enamel cracks and the integrity of the marginal seal of the restoration. Hayashi¹⁹ reports that discoloration may also recur in time from penetration of pigments in the saliva into the dentinal tubules. To help prevent pigment penetration into the dentin, Grossman¹⁸ recommends putting silicone oil in the cavity after bleaching. Silicone oil will not evaporate and has a low surface tension which will help the dentin retain it. If the discoloration occurs 1 to 3 years after the initial treatment, you can retreat using dentist-monitored home treatment.

The Future of Bleaching

The history of bleaching in the last half century has been one of continued improvements in bleaching materials, instrumentations, and chemicals to activate the bleaching action. Consequently, there has been increased inclusion of the problems for which bleaching can be an effective treatment alone, or an adjunctive treatment. This work needs to continue, especially to assess the permanency of bleaching, to compare bleaching to other treatment modalities, and the efficacy of bleaching used alone or in conjunction with other treatments. There needs to be better mechanisms to assess, quantify, and describe discoloration. There also needs to be better understanding of the mechanisms of action so dentists can better predict for which patients it will be most successful and in which patients it will last longer. In fact, it is not clear why both vital and nonvital teeth require renewal within 1 to 3 years. Further studies are necessary to understand the effect of dif-

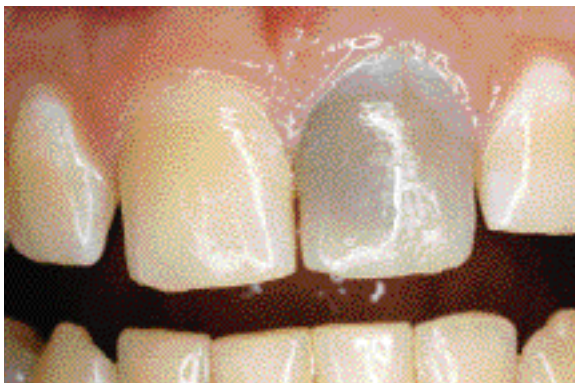

Figure 12–20A: This severely gray-brown nonvital tooth is a fair candidate for bleaching.

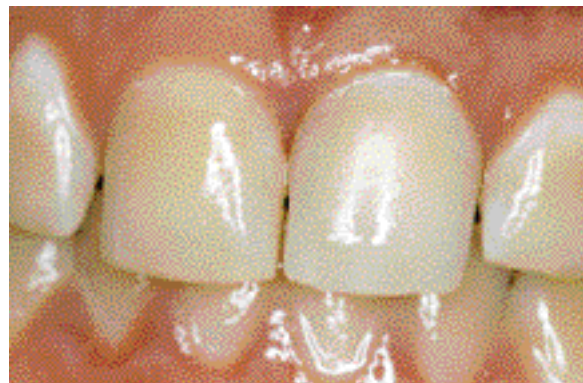

Figure 12–20B: A 3-week walking-bleach technique was sufficient to regain the original tooth color for this man.

ferent bleaching materials on restorative materials. And finally, the sudden surge of bleaching kits intended to be used with little or no dentist monitoring makes the need for more research into the long-term safety and effects of such materials imperative. Dentistry must maintain control of both research and treatment for maximum patient protection and success rates. Newer light activation, such as lasers, also will need long-term studies to verify its true value in the overall technique. As scientists learn more about bleaching efficacy, safety, and longevity, the technique will no doubt continue to be at the top of the list of esthetic modalities.

References

1. Arens D. The role of bleaching in esthetics. *Dent Clin North Am* 1989;33:319–36.
2. Bailey RW, Christen AG. Effects of bleaching technique on the labial enamel of human teeth stained with endemic dental fluorosis. *J Dent Res* 1970;49:168–70.
3. Bailey SJ, Swift EJ. Effects of home bleaching products on composite resins. *Quintessence Int* 1992;23:489–94.
4. Barghi N, Godwin JM. Reducing the adverse effect of bleaching on composite enamel bond. *J Esthet Dent* 1994;6(4):157–61.
5. Barkhordar RA, Pontejos J, Machado S, Watanabe LG. The effect of a bleaching agent on leakage of composite resin (abstract 2437). *J Dent Res* 1991;70:570.
6. Berman LH. Intrinsic staining and hypoplastic enamel: etiology and treatment alternatives. *Gen Dent* 1980;30:484–8.
7. Black GV, McKay FS. Mottled teeth, an endemic developmental imperfection of the enamel of the teeth here-to-fore unknown in the literature of dentistry. *Dent Cosmos* 1916;58:129.
8. Bowles WH. Teeth discolored by minocycline. *Dent Today* 1986;5(2):4.
9. Burger KM, Cooley RL. Effect of carbamide peroxide on composite resins (abstract 2431). *J Dent Res* 1991;70:570.
10. Cohen S, Parkins FM. Bleaching tetracycline-stained vital teeth. *Oral Surg* 1970;29:465.
11. Dodson DL, Bowles WH. Production of minocycline pigment by tissue extracts. *J Dent Res* 1991;70.
12. Dzierzak J. Factors which cause tooth color changes: protocol for in-office “power bleaching.” *Pract Periodontics Aesthet Dent* 1991;3(2):15–20.
13. Friedman J. Variability of lamp characteristics in dental curing lights. *J Esthet Dent* 1989;1:189–90.
14. Friend GW, Jones JE, Wamble SH, Covington JS. Carbamide peroxide tooth bleaching: changes to composite resins after prolonged exposure (abstract 2432). *J Dent Res* 1991;70:570.
15. Garber DA, Goldstein CE, Goldstein RE, Schwartz CG. Dentist-monitored bleaching: a combined approach. *Pract Periodontics Aesthet Dent* 1991;3(2):22–6.
16. Garretson JE. A system of oral surgery. 6th edn. Philadelphia: J.B. Lippincott Co., 1895.
17. Goldstein RE, Garber DA. Complete dental bleaching. Chicago: Quintessence Publishing Co., Inc., [In press].
18. Grossman LI. Endodontic practice. Philadelphia: Lea and Febiger, 1970.
19. Hayashi Y. Bleaching teeth discolored by tetracycline therapy. *Dent Survey* 1980;56:17–25.
20. Haywood VB. The Food and Drug Administration and its influence in home bleaching. *Curr Opin Cosmet Dent* 1993:12–8.
21. Haywood VB. Bleaching of vital and nonvital teeth. *Periodontol Restor Dent* 1992; :142–9.
22. Haywood VB, Houck V, Heymann HO. Night-guard vital bleaching: effects of varying pH solutions on enamel surface texture and color changes. *Quint Int* 1991;22:775–82.
23. Haywood VB. Achieving, maintaining and recovering successful tooth bleaching. *J Esthet Dent* 1996;8(1):31–8.
24. Haywood VB, Leonard RH, Nelson CF. Night-guard vital bleaching longevity and side effects: 13–25 months data. *J Dent Res* 1993;72:208.
25. Hodosh M. A new method of bleaching discolored teeth by the use of a solid state direct heating device. *Dental Digest* 1970;76:344.
26. Ingle JI. Endodontics. Philadelphia: Lea and Febiger, 1967.

27. Jordan RE, Boksmann L. Conservative vital bleaching treatment of discolored dentition. *Compend Contin Educ Dent* 1984;5:803-8.
28. Koa EC, Peng P, Johnston WM. Color changes of teeth and restorative materials exposed to bleaching (abstract 2436). *J Dent Res* 1991;70:570.
29. Mello HS. The mechanism of tetracycline staining in primary and permanent teeth. *J Dent Child* 1967;34:478-87.
30. Nutting EB, Poe GS. A new combination for bleaching teeth. *J S Calif State Dent Assoc* 1963;31:289-91.
31. Pearson HH. Bleaching of the discolored pulpless tooth. *J Am Dent Assoc* 1958;56:64-8.
32. Rosenstiel SF, Gegauff AC, Johnston WM. Duration of tooth colors change after bleaching. *J Am Dent Assoc* 1991;122(4):54-9.
33. Seidler B. Personal communication to R.E. Goldstein.
34. Spasser HF. A simple bleaching technique using sodium perborate. *N Y State Dent J* 1961;27:332-4.
35. Swachman H, Fekete E, Kulezychi L, Foley T. The effect of long-term antibiotic therapy in patients with cystic fibrosis of the pancreas. *Antibiot Annu* 1958;9:692-9.
36. Torneck DC, Titley KC, Smith DC, Adibfar A. Effect of water leaching on the adhesion of composite resin to bleached and unbleached bovine enamel. *J Endod* 1991;17:156-60.
37. Torneck DC, Titley KC, Smith DC, Adibfar A. The influence of time of hydrogen peroxide exposure on the adhesion of composite resin to bleached bovine enamel. *J Endod* 1990;16:123-8.
38. Zaragoza VMT. Bleaching of vital teeth: technique. *EstoModeo* 1984;9:7-30.
- Additional Resources**
- Amengual LJ, Cabanes GG, Cervera SC, et al. Clinical study of a halogen light-activated bleaching agent in nonvital teeth: case reports. *Quintessence Int* 1996;27:383-8.
- Ben-Amer A, Liberman R, Gorfil C, et al. Effect of mouthguard bleaching on enamel surface. *Am J Dent* 1995;8:29-32.
- Bowles WH, Lancaster LS, Wagner MJ. Reflectance and texture changes in bleaching composite resin surfaces. *J Esthet Dent* 1996;8:229-33.
- Brighton DM, Harrington GW, Nicholls JI. Intracanal isolating barriers as they relate to bleaching. *J Endod* 1994;20:228-32.
- Burgess JO, Cardenas HL. Surface roughness of topical fluoride treated glass ionomers. *J Dent Res* 1995;74:108.
- Ciancio SO, Slots J, Reynolds HS. The effect of short-term administration of minocycline HCl on gingival inflammation and subgingival microflora. *J Periodontol* 1982;53:557-61.
- Conti AW, Dickinson GL, Russell CM. Effect of 10% carbamide peroxide on resin composite restorative materials. *J Dent Res* 1995;74:239.
- Curtis JW, Dickinson GL, Downey MC, et al. Assessing the effects of 10 percent carbamide peroxide on oral soft tissues. *J Am Dent Assoc* 1996;127:1218-23.
- Curtis JW, Dickinson GL, Myers ML, et al. Evaluating the effects of a dentist-supervised, patient-applied carbamide peroxide bleaching agent on oral soft tissues. *J Esthet Dent* 1995;7:18-25.
- Ernst CP, Marroquin BB, Willershausen-Zonnchen B. Effects of hydrogen peroxide-containing bleaching agents on the morphology of human enamel. *Quintessence Int* 1996;27(1):53-6.
- Flaitz CM, Hicks MJ. Effects of carbamide peroxide whitening agents on enamel surfaces and caries-like lesion formation: an SEM and polarized light microscopic in vitro study. *ASDC J Dent Child* 1996;63:249-56.
- Frysh H, Bowles WH, Baker, F, et al. Effect of pH on hydrogen peroxide bleaching agents. *J Esthet Dent* 1995;7:130-3.
- Gallin DM. A dual approach to bleaching. *N Y State Dent J* 1996;62(5):34-5.
- Goldstein RE. *Change your smile*. Chicago: Quintessence, 1996.
- Heithersay GS, Dahlstrom SW, Marin PD. Incidence of invasive cervical resorption in bleached root-filled teeth. *Aust Dent J* 1994;39:82-7.

- Heymann HO, Sockwell CL, Haywood VB. Additional conservative esthetic procedures. In: Sturdevant CM, ed. *The art and science of operative dentistry*, 3rd edn. St. Louis: C.V. Mosby Co., 1995;643–7.
- Josey AL, Meyers K, Romanink, Symons. The effect of a vital bleaching technique on enamel surface morphology and the bonding of composite resin to enamel. *J Oral Rehab* 1996;23:244–250.
- Koulaouzidou E, Lambrianidis T, Beltes P, et al. Role of cemento-enamel junction on the radicular penetration of 30% hydrogen peroxide during intracoronal bleaching in vitro. *Endod Dent Traumatol* 1996;12:146–50.
- Lenhard M. Assessing tooth color change after repeated bleaching in vitro with a 10 percent carbamide peroxide gel. *J Am Dent Assoc* 1996;127:1618–24.
- Leonard RH Jr, Bentley CD, Haywood VB, et al. Changes during 10 % carbamide peroxide bleaching. *Quintessence Int* 1994;25:547–50.
- McCracken MS, Haywood VB. Demineralization effects of 10 percent carbamide peroxide. *J Dent* 1996; 24:395–8.
- McEvoy SA. Removing intrinsic stains from vital teeth by microabrasion and bleaching. *J Esthet Dent* 1995;7:104–9.
- Myers ML, Dickinson GL, Curtis JW, et al. Evaluating color change following vital tooth bleaching. *J Esthet Dent* 1995;7:256–62.
- Ngeow WC. Whitening toothpastes—do we need them? [letter] *Br Dent J* 1996;180:283.
- Pimlott JFL, Scott DA. Bleaching gels: the surface effects on resin composite restorations. *J Dent Res* 1995;74:245.
- Rotstein I, Dankner E, Goldman A, et al. Histochemical analysis of dental hard tissues following bleaching. *J Endod* 1996;22(1):23–5.
- Russell CM, Dickenson GL, Downey MC, et al. Dentist-supervised home bleaching with 10 percent carbamide peroxide gel: a six-month study. *J Esthet Dent* 1996;8:177–82.
- Schulte JR, Morrissette DB, Gasior EJ, et al. The effects of bleaching application time on the dental pulp. *J Am Dent Assoc* 1994;125:1330–5.
- Seymour KG. Whitening toothpastes: meeting needs or satisfying demands? [editorial] *Br Dent J* 1996;180:278.
- Ward MT, Tate WH, Powers JM. Surface roughness of composites after polishing with sterilized instruments. *J Dent Res* 1995;74:185.
- Wolfe ID, Reichsmister J. Minocycline hyperpigmentation: skin, tooth, nail and bone involvement. *Cutis* 1964;33:457–8.
- Zalkind M, Arwaz JR, Goldman A, et al. Surface morphology changes in human enamel, dentin and cementum following bleaching: a scanning electron microscopy study. *Endod Dent Traumatol* 1996;12:82–8.

CHAPTER 13

COMPOSITE RESIN BONDING

Throughout this text you will find instances where crowning may have been chosen because laminating with porcelain veneers, or even bonding with composite resin, was not yet available. The major reason why these patient problems/solutions are still included is due to a particular teaching point to be illustrated. In most cases, porcelain laminate veneering would probably be the conservative treatment of choice today.

When the average person visualizes esthetic dentistry, more than likely he or she is actually thinking about composite resin bonding. Whether it is used to replace an unsightly metal filling, to mend fractured teeth, to restructure badly spaced or crowded teeth, or to cover a series of discolored teeth, bonding remains the single most instantaneous transformation of the mouth available to you as a dentist (Figures 13–1A and B). The patient walks in afraid to smile, with a hand in front of his or her mouth—and walks out more attractive, self-confident, and happy.

Development of the acid-etched enamel technique by Buonocore¹³ and the BIS-GMA-based composite resin by Bowen^{10,11} made possible the

direct bonding of composite resin to the facial surface of stained, malposed, fractured, and other teeth requiring esthetic and functional improvement. As Phillips⁹⁰ said, the development of dental polymers and the technology for their use were the principal factors opening up the era of esthetic dentistry and improving and expediting the delivery of dental care. Esthetic dentistry now accounts for almost half of gross dental income.³⁸ Approximately 72% of restorations that replace existing restorations use composite resins.²⁹

Bonding has been termed the most important discovery since the high-speed drill. Certainly bonding was the first of what since have become numerous painless techniques in restorative dentistry, requiring no anesthesia and generally producing little or no discomfort. The technique has the additional advantages of minimal tooth reduction and reversibility. Furthermore, it remains one of the most economic restorative techniques in esthetic dentistry.

But most importantly for the field of esthetic dentistry, the esthetic success of bonding—its ability to change the shape of teeth as well as their color—encouraged dentists to move from a focus

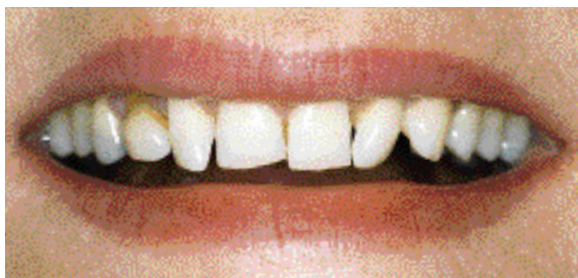

Figure 13–1A: This 57-year-old female was concerned about her unattractive smile. She particularly disliked her “fangs” represented by her spaces and elongated laterals and left cuspid.

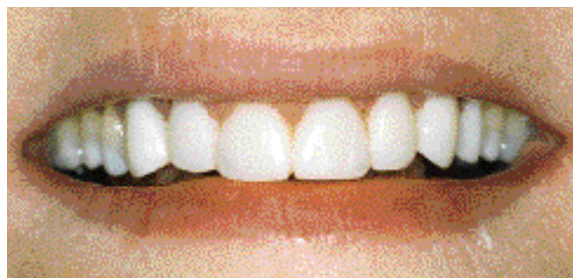

Figure 13–1B: Composite resin bonding, a one-appointment economic alternative, was selected to immediately improve this patient's smile. The deciduous right cuspid was retained and included in the completed bonding. Note also how the smile line appears younger due to improved interincisal relationships.

on individual teeth to the comprehensive consideration of the appearance of the smile and mouth. For the first time dentists began to share fully their patients' concern with not just how the teeth functioned but how they looked. Dentists concerned with esthetic restorations, and increasingly with esthetic improvements on what the patient might have been dealt genetically, became diagnosticians of facial anomalies.

Bonding is in transition at the moment, its various roles in esthetic dentistry changing. To some extent, bonding has undergone some of the same shift in emphasis as crowning underwent a decade earlier. Teeth that would have been reduced and crowned without question in the 1960s were instead bonded with one of the new composite resins in the 1970s, especially after the introduction of high-intensity light-curing to both control and strengthen the bond. Now, in the 1990s, porcelain laminate veneers are being used for many of the same problems for which bonding previously appeared to be such a "miracle solution" (see Chapter 14). Porcelain laminates have many of the same advantages: minimal tooth reduction, little or no discomfort resulting in less need for anesthesia, and fairly rapid transformation since two rather than one appointment is necessary. Their increased expense, time requirement, and relative fragility must be weighed against their superior esthetic effect and longer esthetic life.

Yet no text that purports to cover esthetic dentistry as it is practiced today can relegate bonding to history. Bonding remains the treatment of choice for many conditions—and for many

patients. As is true for bleaching, its lower cost has been one of the routes by which esthetic dentistry has become important and feasible for great numbers of people. The superior handling properties of today's composites, and new techniques that permit good adhesion to biologic structure as well as to dental materials, make bonding the treatment of choice in many circumstances where an esthetic improvement might otherwise not be achievable.

Furthermore, the new composite resins are substantially more resistant to wear than their predecessors. Placed under appropriate conditions and monitored routinely, many restorations can be expected to last a decade or more;^{69,108} Bayne and his colleagues found that the failure rate of 899 composite posterior restorations—sometimes raised as reason to use other treatments than bonding—was in fact less than half that of conventional amalgams at 5 years, suggesting that even posterior composites can provide excellent long-term clinical service.⁷ In fact, Maitland⁷⁴ (Figures 13–2A and B) has said that many of the failings sometimes ascribed to bonding can be avoided by attention to patient selection, material used, and techniques of preparation and finishing.

There are several excellent books to which you can turn for detailed instructions on applying the technique to various situations (Albers,¹ Charbeneau, Feigenbaum and Mopper,³² Jordan,⁵⁴ Phillips and Simonsen¹⁰⁰). This chapter makes no effort to duplicate those, but concentrates on some points that may enhance the esthetic effects of your own techniques. This chapter reviews briefly the categories of bonding in use today, based on the adhe-

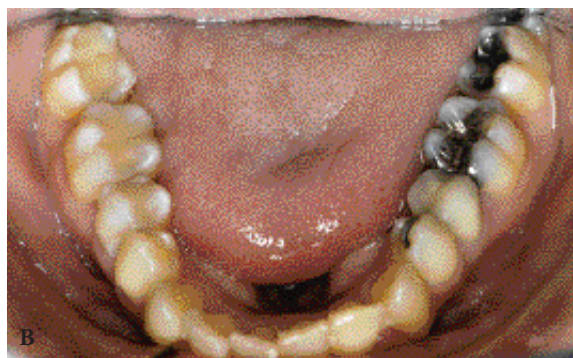
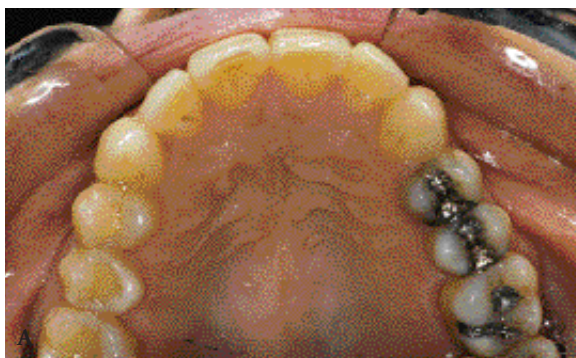
Figure 13–2A and B: These pictures depict a 10-year status of posterior composite restorations on one side and amalgam restorations that were placed on the other side at the same time. All restorations continue to be functional.

sive nature, the basic uses, and the materials and techniques that have broadened the use of bonding in esthetic dentistry. The description of the bonding procedure emphasizes an overlay technique that this author has used for more than 30 years and found to overcome some of the difficulty in maintaining a long esthetic life for bonded teeth. And finally, the chapter concludes with the simplest and yet most overlooked role in esthetic dentistry: education of the patient in the maintenance of his or her new appearance through prevention, care, and an attentive eye to how dental professionals such as hygienists should approach the bonded teeth.

BASIC CATEGORIES OF BONDING IN USE TODAY

The major reason that bonding is so useful in terms of conservative operative dentistry is that composite materials are directly bondable to tooth structure.⁴⁶ While bonding to enamel is by far the most frequently used, reliable, and predictable of all bonding procedures,⁵⁷ as can be seen in the listing of basic uses to follow, the ability of the newer materials to bond to all hard tissue and to dental materials continues to broaden the uses for bonding. Basic categories are:

- bonding composite resin to enamel
- bonding composite resin to dentin
- bonding composite resin to other composites, glass ionomer, and porcelain
- bonding glass ionomer to dentin and enamel
- bonding porcelain to enamel and dentin
- bonding composite resin to metal

Bonding is a highly esthetic method of obtaining both functional and esthetic restoration of individual teeth, using one or more of the above categories. Patients who appear to be difficult to please may be good candidates for bonding, since it is reversible.³³ This allows the flexibility of redoing or altering the shade for this type of patients who may find it difficult to accept an unchangeable porcelain laminate once it is irreversibly bonded to place. Bonding is also an excellent choice for closure of interdental spaces with mesial or distal composite resin augmentation because composite resin can be added for cosmetic purposes without any tooth reduction.³⁷ A possible contraindication for com-

posite restorations would be in the patient who wishes to replace existing posterior amalgams and exhibits a high caries index and/or consistently demonstrates poor oral hygiene.¹⁰⁷

The esthetic effect, even more than the clinical success, will be based on the proper choice of materials and techniques used. With this in mind, bonding can be used in all five classifications of restorations as well as in repairs of chipped or fractured porcelain.

RESTORATIVE USES

Class I Restorations

These include pits and fissures that can be easily, quickly, and esthetically restored by composite resins. As an added bonus, the bonding of small grooves, defects, or pits in individual teeth is an excellent means of preventing either initial or further caries with little or no risk of tooth discoloration as the case may be with amalgam (see Figure 13–23).¹⁸ Life expectancy is the longest in this category, with 10 plus years not uncommon.

When matching an exact shade is important to your patient, be sure to make your shade selection before placing a rubber dam. In the event the tooth is discolored due to an old amalgam restoration, it may be necessary to remove the amalgam first—then make your color selection.

Use a “stock” shade guide supplied by the manufacturer only to select several of the closest shades with which to do your actual shade trial bonding. To achieve the closest match, remove all of the old restorative material plus any stained tooth surface that might mar your esthetic result. Have all your materials ready, including a mylar strip and GCI#3 (Hu-Friedy). Place a small amount of composite resin on the tooth to be matched. Quickly apply the mylar strip using more pressure on one end of the composite so you will achieve a good range of color from thick to thin on the labial surface after polymerization. Then let the tooth regain its moisture until its normal color has returned. Make your shade comparison as quickly as possible, avoiding any long periods of tooth desiccation.

Class II Restorations

If conservative, these can be achieved, both functionally and esthetically, through composite resins. Tunnel preparations are ideal for composite resin or

glass ionomer restorations. Functionally try to salvage as much tooth structure as possible. It is esthetically easier to blend in a composite to existing enamel instead of creating a new color. In addition to conserving tooth structure, Douvitas²⁸ notes that gap formation between resin and enamel occurs most visibly in the cervical wall of Class II restorations, which may be minimized by using a spherical, rather than rectangular, cavity preparation. This class illustrates quite well the role bonding often plays in making esthetic dentistry (as opposed to dentistry for function only) economically available to a larger number of patients. At times, there will be need for larger Class II restorations, especially on the mesial aspect of bicuspid where the labial margin would show if it were amalgam or gold and the patient wants to keep the cost lower than that for a porcelain inlay. This is permissible, provided the patient understands that the life expectancy may be considerably shorter than for other restorative options.

Patients' main objection to amalgam restorations has been either the "silver," "black," or "metal" color of restoration and the darker appearing enamel associated with these restorations.

Esthetically, the Class II restoration can present special problems, especially with a large mesiolabial wall that needs restoring. The shade that blends well with the occlusal portion may not match the proximal wall. You may need to use a more translucent shade or blend a slight blue or violet tint into the proximal portion to obtain a better match. If you use a rubber dam while removing the old restoration, it may be necessary for you to take off the dam during final shade selection, then replace it to continue the procedure. Be sure to allow additional time to accomplish these procedures.

Indirect Posterior Composite Restorations

Emphasis on bonding, esthetics, and tooth conservatism has prompted research for the optimal material for use in posterior tooth-colored restorations. Dental porcelain has basic problems including questionable wear of the opposing dentition, difficulty to modify and polish in the oral cavity, as well as an inherently brittle nature. Polymer-based systems of the past, on the other hand, have lacked sufficient strength and wear-resistance. Recent advances in polymer ceramic technology combined with new fiber developments have generated an entire genre of metal-free restorative materials.

These systems may provide the esthetics, biocompatibility, and enamel wear similar to an ideal resin material while encompassing the flexural strength and fracture resistance of metal-reinforced restorations for anterior and posterior areas.⁹⁶

Although the materials (BelleGlass [Belle de St. Clair/Kerr, Orange, CA], Artglass [Jelenko/Kulzer, Armonk, NY], Sculpture/FibreKor [Jeneric/Pentron, Wallingford, CT], Targis/Vectris [Ivoclar, Amherst, NY]) are many times used for posterior inlays and onlays, for the purpose of this book, they are discussed in Chapter 15. What follows is an overview of one indirect resin material that is primarily used for posterior inlays and onlays.

Concept[®] by Ivoclar/Williams

Concept by Ivoclar is the only indirect resin that has a decade of clinical success behind it and has been evaluated against conventional restorative treatments in university clinical studies. It was reported to rank favorably by both CRA Newsletter and Reality.^{2,52} Concept is a heat- and pressure-cured indirect resin inlay and onlay material. This curing method results in a homogeneous inlay/onlay with an 85% conversion of the free radicals during polymerization which helps to achieve a higher compressive strength and enhanced color stability.^{65a} Concept is a microfill with enamel-like wear that does not abrade the opposing tooth structure.^{14a} It is radiopaque for easy detection of secondary caries and contains ytterbiumtrifluoride which may reduce the chance of recurrent decay.⁵ It is highly polishable and occlusion can be adjusted after cementation without the need for restaining or glazing. Concept is easily repairable in the mouth,⁴³ and proximal contacts can be added chairside with little effort when necessary.

Further, because it is fabricated outside of the mouth, there is greater control of ideal proximal and anatomic contours. The initial intraoral trials for this material appear positive. In a study at the University of Manitoba, Concept restorations were placed in Class II inlay and onlay situations. Amalgam restorations were placed as controls in the same patients. At 3-year recall, the Concept restorations exhibited lower wear rates than that of the amalgam controls. In fact, "97% of the (Concept) restorations showed no clinical evidence of wear whatsoever."⁶⁶ The most favorable uses for this restorative material seem to be in Class I or II inlay situations

rather than in large onlays which replace one or more cusps.

Class III Restorations

These are the major use for composite resins today. Composite resin materials have become the most popular material for Class III, as well as Class IV and Class V, restorations.⁸⁴ These cavity classifications are excellent examples of the use of bonding for esthetic superiority as well as its economic pluses. As Croll and Donley²² point out, when bonded composite resin restorations are placed, finished, and polished correctly, and a suitable shade of composite resin is used, Class III restorations can simulate perfectly the appearance of natural enamel and they last for many years (Figures 13–3A to AA). Composites come in almost every shade, range, translucency, and opacity. Acid etching seals the composite to the enamel for functional soundness. However, you will need to purchase additional shades from several different manufacturers to cover a complete range of color options. Shade selection for the Class III composite can be both time consuming and frustrating. The major problem is choosing a shade that will actually match after you have inserted and finished the restoration. Typically, the first thing you do is place a sample of the intended material on the tooth to be restored. The difficulty is to anticipate the correct amount of material thickness so the final result will match. A good method of accomplishing this is to vary the thickness of the sample by pressing harder on one end with the

mylar strip so you will get a gradation of color and, therefore, get a better indication of just how close your shade will match with the estimated thickness.

Class IV Restorations

These, including chipped or fractured teeth, are one of the top reasons for using composite resin. Frequently, bonding is the ideal solution, providing both the immediate answer to an esthetic emergency and a long-term, low-cost restoration. There is no reason to crown a tooth that has minor chips or a slight fractured piece missing when a direct fill light-polymerized composite restoration is more economic and equally functional and esthetic. Minor chips of posterior teeth also can be repaired easily with composite resin with predictable success.

Class V Restorations

Caries and even large, eroded defects are generally handled with a microfill highly polished restoration which is the treatment of choice. However, some feel that a Class V hybrid composite has better color stability and resistance to abrasion.¹⁰⁶ One disadvantage of microfilled composite, as stated by Davidson and Kemp-Scholte,²³ is its tendency to undergo hygroscopic expansion which produces marginal overhangs. In the less motivated patient, this may result in excessive staining and recurrent caries. When making a shade selection for Class V restorations, first note your patient's lip line. This is particularly important for patients with a medium lip line where the incisal-most margin will show

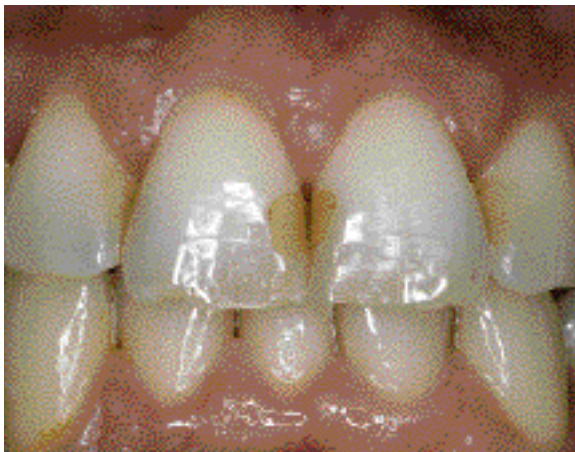

Figure 13–3A: The replacement of discolored anterior restorations with composite resin comprises one of the largest percentages of esthetic restorative dentistry.

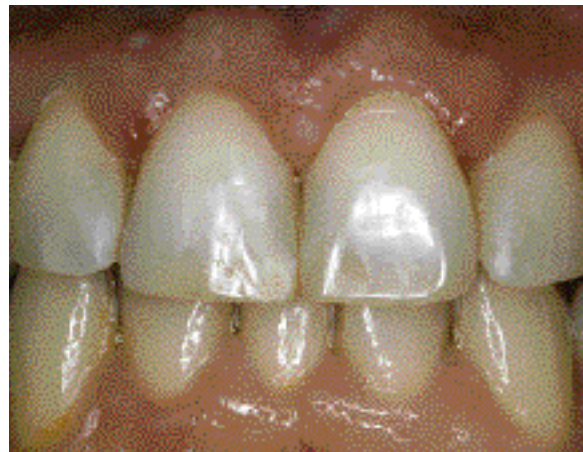

Figure 13–3B: The objective of replacement is to obtain invisible margins and a blending of color to match existing tooth structure.



Figure 13-3C: The basic tooth preparation for the Class III restoration consists of a reverse bevel and an overlaid margin that extends several millimeters past the bevel. This provides extended restoration longevity and a better color blend.

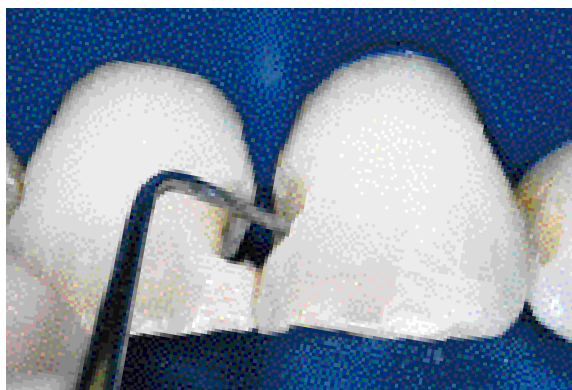

Figure 13-3D: After the old restorative material is removed and a reverse bevel placed, light-polymerized glass ionomer liners are inserted with a Novatech PINT11 (Hu-Friedy).



Figure 13-3E: Dual lights are utilized to accelerate the polymerization process.

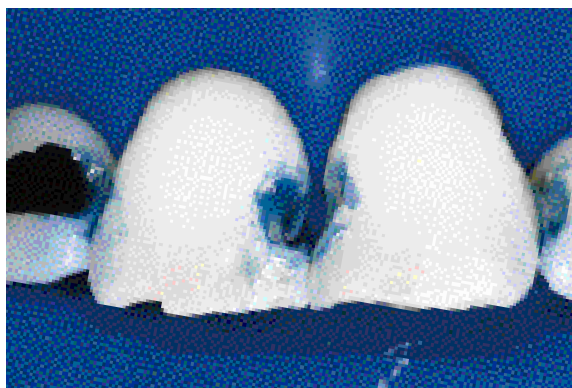


Figure 13-3F: Acid etching should be accomplished for 15 to 20 seconds depending upon manufacturer's instructions.

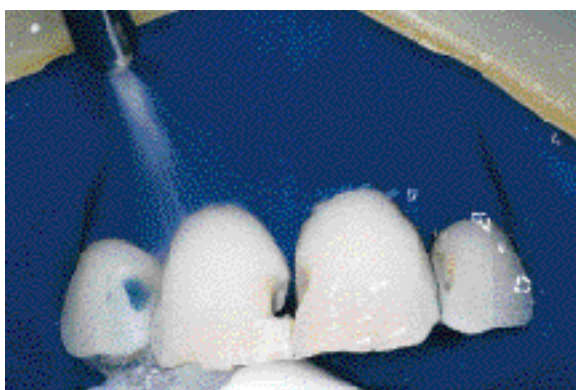

Figure 13-3G: Although 5 to 10 seconds of air/water spray should be sufficient, if the etching medium is a gel, it may take twice as long to completely remove all of the acid.

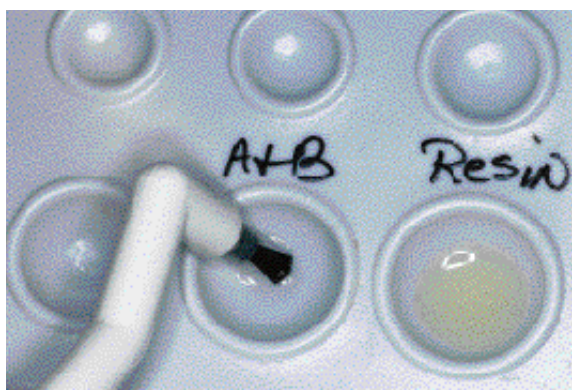


Figure 13-3H: Labeling your dappen dishes when multiple solutions are to be used can help to avoid any confusion.

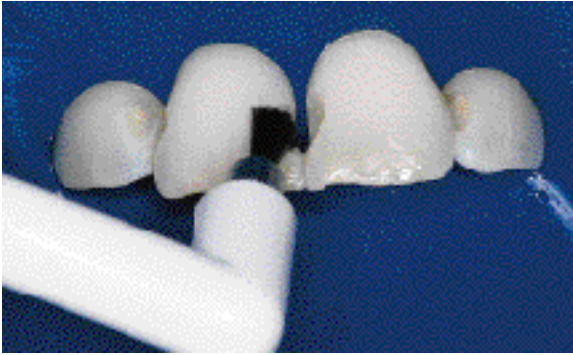


Figure 13-3I: Multiple coats of dentin bonding agent are used on either wet or dry dentin depending upon the technique employed.

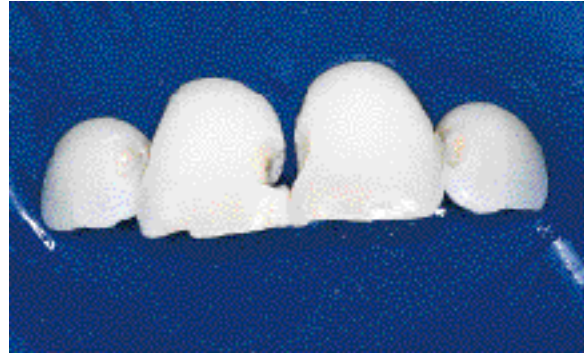


Figure 13-3J: The amount of air drying and polymerization also will depend on the specific manufacturer's instructions. However, the surface should be slightly glossed before polymerization. A properly glossed surface will be a major factor in reducing sensitivity.

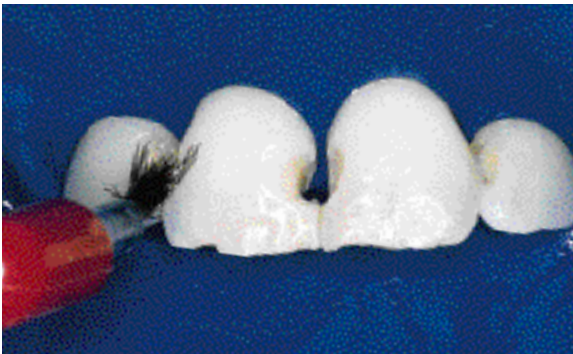


Figure 13-3K: Use different colored brush handles (Centrix, Shelton, CT) to apply the various agents used in the bonding process. Here a red brush is used to apply the final bonding agent.

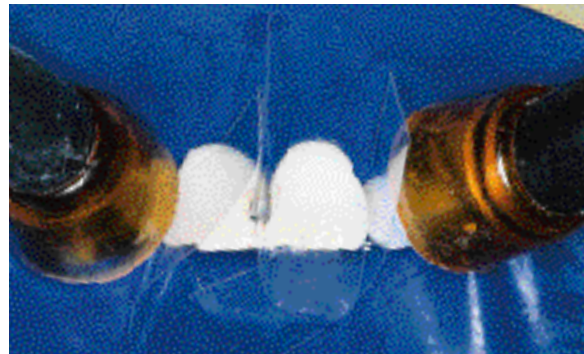


Figure 13-3L: Use a gentle stream of air to ensure a thin layer of the bonding agent. Follow this with labial and lingual polymerization of 20 seconds each.

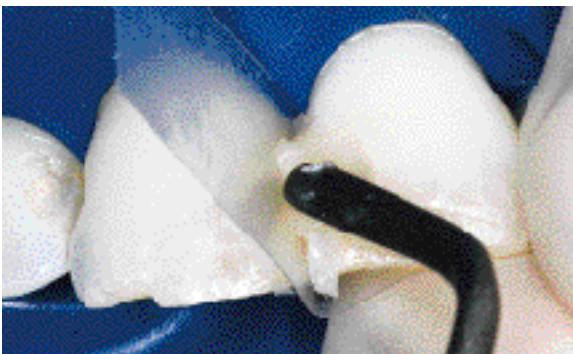


Figure 13-3M: The preselected shade of composite resin is applied with a thin-bonded, nonstick composite instrument (Goldstein 3 [Hu-Friedy, Chicago, IL]) in small increments and polymerized layer by layer. To increase depth of color, consider using a slightly darker shade initially followed by a lighter one, rather than one shade for the entire restoration.



Figure 13-3N: A mylar matrix strip is loosely held to ensure separation and adequate thickness for proper finishing to occur. Polymerize each layer for 60 seconds, both labially and lingually, as each increment of composite material is applied.

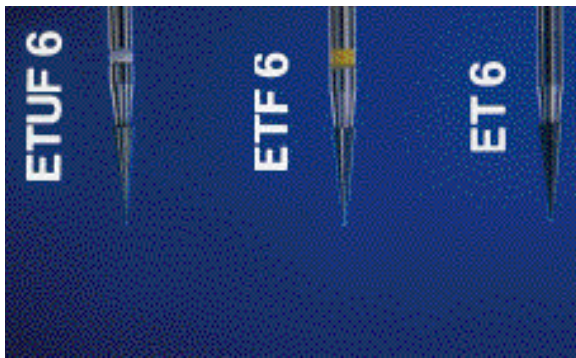


Figure 13-3O: The sequence for finishing requires an entry level instrument of either 8-, 16-, or 30-blade carbide (ET Burs, Brasseler) depending upon the amount of excess composite present.

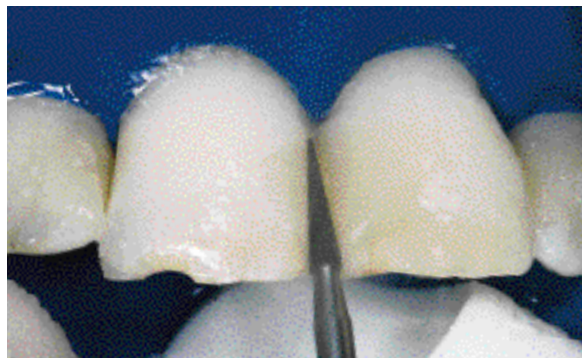


Figure 13-3P: The ET6 8-bladed carbide bur gently removes excess composite at the mesiolabial line angle.

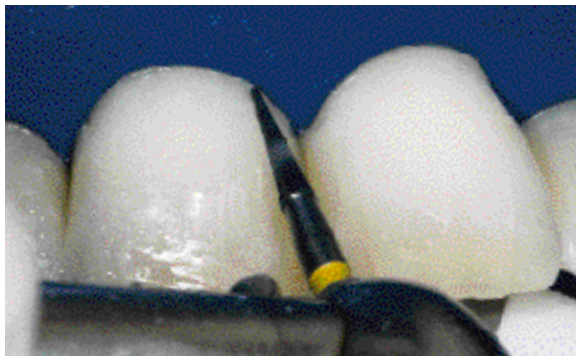


Figure 13-3Q: The ET6F 16-bladed carbide completes gingival contouring.

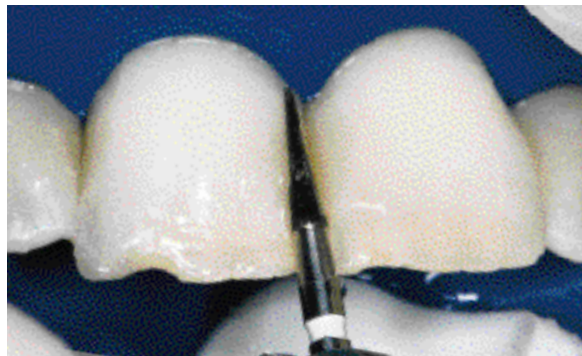


Figure 13-3R: Final labial finishing is done with the ET6UF 30-bladed carbide.

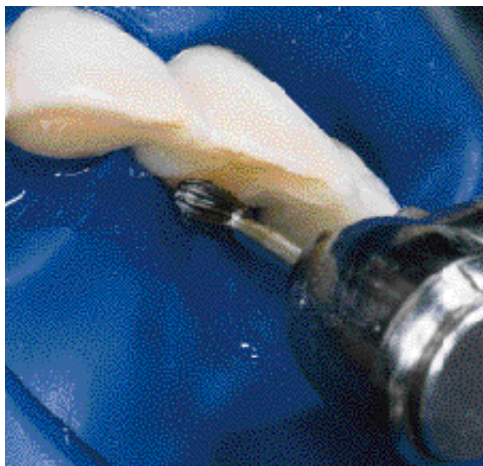

Figure 13-3S: The OS1 finishing bur (ET Series, Brasseler) is the perfect shape to do lingual contouring.

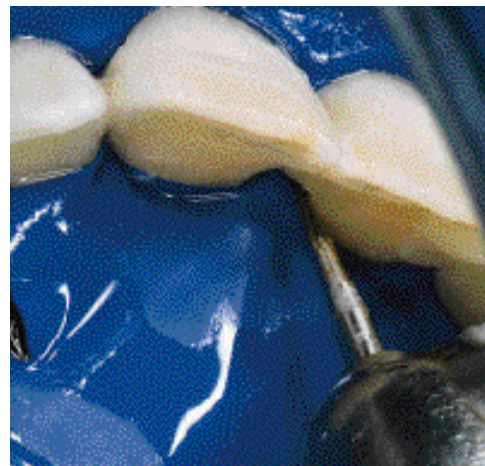


Figure 13-3T: Cervical, interproximal, and lingual margins are finalized with an ET3 or ET4.

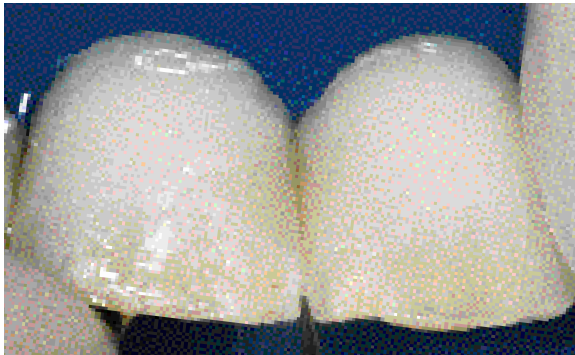


Figure 13-3U: The incisal embrasure is opened by an ET “cutting bur” (Brasseler 132-A).

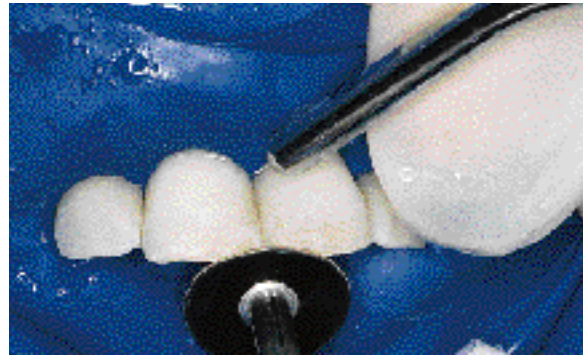

Figure 13-3V: The incisal edge is shaped utilizing the coarse Sof-Lex (3M, St. Paul, MN) disc (black) with water.

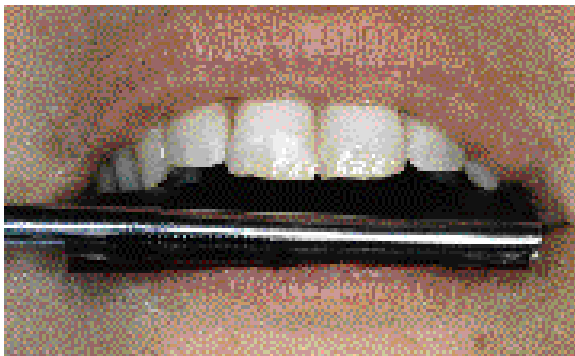


Figure 13-3W: Final occlusion is checked with a microthin articulating paper.

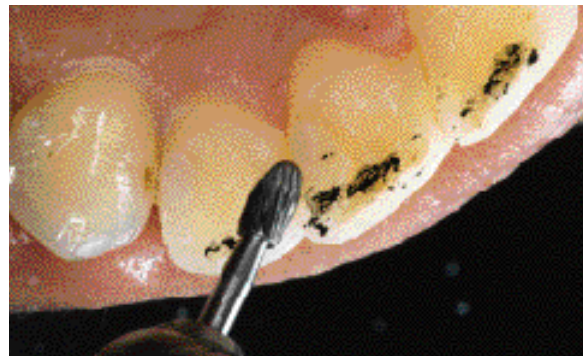

Figure 13-3X: Occlusal adjustments are made with the OS1; however, the OS1F or OS1UF are often preferable to avoid removing too much material at one time.

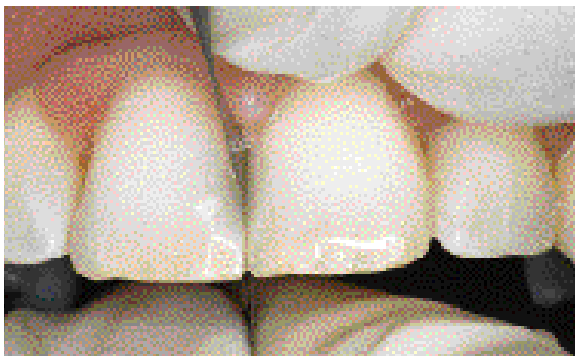


Figure 13-3Y: If contact is too tight, a Compo-Strip (Premier Dental Products, King of Prussia, PA) can be used to make it easier for the patient to floss. Final interproximal finishing is accomplished with abrasive polishing strips (Cosme-dent, Chicago, IL, 3M, St. Paul, MN, Moyco, York, PA, or Shofu Dental, Menlo Park, GA).



Figure 13-3Z: Safe-sided Compo-Strips Premier Dental Products are diamond abrasives in three grits (yellow, 25 microns; red, 45 microns; and blue, 60 microns). When the interproximal contact is adequate, but subgingival finishing is required, use the narrower strips.

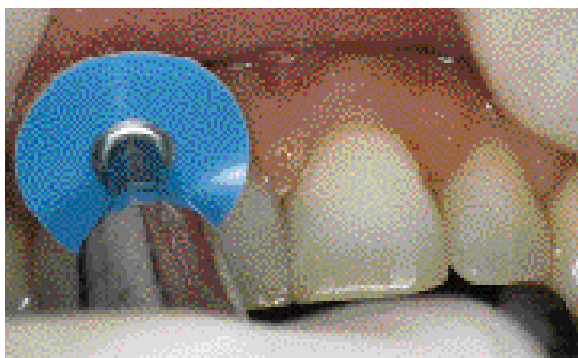


Figure 13-3AA: Final polishing is done with polishing discs (Cosmedent, 3M, Moyco, or Shofu) in sequence dark to light.

during a wide smile. Remember there is a shadow created by the lip line that tends to emphasize the gray shades. Therefore avoid gray or translucent shades if possible, and select the more opaque shades for better blending (Figures 13-4A to I).

Labial Veneer

As previously stated in this chapter, the quickest and most economic method of obtaining an esthetic tooth transformation is through the direct resin labial veneer. Although esthetic perfection may be more easily obtained with the porcelain laminate, the extra time and laboratory costs involved may make the procedure economically difficult for many patients. Therefore, composite resin bonding becomes the restoration of choice for these patients. The best candidate for the direct resin veneer is the monochromatic shaded tooth, since multicolored restorations are much more easily constructed in the laboratory.

A potential dilemma arises when tooth deformity exists on approximately half of the tooth. Do you restore just one half and try to blend a potentially revealing margin or are you better off veneering the entire labial surface and extending your margin subgingivally? One instance where the veneer would be preferred is with the patient who wants to avoid periodic showing of Class III margin. It may be a better choice to veneer the entire labial surface, therefore completely masking the tooth/composite margin. When doing so, consider improving the smile line by extending the labial surface in a buccal direction.

The bonded composite veneer also can be used with porcelain laminates or full crowns when economics is a problem. A good example of this technique would be to either use crowns or porcelain laminates on the anterior teeth for maximum longevity and esthetics, while using direct resin veneers on the bicuspid, and even on the first molars if necessary.

Repairs of Existing Restorations

Chipped or fractured porcelain can be repaired quickly and esthetically with composite resin, using direct intraoral porcelain etching procedures. The esthetic life of this type of repair may be considerably shorter than for a normal bonded restoration, however, ranging anywhere from 6 months to several years. And as with most composite restorations, there will be marginal staining, especially in an anterior porcelain repair, necessitating more frequent maintenance and earlier repeat repairs. To improve the bond to porcelain, use one of the air-abrasive systems with medium pressure and a fine

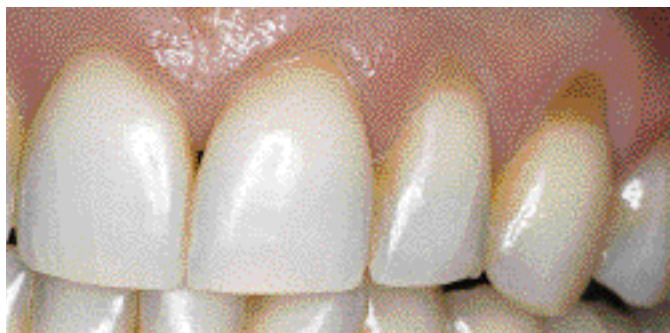

Figure 13-4A: This 38-year-old housewife had severe erosion extending subgingivally from the left central to the left second bicuspid.

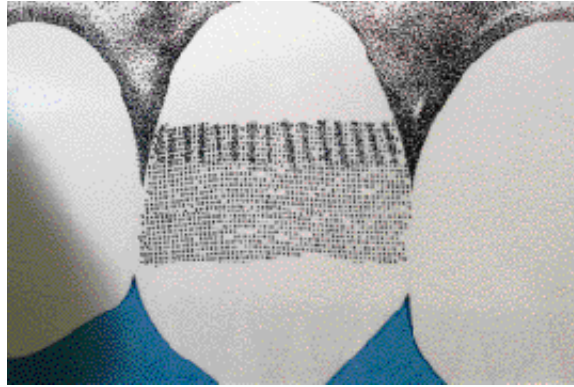


Figure 13-4B: A medium-to-long bevel is cut from the eroded surface into fresh enamel. The labioincisal or labioocclusal margin extends to the point where there is a slight lingual inclination which will help mask the tooth color.

abrasive (Whisperjet, American Dental Technologies; Micro Prep, Lares Technologies; or Mach 5, Kreativ, Inc.).

Provisional Treatment

Creation of anterior guidance or posterior rehabilitation during occlusal therapy for patients with bruxing-associated myofascial pain can be achieved using bonding.³³ A hybrid is usually the material of choice.

Bonding is an excellent treatment selection for young persons who will have continued facial growth since it is likely that passive eruption will leave unsightly lines or the gingival margins of any veneer. But with direct-bonded veneers, the veneer can be replaced or repaired when growth is finished

with either composite resin bonding or porcelain veneering.³⁶

Direct and Indirect Inlays

There are several methods of constructing the posterior inlay. Direct resin inlays can be cured initially in the mouth for shaping, then cured again in the laboratory, and only then bonded into the tooth preparations with resin cements. As Christiansen¹⁶ outlines clearly, this restoration solved some of the problems seen with resin restorations cured directly in the tooth. The shrinkage during polymerization takes place in the oven, and there is less shrinkage in the marginal areas. These restorations are time consuming, but they have excellent appear-

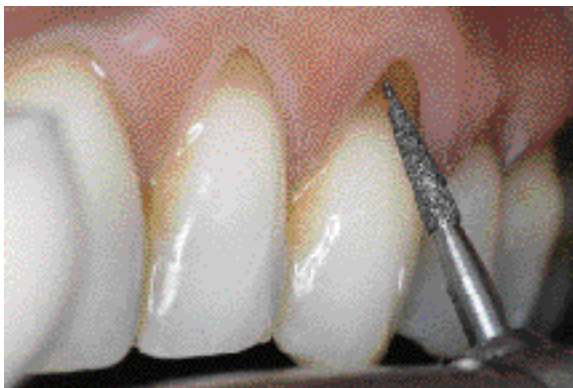

Figure 13-4C: An extra-coarse F6C diamond (Premier) places the labial bevel and roughens the remaining tooth surface to be covered.

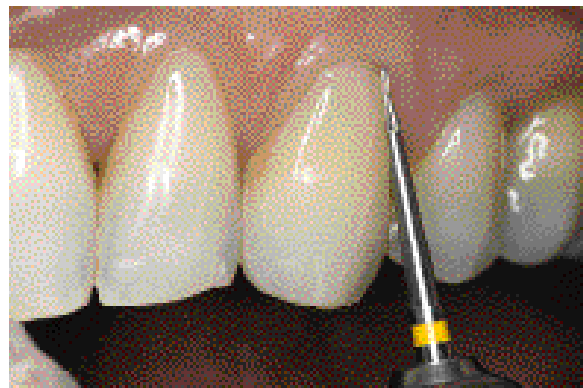

Figure 13-4D: The gingival contour is best created with an ET3F or ET4F (Brasseler) 16-bladed carbide bur.

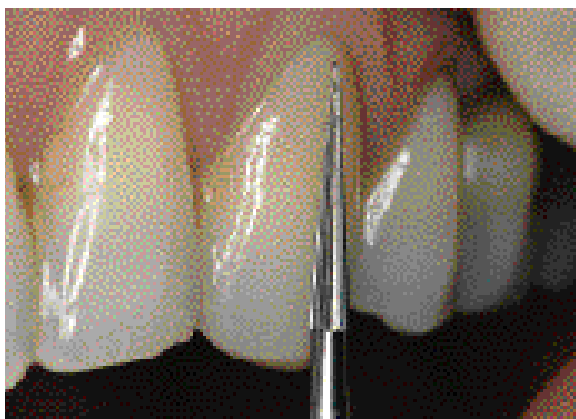


Figure 13-4E: The bulk of the body contour is carved with the ET9F. The instrument's shape helps to achieve a more natural tooth contour and texture.

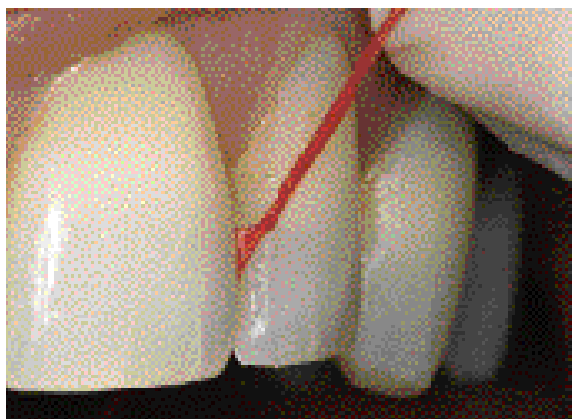


Figure 13-4F: The interproximal areas are checked with dental floss to identify any areas that may need additional finishing.

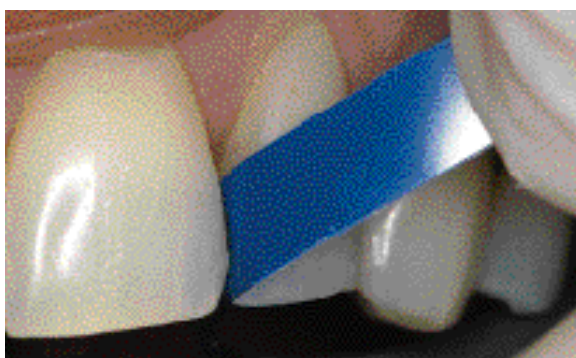


Figure 13-4G: A plastic abrasive strip (Cosmedent) is best used when only a fractional amount of interproximal finishing is still required.

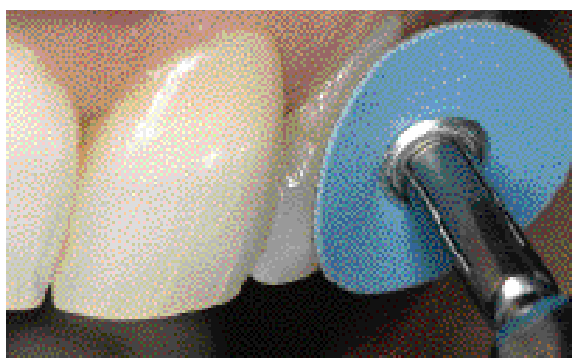

Figure 13-4H: Final polish is completed with a series of abrasive polishing discs, cups, and points in sequence (Cosmedent, 3M, Moyco, Shofu) until the desired luster is achieved.

ance and lasting power. They also have the advantage of being “custom made,” signifying quality and personalization to many patients.⁷¹ One trade-off that must be respected is that indirect curing causes resins to become more brittle and less forgiving under occlusal loads.⁹⁷ Indirect inlays that are constructed in the laboratory have been slowly gaining acceptance. They have the same strength and wear characteristics as the direct resin inlays and onlays, but do require laboratory technicians and, thereby, greater cost. One of the newest methods of constructing posterior inlays is with a computer-assisted manufacturing apparatus (CEREC,

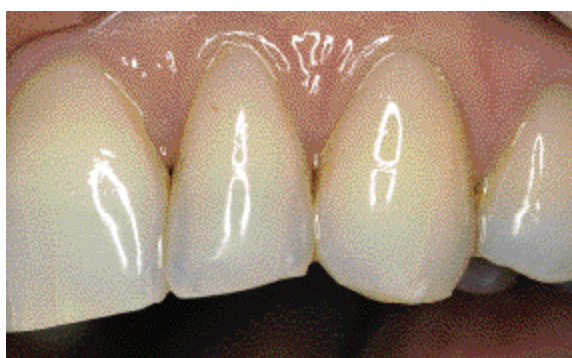

Figure 13-4I: The final result shows a gentle blending of color, form, and texture without a discernible margin.

Sirona, Charlotte, NC; Celay, Vident, Brea, CA). However, these currently feature ceramic materials and are covered in Chapter 14.

MATERIALS

The technique of bonding is heavily material-dependent. Bonding materials were the first esthetically substantial products used in dental restorations that were simultaneously free of mercury, resistant to corrosion, thermally nonconductive, and without galvanic reactions.¹⁰⁵ The availability of new materials for use in bonding has been the major player in the balancing act between esthetics and strength. Excessive rate of wear has been the most serious physical limitation of most dental composite resins, limiting their use, for example, in Class I and II cavities where they are subjected to greater occlusal loads and abrasive actions.⁸² However, the wear rate of posterior composites sealed with a surface-penetrating modified BIS-GMA resin was reduced 50%, as reported by Dickinson et al.²⁵

The continuing improvement in bonding technology has created materials that are lasting and can be polished to a porcelain, tooth-like appearance. Earlier bonding materials had a tendency to stain, especially at the edges, and to wear. This is less true of the newer materials, especially when you pay close attention to preparation, application, and finishing.

As Jordan and Gwinnett⁵⁵ point out, composite materials consist primarily of resin-binding matrix and inorganic filler phases. The resin-binding matrix is fairly consistent, with Bowen's resin bisphenol A-glycidyl methacrylate (BIS-GMA) constituting the resin matrix of most composite materials (although urethane dimethacrylate is occasionally used in some). Composite materials differ primarily in the inorganic filler type and size of particles, and it is these differences that will determine the strength of the bonding—and, inversely, the degree to which the materials can be polished for esthetic appeal, and resistance to discoloration. The ideal composite material would be highly polishable, so that the finished restoration would have the smoothness and reflective quality of enamel. It also would be highly resistant to chipping or fracture, with maximum durability in stress-bearing areas. Unfortunately, you often will be forced to compromise, seeking the best esthetic effect possible within the minimum acceptable risk of fracture.

In general, the different composites have different roles to play. When restorations are in high-stress areas, the greater filler loading of macrofilled composites or hybrids gives them an advantage. When an enamel-like polished surface is required, microfilled composites are the material of choice.³⁰

Concise and extremely detailed comparative summaries of available resins and their recommended uses can be found in newsletters like *The Dental Advisor* (publisher Dental Consultants, Inc., Ann Arbor, Michigan) or CRA Newsletter (3707 Canyon Road, Provo, Utah) and in current journal literature. Although a few commercially available products have various degrees of shades with ranges of opacity, you will find that certain manufacturers tend to place more opacity in their composites than others. Since most BIS-GMA composites are compatible, you may choose to purchase a composite kit with the broadest possible shade range and then add additional individual shades of another brand that may have more or less opacity as you need to have the full range of shades.

Microfilled Composites

The inorganic filler in most microfilled composite materials is colloidal silica, a fine white powder with a particle size of 0.04 microns. When the inorganic filler particle is this small in diameter, it is highly polishable. With proper finishing, the surface is smooth and highly reflective, much as natural enamel. However, the particle size means that the composite will not hold a large amount of inorganic filler. The maximum inorganic loading with a microfilled material may be half that of other composite materials.^{54–56} The microfilled materials, therefore, do best in protected clinical situations such as Class III and Class V labial veneer restorations and small Class IV situations in which the occlusion can be carefully adjusted and controlled.⁵⁴

Small Particle Macrofilled Composites

Composite materials in which the size of the inorganic filler particles is between 1 and 8 microns are only semipolishable, with a duller, less reflective surface after finishing. It is more resistant to fracture, however. This makes them highly appropriate in Class IV situations exposed to heavy occlusal loads but in which esthetic demands are fairly high. Warn your patient about the potential “roughness” so there will be no surprises. Actually, the lack of polishability

may not be too noticeable since saliva will keep the surface wet enough to blend in and look good.

Large Particle Macrofilled Systems

When the inorganic filler particle is greater than 10 microns, it is considered to be nonpolishable. Furthermore, the rough surfaces retain plaque and are quick to discolor, especially for a patient who is not prepared to maintain the restoration with excellent dental hygiene. Nonetheless, the increased fracture resistance makes such composites an excellent choice for many clinical situations. Jordan suggests three: very large coronal restorations exposed to heavy occlusal stress, large incisal restorations on mandibular anterior teeth, and posterior Class II situations where esthetics are a major consideration.⁵⁴⁻⁵⁶

If a larger particle system is your choice, consider using a microfill or polishable hybrid for your final layer in order to gain a superior finish that would be less stainable and feel better to the patient's oral tissues.

Hybrid Composites

These composite materials address the trade-off between esthetics and strength, combining reasonable polishability with increased resistance to fracture. As clinical trials continue to provide data on the long-term effectiveness of these composites, they may well be more widely used. In fact, the trend in composite resin technology for the last decade has been toward smaller average particle size and higher filler loadings.⁶⁹ During recent years, the dental industry has improved the processing of materials to allow for high loading and fine particle texture to be achieved together.⁹² This will eventually result in improved properties and improved appearance of dental materials.

In the meantime, the practitioner who seeks the esthetic desirability of the microfills in situations requiring the durability of the macrofills may use both. Laminating techniques permit the main body of restorations to be built up, first by using the sturdier composite, then, second, by using the microfilled composite as a veneer that can be highly polished.

BONDING TECHNIQUES

The underlying aim of bonding techniques, just as for the selection of materials, is to achieve an esthetic effect while creating a strong retention of

the composite material to the surface and especially the margins of the area to which it has been applied. Not only must the bonded material hold up under stress, but it must eliminate marginal leakage which can destroy, even worsen, esthetic improvement (Figures 13-5A to D).

As with any clinical esthetic procedure, the first step is to make photographic records prior to even cleaning the teeth. This provides the "before" for your restorative "after" shots, and it also provides information about the patient's oral hygiene and stain forming habits that may threaten the esthetic effect you are about to create. This photographic documentation can prove invaluable if later a question arises about what you did and why you did it. Only after the photographs are made should you pumice the area thoroughly and take all steps to provide a thoroughly clean surface.

As noted by Paquette,⁸⁶ failure to remove all debris from every surface of the tooth to be restored may result in a "peeling" of the composite, especially interproximally. It is probably not a good idea to appoint a patient for resin placement on the same day as a recall prophylaxis because crevicular weeping/hemorrhage can undermine every step of the bonding technique. Instead, allow soft tissue to heal and be certain that your patient is maintaining good home care.

Miura et al. have demonstrated that a prophylactic cleaning of enamel raised bond strength by approximately 50%. No wonder Gwinnett calls the interface between resin and tissue the potentially weakest link between restorative resin and enamel. He advocates a thorough dental prophylaxis to remove deposits (including calculus) from the enamel to allow the acidic conditioning agent, namely phosphoric acid, to exert its optimal effect.^{45,46}

Gwinnett also reports that the use of ethanol to remove any residual water from the etched enamel enhances the ability of resin monomers to penetrate the surface irregularities.⁴⁶

An optimal working field can be achieved through careful isolation of the teeth, usually with a rubber dam, after pumicing and rinsing. Do not use prophylactic pastes which contain glycerin and fluoride, however, since these will act as barriers to etching solutions.¹ Brockman has demonstrated that air abrasion prior to etching a tooth for occlusal sealants creates an enhanced retentive surface. Air

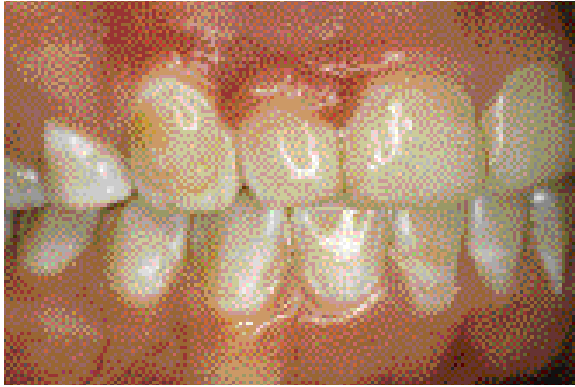

Figure 13-5A: This 14-year-old student was unhappy with her previous bonding which attempted to mask her tetracycline stain. Note how inflamed the right central, lateral, and cuspid gingival tissue was due to overhanging margins.

abrasion increases the number of enamel “tags,” thereby permitting more saturation of the resin.¹²

Possible limitations of routinely using a jet-abrasive instrument may be that the force of the spray can cause gingival hemorrhage or crevicular weeping.

Shade Selection

This step of the procedure merits a significant amount of time to test and consider a complex mix of factors. Recognize that there can be a marked difference, one noticeable to the naked eye, between color shades and resin samples, especially for the incisal colors and the deep and dark colors.⁵⁰ Compounding the difficulty of shade selection are, according to Makinson, color changes that

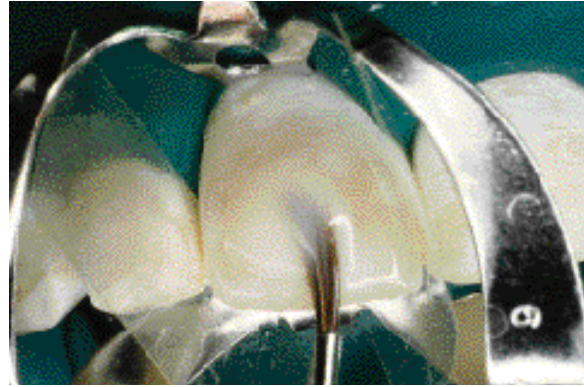


Figure 13-5B: Due to tissue inflammation, a rubber dam was placed and each tooth was individually clamped before it was bonded. Here the first of multiple layers of opaquer is applied and then polymerized.

develop during curing. He found that, in general, all become lighter, with some becoming more opaque and some transparent. It therefore follows that a cured try-in of the shade(s) that you have selected offers a good idea of the color of the final restoration.⁷⁵ These factors include color of the dentin and enamel and, as discussed previously, the color of the liner. Custom composite shade guides may somewhat improve shade matching.⁹¹

In choosing the color, obviously the choice will be made on the closest shade possible to the tooth, available in either a microfill or hybrid composite resin. It may be necessary to use a combination of two or even more shades to arrive at the proper depth of color. If so, always use the darker shade first to achieve a depth

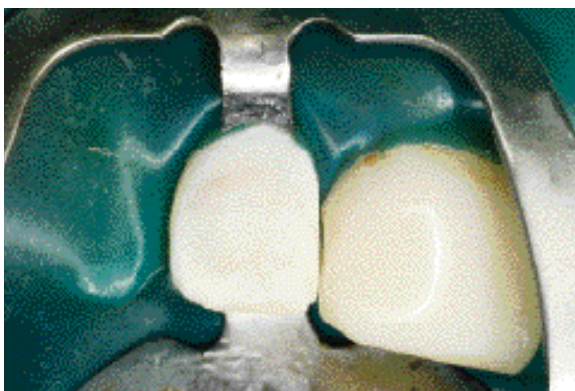

Figure 13-5C: After multiple layers of the lighter shade of microfill composite resin are applied, polymerized, and finished on the right central, the right lateral is treated.

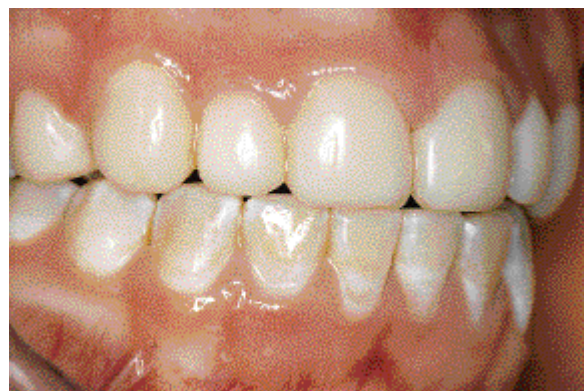

Figure 13-5D: After 2 weeks, note the final result shows a more favorable color and an improved tissue response to properly finished margins.

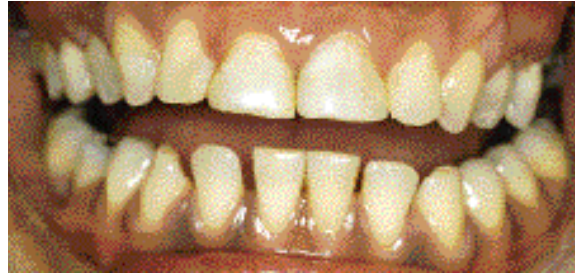

Figure 13-6A: This 37-year-old prima ballerina was dissatisfied with her discolored, protruding, and spaced teeth. Although orthodontics was the strongly suggested treatment of choice, composite resin bonding was chosen instead as an economic and quick compromise solution to her esthetic problem.

of color that will look more natural in the mouth. Although a microfill may be ideal, you may need to switch to a hybrid for the closest match. However, for a Class III restoration in a tooth with multiple shades, the lighter (matching the incisal value) composite should be inserted first, and then layered with the shades that match the gingival portion. You may also perform a cutback and then use stains or darker shades, like the repair technique, to provide the most esthetic result (Figures 13-6A to Y).

Once you have chosen a shade, or better yet, a combination of shades or tints/opagues, dry the tooth and place a small amount of composite resin on the tooth. Using a mylar strip to hold the material in place, polymerize with your curing light. Once you have achieved the desired shade or shades to customize to the tooth, allow the tooth to

become wet again so you can observe how it appears 5 or 10 minutes later. Isolation tends to desiccate the tooth making it appear lighter than it actually will be under normal circumstances, and there is danger in assuming the shade will match if the tooth has been kept dry too long. Therefore, do this step of the shade selection phase of treatment as rapidly as possible. Avoid using cotton rolls and save the tooth drying until the last moment; even then, complete the polymerizing as rapidly as possible. If you anticipate difficulty in matching your patient's tooth color, consider making a separate appointment to spend the necessary time to properly complete this important step.

Tooth Preparation

Most dentists have been taught standard preparation designs intended to conserve tooth structure

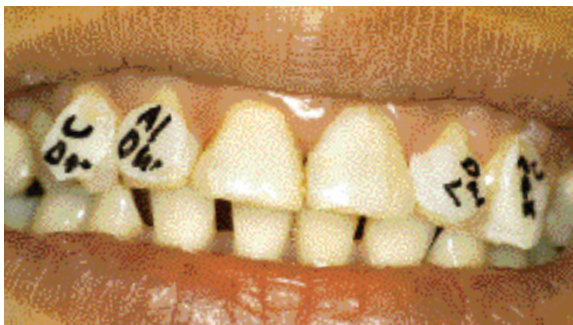

Figure 13-6B: Multiple shades of composite resin from different manufacturers were applied and polymerized to help determine which shade to use.

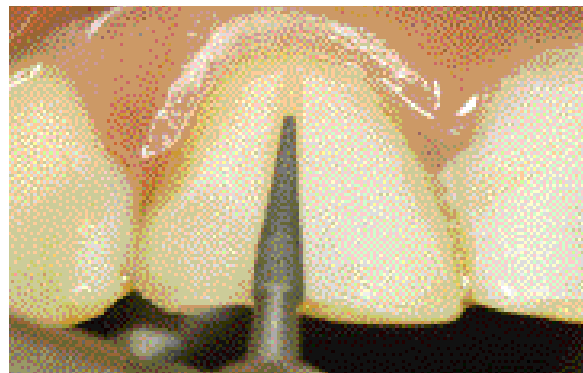


Figure 13-6C: To remove previous bonding on the central incisors, an extra-coarse diamond (F6-C Premier Dental Products) sections the old composite material.

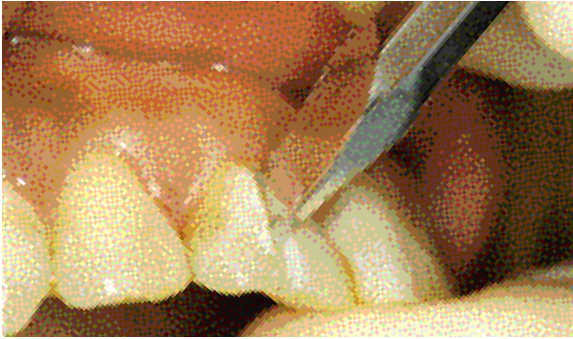


Figure 13-6D: Next, a Goldstein crown remover (CR 10-EUO1851-Hu-Friedy) was used to safely torque off the material.

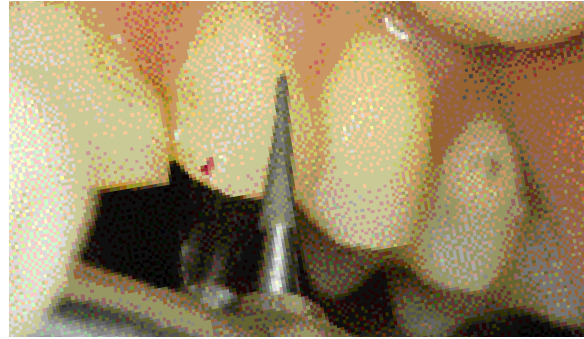


Figure 13-6E: An extra-coarse diamond is used to reduce the labial flair of the maxillary incisors. The pulp tissue must be carefully examined through radiographs in order to avoid pulp exposure.

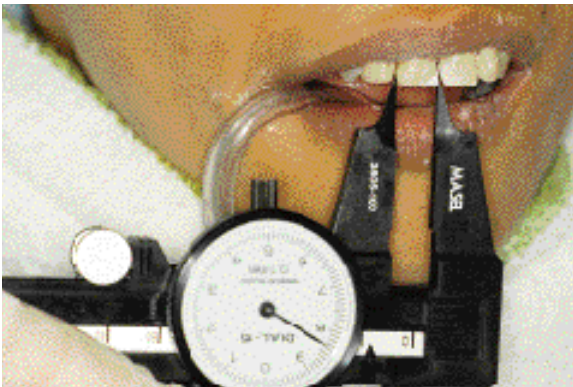


Figure 13-6F: A dental dial caliper (Masel Orthodontics, Bristol, PA) is used to measure and help calculate proper proportions and sizing for the new restorations.

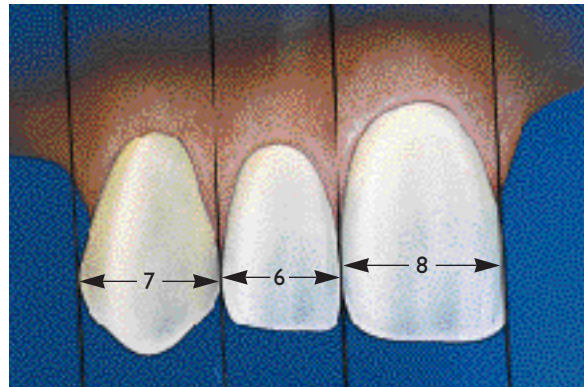


Figure 13-6G: Based on Beaudreau^{8b} and Kinzer,^{65b} (“references” for each) the average width of the central, lateral, and cuspid is 8, 6, and 7 mm, respectively.

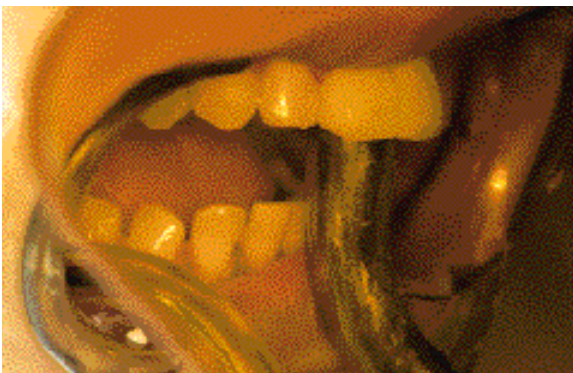

Figure 13-6H: Composite resin is applied in incremental layers on the central incisors first. During polymerization, a protective eye shield is used.

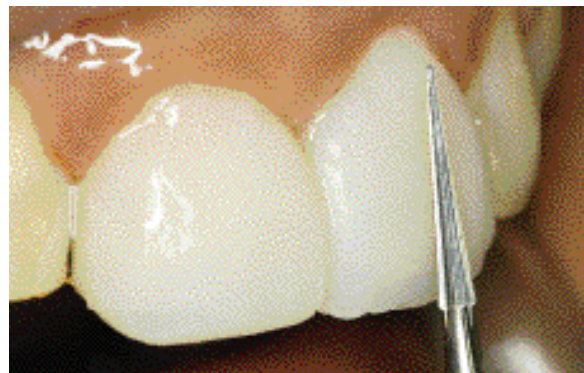

Figure 13-6I: The polymerized composite resin is finished with an ET9 (Brasseler) in as vertical a plane as possible.

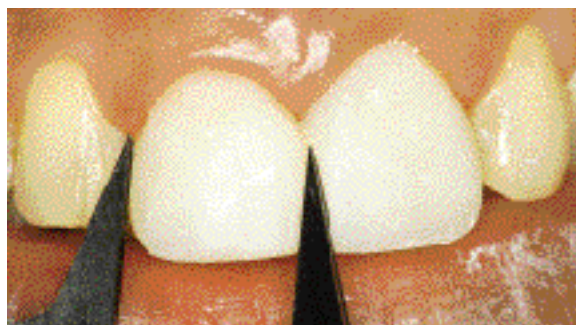

Figure 13-6J: The width of the central incisors is continuously verified with the dental dial caliper (Masel Orthodontics) to ensure accuracy before proceeding with the lateral incisor restorations.

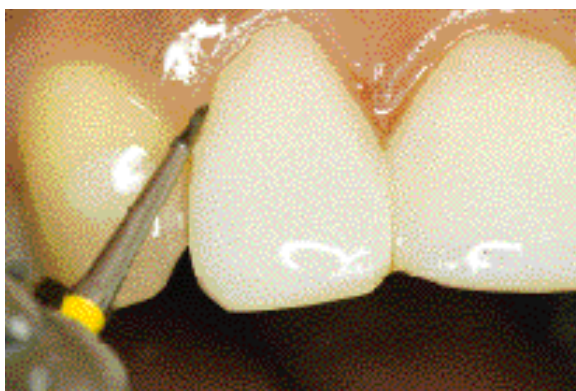

Figure 13-6K: Next, the right and left lateral incisors are completely finished before treatment is begun on the cuspids.

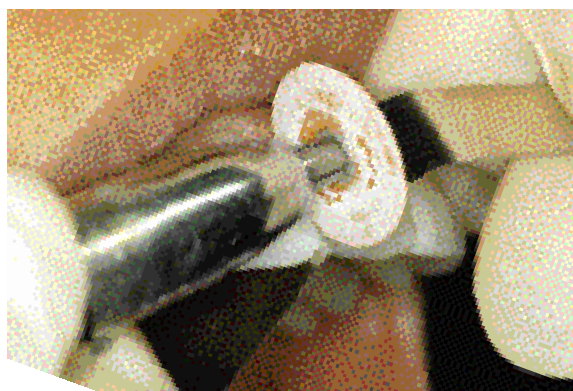


Figure 13-6L: Use an ultrathin, dead-soft matrix band in the interproximal area to protect the previously polished adjacent restorations.

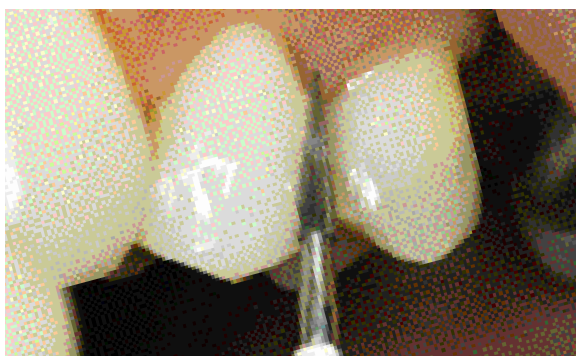

Figure 13-6M: The remaining contralateral teeth are bonded and finished two at a time.

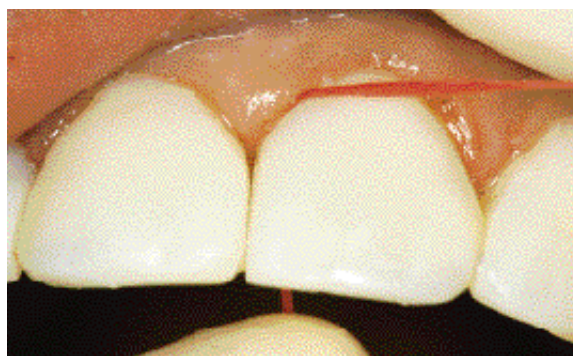


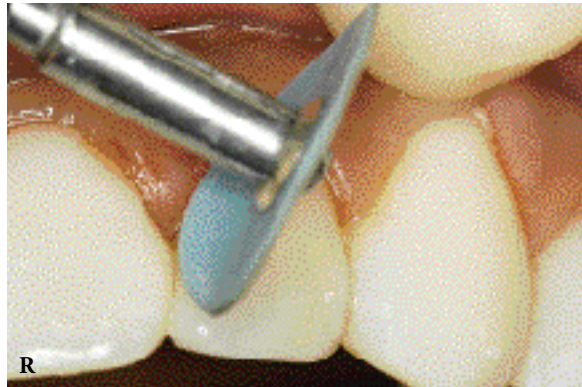
Figure 13-6N: Use dental floss to help discover any previously undetected overhangs.

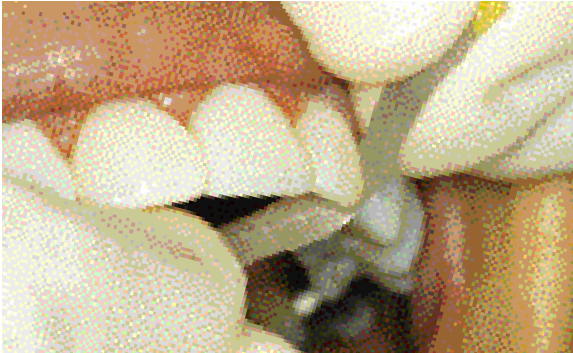

Figure 13-6O: The ultrathin Compo-Strip (Premier Dental Products) is carefully used to help contour the interproximal area.

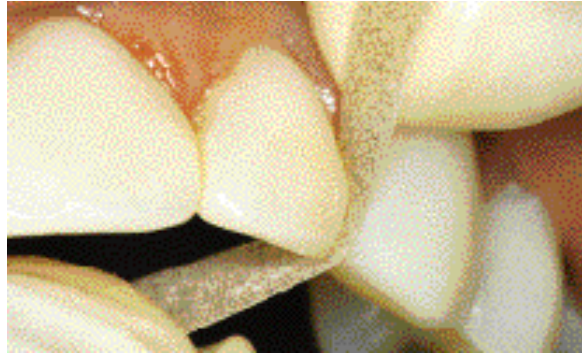

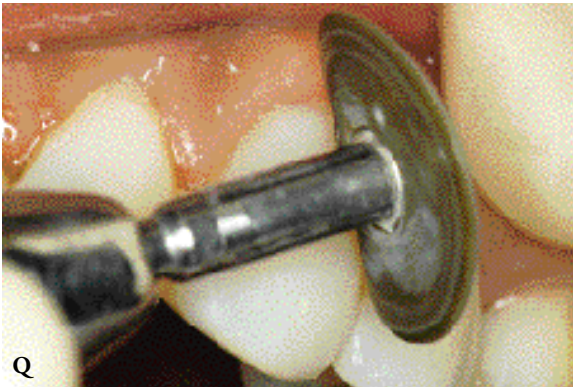Figure 13-6P: Final interproximal polishing is done with less abrasive plastic finishing strips (Cosmedent, 3M, GC Dental, or Moyco).



Figures 13-6Q and R: Gingival contours can be finished best by mounting the discs in both directions and using a pushing or pulling force on the rotating disc, always with water, as seen in the above photographs. Polishing cups and points can also be used if desired.

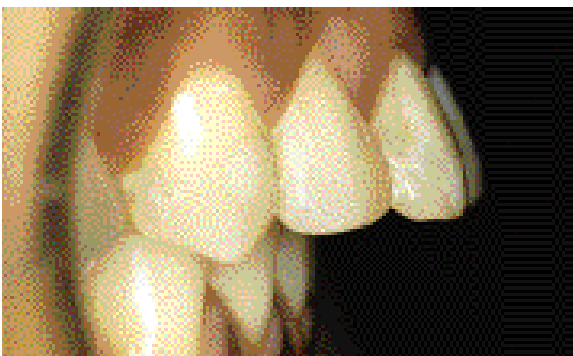

Figure 13-6S: This before lateral view reveals the extent of protrusion, not only of the teeth but the bonding as well.

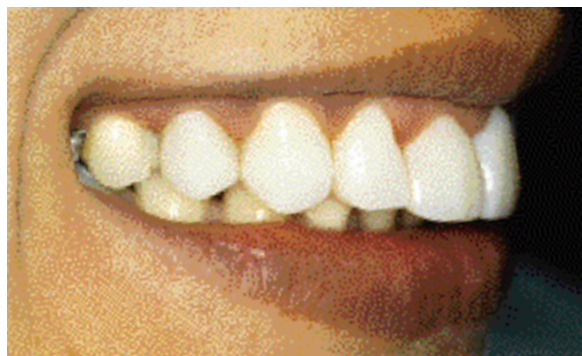

Figure 13-6T: Note in this after view of the anterior teeth how much less protrusion has been achieved.

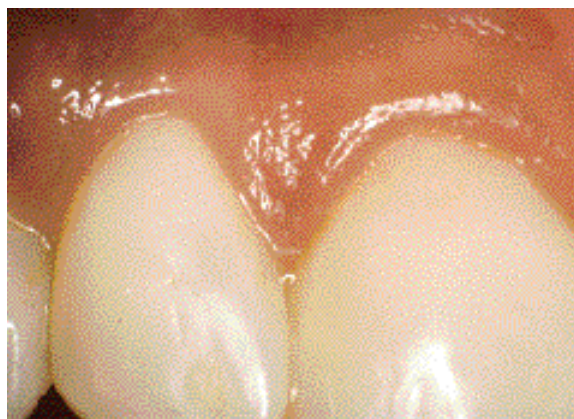


Figure 13–6U: Several weeks after the restorations were completed, the gingival tissue appears to be responding well to the subgingival composite resin margins.

and preserve natural tooth contacts whenever possible. A 90-degree angle of exit is often used when maximum conservation of tooth structure is desired.¹ A chamfer in enamel also allows for a 90-degree angle of exit, which provides a more durable margin, but it is the least conservative design and most dentists turn to it only when maximum retention is necessary.

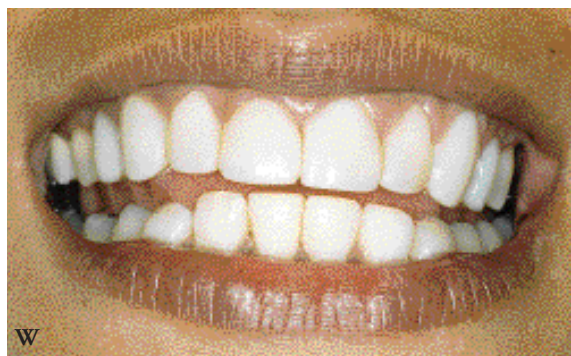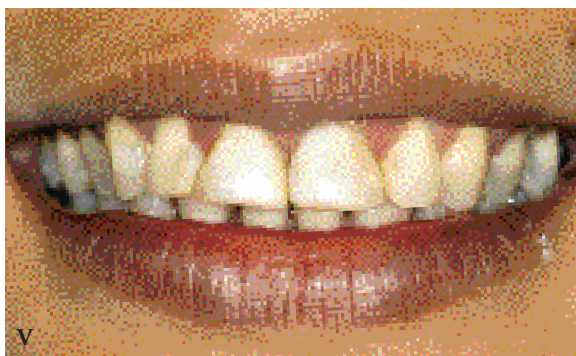The most commonly used finish line, a 45-degree bevel on the enamel, also conserves much of the tooth structure and provides more exposure to the ends of the enamel rods while providing a superior seal to enamel, particularly at the gingival margins.^{20,49}

Myers and Butts believe that a bevel of the cavosurface enamel provides increased surface area for resin bonding, reduces microleakage, and improves

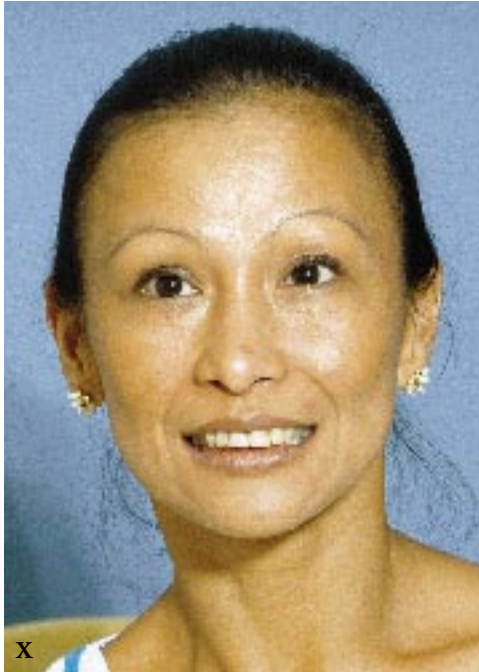esthetics in restorations of permanent teeth with acid-etch composite resin.⁸⁵ Moore and Vann found that beveling the margin of posterior composite resins reduces microleakage.⁸³

THE OVERLAY METHOD

For the past 30 years the author has used a somewhat different preparation design, which he called the overlay technique: a procedure that greatly enhances the esthetic appeal of the bonding without sacrificing stability (Figures 13–7A to H). A 4- to 5-mm long finish line is placed past the bevel of the cavosurface margin of a Class III, IV, or V restoration (Figure 13–7C). Although in normal circumstances undercutting will not be necessary, some roughening of the enamel can enhance the color blend as well as surface retention.



Figures 13–6V and W: Before and after comparison of the patient's smile shows how improved proportions and a lighter tooth shade enhance the smile line.



Figures 13–6X and Y: Full face comparison shows how makeup and a different hairstyle complement the new smile.

This overlay technique means that the actual margin of the new restoration overlays the beveled and roughened tooth surface. This has several advantages. Esthetic restorations often are trade-offs between beauty and strength—or perhaps more accurately between esthetic appeal the day the patient leaves the office and esthetic appearance some months or years later. The overlay technique provides the best esthetic result today and yet also greatly enhances the durability and esthetic life of the restoration for the future.

First, it enhances the color blend from the gingival to the incisal or occlusal part of the labial or lingual surface. With a variable margin, there is a natural transition to and through the different colors of your patient's enamel.

Second, the overlay technique has an extremely important function as a method for tooth lengthening. Figures 13–7I to N illustrate the technique of beveling the labioincisal surfaces of mandibular anterior incisors or shortening the entire incisal surface to allow for the lengthening of the maxillary anterior teeth. The decision of whether to bevel or shorten is dependent largely upon the incisal plane

and the arc of the mandibular anterior teeth. Although orthodontic therapy is generally the treatment of choice, many patients elect the restorative compromise. Further, composite resin overlay can extend the longevity of the restoration by providing resiliency as a measure of protection against possible future fracture. Figure 13–7O illustrates this so-called “cushion effect.” This patient sustained a fall which fractured her composite restorations, but none of her teeth.

Third, depending on the patient's lip line, staining is less likely to be objectionable because margins

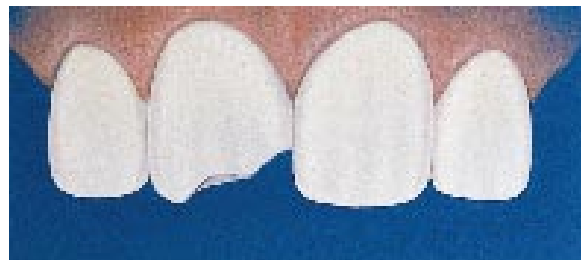


Figure 13–7A: The fractured right central incisor requires repair with composite resin. Two major options for repair are the chamfer-shoulder and the overlay techniques.

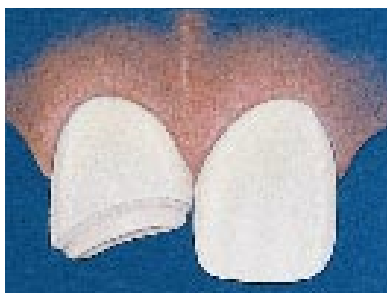


Figure 13-7B: This drawing illustrates the chamfer-shoulder preparation. Note the margin is situated just above the fracture site.

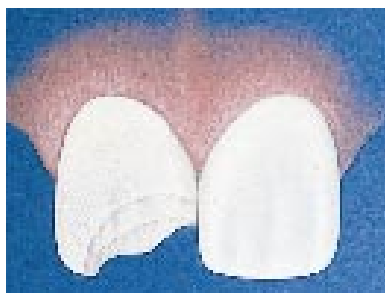


Figure 13-7C: The overlay technique requires a long bevel and an overlaid margin that extends into the cervical portion of the labial surface and in many instances, subgingivally.

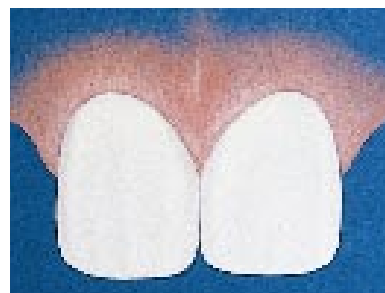



Figure 13-7D: If done correctly, both techniques can produce an esthetic result with invisible margins.

are usually placed out of sight either subgingivally or high enough to be concealed by the lip line. A major esthetic problem with any composite restoration is the staining that almost invariably occurs at the margin of tooth and composite. The overlay technique provides the restoration a longer esthetic life without

having to pursue a repair technique; staining can usually be corrected by merely polishing the stain away  new margin further up or down the enamel surface. Figures 13-8A to P illustrate how much easier it is to freshen a tooth with an overlay technique versus the chamfer-shoulder method.

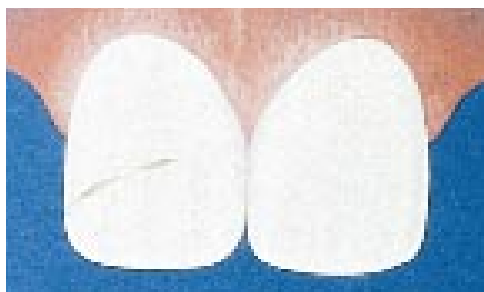


Figure 13-7E: When the inevitable staining occurs, it appears at the marginal junction between tooth and composite resin. Here, stain is seen at the labial margin of the chamfer-shoulder technique. A repair procedure will be required to remove the stain.




Figure 13-7F: With the overlay technique, stain will usually appear closer to the cervical margin, and is much easier to eliminate using a simple polishing procedure.

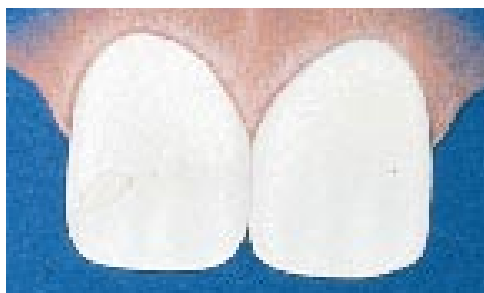

Figure 13-7G: Since simple polishing would result in a concavity, the chamfer-shoulder technique requires a cut and patch repair to eliminate stain.

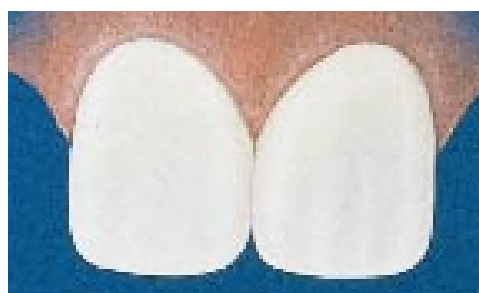

Figure 13-7H: In the overlay technique, stain can be removed simply by finishing with a 30-blade carbide bur and repolishing, thus achieving a more conservative and economic solution. These advantages, plus the ability to achieve a good color blend, make the overlay method the technique of choice.

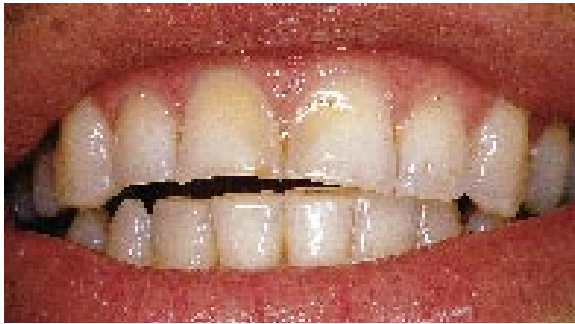

Figure 13-7I: This 23-year-old dancer was concerned about her unattractive smile. In addition to facial enamel erosion, she had worn her maxillary anterior teeth so much from bruxism that it made her smile appear deformed.

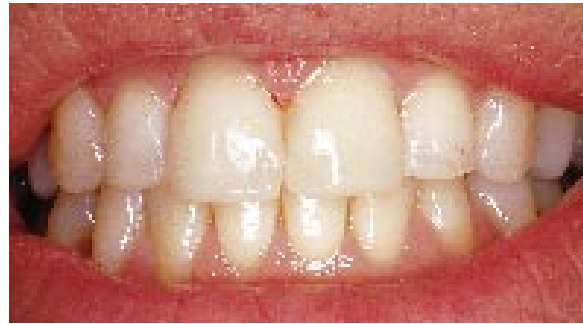
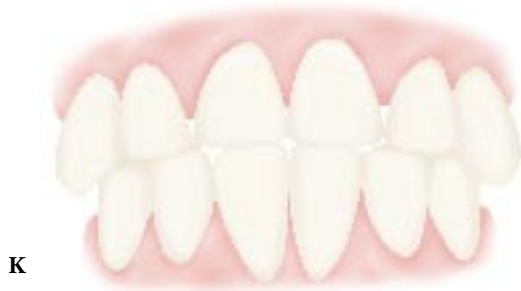
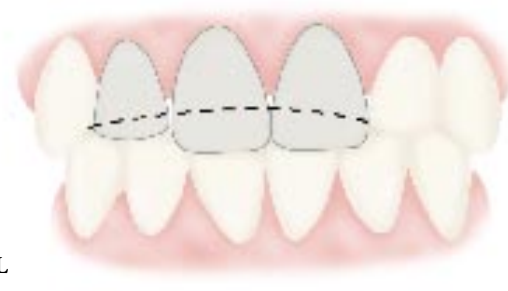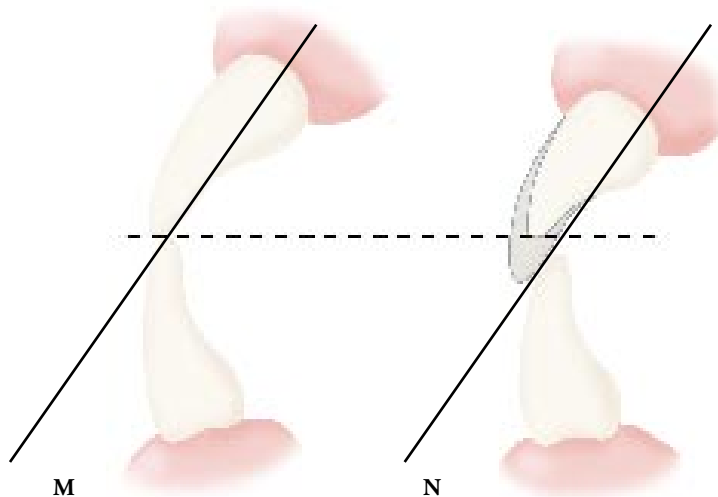
Figure 13-7J: The patient chose an economical and immediate result using composite resin bonding to achieve the effect of long-looking anterior teeth. The incisal edges of the mandibular incisors were cosmetically contoured to compensate for the new length of the maxillary anterior incisors.



K



L



M

N

Figures 13-7K to N: The technique of beveling and shortening the mandibular anterior incisors demonstrates how the occlusion is compensated for, which allows the bonded maxillary teeth to function virtually parallel to the original lateral and protrusive pathways.

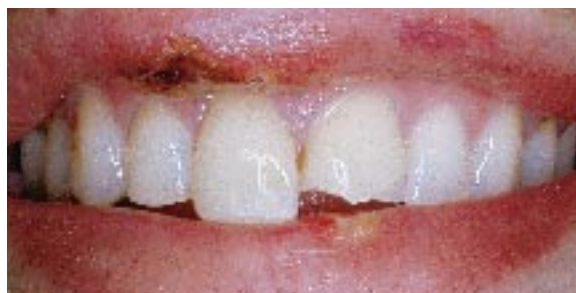

Figure 13-7O: Five years after treatment was completed, the patient fell down a concrete stairway, fracturing the bonding of one tooth, but not the enamel. Note that the composite resin seemed to act as a “shock absorber” to the natural enamel, which remained intact and required only a 1-hour repair technique.

Fourth, it also is a more forgiving preparation. With its gentle lines and lack of precise margins, it becomes an easier restoration to complete.

Acid Etch

As Phillips points out,⁹⁰ there are two basic mechanisms for bonding. The purely mechanical can be

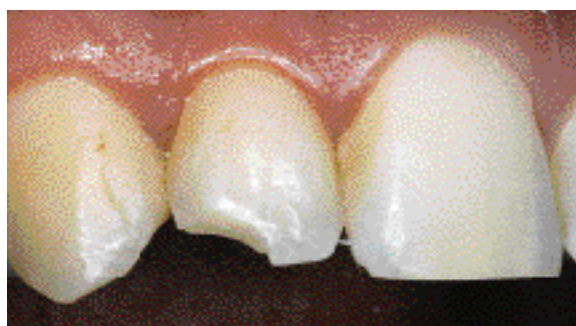
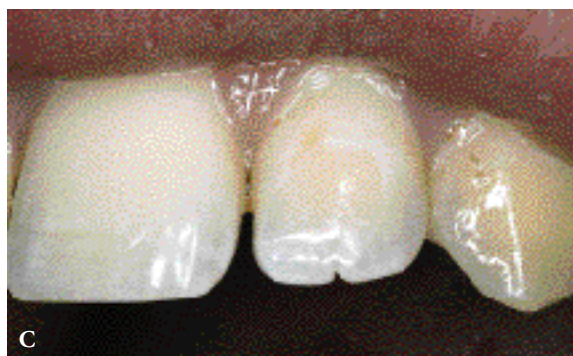
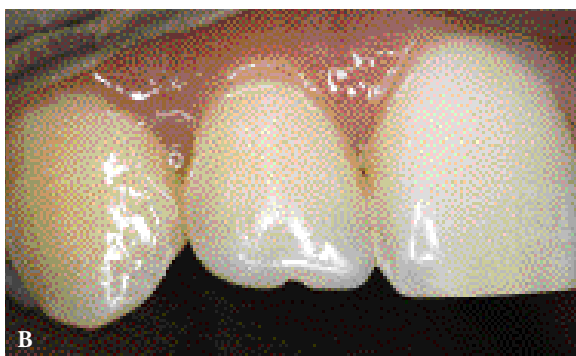Figure 13-8A: This 18-year-old fractured his right lateral incisor in a sports accident.



Figures 13-8B and C: The final bonded result shows a composite resin with a color blend that successfully masks the restoration margin. Note the maxillary left lateral reveals an incisal notch that was also incorporated into the restoration of the right lateral.

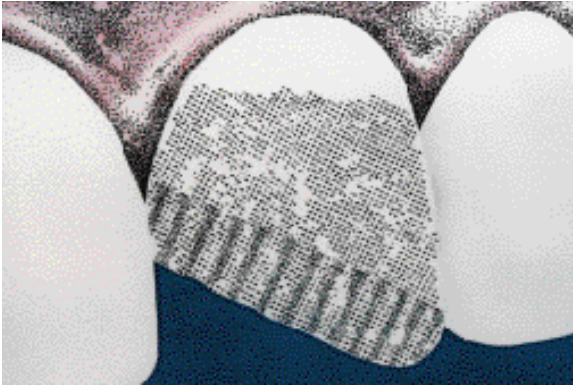


Figure 13-8D: The overlay technique is used to repair the fractured tooth and includes a long bevel and a margin that extends well past the bevel.

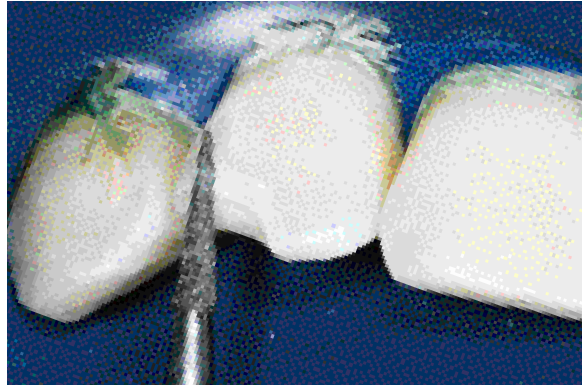

Figure 13-8E: Following shade determination and after placing the rubber dam, a long bevel is created with an extra-coarse diamond (F6C, Premier Dental Products). It is also useful to roughen the enamel surfaces that will be bonded to increase physical retention.

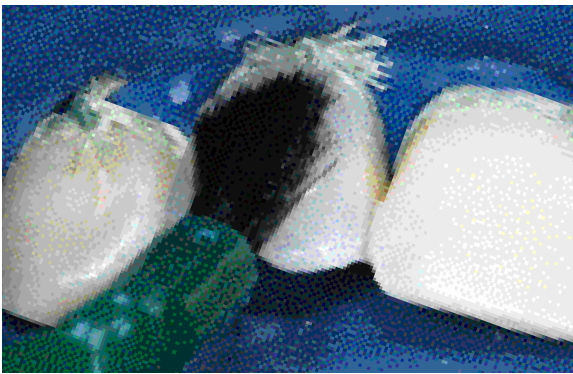

Figure 13-8F: Acid-etching is accomplished with a liquid 35% phosphoric acid.

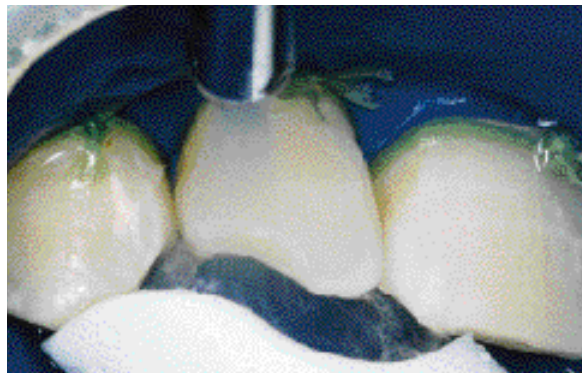


Figure 13-8G: Air/water spray is used in an incisal direction from 5 to 10 seconds with the help of high-speed suction.

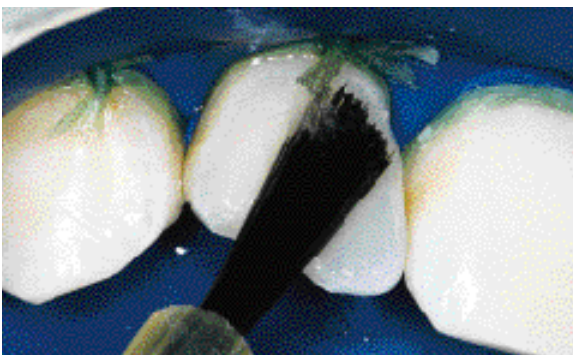


Figure 13-8H: Dentin-enamel primer is applied in multiple coats and then dried, revealing a semigloss, and then polymerized.

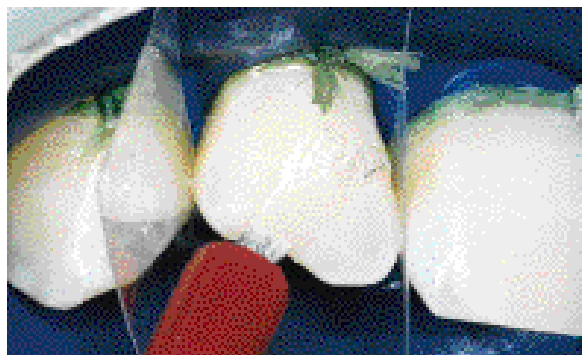


Figure 13-8I: A wraparound mylar strip maintains separation of contacts as the bonding resin is applied and then polymerized for 20 seconds labially and lingually.

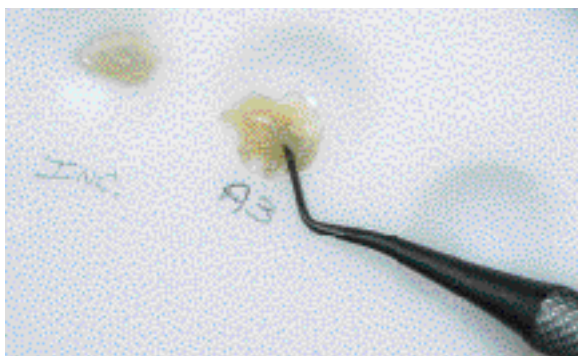


Figure 13-8J: Different colored shades of the preselected composite are dispensed onto a light protected palate (Renamel, Cosmedent).

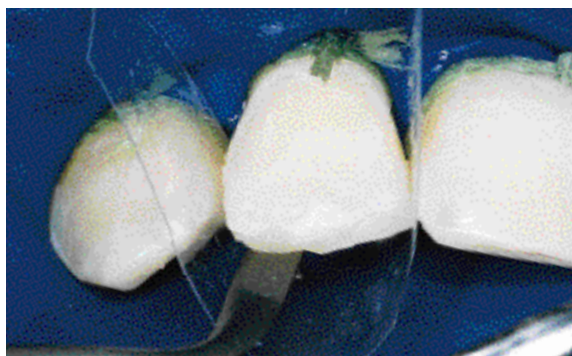


Figure 13-8K: Initial increments of the darker shade are placed followed by an incisal overlay. The GCI #3 (Hu-Friedy) is used in setting, sweeping motion while occasionally being wiped with a drop of bonding agent on a 2x2 gauze to help prevent the composite from sticking to the instrument.




Figure 13-8L: These six GCI instruments are designed to insert composite resin in every conceivable situation. Being anodized aluminum, they are lightweight, but thin enough to enter the gingival sulcus when necessary. The same set in stainless steel is also available (Flexi-Thin, Hu-Friedy).



Figure 13-8M: The final layer should cover the entire restoration surface to avoid incremental margins, and polymerized for 60 seconds with conventional light or 10 seconds with laser or xenon lights.

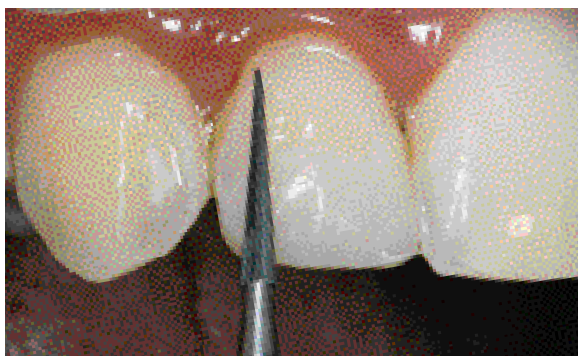


Figure 13-8N: Finishing can begin with the 16-bladed ET9F (Brasseler) since very little excess is present.

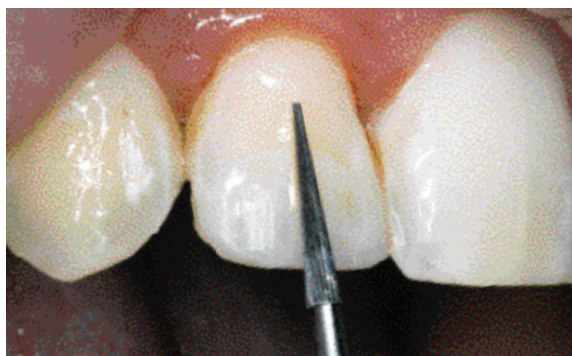

Figure 13-8O: Final texturing and finishing is done with the ET9UF 30-bladed carbide (Brasseler).

illustrated by acid-etching of enamel to provide resin tag formation into the surface roughnesses. Adhesive bonding implies molecular attraction between the adhesive and the substrata and is the basis of dentin-bonding agents and polyacrylic acid cements.

The significance of bonding materials to tooth structure is not, of course, purely esthetic. They also serve to protect enamel rods and dentinal tubules, which are inherently opened during preparation, from the effects of bacterial contamination by saliva. In fact, they must protect in order to obtain a satisfactory long-term esthetic and functional result. If microleakage occurs because of lack of a true seal of the restoration, then acids and microorganisms may penetrate from the margins down along the interface, which can lead to stain or even to secondary caries.⁵³ If leakage progresses down and across the floor of the preparation, it also can produce pulpal irritation.⁹⁰ However, studies would indicate that restorative materials produce pulpal reactions only when there is bacterial leakage and little or no irritation if bacterial influences are effectively controlled.⁴ Cariostatic fluoride-releasing composites may serve to limit recurrent caries, as proposed by Temin et al.¹⁰² Resin-bonded inlay restorations can provide superb marginal seal, especially at the cervical restoration/dentin interface.⁹⁹

If both enamel and dentin are involved, it is best to etch the enamel with a gel since the gel causes localized penetration that is deeper and wider.⁶ It also is self-limiting. It remains exactly where you place it, instead of “running all over the place” on tissue or adjacent teeth or even on unwanted same tooth surface. A 15- to 30-second gel application should be sufficient to etch the enamel. Although it is not necessary to etch glass ionomer, some clinicians feel a 5-second final etch on just this portion will condition any remaining tooth structure as well as the base itself. However, it is important to consider the individual tooth. Young teeth generally etch more quickly than older teeth. The fluoride content of the teeth also affects etching time, as does whether or not the enamel has been freshly cut. Freshly cut enamel etches faster than unprepared enamel.¹

Dentin Preparation

To remove or to leave the dentinal smear layer intact may be controversial. However, the following guidelines, supplemented by research, are helpful.

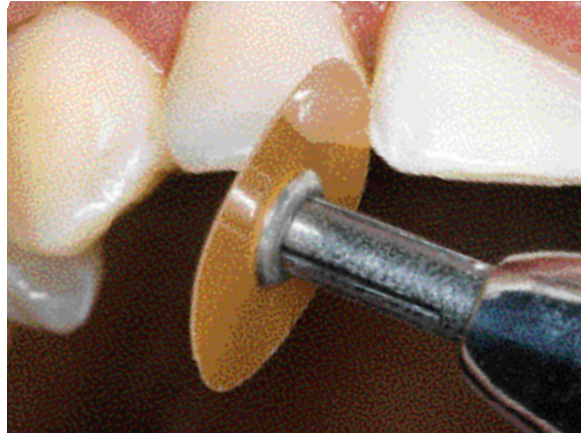


Figure 13–8P: Although conventional polishing discs can nicely finish the restoration, use the ultrathin plastic pop-on discs (Cosmedent) for interproximal polishing.

First, and most important, is determining the esthetic need of the patient. This need filters down to the individual need or requirement of individual teeth. It should be further based on a tooth-to-tooth analysis, upper to lower arch comparison, tooth to soft tissue, the smile, or a combination of all the above.

The esthetic need of a patient is determined by considering several parameters:

1. Do you need to make the tooth or teeth more opaque, or develop a depth of color? (Figures 13–9A to H). Depth can be achieved by bonding the darker shade first, then adding incremental veneered layers of lighter or transparent shades.
2. What do you need to do to obtain your best color? This often means mixing and blending composites, or even tints or opaques, from different manufacturers.
3. For what purpose is the composite being used? For facial bonding? Occlusal pits? Class V? The composite(s) you select must, at best, be capable of withstanding the long-term functional stress placed on it by the intended restorations.

Available composite systems generally fall into the following categories:

- those formulated to match a few shades most commonly found in the general public.

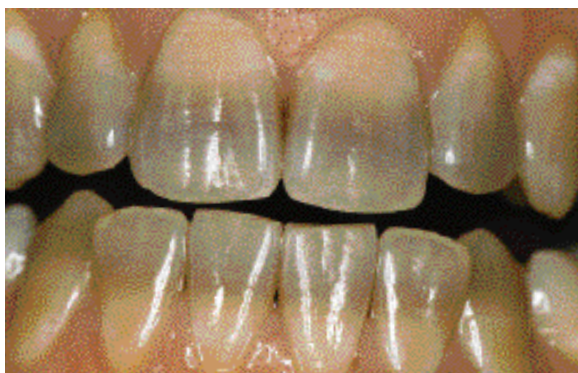

Figure 13-9A: Extremely dark tetracycline stained teeth provide the most difficult challenge for direct resin full veneer bonding. This 24-year-old student wanted a conservative and economic solution to her esthetic problem without reducing her enamel surface.




Figure 13-9B: Various composite stains from different manufacturers are placed on a palette (Cosmedent).

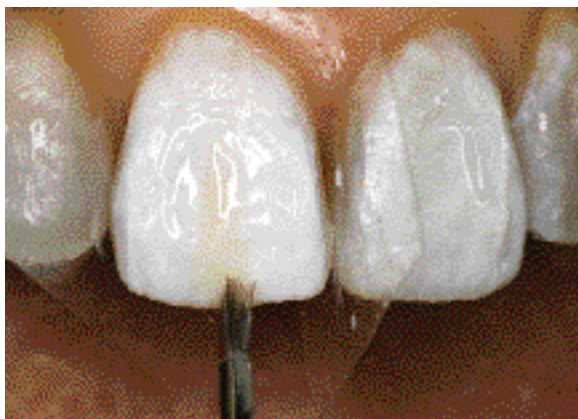

Figure 13-9C: To best obtain a natural-looking polychromatic tooth color first mask the tetracycline discoloration with multiple layers of opaquer (Cosmedent, Chicago, IL or Den-Mat, Santa Maria, CA). Next, orange/brown stain is applied as a thin stripe down the center of the labial surface to give an appearance of underlying dentin.

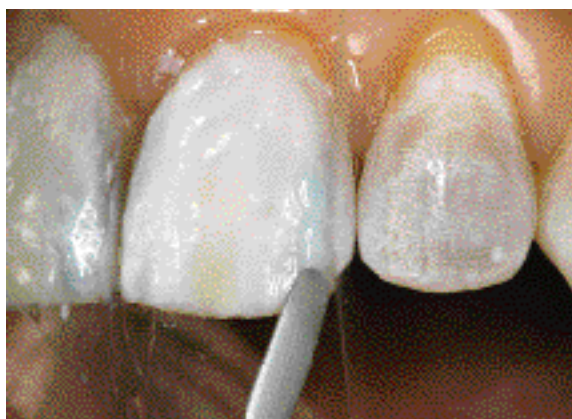

Figure 13-9D: Medium to light blue stain is thinly applied in a vertical stripe at both mesial and distal line angles to help simulate the appearance of enamel.

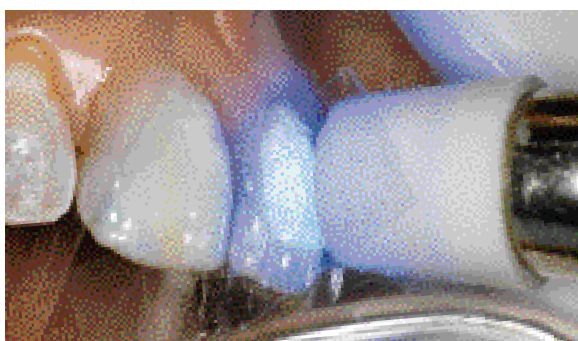

Figure 13-9E: Full polymerization is completed for each central incisor.

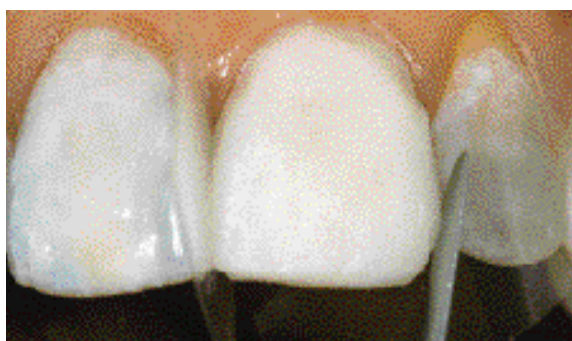

Figure 13-9F: Next, the preselected body shade is uniformly applied over the opaqued and stained layers with the anodized aluminum GC3 instrument (Hu-Friedy).

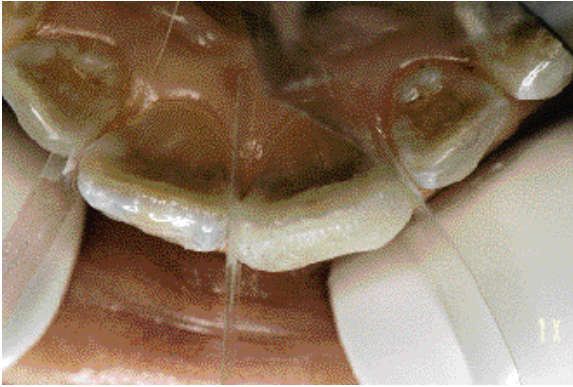


Figure 13-9G: This incisal view of the polymerized left central incisor shows the approximate thickness necessary to mask the dark tetracycline stain.

- those manufactured in gingival, body, and incisal shades, as well as tints and opaques, to help create more difficult, multicolored shading (Figures 13-10A to F and 13-11A to C).

A second consideration in determining whether or not to remove the smear layer should be based on the manufacturer's directions. Because certain bonding systems are matched to the same or different composite systems, in order to obtain the strongest bond, the manufacturer's directions (which may mean removing or leaving the smear layer) should be followed. However, the composite brand and shade you have chosen may not be compatible with a particular bonding agent. Or, you may have chosen a custom-blended mixture which calls for a different bonding agent formulated to enhance the bonding of your composite. Universal bonding systems may hopefully eliminate this decision making.

A third consideration is based on the individual's sensitivity after dental procedures, especially if there is an abundance of freshly cut dentin or a large pulp. Current opinion is divided into those who feel post-operative sensitivity is caused by bacteria retained in the smear layer and others who say its removal leaves the dentinal tubules open, thereby exposing the pulp to irritants in the bonding materials themselves.⁷⁹

Lastly, bonding agents being used to decrease sensitivity (cervical abrasion, for example) usually call for the removal of the smear layer.

The emphasis on a "total-etch" system has created a new awareness of all the parameters of dentin

bonding. Kanca,⁶¹ and others cite the additive adhesion strength values created with the "total-etch" technique which could well make for longer-term, esthetically superior restorations requiring less maintenance. Only time will tell regarding the long-term safety as well as any extended esthetic benefits.

McLean and others⁷⁸ described what is called the "sandwich technique" using composite resin on the glass ionomer-coated dentinal surface of a cavity preparation (Figures 13-12A to E). The newer glass ionomer liners are presently highly suited materials to use as liners and bases under almost any restorative materials. They provide an adequate amount of opacity and have the added advantages of bonding to dentin or resin, releasing fluoride, and not causing harm to the pulp,¹ and even reducing sensitivity.^{59,60} Most recently they have been used in preventive restorations such as small occlusal cavities where small carious lesions have extended into dentin.³⁵ Hembree^{48a} found that less microleakage occurred at gingival margins of Class II restorations when a glass ionomer cement was used as a liner. The liner should be close to the color of the dentin (not opaque white which is difficult to mask). The exception is when replacing an amalgam that has left a stain; in this case, the liner may need to be somewhat lighter to cover the dark stain.

Following etching, immediately rinse thoroughly with an air/water spray, for 10 to 15 seconds, and dry with compressed air to make sure your etched surface looks "chalky white." If a dentin bonding

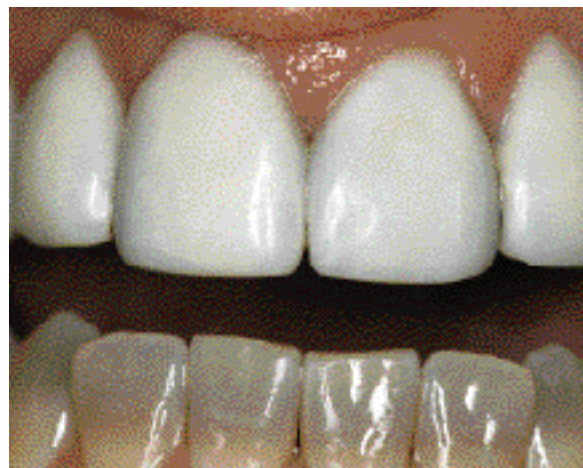

Figure 13-9H: This final view of the polished restorations shows how the inlaid colors increase the appearance of naturalness.

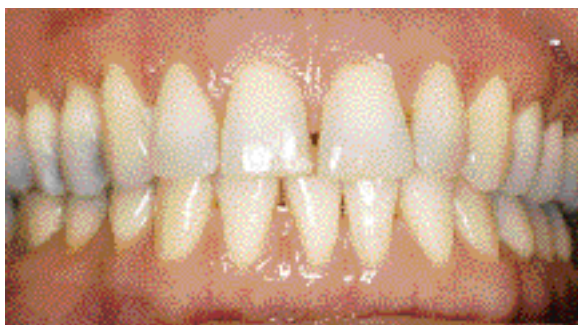

Figure 13-10A: This 46-year-old businesswoman was concerned about the wear and the loss of interdental tissue between the central incisors. Composite resin bonding was chosen as a conservative, reversible, one-appointment restoration.

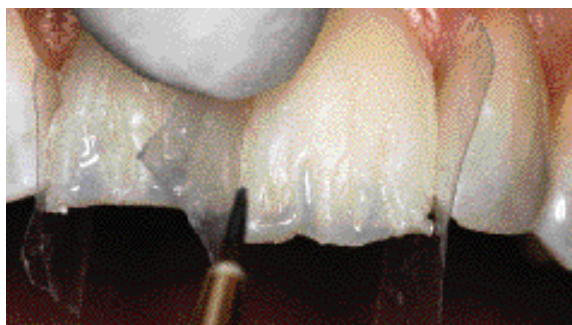


Figure 13-10B: After building up the preselected body shade, the incisal portion was serrated with a GCI3 (Hu-Friedy). Next, medium blue stain was placed and polymerized in the serrated areas to help simulate incisal translucency.

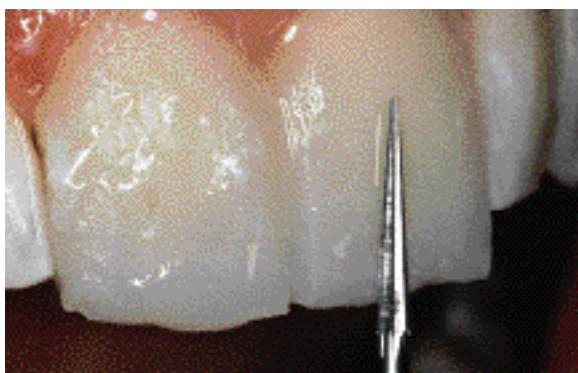


Figure 13-10C: An incisal or more translucent layer of composite resin was placed and polymerized over the blue stained layer. Finishing is carefully done with a 9-mm long ETa (Brasseler).

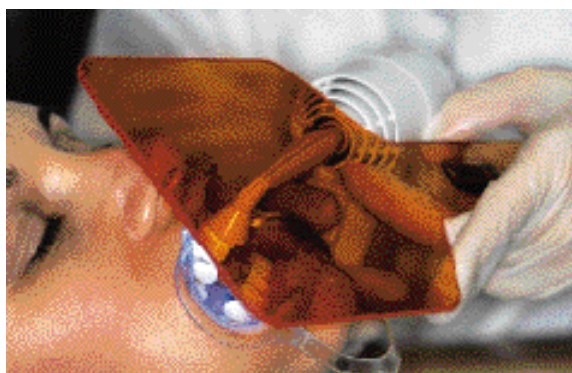

Figure 13-10D: Following final polish, the restorations are repolymerized to maximize the outer hardness.

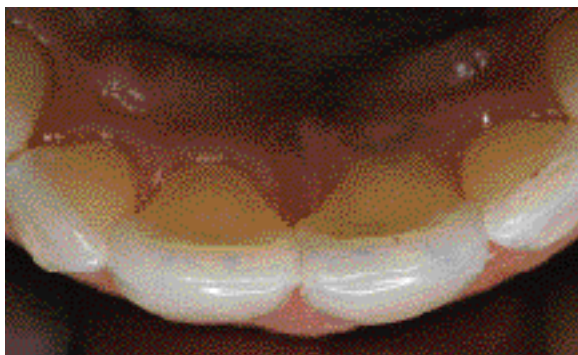

Figure 13-10E: This incisal view reveals the presence of the inlaid stain.

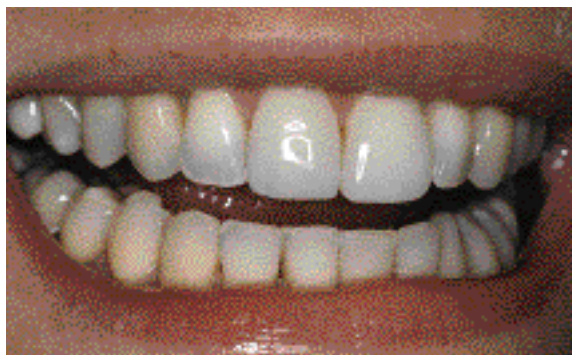

Figure 13-10F: The completed restorations provide a younger looking smile line as well as close the previously open gingival embrasure. Although there is the appearance of a slight amount of incisal translucency, it can be enhanced by additional labial finishing.

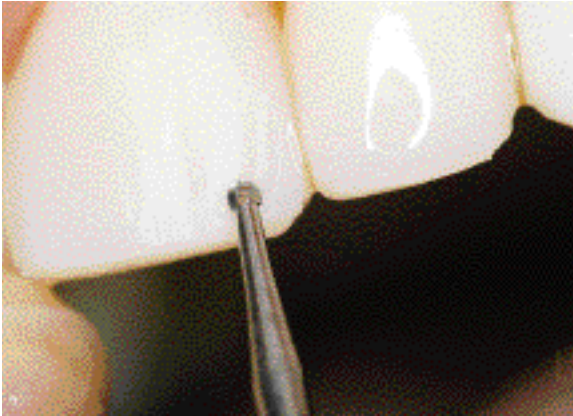


Figure 13-11A: A more precise method of achieving spot staining can be obtained by slightly cutting back the finished composite restoration.

agent is going to be used, then, depending on the manufacturer's instructions, you may also need to use a dentin conditioner after acid-etching the enamel. Different products require different rinsing and drying, so a careful reading of the manufacturer's instructions is essential. Generally a 15- to 20-second etch is sufficient with an equal time in water rinsing the surface thoroughly. However, if water and air spray are used, a shorter rinse time (5 to 10 seconds) is sufficient.

It should be noted that Gwinnett advocates an extra 10 seconds of air/water rinsing if a gel etch is used to prevent its cellulose vehicle from becoming a contaminant which may reduce bond strength.⁸¹ It is also essential to have an oil-free air and air-water spray to prevent contamination which diminishes bond strength.

If the total-etch technique is to be used, certain manufacturers stress leaving the surface wet rather than drying it out before placing your dentin bonding agent. They also advocate dabbing the preparation with a moistened cotton pledget to create a uniform amount of "wetness" to the place you will put the dentin bonding agent.

The overlay technique described above provides a broader surface for the acid process to achieve its primary function: to eliminate the gap that often results at the enamel boundary when the enamel interface contracts from polymerization shrinkage. The phosphoric acid etching before the resin mate-

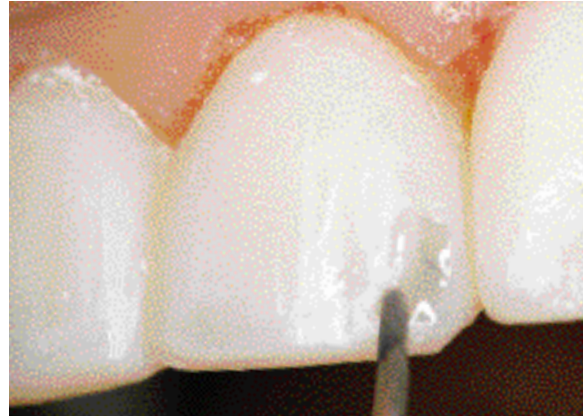

Figure 13-11B: A mild gray stain is placed and polymerized to help simulate a subtle translucency. Either body or incisal colored composite resin is applied and polymerized over the stained area.

rials are placed helps to eliminate this gap at the enamel boundary, thus enhancing the marginal seal.

Polymerization

All bonding materials are produced to be polymerized either chemically—known as self-curing—or by light. Other composite resins are dual-cure, i.e., when the base and catalyst pastes are mixed together, they can be light cured, allowed to self-cure, or both light and self-cured together. For most dentists today, light-curing has become the method of choice because a higher degree of polymerization is possible.^{18,70,72} Phillips summarizes these advantages succinctly: The single paste formulations do not require mixing, so there is less porosity in the restoration, making it more resistant to wear. The surface should be perfectly smooth, enamel-like, and free of irregularities. Photocuring provides sufficient working time for more precise and esthetic

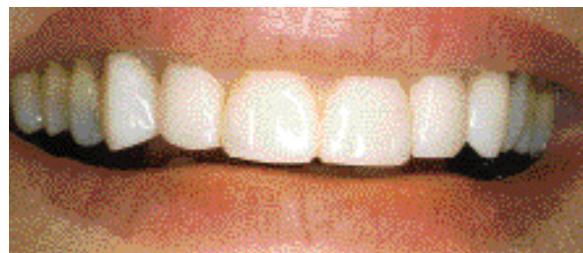

Figure 13-11C: The polished restorations achieve the feeling of slight translucency. If a more intense translucency is desired, use a darker gray or blue stain.

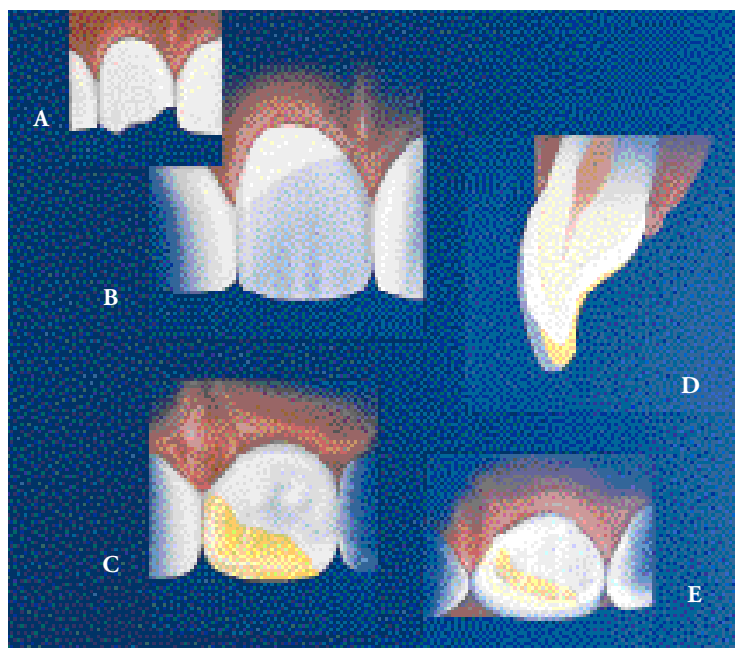


Figure 13-12: A, Fractured right central incisor. B, A highly polishable microfill labial veneer has been placed by using the overlay technique with margins extended to the cervical third of the labial surface. C, The lingual view shows the restoration with a stronger and more durable hybrid composite. D, A sagittal view that shows the “sandwich” outline of both composites in their relative positions. E, The blend of the two composites from the incisal view.

insertion of the materials. This works especially well with resins used incrementally for color match and improved margin adaptation. The cure is faster and more complete; margins can be feather-edged without concern that the thin, frail marginal areas will be insufficiently cured.⁸⁹

Some clinicians use a light shade of microfilled composite in the proximal box of a Class II restoration (Figures 13-13A to Z) for two reasons.

First, the lower viscosity of microfilled resin allows you to tease in the composite past the cavo-

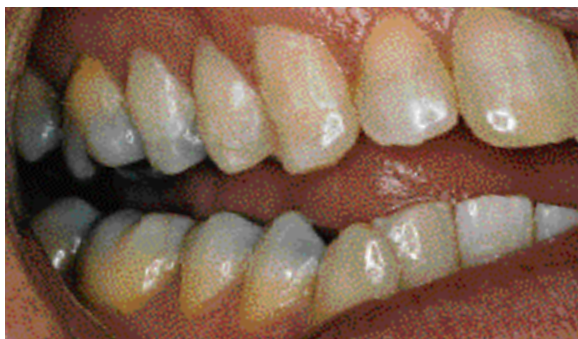

Figure 13-13A: Facial surface discoloration caused concern to this 50-year-old man.

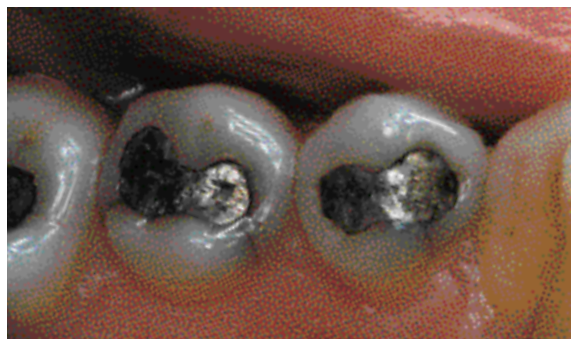

Figure 13-13B: This occlusal view points out the defective margins, stained microcracks, and aging amalgam restorations which were the main causes of the facial surface discoloration.

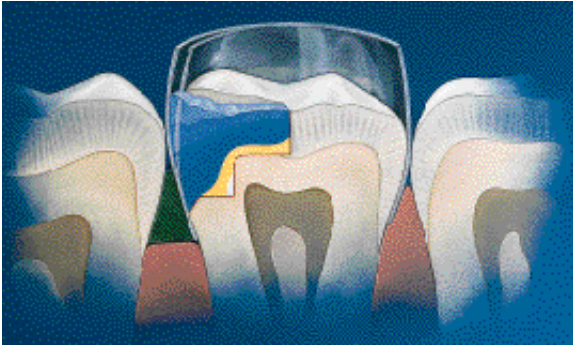


Figure 13-13C: This schematic drawing illustrates the layering technique used to construct a properly contacting Class II restoration. After optional pulp protection (white) a glass ionomer protective layer (yellow) is used to offer the benefits of fluoride. The deep-to-light layers of blue indicate the layering technique by polymerizing the layers one at a time. Note also the tight seal offered by wedging that initially aids in gingival margin closure. After sealing the gingival margin, relax the ultrathin dead-soft matrix band to obtain maximum contact with the adjacent tooth.

surface margins, minimizing voids and polymerization shrinkage.

Second, lighter colored composites typically cure more totally than darker shades.

While esthetics may be the primary reason for bonding, the trade-off is usually between superb esthetic restoration the day the patient leaves the office and a sometimes less than excellent result that endures and is likely to be esthetically appealing for more years. Good polymerization does not involve such a trade-off. Maximum polymerization is important to the clinical as well as the esthetic success of the restoration, and in fact a 20-second repolymerization of the restoration following final finish can provide an even stronger and longer-lasting finish. After final etching and conditioning, thoroughly dry the preparation and apply the bonding agent on both dentin and enamel.⁸¹ Some agents will require more than one coat, as will be described in the manufacturer's directions. The bonding agent should not be allowed to pool because it may be mistaken for recurrent caries on a radiograph, as demonstrated by Hardison et al.⁴⁷ He advocates gently blowing the bonding resin after its application to a thin, even coat. Thinning the bonding agent, however, is best determined by following the manufacturer's instructions. Some are not to be thinned as shown in the research of

Hilton et al., who found lowered bond strengths in three agents that were tested with air-thinning.^{48c} However, Schvaneveldt et al. reported significantly higher bond strengths when an agent was polymerized in a nitrogen environment.^{97b} Heymann feels that while the issue of air-thinning is material specific because, for example, some adhesives are filled, the degree of air-thinning is a factor where excessiveness can lower bond strengths.^{48b}

Polymerize with the light of your choice for the specified time (Figure 13-14). Both exposure time and light-tip composite distance are important variables, and Jordan⁵⁴⁻⁵⁶ has recommended that the time be a minimum of 40 seconds and the distance from the light tip to the composite surface should be as close as possible to zero. *Be sure to periodically test your light to make certain it is still strong enough to accomplish deep polymerization.* Apply small increments of your chosen shade and polymerize again with your visible light. The extent of polymerization will depend on several factors including the depth reached by the light, catalyst concentration, and composition of the material. The darker shades usually require differing illumination times.^{8a} Color modifiers also may be mixed with composite restoratives, although this has the disadvantage of weakening the materials and making the curing process somewhat longer and less predictable.¹

Antonson and Benedetto, Friedman, and others have studied the variability of the longitudinal intensity of visible light-curing units, stating that these findings may have an overlooked impact on complete polymerization of critical margin areas or even the polymerization of dentin-bonding materials.^{3,34}

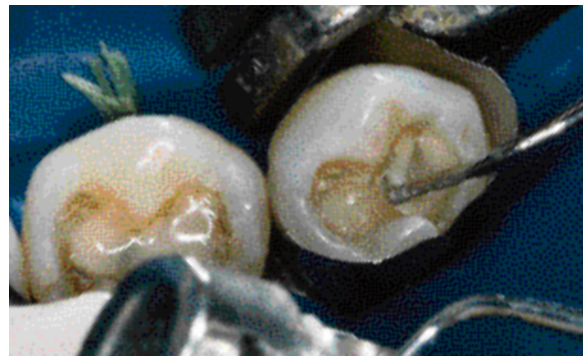


Figure 13-13D: A glass ionomer layer is applied using a Nova-tech PINT 11 instrument (Hu-Friedy), then polymerized.

A decrease in output over time may be attributed to lamp filament burnout, bulb blackening or frosting, and reflector degradation, all of which, says Friedman, mandate lamp replacement at least every 6 months.³⁴

If your light does not have a built-in light meter, then purchase a light meter (Figure 13–14D) (Curing Radiometer, Demetron/Kerr, Danbury, CT; Cure Rite, Efos/Dentsply/Caulk, Milford, DE; SureCure, Ho Dental, Santa Barbara, CA) to monitor each curing unit periodically for the manufacturer's recommended output. Other simple measures call for cleaning the end of the curing tip and/or

replacing it, inspecting and cleaning the filter/reflector, inspecting the bulb and replacing it, and doubling the curing time if using an older curing light.

You might also consider the purchase (or lease) of an argon or plasma arc curing light system. These methods reduce the polymerization time from 60 to 10 seconds, thus saving considerable time over the entire procedure (Figures 13–14E to K).

All composite resins contract, causing dimensional changes, during photopolymerization, and this shrinkage can cause separation between the composite resin mass and adjacent tooth structure. The average shrinkage is about 2 to 3%.²⁶ This can

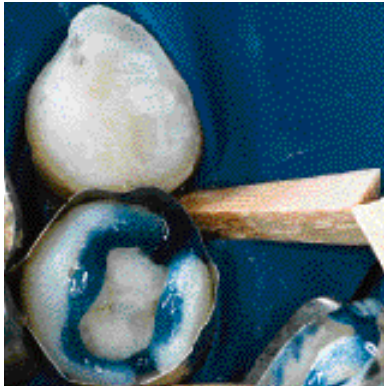


Figure 13–13E: A semisoft gel etch is used to etch the enamel areas for 15 to 20 seconds.

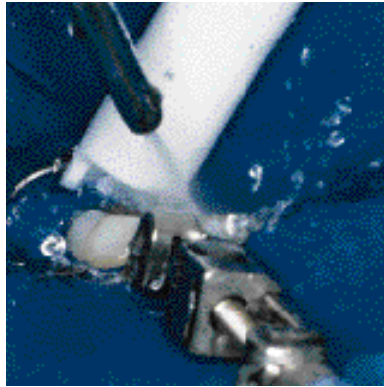


Figure 13–13F: The etched area is washed with a simultaneous combination water-air spray for approximately 5 to 10 seconds.

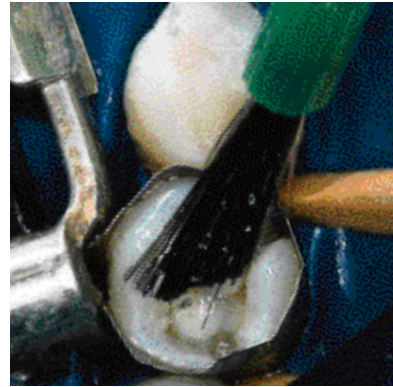


Figure 13–13G: Depending on manufacturer's instructions, multiple coats of a dentin-enamel conditioner and/or priming agent are placed and polymerized.



Figure 13–13H: Next, a light coat of the dentin-enamel bonding agent is placed.

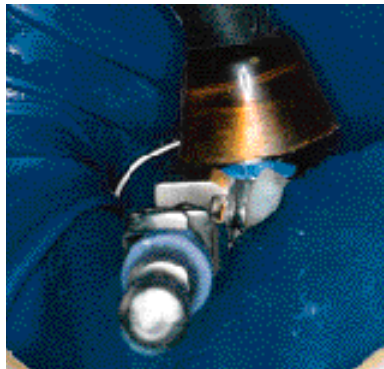


Figure 13–13I: The bonding agent is polymerized, depending on manufacturer's instructions.

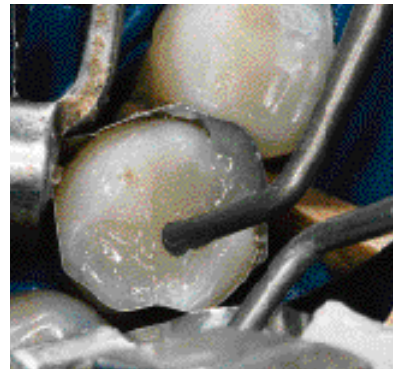


Figure 13–13J: Following initial layering as in diagram in 13–13C, each layer is placed using the appropriate-sized round-end anodized aluminum or stainless steel instrument GCI (Hu-Friedy).

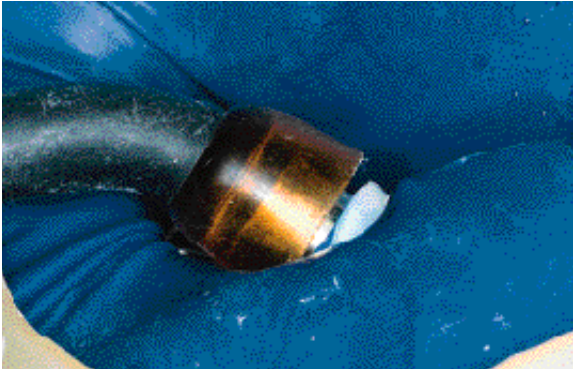


Figure 13-13K: Each layer is laser polymerized for 10 seconds or conventionally polymerized for 60 seconds depending on manufacturer's instructions.

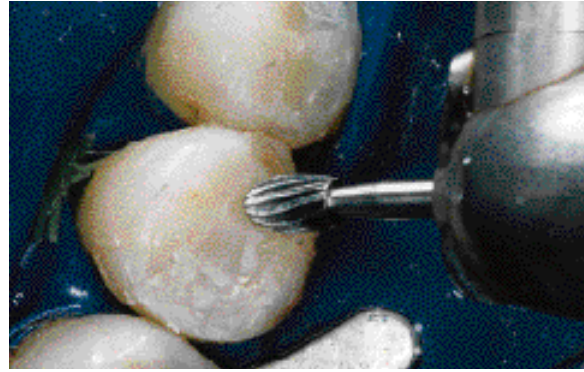


Figure 13-13L: Initial occlusal anatomy is placed using an ET OS1 (Brasseler) either 12- or 16-bladed carbide or 30- or 15-micron diamond depending upon the amount of composite resin to be reduced.




Figure 13-13M: Initial trimming and finishing cuts are done with the OS1, 2, or 3 carbide burs (Brasseler/Komet).

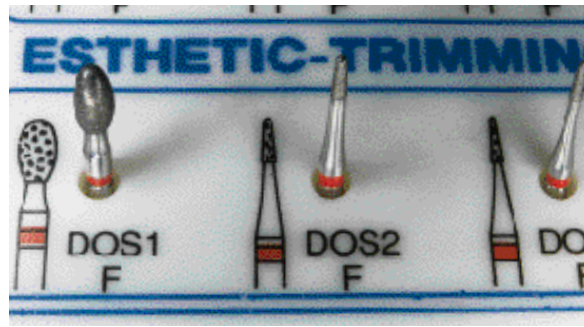

Figure 13-13N: The 30-micron diamonds can also be used for initial trimming and finishing of posterior restorations (ETUF, Brasseler).

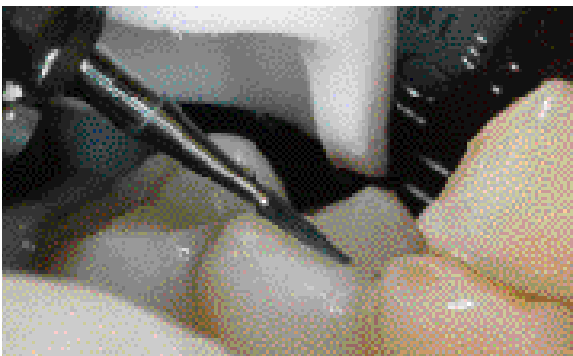


Figure 13-13O: Initial grooves and fissures are carved with an OS2 (Brasseler) 12-bladed instrument.

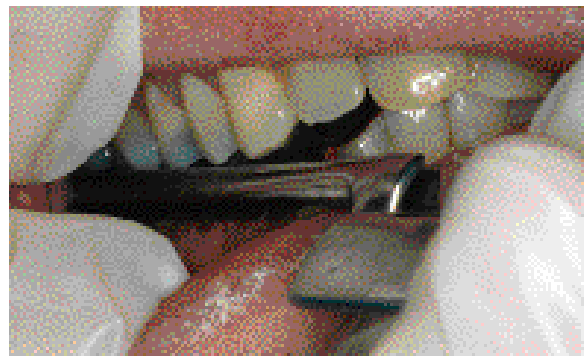

Figure 13-13P: Occlusion is checked with microthin articulating paper.

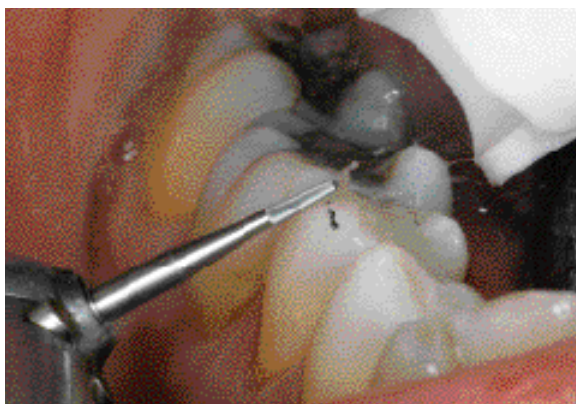

Figure 13–13Q: Either OS1 or OS2 (Brasseler) carbides can be used to perfect the occlusion.

create defects that welcome bacteria and may cause stress on cusps, resulting in sensitivity, occlusal disharmony, even delayed fracture.⁷⁴

Polymerization shrinkage coupled with technique sensitivity can lead to a risk of an open margin, especially in situations where the enamel is thin. These open margins then lend themselves to stain. Since too much polymerization shrinkage can reduce the restoration life expectancy, it is much better to take additional time in curing the composite by adding 3 to 5 layers of materials, making sure the final layer is over the entire restoration, to avoid microscopic composite margins that may attract additional stain. Another advantage in

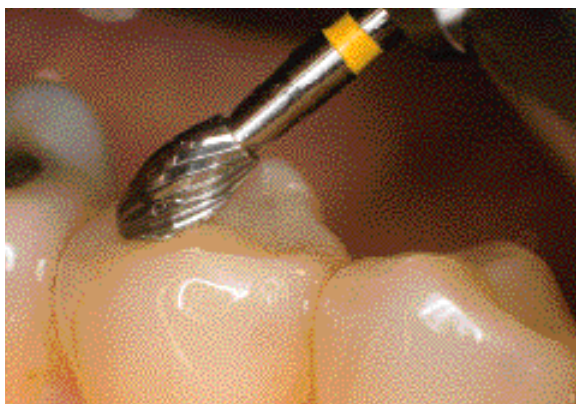


Figure 13–13R: Final contouring and initial finishing are accomplished with the 16-bladed OS1F (Brasseler) carbide.

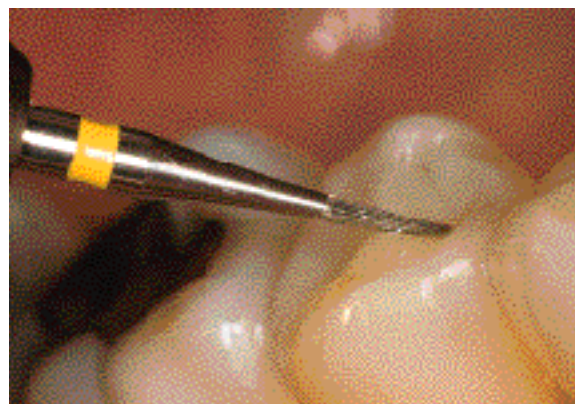

Figure 13–13S: A 16-bladed OS3F (Brasseler) is used to create basic occlusal grooves.

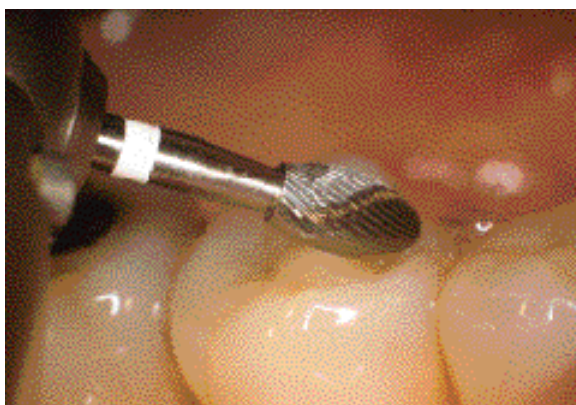

Figure 13–13T: Final occlusal finishing is done with a 30-bladed OS1UF (Brasseler) carbide.

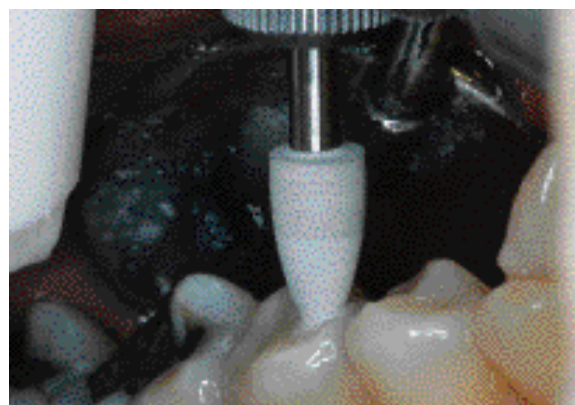


Figure 13–13U: The tapered point abrasive impregnated polisher (Shofu) can be used to polish the occlusal anatomy.




Figure 13-13V: Final polish can be easily achieved using the cups and points shown above (Cosmedent).

building the restoration in this fashion is that you will be able to vary the shade as you add each layer of composite from gingival to the incisal or occlusal margin. Incremental placement, or layering, of light-activated composites also produces a bond strength that compares with, even exceeds, the cohesive strength of the material used.¹⁰³ For these reasons, incremental placement of composite resins, especially in Class V cervical restorations, is the most desirable mode of placement, followed by margin seal procedures.^{63,64}

Finishing the Restoration

Proper finishing of a restoration cannot make up for inadequate preparation or any other step necessary for

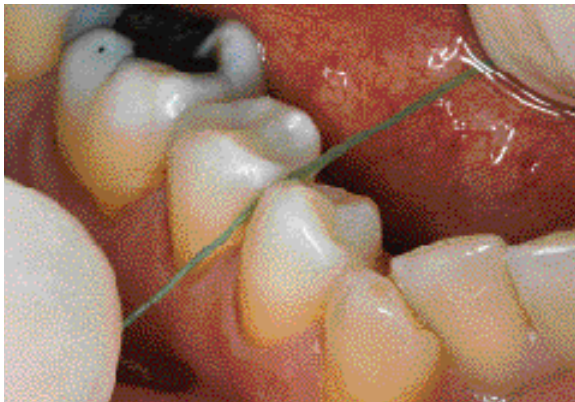

Figure 13-13W: Use dental floss to make certain the contact is polished sufficiently so that no fraying occurs.

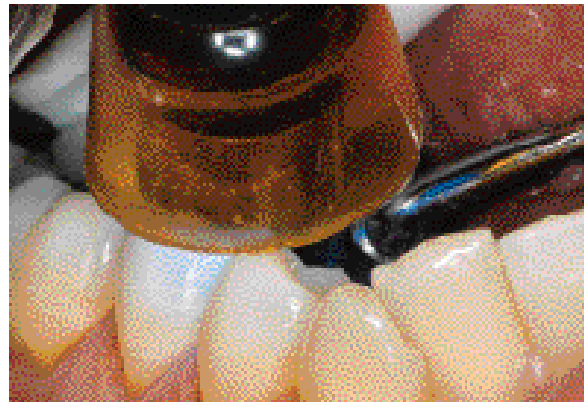

Figure 13-13X: The final result is repolymerized to maximize the outer layer hardness of the polished composite.

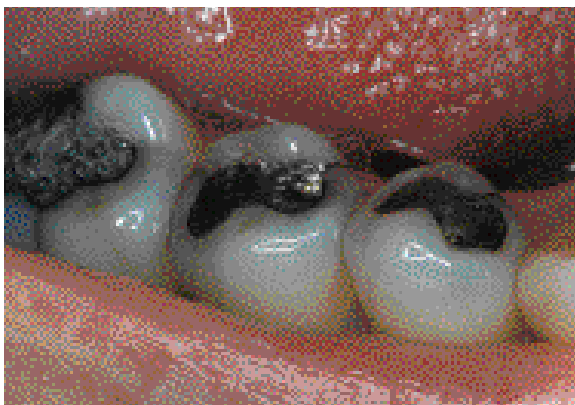

Figure 13-13Y: The before occlusal view of the defective amalgam restorations.

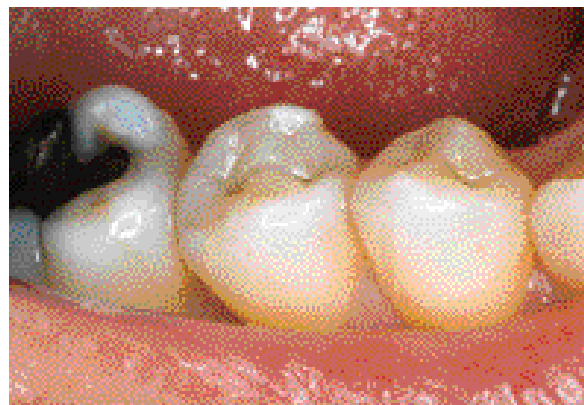

Figure 13-13Z: A more natural look can be achieved by applying acrylic stains in the pits and grooves followed by a clear glaze (Fortify, BISCO Inc., Itasca, IL) which seals the stain in place.



Figure 13-14A: The Optilux 500 (Demetron/Kerr) is an excellent light source for all types of polymerization and can be used for extensive procedures since it does not overheat, an occurrence which could cause the unit to switch off.

successful esthetic and functional restorations. It can, however, make the difference between an ordinary and an extraordinary esthetic appearance. The objectives of a thorough, well-planned finishing are to improve and finalize restoration margins and contours to help make the restoration biocompatible with both tooth and tissue, and to develop maximum surface luster to enhance esthetics, reduce stain and plaque retention, plus minimize wear and fracture potential. You



Figure 13-14C: Easy to use, the ProLight cordless curing light (Caulk/Dentsply) also has multiple tips, a built-in radiometer, and does not overheat.



Figure 13-14B: Multiple tips (Demetron/Kerr) provide maximum flexibility in all types of bonding situations.

will know you have achieved these objectives if the finished restoration has these qualities:

1. well-finished margins, with no overhang, void, or extension of restorative material that could interfere with tissue health.
2. a sufficiently smooth surface that will not attract bacterial plaque or food stains.
3. suitable surface texture that blends in or matches adjacent or opposing natural teeth.
4. color matching that of the existing adjacent, opposing, or preselected tooth shade.

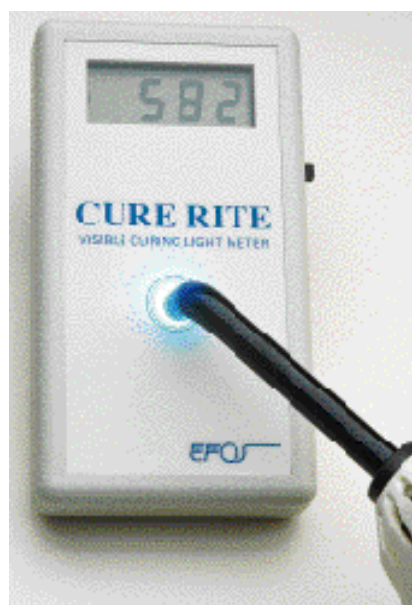


Figure 13-14D: Light tips must be kept clean and your light source periodically checked with one of several diagnostic testing devices (Demetron/Kerr, Efos).

5. a surface finish devoid of too obvious contour, finishing bur, or diamond scratches.

As with etching, numerous articles provide detailed instructions on finishing. But the following provides a brief outline of steps of special significance to an esthetic finish. Roulet and his colleagues recommend using a diamond bur with an abrasive particle size of 15 to 40 μm to contour the facial surface of the restoration.⁹⁶ I suggest you begin with either an E.T. 6 or 9 30-micron diamond or 8-blade carbide (Brasseler) for gross contouring (Figure 13–15). Although Greiff, Burgess, Davis, and Theobald⁴⁴ report no difference between wet and dry polishing, the author has not found this to be the case. All instruments should be used wet to contain the inevitable dust which can produce an extremely bitter taste for the patient.⁶⁷ In addition, Collard, Ladd, and Vogel fear that dental personnel are at a high risk for developing respiratory silicosis if the dust is not minimized, and they recommend the use of face masks during composite finishing.¹⁷ The wet finish also avoids frictional heat that may tend to pull up the margin.⁵⁵ Continuing to polish dry after the margin is opened sweeps the composite dust under the margin producing a “white line.” Also, Mazer feels that the initial cracking of a posterior composite is probably caused by the surfacing and finishing process.²⁵ If diamonds are used, finish with the E.T. fine (15-micron diamond) in the same size as above. As reported in a comparison of finishing instruments by Pratten and Johnson,⁹³ an extra-fine diamond with 15- μm particles (E.T. yellow band) produces a surface smoothness superior to white stone and similar to that produced with a carbide bur and rubber point. Diamond finishing with a slow speed produces a somewhat smoother finish than with a high speed. For ultrafine diamond finishing, use an 8-micron diamond (E.T.U.F. 3, 4, 6, or 9).

If carbides are being used, final contouring should be done with the 16-bladed carbides in the same number (E.T. fines). Once the final labial contour is completed, make sure the gingival margins also are contoured correctly with the 3- or 4-mm E.T. in the same sequence. The final instrument subgingivally should be the 30-blade carbide (E.T.U.F.) (Figure 13–16), usually the 3 mm or 4 mm. It is important to use the safe-ended E.T. so the cementum is protected while finishing in this area.

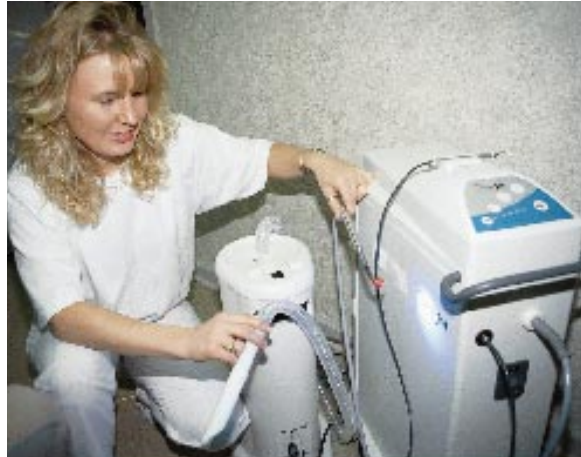

Figure 13–14E: Some manufacturers have taken the approach of mounting a plasma arc curing light on their air-abrasive units (American Dental Technologies, Southfield, MI).

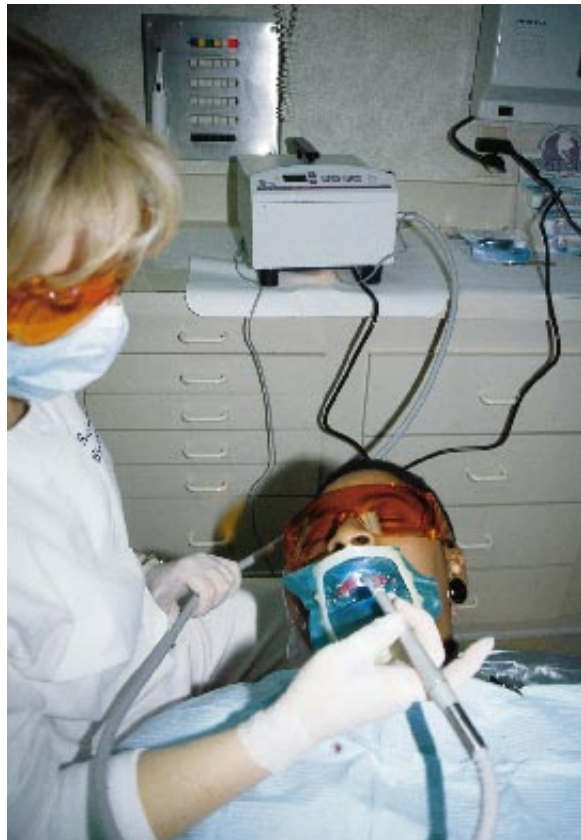

Figure 13–14F: Xenon-Halogen lamp technology for both curing and bleaching is incorporated into the Curinglight 2000 (Kreativ, Albany, OR).

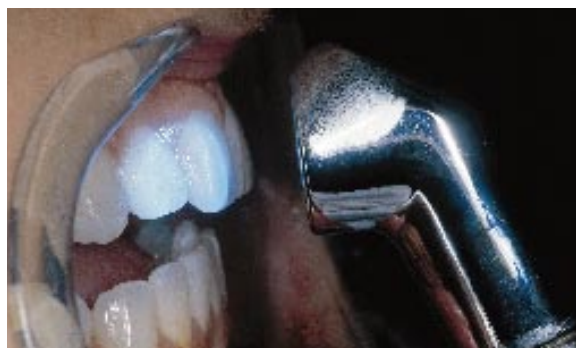

Figure 13–14G: The Dentalaser (Premier Laser Systems, Irvine, CA) features a 12-mm curing light tip for full labial bonding.



Figure 13–14H: The main advantage of argon curing systems is the 5- to 10-second polymerization time. The above picture shows two centrally-installed argon laser polymerization units which provide capability to multiple operatories (Dentalaser, Premier Laser Systems; Precision Curing Unit, ILT, Salt Lake City, UT).



Figure 13–14I: Another advantage of the centrally installed laser is the convenient handpiece mounting.




Figure 13–14J: An alternative location is a clip above the traditional handpiece mount. This is especially helpful with slender handpieces such as the one shown above (Premier Laser Systems, Irvine, CA). Note also the lighted mirror similarly mounted (Den-Lite, Welch Allyn Dental Products, Skaneateles Falls, NY).

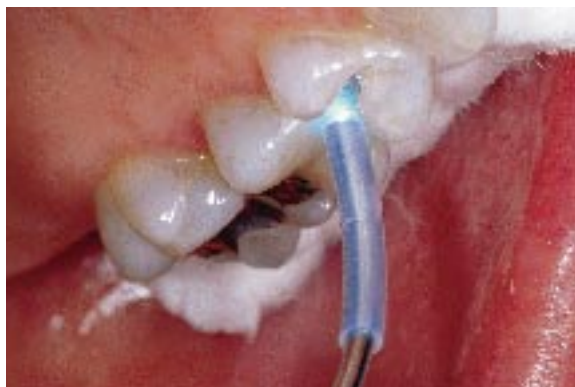

Figure 13–14K: A specialized ultrathin curing tip designed to reach to the depth of Class II restoration preparations and other hard to reach areas has been developed for the Curestar Curing System (Lares, Chico, CA).



Figure 13-15: The E.T. (Brasseler) kits for both diamonds and carbides are divided into three sections for easy entry level contouring and finishing. A minikit contains both anterior and posterior finishing burs for specific blade or grit size.

The necessity for careful choice of instrumentation, and the care in finishing, is well illustrated in a clinical study conducted by Ratanapridakul, Leinfelder, and Thomas.⁹⁴ The authors found that after the first 30 days, resistance to wear was significantly higher for an unfinished group of teeth as compared to those that received a conventional finish. The authors attributed this to possible microcracks generated by the rapidly rotating blades of the finishing instrument. Similar concerns have been expressed by Watson.¹⁰⁶ This is why it is best to use either an 8-bladed carbide or a 30-micron diamond only for bulk reduction. As soon as possible, switch to a 16-bladed carbide or 15-micron diamond for final contouring and initial finishing. The final finishing will be accomplished with either a 30-blade carbide or an 8-micron diamond. Figures 13-17A to C show the type of surface achieved by using 8-, 16-, and 30-bladed carbides. There are times when an endcutting bur is useful. For instance, opening or restoring incisal embrasures can be easily accomplished using the ET3A “cutting” bur (H132A Brasseler) (Figure 13-18).

Polishing will be done by one of the disc systems (Soflex, Cosmedent, Shofu, Moyco, or Caulk/Dentsply) for maximum luster. These discs can produce the smoothest polished surfaces.^{15,107}

Texturing Your Bond and Restoration

If you desire to either mimic adjacent tooth texture or create your own pattern or texture, you will need to alter the finishing procedure slightly.

First, perform your labial and gingival contours using the previously described system. Second, begin disc finishing with the first two coarse discs if using a four-disc finishing system. Third, choose either an ET 6 UF or ET 9 UF 30-bladed carbide or DET 6 UF or DET 9 UF 8-micron diamond to place your desired texture. Be careful to not “ditch” the composite cuts too deep. Make both vertical and horizontal cuts in an asymmetrical pattern.

Fourth, following your placement of the textured surface you are now ready to polish with the remaining two polishing discs in sequence. Be sure to polish wet and vary your polishing angles. The final result should give your bonded restoration a natural-appearing light reflective surface.

Problems in Finishing

Beware of using an inappropriate-sized finishing instrument. For instance, using an ET 9 is appropriate for the labial surface of a central incisor. However, it may not be suitable to finish the gingival margin because of the angle of finish and the necessary amount of torque required. Figure 13-19A shows

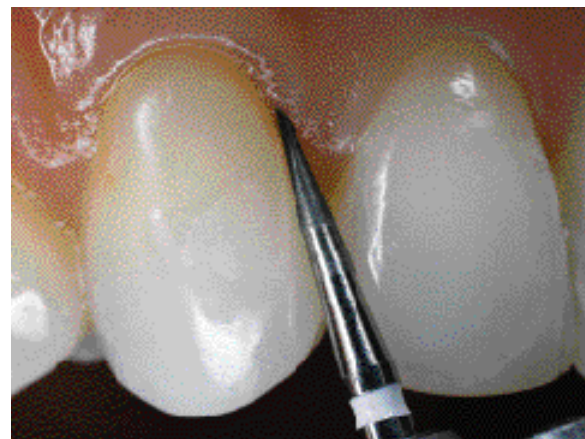

Figure 13-16: Since there is a straight emergence profile as the tooth erupts from the sulcus, the design of the ET3 or ET4 (Brasseler) makes them excellent choices for subgingival finishing. Here, a DET4UF (Brasseler) diamond bur puts the final finish of the cervical margin on the maxillary right cuspid. This 8-micron diamond is especially helpful to reduce gingival irritation (see Figure 13-19A).

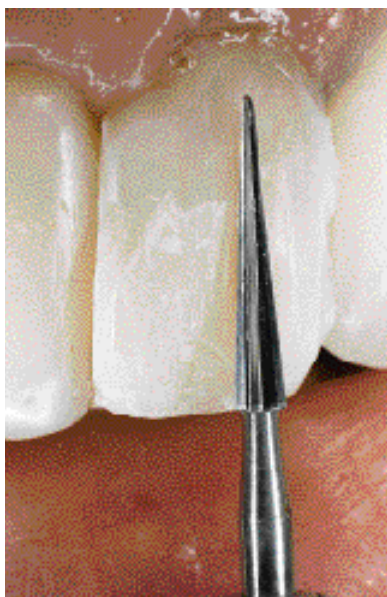

Figure 13-17A: The ET9 8-bladed carbide (Brasseler) should be used on the labial surface when there is considerable bulk present (see Figure 13-19B).

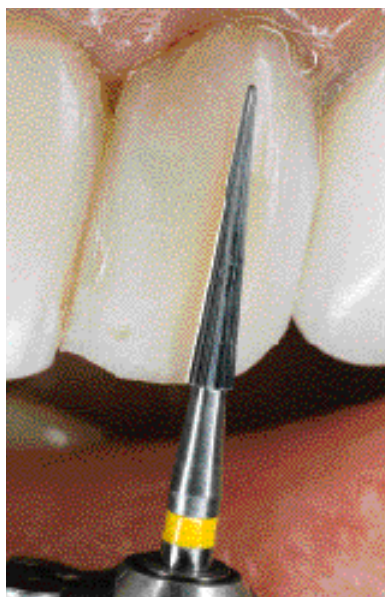


Figure 13-17B: The ET9F 16-bladed carbide (Brasseler) allows you to do more detailed carving while producing a smoother surface.

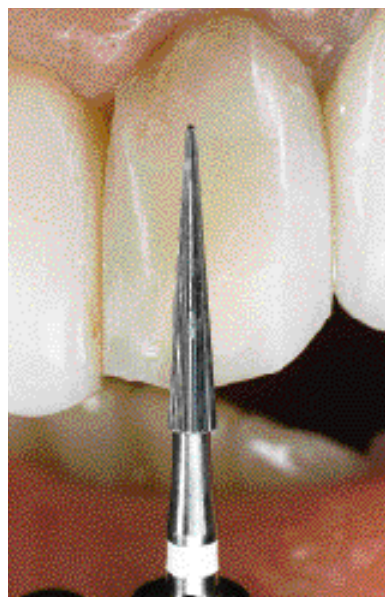

Figure 13-17C: The ET9UF 30-bladed carbide (Brasseler) accomplishes final texturing and an extra-smooth surface. This will be followed by either a 3- or 4-mm ETUF 30-blade carbine (Brasseler) as a final step in contouring and finishing.

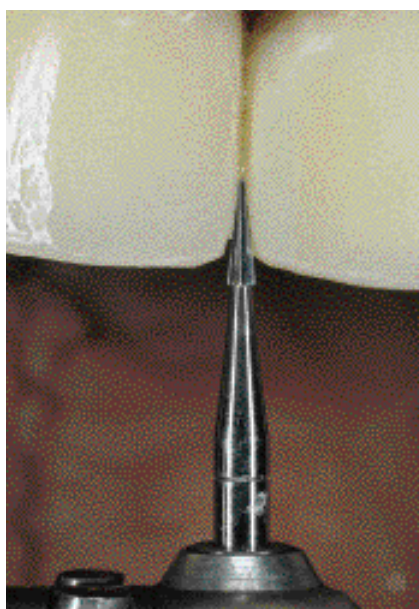


Figure 13-18: The nonsafe-ended ET3A “cutting” bur (H132A [Brasseler]) is a 3-mm carbide that is an excellent design for opening and shaping incisal embrasures as well as removing excess interproximal resin cement.

how finishing should utilize most of the finishing instruments' blades. Figure 13-19B shows how maximum utilization of the longer burs is in the body of the anterior teeth whereas just using the tip would result in lack of support making a bur fracture more likely (Figures 13-19A to C).

A Class V overlay restoration should be overfilled to allow for two-plane finishing. Use an ET 3 or 4 to define the gingival emergence contour. An ET 6 or ET 9 held parallel to the long facial axis establishes the facial height of contour.

If there has been a significant amount of gingival recession, you may opt to duplicate the existing anatomy, or re-establish the facial height of contour at a level closer to the receded gingival margin. This is especially true for the patient who has a high lip line, and whose smile displays the roots of the anterior teeth. Using a darker shade on the roots of these teeth minimizes their “long” appearance.

After the final polish, allow the patient to rinse, then dry the teeth and inspect from different views with the dental light reflecting at varied angles. The

surface should have enamel reflectivity and the veneer should have depth of color that closely mimics teeth. You are looking for small areas that may be insufficiently polished and thus will show scratches. These should be refinished until the restoration is free from surface scratches and other defects. The finished composite restorations should have margins that are not detectable to floss or a sharp explorer.

Interproximal Finishing

The last phase of finishing involves interproximal polishing with abrasive strips. Depending on how much is necessary, your choice to begin may be an extremely thin diamond abrasive strip (Compo-Strip, Premier) (see Figure 13-3Z) followed by a

plastic-backed abrasive strip. Following the sequence of more to less abrasive strip can result in a smooth transition when flossing. When interproximal finishing is complete, there should be no fraying of the floss.

Note the different width strips. A wide one will reduce the contact area between the teeth whereas the narrow ones can be slipped between the teeth using the nonabrasive center part of the strip and placed exactly where stripping is needed. This will prevent unwanted removal of the contact area which could conceivably leave an unsightly space between the newly bonded teeth.

MAINTAINING THE RESTORATION

The most often overlooked means of extending the life and attractiveness of bonding frequently occurs at this point, when you hand the patient the mirror to admire the new look. Here is where you or your assistant should provide instructions to the patient, preferably written, on what to do and what to avoid doing so that the bonding surface is less likely to stain or fracture. Some dentists, like Toffenetti,¹⁰⁴ believe dentists should limit the use of these less-forgiving restorative materials to patients who are “well-motivated to high standards of oral hygiene.” To clean the bonded surface, patients should pay extra attention to oral hygiene—with brushing and careful flossing, with the floss being pulled through the teeth horizontally, not vertically. Also warn your patients about the potential damage of “guillotin-

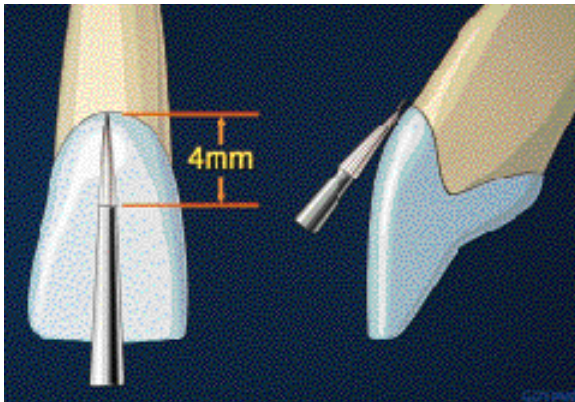


Figure 13-19A: This drawing illustrates the correct length bur for trimming the gingival margin.

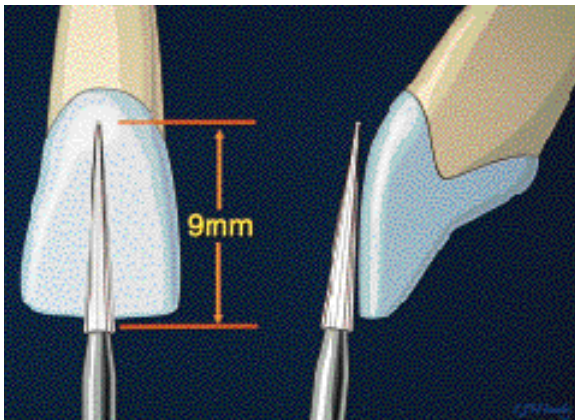


Figure 13-19B: The long facial surface is best served by a 6- or 9-mm finishing bur to make a consistent, smooth, and precise cut.

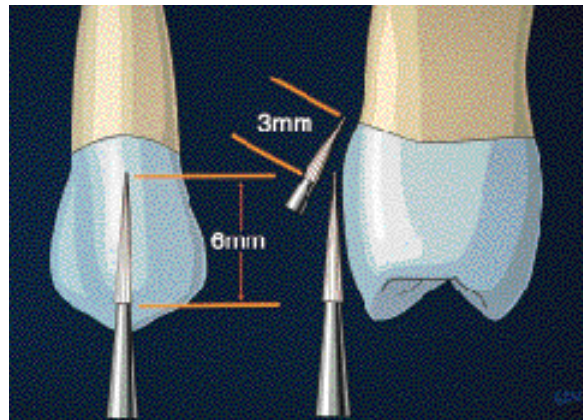


Figure 13-19C: This drawing shows the proper length and shape burs to use for contouring and finishing of posterior restorations.

ing” the papilla. (Refer to Chapter 20, Habits, Vol. II.) This occurs when patients, anxious to clean both sides of the proximal surface, do it so fast that they clean one side then forget to return to the height of contour before cleaning the other tooth. Instead they clean one side and rush the floss to the adjacent tooth surface without realizing they are injuring the interdental papilla.⁵¹

Mouthwashes with high alcohol content should be avoided because they can soften composites. Coffee, tea, and cola drinks can stain the bonded areas even more quickly than they do the original enamel. Should your patients smoke, this is also an excellent time for you to reinforce what the patient’s physician doubtless has been telling him or her about cigarette smoking or other tobacco use. Its deleterious effect on the appearance of the teeth, as well as the health of the oral cavity, is yet another reason to quit. The patient should avoid foods that are likely to stain the teeth. Much of the advice is pure common sense, although Chapter 20, Vol. II outlines in detail some of the ways patients sabotage their restorations by chewing, biting, grinding their teeth, holding objects in the mouth, even just using hard toothbrushes and abrasive toothpaste.^{73,101} Make the patient aware of these dangers, asking what habits they think they have that might cause damage. *Have your patient review the last chapter in “Change Your Smile” (Quintessence, Chicago, IL) which has a patient habit questionnaire dealing with these problems.*

BONDING PROTECTION

Unless your patient has an open bite or a protective occlusion that would prevent unfavorable stress on his/her anterior restorations, consider constructing a special mouthguard to be worn during sleeping or other times of patient need. The most comfortable appliance is one with a hard acrylic outside and soft acrylic inside to provide a “cushion” seat. This appliance is generally made for the maxillary arch (Figure 13–20D). Make certain the appliance is occlusally well balanced so that there are no interferences and all teeth have occlusal stops to prevent eruption.

Beware of the patient who emphatically states “I don’t clench or grind.” Instead look for wear facets on the teeth and remember most everyone can have a stressful sleep at times. It only takes one instance of clenching in eccentric positions to damage your patient’s bonded restorations. A good way for you

and your patient to visualize potential wear patterns is through the use of an intraoral camera. However, the very best way for you to see exactly what is taking place and to communicate it to your patient is through the use of a surgical or operative microscope (Global Surgical). The stereoscopic view as seen by the dentist is outstanding. When connected to a video recorder and monitor, both you and your patient can discover exact habit patterns, making it so much easier for you to suggest preventive measures. Consider imposing limitations on your office warranty if your patient does not accept your recommendations for wearing a protective appliance (Figures 13–20A to D).

Homecare

The immediate homecare of the patient should emphasize the most gentle, but thorough, cleaning. During this time, a chemotherapeutic agent, such as Peridex (Zila) or Listerine (Warner-Lambert, Morris Plains, NJ) can help control plaque. Dipping a Rotodent (Pro-Dentec, Batesville, AR) brush tip in the mouthwash before using is an excellent way to apply the solution and obviates some of the staining problems associated with the mouthwash.³⁹

Although a sizeable portion of the population is capable of adopting good hand brushing habits, using a rotary cleaning device (ProDentec) can make a dramatic difference for most people. Otherwise, patients may miss important areas where plaque can build up resulting at the very least in unattractive stain. It is essential for the patient to receive proper instructions on how to use the device. For instance, a close grip to the actual tooth surface will result in better and easier control (Figures 13–21A and B).

Recall Visits

In this mobile society where your patient may be receiving follow-up care on the other side of the country next year, he or she also needs to be sure that the new dentist or hygienist knows about the proper professional care of bonded teeth. Hygienists should avoid scaling against the margin of bonded teeth; instead do hand scaling with a lateral movement to remove any calculus without a counterforce that could dislodge the restoration. Use of a Cavi-jet (Dentsply, York, PA) or air powder abrasive instruments also pose potential damage to composite restorations.^{19a,95} So do ultra-

sonic and sonic instrumentation.⁹ Certain polishing pastes can also be harmful.⁹⁸ Acidulated fluoride pastes are to be avoided; Miller advocates aluminum oxide polishing paste applied with a wet rotating rubber cup.⁸⁰ Remind patients to always make any dentist or dental hygienist (or for that matter, any physician or anesthesiologist who will be working around the mouth) aware that esthetic dental restorations have been done that could be damaged.

Ideally, the patient should return for a postoperative visit within 1 to 2 weeks to make certain that soft tissue is healing properly. Some additional finishing may need to be done at that time to conform to the patient's emergence profile in order to achieve the highest esthetic and functional gingival margin possible. Until you have evidence of excellent tissue response, continue to have the patient return for periodic postoperative visits.

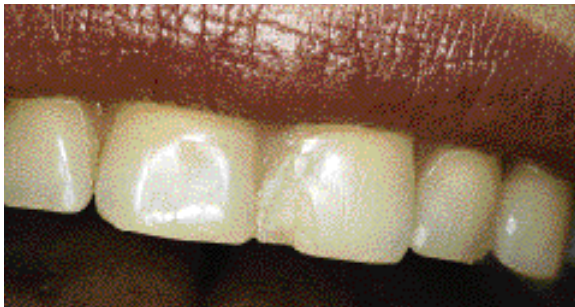

Figure 13-20A: This 36-year-old female fractured her left central incisor because of her clenching habit.

Most patients with esthetic restorations should be asked to return for inspection and hygiene recall within 3 months, in order for you to detect any problems, to make certain that the patient is caring for his or her mouth properly, and to ensure that there are no habits that could esthetically or functionally shorten the normal life span of a restored tooth. Use this recall to look especially at the margins of Class V composite resin restoration since water absorption in restorations without perfect margin seals may begin to cause a cervical overhang within 3 months.⁶⁴ If this happens, refinishing at that time may be required to avoid plaque retention and gingival irritation.

The life expectancy of most bonding may be more than 10 years now, as suggested by Drake et al.²⁹ However, "Change Your Smile" gives a more conservative forecast of 5 to 8 years, depending upon the type of restoration and the patient's cooperation in maintaining it. This point should be

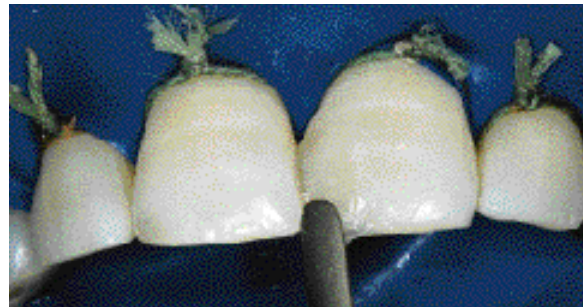


Figure 13-20B: The tooth was repaired using a polishable hybrid on the linguoincisal and microfill on the labial, called a sandwich technique.

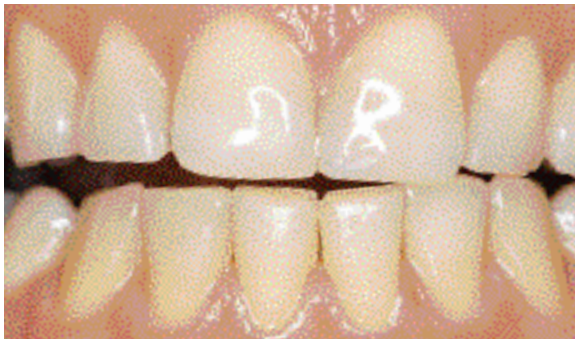

Figure 13-20C: The final result shows the polished microfill blends nicely with the adjacent tooth.

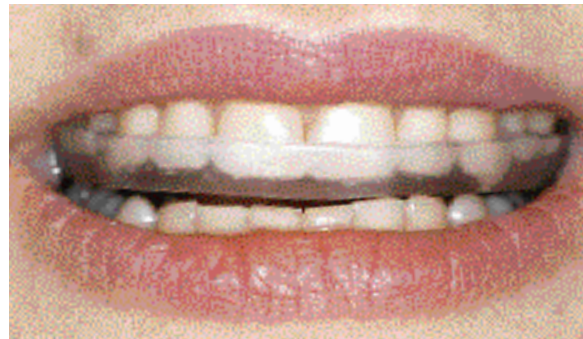

Figure 13-20D: The patient was fitted for a protective night appliance with hard acrylic outside and soft acrylic inside which she could wear during sleeping and times of possible stress.

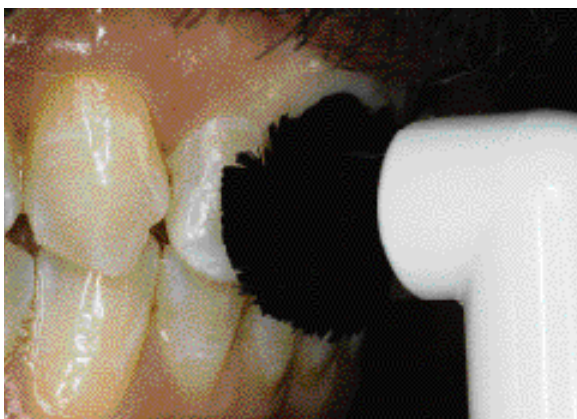

Figure 13-21A: An individual rotary cleaning device (Roto-dent, Pro-Dentec) provides the patient with an excellent means for maintaining the subgingival margin of this bonded veneer.

made: *Dentists or treatment coordinators should always remember that patients have a right to expect indefinite life of the bonding unless the dental professional enlightens them as to a definite range of life expectancy.* Dentists may overestimate the patient's awareness of this. In a study by Goldstein and Lancaster,⁴⁰ almost one in three persons said they believed bonding to be permanent. More recently, Davis et al. found a similar lack of information in the general public concerning the strength of composite resins for posterior restorations.²⁴

Pit and Fissure Stain

"It's just stain" is a typical comment made to patients by dentists when patients inquire about a darkly pitted or stained tooth. No longer is it necessary or even wise to allow these types of stained areas to exist in teeth. As Goldstein and Parkins suggest in their article in the *Journal of the American Dental Association*, changing patterns of dental caries suggest the need for a new emphasis on diagnosing and treating pit and fissure caries.⁴¹ Although occlusal surfaces represent only 12% of the total permanent dentition surface area, occlusal surfaces account for more than 50% of reported caries in school-age children. This would suggest a need to focus on pit and fissure stain. In a National Institute of Dental Research (NIDR) study from 1980 to 1987, it was found that decay in pits and fissures had reduced by only 31% while caries in other surfaces dropped by 51 to 59%. Pit and fissure caries accounted for 80% of total caries in

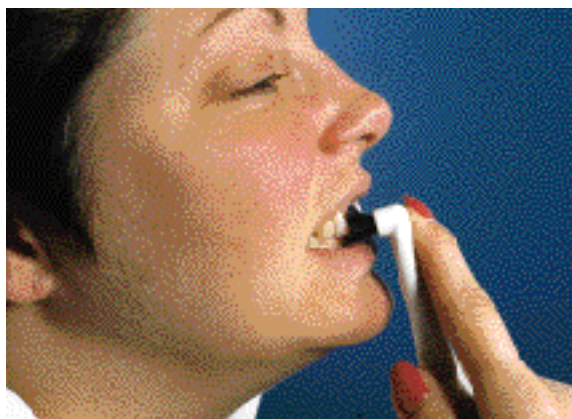

Figure 13-21B: It is essential to properly instruct your patient on the use of this cleaning device. Note that the closer the patient's forefinger is to the brush tip, the more control and thus cleaning efficiency he or she will have.

nonfluoridated water areas and 90% in fluoridated water areas.

Our clinical experience has shown 70 to 75% of these stained areas are involved into the dentin and, in fact, the great majority of them are actually carious lesions. Re-evaluation of the methods used to detect pit and fissure lesions has led to questioning the traditional use of the explorer to probe for caries. Enamel that is undermined with caries but strengthened by fluoride makes decay difficult to detect. A sticky fissure detected by the wedging of an explorer tip is no longer considered the only method for detecting pit and fissure caries (Figures 13-22A and B). In fact, probing of pits and fissures also has been de-emphasized because of its potential for damaging enamel. It is also interesting to note that few of these lesions are actually seen on radiographs as decay, although intraoral video cameras can facilitate the viewing of caries in grooves that are too narrow for the penetration of an explorer tip. However, difficulty in distinguishing a stain on the surface from a darker-colored organic plug within the pit or fissure that can promote caries also contributes to the diagnostic dilemma (Figure 13-22A).

The traditional placement of sealants in pits and fissures without removing the stain or organic plug, and possible underlying caries, is seriously questioned. Shrinkage and marginal wear often lead to undetected marginal leakage. Paterson et al. report that if such leakage occurs over active dentinal

*caries, it may not be detected before pulpal involvement or extensive undermining of enamel and/or cuspal fracture occurs.*⁸⁸

Use of Air-Abrasive Technology

According to Goldstein and Parkins,⁴¹ air-abrasive technology (KCP 1000, 2000, ADT; WhisperJet, American Dental Technologies, Inc., Southfield, MI; MicroPrep, Lares, Fremont, CA; Mach 5, Kreativ, Albany, OR) offers new options in caries diagnosis and treatment. The air-abrasive system uses a narrowly-focused particle stream that abrades tooth structure in proportion to the particle size, air pressure, and nozzle distance employed. The key issue for this newly-revived technology is that it provides a more conservative approach to both diagnosis and treatment of pit and fissure caries than conventional methods. After observing suspiciously stained pits or fissures, one or more short bursts of alpha alumina powder from the air-abrasive system can be used to remove both the stain and organic plug for a more accurate evaluation of the presence of caries. If this is simply stain or the organic plug, the abrasive action will eliminate it while leaving all but a few microns of healthy tooth structure intact. This examination is especially facilitated by the use of an intraoral camera or operative microscope. If there is no decay, the air-abrasively prepared pit or fissure can then be sealed or restored with resin materials.

If underlying caries is detected, further bursts of the abrasive powder stream may be used to completely eradicate the lesion, preserving the maximum amount of healthy tooth structure. (Hand or rotary instruments may be used as well if the area of decay is large.) The air-abrasive technique roughens the tooth surface, leaving it ready for direct bonding

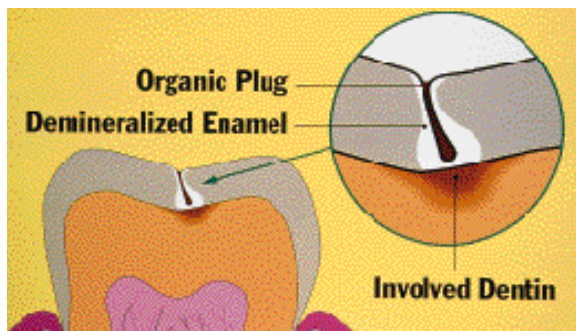


Figure 13-22A: Anatomy of pit and fissure caries.

techniques with or without acid-etching.^{27,31,62,68} The preparation can be restored immediately with either filled or unfilled composite resin. A combined sealant and bonding technique may be considered: if tooth structure has been removed or the anatomy is irregular, restore those areas with a bonded filled resin; the smaller, secondary grooves may then be covered with a sealant, creating a preventive resin restoration (Figures 13-23A to F). With the introduction of flowable composite resins, this procedure can be accomplished in a single step.

Patients like the fact that abrasive technology does not usually require an anesthetic, and therefore an “uncomfortable” injection and associated numbness are often eliminated.¹¹ This also saves time for the dentist because he or she can begin immediately with a happier patient, not waiting for an anesthetic to take effect. The unpleasant heat, pressure, bone-conducted noise and vibration associated with most “drilling” is minimized. This gentleness is confirmed by histologic studies which demonstrate that this technology is much kinder to the pulp.⁶⁷

The esthetic advantage of using air-abrasive technology is the ability to easily eliminate stained (Figures 13-24A to D) and/or carious areas without cutting into the tooth with a rotary handpiece. Patient acceptance is so high that it is a definite

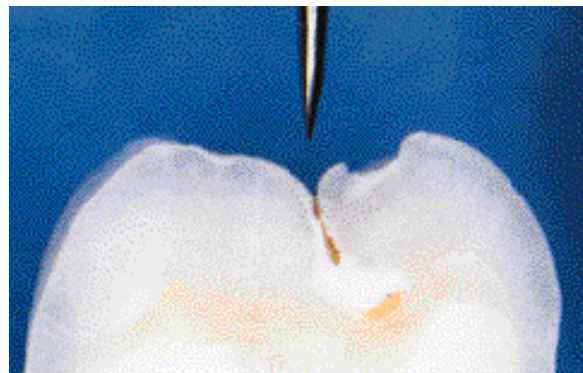


Figure 13-22B: The explorer is often of limited use in the diagnosis of pit and fissure caries since fissures are frequently narrower than the explore tip. This tool would not have aided in the diagnosis of this lesion. Therefore, the only sure way of knowing if a stained pit or fissure is carious is to “spray” it out with air-abrasive technology. (Photo courtesy of Quintessence Publishing Co., Inc. Paterson et al. *Modern concepts in diagnosis and treatment of fissure caries*. Chicago: Quintessence, 1991:14.)

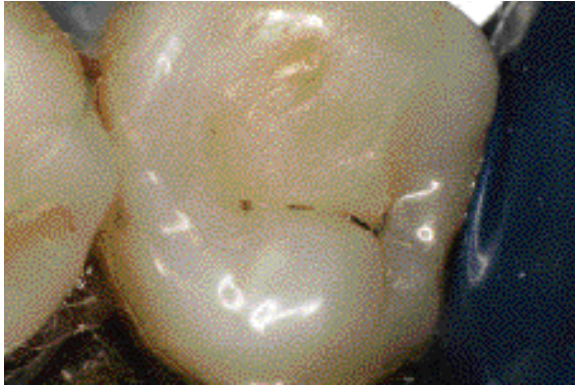


Figure 13–23A: This lower bicuspid reveals a stain.

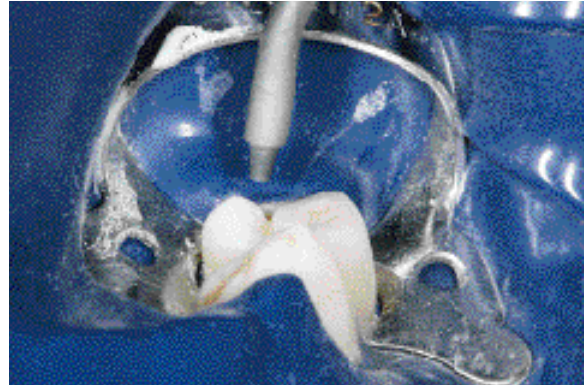


Figure 13–23B: A 3-second burst by an air-abrasive system (KCP, American Dental Technologies) helps determine if the problem is caries or just stain.

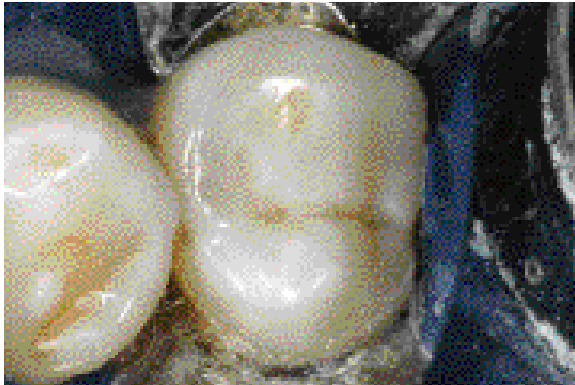


Figure 13–23C: A clinical exam with 2.5 × magnification (Design for Vision, Ronkonkoma, NY) reveals some caries present in the second bicuspid.

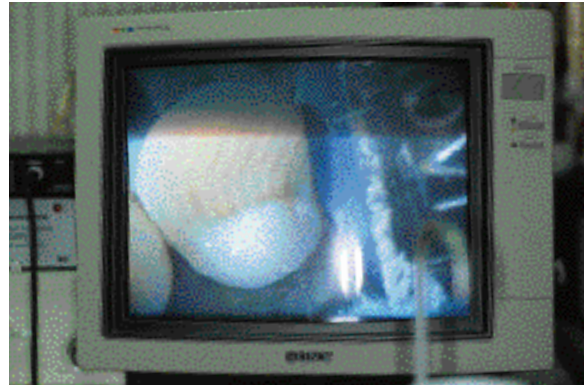

Figure 13–23D: After 7 seconds more using the air-abrasive system with 50-micron alpha alumina with 140 PSI, the tooth is visually inspected using the intraoral camera and video monitor which enlarges the image 20 to 30 times, making any remaining caries easier to detect.



Figure 13–23E: Once all caries is removed, the tooth is restored with a hybrid composite. The final finish is with a 30-bladed carbide finishing bur (OS1 UF, Brasseler).

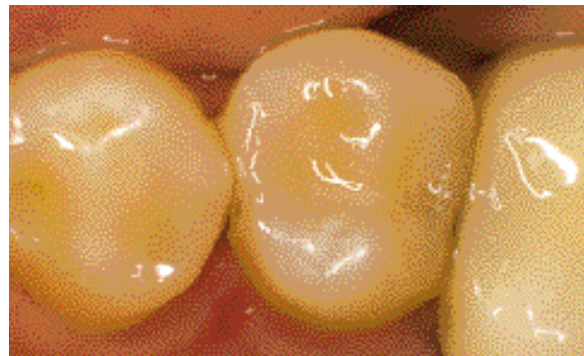

Figure 13–23F: The final bonded restoration helps to eliminate the high bacterial content associated with tooth caries.

practice builder. Psychologically, patients also may feel better about maintaining teeth that have been restored to a natural, healthy appearance, rather than restored teeth that retain unsightly stains around the restoration. Further, patients appreciate the concept of maximizing the conservation of healthy tooth structure by attacking decay at the earliest possible moment. Preliminary studies of shear bond strength also suggest that the roughened surface created by air-abrasive technology may enhance bonding, especially bonding to dentin.⁶⁸

Another major use of air-abrasive technology is the repair of composite resin and porcelain restorations. Until now, no satisfactory method had been devised to etch the existing composite resin when new composite resin was to be added as in a repair or even esthetic enhancement of a discolored com-

posite. By first preparing the surface of the composite with the air-abrasive system, an excellent etched surface exists to help gain greater retention of the newly-bonded composite resin (Figures 13–25A to C). A study by Chen et al. also showed that a 120-second air abrasion provided the highest bond strength of composite resin to porcelain.^{14b}

THE FUTURE

McLean doubts that the ideal restorative material will be achieved until well into the 21st century,⁷⁷ but it is clear that bonding will continue to improve through both materials and technique. The use of erbium: YAG lasers for tooth preparation and etching^{19b} as well as argon and other lasers, some of which feature subsecond polymerization, will result in shorter procedural time and increased restoration strength.⁷⁸ New strength, new direct and indi-

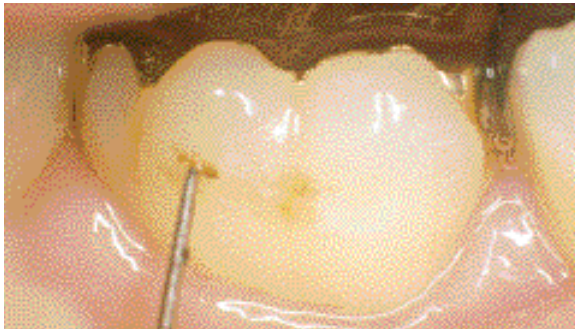


Figure 13–24A: The presence of brown stain bothered this patient because he thought it was decay.

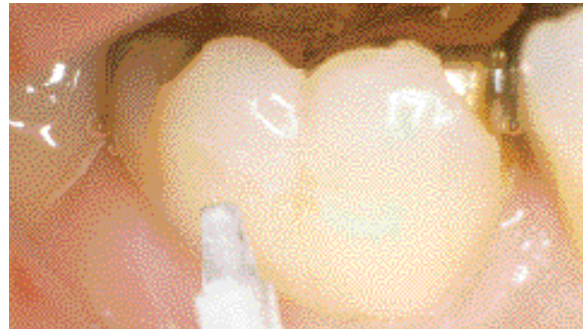

Figure 13–24B: A 5-second burst of air-abrasive technology (American Dental Technologies; Lares; Kreativ) using 50-micron alpha alumina at 140 PSI eliminated the stain.

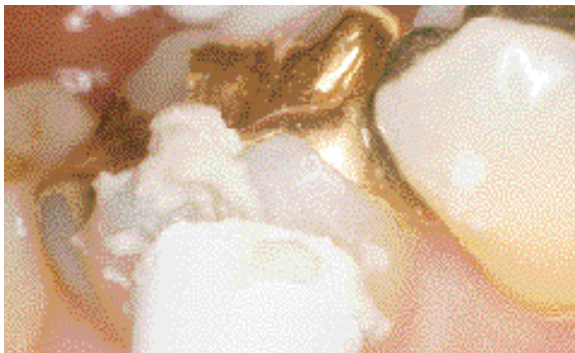

Figure 13–24C: The surface was then thoroughly polished with pumice and a rubber polishing cup.

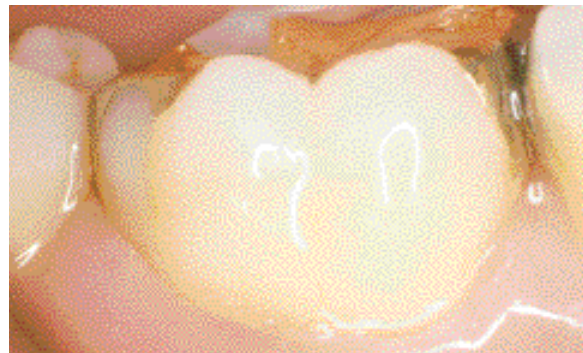

Figure 13–24D: A completely repolished tooth surface reveals the stain has been totally removed.

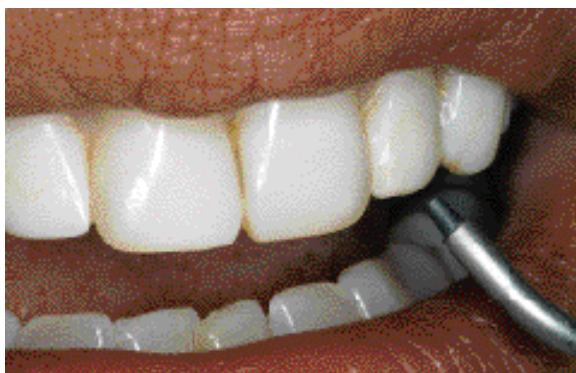

Figure 13-25A: The 5-year-old bonding on this lateral incisor had stain and porosity needing repair. A 10-second application of abrasive technology helped to create a highly bondable "etched" surface.

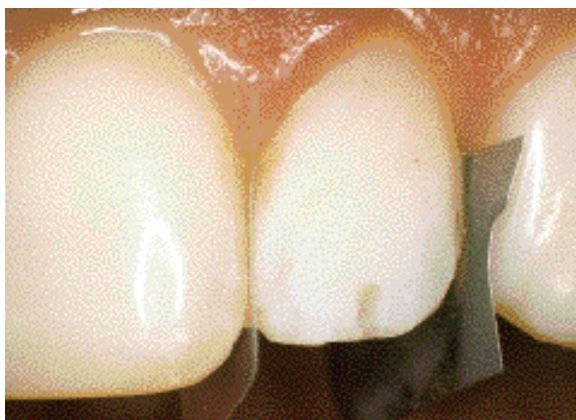

Figure 13-25B: This micromechanically etched surface is now ready to receive the bonding agent.

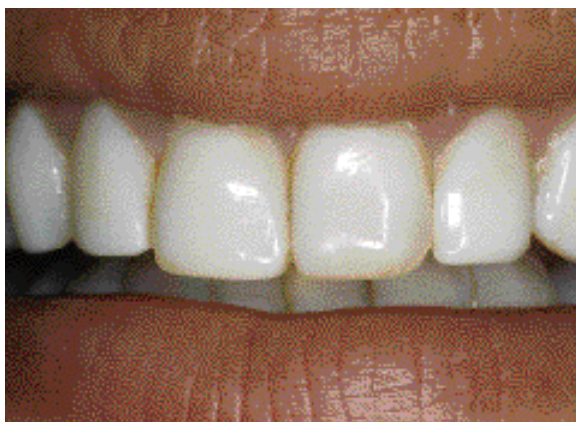

Figure 13-25C: The finished result shows a securely bonded polished surface repair.

rect materials, and perhaps even decreasing costs will bring bonding to larger numbers of people. Furthermore, if current findings continue to hold true, composites will not only become more valuable for esthetics but also for reducing caries,⁹⁰ in combination with glass ionomers and other similar compounds.

References

1. Albers HF. Tooth colored restoratives: a text for selection, placement and finishing. 7th edn. Cotati, CA: Alto Books, 1985.
2. Albers HF. Alternatives for Class II restorations (results of clinical trial of 21 materials at 3 years). CRA Newsletter, May 1994.
3. Antonson DE, Benedetto MD. Longitudinal intensity variability of visible light curing units. *Quintessence Int* 1986;17:819-20.
4. Anusavice KJ. Quality evaluation of dental restorations: criteria for placement and replacement. Chicago: Quintessence Publishing Co. Inc., 1989.
5. Arends J, Ruben J, Dijkman A. The effect of fluoride release from a fluoride-containing composite resin on secondary caries: an in vitro study. *Quintessence Int* 1990;21:671-4.
6. Baharav H, Cardash HS, Helft M, Langsam J. Penetration of etched enamel by bonding agents. *J Prosthet Dent* 1988;59:33-6.
7. Bayne SC, Taylor DE, Roberson TM, Wilder AD, et al. Long term clinical failures in posterior composites. *J Dent Res* 1989;68.
- 8a. Beard CC, Donaldson K, Clayton JA. A comparison of articulator settings to age and sex. *J Prosthet Dent* 1986;56:551-4.
- 8b. Beaudreau DE. Atlas of fixed partial prosthesis. Springfield, IL: Charles C. Thomas, 1975.
9. Bjornson E, Collins DE, Engler WO. Surface alteration of composite resins after curette, ultrasonic, and sonic instrumentation: an in vitro study. *Quintessence Int* 1990;21:381-9.
10. Bowen RL. Development of a silica-resin direct filling material. Report 6333. Washington: National Bureau of Standards, 1958.
11. Bowen R. Properties of a silica-reinforced polymer for dental restorations. *J Am Dent Assoc* 1963;66:57-64.

12. Brockman SL, Scott RL, Erick JD. A scanning electron microscopic study of the effect of air polishing of the enamel-sealant surface. *Quintessence Int* 1990; 21:201-6.
13. Buonocore MG. A simple method of increasing the adhesion of acrylic filling materials to enamel surfaces. *J Dent Res* 1955;34:849-53.
- 14a. Burgoyne AR, Nicholls JI, Brudvik JS. In vitro two-body wear of inlay/onlay composite resin restoratives. *J Prosthet Dent* 1991;65:206-14.
- 14b. Chen JH, Matsumura H, Atsuta M. Effect of different etching periods on the bond strength of a composite resin to a machinable porcelain. *J Dent* 1998; 28(1):53-8.
15. Chen RCS, Chan DCN, Chan KC. A quantitative study of finishing and polishing techniques for a composite. *J Prosthet Dent* 1988;59:292-7.
16. Christensen GJ. Veneering of teeth. State of the art. *Dent Clin North Am* 1985;29:373-91.
17. Collard S, Vogel J, Ladd G. Respirability, microstructure, and filler content of composite dusts. *Am J Dent* 1991;4:143-52.
18. Cooley RL, Barkmeier WW, Matis BA, Siok JF. Staining of posterior resin restorative materials. *Quintessence Int* 1987;18:823-7.
- 19a. Cooley RL, Lubow RM, Brown FH. Effect of air-powder abrasive instrument on porcelain. *J Prosthet Dent* 1988;60:440-3.
- 19b. Cozean C, Arcoria CJ, Pelagalli J, Powell GL. Dentistry for the 21st century? Erbium: YAG laser for teeth. *J Am Dent Assoc* 1997;128(8):1-8.
20. Crim GA. Influence of bonding agents and composites on microleakage. *J Prosthet Dent* 1989;61:571-4.
21. Croll TP. Bonded composite resin crown restoration without enamel reduction. *Quintessence Int* 1987; 18:753-7.
22. Croll TP, Donley KJ. Imperceptible bonded composite resin Class III restoration using labial access. *Quintessence Int* 1990;21:795-9.
23. Davidson CL, Kemp-Scholte. Shortcomings of composite resins in Class V restorations. *J Esthet Dent* 1989;1:1-4.
24. Davis EL, Laura JC, Joynt RB, Wieczkowski G. Determination of demand for posterior resin restorations. *J Prosthet Dent* 1988;59:242-8.
25. Dickinson GL, Leinfelder KF, Mazer RB, Russell CM. Effect of surface penetrating sealant on wear rate of posterior composite resins. *J Am Dent Assoc* 1990;121: 251-5.
26. Donly KJ, Dowell A, Anixiadas C, Croll TP. Relationship among visible light source, composite resin polymerization shrinkage, and hygroscopic expansion. *Quintessence Int* 1990;21:883-6.
27. Doty WD, Pettey D, Holder R, Phillips S. KCP 2000 enamel etching abilities tested. *J Dent Res* 1994; 73(Special issue):411, Abstract 2474.
28. Douvitas G. Effect of cavity design on gap formation in Class II composite resin restorations. *J Prosthet Dent* 1991;65:475-9.
29. Drake CW, Maryniuk GA, Bentley C. Reasons for restoration replacement: differences in practice patterns. *Quintessence Int* 1990;21:125-30.
30. Dunn JR. Microfills retain importance. *Dentist*, 1990;68:29-32.
31. Eakle WS, Goodis HE, White JM, Do HK. *J Dent Res* 1994;73 (Special Edition):131, Abstract 239.
32. Feigenbaum N, Mopper KW. A complete guide to dental bonding. Johnson and Johnson, 1984.
33. Ford RT, Douglas W. The use of composite resin for creating anterior guidance during occlusal therapy. *Quintessence Int* 1988;19:331-7.
34. Friedman J. Variability of lamp characteristics in dental curing lights. *J Esthet Dent* 1987;1:189-90.
35. Garcia-Godoy F, Draheim RN, Titus HW. Preventive glass ionomer restorations. *Am J Dent* 1988;1:97-9.
36. Goldfogle M. Case selection: expert shares tips on direct bonding. *Cosmet Dent GPs* 1990;1:6-7.
37. Goldstein RE. Diagnostic dilemma: to bond, laminate, or crown? *Int J Periodontics Restorative Dent* 1987;8:8-29.
38. Goldstein RE. Personal communication. 1993.
39. Goldstein RE, Garber DA, Schwartz CG, Goldstein CE. Patient maintenance of esthetic restorations. *J Am Dent Assoc* 1992;123:61-6.
40. Goldstein RE, Lancaster JS. Survey of patient atti-

- tudes toward current esthetic procedures. *J Prosthet Dent* 1984;52:775-80.
41. Goldstein RE, Parkins F. Using air-abrasive technology to diagnose and restore pit and fissure caries. *J Am Dent Assoc* 1995;126:761-5.
 42. Goldstein R, Parkins F. Air-abrasive technology: its new role in restorative dentistry. *J Am Dent Assoc* 1994;125:551-7.
 43. Gregory WA, Berry S, Duke E, Dennison JB. Physical properties and repair bond strength of direct and indirect composite resins. *J Prosthet Dent* 1992;68:406-11.
 44. Greiff RM, Burgess JO, Davis RD, Theobald WD. Wet and dry finishing techniques for composite resin. *J Dent Res* 1989;68: .
 45. Gwinnett AJ. Bonding of restorative resins to enamel. *Int Dent J* 1988;38:91-6.
 46. Gwinnett AJ, Matsui A. A study of enamel adhesives: the physical relationship between enamel and adhesive. *Oral Biol* 1967;12:1615.
 47. Hardison JD, Rafferty-Parker D, Mitchell RJ, Bean LR. Radiolucent alos associated with radiopaque composite resin restorations. *J Am Dent Assoc* 1989;118:595-7.
 - 48a. Hembree JH. Microleakage at the gingival margin of Class II composite restorations with glass ionomer liner. *J Prosthet Dent* 1989;61:28-30.
 - 48b. Heymann HO. Personal communication. 1998.
 - 48c. Hilton TJ, Schwartz RS. The effect of air thinning on dentin adhesive bond strength. *Oper Dent* 1995;20:133-7.
 49. Hinoura K, Stecos JC, Phillips RW. Cavity design and placement techniques for class 2 composites. *Oper Dent* 1988;13:12-9.
 50. Hosoya Y, Goto G. Color differences between light cured composite resins and shade guides. *J Dent Res* 1990;69.
 51. Hoye P. Personal communication.
 52. Hoyle P. Indirect Resin Systems. *Reality* 1993;8:121-4.
 53. Jefferies SR, Smith RL, Barkmeier WW, Gwinnett AJ. Comparison of surface smoothness of restorative resin materials. *J Esthet Dent* 1989;1:169-75.
 54. Jordan RE. Resin-enamel bonding. In: Jordan RE, ed. *Esthetic composite bonding: techniques and materials*. Revised edn. Philadelphia: B.C. Decker, Inc., 1988.
 55. Jordan RE, Gwinnett AJ. Methods and materials. In: Jordan RE, ed. *Esthetic composite bonding: techniques and materials*. Revised edn. Philadelphia: B.C. Decker, Inc., 1988.
 56. Jordan RE, Suzuki M. Direct hybrid composite inlay technique. *J Esthet Dent* 1988;(1):57-60.
 57. Jordan RE, Suzuki M, Gwinnett AJ. Conservative applications of acid etch resin techniques. *Dent Clin North Am* 1981;25:307.
 58. Jordan RE, Suzuki M. Clinical evaluation of concept as a posterior composite restorative material in an indirect inlay/onlay technique. St. Louis: Mosby, 1993.
 59. Kanca J. Bonding to tooth structure: a rationale for a clinical protocol. *J Esthet Dent* 1989;1: 135-8.
 60. Kanca J. Composite resin luting materials: a rationale for the '90s. *J Esthet Dent* 1989;1:105-9.
 61. Kanca J. Improving bond strength through acid etching of dentin and bonding to wet dental surfaces. *J Am Dent Assoc* 1992;123:35-43.
 62. Keen DS, von Fraunhofer JA, Parkins FM. Air-abrasive etching bond strengths. *J Dent Res* 1994;73 (Special Issue):131; Abstract 238.
 63. Kemp-Scholte CM, Davidson CL. Marginal sealing of curing contraction gaps in Class V composite resin restoration. *J Dent Res* 1988;67:841-5.
 64. Kemp-Scholte CM, Davidson CL. Overhand of Class V composite resin restorations from hygroscopic expansion. *Quintessence Int* 1989;20:551-3.
 - 65a. Khokhar Z, Razzoog M, Yaman P. Color stability of restorative resins. *Quintessence Int* 1991;22:733-7.
 - 65b. Kinzer RL. Aesthetic factors. In: Clark JW, ed. *Clinical dentistry IV*. New York: Harper and Row, 1976:Ch. 32.
 66. Lambrechts P, Braem M, Vanherle G. Evaluation of clinical performance for posterior composite resins and dentin adhesives. *Oper Dent* 1987;12:53-78.
 67. Laurell K, Carpenter W, Daugherty D, Beck M. Histopathologic effects of kinetic cavity preparation for the removal of enamel and dentin. An in vivo animal study. *Oral Surg Oral Med Oral Pathol Oral Radiol Endod* 1995;80:214-25.

68. Laurell K, Lord W, Beck M. Kinetic cavity preparation effects on bonding to enamel and dentin. *J Dent Res* 1993;72(Special Issue):273, Abstract 1437.
69. Leinfelder KF. Posterior composite resins. *J Am Dent Assoc* 1988;(Special Issue), 21-E-26-E.
70. Leinfelder KF. The amalgam restoration. *Dent Clin North Am* 1983;27:685-96.
71. Levin RP. Composite inlays as management tools in dental practice. *J Esthet Dent* 1989;1:38-40.
72. Lloyd CH. Resistance to fracture in posterior composites. *Br Dent J* 1983;155:411.
73. Lutz F, Krejci I, Oldenburg TR. Elimination of polymerization stresses at the margins of posterior composite resin restorations: a new restorative technique. *Quintessence Int* 1986;17:777-84.
74. Maitland RI. Director posterior composites. *Esthet Dent Update* 1990;1:49-52.
75. Makinson OR. Color changes on curing light-activated anterior restorative resins. *Dent Abstracts* 1989;34:467.
76. McLean JW. Limitations of posterior composite resins and extending their use with glass ionomer cements. *Quintessence Int* 1987;18:517-29.
77. McLean JW. Long-term esthetic dentistry. *Quintessence Int* 1989;20:701-8.
78. McLean JW, Powis DR, Prosser HJ et al. The use of glass-ionomer cements in bonding composite resins to dentine. *Br Dent J* 1985;158:410-4.
79. Meryon SD, Johnson SG. The effect of smear layer removal on the in vitro cytotoxicity of four dental restorative materials. *J Dent* 1989;16:22-6.
80. Miller DL, Hodges KO. Polishing the surface: a comparison of rubber cup polishing and airpolishing. *Probe* 1991;25(3):103, 105-9.
81. Mixson JM, Eick JD, Tira DE, Moore DL. The effects of variable wash times and techniques on enamel-composite resin bond strength. *Quintessence Int* 1988; 19:279-85.
82. Mohd Z, Aziz R. Wear of materials used in dentistry: a review of the literature. *J Prosthet Dent* 1990; 63:342-9.
83. Moore DH, Vann WF. The effect of a cavosurface bevel on microleakage in posterior composite restorations. *J Prosthet Dent* 1988;59:21-4.
84. Mopper KW. The subtleties of anterior direct-bonded Class III restorations. *Pract Periodontics Aesthet Dent* 2(6):17-20.
85. Myers DR, Butts MB. Surface topography of the cavosurface enamel bevel following acid etching in primary teeth. *J Pedod* 1985;10:63-7.
86. Paquette DE, Vann WF, Oldenburg TR, Leinfelder KF. Modified cavity preparation for composite resins in primary molars. *Pediatr Dent* 1983;5:246-51.
87. Nixon RL. The advent of metal-free dentistry: a versatile new fiber and polymer-glass system. *Pract Periodontics Aesthet Dent* 1997;9(8):1-7.
88. Paterson RC, Watts A, Saunders WP, Pitts NB. Modern concepts in the diagnosis and treatment of fissure caries. Chicago: Quintessence, 1991:14-6.
89. Phillips RW. Changing trends of dental restorative materials. *Dent Clin North Am* 1989;33:285-91.
90. Phillips RW. Era of new biomaterials in esthetic dentistry. *J Am Dent Assoc* 1987;(Special Issue):7E-13E.
91. Pink FE. Use of custom composite shade guide for shade determination. *J Dent Res* 1989;69.
92. Pintado MR. Characterization of two small-particle composite resins. *Quintessence Int* 1990;21:843-8.
93. Pratten DH, Johnson GH. An evaluation of finishing instruments for an anterior and a posterior composite. *J Prosthet Dent* 1988;60(2):154-8.
94. Ratanapridakul K, Leinfelder KF, Thomas J. Effect of finishing on the in vivo wear rate of a posterior composite resin. *J Am Dent Assoc* 1989;118:333-5.
95. Reel DC, Abrams H, Gardner SL, Mitchell RJ. Effect of a hydraulic jet prophylaxis system on composites. *J Prosthet Dent* 1989;61:441-5.
96. Roulet JF, Hirt T, Lutz F. Surface roughness and marginal behavior of experimental and commercial composites: an in vitro study. *J Oral Rehabil* 1984;11: 499-509.
- 97a. Rueggeberg RA. Composite inlays: a review of concepts, techniques, and limitations. *Georgia Acad Gen Dent* 1990:Winter.
- 97b. Schvaneveldt SL, Rozmajzl WF Jr, Barkmeier

WW, Latta MA. Bond strength of an adhesive polymerized under nitrogen. *Am J Dent* 1996;9:157-60.

98. Serio R, Litkowski L, Strassler H, Krupa C. The effects of polishing pastes on polished composite resin surfaces. *J Dent Res* 1987;66:211.

99. Shortall AC, Baylis RI, Baylis MA, Grundy JR. Marginal seal comparisons between resin-bonded Class II porcelain inlays, posterior composite restorations, and direct composite resin inlays. *Int J Prosthodont* 1989;2:217-22.

100. Simonsen RJ. Clinical applications of the acid etch technique. Chicago: Quintessence Publishing Co. Inc., 1978.

101. Strassler H, Serio F, Litkowschi L, Moffitt W. Effect of toothpastes on polished composite resin surfaces. *J Dent Res* 1987;66:211.

102. Temin SC, Csuros Z, Mellberg JH. Fluoride uptake form a composite restorative by enamel. *Dent Mat* 1989;5(1):64-5.

103. Terkla LG, Brown AC, Hainisch AP, Mitchem JC. Testing sealing properties of restorative materials against moist dentin. *J Dent Res* 1987;66:1758-64.

104. Toffenetti F. Considerations about esthetics of composite resin restorations. *J Esthet Dent* 1989;1:62-6.

105. Valentine CW. Composite resin restoration in esthetic dentistry. *J Am Dent Assoc* 1987;Special Issue:55E-61E.

106. Watson TF. High speed dental burr/tooth cutting interactions and their implications for adhesive restorative materials. *J Dent Res* 1989;69.

107. Weinstein AR. Anterior composite resins and veneers: treatment planning, preparation, and finishing. *J Am Dent Assoc* 1988;Special Issue:38E-45E.

108. Wilson MA, Wilson NHE, Smith GA. A clinical trial of a visible light-cured posterior composite resin restorative: two year results. *Quintessence Int* 1986;17:151-5.

Additional Resources

Abdalla AI, Alhadainy HA. 2-year clinical evaluation of class I posterior composites. *Am J Dent* 1996;9(4):150-2.

Abdalla AI, Davidson CL. Effect of mechanical load cycling on the marginal integrity of adhesive class I resin composite restorations. *J Dent* 1996;24(1-2):87-90.

Abdalla AI, Davidson CL. Shear bond strength and microleakage of new dentin bonding systems. *Am J Dent* 1993;6:295-8.

The Dental Advisor. Ann Arbor, MI: Dental Consultants.

Status report on enamel bonding of composite, preformed laminate, and laboratory fabricated resin veneers. Council on Dental Materials, Instruments and Equipment. *J Am Dent Assoc* 1984;109:762-4.

Andreasen JO, Andreasen FM. Textbook and color atlas of traumatic injuries to the teeth. St. Louis: Mosby, 1994.

Anzai M, Yoshihashi R, Kobori M, Ohashi M. Synthesis of monomer for radiopaque composite resin and their properties. *J Dent Res* 1989;68.

Applequist EA, Meiers JC. Effect of bulk insertion, per-polymerized resin composite balls, and beta-quartz inserts on microleakage of class V resin composite restorations. *Quintessence Int* 1996;27:253-8.

Arcoria CJ, Vitasek BA, Ferracane JL. Microleakage of composite resin restorations following thermocycling and instrumentation. *Gen Dent* 1990;38:129-31.

Arends J, Ruben J. Chloride release from a composite resin. *Quintessence Int* 1988;19:513-4.

Arends J, van der Zee Y. Fluoride uptake in bovine enamel and dentin from a fluoride-releasing composite resin. *Quintessence Int* 1990;21:541-4.

Asmussen E, Munksgaard EC. Bonding of restorative resins to dentine: status of dentine adhesives and impact on cavity design and filling techniques. *Int Dent J* 1988;38:97-104.

Bader JD, Graves RC, Disney JA, et al. Identifying children who will experience high caries increments. *Community Dent Oral Epidemiol* 1986;14:198-201.

Bader JD, Brown JP. Dilemmas in caries diagnosis. *J Am Dent Assoc* 1993;124(6):48-50.

Baratieri LN. *Dentística: Procedimentos Preventivos e Restauradores*. Brazil: Quintessence, 1992.

Baratieri LN. *Estética: Restauracoes Adesivas Diretas em Dentes Anteriores Fraturados*. Brazil: Quintessence, 1995.

Baratieri LN, Monteiro S Jr, de Albuquerque FM, et al. Reattachment of a tooth fragment with a new adhesive system: a case report. *Quintessence Int* 1994;25:91-6.

- Barnes DM, Holston AM, Strassler HE, Shires PJ. Evaluation of clinical performance of twelve posterior composite resins with a standardized placement technique. *J Esthet Dent* 1990;2:36–43.
- Barnwell S, Cooley R, Dodge W, Dale R. The effect of wet and dry finishing on composite resin surfaces. *J Dent Res* 1989;68.
- Baum L. Principles and practice of operative dentistry. 3rd edn. 1988.
- Berman G, Linden L. The action of the explorer on incipient caries. *Svensk Tandlaek Tidskr* 1969;62: 629–34.
- Berry EA III, Berry LL, Powers JM. Bonding of hybrid ionomer to air-abraded enamel and dentin. *J Dent Res* 1994;73(Special Issue):183, Abstract 654.
- Bertschinger C, Paul SJ, Luthy H, et al. Dual application of dentin bonding agents: effect on bond strength. *Am J Dent* 1996;9:115–9.
- Biederman JD. Direct composite resin inlay. *J Prosthet Dent* 1989;62:249–53.
- Black RB. Application and re-evaluation of air abrasive technic. *J Am Dent Assoc* 1955;50:408–14.
- Blankenau RJ, Barkmeier WM, Powell GL, Kelsey WP. Enhancement of physical properties of resin restorative materials by laser polymerization. *Lasers Surg Med* 1989;9:623–7.
- Blomgren J, Axell T, Sandahl O, et al. Adverse reactions in the oral mucosa associated with anterior composite restorations. *J Oral Pathol Med* 1996;25:311–3.
- Boghosian A. Clinical evaluation of a filled adhesive system in class 5 restorations. *Compend Contin Educ Dent* 1996;17:750–2, 754–7.
- Boksman L, et al. Etched porcelain labial veneers. *Ont Dent* 1985;62(1):15–9.
- Bouschlicher MR, Vargas MA, Denehy GE. Effect of desiccation on microleakage of five class 5 restorative materials. *Oper Dent* 1996;21(3):90–5.
- Bowen RL. Properties of a silica-reinforced polymer for dental restorations. *J Am Dent Assoc* 1963;66:57–64.
- Brockmann SL, Scott RL, Eick JD. The effect of an air-polishing device on tensile bond strength of a dental sealant. *Quintessence Int* 1989;20:211–7.
- Browning WD, Dennison JB. A survey of failure modes in composite resin materials. *Oper Dent* 1996;21(4): 160–6.
- Brunelle JA. U.S. Department of Public Health and Human Services. Oral health of United States children, national and regional findings; 1989; NIH Publication No. 89–2247.
- Bullard RH, Leinfelder KF, Russel CM. Effect of coefficient of thermal expansion on microleakage. *J Am Dent Assoc* 1988;116:871–4.
- Burbach G. Micro-invasive cavity preparation with an air-abrasive unit. *GP* 1993;2(4):55–8.
- Burgess JO, Norling BK, Rawls HR, et al. Directly placed esthetic restorative materials—the continuum. *Compend Contin Educ Dent* 1996;17:731–2.
- Burke FJT, Wilson NHF, Watts DC. The effect of cuspal coverage on the fracture resistance of teeth restored with indirect composite resin restorations. *Quintessence Int* 1993;24:875–80.
- Cahen PM, Obry-Musset AM, Grange D, Frank RM. Caries prevalence in 6- to 15-year-old French children based on the 1987 and 1991 national surveys. *J Dent Res* 1993;72:1581–7.
- Calamia JR. Etched porcelain veneers: the current state of the art. *Quintessence Int* 1985;16:5.
- Calamia JR, Simonsen RJ. Effect of coupling agents on bond strength of etched porcelain. *J Dent Res* 1984;63: 162–362.
- Carvalho RM, Pereira JC, Yoshiyama M, et al. A review of polymerization contraction: the influence of stress development versus stress relief. *Oper Dent* 1996;21(1): 17–24.
- Chalifoux PR. Aesthetic guidelines for posterior composite restorations. *Pract Periodontics Aesthet Dent* 1996;8(1):39–48.
- Chalifoux PR. Checklist to aesthetic dentistry. *PP&A*, 1990;2:9–12.
- Chan DCN. Current methods and criteria for caries diagnosis in North America. *J Dent Educ* 1993;57: 422–7.
- Chan KC, Swift EJ Jr. Marginal seal of new-generation dental bonding agents. *J Prosthet Dent* 1994;72:420–3.
- Chappell RP, Spencer P, Eick JD. The effects of current dentinal adhesives on the dentinal surfaces. *Quintessence Int* 1994;25:851–9.
- Chiba K, Hosoda H, Fusayama T. The addition of an

- adhesive composite resin to the same material: bond strength and clinical techniques. *J Prosthet Dent* 1989; 61:669-75.
- Christiansen GJ. A new technique for restoration of worn anterior teeth. *Oral Health* 1996;86(3):25-7.
- Christensen GJ. Tooth sensitivity related to class I and II resin restorations. *J Am Dent Assoc* 1996;127:497-8.
- Ciamponi AL, Del Portillo Lujan VA, Santos JFF. Effectiveness of reflective wedges on the polymerization of composite resins. *Quintessence Int* 1994;25:599-602.
- Coli P, Brannstrom M. The marginal adaptation of four different bonding agents in class II composite resin restorations applied in bulk or in two increments. *Quintessence Int* 1993;24:583-91.
- Craig RG. Restorative dental materials. 10th edn. St. Louis: Mosby, 1996.
- Craig RG, O'Brien WJ, Powers JM. Dental materials: properties and manipulation. 6th edn. St. Louis: Mosby, 1996.
- Crispin BJ. Contemporary esthetic dentistry: practice fundamentals. Tokyo: Quintessence, 1994.
- Croll TP. Bonded resin sealant for smooth surface enamel defects: new concepts in 'microrestorative' dentistry. *Quintessence Int* 1987;18:5-10.
- Croll TP. Enamel microabrasion. Chicago: Quintessence, 1991.
- Cross TP, Cavanaugh RR. Augmentation of incisor width with bonded composite resin: another look. *Quintessence Int* 1990;21:637-41.
- Davis EL, Joynt RB, Yu X, Wiczekowski G Jr. Dentin bonding system shelf life and bond strength. *Am J Dent* 1993;6:229-31.
- Degrange M, Roulet JF. Minimally invasive restorations with bonding. Chicago, 1997.
- Denehy GE, Cobb DS. A direct composite resin approach to anterior tooth alignment. *Contemporary Esthet and Rest Pract* 1998;2(1):10-22.
- Dickerson WG. A functional and esthetic direct resin technique. *Pract Periodontics Aesthet Dent* 1991;3(7): 43-7.
- Dickerson W. The effect of a dentin primer on enamel bond strength. *Esthet Dent Update* 1994;5:63-4.
- Douglas WH. The esthetic motif in research and clinical practice. *Quintessence Int* 1989;20:739-45.
- Dickinson PT, Powers JM. Evaluation of fourteen direct-bonding orthodontic bases. *Am J Orthod* 1980; 78:630-9.
- Dietschi D, Spreafico R. Adhesive metal-free restorations: current concepts for the esthetic treatment of posterior teeth. Chicago: Quintessence, 1997.
- Donly KJ, Gomez C. In vitro demineralization-remineralization of enamel caries at restoration margins using fluoride-releasing composite resin. *Quintessence Int* 1994;25:355-8.
- Duke ES, Robbins JW, Schwartz RS, et al. Clinical and interfacial laboratory evaluation of a bonding agent in cervical abrasions. *Am J Dent* 1994;7:307-11.
- Eick JD, Fenn H. Polymerization shrinkage of posterior composite resins and its possible influence on postoperative sensitivity. *Quintessence Int* 1986;17:103-11.
- Ericson D, Derand T. Increase of in vitro curing depth of class II composite resin restorations. *J Prosthet Dent* 1993;70:219-23.
- Eli I, Liberman R, Levi N, Haspel Y. Bond strength of jointed posterior light-cured composites: comparison of surface treatments. *J Prosthet Dent* 1988;60:185-8.
- Fahl N Jr. Optimizing the esthetics of class IV restorations with composite resins. *J Can Dent Assoc* 1997; 63(2):108-11, 114-5.
- Fahl N Jr. Predictable aesthetic reconstruction of fractured anterior teeth with composite resins: a case report. *Pract Periodontics Aesthet Dent* 1996;8(1):17-31.
- Farah JW, ed. Anterior and posterior composites. *Dent Advisor* 1991;8(4).
- Faunce FR, Myers DR. Laminate veneer restoration of permanent incisors. *J Am Dent Assoc* 1976;93:790-2.
- Feigenbaum N. Class IV technique overcomes snags in frailty, esthetics. *Dentist* 1990;68:1,38-9.
- Fell WP. One-visit composite and amalgam bonding for strong, aesthetic posterior restorations. *J Am Dent Assoc* 1996;127:1656-8.
- Ferracone JL. Relationship between shade and depth of cure for light-activated dental composite resins. *Dental*
- Ferrari M. The micromorphologic relationship between

- resin and dentin in class V restorations: an in vivo and in vitro investigation. *Quintessence Int* 1994;25:621-5.
- Ferrari M, Davidson CL. Sealing capacity of a resin-modified glass-ionomer and resin composite placed in vivo in class 5 restorations. *Oper Dent* 1996;21(2):69-72.
- Filler SJ, Lazarchik DA, Givan DA, et al. Shear bond strengths of composite to chlorhexidine-treated enamel. *Am J Dent* 1994;7:85-8.
- Fitchie JG, Reeves GW, Scarbrough AR, Hembree JH. Microleakage of two new dentinal bonding systems. *Quintessence Int* 1990;21:749-52.
- Foreman FT. Sealant prevalence and indication in a young military population. *J Am Dent Assoc* 1994;125:182-6.
- Friedl KH, Schmalz G. Placement and replacement of composite restorations in Germany. *Oper Dent* 1995;20:34-8.
- Fritz UB, Finger WJ, Uno S. Resin-modified glass ionomer cements: bonding to enamel and dentin. *Dent Mater* 1996;12:161-6.
- Fusayama A, Kohno A. Marginal closure of composite restorations with the gingival wall in cementum/ dentin. *J Prosthet Dent* 1989;61:293-6.
- Fusayama T. Gingival irritation of restoration margins. *Quintessence Int* 1987;18:215-22.
- Fusayama T. Optimal cavity wall treatment for adhesive restorations. *J Esthet Dent* 1990;2:95-9.
- Garber DA, Goldstein RE. Porcelain and composite inlays and onlays: esthetic posterior restorations. Chicago: Quintessence, 1994.
- Garcia-Godoy F, Draheim RN, Titus HW. Shear bond strength of a posterior composite resin to glass ionomer bases. *Quintessence Int* 1988;19:357-9.
- Gilpatrick RO, Johnson W, Moore D, et al. Pulpal response to dentin etched with 10% phosphoric acid. *Am J Dent* 1996;9(3):125-9.
- Godder B, Zhukovsky L, Trushkowsky R, Epelboym D. Microleakage reduction using glass-ceramic inserts. *Am J Dent* 1994;7:74-6.
- Goldstein RE. Communicating esthetics. *N Y State Dent J* 1985;15:477-9.
- Goldstein RE. Esthetics in dentistry. Philadelphia: J.B. Lippincott, 1976.
- Goldstein RE. Finishing of composites and laminates. *Dent Clin North Am* 1989;33:305-18.
- Greggs TS. Method for cosmetic restoration of anterior teeth. United States Patent Number: 4,473,353. Filled April 15, 1983. Date of Patent: Sept. 25, 1984.
- Hallett KB, Garcia-Godoy F, Trotter AR. Shear bond strength of a resin composite to enamel etched with maleic or phosphoric acid. *Aust Dent J* 1994;39:292-7.
- Handelman SL, Washburn F, Wopperer P. Two-year report of sealant effect on bacteria in dental caries. *J Am Dent Assoc* 1976;93:967-70.
- Hardin JF. Clark's clinical dentistry, 1997 update. St. Louis: Mosby, 1996.
- Herschfeld J. The progress of esthetic restorations in dentistry. *J Phila Cty Dent Soc* 1991;56(6):10-13.
- Heymann, In: Garber DA, Goldstein RE, Feinman RA, eds. Porcelain laminate veneers. Chicago: Quintessence, 1988.
- Hicks MJ. The acid-etch technique in caries prevention: pit and fissure sealants and preventive resin restorations. In: Pinkham JR, ed. Pediatric dentistry: infancy through adolescence. 2nd edn. Philadelphia: W.B. Saunders, 1994:451-82.
- Hilton TJ, Schwartz RS. The effect of air thinning on dentin adhesive bond strength. *Oper Dent* 1995;20:133-7.
- Hinoura K, Onose H, Moore BK, Phillips RW. Effect of the bonding agent on the bond strength between glass ionomer cement and composite resin. *Quintessence Int* 1989;20:31-5.
- Horn HR. Porcelain laminate veneers bonded to etched enamel. *Dent Clin North Am* 1983;27:671-84.
- Hornbrook DS. Optimizing form and function with the direct posterior composite resin: a case report. *Pract Periodontics Aesthet Dent* 1996;8:405-11.
- Hosoya Y. Resin adhesion to the primary enamel: influence of light—irradiation times. *J Clin Pediatr Dent* 1995;19:185-90.
- Hume WR, Gerzia TM. Bioavailability of components of resin-based materials which are applied to teeth. *Crit Rev Oral Biol Med* 1996;7:172-9.
- Ibsen RL, Strassler HE. An innovative method for fixed anterior tooth replacement utilizing porcelain veneers. *Quintessence Int* 1986;17:455.

- Ironside JG, Makinson OF. Resin restorations: causes of porosities. *Quintessence Int* 1993;24:867-73.
- Ishioka S, Caputo AA. Interaction between the dentinal smear layer and composite bond strength. *J Prosthet Dent* 1989;61:180-5.
- Jaarda MJ, Wang RF, Lang BR. A regression analysis of filler particle content to predict composite wear. *J Prosthet Dent* 1997;77(1):57-67.
- Jensen OE, Handelman SL. Effect on autopolymerizing sealant on viability of microflora in occlusal dental caries. *Scand J Dent Res* 1980;88:382-8.
- Jeronimus DJ, Till MJ, Sveen OB. Reduced viability of microorganisms under dental sealants. *J Dent Child* 1975;42:275-80.
- Jordan RE. *Esthetic composite bonding: techniques and materials*. 2nd edn. St Louis: Mosby, 1993.
- Joynt RB, Davis EL, Wiczkowski G, Williams DA. Fracture resistance of posterior teeth restored with glass ionomer-composite resin systems. *J Prosthet Dent* 1989;62:28-31.
- Kanca J. Maximizing the cure of posterior light-activated resins. *Quintessence Int* 1986;17:25-7.
- Kanca J. The effect of thickness and shade on the polymerization of light-activated posterior composite resins. *Quintessence Int* 1986;17:809-11.
- Kanca J. Visible light-activated composite resins for posterior use: a comparison of surface hardness and uniformity of cure. *Quintessence Int* 1985;10:687-90.
- Kanka J III. Microleakage of five dentin bonding systems. *Dent Mater* 1989;5:63-4.
- Kanka J III. Resin bonding to wet substrate. I. Bonding to dentin. *Quintessence Int* 1992;23:39-42.
- Kaplan BA, Goldstein GR, Vijayaraghavan TV, et al. The effect of three polishing systems on the surface roughness of four hybrid composites: a profilometric and scanning electron microscopy study. *J Prosthet Dent* 1996;76:34-8.
- Khokhar ZA, Razzog ME, Yaman R. Color stability of restorative resins. *Quintessence Int* 1991;22:733-7.
- Kidd EA, Beighton D. Prediction of secondary caries around tooth-colored restorations: a clinical and microbiological study. *J Dent Res* 1996;75:1942-6.
- Kildal KK, Ruyter IE. How different curing methods affect the degree of conversion of resin-based inlay/onlay materials. *Acta Odontol Scand* 1994;52:315-22.
- Kilpatrick NM, Murray JJ, McCabe JF. A clinical comparison of a light cured glass ionomer sealant restoration with a composite sealant restoration. *J Dent* 1996;24:399-405.
- Knight GT, Berry TG, Barghi N, Burns TR. Effects of two methods of moisture control on marginal microleakage between resin composite and etched enamel: a clinical study. *Int J Prosthodont* 1993;6:475-9.
- Krejci I, Besek M, Lutz F. Clinical and SEM study of tetric resin composite in posterior teeth: 12-month results. *Am J Dent* 1994;7:27-30.
- Krishnan VK, Bindhu DB, Manjusha K. Studies on microleakage associated with visible light cured dental composites. *J Biomater Appl* 1996;10:348-59.
- Kugel G. Classification and application of cementation alternatives. *Signature* 1997;4(3):8-11.
- Lacy AM. An effective technique for extended proximal contacts in composite resin restorations. *Pract Periodontics Aesthet Dent* 1996;8:287-93.
- Lacy AM. Application of composite resin for single-appointment anterior and posterior diastema closure. *Pract Periodont* 1998;10:279-86.
- Larson TD, Phair CB. The use of a direct bonded microfilled composite resin veneer. *J Am Dent Assoc* 1987;115:449-52.
- Latta GH Jr. The light-cured composite restoration: an adjunct to removable partial prosthodontics. *Compend Contin Educ Dent* 1996;17(2):164.
- Laurell K, Carpenter W, Beck M. Pulpal effects of air-brasion cavity preparation in dogs. *J Dent Res* 1993;72(Special Issue):273, Abstract 1360.
- Leinfelder KF. Evaluation of criteria used for assessing the clinical performance of composite resins in posterior teeth. *Quintessence Int* 1987;18:531-6.
- Leinfelder KF. Posterior composite resins: the materials and their clinical performance. *J Am Dent Assoc* 1995;126:663-76.
- Leinfelder KF. Wear patterns and rates of posterior composite resins. *Int Dent J* 1987;37:152-7.

- Leinfelder KF, Wilder AD, Teixeira LC. Wear rates of posterior composite resins. *J Am Dent Assoc* 1986;112:829–33.
- Liebenberg WH. Occlusal index-assisted restitution of esthetic and functional anatomy in direct tooth-colored restorations. *Quintessence Int* 1996;27(2):81–8.
- Liebenberg WH. Successive cusp build-up: an improved placement technique for posterior direct resin restorations. *J Can Dent Assoc* 1996;62:5501–7.
- Liberman R, Gorfil C, Ben-Amar A. Reduction of microleakage in class II composite resin restorations using retentive pins. *J Oral Rehabil* 1996;23:240–3.
- Li SH, Kingman A, Forthofer R, Swango P. Comparison of tooth surface-specific dental caries attack patterns in U.S. school children from two national surveys. *J Dent Res* 1993;72:1398–405.
- Los SA, Barkmeier WW. Effects of dentin air abrasion with aluminum oxide and hydroxyapatite on adhesive bond strength. *Oper Dent* 1994;19(5):169–75.
- Lussi A. Comparison of different methods for the diagnosis of fissure caries without cavitation. *Caries Res* 1993;27:409–16.
- Lutz F, Krejci I, Luescher B, Oldenburg TR. Improved proximal margin adaptation of Class II composite resin restorations by use of light-reflecting wedges. *Quintessence Int* 1986;17:659–64.
- Lutz FU, Krejci I, Oddera M. Advanced adhesive restorations: the post-amalgam age. *Pract Periodontics Aesthet Dent* 1996;8:385–94.
- Magne P, Dietschi D, Holz J. Esthetic restorations for posterior teeth: practical and clinical considerations. *Int J Periodontics Restorative Dent* 1996;16:104–19.
- Magne P, Holz J. Stratification of composite restorations: systematic and durable replication of natural aesthetics. *Pract Periodontics Aesthet Dent* 1996;8(1):61–8.
- Mathewson RJ, Primosch RE. *Fundamentals of pediatric dentistry*. 3rd edn. Chicago: Quintessence, 1995.
- Matsumura H, Leinfelder KF, Kawai K. Three-body wear of light-activated composite veneering materials. *J Prosthet Dent* 1995;73:233–9.
- McComb D. Adhesive luting cements—classes, criteria, and usage. *Compend Contin Educ Dent* 1996;17:759–62.
- McGuire MK, Miller L. Maintaining esthetic restorations in the periodontal practice. *Int J Periodontics Restorative Dent* 1996;16:230–9.
- McLaughlin G. Porcelain fused to tooth—a new esthetic and reconstructive modality. *Compend Contin Dent Educ* 1985;5:430–5.
- Mednick GA, Loesche WJ, Corpron RE. A bacterial evaluation of an occlusal sealant as a barrier system in humans. *J Dent Child* 1974;41:356–60.
- Meiers JC, Shook LW. Effect of disinfectants on the bond strength of composite to dentin. *Am J Dent* 1996;9:11–4.
- Meskin LH, et al. *The 1996 year book of dentistry*. St. Louis: Mosby, 1996.
- Meskin LH, et al. *The 1997 year book of dentistry*. St. Louis: Mosby, 1997.
- Meyerowitz JM, Rosen M, Cohen J, Becker PJ. *J Dent Assoc S Afr* 1994;49:389–92.
- Millar BJ, Robinson PB, Inglis AT. Clinical evaluation of an anterior hybrid composite resin over 8 years. *Br Dent J* 1997;182(1):26–30.
- Miller LM. Maintaining hybrid and microfill composites. *J Esthet Dent* 1990;2:109–13.
- Miller MB, Castellanos IR, Vargas MA, Denehy GE. Effect of restorative materials on microleakage of class II composites. *J Esthet Dent* 1996;8:107–13.
- Miserendino LJ, Pick RM. *Lasers in dentistry*. Chicago: Quintessence, 1995.
- Mitchem JC. The use and abuse of aesthetic materials in posterior teeth. *Int Dent J* 1988;38(2):119–25.
- Mjor IA. Repair versus replacement of failed restorations. *Int Dent J* 1990;43:466–72.
- Mjor IA. The reasons for replacement and the age of failed restorations in general dental practice. *Acta Odontol Scand* 1997;55(1):58–63.
- Mjor IA, Jokstad A, Qvist V. Longevity of posterior restorations. *Int Dent J* 1990;40:11–7.
- Mjor IA, Quist V. Margin failures of amalgam and composite restorations. *J Dent* 1997;25(1):25–30.
- Morrison AH, Berman L. Evaluation of the Airdent unit: preliminary report. *J Am Dent Assoc* 1953;46:298–303.

- Myers GE. The air-abrasive technique: a report. *Br Dent J* 1954;97(11):291–5.
- Nash R. A predictable restorative Class V erosion technique. *Pract Periodontics Aesthet Dent* 1991;3(2):39–42.
- Nash RW. Cosmetic correction of crowded anterior teeth. *Dent Today* 1991;10(6):48–9.
- Nash RW. Tooth-colored bonded posterior restorations: aesthetic alternatives to amalgam and gold. *Dent Today* 1991;10(2):34–5.
- Nathanson D. Current developments in esthetic dentistry. *Curr Opin Dent* 1991;1:206–11.
- Neo J, Chew CL. Direct tooth-colored materials for noncarious lesions: a 3-year clinical report. *Quintessence Int* 1996;27(3):183–8.
- Neo J, Chew CL, Yap A, et al. Clinical evaluation of tooth-colored materials in cervical lesions. *Am J Dent* 1996;9(1):15–8.
- Nery S, McCabe JF, Wassell RW. A comparative study of three dental adhesives. *J Dent* 1995;23:55–61.
- Newbrun E. Tooth morphology and arch form. In: Newbrun E, ed., *Cariology*. 3rd edn. Chicago: Quintessence, 1989:52.
- Nixon RL. *The chairside manual for porcelain bonding*. Wilmington, DE: B.A. Videographics, 1987.
- O'Brien WJ. *Dental materials and their selection*. 2nd edn. Chicago: Quintessence, 1997.
- Opdam NJ, Roeters JJ, Peters TC, et al. Cavity wall adaptation and voids in adhesive class I resin composite restorations. *Dent Mater* 1996;12:230–5.
- Pagliarini A, Rubini R, Rea M, et al. Effectiveness of the current enamel-dentinal adhesives: a new methodology for its evaluation. *Quintessence Int* 1996;27:265–70.
- Pashley DH. In vitro simulations of in vivo bonding conditions. *Am J Dent* 1991;4:237–40.
- Pashley DH, Depew DD. Effects of the smear layer, copalite, and oxalate on microleakage. *Oper Dent* 1986;11:95–102.
- Pashley EL, Tao L, Mackert JR, Pashley DH. Comparison of in vivo vs. in vitro bonding of composite resin to the dentin of canine teeth. *J Dent Res* 1988;67:467–70.
- Penning C, van Amerongen JP, Seef RE, ten Cate RJ. Validity of probing for fissure caries diagnosis. *Caries Res* 1992;26:445–9.
- Peyton FA, Henry EE. The effect of high-speed burs, diamond instruments and air abrasive in cutting tooth tissue. *J Am Dent Assoc* 1954;49:426–35.
- Pincus CR. Building mouth personality. *J Calif Stud Dent Assoc* 1938;14:125–9.
- Pitts NB, Lond FDS. Current methods and criteria for caries diagnosis in Europe. *J Dent Educ* 1993;57:409–13.
- Powell GC, Kelsey WP, Blankeneau RJ, Barkmeier WW. The use of an argon laser for polymerization of composite resin. *J Esthet Dent* 1989;1:34–7.
- Prati C, Montanari G. Comparative microleakage study between the sandwich and conventional three-increment techniques. *Quintessence Int* 1989;20:587–94.
- Puppala R, Hegde A, Munshi AK. Laser and light cured composite resin restorations: in-vitro comparison of isotope and dye penetrations. *J Clin Pediatr Dent* 1996;20:213–8.
- Purk JH, Eick JD, DeSchepper EJ, Chappell RP, Tira DE. Fracture strength of Class I versus Class II restored premolars tested at the marginal ridge. I. Standard preparations. *Quintessence Int* 1990;21:545–51.
- Reel DC, Mitchell RJ. Fracture resistance of teeth restored with Class II composite restorations. *J Prosthet Dent* 1989;61:177–9.
- Reinhardt J, Capilouto ML, Padgett CD. Composite resin esthetic dentistry survey. *J Dent Res* 1989;68.
- Ripa LW. Occlusal sealants. In: Nitiforuk G, ed. *Understanding dental caries*. Vol. 2: Prevention, basic and clinical aspects. New York: Karger, Basel, 1985:145–73.
- Roeder RA, Berry EA III, You C, Powers JM. Bond strength of composite to air abraded enamel and dentin (Abstract no. 237). *J Dent Res* 1994;73 (Special Issue): 131.
- Roulet JF. Benefits and disadvantages of tooth-colored alternatives of amalgam. *J Dent* 1997;25:459–73.
- Roulet JF. The problems associated with substituting composite resins for amalgam: a status report on posterior composites. *J Dent* 1988;16(3):101–3.
- Rozmajzl WF Jr, Los SA, Albrechtsen LA, et al. Composite to dentin bond strength using a curing unit with nitrogen. *Am J Dent* 1994;7:319–21.
- Rueggeberg FA, Caughman WF, Curtis JW Jr. Effect of light intensity and exposure duration on cure of resin composite. *Oper Dent* 1994;19:26–32.

- Saunders WP, Saunders EM. Microleakage of bonding agents with wet and dry bonding techniques. *Am J Dent* 1996;9(1):34-6.
- Schulein TM, Chan DCN, Reinhardt JW. Rinsing times for a gel etchant related to enamel/composite bond strength. *Gen Dent* 1986;34:296-8.
- Schwartz R, Summitt J, Robbins W, dos Santos J. *Fundamentals of operative dentistry: a contemporary approach*. Chicago: Quintessence, 1996.
- Sheth PJ, Jensen ME, Sheth JJ. Comparative evaluation of three resin inlay techniques: microleakage studies. *Quintessence Int* 1989;20:831-6.
- Shinkai K, Suzuki S, Leinfelder KF, et al. How heat treatment and thermal cycling affect wear of composite resin inlays. *J Am Dent Assoc* 1994;125:1467-72.
- Shintani H, Satou N, Satou J. Clinical evaluation of two posterior composite resins retained with bonding agents. *J Prosthet Dent* 1989;62:627-32.
- Shortall AC. Long-term monitoring of microleakage of composites. Part II: scanning electron microscopic examination of replica patterns of composite tags. *J Prosthet Dent* 1988;60:451-8.
- Shortall AC, Wilson HJ. New materials, bonding treatments and changes in restorative practice. *Br Dent J* 1988;164:396-400.
- Simonsen RJ. Conservation of tooth structure in restorative dentistry. *Quintessence Int* 1985;16:15-24.
- Simonsen RJ. Editorial: Dentin: to etch, or not to etch. *Quintessence Int* 1990;21:75.
- Simonsen RJ. Pit and fissure sealant: theoretical and clinical considerations. In: Frahm RL, Morris ME, eds. *Textbook of pediatric dentistry*. 2nd edn. Baltimore: Williams & Wilkins, 1985:217-34.
- Simonsen RJ. Preventive resin restorations: three-year results. *J Am Dent Assoc* 1980;100:535-9.
- Simonsen RJ. New materials on the horizon. *J Am Dent Assoc* 1991;122(8):25-31.
- Simonsen RJ. The acid etch technique and preventive resin restorations. In: Stallard RE, ed. *A textbook of preventive dentistry*. 2nd edn. Philadelphia: Saunders, 1982:322-8.
- Simonsen RJ, Calamia JR. Tensile bond strength of etched porcelain. *J Dent Res Abstracts* no. 1154. 1983.
- Simonsen RJ, Kanca J. Surface hardness of posterior composite resins using supplemental polymerization after simulated occlusal adjustment. *Quintessence Int* 1986;17:631-3.
- Sjodin L, Uusitalo M, van Dijken J. Resin modified glass ionomer cements. In vitro microleakage in direct class V and class II sandwich restorations. *Swed Dent J* 1996;20(3):77-86.
- Stamm JW, Disney JA, Beck JD, et al. The University of North Carolina caries risk assessment study: final results and some alternative modeling approaches. In: Bowen WH, Tabak LA, eds. *Cariology for the nineties*. Rochester: University of Rochester Press, 1993:209-34.
- Staninec M, Mochizuki A, Tanizaki K, et al. Interfacial space, marginal leakage, and enamel cracks around composite resins. *Oper Dent* 1986;111:14-24.
- Strassler HE, Buchness GF. The Class III acid-etch light polymerized composite resin restoration. *J Esthet Dent* 1990;2:13-6.
- Sturdevant CM, Roberson TM, Heymann HO, Sturdevant JR. *The art and science of operative dentistry*. 3rd edn. St. Louis: Mosby, 1994.
- Sutherland L, Jensen ME, Hawkins BF, Lainson PR. Root caries inhibition using dentin bonding resin and fluoridated varnishes. *J Dent Res* 1989;69.
- Suzuki S, Leinfelder KF. An in vitro evaluation of a copolymerizable type of microfilled composite resin. *Quintessence Int* 1994;25:59-64.
- Suzuki S, Leinfelder KF. Localized wear and marginal integrity of posterior resin composites. *Am J Dent* 1993; 6:199-203.
- Suzuki S, Leinfelder KF. Localized wear and marginal integrity of posterior resin composites. *Am J Dent* 1993; 6:199-203.
- Swift EJ Jr, Perdigao J, Heyman HO. Bonding to enamel: a brief history and state of the art, 1995. *Quintessence Int* 1995;26:95-110.
- Swift EJ Jr, Triolo PT Jr, Barkmeier WW, et al. Effect of low-viscosity resins on the performance of dental adhesives. *Am J Dent* 1996;9:100-4.
- Taira Y, Matsumura H, Yoshida K, et al. Adhesive bonding to dentin with ferrous chloride primers and tri-n-butylborane-initiated luting agents. *J Dent Res* 1996; 75:1859-64.

- Tjan AHL, Bergh BH, Lidner C. Effect of various incremental techniques on the marginal adaptation of Class II composite resin restorations. *J Prosthet Dent* 1987;67:62–6.
- Tjan AHL, Glancy JF. Interfacial bond strengths between layers of visible light-activated composites. *J Prosthet Dent* 1988;59:27–9.
- Triolo PT Jr, Swift EJ Jr, Barkmeier WW. Shear bond strengths of composite to dentin using six dental adhesive systems. *Oper Dent* 1995;20:46–50.
- Triolo PT Jr, Swift EJ, Mudgil A, Levine A. Effects of etching time on enamel bond strengths. *Am J Dent* 1993;6:302–4.
- Tyas MJ. Clinical evaluation of five adhesive systems: three-year results. *Int Dent J* 1996;46(1):10–4.
- Tyas MJ. Clinical performance of two dentine adhesives: 2-year results. *Aust Dent J* 1996;41:324–7.
- Tyas MJ, Beech DR. Clinical performance of three restorative materials for non-undercut cervical abrasion lesions. *Aust Dent J* 1985;30:260–4.
- Unterbrink GL, Muessner R. Influence of light intensity on two restorative systems. *J Dent* 1995;23:183–9.
- Van der Laan-Van Dorp CSE, Exterkate RAM, ten Cate JM. Effect of probing on progression of fissure caries (Abstract no. 9). *Caries Res* 1986;20(2):151.
- Van der Veem HJ, Pilon HJ, Henry PD. Clinical performance of one micro-filled two hybrid anterior composite resins. *Quintessence Int* 1989;20:547–50.
- van Dokken JWV. A 6-year evaluation of a direct composite resin inlay/onlay system and glass ionomer cement-composite resin sandwich restorations. *Acta Odontol Scand* 1994;52:368–376.
- Vargas MA, Denehy GE, Silberman JJ. Bond strength to etched enamel and dentin contaminated with saliva. *Am J Dent* 1994;7:325–7.
- Vanini L, De Simone F, Tammaro S. Indirect composite restorations in the anterior region: a predictable technique for complex cases. *Pract Periodont Aesthet Dent* 1997;9:795–802.
- Vanini L. Light and color in anterior composite restorations. *Pract Periodont Aesthet Dent* 1996;8:673–82.
- Van Noort R. An introduction to dental materials. St. Louis: Mosby, 1995.
- Venhoven BA, de Gee AJ, Werner A, et al. Influence of filler parameters on the mechanical coherence of dental restorative resin composites. *Biomaterials* 1996;17:735–40.
- Versluis A, Douglas WH, Cross M, et al. Does an incremental filling technique reduce polymerization shrinkage stresses? *J Dent Res* 1996;75:871–8.
- Wassell RW, McCabe JF, Walls AWG. Wear rates of regular and tempered composites. *J Dent* 1997;25(1):49–52.
- Weiner RS. The effect of post-cure heat treatment systems on composite resin restorations. *J Am Dent Assoc* 1997;128(1):88.
- Wendt SL Jr, Ziemiecki TL, Leinfelder KF. Proximal wear rates by tooth position of resin composite restorations. *J Dent* 1996;24(1–2):33–9.
- Winkler MM, Lautenschlager EP, Boghosian A, et al. An accurate and simple method for the measurement of dental composite wear. *J Oral Rehabil* 1996;23:486–93.
- Winkler MM, Lautenschlager EP, Boghosian A, et al. Visual versus mechanical wear measurement of dental composite resin. *J Oral Rehabil* 1996;23:494–500.
- Worm DA Jr, Meiers JC. Effect of various types of contamination on microleakage between beta-quartz inserts and resin composite. *Quintessence Int* 1996;27:271–7.
- Yaffe A, Hochman N, Ehrlich J. Severe vertical overlap: a modified method of treatment. *J Prosthet Dent* 1989;62:636–41.
- Yanagawa T, Chigira H, Manabe A, et al. Adaptation of a resin composite in vivo. *J Dent* 1996;24(1–2):71–5.
- Yap AU, Pearson GJ, Billington RW, et al. An in vitro microleakage study of three restorative techniques for class II restorations in posterior teeth. *Biomaterials* 1996;17:2031–5.
- Yoshiyama M, Carvalho RM, Sano H, et al. Regional bond strengths of resins to human root dentine. *J Dent* 1996;24:435–42.

ETCHED PORCELAIN RESTORATIONS: VENEERS AND INLAYS/ONLAYS

In the early part of the 20th century, movie actors frequently had dingy but otherwise healthy anterior teeth reduced for full crowns. Then, in the 1930s, California dentist Charles Pincus developed thin facings of air-fired porcelain that could be fastened in place with adhesive denture powder⁵⁰ (see Chapter 7). While these smiles live on in the film archives and in late-night movies, the veneers themselves were peeled away when the camera was turned off. Nonetheless, with this technique, Pincus had laid the groundwork for a new kind of dentistry, one that considered esthetics not just articulation and function.

Veneering remained merely another form of cosmetics until the techniques and materials evolved to produce strong veneers that could be mechanically bonded to teeth. In 1955, Buonocore's research into the acid-etch technique provided a simple method of increasing the adhesion to enamel surfaces for acrylic filling materials.⁹ His discovery was quickly followed by Bowen's work with filled resins.^{6,7} Only in the 1970s, however, with the introduction of visible light-cured composites, did the dentist have the necessary working time to properly shape direct composite laminate veneers.^{8,40} Even so, these veneers were difficult to do: they were highly technique-sensitive, required extensive clinical chair time, and were frequently subject to in situ polymerization problems.

In the 1970s, Faunce described a one-piece acrylic resin prefabricated veneer as an improved alternative to direct composite resin bonding.^{18,19} The veneer was attached both chemically, with a chemical primer applied to the veneer, and mechanically, with a composite resin to lute the veneer onto the etched tooth. These early indirect veneers and their successors had certain advantages

over the direct veneers. Because they were fabricated by a manufacturer or trained technician, the indirect veneers typically displayed greater anatomical accuracy and almost always required less chair-time for the patient and the dentist. More completely cured through laboratory processing, they were less likely to shrink during polymerization, and they provided superior shading capabilities and control of facial contours.²⁸ The indirect veneers had the additional advantage of being more stain resistant than direct veneers.

Both acrylic resin and microfill resin veneers offer a smooth surface and good masking ability, with very little need for finishing. However, both exhibit poor resistance to abrasion and a tendency to delaminate at the laminate/composite interface, usually due to a weak chemical bond,¹² and the limited bond strength of the indirect acrylic and composite resin veneers restricted their use to anterior teeth or those cases not involving heavy functional contacts.²⁸

It was inevitable that the pioneers in veneers would turn to porcelain, one of the most popular and attractive materials in the dental armamentarium. The concept of acid-etching porcelain and bonding to a tooth with an acid etch technique was first cited in the dental literature in 1975 with Rochette's description of an innovative restoration of a fractured incisor.⁴⁸ Since then, there have been key advances in the development of porcelain veneers and their fabrication and placement.^{4,5,12,13,19,23,24,26,32,40,55}

As the demand for esthetic dental services continues to grow, the development of stronger, more attractive indirect veneers means that there is a wide variety of options to offer your patients for both anterior and posterior restorations. Further-

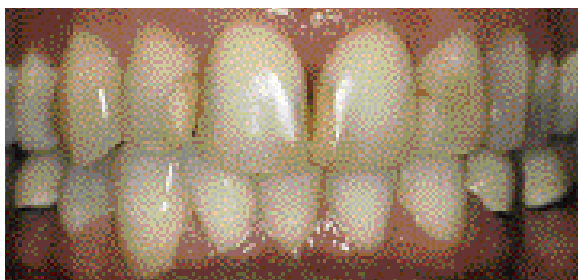

Figure 14-1A: Discolored teeth with large defective old restorations are a prime indication for porcelain laminate veneers.

more, these techniques may need to be combined with bleaching, cosmetic contouring, bonding, crowning, orthodontics, or fixed prosthodontics. As with all esthetic restorations, the patient's face should be the guideline, especially the smile. Bonded anterior restorations are particularly appropriate for patients with a high lipline since the restoration covers the gingival third of the tooth. For patients with a medium lipline, open gingiva embrasures may appear as dark spaces. The restorations should be built with extra interproximal fullness in a darker shade of material from the lingual aspect.⁵⁵ Lower liplines present fewer problems with visible margins, but may indicate a need for lengthening of the teeth in order to show teeth when smiling or speaking. This chapter describes in detail the advantages and disadvantages, the indications and contraindications, and the techniques for using porcelain veneers for anterior teeth and porcelain inlays and onlays for posterior teeth.

PORCELAIN VENEERS

Porcelain is generally considered the most esthetic and biocompatible material available for dental restorations.⁵

Advantages of Porcelain Veneers

1. Natural and stable color. The smooth surface texture and natural color of porcelain are exceptional, and the crystalline structure of porcelain gives it optical refractive properties similar to those of translucent enamel.⁵⁶ Furthermore, porcelain can be internally stained and the ability to adjust the final color of the veneers during placement allows considerable flexibility in final shade adjustments. Texture also is easily developed on the veneer surface

to simulate that of adjacent teeth, and this texture can be maintained indefinitely,^{12,14} as opposed to veneers of cast-glass ceramics.⁵⁹

2. Highly acceptable tensile bond strength. The bond of etched porcelain veneers to enamel is considerably stronger than that of any other material or veneering system. The resin to silane-treated etched porcelain veneer has bond strengths ranging from 2600 to 3200 pounds per square inch (psi) as compared to composite resin veneer to enamel bond strengths of only 900 to 1400 psi.¹³
3. Inherent porcelain strength that permits reshaping teeth.⁴⁷ Although porcelain veneers are themselves rather fragile, once bonded to enamel, the restoration develops high tensile and shear strengths.^{11,12} Porcelain therefore can be used to increase the length of a given tooth by extending it over the incisal edge. In certain instances, porcelain veneers can also be used to repair ceramometal restorations.¹
4. Extremely good biocompatibility with gingival tissues (Figures 14-1A and B). The highly-glazed porcelain surface is less of a depository area for plaque accumulation as compared to any other veneer system, and it appears that some types of porcelain veneers actually deter plaque accumulation.²⁰
5. Long lasting. Once bonded, porcelain veneers develop high tensile and shear strengths and remain in place. For example, a 2-year study

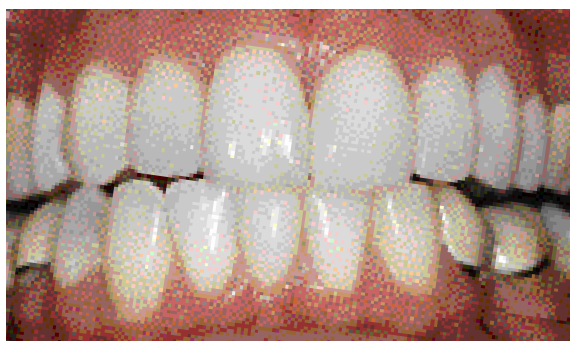

Figure 14-1B: Porcelain laminate veneers offer extremely good biocompatibility with gingival tissues since the highly glazed surfaces deter plaque accumulation. This patient's porcelain laminate veneers were color matched to her lower anterior teeth.

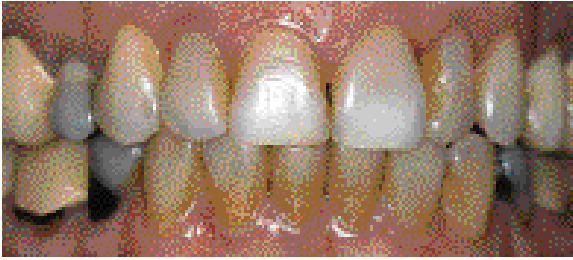

Figure 14-2A: This lady wanted to improve her smile with lighter teeth.

comparing 44 porcelain and 44 resin veneers found that one in five of the resin veneers failed by 2 years compared to none of the porcelain veneers.⁵³

6. Exceptional resistance to wear and abrasion.^{21,55} Porcelain veneers still look good after many years (Figures 14-2A to C).
7. Resistance to stain. The microscopic structure reveals few voids and irregularities that accumulate stain. Also, the highly glazed porcelain surface is very resistant to stain accumulation.
8. More resistant to deleterious effects of solvents, including alcohol, medications, and cosmetics than any composite resin veneer.⁵⁵
9. Much less absorption of fluids than any other veneering materials.^{1,21} Water absorption of resin veneers leads to a decrease in physical properties and increasing wear and surface changes over time.

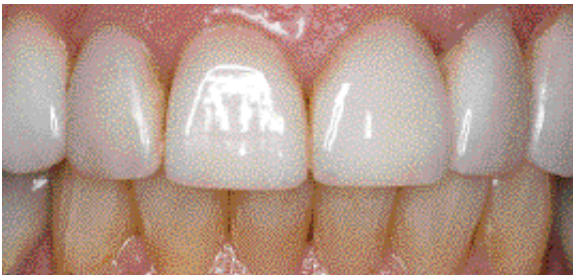

Figure 14-2B: Six anterior porcelain laminates and six posterior ceramic crowns provided the desired result.

10. Surface luster retention. Composite resin tends to lose the initial luster, requiring frequent repolishing. Porcelain retains its glazed luster over the entire life of the restoration.
11. Lack of radiopacity. On radiographs porcelain resembles natural tooth structure, allowing radiographic access to areas that would be shielded by radiopaque restorations.

Disadvantages of Porcelain Veneers

1. Porcelain veneers can be easily repaired once bonded to the enamel, but the repairs are not long lasting due to staining which tends to occur at the margin of composite resin and porcelain.
2. The color cannot be easily modified once bonded in position.
3. Irreversibility of preparation versus little or no preparation for composite resin bonding.
4. Level of difficulty of fabrication and placement, time involved, and expense. The extremely fragile veneers are difficult for the dental laboratory to make and manipulate, and the process requires two appointments, and laboratory fees.
5. Technical difficulties in avoiding overcontours and obtaining closely-fitted porcelain-enamel margins. The margins can be especially brittle and difficult to finish.¹
6. Lower reparability compared to composite veneers. Garber²¹ points out that this disadvantage diminishes with the new materials, because

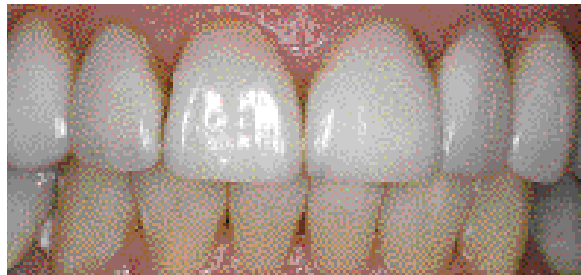

Figure 14-2C: Ten years after placement, the porcelain laminate veneers still look good despite the presence of some tissue recession.

etched porcelain veneers can now be repaired using a dilute buffered solution of hydrofluoric acid for 8 to 15 minutes to etch the porcelain. The veneers are then silanated and coated with a layer of unfilled resin, followed by a color-matched composite repair. But the disadvantage still remains in time and complexity, and unknown durability of the repair.

7. Susceptibility to pitting by certain topical fluoride treatments. Stannous fluoride should not be used with porcelain restorations.

Indications for Porcelain Veneers

The covering power of porcelain veneers and their ability to reshape teeth make this procedure almost ideal for many clinical situations including:

1. Extreme discolorations, such as tetracycline staining, fluorosis, devitalized teeth, and teeth darkened by age which are not conducive to vital bleaching.¹⁷ Porcelain veneers are especially useful for single discolored teeth.
2. Teeth with generalized facial discoloration from amalgam shine-through.⁴⁸
3. Surface defects. Small cracks in the enamel caused by aging, trauma, or ice-chewing can weaken the enamel and stain darkly. In these situations, porcelain laminate veneers will mask the stains and seal and strengthen the teeth. Teeth with numerous shallow, unesthetic restorations on the labial surfaces also can be dramatically improved.
4. Replacement of missing or fractured parts of the teeth.⁵² Nixon⁴⁸ reports the use of veneers on porcelain crowns to repair porcelain fractures.
5. Closing of diastemas, single or multiple spaces between the teeth, and improving the appearance of rotated or malpositioned teeth. Persons who have relatively sound teeth but who do not want to undergo orthodontics may be helped with laminates that create the esthetic illusion of straight teeth.
6. Short teeth.⁴⁸ These teeth can be lengthened to a more esthetic, appropriate size.
7. Malocclusions or periodontally compromised teeth. Porcelain laminates can restore or change the configuration of the lingual surfaces of anterior teeth to develop increased guidance or centric holding areas. Porcelain laminates can also be used to reshape interproximal embrasure spaces when the gingival tissues have receded.
8. Agenesia of the lateral incisor. When the cuspid erupts adjacent to the central incisor in situations in which there is a missing lateral incisor, porcelain veneers can be used to develop a different coronal form of the cuspid, simulating a lateral incisor. This treatment may have to be combined with veneers on the central incisors to obtain a more ideal ratio in the relative proportion of the teeth, because the cuspid is invariably too wide.
9. Progressive wear patterns. If sufficient enamel remains and the desired increase in length is not excessive, porcelain veneers can be bonded to the remaining tooth structure to restore the shape, color, or function of the teeth. Assuming the parafunctional behavior itself is under control, porcelain veneers even can be used to repair dentitions damaged by the effects of anorexia nervosa or bulimia.³
10. Functionally-sound ceramometal or all-ceramic crowns with unsatisfactory color.⁴⁸ The labial surface of the old porcelain is prepared as you would for a conventional laminate. After an impression, a veneer is constructed in the new shade. The existing crown surface is roughened with air abrasion, then etched with a buffered intraoral use hydrofluoric acid and silanated. The laminate is then bonded to place with a resin cement. However, the cost of this procedure is basically the same as making a new crown, so its use should be limited to those patients not wanting their entire crown or bridge remade.

Contraindications for Porcelain Veneers

In comparison to other forms of bonding, porcelain laminate veneers have fewer and more forgiving contraindications. Nonetheless, such contraindications do exist.

1. Patients with certain tooth-to-tooth habits such as bruxism or parafunctional habits such as pencil chewing or ice crushing may place undue stress on the porcelain veneers (Figures 14-3A to I).

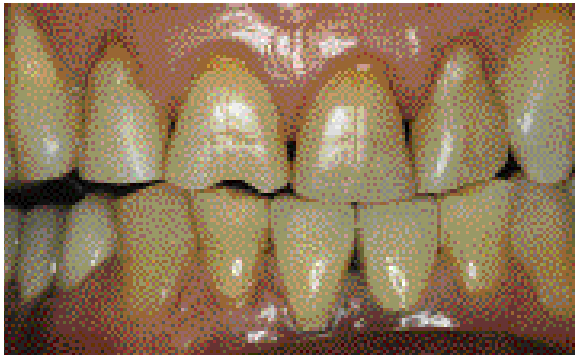

Figure 14-3A: This 66-year-old male had a bruxism habit and was advised by his dentist not to have porcelain laminates.

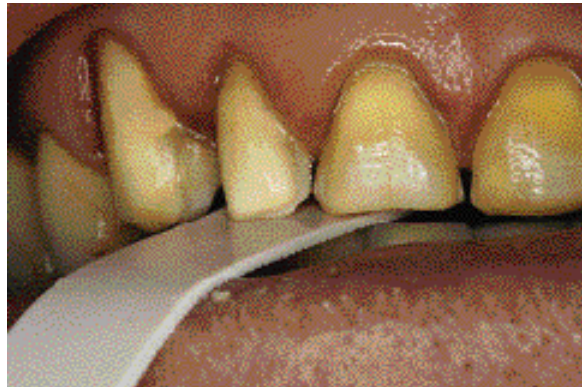

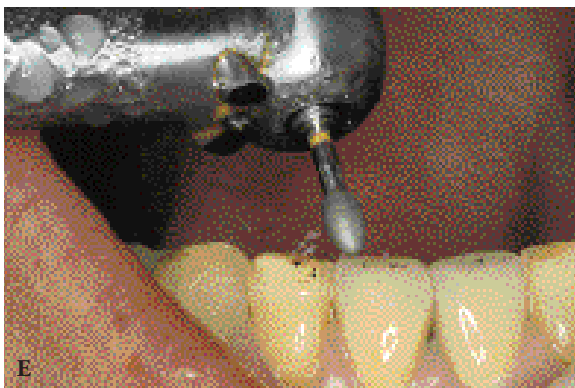
Figure 14-3B: It was determined that proper incisal clearance could be obtained if the preparations were finished to the lingual surface in wraparound fashion as shown in Figure 14-3C. Note the thickness gauge (Bell de St. Claire, Orange, CA) is used to make certain of a uniform reduction of the incisal edge.

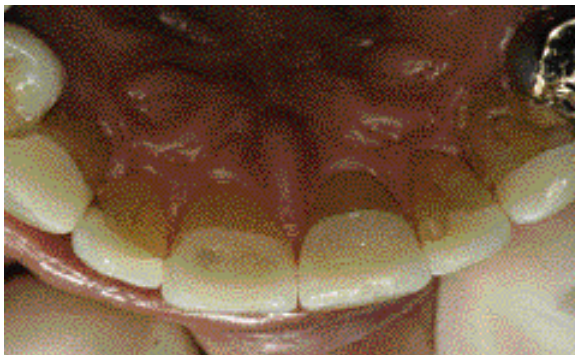

Figure 14-3C: Final laminate try-in shows lingual wrap-around to offer maximum protection from clenching and grinding of the teeth.

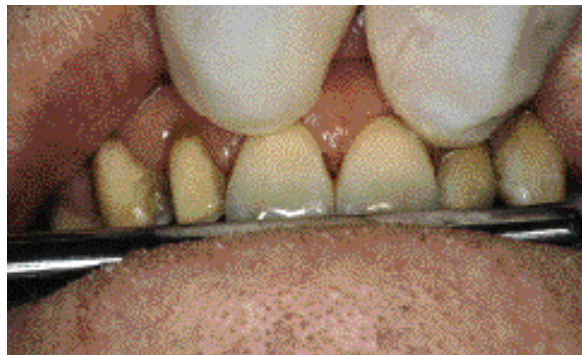
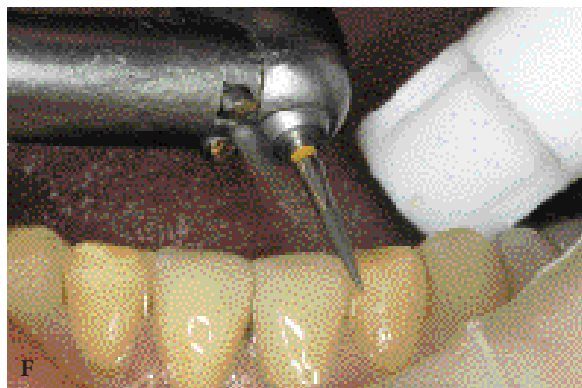
Figure 14-3D: An occlusal adjustment with articulating paper is done after the central incisor laminates are bonded to place.



Figures 14-3E and F: The occlusion is adjusted using the OS1F and ET6F 15-micron diamonds (Brasseler, Savannah, GA) with water spray.



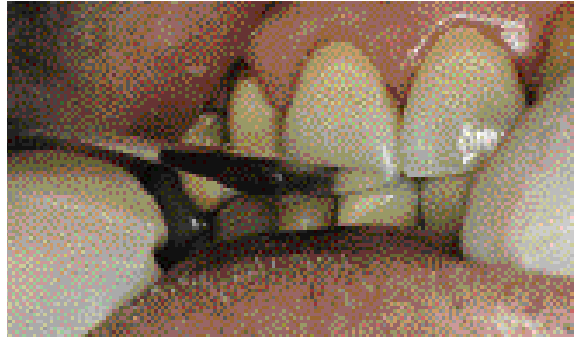

Figure 14-3G: The final check is done with ultra thin (5/1000 inch) articulating film (Artus/DenMat).

2. Enamel should be around the whole periphery of the laminate, not only for adhesion, but more importantly to seal the veneer to the tooth surface. In addition, there should be sufficient enamel available for bonding, since bonds to dentin are generally less retentive and predictable than bonds to enamel. (If the tooth or teeth are composed predominantly of dentin and cementum, crowning may well be the preferable treatment until a stronger and more predictable dentin bonding agent is developed.)
3. Certain types of occlusion may be problems. These include Class III and end-to-end bites. However, there may still be the possibility of cosmetic treatment by contouring the lower incisors and building out the maxillary incisors. An alternative can be a protective bite appliance that the patient to wear after treatment is completed to protect the veneers

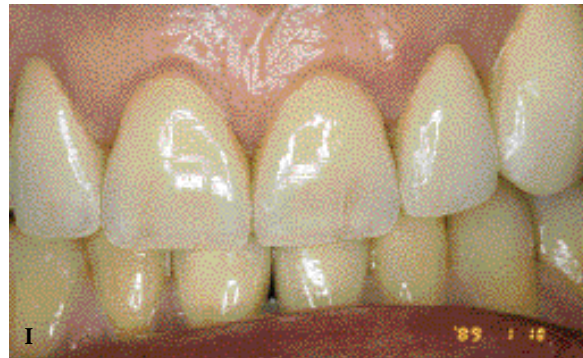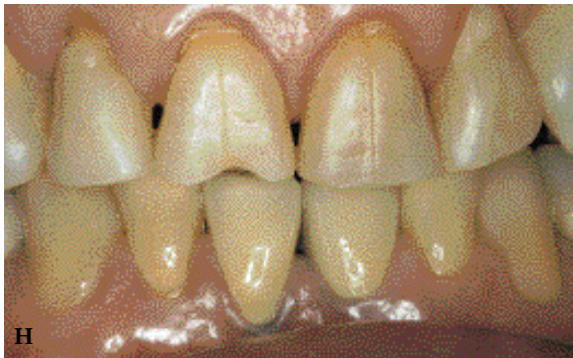from clenching or grinding forces. This appliance would be worn at night or when sleeping, driving, playing sports, etc., as necessary.

4. Deciduous teeth and teeth that have been excessively fluoridated may not etch effectively. In order for porcelain veneers to be successful in these cases, special measures such as aggressive roughening of the enamel surface with an extra-coarse diamond (F6C, Premier Dental Products, King of Prussia, PA) may be required.¹ The newer generation bonding agents can also be an aid.

Technique

Shade Selection

Shade determination begins at the consultation and examination appointment. This is when you need to understand exactly what your patient wants. How light does the patient envision his or her teeth? If your patient is looking for “white”



Figures 14-3H and I: Pretreatment and post-treatment comparison of the teeth shows that the veneers look natural, but lighter, than the original teeth.

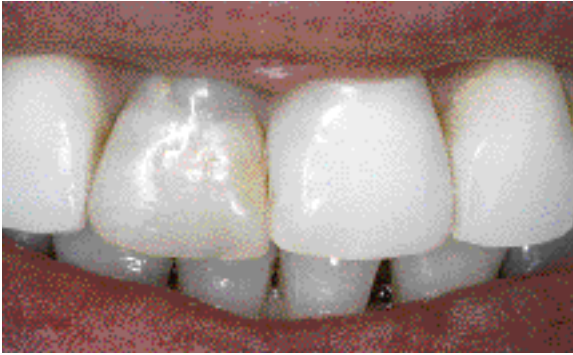

Figure 14-4A: Matching the discolored right central incisor to the left central presents one of the most difficult challenges in dentistry.

teeth, does that mean opaque white or translucent white? You must determine how much leeway you have in arriving at what seems to you the appropriate and agreeable color. The easiest way of accomplishing this is to image your patient on a computer so that you and the patient can see how the different colors will look. However, if your patient is a perfectionist, the best method is to have your ceramist construct several trial laminates made from an impression of your patient's teeth. Thus, several samples of different shade choices can be offered.

If all teeth that show are going to be veneered, then you can proceed with shade selection as you would with any other ceramic restoration. If, however, some teeth are to be covered with porcelain laminate veneers and others are to be bonded or restored, the porcelain veneers should be placed first because of the difficulty in modifying the veneers




Figure 14-4B: This laminate veneer system (Komet/Brasseler) includes four burs to prepare the tooth and four to finish the laminate.

once they are bonded to place. The adjacent teeth can then be easily matched to the final, bonded porcelain veneer color. If your procedure involves matching one discolored tooth (especially a central incisor) to another, provide your ceramist with extra room with additional depth of tooth preparation to add sufficient opacity to the laminate to mask the darkness before exact matching of the required tooth shade.

One of the most important steps in the entire procedure is deciding when, where, and how to record color or shade. This should be done before beginning treatment, at a session when the teeth have not been dried out for any period of time. It should be done inside the operatory using color corrected light (Durotest "power plus" or Phillips color corrected), outside in daylight, and inside using incandescent light. And finally, reconsider the shade after the enamel has been prepared. If the prepared tooth has turned much darker than previously anticipated, you may wish to use either a lighter shade, a shade with more opaquer, or even reprepare the tooth to gain more porcelain thickness and thereby additional



Figure 14-4C: The discolored incisor is painted green to help guide the depth cuts.

room for both color and opaquer. If this is the situation, you should have a consultation with your ceramist if possible. In the event your technician is not available, a photographic consultation may suffice, where you record exactly what the color problems are for your ceramist. However, you may wish to delay taking your final impression pending a joint decision on which approaches to take.

The available shade guides such as the Vita porcelain shade guide, are not ideal for veneers because they are too thick and are composed of several different layers including opaques. It is better for your ceramist to make an individualized shade guide of porcelain veneers exactly as he or she would fabricate them and use this to select a shade.

Tooth Preparation for Veneers

To Reduce or Not. There are different opinions with regard to how much or how little the teeth need to be prepared, that is, reduced, before the application of porcelain veneers. Some clinicians argue that little or no reduction is required. Teeth that will require building out labially for better appearance are a good example of this. Clinicians at

the opposite end of the spectrum argue for a full deep chamfer preparation on the labial aspect of the teeth that extends most or all of the way through the interproximal contact areas.

The most practical approach is to evaluate each patient, and indeed each tooth to be veneered, on the basis of (a) the thickness of the veneer needed for covering or reshaping, (b) the degree of anticipated retention of the veneer, considering the receptivity of the tooth to the bonding agent and placement of the veneer, and (c) recognition of how the increased thickness of the veneered tooth will change its appearance, structure, alignment, and function.

A good example of a patient who requires average reduction is seen in Figure 14–4.

Obviously, the ideal would be a technique that requires no preparation and a veneer that is strong, attractive, and functional, with no subsequent adverse periodontal changes. However, that ideal is seldom the case. Most patients need to have about 50% of the labial and some proximal enamel removed in order not to overbuild the teeth being veneered.

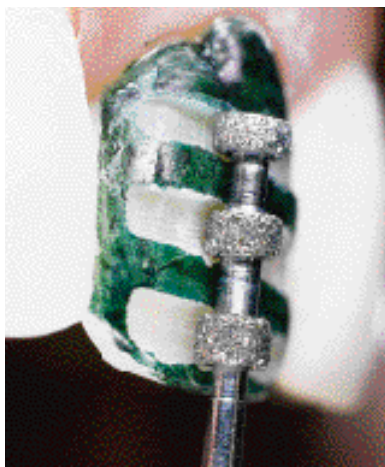

Figure 14–4D: The special three-tier extra-coarse diamond depth cutter (Brasseler, Savannah, GA) comes in 0.5-mm (LVS-1) and 0.3-mm (LVS-2) thicknesses and is so efficient that usually one sweep across the labial surface completes the depth cut. Since the veneer will be approximately 0.6 mm in thickness (up to 0.8 mm in darkly stained teeth), the 0.5-mm bur will generally be the depth cutter of choice unless over-building is desired.

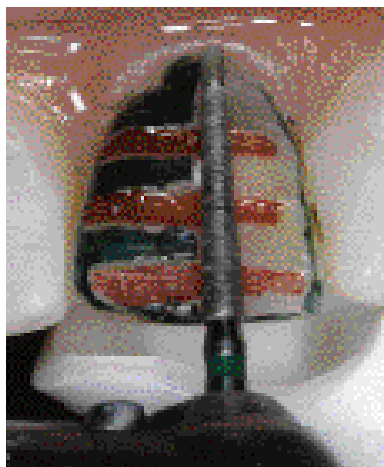


Figure 14–4E: After completing the depth cut (marked in red for illustrative purposes only), the remainder of the preparation is completed with the two-grit diamond. The body of the diamond contains extra-coarse grit, which leaves a rough finish on the preparation to maximize veneer retention.

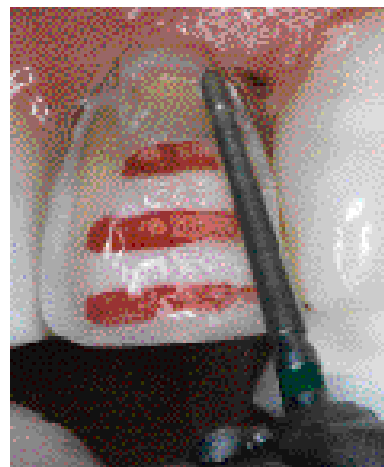

Figure 14–4F: The tip of the two-grit diamond LVS-3 or -4, Brasseler, has a fine grit for marginal finishing. Note how close the preparation was finished to the base of the depth cut as shown by the remaining illustrative red markings.

When to Consider Reduction. Without reduction, the teeth will be larger and more labially positioned. (In lingually-inclined teeth, this may be an advantage.) McLean⁴¹ believes failure to remove proximal enamel can result in the finish line placed too far labially and encroachment on the embrasure areas, resulting in exposure of unsightly porcelain margins that may be difficult to finish. Overcontouring may also produce gingival problems due to an increase in microbial plaque accumulation.

Reduction, however, will:

1. remove convexities and provide a path for insertion in those situations where either the incisal or the interproximal areas are to be included in the veneer.
2. provide space for adequate opaquing or heavier coloring. Darkly stained teeth often require more reduction for opaquing purposes. This will allow for a thicker, more opaque veneer.²¹ For veneers on tetracycline-stained teeth, for example, the underlying tooth color will modify its shade dramatically. This is because, in most cases, the veneer is only 0.5 mm thick and rather translucent. As a result, the actual shade of the porcelain has only a nominal

influence on the final color of the bonded veneer. By reducing the tooth, you usually will be able to neutralize the underlying color and create the illusion of a normal tooth color by having the opaque incorporated into the veneer itself (see Figures 14–11A to D).²² Also, by making room for the application of opaquing layers under the veneer, additional opaquing can be obtained at the cementation appointment by using resin opaquers.

3. provide a definite seat to help position the laminate during placement.
4. prepare a receptive enamel surface for etching and bonding the laminate.
5. allow for a smoother transition from the laminate to the tooth surface, enabling the patient to more easily keep it plaque-free.

Contraindications to reduction include consideration of:

1. the size of the pulp. If young individuals or others with large pulps require laminating, consider another alternative to enamel reduction, especially if you have any indication you might create irreversible sensitivity by reduc-

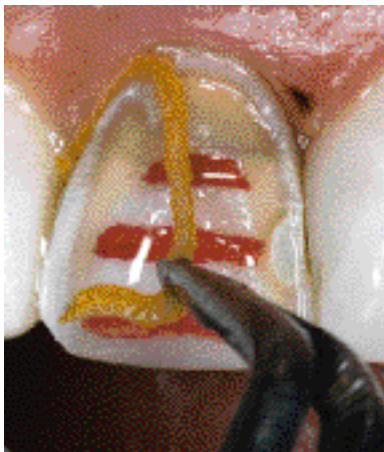

Figure 14–4G: Gingival displacement cord is carefully removed after remaining in the sulcus for approximately 10 minutes.

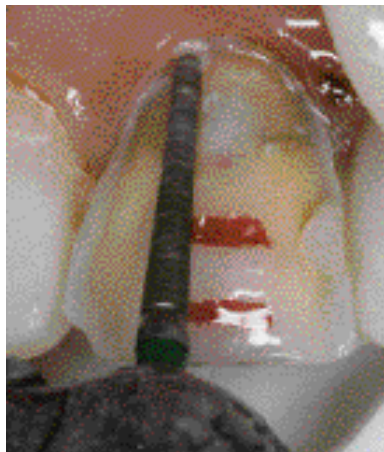


Figure 14–4H: With the tissue displaced, the gingival margin can now be placed just into the gingival sulcus.

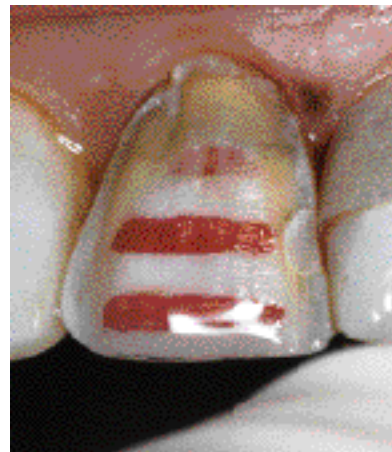

Figure 14–4I: When using the foil technique for laminate construction (see Die versus Foil, page 357), slight separation between the teeth is obtained by using a Compo-Strip (Premier Dental Products) or Reprox diamond strip (Premier Dental Products). The proximal surfaces can then be finished with a sandpaper strip (3M, Moyco, Cosmedent).



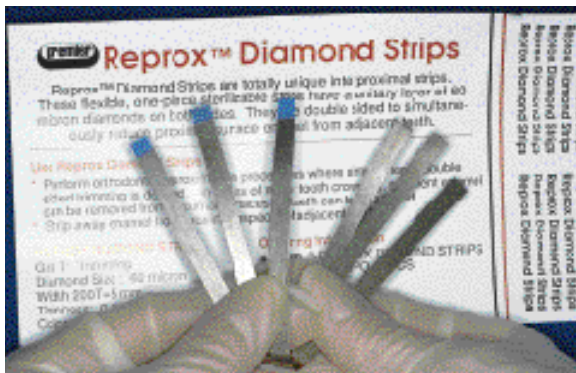

Figure 14-4J: Reprox diamond strips (Premier Dental Products) are rapid cutting because they contain diamond grit on both sides. They are good for modifying interproximal areas.

ing the thickness of the enamel. One alternative is building out each of the teeth slightly to avoid preparation. However, this usually requires including at least 8 to 10 teeth for a natural result.

2. the patient's psychological state and feelings about tooth reduction or veneers. If your patient is apprehensive and unsure, then it is wise to do no reduction. Then if your patient becomes dissatisfied with the veneer or the slightly overbuilt look, you have the option of removing the porcelain veneer and repolishing the enamel, thus returning the patient to a semblance of their preveneer state.

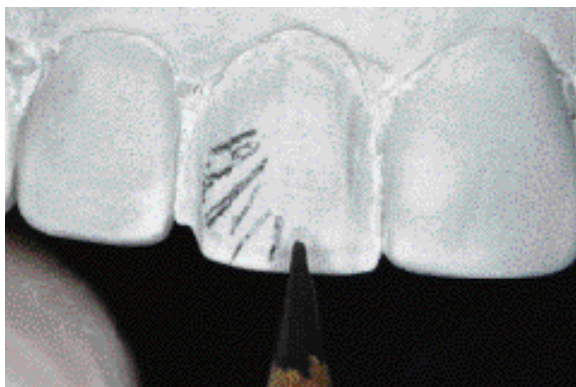


Figure 14-4K: An initial impression is made of the completed preparations and poured in quick set plaster or stone to carefully analyze each tooth. Here the distolabial aspect appears to need slightly more reduction.

TIP: Make sure you take precaution to record the exact amount of overbuilding you intend to do. This should include a set of pre- and post-treatment study casts and photographs. The photographs should include incisal views as well so you can clearly show just how much you have built out labially.

If Reducing, How Much? As a general principle, the enamel should be reduced just as much as necessary to facilitate the placement of an esthetic restoration. Ideally, one would like to remove the same amount of enamel that will eventually be replaced by the laminate and bonding composite resin.

Decisions about reduction need to take into account the relative position of the tooth in the arch. For example, in treating a crowded or rotated tooth or a tooth in labioversion, you may find it advantageous to first bring the offending tooth into alignment with the rest of the arch by reducing its labial contour through cosmetic contouring.

To facilitate placement of interproximal extensions, the margin of the porcelain laminate should be hidden within the embrasure area and, depending upon the individual form of the tooth, extended about halfway into the interproximal contact area. Proper extension will provide additional stability and retention, due to the wraparound effect and, adhering to the general principle of “removal matching replacement” you may want to provide extra reduction in this embrasure area to enable

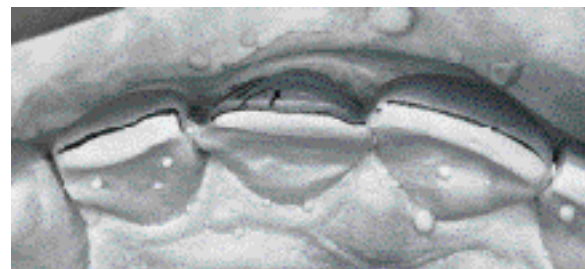


Figure 14-4L: The incisal view is especially helpful in analyzing whether or not more tooth reduction is necessary. Tilting the study cast from buccal to incisal and mesial to distal allows you to verify that you have not left any sharp line angles.

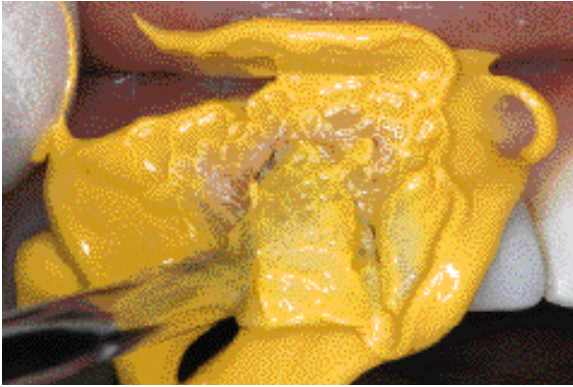


Figure 14-4M: Vinyl polysiloxane (Reposil, Caulk/Dentsply, York, PA) is an excellent material for a final impression. Here, the syringe material has been placed and an air stream gently spreads the material so that you are assured that the entire preparation has been covered and that no air pockets or bubbles exist.

you to thicken porcelain there, strengthening the laminate around the whole periphery.

Another factor to consider in placement of the interproximal margins is the size of the interdental space. If there is an unsightly gap you want to close, the exact placement of the interproximal margin will vary depending upon the size of the space you are trying to close. The larger the space, the further mesiolingually or distolingually you will need to extend your margin. Otherwise, the resultant contact areas will be bulky and a potential food trap.

Decisions about reduction need to take into account the need for a good seal. If at all possible,

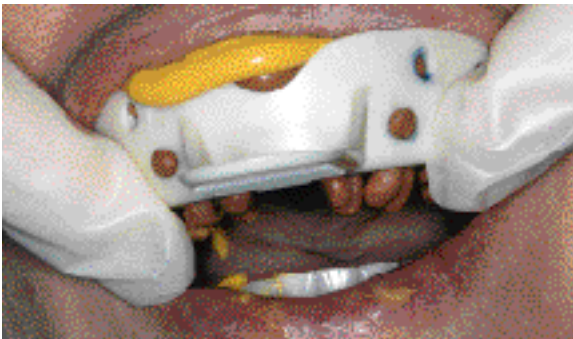


Figure 14-4N: After applying another layer of syringe material, a tray filled with the vinyl polysiloxane putty is pressed into place.

porcelain veneers should be bonded only to enamel,⁴¹ so the margins of the preparation should have enough enamel left to ensure an adequate seal. Ideally, the gingival finish line should be at the gingival margin and apical. Unfortunately, esthetics require any tooth discoloration to be masked, may frequently making it necessary to locate the margins subgingivally, terminating on either dentin or cementum. It is important to remember that while it is sometimes necessary to terminate the veneer on dentin, dentin-bonding has at least two disadvantages: it provides less bond strength than enamel bonding, and it is a less effective seal. There are situations where in small areas some amount of dentin will be exposed by the preparation of the tooth to facilitate cosmetic alignment; this is not necessarily a problem if the area is small and all margins remain on enamel.

Reduction considerations should also include the color of the teeth to be veneered (Figure 14-5). Darkly stained teeth often require more reduction for opaquing purposes. Reid⁵¹ proposed neutralization and use of opaquers at cementation. However, it is the easiest and best solution for the ceramist to build opacity into the laminate itself, thereby eliminating the need to experiment on the tooth for maximum opacity. With tetracycline stains, for example, the finish line must be placed subgingivally to hide the dark discoloration that tends to show through marginal tissue. Tetracycline stains are usually darkest in the cervical region where there is thinner enamel covering the stained dentin, making sufficient enamel reduction more difficult. The tooth also appears darker as the enamel is

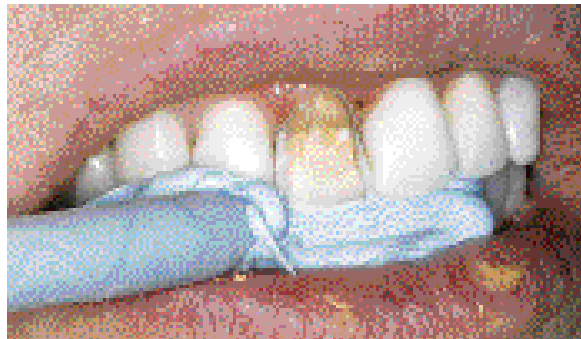

Figure 14-4O: Occlusal registration is also made with vinyl polysiloxane paste (Regisil PB, Caulk/Dentsply, York, PA).

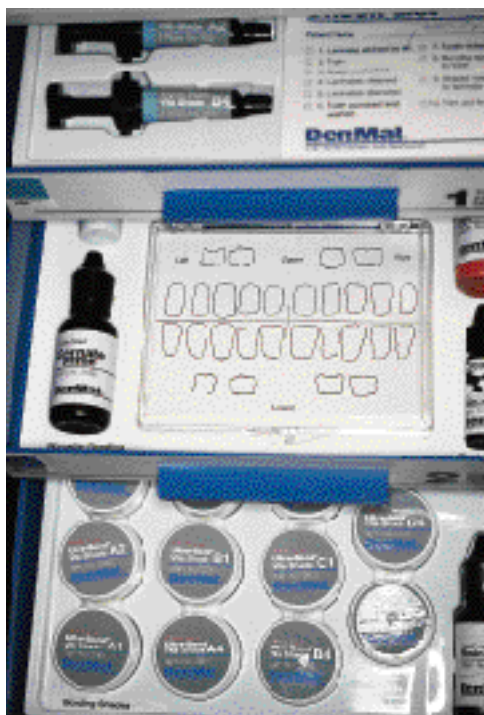

Figure 14-4P: While there are many fine porcelain bonding kits available, this is an example of an all-inclusive kit (DenMat, Santa Maria, CA).

unless the patient has a low lipline and understands and accepts the fact there will be a visible color change between the new laminate and the existing root color. If this is the situation, make sure your patient signs an informed consent documenting acceptance of your intended treatment.

The last, but important, consideration is the ceramist's needs in terms of fabricating an accurately-fitting laminate. It is difficult to work with a porcelain thickness much less than 0.4 mm or to create a laminate that will adjust to a feather edge. This means that the ceramist should be allowed to work with veneers no thinner than 0.4 to 0.6 mm, or about half the thickness of the available enamel.

Enamel Reduction—Technique. The LVS porcelain laminate preparation kit (Brasseler, Savannah, GA) provides a rapid method of measured reduction. First you must decide on the required amount of reduction, using the considerations given previously. In most instances the needed reduction will be 0.5 mm, obtained by using the LVS-1. Small teeth such as the mandibular incisors where the thickness of enamel is considerably less may only require 0.3-mm reduction, and you would use LVS-2. The appropriate LVS diamond depth cutter is selected and gently drawn across the labial surface of the tooth from mesial to distal. This will develop the depth cuts as horizontal grooves, leaving a raised strip of enamel in between (Figure 14-4D). The depth of the cut is limited by the instrument itself.

removed because the underlying stained dentin is more exposed. Actually any tooth in which the cervical area is darker than the intended color of the laminate will need a subgingival margin placement,



Figure 14-4Q: The three drawers contain (top to bottom) try-in pastes and a reminder checklist for assistants; all the necessary bonding solutions for treating both the laminate and the prepared tooth, including special separating strips and a light-rotected box with numbered spaces for each laminate; and composite resin cement with tints and opaques.

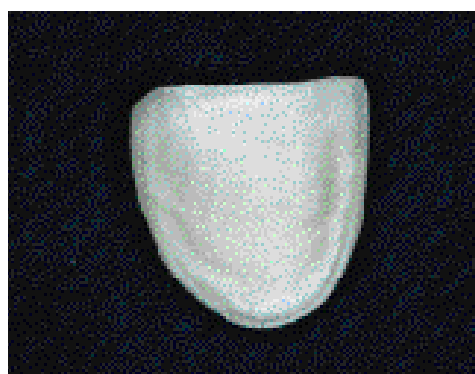

Figure 14-4R: The interior view of the laminate shows the presence of an opaque layer to help mask the dark tooth.

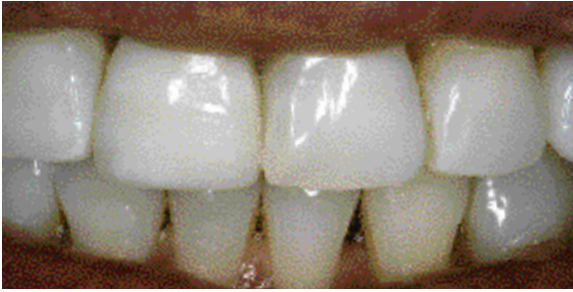

Figure 14-4S: The previously selected cement shade used as try-in paste shows the color is slightly too light. A darker tint or opaquer added to the bonding cement is used to adjust the color appropriately.

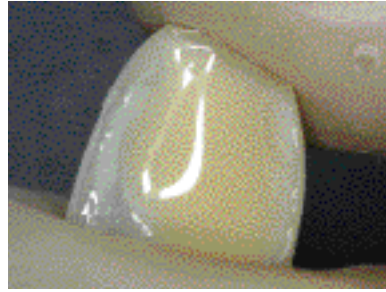


Figure 14-4T: After etching and silanating the interior surface of the porcelain laminate, the tinted cement is added.

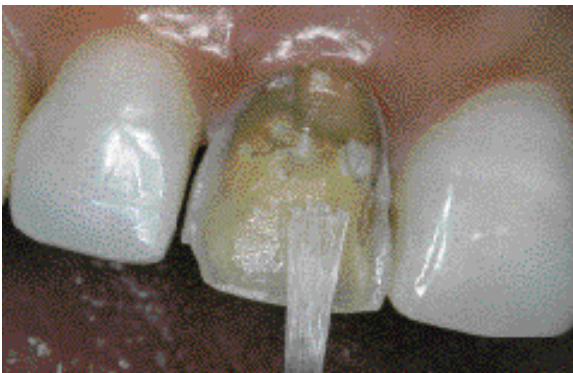

Figure 14-4U: The prepared tooth is cleansed with coarse pumice and etched before the bonding agent is applied.

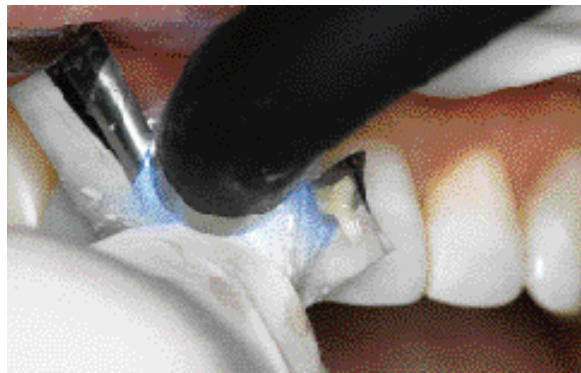

Figure 14-4V: The filled laminate is gently pressed to place, and held there with a gloved finger while polymerizing with the light for 5 to 8 seconds.

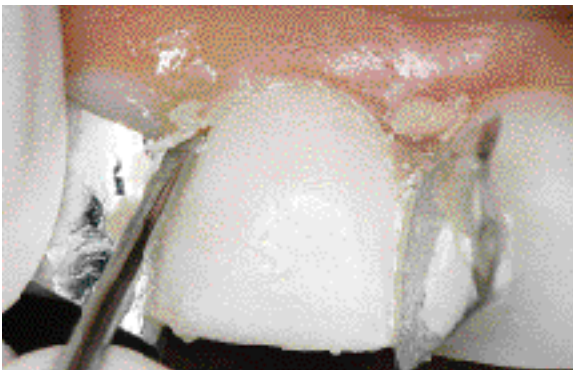


Figure 14-4W: The initial excess cement is easily removed with the chisel end of the Novatech 12 (Hu-Friedy, Chicago, IL) instrument.

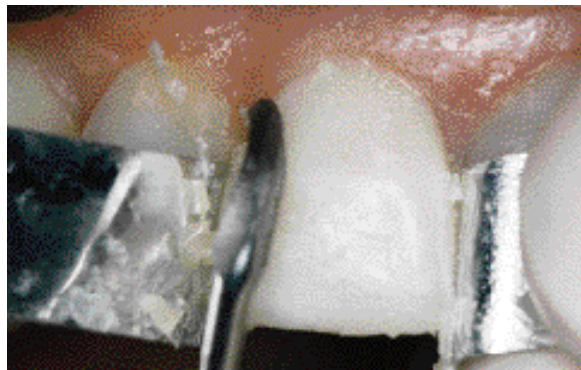

Figure 14-4X: Interproximal excess is removed with the sickle end of the Novatech 12 and the laminate is then completely cured for 60 seconds labially and 60 seconds lingually, or 10 seconds with an argon laser or xenon light. Note the ultrathin separation strips.

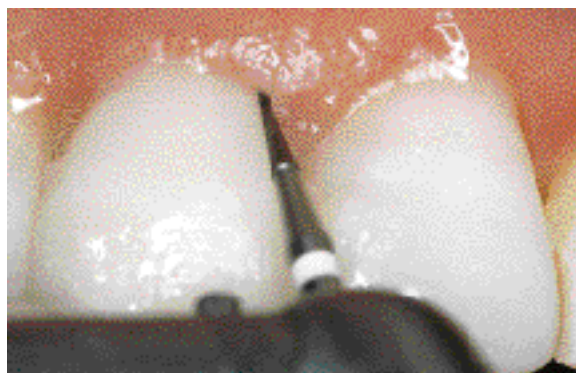


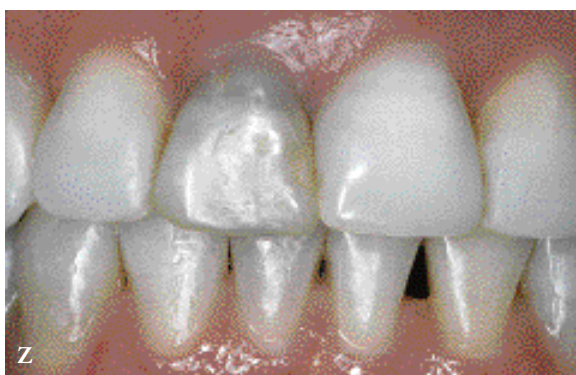Figure 14-4Y: All remaining composite resin cement excess is then removed with the LVS-5 30-blade carbide bur. If contouring is required it can easily be accomplished with the LVS-6, -7, or -8 burs.

The remaining enamel is then reduced to the depth of these initial cuts, using a coarse diamond (LVS-3 or -4). The resulting rough enamel surface facilitates retention and refraction of the light reflected back out through the laminate. At the marginal areas, however, it is desirable to use a finer grit diamond which will create a definitive polished finish line to enhance the seal at the periphery. Thus, the special two-grit LVS-3 or -4 is an ideal instrument to accomplish these tasks (Figures 14-4E and F).

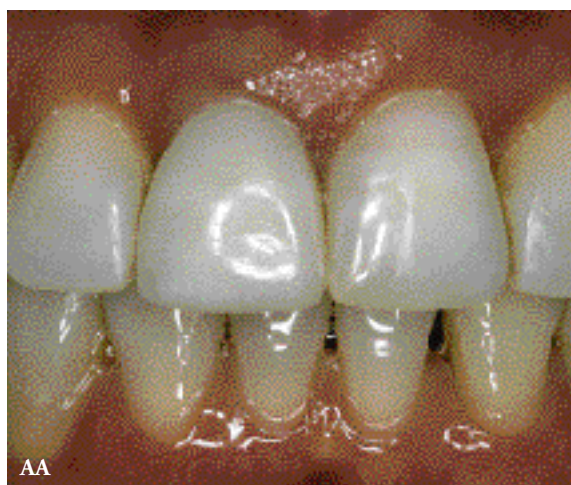The basic preparation should be complete with only the finishing of the final margins remaining. If you plan on placing your gingival margin subgingivally, it is best to begin by displacing the tissue for

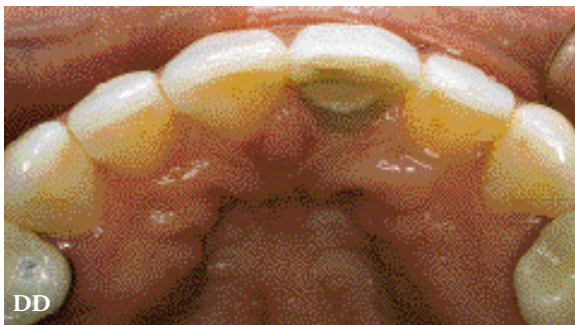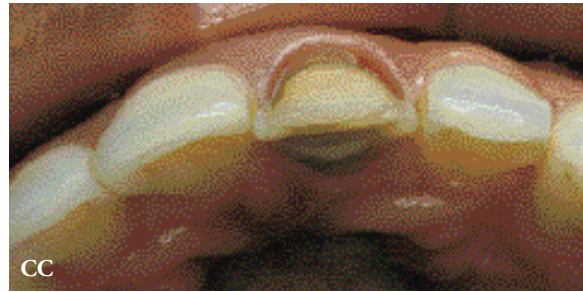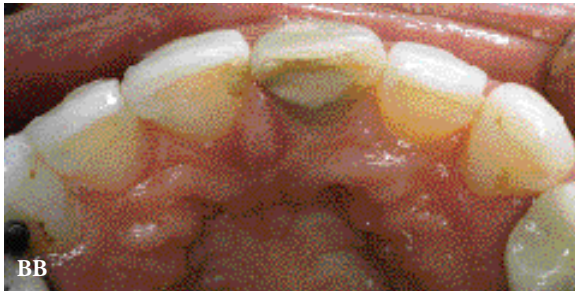10 to 15 minutes with cotton cord saturated with a hemostatic agent. Once this step is completed it will be much easier for you to complete your final margin using the LVS-3 (Figure 14-4H). If the teeth are extremely dark, consider using a deep chamfer or modified shoulder. This will give the technician extra depth, and thus extra veneer thickness, to mask the grayness that can show through the gingiva, especially if the gingival tissue is thin and transparent.

Lower Laminates—Special Considerations. From an esthetic standpoint, the lower laminate can provide an excellent result in most situations (Figure 14-5). However, its life expectancy can be



Figures 14-4Z and AA: Before and after comparison reveal a closely matched result. Note the healthy tissue response despite the subgingival margin.





Figures 14-4BB, CC, and DD: The incisal view comparison shows the amount of reduction necessary to arrive at a correctly-colored porcelain laminate. It is also important to reduce adequately in the interproximal embrasures in order to adequately mask the dark shadows in these areas.

drastically compromised unless the patient's occlusion is favorable. The usual problem with preparations for lower veneers is leaving enough tooth structure remaining after the horizontal and vertical reduction. A potentially weak point is at the incisolabial junction, which must always be sufficiently reduced and rounded to allow the veneer to be thick enough in that area to have the strength to resist fracturing when placed under an occlusal

load (Figure 14-5E). This possibility of fracturing or cracking means greater maintenance for lower laminates in patients with heavy occlusal demands, which includes patients with habits such as severe bruxism or clenching. If this is the situation and if discoloration is the reason for wanting to do lower porcelain laminates, you may wish to try bleaching first to see if the teeth will become light enough to satisfy the patient.

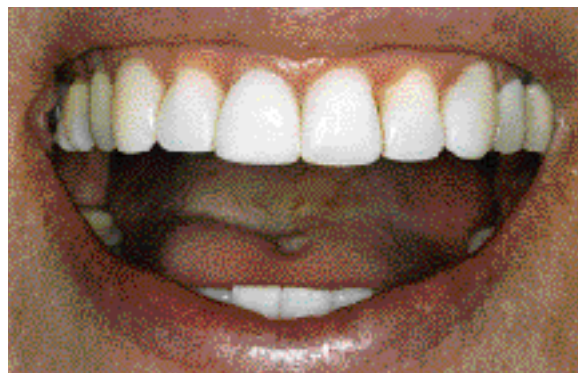

Figure 14-4EE: The patient's final smile line shows improved tooth color and form.

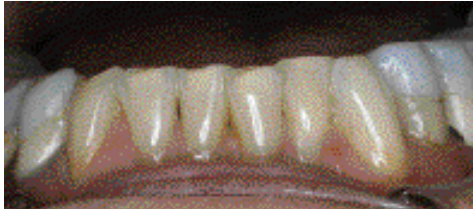

Figure 14-5A: Excessive wear and discoloration of the mandibular incisors prompted this patient to seek esthetic treatment.

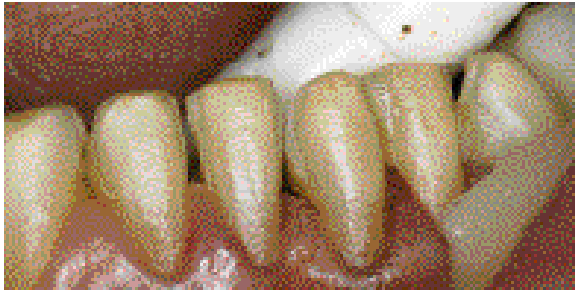

Figure 14-5B: Porcelain laminates were chosen to improve both color and tooth form and the teeth were prepared.

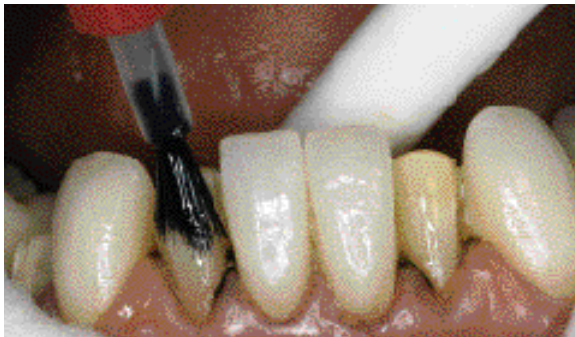

Figure 14-5C: After the central incisors were bonded, the cuspids were placed. The laterals are next.

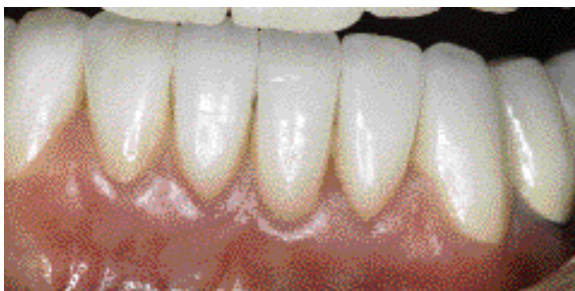

Figure 14-5D: The 30-day recall showed much straighter, brighter, and natural-looking lower incisors.

Also, the incisal edge of lower anteriors is usually the most visible part of the laminate so consider this fact when preparing the tooth. Simply reducing from the labial surface will almost always be insufficient to mask the tell-tale signs of color differences that the laminate has been placed. You need to have sufficient incisal reduction to make a normal incisal edge for that patient.

One advantage of the lower laminate is that it is seldom necessary to go subgingivally, as with the maxillary laminate, because most people do not show the gingival margin of lower anteriors. However, you need to discuss this with your patient. *There are many individuals who do not want to see a margin or be reminded of the previous discoloration regardless of the fact that he or she is the only one who might view the margin.*

Impressions

Although it may be possible to take your impression without further tissue displacement, it is preferable to place a new cotton tissue displacement cord to make certain all margins will be properly recorded. Approximately 5 minutes should be sufficient to gain enough tissue displacement for you to capture the “lip” or actual margin plus a bit

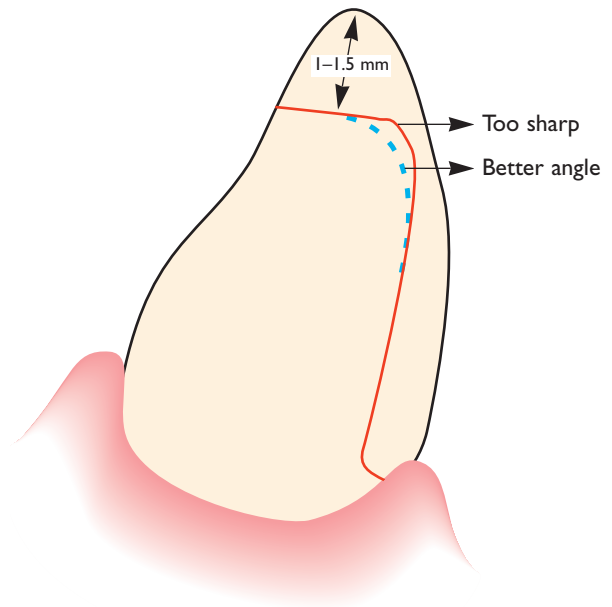


Figure 14-5E: This illustration shows the proper amount of horizontal and vertical reduction necessary for the average porcelain laminate on a lower incisor.

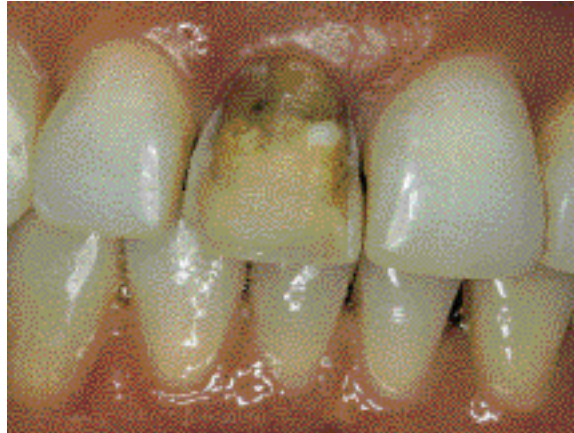

Figure 14-6A: This badly discolored central incisor has been prepared for a porcelain laminate veneer.

of tooth structure gingival to the margin. Obtaining an impression with this extra amount of uncut tooth structure guarantees that your technician will be better able to identify the margins and follow the correct tooth contours.

The actual impression material can vary from polysulfide to hydrocolloid, but the vinyl polysiloxane injection method is the cleanest and easiest. However, if you need maximum flow in order to gain as much lip or gingival margin as possible, the less viscous polysulfide or rubber base will be

best. Hydrocolloid tends to tear in the unprepared, undercut areas below or between the contact areas, so if you choose to use this material, send two impressions or models to the laboratory.

Temporaries. Temporaries for laminates usually are unnecessary because in many situations only half of the enamel surface is removed, not exposing the dentinal tubules. There should be little or no sensitivity and only minimal esthetic compromise. Temporaries also may cause gingival inflammation unless carefully trimmed and polished.

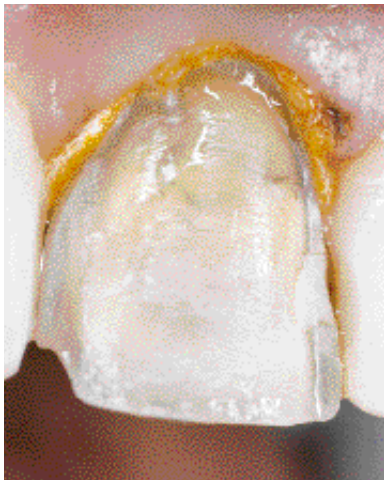

Figure 14-6B: Tissue displacement with retraction cord for 3 to 5 minutes will make it easier to create a more accurate gingival margin for the interim restoration.

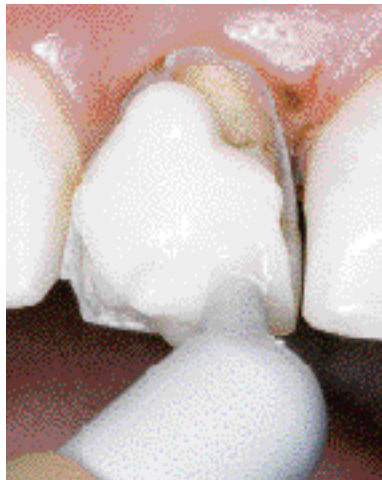

Figure 14-6C: Leftover, outdated, or surplus composite resin can be used as temporary bonding (PrismaFil, Caulk/Dentsply, Milford, DE). No dentin bonding agent should be used.

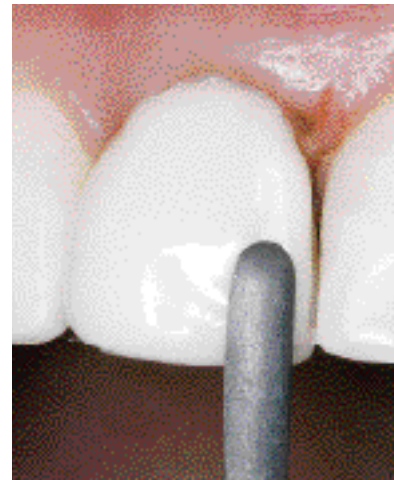

Figure 14-6D: The temporary composite resin veneer is carefully shaped with a Goldstein #3 anodized aluminum, Flexi-Thin instrument (Hu-Friedy, Chicago, IL).

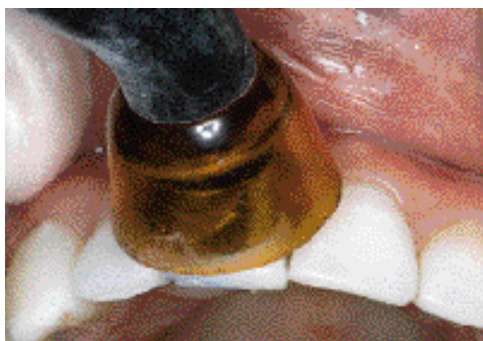

Figure 14-6E: Polymerization should be completed from both the labial and lingual aspects.

Situations that call for temporaries include those in which (a) the teeth have been extensively reduced, particularly if dentin is exposed, and/or sensitivity exists, (b) open contacts have been created that could allow movement of the teeth, or (c) the patient finds that the reduced teeth are too unesthetic for comfort. In these unusual situations, temporaries can be constructed through one of five methods: (1) direct composite veneers, involving the placement of a composite restorative material directly on the unetched surface of the prepared tooth (Figures 14-7A and B); (2) direct composite veneers, involving the placement of a composite restorative material directly on a 1- to 2-mm etched surface of the prepared tooth (Figures 14-8A and B); (3) direct composite veneers using a vacuform matrix made on a preoperative plaster model of the

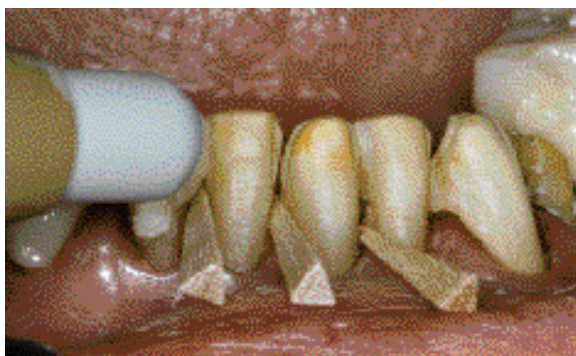


Figure 14-7A: Temporary restorations are necessary on these mandibular incisors to maintain the space and prevent tooth eruption while the final laminates are constructed. While the composite resin bonding is applied, wooden wedges in the embrasures help maintain the open space needed for optimal homecare.

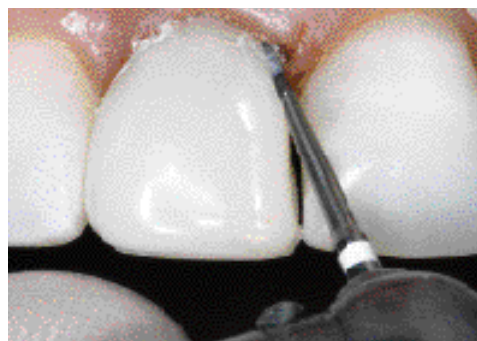

Figure 14-6F: Since the temporary laminate restoration is initially contoured close to the desired final form, only slight finishing with a 30-blade carbide (ET 3UF, Brasseler) is necessary. Additional polishing can be done with a series of impregnated discs (Soflex (3M) or Cosmedent).

patient's mouth; (4) direct acrylic veneers in which methyl methacrylate self-cure acrylic is mixed into a soupy state, flowed into the buccal aspects of a vacuform matrix and allowed to reach the "doughy" stage of curing, and then manipulated into position over the prepared teeth (Figures 14-9A to G); and (5) indirect composite/ acrylic temporaries, which are fabricated in the laboratory on a model of the prepared teeth.

Laboratory Procedures

Making a Model. A master cast that accurately reproduces what exists in the mouth is the neces-

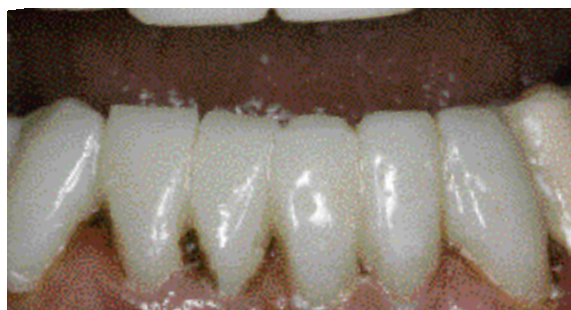

Figure 14-7B: The final bonded temporary veneers are wrapped on to the lingual surfaces for increased retention, strength, and occlusal stability.

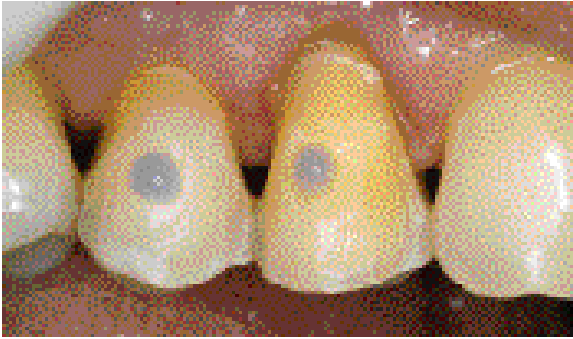


Figure 14-8A: If more retention is desired to hold a temporary veneer in place, a 1-mm diameter etched area in the center of the prepared tooth is all that is necessary.

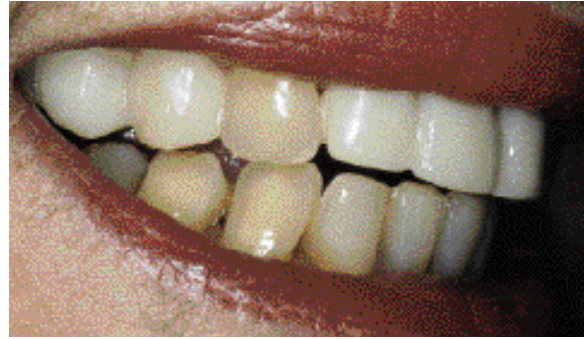

Figure 14-8B: In addition to the 1-mm etch, these temporary veneers on the maxillary right bicuspid are bonded together for maximum retention.

sary next step in the fabrication of veneers. The laboratory laminate fabrication technique, die or foil, may determine the type of impression you take and the type of model you pour.

Foil Versus Refractory Die. There are two basic techniques for fabrication of porcelain laminate veneers, both of which can produce excellent results. The type of impression you take and the type of model you pour may depend upon which technique you use.

In the platinum foil technique (Figure 14-10A to K), the more conventional of the two methods, porcelain is fired over a 0.001-inch thick platinum foil matrix. This technique uses individual removable dies on a master cast poured in conventional die stone. Good delineation of each tooth is assured if the contact points in the mouth are modified by

stripping with an ultrafine diamond strip (CompoStrip, Premier Dental Products).

In the refractory die technique, porcelain is fired directly on a refractory die material. This reduces the cost of construction by eliminating the need for platinum foil. It also avoids some of the shrinkage and distortion that can occur with the more technique-sensitive foil method.

(In our practice we have leaned toward the foil method, but you should use the method you or your technician find most comfortable.)

It may be prudent in the refractory die technique to block out linguointerproximal undercut areas with orthodontic wax before taking the impression. Never do this if the foil technique is being used, however, as the technician will not be able to section

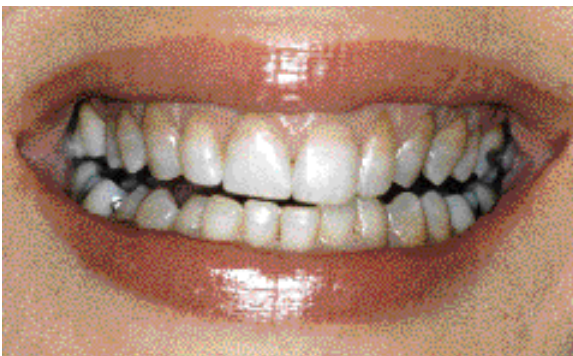

Figure 14-9A: This 40-year-old female chose porcelain laminate veneers to mask her tetracycline stains and to make her arch appear wider.

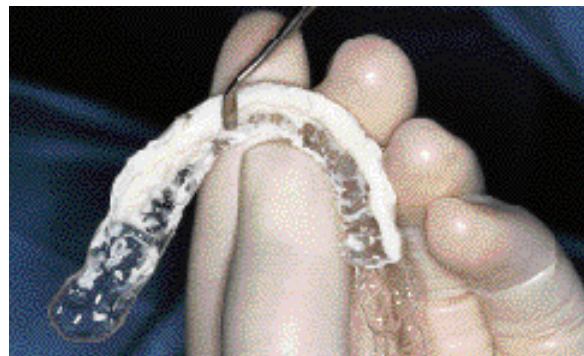

Figure 14-9B: In order to create a removable temporary restoration, a previously-waxed model helped to create the vacuform matrix seen here as it is filled with self-polymerizing acrylic (Duracryl, Masel Ortho Co.).

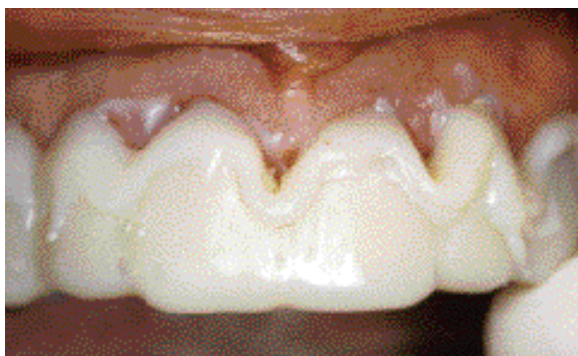

Figure 14-9C: The acrylic filled matrix is vibrated into place. To reduce polymerization shrinkage, apply cool water while quickly removing and reseating the temporary until it is set.

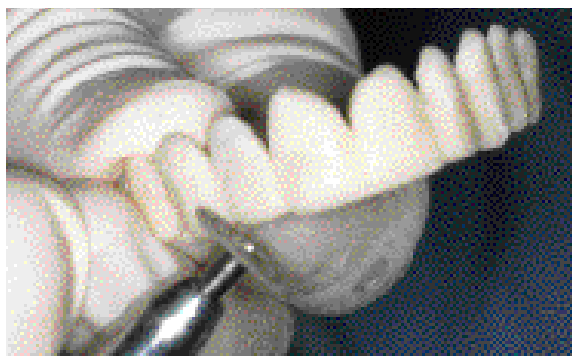

Figure 14-9D: The temporary is carefully trimmed with acrylic burs and an ultrathin diamond disc (Brasseler) to slightly open the embrasure spaces.

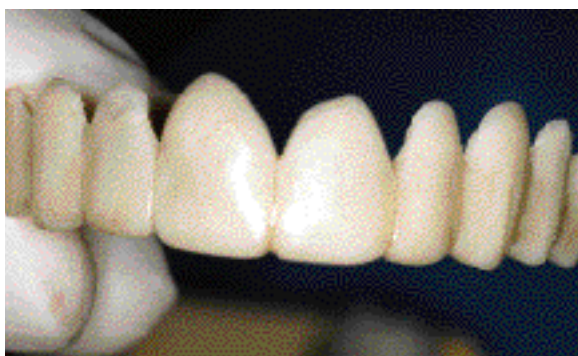

Figure 14-9E: The final temporary can be stained, if necessary, and coated with an acrylic or composite glaze.

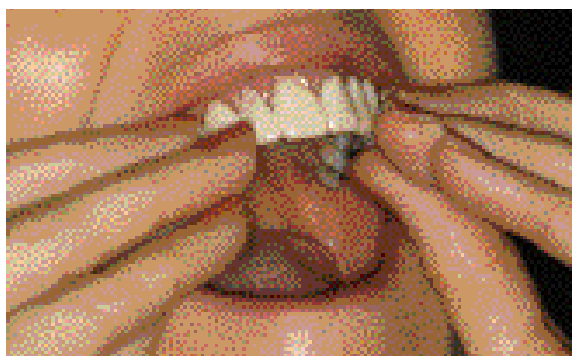

Figure 14-9F: The patient is instructed how to carefully insert and remove the slightly flexible temporary.

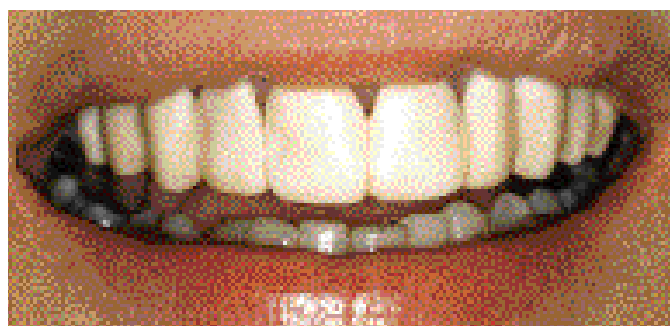

Figure 14-9G: The temporary has sufficient retention because of the side to side flexibility and the fact that it just overlaps the lingual surfaces of the maxillary incisors.

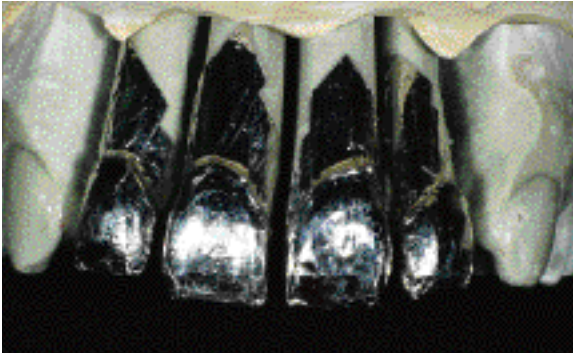


Figure 14-10A: These four veneers are being constructed to help close multiple diastemas. Here platinum foil is adapted to each individual tooth on the master model.

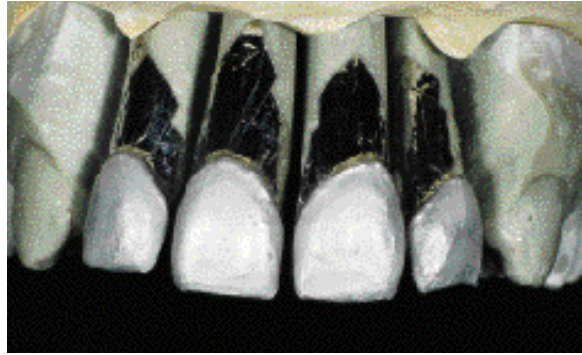


Figure 14-10B: The body porcelain is baked and this initial layer is thinned to outline the margins and surfaces on which the ensuing layers of porcelain will be built.

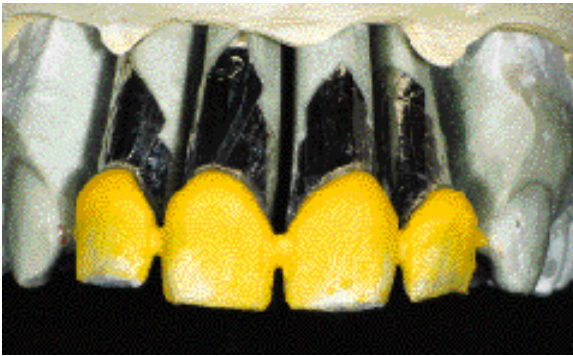


Figure 14-10C: The yellow build-up represents the cervical color blended with opacious dentin.

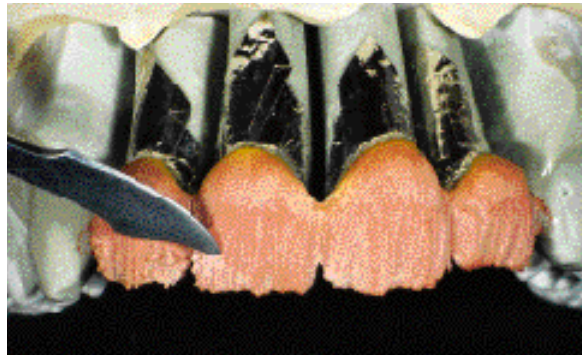


Figure 14-10D: The orange red layer is the body color. After completing the buildup, the incisal area is cut back for incisal porcelain placement.

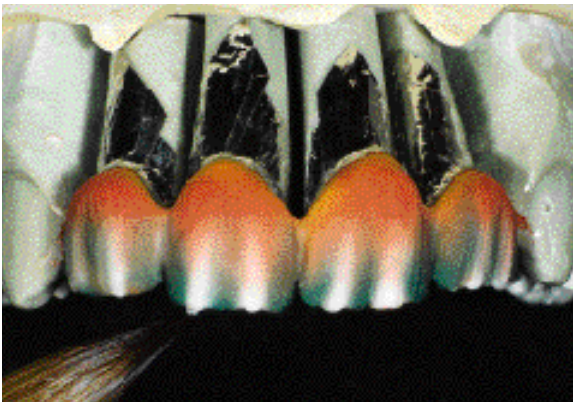


Figure 14-10E: The white color represents translucent blended porcelain and is placed between the more opaquely colored mamelons.

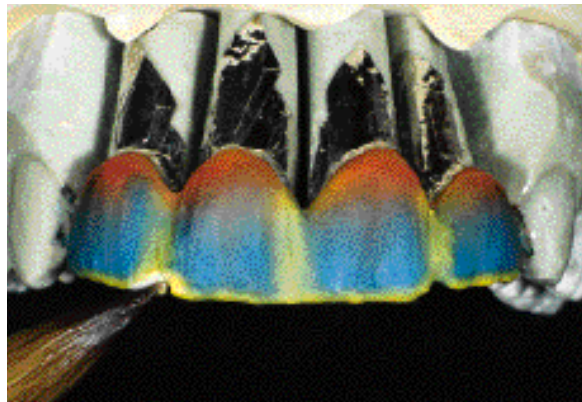


Figure 14-10F: Finally, the blue represents the outer layer, a blend of 50% translucent and 50% incisal color. The yellow creates the "halo" effect and is a 50% mixture of dentin and incisal porcelains.

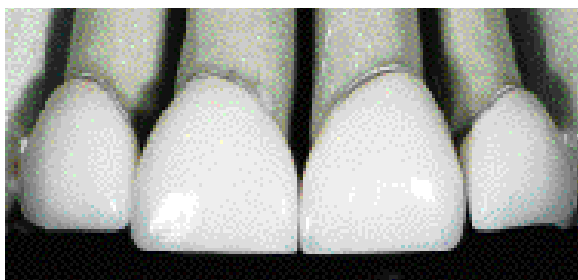


Figure 14-10G: The finished veneers on the master model with no foil.

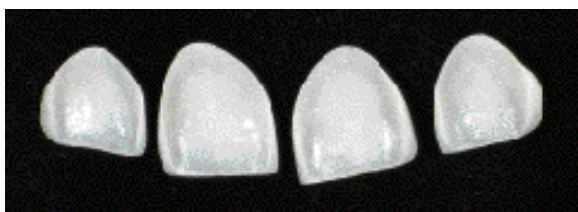


Figure 14-10H: The internal aspect of the unetched veneers.



Figure 14-10I: The lingual and incisal views of veneers when fitted on the master model.

the model. In the refractory technique, it may even be possible to remove the lingual flange of the tray and take only an incisofacial impression.

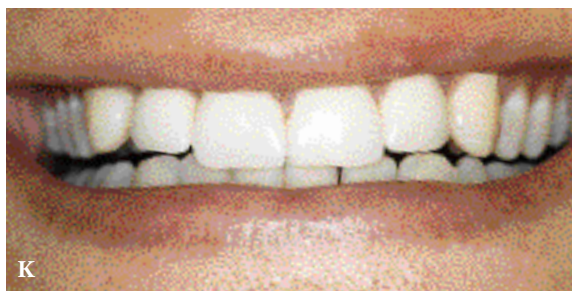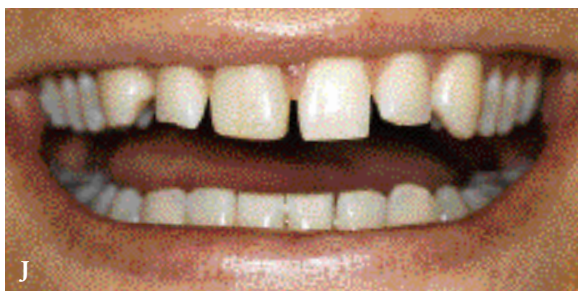Porcelain is an excellent material in terms of color because the amount of opaqueness can be controlled, both through mixture and depth of the veneer.²¹ In tetracycline-stained teeth, for example, you usually will neutralize the underlying color and then create the illusion of normal tooth color by having the opaque incorporated into the porcelain veneer, using the composite cement for additional help if needed. Despite the attractive teeth that can be achieved this way, it is important to remember that the actual shade of the porcelain has only nominal bearing on the bonded final veneer. This is because in most cases the laminate is only 0.5 mm thick and rather translucent. The underlying tooth color and resin can modify its shade dramatically. Fortunately, several systems for opaquing the dark stain exist, one involving the use of opaque powder, another a complex layering²² (Figures 14-11A to D).

The porcelain laminate veneers are then constructed in the ceramic laboratory, following your prescription of form, fit, and color. Although most any porcelain can be baked and etched for a laminate veneer, some of the newer products have been specifically developed for this procedure. They are especially formulated to etch in a more retentive pattern for better bond strength to enamel and to have increased amount of opacifiers and metallic oxide pigments so that within the 0.5 mm thickness of a laminate, intricate characterization and color effects can be developed.

Placement of Veneers

Try-In. Before the porcelain veneers are bonded into place, it is important to go through a try-in stage (Figures 14-12A to D). Try-in is a three phase process:

1. Check the intimate adaptation of each individ-



Figures 14-10J and K: Before and after views showing a more attractive smile.

ual porcelain laminate to the prepared tooth surface. The teeth should first be cleaned with a slurry of fine flour of pumice that contains no oils or fluoride. Next, use a fine composite finishing strip to clean the contact areas. Then each of the veneers is tried in individually (Figure 14–12B), beginning with the distal-most veneer, with the margins checked carefully. (It may be useful to place a drop of glycerin or water on the etched surface to facilitate temporary adhesion of the veneer to the tooth surface.) If the veneer does not go to place immediately, check for any undercuts and contact point impingements and adjust with a 15-micron diamond (LVS-6, Brasseler, Savannah, GA) until it seats easily.

2. After ascertaining individual fit, you should place each laminate on one by one, until all

are in place (Figure 14–12C). Thus you will ascertain if there are any problems with your insertion paths and order of insertion (usually done posterior to anterior, except the centrals and laterals which should be placed centrals first, then laterals). Then check the collective fit and relationship of one laminate to another, especially in the contact areas.

3. Assess the shade and modify it as necessary. Since the prepared tooth color, shade, and opacity of the bonding resin and the veneer itself all contribute to the color of the veneer once in place, this phase of the try-in is essential.

A good initial test is to place one laminate in position with glycerin on the tooth and compare that laminate to a shade tab of the selected shade. If the laminate color is unsatisfactory, use try-in pastes

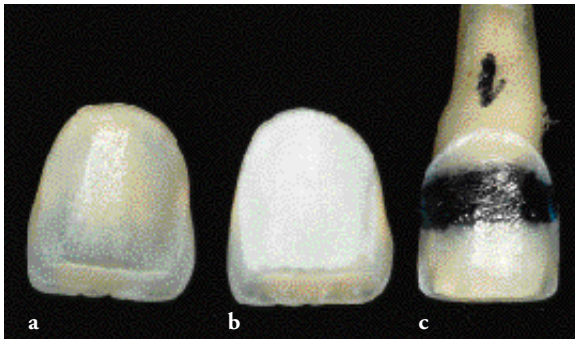


Figure 14–11A: These two porcelain laminate veneers will show the difference between no opaque layer (a) and the effect of a complete opaque layer (b), when placed on an extracted tooth (c). Note the thick black line drawn on the prepared tooth.

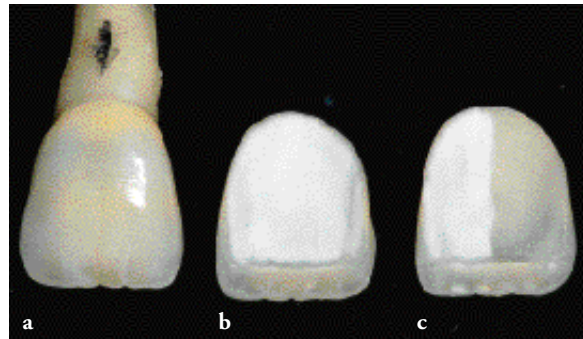


Figure 14–11B: Laminate (a), with no opaque layer, clearly shows the shadow of the horizontal black line. Note new laminate (c) has opaque on only one side.

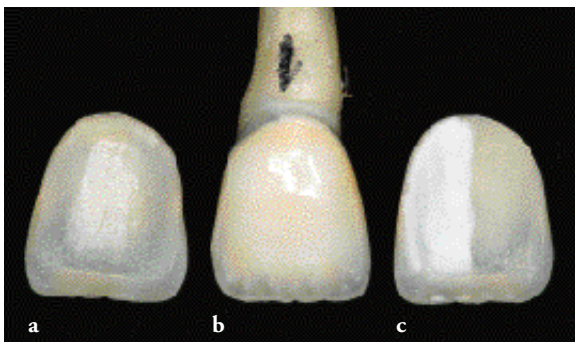


Figure 14–11C: The fully-opaque laminate (b) placed on the extracted tooth shows no evidence of the black line shadowing through.

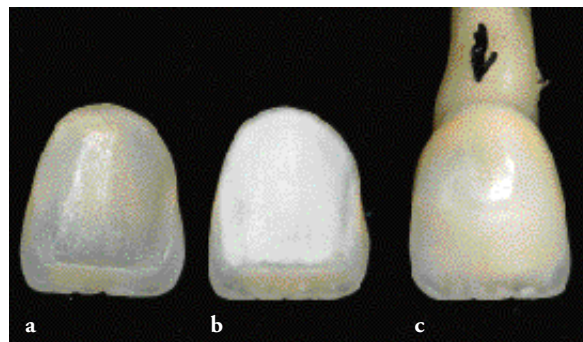


Figure 14–11D: Laminate (c) again shows the effectiveness of the opaque layer, because the black shadow can be seen through the nonopaque half.

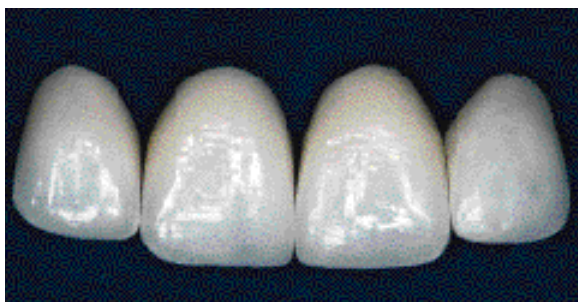


Figure 14-12A: These four porcelain veneers have been etched and are ready for try-in.

that do not polymerize, or place a small portion of the luting composite on the veneer and then reset the veneer on the prepared tooth to check the color. If you or your patient is not happy with the shade, try the veneer with a lighter or darker shade of try-in paste or composite until the right one is found.

There is no absolute method of predetermining the exact shade of the laminate following cementation. However, using try-in pastes that are matched to the final shades can go a long way to satisfying most dentist and patient demands. Even so, there will almost always be a slight shade shift following polymerization. That shift will generally be towards the darker rather than lighter side. So, if you have a choice, choose the lighter shade cement.

If your laminate appears lighter than you wish at the trial phase, try adding tints or opaquer. At times, it may require adding a darker opaquer until it is up to 80% of the total mix in order to make a sufficient shade shift. *However, carefully watch the mixing of the final bonding resin because it may take*

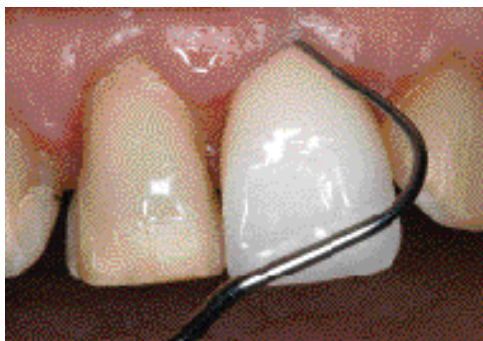


Figure 14-12B: Each veneer is individually fitted and checked for marginal accuracy.

less opaquer in that mix to achieve the same opacity as you got with the try-in pastes.

While it is ideal to have all of the necessary color contained in the porcelain, certain discolorations and problems present in the tooth itself may be too much for the veneer alone to correct, because of its thinness. In these cases, correction can be made for the individual tooth discoloration through the use of resins painted onto the internal surface of the veneer. These resins also can be tried in and redone with different colors, until a satisfactory result is achieved. These then can be cured onto the laminate in very thin layers. In some cases, you may want to lay down a complete layer of opaque as a base. In others, where the teeth are discolored in strips, lines, or small areas, only these discreet areas may need opaquing. When a satisfactory result is achieved, the laminates then can be bonded in position with the usual composite luting cement. This process allows a better coloration of the finished tooth but it does raise problems of added thickness and possible weakening of the bond. You also may need to alter the tooth slightly in the event you need greater composite opaquing. This can be done by slightly preparing a concave area in the tooth under the part of the laminate that requires greater masking.

Caution must be used during this phase of the try-in to avoid exposing the veneer and composite luting agent to the operating light, which may initiate the curing process. It also is important to completely remove the composite material used during the try-in period prior to the final process of luting. Be sure to remember that veneers are fragile and are subject to fracture prior to bonding.⁴⁹

Final Insertion. After you have spent considerable time preparing the teeth, taking impressions, and constructing and trying in your laminates, you approach the most crucial step—that of final insertion or cementation. The reason why this step is potentially the most demanding of all is because the actual final placement, color chosen for the cement, and the ability to achieve lasting adhesion to cementum, dentin, and enamel will ultimately determine how long the laminate remains esthetically and functionally viable.

There are also several phases to this process, which may best be done with a local anesthetic (Figures 14-12A to P).

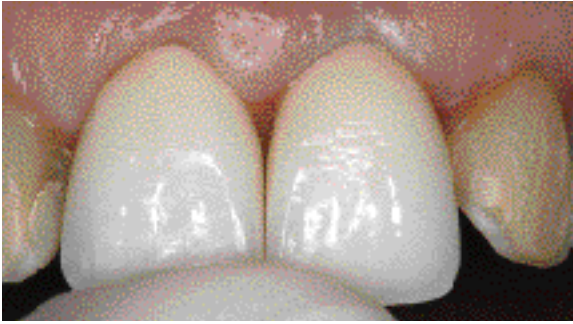

Figure 14-12C: Following individual fitting, pairs, then groups of veneers are checked for proper contact until all are properly related to one another.

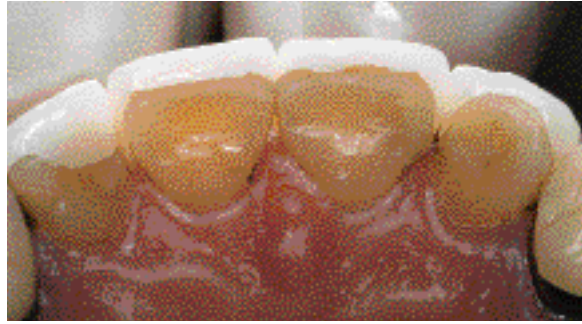


Figure 14-12D: This lingual view shows all of the veneers fitted together with acceptable marginal accuracy.

1. Soft Tissue Control. Gingival retraction cord should be placed to decrease the crevicular fluid flow, which would interfere with the adhesion and seal between the veneer and underlying enamel. It also allows for direct visibility of the gingival margin.

Ideally, a rubber dam is the best way to secure overall moisture control. However, in most instances of subgingival margins it is either impossible or impractical to precisely seat the laminates with a rubber dam in place. Therefore, other methods of securing a dry field must be used. Using the retraction cord can help but if bleeding is present after retraction, due to inadequately healed tissue, either electrosurgery or laser surgery should be con-

sidered. Even several rinses with saline (a teaspoonful of salt to a glass of water) may help to control the seepage. One thing is certain: unless you can control bleeding and gingival seepage, you will drastically shorten the life span of the veneers by reducing bond strength, especially in the gingival area, and increasing the chance for bacterial penetration and eventual unwanted stain beneath the veneer.

2. Silanation. The bond of the porcelain laminate to the tooth is, in fact, a series of links: etched enamel to dental bonding agent to luting composite to unfilled resin to hydrolyzed silane to etched porcelain. Silane greatly enhances the adhesive properties of the resin and thus increases bond strength⁵⁴ (Fig-

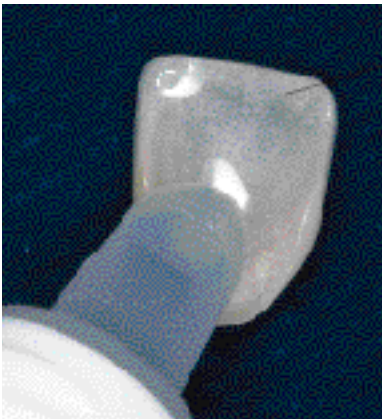


Figure 14-12E: Following color checks with try-in paste, the veneers are cleansed in an ultrasonic bath with denatured alcohol for 10 minutes, then treated with an acid porcelain conditioner for 1 minute.

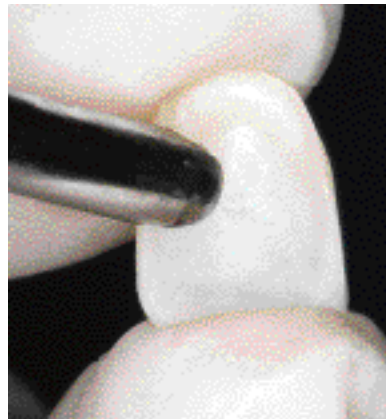


Figure 14-12F: Porcelain conditioner is thoroughly washed off and then air dried.

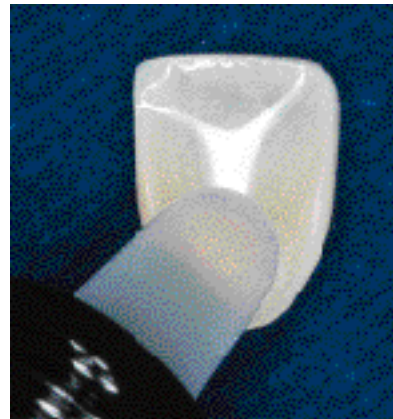


Figure 14-12G: Silane primer is applied according to the manufacturer's instructions.

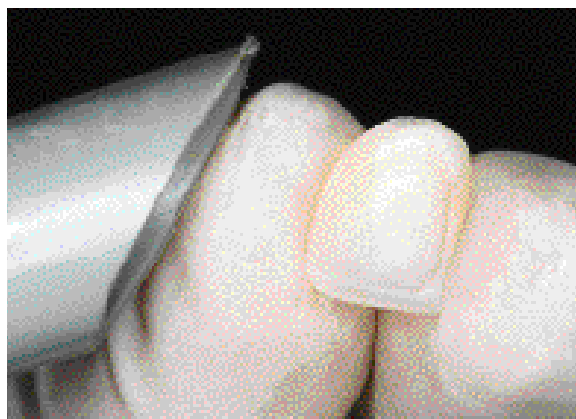


Figure 14–12H: The silane is dried with a warm air dryer or oil and moisture-free laboratory or chairside air syringe.

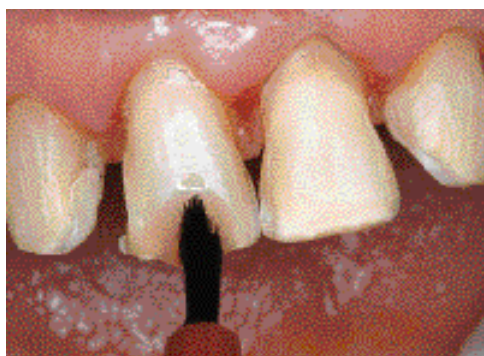

Figure 14–12I: The two central incisor preparations are etched for 15 to 20 seconds.

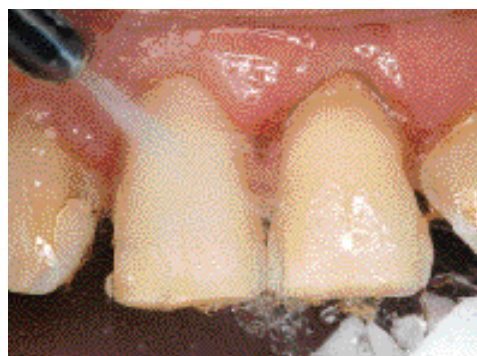


Figure 14–12J: A 10-second air/water spray is used to wash off the etchant.

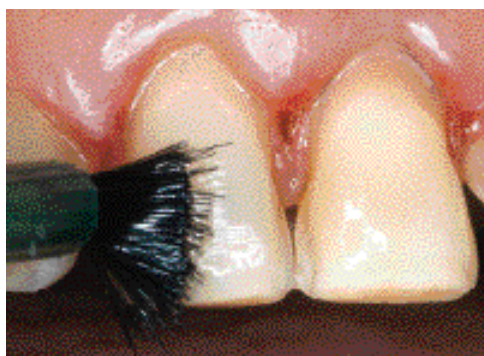

Figure 14–12K: Multiple coats of dentin/enamel bonding agent are applied and then dried and polymerized. The prepared tooth surface should now be slightly glossy. If not, repeat the process.

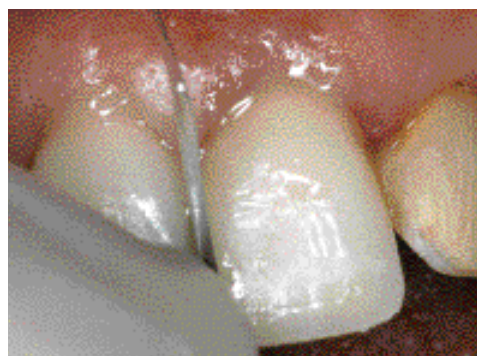

Figure 14–12L: Following application of a pre-bond resin, the two central laminates, filled with cement, are carefully placed and checked with an explorer to certify correct alignment.

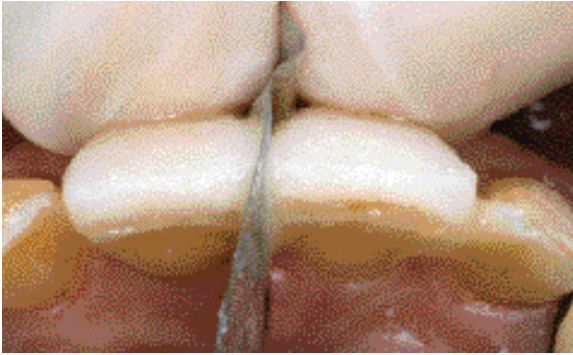

Figure 14-12M: Holding the laminates in place, make certain the ultrathin (5/10,000ths of an inch) matrix (Artus/DenMat) provides adequate separation along the entire contact area.

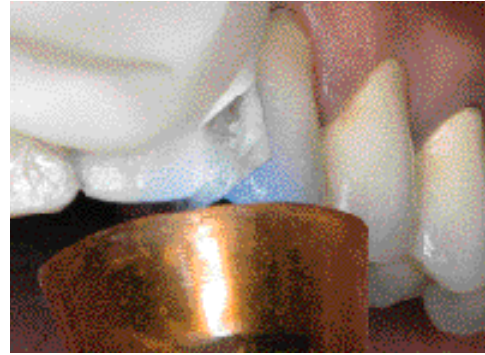


Figure 14-12N: Following a 5- to 8-second initial polymerization, excess cement is trimmed. Next, polymerize each aspect (labial, lingual, and incisal) for 60 seconds with a conventional light for 10 seconds with an argon laser or xenon curing light.

ure 14-12G). Follow the particular manufacturer's instructions exactly, because in certain cases you must treat the etched surface of the veneers with the silane coupling agent before the laminate try-in.

3. Enamel Etching. Each tooth is isolated, then etched with a 30 to 37% phosphoric acid solution for 15 to 20 seconds (Figures 14-12I and J). The etchant must reach the entire periphery of the preparation where a tight seal is critical to the long-term success of the restoration. Gingival displacement is important to expose this margin and prevent contamination. The etching material is then washed from the enamel with copious amounts of water. If the patient rinses or in any way contaminates this etched enamel surface with saliva, the surface must be re-etched for 10 seconds, washed, and dried again.

4. Bonding. The underlying etched tooth surface is coated with multiple applications of a light-activated enamel-dentin bonding agent, which is gently air-dispersed into a thin layer and polymerized. At this point, the tooth surface should be glossy. Depending on manufacturer's instructions, usually a "prebond" resin layer is applied to the tooth surface (Figure 14-12K). The internal aspect of the veneer that has been silanated is now coated with an unfilled resin bonding liquid, which is blown into a thin layer. The composite luting agent is now placed in the laminate. Protect all these materials from strong light to prevent premature polymerization.

5. Placement. Handling a veneer full of cement is not as easy as positioning the cement-free veneer.

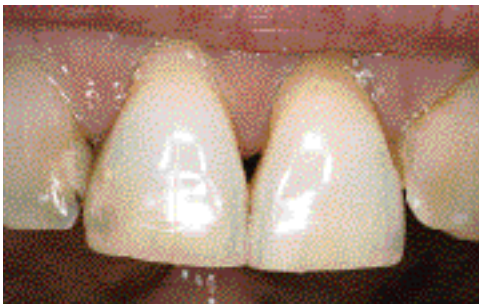


Figure 14-12O: This 60-year-old woman looked older due to her discolored, worn, and eroded incisors.

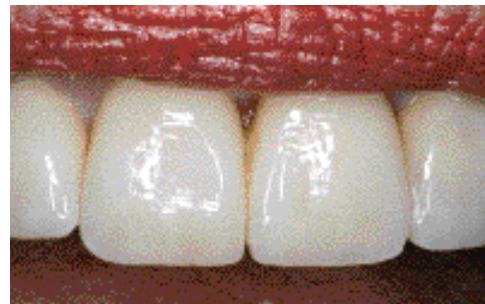

Figure 14-12P: A younger and more attractive appearance was achieved by four porcelain laminate veneers. Note closure of interdental space.

There are veneer carriers similar to suction cups that you may choose to use, although there is the distinct possibility that the suction may break or the veneer may slide off, causing it to drop and break or become contaminated. This is why I generally choose to hold the veneer in my fingers or with cotton pliers until it is placed. The only problem with choosing to finger-hold it is in taking care to avoid pushing the cement away from the edge of the veneer, leaving a void. Also, make sure that you use a well-fitting glove.

The adjacent teeth should be separated with matrix strips during both acid-etching and insertion so the cement does not lock in or adhere to the adjacent tooth (Figure 14–12M). Since most clear mylar strips are too thick, it is much better to use either the Artus strip (found in the middle drawer of the advanced laminate kit [Den-Mat]) or a Toflemire microthin band (Lorvic Corp.). Another choice would be a -soft stainless steel matrix strips (Den-Mat or Parkell). Either of these will allow you to properly seat your veneer.

As you place the veneer, try to line up the incisal edge and the mesiolabial and distolabial line angles with the adjacent teeth. Use a sharp explorer to make certain your gingival margin is in place. Most of all, be careful not to torque the laminate; this could trap an air bubble underneath. The most frustrating area

for this to happen is at the gingival margin since bacteria will usually penetrate, eventually causing a black stain to occur (Figure 14–13). *If you have any idea you might have moved the veneer or caused it to pull away from the tooth in the gingival area, remove it, refill it with cement, and reseal. This is one instance where an ounce of prevention is worth a ton of cure.*

Generally, the distal-most veneers should be seated and polymerized first, followed by the next mesial-most laminate until the cuspids. Then seat both centrals together, then the laterals, and then the cuspids. The pivotal last veneer on each side will give you the most problems because there will be fewer sides to adjust if there is tightness in the fit. *Adjust the contacts of the already-seated veneers until you again achieve a perfect fit.*

6. *Polymerization.* A short polymerization period of about 5 to 8 seconds as you seat each veneer will be sufficient to allow you to remove the greatest bulk of marginal excess. Some flash or excess marginal cement is healthy to make certain that polymerization shrinkage does not cause a marginal void. Remove excess partially-cured composite with a Novatech 12 (Hu-Friedy, Chicago, IL). This double-ended instrument is quite helpful. Its chisel end can gently pry off excess labial and lingual composite cement, and the sickle end is extremely large but perfectly suited to removing

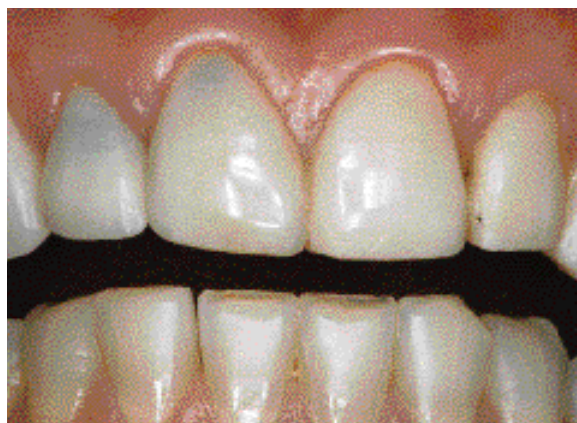

Figure 14–13: Torquing or accidental moisture contamination during cementation can eventually cause marginal leakage. This can result in a black, gray, or blue stain appearing underneath a porcelain laminate. Although it can be repaired (see Vol. II, Chapter 34), the best solution to this problem is remaking of the veneer.




Figure 14-14A: The LVS kit (Brasseler, Savannah, GA) provides the four basic finishers necessary for laminate veneer contouring, trimming, and finishing.

not only excess composite cement but also to performing tissue curettage where necessary.

The polymerization process is completed by curing the various areas of the veneer for at least 60 seconds each, or 10 seconds with an argon laser or xenon light (Figure 14-12N). During this polymerization process it is essential to maintain complete stability of the relationship between the veneer and the underlying tooth. The first finishing instrument is Novatech 12 (Hu-Friedy, Chicago, IL) (see Figure 14-4W and X), followed by the 30-bladed carbide bur (Figure 14-4Y). The ET4UF or LVS-5 (Brasseler, Savannah, GA) is perfectly suited for this purpose.

Although all flash should generally be removed; if you are inserting additional veneers, you may wish to wait until the adjacent veneer is seated before you do any subgingival trimming with the bur to avoid initiating more bleeding or seepage. However, it is important to make sure the occlusion is checked before proceeding to the next veneer.

Be sure to refit your adjacent or next veneer before you attempt to cement it to place. Frequently, a small cement excess or slight placement variation in the previous veneer has caused the fit between them to vary. Use a 15-micron diamond ET6F, or LVS (Brasseler) to slightly shape the adjacent surface, then refit the next veneer until the fit is again perfect before proceeding. If you need to remove the glazed surface of a seated laminate, you

need to repolish the surface with a Soflex (3M) or similar polishing disc system.

Finishing

When polymerization is complete, excess composite should be chipped off and a 30-bladed carbide finishing bur with a straight emergence profile (LVS-5) from the Laminate Veneer System (Brasseler) (Figure 14-14A) should be used to gently remove all remaining excess composite at the gingival margin (Figure 14-14B). Use a copious water spray to avoid heat build-up.

If the veneer surface is not a smooth continuation of the subgingival enamel, then recontour the excess porcelain with a microfine diamond point (LVS-6) (Figure 14-14C). A 15-micron grit polishing diamond (LVS-7) is then used to refine this interface of tooth/composite/porcelain (Figures 14-14D and E). Refine occlusion with microthin articulating film, 0.0008 in., (AccuFilm II, Parkell) and adjust occlusion if necessary with a 15-micron diamond (LVS-8) and final finish with a 30-bladed carbide (ETUF-OS1) (Figures 14-14F and G). For final margin finishing, I recommend you finish with an 8-micron diamond (DET 4, Brasseler) or a 30-bladed carbide ETUF 4 (Brasseler) of the same size (Figure 14-14H). The final polishing of the veneer is done with a series of ceramic polishing points (Porcelain Laminate Polishing Kit, Shofu) (Figure 14-14I) and diamond-dust impregnated paste with nonwebbed rubber cups.

The edge of the rubber cup is brought to just beneath the free gingival margin to bring the junction between the veneer, composite, and tooth to a high luster, ensuring that this area does not become a repository for microbial plaque (Figure 14–14J). This final polishing can take 5 minutes per tooth.

The lingual margin is finished with the LVS-8 to remove excess composite (Figure 14–14F). If the porcelain margin needs refining, use the 15-micron diamond (LVS-7). The polishers are used in sequence (Figure 14–14J)—start with the no-band polishing cups, then the yellow-band, followed by the white-band superfinishers (Figure 14–14K). The final polishing is once again done with diamond dust on the

rotating Shofu cups. The cone-shaped instruments are for the occlusal or lingual surfaces. If necessary, adjust incisal length with a Soflex disk (3M) (Figure 14–14M).

A thorough study by Haywood, Heymann, and Scurria²⁷ compared various instruments and finishing and polishing sequences and found that the best results obtained were with a sequence consisting of diamond instruments with progressively smaller particle sizes at moderate speeds with water coolant, then a 30-blade carbide bur at high speed and dry, followed by a diamond polishing paste with a 2- to 5- μ m particle size. In all polishing sequences, the best results were obtained with each individual

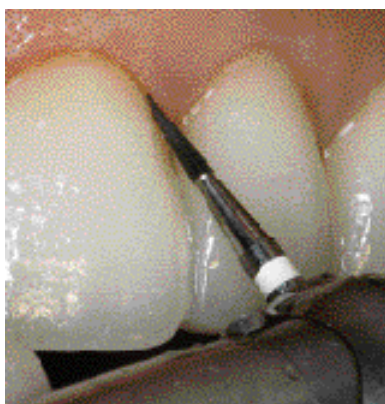

Figure 14–14B: The LVS-5 (Brasseler) is used to trim composite resin flash following polymerization.

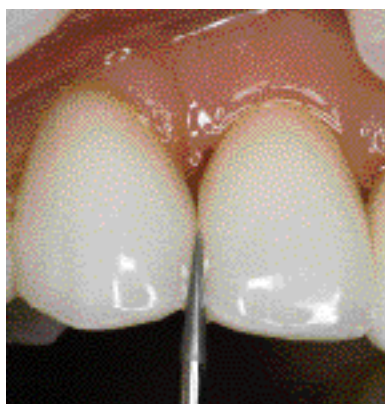


Figure 14–14C: The LVS-6 is used to contour or reshape as necessary.

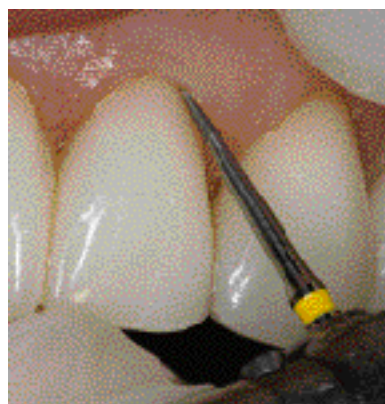


Figure 14–14D: Gingival reduction shaping or contouring can also be easily managed with the LVS-7 15-micron diamond.

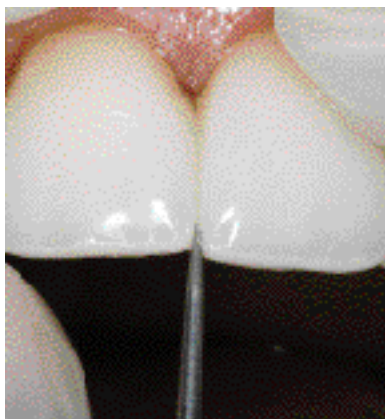


Figure 14–14E: The LVS-7 is also useful for contouring incisal embrasures.

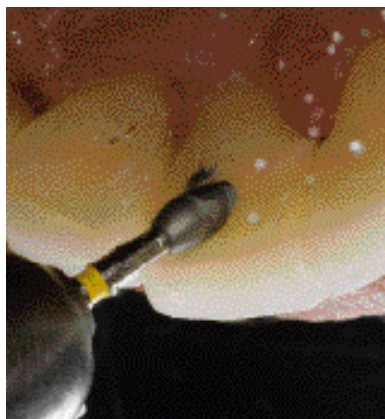

Figure 14–14F: The LVS-8 is helpful to establish appropriate occlusal anatomy and shape lingual surfaces.

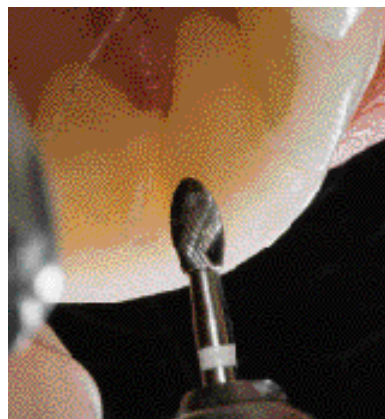

Figure 14–14G: Final porcelain finish should be done with the 30-bladed carbide (ETUF-OS1, Brasseler).

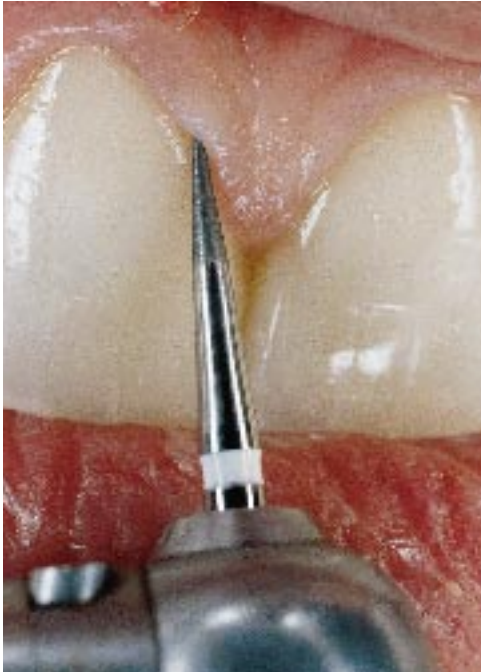

Figure 14-14H: Many clinicians prefer an 8-micron diamond (DET4UF) for final finishing of gingival margins.

instrument when diamond instruments were used at moderate speed, wet, and carbide instruments were used at high speed, dry.

Check the contacts with dental floss (Figure 14-14N) and make minor corrections with a yellow-banded Compo-Strip (Premier Dental Products). If the entire contact area needs thinning, then use the wide banded Compo-Strip (150 UF). If you need to reshape the embrasure area, use the 100 UF strip (Figure 14-14L). Usually just a few back-and-forth motions will be effective. Incisal embrasures can be nicely polished with the ultrathin pop-on discs (3M, or Cosmedent) (Figure 14-14O).

The patient should return at weekly intervals to be monitored for tissue response. In the event of inflammation, the veneers can be further refined with the LVS microfine diamonds for esthetic and functional harmony, making certain that no porcelain or composite impinges on the gingival tissue.

Post-treatment Care and Instructions

Once veneers are cemented and finished, your responsibility diminishes considerably. Your goal at

this point should be to help the patient obtain the longest life expectancy for the veneers as possible. First, and foremost, a night appliance should be constructed to protect the veneers from the possible damage due to abnormal chewing, grinding, or clenching during sleep. One of the easiest to make and most comfortable to wear is a flat upper occlusal plane made of hard acrylic, with a soft acrylic liner (Annalan Labs).

Office-based maintenance should consist of at least four professional cleanings per year. Be sure to train your hygienist to avoid ultrasonic scaling on any tooth with a porcelain veneer, to avoid air-powered abrasive instruments, which can attack the porcelain surface,¹⁵ and when hand scaling, to be careful not to scale against the veneer margin, which could produce chipping, fracture, or worse, debonding. Rather, scale either from the veneer onto the tooth or laterally parallel to the margins.

With care, your patients should have many years benefit from their veneers. Calamia¹⁰ reported a study of 115 etched porcelain veneers 2 to 3 years after placement and found a low fracture rate, low debond rate, no incidence of caries, and minimal negative periodontal response. Strassler recalled 196 porcelain laminates with up to 13 years of service and an average of 10 years. None had debonded and all were color stable. Over the course of this long-term study, only seven laminates needed replacement due to porcelain chipping—a 96.4% rate of success.⁵⁷ Despite the rapid improvements in porcelain and composite resin veneers, however, we



Figure 14-14I: The porcelain laminate polishing kit (Shofu) is most appropriate for final polishing of all porcelain surfaces.

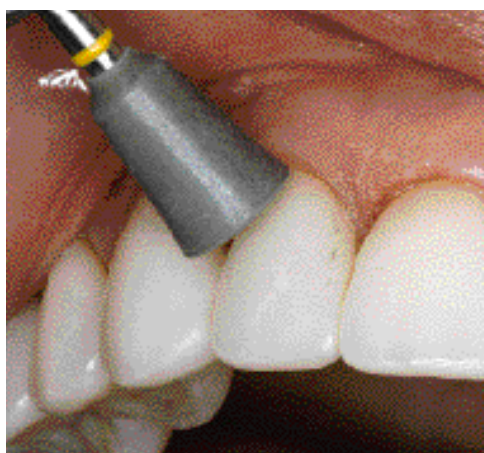

Figure 14-14J: Gingival finishing is best accomplished with the cup-shaped polishers in sequence.

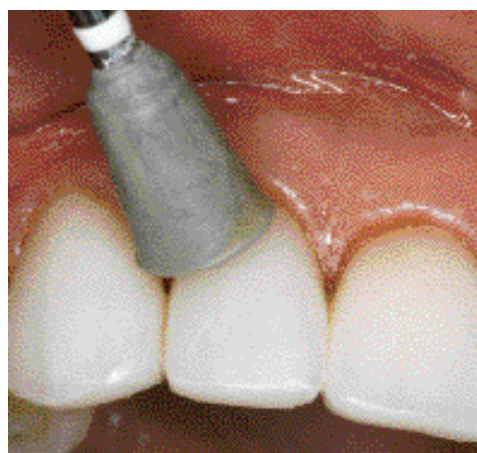

Figure 14-14K: The white-banded finishers provide the final luster.

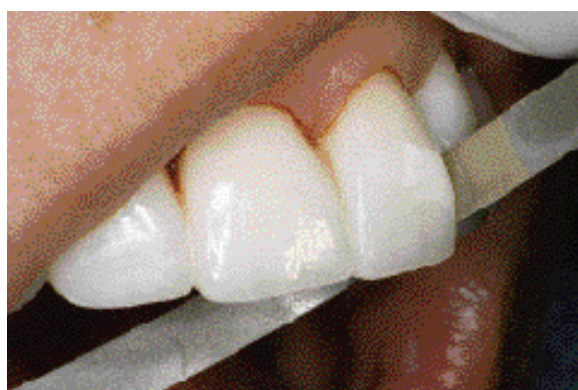

Figure 14-14L: An ultrathin Compo-Strip (Premier Dental Products) followed by abrasive strips, coarse to fine, will provide the best interproximal finish.

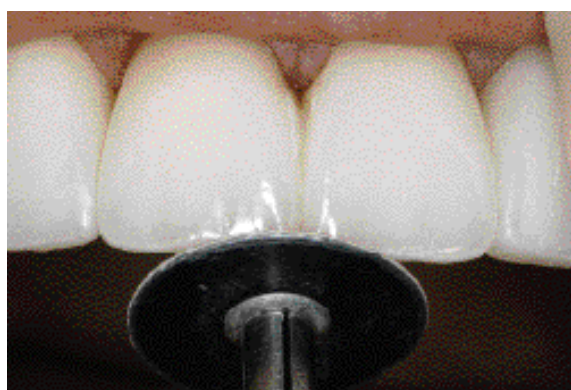


Figure 14-14M: The Soflex (3M) disk is used to adjust the incisal length.

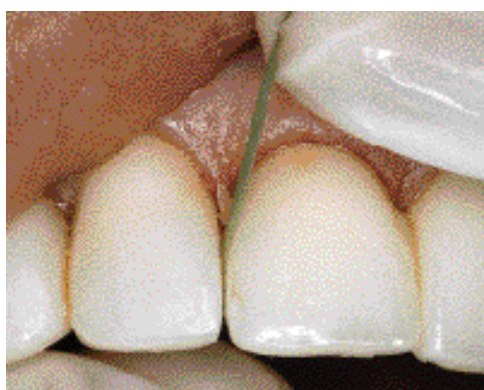

Figure 14-14N: Use waxed or unwaxed floss to test for any overhangs that may still need to be removed.

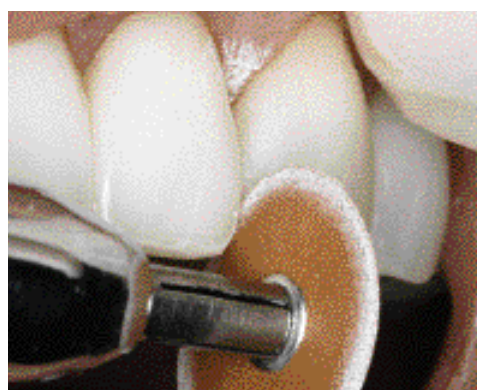

Figure 14-14O: Ultrathin plastic pop-on discs (Cosmedent, or 3M) can effectively reopen closed incisal embrasures.

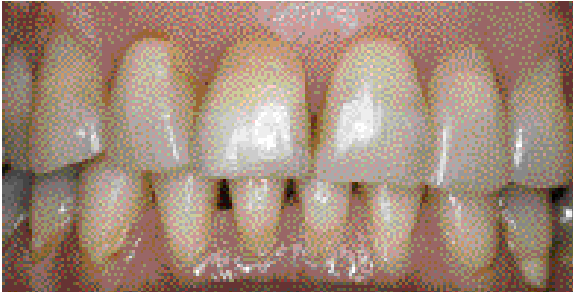

Figure 14-14P: This 49-year-old woman wanted a lighter and more prominent look to her teeth.

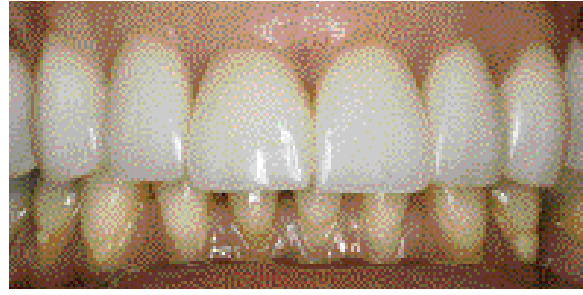

Figure 14-14Q: Twelve porcelain laminates were placed to satisfy this patient's desire for perfection.

find in our practice after 9 years of constructing porcelain veneers that chipping and fracturing still remain a concern. In addition to your responsibilities for material selection, excellent placement, and a strong bond, you have to make certain that your patient understands these risks and his or her responsibilities. These patient instructions fall into three categories.

1. Special care immediately following placement of veneers. During the 72 to 96 hours during which the bonding resin continues to cure, your patient should avoid hard foods, alcohol, some medicated mouthwashes, and extremes in temperature.
2. Eating and other habits must be altered indefinitely to avoid damaging, discoloring, or eroding the veneers. Tell your patient to avoid biting into hard foods, whether candy or meat with bones. Behaviors such as nail biting or pencil chewing endanger their new smile. Many dentists recommend that patients use a soft acrylic mouthguard when involved in sports or activities likely to result in impact to the mouth. Apart from concern with fracturing, your patient also should avoid large amounts of highly-colored foods, or tea and coffee. And finally, the teeth can erode. Intrinsic erosion occurs primarily in anorexia nervosa or bulimia when gastric juices wash over the teeth during induced vomiting. But extrinsic erosion can also occur due to excessive consumption of acidic fruits and juices, which your patient should consume only at mealtimes or shortly before brushing.²

3. Home dental maintenance also takes on a slightly different nature. Instruct your patient to use a soft toothbrush with rounded bristles and to floss as with unrestored teeth. Maintenance of plaque-free teeth is essential to the longevity of the veneers as well as the health of the teeth and supportive tissues. Frequently the enamel has been lost and the softer dentin or cementum tends to decay much faster if not properly maintained. Mechanical plaque removal devices may be useful. In order to properly maintain cervical areas, especially when there is interdental tissue loss, a rotary cleaning device (Rotadent, ProDentec) contains pointed brush tips that can easily clean these areas.

The patient also should avoid acidulated phosphorus fluoride gels³⁷ or acidulated fluoridated mouthrinses, which can damage the surface finish of veneers. Nonacidic fluoride preparations e.g., Prevident 1.1% sodium fluoride (Colgate Oral Pharmaceuticals) are effective in reducing caries and should be considered for patients with extensive porcelain or composite restorations.²⁵ Chlorhexidine antiplaque mouthrinses may stain veneers, although the stain can be removed by a hygienist.²²

ETCHED POSTERIOR PORCELAIN RESTORATIONS

Directly placed composite resins have made a tremendous impact on the field of esthetic restorations. But the current limitations of direct compos-

ites are most evident when you are working with posterior teeth. The development of a wear-resistant, direct composite resin that could stand up to the stresses of posterior occlusion and mastication has proven difficult. Problems include fracture, postinsertion sensitivity, microleakage, loss of surface integrity, occlusal and proximal surface wear, and difficulty securing and maintaining interproximal contact.⁴⁶ Posterior composite placement and finishing techniques are markedly more difficult than for anterior teeth. Investigations using porcelain inlays and onlays were initiated. A 2-year study of 310 posterior etched porcelain resin-bonded restorations by Jensen³⁵ found that ideal ratings for color match were 87.7% at baseline, 92.6% after 1 year, which illustrates how a shade match can improve in time, and 90.9% after 2 years. Having no marginal discoloration was 100% at baseline, 94.8% after 1 year, and 85.4% after 2 years. No loss of anatomic form or clinical wear was detected after 2 years and only one restoration exhibited recurrent caries. Marginal adaptation was 100% at baseline, 94.8% after 1 year, and 90.4% after 2 years. Jensen concluded the restorations “exhibited almost ideal clinical performance including no clinically visible wear after two years.”

Wiley⁶² reviewed concerns of the potentially destructive nature of porcelain on the occluding surface and found that the problems of occlusal surface wear appear to be completely eliminated through use of porcelain rather than a composite resin restorative material. This strength and durability problem occurs in large part because these restorations are 100% filler-particle fired porcelain without any resin to serve as a matrix. However, a major consideration should be the type of opposing occlusion. Porcelain occluding against porcelain works best, with the least amount of opposing wear. Next best would be porcelain against composite, then porcelain against enamel, and the worst is porcelain against gold, which can produce severe wear of the gold surface.

Many researchers and clinical dentists recommend that composite resins be restricted to smaller posterior restorations not subject to strong occlusal forces.³⁴

Another composite option exists for restorations in these heavy stress-bearing areas. Laboratory-processed, indirect composite inlays and onlays are highly esthetic, and because they are bonded in

place, they have been shown to reinforce tooth structure.³⁶ A recent study of long-term clinical failures in indirect posterior composites of several types³ found that the failure rate for 899 composite restorations at 5 years was only 9.2% from all causes, less than half the failure rate of conventional amalgam. The authors conclude that indirect posterior composites can provide excellent long-term clinical service, far superior to the current perception. However, Roulet⁵³ cites numerous studies in his 1997 article where results vary considerably. He concludes by stating that patients need to be informed that tooth-colored inlay's longevity data are often based on analogies and extrapolations, and they are headed for a higher failure rate than amalgam (or gold).

Although new developments continually improve the composite resins used for indirect inlays and onlays (see Chapter 13), porcelain has numerous advantages as described previously throughout this chapter. Some of these are particularly appropriate for inlays and onlays.

Porcelain is most like enamel in appearance and most closely approximates its physical and chemical properties. Etched porcelain bonds successfully to etched enamel, with excellent marginal qualities, when a composite resin-based cement is used.⁴³ Polymerization contraction shrinkage is negligible.³⁸ This bond to the tooth preparation is what gives porcelain, which by itself has a highly breakable nature, its strength as a dental restoration.¹⁶

Indications

Etched porcelain inlays are suitable for any clinical situation for which porcelain's superior esthetics, ability to restore strength to compromised teeth, and conservative treatment are indicated. Garber²¹ gives a list of indications:

1. small to moderate carious lesions for which the patient requests a highly esthetic restoration.
2. large amalgam or composite restorations involving the mesio- or distolingual surface of a cuspid showing unacceptable discoloration or compromised contacts.
3. large carious or traumatic lesions with undermined enamel to the extent that a cast metal restoration or a full crown would otherwise be necessary. In these situations the cross-linked resin-bonded porcelain restoration will

bond to the remaining tooth structure, binding it together into what is, in effect, a homogeneous mass.

4. the endodontically compromised tooth where the access cavity has compromised the strength and prognosis of the tooth. An etched porcelain restoration can be a conservative alternative to a post-and-core and full-coverage crown.
5. heavily undermined incisal edge or proximal surface on an incisor requiring support to keep an otherwise pleasing intact tooth from fracturing.
6. Class IV restorations replacing missing incisal and/or proximal aspects of the tooth.
7. teeth opposed by existing porcelain restorations, which otherwise would tend to wear extensively.
8. teeth where it is difficult to develop retention form. The bonded restoration's adhesive nature may be more effective than other means of developing retention such as pins, periodontal crown lengthening, or a post and core after elective endodontic therapy.
9. patients for whom allergy to metal is proven or suspected.

Contraindications

1. Patients who will not discontinue parafunctional habits that can damage the inlays or onlays.
2. Patients who exhibit aggressive wear.
3. Patients who have gold restorations in opposing teeth.
4. Porcelain inlays and onlays are not simple, and this factor needs to be considered against all the numerous advantages and the situations in which they are an excellent solution to a restorative problem. The problems of maintaining a dry field, obtaining precisely fabricated restorations, and the necessary high degree of attention to detail during placement necessary have been called by Garber a "contraindication in itself" for many dentists.²¹

Technique

Preparation

As Garber points out, laboratory requirements for fabrication of porcelain restorations, as com-

pared to cast restorations, require certain preparation modification. Cavity preparation is somewhat simpler than for gold. All line and point angles should be rounded to facilitate fabrication and decrease the potential for propagation of fractures. The cavosurface angle need not be beveled, and a hollow-ground chamfer confined to the marginal enamel will aid in developing a more effective seal.²¹

The basic premise of the preparation is to preserve all that remains; unlike some other restorations, only those aspects of the tooth already compromised by caries or trauma should be reshaped. This should be done before deciding on the definitive form of the preparation and final restoration. After this is done, the pulpal floor is developed by the addition of a glass ionomer base. Jackson and Ferguson³⁴ recommend covering all remaining dentin with a glass ionomer lining cement. It is their opinion that etching of the glass ionomer is unnecessary, perhaps even undesirable.

To achieve the rounded angles needed for porcelain, the preparation is performed with a two-grit diamond in the shape of a tapered cylinder having a flat end and a rounded "corner" when the flat end and shank meet. A specifically designed instrument with a 0.55-mm tip, a smoother grit at the bottom of the shank, and a coarser grit up the rest of the shank is preferable. This instrument also will produce a flat pulpal floor with calculated divergent axial walls and a rounded line angle between the two highly retentive axial walls. This is due to the hybrid diamond on the shank, which increases the surface area for bonding and develops mechanical retention. Finally, a well-defined cavosurface margin at the occlusal surface is necessary to develop the hollow-ground chamfer at the margin.²¹

Different cavity types will require specific modifications beyond the scope of the book; it is recommended you read Garber²¹ for a complete guide to inlays and onlays. A typical complete procedure is illustrated in Figures 14–15 A to M.

Impression

Impressions for posterior etched porcelain are best taken with vinyl polysiloxane. This will allow additional pours of the impression, if necessary. Since the gingival margin ends in a shoulder, tissue displacement with cotton cord should be sufficient to obtain an excellent, easy-to-read impression of this area.

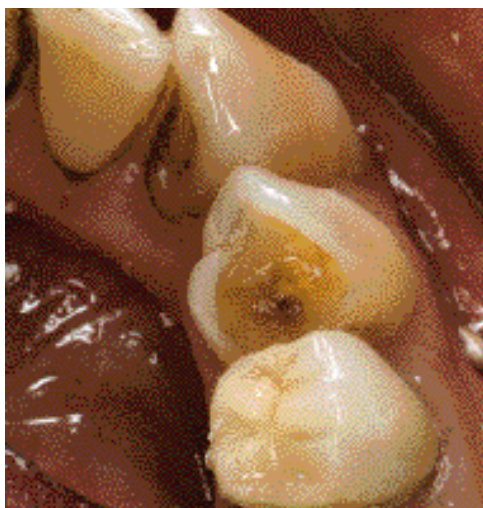

Figure 14-15A: This lower first bicuspid had caries beneath an old restoration.

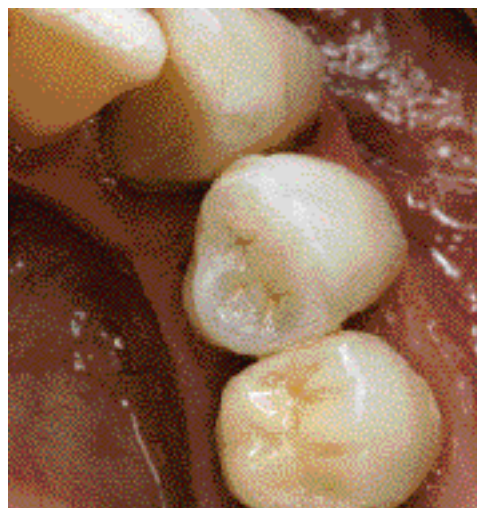


Figure 14-15B: A porcelain onlay is used to restore both function and esthetics.

Insertion

Insertion for the etched porcelain restorations involves try-ins, one at a time, then in groups if necessary. The occlusion should not be evaluated until all of the restorations are initially seated.

Cementation of posterior ceramic inlays and onlays is similar to anterior veneers with certain differences. Foremost is the consideration that the inlay or onlay is much thicker than the anterior veneer, requiring more emphasis on a dual cement, or self curing cement, to bond properly.

Usually, the inlay or onlay matches or blends sufficiently so that the cement can enhance the color matching of the tooth with little effort. However, there are times when it takes a significant

amount of opacifier or stain to influence the shade of the cement sufficiently to blend the color of an inlay or onlay that is too light for the tooth. Such an example is seen in Figure 14-16.

You also have the option following cementation to cut back part of the enamel and blend in a composite resin for greater color perfection.

Finishing

A major consideration in cementation of posterior restorations is the attention that must be paid to removing excess cement in the interproximal areas. The LVS-5 should remove all excess resin cement. A mylar strip through the intact areas during polymerization should only be used if it is approximately five-ten thousandths of an inch thick or less (Artus, Den-

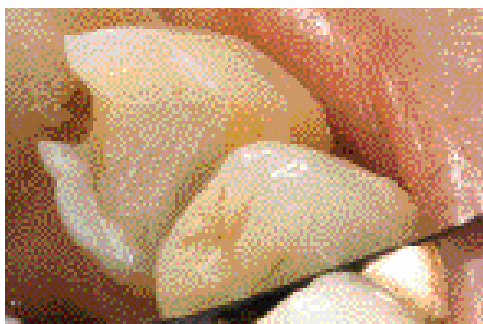

Figure 14-15C: Following conservative tooth preparation, a glass ionomer base is placed in the preparation.

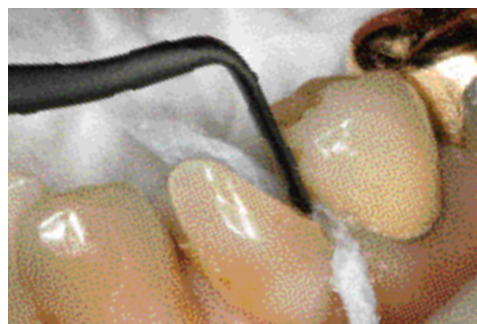

Figure 14-15D: Cotton cord is placed with a GCI mini 3 (Hu-Friedy) for tissue displacement and a vinyl polysiloxane impression is made.

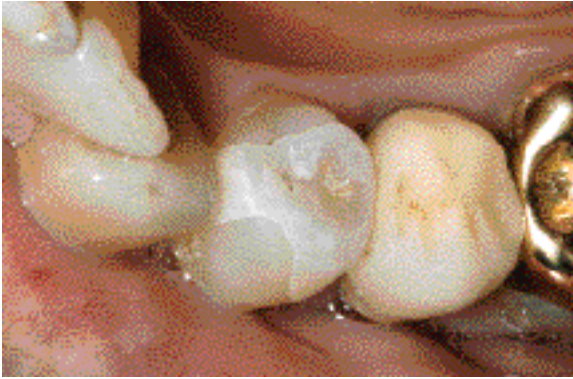

Figure 14-15E: The porcelain onlay is tried in.

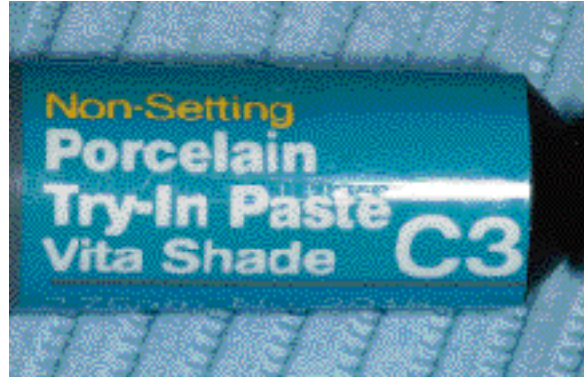

Figure 14-15F: Non-setting porcelain try-in paste (DenMat) helps determine the best color for the resin cement.

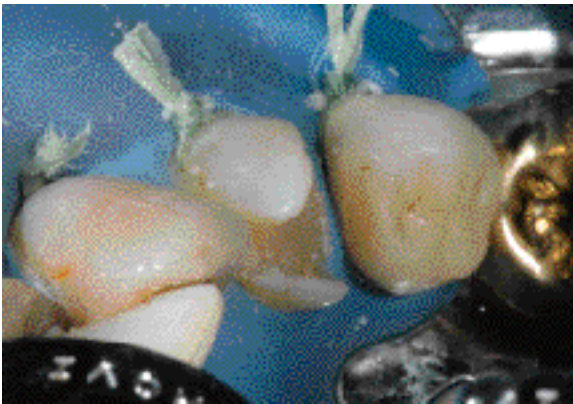


Figure 14-15G: A rubber dam is placed prior to fitting of the onlay with try-in paste.

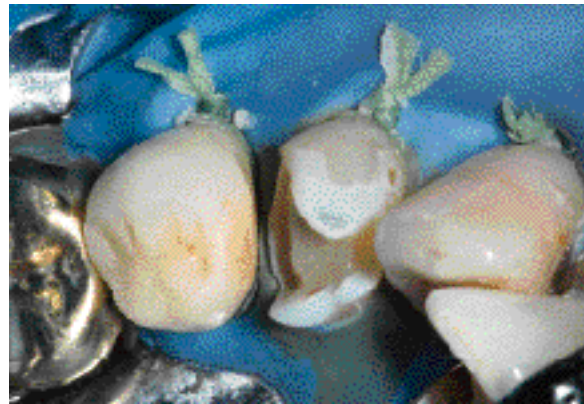

Figure 14-15H: The preparation is cleansed with pumice, then etched with phosphoric acid for 15 to 20 seconds before placing the bonding agent.

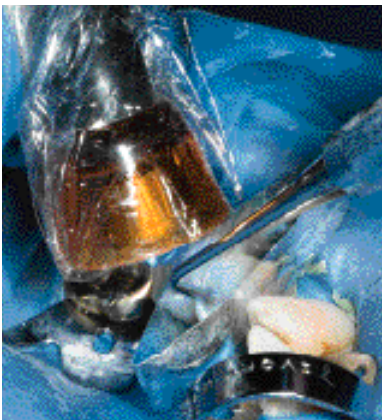

Figure 14-15I: The seated onlay is held in place with a Novatech PINT #11 (Hu-Friedy) instrument and polymerized for approximately 10 seconds to achieve initial set.

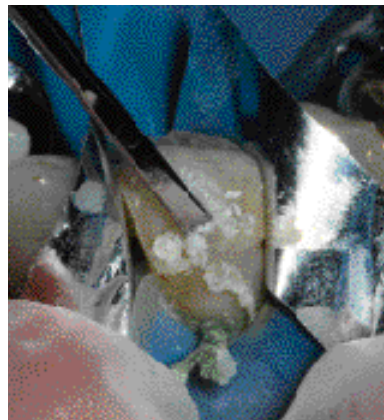


Figure 14-15J: Initial trimming of the excess is done with the chisel end of the Novatech 12 (Hu-Friedy) instrument.

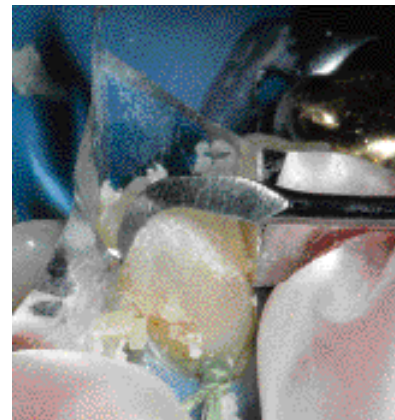


Figure 14-15K: The second stage of the initial trim is done with the sickle side of the Novatech 12 (Hu-Friedy) instrument. After trimming is complete, each surface—labial, lingual, and occlusal—is fully polymerized.

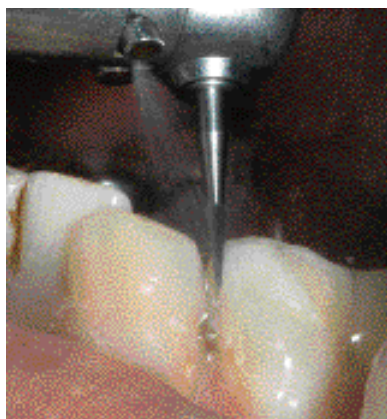

Figure 14-15L: Excess composite is trimmed with an ET4 (Brasseler).

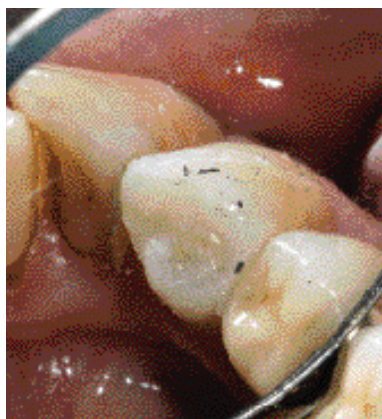

Figure 14-15M: Occlusion will be adjusted with the LVS-8 (Brasseler).

Mat). The danger in using anything thicker than this is in the increased possibility of not fully seating the restoration. It is wiser to insert the inlay or onlay and carefully observe the cementation set, with using a 5- to 8-second polymerization time and then removing

the interproximal excess cement before final polymerization. Make sure that floss will clear the contact area. If the floss does not go through, an ET3 or end cutting ET may be successful in removing the excess. However, if some of these thin pieces remain, they

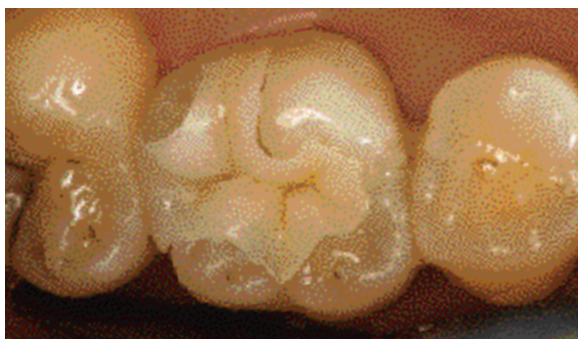

Figure 14-16A: Porcelain inlay try-in reveals that the shade is lighter than the tooth.

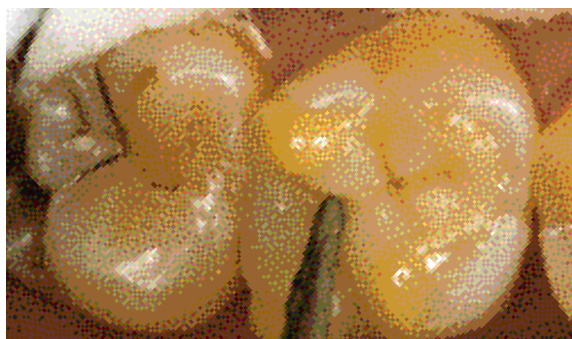


Figure 14-16B: Try-in and seating with a cement that has a yellow tint will alter the final color.

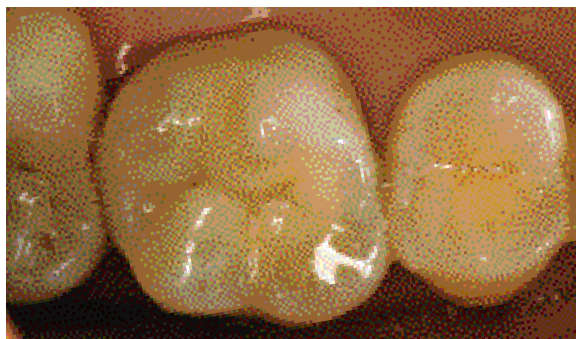
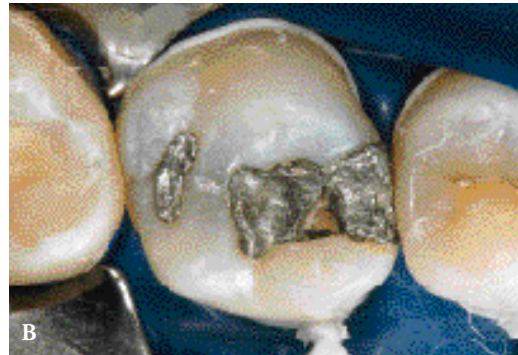
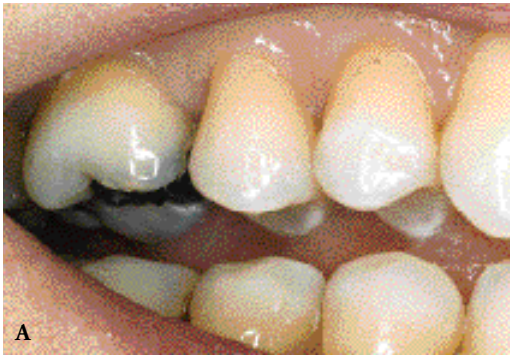
Figure 14-16C: Final result shows the inlay shade blending closer to that of tooth.



Figures 14-17A and B: This 37-year-old woman wanted to replace the defective and aging amalgam in her maxillary right first molar with a more esthetic restoration.

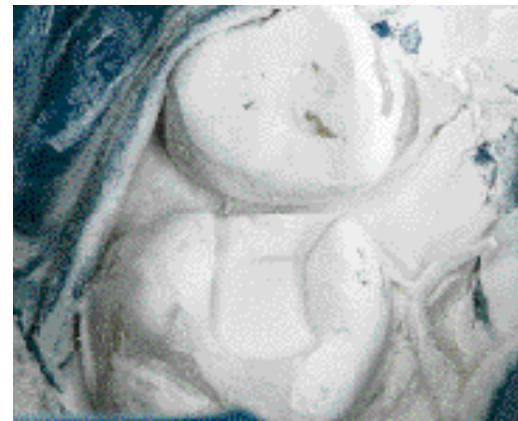
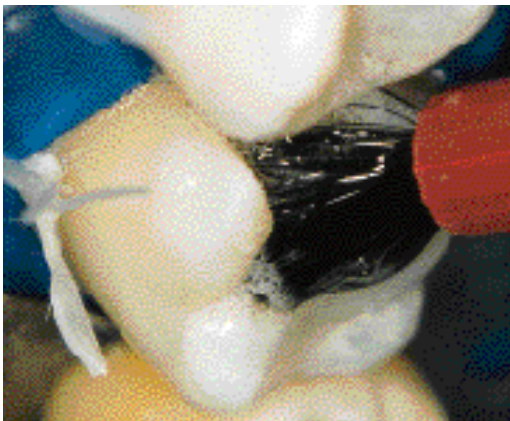


Figure 14-17C: The tooth is isolated with rubber dam and the preparation is coated with Imaging Liquid, a thin, oily substance.

Figure 14-17D: The tooth is sprayed with Imaging Powder, a white powder, to make it photoreceptive.

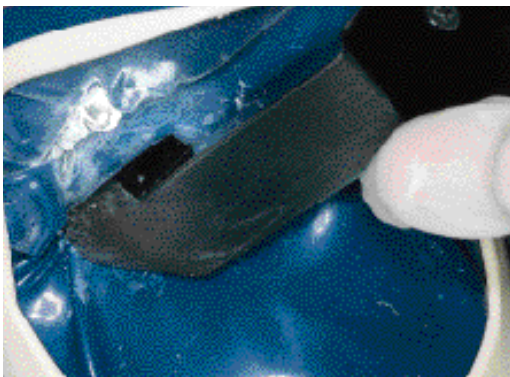


Figure 14-17E: A digitizing camera is used to record exact dimensions instead of making a traditional impression.



Figure 14-17F: The CAD/CAM (CEREC) calculates dimensions before milling of the porcelain inlay.



Figure 14-17G: A block of porcelain has been placed into the machine and is now being milled.




Figure 14-17H: After 7 minutes, the final porcelain restoration drops to the bottom of the tray.

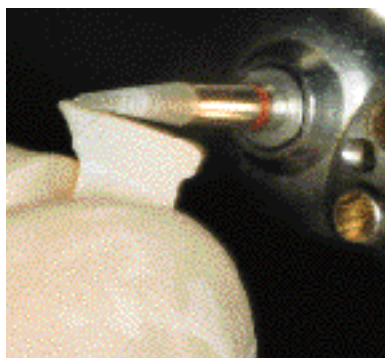


Figure 14-17I: A 30-micron diamond quickly cuts off the porcelain sprue.

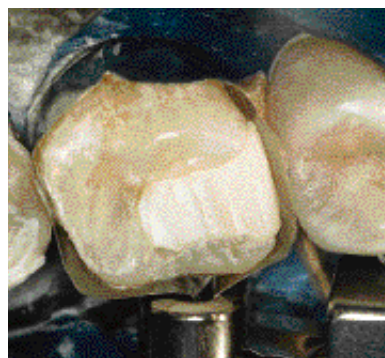

Figure 14-17J: The try-in shows a slight gap that will be filled with resin cement.

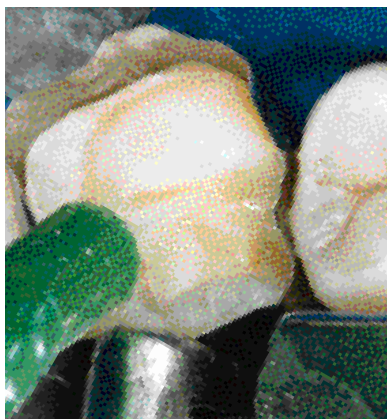


Figure 14-17K: The preparation is etched for 15 to 20 seconds.

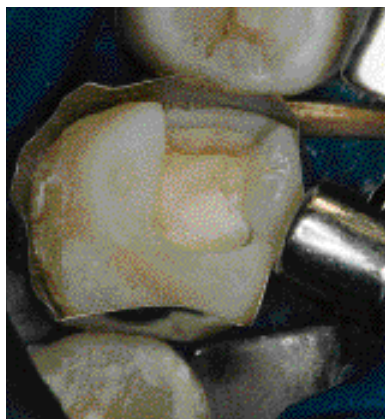


Figure 14-17L: The tooth is partially dried following the acid etch.

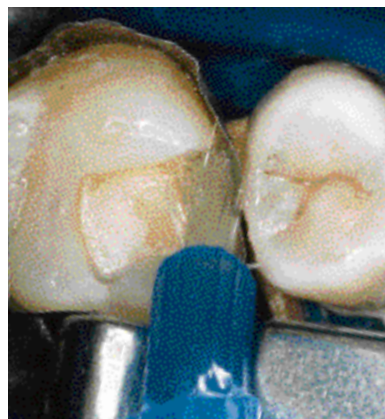


Figure 14-17M: The dentin bonding agent is applied in multiple coats, then air dried and polymerized.

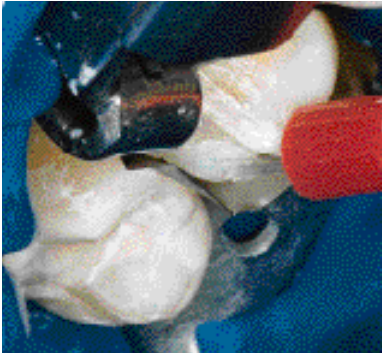


Figure 14-17N: The dentin bonding resin is applied.

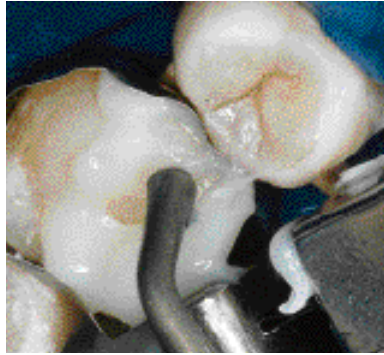


Figure 14-17O: The CEREC inlay is loaded with cement and placed in the preparation using a Goldstein #2 (anodized aluminum) or Flexi-Thin (Hu-Friedy).

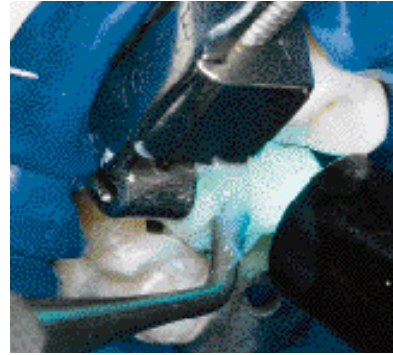


Figure 14-17P: As the inlay is held in place, initial polymerization is done for 5 to 8 seconds.

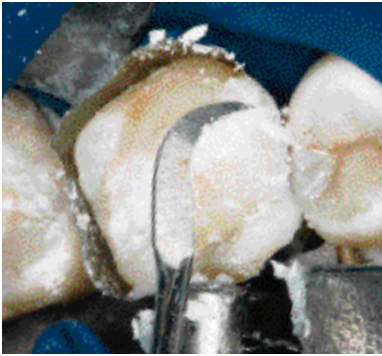


Figure 14-17Q: Preliminary trimming is done with the sickle-ended Novatech 12 (Hu-Friedy).

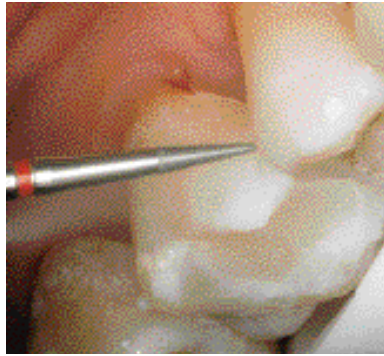


Figure 14-17R: Following final polymerization, contouring, and shaping is done with a DET-4 30-micron diamond (Brasseler).

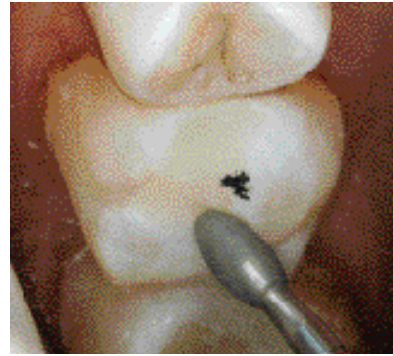

Figure 14-17S: Occlusal contouring, secondary anatomy, and occlusion refined with a DOS-1F 30-micron diamond (Brasseler).

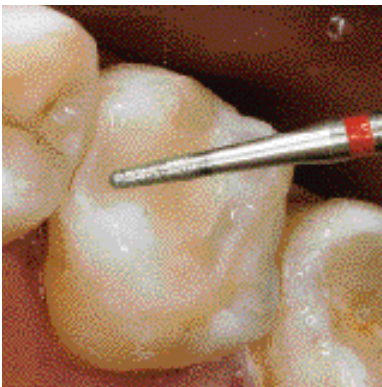

Figure 14-17T: Final occlusal anatomy and grooves are done with DOS 2 and 3 30-micron diamonds in sequence (Brasseler).

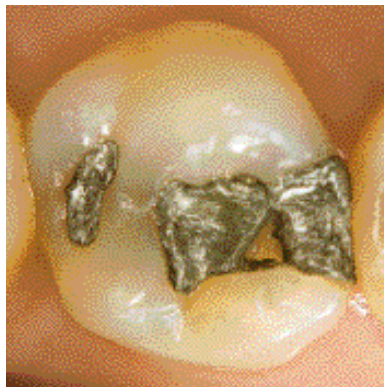


Figure 14-17U: Before photograph shows defective amalgam restorations.

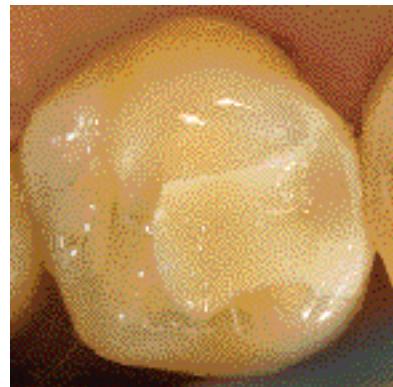

Figure 14-17V: After cementation of CEREC inlay. The disto-occlusal amalgam was separately replaced with a direct filled composite resin rather than doing one larger restoration that would destroy the transverse ridge.




Figure 14–18A: The desk-top Celay (Vident) machine has its own self-contained liquid cooling system.

may eventually be dislodged through normal occlusal function. Therefore, have the patient go home with a well-balanced occlusion, and check within 1 week in order to attempt clearing the contact area if excess

cement still remains. Occlusal adjustment is accomplished by using the OS1 in a 30- or 15-micron grit. If necessary, the OS2 then places or corrects initial grooves, followed by the OS3 for final groove finishing plus smoothing of any pits or fissures. The final finishing is done with either a 30-bladed carbide or 8-mm diamond (DETUF series). Final polishing can be accomplished with impregnated points found in the Shofu porcelain laminate finish-

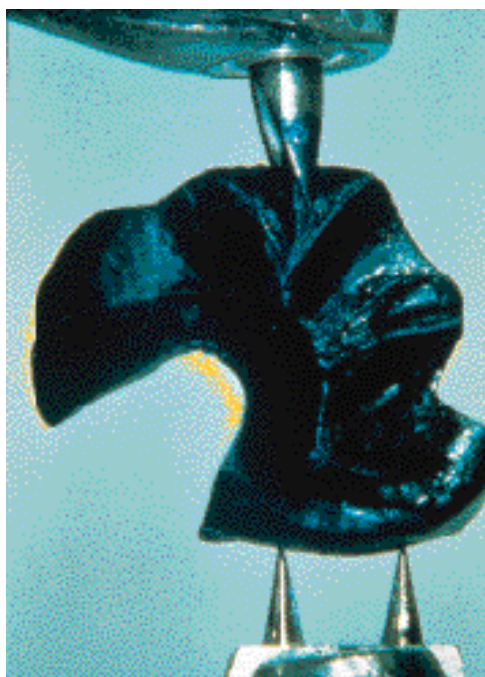

Figure 14–18B: The hardened wax pattern is placed in the scanning, or left side, of the Celay machine. Several different pin configurations are available to hold the different sizes and shapes of patterns.




Figure 14–18C: The proper shade and size of premanufactured Vita Celay porcelain ceramic blank is selected.



Figure 14-18D: The pattern is traced manually and the machine mills the ceramic blank to the exact shape and size of the pattern.

ing kit (see Figure 14-14I) in addition to a series of polishing discs (3M, Cosmedent). A step-by-step finishing sequence can be seen in Figures 14-17R to V.

Patient Instructions

Instructions to patients with new porcelain inlays or onlays are similar to those of porcelain veneers, with emphasis on good homecare and plaque removal.

Alternative Materials and Techniques

In addition to conventional laboratory-fabricated porcelain inlays and onlays, other material choices are:

- a. Dicor
- b. IPS-Empress

Other technique possibilities are:

- a. CEREC
- b. Celay

Dicor

Developed by Dow Corning, this was the first of the castable-glass ceramic systems introduced by

Dentsply. Its accuracy is excellent because it is waxed on a die and cast with the lost-wax technique that is similar to the one used for cast-metal restorations.

Clinically, there is one major difference between this system and the others. In the cast-glass system, it is advisable for the castings to be tried-in at a separate appointment before the surface stains are applied. At that appointment, the restorations are checked for any occlusal or contact discrepancies and adjusted as necessary. When the try-in adjustments are completed to your satisfaction, the restorations are returned to the laboratory, where the surface stains and characterizations are added using specific Dicor-compatible materials. Also, to improve the bonding strength of the composite resin cement to the tooth, the internal surfaces of the restorations are etched with 10% ammonium bifluoride.

Advantages of the cast-glass restoration include fit, wear, thermal cycling, and flexural strength. The fit of cast-glass restorations reportedly supersedes that of conventional porcelain, decreasing the amount of resin bonding composite at the margins. Thus the potential for ditching is decreased. In addition, the wear on the opposing occlusion is predicted to be less than that caused by conventional porcelains. Finally, cast-glass restorations' thermal cycling properties approximate that of enamel, while flexural strength is reportedly greater than conventional enamel.

Disadvantages of the cast-glass restoration include surface colorant, additional chairside time, and tech-

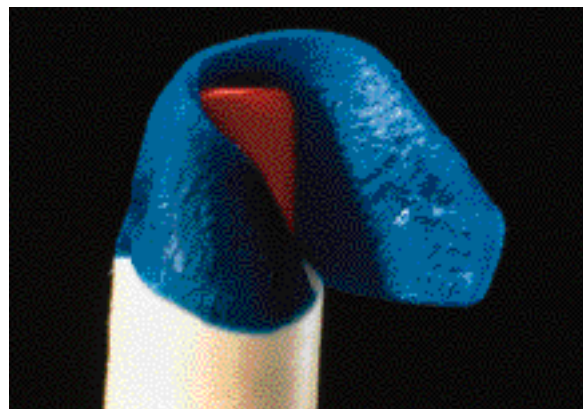


Figure 14-18E: The coping is modeled using the Celay-Tech modeling material, which has been rolled out to an exact thickness.

nique-sensitivity. Since the colorant is a surface stain, any grinding on the restoration leaves an unesthetic opaque white area. Once stained, the surface cannot be adjusted without compromising esthetics. Therefore, it is necessary to allow the additional chairside time for the separate appointment to fit and adjust contacts, anatomic form, and occlusion prior to staining. The entire laboratory process of cast-glass restorations is technique-sensitive, from the casting through to the staining of the restorations.

Unfortunately, a rather high fracture rate has diminished the use of Dicor. Roulet⁵³ reports that after 4 years, inlays placed by senior dental students had a 25% failure rate whereas his own placement showed the same failure rate after a 6-year period.

The IPS-Empress System

Empress is an all-ceramic injection molded material (Ivoclar-Vivadent, Liechtenstein). The restoration is modeled in wax on a custom-shaded die system, then sprued and invested in a special material. After burnout of the wax, and under very high temperature and vacuum, the heat-softened ceramic ingot is heat pressed by hydrostatic pressure into the mold. It should be noted that inlays and onlays are typically fabricated with uncolored ingots and they

then take on the underlying and adjacent tooth colors. This popular method for inlay-onlay ceramic construction is also utilized to fabricate full crowns and is further covered in Chapter 15.

The CEREC System

Exciting advances in esthetic dentistry plus demand for more cosmetic restorations have sparked increased interest in computer-generated restorations. CEREC, an acronym for *ceramic reconstruction*, is a self-contained system that uses an optical scanning procedure that replaces the conventional impression, a monitor, and a computer-controlled milling machine.

CEREC (Sirona) integrates computer technology with CAD/CAM and infrared optical imaging cameras, which then allows the design and milling of these porcelain/ceramic materials.

The system's chief appeal is its immediacy: restorations can be milled, fitted, seated, and finished in a single appointment. Also, while not quite up to the standards of lab-fabricated restorations, these restorations, milled from a block of porcelain, can have an integral color that blends satisfactorily with the natural dentition.




Figure 14-18F: The milling procedure is similar to that used for inlays and onlays. The pattern being traced is on the left, or scanning side of the machine.




Figure 14-18G: As the pattern is being traced on the left side, the coping is being milled on the right side of the machine. Several new tools, specially designed for crowns and bridges, are used to obtain a precise reproduction of the pattern.




Figure 14-18H: Three-unit In-Ceram bridges are fabricated in a similar manner using the larger Vita factory produced In-Ceram bridge blank. The milling procedure is identical to that used for milling crowns and can be completed in about 40 minutes. You can have a finished In-Ceram bridge understructure in just a few hours.

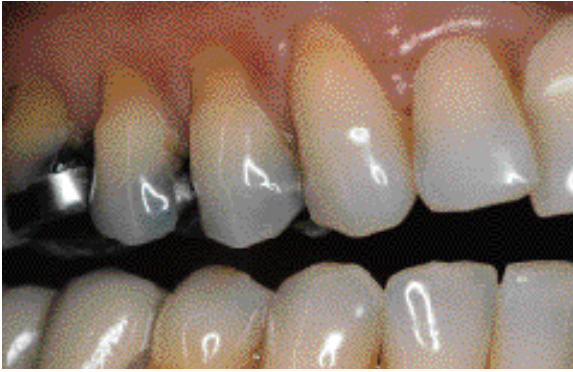

Figure 14-19A: This 62-year-old female had erosion and discoloration of her maxillary teeth. She was particularly concerned about the defective amalgam restorations showing through the maxillary right bicuspids and first molar.

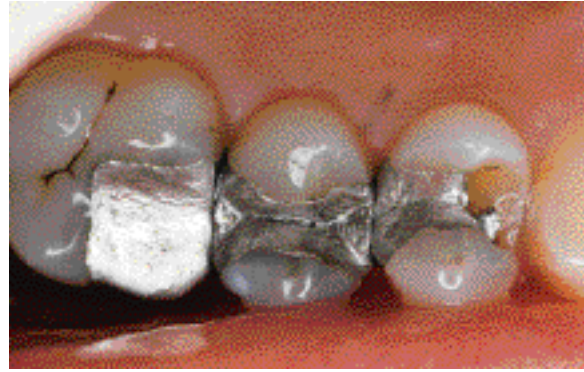

Figure 14-19B: The occlusal view shows how closely involved the posterior amalgams were to the buccal surface. Choices for treating this problem were posterior composites, posterior ceramic inlays/onlays, or full crowns. The compromise solution was the laminate onlay.

An advantage of computer-generated restorations is that they provide a more economical restoration than the traditional, laboratory-produced ones. CEREC is time and cost saving for both patient and dentist since it eliminates the impression, temporary restoration, and the laboratory. Limitations of the early Cerec systems included their inability to do internal staining and the presence of greater marginal gaps than with conventional, indirect laboratory methods. The later generation, Cerec 2 has improved features in several areas the software for the camera and image processing and design automates the calibration function and adds contouring aspects to the design capabilities; the central processing unit is more powerful in terms of speed, memory, and storage while adding color and graphics capabilities; and finally, the 3-D camera

and optical impression hardware have been upgraded in areas such as depth of field and frame frequency. In addition to the inlays and onlays produced by the original systems, the later Cerec 2 can also manufacture veneers and crowns.

Cerec 2 uses Vita Mark II (Vident) ceramic blanks along with new crown manufacturing software to allow for esthetic CAD/CAM anterior crowns and veneers as well as posterior restorations.⁴⁴ The superior esthetics required for anterior restorations may now be achieved through various forms of custom shade modification including external staining (Vita Shading Paste and Glaze, Vident) and in-office firing in a small porcelain furnace (MiniGlaze2, Ney Dental).⁶⁰

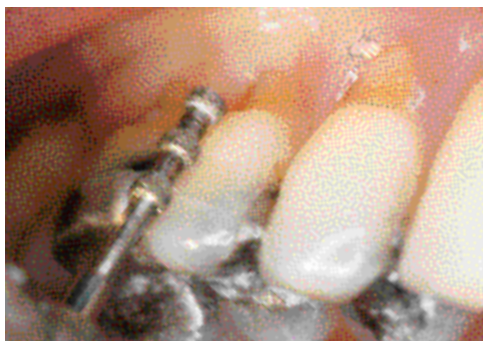

Figure 14-19C: The three-tiered depth cutter (LVS-2, Brasseler) helps gauge the enamel reduction on the labial surface.



Figure 14-19D: The ceramic inlay/onlay system (Brasseler) is used to prepare inlays or onlays.

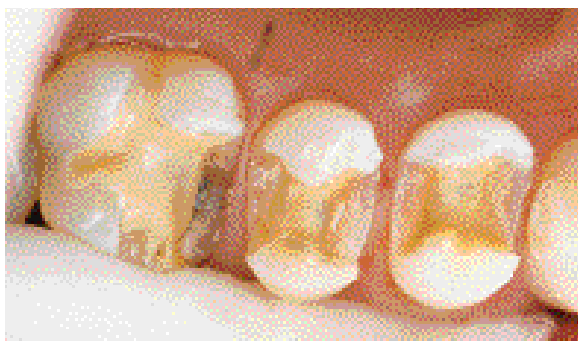

Figure 14-19E: CIP-I (Brasseler) diamond was used to prepare the occlusal portion, removing all defective amalgam, and then glass ionomer liners were placed as build-ups for the dentin defects.

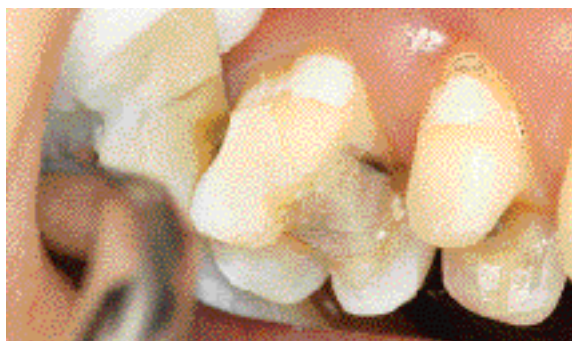

Figure 14-19F: The buccal view shows that the bucco-occlusal wall is reduced sufficiently so that the porcelain can lap over to the occlusal surface and have sufficient thickness and strength to resist breakage.

The improved features, which also include a fully automated grinding process, result in higher accuracy of fit, automatically generated occlusion, free cavity design, overlays as an alternative to full crowns, unlimited anatomical veneer preparation with incisal edge coverage, and increased ease of use.⁴²

Cerec 2 uses a smaller diamond grain size to increase the marginal integrity of the restorations. In a study by Mormann,⁴⁴ grinding precision of the Cerec 2 was a 2.4 times higher than the previous generation of machine. By enlarging the grinding unit from 3 to 6 axes and upgrading the software for the occlusion and the complex machining of the floor parts, design limitations in the early systems have been eliminated. Further, due to more sophisticated technology, anatomically adapted

occlusion can be created, and with little additional work, the occlusion can be morphologically finished using a 40-micron contouring diamond and an 8-micron finishing diamond and be polished with flexible discs.²⁰

The Cerec 2 system's software permits custom veneer preparations with anatomical reduction as well as the design of the veneer and its direct manufacturing. Class IV situation combined with incisal edge coverage may be designed directly without using a wax template for the optical impression. There is also an extended machining option with allows for the direct manufacture of any three-dimensional shape. The veneer technique may also be used for fixing or replacing veneers in existing crowns and bridges.⁴²

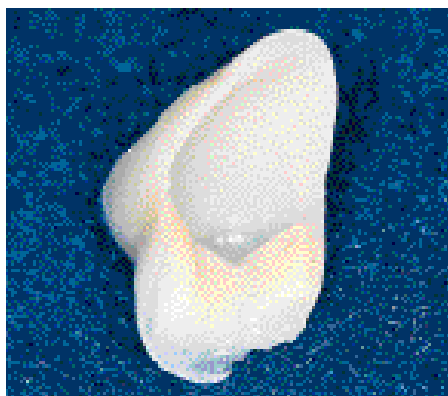

Figure 14-19G: This view of the laminate onlay shows the buccal portion and how it is connected to the posterior inlay portion.

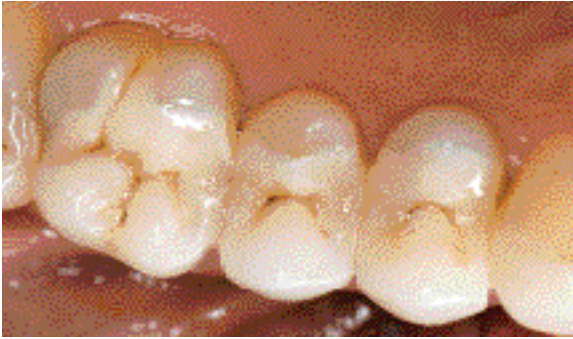

Figure 14–19H: This occlusal view shows the laminates cemented in place. Occlusion is correctly supported and there have been no fractures in the 10-year postoperative history.

The 3-D camera for the Cerec 2 has been redesigned to have a detachable cover that can be heat sterilized. Due to optimization of the optical beam path by means of symmetric beam geometry, major measurement errors in the measuring volume of a typical inlay have been brought down to less than ± 25 micrometer.⁴² therefore, because of both a smaller camera pixel size and the higher accuracy in the depth measuring, the resolution of the optical impression has been doubled when compared to the Cerec 1 unit.

Research. Five-year results of the clinical and scanning electrophotomicrograph (SEM) evaluations of the first CEREC MOD-inlays were reported by Mormann and Krejci who stated “CEREC adhesive ceramic inlays have completed a clinical service time of 5 years with convincing clinical success.”⁴⁵

Isenberg, Essig, and Leinfelder reported 3-year results and noted that “none of the restorations exhibited secondary caries throughout the three-year period. Regardless of the gap dimension, both horizontally and vertically, none of the restorations showed any clinical evidence of marginal discoloration or microleakage.”³³

They concluded that, “on the basis of information generated from this three-year study, it is apparent that the CEREC CAD/CAM system is most effective in developing ceramic restorations of excellent clinical quality. If the marginal gap can be kept to a reasonable small dimension, the clinical success of these ceramic restorations seems assured.”

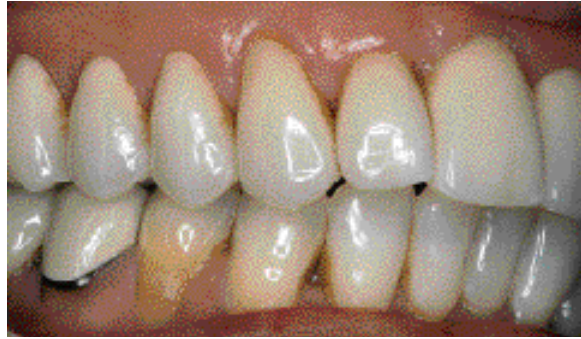

Figure 14–19I: The buccal view shows that the laminate onlays blend in as if they were full crowns. This means from a normal viewing, the restoration looks more like natural tooth, even more so than a simple laminate veneer, which may not overlap onto the occlusal surface.

An earlier study by Sturdevant et al.,⁵⁸ evaluating the marginal gap of CEREC inlays through computer enhancement, reported an average cement thickness of 89 microns on occlusal cavosurface margins. Although some clinicians have questioned the marginal gap created by less than perfect fits, Heymann et al.³¹ in a 2-year study at the University of North Carolina reported excellent clinical performance, with a mean cumulative cement loss of only 50 microns.

In a continuation of the same clinical study,³⁰ Heymann et al. concluded that “after three years of clinical evaluation, CEREC ceramic restorations appear to be among the finest aesthetic posterior restorations ever evaluated in our operative dentistry clinical research program.” No clinical failures have been noted to date in this study.

Further, the 4-year study of 50 inlay Cerec restorations conducted by Heymann et al.²⁹ found that marginal cement loss was relatively low, with an unusual decrease in measured cement wear from the third to the fourth year. They also reported that the inlays rate vary highly in areas such as color matching, interfacial staining, secondary caries occurrence, anatomic contour, marginal adaptation, surface texture, and postoperative sensitivity. They concluded that they expect CAD/CAM restorations to have significant success for this restorative approach.

Shade Selection. Selecting the shade of the CEREC ceramic block requires visualizing the size, shape, and location of your intended restoration. Ide-

ally, determine the block shade at the outset before the tooth has had a chance to dry out and shift color. Choose a colored block slightly darker than you think if you are selecting the color after your preparation is completed. If color characterization is desired, you can make adjustments using stains or shaded bonding materials at the time of cementation.

Preparation. Since the computer cannot accurately read bevels, convexities, steps, or undefined angles, it is important that the prepared walls be as straight, uniform, and flat as possible. The ideal occlusal wall should be vertical and slightly divergent to the occlusal surface as in the typical inlay preparation (see Figure 14–17D). In general, a slightly divergent wall lends itself to a sharper image on the screen, making it easier to be read by the computer. If there is a defect or undercut, use a light polymerized glass ionomer to fill it in.

Optical Impression. The completed preparation is then coated with a special white optical powder, which clearly defines the surfaces and angles for the intraoral camera. For best results, a rubber dam should be used to obtain complete tissue and moisture isolation because oral fluids may contaminate the powder, and the humidity of the oral cavity will tend to fog the camera and give a less-than-clear image.

Design and Milling Procedures. During the design phase the computer analyzes the data, designs the restoration, and provides instructions to the milling machine. This process usually takes from 2 to 8 minutes. The computer then selects the size of the ceramic block to be used in the milling process. A 4-cm diamond wheel, driven by an internal water turbine is then used to automatically mill the restoration according to the instructions received from the computer. This process generally takes 4 to 7 minutes. Although the milling process can produce cuspal inclines on the occlusal surface of the restoration, it cannot create secondary occlusal anatomy. This is developed by the operator intraorally following cementation of the inlay or onlay.

Placement. The marginal gap should be under 100 micrometers, particularly on the occlusal surface. Isenberg et al.³³ indicate that if the gap is small, the wear is minimal. After the fit is assessed and approved, the restoration can be cemented in place using a dual-cure microfilled composite resin

cement. Research has shown that the microfilled particle composite wears two to three times better than a hybrid composite.

The Cerec 2 is a CAD/CAM system that produces full ceramic restorations of various kinds in a single step, by means of a fully automated grinding process, within a short period of time. Although computer-generated restorations can offer a lower costing tooth-colored restoration for the patient, it may not be ideal for the patient who is a color perfectionist. However, it should be noted that, according to Masek,⁵ the ability to modify the ceramic material for specific characterization can be accomplished with predictable results. Therefore, for the great majority of patients, the advantage of a one-appointment ceramic restoration outweighs this slight esthetic deficit and makes it an ideal solution (Figures 14–17A to V).

The Celay System

The Celay System is an extremely accurate and efficient new computerized method for fabricating porcelain inlays, onlays, and veneers and In-Ceram crown copings and bridge frameworks (Figure 14–18A to H). The technique uses the concept of copy-milling, which is similar to making a duplicate key. The restorations are milled from high-strength, premanufactured Vita porcelain and In-Ceram blanks, which have physical properties superior to those of materials used with conventional techniques (Figure 14–18C). The factory-manufactured blanks are homogeneous, have a high density, and virtually zero porosity or residual stress, resulting in low failure rates. Another important consideration is that the blanks use an average 4-micron particle size, which results in their wear characteristics being similar to natural tooth enamel. Although marginal gaps of only 40 to 60 microns can be achieved, Eidenbenz et al. confirmed tolerances held for Forcelay milled inlays were consistently within 50 microns. Kawai et al. reported that their study showed the mean gap with Celay inlays was less than 100 microns, which in their opinion makes it clinically acceptable. Staining and glazing can be added to characterize the finished restoration.

Modeling of the inlay/onlay or veneer pattern can be accomplished either directly or indirectly and takes only 8 to 10 minutes depending upon the complexity of the restoration. All surfaces of the ceramic restoration are then milled on the Celay

machine, including the occlusal morphology. Milling times range from 10 to 15 minutes, allowing for one appointment service for dentists having an in-office laboratory, or even same-day or 1-day turnaround when using a commercial laboratory.

A later addition to the Celay system is the ability to mill In-Ceram crown copings and three-unit In-Ceram bridge frameworks. The technique is similar to that used for fabricating inlays, onlays, and veneers. The crown coping or bridge understructure is modeled using a special, highly-filled, no-shrink composite, which is easily carved with a modeling instrument and hardened with a polymerization light. This pattern is then placed in the left, scanning side of the machine using one of several different methods of fixation to accommodate different configurations (Figures 14–18F to G). The blank is placed in the right, or milling side of the machine. Milling starts with the systematic scanning of the pattern using a series of various scanning tools—a large and a small disc, a ball, and a cylindrical pin followed by a conical pin. Each and every scanning motion is precisely replicated on the milling side using the machine's eight axes of movement, which allow all surfaces of the blank to be milled while still in the machine (Figure 14–18D). Bulk reduction is performed using a rough diamond milling disc followed by a fine milling disc and the ball for final contouring. The cylindrical and conical diamond milling tools allow milling of every detail, even in the smallest areas. Milling time for an In-Ceram crown coping is about 20 minutes and for a three-unit bridge framework it is about 40 minutes (Figure 14–18H). The milled In-Ceram coping is then infiltrated using a special glass for 25 minutes at 1100°C (45 minutes for the bridge framework) using a conventional furnace. The crown or bridge is then built-up using Vitadur Alpha porcelain, which is precisely formulated for the In-Ceram technique. Staining and glazing are done in the usual manner.

Using the Celay technique, a finished, milled In-Ceram crown can be available in about 1½ hours as compared to the conventional technique which requires nearly 18 hours. Similarly, a three-unit bridge can be completed in about 2½ hours.

Laminate Onlay

There are times when you may wish to veneer the buccal surface of a posterior tooth but encounter

a defective one-, two-, or three-surface posterior restoration. The question is: Should you further reduce the buccal wall and have only a strong lingual wall to help retention, or would it be better to save the buccal enamel? You could save the buccal wall by laminating the buccal surface and extending that veneer into the mesio-occlusodistal preparation, making it a laminate onlay (Figure 14–19). If you attempt this type of restoration, make sure that you have adequate bucco-occlusal clearance so that the porcelain is thick enough to be adequately strong in this area to resist fracturing. In addition to conserving enamel, one major advantage of the laminate onlay is in reducing patient cost by combining two restorations into one.

CONCLUSION

The original purpose of offering reversible bonded restorations was to be able to take advantage of future technology. That seems to have been a worthwhile approach. Many patients who 10, 15, even 20 years ago trusted us to give them restorations with what was then a new procedure called bonding, still have their composite resin posterior restorations and veneers in place. Some return to take advantage of the increasingly better materials and replace their composite restorations with porcelain restorations. The future of esthetic restorative dentistry will no doubt see considerable improvement in longer-lasting cementing materials, ease of construction, and in the porcelain materials themselves. Finally, future advancements in CAD–CAM capability will no doubt have a positive effect on all aspects of both anterior and posterior restorations.

[Figures 14–10A to H, 14–11A to D, 14–12A to H, courtesy of Pinhas Adar, M.D.T. Oral Design Center, Atlanta, GA.]

References

1. Alberts HF. Tooth colored restorations, 7th edn. Catato, CA: Alto Books, 1985.
2. Bassiouny MA, Pollack RL. Esthetic management of perimolysis with porcelain laminate veneers. *J Am Dent Assoc* 1987;115:412–7.

3. Bayne SC, Brunson WD, Shurdevant JR, Roberson TM, Wilder AD, Taylor DF. Three-year clinical evaluation of a self-cured posterior composite resin. *Dent Mater* 1989;5:127-32.
4. Boksmán L, et al. Etched porcelain labial veneers. *Ont Dent* 1985;62(1):15-9.
5. Boksmán L, Jordan RE. Posterior composite restoration techniques. *Restorative Dent* 1985;1(5):120, 122, 124-5.
6. Bowe RL. Development of a silica-resin direct filling material. Report 6333. Washington: National Bureau of Standards, 1958.
7. Bowen RL. Properties of a silica-reinforced polymer for dental restorations. *J Am Dent Assoc* 1963;66:57-64.
8. Bowen RL, Paffenbarger GC, Sweeney WT. Bonding porcelain teeth to an acrylic resin denture base. *Dent Assoc* 1967;44:1018-23.
9. Buonocore MG. A simple method of increasing the adhesion of acrylic filling materials to enamel surfaces. *J Dent Res* 1955;34:849-85.
10. Calamia JR. Clinical evaluation of etched porcelain veneers. *Am J Dent* 1989;2(1):9-15.
11. Calamia JR. Etched porcelain facial veneers: a new treatment modality based on scientific and clinical evidence. *NY J Dent* 1983;53:255-9.
12. Calamia JR. Etched porcelain veneers: the current state of the art. *Quintessence Int* 1985;16:5.
13. Calamia JR, Simonsen RJ. Effect of coupling agents on bond strength of etched porcelain. *J Dent Res* 1984;63:162-362.
14. Christiansen GJ. Veneering of teeth. State of the art. *Dent Clin North Am* 1985;29:373-91.
15. Colley RL, Luvlow RM, Brown FH. Effects of air-power abrasive instrument on porcelain. *J Prosthet Dent* 1988;60:440-3.
16. Dietschi, Didier, Maeder, et al. In vitro resistance to fracture of porcelain inlays bonded to tooth. *Quintessence Int* 1990;21:823-31.
17. Faunce FR. Method and apparatus for restoring badly discolored, fractured or cariously involved teeth. U.S. Patent Number: 3,986,261; Filed Dec. 5, 1973; Date of Patent: Oct. 19, 1976.
18. Faunce FR. Tooth restoration with preformed laminated veneers. *Dent Survey* 1977; 53(1):30.
19. Faunce FR, Myers DR. Laminate veneer restoration of permanent incisors. *J Am Dent Assoc* 1976;93:790-2.
20. Feher A, Mormann WH. Die ausarbeitung von lkeramikrestorationen mit superfeinen diamantinstrumenten. *Schweiz Monatsschr Zahnmed* 1995;105:474-9.
21. Garber DA. Direct composite veneer versus etched porcelain laminate veneers. *Dent Clin North Am* 1989; 33:301-4.
22. Garber DA, Goldstein RE, Feinman RA. Porcelain laminate veneers. Chicago: Quintessence Publishing Co., Inc., 1988.
23. Goldstein RE. Communicating esthetics. *NY State Dent J* 1985;15:477-9.
24. Goldstein RE. Esthetics in dentistry. Philadelphia: J.B. Lippincott, 1976.
25. Goldstein RE. Status report: dentistry in the 1980's. *J Am Dent Assoc* 1988;116:617-24.
26. Greggs TS. Method for cosmetic restoration of anterior teeth. United States Patent Number: 4,473,353. Filed April 15, 1983. Date of Patent: Sept. 25, 1984.
27. Haywood VB, Heymann HO, Scurria MS. Effects of water speed and instrumentation on finishing and polishing porcelain intra-orally. *Dent Mater* 1989;5:185-8.
28. Heymann. In: Garber DA, Goldstein RE, Feinman RA, eds. Porcelain laminate veneers. Chicago: Quintessence, 1988;126-32.
29. Heymann HO, Bayne SC, Sturdevant JR, et al. The clinical performance of CAC/CAM generated ceramic inlays. *J Am Dent Assoc* 1996;127:1171-81.
30. Heymann HO, Wilder AD, Sturdevant JR, et al. Three-year clinical performance of CEREC CAD/CAM generated MGC inlays. *J Am Dent Assoc* 1996;127: 1171-81.
31. Heymann HO, Wilder AD, Sturdevant JR, et al. Two-year clinical performance of CEREC CAD/CAM generated inlays. *J Dent Res* 1992;71:207, Abstr 814.
32. Horn HR. A new lamination: porcelain bonded to enamel. *NY State Dent J* 1983;49:401-3.

33. Isenberg BP, Essig ME, Leinfelder KF. Three-year clinical evaluation of CAD/CAM restoration. *J Esthet Dent* 1992;4:234-8.
34. Jackson RD, Ferguson RW. An esthetic, bonded inlay/onlay technique for posterior teeth. *Quintessence Int* 1990;21(1):7-12.
35. Jensen ME. A two year clinical study of posterior etched porcelain resin-bonded restorations. *Am J Dent* 1988;1(1):27-33.
36. Jensen ME, Redford DA, Williams BT, Gardner F. Posterior etched-porcelain restorations: an in vitro study. *Compendium* 1987;8:615-7, 620-2.
37. Jones DA. Effects of topical fluoride preparations on glazed porcelain surfaces. *J Prosthet Dent* 1985;53:483-4.
38. Jordan RE, Suzuki M. The porcelain inlay technique for posterior restoration. *J Esthet Dent* 1989;1:41-4.
39. L'Estrange P, Benenius J, Williams L. Intraoral application of a new technique for clinical examination of oral tissues at high magnification. *Oral Surg Oral Med Oral Pathol* 1989;67:282-5.
40. McLaughlin G. Porcelain fused to tooth—a new esthetic and reconstructive modality. *Compend Contin Dent Educ* 1985;5:430-5.
41. McLean JW. Long-term esthetic dentistry. *Quintessence Int* 1989;20:701-98.
42. Mormann W, Bindl A. The new creativity in ceramic restorations: dental cad-cim. *Quintessence Int* 1996;27:821-7.
43. Mormann WH, Brandestini M, Lutz F, Barbakow F. Chairside computer-aided ceramic inlays. *Quintessence Int* 1989;20:329-39.
44. Mormann WH, Schug J. Grinding precision and accuracy of fit of cerec 2 cad/cam inlays. *JADA* 1997;128:47-53.
45. Mormann W, Krejci I. Computer-designed inlays after five years in-situ: clinical performance and scanning electron microscopic evaluation. *Quintessence Int* 1992;23:109-15.
46. Nasedkin JN. Porcelain posterior resin bonded restoration: current perspectives on esthetic restorative dentistry, Part II. *J Can Dent Assoc* 1988;54:499-506.
47. Nixon R. Use of porcelain laminate veneers enhances foreshortened, worn teeth. *Dent Today* 1984;10:27-31.
48. Nixon R. *The chairside manual for porcelain bonding*. Wilmington, DE: B.A. Videographics, 1987.
49. Oliva RA. Handling and bonding of porcelain veneers: clinical evaluation of a new veneer handling instrument. *Quintessence Int* 1988;19:593-8.
50. Pincus CR. Building mouth personality. *J Calif Stud Dent Assoc* 1938;14:125-9.
51. Reid JS. Tooth color modification and porcelain veneers. *Quintessence Int* 1988;19:477-81.
52. Rochette AL. A ceramic bonded by etched enamel and resin for fractured incisors. *J Prosthet Dent* 1975;33:278-793.
53. Roulet JF. Longevity of glass ceramic inlays and amalgam—results up to 6 years. *Clin Oral Invest* 1997;1:40-6.
54. Rucker LM, Richter W, MacEntree M, Richardson A. Porcelain and resin veneers clinically evaluated: two year results. *J Am Dent Assoc* 1990;121:594-6.
55. Sheth JJ, Jensen ME. Luting interfaces and materials for etched porcelain restorations. *Am J Dent* 1988;1:225-35.
56. Simonsen RI, Calamia JR. Tensile bond strength of etched porcelain. *J Dent Residents Abstracts* no. 1154. 1983;March:
57. Strassler HE, Nathanson D. Clinical evaluation of etched porcelain veneers over a period of 18-42 months. *J Esthet Dent* 1989;1:21-8.
58. Sturdevant HR, Heymann HO, Wilder AD, et al. Composite cement thickness of CEREC CAD/CAM ceramic inlays. *J Dent Res* 1991;70:296, Abstr 245.
59. Tja AHL, Dunn JR, Sanderson LR. Microleakage patters of porcelain and castable ceramic laminate veneers. *J Prosthet Dent* 1989;61:276-82.
60. Weidhahn K. Controlled individualization of cerec veneers, cad/cim in aesthetic dentistry. *Quintessence Int* 1996;173-84.
61. Weinstein AR. Anterior composite resins and veneers: treatment planning, preparing, and finishing. *J Am Dent Assoc Special Issue*:38E-45E, 1988;

62. Wiley MG. Effects of porcelain on occluding surfaces of restored teeth. *J Prosthet Dent* 1989;61:133–7.

Additional Resources

Antonson DE, Benedetto MD. Longitudinal intensity variability of visible light curing units. *Quintessence Int* 1986;17:819–20.

Barghi N, Berry TG. Post-bonding crack formulation in porcelain veneer. *J Esthet Dent* 1997;9:51–4.

Barkmeier WW, Menis DL, Barnes DM. Bond strength of a veneering porcelain using newer generation adhesive systems. *Pract Periodontics Aesthet Dent* 1993;5(6):50–5.

Barnes DM, Strassler HE. Veneers: a comparison of three techniques. *Esthet Dent Update* 1990;1(5):74–80.

Barnes DM, Strassler HE, Holston AM. Castable ceramic veneers. *J Esthet Dent* 1989;1:86–92.

Benenius J, L'Estrange P, Angmar-Mansson B. Erosion: guidelines for the general practitioner. *Aust Dent J* 1988;33:407–11.

Berksun S, Kedici PS, Kalipcilar B. A matrix procedure for reproducing natural or carved tooth contours in porcelain laminate veneers. *J Prosthet Dent* 1994;71:203–5.

Bichacho N. Porcelain laminates: integrated concepts in treating diverse aesthetic defects. *Pract Periodontics Aesthet Dent* 1995;7(3):13–23.

Biderman JD. Direct composite resin inlay. *J Prosthet Dent* 1989;62:294–53.

Blair KF, Koeppen RG, Schwartz RS, Davis RD. Microleakage associated with resin composite-cemented, cast glass ceramic restoration. *Int J Prosthodont* 1993;6:579–84.

Brockman SL, Scott RL, Eick JD. A scanning electron microscopic study of the effect of air polishing on the enamel-sealant surface. *Quintessence Int* 1990;21:201–6.

Burke FJ, Main JR, Watts DC. Glove contamination of etched porcelain surfaces and bond strength to enamel. *Am J Dent* 1996;9(1):40–2.

Cavanaugh RR, Croll TP. Bonded porcelain veneer masking of dark tetracycline dental stains. *Pract Periodontics Aesthet Dent* 1994;6(1):71–9.

Chalifoux PR. Porcelain veneers. *Curr Opin Cosmet Dent* 1994;58–66.

Chalifoux PR, Darvish M. Porcelain veneers: concept, preparation, temporization, laboratory, and placement. *Pract Periodontics Aesthet Dent* 1993;5(4):11–7.

Christiansen GJ. Tooth-colored inlays and onlays. *J Am Dent Assoc* 1988;117(4):12E–7E.

Christiansen GJ. Veneers: state of the art. Oral presentation at American Academy of Esthetic Dentistry, Maui, Hawaii, August 1983.

Collard S, Vogel J, Ladd G. Respirability, microstructure, and filler content of composite dusts. *Am J Dent* 1991;4:143–52.

Comfortes I. Porcelain veneer color blending. *J Calif Dent Assoc* 1996;24(10):45–50.

Comparison of veneer types. *Clinical Research Associates Newsletter*. 1986;10(2).

Costello FW. Porcelain veneer adhesion systems. *Curr Opin Cosmet Dent* 1995:57–68.

Coyne BM, Wilson NH. A clinical evaluation of the marginal adaptation of porcelain laminate veneers. *Eur J Prosthodontics Restorative Dent* 1994;3(2):87–90.

Council on Dental Materials, Instruments, and Equipment, Council on Dental Therapeutics. Status report: effect of acidulated phosphate fluoride on porcelain and composite restorations. *J Am Dent Assoc* 1988;116:115–6.

Davidson CL, Kemp-Scholte CM. Shortcomings of composite resins in Class V restorations. *J Esthet Dent* 1989;1:1–4.

Della Bona A, Northeast SE. Shear bond strength of resin bonded ceramic after different try-in procedures. *J Dent* 1994;22:103–7.

Dickerson WG. A functional and esthetic direct resin technique. *Pract Periodontics Aesthet Dent* 1991;3(7):43–7.

Douvitats G. Effect of cavity design on gap formation in Class II composite resin restorations. *J Prosthet Dent* 1991;65:475–9.

Eames WB, Rogers LB. Porcelain repairs: retention after one year. *Oper Dent* 1979;4:75–7.

- Eidiwany M, Powers JM, George LA. Mechanical properties of direct and post-cured composites. *Am J Dent* 1993;6:222-4.
- Farah JW, ed. Anterior and posterior composites. *Dent Advisor* 1991;8(4).
- Feder BA, Issaquah WA. Combining etched porcelain inlays and onlays with composite resins to restore posterior teeth. *Gen Dent* 1988;36:478-81.
- Freedman, George, Fugazzoto, Paul A, Greggs, Aesthetic supragingival margins. *PP&A* 1990;2(2):35-8.
- Friedl KH, Schmalz G, Hiller KA, Saller A. In-vivo evaluation of a feldspathic ceramic system: 2-year results. *J Dent* 1996;24(1-2):25-31.
- Friedman J. Variability of lamp characteristics in dental curing lights. *J Esthet Dent* 1989;1:189-90.
- Friedman MJ. Current state-of-the-art porcelain veneers. *Curr Opin Cosmet Dent* 1993:28-33.
- Fuzzi M, Bonfiglioli R, Di Febo G, et al. Posterior porcelain inlay: clinical procedures and laboratory technique. *Int J Periodontics Restorative Dent* 1989;9:275-88.
- Fuzzi M, Bouillaguet S, Holz J. Improved marginal adaptation of ceramic veneers: a new technique. *J Esthet Dent* 1996;8:84-91.
- Garber DA. Porcelain laminate veneers: ten years later. Part I: tooth preparation. *J Esthet Dent* 1993;5:56-62.
- Garber DA. Rational tooth preparation for porcelain laminate veneers. *Compendium* 1991;12:316, 318, 320.
- Garber DA, Goldstein RE. Porcelain and composite inlays and onlays. Carol Stream, IL: Quintessence Publishing Co., 1994.
- Gilmour AS, Stone DC. Porcelain laminate veneers: a clinical success? *Dent Update* 1993;20:167-9,171-3.
- Goldstein R. Change your smile. Chicago: Quintessence Publishing Co., Inc., 1984.
- Goldstein RF. Diagnostic dilemma: to bond, laminate or crown? *Gen Dent* 1988;36:159.
- Goldstein RE, Garber DA, Schwartz CG, Goldstein CE. Patient maintenance of esthetic restorations. *J Am Dent Assoc* 1992; 123:61-6.
- Graffeo R, Chang J, Scherer W. An all porcelain lingual bonded retainer: a case study. *J Esthet Dent* 1990;2: 153-5.
- Greggs TS. Personal communication.
- Gwinnett AJ. Bonding of restorative resins to enamel. *Int Dent J* 1988;38:91-6.
- Hardin JF. Clark's clinical dentistry, 1997 update. St. Louis: Mosby, 1997.
- Hardison JD, Rafferty-Parker D, Beam LR. *J Am Dent Assoc* 1989;118:595-7.
- Hembree JH. Comparisons of fit of cad-cam restorations using three imaging surfaces. *Quint Int* 1995;26(2):145-7.
- Heyde JB, Cammarato VT. The laminate veneers. *Dent Clin North Am* 1981;25:337-45.
- Heymann HO, Bayne SC, Sturdevant JR, et al. The clinical performance of CAD-CAM-enervated ceramic inlays: a four-year study. *J Am Dent Assoc* 1996;127:1171-81.
- Hobo S, Iwata T. A new laminate veneer technique using a castable apatite ceramic material. II. Practical procedures. *Quintessence Int* 1985;8:509-17.
- Holtan JR, Lua MJ, Belvedere PC, Lambert DL. Evaluating the effect of glove coating on the shear bond strength of porcelain laminate veneers. *J Am Dent Assoc* 1995;126:611-6.
- Hornbrook DS. Porcelain veneers: optimizing esthetics while reestablishing canine guidance. *Compend Contin Educ Dent* 1995;16:1190,2,4.
- Horn HR. Porcelain laminate veneers bonded to etched enamel. *Dent Clin North Am* 1983;27:671-84.
- Ibsen RI, Strassler HE. An innovative method for fixed anterior tooth replacement utilizing porcelain veneers. *Quintessence Int* 1986;17:455.
- Ishioka S, Caputo AA. Interaction between the dentinal smear layer and composite bond strength. *J Prosthet Dent* 1989;61:180-5.
- Jordan RE, Suzuki M, Sendat A. Clinical evaluation of porcelain laminate veneers: a four year recall report. *J Esthet Dent* 1989;1:126-31.
- Kawai K, Hayashi M, Torii M, et al. Marginal adapt-

- ability and fit of ceramic milled inlays. *J Am Dent Assoc* 1995;126:1414-9.
- Kawai K, Isenberg BP, Leinfelder KF. Effect of gap dimension on composite resin cement wear. *Quintessence Int* 1994;24:53-8.
- Kohkhar ZA, Razzoog ME, Vaman R. Color stability of restorative resins. *Quintessence Int* 1991;22(1):733-7.
- King DG. Methods and materials for porcelain veneers. *Curr Opin Cosmet Dent* 1995:45-50.
- Kourkouta S, Walsh TT, Davis LG. The effect of porcelain laminate veneers on gingival health and bacterial plaque characteristics. *J Clin Periodontol* 1994;21:638-40.
- Kula K, Kula TJ. The effect of topical APF foam and other fluorides on veneer porcelain surfaces. *Pediatr Dent* 1995;17:356-61.
- Kurtz KS. Constructing direct porcelain laminate veneer provisionals. *J Am Dent Assoc* 1995;126:653-6.
- Levin R. The Future of porcelain laminate veneers. *J Esthet Dent* 1989;1:45-6.
- Lewis DG. Dentacolor, "Kind to Opposing Teeth" replaces porcelain. *The Kulzer Communicator* 1988;4(2):1.
- Liebenberg WH. An innovative method for isolation of the working field during bonding of multiple porcelain laminates. 1993;2(4):7-8,10-1.
- Liebenberg WH. Multiple porcelain veneers: a temporization innovation—the peripheral seal technique. *J Can Dent Assoc* 1996;62(1):70-8.
- Liebenberg WH. Porcelain laminate veneers—preparation and isolation innovations. *Gen Dent* 1995;43(1):50-4.
- LoPresti JT, David S, Calamia JR. Microleakage of CAD-CAM porcelain restorations. *Am J Dent* 1996;9:37-9.
- LoPresti JT, Steven D, Calamia JR. Microleakage of cad-cam porcelain restorations. *Am J Dent* 1996;9(1):37-9.
- Mabrito C, Roberts M. Porcelain onlays. *Curr Opin Cosmet Dent* 1995;1-8.
- Makinson OF. Color changes on curing light-activated anterior restorative resins. *Dent Abstracts* 1989;34(1):467.
- Masek RT. Esthetic direct ceramic restorations utilizing cerec 2 cad/cim technology. *AACD Jrnl* 1997;13(3):32-43.
- Matsumura H, Leinfelder KF. Effect of an adhesive primer on the integrity of occlusal veneer-metal interface and wear of composite resin veneered restorations. *J Prosthet Dent* 1993;70:296-9.
- McIntyre FM. Placement of retraction cord during porcelain laminate (veneer) restorative procedures. *J Prosthet Dent* 1993;70:97.
- Meskin LH, et al. *The 1996 year book of dentistry*. St. Louis: Mosby, 1996.
- Meskin LH, et al. *The 1997 year book of dentistry*. St. Louis: Mosby, 1997.
- Meyenberg KH. Modified porcelain-fused-to-metal restorations and porcelain laminates for anterior esthetics. *Pract Periodontics Aesthet* 1995;7:33-44.
- Mormann WH, Brandestini M. The fundamental inventive principles of cerec cad/cam and other cad/cam methods, cad/cim in aesthetic dentistry. *Quint* 1996;81-110.
- Nixon RL. Masking severely tetracycline-stained teeth with ceramic laminate veneers. *Pract Periodontics Aesthet Dent* 1996;8:227-35.
- Millar BJ, Nesbit M. Etched porcelain restorations for patients with microdontia. *Quintessence Int* 1989;20:621-2.
- Miller OD. Use Dentacolor for the TMJ patient. *The Kulzer Communicator* 1988;4(2):5.
- Moghdam B. Intraoral repair of fractured porcelain using porcelain laminate veneer. *Pract Periodontics Aesthet Dent* 1994;6(1):65-6,68.
- Mopper KW. The subtleties of anterior direct-bonded Class III restorations. *Pract Periodontics Aesthet* 2(6):17-20.
- Myers ML, Ergle JW, Fairhurst CW, Ringle RD. Fatigue failure parameters of IPS-Empress porcelain. *Int J Prosthodont* 1994;7:549-53.
- Nash RW. Subtle changes, brighter smiles with porcelain veneers. *Compendium* 1994;15(1):8,10-3.
- Nattress BR, Youngson CC, Patterson CH, et al. An in vitro assessment of tooth preparation for porcelain veneer restorations. *J Dent* 1995;23:165-70.

- Newburg R, Pammeijer CH. Composite resin bonded to porcelain with silane solution. *J Am Dent Assoc* 1988;54:499–506.
- Nixon R. Bonding technique for porcelain veneers. *Forum Esthet Dent* 1985;3(8):1–11.
- Nordbo H, Rygh-Thoresen N, Henaug T. Clinical performance of porcelain laminate veneers without incisal overlapping: 3-year results. *J Dent* 1994;22:342–5.
- O'Neal SJ, Miracle RL, Leinfelder KF. Evaluating interfacial gaps for esthetic inlays. *J Am Dent Assoc* 1993;124(12):48–54.
- Penugonda B, Settembrini L, Scherer W, Hittelman El. Alcohol-containing mouthwashes: effect on composite hardness. *J Clin Dent* 1994;5:60–2.
- Porcelain veneers. *The Adept Report* 1(3):17–27.
- Probster L. Four year clinical study of glass-infiltrated, sintered alumina crowns. *J Oral Rehabil* 1996;23(3):147–51.
- Puy MCL, Navarro LF, Llacer VJF, Ferrandez A. Composite resin inlays: a study of marginal adaptation. *Quintessence Int* 1993;24:429–33.
- Roulet JF, Degrange M. Inlay restorations. *J Calif Dent Assoc* 1996;24(9):48–62.
- Rueggeberg FA. Composite inlays: a review of concepts, techniques, and limitations. *Georgia Acad Gen Dent* 1990;Winter.
- Sheets CG, Ono Y, Taniguchi T. Esthetic provisional restorations for porcelain veneer preparations. *J Esthet Dent* 1993;5:215–20.
- Shets CG, Taniguchi T. Advantages and limitations in the use of porcelain veneer restorations. *J Prosthet Dent* 1990;64:406–11.
- Shortall AC, Baylis RL, Baylis MA, Grundy JR. Marginal seal comparisons between resin-bonded Class II porcelain inlays, posterior composite restorations, and direct composite resin inlays. *Int J Prosthodont* 1989;2:217–23.
- Siervo S, Bandettini B, Siervo P, et al. The CELAY systems: a comparison of the fit of direct and the indirect fabrication techniques. *Int J Prosthodont* 1994;7:434–9.
- Sim C, Ibbetson R. Comparison of fit of porcelain veneers fabricated using different techniques. *Int J Prosthodont* 1993;6(1):36–42.
- Sim C, Neo J, Chua EK, Tan BY. The effect of dentin bonding agents on the microleakage of porcelain veneers. *Dent Mater* 1994;10:278–81.
- Stacey GD. A shear stress analysis of the bonding of porcelain veneers to enamel. *J Prosthet Dent* 1993;70:395–402.
- Strassler HE, Buchness GF. Etched porcelain veneers: our newest cosmetic dentistry treatment modality. *B.C.D.S. Forum* 1985;5(2):7–9.
- Strassler HE. Esthetic restoration of discolored teeth using porcelain laminate veneers. *Comp Cont Educ Dent* 1998;19:447–56.
- Sturdevant CM, Roberson TM, Heymann HO, Sturdevant JR. *The art and science of operative dentistry*. 3rd edn. St. Louis: Mosby, 1994.
- Taleghani M, Leinfelder KF, Lane J. Posterior porcelain bonded inlays. *Compend Contin Educ Dent* 1987;8:410–5.
- Temin SC, Csuros Z, Mellberg JH. Fluoride uptake from a composite restorative by enamel. *Dent Mater* 1989;5(1):64–5.
- Tjan AHL, Bergh BH, Lidner C. Effect of various incremental techniques on the marginal adaptation of Class II composite resin restorations. *J Prosthet Dent* 1992;67:62–6.
- Toh CG. Porcelain laminate veneers—considerations for a successful approach in the conservative treatment of aesthetic problems. *Asian J Aesthet Dent* 1994;2(1):11–7.
- Trushkowsky RD. Masking tetracycline staining with porcelain veneers. *Dent Econ* 1994;84(6):64–5.
- Van der Veen HJ, Pilon HJ, Henry PD. Clinical performance of one micro-filled and two hybrid anterior composite resins. *Quintessence Int* 1989;20:547–50.
- Wartell R. Breakthrough in dental restoratives. *Official Precis of the 1st International Symposium on the Clinical Applications of Laboratory Light Cured Composites*. Valley Forge, PA: December 13, 1984.
- Wat PY, Cheung GS, Kei LH. An improved preparation for indirect porcelain veneers. *Dent Update* 1993;20:72,72–6.

Wiley MG, Windeler AS, Barghi N, Duke SD. The vertical dimensional change resulting from polishing or glazing porcelain. *J Prosthet Dent* 1989;62:32-4.

Willis PJ. Temporization of porcelain laminate veneers. *Compend Contin Educ Dent* 1988;9:352-8.

Williamson RT. Techniques for aesthetic enhancement of porcelain laminate veneer restorations: a case report. *Pract Periodontics Aesthet Dent* 1994;6(4):73-8.

Yamada K. Porcelain laminate veneers for discolored

teeth using complementary colors. *Int J Prosthodont* 1993;6:242-7.

Yoshida K, Kamada K, Tanagawa M, Atsuta M. Shear bond strengths of three resin cements used with three adhesive primers for metal. *J Prosthet Dent* 1996;75:254-61.

Zhukovsky L, Godder B, Settembrini L, Scherer W. Repairing porcelain restorations intraorally: techniques and materials. *Compend Contin Educ Dent* 1996;17(1):18,20,22.

CROWN RESTORATION

A primary objective of crowning is to achieve an esthetic improvement. Corrections in shape, shade, and texture can cause a remarkable change in a patient's self-image. Return of good physiologic form and function may also help prevent further deterioration of the mouth not only by preventing arch collapse, bone loss, and tooth migration, but also by motivating the patient to maintain the new appearance.

Because the full crown has long been successfully used in the treatment of oral diseases, the maintenance of masticatory efficiency, and the restoration of the esthetic appearance of the mouth and face, it has remained one of the restorations of choice for an unesthetic or compromised dentition.

INDICATIONS FOR A FULL CROWN ARE:

1. Teeth with extensive decay
2. Teeth weakened by extensive restorations
3. Teeth with excessive, extensive wear
4. Teeth severely weakened or prone to fracture as a result of endodontic treatment
5. Teeth fractured or compromised with extensive microcracks and needing to be restored
6. Severely extruded teeth (to restore the plane of occlusion)
7. Teeth with an inappropriately short coronal portion
8. Malformed teeth
9. Abutments for fixed partial dentures
10. Long-span fixed partial dentures (where abutment teeth need maximum retention)
11. Teeth with unattractive tissue recession and unsightly interdental spaces

DISADVANTAGES OF A FULL CROWN

These drawbacks can be minimized by a skillfully constructed restoration that is within the physiologic and functional limitations of the mouth: 1. The potential for poor tissue response. 2. The problem of detecting a recurrence of decay under metal or metal-based crowns. 3. Limited life expectancy of the crown, which varies depending upon the fit, type of material used, and ongoing preventive maintenance.

Patients who undergo full-coverage restoration of several teeth or even a single tooth should be informed that the crowns may have to be redone in the future (Figures 15–1A to C). *A crown may remain functionally sound for the life of the tooth; however, its esthetic life expectancy is a different matter.* Soft and hard tissue changes and any discolorations of remaining teeth can contribute to the esthetic deterioration of the existing crowns.

The dentist is obligated to inform the patient of these potential problems and give a complete explanation of the importance of impeccable homecare and compliance with periodic office hygiene recall

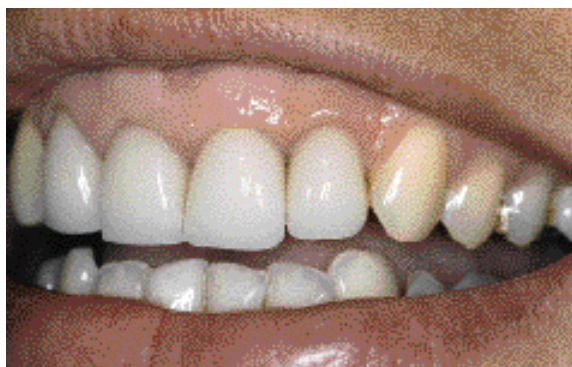

Figure 15–1A: These 25-year-old full porcelain crowns were still serviceable up until the time one of the central incisors fractured.

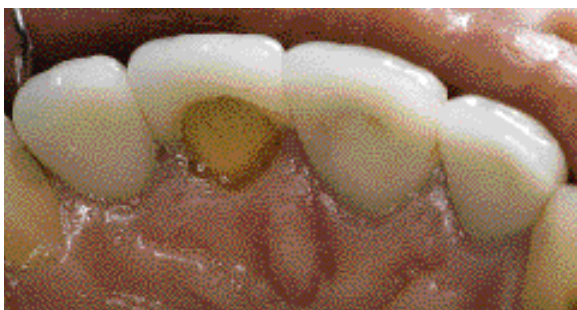


Figure 15-1B: This lingual view shows the type of fracture usually seen when a maxillary full porcelain crown fractures.

appointments. Patients should understand that their financial investment will probably exceed their initial outlay, since even the normal life expectancy of the crowns could be abrogated by traumatic fracture or unusual tissue changes.

The individual crown is one of the most difficult of all dental restorations to construct. Major considerations that confront the dentist are the esthetic diagnosis, the choice of material, and technique, communicating how the crown is to be fabricated to the laboratory technician and the re-evaluation at the final esthetic try-in.

ESTHETIC DIAGNOSIS

The success or failure of the crown restoration is first determined in the diagnostic stage and a great percentage of crown failures result entirely from the lack of proper diagnosis and treatment planning at the outset. At this time you must determine the type of crown to be made, the materials and impression technique to be used, the complexity of staining needed or shading problems that may exist, and various other factors that contribute to esthetic success.

Adjacent teeth as well as opposing ones must be examined and evaluated. For example, an opposing tooth or teeth may need to be reshaped to create a correct plane of occlusion. Unless this is done at the beginning, the problem may not be found until a later visit, possibly long after the crown has been constructed and cemented.

In the diagnostic stage the illusion necessary to create the most favorable alignment of the tooth should be visualized. Your observations should be noted on the chart. At the same time, make a preliminary drawing of the desired shade on a shade

chart (Figure 15-2A). Use colored marking pencils to designate incisal, gingival, and any characterized areas (Figure 15-2B). Clinical examination should also determine if the form of the tooth can be improved simply by reshaping adjacent teeth.

A question that must always be asked is “Can I improve the overall esthetics by bonding or veneering adjacent or opposing teeth?” *Color or silhouette form enhancement of other teeth can often make the difference between an adequate or an excellent result.* For example, the labial surface or incisal edge may need to be altered slightly to allow for better esthetic harmony and function.

Photographs

Instant photographic records can serve as an important diagnostic aid and should be made at this time for several reasons. First, the study of a photo at the initial diagnosis allows both you and your patient to see from the same perspective. Otherwise, if you look at the patient’s tooth and the patient looks at the same tooth in a mirror, the patient’s view is reversed. In addition, seeing the tooth in two dimensions, as in a photograph, is different from looking at the tooth in three dimensions. A two-dimensional photograph makes it easier to study silhouette form and to visually examine both the tooth width and form. Both views are important in developing the best possible treatment plan.

A second reason for taking instant photographs is to be able to begin to accurately calculate how complex the esthetic correction will be. Logically, it should become evident to your patient that the

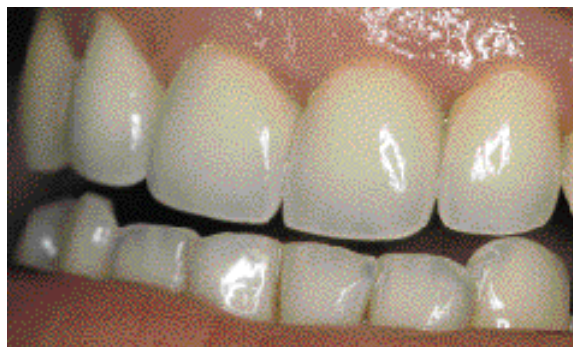

Figure 15-1C: Because the crowns lasted almost twice as long as estimated, the patient was pleased with their life span. Since the patient requested new crowns, one of the new and stronger all-ceramic systems was chosen.

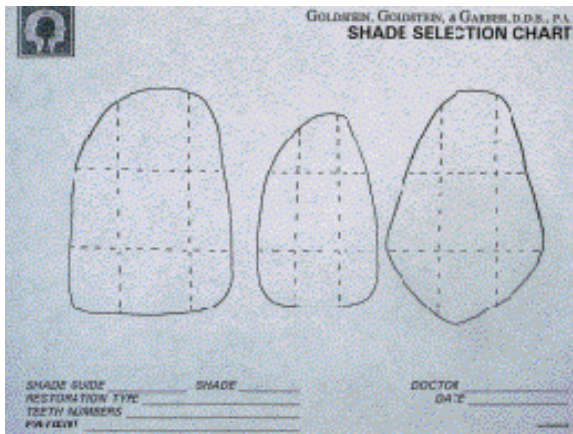


Figure 15-2A: This is an example of a functional shade chart. The teeth are divided into nine sections each for more exact shade mapping.

range of problems present as well as the relative difficulty of the treatment will all affect the case fee. *It is preferable to subtly introduce the relationship between difficulty and fees at this early stage rather than later, after the fact.*

A third reason is to be able to consult with your laboratory technician about the difficulty he or she will encounter with your patient's problem, both from a functional as well as an esthetic viewpoint.

An effective photographic technique has been developed by Kuwata.⁵³ In this quick and easy-to-use system, photos can be recorded on a compact disc and then printed. Since the photos can be made with sophisticated camera equipment, they can be extremely accurate, and of high quality. Another equally effective method is to use an intraoral camera and develop a print or slide that your technician can see at any later time. However, the best, but most expensive, method is to connect your office to your laboratory by modem so it will be possible for you and your technician to see and discuss the photos at the same time. The fact is, there are more choices to create photographic images in the office than ever before. Therefore, there is ample opportunity to improve laboratory communications.

If you determine your patient has complex esthetic or functional problems, consider also using an extraoral videocamera to record your patient in a variety of views including smiling, speaking, laughing, and with lips retracted.

Computer Imaging

Often consultation with your ceramist and any other specialists may be necessary, but these individuals cannot be in your office. Preliminary computer imaging can be completed in your office and the changes or prescription sent via a modem to the ceramist or specialist. Then, while everyone looks at the same images, any aspect of the view or proposed treatment can be reworked to satisfy the patient's cosmetic demands. Viewing the same slide or photograph makes the evaluation easier.

Ideally, your laboratory technician would have the same or similar computer imaging system, which will enable both of you to consult not only at the beginning of treatment but also during the try-in so that any necessary changes can be made.

Taking computer imaging one step further is CAD/CAM, or computer-assisted design/computer-assisted manufacturing. Through optical measuring of the preparation, storage of the measurements in a digital format, and an automated milling machine, it is possible to produce an automatically designed and produced restoration.²⁵ For instance, Rinke et al. in their study indicated that copy-milled (Celay, Mikrona AG, Sprietenbach, Switzerland) In-Ceram crowns (Vita Zahnfabrik) have clinically acceptable margins and fracture strength and reduce laboratory fabrication time. Although dental CAD/CAM is still



Figure 15-2B: Note how specifically the gingival intensity and incisal translucency can be designated with a complete set of felt-tip color pens.

in its infancy, it is believed by many to be the future, as it will virtually eliminate the need for conventional impression-taking and laboratory fabrication, and deliver a restoration of exacting fit and design in just one appointment. Thanks to the pioneering work of Duret,²⁵ future generations of dentists will be more concerned with operating a computer rather than dealing with impression materials and outside laboratories.

TECHNICAL CONSIDERATIONS

Generally, after the preparation is completed the average dentist is involved only in taking an impression and fitting the laboratory-fabricated crown. Few dentists do their own laboratory work and it is not the purpose of this text to duplicate the step-by-step procedures of laboratory technique manuals or to alter the habits of the dentist who has no desire to do his or her own laboratory work. However, it is important that every dentist understand the reasons why esthetic restorations fail, because many times failure arises from poor planning and neglect of details by the dentist or the technician.

Successful esthetic and functional results primarily depend upon adherence to sound principles of correct occlusion, articulation, and contacts. This is dramatically emphasized in a follow-up study of 320 crowns by Gropp and Schwindling.³⁹ Regardless of the materials used, abnormalities of occlusion and articulation were found in 14% of all crowns. Missing contacts were present in 19%, which

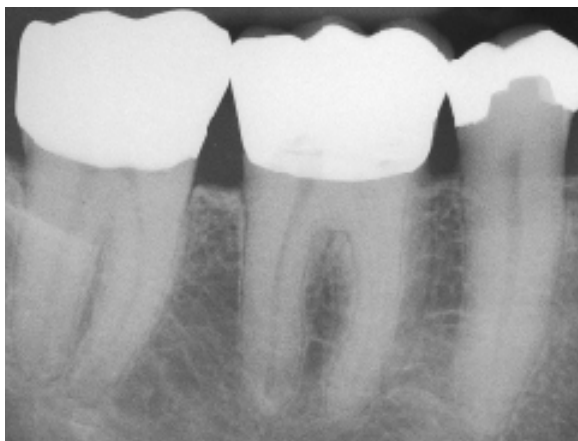

Figure 15-3A: The full gold crown provides excellent marginal adaptation stability as evidenced by this radiograph.

caused noticeable inflammation in 9.5%, pocket formation in 5.5%, and radiographic abnormalities of the marginal periodontium in 6% of the cases. The cervical portion of the tooth was denuded in 31% of the cases, resulting in a 12% incidence of cervical caries. Esthetics cannot fail to be compromised when functional breakdown occurs.

When design is left to the laboratory, be prepared to receive the same type of crowns being used by most dentists in the area. To achieve personalized attention to detail, begin with a clearly defined prescription that tells the laboratory not only the type of material to use but more importantly, how it is to be used.

Choice of Materials with Associated Technique Considerations

The choice of an appropriate restoration material depends upon the functional and esthetic demands that will be placed upon it.

The previous study³⁹ also indicated that, functionally, the all-cast crown was the most successful, especially when precision casting techniques were used. This was followed in clinical acceptance by porcelain-fused-to-metal crowns, full ceramic crowns, and then full acrylic crowns. However, esthetic considerations must also be met. The result is that many different materials can be used, alone or in combination in anterior crowns: gold, resin, porcelain, glass and a combination of gold and resin or metal and porcelain, metal and resin, and glass and porcelain. You should also consider what

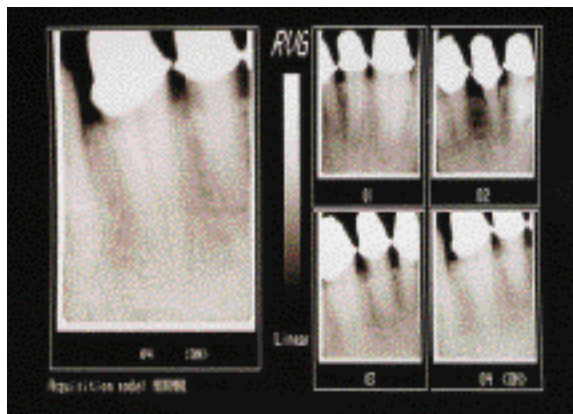


Figure 15-3B: Patients and dentists like the speed of computerized radiographs, which produce less radiation and can be instantly viewed.

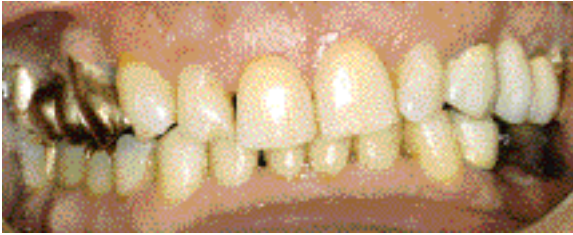

Figure 15-4A: This 69-year-old man had previously been functionally and esthetically satisfied with his all-gold crowns. However, when it came time for replacement, another dentist encouraged the patient to choose ceramometal, which shortly thereafter began to chip.

material, if any, will be chosen for an opposing tooth or teeth and use the same or similar material, if possible. To minimize excessive wear, gold is best against gold, porcelain best against porcelain, etc.

Gold

The full gold crown has always been considered by dentists to be the most functionally sound, longest-lasting restoration of its type. Its excellent marginal adaptation can be seen in Figure 15-3. It is a conservative restoration requiring much less reduction of tooth structure than a porcelain or porcelain-fused-to-metal crown, and its wear rate approximates that of natural enamel. If you are convinced there will be no visibility of the tooth to be crowned, for example, a second molar, ask your patient to go home and look in the mirror while speaking and laughing. It is essential that your patient see for him or herself exactly what teeth do show before making a final decision of what type of crown to have. However, while placing a full gold crown on a lower molar may not be an esthetic problem because it would not be visible to others, there are patients who do not want to see or know that there is gold in their mouth. For them, another material should be chosen. Also, since gold should occlude with gold, and porcelain should occlude with porcelain, a gold crown on a lower tooth could prevent you from placing a full ceramic crown on the opposing maxillary tooth.

Some patients do feel that showing gold is esthetic and for them, an all-gold crown, even if visible, is preferable (Figures 15-4A to C). Still other patients don't mind full gold provided it can be antiqued or etched so it is not as light reflective (Figures 15-5A to C).

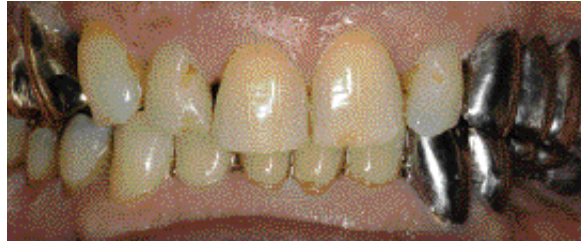

Figure 15-4B: The patient returned and had the restorations replaced with all-gold crowns.

The full gold crown should be used only on teeth with sufficient crown length for retention. Figures 15-6A and B show the proper use of gold restorations in a patient who is willing to have a little gold show. If the amount that appears is a concern to the patient, it can be masked somewhat with an air brush (Paasche) (Figure 15-5B) or air-abrasive technology (American Dental Technology, Kreativ, or Lares). If the choice is to use a three-quarter crown for an anterior tooth, explain to the patient exactly how much gold will show. Let the patient choose between that crown or a more esthetic restoration that shows no gold.

Resins

Resin technology has been one of the most notable advancements in esthetic dentistry, and therefore, it is important to understand a modern




Figure 15-4C: The patient is seen happily smiling with his gold restorations.

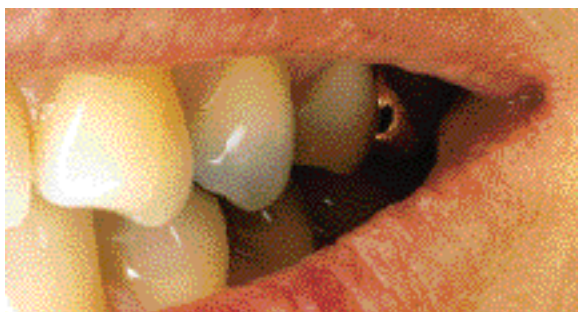

Figure 15-5A: This three-quarter gold crown on the maxillary first molar shows during smiling.

historic perspective of the different materials. Thus, this section presents the early esthetic concept and use of acrylic veneering through to the current formulations for resins currently advocated. Resins are available with varying degrees of translucency, and their ease of manipulation and color matching have made them popular with dentists, while their relatively low cost has made them popular with patients. Two basic types of resins are used: acrylic resins and composite resins. Acrylic resins have been used to veneer crowns for over 5 decades. They achieved popularity almost instantaneously and are still a part of the armamentarium of some dentists. However, there are problems associated with the use of acrylic resins. Research shows that these resins flow and deform even under light loads, so that areas in occlusion or proximal contact must be protected with metal. At times, this metal may be visible and esthetically unacceptable.

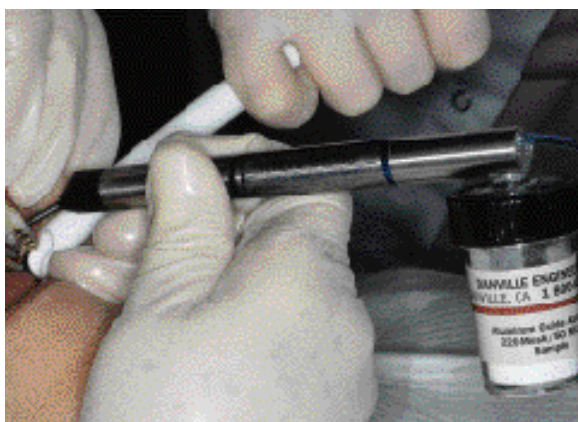


Figure 15-5B: A simple application with a micro-etcher (Paasche) or air-abrasive device dulls or antiques the gold sheen of the crown.

As Braggi stated,¹³ acrylic veneers stain, abrade, are porous, and cause gingival irritation. Acrylic does not bond to metal and must be locked into place mechanically. Since the thermal coefficient of expansion is higher for resins than for metal, a gap may form between the metal and resin into which fluids can seep, hastening discoloration and allowing foul odors to develop. He suggests the use of prefabricated acrylic facings that are harder, less porous, more esthetic, and more tolerable to the tissues. Also, because these prefabricated acrylic facings are more elastic and require less metallic incisal and occlusal protection, they may be used in anterior and posterior regions to achieve a more esthetic result.

Acrylic resin is sometimes used to construct an anterior full crown (Figure 15-7). Translucency, reasonable color stability, ease of construction and color matching, as well as economics have enhanced its popularity as an interim restoration. It is relatively easy to obtain a good fit, and the material is biologically acceptable for short periods. Wear at the contact areas does not appreciably affect arch length or embrasure form. However the material will abrade along the incisal edge. Because it also stains, can be poorly tolerated by tissue, and is too elastic, an acrylic crown should be used as a long-term interim crown only in those instances where it is specifically indicated by circumstances or lifestyle, or when it may take the patient several years before he or she will be in a financial position to undergo correction in metal or ceramics, or a combination of the two.

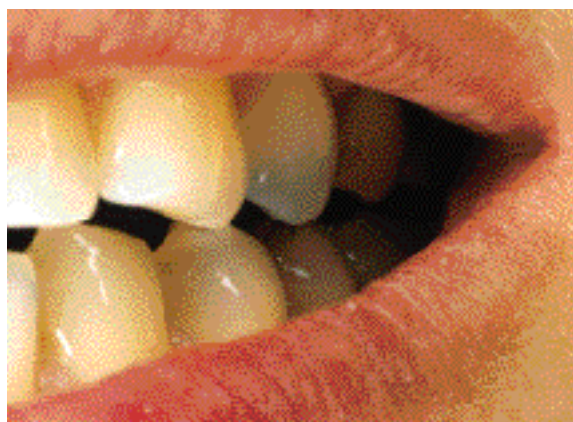

Figure 15-5C: Note the esthetic improvement when the patient smiles.

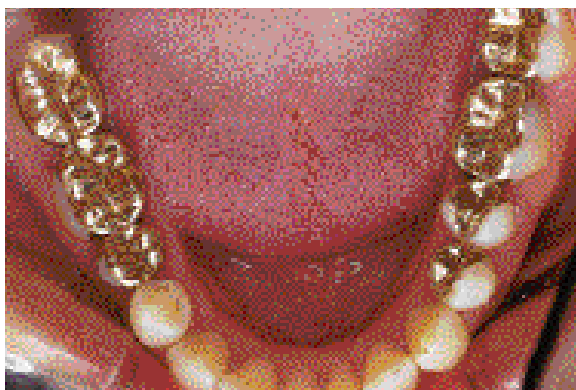

Figure 15-6A: This 35-year-old female wanted the longest-lasting restorations available. Although she did not want gold showing, esthetics were a secondary consideration.

As an example, for teenagers who participate in contact sports, you might suggest this type of crown until their competitive playing days are over. The reason is that porcelain crowns, including those backed by metal, can more easily chip or fracture than those made of the more shock-absorbing acrylic.

To reduce wear and staining, acrylic veneers or crowns can be hardened by heat-processing,¹¹ and curing under pressure.⁸³

A later generation of veneering materials is light polymerized composite resin (Dentacolor, Jelenko/Kulzer, Inc., Isosit-N, Ivoclar; and Visio-Gem, ESPE GmbH). Designed for indirect veneering in the laboratory, these composite resins had definite advantages over acrylic resins.⁷⁸

Using a primer that can bond to metal, composite's coefficient of thermal expansion is lower, and

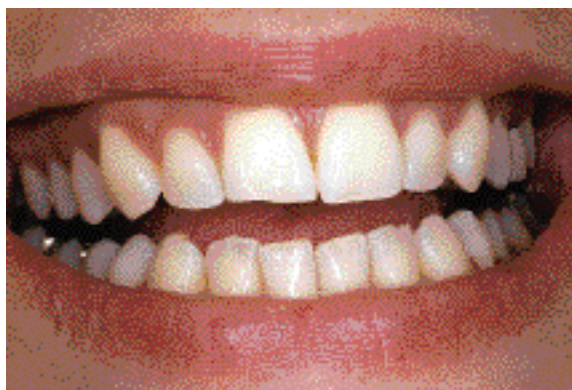

Figure 15-6B: The two small areas of gold that showed when she smiled did not concern this patient.

its tensile and compressive strengths are higher. There is less abrasion and less shrinkage during curing. Composite resin crowns have a distinct advantage in that they are easily repaired in the mouth in the event of chipping or fracture.

O'Neal et al. clinically evaluated composite resin veneered metal crowns, and state that over a 2-year period, "color stability, surface texture, lack of microleakage, and overall wear resistance were not appreciably different from the result one would find with porcelain veneers."⁶⁷

Composite resins can also be valuable in the repair of ceramometal restorations from which the porcelain has fractured. If the restoration is otherwise serviceable then the porcelain may be repaired by first creating micromechanical retention with an air abrasive, then acid-etching, using silane cou-

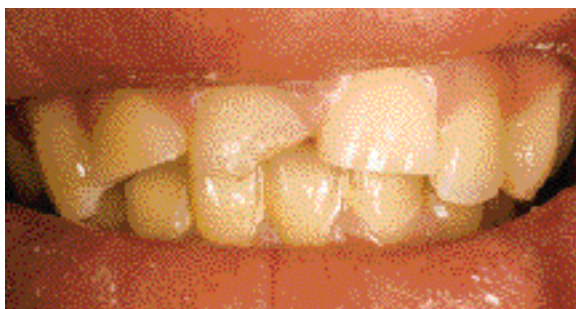

Figure 15-7A: A serious automobile accident caused extensive injuries, including fractures of the anterior incisors.

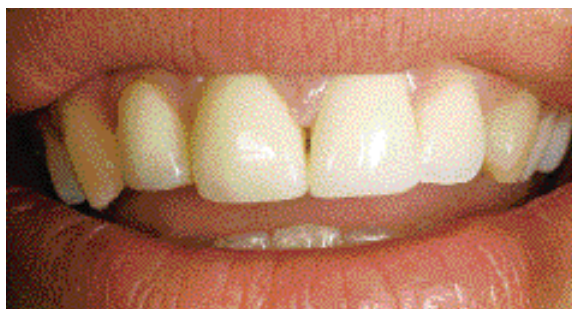

Figure 15-7B: Heat-cured full acrylic crowns were constructed as a long-term, but interim, solution until it could be determined if the extensive lingual fractures would require endodontic or periodontal therapy.

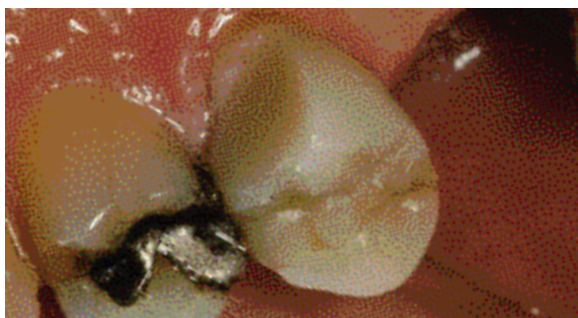


Figure 15-8: This indirect, composite resin crown fractured after only short-term use. (Photo courtesy of Dr. Joseph Greenberg, Philadelphia, PA.)

pling agents, and bonding with composite resin (see Vol. II, Chapter 34, Esthetic Repairs).

One of the major problems with indirect veneers of composite resins is occlusal wear. For example, Gallegos and Nicholls found that when opposing porcelain over a period of time, Isosit-N lost approximately 70% of its matrix filler, which was greater than that of Visio-Gem, but significantly less than the loss of porcelain under the same simulated functional forces.³¹

Another problem with indirect composite resins is that they tend to chip away from the restoration (Figure 15-8). Greenberg, studying Visio-Gem (ESPE) cautions that it must be at least 1.5 mm thick and should not be used on masticatory surfaces because of its potential to chip.

Ceramic Polymers

A significant advancement in resin technology is exemplified by several unique materials. Although each formulation is somewhat different, as a group they provide an exciting breakthrough for esthetic ceramic alternatives.

BelleGlass

BelleGlass (Belle de St. Clair) consists of a mixture of aliphatic and urethane dimethacrylate resins; it and Concept are the only heat- and pressure-cured indirect composite systems. The elevated temperature is used to extend the polymer conversion to a reported rate of 98.5%.⁸ The pressure (80–85 psi) significantly reduces the presence of voids in the material that usually develop during direct condensation or indirect fabrication⁸⁸ and prevents volatilization of the monomer at these higher temperatures. Most importantly, however,

the entire curing procedure is conducted in a nitrogen atmosphere. The constant presence of an inert gas results in elimination of internal and external oxygen. This, in turn, permits more of the resin volume to be polymerized. A recently-completed 5-year study at the University of Alabama Dental School⁶⁵ has shown that the wear of BelleGlass inlays and onlays averaged less than 1.5 μm per year. Furthermore, no incidences of fractures or marginal deterioration were observed. The material has also been recommended for veneers, crowns, and reinforced provisional restorations.

Artglass

Artglass (Jelenko/Kulzer) is a polyglass, a new class of indirect restorative material with improved resin and filler technology and was designed as an alternative to porcelain. Artglass is composed of multi-functional methacrylates, bifunctional monomers, 20% silica filler, and microglass filler. The 20% silica filler reportedly reduces slumping and improves sculptability. A high-output strobe light is used to cure the material. Artglass is available in 16 Vita shades and can be repaired intraorally using Artglass liquid and Charisma (Jelenko/Kulzer) composite. The material has been proposed for use in metal and nonmetal crowns, inlays, onlays, and veneers. While it has not had long-term clinical studies, a 6-month clinical evaluation of 100 Artglass cases shows excellent promise.⁷⁶ For example, the material showed good marginal integrity, contour, anatomy, and patient satisfaction. At 6-month recall, there was no visible leakage, shade change, sensitivity, chipping, or visible wear. Further, Artglass was found to be more wear resistant than conventional composites but less wear resistant than ceramic restorations. It was, however, kinder to opposing tooth structure, causing less wear than ceramic restorations. There was a 1% fracture rate that seemed to be related to inadequate thickness of Artglass material.

Sculpture/FibreKor (Jeneric/Pentron)

This restorative system is composed of a PCDMA resin and unique glass filler with promising wear characteristics (<m./year),⁸⁹ that is reinforced with an advanced glass fiber. Independent research shows flexural strengths approaching 1000 MPa.²⁹ Sculpture is highly filled and stain resistant due to low water sorption (9 to 12mg/mm³)⁴⁷ and lab processing which uses light, heat, and vacuum. In

addition, FibreKor, a glass fiber reinforcing material, lends both structural integrity and translucency to the restorations. The material shows biocompatibility, noncytotoxicity,⁵⁷ and the restorations are easily polished and repaired intraorally. This system was developed to offer a metal-free alternative to porcelain-fused-to-metal bridgework and may be used for inlays, onlays, full-coverage crowns, single-pontic inlay or onlay bridges, single-pontic full-coverage bridges, “Maryland”-type bridges, and Encore bridges. Its shock-absorbing properties⁵⁶ make Sculpture appropriate for single-pontic implant-supported bridges. Although the technique is referred to as minimally invasive, an additional 2.0 mm × 2.0 mm × 2.0 mm “rest seat” or proximal box is required in the surfaces of the crown preparations proximal to the pontic area for bridges to allow room for the FibreKor bar. Crown preparation reduction, similar to that required for an all-ceramic crown, is 1.5- to 2.0-mm incisal/occlusal reduction with a 1.0- to 1.5-mm shoulder.

Targis/Vectris (Ivoclar/Williams)

Ivoclar’s new system is composed of Targis, a new Ceromer restorative material, and Vectris, a fiber-glass-reinforced composite similar to FibreKor. The Ceromers (*ceramic optimized polymers*) like Targis were designed to combine the advantages of ceramics—durable esthetic quality, abrasion resistance, and high stability—with those of state-of-the-art composite material: ease of final adjustment, excellent polishability, enamel-like translucency and fluorescence, intraoral or chairside repair of restorations, and low degree of both brittleness and susceptibility to fracturing. Internal studies show an enamel-like hardness and high flexural strength.⁵² Targis can be used for inlays and onlays, veneers, anterior crowns, and metal-free posterior crowns or bridges when combined with Vectris. It can also be layered on a metal framework for use in telescopic crowns, metal-framework bridges, and implant suprastructures.

The Vectris fiber-reinforced composite is composed of several layers of fiber wafers. This technology was actually developed for, and is currently being used in, the aeronautical and ship-building industries. It adds high flexural strength (approximately 1000 MPa)⁸⁰ while preserving the translucency found in natural teeth. Also, it is vacuum- and pressure-fitted to the die for good marginal adaptation and shows a high degree of biocompatibility.

While long-term research is necessary, current evidence indicates that these materials may be promising as strong and esthetic alternatives to porcelain fused-to-metal-restorations. The biggest question is how the polymer matrix will hold up over time.

The ideal full crown material still eludes dentistry. Nevertheless, the quest for prosthetic advancements in both materials and techniques have made the newer choices more acceptable both functionally and esthetically. In Chapter 13, you will find a discussion of several resin derivative materials suitable for full crowns. As with some of the newer ceramic materials described in this chapter, scientific research evaluations are still forthcoming. Current ceramic restorations use copings made of cast-metal, aluminous porcelain, cast-ceramic, pressed ceramic, or gold foil to enhance retention, strength, and provide intrinsic color.

A decade ago, materials used for all-ceramic restorations were prone to fracture, curtailing their use in high stress-bearing areas, including even short fixed prostheses.

Aluminous-core ceramics were developed to address this problem. Glass and leucite infiltration of the porous framework were found to limit crack propagation and impart a higher bend strength by increasing compressive forces at the core interface. Current ceramic techniques can be mainly divided into pressing, slip casting, and injection molding.^{55,75} Fired feldspathic porcelains are also being used.

While beyond the scope of this clinically-oriented text to fully discuss marginal integrity, flexural strength, crack propagation, and other important parameters of the various ceramic systems, much of the research addresses these topics.^{2-4,6,16,23,37,41,84,87} *Current Opinion in Dentistry*, *The Journal of Prosthetic Dentistry*, *International Journal of Prosthodontics*, *Journal of Esthetic Dentistry*, *Dental Materials*, *Journal of Dental Research*, and others fully address this subject. In addition, there are informative texts devoted to dental ceramics, like those of Preston,⁷⁴ McLean and Yamamoto,^{92B} Kuwata,⁵³ and Sieber.⁸² Therefore, the emphasis here will be on the esthetic uses of the major available ceramic crown systems.

All-Porcelain Crowns

Full feldspathic porcelain crowns manufactured on platinum foils were one of the first attempts to

fortify the strength of all-ceramic restorations. Today other processes are being used in all-porcelain crown fabrication.

Advantages. An all-porcelain crown is still considered by many dentists to be the most life-like and esthetically pleasing restoration. It is translucent, color-stable, brilliant, and life-like. If constructed over a uniformly reduced and balanced preparation, it has a long life expectancy in most patients. A properly fabricated and artistically produced porcelain crown is often almost impossible to detect visually. The advent of vacuum firing has reduced bubbles, producing a fine-textured restoration with improved translucency and increased impact strength. Acid-etching and adhesive bonding cements have also enhanced the physical properties of the all-porcelain crown.

Porcelain is biologically acceptable, and well tolerated by the soft tissues (Figure 15-9). This is illustrated by a case involving full porcelain anterior crowns combined with ceramometal in the rebuilt posterior arch (Figures 15-10A and C). Note the tissue response in Figure 15-10. A high degree of naturalness was obtained by use of vacuum-fired porcelain.

In a survey, Lehman⁵⁴ found that porcelain abrades at approximately the same rate as the natural dentition; therefore, an all-porcelain crown is a restoration able to withstand normal wear.

Porcelain crowns cemented on natural abutments and those cemented on artificial supports have the same incidence of fracture; therefore, a porcelain crown can be successfully used after a cast-metal post and core has been placed on a non-vital tooth.^{54,71}

Disadvantages. The main problem with the all-porcelain crown is its fragility when cemented with conventional cements. The margin of the porcelain crown may not be as accurate as a cast margin and a cement line of varying dimensions can form that tends to wash out and stain when conventional cements are used.⁷¹ Therefore, resin or resin ionomer-type cements are recommended.

The newer cementing agents decrease the wash-out phenomenon. They provide substantial retention and marginal integrity and therefore less staining.⁹¹ (See Vol. III, Chapter 43 on cementation.)

Aside from staining, Zena and Abbott⁹⁴ propose that cervical shadowing or “black line” is caused by “disruption of the light harmony between the root and crown” of the prepared tooth and the overlying soft tissues. That is, the dentin and root structure of a tooth refract less ambient light leaving a darkened, shadowed appearance of the root surface, as do metal substructures, such as metal posts and cores. To avoid this esthetic problem, you should place the facial margin subgingivally, but no more than halfway between the gingival crest and the depth of the sulcus. A soft tissue model can be used to ensure ideal facial emergence from the gingiva.

Because of this and other problems, the reinforced porcelain crowns, such as aluminous porcelain, shrink-free cast glass, pressed ceramic, or porcelain fused to metal are usually preferred.

Indications. The all-porcelain crown is indicated when:^{14,19,30}

1. There is too little tooth structure to reduce the tooth sufficiently for porcelain fused to metal with an all-porcelain occlusal surface.
2. Obtaining the best esthetic result is the single most important consideration.
3. The patient is allergic to metal.

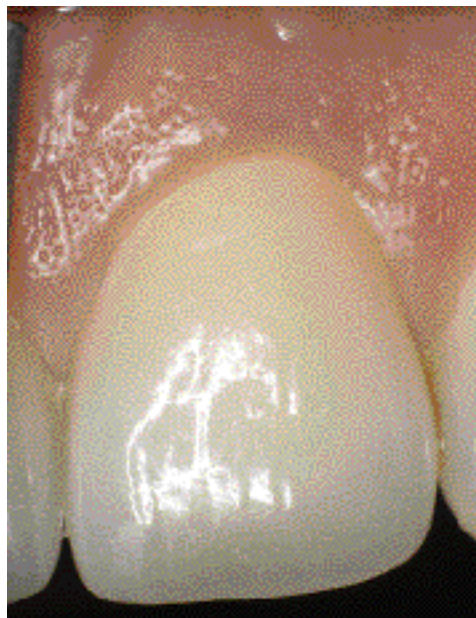
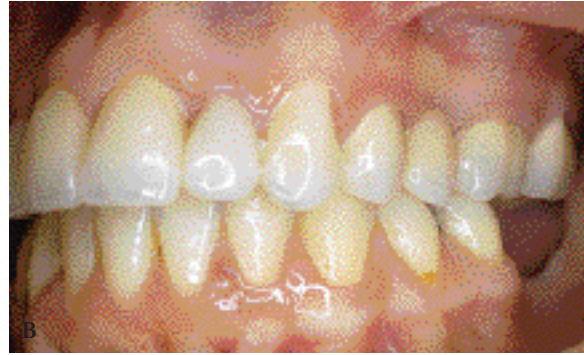
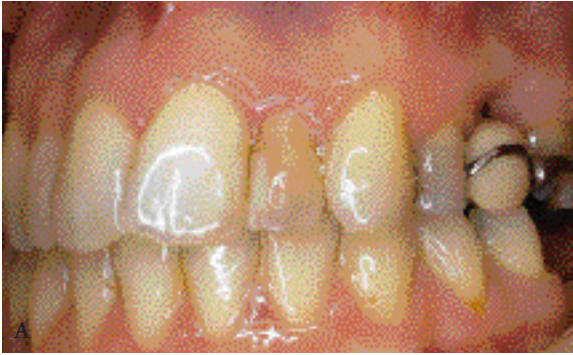Figure 15-9: An excellent tissue response is typical of this well-fitting, all-ceramic crown.



Figures 15–10A and B: This patient was displeased with her smile and requested full porcelain crowns for the longest restorative life expectancy.

Contraindications. The all-porcelain crown should not be used when:

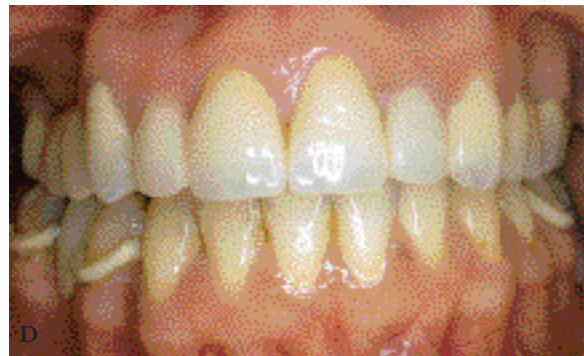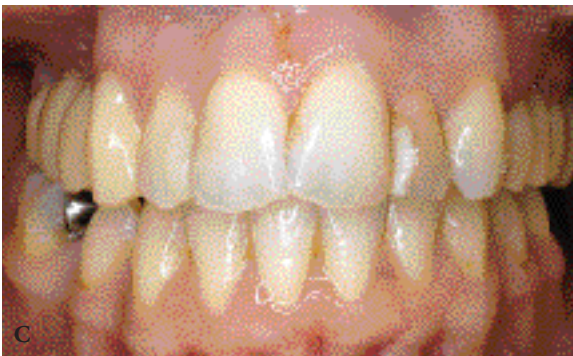1. The natural tooth is not completely erupted.
2. Preparation of the all-porcelain crown would unavoidably cause pulpal involvement.
3. The patient participates in contact sports or has a parafunctional habit, such as pipe smoking, that involves heavy contact on small areas of the dentition.
4. The patient habitually grinds or clenches the teeth.
5. The patient requires a reinforced restoration, such as a posterior fixed bridge.

Preparation. Successful esthetic and functional results obtained with all-porcelain crowns cannot be credited solely to the quality of the particular

material used. The method of preparation also has a significant influence on the final result. Control over the esthetics in the anterior porcelain crown is determined by the fit of the crown and its proper termination within the gingival sulcus.

Strict observance of the rules of tooth preparation soft tissue management and techniques of impression are essential. Failure in any of these steps may result in poor crown adaptation, gingival irritation or destruction, and the resulting changes in tissue appearance.

An adequately deep, clearly-defined shoulder is necessary to achieve good margins and provide strength.⁵⁹ The strength of a porcelain restoration is highly dependent upon proper crown preparation. Advocating careful preparation, Berger states that the shoulder should be carefully developed and brought to its final finishing line in the sulcus late



Figures 15–10C and D: A high degree of naturalness was obtained in these anterior all-porcelain crowns. Proper texture, shade variation, incisal translucency, contours, and embrasures contribute to the esthetic result. There is a positive tissue response surrounding the well-fitting, all-porcelain margins. Note the temporary, tooth-colored clasp partial in place.

in the process of preparing the tooth rather than establishing its location early in the procedure.⁹

Every effort should be made to minimize injury to the gingival tissues. The margin preparation must never exceed the depth of the sulcus. In a healthy mouth this distance may only be 1 to 3 mm. Therefore, the margin of the crown should be ideally placed in the sulcus $1/2$ to 1 mm below the gingival crest.^{21,66} Placing the margin of the shoulder as deep as possible into the sulcus can be a grave error. If the biologic width is compromised, there is a potential for changes in the underlying osseous structure with possible gingival recession and/or pocket formation. If recession can be avoided, then a major problem in esthetics is eliminated.⁶⁶

Tooth structure apical to the margin is important also to ensure maintenance of the integrity of the gingival attachment apparatus. Extension of the crown too far apically can damage the attachment apparatus during try-in. Also, if the finish line is in an area that is inaccessible for cement removal, plaque can accumulate and inflammation will result.⁶⁶

Kaiser and Newell state that margins should not be placed over 1.0 mm subgingivally to the retracted level of the free gingival margin to ensure that the margin is hidden under the healthy tissue.⁵⁰ They further emphasize that the potential for tissue recession is greatly dependent on its health prior to preparation, and they endorse the use of a nonmed-

icated retraction cord of a size that does not require excessive pressure for its placement into the sulcus.

The problem of tissue recession may occur regardless of the care taken not to irritate the gingival fibers during preparation. The best way to avoid irritation is to extend the gingival margin into the sulcus with a beveled end-cutting diamond stone designed to help protect the tissue (Figures 15–11A and B).

Deflection during gingival retraction and impression techniques can also produce enough irritation to the tissue to cause shrinkage and to eventually expose a margin; therefore, use extreme care to avoid unnecessary deflection, both in duration and force, when inserting the cord.

In the event that the tissue recedes after the impression, exposing the margin, the labial margin can be recut and extended into the gingival sulcus even at the try-in appointment. Make certain the new shoulder margin is recorded in the impression material and pour a new die. With all-ceramic materials, it is possible to add new porcelain at the marginal areas. Refit the crown with softened low-fusing compound or self-curing acrylic attached to the labial margin. After adapting foil to the new margin, the ceramist can correct the porcelain margin discrepancy.

If the gingiva recedes, exposing the gingival collar in a patient with an otherwise satisfactory ceramometal restoration, there are techniques that can

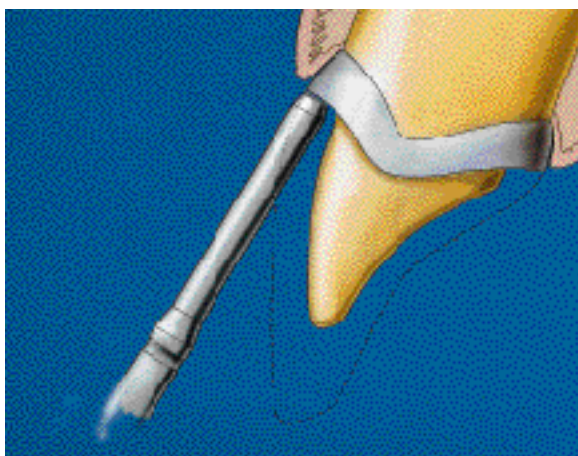


Figure 15–11A: This beveled end-cutting diamond (TPE-Shofu or TGE-Premier Dental Products) helps protect the gingival tissue as it extends the shoulder margin subgingivally.

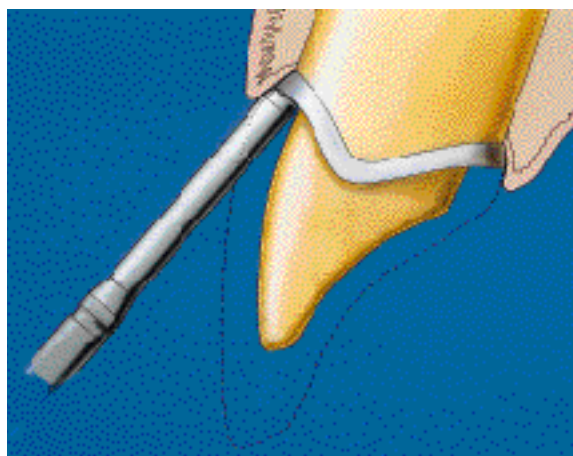


Figure 15–11B: As the diamond cuts the shoulder deeper into the gingival sulcus, the bevel protects the gingival epithelium by pushing it out of the way.

be used intraorally to mask the metal.⁶⁸ Bertolotti advocates a direct adhesive bonding with the intraoral tin plating of the noble metal substructure.¹⁰ This technique can be difficult to accomplish.

Interproximal contacts between full crown restorations or with the natural dentition also play a role in maintaining gingival health. Southard et al. present a study from which they conclude that “posterior dental contact tightness, generally regarded by dentists as a static feature of occlusion, varies significantly as a function of posture.”⁸⁵ The recumbent patient showed a mean decrease in posterior contact tightness, which increased after a return to an upright position. Aside from gingival health, as proposed by Sturdevant, excessive pressure between restored teeth may ultimately result in undesirable tooth movement.⁸⁵ From an esthetic standpoint, such shifting of the teeth may compromise the optimal restorative results you worked so hard to achieve.

Following the construction of the crown, check the shoulder fit and contour of the crown. Remove rough or excess porcelain, as it will increase plaque retention and cause gingival irritation. A poor marginal fit may eventually produce granulation tissue or gingival recession, which, in turn, may cause the gingival tissues to appear bluish or become puffy and reddened. Blame may be erroneously placed on the restoration rather than on poor planning or technique.⁹ Some nonpathologic tissue changes occur with time. Under these circumstances, replacement for purely esthetic reasons is a matter for the patient to decide.

Friedman and Jordan suggest that composite luting or bonding of the porcelain crown may reduce the incidence of fracture, and cite research that concludes that bonded porcelain crowns strengthen the remaining tooth structure to a degree comparable to the strength of a fully-intact normal tooth.⁷⁵

In addition, the use of composite luting materials instead of traditional cements provides more control over the color of the restored tooth, because the composite functions like a core stain.²⁸

Jendressen et al. report the marketing of a method of ion-strengthening, which is said to leave the cooling surface of all-porcelain or porcelain-fused-to-metal crowns in a state of compression, increasing strengths from 20 to 83% over untreated

crowns. They conclude that the procedure was “found to be a simple and practical approach to strengthening completed ceramic restorations.”⁴⁶

Jacobi and El-Sheriff have used a porcelain, reverse, three-quarter crown which mimics a porcelain laminate veneer when there is deep discoloration or slight malposition, or for teeth that have been damaged by caries or trauma that does not involve the gingival two-thirds of the lingual surface. They feel the advantages of using this restoration over a full porcelain crown are: less removal of tooth structure, a reduced potential for gingival irritation, and in a normal occlusion, centric stops in enamel. Advantages over a porcelain veneer are its superior strength and increased ability to mask discoloration.^{26,44}

The Alumina Reinforced Porcelain Crown

McLean was the first to use a high-strength aluminous porcelain core in the construction of the porcelain crown. He showed how this technique strengthens the internal aspect and increases the resistance of the crown to crack propagation.⁶¹⁻⁶³

When restoring fractured anterior teeth it must be remembered that many patients do not want gold to show, even on the lingual surfaces. Whereas conventional full coverage crowns using resin or porcelain-faced veneers may prove excessively thick, porcelain reinforced with alumina allows construction of anterior crowns with a thickness of only 1.3 to 1.5 mm on each surface of the tooth. With cement, this results in a total thickness of 1.5 to 2.0 mm, which is considerably less thickness than required with all-porcelain crowns. Thus, the use of aluminized porcelain can satisfy tooth strength requirements and still fulfill esthetic thickness requirements.

When sufficient reduction is obtained, the aluminous porcelain crown is esthetically successful. When crowning lower posterior teeth, make sure you have adequately reduced the occlusal table at least 2 mm, especially at the central fossa. Otherwise, the aluminous core of an all ceramic restoration will not allow proper depth of porcelain for central groove anatomic carving (Figure 15–21).

Figure 15–12 shows replacement of an anterior full crown with a reinforced aluminous porcelain restoration. Modern techniques have eliminated the earlier problem of the inner alumina core showing through the outer porcelain.

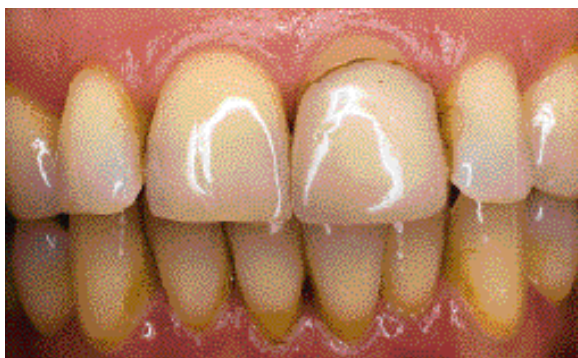

Figure 15-12A: One of the major reasons for anterior crown replacement is the presence of tissue recession. Although this 15-year-old crown was still functional, it became an esthetic problem for the patient.

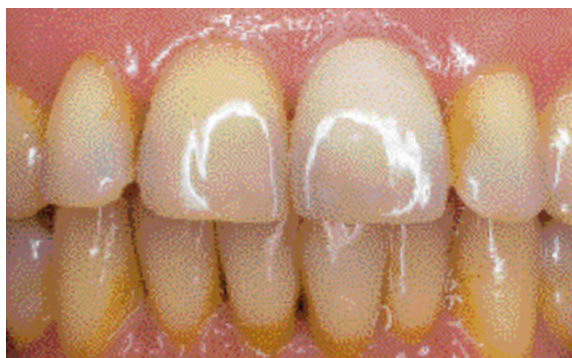

Figure 15-12B: A new aluminous porcelain crown was made and the subgingival margins improve the patient's appearance.

Indications^{18,23}

1. There is a shoulder thickness of only 0.5 mm possible on the labial surface of most incisors (preferably 1 mm on larger centrals).
2. There is an occlusal clearance of more than 0.5 mm in all lateral excursions (preferably 1 mm).

Contraindications

1. The preparation is conical with a little retention.
2. Short teeth or where there is too little tooth structure to support such a restoration.
3. Where occlusal clearance is less than 0.5 mm.

Advantages

1. Clinical experience with 1334 aluminous porcelain crowns over 3¹/₂ years by McLean indicates

that these crowns can withstand torque better than conventional porcelains with a fracture rate slightly less than 0.5%.⁶²

2. As Abramowsky states, pure alumina is six times stronger than standard porcelains, which are vacuum-fired.¹ By combining an alumina core and standard porcelain, you get a restoration with twice the strength of porcelain alone. The alumina core also increases the impact resistance in the biting area.
3. Low thermal conductivity.
4. During processing, alumina and porcelain unite by a chemical bond, so there is practically no problem in adhesion of the different materials.
5. Both materials exhibit the same expansion and

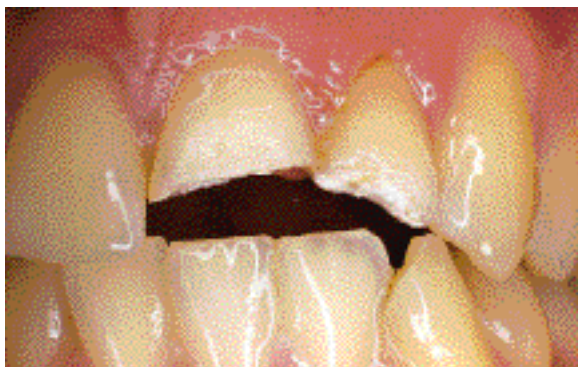

Figure 15-13A: These fractured maxillary incisors are to be restored with aluminous porcelain crowns.

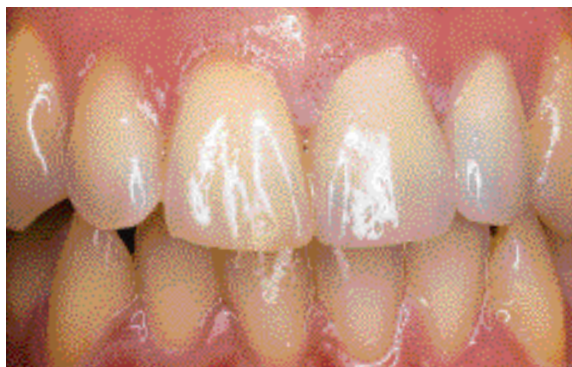

Figure 15-13B: A natural appearance is created with stains and texture.

contraction coefficients; thus, they do not require adjustment of the thermal expansion coefficients as when different materials, such as metal and porcelain, are used.

6. Good color consistency. Provided the porcelain's maturing temperature is not exceeded, the crowns may be fired three or four times without loss of color.

Esthetic Considerations

Maximum esthetics can only be achieved if a minimum thickness of 1 mm exists on the labial surface, since 0.5 mm is required for the opaque aluminous porcelain core. However, if this thickness is unattainable on the labial surface, the normal core material may be thinned in this area and then replaced by a grayish blue alumina core material of greater translucency. The thicker areas

located gingivally and palatally will provide considerable reinforcement when compared with the conventional porcelain crown.

Different hues of aluminous porcelain may be used to build up the core unit. For example, a darker cervical area intensifies the gingival collar, while the use of separate gray yellow or light gray on the mesial and distal surfaces increases the translucent appearance of the enamel when in the interproximal areas.

A central body effect may be achieved with light or dark yellow core colors. Figure 15-13 illustrates esthetic restoration of fractured maxillary incisors with aluminous porcelain crowns. Combining body and incisal shades with surface stains helps to create a natural appearance. Note how texture and highlights are used to match corresponding teeth in the arch.

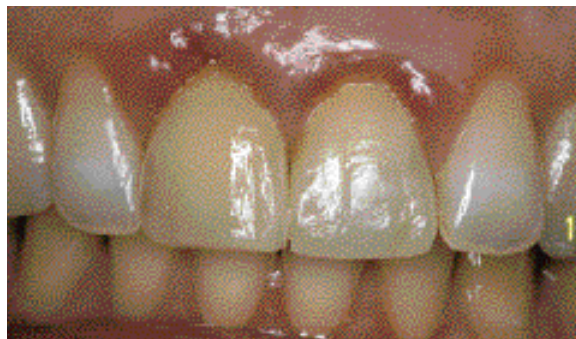

Figure 15-14A: This 37-year-old female had an allergic reaction around her previous maxillary central crowns. In addition, the crowns were gingivally undercontoured and contained marginal ledges.

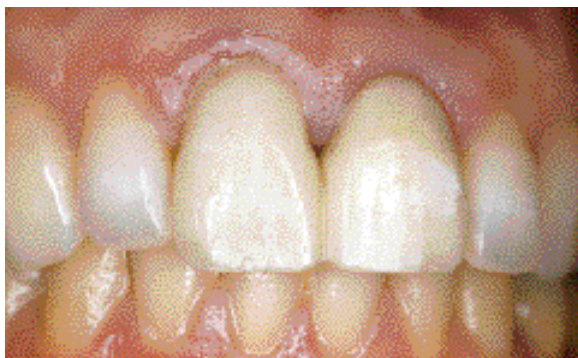

Figure 15-14B: Well-fitting temporary crowns plus conservative periodontal therapy helped restore the tissue to good health.

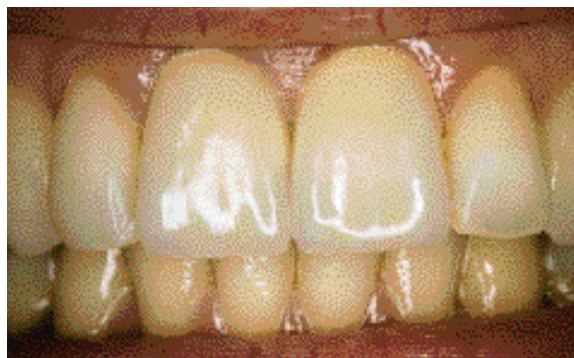

Figure 15-14C: Two Hi-Ceram crowns were constructed that show improved functional and esthetic contours, provided adequate tissue support, and improved the gingival health.


Table 15–I Troubleshooting Esthetics Guide for All-Porcelain Crowns^{7a,14b,17,22,54,55}

PROBLEM	SOLUTION
1. Tooth preparation is visible through porcelain	Add porcelain to labial aspect. Reprepare the tooth to allow porcelain to be thicker.
2. Teeth are unnaturally even	Provide for variation in tooth length and enhance illusion of spacing by shading and shape. Open incisal embrasures.
3. Glaze is too high	Break up light being reflected by texturing the porcelain.
4. Crown is too opaque	Use more incisal shading or surface stains.
5. Shade varies excessively	Select shade using color-corrected artificial light and outside light. Laboratory must use same lighting. Stain by using sectional shade chart (see Figure 15–2A).
6. Crown shade is dull	May be due to use of opaque-type cement. Use a cement with more translucency, such as silicophosphate, composite, or glass ionomer.
7. Porcelain is fractured	Correct to minimal occlusion in anterior teeth. Provide greater thickness of porcelain. Reduce stress factors by removing sharp edges or corners in tooth preparation. Avoid inadequate length of preparation. Change to aluminous porcelain or ceramometal.

Hi-Ceram

Hi-Ceram (Vita Zahnfabrik) was developed in 1985, borrowing a technique from industrial manufacturing. It is a system similar to the aluminous core porcelain crown, using an epoxy die, a swagged resin coping, and conventionally applied porcelain.

Although anterior crowns are its primary indication (Figure 15–14), posterior crowns can also be used when occlusal conditions are favorable (Figures 15–15A to D). This mainly occurs in patients who do not want a metal core, are allergic to metal, or require some light reflection off the tooth through the core for esthetic purposes.

In-Ceram

In-Ceram (Vita) features an aluminum oxide core, which is infiltrated with glass material to produce an extremely strong, internally shaded core that is reported to have three times the strength of conventional aluminous cores.^{55,75} This increased strength is achieved because the densely stacked

alumina particles limit crack propagation. The core is then layered with conventional porcelain, which is keyed to the Lumin shade guide. Improved esthetics via core color selection and intrinsic staining, plus porcelains matched specifically to this system, produce a highly esthetic restoration. In-Ceram is especially indicated when you would like to restore with an all-ceramic material and require increased strength, such as in the patient with a deep overbite or edge-to-edge occlusion.

Because of its strength, posterior crowns may be produced with a higher confidence against fracture. However, it is still not recommended by the manufacturer for bridges. The addition of zirconium to the core may allow future prostheses to be placed with greater confidence, as clinical trials have shown increased fracture toughness on the order of threefold over glass-reinforced aluminous cores.⁵⁵ The elimination of a metal substructure can eliminate some of the esthetic problems associated with metal masking.

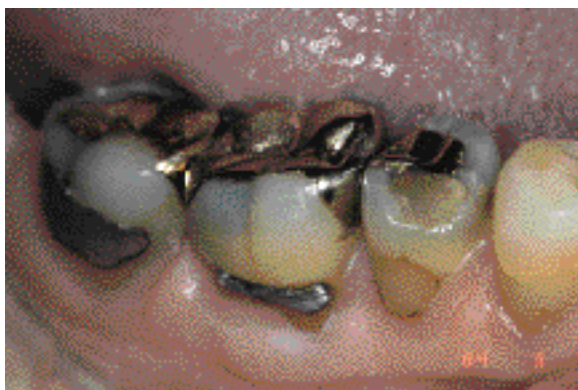

Figure 15-15A: This 79-year-old woman wanted her mandibular right second bicuspid to blend in with her first bicuspid, preferably with an all-ceramic crown.

In the past, one drawback with In-Ceram and Hi-Ceram restorations was the clinical perception of excessive opacity. It was helpful, however, in masking extremely discolored teeth. The recent development of opalescent body and incisal porcelains improves its translucency and also provides shades that more closely mimic the warm, orange tones of the natural dentition. They rely on the optical properties of light dispersion as opposed to color characterization by internal staining.

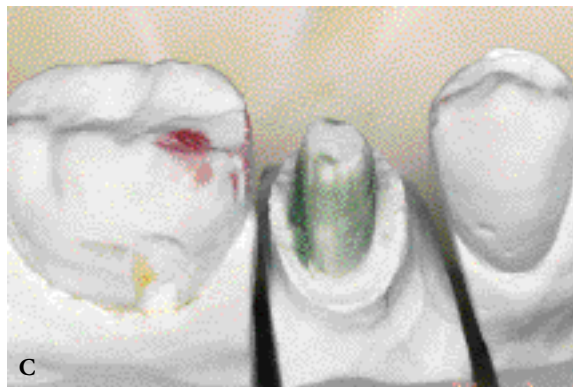
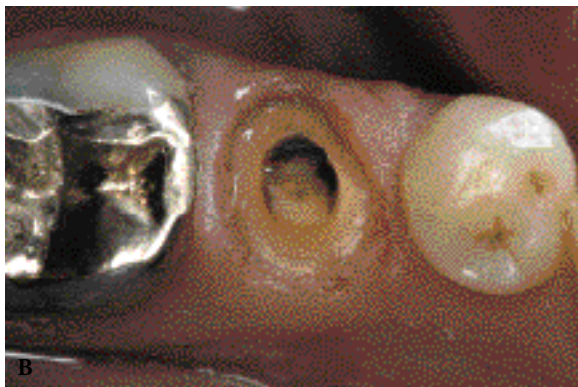Procera AllCeram

For patients who demand the ultimate in an all-ceramic crown, the Procera AllCeram System (Nobel Biocare, Sweden) offers an exceptionally strong all-ceramic core to build on. Procera embraces the concept of CAD/CAM and advanced powder technol-

ogy to fabricate an all-ceramic crown incorporating a densely sintered, high-purity aluminum oxide coping. A computer-controlled design system in the dental office collects tooth preparation and coping design data which is transmitted via modem to the manufacturing site. After fabrication, the coping is delivered to the dental laboratory where the ceramist completes the restoration with the addition of veneering porcelain. This system produces a crown that is durable, color-stable, translucent without being transparent, and biocompatible with the opposing dentition (Figures 15-15A to L).⁷⁷

Procera AllCeram shows strength values never before reached by an all-ceramic restoration. Wagner and Chu⁹⁰ reported significant differences in flexural strength for Procera when compared to other materials: AllCeram was 687 MPa, In-Ceram (Vident), 352 MPa, and IPS-Empress (Ivoclar), 134 MPa.

Sadan et al.⁷⁹ report that because the high-purity aluminum oxide copings are fabricated in an industrial process, the risk of introducing microcracks and flaws into the completed restoration is minimized. Further, the high strength and accuracy of fit of the copings permit the utilization of these crowns in any segment of the dental arch. Labor-intensive, time-consuming, and technique-sensitive procedures for coping fabrication are eliminated while achieving an esthetic, strong, and durable restoration in a practical and simplified manner. Today, the Procera application is used for the single crown. However, continued development is expected to produce the capability for multiple



Figures 15-15B and C: A correctly prepared tooth has a heavy shoulder and rounded internal line angles.

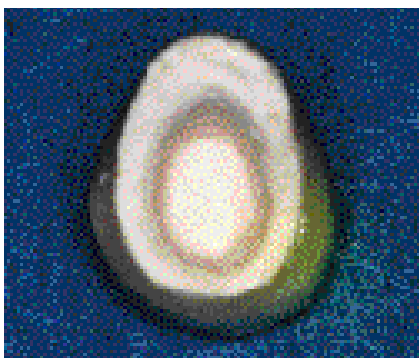


Figure 15-15D: This internal view shows the opaqueness of the inner core and the increased labial thickness for greater shade control.

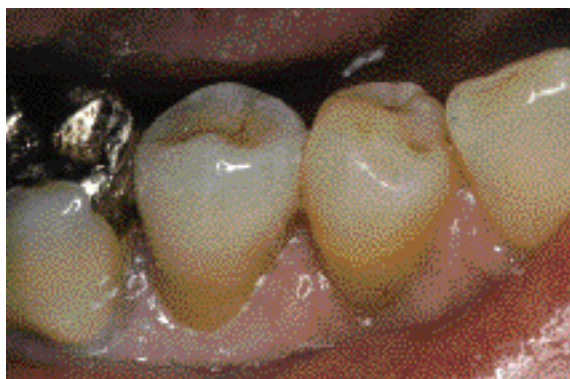

Figure 15-15E: The final crown demonstrates how darker gingival stains help to make the restoration appear more natural.

unit all-ceramic anterior and posterior fixed bridges as well as laminate veneers.

Foil Substructure—Renaissance and Sunrise

Another technique for porcelain uses a thin metal matrix (Renaissance, Ivocar North America). The porcelain is bonded to this matrix, which is actually a coping made of thin multiple layers of gold palladium alloy bonded together with the central layer being pure palladium. The outer layer is coated with 24 karat gold, and the porcelain is then baked onto this matrix (Figures 15-16A to D).

The preparation for the Renaissance crown can be more shallow than for other ceramic crowns, making it particularly useful in esthetically demanding areas, which have too little room for normal tooth reduction. This type of crown is suitable not only for single units in the anterior and

posterior areas, but also in certain favorable instances for small-span fixed bridges. However, it is not meant for inlays, onlays, or veneers.

A major advantage of this technique is the speed in which a restoration can be constructed.

The Sunrise ceramic system (Tanaka Dental Products) utilizes a 50-micron thick, yellow-colored foil containing approximately 99% gold and platinum with 1% rare earth metals, which allows chemical fusion of the porcelain to the outside surface. After the creation of the foil substructure, according to Boghosian, virtually any type of porcelain may be applied using conventional layering techniques.²⁸

Like Renaissance, the greatest advantage of this system is that a conservative tooth preparation, with as little as 1.0-mm reduction, is sufficient to produce a restoration with an acceptable esthetic result. An

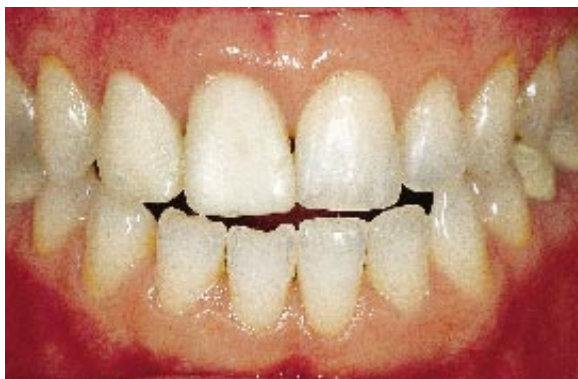

Figure 15-15F: This forty-year-old patient was unhappy with her previous crowns on her right central and lateral incisors, as well as the appearance of the other maxillary anterior teeth.

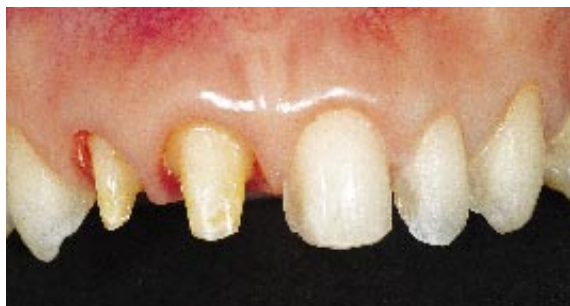

Figure 15-15G: The two crowns were reprepared, and the left central and lateral and the two cuspids were prepared for porcelain laminates. If the patient had been satisfied with the rest of the smile, then it would only have been necessary to replace the two crowns. However, to enhance the overall appearance and improve shape, texture and color, combination therapy was performed.



Figure 15-15H: Once the dyes are fabricated, each individual dye (teeth nos. 7 and 8) is placed on a scanner.

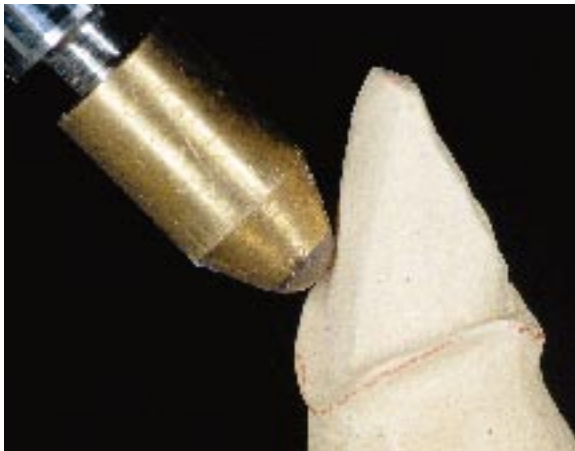

Figure 15-15I: The scanning probe reads every part of the tooth surface and inputs the measurements into the computer. Next the finish line and thickness of ceramic coping is established.

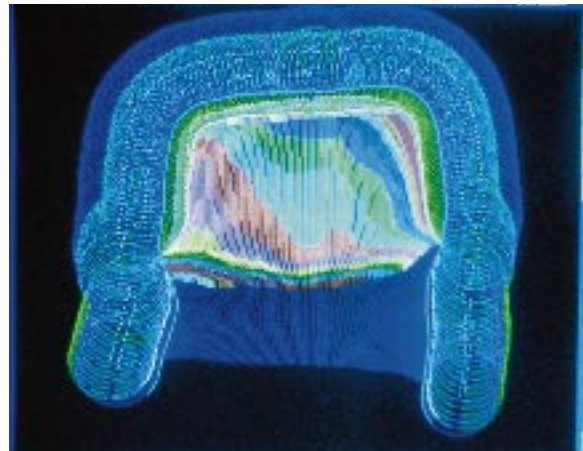


Figure 15-15J: This three-dimensional computer image is an example of the type of complete design for a molar all-ceramic core. The information is sent via modem to Sweden.

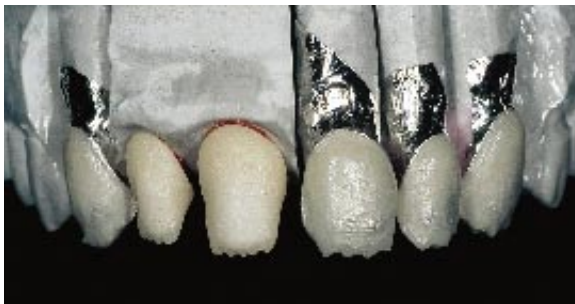

Figure 15-15K: Procera cores are fabricated in Sweden and sent to the dental office or lab in four days. Porcelain laminate preparations are prepared on foil and opacious dentin applied then baked. Next, full-body and incisal affects will complete the laminate and full-crown build-ups simultaneously.

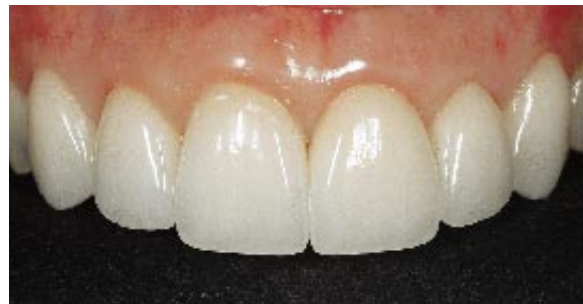

Figure 15-15L: The final laminate veneers are bonded with Choice (Bisco) translucent dual cure resin cement and the crowns are final cemented with Panavia (Kuraray). Note the harmonious blend of color and internal characterization.

additional advantage of Sunrise, according to Hummert et al., is that the foil substructure resists deformation during the firing process, providing marginal adaptation within the range of clinical acceptance.⁴¹

Dicor

Dicor (Dentsply) is a castable ceramic that is used with the lost-wax technique. Dicor is especially indicated for reproducing teeth that are highly translucent. McLean⁶⁰⁻⁶³ describes the use of castable glass crowns as being good for young patients with translucent teeth to be matched. Problems may be encountered when one tries to match older teeth or teeth that have internal defects or pronounced areas of different color. As a result, a Dicor restoration placed over amalgam or cast gold in the prepared tooth may not sufficiently hide the metal unless a colored opaque cement is used (Figures 15-17A to D).

The cast-glass preparation requires a shoulder with rounded gingivoaxial line angles, or a deep (120-degree) chamfer. The axial surfaces should be reduced by 1.3 to 1.5 mm and the incisal or occlusal surface by 1.5 to 2.0 mm (Figures 15-18A to D). The preparation should be free of undercuts.

Impressions, models, and dies are obtained in the usual manner. The crown is waxed to full contour, sprued, and invested in a phosphate-bonded investment. Once the crown is cast, it is then heated (cerammed) to increase its strength, and then shaded with surface stains to match the shade and create translucency.

Geller^{34,35} has described another application for castable glass. This application involves using the cast glass as a substructure core, upon which porce-

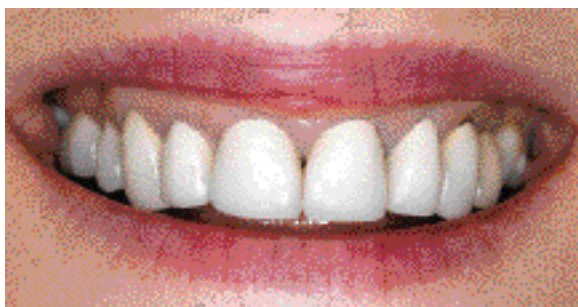

Figure 15-16A: This 42-year-old author and television personality was concerned about how unattractive her smile appeared on video. She complained her crowns were too opaque, too light, and too wide. Note the unattractive reverse smile line created by cuspids that were longer than the centrals.

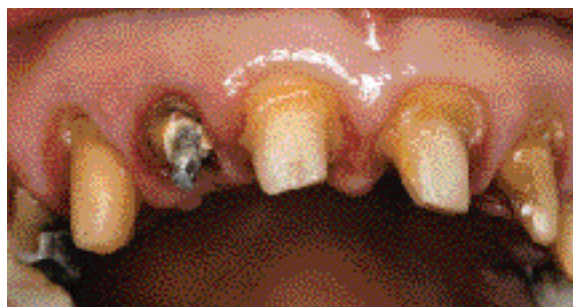

Figure 15-16B: The old crowns were removed and the teeth were repaired to allow for better proportion in the new restorations. Conservative periodontal therapy plus well-fitting temporary restorations helped to achieve gingival shrinkage and healthy tissue.

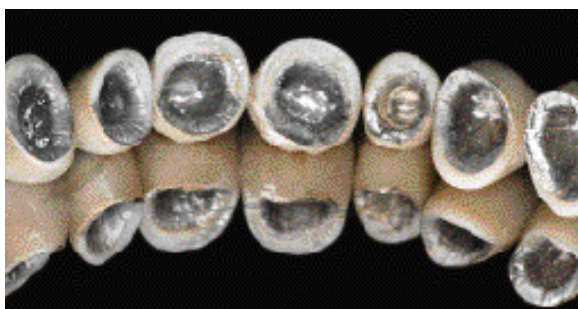

Figure 15-16C: The porcelain was baked onto a gold palladium matrix.

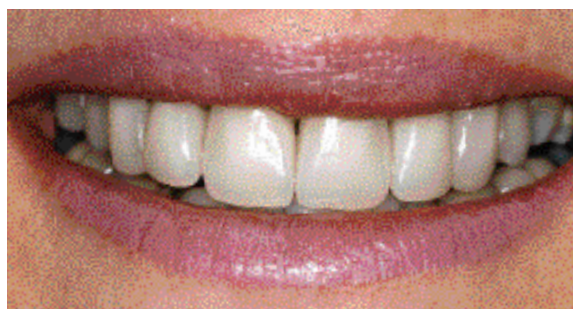

Figure 15-16D: The patient was pleased with her new smile because of the natural-appearing, shaded crowns. The cuspids were shortened and the rounded incisal edges of the anterior crowns mimic the curve of the lower lip for a younger, more attractive look.

lain Vitadur N or Vitadur Alpha can be baked (Willi's glass). The advantages to using cast glass in this manner include precise marginal fit, margins that do not distort from multiple firings during the porcelain build-up process, favorable reaction of periodontal tissue to the glazed material, and improved esthetics. The combination of a more translucent core, over which internally stained colors and effects are built in, can provide a highly esthetic result (Figure 15–19). A similar process has been developed for Dicor (Dentsply).

One major limitation of cast-glass restorations is the need to try in the restorations after being cerammed and before staining (Figures 15–20A to C). However, this also allows you to check for ideal morphology and occlusion. Also, because the

Dicor ceramic is somewhat fragile, it may be wise to avoid using it to restore a tooth under great functional stress, such as in a patient with a deep overbite or edge-to-edge occlusion.

IPS-Empress

IPS-Empress (Ivoclar, North America) is a heat-pressed ceramic that produces consistent results without additional time-consuming crystallization procedures as with Dicor. This material has two different crown-fabrication techniques. One uses the colorless material to form the complete restoration, using the lost-wax technique, which is then shaded with surface colorization. Garber feels these restorations are primarily indicated for molar crowns, inlays, and veneers that are bonded with resin cements.^{32,33}

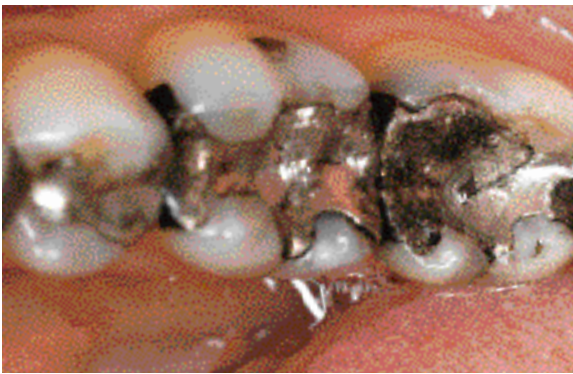

Figure 15–17A: This 51-year-old business woman wanted to replace her defective amalgam restorations with esthetic crowns that did not contain metal.

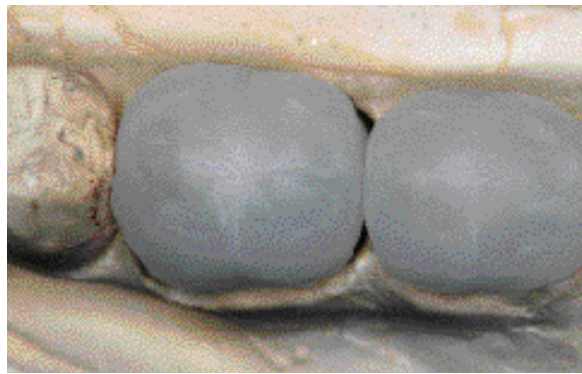


Figure 15–17B: Two cast-glass (Dicor, Dentsply) crowns were constructed for the first and second molars while more conservative porcelain onlays were made for the bicuspids.

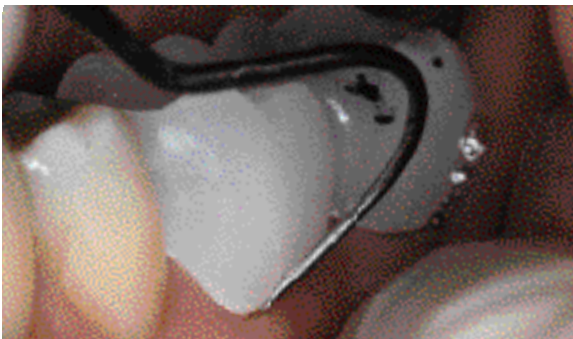


Figure 15–17C: The cerammed crowns are tried-in to make sure the margins and occlusion are perfect before external surface staining takes place.

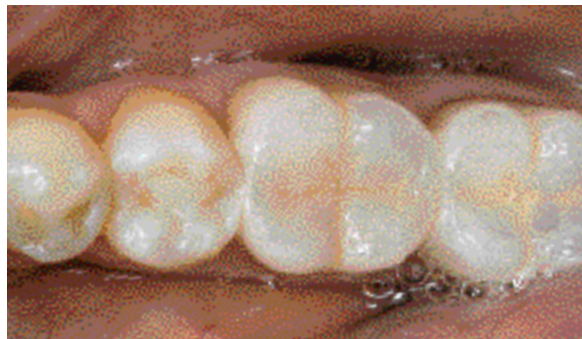

Figure 15–17D: The four ceramic restorations are cemented to place. Since the two cast-glass crowns were placed over amalgam-stained dentin, a colored opaque cement was used to help mask the discoloration.




Figure 15-18A: The S2C diamond (Ceramatique Kit, Premier Dental Products) is a perfect shape and grit to create a 2-mm reduction on the occlusal surface of posterior teeth.

A unique shade guide, a Chromoscope, is used for the ceramic shade selection. Because the ceramic material is somewhat translucent, the color of the underlying tooth structure will be transmitted through it. To account for this effect, the die material is available in seven different dentin shades to reproduce the shade of the dentin of the prepared tooth. A specially-formulated shade guide, the stump or “dentin” shade guide, is used after tooth preparation to select the shade to be used. The shaded die materials contribute to the highly esthetic outcome of these restorations as well as the material’s inherent natural fluorescence.

The completion of the restoration can then be achieved in two ways—surface staining or a layering technique. Surface staining involves using gly-

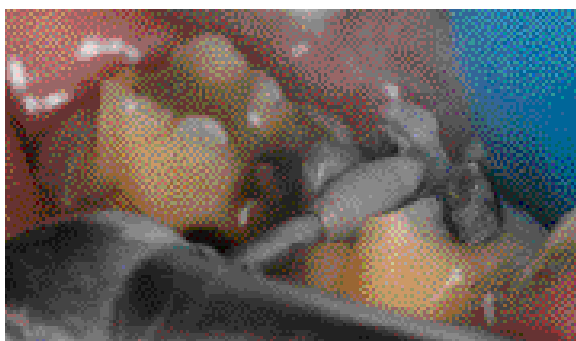


Figure 15-18C: Here the S2C is used to reduce the mandibular right first molar by 2 mm.

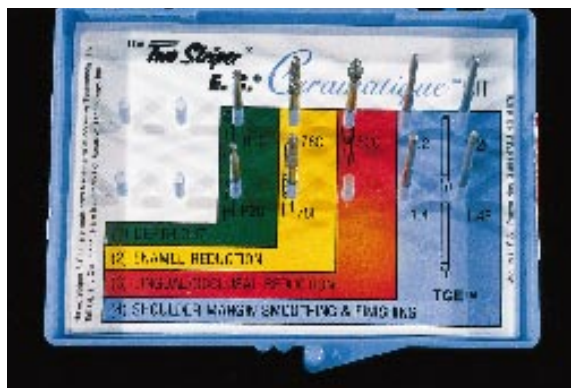


Figure 15-18B: The Ceramatique Kit (Premier Dental Products) provides an efficient method for crown preparation featuring full-shoulder margins.

erine to transmit the color of the dentin-shaded die through to the final shaded restoration. The final intrinsically-characterized restoration may require between two and four firings.

The layering technique of IPS Empress is a method recommended for developing ideal esthetics in the anterior region. An anatomic coping is fabricated from a colored ingot, and a cut-back is done to provide the space required for the enamel and incisal layers. Body and incisal porcelain and modifiers are applied when necessary to further customized internal structure and the tooth form is fully developed and shaped.³³ With thermocycling treatments required for shading and glazing, the final maturation of the IPS Empress leucite-reinforced structure improves the mechanical properties to the levels reported.⁵⁵

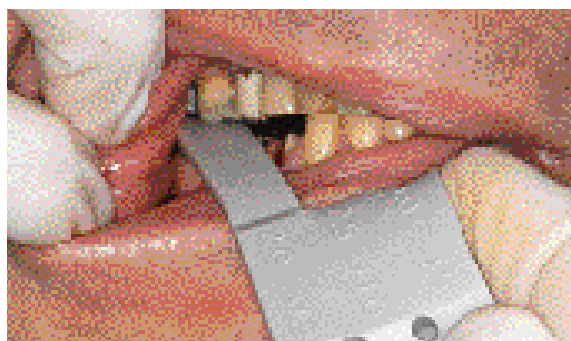

Figure 15-18D: A 2-mm flexible clearance tab (Bell de St. Claire) is used to verify that adequate clearance has been established.

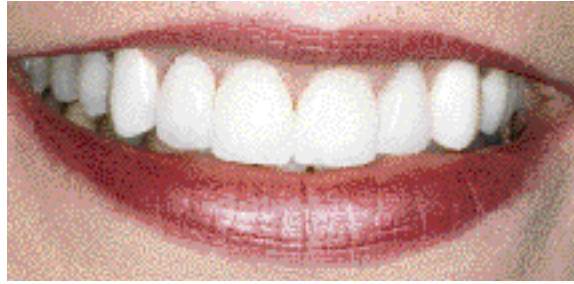

Figure 15-19: Developed by master ceramist, Willi Geller, these Vitadur-N (Vita) crowns are built over Dicor cast-glass cores for enhanced marginal stability and esthetics.

From an esthetic standpoint, surface characterization seems to be less crucial for IPS Empress, which is less opaque than conventional aluminous core restorations but less translucent than Dicor. IPS Empress has multiple ingots that provide differ-

ent levels of translucency. To match more complex tooth shades, a body build-up (simulating dentin) is created, which is then covered with veneering porcelain up to 0.3 mm thick.⁵⁵ Lehner and Scharer have found that several coats of a heavily pigmented

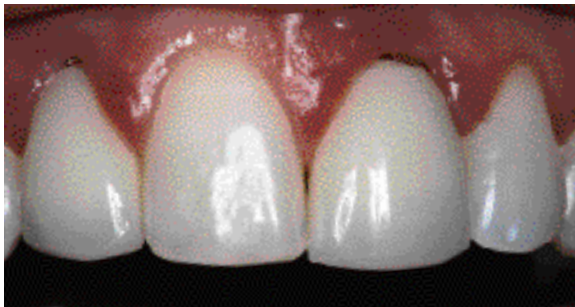

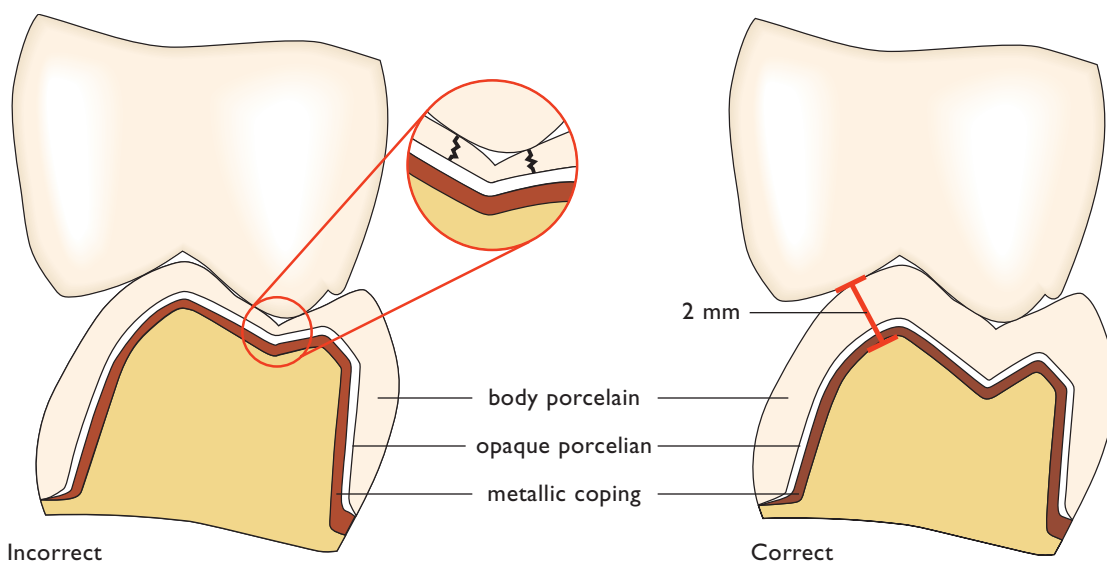
Figure 15-20A: This 43-year-old woman complained of several years of continuously bleeding gums from around all of her ceramic crowns.

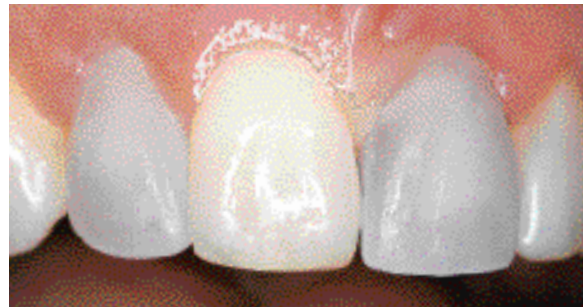

Figure 15-20B: Carefully-fitted treatment crowns plus meticulous soft tissue management stopped the bleeding and improved the tissue appearance. Here two cast-glass crowns are being fitted and contoured before final staining.

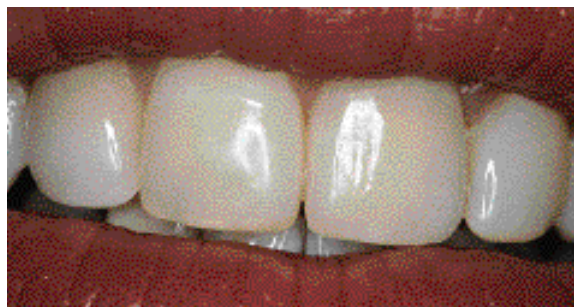

Figure 15-20C: The final crowns are color-blended, textured, and shaped to match the adjacent teeth. See how important healthy interdental papillae are to the overall esthetic result.



Figures 15–21A and B: A major problem with posterior ceramometal restorations is insufficient occlusal reduction in order to create uniform thickness of the porcelain. The failure to do this is one of the most frequent causes of fracture.

stain followed by a glaze (to total 50 to 60 microns in thickness) will enhance fracture resistance to external compressive forces.

Advantages of the Empress system include simple processing, accurate reproduction of the wax pattern and margins, high flexural and tensile strength (which increases with each firing), and good esthetics. This new line of ceramic materials has a high degree of stability during the subsequent shading or layering technique.

Summary

The pitfalls of all-ceramic crowns are based on fracture potential (Figures 15–21A and B) and the loss of surface stains, if utilized, when occlusal adjustments are needed. This is especially true of lower anterior teeth, including premolars, where the incisal or occlusal surface is visible during speech. In these instances, you should adjust the opposing upper dentition or prosthesis, if possible, to avoid esthetic compromise.

Because Dicor and, sometimes IPS Empress, rely on external characterization, you may wish to avoid using these systems on lower anterior teeth unless they are in a protected occlusal scheme or you can adjust the lingual surfaces of maxillary incisors when necessary (Figure 15–22). For this reason, Lehner and Scharer point out that long-lasting esthetic

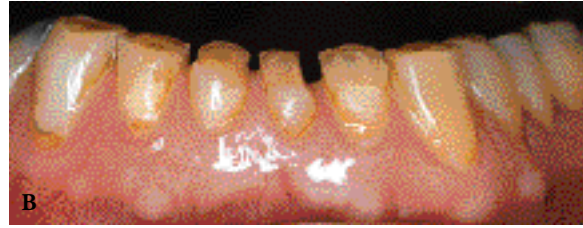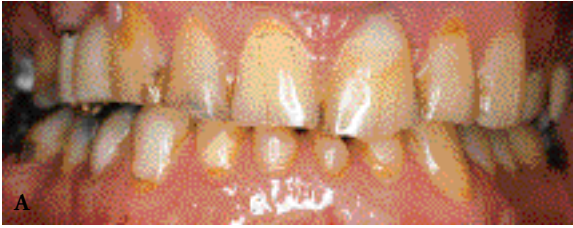results may be better achieved by using materials that allow internal stains and shades rather than relying only on thin surface stains.⁵⁵ Also, external surface characterization is subject to surface loss due to the prescription stannous fluoride gels. Neutral fluorides must be prescribed for these patients.

One of the problems with shaded porcelain is that over the years, it loses its color as a result of functional demands and abrasion.⁵⁵ Surface roughness appears⁵⁵ and there is clinical evidence that these materials generally abrade the enamel of the opposing teeth.⁵⁴

The color of an IPS Empress restoration, when fabricated from a colored ingot, is impervious to surface abrasion and occlusal attrition. However, if surface staining is done, it may lose its color over a period of time.

Preston devotes an entire text to the proceedings of the Fourth International Symposium on Ceramics, which compares the various porcelain systems and notes inherent advantages and disadvantages of each. He notes that flexural strength among the high strength ceramics was highest for high-alumina (98%), with almost a fourfold advantage over the all-ceramic, Dicor, and aluminous-core porcelain, in that order.⁷⁴

Marginal adaptation and occlusal harmony are dependent upon the skill of your ceramist who



Figures 15–22A and B: This 71-year-old man wanted the best esthetic result without using metal on his lower anterior crowns. By cosmetically contouring the lingual surfaces of the maxillary anterior teeth, it was possible to create a favorable occlusion for cast-glass crowns.

often has personal preferences and sometimes, understandably, business interests with certain ceramic manufacturers. You therefore must choose your ceramist (or ceramists) based on the unique needs of your practice and the results he or she can consistently deliver. If you wish to use a ceramic system that esthetically falls out of the options your ceramist has to offer, consider another laboratory. For instance, you can send out your impression or model for a specific ceramic or glass core with the crown then completed by your in- or out-of-office laboratory.

Regardless of which system you may choose for a particular patient you should be able to achieve an acceptable esthetic result. Most systems have an esthetic range that will allow them to be used for your planned restoration. Only in cases of extreme opacity or translucency will it make a difference. This is one reason why the ceramometal restoration has remained so popular throughout the dental world.

Ceramometal Restorations

Porcelain Fused to Metal

History. Ceramometal has been one of the most important advances for esthetic dentistry in modern times. According to Kuwata,⁵³ in his new book, “Creating Harmony in Dental Ceramics,” Katz and Katz were the earliest pioneers in ceramometal who, in the late 1940s, first conceived and developed the materials and technology. Later, with major investment backing from the Weinstein brothers, the first patent was granted for fused porcelain to metal. Although many people have played an important role in the early development, Kuwata’s contributions were significant particularly in the areas of particle size and color pigment selection as well as his research on the coefficient of thermal expansion and bond strength between porcelain and metal.

From an esthetic viewpoint, porcelain is presently the only material capable of maintaining its surface texture and color for extended periods without losing its naturalness. However, because of excessive fragility, porcelain alone has its limitations. This limitation is overcome by the use of porcelain-fused-to-metal alloys.

Precious/Nonprecious. The ADA has developed a classification system for casting alloys. The classification is: high noble—greater than or equal to 60% gold, platinum, and palladium, or gold greater than or equal to 40%; noble—greater than or equal to 25% gold, platinum, and palladium; and base—less than 25%. (Noble metals are gold, platinum, palladium, and other platinum-group metals.) In the early 1970s, increased fluctuation in the cost of gold sparked interest in alternative metals for casting, so base metals were developed. These metals are based on nickel and chromium. Other nonprecious ingredients are added to base metals to modify their properties, casting accuracy, and porcelain to metal compatibility.

Gettleman defines noble metals differently. Noble metals, he states, are alloys of gold, palla-

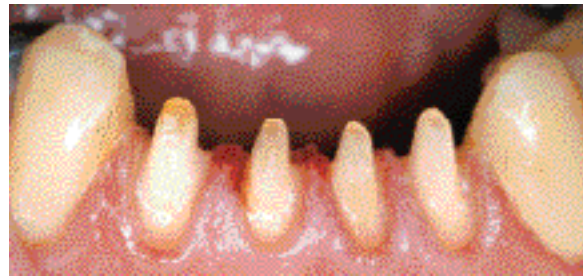

Figure 15–22C: The four incisors are prepared and ready for the impression.

dium, and silver (not a noble metal), with smaller amounts of iridium, ruthenium, and platinum. They are primarily used as a substructure for ceramic application, with the rest used as inlays, onlays, and unveneered crowns. Base metal alloys, principally made of nickel, chromium, and beryllium are used widely in the United States, due to their lower cost and higher mechanical properties.³⁶ Most of the alternative base-metal casting alloys, he states, have superior mechanical strength, porcelain bond strength, high-temperature sag resistance, and corrosion resistance. The principle deficiencies of base metals are the potential for allergic reaction in patients who are hypersensitive to nickel, chromium, or beryllium.

When selecting an alloy the decision should be based on the type of restoration involved. The porcelain to be used is an important factor in that only certain porcelains are compatible with specific metals. When a tooth is to be restored with a porcelain-fused-to-metal restoration, the alloy should be less than 5% silver due to the adverse effect silver has on porcelain color.²⁰

Different alloys offer different degrees of hardness; the differences are a result of the minor constituents added. For example, copper is added as a hardener. A long-span bridge would require a harder alloy than a single unit or a short-span bridge.²¹

Nickel chromium base alloys also result in color changes, which are detectable by trained dental observers under ideal viewing conditions. However, it may be well within an acceptable range under normal viewing conditions.²⁰

Indications

Ceramometal crowns are indicated when:

1. extreme malformation or malposition, advanced caries, or hypoplasia create esthetic problems;
2. occlusal forces, the area of occlusion, or clasping of a tooth contraindicates an all-porcelain crown or acrylic veneer;
3. a porcelain-fused-to-metal crown on a posterior tooth would occlude with porcelain;
4. an abutment for a bridge or removable prosthesis is required;
5. there is insufficient tooth structure remaining to construct a porcelain laminate veneer.

Contraindications

1. Adequate tooth structure cannot be removed to allow ample space for both metal and porcelain.
2. The clinical crown is too short. Since an incisal or occlusal reduction of 2 mm is essential to allow space for metal and porcelain coverage, retention and stability of the crown may be inadequate.
3. Use in extensive long-span bridges or splints is not routinely recommended because of the greater possibility of warping or flexing of the metal substance and subsequent fracturing of the porcelain. It may be prudent to break up any long spans with copings or interlocking attachments.

Technical Problems

1. Pulp exposure can occur if required tooth structure is removed to allow for thickness of materials and to achieve sufficient parallelism for crown retention after insertion.
2. The shrinkage and flow of porcelain during the baking process can alter the occlusion.¹⁵
3. Breakage can be minimized by careful attention to tooth preparation, coping design, and by the use of carefully matched metal alloy substructures and porcelain.
4. The teeth of splints or fixed partial dentures using porcelain fused to metal suffer a loss of separateness that detracts from the appearance. As Bronstein points out, ideal deep interproximal carving is greatly limited by the proximity of the metal truss arms, which join the crowns. This is not as much of a problem in posterior segments of the mouth, where shadows and oblique angles make them less visible.²²

Advantages

1. Porcelain fused to metal can be used to crown the abutment teeth of removable clasp-type partial dentures, since it resists abrasion by the clasp arms, and if necessary, rest seats can be made in the metal framework.
2. Porcelain may be contoured to provide desirable retentive undercuts and guiding planes for removable partial dentures.
3. A light surface glaze is attainable that minimizes abrasion on the inner surface of a partial denture clasp.

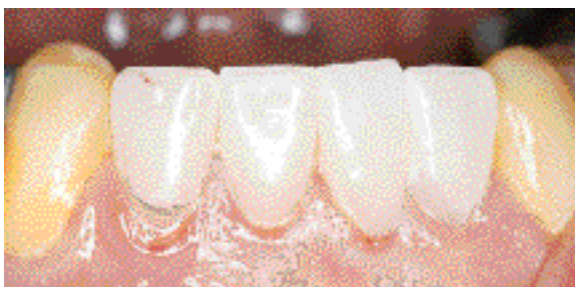

Figure 15-22D: It is essential that the occlusion be carefully and completely adjusted during the try-in.

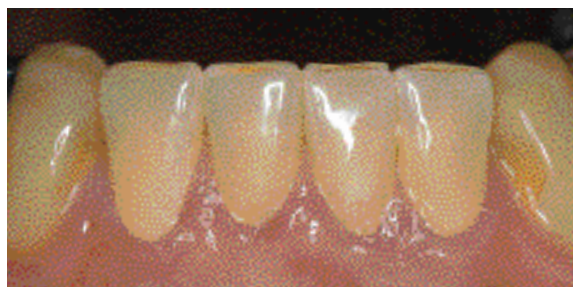

Figure 15-22E: The final shade is slightly lighter than, but in the same range as, the cuspid.

4. They can be used for the placement of internal attachments for removable partial dentures. The cast metal can contain the female portion of the attachment.
5. Metal permits a superior marginal seal and adds strength.²⁴

Adjunctive Procedures

As noted by Pameijer,⁶⁹ the fabrication of a soft tissue cast has been strongly advocated during the last decade or so to give the laboratory technician essential information concerning the morphology of the gingival tissues surrounding the metal casting. An accurate replication of the height and contour of the marginal gingiva and of the interdental papilla is very helpful in establishing the emergence profile and cervical contour, and helps the technician control the length of the metal collar for subgingival margins.

When writing the laboratory prescription, include as much information as possible in order to aid the technician in creating appropriately shaped teeth. Final shaping and contouring to reflect personality, age, and sex should also be done at this time.³⁸

Esthetic Considerations

Loss of individuality in the anterior segment can be significantly improved by the use of unit-built central and lateral incisors or by staining the porcelain. Eliminating the metal collar with an all-ceramic margin improves esthetics. The copings used to carry the unit-built crowns are designed so that no metal overlaps the labial segment of the shoulder, thus guarding against a gray blue tinge in the area of the gingival tissue. There should be subtle variation in the body and incisal porcelain to break up light and thus help create the illusion of naturalness.⁶⁹

The success of a porcelain shoulder restoration depends on proper tooth preparation.⁴⁰ The ceramometal preparation is altered by finishing the labiogingival portion of the metal back to the gingivopulpal line angle, leaving metal substructure against the axial wall (which is 0.3 to 0.5 mm thick). This allows for an opaque porcelain layer from 0.2 to 0.3 mm thick and 0.7 to 1.0 mm of shoulder porcelain.

The advantage of a porcelain shoulder in a porcelain-fused-to-metal crown, according to Harrison et al., is that the finish line can be kept supragingival or just slightly apical to the free gingival margin. Its major disadvantage is that the loss of metal along the facial margin may give less than an optimal margin closure, and it is possible that fracture of the facial porcelain caused by a lack of metal support may be increased. For this reason you must be careful if using a direct lift-off margination technique to avoid displacement or breaking of the porcelain shoulder build-up and deformation during firing.⁴⁰ However, the use of a bonded resin cement to either etched enamel or dentin helps to seal the margin and at the same time offers additional marginal support.

When both esthetics and strength are essential, consider the ceramometal butt joint (refer to Figure 15-30). This type of crown provides almost all the esthetics necessary and, yet, the metal core adds great strength. Further discussion of esthetic considerations may be found later in this chapter.

Garber,³³ discussing ceramometal restorations, notes that the general public has an ever-increasing demand for esthetics. New approaches to the ceramometal system compensate for the inherent esthetic problems with the advent of opalescent

ceramic systems—Vintage Opal Porcelain (Shofu); Creation Porcelain (Jensen); and Omega Ceramic (Vita Co.).

These systems are based on the concept of opalescence, a naturally occurring phenomenon in the semiprecious opal stone. An opal’s surface resembles that of enamel in opacity and translucency, so by mimicking enamel with a specially-filled ceramic, which maintains its opalescence dur-

ing firing, the ceramometal restoration appears more natural. An additional advantage is that laboratory construction is simplified, using only a two-layer build-up, versus the three needed for conventional porcelain restorations.³³

Technical Considerations

Substructure Design. After diagnosis, treatment planning, and tooth preparation, the design of the metal substructure is of the greatest importance. As

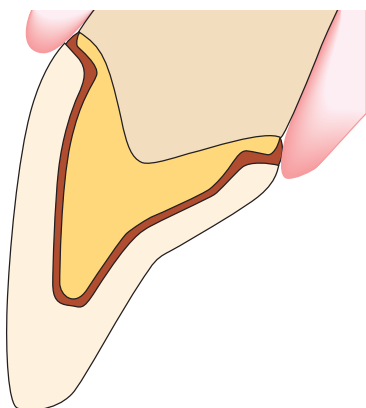


Figure 15-23A: The beveled shoulder margin can work well both labially and lingually when the patient has a low lip-line or thick fibrous gingival tissue that diminishes the chance of tissue recession.

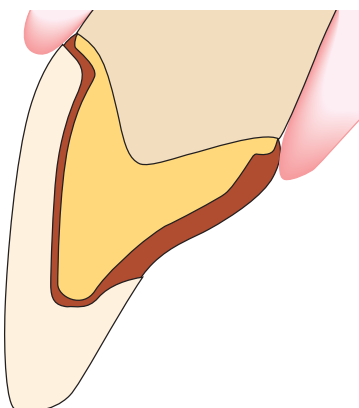


Figure 15-23B: An alternative to the porcelain lingual surface is to place the occluding lingual surface in metal.

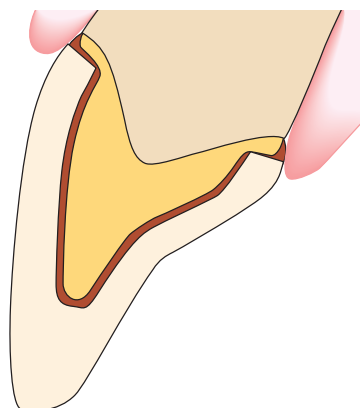


Figure 15-23C: For most situations the best esthetic margin is the porcelain butt joint.

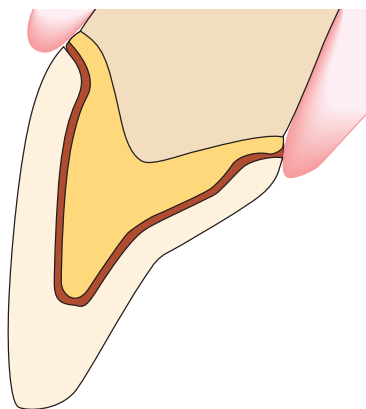


Figure 15-23D: There are situations where the chamfer margin is a good replacement for the beveled shoulder.

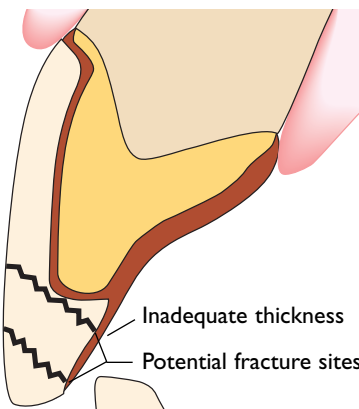


Figure 15-23E: An inadequate thickness of incisal metal can potentiate fracture especially if the ceramometal junction occurs in an occluding area.

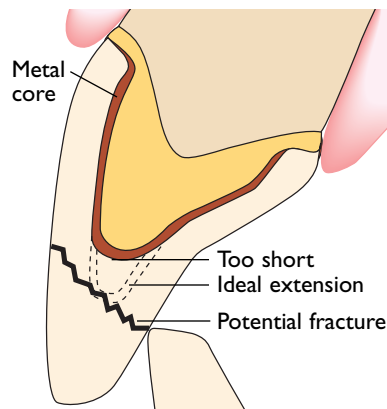
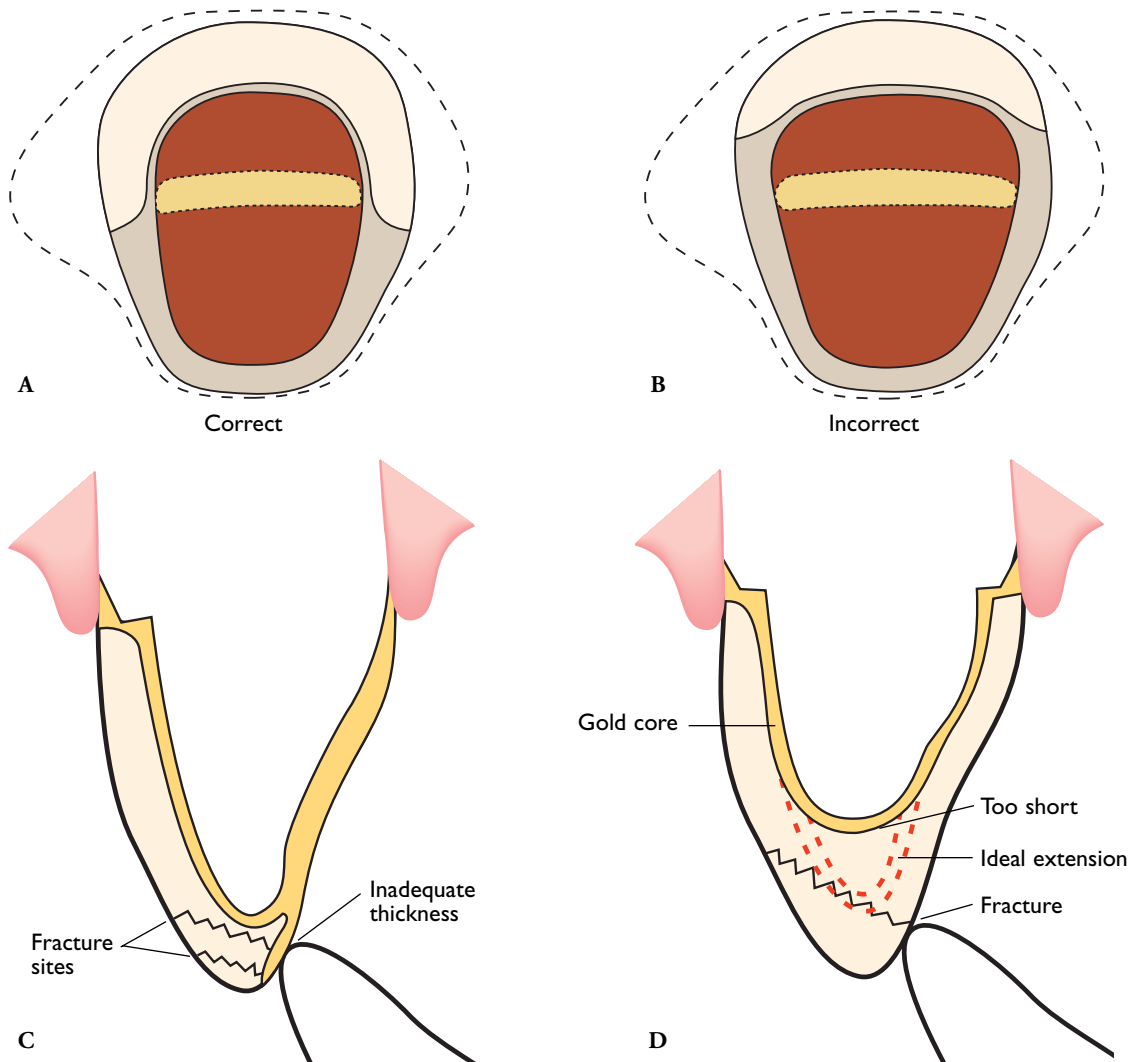


Figure 15-23F: The metal should always be constructed to provide for uniform porcelain thickness. If the substructure is too short it may require too much porcelain incisally, which could significantly weaken the restoration, causing fracture.

Dresden²⁴ states, poor design of the substructure is probably the primary reason for failure of the ceramometal restoration. Because of the strong influence of the undercoat masking the metal framework on the final shade, uniform thickness of the body porcelain is paramount. Specific case design is usually determined by the nature of the preparation in relation to the esthetic and functional requirements. There are several major considerations in creating

the metal substructure. The metal should be constructed to provide a uniform thickness of porcelain. Since labial surfaces may be particularly weak at the incisal and gingival areas, there should be incisal and gingival thickness to support the porcelain required for a full shoulder margin. A metal reinforced margin such as a chamfer or beveled shoulder can increase the strength. These may be designed in several ways for maximum function and



Figures 15–24A to D: These illustrations show the method of extending the porcelain well into the gingival embrasures for maximum esthetics. They also help to point out the use of rounded inner line angles to avoid potential points of cleavage, which may occur if there is stress on the porcelain.

esthetics. Figure 15–23A illustrates the beveled shoulder labially and lingually with porcelain fused to metal. The porcelain gingival margin is extended below the gingival crest. An alternative to this is porcelain coverage with the occluding surface in metal (Figure 15–23B). Alternatives to the beveled shoulder margin are the porcelain butt joint (Figure 15–23C) and the chamfer margin (Figure 15–23D). The surfaces of the metal to which the porcelain is to be bonded must be well rounded with no sharp angles in concavities and convexities (Figures 15–24A and D). Especially sharp inner angles must be avoided, because porcelain shrinks between 15 and 20% upon firing, and a layer of metal oxide develops to create a bond between metal and porcelain. Potential points of cleavage, which may occur if there is stress on the porcelain, will also be avoided by smoothing off any sharp angles.^{24,81} Also, if the metal is too thin (less than 0.4 mm), porcelain shrinkage during firing can distort the fit of the metal substructure.

Fracture can also occur if the coping is poorly designed with an inadequate thickness of incisal metal (Figure 15–23E). This may result from deformation of the metal under masticatory stresses or when seating the preparation in the mouth. According to MacGibbon, failures may be due to the great difference between the elasticity of the porcelain and that of the metal employed.⁵⁸ Be certain, therefore, that the incisal metal coverage is thick and broad, not thin towards the lingual surface.

If the substructure is too short it may require too much porcelain incisally and that could significantly weaken the restoration (Figure 15–23F). The coping should be built up to allow for uniform porcelain thickness.³⁵ This principle also applies to full coverage, porcelain-fused-to-metal posterior restorations. Uniform material thickness is illustrated in Figure 15–25A. Note that the metal may be designed to go higher in the linguogingival area, unless the patient objects to the slight display of metal.

The type of labiogingival junction of porcelain and metal also depends upon esthetic demands. If the patient has a high lipline, the porcelain should end beneath the crest of the gingiva. For upper posterior teeth, never place the visible porcelain-metal junction at the bucco-occlusal line angle in an occluding area, as this is a potential site of fracture. Instead, finish the porcelain on the lingual surface or half way between the tip of the buccal cusp and the central fossa (Figure 15–25B).

Preparation

Certain factors must be considered in preparation for ceramometal restorations. First there must be adequate space for porcelain, opaque, and metal coverage (Figure 15–26). For anterior teeth this means reduction of 1.5 mm axially and 2 mm incisally. Coughlin says the labioincisal reduction of the anterior teeth or the buccal cusp in posterior teeth should not be less than 2.0 mm and should roughly duplicate the contours of the original surface in order to gain uniformly adequate space for a metal

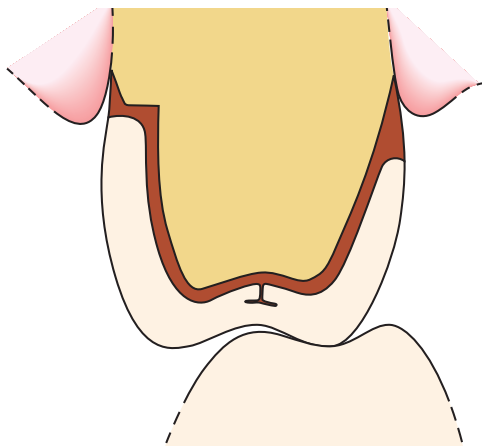


Figure 15–25A: The strongest ceramometal restoration is one that features wraparound, uniform porcelain thickness.

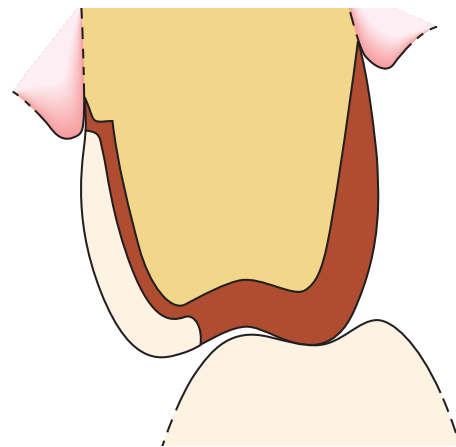


Figure 15–25B: Place ceramometal junctions in low- or no-stress areas.

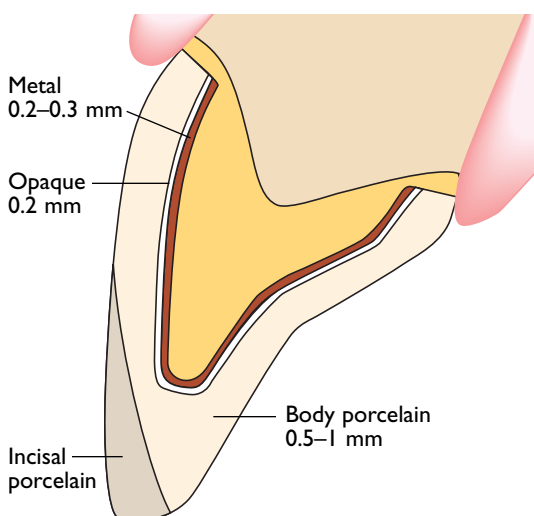


Figure 15-26: This diagram illustrates the correct thickness of the various components in an anterior ceramometal restoration using a porcelain butt joint margin.

coping, opaque porcelain, and body porcelain into which can be built occlusal anatomy.¹⁸ The lingual cusp and marginal ridge should have a clearance of at least 1.0 to 1.5 mm in all lateral excursions. If this is sacrificed, shade control suffers, because all porcelains need depth to maintain shade. The porcelain must not be less than 0.5 mm thick anywhere. Otherwise, the shade is progressively lightened. To contour the porcelain properly, do not drop below 1 mm thickness or at the other extreme, leave the crown unnecessarily bulky. Good porcelain coverage in the anterior restoration is illustrated in Figure 15-16. Correct porcelain coverage design for the posterior restoration is illustrated in Figure 15-27.

Esthetic Use of Porcelain Fused to Metal

Problem. A 38-year-old woman presented with fractured restorations, caries, defective crowns, discoloration, and generalized breakdown of the posterior quadrants (Figures 15-28A and B). The patient professed the desire for cosmetic reconstruction showing no metal.

Treatment. This mouth was treated with quadrant replacement of defective restorations. The treatment included treatment crowns first, and ceramometal crowns later.

Result. Before (Figure 15-28B) and after (Figure 15-28D) buccal views illustrate correct gingival

embrasure and crown form. The effect of incorporating varying shades of porcelain to create a blended gingival-to-incisal tone is apparent. (In order to obtain a predictable metal collar that will not show, a direct try-in should be used.)

Discussion. It is not too difficult to see why the patient, a performer, took little pride in her previously unattractive mouth. Replacing the defective restorations with esthetic porcelain-fused-to-metal crowns gave the patient a new appreciation of oral hygiene. She knows and practices techniques of caries prevention. Treatment like this can make dental missionaries out of dental cripples.

Since this patient was given a 5- to 15-year range of esthetic life expectancy, she was happy the crowns remained cosmetically pleasing for 16 years. Eventual periodontal disease and resulting surgery caused tissue margins to become visible (Figure 15-28E). However, patients who read the treatment summaries in “Change Your Smile,” for example, are provided with esthetic life expectancy ranges for all types of restorations and are not “surprised” with eventual esthetic changes.

Choice of Margin. Deciding what type margin is obtainable is a prerequisite to crown selection. The best functional margin is gold supragingivally. However, when esthetics are of concern, the procedures of masking or covering the metal become essential.

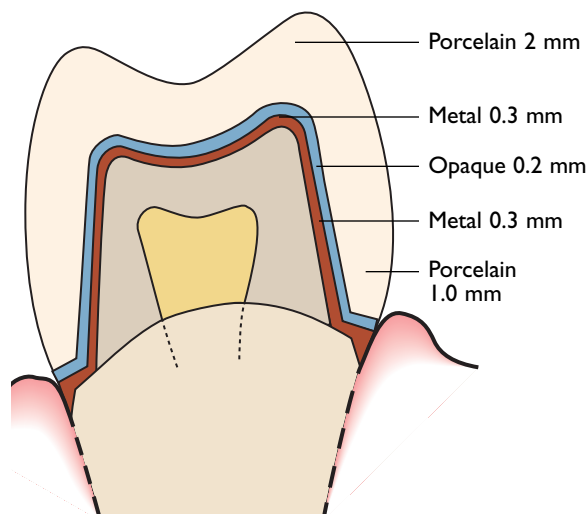
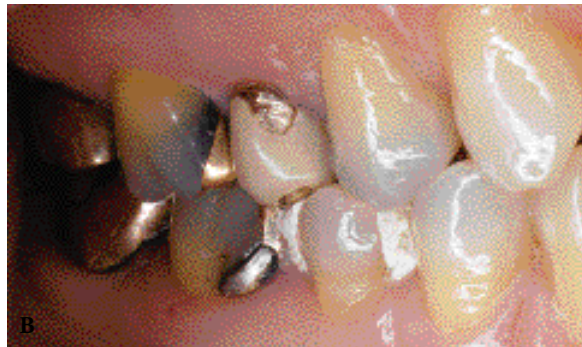
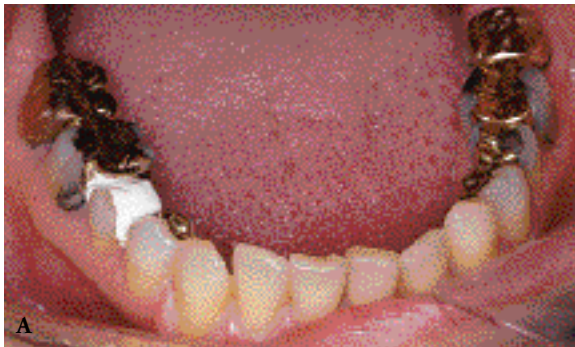
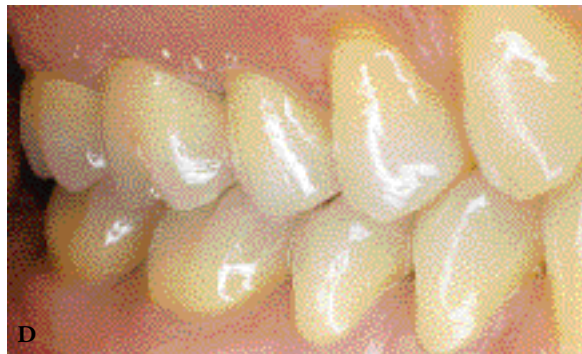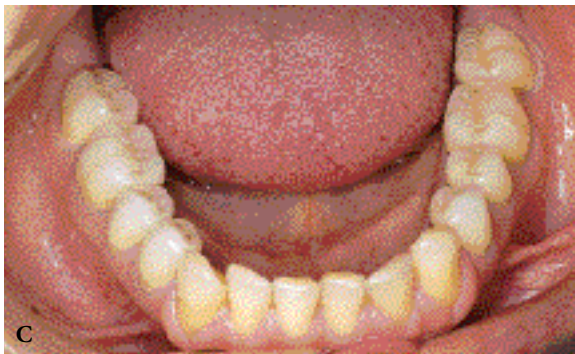Figure 15-27: This diagram illustrates the correct thickness of a posterior ceramometal restoration using a bevel shoulder margin.

Begin by determining how much of the tooth will show during the widest possible facial expressions. If the patient has a low lipline, explain that a metal margin will not show and give your patient a mirror to view his or her smile. Nevertheless, the mere presence of metal in the mouth is enough to

bother some patients. Patients who have a high or medium lipline pose a different problem, because metal will show. Evaluate the extent of the patient's concern and carefully explain treatment alternatives. If the patient's prime concern is esthetic, the exposed metal must be covered or a porcelain butt



Figures 15-28A and B: This 38-year-old woman presented with a fractured restoration, caries, defective crowns, discoloration, and generalized breakdown of the posterior arches.



Figures 15-28C and D: Several weeks after crown placement, good tissue health is apparent.

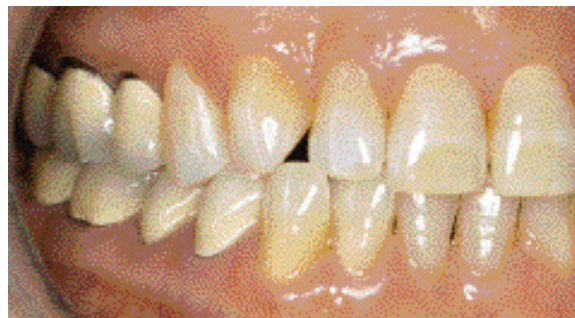

Figure 15-28E: Sixteen years after crown placement, periodontal surgery exposed the crown margins even though the restorations were still functionally sound.

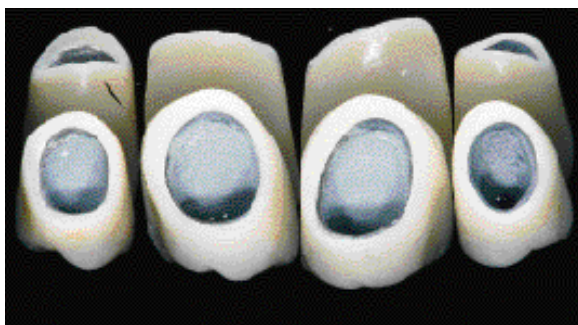


Figure 15-29A: Porcelain butt margins on four anterior crowns. The metal does not extend onto the shoulder.

joint must be used. Healthy tissue is one form of coverage while elimination of metal in this area is an alternative. Determine the depth of the sulcus. An adequate crevice depth of 2.5 mm is sufficient to mask a metal margin when using a beveled shoulder with the porcelain-fused-to-metal crown. When the crevice is not deep enough, either an all-ceramic crown or a porcelain-fused-to-metal crown with a porcelain butt joint should be used.

If periodontal disease is present, control of the depth of the sulcus is feasible if there is prior discussion of the esthetic goals among patient, dentist, and specialist. According to Kramer, periodontal treatment can be successful and still leave a manageable 2-mm deep sulcus to hide the metal margin.⁵¹

A number of finish line shapes have been discussed, including the labial shoulder chamfer and beveled shoulder. Any one of these provides adequate reduction in the labiocervical area, providing for good functional and esthetic results. This becomes particularly important where the maxillary anteriors or bicuspid are involved. Consideration must be given to how the finish line will ultimately relate to the marginal adaptation of the crown in the labial or buccal areas.

The possible labial margin designs using the previously mentioned finish lines include: (1) a labiokingival porcelain-metal chamfer margin, (2) a labiokingival metal collar, and (3) a porcelain butt joint. Almost always this can be hidden under the gingival sulcus, especially in maxillary anteriors and premolars. When the tissue is either thin and transparent or at zero sulcus depth, a porcelain butt joint is preferred. In designing the substructure, labial metal is carried to the shoulder but not on to

it (Figure 15-29A). Figure 15-29B shows the result in the mouth.

The labiokingival metal collar margin has an esthetic disadvantage in anterior restorations in cases where the metal collar is located incisal to the free marginal gingiva, thereby allowing for an unsightly display of metal. If the free gingival tissue on the labial is thin, the metal collar may create a dark bluish gray at the margin. Therefore, the metal collar seems most useful in the cervical areas of maxillary molars and in all mandibular teeth where the cervical areas are not visible, even if the patient smiles broadly.

Currently, according to Ianzano, there are three main techniques being advocated for the fabrication of the metal collarless crown, but the finish line for all three techniques is identical. The facial finishing line should be a 90-degree shoulder of 1.5 mm in depth. This provides enough depth for adequate esthetic characteristics and sufficient bulk to provide strength. The lingual finishing line can be whatever the dentist would like to use with a traditional metal-ceramic restoration.⁴²

The coping designs, as detailed by Anusavice, may terminate at the axiokingival junction or with the extension of the coping along the gingival floor but short of the facial margin. The most esthetic option is associated with the metal coping restricted to the axial wall and not extending into the shoulder area of the porcelain butt joint margin⁵ (Figures 15-30A and B).

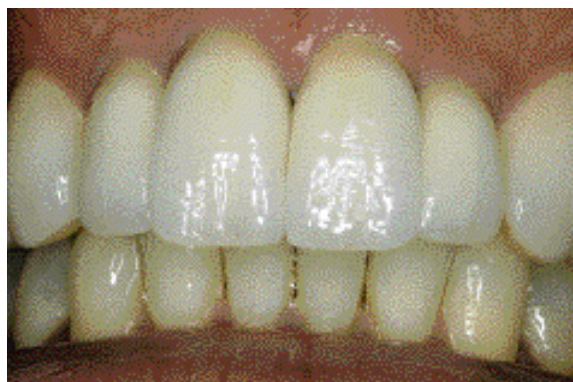

Figure 15-29B: The finished result shows no evidence of metal discoloration.

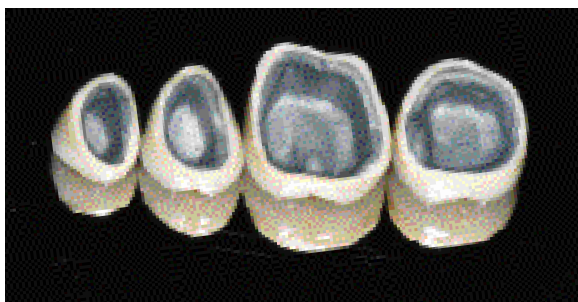

Figure 15-30A: These four ceramometal crowns contain metal copings restricted to the axial wall. By not extending into the shoulder area, they provide strength as well as maximum esthetics.

A precise margin is difficult to obtain in porcelain but methods have been developed to improve the fit in this critical area. Salvo describes the use of light-polymerized shoulder porcelain.¹¹³

Jacobi and Brooks use shoulder porcelain powder and unfilled light-cured resin in a 2 to 1 powder to liquid ratio to form a thick paste, which is added during the try-in to the facial margin. The crown is seated on the prepared tooth and the marginal area cured for 40 seconds, and then refined with discs. The crown is then fired to remove the organic resin binder and reglazed.⁴³ Pinnell et al. advocate a similar technique using body porcelain with a light-cured bonding agent, which they feel possesses a superior color.⁷³

HOW TO CHOOSE THE RIGHT CROWN FOR ESTHETICS

There is no one ideal crown for all situations. Each case is different with varying factors that influence the choice of crowns. Patients have different esthetic demands that may or may not compromise function. The decision that one restoration is more esthetic than another is essentially based on visual interpretation. In certain mouths, anything will do (uniform tooth color, no distinguishing marks, etc.). In others, different identifying marks have to be matched and a decision must be made as to whether to use gold, nonprecious metal, acrylic, or porcelain.

You should balance esthetics and function for each patient, and that balance will be different for each patient. To make the decision, therefore, there must be an understanding of certain principles. Assuming the all-gold crown to be the most func-

tional, it is the restoration of choice when esthetic needs are not compromised. So, for posterior teeth, if the patient agrees, full or partial coverage in gold should be used. Otherwise, a less functional but more esthetic crown should be recommended.

The choice is ultimately based upon a consideration and balancing of many factors.

1. Lipline. Does the gingival margin show when the patient speaks, smiles, or laughs? If so, you should select a crown system with an all-ceramic margin. Is the tooth to be crowned visible when smiling? Figure 15-31A shows a wide smile line of a 39-year-old female. Since she did not expose the first molar, the patient was encouraged to have a full gold crown constructed (Figure 15-31B). A brushed or “antiqued” gold surface, rather than polished, is often more esthetically acceptable. Gold should always be considered the functional restoration of choice.
2. Length of esthetic life expected by both patient and dentist. This is a function of several factors:
 - (a) Wear patterns. Will acrylic or composite last as long as porcelain?
 - (b) Acid content of the saliva. Acid level and the amount of stain accumulated by natural and restored teeth are indicators of the life expectancy of acrylic, composite resin, and even cementing materials.
 - (c) Condition of previously placed crowns. For example, a gold-acrylic veneer crown may

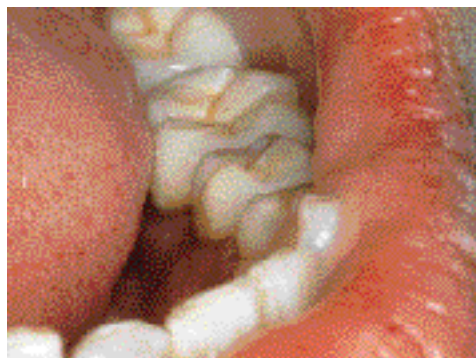

Figure 15-30B: The full shoulder butt joint is a good choice for patients who do not want to show a metal margin even on the lingual surface.

be functionally long-lasting, but the acrylic usually loses its original appearance and requires veneering or remaking, depending on whether the restoration can be removed.

3. Space limitations in tooth preparation. For example, will the pulp preclude sufficient reduction for metal plus opaque plus porcelain? Evaluate the alveolar support.
4. Occlusion. Is the occlusion favorable for a full porcelain occlusal surface? It is always best to have porcelain functioning against porcelain. If the opposing occlusal surface is gold, chances are the porcelain occlusal surface will wear the gold considerably faster. Even enamel can wear quickly against a porcelain occlusal surface. Therefore, if porcelain against enamel is the choice, make sure the porcelain is highly polished following any occlusal adjustment to reduce the amount of enamel wear.
5. The gingival sulcus. How deep is it? Is the type of tissue sufficient to mask a gold collar? Can you predict the long-term health of the sulcus? Even the most perfect gingival sulcus can become diseased and deformed within days, so you can never really be certain of long-term gingival margin coverage. This is the best reason to protect yourself and your patient if your patient has a high lipline, by selecting an esthetic margin such as the porcelain butt joint.
6. Tissue type. Is the tissue thin and transparent, or thick and fibrous? The thin, transparent type will be the most likely to recede or to

show a metal margin. On the other hand, if your patient possesses thick fibrous tissue, you will probably be able to choose a metal margin and be esthetically protected.

7. Appearance of surrounding teeth. How much translucency or opacity exists in adjacent or opposing teeth? Do they need to be contoured or bleached before beginning treatment?
8. Financial considerations. Is the patient willing to pay for use of a high-quality laboratory or master ceramist, including specialized characterization procedures or does he or she want the most economical treatment? Certainly, one of your toughest decisions will be to match your fee to the level of difficulty presented by your patient. This difficulty may be expressed by the esthetic requirements of your patient, or even by your patient's attitude.

All these questions should be answered by the patient and dentist before a final decision is made. Many times, this choice cannot be made until the teeth are actually prepared, in order to determine how much space is available for the restoration.

The mouth must also be as disease-free as possible. The type of restoration should never be decided at the first or second appointment if there is periodontal disease or advanced caries or posterior bite collapse. Because the condition of the mouth can change, any decision would be premature. Since esthetic correction is accomplished in the temporary crowns or provisional splits, final decisions can be postponed and the options re-evaluated later.

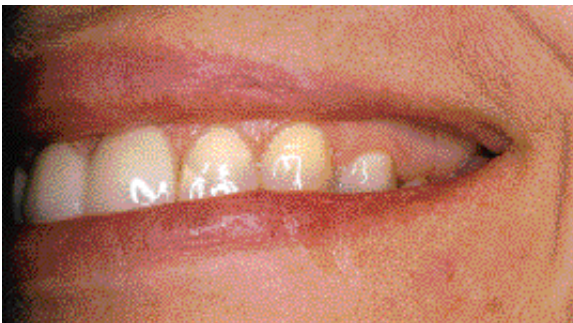

Figure 15-31A: It is important to always examine the patient's widest smile before determining crown type. This patient needs a crown on the first molar and reveals only back to the second bicuspid during widest smiling.

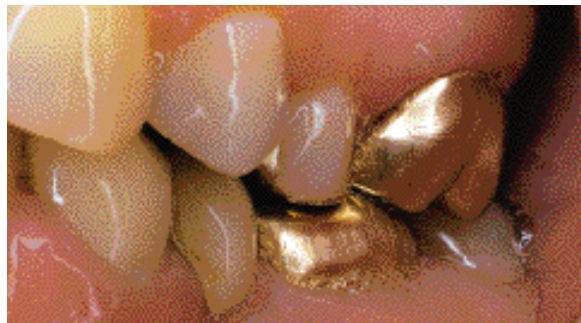

Figure 15-31B: This patient chose full gold crowns to obtain maximum longevity because she felt confident that the gold would not be visible to others.

Basically, when esthetics is a primary concern in both anterior and posterior teeth, the porcelain-fused-to-metal restoration is a good choice for a long functional life and excellent esthetics. When there are limitations to the use of ceramometal anterior crowns, a shrink-free reinforced high-strength porcelain, cast-glass, or a foil-type (Renaissance) crown are alternate choices. If porcelain is contraindicated, either an acrylic or composite resin crown can be considered.

Specific Problem—The Discolored Pulpless Tooth

Crowning one central incisor to match an adjacent tooth is one of the most difficult tasks in esthetic dentistry (see Figures 15–39A and B). When the compromised tooth happens to be nonvital and discolored, the procedure can become even more complex. The goal is to decide what type of restoration can best solve your patient's problems. The decision depends upon what type of discoloration is present and whether or not a post and core will be needed that also could complicate the use of an all-ceramic crown. Recently, translucent ceramic posts (Cerapost, Brasseler and Cosmopost, Ivoclar) offer an alternative to metal posts. Another technique uses fiber-reinforced (Ribbond) composite resin in the root canal to retain the core. However, the problem remains the same—that of masking the underlying discolored tooth.

If discoloration is the only problem, you may choose a more conservative approach and use a porcelain laminate veneer. However, this approach may make it more difficult to obtain a perfect match. Even if you remove extra tooth structure, the problem of obtaining an optimal result can be made more difficult due to the effect of the underlying composite resin cement on the shade of the porcelain veneer. The tooth shade can also vary somewhat after seating the veneer because of a color shift in the polymerized composite resin cement. In fact, it may take several days to a week for the final color to be apparent, and by that time, you will obviously have no ability to change the color. Therefore, a crown may be the preferable choice, especially if your patient is a perfectionist. The crown shade can be altered as many times as necessary until you obtain the proper color.

Opaquing

Although an opaque can be applied to the tooth to mask the core, and could conceivably help if your

restoration is either a porcelain veneer or an all-ceramic or glass crown, it still may be insufficient to mask the darkened tooth. The most predictable way is to have the laboratory incorporate the correct amount of opaquer in the ceramic material itself. Although this may sound like a simple solution, it is not. Until you actually seat the crown with cement you will not be assured your choice of material and opaquer is a perfect one.

The most effective solution to this problem is to use a ceramometal crown with a metal substructure that is fully opaqued, masking out even the darkest of teeth or metal post and core. Masking of the opaque layer is also an esthetic necessity. It can be accomplished either by thickening the body porcelain layer or by tinting the opaque.

To optimize esthetics, a porcelain shoulder that wraps around the entire preparation is quite effective, using metal along the axial walls only and not encroaching upon the visible marginal areas (see Figures 15–30A and B).

PRINCIPLES FOR ESTHETIC RESTORATIONS

There is no substitute for the beautiful, healthy appearance of tooth enamel. This is precisely why it is so important to apply every conceivable esthetic principle in construction of a ceramometal restoration. Using these principles is the best means of achieving the goal of a truly esthetic restoration.

The concerned dentist must continually study the subject of esthetics, not only by attending courses and reading the literature, but by being a keen observer of the natural smile. Shapes of teeth and their arrangement in the arch are crucial to obtain an esthetic result in artificial restorations, as the objective is to make the artificial restoration look believably natural. The following discusses some of these principles and solutions to the most common esthetic problems.

Lipline

The type of lipline almost always determines the number of teeth to restore. Observe not only the number of teeth exposed when the patient is smiling naturally, but also note every tooth that is visible when the patient smiles widely. This is necessary to properly analyze the esthetic component (the teeth visible during smiling) in order to communicate to

the patient exactly how the smile will look after restorative treatment. Often the patient will seek to restore only the six anterior teeth, failing to realize that the improved shade or character of the restorations may call attention to the adjacent untreated teeth, which will no longer match. Thorough explanation of the smile analysis is necessary so that the patient can understand the results of the restoration before treatment begins. In addition, the use of lateral close-up and full-face views with computer imaging is essential in this instance. Few patients can visualize their smile past the six front teeth.

To determine whether the lipline is high, medium, or low, observe the tooth length exposed when the patient smiles.

High Lipline. A high lipline is one in which all supragingival tooth structure and some gingival tissue are visible upon smiling. The patient with the high lipline may not be the best candidate for a full crown because tissue tends to recede in time and a previously-concealed margin may become visible. If the restoration is ceramometal, even a small metal collar may become exposed.

Thin, transparent gingival tissue is more apt to recede after impression techniques have been performed. Even if the margin is not exposed upon insertion of the crown, such exposure may occur at a later time and make the patient extremely unhappy. If possible, it is preferable to suggest a compromise treatment plan using composite resin bonding or porcelain veneers.

When the patient has a high lipline and a full crown becomes a necessary restorative choice, you should use a full shoulder preparation on the labial surface with a porcelain butt joint as the margin. This will assist in maintaining an acceptable esthetic appearance if the tissue does recede in the future.

In the event that the tissue recedes after the impression appointment but before cementation, an immediate repair can be made to a porcelain butt margin. Even at the try-in appointment the labial shoulder margin can be extended into the gingival sulcus. Refit the crown with softened low-fusing compound attached to the labial margin. Make certain the new shoulder margin is recorded in the compound and pour a new die. After adapting foil to the die, the compound is removed and the porcelain added to establish the margin. An alternative impres-

sion compound would be polyether (Impregum, ESPE) since it has sufficient body hardness and is tenacious enough to record the new margin if you can achieve adequate tissue displacement.

Medium Lipline. A medium lipline is one that shows up to, but does not include, the cervical margin of the anterior teeth. A small portion of the interproximal gingival papilla also shows in a wide smile. The medium lipline presents only moderate difficulty in crown restoration, because the gingival margin is only seen in the widest of smiles. For normal speaking or slight smiling there is no exposure of this area, thus a slight hint of a metal collar should present no unusual difficulty for most patients. However, for those patients who are extremely critical of any metal showing, the porcelain butt joint should again be used.

Low Lipline. In a low lipline the gingival margin is never revealed; therefore, no problem exists with exposed margins except, possibly, in the patient's mind. A ceramometal restoration with a metal collar is an ideal restoration for a patient with a low lipline and, since the metal collar cannot be seen unless the patient retracts the lip with his or her fingers to look at the gingival margin, it becomes important to communicate this fact and allow the patient to participate in the final decision about treatment. It is necessary to explain to the patient exactly why his or her lipline will allow you to create the best possible biocompatible restoration. However, some patients, even those with low liplines, may have emotional reservations about the presence of exposed metal in their mouths; therefore, this must be dealt with on a psychological as well as a functional basis.

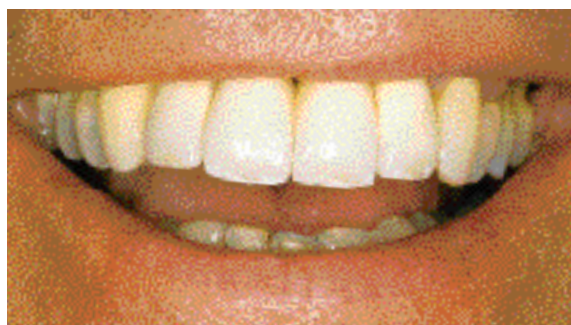

Figure 15-32: An arch and lip irregularity in the patient's smile causes more teeth to show on the patient's left side.

Arch Irregularity

An arch irregularity generally exposes more coronal area on one side of the mouth than the other upon smiling (Figure 15–32). It is essential that your patient is made aware of this problem during the diagnostic stage. Your patient needs to know that the crowns may not be bilaterally symmetrical in the final restoration. Take both full-face and close-up prerestorative photographs to preserve a good record of the patient's original intraoral condition in both smiling and lip-retracted positions. Computer imaging is also helpful to point out to the patient the irregularity and what you can do, if anything, to correct it.

Inclination of Teeth

The inclination of teeth is an important consideration in the ceramometal restoration because of the inherent qualities that exist in a crown with metal, opaque, and porcelain layers. Proper color must be built into the restoration rather than relying on the use of surface stains. This will prevent lingually-inclined upper anteriors from appearing to have different and darker shades in low-lighting conditions. This may also apply in the case of extreme labially-tipped upper incisors. Under certain conditions, when the head is tilted back exposing more of the lingual surface, the same situation may occur.

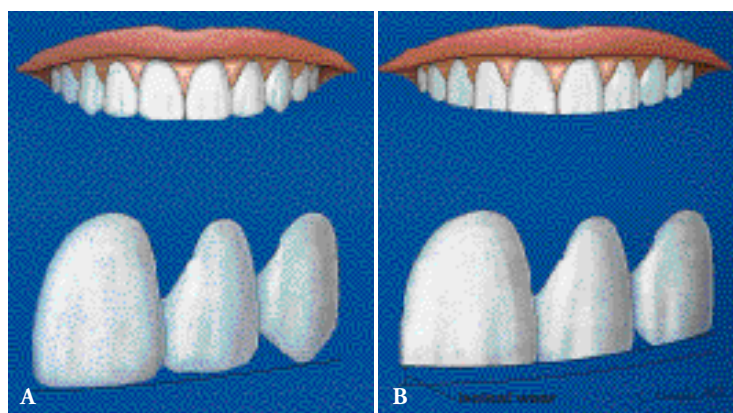
Lingually-inclined maxillary posterior teeth may need to be built out labially to achieve the most

attractive smile (see Figure 14–10A). *Failure to do this may result in improved anterior teeth if you are restoring them, only to find that negative or too much space remains on both sides of the smile due to the lingually-inclined bicuspids and molars.*

If the crowns are satisfactory in their form and shade reproduction, the next concern is that they appear natural in their surroundings. Three factors that most often influence this are interincisal distance, and incisal and gingival embrasures.

Interincisal Distance

The interincisal distance refers to the difference in incisal lengths of the maxillary central and lateral incisors. Generally, the central incisors should be slightly longer than the lateral incisors. The greater the distance, the younger the smile appears (Figure 15–33). As teeth wear, the incisal length of the centrals becomes reduced, making the four maxillary anterior teeth more equal in length. If an older look is desired, less interincisal distance is used. If a younger look is the objective, a greater interincisal distance is incorporated. This must be coordinated with incisal guidance, the incisal table of the mandibular incisors, and the cusp tips of the posterior teeth. Some patients can tolerate longer central incisors, whereas others may complain that their lips cannot accept the added length. Even speech can be a problem for them. Whenever planning a greater interincisal distance, make the correction in the temporary restoration. The patient should func-



Figures 15–33A and B: Aging in the smile line can be influenced by varying the interincisal distance. A, This is a more youthful smile because of greater interincisal distance than B, which depicts increased wear and thereby an older smile.

tion with this for several weeks to determine the suitability of the altered incisal length.

When a high lipline exposes all of the upper teeth in almost every facial expression, it is usually advantageous to vary the interincisal distance. Even altering the length of the central incisors by making one slightly longer than the other can create a more natural appearance, since this is frequently found in the natural dentition.

Incisal Embrasure

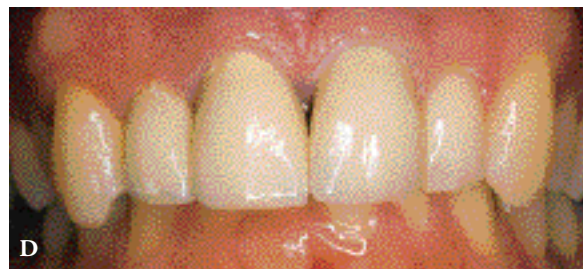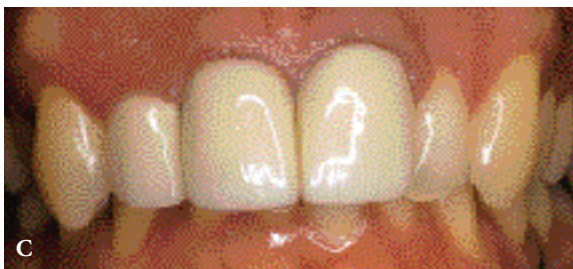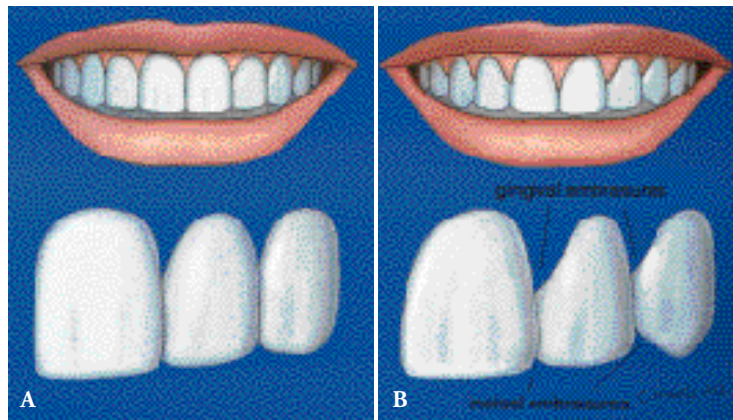
The incisal embrasure refers to the space between the incisal tables of adjacent teeth. Lack of proper incisal embrasures usually results in an artificial-appearing restoration (Figures 15–34A and D). In each patient, it is usually best to duplicate the adjacent, natural incisal embrasures. Study photographs of your patient's smile as well as other people's smiles to appreciate the variation of incisal embrasures that exists in different individuals. An entire personality or cosmetic change can result

from increasing or decreasing embrasure length and width.

Gingival Embrasure

The esthetic restoration requires an adequate zone of attached gingiva and a proper embrasure that permits interdental tissue to exist without impingement (Figures 15–34A to D). One cause of an unesthetic restoration is inflamed tissue due to overbuilding porcelain in the gingival area. The best prevention is, at the try-in, to mark the porcelain with a sharp pencil and open the area between adjacent teeth to encourage healthy tissue. An alternative method of creating proper gingival embrasures is to make a duplicate model showing exactly where the tissue is. Because tissue must be adequately supported, undercontouring porcelain may also cause a problem. *A correct emergence profile is essential for both functional maintenance and an esthetic appearance.*

The stage at which most problems should be resolved is before the impression, at the time you



Figures 15–34A to D: Properly formed incisal and gingival embrasures are necessary for an esthetic restoration. A and C show the “chicklet” appearance of a typical restoration lacking well-formed incisal and gingival embrasures. Absence of the gingival embrasures produces gingival impingement resulting in inflammatory response, which is unesthetic and functionally unacceptable. B and D show esthetic improvement when both gingival and incisal embrasures have been included.

make the temporary restoration. There are several reasons why all intended corrections should be incorporated in the temporary restorations. First, it allows the patient to wear the new look and to adjust to any esthetic and functional changes. Many esthetic changes may not be readily accepted by one's peers. This type of criticism is better to be received and evaluated during the temporary phase.

Second, it allows evaluation of the preparation before taking final impressions. After the intended shape and contour of the temporary restoration is completed, examine the thickness in every portion to be sure there will be sufficient room for metal, opaque, and body and incisal porcelains. If there are thin spots due to the labial convexities that are necessary to achieve an esthetic result, then alter your preparation to gain extra space for the final restoration. *When presence of pulp tissue makes it impossible to remove additional tooth structure without potential damage, inform the patient that a vital pulp extirpation might be necessary to achieve the desired esthetic correction.* It is important that your patient be a part of this decision, especially if the esthetic result would be compromised by an inadequate tooth preparation.

Another reason for making the temporary restoration before the impression is to examine the occlusion and make any alterations on the opposing arch that will improve the result. These types of changes can only be made during tooth preparation. If you wait until the esthetic try-in, the final restoration may be a compromise rather than the esthetic result it can and should be. Always try to anticipate decisions of this sort so your patient will be prepared and not become defensive when you realize too late you must reduce the opposing arch.

Tooth Contour and Shape

After the restorative material has been chosen, the next important factor is the shape and contour of the restoration. Natural teeth have rounded contours rather than the squareness often found in unnatural-appearing restorations. This is seen especially in the anterior teeth, where many ceramists tend to flatten the labial surfaces rather than place the proper contour in the mesial and distal aspects of that surface. Another common fault is lack of critical viewing from the incisal or occlusal aspect.

The ceramist is usually confronted with the problem of matching the contours of adjacent teeth.

However, the esthetic appearance of the restoration can usually be improved by first altering the form of the adjacent teeth through cosmetic contouring.

Yuodelis and co-workers found that, although correct morphological contours are a vital part of any esthetic restoration, they are of paramount importance during dental procedures that involve full-coverage restorations.⁹³ It has been suggested that the facial and lingual enamel bulges of human teeth protect the free gingival margin from the trauma of occlusion by deflecting food over the gingival crevice and onto the keratinized gingival tissue. Kramer, however, questions the effect of the curve and the evidence that indicates that crown contours protect tissue.⁵¹

Since microbial plaque is the principal cause of both caries and periodontal disease, its retention by tooth surfaces is to be avoided. Clinically, plaque retention is greatest in inaccessible areas, particularly the interproximal and the facial and lingual cervical areas of the teeth. To keep these areas plaque-free, the relationship of morphology of crown contour and degree of accessibility must be understood. Overcontouring can encourage debris accumulation that may lead to functional and esthetic breakdown of supporting tissues.

In an experiment conducted by Perel that supports these findings, the effect of crown contours on gingiva was clearly demonstrated.⁷⁰ The mandibular teeth of mongrel dogs were remodeled by removing tooth structure from the labial, buccal, or lingual surfaces in different parts of the mouth. The labial surfaces of some teeth were overcontoured using self-curing resin. Results showed that supragingival undercontouring caused no apparent gingival pathology; whereas overcontouring caused inflammation and then collection of debris, hyperplasia, and engorgement of the marginal gingiva, scant keratinization, and deterioration of the fibers of the gingival collar.⁷⁰

Thus, it may be seen that this so-called protective function of convex crown contour may in reality trap food and prevent vital stimulation of the gingival margin. In addition, particularly after periodontal therapy that involves osseous resection, a longer-than-normal clinical crown may be left. These lengthened clinical crowns are more difficult to keep plaque-free due to the exposed furcations and differ-

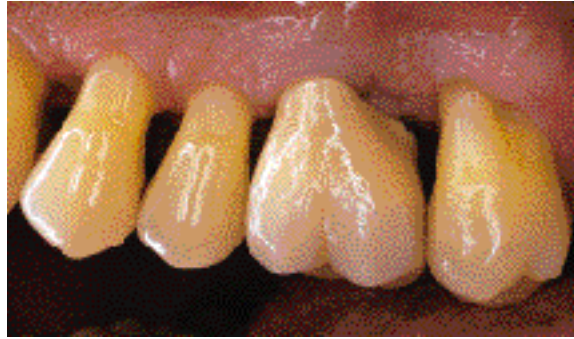

Figure 15–35: In patients with hemisected molars, the design should include more porcelain coverage in the interproximal areas to avoid dark shadows caused by the anatomic shaping of the hemisected root area.

ent root shapes, especially proximal convexities which are much harder to clean.⁹³ In such cases, for an esthetic long-term result, the final restoration should not follow the original anatomic contour; instead it should recreate at least the gingival contours of the root portion. This makes the gingival third of the furcation areas more accessible for cleaning.

While crown contour must establish an esthetic result, it must not compromise the patient's oral health. Although this responsibility lies solely in the hands of the dentist, too many practitioners try to pass it off onto the technician. Although tooth preparation is extremely important to guarantee that the laboratory technician has sufficient room to create a well-shaped and contoured restoration. Even though the lab procedure begins with the technician, it certainly ends with the dentist at

chairside. *No matter how well the technician has created a crown, some improvement and personalized changes can usually be performed by the dentist at chairside during the try-in appointment.* Naturally, the better the technician, the less adjustment is necessary by the dentist. A faithful duplication of the matching tooth in the patient's natural dentition usually gives the best esthetic result, although occasionally an increase or diminution in overall size may be necessary due to tooth movement. The basic curves, angles, heights or contours, contact areas, and general outline form should be duplicated as closely as possible. Areas that need special attention are the mesial and distal incisal angles, the areas of contact, the concavities and convexities at the labial line angles in the gingival third of the crown, and the thickness of the incisal edge labiolingually.

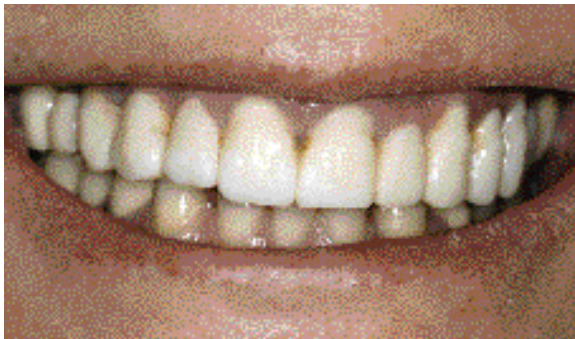

Figure 15–36A: Shows a more masculine appearing form to the crowns.

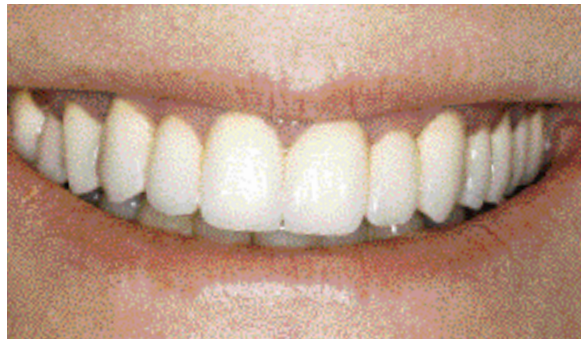

Figure 15–36B: Shows a new arrangement to the same patient, which is based on slightly more feminine or "softer" carving to the crowns.

In addition, esthetic problems caused by furcations or hemisections require special shaping. Hemisected teeth can be esthetically restored with a porcelain-fused-to-metal crown. In cases where the hemisected root will show the metal collar as a dark line or shadow, the substructure design should include more porcelain coverage in these interproximal surfaces. Figure 15–35 illustrates correct contours on a maxillary first molar where the distobuccal root has been previously hemisected. The esthetic importance of correct embrasure form cannot be overlooked. Overcontouring of the crown can give a visual effect of crowding and accentuate shadows. Overcontouring on the labial surfaces in the cervical half can make the tooth appear more prominent.

A patient's appearance can be considerably altered depending upon the shape of the crowns (Figure 15–36A). Notice how different the smile can look when rounder, softer contours are used (Figure 15–36B).

Another important factor to consider in the contour of the restoration is the shape of the pulp. As Pincus pointed out, if the pulp is unusually wide, this may be a contraindication for crowning. When some type of correction is imperative, a wide pulp requires a shallow preparation and a temporary crown for 6 months to 1 year to induce pulp recession through the formation of secondary dentin. The smaller the pulp in height and width, the greater the amount of tooth correction that can be made when necessary.⁷²

Final Esthetic Try-In

The last chance to make corrections is at the esthetic try-in. Staining, final shaping, and contouring to influence personality, age, and sex, and any other improvements should be done or planned at this time. The ceramist then has to add the necessary final touches to make an attractive and natural-appearing restoration, usually without seeing the patient. These changes must be determined at the chair. When writing the laboratory prescription, include as much information as possible in order to aid the technician.

Tooth Size

Computer imaging can help you in correctly proportioning the teeth. The principles of divine proportion (see Chapter 9) should be built into your software program to give you a better idea of

proper relative tooth size for your patient. Beaudreau suggests that the teeth can be proportioned in a general sense.⁷⁶ He proposes that when the central incisors are 8 mm wide, the cuspids should be approximately 7 mm wide, and the laterals should be 6 mm wide (Figure 15–37). Therefore the lateral should be approximately 25% smaller in width than the central incisor and the cuspid is approximately 13% narrower than the central incisor.

Long Teeth. There are generally two causes of an extra-long tooth. The most common is gingival irritation resulting from an overcontoured crown which, lacking embrasure spaces, causes an apical migration of the tissue. This problem is especially troublesome in the patient with a high lipline, where tooth symmetry, or lack of it, is all too apparent upon smiling. Curettage or other periodontal procedures should be instituted before restorative treatment. Then replacement of the pre-existing crown, with root or gingival tissue simulated by the use of stains, can correct the problem.

Long teeth may also be the result of periodontal surgery. A major consideration in crown preparation in these patients is the difficulty in preparing a proper shoulder on the root. Consequently, the resulting thin chamfer or knife-edge preparation does not allow for sufficient marginal depth to accommodate porcelain to conceal the metal color. An alternative is to use a nonprecious alloy, which will allow greater support with a thinner metal. In the final analysis, the patient's lipline can make the difference. If the patient has a medium or low lipline, there should be no problem.

When patients have extensive loss of interproximal tissue due to periodontal surgery there are two solutions that can generally be applied to crown restorations: a removable, interproximal tissue insert, or the addition of pink porcelain to the restoration to simulate interproximal tissue.

This latter approach involves raising the contact gingivally in porcelain and adding additional material lingually to close the space (see Chapter 8, Special Effects, Figure 8–52). One of the main problems with this technique is the difficulty in matching the pink tone of the individual patient's gingiva. Request your laboratory to make you several shade tabs of different combinations of pink porcelains to provide a range for matching the patient's gingival color.

An alternative to one of the prosthetic solutions to loss of interdental space is the possibility of orthodontic extrusion; this can sometimes work well when there are limited numbers of teeth involved.

Short Teeth. If the tooth appears too short, first explore the possibility of lengthening it by periodontal surgery. If not feasible, then resort to illusions in the crown to give an appearance of greater length. Eliminate horizontal lines and emphasize vertical characterizations and texture. Flatten the gingivoincisor dimension to help emphasize length. Rounding the proximal surfaces will make the tooth appear longer. Use stains to emphasize the length by darkening the interproximal porcelain and lightening the vertical dimension of the crown. Try to create vertical highlights by creating vertical, parallel lines on the labial surface that will reflect light in a vertical dimension (see Chapter 8).

Correct Occlusal Registration

An accurate bite registration is essential in obtaining a successful esthetic result. Alterations of the porcelain to correct the occlusion may remove occlusal or incisal translucency built into the shade. For this reason, it is mandatory to determine the final tooth length in the temporary prosthesis, and once this dimension is determined, to make an impression of the temporary crowns for duplication of the length in the final restorations. Failure to do this may result in the crowns being too long at the try-in appointment.

If this is the case, use computer imaging to first model the proposed changes to, hopefully, avoid overcutting the porcelain and ruining the appearance of the inlaid incisal staining. If you and your patient still want the teeth shortened, appropriate inlaid staining will again have to be incorporated into the new incisal edge.

Tooth Arrangement

When the arch length to be restored is too small for normally-sized crowns, it is sometimes better to overlap the lateral or central incisor crowns, when the patient permits, rather than simply reproducing smaller teeth. Another option is use of slightly larger crowns and elimination of one tooth in the restored arch. The solution should always depend upon the patient's facial features, expressions, overall personality, and personal preferences. The intended correction should be made first on study

casts and with computer imaging so both you and your patient can visualize and approve. Then, it is done on the temporary prosthesis so the patient can live with it before it is incorporated into the final porcelain restoration.

Shade

In order to deal with the perplexing problems of matching teeth, a thorough understanding of color is mandatory (see Chapter 10). With this increased knowledge and by applying some of the principles outlined in this chapter, more successful shade matching can be attained.

It has been shown by Culpepper⁸ and others that one of the weakest links in shade taking, regardless of shade guide or system used, is the eyes of the individual dentist. Although there have been many experiments in shade matching, few, if any, could be considered successful. What they did show was not only the tremendous variability in the way different dentists see color, but also the inconsistency in a given dentist's evaluation and judgment of color when tested at different times. Eyesight changes with age and it also varies day to day, hour to hour, and appointment to appointment. This explains how a dentist can select a shade, then look at this shade several days, or even minutes, later and see a different color. It also helps to explain how, regardless of how much care is taken, shades will sometimes be missed. Also, shade guides are just that, guides. The matching of tooth color must be individualized for each patient.

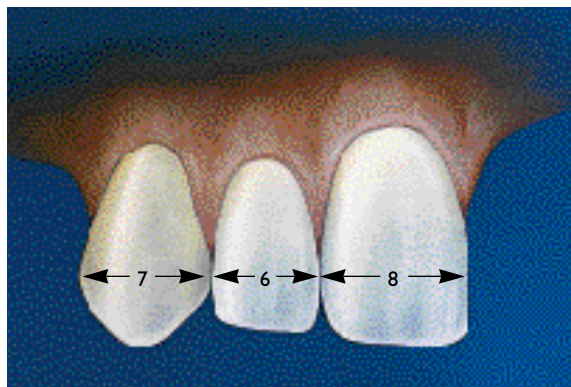
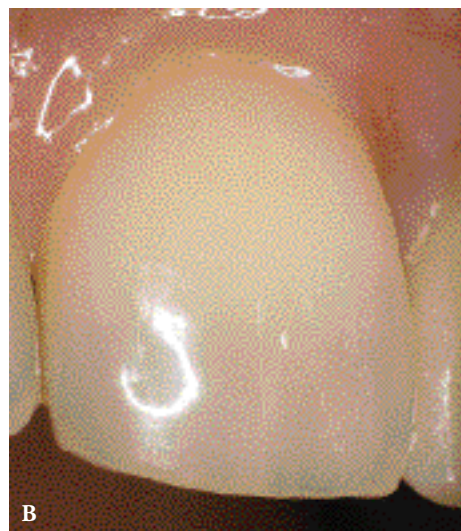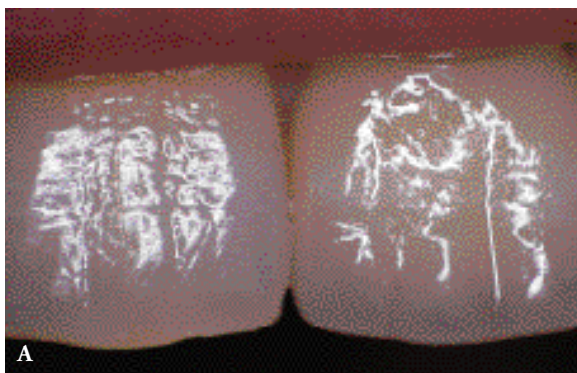


Figure 15-37: The width of the maxillary teeth in the natural dentition has a definite size variance. These dimensions can be used as a guide to the approximate proportion of anterior tooth width.



Figures 15-38A and B: These are good examples of how teeth vary from being highly texturized to being nontexturized. In Figure 15-38A, the left central incisor is the new crown. Realism is produced by duplicating existing texture on adjacent or opposing teeth.

Texture

After shape and shade selection, surface texture and characterization are important adjuncts to a natural esthetic appearance. An attempt should be made to copy the surface texture of adjacent teeth. Study natural teeth to note how small facets create natural shadows. Figures 15-38A and B show examples of highly textured and nontextured teeth. Realism is produced by duplicating existing irregularities and heights of contour of adjacent teeth. Maximum highlights are reflected from the heights of contour, but realize that overprominent ridges and grooves on the labial surface are often associated with false teeth and add little to the esthetics

of the restoration. A smooth, unbroken surface gives the impression of a long tooth, while texture can give the impression of a smaller tooth. At the try-in appointment, the moistened surface should be compared to adjacent teeth. This is most important when a single crown is to be placed next to a natural tooth (Figures 15-39A and B).

An alternative method is to use a good color balanced video camera. Videotape is an inexpensive method to convey to your technician an actual color representation of the condition of your patient's adjacent teeth, including shade variations.

Light

The light used to take a shade is critical. Since the eyes of the dentist and the laboratory technician are different, an error in color and judgment can be

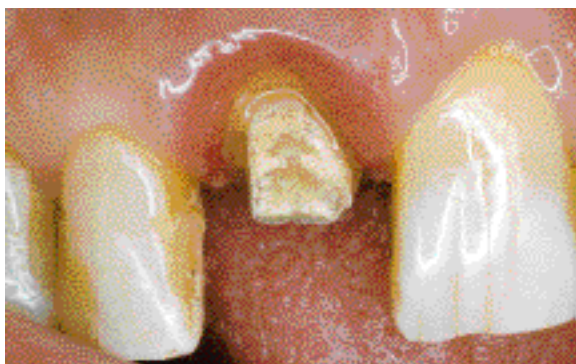

Figure 15-39A: The most difficult esthetic restorative procedure in dentistry is matching one central incisor to another. This patient desired a natural-looking result rather than alter his existing teeth.

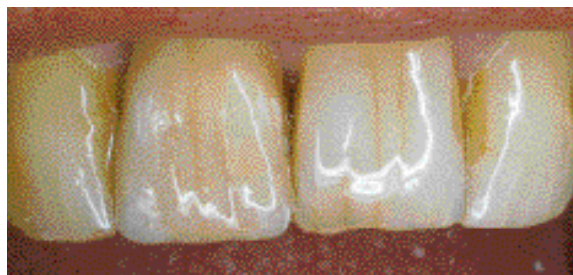

Figure 15-39B: Although not every nuance was duplicated, the basic shade differences, color intensity, and location of stains, as well as texture all contribute to making this right central incisor look natural.

compounded by using different kinds of light. For this reason, it is best for both the technician and dentist to use the same color-corrected light source. The best light source for color selection is the light through a window with a northern exposure. If this is not available, take your patient outside, preferably with your assistant and laboratory technician. Be sure to include a full-face mirror for your patient so he or she can participate in the selection procedure. An overcast sky is preferable, since a bright sky has a blue component that enhances the green color of the tooth. Early morning and late afternoon sunlight has a yellow component that enhances the yellow hue in the tooth. Inside, see how the shade may differ in incandescent light and in the lighting of your treatment room.

Even if outside light is available, you should use color-corrected fluorescent bulbs in your treatment rooms. In fact, one of the best light sources available today is the color-corrected fluorescent bulb (Durotest). Used by major industries concerned with color control, it closely reproduces natural daylight and allows the truest relationship to exist between the shade guide and tooth. Request that your laboratory use them, because they can help achieve the best esthetic color result.

As an alternative there are several hand-held light sources that you can use to help take a shade (Vident Systems, Efos Inc. Engineered Fibre-optic Systems). Ultimately, you will be using three light sources:

1. fluorescent light (Figure 15–40A).
2. outside light (Figure 15–40B).
3. incandescent light (Figure 15–40C).

In the event the shade appears different in the various light sources, make sure your patient is aware of this difference. Then ask in which light source he or she will be seen most of the time or in which light condition he or she wants the restoration to best match. *Although the entire dental team may participate in shade selection, the ultimate decision must rest with your patient.* Be sure to have your patient sign off on this final color selection. Otherwise, your patient may blame you if he or she becomes dissatisfied with the color of the final crowns.

Women should remove their lipstick before considering shades. When choosing the gingival shade, the lips of the patient should be raised and the

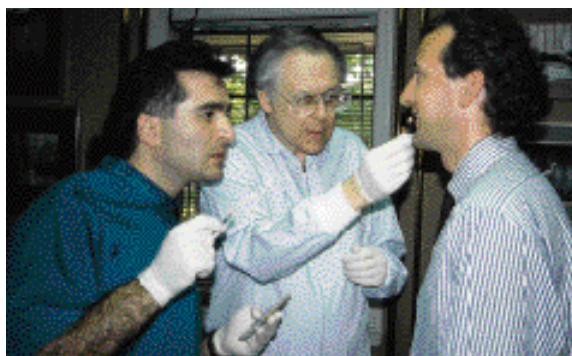

Figure 15–40A: Since your patient is normally seen in the treatment room, this is the first place to record your shade. (Ideally, you have color-corrected fluorescent light, so for another view, tilt the patient's head back to provide as much light as possible on the teeth.)

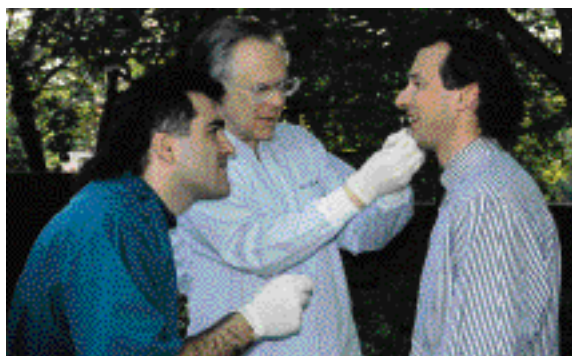

Figure 15–40B: It is important to take your patient, a facial mirror, and your team, if possible, to an outside area where both shaded and direct natural light is available for a second evaluation.




Figure 15–40C: Finally, try to have one area in your office with incandescent light to also compare your preselected shade to this condition. Ideally, the shade section should be consistent under all light sources; if not, now is the time to decide from which light source you and your patient wish to choose.

incisal portion of the teeth covered. For selection of the incisal shade, the patient's lips should be in a speaking position to give you a better concept of shade and to eliminate any influence from the gingival third of the tooth.

If using lip retractors, avoid drying out the teeth. Keep them wet during the entire process or the existing teeth may dry out sufficiently to change color.

When selecting the shade, the patient's head should be erect and at your eye level. The dentist should stand between the patient and the light source. If there is no outside light, and only color-corrected light from overhead fixtures is being used, it may be necessary to tilt the patient back so that the light hits the tooth directly.

What to Record

In order to construct a complete and accurate shade chart of a tooth, it is necessary to be able to see different colors in different sections of the tooth. Although dramatic differences may usually be seen in the broad gingival, body, and incisal portions of the tooth, there are often more subtle variations that occur in smaller areas of the tooth, varying with the angle at which you view the tooth. For example, a translucency may occur at either the mesial or distal line angle. It is rarely straight across or consistent, but often a broken line along the incisal one-third or one-fourth of the tooth and takes different shapes and forms in each tooth.

This should all be recorded on a shade chart that divides the teeth into sections to give the ceramist an understanding of where the colors are located. In this respect, a complete set of felt-tip colored pens is helpful (see Figure 15-2B). The different colors in the tooth can be diagrammed easily to give the technician a better understanding. In order to be as precise as possible, it may be necessary to give the technician several different shade tabs, with only portions of each marked, to correspond with specific sections of the tooth where that specific color is located. This way, the ceramist has a better idea of the hue, value, and chroma to be used. The shade will also depend upon the position of the teeth. If central or lateral incisors are tilted lingually, the light is reflected differently than if they were in a marked labial inclination. If the patient is in a Class II or protrusive arrangement, choose a deeper or darker shade, since a lighter shade is more conspicuous and creates the

appearance of false teeth. In a Class II patient with a high lipline, it is best to overdramatize the difference between the shades within the tooth. Accentuate the blues, greens, and oranges and include any imperfections that simulate naturalness. Light reflection from a protruding tooth is much greater than from a tooth that is positioned lingually and is thus shielded by the lips during smiling or speaking.

Conversely, beware of a dark tooth that is well concealed by the lips. In order to match this tooth, it is best to do so by choosing the appropriate shade of the basic porcelain. Frequently, to match the darker tooth, a mistake is made by using a light colored porcelain with surface stains to darken it. This may result in metamerism, or a tooth that will look different in different kinds of light. In changing light conditions, reflections will make the tooth look darker than it really is. It is critical to take sufficient time to choose the best possible shade and to view it under different forms of light before a final decision is made.

Shade selection should be as accurate as possible because, as shown by Mulla and Weiner, the appearance of the restoration that has been extrinsically stained cannot be precisely predicted. The changes for a particular type of stain, however, appear consistent, and it may be possible to judge the amount of stain to be applied on the basis of prior experience.⁶⁴

McLean notes that custom staining should not be used for alteration of incorrect colors, except in marginal cases, but rather that custom staining be confined only to creating surface defects or colors that are present on the natural tooth surface. If you can narrow the choice of the basic shade to two, the one higher in value should be chosen, because a value can be lowered by staining, but a low value cannot be made lighter.⁶⁰⁻⁶³

However, there is no doubt that the most esthetic and esthetically long-lasting ceramic crown is one that has been constructed with color incorporated into the porcelain internally, rather than by staining the surface. The internal color can come from layers of different shades of porcelain, from inlaid stains, or from special effects included into the building process. Good examples of natural-appearing, internally-shaded, all-ceramic crowns are in Figure 15-41.

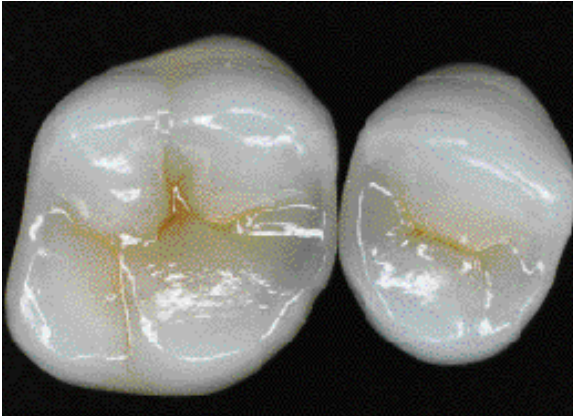


Figure 15-41: This is a good example of natural-appearing, internally-shaded, all-ceramic crowns. Note the variance in occlusal translucency and the staining of various grooves and fissures.

Areas of stain, hypocalcification, translucency, crack lines, or other artifacts that you want in the crown should be carefully placed on the shade chart to record their exact position on the tooth. The more accurate the rendition, the better the final result.

For anterior crowns, if there are no adjacent, opposing, or nearby natural anterior teeth to match, evaluate the shape, texture, and shade of the uncrowned, posterior teeth. Note the presence or absence of multiple colors, translucencies, or artifacts. The posterior teeth can serve as a relative guide for the missing anterior teeth. You can also ask your patient to furnish photographs that clearly show the anterior teeth when they were unrestored. If there are no photographs or unmarked or undamaged teeth in the mouth, you are free to choose any acceptable shade. Since this all must be done before you begin any treatment on the tooth, a preliminary shade chart should be completed at the first appointment. The tooth should be checked again at the next appointment to confirm or make any necessary changes. Also take color photographs of the patient during one of these visits to obtain an accurate guide which may be given to the laboratory technician when the preparations are completed and impressions are made. Make certain that the color photograph is an accurate representation of the actual tooth shade. The technician must be able to see the color and any shade differences, and to grasp a visual concept of the shape and characterization of the tooth.

There is a definite advantage to having one's own laboratory technician or having an outside technician present at a shade-taking visit. The technician can see the shade as you take it. Frequently, the technician will suggest certain shades based upon his or her knowledge and experience with porcelain in the laboratory.

Shade Guides. It is obvious that whatever manufacturer's product is being used, the corresponding shade guide should also be used. But be careful because even the shade tabs of one shade number may differ from one supposedly identical shade guide to another. You may also find that there are many times when the only way to arrive at a proper representation of the colors involved is to use different manufacturers' shade guides. You can even use three different manufacturers' shade tabs to delineate separate cervical, body, and incisal parts of a patient's tooth.

Many dentists like to develop their own shade guides. Usually, this is done by dentists who have their own laboratory technicians. However, it can also be done by an outside laboratory, if the dentist requests it. Because of the multiplicity of shade guides (Figure 15-42) and the variety of shades made by individual manufacturers, the exact shade button (or buttons) that was chosen should be sent to the laboratory. The metal backing must be the same as routinely employed for the individual den-



Figure 15-42: It is ideal to use the same manufacturer's shade guide as the porcelain selected. However, if your goal is to match an existing tooth, find a shade tab that comes as close as possible to the tooth to be matched (regardless of the manufacturer) and send that to the laboratory.

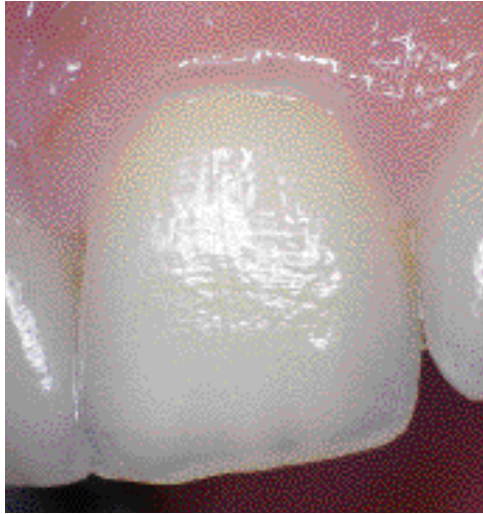


Figure 15-43A: Part of the beauty of the healthy, natural tooth is incisal translucency. Note how the opaqueness of the incisal edge highlights this translucency.

tist's everyday application, including the usual opaque and porcelain thickness.

Probably the most difficult task after the shade has been taken is communicating this to the laboratory so that a reasonably accurate crown comes back for the try-in. Naturally some correction can be done with staining (provided the needed value is higher and the chroma is lower), but the closer the original match, the easier and better the final esthetic result will be. Send the photographs, including one of the selected shade tabs adjacent to the prepared tooth, and your shade tabs, shade chart, notes on texture, and characterization, models, and anything else that can help. Remember, unless you have an in-office laboratory, your ceramist will most likely never have seen your patient, and he or she will have to rely totally on your information to create the crown. Again, the more accurate the information, the better the result.

Convey also to the laboratory technician the intensity of the different hues. For instance, in the incisal coloration or translucency, how gray or how blue is a "grayish" or "bluish" tint? (Figures 15-43A and B). Unless some type of shade guide with approximating color can be given to the ceramist, it is mere guesswork as to what shade is being requested.

Review of Tips for Shade Matching.

1. Determine the correct hue; different shades within the hue can then be selected (chroma-value).
2. Do not look too long at any particular shade, but compare several different ones with the patient in different positions. In addition to observing the tooth directly, try looking slightly away from the tooth so that just a color difference can be seen out of the corner of the eye. The shade that blends most closely with the tooth will usually be the correct one.
3. Make sure the patient is not wearing any brightly colored makeup or clothing. If so, drape the patient in a neutral colored apron.
4. Do not be limited by one shade guide. Use shades from different guides to let the ceramist know exactly what color occurs in different parts of the tooth.
5. Use three different light sources: fluorescent, natural, and incandescent. When using outside lighting, avoid direct sunlight. Choose a shaded area that is bright enough to permit visualization of the important differences between teeth. In order to determine the proper value level, it is best to squint.

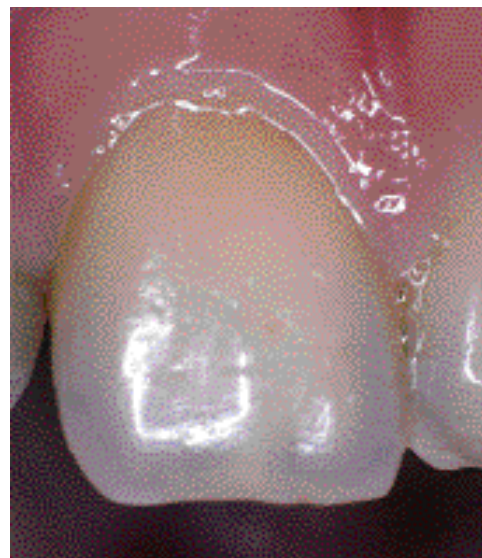


Figure 15-43B: Translucency may occur at either the mesial or distal line angle and is rarely straight across or consistent.

Table 15–2 Advantages and Disadvantages of Bonding, Laminating, and Crowning

PROCEDURE	ADVANTAGES	DISADVANTAGES
Bonding	<ol style="list-style-type: none"> 1. No anesthesia required 2. Little or no tooth reduction necessary 3. Immediate esthetic results 4. Color change possible 5. Less expensive than crowning or laminating 6. Can usually be a reversible process 	<ol style="list-style-type: none"> 1. Can chip or stain 2. Has a limited esthetic life 3. May not work if insufficient tooth structure 4. Limited ability to realign teeth 5. Teeth may appear somewhat thicker without enamel reduction
Laminating	<ol style="list-style-type: none"> 1. Little tooth reduction required 2. Highly esthetic 3. Does not stain 4. Can mask dark color 5. Longer esthetic life than bonding 6. Easier to obtain good tooth form and proportion 7. Less wear than bonding 8. May not require anesthesia 	<ol style="list-style-type: none"> 1. Can chip or fracture; repairs may be difficult or impossible 2. More costly than bonding 3. Requires two appointments 4. Irreversible procedure if tooth form altered 5. Limited ability to realign teeth 6. Teeth may appear thicker unless sufficient enamel reduction is performed
Crowning	<ol style="list-style-type: none"> 1. Teeth can be lightened to any shade 2. Some realignment of teeth is possible 3. Can serve as abutment for fixed or removable restorations 4. Longer esthetic life than bonding or laminating 5. Offers greatest latitude in improving tooth form and proportion 6. Most “natural” results 	<ol style="list-style-type: none"> 1. Can fracture 2. Requires anesthesia 3. Original tooth form altered 4. More costly than bonding 5. Requires two or more appointments 6. An irreversible procedure

To achieve a highly esthetic result in a single crown, meticulous attention must be given to each of the various esthetic considerations. If care is applied to each step, both you and your patient can enjoy the result: an esthetic, harmonious appearance of the mouth and face.

PATIENT MAINTENANCE

Much of the longevity and esthetic success of the crown restoration relies on both maintenance and prevention routines adopted by your patient. However, you can provide him or her with the best chance for longevity by making sure that you have created the most maintainable restoration possible. This means that you have provided for:

- marginal integrity during the impression, construction, and finishing stages of the crown;
- strong interproximal contact areas;

- restoration contours and materials that resist the retention of plaque and food particles; and
- the complete removal of excess cements and calculus.

Next, it is incumbent upon you to have a strong, comprehensive, and flexible patient maintenance program that focuses on inspiring participation by your patients. Promote positive programs with careful professional monitoring. These programs should be tailored to each patient’s existing oral condition as well as life style. It is especially important not to overwhelm a patient with too many tasks and devices, particularly with the mobile life style of today’s society. As an example, less tasks for the patient coupled with more frequent prevention visits to your office may be a better solution. The frequency of these in-office visits with your hygienist can vary from three to six times yearly, or even more in certain situations.

Motivation differs among patients and not everyone will respond equally. Many patients will follow your esthetic maintenance and soft tissue management instructions to the letter. Others will continue with or fall back on old habits and ignore your prescribed instructions. You can threaten that the breakdown and failure of the restoration may cause the patient to need even more drastic restorative treatment, which may include pain, and additional money and time. For these recalcitrant patients, and perhaps for all your patients, and quite possibly for your own protection, it is best to put your patient maintenance and prevention instructions in writing, and have the patient sign two copies. Keep one in the patient chart as part of the official record and send the other copy home with the patient.

Regardless of the prevention agenda you devise for your patients, the basics in oral hygiene care need to be reinforced:

- thorough brushing on a daily basis, preferably with a rotary cleaning device (Rotadent, Pro-Dentec);
- daily flossing regardless of the brushing method used; and
- plaque-reducing rinses.

It is important for the dental hygienist to make a critical evaluation of homecare during a prevention appointment for both the patient and dentist. It is equally important for the hygienist to adjust the hygiene procedures for patients with esthetic restorations. Of significant importance in assuring ideal service and longevity of a porcelain restoration is its treatment during routine dental prophylaxis. Sposetti, Jones, and Wunderlich, as well as many others, have demonstrated the ability of acidulated fluoride gel to etch a porcelain surface.^{48,86,92,92A} Therefore, a neutral pH product should be substituted for patients with ceramic restorations. Additionally, never use ultrasonic scalers or air-abrasive polishing systems as they may damage the surface of the restoration.

Finally, always attempt to encourage your patient to be part of the “oral care team” that is dedicated to maximizing the investment in his or her mouth.

CONCLUSION

Although unique problems occur in the construction of a crown, if properly fabricated, this restoration can be as esthetically pleasing as any other type of restoration. Knowing its limitations and providing for and adhering to the basic esthetic principles outlined in this chapter will help ensure successful results. The dentist interested in obtaining predictable results with esthetic restorations is urged to continually study natural and artificial dentitions (Table 15–2).

Figures 15–22; 15–30A,B; 15–41 courtesy of Pinhas Adar, M.D.T. Oral Design Center, Atlanta, GA.

References

1. Abramowsky JC. Porcelain as an esthetic restorative material. *Dent Clin North Am* 1963;831.
2. Anusavice KJ, Carroll JE. Effect of incompatibility stress on the fit of PFM crowns. *Dent Abstracts* 1990; 217.
3. Anusavice KJ, Dehoff PH, et al. Influence of tempering and contraction mismatch on crack development in ceramic surfaces. *J Dent Res* 1989;68:1162–87.
4. Anusavice KJ, Hojjatie B. Effect of thermal tempering on strength and crack propagation behavior of feldspathic porcelains. *J Dent Res* 1991;70:1009–13.
5. Anusavice KJ, Hojjate B. Stress distribution in metal-ceramic crowns with a facial porcelain margin. *J Dent Res* 1987;66:1493–8.
6. Anusavice KJ, et al. Delayed crack development in porcelain due to incompatibility stress. *J Dent Res* 1988;67:1086–97.
- 7a. Bartel JC. Porcelain as an esthetic restorative material. *Dent Clin North Am* 1963;831.
- 7b. Beaudreau DE. Atlas of fixed partial prosthesis. Springfield, Ill: Charles C. Thomas, 1975.
8. Bennett ME, Puckett AD, Parsel DE, Roberts SB. Conversion of a heat and pressure cured composite. [abstract 2188]. *J Dent Res* 1996; 75 Spec. Issue: 291.
9. Berger CC. Control of esthetics for anterior crowns. *Dent Survey* 1965;41:54.

10. Bertolotti RL. *Quintessence Int* 1990;21:643–6.
11. Binkley CJ, Irvin PT. Reinforced heat-processed acrylic resin provisional restorations. *J Prosthet Dent* 1987;57:689–91.
12. Boghosian AA. Sunrise: a new and versatile ceramic system. *Pract Periodontic Aesthet* 1990;2(3):21–4.
13. Braggi A. Esthetic crowns on vital teeth. *Odont Pract* 1970;5:197.
14. Brecker SC. Clinical procedures in occlusal rehabilitation. Philadelphia: W.B. Saunders, 1966.
- 14b. Brecker SC. Procedures to improve esthetics in restorative dentistry. *J N Carolina Dent Soc* 1957;4:33.
15. Bronstein BR. Problems in porcelain rehabilitation. *J Prosthet Dent* 1967;17:79.
16. Chan C, Haraszthy G, Geis-Gerstorer J, et al. Scanning electron microscopic studies of the marginal fit of three esthetic crowns. *Quintessence Int* 1989; 10: 189–93.
17. Contino RM. The effective use of gold and porcelain [lecture]. 1974 Jan. 30; Miami Winter Meeting. Miami, Florida.
18. Coughlin JW. Variabilities in the bonded porcelain veneer crown. *J Acad Gen Dent* 1970;18:30.
19. Crispin BJ, Okamoto SK, Globe H. Effect of porcelain crown substructures on visually perceivable value. *J Prosthet Dent* 1991;66:209–11.
20. Crispin BJ, Seghi RR, Globe H. Effect of different metal ceramic alloys on the color of opaque and dentin porcelain. *J Prosthet Dent* 1991;65:351–6.
21. Crispin BJ, Watson JF. Esthetic considerations for the placement of anterior crown margins. *J Prosthet Dent* 1980;44:290.
22. Culpepper WD. A comparative study of shade matching procedures. *J Prosthet Dent* 1970;24:166.
23. Davis DR. Comparison of fit of the two types of all-ceramic crowns. *J Prosthet Dent* 1988;59(1):12–6.
24. Dresen JD. Porcelain-fused-to-metal restorations. *Northwest J Dent* 1970;49:123.
25. Duret F, Preston J. CAD/CAM imaging in dentistry. *Curr Opin Dent* 1991;1:150–4.
26. El Sherif MH, Jacobi R, Lindke L. The ceramic reverse three-quarter crown for anterior teeth: laboratory procedures. *J Prosthet Dent* 1990;64:127–30.
27. Feinburg E. Full mouth restoration. Philadelphia: J.B. Lippincott, 1971.
28. Freidman M, Jordan RE. Bonded porcelain crowns. *J Esthet Dent* 1989;1:120–5.
29. Freilich MA, Karmaker AC, Burstone CJ, Goldberg AJ. Flexure strength of fibre-reinforced composites designed for prosthodontic application [abstract]. *J Dent Res* 1997;76 Spec. Issue:138.
30. Fuzzi M, et al. Marginal fit of three different porcelain onlays bonded to tooth: an in vitro study. *Int J Periodontics Restorative Dent* 1991;11:302–14.
31. Gallegos LI, Nicholls JL. University of Washington, School of Dentistry, SM-56, Seattle, 98195 (Nicholls). *J Prosthet Dent* 1988;60:172–7.
32. Garber DA. Ceramic or ceramist? Category 1—the ceramic restoration. *Compend Contin Educ Dent Vol XIII(4):257–66.*
33. Garber DA. Esthetics and the ceramo-metal restoration. *Compend Contin Educ Dent* 1992.
34. Geller W, Kwiatkowski SJ. The Willis's glass crown: a new solution in the dark and shadowed zones of esthetic porcelain restorations. *Quintessence Dent Technol* 1987;11:233–42.
35. Geller W, Kwiatkowski SJ. Willis Glass: Glaskeramische Synthese zur Vermeidung der Dunkel—und Schattenzonen im Gingivalbereich. *Quintessenz Zahntech* 1987;13:39–57.
36. Gettleman L. Noble alloys in dentistry. *Curr Opin Dent* 1991;2:218–21.
37. Gmur O. News about metal porcelain technique. *Zahntechnik (Berl)* 1970;28:450.
38. Goldstein RE, Feinman RA, Garber DA. Esthetic considerations in the selection and use of restorative materials. *Dent Clin North Am* 1983;27:723–30.
39. Gropp HP, Schwindling R. Statistical findings regarding faulty crown construction and consequences for the teeth, periodontium and gingiva. *Dtsch Zahnartzl Z* 1971;26:734.

40. Harrison L, Huggman T, Goldfogel M. All-porcelain labial margin for ceramo-metal crowns. *J Esthet Dent* 4:154-8.
41. Hummert T, Barghi N, Berry T. Post cementation marginal fit of a new ceramic foil crown system. *J Prosthet Dent* 1992;68:776-70.
42. Ianzano JA, Hill TJ. The fabrication and clinical utilization of the collarless veneer crown. *QDT Yearbook* 1988;75-81.
43. Jacobi R, Brooks TD. An intraoral lift technique for refining porcelain margins. *J Prosthet Dent* 1988;60:433-5.
44. Jacobi R, El-Sherif MH. Use of the reverse three-quarter crown: a case report. *Quintessence Int* 1989;20:185-8.
45. Jacobi R, Shillingburg HT Jr, Duncanson MG Jr. A comparison of the abrasiveness of six ceramic surfaces and gold. *J Prosthet Dent* 1991;66:303-9.
46. Jendresen MD, et al. Report of the committee on scientific investigation of the American Academy of Restorative Dentistry. *J Prosthet Dent* 1991;66:117-9.
47. Jia W, Yang Z, Prasad A. Polymer based Conquest Sculpture crown and bridge composite material properties according to ISO and ADA standards/specifications. Wallingford, CT: Jeneric/Pentron, 1997:1-10.
48. Jones DA. Effects of topical fluoride preparations on glazed porcelain surfaces. *J Prosthet Dent* 1985;53:483-4.
49. Jordan RE, Suzuki M. Clinical evaluation of Concept as a posterior composite restorative material in an indirect inlay/onlay technique.
52. Krejci I, Reich T, Lutz F, Albertoni M. In-Vitro-Testverfahren zur Evaluation dentaler Restaurationssysteme 1. Computergesteuerter Kausimulator. *Schweiz Monatsschr Zahmed* 1990;100:953-60.
53. Kuwata M. Creating harmony in dental ceramics (form, color, and illusion). Tokyo: Ishiyaku, 1998.
54. Lehman MI. Stability and durability of porcelain jacket crowns. *Br Dent J* 1967;23:419.
55. Lehner CR, Scharer P. All-cerami crowns. *Curr Opin Dent Prosthodont Endod* 1992;45-52.
56. Li Y. Effect of Conquest Sculpture Composite Resin on oral mucous membranes of Golden Syrian hamster. Wallingford, CT: Jeneric/Pentron, 1996:1-14.
57. Li Y. Evaluation of cytotoxicity of extracts of FibreKor using the agar diffusion method. Wallingford, CT: Jeneric/Pentron, 1997:1-6.
58. MacGibbon DJ. The failure of a porcelain-fused-to-metal crown. *Dent Digest* 1971;77:520.
59. Mahalick JA, Knapf J, Weiter EJ. Occlusal wear in prosthodontics. *J Am Dent Assoc* 1971;82:154.
60. McLean JW. Ceramics in clinical dentistry. *Br Dent J* 1988;March 19:164(6), 187-94.
61. McLean JW. Dental ceramics: proceedings of the First International Symposium on Ceramics. Chicago: Quintessence Publishing Co., 1983.
62. McLean JW. The alumina reinforced porcelain jacket crown. *J Am Dent Assoc* 1967;75:621.
63. McLean JW, Hughes TH. The reinforcement of dental porcelain with ceramic oxides. *Br Dent J* 1965;119:251.
64. Mulla FA, Weiner S. Effects of temperature on color stability of porcelain stains. *J Prosthet Dent* 1991;65:507-12.
65. Nash R, Leinfelder K, Radz G. An improved composite-onlay system. *Compend Contin Educ Dent* 1997;18(2):98-104.
66. Nevins M, Skurow H. The intracervicular restorative margin, the biologic width and the maintenance of the gingival margin. *Int J Periodontics Restorative Dent* 1984;3:31-49.
67. O'Neal SJ, Leinfelder KF, Barrett CE. Clinical evaluation of Dentacolor as a posterior veneering agent. *J Esthet Dent* 1989;1:29-33.
68. Omar R. Scanning electron microscopy of the marginal fit of ceramo-metal restorations with facially butted porcelain margins. *J Prosthet Dent* 1987;58:13-8.
69. Pameijer JHN. Soft tissue master cast for esthetic control in crown and bridge procedures. *J Esthet Dent* 1989;1:47-50.
70. Perel ML. Axial crown contours. *J Prosthet Dent* 1971;25:642.
71. Peyton FA, Craig RG. Restorative dental materials. 4th edn. St. Louis: C.V. Mosby, 1971.

72. Pincus CL. Cosmetics—the psychologic fourth dimension in full mouth rehabilitation. *Dent Clin North Am* 1967;71–88.
73. Pinnell DC, Latta GH, Evans JG. Light-cured porcelain margins: a new technique. *J Prosthet Dent* 1987;58:50–2.
74. Preston J. *Prospectives in dental ceramics: proceedings of the 4th international symposium on ceramics*. Chicago, Il: Quintessence Publishing Co. Inc., 1988:154.
75. Probst L. Compressive strength of the two modern all-ceramic crowns. *Int J Prosthodont* 1992;5:409–14.
76. Product update: Artglass. *Dent Advisor* 1997; 14(3):1–2.
77. Razzoog ME, Lang BR. Research evaluations of a new all-ceramic system. *Pract Periodontics Aesthet* 1998;1(10):1–3.
78. Rehany A, Hirschfeld Z. Veneering serviceable restorations. *Quintessence Int* 1988;19:787–92.
79. Sadan A, Hegenbarth EA. A simplified and practical method for optimizing aesthetic results utilizing a new high-strength all-ceramic system. *Pract Periodontics Aesthet* 1998;1(10):4–9.
80. Seghi RR, Soerensen JA. Relative flexural strength of six new ceramic materials. *Int J Prosthodont* 1995; 8:239–46.
81. Shelby DS. Esthetics and fixed restorations. *Dent Clin North Am* 1967; 57.
82. Sieber C. Illumination in anterior teeth. *Quintessence Dent Technol* 1992;15:81–8.
83. Solnit SG. The effect of methylmethacrylate reinforcement with silane-treated and untreated glass fibers. *J Prosthet Dent* 1991;66:310–14.
84. Sorenson JA. A standardized method for the determination of crown margin fidelity. *J Prosthet Dent* 1990;64:18–24.
85. Southard TE, Southard KA, Tolley EA. Variation of approximal tooth contact tightness with postural change. *J Dent Res* 1990;69:1776–9.
86. Sposetti VJ, Shen C, Levin AC. The effect of topical fluoride application on porcelain restorations. *J Prosthet Dent* 1986;55:677–82.
87. Stannard JG, et al. Effect of multiple firing on the bond strength of selected matched porcelain-fused-to-metal combinations. *J Prosthet Dent* 1990;63:627–9.
88. Strohaber R, Mattie D. A scanning electron microscope comparison of microfilled fixed prosthodontic resins. *J Prosthet Dent* 1987;5:559–65.
89. Suzuki S. *Comparative wear study of Sculpture and Artglass*. Wallingford, CT: Jeneric Pentron, 1996:1–6.
90. Wagner WC, Chu TM. Biaxial flexural strength and indentation fracture toughness of three new dental core ceramics. *J Prosthet Dent* 1996;76:140–4.
91. Weinberg LA. Esthetics and the gingivae in full coverage. *J Prosthet Dent* 1960;10:737.
- 92A. Wunderlich RC, Yaman P. In vitro effect of fluoride on dental porcelain. *J Prosthet Dent* 1986;55:385–8.
- 92B. Yamamoto M. *Metal ceramics*. Chicago: Quintessence, 1995:922.
93. Yuodelis RA, Weaver JD, Sapkos S. Facial and lingual contours of artificial complete crown restorations and their effect on the periodontium. *J Prosthet Dent* 1973;29:61.
94. Zena RB, Abbott LJ. Light harmony of crowns and roots: understanding and managing the black line phenomenon. *Pract Periodontics Aesthet* 1991;3(4):27–31.

Additional Resources

Abbate MF, Tjan AHL, Fox WM. Comparison of the marginal fit of various ceramic crown systems. *J Prosthet Dent* 1989;61:627–531.

Adamczyk E. Plaque accumulation on crowns made of various materials. *Int J Prosthodont* 1990;3:285–91.

Aranda R, Barghi N. An evaluation of four techniques for consideration of three opaque porcelains. *J Prosthet Dent* 1988;60:29–31.

Bader HI, Dubrovic D. Comparison of a powered rotary plaque removing device (Rotadent) in controlling chlorhexidine stain as compared with manual technique. *J Dent Res* [In press].

Barnes CM, Hayes EF, Leinfelder KF. Effect of an air abrasive polishing system on restored surfaces. *Gen Dent* 1987;35:186–9.

- Barreiro MM, Reisgo O, Vicente EE. Phase identification in dental porcelains for ceramo-metallic restorations. *Dent Mater* 1989;5:55-6.
- Bassett JL. Replacement of missing mandibular lateral incisors with a single pontic all-ceramic prosthesis: a case report. *Pract Periodont Aesthet* 1997;9:455-61.
- Bomba JL. Tooth-colored restoratives. In: *Current therapy in dentistry*. Vol. 4. C.V. Mosby, Co., 1970:242.
- Boyd RL, Murra P, Robertson PB. Effect of rotary electric toothbrush vs. manual toothbrush on periodontal status during orthodontic treatment. *Am J Orthod Dentofacial Orthop* 1989;96:342-7.
- Boyd RL, Robertson PB, Murray P. Effect on periodontal status of rotary electric toothbrushes vs. manual toothbrushes during periodontal maintenance; I. clinical results. *J Periodontol* 1989;60:390-5.
- Burch JG. Ten rules for developing crown contours in restorations. *Dent Clin North Am* 1971;15:611.
- Burch JG, Miller JB. Evaluation crown contours of a wax pattern. *J Prosthet Dent* 1973;30:454.
- Burke FJR, Qualtrough AJE, Wilson NHF. A retrospective evaluation of a series of dentin-bonded ceramic crowns. *Quintessence Int* 1998;29:103-6.
- Campbell SD. Esthetic modification of cast dental-ceramic restorations. *Int J Prosthodont* 1990;3:123-9.
- Chalifoux PR. Anterior porcelain veneers, three-quarter crowns and full crowns. *Contemporary Esthet and Rest Pract* 1998;2(1):52-61.
- Christensen GJ. Esthetic dentistry and esthetics. *Quintessence Int* 1989;20:747-53.
- Christensen GJ, Lundeen HC. Restorative dentistry in general practice. In: *Dental specialties in general practice*. Philadelphia: W.B. Saunders, 1969.
- Christensen RP, Christensen GJ. Comparison of instruments and commercial pastes used for finishing and polishing composite resin. *Gen Dent* 1981;29:40-5.
- Claus H. VITA In-Ceram, a new system for producing aluminum oxide crown and bridge substructures. *Quintessenz Zahntech* 1990;16:35-46.
- Cohn LA. Integrating treatment procedures in occluso-rehabilitation. *J Prosthet Dent* 1957;7:511.
- Cooley RL, Lubow RM, Brown FH. Effect of air-power abrasive instrument on porcelain. *J Prosthet Dent* 1988;60:4403.
- Coransson P, Nyman L. A survey of methods of gingival margin preparation. *Sverige Tandlakarforb Tidn* 1969;61:1149.
- Council on Dental Materials. Classification system for cast alloys. *J Am Dent Assoc* 1984;109(5):766.
- Courtade GL. Creating your own "dentin." Procedures for rebuilding badly broken-down teeth. *Dent Clin North Am* 1963:805.
- Craig RG, El Brashi MK, Peyton FA. Stress distribution in porcelain-fused-to-gold crowns and preparations constructed with photoelastic plastics. *J Dent Res* 1971;50:1278.
- Crispin BJ, Hewlett E, Seghi R. Relative color stability of ceramic stains subjected to glazing temperatures. *J Prosthet Dent* 1991;66:20-3.
- Culpepper WD. Concepts related to the preparation of teeth for fixed prosthodontics. *J Dent Educ* 1970;34:258.
- Custer F, Coyle T. Techniques influencing strength of the porcelain-fused-to-metal restorations. *N Y J Dent* 1969;39:119,165.
- Deutsch S. Evaluation of success of jacket crowns made from keradens material and of plastic jacket crowns. *Dent Abstracts* 1971;21:395.
- Diez AG. Cosmetic aspects of veneer crowns. *Odontoiatria* 1967;19:553.
- Donovan TE. Ceramic restorations: cast metal and cast glass. *Curr Opin Dent* 1991;1:133-7.
- Dunlap JE. Homecare that works. *Dent Today* 1990;28:59.
- Dupont R. Large ceramo-metallic restorations. *Int Dent J* 1968;18:288.
- Dyer SR, Sorenson JA. Flexural strength and fracture toughness of fixed prosthodontic resin composites. *J Dent Res (Special Issue)* 1998;77:160, (Abstract no. 434).
- Dykema R, Goodacre C, Phillips R. *Johnston's modern practice in fixed prosthodontics*. 4th Ed. Philadelphia, PA. W.B. Saunders Co., 1986.

- Eichner K. The crown margin and the marginal periodontium from the clinical point of view. *Dtsch Zahnarztl Z* 1969;24:741.
- Eichner K, von Radnoth MS. The gold-porcelain interface: a comparison of studies undertaken, using the electron and scanning electron microscope. *Det Sci Res* 1971;2:7.
- Eissmann HF, Rake RA, Noble WH. Physiologic design criteria for fixed dental restorations. *Dent Clin North Am* 1971;15:543.
- Fan PL, Stanford JW. Ceramics: their place in dentistry. *Int Dent J* 1987;37:197-200.
- Farrah JW, Powers JM. Fiber Reinforced Composites, *The Dental Advisor* 1998;15(2):1-5.
- Felton DA, et al. Effect of air abrasives on marginal configurations of porcelain-fused-to-metal alloys: an SEM analysis. *J Prosthet Dent* 1991;65:38-43.
- Freilich MA, Meiers JC, Duncan JP, Goldberg AJ. Fiber reinforcement in laboratory and chairside-fabricated prostheses. *Contemporary Esthet and Rest Pract* 1998;2(1):32-45.
- Freyberger F. The choice of shade for composite crowns. *ZWR* 1971;80:734.
- Freyberger P. Are porcelain or ceramic prostheses contraindicated in periodontally diseased or endangered dentitions? *Dtsch Zahnarztl Z* 1969;24:137.
- Gausch K. Accumulated experience in the field of dental porcelain. *Oest Z Stomatol* 1969;66:255.
- Goeller I, Meyer JM, Nally JN. Comparative study of three coating agents and their influence on bond strength of porcelain-fused-to-gold alloy. *J Prosthet Dent* 1972;28:504.
- Goldberg AJ, Bursone CJ. The use of continuous fiber reinforcement in dentistry. *Dent Mat* 1992;8:197-202.
- Goldfogel MH, Bomberg TJ. Custom characterization of the porcelain-fused-to-metal restoration. *Quintessence Dent Technol* 1987;11:181-5.
- Goldstein RE. Diagnostic dilemma: to bond, laminate, or crown? *Int J Periodontics Restorative Dent* 1987;5:9-12.
- Goldstein RE. Esthetic principles for ceramo-metal restorations. *Dent Clin North Am* 1988;21:803-22.
- Goldstein RE. Finishing of composites and laminates. *Dent Clin North Am* 1989;33:305-18.
- Goldstein RE, Goldstein C. Is your case really finished? *J Clin Orthod* 1988;22:702-13.
- Goodacre CJ, Lund MR. Insights into current ceramic systems. *J Indiana Dent Assoc* 1973;52:161.
- Gottlieb A. Avoidance of problems in porcelain-fused-to-metal fixed partial dentures. *Tic* 1970;29:8.
- Grajower R, Zuberi Y, Lewinstein I. Improving the fit of crowns with die spacers. *J Prosthet Dent* 1989;61:555-63.
- Greenstein G, Berman D, Jaffin R. Chlorhexidine, an adjunct to periodontal therapy. *J Periodontol* 1986;57:370-7.
- Guyer SE. Multiple preparations for fixed prosthodontics. *J Prosthet Dent* 1970;23:529.
- Hastings JH. Effective color mapping and shade selection for the IPS Empress restoration. *Laboratory Digest* 1996;2(1):10-15.
- Haywood VB, Heymann HO, Kuay RP, et al. Polishing porcelain veneers and SEM and specular reflectance analysis. *Dent Mater* 1988;4:116-21.
- Haywood VB, Heymann HO, Scurria MS. Effects of water speed and experimental instrumentation on finishing and polishing porcelain intraorally. *Dent Mater* 1989;5:185-8.
- Herzberg TW, Gettleman L, Webber RL, Moffa JP. Effect of a metal surface treatment on the masking power of opaque porcelain. *J Dent Res* 1972;51:468.
- Hofmann M, Guller R. Untersuchungen über den Einfluss der Schulterform auf die Bruchfestigkeit von Mineral-mantelkronen. *Dtsch Zahnarztl Z* 1969;24:778.
- Holmes JR, Sulik WD, Holland GA, Bayne SC. Marginal fit of castable ceramic crowns. *J Prosthet Dent* 1992;5:594-9.
- Hughes TH. Reinforcement of dental porcelains with ceramic oxides. I. *Zahnarztl Welt* 1969;78:311.
- Hummert T, Barghi N, Berry T. Effect of fitting adjustments on compressive strength of a new crown system. *J Prosthet Dent* 1991;66:177-81.
- Johnston JF. *Modern practice in dental ceramics*. Philadelphia: W.B. Saunders, 1967.

- Johnston JF, Mumford G, Dykema RW. The porcelain veneered gold crown. *Dent Clin North Am* 1963;8:53.
- Jones MD, Dykema RW, Klein AI. Television, micro-measurement of vented and non-vented cast crown marginal adaptation. *Dent Clin North Am* 1971;15:663.
- Karmaker AC, DiBenedetto AT, Goldberg AJ. Continuous fiber reinforced composite materials as alternative for metal alloys used for dental appliances. *J Biomater Appl* 1997;11:318–28.
- Katz SR. Aesthetics in ceramics. *J Can Dent Assoc* 1966;32:224.
- Kepron D. Experiences with modern occlusal concepts. *Dent Clin North Am* 1971;15:595.
- Kobayakawa K, et al. Studies on the fitness of the alumina-reinforced porcelain jacket crown. *J Hiroshima Univ Dent Soc* 1969;1:146.
- Koper A, Grodon DC. Esthetics in oral restorations [course]. University of California School of Dentistry, Dec. 3, 1971.
- Larato DC. The effect of crown margin extension on gingival inflammation. *J S Calif Dent Assoc* 1969;37:476.
- Lee CR, Pierpont HP, Strickler ER. The effect of bead attachment systems on casing patterns and resultant tensile bond strength of composite resin veneer cast restorations. *J Prosthet Dent* 1991;66:623–30.
- Lev M. Practical aspects of porcelain-to-gold ceramics. *Schweiz Mschr Zahnheilk* 1968;78:1.
- Love JW, Surg CL, Killoy WJ, et al. The effectiveness of a rotary action power toothbrush vs. a manual brush [abstract no. 98]. *J Dent Res* 1988;67:125.
- Lund PS, Aquilino SA, Dixon DJ. Evaluation of the color and appearance of a new textured opaque porcelain. *Int J Prosthodont* 1991;4:548–54.
- Lundeen HC. Occlusal morphologic consideration for fixed restorations. *Dent Clin North Am* 1971;15:649.
- Luthy H, Dong JK, Wohlwend A, Scharer P. Heat-pressed ceramics: influence of pressing and heat treatment on strength [abstract]. *J Dent Res* 1991.
- Malament KA, Grossman DG. The cast glass-ceramic restoration. *J Prosthet Dent* 1987;57:674–5.
- Mannerberg F. Gingival changes after porcelain crown therapy. *Odontol Rev* 1971;22:155.
- Marra LM. An historical review of full coverage of the natural dentition. *N Y Dent J* 1970;30:147.
- Mathe G. Color problems in anterior crown and fixed partial dentures. *Zahnarztl Welt* 1979;78:1097.
- McCloskey DT. Porcelain jackets under stress. *J Dent Res* 1927;7:417.
- McDermott DE. Porcelain fused to gold. *J Ont Dent Assoc* 1968;45:230.
- Miller IF, Belsky MW. The full shoulder preparation for periodontal health. *Dent Clin North Am* 1963:83.
- Miller IF, Feinberg E. Full coverage restorations. *J Prosthet Dent* 1962;12:317.
- Miller IF, Field LL. Epoxy resin—a new medium in full coverage for restorative dentistry. *Dent Clin North Am* 1963:791.
- Miller LM. Maintaining esthetic restorations. Houston: Reality, 1989.
- Minker JS. Simplified full coverage preparations. *Dent Clin North Am* 1965:355.
- Mitchell RG. Methods used to obtain optimum esthetics in the porcelain gold crown. *Texas Dent J* 1968;85:7.
- Moulton GH. Porcelain veneer crown. *Northwest Dent* 1959;38:363.
- Mumford G, Ridge A. Dental porcelain. *Dent Clin North Am* 1971;15:33.
- Murray P, Boyd RL, Daly RP, et al. Effect of periodontal status of rotary electric toothbrushes vs. manual toothbrushes during periodontal maintenance: II Microbiological results. *J Periodontol* 1989;60:396–401.
- Nash LB. Post-treatment care of composite veneers. *Pract Periodontics Aesthet Dent* 1991;2(2):28–9.
- Naylor WP. Prosthodontic items of interest. *Int J Prosthodont* 1989;2(1):98.
- Naylor WP. Prosthodontic items of interest. *Int J Prosthodont* 1990;3:501.
- O'Brien W. Dental materials properties and selection. Chicago, IL: Quintessence Publishing Co., Inc., 1989.

- Orkin DA, Reddy J, Bradshaw D. The relationship of the position of crown margins to gingival health. *J Prosthet Dent* 1987;57:421-4.
- Pensler AV. Shade selection: problems and solutions. *Comp Cont Educ Dent* 1998;19:387-96.
- Preiskel H. Telescopic prostheses. *Isr J Dent Med* 1969;18:12.
- Probster L, Diehl J. Slip-casting alumina ceramics for crown and bridge restorations. *Quintessence Int* 1992;23:25-31.
- Reel DC, Abrams H, Gardner S, Mitchell RJ. Effect of a hydraulic jet prophylaxis system on composites. *J Prosthodont* 1989;61:441-5.
- Ritze H. The restoration of anterior teeth; plastic material or porcelain? *Dtsch Zahnarztl Z* 1969;24:905.
- Rosenblum MA, Schulman A. A review of all-ceramic restorations. *J Am Dent Assoc* 1997;128:687-701.
- Ross IF. Occlusion: a concept for the clinician. St. Louis: C.V. Mosby, 1970.
- Ross IF. The relation between periodontal therapy and fixed restorative care. *J Periodontol* 1971;42:13.
- Saklad MJ. Achieving esthetics with the porcelain jacket. *Dent Clin North Am* 1967;Mar:41.
- Saleski DG. Color, light, shade matching. *J Prosthet Dent* 1972;27:263.
- Sced IR, McLean JW. The strength of metal ceramic bonds with base metals containing chromium. *Br Dent J* 1972;132:232.
- Schillingburg HT, Hobo S, Fisher DW. Preparation design and margin distortion in porcelain-fused-to-metal restorations. *J Prosthet Dent* 1973;29:276.
- Schwartz NL, et al. Unserviceable crowns and fixed dentures. Lifespan and causes for loss of serviceability. *J Am Dent Assoc* 1970;81:1395.
- Schweitzer JM. Concepts of occlusion—a discussion. *Dent Clin North Am* 1963:649.
- Schweitzer JM. Oral rehabilitation problem cases. Vols. 1 and 2. St. Louis: C.V. Mosby, 1964.
- Schweitzer JM. Restorative dentistry, a half century of reflections. *J Prosthet Dent* 1974;31:22.
- Scrivner EI. Gingival tissue management during fixed prosthodontic procedures. *Dent Clin North Am* 1973;15:587.
- Seymour M. Personal communication, Feb. 2, 1974.
- Shelby DS. Practical considerations and design of porcelain fused to metal. *J Prosthet Dent* 1962;12:542.
- Singer F. Veneer crowns. *Dtsch Zahnrstl Z* 1969;24:711.
- Skurow HM, Lytle JD. The interproximal embrasure. *Dent Clin North Am* 1971;15:641.
- Sorenson JA, Knode H, Torres TJ. In-Ceram all-ceramic bridge technology. *Quintessence Dent Technol* 1992.
- Southan DE, Jorgensen KD. An explanation for the occurrence of internal faults in porcelain jacket crowns. *Aust Dent J* 1973;18:152.
- Stein RS. Ceramo-metal and aluminous porcelain restoration [course]. *Coll Dent Medicine*, Charleston, SC, Dec. 11-12, 1971.
- Strassler HE, Moffitt W. The surface texture of composite resin after polishing with commercially available toothpastes. *Compend Contin Educ Dent* 1987;8:826-30.
- Straussberg G, Katz G, Kuwata M. Design of gold supporting structure for fused porcelain restorations. *J Prosthet Dent* 1966;16:928.
- Tashma JL. Coloring somatoprotheses. *J Prosthet Dent* 1967;17:303.
- Taylor AG. Porcelain fused to gold. *J Ont Dent Assoc* 1968;45:143-5.
- Tergis MJL. The proper geometry of preparation and case design in porcelain-on-gold restoration. *J Acad Gen Dent* 1971;19:15.
- Thomas JE, Lacroix R, Villemot J. Color in ceramics. *Ann Odontostomatol* 1967;24:209.
- Tobelem AL. Ceramometallic compounds. *Rev Fr Odontostomatol* 1968;1:1279.
- Tsibidis O, Vryonis P. Dicor veneers. *QDT Yearbook* 1988:69-74.
- Tuccillo JJ, Nielsen JP. Shear stress measurements at a dental porcelain-gold bond interface. *J Dent Res* 1972;51:626.

Tylman SD. Theory and practice of crown and fixed partial prosthodontics. 6th edn. St. Louis: C.V. Mosby, 1970.

Tysowsky GW, Dyer SR, Berge HX. Current evaluations of a fiber-reinforced composite and ceromer system. *Pract Periodont Aesthet Dent* 1998;(Suppl)3:1-3.

Uruta K. Construction of full bake porcelain jacket crowns. *JAPDSA* 1968;1:27.

Uruta K. Shapes of preparations for porcelain jacket crowns. *Shikwa Gakuho* 1971;71:1.

Vickery RC, Badinelli LA. Nature of attachment forces on porcelain-gold systems. *J Dent Res* 1968;47:683.

Voss R. Stability of metal-ceramic crowns. *Dtsch Zahnarztl Z* 1969;24:726.

Vyronis P. A manual for the fabrication of the complete porcelain margin. Stock J Pub. Pty. Ltd., 1984.

Vyronis P. A simplified approach to the complete porcelain margin. *J Prosthet Dent* 1979;42:592-3.

Vyronis P. Esthetics and function in multiple unit bridges. *Quintessence Dent Technol* 1981;3:237-41.

Wade AB. Occlusal rehabilitation and in particular selective grinding. *J Dent Med* 1963;18:71.

Watson JF, Crispin BJ. Margin placement of esthetic veneer crowns. Part III: Attitudes of patients and dentists. *J Prosthet Dent* 1981;44:499-501.

Weaver JD, Johnson GH, Bales DJ. Marginal adaptation of castable ceramic crowns. *J Prosthet Dent* 1991;66:747-53.

White SN, Sorenson JA, Kang SK, Caputo AA. Microleakage of new crown and fixed partial denture agents. *J Prosthet Dent* 1992;67:156-561.

Wohlwend A, Scharer P. The Empress technique: a new technique for the fabrication of full ceramic crowns, inlays, and veneers [in German]. *Quintessenz Zahntech* 1990;16:966-78;English reprints, 1991.

Zitterbart P. Effectiveness of ultrasonic scalers: a literature review. *Gen Dent* 1987;35:295-7.

Appendix A

PATIENT _____ EXAMINER _____ DATE _____

1. MEET THE PATIENT (Patient Esthetic History)


Unprompted Patient History — “What bothers you about your dental appearance?”

History of Esthetic Change _____

Patient Desires _____

Old Records: Photos _____ Study Casts _____ Radiographs _____

2. MEET THE FACE (Facial Examination)



Interpupillary Line _____

Facial Symmetry _____

Lip Symmetry _____

Philtrum location _____

Movement symmetry — repose _____

Smile _____

Grimace _____

Speaking _____

3. MEET THE MOUTH (Intraoral Examination)

A. STAGING OF THE MOUTH

Smile line

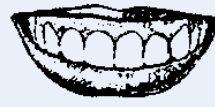Upper lip line classification



average _____



low _____



high _____

Tooth — lower lip position



touching _____



not touching _____



slightly covered _____


Tooth prominence on stage

average _____

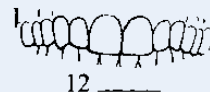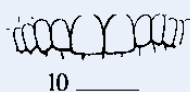
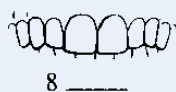

receding _____

prominent _____

Incisal edge alignment to lower lip



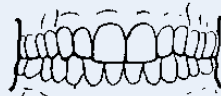
Horizontal tooth display



Vestibular space



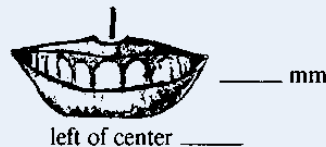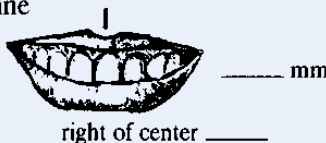B. LIP LINE — Draw at maximum exposure



horizontal tooth display _____
 vertical tooth display _____
 gingival display _____

C. TOOTH MIDLINE

Central incisors to upper lip midline



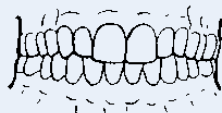
Upper and lower arch relations _____

Canine distance to midline _____

Appearance of symmetry horizontal _____ asymmetrical _____

radiating 1° _____ 2° _____ 3° _____

D. HORIZONTAL INCISAL AND CEJ LEVELS



Draw in lip horizontal relative to true horizontal.
 Draw in incisal horizontal and midline.
 Draw in gingival line horizontal.

E. GINGIVAL CHARACTERISTICS (visible on stage)

	YES	NO		YES	NO
Abnormal gingival appearance	<input type="checkbox"/>	<input type="checkbox"/>	Excessive gingival display	<input type="checkbox"/>	<input type="checkbox"/>
Gingival inflammation	<input type="checkbox"/>	<input type="checkbox"/>	Location _____		
Location _____			Collapsed edentulous ridge	<input type="checkbox"/>	<input type="checkbox"/>
Thin gingiva	<input type="checkbox"/>	<input type="checkbox"/>	Location _____		
Thick gingiva	<input type="checkbox"/>	<input type="checkbox"/>	Type: vertical _____		
Gingival recession	<input type="checkbox"/>	<input type="checkbox"/>	horizontal _____		
Location _____			combination _____		
Gingival hyperplasia	<input type="checkbox"/>	<input type="checkbox"/>	Potential collapse from periodontal surgery	<input type="checkbox"/>	<input type="checkbox"/>
Location _____			Location _____		
"Black triangles"	<input type="checkbox"/>	<input type="checkbox"/>	Potential collapse from extractions	<input type="checkbox"/>	<input type="checkbox"/>
Location _____			Location _____		
"Altered passive eruption"	<input type="checkbox"/>	<input type="checkbox"/>	Potential gingival defect from periodontal surgery	<input type="checkbox"/>	<input type="checkbox"/>
Location _____			Location _____		

F. TOOTH CHARACTERISTICS (visible on stage)

	YES	NO		YES	NO
Flared teeth	<input type="checkbox"/>	<input type="checkbox"/>	Attrition	<input type="checkbox"/>	<input type="checkbox"/>
Location _____			Location _____		
Diasthema	<input type="checkbox"/>	<input type="checkbox"/>	Type _____		
Location _____			Chipped teeth	<input type="checkbox"/>	<input type="checkbox"/>
Overlapped teeth	<input type="checkbox"/>	<input type="checkbox"/>	Location _____		
Location _____			Inadequate restorations	<input type="checkbox"/>	<input type="checkbox"/>
Discolored teeth	<input type="checkbox"/>	<input type="checkbox"/>	Location _____		
Location _____			Surface texture — smooth	<input type="checkbox"/>	<input type="checkbox"/>
Type _____			light	<input type="checkbox"/>	<input type="checkbox"/>
Shade _____			medium	<input type="checkbox"/>	<input type="checkbox"/>
			high	<input type="checkbox"/>	<input type="checkbox"/>

4. MEET THE FUNCTION (Functional Examination)

DENTOLABIAL RELATIONS IN REPOSE



“Normal”



Trapped lip



Open

Other

PHONETICS

F-V Position

	YES	NO		YES	NO
Upper incisor to lower lip — incorrect	<input type="checkbox"/>	<input type="checkbox"/>	Vertical tooth — lip overlap	_____ mm.	

S — Position

	YES	NO		YES	NO
Sound is not clear	<input type="checkbox"/>	<input type="checkbox"/>	Tooth contact in “S” position	<input type="checkbox"/>	<input type="checkbox"/>
Normal lisp	<input type="checkbox"/>	<input type="checkbox"/>	Location _____		
Acquired “S” sound deficiency	<input type="checkbox"/>	<input type="checkbox"/>	Horizontal movement	_____ mm.	
Interproximal air escape	<input type="checkbox"/>	<input type="checkbox"/>	Vertical movement	_____ mm.	
Overclosure of occlusal vertical dimension	<input type="checkbox"/>	<input type="checkbox"/>	Posterior tooth clearance	_____ mm.	
Lack of anterior tooth length	<input type="checkbox"/>	<input type="checkbox"/>	Anterior tooth clearance	_____ mm.	

Swallowing

	YES	NO		YES	NO
Abnormal swallow — visceral	<input type="checkbox"/>	<input type="checkbox"/>	Abnormal swallow acquired	<input type="checkbox"/>	<input type="checkbox"/>
Abnormal swallow — somatic	<input type="checkbox"/>	<input type="checkbox"/>	Problematic tongue size	<input type="checkbox"/>	<input type="checkbox"/>

INCISAL GUIDANCE — OCCLUSION

Orthodontic Class _____ Overbite _____ mm. Overjet _____ mm.

	YES	NO		YES	NO
Tooth size to arch size discrepancy	<input type="checkbox"/>	<input type="checkbox"/>	Further orthodontic study necessary	<input type="checkbox"/>	<input type="checkbox"/>
Lack posterior tooth disclusion in protrusive contacting movements	<input type="checkbox"/>	<input type="checkbox"/>	Fremitus upper anterior tooth in intercuspal position	<input type="checkbox"/>	<input type="checkbox"/>
Location _____			Location _____		
Lack posterior tooth disclusion in lateral contacting movements	<input type="checkbox"/>	<input type="checkbox"/>	Class _____		
Location _____			Fremitus upper anterior tooth in contacting movements	<input type="checkbox"/>	<input type="checkbox"/>
Lack posterior teeth to stabilize occlusal vertical dimension	<input type="checkbox"/>	<input type="checkbox"/>	Location _____		
Upper anterior teeth displaced in intercuspal position	<input type="checkbox"/>	<input type="checkbox"/>	Class _____		
Location _____			Diasthema is present	<input type="checkbox"/>	<input type="checkbox"/>
			Diasthema is normal	<input type="checkbox"/>	<input type="checkbox"/>
			Diasthema is acquired	<input type="checkbox"/>	<input type="checkbox"/>

DISEASE SUMMARY (pertinent to esthetic display)

	YES	NO		YES	NO
Active periodontal disease	<input type="checkbox"/>	<input type="checkbox"/>	Mobility	<input type="checkbox"/>	<input type="checkbox"/>
Probing depth beyond 4 mm.	<input type="checkbox"/>	<input type="checkbox"/>	Location _____		
Location _____			Degree _____		
Depth _____			Caries	<input type="checkbox"/>	<input type="checkbox"/>
Attachment level less than 75%	<input type="checkbox"/>	<input type="checkbox"/>	Location _____		
Location _____			Endodontic disease	<input type="checkbox"/>	<input type="checkbox"/>
Amount _____			Location _____		

HABITS

	YES	NO	Comments _____
Occlusal habit — tooth to tooth	<input type="checkbox"/>	<input type="checkbox"/>	_____
Occlusal habit — oral musculature to tooth	<input type="checkbox"/>	<input type="checkbox"/>	_____
Occlusal habit — foreign object to tooth	<input type="checkbox"/>	<input type="checkbox"/>	_____

Esthetic precautions and proposals in treatment _____

T#	Diagnosis & Treatment	Fee
1		
2		
3		
4		
5		
6		
7		
8		
9		
10		
11		
12		
13		
14		
15		
16		

Total _____

T#	Diagnosis & Treatment	Fee
17		
18		
19		
20		
21		
22		
23		
24		
25		
26		
27		
28		
29		
30		
31		
32		

Total _____

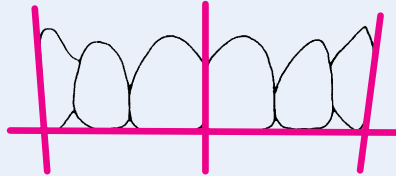
Appendix B

FOR _____
 DUE _____
 DR. _____

UPPER ANTERIORS

INCISAL PLANE

- ALIGNED WITH BENCH-TOP
- SAME AS MOUNTED CAST of TEMPS
- CENTRAL EMBRASURE VERTICAL



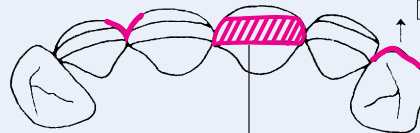
INCISAL EDGE POSITION

- FOLLOW E/O CAST
- COPY CAST of TEMPS
- COPY CAST of ORIGINAL
- NO CONTACT
- LABIALS ALIGNED IN PROTRUSIVE EDGE-TO-EDGE with AG TABLE



LABIAL EMBRASURES

- FORMED BY CONVEX PROXIMALS



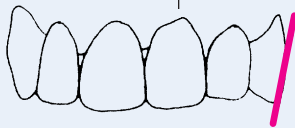
- CUSPID MES-LAB LINE ANGLE FACES FORWARD

- INCISAL EDGES OUTLINED BY LINE ANGLES

- _____

EMERGENCE CONTOUR

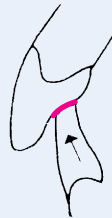
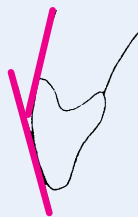- STRAIGHT or CONCAVE
- FOLLOW TISSUE MODEL
- NO BULGE AT MARGIN
- ALL SPACES CLOSED



- TRIGONAL SHAPE ON PONTICS
- GINGIVAL MARGIN SAME AS TEMPS
- CUSPID PROFILE

LABIAL CONTOUR

- ALIGNED WITH ALVEOLAR CONTOUR
- 2 PLANES FOR LABIAL CONTOUR
- COPY TEMPS

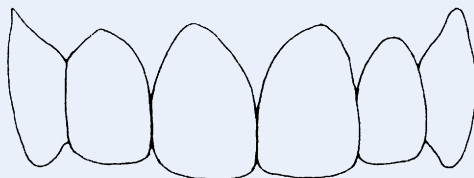


- DEFINITE STOP FOR LOWER ANTERIORS

- NO CONTACT

- SPECIAL INSTRUCTIONS

- SHADE INSTRUCTIONS



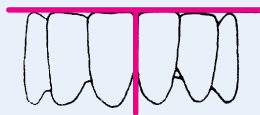
- CHECK CONTACTS ON SOLID MODEL

FOR _____
 DUE _____
 DR. _____

LOWER ANTERIORS

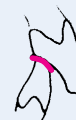INCISAL PLANE

- COPY CAST of TEMPS
- INCISAL PLANE aligned with bench top
- LABIAL EMBRASURES aligned with VERTICAL
-



INCISAL EDGE POSITION

- FOLLOW E/O CAST
- COPY CAST of TEMPS
- COPY CAST of ORIGINAL
- INCISAL EDGES MEET DEFINITE STOP
- NO ANTERIOR CONTACT



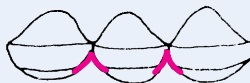INCISAL EDGE CONTOUR

- OUTLINED BY LINE ANGLES
- INCISAL EDGE HIGHER ON LINGUAL
- INCISAL EDGE WIDER AT LINGUAL
- DEFINITE LABIO-INCISAL LINE ANGLE
- LINGUAL STRAIGHT or SLIGHTLY CONCAVE



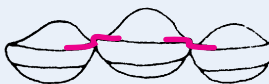LABIAL EMBRASURES

- FORMED BY CONVEX PROXIMAL SURFACES



LINGUAL SILHOUETTE

- FROM SLIGHT OFFSET OF INCISAL EDGES



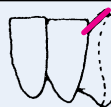
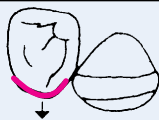INCISAL EDGE SILHOUETTE

- FROM SLIGHT ANGULATION OF FLAT EDGES
- PATIENT WANTS EVEN



CUSPID

- MES-LAB LINE ANGLE POINTS FORWARD
- SHOW LINGUAL OF CUSPID FROM LABIAL VIEW



EMERGENCE CONTOUR

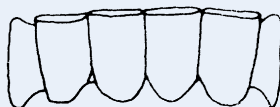
- RELATE TO SOFT TISSUE MODEL
- NO METAL EXPOSED
- PORCELAIN MARGIN
- METAL EXPOSURE OK



LABIAL CONTOUR

- RELATE LABIAL CONTOUR TO E/O
- TO CAST OF ORIGINAL
- TO CAST OF TEMPS
- NO BULGE AT MARGIN

- SPECIAL INSTRUCTIONS

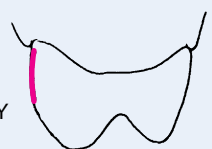


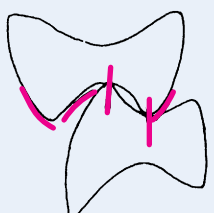
- SHADE INSTRUCTIONS

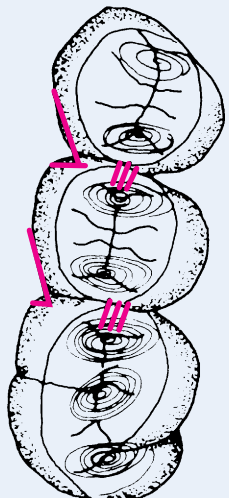
- CHECK CONTACTS ON SOLID MODEL

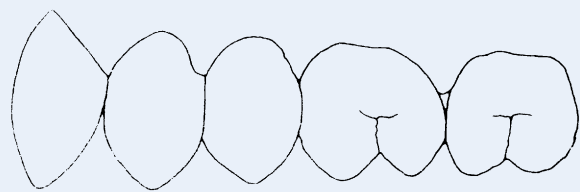
UPPER POSTERIOR

FOR _____
 DUE _____
 DR. _____

<p>PLANE of OCCLUSION</p> <ul style="list-style-type: none"> <input type="checkbox"/> ALIGN with BENCH <input type="checkbox"/> COPY CAST of TEMPS <input type="checkbox"/> COPY CAST of ORIGINALS <input type="checkbox"/> _____ 	<p>EMERGENCE CONTOUR</p> <ul style="list-style-type: none"> <input type="checkbox"/> USE TISSUE MODEL <input type="checkbox"/> NEARLY VERTICAL <input type="checkbox"/> STRAIGHT or SLIGHTLY CONVEX 
--	--

<p>BUCCAL CONTOUR</p> <ul style="list-style-type: none"> <input type="checkbox"/> OVERJET for CHEEK BITING PROTECTION <input type="checkbox"/> TAPER BUCCAL CONTOUR IN <input type="checkbox"/> CUSP TIP CONTACT (NO SURFACE to SURFACE) <p>LINGUAL CONTOUR</p> <ul style="list-style-type: none"> <input type="checkbox"/> TAPER LINGUAL INTO OCCLUSAL <input type="checkbox"/> PROTECTION for TONGUE BITING 	
--	--

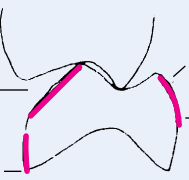
<p>OCCLUSAL CONTOUR</p> <ul style="list-style-type: none"> <input type="checkbox"/> CONTOURS TAPER IN TO OCCLUSAL TABLE <input type="checkbox"/> DEFINITE GROOVES <input type="checkbox"/> MARGINAL RIDGES ALL EVEN <input type="checkbox"/> BUCCAL SURFACES ALL ALIGNED <input type="checkbox"/> FOSSAE OPENED FOR CUSP TIP 	
<p><input type="checkbox"/> SPECIAL INSTRUCTIONS</p>	<p>CONTACTS</p> <ul style="list-style-type: none"> <input type="checkbox"/> CHECK on SOLID CAST <input type="checkbox"/> EACH CONTACT PROTECTS INTERDENTAL PAPILLA

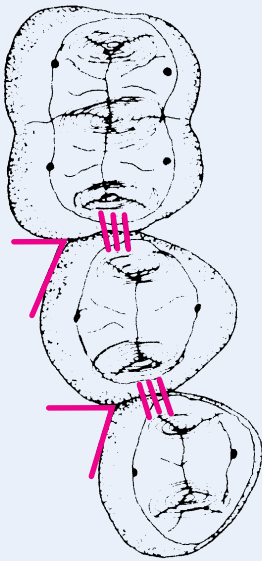
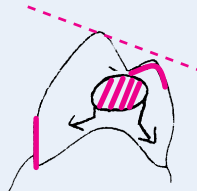
<p><input type="checkbox"/> SPECIAL INSTRUCTIONS</p>	<p><input type="checkbox"/> SHADE INSTRUCTIONS</p>
	
<ul style="list-style-type: none"> <input type="checkbox"/> INDIVIDUALIZED CUSPS <input type="checkbox"/> SHOW NO METAL in INTERPROXIMAL <input type="checkbox"/> SHOW NO METAL at MARGIN <input type="checkbox"/> METAL DISPLAY at MARGIN OK <input type="checkbox"/> CLOSE SPACES 	

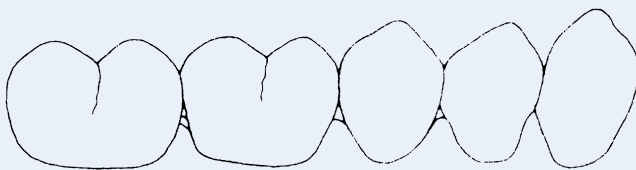
FOR _____
 DUE _____
 DR. _____

LOWER POSTERIOURS

PLANE of OCCLUSION <input type="checkbox"/> COPY CAST of TEMPS <input type="checkbox"/> ALIGN WITH BENCH <input type="checkbox"/> DON'T ALTER <input type="checkbox"/> USE FLAG <input type="checkbox"/> _____	CUSP TIP POSITION <input type="checkbox"/> AS MARKED ON UPPER CAST <input type="checkbox"/> ALIGN with CENTRAL GROOVE of UPPER <input type="checkbox"/> _____	FOSSAE CONTOUR <input type="checkbox"/> CR CONTACT ONLY <input type="checkbox"/> USE FOSSA GUIDE <input type="checkbox"/> _____
--	---	---

BUCCAL CONTOUR <input type="checkbox"/> TAPER IN FOR CHEEK BITING PROTECTION <input type="checkbox"/> HEIGHT OF CONTOUR AT JUNCTION of LOWER THIRD <input type="checkbox"/> STRAIGHT or SLIGHTLY CONCAVE EMERGENCE CONTOUR <input type="checkbox"/> VERTICAL EMERGENCE		LINGUAL CONTOUR <input type="checkbox"/> TONGUE BITING PROTECTION <input type="checkbox"/> TAPERED IN/ON LINGUAL <input type="checkbox"/> CORRECT LINGUAL HEIGHT of CONTOUR
---	---	---

OCCLUSAL CONTOUR <input type="checkbox"/> CONTOURS TAPER IN TO OCCLUSAL TABLE <input type="checkbox"/> DEFINITE GROOVES <input type="checkbox"/> MARGINAL RIDGES ALL EVEN <input type="checkbox"/> FOSSAE OPENED FOR CUSP TIP CONTACT ONLY <input type="checkbox"/> BUCCAL SURFACES ALIGNED and PARALLEL <input type="checkbox"/> MESIAL 1/3 ALIGNED FACING FORWARD		FIRST PREMOLAR <input type="checkbox"/> LINGUAL CUSP of FIRST PREMOLAR KEPT LOW 
		CONTACTS <input type="checkbox"/> EACH CONTACT PROTECTS INTERDENTAL PAPILLA <input type="checkbox"/> CHECK on SOLID CAST

<input type="checkbox"/> SPECIAL INSTRUCTIONS	<input type="checkbox"/> SHADE INSTRUCTIONS
	
<input type="checkbox"/> INDIVIDUALIZED CUSPS <input type="checkbox"/> SHOW NO METAL IN INTERPROXIMAL <input type="checkbox"/> SHOW NO METAL AT MARGIN <input type="checkbox"/> METAL DISPLAY AT MARGIN OK <input type="checkbox"/> CLOSE SPACES	

Appendix C

Manufacturer Index

Advanced Learning Technologies
200 South East Park Plaza Drive
Suite 100
Vancouver, WA 98684
360-892-1298; 800-505-4430

American Dental Technologies
(also owns KCP)
18860 West Ten Mile Road
Southfield, MI 48075

Annalan Lab
302 Florence Avenue
Union Beach, NJ 07735
800-222-0495; 908-264-8950

Bisco Dental Products
1100 West Irving Park Road
Schaumburg, IL 60193
847-534-6000

Brasseler USA
800 King George Boulevard
Savannah, GA 31419
800-841-4522

Buffalo Dental Mfg. Co. Inc.
99 Lafayette Drive
Syosset, NY 11791
516-496-7220

Centrix
770 River Road
Shelton, CT 06484
800-235-5862

Colgate Oral Pharmaceuticals
1 Colgate Way
Canton, MA 02021
617-821-2880

Columbia Scientific
8940-K Old Annapolis Road
Columbia, MD 21045
410-964-3110

Cosmedent Inc.
5419 N. Sheridan Way
Chicago, IL 60640
773-989-6844

Cygnus Imaging
8240 East Gelding Drive
Scottsdale, AZ 85260
800-626-2664; 602-905-1500

Den-Mat Corporation
2727 Skyway Drive
Santa Maria, CA 93455
800-443-6628

Dentsply Cavitron Ash
1301 Smile Way
York, PA 17404
717-767-8533

Dental Development and Mfg. Corp.
653 Washington Avenue
Brooklyn, NY 11238

Designs for Vision Inc.
760 Koehler Avenue
Ronkonkoma, NY 11779
516-585-3300

Dentsply/Caulk
38 West Clark Avenue
Milford, DE 19963
800-532-2855

DEXIS
ProVision Dental
203 Bryant Street, Suite 003
Palo Alto, CA 94302
888-88-DEXIS

DMD (Dental/Medical Diagnostics)
200 North West Lake Boulevard, #202
West Lake, CA 91362

Duro-Test
9 Law Drive
Fairfield, NJ 07004
800-289-3876; 973-808-1800

Dynamic Dental Systems
427 Green Street North West
Gainesville, GA 30501
800-770-8567; 714-650-8522

Ellman International, Inc.
1135 Railroad Avenue
Hewlett, NY 11557
800-835-5355

Espe America
1710 Romano Drive
Norristown, PA 19404
610-277-3800

GAC International Inc.
185 Oval Drive
Central Islip, NY 11722
516-582-5700

G C America
3737 West 127th Street
Chicago, IL 60658
800-323-3386; 708-597-0900

Global Surgical Corp.
3610 Tree Court Industrial Boulevard
St. Louis, MO 63122-6622
800-861-3585; 314-861-3388

Hu-Friedy Manufacturing Co. Inc.
3232 North Rockwell
Chicago, IL 60618

ILT/Britesmile
3828 South Main Street
Salt Lake City, UT 84115
(800) 288-0555

Ivoclar North America
175 Pine View Drive
Amherst, NY 14228
716-691-2296

Jelenko/Kulzer
99 Business Park Drive
Armonk, NY 10504
800-431-1785

Jeneric/Pentron Inc.
53 North Plains Industrial Road
Wallingford, CT 06492
203-265-7397

Johnson and Johnson
Dental Products Company
199 Grandview Road
Skillman, NJ 18558

Kerr Manufacturing Co.
(also owns belle de st. clair and
Demetron)
1717 West Collins Avenue
Orange, CA 92667
800-322-6666; 714-516-7400

Kreativ Inc.
1517 Industrial Way South West
Albany, OR 97321
770-643-2003

Lares Research, Inc.
(also owns Sunrise Technologies dental
division)
295 Lockheed Avenue
Chico, CA 95973
800-347-3298; 916-345-1767

462 Esthetics in Dentistry

Lester A. Dine Inc.
351 Hiatt Drive
Palm Beach Gardens, FL 33418
561-624-9100

The Lorvic Corp.
8810 Frost Avenue
St. Louis, MO 63134

Luxar Corporation
19204 North Creek Parkway
Bothell, WA 98011-8205
800-548-1482; 206-483-4142

Masel
2701 Bartram Road
Bristol, PA 19007
215-785-1600

Milestone Scientific
151 South Pfingsten Road
Deerfield, IL 60015
800-862-1125; 847-272-3207

E.C. Moore Co.
13325 Leonard
Dearborn, MI 48126

The J. Bird Moyer Co. Inc.
21st and Clearfield
Philadelphia, PA 19132

Moyco Union Broach
589 Davies Drive
York, PA 17402
717-840-9335

New Image Industries
2283 Cosmos Court
Carlsbad, CA 92009
800-534-7349; 619-930-9900

Ney Dental Intl.
1280 Blue Hills Avenue
Bloomfield, CT 06002

Nobel Biocare USA, Inc.
777 Oakmont Lane, Suite 100
Westmont, IL 60559
800-891-9191; 708-654-9100

Oral B
600 Clipper Drive
Belmont, CA 94002
415-592-4059

Paasche Airbrush Co.
1909 West Diversey Parkway
Chicago, IL 60614

Parkell Today
155 Schmitt Boulevard
Farmingdale, NY 11735
516-249-1134

Pascal Co. Inc.
2929 North East Northrup Way
Bellvue, WA 98004

Polaroid Corporation
575 Technology Square
Cambridge, MA 02139
800-662-8337

Premier Dental Products
3600 Horizon Drive
King of Prussia, PA 19406
610-239-6000

Premier Laser Systems
3 Morgan
Irvine, CA 92718
714-859-0656

Proctor and Gamble
10200 Alliance Road
Cincinnati, OH 45242

Pro-Dentec
633 Lawrence Street
Batesville, AR 72503
501-698-2300

Pulpdent Corp. of America
80 Oakland Street
Watertown, MA 02272
617-926-6666

Quintessence Publishing
551 North Kimberly Drive
Carol Stream, IL 60188-1881
800-621-0387; 630-582-3223

Reliance Dental Mfg. Co.
5805 West 117th Place
Worth, IL 60482

Rocky Mountain Orthodontics
650 West Colfax Avenue
Denver, CO 80204
303-592-8202

Sci-Can, Inc.
2002 Smallman Street
Pittsburgh, PA 15222
800-572-1211; 412-281-6780

Sci-Tech Dental Corp.
562 1st Avenue South, Suite 700
Seattle, WA 98104
800-524-6984; 206-382-0880

Septodont
245 C. Quigley Boulevard
New Castle, DE 19720
800-872-8305; 302-328-1102

Shofu Dental Corp.
4025 Bohannon Drive
Menlo Park, CA 94025
415-324-0085

Sirona Dental Systems
11727 Fruehauf Drive
Charlotte, NC 28273
704-523-3324; 704-519-0370

Tanaka Dental
5135 Golf Road
Skokie, IL 60077

George Taub Products
277 New York
Jersey City, NJ 07307

Telemetrics, Inc.
6 Leighton Place
Mahwah, NJ 07430
201-848-9818

3M
Dental Products Division
3M Center Bldg. 275-2E-03
St. Paul, MN 55144-1000
612-733-2968

TP Orthodontics Inc.
100 Center Plaza
LaPorte IN 46350
219-785-2591

Trophy USA Inc.
2252 Northwest Parkway, Suite F
Marietta, GA 30067
800-642-1246; 770-271-8084

Ultradent
505 West 10200 South
South Jordan, UT 84095
800-552-5512; 801-572-4200

Van-R Dental Products
1000 Hueneme Road
Oxnard, CA 93033

Vident
3150 East Birch Street
Brea, CA 92621
714-961-6224

Warner-Lambert Co.
201 Tabor Road
Morris Plains, NJ 07950

Welch Allyn Dental Products
4619 Jordan Road
Skaneateles Falls, NY 13153
800-867-3832; 315-685-9514

S.S. White Dental Products
1145 Towbin Avenue
Lakewood, NJ 08701

Zila
5227 North 7th Street
Phoenix, AZ 85014-2817
800-922-7887; 602-266-6700

Appendix D

Product Index

- Air-abrasive technology — American Dental Technologies, Kreativ Inc.
- AccuFilm II — Parkell Today
- Acrylic liner — Annalan Labs
- Air-abrasive unit/plasma arc curing light — American Dental Technologies
- Air-abrasive unit/plasma arc curing light — Lares Research
- All-Bond 2 — Bisco Dental Products
- Apollo — Dental/Medical Diagnostics Systems
- Artglass — Jelenko/Kulzer
- Artificial dam material — Den-Mat
- Artificial dam material — Ultradent
- Artus strip — Den-Mat
- BelleGlass — belle de st. clair, Kerr
- Bleaching tool — Moyco Union Broach
- Busch chipless porcelain stones — Pfingst and Co.
- Cavi-jet — Dentsply Preventative Care
- Celay — Mikrona AG
- Celay — Vident
- Ceramatique Kit — Premier Dental Products
- CEREC — Siemens
- Charisma — Jelenko/Kulzer
- Choice dual cure resin cement — Bisco
- Colored brush handles — Centrix
- Compo-Strip — Premier Dental Products
- Creation Porcelain — Jensen
- Crown remover, CR 10-EUO1851 — Hu-Friedy
- Cure Rite — Efos/Dentsply/Caulk
- Curestar Curing System — Lares Research
- Curing Radiometer — Demetron/Kerr
- Curinglight 2000 — Kreativ Inc.
- Dedeco chipless porcelain stones — Dedeco International Ltd.
- Dentacolor — Jelenko/Kulzer
- Dental dial caliper — Masel Orthodontics
- Dentalaser — Premier Laser Systems
- Dentin Bloc — Colgate Oral Pharmaceuticals
- DET6, DET3 — Brasseler
- Dicor MGC — Dentsply/Caulk
- ET Burs — Brasseler
- ET OS1 — Brasseler
- F6C diamond bur — Premier Dental Products
- GCI Mini 3 — Hu-Friedy
- Gluma Desensitizer — Jelenko/Kulzer
- Goldstein 3 — Hu-Friedy
- Hi-Ceram — Vita Zahnfabrik
- Illuminator — Moyco Union Broach
- In-Ceram — Vita Zahnfabrik
- IPS-Empress — Ivoclar
- Isosit-N — Ivoclar
- Air-abrasive technology, KCP 1000, 2000 — American Dental Technologies
- Komet — Brasseler
- Listerine — Warner-Lambert
- LVS Porcelain Laminate Preparation Kit — Brasseler
- Mach 5 — Kreativ, Inc.
- Micro Prep — Lares Research
- Microscope — Global Surgical
- Nova-Creation — Jensen Industries
- Novatech 12 — Hu-Friedy
- Novatech PINTii — Hu-Friedy
- Omega Ceramic — Vita
- Optilux 500 — Demetron/Kerr
- Oraseal — Ultradent
- Pain-Free — Parkell Today
- Panavia — Kuraray
- Peridex — Procter and Gamble
- Peroxyborate monohydrate — Amosan
- Polaroid — Polaroid Corporation
- Porcelain Laminate Polishing Kit — Shofu Dental Corp.
- Porcelain Try-In Paste — Den-Mat
- Precision Curing Unit — ILT Britesmile
- Prema — Premier Dental Products
- Prevident 1.1% Sodium Fluoride — Colgate Oral Pharmaceuticals
- Procera AllCeram System — Nobel Biocare USA, Inc.
- ProLight cordless curing light — Dentsply/Caulk
- Prophy-Jet — Dentsply, Inc.
- Regisil PB — Dentsply/Caulk
- Renaissance — Ivoclar
- Reprosil — Dentsply/Caulk
- Reprox diamond strip — Premier Dental Products
- Rotadent — Pro-Dentec
- Sandpaper disc — 3M
- Sandpaper disc — Cosmedent
- Sculpture/FibreKor — Jeneric/Pentron
- Shofu Cosmetic Contouring Kit — Shofu Dental Corp.
- Shofu chipless porcelain stones — Shofu Dental, Lab Division
- Soflex — 3M
- Soft-Tray — Ultradent Products, Inc.
- Stainless steel matrix — Parkell Today
- Sunrise ceramic system — Tanaka Dental Products
- SureCure — Ho Dental
- Targis/Vectris — Ivoclar
- T-Scan — Tek-Scan
- Telescope — Designs for Vision
- Thickness gauge — belle de st. clair, Kerr
- Toflemire microthin band — Lorvic Corp.
- Victor voice-activated charting — Pro-Dentec
- Vident Systems — Efos (Engineered Fibre Optic Systems) Inc.
- Vintage Opal Porcelain — Shofu Dental Corp.
- Visio-Gem — Espe America
- Vitadur-N — Vita
- Vita-Mark II — Vita/Vivadent USA
- Whisperjet — American Dental Technology

Index

Numerals in italics indicate figures.

- Acid etching
 - causing pulpal irritation, 66
 - and Class III restorations, 277, 281
 - in composite resin bonding, 282, 300, 301, 303
 - in porcelain laminate restorations, 365–66
 - development of, 277, 339
 - to enhance the physical properties of porcelain crowns, 404
- Acrylic resin
 - in crowns, 398, 400–401, 401
 - veneers, 340, 400
- Adenoids, 107
- Advertising dental services, 51–53
- Age characteristics, incorporating in restoration work, 161–63
- Aging
 - and discoloration of teeth, 250–51
 - disorders related to, 105, 107–8, 117–18
 - effects on teeth, 161–63, 164
 - restorative techniques for the effects of, 161–63
- Air-abrasive technology
 - combined with plasma arc curing lights, 315
 - contraindicated for porcelain restorations, 369, 444
 - for pit and fissure caries, 323, 324–26, 325
 - in composite resin bonding, 286–87, 290–91
- Alcohol markers, 163, 230–31
- Allergies, 71, 120, 250
- Alumina reinforced porcelain crowns, 407–9, 408
- Alveolar ridge, 113
- Amalgam removal, prophylactic, 67–68
- Amelogenesis imperfecta, 250
- Ammonium bifluoride, 382
- Anorexia nervosa, 342, 371
- Anterior teeth
 - artificial
 - techniques to create a narrower appearance, 148–49
 - techniques to create a wider appearance, 152–53
 - contouring, 232–33
 - crowded, as a contraindication for cosmetic contouring, 228
 - occlusion, improved with composite resin bonding, 287
 - restorations, large, as a contraindication for cosmetic contouring, 227–28
- Arch
 - alignment, 24
 - collapse, preventing, 395
 - correcting a protruded, 85
 - form, 102, 109, 112–13, 194–95
 - irregularity, 431, 432
 - irregularity, treatment for, 160–61, 161
- Argon laser light, used for polymerization of porcelain restorations, 367
- Artglass, for crown restorations, 402
- Artificial teeth
 - arrangement of
 - for too-short teeth, 155
 - to improve the appearance of crooked teeth, 159–60
 - when space available is narrower than ideal replacement tooth, 153
 - when space available is wider than ideal replacement tooth, 150
 - contouring
 - to create appropriate restorations for older patients, 164
 - to express a patient's personality, 167–70, 169
 - to lengthen the appearance of a short tooth, 155
 - to narrow the appearance of a wide tooth, 147–49, 148–49
 - to shorten the appearance of a long tooth, 155–56, 157
 - to widen the appearance of a narrow tooth, 150–53, 153–54
 - staining
 - for older patients, 161, 163–64, 166
 - to express a patient's personality, 167–70
 - to lengthen the appearance of a short tooth, 155
 - to mask gingival recession, 158–59, 159
 - to narrow the appearance of a wide tooth, 149–50, 150
 - to shorten the appearance of a long tooth, 156, 158
 - to widen the appearance of a narrow tooth, 153
- Asthma, 101, 107
- BelleGlass, for crown restorations, 402
- Bilirubin, 245, 250
- Biopsy, excisional, 107
- BIS-GMA resin, 289
- Bite, extreme anterior open, 107, 108
- Black light
 - effect on color hue, 210
 - used in assessing tooth color, 142
- Bleaching
 - as an alternative to crowning, 66
 - children's teeth, 254–55
 - combined with bonding, 251, 253–54
 - combined with crowning, 251, 253
 - combined with orthodontics, 253
 - combined with periodontics, 253
 - combined with veneering, 251
 - contraindications for, 251
 - for elderly patients, 255
 - isolating teeth for, 256, 256–58
 - history of, 245–46
 - home treatments, 246, 247, 251, 255
 - maintaining results of, 268
 - matrix-monitored, 264–67
 - nightguard, 264
 - of non-vital teeth, 268–73
 - of pulpless teeth, 268–70
 - over-the-counter systems, 267–68
 - power/matrix, of vital teeth, 265
 - precautions, 78, 81
 - risks associated with, 74–75
 - techniques of, 256–73, 256–64, 266–67
 - treatment sequence, 251–52
 - “walking bleach” technique, 269, 272, 272
- Body
 - posture, 102, 102–3
 - proportions, 204, 204
- Bonding, *see* Composite resin bonding
- Bridgework
 - In-Ceram bridge, 382, 387
 - metal-free alternative to porcelain fused to metal, 403
 - restorations, 129
- Brushing techniques, for maintaining composite resin restorations, 320
- Bruxism, 225–26, 226, 287, 342, 343, 353
- Bulimia, 342, 371
- Burning mouth syndrome (BMS), 118
- CAD/CAM technology
 - and CEREC system, 377, 382–86

- for communicating with lab technicians about color, 219
 - for constructing posterior inlays, 288–89
 - for creating three-dimensional diagnostic models, 35
 - in crown restoration, 397–98, 411
 - in etched porcelain restoration, 377, 387
 - Calcium hydroxide therapy, 75
 - Cameras
 - intraoral
 - for communicating with lab technicians about requirements, 147
 - for determining wear patterns, 320
 - for locating caries, 322
 - for matching color, 216
 - in patient examination, 24, 26–29, 28–30
 - extraoral
 - 35mm, 89–90
 - choosing film for, 97–98
 - features of, 91–95
 - Polaroid, 88, 147
 - video action, 25, 28, 99–100
 - video disk, 99
 - see also* Photography
 - Carbamide peroxide, 266, 268
 - Caries
 - discoloration caused by, 249
 - pit and fissure, 322
 - relationship to tooth contour and shape, 434
 - susceptibility to, as a contraindication for cosmetic contouring, 227
 - Cast glass
 - as a laminating material, 381–82
 - in crown restorations, 404, 414–15, 415, 417, 419, 421, 430
 - Catenary curve, of dental arch, 112–13, 112–14
 - Celay System, 380, 381, 386–87, 397
 - Centers for Disease Control (CDC), 66
 - Cephalometrics, 199
 - Ceramic polymers, in crown restorations, 402–3
 - Ceramic reconstruction system, *see* CEREC
 - Ceramometal crown restorations
 - adjunctive procedures, 421
 - advantages of, 420–21
 - choice of margin, 425–28
 - color of, 342
 - classification system, 419–20
 - esthetic considerations, 421, 425, 426
 - for patients with a low lipline, 431
 - history of, 419
 - inclination of teeth and, 432
 - indications and contraindications, 420
 - opacity, 430
 - preparation for, 424–25
 - technical considerations, 420, 422–24, 422–25
 - Cerebral palsy, 250
 - CEREC (ceramic reconstruction) system, 377, 379, 382–86
 - Ceromers (ceramic optimized polymers), 403
 - “Change Your Smile,” 18–20, 53–54, 320–21, 425
 - Chlorhexidine, 371
 - Chromoscope, 416
 - Clark color guide, 213–14
 - Cleft palate, 107, 250
 - Clinical examination, *see* Patient evaluation
 - Color
 - dimensions of, 207–13
 - gingival, 436
 - modifying, 217–18
 - Pincus principles relating to, 124, 125, 127
 - recording, 440–41
 - selecting and specifying, 213–17, 218–19; *see also* Shade selection for restorations
 - see also* Bleaching, Discoloration, Staining
 - Communicating with patients, *see* Dentist-patient relationship
 - Composite resin bonding
 - acid etch technique and, 300, 303, 339
 - categories of, 279
 - combined with crowns or laminates, 286
 - compared to crowning, 443
 - compared to porcelain laminating, 278, 443
 - crown restoration, 401–2
 - current use of, 277–79
 - “cushion effect” of overlay technique, 297
 - dentin preparation, 303, 305–6
 - direct inlays, 287–89
 - finishing techniques, 284–86, 295, 312, 313–19, 317–18
 - for anterior guidance, 287
 - for Class I restorations, 279
 - for Class II restorations, 279–80, 289–90, 308
 - for Class III restorations, 281, 281–86, 289, 292
 - for Class IV restorations, 281
 - for Class V restorations, 281, 286, 318
 - for crown restoration, 401–2
 - for inlays, 287–89
 - for labial veneers, 286
 - for patients with a high lipline, 431
 - for posterior rehabilitation, 287
 - for repairing existing restorations, 286–87
 - hybrids, 290
 - indirect inlays, 287–89, 372
 - interdental tissue addition, 176, 178–79, 179
 - labial veneer, 286
 - legal considerations, 66
 - life expectancy of, 68, 278, 278, 321–22
 - macrofilled, 289–80
 - maintaining, 319–20
 - marginal leakage, eliminating, 290, 305
 - materials, 289–90
 - microfilled, 289, 308
 - overlay technique, 296–300, 297–301, 307
 - polymerization, 282–83, 287, 292, 293, 307–13, 311
 - preparing teeth for, 290, 292, 293, 296
 - rate of wear, 289
 - repairing, 325
 - restorative uses, 279–89
 - “sandwich technique,” 305, 308
 - shade selection, 291, 292
 - shrinkage, 310, 312
 - staining of, 322
 - temporary bonding of laminates, 355–56, 355
 - texturing, 317
 - to mask loss of interdental tissue, 174
 - “total etch” technique, 306–7
 - types of, 279
 - veneers, 339
- Computer imaging
 - and patient evaluation, 25, 30–34, 32–34, 42
 - for collecting data over a lifetime, 104
 - for planning contouring, 229, 231
 - for predicting outcomes of bleaching, 251
 - for predicting outcomes of crown restoration, 396–97, 431–32
 - for predicting outcomes of staining, 143–44
 - to achieve correct occlusion, 437
 - to proportion teeth, 436
- Computer-generated restorations, *see* CAD/CAM technology
- Concept®, composite resin, 280
- Consent to treatment, 35, 66, 69–71, 69–71, 73, 73–77, 77
- Contouring, cosmetic
 - benefits of, 223–24
 - compared to orthodontics, 227
 - contraindications for, 226–28
 - for improving arch appearance, 129
 - history of, 223
 - indications for, 224–25
 - planning for, 229–30
 - principles of, 134–36, 228–29, 231–33
 - scheduling of, 232

- techniques of, 230–43
 to alter tooth form, 238–39, 239,
 to correct overlapping incisors,
 239–41, 240, 242–43, 242–43
 to create the appearance of straighter
 teeth, 233–38, 233–38
 to reduce large teeth, 241–42, 241–42
- Crowns
 all-porcelain, 403–7, 404–5, 410
 alumina reinforced porcelain, 407–9,
 408
 arch irregularity and, 432
 ceramic polymers, 402–3
 ceramometal, 419–28
 choice of materials, 398–99, 428–30
 compared to bonding and laminating,
 443
 compared to conservative treatment,
 24
 compared to contouring, 224
 compared to laminating, 277
 composite resin veneered metal, 401
 composite resins, 290, 399–402
 contouring as a substitute for, 224
 Dicor, 414–15
 durability of, 129
 endodontic therapy and, 35
 fractures in porcelain, 68
 full, 174, 395–96
 gingival embrasure and, 433–34
 gold, 5, 399, 399–401
 Hi-Ceram, 409, 410
 In-Ceram, 410–11
 incisal embrasure and, 433
 inclination of teeth and, 432
 intercuspal distance and, 432–33
 IPS-Empress, 415–18
 legal considerations, 66
 lipline and, 430–31
 longevity of, 68
 maintenance by patient, 443–44
 metal collarless, 427
 opaquing, 430
 open-faced, 6
 overcontouring, 434
 planning, 396
 porcelain, *see* Porcelain crown
 restorations
 preparation for, 411
 problems with, 67, 78
 Procera AllCeram, 411–12
 Renaissance, 412
 replacement of, 74–75
 shade selection for, 416, 437
 size of, 130
 spacing of, 130, 130
 Sunrise ceramic system, 412, 414
 texture of, 438
 tooth arrangement and, 437
 tooth contour and shape, 434–35
 tooth size and, 436–37
- Curing methods, 307, *see also*
 Polymerization
- Curettage, 436
- Cuspids
 distorted, corrected with contouring,
 239, 239
 replacement techniques
 to create a narrower appearance,
 148, 148
 to create a wider appearance, 152,
 153
 worn, 238–39, 238–39
- Cystic fibrosis, 246
- Dam, rubber, *see* Rubber dam
- Dental esthetics
 biology of, 101–121
 color principles, 207–20
 geometrical principles of proportion,
 187–206
 history of, 3–4
 legal considerations of, 35, 44–45,
 47–48, 55, 65–82, 83, 99, 104,
 118
 motion picture industry's use of,
 131–32
 Pincus principles, 123–32
 psychological/emotional implications
 of, 7–11, 19, 104
 social context of, 4–6
- Dental history of patient, 38, *see also*
 Medical history
- Dentin
 bonding agents and sealers, used as
 desensitizers for contouring, 232
 color of, 245
 preparation for composite resin
 bonding, 303, 305, 307
- Dentist-patient relationship, 10–11,
 17–22, 28, 31–32, 45, 99
see also Hygienist, role of; Marketing;
 Patient evaluation; Treatment
 coordinator, role of
- Desensitizers, use in contouring, 232
- Developmental abnormalities, 224
- Diagnosis, *see* Patient evaluation
- Diagnostic models, *see* Models
- Diastemas
 and self-image, 5
 arrangement of artificial teeth, 152, 169
 closing, 342
 development of in adulthood, 107
 incisal, 148
- Dicor
 as alternative to porcelain
 inlays/onlays, 381–82
 crowns, 414–15, 418
- Discoloration of teeth
 as evidence of patient's level of oral
 care, 21
 caused by dental treatments, 241, 249
 caused by disease, 250
 cause of social and psychological
 difficulties, 245
 due to aging, 250–51
 fillings, discolored, 4
 fluorosis staining, 245, 248–49, 259,
 261, 342
 food and chemical stains, 107,
 245–46, 249
 intrinsic, 246
 minocycline staining, 248, 249, 261
 of non-vital teeth, 430
 pit and fissure stains, 322
 removal with air-abrasive technology,
 323, 324, 325
 removal with contouring, 224–25, 227
 tetracycline staining
 corrected by bleaching, 66,
 247–49, 251, 256, 259, 261,
 265–66
 corrected by composite resin
 bonding, 7, 304
 corrected with porcelain veneers,
 342, 347, 349, 360
 degrees of, 247–48
 susceptibility to, 246
 tobacco stains, 245–46, 250, 320
see also Color, Stains
- Disinfection, impression, 66
 “Divine Proportion,” 187–206
 Dry mouth syndrome, 102, 255
 Dyskinesia, 118
- Educational materials, 18
- Emphysema, 101, 120
- Empress, *see* IPS-Empress inlays/onlays
- Enamel
 hypoplasia, *see* Endemic enamel
 fluorosis
 loss of, as a contraindication for
 bleaching, 251
 reduction method, to prepare teeth for
 laminating, 350–54
 thin, as a contraindication for
 cosmetic contouring, 226–27
- Endemic enamel fluorosis, 248
- Endodontic treatment, 35, 41
- Erythroblastosis fetalis, 250
- Esthetics, *see* Dental esthetics
- Evaluation, patient, *see* Patient evaluation
- Face
 analysis of, 24–25
 height and contours, 113–15
 ideal proportions of, 196–203, 196–203
 muscles of, 104–5, 111, 195
 myofacial pain, 287
 normal proportions of, 187–89
 shape, influencing with esthetic
 dentistry, 132, 161
 tension, 104

- Facial tics, 104
 Fees, setting, 38, 43–48
 Fibonacci series, applied to esthetic dentistry, 191, 205
 Fluoride, 245
 Fluorosis staining, 248–49, 259, 261, 342

 Gender differences, 228, 435, *see also* Sex characteristics
 Gingival
 color, matching, 436
 embrasure, esthetic considerations, 433–34, 433
 hemorrhage, 291
 recession, masking the appearance of, 158–59, 159
 sulcus, depth of, and choice of crown material, 429
 Glass, *see* Artglass, BelleGlass, Cast glass
 Gold
 and discoloration of teeth, 249
 crowns, 5, 399, 399–401, 428–29, 429
 margins, for ceramometal restorations, 425
 restorations in opposing teeth, 373
 Golden proportions
 as a principle for contouring, 228
 explained, 187, 189–205, 189–209
 measuring, 190, 196–99
 Growth, and facial proportions, 187–89
 Guarantee, *see* Warranty

 Hand, proportions of, 204
 Hayashi Shade Guide, 211, 213–14
 Head
 flexion, 102
 posture of, 108
 Hemisected teeth, 435, 436
 Hi-Ceram crowns, 409, 410–11
 Hip alignment, 103
 “Hollywood facings,” *see* Porcelain, laminate/veneer
 Honesty of dentists, questioned, 52
 Hormonal disorders, 107
 Hydrochloric acid, use in microabrasion, 261
 Hydrocolloid, use in taking impressions of teeth, 355
 Hydrogen peroxide, for bleaching teeth, 245, 266
 Hygienist, role of, 22–23
 Hypocalcification, 227
 Hypothyroidism, 129

 Illuminator, used in bleaching, 259, 259
 Illusion, principles of, 133–37, 134–35
 Impression disinfection, requirements for, 66
 In-Ceram
 bridge, 382, 386
 crown, 386–87, 397, 410–11

 Incisal embrasure, esthetic considerations, 433, 433
 Incisors
 agenesis of lateral, 342
 beveling and shorting, 299
 crowning one to match the other, 430, 438
 excessive uniformity of maxillary, 225–26, 225
 overlapping, 239–43, 240, 242–43
 replacement techniques to create a narrower appearance, 147–48, 148
 replacement techniques to create a wider appearance, 152, 152–53
 replacing missing, 174–78, 176–78
 restorations, 290
 wear effects in older patients, 163–65, 164–65

 Inlays
 direct composite resin, 287–88, 372
 etched porcelain, 372–74, 376, 380–81
 indirect composite resin, 288–89, 372
 Insurance
 patient’s, 19, 27, 38, 76
 professional liability, 65
 Intercanine width, overexpanded lower, 195
 Interdental addition
 composite resin, 174, 178–79, 179
 fixed porcelain, 174–78, 175–78
 Interdental spaces, closing with composite resin bonding, 279
 Interincisal distance, esthetic considerations, 432–33
 Intraoral camera, *see* Camera, intraoral
 Intraoral markers, *see* Alcohol markers
 Intraoral volume, constant, 114–16
 Ion-strengthening, 407
 IPS-Empress
 crowns, 411, 415–18
 inlays/onlays, 381–82
 Isolating teeth
 for bleaching, 251, 254, 256, 256–58
 for composite resin bonding, 290
 for inserting porcelain veneers, 363
 for posterior porcelain restorations, 377

 Jadeite inlays, 3, 4
 Jaundice, 250
 Jaw
 position, 109
 problems, 102, 107–8

 Labial veneer, 286
 Laboratory technician, communicating with, 143–44, 147, 216–18, 442
 Laminating, *see* Porcelain, laminate/veneer
 Lasers
 used in bleaching, 259, 274
 used in composite resin bonding, 325

 Legal considerations of esthetic dentistry, 35, 44–45, 47–48, 55, 65–82, 83, 99, 104, 118
 Lesions, Class V, 251
 Liability, *see* Legal considerations
 Light
 and shade selection for crown restorations, 438–40, 439
 effect on color, 210, 218
 in polymerization of composite resin, 309–10, 315–16, 365
 reflected by teeth, 124–26, 131, 133, 142, 228
 see also Color, Polymerization
 Lip retractors, *see* Retractors, lip
 Lips
 corrective surgery for, 105–6, 106
 shape and position of, 109–12, 110–11, 116, 116
 thrusting of, 119
 Lipline, esthetic considerations of, 430–31, 433, 436
 Lymphoid growth, 120

 Magnifying lenses, used in clinical examination, 24
 Malpractice, *see* Legal considerations
 Mandible
 protrusion of, 102
 structure of, 102
 Marketing, 51–63
 Maxilla, variations in size, 119–20
 Medical history of patient, 35–38, 36–37, 71
 Mercury, allergy to, 67
 Metabolic disorders, 107
 Metals, used in ceramometal restorations, 419–20
 Microabrasion, to remove discoloration, 261
 Microcracks
 creating, 168
 creating effect of in artificial teeth, 143, 144, 150
 hidden, 24
 revealed by intraoral camera, 27
 revealed with transillumination, 26, 28
 susceptibility to discoloration affected by, 245
 Micrognathia, 107
 Migration of teeth with age, 163
 Minocycline staining, 248, 249, 261
 Models
 creating, 126–27
 use of diagnostic, 35, 41, 229–30, 230
 Mongolism, 107
 Morphogenesis, disorders of, 107
 Mouth breathing, 120
 Mouthguard, to protect composite resin restoration, 320, 321

- Mouthrinses
 effect on composite resins, 320
 effect on porcelain veneers, 371
- Munsell Color Order System, 208–11, 210, 213–14
- Muriatic acid, 261
- Muscles, facial, 104–5, 111, 195
- National Institute of Dental Research, 119
- Neck position, 102
- Negligence, *see* Legal considerations
- Occlusion
 analysis of by T-Scan, 29–30
 changes in, 109, 111, 117
 choice of crown material affected by, 429
 contouring to correct problems of, 225, 227–29
 correct, 437
 porcelain laminating to correct problems of, 342, 343
 problems with, 227, 344
 therapy for, 287
- Occupational Safety and Health Administration (OSHA), 47, 56, 66, 81
- Office, appearance of dentist's, 51–52, 54–57
- Ohaguro (decorative tooth staining), 3–4
- Opalescence, of ceramometal restorations, 422
- Oral surgery, 41
- Orthodontics
 adult, 128–29, 131
 contouring as an alternative to, 225, 227
 improperly performed, 107
 in conjunction with esthetic treatment, 40
- Orthognathic surgery, 107
- Overbite, 109, 118
- Overcontouring, problems caused by, 434, 436
- Overjet, 102, 109, 119
- Pain, myofacial, 287
- Patient education, 54, 59–61
- Patient evaluation
 clinical examination, 23–26
 diagnostic analysis form, 26–27
 evaluation chart, 25, 26
 examination of movement and physiology, 119
 for appropriateness of contouring, 229–30
 initial observation, 21–22
 medical/dental history, 35–38
 patient records, 34–35, 68–72
 patient's personality, 17–19, 104
 patient's reasons for seeking treatment, 9–11
 periodontal charting, 24, 30
 problem patients, 42–45
 T-Scan, 29–30
 use of computer imaging for, 30–34
 use of diagnostic models, 34
 use of intraoral camera for, 26–28
 use of video for, 28
 X-rays, 28–29
see also Photography
- Patient records, 34–35, 68–72, *see also* Photography, before and after records
- Payment plans, 38, 45
- Periodontal
 charting, 24, 30
 disease, 429, 434
 surgery, 436
 treatment, 40–41
- Periodontium, injured, 225
- Personality types, 17–18
- Pharynx, venous congestion of, 120
- Photocuring, *see* Polymerization
- Photography
 before and after records, 54, 81, 83–88, 85–93, 290
 before bleaching, 255
 before staining, 147
 in patient evaluation, 25, 28, 30
 use in planning crown restorations, 396–97
 used to match color, 216
see also Camera, Patient evaluation
- Pincus, Charles, 123–32
- Plaque, 21, 24, 43, 102, 434
- Plaque-reducing rinses, 444
- Plastic surgery, 43
- Platinum foil technique for creating porcelain veneers, 357, 359
- Polymerization techniques
 used in bleaching, 259
 used in composite resin bonding, 282–83, 287, 292, 293, 307–13, 311
 used in porcelain restorations, 366–67
- Polysulfide, 355
- Porcelain
 chipped or fractured, repairing, 286–87
 compared to plastic/acrylic, 128–29
 crown restoration, 402, 404–5
 advantages and disadvantages of, 403
 alternatives to, 430
 alumina reinforced, 407–9, 408
 indications and contraindications for, 403–5
 pitfalls of, 418
 preparation for, 405–7, 406
 three-quarter crown, 407
 troubleshooting esthetics guide for, 410
- fabrication techniques, 217
 interdental tissue addition, fixed, 174–78, 175–78
- laminare/veneer
 advantages and disadvantages of, 340–42
 as alternative to full crowning, 66–67, 75
 bonding, 365
 building mouth personality with, 129
 compared to bonding and crowning, 443
 development of techniques, 339
 enamel etching, 365
 fabricating, 357, 359
 finishing, 356, 367–69, 368–70
 for discolored teeth, 430
 for high lipline, 431
 for lower anterior teeth, 352–54
 indications and contraindications, 342, 344
 insertion of, 362–67
 life expectancy of, 369
 maintenance, 369, 371
 onlay, 381, 383–85
 origins of, 339
 placement, 351, 365–66
 polymerization, 356, 362, 366–67
 reduction of teeth for, 346–54, 253
 repairing, 341
 resistance to staining, 341
 shade selection, 344–46, 351
 silanation, 363–65, 364
 soft tissue control and, 363
 strength of, 340
 susceptibility to pitting, 342
 taking impressions for, 349, 354–55
 temporaries, 355, 355–56
 try-in, 343, 360–62
 use in motion picture industry, 131, 339
- papilla, cantilevered, 176
- posterior restorations, etched
 advantages and disadvantages of, 371–72
 alternative materials and techniques, 381–87
 color matching, 374, 376
 fabrication of, 377–79
 finishing, 374, 376, 380–81
 impressions for, 373
 indications and contraindications for, 372–73
 insertion, 374
 laminate onlay, 381
 patient instructions for, 381
 polymerization, 376
 preparing teeth for, 373
 try-ins, 374, 376
 staining of, *see* Staining

- Porphyria, 250
- Posterior teeth
 artificial
 techniques to create a narrower appearance, 148–49
 techniques to create a wider appearance, 152–53
 composite resin bonding for, 280, 290
 crowns for, 410
 inlays, onlays, 280, 288
 porcelain restorations, *see* Porcelain, posterior restorations
- Privacy, 20
- Problem patients, 76, 104
- Procera AllCeram crowns, 411–12, 413
- Professional journals, 53
- Prognathism, 107
- Proportions, *see* Face; Body; Golden proportions
- Pseudopognathic occlusion, 103
- Pseudopognathism, 107
- Pulmonary disorders, 107, 120
- Pulp
 canals, long, 226
 extirpation, vital, 434
 large, as a contraindication for bleaching, 251
 necrosis, 269
 recessive, 130
 shape of, 436
- Pulpitis, 66
- Pulpless teeth, bleaching of, 268–69
- Radiography, *see* X-rays
- Radiovisiography (RVG), 28–30, 30, 66
- Receptionist, role of, 17, 54
- Referrals
 from other dentists, 20, 53
 to other dentists, 42–44, 76
 to specialists, 40–41
- Refractory die technique for creating porcelain veneers, 357, 360
- Release of claims form, 79
- Renaissance metal matrix and porcelain crown, 412, 430
- Resin inlay, indirect, *see* Concept®
- Resins, acrylic, *see* Acrylic resins
- Resins, composite, *see* Composite resin bonding
- Respiratory problems, 101–2
- Retractors, lip, 87, 89, 91, 98, 440
- Rhinoplasty, 85
- Root canal
 and bleaching techniques, 269–70
 discoloration caused by sealers, 250
 therapy for caries or thickened apices, 35
- Root resorption, 74–75, 129
- Rotation of teeth with age, 163
- Rubber dam
 in posterior porcelain restorations, 377
- patient aversion to, 267
 used in bleaching, 251, 254, 256, 256–58
 used in composite resin bonding, 290
 used in inserting porcelain veneers, 363
 “Sacred geometry,” 187
- Saliva
 acid content of, and life expectancy of crowns, 428
 and discoloration of teeth, 273
 diminution of due to respiratory disorders 102
- Scoliosis, 108
- Sculpture/FibreKor system, 402–3
- Self-evaluation by patient, 19–20
- Separation between teeth, insufficient, 160, 160
- Septum, deviated, 120
- Sex characteristics of teeth, 166–67, 167; *see also* Gender differences
- Shade selection for restorations
 difficulties with, 437–38
 for composite resin bonding, 279–80, 291–92
 for crowns, 416, 437
 for porcelain veneers, 344–46, 362
 lighting for, 438–40, 439, 442
 recording shades, 440–41
 shade guides, 213–15, 279, 346, 416, 437, 441–42
 tips for matching shades, 442
see also Color
- Shaping, *see* Contouring, cosmetic
- Shofu Cosmetic Contouring Kit, 233, 263
- Silane, 363, 363–64, 365
- Silicone oil, 273
- Skeletal proportions, 200
- Smile Analysis, 19–20, 38, 40
- Smoking, *see* Discoloration of teeth, tobacco stains
- Soft tissue management therapy, 24
- Specialist treatment, *see* Endodontic treatment, Oral surgery, Orthodontics, Periodontic treatment
- Spectatone color guide, 214
- Spectrophotometry, 219
- Speech
 affected by poor restoration work, 101
 correction of sibilance with dental work, 131
 retraining in, after dental restoration, 118
 sibilance, 108
- Staining, of restoration materials
 behavior of colors under black light, 141, 142
 color altered by firing, 143
 combined with glaze, 140, 143
 communicating with laboratory technician about, 143–44, 147
- guide for, 145–46
 incorporating into the body of the restoration, 138
 reasons for, 137
 surface staining of crowns, 416
 techniques for, 138–47, 138–46, 149–50, 441
 uses and misuses of, 440
see also Artificial teeth, Staining, Color, Shade selection
- Stains on teeth, *see* Discoloration of teeth
- Stannous fluoride
 as a desensitizer for contouring, 232
 gels, prescription, 418
- Sterilization, *see* Disinfection
- Subgingival margins, 67
- Sunrise ceramic system, 412
- Superoxol, for bleaching teeth, 269
- Swallowing, problems of, 119
- Targis/Vectris system, 403
- Tay-Sachs disease, 107
- Teeth
 assessing and recording color of, 437–41
 chipped, 224
 color of, 124, 125, 127
 contour and shape, 125–27, 434–36
 cosmetic reshaping of, *see* Contouring, cosmetic
 deciduous, 344
 differentiation between teeth, insufficient, 160, 160
 discoloration of, *see* Discoloration of teeth
 disruption of, 109
 extruded, 224
 fractured, 224, 300–303
 hemisected, 435
 hypersensitive, 226, 251
 inclination of, 113, 114–15, 432
 isolating for treatment, *see* Isolating teeth
 long, 436–37
 loss of, 107
 migration of, preventing, 395
 rotation of, 107
 separation between, insufficient, 160, 160
 short, 342, 437
 size of, 436
 surface defects of, 342
 texture of, 124, 126–27
see also Anterior teeth, Cuspids, Incisors, Posterior teeth
- Telescopes, 174
- Temporary restoration, importance of, 434
- Temporomandibular joint (TMJ), 35
- Tetracycline staining
 corrected by bleaching, 66, 245–48, 247–49, 251, 259, 261, 265–66

470 Esthetics in Dentistry

- corrected by composite resin bonding, 7, 304
- corrected with porcelain veneers, 342, 347, 349, 360
- diagnosing with ultraviolet light, 256
- Tissue, interdental, loss of, 170–79, 172–76
- Tongue
 - abnormal position of, 120
 - structure of, 104
 - thrusting, 119
- Tonsils, 107
- “Total etch” system, 305
- Training
 - of dentist, 52, 66
 - of staff, 58–59
- Transillumination, 25, 256
- Treatment coordinator, role of, 38, 44–45
- Treatment plan
 - final, 41–42
 - patient’s agreement to, 44–45
 - phases of, 44–45
 - preliminary, 38
 - preparing alternative treatment plans, 17, 21–22, 46
 - suggested planning form, 39
- Try-in, esthetic, 68, 436
- T-Scan occlusal analysis, 29–30
- Ultrasonic scalers, 444
- Ultraviolet light, for diagnosing tetracycline stains, 256
- Urethane dimethacrylate, 289
- Vacuform matrix/composite resin technique, 144, 147
- Veneers, *see* Composite resin bonding, Porcelain laminate/veneer
- Verkrupte Kopf syndrome (VKS), 118
- Video
 - used for educating patients, 54–56
 - used for matching color, 438
 - used for training staff, 59–61
- Vinyl polysiloxane method, for making impressions, 349, 355, 373
- Vita Mark II ceramic, 386
- Vital pulp extirpation, 434
- Voice-activated periodontal charting, 30, 31, 35
- “Walking” bleach, 269, 272, 272
- Warranty, 45, 47–48, 68
- Wax
 - applied directly to teeth to show effects of restoration, 144
 - study models, 35, 41–42, 41–42
- Wear, *see* Bruxism
- Wrinkles, facial, 43, 85, 99
- Xenon light, used for polymerization of porcelain restorations, 315, 367
- X-rays, 28–29, 35, 66, 129, 230, 256, 398
- Ytterbiumtrifluoride, 280