

---

# Female Urology

---

A Practical Clinical Guide

---

Edited by

**Howard B. Goldman, MD**

**Sandip P. Vasavada, MD**

---

 HUMANA PRESS

## FEMALE UROLOGY

# CURRENT CLINICAL UROLOGY

---

Eric A. Klein, MD, SERIES EDITOR

- Female Urology: A Practical Clinical Guide*, edited by **Howard Goldman and Sandip P. Vasavada**, 2007
- Urinary Stone Disease: The Practical Guide to Medical and Surgical Management*, edited by **Marshall L. Stoller and Maxwell V. Meng**, 2007
- Peyronie's Disease: A Guide to Clinical Management*, edited by **Laurence A. Levine**, 2006
- Male Sexual Function: A Guide to Clinical Management, Second Edition*, edited by **John J. Mulcahy**, 2006
- Advanced Endourology: The Complete Clinical Guide*, edited by **Stephen Y. Nakada and Margaret S. Pearle**, 2005
- Oral Pharmacotherapy of Male Sexual Dysfunction: A Guide to Clinical Management*, edited by **Gregory A. Broderick**, 2005
- Urological Emergencies: A Practical Guide*, edited by **Hunter Wessells and Jack W. McAninch**, 2005
- Management of Prostate Cancer, Second Edition*, edited by **Eric A. Klein**, 2004
- Essential Urology: A Guide to Clinical Practice*, edited by **Jeannette M. Potts**, 2004
- Management of Benign Prostatic Hypertrophy*, edited by **Kevin T. McVary**, 2004
- Pediatric Urology*, edited by **John P. Gearhart**, 2003
- Laparoscopic Urologic Oncology*, edited by **Jeffrey A. Cadeddu**, 2004
- Essential Urologic Laparoscopy: The Complete Clinical Guide*, edited by **Stephen Y. Nakada**, 2003
- Urologic Prostheses: The Complete Practical Guide to Devices, Their Implantation, and Patient Follow-Up*, edited by **Culley C. Carson, III**, 2002
- Male Sexual Function: A Guide to Clinical Management*, edited by **John J. Mulcahy**, 2001
- Prostate Cancer Screening*, edited by **Ian M. Thompson, Martin I. Resnick, and Eric A. Klein**, 2001
- Bladder Cancer: Current Diagnosis and Treatment*, edited by **Michael J. Droller**, 2001
- Office Urology: The Clinician's Guide*, edited by **Elroy D. Kursh and James C. Ulchaker**, 2001
- Voiding Dysfunction: Diagnosis and Treatment*, edited by **Rodney A. Appell**, 2000
- Management of Prostate Cancer*, edited by **Eric A. Klein**, 2000

# FEMALE UROLOGY

---

*A PRACTICAL CLINICAL GUIDE*

*Edited by*

**HOWARD B. GOLDMAN, MD**

*Section of Female Urology and Voiding Dysfunction*

*The Glickman Urological Institute*

*The Cleveland Clinic*

*and*

*Department of Urology and Reproductive Biology*

*CASE School of Medicine*

*Cleveland, Ohio*

**SANDIP P. VASAVADA, MD**

*Section of Female Urology and Voiding Dysfunction*

*The Glickman Urological Institute*

*The Cleveland Clinic*

*Cleveland, Ohio*



**HUMANA PRESS**  
TOTOWA, NEW JERSEY

© 2007 Humana Press Inc.  
999 Riverview Drive, Suite 208  
Totowa, New Jersey 07512

**humanapress.com**

For additional copies, pricing for bulk purchases, and/or information about other Humana titles, contact Humana at the above address or at any of the following numbers: Tel.: 973-256-1699; Fax: 973-256-8341, E-mail: [orders@humanapr.com](mailto:orders@humanapr.com); or visit our Website: <http://humanapress.com>

All rights reserved.

No part of this book may be reproduced, stored in a retrieval system, or transmitted in any form or by any means, electronic, mechanical, photocopying, microfilming, recording, or otherwise without written permission from the Publisher.

All articles, comments, opinions, conclusions, or recommendations are those of the author(s), and do not necessarily reflect the views of the publisher.

Due diligence has been taken by the publishers, editors, and authors of this book to assure the accuracy of the information published and to describe generally accepted practices. The contributors herein have carefully checked to ensure that the drug selections and dosages set forth in this text are accurate and in accord with the standards accepted at the time of publication. Notwithstanding, as new research, changes in government regulations, and knowledge from clinical experience relating to drug therapy and drug reactions constantly occurs, the reader is advised to check the product information provided by the manufacturer of each drug for any change in dosages or for additional warnings and contraindications. This is of utmost importance when the recommended drug herein is a new or infrequently used drug. It is the responsibility of the treating physician to determine dosages and treatment strategies for individual patients. Further it is the responsibility of the health care provider to ascertain the Food and Drug Administration status of each drug or device used in their clinical practice. The publisher, editors, and authors are not responsible for errors or omissions or for any consequences from the application of the information presented in this book and make no warranty, express or implied, with respect to the contents in this publication.

Production Editor: Amy Thau

Cover design by Karen Schulz.

This publication is printed on acid-free paper.   
ANSI Z39.48-1984 (American National Standards Institute) Permanence of Paper for Printed Library Materials.

**Photocopy Authorization Policy:**

Authorization to photocopy items for internal or personal use, or the internal or personal use of specific clients, is granted by Humana Press Inc., provided that the base fee of US \$30.00 per copy is paid directly to the Copyright Clearance Center at 222 Rosewood Drive, Danvers, MA 01923. For those organizations that have been granted a photocopy license from the CCC, a separate system of payment has been arranged and is acceptable to Humana Press Inc. The fee code for users of the Transactional Reporting Service is: [978-1-58829-701-3/07 \$30.00].

Printed in the United States of America. 10 9 8 7 6 5 4 3 2 1  
eISBN:978-1-59745-368-4

Library of Congress Cataloging-in-Publication Data

Female urology : a practical clinical guide / edited by Howard B. Goldman, Sandip P. Vasavada.

p. ; cm. — (Current clinical urology)

Includes bibliographical references and index.

ISBN 978-1-58829-701-3 (alk. paper)

1. Urogynecology. I. Goldman, Howard B. II. Vasavada, Sandip P. III. Series.

[DNLM: 1. Genital Diseases, Female—Case Reports. 2. Urogenital Diseases—Case Reports. 3. Pelvic Floor—physiopathology—Case Reports. 4. Urinary Incontinence—Case Reports. 5. Urologic Surgical Procedures—Case Reports. WJ 190 F32994 2007]

RG484.F464 2007

616.6—dc22

2006026761

# Dedication

---

*To my wife, Suri, and my children, Joshua, Ari, Michal, and Yonatan, for their support, patience, and encouragement, and to my parents for their years of advice and encouragement.*

—HBG

\* \* \*

*To my wife, Pauravi, and my children, Samir, Sarinna, and Alisha, and my parents for all your support, as you have all truly challenged and inspired me, and for that, I am eternally grateful.*

—SPV

# Preface

---

The specialty of female pelvic medicine and reconstructive surgery is ever changing. We have seen the evolution of procedures that have minimized the invasiveness of surgery while continuously decreasing morbidity. We are now in an era where we are using validated instruments instead of relying on physician only assessment and have incorporated measures including quality of life instruments to get to the core question, which is, “Have we really helped the patient with these interventions?”

To this end, we have developed *Female Urology: A Practical Clinical Guide* to incorporate some of the newer concepts in female pelvic medicine as they relate to anatomy, bladder physiology, and urodynamics testing. However, perhaps the most exciting part of this book is the case studies, in which noted experts from around the world comment on complex cases common to urological practice. Hopefully, this section will allow the reader to compare their own evaluation and treatment plans to that of the experts, and potentially improve their ability to manage these types of patients.

We want to thank our authors for the time, dedication, and effort necessary to help us produce such a multi-dimensional text and also thank you, the readers for your constant quest for knowledge to enhance the goal of improved patient care.

*Howard B. Goldman, MD*  
*Sandip P. Vasavada, MD*

# Contents

---

Dedication .....	v
Preface .....	vii
Contributors .....	xiii
List of Color Plates .....	xvii

## Part I. Evaluation

1. Anatomy of Pelvic Support .....	3
<i>Melissa Fischer, Priya Padmanabhan, and Nirit Rosenblum</i>	
2. Neurophysiological Control of the Lower Urinary Tract .....	19
<i>Toby C. Chai and Todd J. Lehrfeld</i>	
3. Office Evaluation of Urinary Incontinence .....	35
<i>Adonis Hijaz and Firouz Daneshgari</i>	
4. Urodynamic Evaluation of Female Stress Urinary Incontinence .....	41
<i>Kelly M. Maxwell and J. Quentin Clemens</i>	
5. Urodynamic Assessment of Overactive Bladder: <i>Neurogenic and Nonneurogenic</i> .....	51
<i>Gary E. Lemack</i>	

## Part II. Treatment

6. Conservative Therapy for Incontinence .....	63
<i>Diane K. Newman</i>	

### Part A. Stress Urinary Incontinence

7. Pharmacological Therapy for Stress Urinary Incontinence .....	83
<i>Harriette M. Scarpero</i>	
8. Urethral Injectables for Stress Urinary Incontinence .....	97
<i>R. Duane Cespedes</i>	
9. Midurethral Slings .....	111
<i>Gregory T. Bales and Paula A. Fedunok</i>	
10. Bladder Neck Slings for Stress Urinary Incontinence .....	131
<i>O. Lenaine Westney</i>	
11. Complications of Sling Surgery .....	159
<i>Suzette E. Sutherland</i>	

### Part B. Overactive Bladder

12. Pharmacological Therapy for Overactive Bladder .....	177
<i>H. Mallory Reeves, Eric S. Rovner, and Alan J. Wein</i>	
13. Intravesical Treatments for Overactive Bladder .....	201
<i>Craig B. Slotoroff, Dolores Shupp-Byrne, and Patrick J. Shenot</i>	
14. Urological Applications of Botulinum Toxin .....	213
<i>Courtenay K. Moore and Howard B. Goldman</i>	



15. Nonsacral Neuromodulation .....	221
<i>Richard C. Bennett, Andrew Bernstein, and Kenneth M. Peters</i>	
16. Sacral Neuromodulation for the Treatment of Overactive Bladder .....	237
<i>Anurag K. Das</i>	
17. Augmentation Cystoplasty .....	251
<i>Michael A. Aleman, Joseph B. Abdelmalak, and Raymond R. Rackley</i>	
18. Mixed Incontinence: <i>Defining Symptoms, Management, and Outcomes</i> .....	261
<i>Roger Dmochowski and Harriette M. Scarpero</i>	
<b>Part C. Prolapse</b>	
19. Evaluation and Management of Anterior Vaginal Wall Prolapse .....	267
<i>Sandip P. Vasavada and Matthew D. Barber</i>	
20. Treatment of Posterior Vaginal Wall Prolapse .....	281
<i>David A. Ginsberg</i>	
21. Diagnosis and Mangement of Apical Prolapse .....	297
<i>Daniel S. Elliott</i>	
<b>Part D. Reconstruction</b>	
22. Evaluation and Management of Vesicovaginal Fistulas .....	309
<i>Matthew P. Rutnam, Donna Y. Deng, and Larissa V. Rodriguez</i>	
23. Female Urethral Diverticula .....	327
<i>Erin Gibbons and Wendy W. Leng</i>	
<b>Part III. Case Studies</b>	
1. Recurrent Stress Urinary Incontinence .....	343
<i>Jerry Blaivas</i>	
2. Recurrent Urinary Tract Infections and Pelvic Organ Prolapse .....	345
<i>Jennifer Takacs and Philippe Zimmern</i>	
3. Mixed Incontinence .....	351
<i>Wachira Kochakarn and Gary E. Leach</i>	
4. Urinary Tract Infections and Pelvic Pain .....	357
<i>Suzette E. Sutherland</i>	
5. Multiple Sclerosis and Voiding Dysfunction .....	361
<i>E. James Wright</i>	
6. <i>De novo</i> Overactive Bladder Symptoms After a Sling .....	365
<i>Victor W. Nitti, Carl G. Klutke, and Travis L. Bullock</i>	
7. Recurrent Pelvic Organ Prolapse .....	371
<i>Christopher C. Roth and J. Christian Winters</i>	
8. Recalcitrant Urinary Frequency and Urgency .....	375
<i>Michael Chancellor and Gamal M. Ghoniem</i>	
9. Difficulty Voiding and Overactive Bladder Symptoms .....	379
<i>Michael J. Kennelly and Deborah Lightner</i>	
10. Post-Hysterectomy Incontinence .....	385
<i>Courtenay K. Moore</i>	
11. Severe Incontinence After Multiple Prior Procedures .....	387
<i>Roger Dmochowski</i>	

---

12. Urinary Frequency and Pelvic Pain .....	391
<i>E. Ann Gormley and Jeffery P. Weiss</i>	
13. Pelvic Organ Prolapse .....	397
<i>Shlomo Raz, Matthew P. Rutman, and Kathleen C. Kobashi</i>	
14. Recurrent Pelvic Organ Prolapse After Colpocleisis .....	405
<i>Raymond Rackley</i>	
15. Stress Incontinence and Straining to Void .....	407
<i>Steven Siegel</i>	
16. Male With Post-Prostatectomy Incontinence .....	411
<i>Craig V. Comiter and Fred E. Govier</i>	
17. Mixed Incontinence in Elderly Woman .....	417
<i>Tomas L. Griebeling</i>	
18. Male With Post-Prostatectomy Incontinence: <i>Status Post-removal</i> <i>of Eroded Artificial Sphincter</i> .....	421
<i>Ajay Singla</i>	
Index .....	423

# Contributors

---

- JOSEPH B. ABDELMALAK, MD • *Section of Female Pelvic Medicine and Reconstructive Surgery, The Glickman Urological Institute, The Cleveland Clinic, Cleveland, OH*
- MICHAEL A. ALEMAN, MD • *Department of Urology, The University of Tennessee Health Science Center, Memphis, TN*
- GREGORY T. BALES, MD • *Section of Urology, University of Chicago Hospital, Chicago, IL*
- MATTHEW BARBER, MD • *Section of Urogynecology and Reconstructive Pelvic Surgery, The Cleveland Clinic, Cleveland, OH*
- RICHARD C. BENNETT, MD • *Department of Urology, William Beaumont Hospital, Royal Oak, MI*
- ANDREW BERNSTEIN, MD • *Department of Urology, William Beaumont Hospital, Royal Oak, MI*
- JERRY G. BLAIVAS, MD • *Department of Urology, Weill Medical College of Cornell University, New York, NY*
- TRAVIS L. BULLOCK, MD • *Department of Surgery, Division of Urology, Washington University School of Medicine, St. Louis, MO*
- R. DUANE CESPEDES, MD • *Director, Female Urology and Urodynamics, Department of Urology (MCSU), Wilford Hall Medical Center, Lackland AFB, TX; Department of Urology, University of Texas Health Sciences Center at San Antonio, San Antonio, TX*
- TOBY C. CHAI, MD, FACS • *University of Maryland, Baltimore, MD*
- MICHAEL CHANCELLOR, MD • *Department of Urology and OBGYN, University of Pittsburgh School of Medicine, Pittsburgh, PA*
- J. QUENTIN CLEMENS, MD • *Section of Voiding Dysfunction and Female Urology, Department of Urology, Northwestern University Feinberg School of Medicine, Chicago, IL*
- CRAIG V. COMITER, MD • *Department of Surgery/Urology, University of Arizona Health Sciences Center, Tucson, AZ; Section of Urology, University of Arizona Health Sciences Center, Tucson, AZ*
- FIROUZ DANESHGARI, MD • *Center for Female Pelvic Medicine and Reconstructive Surgery, The Glickman Urological Institute at The Cleveland Clinic, Cleveland, OH*
- ANURAG K. DAS, MD, FACS • *Center for Neurourology and Continence, Beth Israel Deaconess Medical Center, Harvard Medical School, Boston, MA*
- DONNA Y. DENG, MD • *Department of Urology, UCSF School of Medicine, San Francisco, CA*
- ROGER DMOCHOWSKI, MD, FACS • *Department of Urologic Surgery, Vanderbilt University Medical Center, Nashville, TN*
- DANIEL S. ELLIOTT, MD • *Department of Urology, Section of Female Urology and Voiding Dysfunction, Mayo Clinic, Rochester, MN*
- PAULA A. FEDUNOK, PA-C • *Section of Urology, University of Chicago Hospital, Chicago, IL*

- MELISSA FISCHER, MD • *Department of Female Urology, Urodynamics and Pelvic Reconstructive Surgery, New York University School of Medicine, New York, NY*
- GAMAL M. GHONIEM, MD, FACS • *Section of Voiding Dysfunction, Female Urology and Reconstruction, The Cleveland Clinic; Department of Surgery/Urology NSU, OSU and USF, The Cleveland Clinic; Chairman of Medical Student Education, The Cleveland Clinic, Weston, FL*
- ERIN GIBBONS, MD • *Department of Urology, University of Pittsburgh School of Medicine, Pittsburgh, PA*
- DAVID A. GINSBERG, MD, FACS, USC • *Department of Urology, USC Keck School of Medicine, Los Angeles, CA; Department of Urology, Rancho Los Amigos National Rehabilitation Center, Downey, CA*
- HOWARD B. GOLDMAN, MD • *Section of Voiding Dysfunction and Female Urology, The Glickman Urological Institute, The Cleveland Clinic, Cleveland, OH; Department of Urology and Reproductive Biology, CASE School of Medicine, Cleveland, OH*
- E. ANN GORMLEY, MD • *Department of Surgery, Section of Urology, Dartmouth-Hitchcock Medical Center, Lebanon, NH*
- FRED E. GOVIER, MD • *Department of Urology and Renal Transplantation, Virginia Mason Medical Center, Seattle, WA*
- TOMAS L. GRIEBLING, MD, FACS, FGSA • *Department of Urology, University of Kansas, Lawrence, KS*
- ADONIS HIJAZ, MD • *The Glickman Urological Institute at The Cleveland Clinic, Cleveland, OH*
- MICHAEL J. KENNELLY, MD, FACS • *Charlotte Continenence Center, Charlotte Institute of Rehabilitation, Carolinas Medical Center, Charlotte, NC; Department of Urology, McKay Urology, Charlotte Institute of Rehabilitation, Carolinas Medical Center, Charlotte, NC*
- CARL G. KLUTKE, MD • *Department of Surgery, Division of Urology, Washington University School of Medicine, St. Louis, MO*
- KATHLEEN C. KOBASHI, MD • *Continenence Center at Virginia Mason Medical Center, Seattle, WA; Section of Urology and Renal Transplant, University of Washington, Virginia Mason Medical Center, Seattle, WA*
- WACHIRA KOCHAKARN, MD • *Section of Urology, Department of Surgery, Ramathidbodi Hospital, Mahidol University, Bangkok, Thailand; Faculty of Medicine FACS, Ramathidbodi Hospital, Mahidol University, Bangkok, Thailand*
- GARY E. LEACH, MD • *Tower Urology Institute for Continenence, Cedars-Sinai Medical Center, Los Angeles, CA; Center for Female Pelvic Health, Cedars-Sinai Medical Center, Los Angeles, CA*
- GARY E. LEMACK, MD • *Department of Urology, UT Southwestern Medical Center, Dallas, TX*
- WENDY W. LENG, MD • *Department of Urology, University of Pittsburgh School of Medicine, Pittsburgh, PA*
- DEBORAH LIGHTNER, MD • *Department of Urology, Mayo Clinic, Rochester, MN*
- KELLY M. MAXWELL, MD • *Department of Urology, Northwestern University Feinberg School of Medicine, Chicago, IL*
- COURTNEY MOORE, MD • *Female Pelvic Medicine and Reconstructive Surgery, The Glickman Urological Institute, The Cleveland Clinic, Cleveland, OH*
- DIANE K. NEWMAN, RNC, MSN, CRNP, FAAN • *Division of Urology, Penn Center for Continenence and Pelvic Health, Philadelphia, PA*

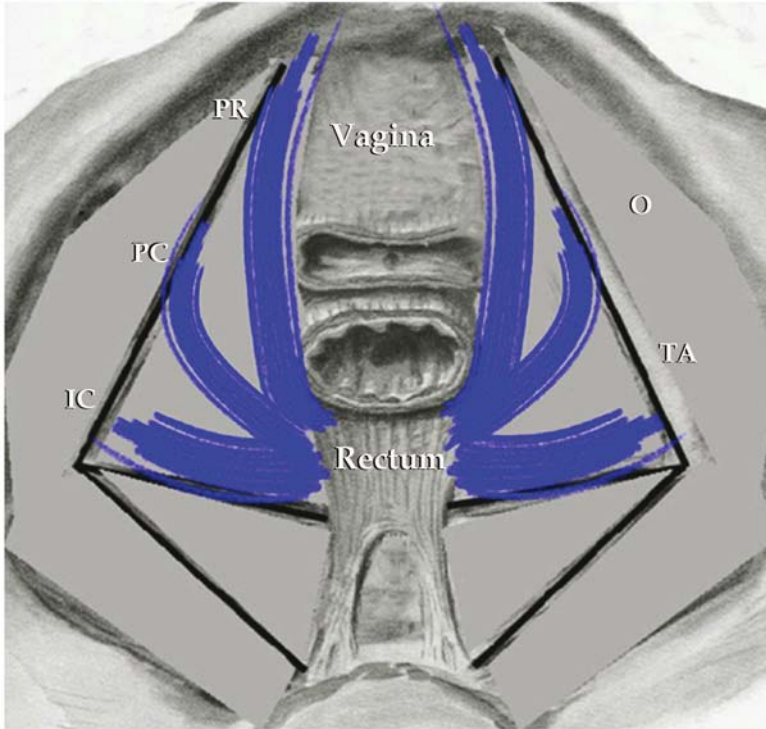
- VICTOR W. NITTI, MD, FACS • *Department of Urology, New York University School of Medicine, New York, NY*
- PRIYA PADMANABHAN, MD • *Department of Urology, New York University School of Medicine, New York, NY*
- KENNETH M. PETERS, MD • *Department of Urology, William Beaumont Hospital, Royal Oak, MI*
- RAYMOND RACKLEY, MD • *Section of Female Pelvic Medicine and Reconstructive Surgery, The Glickman Urological Institute, The Cleveland Clinic, Cleveland, OH*
- SHLOMO RAZ, MD • *Department of Urology, Female Urology and Reconstructive Surgery, UCLA School of Medicine, Los Angeles, CA; Department of Pelvic Medicine, UCLA School of Medicine, Los Angeles, CA*
- LARISSA V. RODRÍGUEZ, MD • *Department of Urology, David Geffen School of Medicine—UCLA, Los Angeles, CA*
- NIRIT ROSENBLUM, MD • *Department of Urology, New York University School of Medicine, New York, NY*
- CHRISTOPHER C. ROTH, MD • *Department of Urology, LSU/Ochsner Urology Program, New Orleans, LA*
- ERIC S. ROVNER, MD • *Department of Urology, Medical University of South Carolina, Charleston, SC*
- MATTHEW P. RUTMAN, MD • *Department of Urology, Columbia University School of Medicine, New York, NY*
- HARRIETTE M. SCARPERO, MD • *Department of Urologic Surgery, Vanderbilt University Medical Center, Nashville, TN*
- PATRICK J. SHENOT, MD • *Department of Urology, Jefferson Medical College, Department of Urology, Philadelphia, PA*
- DOLORES SHUPP-BYRNE, PhD • *Department of Urology, Jefferson Medical College, Philadelphia, PA*
- STEVEN SIEGEL, MD • *Metro Urology, Centers for Continence Care and Female Urology, Minneapolis/St. Paul, MN*
- AJAY SINGLA, MD, FACS, FRCS, FICS • *Department of Urology and Gynecology and Department of Biomedical Engineering, Wayne State University, Detroit, MI; Vice President and Urology Chair, International College of Surgeons-US Section*
- CRAIG B. SLOTOROFF, MD • *Jefferson Medical College, Department of Urology, Philadelphia, PA*
- SUZETTE SUTHERLAND, MD • *Metro Urology, Centers for Continence Care and Female Urology, Plymouth, MN*
- JENNIFER TAKACS • *Department of Urology, UT Southwestern Medical Center, Dallas, TX*
- SANDIP VASAVADA, MD • *Section of Female Urology and Voiding Dysfunction, The Glickman Urological Institute, The Cleveland Clinic, Cleveland, OH*
- JEFFREY P. WEISS, MD • *Department of Urology, The James Buchanan Brady Department of Urology, The Joan and Sanford I. Weill Medical College of Cornell University, New York, NY*
- O. LENAINE WESTNEY, MD • *Division of Urology, University of Texas Medical School at Houston, Houston, TX*
- J. CHRISTIAN WINTERS, MD • *Department of Urology and Department of Female Urology and Voiding Dysfunction, Ochsner Health Systems, New Orleans, LA*
- E. JAMES WRIGHT, MD • *Department of Urology, Johns Hopkins Bayview Medical Center, John Hopkins University, Baltimore, MD*
- PHILIPPE E. ZIMMERN, MD • *Department of Urology, UT Southwestern Medical Center, Dallas, TX*

# List of Color Plates

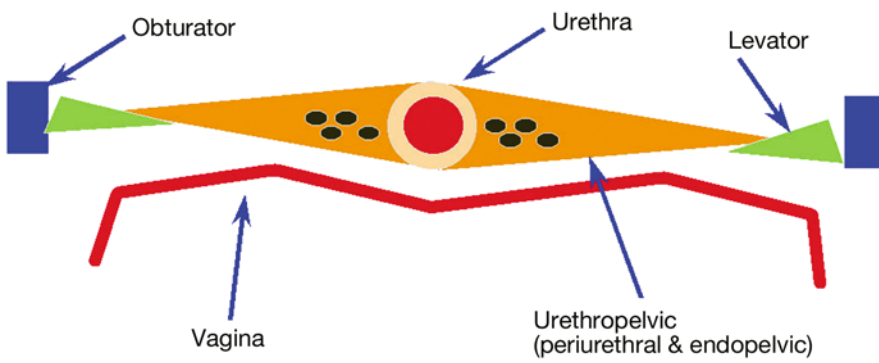
---

Color insert appears following p. 174

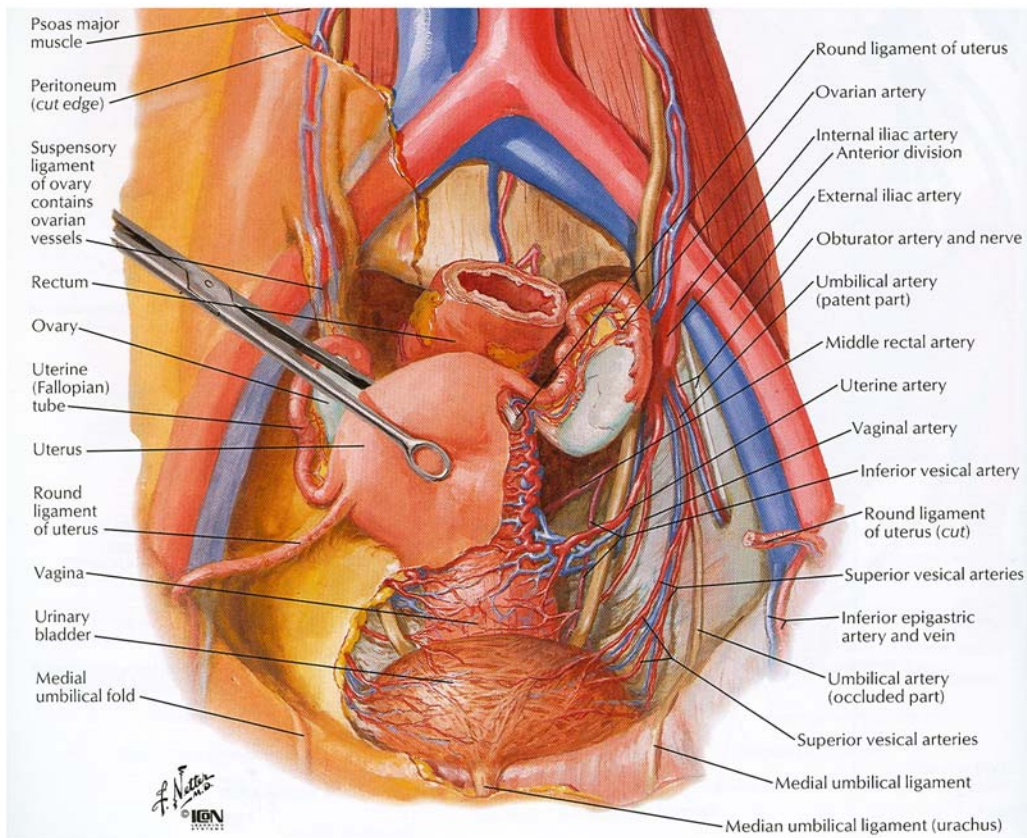
- Color Plate 1.**      *Fig. 1.4. See legend on p. 6 and discussion on p. 5.*
- Color Plate 2.**      *Fig. 1.7. See legend on p. 8 and discussion on p. 6.*
- Color Plate 3.**      *Fig. 1.8. See legend on p. 9 and discussion on p. 7.*
- Color Plate 4.**      *Fig. 1.9. See legend on p. 10 and discussion on p. 9.*
- Color Plate 5.**      *Fig. 11.1. See legend and discussion on p. 161.*
- Color Plate 6.**      *Fig. 11.2. See legend and discussion on p. 162.*
- Color Plate 7.**      *Fig. 11.3. See legend on p. 163 and discussion on p. 162.*
- Color Plate 8.**      *Fig. 11.4. See legend on p. 163 and discussion on p. 162.*
- Color Plate 9.**      *Fig. 11.5. See legend and discussion on p. 164.*
- Color Plate 10.**     *Fig. 11.6. See legend on p. 167 and discussion on p. 166.*
- Color Plate 11.**     *Fig. 11.7. See legend on p. 167 and discussion on p. 166.*
- Color Plate 12.**     *Fig. 14.1. See legend on p. 218 and discussion on p. 217.*
- Color Plate 13.**     *Fig. 22.4. See legend on p. 316 and discussion on p. 315.*
- Color Plate 14.**     *Fig. 22.5. See legend on p. 317 and discussion on p. 316.*
- Color Plate 15.**     *Fig. 22.9. See legend on p. 323 and discussion on p. 322.*



Color Plate 1. Fig. 1.4. See legend on p. 6 and discussion on p. 5.

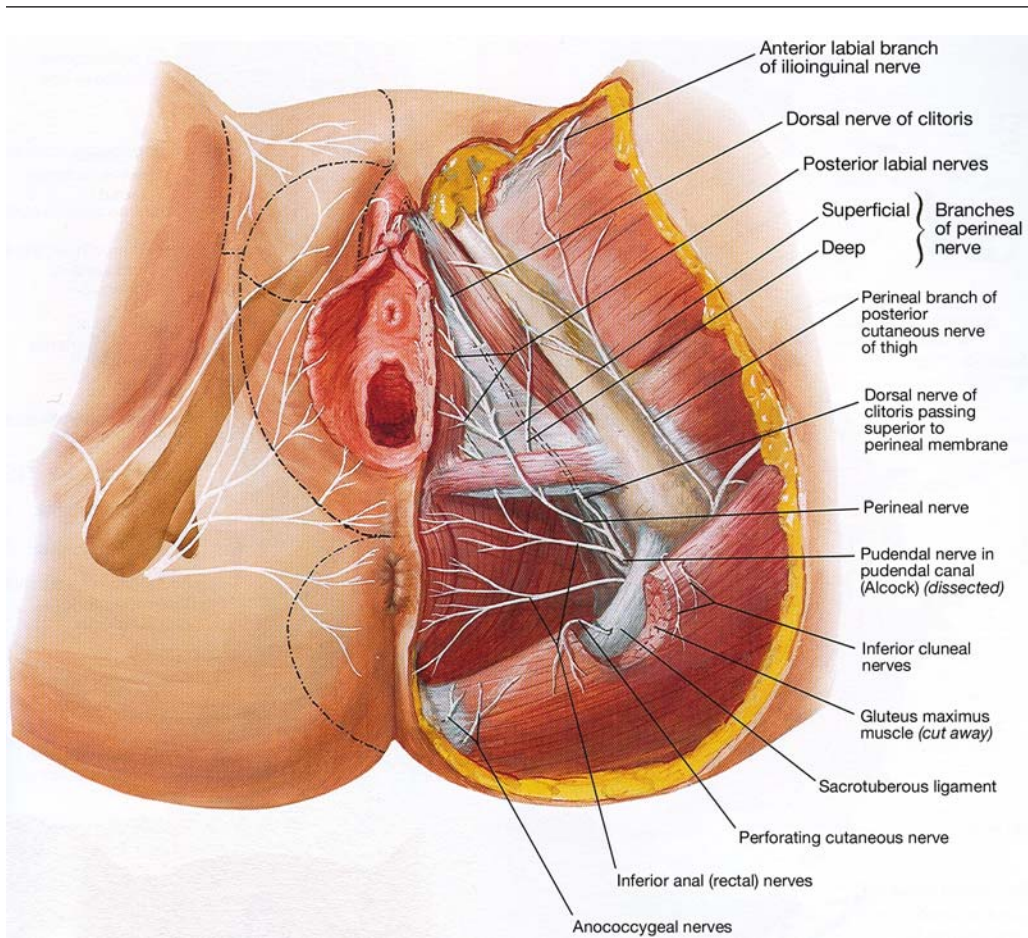


Color Plate 2. Fig. 1.7. See legend on p. 8 and discussion on p. 6.

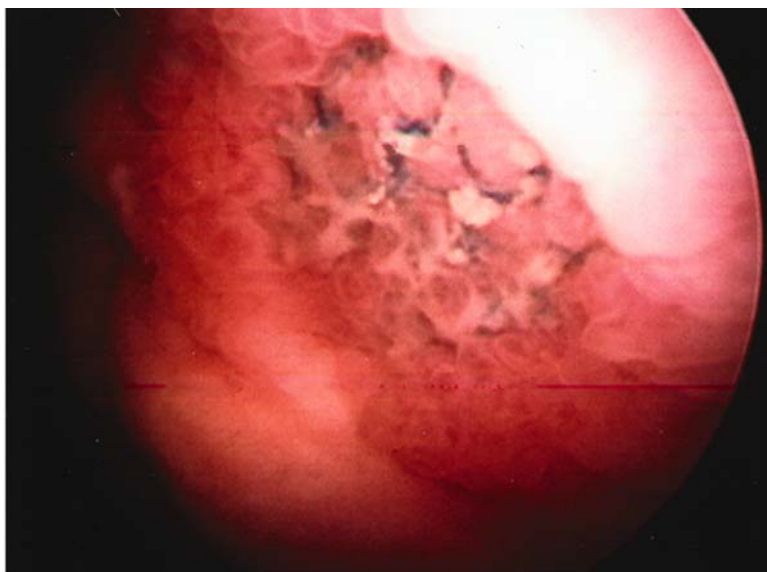


Color Plate 3. Fig. 1.8. See legend on p. 9 and discussion on p. 7.

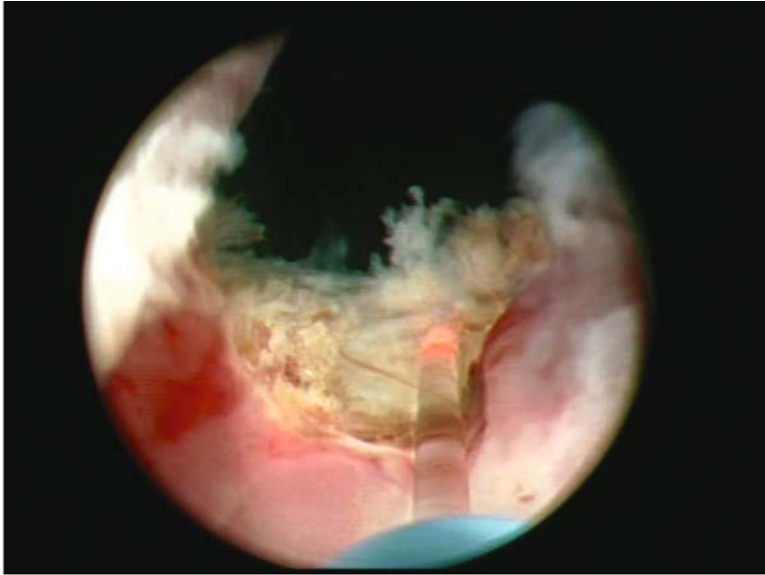



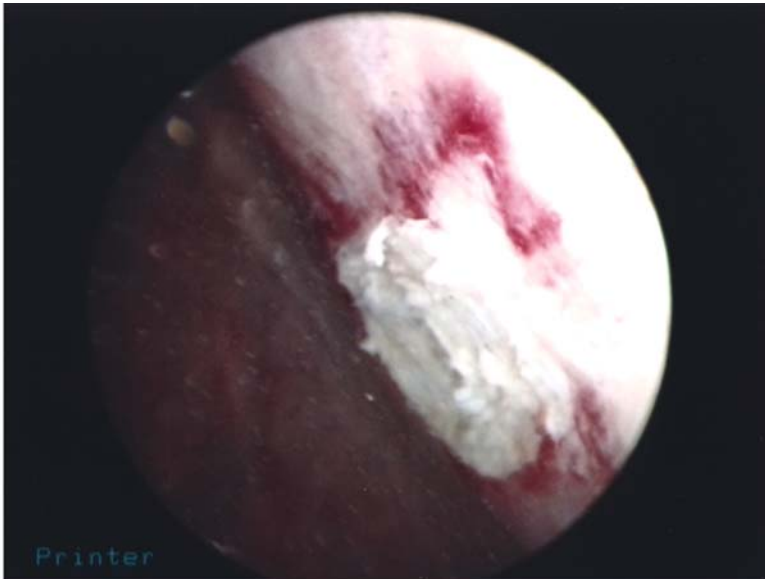Color Plate 4. Fig. 1.9. See legend on p. 10 and discussion on p. 9.



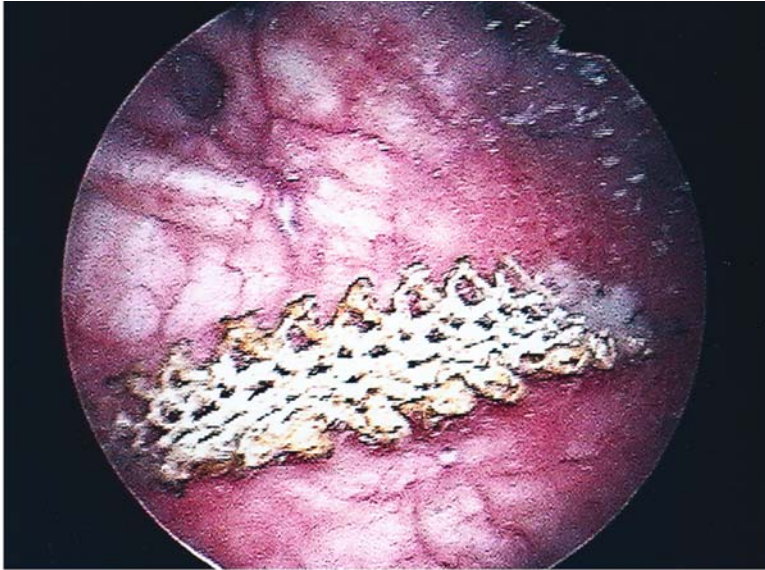
Color Plate 5. Fig. 11.1. See legend and discussion on p. 161.



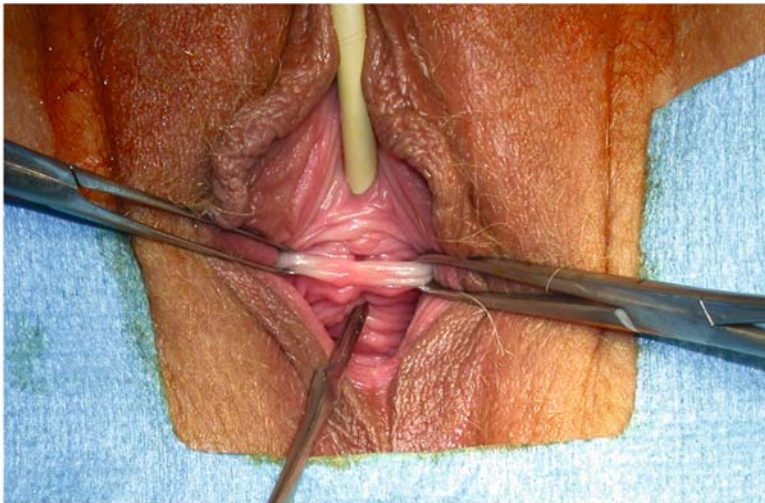
Color Plate 6. Fig. 11.2. *See legend and discussion on p. 162.*



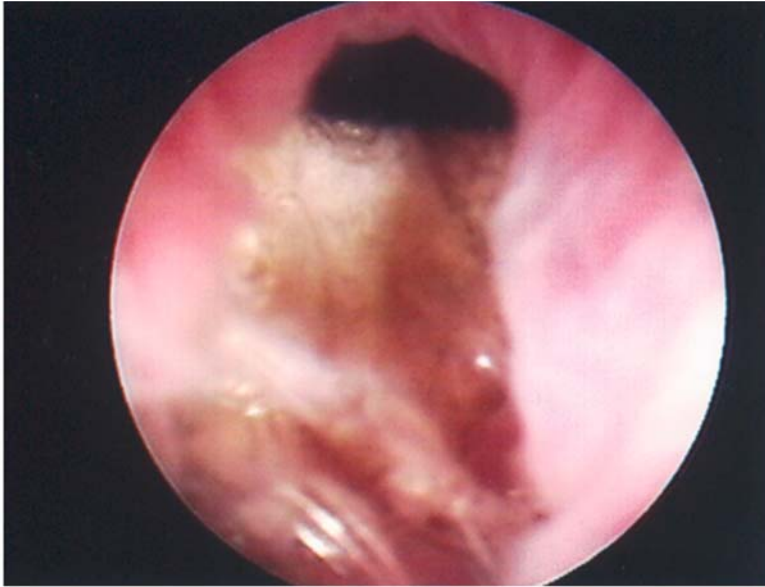Color Plate 7. Fig. 11.3. *See legend on p. 163 and discussion on p. 162.*



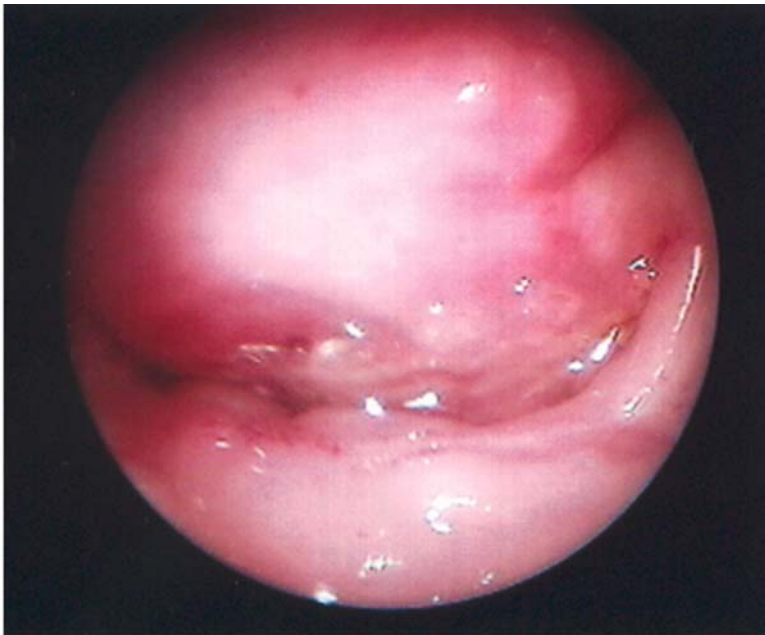Color Plate 8. Fig. 11.4. *See legend on p. 163 and discussion on p. 162.*



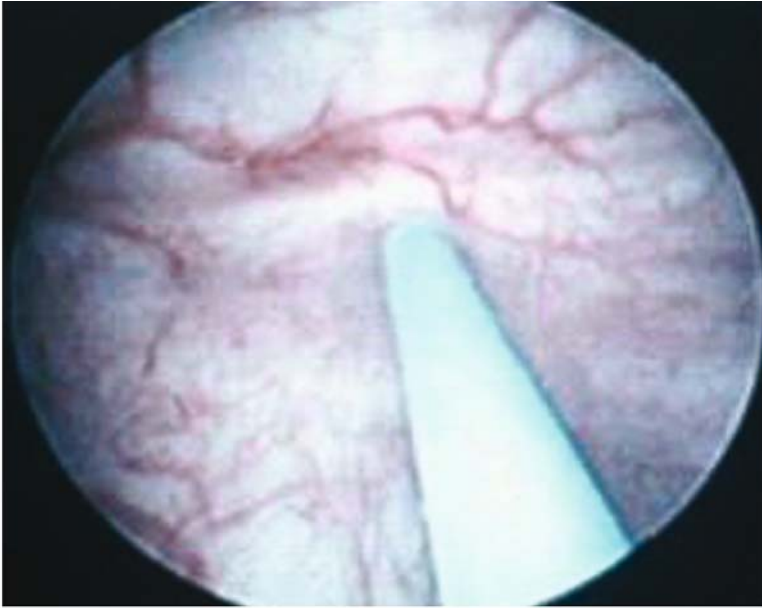
Color Plate 9. Fig. 11.5. *See legend and discussion on p. 164.*



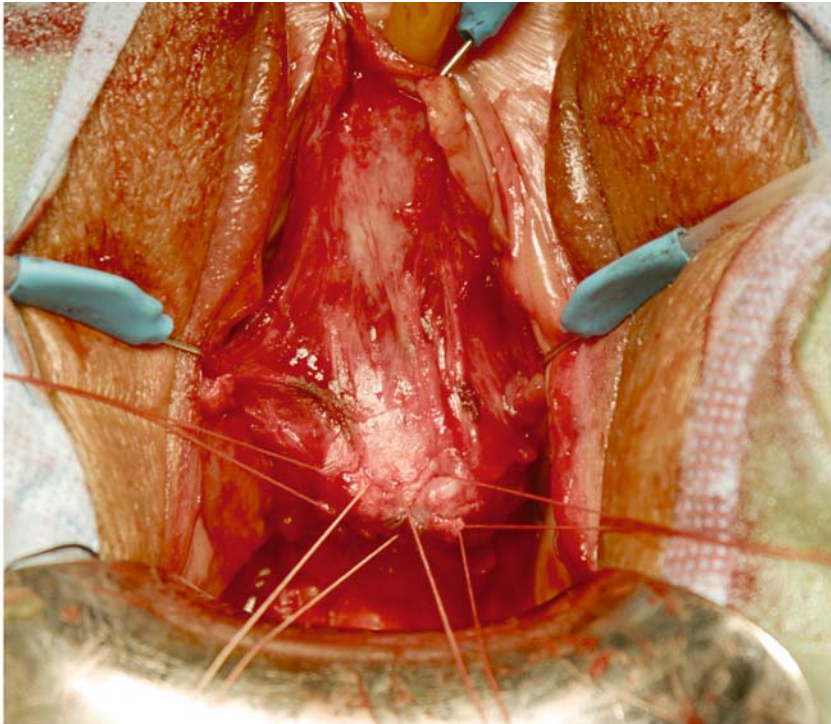
Color Plate 10. Fig. 11.6. *See legend on p. 167 and discussion on p. 166.*



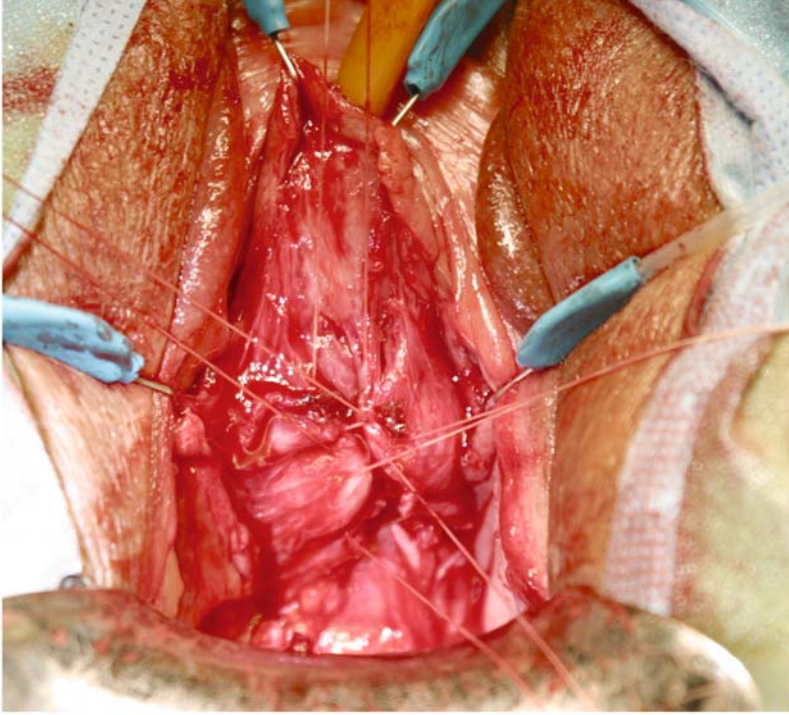
Color Plate 11. Fig. 11.7. *See legend on p. 167 and discussion on p. 166.*



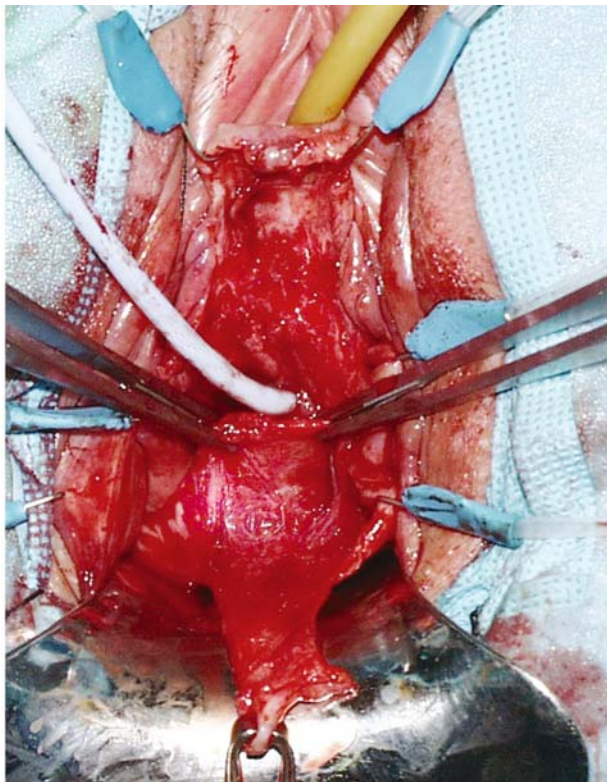
Color Plate 12. Fig. 14.1. *See legend on p. 218 and discussion on p. 217.*



Color Plate 13. Fig. 22.4. *See legend on p. 316 and discussion on p. 315.*



Color Plate 14. Fig. 22.5. *See legend on p. 317 and discussion on p. 316.*



Color Plate 15. Fig. 22.9. *See legend on p. 323 and discussion on p. 322.*

---

# I EVALUATION

---

---

# 1 Anatomy of Pelvic Support

---

*Melissa Fischer, MD, Priya Padmanabhan, MD,  
and Nirit Rosenblum, MD*

## **CONTENTS**

INTRODUCTION  
BONY PELVIS  
MUSCULATURE AND FASCIAE OF THE PELVIS  
PELVIC CIRCULATION  
FEMALE PELVIC VISCERA  
PERINEUM  
CONCLUSION  
REFERENCES

---

## **INTRODUCTION**

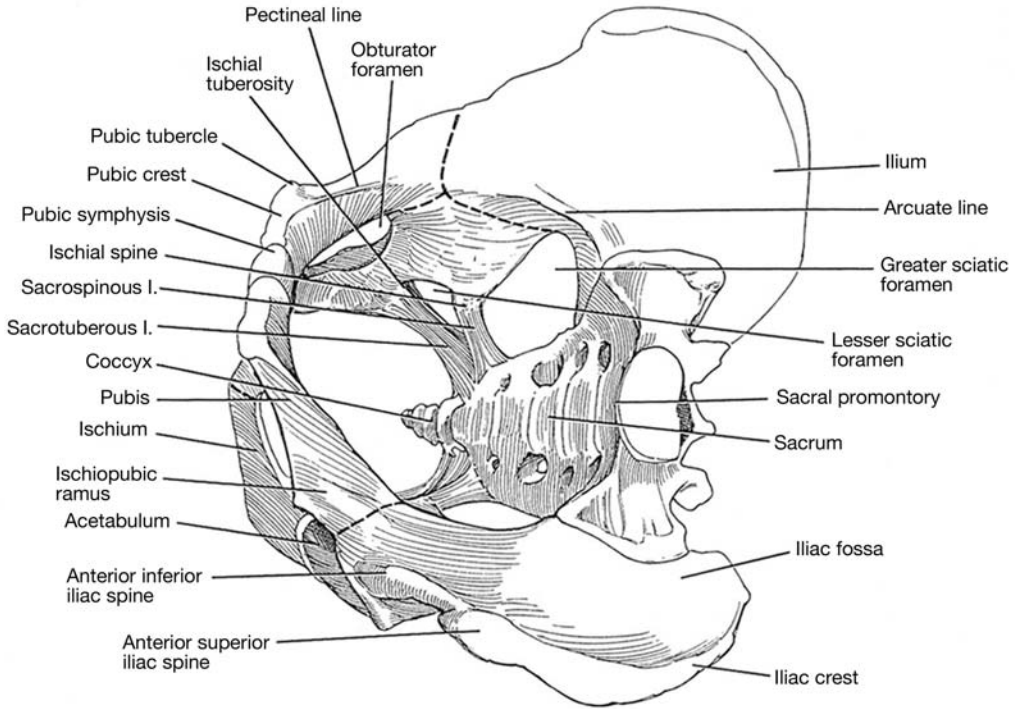
Female pelvic anatomy can be a conceptual challenge. To understand the function of the pelvis, one must understand the basic anatomy and then the dynamic nature of the structures that allow for urinary and bowel continence in a variety of circumstances. An understanding of normal anatomy and function provides the clinician with a framework for understanding the pathophysiology of pelvic organ prolapse and female urinary incontinence. The evaluation of female urinary incontinence often involves the recognition and treatment of concurrent pelvic abnormalities, such as cystocele, uterine prolapse, enterocele, rectocele, or perineal laxity. The factors responsible for pelvic floor relaxation rarely affect isolated anatomic areas. This chapter provides a detailed description of normal female pelvic anatomy, and an emphasis is placed on key surgical landmarks for reestablishing normal anatomy.

## **BONY PELVIS**

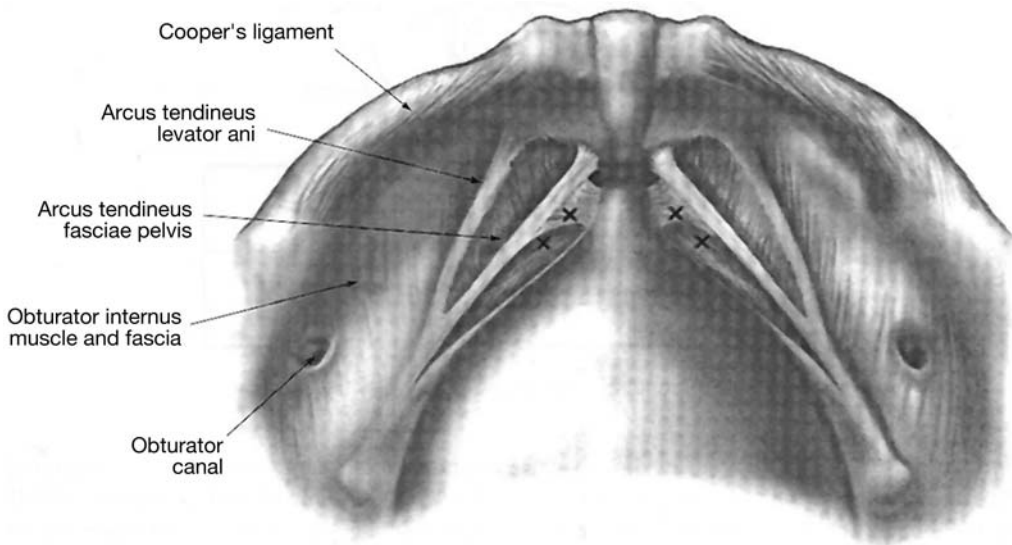
The bony pelvis is comprised of the sacrum, coccyx, and two innominate bones, formed by the fusion of the iliac, ischial, and pubic bones (Fig. 1) (1). An opening is found between the pubic and ischial bones, medial to the acetabulum, known as the obturator foramen. The ischiopubic ramus is the medial fusion of the pubic and ischial bones. Transobturator devices used during antiincontinence procedures are passed around the midpoint of this structure through the obturator foramen. The pectineal line on the anteromedial aspect of the pubic bone is an important surgical landmark for retropubic urethral suspensions (Fig. 2). The supporting sutures are often placed in Cooper's (pectineal) ligament, which overlies the pectineal line (1).

From: *Current Clinical Urology: Female Urology: A Practical Clinical Guide*  
Edited by: H. B. Goldman and S. P. Vasavada © Humana Press Inc., Totowa, NJ



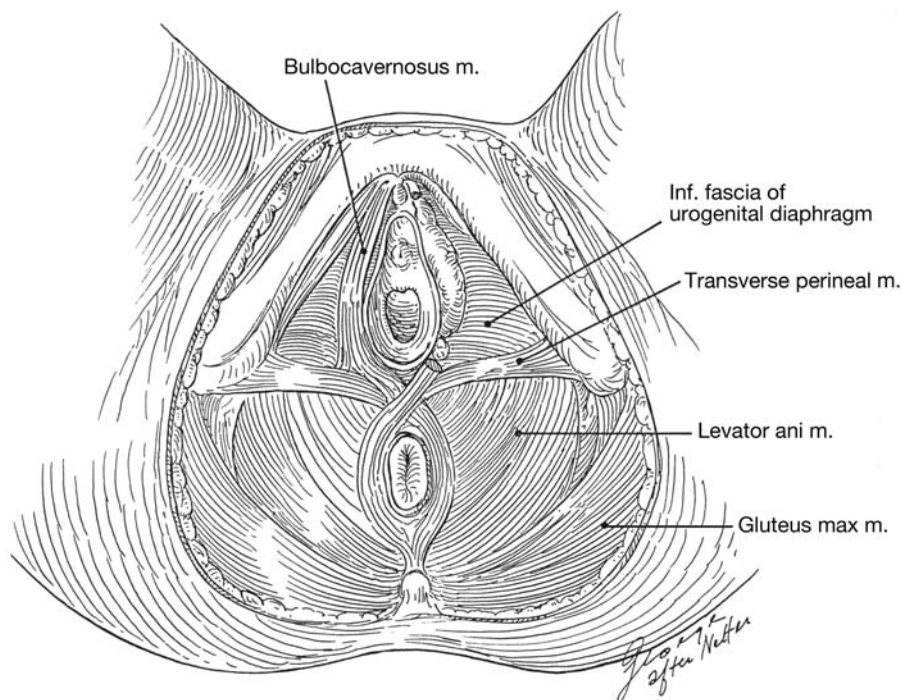


**Fig. 1.** The bones of the pelvis. (From ref. 13.)



**Fig. 2.** Surgical landmarks for retropubic urethral suspensions. (From ref. 14.)

The pelvic floor is diamond shaped, with the pubic symphysis anteriorly, the sacrum posteriorly, and the ischial spines laterally as its apices. These structures provide the main anchoring points for the supporting structures of the pelvic floor (2). The sacrospinous ligaments (SSLs) span the posterior aspect of the pelvic floor from the ischial spines to



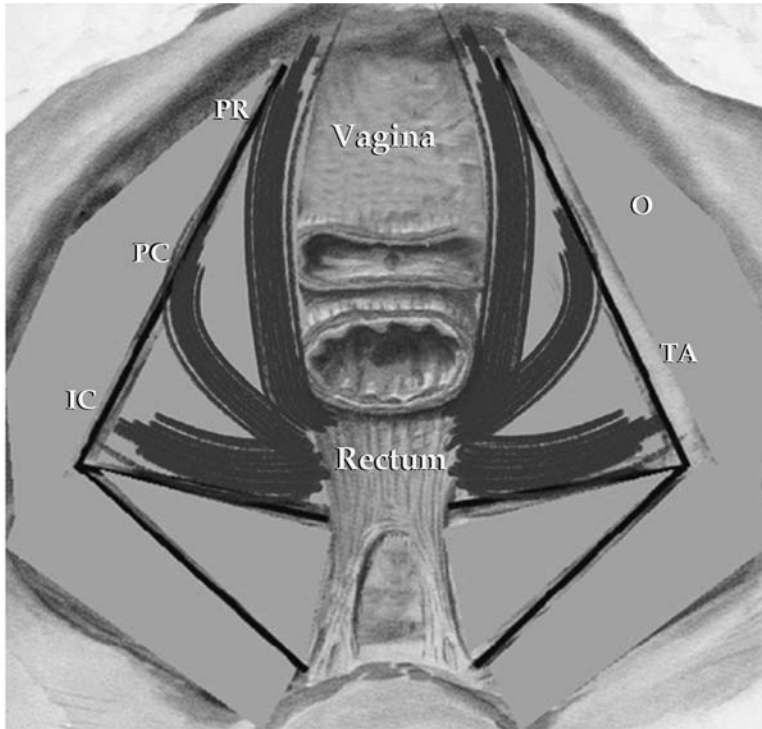
**Fig. 3.** Pelvic floor musculature and perineal body. (From ref. 15.)

the anterolateral aspect of the sacrum and coccyx, creating the greater and lesser sciatic foramina (Fig. 1). The SSLs are instrumental in many prolapse repair techniques. Medially, the SSL fuses with the sacrotuberous ligament, and together they serve to stabilize the sacroiliac joint (3).

## MUSCULATURE AND FASCIAE OF THE PELVIS

The striated musculature of the pelvic floor provides dynamic support for the visceral contents of the abdominopelvic cavity. The pelvic floor consists of the pelvic diaphragm and the perineal membrane, which are described separately (Fig. 3) (3). The pelvic diaphragm refers to the levator ani group (LAG), the coccygeus muscles, and the associated fascia. The coccygeus muscle runs between the ischial spine and the lateral aspect of the sacrum and coccyx, overlying the SSL. The LAG is comprised of the puborectalis, pubococcygeus, and iliococcygeus, named according to their respective points of origin (Fig. 4). These muscles form a shelf of support for the pelvic organs. The pelvic diaphragm is innervated by proximal branches of the pudendal nerve and directly innervated by S3 and S4 sacral nerve roots (4). The pudendal nerve is described in more detail in the section on pelvic circulation.

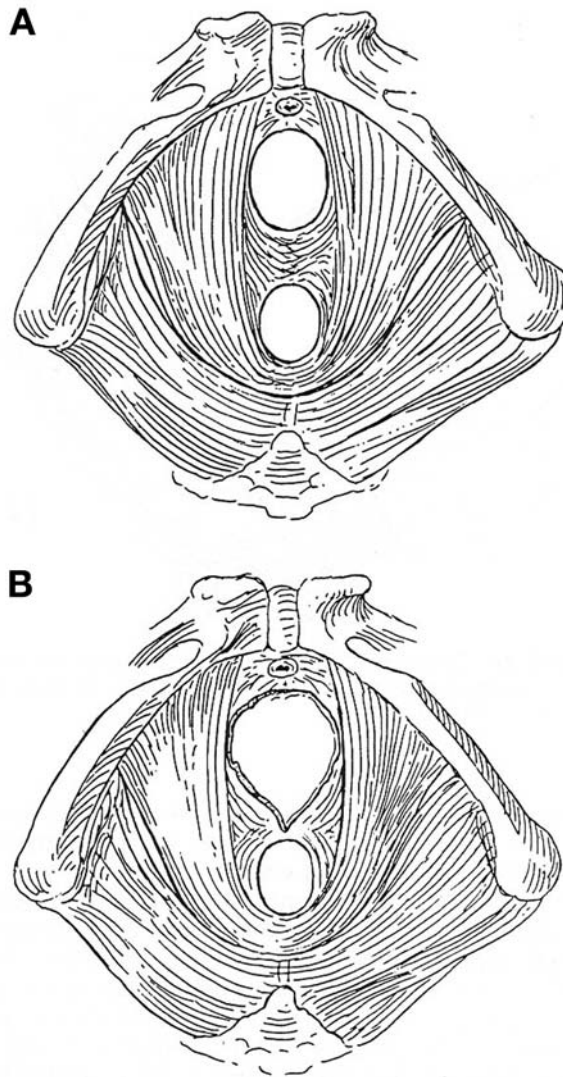
Laterally, this broad sheet of muscle is attached to the pelvic sidewall by the arcus tendineus fasciae pelvis (ATFP). The ATFP is a curvilinear condensation of the pelvic fascia overlying the obturator internus muscle from the ischial spine to the lower aspect of the pubic symphysis. The obturator internus is located on the pelvic sidewall and passes through the lesser sciatic foramen to insert on the greater trochanter of the femur (2). The ATFP provides support for the majority of the anterior pelvic diaphragm to the bony pelvis and is often utilized for support during pelvic floor reconstruction.



**Fig. 4.** Levator ani group (LAG). PR, puborectalis; PC, pubococcygeus; IC, iliococcygeus; O, obturator foramen; TA, tendinous arc of the obturator muscle.

Midline apertures in the LAG allow passage of the urethra, vagina, and rectum. These apertures are collectively referred to as the levator hiatus. The dimensions of the hiatus can vary depending on parity (Fig. 5). The LAG and associated fascial attachments provide a dynamic hammock of support for these structures, contributing significantly to urinary and fecal continence. The endopelvic fascia is a viscerofascial layer, superior to the LAG, just beneath the peritoneum and covering adjacent organs (2). There are several condensations of levator ani fascia that serve discrete functions. For example, the medial edge of the LAG fascia corresponds anteriorly, around the bladder, to the pubocervical fascia and posteriorly, around the cervix, to the cardinal and uterosacral ligaments. The uterosacral and cardinal ligaments are important fascial condensations involved in supporting the uterus and upper vagina and are discussed in the section on genital structures.

The pubocervical fascia, also known as the vesicopelvic ligament, is a continuous band of connective tissue from the pubic symphysis to the cervix (Fig. 6). The fascia is a fusion of the superior layer of levator ani fascia (endopelvic fascia) and the posterior layer. The fascia fuses anteriorly with the periurethral, perivesical, and anterior vaginal wall fascia and posteriorly to the cardinal ligament complex. Attenuation of this fascial support, either laterally from the ATFP or centrally, results in a cystocele. The pubourethral ligaments support the urethra to the inferior pubis, just proximal to the striated sphincter. The urethropelvic ligaments are derived from a fusion of the endopelvic and periurethral fascia and are continuous with the pubocervical fascia laterally (Fig. 7). These ligaments attach laterally to the ATFP on the pelvic sidewall, providing crucial



**Fig. 5.** Levator hiatus. (A) Normal levator floor and vaginal hiatus. (B) Attenuation and separation of the levator fibers and widening of the posterior vaginal hiatus with parity. (From ref. 15.)

support to the urethra and anterior vaginal wall. An understanding of the supporting structures of the pelvis is essential for successful reconstructive surgery.

### PELVIC CIRCULATION

The arterial blood supply to the pelvis and perineum are briefly reviewed. Venous drainage for the most part parallels the arterial vessels. The aorta bifurcates at the level of the fourth lumbar vertebrae into the common iliac arteries (Fig. 8). The arteries run anterior and lateral to the veins at this level (1). The common iliacs divide into the external and internal iliac arteries at the level of the sacroiliac joint. The external iliac runs along the medial aspect of the iliopsoas and exits the pelvis posterior to the inguinal ligament as the femoral artery. In pelvic reconstructive surgery, the pertinent branches

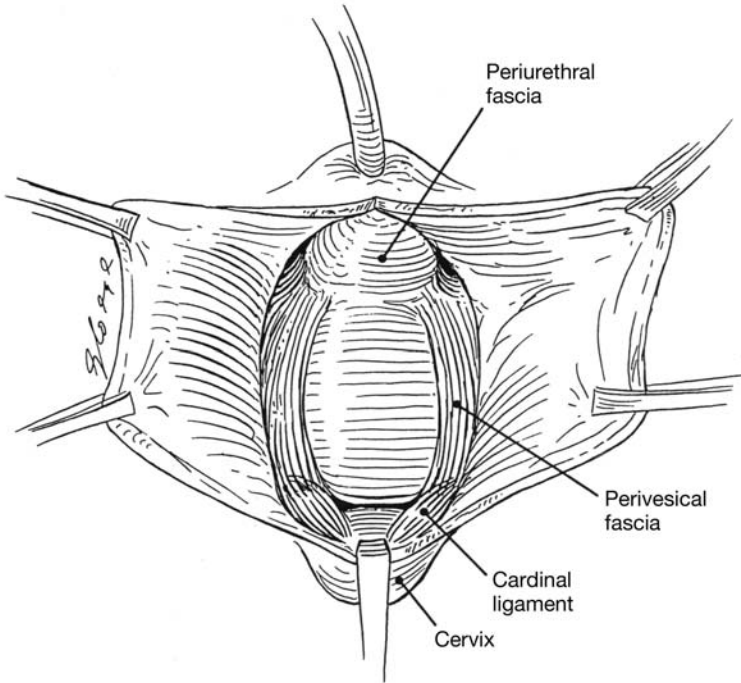


Fig. 6. Anterior vaginal fascial support. (From ref. 15.)

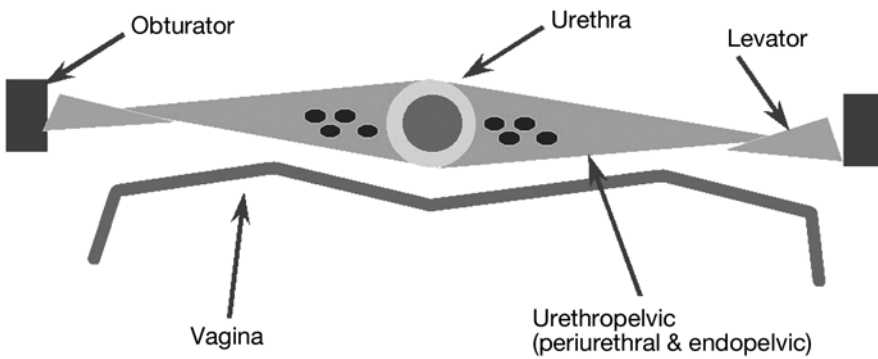
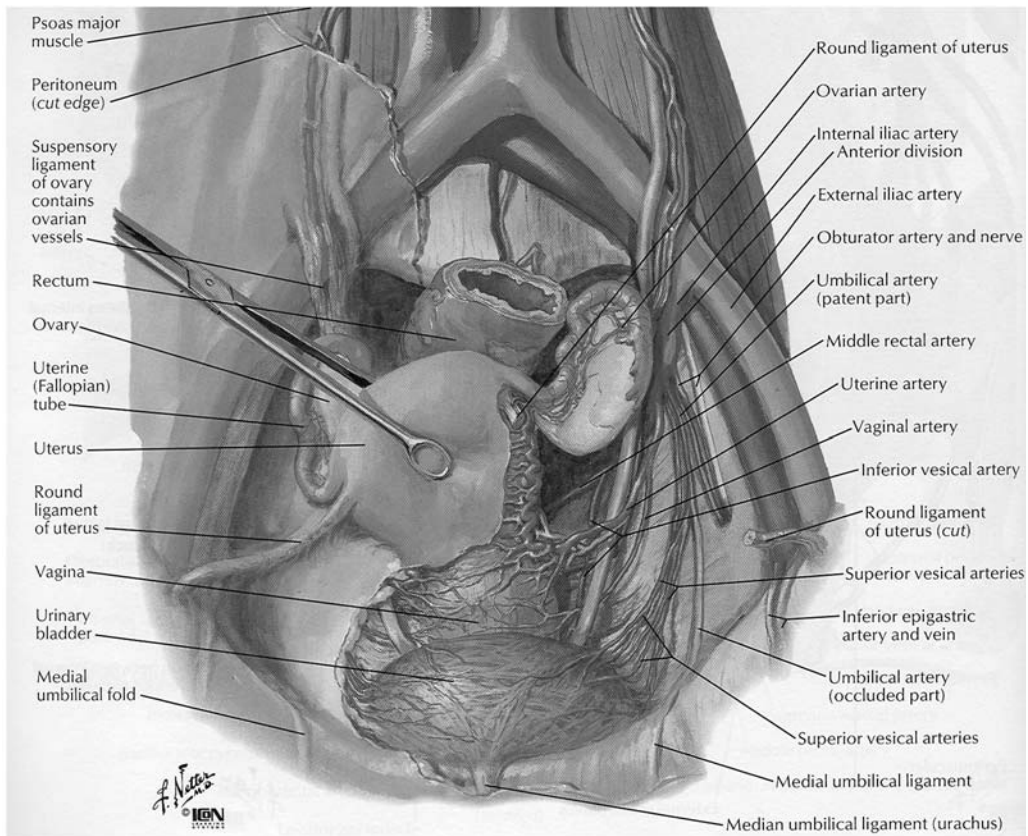


Fig. 7. Schematic of urethral and anterior vaginal wall support.

of the femoral artery are the external pudendal artery to the labial fibrofatty pad and the inferior epigastric artery, which supplies the rectus abdominus muscle. These relationships are important during rotational flap techniques.

The internal iliac artery divides into an anterior and posterior trunk. The posterior trunk gives off the superior gluteal, ascending lumbar, and lateral sacral arteries. The anterior trunk has seven branches: superior vesical, middle rectal, inferior vesical, uterine, internal pudendal, obturator, and inferior gluteal arteries (1). The course and relationships of several of the branches are highlighted as they pertain to pelvic floor surgery.

The obturator canal is an opening in the membrane overlying the obturator internus through which the obturator vessels and nerve pass. The obturator nerve arises from the

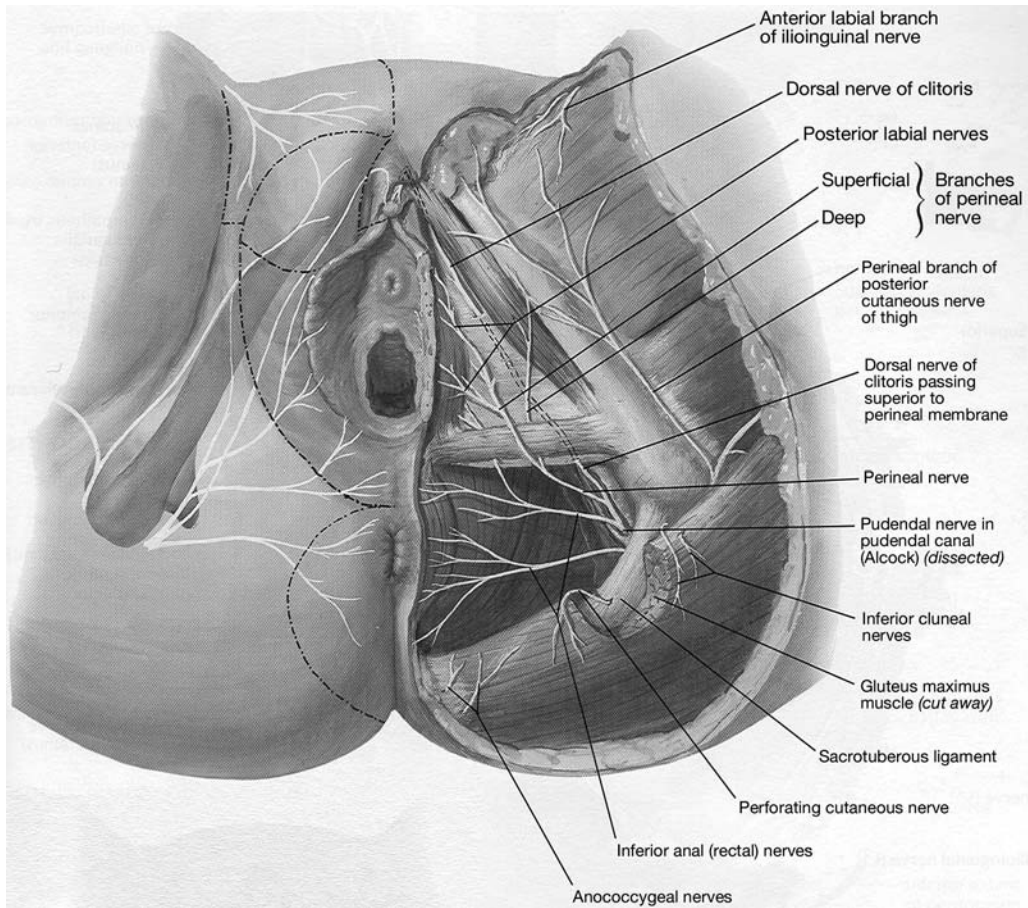


**Fig. 8.** Pelvic circulation. (From ref. 16.)

L2 through S1 nerve roots and exits the pelvis through the obturator canal, where it divides into anterior and posterior divisions to supply the muscles of the adductor compartment. The obturator canal is nearly 5 cm superolateral to the midpoint of the ischiopubic ramus. This relationship should be kept in mind when passing a device around the ischiopubic ramus for a transobturator procedure (5).

The internal pudendal vessels and the pudendal nerve (S2–S4) exit the pelvis through the greater sciatic foramen, wrapping around the ischial spine and SSL laterally (Fig. 9). Care must be taken to avoid these structures when placing sutures in the SSL. The pudendal nerve and vessels then pass through the lesser sciatic foramen and course alongside the lateral aspect of the ischiorectal fossa to enter the pudendal canal (Alcock's canal) in the posterior perineum. The pudendal nerve branches into the inferior rectal, perineal, and dorsal (clitoral) nerves (6).

Understanding lymphatic drainage is mainly significant in treating pelvic malignancy but can be relevant in inflammatory states. The pattern of lymphatic drainage parallels the venous circulation. The vulvar lymphatic vessels, including the distal urethra and lower third of the vagina, drain into the inguinal lymph nodes. The bladder, proximal urethra, uterus, and upper two-thirds of the vagina drain into the pelvic lymph nodes (obturator, internal, and external iliac). The ovarian lymphatics follow the gonadal vessels and drain into the para-aortic nodes (3).



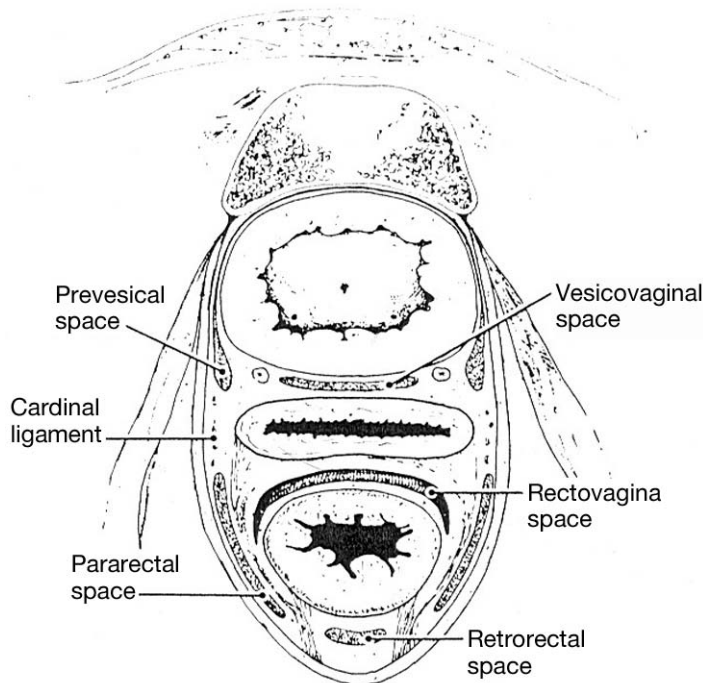
**Fig. 9.** Nerves of the female perineum. (From ref. 16.)

## FEMALE PELVIC VISCERA

### *Lower Urinary Tract*

The bladder is comprised of the body and the trigone and normally serves to store urine at low pressures and effectively contract to urinate (7). The bladder is composed of an inner transitional epithelium, a multilayer muscular wall, and an outer serosal covering. The exact dimensions and configuration of the bladder vary considerably depending on degree of distention, prolapse, or other pathology. The bladder base and urethra rest on the anterior vaginal wall (1). The bladder is an extraperitoneal organ covered by peritoneum at the dome superiorly and posteriorly. The peritoneum then reflects onto the anterior vagina and uterus, forming the vesicouterine pouch, and continues over the posterior uterus and onto the rectum, creating the rectouterine space or pouch of Douglas (Fig. 10) (3). The peritoneum in the rectouterine space may herniate into the posterior vagina, resulting in an enterocele.

The ureter is a continuation of the renal collecting system and transports urine from the kidney to the bladder (8). The ureter courses inferiorly and medially; below the inferior border of the sacrum, the ureter is referred to as the lower, distal, or pelvic ureter. The position of the distal ureter can be affected by bladder distention or



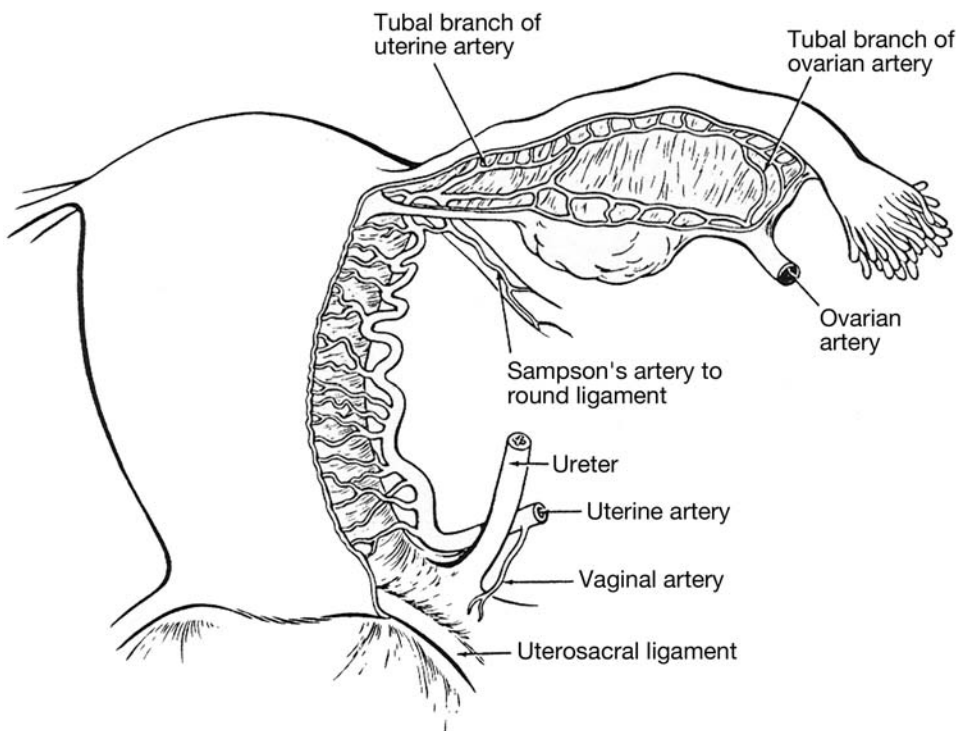
**Fig. 10.** Peritoneal cleavage planes. (From ref. 3.)

significant prolapse, and it is susceptible to injury during pelvic reconstruction. The ureter crosses anterior to the common iliac vessels at the bifurcation medial to the ovarian vessels. The course of the ureter is retroperitoneal and runs deep to the base of the broad ligament before traveling through the cardinal ligament, where the ureter passes underneath the uterine artery (Fig. 11) (3). The ureter is located in the anterior vaginal wall before entering the bladder and is usually 1.5 cm superolateral to the cervix (1).

The female urethra is approx 4 cm in length and extends from the bladder neck to the external urethral meatus (1). As mentioned, the midportion of the urethra is attached to the inferior pubis by the pubourethral ligaments. The ligaments divide the urethra into proximal and distal halves; the external sphincter is just distal to the ligaments. The urethra is typically divided into three portions: proximal, mid, and distal. The proximal urethra is responsible for passive continence. The midportion, which contains the rhabdosphincter, is responsible for passive and active continence. The distal one-third is principally a conduit and, if damaged or resected, usually does not have an impact on continence. The epithelium of the urethra varies proximal to distal, transitional to non-keratinized squamous epithelium, respectively. Many small glands communicate with the urethra and may be a source of urethral diverticula. The urethra is bordered laterally by two small labia, which contain minor vestibular glands. The Skene ducts open on the inner aspect of these labia and when inflamed can be palpated on the distal anterior vaginal wall as a suburethral mass (3).

The mechanism of continence is multifactorial. Innate properties of the urethra provide a measure of control. The urethral epithelium has many infoldings, which result in a mucosal seal (Fig. 12). The surrounding vascular spongiosum and outer musculofascial





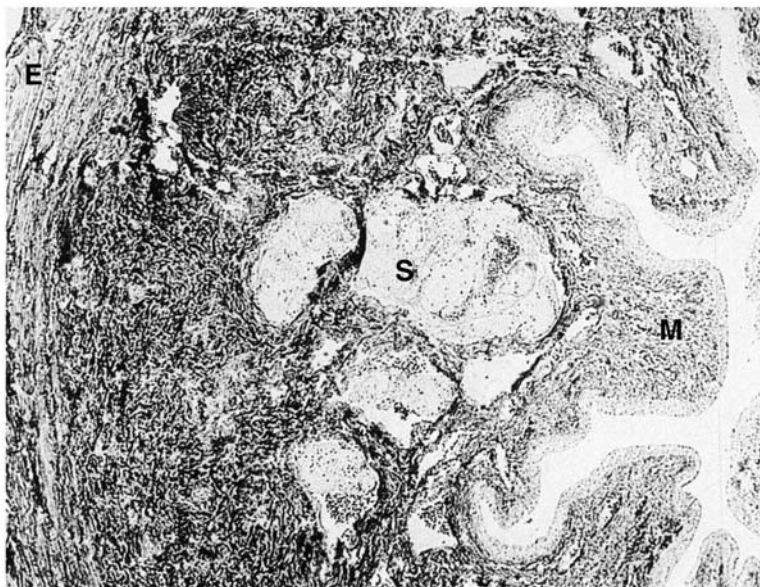
**Fig. 11.** Course of the ureter. (From ref. 3.)

layer provide additional compression of the urethra. The urethropelvic ligaments provide passive and active support. They suspend the bladder neck and urethra in a higher retro-pubic position than the more dependent bladder base, creating a valvular effect. During increased activity of the LAG, the ligaments are drawn laterally, increasing compression of the urethra and thereby augmenting continence. Finally, the urethral striated sphincter provides resting tone, contributing to the closing forces of the urethra, and allows for reflex and voluntary urinary control.

The ability to store urine safely and effectively and volitionally void at desired times is a complex process involving the central nervous system and an intact spinal cord. Innervation of the bladder and urethra is briefly reviewed as it is pertinent to urinary continence (Fig. 13). The urinary system is regulated by autonomic and motor neurons. The sympathetic nerves arise from the thoracolumbar region (T10–L2) and are carried via the hypogastric nerve, which mediates storage. The parasympathetic nerves originate from the sacral cord (S2–S4), are carried via the pelvic nerve, and facilitate detrusor contraction and voiding. The pudendal nerve, as described in the section on pelvic circulation, also originates from the sacral cord and innervates the urethral rhabdosphincter. Afferent or sensory fibers, which are important during the storage phase, are carried via the pelvic, hypogastric, and pudendal nerves (9).

### ***Genital Structures***

The uterus is a fibromuscular organ with dimensions and exact orientation that vary considerably depending on hormonal status, age, and parity (3). It is comprised of two



**Fig. 12.** Urethral histology. E, urethral epithelium; S, surrounding vascular spongiosum; M, outer musculofascial layer.

parts, an upper muscular corpus and a lower fibrous cervix. The uterus is lined by a unique epithelium, the endometrium. The external cervical os is lined by squamous epithelium and more proximally by columnar epithelium. The uterus and cervix are supported by surrounding ligaments and fascia (Fig. 14). The cardinal ligaments are dense, triangular condensations of pelvic fascia that originate from the pelvic sidewall and insert into the lateral aspects of a fascial ring encircling the uterine cervix. The cardinal ligaments support the uterus and vaginal apex and, as mentioned, fuse with the pubocervical fascia, providing support for the bladder base (2). The cardinal ligaments fuse posteriorly with the uterosacral (sacrouterine) ligaments, which stabilize the uterus, cervix, and upper vagina posteriorly to the sacrum. In addition, the broad ligaments are fascial condensations covered by anterior and posterior sheets of peritoneum, which provide lateral support for the more superior portion of the uterus. Many important structures travel within the broad ligament, the fallopian tubes, the round and ovarian ligaments, and the uterine and ovarian vessels. The uterine arteries enter near the junction of the corpus and the cervix; however, this position varies considerably (Fig. 11) (3).

The vagina is a hollow viscus with shape that is determined by the structures that surround it. The vagina receives blood supply from downward branches of the uterine artery and vaginal branches of the internal iliac (3). It is made up of an inner epithelium layer, a stratified squamous epithelium, an inner muscular layer, and an outer fibrous layer. The upper vagina is maintained in a nearly horizontal axis by fascial support and inferiorly by the LAG shelf on which it is resting (Fig. 15). When this orientation is altered postpartum or iatrogenically, vaginal prolapse may occur (2). Maintaining functional depth and an adequate hiatus are important considerations in women who desire future sexual activity.

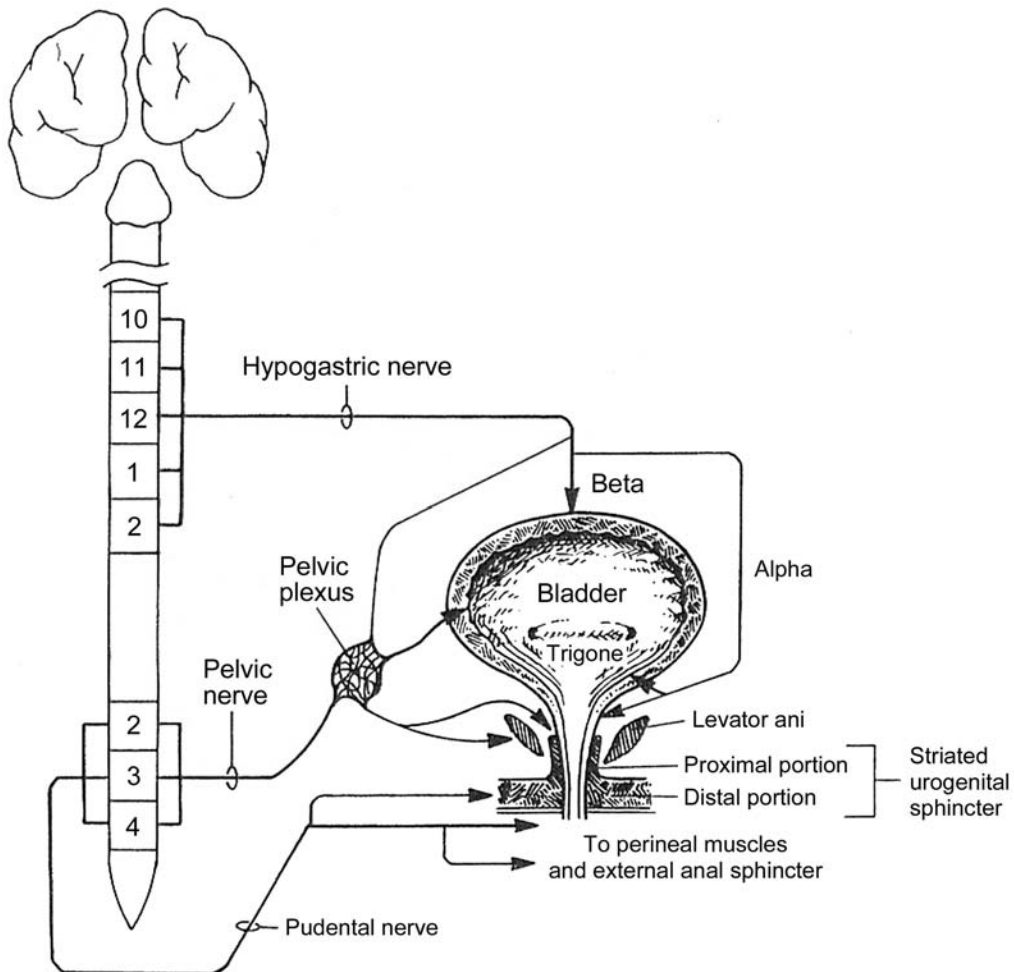


Fig. 13. Bladder and urethral innervation and mechanism of continence. (From ref. 17.)

## PERINEUM

The anatomic boundaries of the perineum are the pubis, thighs, and buttocks and can be divided into an anterior urogenital and a posterior anal triangle by drawing a line between the ischial tuberosities (Fig. 3) (7). The perineal body is a tendinous structure in the midline of the perineum between the anus and the vaginal introitus, which provides a central point of fixation for the superficial transverse perineal muscle, the striated urogenital sphincter (formerly the deep transverse perineal muscle), the bulbocavernosus muscles anteriorly, and the external anal sphincter posteriorly (3). The perineal membrane, formerly the urogenital diaphragm, refers principally to the deep transverse perineal muscles and associated superior and inferior fascia. This fibromuscular sheet is triangular shaped, with openings for the urethra and vagina, and supports the anterior triangle. Voluntary contraction of the perineal membrane results in vaginal compression and provides stability to the perineum during periods of increased intrabdominal pressure.

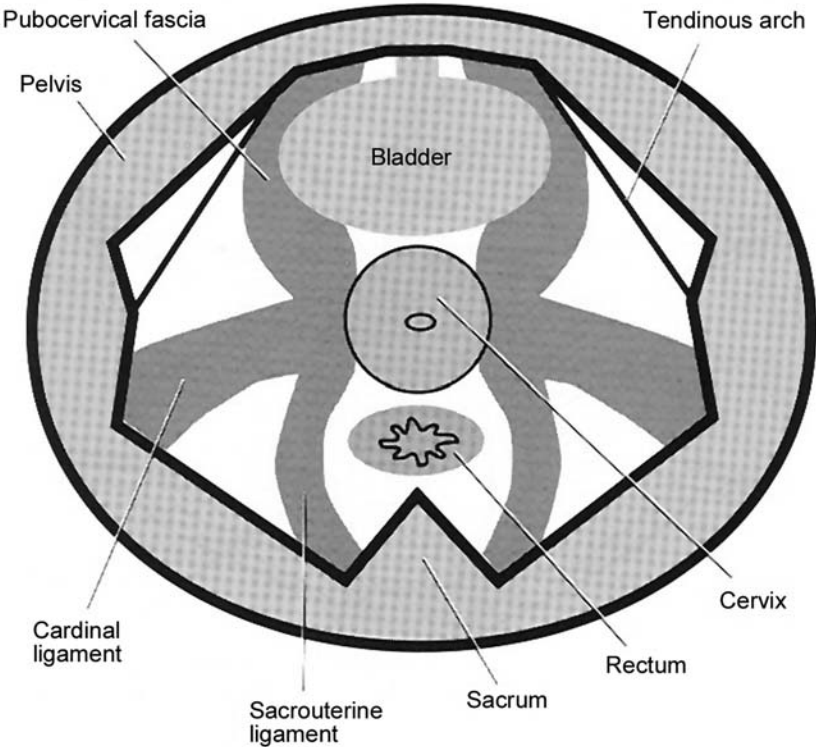


Fig. 14. Schematic diagram of normal uterine support. (From ref. 7.)

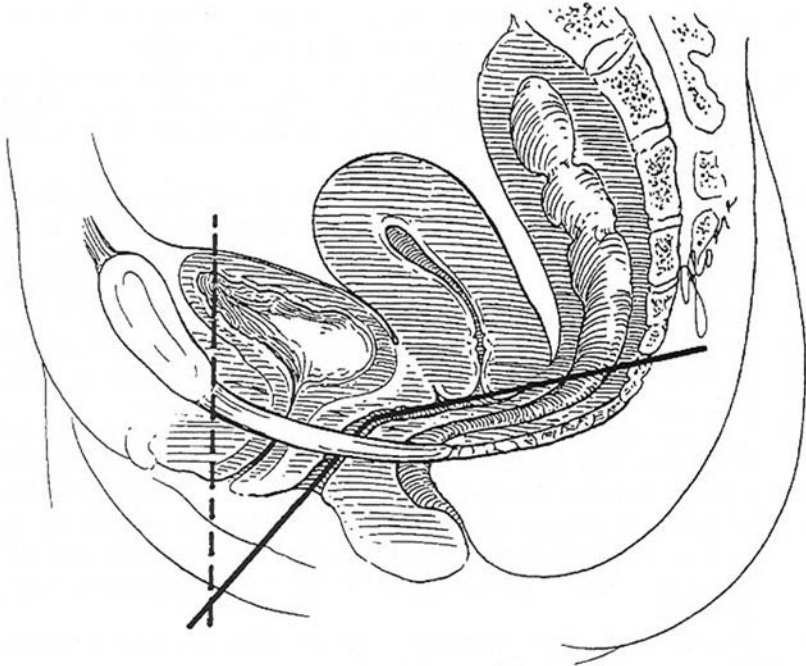
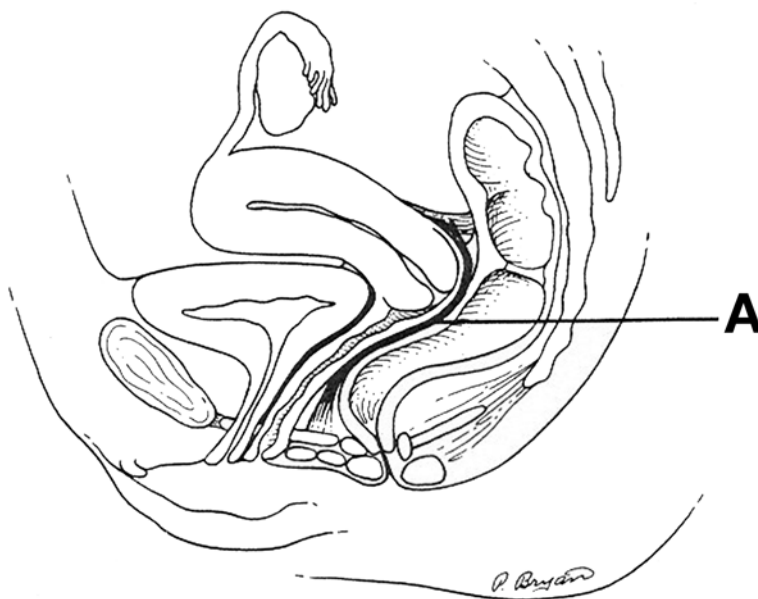


Fig. 15. Schematic diagram of normal vaginal support. (From ref. 7.)

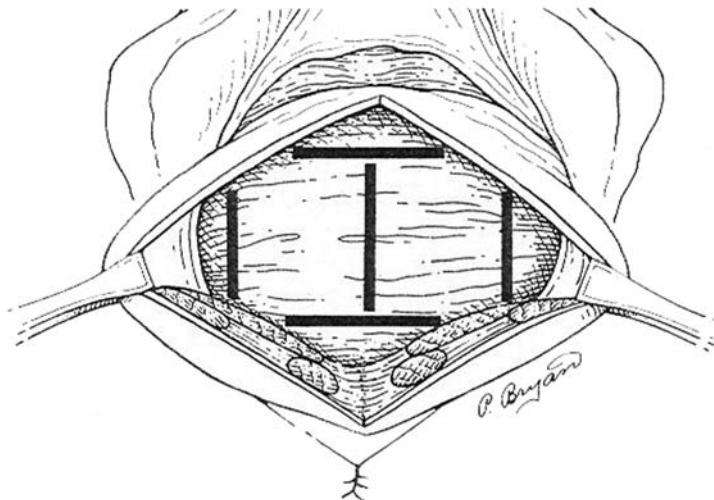


**Fig. 16.** Schematic diagram of the rectovaginal septum. (From ref. 11.)

The clitoris is located at the apex of the urogenital triangle and is composed of a glans, shaft, and crura. The shaft is anchored to the pubic bone by the suspensory ligament. The crura run posterolaterally along the pubic rami. The urogenital triangle is bordered laterally by the ischiocavernosus muscles, which originate from the ischial tuberosities and the free posterior crura and insert onto the anterior crura and the body of the clitoris (3). The bulbocavernosus muscles run on each side of the vaginal vestibule beneath the labia majora from the pubis to the perineal body. Beneath the bulbocavernosus muscles are the vestibular bulbs, which are highly vascular erectile tissue. The Bartholin gland is found at the inferior aspect of the bulb; therefore, care should be taken to minimize bleeding when dissecting in this area (3). Of clinical significance, a fibrous fat pad lies just beneath the skin of the labia majora, which can be used as a vascularized flap (Martius flap) when a multilayer vaginal closure is necessary. The strength of the graft is derived from termination of the round ligament into the fibrofatty tissue. The flap can be based inferiorly off the inferior labial artery, a branch of the internal pudendal, or superiorly off the superficial external pudendal artery (10).

The posterior triangle is described briefly as it relates to posterior vaginal wall prolapse. The anatomy and function of the anal continence mechanism is complex and is outside the scope of this text; however, defecatory, voiding, and sexual issues are all interrelated and should be addressed during evaluation. The apex of the posterior or anal triangle is the coccyx. The anus is located in the midline. An important space within the posterior triangle is the posterior aspect of the ischiorectal fossa through which the pudendal vessels and nerves traverse. This fossa is bordered by the LAG superomedially, the obturator internus anterolaterally, and the skin inferiorly (3).

The rectovaginal septum is an extension of the peritoneal cul-de-sac between the posterior vagina and the rectum to the perineal body, separating the urogenital and rectal compartments (Fig. 16) (11). The septum is comprised of two distinct layers: the vaginal



**Fig. 17.** Schematic diagram of various breaks in the rectovaginal septum seen in patients with rectoceles. (From ref. 11.)

wall fascia and the prerectal fascia. It is only distally, at the perineal body, that they fuse. Proximally, the septum merges with the cardinal-uterosacral ligament complex, providing support for the posterior vaginal apex. Laterally, this fascial layer attaches to the ischiococcygeus and pubococcygeus just below the ATRF (11). Furthermore, the pubococcygeus muscle provides support for the proximal posterior vagina and intrapelvic rectum. Transverse detachment of the rectovaginal septum from the perineal body may result in a distal rectocele, or disruption of the prerectal fascia may result in a more proximal rectocele (Fig. 17).

## CONCLUSION

Each year in America an estimated 400,000 women undergo surgery for pelvic floor dysfunction. Nearly 30% of the surgeries performed are reoperations (12). Clinicians must have a clear understanding of functional anatomy and pathophysiology to accurately diagnose and effectively treat disorders of the female pelvis. Successful pelvic floor reconstruction requires consideration of the primary concern and any other often-associated pelvic floor disorders.

## REFERENCES

1. Brooks JD. Anatomy of the lower urinary tract and male genitalia. In: *Campbell's Urology*, 8th ed. (Walsh PC, Retik AB, Vaughan ED, Wein AJ, eds.), Saunders, Philadelphia, 2002;41–80.
2. Klutke CG, Siegel CL. Functional female pelvic anatomy. *Urol Clin North Am* 1995;22:487–498.
3. De Lancey JO. Surgical anatomy of the female pelvis. In: *Te Linde's Operative Gynecology*, 9th ed. (Rock JA, Jones HW, eds.), Lippincott, Williams, and Wilkins, Philadelphia, 2003;63–93.
4. Strohbehm K. Normal pelvic floor anatomy. *Obstet Gynecol Clin North Am* 1998;25:683–705.
5. Whiteside JL, Walters MD. Anatomy of the obturator region: relations to a trans-obturator sling. *Int Urogynecol J* 2004;15:223–226.
6. Bartsch G, Strasser H, Poisel S. Surgical anatomy of the genitourinary system. In: *Adult and Pediatric Urology*, 4th ed. (Gillenwater JY, Grayhack JT, Howards SS, Mitchell ME, eds.), Lippincott, Williams, and Wilkins, Philadelphia, 2002;3–46.

7. Wahle G, Young G, Raz S. Anatomy and pathophysiology of pelvic support. In: *Female Urology, 2nd ed.* (Raz S, ed.), Saunders, Philadelphia, 1996;57–72.
8. Kabalin J. Surgical anatomy of the retroperitoneum, kidneys and ureter. In: *Campbell's Urology, 8th ed.* (Walsh PC, Retik AB, Vaughan ED, Wein AJ, eds.), Saunders, Philadelphia, 2002;3–40.
9. Chancellor M, Yoshimura N. Physiology and pharmacology of the bladder and urethra. In: *Campbell's Urology, 8th ed.* (Walsh PC, Retik AB, Vaughan ED, Wein AJ, eds.), Saunders, Philadelphia, 2002; 831–886.
10. Stothers L, Chopra A, Raz S. Vesicovaginal fistula. In: *Female Urology, 2nd ed.* (Raz S, ed.), Saunders, Philadelphia, 1996;490–506.
11. Richardson AC. The rectovaginal septum revisited: its relationship to rectocele and its importance to rectocele repair. *Clin Obstet Gynecol* 1993;36:976–983.
12. DeLancey JO. The hidden epidemic of pelvic floor dysfunction: achievable goals for improved prevention and treatment. *Am J Obstet Gynecol* 2005;192:1488–1495.
13. Hinman F Jr. *Atlas of Urosurgical Anatomy*, Saunders, Philadelphia, 1993.
14. Paraiso MFR, Falcone T. Laparoscopic surgery for genuine stress incontinence and pelvic organ prolapse. In: *Urogynecology and Reconstructive Pelvic Surgery* (Walters MD, Karram MM, eds.), Mosby-Yearbook, St. Louis, MO, 1999, p. 199:213–226.
15. Raz S, Little NA, Juma S. Female urology. In: *Campbell's Urology, 6th ed.* (Walsh PC, Retik AB, Stamey TA, Vaughan ED Jr, eds.), Saunders, Philadelphia, 1992, p. 2783:2782–2828.
16. Netter FH. *Atlas of Human Anatomy*. Icon Learning Systems, Teterboro, NJ, 2003.
17. Benson JT, Walters MD. Neurophysiology of the lower urinary tract. In: *Urogynecology and Reconstructive Pelvic Surgery* (Walters MD, Karram MM, eds.), Mosby-Yearbook, St. Louis, MO, 1999;31–43.

---

# 2 Neurophysiological Control of Bladder Function

---

*Toby C. Chai, MD, FACS and Todd J. Lehrfeld, MD*

## CONTENTS

INTRODUCTION  
HIGHER LEVEL CENTRAL NERVOUS SYSTEM CONTROL  
OF MICTURITION AND STORAGE  
CONCLUSION  
REFERENCES

---

## INTRODUCTION

Normal bladder function is characterized by storage of adequate volumes of urine at low pressures without leakage and without unwanted bladder sensations (urgency) interspersed with short time periods of efficient unimpeded expulsion of urine. Tightly regulated neural control of the bladder and outlet (urethral complex, i.e., internal and external urethral sphincters) is required for the proper integration of urinary storage and expulsion. The bladder and internal urethral sphincter are comprised of smooth muscle fibers, whereas the external urethral sphincter is composed of skeletal striated muscle fibers. Although we have learned much of bladder neurophysiology from studying animal models, the actual pathological defects in bladder dysfunction frequently encountered clinically, such as urinary incontinence (both stress and urge), nonneurogenic detrusor overactivity, hypersensitive bladder syndromes (e.g., overactive bladder [OAB] and interstitial cystitis [IC]), and nonobstructive urinary retention, remain elusive. Animal models have helped test etiological theories and define treatment modalities for disorders of micturition and urinary continence. This review focuses on data obtained from experiments performed with human tissues if available.

There is less published literature about neurophysiological control of urethral function compared with that of the bladder. In addition, the functional framework of the urethral complex is opposite that of the bladder: during storage, the urethra is contracted, and the bladder is relaxed; during expulsion, the urethra is relaxed, and the bladder is contracted. Therefore, treatments designed to reverse bladder dysfunction would require opposite effects on the urethra.

The bladder is unique among autonomically innervated organs because of the high degree of conscious or voluntary control that can be exerted on its function. This means that well-established neural connections from higher neural centers (e.g., cerebral cortex) to the bladder exist. Therefore, the neural control of bladder function is complex, and a neurophysiological defect anywhere from the cerebral cortex to the bladder can result



in bladder dysfunction. This complexity in part explains our limited understanding of the pathophysiology of bladder dysfunction and the limited treatments available for these bladder problems. This chapter's intent is to present a review of current literature on bladder neurophysiology and its clinical relevance. Literature from experimental studies utilizing humans or human bladder tissues is emphasized for maximal clinical relevance.

### *Bladder Efferent Pathway*

#### **PERIPHERAL EFFERENT NEURAL PATHWAYS**

The motor pathway to the bladder is *autonomic*, meaning that there is at least one synapse prior to the synapse at the motor neuromuscular junction (nerve terminal and bladder smooth muscle fiber). The bladder efferent neuronal bodies originate from the S2–S4 spinal cord within the sacral parasympathetic nucleus, which is situated between the ventral and dorsal horn gray matter (Fig. 1, area 5). The preganglionic axons exit the spinal cord in the ventral roots and merge into the periphery in the pelvic nerves. These pelvic nerves synapse at ganglia within the periphery at the pelvic plexus or even within the bladder wall (intravesical ganglia; Fig. 1B) (1,2). The postganglionic nerves then synapse onto the bladder smooth muscle cells. The end effect of activation of the efferent pathway is a coordinated, efficient bladder contraction that results in bladder emptying.

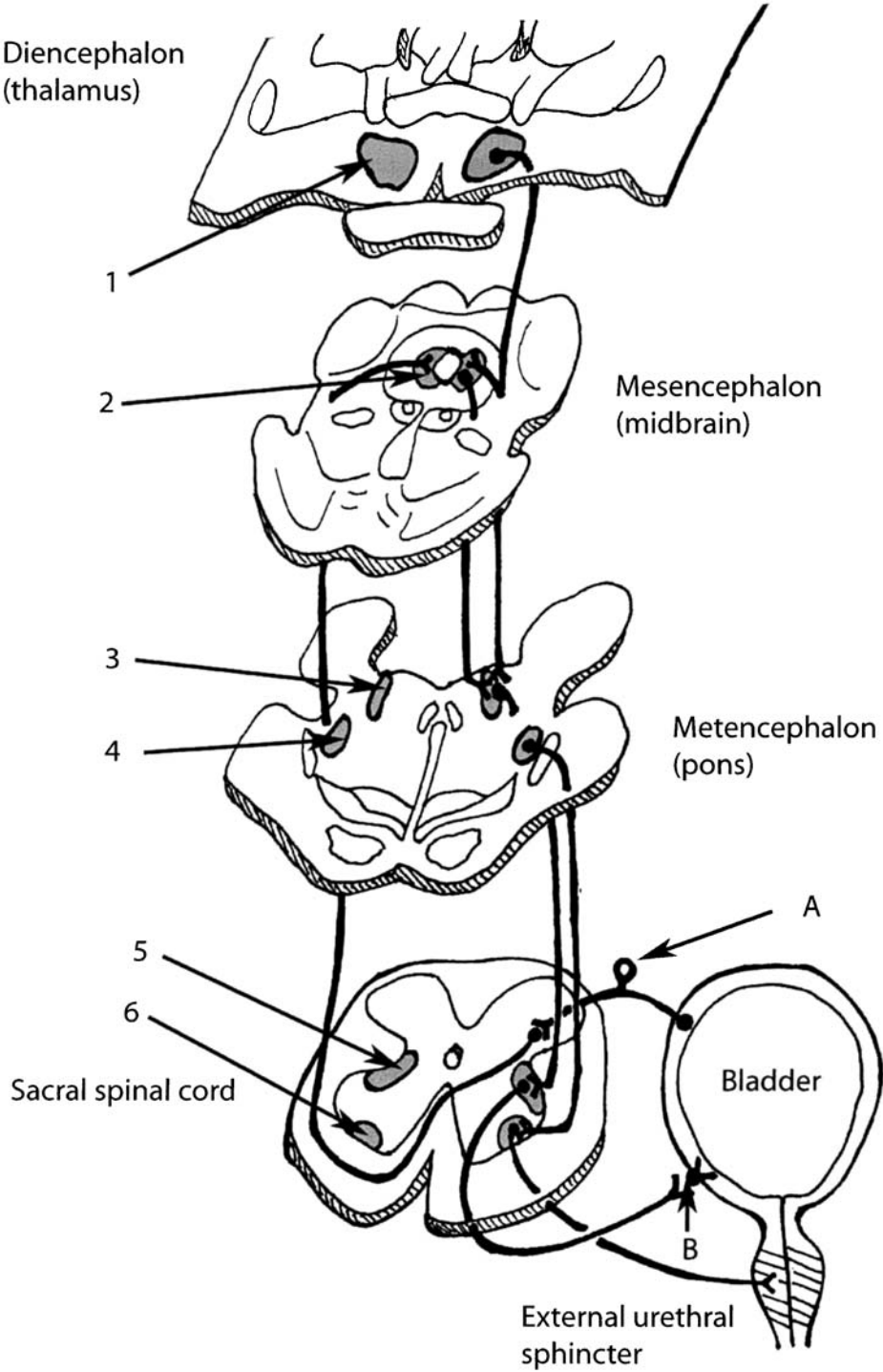
The sympathetic motor neuronal bodies reside in the thoracolumbar spinal cord. The preganglionic motor fibers exit the spinal cord within the ventral nerve roots. The preganglionic fibers synapse on the postganglionic nerve at the paravertebral ganglia, which lie close to the spinal cord. The postganglionic nerve becomes the hypogastric nerve, closely following the hypogastric artery to innervate the bladder.

Although the role of the sympathetic motor innervation in normal bladder function is not totally clear in the human, work in the cat suggests that it has a role in maintenance of urinary continence. Activation of sympathetic outflow to the bladder via stimulation of bladder afferents in anesthetized cats caused the bladder to relax and urethra to contract (3,4). This vesicosympathetic pathway may have importance in maintaining continence in humans. The relaxation of the bladder may be through inhibition of the parasympathetic intravesical ganglia or through activation of  $\beta_3$ -adrenergic receptor ( $\beta_3$ -AR) on the bladder. The human bladder smooth muscle has been found to have  $\beta_3$ -AR, which may mediate its relaxation (5). Therefore, the concept of using a  $\beta_3$ -AR agonist for detrusor overactivity is under active investigation.

#### **DETRUSOR SMOOTH MUSCLE SIGNALING**

The neurotransmitter released by the preganglionic parasympathetic nerves is acetylcholine. The postganglionic parasympathetic nerves also release acetylcholine, which binds to muscarinic receptors (M2 and M3) on the bladder smooth muscle cells to initiate the excitation-contraction event. Bladder smooth muscle contraction mechanisms have been extensively studied because it is easy to obtain smooth muscle from animal models, both in normal and experimentally induced diseased states (e.g., bladder outlet obstruction [BOO], diabetes, inflammation models). One must remember, however, that muscle bath experiments are *in vitro* studies in which the bladder has been typically stripped of the urothelium and neural input; thus, the findings from organ baths do not necessarily reflect the complete *in vivo* picture.

In the normal human bladder, although M2 receptors predominate in quantity (70% of total muscarinic receptors), it is actually the M3 receptors (30% of total) that are



**Fig. 1.** 1, medial preoptic (MPO) area; 2, periaqueductal gray (PAG) area; 3, pontine micturition center (PMC), M region, or Barrington's nucleus; 4, L region; 5, sacral parasympathetic nucleus; 6, Onuf's nucleus; A, dorsal root ganglia; B, intramural ganglia. See text for details.

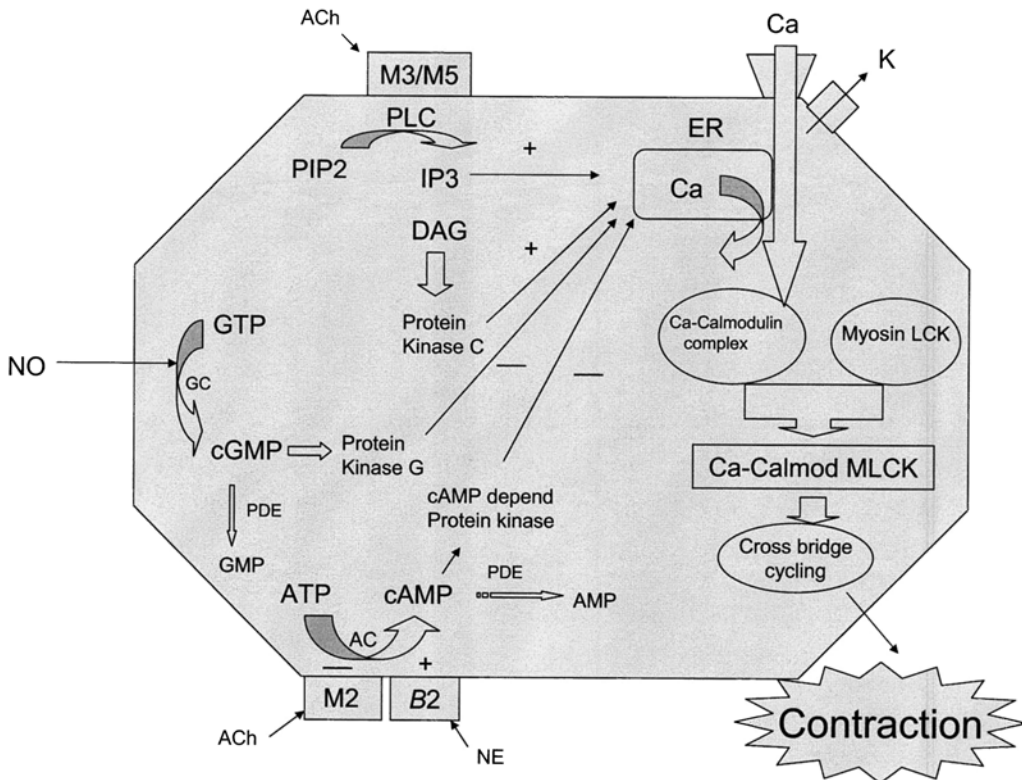
responsible for contractions measured in an organ bath (6,7). However, M2 receptors, not M3 receptors, mediate organ bath contractions in spinal cord-injured humans (8). It was also shown that mRNA for M3 receptor decreased as a function of aging in the human bladder (9), possibly explaining decreased contractility of the bladder in the elderly. Another study suggested that unique variations in expression of M2 and M3 receptors could explain variable responses to antimuscarinics (10).

It has always been supposed that the mechanism of action of antimuscarinics in treating patients with urinary urgency, frequency, and urge incontinence (OAB) is blockade of presumed unwanted and “uninhibited” bladder smooth muscle contractions mediated by either M2 or M3 receptors. Whether these presumed pathological detrusor smooth muscle contractions are pathophysiological, whether there is an alteration in muscarinic receptor phenotype distribution (M2:M3 ratio), or whether the primary pathology in OAB is in the motor efferent pathway is not currently known. The physiological defect in OAB may not lie completely in the bladder motor pathway and may also involve the sensory pathway. It certainly would seem logical that urinary urgency is a sensory-initiated phenomenon. Nevertheless, the efficacy of antimuscarinics for treatment of OAB symptoms has been shown in multiple large clinical trials (11).

Muscarinic receptor activation can initiate various cascades of secondary messenger events, which ultimately increases intracellular cytosolic calcium, the trigger for smooth muscle contraction (Fig. 2). The prototypical smooth muscle contraction signaling by increased cytosolic calcium is best explained by M3 receptor activation. M3 activation results in activation of phospholipase C, which hydrolyzes phosphoinositide-4, 5-bisphosphate with subsequent release of inositol triphosphate (IP3) and diacylglycerol (DAG) (12). DAG activates protein kinase C, which can increase cytosolic calcium through release of intracellular stores. IP3 activates release of calcium from the sarcoplasmic reticulum. These events ultimately result in increased cytosolic calcium. Surprisingly, this prototypical sequence of events of phospholipase C activation and IP3 and DAG release was not critical to M3-mediated human detrusor smooth muscle contraction (13), demonstrating that there are species differences in secondary messenger events even if M3 receptor activation is the upstream event. The contractions in human detrusor smooth muscle were largely mediated by calcium influx through L-type, voltage-dependent channels (Fig. 2) (nifedipine-sensitive channels).

The mechanism by which M2 receptors mediate detrusor smooth muscle contraction is less direct than for M3 receptors, although increased cytosolic calcium is still the ultimate event (Fig. 2) (14,15). It is important to understand downstream events of M2 receptor-mediated contractions as it has been shown that human bladders obtained from spinal cord-injured patients have M2-mediated contractions (8). Activated M2 receptors interact with the Gi unit of the G-family of signaling proteins. Gi then inhibits adenylyl cyclase, resulting in decreased cytosolic adenosine monophosphate (cAMP). If cAMP is decreased by M2 receptor activation, then cytosolic calcium will be increased, which can lead to muscle contraction. Increased intracellular cAMP is also the key event when the  $\beta$ -adrenergic receptor is activated, with resultant adenylyl cyclase activity (Fig. 2). M2 receptor activation could induce smooth muscle contraction by counteracting sympathetic effects on detrusor smooth muscle.

Receptors other than M3 may also mediate bladder contractions. This was based on findings that bladder contractions in animals were resistant to both cholinergic and adrenergic blockade (termed nonadrenergic, noncholinergic-mediated bladder contractions) (16). For example, in humans, it was shown that the purinergic agent adenosine



**Fig. 2.** Representation of a detrusor smooth muscle cell. See text for details.

triphosphate (ATP) can cause bladder smooth muscle contractions (17). These ATP-mediated contractions occur through the P2X1 receptors on the bladder smooth muscle (18). In disease states, bladder contractions could shift from muscarinic- to purinergic-mediated mechanisms. In humans, it has been shown that bladder smooth muscle strips obtained from patients with IC are much more responsive to ATP compared to control human bladder strips (19). Also, in aging, the human detrusor has an increased purinergic trigger as the basis for its contractions (20).

The excitation-coupling that occurs in the detrusor smooth muscle is triggered by increased cytosolic calcium. Calcium binds to calmodulin and causes a conformational change in calmodulin-exposing sites, which interact with myosin light-chain kinase. Myosin light-chain kinase activation phosphorylates myosin light chain (MLC) protein, which results in cycling of myosin crossbridges (heads) along actin filaments and the development of tension (Fig. 2). Furthermore, phosphorylation of MLC activates myosin adenosine triphosphatase ATPase, which hydrolyzes ATP to provide energy for detrusor smooth muscle contraction. A secondary excitation-coupling mechanism that is calcium independent can also occur via the rho-rho-kinase pathway. This pathway is dependent on inhibition of MLC dephosphorylation (via inhibition of myosin phosphatase; 21). The rho-rho-kinase pathway has been shown to mediate human detrusor smooth muscle contractions (13,22). The rho-rho-kinase pathway may represent another therapeutic target, assuming either it is pathologically altered in disease or it can be harnessed to compensate for defects in the calcium-dependent excitation-coupling pathway.

One clinical condition that seems to be directly related to the efferent system is that of idiopathic nonobstructive urinary retention. When patients present in urinary retention without identifiable BOO, it is presumed that the detrusor smooth muscle is dysfunctional in its ability to generate a contraction. However, treatment with oral urecholine, a muscarinic agonist, has not proven to be uniformly useful clinically even though the first description of its use was over half a century ago (23). Failure of the smooth muscle to contract may be caused by a variety of reasons, including failure of the efferent nerves to release acetylcholine, failure of the urethra or bladder outlet (pelvic floor) to relax, or failure of excitation-contraction coupling at any point along the pathway from muscarinic receptor activation to force generation. A synopsis of the complexities of smooth muscle function in the lower urinary tract has been published (24).

### **CLINICAL MEASURES OF BLADDER EFFERENT PATHWAY**

The clinical tool used to measure detrusor contraction is the cystometrogram. An increase in intravesical pressure is measured during a detrusor contraction. When simultaneous uroflowmetry is obtained during the voiding phase of the cystometrogram, a pressure-flow study (PFS) is created. The primary goal of analyzing components of the PFS data (e.g., maximum detrusor pressure, maximum urinary flow rate) is to determine whether there is an element of BOO. BOO should result in a high detrusor contraction pressure with decreased maximal flow rate. Various mathematical constructs derived from the PFS data have been proposed to help stratify patients into the obstructed vs nonobstructed category (25,26).

Although the goal of the PFS is to determine the presence of BOO, using an occlusive bladder catheter to measure isovolumetric bladder contraction pressure has been advocated to measure detrusor contractile strength (27). Impaired detrusor contractility has been underrecognized (28), especially if isovolumetric bladder contraction pressures are not determined. Currently, the primary and most effective treatment of detrusor failure remains intermittent clean catheterization.

## ***Bladder Afferent Pathway***

### **AFFERENT NEURAL PATHWAYS**

Conventionally, the bladder afferent pathway begins with sensory nerve endings within the bladder wall, which is responsive or triggered by stretch (29). Traditionally, it was thought that the afferent fibers terminated in the lamina propria. However, recently sensory afferent fibers were seen to extend into the rat bladder urothelium, intermingling with urothelial cells (30). In humans, substance P-containing nerve terminals (a marker for sensory fibers) have been found to be in close approximation to the urothelium (31). These fibers are part of the bipolar sensory nerve with the neural soma (bodies) residing in the dorsal root ganglia. The other end of the sensory nerve fiber terminates in the dorsal horn of the gray matter in the spinal cord, where descending pathways can modulate afferent input (32). Furthermore, afferent fibers can synapse onto the sacral parasympathetic nuclei to modulate the efferent outflow to the bladder (33).

The bladder sensory nerves travel in the periphery within the pelvic, hypogastric, and pudendal nerves. These sensory nerves are comprised of A- $\delta$  myelinated fibers and c-fiber unmyelinated. The A- $\delta$  fibers respond to pressure and stretch and initiate the micturition reflex (34). The c-fibers are normally silent, but in animal models with experimentally injured states such as inflammation and spinal cord injury, these fibers

are activated (35,36). Patients with BOO (males and females) have been shown to have a positive bladder ice-water test, which correlates with activation of the c-fibers (37). C-fibers, in addition to responding to ice water, also respond to capsaicin, a neurotoxin isolated from hot peppers. Capsaicin, and its derivatives such as resiniferatoxin, has been proposed to be used to block activated c-fibers in disease states. It has been proposed that IC results from activation of c-fibers, which can then transmit signals of pain and burning. However, a large, multicenter, placebo-controlled clinical trial of intravesical resiniferatoxin for IC symptoms showed no clinical benefit (38), arguing against c-fiber activation as the cause of IC symptoms.

Studies of the human bladder sensory pathway have been difficult because of lack of appropriate sensory measurement tools and inability to obtain dorsal root ganglia where sensory nerve cells reside. Our understanding of human bladder neurophysiology has traditionally focused on the efferent pathway primarily because of resources available to study bladder smooth muscle physiology, with most resources borrowed from other areas, such as vascular smooth muscle. However, advances in treatment for bladder symptoms such as urinary frequency, urinary urgency, and bladder pain require better understanding of how bladder sensory signals are processed. A review of bladder sensory processing has been published (39).

The neurotransmitters responsible for sensation in the human bladder, whether in normal or diseased states, is not completely known. Putative sensory neurotransmitters derived from animal studies include substance P, calcitonin gene-related peptide (CGRP) and corticotrophin releasing factor (CRF) (40,41). The importance of P2X3/P2X2 purinergic receptors to bladder sensory processing has been shown with knockout animal models. P2X3 and P2X2 knockout mice have increased bladder capacity and decreased voiding frequency consistent with decreased afferent signaling into the micturition reflex (42).

## UROTHELIAL AFFERENT SIGNALING

The bladder urothelium has been conventionally thought to function only as a barrier, protecting the underlying stroma from potential urinary irritants. The bladder urothelial cell has been shown to have neuronal-like properties (43). See Fig. 3 for the graphical representation of urothelial cell signaling mechanisms. The urothelial cell can release neurotransmitters such as ATP (44–46), nitric oxide (47), and acetylcholine (20). The urothelial cell also expresses receptors that are typical signal transduction receptors found on neurons, including muscarinic receptors (48), TRPV1 or “hot” receptors (30,49), TRPM8 or “cool” receptors (49), and purinergic receptors P2X3 and P2X2 (50,51). The first work to suggest urothelial sensory ability was that by Ferguson et al., which showed that rabbit bladder urothelium releases ATP in response to stretching (44). This finding has been reproduced in other species, including humans, and using different experimental techniques to stretch the urothelium (45,46).

The importance of bladder urothelial cell in bladder sensory signaling has been shown in the human condition of IC. Bladder urothelial cells from patients with IC have increased ATP release in response to stretching (45). Increased ATP released by the urothelial cells could bind to P2X3 receptors on sensory nerve endings within the urothelium to transduce increased sensation during bladder filling, which is a common symptomatic finding in IC. Furthermore, IC cells express more P2X3 and P2X3 receptors, which suggests that the augmented ATP release by the IC urothelial cells could serve an autocrine role (50,51).

### CLINICAL MEASURES OF BLADDER AFFERENT ACTIVITY

The clinical measurement of bladder sensory signals traditionally has been based on urodynamic measurement of three sensory thresholds: first sensation of filling, first desire to void, and strong desire to void (52). Each of these sensations was easily distinguishable from the others. These thresholds have clinical utility, for example, in IC, in which the bladder capacity is significantly diminished because of pain with bladder filling (53). This study also suggested that central processing of pain was altered in patients with IC.

A constant current electrical stimulus was applied to the bladder urothelium via an intravesical electrode to determine sensory thresholds (54). This methodology is purported to provide reliable measures of spinal sensory and peripheral sensory nerve function from the large and small myelinated and unmyelinated nerve fibers.

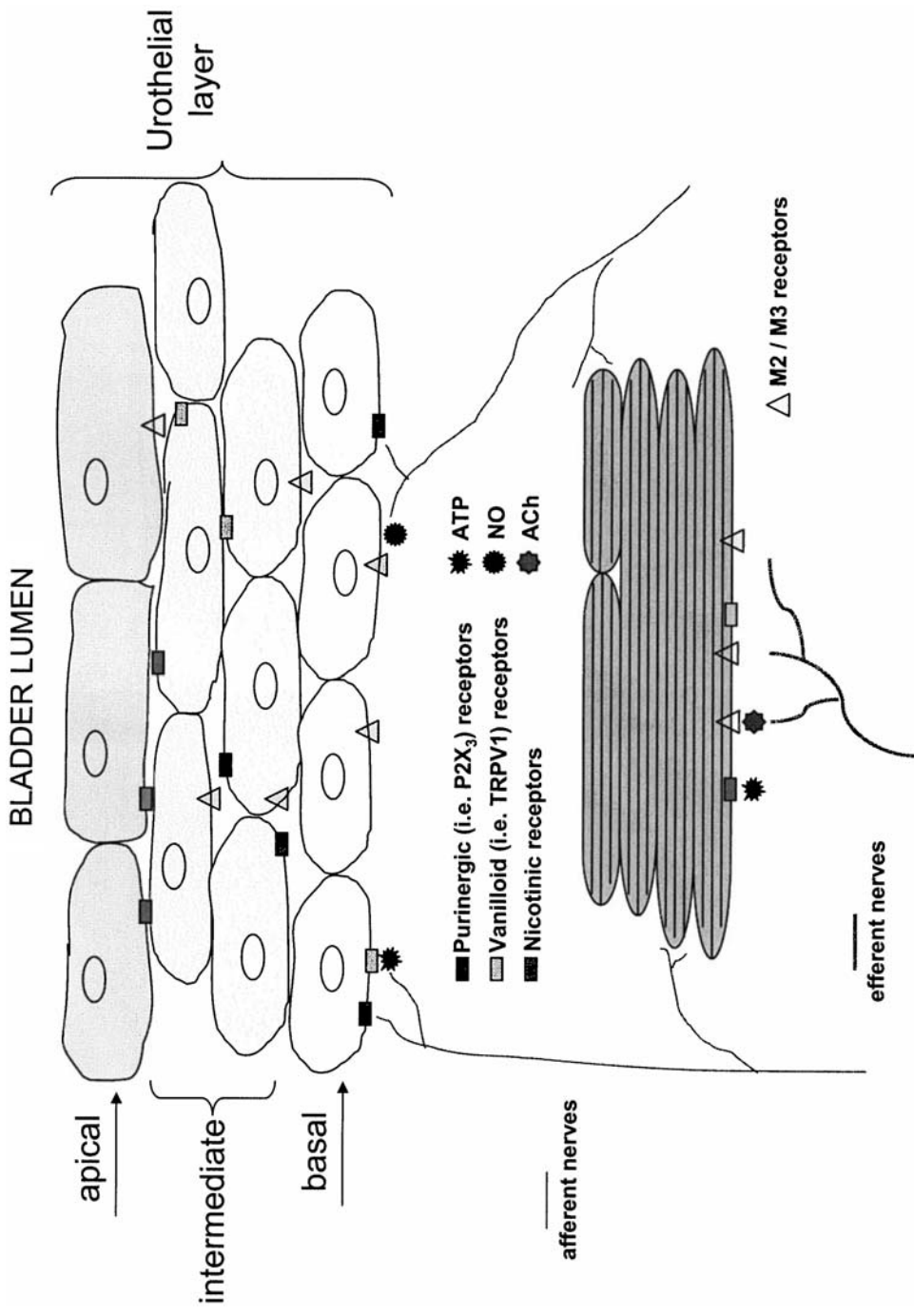
The intent of an ice-water test is to induce a reflex bladder contraction through rapid infusion of ice water into the bladder and activation of the c-fibers, which ultimately trigger bladder contraction. The clinical utility of this method of sensory testing in routine practice has not been established. The high incidence of positive ice-water test in a population of bladder-obstructed patients has been suggested to reflect bladder neuroplasticity (37). The ice-water test is negative in control individuals without voiding symptoms.

### HIGHER LEVEL CENTRAL NERVOUS SYSTEM CONTROL OF MICTURITION AND STORAGE

Bladder afferents transmit bladder sensory signals to the periaqueductal gray (PAG), an area of the midbrain associated with nociception and emotion (Fig. 1, area 2). When the bladder is sufficiently full, the PAG activates the pontine micturition center (PMC, M region, or Barrington's nucleus; Fig. 1, area 3). The neurons from the PMC synapse on the parasympathetic nucleus in the sacral spinal cord (Fig. 1, area 5) to signal a bladder contraction. Centers higher than the PAG may contribute to micturition, including the medial preoptic area of the thalamus (Fig. 1, area 1). The L region of the pontine area projects to Onuf's nucleus (Fig. 1, area 4). Onuf's nucleus is motoneurons that project to the urethral sphincter and pelvic floor. There, activities of the M and L regions are reciprocal. When the M region is activated, the L region must be inhibited (or deactivated) to allow simultaneous bladder contractions and urethral relaxation (55,56).

The high degree of volitional control of bladder function is unique for the bladder compared to other visceral organs. Investigators have studied the human brain using either positron emission tomography or functional magnetic resonance imaging during bladder storage and emptying and have found similar areas of activation, the PMC and PAG, as compared to those found in animal models such as the cat and rat (57–59). There are several other areas that have increased activity, which demonstrates a complex visceral-sensory motor program is involved in continence and micturition. Functional magnetic resonance imaging studies were performed on subjects without neurological disease but with “poor bladder control” on urodynamics. These findings were compared to control patients with normal bladder control (60). Patients with poor bladder control had less activation of the orbitofrontal cortex during bladder filling. Therefore, activity of the orbitofrontal cortex suppresses promicturition signals.

The descending pathways from the PMC to the sacral parasympathetic nucleus respond to adrenergic receptor agonists/antagonists (61,62) in modulating the micturition



**Fig. 3.** Urothelial cells can function as both sensory and transducer cells by receiving and sending signals to neighboring urothelial cells, nerves, or detrusor smooth muscle. See text for details.



reflex. Intrathecal adrenergic agonists augment the micturition reflex (promote bladder emptying), whereas adrenergic antagonists inhibit the micturition reflex (promote bladder storage). These findings are interesting in the context of  $\alpha$ -blocker use in treatment of benign prostatic hyperplasia and lower urinary tract symptoms (LUTS), such as urinary frequency and urgency. The mechanism of action for  $\alpha$ -blockers in treatment of benign prostatic hyperplasia has traditionally been thought to be relaxation of prostatic smooth muscle with subsequent decreased “dynamic” tone of the prostatic urethra (63). Another effect on the prostate may be apoptosis of prostatic glandular cells (64). However, the therapeutic effect of  $\alpha$ -blockers in decreasing urinary frequency and urgency may also target the central descending efferent pathways onto the sacral spinal cord and thereby inhibit the micturition reflex. Furthermore, elevated catecholamine states such as hypertension have been associated with increased LUTS in both animals and humans (65,66). These findings suggest that the beneficial actions of  $\alpha$ -blockers in LUTS may be more complex than previously thought.

The association of depression and urge incontinence further highlights the complexity of bladder control at supraspinal levels. Investigators have found a high association between depression and idiopathic urinary incontinence (e.g., urge incontinence) (67,68). As shown in a rat model, reduction of central nervous system serotonin by clomipramine induced bladder overactivity (69). Furthermore, the bladder overactivity in serotonin-depleted animals could be reversed by treating the animals with the serotonin reuptake inhibitor fluoxetine.

The importance of CRF, a stress-related neurotransmitter, to bladder function was reviewed in ref. 70. The classical role of CRF, a 41-amino acid peptide released by the paraventricular nucleus of the hypothalamus during stress, is stimulation of the anterior pituitary to release adrenocorticotrophic hormone. The adrenocorticotrophic hormone then stimulates stress steroid release from the adrenal cortex. This constitutes the hypothalamus-pituitary-axis response to stress. However, CRF has also been implicated as a neurotransmitter/neuromodulator in a variety of nonhypophyseal neuronal systems, including the neural control of bladder function. The PMC is richly innervated with CRF-containing neurons (71), demonstrating the importance of CRF in bladder control. CRF-containing neurons have also been detected in areas such as the dorsal raphe nucleus (associated with depression), amygdala (relay center for emotional stress and visceral pain), and the hippocampus (associated with memory). These findings help support an association among stress responses, depression, visceral pain, and micturitional disturbances. However, it has not been determined whether a primary bladder condition (such as IC or OAB) leads to depression or whether depression leads to bladder symptoms.

### *Urethral Efferent Pathway*

The urethra is a complex organ in that it is comprised of both smooth and striated muscle. The smooth muscle component is autonomically innervated; whereas the striated portion is somatically innervated. The striated portion of the urethra in both males and females is called the *rhabdosphincter* or the *external urethral sphincter*. The motor neuron for the rhabdosphincter arises from the S2–S4 spinal cord at Onuf’s nucleus, which is more ventrally located than the sacral parasympathetic nucleus in the gray matter. This nerve exits along with the parasympathetic motor nerves within the S2–S4 ventral nerve roots. However, the somatic motor innervation to the rhabdosphincter runs in the pudendal nerve. The rhabdosphincter in the human is comprised of both slow- and

fast-fatigue fibers, possibly explaining the ability of this sphincter to maintain tone over a long period of time (72).

The internal urethral sphincter is located proximal to the rhabdosphincter and is primarily sympathetically innervated (73). The internal urethral sphincter is located in direct proximity to the bladder neck. The sympathetic innervation of the internal urethral sphincter in males allows for closure of this area during ejaculation, thus preventing retrograde semen flow. Furthermore, the traditional mechanism of action of  $\alpha$ -blockers in treatment of LUTS secondary to benign prostatic hyperplasia was thought to be relaxation of this internal urethral sphincter. However, as mentioned in the section on bladder efferent pathways,  $\alpha$ -blockers may also work at the level of the spinal cord, modulating (inhibiting) descending influences on micturition pathways.

A review on the use of duloxetine, a serotonin-norepinephrine reuptake inhibitor, to modulate the contractility of the external urethral sphincter and bladder capacity was published (74). Normally, descending pathways from higher centers promoting urine storage (bladder relaxation and urethral contraction) synapse on Onuf's motor neurons, and the neurotransmitters involved at these synapses are norepinephrine and serotonin. The proposed mechanism of action of duloxetine, then, is augmentation of this urine storage reflex. Therefore, a blockade of reuptake of these neurotransmitters would augment activity of motor neurons in Onuf's nucleus with resultant increased tone of the external urethral sphincter. The effectiveness of duloxetine in decreasing stress urinary incontinence in females has been shown in a placebo-controlled clinical trial (75).

Internal urethral dysfunction has been reported in young males (76–78). These patients have BOO caused by presumed inappropriately high internal urethral tone. Treatment with  $\alpha$ -blockers and incision of the internal urethral sphincter and bladder neck have been described as clinically effective.

The use of animal models to study urethral efferent function can result in different findings in different species. The presence of a high-frequency oscillation of the rat urethral sphincter is seen during electromyographic studies of the urethral muscular function (79). The reason for the oscillations is unknown but probably reflects either facilitation of bladder emptying or behavioral adaptation for marking territory. However, these urethral oscillations were not seen in guinea pigs (80,81). Human urethral electromyographic measurements have not demonstrated this oscillatory urethral muscle activity (82). These findings suggest that the guinea pig urethra is a better model for human urethral function (81).

### *Urethral Afferent Pathway*

The urethral sensory innervation schema is similar to that of the bladder in that sensory nerves can travel along the pudendal, pelvic, and hypogastric nerves (83). The sensory fibers synapse within the dorsal horn of the S2–S4 spinal cord (those that travel in pudendal and pelvic nerves) and the thoracolumbar spinal cord (hypogastric nerve).

Fluid traversing the urethra activates the afferent pathway. These afferent fibers in turn reinforce the bladder to contract more efficiently, probably through facilitatory descending input. This urethrovesical reflex has been shown in humans (84,85). An urethrovesical reflex that promotes urinary storage can also occur. It has been shown that voluntary contraction of the external urethral sphincter can induce inhibition of bladder contractions as well (86). This reflex may be the basis for how Kegel exercises may induce bladder relaxation and prevent urge incontinent episodes.

## CONCLUSION

The neural control of the bladder and the urethra is complex. Integrated knowledge of the current peer-reviewed literature allows a framework in which to correlate clinical bladder emptying and storage problems. A tenet is that findings from animal models should be verified in the human to validate relevancy. Once the pathophysiology is identified and correlated in humans, targeted therapies can be developed. The continued refinement of understanding of bladder/urethral neurophysiology is critical in advancing the care of patients with bladder dysfunction.

## REFERENCES

1. Gilpin CJ, Dixon JS, Gilpin SA, Gosling JA. The fine structure of autonomic neurons in the wall of the human urinary bladder. *J Anat* 1983;137:705–713.
2. Crowe R, Haven AJ, Burnstock G. Intramural neurons of the guinea-pig urinary bladder: histochemical localization of putative neurotransmitters in cultures and newborn animals. *J Auton Nerv Syst* 1986; 15:319–339.
3. de Groat WC, Theobald RJ. Reflex activation of sympathetic pathways to vesical smooth muscle and parasympathetic ganglia by electrical stimulation of vesical afferents. *J Physiol* 1976;259:223–237.
4. de Groat WC, Lalley PM. Reflex firing in the lumbar sympathetic outflow to activation of vesical afferent fibres. *J Physiol* 1972;226:289–309.
5. Takeda M, Obara K, Mizusawa T, et al. Evidence for  $\beta_3$ -adrenoceptor subtypes in relaxation of the human urinary bladder detrusor: analysis by molecular biological and pharmacological methods. *J Pharmacol Exp Ther* 1999;288:1367–1373.
6. Chess-Williams R, Chapple CR, Yamanishi T, Yasuda K, Sellers DJ. The minor population of M3-receptors mediate contraction of human detrusor muscle in vitro. *J Auton Pharmacol* 2001;21: 243–248.
7. Fetscher C, Fleichman M, Schmidt M, Kregge S, Michel MC. M(3) muscarinic receptors mediate contraction of human urinary bladder. *Br J Pharmacol* 2002;136:641–643.
8. Pontari MA, Braverman AS, Ruggieri MR Sr. The M2 muscarinic receptor mediates in vitro bladder contractions from patients with neurogenic bladder dysfunction. *Am J Physiol Regul Integr Comp Physiol* 2004;286:R874–R880.
9. Mansfield KJ, Liu L, Mitchelson FJ, Moore KH, Millard RJ, Burcher E. Muscarinic receptor subtypes in human bladder detrusor and mucosa, studied by radioligand binding and quantitative competitive RT-PCR: changes in ageing. *Br J Pharmacol* 2005;144:1089–1099.
10. Sigala S, Mirabella G, Peroni A, et al. Differential gene expression of cholinergic muscarinic receptor subtypes in male and female normal human urinary bladder. *Urology* 2002;60:719–725.
11. Chapple C, Khullar V, Gabriel Z, Dooley JA. The effects of antimuscarinic treatments in overactive bladder: a systematic review and meta-analysis. *Eur Urol* 2005;48:5–26.
12. Caulfield MP, Birdsall NJM. International Union of Pharmacology. XVII. Classification of muscarinic acetylcholine receptors. *Pharmacol Rev* 1998;50:279–290.
13. Schneider T, Fetscher C, Kregge S, Michel MC. Signal transduction underlying carbachol-induced contraction of human urinary bladder. *J Pharmacol Exp Ther* 2004;309:1148–1153.
14. Braverman AS, Ruggieri MR. Selective alkylation of rat urinary bladder muscarinic receptors with 4-DAMP mustard reveals a contractile function for the M2 muscarinic receptor. *J Recept Signal Transduct Res* 1999;19:819–833.
15. Hegde SS, Choppin A, Bonhaus D, et al. Functional role of M2 and M3 muscarinic receptors in the urinary bladder of rats in vitro and in vivo. *Br J Pharmacol* 1997;20:1409–1418.
16. de Groat WC, Saum WR. Synaptic transmission in parasympathetic ganglia in the urinary bladder of the cat. *J Physiol* 1976;256:137–158.
17. Hoyle CH, Chapple C, Burnstock G. Isolated human bladder: evidence for an adenine dinucleotide acting on P2X-purinoceptors and for purinergic transmission. *Eur J Pharmacol* 1989;174:115–118.
18. Hardy LA, Harvey IJ, Chambers P, Gillespie JI. A putative alternatively spliced variant of the P2X(1) purinoreceptor in human bladder. *Exp Physiol* 2000;85:461–463.
19. Palea S, Artibani W, Ostardo E, Trist DG, Pietra C. Evidence for purinergic neurotransmission in human urinary bladder affected by interstitial cystitis. *J Urol* 1993;150:2007–2012.

20. Yoshida M, Miyamae K, Iwashita H, Otani M, Inadome A. Management of detrusor dysfunction in the elderly: changes in acetylcholine and adenosine triphosphate release during aging. *Urology* 2004;63 (3 suppl 1):17–23.
21. Kitazawa T, Masuo M, Somlyo AP. G protein-mediated inhibition of myosin light-chain phosphatase in vascular smooth muscle. *Proc Natl Acad Sci USA* 1991;88:9307–9310.
22. Takahashi R, Nishimura J, Hirano K, Seki N, Naito S, Kanaide H. Ca<sup>2+</sup> sensitization in contraction of human bladder smooth muscle. *J Urol* 2004;172:748–752.
23. Lee LW. The use of urecholine in the management of chronic urinary retention. *J Urol* 1950;64: 408–412.
24. Christ GJ, Liebert M. Proceedings of the Baltimore Smooth Muscle Meeting: identifying research frontiers and priorities for the lower urinary tract. *J Urol* 2005;173:1406–1409.
25. Abrams PH, Griffiths DJ. The assessment of prostatic obstruction from urodynamic measurements and from residual urine. *Br J Urol* 1979;51:129–134.
26. Schafer W. Analysis of bladder-outlet function with the linearized passive urethral resistance relation, linPURR, and a disease-specific approach for grading obstruction: from complex to simple. *World J Urol* 1995;13:47–58.
27. Griffiths DJ. Assessment of detrusor contractility strength or contractility. *Neurourol Urodynam* 1991; 10:1.
28. Griffiths DJ. Editorial: bladder failure—a condition to reckon with. *J Urol* 2003;169:1011–1012.
29. Bahns E, Halsband U, Janig W. Responses of sacral visceral afferents from the lower urinary tract, colon and anus to mechanical stimulation. *Pflugers Arch* 1987;410:296–303.
30. Birder LA, Kanai AJ, de Groat WC, et al. Vanilloid receptor expression suggests a sensory role for urinary bladder epithelial cells. *Proc Natl Acad Sci USA* 2001;98:13,396–13,401.
31. Wakabayashi Y, Tomoyoshi T, Fujimiya M, Arai R, Maeda T. Substance P-containing axon terminals in the mucosa of the human urinary bladder: pre-embedding immunohistochemistry using cryostat sections for electron microscopy. *Histochemistry* 1993;100:401–407.
32. de Groat WC, Nadelhaft I, Milne RJ, Booth AM, Morgan C, Thor K. Organization of the sacral parasympathetic reflex pathways to the urinary bladder and large intestine. *J Auton Nerv Syst* 1981;3: 135–160.
33. Morgan C, Nadelhaft I, de Groat WC. The distribution of visceral primary afferents from the pelvic nerve to Lissauer's tract and the spinal gray matter and its relationship to the sacral parasympathetic nucleus. *J Comp Neurol* 1981;201:415–440.
34. Habler HJ, Janig W, Koltzenburg M. Myelinated primary afferents of the sacral spinal cord responding to slow filling and distension of the cat urinary bladder. *J Physiol* 1993;463:449–460.
35. Cheng CL, Liu JC, Chang SY, Ma CP, de Groat WC. Effect of capsaicin on the micturition reflex in normal and chronic spinal cord-injured cats. *Am J Physiol* 1999;277:R786–R794.
36. Habler HJ, Janig W, Koltzenburg M. Activation of unmyelinated afferent fibres by mechanical stimuli and inflammation of the urinary bladder in the cat. *J Physiol* 1990;425:545–562.
37. Chai TC, Gray ML, Steers WD. The incidence of a positive ice water test in bladder outlet obstructed patients: evidence for bladder neural plasticity. *J Urol* 1998;160:34–38.
38. Payne CK, Mosbaugh PG, Forrest JB, et al. and the ICOS RTX Study Group (Resiniferatoxin Treatment for Interstitial Cystitis). Intravesical resiniferatoxin for the treatment of interstitial cystitis: a randomized, double-blind, placebo controlled trial. *J Urol* 2005;173:1590–1594.
39. Wyndaele JJ, De Wachter S. The basics behind bladder pain: a review of data on lower urinary tract sensations. *Int J Urol* 2003;suppl:S49–S55.
40. de Groat WC. Neuropeptides in pelvic afferent pathways. *Experientia* 1987;43:801–813.
41. Kawatani M, Suzuki T, de Groat WC. Corticotropin releasing factor-like immunoreactivity in afferent projections to the sacral spinal cord of the cat. *J Auton Nerv Syst* 1996;61:218–226.
42. Cockayne DA, Dunn PM, Zhong Y, et al. P2X2 knockout mice and P2X2/P2X3 double knockout mice reveal a role for the P2X2 receptor subunit in mediating multiple sensory effects of ATP. *J Physiol* 2005;567:621–639.
43. Birder L. Role of the urothelium in bladder function. *Scand J Urol Nephrol* 2004;suppl(215): 48–53.
44. Ferguson DR, Kennedy I, Burton TJ. ATP is released from rabbit urinary bladder epithelial cells by hydrostatic pressure changes—a possible sensory mechanism? *J Physiol* 1997;505:503–511.
45. Sun Y, Keay S, De Deyne PG, Chai TC. Augmented stretch activated adenosine triphosphate release from bladder uroepithelial cells in patients with interstitial cystitis. *J Urol* 2001;166:1951–1956.

46. Sun Y, MaLossi J, Jacobs SC, Chai TC. Effect of doxazosin on stretch-activated adenosine triphosphate release in bladder urothelial cells from patients with benign prostatic hyperplasia. *Urology* 2002;60:351–356.
47. Birder LA, Apodaca G, De Groat WC, Kanai AJ. Adrenergic- and capsaicin-evoked nitric oxide release from urothelium and afferent nerves in urinary bladder. *Am J Physiol* 1998;275:F226–F229.
48. Chess-Williams R. Muscarinic receptors of the urinary bladder: detrusor, urothelial and prejunctional. *Auton Autacoid Pharmacol* 2002;22:133–145.
49. Stein RJ, Santos S, Nagatomi J, et al. Cool (TRPM8) and hot (TRPV1) receptors in the bladder and male genital tract. *J Urol* 2004;172:1175–1178.
50. Sun Y, Chai TC. Up-regulation of P2X3 receptor during stretch of bladder urothelial cells from patients with interstitial cystitis. *J Urol* 2004;171:448–452.
51. Tempest HV, Dixon AK, Turner WH, Elneil S, Sellers LA, Ferguson DR. P2X and P2X receptor expression in human bladder urothelium and changes in interstitial cystitis. *BJU Int* 2004;93:1344–1348.
52. Wyndaele JJ. The normal pattern of perception of bladder filling during cystometry studied in 38 young healthy volunteers. *J Urol* 1998;160:479–481.
53. Ness TJ, Powell-Boone T, Cannon R, Lloyd LK, Fillingim RB. Psychophysical evidence of hypersensitivity in subjects with interstitial cystitis. *J Urol* 2005;173:1983–1987.
54. Ukimura O, Ushijima S, Honjo H, et al. Neuroselective current perception threshold evaluation of bladder mucosal sensory function. *Eur Urol* 2004;45:70–76.
55. Holstege G, Kuypers HG, Boer RC. Anatomical evidence for direct brain stem projections to the somatic motoneuronal cell groups and autonomic preganglionic cell groups in cat spinal cord. *Brain Res* 1979;171:329–333.
56. Holstege G, Griffiths D, de Wall H, Dalm E. Anatomical and physiological observations on supraspinal control of bladder and urethral sphincter muscles in the cat. *J Comp Neurol* 1986;250:449–461.
57. Blok BF, Willemsen AT, Holstege G. A PET study on brain control of micturition in humans. *Brain* 1997;120:111–121.
58. Blok BF, Sturms LM, Holstege G. Brain activation during micturition in women. *Brain* 1998;121:2033–2042.
59. Zhang H, Reitz A, Kollias S, Summers P, Curt A, Schurch B. An fMRI study of the role of suprapontine brain structures in the voluntary voiding control induced by pelvic floor contraction. *Neuroimage* 2005;24:174–180.
60. Griffiths D, Derbyshire S, Stenger A, Resnick N. Brain control of normal and overactive bladder. *J Urol* 2005;174:1862–1867.
61. Sugaya K, Nishijima S, Miyazato M, Ashitomi K, Hatano T, Ogawa Y. Effects of intrathecal injection of tamsulosin and naftopidil,  $\alpha$ -1A and -1D adrenergic receptor antagonists, on bladder activity in rats. *Neurosci Lett* 2002;328:74–76.
62. Yoshiyama M, De Groat WC. Role of spinal  $\alpha$ 1-adrenoceptor subtypes in the bladder reflex in anesthetized rats. *Am J Physiol Regul Integr Comp Physiol* 2001;280:R1414–R1419.
63. Lepor H.  $\alpha$ -Adrenergic antagonists for the treatment of symptomatic BPH. *Int J Clin Pharmacol Ther Toxicol* 1989;27:151–155.
64. Chon JK, Borkowski A, Partin AW, Isaacs JT, Jacobs SC, Kyprianou N.  $\alpha$ 1-Adrenoceptor antagonists terazosin and doxazosin induce prostate apoptosis without affecting cell proliferation in patients with benign prostatic hyperplasia. *J Urol* 1999;161:2002–2008.
65. Sugaya K, Kadekawa K, Ikehara A, et al. Influence of hypertension on lower urinary tract symptoms in benign prostatic hyperplasia. *Int J Urol* 2003;10:569–574.
66. Persson K, Pandita RK, Spitsbergen JM, Steers WD, Tuttle JB, Andersson KE. Spinal and peripheral mechanisms contributing to hyperactive voiding in spontaneously hypertensive rats. *Am J Physiol* 1998;275:R1366–R1373.
67. Zorn BH, Montgomery H, Pieper K, Gray M, Steers WD. Urinary incontinence and depression. *J Urol* 1999;162:82–84.
68. Nygaard I, Turvey C, Burns TL, Crischilles E, Wallace R. Urinary incontinence and depression in middle-aged United States women. *Obstet Gynecol* 2003;101:149–156.
69. Lee KS, Na YG, Dean-McKinney T, Klausner AP, Tuttle JB, Steers WD. Alterations in voiding frequency and cystometry in the clomipramine induced model of endogenous depression and reversal with fluoxetine. *J Urol* 2003;170:2067–2071.

70. Klausner AP, Steers WD. Corticotropin releasing factor: a mediator of emotional influences on bladder function. *J Urol* 2004;172:2570–2573.
71. Valentino RJ, Page ME, Luppi PH, Zhu Y, Van Bockstaele E, Aston-Jones G. Evidence for widespread afferents to Barrington's nucleus, a brainstem region rich in corticotropin-releasing hormone neurons. *Neuroscience* 1994;62:125–143.
72. Gosling JA, Dixon JS, Critchley HO, Thompson SA. A comparative study of the human external sphincter and periurethral levator ani muscles. *Br J Urol* 1981;53:35–41.
73. Tulloch AG. Sympathetic activity of internal urethral sphincter. In empty and partially filled bladder. *Urology* 1975;5:353–355.
74. Thor KB, Donatucci C. Central nervous system control of the lower urinary tract: new pharmacological approaches to stress urinary incontinence in women. *J Urol* 2004;172:27–33.
75. Dmochowski RR, Miklos JR, Norton PA, et al. and the Duloxetine Urinary Incontinence Study Group. Duloxetine vs placebo for the treatment of North American women with stress urinary incontinence. *J Urol* 2003;170:1259–1263.
76. Trockman BA, Gerspach J, Dmochowski R, Haab F, Zimmern PE, Leach GE. Primary bladder neck obstruction: urodynamic findings and treatment results in 36 men. *J Urol* 1996;156:1418–1420.
77. Nitti VW, Lefkowitz G, Ficazzola M, Dixon CM. Lower urinary tract symptoms in young men: videourodynamic findings and correlation with noninvasive measures. *J Urol* 2002;168:135–138.
78. Woodside JR. Urodynamic evaluation of dysfunctional bladder neck obstruction in men. *J Urol* 1980;124:673–677.
79. Streng T, Santti R, Andersson KE, Talo A. The role of the rhabdosphincter in female rat voiding. *BJU Int* 2004;94:138–142.
80. Van Asselt E, Groen J, Van Mastrigt R. A comparative study of voiding in rat and guinea pig: simultaneous measurement of flow rate and pressure. *Am J Physiol* 1995;269:R98–R103.
81. Walters RD, McMurray G, Brading AF. Comparison of the urethral properties of the female guinea pig and rat. *Neurourol Urodyn* 2006;25:62–69.
82. Mahajan ST, Fitzgerald MP, Kenton K, Shott S, Brubaker L. Concentric needle electrodes are superior to perineal surface-patch electrodes for electromyographic documentation of urethral sphincter relaxation during voiding. *BJU Int* 2006;97:117–120.
83. Russo A, Conte B. Afferent and efferent branching axons from the rat lumbo-sacral spinal cord project both to the urinary bladder and the urethra as demonstrated by double retrograde neuronal labeling. *Neurosci Lett* 1996;219:155–158.
84. Shafik A, Shafik AA, El-Sibai O, Ahmed I. Role of positive urethrovesical feedback in vesical evacuation. The concept of a second micturition reflex: the urethrovesical reflex. *World J Urol* 2003;21:167–170.
85. Gustafson KJ, Creasey GH, Grill WM. A urethral afferent mediated excitatory bladder reflex exists in humans. *Neurosci Lett* 2004;360:9–12.
86. Shafik A. A study of the continence mechanism of the external urethral sphincter with identification of the voluntary urinary inhibition reflex. *J Urol* 1999;162:1967–1971.

---

# 3 Office Evaluation of Urinary Incontinence

---

*Adonis Hijaz, MD and Firouz Daneshgari, MD*

## **CONTENTS**

INTRODUCTION  
HISTORY  
FLUID INTAKE/VOIDING DIARY  
PHYSICAL EXAMINATION  
LABORATORY TESTS  
MULTICHANNEL URODYNAMICS  
REFERENCES

---

## **INTRODUCTION**

The goals of the basic evaluation are to confirm urinary incontinence (UI) and to identify factors that may be contributing to or resulting from UI. The general evaluation of UI should include a history, fluid intake/voiding diary, physical examination, urinalysis, urine culture, and measurement of postvoid residual urine. For selected patients, a blood test (urea and creatinine), urodynamic evaluation, cystoscopy, and imaging studies of the urinary tract or the central nervous system may be recommended.

## **HISTORY**

A patient's history should include the problem's onset, duration, progression, evolution, and precipitating factors (Valsalva maneuvers, change of position). A clear understanding of the severity of the problem and its impact on quality of life should be sought. A patient's expectations from treatment should also be noted for it is often essential to make these conform to realistic results. Important associated urinary symptoms such as pain, burning, frequency, urgency, hesitancy, postvoid dribbling, nocturia, nocturnal enuresis, hematuria, constipation, fecal incontinence, sexual dysfunction, dyspareunia, and prolapse symptoms should also be recorded.

Structured condition-specific questionnaires may be used and may be administered either by the clinician or self-administered. Questionnaires may facilitate disclosure of embarrassing symptoms, ensure that symptoms are not omitted, and standardize information, thereby aiding in follow-up of intervention and research.

A thorough review of the patient's medical history is recommended to ascertain any conditions that possibly interfere with urinary output, such as renal insufficiency, diabetes mellitus, congestive heart failure, pelvic radiation therapy for treatment of cancer, or

neurological diseases such as multiple sclerosis, Parkinson's disease, or stroke. Chronic constipation, for example, has been associated with voiding difficulties, urgency, stress incontinence, and increased bladder capacity. For certain patients, an assessment of mobility and living environment is also important. All medications taken by the patient, including antihypertensive drugs, diuretics, sedatives, hypnotics, analgesics, and anti-depressants must be documented. Intake of caffeine should be determined because it is also associated with overactive bladder symptoms. Finally, strong coughing associated with chronic pulmonary disease can markedly worsen the symptoms of stress urinary incontinence (SUI).

A review of the patient's obstetric history is also important. This includes parity, types of delivery, perineal repairs, and difficult deliveries.

Last, the surgical history should include all genitourinary surgical interventions for treatment of incontinence or pelvic prolapse.

### FLUID INTAKE/VOIDING DIARY

Patient histories regarding frequency and severity of urinary symptoms are often inaccurate. A more reliable indicator of symptoms is a fluid intake/voiding diary, which should be distributed to patients. They would be instructed to document in it the amount and type of fluid consumed and the volume and time of voiding and leakage and to note events associated with each incontinence episode.

### PHYSICAL EXAMINATION

A complete physical examination is essential, and special emphasis should be given to the abdominal, pelvic, genital, and neurological examinations.

- *Abdomen:* Inspect the abdomen for surgical scars and obesity and palpate for any abdominal or retroperitoneal masses or bladder distension.
- *Genitals:* Inspect the external genitalia for any abnormalities (e.g., Bartholin's cyst, condyloma, adhesion, and scar formation) and for atrophy of the vaginal epithelium, specifically shiny cell wall or loss of rugae. In addition, inspect for periurethral and urethral lesions (e.g., mucosal prolapse, carbuncle, condyloma, Skene's abscess, or stenosis). Palpate for scarring, fibrosis, or tenderness, suggesting urethritis or urethral diverticulum. And, with the patient placed in the lithotomy position, measure urethral hypermobility by placing a Q-tip in the urethra to the level of the bladder neck. The patient should be asked to cough and strain. A deflection of the Q-tip greater than 30° suggests significant urethral hypermobility. Conversely, the absence of a hypermobile urethra based on the Q-tip test suggests intrinsic sphincteric deficiency. Determine postvoid residual urine by bladder ultrasound or straight catheterization. Inspect the anterior, posterior, and apical aspects of the vaginal vault with the posterior blade of a Grave's speculum. With the patient at rest and after she strains, palpate the pelvic floor muscles. Finally, ascertain the various components of prolapse (e.g., cystocele, rectocele, enterocele, or uterine prolapse).
- *Neurological examination:* Examine the general neurological status, perineum, and lower extremities for the presence of tremor, loss of cognitive function, weakness, or gait abnormality. Examine the back for asymmetry of bone contours, for skin dimples or scar. Evaluate the S2–S4 nerve roots by the bulbocavernosus reflex (contraction of the external anal sphincter when pressure is applied to the clitoris). Evaluate lower extremities by testing typical sensory patterns and evaluate deep-tendon and primitive



reflexes that may bear anatomic and etiologic significance. A stocking pattern of sensory loss may be indicative of metabolic neuropathies such as diabetes or alcoholism. The Babinski sign (primitive reflex) and ankle clonus suggest suprasacral cord lesions. Deep tendon reflexes of the quadriceps (L4) and Achilles tendon (S1) can demonstrate segmental spinal cord function as well as suprasegmental function.

- *Provocation test/simple cystometrogram*: A sterile catheter is inserted in the patient's bladder, residual urine is collected, and then a 50-cc syringe without its piston is attached to the catheter and held above the bladder level. The patient is then asked to sit or stand, and the bladder is filled with 50-cc aliquots of sterile water from the syringe. Patient's first sensation and maximum capacity are noted. The column of water in the syringe is observed for any rise that can be caused by detrusor overactivity. The catheter is then removed and the patient is asked to cough in various positions (supine, sitting, or standing). Loss of urine in spurts associated with the coughs suggests the diagnosis of SUI.

### LABORATORY TESTS

- *Urinalysis* is performed to exclude hematuria, pyuria, bacteriuria, glycosuria, and proteinuria.
- *A urine culture* is obtained for evidence of bacteriuria or pyuria.
- *Urine cytology* is indicated to screen for bladder cancer if there is evidence of hematuria (2–5 red blood cells per high-power field) and frequency or urgency.
- *Serum urea nitrogen (BUN)* and *serum creatinine level* determinations are indicated in patients with a history or findings of severe voiding dysfunction. Furthermore, excess fluid intake may be reflected in an abnormally low serum urea nitrogen level.
- *Vaginal swabs* are used for culturing ureaplasma and chlamydia.

### MULTICHANNEL URODYNAMICS

The workup described constitutes the basic office assessment (BOA) of UI; it is generally accepted. However, the role of urodynamics in the evaluation of patients with UI is controversial. This is because the true impact of urodynamics on clinical diagnosis, management plans, and patient's outcome has not been studied in a well-designed manner. As indicated by the Second International Consultation on Incontinence (ICI 2001): "In spite of the fundamental importance of urodynamics, the committee has found that for each type of test the evidence for ability or inability of urodynamic investigation to improve or at least predict the outcome of treatment of incontinence is based either on case series (level 4 evidence) or expert opinion (level 5 evidence)," (1). Nevertheless, they recommended urodynamic testing in the evaluation of UI under the following conditions:

- Prior to invasive treatments.
- After treatment failures.
- As part of a long-term surveillance program in neurogenic lower urinary tract dysfunction.
- In complicated incontinence.

Complicated incontinence includes recurrent incontinence and incontinence associated with the following: pain, hematuria, recurrent infection, voiding symptoms, pelvic irradiation, radical pelvic surgery, and suspected fistula.

The Agency for Health Care Policy and Research recommended considering surgery without referral for urodynamic testing for patients with symptoms of pure stress urinary loss and with a voiding history and physical examination results suggestive of pure hypermobility genuine stress incontinence (GSI), which includes the following (2):

1. Urine loss occurs only with physical exertion (history and stress test).
2. Voiding habits are normal (fewer than eight episodes per day and fewer than two episodes per night).
3. There is no neurological history and no neurological findings.
4. Patient has no history of antiincontinence or radical pelvic surgery.
5. Pelvic examination documents hypermobility of the urethra and bladder neck, pliable and compliant vaginal wall, and adequate vaginal capacity.
6. Postvoid residual volume is normal.
7. Patient is not pregnant.

Weidner et al. (3) reported that satisfying all Agency for Health Care Policy and Research criteria would predict GSI with high C statistics of 0.807; however, the findings applied to only 7.8% of the women seen in a tertiary care center. When Weber et al. (4) conducted a cost-effectiveness analysis of preoperative testing (BOA vs urodynamics) for SUI using a decision analysis model, they concluded that present findings suggest that, in adult women with SUI symptoms, urodynamic testing provides only a modest improvement in diagnostic accuracy compared to BOA. The effectiveness of therapy was similar regardless of which type of preoperative evaluation was used. At a GSI prevalence of 0.79 or less, urodynamic testing outweighed the BOA because it is both less costly and more effective. However, at a GSI prevalence of 0.85 or above, the BOA outweighed urodynamic testing. Thus, in this model, cost-effectiveness was essentially related to the prevalence of GSI, which—at least in the Weidner et al. report—was shown to be practice dependent.

The following procedures apply to selected patients with a history or physical findings suggestive of underlying urologic disease, prolapse, hematuria, recurrent infection, or recent history of an abdominal or pelvic procedure.

- *Cystoscopy* plays a limited role in the evaluation of patients with a straightforward, isolated SUI (level B evidence). However, cystoscopy may be indicated in further evaluation when the following conditions are present: sterile hematuria or pyuria (level B recommendation); when urodynamics fails to duplicate symptoms (level C recommendation); and in new onset of irritative voiding symptoms, bladder pain, recurrent cystitis, or suspected foreign body (level B recommendation). Examination of the urethra may reveal a diverticulum, fistula, stricture, or urethritis. The bladder is inspected for mucosal or trigonal abnormalities, trabeculation, foreign bodies, and stones. Bladder-neck hypermobility and intrinsic sphincteric deficiency may also be reassessed by having the patient cough or strain with the scope in the midurethra.
- *Urinary tract imaging* plays a limited role in the evaluation of the uncomplicated case of female incontinence. Intravenous pyelography, voiding cystourethrography (VCUG), and ultrasound studies are commonly employed for evaluation of the upper and lower urinary tract, but in the assessment of UI, these are never first-line studies.
- *Intravenous pyelography* is indicated if the patient's history suggests the presence of an ectopic ureter, hematuria, or recurrent urinary tract infections, and if hydronephrosis is found during ultrasound or computed tomography studies.

- *Ultrasonography* is useful for the evaluation of the upper urinary tract, particularly to detect hydronephrosis caused by elevated bladder pressure in patients with neurogenic bladder-sphincteric dysfunction. In addition to the analysis of pelvic pathology, ultrasound has been used to determine a postvoid residual volume and to detect urethral diverticulum.
- *VCUG* is a simple, safe, and reliable examination that determines the integrity of the female lower urinary tract when bladder or urethral pathology is suspected, such as vesicovaginal or urethrovaginal fistulas, urethral diverticulum, or bladder prolapse. Now, although urethral hypermobility may be detected on rest and strain views, the VCUG is of limited reliability in providing conclusive evidence of intrinsic sphincteric deficiency because bladder pressure is not recorded during the examination.

### REFERENCES

1. Abrams P, Cardozo L, Khoury S, Wein A, eds. *Incontinence. Second International Consultation on Incontinence, 2nd ed.*, Plymbridge Distributors, Plymouth, UK, 2002.
2. Agency for Health Care Policy and Research. *Urinary Incontinence Clinical Practice Guidelines*, US Department of Health and Human Services, Agency for Health Care Policy and Research, Washington, DC, 1996.
3. Weidner AC, Myers ER, Visco AG, Cundiff GW, Bump RC. Which women with stress incontinence require urodynamic evaluation? *Am J Obstet Gynecol* 2001;184:20–26.
4. Weber AM, Taylor RJ, Wei JT, Lemack G, Piedmonte MR, Walters MD. The cost-effectiveness of preoperative testing (basic office assessment vs urodynamics) for stress urinary incontinence in women. *BJU Int* 2002;89:356–363.

---

# 4 Urodynamic Evaluation of Female Stress Urinary Incontinence

---

*Kelly M. Maxwell, MD,  
and J. Quentin Clemens, MD, MSCI*

## **CONTENTS**

INTRODUCTION  
LEAK-POINT PRESSURES  
URETHRAL PRESURE PROFILOMETRY  
URETHRAL RETRORESISTANCE PRESSURE  
ROLE OF URODYNAMIC TESTING IN THE ASSESSMENT OF FEMALE SUI  
REFERENCES

---

## **INTRODUCTION**

The American Urological Association has published guidelines for the surgical management of female stress urinary incontinence (1). According to these guidelines, the objective demonstration of stress urinary incontinence should be documented prior to initiating surgical therapy. This can be accomplished with physical examination (filling the bladder and observing stress incontinence with cough or Valsalva maneuver) or with urodynamic testing. This chapter reviews the various urodynamic techniques used to assess the presence and severity of female stress urinary incontinence.

## **LEAK-POINT PRESSURES**

Leak-point pressures are an integral part of urodynamic testing. To understand the utility of leak-point pressures (LPPs) in the evaluation and management of the stress incontinent patient, it is critical to define our terms and the clinical situations to which they apply. There is considerable confusion because there are two main LPPs, and they are known by several names; in fact they are used in different clinical settings.

### ***Detrusor Leak-Point Pressure***

Detrusor leak-point pressure (DLPP), also referred to as bladder leak-point pressure, is not a measure of stress urinary incontinence (SUI). However, it is often confused with other LPP measurements used to assess SUI, so a brief review is pertinent. DLPP refers to the lowest measured value of bladder pressure at which urine leakage is noted without detrusor contraction or increases in abdominal pressure. In other words, DLPP is the bladder pressure required to overcome fixed urethral resistance during *passive* bladder filling in urodynamic testing, and it is marked by leakage.

From: Current Clinical Urology: Female Urology: A Practical Clinical Guide  
Edited by: H. B. Goldman and S. P. Vasavada © Humana Press Inc., Totowa, NJ

DLPP was first described in a study of myelodysplastic children; it was noted that children with higher DLPPs ( $>40$  cm H<sub>2</sub>O) developed upper tract damage; those with lower DLPPs did not (24). Ultimately, DLPP reflects urethral resistance and bladder compliance ( $C = \Delta V/\Delta P$ ). Whether a patient's DLPP is high because of excess urethral resistance or low compliance, the end result is a high-pressure system that is at risk for upper tract damage as the increasing bladder pressure overcomes the ureteral expulsive pressure and reflux ensues. DLPP is useful in the evaluation and management of neurogenic bladders in relation to the storage and compliance as a predictor of upper tract health. However, it is not applicable for the assessment of SUI.

### ***Abdominal Leak-Point Pressure (Valsalva Leak-Point Pressure)***

Abdominal leak-point pressure is the lowest bladder pressure at which leakage occurs with stress (Valsalva or cough) without detrusor contraction. This measurement is commonly referred to as the Valsalva leak-point pressure (VLPP) but is also known as stress leak-point pressure or cough leak-point pressure (CLPP) depending on the source of increased intraabdominal pressure. For the purposes of this chapter, we use VLPP because Valsalva is the most common source of stress in urodynamic testing.

Conceptually, VLPP is a dynamic test that reflects the urethral resistance by measuring the intraabdominal pressure that is sufficient to drive urine across the urethral unit. Stratification of severity and type of stress incontinence based on VLPP measurements are described in the section on interpretation.

### ***Techniques***

The initial description of the VLPP measurement by McGuire et al. utilized a 10-French triple-lumen pressure-transducing catheter to fill the bladder with contrast to 150 cc with the patient in the upright position. A Valsalva maneuver was performed, and the leak point was defined as the pressure at which contrast was seen to pass through the bladder neck on fluoroscopy (Fig. 1) (2). Numerous subsequent studies have been published using variations of this technique, which has led to difficulty in interpretation of the VLPP measurements and clinical application across studies.

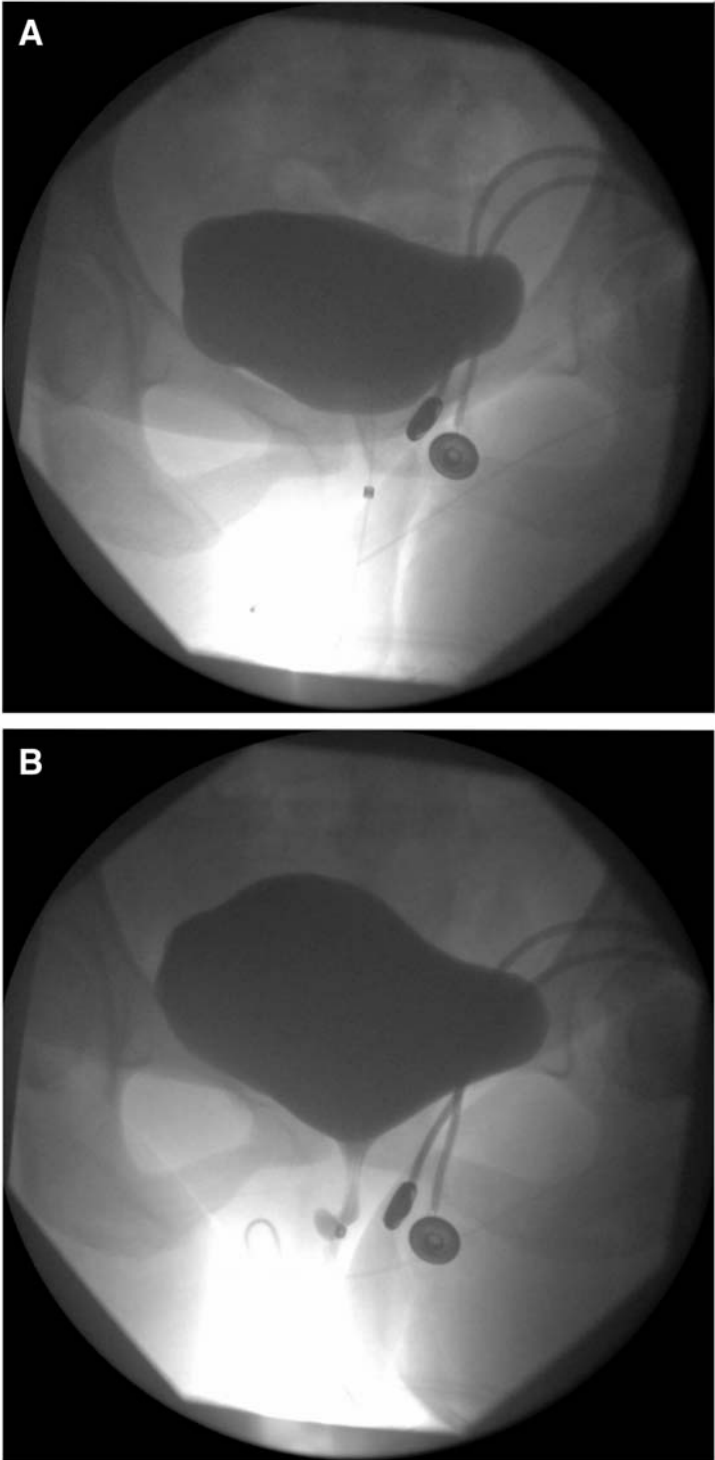
In general, there are six components of VLPP testing that affect the outcome: patient position, catheter size, transducer zeroing, bladder volume, method of leakage observation, and type of stress used to generate increased intraabdominal pressure. It is important to recognize that using absolute numbers for diagnosis is problematic, and caution must be taken to recognize the parameters that are used for interpretation.

#### **PATIENT POSITION**

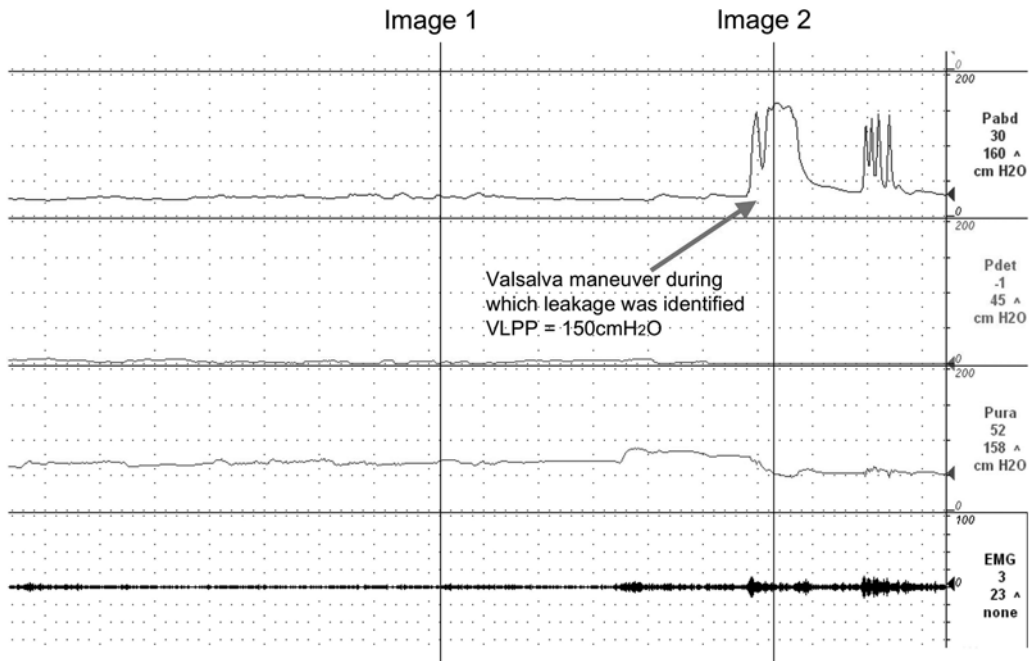
VLPP was originally described with patients in the upright position, although several authors have used the sitting position. One study reported that CLPP measurements were not affected by patient positioning, and the authors recommended utilizing the positioning that best fits the equipment and patient preference (3).

#### **CATHETER SIZE**

VLPP has been described with 3-, 8-, and 10-French catheters. It has been demonstrated that larger catheter size results in higher VLPP, possibly because of mild obstruction from the larger catheters (4). At present, there is no standardized catheter size, and the choice is based on practitioner preference.



**Fig. 1.** (A; top) and (B; bottom) correspond to the indicated locations on the urodynamic tracing in Figure 2. With Valsalva maneuver, contrast is seen to pass through the bladder neck (bottom image).



**Fig. 2.** Multichannel urodynamic study demonstrating stress urinary incontinence.

### TRANSDUCER ZEROING

VLPP measurements can be zeroed to the patient or to atmospheric pressure. The original description of VLPP measurements to diagnose the types of stress incontinence was zeroed to atmospheric pressure.

### BLADDER VOLUME

McGuire et al. first described VLPP at a bladder volume of 150 mL (2). Later studies used 250-mL volumes; others have recommended utilizing near-capacity or capacity volumes by data obtained from voiding diaries. Notably, larger volumes have been associated with lower VLPP measurements. Therefore, if leakage is not observed at lower volumes, the bladder can be filled to near capacity, and repeat testing can be performed to see if leakage can be provoked.

### METHOD OF OBSERVATION OF LEAKAGE

Leakage can be observed via patient report, direct observation, or fluoroscopy. Fluoroscopy is the most definitive way to measure leakage objectively, although it adds expense to the exam and is not always readily available. When possible, it should be part of the urodynamic assessment.

### TYPE OF STRESS

Stress may be induced by Valsalva or cough. There is discussion in the literature regarding the different effects of the two mechanisms on intra-abdominal pressure. Some authors have noted that CLPPs are higher than VLPPs. This is thought to be because of reflex contraction of the urethral mechanism during the transient cough,

which is not observed during the slow progressive stress of a Valsalva maneuver. Most urodynamicists would start with VLPP measurement and if negative proceed to CLPP measurements.

### *Interpretation*

The utility of VLPP lies in its potential to quantify the severity of stress incontinence. Studies have shown that VLPP above 120 cm H<sub>2</sub>O are typically consistent with type I stress incontinence (urethral hypermobility <2.0 cm); VLPPs between 60 and 120 cm H<sub>2</sub>O are found with type II stress incontinence (urethral hypermobility >2.0 cm), and those patients with VLPPs below 60 cm H<sub>2</sub>O commonly demonstrated type III stress incontinence (intrinsic sphincter deficiency). Although this is an attractive algorithm and would apparently lend itself to the determination of appropriate treatment (suspension vs sling vs bulking agents), the variations in technique have a great impact on the results of a given VLPP measurement. Therefore, comparison is difficult across centers and even practitioners.

At present, measurement of the VLPP is useful in characterizing a specific patient's urethral resistance. If a practitioner utilizes the same techniques with every patient, the practitioner may use the experience to help stratify patients and determine the best treatment option. It is not possible to generalize the measurements of VLPP across patients in different study conditions; therefore, unless universal techniques are adopted and carefully studied, the primary usefulness of VLPP will remain in the hands of individual urologists to interpret.

## URETHRAL PRESSURE PROFILOMETRY

Historically, the first urodynamic parameter measured to characterize stress incontinence was the resting urethral pressure profile (UPP), which was based on the idea that continence is maintained as long as urethral pressure exceeds intravesical pressure. It was thought that measuring the pressure exerted by the urethra in relation to the intravesical pressure would predict both presence and severity of stress incontinence. Although this is conceptually reasonable, the pressure measurements of both symptomatic incontinent patients and controls overlap so widely that no conclusions can be made by the absolute measurements. Furthermore, the measured values vary widely depending on the study conditions. Despite numerous efforts to derive additional urodynamic parameters based on UPP measurements, none of these have been demonstrated to correlate reliably with the presence of stress incontinence. In the following sections, we outline the components of urethral pressure profilometry and discuss the techniques and limitations of these measurements.

### *Relationship Between UPP and Urethral Anatomy*

Multiple studies of the structural and functional composition of the female urethra have been performed. Both the intrinsic urethral components and surrounding structures have been identified as contributors to urethral continence. The current understanding of urethral function is complex but essentially reflects a combination of sphincteric components and structural support of the bladder neck and urethra. Components of urethral closure have been described by Rud et al. in a systematic study of the effects of muscular and vascular contributions to UPP (5). The conclusion of this work was that approximately one-third of the urethral closure is dependent on striated sphincter



and pelvic floor musculature, one-third is caused by blood flow, and the final one-third is related to periurethral and connective tissues. Ultimately, the exact anatomy and function of the female urethra has yet to be fully elucidated, and measurements of urethral pressure must be considered a summation of a number of complex interactions.

### ***UPP and Urethral Closure Pressure Profile***

The UPP is the direct measurement of urethral pressure at rest. Urethral pressure measurement was first described by Bonney in 1923 as the pressure required to infuse fluid retrograde into the urethra as measured by an external manometer (6). Although the measurement techniques have evolved significantly from fluid perfusion catheters to membrane, microtip, and fiber-optic catheters, the underlying concept remains unchanged; the static urethral pressure is measured throughout its length, and a topographical pressure curve is generated. Several parameters can be measured from this curve; the International Continence Society has recommended a standard nomenclature (7). Maximum urethral closure pressure (MUCP) is the difference of maximum urethral pressure (MUP) and bladder pressure ( $MUCP = MUP - P_{ves}$ ) and correlates to the junction of the striated and smooth muscle sphincters. Functional profile length is the total length at which urethral pressure exceeds bladder pressure and represents the total length of urethra that contributes to continence.

The urethral closure pressure profile (UCPP) involves the same techniques of urethral pressure measurement but further delineates intra-abdominal and detrusor pressures. A total of six measurements is required: perineal electromyography, intravesical pressure  $P_{ves}$ , intra-abdominal pressure  $P_{abd}$ , intraurethral pressure  $P_{ura}$ , true detrusor pressure  $P_{det}$ , and urethral closure pressure (UCP). Many of the parameters measured in the UCPP have been studied regarding both prediction of stress incontinence and the response to surgical intervention, without reliable results. Whether measuring MUCP or total functional length, the overlap of continent and incontinent subjects precludes using these parameters to stratify patients in the workup for stress incontinence. The only parameter that has been shown to correlate with operative result is an MUCP less than 20 cm H<sub>2</sub>O, which is considered to be indicative of intrinsic sphincter deficiency.

Weber reviewed the published literature on UPP and female SUI in 2001 and concluded that, although the terms of UPP are consistently defined, the techniques used to measure UPP are not standardized, and results are therefore variable. In addition, patients with an MUCP less than 20 cm H<sub>2</sub>O have been shown to have higher failure rates after suspension procedures, but as Weber pointed out, these are based on retrospective studies only (8).

### ***Dynamic UPP: Cough and Valsalva***

Similar to the VLPP, dynamic UCPPs are an attempt to measure the urethral response to stress. This is thought to more appropriately characterize the presence and severity of stress incontinence than the static measurement of resting UPP and MUCP. There are two types of dynamic UPP: Valsalva and cough. Valsalva UPP is measured by manually withdrawing the urethral pressure transducing catheter while the patient sustains maximum Valsalva effort. Cough UPP is measured with the patient coughing every 2–3 s while the catheter is manually withdrawn. During both tests, the urethral meatus is monitored for leakage. The pressure is measured in the same way as static UPPs are obtained.

### ***Pressure Transmission Ratio***

More recently, the pressure transmission ratio (PTR) has been described (9). In this measurement, the functional urethral length is divided into quarters, and the PTR is calculated for each quarter using the equation  $(\Delta P_{\text{ura}}/\Delta P_{\text{ves}}) \times 100\%$ . Lower PTRs are consistent with SUI, although significant overlap exists between continent and incontinent patients, and no set cutoff has been determined.

### ***Techniques of Profile Measurement***

Whether measuring resting UPP, UCP, or dynamic UPP, the study conditions are similar. Patients are typically studied while seated with a full bladder in a urodynamic chair. A specialized catheter (most commonly a microtip catheter) is inserted intravesically with a transducer measuring the intravesical pressure and an additional transducer located 6 cm more proximally measuring the urethral pressure. An additional pressure probe is inserted either intravaginally or rectally to measure  $P_{\text{abd}}$ , and external electrodes are applied to record electromyographic activity. Similar to VLPP measurement, there are many variables that affect the results of a UPP study. The following discussion is a summary of the important variables.

#### **CATHETER CHOICE**

UPP was first described using perfusion catheters in which the pressure measured reflected the pressure required to lift the urethral wall from the catheter side holes. Membrane catheters function by the same mechanism, but the catheter tip is surrounded by a balloon or membrane to prevent loss of infusion fluid during measurement, a shortcoming that was identified in the perfusion catheters. Microtip catheters are the most commonly used at present, and pressure is measured by a pressure-sensitive transducer that allows for dynamic pressure measurement. Finally, fiber-optic catheters similarly measure the urethral pressure in a direct manner. As described in the evaluation of LPPs, the catheter size has been shown to affect the results of UPP measurements, with larger-bore catheters resulting in higher UPP pressure measurements.

#### **PATIENT POSITION**

The UPP can be measured with the patient in the supine, seated, or standing position. At present, the only conclusion obtained from many studies comparing UPP measurements in different patient positions is that position affects the results of the UPP in some patients but not in a predictable or reproducible manner. From supine to seated to standing measurements, some studies have reported increasing, decreasing, or no change, respectively, in UPP measurement (8).

#### **CATHETER WITHDRAWAL SPEED AND ORIENTATION**

Commonly, the withdrawal speed used is 1–2 mm/s. Orientation of the catheter transducer can change the results of the test. With the transducer at the 12 o'clock position, the pressure recorded will be elevated, whereas at the 6 o'clock position it will be decreased. Therefore, the UPP is measured with the transducer oriented at a lateral position (6 or 9 o'clock).

#### **ZEROING OF PRESSURE SENSORS**

As with LPP measurement, the pressure recorded will depend on whether the transducer is zeroed to the patient or to the atmosphere. It is important to consider the starting point for accurate interpretation.

### *Interpretation*

Interpreting UPP measurements for stress-incontinent patients is problematic. Lack of standardization in technique and the number of measurement variables contribute to the significant overlap of measurements in stress-incontinent patients and controls. Stratification of severity and type of incontinence has only been described for the low-pressure urethra with a MUCP less than 20 cm H<sub>2</sub>O, which has been related to type III or intrinsic sphincter deficiency. At present, despite wide usage and much effort to describe derivations of urethral pressure profilometry, it is not a standardized, reproducible, or predictive test of SUI. The main utility of this test may be to follow individual patient outcomes throughout treatment.

### URETHRAL RETRORESISTANCE PRESSURE

A new urodynamic measurement system for urethral retroresistance pressure (URP) has been described. URP is defined as the pressure required to achieve and maintain an open urethral sphincter and is measured by occluding the urethral meatus with a cone-tipped plug placed 5 mm in the urethra. Sterile fluid is then infused retrograde at a rate of 1 mm/s while the required pressure is measured on a pressure vs time plot, and the plateau of the asymptotic curve represents the URP (10,11).

In a randomized, multicenter trial of 258 symptomatic females, URP, LPP, and MUCP were measured after assessment of incontinence severity by validated questionnaires. The authors concluded that URP has a consistent relationship to incontinence severity, whereas MUCP and LPP were not reliably decreased in patients with increased degrees of incontinence (10). In a second study, 61 asymptomatic females underwent URP measurement after confirming a negative standing stress test; the goal was to characterize the distribution and reproducibility of URPs in asymptomatic women (11). The URP measurements in this population exhibited a normal distribution, and in 32 females who underwent retesting 3–7 d later, there was no statistically significant difference between test and retest URP measurements. Furthermore, when comparing the symptomatic and asymptomatic premenopausal patients, the mean URP was significantly different.

This work represents an attempt to define and characterize a novel approach to measuring urethral function with the goal of finding a parameter that is reproducible, accurately identifies stress incontinent patients, and predicts treatment outcome. Although initial investigations of URP are promising, it remains investigational and will require further evaluation before its clinical utility can be determined.

### ROLE OF URODYNAMIC TESTING IN THE ASSESSMENT OF FEMALE SUI

Although urodynamic testing is frequently performed as part of the evaluation of SUI, the benefits obtained by performing such testing have not been well defined. Advocates of a “minimalist” approach argue that direct observation of stress incontinence on physical examination is sufficient to allow the treating physician to proceed with surgery in the majority of patients. Some studies have indicated that routine performance of urodynamics in the evaluation of female stress incontinence is not cost-effective (12,13). This opinion has perhaps become more prevalent with the advent of minimally invasive midurethral sling procedures, which have yielded good continence results in large, heterogeneous patient samples. Advocates for urodynamic testing argue that important

information about concomitant bladder dysfunction (detrusor overactivity, compliance abnormalities, poor detrusor contractile function) may significantly alter the treatment approach in certain patients. Furthermore, identification of urodynamic intrinsic sphincter deficiency does appear to significantly reduce the stress incontinence cure rate for midurethral slings (14,15).

Currently, it is not known if routine urodynamic assessment improves outcomes prior to stress incontinence surgery. Therefore, the decision to perform this testing is individualized based on the availability of the testing equipment, the expertise of the treating physician, and the complexity of the patient. The utility of preoperative urodynamic testing will continue to be controversial until definitive studies are carried out to examine the issue. Ideally, these would be multicenter, prospective, randomized trials involving women who have undergone standardized urodynamic testing, with the treating physician blinded to the urodynamic outcomes in one group and aware of the outcomes in the other.

## REFERENCES

1. Leach GE, Dmochowski RR, Appell RA, et al. Female Stress Urinary Incontinence Clinical Guidelines Panel summary report on surgical management of female stress urinary incontinence. *J Urol* 1997;158:875–880.
2. McGuire EJ, Fitzpatrick CC, Wan J, et al. Clinical assessment of urethral sphincter function. *J Urol* 1993;150(5 pt 1):1452–1454.
3. Stiltberg H, Larsson G, Victor A. Reproducibility of a new method to determine cough-induced leak-point pressure in women with stress urinary incontinence. *Int Urogynecol J* 1996;7:13–19.
4. Bump RC, Elser DM, McClish DK. Valsalva leak point pressures in adult women with genuine stress urinary incontinence: reproducibility, effect of catheter caliber, and correlations with passive urethral pressure profilometry. *Neurourol Urodyn* 1993;12:307–308.
5. Rud T, Andersson KE, Asmusen M, Hunting A, Ulmsten U. Factors maintaining the intraurethral pressure in women. *Invest Urol* 1980;17:343–347.
6. Bonney V. On diurnal incontinence of urine in women. *J Obstet Gynaecol Br Emp* 1923;30:358–365.
7. Lose G, Griffiths D, Hosker G, et al. Standardisation of urethral pressure measurement: report from the Standardisation Sub-Committee of the International Continence Society. *Neurourol Urodyn* 2002;21:258–260.
8. Weber AM. Is urethral pressure profilometry a useful diagnostic test for stress urinary incontinence? *Obstet Gynecol Surv* 2001;56:720–735.
9. Bump RC, Copeland WE, Jr, Hurt WG, Fantl JA. Dynamic urethral pressure/profilometry pressure transmission ratio determinations in stress-incontinent and stress continent subjects. *Am J Obstet Gynecol* 1988;159:749–755.
10. Slack M, Culligan P, Tracey M, Hunsicker K, Patel B, Sumeray M. Relationship of urethral retro-resistance pressure to urodynamic measurements and incontinence severity. *Neurourol Urodyn* 2004;23:109–114.
11. Slack M, Tracey M, Hunsicker K, Godwin A, Patel B, Sumeray M. Urethral retro-resistance pressure: a new clinical measure of urethral function. *Neurourol Urodyn* 2004;23:656–661.
12. Diokno AC, Dimaculangan RR, Lim EU, Steinert BW. Office based criteria for predicting type II stress incontinence without further evaluation studies. *J Urol* 1991;161:1263–1267.
13. Weber AM, Taylor RJ, Wei JT, Lemack G, Piedmonte MR, Walters MD. The cost-effectiveness of preoperative testing (basic office assessment vs urodynamics) for stress urinary incontinence in women. *BJU Int* 2002;89:356–363.
14. Liapis A, Bakas P, Salamalekis E, Botsis D, Creatas G. Tension-free vaginal tape (TVT) in women with low urethral closure pressure. *Eur J Obstet Gynecol Reprod Biol* 2004;116:67–70.
15. Paick JS, Ku JH, Shin JW, Son H, Oh S, Kim SW. Tension-free vaginal tape procedure for urinary incontinence with low Valsalva leak point pressure. *J Urol* 2004;172:1370–1373.

---

# 5

## Urodynamic Assessment of Overactive Bladder

*Neurogenic and Nonneurogenic*

---

*Gary E. Lemack, MD*

### CONTENTS

INTRODUCTION

WHO REQUIRES URODYNAMICS?

KEY COMPONENTS IN URODYNAMIC TESTING  
OF OVERACTIVE BLADDER

FINDINGS IN NONNEUROGENIC OVERACTIVE BLADDER

FINDINGS IN NEUROGENIC OAB

CONCLUSION

REFERENCES

---

### INTRODUCTION

Urodynamic studies (UDS) generate information about bladder function that, currently, no other testing can provide. Though clearly not necessary to evaluate all lower urinary tract symptoms (LUTS), UDS can be useful when confronted with situations in which the normal noninvasive parameters used to assess LUTS, such as questionnaires, flow rates, and postvoid residual testing, are not helpful. There are a few keys to developing a successful urodynamic laboratory and to conducting studies that can be readily interpreted and utilized for clinical planning. Perhaps the foremost among these are the ability to re-create the LUTS in question during the UDS and training capable technicians who understand the equipment and the patients so that they are able to accomplish this task. Having the clinician present or readily available during the study is essential to generating interpretable data. A poorly conducted UDS test will tell you nothing about the symptom or problem in question, may only serve to further muddy the clinical picture, and may dissuade the patient from further care. On the other hand, a properly conducted test will give insight into the pathophysiology underlying the clinical condition, may provide some type of assessment of risk to the patient of leaving the condition untreated, and will clearly help guide management.

This chapter discusses the role of UDS in assessing patients with overactive bladder (OAB), both neurogenic and idiopathic, and the common findings seen in each of these conditions are reviewed.

## WHO REQUIRES URODYNAMICS?

The issue of the optimal evaluation for OAB remains contentious. Although few would argue that patients with known neurological conditions and bladder dysfunction merit a thorough urodynamic evaluation to establish risk assessment and determine appropriate therapy, the same cannot be universally said of patients with OAB symptoms and no known neurological condition.

It seems clear that, in most patients with classic urinary symptoms of urinary urgency, frequency with or without urge urinary incontinence, a thorough history, physical examination, and urinalysis should be carried out prior to instituting any type of medical therapy for OAB. It is further clear that validated urinary questionnaires and voiding diaries, at least 48–72 h in duration, can provide additional information about severity of frequency and incontinence, functional bladder capacity, overall urine production, and degree of nocturia, which may be difficult to ascertain otherwise (1). Each of these assessments can provide insight into the proper treatment. Measuring postvoid residual in women without prolapse, previous incontinence, or prolapse surgery; no history of recurrent bladder infections; and without voiding symptomatology (straining, hesitancy, staccato voiding) is generally considered unnecessary in most patients with OAB symptoms because overall the prevalence of elevated residuals is low (2).

The controversy surrounding the use of urodynamic testing in OAB involves three basic principles. The first principle is that many women with no specific bladder complaints will be found to have “abnormal” findings on urodynamic testing. Indeed, idiopathic detrusor overactivity may be found in up to 69% of asymptomatic patients undergoing ambulatory UDS (3). Advocates of ambulatory urodynamic studies note that these outpatient studies may establish a diagnosis in as many as 56% of patients in whom conventional studies were unable to do so (4). Still, although some contend that urodynamically diagnosed bladder dysfunction may merit treatment in women with LUTS who do not specifically complain of OAB-type symptoms (5), more often than not it is unclear that findings noted only during urodynamics require treatment.

Indeed, the inability of UDS to correlate closely with LUTS is the second principle surrounding the controversy of UD usefulness. Because conventional in-office studies take place over a short window of time, it is not uncommon for them to inadequately demonstrate the cause of LUTS, particularly in the case of urgency and urge incontinence. In general, about 18–23% of patient with OAB-type symptoms and incontinence may have normal urodynamic findings (6,7). Furthermore, a meta-analysis of studies investigating the ability of UD testing to diagnose bladder dysfunction accurately noted a sensitivity of only 45–72% for OAB/urge incontinence, with somewhat higher figures noted for stress incontinence (8). We found that utilizing the Urogenital Distress Inventory Questionnaire allowed us to improve the sensitivity of diagnosing detrusor overactivity in patients with either urinary frequency or urge incontinence to 75–83%, although the questionnaire was inadequate at predicting voiding disturbances (9).

Last, it is unclear, even if one can accurately diagnose OAB in patients with LUTS highly suggestive of this condition, that urodynamic findings will allow us to predict optimal treatment based on UD findings. For example, it has not been conclusively demonstrated that particular anticholinergic medications are superior based on indices of bladder function obtained during cystometry (such as capacity, threshold volume for detrusor contractions, or amplitude of detrusor contractions) or that overall treatment response to any anticholinergic medication is predictable based on UD findings.

A crossover study of tolterodine and oxybutynin noted no difference in treatment efficacy based on severity of OAB as defined urodynamically, although there was the suggestion that patients with high-amplitude contractions did not fare as well on either medication (10). Other studies have noted no influence of urodynamic parameters on efficacy of medical treatment, local estrogen, or bladder training (11,12).

Therefore, the decision to perform urodynamics remains controversial and, in many cases, experientially based. Among the most commonly accepted reasons to perform urodynamic testing in nonneurogenic female patients with OAB symptoms include failure to respond adequately to pharmacological management, the presence of voiding symptoms, history of incontinence or prolapse surgery, recurrent urinary tract infections, and concurrent pelvic prolapse. Male patients, many of who are commonly treated with  $\alpha$ -blockers or 5 $\alpha$ -reductase inhibitors, may require urodynamics if medical management does not improve symptoms, particularly if surgery for presumed outlet obstruction is under consideration.

### KEY COMPONENTS IN URODYNAMIC TESTING OF OVERACTIVE BLADDER

After the decision is made to proceed with urodynamic testing, the next consideration is the type of testing to be conducted. Most current urodynamic machines offer only multiple-channel testing because single-channel testing is prone to considerable artifacts. In general, because it is difficult to predict for the presence of specific voiding dysfunction in women based on urinary symptoms alone (9), it is good urodynamic practice always to perform a pressure flow study at the end of filling to assess for voiding disturbance. Although controversial, the use of patch or needle electromyographic perineal electrodes can assess for lack of pelvic floor relaxation or external sphincter dyssynergia in patients at risk. The addition of simultaneous cystourethrography (videourodynamics), although clearly not always mandated, does allow further evaluation of the outlet during voiding, which can aid in determining the level of obstruction and evaluating the bladder for foreign bodies, vesicoureteral reflux, and diverticula. Although it may not be universally available, the addition of imaging of the lower urinary tract during urodynamic testing may be most useful when evaluating patients with known neurological conditions, young men with severe LUTS, and women with possible pelvic floor dysfunction.

Typically, a 6- or 7-French dual-lumen urethral urodynamic catheter is used, along with either a rectal or vaginal catheter to assess extravesimal pressure fluctuations. Patients are typically standing for the study, particularly if they are also complaining of stress incontinence, or they sit in a urodynamics chair. Fluid (room temperature sterile water or radiographic contrast) is instilled at 25–100 mL/min, keeping in mind that OAB contractions can be elicited by more rapid rates of filling, by utilizing a cold filling solution, and by performing certain provocative maneuvers during filling (such as heel bouncing). The threshold volume for OAB contractions should be noted in addition to the amplitude of the overactive contraction because there are some data to suggest that the severity of the contraction may correlate with the nature of the disease process responsible for detrusor overactivity (DO) (13). Many patients will attempt to suppress leakage that may accompany the contraction, and if leakage still ensues, it should be recorded, as should the maximum bladder capacity. Compliance should also be assessed because altered compliance may be responsible for upper tract deterioration,

particularly in neuropathic bladders. Although widely accepted cutoff values for outlet obstruction in women are still lacking, a number of strategies have been proposed (14–16), and a properly conducted voiding study (adjust transducers as the patient sits to void) is imperative after the conclusion of filling.

## FINDINGS IN NONNEUROGENIC OVERACTIVE BLADDER

Although no clear criteria exist for differentiating neurogenic from idiopathic DO, it has been suggested that unstable bladder contractions occurring as a result of neurological disease may be more likely to result in urge incontinence (17) and have a greater amplitude. Regardless, perhaps the most common urodynamic pattern seen in patients with idiopathic OAB is symptomatic urgency reported during filling without the finding of DO (so-called sensory urgency). It is well established that, in up to 74% of patients with frequency or urgency symptoms and in as many as half of patients with urge UI, DO may not be seen during urodynamic testing (18). Interestingly, data suggest that, of the four symptoms most commonly associated with OAB (frequency, urgency, nocturia, and urge incontinence), it is the specific complaint of frequency that may be most readily linked to the urodynamic finding of DO (19). Frequency and urgency symptoms and urge incontinence all appear to be associated with earlier first sensation during UDS.

In general, nonphasic low-grade overactive contractions during voiding appear to be the most common pattern seen with idiopathic detrusor overactivity. In general, these contractions are associated with urgency. Frequently, simultaneous electromyographic activity associated with a conscious contraction of the pelvic floor to avoid leakage is also seen (Fig. 1).

Idiopathic detrusor overactivity need not always be completely benign, however. Even patients without a clear neurological basis for their overactivity may experience intense detrusor spasms resulting in significant incontinence. Presumed bladder wall damage from other processes, such as radiation, may induce changes in bladder wall compliance (Fig. 2), resulting in severe frequency and OAB symptoms. Radiation can also induce high-grade bladder overactivity even several years out from the time of treatment, as seen in the urodynamics obtained from a woman who was over two decades out from radiation treatment for uterine cancer who suffered from intense urinary urgency and extreme frequency (Fig. 3).

Stress-induced OAB contractions have also been described. Although the precise etiology is not proven, it is believed that coughing or other maneuvers that induce urine to be deposited beyond the bladder neck into the proximal urethra can induce bladder overactivity. Typically, leakage associated with stress-induced overactivity is difficult to differentiate based on history or physical examination alone, and UDS are the most effective means of determining the true cause of incontinence, which often is a result of both sphincteric weakness and abnormal detrusor instability (Fig. 4).

Terminal detrusor overactivity, which occurs at the end of filling, can develop in the absence of any definable intrinsic bladder or bladder outlet abnormality and may be associated with urge incontinence when the bladder contraction cannot be suppressed (Fig. 5). In an analysis of urodynamic characteristics of DO, Defreitas and colleagues noted that men with BOO-induced DO were more likely to have terminal DO only in comparison with men with DO secondary to Parkinson's disease (PD), in whom the DO occurred throughout filling (17). In many cases, the urge to void can be temporarily suppressed, and the bladder contraction itself can subside if filling is terminated.



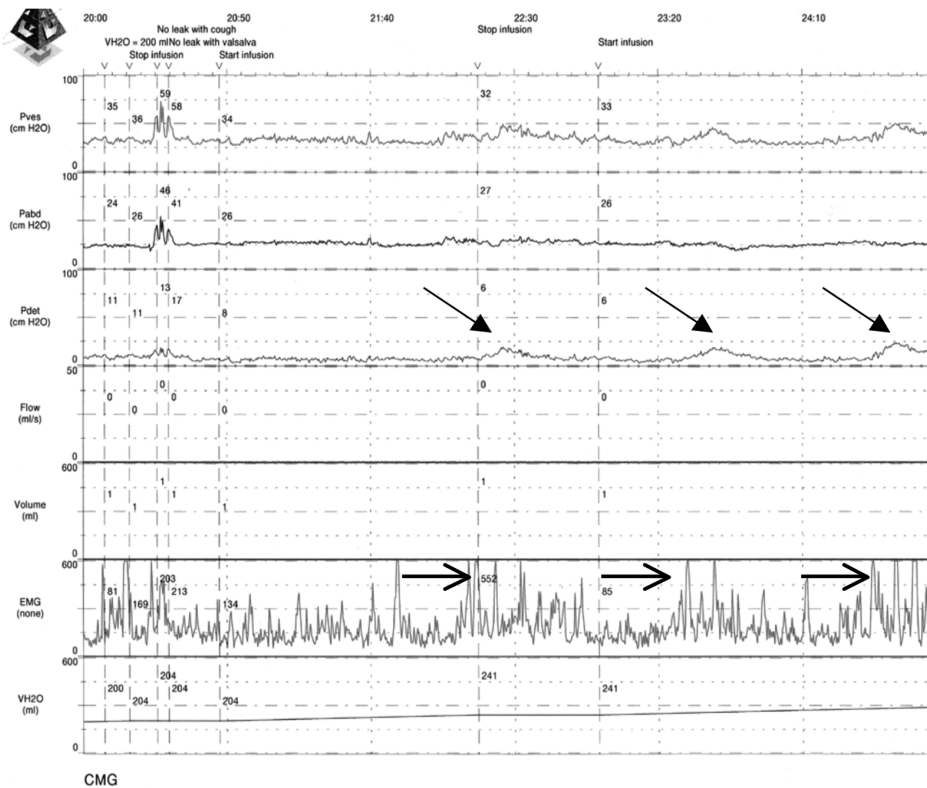


Fig. 1. Nonphasic detrusor overactivity. Note simultaneous low-grade detrusor contractions (closed arrows) and increased sphincteric activity (open arrows).

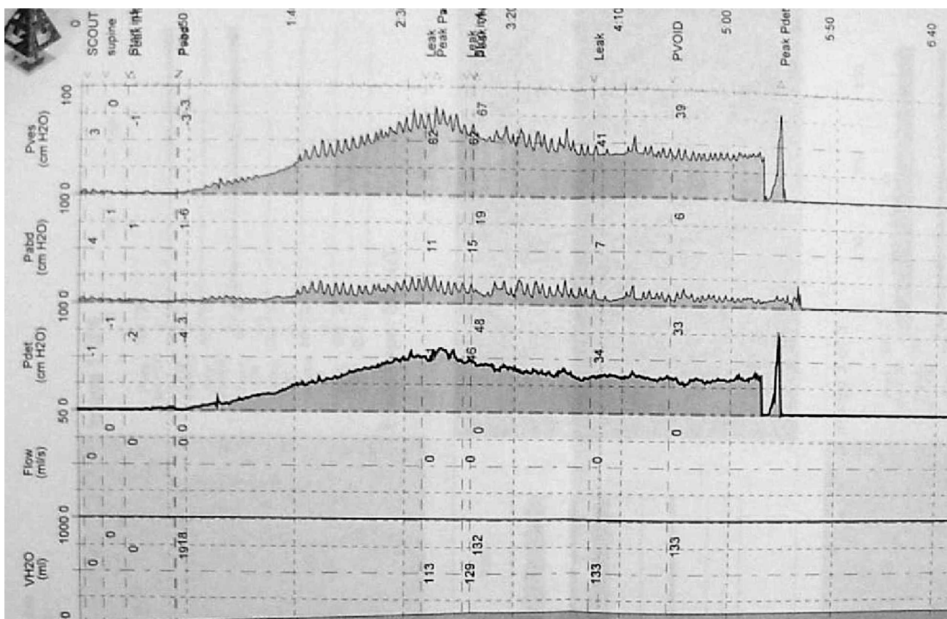
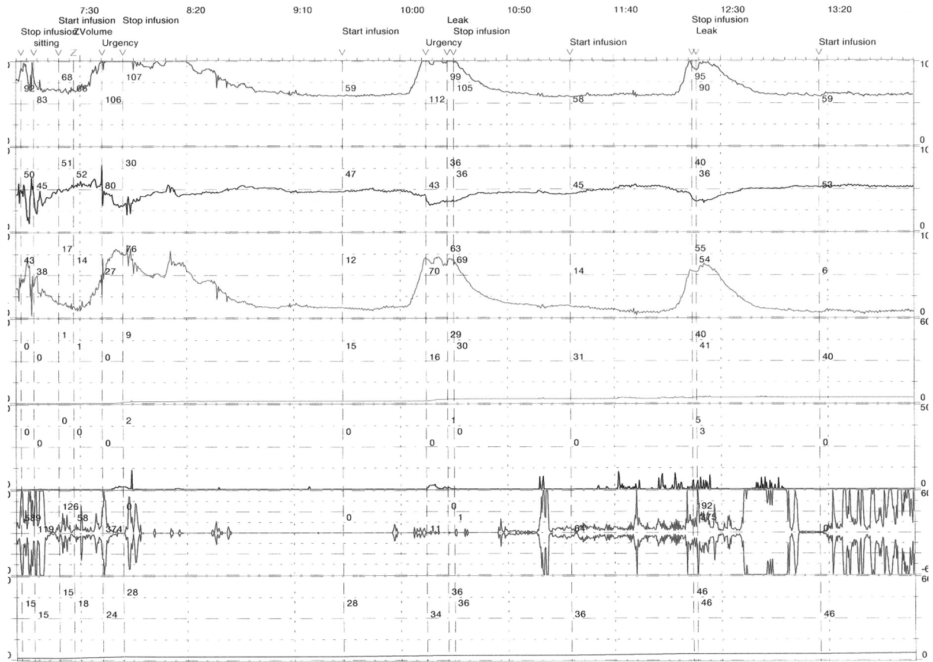
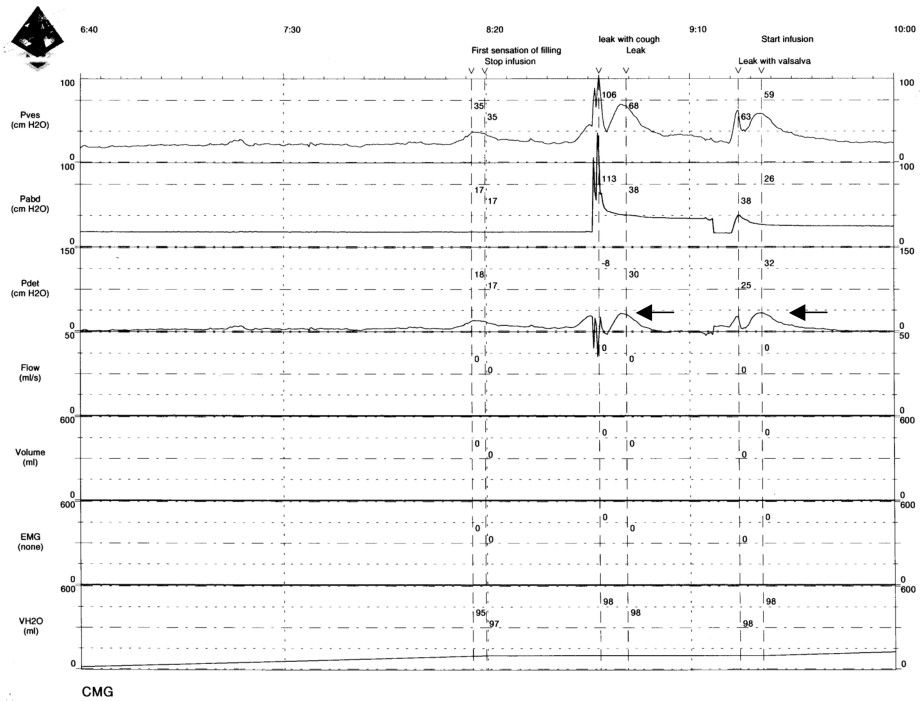


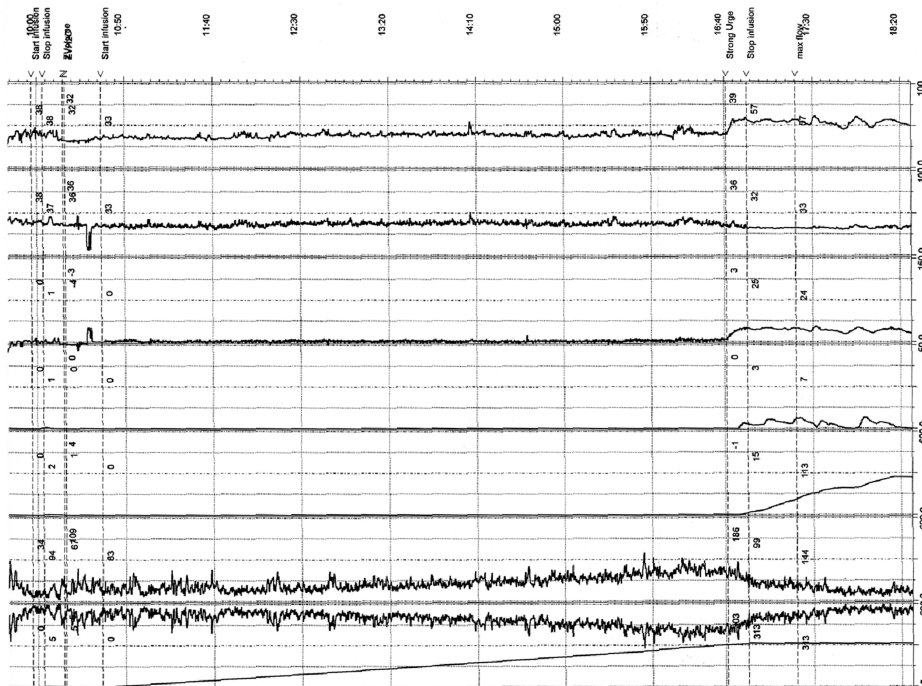
Fig. 2. Loss of compliance in patient with OAB symptoms.



**Fig. 3.** Intense periodic overactive detrusor contractions in patient treated with radiation treatment for uterine cancer over two decades prior to study.



**Fig. 4.** Stress-induced detrusor overactivity. Note detrusor contraction (closed arrow) induced by cough and Valsalva. Patient leaks with both cough/Valsalva and at time of detrusor overactive contraction.



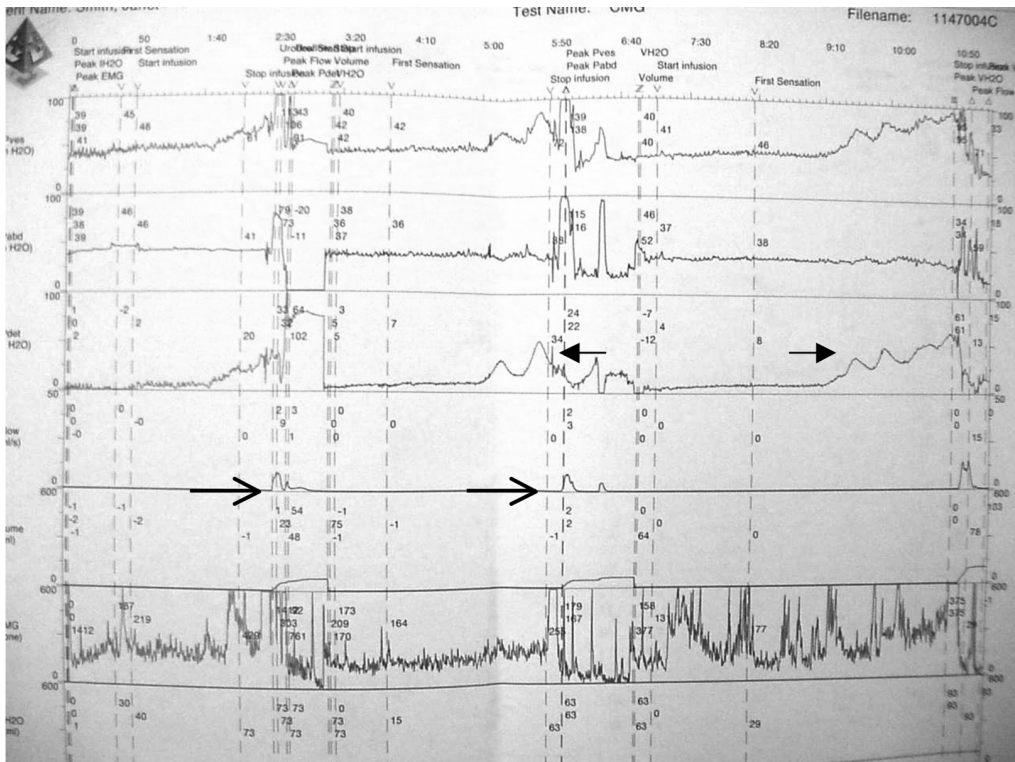
**Fig. 5.** Terminal detrusor overactivity. Note detrusor contraction occurs prior to terminating filling and is associated with urgency. Patient was not instructed to suppress voiding. Note sphincteric relaxation.

If terminal DO occurs after a normal fill volume, then typically this urodynamic pattern would be associated with urgency and potential urge incontinence episodes in the absence of severe frequency.

## FINDINGS IN NEUROGENIC OAB

Patients with neurogenic OAB tend to have severe symptoms that are more difficult to treat pharmacologically. It is not immediately clear that the overactive contractions experienced by patients with neurological conditions are necessarily of greater amplitude or occur earlier during filling, although there is some indirect evidence to support this contention (13). Phasic detrusor contractions that crescendo and result in urge-related urine leakage appear to be more commonplace in patients with neurogenic overactivity, for example, in patients with multiple sclerosis (MS) (Fig. 6). Voiding dysfunction, either with or without DO, also appears to be common in patients with MS. True detrusor external sphincter dyssynergia may be present in many as 40% of patients with LUTS secondary to MS (20); the incidence of bladder neck dyssynergia independent of detrusor overactivity may be even higher.

Patients with movement disorders also appear largely to suffer from DO on urodynamic testing. One unique finding among patients with movement disorders involves external sphincteric testing. Incompetent external sphincteric function resulting from denervation secondary to neuronal cell loss in the anterior horn of Onuf's nucleus is present in the majority of patients with multiple system atrophy and can lead to debilitating urinary incontinence (21). Both sphincteric deficiency and sphincteric bradykinesia (failure to relax) have been described in patients with PD, making surgical endeavors



**Fig. 6.** Phasic detrusor overactivity (closed arrows) resulting in urinary leakage (open arrows) in patient with multiple sclerosis and urge incontinence.

to treat BOO presumed secondary to prostatic obstruction treacherous because incontinence rates following transurethral prostatectomy among patients with PD have historically ranged as high as 20%. It is unclear whether this dismal rate of success will be improved with other heat-based prostatic treatments.

Patients with interruptions of the spino-bulbo-spinal pathway, typically as a result of spinal cord injury, may have debilitating urinary incontinence in addition to severely impaired bladder emptying secondary to detrusor external sphincter dyssynergia (Fig. 7). In these instances, detrusor pressures may remain elevated because of the sustained detrusor contraction (particularly true in spinal cord injury) in the absence of external sphincter, and frequently bladder neck, relaxation. Concurrent fluoroscopic monitoring can be useful to evaluate for bladder wall abnormalities or vesicoureteral reflux and further evaluate sphincteric function. In patients with severe or detrusor dysfunction, bladder diverticula can develop (Fig. 8), which can ultimately result in further impairment of bladder drainage and create a haven for the development of bladder stones and malignant bladder lesions.

## CONCLUSION

Urodynamic testing remains an integral part of the complete evaluation of patients with OAB symptoms, particularly those who fail to respond to conventional management strategies, those with specific complaints of voiding dysfunction, and those with

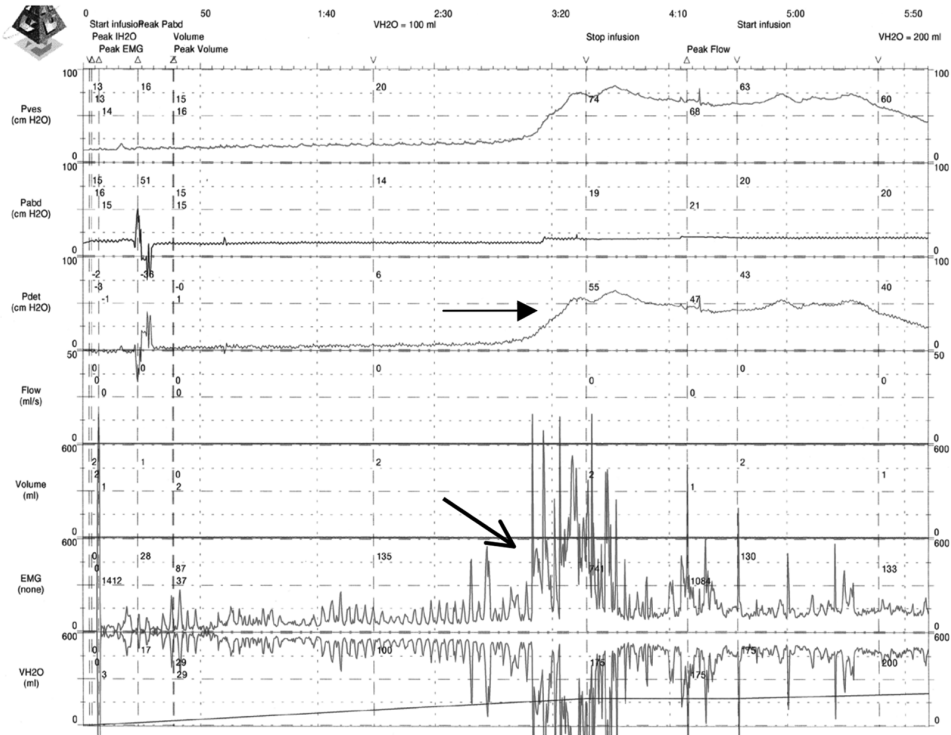


Fig. 7. Detrusor sphincter dyssynergia in patient with T5 spinal cord injury. Note sustained intra-vesical pressure elevation (closed arrow) and simultaneous sphincteric activity (open arrow).

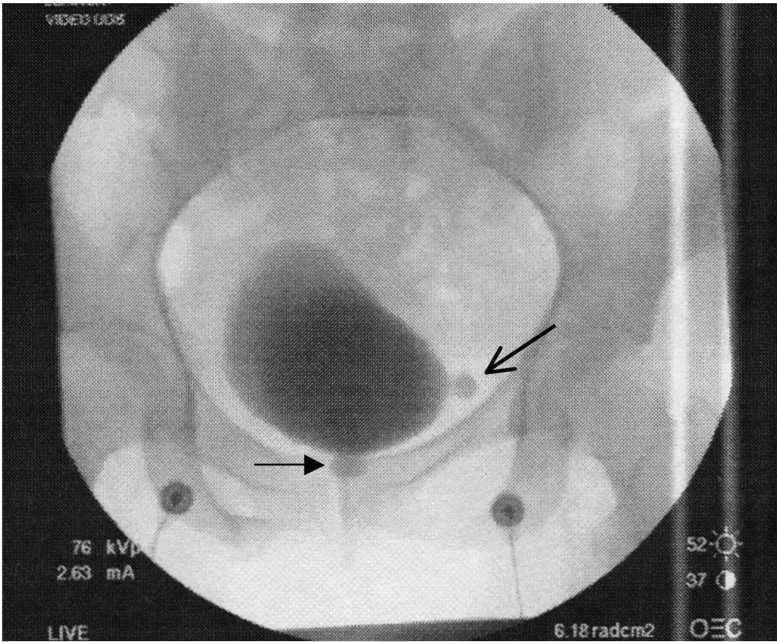


Fig. 8. Video picture during voiding attempt in patient with detrusor sphincter dyssynergia. Note ballooning of proximal urethra (closed arrow) and left-sided diverticulum (open arrow).

neurogenic bladder disease. Although the urological community continues to search for less-invasive means of monitoring bladder function, at the present time multichannel urodynamic testing is the most accurate and reliable assessment tool, and it provides a means of directing appropriate therapeutic strategies, determining treatment response, and monitoring for disease progression.

## REFERENCES

1. Klovning A, Hunskaar S, Eriksen BC. Validity of a scored urological history in detecting detrusor instability in female urinary incontinence. *Acta Obstet Gynecol Scand* 1996;75:941–945.
2. Bonde HV, Sejr T, Erdmann L, et al. Residual urine in 75-year-old men and women. A normative population study. *Scand J Urol Nephrol* 1996;30:89–91.
3. van Waalwijk van Doorn ES, Meier AH, Ambergen AW, Janknegt RA. Ambulatory urodynamics: extramural testing of the lower and upper urinary tract by Holter monitoring of cystometrograms, uroflowmetry, and renal pelvic pressures. *Urol Clin North Am* 1996;23:345–371.
4. Swithinkbank LV, James M, Shepherd A, et al. Role of ambulatory urodynamics monitoring in clinical urological practice. *Neurourol Urodyn* 1999;20:249–257.
5. Digesu GA, Khullar V, Cardozo L, Salvatore S. Overactive bladder symptoms: Do we need urodynamics? *Neurourol Urodyn* 2003;22:105–108.
6. Sand PK, Hill RC, Ostergard DR. Incontinence history as a predictor of detrusor instability. *Obstet Gynecol* 1988;71:257–260.
7. De Muylder X, Clae H, Neven P, De Jaeger K. Usefulness of urodynamic investigation in female incontinence. *Eur J Obstet Gynecol Reprod Biol* 1992;44:205–208.
8. Colli E, Artibani W, Goka J, Parazzini F, Wein A. Are urodynamic tests useful tools for the initial conservative management of non-neurogenic urinary incontinence? A review of the literature. *Eur Urol* 2003;43:63–69.
9. Lemack GE, Zimmern PE. Predictability of urodynamic findings based on the Urogenital Distress Inventory Questionnaire. *Urology* 1999;54:461–466.
10. Giannitsas K, Perimenis P, Athanasopoulos A, Gyftopoulos K, Nikiforidis G, Barbalias G. Comparison of the efficacy of tolterodine and oxybutynin in different severity grades of idiopathic detrusor overactivity. *Eur Urol* 2004;46:776–783.
11. Wagg A, Bayliss M, Ingham NJ, Arnold K, Malone-Lee J. Urodynamic variables cannot be used to classify the severity of detrusor instability. *BJU* 1998;82:499–502.
12. Høltedahl K, Verelst M, Schiefloe A, Hunskaar S. Usefulness of urodynamic examination in female urinary incontinence—lessons from a population-based, randomized, controlled study of conservative treatment. *Scand J Urol Nephrol* 2000;34:169–174.
13. Lemack GE, Zimmern PE, Frohman E, Hawker K, Ramnarayan P. Urodynamic distinctions between idiopathic detrusor overactivity and detrusor overactivity secondary to multiple sclerosis. *Urology* 2006; 67:960–964.
14. Lemack GE, Zimmern PE. Pressure flow analysis may aid in identifying women with outflow obstruction. *J Urol* 2000;163:1823–1828.
15. Nitti VW, Tu LM, Gitlin J. Diagnosing bladder outlet obstruction in women. *J Urol* 1999;161: 1535–1540.
16. Blaivas JG, Groutz A. Bladder outlet obstruction nomogram for women with lower urinary tract symptomatology. *Neurourol Urodyn* 2000;19:553–564.
17. Defreitas GA, Lemack GE, Zimmern PE, Roehrborn CG, Dewey RB. A urodynamic comparison of patients with Parkinson's disease and males with lower urinary tract symptoms: distinguishing neurogenic from non-neurogenic detrusor overactivity. *J Urol* 2003;169:1506–1509.
18. Fitzgerald MP, Brubaker L. Urinary incontinence symptom scores and urodynamic diagnoses. *Neurourol Urodyn* 2003;21:30–35.
19. Van Brummen HJ, Heintz APM, van der Vaart CH. The association between overactive bladder symptoms and objective parameters from the bladder diary and filling cystometry. *Neurourol Urodyn* 2004;23:38–42.
20. Araki I, Matsui M, Ozawa K, Takeda M, Kuno S. Relationship of bladder dysfunction to lesion site in multiple sclerosis. *J Urol* 2003;169:1384–1387.
21. Kirby RS, Fowler CJ, Gosling J, et al. Urethro-vesical dysfunction in progressive autonomic failure in multiple systems atrophy. *J Neurol Neurosurg Psychiatry* 1986;49:554–562.

---

# 6 Conservative Therapy for Incontinence

---

*Diane K. Newman, RNC, MSN, CRNP, FAAN*

## **CONTENTS**

INTRODUCTION  
LIFESTYLE CHANGES/BEHAVIOR MODIFICATION  
TOILETING PROGRAMS  
PELVIC FLOOR MUSCLE REHABILITATION OR TRAINING  
CONCLUSION  
REFERENCES  
APPENDIX

---

## **INTRODUCTION**

Conservative therapy is an accepted treatment option for persons with urinary incontinence (UI) and overactive bladder (OAB). These interventions improve symptoms through identification of lifestyle habits (e.g., smoking, excess weight, dietary bladder irritants, inadequate fluid intake, bowel habits, physical activities and exercises) and changing a person's behavior, environment, or activity that are contributing factors or triggers (Newman, 2005). Interventions such as bladder retraining (BT) and pelvic floor muscle (PFM) rehabilitation or training (PFMT) attempt to decrease incontinence and OAB symptoms through increasing awareness of the function and coordination of the PFM to gain muscle identification, control, and strength and to decrease bladder overactivity. These interventions are referred to as *behavioral treatments* as they involve learning new skills and altering behavior through extensive one-on-one patient instruction. Toileting programs (e.g., habit training and prompted voiding [PV]) are used for more care-dependent persons. The International Consultation on Incontinence has published recommendations from evidence-based research for conservative treatments. These are outlined in Table 1. This chapter discusses the use of conservative therapy in clinical practice.

## **LIFESTYLE CHANGES/BEHAVIOR MODIFICATION**

In many instances, lifestyle practices can contribute to or cause urinary tract symptoms of UI, urgency, and frequency. Patients can improve symptoms by lifestyle modifications incorporated into their overall treatment program (Nygaard et al., 2002). Clinicians in all care settings can teach these techniques through easy patient education material as outlined in the Patient Guide (Newman, 2004, 2007). There are five key components to lifestyle modification:

**Table 1**  
**Recommendations for Conservative Therapy**

The following are recommendations concerning specific conservative therapies by committees for the International Consultation on Incontinence (Fonda et al., 2005; Newman et al., 2005; Wilson et al., 2005). The following levels of evidence were used:

Grade A: Good-quality randomized controlled trials

Grade B: Good quality prospective “cohort” studies, case-control studies, or case series studies

Grade C: Expert opinion

- Nursing home residents should receive adequate oral hydration to increase voided volume. Grade C
- Conflicting evidence on whether caffeine intake is associated with UI. Grade B
- Decreased caffeine intake should be considered for frail elderly. Grade C
- Chronic straining caused by constipation may be a risk factor for pelvic organ prolapse and UI; no intervention trials have examined the impact of resolving constipation on UI. Grade B/C
- Obesity is an independent risk factor for urinary incontinence, and weight morbidly obese women may decrease incontinence. Grade B
- No data have been reported examining whether smoking cessation resolves incontinence. Grade B/C
- Prompted voiding should be offered to decrease daytime UI in nursing home residents and homebound older adults if caregivers comply with the protocol. Grade A
- Bladder training and PFMT might be similarly effective for women with SUI, urge UI, or mixed UI. Grade B
- PFMT should be a standard component of prenatal and postpartum care. Grade B
- Primiparous women should be offered a sufficiently intensive and supervised antenatal PFMT program to prevent postnatal UI. Grade B
- Supervised PFMT is more effective than standard care for the treatment of UI at 3 mo postpartum. Grade B
- PFMT and vaginal cones might have similar effectiveness for women with SUI. Grade B
- Further investigation is warranted to assess the efficacy of PFMT and bladder training for primary prevention of UI in older adults. Grade B
- For women with SUI or mixed UI, a combination of bladder training/PFMT may be more effective than PFMT alone in the short term (3 mo), but any additional benefit may not be maintained longer term (6 mo). Grade B
- Clinicians should provide the most intensively supervised PFMT program possible within service constraints. Grade B
- There does not appear to be any posttreatment benefit of biofeedback- (home or clinic) assisted PFMT over PFMT alone. Grade B
- PFMT might be better than electrical stimulation for women with SUI. Grade B
- PFMT might be better than oxybutynin for women with detrusor overactivity or detrusor overactivity and urodynamic SUI. Grade B
- PFMT might be less effective than surgery for women with urodynamically proven SUI. Grade B

1. Altering fluid intake (decreasing to reduce incontinence and frequency, increasing to improve urine concentration).
2. Modifying the diet to eliminate possible bladder irritants (e.g., reducing caffeine, alcohol, and carbonated beverages).
3. Regulating bowel function to avoid constipation and straining during bowel movement.



4. Quitting smoking.
5. Reducing weight.

### ***Fluid Management***

Individuals may subscribe to either restrictive or excessive fluid intake behavior. Adequate fluid intake is needed to eliminate irritants from the bladder. Underhydration may play a role in the development of urinary tract infections (UTIs) and decreases the functional capacity of the bladder (Dowd, 1996). Excessive fluid intake can trigger incontinence and OAB. Surveys of community-residing elders reported self-care practices to include self-imposed restrictions of fluids as they fear UI, urinary urgency, and frequency (Engberg et al., 1995; Johnson et al., 2000). Adequate fluid intake is important for older adults, who already have a decrease in their total body weight and are at increased risk for dehydration. Fluid intake should be regulated to 6- to 8-oz glasses or 30 cc/kg body weight per day with a 1500 mL/d minimum at designated times unless contraindicated by a medical condition.

However, the research showing the relationship of quantity of fluid intake to urinary symptoms is inconclusive. Certain professionals who drank less while working to decrease their voiding frequency were at higher risk of UTI (Nygaard and Linder, 1997). In a geriatric population, there appears to be a strong relationship among evening fluid intake, nocturia, and nocturnal voided volume. Aging causes an increase in *nocturia*, defined as the number of voids recorded from the time the individual goes to bed with the intention of going to sleep to the time the individual wakes with the intention of rising. Nocturia is an average of less than two nocturnal voids per night. Nocturia can be diagnosed as nocturnal polyuria, which causes the largest amount of urine production to occur at rest while the person is supine. Chronic medical conditions such as congestive heart failure, venous stasis with peripheral edema, hypoglycemia and excess urine output, obstructive sleep apnea, and diuretics as well as evening/nighttime fluid consumption are causes of nocturnal polyuria. Patients who develop edema of the lower extremities should be advised to elevate their lower extremities on a stool or recliner during the day or to lie in bed for a nap before lunch to stimulate natural diuresis and reduce the amount of voiding during the night. To decrease nocturia precipitated by drinking fluids primarily in the evening or with dinner, the patient should be instructed to reduce fluid intake after 6 PM and shift intake toward the morning and afternoon.

### ***Influence of Bladder Irritants***

Common dietary staples can cause diuresis or bladder irritability, contributing to OAB and incontinence symptoms. Caffeine is an ingredient found in certain beverages, foods, and medications and is felt to have an impact on urinary symptoms by causing a significant rise in detrusor pressure and an excitatory effect on detrusor contraction.

The consumption of caffeinated beverages, foods, and medications should not be underestimated. In the United States, over 80% of the adult population consumes caffeine in the form of coffee, tea, or soft drinks on a daily basis. In addition, the US Food and Drug Administration has listed that more than 300 drugs bought off the shelf in pharmacies and retail drug stores contain caffeine (Newman, 2004, 2005).

In addition to caffeine, alcohol is felt to have a diuretic effect that can lead to increased frequency. Alcohol with dinner or consumed during evening hours may be a contributing factor for nocturia. Anecdotal evidence suggests that eliminating

dietary factors such as artificial sweeteners (aspartame) and certain foods (e.g., highly spiced foods, citrus juices, and tomato-based products) may play a role in continence (Newman, 2007).

Working women surveyed reported fluid intake limitations and avoidance of caffeinated beverages as strategies to avoid urinary symptoms (Fitzgerald et al., 2000). Research has shown that urine leakage can be decreased when caffeine consumption is reduced (Arya et al., 2000; Tomlinson et al., 1999). Therefore, clinicians believe that OAB symptoms of urgency, frequency, and urge UI have been shown to improve when women practice BT and caffeine reduction. Assessment of daily caffeine intake on all patients with UI and OAB and instructions on the correlation between symptoms and caffeine intake are integral to clinical practice. It is recommended that patients with incontinence and OAB avoid excessive caffeine intake (e.g., no more than 200 mg/d, 2 cups). The patient should be instructed to eliminate the identified product on a “one-by-one” basis to see if symptoms decrease or resolve.

### ***Regularity of Bowel Function***

Chronic constipation (defined as having fewer than three stools per week) and straining during defecation can contribute to UI and OAB. The close proximity of the bladder and urethra to the rectum and their similar nerve innervations make it likely that there are reciprocal effects between them (Dohil et al., 1994). Studies of severely constipated women who over a prolonged period have strained during defecation have demonstrated changes in pelvic floor neurological function (Snooks et al., 1985).

Lubowski et al. (1988) reported that denervation of the external anal sphincter and PFM may occur in association with a history of excessive straining on defecation. Many believe that if these are lifetime habits, then they may have a cumulative effect on pelvic floor and bladder function. Self-care practices that promote bowel regularity should be an integral part of any treatment care plan. Suggestions to reduce constipation include the addition of fiber to the diet, increased fluid intake, regular exercise, external stimulation, and establishment of a routine defecation schedule. High fiber intake must be accompanied by sufficient fluid intake. Improved bowel function can also be achieved by determining a timetable for bowel evacuation so that the patient can take advantage of the urge to defecate.

### ***Smoking***

Conditions exist in which increased intraabdominal pressure may promote the development of UI and urinary urgency, particularly in women. These conditions include pulmonary diseases such as asthma, emphysema, and chronic cough such as seen in persons who smoke. Smoking increases the risk of developing all forms of UI, and stress UI (SUI) in particular, depending on the number of cigarettes smoked (Bump and McClish, 1992, 1994). Causes appear to be related to more frequent and violent coughing, which causes downward pressure on the pelvic floor, causing repeated stretch injury to the pudendal and pelvic nerves. Nicotine may contribute to detrusor contractions, and tobacco products may have antiestrogenic hormonal effects that may have an impact on the collagen synthesis. No data have been reported examining whether smoking cessation in women resolves incontinence. However, in clinical practice, women who smoke are educated on the relationship between smoking and UI, and strategies designed to discourage women from smoking are often suggested; however, no evidence supports their effectiveness.

### *Obesity*

Obesity has been identified as an independent risk factor for the development of SUI and mixed UI in women (Wilson et al., 2005). The SUI seen in obesity may be secondary to increases in intraabdominal pressure on the bladder and greater urethral mobility. Also, obesity may impair blood flow or nerve innervation to the bladder. Weight loss is an acceptable treatment option for morbidly obese women. Research has shown that SUI symptoms decrease in morbidly obese women who undergo extreme weight loss after gastric bypass surgery (Bump et al., 1992). At this time, weight loss may resolve incontinence in women who are moderately obese (Subak et al., 2005).

### TOILETING PROGRAMS

The Cochrane Collaboration has published systematic reviews for toileting programs that include habit training, timed or scheduled voiding, and PV (Eustice et al., 2002; Ostaszkiwicz et al., 2002a, 2002b). These programs are reviewed in Table 2. These programs can be utilized to improve continence, especially in frail elders who are homebound or reside in an institution (Lekan-Rutledge and Colling, 2003). Excluded from these programs are residents with mobility impairment necessitating a mechanical or multiple person transfer; those terminally ill, comatose, or severely behaviorally disturbed residents are excluded from a PV trial. However, the frequency of toileting assists by nursing staff in nursing homes in the United States is inadequate to maintain continence. Therefore, there is a need to combine toileting programs with interventions geared to nursing staff.

*Scheduled toileting and habit training* are toileting a person on fixed schedules whether or not a sensation to void is present. The goal is to toilet or have the person void prior to involuntary urine loss, thus maintaining continence but not modifying bladder function. Prefixed times such as every 2–3 h have been adopted for toileting programs in institutions such as nursing homes. A more realistic schedule may be developed around certain daily routines, such as on awakening, before or after meals, and at bedtime, or based on patterns identified in a voiding record. Regular voiding prevents chronic bladder distension and its sequelae (e.g., compromised detrusor contractility caused by overstretching of the muscle fibers); UTI (because of urine stasis and a poorly perfused bladder wall); and urine leakage with activity (caused by elevated intravesical pressures).

PV is a type of scheduled toileting program that employs behavior modification to reinforce both appropriate toileting behaviors and the individual's desire to stay dry. PV has been shown to reduce UI episodes by up to 33% in nursing home residents regardless of their type of UI or cognitive deficit (Ouslander et al., 1995). Requirements for inclusion in this program are ability to

- Respond appropriately.
- State one's name.
- Reliably point to one of two objects.

There are five major steps of a prompted voiding program: (1) scheduled checking to allow the patient to request toileting; (2) discussing with the patient the incontinence problem; (3) prompting the patient to void; (4) providing positive reinforcement to the patient for making an effort to use the toilet; and (5) if incontinent, then indicate to the patient that the expectation is that they stay dry (Engberg et al., 2002; Newman, 2007; Ouslander et al., 1995).

Table 2  
Types of Bladder Programs

<i>Program</i>	<i>Changes in intervoid intervals (times between voiding)</i>			<i>Patient profile</i>	<i>Approach</i>
	<i>Other terms</i>	<i>Unchanged</i>	<i>Spinal cord injury causing neurogenic bladder</i>		
Scheduled or timed voiding	Scheduled voiding Timed toileting	Unchanged	Spinal cord injury causing neurogenic bladder Cognitively impaired, available and compliant caregiver	Fixed voiding regimen (e.g., every 2 or 3 h) Techniques to facilitate or “trigger” voiding may be helpful (e.g., crede maneuver, running water at the sink, placing hands in a basin of warm water, drinking warm fluids, pouring warm water on the perineum)	
Habit	Habit training (including patterned urge response) Bladder drill	Increased or decreased	Spinal cord injury Cognitively impaired, available and compliant caregiver	Assigned toileting schedule (every 2–3 h); schedule should be determined by voiding pattern determined from a voiding diary; encourage delaying toileting until the set times unless urge is unbearable	
Prompted voiding	Bladder training	Prompting schedule	Cognition requires that the patient be able to state name and reliably point to one of two objects Available and compliant caregiver	Prior to implementing a PV program, a trial should be done for 3 consecutive days; predictors of a good response include those residents who Respond to prompts when toileting Void a high maximum volume of urine (>150 mL) Have appropriate number of voids (voids at least 50% of the time into a toileting receptacle) Have incontinence frequencies <4 episodes in 12 h (baseline incontinence rate)	
Bladder retraining	Bladder training Bladder reeducation Behavioral training Urge suppression or inhibition	Increased	Cognitively and neurologically intact persons who are motivated to change symptoms	Have normal PVR urine volume (<150–120 mL) Patients are instructed to void during specific intervals (e.g., every 30 min or 1 h); if urge occurs during the interval, distraction or relaxation techniques or self-affirming statements are used to decrease urgency; over time, voiding interval increased at comfortable intervals until a maximum of every 3–4 h is reached	

BT helps to restore normal bladder function by gradually increasing the intervals between voiding in an attempt to correct urinary frequency and eventually diminish urgency. Mechanisms of action are not well understood, but it is felt that BT improves cortical inhibition over detrusor contractions, facilitates cortical ability over urethral closure during bladder filling, strengthens pelvic striated muscles, and alters behaviors that affect continence (e.g., frequent response to urgency). The patient is provided information about normal bladder control and given methods called *urge suppression strategies* to control the urgency. The main outcomes for a BT program are to (1) improve bladder overactivity by controlling urgency and decreasing frequency; (2) increase bladder capacity; and (3) reduce urge incontinence episodes (Newman, 2005). BT is most appropriate for patients with all types of UI and OAB, are motivated and can comprehend, and who can read and follow instructions (Roe et al., 2002).

The most common BT protocol is provided in an outpatient or office practice program supervised by a knowledgeable clinician. The patient is assigned an initial voiding interval, typically beginning every 30–60 min during waking hours (Wilson et al., 2005; Wyman, 2003). The voiding intervals are based on the baseline micturition frequency as determined by the bladder diary. Initially, it is important for the patient with urgency to schedule short voiding intervals as the shorter intervals will decrease or eliminate these symptoms (Newman, 2005). The goal is for the patient to void “before” the urge sensation of bladder fullness. The patient is taught methods to resist or inhibit the urge sensation so an expanded voiding interval can be adopted. Improving the ability to suppress the urge sensation and eventually diminish urgency will enable the patient to adopt a more normal voiding pattern. There are several strategies or techniques used to control and inhibit the urge sensation, including slow, deep breathing to consciously relax the bladder to combat a stressful rush to the toilet or performing five or six rapid, deliberate, and intense pelvic muscle contractions of 2–3 s long. The scheduled intervals between voiding are increased by 15–30 min each week depending on the tolerance of the schedule (e.g., fewer incontinence episodes, less frequency) until a voiding interval of 3–4 h or longer is achieved. The use of reminders such as a kitchen timer or stopwatch can be beneficial in helping the patient keep on a schedule (Newman, 2005). Self-monitoring through the use of bladder diaries is essential to evaluate adherence and to determine the next weekly voiding interval.

As with most behavioral interventions, the relationship between the clinician and patient is important to the success of the retraining. The clinician must monitor the patient’s progress and provide praise and encouragement if appropriate.

It is felt by most experts that, in patients with OAB symptoms, combining behavioral interventions with treatments such as drug therapy is the most efficacious (Burgio et al., 2002; Mattiasson et al., 2003).

## PELVIC FLOOR MUSCLE REHABILITATION OR TRAINING

The primary technique of conservative therapy is PFMT with or without biofeedback. The rationale for this is that mastering a voluntary contraction of the PFM will help to increase pressure in the urethra, inhibit detrusor contractions, and control leakage of urine. It is a skill that patients seldom master on their first try, but with repeated training, it can be used successfully and provide significant improvement in reducing incontinence episodes.

### *Pelvic Floor Muscle Exercises*

Pelvic floor muscle exercises (PFMEs) were introduced in the 1940s by Dr. Arnold Kegel and have been referred to as *Kegel exercises*. Research on exercising the pelvic floor most recently has centered on specific PFME or PFMT, and data have accumulated concerning the efficacy of these exercises in decreasing all types of incontinence and OAB symptoms of urgency and frequency in cognitively intact, motivated, and neurologically intact patients (Wilson et al., 2005).

The proposed mechanisms of action for PFMEs include (1) urethral closure through increases in urethral pressure; (2) mechanical pressure rise that causes lifting of the endopelvic fascia, which presses it upward toward the pubic symphysis; and (3) a pelvic muscle “reflex” contraction that precedes increased bladder pressure and may inhibit bladder overactivity (Newman, 2005).

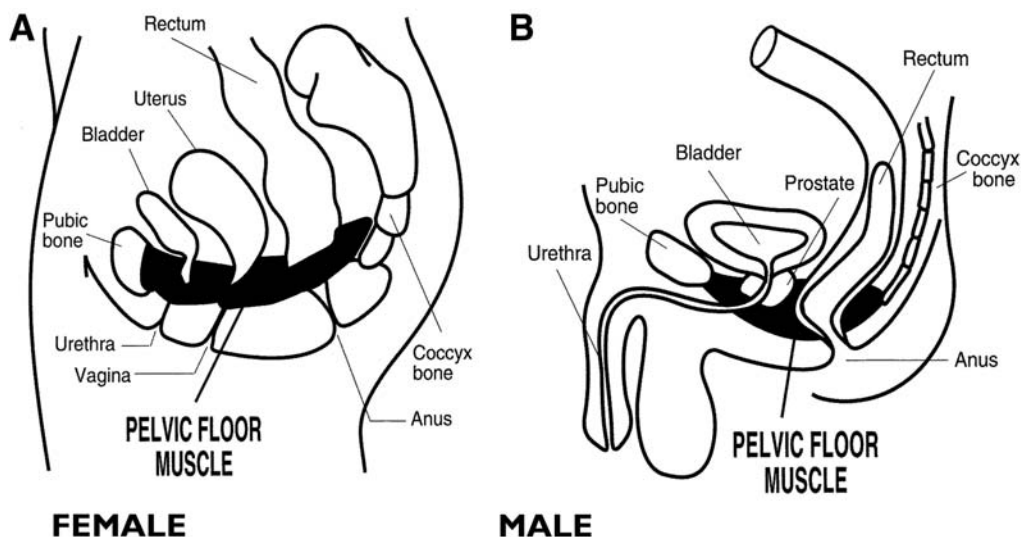
The PFM is under voluntary control, and exercises of this striated skeletal muscle consists of contractions of two types of muscle fibers: type I, slow-twitch muscle fibers; and type II, fast-twitch muscle fibers. Type I (80%) muscle fibers produce less force on contraction and assist in improving muscle endurance by generating a slower, more sustained but less-intense contraction to maintain a general level of pelvic support and urethral closure pressure. Type II or fast-twitch fibers cause strong and forceful muscle contractions, build pelvic muscle strength, and are most helpful during sudden increases in intraabdominal pressure by contributing to urethral closure. The use of pictures or diagrams of the PFM and its support for the pelvic organs are helpful when educating patients (*see* Fig. 1 A, female; B, male).

Clinicians should provide specific instructions on location and isolation of the PFM. The following instructions can be used when asking the patient to contract or tighten the pelvic muscle:

- Without tensing the muscles of the legs, buttocks, or abdomen, imagine trying to control the passing of gas or pinching off a stool by tightening the ring of muscles around the anus. A closing-and-lifting sensation should be felt.
- For men, ask them to imagine moving the penis up and down without moving any other part of the body.

Patients should be cautioned not to perform these exercises during voiding and not to stop and start urine flow as a form of exercising. This exercise has good face validity for effectiveness because many patients initially report an inability to stop the urine flow when it begins. However, there is some controversy over this practice because it is non-physiological and can be harmful. Also, patients should not overexercise the PFM as women can develop levator ani myalgia by performing excessive exercises (DeLancey et al., 1993).

Once the patient is able to identify the muscle, he or she is instructed to perform a series of “quick flicks” or 2-s contractions followed by sustained (endurance) contractions of 5 s and longer as part of a daily exercise regimen. It is equally important to control both muscle tightening and relaxing, to relax for the same amount of time the muscle is contracted, and to relax completely between each muscle contraction. The patient is encouraged to aim for a high level of concentrated effort with each PFM contraction as greater contraction intensity is associated with improvement in PFM strength (Bo and Talseth, 1996; Newman, 2005). Patients are given the following instructions about positions to use when performing these exercises:



**Fig. 1.** Side view of female (A) and male (B) anatomy depicting the position of the pelvic floor muscle. Copyright Diane K. Newman.

- Sit upright in a straight-back chair, knees slightly apart, and feet flat on the floor or legs stretched out in front and crossed at the ankles.
- Stand by a chair; keep back straight and knees slightly bent with feet shoulder-width apart and toes slightly pointed outward.
- Lie on the back flat or with head slightly elevated, knees bent, and feet slightly apart.

A minimum of 30–45 PME per day is recommended. A gradual increase in number of contractions over a period of PME practice has been shown to increase muscle strength significantly and decrease urine loss. An *exercise prescription* as shown in Table 3 can be used in clinical practice when recommending PFMT.

The patient should also be taught a preventive PFM contraction referred to as the *knack* (Miller et al., 2001). The *knack* is the skill of consciously timing an intentional contraction of the PFM just before and throughout the activity that causes an increase in intraabdominal pressure (Miller et al., 1996). This technique is an acquired motor skill that requires the patient to anticipate urine leakage. Contracting the PFM before sneezing, coughing, lifting, standing, or swinging a golf club can prevent SUI from occurring. The muscle also can be contracted when a strong urge to void occurs. Repeated correct contractions of the pelvic floor, strengthening the PFM in a regular, intensive, and long-lasting training program, are essential for effective improvement through PFMT. Results may not occur until after 6–8 wk of exercise, and optimal results usually take longer. For muscle contractility to improve, five principles of muscle training must be considered (Newman, 2003):

1. *Strength*: maximum force or contraction that a muscle can generate.
2. *Power*: referred to as quick flicks or the ability for the muscle to contract-relax as quickly and strongly as possible.
3. *Endurance*: muscle is timed until it fatigues, up to 10 s.
4. *Repetitions*: number of times (up to 10) a muscle contraction of equal force that can be repeated. Use at least a 5-s muscle relaxation between each contraction (easily fatigable)

**Table 3**  
**Exercise Prescription Sample**

Please complete the following exercises:

1. Short quick exercise: Contract the muscle for 2 s and immediately relax.
2. Long sustained exercise: Contract the muscle and hold the contraction for a count of 10, then immediately relax for a count of 10.

*Exercise session*

Lying Down	Do 10 exercises holding for 2 s
	Do 10 exercises holding for 10 s
Sitting	Do 10 exercises holding for 2 s
	Do 10 exercises holding for 10 s
Standing	Do 10 exercises holding for 2 s
	Do 10 exercises holding for 10 s

3. Be sure to rest your muscle after each muscle contraction for the same length of the contraction or longer. Do two exercise sessions per day for a total of 60 exercises every day.
4. When you have completed both types of exercises in all three positions, you will have completed one session.

*Special tips*

- Always empty your bladder prior to beginning your exercise session.
- Count out loud with sustained or long exercises; remember to keep breathing.
- Keep your stomach, leg, and buttock muscles relaxed. Rest your hand on your stomach, which should not move or tense.
- If it helps, take a deep breath between each exercise to help keep other muscles relaxed.

---

© 2000 Diane K. Newman.

muscles need a chance to recover) without permitting excessive rest periods for strong muscles.

5. *Fatigue*: failure to maintain the required or expected force of the pelvic muscle contraction for more than one or two times in succession.

The tone of the PFM is also important. *Low muscle tone* is the impaired ability to isolate and contract the PFM in the presence of weakness and atrophy. *High muscle tone* refers to the clinical condition of hypertonic, spastic PFM with resultant impairment of muscle isolation, contraction, and relaxation. A high resting baseline with high variability and occasional spasms may be seen in patients with chronic pelvic pain syndromes (e.g., painful bladder syndrome) (Fletcher, 2005). Rehabilitating the PFM can be central in resolving pain when muscle spasm is present. Using PME on patients with high tone to enhance muscle relaxation is referred to as *down training*. Teaching a muscle to relax is often more difficult than teaching it how to contract (up training) as the feeling of relaxation is small.

Most clinicians in this field have relied on the use of verbal and written instructions for patients to use for home practice of PMEs. Self-monitoring practice through the use of a calendar record, audio- and videotaped material that review the exercises can improve protocol compliance (Newman, 2007).

Research in the area of PMEs is extensive, but long-term results have been reported only rarely (Bo and Talseth, 1996). Cure rates for PFMT range from 16 to 27% and



improvement rates from 48 to 80.7%. However, the most critical variables in PFMT are isolation of the PFM and adherence to a prescribed exercise regimen.

### *Use of Biofeedback Therapy*

The basic debate regarding efficacy of PFMT involves the added benefit of adjunct techniques such as biofeedback using electromyography (EMG) or other methods. *Biofeedback* is the technique by which information regarding physiologic processes, in this case PFM contractions and relaxations, is displayed in a form understandable to the patient to permit self-regulation of these events. Biofeedback therapy uses either EMG or manometric pressure. EMG measures electrical activity of a muscle in microvolts. The advantage of EMG over manometric pressure is that, provided the machinery is sufficiently sophisticated with adequate filtering, EMG apparatus can engage the use of the newer types of electrodes that are lightweight and designed to stay in place, hence allowing more functional positions during assessment and treatment (Newman, 2003). Also, EMG can be multichannel, which allows the simultaneous reinforcement of contractions of the PFM and inhibition of accessory muscles (e.g., abdominal muscle contractions). A common error in contracting the PFM is to contract the abdominal, gluteal, or adductor muscles simultaneously. This may mask the strength of the PFM contraction. Abdominal contraction increases intra-abdominal pressure, which mechanically elevates bladder pressure, so it is important to measure concurrent use of abdominal contraction (Sapsford and Hodges, 2001). When an additional muscle group is contracting at the same time as the pelvic floor, it is called *recruitment*. Monitoring for accessory muscle recruitment during initial EMG and subsequent visits are necessary until recruitment stops and should be considered for all patients.

Four methods of EMG measurements have been used in the investigation of lower urinary tract dysfunction (Workman et al., 1993):

- Vaginal sensor.
- Anal sensor or plug electrode.
- Surface skin electrodes.
- Needle electrodes.

Vaginal and anal sensors are internal probes designed to provide accurate detection of EMG muscle activity. The accuracy of longitudinal sensing electrodes has been shown to be virtually identical to the gold standard of inserted needle electrodes. However, the use of vaginal or rectal sensors is limited in patients with severe pelvic pain, for whom insertion of the sensor causes discomfort; pregnancy; recent pelvic or rectal surgery; and atrophic vaginitis. Skin electrodes are relatively noninvasive and well tolerated and provide quantitative information about muscle activity. Needle electrodes are primarily used during urodynamic testing. The EMG data are measured in microvolts. The actual threshold of PFM required for maintaining continence is unknown at this time, as are the normal values for PFM strength.

The baseline and all follow-up EMG recordings should include two sets of measurements of maximum or short/quick muscle contractions of 2-s duration with an equal amount of resting muscle activity and sustained or long muscle contractions (5, 10, or 30 s) with resting muscle activity for the same length of time as muscle contraction. The ability to relax one's pelvic muscle following a contraction is most important if one is to gain control and coordination of these muscles.

*Manometry* is the use of an instrument to detect, assess, and record pressure. A pressure perineometer first described by Kegel consists of a vaginal or rectal probe with a connector tube to a manometer. The pressure changes can be measured in centimeters of water (cm H<sub>2</sub>O) or millimeters of mercury (mmHg) (Theofrastous et al., 2002). Although manometers and pressure sensors are available with certain clinical systems and have been used in several clinical trials, they are primarily used for treatment of rectal dysfunction.

Different biofeedback methods can be used in PFMT (Newman, 2007), including proprioception and verbal encouragement:

- Digital (e.g., vaginal or rectal) PFM assessment of the levator ani muscle is a form of biofeedback and is an important component of teaching correct pelvic muscle contraction and muscle awareness (Bo and Finckenhagen, 2001). Appropriate treatment with PFMT should always include an assessment of PFM contraction and relaxation because the effect of PFMT is dependent on whether the contractions and relaxations are performed correctly.
- Verbal feedback of a voluntary contraction can also encourage and assist in enhancing patient effort. The levator ani can be palpated in the 4 and 8 o'clock positions, just superior to the hymenal ring. Pain or discomfort during palpation may indicate high-tone pelvic muscle.
- Manometric and EMG biofeedback not only helps in PFMT awareness, but also provides interest, challenge, and reward for effort, a greater feeling of control, and progress monitoring.

Research, in both men and women, is extensive in detailing the efficacy of the use of biofeedback-assisted behavioral therapy for PFMT. However, there is debate over the use of adjuncts such as biofeedback therapy (Wilson et al., 2005). The consensus is that conservative therapy combining lifestyle changes, toileting or BT programs, and PFMT with or without biofeedback is most effective when provided by a clinician who specializes in the area of pelvic floor dysfunction. Clinician-supervised PFMT with biofeedback is felt to provide the most favorable long-term results, and many multidisciplinary pelvic floor dysfunction or "continence" centers provide these services (Newman, 2007). Augmenting drug therapy with a supervised bladder training program is felt to yield the best outcomes in the treatment of urge incontinence and OAB (Burgio et al., 2002).

### *Use of Vaginal Weights*

Vaginal weights are another example of an adjunct technique that can be used in PFMT. They have been most successful as part of a structured resistive pelvic exercise program in woman with SUI. The weights are made of plastic and shaped like a tampon. All weights are identical in size but have increasing weight. The idea is that the stronger the PFM becomes, the higher the weight of a cone must be to stimulate the PFM to hold the weight inside the vagina. The user is instructed to insert the lightest weight into the vagina in the position of a tampon. The user then walks around for up to 15 min contracting the PFM to prevent the weight from slipping out. If the weight is easily retained during this time, then the next-heaviest weight is introduced, and the procedure is repeated until a weight of a certain heaviness slips out. To increase the exercise value of these weights, the woman is instructed to practice retaining the weight during coughing, jumping, or any stress-provoking act that causes incontinence. Theoretically, when the

weight is placed in the vagina it provides sensory feedback and prompts a PFM contraction to keep it from slipping out. The perceived advantages of vaginal weight training are that it involves less teaching time, can be self-taught, may be motivational, and can be used with minimal supervision. The weights can be purchased at [www.seekwellness.com](http://www.seekwellness.com).

Weighted vaginal cones are better than no active treatment, but on the other hand, they add no benefit to a PFMT program (Herbison et al., 2002). Although vaginal weight training may take less instructional time in terms of office practice, it may be less acceptable to some women than PFME alone, as noted by higher attrition rates in some clinical trials (Cammu and Van Nylen, 1998). Reasons given for their nonuse were aesthetic dislike, unpleasantness, discomfort, difficulty in insertion, or bleeding (Wyman, 2003).

### *Pelvic Floor Electrical Stimulation*

Pelvic floor electrical stimulation (PFES) is the application of low-grade electrical stimulation to the PFM to stimulate the muscle to contract. PFES has a twofold action: contraction of PFM and inhibition of unwanted detrusor contractions. PFES for SUI is the result of stimulation of afferent fibers of the pudendal nerve activating both the pelvic floor and periurethral muscles. For urge UI and OAB, bladder inhibition occurs through pudendal- (afferent) to-pelvic (efferent) nerve reflex and a pudendal-to-hypogastric reflex.

Electrical stimulation can be performed in the clinician's office and is prescribed as a home program using a battery-operated home unit. The delivery of the electrical current to the tissues is via a sensor with vaginal or rectal sensors preferred. There are many differences in clinical application that have not yet been investigated. For example, some clinicians suggest that active electrical stimulation (i.e., the patient voluntarily contracts the PFM during stimulation) is better than passive electrical stimulation, but the effect of these two approaches has not yet been evaluated. Equally, it may be that some populations or subgroups of patients benefit from electrical stimulation more than others.

The home program consists of using the stimulator for 15 min twice a day for several weeks to months, although the length of time and number of treatments are highly variable. The patient is instructed to use the maximum tolerable level during stimulation. However, with the wide variations in stimulation parameters, including time, intensity, and frequency of sessions, it is difficult to make comparisons across studies. Given the equivocal results, the benefit of electrical stimulation in SUI, urge, and mixed UI in women remains controversial (Wilson et al., 2005).

## CONCLUSION

Conservative therapy is considered front-line treatment for persons with SUI, urge, or mixed UI and for those with OAB. These treatments, especially lifestyle interventions, can be offered to patients in the primary care setting before or with medication therapy. Clinicians need to become familiar with the different conservative therapies to maximize improvement in these chronic conditions.

## REFERENCES

- Arya LA, Myers DL, Jackson ND. Dietary caffeine intake and the risk for detrusor instability: a case-control study. *Obstet Gynecol* 2000;96:85–89.
- Bo K, Finckenhagen B. Vaginal palpation of pelvic floor muscle strength: inter-test reproducibility and comparison between palpation and vaginal squeeze pressure. *Acta Obstet Gynecol Scand* 2001;80: 883–887.

- Bo K, Talseth T. Long-term effect of pelvic floor muscle exercise 5 yr after cessation of organized training. *Obstet Gynecol* 1996;87:261–265.
- Bump RC, McClish DM. Cigarette smoking and urinary incontinence. *Am J Obstet Gynecol* 1992;167:1214–1218.
- Bump RC, McClish DM. Cigarette smoking and pure genuine stress incontinence of urine. A comparison of risk factors and determinants between smokers and nonsmokers. *Am J Obstet Gynecol*; 1994;170:579–582.
- Bump RC, Sugeran H, Fantl JA, McClish DM. Obesity and lower urinary tract function in women: effect of surgically induced weight loss. *Am J Obstet Gynecol* 1992b;166:392–399.
- Burgio K, Goode PS, Locher JL, et al. Behavioral training with and without biofeedback in the treatment of urge incontinence in older women. *JAMA* 2002;288:2293–2299.
- Cammu H, Van Nylen M. Pelvic floor exercises vs vaginal weight cones in genuine stress incontinence. *Eur J Obstet Gynecol Reprod Biol* 1998;77:89–93.
- DeLancey JO, Sampsel CM, Punch MR. Kegel dyspareunia: levator ani myalgia caused by overexertion. *Obstet Gynecol* 1993;82(40, pt 2):658–659.
- Dohil R, Roberts E, Jones K, Jenkins HR. Constipation and reversible urinary tract abnormalities. *Arch Dis Child* 1994;70:56–57.
- Dowd TT, Campbell JM, Jones JA. Fluid intake and urinary incontinence in older community-dwelling women. *Journal of Community Health Nursing*. 1996;13(3):179–186.
- Engberg SJ, McDowell BJ, Burgio KL, Watson JE, Belle S. Self-care behaviors of older women with urinary incontinence. *J Gerontol Nurs* 1995;21:7–14.
- Engberg SJ, Sereika SM, McDowell BJ, Weber E, Brodak I. Effectiveness of prompted voiding in treating urinary incontinence in cognitively impaired homebound older adults. *J Wound Ostomy Continence Nurs* 2002;29:252–265.
- Eustice S, Roe B, Paterson J. Prompted voiding for the management of urinary incontinence in adults. *Cochrane Incontinence Group, Cochrane Database Syst Rev* 2000;(2):CD002113.
- Fitzgerald S, Palmer MH, Berry SJ, Hart K. Urinary incontinence: impact on working women. *AAOHN J* 2000;48:112–118.
- Fletcher E. Differential diagnosis of high-tone and low-tone pelvic floor dysfunction. *J Wound Ostomy Continence Nurs* 2005;32(3S):510.
- Fonda D, DuBeau CE, Harari D, Ouslander JG, Palmer M, Roe B. Incontinence in the frail elderly. In: *Incontinence, Proceedings From the Third International Consultation on Incontinence* (Abrams P, Cardozo L, Khoury S, Wein A, eds.), Health Publication, Plymouth, UK, 2005, pp. 1163–1240.
- Herbison P, Plevnik S, Mantle J. Weighted vaginal cones for urinary incontinence. *Cochrane Database Syst Rev* 2002;(1):CD002114.
- Johnson TM, Kincade JE, Bernard SL, Busby-Whitehead J, DeFries GH. Self-care practices used by older men and women to manage urinary incontinence: results from the national follow-up survey on self-care and aging. *J An Geriatr Soc* 2000;48:894–902.
- Lekan-Rutledge D. Diffusion of innovation. *J Gerontol Nurs* April 2000:25–33.
- Lekan-Rutledge D, Colling J. Urinary Incontinence in the frail elderly. *AJN*. March, [Suppl], 2003: 36–40.
- Lubowski DZ, Swash M, Nicholls RJ, Henry MM. Increase in pudendal nerve terminal motor latency with defaecation straining. *Br J Surg* 1988;75:1095–1097.
- Mattiasson A, Blaakaer J, Hoye K, Wein AJ, and the Tolterodine Scandinavian Study Group. Simplified bladder training augments the effectiveness of tolterodine in patients with an overactive bladder. *BJU Int* 2003;91:54–60.
- Miller J, Aston-Miller J, DeLancey J. The knack: use of precisely-timed pelvic muscle contraction can reduce leakage in SUI. *Neurourol Urodyn* 1996;15:302–393.
- Miller JM, Perucchini D, Carchidi L, DeLancey JOL, Ashton-Miller JA. Pelvic floor muscle contraction during a cough and decreased vesical neck mobility. *Obstet Gynecol* 2001;97: 255–260.
- Newman DK. *Clinical Manual—Pelvic Muscle Rehabilitation*, Prometheus, Dover, NH, 2003, pp. 89–98.
- Newman DK. Lifestyle Interventions. In: *Pelvic Floor Disorders* (Bourcier AP, McGuire EJ, and Abrams P, eds.), Elsevier Saunders, Philadelphia, 2004, pp. 269–276.

- Newman DK. Behavioral treatments. In: *Female Urology, Urogynecology, and Voiding Dysfunction* (Vasavada SP, Appell RA, Sand PK, Raz, S, eds.), New York: Marcel Dekker, New York, 2005, pp. 233–266.
- Newman DK. *Managing and Treating Urinary Incontinence, 2nd ed.*, Health Professions Press, Baltimore, MD, 2006.
- Newman DK, Denis L, Gruenwald I, et al. Promotion, education and organization for continence care. In: *Incontinence, Proceedings From the Third International Consultation on Incontinence* (Abrams P, Cardozo L, Khoury S, Wein A, eds.), Health Publication, Plymouth, UK, 2005, pp. 35–72.
- Nygaard I, Bryant C, Dowell C, Wilson PD. Lifestyle interventions for the treatment of urinary incontinence in adults. (Protocol) *Cochrane Database of Systematic Reviews* 2002, Issue 1 Art. No.: CD003505. DOI:10.1002/14651858.CD003505.
- Nygaard IE, Linder M. Thirst at work—an occupational hazard? *Int Urogynecol Pelvic Floor Dysfunct* 1997;8:340–343.
- Ostaszkiwicz J, Johnston L, Roe B. Timed voiding for the management of urinary incontinence in adults. *Cochrane Database of Systematic Reviews* 2004, Issue 1. Art. No.: CD002802. DOI: 10.1002/14651858.CD002802.pub2.
- Ostaszkiwicz J, Johnston L, Roe B. Habit retraining for the management of urinary incontinence in adults. *Cochrane Database of Systematic Reviews* 2004, Issue 2. Art. No.: CD002801. DOI: 10.1002/14651858.CD002801.pub2.
- Ouslander JG, Schnelle JF, Uman G, et al. Predictors of successful prompted voiding among incontinent nursing home residents. *JAMA* 1995;273:1366–1370.
- Roe B, Williams K, Palmer M. Bladder training for urinary incontinence in adults. *Cochrane Database Syst Rev* 2002;(2).
- Sapsford R, Hodges P. Contraction of the pelvic floor muscles during abdominal maneuvers. *Arch Phys Med Rehabil* 2001;82:1081–1088.
- Snooks SJ, Barnes PRH, Setchell M, Henry MM. Damage to the innervation of pelvic floor musculature in chronic constipation. *Gastroenterology* 1985;89:977–981.
- Subak LL, Whitcomb E, Shen H, Saxton J, Vittinghoff J, Brown JS. Weight loss: a novel and effective treatment for urinary incontinence. *J Urol* 2005;174:190–195.
- Tampakoudis P, Tantanassis T, Grimbizis G, Papeletsos M, Mantalenakis S. Cigarette smoking and urinary incontinence in women—a new calculative method of estimating the exposure to smoke. *Eur J Obstet Gynecol Reprod Biol* 1995;63:17–30.
- Tomlinson B, Dougherty M, Pendergast J, Boyington A, Coffman M, Pickens S. Dietary caffeine, fluid intake and urinary incontinence in older rural women. *Int Urogynecol J* 1999;10:22–28.
- Wilson PD, Berghmans B, Hagen S, et al. Adult conservative management. In: *Incontinence, Proceedings From the Third International Consultation on Incontinence* (Abrams P, Cardozo L, Khoury S, and Wein A, eds.), Health Publication, Plymouth, UK, 2005, pp. 855–964.
- Workman D, Cassis J, Dougherty M. Validation of surface EMG as a measure of intravaginal and intraabdominal activity: implications for biofeedback-assisted Kegel exercises. *Psychophysiology* 1993 30:120.
- Wyman JF. Treatment of urinary incontinence men and older women. *Am J Nurs* March 2003; suppl:26–35.

## APPENDIX

### ***Patient Guide: Controlling Your Bladder Symptoms***

Common bladder symptoms include

- Urinary urgency:* sudden and strong sensation to urinate immediately
- Frequency:* urinating often, usually more than eight times in a day
- Urinary incontinence:* accidental leakage of urine

Special exercises and medications are available to reduce common bladder symptoms. In addition, many people find that specific diet and lifestyle changes may help reduce bladder problems.

### ***Pelvic Floor Muscle Exercises***

Bladder control depends on muscles working together when the bladder is filling: The bladder muscle should be relaxed, and the muscle around the urethra (the tube that urine passes through), called the pelvic floor muscle, should be tight. Exercises that strengthen the pelvic floor muscle can help hold urine inside the bladder, preventing leakage. These are commonly called pelvic floor muscle exercises or Kegel exercises, named after the doctor who developed them. To perform a pelvic floor muscle exercise, imagine that you are trying to control the passing of gas or pinching off a stool. Or, imagine you are in an elevator full of people, and you feel the urge to pass gas. What do you do? You tighten or pull in the ring of muscle around your rectum, your pelvic floor muscle. Women will feel a lifting sensation in the area around the vagina or pulling in of the rectum. Men may see their penis lift or feel a pulling in of the rectum. One exercise consists of both tightening and relaxing the muscle. Start by tightening the muscle for 5 s and build until you can hold the tightening for 10 s. Be sure to relax completely between each muscle tightening.

### ***Bladder Retraining***

Bladder control can be improved by scheduling bathroom trips. The schedule is changed over a period of weeks or months to gradually increase the time between trips. For example, a person who normally goes to the bathroom every hour could plan to go every hour and 15 min. After maintaining the new schedule for a few days, the time could be increased to every hour and 30 min. The goal is to void no more than every 3–4 h. If you get the *urge* to void and it is not yet your scheduled voiding time, then stop all activity and sit down if possible. Then, try one of these techniques to help you lessen the urge, which will cause the bladder to relax and give you more time to get to the bathroom:

- Take some slow, deep breaths through your mouth, concentrating on your breathing; or, concentrate on an activity, such as taking a vacation, visiting a friend, counting backward from 100, or reciting the words of a favorite song or nursery rhyme.
- Tighten your pelvic floor muscle quickly several times in a row.

### ***Monitor Your Diet and Medications***

Certain foods and beverages can irritate the bladder and make symptoms worse. These include alcoholic beverages; caffeinated foods or carbonated beverages (soft drinks, coffee or tea, chocolate); tomato-based products; citrus fruits and juices; spicy foods; and artificial sweeteners (e.g., Equal). Also, some over-the-counter medications and prescription drugs (e.g., Excedrin, Midol, Anacin, Dristan, Sinarest) can worsen bladder problems. Do not stop taking prescription drugs without talking to your health care provider first.

### ***Maintain Bowel Regularity***

Keeping healthy bowel habits may lessen bladder symptoms. Some suggestions include (1) increase such fiber-rich foods as beans, pasta, oatmeal, bran cereal, whole wheat bread, and fresh fruits and vegetables in your diet; (2) exercise to maintain regular bowel movements; (3) drink plenty of nonirritating fluids (water); (4) see your doctor if you have bowel problems.

### ***Maintain a Healthy Weight***

Being overweight can put pressure on your bladder, which may cause leakage of urine when you laugh or cough. If you are overweight, then weight loss can reduce pressure on your bladder.

### ***Stop Smoking***

Cigarette smoking is irritating to the bladder muscle. It can also lead to coughing spasms, which can cause urinary leakage.

---

# 7 Pharmacological Therapy for Stress Urinary Incontinence

---

*Harriette M. Scarpero, MD*

## *CONTENTS*

ANATOMIC AND FUNCTIONAL INFLUENCES ON CONTINENCE  
HORMONE REPLACEMENT THERAPY  
IMIPRAMINE  
 $\alpha$ -ADRENERGIC AGONISTS  
 $\beta_2$ -ADRENOCEPTOR AGONISTS AND ANTAGONISTS  
SEROTONIN AND NOREPINEPHRINE REUPTAKE INHIBITORS  
CONCLUSION  
REFERENCES

---

Stress urinary incontinence (SUI) is the involuntary loss of urine with activities that increase intra-abdominal pressure, such as coughing, sneezing, and walking. Treatment options vary and include behavioral modifications, pelvic floor muscle exercises (PFMEs), barrier methods, bulking agents, and surgery. No drug approved by the Food and Drug Administration (FDA) exists for SUI. A few agents are occasionally used off label for SUI, but randomized controlled trials proving their efficacy and safety for this indication are lacking.

Urinary incontinence (UI) of any type is an important health concern that often has a substantial effect on an individual's perception of well-being, body image, and quality of life (QOL). It is estimated that 13 million people in the United States, of which 11 million are women, suffer from UI (1). The actual prevalence of UI in women is not known. Most women who experience UI never seek or receive treatment (2,3). A limitation of existing national databases is that they capture only the minority of incontinent women who are treated for incontinence.

The economic impact of UI is better understood and formidable. According to the recently published Urologic Diseases in America Project, UI in women was the chief reason for more than 1 million office visits in the year 2000 at a cost of \$452 million (4). Despite the public's recognition of the disorder, embarrassment and fear that surgery is the only treatment option can still inhibit a woman from discussing incontinence with her physician. A prodigious growth of information and treatment options for UI has developed, but SUI remains without an effective pharmacological treatment.



## ANATOMIC AND FUNCTIONAL INFLUENCES ON CONTINENCE

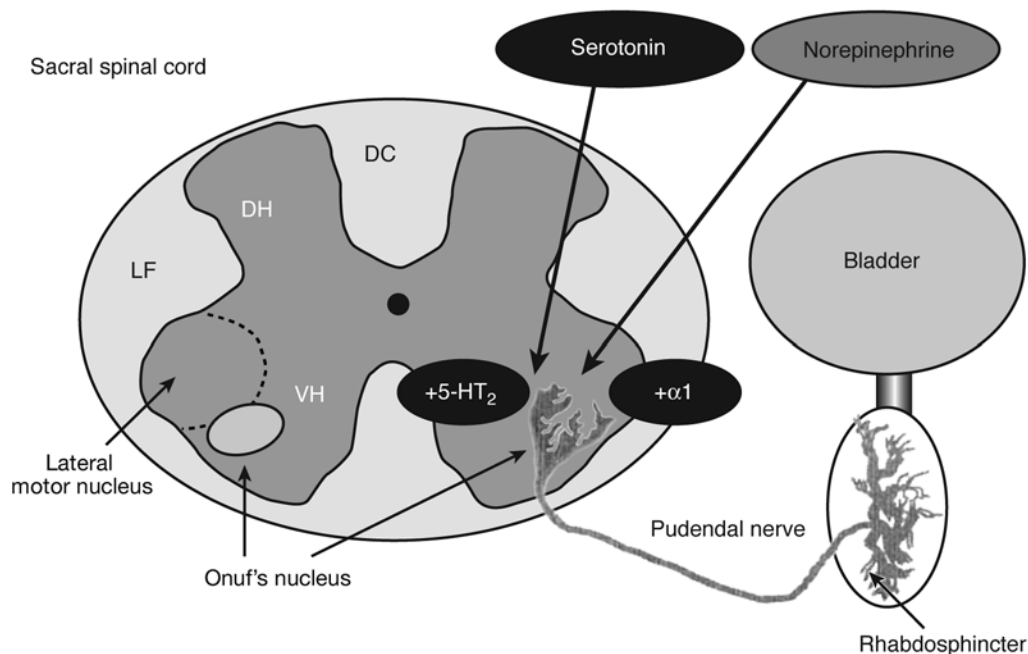
Female continence is maintained by the interplay of several anatomic and functional mechanisms. With increases in intraabdominal pressure, the abdominal pressure is passively transmitted to the proximal urethra, followed by active contraction of the striated external sphincter. The suburethral supportive layer of periurethral fascia, anterior vaginal wall, and levator ani muscles act as a backboard of support against which the urethra is compressed during increases in intraabdominal pressure so that leakage does not occur. Also contributing to continence is reflex contraction of the levator muscles that directly increases midurethral pressure. Addition of voluntary contractions of levator and obturator muscles to increase tension on the urethropelvic ligaments does the same. Alteration or damage to any of these anatomic structures may result in SUI, and anti-incontinence surgery attempts to restore the anatomic deficits contributing to leakage.

However, prevailing theories of continence hold that the etiology of SUI is not purely anatomic. Functional factors such as the intrinsic urethral function are responsible as well, a concept illustrated by the observation that not all women with hypermobility of the urethrovesical unit leak. The intrinsic function of the urethra is related to its makeup of smooth and striated muscle, connective tissue, vascular plexus, and mucosa, which together provide inwardly directed forces that help coaptation and, ultimately, continence.

Nervous system control of the lower urinary tract is another integral part of its physiology and the pathophysiology of incontinence. It plays a crucial role in determining the detrusor capacity and compliance as well as urethral competence necessary to maintain or restore continence. Extrinsic efferent innervation of the lower urinary tract includes three major nerves carrying the three principal divisions of the peripheral nervous system: sympathetic, parasympathetic, and somatic. Activity of the detrusor smooth muscle, bladder neck muscles, and internal sphincter are autonomically controlled, whereas the striated muscle of the external sphincter is controlled by the somatic branch of the peripheral nervous system (5).

The autonomic nervous system predominates in the lower urinary tract. The hypogastric nerve carries sympathetic input responsible for bladder relaxation and exerts its effect through  $\beta$ -adrenergic receptors ( $\beta_3$ ) at the detrusor and  $\alpha_1$ - ( $\alpha_1$ ) receptors in the bladder neck and proximal urethra. The pelvic nerve carries parasympathetic input for bladder contraction via acetylcholine stimulation of muscarinic receptors ( $M_3$ ) in the body of the detrusor. The distribution of autonomic receptors in the lower urinary tract varies. Numerous types of postsynaptic nerve receptors exist:  $\alpha$ -adrenergic,  $\beta$ -adrenergic, cholinergic, histaminic, and serotonergic. In general,  $\beta$ -adrenergic stimulation produces smooth muscle relaxation, and  $\alpha$ -adrenergic and cholinergic stimulation cause muscle contraction.

Specific receptor functions at specific lower urinary tract sites are still incompletely understood. The detrusor is predominantly supplied with postganglionic parasympathetic cholinergic nerve terminals. Few noradrenergic nerves targeting  $\beta$ -adrenergic receptors are found at the trigone and none in the detrusor. The  $\beta$ -adrenergic receptors in the detrusor facilitate relaxation and bladder filling. Cholinergic receptors in the dome are responsible for detrusor contraction during micturition. The  $\alpha$ -adrenergic receptors of the  $\alpha_1$ -subtype are found in low density in the detrusor, and other  $\alpha$ -adrenoceptors are absent. Newly recognized serotonin (5-HT) receptors within the detrusor appear to facilitate neuromuscular cholinergic transmission (6).  $H_1$  histamine receptors have also been identified in the detrusor, but currently no role for histamine as a neurotransmitter in the lower urinary tract has been discovered (7).



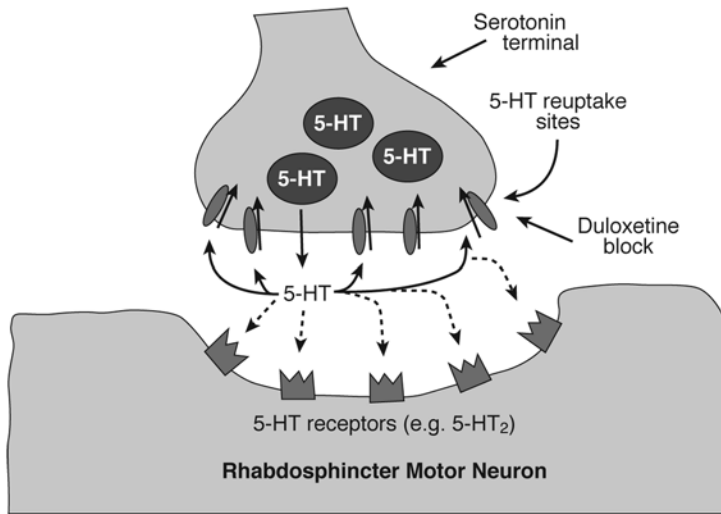
**Fig. 1.** Peripheral nervous system.

Neural control of the urethral muscle itself is supplied by all three divisions of the peripheral nervous system (Fig. 1). Sympathetic preganglionic neurons in the upper lumbar spinal cord give rise to preganglionic axons, which are carried along the inferior splanchnic nerves. Some axons synapse with sympathetic postganglionic nerves within the inferior mesenteric ganglion and project along the hypogastric nerve; other preganglionic axons pass through the ganglion and continue along the hypogastric nerve to innervate postganglionic sympathetic neurons in the pelvic plexus (8). Sympathetic postganglionic fibers are primarily noradrenergic and innervate longitudinal and circular smooth muscle in the urethra (8).

Parasympathetic innervation from parasympathetic preganglionic neurons in the sacral spinal cord begets preganglionic axons, which are carried on the pelvic nerve to connect with parasympathetic postganglionic neurons in the pelvic nerve, which connect with parasympathetic postganglionic neurons in the pelvic plexus. Most parasympathetic postganglionic neurons are primarily cholinergic and innervate longitudinal and circular smooth muscle (9).

Somatic innervation arising from urethral sphincter motor neurons in the ventral horn of the sacral spinal cord, in a region known as Onuf's nucleus, are cholinergic motor axons. They are carried along the pudendal nerve and make direct synaptic connections with the striated sphincter (Fig. 2) (10). Reflex control of the urethral innervation is through a series of spinal and supraspinal reflexes. The primary transmitter for these reflexes is glutamate, and 5-HT and norepinephrine (NE) exert some neuromodulatory control (10).

Newer investigation into the pharmacological treatment of UI has targeted the central nervous system (CNS) and peripheral innervation of the lower urinary tract. Several CNS transmitter systems have been found to modulate voiding, and two important ones are the serotonergic and noradrenergic systems of the brainstem. Neuroanatomical



**Fig. 2.** Cholinergic motor axons making synaptic connections with the striated sphincter.

studies demonstrate high densities of serotonergic and noradrenergic terminals in areas of the spinal cord associated with lower urinary tract reflex pathways, such as Onuf's nucleus (10). The most promising new investigational agent for SUI is directed at these neurotransmitters for the purpose of increasing neural activity to the external sphincter.

## HORMONE REPLACEMENT THERAPY

The female genital tract and urinary tract are intimately connected from early development, both embryologically derived from the urogenital sinus. Estrogen receptors have been located within the vagina, urethra, bladder, and pelvic floor muscles, indicating the estrogens have a significant effect on the anatomic and functional roles of the urogenital organs (11). Many women notice that their urinary symptoms, including UI, may be affected by their menstrual cycle, and these changes have been demonstrated urodynamically (12,13). The influence of hormonal fluctuations in estrogen and progesterone is also noted in the increased incidence of urgency, frequency, and detrusor overactivity in pregnancy. The urogenital effect of estrogen variations becomes even more noticeable after menopause. As estrogenization of the vaginal tissues wanes after menopause, women often experience irritative vaginal and lower urinary tract symptoms. The increased incidence of bothersome lower urinary tract symptoms and vaginal atrophy after menopause has led to the use of hormone replacement therapy (HRT) for their treatment. The presumed benefits of HRT to the urogenital tract have been far reaching, although without much rigorous medical substantiation by large randomized and placebo-controlled trials.

Although rarely used as primary therapy for SUI, HRT has been advocated commonly for its treatment. The rationale behind its use stems from several theories of the role of estrogen in the lower urinary tract. Estrogens may have an impact on continence by increasing urethral resistance, raising the sensory threshold of the bladder, increasing  $\alpha$ -adrenoreceptor sensitivity in the urethral smooth muscle, or promoting  $\beta_3$ -adrenoreceptor-mediated relaxation of the detrusor muscle (14,15). HRT is also thought to increase the number of epithelial cells lining the bladder and urethra, improve the thickness

and quality of the subepithelial vascular plexus, and thus improve the coaptation of urethral walls and urethral resistance (16). Overall, many claims have been made regarding the benefit of estrogens for lower urinary tract symptoms. Data from several large studies described in this section have finally elucidated the effect of conjugated estrogens on the condition of SUI.

The role of estrogens for the treatment of SUI is at best controversial. Until recently, the majority of studies examining the use of estrogen for UI were observational series examining a wide range of different preparations, dosages, and routes of administration. In addition, the inconsistent use of progestogens for endometrial protection was a confounding factor in several studies (17). Older studies document an increase in the maximum urethral pressure and symptomatic improvement in 65–70% of stress incontinent women using oral estrogens (18). Several reviews and meta-analyses of the literature on this subject demonstrated the limitations of many of the available studies: small numbers, lack of randomization, and lack of placebo control (19–21). Results vary, pointing out the limitations of meta-analysis as well and that conclusions can really only be made from a well-designed randomized clinical trial with an adequate control. According to the Cochrane Database of Systemic Reviews, 28 trials including 2926 women reported using estrogens in a variety of combinations, dosages, routes of administration, and duration of therapy for UI (22). The consensus of these trials was that the rate of subjective improvement and cure of both stress and urge incontinence were statistically higher in women receiving estrogens as compared to women receiving placebo. A meta-analysis of 87 articles on the use of estrogens for SUI revealed that estrogens were not effective treatment for SUI, although they may provide improvement in the symptoms of urgency and the prevention of recurrent urinary tract infections in the postmenopausal woman when administered topically (23).

Two relatively small randomized and placebo-controlled trials of HRT for the treatment of postmenopausal SUI were conducted with similar results. In 83 women with urodynamic evidence of SUI or detrusor overactivity, conjugated equine estrogens (CEE) and medroxyprogesterone given orally for 3 mo produced no significant change in the number of incontinence episodes after treatment, no change in the QOL measures, or no change in patient perception of improvement (20). A similar double-blind, placebo-controlled randomized trial of 67 women with genuine SUI not treated with HRT found no significant effect over placebo of 2 mg estradiol valerate given for 6 mo (24). Neither study addressed the use of HRT for prevention or as adjunctive treatment.

The Heart and Estrogen/Progestin Replacement Study was designed as a randomized controlled trial to evaluate daily oral conjugated estrogen plus medroxyprogesterone acetate (MPA) therapy for the prevention of coronary heart disease events in postmenopausal women with known coronary disease (25). As a separate evaluation in this population, 1525 (55%) of the 2763 women who had at least weekly UI at the initiation of the study were evaluated for change in the severity of incontinence. Women were randomly assigned to HRT or placebo and followed for 4.1 yr. Incontinence improved in 26% of the placebo group as compared to 21% in the HRT group. Conversely, 27% of the placebo group and 39% of the HRT group realized a worsening of symptoms, which was a statistically significant difference. Furthermore, the incidence of incontinence episodes per week increased by an average of 0.7 in the HRT group and decreased by 0.1 in the placebo group, also a statistically significant difference.

Findings of the Women's Health Initiative support a higher risk of UI in women receiving CEE alone and CEE with MPA (26). This multicenter, double-blind,

placebo-controlled, randomized trial of HRT in 27,347 postmenopausal women sought to assess the effect of HRT on the incidence and severity of symptoms of stress, urge, and mixed incontinence. Results revealed that HRT (both CEE alone and CEE with MPA) increased the incidence of all types of UI at 1 yr among women who were continent before HRT. Furthermore, the risk of developing SUI was the highest. HRT also worsened preexisting UI at 1 yr.

A reasonable conclusion from the more recent clinical trials is that conjugated estrogens with or without MPA have no place in the treatment of SUI. Less is known about topical local hormone replacement for the treatment of UI.

## IMIPRAMINE

The tricyclic antidepressant imipramine is indicated for nocturnal enuresis and is often used off label for SUI, mixed incontinence, and urinary urgency incontinence. Imipramine has several effects in both the central and peripheral nervous system. Despite its long-time use for UI, the exact mechanism of action most responsible for action on the lower urinary tract has not always been clear because it has so many pharmacological actions. It has a systemic anticholinergic effect but none on the bladder itself. It has a sedative and antihistamine effect. It directly stimulates  $\alpha$ -adrenergic receptors in the bladder neck and urethra (27). Imipramine also inhibits the reuptake of NE and 5-HT in the adrenergic nerve endings in the urethra. The increased presence of NE allows for greater stimulation of urethral smooth muscle. In addition, through its inhibition of the reuptake of NE and 5-HT, increased striated sphincter tone by action at the spinal cord level (Onuf's nucleus) is possible. In all, imipramine potentially has three therapeutic modalities in incontinence therapy: CNS activity modulation, modulation of bladder and urethral activity, and modulation of urine output (28).

In the CNS, imipramine has shown affinity for adrenergic  $\alpha_1$ -, 5-HT<sub>2</sub>-, H<sub>1</sub>-, and muscarinic receptors and no affinity for adrenergic  $\alpha_2$ -, 5-HT<sub>1</sub>-, and H<sub>2</sub>-receptors (28). Imipramine is a potent inhibitor of NE reuptake in the rat brain and with weaker inhibition of 5-HT reuptake. The increased availability of neurotransmitter at the postsynaptic membrane caused by reuptake inhibition seems acutely to facilitate storage of urine through centrally decreased detrusor activity. After prolonged administration, this effect tends to disappear. Activity in Onuf's nucleus of the sacral cord, which controls activity of the external urethral sphincter, is influenced by noradrenergic and serotonergic innervation projections of supra- and intraspinal origins. The effect at Onuf's nucleus is to stabilize the urethral sphincter.

At the level of peripheral nerves, imipramine inhibits NE reuptake, which enhances detrusor muscle relaxation through  $\beta$ -adrenergic receptors (29). Evidence of a direct smooth muscle relaxing effect that contributes to larger storage function exists, but the peripheral anticholinergic activity of imipramine is not considered significant (30). Debate continues, however, regarding whether the observed functional alteration in external sphincter tone is a central or peripheral mechanism.

Another interesting action of imipramine in the urinary tract is its effect on the excretion of antidiuretic hormone (31). Imipramine induces an antidiuresis secondary to an antidiuretic hormone-independent renal mechanism that conserves fluid by decreasing solute excretion. This action is most evident in nocturnal polyuric patients and is the rationale behind its indication for nocturnal enuresis.

Imipramine also has been used for the treatment of SUI for its  $\alpha$ -stimulating effect at the urethra, which can increase the urethral closure pressure and functional urethral length. Available data on the use of imipramine are largely anecdotal. No randomized controlled studies of imipramine for SUI have been done. In small, uncontrolled studies, cure rates of 35–70% have been reported (32,33).

Side effects are numerous and related to its anticholinergic properties of dry mouth, weakness, fatigue, sedation or mania, parkinsonian effects, orthostatic hypotension, sweating, arrhythmia, and sexual dysfunction, which may preclude the use of the drug (34). The usual starting dose of imipramine is 25 mg daily, but this may be slowly titrated up by 25- to 50-mg increments each week to a total maximum daily dosage of 150 mg. Patients must be cautioned against the abrupt cessation of the drug after prolonged use and instead should taper off the drug. Imipramine is toxic in high doses, and overdose can produce lethal cardiac dysrhythmia or conduction blocks (35). It is prudent to consider a pretreatment electrocardiogram before initiating imipramine therapy.

Although studies demonstrating myriad actions by imipramine on the lower urinary tract exist, there are few clinical data showing a significant positive effect for SUI. Ultimately, data in support of imipramine for the treatment of SUI are scarce, and larger randomized controlled studies are necessary to validate its use.

### $\alpha$ -ADRENERGIC AGONISTS

Increased outlet resistance theoretically should be able to be achieved by the use of  $\alpha$ -adrenergic agonists to stimulate the large number of  $\alpha_1$ -receptors at the proximal urethra and sphincter. Contraction of the  $\alpha$ -receptors in the proximal urethra leads to an increase in the maximum urethral pressure and maximum urethral closure pressure. However, currently available agents are nonselective and produce significant adverse side effects, including blood pressure elevation, anxiety, insomnia, headache, tremor, weakness, palpitations, cardiac arrhythmias, and respiratory difficulties. These drugs must be used with caution in women with hypertension, cardiovascular disease, or hyperthyroidism. Side effects have been so prevalent and dangerous that in November 2000 the FDA issued a public health advisory concerning phenylpropanolamine (PPA). The FDA requested that all drug companies discontinue marketing products containing PPA, and PPA has now been removed from the market. Results of several small clinical studies using PPA for the treatment of SUI are now only of historical interest and therefore are not addressed in this chapter.

Ephedrine and its stereoisomer pseudoephedrine are sympathomimetic agents that increase the release of NE from sympathetic neurons and stimulate  $\alpha$ - and  $\beta$ -adrenergic receptors. Few studies exist to support the use of ephedrine. In a small study of 38 patients with sphincteric incontinence, 27 achieved a “good-to-excellent” result with ephedrine sulfate (36). Continence was improved mostly in the patients who experienced mild SUI. With either agent, tachyphylaxis may develop after prolonged use, perhaps because of depletion of NE stores. Although pseudoephedrine is available in the United States without a prescription in the form of Sudafed, access to this compound is limited in many parts of the country because it is a key ingredient in the making of methamphetamine.

Several pharmacological studies revealed that the  $\alpha_{1A}$ -subtype is the predominant  $\alpha$ -adrenoceptor subtype in the human lower urinary tract, and the  $\alpha_{1L}$ -adrenoceptor is the receptor subtype primarily involved in NE-induced contraction of the lower urinary tract. In theory, an adrenoceptor agonist selective for the  $\alpha_{1L}$ -subtype may produce fewer

side effects. Several agents with  $\alpha_{1A/1L}$ -adrenoceptor selectivity have been identified: methoxamine and NS-49 are two such  $\alpha$ -adrenoceptor agonists with known ability to induce contractions in the male and female urethra (37–39).

A clinical trial of another selective  $\alpha_{1A/1L}$ -adrenoceptor partial agonist, Ro 115–1240, was undertaken in women with mild-to-moderate SUI (40). There were 37 women who received 1.5 mg of the drug twice a day or matching placebo for 2–4 wk. For those completing the study, the drug produced a 53% reduction in incontinence episode frequency (IEF) compared to a 34% reduction in IEF produced by placebo. Overall, the drug provided a 19% improvement over placebo (41). Adverse events were mild and transient: headache, chills, piloerection, and pruritus. No significant cardiovascular effect was seen. Neither drug nor placebo produced a significant difference in mean systolic blood pressure or diastolic blood pressure. Scalp tingling was the only adverse event responsible for discontinuation of the drug in one patient.

In general, currently available  $\alpha$ -adrenergic agonists provide moderate improvement in a subset of patients with mild SUI. The potential adverse side effects have greatly diminished their utility and are responsible for the removal of PPA from the market. Given the perceived lack of safety associated with PPA, it is reasonable to assume that other agents in this group could potentially be unsafe, and therefore risk far outweighs benefit with this class of drug at this time. The  $\alpha_{1A/1L}$ -subtype selective  $\alpha$ -agonists may have potential in the treatment of SUI with remarkably fewer side effects, but larger randomized controlled trials are necessary.

## $\beta_2$ -ADRENOCEPTOR AGONISTS AND ANTAGONISTS

Clenbuterol is a  $\beta_2$ -adrenoceptor agonist available in Japan for the treatment of SUI. In a small clinical study examining the effect of clenbuterol on frequency of incontinence episodes, amount of leak, and patient impression of improvement, results showed 73% clinical efficacy, defined as any degree of improvement in outcome measures, compared to 55% response in women receiving placebo (42). This effect may be because of relaxation of the detrusor and facilitation of storage more than an effect at the outlet because stimulation of  $\beta$ -adrenoreceptors would be expected to contribute to relaxation rather than contraction of urethral smooth muscle.

A second trial that compared clenbuterol to PFMEs showed a 76.9% improvement in IEF, amount of leakage, and patient impression of improvement during 12 wk of treatment. PFME alone provided a 52.6% improvement, and PFME with clenbuterol produced an 89.5% improvement (43).

Propranolol, a  $\beta$ -adrenergic antagonist, has been studied for the treatment of SUI, but no drug in this class has been approved for SUI or has been tested in randomized controlled trials (44,45).

## SEROTONIN AND NOREPINEPHRINE REUPTAKE INHIBITORS

Duloxetine, a centrally acting agent, affects SUI by blocking the reuptake of 5-HT and NE in Onuf's nucleus, where the pudendal motor neurons are located in the spinal cord. When higher levels of 5-HT and NE exist, there is increased activity on more postsynaptic receptors, greater activation of pudendal nerve motor neurons, and increased urethral sphincter tone. Duloxetine has shown little or no inhibition of dopamine reuptake or affinity for histaminergic, dopaminergic, adrenergic, or cholinergic receptors; therefore, potentially it may produce few side effects.

In the anesthetized cat model, under conditions of bladder irritation from the infusion of acetic acid, duloxetine reduced the bladder activity and increased periurethral striated sphincter activity eightfold (46). This effect was primarily central because the drug had no effect on bladder contractions evoked by direct electrical stimulation of efferent fibers in the pelvic nerve. Interestingly, the sphincter activity was not increased during bladder contraction in micturition. The difference is glutamate. During filling and storage, glutamate, a stimulatory neurotransmitter, is activated and increases tone in the sphincter. Glutamate is deactivated during voiding, allowing relaxation of the sphincter. Duloxetine does not appear to affect urethral activity when glutamate is deactivated; therefore, it does not affect voiding.

In human studies, duloxetine was found to be safe and well tolerated in healthy adults. A large phase II trial from 48 US study centers, evaluated the efficacy and safety in women with SUI (47). The 533 women enrolled experienced at least four incontinent episodes per week, had normal bladder capacity, and had no prior continence surgery; 86 women underwent urodynamic studies testing, and 92% had urodynamic evidence of SUI. Women were randomized to 12 wk of treatment with placebo or duloxetine at one of three doses: 20, 40, or 80 mg/d. Duloxetine at all doses performed better than placebo, and response was dose dependent. Results showed that 80 mg/d provided better results in all end points measured: IEF, Patient Global Impression of Improvement (PGI-I) scale, and Incontinence Quality of Life (I-QOL) questionnaire. The median IEF decrease was 64% for duloxetine 80 mg/d compared with 41% with placebo. A total of 18.7% of patients receiving 80 mg/d duloxetine experienced complete elimination of their incontinence on the voiding diary, yet, remarkably, so did 15.2% of women receiving placebo (47).

Improvements in IEF were significant by 4 wk after treatment, and a concurrent increase in the average voiding interval in duloxetine groups was also observed. In a specific subset of 163 patients with more severe SUI, defined as at least 14 incontinent episodes per week, duloxetine produced a 49–64% reduction in IEF compared to 30% with placebo. Adverse events with the use of duloxetine were generally mild. Nausea was the most common adverse event that led to discontinuation. Nausea (that was dose related) occurred in 13% of women taking 80 mg/d duloxetine and in 2% taking placebo.

Phase III studies, enrolling 683 women, were undertaken in North America to confirm efficacy and safety (48). These women with predominant SUI had at least seven weekly episodes of SUI. They were randomly assigned to either 80 mg/d duloxetine or placebo for 12 wk. Women receiving duloxetine showed statistically significant reductions of IEF vs placebo (50 vs 27%,  $p < 0.001$ ). Even women with severe or high-grade SUI showed equivalent improvement, indicating that duloxetine was effective in SUI of all degrees. Improvements in QOL were statistically significant in the total population of women with severe SUI (+11 vs +6.8,  $p < 0.001$ ). Improvements were associated with significant increases in voiding intervals, indicating that the response was not to voiding more frequently. A full 10.5% of duloxetine-treated patients and 5.9% of placebo-treated patients had no incontinent episodes ( $p < 0.05$ ).

In 436 patients with more than 14 incontinent episodes per week or severe SUI, improvements in IEF and I-QOL were similar. Of particular clinical importance, duloxetine patients had statistically significant improvements compared with placebo in three I-QOL domains: avoidance and limiting behavior, social embarrassment, and psychosocial impact. Based on the PGI-I, 62% of patients receiving duloxetine considered their incontinence to be better compared with 39.6% of patients receiving



placebo ( $p < 0.001$ ). An extension trial was initiated and completed in this study, with approx 90% of patients who completed the duloxetine arm going on to the extension. Nausea, reported by 22.7% of patients, was the most common cause of discontinuation of the study. Of patients experiencing nausea, 91% developed the symptom within the first 4 wk of treatment and most within the first 2 d. The nausea was considered mild to moderately severe in 78 patients (87%), and 58 (74%) of these completed the study.

A phase III trial conducted in Europe and Canada of 494 women with SUI demonstrated similar results (49). Duloxetine achieved a 50% median decrease in IEF compared to 29% for the placebo treatment ( $p = 0.002$ ). Comparable results were found in women with severe SUI. Of women receiving duloxetine, 52% demonstrated a 50–100% reduction in IEF compared to 34% of women taking placebo ( $p < 0.001$ ). The duloxetine group also showed significantly greater improvement in I-QOL scores (7.3 vs 4.3,  $p = 0.008$ ) Millard et al. conducted a similar study across four continents in 458 women with predominant SUI. Participants were randomly assigned to either 80 mg/d duloxetine or placebo. Results were in keeping with the other phase III trials (50).

Another phase III, double-blind, placebo-controlled trial investigated the efficacy and safety of duloxetine in women with severe SUI symptoms (>14 incontinence episodes per week) and urodynamically confirmed pure SUI who were awaiting surgery for SUI (51). In 14 centers, 109 female participants were randomly assigned to placebo or duloxetine for 8 wk. Doses for the first 4 wk were 80 mg/d, and they were 120 mg/d for the last 4 wk. In addition to the usual efficacy variables (IEF, I-QOL, and PGI-I), the continence pad usage and willingness of patients to proceed with surgery were also assessed. Response was defined as decreased weekly IEF of 50% or more. Response was significantly greater with duloxetine than placebo in patients with and without intrinsic sphincter deficiency. Response was also rapid: 61% responded within 3 d, 75% within 5 d, and 100% within 2 wk. Significant decreases were seen in pad usage (−34.5 vs −4.8%,  $p = 0.008$ ). More patients receiving duloxetine perceived their incontinence as much or very much better (33.3 vs 7.7%,  $p = 0.003$ ). At the conclusion of the study, 20% of patients receiving duloxetine indicated that they were no longer interested in surgery as compared to 0% in the placebo group. The increased dose of 120 mg/d did increase efficacy, but the change did not differ statistically from the 80 mg/d dose.

Ghoniem et al. compared the effectiveness of combined pelvic floor muscle training (PFMT) and duloxetine with sham PFMT and placebo for 12 wk (52). In addition, the effectiveness of combined treatment vs single treatment, single treatment vs other single treatment, and single treatment vs no treatment was evaluated. In a double-blind, randomized, controlled trial, 201 women with SUI ( $\geq 2$  incontinence episodes per day) from 17 centers in the United States and Europe were enrolled. Women were randomly assigned to one of four combinations: 80 mg/d duloxetine with sham PFMT, placebo and drug, drug and PFMT, and placebo with sham PFMT. Efficacy measures were IEF, number of continence pads used, and I-QOL. Duloxetine with or without PFMT showed superior reduction in IEF over no treatment or PFMT alone. Analysis of the number of continence pads used and I-QOL scores demonstrated greater improvement with combined treatment rather than single treatment. Overall, data supported improved efficacy of combined PFMT and duloxetine. In this study, as in other phase III clinical trials, more duloxetine-treated patients than placebo-treated patients discontinued because of adverse events. Nausea was the prevailing cause for discontinuation, but 83% of those who experienced nausea (33 of 40) completed the study.

## CONCLUSION

SUI is a medical condition rarely treated pharmacologically. Currently, no FDA-approved drug exists for SUI, and the medications commonly used to treat it are used off label. Factors that influence treatment choice are the nature of the UI, the amount of bother it causes, whether prior treatment has been instituted, and how successful any prior treatment was. Most important, a woman should be given all of her options, the risks of therapy, and the percentage likelihood of cure/improvement with each so that she may make a truly informed decision. Currently available pharmacological agents lack proven efficacy and have a high incidence of bothersome side effects.

Imipramine,  $\alpha$ -adrenergic agonists, and estrogens have been tried with anecdotal success. Important new data about estrogens calls their use into question. Investigation into the use of  $\beta$ -adrenergic antagonists,  $\beta$ -adrenergic agonists, and combined 5-HT and NE reuptake inhibitors is ongoing. Duloxetine is a balanced dual 5-HT and NE reuptake inhibitor that is currently FDA approved for depression and diabetic neuropathy (Cymbalta) and has been investigated for SUI indication. It is the most exciting new development in the pharmacotherapy of SUI in recent decades, but the manufacturer withdrew its application to the FDA. In open-label extensions of controlled studies of Cymbalta for SUI in adult women, a higher-than-expected rate of suicide attempts was observed that was not seen in controlled trials of Cymbalta for treatment of depression or diabetic neuropathic pain (53). Currently, duloxetine is not approved for the treatment of SUI, and the FDA is evaluating additional data. Effective and well-tolerated medical therapy for SUI remains elusive.

## REFERENCES

1. National Kidney and Urologic Diseases Information Clearing House. *Urinary Incontinence in Women*, National Institutes of Health Publications No. 02-4132, National Institute of Diabetes and Digestive and Kidney Diseases, National Institutes of Health, Bethesda, MD, 2002.
2. Kinchen KS, Burgio K, Diokno AC, et al. Factors associated with women's decisions to seek treatment for urinary incontinence. *J Women's Health* 2003;12:687-698.
3. Hunskaar S, Lose G, Sykes D, et al. The prevalence of urinary incontinence in women in four European countries. *BJU Int* 2004;93:324-330.
4. Thom DH, Nygaard IE, Calhoun EA. Urologic Diseases in American Project: urinary incontinence in women—national trends in hospitalization, office visits, treatment and economic impact. *J Urol* 2005; 173:1295-1301.
5. Mahony DT, Laferte RO, Blais DJ. Integral storage and voiding reflexes. Neurophysiologic concept of continence and micturition. *Urology* 1977;9:95-106.
6. Tonini M, Messori E, Franceschetti GP, et al. Characterization of the 5-HT receptor potentiating neuromuscular cholinergic transmission in strips of human isolated detrusor muscle. *Br J Pharmacol* 1994;113:1-2.
7. Creed KE, Tulloch AGS. The action of imipramine on the lower urinary tract of the dog. *Br J Urol* 1982;54:5-10.
8. Thor KB, Donatucci C. Central nervous system control of the lower urinary tract: new pharmacological approaches to stress urinary incontinence in women. *J Urol* 2004;172:27-33.
9. deGroat WC, Fraser MO, Yoshiyama M, et al. Neural control of the urethra. *Scand J Urol Nephrol Suppl* 2001;207:35-43.
10. Thor KB. Targeting serotonin and norepinephrine receptors in stress urinary incontinence. *Int J Gynaecol Obstet* 2004;86:S38-S52.
11. Iosif CS, Batra S, Ek A, et al. Estrogen receptors in the human female lower urinary tract. *Am J Obstet Gynecol* 1981;141:817-820.
12. Iosif CS, Bekassy Z. Prevalence of genito-urinary symptoms in the late menopause. *Acta Obstet Gynecol Scand* 1984;63:257-260.

13. Hextall A, Bidmead J, Cardozo L, et al. Hormonal influences on the human female lower urinary tract: a prospective evaluation of the effects of the menstrual cycle on symptomatology and the results of urodynamic investigation. *Neurourol Urodyn* 1999;18:282–283.
14. Kinn AC, Lindskog M. Oestrogens and phenylpropanolamine in combination for stress incontinence. *Urology* 1988;32:273–280.
15. Matsubara S, Okada H, Shirakawa GA, et al. Oestrogen levels influence  $\beta_3$ -adrenoreceptor mediated relaxation of the female rat detrusor muscle. *Urology* 2002;59:621–625.
16. Smith PJB. The effect of oestrogens on bladder function in the female. In: *The Management of the Menopause and Postmenopausal Years* (Campbell S, ed.), MTP, Camforth, UK. 1976, pp. 291–298.
17. Robinson D, Cardozo L. Oestrogens and the lower urinary tract. *BJOG* 2004;111:10–14.
18. Rud T. The effects of oestrogens and gestagens on the urethral pressure profile in urinary continent and stress incontinent females. *Acta Obstet Gynaecol Scand* 1980;59:265–270.
19. Zullo MA, Oliva C, Falconi G, et al. Efficacy of oestrogen therapy in urinary incontinence. A meta-analytic study. *Minerva Ginecol* 1998;50:199–205.
20. Fantl JA, Bump RC, Robinson D, et al. Efficacy of oestrogen supplementation in the treatment of urinary incontinence. *Obstet Gynaecol* 1996;88:745–749.
21. Sultana CJ, Walters MD. Oestrogen and urinary incontinence in women. *Maturitas* 1995;20:129–138.
22. Moerher B, Hextall A, Jackson S. Oestrogens for urinary incontinence in women. *Cochrane Database Syst Rev* 2003;(2):CD001405.
23. Hextall A. Oestrogens and lower urinary tract functions. *Maturitas* 2002;36:83–87.
24. Jackson S, Shepherd A, Brookes S, et al. The effect of oestrogen supplementation on post-menopausal urinary stress incontinence: a double-blind, placebo controlled trial. *Br J Obstet Gynaecol* 1999;106:711–718.
25. Grady D, Brown JS, Vittinghoff E, et al. Postmenopausal hormones and incontinence: the heart and estrogen/progestin replacement study. *Obstet Gynecol* 2001;97:116–120.
26. Hendrix SL, Cochrane BB, Nygaard IE, et al. Effects of estrogen with and without progestin in urinary incontinence. *JAMA* 2005;293:935–948.
27. Khanna OP, Heber D, Gonick P. Cholinergic and adrenergic neuroreceptors in urinary tract of female dogs; evaluation of function with pharmacodynamics. *Urology* 1975;5:616–623.
28. Hunsballe JM, Djurhuus JC. Clinical options for imipramine in the management of urinary incontinence. *Urol Res* 2001;29:118–125.
29. Zinner NR, Koke SC, Viktrup L. Pharmacotherapy for stress urinary incontinence: present and future options. *Drugs* 2004;64:1503–1516.
30. Labay P, Boyarsky S. The action of imipramine on the bladder musculature. *J Urol* 1973;109:385–387.
31. Tomasi PA, Siracusano S, Monni AM, et al. Decreased nocturnal urinary antidiuretic hormone excretion in enuresis is increased by imipramine. *BJU Int* 2001;88:932–937.
32. Gilja I, Radej M, Kovacic M, et al. Conservative treatment of female stress incontinence with imipramine. *J Urol* 1984;132:909–911.
33. Lin HH, Sheu BC, Lo MC, et al. Comparison of treatment outcomes for imipramine for female genuine stress incontinence. *Br J Obstet Gynaecol* 1999;106:1089–1092.
34. Frazer A. Pharmacology of antidepressants. *J Clin Psychopharmacol* 1997;17:2S–18S.
35. Viktrup L, Bump RC. Pharmacological agents used for the treatment of stress urinary incontinence in women. *Curr Med Res Opin* 2003;19:485–490.
36. Diokno A, Taub M. Ephedrine in treatment of urinary incontinence. *Urology* 1975;5:624–627.
37. Bishop MJ, Barvian KA, Berman J, et al.  $\alpha_1$ -Adrenoceptor agonists: the identification of novel  $\alpha_{1A}$  subtype selective 2-heteroaryl-2-(phenoxyethyl) imidazolines. *Bioorg Med Chem Lett* 2002;12:471–475.
38. Radley SC, Chappelle CR, Bryan NP, et al. Effect of methoxamine on maximum urethral pressure in women with GSI; a placebo-controlled, double-blind crossover study. *Neurourol Urodyn* 2001;20:43–52.
39. Nishimatsu H, Moriyama KH, Hamada Y, et al. Contractile response to  $\alpha_1$ -adrenoceptor agonists in isolated human male and female urethra. *BJU Int* 1999;84:515–520.
40. Musselman DM, Ford AP, Gennevois DJ, et al. A randomized crossover study to evaluate Ro 115–1240, a selective  $\alpha_{1A/1L}$  adrenoceptor partial agonist in women with stress urinary incontinence. *BJU Int* 2004;93:78–83.
41. Wein AJ. A randomized crossover study to evaluate Ro 115–1240, a selective  $\alpha_{1A/1L}$  adrenoceptor partial agonist in women with stress urinary incontinence [editorial comment]. *BJU Int* 2004;93:1115.
42. Yasuda K, Kawabe K, Takimoto Y, et al. A double-blind clinical trial of  $\beta_2$ -adrenergic agonist in stress incontinence. *Int Urogynecol J* 1993;4:146–151.

43. Ishiko O, Ushiroyama T, Saji F, et al.  $\beta_2$ -Adrenergic agonists and pelvic floor exercises for female stress incontinence. *Int J Gynaecol Obstet* 2000;71:39–44.
44. Gleason DM, Reilly RJ, Bottacini MR, et al. The urethral continence zone and its relation to stress incontinence. *J Urol* 1974;112:81–88.
45. Kaisary AV.  $\beta$ -Adrenoceptor blockade in the treatment of female urinary stress incontinence. *J Urol* 1984;90:351–353.
46. Thor KB, Katofiasc MA. Effects of duloxetine, a combined serotonin and norepinephrine reuptake inhibitor, on central neural control of lower urinary tract function in the chloralose-anesthetized female cat. *J Pharmacol Exp Ther* 1995;274:1014–1024.
47. Norton PA, Zinner NR, Yalcin I, et al. Duloxetine vs placebo in the treatment of stress urinary incontinence. *Am J Obstet Gynecol* 2002;187:40–48.
48. Dmochowski RR, Miklos JR, Norton PA, et al. Duloxetine vs placebo for the treatment of North American women with stress urinary incontinence. *J Urol* 2003;170:1259–1263. Erratum in: *J Urol* 2004;171:360.
49. Van Kerrebroeck P, Abrams P, Lange R, et al. Duloxetine vs placebo in the treatment of European and Canadian women with stress urinary incontinence. *BJOG* 2004;111:249–257.
50. Millard RJ, Moore K, Rencken R, et al. Duloxetine vs placebo in the treatment of stress urinary incontinence: a four-continent randomized clinical trial. *BJU Int* 2004;93:311–318.
51. Cardozo L, Drutz HP, Baygani SK, et al. Pharmacological treatment of women awaiting surgery for stress urinary incontinence. *Obstet Gynecol* 2004;104:511–519.
52. Ghoniem GM, Van Leeuwen JS, Elser DM, et al. A randomized controlled trial of duloxetine alone, pelvic floor muscle training alone, combined treatment and no active treatment in women with stress urinary incontinence. *J Urol* 2005;173:1647–1653.
53. US Food and Drug Administration Web site. Available at: <http://www.fda.gov/cder/drug/infopage/default.htm>.

# II

---

## TREATMENT

---

# II

---

## PART A: STRESS URINARY INCONTINENCE

---

# II

---

## PART B: OVERACTIVE BLADDER

---

# II

---

## PART C: PROLAPSE

---



# II

---

## PART D: RECONSTRUCTION

---

---

# 8

## Urethral Injectables for Stress Urinary Incontinence

---

*R. Duane Cespedes, MD*

### CONTENTS

HISTORICAL PERSPECTIVE  
PATIENT SELECTION  
SURGICAL TECHNIQUE  
RESULTS  
COMPLICATIONS  
OTHER FDA-APPROVED INJECTABLE AGENTS  
CONCLUSION  
REFERENCES

---

### HISTORICAL PERSPECTIVE

The use of bulking agents dates to 1938, when Murless injected sodium morrhuate, a sclerosing agent, into the anterior vaginal wall of 20 incontinent women (1). The inflammatory response compressed the urethra, providing improved continence in 17 women; however, complications precluded further use of the agent. In 1955, Quackels successfully treated two patients with periurethral paraffin injections (2). Sachs utilized Dondren, a sclerosing agent, in 1963; however, pulmonary emboli complicated the procedure (3).

The modern era of bulking agents began when Berg and later Politano and associates popularized the use of polytetrafluoroethylene (PTFE; Teflon, Polytef, and Urethrin) in the early 1970s (4,5). This agent is a thick paste, with most of the particles ranging in size from 4 to 100  $\mu\text{m}$ . PTFE was extensively used until 1984, when animal studies demonstrated particle migration and granuloma formation in the brain, liver, spleen, and lungs, dampening enthusiasm for this agent. PTFE is not currently approved by the Food and Drug Administration (FDA) as a bulking agent.

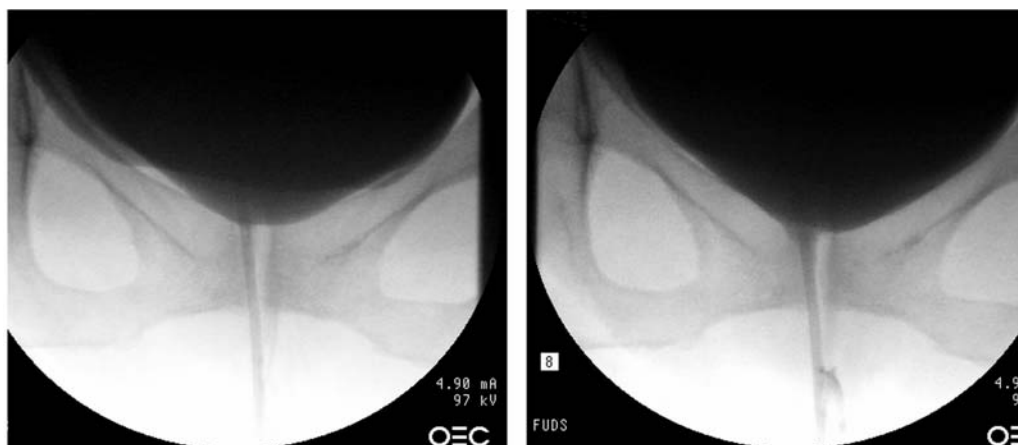
In 1989, autologous fat was first described as an injectable bulking agent by Gonzales-Garibay and colleagues (6). A report by Santarosa and Blaivas on 15 patients noted that 5 patients were cured and 5 significantly improved with 11-mo follow-up (7). In contrast, others have reported high reabsorption rates and poor long-term results (8). In addition, one fatal case of pulmonary fat embolism has been reported (9). Because of the labor-intensive nature of fat harvesting, poor long-term results, and potential complications, autologous fat injection is not commonly used in the treatment of incontinence.

In 1993, the FDA approved the usage of bovine collagen as a new, minimally invasive treatment for stress incontinence. Glutaraldehyde crosslinked (GAX) collagen (Contigen, CR Bard Co., Covington, GA) is a highly purified bovine dermal collagen crosslinked with glutaraldehyde and suspended in a phosphate base. GAX collagen contains 3.5% collagen by volume and contains approx 95% type 1 collagen and 1–5% type 3 collagen. It is prepared by selective hydrolysis of the nonhelical amino terminal and carboxyl terminal segments (telopeptides) of the collagen molecules. Because the telopeptides are the antigenic markers for collagen, GAX collagen has less antigenicity. The glutaraldehyde crosslinking also reduces hydrolysis by fibroblast-secreted collagenases. As a result, GAX collagen is reabsorbed much slower than previous collagen compounds used in cosmetic surgery (10). GAX collagen is biocompatible and does not cause foreign body reaction, and particle migration has not been demonstrated. A mild inflammatory reaction does occur, which appears to result in replacement of the bovine collagen by the patient's own collagen (11). Last, GAX collagen is easily injected through a small needle, allowing precise placement of the collagen using standard equipment and local anesthesia. Because GAX collagen remains the most commonly used injectable agent in the treatment of stress urinary incontinence (SUI) in females and many of the principles apply to other injectables, this chapter focuses on its use.

### PATIENT SELECTION

There are two general etiologies for urinary incontinence: dysfunction of the bladder or of the urethral sphincter. Bladder conditions that can produce incontinence include detrusor instability and poor detrusor compliance. Detrusor instability (also called an overactive bladder) is common in elderly patients and is manifested by a sudden urge to void that cannot be inhibited. If severe, then urgency may result in urge incontinence. Poor detrusor compliance is characterized by an abnormal increase in detrusor pressure as a result of filling (12). This condition is most commonly seen in patients with neurogenic bladders and after pelvic irradiation. It is important to distinguish these forms of incontinence from SUI as neither overactive bladder nor poor compliance is treatable with injectable agents.

The classification of patients with SUI has undergone many changes (13). An analysis of abdominal (or Valsalva) leak-point pressure (ALPP) data using fluoroscopic imaging in a prospective study of females with stress incontinence found three relatively distinct groups of patients (14). Some incontinent patients demonstrated high abdominal leak-point pressures ( $>100$  cm  $H_2O$ ); another group demonstrated very low leak point pressures ( $<60$  cm  $H_2O$ ); last, a smaller group of patients was in the gray zone (ALPP between 60 and 100 cm  $H_2O$ ) (15). Type III stress incontinence, more recently called intrinsic sphincter deficiency (ISD), is characterized by a low ALPP ( $<60$  cm  $H_2O$ ) and little or no urethral mobility with straining (Fig. 1). It is well established that patients with ISD are at increased risk of failing a suspension procedure, and treatment with one of the sling procedures or an injectable agent is recommended (16–20). As ISD is most often associated with prior failure of a surgical procedure or with elderly females, collagen injections provide a minimally invasive method of attaining continence. Early studies demonstrated that patients successfully treated with collagen injections had an average increase in the ALPP of 31 cm  $H_2O$ ; however, there was little change in the voiding pressure because muscular relaxation allowed the bladder neck to open widely (21).

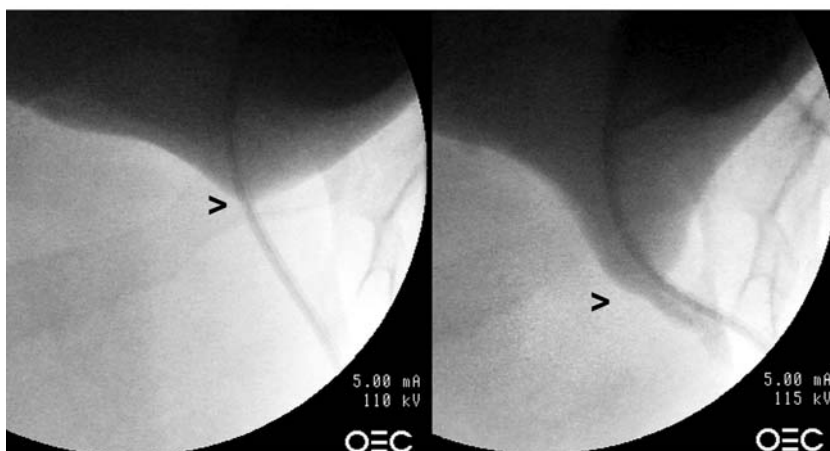


**Fig. 1.** Intrinsic sphincter deficiency in a 63-yr-old female previously treated with a retropubic suspension. During a Valsalva maneuver, the bladder neck opened at a low leak-point pressure with minimal mobility of the bladder neck with resulting incontinence.

Type II stress incontinence is associated with urethral hypermobility, and incontinence occurs at higher ALPPs, usually greater than 100 cm H<sub>2</sub>O (Fig. 2). On physical examination, the urethra is mobile in conjunction with prolapse of the adjacent vaginal wall. All incontinence procedures that provide support and immobilize the urethra work reasonably well. Although collagen has shown good efficacy in treating patients with hypermobility, it is rarely used because sling procedures are associated with better long-term results in this younger group of patients.

As with any procedure, proper patient selection is the key to therapeutic success and patient satisfaction. The ideal candidate for collagen injections is one with ISD, minimal urethral mobility, and normal detrusor function. Clinically, these female patients are often elderly and have some degree of detrusor instability. Detrusor instability that coexists with SUI is not a contraindication for collagen injection; however, it is prudent to treat the instability medically before continuing to collagen injections. The patient must also know that multiple injections 4–6 wk apart will be required, and that transient urinary retention requiring intermittent catheterization may occur in rare circumstances. In most cases, only two or three total injections will be required to achieve dryness. In addition, as collagen is slowly reabsorbed and replaced by the patient's own collagen, some patients will require reinjection in the future even if they are continent for many years. If the patient is unwilling to undergo a minimum of two injections and perform transient self-catheterization if retention occurs, then other therapies should be discussed with the patient.

The only absolute contraindications to collagen injections are an untreated urinary tract infection and hypersensitivity to the material. Therefore, all patients are skin tested using 0.1 mL of the more immunogenic noncrosslinked collagen 30 d before collagen treatments are started. The overall hypersensitivity rate has been reported as between 2 and 5% (22). Extra caution should be used in immunocompromised patients and patients on steroids because they may not react to the skin test even if they are allergic to bovine collagen. Last, collagen injections have not been well studied in pregnant women, and other alternatives should be considered.



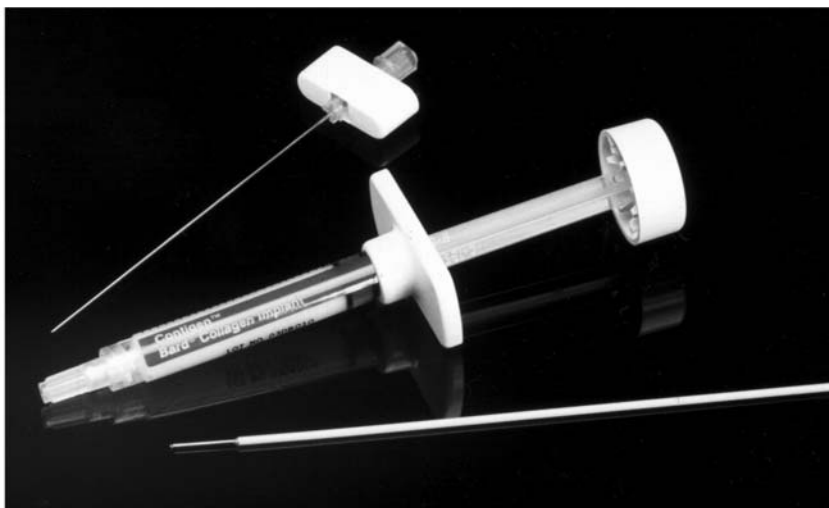**Fig. 2.** Fluorourodynamic study demonstrating incontinence secondary to urethral hypermobility. During a Valsalva maneuver, the bladder neck (at the arrows) rotates posteriorly, and incontinence occurs.

### SURGICAL TECHNIQUE

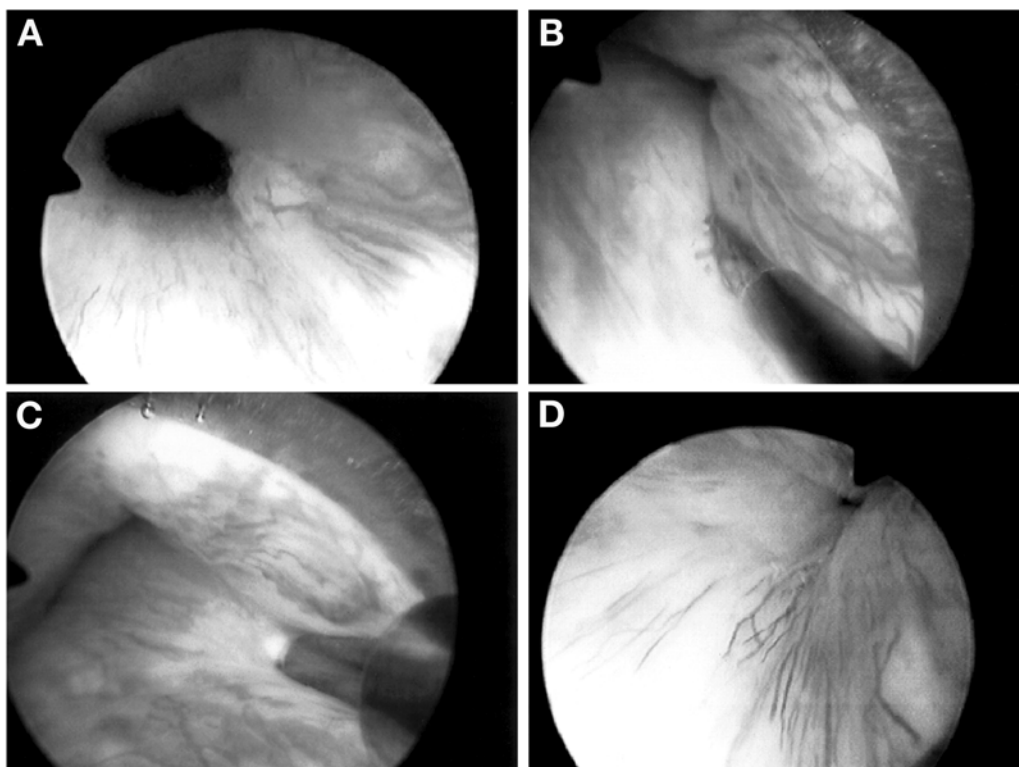
Collagen may be injected using either a periurethral or a transurethral approach (Fig. 3). The initial studies were performed using the periurethral approach; however, now that specialized transurethral instrumentation exists, the transurethral approach has become more popular (23). The endoscopic injection procedure can be performed with minimal patient discomfort in the outpatient setting using a local anesthetic. If performed in the operating room, then sedation or general anesthesia is usually favored as spinal anesthesia may cause prolonged urinary retention. The patient normally takes a single dose of a fluoroquinolone antibiotic preinjection and an additional dose the next day. The patient is then placed in the lithotomy position, and the perineum and vagina are prepped and draped. We use the Wolf 21-French panendoscope, which has a Nesbit-type working element and rigid 23-gage needle (Richard Wolf Instruments, Vernon Hills, IL).

The key to obtaining good results with collagen is the precise placement of the transurethral needle, ensuring accurate placement of the collagen. In addition, less collagen is wasted, improving cost-effectiveness. Collagen injections in females usually require only two injection sites as the collagen usually dissects circumferentially around the bladder neck if the proper plane is found. Normally, the 4 and 8 o'clock positions are selected at the bladder neck. A small amount (0.2–0.5 mL) of 1% plain lidocaine is injected first to decrease pain and to help in dissecting the appropriate plane for the collagen to fill. Without withdrawal of the needle, the collagen syringe is attached, and the collagen is injected slowly. It usually takes at least 2–3 min to inject each syringe. Collagen will fill the submucosal plane and effectively “close off” the bladder neck (Fig. 4). Resist the temptation to overinject as the mucosa will rupture, and all the collagen will be lost. The injection of collagen requires tissue “expansion” and as such must be done slowly over a relatively long period of time to decrease the chances of tissue rupture.

Certain technical aspects of the injection are important to understand. If the needle is placed too deep, then collagen is wasted, and the desired bulging of the urethral mucosa does not occur. Generally, only 1–2 mL need to be injected before this bulging



**Fig. 3.** A syringe of GAX collagen (Bard, Covington, GA) shown with both the periurethral and transurethral injection needles.



**Fig. 4.** In this series of intraoperative photographs, the open bladder neck is sequentially closed by the injection of collagen: (A) preoperative view; (B) the needle has been inserted into the right side of the bladder neck, with bulging of the mucosa to the midline seen. (C) The left side of the bladder neck is closed with collagen; (D) the final result. Normally, only two injection sites are needed in female patients, and only one or two syringes of collagen are injected per visit.

Table 1  
Results Using GAX Collagen for Incontinence in Females

<i>Authors</i>	<i>No. of pts</i>	<i>Mean follow-up (mo)</i>	<i>Mean (cc) cumulative volume</i>	<i>Cured (%)</i>	<i>Significantly improved (%)</i>	<i>Failed (%)</i>
O'Connell (18)	44	N/A	9.1	45	18	12
Monga (19)	29	24	10.8	48	20	N/A
Cross (28)	139	18	N/A	74	N/A	5
				(dry + significantly improved)		
Appell (31)	149	12	19.2	80.8	N/A	N/A
Hershorn (20)	31	8.4	12.7	48	41	9
Stricker (38)	50	11	14.4	42	40	14
Kieswetter (39)	16	4.5	N/A	43	50	18
Richardson (40)	42	46	28.3	40	43	17

N/A, not available.

is evident. Conversely, if the needle depth is too shallow, then a small amount of collagen will cause a mucosal *bleb*, identified by the lack of blood vessels in the lining of the tissue. This bleb will eventually rupture, creating a defect and loss of all collagen injected.

Ideally, the collagen should be injected slowly using the fewest injection sites possible. Avoid injecting directly into the external sphincter as this may result in dysuria and perineal pain. Usually, one syringe (2.5 mL) or occasionally two syringes are used per session depending on the degree of coaptation achieved. The end point of the procedure is visual closure of the bladder neck without leakage of urine in response to increased intra-abdominal pressure. To test the efficacy of the injection, leave the bladder half full, remove the scope, and have the patient cough. If leakage occurs, more collagen can be given but keep in mind that if more than two syringes are required to close the bladder neck completely, then the injection is likely in the wrong plane.

Postoperatively, an indwelling catheter should be avoided as collagen may be "squeezed out" through the injection sites or the collagen may be molded around the catheter, reducing efficacy. All patients must be able to void prior to leaving the clinic or be taught clean intermittent catheterization using a 10- to 14-French catheter.

## RESULTS

Multiple studies have reported good results using collagen in selected patients (Table 1). In 1990, the initial studies using collagen reported that 78% of females became dry, and overall 93% were significantly improved (24). Dryness was achieved in 88% using three or fewer injections, and 58% required only one injection. At 2 yr, of patients rendered initially dry, 78% remained dry, demonstrating the durability of collagen injections in females.

Monga and colleagues reported a 68% subjective cure rate and 48% objective cure rate at 24 mo postcollagen injection (19). This group was also the first to report a sustained decrease in the symptoms of urge incontinence; although unexpected, this may greatly benefit these hard-to-treat patients.

Steele and colleagues compared the results of using collagen in patients with and without urethral hypermobility (25). Of 40 patients, 9 were diagnosed with hypermobility. They reported a subjective dry rate of 76% in the hypermobile group compared to 46% of the nonmobile group. It is clear that many patients with hypermobility can be treated successfully using collagen; however, it is important to remember that patients in this group are typically younger and usually have pelvic prolapse in other areas. Therefore, a sling procedure and prolapse repair should be considered in this group.

In a review of a small urban practice, Tschopp and colleagues examined the durability of collagen injection in 99 women (26). A success rate of 56% with a follow-up of 9 mo was reported. They concluded that collagen injection has minimal morbidity with good success in appropriate patients.

In 1995, O'Connell et al. reported their results using collagen injections. Patient response to treatment was evaluated by the change in the number of pads required to effect significant improvement. Cure was achieved for 63%, with four patients having previously used greater than 10 pads per day prior to injection. No major complications were noted (18).

Moore et al. provided an objective report of collagen injections using exams, pad tests, and urodynamic evaluation in postoperative follow-ups (27). They found significant decreases in pad number and weight from baseline, with no difference in residual volume, voided volume, or flow rate. Interestingly, two women reported only "improvement" yet were objectively cured; conversely, one patient felt she was cured, yet leaked 11 g urine on pad testing. Two patients developed cystitis; however, no patients experienced urinary retention.

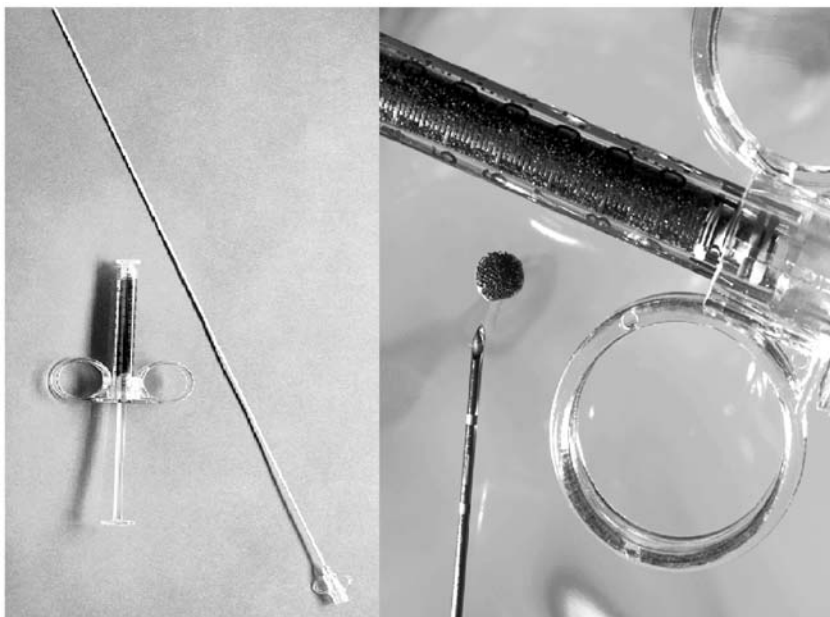
Cross et al. reported their long-term follow-up of patients treated with collagen injections over a period of 36 mo (28). Through telephone interviews and chart review, they reported an overall 74% dry or improved rate, with 72% achieving continence after two or fewer injections. Reinjections were required in 11 patients to regain dryness in this series.

It is important to note that the results of collagen injection therapy cannot be directly compared to other modalities used to treat ISD because it is a biodegradable bulking agent (29). In some cases of so-called treatment failure, the procedures were in fact not failures but incomplete treatments. Simply injecting once or twice to "see what happens" is inappropriate, and all patients should receive at least three injections and 10 mL collagen before being declared a treatment failure and another therapy is initiated. In addition, a patient who is dry for 2 yr and then begins to leak again is a cure and not a treatment failure. The patient simply needs another injection—a feature known and understood when using injectable agents. Therefore, in reviewing the results of injectable agent studies, these caveats should be kept in mind.

## COMPLICATIONS

Overall, collagen injection has few side effects, and most are minor. The risk of postoperative urinary tract infection probably varies depending on whether preoperative antibiotics are given; however, this has not been proven in controlled trials. The risk of urinary tract infections appears to vary between 1.4 and 6% (22,24,30). A periurethral abscess has been reported, but these are fortunately rare (30). Symptomatic hematuria (even in patients on anticoagulants) or prolonged perineal pain is uncommon and self-limited (22).





**Fig. 5.** A syringe of Durasphere and the required specialized needle are seen on the left side of the photograph. On the right side, a close-up view of the Durasphere particles and carrier is shown.

Transient postinjection urinary retention requiring intermittent catheterization was reported in 4% by Cross et al.; permanent retention in the nonneurologic patient has been reported in only one patient (28,31).

The fear of particle migration has concerned users of injectable materials since the initial reports by Malizia; however, there have been no such reports using GAX collagen as an injectable agent (32). The immunogenicity of GAX collagen has also been extensively evaluated. In 1998, Leonard found that 3 of 10 children developed antibodies to the bovine collagen, but there was no seroconversion to antibodies that crossreacted with human collagen (33). Hypersensitivity has previously been shown to be in the range of 2 to 5%; however, Stothers and Goldenberg reported three cases of delayed patient hypersensitivity to the agent (34). Despite initial negative skin tests, each of these patients developed distinct induration at the forearm test site after they received the first transurethral injection 4 wk later. Two of the three reported arthralgias, and all responded to conservative management.

## OTHER FDA-APPROVED INJECTABLE AGENTS

### *Carbon-Coated Beads (Durasphere)*

Durasphere (Boston Scientific, Natick, MA) is a relatively new nonantigenic injectable agent (no skin test required) composed of nonabsorbable, pyrolytic, carbon-coated zirconium oxide beads suspended in a 2.8% glucan carrier gel (35) (Fig. 5). Table 2 provides a list of the injectable agents currently available or in development.

The majority of Durasphere particles are in the 251- to 300- $\mu\text{m}$  range, more than three times larger than the 80- $\mu\text{m}$  threshold for particle migration, minimizing the potential for migration. From 1996 to 1998, there were 355 women enrolled in a

Table 2  
Injectable Agents Currently in Use or in Development

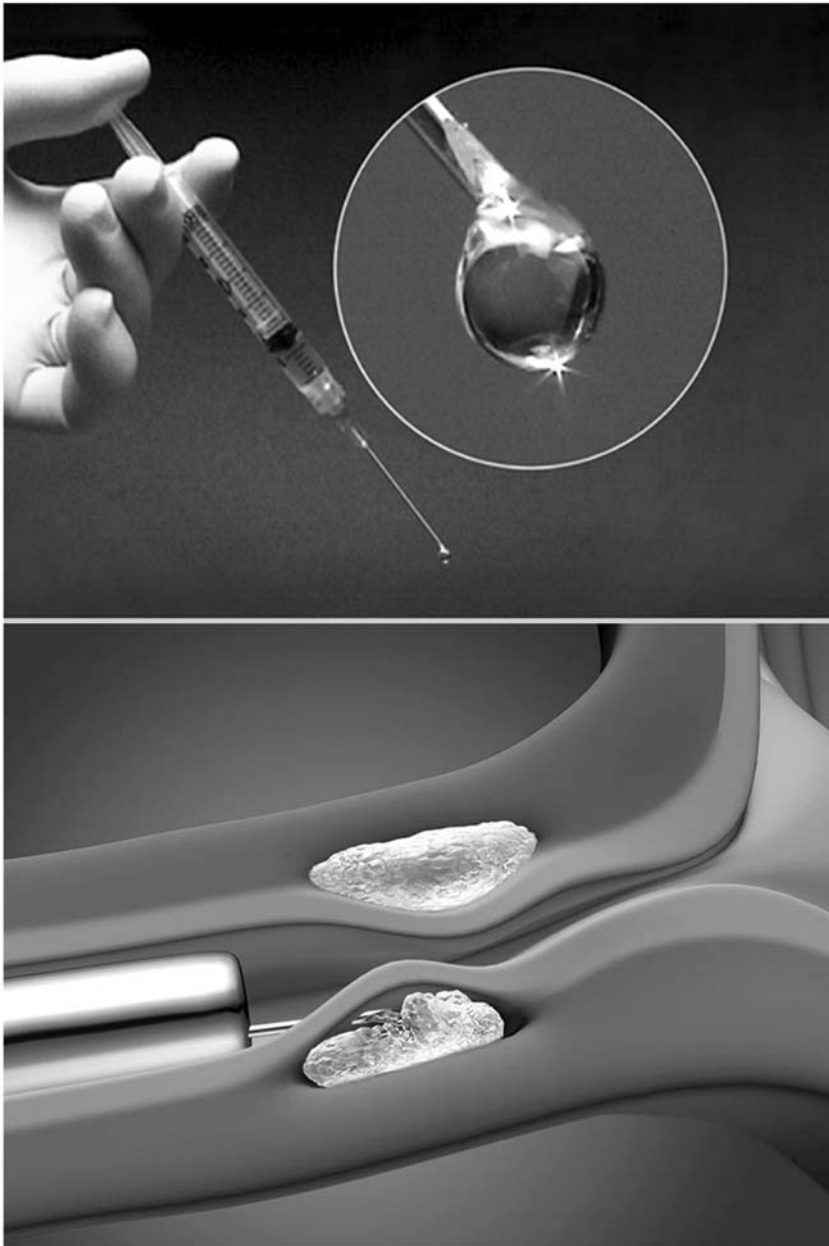
<i>Compound</i>	<i>Name</i>	<i>Company</i>	<i>FDA approved?</i>
Bovine collagen	Contigen <sup>®</sup>	CR Bard	Yes
GAX crosslinked carbon-coated beads	Durasphere EXP <sup>®</sup>	Boston Scientific	Yes
DMSO and ethylene vinyl alcohol copolymer	Tegress <sup>®</sup>	CR Bard	Yes
Adjustable volume balloons	ACT <sup>®</sup>	Uromedia	No
Calcium hydroxylapatite	Coaptite <sup>®</sup>	Bioform	No
Hyaluronic acid and dextranomer microspheres	Zuidex <sup>®</sup>	Q-Med	No
Crosslinked hyaluronic acid	Hyalgel <sup>®</sup>	Biomatrix	No
Silicone polymer copolymer/DMSO	Macroplastique <sup>®</sup>	Uroplasty	No
Implantable microballoons	Urovive <sup>®</sup>	American Medical Systems	No

randomized, controlled, double-blind study to compare the safety and efficacy of this material with GAX collagen (35). At 12 mo, the investigators found that 66.1% of Durasphere patients were dry or significantly improved compared to 65.8% of collagen patients. At 1 yr after the last injection, 80.3% of the Durasphere patients were dry or significantly improved compared to 69.1% in the collagen group. The number of injections given was similar in both groups (1.6), but a significantly smaller volume was required in the Durasphere group. A long-term follow-up comparison between collagen and Durasphere revealed no significant difference in efficacy (36). Adverse events were similar in the two groups except for a slightly higher urgency/retention rate in the Durasphere arm. The theoretical advantages of this agent are improved durability compared to GAX collagen, room temperature storage, and the ability to treat immediately as skin testing is not required. Unfortunately, injection requires a larger, 18-gauge needle, and the radio-opaque beads can separate from the viscous glucan carrier, requiring specialized injection techniques and making it more difficult to inject than collagen.

In a small study, Pannek and colleagues also demonstrated bead migration in 2 asymptomatic patients (37). A modified version, called Durasphere EXP, was introduced. The radiolucent, pyrolytic, carbon-coated beads are suspended in a water-based carrier, allowing for easier injection than the previous version. Long-term clinical results are not yet available, but theoretically these should be similar to the original compound.

### *Ethylene Vinyl Alcohol Copolymer (Tegress)*

Tegress (C. R. Bard, Murray Hill, NJ) is the newest injectable agent approved by the FDA (Fig. 6). Tegress is composed of ethylene vinyl alcohol copolymer suspended in dimethyl sulfoxide (DMSO). Tegress can be injected through a 25-gauge needle because of its low viscosity but solidifies after injection. On injection and when exposed to



**Fig. 6.** Tegress is a clear liquid prior to injection (upper image) but becomes a gelatinous compound when injected into the urethra, as seen in the lower image.

any aqueous solution, the DMSO diffuses out of the compound, causing the injected liquid to change into a gelatinous mass. This phase transformation takes place rapidly, usually within 60 s of injection. Like Durasphere, Tegress does not require skin testing and has no known immediate or delayed antigenic properties. Refrigeration is also not required for Tegress. The volume of Tegress remains essentially unchanged after injection—basically, “what you see is what you get.” Of note, volume loss to absorption of the aqueous carrier when using collagen has previously been overcome by simply

overinjecting. At 1 yr postinjection, results from the multicenter trial comparing collagen to Tegress revealed 39 vs 55% dry, respectively, and a mean pad weight 30% better than collagen. The complication rates were similar in both groups.

The injection of Tegress is more complex than for collagen as the needle must be carefully primed with material, and the injection is placed closer to the midurethra and into a slightly deeper plane. Approximately 1 mL is typically injected into each side of the urethra over a 1-min time frame. After injecting, the needle should be left in place for 1 min to minimize extravasation of material into the urethra. The needle is then slowly twisted as it is removed so that no material “tails” are left in the urethra. If this does occur, then the stringlike tails can simply be knocked off with the scope.

**Editor’s note:** Tegress is no longer marketed by the manufacturers HB6.

## CONCLUSION

As with any procedure, the results obtained with injectable agents greatly depend on patient selection, expertise in performing the procedure, and the use of specialized equipment. Patient satisfaction depends on understanding the treatment options and, if collagen or another injectable is selected, knowing that multiple injections will be necessary, with periodic reinjections after dryness is achieved to restore continence. In addition, when performed in the clinic using local anesthesia, injectable agents give patients who are poor surgical candidates or are on anticoagulant therapy the opportunity to achieve continence. Overall, injection therapy for stress incontinence is easy to perform, minimally morbid, and convenient for the patient and remains cost-effective, especially when performed in the outpatient office setting. The addition of Tegress to the list of injectable agents may make the ongoing search for an inexpensive, nonantigenic, easily injected, and durable injectable agent a reality, but further study will be needed.

## ACKNOWLEDGMENT

The opinions contained herein are those of the author and are not to be construed as reflecting the views of the Air Force or the Department of Defense.

## REFERENCES

1. Murless BC. The injection treatment of stress incontinence. *J Obstet Gynecol Br Emp* 1938;45: 521–524.
2. Quackels R. Deux incontineces après adenoectomic queries par injection de paraffine dans le perinee. *Acta Urol Belg* 1955;23:259–262.
3. Sachse H. Treatment of urinary incontinence with sclerosing solutions. Indications, results, complications. *Urol Int* 1963;15:225–229.
4. Berg SL. Polytef augmentation urethroplasty. Correction of surgically incurable urinary incontinence by injection technique. *Arch Surg* 1973;107:379–381.
5. Politano VA, Small MP, Harper JM. Periurethral Teflon injection for urinary incontinence. *J Urol* 1974;111:180–183.
6. Gonzales-Garibay S, Jimeno C, York M, et al. Endoscopic autotransplantation of fat tissue in the treatment of urinary incontinence in the female. *J Urol (Paris)* 1989;95:363–366.
7. Santarosa RP, Blaiwas JG. Periurethral injection of autologous fate for the treatment of sphincter incontinence. *J Urol* 1994;151:607–608.
8. Trockman BA, Leach GE. Surgical treatment of intrinsic urethral dysfunction. Injectables (fat). *Urol Clin North Am* 1995;22:665–671.

9. Currie L, Drutz HP, Oxorn D. Adipose tissue and lipid drop embolism following periurethral injection of autologous fat. case report and review of the literature. *Int Urogyn J* 1997;8:923–926.
10. Stegman SJ, Chu S, Bensch K. A light and electron microscopic evaluation of Zyderm collagen and Zylplast implants in aging human facial skin. *Arch Dermatol* 1987;123:1644–1649.
11. Canning D, Peters C, Gearhart J, et al. Local tissue response to glutaraldehyde crosslinked collagen in the rabbit bladder. *J Urol* 1988;139:258–259.
12. Cespedes RD, McGuire EJ. Proper diagnosis. A must before surgery for stress incontinence. *J Endourol* 1996;10:201–205.
13. Blaivas JG, Olsson CA. Stress incontinence. Classification and surgical approach. *J Urol* 1988;139:737–741.
14. McGuire EJ, Fitzpatrick CC, Wan JH, et al. Clinical assessment of urethral sphincter function. *J Urol* 1993;150:1452–1455.
15. Cespedes RD, McGuire EJ. Leak Point Pressures. In: *Practical Urodynamics* (Nitti V, ed.), Saunders, Philadelphia, 1998, pp. 94–107.
16. McGuire EJ, O’Connell HE. Surgical treatment of intrinsic sphincter dysfunction. *Slings. Urol Clin North Am* 1995;22:657–664.
17. Blaivas JG, Jacobs BZ. Pubovaginal fascial sling for the treatment of complicated stress urinary incontinence. *J Urol* 1991;145:1214–1217.
18. O’Connell HE, McGuire EJ, Aboseif S, Usui A. Transurethral collagen therapy in women. *J Urol* 1995;154:1463–1465.
19. Monga AK, Robinson D, Stanton SL. Periurethral collagen injections for genuine stress incontinence. A 2 yr follow-up. *Br J Urol* 1995;76:156–160.
20. Herschorn S, Steele D, Radomski S. Long term follow-up of intraurethral collagen for female stress incontinence. *J Urol* 1995;153:433A. Abstract 818.
21. Appell R. Periurethral collagen injection for female incontinence. *Problems in urology* 1991;5:134–140.
22. Winters JC, Appell R. Periurethral injection of collagen in the treatment of intrinsic sphincter deficiency in the female patient. *Urol Clin North Am* 1995;22:673–678.
23. McGuire EJ, English SF. Periurethral collagen injection for male and female sphincteric incontinence: indications, techniques and results. *World J Urol* 1997;15:306–309.
24. CR Bard Company. PMAA submission to US FDA for IDE G850010, 1990.
25. Steele AC, Kohli N, Mickey MM. Periurethral collagen injection for stress incontinence with and without urethral hypermobility. *Obstet Gyn* 2000;55:357–358.
26. Tschopp PJ, Wesley-James T, Spekkens T, Lohfeld L. Collagen injections for urinary stress incontinence in a small urban urology practice: time to failure analysis of 99 cases. *J Urol* 1999;162:779–782.
27. Moore KN, Chetner MP, Metcalfe JB, Griffiths DJ. Periurethral implantation of glutaraldehyde cross-linked collagen (Contigen) in women with type II or III SUI: quantitative outcome measures. *Br J Urol* 1995;77:359–363.
28. Cross C, English SF, Cespedes RD, McGuire EJ. A follow-up on transurethral collagen injection therapy for urinary incontinence. *J Urol* 1998;159:106–108.
29. McGuire EJ, Appell RA. Transurethral collagen injection for urinary incontinence. *Urology* 1994;43:413–415.
30. McClennan MT, Bent AE. Suburethral abscess. A complication of periurethral collagen injection therapy. *Obstet Gyn* 1998;92:650–652.
31. Appell R. Use of collagen injections for treatment of incontinence and reflux. *Adv Urol* 1992;5:145–165.
32. Malizia AA Jr, Reiman HM, Myers RP, et al. Migration and granulomatous reaction after periurethral injection of polytef (Teflon). *JAMA* 1984;251:3277–3279.
33. Leonard MP, Dector R, Hills K, Mix LW. Endoscopic subureteral collagen injection: are immunological concerns justified? *J Urol* 1998;160:1016–1022.
34. Stothers L, Goldenberg SL. Delayed hypersensitivity and systemic arthralgia following transurethral collagen injection for stress urinary incontinence. *J Urol* 1998;159:1507–1510.
35. Lightner D, Calvosa C, Anderson R, et al. A new injectable agent for treatment of stress urinary incontinence: results of a multicenter, randomized, double blind study of Durasphere. *Urology* 2001;58:12–15.

36. Chrouser KL, Fick F, Goel A, et al. Carbon coated zirconium beads in  $\beta$ -glucan gel and bovine glutaraldehyde cross-linked collagen injections for intrinsic sphincter deficiency: continence and satisfaction after extended follow-up. *J Urol* 2004;171:1152–1155.
37. Pannek J, Brands FH, Senge T. Particle migration after transurethral injection of carbon coated beads for stress urinary incontinence. *J Urol* 2001;166:1350–1353.
38. Stricker P, Haylen B. Injectable collagen for type 3 female stress incontinence: the first 50 Australian patients. *Med J Aust* 1993;158:89–92.
39. Kieswetter H, Fischer M, Wober L, Flamm J. Endoscopic implantation of collagen (GAX) for the treatment of urinary incontinence. *Br J Urol* 1992;69:22–25.
40. Richardson TD, Kennelly MJ, Faerber GJ. Endoscopic injection of glutaraldehyde cross-linked collagen for the treatment of intrinsic sphincter deficiency in women. *Urology* 1995;46:378–381.

---

# 9 Midurethral Slings

---

*Gregory T. Bales, MD, and Paula A. Fedunok, PA-C*

## **CONTENTS**

INTRODUCTION  
HISTORY AND BACKGROUND  
PATIENT SELECTION  
ANESTHETIC REQUIREMENTS  
TECHNIQUES  
MATERIALS  
OUTCOMES  
COMPLICATIONS  
SUMMARY  
REFERENCES

---

## **INTRODUCTION**

An evolution in sling procedures has occurred, from bladder neck slings to slings located at the midurethral level, making midurethral slings the cornerstone of antiincontinence surgery. This is mostly because these midurethral procedures have proved durable, reproducible, and highly effective. This chapter focuses on the attributes of midurethral slings that make them so efficacious. Based on review of pertinent literature, the midurethral sling techniques and corresponding postoperative outcomes are discussed. In addition, a current compilation of complications and related problems with these procedures is reviewed. Finally, a historical perspective on the genesis of the midurethral approach is included.

## **HISTORY AND BACKGROUND**

Literature on sling procedures for the treatment of female incontinence can be found as far back as 1910 in a report by Goebell (1). He described a pubovaginal sling (PVS) fashioned from pyramidalis muscle. Other reports were described in subsequent years as surgeons experimented with different materials and sling placement techniques (2,3). As slings evolved, autologous, cadaveric, and synthetic materials were all utilized for placement at the bladder neck and proximal urethra. These materials were tensioned via suture suspension and generally secured to the overlying rectus fascia. This practice lifted the bladder neck, restoring the anatomic position of the urethra and creating a partial obstruction necessary to prevent leakage with stress activities. Unfortunately, applying the correct tension was difficult and patient specific, and these slings also

caused difficulty voiding and other symptoms of urinary dysfunction, such as *de novo* urgency (4,5).

In the later part of the 20th century, these vaginal sling procedures were also still competing with abdominal anti-incontinence procedures such as the Marshall-Marchetti-Krantz and Burch procedures (6,7). Neither of these abdominal procedures provided satisfactory long-term durability, and both required a hospital stay of several days and often caused other associated perioperative morbidities (8,9). As a result, sling procedures gradually regained popularity as refinements in technique allowed these cases to be undertaken on an outpatient basis as well as with reduced morbidity and decreased hospital stays (10).

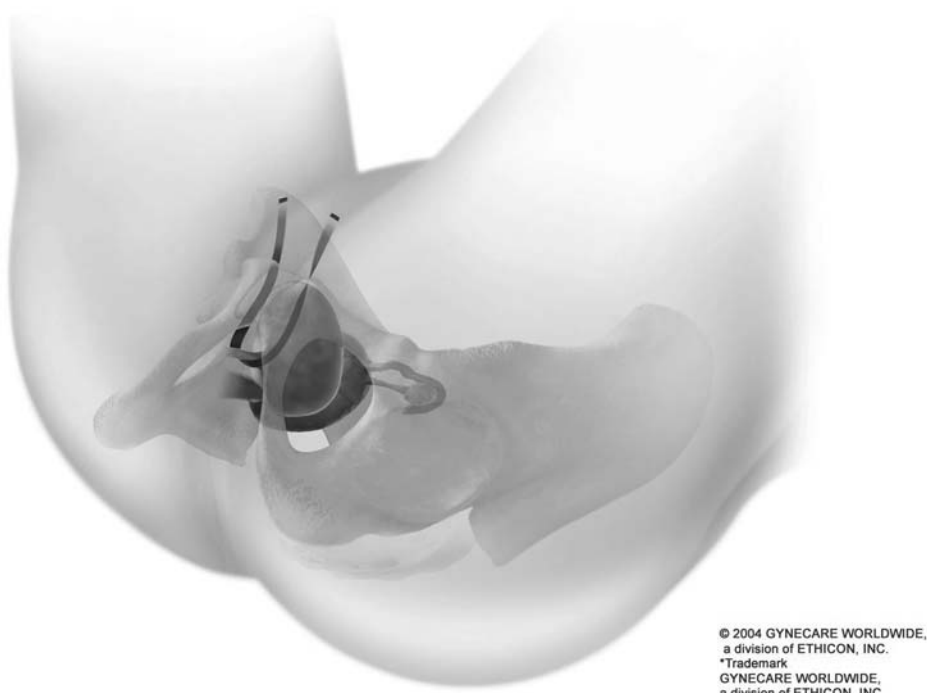
In 1995, Ulstern and coworkers first described the intravaginal slingplasty, a minimally invasive sling procedure that focused on a more distal midurethral sling placement (11,12). Originally trialed in Sweden and Australia, it was determined that, unlike the more proximal bladder neck slings, the midurethral sling caused less interference with bladder neck funneling and potentially less voiding dysfunction. The slings were also not placed under tension, and their effect was the result of a backboard-type support immobilizing the urethra and keeping the urethra from opening during Valsalva and other exertional activities. In addition to their distal and tensionless placement, the procedure was generally reproducible from patient to patient.

Based on Ulstern's original midurethral sling model, the tension-free vaginal tape (TVT) was introduced in 1998 in a commercially available kit as the first midurethral procedure (13). The actual TVT sling comprised a slender strip of polypropylene housed in a plastic sleeve and attached on either end to a trocar. The sling was developed as a vaginally placed procedure by which the trocars would be directed from the vagina under the pubic bone and the mesh pulled out retropubically through the abdominal wall on both sides (Fig. 1). Since 1998, the trocars have been modified and are now thinner in profile than the originally introduced product. In addition, the tape itself is now dyed a bluish-purple so it can be more easily visualized after placement. However, the integrity of the concept has not changed since introduction of the product.

As expected, the midurethral sling has undergone multiple modifications to both the surgical technique and the sling material in an effort to appeal to the full spectrum of pelvic surgeons. The suprapubic arc (SPARC) technique was the first top-down retropubic sling manufactured. Comprised of a polypropylene mesh with characteristics similar to the TVT, the top-down approach allows the surgeon to insert the trocar from above through the abdominal wall first, directing it out a vaginal incision. To accommodate practitioners who felt more comfortable with the SPARC, the manufacturers of TVT have modified their kit to include an attachment that can be connected to the standard trocars also to allow a top-down approach. Although the TVT and SPARC represent two of the most common approaches to placing the retropubic midurethral sling, numerous sling products are now available from various manufacturers (Table 1).

A more recent refinement in technique allows surgeons to utilize the obturator foramen rather than the retropubic space as a means to situate the sling under the urethra. Figures 1 and 2 show schematics of how both the retropubic and obturator slings are anatomically situated. For many practitioners, the transobturator route has become the preferred access to placing the midurethral slings because of the uniformity of the anatomy and a perception that this approach poses less risk for bladder injury and



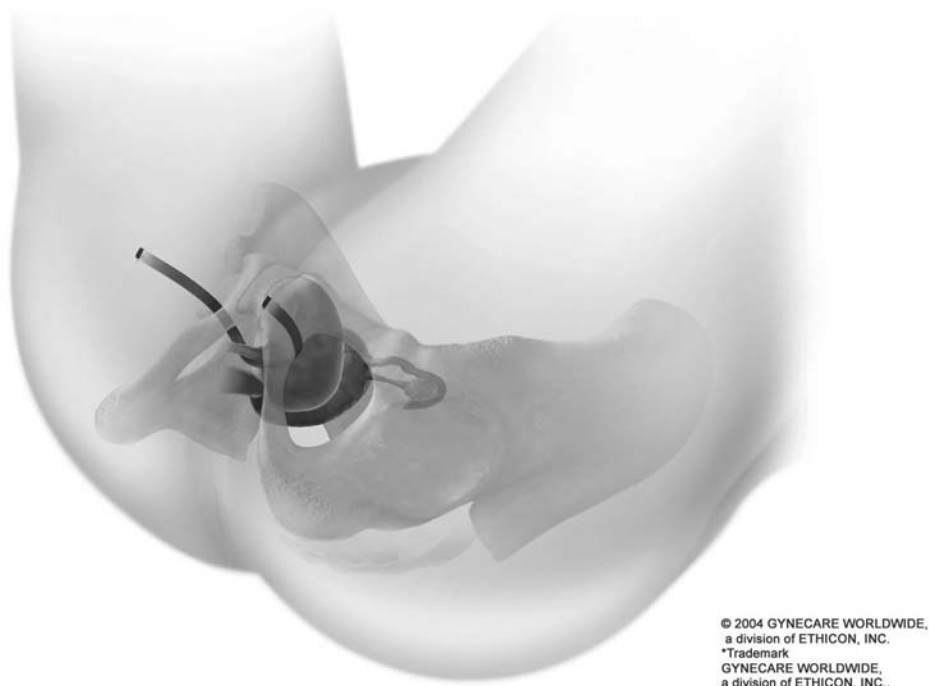


© 2004 GYNECARE WORLDWIDE,  
a division of ETHICON, INC.  
\*Trademark  
GYNECARE WORLDWIDE,  
a division of ETHICON, INC.,

**Fig. 1.** Schematic representation of TVT.

**Table 1**  
**Retropubic and Obturator Sling Products**

<i>Product</i>	<i>Manufacturer</i>	<i>Synthetic</i>	<i>Weave type</i>	<i>Procedure</i>
<i>Retropubic</i>				
Advantage	Boston Scientific	Polypropylene	Monofilament	Bottom to top
IVS Tunneler	US Surgical	Polypropylene	Multifilament	Bottom to top
Suprapubic arc sling (SPARC)	American Medical Systems	Polypropylene	Monofilament	Top to bottom
Transvaginal tape (TVT)	Ethicon Inc.	Polypropylene monofilaments	Monofilament	Bottom to top
<i>Transobturator</i>				
Monarc Subfascial Hammock (Monarc)	American Medical Systems	Polypropylene	Monofilament	Out to in
ObTape	Porges-Mentor	Polypropylene	Monofilament	Out to in
ObTryx	Boston Scientific	Polypropylene	Monofilament	Out to in
TVT-Obturator	Ethicon Inc.	Polypropylene	Monofilament	In to out
UraTape	Porges-Mentor	Polypropylene	Monofilament	Out to in



**Fig. 2.** Schematic representation of TVT-obturator.

bowel perforation. The various transobturator products currently available are depicted in Table 1.

Variability can also be seen in the sling materials regarding the weave, filament size, and mono- or multifilament nature of the product (14). Furthermore, the different manufacturers employ different methods of connecting the mesh to the trocars. Finally, the various trocars each have their own shape and other unique characteristics. Many practitioners find one device with which they are most comfortable after a period of trial and error with the assorted sling products.

### PATIENT SELECTION

In general, all patients with stress urinary incontinence (SUI) are candidates for midurethral slings. Patients with mixed incontinence still can benefit from a sling as this addresses one component of the pathology (15). Within the elderly population, it is thought that the minimal dissection requirements and shorter operative times required for midurethral slings may make this procedure ideal. A study by Walsh et al. found that TVT patients exceeding 70 yr of age experienced minimal morbidity as well as significant improvement in both incontinence and quality-of-life scores (16). In addition, several groups specifically investigated the impact of body mass index (BMI) on the success of the TVT procedure, and each found no BMI-related differences in either efficacy or morbidity between groups with normal vs elevated BMIs (17–19). These two subgroups of patients, the elderly and obese, are therefore excellent candidates for midurethral procedures.

## ANESTHETIC REQUIREMENTS

One of the proposed benefits to midurethral sling surgery is the minimal amount of anesthetic requirements. Both the Marshall-Marchetti-Krantz and the Burch procedures are performed through abdominal incisions; thus, patients require either spinal or general anesthesia. Today, there are a number of investigators who perform the midurethral procedures with local anesthesia or intravenous sedation (20,21). This further underscores the simplicity of these procedures and improves patient acceptance.

Niemczyk et al. were early proponents of performing TVT procedures under a local anesthetic with minimal sedation (22). In their series, 100 patients undergoing TVT were evaluated prospectively with history and pelvic examinations, urodynamics, and outcome and satisfaction questionnaires. Of the patients, 97 then had the procedure performed under local anesthesia with intravenous sedation. The surgical time averaged 35.5 min, and within 24 h after the procedure, 95% of patients were able to void successfully. Using postoperative questionnaires for data collection, Niemczyk's group concluded that the TVT procedure performed under a local anesthetic may prove to be the operation of choice to treat SUI for many women.

Lo et al. conducted a review of surgical outcomes following use of local and intravenous anesthesia in a group of 45 elderly women undergoing TVT for SUI (23). Per report, their mean operating time was 21 min (range 18 to 35), and mean postoperative hospital stay was 24.2 h (range 12 to 72). These physicians summarized by saying that the TVT procedure can be performed under local/intravenous anesthesia with safe and effective results in patients over 65 yr of age.

## TECHNIQUES

Because all midurethral slings are situated under the middle portion of the urethra in a tensionless fashion, the routes taken in putting the sling at this location may vary. Slings can be placed either retropubically or via a transobturator approach. It should be noted that great care should always be taken to cover the sling with full-thickness vaginal wall regardless of the placement technique used.

### *Retropubic*

The retropubic slings, which include the TVT and SPARC, require blind passage of trocars and mesh through the retropubic space. This may be accomplished both by beginning vaginally and advancing out to the suprapubic area and by starting suprapubically and working down into the vagina. Physicians may frequently refer to these options as inside-out or in-to-out vs a top-down or out-to-in approach, respectively. The original and best-studied TVT sling uses an in-to-out approach by which a small (2–3 cm) incision is made in the vagina midurethrally, and the trocars are directed from the midurethral location up behind the pubic bone and out the abdominal wall. This is done bilaterally and allows the hammock-type sling to be well positioned at the location of the midurethral incision under the vaginal wall (Fig. 1).

The alternative top-down approach, which is employed in the SPARC system as well as others, again involves making an initial midurethral vaginal incision and dissecting superolaterally toward the endopelvic fascia. These approaches differ from the original TVT, however, because bilateral abdominal stab incisions are then made, and the accompanying trocars are directed from above, behind the pubic bone and inferomedially

onto the surgeon's fingertip within the vagina. The fingertip guidance allows the correct placement of the trocar into the midurethral position.

Regardless of the approach, cystoscopy is essential to confirm that the bladder has not been perforated prior to completing the procedure. If the trocar has violated the bladder or urethral epithelium, then the trocar can be repositioned to avoid placing the sling in an aberrant location. In general, a bladder laceration will not cause significant morbidity as long as the injury is identified and corrected during the procedure. Most physicians will leave a catheter transiently postoperatively when a bladder laceration has occurred.

### *Transobturator*

The retropubic midurethral slings have been well studied, and their efficacy is clear, but it is also understood that blind trocar passage via this route can jeopardize the bowel (24). In an attempt to minimize the risk of bowel injury, Delorme introduced a novel transobturator approach to sling placement that would allow surgeons to avoid passing trocars through the retropubic space (25). In 2003, his system was approved by the Food and Drug Administration in the United States and became commercially available as the ObTape transobturator sling. In this approach, a midurethral incision is again made, but trocars are inserted lateral to the labia, perforate through the obturator membrane bilaterally, and are then brought in through the previously made vaginal incision.

Like the aforementioned retropubic midurethral slings, the transobturator approach has been modified by various manufacturers, and currently the obturator positioning can be accessed with either a vaginal-to-obturator (in-to-out) or an obturator-to-vaginal (out-to-in) approach, depending on surgeon preference. The efficacy and complications do not appear to differ between the in-to-out or out-to-in procedures. It should be stressed that the final midurethral location of these slings will be the same regardless of the placement technique, and this is why outcomes appear similar.

Since their introduction, these newer transobturator slings have evolved and currently have been well accepted in the urologic and urogynecologic communities (Table 1). The anatomic concerns involved in directing the slings through the obturator foramen chiefly center on avoiding the obturator nerve and vessels, which are located superolaterally in the obturator foramen. Great care must be taken to stay medial alongside the inferior pubic ramus when directing the trocars in obturator sling placement. The newer obturator approaches do not have as lengthy a follow-up as the retropubic slings, although the use of the obturator route likely will continue to expand as more surgeons are introduced to this technique.

### *Percutaneous*

Because the majority of surgeons avail themselves of the manufactured midurethral sling kits, several investigators have explored cutting and tailoring a piece of prepackaged "off-the-shelf" mesh and using it to perform a midurethral sling procedure (46,47). The primary objective with this technique is still to achieve a tensionless synthetic material under the midurethra while minimizing the costs associated with the packaged sling kits. The operative technique is performed by utilizing Stamey needles as the carrier to place the sling material at the level of the midurethra. Much like the kit procedures, great care is taken to ensure that the sling is not placed under tension, and cystoscopy should be performed intraoperatively to rule out any bladder or urethral violations.

Table 2  
Commercially Available Meshes and Grafts

<i>Basic component</i>	<i>Trade name</i>	<i>Type/processing</i>
<i>Synthetic meshes</i>		
Polypropylene	Marlex (CR Bard)	Monofilament
	Prolene (Ethicon)	Monofilament
	Atrium (Atrium)	Monofilament
Polytetrafluoroethylene (PTFE)	Teflon (CR Bard)	Monofilament
	Expanded PTFE	Gore-Tex (WL Gore)
Polyethylene terephthalate	Mersilene (Ethicon)	Multifilament
Polyglycolic acid	Dexon (Davis & Geck)	Multifilament
Polyglactin 910	Vicryl (Ethicon)	Multifilament
<i>Natural grafts</i>		
Human dermis	Repliform (Boston Scientific)	Freeze-dried/chemical
	Duraderm (CR Bard)	Freeze-dried
	Duraderm (CR Bard)	Freeze-dried/irradiated
Human fascia lata	Tutoplast (Mentor)	Tutoplast process
Porcine small intestinal submucosa	Stratasis (Cook)	Freeze-dried

## MATERIALS

As the midurethral sling procedures have grown in popularity after the original success with the TVT, manufacturers have developed various products that employ similar technology. One way in which the products differ is by including different synthetic or natural substances as the sling product itself. Although a comprehensive overview of the biology of how synthetics and natural substances are incorporated into host tissues is beyond the scope of this chapter, this section briefly reviews some of the properties of the different materials utilized in the competing sling technologies (Table 2).

As mentioned, there are two subgroups of materials employed for the midurethral slings: synthetics and naturally occurring substances. Loosely defined, any natural or synthetic substance that incorporates or integrates into a patient's tissues during the treatment is defined as a *biomaterial* (26). The ideal (graft) compound would be inert, sterile, noncarcinogenic, and mechanically durable. Furthermore, the foreign body should cause no inflammatory or immune reaction, must withstand modification by body tissues, and should be inexpensive, convenient, and easy to use (27).

Synthetics can be absorbable or nonabsorbable. Absorbable meshes have generally fallen into disfavor because of poor tensile strength and poor scar formation, leading to high recurrence rates (28). Nonabsorbable meshes, like the Prolene used in the TVT, have enjoyed much greater success. The unique properties of nonabsorbable synthetics are the pore size and filament type. In general, acceptable pore sizes are greater than 75–100  $\mu\text{m}$  because they allow access to fibroblasts and collagen and allow immune cells to scavenge for bacteria (29). The Prolene mesh used in the TVT, as well as others commonly utilized in pelvic reconstructive surgery, has a pore size greater than 75  $\mu\text{m}$ . Smaller pore sizes allow passage only to histiocytes, and adhesion to host tissue is therefore unstable (27).

The filament type also contributes to overall mesh function. Polypropylene, which is commercially packaged as Marlex and Prolene, is a monofilament. By contrast, several competing meshes, such as Gortex, Mersilene, Dexon, and Vicryl, are multifilament. Multifilaments have small interstices that may prevent access to key immune cells and contribute to higher infectious complications, which can lead to erosion. Mersilene mesh use, for example, is now discouraged because of the high erosion and fistula rates with bowel (30). With Prolene and other monofilament large-pore meshes, erosions as well as infectious complications are uncommon.

The natural materials used in slings can be classified as autologous, allografts, or xenografts. The autologous slings utilized historically enjoyed good success except for the obvious disadvantage of increased morbidity, risk of wound infections, and longer recovery times associated with the additional incision at the tissue harvest site (21). Allografts save the added step of tissue harvest, but concerns have arisen with allograft stability. Several different processes are employed to prepare the allografts, including irradiation, freeze-drying, or solvent dehydration (31). Fitzgerald et al. found a high rate of failure with allografts owing to dissolution of the cadaveric fascia (32). In addition, some reports have demonstrated DNA fragments in the allografts, and a potential for HIV transmission exists (33,34). Prion transmission has also been cited as a potential risk as prions are resistant to  $\gamma$ -irradiation and autoclaving (35).

Xenografts have been described as a useful sling material for correcting SUI. The greatest experience has been with porcine small intestine submucosa (SIS) and dermis. SIS maintains strong tensile strength, is biocompatible, and minimizes inflammatory reaction (36). One report with SIS revealed a 4-yr cure rate of 93% for SUI with no infections or graft erosions (37). Overall, natural materials will continue to be studied in sling and pelvic floor procedures but likely will never demonstrate the consistent durability of the synthetics.

## OUTCOMES

### *Retropubic*

There have been multiple studies that have addressed outcomes after midurethral slings. One of the difficulties inherent in interpreting the results of these investigations is the variety of outcome measures utilized. Also, the cohort of patients treated in many centers is heterogeneous, which affects outcomes. In addition, there is significant variation in the length of follow-up performed. As a result, it can be difficult to make meaningful comparisons between the types of midurethral slings employed. Nevertheless, this section attempts to provide a general overview of the results seen with these sling procedures.

Several French investigators were early proponents of midurethral repairs. Villet et al. looked at 124 consecutive patients treated for SUI with a TVT (38). Preoperatively, all patients completed a urodynamic assessment and exhibited urine leak with a stress test. Of the women, 54 (44%) also had some clinical signs of urgency. Outcomes were assessed by patient satisfaction questionnaires. With a mean follow-up of 32.5 mo, this group found that 110 (88.7%) patients became totally continent, 10 (8%) improved, and 4 (3.3%) failed the procedure. Overall, 117 patients (94.3%) were subjectively satisfied. In addition, urgency resolved in 38 of the 54 patients (70%). This group of investigators concluded the TVT technique was valuable because of the good outcomes and reproducibility of the procedure.

Another European group evaluated outcomes in 191 patients who underwent a TVT sling (39). Preoperatively, 127 women (66%) had SUI alone; 64 (34%) had mixed incontinence, although none of the patients underwent urodynamic assessment. Thirty-four women (18%) underwent a concomitant surgical procedure, and the group utilized both local and spinal anesthesia. All together, 164 (86%) of patients were completely cured, and 23 patients (12%) experienced no improvement. Sixty percent had less urge incontinence. A further breakdown of their results revealed cure rates were as follows: 97% among SUI patients vs 69% among mixed incontinence patients. There was no difference seen in outcomes between local or spinal anesthesia groups or when comparing TVT alone vs TVT in combination with other surgery. They concluded that TVT was an acceptable choice for patients with either SUI or mixed incontinence, but that lower success is seen with TVT performed for patients with mixed incontinence.

The midurethral slings can be combined with other surgical repairs without compromising success. This has been demonstrated in multiple studies, such as the Laurikanen and Kiillholma study (39). In another investigation, Groutz et al. studied the efficacy and safety of the TVT procedure in 100 consecutive women with significant genitourinary prolapse and occult SUI (40). Interestingly, none of the women complained of SUI preoperatively; however, all had urodynamically confirmed occult SUI after repositioning of the prolapse. Surgical intervention comprised transvaginal prolapse repair and prophylactic TVT procedure. At a mean follow-up of 27 mo, only two patients had developed SUI. However, postoperative urodynamic studies revealed asymptomatic sphincteric incontinence in 15 (15%) other patients. Furthermore, 13 (72%) of 18 patients with preoperative urge incontinence had postoperative persistent urge incontinence. These physicians concluded that the TVT procedure is effective and safe when used for occult SUI in patients undergoing prolapse repair.

Although the above reports dealing with midurethral sling outcomes primarily looked at TVT, other articles have evaluated results with other midurethral approaches. The safety and efficacy of the suburethral polypropylene (SPARC) procedure was reported by Deval et al. in a prospective multicenter trial of the suprapubic approach of SPARC taping for the treatment of genuine SUI (41). One hundred four consecutive women underwent SPARC at three centers. All women had urethral hypermobility preoperatively, and detrusor instability was ruled out by cystometry. Subjective and objective cure rates were evaluated by questionnaires as well as clinical and urodynamic examination. Objective cure rate was 90.4%, and this group found no difference in improvement between patients with preoperative genuine SUI and those with mixed incontinence. Interestingly, the subjective cure rate was 72%. These authors found a higher bladder injury rate in women with previous incontinence surgery (36.3 vs. 7.5%). Also, 12% of women developed *de novo* urge symptoms. Overall, these investigators concluded the SPARC procedure is safe and effective despite a relatively high incidence of *de novo* urgency.

Several comparative trials have been performed analyzing midurethral sling outcomes compared to more traditional antiincontinence procedures. Chung and Chung retrospectively evaluated outcomes in 91 cases of TVT alone or in combination with other procedures compared to outcomes in 51 cases of laparoscopic Burch procedure (42). They also divided the patients into groups based on BMI. Results between the groups demonstrated comparable symptom improvement and cure rates. Operative time for TVT ranged from 18 to 40 min; the laparoscopic Burch procedures took over 1 hr. In addition, these physicians concluded that the TVT was safer and more minimally invasive for patients regardless of their BMI.

Another comparative evaluation was performed by Paraiso et al. (9). In this study, 72 women were randomly assigned to receive either laparoscopic Burch colposuspension or TVT. The mean operative time was significantly greater in the laparoscopic Burch group. Furthermore, postoperative urodynamic studies revealed a higher rate of SUI in the laparoscopic Burch group at 1-yr follow-up, 18.8 vs 3.2% in the TVT patients. The investigators concluded that the TVT procedure results in greater objective and subjective cure rates for SUI than does laparoscopic Burch colposuspension.

In an effort to better define long-term results, Nilsson et al. prospectively evaluated and followed 90 consecutive patients who had a TVT operation (43). Their median follow-up was an impressive 56 mo, with some patients assessed nearly 7 yr after surgery. In this group, 72 of 85 evaluated patients (84.7%) were both objectively and subjectively cured. Another 9 patients (10.6%) were significantly improved, and 4 (4.7%) were regarded as failures. Furthermore, no patient complained of long-term voiding difficulties, and no tapes eroded or extruded. In addition, 14 of 25 patients (56%) with preoperative complaints of urgency saw their symptoms relieved. This article was one of the first to conclude that TVT fulfilled the high expectations of long-term cure, as suggested by previous short-term reports.

### *Transobturator*

Short-term data regarding the efficacy and complications associated with the newer transobturator slings suggest that these products perform as well as their retropubic counterparts and may perhaps cause fewer complications. Ansyer et al. retrospectively analyzed two groups of patients with similar characteristics except that one group ( $n = 25$ ) had received a retropubic and the other ( $n = 24$ ) a transobturator sling procedure (44). Two bladder injuries occurred with the retropubic approach, whereas none occurred with the transobturator approach. Overall, however, these investigators found similar continence results and concluded that the obturator approach achieves comparable efficacy to the retropubic technique.

Another group of doctors from Lyon, France also compared the obturator route with the TVT (45). In their retrospective study, one 18-mo period of 94 tension-free obturator tape cases was compared to an 18-mo period of 99 TVT procedures. The TVT surgeries had immediately preceded the change in approach to the obturator route. All operations were performed by the same surgeon using the same Prolene mesh, and no concomitant procedures were added. Their outcome analysis showed that the obturator sling cure rates were identical to those seen with the classic retropubic TVT approach. Further analysis showed bladder injuries were more frequent in the TVT group (10 vs 0%), as were hemorrhagic complications (10 vs 2%), although the differences were not statistically significant. These investigators determined that, because of the simplicity and safety of the procedure along with the excellent continence results, the obturator approach represents the best method of suburethral tape insertion.

### *Percutaneous*

In a controlled trial, Hung et al. prospectively analyzed two groups of patients undergoing treatment of SUI, one group undergoing a standard TVT procedure ( $n = 23$ ) and the other group, for financial reasons, electing polypropylene mesh off the shelf placed in a conventional pubovaginal fashion using Stamey needles ( $n = 57$ ) (46). Eighty women were therefore included, and the mean follow-up was 23 mo for the TVT technique and 20 mo for the PVS procedure. Postoperatively, SUI (91.3 vs 93.0%), concomitant urge



symptoms (85.0 vs 85.3%), and the negative impact of incontinence and urogenital distress on patients' quality of life (79.8 vs 77.8% and 77.4 vs 68.8%, respectively) had improved markedly. These physicians concluded that both techniques were effective treatment modalities for female SUI. However, interestingly, the TVT was not as effective in this series in treating overweight or obese women as the PVS procedure.

In a review article, Rackley et al. compared the percutaneous vaginal tape (PVT) sling experience with that of the TVT (47). PVT procedural steps were analogous to the TVT insofar as both procedures use sling material composed of polypropylene mesh, and both require placement of the material at the midurethral level using a retropubic approach. In the case of the PVT, the mesh is placed in an antegrade fashion using a percutaneous ligature carrier, and in the case of the TVT, a typical retrograde technique using vaginal trocars is employed. It was found that both techniques are reproducible, easy to master, and minimally invasive with respect to tissue handling. In addition, a cost savings was realized when the PVT was employed. Most important, reported outcomes with the PVT were comparable to the TVT experience, and both repairs appeared durable over several years of surveillance.

## COMPLICATIONS

Since the introduction of the TVT in 1998, the synthetic midurethral tension-free slings have revolutionized the treatment of female stress incontinence. A big reason for their appeal to both patients and surgeons has been reduced operative and anesthetic times and excellent efficacy. However, another significant advantage is the safety profile of these techniques. Studies now clearly demonstrate that fewer complications occur when midurethral slings are compared to other antiincontinence procedures, particularly those requiring an abdominal incision (48). Although data have consistently supported the favorable safety reputation of the midurethral sling, it is important to recall that these slings use a heterogeneous group of procedures. Variability in patient selection, mesh type, sling placement technique, surgeon experience, and patient follow-up make analysis of the literature difficult. Within these limitations, synthetic midurethral sling studies with short- and medium-term follow-up can be found abundantly in the literature, and the various complications and their management strategies are outlined next.

### *Intraoperative Complications*

The most prevalent intraoperative midurethral sling complications are urethral, bladder, and bowel injuries; vascular injuries; bleeding; and hematoma formation. To date, these have been primarily described in patients undergoing retropubic slings, procedures that require blind passage of mesh through the retropubic space using trocars or needles to perforate the endopelvic fascia. The retropubic midurethral sling can be placed in either an antegrade or a retrograde fashion, and several studies have sought to establish the superior safety of one approach over the other.

The largest body of data exists for the TVT, a sling that is traditionally placed in an in-to-out, retrograde fashion. Studies support its excellent safety profile. In a survey investigation by Agonstini et al., input was received from 21 urologists and 71 gynecologists, who reported a combined experience of 12,280 TVT procedures (49). Although urethral injuries were not mentioned, 901 bladder injuries (7.34%), 26 vaginal healing defects (0.21%), 3 bowel perforations (0.02%), and 39 (0.32%) retropubic or vulvovaginal hematomas were reported.

The TVT can be performed either alone or in combination with other surgical procedures, such as a hysterectomy or prolapse repair, with no significant increase in complications. In their cohort of 313 TVT patients receiving such combination surgeries, Levin et al. reported a 5.1% bladder injury rate (16 patients), but no other complications (50). In Karram's series of 350 TVT patients, some undergoing multiple procedures, the group noted a 4.9% bladder perforation rate, no urethral injuries, and a 1% significant bleeding rate (51). Similarly, Debodinance et al. found that when 256 patients underwent TVT either alone or in combination with other vaginal surgeries, bladder perforation occurred at a rate of 5.5%, and urethral injury and retropubic hematoma both had rates of 0.4% (52).

The SPARC procedure, which is newer than the TVT, is placed via a descending rather than an ascending retropubic approach. Despite this difference, studies thus far have failed to establish the superior safety of one over the other. Andonian et al. found that when 84 women were randomly assigned to receive either a SPARC ( $n = 41$ ) or a TVT ( $n = 41$ ), bladder perforation rates were high in both groups (24 vs 23%, respectively), but patients in the SPARC cohort experienced additional complications, including one tape erosion and one infected pelvic hematoma (53). When Tseng et al. evenly randomized 62 patients to receive either a SPARC or a TVT procedure, the authors clinically noted differences between the group outcomes, but no statistically significant differences were seen (54). These researchers reported four (12.9%) and zero respective bladder injuries, and as determined by postoperative pelvic ultrasound, three (9.7%) and five (16.1%) respective retropubic hematomas greater than 5 cm. Despite the hematomas, no patients experienced significant bleeding according to the authors.

The possibility of blood vessel injury and significant bleeding is a concerning although infrequent complication of the retropubic sling procedures. In a retrospective chart review series by Kobashi and Govier, 140 patients underwent placement of a SPARC sling and spent one night in the hospital for observation (24). Six patients (4.3%) experienced perioperative complications, including one bowel perforation and five significant bleeding episodes (3.6%), with four patients requiring transfusion and one requiring percutaneous drainage of a hematoma. Although it is unclear whether the afflicted patients were symptomatic with these bleeds, the authors, who used a postoperative day 1 hematocrit to assess each patient, found an overall mean drop in hematocrit levels of 7.1% secondary to SPARC surgery. Their group proposes that the incidence of bleeding with these procedures may be more significant than many surgeons realize.

With either approach, knowledge of the neurovascular anatomy is critical, and patients with prior vaginal or abdominopelvic surgeries may present an increased surgical risk due to both altered anatomy and fibrotic tissue. Ultrasonography can be used to identify interceding bowel prior to introducing trocars. For the most part, case reports of serious bleeding are mentioned infrequently throughout the literature, and the prevalence of this complication appears less than 1% (49). Per report, most intraoperative bleeding is mild to moderate and can be managed conservatively with compression (55).

A recent modification to the midurethral sling procedure involves a transobturator approach. The benefits of this approach seem to be fewer intraoperative bowel and bladder injuries because the retropubic space is not crossed. Although no large studies compare the intraoperative complications of the retropubic to the transobturator approach, trends appear to favor the transobturator in smaller series. Ansquer et al., in a non-randomized trial comparing the retropubic ( $n = 25$ ) and obturator ( $n = 24$ ) approaches found similar rates of cure and symptom improvement, but noted two vs zero bladder

injuries, respectively (44). Similarly, in a randomized trial by deTayrac et al. in which 31 patients received a TVT and 30 patients received a TVT-obturator, bladder injuries were 0 and 3 (9.7%), respectively (56). The safety record of the transobturator approach was reinforced by two separate series of 80 and 150 patients, each receiving the transobturator UraTape for stress incontinence. No intraoperative complications were reported by either set of investigators (57,58).

Because of the perceived safety of the transobturator technique, many surgeons report no need for intraoperative cystoscopy, a procedure that can diagnose bladder perforation during midurethral sling surgery. Accounts of bladder laceration during transobturator sling placement can be found in the literature, although infrequently, and routine cystoscopic surveillance must still be recommended (59,60). Intravesical injuries may be discovered in a delayed fashion (61). In one transobturator sling series by Levin et al., two injuries were detected at 3 and 15 mo postoperatively (50).

### *Postoperative Complications*

#### **EROSION AND INFECTION**

Included in the list of early postoperative complications are vaginal and urethral erosions; infections of mesh, soft tissue, and bone; fistulas; and transient postoperative urinary retention. With the exception of urinary retention, it is thought that the type of synthetic mesh used and patient factors such as wound healing play into the development of these complications. Arguably, synthetic mesh has added a durability to incontinence repairs that has not been seen with prior surgical techniques. However, mesh has also contributed to the development of postoperative complications requiring novel management strategies.

Erosions, which are thought to be caused in part by an immunologic response to the foreign body mesh, are a relatively rare sling complication (0.26–1.8%) when polypropylene material is used (49,62–64). As a result, this synthetic is currently incorporated into most sling kits and used off the shelf in many “homemade” slings (65–67). Vaginal erosions most commonly present with palpable mesh and vaginal discharge, although vaginal pain, dyspareunia, and partner discomfort during intercourse may also be presenting symptoms (63,68,69). Urethral erosions may cause urinary retention, urethral bleeding, or pain, or they may present as recurrent stress incontinence (63,68,70). It is important to note that 35% of vaginal erosions and 89% of urethral erosions may be completely asymptomatic and may be discovered incidentally on exam or cystoscopy (63). With either complication, delayed presentation is a consideration.

In small slings series utilizing other than polypropylene mesh, increased incidences of erosion can be seen. In a prospective study of 10 patients receiving 2 × 10 cm silicone-coated polyester slings secured with bone anchors, 2 patients (20%) experienced erosion at 6 and 10 mo postoperatively and underwent subsequent mesh removal (71). Kato et al. had similar results with the Vesica system, which utilizes a bovine collagen-injected woven polyester with bone anchors (72). In their series of 19 patients, 4 (21%) developed vaginal erosion and required total ( $n = 3$ ) or partial ( $n = 1$ ) mesh removal. When Mersilene mesh was used in a series of 176 sling patients, a 4% ( $n = 8$ ) erosion rate was reported (73). In a series of 141 patients, use of Gortex as a sling material resulted in 5 patients (3.6%) developing granulation tissue and requiring mesh removal (74). In a study using UraTape, which is a transobturator sling made of silicone-coated polypropylene, Cindolo et al. reported only 1 erosion in an 80-patient series (57).

Management of sling erosions usually begins conservatively. Kobashi and Govier reported spontaneous vaginal healing of SPARC sling erosions in four women when vaginal rest was prescribed for 3 mo (69). Investigators also reported use of estrogen cream intravaginally to promote spontaneous resolution of vaginal erosions (73).

When conservative measures fail or vaginal nonhealing is a result of a refractory infection, partial or complete mesh removal must be performed. One minimally invasive surgical management strategy involves trimming exposed mesh and granulation tissue and reclosing the vagina in two layers. Myers and LaSala reported complete resolution of erosion of Mersilene mesh in all seven patients undergoing this procedure (75). Frequently, removal of the exposed mesh will not jeopardize continence, and after complete healing, many investigators agree that a second sling can be replaced with minimal complication (76).

Persistent vaginal infections, although likely underreported, are a risk related to synthetic use (48). With use of monofilament polypropylene mesh, the infection rate is low, ranging between 0.4 and 2% (77,78). Other synthetics are associated with higher infection rates. For instance, when polyfilament polypropylene mesh slings were placed by Bafghi et al. in a series of 149 women, 11 patients (7.5%) experienced vaginal infection, with 6 patients requiring unilateral and 4 requiring bilateral mesh removal (79).

Reports suggested that bone anchors have also been associated with infections, including osteomyelitis, which may commonly be unresponsive to conservative management (80). However, when using bone anchors to secure either a polyethylene mesh In-Taca sling (15 patients) or a fascia lata sling (46 patients), Schulte-Baukloh et al. concluded that the sling material used rather than the bone anchors were the cause of infection (81). They found that 33% of patients with polyethylene and 15% of patients with fascia lata developed infections. Shah et al., in a 5-yr follow-up of 58 patients receiving a polypropylene sling secured with bone anchors, reported no infections, nonhealing, or erosion of the slings (82).

Infections, because of their heterogeneous nature, must be managed on a case-by-case basis. Although most surgeons agree that a trial with topical anesthetics, such as intravaginal betadyne, and systemic antibiotics is worth trying, many patients will require complete or partial mesh removal (79). Both retropubic and transobturator slings can harbor infection across the entire mesh surface, and necrotizing surgical site infections, abscesses, fistulas, and other unique presentations have been described in case reports (83–86). Fistulas are not reported often in conjunction with midurethral sling placement, but Glavind and Larsen reported 1 fistula complication in a series of 31 patients receiving TVT slings (87). This patient had a prior Kelly plication.

## VOIDING AND SEXUAL DYSFUNCTION

Late complications consist primarily of voiding dysfunction and include urinary retention and obstructive symptoms; irritative symptoms such as urgency, frequency, *de novo* detrusor instability, and urge incontinence; as well as return of stress incontinence. Sexual dysfunction following sling surgery has also been reported.

During the immediate postoperative period, transient voiding difficulties and increased postvoid residuals are not uncommon. Because midurethral slings are not placed under tension, the etiology of this syndrome is poorly understood. Expectant management strategies include teaching double-voiding, self-intermittent catheterization, and placing prophylactic suprapubic cystostomy tubes or indwelling urethral Foley catheters at the time of sling surgery. In an attempt to define which strategy

helps patients recover normal voiding more quickly, Gandhi et al. performed a retrospective analysis of 161 TVT patients who had used either intermittent catheterization or continuous Foley drainage following surgery (88). Their group determined that normal voiding returned significantly faster (8 d vs 12 d, respectively) in the Foley drainage group.

Many studies have been conducted to assess the long-term urodynamic and symptomatic voiding changes that can accompany midurethral sling placement. Although most patients are satisfied with these slings, those dissatisfied complain of symptoms that include hesitancy, straining, or sensation of incomplete emptying, often caused by inadvertent persistent urethral obstruction. In one retrospective series of 600 patients receiving TVT slings, Klutke et al. noted a 2.8% incidence (17 patients) of bothersome obstructive symptoms requiring transvaginal sling release (20). In their series, all patients experienced resolution of symptoms with this procedure, although one patient experienced return of stress incontinence.

Prospective studies using urodynamics to evaluate pre- and post-TVT voiding parameters are common, and although studies agree that both subjective and objective changes occur after a sling is placed, they disagree on the significance of these changes. Lukacz et al., analyzing data from 65 patients undergoing TVT, found that although TVT does significantly reduce flow rates, patient detrusor pressures, and residual urine measurements, subjective voiding symptoms are not clinically impaired (89). In a similar study with 1-yr follow-up of 45 patients who underwent TVT, a significant reduction in flow rate, increase in postvoid residuals, and changes in pressure flow data were noted, although only 1 patient was considered urodynamically obstructed (90). Another TVT study that followed 145 TVT patients at yearly intervals found that although there were initial changes in obstructive parameters, the flow rates, postvoid residuals, and subjective symptoms seemed to normalize in the interval between 1 and 2 yr postoperatively (91).

Postoperative voiding dysfunction may correlate with low preoperative flow rates, preoperative vault prolapse, or concomitant vault suspension surgery (92). The incidence of prolonged voiding dysfunction following TVT ranges between 1.9 and 2.8% (20,93). In a large series of 1,175 patients who underwent a TVT midurethral sling procedure, 1.9% (23 women) required surgical intervention for voiding dysfunction refractory to conservative management (93). In this series, Rardin et al. performed sling release on 23 women (1.9%) an average of 17.3 wk from sling placement (93). After release, all patients experienced resolution of incomplete emptying and irritative voiding symptoms over a 6-wk period; however, three patients (13%) reported complete recurrence of stress incontinence equal to or worse than their baseline leakage.

When patients are unequivocally obstructed, surgical sling release is always necessary. Ozel et al. found that when obstruction was identified early in two transobturator patients, the anterior vaginal incision could be opened and the sling loosened without transecting or removing the mesh (94). This procedure, however, will likely be impossible in the late postoperative period when tissue ingrowth has occurred around the sling. Other investigators described a sling release procedure that entails either transecting or segmentally excising a portion of the suburethral mesh (92,95). Should a patient have recurrent stress incontinence, placement of a second midurethral sling remains a curative option (20,96).

*De novo* overactive bladder symptoms are another reported complication of slings; again, this has been studied most rigorously in the TVT population. Interestingly, typical

results demonstrate that midurethral slings contribute more to resolution of frequency, urgency, and urge incontinence than they do to the cause of these symptoms.

A review was performed on 98 patient charts following TVT surgery, and it was revealed that only 8.7% of 98 patients started taking anticholinergic medications after sling placement, whereas 57.7% of patients who used this class of medications prior to surgery no longer needed them following surgery (97). In another series of 256 TVT placements, 12% of patients experienced *de novo* urinary urgency, but again, it was noted that 50% of patients with preoperative urgency experienced resolution of this symptom after the operation (52).

Obviously, outright sling failures as well as subjective or objective return of SUI may occur postoperatively. By all accounts, a second sling procedure may correct the stress incontinence without significant operative complications (98). Prior to placing another sling, however, a thorough examination, including urodynamics, should focus on excluding alternate causes for incontinence, such as a fistula and *de novo* urge incontinence.

The topic of patient and partner sexual satisfaction following synthetic midurethral slings has not received much attention in the literature. In a retrospective study utilizing 65 responses in mailed questionnaires from women who had undergone TVT, 17 women (26%) described intercourse as better after surgery, 47 women (73%) said it was unchanged, and 1 woman reported a worse experience because of worsening incontinence (99). Two European studies that also used self-administered mailed questionnaires to collect data found greater prevalence of sexual dissatisfaction following TVT surgery. Of the 55 TVT patients who completed questionnaires, 8 (14.5%) reported dyspareunia after surgery, and 3 (5.4%) reported loss of libido (100). In the United Kingdom, of the 43 sexually active patients surveyed, most reported no change in sexual function (72%), 2 patients (4.7%) reported improvement, and 6 (14%) reported worsening function because of loss of libido (101). Overall, researchers have generally concluded that the TVT procedure has little effect on sexual function.

## SUMMARY

Midurethral slings have taken their place as a first-line simple reproducible procedure for incontinence. A wealth of studies has now confirmed the efficacy of these procedures. Although not entirely complication free, multiple investigators have determined that the overall complication rate is low and acceptable. Easily learned, the midurethral slings have rapidly become first line antiincontinence procedures for many physicians. Continued refinements in technique in achieving midurethral tensionless positioning should further improve what is already a technically sound and successful operation.

## REFERENCES

1. Goebell R. Zur operativen Beseitigung der angeborenen Incontinentia Versicae. *Dtschr Gynakol Urol* 1910;2:187-191.
2. Frangenheim P. Zur operativen behandlung der Inkontinenz der mannlichen Harnrohe. *U Deutsche Gesell Chir*, 43rd Congress 1914;149:138-156.
3. Stoekel EP. Treatment of incontinence of urine in traumatic injuries of the sphincter muscle. *Zentralbl Gynakol* 1921;45:17-19.
4. Blaivas JG, Jacobs BZ. Pubovaginal fascial sling for the treatment of complicated stress urinary incontinence. *J Urol* 1991;145:1214-1218.
5. McGuire E, O'Connell HE. Surgical treatment of intrinsic urethral dysfunction. *Urol Clin North Am* 1995;22:657-664.

6. Marshall FV, Marchetti AA, Krantz KE. The correction of stress incontinence by simple vesico-urethral suspension. *Surg Gynecol Obstet* 1949;88:509–518.
7. Burch JC. Urethrovaginal fixation to Cooper's ligament for the correction of stress incontinence, cystocele and prolapse. *Am J Obstet Gynecol* 1961;81:281.
8. Milani R, Scalabrino S, Quadri G, Algeri M, Marchesin R, Marshall-Marchetti-Krantz procedure and Burch colposuspension in the surgical treatment of female urinary incontinence. *Br J Obstet Gynaecol* 1985;92:1050–1053.
9. Paraiso MF, Walters MD, Karram MM, Barber MD. Laparoscopic Burch colposuspension vs tension-free vaginal tape: a randomized trial. *Obstet Gynecol* 2004;104:1249–1258.
10. Taub DA, Hollenbeck BK, Wei JT, Dunn RL, McGuire EJ, Latini JM. Complications following surgical intervention for stress urinary incontinence: a national perspective. *Neurourol Urodyn* 2005 Sep 19 [Epub].
11. Ulmsten U, Petros P. Intravaginal slingplasty (IVS): an ambulatory surgical procedure for treatment of female urinary incontinence. *Scand J Urol Nephrol* 1995;29:75–82.
12. Ulmsten U, Henriksson L, Johnson P, Varhos G. An ambulatory surgical procedure under local anesthesia for treatment of female urinary incontinence. *Int Urogynecol J Pelvic Floor Dysfunct* 1996;7:81–85.
13. Ulmsten U, Falconer C, Johnson P, et al. A multicenter study of tension-free vaginal tape (TVT) for surgical treatment of stress urinary incontinence. *Int Urogynecol J Pelvic Floor Dysfunct* 1998;9: 210–213.
14. Staskin DR, Plzak L. Synthetic slings: pros and cons. *Curr Urol Rep* 2002;3:414–417.
15. Osman T. Incontinence surgery for patients presenting with mixed incontinence and a normal cystometrogram. *BJU Int* 2003;92:964–968.
16. Walsh K, Generao SE, White MJ, Katz D, Stone AR. The influence of age on quality of life outcome in women following a tension-free vaginal tape procedure. *J Urol* 2004;171:1185–1188.
17. Mukherjee K, Constantine G. Urinary stress incontinence in obese women: tension-free vaginal tape is the answer. *BJU Int* 2001;88:881–883.
18. Raffi A, Darai E, Haab F, Samain E, Levardon M, Deval B. Body mass index and outcome of tension-free vaginal tape. *Eur Urol* 2003;43:288–292.
19. Lovatsis D, Gupta C, Dean E, Lee F. Tension-free vaginal tape procedure is an ideal treatment for obese patients. *Am J Obstet Gynecol* 2003;189:1601–1604; discussion 1604–1605.
20. Klutke C, Siegel S, Carlin B, Paszkiewicz E, Kirkemo A, Klutke J. Urinary retention after tension-free vaginal tape procedure: incidence and treatment. *Urology* 2001;58:697–701.
21. Haab F, Sananes S, Amarenco G, et al. Results of the tension-free vaginal tape procedure for the treatment of type II stress urinary incontinence at a minimum follow-up of 1 yr. *J Urol* 2001;165:159–162.
22. Niemczyk P, Klutke JJ, Carlin BI, Klutke CG. United States experience with tension-free vaginal tape procedure for urinary stress incontinence: assessment of safety and tolerability. *Tech Urol* 2001;7:261–265.
23. Lo TS, Huang HJ, Chang CL, Wong SY, Horng SG, Liang CC. Use of intravenous anesthesia for tension-free vaginal tape therapy in elderly women with genuine stress incontinence. *Urology* 2002;59:349–353.
24. Kobashi KC, Govier FE. Perioperative complications: the first 140 polypropylene pubovaginal slings. *J Urol* 2003;170:1918–1921.
25. Delorme E. Transobturator urethral suspension: mini-invasive procedure in the treatment of stress urinary incontinence in women [in French]. *Prog Urol* 2001;11:1306–1313.
26. Beiko DT, Knudsen BE, Watterson JD, Denstedt JD. Biomaterials in urology. *Curr Urol Rep* 2003;4: 51–55.
27. Karlovsky ME, Thakre AA, Rastinehad A, Kushner L, Badlani GH. Biomaterials for pelvic floor reconstruction. *Urology* 2005;66:469–475.
28. Sand PK, Koduri S, Lobel RW, et al. Prospective randomized trial of polyglactin 910 mesh to prevent recurrence of cystoceles and rectoceles. *Am J Obstet Gynecol* 2001;184:1357–1362.
29. Boubllil V, Ciofu C, Traxer O, Sebe P, Haab F. Complications of urethral sling procedures. *Curr Opin Obstet Gynecol* 2002;14:515–520.
30. Cosson M, Debodinance P, Boukerrou M, et al. Mechanical properties of synthetic implants used in the repair of prolapse and urinary incontinence in women: which is the ideal material? *Int Urogynecol J Pelvic Floor Dysfunct* 2003;14:169–178.
31. Gallentine ML, Cespedes RD. Review of cadaveric allografts in urology. *Urology* 2002;59:318–324.

32. Fitzgerald MP, Mollenhauer J, Brubaker L. Failure of allograft suburethral slings. *BJU Int* 1999;84:785–788.
33. Hathaway JK, Choe JM. Intact genetic material is present in commercially processed cadaver allografts used for pubovaginal slings. *J Urol* 2002;168:1040–1043.
34. Wilson TS, Lemack GE, Zimmern PE. Management of intrinsic sphincteric deficiency in women. *J Urol* 2003;169:1662–1669.
35. Cashman NR. A prion primer. *CMAJ* 1997;157:1381–1385.
36. Knapp PM, Lingeman JE, Siegel YI, Badylak SF, Demeter RJ. Biocompatibility of small-intestinal submucosa in urinary tract as augmentation cystoplasty graft and injectable suspension. *J Endourol* 1994;8:125–130.
37. Rutner AB, Levine SR, Schmaelzle JF. Processed porcine small intestine submucosa as a graft material for pubovaginal slings: durability and results. *Urology* 2003;62:805–809.
38. Villet R, Atallah D, Cotellet-Bernede O, Gadonneix P, Salee-Lizee D, van den Akker M. Treatment of stress urinary incontinence with tension-free vaginal tape (TVT). Mid-term results of a prospective study of 124 cases [in French]. *Prog Urol* 2002;12:70–76.
39. Laurikainen E, Kiilholma P. The tension-free vaginal tape procedure for female urinary incontinence without preoperative urodynamic evaluation. *J Am Coll Surg* 2003;196:579–583.
40. Groutz A, Gold R, Pauzner D, Lessing JB, Gordon D. Tension-free vaginal tape (TVT) for the treatment of occult stress urinary incontinence in women undergoing prolapse repair: a prospective study of 100 consecutive cases. *Neurourol Urodyn* 2004;23:632–635.
41. Deval B, Levardon M, Samain E, et al. A French multicenter trial of SPARC for stress urinary incontinence. *Eur Urol* 2003;44:254–258.
42. Chung MK, Chung RP. Comparison of laparoscopic Burch and tension-free vaginal tape in treating stress urinary incontinence in obese patients. *JLS* 2002;6:17–21.
43. Nilsson CG, Kuuva N, Falconer C, Rezapour M, Ulmsten U. Long-term results of the tension-free vaginal tape (TVT) procedure for surgical treatment of female stress urinary incontinence. *Int Urogynecol J Pelvic Floor Dysfunct* 2001;12(suppl 2):S5–S8.
44. Anquer Y, Marcollet A, Yazbeck C, et al. The suburethral sling for female stress urinary incontinence: a retropubic or obturator approach? *J Am Assoc Gynecol Laparosc* 2004;11:353–358.
45. Mellier G, Benayed B, Bretones S, Pasquier JC. Suburethral tape via the obturator route: is the TOT a simplification of the TVT? *Int Urogynecol J Pelvic Floor Dysfunct* 2004;15:227–232.
46. Hung MJ, Liu FS, Shen PS, Chen GD, Lin LY, Ho ES. Analysis of two sling procedures using polypropylene mesh for treatment of stress urinary incontinence. *Int J Gynaecol Obstet* 2004;84: 133–141.
47. Rackley RR, Abdelmalak JB, Tchetchgen MB, Madjar S, Jones S, Noble M. Tension-free vaginal tape and percutaneous vaginal tape sling procedures. *Tech Urol* 2001;7:90–100.
48. Debodinance P, Delporte P, Engrand JB, Boulogne M. Complications of urinary incontinence surgery: 800 procedures. *J Gynecol Obstet Biol Repro (Paris)* 2002;31:649–662.
49. Agonstini A, Bretelle F, Franchi F, Roger V, Cravello L, Blanc B. Immediate complications of tension-free vaginal tape (TVT): results of a French survey. *Eur J Obstet Gynecol Reprod Biol* 2005 Aug 8 [Epub].
50. Levin I, Groutz A, Gold R, Pauzner D, Lessing JB, Gordon D. Surgical complications and medium-term outcome results of tension-free vaginal tape: a prospective study of 313 consecutive patients. *Neurourol Urodyn* 2004;23:7–9.
51. Karram MM, Segal JL, Vassallo BJ, Kleeman SD. Complications and untoward effects of the tension-free vaginal tape procedure. *Obstet Gynecol* 2003;101(5 pt 1):929–932.
52. Debodinance P, Delporte P, Engrand JB, Boulogne M. Tension-free vaginal tape (TVT) in the treatment of urinary stress incontinence: 3 years experience involving 256 operations. *Eur J Obstet Gynecol Reprod Biol* 2002;105:49–58.
53. Andonian S, Chen T, St. Denis B, Corcos J. Randomized clinical trial comparing suprapubic arch sling (SPARC) and tension-free vaginal tape (TVT): one-year results. *Eur Urol* 2005;47: 537–541.
54. Tseng LH, Wang AC, Lin YH, Li SJ, Ko YJ. Randomized comparison of the suprapubic arc sling procedure vs tension-free vaginal taping for stress incontinent women. *Int Urogynecol J Pelvic Floor Dysfunct* 2005;16:230–235.
55. Spinosa JP, Dubuis PY. Suburethral sling inserted by the transobturator route in the treatment of female stress urinary incontinence: preliminary results in 177 cases. *Eur J Obstet Gynecol Reprod Biol* 2005;123:212–217.



56. deTayrac R, Deffieux X, Droupy S, et al. A prospective randomized trial comparing tension-free vaginal tape and transobturator suburethral tape for surgical treatment of stress urinary incontinence. *Am J Obstet Gynecol* 2004;190:602–608.
57. Cindolo L, Salzano L, Rota G, Bellini S, D’Afiere A. Tension-free transobturator approach for female stress urinary incontinence. *Minerva Urol Nefrol* 2004;56:89–98.
58. Delorme E, Droupy S, de Tayrac R, Delmas V. Transobturator tape (Uratape): a new minimally-invasive procedure to treat female incontinence. *Eur Urol* 2004;45:203–207.
59. Hermieu JF, Messas A, Delmas V, Ravery V, Dumonceau O, Boccon-Gibon L. Bladder injury after TVT transobturator. *Prof Urol* 2003;13:115–117.
60. Minaglia S, Ozel B, Klutke C, Ballard C, Klutke J. Bladder injury during transobturator sling. *Urology* 2004;64:376–377.
61. Shobeiri S, Garely AD, Chesson RR, Nolan TE. Recognition of occult bladder injury during the tension-free vaginal tape procedure. *Obstet Gynecol* 2002;99:1067–1072.
62. Wang AC, Lee LY, Lin CT, Chen JR. A histologic and immuno-histochemical analysis of defective vaginal healing after continence taping procedures: a prospective case-controlled pilot study. *Am J Obstet Gynecol* 2004;191:1868–1874.
63. Hammad FT, Kennedy-Smith A, Robinson RG. Erosions and urinary retention following polypropylene synthetic sling: Australasian Survey. *Eur Urol* 2005;47:641–646.
64. Wang KH, Wasng KH, Neimark M, Davila GW. Voiding dysfunction following TVT procedure. *Int Urogynecol J Pelvic Floor Dysfunct* 2004;13:353–357; discussion 358.
65. Laurikainen E, Rosti J, Pitkanen Y, Kiiholma P. The Rosti sling; a new, minimally invasive, tension-free technique for the surgical treatment of female urinary incontinence—the first 217 patients. *J Urol* 2004;171:1576–1580.
66. Demirci F, Ozdemir I, Yucel O, Alhan A. A new, simple, safe, effective and cost-effective procedure for genuine stress incontinence: midurethral polypropylene sling. *Aust N Z J Obstet Gynaecol* 2003;43:58–60.
67. Rodriguez LV, Berman J, Raz S. Polypropylene sling for treatment of stress urinary incontinence: an alternative to tension-free vaginal tape. *Tech Urol* 2001;7:87–89.
68. Clemens JQ, DeLancey JO, Faerber GJ, Westney OL, McGuire EJ. Urinary tract erosions after synthetic pubovaginal slings: diagnosis and management strategy. *Urology* 2000;56:589–594.
69. Kobashi KC, Govier FE. Management of vaginal erosion of polypropylene mesh slings. *J Urol* 2003;169:2242–2243.
70. Wai CY, Atmip SD, Williams KN, Schaffer JI. Urethral erosion of tension-free vaginal tape presenting as recurrent stress urinary incontinence. *Int Urogynecol J Pelvic Floor Dysfunct* 2004;15:353–355.
71. Comiter CV, Colegrove PM. High rate of vaginal extrusion of silicone-coated polyester sling. *Urology* 2004;63:1066–1070.
72. Kato K, Hirata T, Suzuki K, Yoshida K, Murase T. Sling removal after the Vesica sling and tension-free vaginal tape (TVT) procedures [in Japanese]. *Nippon Hinyokika Gakkai Zasshi* 2004;95:17–24.
73. Young SB, Howard AE, Baker SP. Mersilene mesh sling; short- and long-term clinical and urodynamic outcomes. *Am J Obstet Gynecol* 2001;185:32–40.
74. Choe JM, Staskin DR. Gore-Tex patch sling; 7 yr later. *Urology* 1999;54:641–646.
75. Myers DL, LaSala CA. Conservative surgical management of Mersilene mesh suburethral sling erosion. *Am J Obstet Gynecol* 1998;179(6 pt 1):1424–1428; discussion 1428–1429.
76. Tsui KP, MG SC, Tee YT, Yeh GP, Chen GD. Complications of synthetic graft materials used in suburethral sling procedures. *Int Urogynecol J Pelvic Floor Dysfunct* 2005;16:165–167.
77. Abouassaly R, Steinberg JR, Lemieux M, et al. Complications of tension-free vaginal tape surgery: a multi-institutional review. *BJU Int* 2004;94:110–113.
78. Romero Maroto J, Prieto Chaparro L, Lopez Lopez C, Quilez Fenoll JM, Bolufer Nadal S. Prolene mesh sling in the treatment of stress urinary incontinence. Integral treatment of pelvic floor anomalies. Long-term results [in Spanish]. *Arch Esp Urol* 2002;55:1057–1074.
79. Bafghi A, Benizri EI, Trastour C, Benizri EJ, Michiels JF, Bongain A. Multifilament polypropylene mesh for urinary incontinence: 10 cases of infections requiring removal of the sling. *BJOG* 2005 Mar; 112:376–378.
80. Fialkow MF, Lentz GM, Miller EA, Miller JL. Complications from transvaginal pubovaginal slings using bone anchor fixation. *Urology* 2004;64:1127–1132.

81. Schulte-Baukloh H, Thalau F, Sturzebecher B, Knispel HH. Pubovaginal bone anchor fixation with polyethylene vs fascia lata slings in the treatment of female stress incontinence: sling material and processing are predominant factors in success. *Can J Urol* 2005;12:2581–2587.
82. Shah DK, Paul EM, Amukele S, Eisenberg ER, Badlini GH. Broad based tension-free synthetic sling for stress urinary incontinence: 5-year outcome. *J Urol* 2003;170:849–851.
83. Connolly TP. Necrotizing surgical site infection after tension-free vaginal tape. *Obstet Gynecol* 2004;104:1275–1276.
84. Goldman HB. Large thigh abscess after placement of synthetic transobturator sling. *Int Urogynecol J Pelvic Floor Dysfunct* 2006;17:295–296.
85. Bafghi A, Caruba C, Benizri E, Benizri E, Bongain A. Chronic TVT infection: mechanisms and consequences [in French]. *Prog Urol* 2004;14:1191–1193.
86. Mahajan ST, Kenton K, Bova DA, Brubaker L. Transobturator tape erosion associated with leg pain. *Int Urogynecol J Pelvic Floor Dysfunct* 2006;17:66–68.
87. Glavind K, Larsen EH. Results and complications of tension-free vaginal tape (TVT) for surgical treatment of female stress urinary incontinence. *Int Urogynecol J Pelvic Floor Dysfunct* 2001;12:370–372.
88. Gandhi S, Beaumont JL, Goldberg RP, Kwon C, Abramov Y, Sand PK. Foley vs intermittent self-catheterization after transvaginal sling surgery; which works best? *Urology* 2004;64:53–57.
89. Lukacz ES, Lubner KM, Nager CW. The effects of the tension-free vaginal tape on voiding function: a prospective evaluation. *Int Urogynecol J Pelvic Floor Dysfunct* 2004;15:32–38.
90. Sander P, Moller LM, Rudnicki PM, Lose G. Does the tension-free vaginal tape procedure affect the voiding phase? Pressure-flow studies before and 1 year after surgery. *BJU Int* 2002;89:694–698.
91. Dietz HP, Ellis G, Wilson PD, Herbison P. Voiding function after tension-free vaginal tape: a longitudinal study. *Aust N Z J Obstet Gynaecol* 2004;44:152–155.
92. Wang KH, Wang KH, Neimark M, Davila GW. Voiding dysfunction following TVT procedure. *Int Urogynecol J Pelvic Floor Dysfunct* 2002;13:353–357.
93. Rardin CR, Rosenblatt PL, Kohli N, Miklos JR, Heit M, Lucente VR. Release of tension-free vaginal tape for the treatment of refractory postoperative voiding dysfunction. *Obstet Gynecol* 2002;100(5 pt 1):898–902.
94. Ozel B, Minaglia S, Hurtado E, Klutke CG, Klutke JJ. Treatment of voiding dysfunction after transobturator tape procedure. *Urology* 2004;64:1030.
95. Goldman HB. Simple sling incision for the treatment of iatrogenic urethral obstruction. *Urology* 2003;62:714–718.
96. Kato K, Hirata T, Suzuki K, Yoshida K, Murase T. Sling removal after the Vesica sling and tension-free vaginal tape (TVT) procedures [in Japanese]. *Nippon Hantokika Gakkai Zasshi* 2004;95:17–24.
97. Segal JL, Vassallo V, Kleeman S, Silva WA, Karram MM. Prevalence of persistent and de novo overactive bladder symptoms after the tension-free vaginal tape. *Obstet Gynecol* 2004;104:1263–1269.
98. Riachi L, Kohli N, Miklos J. Repeat tension-free transvaginal tape (TVT) sling for the treatment of recurrent stress urinary incontinence. *Int Urogynecol J Pelvic Floor Dysfunct* 2002;13:133–135.
99. Elzevier HW, Venema PL, Lycklama a Nijeholt AA. Sexual function after tension-free vaginal tape (TVT) for stress incontinence: results of a mailed questionnaire. *Int Urogynecol J Pelvic Floor Dysfunct* 2004;15:313–318.
100. Mazouni C, Karesenty G, Cretelle F, Bladou F, Gamerre M, Serment G. Urinary complications and sexual function after the tension-free vaginal tape procedure. *Acta Obstet Gynecol Scand* 2004;83:955–961.
101. Maaaita M, Bhaumik J, Davies AE. Sexual function after using tension-free vaginal tape for the surgical treatment of genuine stress incontinence. *BJU Int* 2002;90:540–543.

---

# 10 Bladder Neck Slings for Stress Urinary Incontinence

---

*O. Lenaine Westney, MD*

## *CONTENTS*

INTRODUCTION

HISTORY

PATIENT SELECTION

SURGICAL TECHNIQUE AND VARIATIONS

MATERIAL, EQUIPMENT, AND TECHNICAL VARIATIONS

REFERENCES

---

## INTRODUCTION

The title of this chapter reflects the need to specify anatomical placement when discussing slings. A decade ago, such a distinction was unnecessary as bladder neck positioning was standard. The birth, continued evolution, and success of the midurethral sling have altered the role of the bladder neck sling. This chapter discusses the history, applications, patient selection, technique, materials success rates, and complications of the bladder neck sling.

## HISTORY

The concept of suburethral support to treat urinary incontinence dates to the early 1900s. Giordano was the first to describe utilization of the gracilis muscle to partially encircle the urethra in 1907 (1). Goebell adapted the approach to treat two myelodysplastic children using the pyramidalis muscle in lieu of gracilis (2). The pyramidalis sling was sutured underneath the urethra at the urethrovesical junction. Stoeckel modified the Goebell technique by adding a plication of the vesical neck (3). The introduction of fascial material was proposed by Frangenheim, who reported the use of rectus abdominis muscle and fascia (4). Millin, Aldridge, and Studdiford followed with varying techniques using rectus abdominis fascia to support the urethra (5–7).

Other native materials, such as levator ani (8), bulbocavernosus muscle (9), palmaris longis fascia (10), lyophilized dura mater (11), fascia lata (12,13), and vaginal wall (14,15), have been used for slings (16). Xenograft materials, including porcine dermis and small intestine submucosa (SIS), have been processed as alternative biologics. Synthetic materials have also been used for suburethral compression.

Historically, although the continence rates with these materials have been good, the complications—vaginal wall erosions and urethral transection/sloughing—requiring sling removal have been dismal (17). The more severe complications seem to be sling tension and infectious related. In the absence of excessive tension, the practice of aseptic technique, and in the presence of good blood supply, nontension synthetic slings have had fewer such problems (18). In addition, attention has been given to the importance of structural characteristics and host reaction to synthetic materials in adverse events (19).

Despite introduction in the early 20th century, Wharton and TeLinde noted that the perception of technical difficulty and complications prevented the pubovaginal sling from becoming a popular procedure in the mid-1900s (20). In their technical report, little morbidity was noted. The initial indication for a sling procedure for stress urinary incontinence (SUI) was failure of a more conventional procedure (i.e., anterior colporrhaphy). Jeffcoate used the Aldridge technique in 40 women whom he determined required more than an anterior repair (21).

Several independent investigators in the 1970s reported the existence of stress incontinence in the absence of urethral hypermobility. Robertson identified the “stovepipe” urethra, which was characterized by poor closure (22). Green and Hodgkinson separately described the radiological appearance of a urethra—immobile and incompetent—leaking fluid easily with increasing abdominal pressure (23,24).

The urodynamic era brought the classification of intrinsic sphincter deficiency (ISD) or type III SUI as a definable entity, identifying the ideal group for treatment with a pubovaginal sling (25). Slings have been used successfully for ISD secondary to myelodysplasia (26), urethral erosion secondary to a long-term indwelling Foley catheter (27), urethral trauma (28), or associated with a urethral diverticulum (29). Still, however, the sling technique did not gain widespread use until reintroduction by McGuire and Lytton in 1978 (30). In this technical description, the fascial strip was left in continuity with the abdominal rectus muscle sheath. Blaivas is credited with the transition to free autologous graft segments anchored by suture and tied over the rectus fascia (31).

In the mid-to-late 1990s, there were many reports of the application of pubovaginal sling for all types of SUI (32–34). The pubovaginal sling became the treatment of choice—primary and secondary—for stress incontinence attributed to urethral hypermobility or ISD. In support of this progression, the American Urological Association Stress Incontinence Guidelines Treatment Panel confirmed that sling procedures and retropubic suspension were superior to needle suspensions and anterior colporrhaphy for surgical treatment of female urinary incontinence (35).

## PATIENT SELECTION

Increasingly, suitability for a bladder neck sling is based on the inability for a less-invasive procedure to confer sufficient urethral coaptation to restore continence or after multiple failures of alternate techniques. The history of prior anti-incontinence procedures in itself predisposes toward the presence of ISD. McGuire previously demonstrated that women are more likely to have type III SUI after a prior anticontinence procedure (36). Evaluation should include a complete history and physical examination, stress test, 3-d voiding diary, 24-h pad test, validated urinary symptom disease-specific questionnaire, and urodynamic evaluation.

Valsalva leak-point pressure (VLPP) is a functional measure of the coaptation and closure capabilities of the proximal urethra to withstand intraabdominal pressure

fluctuations. This value is recorded in centimeters of water pressure. The upper limit for ISD has not been well defined; however, readings below 60 cm H<sub>2</sub>O are accepted as true ISD. The growing perception is that varying amounts of dysfunction are present in all degrees of urinary incontinence. The low-pressure urethra has also been described using maximal urethral closure pressure (MUCP) less than 20 cm H<sub>2</sub>O. Sand et al. initially identified low MUCP in a group of women who failed retropubic suspension (37). The measurement is not active and therefore may reflect a different aspect of the same condition. This may explain why the correlation between VLPP and MUCP has ranged between 50 and 65% (38–40). The presence of both, however, is reflective of poor urethral function. Urodynamic technique is reviewed in Chapter 4.

Patients with urethral tissue loss in the area of the bladder neck secondary to trauma or fistulas will require reconstruction of the bladder neck mechanism (i.e., coaptation). This situation obviates the need for a pubovaginal sling composed of autologous material. Similarly, in patients with a urethral diverticulum complicated by incontinence prior to excision or in whom an extensive resection in the bladder neck area is projected, supplementation of the bladder neck support with an autologous or allograft sling is indicated. In both cases, biologics are suggested because of the requisite tension and reduction of erosion/urethral transection of compromised tissue (41).

## SURGICAL TECHNIQUE AND VARIATIONS

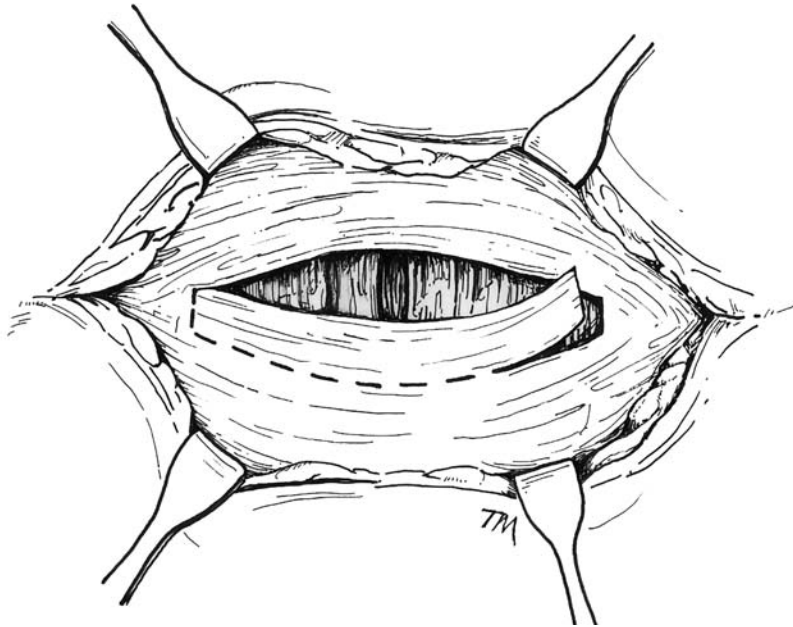
The bladder neck sling has been subject to multiple variations of every aspect of the procedure. With the exception of sling material, few of these alternations have been prospectively compared. Therefore, the majority of these permutations are surgeon preference. The following technique is a basic description of a 6- to 8-cm autologous rectus fascial sling.

### *Pubovaginal Sling (Autologous Rectus Fascia)*

For the autologous rectus fascia sling, general or spinal anesthesia is administered. The patient is placed in modified dorsal lithotomy position with the legs elevated in Yellowfin stirrups (Allen Medical Systems, Acton, MA) positioned to avoid pressure on the calf. The legs are flexed gently at the hip to allow free simultaneous access to the suprapubic area and vagina. A 16-French Foley catheter is placed, and the balloon is inflated with 10 cc saline to facilitate palpation of the bladder neck and urethra. In lieu of placing the catheter to drainage, it is clamped with a Kelly and released after passing the sling sutures to evaluate for hematuria. A weighted vaginal retractor (Scherback retractor, Aesculap Co., San Francisco) is placed. The labia majora may be sewn laterally or a Gelpi retractor used (Miltex Inc., York, PA), if necessary. Alternatively, a Gen II Lonestar (Lone Star Medical Products, Stafford, TX) retractor may be utilized for retraction.

The suprapubic incision and dissection are performed first to minimize bleeding time from the well-vascularized vaginal wall. An 8-cm Pfannenstiel incision is made about 2–3 cm superior to the pubis. The rectus fascia is identified and exposed for the entire length of the wound. The fascia is incised transversely for 6–8 cm, 3–4 cm superior to the pubis. The underlying rectus muscle is dissected from the fascia to ease in sling harvest and fascial closure. In addition, the lateral border of the rectus muscle should be exposed for sling suture passage.

Usually, the sling is harvested from the lower fascial leaf (Fig. 1). The sling dimensions should be 6–8 cm long and 1–1.5 cm in the midline, tapering to 1–0.8 cm at the ends.

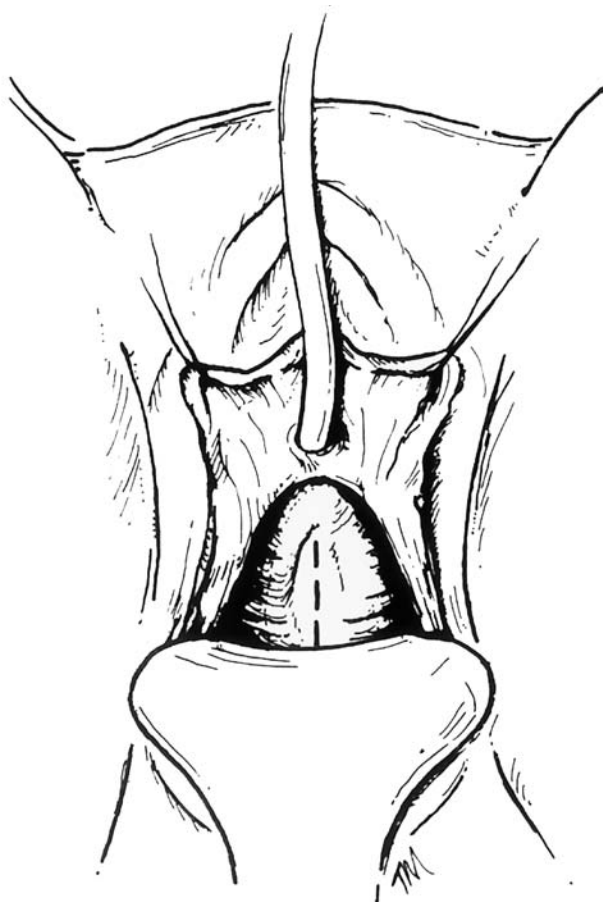


**Fig. 1.** Rectus fascial sling harvest. (From ref. 131 with permission.)

Zero Vicryl (polyglactin 910, Ethicon Inc., Somerville, NJ) sling sutures are placed perpendicular to the direction of the fibers approx 0.5 cm from the ends, incorporating the full width of the sling. Permanent suture is unnecessary based on the fixation of the sling at the level of the endopelvic fascia by 3 wk postoperatively. Permanent suture may represent a source of discomfort, especially in patients with little subcutaneous fat. From above, entry into the retropubic space is obtained by bluntly piercing the transversalis fascia lateral to the rectus muscle and advancing the index finger along the posterior surface of the pubis. In patients who have had a prior retropubic or needle suspension, this may be difficult. It may be necessary to place the tips of a Metzenbaum scissors on the posterior surface of the pubis and advance slowly into the retropubic space.

The vaginal portion of the procedure is initiated by placing an Allis clamp on the anterior vagina wall midway between the urethral meatus and bladder neck for superior traction. Injectable saline or local anesthetic may be infiltrated to aid in dissection prior to the incision. An inverted U or midline incision is made over the proximal urethra (Fig. 2). The mucosa is dissected from the white periurethral fascia. If the periurethral fascia is breached, then profuse bleeding from the corpora spongiosum may result. Once the appropriate level of dissection is identified, bleeding can be controlled by reapproximating the periurethral fascia over the spongiosal tissue with an absorbable figure-of-eight suture.

Dissection is initiated using a Church scissors, which are helpful in atrophic or scarred vaginal tissue. When the correct plane has been identified, Metzenbaum scissors are used. The retropubic space is entered by perforating the endopelvic fascia with Metzenbaum scissors pointed slightly superiorly and laterally (Fig. 3). After the endopelvic fascia has been opened, the scissors are spread to accommodate the sling width. Simultaneous palpation of the retropubic dissection from the vaginal and suprapubic

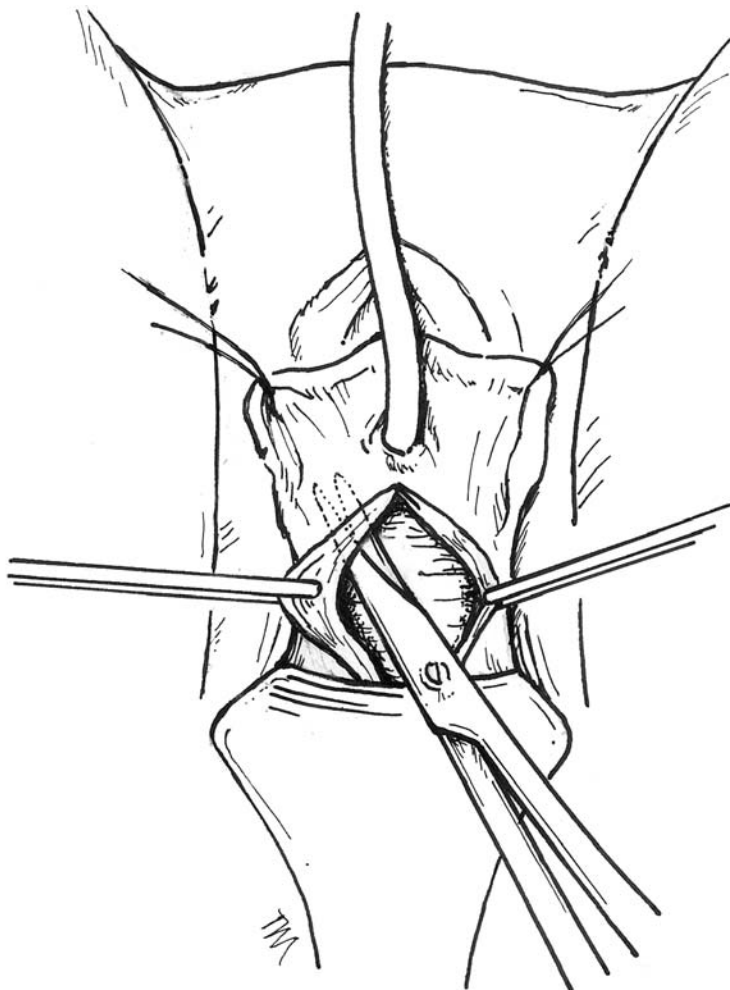


**Fig. 2.** Vertical vaginal wall incision centered over the bladder neck.

approaches is performed manually to confirm that the bladder is safely medial, and the passage is ready for sling suture transfer.

A Crawford or Sarot clamp is placed from above lateral to the rectus muscle and directed into the vaginal incision. The clamp should be in contact with the pubic periosteum and the index finger of the vaginal operator at all times (Fig. 4). The Foley is unclamped, and the bladder is partially drained to evaluate for hematuria after each clamp is passed. When the bladder is densely adherent to the pubis, Stamey (Cook Urological, Spencer, IN) ligature carriers may be utilized to transfer the sling sutures. Both ligature carriers should be passed, then cystoscopy performed with a 70° lens to ensure that bladder perforation has not occurred. Injuries occur at the 11 and 1 o'clock positions, near the dome of the bladder. Detrusor injury with Stamey or Raz ligature carriers may be missed if not evaluated cystoscopically.

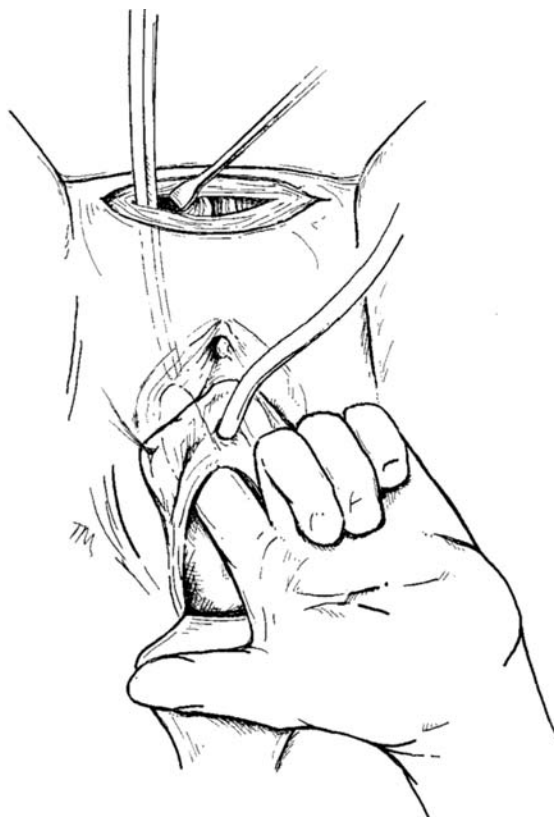
Conversely, perforation of the bladder with larger and more blunt clamps is usually heralded by gross hematuria (Fig. 5). The sling is centered, positioned at the level of the bladder neck, and secured by suturing the sling to the periurethral fascia with a 3-0 Vicryl suture (Fig. 6). The ends of the sling are seated in the retropubic space. The vaginal mucosa is closed with 2-0 absorbable suture in an interrupted or running locking fashion.



**Fig. 3.** Entrance into the retropubic space (vaginal approach). Scissors are oriented parallel to the perineum. (From ref. 131.)

The sling sutures are passed through the inferior leaf of rectus fascia using a sharp right angle clamp. The rectus fascia is closed with zero polyglactin in a running fashion. The vaginal retractor is removed; the sling sutures are pulled up to remove any slack. The sutures are tied over the rectus fascia with the least amount of tension required to prevent urethral motion (Fig. 7). This roughly corresponds to one or two fingers between the knot and the rectus fascia. In addition, preoperative assessment of the abdominal leak-point pressure and the amount of urethral mobility are helpful in making this decision. Inject 10 mL 0.25% bupivacaine in the subcutaneous tissue. Scarpa's fascia is approximated with interrupted absorbable suture. The skin is closed with absorbable suture (4-0 monocryl or polydioxanone) in a subcuticular running fashion. The Foley catheter is placed to straight drainage. A betadine-soaked or estrogen cream-laced gauze is packed within the vaginal vault. The average operative time with a suprapubic and vaginal operator is 30 min.





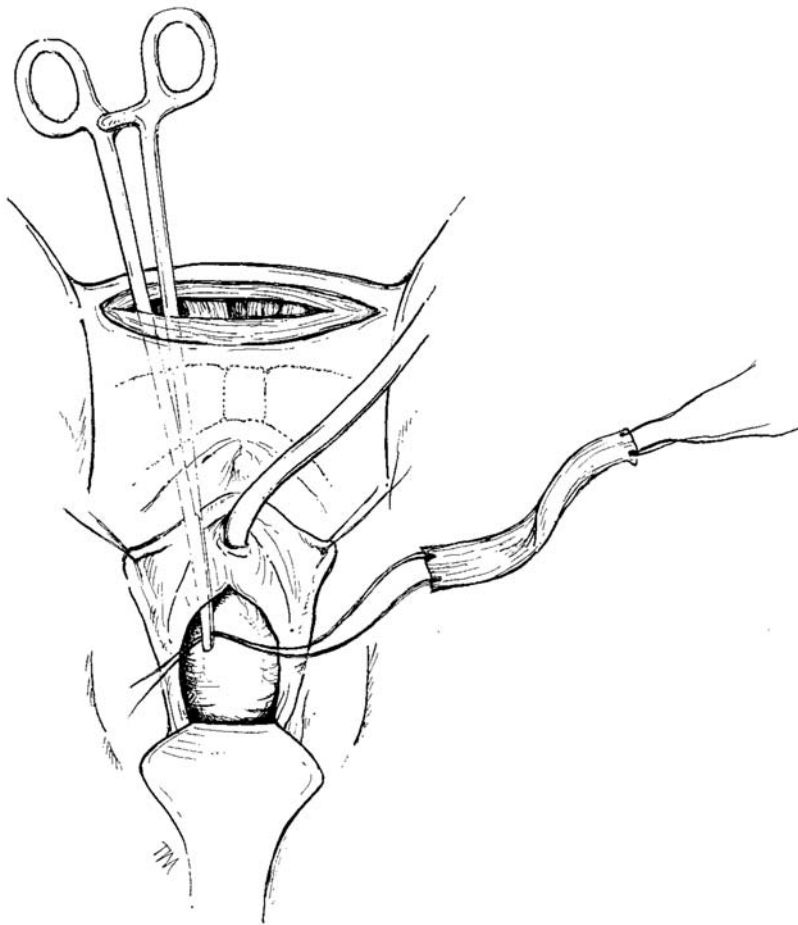
**Fig. 4.** Passage of the Sarot or Crawford clamp through retropubic tunnel with guidance from the vaginal operator. (From ref. 131 with permission.)

### ***Pubovaginal Slings in the Repair of Urethral Diverticula***

For pubovaginal slings in the repair of a urethral diverticulum, the diverticulum should be completely dissected circumferentially and excised from the urethra at the intersection with the ostium. As much periurethral fascia as possible should be preserved. The urethral opening is closed in two layers—simple interrupted, then Lembert sutures—with 4-0 polyglactin suture. The urethral muscularis is approximated over the suture line with 3-0 polyglactin suture. The sling is fashioned and positioned in a manner such that the fascial defect and the bladder neck are appropriately addressed. In cases of recurrent diverticulum with compromised appearing periurethral tissue, the addition of a Martius flap may be indicated. If stress incontinence is not present or the dissection is extensive, then a fascial defect may be directly patched with the autologous rectus fascia secured laterally to the periurethral fascia (Fig. 8A, B) The vaginal mucosa is closed in the standard fashion.

### ***Postoperative Care***

The vaginal pack is removed on postoperative d 1. The Foley catheter is removed on postoperative day 1 or 2 depending on how well the patient is ambulating. If urethral diverticulectomy is performed, then the catheter is removed in the clinic at 2–3 wk postoperatively with a voiding cystourethrogram. After catheter removal, the patient receives intermittent catheterization instruction and catheterizes for postvoid residuals



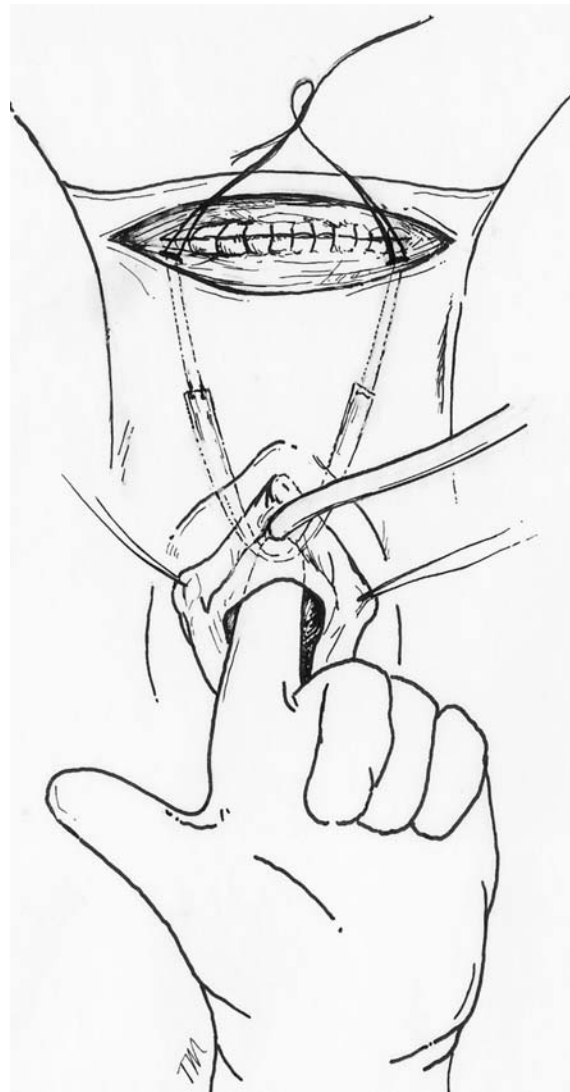
**Fig. 5.** The sling sutures are passed to the suprapubic incision. (From ref. 131 with permission.)

every 4 h and as needed. The patient may cease catheterizing when the postvoid residuals are 60 mL or less for 24 h. Patients are instructed not to engage in any vigorous physical activities, primarily bending over and lifting, for 4–6 wk. Intercourse may be resumed at 3 wk. Postoperative antibiotics are not routinely given except in cases of urethral diverticulectomy. The patient returns for postoperative follow-up in the clinic about 3 wk after the procedure.

## MATERIAL, EQUIPMENT, AND TECHNICAL VARIATIONS

### *Sling Material Selection*

The most desirable sling material (Table 1) would combine effectiveness, nonreactivity, and durability at a reasonable cost. Autologous rectus fascia and fascia lata meet these criteria at the cost of discomfort at the harvest sites. The use of allograft, xenograft, and synthetic materials has the advantages of decreased patient pain and disability. However, the individual host response to some materials is unpredictable.

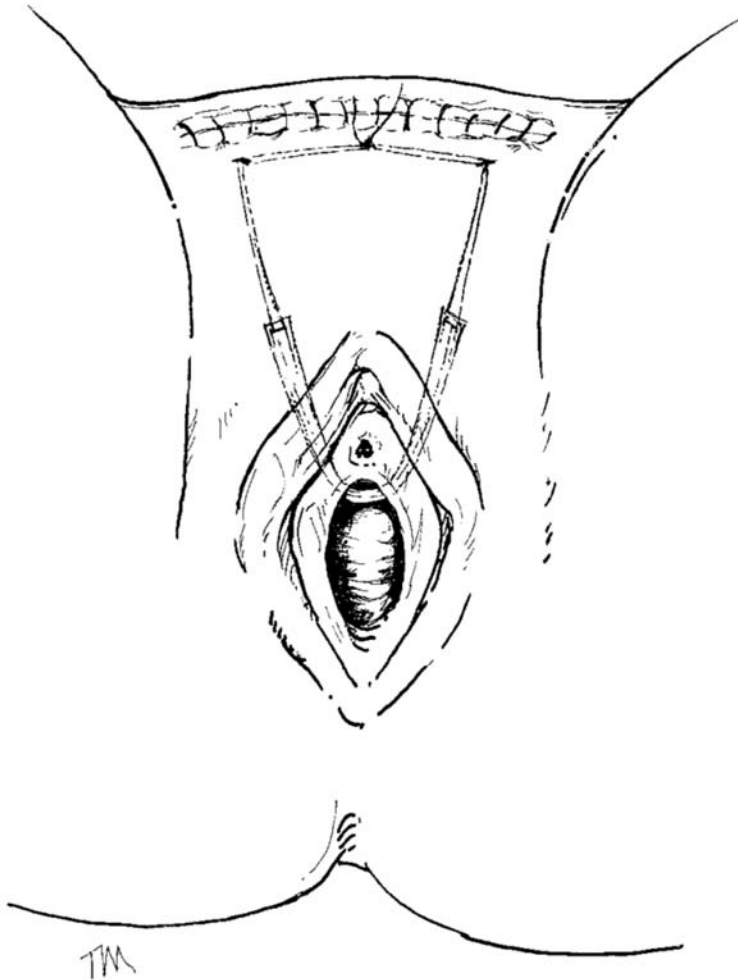


**Fig. 6.** Fascial sling positioned at the bladder neck.

#### **AUTOLOGOUS MATERIAL**

**Rectus Fascia.** The long-term success rates for autologous rectus fascial slings have ranged from 73 to 92% (33,34,42). Rectus fascia has been the most widely utilized autologous sling material. The primary drawbacks are (1) the need for harvest, particularly in the case of full-length slings, and (2) increased suprapubic discomfort. The history and surgical technique have been reviewed previously.

**Fascia Lata.** Fascia lata gained popularity secondary to the ability to obtain longer fascial strips even in the presence of multiple prior abdominal incisions. This remains, however, at the theoretical cost of additional incisions, pain, and repositioning for the patient. Success rates with fascia lata have been demonstrated to be equal to those for rectus fascia, although not in a randomized fashion (13,43,44). The complications

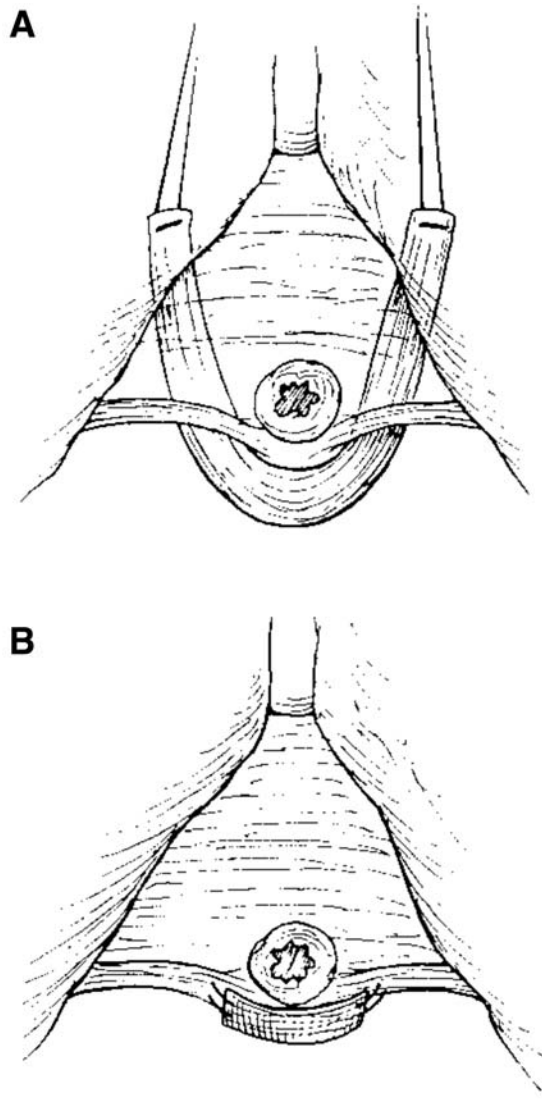


**Fig. 7.** Completed pubovaginal fascial sling after suprapubic sutures are tied.

directly attributable to the harvest are hematoma (1%), seroma (3%), thigh cellulitis (7%), tendonitis, and hernia (45). There are multiple minor variations; however, the standard technique is reviewed.

**Fascia Lata Harvest Technique.** For fascia lata harvest, the patient is positioned in the full lateral position. The lateral thigh is fully prepped from the iliac crest to below the knee. The greater trochanter and lateral malleolus are identified with a surgical marker. Parallel horizontal incisions spaced 2–3 cm apart are placed along the course of the fascia lata. The number of incisions is dependent on the desired length of fascia. Metzenbaum scissors and manual dissection are utilized to connect the incisions subcutaneously. The fascia is transected at the inferior and superior limits of the dissection. The incisions are reapproximated, and a pressure dressing is applied to the thigh (43). In lieu of manual sharp and manual dissection, use of a fascial stripper has been described eliminating the need for multiple incisions (46).

**Vaginal Wall.** The vaginal wall sling was first introduced by Raz in 1989 (14). A brief description of the technique follows. The anterior wall of the vagina is infiltrated with saline. A rectangular portion of vaginal wall centered at the bladder neck is dissected



**Fig. 8.** (A) Fascial sling placed under the periurethral fascial defect and bladder neck. (B) Autologous or cadaveric fascial patch positioned under periurethral fascial defect only.

free from its ligamentous attachments. A 1-0 polypropylene suture is run along the lateral edges of the sling. A small suprapubic incision is made to accommodate passage of Peyrera needles for sling suture passage. The sutures are tied together over the rectus fascia. The vaginal mucosa is closed, burying the vaginal wall sling. Stress incontinence cure rates for this procedure have ranged from 71 to 97% with variable lengths of follow-up (47–49). Some evidence suggests that the efficacy is significantly lower in patients with severe ISD (50). The utilization of buried epithelialized vaginal wall mucosa generates a complication specific to this type of sling: the vaginal wall inclusion cyst. Reports of this unusual occurrence have been sporadic and are notably absent in larger series (51,52). Stothers described a variation of the procedure in which the vaginal mucosa is not covered (53).

Table 1  
Sling Technique Variations

Reference	Accrual years	n evaluable	Sling material	Suture material	Sling dimensions (cm)	Suture passage	Anchoring mechanism	Method of tension
33	Approx 82-97	251	ARF	2-0 nonabsorbable	2 × 15	Long Debakey clamp	Suture	Tied loosely
42	NS	128	ARF	2-0 nonabsorbable	2 × 15	Long Debakey clamp	Suture	NS
34	93-96	247	ARF	Zero PG	1-1.5 × 6-8	Sarot clamp	Suture	1-2 fingers between knot and RF
32	NS	60	ARF	1-0 PP	2 × 6-8	Long Debakey or Sarot clamp	Suture	Elimination of mobility; 2 finger breadths
130	95-98	134/140	ARF (49) AFL (22) CFL (63)	2-0 PP	2 × 12	Long Debakey or Sarot clamp	Suture	Minimal
13	94-95	30/32	AFL	2-0 PP	2.5 × 24-28	Kelly clamp	Sling to sling	1 finger between sling and rectus
15	90-96	42/52	VWS	Zero PP	2- to 3-cm vaginal flap	Stamey needle	Suture	Light tension; cysto
49	93-99	373	VWS	No. 1 PP	NS	Peyrera needle	Suture	1-2 fingers between knot and RF
60	96-99	91/104	CFL	1-0 PP	2 × 15	Double-pronged Peryera	Suture	Without tension

106	98-99	145/154	CFL	No. 1 PP	4 × 7 folded	None	TV bone anchor Suture	Without undue tension
69	NS	25	CD	Zero PG	2 × 12	Sarot or Kelly	Suture	Minimal
68	98-03	234/253	CD	PP	2 × 4	None	TV bone anchor Suture	Cystoscope @ 45°
111	NS	74	PD	No. 1 PG	2 × 10-12	15° Stamey needle	Suture	Minimal; stress test
78	99-02	152	SIS	No. 1 PP	2 × 10	None	TV bone anchor Suture	None
131	NS	48	ARF (32); Gortex (16)	3-0 PG × 4	1.5 × 12	NS	Suture	Leak point
17	86-91	108	PTFE	None	.8-1.5 × 20		Sling to rectus fascia Suture	Q-tip angle: -5-10°
86	89-94	90/141	PTFE patch	2.0 PTFE	1.5 × 3.5 cm	NS	Suture	NS
87	89-98	72/84	PTFE patch	No. 2 nylon	1.5 × 3.0	"Needle"	Suture	Bladder neck US
90	86-92	88	Marlex	None	2 × NS	Clamp	Material to Cooper's ligament	Midretropubic position
97	90-00	136/176	Mersilene	None	1-3 × 30	None	Material to fascia	No tension
92	NS	64	Prolene mesh	None	2 × 30	Curved Kelly clamp	Mesh to mesh	Cystoscopy; stress test

NS, nonspecified; ARF, autologous rectus fascia; AFL, autologous fascia lata; CFL, cadaveric fascia lata; VWS, vaginal wall sling; CD, cadaveric dermis; PD, porcine dermis; SIS, small intestinal submucosa; PTFE, polytetrafluoroethylene; PP, polypropylene; PG, polyglactin; TV, transvaginal; RF, rectus fascia; US, ultrasound.

## *Allograft*

### **CADAVERIC FASCIA LATA**

Handa et al. reported the first use of cadaveric fascia lata for female urinary incontinence (54). Surgical series evaluating the success rate of the cadaveric fascia lata sling have had variable results. Clarification of the true efficacy of a sling consisting of this material has been hampered by heterogeneous material sources with different proprietary processing techniques ( $\gamma$ -irradiation, freezing, solvent dehydration, and so on) and the failure to compare the sling directly to autologous fascia lata in a randomized fashion. There is insufficient information to determine the individual contributions of the tissue-processing and host-vs-graft factors to the outcome. However, there have been several reports revealing histological evidence of poor incorporation of the graft into the surrounding host tissue to complete degradation (55,56).

Bent et al. compared autologous and cadaveric fascia lata sling groups in a nonrandomized fashion and noted similar stress incontinence cure rates at 42.4 and 35.2 mo, respectively. However, the cadaveric fascia group had a significantly higher incidence of *de novo* urge incontinence (57). Repeatedly, early reports of good results are not supported with longer term reports verifying the results.

In contrast, Brown and Govier reported a comparative study between cadaveric and autologous fascia lata. Patients (121) received cadaveric fascia lata slings sourced as fresh frozen from a single local tissue bank. Of 104 evaluable patients at a mean follow-up of 12 mo, the early failure (>3 pads/d postoperatively) rate was 7% (58). In a follow-up report in 2002, there were eight additional failures occurring between 4 and 13 mo. Of 8 patients, 5 underwent postfailure urodynamics, demonstrating a mean leak-point pressure of 33.5 cm H<sub>2</sub>O. Similarities in these patients included prior antiincontinence surgeries, and three of eight had neurological diagnoses (59). In comparison, at a mean follow-up of 19.4 mo, Amundsen et al. reported an 84% cure and improved rate post-cadaveric fascia lata sling from a single tissue source. The processing technique utilized for the material, however, was solvent dehydration (60).

### **CADAVERIC DERMIS/ACELLULAR COLLAGEN MATRIX**

Since the early 1990s, decellularized cadaveric dermis has been utilized in the treatment of burns. Its usage has been extended to a wide range of plastic and reconstructive applications, including abdominal wall and pelvic reconstruction, tympanoplasty, rhinoplasty, and cleft palate repair (61–64). There are comparatively few published data on the use of cadaveric dermis for pubovaginal slings. Cadaveric dermis has been proven safe, but with variable results linked to the quality and processing of the tissue and the subsequent host reaction.

Several studies have demonstrated revascularization of decellularized human dermis in animal models (65,66). One perceived advantage of dermis is the ability to attain a consistent thickness facilitated by dermatome harvest. In addition, the possibility for suture pull through is theoretically reduced because of the lack of striations in the tissue. Improved strength in comparison with cadaveric fascia lata was proven by Choe et al. Tensile strength was analyzed in full-length and patch slings composed of dermis (autologous and decellularized), rectus fascia, cadaveric fascia lata (freeze-dried,  $\gamma$ -irradiated), Gore-Tex<sup>®</sup> (W. L. Gore & Associates Inc., Flagstaff, AZ), and polypropylene. The greatest tensile strength was possessed by the full-length synthetic and dermis (autologous and decellularized) slings (67).



Two surgical series reported the use of cadaveric human dermis for slings. Crivellaro et al. presented a mean 18-mo follow-up of 234 of 253 patients who underwent placement of a transvaginal sling composed of Repliform™ cadaveric human dermal allograft (LifeCell Corp., The Woodlands, TX) with bone anchor fixation (68). Subjective outcomes were determined using UDI-6 and IIQ-7 questionnaires. Based on patients' responses, the cure and improvement from SUI symptoms was 78%. In comparison, Owens and Winters reported on 14 patients with a mean follow-up of 14.8 mo (8–23 mo) (69). The sling was composed of a 2 × 12 Duraderm™ (C. R. Bard, Covington, GA) human dermis graft with suture fixation. Between 6 and 12 mo, the dry and improved rates changed from 68 to 32% and 24 to 36%, respectively. This reflects a significant downward migration in efficacy during that time period. Of note, in one patient who underwent repeat autologous pubovaginal sling, no remnants of the dermal graft material could be identified intraoperatively.

### *Xenograft*

#### **PORCINE DERMIS MATRIX**

Similar to human dermis, porcine dermis is deepithelialized, lyophilized, and sterilized. Reports of slings composed of porcine dermis began to appear in the literature in the late 1980s (70,71). Material processing during that time included glutaraldehyde crosslinking, which not only protected the material from degradation but also potentiated graft mineralization. Currently available porcine dermis is crosslinked with hexamethylenediisocyanate and  $\gamma$ -irradiated. Early success rates with the porcine dermis sling appear to be similar to other biologics.

Barrington et al. reported on a group of 40 patients who received a porcine dermis sling. At a mean follow-up of 12 mo (6–18 mo) with no patient loss, the cure rate was 85% (72). The material, however, does not appear exempt from failure caused by unpredictable host response. Gandhi et al. performed histopathological examination of tissue from women who underwent reoperation after porcine dermis sling for urinary retention or recurrent stress incontinence. Pathological evaluation demonstrated limited collagen remodeling, with evidence of foreign body reaction in some specimens. The light microscopic appearance was highly variable between patients with the same surgical indications (73).

#### **PORCINE SMALL INTESTINAL SUBMUCOSA**

Porcine SIS (Cook Urologic, Spencer, IN) is processed via a proprietary technique that converts porcine jejunum into a collagen matrix, with endogenous growth factors stimulating host neovascularization and cell proliferation. Animal studies have demonstrated complete replacement of SIS with host tissue within 90 d from implantation (74). In humans, Wiedemann and Otto examined the tissue of patients who required reoperation because of recurrent SUI. In contrast to the similar study of porcine dermis slings by Gandhi et al., there was no evidence of inflammatory reaction (75).

The material is supplied in differing thicknesses (one, four, and eight ply) depending on whether the intended use is reconstructive or for incontinence (bladder neck or tension-free midurethral) (76). Bladder neck slings utilizing four-ply SIS have demonstrated good results in the pediatric neurogenic and female nonneurogenic populations. Missieri et al. (77) reported a 75% dry rate for a group of 26 neuropathic patients with leak-point pressures of 25 cm H<sub>2</sub>O or less. Similarly, Rutner et al. reviewed

a mean 2.3-yr follow-up of 152 patients who underwent SIS sling with bone anchor fixation. They reported a 93.4% dry rate with seven failures, two of which were clearly bone anchor related (78).

Regarding strength, Kubricht et al. analyzed tensile strength of SIS and cadaveric fascia lata via a pull-through analysis using polypropylene and polyglactin suture (79). Although the load could be improved based on the technique used for folding the graft ends and suture placement, the cadaveric fascia lata demonstrated more tensile strength than the SIS. It should be noted, however, that single-ply SIS was utilized in this study.

### *Synthetic Materials*

The availability and use of synthetic material pre-dates allografts. However, the initial studies for the application of female incontinence were complicated by high erosion and infection rates. More contemporary data suggest that shorter operative times, antibiotic prophylaxis, and vaginal preparation have combined to decrease the complication rates (80,81). Synthetic meshes are categorized based on their filamentous composition (mono or multi) and pore size (macro or micro). Interstices less than 75 nm are not sufficient for the passage of inflammatory agents and completion of the process of fibrous and neovascular ingrowth (82). In the microporous category, those with pores less than 10  $\mu\text{m}$  allow for the possibility of bacterial entrance and proliferation without the threat of a neutrophil and macrophage response.

#### **POLYTETRAFLUOROETHYLENE**

The use of polytetrafluoroethylene (PTFE; Gore-Tex) in general and vascular surgery pre-dates its introduction to stress incontinence procedures by over a decade (83,84). Both full-length (20- to 30-cm) and patch-type (30- to 35-mm) slings have been utilized (85–87). In lieu of simple suspension of the expanded PTFE patch, the periurethral fascia and pubourethral ligaments are integrated into the bladder neck support. High rates of sling removal related to vaginal erosion, sinus tract formation, and abdominal wound abscess reported separately by Weinberger and Bent in the early 1990s decreased markedly by later in the decade (88).

#### **POLYPROPYLENE MESHES**

Marlex (C. R. Bard/Davol, Cranston, RI) and Prolene (Ethicon) are both composed of monofilament polypropylene mesh but differ in porosity and stiffness (41,89).

**Marlex.** The largest series discussing the utilization of Marlex slings has been reported by Morgan et al. in Toronto in Canada. These selection criteria focused on patients with recurrent SUI after retropubic or other suspension procedures (90). One unique technical element was the attachment of the sling material to Cooper's ligament.

**Prolene.** As initially described by Ulmsten et al., the majority of available distal urethral slings are composed of Prolene (91). However, there are series utilizing the mesh as a bladder neck sling. Kuo reported the long-term results of 108 patients treated with a polypropylene mesh sling for varying types of stress incontinence. The cure and improvement rate was 85.2%, with a patient satisfaction level of 89.8% (92).

**Silicone Elastomer.** For silicone elastomer (Silastic, Dow Corning Corp., Midland, MI), Stanton et al. introduced the usage of a sling composed of a 1  $\times$  19 cm Silastic strip anchored to the ileopectineal ligament in 1985 (93). Despite a follow-up report demonstrating a durable success rate of 71% at 5 yr, the material has not been widely utilized because of high erosions and *de novo* detrusor instability rates (94).

## POLYESTER MESHES

**Polyethylene Terephthalate.** Mersilene (Ethicon) is a polyethylene terephthalate multifilamented polyester mesh. Williams and TeLinde introduced the use of Mersilene tape slings in 1962 (95). Initially, the narrow tape had unacceptable erosion rates. Moir revised the technique by devising the “gauze hammock” variation (96). In contemporary series, the complication rate has been decreased markedly by increasing the suburethral portion of the tape to 3 cm (97,98). In the recent past, a sling composed of polyester with various additional preparations has been linked to complications reminiscent of early synthetic slings.

**Bovine Collagen-Injected Polyester.** Kobashi et al. reported on 34 women from five centers who received slings made from polyester pressure injected with bovine collagen (ProteGen<sup>®</sup>, Boston Scientific, Natick, MA) and required removal of the slings for erosion, infection, or pain (99). Although the report was limited to patients with complications only, the number of women and their time to erosion represented a significantly higher rate and earlier presentation than for other currently used synthetic materials. The product was recalled in January 1999, citing a higher-than-acceptable overall rate of complications.

**Silicone-Coated Polyester.** Govier et al. reported the results of a premarket study of bone-anchored slings using a polyester coated with silicone (American Medical Systems, Minnetonka, MN) (100). Of the patients, 31 experienced vaginal extrusion of the material. Attempts to excise portions of the mesh combined with repeat closure were failures. The investigators theorized the formation of a biofilm similar to that associated with an artificial urinary sphincter prevented salvage of the sling procedures.

### *Suture Selection*

After the description of detached sling material by Blaivas, the need for suspension suture material arose. In this description, 2-0 polyester suture was selected as the material. Since that time, Prolene suture has been the more common choice. However, Cespedes et al. proposed a transition from polypropylene suture to polyglactin suture (101). The rationale behind the change was twofold: (1) the belief that permanent sling fixation occurs where the material traverses the endopelvic fascia, and (2) knotted prolene suture could be uncomfortable in the thin patient and a source for suture granuloma.

There have been no randomized studies with suspension suture as the single variable under examination. However, in an in vitro comparison between cadaveric fascia lata and small intestinal submucosa by Kubricht et al., polypropylene and polylactin were compared (79). In suture pull analysis measured by a tensiometer, the mean suture breaking load (in pounds) of 1-0 and 2-0 polyglactin was greater than 1-0 polypropylene. The strength of the suture is unlikely to persist after degradation of in vivo polyglactin initiates.

### *Method of Suspension*

## SUTURE

For the majority of pubovaginal sling series, the mechanism of suspension is via sutures. Various techniques have been utilized to tie the suture over the rectus fascia. The sides are tied to each other across the midline or with the assistance of a two-pronged needle passer, tied over a fascial bridge. When the material is of sufficient length, the material can be sutured to itself or directly to the fascia. Sling suspension methods have

not been examined in a randomized fashion; therefore, surgeon preference or patient diagnosis is the primary basis for selection.

### **BONE ANCHOR**

Leach and subsequently Benderev reported the use of percutaneous suprapubically placed bone anchors in needle suspension (102,103). Appell et al. combined this fixation method with a 2 × 6 cm piece of polypropylene mesh (Vesica™, Microvasive/Boston Scientific Corp., Natick, MA). Short-term results have the typical high continence rates (104). However, Reid and Parys reported 5-yr follow-up of 40 patients that demonstrated a dramatic decline in efficacy, from 85 at 6 mo to 31% at 5 yr (105). Reoperation of failed procedures demonstrated fraying of the suspension suture at the level of the bone anchor.

Madjar et al. were the first to report utilization of a transvaginal placement of titanium bone anchors in the symphysis utilizing an angled disposable drill (106). Full-length sutures or a suture loop are swedged on the anchor to permit for attachment to the material of the surgeon's choice. The results of bone-anchored slings are highly variable, possibly secondary to the wide variety of sling materials utilized in different reports. Carbone et al. reported a series of 200 patients who underwent procedures with cadaveric fascia lata anchored with transvaginal bone anchors. The early failure rate was exceedingly high at 31% (107). When the material and suspension method are both novel, assignment of culpability is difficult. Although the bone anchors appeared to be intact at operation and the sling material was degraded or absent in many cases, it should be noted that neither fascial source nor preparation was uniform. Complications specific to bone anchors—osteitis pubis and osteomyelitis—are discussed at the end of the chapter.

### *Incisions*

The presence and size of a suprapubic incision depend on the need for rectus fascial harvest and the method of suspension, including the suture-passing instruments. In the absence of the need to obtain material, the suprapubic incision need only be of sufficient size to accommodate the passing instruments. The standard pubovaginal sling with rectus fascia harvest is performed via a suprapubic incision measuring at least 6–8 cm. When cadaveric or xenograft material is used, a single 2-cm central incision or use of two separate lateral incisions is adequate.

### *Sling Tension*

One of the most debated components of the bladder neck sling technique is the ideal amount of tension applied to the bladder neck by the sling. Insufficient tension results in clinical failure—immediate or delayed. Conversely, excessive tension may be heralded by *de novo* irritative voiding symptoms (urgency, frequency, and urge incontinence) or urinary retention. Subjective descriptions such as “without tension” or “loosely,” or variables such as “two fingers between the rectus fascia and the knot” as in the prior operative description are prevalent (108).

In the interest of devising more objective measures, cystoscopic deflection during tying (109), intraoperative Q-tip test (110), stress test (111) spacers, and intraoperative ultrasound (112) are used. Multiple attempts have been made to standardize the

Table 2  
Series Outcome Measures

Reference	Accrual years	n evaluable	Sling material	Mean months follow-up (range or SD)	Outcome measurement	Questionnaire	Post-op pad test
33	Approx 82–97	251	ARF	36 (12–180)	Blaivas category	Validated	Yes
42	NS	128	ARF	44.9	Outpatient follow-up	None	No
34	93–96	247	ARF	51 (22–68)	Questionnaire	UDI-6	No
32	NS	60	ARF	25.1 (11–34)	Outpatient follow-up	None	No
130	95–98	134/140	ARF (49) AFL (22)	29 ± 3 (autograft)	phone questionnaire	Self-designed	No
13	94–95	30/32	CFL (63) AFL	44 ± 7 (allograft)	Telephone questionnaire	Self-designed	No
15	90–96	42/52	VWS	14 (3–33)	Telephone questionnaire	Self-designed	No
49	93–99	373	VWS	31 (5–67)	F/U	Self-designed	No
60	96–99	91/104	CFL	39.8 (±11.4)	Questionnaire	UDI-6, IIQ-7	No
106	98–99	145/154	CFL	19.4 (± 10.3)	Questionnaire	Self-designed	No
69	NS	25	CD	10.6 (6–16)	Phone questionnaire	Self-designed	No
68	98–03	234/253	CD	14.8 (8–23)	Questionnaire	UDI-6, IIQ-7	No
110	NS	74	PD	18 (6–54)	Stress test;	Self-designed	No
78	99–02	152	SIS	12 (6–24)	mail questionnaire	Not stated	No
131	NS	48	ARF (32)	27.6 (4–48)	F/U and questionnaires	None	No
17	86–91	108	Gortex (16) PTFE	30–38	Urodynamics	None	No
86	89–94	90/141	PTFE patch	10 (2–39)	Mail questionnaire	MESAAQ	No
87	89–98	72/84	PTFE patch	51 (27–84)	Questionnaire	Self-designed	No
90	86–92	88	Marlex	75 ± 37 (type II) 50 ± 28 (type III)	Questionnaire	Self-designed	No
97	90–00	136/176	Mersilene	49.7 (1–84)	Stress test; urodynamics	None	No
92	NS	64	Prolene mesh	30 (5–107)	Blaivas category	None	Yes

NS, nonspecified; ARF, autologous rectus fascia; AFL, autologous fascia lata; CFL, cadaveric fascia lata; VWS, vaginal wall sling; CD, cadaveric dermis; PD, porcine dermis; SIS, small intestinal submucosa; PTFE, polytetrafluoroethylene; PP, polypropylene; PG, polyglactin; TV, transvaginal; RF, rectus fascia; US, ultrasound; UDI-6, Urogenital Distress Inventory-6; IIQ-7, Incontinence Impact Questionnaire-7.

Table 3  
Sling Results and Complications

Ref.	Accrual years	n	Evaluable	Sling material	Dry	Improved	Failure	Retention	De novo urge	Late failure	Bladder perforation	Urethral erosion	Vaginal erosion/sinus tract, granulatio	Pain	Suprapubic wound infection	Urethrolysis/sling removal
33	Approx 82-97	251	ARF	ARF	73%	19%	8%	2%	3%	0.60%	0%	0%	0%	0.30%	0%	2%
42	NS	128	ARF	ARF	73.40%	20.20%	6.30%	11.10%	10%	13.30%	3.70%	0%	0%	0.8	42%	0%
34	93-96	247	ARF	ARF	88.00%	8.80%	3.20%	2.00%	7.00%	8.00%	0%	0%	0%	NS	NS	2.00%
32	NS	80	ARF	ARF	95%		5%	0%	5%		0%	0%	0%	5%	0%	0%
130	95-98	134/140	ARF (49)	ARF/AFL	ARF/AFL	ARF, AFL	ARF, AFL	ARF, AFL	ARF/AFL	ARF/AFL	1.40%	0%	0%	0%	5.6%	1.4%
			AFL (22)	CFL (63)	77%	AFL 13%	AFL 10%	4.2%	28%						(auto-graft)	
					CFL	CFL	CFL	CFL	CFL							
13	94-95	30/32	AFL	AFL	71%	13%	16%	1.5%	5%		0%	0%	0%	3%	0%	3%
15	90-96	42/52	VWS	VWS	70%	20%	10%	6%	9%		0%	0%	0%	7%	2%	0%
49	93-99	373	VWS	VWS	55%	19%	26%	12%	8%		0%	2%	2%	NS	3%	0%
					96%			1%								
60	96-99	91/104	CFL	CFL	63%	21%	16%	1%	15%		0%	0%	0%	0%	0%	1%
106	98-99	145/154	CFL	CFL	60%	9%	31%	0%	3%		0%	0%	0%	17%	0%	0%
69	NS	25	CD	CD	32%	36%	32%	12%	0%	24%	NS	0%	0%	NS	NS	0%

68	98-03	234/253	CD	56%	40%	4%	2%	5%	2%	0%	0%	5%	0%	0%
110	NS	74	PD	89.20%	2.70%	8.10%	8.10%	6%	0%	0%	0%	1.4	0%	6.80%
78	99-02	152	SIS	93.40%	2%	4.60%	0.70%	7%	1.30%	0%	0%	minimal	0%	0.70%
131	NS	48	ARF (32)	81.2%	18.8%	18.8%	(ARF)	12.5%	15.5%	0%	12.5%	NS	NS	12.50%
			Gore-Tex (16)	(ARF) 100%				(Gore- Tex)	(ARF)		(Gore- Tex)			
17	86-91	108	PTFE	61%	39%	8%	8%	33%	NS	0%	25.50%	1%	12%	22.40%
86	89-94	90/141	PTFE patch	89%	11%	8%	8%	9.6%	0%	0%	5%	0%	0%	2.20%
87	89-98	72/84	PTFE patch	78%	14%	8%	NS	15%	0%	0.90%	0%	11%	NS	0.90%
90	86-92	88	Marlex	85.20%	9.10%	5.70%	2.30%	6.80%	0%	0%	0%	2.20%	0%	0%
97	90-00	136/176	Mersilene	95%	5%	5%	5.00%	8.80%	4%	0.50%	0.50%	4%	1%	2.00%
92	NS	64	Prolene mesh	81%*	16%*	3%	5%	5%	2%	NS	0%	0%	17%	3%

NS, nonspecified; ARF, autologous rectus fascia; AFL, autologous fascia lata; CFL, cadaveric fascia lata; VWS, vaginal wall sling; CD, cadaveric dermis; PD, porcine dermis; SIS, small intestinal submucosa; PTFE, polytetrafluoroethylene; PP, polypropylene; PG, polyglactin; TV, transvaginal; RF, rectus fascia; US, ultrasound.

tension utilizing either a sound or cystoscope in the urethra. Rovner et al. (109) described tying the sling sutures while positioning a cystoscope sheath in the urethra at 20–30° to the horizontal plane. Nguyen et al. (110) performed a Q-tip test while tying the suspension sutures to simultaneously measure the urethrovesical junction angle. In a group of 160 patients who underwent vaginal wall sling, utilization of this technique resulted in no unexpected urinary retention and a recurrent SUI rate of 6.8%. Finally, there have been formulas based on patient anteroposterior dimensions and body weight that dictate the amount of suture exposed above the level of the rectus abdominus fascia (113,114).

The need for postoperative adjustment has been addressed by several investigators. Choe and Palma et al. reported “tightening” slings by extending the previously tied suspension sutures using a loop technique (115,116). The initial suture material must be nonabsorbable to utilize this option in a delayed fashion. In addition, there are several adjustable sling systems that allow changes in tension postoperatively (117). As utilization of the sling transitions to patients with severe ISD, tension may be varied directly with preoperative VLLP.

### ***Outcome Measurements and Results***

The outcome measurements and results for multiple pubovaginal sling series are detailed in Tables 2 and 3. The comparison of results for different studies are complicated by nonstandardized outcome measures. In addition, objective measures such as postoperative pad test, stress test, or urodynamics are often absent from reports. Finally, length of follow-up is often insufficient to determine the efficacy of the procedure. Results should be interpreted based on an intent-to-treat analysis. Success rates calculated from patients available for follow-up may underestimate failure rates. If clinical follow-up is unavailable, then mail or telephone completion of a standardized questionnaire is reasonable for determination of patient perception and satisfaction with the procedure.

### ***Complications***

#### **BLADDER INJURY**

Bladder injuries are most frequently encountered when passing instruments to the vaginal incision for sling transfer (Table 3). Patients with prior bladder neck sling procedures, retropubic suspensions, or pelvic surgery are at higher risk for this complication because of adhesions of the space of Retzius. Suspicion should be heightened when instrument passage is difficult. The Foley catheter should be evaluated to check for blood-tinged urine. In the event of any questions, cystoscopy is the best option to check for bladder perforation. Recognized injuries are treated with Foley catheter drainage for 5–7 d.

#### **URINARY RETENTION**

The incidence of prolonged urinary retention in large series ranges from 0 to 12%. As stated by Webster (118), the temporal relationship between the surgery and the onset of urinary retention should indicate an obstructive etiology. Transvaginal urethrolysis is the treatment for retention secondary to outlet obstruction. Urethrolysis may consist of dividing the sling, removal of a small suburethral segment, or sharp dissection of the tissue underneath the urethra to the level of the endopelvic fascia bilaterally (118–120).



### **DE NOVO URGENCY/URGE INCONTINENCE**

The reported incidence of postoperative new onset urgency is 0–33%. The differentiation between isolated *de novo* urgency/urge incontinence and partial outlet obstruction is difficult. Urodynamics are necessary to identify those patients requiring relief of partial bladder outlet obstruction.

### **VAGINAL EROSION**

Erosion of sling material may be heralded by bloody or profuse vaginal discharge or uncomfortable intercourse for the male partner. In some cases, local therapy with vaginal estrogen preparations results in successful reepithelialization of the mucosal defect. Small defects (<5 mm) may be treated conservatively with abstinence, metronidazole gel, and vaginal estrogen. In cases of larger areas of exposed mesh or failure of conservative management, outpatient excision with elevation of mucosal flaps is generally successful (121–123).

### **URETHRAL EROSION/TRANSECTION**

Although most urethral erosion and transactions are linked to the use of synthetic material, this complication has been reported with autologous fascia (124). Tension in combination with poorly vascularized tissue can produce this complication. Generally, it may be heralded by obstructive voiding symptoms and urinary tract infections.

### **OSTEITIS PUBIS/OSTEOMYELITIS**

Bony complications may result after suture or anchor placement in the periosteum or bony cortex, respectively (125,126). Transabdominally placed anchors predated transvaginal ones; therefore, the information reflecting the incidence of complications is more mature. Goldberg et al. reported a 1.3% incidence of bony-related infections in suprapubically placed bone anchors (127). Frederick et al. performed a literature review of 1228 transvaginal bone anchor sling procedures, including 440 from the authors. The resulting rates of osteitis pubis and osteomyelitis were 0.16 and 0.8%, respectively (128).

Symptoms consist of pelvic pain, which may be accompanied by a draining vaginal sinus tract, and vaginal granulation tissue (129). Diagnosis is based on the combined findings on imaging studies, which may include plain films, magnetic resonance imaging, computed tomography, and bone scans. Osteitis pubis is managed conservatively with activity restriction and nonsteroidal antiinflammatory medication. In osteomyelitis, intravenous antibiotics are combined with surgical extraction of the anchors and associated synthetic suture. Usually, destruction of the bone facilitates the removal of the anchors. When the bony structure remains intact, fluoroscopy and orthopedic instruments are necessary to facilitate removal.

## **REFERENCES**

1. Giordano D. Twentieth Congress, *Franc de Chir* 506, 1907.
2. Goebell R. Zur operativen Beseitigung der angeborenen Incontinentia vesicae. *Atschr F Gynäk n Urol* 1910;2:187–191.
3. Stoeckel W. Über die Verwendung der Muscul: Pyramidales bei der operativen Behandlung der Incontinentia urinae. *Zentralbl F Gynäk* 1917;41:11–19.
4. Frangenheim P. Zur operativen Behandlung der Inkontinenz der männlichen Harnröhre. *Verhandl d Deutsch Gesellsch F Chir* 1914;43:149–152.

5. Millin T. Some observations on the surgical treatment of urinary incontinence. *Proc R Soc Med* 1939; 32:777–778.
6. Aldridge AH. Transplantation of fascia for relief of urinary stress incontinence. *Am J Obstet* 1942; 44:398–411.
7. Studdiford WE. The problem of stress incontinence and its surgical relief. *SGO* 1942;83:742–750.
8. Squier JB. Postoperative urinary incontinence: urethroplastic operation. *Med Rec* 1911;79:868.
9. Martius H. Sphincter-und Harnrohrplastik aus dem Musculus Bulbocavernosus. *Chirurg* 1929;1: 769–773.
10. Poliak A, Daniller AI, Liebling RW. Sling operation for recurrent stress incontinence using the tendon of palmaris longus. *Obstet Gynecol* 1984;63:850–854.
11. Enzelsberger H, Helmer H, Schatten C. Comparison of Burch and Lyodura sling procedures for repair of unsuccessful incontinence surgery. *Clin Obstet Gynecol* 1996;88:251–256.
12. Parker RT, Addison WA, Wilson CJ. Fascia lata urethroplastic suspension for recurrent stress urinary incontinence. *Am J Obstet Gynecol* 1979;135:843–852.
13. Govier FE, Gibbons RP, Correa RJ, et al. Pubovaginal slings using fascia lata for the treatment of intrinsic sphincter deficiency. *J Urol* 1997;157:117–121.
14. Raz S, Siegel AL, Short JL, et al. Vaginal wall sling. *J Urol* 1989;141:43–46.
15. Litwiller SE, Nelson RS, Fone PD, et al. Vaginal wall sling: long-term outcome analysis of factors contributing to patient satisfaction and surgical success. *J Urol* 1997;157:1279–1282.
16. Westney OL, McGuire EJ. Pubovaginal sling. In: *Atlas of the Urologic Clinics of North America: Vaginal Reconstructive Surgery*, Vol. 8. 2000, pp. 23–38.
17. Weinberger MW, Ostergard DR. Long-term clinical and urodynamic evaluation of the polytetrafluoroethylene suburethral sling for treatment of genuine stress incontinence. *Obstet Gynecol* 1995; 86:92–96.
18. Rezapour M, Ulmsten U. Tension-free vaginal tape (TVT) in women with recurrent stress urinary incontinence—a long-term follow up. *Int Urogynecol J Pelvic Floor Dysfunct* 2001;12(suppl 2): S9–S11.
19. Cervigni M, Natale F. The use of synthetics in the treatment of pelvic organ prolapse. *Curr Opin Urol* 2001;11:429–435.
20. Wharton LR, TeLinde RW. An evaluation of fascial sling operation for urinary incontinence in female patients. *J Urol* 1959;82:76–79.
21. Jeffcoate TNA. The results for the Aldridge sling operation for urinary stress incontinence. *J Obstet Gynaecol* 1956;63:36.
22. Robertson JR. Ambulatory gynecologic urology clinic. *Clin Obstet Gynecol* 1974;17:255–276.
23. Green TH Jr. Development of a method for the diagnosis and treatment of urinary stress incontinence. *Am J Obstet Gynecol* 1962;83:632.
24. Hodgkinson CP. Stress urinary incontinence. *Obstet Gynecol* 1976;47:255.
25. McGuire EJ, Fitzpatrick CC, Wan J, et al. Clinical assessment of urethral sphincter function. *J Urol* 1993;150(5 pt 1):1452–1454.
26. McGuire EJ, Wang C, Usitalo H, et al. Modified pubovaginal sling in girls with myelodysplasia. *J Urol* 1986;135:94–96.
27. Chancellor MB, Erhard MJ, Kiilhoorma PJ, et al. Functional urethral closure with pubovaginal sling for destroyed female urethra after long-term urethral catheterization. *Urology* 1994;43: 499–505.
28. Woodside JR. Pubovaginal sling procedure for the management of urinary incontinence after urethral trauma in women. *J Urol* 1987;138:527–528.
29. Swierzewski SJ, McGuire EJ. Pubovaginal sling for treatment of female SUI complicated by urethral diverticulum. *J Urol* 1993;149:1012–1014.
30. McGuire EJ, Lytton B. Pubovaginal sling procedure for stress incontinence. *J Urol* 1978;119:82–84.
31. Blaivas JG, Jacobs BZ. Pubovaginal fascial sling for the treatment of complicated stress urinary incontinence. *J Urol* 1991;145:1214–1218.
32. Zaragoza MR. Expanded indications for the pubovaginal sling: treatment of type 2 or 3 stress incontinence. *J Urol* 1996;156:1620–1622.
33. Chaikin DC, Rosenthal J, Blaivas JG. Pubovaginal sling for all types of stress urinary incontinence: long-term analysis. *J Urol* 1998;160:1312–1316.
34. Morgan TO Jr, Westney OL, McGuire EJ. Pubovaginal sling: 4-yr outcome analysis and quality of life assessment. *J Urol* 2000;163:1845–1848.

35. Leach GE, Dmochowski RR, Appell RA, et al. Female Stress Urinary Incontinence Clinical Guidelines Panel summary report on surgical management of female stress urinary incontinence. The American Urological Association. *J Urol* 1997;158:875–880.
36. McGuire EJ. Urodynamic findings in patients after failure of stress urinary incontinence operations. *Clin Biol Res* 1981;78:351–360.
37. Sand PK, Bowen LW, Panganiban R, Ostergard DR. The low-pressure urethra as a factor in failed retropubic urethropexy. *Obstet Gynecol* 1987;69:399–402.
38. Swift SE, Ostergard DR. A comparison of stress leak-point pressure and maximal urethral closure pressure in patients with genuine stress incontinence. *Obstet Gynecol* 1995;85:704–708.
39. Sultana CJ. Urethral closure pressure and leak-point pressure in incontinent women. *Obstet Gynecol* 1995;86:839–842.
40. Bump RC, Coates KW, Cundiff GW, Harris RL, Weidner AC. Diagnosing intrinsic sphincter deficiency: comparing urethral closure pressure, urethral axis, and Valsalva leak point pressures. *J Obstet Gynecol* 1997;177:303–310.
41. Morgan JE, Farrow GA, Stewart FE. The Marlex sling operation for treatment of recurrent stress urinary incontinence: a 16-year review. *Am J Obstet Gynecol* 1985;151:224–226.
42. Rodrigues P, Hering F, Meler A, Campagnari JC, D'Império M. Pubo-fascial vs vaginal sling operation for the treatment of stress urinary incontinence: a prospective study. *Neurourol Urodyn* 2004; 23:627–631.
43. Beck RP, McCormick S, Nordstrom L. The fascia lata sling procedure for treating recurrent genuine stress incontinence of urine. *Obstet Gynecol* 1988;72:699–703.
44. Latini JM, Lux MM, Kreder KJ. Efficacy and morbidity of autologous fascia lata sling cysto-urethropexy. *J Urol* 2004;171:1180–1184.
45. Walter AJ, Hentz JG, Magrina JF, Cornella JL. Harvesting autologous fascia lata for pelvic reconstructive surgery: techniques and morbidity. *Am J Obstet Gynecol* 2001;185:1354–1358.
46. Chibber PJ, Shah HN, Jain P. A minimally invasive technique for harvesting autologous fascia lata for pubo-vaginal sling suspension. *Int Urol Nephrol* 2005;37:43–46.
47. Raz S, Stothers L, Young GPH, et al. Vaginal wall sling for anatomical incontinence and intrinsic sphincter dysfunction: efficacy and outcome analysis. *J Urol* 1996;156:166–170.
48. Lobel RW, Sand PK. Long-term results of vaginal wall suburethral sling. *J Urol* 1997;157(suppl): 459. Abstract 1796.
49. Kaplan SA, Te AE, Young GPH, Andrade A, Cabelin MA, Ikeguchi EF. Prospective analysis of 373 consecutive women with stress urinary incontinence treated with a vaginal wall sling: the Columbia-Cornell University experience. *J Urol* 2000;164:1623–1627.
50. Goldman HB, Rackley RR, Appell RA. The *in situ* anterior vaginal wall sling: predictors of success. *J Urol* 2001;166:2259–2262.
51. Baldwin DD, Hadley HR. Epithelial inclusion cyst formation after free vaginal wall swing sling procedure for stress urinary incontinence. *J Urol* 1997;157:952.
52. Woodman PJ, Davis GD. The relationship of the *in-situ* advancing vaginal wall sling to vaginal epithelial inclusion cyst. *Int Urogynecol J Pelvic Floor Dysfunct* 2000;11:124–126.
53. Stothers L. Anterior vaginal wall sling. In: *Glenn's Urologic Surgery, 5th ed.* (Graham SD Jr, ed.), Lippincott-Raven, Philadelphia, 1998, pp. 329–335.
54. Handa VL, Jensen JK, Germain MM, et al. Banked human fascia lata for the suburethral sling procedure: a preliminary report. *Obstet Gynecol* 1996;88:1045–1049.
55. Fitzgerald MP, Mollenhauer J, Bitterman P, et al. Functional failure of fascia lata allografts. *Am J Obstet Gynecol* 1999;181:1339–1344.
56. Carbone JM, Kavalier E, Hu JC, et al. Pubovaginal sling using cadaveric fascia and bone anchors: disappointing early results. *J Urol* 2001;165:1605–1611.
57. McBride AW, Ellerkmann RM, Bent AE, Melick CF. Comparison of long-term outcomes of autologous fascia lata slings with Suspend Tutoplast fascia lata allograft slings for stress incontinence. *Am J Obstet Gynecol* 2005;192:1677–1681.
58. Brown SL, Govier FE. Cadaveric vs autologous fascia lata for the pubovaginal sling: surgical outcome and patient satisfaction. *J Urol* 2000;164:1633–1637.
59. O'Reilly KJ, Govier FE. Intermediate term failure of pubovaginal slings using cadaveric fascia lata: a case series. *J Urol* 2002;167:1356–1358.
60. Amundsen CL, Visco G, Ruiz H, Webster GD. Outcome in 104 pubovaginal slings using freeze-dried allograft fascia lata from a single tissue bank. *Urol* 2000;56(suppl 6A):2–8.

61. Butler CE, Langstein HN, Kronowitz SJ. Pelvic, abdominal, and chest wall reconstruction with alloderm in patients at increased risk for mesh-related complications. *Plast Reconstr Surg* 2005; 116:1263–1277.
62. Benecke JE Jr. Tympanic membrane grafting with alloderm. *Laryngoscope* 2001;111:1525–1527.
63. Gyskiewicz JM, Rohrich RJ, Reagan BJ. The use of alloderm for nasal contour deformities. *Plast Reconstr Surg* 2001;107:561–570.
64. Clark JM, Saffold SH, Israel JM. Decellularized dermal grafting in cleft palate repair. *Arch Facial Plast Surg* 2003;5:40–44.
65. Menon NG, Rodriguez ED, Byrnes CK, Giroto JA, Goldberg NH, Silverman RP. Revascularization of human acellular dermis in full-thickness abdominal wall reconstruction in the rabbit model. *Ann Plast Surg* 2003;50:523–527.
66. Eppley BL. Experimental assessment of the revascularization of acellular human dermis for soft-tissue augmentation. *Plast Reconstr Surg* 2000;107:757–762.
67. Choe JM, Kothandapani R, James L, Bowling D. Autologous, cadaveric, and synthetic materials used in sling surgery: comparative biomechanical analysis. *Urology* 2001;58:482–486.
68. Crivellaro S, Smith JJ, Kocjancic E, Bresette JF. Transvaginal sling using acellular human dermal allograft: safety and efficacy in 253 patients. *J Urol* 2004;172:1374–1378.
69. Owens DC, Winters JC. Pubovaginal sling using Duraderm™ graft: intermediate follow-up and patient satisfaction. *Neurourol Urodyn* 2004;23:115–118.
70. Jarvis GJ, Fowlie A. A clinical and urodynamic assessment of the porcine dermis bladder sling in the treatment of genuine stress incontinence. *Br J Obstet Gynaecol* 1985;92:1189–1191.
71. Iosif CS. Porcine corium sling in the treatment of urinary stress incontinence. *Arch Gynecol* 1987; 240:131–136.
72. Barrington JW, Edwards G, Arunkalaivana AS, Swart M. The use of porcine dermal implant in a minimally invasive pubovaginal sling for genuine stress incontinence. *BJU Int* 2002;90:224–227.
73. Gandhi S, Kubba LM, Abramov Y, et al. Histopathologic changes of porcine dermis xenograft for transvaginal suburethral slings. *Am J Obstet Gynecol* 2005;192:1643–1648.
74. Sandusky GE Jr, Badylak SF, Morff RF, Johnson WD, Lantz G. Histologic findings after in vivo placement of small intestine submucosal vascular grafts and saphenous vein grafts in the carotid artery in dogs. *Am J Pathol* 1992;140:317–324.
75. Wiedemann A, Otto M. Small intestinal submucosa for pubourethral sling suspension for the treatment of stress incontinence: first histopathological results in humans. *J Urol* 2005;174(4 pt 2): 1680–1682.
76. Gomelsky A, Dmochowski RR. Autograft, allograft and xenograft sling: how are they different? *Cont Urol May* 1, 2005.
77. Misseri R, Cain MP, Casale AJ, Kaefer M, Meldrum KK, Rink RC. Small intestinal submucosa bladder neck slings for incontinence associated with neuropathic bladder. *J Urol* 2005;174:1680–1682.
78. Rutner AB, Levine SR, Schmaelzle JF. Process porcine small intestine submucosa as a graft material for pubovaginal slings: durability and results. *Urology* 2003;62:805–809.
79. Kubricht WS, Williams BJ, Eastham JA, Venable DD. Tensile strength of cadaveric fascia lata compared to small intestinal submucosa using suture pull through analysis. *J Urol* 2001;165: 486–490.
80. Norris JP, Breslin DS, Staskin DR. Use of synthetic material in sling surgery: a minimally invasive approach. *J Endourol* 1996;10:227–230.
81. Persson J, Iosif C, Wolner-Hanssen P. Risk factors for rejection of synthetic suburethral slings for stress urinary incontinence: a case-control study. *Obstet Gynecol* 2002;99:629–634.
82. White TA. The effect of porosity and biomaterial on the healing and long-term mechanical properties of vascular prostheses. *ASAIO J* 1988;11:95–100.
83. Matsumoto H, Hasegawa T, Fuse K. A new vascular prosthesis for a small-caliber artery. *Surgery* 1973;74:519–523.
84. Sher W, Pollak D, Paulides CA, Matsumoto T. Repair of abdominal wall defects: Gore-Tex vs Marlex graft. *Am Surg* 1980;46:618–623.
85. Errando C, Batista JE, Arano P. Polytetrafluoroethylene sling for failure in female stress incontinence surgery. *World J Urol* 1996;14:S48–S50.
86. Choe JM, Staskin DR. Gore-Tex patch sling: 7 yr later. *Urology* 1999;54:641–646.
87. Yamada T, Kamata S, Nagahama K, Ichiyonagi N, Horiuchi S, Saitoh H. Polytetrafluoroethylene patch sling for type 2 or type 3 stress urinary incontinence. *Int J Urol* 2001;8:675–680.

88. Summitt RL, Bent AE, Ostergard DR, et al. Suburethral sling procedure for genuine stress incontinence and low urethral pressure. A continued experience. *Int Urogynecol J* 1992;3:18–21.
89. Voyles CR, Richardson JD, Bland SM, et al. Emergency abdominal wall reconstruction with polypropylene mesh: short-term benefits vs long-term complications. *Ann Surg* 1981;194:219–223.
90. Morgan JE, Heritz DM, Stewart FE, et al. The polypropylene pubovaginal sling for the treatment of recurrent stress urinary incontinence. *J Urol* 1995;154:1013–1014.
91. Ulmsten U, Henriksson L, Johnson P, Varhos G. An ambulatory surgical procedure under local anesthesia for treatment of female urinary incontinence. *Int Urogynecol J Pelvic Floor Dysfunct* 1996;7:81–85.
92. Kuo HC. Long-term surgical results of pubovaginal sling procedure using polypropylene mesh in the treatment of stress urinary incontinence. *Urol Ing* 2005;74:147–152.
93. Stanton SL, Brindley GS, Holmes DM. Silastic sling for urethral sphincter incompetence in women. *Br J Obstet Gynaecol* 1985;92:747–750.
94. Chin YK, Stanton SL. A follow-up of silastic sling for genuine stress incontinence. *Br J Obstet Gynaecol* 1995;102:143–147.
95. Williams TJ, TeLinde RW. The sling operation for urinary incontinence using Mersilene ribbon. *Obstet Gynecol* 1962;19:241–245.
96. Moir JC. The gauze-hammock operation. *J Obstet Gynaecol Br Commonw* 1968;75:1–9.
97. Young SB, Howard AE, Baker SP. Mersilene mesh sling: short- and long-term clinical and urodynamic outcomes. *Am J Obstet Gynecol* 2001;185:32–40.
98. Clemons JL, Aguilar VC, Sokol EF, Sung VW, Myers DL. Suburethral sling treatment of occult stress incontinence and intrinsic sphincter deficiency in women with severe vaginal prolapse of the anterior vs. posterior/apical compartment. *Am J Obstet Gynecol* 2005;192:1566–1572.
99. Kobashi KC, Dmochowski R, Mee SL, et al. Erosion of woven polyester pubovaginal sling. *J Urol* 1999;162:2070–2072.
100. Govier FE, Kobashi KC, Kuznetsov DD, et al. Complications of transvaginal silicone-coated polyester synthetic mesh sling. *Urology* 2005;66:741–745.
101. Cespedes RD, Cross CA, McGuire EJ. Pubovaginal fascial slings. *Tech Urol* 1997;3:195–201.
102. Leach GE. Bone fixation technique for transvaginal needle suspension. *Urology* 1988;31:388–390.
103. Benderev TV. A modified percutaneous outpatient bladder neck suspension system. *J Urol* 1994;152:2316–2320.
104. Hom D, Desautel MG, Lumerman JH, Feraren RE, Badlani GH. Pubovaginal sling using polypropylene mesh and vesica bone anchors. *Urology* 1998;51:708–713.
105. Reid SV, Parys BT. Long-term 5-yr follow-up of the results of the Vesica procedure. *J Urol* 2005;173:1234–1236.
106. Madjar S, Beyar M, Nativ O. Transvaginal bone anchored sling. *Urology* 2000;55:422–426.
107. Carbone JM, Kavalier E, Hu JC, Raz S. Pubovaginal sling using cadaveric fascia and bone anchors: disappointing early results. *J Urol* 2001;165:1605–1611.
108. Blaivas JG, Morgan JE, Heritz DM, et al. The polypropylene pubovaginal sling for the treatment of recurrent stress urinary incontinence. *J Urol* 1995;154:1013–1015.
109. Rovner ES, Ginsberg DA, Raz S. A method for intraoperative adjustment of sling tension: prevention of outlet obstruction during vaginal wall sling. *Urology* 1997;50:273–276.
110. Nguyen A, Mahoney S, Minor L, Ghoneim G. A simple objective method of adjusting sling tension. *J Urol* 1999;162:1674–1676.
111. Arunkalaivanan AS, Barrington JW. Randomized trial of porcine dermal sling (Pelvicol™ implant) vs tension-free vaginal tape (TVT) in the surgical treatment of stress incontinence: a questionnaire-based study. *Int Urogynecol J* 2003;14:17–23.
112. Yamada T, Mizuo T, Kawakami S, Watanabe T, Negishi T, Oshima H. Application of transrectal ultrasonography in modified Stamey procedure for stress urinary incontinence. *J Urol* 1991;146:1555–1558.
113. Choe JM. Preventing urethral obstruction using the 6-point fixation and weight-adjusted spacing nomogram during sling surgery. *Int Urogynecol J* 2001;12:122–128.
114. Ezzat I. Sling operations in the treatment of stress urinary incontinence: how to adjust sling tension. *J Obstet Gynecol Res* 2001;29:374–379.
115. Choe J. Suprapubic sling adjustment: minimally invasive method of curing recurrent stress incontinence after sling surgery. *J Urol* 2002;168:2059–2092.

116. Palma PC, Riccetto CL, Dambros M, Thiel M, De Fraga R, Netto NR Jr. Safyre™: a readjustable minimally invasive sling for female urinary stress incontinence *Int Braz J Urol* 2003;29:353–359.
117. Iglesias X, Espuña M. Surgical treatment of urinary stress incontinence using a method for post-operative adjustment of sling tension (Remeex system). *Int Urogynecol J Pelvic Floor Dysfunct* 2003;14:326–330.
118. Carr LK, Webster GD. Voiding dysfunction following incontinence surgery: diagnosis and treatment with retropubic or vaginal urethrolysis. *J Urol* 1997;157:821–823.
119. Nitti VW, Carlson KV, Blaivas JG, Dmochowski RR. Early results of pubovaginal sling lysis by midline sling incision. *Urology* 2002;59:47–52.
120. Cross CA, Cespedes RD, English SF, et al. Transvaginal urethrolysis for urethral obstruction after anti-incontinence surgery. *J Urol* 1998;159:1199–1201.
121. Deffieux X, de Tairac R, Huel C, et al. Vaginal mesh erosion after transvaginal repair of cystocele using Gynemesh or Gynemesh-Soft in 138 women: a comparative study. *Int Urogynecol J Pelvic Floor Dysfunct* 2006;4:1–7.
122. Myers D, LaSala C. Conservative surgical management of Mersilene mesh suburethral sling erosion. *Am J Obstet Gynecol* 1998;179:1424–1429.
123. Birch C. The use of prosthetics in pelvic reconstructive surgery. *Ballière's Best Pract Res Clin Obstet Gynaecol* 2005;19:979–991
124. Amundsen CL, Flynn BJ, Webster GD. Urethral erosion after synthetic and nonsynthetic pubovaginal slings: differences in management and continence outcome. *J Urol* 2003;170:134–137.
125. Kammerer-Doak DN, Cornella JL, Magrina JF, et al. Osteitis pubis after Marshall-Marchetti-Krantz urethropexy: a pubic osteomyelitis. *Am J Obstet Gynecol* 1998;179:586–590.
126. Hall J, Napier-Hemy R, O'Reilly PH. Osteomyelitis complicating Burch colposuspension. *Br J Urol* 1996;77:470–471.
127. Goldberg RP, Tchetgen MB, Sand PK, et al. Incidence of osteomyelitis after bladder neck suspension using bone anchors. *Urology* 2004;63:704–708.
128. Frederick RW, Careyn JM, Leach GE. Osseous complications after transvaginal bone anchor fixation in female pelvic reconstructive surgery: report from single largest prospective series and literature review. *Urology* 2004;64:669–674.
129. Fialkow MF, Lentz GM, Miller EA, Miller JL. Complications from transvaginal pubovaginal slings using bone anchor fixation. *Urology* 2004;64:1127–1132.
130. Flynn BJ, Yap WT. Pubovaginal sling using allograft fascia lata vs autograft fascia for all types of stress urinary incontinence: 2-year minimum follow-up. *J Urol* 2002;167:608–612.
131. Barbaliás G, Liatsikos E, Barbaliás D. Use of slings made of indigenous and allogenic material (Gore-Tex) in type III urinary incontinence and the comparison between them. *Eur Urol* 1997;31:394–400.

---

# 11

## Complications of Sling Surgery

---

*Suzette E. Sutherland, MD*

### CONTENTS

INTRODUCTION  
INTRAOPERATIVE COMPLICATIONS  
POSTOPERATIVE COMPLICATIONS  
CONCLUSION  
REFERENCES

---

### INTRODUCTION

Until recently, abdominal Burch colposuspension was considered the gold standard for the surgical treatment of stress urinary incontinence (SUI) (1,2). However, the introduction of vaginal sling surgery has been met with great enthusiasm because of comparable efficacy, but with lower surgical morbidity (3). With the advent of minimally invasive, tension-free, midurethral vaginal slings (4), colposuspension has been replaced as the most frequently performed procedure for SUI associated with urethral hypermobility with or without concomitant intrinsic sphincter deficiency (5). Although the incidence of significant complications has been low, the learning curve for vaginal sling surgery still needs to be respected.

With respect to bladder neck slings, autologous fascia (rectus fascia or fascia lata of the thigh) has been the most commonly used material. Although success rates have been high (6), potential disadvantages include graft harvest site incision size and morbidity, inconsistent graft strength, and unavailability of satisfactory fascia. Cadaveric and porcine materials have been tried but are associated with higher-than-expected intermediate failures (7–9) because of rapid loss of tensile strength and stiffness over time (10). Commercially processed cadaveric allografts have been shown to retain intact genetic material and antigenicity, with associated concerns for potential virus or prion transmission and tissue rejection (11,12). A variety of synthetic materials have been tried with pubovaginal sling techniques, many of which have been associated with increased postoperative voiding dysfunction and tissue erosion rates compared to autologous fascia. Prevalent functional problems include postoperative voiding dysfunction (2–37%), urinary retention or incomplete bladder emptying requiring long-term Foley or self-catheterization (2–8%), persistent urge incontinence (3–30%), and *de novo* urge incontinence (7%) (13–15).

Complications associated with the loosely placed, tension-free midurethral slings appear to be less severe and possibly less common, especially regarding significant postoperative obstruction and voiding dysfunction (0.9–5%) requiring subsequent

sling revision (1.9–5%). Although rare, other reported complications include bleeding (0.9%), intraoperative bladder perforation (4.9–9%), recurrent urinary tract infection (1–10.9%), vaginal or urethral mesh erosion (0.9–1%), and nerve injury (0.9–3%) (16–19).

## INTRAOPERATIVE COMPLICATIONS

### *Bleeding/Hematoma Formation*

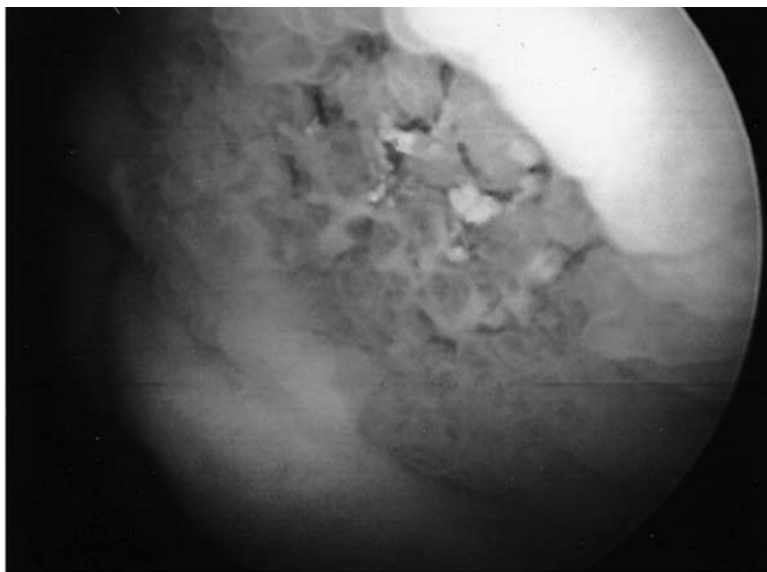
According to the Food and Drug Administration's MAUDE (Manufacturer and User Facility Device Experience) database (20), life-threatening bleeding associated with 33 major vessel injuries has resulted in two known deaths following retropubic tension-free vaginal tape (TVT) procedures. Other self-reported vascular complications during TVT trocar passage include injuries to the inferior epigastric, obturator, external iliac, and femoral vessels. A few case reports described retropubic hematomas requiring blood transfusions and catastrophic bleeding requiring surgical intervention (21–23).

It has been suggested that the technique associated with the TVT procedure, specifically passage of the retropubic trocars in a down-up motion from the vaginal incision to the suprapubic incision, provides only a small zone of surgical safety and potentially less control within that zone during needle passage as compared to its sling predecessors, which utilize a finger-guided up-down retropubic needle passage for sling placement. Detailed anatomical cadaveric dissections demonstrate the effect within the retropubic space of small deviations laterally or cephalad during upward passage of the trocar. The vulnerable vessels (the obturator, inferior epigastric, superficial epigastric, and external iliac) were reported to be 3.2, 3.9, 3.9, and 4.9 cm from the path of ideal trocar passage, respectively (24).

Regardless of the technique utilized for trocar passage, instrument control during blind retropubic passage is of utmost importance to prevent such iatrogenic injuries. Nevertheless, the overall incidence of such bleeding complications is still low. In a large cohort of 1455 TVT patients, Kuuva and Nilsson reported 0.1% incidence of major vessel injuries (25). In other large series, the incidence of significant retroperitoneal bleeding was between 0.9 and 2.5% (18,26), with urgent surgical intervention for hemostasis performed in 0.5% (27). The incidence of significant hematoma formation requiring subsequent surgical evacuation was 0.7% (17,18,25).

Although similar retroperitoneal bleeding during other sling procedures can still occur, more serious large-vessel injuries have yet to be described. This may be partly due to the overall smaller number of non-TVT retropubic slings performed as they were introduced significantly later to the surgical market. In one retrospective review of 140 suprapubic arc (SPARC) cases, a mean reduction in hematocrit of 7.1% (range 1 to 14%) was seen on postoperative day 1. Despite a reported mean intraoperative blood loss of 170 cc (range 50 to 700 cc), 6 (4.3%) patients required some degree of immediate resuscitative care, with 4 (2.8%) of these requiring blood transfusion (2–6 U packed red blood cells). Retropubic hematoma formation requiring percutaneous drainage for symptomatic relief was also noted in 1 patient (28). In another larger review of 445 SPARC slings, only one case of significant retroperitoneal hematoma requiring blood transfusion was described. Only one other patient required postoperative blood replacement, but underwent a concomitant cystocele repair (29).





**Fig. 1.** TVT mesh embedded in mucosa. (Courtesy of Dr. Howard B. Goldman, Cleveland Clinic Foundation, Cleveland, OH.)

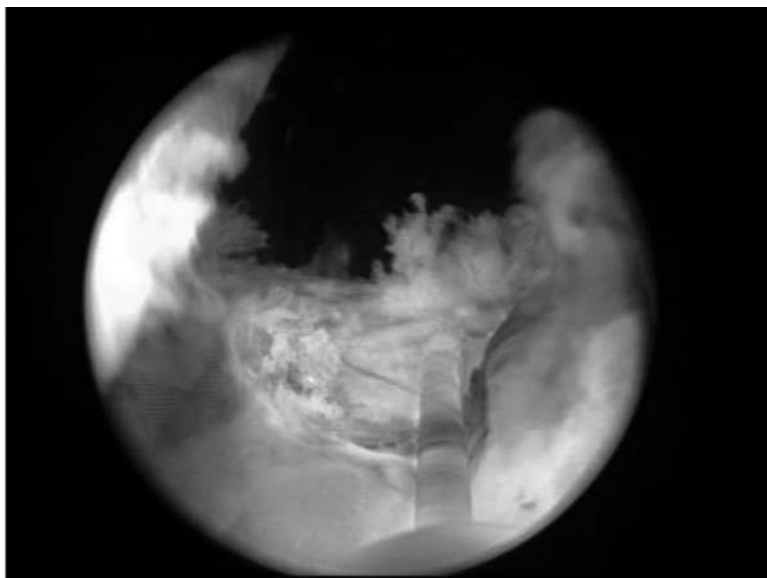### *Visceral Injuries*

#### **BLADDER PERFORATION**

Although reported rates of bladder perforation during retropubic midurethral sling procedures reach 25%, more recent large, multicenter trials observed much smaller rates of 3.8–6.7% (17,25,26,29). Increasing the risk for such intraoperative injury is prior anti-incontinence or pelvic surgery. In a study involving more than 2500 patients, Tamussino et al. reported a twofold increase in bladder injury rates in patients with a previous history of incontinence surgery as compared to surgically naive patients (4.4 vs 2%) (30). When recognized and corrected at the time of trocar perforation, conservative management with short-term (3–5 d) catheterization can avoid potential long-term sequelae (31). Careful inspection with cystoscopy must be performed intraoperatively so an inadvertent bladder perforation is not missed. The need for familiarity and expertise with cystoscopy must be emphasized.

With the newer transobturator approaches to midurethral sling placement, the theoretical risk of visceral perforation is eliminated by remaining below the endopelvic fascia with needle trocar passage. In a review of 107 inside-out transobturator tape procedures, no such bladder injuries were reported (32). A review of the experience within my institution of over 300 outside-in transobturator Monarc procedures revealed the same (33).

Missed bladder perforations with subsequent intravesical placement of mesh present a problem (Fig. 1). Although few, various examples have been reported. Missed bilateral bladder perforation with the Sabre (bioresorbable) pubovaginal sling was found 10 mo after placement and associated with chronic intractable pelvic pain and SUI (34). Volkmer et al. reported two intravesical slings following TVT placement (35). Complete sling removal by an open suprapubic approach has generally been advocated. However, Hodroff et al. took a minimally invasive transurethral approach to intravesical sling removal with the use of the holmium laser. In three cases, the laser was used to ablate



**Fig. 2.** Holmium laser of mesh puncture site at bladder neck. (Courtesy of Dr. Andrew Portis, Metro Urology, St. Paul, MN.)

the mesh at a point slightly deeper than mucosa to allow the mucosa to grow over the puncture sites (Figs. 2 and 3). The excised mesh tape was then removed from the bladder transurethrally with a flexible grasper (Fig. 4). There were no bladder perforations during the laser intervention, and complete reepithelialization was seen cystoscopically in all cases at 1 mo (36).

### **BOWEL PERFORATION**

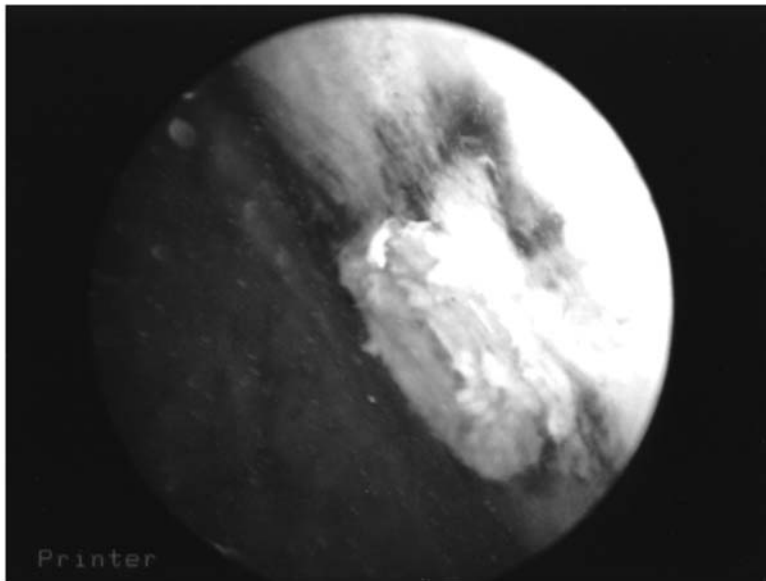
Although few reports of bowel perforation during sling surgery have appeared in the literature (27–29,37,38), the potential seriousness of such an iatrogenic injury cannot be overlooked. According to the US Food and Drug Administration’s MAUDE database (20), six deaths have occurred as a result of unrecognized bowel injury following minimally invasive retropubic sling procedures. Such complications indicate the importance of proper patient selection as well as the need for vigilant postoperative monitoring of side effects. Previous pelvic transperitoneal procedures may result in bowel adhesions within the retropubic space, increasing the risk of inadvertent visceral injury during “blind passage” of the trocars. Keeping the location of the trocars snug along the posterior aspect of the pubic symphysis during passage may help to reduce this risk. Any symptoms of pelvic or abdominal pain, bowel obstruction, fever, or certainly suspicious drainage from the suprapubic puncture sites should be investigated promptly. Computed tomographic imaging may prove helpful, but with a high index of suspicion, emergent exploratory laparotomy is recommended for complete mesh removal and repair.

## **POSTOPERATIVE COMPLICATIONS**

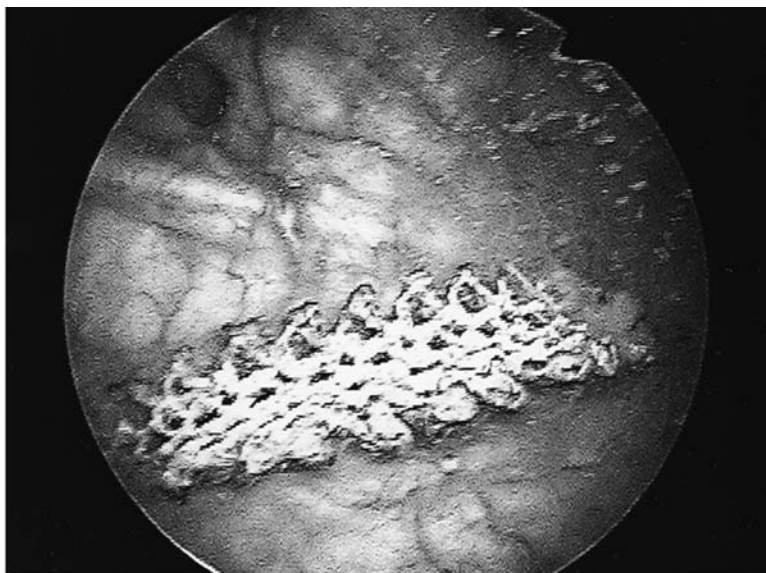
### ***Postoperative Voiding Dysfunction***

#### **URINARY RETENTION**

The incidence of urethral obstruction after vaginal sling placement is reportedly 1.9–5% (19,39). It is most often identified by postoperative changes in voiding and type of

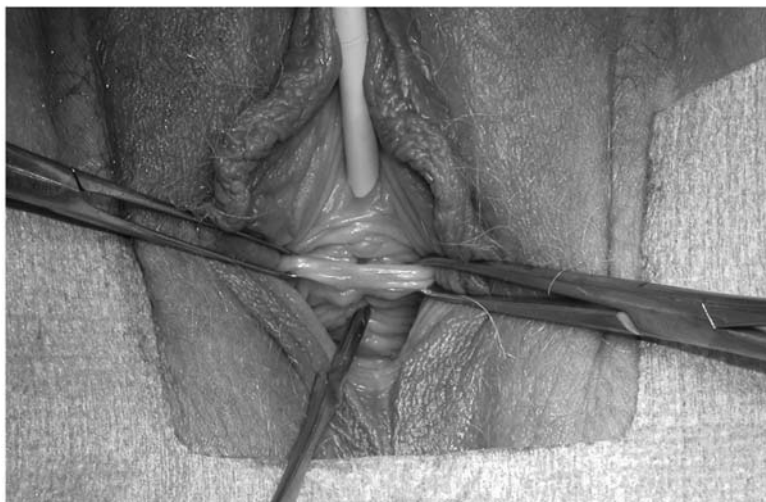


**Fig. 3.** Puncture site in bladder after mesh removed and holmium laser treatment of mucosa. (Courtesy of Dr. Andrew Portis, Metro Urology, St. Paul, MN.)



**Fig. 4.** Excised mesh freely floating in the bladder. Remnant removed transurethrally with flexible grasper. (Courtesy of Dr. Andrew Portis, Metro Urology, St. Paul, MN.)

incontinence. The diagnosis is usually obvious in a patient with prolonged postoperative urinary retention or with incomplete bladder emptying in whom unobstructed voiding was experienced preoperatively. *De novo* urge incontinence with postural voiding (leaning forward to void) is the more common presentation. In addition, cystoscopy can play a vital role by revealing fixed retropubic urethral angulation or by visually confirming urethral obstruction.



**Fig. 5.** Obstructing mesh placed too distally. Scapel indicates appropriate midurethral position. (Courtesy of Dr. Oscar Aguirre, Urogynecology Associates of Colorado, Denver, CO.)

To avoid long-term complications, vigilant observation for signs of obstruction is needed. When recognized early within the first few postoperative weeks, a simple sling adjustment can be made by loosening the sling via the midurethral incision. As significant tissue ingrowth of the mesh would not have yet occurred, the sling is still movable within the tissues. Following full tissue incorporation of the mesh, however, loosening is no longer an option, but a simple suburethral sling incision has been described with good results. In the majority of cases, this maneuver provides relief of obstruction from excess sling tension under the urethra without return of SUI (19,39). More significant and complex obstruction may require formal urethrolisis (vaginal, suprameatal, or retropubic approach) with or without tissue interposition (i.e., Martius fat pad) to reduce the risk of recurrence.

Following referral for postoperative obstructive voiding after TVT placement, a few cases were associated with an unusual complaint of a retrograde trajectory of the urinary stream causing buttock cheek wetting during voiding. In these cases, the sling was tightly located under the distal quarter of the urethra rather than in the midurethral position (Fig. 5). Following sling incision, one patient underwent subsequent abdominal paravaginal repair and repeat TVT for treatment of prolapse and recurrent severe incontinence. At the time of retropubic dissection, no mesh was located in the space of Retzius. Further exploration found that the prior tape had been passed anterior to the symphysis (O. Aguirre, Director, Urogynecology Associates of Colorado, Denver, personal correspondence).

### **DE NOVO URGENCY, FREQUENCY, URGE INCONTINENCE**

*De novo* overactive bladder (OAB) symptoms and urge incontinence are known risks of anti-incontinence procedures, with a reported incidence of 3–24% after bladder neck sling procedures and 6.1–12.5% following retropubic midurethral sling procedures (TVT/SPARC) (25,29,40–43). This compares to a 5–32% rate of *de novo* bladder overactivity following the previous gold standard, the retropubic colposuspension.

It has been suggested that, because the TVT is placed without tension at the level of the midurethra, it should result in a lower rate of voiding dysfunction, *de novo* urge

incontinence, and OAB symptoms. Appropriate intraoperative sling tensioning, however, is key. Albeit less frequent, postoperative voiding dysfunction and *de novo* bladder overactivity can still be experienced after retropubic midurethral slings (4.3–10% and 6–15%, respectively) (18,44–46).

Even fewer postoperative voiding difficulties have been described with the newer transobturator slings. In a retrospective comparison of retropubic vs transobturator slings, Ansquer et al. noted an overall 40% rate of postoperative voiding difficulties following retropubic slings, with only 8% extending longer than 1 wk; this compared to 8% overall and 0% beyond 1 wk for their transobturator slings (47). Although the U-shaped placement of retropubic approaches can cause kinking of the urethra, the relative horizontal positioning through transobturator placement decreases this risk of overcorrection. It has also been hypothesized that mesh in the retropubic space may cause direct compression and irritation on the lateral bladder walls during filling, thereby leading to *de novo* symptoms of bladder overactivity. The possibility of this is eliminated with the transobturator method, by which both trocar passage and mesh placement remain below the endopelvic fascia.

### ***Resolution of Overactive Bladder Symptoms/Urge Incontinence***

Previous studies have shown that 50–74% of patients with mixed incontinence are cured of their urge incontinence after appropriate surgical support of the bladder neck (48–51). In addition, as many as 57% of patients with preoperative OAB symptoms have experienced complete resolution of these symptoms following a midurethral TVT and no longer required anticholinergic therapy (44,52). Theoretically, a severely weak urethral sphincter mechanism associated with intrinsic sphincter deficiency results in funneling of the proximal urethra. When bladder filling occurs, or when intraabdominal pressure increases, urine enters the proximal urethra through the weak, open sphincter, producing sensory stimulation through a urethral-bladder reflex, which leads to reflex contractions of the bladder. Eliminating the initial unwanted leak of urine into the proximal urethra through improved suburethral support may abolish such reflex-initiated symptoms of OAB and urge incontinence (50,53,54).

### ***Vaginal and Urethral Erosion***

Historically, the concern associated with the use of synthetic materials has been that of postsurgical infection and tissue erosion. Clearly, with the use of “traditional” tight sling techniques, the risk of urinary tract erosion increases when synthetic materials are used. *Urethral erosion*, defined as sling material entering the urethral lumen, is most commonly thought to be caused by excess sling tension under the urethra. Another possibility, however, can be technical error, such as inadvertent urethral entry or dissection in a plane too close to the urethra. Compromising the thickness of the suburethral tissue may result in urethral devascularization.

Patient factors, such as urethral atrophy with a compromised blood supply because of prior radiation therapy or estrogen deficiency may also be implicated. Iatrogenic factors, such as traumatic urethral catheterization or forceful urethral dilation and sagittal rotation in attempts to loosen a sling, have also been reported as possible contributors to sling erosion (55,56). A few cases have been known to occur by inadvertent passage of the trocars through the urethra at the time of surgery. In cases of urethral erosion, complete sling excision has been advocated.

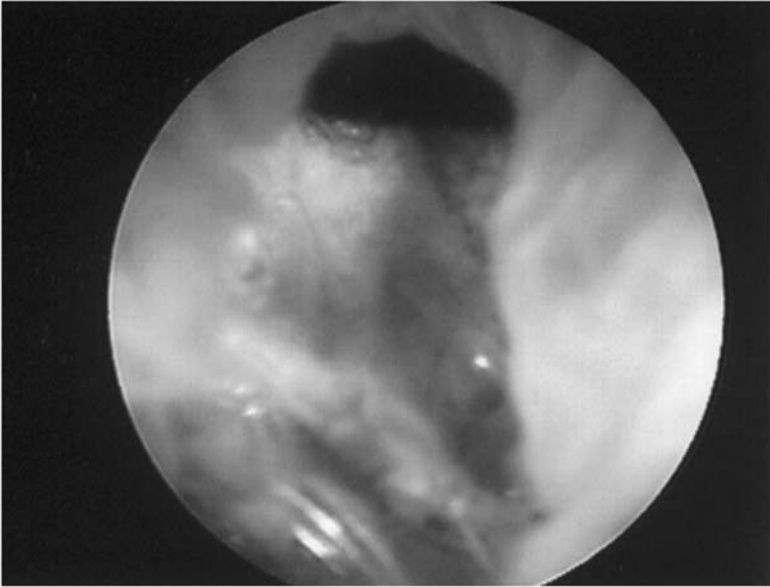The hypothesis, however, surrounding the potential generation of a synthetic-induced foreign body inflammatory reaction, subsequently resulting in higher risk of infection, erosion, and perhaps fistula formation, has yet to be proven in a comparative trial with nonsynthetic materials. To date, there are few series reported in the literature of urethral or vaginal mesh erosion. A meta-analysis performed by the American Urological Association Clinical Guidelines Panel of the literature on surgical management of female SUI using synthetic slings identified a 2.7% rate of urethral erosion and a 0.7% rate of vaginal extrusion (42). The conditions, however, may be underidentified or underreported as others have reported such mesh erosion rates of various synthetic sling materials at up to 23% (57–64). Differences in erosion rates, clinical characteristics, and appropriate management are clearly related to surgical technique and the material of synthetic mesh utilized. With the introduction of loosely woven, monofilament mesh into the world of anti-incontinence sling surgery, healing-related complications have decreased considerably. The large pore (>75  $\mu$ ) polypropylene slings provide improved tissue ingrowth, resulting in better integration of the sling with the host tissue, and limited secondary inflammation, infection, or erosion (65).

The first synthetic slings made of woven polyester and other tightly woven material were known to erode 15 times more often than nonsynthetic slings (autologous, allograft, and xenograft slings). In one multicenter series, 34 women with woven polyester slings treated with pressure-injected bovine collagen (ProteGen) were referred for problems with erosion, infection, or pain at a mean of 8 mo following sling placement. In this cohort of 34 patients, 7 (21%) had isolated urethral erosion, 17 (50%) had vaginal extrusion, and 6 (18%) were associated with urethrovaginal fistulas. All slings required removal (66). Owing to this high complication rate, ProteGen was recalled in 1999 and is no longer available in the United States.

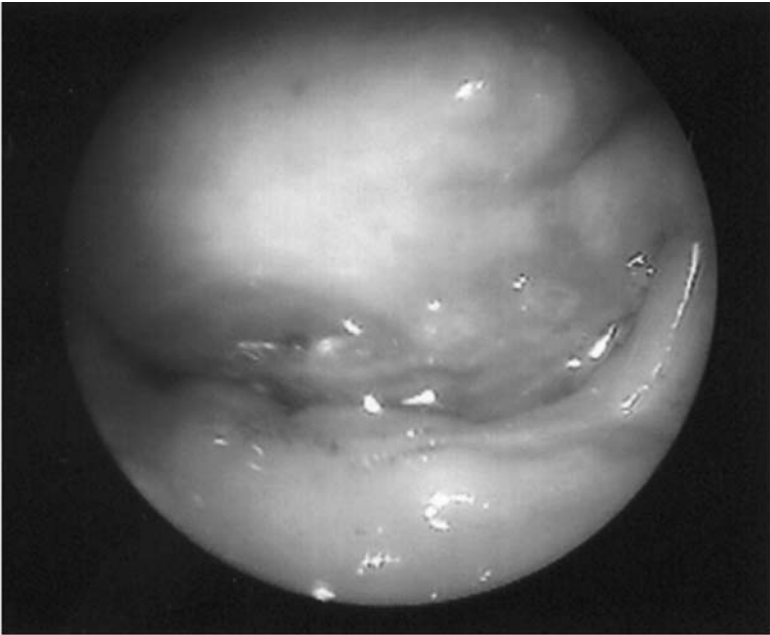
Silicone-coated polyester slings have not performed any better, with a 20% vaginal exposure rate noted at 6 and 10 mo in a single series (57). Another study looking at the use of silicone slings (silicone rubber reinforced with woven polyethylene) was halted early as five of the seven slings resulted in erosion, infection, and sinus tract formation (67). A fusion-welded, thermally bonded, nonwoven, nonknitted polypropylene mesh (Uratape/Obtape, Mentor-Porges, Le Plessis-Robinson, France) experienced a 13.8% rate of vaginal mesh exposure (68). The poor incorporation of the sling was thought to be associated with unique characteristics of the mesh. Specific modifications to this mesh caused a shrinkage of the pore size (50  $\mu$ ), leaving it smaller than the minimal 75  $\mu$  recommended to ensure adequate macrophage and leukocyte infiltration as well as vascular and tissue ingrowth (69).

An interesting case of simultaneous urethral erosion of a ProteGen bladder neck sling and midurethral TVT with intervening urethrovaginal fistula has also been described (70) (Figs. 6 and 7). The TVT was placed after the bladder neck ProteGen sling in an attempt to treat persistent SUI. Removal of all mesh and repair of the urethrovaginal fistula were successfully performed transvaginally. A new pubovaginal sling of autologous rectus fascia was placed over a Martius fat pad, with successful results reported at 3-mo follow-up.

Vaginal mesh exposure, or extrusion, is most commonly detected by the patient's sexual partner during intercourse (scratching sensation) or thorough vaginal inspection during postoperative physical examinations. Many women with small areas of vaginal mesh extrusion are asymptomatic, but some extrusions have been associated with symptoms of minimal, yet persistent, vaginal discharge or spotting, vaginal or pelvic



**Fig. 6.** Eroded ProteGen sling at bladder neck (background) and eroded polypropylene sling at midurethra (foreground). (Courtesy of Dr. Howard B. Goldman, Cleveland Clinic Foundation, Cleveland, OH.)



**Fig. 7.** Exposed vaginal mesh with urethrovaginal fistula seen on vaginoscopy. (Courtesy of Dr. Howard B. Goldman, Cleveland Clinic Foundation, Cleveland, OH.)

discomfort, recurrent urinary tract infection, or, in the case of concomitant infection, symptoms of fever or malaise (66).

In the past, recommendations were made to completely remove any eroded synthetic material. This is appropriate when the erosion involves the bladder or urethra (67,71, 72). However, in cases limited to extrusion of loosely woven polypropylene mesh within the vagina, conservative management or observation may prove successful. Such was reported in four SPARC cases of small (<1 cm) polypropylene mesh extrusion, with complete spontaneous reepithelialization over the mesh following 3 mo of observation (73). The large interstices associated with loosely woven polypropylene mesh allow for tissue ingrowth and integration of the graft into the surrounding tissues. Some recommend the addition of local estrogen therapy to augment the healing process. This conservative management may also prove successful with autologous and allograft materials. However, other, more tightly woven, synthetic materials, such as polyester and silicone slings, should be removed entirely, even in cases of vaginal extrusion, because it is unlikely that epithelialization over these materials will occur (58,61, 63–67). In the case of larger or nonhealing, uninfected extrusion, there is no need for entire mesh removal. Simple exposed mesh excision and covering with a healthy vaginal flap is recommended.

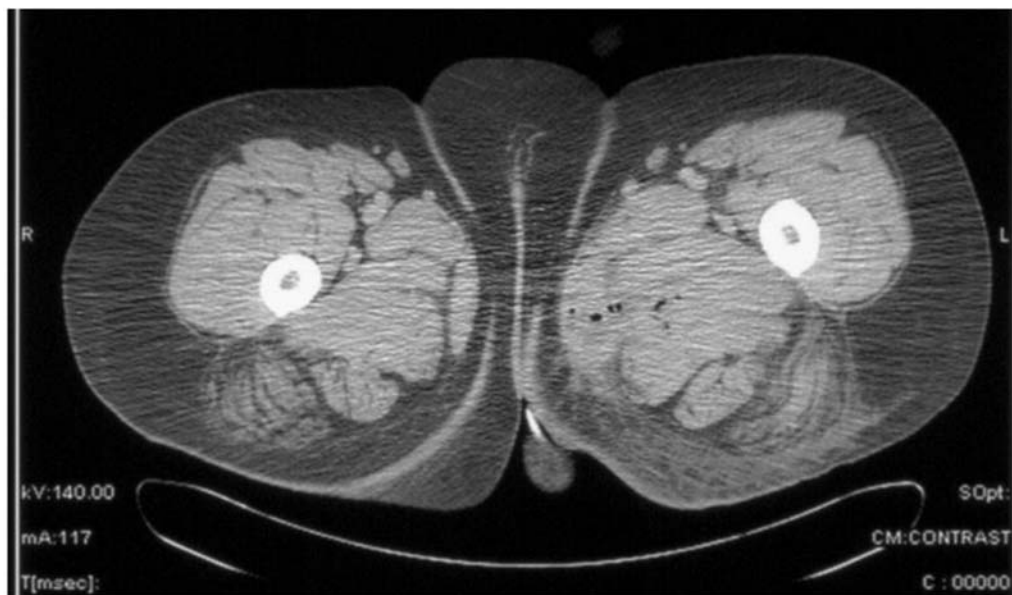With respect to the cause of vaginal mesh extrusion, one theory suggests that subclinical infection of sling material impedes wound healing, thereby resulting in wound separation, presenting as erosion (66). With this in mind, the routine use of perioperative prophylactic antibiotics and a thorough preoperative vaginal scrub was advocated, with a significant reduction in subsequent vaginal mesh extrusion appreciated (74). Tightly woven meshes have been associated with a higher incidence of vaginal extrusion, possibly because of incomplete incorporation and subsequent rubbing against the host tissue, causing undue friction and chronic mechanical irritation to the tissues (67,68). Another problem may be related to surgical technique (75). Excessive thinning of the vaginal mucosa, resulting in devascularization during dissection, will likely increase the risk of subsequent mesh exposure. Appropriate thickness of the vaginal wall flap must be maintained to ensure tissue viability and ensure proper healing.

### ***Infection/Abscess***

An interesting case of bladder wall abscess following intravaginal slingoplasty (IVS) midurethral sling placement was reported that was diagnosed at 8 mo after evaluation for persistent unilateral lower abdominal pain (76). In a series of over 1500 midurethral sling procedures using different types of synthetic mesh (TVT, SPARC, IVS, Uretex, Monarc), only four cases of abscess formation were reported, and all were seen with the IVS mesh (77). Bafghi et al. noted a 7.4% rate of retropubic space abscess formation following IVS mesh use and suggested small mesh pore size associated with the IVS product impedes effective host immune activity (78). Similarly, in an *in vivo* comparison study of three different polypropylene mesh slings (Monarc-type I mesh, pore size 1 mm<sup>2</sup>; Obtape-type II mesh, pore size <75 μ; IVS-type III mesh, pore size <75 μ), Slack et al. noted increasingly greater inflammation and less fibrous tissue ingrowth and mesh incorporation with both the Obtape and IVS because of their closely spaced filaments and smaller pore size (65). Other *in vivo* studies with similar findings have likewise supported the utilization of large-pore (>75 μ), type I mesh for surgical implantation (79,80).

A review of infectious complications unique to the transobturator approach included an infected hematoma near the obturator foramen (81), a small thigh abscess with associated superficial thrombophlebitis (32), and a large thigh abscess tracking from the obturator





**Fig. 8.** Large left thigh abscess (see air within tissue) following transobturator sling procedure. (Courtesy of Dr. Howard B. Goldman, Cleveland Clinic Foundation, Cleveland, OH.)

externus distally along the gracilis and adductor magnus muscles halfway to the knee (Fig. 8) (82). All responded to surgical drainage, debridement, and appropriate antimicrobial therapy.

### ***Bone Anchors***

The use of bone anchors in an attempt to stabilize the mesh to the pubic bone does not seem to result in improved efficacy over existing nonanchoring techniques but carries with it a risk of osteomyelitis. Cases of both osteomyelitis and retropubic abscesses have been reported following bone-anchoring sling procedures (83,84). A 10-yr review of the literature done in 2001 yielded 6 cases of osteomyelitis in 1018 bone anchor procedures, for an overall incidence of 0.6% (85). However, in a more recent multicenter study involving major referral centers in the United States, a higher osteomyelitis incidence of 1.3% was reported following bone-anchored bladder neck suspension (87). Although the most common offending organism in such infections has been *Staphylococcus epidermidis* (83), a more serious case of pelvic actinomycosis following placement of a bone-anchored sling has been reported (87). Appropriate treatment of actinomycosis infection requires prolonged antibiotic for 6–12 mo. In spite of the rare incidence of postoperative osteomyelitis, each case incurs substantial morbidity and requires aggressive multimodal medical and surgical treatment to include exploratory laparotomy, anchor removal, bony debridement, and prolonged parenteral antibiotics (83).

### **CONCLUSION**

The tension-free midurethral sling has rapidly become the most frequently performed anti-incontinence procedure for women, having surpassed the traditional abdominal Burch colposuspension. The advent of synthetic slings brought specific advantages,

such as eliminating the need for fascial graft harvest, decreased morbidity, ease of use, and comparable efficacy to other anti-incontinence procedures. Loosely woven monofilament material such as polypropylene has gained popularity by demonstrating good tissue ingrowth with limited inflammatory reaction, thereby reducing postoperative healing complications.

Despite these advantages, significant complications associated with bleeding, visceral perforation, postoperative voiding dysfunction, and mesh erosion have occurred following minimally invasive sling surgery. However, the incidence of these complications seems to be on the decline according to more recent reports from larger series. This may be due to the development of improved surgical techniques, advances in synthetic materials, and/or the learning curve of the procedure. Nevertheless, such complications can result in devastating consequences and underscore the importance of proper patient selection, surgical precision, and vigilant postoperative care.

## REFERENCES

1. Burch JC. Urethrovaginal fixation to Cooper's ligament for correction of stress incontinence, cystocele, and prolapse. *Am J Obstet Gynecol* 1961;81:281–290.
2. Tanagho EA. Colpocystourethropey: the way we do it. *J Urol* 1976;116:751–753.
3. Ward KL, Hilton P. A prospective multicenter randomized trial of tension-free vaginal tape and colposuspension for primary urodynamic stress incontinence: 2-yr follow-up. *Am J Obstet Gynecol* 2004;190:324–331.
4. Ulmsten U, Petros P. Intravaginal slingoplasty (IVS): an ambulatory surgical procedure for treatment of female urinary incontinence. *Scand J Urol Nephrol* 1995;29:75–82.
5. Kim HL, Gerber GS, Patel RV, et al. Practice patterns in the treatment of female urinary incontinence: a postal and Internet survey. *Urology* 2001;57:45–48.
6. Latini JM, Lux MM, Kreder KJ. Efficacy and morbidity of autologous fascia lata sling cystourethropey. *J Urol* 2004;171:1180–1184.
7. O'Reilly KJ, Govier FE. Intermediate term failure of pubovaginal slings using cadaveric fascia lata: a case series. *J Urol* 2002;167:1356.
8. Huang YH, Lin AT, Chen KK, Pan CC, Chang LS. High failure rate using allograft fascia lata in pubovaginal sling surgery for female stress urinary incontinence. *Urology* 2001;58:943.
9. FitzGerald MP, Mollenhauer J, Bitterman P, Brubaker L. Functional failure of fascia lata allografts. *Am J Obstet Gynecol* 1999;181:1339.
10. Dora CD, Dimarco DS, Zobitz ME, Elliott DS. Time dependent variations in biomechanical properties of cadaveric fascia, porcine dermis, porcine small intestine submucosa, polypropylene mesh and autologous fascia in the rabbit model: implications for sling surgery. *J Urol* 2004;171:1970–1973.
11. Hathaway JK, Choe JM. Intact genetic material is present in commercially processed cadaver allografts used for pubovaginal slings. *J Urol* 2002;168:1040–1043.
12. Fitzgerald MP, Mollenhauer J, Brubaker L. The antigenicity of fascia lata allografts. *BJU Int* 2000;86:826.
13. Jarvis GJ. Surgery for genuine stress incontinence. *Br J Obstet Gynaecol* 1994;101:371–344.
14. Bidmead J, Cardozo L. Sling techniques in the treatment of genuine stress incontinence. *Br J Obstet Gynaecol* 2000;107:147–156.
15. Chaikin DC, Rosenthal J, Blaivas JG. Pubovaginal fascial sling for all types of stress urinary incontinence: long-term analysis. *J Urol* 1998;160:1312–1316.
16. Gomelsky A, Scarpero HM, Dmochowdki RR. Sling surgery for stress urinary incontinence in the female: what surgery, which material? *AUA Update Series* 2003;22:266–275.
17. Tamussino KF, Hanzal E, Kolle D, Ralph G, Riss PA. Tension-free vaginal tape operation: results of the Australian registry. *Obstet Gynecol* 2001;98:732–736.
18. Karram MM, Segal J, Vassallo BJ, Kleeman SD. Complications and untoward effects of the tension-free vaginal tape procedure. *Obstet Gynecol* 2003;101:929–932.
19. Klutke C, Siegel S, Carlin B, Paskiewicz E, Kirkemo A, Klutke J. Urinary retention after tension-free vaginal tape procedure: incidence and treatment. *Urology* 2001;58:697.

20. Food and Drug Administration Manufacturer and User Facility Device Experience database—(MAUDE) file formats for FOI releasable data. Events between January 1999 and July 2005. Available at: [www.fda.gov/cdrh/maude.html](http://www.fda.gov/cdrh/maude.html). Accessed August 2005.
21. Vierhout ME. Severe hemorrhage complicating tension-free vaginal tape (TVT): a case report. *Int Urogynecol J Pelvic Floor Dysfunct* 2001;12:139–140.
22. Zilvert AW, Farrell SA. External iliac artery laceration during tension-free vaginal tape procedure. *Int Urogynecol J Pelvic Floor Dysfunct* 2001;12:141–143.
23. Walters MD, Tulikangas PK, LaSala C, Muir TM. Vascular injury during tension-free vaginal tape procedure for stress urinary incontinence: a case report. *Obstet Gynecol* 2001;98:957–959.
24. Muir TW, Tulikangas PK, Paraiso MF, Walters MD. The relationship of tension-free vaginal tape insertion and the vascular anatomy. *Obstet Gynecol* 2003;101:933–936.
25. Kuuva N, Nilsson CG. A nationwide analysis of complications associated with the tension-free vaginal tape (TVT) procedure. *Acta Obstet Gynecol Scand* 2002;81:72.
26. Abouassaly R, Steinberg JR, Lemieux M, et al. Complications of tension-free vaginal tape surgery: a multi-institutional review. *BJU Int* 2004;94:110–113.
27. Meschia M, Pifarotti P, Vernasconi F, et al. Tension-free vaginal tape: analysis of outcomes and complications in 404 stress incontinent women. *Int Urogynecol J Pelvic Floor Dysfunct* 2001;12:S24–S27.
28. Kobashi KC, Govier FE. Perioperative complications: the first 140 polypropylene pubovaginal slings. *J Urol* 2003;170:1918–1921.
29. Hodroff MA, Sutherland SE, Kesha JB, Siegel SW. Treatment of stress incontinence with the SPARC sling: intraoperative and early complications of 445 patients. *Urology* 2005;66:760–762.
30. Tamussino K, Hanzal E, Kolle D, et al. The Austrian tension-free vaginal tape registry. *Int Urogynecol J Pelvic Floor Dysfunct* 2001;12(suppl 2):S28–S29.
31. Ward K, Hilton P. Prospective multicenter randomized trial of tension-free vaginal tape and coposuspension as primary treatment for stress incontinence. *BMJ* 2002;325:1–7.
32. de Laval J. New surgical technique for the treatment of female stress urinary incontinence: transobturator vaginal tape inside-out. *Eur Urol* 2003;44:724–730.
33. Lewis TE, Sutherland SE, Kesha JB, Siegel SW. Monarc transobturator sling: short-term analysis of safety and efficacy. Publication pending.
34. Tunuguntla HSGR, Gousse AE. Missed bilateral bladder perforation during pubovaginal sling procedure. *J Urol* 2004;172:189–190.
35. Volkmer BG, Nessler T, Rinnab L, Schradin T, Hautmann RE, Gottfried HW. Surgical intervention for complications of the tension-free vaginal tape procedure. *J Urol* 2003;169:570.
36. Hodroff M, Portis A, Siegel S. Endoscopic removal of intravesical polypropylene sling with the holmium laser. *J Urol* 2004;172:1361–1362.
37. Leboeuf L, Tellez CA, Ead D, Gousse AE. Complication of bowel perforation during insertion of tension-free vaginal tape. *J Urol* 2003;170:1310–1311.
38. Peyrat L, Boutin JM, Bruyere F, Haillot H, Fakfak H, Lanson Y. Intestinal perforation as a complication of tension-free vaginal tape procedure for urinary incontinence. *Eur Urol* 2001;39:603.
39. Rardin CR, Rosenblatt PL, Kohli N, Miklos JR, Heit M, Lucente VR. Release of tension-free vaginal tape for the treatment of refractory postoperative voiding dysfunction. *Obstet Gynecol* 2002;100:898–902.
40. Jeffrey L, Deval B, Birsan A, et al. Objective and subjective cure rates after tension free vaginal tape for treatment of urinary incontinence. *Urology* 2001;58:702–706.
41. Maher CF, Dwyer PL, Carey MP, Moran PA. Colposuspension or sling for low urethral pressure stress incontinence? *Int Urogynecol J Pelvic Floor Dysfunct* 1999;10:384–389.
42. Leach FE, Dmochowski RR, Appell RA, et al. Female Stress Urinary Incontinence Clinical Guidelines Panel summary report on surgical management of female stress urinary incontinence. The American Urological Association. *J Urol* 1997;158:875–880.
43. Langer R, Ron-el R, Newman M, Herman A, Caspi E. Detrusor instability following colposuspension for urinary stress incontinence. *Fr J Obstet Gynaecol* 1988;95:607–610.
44. Segal JL, Vassallo B, Kleeman S, Silva WA, Karram MM. Prevalence of persistent and *de novo* overactive bladder symptoms after the tension-free vaginal tape. *Obstet Gynecol* 2004;104:1263–1269.
45. Haab F, Sananes S, Amarenco G, et al. Results of the tension-free vaginal tape procedure for the treatment of type II stress urinary incontinence at a minimum follow-up of 1 year. *J Urol* 2001;165:159–162.

46. Moran PA, Ward KL, Johnson D, Smirni WE, Hilton P, Bibby J. Tension-free vaginal tape procedure for primary genuine stress incontinence: a two-centre follow-up study. *Br J Urol Int* 2000;86:39–42.
47. Ansquer Y, Marcollet A, Yazbeck C, et al. The suburethral sling for female stress urinary incontinence: a retropubic or obturator approach? *J Am Assoc Gynecol Laprosc* 2004;11:353–358.
48. Morgan TO, Westney OL, McGuire EJ. Pubovaginal sling: 4-year outcome analysis and quality of life assessment *J Urol* 2000;163:1845–1848.
49. Walters M. Retropubic operations for genuine stress incontinence. In: *Urogynecology and Reconstructive Pelvic Surgery, 2nd ed.* (Walters MD, Karram MM, eds.), Mosby, St. Louis, MO, 1999, pp. 159–169.
50. Fulford SCV, Flynn R, Barrington J, Appanna T, Stephenson TP. An assessment of the surgical outcome and urodynamic effects of the pubovaginal sling for stress incontinence and the associated urge syndrome. *J Urol* 1999;162:135–137.
51. McGuire EG, Lytton B. Pubovaginal sling procedure for stress incontinence. *J Urol* 1978;119:82.
52. Nilsson CG, Kuuva N, Falconer C, et al. Long-term results of the tension-free vaginal tape (TVT) procedure for surgical treatment of female stress urinary incontinence. *Int Urogynecol J* 2001;2(suppl):S5–S8.
53. Gustafson KJ, Creasy GH, Grill WM. A urethral afferent mediated excitatory bladder reflex exists in humans. *Neurosci Lett* 2004;360:9–12.
54. Koonings P, Bergman A, Ballard CA. Combined detrusor instability and stress urinary incontinence: where is the primary pathology? *Gynecol Obstet Invest* 1988;26:250.
55. Amundsen CL, Flynn BJ, Webster GD. Urethral erosion after synthetic and nonsynthetic pubovaginal slings: differences in management and continence outcome. *J Urol* 2003;170:134–137.
56. Golomb J, Groutz A, Mor Y, Leibovitch I, Ramon J. Management of urethral erosion caused by a pubovaginal fascial sling. *Urology* 2001;57:159.
57. Comiter CV, Colegrove PM. High rate of vaginal extrusion of silicone-coated polyester sling. *Urology* 2004;63:1066–1070.
58. Staskin DR, Choe JM, Breslin DS. The Gore-Tex sling procedure for female sphincteric incontinence: indications, technique, and results. *World J Urol* 1997;15:295.
59. Barbalias G, Liatsikos E, Barbalias D. Use of slings made of indigenous and allogenic material (Gortex) in type III stress urinary incontinence and comparison between them. *Eur Urol* 1997;31:394.
60. Hom D, Desautel MG, Lumerman JH, Feraren RE, Badlani GH. Pubovaginal sling using polypropylene mesh and Vesica bone anchors. *Urology* 1998;51:708.
61. Chin YK, Stanton SL. A follow-up of silicone sling for genuine stress incontinence. *Br J Obstet Gynaecol* 1995;102:143.
62. Bent AE, Ostergard DR, Zwick-Zaffuto M. Tissue reaction to expanded polytetrafluoroethylene suburethral sling for urinary incontinence: clinical and histologic study. *Am J Obstet Gynecol* 1993;169:1198.
63. Morgan JE, Farrow GA, Stewart FE. The Marlex sling operation for the treatment of recurrent stress urinary incontinence: a 16-year review. *Am J Obstet Gynecol* 1985;151:224.
64. Stanton SL, Brindley GS, Holmes DM. Silastic sling for urethral sphincter incompetence in women. *Br J Obstet Gynaecol* 1985;92:747–750.
65. Slack M, Sandhu JS, Staskin DR, Grant RC. In vivo comparison of suburethral sling materials. *Int Urogynecol J Pelvic Floor Dysfunct* 2006;17(2):106–110.
66. Kobashi KC, Dmochowski R, Mee SL, et al. Erosion of woven polyester pubovaginal sling. *J Urol* 1999;162:2070.
67. Duckett JRA, Constantine G. Complications of silicone sling insertion for stress urinary incontinence. *J Urol* 2000;163:1835.
68. Domingo S, Alama P, Ruiz N, Perales A, Pellicer A. Diagnosis, management and prognosis of vaginal erosion after transobturator suburethral tape procedure using a nonwoven thermally bonded polypropylene mesh. *J Urol* 2005;173:1627–1630.
69. Amid P. Classification of biomaterials and their related complications in abdominal wall hernia surgery. *Hernia* 1997;1:5.
70. Gerstenbluth RE, Goldman HB. Simultaneous urethral erosion of tension-free vaginal tape and woven polyester pubovaginal sling. *J Urol* 2003;170:525–526.
71. Sweat SD, Itano NV, Clemens JZ, et al. Polypropylene mesh tape for stress urinary incontinence: complications of urethral erosion and outlet obstruction. *J Urol* 2002;168:144.

72. Clemens JA, DeLancey JO, Faerber GJ, Westney OL, McGuire EJ. Urinary tract erosions after synthetic pubovaginal slings: diagnosis and management strategy. *Urology* 2000;56:589.
73. Kobashi KC, Govier FE. Management of vaginal erosion of polypropylene mesh slings. *J Urol* 2003;169:2242–2243.
74. Persson J, Iosif C, Wolner-Hanssen PAL. Risk factors for rejection of synthetic suburethral slings for stress urinary incontinence: a case-control study. *Obstet Gynecol* 2002;99:629–634.
75. Norris JP, Breslin DS, Staskin DR. Use of synthetic material in sling surgery: a minimally invasive approach. *J Endourol* 1996;10:227–230.
76. Madjar S, Frischer Z, Nieder AM, Waltzer WC. Bladder wall abscess following midurethral sling procedure. *Int Urogynecol J Pelvic Floor Dysfunct* 2006;17(2):180–181.
77. Fischer A, Zachmann S, Fink T. Alloplastic materials in pelvic floor surgery experiences reported for prolapse and incontinence procedures. Abstract presented at: ICS meeting; 2003; Florence, Italy. Available at: <http://www.icsoffice.org/publications/2003/pdf/515.pdf>. Accessed August 2005.
78. Bafghi A, Benizri EI, Trastour C, Benizri EJ, Michiels JF, Bongain A. Multifilament polypropylene mesh for urinary incontinence: 10 cases of infection requiring removal of the sling. *BJOG* 2005;112:376–378.
79. White RA, Hirose FM, Sproat RW, Lawrence RS, Nelson RJ. Histopathologic observations after short-term implantation of two porous elastomers in dogs. *Biomaterials* 1981;2:171–176.
80. White RA. The effect of porosity and biomaterial on the healing and long-term mechanical properties of vascular prosthesis. *Trans Am Soc Artif Intern Organs* 1988;34:95–100.
81. Game X. Obturator infected hematoma and urethral erosion following transobturator tape implantation. *J Urol* 2004;171:1629.
82. Goldman HB. Large thigh abscess after placement of synthetic transobturator sling. *Int Urogynecol J Pelvic Floor Dysfunct* 2006;17(3):295–296.
83. Graham CW, Dmochowski RR. Pubic osteomyelitis following bladder neck surgery using bone anchors: a report of nine cases. *J Urol* 2002;168:2055–2058.
84. Enzler M, Agins HJ, Kogan M, et al. Osteomyelitis of the pubis following suspension of the neck of the bladder with use of bone anchors. A report of four cases. *J Bone Joint Surg Am* 1999;81:1736.
85. Rackley RR, Abdelmalak JB, Madjar S, et al. Bone anchor infection in female pelvic reconstructive procedures: a literature review of series and case reports. *J Urol* 2001;165:1975.
86. Goldberg RP, Tchetgen MB, Snad PK, et al. Incidence of pubic osteomyelitis after bladder neck suspension using bone anchors. *Urology* 2004;63:704–708.
87. Abramov Y, Sand PK, Gandhi S, Botros-Brey S, Goldberg RP. Chronic pelvic actinomycosis following a bone anchored sling procedure. *J Urol* 2004;171:2381.

---

# 12 Pharmacological Therapy for Overactive Bladder

---

*H. Mallory Reeves, MD, Eric S. Rovner, MD,  
and Alan J. Wein, MD*

## *CONTENTS*

INTRODUCTION  
UROSELECTIVITY  
SPECIFIC AGENTS  
CONCLUSION  
REFERENCES

---

## INTRODUCTION

Multiple classes of drugs, drug therapies, and other pharmacological agents are potentially useful to decrease bladder contractility or decrease sensation and thereby treat overactive bladder (OAB) (*see* Table 1), but few have been utilized clinically (1). Antimuscarinic agents are the only oral class of drugs that have demonstrated proof of concept in managing this disorder and remain the most commonly prescribed treatment. Since Diokno and Lapides described the properties and application of oxybutynin chloride in the therapy of urinary dysfunction, antimuscarinic therapy has remained the mainstay of therapy for detrusor overactivity and, more recently, the symptom complex known as OAB (2,3). According to the International Continence Society (ICS), OAB is classified as a symptom syndrome and is characterized by urgency, with or without incontinence and sometimes with frequency and nocturia (4). These symptoms are suggestive of detrusor overactivity (that is, urodynamically demonstrable IVCs) but can be attributed to other forms of voiding or urinary dysfunction as well.

Despite years of basic science and clinical research, the optimal pharmacotherapy for OAB has not yet been identified. The ideal or optimal pharmacological treatment for OAB would be universally efficacious in relieving or curing the symptoms of OAB completely without side effects, adverse events, effects on other organs, or interactions with other drugs; would have no contraindications; and finally, could be administered conveniently, easily, and inexpensively. Unfortunately, none of the existing or currently emerging agents meet all of these criteria. Advancements in the understanding of the pathophysiology of OAB and the multiple, nonautonomic mechanisms that may responsible for the clinical manifestations of the condition promise to provide a whole new array of pharmacological options (1,5). Other future potential (and in some cases theoretical) therapies that are not yet near clinical application include genetic manipulation; tissue engineering; characterization and manipulation of purinergic pathways, including

From: Current Clinical Urology: Female Urology: A Practical Clinical Guide  
Edited by: H. B. Goldman and S. P. Vasavada © Humana Press Inc., Totowa, NJ

Table 1  
Potential Pharmacological Therapy for OAB

---

Anticholinergic agents
Musculotropic relaxants
Calcium antagonists
Potassium channel openers
Calcium channel modulators
Prostaglandin inhibitors
$\beta$ -Adrenergic agonists
$\alpha$ -Adrenergic antagonists
Tricyclic antidepressants
Dimethyl sulfoxide (DMSO)
Phosphodiesterase inhibitors
Modulators of:
Serotonin
Nitric oxide
Calcitonin gene-related peptide
Vasoactive intestinal polypeptide
Neuropeptide Y
Endothelins
Bradykinins
GABA
Enkephalins
Nociceptin
Polysynaptic inhibitors
Tachykinin receptor antagonists
Purinerbic antagonists

---

*Source:* Adapted from ref. 1.

modulation of the P2X receptor; phosphodiesterase inhibitors; tachykinin receptor antagonists (neurokinin antagonists); and alteration of central dopaminergic, GABA-ergic, and enkephalergic pathways (6). However, because of their limited clinical utility at present, these therapies are not considered further here.

For many years, widely available and well-studied agents for OAB in the United States included oxybutynin, tolterodine, propantheline, dicyclomine, and hysocyamine. Several new oral antimuscarinic agents have become available. This chapter attempts to highlight some of the existing, clinically available therapies for the pharmacological treatment of OAB.

## UROSELECTIVITY

Most of the neurohumoral stimulus for physiological bladder contraction, both volitional and involuntary, is from acetylcholine (ACh)-induced stimulation of autonomic, postganglionic parasympathetic muscarinic cholinergic receptor sites on bladder smooth muscle. The majority of current pharmacotherapy for OAB is therefore directed toward the muscarinic receptor. Because autonomic innervation, receptors, and receptor content are ubiquitous throughout the human body's organ systems, there are no agents in clinical use that are purely selective for action on the lower urinary tract, that is, uroselective. Thus, the majority of side effects attributed to drugs facilitating bladder

storage or emptying are the collateral effects on organ systems that share some of the same neurophysiological or neuropharmacological characteristics as the lower urinary tract. The problems are (1) how to affect bladder function without interfering with the function of other organ systems (uroselectivity) and (2) how to eliminate overactivity without disturbing normal micturition (7).

In general, drug therapy for all lower urinary tract dysfunction is hindered by a lack of uroselectivity, which may explain problems with efficacy and tolerability in OAB pharmacotherapy (1,8). Many of the drugs described are highly effective agents; however, dose-dependent systemic adverse effects can often limit the physician's ability to exploit a given drug's therapeutic effects. Escalating dosages may lead to increasing unwanted effects on other organ systems, which may result in not reaching a therapeutic dose. Nevertheless, improvements in uroselectivity can be approached in a number of ways: (1) receptor selectivity; (2) organ selectivity; and (3) alterations in drug delivery, metabolism, and distribution. Receptor selectivity may be of little use unless the receptor is not expressed in other organs or unless a receptor subtype exists that is specific for the organ under treatment or its neurological connections.

Organ specificity indeed may be the "magic bullet" of drug therapy. The ideal organ-selective drug for the lower urinary tract would exert desirable effects only on the bladder and/or urethra thus eliminating side effects. Theoretically, the concept of organ specificity is attractive, but practically and clinically it is very difficult to achieve. Alternate drug delivery systems may be helpful by increasing the target concentration of an agent (e.g., intravesical therapy) or by changing the metabolism of a drug to lower the concentration of a metabolite particularly productive of side effects. Certain drugs or their metabolites may be prevented from gaining access to a potentially troublesome site of activity (through the blood-brain barrier, e.g.) either by virtue of their innate characteristics or by alteration.

Given our current state of imperfection in this area, it is important to distinguish potential laboratory effects from real clinical effects, both beneficial and adverse. Commercial or marketing claims of superiority of one agent based on organ or receptor selectivity or alternative mechanisms of drug delivery should be subject to strong scrutiny and be supported by both laboratory and clinical data. In the absence of such data, these claims have little scientific merit and are more theoretical than real.

## SPECIFIC AGENTS

### *Relatively Pure Antimuscarinic Agents*

Antimuscarinic agents such as atropine inhibit normal and involuntary contractions (IVCs) of the bladder (9–11). Generally, volume to the first IVC increases, the amplitude of the IVC decreases, and the total bladder capacity increases (12). Anticholinergic agents do not significantly alter bladder compliance in normal individuals or in those with detrusor overactivity in whom the initial slope of the filling curve on cystometry is normal prior to the IVC (12). The effect of pure antimuscarinics in patients who exhibit only decreased compliance has not been well studied.

Although it is widely accepted that there is no sacral parasympathetic outflow to the bladder during normal filling, antimuscarinic drugs increase and cholinomimetic and anticholinesterase inhibitors decrease bladder capacity (13). It is during this phase of the micturition cycle (filling and storage) that antimuscarinic agents are thought to exert their favorable effects.



Andersson and Yoshida have proposed that one potential mechanism by which these drugs act during bladder filling to reduce detrusor overactivity is via an effect on afferent activity (14). Antimuscarinic drugs seem to affect the sensation of urgency during filling, suggesting ongoing ACh-mediated stimulation of detrusor tone. Furthermore, a basal release of ACh has been demonstrated from nonneuronal, perhaps urothelial, as well as neuronal sources in the human bladder, which may be related to stretching of the bladder wall as it fills (15). If this is the case, agents that inhibit ACh release or activity during bladder filling could contribute to bladder relaxation or maintenance of low bladder tone during this phase of the micturition cycle with a consequent decrease in symptomatology unrelated to the occurrence of an IVC.

The designations  $M_1$  through  $M_5$  are used to describe the pharmacological and molecular subtypes of muscarinic ACh receptors (16). Human urinary bladder smooth muscle contains a mixed population of  $M_2$  and  $M_3$  subtypes, with a predominance of  $M_2$  receptors (80% of the total muscarinic receptor population) (17). Although the minor population of  $M_3$  receptors is believed primarily responsible for mediating bladder contraction (18), experimental evidence suggests that  $M_2$  receptors are also involved in bladder contractility in some species and in certain types of lower urinary tract dysfunction (19–23). As mentioned, available antimuscarinic agents are limited by a lack of selectivity that is responsible for the classic anticholinergic side effects. Although  $M_3$ -selective agents have the potential to eliminate some of these side effects, the  $M_3$  receptors in lower urinary tract tissues appear identical to those elsewhere in the body (24). However, if some as-yet-undefined heterogeneity among  $M_3$  receptors in various tissues is uncovered, then it may be reasonable to postulate a “uroselective” agent acting only on the muscarinic receptors in the lower urinary tract.

The potential side effects of all antimuscarinic agents include inhibition of salivary secretions (xerostomia or dry mouth); blockade of the sphincter muscles of the iris and the ciliary muscle of the lens to cholinergic stimulation (blurry vision); tachycardia; drowsiness; cognitive dysfunction; inhibition of gut motility (constipation); and inhibition of sweat gland activity. Agents that possess ganglionic-blocking activity may also cause orthostatic hypotension and erectile dysfunction at the high doses generally required for manifestation of nicotinic activity. In general, antimuscarinic agents are contraindicated in patients with narrow-angle glaucoma and should be used with caution in patients with significant bladder outlet obstruction.

#### **ATROPINE SULFATE (DL-HYOSCYAMINE)**

Atropine sulfate (DL-hyoscyamine) is rarely used to treat OAB because of its adverse systemic effects (19). The pharmacologically active portion of the racemic mixture of atropine is L-hyoscyamine. This agent and hyoscyamine sulfate are reported to produce anticholinergic actions and side effects similar to other belladonna alkaloids. Hyoscyamine sulfate is also available in a sublingual formulation. The formulation offers a theoretical advantage regarding absorption and metabolism, but controlled studies of its effects on bladder hyperactivity are lacking (19).

#### **PROPANTHELINE BROMIDE**

Proprantheline bromide is a nonselective antimuscarinic agent that, as a quaternary ammonium compound, has low and varying biological availability. It is metabolized quickly to inactive metabolites. The usual adult dose is 15–30 mg every 4–6 h, but titration is often necessary, and higher doses sometimes are required. Little evaluable data on the

drug's effectiveness in treating OAB is available. The Agency for Health Care Policy and Research (AHCPR) Urinary Incontinence Guideline Panel reviewed five randomized controlled trials (RCTs) of propantheline (25). Of the total number of patients enrolled, 82% were female. Reports of cure ranged from 0 to 5% (all figures refer to percentage effect on drug minus percentage effect on placebo), reductions in urge incontinence ranged from 0 to 53%, side effects ranged from 0 to 50%, and dropouts ranged from 0 to 9%.

### TOLTERODINE TARTRATE

Developed specifically for treatment of OAB, tolterodine tartrate is not muscarinic receptor subtype specific but demonstrates some selectivity for the bladder over salivary gland in certain experimental models (26–28). Clinically, it seems to have a favorable side-effect profile not only on dry mouth but also on bowel and central nervous system (CNS) effects (17). The immediate-release (IR) formulation of tolterodine is available in 1- and 2-mg tablets and is dosed twice daily. The drug is primarily metabolized by the liver, with the primary hepatic metabolite possessing near-equivalent antimuscarinic potency.

A number of clinical trials have evaluated the efficacy and tolerability of tolterodine. Stahl and colleagues first studied the effect of a single 6.4-mg dose on bladder and salivary function (29). At 5 h after administration, the effects on the bladder were maintained, but no significant effects on salivation were detected. Stimulated salivation was inhibited only near the time of peak serum levels.

Appell reported on a pooled analysis of 1120 patients in whom tolterodine (1 or 2 mg twice daily) was compared with IR oxybutynin (5 mg three times daily) or placebo (30). Compared with placebo, both active drugs significantly decreased the number of incontinent episodes and micturitions occurring in 24 h and increased the volume voided per micturition. Mean episodes of urge urinary incontinence (UUI) decreased from 40 to 60%, and frequency of urination decreased by approx 20% compared to baseline. The 2-mg dose of tolterodine (twice daily) and the 5-mg (three times daily) dose of oxybutynin were equally efficacious, but tolerance was significantly better with tolterodine when adverse events such as dry mouth (frequency and intensity), dose reductions, and patient withdrawals were considered.

Chancellor and Freedman conducted a large double-blind study comparing tolterodine (2 mg twice daily) with placebo (31). Tolterodine reduced urge incontinence episodes and produced significant reductions in micturition frequency and pad use compared with placebo. Of tolterodine-treated patients, 2% reported severe dry mouth, and 10% reported moderate dry mouth, compared with 0 and 2%, respectively, of placebo patients. Mild dry mouth was reported by 18% of drug-treated patients and by 6% of placebo-treated patients. Constipation was reported by 7% of tolterodine recipients and 4% of placebo recipients. The profile and frequency of other adverse events in the two treatment groups were similar. CNS adverse events were not significantly different between the tolterodine and placebo groups.

Kreder et al. studied the effects of tolterodine IR in patients with pure UUI vs those with urge-predominant mixed urinary incontinence (UI) (32). At the end of the 16-wk trial, there was no statistical difference between the two groups with respect to reductions in total UI episodes, patient-reported cure rate, or reduction in pad use (67 vs 75%, 39 vs 44%, and 21 vs 27%, mixed UI vs pure UUI, respectively; all difference not significant [NS],  $p < 0.05$ ). The reported incidence of side effects in this trial was similar to that previously reported in other studies.

Tolterodine is available in an extended-release (ER), once-daily formulation. The pharmacokinetic profile of the ER formulation (tolterodine ER) and dosing can be seen in Tables 2 and 3, respectively. Von Kerrebroeck and colleagues compared this agent to the twice-daily formulation and placebo as part of the largest trial ever performed in patients with OAB (33). In this pivotal study, the median number of UI episodes in patients receiving the once-daily formulation, the twice-daily formulation, and placebo were reduced by 71, 60, and 33%, respectively. Both preparations were statistically superior to placebo, and the once-daily preparation was statistically more effective than the twice-daily preparation using this outcome indicator. Statistically significant improvements in all other micturition diary variables were recorded for both formulations over placebo. The incidence of dry mouth was 23% for once-daily tolterodine, 30% for twice-daily tolterodine, and 8% for placebo. Khullar et al. compared tolterodine ER with placebo in an 8-wk, double-blind, randomized, controlled trial involving 854 women with urge-predominant mixed UI. Tolterodine ER significantly reduced weekly UUI episodes ( $-12.3$ ) and daily micturition frequency ( $-2.1$ ) and increased the median volume voided/micturition ( $+34$  mL) compared with placebo ( $-8.0$ ,  $-1.3$ , and  $+19$  mL, respectively;  $p < 0.0001$ ) (34).

Furthermore, the overall efficacy of tolterodine ER does not seem to be markedly different between those who have severe UI at baseline compared to those who have less-severe UI. In a post hoc analysis from the Von Kerrebroeck study (33), Landis et al. (35) compared those with severe UI ( $<20$  episodes of UI per week) to those with less-severe UI ( $<21$  episodes of UI per week) and found that the improvement in UI episodes was no different between the two groups (71 vs 68%, severe vs nonsevere; NS,  $p < 0.05$ ).

Using an evidence-based approach, the pharmacology subcommittee from the Proceedings of the Third International Consultation on Incontinence (ICI) recommended tolterodine for the treatment of UUI (36).

## TROSPIUM CHLORIDE

Trospium chloride is an antimuscarinic agent with atropine-like effects. It possesses no selectivity for muscarinic receptor subtypes  $M_1$ – $M_5$ . In contrast to other agents, it contains a highly charged quaternary ammonium group that may limit penetration across the blood-brain barrier (37). This may explain why few, if any, central anticholinergic effects have been reported with administration of the drug (38,39). The pharmacokinetic profile and dosing for trospium can be seen in Tables 2 and 3, respectively.

The exact metabolic pathway for trospium is not well defined, but approx 5–10% of an oral dose undergoes absorption. Of this absorbed oral dose, 60% of the drug is excreted in the urine as the active unaltered, unmetabolized compound. The presence of unaltered, unmetabolized drug in the urine following oral dosing has been hypothesized to be responsible for some of the favorable effects on the bladder relative to those seen on the salivary gland (40).

In support of this, it is known that muscarinic receptor density in the urothelium is significantly greater than that seen in the detrusor muscle, and that the urothelium may modulate the activity of the underlying smooth muscle of the detrusor (41). It is interesting to speculate whether these urothelial muscarinic receptors may have a role in bladder overactivity and, if so, whether there exists any role for direct muscarinic blockade of the urothelium in treating symptoms of the OAB. On the negative side of this argument, however, is the fact that there is no evidence for augmented efficacy of this agent over others that do not achieve a significant urinary concentration.

Table 2  
Selected Pharmacokinetics of Commonly Used Antimuscarinic OAB Agents in the United States

Agent	Bioavailability (%)	$t_{max}$ (h)	$t_{1/2}$ (h)	Protein bound (%)	Excreted unchanged in urine (%)	Active metabolites	Metabolism	Effect of food on pharmacokinetics
Tolterodine extended release <sup>a</sup>	10–74	2–6	8.4	>96	<1% (<14% including active metabolite)	Yes	Liver: CYP2D6 and CYP3A4	No
Oxybutynin extended release <sup>a</sup>	156–187% greater than IR form (IR form $\approx$ 6)	11.8–12.7	12.4–13.2	n/a	<0.1%	Yes	Liver: CYP3A4	No
Solifenacin <sup>a</sup>	90	3–8	45–68	96	<15%	Minimal	Liver: CYP3A4	No
Darifenacin <sup>a</sup>	15–19	5.2–7.6	12–19.95	98	<3%	No	Liver: CYP2D6 and CYP3A4	No
Trospium <sup>a</sup>	4–16.1	5.3	18.3	50–85	60	No	Not well defined but eliminated at least in part by active tubular (renal) secretion	Yes
Oxybutynin patch <sup>c</sup>	n/a	10–48	7–8 <sup>b</sup>	n/a	<0.1%	Yes	CYP3A4	No

<sup>a</sup> $t_{max}$  = time to maximum serum concentration.

<sup>b</sup> $t_{1/2}$  = terminal elimination half-life.

n/a, not available.

<sup>c</sup>From prescribing information/product label.

<sup>d</sup>Following removal of the patch.

**Table 3**  
**Recommended Dosing of Commonly Utilized Antimuscarinic Agents in the United States**

	<i>Available doses</i>	<i>Dose range</i>	<i>Regimen</i>
Tolterodine extended release	2- and 4-mg tablet	2–4 mg	Daily
Oxybutynin extended release	5-, 10-, and 15-mg tablet	5–30 mg	Daily
Darifenacin	7.5- and 15-mg tablet	7.5–15 mg	Daily
Solifenacin	5- and 10-mg tablet	5–10 mg	Daily
Trospium	20-mg tablet	20 mg	Twice daily
Oxybutynin patch	3.9-mg/d patch	3.9-mg/d patch	Every 3 d

Trospium is a well-studied compound; however, many of the earlier trospium studies utilized urodynamic parameters (as opposed to voiding diaries) as end points, making comparison to other antimuscarinic agents difficult. Cardozo et al. reported the results of a randomized, double-blind, placebo-controlled study of 20 mg trospium twice daily in 208 patients with idiopathic detrusor instability (42). Volume to first contraction and bladder capacity were significantly improved in the treated as compared to the placebo groups ( $p < 0.05$ ), and there was more than a threefold difference in the number of patients reporting significant improvement in their symptoms in favor of trospium. Side effects and safety parameters were similar between groups, and no CNS effects were reported in patients receiving trospium. Similar results have been reported by other authors in patients without (43) and with neurogenic bladder dysfunction (44).

Results from two large, multicenter, double-blind, placebo-controlled studies have been published, involving a total of 1181 patients with OAB (45,46). In both studies, patients were randomly assigned to 20 mg trospium chloride twice daily or placebo for 12 wk. Symptoms were recorded in a voiding diary, and patients assessed the severity of their urgency symptoms using the validated Indevus Urgency Severity Scale. In both studies, trospium was associated with significantly greater reductions in urinary frequency, number of urge incontinence episodes, and Indevus Urgency Severity Scale scores and significantly greater increases in average volume voided per void compared with placebo ( $p < 0.001$ ). Treatment effects were apparent early on, with improvement in all assessment parameters by week 1 ( $p < 0.005$ ).

Trospium has been compared to other antimuscarinic agents, such as oxybutynin and tolterodine. In one study, trospium was as effective as oxybutynin in patients with hyperreflexia caused by spinal cord injury but had fewer adverse effects (37). Halaska and colleagues reported on the long-term (52 wk) results of 358 patients with urge syndrome treated with either 20 mg trospium twice daily or 5 mg oxybutnin twice daily (47). There were statistically significant improvements for both drugs in diary parameters such as micturition frequency, UI episodes, and urge episodes as well as urodynamic outcome measures, including cystometric capacity. The risk of dry mouth during the study was greater with oxybutynin, suggesting a favorable tolerability profile for trospium. Reported in abstract form only, trospium was compared with tolterodine IR 2 mg twice daily in a placebo-controlled study (48). The efficacy and safety profiles of the two agents were similar, and both reduced urinary frequency relative to placebo.

The ICI Subcommittee on Pharmacology concluded, based on well-done clinical trials, that trospium is an effective and safe option for the treatment of UUI (36).

## DARIFENACIN

Darifenacin is a once-daily, relatively selective M<sub>3</sub> receptor antagonist. The potential implications of the high degree of M<sub>3</sub> selectivity of this agent are interesting. It is well established that activation of the M<sub>3</sub> receptor in the detrusor is responsible, at least in part, for both normal volitional bladder emptying and the involuntary bladder contractions responsible for symptoms related to OAB. Thus, although it is possible to speculate that highly selective blockade of the M<sub>3</sub> receptor would be beneficial in maximally reducing symptoms of OAB while sparing blockade of the other muscarinic subtypes throughout the body, it is unclear whether such an agent would also result in improved tolerability given its likely systemic effects on M<sub>3</sub> receptors elsewhere, including those in the salivary glands, gut, and CNS.

In addition, it is possible to consider that this particular agent, because of its relative lack of selectivity for other muscarinic receptor subtypes, may have fewer collateral effects on end organs possessing a significant density of muscarinic receptors other than the M<sub>3</sub> subtype, such as the heart (M<sub>2</sub>) and brain (M<sub>1</sub>, M<sub>2</sub>, M<sub>4</sub>, and M<sub>5</sub>), thus providing an additional margin of safety. The pharmacokinetic profile and dosing of darifenacin can be seen in Tables 2 and 3, respectively. Organ selectivity for the bladder over the salivary glands has been demonstrated in some animal models (49,50), but the clinical importance of this finding has not been established (19).

Small, early studies proved efficacy, but in small doses that did not cause salivary problems, darifenacin was no more effective than placebo (51,52). Haab et al. (53) reported on a multicenter, placebo-controlled trial of darifenacin. Patients (561) were randomly assigned to three different doses of active drug (3.75, 7.5, and 15 mg) and treated for 12 wk. At the higher doses (7.5 and 15 mg), median reductions in UI episodes per week were statistically significant compared with placebo (−67.7, −72.8, and −55.9% for the 7.5 and 15 mg doses and placebo, respectively) and comparable to that reported in other trials of antimuscarinic compounds in patients with OAB. Statistically significant improvements in urinary frequency, mean volume per void, number of urgency episodes per day, and severity of urgency were also reported. Dry mouth was reported by 18.8, 31.3, and 8.5% of patients in the 7.5-mg, 15-mg, and placebo groups, respectively, but there were no patient withdrawals caused by this adverse event. Constipation was noted in 14.4, 13.9, and 6.7% of patients in 7.5-mg, 15-mg, and placebo groups, respectively, but only 0.9% of patients discontinued the active drug because of this event. CNS and cardiac safety profiles were comparable to placebo.

Steers et al. compared darifenacin to placebo in a large, multicenter RCT involving 398 patients with OAB (54). Efficacy was evaluated at 2 and 12 wk for primary end points (change in incontinence episodes from baseline) and secondary end points, which included frequency and urgency episodes/day, bladder capacity, urgency severity, nocturia, and number of significant leaks/week. Dose escalation from 7.5 to 15 mg was permitted in the darifenacin arm, and 59% of patients opted for the higher dose. Overall, there was a significant reduction in the median number of incontinent episodes in the darifenacin-treated group compared to placebo (−62.9 vs −48.1%, drug vs placebo, respectively;  $p = 0.035$ ). Darifenacin also achieved statistically significant improvements in the secondary efficacy variables of significant leaks/week, frequency, bladder capacity, urgency, and urgency severity.

Cardozo and Dixon evaluated a novel efficacy parameter in a multicenter, double-blind RCT with a primary end point of change in warning time (55). *Warning time* was

defined as the time from the first sensation of urgency to voluntary micturition or incontinence. Treatment resulted in significant improvements in warning time when compared to placebo, with a median increase of 4.3 min in the darifenacin-treated patients compared with those treated with placebo ( $p = 0.003$ ). In theory, increasing warning time would extrapolate to improvements in symptoms and a decrease in incontinence episodes, but these were not extensively assessed as additional variables, and a change in warning time has not been correlated with a change in symptoms. There was a statistically significant reduction in the severity of urgency vs placebo in the clinic setting ( $p = 0.035$ ) but not at home.

As mentioned, cognitive impairment with antimuscarinic agents may be caused by interaction with other cholinergic receptors, including the  $M_1$  receptors. It has been postulated that darifenacin with its  $M_3$  selectivity might be associated with fewer unwanted CNS effects. Lipton et al. assessed the cognitive effects of darifenacin on unimpaired/minimally impaired elderly patients in a double-blind, three-period crossover trial (56). Darifenacin formulations used in the study were the IR tablets (5 mg three times daily) and the sustained-released tablets (3.75, 7.5, or 15 mg daily) in addition to a placebo arm. Patients were randomly assigned to three of these five treatments for 2 wk at a time with a 7-d washout between treatments. There was no statistical difference compared to placebo for the mean change from baseline of word recognition sensitivity, speed of choice reaction time, and memory scanning sensitivity. Likewise, no effect was seen on simple reaction time, digit vigilance speed or accuracy, or word recognition speed. This held true for memory scanning speed as well, except for the 3.75-mg dose, which showed a decrease in this cognitive parameter when compared to placebo. Last, there was no effect on self-rated alertness or contentment, but interestingly, the 15-mg dose showed a decrease in self-rated calmness, and the 3.75-mg dose demonstrated improvement ( $p = 0.007$  and  $p = 0.046$ , respectively).

The ICS at the Third Consultation on Incontinence endorsed darifenacin as efficacious and safe based on strong, good-quality RCTs (36).

## SOLIFENACIN

Solifenacin is a novel once-daily antimuscarinic agent. It is an isoquinolone carboxylate derivative that may demonstrate organ selectivity for the bladder vs salivary glands in some animal models (57–59). The half-life of the drug is quite long at almost 60 h; however, the clinical significance of this unusual pharmacokinetic property is unclear. Other pharmacokinetic parameters are outlined in Table 2.

Cardozo et al. randomly assigned 911 patients to receive either 5 or 10 mg solifenacin or placebo in a 12-wk multicenter trial (60). The primary outcome variable was change in urinary frequency. Secondary efficacy variables assessed included urinary urgency, nocturia, volume voided, total incontinence episodes, and UUI episodes. As compared to placebo (–1.59), micturitions per 24 h were statistically significantly decreased with 5 mg solifenacin (–2.37,  $p = 0.0018$ ) and 10 mg solifenacin (–2.81,  $p = 0.0001$ ). The 5-mg solifenacin dose showed improvement in reduction in the number of nocturia episodes compared to placebo, but this did not reach statistical significance. All other treatment effects reached statistical significance. Based on a 3-d voiding diary, 50.3 and 49.7% of patients treated with 5 and 10 mg solifenacin, respectively, had no incontinence at the conclusion of the study; however, the percentage of dry patients in the placebo arm was not reported. Side effects were more prominent in the 10-mg group, but both strengths were well tolerated when compared to placebo.

Solifenacin has been compared to tolterodine in several studies. Chapple and colleagues randomly assigned 225 patients to four different doses of solifenacin (2.5, 5, 10, or 20 mg daily), IR tolterodine (2 mg twice daily), or placebo (61). The primary efficacy variable was urinary frequency (mean number of micturitions per 24 h). The 5-, 10-, and 20-mg dosages of solifenacin showed statistically significant changes in reducing urinary frequency compared to placebo (mean reductions  $-2.21$ ,  $-2.47$ , and  $-2.75$  daily voids for the 5-, 10-, and 20-mg doses, respectively vs  $-1.03$  for placebo); however, the groups receiving the 2.5-mg dose of solifenacin and tolterodine did not (mean reductions  $-1.45$  and  $-1.79$  for 2.5 mg solifenacin and tolterodine, respectively). Notably, there were no statistically significant differences seen between solifenacin and tolterodine compared to placebo in two other secondary outcome variables (mean reduction in incontinent episodes and urgency episodes). Dry mouth was reported by 2.6% in the placebo group compared to 14, 14, and 38% for the 5-, 10-, and 20-mg doses of solifenacin, respectively, and 24% for the tolterodine group.

In another study by Chapple et al., 5 and 10 mg solifenacin were compared to IR tolterodine (2 mg twice daily) and placebo in 1033 patients (62). The 5- and 10-mg doses of solifenacin demonstrated statistically significant decreases in UUI episodes, total incontinence episodes, and urgency episodes compared to placebo, but tolterodine did not. All three active treatments showed statistically significant improvements in mean volume voided per void and micturition frequency. Dry mouth was reported by 18.6% in the tolterodine group compared to 4.9% in the placebo group and 14 and 21.3% of patients receiving the 5- and 10-mg doses of solifenacin, respectively.

As with darifenacin, the Third Consultation on Incontinence endorsed solifenacin as effective and with an acceptable adverse event profile based on strong, good-quality RCTs (36).

### *Anticholinergic Agents With Mixed Actions*

In addition to their antimuscarinic properties, anticholinergic agents with mixed actions induce multiple *in vitro* actions, including an independent “musculotropic” or “antispasmodic” action directly on smooth muscle. This effect occurs at a site that is metabolically distal to the cholinergic or other contractile-receptor mechanism and is possibly related to calcium channel blockade. *In vitro*, its direct smooth muscle relaxant effects are reportedly 500 times weaker than its antimuscarinic effects (10). These drugs may also possess some local anesthetic properties that, like the direct musculotropic relaxant effects, may only be relevant when given intravesically. When administered orally, the clinical relevance of these actions is unclear (10,17). However, if any of these agents exerted a clinically significant direct inhibitory effect independent of their antimuscarinic action, there would be a therapeutic rationale for combination therapy with a relatively pure anticholinergic agent.

#### **OXYBUTYNIN CHLORIDE**

Oxybutynin chloride is a potent muscarinic receptor antagonist with some degree of selectivity for  $M_3$  and  $M_1$  receptors. In human tissues, it has a higher affinity for muscarinic receptors in the parotid gland than it does for those in the bladder (17). Oxybutynin was originally developed to treat gastrointestinal hypermotility disorders. Diokno and Lapidus first reported on its urological applications in 1972 (2).

This agent is a well-absorbed tertiary amine that undergoes an extensive first-pass metabolism. The pharmacological properties of its active metabolite are similar to those



of the parent compound, but they occur at concentrations six times higher. The major metabolite is also thought to cause the majority of this agent's adverse effects (63,64). Reducing the extent of first-pass metabolism by intravesical administration and transdermal or rectal administration are potential avenues to improve tolerability (65,66). Oxybutynin's side effects are antimuscarinic and are dose related.

An additional theoretical consideration is its physiochemical composition, which might permit relatively greater penetration into the CNS through the blood-brain barrier. The agent is relatively small, uncharged, and lipophilic. This may account for some of the reports of adverse CNS effects seen with this agent, especially in the geriatric population (67,68).

Initial reports documented the agent's success in depressing detrusor overactivity in patients with neurogenic bladder dysfunction; subsequent reports documented its success in inhibiting other types of bladder hyperactivity as well (9). The recommended oral adult dose of the IR formulation is 5 mg three or four times daily, although lower doses have been suggested. No antimuscarinic drug has yet been objectively demonstrated as more efficacious at relieving OAB symptoms than IR oxybutynin, and it remains the most inexpensive agent in its class. However, given the multiple alternative agents now available, the inconvenient dosing regimen, as well as the relatively unfavorable antimuscarinic side effect profile, the IR form of this agent has only limited usage. The AHCPR Urinary Incontinence Guideline Panel reviewed six RCTs (25). Reports of cure ranged from 28 to 44%, reductions in urge incontinence from 9 to 56%, side effects from 2 to 66%, and dropouts from 3 to 45%. In a review of 15 RCTs of 476 patients treated with oxybutynin, Thüroff et al. reported a mean decrease in incontinence of 52% and a mean reduction in frequency of micturitions for 24 h of 33% (69). The overall subjective improvement rate was 74% (range 61 to 100%). Side effects were reported by a mean of 70% (range 17 to 93%) of patients.

The once-daily formulation of oxybutynin considerably improved the convenience and tolerability of this agent compared to the IR tablet. The ER formulation of oxybutynin (oxybutynin ER) uses an innovative osmotic drug delivery system to release the drug at a controlled rate over 24 h. This formulation overcomes the marked peak-to-trough fluctuations in plasma levels of both the drug and the metabolites that occur with IR oxybutynin (70). The pharmacokinetic profile of the ER formulation is seen in Table 2. A trend toward a lower incidence of dry mouth with oxybutynin ER was attributed to reduced first-pass metabolism and to the maintenance of lower and less-fluctuating plasma levels of drugs.

Clinical trials of oxybutynin ER have concentrated primarily on comparing this drug with IR oxybutynin, although trials comparing it to both IR tolterodine (71) and ER tolterodine (72) have been published. Anderson et al. reported on a multicenter, randomized, double-blind study on 105 patients with urge incontinence or mixed incontinence with a clinically significant urge component. This was a dose titration study, and all had been prior positive responders to IR oxybutynin (73). The number of weekly urge incontinence episodes decreased from 27.4 to 4.8 after ER and from 23.4 to 3.1 after IR oxybutynin, and total incontinence episodes decreased from a mean of 29.3 to 6 and from 26.3 to 3.8, respectively. Dry mouth of any severity was reported by 68 and 87% of the controlled and IR groups, respectively, and moderate or severe dry mouth occurred in 25 and 46%, respectively. The relatively high rate of dry mouth reported in this study is likely because of its forced dose titration design, in which the investigators increased the dosage until a maximal dose of 30 mg was achieved or the patient reported

intolerable side effects. Curiously, a statistically greater percentage increase in voiding frequency was seen in the patients taking ER doses (54%) than in the patients taking the IR form (17%). The reason for the increase in urinary frequency seen in this study is unclear and is at odds with nearly all other antimuscarinic studies in which urinary frequency was measured as an outcome parameter.

Another study included 226 patients with urge incontinence (74). These were prior responders to anticholinergic therapy who had seven or more urge incontinence episodes per week. Reductions in UUI episodes from baseline to the end of treatment were from 18.6 to 2.9 per week (83% mean decrease) and from 19.8 to 4.4 per week (76% mean decrease) in the ER and IR oxybutynin groups (difference nonsignificant), respectively. The incidence of dry mouth increased with dose in both groups, but there was no statistically significant difference in dry mouth rates between the groups: 47.7 and 59.1% for the ER and IR groups, respectively. However, a significantly lower proportion of patients taking the ER form had moderate-to-severe dry mouth or any dry mouth compared with those taking IR oxybutynin.

Appell and colleagues compared oxybutynin ER with tolterodine IR (71). Of 378 patients enrolled, 332 completed the 12-wk study. Compared to baseline, weekly urge incontinence episodes were reduced (25.6 to 6.1 vs 24.1 to 7.8, oxybutynin ER and tolterodine IR groups, respectively) as was urinary frequency (91.8 to 67.1 vs 91.6 to 71.5 episodes per week, respectively). There was a statistically significant difference between the two drugs, favoring oxybutynin in both of these outcome parameters.

Diokno et al. directly compared the ER formulations of oxybutynin and tolterodine in patients with severe UUI and found no difference in efficacy with respect to reducing incontinent episodes (72). At the conclusion of the 12-wk study, there was no difference between the two agents with respect to the reduction of UUI episodes from baseline (87 vs 81% reduction, oxybutynin vs tolterodine, respectively;  $p < 0.05$ ); however, more patients gained complete continence on oxybutynin (23 vs 17%, oxybutynin vs tolterodine, respectively). In comparison with oxybutynin ER, dry mouth was less frequently reported with tolterodine ER (22%) than with oxybutynin ER (30%;  $p = 0.02$ ).

The ICI committee recommended oral oxybutynin for the treatment of UUI based on good-quality studies (36).

### TRANSDERMAL OXYBUTYNIN CHLORIDE

A transdermal delivery system for oxybutynin was introduced. The patch is applied for 3 d and then replaced. The potential advantages of this delivery method include patient dosing convenience and the achievement of steady serum drug levels with reduced portal delivery and thus a reduction in the hepatic metabolite.

Davila and colleagues reported the results of a randomized, double-blind, double-dummy, dose escalation study comparing a transdermal delivery system to oral IR oxybutynin for urodynamically confirmed UUI (77). All patients had previously been diagnosed with motor urge incontinence and had demonstrated symptomatic improvement with anticholinergic therapy. Compared to baseline, daily incontinence episodes decreased significantly in both groups (66 vs 72% in the patch vs oral groups, respectively). There was no significant difference in reduction in incontinence episodes between the two groups ( $p = 0.39$ ). Dry mouth of any type was noted in 38 and 94% of patients in the patch and oral groups, respectively. Of patients in the active transdermal patch group, 39% had some degree of erythema at the patch site compared to 22% in the placebo group.

The transdermal patch was also evaluated by Dmochowski and colleagues in patients with OAB and urge or mixed incontinence (78). Patients were randomly assigned to 12 wk of double-blind daily treatment with a total of 1.3, 2.6, or 3.9 mg oxybutynin delivered via a transdermal delivery system or a placebo patch administered twice weekly, followed by a 12-wk open-label, dose titration period to assess efficacy and safety further. Compared to placebo, the 3.9-mg patch significantly reduced the number of weekly incontinent episodes ( $-19.5$  vs  $-14.5$  episodes per week, patch vs placebo, respectively;  $p = 0.0165$ ); reduced daily urinary frequency ( $-2.3$  vs  $-1.7$  micturitions per day, patch vs placebo, respectively;  $p = 0.0457$ ) and increased average voided volume (24 vs 6 cc per void, patch vs placebo, respectively;  $p = 0.0063$ ). Other than a significant increase in volume voided with the 2.6-mg patch compared to placebo, there were no other differences between placebo and the 1.3- or 2.6-mg patch in any of the outcomes reported in the double-blind portion of the study. In the open-label dose titration portion of the study, a sustained reduction of almost three incontinence episodes per day was noted in all groups. Overall, dry mouth was reported by 4.6, 6.8, and 9.6% of patients in the 1.3, 2.6-, and 3.9-mg patch groups, respectively, compared to 8.3% of patients receiving placebo. This difference was not statistically significant. The most commonly reported treatment-related adverse events were erythema at the patch site.

The transdermal delivery system (3.9-mg patch) was also compared to sustained-release tolterodine (4 mg daily) in 361 patients with urge or mixed urinary incontinence (79). Median reductions in urinary incontinence episodes and micturition frequency were similar between the two agents. Dry mouth of any type was reported by 7.3, 4.1, and 1.7% in the tolterodine, patch, and placebo groups, respectively. Patch site reactions of any type (erythema, pruritis, etc.) were noted in 5.7, 26.4, and 6.9% in the tolterodine, patch, and placebo groups, respectively.

Overall, the patch is well tolerated and may offer an alternative for some patients with OAB. It does not appear to be more efficacious than either IR oxybutynin or tolterodine. Some patients may experience local reactions at the patch site, however. The patch site reactions are generally mild and self-limited. Some patients may use topical corticosteroids to relieve local symptoms at the patch site.

### **DICYCLOMINE HYDROCHLORIDE**

Dicyclomine hydrochloride is reported to possess a direct relaxant effect on smooth muscle in addition to an antimuscarinic action. However, it is not widely used to treat OAB. The ICI (Committee on Pharmacology) (36) rated this drug as effective based on pharmacological and physiological evidence, but clinical evidence from good-quality, randomized control trials was lacking. The ICI failed to recommend dicyclomine for use (36).

### **FLAVOXATE HYDROCHLORIDE**

Flavoxate hydrochloride was originally thought to be a weak anticholinergic agent and to possess a direct inhibitory action. Some authors suggested that the agent demonstrates no anticholinergic effects but does have moderate calcium antagonist activity, local anesthetic properties, and the ability to inhibit phosphodiesterase (17). Overall, favorable clinical effects have been reported in some series of patients with frequency, urgency, and incontinence and in patients with urodynamically documented detrusor hyperreflexia (80). However, Briggs and colleagues reported essentially no effect on neurogenic detrusor overactivity in an elderly population (81). A similar conclusion was reached

by Chapple and associates in a double-blind, placebo-controlled, crossover study of idiopathic detrusor overactivity (82). Reported side effects are few. The drug failed to achieve a “recommended” assessment by the ICI, which noted that cogent evidence of pharmacological or physiological efficacy (or both) was lacking for this agent as was evidence for its efficacy from good-quality RCTs (36).

### *Tricyclic Antidepressants*

Many clinicians believe that tricyclic antidepressants are useful agents for facilitating urine storage because they decrease bladder contractility and increase outlet resistance (83). These agents have been the subject of numerous pharmacological investigations to determine the mechanisms of action responsible for their varied effects (84,85). Most data are from attempts to explain the antidepressant properties of these agents and therefore are primarily from CNS tissue. The results, conclusions, and speculations inferred from the data are extremely interesting, but it is unknown whether they have relevance for the lower urinary tract.

All of these agents possess varying degrees of at least three major pharmacological actions: (1) They have central and peripheral anticholinergic effects at some, but not all, sites; (2) they block the active transport system in the presynaptic nerve ending, which is responsible for the reuptake of the released amine neurotransmitters norepinephrine and serotonin; and (3) they are sedatives, an action that occurs presumably on a central basis but may be related to antihistaminic properties. Imipramine and doxepin are the most commonly prescribed tricyclics for detrusor overactivity; data on their efficacy and tolerability for this indication are reviewed next.

#### **IMIPRAMINE**

Although this agent has prominent systemic anticholinergic effects, it has only a weak antimuscarinic effect on bladder smooth muscle (86). It does, however, exert a strong direct inhibitory effect—which is neither anticholinergic nor adrenergic—on bladder smooth muscle (87,88). The exact mechanism by which imipramine inhibits bladder activity is unknown. It has been postulated that these effects may be caused by increased serotonin activity (because of reuptake blockade) in the CNS. This may involve a direct inhibition of normal excitatory pathways or a depression of afferent ascending neural activity (89,90).

Clinically, imipramine has been effective in decreasing bladder contractility and increasing outlet resistance (91,92). The AHCPR combined results for imipramine and doxepin, citing only three RCTs and an unknown percentage of female patients (25). Percentage cures were listed as 31%, percentage reduction in urge incontinence as 20–77%, and percentage side effects as 0–70%.

The usual daily adult dosage for voiding dysfunction is 25–75 mg. The effects of imipramine on the lower urinary tract may be additive to those of the atropine-like agents. Consequently, combining imipramine with an antimuscarinic or an antispasmodic is sometimes especially useful for decreasing bladder contractility. However, caution is advised because when imipramine is used in conjunction with an atropine-like agent, the anticholinergic side effects of the drugs may also be additive. When used in the larger doses employed for antidepressant effect, the most frequent side effects of imipramine are anticholinergic. Although uncommon, serious other side effects can occur, including CNS effects, postural hypotension, cardiac toxicity, weakness, and fatigue.

### *Botulinum Toxin*

Botulinum toxin (BTX) is produced by the bacteria *Clostridium botulinum* and is one of the most potent biological toxins known to man. Only recently has this agent been adapted into a useful agent for the treatment of a variety of urological and nonurological conditions. BTX has been used successfully for the treatment of striated sphincter dyssynergia in patients with spinal cord injury (93) and has restored voiding by Valsalva in some patients with detrusor acontractility (94). Intravesical injections have been given for both neurogenic and nonneurogenic OAB (95).

There are four genetically distinct groups of the anaerobe that produce seven different immunogenic toxins, labeled A to G. The mechanism of action, at least on the motor side, is ultimately by the interruption of fusion of vesicles containing ACh to the plasma membrane, preventing release of ACh at the neuromuscular junctions. The clinical effects appear 24–72 h after injection, and reinnervation has continued for up to 12 mo, at least in some striated muscles. Because patients with OAB also have reported a marked reduction in urgency, there exists the possibility that, in addition to the motor effects, an as-yet-undefined sensory effect may be present as well. Cholinergic blockade at the neuromuscular junction would not explain a sensory effect, and BTX-A is not known to be toxic to afferent C fibers. BTX-A is known to improve certain chronic pain conditions of neurological origin, and several authors have speculated that afferent mechanisms are affected by some pathway currently unknown, possibly involving muscle spindles, suburothelial myofibroblasts, or interstitial cells (95).

Detrusor striated sphincter dyssynergia, a neurologically mediated involuntary activation of the striated pelvic floor muscle coincident with a detrusor contraction seen in some individuals with spinal cord lesions, has been relieved by transurethral or transperineal injection after a single dose of 100 U, with the effects lasting for 3–9 mo. The dose for OAB has varied between 100 and 300 U BTX-A injected in separate aliquots in over 20–30 points throughout the bladder but sparing the trigone. The duration of effect has been longer in these patients than in patients injected for DSSD, and this may indicate a difference in response between smooth and striated muscle. Patients undergoing intradetrusor injection should be warned about urinary retention and the possibility of requiring clean intermittent catheterization or even suprapubic drainage afterward. The side effects in patients treated for urological problems have been rare. There is a possibility of a rash or mild flulike illness, the latter occurring 1–2 wk after injection.

Reitz and Schurch reviewed 200 cases of neurogenic overactivity treated with BTX, 188 of whom were already on clean intermittent catheterization, with 12 on indwelling catheter drainage (96). Dysfunction etiology was spinal cord injury in 167; there were 22 with myelomeningocele and 11 with multiple sclerosis. At 3 mo, the mean cystometric bladder capacity increased from 272 to 420 mL, the mean maximal voiding pressure from 61 to 30 cm H<sub>2</sub>O, and the mean bladder compliance increased from 32 to 72 mL/cm H<sub>2</sub>O. Of the 180 incontinent patients, 132 reported complete continence after treatment; 48 reported improvement but some level of continuing incontinence. Anticholinergic medication could be “considerably reduced” in 118 patients but discontinued entirely in only 45. The duration of induced changes was 9 mo or more. There were no injection-related complications or toxin-related side effects reported.

Schurch and colleagues treated 31 patients with neurogenic detrusor overactivity with BTX injected directly into the detrusor muscle (97). Up to 30 injection sites were used per patient. The authors noted a significant rise in maximum bladder capacity and

a significant decrease in mean maximum detrusor voiding pressure 6 wk following injection. There were no adverse effects from therapy.

More recent studies have addressed the use of BTX in nonneurogenic detrusor overactivity patients. Rapp et al., in a prospective open-label pilot study, injected 35 patients transurethraly with a total of 300 U BTX-A at various sites in the bladder but avoiding the area around the ureteral orifice (98). Patients were assessed by the Incontinence Impact Questionnaire (IIQ-7) and the Urogenital Distress Inventory (UDI-6) pre- and posttreatment. Urodynamic parameters or diary information were not end points. At 3 wk posttreatment, there was a significant improvement in questionnaire scores. At 6 mo, 14 of the 24 patients who were evaluable maintained a statistically significant improvement in scores. No major side effects were reported.

In another small prospective trial, Kessler et al. enrolled 22 patients; 11 had idiopathic overactivity. In a similar fashion, 300 U BTX-A was injected among 30 sites (99). The entire trigone in this study was spared. Patients were extensively evaluated pretreatment and had clinical and urodynamic follow-up 7–10 d posttreatment and then were followed clinically every 3 mo. There was a statistically significant improvement in frequency, nocturia, number of pads in 24 h, maximum cystometric bladder capacity, bladder compliance, maximum detrusor pressure, and pressure at maximum flow. When compared to the patients with neurogenic overactivity, there were no statistical differences in treatment effect or duration of effect.

Werner et al. reported on 26 women with detrusor overactivity with incontinence and UUI who underwent transurethral injection of a total of 100 U BTX-A in 30 sites (100). Again, the trigone was spared. Patients were evaluated at 4, 12, and 36 wk postinjection. There was a significant improvement in maximum cystometric bladder capacity and compliance at 4 and 12 wk and volume at first desire to void and volume at strong desire to void at 12 wk and significant reductions in frequency and nocturia at 4 and 12 wk. There were no reports of retention or toxin-related side effects.

In summary, the intravesical use of BTX appears safe and effective, albeit invasive. Larger controlled trials are warranted.

### *Decreasing Sensory Input*

Decreasing afferent input would be an ideal treatment for sensory disorders and for overactivity in a bladder with relatively normal elastic and viscoelastic properties in which the sensory afferents constitute the first limb in an abnormal micturition reflex. Maggi and coworkers have written extensively about this type of treatment, specifically with reference to the properties of capsaicin (101–103).

### *Capsaicin*

An irritant and algesciogenic compound obtained from hot red peppers, capsaicin has highly selective effects on a subset of mammalian sensory neurons, including polymodal receptors and warm thermoreceptors (104). It activates polymodal nociceptive neurons by opening a cation-selective ion channel, allowing an influx of calcium and sodium ions that depolarize neuronal pain fibers (105,106). This ion channel is known as the vanilloid-receptor subtype 1. Repeated administration of capsaicin desensitizes and inactivates sensory neurons by several mechanisms. Systemic and topical capsaicin produce a reversible antinociceptive and anti-inflammatory action after an initially undesirable algescic effect. Local or topical application blocks C-fiber conduction and

inactivates neuropeptide release from peripheral nerve endings, accounting for local antinociception and reduction of neurogenic inflammation.

DeRidder and Baert, in an excellent review article (107), summarized trials to date as detailed by deSèze and colleagues (108). Of 49 patients with multiple sclerosis, 13 (27%) reported excellent results, and 27 (55%) noted improvement. DeRidder and Baert also cited double-blind trials that used placebo or a vehicle (30% ethanol in saline), showing clearly that capsaicin produced the positive result.

### RESINIFERATOXIN

Resiniferatoxin (RTX) is the principle active ingredient in the drug euphorbium, the air-dried latex of the cactuslike plant *Euphorbia resinifera*, which is chemically related to the phorbol esters (107,109). RTX is likewise a vanilloid and is, in fact, an ultrapotent (1000X) analog of capsaicin, but with minimal initial excitatory effect. RTX may induce desensitization in concentrations that are so low that no noxious effects are elicited (109).

Neither capsaicin nor RTX is approved for clinical use in the United States. However, the intravesical use of such agents has the potential to contribute significantly to the treatment of bladder overactivity in patients with neurogenic and other types of lower urinary tract dysfunction. Theoretically, activities affected by these agents should include only those subserved by small unmyelinated afferent C fibers. A micturition reflex stimulated via myelinated A $\delta$  afferent fibers should not be affected by capsaicin-like agents. Trials are ongoing with RTX in the United States.

### *Estrogens for Overactive Bladder*

The role of estrogen therapy in the treatment of bladder overactivity and stress incontinence has remained controversial. Unfortunately, most reported studies are observational and not randomized, blinded, or controlled. The situation is further complicated by the fact that a number of different types of estrogen have been used with varying doses, routes of administration, and treatment duration—some with progestational agents and some without. Some authorities even seem to advocate opposite positions on this question in different articles. If estrogen has a role in treating lower urinary tract symptoms in the postmenopausal female, then it is most likely through one or more of the following mechanisms: (1) raising the sensory threshold of the bladder or urethra; (2) increasing the  $\alpha$ -adrenoceptor sensitivity in urethral smooth muscle; (3) increasing urethral resistance by mechanism no. 2 or by another mechanism; or (4) correcting underlying urogenital atrophy or other pelvic floor musculofascial pathology.

The Cochrane group reported on estrogen therapy for the treatment of urinary incontinence (110), with 28 trials reviewed, which included 2926 women. In comparing estrogen to placebo for the treatment of UI, the preponderance of evidence suggested that estrogen was superior. Approximately 50% of subjects in the reviewed trials were either cured or improved in the estrogen arms compared to only 25% of subjects in the placebo arms. The effect appeared greater in patients with UUI as opposed to stress UI, although it was stated in the analysis that it was unclear whether this was a real difference or caused by artifact secondary to methodological problems. In this analysis, it was suggested that combining estrogen therapy with a progestational agent may negate the favorable effect of estrogens on UI. Finally, the optimal dosage, method of administration, and duration of therapy remain poorly defined.

In contrast to the Cochrane review, Hendrix et al. reported on the urinary incontinence outcomes of the Women's Health Initiative (111). This was a multicenter, double-blind, placebo-controlled trial that randomly assigned 27,347 postmenopausal women to either conjugated equine estrogen or conjugated equine estrogen plus medroxyprogesterone acetate vs placebo. More than 23,000 women had outcome information available on urinary incontinence symptoms at baseline and after 1 yr. Subgroup analyses were reported that divided the types of incontinence into stress, urge, and mixed in relation to multiple demographic and medical parameters. The analyses concluded that both the estrogen alone and estrogen-plus-progestin groups had an increased relative risk of worsening of the severity of existing UI symptoms (regardless of the type of incontinence reported at baseline) and, furthermore, an increased risk of developing incontinence in those who were continent at baseline. These authors recommended against the use of estrogens or estrogens in combination with progestational agents for the treatment of existing incontinence or as a preventive measure against the development of incontinence in continent women.

## CONCLUSION

Notwithstanding suggestions to the contrary, none of the existing pharmacotherapies for OAB are either absolutely selective for the bladder or universally efficacious. Dose-dependent side effects such as dry mouth and constipation limit the utility of the oral antimuscarinic agents in particular. Furthermore, although statistically significant and well-documented reductions in frequency, urgency, and urinary incontinence episodes have been noted in published randomized, double-blind, placebo-controlled studies, complete "cure" of OAB is not commonly seen clinically. A comprehensive systematic review of currently available anticholinergic medications by the Cochrane group concluded the following: "The use of anticholinergic drugs by people with OAB syndrome results in statistically significant improvement in symptoms. However, the clinical significance of these differences is uncertain.... Dry mouth is a common side effect of therapy," (112). Given this statement, it is hoped that ongoing and promising investigations into the etiology and therapy of OAB will lead to further improvements for the pharmacological treatment of this highly prevalent condition.

## REFERENCES

1. Andersson K-E, Wein AJ. Pharmacology of the lower urinary tract: basis for current and future treatments of urinary incontinence. *Pharmacol Rev* 2004;56:581–631.
2. Diokno AC, Lapides J. Oxybutynin: a new drug with analgesic and anticholinergic properties. *J Urol* 1972;108:307–309.
3. Rovner ES, Wein AJ. Modern pharmacotherapy of urge urinary incontinence in the USA: tolterodine and oxybutynin. *BJU Int* 2000;86(suppl 2):44–53.
4. Abrams P, Cardozo L, Fall M, et al. The standardisation of terminology of lower urinary tract function: report from the Standardisation Sub-committee of the International Continence Society. *Neurourol Urodyn* 2002;21:167–178.
5. Sellers DJ, Chapple CR, Chess-Williams R. Potential therapeutic targets for treatment of the overactive bladder. *World J Urol* 2001;19:307–311.
6. Yoshimura N, Chancellor M. Current and future pharmacological treatment for overactive bladder. *J Urol* 2002;168:1897–1913.
7. Andersson KE. The overactive bladder: pharmacologic basis of drug treatment. *Urology* 1997;50:74–84.
8. Andersson KE. The concept of uroselectivity. *Eur Urol* 1998;33(suppl 2):7–11.
9. Andersson K-E. Current concepts in the treatment of disorders of micturition. *Drugs* 1988;35:477–494.
10. Andersson K-E. Advances in the pharmacological control of the bladder. *Exp Phys* 1999;84:195–213.



11. Jensen DJ. Pharmacological studies of the uninhibited neurogenic bladder. II. The influence of cholinergic excitatory and inhibitory drugs on the cystometrogram of neurological patients with normal and uninhibited neurogenic bladder. *Acta Neurol Scand* 1981;64:175–195.
12. Wein AJ. Neuromuscular dysfunction of the lower urinary tract and its management. In: *Campbell's Urology, 8th ed.*, (Walsh PC, Retik A, Vaughan ED Jr, et al. eds.), Saunders, Philadelphia, 2002; p.931–967.
13. Andersson K-E. Changes in bladder tone during filling: pharmacological aspects. *Scand J Urol Nephrol* 1999;201:67–72.
14. Andersson K-E, Yoshida M. Antimuscarinics and the overactive detrusor— which is the main mechanism of action? *Eur Urol* 2003;43:1–5.
15. Yoshida M, Inadome A, Murakami S, et al. Effects of age and muscle stretching on acetylcholine release in isolated human bladder smooth muscle [abstract]. *J Urol* 2002;167:40.
16. Caulfield MP. Muscarinic receptors—characterization, coupling and function. *Pharmacol Ther* 1993; 58:319–379.
17. Chapple CR. Muscarinic receptor antagonists in the treatment of overactive bladder. *Urology* 2000; 55:33–46.
18. Fetscher C, Fleichman M, Schmidt M, et al. M(3) muscarinic receptors mediate contraction of human urinary bladder. *Br J Pharmacol* 2002;136:641–643.
19. Andersson K-E, Appell R, Cardozo L, et al. Pharmacological treatment of urinary incontinence. In *Incontinence* (Abrams P, Khoury S, Wein AJ, eds.), Health Publication, Plymouth, UK, 1999, pp. 447–486.
20. Braverman A, Legos J, Young W, et al. M<sub>2</sub> receptors in genitourinary smooth muscle pathology. *Life Sci* 1999;64:432.
21. Braverman AS, Ruggieri MR, Pontari MA. The M<sub>2</sub> muscarinic receptor subtype mediates cholinergic bladder contractions in patients with neurogenic bladder dysfunction. *J Urol* 2001;165:36.
22. Chapple CR, Yamanishi T, Chess-Williams R. Muscarinic receptor subtypes and management of the overactive bladder. *Urology* 2002;60:82–88.
23. Pontari MA, Braverman A, Ruggieri MR. The M<sub>2</sub> muscarinic receptor mediates in-vitro bladder contractions from patients with neurogenic bladder dysfunction. *Am J Physiol Regul Integr Comp Physiol* 2004;286:R874–R880.
24. Caulfield MP, Birdsall NJ. International Union of Pharmacology XVII. Classification of muscarinic acetylcholine receptors. *Pharmacol Rev* 1998;50:279–290.
25. Agency for Health Care Policy and Research: Urinary Incontinence Guideline Panel. *Urinary Incontinence in Adults: Clinical Practice Guidelines* (AHCPR publication no. 92-0038), Public Health Service, US Department of Health and Human Services, Rockville, MD, 1992.
26. Nilvebrant L, Sundquist S, Gilberg PG. Tolterodine is not subtype (M<sub>1</sub>–M<sub>5</sub>) selective but exhibits functional bladder selectivity in vivo. *Neurourol Urodyn* 1996;15:310–311.
27. Nilvebrant L, Hallen B, Larsson G. Tolterodine—a new bladder selective muscarinic receptor antagonist: preclinical pharmacological and clinical data. *Life Sci* 1997;60:1129–1136.
28. Nilvebrant L, Andersson KE, Gillberg PG, et al. Tolterodine—a new bladder-selective antimuscarinic agent. *Eur J Pharmacol* 1997;327:195–207.
29. Stahl MM, Ekstrom B, Sparf B, et al. Urodynamic and other effects of tolterodine: a novel antimuscarinic drug for the treatment of detrusor overactivity. *Neurourol Urodyn* 1995;14:647–655.
30. Appell RA. Clinical efficacy and safety of tolterodine in the treatment of overactive bladder: a pooled analysis. *Urology* 1997;50:90–96.
31. Chancellor MB, Freedman S. Tolterodine, an effective and well tolerated treatment for urge incontinence and other overactive bladder symptoms. *Clin Drug Invest* 2000;19:83–91.
32. Kreder KJ, Brubaker L, Mainprize T. Tolterodine is equally effective in patients with mixed incontinence and those with urge incontinence alone. *BJU Int* 2003;92:418–421.
33. Van Kerrebroeck P, Kreder K, Jonas U, et al. Tolterodine once-daily: superior efficacy and tolerability in the treatment of the overactive bladder. *Urology* 2001;57:414–421.
34. Khullar V, Hill S, Laval KU, et al. Treatment of urge-predominant mixed urinary incontinence with tolterodine extended release: a randomized, placebo-controlled trial. *Urology* 2004;64: 269–274.
35. Landis JR, Kaplan S, Swift S, et al. Efficacy of antimuscarinic therapy for overactive bladder with varying degrees of incontinence severity. *J Urol* 2004;171:752–756.
36. Andersson K-E, et al. Pharmacological treatment of urinary incontinence. In *Incontinence, 3rd ed.* (Abrams P, Cardozo L, Khoury S, et al. eds.), Health Publication, Plymouth, UK, 2005, pp. 809–854.

37. Madersbacher H, Stohrer M, Richter R, et al. Trospium chloride vs oxybutynin: a randomized, double-blind, multicentre trial in the treatment of detrusor hyper-reflexia. *Br J Urol* 1995;75: 452–456.
38. Pietzko A, Dimpfel W, Schwantes U, et al. Influences of trospium chloride and oxybutynin on quantitative EEG in healthy volunteers. *Eur J Clin Pharmacol* 1994;47:337–343.
39. Todorova A, Vonderheid-Guth B, Dimpfel W. Effects of tolterodine, trospium chloride, and oxybutynin on the central nervous system. *J Clin Pharmacol* 2001;41:636–644.
40. Hofner K, Oelke M, Machtens S, et al. Trospium chloride—an effective drug in the treatment of overactive bladder and detrusor hyperreflexia. *World J Urol* 2001;19:336–343.
41. Hawthorn M, Chapple CR, Cock M, et al. Urothelium derived inhibitory factor(s) influences on detrusor muscle contractility in vitro. *Br J Pharmacol* 2000;129:416–419.
42. Cardozo L, Chapple CR, Toozs-Hobson P, et al. Efficacy of trospium chloride in patients with detrusor instability: a placebo-controlled, randomized, double-blind, multicentre clinical trial. *BJU Int* 2000;85: 659–664.
43. Alloussi S, Laval KU, Ballering-Bruhl B, et al. Trospium chloride (Spasmo-lyt) in patients with motor urge syndrome (detrusor instability): a double-blind, randomised, multicentre, placebo-controlled study. *J Clin Res* 1998;1:439–451.
44. Stohrer M, Bauer P, Giannetti BM, et al. Effect of trospium chloride on urodynamic parameters in patients with detrusor hyperreflexia to spinal cord injuries. A multicentre placebo-controlled double-blind trial. *Urol Int* 1991;47:138–143.
45. Rudy D, et al. A multicenter, randomized, placebo-controlled trial of trospium chloride in overactive bladder patients [abstract]. Presented at: annual meeting of the International Continence Society; 2004. Paris, France, August 25–27, 2004.
46. Zinner N, Gittelman M, Harris R, et al. Trospium chloride improves overactive bladder symptoms: a multicenter phase III trial. *J Urol* 2004;171:2311–2315.
47. Halaska M, Ralph G, Wiedemann A, et al. Controlled, double-blind, multicentre clinical trial to investigate long-term tolerability and efficacy of trospium chloride in patients with detrusor instability. *World J Urol* 2003;20:392–399.
48. Juneman K, et al. Efficacy and tolerability of trospium chloride and tolterodine in 234 patients with urge syndrome [abstract]. *Neurourol Urodyn* 2000;19:488–490.
49. Newgreen DT, Anderson DWP, Carter AJ. Darifenacin: a novel bladder-selective agent for the treatment of urge incontinence [abstract]. *Neurourol Urodyn* 1995;14:95.
50. Wallis RM, Napier CM. Muscarinic antagonists in development for disorders of smooth muscle function. *Life Sci* 1999;64:395–401.
51. Rosario DJ, Cutinha PE, Chapple CR. The effects of single-dose darifenacin on cystometric parameters and salivary flow in patients with urge incontinence secondary to detrusor instability [abstract]. *Eur Urol* 1996;30:240.
52. Rosario DJ, Smith DJ, Radley SC, et al. Pharmacodynamics of anticholinergic agents measured by ambulatory urodynamic monitoring: a study of methodology. *Neurourol Urodyn* 1999;18:223–233.
53. Haab F, Stewart L, Dwyer P. Darifenacin, an M<sub>3</sub> selective receptor antagonist, is an effective and well tolerated once-daily treatment for overactive bladder. *Eur Urol* 2004;45:420–429.
54. Steers W, Corcos J, Foote J, et al. An investigation of dose titration with darifenacin, an M<sub>3</sub>-selective receptor antagonist. *BJU Int* 2005;95:580–586.
55. Cardozo L, Dixon A. Increased warning time with darifenacin: a new concept in the management of urinary urgency. *J Urol* 2005;173:1214–1218.
56. Lipton RB, Kolodner K, Wesnes K. Assessment of cognitive function of the elderly population: effects of darifenacin. *J Urol* 2005;173:493–498.
57. Hegde SS, Mammen M, Jasper JR. Antimuscarinics for the treatment of overactive bladder: current options and emerging therapies. *Curr Opin Invest Drugs* 2004;5:40–49.
58. Ikeda K, Kobayashi S, Suzuki M, et al. M(3) receptor antagonism by the novel antimuscarinic agent solifenacin in the urinary bladder and salivary gland. *Naunyn Schmiedebergs Arch Pharmacol* 2002; 366:97–103.
59. Kobayashi S, Ikeda K, Miyata K. Comparison of in vitro selectivity profiles of solifenacin succinate (YM905) and current antimuscarinic drugs in bladder and salivary glands: a Ca<sup>2+</sup> mobilization study in monkey cells. *Life Sci* 2004;74:843–853.
60. Cardozo L, Lisek M, Millard R, et al. Randomized, double-blind placebo controlled trial of the once daily antimuscarinic agent solifenacin succinate in patients with overactive bladder. *Journal of Urology* 2004;172:1919–1924.

61. Chapple CR, Arano P, Bosch JL, et al. Solifenacin appears effective and well tolerated in patients with symptomatic idiopathic detrusor overactivity in a placebo- and tolterodine-controlled phase 2 dose-finding study. *BJU Int* 2004;93:71–77.
62. Chapple CR, Rechberger T, Al Shukri S, et al. Randomized, double-blind placebo- and tolterodine-controlled trial of the once-daily antimuscarinic agent solifenacin in patients with symptomatic overactive bladder. *BJU Int* 2004;93:303–310.
63. Buysse G, Waldeck K, Verpoorten C, et al. Intravesical oxybutynin for neurogenic bladder dysfunction: less systemic side effects to reduced first pass metabolism. *J Urol* 1998;160:892–896.
64. Hughes KM, Lang JC, Lazare R, et al. Measurement of oxybutynin and its N-desethyl metabolite in plasma, and its application to pharmacokinetic studies in young, elderly and frail elderly volunteers. *Xenobiotica* 1992;22:859–869.
65. Dmochowski RR, Staskin DR. Advances in drug delivery: improved bioavailability and drug effect. *Curr Urol Rep* 2002;3:439–444.
66. Gupta S, Sathyan G, Mori T. New perspectives on the overactive bladder: pharmacokinetics and bioavailability. *Urology* 2002;60:78–80.
67. Donnellan CA, Fook L, McDonald P, et al. Oxybutynin and cognitive dysfunction. *BMJ* 1997;315:1363–1364.
68. Katz IR, Sands LP, Bilker W, et al. Identification of medications that cause cognitive impairment in older people: the case of oxybutynin chloride. *J Am Geriatr Soc* 1998;46:8–13.
69. Thuroff J, Abrams P, Chartier-Kasher E, et al. Medical treatment and medical side effects in urinary incontinence in the elderly. *World J Urol* 1998;16:548–561.
70. Gupta SK, Sathyan G. Pharmacokinetics of an oral once-a-day controlled-release oxybutynin formulation compared with immediate-release oxybutynin. *J Clin Pharmacol* 1999;39:289–296.
71. Appell RA, Sand P, Dmochowski R, et al. Prospective randomized controlled trial of extended-release oxybutynin chloride and tolterodine tartrate in the treatment of overactive bladder: results of the OBJECT Study. *Mayo Clinic Proc* 2001;76:358–363.
72. Diokno AC, Appell RA, Sand PK, et al. Prospective, randomized, double-blind study of the efficacy and tolerability of the extended-release formulations of oxybutynin and tolterodine for overactive bladder: results of the OPERA trial. *Mayo Clinic Proc* 2003;78:687–695.
73. Anderson RU, Mobley D, Blank B, et al. Once daily controlled vs immediate release oxybutynin chloride for urge urinary incontinence. OROS Oxybutynin Study Group. *J Urol* 1999;161:1809–1812.
74. Versi E, Appell R, Mobley D, et al. Dry mouth with conventional and controlled-release oxybutynin in urinary incontinence. The Ditropan XL Study Group. *Obst Gynecol* 2000;95:718–721.
75. Collas D, Malone-Lee JG. The pharmacokinetic properties of rectal oxybutynin—a possible alternative to intravesical administration. *Neurourol Urodyn* 1997;16:346–350.
76. Winkler HA, Sand PK. Treatment of detrusor instability with oxybutynin rectal suppositories. *Int Urogynecol J* 1998;9:100–102.
77. Davila GW, Daugherty CA, Sanders SW, et al. A short-term, multicenter, randomized double-blind dose titration study of the efficacy and anticholinergic side effects of transdermal compared to immediate release oral oxybutynin treatment of patients with urge urinary incontinence. *J Urol* 2001;166:140–145.
78. Dmochowski RR, Davila GW, Zinner NR, et al. Efficacy and safety of transdermal oxybutynin in patients with urge and mixed urinary incontinence. *J Urol* 2002;168:580–586.
79. Dmochowski RR, Sand PK, Zinner NR, et al. Comparative efficacy and safety of transdermal oxybutynin and oral tolterodine vs placebo in previously treated patients with urge and mixed urinary incontinence. *Urology* 2003;62:237–242.
80. Jonas U, Petri E, Kissel J. Effect of flavoxate on uninhibited detrusor muscle. *Eur Urol* 1979;5:106–109.
81. Briggs RS, Castleden CM, Asher MJ. The effect of flavoxate on uninhibited detrusor contractions and urinary incontinence in the elderly. *J Urol* 1980;123:665–666.
82. Chapple CR, Parkhouse H, Gardener C, et al. Double-blind placebo controlled crossover study of flavoxate in the treatment of idiopathic detrusor instability. *Br J Urol* 1990;66:491–494.
83. Wein AJ. Pharmacology of incontinence. *Urol Clin North Am* 1995;22:557–577.
84. Baldessarini RJ. Drugs and the treatment of psychiatric disorders: depression and mania. In: *Goodman and Gilman's The Pharmacological Basis of Therapeutics* (Hardman JG, Limbird LE, Molinoff PB, et al., eds.), McGraw-Hill Health Professions Division, New York, 1996, pp. 431–461.

85. Richelson E. Pharmacology of antidepressants—characteristics of the ideal drug. *Mayo Clinic Proc* 1994;69:1069–1081.
86. Levin RM, Staskin DR, Wein AJ. Analysis of the anticholinergic and muscolotropic effects of desmethylimipramine on the rabbit urinary bladder. *Urol Res* 1983;11:259–262.
87. Levin RM, Wein AJ. Comparative effects of five tricyclic compounds on the rabbit urinary bladder. *Neurourol Urodynamics* 1984;3:127–135.
88. Olubadewo J. The effect of imipramine on rat detrusor muscle contractility. *Arch Int Pharmacodyn Ther* 1980;245:84–94.
89. Andersson KE. Treatment of overactive bladder: other drug mechanisms. *Urology* 2000;55:51–57.
90. Espy MJ, Du HJ, Downie JW. Serotonergic modulation of spinal ascending activity and sacral reflex activity evoked by pelvic nerve stimulation in cats. *Brain Res* 1998;798:101–108.
91. Castleden CM, George CF, Renwick AG, et al. Imipramine—a possible alternative to current therapy for urinary incontinence in the elderly. *J Urol* 1981;125:318–320.
92. Cole AT, Fried FA. Favorable experiences with imipramine in the treatment of neurogenic bladder. *J Urol* 1972;107:44–45.
93. Dykstra DD, Sidi AA, Scott AB, et al. Effects of botulinum A toxin on detrusor-sphincter dyssynergia in spinal cord injury patients. *J Urol* 1988;139:919–922.
94. Phelan MW, Franks M, Somogyi GT, et al. Botulinum toxin urethral sphincter injection to restore bladder emptying in men and women with voiding dysfunction. *J Urol* 2001;165:1107–1110.
95. Harper M, Fowler C, Dasgupta P. Botulinum toxin and its applications in the lower urinary tract. *BJU* 2004;93:702–706.
96. Reitz A, Schurch B. Intravesical therapy options for neurogenic detrusor overactivity. *Spinal Cord* 2004;42:267–272.
97. Schurch B, Stohrer M, Kramer G, et al. Botulinum-A toxin for treating detrusor hyperreflexia in spinal cord injured patients: a new alternative to anticholinergic drugs? Preliminary results. *J Urol* 2000;164:692–697.
98. Rapp D, et al. Use of botulinum-A toxin for the treatment of refractory overactive bladder symptoms: an initial experience. *Urology* 2004;63:1071–1075.
99. Kessler T, et al. Botulinum-A toxin injections into the detrusor: an effective treatment in idiopathic and neurogenic detrusor overactivity. *Neurourol Urodyn* 2005;24:236.
100. Werner M, et al. Efficacy of botulinum-A toxin in the treatment of detrusor overactivity incontinence: a prospective nonrandomized study. *Am J Obstet Gynecol* 2005;192:1740.
101. Maggi CA, Barbanti G, Santicoli P, et al. Cystometric evidence that capsaicin sensitive nerves modulate the afferent branch of micturition reflex in humans. *J Urol* 1989;142:150–154.
102. Maggi CA. Therapeutic potential of capsaicin-like molecules: studies in animals and humans. *Life Sci* 1992;51:1777–1781.
103. Maggi CA. Capsaicin and primary afferent neurons: from basic science to human therapy? *J Auton Nerv Syst* 1993;33:1–14.
104. Dray A. Mechanism of action of capsaicin-like molecules on sensory neurons. *Life Sci* 1992;51: 1759–1765.
105. Caterina JJ, Schumacher MA, Tominaga M, et al. The capsaicin receptor: a heat-activated ion channel in the pain pathway. *Nature* 1997;389:816–824.
106. Caterina MJ, Rosen TA, Tominaga M, et al. A capsaicin-receptor homologue with a high threshold for noxious heat. *Nature* 1999;398:436–441.
107. DeRidder D, Baert L. Vanilloids and the overactive bladder. *BJU Int* 2000;86:172–180.
108. DeSeze M, Wiart L, Ferriere J, et al. Intravesical instillation of capsaicin in urology: a review of the literature. *Eur Urol* 1999;36:267–277.
109. Chancellor MB, de Groat WC. Intravesical capsaicin and resiniferatoxin therapy: spicing up the ways to treat the overactive bladder. *J Urol* 1999;162:3–11.
110. Moehrer B, Hextall A, Jackson S. Oestrogens for urinary incontinence in women. *Cochrane Database Syst Rev* (1), 2003.
111. Hendrix SL, Cochrane BB, Nygaard IE, et al. Effects of estrogen with and without progestin on urinary incontinence. *JAMA* 2005;293:935–948.
112. Hay-Smith J, Herbison P, Ellis G, et al. Anticholinergic drugs vs placebo for overactive bladder syndrome in adults. *Cochrane Database Syst Rev* CD003781, 2002.

---

# 13 Intravesical Treatments for Overactive Bladder

---

*Craig B. Slotoroff, MD, Dolores Shupp-Byrne, PhD,  
and Patrick J. Shenot, MD*

## *CONTENTS*

ANATOMY AND FUNCTION OF THE UROEPITHELIUM  
EFFERENT INNERVATION OF THE URINARY BLADDER  
INTRAVESICAL OXYBUTYNYN  
AFFERENT INNERVATION OF THE URINARY BLADDER:  
A $\delta$  AND C FIBERS  
VANILLOID PHARMACOLOGY  
CLINICAL RESULTS OF INTRAVESICAL CAPSAICIN  
CLINICAL RESULTS OF INTRAVESICAL RESINIFERATOXIN  
TECHNIQUE OF INTRAVESICAL CAPSAICIN  
AND RESINIFERATOXIN ADMINISTRATION  
CONCLUSION  
REFERENCES

---

Overactive bladder (OAB) is a recently defined symptom complex that includes urinary urgency with or without urge incontinence, urinary frequency (voiding eight or more times in a 24-h period), and nocturia (awakening two or more times at night to void) (1–3). The overall prevalence of OAB in Western Europe and the United States is 16–17% (4,5). The symptoms of OAB can affect quality of life and are associated with social, occupational, and psychological disruption.

Pharmacological treatment has become the cornerstone for treating OAB, with most clinical therapies targeting the efferent branch of the micturition reflex. Oral antimuscarinic drugs are currently the first-line pharmacological treatment for OAB, but these medications are not always effective and are associated with side effects that can limit their clinical use. As an alternative, intravesical (topical) therapies have been suggested to achieve a profound inhibition of the overactive detrusor and to avoid high systemic drug levels.

Currently available intravesical treatment options act either on the afferent arc of the micturition reflex, such as vanilloids, or on the efferent cholinergic transmission to the detrusor muscle, such as intravesical oxybutynin. Although intravesical oxybutynin has been established as an effective therapy in patients with neurogenic bladder dysfunction, it is not commonly utilized because of the need for frequent dosing via urethral catheterization. Intravesical capsaicin has been shown to improve clinical

and urodynamic parameters in patients with various voiding dysfunction. This noxious compound may, however, cause significant pain in some patients. Although the intravesical instillation of resiniferatoxin (RTX) is a promising option, randomized placebo-controlled studies to prove its safety and efficacy are still missing.

The exact mechanism of action for some of these agents is unknown, and the transport of the drug across the urothelium is complex and not well understood. The penetration of the agent to the target tissue depends on pressure gradients, time of exposure, pH of the urine, molecular weight of the substance, degree of ionization of the molecule, and the patient's urinary output. All of these factors can potentially impact the efficacy of the treatment. The purpose of this chapter is to review the various agents currently underutilized or under study for clinical use.

## ANATOMY AND FUNCTION OF THE UROEPITHELIUM

The internal surface of the urinary bladder is lined with transitional epithelium. Three distinct layers of the uroepithelium have been described (6). Large umbrella cells form the superficial lining of the bladder urothelium. The permeability barrier of the urothelium is maintained in this stratum by tight junctions that prevent the paracellular passage of urinary solutes across this outer layer into the bloodstream. Umbrella cells are associated with a group of crystalline protein plaques called *uroplakins* that also contribute to the permeability barrier of the urothelium. Beneath the umbrella cell layer is the intermediate layer of moderately sized cells and a basal layer of small cells (7).

In the bladder, suburothelial afferent fibers form a dense plexus that innervates the both the detrusor itself and the basal layer of the urothelium (8). These afferent fibers are critical for sending sensory input to the central nervous system. The uroepithelium was once thought to serve only as a passive barrier to the contents of the bladder, but in addition to its barrier function, there is a growing body of evidence that confirms reciprocal communication between the neuronal system and the uroepithelium. This implies that the uroepithelium likely plays a significant role in regulating bladder activity via a number of neuronlike properties that modulate bladder sensory function and may represent a potential novel therapeutic target for pharmacological intervention for bladder dysfunction.

## EFFERENT INNERVATION OF THE URINARY BLADDER

Acetylcholine, which interacts with muscarinic receptors on the detrusor muscle, is the predominant peripheral neurotransmitter responsible for bladder contraction. Five muscarinic receptor subtypes have been identified in the human bladder, with the  $M_2$  and  $M_3$  subtypes likely playing the greatest role in bladder contraction (9). Because detrusor contractility is mediated by cholinergic muscarinic receptors, antimuscarinic agents are the mainstay of therapy for OAB (10).

## INTRAVESICAL OXYBUTYNIN

Oxybutynin, a nonselective antimuscarinic agent, has been extensively utilized for over 30 yr in the management of lower urinary tract symptoms resulting from detrusor overactivity (11). The efficacy of oxybutynin in the management of detrusor overactivity has been confirmed in double-blind, placebo-controlled trials (12,13). Most side effects have been related to the anticholinergic effects of oxybutynin, with dry

mouth the most common complaint, often resulting in drug discontinuation or dosage reduction (14–16).

Brendler et al. performed the first pilot study on the use of intravesical oxybutynin in 1989 (17). They reported the rationale to attempt intravesical treatment was that the development of side effects could be minimized if systemic blood levels of oxybutynin chloride could be reduced at the same time that high bladder tissue levels were achieved. Oxybutynin was crushed and dissolved into 20–30 mL water; then, the medication was instilled twice daily with the solution retained for 30 min. In the 10 patients with hyperreflexic bladders who were able to complete the study, the mean bladder capacity increased from 224 to 360 mL, all 10 became continent, and the mean maximum filling pressure decreased from 33 to 24 cm H<sub>2</sub>O. No side effects were observed. These findings were corroborated by others, who demonstrated that intravesical oxybutynin has clinical efficacy with minimal systemic side effects (18,19).

Despite the apparent efficacy of the intravesical administration of oxybutynin, this mode of administration has not found widespread use. The need to catheterize multiple times daily to instill this medication has limited its utility to patients on a regular schedule of intermittent catheterization. In this population it does appear to be a safe, effective and well-tolerated therapy.

### AFFERENT INNERVATION OF THE URINARY BLADDER: A $\delta$ AND C FIBERS

Normal storage of urine is dependent on spinal reflex mechanisms that activate somatic and sympathetic pathways to the bladder outlet and detrusor muscle as well as tonic inhibitory pathways that suppress parasympathetic excitatory activity, leading to detrusor relaxation and bladder filling. Micturition requires efferent nerve input to the bladder from the spinal cord as well as afferent input from the bladder to the central nervous system. Sensory information, including the sensations of bladder fullness and pain, is conveyed to the spinal cord via afferent fibers in the pelvic and hypogastric nerves. The most important afferents controlling the micturition process are small myelinated A $\delta$  fibers, which transmit signals mainly from mechanoreceptors that detect wall tension and bladder fullness, and unmyelinated C fibers, which detect noxious signals and initiate painful sensations (20–23). At other sites in the body, such as the skin and mucous membranes, C-fiber afferents transmit nociceptive information into the central nervous system and modulate various reflex responses to noxious stimuli such as hot temperatures.

Following suprasacral spinal cord injury, there is significant reorganization of micturition reflexes, which leads to the emergence of primitive spinal bladder reflexes triggered by C-afferent neurons. Afferent C-fiber activation may also occur in infectious or irritative conditions in the bladder and serve to facilitate or trigger voiding. This may be viewed as a defense mechanism to eliminate bladder irritants or bacteria. Bladder wall C-fibers may be responsible for afferent signals that trigger nonneurogenic detrusor overactivity. As specific C-fiber neurotoxins, capsaicin and RTX, its ultrapotent analog, may be used to study and treat lower urinary tract dysfunction (24).

### VANILLOID PHARMACOLOGY

Current pharmacological treatment of the OAB relies on partially blocking the efferent parasympathetic innervation to the detrusor with anticholinergic drugs. Often, these

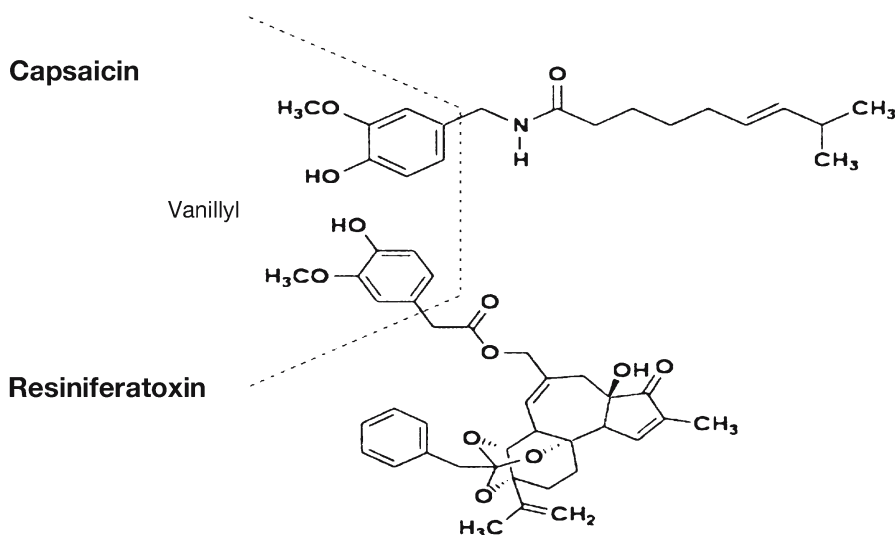


Fig. 1. Chemical structures of capsaicin and resiniferatoxin.

drugs have troublesome side effects and are used in doses insufficient to provide significant clinical benefit. The afferent pathways of the voiding reflex may be targeted by intravesical instillation of drugs with relative selectivity for sensory nerves. Capsaicin and RTX are potent neurotoxins that desensitize these C-fiber afferent neurons that may be responsible for signals that trigger detrusor overactivity.

Hot peppers have been eaten and used by humans since prehistorical times (25). Hogsyes, in 1878, reported that the pungent and irritant action of capsicol, an extract of *Capsicum*, is mediated by sensory nerves (26). Capsaicin and its ultrapotent analog, RTX, collectively belong to a class of neurotoxic agents referred to as *vanilloids*. RTX is isolated from some species of *Euphorbia*, a cactuslike plant. These compounds are characterized by a terminal homovanilloid moiety that interacts with a specific membrane receptor (Fig. 1). The action of vanilloid compounds on sensory neurons is mediated via interaction of the homovanilloid moiety with the vanilloid receptor TRPV1 (transient receptor potential V1 or VR1 receptor), a nonspecific heat-gated cation channel that mediates the influx of calcium and sodium resulting in depolarization of nociceptive afferents to initiate a nerve impulse passing through the dorsal root ganglion into the central nervous system (27,28). Vanilloid receptors are expressed not only by small unmyelinated C fibers, but also by uroepithelial cells themselves.

As intracellular calcium levels rise, voltage-sensitive calcium channels are first activated, leading initially to local transmitter release, and then inhibited, serving to block the same response. Noxious temperatures are also sensed via this mechanism, explaining the characteristic sensation of heat experienced when eating chili peppers (29). Therefore, capsaicin mimics the action of physiological/endogenous stimuli that activates the “nociceptive pathway.” At the molecular level, nociception is carried out by ion channels or receptors.

Both capsaicin and RTX cause initial excitation of sensory neurons, with a subsequent lasting refractory state termed *desensitization*. Jancso discovered that animals treated with capsaicin, after a period of initial intense excitation of sensory neurons,



Table 1  
Pungency of Capsaicin, Resiniferatoxin, and Various Peppers

<i>Pepper</i>	<i>Heat level comparison</i>	
	<i>Scoville value</i>	
Bell, sweet Italian	0–1	
Perpperoncini	100–500	
Jalapeño	1000	
Cayenne	30,000–50,000	
Thai	50,000–100,000	
Jamaican hot	100,000–200,000	
Habanero	100,000–300,000	
Pure capsaicin	16,00,000	
Resiniferatoxin	16,000,000,000	

become unresponsive to noxious chemical stimuli and fail to develop inflammation (30,31). Many studies have since confirmed this finding and established capsaicin as a useful agent for the study of sensory neuron function (32).

### *Vanilloid Potency*

The Scoville heat unit scale is commonly used commercially to compare the potency of pepper strengths. Wilbur Scoville in 1912 calibrated the potency of peppers by extracting capsicum in alcohol and diluting it until pungency was first detected after placing a drop on his tongue (33). This technique has since been standardized using high-pressure liquid chromatography. In fact, if all known peppers were measured using this technique, then their scale of pungency would range from 1 Scoville unit for the bell pepper up to 300,000 units for the habanero pepper. Pure capsaicin has a Scoville heat unit score of 16 million, and RTX registers at 16 billion Scoville heat units, which is 1000 times the potency of capsaicin (Table 1).

### *Sensitization (Acute Excitatory Effects)*

On first contact with capsaicin, afferent neurons are invariably stimulated, and there seems to be no apparent difference whether the drug is applied to the peripheral or central endings or to the cell bodies of sensory neurons. Administration of vanilloids to peripheral nerve endings results in depolarization and discharge of action potentials, which in turn evokes a characteristic burning sensation via stimulation of C-fiber polymodal nociceptors. Acute activation of the sensory neurons via the vanilloid receptor TRPV1 results initially in depolarization and transmitter (peptide) release with eventual neuronal degeneration (34,35) (Fig. 2).

### *Desensitization (Secondary Neurotoxic Effects)*

Following vanilloid-induced stimulation of primary afferent neurons, excitation subsides, and the neurons become unresponsive to further applications of drug. Capsaicin desensitization is characterized by long-lasting, reversible suppression of sensory neuron activity (36). The rate and duration of desensitization are related to the dose and time of exposure to capsaicin and the time interval between consecutive dosing (37).

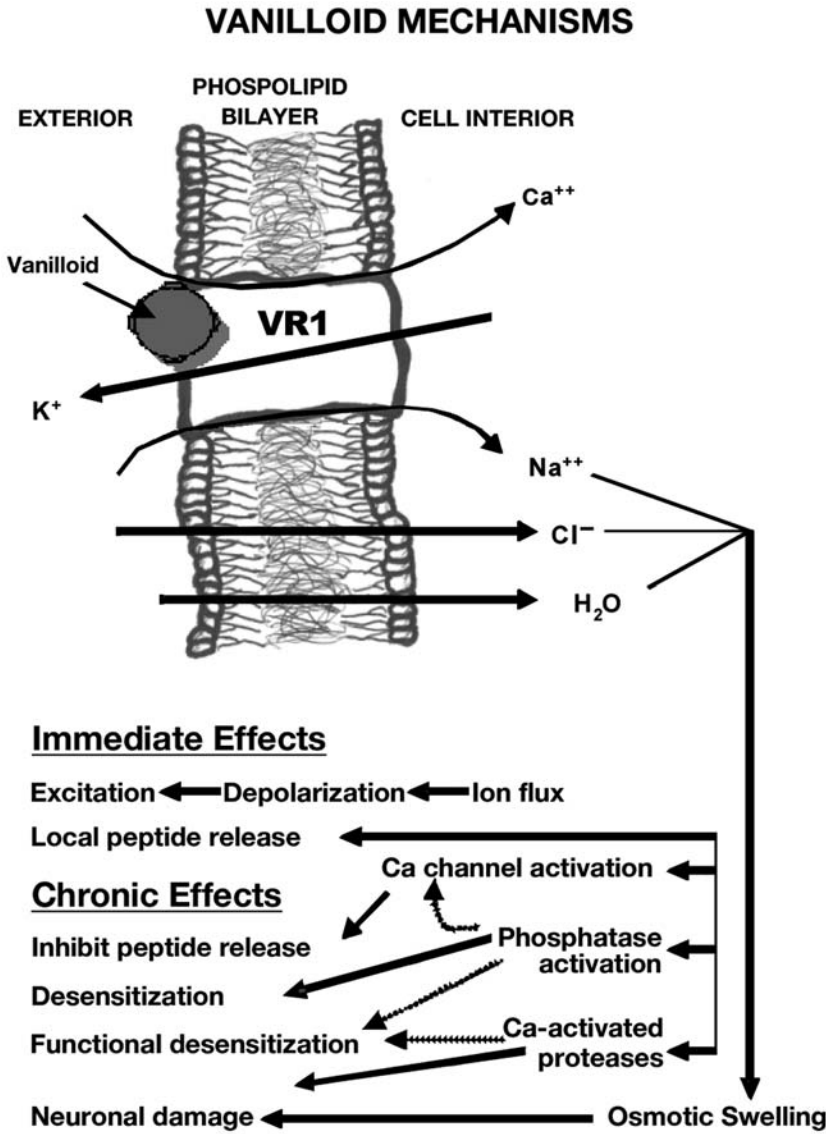


Fig. 2. The mechanism of vanilloid-induced neuronal excitation and desensitization.

Although C-fiber neurons have well-described afferent functions, they likely have important efferent functions as well, including the local release in the periphery of substance P, neurokinin A, calcitonin gene-related peptides, and other neuropeptides that directly and indirectly produce tissue inflammation (38–40). Desensitization of capsaicin-sensitive nerve fibers is associated with eventual depletion of transmitter neuropeptides (41–43).

## CLINICAL RESULTS OF INTRAVESICAL CAPSAICIN

### *Hypersensitivity Disorders*

Because capsaicin and RTX selectively activate sensory C fibers that convey information about noxious stimuli to the central nervous system, the use of intravesical capsaicin

or RTX for interstitial cystitis and other types of sensory or inflammatory bladder conditions is logical.

Maggi et al. reported the clinical urological application of intravesical capsaicin (44). Intravesical instillation of capsaicin (0.1–10  $\mu\text{M}$ ) in six patients with bladder hypersensitivity produced a concentration-related reduction of the first desire to void, bladder capacity, and pressure threshold for micturition. All reported disappearance or marked attenuation of their symptoms for a few days after capsaicin application. In three other patients, intravesical instillation of the vehicle (0.1% ethanol in saline) alone did not produce significant cystometric changes or modify the symptomatology, suggesting that capsaicin-sensitive nerves exist in the human bladder. A second series of intravesical capsaicin, a randomized placebo-controlled trial, in patients with bladder hypersensitivity confirmed the beneficial effect of intravesical instillation of capsaicin on voiding parameters but did not confirm improvement in pain score after capsaicin treatment compared to placebo (45).

Although intravesical capsaicin has been proposed as a treatment option for interstitial cystitis, its utility has not been widely explored. One small pilot study of intravesical capsaicin in five patients with interstitial cystitis using National Institute of Diabetes and Digestive and Kidney Diseases criteria demonstrated subjective improvement in both symptom and pain score in four of five patients (46).

### *Neurogenic Detrusor Overactivity*

Fowler and associates reported the first clinical experience with capsaicin in neurologically impaired patients with intractable incontinence caused by multiple sclerosis and spinal cord injury (47,48). They reported that, after a single intravesical instillation of capsaicin (1–2 mM) for 30 min, 10 of 14 patients exhibited an improved bladder capacity for up to 9 mo without toxicity. Similar findings were noted in small studies in other patients with neurogenic detrusor overactivity (49,50).

De Ridder et al. described the long-term outcome of intravesical capsaicin instillation in 79 patients with spinal cord disease and treatment-resistant urinary incontinence (51). Repeated intravesical instillation of intravesical 1–2 mM capsaicin in 30% ethanol capsaicin was effective and persisted for up to 3–5 yr. In patients with phasic detrusor hyperreflexia, complete continence was achieved in 44%, satisfactory improvement occurred in 36%, and treatment failure occurred in 20%. Clinical benefit from a single instillation lasted 3–6 mo and was repeated in some patients with similar improvement. There was no clinical or urodynamic improvement in patients treated with the ethanol vehicle alone and no reported long-term complications.

There have been only a few reported randomized placebo-controlled studies of capsaicin in patients with neurogenic detrusor overactivity. The results of these trials have been mixed. Wiart et al. reported that a single intravesical instillation of 1 mM capsaicin resulted in clinical improvement with significant regression of urine leakage episodes and urgency compared with those receiving vehicle (30% ethanol) alone (52). These findings were supported by a later study in a similar population (53). A third placebo-controlled crossover study of 12 patients by Petersen et al. showed no benefit to intravesical capsaicin treatment therapy in patients with neurogenic detrusor overactivity (54).

### *Resiniferatoxin*

RTX is an ultrapotent capsaicin analog present in the latex of the cactuslike plant *Euphorbia resinifera* (55). It mimics most biological characteristics of capsaicin, with approx 1000-fold higher potency and minimal initial acute excitatory effects (28). There

are significant differences in biologic response between RTX and capsaicin. RTX and capsaicin show striking differences in relative potencies to excite and desensitize primary sensory neurons. In most cases, when RTX and capsaicin differ in potency of a particular biological end point, the response is such that RTX preferentially causes desensitization, and capsaicin administration leads to profound excitation.

Intravesical RTX in concentrations as low as 100 nM induced full desensitization, whereas capsaicin required 1 mM solutions to induce the same effect (56–58). In addition, 100 nM RTX solutions were much less irritating to bladder afferents than 1 mM capsaicin solution. RTX-induced desensitization may occur at concentrations so low that no noxious effect is elicited. Because of its potency and unique property of preferential desensitization, there has been much interest in the application of RTX therapy for patients with interstitial cystitis and detrusor overactivity.

## CLINICAL RESULTS OF INTRAVESICAL RESINIFERATOXIN

### *Interstitial Cystitis*

The positive findings of a number of small pilot studies evaluating the efficacy of capsaicin in interstitial cystitis logically has led to interest in the utilization of RTX in the treatment of this poorly understood condition. Most of these studies were poorly controlled, but one small placebo-controlled study did suggest that RTX was effective in the treatment of urinary frequency, urgency, and pelvic pain (59). A relatively large, randomized, double-blind, placebo-controlled trial of a single dose of 0.01–0.10  $\mu$ M RTX found that it was not effective in improving overall symptoms, pain, urgency, frequency, nocturia, or voided volume during 12-wk follow-up (60).

### *Neurogenic Detrusor Overactivity*

The first clinical use of RTX in patients with neurogenic detrusor overactivity was reported by Cruz et al. in 1997 (56). They treated seven patients with intravesical instillation of 50–100 nM RTX dissolved in 100 mL solution of 10% alcohol. Itching or mild discomfort were the only symptoms evoked in four patients during the first minutes of the treatment. Temporary exacerbation of bladder symptoms, as seen during the first 1–2 wk after capsaicin administration, did not occur. In five of the seven patients, urinary frequency decreased by 33–58%, and this effect was detected as soon as the first day after treatment. Three patients were incontinent and became dry most days. Improvement was sustained up to 3 mo, the longest follow-up available. Four patients had urodynamic improvement with a rise in maximum cystometric capacity, increasing from 50 to 900% of pretreatment cystometric capacity.

Lazzeri et al. reported using intravesical RTX (10 nM) in eight normal patients and seven patients with OAB (57). RTX did not decrease the volume required to elicit the first desire to void and did not produce warm or burning sensations at the suprapubic or urethral level during infusion in normal subjects. Mean capacity increased significantly in patients with overactivity immediately after instillation but was not significantly increased after 4 wk. As a group, there was no significant improvement in bladder capacity, but two patients with detrusor hyperreflexia did improve urodynamically in conjunction with clinical improvement in frequency, nocturia, and incontinence episodes.

Although the results of several small studies suggest that intravesical RTX may have a role in the treatment of refractory neurogenic detrusor overactivity, its efficacy has not been conclusively confirmed in any randomized controlled trials (61–64). RTX has

been demonstrated to adsorb to polyethylene, polyvinylchloride, and latex (but not silicone or glass) catheters and containers. These materials were used in some of these studies, possibly leading to lower-than-expected drug delivery, thereby confounding the results obtained (Afferon Corp., Wayne, PA, unpublished data).

A double-blind, randomized, controlled study comparing the efficacy and tolerability of RTX to capsaicin demonstrated significant clinical improvement in approximately two-thirds of patients with neurogenic detrusor overactivity for 90 d after treatment with either agent (65). Patients in the capsaicin arm were treated with capsaicin dissolved in a novel glucidic solvent; the RTX used in this study was diluted in 10% ethanol. There were no significant differences in the incidence, nature, or duration of side effects in capsaicin- vs RTX-treated patients, suggesting the importance of considering the role of vehicle solvent when interpreting the efficacy and tolerance of vanilloid instillation.

RTX has also been compared with intravesical botulinum type A toxin injections into the detrusor muscle in patients with spinal cord injury and refractory detrusor overactivity (66). With both treatments, there was a significant reduction in mean catheterization and episodes of incontinence and a significant increase in mean first involuntary detrusor contraction and in mean maximum bladder capacity at 6, 12, and 24 mo after therapy. Both RTX and botulinum type A toxin resulted in beneficial clinical and urodynamic results, with reduction of detrusor overactivity and restoration of urinary continence in most patients. Botulinum type A toxin injection, however, provided better clinical and urodynamic benefits than intravesical RTX.

### *Nonneurogenic Detrusor Overactivity*

Enthusiasm for intravesical RTX as a treatment for neurogenic detrusor overactivity has led to its investigation as a potential therapy for nonneurogenic detrusor overactivity. RTX instillation may delay or suppress involuntary detrusor contractions and increase mean maximal cystometric capacity for at least 90 d (67). Relatively modest improvements in clinical symptoms have been noted in several studies of patients with non-neurogenic detrusor overactivity (68–70). To date, there has been no well-controlled randomized trial.

### TECHNIQUE OF INTRAVESICAL CAPSAICIN AND RESINIFERATOXIN ADMINISTRATION

Neither capsaicin nor RTX is currently approved for routine clinical intravesical use. Insertion of a small silicone urethral catheter with balloon occlusion of the bladder neck is recommended. Care must be taken to avoid contact with polyethylene, polyvinylchloride, or latex, which may result in a diminished effective administered dose. Intravesical lidocaine is commonly instilled prior to drug administration. Although a 1–2% lidocaine solution is most commonly utilized, there is evidence that 4% lidocaine may improve tolerability (61).

Capsaicin has generally been used as a 1–2 mM solution dissolved in 30% ethanol in saline. RTX is administered as a 0.05–0.10  $\mu$ M solution in 10% ethanol. Both agents are typically left in the bladder for approx 30 min.

### CONCLUSION

Intravesical instillation of pharmacological agents appears to be a promising therapy for the treatment of neurogenic and nonneurogenic detrusor overactivity. Although

direct instillation of oxybutynin appears to be effective, this mode of administration has not been widely adopted because of the need for frequent instillation of this agent.

A single instillation of the vanilloids capsaicin or RTX, however, may result in long-lasting desensitization of sensory nerves on the afferent limb of the voiding reflex without systemic side effects. Numerous studies have demonstrated improvement in lower urinary tract symptoms with minimal long-term complications. Despite over a decade of experience with these neurotoxic agents, however, the true efficacy of these compound has not been clearly defined. RTX, which appears to have efficacy similar to capsaicin but with fewer side effects, holds greater promise as a safe, effective treatment for detrusor overactivity. Prospective randomized, placebo-controlled studies are necessary to truly define the role of intravesical vanilloid therapy in the management of patients with OAB.

## REFERENCES

1. Abrams P, Wein AJ, eds. The Overactive Bladder: From Basic Science to Clinical Management Consensus Conference. *Urology* 1997;50(suppl):1-114.
2. Abrams P, Wein AJ, eds. Overactive Bladder and Its Treatments Consensus Conference. *Urology* 2000;55(suppl):1-84.
3. Staskin DR, Wein AJ, eds. New perspectives on the overactive bladder. *Urology* 2002;60(suppl): 1-104.
4. Milsom I, Abrams P, Cardozo L, Roberts RG, Thuroff J, Wein AJ. How widespread are the symptoms of an overactive bladder and how are they managed? A population-based prevalence study. *BJU Int* 2001;87:760.
5. Stewart W, Herzog AR, Wein A, et al. Prevalence and impact of overactive bladder in the US: results from the NOBLE program. *Neurourol Urodyn* 2001;20:406.
6. Lewis SA. Everything you wanted to know about the bladder epithelium but were afraid to ask. *Am J Physiol Renal Fluid Electrolyte Physiol* 2000;278:F867.
7. Born M, Pahner I, Ahnert-Hilger G, Jons T. The maintenance of the permeability barrier of bladder facet cells requires a continuous fusion of discoid vesicles with the apical plasma membrane. *Eur J Cell Biol* 2003;82:343.
8. Andersson KE. Bladder activation: afferent mechanisms. *Urology* 2002;59(5 suppl 1):43.
9. Harris DR, Marsh KA, Birmingham AT, Hill SJ. Expression of muscarinic M<sub>3</sub>-receptors coupled to inositol phospholipid hydrolysis in human detrusor cultured smooth muscle cells. *J Urol* 1995;154:1241.
10. Andersson KE. Drug therapy for urinary incontinence. *Baillieres Best Pract Res Clin Obstet Gynaecol* 2000;14:291.
11. Diokno AC, Lapidus J. Oxybutynin: a new drug with analgesic and anticholinergic properties. *J Urol* 1972;108:307.
12. Gajewski JB, Awad SA. Oxybutynin vs propantheline in patients with multiple sclerosis and detrusor hyperreflexia. *J Urol* 1986;135:966.
13. Thuroff JW, Bunke B, Ebner A, et al. Randomized, double-blind, multicenter trial on treatment of frequency, urgency and incontinence related to detrusor hyperactivity: oxybutynin vs propantheline vs placebo. *J Urol* 1991;145:813.
14. Gleason DM, Susset J, White C, Munoz DR, Sand PK. Evaluation of a new once-daily formulation of oxybutynin for the treatment of urinary urge incontinence. *Urology* 1999;54:420.
15. Anderson RU, Mobley D, Blank B, Saltzstein D, Susset J, Brown JS. Once daily controlled vs immediate release oxybutynin chloride for urge urinary incontinence. *J Urol* 1999;161:1809.
16. Birns J, Lukkari E, Malone-Lee JG. A randomized controlled trial comparing the efficacy of controlled-release oxybutynin tablets (10 mg once daily) with conventional oxybutynin tablets (5 mg twice daily) in patients whose symptoms were stabilized on 5 mg twice daily of oxybutynin. *BJU Int* 2000;85:793.
17. Brendler CB, Radebaugh LC, Mohler JL. Topical oxybutynin chloride for relaxation of dysfunctional bladders. *J Urol* 1989;141:1350.
18. Greenfield SP, and Fera M. The use of intravesical oxybutynin chloride in children with neurogenic bladder. *J Urol* 1991;146:532.

19. Weese DL, Roskamp DA, Leach GE, Zimmern PE. Intravesical oxybutynin chloride: experience with 42 patients. *Urology* 1993;41:527.
20. de Groat WC, Kawatani M, Hisamitsu T, et al. Mechanisms underlying the recovery of urinary bladder function following spinal cord injury. *J Auton Nerv Syst* 1990;30:571.
21. Yoshimura N, Erdman SL, Snider NW, de Groat WC. Effects of spinal cord injury on neurofilament immunoreactivity and capsaicin sensitivity in rat dorsal root ganglion neurons innervating the urinary bladder. *Neuroscience* 1998;83:633.
22. Kawatani M, Whitney T, Booth AM, de Groat WC. Excitatory effect of substance P in parasympathetic ganglia of the cat urinary bladder. *Am J Physiol* 1989;257:R1450.
23. Maggi CA, Santicioli P, Patacchini R, et al. Regional differences in the motor response to capsaicin in the guinea pig urinary bladder: relative role of pre- and postjunctional factors related to neuropeptide-containing sensory nerves. *Neuroscience* 1988;27:675.
24. Maggi CA. Capsaicin and primary afferent neurons: from basic science to human therapy. *J Auton Nerv Syst* 1991;33:1.
25. Lembeck F. Capsicum and capsaicin: past, present and future. *Acta Physiol Hung* 1987;69:265.
26. Dasgupta P, Fowler CJ. Chilies: from antiquity to urology. *Br J Urol* 1997;80:845.
27. Montell C. Physiology, phylogeny, and functions of the TRP superfamily of cation channels. *Science's Stake: Signal Trans Knowl Environ* 2001;(90):RE1.
28. Vennekens R, Voets T, Bindels RJ, Droogmans G, Nilius B. Current understanding of mammalian TRP homologues. *Cell Calcium* 2002;31:253.
29. Clapham DE. Some like it hot: spicing up ion channels. *Nature* 1997;389:783.
30. Jancso N. Role of the nerve terminals in the mechanism of inflammatory reactions, *Bull Millard Fillmore Hosp* 1960;7:53.
31. Jancso N, Jancso GA, Szolcsanyi J. The role of sensory nerve endings in neurogenic inflammation induced in human skin and in the eye and paw of the rat. *Br J Pharmacol* 1968;33:32.
32. Holzer, P. Capsaicin: cellular targets, mechanisms of action, and selectivity for thin sensory-neurons. *Pharmacol Rev* 1991;43:143.
33. Scoville W. Note on capsicum. *J Am Pharm Assoc* 1912;1:453.
34. Kawatani M, Whitney T, Booth AM, de Groat WC. Excitatory effect of substance P in parasympathetic ganglia of the cat urinary bladder. *Am J Physiol* 1989;257:R1450.
35. Szallasi A, Blumberg PM. Vanilloid receptors: new insights enhance potential as therapeutic target. *Pain* 1990;30:571.
36. Craft RM, Cohen SM, Porreca F. Long-lasting desensitization of bladder afferents following intravesical resiniferatoxin and capsaicin in the rat. *Pain* 1995;61:317.
37. Szolcsanyi J, Jancso-Gabor A, Joo F. Functional and fine structural characteristics of the sensory neuron blocking effect of capsaicin. *Naunyn Schmiedebergs Arch Pharmacol* 1975;287:157.
38. Buck SH, Burks TF. The neuropharmacology of capsaicin: review of some recent observations. *Pharmacol Rev* 1986;38:179.
39. Ghatei MA, Gu J, Mulderry PK, et al. Calcitonin gene-related peptide (CGRP) in the female rat urogenital tract. *Peptides* 1985;6:809.
40. Maggi CA. Therapeutic potential of capsaicin-like molecules: studies in animals and humans. *Life Sci* 1992;51:1777.
41. Sharkey KA, Williams RG, Schultzberg M, Dockray GJ. Sensory substance P-innervation of the urinary bladder: possible site of action of capsaicin in causing urine retention in rats. *Neuroscience* 1983;19:861.
42. Jessell TM, Iversen LL, Cuello AC. Capsaicin-induced depletion of substance P from primary sensory neurons. *Brain Res* 1978;152:183.
43. Kashiba H, Ueda Y, Senba E. Systemic capsaicin in the adult rat differentially affects gene expression for neuropeptides and neurotrophin receptors in primary sensory neurons. *Neuroscience* 1997;76:299.
44. Maggi CA, Barbanti G, Santicioli P, et al. Cystometric evidence that capsaicin-sensitive nerves modulate the afferent branch of micturition reflex of humans. *J Urol* 1989;142:150.
45. Lazzeri M, Beneforti P, Benaim G, Magi CA, Lecci A, Turini D. Intravesical capsaicin for treatment of severe bladder pain: a randomized placebo controlled study. *J Urol* 1996;156:947.
46. Flood H, Ireland L, Byrne DS, et al. Intravesical capsaicin for interstitial cystitis. *J Urol* 1997;157:254A.
47. Fowler CJ, Jewkes D, McDonard WJ, Lynn B, de Groat WC. Intravesical capsaicin for neurogenic bladder dysfunction. *Lancet* 1992;339:1239.

48. Fowler CJ, Beck RO, Gerrard S, Betts CD, Fowler CG. Intravesical capsaicin for treatment of detrusor hyperreflexia. *J Neurol Neurosurg Psychiatry* 1994;57:169.
49. Geirsson G, Fall M, Sullivan L. Clinical and urodynamic effects of intravesical capsaicin treatment in patients with chronic traumatic spinal detrusor hyperreflexia. *J Urol* 1995;154:1825.
50. Das AS, Chancellor MB, Watanabe T, Sedor J, Rivas M. Intravesical capsaicin in neurogenic impaired patients with detrusor hyperreflexia. *J Spinal Cord Med* 1996;19:190.
51. De Ridder DD, Chandramani V, Dasgupta P, van Poppel H, Baert L, Fowler CJ. Intravesical capsaicin as a treatment for refractory detrusor hyperreflexia: a dual center study with long term follow-up. *J Urol* 1997;158:2087.
52. Wiart L, Joseph PA, Petit H, et al. The effects of capsaicin on the neurogenic hyperreflexic detrusor. A double blind placebo controlled study in patients with spinal cord disease. Preliminary results. *Spinal Cord* 1998;36:95.
53. de Seze M, Wiart L, Joseph PA, Dosque JP, Mazaux JM, Barat M. Capsaicin and neurogenic detrusor hyperreflexia: a double-blind placebo-controlled study in 20 patients with spinal cord lesions. *Neurourol Urodyn* 1998;17:513.
54. Petersen T, Nielsen JB, Schroder HD. Intravesical capsaicin in patients with detrusor hyper-reflexia—a placebo-controlled cross-over study. *Scand J Urol Nephrol* 1999;33:104.
55. Caterina MJ, Schumacher MA, Tominaga M, Rosen TA, Levine JD, Julius D. The capsaicin receptor: a heat-activated ion channel in the pain pathway. *Nature* 1997;389:816.
56. Cruz F, Guaraes M, Silva C, Reis M. Suppression of bladder hyperreflexia by intravesical resiniferatoxin. *Lancet* 1997;350:640.
57. Lazzeri M, Beneforti P, Turini D. Urodynamic effects of intravesical resiniferatoxin in humans: preliminary results in stable and unstable detrusor. *J Urol* 1997;158:2093.
58. Lazzeri M, Beneforti P, Turini D, Spinelli M, Zanollo A. Intravesical resiniferatoxin for the treatment of detrusor hyperreflexia refractory to capsaicin. *J Urol* 1998;159:83A.
59. Lazzeri M, Beneforti P, Spinelli M, Zanollo A, Barbagli G, Turini D. Intravesical resiniferatoxin for the treatment of hypersensitive disorder: a randomized placebo controlled study. *J Urol* 2000;164 (3 pt 1):676.
60. Payne CK, Mosbaugh PG, Forrest JB, et al. ICOS RTX Study Group (Resiniferatoxin Treatment for Interstitial Cystitis). Intravesical resiniferatoxin for the treatment of interstitial cystitis: a randomized, double-blind, placebo controlled trial. *J Urol* 2005;173:1590.
61. Watanabe T, Yokoyama T, Sasaki K, Nozaki K, Ozawa H, Kumon H. Intravesical resiniferatoxin for patients with neurogenic detrusor overactivity. *Int J Urol* 2004;11:200.
62. Kim JH, Rivas DA, Shenot PJ, et al. Intravesical resiniferatoxin for refractory detrusor hyperreflexia: a multicenter, blinded, randomized, placebo-controlled trial. *J Spinal Cord Med* 2003;26:358.
63. Kuo HC. Effectiveness of intravesical resiniferatoxin in treating detrusor hyper-reflexia and external sphincter dyssynergia in patients with chronic spinal cord lesions. *BJU Int* 2003;92:597.
64. Silva C, Rio ME, Cruz F. Desensitization of bladder sensory fibers by intravesical resiniferatoxin, a capsaicin analog: long-term results for the treatment of detrusor hyperreflexia. *Eur Urol* 2000;38:444.
65. de Seze M, Wiart L, de Seze MP, et al. Intravesical capsaicin vs resiniferatoxin for the treatment of detrusor hyperreflexia in spinal cord injured patients: a double-blind, randomized, controlled study. *J Urol* 2004;171:251.
66. Giannantoni A, Mearini E, Di Stasi SM, et al. New therapeutic options for refractory neurogenic detrusor overactivity. *Minerva Urol Nefrol* 2004;56:79.
67. Silva C, Ribeiro MJ, Cruz F. The effect of intravesical resiniferatoxin in patients with idiopathic detrusor instability suggests that involuntary detrusor contractions are triggered by C-fiber input. *J Urol* 2002;168:575.
68. Yokoyama T, Nozaki K, Fujita O, Nose H, Inoue M, Kumon H. Role of C afferent fibers and monitoring of intravesical resiniferatoxin therapy for patients with idiopathic detrusor overactivity. *J Urol* 2004;172:596.
69. Palma PC, Thiel M, Riccetto CL, Dambros M, Miyaoka R, Netto NR Jr. Resiniferatoxin for detrusor instability refractory to anticholinergics. *Int Braz J Urol* 2004;30:53.
70. Kuo HC. Multiple intravesical instillation of low-dose resiniferatoxin is effective in the treatment of detrusor overactivity refractory to anticholinergics. *BJU Int* 2005;95:1023.



---

# 14 Urological Applications of Botulinum Toxin

---

*Courtenay K. Moore, MD  
and Howard B. Goldman, MD*

## CONTENTS

INTRODUCTION  
APPLICATIONS IN UROLOGY  
INJECTION TECHNIQUES  
ADVERSE EVENTS AND CONTRAINDICATIONS  
CONCLUSION  
REFERENCES

---

## INTRODUCTION

Botulinum toxin is a neurotoxin produced by the Gram-positive, rod-shaped anaerobic bacterium *Clostridium botulinum* (1). First discovered in 1897 by Professor Pierre Emile van Ermengem of Ellezelles, Belgium botulinum toxin is the most poisonous naturally occurring toxin known to man (2). Seven immunologically distinct antigenic subtypes of botulinum toxin have been isolated: A, B, C1, D, E, F, and G (1). Only types A and B are available for use clinically. Botulinum type A toxin (BTX-A), known as Botox<sup>®</sup> in the United States and Dysport<sup>®</sup> in the United Kingdom, is more potent and has a longer duration of action than type B (1,2). Type B is commercially available in the United States as MyoBloc<sup>®</sup> and in Europe as NeuroBloc<sup>®</sup> (2).

Botulinum toxin exerts its effects by binding to the peripheral cholinergic terminals and inhibiting the release of acetylcholine at the neuromuscular junction. As a result, flaccid paralysis ensues. There are four steps involved in this process: binding, translocation, cleavage, and inhibition of neurotransmitter release (2). Botulinum toxin is made within the bacterial cytosol and released as a 150-kDa polypeptide chain (2). Proteolytic cleavage results in a heavy (100 kDa) and light (50 kDa) chain, which are linked by heat labile disulfide bonds (1). Neither chain can exert neurotoxicity independently (1). The heavy chain is responsible for binding to the nerve terminal at the neuromuscular junction. The light chain, which is internalized by endocytosis, actively cleaves a specific site on the protein complex responsible for docking and release of vesicles containing neurotransmitters into the neuromuscular junction (1,3). By cleaving protein receptors within the nerve terminals, botulinum toxin prevents the normal vesicular transport and release of acetylcholine from the motor nerve terminals into the neuromuscular junction (2).

Based on histological evidence, recovery of chemodenervation occurs after 3–6 mo. This results from the turnover of the presynaptic molecules and nerves sprouting from the nerve terminal forming a new functional synapse (1). Affected nerve terminals do not degenerate, and axonal sprouting and formation of new synaptic contacts can recover function. The time necessary to recover function after botulinum toxin paralysis depends on the subtype of botulinum toxin as well as the type of nerve terminal (2). Chemodenervation lasts between 3 and 6 mo when injected into the neuromuscular junction of skeletal muscle and considerably longer, up to 1 yr, when injected into the autonomic neurons of smooth muscle (2,3).

## APPLICATIONS IN UROLOGY

Botulinum toxin was first approved by the Food and Drug Administration in 1989 for use in patients with strabismus and blepharospasm (1). Since then, its use has been extended to cervical dystonia, cosmesis, hypersecretory disorders, and overactive muscle disorders. Although not Food and Drug Administration approved, botulinum toxin has been used in urology to treat neurogenic and nonneurogenic detrusor overactivity (DO), detrusor-sphincter dyssynergia (DSD), motor and sensory urge, and more recently chronic pain syndromes.

### *Detrusor Overactivity in Adults*

The use of botulinum toxin in neurogenic DO was first pioneered by Schurch in 2000 (2). BTX-A (200 or 300 U) was injected into the trigone of 21 spinal cord injury (SCI) patients with DO and urge incontinence managed with clean intermittent catheterization (4). At 6 wk, 17/19 patients were completely continent. Urodynamic evaluation revealed significant increases in mean reflex volume, maximum cystometric capacity, and postvoid residual urine and a decrease in detrusor voiding pressure. Of the 11 patients available for follow-up at 16 and 36 wk, improvements in bladder function and urodynamic parameters persisted. Similarly, significant increases were noted in cystometric bladder capacity, reflex volume, and bladder compliance and a decrease in mean voiding pressures in a retrospective multicenter European study of 200 patients with neurogenic DO (5).

Schurch compared two different doses of BTX-A in a double-blind, multicenter, randomized, placebo-controlled study of 59 patients with neurogenic DO (6). Over 24 wk, there was rapid and sustained reduction in the number of incontinence episodes, increase in maximum cystometric capacity, and decrease in mean detrusor pressure.

In a study of 66 patients with neurogenic DO, Grosse et al. examined the effect of repeat detrusor injections of BTX-A. After each BTX-A injection, cystometric capacity and reflex volume increased significantly, and the number of reflex contractions decreased significantly from baseline (7). Repeat injections were as effective as the first injection, indicating no evidence of drug resistance.

Given the benefits of botulinum toxin in patients with neurogenic DO, its use has been expanded to patients with idiopathic refractory DO. Dykstra et al. conducted a pilot study looking at the dose-escalation study of Botox-B in 15 women with idiopathic DO. All but one patient reported decreased urgency and frequency and no incontinence (8). Although the degree of response was similar among all doses, the duration of response was dose dependent, with the greatest duration seen at 10,000 and 15,000 U.

Rapp et al. also looked at the effect of BTX-A in the management of 35 patients with urgency, frequency, and urge incontinence (9). At 3 wk, the mean Incontinence Impact Questionnaire (IIQ-7) and Urogenital Distress Inventory (UDI-6) decreased significantly. Overall, 60% of patients experienced improvement in voiding symptoms.

Rajkumar et al. had similar improvements using 300 U BTX-A in 15 women with refractory idiopathic DO (10). In 14 of the patients, symptoms of urgency and frequency improved immediately after treatment. Urodynamics revealed an increased volume at first desire in 13 patients, an increase in maximum cystometric capacity in 10 patients, and elimination of DO in 6 patients. The improvement in symptoms lasted up to 24 wk.

Although studies support the use of BTX-A in both neurogenic and idiopathic DO, few studies have sought to answer the question in which population (neurogenic or idiopathic DO) is BTX-A most effective? Popat et al. in an open-label prospective study compared the 4-d voiding diaries and urodynamics of 44 patients with neurogenic DO to 31 patients with idiopathic DO (11). At 16 wk, both groups had an increase in maximum cystometric capacity, a decrease in maximum detrusor pressure, a decrease in the number of voids per 24 h, and a decrease in the number of incontinent episodes. Patients with neurogenic DO were more likely to require self-catheterization (69%) than those patients with idiopathic DO (19.3%) (11). This difference may be partly because of the differences in treatment dose; patients with neurogenic DO received 300 U BTX-A; patients with idiopathic DO received 200 U.

### ***Detrusor Overactivity in Children***

Unlike the adult urology literature, there are only four published articles on the use of BTX-A in children with neurogenic DO (12). In the first published study, 20 children (median age 11.4 yr) with neurogenic DO were injected with 12 U/kg BTX-A up to a maximum of 300 U at 30–50 sites (13). Urodynamic follow-up 2–4 wk after injections revealed significant increases in mean reflex volume and maximal bladder capacity as well as a decrease in maximal detrusor pressure (13). At 6 mo, the change in maximal bladder capacity persisted; however, the decrease in maximum detrusor pressure did not.

Riccabona et al. looked at the effects of trigone-sparing BTX-A injections (10 U/kg up to a maximum of 360 U) in 15 patients with myelomeningocele (mean age 5.8 yr) (14). After the first injection, statistically significant changes were noted in mean reflex volume, maximum detrusor pressure, maximum bladder capacity, detrusor compliance, and urinary continence. Yet, unlike Schulte-Baukloh's study, the mean durability of the BTX-A injections was 10.5 mo (13).

Like adults, children show no evidence of drug tolerance after repeat BTX-A injections. In a study by Schulte-Baukloh et al. of 10 children with neurogenic DO who had undergone at least three BTX-A injections, there were no statistically significant differences in urodynamic parameters between injections. The urodynamics outcomes after the first BTX-A injections were similar to urodynamics outcomes after the third and fifth injections (15).

To date there is only one published study on the use of BTX-A in children with idiopathic DO (12). Eleven children (mean age 10 yr) with idiopathic DO refractory to medical therapy were injected with either 125 or 250 U BTX-A (16). The patients experienced an increase in functional bladder capacity and a decrease in idiopathic DO and urgency symptoms.

### ***Detrusor Sphincter Dyssynergia***

The most widespread application of Botox for urethral conditions is for external sphincter dyssynergia (3). Dykstra, in 1988, was the first to use botulinum toxin for DSD (4). In a study of 11 patients with SCIs and DSD, Dykstra et al. injected BTX-A into the external urethral sphincter (17). Of the 11 patients, 10 showed signs of sphincter denervation on electromyography. Urethral pressure profiles and postvoid residual volumes were decreased.

The largest series assessing the effect of BTX-A on patients with SCI and DSD was conducted by Schurch et al. in 1996 (18). Three different protocols using two different formulations of BTX-A toxin were injected into 24 patients; 87% (21/24) of patients had improvements in urodynamic parameters regardless of the protocol or formulation used. Complete disappearance of DSD was noted in 8/21 patients; mean maximum urethral pressure during DSD decreased by 48%, mean duration of DSD decreased by 47%, and mean urethral sphincter pressure decreased by 20%.

More recently, de Seze et al. in a randomized, double-blind, lidocaine-controlled study of 13 SCI patients with DSD, found botulinum toxin to significantly reduce postvoid residuals and maximal urethral pressures at 1, 7, and 30 d when compared to lidocaine (19).

### ***Urinary Retention/Voiding Dysfunction***

Several studies have looked at the role of BTX-A injections into the external urethral sphincter in patients with voiding dysfunction and urinary retention. Phelan et al., in a prospective study of 21 patients with voiding dysfunction, injected 80–100 U BTX-A into the external urethral sphincter. After the BTX-A injection, all but one patient were able to void spontaneously, and all but two discontinued catheterization (20).

Kuo looked at the clinical effects and urodynamic parameters of 50 U BTX-A in 103 patients with various types of lower urinary tract dysfunction. Overall, 84.5% of patients had a decrease in maximum voiding pressure, maximal urethral closure pressure, and postvoid residual (21). Indwelling Foley catheters and clean intermittent catheterization were discontinued in 87% of patients.

### ***Pelvic Pain/Chronic Prostatic Pain/Interstitial Cystitis***

Although several studies have begun to explore the use of BTX-A in the treatment of pelvic pain, the mechanism of action by which BTX produces an antinociceptive effect is unknown. Animal studies have shown that, in addition to blocking acetylcholine release from motor neurons, BTX also inhibits the release of neurotransmitters involved in sensory pathways (3). BTX has been shown to inhibit the release of substance P and glutamate, neuropeptides involved in sensory and nociceptive pathways (3). In another cyclophosphamide-induced cystitis animal model, BTX-A inhibited the afferent neural response via inhibition of mechanoreceptor-mediated release of adenosine triphosphate, suggesting that intravesical instillation of BTX-A may alleviate the clinical symptoms of urgency, frequency, and pain (22).

In an acetic acid-induced rat bladder pain model, calcitonin gene-related peptide, a capsaicin-sensitive neuropeptide that helps regulate micturition and mediates painful bladder sensation, was reduced in animals that received intravesical Botox. This finding suggests that BTX inhibits calcitonin gene-related peptide release, thereby suppressing bladder pain (23).

Clinically, the literature on BTX in the treatment of pelvic pain syndromes is limited. Zermann et al. performed transurethral perisphincteric injection of BTX-A into 11 men with chronic prostatic pain (24). Of the 11 patients, 9 reported subjective pain relief, with an average decrease in pain on a visual analogue scale from 7.2 to 1.6. Postinjection urodynamics showed a decrease in functional urethral length, urethral closure pressure, and postvoid residual and an increase in the peak and average flow rates.

Jarvis et al. conducted a pilot study evaluating the effect of BTX-A injection into the levator ani of 12 women with chronic pelvic pain and pelvic floor hypertonicity (25). Under conscious sedation, women were injected with 40 U BTX-A into the puborectalis and pubococcygeus bilaterally. Pelvic floor manometry showed a 37% reduction in resting pressure at week 4 and a 25% reduction at week 12. Significant improvements were noted in quality of life, dyspareunia, nonmenstrual pelvic pain, and dyschesia but were not statistically significant.

Two studies looked at the antinociceptive effect of BTX on patients with interstitial cystitis (IC). The first study conducted at the Cleveland Clinic Foundation and retrospectively evaluated the effect of two different treatment protocols on 10 patients meeting the National Institute of Diabetes and Digestive and Kidney Diseases criteria for IC. The first five patients received submucosal injections; the second five received intravesical instillations. Neither group showed statistically significant changes in subjective or objective outcome measures (3).

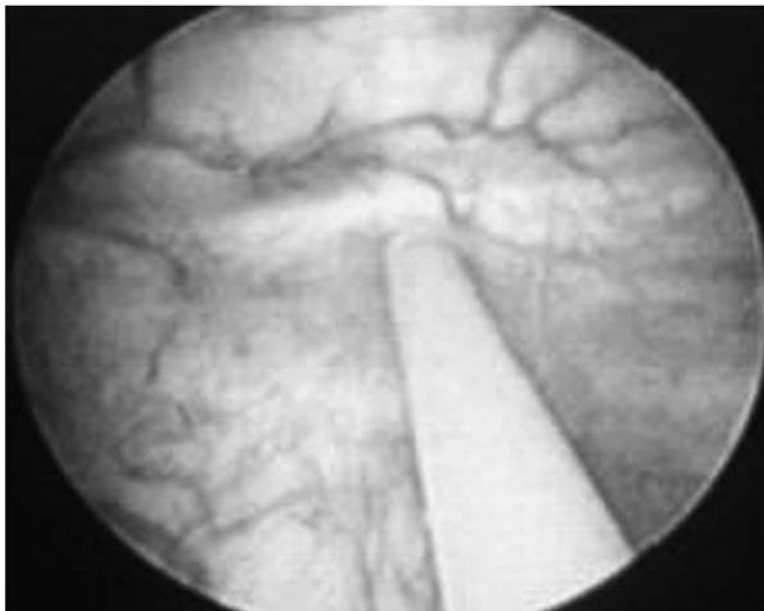
The second study, conducted by Smith et al., injected the detrusor of 13 female patients with refractory IC (26). Overall, 69% of patients noted subjective improvement. Statistically significant improvements were noted in the Interstitial Cystitis Symptom Index and Interstitial Cystitis Problem Index as well as daytime frequency, nocturia, and pain. On urodynamics, statistically significant improvements were noted in first desire to void and maximum cystometric capacity.

## INJECTION TECHNIQUES

### *Bladder*

This procedure is routinely performed in the outpatient setting. With the patient in the lithotomy position, 100 cc 2% lidocaine solution are instilled in the bladder and allowed 15–20 min to take effect (3). In females, a 23-French rigid cystoscope with a collagen injection needle is inserted per urethra. In males, the flexible cystoscope is used. Depending on the institution, the bladder is injected with 100–300 U Botox. Each vial of Botox contains 100 U. Each vial is diluted into 3 mL normal saline, yielding a concentration of 33.3 U/1 mL. Approximately 30 submucosal injections are made into the detrusor muscle, avoiding extravasation into the bladder serosa. Some have anecdotally reported better results when diluting each 100 U Botox into 10 mL saline, yielding a concentration of 10 U/1.0 mL. Theoretically, this may allow for greater dispersal of the Botox within the detrusor muscle.

Injection sites vary, depending on whether the trigone-sparing technique is used. If the trigone-sparing technique is used, then the 30 injections are distributed between the bladder base and lateral walls, sparing the trigone (Fig. 1). If the trigone is injected, then six injections (or 20% of the total volume) are injected into the trigone. Proponents of trigonal injection argue that, by placing Botox in the trigone, an area of greater nerve density, patients will have a better clinical response. However, opponents argue that



**Fig. 1.** Cystoscopic injection of BTX-A into the detrusor muscle. (Courtesy of the Cleveland Clinic Foundation, Cleveland, OH.)

trigonal injection could result in distal ureteral paralysis and subsequent ureteral reflux. This theoretical concern has not been observed clinically.

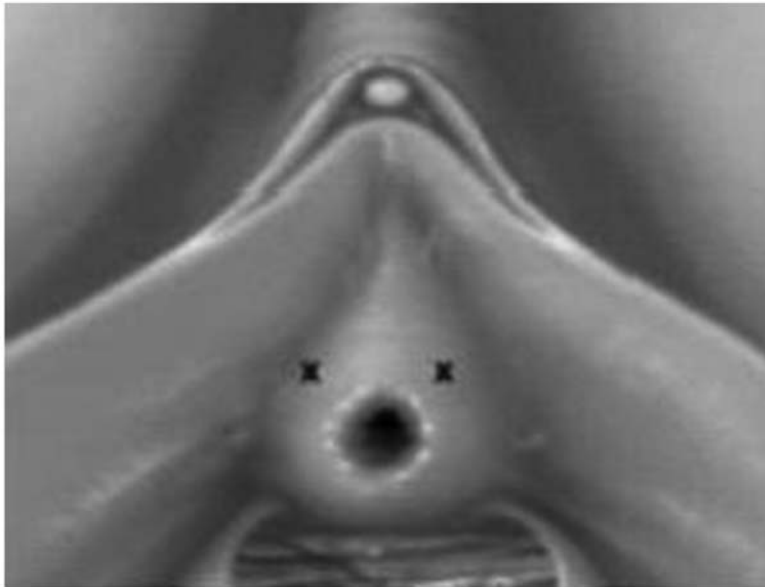
### *Urethral*

The urethra can be injected in one of two ways: cystoscopically or periurethrally. The first involves localization of the external sphincter using the rigid cystoscope and collagen needle, and 100–200 U are injected into the sphincter under direct vision equally at 3, 6, 9, and 12 o'clock (26). In women, an alternate technique, the periurethral technique, can be performed easily. Using a spinal needle, 100–200 U Botox are injected into the external sphincter muscle at the 2 and 10 o'clock positions (Fig. 2). Additional guidance with auditory or needle electromyography may provide further confirmation of the appropriate injection site.

## ADVERSE EVENTS AND CONTRAINDICATIONS

Side effects of BTX are rare when used for urological applications. Not only are the injections localized with little systemic absorption, but also the doses are well below (a thousandth) the presumed fatal dose in a 70-kg male (2). However, in 2002 Wyndaele and Van Dromme reported two cases of generalized muscle weakness in paraplegic and tetraplegic patients (1,2). Interestingly, both patients had return of bladder spasticity within 2 mo, prompting the authors to speculate that there was perivesical diffusion through these thin-walled bladders (2). In addition, patients should be warned about the possibility of urinary retention after BTX secondary to detrusor hypocontractility.

Repeat injection of BTX-A can cause immune responses in less than 5% of patients. Patients undergoing repeat injections are at risk of forming neutralizing antibodies that interfere with the efficacy of Botox therapy (3). Therefore, the use of other BTX



**Fig. 2.** Peri-urethral injection of BTX-A into the external sphincter muscle at 2 and 10 o'clock (X).(Courtesy of the Cleveland Clinic Foundation, Cleveland, OH.)

serotypes that do not cause immune reactions, like BTX-C, are under investigation (2). In patients receiving Botox injections for cervical dystonia, spacing injection cycles by a minimum of 12 wk has drastically reduced the formation of neutralizing antibodies (3).

Contraindications to Botox injections include patients with a preexisting neuromuscular disease such as myasthenia gravis, Eaton-Lambert syndrome, and amyotrophic lateral sclerosis (Lou Gherig disease) (2,3). Botox should also be avoided in patients who are breast-feeding, pregnant, or using agents that potentiate neuromuscular weakness, such as aminoglycosides (2,3). Patients should be informed that some formulations of BTX include stabilizers such as albumin derived from human blood, which may be of religious or cultural significance (3).

## CONCLUSION

Botulinum toxin therapy is emerging as an alternative therapeutic option in adults with debilitating chronic urological conditions such as DSD, neurogenic and nonneurogenic DO, and pelvic pain syndromes. The use of botulinum toxin is rapidly expanding to include the pediatric population as well as patients with visceral pain syndromes. Given its low side-effect profile and duration of action (9–12 mo), botulinum toxin offers an attractive alternative to conservative medical therapy and invasive surgery.

## REFERENCES

1. Leippold T, Reitz A, Schurch B. Botulinum toxin as a new therapy option for voiding disorders: current state of the art. *Eur Urol* 2003;44:165.
2. Sahai A, Khan M, Fowler CJ, et al. Botulinum toxin for the treatment of lower urinary tract symptoms: a review. *Neurourol Urodyn*, 2005;24:2.

3. Frenkl TL, Rackley RR. Injectable neuromodulatory agents: botulinum toxin therapy. *Urol Clin North Am* 2005;32:89.
4. Schurch B, Stohrer M, Kramer G, et al. Botulinum-A toxin for treating detrusor hyperreflexia in spinal cord injured patients: a new alternative to anticholinergic drugs? Preliminary results. *J Urol* 2000;164:692.
5. Reitz A, Stohrer M, Kramer G, et al. European experience of 200 cases treated with botulinum-A toxin injections into the detrusor muscle for urinary incontinence to neurogenic detrusor overactivity. *Eur Urol* 2004;45:510.
6. Schurch B, de Seze M, Denys P, et al. Botox Detrusor Hyperreflexia Study Team. Botulinum toxin type A is a safe and effective treatment for neurogenic urinary incontinence: results of a single treatment, randomized, placebo controlled 6-month study. *J Urol* 2005;174:196–200.
7. Grosse J, Kramer G, Stohrer M. Success of repeat detrusor injections of botulinum A toxin in patients with severe neurogenic detrusor overactivity and incontinence. *Eur Urol* 2005;47:653.
8. Dykstra D, Enriquez A, Valley M. Treatment of overactive bladder with botulinum toxin type B: a pilot study. *Int Urogynecol J Pelvic Floor Dysfunct* 2003;14:424.
9. Rapp DE, Lucioni A, Katz EE, et al. Use of botulinum-A toxin for the treatment of refractory overactive bladder symptoms: an initial experience. *Urology* 2004;63:1071.
10. Rajkumar GN, Small DR, Mustafa AW, et al. A prospective study to evaluate the safety, tolerability, efficacy and durability of response of intravesical injection of botulinum toxin type A into detrusor muscle in patients with refractory idiopathic detrusor overactivity. *BJU Int* 2005;96:848.
11. Popat R, Apostolidis A, Kalsi V, et al. A comparison between the response of patients with idiopathic detrusor overactivity and neurogenic detrusor overactivity to the first intradetrusor injection of botulinum-A toxin. *J Urol* 2005;174:984.
12. Schurch B, Corcos J. Botulinum toxin injections for paediatric incontinence. *Curr Opin Urol* 2005;15:264.
13. Schulte-Baukloh H, Michael T, Sturzebecher B, et al. Botulinum-a toxin detrusor injection as a novel approach in the treatment of bladder spasticity in children with neurogenic bladder. *Eur Urol* 2003;44:139.
14. Riccabona M, Koen M, Schindler M, et al. Botulinum-A toxin injection into the detrusor: a safe alternative in the treatment of children with myelomeningocele with detrusor hyperreflexia. *J Urol* 2004;171:845.
15. Schulte-Baukloh H, Knispel HH, Stolze T, et al. Repeated botulinum-A toxin injections in treatment of children with neurogenic detrusor overactivity. *Urology* 2005;66:865.
16. Schulte-Baukloh H, Michael T, Sturzebecher B, Knispel HH. Botulinum-a toxin detrusor injection as a novel approach in the treatment of bladder spasticity in children with neurogenic bladder. *Eur Urol* 2003;44:139–143.
17. Dykstra DD, Sidi AA, Scott AB, et al. Effects of botulinum A toxin on detrusor-sphincter dyssynergia in spinal cord injury patients. *J Urol* 1988;139:919.
18. Schurch B, Hauri D, Rodic B, et al. Botulinum-A toxin as a treatment of detrusor-sphincter dyssynergia: a prospective study in 24 spinal cord injury patients. *J Urol* 1996;155:1023.
19. de Seze M, Petit H, Gallien P, et al. Botulinum a toxin and detrusor sphincter dyssynergia: a double-blind lidocaine-controlled study in 13 patients with spinal cord disease. *Eur Urol* 2002;42:56.
20. Phelan MW, Franks M, Somogyi GT, et al. Botulinum toxin urethral sphincter injection to restore bladder emptying in men and women with voiding dysfunction. *J Urol* 2001;165:1107.
21. Kuo HC. Botulinum A toxin urethral injection for the treatment of lower urinary tract dysfunction. *J Urol* 2003;170:1908.
22. Smith CP, Vemulakonda VM, Kiss S, et al. Enhanced ATP release from rat bladder urothelium during chronic bladder inflammation: effect of botulinum toxin A. *Neurochem Int* 2005;47:291.
23. Chuang YC, Yoshimura N, Huang CC, et al. Intravesical botulinum toxin administration produces analgesia against acetic acid induced bladder pain responses in rats. *J Urol* 2004;172:1529.
24. Zermann D, Ishigooka M, Schubert J, et al. Perisphincteric injection of botulinum toxin type A. A treatment option for patients with chronic prostatic pain? *Eur Urol* 2000;38:393.
25. Jarvis SK, Abbott JA, Lenart MB, et al. Pilot study of botulinum toxin type A in the treatment of chronic pelvic pain associated with spasm of the levator ani muscles. *Aust N Z J Obstet Gynaecol* 2004;44:46.
26. Smith CP, Radziszewski P, Borkowski A, et al. Botulinum toxin A has antinociceptive effects in treating interstitial cystitis. *Urology* 2004;64:871.



---

# 15

## Nonsacral Neuromodulation

---

*Richard C. Bennett, MD, Andrew Bernstein, MD,  
and Kenneth M. Peters, MD*

### CONTENTS

INTRODUCTION  
TIBIAL NERVE STIMULATION  
ANOGENITAL ELECTRICAL STIMULATION  
PUDENDAL NERVE STIMULATION  
CONCLUSION  
REFERENCES

---

### INTRODUCTION

Neuromodulation is becoming a mainstay as a treatment modality for idiopathic voiding dysfunction. Neuromodulation and neurostimulation have been applied to the sacral nerves and their more distal branches at the level of the anus, vagina, and penis. Sacral nerve stimulation has been approved by the Food and Drug Administration (FDA) since 1997 for the treatment of urinary urge incontinence, urgency, frequency, and refractory retention. Neuromodulation utilizing more distal branches of the sacral nerve roots may have added outcome-related benefits and can be less invasive.

### TIBIAL NERVE STIMULATION

Percutaneous posterior tibial nerve stimulation has emerged as a form of neuromodulation that is both inexpensive and minimally invasive. The posterior tibial nerve is a mixed nerve containing L5–S3 fibers, and it originates from the same spinal segments as the parasympathetic innervation of the bladder. Stimulation of the nerve inhibits bladder activity by depolarizing somatic sacral and lumbar afferent fibers. Afferent stimulation provides central inhibition of the preganglionic bladder motor neurons through a direct route in the sacral cord (1).

Tibial nerve stimulation was first described in 1983. McGuire and colleagues showed efficacy in the treatment of a variety of voiding dysfunctions related to detrusor overactivity by electrical stimulation of the tibial nerve. His group reported on 16 patients with involuntary bladder contractions of varying etiology who were treated with common peroneal or posterior tibial nerve patch electrode stimulation. Initially, 12 patients were dry, 3 were improved, and 1 was “possibly improved” (2). Okada and coworkers in 1998 reported a positive experience with transcutaneous stimulation of the thigh muscle in 19 patients with detrusor overactivity; the maximal cystometric capacity was increased by 57% in 11 of 19 patients (3). Vereecker and associates,

From: Current Clinical Urology: Female Urology: A Practical Clinical Guide  
Edited by: H. B. Goldman and S. P. Vasavada © Humana Press Inc., Totowa, NJ

however, were unable in 1984 to suppress hyperactivity by this method in patients with suprasacral spinal cord injury or disease (4).

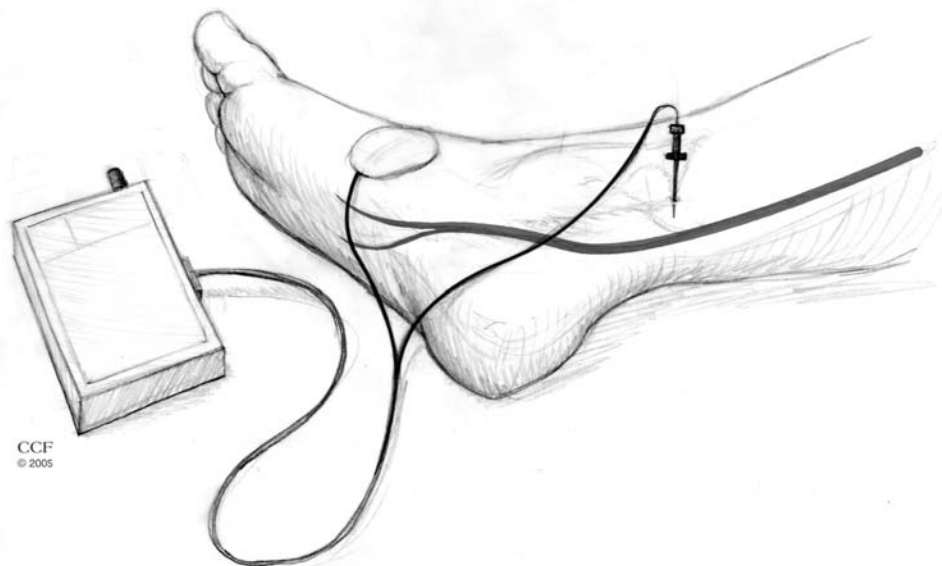
Posterior tibial nerve stimulation is typically performed with patients in the supine position with the knees abducted and the soles of the feet together. A 34-gauge needle is inserted 3 cm into the skin at a level three fingerbreadths cephalad to the medial malleolus. An electrode is placed on the arch of the ipsilateral foot (Fig. 1). The amplitude of the stimulation is increased until the large toe curls or the toes fan. Each session lasts for approx 30 min.

Vandoninck et al. in 2004 reported on their outcomes in 39 patients with chronic voiding dysfunction who were treated with tibial nerve stimulation. All patients had detrusor underactivity with elevated postvoid residual urine or complete urinary retention; each patient performed self-catheterization. Each patient underwent 12 weekly tibial nerve stimulations at the medial malleolus for 30 min each. In measuring objective success, the primary outcome was measured as total voided volume along with total catheterized volume. In 41% of the patients, 24-h catheterized volume was reduced by 50%. An additional 26% noted 25–50% reduction in their residuals. Subjectively, 59% of the patients chose to continue treatment. Urodynamic testing was also performed. Although patients' cystometric capacity remained the same, detrusor pressure at maximum flow increased from 25 to 33 cm H<sub>2</sub>O, a statistically significant difference. In addition, both the bladder contractility index ( $BCI = P_{det} \times Q_{max} + 5 \times Q_{max}$ ) as well as the bladder voiding efficiency [ $BVE = 100 \times (\text{Voided volume} / \text{Total bladder capacity})$ ] showed statistically significant increases. Detrusor instability did exist in five patients at baseline. After stimulation, detrusor instability appeared in three patients, disappeared in two, and appeared *de novo* in seven patients. No significant side effects were reported (5).

Van Balken et al. reported on their treatment of patients with bladder overactivity as well as idiopathic urinary retention. In 37 patients with overactive bladder, 22 reported subjective improvement and requested continuation of therapy. However, all 37 showed significant improvement in day and night voiding frequency. In 30 urge incontinent patients, all 30 showed reduction in their incontinent episodes, pad use, and severity of leakage. Finally, for 12 patients with idiopathic urinary retention, a decrease in number and volume of catheterizations was reported, but this did not reach statistical significance. They concluded that percutaneous tibial nerve stimulation is a promising, cost-effective, and easily applicable treatment for lower urinary tract dysfunction (6).

Ruiz reported on 51 patients treated over 3 yr for similar symptom complexes; 25 patients described the frequency-urgency syndrome, 22 described urge incontinence, and 3 carried a diagnosis of interstitial cystitis (IC). Patients underwent 10, 30-min sessions in which the tibial nerve was stimulated using a similar technique as in prior articles. Mean follow-up was 21 mo. Across the entire patient population, they reported statistically significant improvement in all seven categories measured: daytime frequency, daytime voided volume, daytime leakage episodes, nighttime frequency, nighttime leakage episodes, nighttime voided volume, and hypogastric/suprapubic pain (7).

Posterior tibial nerve stimulation was also evaluated in the acute setting by Amarenco et al. in 2003. They studied 44 patients with irritative lower urinary tract symptoms, including uninhibited detrusor contractions as seen on filling cystometrogram (CMG). The etiology was demonstrable in 37 patients, including multiple sclerosis, spinal cord injury, brain injury, and Parkinson's disease; the remaining 7 patients had idiopathic detrusor overactivity. Cystometry was performed at a rate of 50 cc/min using an 8-French



**Fig. 1.** Stimulation of the posterior tibial nerve.

catheter. Patients were filled until they experienced uninhibited bladder contractions, leakage was observed, or they achieved a volume of 400 cc. A CMG was performed again after posterior tibial nerve stimulation was initiated. A positive test consisted of an increase in the bladder volume at which a contraction occurred of 100 cc or greater or if that involuntary contraction occurred at a bladder volume that was 50% greater than baseline. Of 44 cases, 22 (50%) tested positive. Further urodynamic data were collected. Mean bladder volume at which the first involuntary contraction occurred was 162 cc at baseline and increased to 232 cc after stimulation. Maximum cystometric capacity was 221 cc at baseline, which increased to 277 cc after stimulation (1).

Finally, posterior tibial nerve stimulation has been applied to the IC population, a subset of patients with voiding dysfunction. Zhao et al. applied posterior tibial nerve stimulation to 14 patients diagnosed with IC. Patients were treated during a total of 10, 30-min sessions. One patient withdrew from the study, leaving 13 patients who completed the course of therapy. The results did not meet clinical significance in pain, voided volume, and quality-of-life scores (8).

Clearly, neuromodulation is a feasible, efficient, and effective treatment modality for a variety of lower urinary tract dysfunctions. Posterior tibial nerve stimulation has emerged as a subdivision of this growing field. The lure of the tibial nerve is that it is easily accessible without requiring an operating room or an anesthetic. As with all novel techniques, the data were initially anecdotal and are now becoming more standardized. Studies with modest numbers have shown efficacy. Larger studies need to be performed, particularly in a randomized, blinded fashion to truly examine the long-term efficacy of this exciting technique.

## ANOGENITAL ELECTRICAL STIMULATION

Literature began to appear in the 1970s regarding the treatment of overactive bladder with electrical stimulation. The technique can now be considered an established

treatment option (9). An overall review of the literature since that time shows a dichotomy of response rates and cure rates.

The method of anogenital stimulation is via vaginal/anal plugs equipped with electrodes or circular penile electrodes. Two strategies exist for anogenital electrical stimulation: long term and short term. Long-term outpatient stimulation is mainly used to treat stress incontinence. This form of treatment requires months of home stimulation for several hours per day. Short-term treatment consists of maximal stimulation for a limited number of 10- to 15-min sessions. Maximal stimulation utilizes the highest intensity the patient will tolerate, usually 1.5–2 times the perception threshold (10). This form of treatment can be either home based or in the physician's office. Optimal results have been reported using a frequency of 20 Hz in the physician-supervised setting (11). The minimum number of treatments is not well established. Primus and Kramer found that some patients did not improve until 5 treatments had been given and recommended giving at least 10 treatments (12).

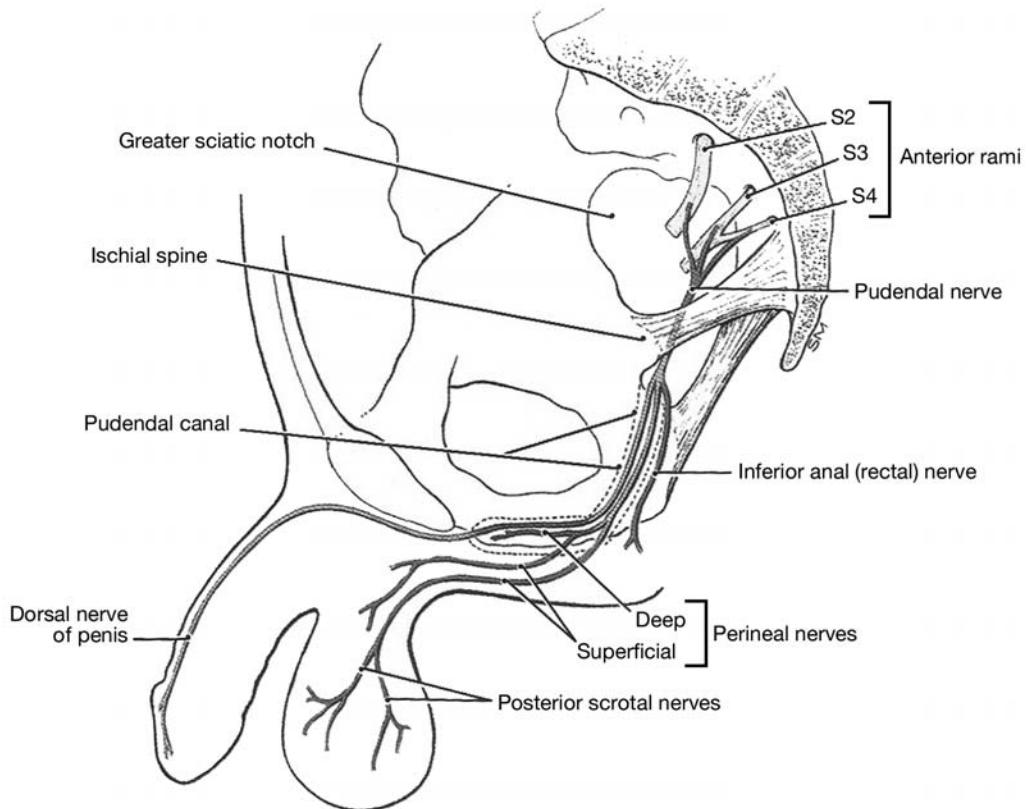
Patient selection has shown to have a great impact on the success rate of anogenital stimulation. The subjective cure or improvement rate is reportedly as high as 85%. Primus and Kramer obtained a success rate of 64% at 2 yr in patients with idiopathic detrusor instability. However, all patients with multiple sclerosis who responded initially relapsed within 2 mo (12). Poor results have been reported in elderly cognitively impaired patients and patients with spinal cord injuries (11). Failure of pharmacotherapy does not appear to portend a poor response to anogenital stimulation (12,13).

Few long-term studies are available regarding the efficacy of anogenital stimulation. In a 2-yr follow-up of the 45 patients studied by Primus and Kramer, 64% still reported satisfaction. Several patients need retreatment to remain satisfactory, and the remainder relapsed (12). The 85% initial success rate reported by Eriksen et al. in 48 patients with idiopathic detrusor instability dropped to 77% at 1 yr (13). Ten years later, 27 of these patients were available for review; 78% had symptoms of urge incontinence. However, 30% leaked less than once a week, and 60% reported satisfaction with maximal electrical stimulation and would recommend it to a friend (14).

## PUDENDAL NERVE STIMULATION

Contemporary sacral nerve root stimulation consists of implantation of a tined electrode in the S3 sacral foramen with subsequent connection to an implantable pulse generator (IPG) (InterStim<sup>®</sup>, Medtronic Inc., Minneapolis, MN). Sacral root neuromodulation inhibits the micturition reflex through stimulation of spinal tract neurons and afferent pathways (9). One limitation of the selection of S3 is that only one of the three afferent pathways inducing the inhibitory reflex is stimulated.

Selection of the pudendal nerve as a site of stimulation provides afferent stimulation of S2, S3, and S4. Afferent pudendal nerve stimulation has been demonstrated to inhibit the micturition reflex, abolish uninhibited detrusor contractions, and increase bladder capacity in animals and humans (15–22). Vodusek et al. (18) showed that detrusor contractions at low volumes of bladder filling were reduced or abolished by stimulating the dorsal penile or clitoral nerves transcutaneously in patients with spinal cord lesions. By stimulating the pudendal nerve close to the ischial spine using bipolar electrodes, Vodusek et al. later reported electrical stimulation increased the micturition threshold and inhibited detrusor activity.




**Fig. 2.** Pudendal nerve anatomy.

### *Anatomy of the Pudendal Nerve*

The pudendal nerve originates from the S2, S3, and S4 sacral nerve roots. The main trunk of the pudendal nerve takes an extrapelvic course superficial to the coccygeus muscle. The main trunk passes over the ischial spine and enters Alcock's (pudendal) canal. In the upper half of the pudendal canal, the pudendal nerve gives rise to the inferior rectal nerve. The inferior rectal nerve exits the pudendal canal medially and extends motor and sensory branches. Motor branches innervate the levator ani; the cutaneous branches innervate the perianal skin and the scrotum or labia. The inferior rectal nerve terminates in multiple branches to the external anal sphincter. At the end of the pudendal canal, the pudendal nerve gives rise to two branches, the perineal nerve and the deep dorsal nerve of the clitoris/penis. The deep dorsal nerve continues as a terminal branch to the penis or clitoris. The perineal nerve divides into the scrotal/labial branch and two muscular branches to the bulbocavernosus and the striated urethral sphincter (23,24). The optimum point of pudendal nerve stimulation is at the level of the ischial spine, proximal to the branch points (Fig. 2).

### *Devices Available for Pudendal Nerve Stimulation*

Currently, the pudendal nerve can be stimulated on a chronic basis using either a tined quadripolar lead (Medtronic) or an implantable microstimulator (bion<sup>®</sup>, Advanced



**Fig. 3.** Tined quadrapolar lead.

Bionics, Valencia, CA). Neither of these applications is FDA approved for pudendal stimulation. The development of a tined lead for sacral nerve stimulation allows for implantation of the lead without suture fixation (Fig. 3). This feature makes it possible to deploy the lead at other sites, such as the pudendal nerve. The advantage is that the lead can be placed at the pudendal nerve via a posterior approach, externalized, and tested as an outpatient to assess clinical response. If the patient demonstrates significant improvement in voiding symptoms, then a permanent IPG can be placed in a subcutaneous pocket in the upper buttock.

The bion microstimulator is a miniature, self-contained, rechargeable implantable neurostimulator that is designed as a platform technology and is intended to treat a wide variety of disorders through direct electrical stimulation. This device is approved in Europe for commercial use in pudendal nerve stimulation and is in clinical trials in the United States for urinary urge incontinence, urgency/frequency, and chronic headache. The fully integrated microstimulator contains a rechargeable battery, a radio transmitter and antenna for bidirectional telemetry, a programmable microchip, and a stimulating electrode. The implant measures 28 mm in length and 3.2 mm in diameter and has a mass of only 0.7 g (Fig. 4).

### ***Patient Selection***

Chronic pudendal neuromodulation is not yet approved by the FDA for the treatment of voiding dysfunction. With appropriate informed consent, patients suffering from



**Fig. 4.** The bion microstimulator.

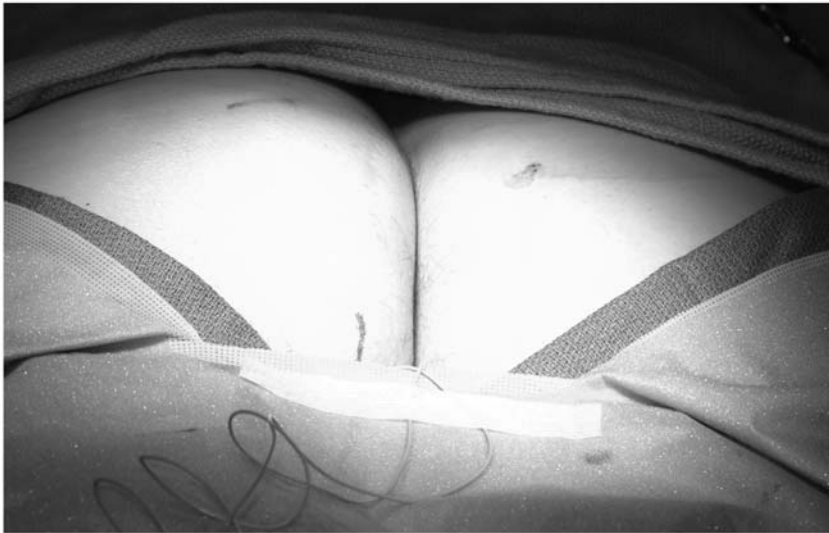refractory voiding dysfunction, including urinary urgency, frequency, urge incontinence, and nonobstructive urinary retention, could be candidates for pudendal neurostimulation. In addition, patients who trialed sacral nerve stimulation but did not respond may benefit from pudendal nerve stimulation. Other disease states that may be considered include IC and neurogenic bladder, including partial spinal cord injury, multiple sclerosis, Parkinson's disease, and other neurological disorders.

A voiding diary should be completed that evaluates time of voids, voided volumes, incontinent episodes, urge scores, pain scores, bowel function, and catheterized volumes if in retention. This baseline information allows accurate postoperative evaluation of patient progress. Because at the present these procedures can only be done "on protocol," appropriate Human Investigation Committee approval is required with signature of an informed consent form.

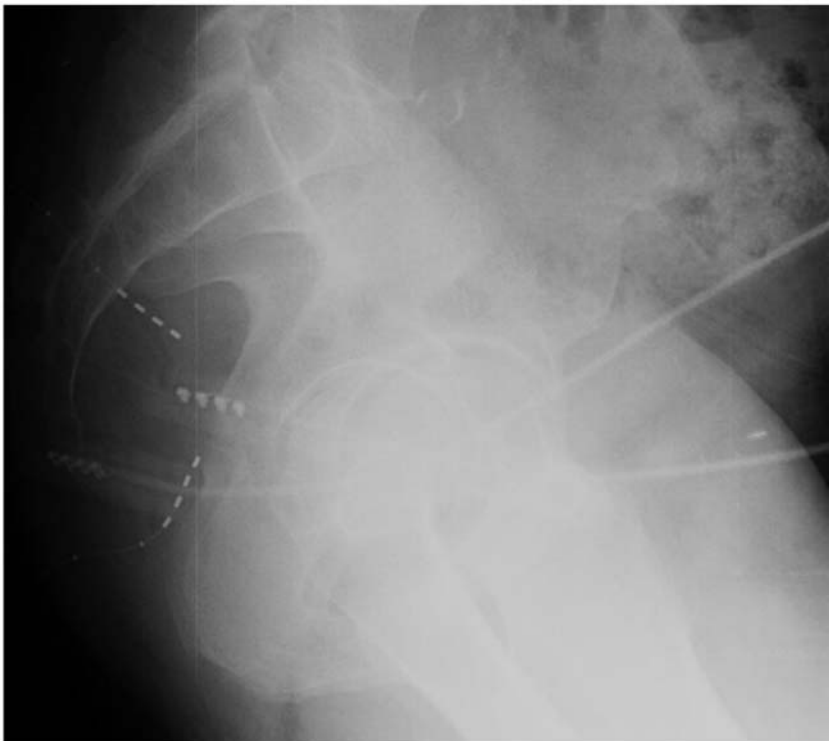### *Procedure*

#### **USING INTERSTIM TINED QUADRIPOlar LEAD**

**Preoperative Preparation and Patient Positioning.** Administer broad-spectrum intravenous antibiotics such as ampicillin and gentamycin. Place the patient in the prone position with appropriate padding and support. Provide light sedation such as Versed®. Perform a thorough betadine prep of the lower back, buttock, and anus. Place either needle or patch electrodes at the external anal sphincter and connect to an electromyographic (EMG) device (Fig. 5). Use fluoroscopy to image the pelvis in the lateral position to identify the ischial tuberosity and ischial spine (Fig. 6).



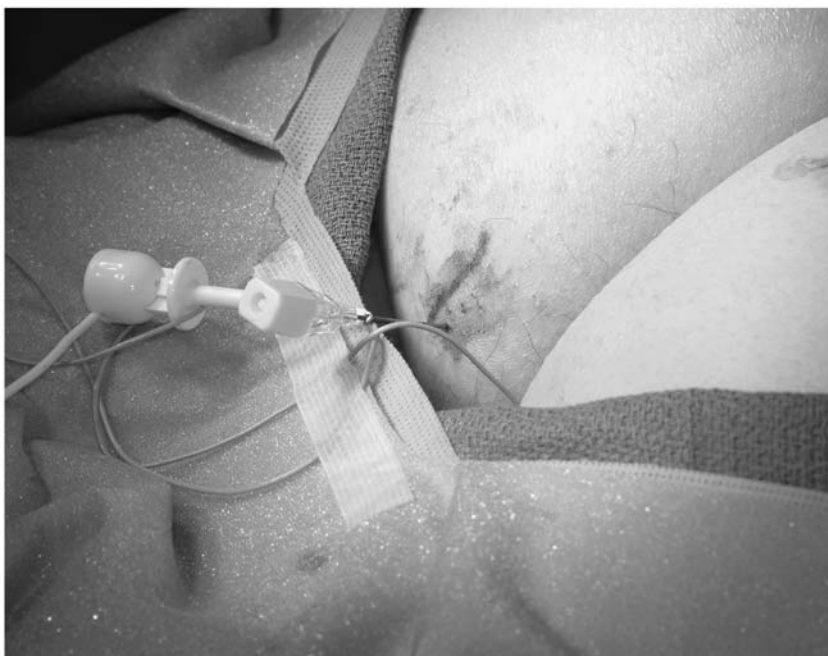**Fig. 5.** EMG electrode at external anal sphincter.



**Fig. 6.** Lateral radiograph of sacral and pudendal quadrapolar leads.

**Identification of the Pudendal Nerve.** Palpate the ischial tuberosity posteriorly; anesthetize the skin 1 cm medial to the tuberosity with 1% lidocaine. Advance a 5.0-in. foramen needle through the skin toward the ischial spine. Stimulate the proximal end of the foramen needle with the standard clip-on stimulating cord (Fig. 7). Begin





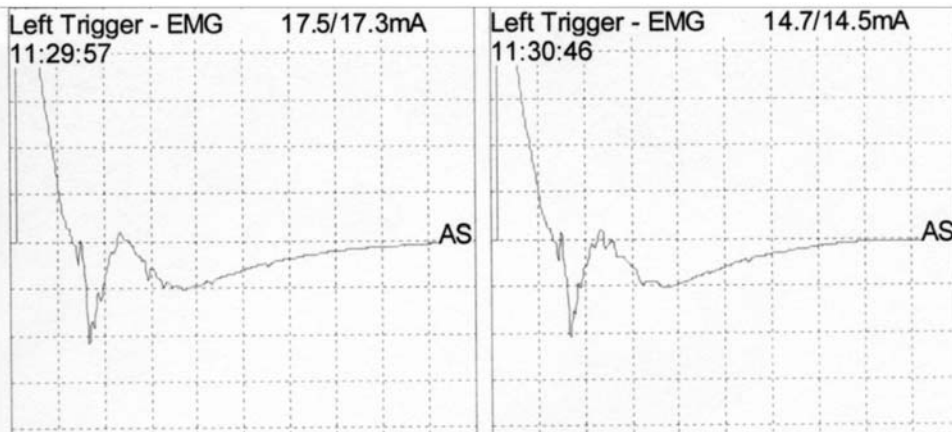
**Fig. 7.** Stimulation of foramen needle near ischial spine.

stimulation at 1 Hz and slowly increase from 1 to 10 mA while examining the anal sphincter and monitoring the EMG tracing. Typical motor response is contraction of the external anal sphincter. This should be confirmed as pudendal stimulation by seeing a classic compound muscle action potential consistent with pudendal stimulation (Fig. 8). Assess the patient's sensory response. A typical response is comfortable pulsating noted in the vagina, scrotum, perineum, or rectum. The nerve of the obturator internus sits close to Alcock's canal; be certain there is no leg rotation noted during the acute testing. If leg movement is seen, then reposition the needle until only the pudendal stimulation is identified.

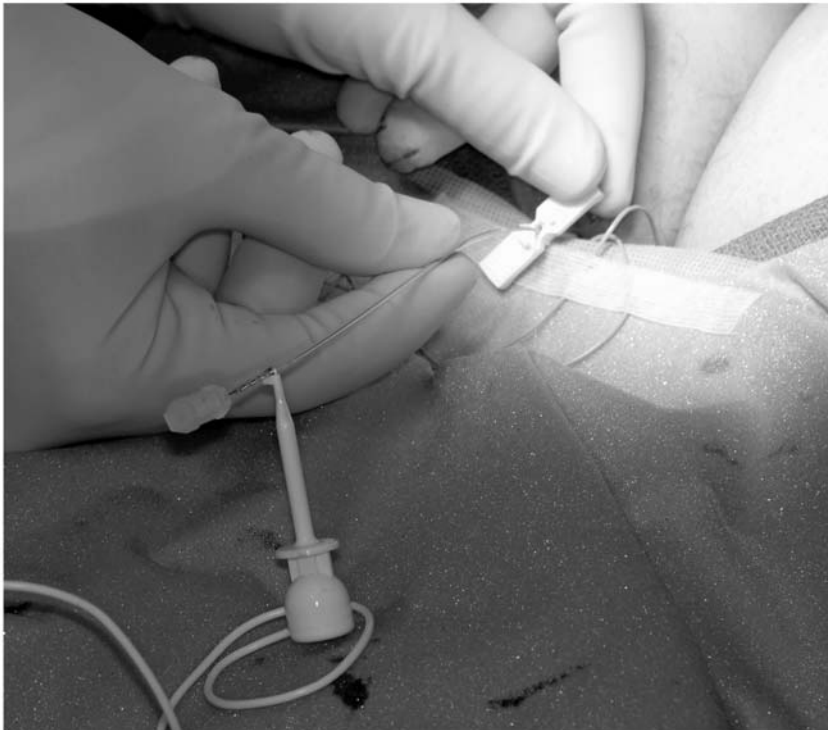**Placement of Quadripolar Tined Lead.** Once the pudendal nerve is identified, advance the directional guide wire and remove the foramen needle. Make a small skin nick alongside the wire. Next, advance the lead introducer over the directional guide wire toward the ischial spine using fluoroscopy. The proximal metal trochar of the lead introducer can be stimulated with the standard stimulation cord. Reconfirm pudendal stimulation and advance the quadripolar lead through the lead introducer and test each electrode in the standard fashion (Fig. 9). The ideal placement would be identification of pudendal stimulation on all four electrodes. Deploy the tines by removing the lead introducer.

**Externalizing the Percutaneous Extension Lead.** The current quadripolar lead is too short to reach the upper buttock, where a future IPG will be placed. Thus, the lead is tunneled to a 1-cm midbuttock incision and connected to the temporary percutaneous extension lead. This lead is tunneled out the contralateral side and externalized. A redundant lead is placed in a subcutaneous pocket underneath the skin, and the incision is closed.

**Stage I Test.** Patients are discharged with the standard Medtronic stimulation box, and stimulation is set to a comfortable sensation for the patient. Voiding diaries are kept



**Fig. 8.** Compound muscle action potential, consistent with pudendal stimulation.



**Fig. 9.** Quadrupolar lead advanced through lead introducer.

for 7–14 d, and if 50% or greater improvement is noted, then the lead is connected to an IPG. If no improvement is noted, then the lead is explanted.

**Implantation of IPG or Removal of Lead.** If the subject does not respond to the stimulation, the midbuttock incision is opened, and the tined lead is removed by gentle traction. If an IPG is to be placed, then a standard site is chosen on the upper buttock, and a subcutaneous pocket is created. A 25-cm extension lead is attached to the IPG and tunneled to the midbuttock incision. The tined lead is freed from this incision;

the percutaneous extension lead is removed. Then, the distal end of the 25-cm IPG extension is connected to the proximal end of the tined lead in the standard fashion. The lead and its connector are placed in the midbuttock subcutaneous pocket.

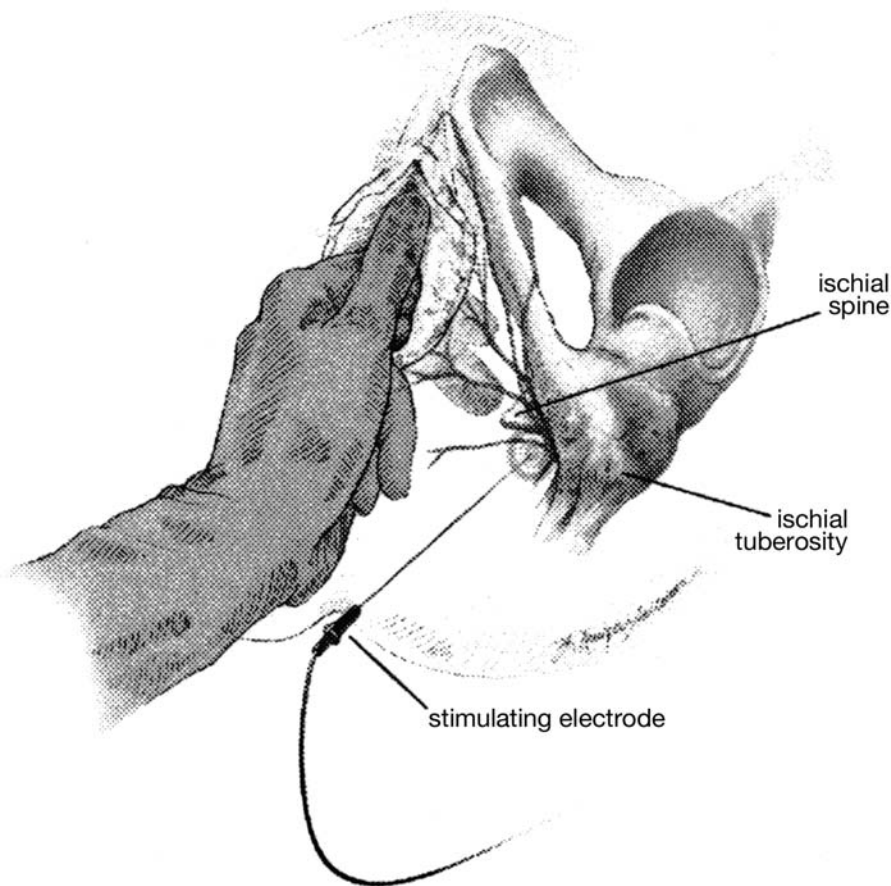
**Outcomes of Pudendal Stimulation Using a Tined Quadripolar Lead.** A direct comparison of the efficacy of pudendal and sacral nerve stimulation has been completed. This was a randomized, single-blinded, single-center trial in which each subject had both a sacral and a pudendal lead placed as part of an approved protocol. Subjects were randomly assigned to begin stimulation on either the sacral or pudendal electrode. In a blinded fashion, each lead was tested for 7 d. Voiding diaries and questionnaires were completed. Subjects rated their percentage improvement on each lead and based on response chose the one to be implanted to a permanent generator. Analysis of the data demonstrated the time to place the sacral lead was 25.85 vs 23.71 min for the pudendal lead ( $p = 0.57$ ). Of 30 subjects, 24 (80%) responded and had an IPG implanted, with 19/24 (79.2%) choosing pudendal and 5/24 (20.8%) choosing sacral. The order in which the lead was stimulated had no impact on the final lead implanted. Pudendal nerve stimulation had significantly higher improvement in symptoms than sacral nerve stimulation, 51 vs 37%, respectively ( $p = 0.02$ ). On a seven-point scale from markedly worse to markedly better, pudendal nerve stimulation was superior to sacral nerve stimulation for pelvic pain ( $p = 0.024$ ), urgency ( $p = 0.005$ ), frequency ( $p = 0.007$ ), and bowel function ( $p = 0.049$ ). This preliminary study demonstrated that pudendal nerve stimulation is feasible, safe, and effective using a tined quadripolar lead (25).

#### PUDENDAL NERVE STIMULATION USING THE BION

The bion is placed at Alcock's canal in a minimally invasive fashion through a small incision in the perineum. Its stimulation parameters can be adjusted using a physician programmer, and the patient has a personal remote, allowing for adjustment of the level of stimulation. The battery is recharged by sitting on a charging pad daily for 20–60 min, and the battery life is 15–20 yr.

**Percutaneous Screening Test.** Prior to implantation of a permanent bion, a percutaneous test is performed in the office. The patient is placed in the lithotomy position at a 45° angle; the vagina and perineum are prepped and draped in the normal sterile fashion. Surface EMG electrodes are placed at the anal sphincter. A computerized CMG is performed at a fill rate of 25 cc/min while measuring the volume at first sensation, first urge, maximum cystometric capacity, and volume at first unstable contraction. Next, the ischial tuberosity is palpated and marked with a marking pen. The ischial spine is palpated through the vagina or rectum (site of Alcock's canal). The skin is anesthetized approx 1.5 cm medial to the ischial tuberosity. With a finger in the vagina or rectum, palpating the ischial spine, a stimulating needle is advanced through the perineum toward the ischial spine while applying electrical stimulation (Fig. 10).

Compound muscle action potentials are measured. Muscle contractions are assessed by direct vision and palpation. A good response is contraction of the bulbocavernosus muscle and external anal sphincter. Poor response includes contraction of the obturator internus, leg adductors, or lower extremity muscles. Sensory response is determined, and a pulsating or tingling in the vaginal, vulvar, or anal regions is optimum. Poor responses include leg or foot twitching or pain. Once needle placement is confirmed, the pudendal nerve is stimulated for 15 min at a pulse frequency of 20 Hz, pulse width of 200  $\mu$ s, 50% duty cycle, and pulse amplitude up to 10.0 mA. The bladder is emptied with a catheter, and the urodynamic catheter is replaced. The CMG is repeated while stimulation



**Fig. 10.** Percutaneous screening test.

continues. A 50% increase in the volume of first sensation, first urge, cystometric capacity, or volume at unstable bladder contraction constitutes a positive test supporting implantation of the permanent bion<sup>®</sup> device.

**Implantation of the Bion.** For implantation of the bion, preoperative broad-spectrum antibiotics are administered. The patient is brought to the operating room, lightly sedated, and placed in the lithotomy position. The perineal area is prepped and draped in the normal sterile fashion. Surface EMG electrodes are placed on the outside of the anal sphincter and connected to an electrodiagnostic monitor. The medial aspect of the ischial tuberosity is marked; the skin is infiltrated with 1% lidocaine approx 1.5 cm medial to the tuberosity, and a 2- to 3-mm incision is made. The bion implant tools include a blunt dissector/stimulator, introducer, bion holder, and placement device (Fig. 11). With a finger palpating the ischial spine through the vagina or rectum, the blunt dissector and introducer are inserted together toward the target (Fig. 12). Fluoroscopy in the lateral position can help direct the bion toward the ischial spine. Clinical and electrophysiological responses facilitate placement as described.

Once the pudendal nerve is confirmed, the blunt dissector is removed, leaving the introducer in place. The bion in its holder is advanced through the introducer, and the placement tool is advanced through the bion holder and locked in place by rotating

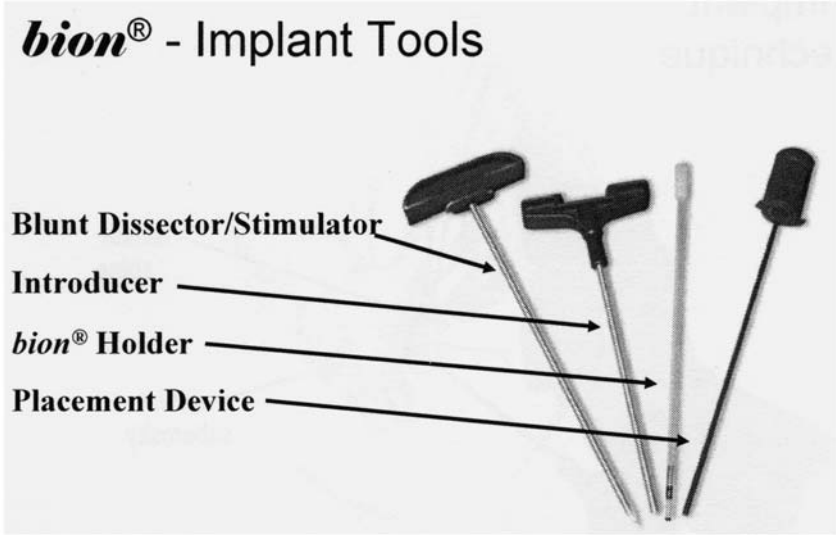

Fig. 11. Implantation tools.

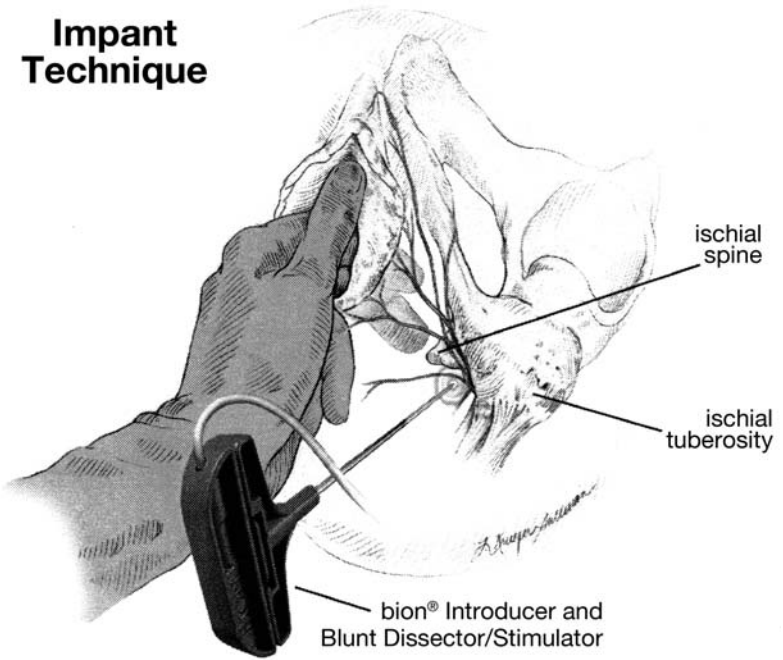


Fig. 12. Implantation of bion microstimulator.

clockwise until it “clicks” into place. The bion is turned on and activated with a frequency of 20 Hz, pulse width of 200  $\mu$ s, continuous duty cycle, and 5- to 10-mA amplitude. Sensory, motor, and electrodiagnostic responses are assessed. Once the location is optimized, the bion is delivered by retracting the bion holder. Retraction is performed by turning the thumbscrew clockwise until it can be turned no further. This

deposits the bion at the site of stimulation. The bion is deactivated, the introducer is removed, and a Steri-Strip™ is placed over the skin incision site.

**Postoperative Follow-Up.** At 1 wk following implantation, the patient returns to the office for programming of the bion and education regarding the system components. The clinician's programmer communicates with the bion and allows the stimulator to be activated and adjusted. Possible adjustments include frequency, pulse width, burst mode, and stimulation limits. The programmer monitors battery life and time the device was activated and gives a history of recharging events. The patients have their own home kit consisting of a remote control, base station/charger, and chair pad used to charge the bion. The bion should last 15–20 yr and can be recharged even if the battery is allowed to deplete completely. The benefits of the bion are its small size and minimally invasive approach to implantation. The results of the clinical trials will determine its future in treating voiding dysfunction.

## CONCLUSION

The use of neuromodulation has led to a major advance in our ability to treat patients suffering from voiding dysfunction who have been refractory to standard therapies. In the past, these patients either continued to suffer from their disease or underwent irreversible surgeries such as bladder augmentation or urinary diversion to control their symptoms. Neuromodulation continues to be developed, and the pudendal nerve appears to be a safe and effective area to stimulate. Studies are ongoing to assess the feasibility of placing a tined quadripolar lead or the bion microstimulator at the pudendal nerve. More patients and longer-term follow-up are needed before this approach is considered standard of care.

## REFERENCES

1. Amarencio G, Ismael SS, Even-Schneider A, et al. Urodynamic effect of acute transcutaneous posterior tibial nerve stimulation in overactive bladder. *J Urol* 2003;169:2210–2215.
2. McGuire EJ, Shi-Chun Z, Horwinski ER. Treatment for motor and sensory detrusor instability by electrical stimulation. *J Urol* 1983;129:78–84.
3. Okada N, Igawa Y, Ogawa Y, Nishizawa O. Transcutaneous electrical stimulation of thigh muscles in the treatment of detrusor overactivity. *Br J Urol* 1998;81:560–564.
4. Vereecker RL, Das RJ, Grisar P. Electrical sphincter stimulation in the treatment of detrusor hyperreflexia of paraplegia. *Neurourol Urodyn* 1984;3:145–149.
5. Vandoninck V, van Balken MR, Finazzi Agro E, et al. Posterior tibial nerve stimulation in the treatment of voiding dysfunction. *Neurourol Urodyn* 2004;23:246–251.
6. Van Balken M, Vandoninck V, Gisolf KW, et al. Posterior tibial nerve stimulation as neuromodulative treatment of lower urinary tract dysfunction. *J Urol* 2001;166:914–918.
7. Ruiz BC. Peripheral afferent nerve stimulation for treatment of lower urinary tract irritative symptoms. *Eur Urol* 2004;45:65–69.
8. Zhao J, Nordling J. Posterior tibial nerve stimulation in patients with intractable interstitial cystitis. *BJU Int* 1994;94:101–104.
9. Weil EH, Ruiz-Cerda JL, Erdmans PH, Janknegt RA, Bemelmans BL, van Kerrebroeck PE. Sacral root neuromodulation in the treatment of refractory urinary urge incontinence: a prospective randomized clinical trial. *Eur Urol* 2000;37:161–171.
10. Geirsson G, Fall M. Maximal functional electrical stimulation in routine practice. *Neurourol Urodyn* 1997;16:559–565.
11. Ohlsson BL. Effect of some different pulse parameters on the perception of intravaginal and intra-anal electrical stimulation. *Med Biol Eng Comput* 1988;26:503–508.
12. Primus G, Kramer G. Maximal external electrical stimulation for treatment of non-neurogenic urinary urgency and/or urge incontinence. *Neurourol Urodynam* 1996;15:187–194.

13. Eriksen BC, Bergmann S, Eik-Nes SH. Maximal electrode stimulation of the pelvic floor in female idiopathic detrusor instability and urge incontinence. *Neurourol Urodyn* 1989;8:219–230.
14. Bratt H, Salvesen KA, Eriksen BC, Kulseng-Heanssen S. Long-term effects ten years after maximal electrostimulation of the pelvic floor in women with unstable detrusor and urge incontinence. *Acta Obstet Gynecol Scand* 1998;77(suppl 168):22–24.
15. Fall M, Erlandson BE, Carlsson CA, Lindstrom S. The effect of intravaginal electrical stimulation on the feline urethra and urinary bladder. Neuronal mechanisms. *Scand J Urol Nephrol* 1978;344(suppl pt 2):19–30.
16. Lindstrom S, Fall M, Carlsson CA, Erlandson BE. The neurophysiologic basis of bladder inhibition in response to intravaginal electrical stimulation. *J Urol* 1983;129:405–410.
17. Light J, Vodusek D, Libby J. Inhibition of detrusor hyperreflexia by a selective electrical stimulation of the pudendal nerve. *J Urol* 1986;135:198.
18. Vodusek D, Light J, Libby J. Detrusor inhibition induced by stimulation of pudendal nerve afferents. *Neurourol Urodyn* 1986;5:381–389.
19. Erickson B, Bergmann S, Eik-Nes S. Maximal electrostimulation of the pelvic floor in female idiopathic detrusor instability and urge incontinence. *Neurourol Urodyn* 1989;8:219–230.
20. Lindstrom S, Sudsuang R. Functionally specific bladder reflexes from pelvic and pudendal nerve branches: an experimental study in the cat. *Neurourol Urodyn* 1989;8:392–393.
21. Fall M, Lindstrom S. Electrical stimulation: a physiologic approach to the treatment of urinary incontinence. *Urol Clin North Am* 1991;18:393–407.
22. Wheeler J, Walter J. Bladder inhibition by dorsal penile nerve stimulation in spinal cord injured patients. *J Urol* 1992;147:100–103.
23. Borirakchanyavat S, Aboseif PR, Tanagho EA, Lue TF. Continence mechanism of the isolated female urethra: an anatomical study of the intrapelvic somatic nerves. *J Urol* 1997;158:822–826.
24. Shafik A, Doss S. Surgical anatomy of the somatic terminal innervation to the anal and urethral sphincters: role in anal and urethral surgery. *J Urol* 1999;161:85–89.
25. Peters KM, Feber K, Bennett R. Sacral vs pudendal nerve stimulation for voiding dysfunction: a prospective, single blinded, randomized, crossover trial. *Neurourol Urodyn* 2005;24:159–160.

---

# 16 Sacral Neuromodulation for the Treatment of Overactive Bladder

---

*Anurag K. Das, MD, FACS*

## *CONTENTS*

INTRODUCTION  
CASE 1  
CASE 2  
HISTORY  
MECHANISM OF ACTION  
INDICATIONS  
TEST PROCEDURE  
IMPLANTABLE PULSE GENERATOR IMPLANTATION PROCEDURE  
RESULTS  
COMPLICATIONS  
CASE STUDIES  
DISCUSSION  
REFERENCES

---

## INTRODUCTION

Urinary frequency/urgency and urinary urge incontinence, collectively referred to as *overactive bladder*, represent common problems in the urologist's practice. Although pharmaceutical management and pelvic floor rehabilitation combined with behavioral modification helps many patients with overactive bladder symptoms, a substantial minority of patients are refractory to these interventions. In such refractory cases, sacral neuromodulation, a minimally invasive and reversible treatment, provides an attractive alternative prior to consideration of more invasive and irreversible treatment modalities. This chapter reviews the current state of sacral neuromodulation for the treatment of refractory voiding dysfunction, with emphasis on the techniques, efficacy, risks, and benefits of this procedure.

Overactive bladder (OAB) is a common syndrome defined by the International Continence Society as "urgency with or without urge incontinence, usually with frequency and nocturia in the absence of other pathological or metabolic conditions to explain these symptoms" (1). Most cases of OAB are idiopathic, and many respond to behavioral modification or antimuscarinic medications. However, it is not uncommon for patients not to respond to these interventions and be classified as having refractory OAB symptoms. Two such refractory cases are illustrated next.



### CASE 1

A 42-yr-old white female presents with complaints of urinary urge incontinence. She leaks in large amounts, generally on her way to the bathroom, but also with changes in position, such as getting out of a chair or bed. She has been tried on various combinations of anticholinergic and tricyclic medications without significant improvement at tolerable doses, and the medications further worsened her constipation, which is already a problem for her. She has been taught guarding maneuvers, behavioral modification, and pelvic floor rehabilitation without satisfactory improvement in her symptoms. Past medical history is otherwise unremarkable, and past surgical history is remarkable for appendectomy and hysterectomy (for large fibroids). There is no history of back problems or neurological disease. Physical examination is unremarkable and urogenital examination reveals a normal meatus, minimal cystourethrocele, and normal neurological examination, including perianal sensation and rectal sphincter tone.

Voiding diary reveals a functional bladder capacity of 300 mL, average voided volume of approx 160 mL, and two or three large-volume leakage episodes daily. Urodynamic studies in the standing position at a fill rate of 60 mL/min with room temperature sterile contrast material reveal phasic detrusor overactivity starting at volumes of 120–140 mL with large-volume leakage. Bladder is normally oriented, and the patient is able to void to completion with low voiding pressures.

### CASE 2

A 32-yr-old white female presents with complaints of urinary frequency and urgency. She was a bedwetter as a child until the age of 8, suffered from numerous “urinary tract infections,” and had undergone a urethral dilation. She also complains of irritable bowel syndrome with alternating diarrhea and constipation but denies migraine headaches, fibromyalgia, or other pain or discomfort. She believes she has always voided more frequently than her friends and siblings, but over the last 2 yr, the situation has worsened to the point at which it is interfering with her work and life. She voids at least every hour, and if she is “stressed,” then she may void as often as every 15 min. She has been treated for multiple urinary tract infections, but there are no positive bacterial cultures. She has been tried on anticholinergic medications without any improvement and on tricyclics with mild improvement. Formal biofeedback and pelvic floor rehabilitation have been partly efficacious, and a 6-mo trial of Elmiron was not helpful. Past medical and surgical histories are otherwise unremarkable.

On examination, she is anxious, but otherwise the examination is unremarkable. On genitourinary examination, there is increased pelvic floor tone, and neurological examination is normal. Voiding diary reveals 20 voids in 24 h with a functional bladder capacity of 250 mL (first morning void); the average voided volume is 90 mL. Urodynamic studies reveal first sensation at a volume of 25 mL and urge at 75 mL. Patient is unable to void with catheters in place. Bladder capacity under anesthesia is 900 mL, and no significant glomerulations or submucosal hemorrhages are noted.

Both these patients represent significant challenges to therapy. Although frequency/urgency syndromes and urge incontinence are common and many patients can be adequately managed with combinations of behavioral therapy, pelvic floor rehabilitation, and pharmaceutical therapy, a significant minority of patients do not respond adequately to these measures and desire further treatment. Options are generally limited and require major surgical procedures such as augmentation cystoplasty, which can often result

in incomplete emptying and need for intermittent catheterization, an alternative not acceptable for many such patients. Sacral neuromodulation (SNS), a minimally invasive treatment alternative, has been used in the treatment of refractory OAB with reasonable success rates in appropriately selected patients. This chapter reviews the history, indications, mechanism of action, techniques, and outcomes of SNS.

## HISTORY

The use of electrical stimulation for treatment of various disorders has a long and colorful history. Electrical stimulation was used for such disease processes as excess libido and, of course, depression. Caldwell and coworkers (2,3) used electrical stimulation of the pelvic floor using implanted electrodes in an attempt to treat stress urinary incontinence and attempted to treat neurogenic incontinence with an implantable stimulator.

With advances in cardiac pacing and the improved understanding and miniaturization of electronic instruments, interest in neuromodulation of bladder function was revived in the 1970s and 1980s. The Department of Urology at the University of California, San Francisco, led by Drs. Richard Schmidt and Emil Tanagho, was instrumental in performing some of the early work and laying the foundation for the use of SNS for the treatment of refractory voiding dysfunction. Drs. Craggs and Fowler in London and Drs. DeGroat and Chancellor at the University of Pittsburgh have performed further work on the mechanism of action of SNS.

The initial large-scale trials were performed in the mid-1990s when Medtronic Incorporated bought the technology from a struggling startup company and completed the Food and Drug Association trials, leading to the approval of SNS for the treatment of urge incontinence in 1997 and for frequency/urgency in 1999. Initially, SNS was performed as a two-stage procedure, and the quadripolar lead electrode was placed through an open sacral incision; the implantable pulse generator (IPG) was placed in the abdomen. The procedure was relatively involved and took approx 2 h to perform.

The first major change was placement of the IPG in the upper buttock region. This helped decrease both the time needed to perform the procedure and the rate of infection. The next major change was the development of the tined lead, allowing percutaneous lead placement under fluoroscopy. This change made the procedure less invasive and further decreased the time needed to perform it.

Initially, there was significant resistance from the established urologic community, especially in the United States, in accepting a treatment option that did not involve traditional treatments of the bladder or urethra, but SNS has become much more accepted as a reasonable alternative for the treatment of refractory voiding dysfunction (4).

## MECHANISM OF ACTION

The mechanism of action of SNS is not completely understood. Chancellor and coworkers (5,6) have suggested SNS improves somatic afferent inhibition of sensory processing in the spinal cord. Because the S2–S4 nerve roots provide the primary autonomic (parasympathetic through the pelvic nerve) and somatic (pudendal nerve) innervation to the bladder, urethra, and pelvic floor, SNS somehow helps in the treatment of OAB by “inhibiting” these nerve roots. Further data to support the view that afferent pathways play a role in SNS-related symptom improvement came from Fowler and colleagues (7,8), who suggested that neuromodulation affects afferent pathways, probably through mediating changes in spino-bulbo-spinal pathways to the pontine

micturition center. Because visceral afferents require higher stimulation amplitudes (9), it is more likely that somatic afferents play a more important role in the mechanism involved, thus the term *somatic afferent inhibition*.

Thon and Jonas (10) have noted that the beneficial effect of SNS can occur without efferent activation of muscle fibers. Others, including Schmidt, have felt strongly that efferent-mediated strengthening of the pelvic floor and external sphincter results in improved voiding dysfunction through augmentation of the guarding reflex (personal communication). It is likely that both efferent and afferent mechanisms play a role, with patients primarily with frequency and urgency helped more through afferent sensory mechanisms, and those with primarily urge incontinence improving as a result of increased efferent activity. Unfortunately, animal models have been difficult to develop, especially for sensory frequency, but previous work in rats and pigs suggests a role for both afferent and efferent mechanisms (11–13).

## INDICATIONS

SNS is indicated for the treatment of refractory urge incontinence and refractory urinary frequency/urgency syndromes, or refractory OAB, depending on one's preference. Generally, patients who have failed or could not tolerate more conservative therapies, such as behavioral modification, pelvic floor rehabilitation (including pelvic floor biofeedback/muscular vaginal electrical stimulation), and anticholinergic/antimuscarinic medications, are given a trial of SNS. Some physicians exhaust all possible options, including high-dose combinations of antimuscarinics and tricyclic antidepressants, before considering neuromodulation as an option, the step prior to significantly more invasive options such as augmentation enterocystoplasty; others will move to SNS earlier.

In the United States, the current approval is for the treatment of refractory urinary frequency/urgency syndromes and urinary urge incontinence of nonneurogenic etiology. It is important to remember that patients with neurological disease were excluded in the pivotal trials, and although there is some evidence that patients with certain neurological diseases may respond well to SNS, this population has not been studied in any well-designed, systematic, prospective clinical trials. Furthermore, it is not possible in the scope of this text to discuss an acceptable definition of *interstitial cystitis*, but the prevailing data would suggest that patients with significant frequency and urgency but without significant pain respond exceedingly well to SNS. Some investigators have achieved good results in patients with a significant component of pelvic pain (14–16); others, myself included, have noted that patients with significant chronic pelvic pain, especially pelvic pain without frequency and urgency, do not respond well in the long term, although they may have an initial good result lasting 3–6 mo.

All patients considered for SNS should have a complete history and physical examination, including a genital, rectal, and neurological examination. These patients should perform accurate voiding diaries and undergo urodynamic studies to confirm the diagnosis and ascertain whether they are suitable candidates. These patients should have failed or could not tolerate more conservative therapies such as behavioral modification or appropriate medications. One suitable algorithm is shown in Fig. 1.

## TEST PROCEDURE

The test procedure can be performed in two distinct locations and provides a short-term trial of SNS. It lets the patient and physician decide whether the benefits of permanent

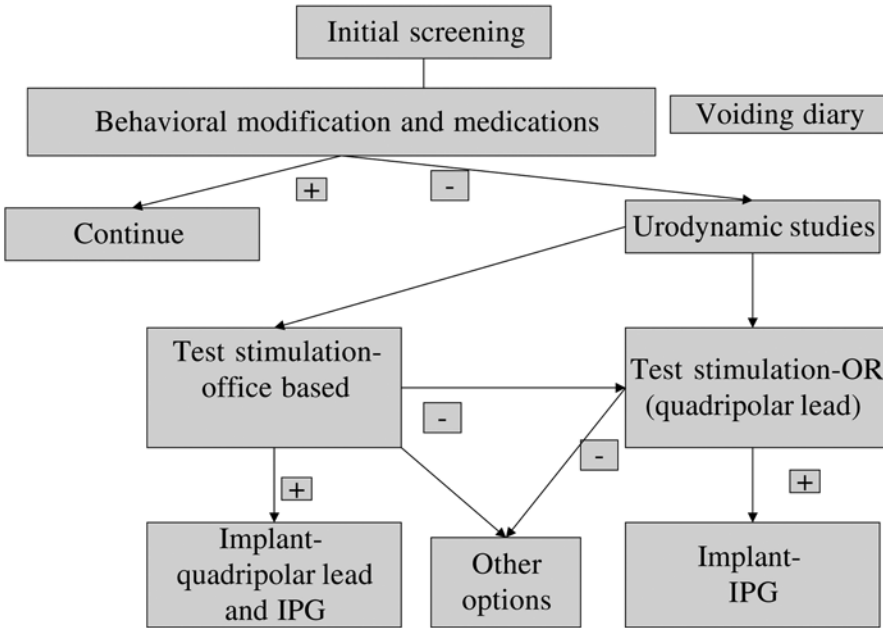



Fig. 1. Algorithm for refractory overactive bladder.

IPG implantation is worth weighing the benefits, risks, and costs of the therapy. The patient performs a 2- to 3-d voiding diary prior to the test procedure. The test procedure can be performed in the office, ambulatory surgery unit, or operating room setting under straight local anesthesia under fluoroscopy guidance. The early pioneers of the procedure performed it without fluoroscopy, but most practitioners perform it with fluoroscopic guidance.

The patient is placed in the prone position with one or two pillows under the lower abdomen to improve the sacral approach. The sacrum is prepped with antiseptic solution, and the sacral notches and coccygeal drop-off are identified by palpation or fluoroscopy. S3 is usually located 1.5–2 cm lateral to the midline at the level of the sacral notches or about 9 cm above the coccygeal drop-off. Local anesthesia is achieved from S2–S4 over the underlying skin and subcutaneous tissues, making certain not to enter the foramen.

Utilizing the previously mentioned landmarks and fluoroscopic guidance, primarily with lateral imaging, insulated foramen needles are placed percutaneously in the S3 and S4 foramen (Fig. 2), and the sensory and motor responses are identified. Sensory responses generally include a tingling, pulling, or vibratory sensation in the vagina and rectum in women and in the scrotum, phallus, and rectum in men. Motor responses include levator tightening (bellows response) and plantar flexion of the big toe. Sometimes, at S3 plantar flexion of the entire foot is noted. In such cases, S4 may be the more appropriate foramen as most patients are significantly bothered by such a foot response.

Once the appropriate responses have been obtained, an insulated wire is placed through the 18-gage needle into the foramen, and the needle is removed. Two or more such wires can be left in, and the patient can try out left and right sides or S3 and S4 and decide on the best response because these temporary wires are inexpensive and easy to place. The wires are taped in place and attached to an external neurostimulator, which the patient is taught how to adjust for optimal results. The patient maintains



**Fig. 2.** Bilateral needle placement in S3 foramen. The approach is at an approx 60° angle.

stimulation at a comfortable level (it should not be painful) and completes a voiding diary to provide objective data while undergoing neuromodulation.

Based on the patient's subjective experience and the objective data obtained through the voiding diary, a final decision can be made to proceed or not proceed with permanent implantation. Usually, the patient needs to exhibit significant subjective improvement, and the voiding diary should show at least 50% improvement in voiding parameters to warrant proceeding. In equivocal cases, or if the insulated wires move, a trial can be carried out with a quadripolar tined electrode before making a final decision.

Alternatively, the test stimulation can be carried out with a permanent quadripolar tined lead. The initial procedure is similar to the test stimulation described but cannot be performed in the office setting. Broad-spectrum antibiotics are given, and adequate monitored anesthesia care anesthesia is obtained. Once the needles have been placed in the appropriate foramen and the sensory and motor responses obtained, a decision is made to use the best responses. The needle's stylet is removed, a guide wire is inserted, and the tract is dilated over the guide wire under fluoroscopic guidance once the needle has been removed. The sheath from the dilating apparatus is then left in; the tined lead (so called as it has tines that hold it in place) is inserted, and its position is optimized by again checking the neural responses. The sheath is then removed, and the tines hold the lead in place. The tined lead is now tunneled to the location of the eventual IPG,

where it is connected to an externalizing wire, and then another tunnel is created to externalize the connection and to prevent infection.

One advantage of this procedure is that the same responses should be obtained once the external neurostimulator is replaced by the permanent IPG because the lead-nerve interface does not change. The tined lead also does rarely migrates, and thus a 1- to 2-wk trial can be easily done; such long trials are less common with the insulated wire leads, which migrate at an approx 10–15% rate. Disadvantages include the cost (~\$2000 for one lead only, not including related operating room costs); the inability to place more than one lead (without further increasing costs); and the need to remove the lead with local anesthesia, usually in the operating room setting, if there is not sufficient improvement for the patient. Nonetheless, the majority of physicians performing SNS in the United States perform it with the tined lead.

### IMPLANTABLE PULSE GENERATOR IMPLANTATION PROCEDURE

Patients who have undergone successful test stimulation with the tined lead are brought back to the operating room. The site of the connection in the upper buttock area, 4 cm below the posterior iliac crest, is opened after broad-spectrum intravenous antibiotic coverage is provided. An appropriate size pocket is created at a depth of 1.5–2 cm. The previous connection is taken down, and a new connection is made from the lead to a 10-cm connecting lead, which is then connected to the IPG (Fig. 3). After copious amounts of antibiotic irrigation, the incision is closed in two layers. If the patient underwent traditional insulated wire test stimulation, then the wire leads are generally removed in the office.

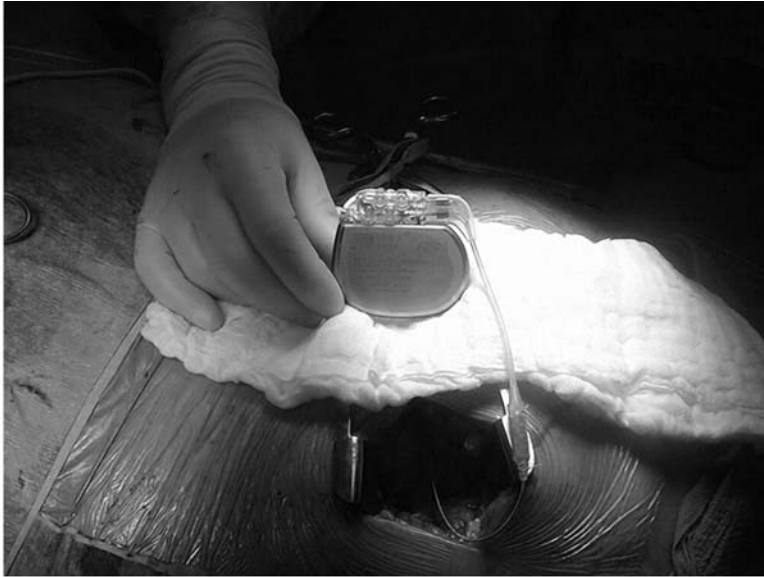After an interval of 2 wk or more, the patient is brought back to the operating room and a tined quadripolar lead electrode is placed as described. An incision is made over the upper buttock area, 4 cm below the posterior iliac crest, and an appropriate pocket is created. The connections are then made from the lead to the 10-cm connecting lead to the IPG. Incision is closed with no tension on the skin, and the patient is kept on oral antibiotics for 1 wk. The procedure is performed on an outpatient basis. Figure 4 depicts a plain film lateral view of lead at S3 and implantable pulse generator in place.

The IPG is programmed, and the patient is taught to set the unit at a comfortable setting at which the stimulation can be felt but is not painful. The patient is able to control the amplitude and to turn the unit on and off; the IPG is completely programmable using an external programmer. Thus, the various parameters can be adjusted on a routine basis as necessary to provide optimal stimulation and results. Some investigators have performed bilateral stimulation, and although this is theoretically appealing, currently there are not enough data to differentiate if this approach may provide better results (17).

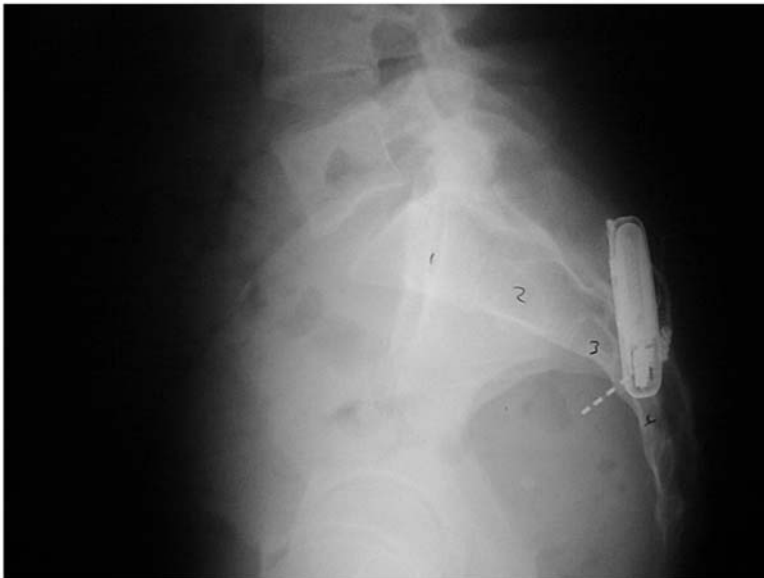### RESULTS

The results of the prospective, randomized, multicenter study (MDT-103 study sponsored by Medtronic), which led to the Food and Drug Administration approvals for urge incontinence and frequency/urgency, represent the best-available objective data.

Schmidt (18) reported the urge incontinence data in 1999. Based on voiding diary data, patients with refractory urge incontinence underwent test stimulation. Those with a successful test stimulation were randomly assigned to an immediate stimulation and a delayed group. The immediate group included 34 patients who underwent implantation and were followed for 6 mo. The delay group comprised 42 patients who received



**Fig. 3.** Implantable pulse generator being placed in upper buttock subcutaneous pocket.



**Fig. 4.** Later plain film showing quadripolar lead and IPG in place. Note that generally two or three electrode leads are anterior to the sacrum.

standard medical therapy for 6 mo and then were offered implantation. At 6 mo, the number of daily incontinence episodes, severity of episodes, and number of absorbent pads or diapers replaced daily because of incontinence were significantly reduced in the immediate stimulation group compared to the delay group (all  $p < 0.0001$ ). Of the 34 stimulation group patients, 16 (47%) were completely dry, and an additional 10 (29%)

demonstrated a greater than 50% reduction in incontinence episodes 6 mo after implantation. Efficacy was sustained for 18 mo. Complications included IPG site pain in 15.9% of the patients, implant site pain in 19.1%, and lead migration in 7.0%. Surgical revision was required in 32.5% of patients. There were no reports of permanent injury or nerve damage.

As reported by Hassouna et al. (19) in 2000, their frequency/urgency group consisted of 51 patients from 12 centers who underwent baseline assessment, including a detailed voiding diary, urodynamic evaluation, and office-based test stimulation under local anesthesia of the sacral nerves at S3 or S4. Patients demonstrating a satisfactory response to trial stimulation were randomly divided into a stimulation group (25 patients) and a control group (26 patients). An IPG was implanted immediately in the stimulation group and after 6 mo in the control group. Patients were followed at 1, 3, and 6 mo and at 6-mo intervals for up to 2 yr after implantation of the IPG. The primary study variables included the number of voids daily, volume voided per void, and degree of urgency prior to voiding. Compared to the control group, 6-mo results demonstrated statistically significant improvements ( $p < 0.0001$ ) in the stimulation group with respect to the number voids daily ( $16.9 \pm 9.7$  to  $9.3 \pm 5.1$ ); volume voided per void ( $118 \pm 74$  to  $226 \pm 124$  mL); and degree of urgency based on a 0–3 scale ( $2.2 \pm 0.6$  to  $1.6 \pm 0.9$ ). Patients in the control group showed no significant changes in voiding parameters at 6 mo. Significant improvements were also noted in the short-form-36 quality-of-life parameters in favor of the stimulation group.

Many short-term uncontrolled studies have also shown significant improvement in OAB symptoms (20–22). Shaker and Hassouna (22) reported on 18 patients with refractory urge incontinence who had an average follow-up of 18.8 mo (range 3–83). SNS in these patients showed a marked reduction in leakage episodes, from 6.49 to 1.98 times per 24 h. Eight patients (44%) became completely dry, and 4 had average leakage episodes of 1 or less daily.

Dijkema (21) reported that 19 of 23 patients with an implanted neuroprosthesis for neuromodulation had a more than 50% improvement in their main symptoms after a median follow-up of 12 mo. In urge-incontinent patients, the number of leakage episodes decreased from 7.4 to 1.5/d, and the functional capacity increased from 135 to 227 mL.

Grunewald and Jonas (20) reported on 55 patients with a mean postoperative follow-up of 44.3 mo. Lasting symptomatic improvement of more than 50% was achieved in 16 of 21 patients with motor urge incontinence (76.2%).

Quality-of-life improvements have also been noted. Das et al. (23) reported on a cohort of patients from the MDT-103 study in which the Beck Depression Index and the Medical Outcomes Study Short-Form 36 were used to assess depression and health-related quality of life (HRQOL) at baseline and at two follow-up visits. The subjects had detectable levels of depression and reduced quality of life at baseline. Those implanted with the neurostimulator reported significant improvements in both HRQOL scores and depression at 3 and 6 mo; those assigned to the delayed implant group showed a slight worsening of HRQOL and depression from baseline to 3 mo that continued through the 6-mo visit.

Several authors have also reported good results in patients with interstitial cystitis. Comiter, Peters, Whitmore and coworkers (14,16,24) have all shown short-term effectiveness in this population. There is certainly an issue of semantics as some of these patients primarily had frequency and urgency with a relatively small component of chronic pelvic pain, and those patients should be expected to do reasonably well.



Comiter (14) reported on 17 patients undergoing IPG placement. At an average follow-up of 14 mo, mean daytime voids improved from 17.1 to 8.7 ( $p < 0.01$ ). Mean voided volume increased from 111 to 264 mL ( $p < 0.01$ ). These results are similar to most other studies in patients with frequency/urgency. However, he also reported that average pain score decreased from 5.8 to 1.6 points on a scale of 0 to 10 ( $p < 0.01$ ), and the Interstitial Cystitis Symptom and Problem Index (a validated questionnaire for interstitial cystitis-related symptoms) scores decreased from 16.5 to 6.8 and 14.5 to 5.4, respectively ( $p < 0.01$ ). The effectiveness of SNS for significant, chronic pelvic pain remains unclear, although one study demonstrated decreased narcotic requirements in this population (15).

On the other hand, few long-term data are available. Elhilali et al. (25) reported long-term (13-yr) data on 52 patients who were followed closely. Of the 52 patients, 11 were not available for evaluation. Of the 41 remaining patients, 22 had urgency/frequency syndrome, 6 had urgency incontinence, 9 had urinary retention, and 4 had interstitial cystitis with intractable pelvic pain. Five required explantation and were offered reimplantation but declined. Of the 22 patients in the urgency/frequency group, 10 (45%) had persistent improvement. In the urge incontinence group, 3 of the 6 patients required explantation, and only 1 (17%) reported lasting improvement in the frequency of incontinence episodes.

Similarly, I presented (26) data looking at long-term quality-of-life changes based on SF-36 scores, which showed significant improvement lasting through 3 yr, but by 5 yr there were no statistically significant differences in quality-of-life scores compared to baseline. Interestingly, based on the same study cohort, there continued to be statistically significant improvements in frequency/urgency and urge incontinence based on voiding diary data presented by Van Kerrebroeck (26).

If unilateral stimulation is helpful, then can bilateral stimulation provide better results? Scheepens et al. (27), in a prospective, randomized, crossover trial, investigated 33 patients who were randomly assigned to start with bilateral or unilateral stimulation. Between the stimulation episodes, a 2-d washout interval was scheduled. Results were based primarily on voiding diaries. No statistically significant improvement was credited to bilateral stimulation compared to unilateral stimulation. Hohenfellner et al. (28) also investigated this topic, but the procedure their group performed included a sacral laminectomy with placement of cuff electrodes and thus was far more morbid than current procedures. Thus, their data are difficult to compare with data of most other investigators.

## COMPLICATIONS

Over the years, percutaneous test stimulations have been exceedingly safe as only a 20-gauge needle and thin wires that passed through this needle were used. The main problem with the procedure, as discussed, was lead migration, occurring in about 15% of cases. With the advent of the coiled wire, the lead migration rate dropped, although this has never been quantified in a randomized trial. In the multicenter MDT-103 trial, about 33% of patients undergoing permanent implantation of lead (open) and IPG required revision surgery. The probability of such a revision decreased from 29% in the first 6 mo to 12% in the second 6 mo. Most common reasons for revisions included pain at the lead or IPG site, lead migration, or infection. Similar complication and revision rates have been found in other trials (25,29). There were no reported permanent nerve

injuries in this series. With placement of the IPG in the upper buttock region as opposed to the abdomen, some decrease in IPG site pain has been recorded as the IPG no longer wedges between the anterior superior iliac spine and the rib cage.

Today, most physicians, at least in the United States, have moved to the two-stage implant utilizing the tined quadripolar lead electrode. Spinelli et al. and Vasvada and Hijaz reported the rate of lead migration with this electrode as relatively low (30,31). However, migration of the tined lead does occur and may be more common in thinner patients (32). Pain at the site of the electrode with this approach is less common. However, the infection rate in the Vasavada and Hijaz series was 10% or slightly higher than for the multicenter series (6%). Their overall revision rate was about 20%, moderately lower than for the multicenter series. With continued technical improvements, further lowering of the revision rates can be expected.

## CASE STUDIES

Returning to the cases presented at the beginning of this chapter, the first case study patient underwent a trial of SNS utilizing percutaneous wires placed at both S3 nerve roots. The trial was performed for 7 d, 3 on the left and 4 on the right. There was significant subjective improvement, and objective voiding diaries showed a decrease in incontinence episodes to only two small-volume episodes in 3 d on the left side. The right side also showed significant improvement, but the patient subjectively felt the left side was better. The patient underwent open implantation of quadripolar lead electrode and IPG under general anesthesia and has been followed for over 5 yr with minimal incontinence requiring use of a liner primarily for safety.

The second case study patient underwent placement of a tined quadripolar lead electrode under monitored anesthesia care and local anesthesia. Both S3 roots were tested, and the electrode was placed on the left side. The patient did have moderate discomfort at the site of electrode placement, but voiding function improved subjectively and objectively. The average volume voided increased to almost 200 mL, and number of voids decreased to 10–11/24 h. Urgency also improved, and the patient was able to sleep through the night on two of the seven nights. She underwent IPG placement under the same anesthetic regimen and has been stable for over 2 yr, requiring no medications. She does have complaints of some discomfort at the site of the IPG, but this does not require pain medications and has not bothered her enough to warrant change of the IPG site.

These cases represent the best possible results obtained with the use of SNS, and certainly there are many other patients who do not respond to the test stimulation or after responding to the test stimulation only respond to the implanted device for a short time period. Nonetheless, in this difficult population with limited therapeutic choices, SNS represents the most appropriate therapeutic option once behavioral treatments and pharmacotherapy have failed.

## DISCUSSION

SNS has become a useful and necessary technique for the treatment of refractory OAB. From 1997, when fewer than a dozen physicians in the United States were using this technique, there have been tremendous changes. Today, most residents are exposed to SNS in their training programs, and there are few urogynecologists or urologists specializing in female urology and incontinence who are not well versed

in SNS practice. Attention is now turned to even smaller devices with rechargeable batteries to make the procedure increasingly minimally invasive. Furthermore, electrode placement to directly stimulate the pudendal nerve (33,34) by a variety of techniques is under study.

Although minimally invasive, some of these techniques currently do have some significant limitations, although with some technical advances these limitations can be remedied. However, it is unclear whether pudendal stimulation may successfully treat some of the patients refractory to SNS treatment. It is also unclear if long-term pudendal stimulation may be better tolerated by patients when compared to SNS. It is hoped that well-designed, randomized, prospective clinical trials will help answer some of these questions.

In the meantime, patients presenting with OAB symptoms not responding to pharmacotherapy and behavioral therapy are best managed with SNS. Whether the more traditional percutaneous test stimulation is initially carried out or whether the tined quadripolar lead is initially placed remains the preference and judgment of the surgeon in discussions with the patient. With the continued evolution of the procedure, it has become less invasive, and the complication and revision rates are gradually decreasing. Future advances will likely lead to increasingly minimally invasive procedures with a smaller IPG and the likely use of pudendal nerve stimulation in selected patients.

## REFERENCES

1. Abrams P, Cardozo L, Fall M, et al. The standardization of terminology of lower urinary tract function: report from the Standardisation Sub-committee of the International Continence Society. *Neurourol Urodyn*, 2002;21:167–178.
2. Caldwell KP. The electrical control of sphincter incompetence. *Lancet* 1963;2:174–175.
3. Caldwell KP, Flack FC, Broad AF. Urinary incontinence following spinal injury treated by electronic implant. *Lancet* 1965;39:846–847.
4. Abrams P, Blaivas JG, Fowler CJ, et al. The role of neuromodulation in the management of urinary urge incontinence. *BJU Int* 2003;91:355–359.
5. Leng WW, Chancellor MB. How sacral nerve stimulation neuromodulation works. *Urol Clin North Am* 2005;32:11–18.
6. Yoshimura N, Seki S, Chancellor MB, de Groat WC, Ueda T. Targeting afferent hyperexcitability for therapy of the painful bladder syndrome. *Urology* 2002;59(5 suppl 1):61–67.
7. Fowler CJ, Swinn MJ, Goodwin RJ, Oliver S, Craggs M. Studies of the latency of pelvic floor contraction during peripheral nerve evaluation show that the muscle response is reflexly mediated. *J Urol* 2000;163:881–883.
8. Goodwin RJ, Swinn MJ, Fowler CJ. The neurophysiology of urinary retention in young women and its treatment by neuromodulation. *World J Urol* 1998;16:305–307.
9. van Balken MR, Vergunst H, Bemelmans BL. The use of electrical devices for the treatment of bladder dysfunction: a review of methods. *J Urol* 2004;172:846–851.
10. Thon WF, Baskin LS, Jonas U, et al. Neuromodulation of voiding dysfunction and pelvic pain. *World J Urol* 1991;9:138–141.
11. Mersdorf A, Tanagho EA, Jakse G. Electrical neurostimulation in the male Wistar rat: proximal stimulation of the nervi pelvici sive pudendus. *Investig Urol (Berl)* 1994;5:152–156.
12. Mersdorf A, Schmidt RA, Tanagho EA. Urodynamic evaluation and electrical and pharmacologic neurostimulation. The rat model. *Urol Res* 1993;21:199–209.
13. Schultz-Lampel D, Jiang C, Lindstrom S, Thuroff JW. Experimental results on mechanisms of action of electrical neuromodulation in chronic urinary retention. *World J Urol* 1998;16:301–304.
14. Comiter CV. Sacral neuromodulation for the symptomatic treatment of refractory interstitial cystitis: a prospective study. *J Urol* 2003;169:1369–1373.

15. Peters KM, Konstandt D. Sacral neuromodulation decreases narcotic requirements in refractory interstitial cystitis. *BJU Int* 2004;93:777–779.
16. Peters KM, Carey JM, Konstandt DB. Sacral neuromodulation for the treatment of refractory interstitial cystitis: outcomes based on technique. *Int Urogynecol J Pelvic Floor Dysfunct* 2003;14:223–228; discussion 228.
17. Hohenfellner M, Schultz-Lampel D, Dahms S, Matzel K, Thuroff JW. Bilateral chronic sacral neuromodulation for treatment of lower urinary tract dysfunction. *J Urol* 1998;160(3 pt 1):821–824.
18. Schmidt RA, Jonas U, Oleson KA, et al. Sacral nerve stimulation for treatment of refractory urinary urge incontinence. Sacral Nerve Stimulation Study Group. *J Urol* 1999;162:352–357.
19. Hassouna MM, Siegel SW, Nyeholt AA, et al. Sacral neuromodulation in the treatment of urgency-frequency symptoms: a multicenter study on efficacy and safety. *J Urol* 2000;163:1849–1854.
20. Gruenewald V, Jonas U. Neurostimulation for lower urinary tract voiding problems. *Curr Urol Rep* 2000;1:199–203.
21. Dijkema HE, Weil EH, Mijs PT, Janknegt RA. Neuromodulation of sacral nerves for incontinence and voiding dysfunctions. Clinical results and complications. *Eur Urol* 1993;24:72–76.
22. Shaker HS, Hassouna M. Sacral nerve root neuromodulation: an effective treatment for refractory urge incontinence. *J Urol* 1998;159:1516–1519.
23. Das AK, Carlson AM, Hull M. Improvement in depression and health-related quality of life after sacral nerve stimulation therapy for treatment of voiding dysfunction. *Urology* 2004;64:62–68.
24. Whitmore KE, Payne CK, Diokno AC, Lukban JC. Sacral neuromodulation in patients with interstitial cystitis: a multicenter clinical trial. *Int Urogynecol J Pelvic Floor Dysfunct* 2003;14:305–308; discussion 308–309.
25. Elhilali MM, Khaled SM, Kashiwabara T, Elzayat E, Corcos J. Sacral neuromodulation: long-term experience of one center. *Urology* 2005;65:1114–1117.
26. Das A, Hull M. Long-term results of quality of life indicators following sacral neuromodulation for refractory voiding dysfunction. *AUA Annual Meeting May 9, 2004, San Francisco, CA.*
27. Scheepens WA, de Bie RA, Weil EH, van Kerrebroeck PE. Unilateral vs bilateral sacral neuromodulation in patients with chronic voiding dysfunction. *J Urol* 2002;168:2046–2050.
28. Hohenfellner M, Dahms SE, Matzel K, Thuroff JW. Sacral neuromodulation for treatment of lower urinary tract dysfunction. *BJU Int* 2000;85(suppl 3):10–19; discussion 22–23.
29. Ferulano GP, La Manna S, Dilillo S. [Sacral neuromodulation in fecal continence disorders]. *Recenti Prog Med* 2002;93:403–409.
30. Spinelli M, Giardiello G, Gerber M, Arduini A, van den Hombergh U, Malaguti S. New sacral neuromodulation lead for percutaneous implantation using local anesthesia: description and first experience. *J Urol* Nov 2003;170:1905–1907.
31. Hijaz A, Vasavada S. Complications and troubleshooting of sacral neuromodulation therapy. *Urol Clin North Am* 2005;32:65–69.
32. Kessler TM, Madersbacher H, Kiss G. Bilateral migration of sacral neuromodulation tined leads in a thin patient. *J Urol* 2005;173:153–154.
33. Bosch JL. The bion device: a minimally invasive implantable ministimulator for pudendal nerve neuromodulation in patients with detrusor overactivity incontinence. *Urol Clin North Am* 2005;32:109–112.
34. Spinelli M, Malaguti S, Giardiello G, Lazzeri M, Tarantola J, Van Den Hombergh U. A new minimally invasive procedure for pudendal nerve stimulation to treat neurogenic bladder: description of the method and preliminary data. *Neurol Urol Urodyn* 2005;24:305–309.

---

# 17 Augmentation Cystoplasty

---

*Michael A. Aleman, MD, Joseph B. Abdelmalak, MD,  
and Raymond R. Rackley, MD*

## **CONTENTS**

INTRODUCTION  
INDICATIONS AND CONTRAINDICATIONS  
ALTERNATIVES TO AUGMENTATION  
SURGICAL TECHNIQUE OF BLADDER AUGMENTATION  
RESULTS AND COMPLICATIONS  
CONCLUSION  
REFERENCES

---

## **INTRODUCTION**

Many disease processes can result in an “end-stage” bladder that has a small capacity, poor compliance, and high storage pressures. When surgical intervention is contemplated, the ultimate goals are the preservation of renal function and the restoration or preservation of continence. In carefully selected patients, augmentation cystoplasty can be used to achieve those goals.

## **INDICATIONS AND CONTRAINDICATIONS**

Augmentation cystoplasty is typically indicated for many conditions that result in a small, contracted, poorly compliant bladder. These can include tuberculosis, schistosomiasis, radiation cystitis, chemotherapy-induced cystitis, or multiple previous bladder operations. Perhaps most commonly in the United States, augmentation cystoplasty is performed in patients with neuropathic bladder dysfunction or refractory detrusor instability. Augmentation has been used in interstitial cystitis, with poorer results noted in patients with larger bladder capacities under anesthesia and those requiring self-catheterization postoperatively (1).

Augmentation cystoplasty may also be used as a method of urinary diversion in patients with neuropathic bladders or lower urinary tract anomalies who have previously had urinary diversion (2). In renal transplant candidates, augmentation may safely be performed prior to transplantation or after transplantation, with good results seen in both adult and pediatric populations (3,4). Simultaneous transplantation and bladder augmentation may be associated with a higher risk of infectious complications (5).

As the risk of urinary retention requiring intermittent self-catheterization ranged from 14 to 100% in several series, a patient’s inability or unwillingness to perform intermittent self-catheterization is a contraindication. Insufficient healthy bowel, as in

short-gut syndrome, Crohn's disease, or radiation enteritis, is another contraindication. Impairment in renal function can be a relative contraindication; however, the risk of renal functional decline from the augmentation must be weighed carefully against the risk of decline caused by the patient's high-pressure, poorly compliant bladder. As there are no prospective randomized studies examining this question, the use of augmentation in patients with impaired renal function should be done only after a careful evaluation and risk assessment.

## ALTERNATIVES TO AUGMENTATION

Before the consideration of augmentation cystoplasty, all less-invasive options for the treatment of the low-compliance, low-capacity, overactive bladder should be tried. These include pelvic floor rehabilitation, behavioral modifications (timed and prompted voiding), and antimuscarinic agents.

The role of augmentation cystoplasty in cases of refractory detrusor overactivity changed with the introduction of two less-invasive treatment modalities. Sacral neuromodulation and botulinum toxin injection therapy have demonstrated efficacy in cases of detrusor overactivity refractory to medical therapy and are discussed elsewhere in this book. It should be noted, though, that studies examining predictors of failure of these modalities have begun to appear in the literature; success rates of botulinum toxin (6) are lower in patients with small, poorly compliant bladders, and sacral neuromodulation appears to have higher failure rates in neurogenic voiding dysfunction (7)—both populations in which augmentation is often considered. Still, the less-invasive nature of these procedures, combined with their reversibility and favorable side-effect profiles, suggest that they should be attempted in many cases prior to considering augmentation cystoplasty.

## SURGICAL TECHNIQUE OF BLADDER AUGMENTATION

Patients receive a bowel prep the day before surgery. Regardless of the section of bowel selected, several principles apply to all cases of augmentation cystoplasty. The bowel segment should be detubularized to prevent rhythmic peristaltic contractions, which can lead to incontinence or high storage pressure, and to provide the maximum increase in bladder volume for a given length of bowel. Absorbable sutures should be used wherever there is contact with the intraluminal surface of the bladder or augment. The bowel segment needs to have an adequate mesentery to reach the opened bladder without tension. The opening in the bladder can be transverse, longitudinal, or cruciate, but in all cases it should be opened as wide as possible. This helps to prevent the anastomosis of the bowel and bladder from contracting, such that the augment effectively becomes a poorly draining diverticulum. Finally, it is routinely recommended that a suprapubic catheter be placed through the native bladder wall and a drain left in the space of Retzius near, but not on, the anastomotic line to allow adequate bladder drainage and drainage of any extravasated urine, respectively.

There is no distinct advantage of any bowel segment over another, with perhaps the exception of the jejunum, which leads to greater metabolic derangements than other segments when used in urinary diversions (8). When ileum is utilized, a segment 25 cm long (or longer, depending on the desired capacity) is typically harvested at least 25 cm proximal to the ileocecal valve (to prevent bile acid malabsorption) (9). The cecum, with its large lumen, has been used without detubularization (10), but detubularization

is currently preferred to prevent colonic contractions (11). The ileocecal segment can be detubularized to create an augment; historically, this segment has been avoided because of concerns of diarrhea and malabsorption (12).

More recently, as the ileocecal segment has been successfully used as a continent catheterizable diversion, the use of this segment as a catheterizable augment segment has become an option (13). The lack of severe metabolic derangements or diarrhea in this series of 23 patients, along with larger reports of ileocecal diversion causing metabolic derangements and diarrhea in 5.5 and 2.7% of patients, respectively (14), suggest that the use of this segment is a viable option, especially if the patient desires a continent catheterizable augment and has an inability to use the native urethra.

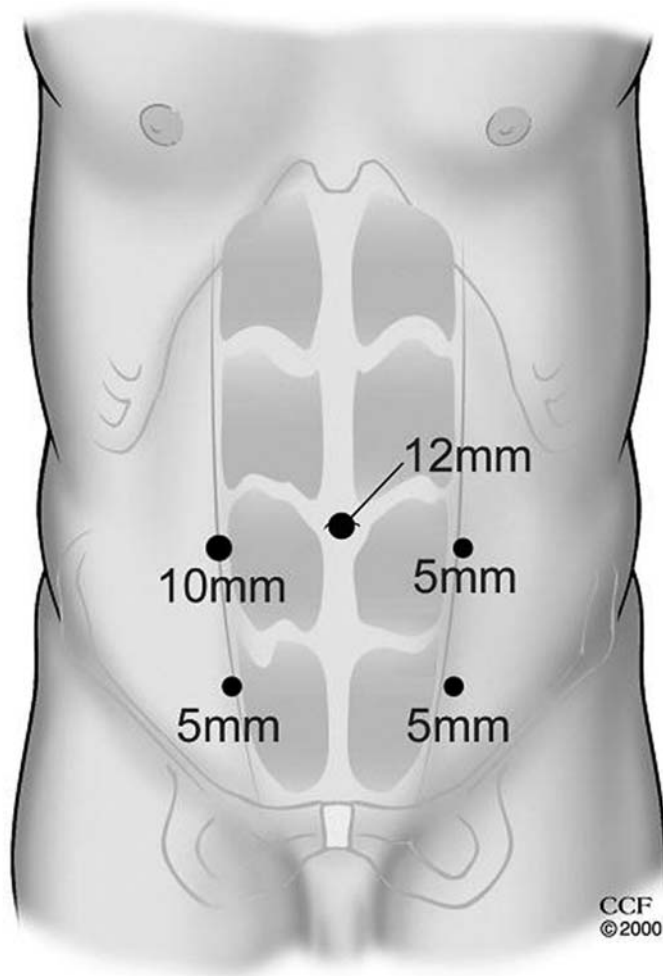
The sigmoid colon is ideally located for use as an augment, and is often large in patients with neurological voiding dysfunction. It may be associated with a lower rate of bowel obstruction than ileum (15).

Finally, stomach may be harvested as an augment patch, using the antrum with the left gastroepiploic artery as its blood supply or the body with a blood supply from either the right or left gastroepiploic artery. Although the stomach's lack of significant electrolyte absorption makes it appealing in cases with impaired renal function and a resultant acidosis, the acid-secreting nature of the stomach can cause the hematuria-dysuria syndrome, hypochloremic hyponatremic alkalosis, and hypergastrinemia (16). The gastric complications of partial gastrectomy (dumping syndrome, early satiety), combined with the bladder complications, have relegated the use of stomach in augmentation to a last resort role.

A low-midline incision is typically used for augmentation cystoplasty; a Pfannensteil incision may also be used, but this can limit the surgical options if ileum or sigmoid colon intraoperatively appears suboptimal. If the cecum and right colon are utilized, then this usually requires extension of the midline incision several centimeters above the umbilicus. Laparoscopic augmentation has been reported as either a completely laparoscopic technique (17) or with the bowel harvesting, reanastomosis, and detubularization performed extracorporeally via a 2-cm extension of the umbilical stoma (18).

The port sites for laparoscopic augmentation are shown in Fig. 1. In all cases of augmentation cystoplasty, whether open or laparoscopic, the basic steps are identical. Access is gained to the peritoneal cavity. The space of Retzius is entered, and the loose areolar tissue around the bladder is bluntly dissected to expose the anterior bladder neck and perivesical spaces. The bladder is filled with sterile irrigant, and a wide cystotomy is created (horizontally, vertically, or in a cruciate fashion). It may be preferable to delay the cystotomy until the bowel has been harvested and detubularized as the cut bladder edges will often retract significantly. The appropriate bowel segment is harvested on its mesentery; bowel continuity is reestablished, and the bowel segment is detubularized (Fig. 2). The bowel segment is then sewn to the opened bladder in a watertight fashion with absorbable sutures (Fig. 3). Prior to placing the last few sutures, a cystostomy catheter is placed through the native bladder and out through a suprapubic stab incision. The bladder is then irrigated through the urethral or suprapubic catheter to ensure a watertight anastomosis. A closed drain is left in the pelvis, near but not directly over the bowel-bladder anastomosis.

When a continent catheterizable stoma is desired, we typically harvest the ileocecal segment and detubularize the cecum. The detubularized cecum is then sutured half-closed, with the dependent portion left open for anastomosis to the bladder. The terminal ileum is tapered by firing a stapler lengthwise alongside a 14- or 16-French catheter

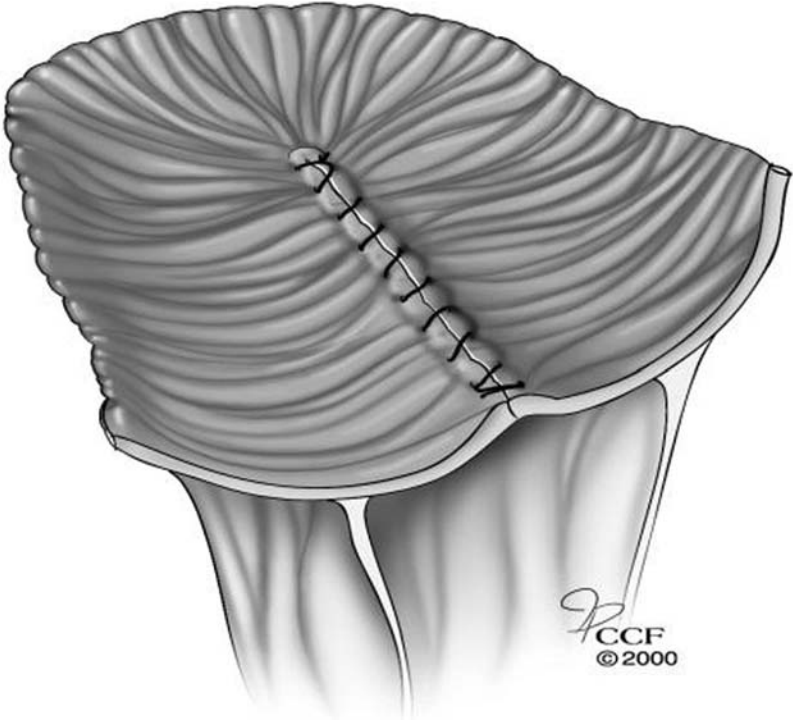


**Fig. 1.** Typical port positions for laparoscopic augmentation cystoplasty.

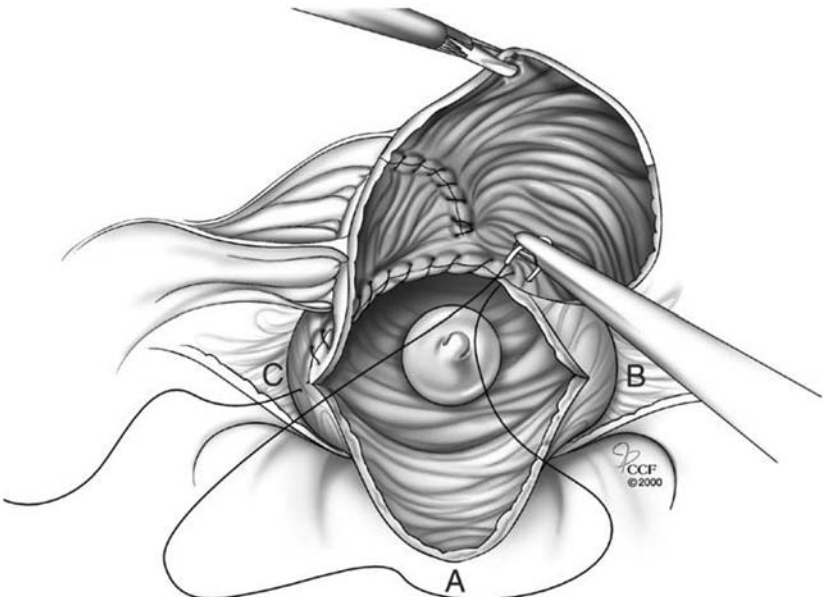
(Fig. 4). The ileocecal valve is then intussuscepted using permanent sutures passed through the serosal surface of the ileum and cecum. The cecum is then sutured to the widely opened bladder, and a catheterizable stoma is matured at the umbilicus (Fig. 5).

Postoperatively, the patient is instructed to irrigate the suprapubic tube and urethral catheter several times a day to prevent mucus plugging; this irrigation is typically later reduced to an as-needed basis; in patients with sensory impairment, it may be wise to continue a standard irrigation protocol, especially for stone prevention (19). The closed drain is typically removed when outputs have been consistently low (less than 100 cc per day) and the patient is ambulatory or regularly out of bed. The bladder is left to continuous drainage via the suprapubic tube, the urethral catheter, or both for 3–4 wk. After the urethral catheter is removed, the patient can begin voiding trials by clamping the suprapubic tube. If a continent catheterizable stoma was created, then a catheter is left in place in the stoma for 4–6 wk, at which time the patient begins intermittent catheterization. The suprapubic tube is typically removed at 4–6 wk postoperatively.

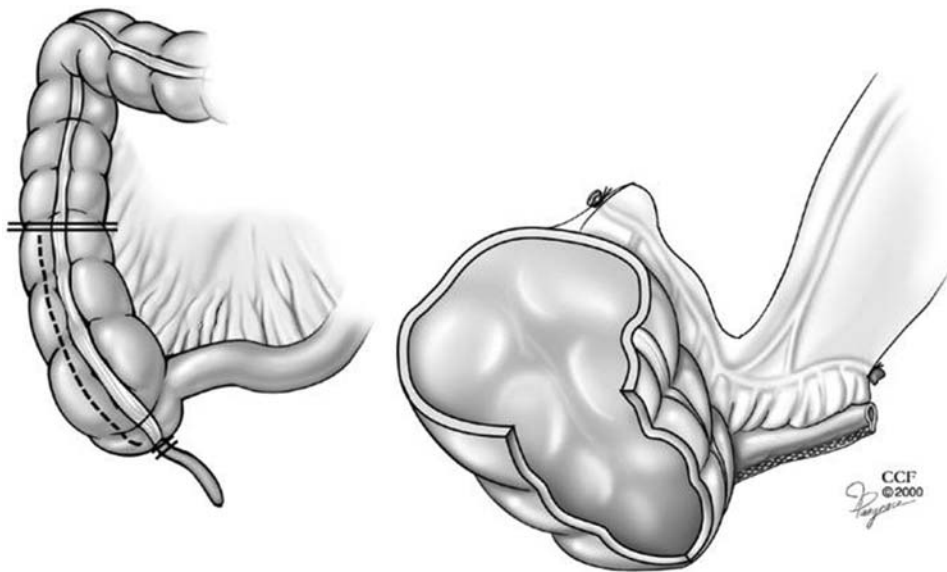




**Fig. 2.** The ileal segment is detubularized by opening its antimesenteric edge, forming a U, and suturing the adjacent sides of the U together.



**Fig. 3.** A watertight bowel-bladder anastomosis is created with a running suture.



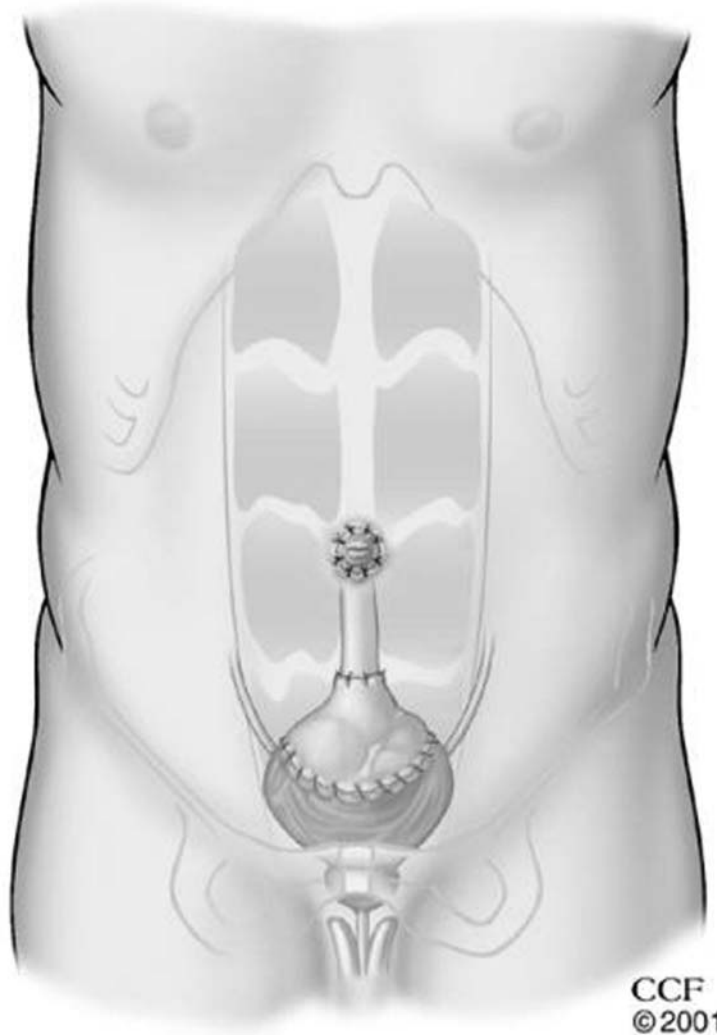
**Fig. 4.** The cecum is detubularized, and the terminal ileum is tapered by firing a GIA stapler alongside a 14- to 16-French catheter.

Follow-up of patients should include a functional lower urinary tract study (videourodynamics, or at least voiding diary, flow rate, and postvoid residual) within the first 6–12 mo to determine capacity and voiding efficiency; blood chemistries including electrolytes, serum urea nitrogen, and creatinine should also be followed periodically along with upper tract sonography. As there have been several reports of bladder cancer (typically adenocarcinoma) developing in augmented bladders with a lag time of less than 20 yr (20), annual cystoscopic surveillance should begin within 10 years after augmentation.

## RESULTS AND COMPLICATIONS

The “success” of augmentation cystoplasty is difficult to define simply as most studies deal with distinct patient populations with different expectations, ranging from children with myelomeningocele to adults with refractory overactive bladder. Also, concomitant procedures are often performed to address deficiency of the urinary sphincter (sling procedures or artificial urinary sphincter). Finally, the definition of success varies among studies, with renal function, continence, voluntary voiding, and quality of life as measured outcomes indicative of success or failure. With *success* defined as continent with stable renal function, most studies report success rates between 63 and 100% (21).

Patients continent preoperatively have higher continence rates, and those with an open bladder outlet on videourodynamic evaluation preoperatively have lower rates (22). There is some debate regarding whether an artificial urinary sphincter should be implanted at the time of augment; although this has been shown not to increase infection rates (23), given that some incontinent patients will gain sufficient control with augmentation alone, it is questionable whether they should be subjected to an additional procedure that may be unnecessary. The decision to perform anti-incontinence procedures at the time of augmentation needs to be individualized, perhaps selecting



**Fig. 5.** The continent catheterizable stoma can be matured at the umbilicus (shown) or in the right lower quadrant.

only the patients with a high likelihood of postoperative incontinence for concomitant procedures.

Early complications of augmentation include those common to all major abdominal operations involving bowel resection and anastomosis: hemorrhage in 0.6–6.7%, infection in 1.5–9%, small bowel obstruction in 1.5–8.7%, deep vein thrombosis/pulmonary embolism in 1.1–7.1%, myocardial infarction in 0–1.7%, and death in 0–3.2% (21). Fistulas can occur in up to 29.7% of cases and typically involve the anastomotic line between the bladder and bowel segment. This can typically be managed successfully with adequate drainage; only 1–2% require an additional operative procedure to treat the fistula (24).

Late complications include bowel dysfunction, metabolic derangements, bladder calculi, bladder perforation, and increased carcinoma risk. Bowel dysfunction includes

diarrhea, which may occur in up to 16% of cases (25), and  $B_{12}$ /bile salt malabsorption if the terminal ileum is utilized. Acid reabsorption from the urine in ileal and colonic augments results in increased serum chloride and decreased bicarbonate; typically, frank acidosis does not occur if renal function is normal, although occasionally alkali therapy with bicarbonate supplements is necessary. This is avoided when gastric segments are used, but their unique complications are discussed above.

Calculi formation occurs in up to 50% of patients depending on the length of follow-up, with struvite stones the most common type. A strict protocol of biweekly saline/gentamicin irrigation appeared to reduce the incidence of stone formation from 43 to 7% in one series (19). Although asymptomatic bacteruria is common after enterocystoplasty, it is usually left untreated unless the patient is symptomatic or the organism is a urea-splitting bacteria, which may lead to struvite stone formation.

Bladder perforation has been reported in 3–9% of patients with augments, often in patients using clean intermittent catheterization with poor technique or compliance (26). However, “spontaneous” perforations in patients voiding voluntarily have also been reported (24), so this diagnosis should always be suspected in any augment patient with signs of peritonitis.

Bladder carcinoma risk, particularly adenocarcinoma, appears to be increased several-fold over the general population. The lag time appears to be under 20 yr, and therefore surveillance cystoscopy should begin at postoperative yr 10 (20).

Complications, both minor and severe, are common after augmentation cystoplasty; this is evidenced in a study with long-term follow-up (mean 8 yr), which reported a need for a subsequent procedure in 46% of patients (27). Even with this high reoperative rate, most patients in this series reported satisfaction with their augmentation cystoplasty.

## CONCLUSION

Augmentation cystoplasty is a time-tested procedure that has been shown in several retrospective studies to effectively increase bladder storage capacity, maintain stable renal function, improve quality of life, and promote continence in patients with small, poorly compliant bladders. Its role may be diminishing with the advent of botulinum toxin therapy and neuromodulation, but in the severely afflicted patient, it will likely remain an option for the foreseeable future. Complications and the need for subsequent procedures are common, and the decision to proceed with augmentation cystoplasty requires a long-term commitment from the clinician and a lifelong follow-up regimen for the patient.

## REFERENCES

1. Webster GD, Maggio MI. The management of chronic interstitial cystitis by substitution cystoplasty. *J Urol* 1989;141:287–291.
2. Gonzalez R, Sidi AA, Zhang G. Urinary undiversion: indications, technique and results in 50 cases. *J Urol* 1986;136:13–16.
3. Fontaine E, Gagnadoux MF, Niaudet P, Broyer M, Beurton D. Renal transplantation in children with augmentation cystoplasty: long-term results. *J Urol* 1998;159:2110–2113.
4. Power RE, O'Malley KJ, Khan MS, Murphy DM, Hickey DP. Renal transplantation in patients with an augmentation cystoplasty. *BJU Int* 2000;86:28–31.
5. Thomalla JV, Mitchell ME, Leapman SB, Filo RS. Renal transplantation into the reconstructed bladder. *J Urol* 1989;141:265–268.
6. Altaweel W, Jednack R, Bilodeau C, Corcos J. Repeated intradetrusor botulinum toxin type A in children with neurogenic bladder due to myelomeningocele. *J Urol* 2006;175:1102–1105.

7. Hohenfellner M, Humke J, Hampel C, et al. Chronic sacral neuromodulation for treatment of neurogenic bladder dysfunction: long-term results with unilateral implants. *Urology* 2001;58:887–892.
8. Klein EA, Montie JE, Montague DK, Kay R, Straffon RA. Jejunal conduit urinary diversion. *J Urol* 1986;135:244–246.
9. Hofmann AF, Poley JR. Role of bile acid malabsorption in pathogenesis of diarrhea and steatorrhea in patients with ileal resection. I. Response to cholestyramine or replacement of dietary long chain triglyceride by medium chain triglyceride. *Gastroenterology* 1972;62:918–934.
10. Whitmore WF 3rd, Gittes RF. Reconstruction of the urinary tract by cecal and ileocecal cystoplasty: review of a 15-yr experience. *J Urol* 1983;129:494–498.
11. Sidi AA, Reinberg Y, Gonzalez R. Influence of intestinal segment and configuration on the outcome of augmentation enterocystoplasty. *J Urol* 1986;136:1201–1204.
12. Fromm D. Ileal resection, or disease, and the blind loop syndrome: current concepts of pathophysiology. *Surgery* 1973;73:639–648.
13. Sutton MA, Hinson JL, Nickell KG, Boone TB. Continent ileocecal augmentation cystoplasty. *Spinal Cord* 1998;36:246–251.
14. Webster C, Bukkapatnam R, Seigne JD, et al. Continent colonic urinary reservoir (Florida pouch): long-term surgical complications (greater than 11 yr). *J Urol* 2003;169:174–176.
15. Shekarriz B, Upadhyay J, Demirbilek S, Barthold JS, Gonzalez R. Surgical complications of bladder augmentation: comparison between various enterocystoplasties in 133 patients. *Urology* 2000;55:123–128.
16. Plawker MW, Rabinowitz SS, Etwaru DJ, Glassberg KI. Hypergastrinemia, dysuria-hematuria and metabolic alkalosis: complications associated with gastrocystoplasty. *J Urol* 1995;154:546–549.
17. Elliott SP, Meng MV, Anwar HP, Stoller ML. Complete laparoscopic ileal cystoplasty. *Urology* 2002;59:939–943.
18. Gill IS, Rackley RR, Meraney AM, Marcello PW, Sung GT. Laparoscopic enterocystoplasty. *Urology* 2000;55:178–181.
19. Hensle TW, Bingham J, Lam J, Shabsigh A. Preventing reservoir calculi after augmentation cystoplasty and continent urinary diversion: the influence of an irrigation protocol. *BJU Int* 2004;93:585–587.
20. Soergel TM, Cain MP, Misseri R, Gardner TA, Koch MO, Rink RC. Transitional cell carcinoma of the bladder following augmentation cystoplasty for the neuropathic bladder. *J Urol* 2004;172:1649–1651.
21. Greenwell TJ, Venn SN, Mundy AR. Augmentation cystoplasty. *BJU Int* 2001;88:511–525.
22. Medel R, Ruarte AC, Herrera M, Castera R, Podesta ML. Urinary continence outcome after augmentation ileocystoplasty as a single surgical procedure in patients with myelodysplasia. *J Urol* 2002;168:1849–1852.
23. Catto JW, Natarajan V, Tophill PR. Simultaneous augmentation cystoplasty is associated with earlier rather than increased artificial urinary sphincter infection. *J Urol* 2005;173:1237–1241.
24. Flood HD, Malhotra SJ, O’Connell HE, Ritchey MJ, Bloom DA, McGuire EJ. Long-term results and complications using augmentation cystoplasty in reconstructive urology. *Neurourol Urodyn* 1995;14:297–309.
25. Wood GA, Heathcote PS, Nicol DL. Bowel motility after enterocystoplasty. *Br J Urol* 1998;81:565–568.
26. Elder JS, Snyder HM, Hulbert WC, Duckett JW. Perforation of the augmented bladder in patients undergoing clean intermittent catheterization. *J Urol* 1988;140:1159–1162.
27. Quek ML, Ginsberg DA. Long-term urodynamics follow-up of bladder augmentation for neurogenic bladder. *J Urol* 2003;169:195–198.

---

# 18

## Mixed Incontinence

*Defining Symptoms, Management, and Outcomes*

---

*Roger Dmochowski, MD, FACS  
and Harriette M. Scarpero, MD*

### CONTENTS

INTRODUCTION  
DEFINITIONS AND APPROACH  
EXPECTATIONS FOR RESULTS  
CONCLUSION: WHAT WE DO  
REFERENCES

---

### INTRODUCTION

Mixed urinary incontinence (MUI) has been presumed to account for at least one-third of all cases of incontinence in women, yet estimates of this symptom complex have ranged as high as 60%. The wide range of incidence rates associated with MUI arise in part because of vastly differing definitions and measures of the components (urge and stress urinary symptoms) that contribute to the composite presentation of MUI. General suppositions regarding MUI have been generally that the mixed scenario responds less favorably to intervention, regardless of type. Behavioral, pharmacological, and surgical strategies have all been proposed for the management of MUI; however, no clear approach yet exists for management of the unique woman presenting with symptoms of MUI. Evidence exists to support the primary and durable role of surgical intervention for the stress component, but study design issues (such as reproducible outcome parameters) make generalization of any reported results to the broad population problematic.

### DEFINITIONS AND APPROACH

MUI is loosely defined as the occurrence of stress (activity/exertion related) incontinence concomitantly associated with bothersome urinary irritative symptoms (urinary frequency, urgency, and urge incontinence). Moreover, approx 30–50% of women with MUI will misperceive stress incontinence as an urgency event. Nonurge, nonstress incontinence (insensate, unconscious, or spontaneous incontinence) represents another, less clearly ascribable symptom that is posited to arise from detrusor overactivity occurring in the absence of sensory urgency (motor detrusor overactivity uncoupled from any bladder sensation). Further complicating the MUI presentation is the superimposition of urinary frequency as a behavioral response to the bothersome urinary symptoms.

From: Current Clinical Urology: Female Urology: A Practical Clinical Guide  
Edited by: H. B. Goldman and S. P. Vasavada © Humana Press Inc., Totowa, NJ

Perhaps the most difficult symptom to categorize is the gravitational loss of urine occurring on nocturnal arising (or awakening) with a full bladder because this may be a varying mix of the two main symptomatic components. We still find this the most problematic scenario in which to obtain reasonable success. Therefore, the symptoms of MUI must clearly be assessed prior to intervention so possible treatment-related outcomes can be reported lucidly.

Evaluation of the woman with MUI must use tools that are reproducible, clearly assess and stratify component symptoms, and adequately assess patient approbation of therapeutic impact. We suggest a rather simplistic approach. Components of the screening assessment include history and physical (including a provocative stress test), assessment of symptom-specific quality of life (using instruments such as the overactive bladder questionnaire), and one item evaluation of symptom impact (such as the Patient Perception of Bladder Condition).

Certainly, more exhaustive evaluation, including pad testing and urodynamics, can be insinuated into the paradigm at this stage; however, if initial intervention is nonsurgical (behavioral or pharmacological), then the screening assessment is sufficient. Any patient who does not achieve acceptable symptomatic response or who is considering surgical intervention should then be considered for more invasive evaluation to objectify symptoms better. Incumbent in this assessment is an early appraisal of patient expectations and a realistic discussion of outcomes as symptomatic modulation with therapy will run the gamut from cure of symptoms to object failure, with exacerbation of one or all components of the MUI presentation.

## EXPECTATIONS FOR RESULTS

The outcomes of a variety of interventions have been reported for MUI. Comparability of these outcomes is difficult because of inherent differences in entry populations, study design, and outcome reporting.

### *Behavioral and Pharmacological Outcomes*

Pharmacological intervention for MUI is usually coupled with conservative measures such as behavioral therapy in clinical practice and in drug trials (the impact of diary record keeping and repetitive symptom assessment cannot be minimized in a symptom complex with so strong a behavioral overlay). A variety of conservative measures has been utilized for urgency and urge incontinence in those patients with mixed symptoms; these measures include behavioral therapies, biofeedback, and treatment with anticholinergic agents. Approximately two-thirds of patients derive benefit for their urgency with anticholinergic agents.

Post hoc review of large-scale clinical trials concluded that anticholinergic agents were beneficial for reducing incontinence episodes, urinary frequency, and urinary urgency in patients with mixed symptomatology, and that these reductions were retained throughout the trial period. Although these data are specific to one agent, we presume, based on our clinical experience, that the degree of benefit of combined therapy can be generalized to the entire MUI population (1,2).

Topical estrogen has been extensively evaluated as an isolated intervention for MUI (although usually for the component symptoms of urge or stress). Therapeutic results are of minimal magnitude (except for the possible response of subjective urgency).

### *Surgical Outcomes*

Surgical intervention for stress-predominant MUI, regardless of whether motor bladder overactivity is identified preoperatively, is more likely to be successful (in terms of symptom improvement or resolution) than in the case of MUI with predominant preoperative urge. A caveat to this generalization is the circumstance of high-pressure (over 25 cm H<sub>2</sub>O) detrusor overactivity at low bladder volumes, which militates against surgical success. Although reported symptom improvement or cure rates vary with surgical management in the stress-predominant group, this group had measurably greater improvement than their urge-predominant peers (2.5 times greater).

Modern surgical series consistently demonstrate improvement in surgical outcomes for stress-predominant MUI regardless of sling type. In studies that have segregated urgency as either motor or sensory, a salubrious effect of intervention has been noted for both symptoms, although to different degrees. In general, cure (58.5%) and improvement (17.1%) in urgency/urge incontinence are more commonly seen in patients with evidence of motor overactivity on urodynamics compared to only 39.3% (cure) and 39.1% (improvement) in those women with no identifiable motor overactivity (sensory instability). Using an arbitrary value of 15 cm H<sub>2</sub>O, women with motor overactivity below this magnitude had a better chance of symptomatic resolution than those with phasic detrusor pressures greater than this value (3).

Midurethral slings have also demonstrated efficacy in women with mixed symptomatology. Although the magnitude of benefit is less than in those women with “pure” stress urinary incontinence (SUI; 95.5%), women with MUI (78.1%) do demonstrate benefit from midurethral procedures. The authors of this study suggested that poor urethral function contributes to persistent urgency symptoms. However, modulation of low-pressure outlet may benefit at least some individuals with MUI; therefore, primary surgery may be useful in well-selected patients (4,5).

Others have also found benefit for MUI in women undergoing midurethral slings. Resolution rates of 85% in MUI patients have been reported; however, urodynamics were not used to characterize the study populations. Other authors have concluded that these response rates justify the use of midurethral slings in these populations.

Therefore, data exist to support the benefit of minimally invasive midurethral slings for patients with MUI. In general, resolution of urgency in patients undergoing surgical procedures for SUI occurs in 50–70%; however, these rates are dependent on initial quantification and definition of the symptomatic components of the MUI complex.

### **CONCLUSION: WHAT WE DO**

Our philosophy is that the most bothersome symptom should be approached first possibly to lessen the impact of the secondary symptom. The use of the proposed paradigm for assessment is a reasonable starting point. The addition of a short-term (3-d) voiding diary allows additional objectification of the presenting symptoms and is a facile tool for defining baseline severity and for monitoring outcomes. No reproducible instrument yet exists to clearly assess MUI component contributions and severity; therefore, a combination of tools is best to accomplish this task. Urodynamic studies may have predictive benefit for some patients with mixed symptoms to elucidate the gravity of urethral dysfunction and certain aspects of detrusor dysfunction (such as high-pressure detrusor overactivity) that may have an impact on outcome.



Using this paradigm, initial intervention can be promulgated to address the most bothersome symptom. After initial response is established, tailored therapy for secondary symptoms can then be undertaken. For example, stress-predominant MUI could undergo intervention for SUI with secondary interventions for urge urinary incontinence predicated on results of the primary intervention. MUI with a strong urge component could undergo therapy to modulate the urgency symptoms, including anticholinergics or secondary treatments in pharmacological failures (neuromodulation or botulinum toxin), followed by SUI interventions for persistent outlet symptoms.

Individualized therapy based on symptomatic segregation, with therapy promulgated based on the most bothersome symptom, with secondary interventions reserved for either persistence of the primary symptom or bother arising from the less-prominent initial symptom. In those individuals with relatively equal bother or who are unable to segregate their symptoms, more intensive evaluation (such as urodynamics) may provide guidance to initiate therapy. Alternatively, conservative or minimally invasive intervention may be initiated to establish response, followed by more intensive intervention for nonresponse. Ideally, patients should be informed regarding which symptoms may persist or become problematic postintervention.

## REFERENCES

1. Khullar V, Hill S, Laval KU, Schiotz HA, Jonas U, Versi E. Treatment of urge-predominant mixed urinary incontinence with tolterodine extended release: a randomized, placebo-controlled trial. *Urology* 2004;64:269–274; discussion 274–275.
2. Kreder KJ Jr, Brubaker L, Mainprize T. Tolterodine is equally effective in patients with mixed incontinence and those with urge incontinence alone. *BJU Int* 2003;92:418–421.
3. Segal JL, Vassallo B, Kleeman S, Silva WA, Karram MM. Prevalence of persistent and *de novo* overactive bladder symptoms after the tension free vaginal tape. *Obstet Gynecol* 2005;104:1263–1269.
4. Abdel-Hady ES, Constantine G. Outcome of the use of tension-free vaginal tape in women with mixed urinary incontinence, previous failed surgery, or low Valsalva pressure. *J Obstet Gynaecol Res* 2005;31:38–42.
5. Lin LY, Yeh NH, Lin CY, et al. Comparisons of urodynamic characteristics between female patients with overactive bladder plus stress urinary incontinence. *Urology* 2004;64:945–949.

---

# 19 Evaluation and Management of Anterior Vaginal Wall Prolapse

---

*Sandip P. Vasavada, MD  
and Matthew D. Barber, MD, MHS*

## CONTENTS

INTRODUCTION  
EVALUATION  
SURGICAL TECHNIQUES  
OUTCOMES  
COMPLICATIONS  
REFERENCES

---

## INTRODUCTION

Prolapse of the anterior vaginal wall is the most common presentation of pelvic organ prolapse. Studies suggested that, of the various segments of the vagina that may be involved in prolapse (anterior, posterior, or apical), the anterior vaginal wall is the segment most likely to demonstrate recurrent prolapse after reconstructive surgery. In addition, normal anterior vaginal support plays an important role in supporting the urethra, and loss of this support can contribute to the development of stress urinary incontinence. It is therefore important that the pelvic reconstructive surgeon understand the normal support mechanisms of the anterior vaginal wall and the full spectrum of techniques for correction of anterior vaginal prolapse and cystoceles.

Underlying the vaginal epithelium is the vaginal muscularis, a well-developed layer primarily made up of smooth muscle along with collagen and elastin (7). Some have labeled this layer of the anterior vaginal wall the *pubocervical fascia* or *vesicopelvic fascia*. In actuality, the use of the term *fascia* is a misnomer as it does not accurately reflect the histology of the vagina.

There are four defects one may see in advanced anterior vaginal prolapse, including (1) defects or attenuation of the vaginal muscularis in the midline (central defect), (2) loss of lateral attachments from the anterior vagina to the pelvic sidewall (lateral or paravaginal defect), (3) loss of bladder neck support, and (4) separation of the cardinal-uterosacral ligament complex from the vaginal apex (superior defect). These four defects accompany most large cystoceles and must be corrected to achieve good support, elevation of the bladder base, and a solid, durable repair.

## EVALUATION

### *History*

Patients with anterior vaginal prolapse often complain of symptoms directly related to the prolapse as well as symptoms of bladder dysfunction. Patients with prolapse at or beyond the level of the hymen often complain of pelvic pressure and bulging. Stress urinary incontinence commonly occurs in association with anterior vaginal prolapse, and approximately one-third of women with stage II or greater prolapse will complain of symptoms of urinary urgency, frequency, or urge incontinence. Symptoms of voiding dysfunction such as a feeling of incomplete emptying, intermittent or reduced urine flow, or the need to splint to complete urination are common in women with prolapse beyond the hymen. Sexual difficulty is also a common complaint of women with advanced prolapse. In addition to this functional assessment, a detailed history of previous prolapse or antiincontinence surgery should also be elicited.

### *Physical Examination*

A pelvic examination should be performed with the patient in the lithotomy position. A detailed assessment of the support of all segments of the vagina should be made using the International Continence Society's Pelvic Organ Prolapse Quantification (POP-Q) system. In addition, an assessment for central, lateral, and superior anterior vaginal support defects should be performed. If physical findings do not correspond to symptoms or if the maximum extent of the prolapse cannot be confirmed, then the woman should be examined in the standing position.

A curved ring forceps is placed in the lateral vaginal sulci and directed toward the ischial spines along the course of the arcus tendineus fasciae pelvis (ATFP) to reproduce the lateral support of the vagina. A Sims speculum is placed posteriorly to expose the anterior vaginal wall and reduce any posterior prolapse. The patient is asked to strain maximally, and if complete reduction of the anterior prolapse occurs with the ring forceps in this position, she is thought to have paravaginal defects. If, when she strains, the anterior vagina continues to bulge between the arms of the ring forceps without any evidence of reduction, then this suggests a midline loss of support. If supporting the lateral vagina results in partial reduction of the prolapse, then she is thought to have lost both midline and lateral support. Unilateral elevation of each vaginal sulcus allows differentiation of bilateral and unilateral paravaginal defects.

### *Diagnostic Tests*

#### **URODYNAMICS**

Symptoms of urinary incontinence and voiding dysfunction are common in women with advanced vaginal prolapse. In addition, because significant anterior vaginal prolapse often results in urethral kinking that may mask underlying stress incontinence, it is our practice to obtain preoperative urodynamics with vaginal packing or pessary placement to evaluate the lower urinary tract in these patients.

#### **CYSTOSCOPY**

To detect concurrent bladder pathology, preoperative office cystoscopy is useful in the evaluation of the prolapse patient with lower urinary tract symptoms such as urinary urgency, hematuria, and obstructed voiding. In addition, we have found it useful

to use a “light test” to differentiate a cystocele more accurately from other types of vaginal prolapse. This is performed during cystoscopy with the tip of the cystoscope aimed downward to confirm the cystocele from an enterocele. Although this test is simple, it can yield important information as well.

## SURGICAL TECHNIQUES

Surgical correction of anterior vaginal prolapse can be accomplished through a vaginal, abdominal, or laparoscopic approach. The appropriate route of surgery is determined by several factors, including the preoperative evaluation of anterior vaginal support defects, the presence of other vaginal support defects, history of previous reconstructive or antiincontinence surgery, the patient’s surgical risk, and surgeon skill and preference. It is quite important to realize that, in our experience, it is rare that a patient with advanced anterior vaginal prolapse has an isolated anterior support defect; almost universally, an apical support defect exists when the prolapse is beyond the hymen.

For this reason, it is essential to include a vaginal vault suspension procedure as part of the surgical correction of anterior vaginal prolapse in these women. In addition, because of the contribution of anterior vaginal support to the urinary continence mechanism, preferential support of the bladder neck using a pubovaginal sling, retropubic urethropexy, bladder neck plication, or some similar technique should be performed routinely as part of any anterior vaginal reconstruction.

### *Anterior Colporrhaphy*

Anterior vaginal prolapse resulting from a central defect is best corrected through a transvaginal approach. The anterior colporrhaphy was popularized by Howard Kelly in 1912 (9), and although no longer an acceptable treatment for stress urinary incontinence, it remains a commonly used technique for transvaginal correction of anterior vaginal prolapse. Although many variations of this technique have been described in the last century, the basic approach is similar to that originally described by Kelly.

There has been growing interest in the use of synthetic mesh or biologic grafts in the surgical repair of cystoceles to reduce the risk of prolapse recurrence. The role of mesh or tissue grafts in the surgical correction of prolapse is currently unknown as few randomized trials investigating these techniques exist. However, the limited evidence that is available remains promising. We describe our technique for both the traditional anterior colporrhaphy and the mesh or graft patch repair.

#### TRADITIONAL APPROACH

Traditionally, the patient is placed in dorsal lithotomy position in candy cane or Allen stirrups. A Foley catheter is placed for dependent drainage. A weighted speculum is placed in the vagina, and a midline vaginal incision is made with a scalpel. Sterile saline or local anesthetic can be injected into the anterior vaginal wall prior to incision if desired. If performed along with a vaginal hysterectomy, then it is useful to complete the hysterectomy before beginning the anterior vaginal dissection. Sharp dissection is carried laterally to remove the vaginal epithelium from the vaginal muscularis up to the lateral sulcus. The retropubic space is entered sharply with the curved Mayo scissors to allow palpation of the pubic bone if simultaneous pubovaginal sling is required. Alternatively, it can be preserved if a tension-free or other midurethral sling is to be performed.

Also, one may curtail the incision immediately below the bladder neck to allow a tension-free midurethral sling to be placed through a separate incision.

After completing the dissection, the vaginal muscularis is plicated in the midline using several interrupted stitches of delayed absorbable or permanent suture, thereby repairing the central defect and elevating the bladder base and anterior vagina. If a sling is not performed, then the bladder neck can be preferentially supported by plicating the periurethral tissue underneath the bladder neck (Kelly plication). After completing the anterior colporrhaphy, repair of lateral or apical support defects is then performed. The excess vaginal epithelium is then trimmed, and the incision is closed using a 2-0 polyglycolic acid suture. A vaginal pack is then placed for postoperative hemostasis. Cystoscopy should then be performed to ensure bladder and ureteral integrity (*see* Tables 1 and 2).

### ***Mesh or Graft Patch Repair***

A central defect repair using mesh or tissue graft patch begins similar to the traditional repair. After completion of the vaginal dissection, the cardinal ligaments are isolated and plicated with 2-0 polyglycolic acid sutures to correct their separation and laxity. The sutures are placed into the levator fascia on each side, thereby preventing the sliding defect herniation of the bladder base. In addition, the cardinal ligaments form the base of the cystocele repair and anchor the posterior portion of the patch (Fig. 1).

The vaginal muscularis is plicated after the central defect cystocele may be reduced with use of an absorbable mesh. The fascia is reapproximated with horizontal mattress sutures of delayed absorbable or permanent suture. The tissue is brought to the midline, over the mesh, to facilitate reapproximation without tension; this maneuver also helps reduce the incidence of ureteric injury. Prior to this, intravenous indigo carmine dye is administered to ensure patency of the ureters. A separate set of polyglycolic acid sutures is placed into the levator fascia distally at the level of the bladder neck to support the distal portion of the patch.

A segment of allograft, xenograft, or synthetic mesh is then fashioned such that the width spans from the obturator fascia to the contralateral side. The sutures are placed in the corners of the patch 5 mm from the edge. The length of the patch segment depends on the size of the cystocele and the distance between the pubic bone and the cardinal ligaments. A 5- to 7-cm segment will usually fit this distance appropriately. The lower set of sutures (through the cardinal ligaments) is placed through the patch segment in a similar fashion (Fig. 2). The excess vaginal epithelium is then trimmed, and the incision is closed using a 2-0 polyglycolic acid suture incorporating the underlying mesh to prevent any dead space for fluid accumulation. A vaginal pack is then placed for postoperative hemostasis (*see* Tables 3 and 4).

### ***Paravaginal Defect Repair***

The goal of the paravaginal defect repair is to correct anterior vaginal wall prolapse that results from loss of lateral support by reattaching the lateral vaginal sulcus to its normal lateral attachment site. The lateral vagina attaches to the levator ani muscle on each side along a line from the anterior pubic rami to the ischial spine, known as the *white line* or ATFP. The ATFP is formed from a condensation of the obturator internus and levator ani fascia and is composed primarily of organized fibrous collagen, making the lateral connective tissue attachment of the vagina denser than the superior/apical

Table 1  
Outcome of Anterior Colporrhaphy Alone for Treatment of Anterior Vaginal Prolapse

<i>Author (year)</i>	<i>No. of patients</i>	<i>Study design</i>	<i>Mean follow-up</i>	<i>Recurrence (%)</i>
Macer (1978) (11)	76	Retrospective cohort	5–20 yr	20
Walter et al. (1982) (27)	86	Prospective cohort	1–2.5 yr	0
Stanton et al. (1982) (26)	73	Prospective cohort	2 yr	15
Porges and Smilen (1994) (17)	486	Retrospective cohort	2.6 yr	3
Smilen et al. (1998) (25)	245	Retrospective cohort	6 mo	9.4
Weber et al. (2001) (28)	74 <sup>a</sup>	RCT	23.3 mo	54–70

RCT, randomized controlled trial.

<sup>a</sup>A total of 114 subjects were enrolled in this trial; 74 subjects underwent either a traditional anterior colporrhaphy ( $n = 39$ ) or an “ultralateral” anterior colporrhaphy ( $n = 33$ ) without graft augmentation.

Table 2  
Anterior Colporrhaphy and Needle Suspension for Treatment of Anterior Vaginal Prolapse

<i>Author (year)</i>	<i>No. of patients</i>	<i>Study design</i>	<i>Mean follow-up (yr)</i>	<i>Recurrence (%)</i>
Raz et al. (1989) (18)	120	Retrospective cohort	0.5–5	2.5
Miyazaki and Miyazaki (1994) (15)	27	Retrospective cohort	3.5–4	59
Bump et al. (1996) (3)	32	RCT	0.5	50
Dmochowski et al. (1997) (5)	47	Retrospective cohort	1.25–6.75	17–40
Migliari and Usai (1999) (13)	15	Retrospective cohort	1.5–3.25	7

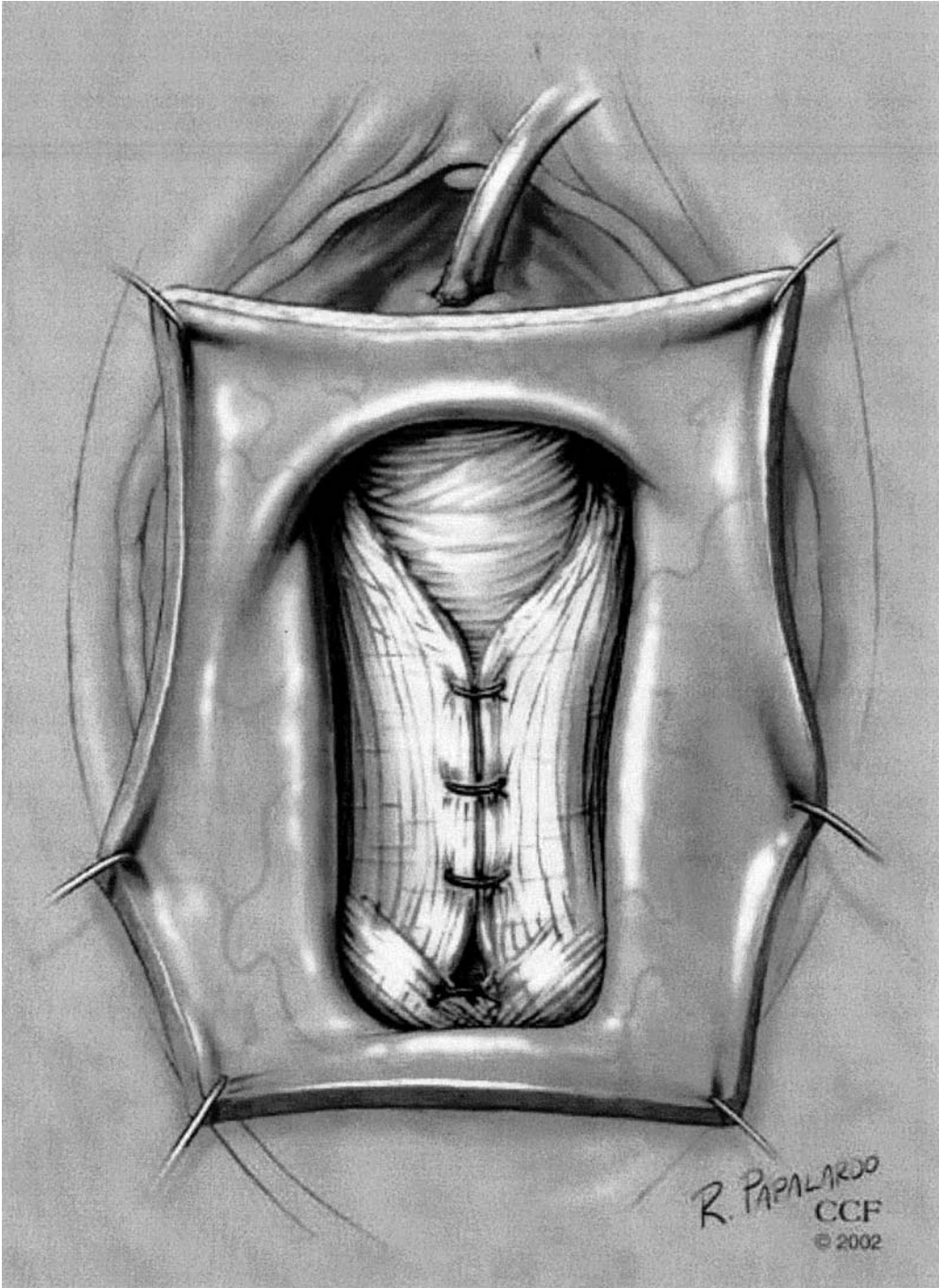
RCT, randomized controlled trial.

connective tissue support of the cardinal and uterosacral complex. The paravaginal defect repair can be performed retropubically or vaginally.

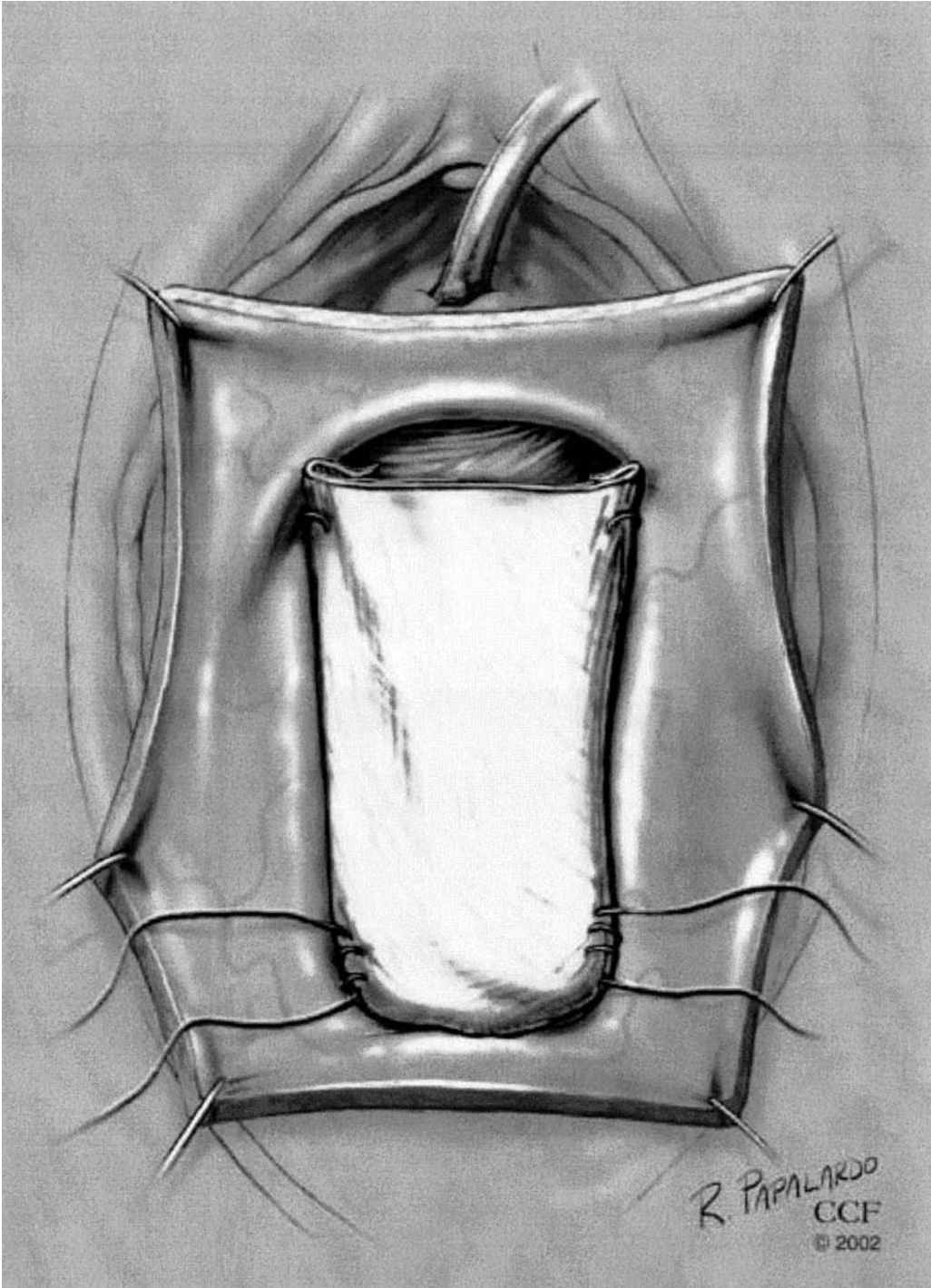
### RETROPUBIC APPROACH

The retropubic approach for the repair of paravaginal defects can be performed via laparotomy or laparoscopy. In our opinion, the surgical technique for these two approaches, other than the means of access to the retropubic space, should be identical.

The patient is placed in modified lithotomy position using low leg holders such as Allen stirrups and is draped to allow both abdominal and vaginal access. The bladder is drained with a Foley catheter. The abdomen may be entered through either a transverse or a vertical abdominal incision or laparoscopy. The retropubic space is entered, and the bladder is retracted medially to expose the lateral aspect of the retropubic space. The pubic bone, obturator muscle, obturator fossa, and neurovascular bundle are identified. Blunt dissection is used to identify the lateral vagina, urethra, and ischial spine. The normal site of lateral vaginal attachment on the pelvic sidewall from the interior aspect of the superior pubic ramus to the ischial spine is then identified. If the lateral vagina is avulsed from this attachment site, then a paravaginal defect is present. As physical examination is less than perfect in identifying paravaginal detachment,



**Fig. 1.** Application sutures of zero polyglycolic and through pubocervical fascia to bring back to toward the midline.



**Fig. 2.** Patch augmentation of anterior vaginal wall prolapse repair.



**Table 3**  
**Anterior Colporrhaphy and Simultaneous Sling/Anti-Incontinence Procedure**  
**for Treatment of Anterior Vaginal Prolapse**

<i>Author (year)</i>	<i>No. of patients</i>	<i>Study design</i>	<i>Mean follow-up (yr)</i>	<i>Recurrence (%)</i>
Cross et al. (1997) (4)	42	Retrospective cohort	1–3.25	8–17
Safir et al. (1999) (21)	130	Retrospective cohort	0.5–3.5	4–5

a bilateral assessment of paravaginal support should be made in all patients in whom paravaginal defects are suspected.

The surgeon's nondominant hand is placed into the vagina and used to elevate the lateral superior vaginal sulcus to its site of normal attachment along the course of the ATFP. Typically, four to six simple interrupted stitches of nonabsorbable suture (0 or 2-0) are used to reattach the lateral vagina to the ATFP. The first suture is placed through full thickness (excluding the vaginal epithelium) of the lateral vaginal apex and then through the ATFP and the aponeurosis of the levator ani muscle just distal to the ischial spine. This suture is tied and cut. Additional sutures are placed at 1-cm intervals through the lateral vaginal wall and into the levator ani aponeurosis along the entire course of the ATFP. In patients with a cystocele and genuine stress incontinence, many surgeons combine an abdominal paravaginal repair with a Burch colposuspension.

At the end of the procedure, cystoscopy should be performed to document ureteral patency and the absence of intravesical sutures. Closed-suction drainage of the retropubic space is rarely indicated. Postoperatively, the bladder is drained with either a transurethral or suprapubic catheter until normal voiding occurs (*see* Table 5).

### ***Vaginal Approach***

Paravaginal defect repair using the transvaginal approach can be more challenging than the retropubic approach but offers the advantage of avoiding an abdominal incision and facilitating a concurrent central defect repair for those women with loss of midline as well as lateral anterior vaginal support. The technique begins similar to that of the central defect repair. A midline vertical incision is made through the vaginal epithelium from the midurethra to the vaginal apex. The vaginal epithelium is then sharply dissected off the underlying vaginal muscularis, and the dissection is continued laterally to the pelvic sidewall from immediately behind the pubic rami to the level of the ischial spine.

Visualization of the adipose tissue of the retropubic space from this transvaginal approach confirms the presence of a paravaginal defect as normal lateral attachment of the anterior vaginal wall would preclude this. If visualization is limited, then gentle palpation of the lateral attachment site can be used. The ability of the examining finger to enter the retropubic space indicates a paravaginal defect. Every precaution should be taken to avoid iatrogenic creation of paravaginal defects with dissection, palpation, or retractors.

Once a paravaginal defect is identified, the normal site of lateral attachment of the vagina should be clearly visualized. This can be facilitated by placing a gauze sponge through the paravaginal defect into the retropubic space and using a narrow Deaver retractor to retract the sponge, underlying adipose tissue, and lateral bladder anteriorly.

**Table 4**  
**Anterior Colporrhaphy With Patch Augmentation of Repair**  
**for Treatment of Anterior Vaginal Prolapse**

<i>Author (year)</i>	<i>Patch material</i>	<i>No. of patients</i>	<i>Study design</i>	<i>Mean follow-up</i>	<i>Recurrence</i>
Groutz et al. (2001) (8)	Cadaver fascia	21	Retrospective cohort	20 mo	0%
Kobashi et al. (2000) (10)	Cadaver fascia	50	Prospective cohort	6 mo maximum	0%
Migliari et al. (2000) (14)	Polypropelene mesh	12	Retrospective cohort	20.5 mo	25% grade I cystocele
Weber et al. (2001) (28)	Polyglactin 910 mesh	35	RCT	23.3 mo	58%

RCT, randomized controlled trial.

A Briesky-Navratil retractor can then be used to retract the remainder of the bladder medially, thereby clearly exposing the levator ani muscle and the course of the ATFP from the ischial spine to the inferior aspect of the pubic ramus.

Four to six interrupted nonabsorbable sutures (0 or 2-0) are placed through the ATFP and the aponeurosis of the levator ani muscle from the level of the ischial spine to the pubic symphysis at 1-cm intervals and their needles left on. Once all of the stitches are placed through the ATFP, the sponge in the retropubic space is removed. Each stitch is then placed through the lateral edge of the detached vaginal muscularis (pubocervical or vesicopelvic fascia) at their corresponding level and then tied.

Once paravaginal support has been assessed and, if necessary, restored on both sides, a midline plication of pubocervical fascia (anterior colporrhaphy), a bladder neck plication, or sling can be performed as necessary. The vaginal epithelium is then trimmed and closed. If a vaginal hysterectomy is needed, then this should be performed prior to the paravaginal defect repair. If a vaginal vault suspension or culdeplasty is necessary, then these sutures should be placed prior to the paravaginal defect repair but not tied until the paravaginal defect repair has been completed. As with the retropubic approach, cystoscopy should be performed at the end of the procedure to confirm ureteral patency and the absence of intravesical sutures. Transurethral or suprapubic bladder drainage should continue until normal voiding occurs (*see* Table 6).

## OUTCOMES

### *Anterior Colporrhaphy*

Outcomes of the traditional anterior colporrhaphy are largely limited to retrospective reviews and case series. Reporting of outcomes has been extremely subjective, and prior to the advent of the POP-Q system, pre- and postoperative staging has been variable between surgeons. Nonetheless, the reported recurrence rates after anterior vaginal wall prolapse repair have been high (range 0 to 59%).

A randomized trial performed by at the Cleveland Clinic compared traditional anterior colporrhaphy, an ultralateral anterior colporrhaphy technique, and a traditional anterior colporrhaphy with polyglactin 910 mesh for treatment of symptomatic anterior vaginal prolapse. After a median follow-up of 23.3 mo, the recurrence rate (defined as

**Table 5**  
**Outcomes of Abdominal Paravaginal Repair for Treatment of Anterior Vaginal Prolapse**

<i>Authors (year)</i>	<i>No. of patients</i>	<i>Study design</i>	<i>Mean follow-up</i>	<i>Cure (%)</i>
Richardson et al. (1976) (19)	60	Retrospective cohort	20 mo	97
Richardson et al. (1981) (20)	233	Retrospective cohort	NR	95
Shull and Baden (1989) (23)	149	Retrospective cohort	48 mo	95
Bruce et al. (1999) (2)	52	Retrospective cohort	17 mo	92
Scotti et al. (1998) (22)	40	Prospective cohort	39 mo	97

NR, not reported.

**Table 6**  
**Outcomes of Vaginal Paravaginal Repair for Treatment of Anterior Vaginal Prolapse**

<i>Author (year)</i>	<i>No. of patients</i>	<i>Study design</i>	<i>Mean follow-up</i>	<i>Cure (%)</i>
White (1909) (29)	19	Retrospective cohort	NR	100
Shull et al. (1994) (24)	62	Retrospective cohort	1.6 yr	76
Farrell and Ling (1997) (7)	27	Retrospective cohort	8 mo	80
Nguyen and Bhatia (1999) (16)	10	Retrospective cohort	1 yr	100
Elkins et al. (2000) (6)	25	Retrospective cohort	NR	76
Mallipeddi et al. (2001) (12)	35	Retrospective cohort	20 mo	97
Young et al. (2001) (30)	100	Retrospective cohort	11 mo	78

NR, not reported.

prolapse that extends 1cm proximal to the hymen or greater) was 30–46%, and there was no difference in efficacy between the three groups (28).

Insofar as patch augmentation of standard anterior colporrhaphy is concerned, there exist few peer-reviewed manuscripts on the subject. This is largely because follow-up is short, and often postoperative evaluations have not rigorously adhered to pre- and postoperative POP-Q measurements to ascertain differences in the repairs. Nonetheless, the few reports in the literature are encouraging and suggest that routine use of patch augmentation with a variety of materials may decrease the alarmingly high rate of recurrent anterior vaginal wall prolapse and do so with minimal morbidity.

### *Paravaginal Repair*

The paravaginal defect repair has been widely used for correction of anterior vaginal prolapse thought to result from lateral vaginal detachment. Like anterior colporrhaphy, current evaluation of the success rate of this procedure for treatment of anterior vaginal prolapse is limited to case series and retrospective reviews. Reports of retropubic paravaginal repair demonstrate anatomic success rates ranging from 92 to 97% for the abdominal approach.

There are few long-term data on the efficacy of laparoscopic paravaginal repair for the treatment of anterior vaginal prolapse. Reports of vaginal paravaginal repair demonstrate success rates of 76–100% (*see* Table 6) after variable lengths of follow-up. Failure or recurrence of anterior vaginal prolapse after paravaginal defect may occur laterally,

centrally, or both. Studies that have differentiated lateral from central recurrence have revealed that central recurrence (22–25%) is more common than lateral recurrence (2–8%). To date, there are no studies comparing paravaginal defect repair with or without midline anterior repair to traditional anterior colporrhaphy alone.

## COMPLICATIONS

Intraoperative complications after repair of anterior vaginal prolapse are, for the most part, infrequent. Febrile morbidity occurs in 6–20% of patients and is most often self-limited. Lower urinary tract injury occurs in 0–4%, similar to other pelvic reconstructive procedures. Excessive blood loss may occur, requiring blood transfusion. This is infrequent with anterior colporrhaphy and retropubic paravaginal repair.

Although paravaginal repair through the vaginal approach offers some potential advantages over the retropubic approach, including shorter recovery time, the ability simultaneously to correct midline anterior defects, and the avoidance of an abdominal incision, it may have a higher rate of intraoperative hemorrhage and blood transfusion, as high as 9–12% in some series. This is in contrast to a transfusion rate of 0–4% in series of abdominal paravaginal defect repair. The limited exposure and technical challenge of the vaginal approach likely explains this difference.

Postoperative complications from the repair of advanced anterior vaginal prolapse are not unlike those of other vaginal reconstructive procedures. These may include prolonged urinary retention, *de novo* urinary urge or stress incontinence, recurrent prolapse, or vaginal shortening. Urinary retention is usually a transient phenomenon and often resolves on its own. Rarely, one may require a prolonged course of suprapubic catheter drainage or intermittent catheterization until satisfactory spontaneous voiding occurs. *De novo* urinary incontinence (urge or stress) may occur in a small portion of patients, possibly those with higher-grade prolapse and long-term obstruction. Urge incontinence may subside with time but often requires behavioral therapeutic modifications as well as anticholinergic therapy to assist in controlling symptoms. New-onset stress incontinence may result from inadequate bladder neck and urethral support or be caused by intrinsic sphincteric dysfunction. Accordingly, some advocate routine placement of a sling or some form of bladder neck support to minimize this potential.

In our experience, patients with stage III–IV cystoceles often require concomitant surgical procedures to correct other, often-severe defects in pelvic floor support in the form of enterocele, rectocele, or uterine prolapse. Simply repairing the cystocele without addressing these other potential defects in pelvic support may lead to recurrent vaginal bulges and require secondary procedures. As the anterior vaginal wall is transferred superiorly, this may allow a weakened cul de sac and posterior vaginal wall to prolapse in the form of an enterocele or rectocele. Vaginal shortening can be avoided by minimizing the amount of anterior vaginal wall tissue that is excised; thus, this should be a rare complication.

Ureteric obstruction may occur postoperatively despite demonstration of patency on cystoscopic examination as kinking of the ureters results from the support sutures. If this occurs, then one must address the obstruction by placement of either a stent or percutaneous nephrostomy tube and passage of a guide wire down the narrowed channel. After a period of observation, if no patency ensues, then one may proceed with ureteric reimplantation. Our preference is to not disturb the repair site and therefore avoid transvaginal exploration.

## REFERENCES

1. Barber MD, Cundiff GW, Weidner AC, Coates KW, Bump RC, Addison WA. Accuracy of clinical assessment of paravaginal defects in women with anterior vaginal wall prolapse. *Am J Obstet Gynecol* 1999;181:87–90.
2. Bruce GR, El-Galley RES, Galloway NTM. Paravaginal defect repair in the treatment of female stress urinary incontinence and cystocele. *Urology* 1999;54:647–651.
3. Bump RC, Hurt WG, Theofrastous JP, et al. Randomized prospective comparison of needle colposuspension versus endopelvic fascia plication for potential stress incontinence prophylaxis in woman undergoing vaginal reconstruction for stage III or IV pelvic organ prolapse. *Am J Obstet Gynecol* 1996;175:326–333.
4. Cross CA, Cespedes RD, McGuire EJ. Treatment results using pubovaginal slings in patients with large cystoceles and stress incontinence. *J Urol* 1997;158:431–434.
5. Dmochowski RR, Zimmern PE, Ganabathi K, et al. Role of the four-corner bladder neck suspension to correct stress incontinence with mild to moderate cystocele. *Urology* 1997;49:35–40.
6. Elkins TE, Chesson RR, Videla F, Menefee S, Yordan R, Barksdale PA. Transvaginal paravaginal repair: a useful adjunctive procedure in pelvic relaxation surgery. *J Pelvic Surg* 2000;1:11–15.
7. Farrell SA, Ling C. Currycombs for the vaginal paravaginal defect repair. *Obstet Gynecol* 1997;90:845–847.
8. Groutz A, Chaikin DC, Theusen E, Blaivas JG. Use of cadaveric solvent-dehydrated fascia lata for cystocele repair—preliminary results. *Urology* 2001;58:179–183.
9. Kelly HA. Incontinence of urine in women. *Urol Cutaneous Rev* 1913;17:291–293.
10. Kobashi KC, Mee SL, Leach GE. A new technique for cystocele repair and transvaginal sling: the cadaveric prolapse repair and sling (CAPS). *Urology* 2000;56:9–14.
11. Macer GA. Transabdominal repair of cystocele, a 20-year experience, compared with traditional vaginal approach. *Am J Obstet Gynecol* 1978;13:203–207.
12. Mallipeddi PK, Steele AC, Kohli N, Karam MM. Anatomic and functional outcome of vaginal paravaginal repair in the correction of anterior vaginal prolapse. *Int Urogynecol J* 2001;12:83–88.
13. Migliari R, Usai E. Treatment results using a mixed fiber mesh in patients with grade IV cystocele. *J Urol* 1999;161:1255–1258.
14. Migliari R, De Angelis M, Madeddu G, Verdacchi T. Tension-free vaginal mesh repair for anterior vaginal wall prolapse. *Eur Urol* 2000;38:151–155.
15. Miyazaki FS, Miyazaki DW. Raz four-corner suspension for severe cystocele: poor results. *Int Urogynecol J* 1994; 5:94–97.
16. Nguyen JK, Bhatia NN. Transvaginal repair of paravaginal defects using the capio suturing device: a preliminary experience. *J Gynecol Tech* 1999;5:51–54.
17. Porges RF, Smilen SW. Long-term analysis of the surgical management of pelvic support defects. *Am J Obstet Gynecol* 1994;171:1518–1528.
18. Raz S, Klutke CG, Golombe J. Four-corner bladder and urethral suspension for moderate cystocele. *J Urol* 1989;142:712–715.
19. Richardson AC, Lyon JB, Williams NL. A new look at pelvic relaxation. *Am J Obstet Gynecol* 1976;126:568–571.
20. Richardson AC, Edmonds PB, Williams NL. Treatment of stress urinary incontinence due to paravaginal fascial defects. *Obstet Gynecol* 1981;57:357–362.
21. Safir MH, Gousse AE, Rovner ES, et al. 4-defect repair of grade 4 cystocele. *J Urol* 1999;161:587–594.
22. Scotti RJ, Garely AD, Greston WM, Flora RF, Olson TR. Paravaginal repair of lateral vaginal wall defects by fixation to the ischial periosteum and obturator membrane. *Am J Obstet Gynecol* 1998;179:1436–1445.
23. Shull BL, Baden WF. A six-year experience with paravaginal defect repair for stress urinary incontinence. *Am J Obstet Gynecol* 1989;160:1432–1439.
24. Shull BL, Benn SJ, Kuehl TJ. Surgical management of prolapse of the anterior vaginal segment: an analysis of support defects, operative morbidity and anatomic outcomes. *Am J Obstet Gynecol* 1994;171:1429–1439.
25. Smilen SW, Saini J, Wallach SJ, Porges RF. The risk of cystocele after sacrospinous ligament fixation. *Am J Obstet Gynecol* 1998;179:1465–1472.
26. Stanton SL, Hilton P, Norton C, Cardozo L. Clinical and urodynamics effects of anterior colporrhaphy and vaginal hysterectomy for prolapse with or without incontinence. *Br J Obstet Gynaecol* 1982;89:459–463.

27. Walter S, Olesen KP, Hald T, et al. Urodynamic evaluation after vaginal repair and colposuspension. *Br J Urol* 1982;54:377–380.
28. Weber AM, Walters MD, Piedmonte MR, Ballard LA. Anterior colporrhaphy: a randomized trial of three surgical techniques. *Am J Obstet Gynecol* 2001;185:1299–1306.
29. White GR. Cystocele. *JAMA* 1909;21:1707–1710.
30. Young SB, Daman JJ, Bony LG. Vaginal paravaginal repair: one-year outcomes. *Am J Obstet Gynecol* 2001;185:1360–1367.

---

# 20

## Treatment of Vaginal Wall Prolapse

---

*David A. Ginsberg, MD, FACS*

### CONTENTS

INTRODUCTION  
ANATOMY  
SYMPTOMS  
DIAGNOSIS  
INDICATIONS FOR SURGERY  
SURGICAL REPAIR OF RECTOCELE  
CONCLUSION  
REFERENCES

---

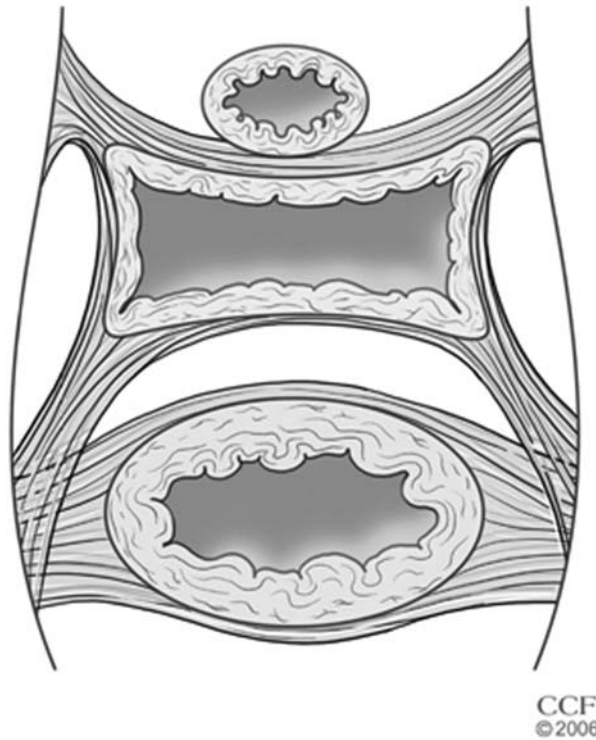
### INTRODUCTION

A rectocele occurs secondary to a defect in the supporting fascia of the rectum, which results in herniation of the anterior rectal and posterior vaginal wall into the lumen of the vagina. The true incidence of rectocele is clearly not well identified, as exemplified by prior literature, which places the prevalence at a range from 18 to 80% of the general population (1,2). Wells et al. reported a 12% incidence of rectoceles on physical examination when evaluating patients complaining of urinary incontinence (3). However, Raz et al. noted the need for rectocele repair in 65% of patients who underwent repair of a grade IV cystocele (4).

The natural history of rectocele (and all types of pelvic organ prolapse) is also poorly studied and poorly understood. Handa et al. evaluated a total of 412 women with annual pelvic examinations over a 2- to 8-yr period. They noted a baseline rectocele rate of 5.7 cases (12.9%) over 100 women-years. The progression rate for stage I rectocele was noted to be 13.5 per 100 women-years; the regression rate for stage I rectocele was noted to be 22 per 100 women-years (5). This high spontaneous regression rate suggests that mild rectoceles should be managed conservatively secondary to allowing for natural resolution of the defect.

Anatomic alterations to the pelvic floor secondary to childbirth are usually the primary predisposing factor leading to rectocele formation. Other risk factors include aging, loss of estrogen, obesity, smoking, strenuous work/physical activity, and chronic abdominal straining, which is often seen in patients with chronic respiratory diseases/cough, constipation, and other defecatory disorders and bladder outlet obstruction. Changes to the vaginal axis seen after colposuspension can also result in loss of supporting structures to the posterior vaginal wall and subsequent rectocele formation.

From: Current Clinical Urology: Female Urology: A Practical Clinical Guide  
Edited by: H. B. Goldman and S. P. Vasavada © Humana Press Inc., Totowa, NJ



**Fig. 1.** Illustration of supporting fascial layers of rectum. The pararectal fascia attaches laterally to the pelvic sidewall and sweeps medially to surround the rectum. The prerectal fascia is positioned anterior to the rectum, from the cul-de-sac to the central tendon, and forms the anterior border of the rectovaginal space. (Reprinted from ref. 53 with permission from Elsevier.)

## ANATOMY

To understand the concepts underlying repair of pelvic floor relaxation, the anatomy of the normal pelvic floor support system should be briefly reviewed. The fascial support of the rectum consists of the prerectal fascia and the pararectal fascia. The prerectal fascia runs anterior to the rectum, from the pouch of Douglas to the central tendon, and has also been referred to as endopelvic fascia, vaginal fascia, rectovaginal septum, Denonvillier's fascia, and the fibromuscular wall of the vagina (6–10). No matter what this entity is called, it is this layer of tissue that prevents protrusion of the rectum into the vagina. A virtual space exists between the posterior vaginal wall and the prerectal fascia, which offers a convenient plane of dissection during rectocele repair. The pararectal fascia originates from the lateral pelvic sidewall and sweeps medially to the rectum, splitting into anterior and posterior sheets and forming a fibrous envelope around the rectum (Fig. 1).

The normal vaginal axis seen in the well-supported pelvic floor conveniently protects against rectocele formation and further pelvic prolapse. Two distinct areas of the vagina are seen if a normal vaginal axis is maintained. The proximal vagina lies at a 110–120° angle to the horizontal. The distal vagina, with the slinglike support provided by the levators, forms an angle of 45° from the vertical, which results in a midvaginal angle of 110–130°. In women with significant pelvic floor prolapse, levator plate laxity, and



levator hiatus, widening results in a disappearance of the normal curvature of the vagina and a near-vertical vaginal axis, which facilitates rectocele formation.

Childbirth results in several events that weaken the pelvic floor support system: (1) Passage of the child's head through the birth canal stretches the prerectal and pararectal fascia and detaches the prerectal fascia from the perineal body (11); (2) the levator musculature and its fascia are weakened, which allows the levator hiatus to widen and causes sagging of the levator plate (12); (3) the normal compensatory narrowing of the vaginal opening is rendered ineffective secondary to widening of the anogenital hiatus and damage to the UG diaphragm.

There are several sites where "breaks" of the rectovaginal septum have been commonly noted, leading to rectocele formation (Fig. 2) (13,14). The most common site is a transverse separation above the perineal body attachment, leading to a low rectocele. Other common sites include a midline vertical defect and an apical transverse break, which can be secondary to a poorly repaired (or poorly healed) episiotomy. A lateral separation on one side has also been described but is much less commonly seen.

## SYMPTOMS

Many rectoceles are asymptomatic when diagnosed and are purely an incidental finding at time of examination. If symptoms are present, then a wide variety of complaints has been noted with relaxation of the posterior floor, both specific and nonspecific to the prolapse. The most commonly noted complaint is constipation, identified in up to 75–100% of patients with rectoceles (1). Other rectal symptoms can include a sense of incomplete defecation; stool pocketing; the need to manually compress the vagina, rectum, or perineum to allow for stool passage; rectal bleeding; and fecal or flatal incontinence (15–18).

The causal relationship of rectal symptoms to the anatomic findings is not always clear, and often the correlation between the two is poor (19). The fact that many patients continue to complain of constipation after rectocele repair exemplifies the poor correlation between anatomic findings and symptoms (20). In addition, other colorectal disorders can cause symptoms that are similarly seen with posterior floor relaxation. Other symptoms related to the prolapse itself may include complaints of a vaginal bulge, dyspareunia, perineal or lower abdominal pressure, and low back pain, which worsens during the day and improves with lying down.

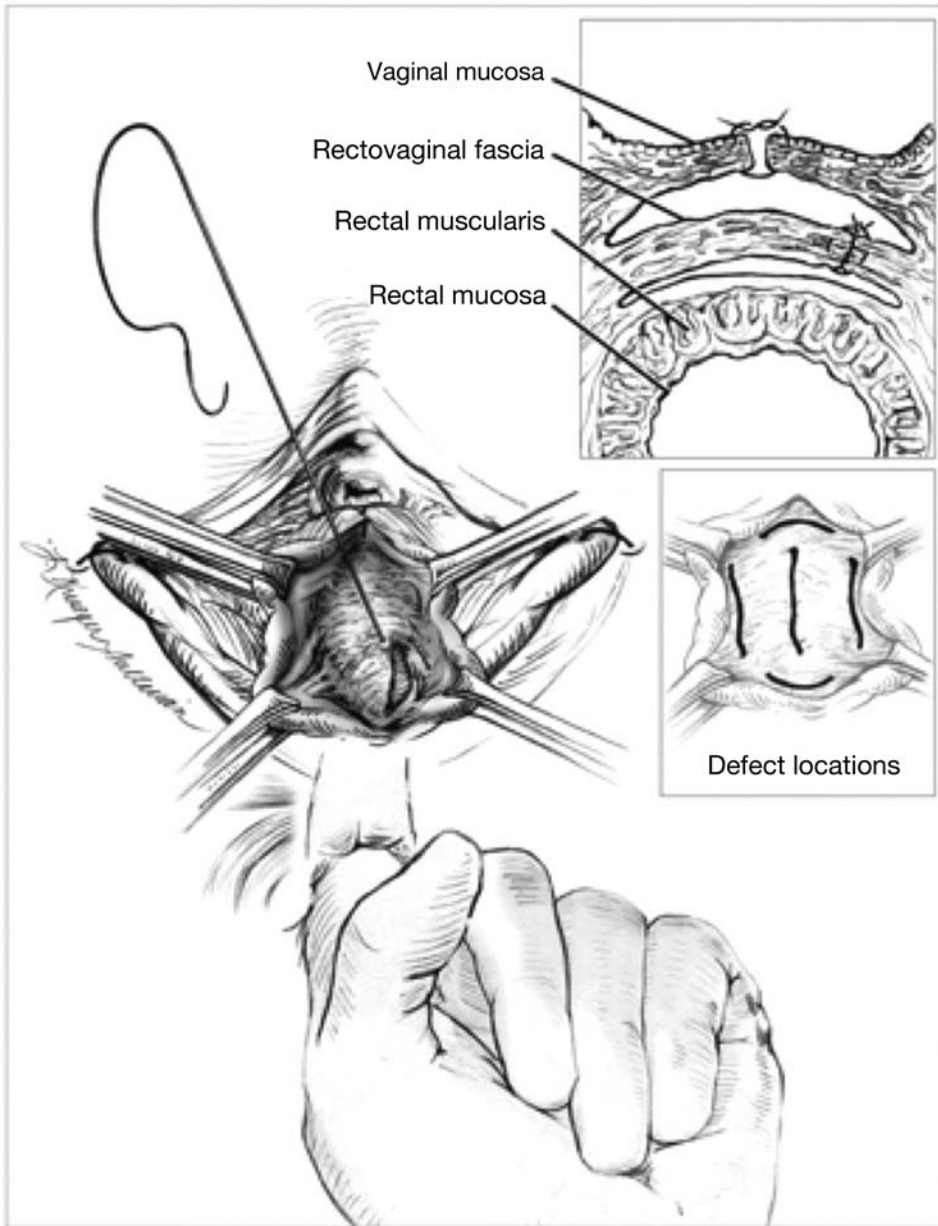
## DIAGNOSIS

### *History*

History should focus on issues related to bowel and sexual function. Constipation is a common complaint in older adults, and it should not be assumed that all patients with constipation and posterior floor relaxation have this secondary to rectocele. Constipation is often of multifactorial origin, and if significant bowel dysfunction is noted, then referral to a gastroenterologist or colorectal surgeon should be considered prior to undertaking any type of pelvic reconstructive procedure.

### *Examination/Grading*

Assessment for a posterior wall defect should be part of any routine pelvic examination made for the evaluation for urinary incontinence or pelvic organ prolapse. The patient



**Fig. 2.** Illustration of defect-directed rectocele repair. The upper inset demonstrates the layers involved in repair (cross section), and the lower inset demonstrates the potential location of tears in the rectovaginal fascia.

is first examined in the lithotomy position. Evaluation of the posterior compartment is best accomplished using half of a vaginal speculum to displace the anterior vaginal wall anteriorly. Bulging of the posterior vaginal wall with Valsalva maneuver or cough suggests the presence of a rectocele. A rectovaginal examination allows for evaluation of the rectovaginal septum. Isolated breaks of the septum may be identified by placing a finger in the rectum and lifting up the posterior vaginal wall at the location of maximal

laxity. A high rectocele may be difficult to distinguish from an enterocele. Rectovaginal exam may help with this differentiation, as may exam in the upright position. Defects of the perineal body should also be noted during pelvic examination. A perineal body defect is associated with a widened introitus with straining and a decreased distance from the posterior vaginal margin to the anterior anal margin.

Grading of rectocele can be done with either the Baden-Walker grading system or the Pelvic Organ Prolapse Quantification (POP-Q) system. The POP-Q system focuses on the descent of the vaginal wall and has been found to be highly reproducible (21). However, it is complex and avoids terms such as cystocele, rectocele, and the like, which allows for description of what is involved in the prolapse. Measurement of the perineal body and genital hiatus are standard components of the POP-Q system.

The final component of examination of the posterior compartment includes evaluation of the anal sphincter. This includes assessment of resting tone, identification of the patient's ability to actively contract the sphincter (and teaching of this maneuver if needed), and reflex sphincteric activity. Poor sphincter tone and activity can contribute to fecal and flatal incontinence and can have an impact on the success of repair. Thus, identification of this prior to surgery is important, and the potential implication of these findings can be discussed prior to surgical intervention. In addition, if poor sphincter tone and activity are thought to be secondary to neurological defects, then this should also be evaluated prior to any surgical intervention.

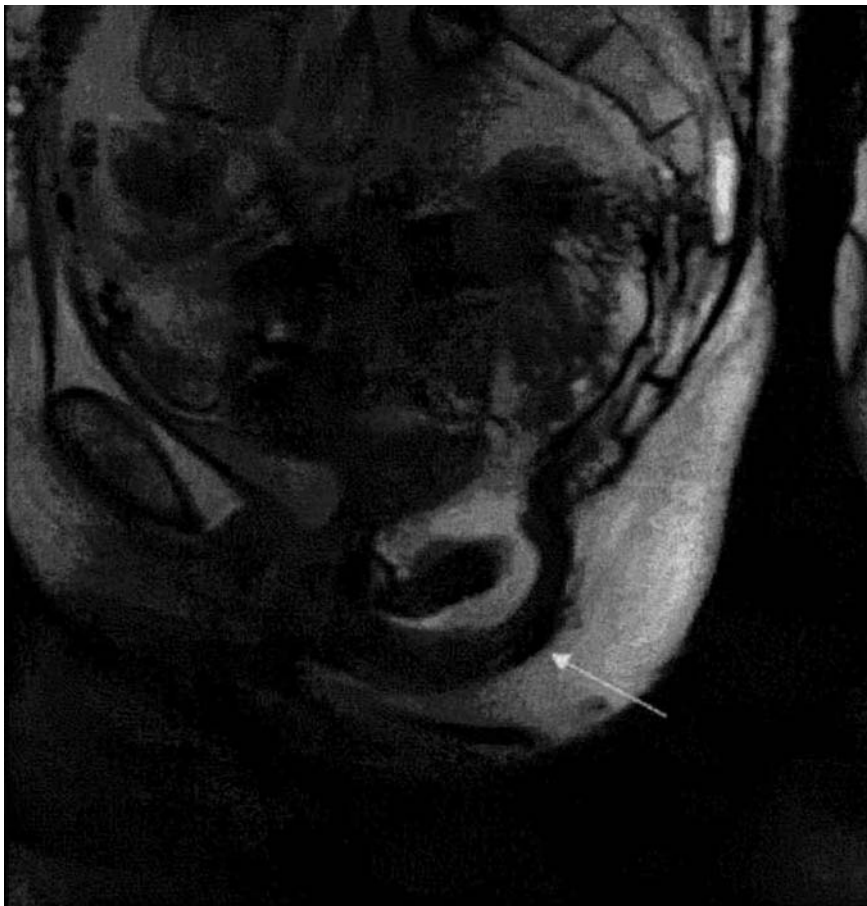### *Investigations*

The sensitivity and positive predictive value of physical examination alone to correctly identify all posterior floor defects was found to be less than 40% (22). In addition, the differentiation between a high rectocele and an enterocele can often be a challenge. This has led to the use of various radiographic techniques to aid in the diagnosis of posterior floor defects.

Defecating proctography involves filling the rectum with barium and fluoroscopically evaluating the patient at rest, on contraction of the pelvic floor, with Valsalva, and during defecation. However, proctography does not appear to have significantly greater sensitivity compared to physical examination to identify rectocele. In addition, Shorvon et al. showed that 60% of asymptomatic volunteers have rectoceles of moderate size or larger as identified by proctography (23). The identification of postdefecation trapping of barium was initially thought to be of clinical significance with proctography and would suggest that the patient would benefit from repair. However, subsequent studies have shown little correlation among clinical symptoms, barium trapping, and presence of a rectocele (24–27). The applicability of this test to identify patients with symptomatic rectoceles requiring surgical repair and its ability to predict outcome do appear to be limited (28).

A more useful test is dynamic magnetic resonance imaging, which allows for evaluation of the entire pelvis in addition to the posterior floor. Images are obtained at rest and with straining. This test can provide for evaluation of pelvic organ prolapse of each compartment and can be especially helpful when examination alone is unable to identify the exact location of a defect. In addition, other pelvic pathology, such as rectal intussusception or urethral diverticulum, could be identified preoperatively, which would have a significant impact on operative decision making.

Ultrasound has been unsuccessfully used in the past to assess prolapse size and location (29). Endoanal ultrasound is best used to evaluate for sphincter integrity. If a



**Fig. 3.** Dynamic MRI of the pelvic floor. Midline sagittal image obtained during evacuation of rectal contrast demonstrates marked posterior bulging of the pelvic floor (arrow).

sphincter defect is present, then this may lead to collaboration with a colorectal surgeon for repair. Last, colonic transit studies can be helpful in the evaluation of patients with chronic constipation and posterior floor relaxation; if a significantly slow transit time throughout the colon is identified, then that patient may not be helped with rectocele repair, and a potentially unnecessary surgery can be avoided.

### INDICATIONS FOR SURGERY

The majority of rectocele repairs are done coincident with repair of associated pelvic floor relaxation and organ prolapse. Patients with symptomatic posterior vaginal wall defects should undergo surgical correction. Common symptoms of a rectocele include sensation of a vaginal bulge, constipation, dyspareunia, the need to splint to defecate, and a sense of incomplete defecation. The repair of asymptomatic defects coincident with other vaginal surgery is not as well accepted. Arguments against repair of an asymptomatic rectocele include postoperative coital dysfunction and rectal injury. Jeffcoate described a 30% rate of discontinued coitus or dyspareunia after anterior and posterior repair (30). However, reviews evaluating outcomes using present-day techniques

of rectocele repair described a 0–9% incidence of coital dysfunction (31–33), and rectal injury has not been a concern.

Arguments favoring repair of asymptomatic pelvic floor relaxation during concomitant vaginal surgery include the risk of larger and symptomatic pelvic prolapse (i.e., rectocele, enterocele, uterine prolapse) if repair is not accomplished and the possibility that results of simultaneous antiincontinence surgery are improved if repair is done. Antiincontinence procedures orient the vagina in a vertical axis; however, pelvic floor repair helps restore the normal, near-horizontal axis of the vagina. Restoration of this axis should minimize the risk of postoperative prolapse, result in a more effective transmission of intra-abdominal pressure to the pelvis, and should improve the results of antiincontinence surgery by helping provide a strong backboard against which the bladder neck and urethra (which are secondarily supported by the pelvic floor) can be compressed. These arguments, combined with the ability to accomplish this surgery without introducing significant perioperative morbidity, lend to the recommendation that asymptomatic moderate or severe pelvic floor weakness be corrected at the time of concurrent vaginal procedures.

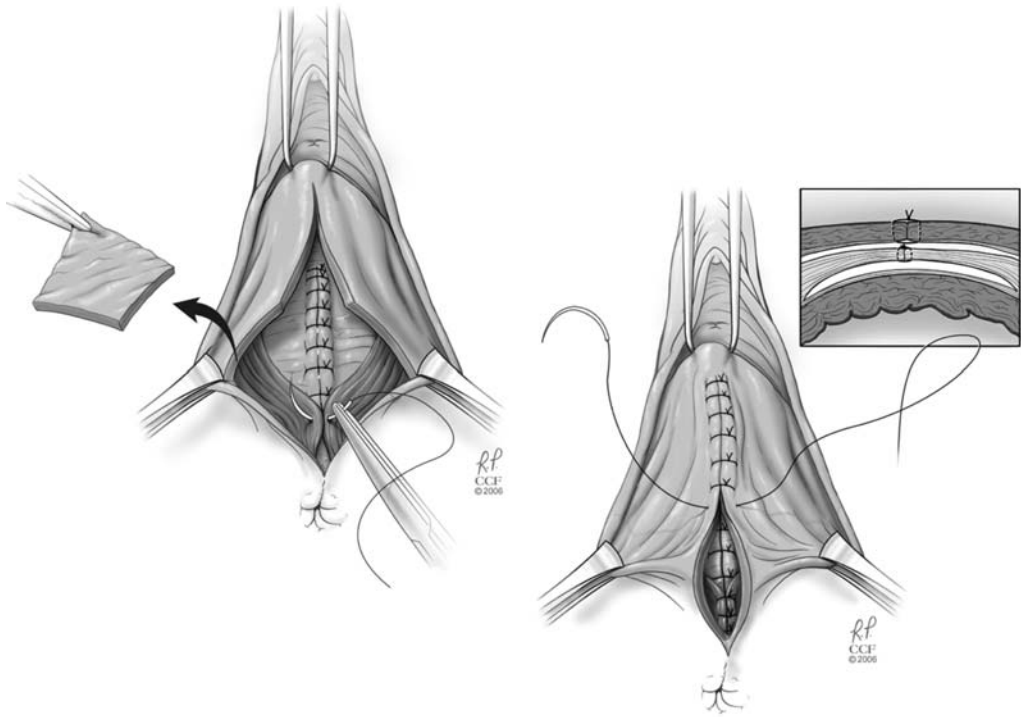
## SURGICAL REPAIR OF RECTOCELE

The essential goals of rectocele repair include (1) plication of the prerectal and pararectal fascia; (2) narrowing of the levator hiatus by reapproximating the prerectal levator fibers; and (3) repair of the perineal body. Several techniques have been described for repair of posterior floor relaxation; these are reviewed. Preoperative preparation for repair includes a clear liquid diet beginning 2 d prior to surgery and bowel preparation with the use of oral laxatives. Broad-spectrum intravenous antibiotics to cover anaerobes, Gram-negative bacilli, and group D enterococci are administered preoperatively. In addition, several months of hormone replacement therapy can be instituted prior to repair in patients with evidence of atrophic vaginitis to allow for healthier vaginal tissue at the time of repair.

### *Traditional Posterior Colporrhaphy*

The patient is positioned in the dorsal lithotomy position, and labial retraction sutures can be placed to aid in exposure. Allis clamps are placed in the midline of the posterior vaginal wall from the vaginal apex to 1–2 cm above the hymen. If a perineal repair is to be done, then Allis clamps are also placed midline between the hymen and anus (to mark the inferior extent of the repair) and bilaterally on the labia minora to allow for estimation of the caliber of the repaired vaginal introitus. The final hiatus should easily admit three fingerbreadths to avoid excessive postoperative narrowing. The four inferior Allis clamps serve as markers for a diamond-shaped incision, and the overlying mucosa is removed (Fig. 4). A midline incision is then made from vaginal apex to the top of this diamond, and the overlying vaginal wall is laterally freed off of the attenuated fascia and rectum with a combination of sharp and blunt dissection.

Repair is performed using 0 or 00 absorbable sutures. Initially, the lateral rectovaginal fascia is plicated together, followed by a levator ani layer, which is plicated in the midline. Some surgeons elect to place a finger in the rectum during this point of the repair. Displacement of the rectum downward helps to identify the appropriate layers of tissue and can protect the rectum during suture placement. Perineal repair involves placement of deep plication sutures into the puborectalis portion of the levator ani muscle. Excess



**Fig. 4.** Illustration of posterior colporrhaphy. The upper inset demonstrates the layers involved in repair (cross section).

vaginal wall is excised, and the vaginal wall is closed. Patients are sent home on stool softeners for 1 mo and instructed to refrain from sexual activity for 6 wk.

With a mean follow-up of 42.5 mo, Kahn and Stanton retrospectively reviewed their results with posterior colporrhaphy and found an anatomical cure rate of 76% (34). The primary concern with this procedure is postoperative vaginal scarring, narrowing, and dyspareunia. Repair of the defect with a levatoroplasty provides good anatomic support in terms of recurrence of prolapse. However, this is fundamentally a nonanatomic repair, which can lead to a suboptimal clinical outcome. Dyspareunia has been reported in 20–50% of patients (20,31,34,35), and residual issues with bowel emptying have been reported in 49–62% of patients undergoing posterior colporrhaphy (16,20,34). In addition, the study by Kahn and Stanton noted *de novo* bowel symptoms in a good number of patients, including complaints such as incomplete emptying (22%), constipation (23%), and fecal incontinence (8%).

#### ***Plication of Prerectal and Pararectal Fascia and Levator Reconstruction***

The patient is placed in the dorsal lithotomy position, and a rectal packing is placed to aid in identification of the rectum intraoperatively. Anti-incontinence surgery, cystocele repair, enterocele repair, and vaginal hysterectomy, if indicated, are accomplished first. Labial retraction sutures and a ring retractor with hooks, applied to the perineum, aid in lateral exposure of the vaginal vault. The anterior vaginal wall is retracted upward with a Haney or right-angle retractor to improve visualization and help prevent excessive narrowing of the vagina.

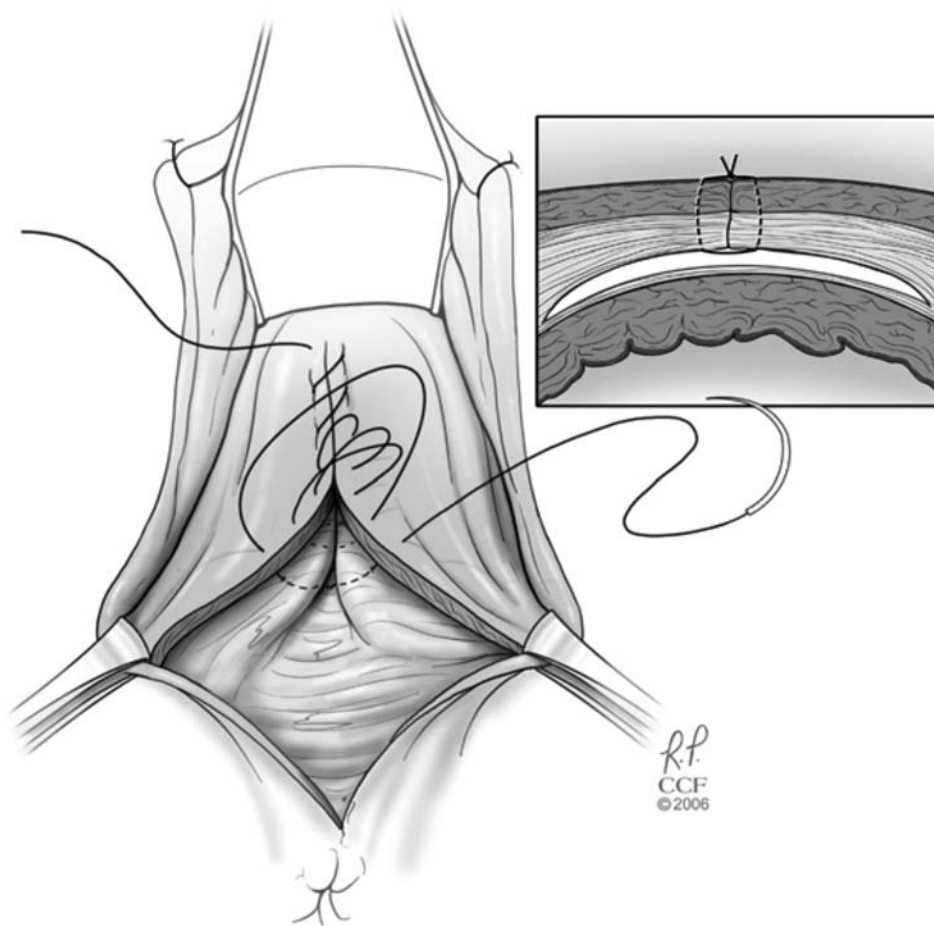
The repair begins with the placement of two Allis clamps at the posterior margin of the introitus at the 5 and 7 o'clock positions. Utilizing a V-shaped incision, a triangular segment of perineal skin is excised between the Allis clamps, exposing the attenuated perineal body. Allis clamps are then placed in the midline of the posterior vaginal wall, grasping and elevating the rectocele at its midpoint. An inverted V-shaped incision is then made from the site of the previous incision, with the apex of the incision up to the proximal aspect of the rectocele. This is a superficial incision through the vaginal wall only; a deeper dissection at this point risks injury to the rectum.

Metzenbaum scissors are then used to sharply develop a plane from the lateral margins of the incision, dissecting between the herniated rectal wall and the vaginal wall. Staying as close as possible to the vaginal wall to avoid injury to the rectum, dissection is performed between the herniated rectal wall and the vaginal wall, exposing the attenuated prerectal fascia. The triangular island of posterior vaginal wall created by the inverted V-shaped incision is sharply excised off the prerectal levator fascia and fibers. The prerectal fascia is exposed by sliding the Metzenbaum scissors under the posterior vaginal wall from the apex of the previous incision to the cuff of the vagina. The posterior vaginal wall is then incised along the midline, and an appropriately sized rectangular strip of excess posterior vaginal wall is excised (greater severity of prolapse necessitates a wider resection of posterior vaginal wall), exposing the attenuated pararectal and prerectal fascia proximally.

At this point, attention is turned toward repair of the rectocele. The anterior vaginal wall is retracted upward, and the distal rectum is retracted downward with a Haney or right-angle retractor. This protects the rectum, reduces the rectocele, helps avoid excessive vaginal narrowing during the repair, and facilitates reapproximation of the pararectal and prerectal fascia. Reconstruction begins at the apex of the rectocele and is carried out to the level of the levator hiatus with a running, locking, 2-0 polyglycolic acid suture. Each needle passage incorporates the edge of the vaginal wall and generous bites of the prerectal fascia and the pararectal fascia bilaterally (Fig. 5). The initial bite of this portion of the repair attempts to reapproximate the sacrouterine/cardinal ligament complex to decrease the risk of subsequent enterocele formation. The repair of the floor is finished with reapproximation of the levator hiatus using a figure-of-eight 2-0 polyglycolic acid suture, closing the distal posterior vaginal wall to the level of the perineum. Reapproximation of the prerectal levator fascia at this level restores the normal caliber of the introitus.

The repair is completed perineally using vertical mattress sutures of 2-0 polyglycolic acid to approximate the bulbocavernosus, transverse perineal, and external anal sphincter muscles. This brings together the muscles of the Urogenital (UG) diaphragm, reconstructing and providing support to the central tendon. The perineal skin is closed with a running 4-0 polyglycolic acid suture and an antibiotic-impregnated vaginal packing is placed. Patients are sent home on stool softeners for 1 mo and instructed to refrain from sexual activity for 6 wk.

The results of this technique have been reviewed in a total of 380 patients with an average follow-up of 22 mo. The majority of patients (69%) had an asymptomatic rectocele that presented with concomitant other pelvic pathology (i.e., stress incontinence, cystocele, etc.). Rectocele recurrence rate grade II or higher was noted in 4% of patients, resulting in anatomic success in 96% of patients. The most common presenting complaint related to the rectocele was constipation, which was noted in 26% of patients preoperatively and was improved in 67% of these patients after repair (36).



**Fig. 5.** Illustration of plication of prerectal and pararectal fascia. Absorbable suture is placed in a running fashion, incorporating pararectal fascia, prerectal fascia, and vaginal wall.

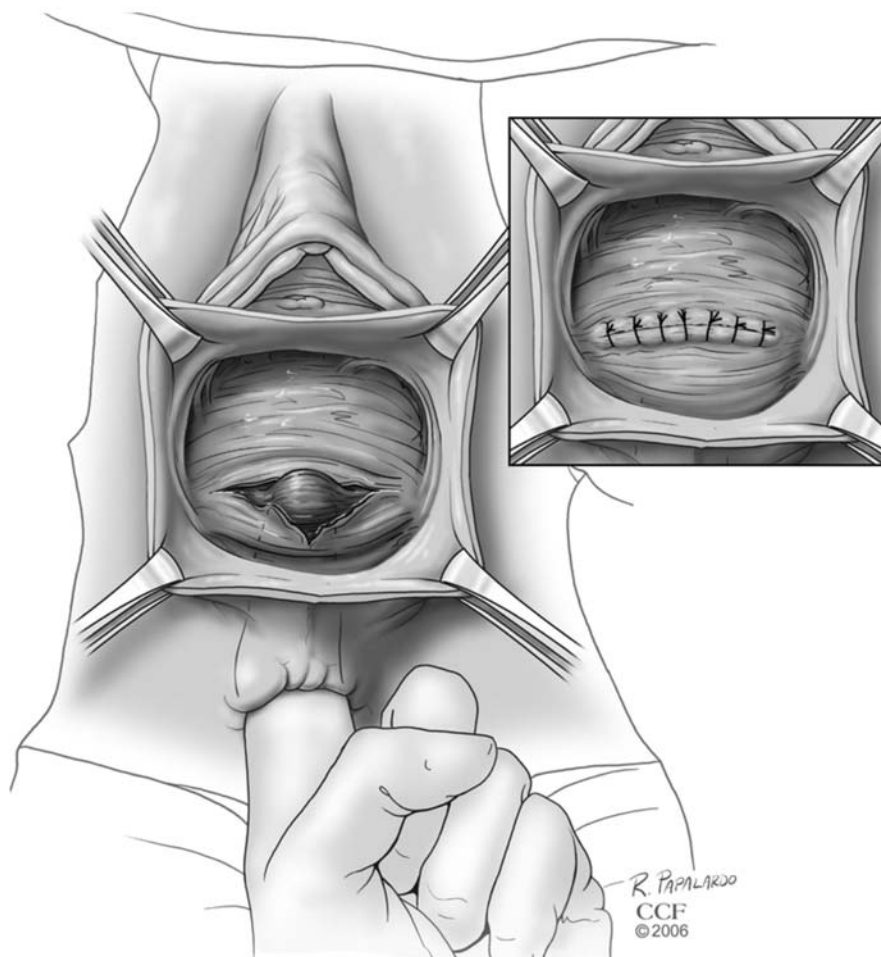
### ***Defect-Specific Rectocele Repair***

Defect-specific rectocele repair was originally described in 1993 by Richardson (37). With this technique, the repair of the posterior vaginal floor is not universally plicated, but rather repair is directed at specific fascial defects.

Initially, a diamond-shaped incision is made from the perineum to the apex of the vagina. The width of this incision is based on the approximation of the introitus to a postoperative diameter of three fingerbreadths. The perineal skin is excised, and the posterior vaginal wall is mobilized off the anterior rectal wall from the apex to the tendinous arch of the levators laterally and to the perineal body inferiorly. It is important to leave all of the fascial layers on the rectum during this dissection and not remove or disturb these supporting tissues when mobilizing the posterior vaginal wall.

At this point, the repair is performed using 2-0 absorbable sutures. The surgeon's nondominant index finger is placed in the rectum. Elevation of the anterior rectal wall facilitates identification of fascial defects. The most commonly noted defect is a low transverse break between the rectovaginal septum and the perineal edge with repair reapproximating the tear transversely (Fig. 6). Another commonly noted defect is a



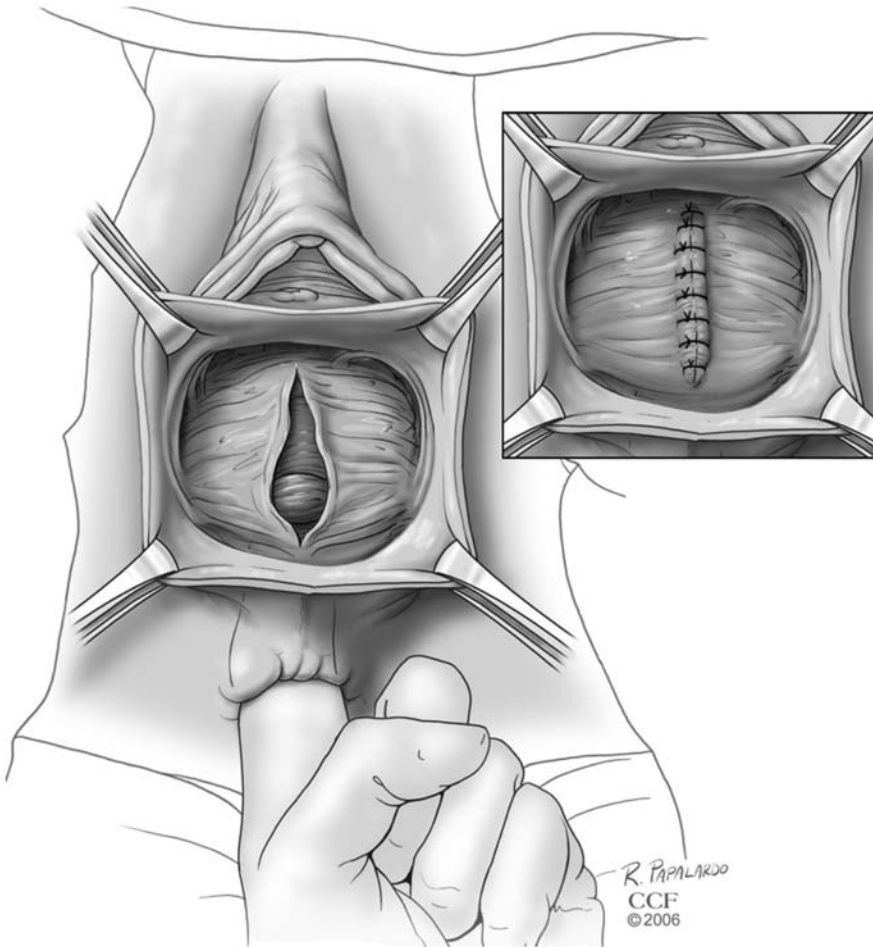


**Fig. 6.** Illustration of defect-specific rectocele repair. Absorbable, interrupted sutures are used to repair a low transverse defect.

longitudinal midline defect, which is repaired with interrupted sutures in the midline (Fig. 7). As illustrated in Figs. 6 and 7, the direction of the suture line conforms to the shape and direction of the defect. Any other residual breaks that are palpable should be repaired as well. Excess vaginal wall is then excised and closed with a 3-0 absorbable suture; if needed, a perineal repair is performed.

Theoretically, this repair is attractive as only the defect is repaired, thus minimizing excessive dissection and plication of tissue layers unnecessarily. With follow-ups ranging from 12 to 36 mo, anatomic cure was noted from 77 to 92% of patients in four studies that reviewed patients undergoing this repair (38–41).

Porter et al. evaluated perioperative dyspareunia using the Watts Sexual Function Questionnaire. They found dyspareunia improved in 73%, worsened in 19%, and noted as a *de novo* complaint in 2.4% of patients (38). Cundiff et al. reported an 84% improvement in constipation (39), although that degree of improvement was not reflected in other studies (38,40). The fact that by 1 yr postoperatively 64% of patients in the study by Kenton et al. (40) had returned to their preoperative practice of splinting reflects the multifactorial nature of defecatory dysfunction in these patients and suggests that these



**Fig. 7.** Illustration of defect-specific rectocele repair. Absorbable, interrupted sutures are used to repair a midline longitudinal defect.

bowel issues are often reflective of much more than just the anatomic defect noted with a rectocele. Finally, a retrospective comparison of site-specific repair vs standard posterior colporrhaphy (without levator placcation) by Abramov et al. found the defect-specific repair to be associated with higher recurrence rates. There were no significant differences between the two repairs regarding postoperative bowel symptoms (42).

### ***Rectocele Repair With Mesh***

The use of graft material to augment rectocele repair has been described with both defect-directed repairs and traditional colporrhaphy. Grafts have also been used with laparoscopic techniques, which are described in the next section. The increased use of various grafts to help provide further posterior support has coincided with the increased popularity of both synthetic and allograft materials in the repair of anterior laxity and for the treatment of stress urinary incontinence.

Kohli and Miklos reviewed their experience using a rectangular segment of cadaveric dermis to augment a defect-directed repair in 43 women. After the repair, the dermal

graft was secured proximally to the rectovaginal fascia, laterally to the arcus tendinus, and distally to the perineal body. They found a 93% cure rate in 30 women available for examination with a mean follow-up of 12.0 mo (43). de Tayrac et al. reviewed their results using polypropylene mesh attached to a combined bilateral sacrospinous fixation proximally and to the perineal body distally. No other posterior repair was done; all of the support posteriorly was based on the mesh. With a median follow-up of 22.7 mo in 26 patients, they reported 92.3% anatomic cure rate and improvement in symptoms and quality of life for all but 1 patient. They also noted a 12% rate of vaginal erosion and a 7.7% rate of dyspareunia (44).

Mesh erosion can be a serious problem, with vaginal erosion leading to vaginal discharge, bleeding, and dyspareunia. Erosion of mesh into the rectum is an uncommon but potentially serious complication of this class of repair that can lead to rectovaginal fistula, the need for fecal diversion with colostomy construction, and significant morbidity (45). With this potential morbidity, it is important to evaluate whether graft material allows for a greater improvement in anatomic and symptomatic cure while not increasing perioperative morbidity and complications.

Sand et al. did evaluate 143 patients prospectively, with 70 women undergoing traditional colporrhaphy and 73 women undergoing traditional colporrhaphy and placement of a polyglactin mesh in conjunction with other prolapse repair. There was no difference in recurrence rates with or without mesh; quality-of-life issues such as bowel and sexual function were not assessed in this study (46).

Clearly more studies are needed in the future to ascertain whether there is an optimal graft to use in rectocele repair and, if so, whether the material is able to decrease recurrence rates, improve quality of life, and minimize morbidity. It is also important to remember that grafts can shrink over time when measuring graft size at the time of repair. If the graft shrinks too much, the result can be loss of posterior wall flexibility and rectal compression, which can lead to fecal urgency, obstruction, and dyspareunia.

Finally, several authors have described the use of mesh transabdominally, often done in conjunction for total pelvic prolapse with concomitant abdominal sacrocolpopexy. Baessler and Schuessler described using posterior extensions of Gore-Tex in 31 women undergoing concomitant abdominal sacrocolpopexy. With a mean follow-up of 26 mo, they noted a 57% rectocele recurrence rate and have abandoned the procedure (47). Sullivan et al. evaluated their experience in 205 patients with a mean follow-up of 60 mo. This group, using Marlex mesh secured between the sacrum and the perineal body, noted an anatomic cure rate of 100%. Erosion of Marlex into rectum or vagina was noted in 5% of patients, and overall satisfaction for the correction of the patient's primary symptoms were 68, 73, and 74% with early (0.5–3 yr), middle (>3–6 yr), and late (>6 yr) follow-up, respectively (48).

### *Laparoscopic Repair*

The use of laparoscopy to correct posterior floor laxity has been described in a few reports. Repair has been described in conjunction with laparoscopic sacrocolpopexy and has also been done using graft materials (49). Without the use of an adjuvant graft material, the repair should be done laparoscopically as it would be done open. The rectovaginal space is opened to the perineal body. The perineal body is sutured to the rectovaginal septum, and any defects that are noted in the rectovaginal septum itself are repaired. If the rectovaginal fascia is detached from the iliococcygeus fascia, then

it should be reattached, and the medical aspect of the levator muscles can be plicated, taking care to avoid a posterior vaginal ridge (50).

Lyons and Winer first described laparoscopic rectocele repair. They incorporated a polyglactin mesh from the uterosacral ligament complex to the perineal body and cited an 80% success rate at 1 yr (51). Gadonneix et al. reviewed their experience using meshes placed anteriorly and posteriorly in 47 women undergoing laparoscopic sacrocolpopexy. They noted a 12% recurrence rate, which only occurred in women also undergoing simultaneous laparoscopic Burch (49).

## CONCLUSION

Rectocele is a common defect seen in patients with pelvic prolapse. A variety of symptoms can be associated with rectocele. Many of the complaints associated with laxity of the posterior vagina floor are related to sexual dysfunction, bowel dysfunction, or other nonspecific symptoms. The goal of repair is to restore the normal vaginal axis, repair the widened vaginal hiatus, maintain vaginal length, and maintain (or improve) bowel and sexual function. Several techniques have been described to surgically address these goals; however, it is important to note that comparative studies between different techniques do not exist. The optimal procedure is likely the technique that each individual surgeon is most comfortable performing.

Anatomic cure does not necessarily equal a good functional outcome. This is often seen with bowel dysfunction associated with a rectocele preoperatively. This is often of multifactorial etiology and may not be improved with repair. In addition, postoperative dyspareunia remains an issue. Therefore, the management of patient expectations in terms of functional outcomes is important. Finally, a prospective, randomized trial to compare both anatomic cure and quality-of-life outcomes between the various techniques is needed in the future.

## REFERENCES

1. Mollen RM, van Larrhoven CJ, Kuijpers JH. Pathogenesis and management of rectoceles. *Sem Colorectal Surg* 1996;7:192–196.
2. Hendrix SL, Clark A, Nygaard I, Aragaki A, Barnabei V, McTiernan A. Pelvic organ prolapse in the Women's Health Initiative: gravity and gravidity. *Am J Obstet Gynecol* 2002;186:1160–1166.
3. Wells TJ, Brink CA, Diokno AC. Urinary incontinence in elderly women: clinical findings. *J Am Geriatr Soc* 1987;35:933–939.
4. Raz S, Little NA, Juma S, Sussman EM. Repair of severe anterior vaginal wall prolapse (grade IV cystourethrocele). *J Urol* 1991;146:988–992.
5. Handa VL, Garrett E, Hendrix S, Gold E, Robbins J. Progression and remission of pelvic organ prolapse: a longitudinal study of menopausal women. *Am J Obstet Gynecol* 2004;190:27–32.
6. Goff BH. Histological study of the perivaginal fascia in a nullipara. *Surg Gynecol Obstet* 1931;52:32–42.
7. Milley PS, Nichols DH. A correlative investigation of the human recotvaginal septum. *Ana Rec* 1968;163:443–444.
8. Ricci JV, Lisa JR, Thom CH, Kron WL. The relationship of the vagina to adjacent organs in reconstructive surgery: a histologic study. *Am J Surg* 1947;74:387–410.
9. Ricci JV, Thom CH, Kron WL. Cleavage planes in reconstructive vaginal surgery. *Am J Surg* 1948;76:354–363.
10. Weber AM, Walters MD. What is vaginal fascia? *A U G S Q Rep* 13, 1995.
11. Kuhn RJ, Hollycock VE. Observations on the anatomy of the recotvaginal pouch and septum. *Obstet Gynecol* 1982;59:445–447.
12. Berglas B, Rubin IC. Study of the supportive structure of the uterus by lavatory myography. *Surg Gynecol Obstet* 1953;97:677–692.

13. Richardson AC. The rectovaginal septum revisited: its relationship to rectocele and its importance in rectocele repair. *Clin Obstet Gynecol* 1993;36:976–983.
14. Richardson AC. The anatomic defects in rectocele and enterocele. *J Pelvic Surg* 1995;1:214–221.
15. Walters MD. Pelvic organ prolapse: cystocele and rectocele. In: *Clinical Urogynecology* (Walters MD, Karram MM, eds.), Mosby, St. Louis, MO, 1993, pp. 225–235.
16. Mellgren A, Anzen B, Nilsson BY, et al. Results of rectocele repair. A prospective study. *Dis Colon Rectum* 1995;38:7–13.
17. Karlbom U, Graf W, Nilsson S, Pahlman L. Does surgical repair of a rectocele improve rectal emptying? *Dis Colon Rectum* 1996;39:1296–1302.
18. Murthy VK, Orkin BA, Smith LE, Glassman LM. Excellent outcome using selective criteria for rectocele repair. *Dis Colon Rectum* 1996;39:374–378.
19. Van Laarhoven CJ, Kamm MA, Bartram CI, Halligan S, Hawley PR, Phillips RK. Relationship between anatomic and symptomatic long-term results after rectocele repair for impaired defecation. *Dis Colon Rectum* 1999;42:204–210.
20. Arnold MW, Stewart WR, Aguilar PS. Rectocele repair: Four year's experience. *Dis Col Rectum* 1990;33:684–687.
21. Hall AF, Theofrastous JP, Cundiff GW, et al. Interobserver and intraobserver reliability of the proposed International Continence Society, Society of Gynecologic Surgeons, and American Urogynecologic Society pelvic organ prolapse classification system. *Am J Obstet Gynecol* 1996;175:1467–1470.
22. Burrows LJ, Sewell C, Leffler KS, Cundiff GW. The accuracy of clinical evaluation of posterior vaginal wall defects. *Int Urogynecol J Pelvic Floor Dysfunct* 2003;14:160–163.
23. Shorvon PJ, McHugh S, Diamant NE, Somers S, Stevenson GW. Defecography in normal volunteers: results and implications. *Gut* 1989;30:1737–1749.
24. Kelvin FM, Maglinte DD, Hale DS, Benson JT. Female pelvic organ prolapse: a comparison of triphasic dynamic MR imaging and triphasic fluoroscopic cystocolpoproctography. *AJR Am J Roentgenol* 2000;174:81–88.
25. Ting KH, Mangel E, Eibl-Eibesfeldt B, Muller-Lissner SA. Is the volume retained after defecation a valuable parameter at defecography? *Dis Colon Rectum* 1992;35:762–767.
26. Hutchinson R, Mostafa AB, Kumar D. Rectoceles: are they important? *Int J Colorectal Dis* 1993;8:232–233.
27. Halligan S, Bartram CI. Is barium trapping in rectoceles significant? *Dis Colon Rectum* 1995;38:764–768.
28. Felt-Bersma RJ, Cuesta MA. Rectal prolapse, rectal intussusception, rectocele, and solitary rectal ulcer syndrome. *Gastroenterol Clin North Am* 2001;30:199–222.
29. Monga A. Management of the posterior compartment. *BJOG* 2004;111(s1):73–78.
30. Jeffcoate TN. Posterior colpoproctorrhaphy. *Am J Obstet Gynecol* 1958;77:490–502.
31. Haase P, Skibsted L. Influence of operations for stress incontinence and/or genital descensus on sexual life. *Acta Obstet Gynecol Scand* 1988;67:659–661.
32. Nichols DH. Posterior colporrhaphy and perineorrhaphy: separate and distinct operations. *Am J Obstet Gynecol* 1991;164:714–721.
33. Pratt JH. Surgical repair of rectocele and perineal lacerations. *Clin Obstet Gynecol* 1972;15:1160–1172.
34. Kahn MA, Stanton SL. Posterior colporrhaphy: its effects on bowel and sexual function. *Br J Obstet Gynaecol* 1997;104:82–86.
35. Francis WJA, Jeffcoate TNA. Dyspareunia following vaginal operations. *J Obstet Gynaecol Br Comm* 1961;68:1–10.
36. Rosenblum N, Eilber KS, Rodriguez LV. Rectocele repair/posterior colporrhaphy. In: *Female Urology, Urogynecology and Voiding Dysfunction* (Vasavada SP, Appell RA, Sand PK, Raz S, eds.), Dekker, New York, 2005, pp. 717–733.
37. Richardson AC. The rectovaginal septum revisited: its relationship to rectocele and its importance in rectocele repair. *Clin Obstet Gynecol* 1993;36:976–983.
38. Porter WE, Steele A, Walsh P, Kohli N, Karram MM. The anatomic and functional outcomes of defect-specific rectocele repairs. *Am J Obstet Gynecol* 1999;181:1353–1358.
39. Cundiff GW, Weidner AC, Visco AG, Addison WA, Bump RC. An anatomic and functional assessment of the discrete defect rectocele repair. *Am J Obstet Gynecol* 1998;179:1451–1456.
40. Kenton K, Shott S, Brubaker L. Outcome after rectovaginal fascia reattachment for rectocele repair. *Am J Obstet Gynecol* 1999;181:1360–1363.

41. Singh K, Cortes E, Reid WM. Evaluation of the fascial technique for surgical repair of isolated posterior vaginal wall prolapse. *Obstet Gynecol* 2003;101:320–324.
42. Abramov Y, Gnadhi S, Goldberg RP, Botros SM, Kwon C, Sand PK. Site-specific rectocele repair compared with standard posterior colporrhaphy. *Obstet Gynecol Surv* 2005;60:297–298.
43. Kohli N, Miklos JR. Dermal graft-augmented rectocele repair. *Int Urogynecol J Pelvic Floor Dysfunct* 2003;14:146–149.
44. de Tayrac R, Picone O, Chauveaud-Lambling A, Fernandez H. A 2-yr anatomical and functional assessment of transvaginal rectocele repair using a polypropylene mesh. *Int Urogynecol J Pelvic Floor Dysfunct* 2005, May 21 (Epub).
45. Goh JTW, Dwyer PL. Effectiveness and safety of polypropylene mesh in vaginal prolapse surgery. *Int Urogynecol J* 2001;12:90.
46. Sand PK, Koduri S, Lobel RW, et al. Prospective randomized trial of polyglactin 910 mesh to prevent recurrence of cystoceles and rectoceles. *Am J Obstet Gynecol* 2001;184:1357–1362.
47. Baessler K, Schuessler B. Abdominal sacrocolpopexy and anatomy and function of the posterior compartment. *Obstet Gynecol* 2001;97:678–684.
48. Sullivan ES, Longaker CJ, Lee PY. Total pelvic mesh repair: a ten-year experience. *Dis Colon Rectum* 2001;44:857–863.
49. Gadonneix P, Ercoli A, Salet-Lizee D, et al. Laparoscopic sacrocolpopexy with two separate meshes along the anterior and posterior vaginal walls for multicompartiment pelvic organ prolapse. *J Am Assoc Gynecol Laparosc* 2004;11:29–35.
50. Paraiso MFR, Falcone T. Laparoscopic surgery for genuine stress urinary incontinence and pelvic organ prolapse. In: *Clinical Urogynecology, 2nd ed.* (Walter MD, Karram MM, eds.), Mosby, St. Louis, MO, 2000, pp. 197–209.
51. Lyons TL, Winer WK. Laparoscopic rectocele repair using polyglactin mesh. *J Am Assoc Gynecol Laparosc* 1997;4:381–384.

---

# 21

## Diagnosis and Management of Apical Prolapse

---

*Daniel S. Elliott, MD*

### CONTENTS

INTRODUCTION  
PREOPERATIVE EVALUATION  
MANAGEMENT OF APICAL PROLAPSE  
CONCLUSION  
REFERENCES

---

### INTRODUCTION

It is estimated that one in nine women in the United States will undergo a hysterectomy during their lifetime, and up to 10% of these women will need surgical repair for treatment of a symptomatic vaginal vault prolapse (1). The search for the repair that offers the best combination of the most effective, safest, and most durable for the treatment of apical prolapse is an ongoing process, as evidenced by the multiple surgical approaches available to treat this problem. Clearly, no one surgical approach is ideal for every patient. However, as the known risk factors for prolapse, such as age, obesity, and hysterectomy, continue to increase in the United States, so does the need for continuing the search for better means to repair vaginal vault prolapse (2–4).

Prior to discussion of the treatment options for this condition, it is imperative for the treating surgeon to have a good understanding of the preoperative evaluation, including an awareness of the symptoms and how to diagnose posthysterectomy prolapse.

### PREOPERATIVE EVALUATION

It is important to be cognizant that defects of vaginal support may occur with and without any concurrent symptoms. Therefore, it is imperative for the evaluating physician not only to ask the pertinent questions during the history taking but also to perform an accurate physical exam. Symptoms may be falsely attributed to a prolapse that may actually be caused by other underlying and unrelated medical conditions, which if missed may compromise the success of the prolapse surgery or may lead to false expectations by the patient. Therefore, proper counseling of the patient can help reduce postoperative patient dissatisfaction.

**Table 1**  
**Predisposing Factors to Posthysterectomy Prolapse**

---

Race
History vaginal delivery
Increased age and menopause
Obesity
Smoking
Lung disease/chronic cough
Chronic constipation
Heavy lifting

---

Adapted from ref. 41.

### *Past Medical History*

There are several factors that predispose a given patient to prolapse (and subsequent postoperative recurrence) and need to be sought during the preoperative evaluation. A preponderance of significant risk factors should be weighed into the equation in determining the best treatment option for a patient. Factors known to either increase or directly cause not only posthysterectomy prolapse but all pelvic organ prolapses in general are noted on Table 1. Any factors that predispose the patient to repetitive lifting or coughing or factors that can affect proper healing should be especially focused on because this may affect the type of repair chosen.

### *Apical Prolapse Symptoms*

Symptoms possibly associated with apical prolapse are outlined in Table 2. There are no true absolutely specific symptoms of a prolapse that will guide the physician to the diagnosis. This is an especially important issue when counseling patients with a history of pelvic pain, pelvic pressure, dyspareunia, and urinary frequency/urgency. The surgeon must discuss these symptoms with the patient preoperatively so that the patient has realistic expectations and goals of surgery. If a patient with pelvic pain preoperatively falsely expects her symptoms will be either partially or completely resolved following repair of her apical prolapse and they are not, then the surgeon can expect a long and drawn out postoperative time period with the patient.

A good voiding history needs to be obtained from all patients with prolapse. Mayne and Assassa reported that up to 45% of women will have a complaint of concurrent voiding dysfunction, and up to 26% of these women will have clinically significant symptoms that will require therapeutic intervention (5). The presence of frank or occult stress incontinence needs to be sought during the history taking and during the physical exam. If overactive bladder symptoms are present, then consideration should be given to managing this problem before treatment of the prolapse because many women will falsely attribute the urge symptoms to the presence of the prolapse. It is true that urge symptoms may be secondary to the prolapse; however, as stated, urge symptoms may be unrelated and therefore consideration of attempted management should at least be given before surgical intervention.

Patient lifestyle issues should be discussed, focusing on aspects such as a patient's need for repetitive lifting or exercise expectations. An individual with a sedentary vs an active lifestyle will need to be counseled differently on the treatment options and



Table 2  
Pelvic Prolapse Symptoms

---

Pelvic pressure
Pelvic pain
Dyspareunia
Voiding complaints
Hesitancy
Poor emptying
Splinting
Frequency/urgency
Fecal complaints
Constipation
Splinting
Fecal urgency/incontinence

---

the potential risk of prolapse recurrence. Also, a patient's sexual activity level and expectations should be discussed in an open matter because various prolapse repairs can affect sexual activity and intercourse.

### *Physical Exam*

The physical exam remains the cornerstone of diagnosis. Several factors will need to be considered while performing the exam:

1. The exam needs to be done with the patient straining to fully assess the degree of prolapse.
2. All components of the vaginal vault must be independently evaluated.
3. If an anterior component prolapse is present, then this should be reduced, and the patient should Valsalva to evaluate the presence or absence of concurrent urinary incontinence.

Certain patients are unable to Valsalva with sufficient force to allow adequate examination. In these patients, it may be helpful for the exam to take place with the patient sitting more upright or standing. An apical prolapse and a large anterior or posterior compartment prolapse may be difficult to distinguish on physical exam. Anatomically, the enterocele extends down from the apex, and a half speculum placed either anteriorly or posteriorly aids in determining the exact location of the prolapse. Also, a concurrent rectal exam while the patient strains aids in accurate diagnosis. While the patient strains, the rectovaginal septum can be palpated to determine if an enterocele bulge exists.

Failure to assess all vaginal compartments and the presence or absence of urinary incontinence accurately will lead to an insufficient treatment plan for the patient and subsequent failure of whichever procedure is chosen. However, once the correct diagnosis is made, then choosing a treatment plan and correct counseling of the patient becomes much easier.

## MANAGEMENT OF APICAL PROLAPSE

### *Observation*

Patients, especially ones with a mild prolapse or only minimal symptomatology need to be counseled on the potential benefit of observation. This is especially important when considering the high (up to 30%) reoperation rate (6).

### *Nonsurgical*

Pessaries are the mainstay of nonsurgical management of apical prolapse. Several investigators have shown that although pessaries may be an effective treatment option for women who decline surgery, over 20% of those women eventually discontinued their use (7). Complications from long-term pessary use include vaginal mucosa irritation and ulceration, which can lead to fistula formation and bowel herniation (8–10).

### *Surgical*

The choice of surgical approach depends on multiple factors. Factors to be considered include the precise support deficit, the etiology of the defect (i.e., chronic lifting, posthysterectomy, chronic cough, status after previous attempted repair, and route of previous repair), and to no small extent, the experience of the surgeon.

The surgical approach can be divided into three main categories: vaginal, abdominal, and laparoscopic.

#### **TRANSVAGINAL REPAIR**

Transvaginal repairs have the goal of either restoring a more normal vaginal anatomy or being obliterative. Obliterative procedures such as colpectomy or colpocleisis have cure rates ranging from 85 to 100% (11,12). Ideal patients for such obliterative procedures include patients who no longer desire sexual intercourse. Complications are rare with these procedures; however, the most common complication is *de novo* development of stress urinary incontinence in 1–9% (13,14).

Table 3 outlines the multiple types of transvaginal apical repairs (6,15–23). The type of surgical repair chosen should be dictated by surgeon's preference and past experience. No single transvaginal procedure has clearly been vastly superior in either anatomical or symptomatic cure (6). However, the surgeon's skill level with a given approach should always be considered an important factor when choosing an operative approach, especially when considering the high failure rate and subsequent reoperation rate when the procedure is performed perfectly and in experienced hands. There is no reason to further increase the odds of failure by attempting a procedure with which one feels uncomfortable without assistance from another, more experienced surgeon.

A detailed description of each transvaginal repair is beyond the scope of this text. However, briefly, a sacrospinous ligament fixation procedure involves the fixation of the apex of the vagina to the sacrospinous ligament and suspends the upper vagina over the levator plate. Because of the anatomic proximity of the pudendal nerve and vessels, sciatic nerve, ureter, and rectum, the surgeon needs to be careful not to incorporate the adjacent structures into the suspension (16). However, if the anatomic relationships are carefully noted during the case, the sacrospinous ligament suspension can be performed safely.

Uterosacral ligament suspension or Mayo culdoplasty involves placing one or more McCall sutures into the uterosacral ligaments. This will accomplish two things. First, it will approximate the uterosacral ligaments, thereby obliterating the enterocele by closing the cul-de-sac. Second, it will elevate and support the vaginal vault (19–22). As with any transvaginal procedure, adjacent anatomic structures can be inadvertently injured. Specifically with the uterosacral suspension, the ureters, bowel, and bladder can be either directly injured or indirectly "kinked," as in the case with the ureters. However, careful intraoperative observation should detect these injuries, and they can be corrected with minimal sequelae.

**Table 3**  
**Case Series Cure Rates for Transvaginal and Transabdominal Procedures for Apical Prolapse**

<i>Repair</i>	<i>Ref.</i>	<i>No. of patients</i>	<i>Follow-up (mo)</i>	<i>Anatomic cure</i>	<i>Symptomatic cure</i>
Sacrospinous fixation	15	122	24	79	92
	16	26	30	87	100
	17	36	19	67	94
	18	81	1.5	81	Not reported
Uterosacral suspension	19	28	33	94	81
	20	168	Jun-36	87	Not reported
	21	46	16	94	90
	22	289	1.5	87	Not reported
Iliococcygeus suspension	17	36	21	53	91
	22	42	1.5	95	Not reported
	24	110	36	96	Not reported

Adapted from ref. 6.

In experienced hands, transvaginal repair “success rates” range between 67 and 100%, and symptomatic cure rates range from 92 to 100% (6). In comparison, transabdominal sacrocolpopexy has been shown in multiple studies to have one of the highest long-term success rates for durable repair of severe vault prolapse (93–100%) (25–33). Unfortunately, data available that compare transvaginal vs transabdominal apical repairs are sparse. Two prospective randomized studies have been completed comparing the results of transvaginal vs transabdominal repairs (34,35).

Benson et al. performed a randomized study comparing bilateral sacrospinous fixation vs abdominal sacrocolpopexy with a mean follow-up of 2.5 yr. In the 80 women who completed the study, the sacrocolpopexy group was twice as likely to have a successful outcome and 50% less likely to require reoperation (16 vs 33%) (34). The results led the authors to terminate the study early.

However, in contrast, in a study completed by Maher et al., 95 women were randomly assigned to two treatment arms (sacrocolpopexy vs sacrospinous fixation). This study determined, at a mean follow-up of 24 mo, that there was no difference in subjective success rate (94% sacrocolpopexy vs 91% sacrospinous fixation), and there were no differences in the objective cure rate (76 vs 69%, respectively) (35). Maher et al. concluded that because there were no differences in cure rates and the complication rate, operating time, and time to recovery were higher in the sacrocolpopexy group, that for most patients the transvaginal repair would be sufficient. Both studies, however, did agree that the sacrocolpopexy had better anatomical results.

## TRANSABDOMINAL

As mentioned, the transabdominal sacrocolpopexy has been shown in multiple studies to have one of the highest long-term success rates for durable repair of severe vault prolapse (93–100%) (25–33). In addition to a high success rate and durable results, other advantages of the sacrocolpopexy approach with the use of synthetic material to repair vault prolapse can be summarized as follows:

1. Support of the vaginal vault to the anterior surface of the sacrum preserves (or restores) the normal axis of the vagina.
2. Maximal vaginal depth can be preserved, which is especially important in patients who desire continued sexual activity and in patients with an already foreshortened vagina from previous surgery.
3. Use of synthetic suspensory material can provide a source of strength in patients for whom the native tissue with prolapse is weak.

Potential candidates for the open procedure tend to be younger, more active, and more likely to be leading an active lifestyle. Other important indications are concurrent medical conditions such as chronic cough, chronic obstructive pulmonary disease, and asthma. These conditions place chronic and repeated increased intraabdominal pressure on the repair. Unfortunately, because of the morbidity of the open transabdominal procedure, many patients are unable to tolerate the surgery. Therefore, many of these patients are treated via a transvaginal approach.

Goals of every surgical repair of vaginal vault prolapse include restoration of proper anatomy, maintenance of sexual function, and durability. The main advantage to the vaginal approach has historically been decreased morbidity, including shorter hospitalization and convalescence (20,36). Unfortunately, long-term success rates with transvaginal repairs are consistently lower compared to an abdominal approach, such as sacrocolpopexy (34).

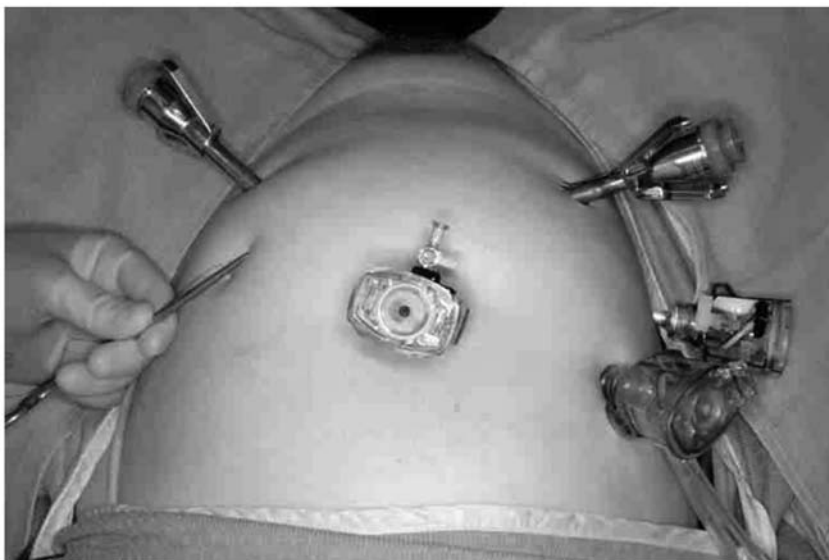In an effort to balance the benefit of the open sacrocolpopexy (durable repair) with the advantage of a vaginal repair (reduced morbidity), many attempts have been made to treat the vault prolapse via laparoscopic sacrocolpopexy (37,38). Unfortunately, technical difficulties in actually accomplishing the procedure and the potentially significant increase in operative time have greatly limited its widespread use. To address these specific limitation of laparoscopic repairs, advances in robotic surgery may be an answer.

Telerobotics provide technical features such as three-dimensional vision, increased robotic instrument maneuverability, and physiologic tremor filtering. These factors provide an ergonomic environment for the surgeon that simplifies performance of complex laparoscopic tasks. The technique of robotic-assisted laparoscopic sacrocolpopexy can use any type of synthetic graft material utilized in the open procedure. The ultimate goal of the robotic-assisted laparoscopic sacrocolpopexy should be threefold: (1) provide the most durable repair for vaginal vault prolapse; (2) minimize the morbidity associated with transabdominal procedures; and (3) provide a procedure that can be accomplished within a reasonable operative time (39).

### **ROBOTIC-ASSISTED LAPAROSCOPIC SURGICAL TECHNIQUE**

The daVinci<sup>®</sup> robot (Sunnyvale, CA) is an integrated computer-based system consisting of two interactive robotic arms, a camera arm, and a remote control with three-dimensional vision capability. The daVinci robot uses instruments with 6° of freedom that provide the same flexibility as the human wrist. The working robotic arms are attached to reusable 8-mm trocars; the camera is placed through a standard 12-mm laparoscopic port. For optimal robot function and to minimize risk of collisions, the angle created by the camera port and each working robotic port should be obtuse and the distance between the ports at least one handbreadth.

With robotic surgery, the motions of the surgeon at the remote control unit are replicated by the robotic arms placed within the patient. Tactile feedback is not available with



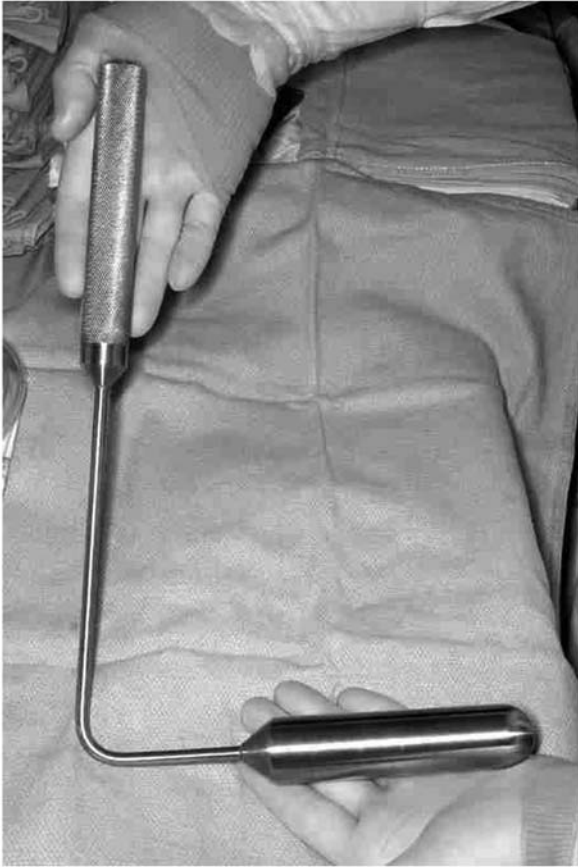
**Fig. 1.** Port site for laparoscopic sacrocolpopexy.

daVinci; therefore, increased reliance on visual input is required. During robotic surgery, an assistant surgeon is scrubbed at the operating table. The assistant performs a variety of important robot-related tasks, including alignment and exchange of instruments on the robotic arms. Furthermore, the assistant performs operative maneuvers with conventional instruments, including tissue countertraction, hemostasis, hemoclip application, suction, and assistance during suturing. Most important, the scrubbed assistant is available in the event that an emergent conversion would be required.


For the procedure, the patient is placed in the dorsal lithotomy position on the operating table. After general anesthesia is established, a nasogastric tube is placed, and both arms are tucked beside the torso. The patient is prepped from the nipples to proximal thigh, including the vagina.

After abdominal insufflation using a Varus needle, a periumbilical Visiport is placed under direct vision to avoid visceral or vascular injury. Two standard laparoscopic ports are next introduced under direct vision: one 10-mm port right subcostal lateral to the rectus and one 5-mm port one handbreadth inferior laterally (Fig. 1). These ports are used for retraction during the procedure. Next, two 8-mm robotic ports are placed lateral to the rectus two fingerbreadths superior to the iliac crest.

At this point, using standard laparoscopy, a retracting suture is placed through the sigmoid tenia eventually to help in exposing the sacral promontory. The next step is dissection of the bladder from the anterior vaginal wall using forceps and scissors with cautery. A customized handheld vaginal retractor manufactured at the Mayo Clinic (Fig. 2) is used to facilitate the dissection, which should be a relatively bloodless plane. Posteriorly, the peritoneal reflection is then incised to mobilize the vagina. Both of these dissections should be carried out as distal (toward the introitus) as possible to maximize the support given by the Y graft. After adequate vaginal mobilization, the sacral dissection, with careful attention to avoid sacral venous complexes, is accomplished. Once the shiny periosteum is exposed, the polypropylene Y graft (IntePro™, American Medical Systems, Minnetonka, MN) (Fig. 3) is brought into the field through the 10-mm port.



**Fig. 2.** Handheld vaginal retractor.



**Fig. 3.** Polypropylene Y graft (IntePro).

The robot is now docked with the base positioned at the foot of the bed. The main reason to utilize the robot at this point is to facilitate and greatly reduce the operative time needed for suturing of the graft to the vagina and the sacrum. The Y-shaped graft is inserted via a port. The graft is then robotically sutured using 1.0 Gore-Tex. The 30° lens and vaginal retractor maximize exposure for placement of the sutures. The posterior sutures are passed first because they are more difficult, followed by suturing the anterior portion of the Y graft to reduce the difficulty of the process. The tail end of the graft is then sutured to the sacral promontory using three or four interrupted sutures, with careful attention to avoid any undue tension on the vagina. A standard Halban's culdoplasty with plication of the uterosacral ligaments further aids the prevention of recurrent vaginal prolapse. The posterior peritoneum is then closed to completely retroperitonealize the graft (40).

## CONCLUSION

The cornerstone of management of apical prolapse must be an accurate preoperative evaluation and diagnosis. Good arguments can be made with transvaginal, transabdominal, or laparoscopic management of apical prolapse; however, if incorrect or insufficient evaluation of the concurrent problems of a patient is performed, then the patient will most likely be less than satisfied with the end result.

## REFERENCES

1. Marchionni M, Bracco GL, Checcucci V, et al. True incidence of vaginal vault prolapse. Thirteen years of experience. *J Reprod Med* 1999;44:679–684.
2. Dwyer PL, Lee ETC, Hay DM. Obesity and urinary incontinence in women. *Br J Obstet Gynaecol* 1988;95:91–96.
3. Virtanen HS, Makinen JI. Retrospective analysis of 711 patients operated on for pelvic relaxation in 1983–1989. *Int J Gynecol Obstet* 1993;42:109–115.
4. Olsen A, Smith V, Bergstrom J, Colling J, Clark A. Epidemiology of surgically managed pelvic organ prolapse and urinary incontinence. *Obstet Gynecol* 1997;89:501–506.
5. Mayne CJ, Assassa RP. Epidemiology of incontinence and prolapse. *Int J Obstet Gynaecol* 2004;111 (suppl 1):2–4.
6. Cundiff, G. An 80-year-old woman with vaginal prolapse. *JAMA* 2005;293:2018–2027.
7. Sulak PJ, Kuehl TJ, Shull BL. Vaginal pessaries and their use in pelvic relaxation. *J Reprod Med* 1993;38:919–923.
8. Muram D, Summitt RL, Feldment N. Vaginal dilators for intermittent pelvic support: a case report. *J Reprod Med* 1990;35:303–304.
9. Goldstein I, Wise GJ, Tancer ML. A vesicovaginal fistula and intravesical foreign body: a rare case of neglected pessary. *Am J Obstet Gynecol* 1990;163:589–591.
10. Ott R, Richter H, Behr J, Scheele J. Small bowel prolapse and incarceration caused by a vaginal ring pessary. *Br J Surg* 1993;80:1157–1159.
11. DeLancey JO, Morley GW. Total colpopoiesis for vaginal eversion. *Am J Obstet Gynecol* 1997;176: 1228–1232.
12. Ridley JH. Evaluation of the colpopoiesis operation: a report of fifty-eight cases. *Am J Obstet Gynecol* 1972;113:1114–1119.
13. Fitzgerald MP. Colpopoiesis and urinary incontinence. *Am J Obstet Gynecol* 2003;189:1241–1244.
14. von Pechmann WS, Mutone M, Fyffe J, Hale DS. Total colpopoiesis with high levator plication for the treatment of advanced pelvic organ prolapse. *Am J Obstet Gynecol* 2003;189:121–126.
15. Nieminen K, Huhtala H, Heinonen PK. Anatomic and functional assessment and risk factors of recurrent prolapse after vaginal sacrospinous fixation. *Acta Obstet Gynecol Scand* 2003;82:471–478.
16. Guner H, Noyan V, Tiras MB, Yildiz A, Yildirim M. Transvaginal sacrospinous colpopexy for marked uterovaginal and vault prolapse. *Int J Gynaecol Obstet* 2001;74:165–170.
17. Maher CF, Murray CJ, Carey MP, Dwyer PL, Ugoni AM. Iliococcygeus or sacrospinous fixation for vaginal vault prolapse. *Obstet Gynecol* 2001;98:40–44.

18. Shull BL, Capen CV, Riggs MW, Kuehl TJ. Preoperative and postoperative analysis of site-specific pelvic support defects in 81 women treated with sacrospinous ligament suspension and pelvic reconstruction. *Am J Obstet Gynecol* 1992;166:1764–1768.
19. Amundsen CL, Flynn BJ, Webster GD. Anatomical correction of vaginal vault prolapse by uterosacral ligament fixation in women who also require a pubovaginal sling. *J Urol* 2003;169:1770–1774.
20. Karram M, Goldwasser S, Kleeman S, Steele A, Vassallo B, Walsh P. High uterosacral vaginal vault suspension with fascial reconstruction for vaginal repair of enterocele and vaginal vault prolapse. *Am J Obstet Gynecol* 2001;185:1339–1342.
21. Barber MD, Visco AG, Weidner AC, Amundsen CL, Bump RC. Bilateral uterosacral ligament vaginal vault suspension with site-specific endopelvic fascia defect repair for treatment of pelvic organ prolapse. *Am J Obstet Gynecol* 2000;183:1402–1410.
22. Shull BL, Bachofen C, Coates KW, Kuehl TJ. A transvaginal approach to repair of apical and other associated sites of pelvic organ prolapse with uterosacral ligaments. *Am J Obstet Gynecol* 2000;183:1365–1373.
23. Shull BL, Capen CV, Riggs MW, Kuehl TJ. Bilateral attachment of the vaginal cuff to iliococcygeus fascia: an effective method of cuff suspension. *Am J Obstet Gynecol* 1993;168:1669–1674.
24. Meeks GR, Washburne JF, McGehee RP, Wisner WL. Repair of vaginal vault prolapse by suspension of the vagina to iliococcygeus (prespinous) fascia. *Am J Obstet Gynecol* 1994;171:1444–1452.
25. Addison WA, Timmons MC. Abdominal approach to vaginal eversion. *Clin Obstet Gynecol* 1993;36:995–1004.
26. Timmons MC, Addison WA, Addison SB, Cavenar MG. Abdominal sacral colpopexy in 163 women with posthysterectomy vaginal vault prolapse and enterocele. *J Repro Med* 1992;37:323–327.
27. Cundiff GW, Harris RL, Coates K, Low VHS, Bump RC, Addison WA. Abdominal sacral colpoperi-neopexy: a new approach for correction of posterior compartment defects and perineal descent associated with vaginal vault prolapse. *Am J Obstet Gynecol* 1997;177:1345–1353.
28. Snyder TE, Krantz KE. Abdominal-retroperitoneal sacral colpopexy for the correction of vaginal prolapse. *Obstet Gynecol* 1991;77:944–949.
29. Menefee SA, Miller KF, Wall LL. Results of abdominal sacral colpopexy using polyester mesh in the treatment of posthysterectomy vaginal vault prolapse and enterocele. *Obstet Gynecol* 1999;54:563–565.
30. Reddy K, Malik TG. Short-term and long-term follow-up of abdominal sacrocolpopexy for vaginal vault prolapse: initial experience in a district general hospital. *J Obstet Gynaecol* 2002;22:532–536.
31. Addison WA, Timmons MC, Wall LL, Livengood CH. Failed abdominal sacral colpopexy: observations and recommendations. *Obstet Gynecol* 1989;74(3 pt 2):480–483.
32. Addison WA, Timmons MC. Abdominal sacral colpopexy for the treatment of vaginal vault prolapse with enterocele. In: *Te Linde's Operative Gynecology, 8th ed.* (Rock JA, Thompson JD, eds.), Lippincott-Raven, Philadelphia, 1997.
33. Webb MJ, Aronson MP, Ferguson LK, Lee RA. Posthysterectomy vaginal vault prolapse: primary repair in 693 patients. *Obstet Gynecol* 1998;92:281–285.
34. Benson JT, Lucente V, McClellan E. Vaginal versus abdominal reconstructive surgery for the treatment of pelvic support defects: a prospective randomized study with long-term outcome evaluation. *Am J Obstet Gynecol* 1996;175:1418–1421; discussion 1421–1422.
35. Maher CF, Qatawneh AM, Dwyer PL, Carey MP, Cornish A, Schluter PJ. Abdominal sacral colpopexy or vaginal sacrospinous colpopexy for vaginal vault prolapse: a prospective randomized study. *Am J Obstet Gynecol* 2004;190:20–26.
36. Podratz LK, Ferguson VR, Lee RA, Symmonds RE. Abdominal sacral colpopexy for posthysterectomy vaginal vault descensus. *Obstet Gynecol* 1995;50:719–720.
37. Ostrzenski A. Laparoscopic colposuspension for total vaginal prolapse. *Int J Gynaecol Obstet* 1996;55:147–152.
38. Cosson M, Rajabally R, Bogaert E, Querleu D, Crepin G. Laparoscopic sacrocolpopexy, hysterectomy, and Burch colposuspension: feasibility and short-term complications of 77 procedures. *J Soc Laparoendosc Surg* 2002;6:115–119.
39. Elliott DS, Frank I, DiMarco DS, Chow GK. Gynecological use of robotically assisted laparoscopy: sacrocolpopexy for the treatment of high-grade vaginal vault prolapse. *Am J Surg* 2004;188(suppl):52S–56S.
40. DiMarco DS, Chow GK, Gettman MT, Elliott DS. Robotic-assisted laparoscopic sacrocolpopexy for treatment of vaginal vault prolapse. *Urology* 2004;63:373–376.
41. Bump RC, Norton PA. Epidemiology and natural history of pelvic floor dysfunction. *Obstet Gynecol Clin North Am* 1998;25:723–746.



---

# 22

## Evaluation and Management of Vesicovaginal Fistulas

---

*Matthew P. Rutman, MD, Donna Y. Deng, MD,  
and Larissa V. Rodríguez, MD*

### CONTENTS

INTRODUCTION  
ETIOLOGY  
PREVENTION  
DIAGNOSIS  
CONSERVATIVE MANAGEMENT  
OPERATIVE MANAGEMENT  
COMPLEX FISTULAS  
TISSUE INTERPOSITION  
INTRAOPERATIVE COMPLICATIONS  
POSTOPERATIVE MANAGEMENT (TRANSVAGINAL REPAIR)  
OUTCOMES  
POSTOPERATIVE COMPLICATIONS  
CONCLUSION  
REFERENCES

---

### INTRODUCTION

A vesicovaginal fistula (VVF) is an abnormal communication between the bladder and vagina, resulting in continuous leakage of urine through the vagina. It is one of the most significant and devastating conditions in female urology and urogynecology. VVFs have been recognized and described since ancient times, but successful repair was not reported until James Marion Sims' first paper in 1852 (1). His transvaginal repair included the use of silver wire sutures. Many principles he originally described are still applicable. Subsequent advances included the first "layered" repair by Mackenrodt (2) and the interposed labial fat graft of Martius (3) in the late 1920s.

The most common cause of VVF in developing countries remains obstetric trauma. Prolonged and obstructed labor leads the fetal head to cause pressure necrosis of the anterior vaginal wall and the underlying bladder neck and urethra, resulting in a large area of tissue damage. This is in stark contrast to developed countries, where the large majority of fistulas are the result of complications of gynecological and other pelvic surgery. Regardless of the cause, surgical repair remains the gold standard and primary treatment of VVF. This chapter focuses on VVF secondary to causes other than obstetric trauma.

## ETIOLOGY

In the United States and other industrialized nations, VVFs occur as a result of surgical trauma, with the most common cause laparoscopic, abdominal, or vaginal hysterectomy. Inadvertent suture placement into the bladder during vaginal cuff closure results in tissue necrosis and subsequent fistula formation. Excessive blunt dissection of the bladder can result in ischemia or an unrecognized tear in the posterior bladder wall, with resultant fistula formation. Around 75% of VVFs are reported to occur after hysterectomy for benign disease (4). The overall incidence of VVF after hysterectomy is approx 0.5–1% (5). VVFs have also been documented after sling procedures, cystocele repair, colposuspension procedures, and urethral or bladder diverticulectomy. Overall, approx 90% of VVFs in North America are caused by obstetric and gynecologic procedures. Six percent are caused by radiation, and the remaining 4% are caused by one of the following: advanced local malignancy (vaginal, cervical, and endometrial); inflammatory bowel disease; foreign bodies; and infectious processes of the urinary tract (4).

## PREVENTION

Recognizing that the majority of VVFs result as a complication of hysterectomy, it is paramount that the surgeon takes critical steps to prevent their occurrence. Risk factors for fistula development include history of cesarean section, endometriosis, cervical conization, and radiation treatment (6). The bladder is most often injured during the dissection of the posterior bladder wall from the anterior surface of the uterus at the level of the vaginal cuff during an abdominal hysterectomy. Placement of an indwelling Foley catheter and meticulous sharp dissection can diminish inadvertent bladder injury. Iatrogenic injuries can be nearly impossible to avoid with difficult reoperations and the resulting dense adhesions that obliterate surgical planes. This is an accepted risk, but every attempt should be made to diagnose and repair the injury intraoperatively.

Instilling the Foley catheter with methylene blue to check for leakage is a simple but effective way to ensure bladder integrity. If a bladder injury occurs, then it should be repaired with a two-layer closure, and a drain should be placed. An interposition flap should be used in selected cases if there is any doubt about the repair. Discovery and repair of a bladder injury intraoperatively will mandate keeping the bladder drained with a catheter for longer than the usual 1–2 d posthysterectomy.

## DIAGNOSIS

### *Symptoms and Signs*

Typically, patients will present with continuous urinary drainage (day and night) from the vagina shortly after gynecologic/pelvic surgery. Any patient who presents with urinary incontinence early after pelvic surgery should be evaluated for a VVF. The fistula may manifest itself immediately postoperatively but often becomes clinically apparent days to weeks later. Of patients with a VVF, 10% have an associated ureterovaginal fistula (7). VVFs tend to present earlier than ureterovaginal fistulas. In the early postoperative period, patients may present with fevers, ileus, abdominal pain, hematuria, or lower urinary tract symptoms.

VVFs after prior radiation therapy may present anywhere from 6 mo to 20 yr after treatment (8). Fluid draining from the vagina can be urine, lymph, peritoneal fluid, fallopian tube fluid, or vaginal secretions. Other diagnoses to consider in the differential

include urethrovaginal fistula, ureterovaginal fistula, ectopic ureter, peritoneal fluid drainage, and vaginal cuff infection.

### *Diagnosis*

To confirm that the fluid leaking from the vagina is urine, it can be sent for creatinine level. Elevated levels of creatinine, relative to serum, will confirm a fistula between the urinary tract and the vagina. Physical examination remains the most critical element in the evaluation of a woman with a suspected fistula. The depth, diameter, mobility, and mucosa of the vagina must be evaluated. In addition, concomitant prolapse, urethral hypermobility, and incontinence should be assessed. Vaginal examination with two half speculums can assist in isolating the point of leakage. After hysterectomy, VVF are most commonly found at the level of the vaginal cuff. Pooling of urine at the vaginal apex and in the fornices can often be visualized. The neighboring vaginal mucosa may appear erythematous and edematous, making it difficult to identify the opening. Placing a Foley catheter into the bladder can assist if the balloon is seen.

If all of these measures fail to identify a fistula, then dye tests are performed for confirmation. Methylene blue can be instilled through the Foley catheter and the vagina inspected for leakage of blue fluid. Having the patient ambulate with a vaginal pack in place will often stain the packing. If this does not confirm the diagnosis, then the patient should be given oral phenazopyridine, which stains the urine orange. The vagina is then packed, and orange staining confirms a fistula. A positive phenazopyridine test with a negative methylene blue instillation strongly suggests a ureterovaginal fistula.

Patients with a urinary fistula should undergo cystoscopy and an upper tract evaluation. Cystoscopy typically identifies the size and location of the fistula and its relationship to the ureteral orifices. It is important to ascertain adequate bladder capacity and rule out foreign body as the source of the fistula. Careful surveillance for multiple fistulas is imperative. For patients with a radiation- or malignancy-associated fistula, biopsy of the site is mandatory prior to repair. Upper tract evaluation can be done with intravenous pyelography, retrograde pyelography, or computed tomography. Although the ipsilateral kidney can appear normal with prompt drainage, ureteral involvement can be demonstrated by hydronephrosis or extravasation on intravenous pyelography. Retrograde pyelography remains the most sensitive test to evaluate for ureteral involvement in the presence or absence of a VVF. Voiding cystourethrogram helps to identify the presence and location of a fistula and should be performed in all patients. Coexisting vesicoureteral reflux, urethral diverticulum, stress incontinence, or cystocele can be identified, which may alter the surgical plan. Furthermore, voiding cystourethrogram can help elucidate fistulas involving the rectum or uterus. Finally, vaginoscopy can assist in identifying the vaginal communication.

## CONSERVATIVE MANAGEMENT

Small VVFs may close spontaneously with continuous Foley catheter drainage in up to 10% of cases. By the time patients have sought consultation with a specialist, this has usually been attempted. Three weeks of drainage is a reasonable option if the fistula is discovered early in the postoperative period. Antibiotic therapy and estrogen replacement may assist with spontaneous closure. Surgical repair must be considered if this measure fails. Mature fistula tracts are unlikely to resolve with this technique.

Another conservative treatment option includes fulgurating the lining of the fistula tract. However, this should not be attempted with large fistulous tracts. In fistulas less than 3 mm, Stovsky et al. reported closure in 11 of 17 patients with fulguration and 2 wk of catheter drainage (9). Reports have shown success with fibrin therapy to treat small VVFs (10). Most conservative measures ultimately fail in the attempt to cure VVFs. Formal surgical repair remains the gold standard. For larger, complex, and radiation-induced fistulas, there is little role for conservative treatment.

## OPERATIVE MANAGEMENT

### *Preoperative Considerations*

Prior to formal repair of a VVF, multiple factors must be considered to optimize the chances of a successful first repair. Historically, most authors advocated waiting 3–6 mo prior to surgical repair to allow the fistula to mature completely (11,12). This allowed a maximal healing period during the posthysterectomy inflammatory stage. Women with VVFs experience enormous social, physical, and psychological stress, hindering their quality of life. Many contemporary authors have reported excellent results with early repair, avoiding the great patient distress throughout the waiting period (13,14).

Early transvaginal repair is typically performed 2–3 wk after the time of injury. This early repair is most commonly performed in women who develop fistulas after abdominal hysterectomy. Because of the distressing nature of VVF, we advocate early repair in the large majority of patients. Patients with pelvic abscesses or vaginal cuff infections are not early repair candidates and must be treated with long-term antibiotics prior to any attempt. In addition, patients with prior failed repairs and radiation-associated fistulas are not candidates for early intervention and should wait several months prior to formal repair.

The most appropriate approach to surgical repair of VVF is the one most familiar to the individual surgeon. Utilizing an abdominal, vaginal, or laparoscopic approach will depend on the surgeon's training, experience, and comfort level. Regardless of the approach, the highest success rates are associated with the first operation. Classically, the location of the fistula dictated the surgical approach. Supratrigonal fistulas were repaired transabdominally, and infratrigonal and bladder neck fistulas were repaired vaginally. Good surgical technique with tissue interposition allows even complex high VVFs to be repaired with a transvaginal approach.

The main advantage of the abdominal approach is the ability to perform simultaneous procedures for coexisting intraabdominal pathology. These include ureteral reimplantation, augmentation cystoplasty, and repair of bowel fistulas. The vaginal approach avoids the morbidity of an abdominal incision with possible bladder bivalving. It is associated with a shorter hospital stay and quicker patient convalescence. We prefer the transvaginal approach for the overwhelming majority of VVFs. This approach is the major focus of the chapter.

Many principles are integral in fistula repair regardless of the approach. Excellent exposure with watertight, tension-free closure utilizing multiple, nonoverlapping suture lines provides an approx 90% chance of cure on the first attempt. Continuous catheter drainage postoperatively is mandatory. If any question exists concerning integrity of the repair, then interpositional grafts augment the chance for cure.

Outpatient preoperative antibiotics clear any associated infection and provide a sterile environment for repair. Routine urine culture should document absence of infection

prior to surgery. Estrogen-containing vaginal cream is used in the postmenopausal or posthysterectomy patient to improve the quality of the vaginal tissues. Broad-spectrum intravenous antibiotics are provided in the preoperative area.

Traditional repair of VVFs included excision of the tract to provide clean and vascular edges, which was thought to increase chances for cure. Raz and associates demonstrated excellent results and no adverse outcomes without excising the fistulous tract (15,16). Excision of the fistula not only enlarges the tract but also potentially causes iatrogenic bleeding, requiring hemostatic measures that may inhibit healing. Excising a fistulous tract located near the ureteral orifices may result in injury to the trigone and ureters and require concomitant ureteral reimplantation.

The surgeon must be familiar with several techniques for interposition of tissue. It is difficult to predict accurately which fistulas will require the additional layer of coverage to avoid a tenuous repair. These grafts are often necessary in large, complex, postradiation, and failed primary repairs.

Preoperative evaluation should identify those patients who have concomitant stress urinary incontinence. The incidence of stress urinary incontinence after VVF repair ranges from 7 to 27% (17–20). Simultaneous sling procedure or bladder neck suspension can be performed to avoid the need for a second procedure. Concomitant repair for stress incontinence has been shown to have no increase in fistula recurrence rate (21). Simultaneous repair obviates the need for a second incontinence procedure and the patient distress of persistent incontinence despite a successful VVF repair.

It is extremely important to consider the sexual function of the patient and ensure preservation of vaginal depth in the sexually active patient. Local estrogen replacement should be used in patients with vaginal atrophy. Patients who are sexually active may require rotational flaps in cases with vaginal stenosis or large fistulas.

### *Transvaginal Operative Technique*

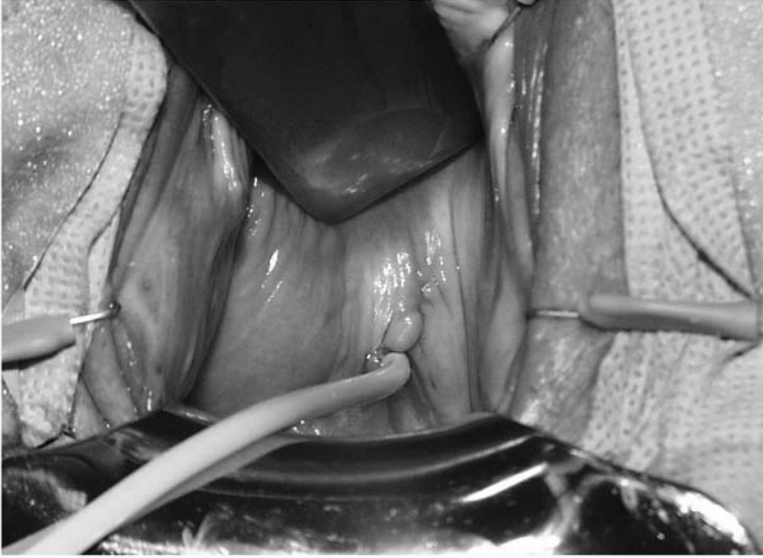We routinely repair VVFs through a vaginal approach and describe the basic technique. This avoids the morbidity of a laparotomy and is performed on an outpatient basis.

#### **STEP 1: PATIENT PREPARATION**

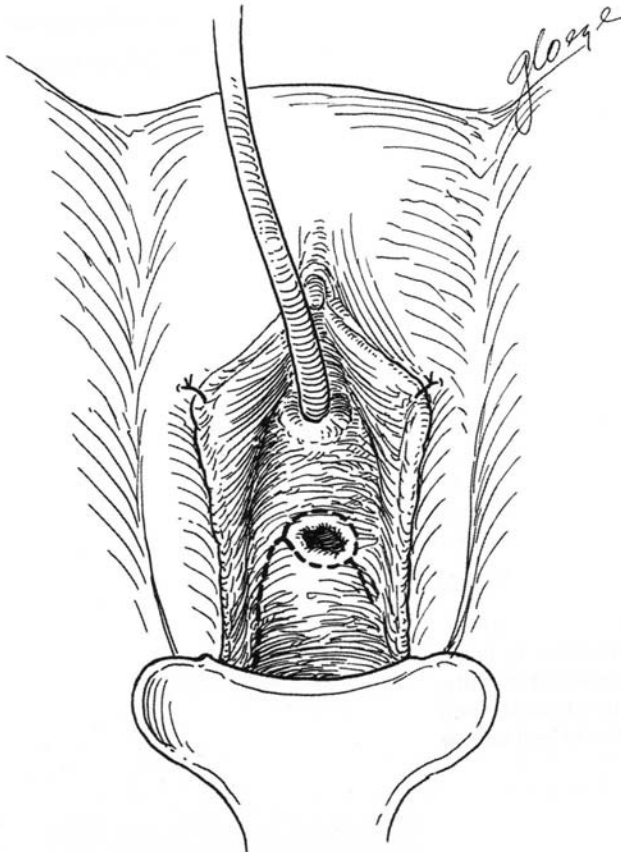
The patient is placed in the low lithotomy position and prepped in standard sterile fashion with an iodine-based wash. The labia are sutured apart and a ring retractor is placed for optimal exposure. Cystoscopy with ureteral catheterization is done when the fistula is located in close to the ureteral orifices. A headlight provides excellent visualization for the primary surgeon. A urethral Foley catheter is placed, and the bladder is filled with normal saline. A curved Lowsley retractor assists in placement of a 16-French suprapubic catheter through a small suprapubic puncture. A relaxing incision (posterolateral episiotomy) may be necessary for vaginal vault exposure in cases with a narrow or stenotic vagina. An Allis clamp is used to elevate the anterior vaginal wall, and a posterior weighted speculum is positioned.

#### **STEP 2: ISOLATION OF FISTULA**

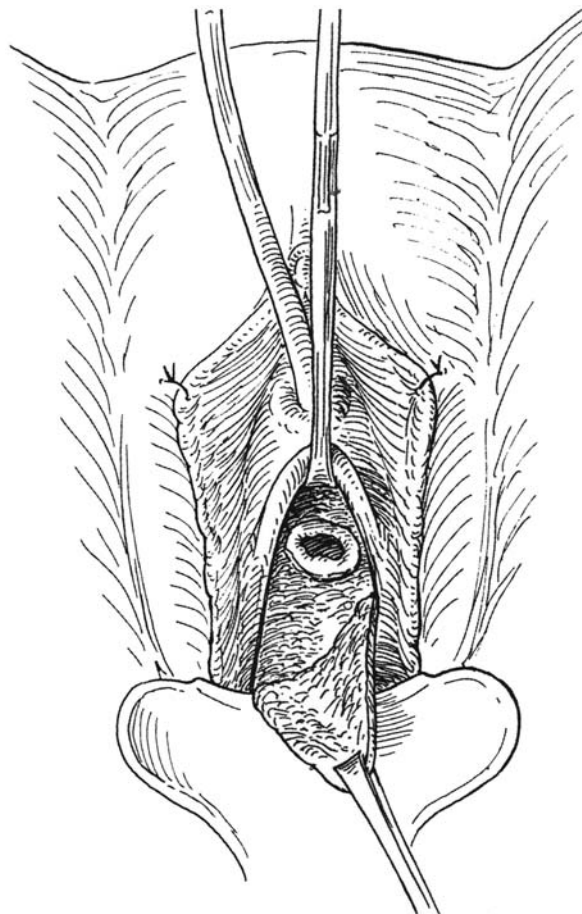
The fistulous tract is identified and catheterized with an 8- or 10-French Foley catheter aiding in retraction throughout flap dissection (Fig. 1). Metal sounds may assist in dilating the tract prior to catheter placement. Intravesical methylene blue may help visualize the tract. An inverted J incision is made, with careful attention paid to circumscribe the fistulous tract (Fig. 2). The long end of the J should extend to the apex of the



**Fig. 1.** Catheterization of fistulous tract.



**Fig. 2.** Inverted J incision around the fistulous tract.



**Fig. 3.** Development of vaginal flaps.

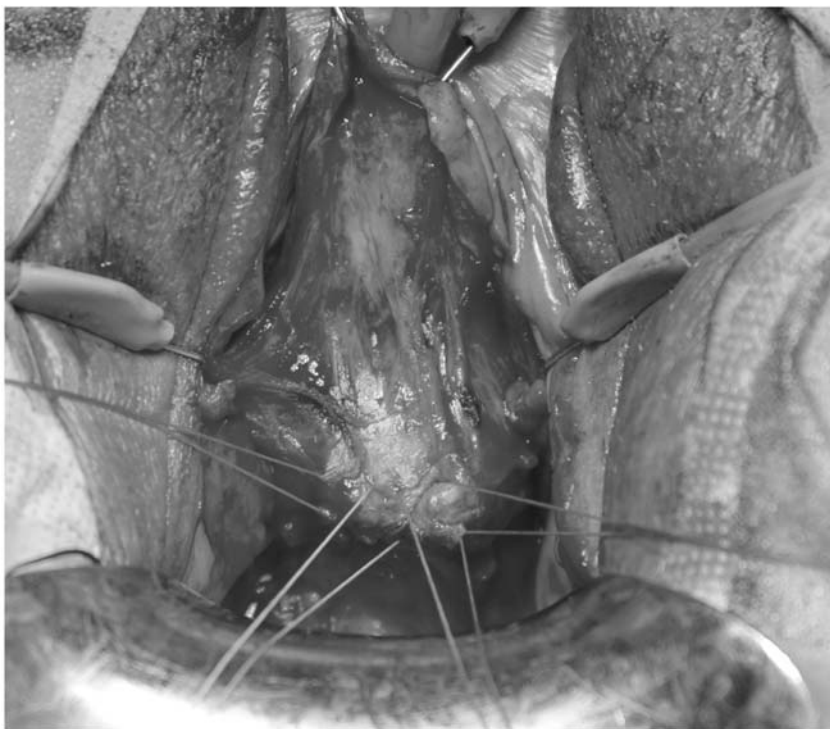vagina, facilitating later advancement and rotation of a posterior flap. Fistulas located high in the vaginal cuff may require an inverted incision, with the base of the flap facing the urethral meatus.

### **STEP 3: CREATION OF FLAPS**

Anterior- and posterior-based vaginal flaps are dissected on each side of the fistulous tract, beginning with healthy tissue away from the opening of the fistula (Fig. 3). This allows a natural plane of dissection and helps prevent enlargement of the fistulous tract or inadvertent bladder perforation. The ring of vaginal tissue circumscribing the fistulous tract is left intact. The flaps are developed at least 2–4 cm away from the fistulous tract to expose the underlying perivesical fascia. The flaps are now retracted with the hooks of the ring retractor.

### **STEP 4: CLOSURE OF FISTULA**

The standard VVF repair is done in three layers. The first layer closes the epithelialized edges of the fistula tract and a few millimeters of the surrounding tissue (including bladder wall) with interrupted 3-0 absorbable sutures (Vicryl) in a transverse fashion (Fig. 4). The



**Fig. 4.** First layer of repair: transverse closure of fistulous tract without excision.

fistula catheter is removed, and the sutures are tied, closing the fistulous tract. The second layer of repair incorporates the perivesical fascia and deep muscular bladder wall using the same suture material (Fig. 5). The sutures are placed at least 1 cm from the prior suture line and secured tension-free, imbricating the first layer. The suture should be placed in a line perpendicular to the first suture layer to minimize overlapping suture lines.

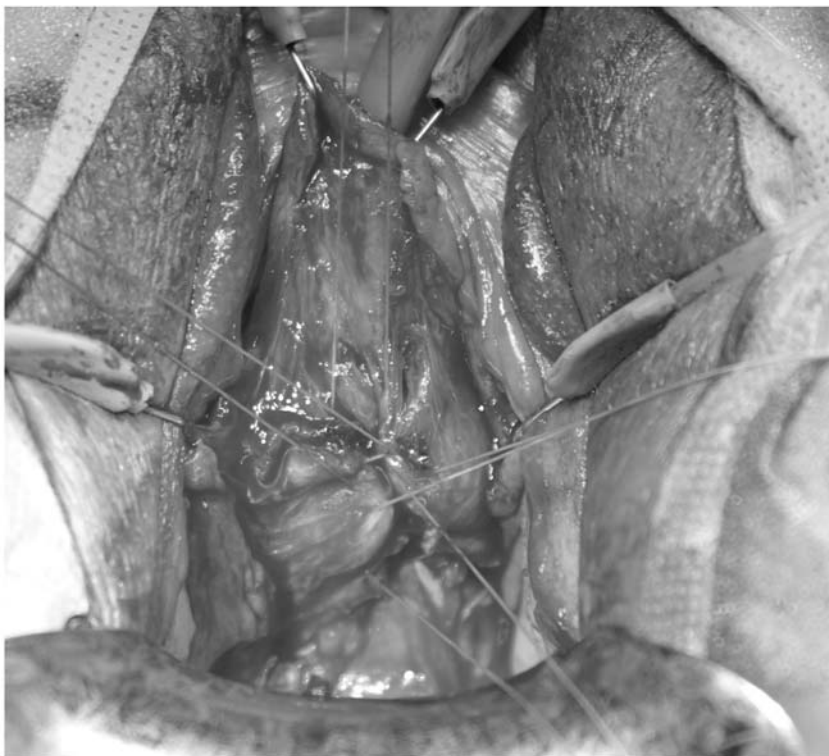The bladder is filled with indigo carmine diluted in saline, and the integrity of the repair is tested. In a standard VVF repair (without tissue interposition), the procedure is now completed. The previously raised posterior flap is rotated beyond the fistula closure site by at least 3 cm (Fig. 6). Excess vaginal flap tissue is excised. The vaginal wall is closed using a running, locking absorbable 2-0 suture (Vicryl) covering the tract with healthy vaginal tissue and providing a third layer of closure with no overlapping suture lines. An antibiotic-impregnated vaginal pack is placed, and the urethral and suprapubic catheters are left to dependent drainage.

The majority of uncomplicated VVFs require a three-layer, tension-free repair. Complicating factors that mandate additional protection include prior radiation, failed prior surgery, and poor tissue quality. These conditions require tissue interposition and are described.

### ***Transabdominal Technique***

In our hands, the abdominal approach is utilized only in select patients requiring concomitant abdominal procedures such as augmentation cystoplasty or ureteral reimplantation. Preoperative bowel preparation is mandatory when bowel augmentation is





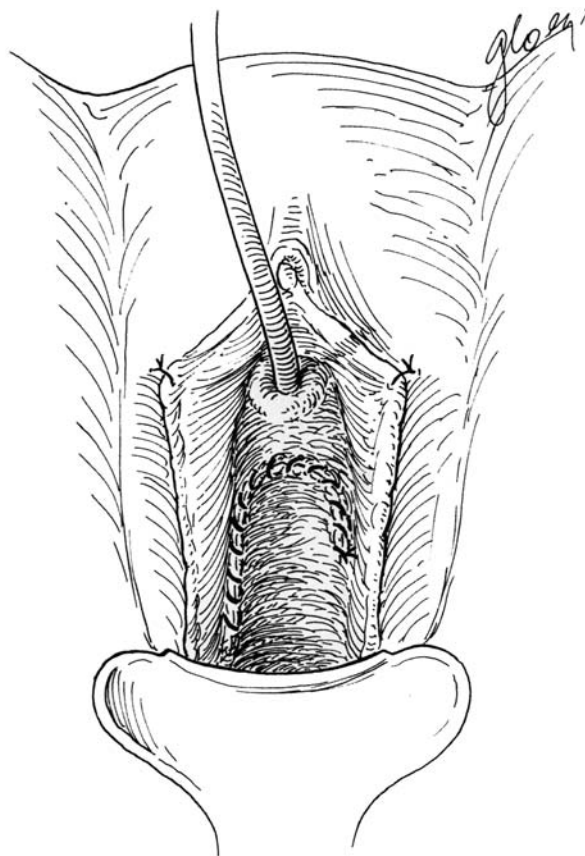
**Fig. 5.** Second layer of repair: imbricate first layer with perivesical fascia.

anticipated. The patient is placed supine with the legs slightly abducted for intraoperative vaginal access. The vagina and lower abdomen are prepped in standard fashion, and a suprapubic tube is placed with a Lowsley retractor. A urethral catheter is placed into the bladder for maximal drainage. A Pfannenstiel or lower midline incision is made, and the space of Retzius is developed. An extraperitoneal approach can be used, although an intraperitoneal approach assists in optimizing exposure and allowing an omental flap to be positioned.

Identification of the fistula may be aided by intravesical instillation of methylene blue. The dome of the bladder is elevated, and dissection is performed between the base of the bladder and vagina toward the fistulous tract. The bladder is dissected free from the vagina with margins of at least 3 cm, and the fistulous tract is identified. The bladder is opened only in the area of the fistula without excising the fistula or bivalving the bladder. The bladder and vaginal defects are each repaired in two layers using interrupted, absorbable suture. Interposition with omentum, perivesical fat, or peritoneum provides an additional layer of coverage. Unless a transvesical approach is taken, there is no need for pelvic drainage. The abdominal wound is then closed, and the suprapubic and urethral catheters are left to dependent drainage.

### ***Other Techniques***

Other authors advocate the O'Connor technique, a transvesical approach with bivalving of the bladder (11). An anterior cystostomy is made in the sagittal plane and extended posteriorly to the fistula. The bladder is mobilized completely from the vagina, and



**Fig. 6.** Third layer of repair: vaginal flap advancement.

the fistula is excised. The openings in the bladder and vagina are closed separately in two layers with interrupted 2-0 absorbable suture. An omental flap is placed between the vagina and bladder, and the wound is closed. Reported success rates range from 87 to 100% (22–24).

The Latzko operation, described in 1942, uses a partial colpocleisis to treat VVFs (25). The operation consists of denuding of the surrounding vaginal wall and preservation of the fistulous tract. A separate layered closure is then performed, including the bladder, VVF, and vagina. A theorized drawback to this procedure is vaginal shortening. However, success rates of 93 and 95% have been reported in two series of 43 and 20 patients, respectively, with no significant patient-reported sexual dysfunction or vaginal shortening (26,27). The technique is still commonly performed by gynecologists today because of its technical ease and minimal morbidity.

Transurethral suture cystorrhaphy with fistula tract preservation has been described as a minimally invasive alternative for smaller fistula (5–8 mm) located away from the ureteral orifices. The technique requires fulguration of the tract and surrounding bladder mucosa. This is followed by combined transurethral/abdominal endoscopic suture placement. A minimum 2- to 3-wk period of bladder drainage is necessary. Eight of 11 patients (73%) treated with this technique were cured (28).

VVF repair has been described laparoscopically with the explosion of minimally invasive surgery (29). The approach was first described in 1994 and has undergone

various modifications, including use of an endostapler, omental interposition, as well as layered closure (30). Robotic-assisted laparoscopic repair has also been successfully performed (31).

## COMPLEX FISTULAS

Complex VVFs include those associated with prior radiation or malignancy, recurrent fistulas, large (greater than 2 cm) fistulas, fistulas involving the trigone and bladder neck, and those associated with poor tissue quality (ischemia or hormone deficiency) or difficult closure. These cases mandate additional steps to the standard transvaginal VVF repair. Multiple techniques of tissue interposition exist; all provide an additional layer of closure and enhance the quality of the fistula repair.

### *Radiation Fistulas*

Radiation-induced VVFs require special consideration. The fistulous tract typically forms in the trigone region because it is in a relatively fixed position, and radiation effects are more likely to occur. Radiation fistulas have been reported in 1–5% of patients treated for cervical or uterine carcinoma. The fistulas often present in a delayed fashion and can present 15–20 yr later (32). Fistulas occurring after radiation should always be biopsied to rule out recurrence of the primary malignancy.

Radiation-induced fistulas occur secondary to obliterative endarteritis in the irradiated field (32). The microvascular injury compromises healing and affects the tissues surrounding the fistula, complicating an already-difficult repair. Videourodynamics and cystoscopy allow assessment of compliance and bladder capacity. If there is adequate compliance and capacity, then transvaginal repair is performed with certain modifications. Tissue interposition with a Martius graft or omental flap is critical, as is prolonged post-operative catheter drainage. If the bladder has small capacity and poor compliance, then augmentation cystoplasty is required, and an abdominal approach is taken. Careful inspection of the bowel is necessary to ensure usage of a nonirradiated segment. Tissue interposition and prolonged catheter drainage are necessary steps, regardless of the approach, when repairing radiation-induced VVFs.

## TISSUE INTERPOSITION

### *Martius Graft*

The Martius graft (fibrofatty labial flap) was first described in 1928 (3). This technique is commonly used in reconstructive surgery and has great utility in VVF, rectovaginal fistula, urethrovaginal fistula, and urethral reconstruction. It has high reported success rates in complex fistula repair and is a convenient source of interposition in transvaginal vesicovaginal repair (33). We use a Martius flap when the fistula is located high in the urethra and bladder neck region.

The Martius graft is a long band of adipose tissue from the labia majora. It has excellent vascularity and strength (contains end fibers of round ligament). The blood supply is threefold: (1) Branches of the external pudendal artery supply the graft superiorly and anteriorly; (2) obturator branches enter the graft at its lateral border; (3) inferior labial artery and vein supply the graft inferiorly. The graft may be mobilized superiorly or inferiorly depending on the desired location of transfer.

The first two layers of the fistula are closed as described. The vaginal flaps are left intact, and the labial retraction suture is removed. A vertical incision is then made over the labia

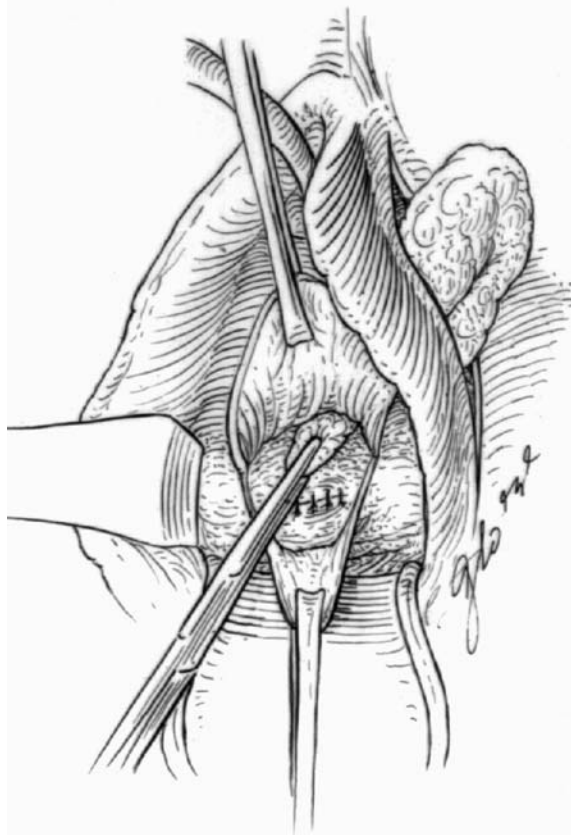


**Fig. 7.** Mobilization of Martius flap based on inferior pedicle.

majora, and the subcutaneous tissues are dissected laterally to the lateral border of the dissection, the labiocrural fold. The flap is dissected posteriorly to Colles fascia and medially to the labia minora/bulbocavernosus muscle. The main vascular supply is at the base, and the entire thickness of the fat pad is encircled by a Penrose drain. The superior and anterior segment of the graft is clamped, transected, and suture ligated. The remaining dissection is completed, and the flap is now freed, except at its base (Fig. 7A). A tunnel is then created between the vaginal wall and the perivaginal tissues. The graft is then passed from the labial area to the vaginal area (through the tunnel) with the aid of a hemostat (Fig. 7B). The Martius graft is placed over the fistula site and secured tension free with interrupted absorbable suture. The posterior vaginal wall flap is advanced and closed as described, providing a fourth layer of closure. A light pressure dressing may be applied, and ice packs are routine. Most series report success rates greater than 90% in fistula repairs with Martius flap (20,34–36). Eilber et al. reported a 97% cure rate with transvaginal repair using Martius graft interposition in 34 patients with complex fistulas (37).

### ***Peritoneal Flap***

We utilize a peritoneal flap in the repair of high fistulas located at the vaginal vault, which are seen most commonly after hysterectomy. Extending a Martius graft to this location may result in inadvertent vaginal shortening. A peritoneal flap is an easily available, well-vascularized tissue and can be harvested without a second incision.



**Fig. 8.** Transfer of Martius flap to cover fistula repair.

The fistula repair begins as described in the first three steps of the transvaginal technique. The fistula is now circumscribed, and vaginal flaps are prepared. A catheter in the fistula can help in dissection of the flap. Sharp dissection is used to expose the peritoneum and preperitoneal fat. The fistulous tract is then closed in two layers as described. The preperitoneal fat and peritoneum are now advanced to cover the fistula repair and secured to the perivesical fascia with tension-free interrupted sutures (Fig. 8). The posterior vaginal flap is then advanced and closed. Raz et al. reported a 91% success rate in their initial experience using a peritoneal flap in 11 patients with VVF (38). Eilber et al. reported a 96% cure rate using a peritoneal flap in 83 patients who underwent complex fistula repair (37). It has high success rates, minimal morbidity, and equal outcomes to a Martius graft without a second incision.

### ***Omental Interposition***

Omental interposition is the preferred source of tissue interposition in the abdominal approach for fistula repair, although it can be accessed transvaginally in women who have had previous procedures. Understanding the blood supply to the omentum is critical. Vascular supply to the omentum is derived from the right gastroepiploic artery (branch off the gastroduodenal artery) and the left gastroepiploic artery (branch off the splenic artery). The right and left omental arteries take origin from their respective gastroepiploic

branches and unite at the inferior aspect of the stomach in a U-shaped fashion. Variably, there is a middle omental artery that bisects the U into two sections. Omental flaps are typically based on the right gastroepiploic artery as it is the dominant supply in the majority of cases.

The omentum can be redundant in certain cases and reaches into the pelvis with minimal or no mobilization. Prior surgery or radiation may affect the mobility and amount of omentum available. If the omentum only requires minimal mobilization, then an L-shaped incision below the transverse colon (based on the right omental artery) may be all that is necessary. Additional length can be obtained by dissecting the omentum off its attachments to the transverse colon. In cases requiring major mobilization, the left short gastric arteries are taken down, the transverse colon attachments are dissected off, and an incision is made down the center of the omentum. Regardless of the harvest technique, the result is an omental graft that can be placed between the bladder and vagina for an additional layer of protection.

### ***Full-Thickness Labial Flap***

In complex cases with loss of vaginal wall, insufficient vaginal epithelium may prevent primary vaginal closure. A full-thickness labial flap can be rotated to substitute for the missing vaginal wall. This provides a well-vascularized fibrofatty layer and full-thickness skin coverage. The fistula is closed as described, and the vascularized flap is rotated to provide full-thickness skin coverage.

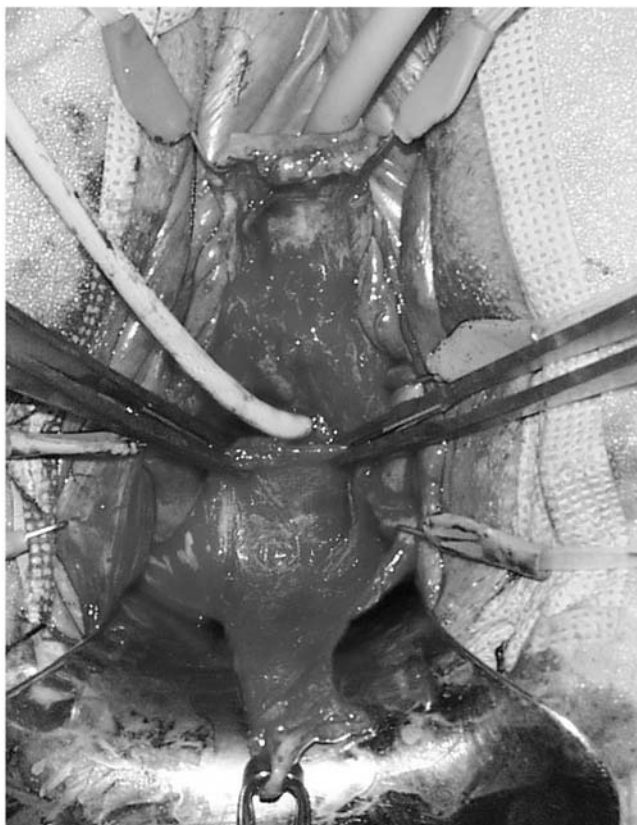After closure of the fistula, a U-shaped incision is made over the labia, including the lateral labial skin and underlying tissue (Fig. 9). The base of the flap is at the level of the posterior fourchette. The flap is dissected from the fascia overlying the pubic bone and then rotated to cover the repair. Interrupted absorbable sutures are used to secure the edges in place (39). Small series have reported excellent results. Carr and Webster reported excellent outcomes in four patients (40). Margolis et al. reported initial 100% success in four patients, with one delayed recurrence (33). Postoperative complications include sensory deficit at the harvest site, poor cosmetic result, wound infection, and flap sloughing.

### ***Gluteal Skin Flap***

Gluteal skin flaps are used mainly in patients with postradiation fistulas or severe vaginal wall atrophy with no other available and viable skin source. The first two layers of the fistula are closed and the vaginal flaps raised as described for uncomplicated VVF repair. A longitudinal incision is made in the vaginal wall toward the midportion of the labia majora. This is then extended in a semicircular fashion in the gluteal skin. The skin is undermined, and the flap is rotated and advanced into the vaginal canal to cover the fistula repair. The flap is secured with interrupted, absorbable sutures, and the vaginal flaps are secured to the skin flap edges (41). Complications include wound infection, sloughing of the flap, and injury to the anal sphincter (42). Careful surgical technique is mandatory to avoid the last complication.

### ***Myocutaneous Gracilis Flap***

The gracilis muscle-based myocutaneous flap has been frequently described in association with repair of the postradiation VVF in patients with vaginal atrophy or absence. The gracilis muscle is a long, slender muscle that extends from the inferior



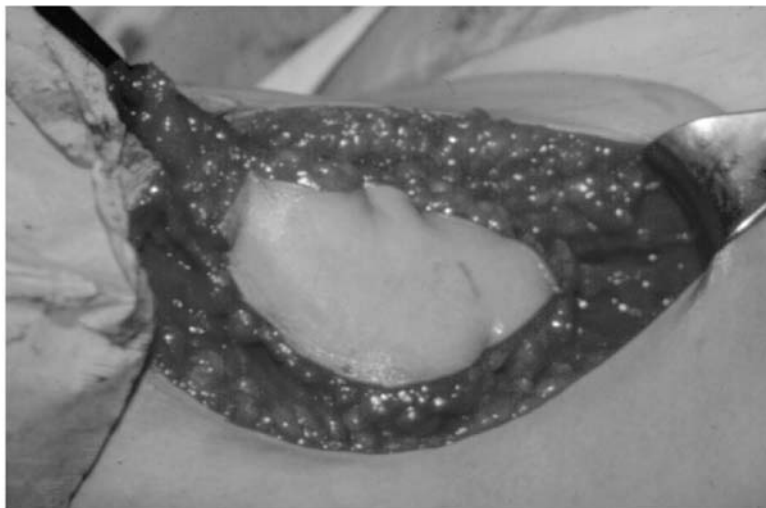
**Fig. 9.** Peritoneal flap advancement.

pubic symphysis to the medial condyle of the femur. It is an accessory muscle used for thigh adduction and knee flexion and can be sacrificed without loss of function. It sits between the adductor longus laterally and the adductor magnus medially. Its blood supply is derived from a branch of the deep femoral artery: the medial femoral circumflex artery.

The flap is harvested with a tennis racquet incision on the medial aspect of the thigh over the gracilis muscle. It begins 10 cm below the pubic tubercle and extends 20 cm toward the knee (Fig. 10). The skin island should not include the distal third of the muscle. The skin and underlying muscle are mobilized, with care taken to preserve the vascular supply. The gracilis is transected at its distal insertion. A tunnel is then created underneath the medial aspect of the thigh and labia, and the flap is transferred to the vaginal area for additional coverage of the fistula tract and reconstruction of the vaginal canal. This can result in considerable cosmetic scarring, but there is no functional defect. No large series exists documenting the gracilis flap, but several authors reported good outcomes in small series (42–44).

### INTRAOPERATIVE COMPLICATIONS

Bleeding and ureteral injury represent the two major potential intraoperative complications. Hemostasis is critical during the vaginal flap dissection. Electrocautery



**Fig. 10.** Gracilis myocutaneous flap.

should be avoided and bleeding controlled with fine absorbable sutures. Anything less than perfect hemostasis can cause hematoma formation and possible disruption of the fistula repair.

Ureteral catheterization is recommended for fistulas close to the trigone because of the higher risk of iatrogenic ureteral injury. Fistulas located elsewhere do not require this maneuver. If there is any concern about ureteral injury, then perform cystoscopy after intravenous indigo carmine is administered to ensure integrity. Ureteral catheterization can be performed if any doubt exists.

### POSTOPERATIVE MANAGEMENT (TRANSVAGINAL REPAIR)

Postoperatively, the vagina is packed with an antibiotic-impregnated gauze that is left for several hours. Surgery for transvaginal repair is performed on an outpatient basis. The suprapubic and Foley catheters (joined to a Y connector) are left to dependent drainage for a minimum of 2–3 wk. Anticholinergics are given to minimize bladder spasm and augment patient comfort. An oral quinolone or cephalosporin is continued for 1 wk. Patients are instructed to resume normal activity except for strenuous exercise. In addition, sexual intercourse is prohibited for 12 wk. The urethral catheter is removed 2–3 wk after surgery, and a suprapubic cystogram is performed. If the cystogram demonstrates no extravasation, then the suprapubic catheter is removed.

### OUTCOMES

Many factors must be considered when assessing patient outcomes. Cure rate, morbidity, and patient satisfaction are critical factors in determining patient success and the ideal approach. There have been no prospective, randomized studies comparing vaginal and abdominal approaches in VVF repair. Future efforts should address these critical factors missing in the reported literature. Many series have shown success rates of 90–100% with both approaches (15,45–47). The best approach remains the one with which the surgeon has the most technical expertise and experience.



## POSTOPERATIVE COMPLICATIONS

Early postoperative complications include vaginal bleeding, bladder spasms, and vaginal infection. These must be treated immediately and aggressively to avoid fistula recurrence. Secondary vaginal bleeding is treated with repacking and bed rest. Anticholinergics should minimize bladder spasms. B and O suppositories can be used if required. Ileus after abdominal approaches is not uncommon. Perioperative antibiotics continued in the postoperative period are important in preventing vaginal infections.

The most important delayed complication is fistula recurrence. Others include vaginal shortening and stenosis and unrecognized ureteral injury. Tension-free, multilayer closure with tissue interposition as needed results in a greater than 95% success rate. Fistula recurrence does not mandate an abdominal approach. A second vaginal repair may be performed with a Martius graft or peritoneal flap. A 3-mo waiting period after prior repair allows for resolution of postoperative inflammation. Care must be taken to minimize excess resection of the vaginal wall and avoid significant shortening and stenosis. In these cases, secondary vaginoplasty is required. Unrecognized ureteral injury typically presents as an obstruction, not a leak. An antegrade approach with percutaneous nephrostomy is preferred. A retrograde procedure via a transurethral approach can disrupt the repair and should not be performed.

## CONCLUSION

VVF represents one of the devastating morbidities in the female after gynecologic and pelvic surgery. Transvaginal surgical repair is an outpatient procedure associated with high success rates, minimal morbidity, and quick convalescence times. It remains our preferred method of repair in all but the select few cases requiring concomitant abdominal surgery.

## REFERENCES

1. Sims J. On the treatment of vesico-vaginal fistula. *Am J Med Sci* 1852;23:59.
2. Mackenrodt A. Die operative Heilung grosser Blasencheindenfisteln. *Zentralbl Gynakol* 1894;8:180.
3. Martius H. Uber die Behandlung von Blaseschedienfisteln, insbesondere met Hilfe einer Lappenplastik. *Geburtshilfe Gynakol* 1932;103:22.
4. Lee RA, Symmonds RE, Williams TJ. Current status of genitourinary fistula. *Obstet Gynecol* 1988;72:313–319.
5. Drutz HP, Mainprize TC. Unrecognized small vesicovaginal fistula as a cause of persistent urinary incontinence. *Am J Obstet Gynecol* 1988;158:237–240.
6. Kursh ED, Morse RM, Resnick MI, et al. Prevention of the development of a vesicovaginal fistula. *Surg Gynecol Obstet* 1988;166:409–412.
7. Symmonds RE. Incontinence: vesical and urethral fistulas. *Clin Obstet Gynecol* 1984;27:499–514.
8. Graham J. Vaginal fistulas following radiotherapy. *Surg Gynecol Obstet* 1965;120:1019–1030.
9. Stovsky MD, Ignatoff JM, Blum MD, et al. Use of electrocoagulation in the treatment of vesicovaginal fistulas. *J Urol* 1994;152:1443–1444.
10. Morita T, Tokue A. Successful endoscopic closure of radiation induced vesicovaginal fistula with fibrin glue and bovine collagen. *J Urol* 1999;162:1689.
11. O’Conor VJ Jr. Review of experience with vesicovaginal fistula repair. *J Urol* 1980;123:367–369.
12. Wein AJ, Malloy TR, Carpiniello VL, Greenberg SH, Murphy JJ. Repair of vesicovaginal fistula by a suprapubic transvesical approach. *Surg Gynecol Obstet* 1980;150:57–60.
13. Raz S, L. N, Juma S. Female urology. In: *Campbell’s Urology, 6th ed.* (R. A. Walsh PC, Stamey TA, eds.), Saunders, Philadelphia, 1992, Vol. 3, pp. 2782–2828.
14. Blaivas JG, Heritz DM, Romanzi LJ. Early versus late repair of vesicovaginal fistulas: vaginal and abdominal approaches. *J Urol* 1995;153:1110–1113.

15. Leach GE, Raz S. Vaginal flap technique: a method of transvaginal vesicovaginal fistula repair. In: *Female Urology, 2nd ed.* (Raz S, ed.), Saunders, Philadelphia, 1992, Vol. 1, pp. 372–377, 1992.
16. Zimmern PE, Hadley HR, Staskin D, et al. Genitourinary fistulas: vaginal approach for repair of vesicovaginal fistulas. *Clin Obstet Gynaecol* 1985;12:403–413.
17. Hassim AM, Lucas C. Reduction in the incidence of stress incontinence complicating fistula repair. *Br J Surg* 1974;61:461–465.
18. Lavery DW. Vesico-vaginal fistulae; a report on the vaginal repair of 160 cases. *J Obstet Gynaecol Br Emp* 1955;62:530–539.
19. Gray PH. Obstetric vesicovaginal fistulas. *Am J Obstet Gynecol* 1970;107:898–901.
20. Hilton P. Urodynamic findings in patients with urogenital fistulae. *Br J Urol* 1998;81:539–542.
21. Arrowsmith SD. Genitourinary reconstruction in obstetric fistulas. *J Urol* 1994;152:403–406.
22. Cetin S, Yazicioglu A, Ozgur S, et al. Vesicovaginal fistula repair: a simple suprapubic transvesical approach. *Int Urol Nephrol* 1988;20:265–268.
23. Nesrallah LJ, Srougi M, Gittes RF. The O’Conor technique: the gold standard for supratrigonal vesicovaginal fistula repair. *J Urol* 1999;161:566–568.
24. Motiwala HG, Amlani JC, Desai KD, et al. Transvesical vesicovaginal fistula repair: a revival. *Eur Urol* 1991;19:24–28.
25. Latzko W. Postoperative vesicovaginal fistulas; genesis and therapy. *Am J Surg* 1942;58:211.
26. D’Amico AM, L. K. Latzko repair of vesicovaginal fistula. *J Urol* 1999;161:202.
27. Tancer ML. The post-total hysterectomy (vault) vesicovaginal fistula. *J Urol* 1980;123:839–840.
28. Mckay H. Transurethral suture cystorrhaphy as a minimally invasive alternative. *J Endourol* 2004;18:487.
29. Ou CS, Huang UC, Tsuang M, et al. Laparoscopic repair of vesicovaginal fistula. *J Laparosc Adv Surg Tech A* 2004;14:17–21.
30. Nezhat CH, Nezhat F, Nezhat C, et al. Laparoscopic repair of a vesicovaginal fistula: a case report. *Obstet Gynecol* 1994;83:899–901.
31. Melamud O, Eichel L, Turbow B, et al. Laparoscopic vesicovaginal fistula repair with robotic reconstruction. *Urology* 2005;65:163–166.
32. Perez CA, Grigsby PW, Lockett MA, et al. Radiation therapy morbidity in carcinoma of the uterine cervix: dosimetric and clinical correlation. *Int J Radiat Oncol Biol Phys* 1999;44:855–866.
33. Margolis T, Elkins TE, Seffah J, et al. Full-thickness Martius grafts to preserve vaginal depth as an adjunct in the repair of large obstetric fistulas. *Obstet Gynecol* 1994;84:148–152.
34. Elkins TE, DeLancey JO, McGuire EJ. The use of modified Martius graft as an adjunctive technique in vesicovaginal and rectovaginal fistula repair. *Obstet Gynecol* 1990;75:727–733.
35. Punekar SV, Buch DN, Soni AB, et al. Martius’ labial fat pad interposition and its modification in complex lower urinary fistulae. *J Postgrad Med* 1999;45:69–73.
36. Rangnekar NP, Imdad Ali N, Kaul SA, et al. Role of the martius procedure in the management of urinary-vaginal fistulas. *J Am Coll Surg* 2000;191:259–263.
37. Eilber KS, Kavalier E, Rodriguez LV, et al. Ten-year experience with transvaginal vesicovaginal fistula repair using tissue interposition. *J Urol* 2003;169:1033–1036.
38. Raz S, Bregg KJ, Nitti VW, et al. Transvaginal repair of vesicovaginal fistula using a peritoneal flap. *J Urol* 1993;150:56–59.
39. Raz S. *Atlas of Transvaginal Surgery, 2nd ed.*, Saunders, Philadelphia, 2002.
40. Carr LK, Webster GD. Full-thickness cutaneous martius flaps: a useful technique in female reconstructive urology. *Urology* 1996;48:461–463.
41. Stothers L, C. A, Raz S. Vesicovaginal fistula. In: *Female Urology, 2nd ed* (Raz S, ed.), Saunders, Philadelphia, 1996, Vol. 1, pp. 490–506.
42. Wang Y, Hadley HR. The use of rotated vascularized pedicle flaps for complex transvaginal procedures. *J Urol* 1993;149:590–592.
43. Gerges DG, Mesfen W. [Repair of a complex vesicovaginal fistula using a musculocutaneous flap of the gracilis muscle]. *J Urol (Paris)* 1984;90:491–493.
44. Ingelman-Sundberg A. Surgical treatment of urinary fistulae. *Zentralbl Gynakol* 1978;100:1281.
45. Langkilde N. C, Pless TK, Lundbeck F, et al. Surgical repair of vesicovaginal fistulae—a ten-year retrospective study. *Scand J Urol Nephrol* 1999;33:100–103.
46. Diaz Calleja E, Calatrava Gadea S, Caldentey Garcia M, Moreno Perez F, Lapuerta Torres E, Garcia Victor F. Surgical repair of vesico-vaginal fistulae with abdominal-transvesical approach. Comments on this technique with long-term results. *Arch Esp Urol* 1997;50:55–60.
47. Frohmuller H, H. G. Transvaginal closure of vesicovaginal fistulas. *Urology A* 1998;37:102.

---

# 23

## Female Urethral Diverticula

---

*Erin Gibbons, MD and Wendy W. Leng, MD*

### CONTENTS

INTRODUCTION
ETIOLOGY
CLASSIFICATION
INCIDENCE
PRESENTATION AND EVALUATION
TREATMENT
PATHOLOGY
CONCLUSION
CASE 1
CASE 2
CASE 3
REFERENCES

---

### INTRODUCTION

The first clinical description of a female urethral diverticulum is credited to Dr. John Hey in 1805. In his essay “Of Collections of Pus in the Vagina,” Dr. Hey described the diagnosis and treatment of this entity, which included a transvaginal incision, and packing of the diverticular sac with lint (1). Over the next 150 yr, the medical literature offers scant references pertaining to the topic of female urethral diverticula. However, in 1956, with the advent of a new diagnostic tool in the form of positive pressure urethrography (PPU), the detection and diagnosis of female urethral diverticula demonstrated a predictable dramatic increase (2).

### ETIOLOGY

Since the first reports of a female urethral diverticulum, clinicians have debated whether the condition represented a congenital vs acquired process. In 1890, Routh proposed a pathogenesis mechanism of obstruction and infection within the periurethral glands (3). However, during much of the 20th century, several authors argued that the primary etiology was congenital. Johnson described several possibilities for congenital diverticula, including Gartner’s ducts, fusion of primal folds, primordial cell rests, vaginal wall inclusion cysts, and dilation of the paraurethral glands (4).

It was not until Huffman detailed the fine network of periurethral glands communicating with the urethral lumen that an infectious process for the development of urethral

diverticula was deemed plausible. By combining transverse sections of the urethra with paraffin wax modeling; Huffman was able to demonstrate that the majority of periurethral ducts empty into the middle and distal third of the urethra, with the highest concentration located dorsolaterally. In addition, he demonstrated that inflammation was common within these ducts (5). It is now widely accepted that obstruction of the periurethral glands leads to swelling, pain, infection, and often a palpable urethral mass.

## CLASSIFICATION

Several classification systems over since the mid-20th century have been proposed to better describe the characteristics, location, and treatment of female urethral diverticula. It is important to review the diverticular anatomy to understand these different classifications better.

Urethral diverticula are commonly cystic and communicate with the urethral lumen by an ostium. Typically, the mean diameter of a detected urethral diverticulum sac is 1.5–2.0 cm; the ostium size ranges from 1 to 5 mm (6–8). As Huffman had delineated with his meticulous anatomic characterization of the periurethral glandular system, the highest concentration of periurethral ducts converge at the middle third of the urethra, more specifically, at the posterolateral aspect. Therefore, it is not surprising that the ostial opening of most urethral diverticula are detected within the middle third of the urethra on the posterolateral aspect. The cystic component of the diverticula can take the form of varying shapes: a single sphere, multiloculated, saddle shaped, or near circumferential. In a series of 61 patients, Leach et al. reported that 55 (90%) of urethral diverticula were single spheres (8).

Lang and Davis described the earliest classification system in 1959 (9). This system was based on morphology as evident with the newly described diagnostic technique of PPU. They classified the diverticulum as simple, multiple, or complex. However, no indication of urethral location is included in their categorization. Subsequently, Ginsburg and Genadry proposed a modified classification system based on the location of the diverticula within the proximal, mid-, or distal urethra (10).

A more complex contemporary classification proposed by Leach et al. incorporates several characteristics of the diverticula (8). The acronym LNSC3 is used to describe the following six parameters: location (L) to the distal, mid-, or proximal urethra; number (N) of diverticula as single or multiple; size (S) in centimeters; configuration (C1) as single, loculated, or saddle shaped; communication (C2) of the ostium to the distal, mid-, or proximal urethra; and urinary continence (C3). This system, although too complex for widespread clinical use, does allow for improved comparison of various research study populations.

Another classification system that may prove more helpful to the operative planning is based on the integrity of the periurethral fascia. Leng and McGuire divided their series of 18 patients into true diverticula vs pseudodiverticula. A *true diverticulum* is described as having an intact periurethral fascia with a narrow neck ostium. This is the classically described diverticulum that occurs as a result of obstruction and inflammation. The *pseudodiverticulum*, in contrast, represents a mucosal extrusion through a defect in the periurethral fascia. Typically, this clinical entity is more characteristic of a patient with a history of prior urethral, vaginal, or bladder surgeries (i.e., bladder neck suspension, anterior colporrhaphy, or prior urethral diverticulectomy) in which the periurethral fascial layer had been violated (11).

## INCIDENCE

The diagnosis of female urethral diverticula in the general population is rare. With improvement in diagnostic methods, the incidence has remained between 0.6 and 5%, with the majority of women presenting in the third to fifth decades of life (12,13). Nevertheless, the true prevalence and incidence of the condition remains unknown. In one of the few clinical series of its kind, Andersen in 1967 tried to gauge the incidence of female urethral diverticula within his patient population. He performed PPU on a cohort of 300 consecutive women patients without voiding symptoms and discovered that 3% of these women had asymptomatic urethral diverticula (13). On the other hand, of the collective experience from contemporary case series describing women with long-term voiding symptoms, urethral diverticula have been identified in up to 40% (14).

No specific risk factors have been identified that predispose some women to the development of urethral diverticula. Previously, multiparity and traumatic childbirth were thought to increase the risk of diverticula development. However, in one case series, 31% of the patients were nulliparous (12). With respect to pseudodiverticula, Leng and McGuire found that the defect was clearly related to prior diverticulectomy or urethral/anterior vaginal surgery (11). Although not a risk factor, stress urinary incontinence is commonly diagnosed in combination with urethral diverticula. Several clinical series have reported that between 28 and 60% of patients diagnosed with urethral diverticula also have evidence of concomitant stress urinary incontinence (6,11,14).

## PRESENTATION AND EVALUATION

Much of the difficulty in the diagnosis of female urethral diverticulum stems from the variable clinical presentations. As the case vignettes in this chapter highlight, patients can present with a wide range of fairly common and nonspecific lower urinary tract symptoms. Although the classic textbook description refers to the three Ds (symptoms of dribbling, dyspareunia, and dysuria), more commonly patients present with vague complaints of irritative voiding symptoms. In several studies, the most common voiding symptoms were urinary incontinence (33–60%) and urinary frequency (22–50%). Complaints of recurrent urinary tract infections (33–61%) can occur secondary to urinary stasis in the diverticulum, leading to bacterial cystitis. However, the typical patient with this condition has persistent lower urinary tract symptoms in the absence of documented bladder infection. Pressure from the diverticulum can lead to dyspareunia (5–70%) and ill-defined pelvic pain (5–60%) (14–18).

Not surprisingly, given the difficult nature of diagnosis, we can only speculate regarding the natural history of female urethral diverticula. The available literature would suggest that the duration of symptoms prior to the diagnosis of a urethral diverticulum varies from a few months to several years. Patients have often been treated by several physicians for a range of urologic conditions before definitive diagnosis. In a review of 46 women diagnosed with urethral diverticulum, Romanzi et al. reported that 83% of patients were referred for evaluation of persistent lower urinary tract symptoms. Prior diagnoses included vulvodynia (42%), chronic pelvic pain syndrome (27%), and interstitial cystitis (19%) (15). Thus, more often than we care to admit, such patients are more likely given the diagnoses of despair. This can then set them up for a lifetime of chronic symptom management and poorly defined diagnostic and treatment algorithms rather than a discrete, treatable condition.

A detailed clinical history is paramount in the evaluation for urethral diverticula. As detailed, a history of persistent lower urinary tract symptoms despite adequate treatment for more common urologic conditions should increase suspicion of a potentially undiagnosed urethral diverticulum. In addition, a previous history of surgical procedures for incontinence or urethral reconstruction may indicate a pseudodiverticulum. The physical exam should include a careful inspection and palpation of the urethra to locate a tender mass along its course. In a review by Romanzi et al., 52% of patients had a distinctly palpable mass on exam, and 25% had fluid expressed from the diverticulum into the urethra (15). Although a palpable urethral mass is concerning for a urethral diverticulum, the differential diagnosis must necessarily include ectopic ureterocele, urethrocele, Gartner's duct cysts, and urethral carcinoma.

Along with a careful history and physical exam, several diagnostic studies can be used to aid in the diagnosis and characterization of urethral diverticula. There has been much debate surrounding the most accurate and cost-effective diagnostic modality. Although easy to perform, urethroscopy is no longer preferred for diagnosing urethral diverticula. Urethral folds can make identification of the pinpoint tracts difficult, and anterior vaginal wall pressure will not always milk fluid into the urethral lumen. So, in general, the diagnostic yield of urethroscopy is too low to justify the potential exacerbation of symptoms associated with urethral manipulation by this technique.

Traditionally, the use of voiding cystourethrography (VCUG) has served as the mainstay for diagnosing urethral diverticula. To begin, a scout film should show the inferior pubic rami to ensure that the urethra will be visible. Next, the bladder is filled with 20% iodinated contrast until the patient feels full. In the upright position, the patient is asked to void while fluoroscopy is used to obtain posterolateral, anterior-posterior, and oblique views of the pelvis. Although VCUG is a commonly utilized diagnostic tool in urology, the reported sensitivity of VCUG for detection of urethral diverticula varies widely, from 44 to 95% (17,19).

In 1956, Davis and Cian described the use of a specialized double-balloon catheter for performing PPU (2). The triple-lumen, double-balloon catheter is placed into the bladder, and the first balloon is inflated to 30 mL and seated at the trigone to create a bladder neck seal. The second balloon can either be fixed or sliding, is inflated to 20 mL, and forms another seal at the urethral meatus. Thus, this customized diagnostic catheter allows for isolation of the urethra between the balloons. Using fluoroscopy, contrast is injected through the catheter, flowing out the midurethral port of the catheter to allow urethral distension and, theoretically, filling of any diverticulum cavity. Interestingly, with the advent of double-balloon PPU, Davis and Telinde reported that the subsequent year yielded a dramatically increased diagnosis rate of 50 cases of female urethral diverticula at Johns Hopkins Medical Center. This was clearly a vast increase in annual detection rate considering the fact that in the preceding 50-yr interval at Johns Hopkins Hospital only nine cases of female urethral diverticula had been identified (20).

Traditionally, PPU has been considered difficult to perform compared to VCUG because of leakage around the double balloons, and patient discomfort warranted sedation. However, the instillation of viscous lidocaine in patients with discomfort on prior pelvic exams has been reported to aid in performing PPU, obviating the need for routine patient sedation (17). Several studies have compared PPU with VCUG. In a contemporary series by Jacoby et al., the sensitivity of PPU and VCUG were reported to be 100 and 44%, respectively. The diverticula, which had been undetected with VCUG, were determined to have a relatively small diameter, less than 15 mm (17). Several other

studies have confirmed the increased sensitivity of PPU over VCUG, especially with respect to smaller diverticula (21,22).

Other radiological modalities have been tested for the diagnosis of urethral diverticula. Lee and Keller first described the use of sonography for the identification of urethral diverticula in 1977 (23). Since the 1970s, advancements in sonography with development of higher frequency probes for transvaginal, transperineal, and endourethral approaches have led to better sonographic visualization. Urethral diverticula appear as hypoechoic cavities when compared to surrounding periurethral tissue. Calculi or debris within the diverticula can be identified because of acoustic shadowing. In a prospective study, Siegel et al., using just such a range of diagnostic tools, evaluated 19 patients with urethral symptoms. VCUG was compared with transvaginal, transperineal, or urethral sonography. Although both VCUG and sonography diagnosed 86% of the urethral diverticula, sonography was better able to identify the neck of the diverticula and characterize the extent of the lesion (24). Intraoperative urethral ultrasound has also been used to better identify the size and orientation of lesions even when preoperative VCUG, PPU, and transvaginal ultrasounds were negative (25). Yet, despite these cited theoretical advantages, sonography has not displaced contrast urethrography as the diagnostic test of choice. Sonography remains highly operative dependent, offers a small field of view, and cannot reliably differentiate types of periurethral lesions.

The use of magnetic resonance imaging (MRI) for the evaluation of the female urethra has also increased. Ongoing advancements in MRI technology with external, endorectal, and endovaginal coils have enhanced the sensitivity of MRI in detecting pathology of the female urethra. In a retrospective review of 129 woman with lower urinary tract symptoms, Lorenzo et al. found that endorectal coil MRI was useful in diagnosing and characterizing patients with periurethral fibrosis, urethral diverticula, and periurethral inflammation (26). Regarding female urethral diverticula, both T1- and T2-weighted images are obtained. On T1-weighted images, urethral diverticula have a low signal intensity; however, on contrast-enhanced T1-weighted images, the diverticulum has an increased signal intensity after voiding. Diverticula appear as high-intensity signals on T2-weighted images (27).

Several studies have compared the diagnostic capabilities of MRI, PPU, and VCUG in the detection and characterization of urethral diverticula. Neitlich et al. reviewed the results of 13 patients with clinically suspected urethral diverticula. All patients underwent both PPU and MRI evaluation for urethral diverticulum. After the initial evaluation with PPU, all were reevaluated with an external coil MRI. Of the four patients with MRI-detected and surgically confirmed urethral diverticula, three had been missed with urethrogram imaging (28).

With respect to MRI vs VCUG, Blander et al. retrospectively reviewed a series of 27 women radiographically diagnosed with urethral diverticula. All patients had been evaluated with VCUG and endoluminal MRI. In all cases, endoluminal MRI identified the diverticulum, compared with 23 of 27 cases detected with VCUG. In addition, at time of surgical exploration, the VCUG findings underestimated the size and complexity of the diverticula in 52% of the cases (29).

Similarly, MRI also demonstrates the added capability of defining noncommunicating periurethral cysts, which may cause the same clinical symptomatology. Daneshgari et al. described three clinical cases in which urethral MRI revealed noncommunicating intraurethral wall diverticula. All three patients had long-standing histories of lower urinary tract symptoms, unremarkable urethrography imaging, and prolonged treatments

for presumed interstitial cystitis. In each of these cases, diverticulectomy was successful, and each patient became symptom free postoperatively (30).

With advancements in computed tomographic (CT) imaging and software applications, multidetector CT (MDCT) scanners allow rapid scanning and improved resolution. Reports in the radiologic literature suggest that MDCT scanning in conjunction with instilled cystogram contrast allows far superior urethral imaging than traditional VCUG. The examples of the three-dimensional reformatted images of the urethra taken with this protocol offer superior detailed imaging. Two cases have been reported for which MDCT delineated the ostium of the urethral diverticulum. In both of these cases, preceding conventional VCUG, transvaginal ultrasound, and MRI failed to identify the ostium. Furthermore, intraoperative identification of the ostium correlated with the MDCT findings in both cases (31).

MDCT scanning has also been used for so-called virtual CT urethroscopy. The authors cited a particular example for which conventional VCUG proved unremarkable in a woman with a suspected urethral diverticulum. Comparative MDCT scanning, on the other hand, revealed an impressive horseshoe-shaped diverticulum as well as the location of its ostium (32). Although such state-of-the-art CT imaging of the lower urinary tract is impressive to behold, the future role for this imaging modality is evolving. There are pertinent limitations to consider: (1) The scan is still relatively time consuming; (2) it requires that the patient be able to void in the prone position; and (3) the necessary radiation exposure must be taken into consideration given that most patients are of reproductive age.

## TREATMENT

As discussed, several different classification systems have evolved in efforts to better categorize urethral diverticula. Although the classification systems use different criteria, each is intended to integrate findings from the history and physical exam and imaging modalities to assist in treatment planning. Although surgical excision of the diverticulum is the most common treatment option, there are instances when conservative management is preferred or worthwhile. In particular, a patient with minimal symptoms might choose to try conservative therapy. This essentially entails suppression-dose antibiotics, low-dose anticholinergic agents, and sitz baths. Certainly, there will be occasions when the diverticulum is too small in caliber to allow surgical delineation and excision. Then, diverticulotomy may offer relief, but with the patient's understanding that recurrence is possible. In addition, some have described that dilation of the diverticular orifice, manual decompression after voiding, and packing of the diverticulum can allow for some relief of symptoms without invasive surgery (14).

Several surgical approaches have been developed throughout the years as the awareness of the condition and anatomy of female urethral diverticula grew. Historically, techniques have included incision and drainage with packing of the defect, endoscopic incision, and open marsupialization.

Ellik first described incision and drainage in the 1950s, followed by packing of the cavity with cellulose (Oxycel [BD, Franklin Lakes, NJ] or Gelfoam [Pharmacia, Kalamazoo, MI]), thus leading to obliteration of the cavity by fibrosis (33). However, adequate packing of large, multiloculated diverticula can be difficult, if not unfeasible. Mizrahi and Bitterman described using polytetrafluoroethylene (polytef [Gore-Tex Inc, Flagstaff, AZ]) as a packing agent with demonstration of a normal appearing urethra on urethrography at one year (34).



Although endoscopy has long been used in the diagnosis of urethral diverticula, it can also serve as an intraoperative tool for localizing the ostium of the diverticulum. Lapedes described an endoscopic diverticulotomy useful for immediate drainage of the cavity. A transurethral incision of the diverticular ostium and roof with a curved knife electrode allows for drainage of the diverticular contents into the urethra (35).

In 1970, Spence and Duckett described an open marsupialization technique in which the posterior wall of the urethra is split open from the ostium to the meatus. The wall of the diverticulum is then approximated to the vaginal mucosa with locking chromic sutures. Clearly, this type of meatotomy was only recommended for diverticula in the distal third of the urethra (36). Although in a long-term follow-up by Roehrborn there were no recurrences in all 16 patients, 3 patients did report stress incontinence (37).

The current treatment of choice is complete excision of the urethral diverticulum. Whenever feasible, this approach theoretically reduces the risk of diverticulum recurrence. In fact, historically, as far back as 1890, Routh recommended complete excision and closure of the vaginal mucosa when inflammation and infection were not a concern (3). Some references describe techniques to better identify the boundaries of the diverticular cavity during operative dissection, such as transurethral packing of the cavity, transvaginal placement of a Foley catheter into the diverticulum, and staining of the diverticular walls with methylene blue (38–40).

Rovner and Wein described an innovative surgical technique for the excision of complex, near-circumferential urethral diverticula. They describe urethral transection to allow improved exposure and resection of the dorsal aspect of the diverticular sac. At the conclusion, the urethra is reanastomosed in a primary end-to-end fashion. Alternatively, when extensive dissection leads to a compromised segment of urethral wall with significant surrounding dead space, the urethra can be wrapped with the dorsal surface remnants of the diverticular wall to reinforce the urethral reconstruction (41). Although this does not allow for the ideal complete excision, the authors contended that postoperatively these patients remain relatively asymptomatic. Their article highlights the lack of literature available to guide management for these most complex of female urethral diverticula.

Although a number of technical variations on the operative excision have been described, all essentially adhere to the principles of careful mobilization of periurethral tissue layers, preservation of the periurethral fascial layer, and complete excision of the diverticular sac down to the level of the communicating ostium at the urethra. At the end of the operation, careful attention to reapproximation of the periurethral layers will help prevent development of pseudodiverticula.

In our practice, we begin with either a general or spinal anesthetic and then place the patient in a modified dorsolithotomy position. Rigid cystoscopy is not always necessary at the beginning of the procedure. However, if the diverticulum is not easily identified or if it is decompressed, then a small stent coiled into the diverticulum may aid in the dissection.

After placement of a 16-French urethral Foley catheter, a Lone Star perineal retractor and weighted vaginal speculum are placed to aid operative exposure. We begin with an inverted U incision centered over the bulge of the diverticulum and dissect the vaginal mucosa off the periurethral fascia. Using a transverse incision, the periurethral fascia is incised and sharply dissected from the diverticular sac. As the ostium of the sac is encountered, it is transected at the level of the urethra. Closure of the urethral mucosa is accomplished with a running 4-0 absorbable suture in a vertical direction. A Martius

flap may be placed adjacent to the urethral closure if tissue vascularity is poor or if multiple repairs have previously been performed. Next, the muscularis is reapproximated with 3-0 absorbable sutures. The periurethral fascia is then closed so the suture line is perpendicular to the urethral closure with a 3-0 absorbable suture.

If preoperative urodynamics indicate the coexistence of stress urinary incontinence, then a pubovaginal sling can also be placed at the same setting. There are sufficient reports in the contemporary literature to suggest that concomitant retropubic manipulation to place a pubovaginal sling is not contraindicated in this setting. The vaginal mucosa is then reapproximated using interrupted or a running 2-0 absorbable suture. Meticulous hemostasis is required throughout the closure to avoid the development of a hematoma.

The presence of a pseudodiverticulum may not be discernible until the time of surgery. In such a scenario, urethroscopy under anesthesia reveals a wide-mouthed ostium to the diverticulum sac, thus demonstrating that a sizable defect in the periurethral fascia exists. When a urethral pseudodiverticulum is encountered, the edges of the periurethral fascial defect are identified and carefully dissected away from the diverticular sac. Excision of the sac and closure of the urethra are carried out as described. Closure of the periurethral fascia is dependent on the quality of the fascia and the size of the defect. If the defect is small, then the fascia can be closed primarily with 3-0 absorbable sutures as described. However, with larger defects, autologous or allograft fascia may be used to patch the periurethral fascia. When stress incontinence is demonstrated by preoperative urodynamics, the placement of a concomitant pubovaginal sling serves a dual role: to correct the underlying stress incontinence and to patch the fascial defect (11).

Potential postoperative complications include urethrovaginal fistula development and recurrence of the diverticulum. The true incidence of diverticula recurrence remains unknown. In one effort to assess such complications, Ganabathi et al.'s case series of 56 transvaginal diverticulectomy patients reported complications that included urethrovaginal fistula in 1.7%, recurrent diverticula in 3.5%, and transient early urinary tract infections in 10.7% (19).

## PATHOLOGY

Surgical management of urethral diverticula may be complicated or altered by coexisting pathology, such as calculi or tumors. Urinary stasis and infection facilitate the formation of stones, which can be identified in up to 10% of cases. Wang and Wang reported 7.7% of women undergoing diverticulectomy were found to have calculi within the diverticular cavity (21).

Carcinoma arising from a urethral diverticulum was first reported by Hamilton and Leach in 1951 (42). Unlike primary urethral carcinomas, which are most commonly squamous cell in origin, those arising from a urethral diverticulum are more likely to be either adenocarcinoma or transitional cell carcinoma. In a review of 59 cases of urethral diverticular carcinoma, Clayton et al. reported adenocarcinoma in 56%, transitional cell in 29%, and squamous cell in 15% (43). The most common presenting symptom was urethral bleeding in 51% of patients.

There is no consensus regarding optimal treatment strategies as female urethral carcinoma is such a rare entity. Experience with treatment regimens have spanned the gamut of diverticulectomy alone, radiation alone or after diverticulectomy, anterior

exenteration, and chemotherapy with radiation (44,45). In a review of the collective experience reported in the medical literature, Rajan et al. described the presentation, treatment, and outcomes of 68 cases. Rajan et al. concluded that anterior exenteration with total urethrectomy and wide vaginal wall excision appeared to be more successful than diverticulectomy alone, radiation, or combination therapy (45).

## CONCLUSION

Although still believed to be a rare clinical entity, urethral diverticulum should be suspected in a woman presenting with long-standing irritative voiding symptoms. A detailed history and physical exam, along with appropriated diagnostic studies, can elucidate the diagnosis. With further advancements in imaging technology, the ability to detect urethral diverticula and plan surgical treatment should continue to improve. Prior to surgical management with diverticulectomy, evaluation for concomitant stress urinary incontinence is imperative for successful outcomes. In addition, knowledge of complicating factors and diverticular pathology aids in successful surgical management.

## CASE 1

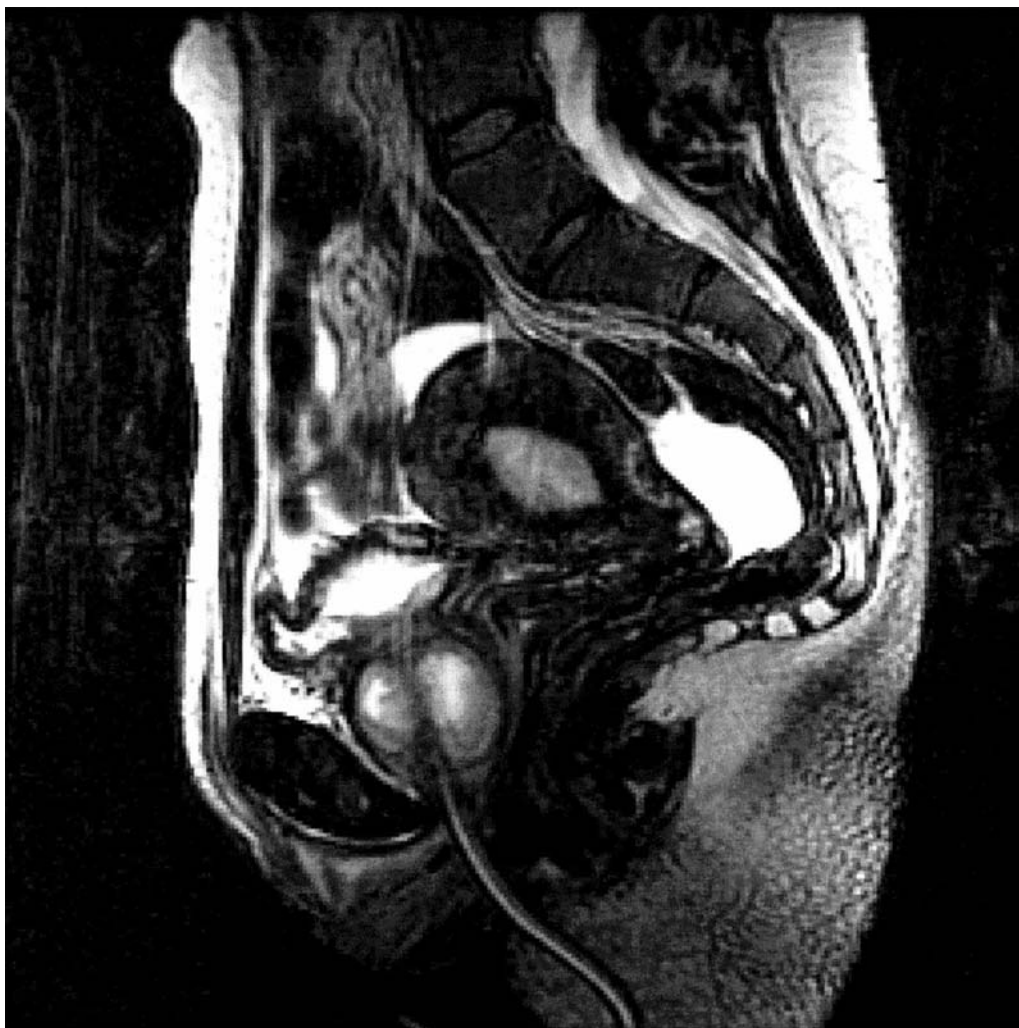U. D., a 28-yr-old African-American woman in otherwise excellent health, described the onset of several days of voiding symptoms, namely, dysuria, frequency, urgency, hesitancy, and weak stream. By the time she presented to her local emergency room, she complained of lower abdominal pain, urgency, and inability to void with significant straining. CT scan of the abdomen and pelvis was notable for a markedly distended bladder and a fluid-filled structure, measuring approx  $3 \times 4$  cm, just below the base of the bladder. A urethral Foley catheter was placed and evacuated a 1000-mL bladder volume.

The patient was then referred for subspecialty urology care at our clinic. With the urethral Foley catheter still in place, a urethral MRI was performed a few weeks later. This demonstrated the same predominantly fluid-filled structure just below bladder neck (*see* Fig. 1), consistent with a large proximal urethral diverticulum. The thick-walled diverticulum was circumferential and measured  $3.7 \times 3.6$  cm. The diverticulum ostium appeared to be located at the left posterolateral aspect. With this anatomic delineation of the urethral diverticulum, we then proceeded with transvaginal urethral diverticulectomy soon afterward. Postoperatively, a pull-out urethrogram demonstrated no evidence of contrast extravasation, and the patient remains asymptomatic.

## CASE 2

N. C. is a 60-yr-old Caucasian woman who presented for evaluation of repeated flare-ups of lower urinary tract symptoms, namely, vaginal pressure, urgency, and dysuria. The patient reported that she was diagnosed with urethral stenosis in the 1970s, for which she had undergone periodic urethral dilations. At that time, evaluation had included unremarkable intravenous pyelography and cystoscopy. Whereas in the past urethral dilations appeared to quell her symptoms, more recent urethral dilations by her local urologist had exacerbated the above-described dysuria, urgency, and nagging sensation of vaginal pressure.

Between symptom flares, the patient described normal voiding patterns without dysuria, incontinence, and postvoid dribbling. She was not sexually active. Her exam demonstrated normal external genitalia. The anterior vaginal wall was well supported



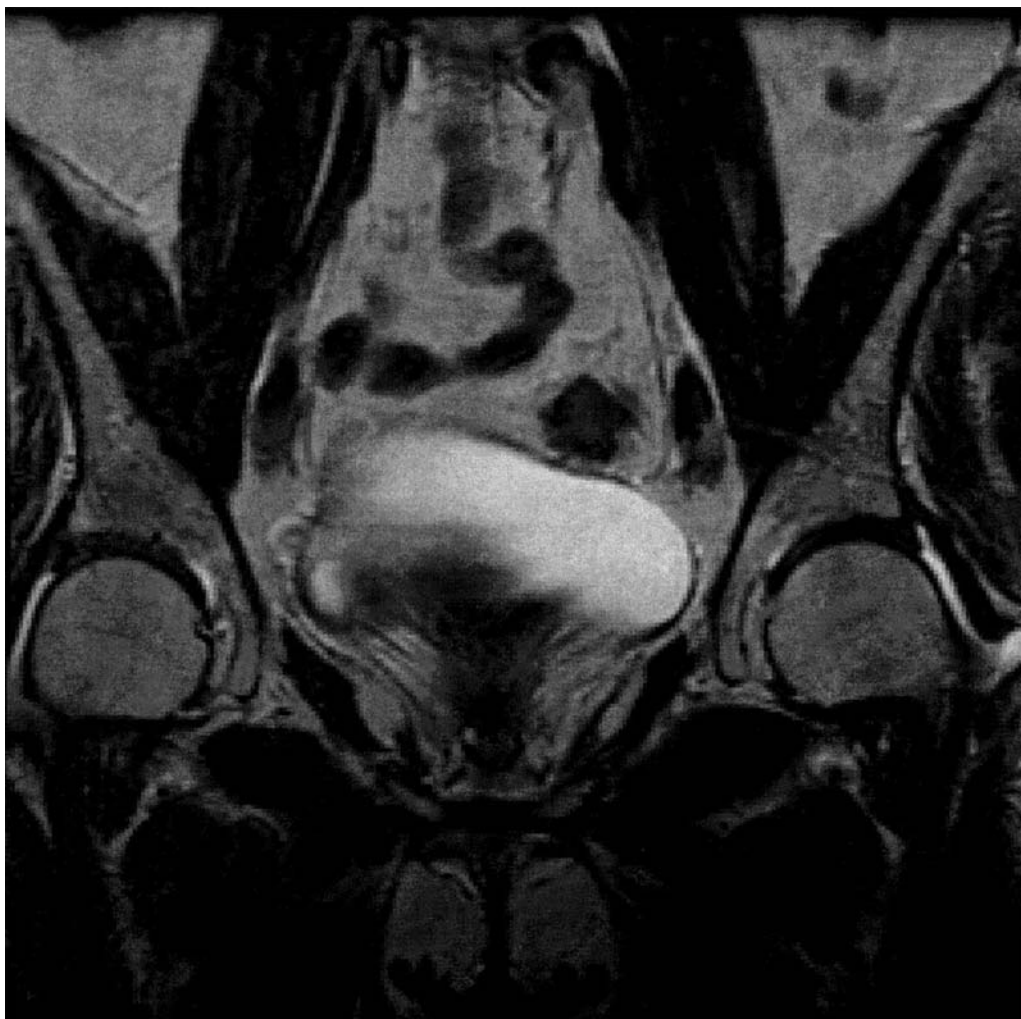**Fig. 1.** Sagittal magnetic resonance imaging shows this large circumferential proximal urethral diverticulum, just below the bladder base, causing urethral obstruction symptoms.

without palpable urethral mass or cystic structure. No discharge was emitted from the urethral meatus during exam.

Although the patient did have a history of sporadic documented urinary tract infections, her urine culture from this evaluation was negative. Office cystoscopy was unremarkable for bladder pathology, urethral stricture, or suggestion of urethral diverticulum. The patient continued to experience waxing and waning lower urinary tract symptoms, mostly nagging urethral pressure, with episodic urgency and frequency of urination. She voiced her frustrations with the unpredictable nature of her symptoms.

At this point, a urethral MRI was ordered (*see* Fig. 2). The MRI demonstrated a small, 2- to 3-mm focus of high signal intensity adjacent to the urethra on T2-weighted images, which appeared consistent with a small urethral diverticulum.

Given the small size of this lesion, surgical excision was not deemed feasible. Conservative management has helped to control the symptoms.

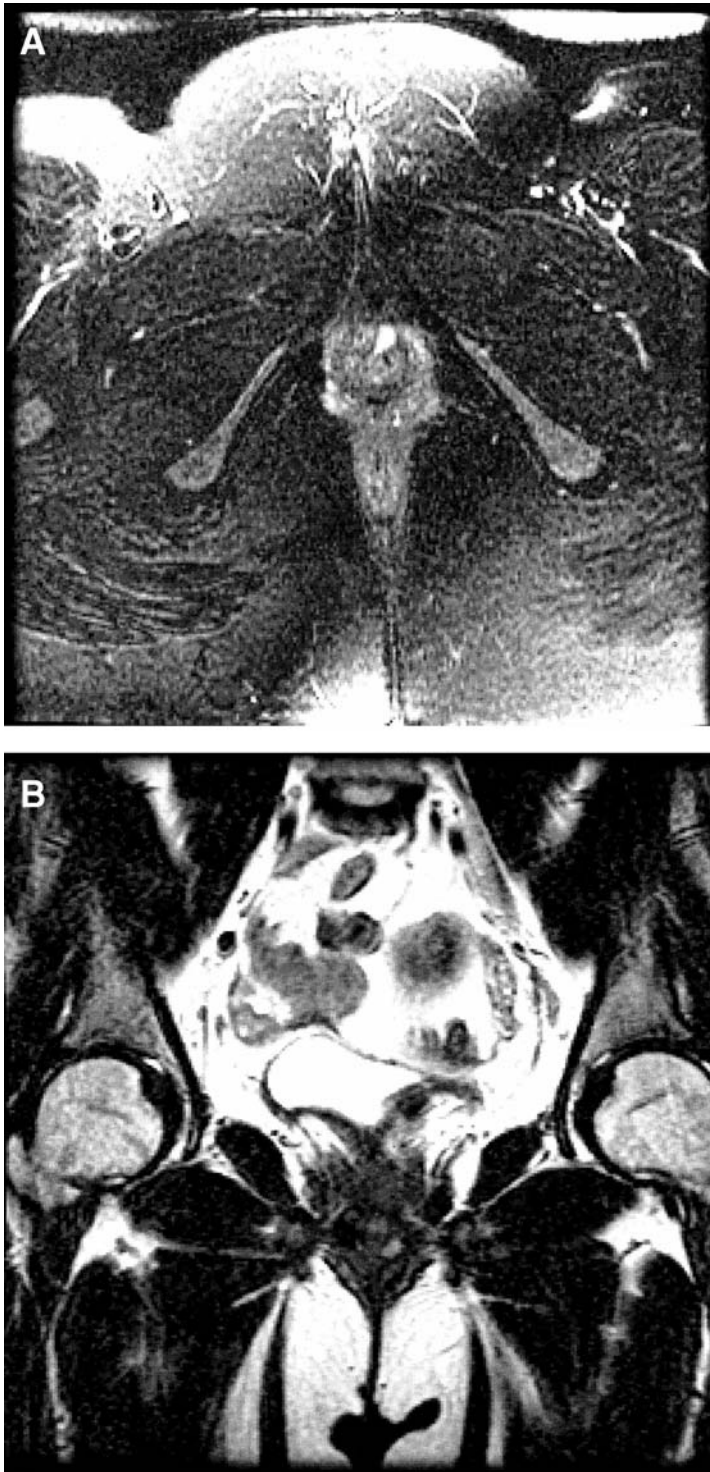


**Fig. 2.** Magnetic resonance image of patient described in Case 2. T2-weighted fast spin echo image in coronal plane shows the small focus of high signal intensity adjacent to the midurethra, consistent with a urethral diverticulum.

### CASE 3

M. X. is a 21-yr-old Caucasian woman with a 2-yr history of lower urinary tract symptoms. She distinctly recalled that her problem began 2 yr ago with the acute onset of vaginal swelling, and a bulge developed. She described intermittent voiding symptoms (urinary hesitancy, intermittency), as well as dysuria, postvoid dribble, and dyspareunia. However, what she initially believed to be a bout of cystitis yielded repeatedly unremarkable urinalyses and cultures. She was seen and treated by a number of specialists for possible interstitial cystitis and possible endometriosis. Despite trials of overactive bladder pharmacotherapy, cystoscopic hydrodistension, and a course of intravesical dimethyl sulfoxide, the patient was no better.

She presented to our subspecialty clinic at the university for consultation. In addition to the above-described lower urinary tract symptoms, the urine dipstick was unremarkable.



**Fig. 3.** (A) Transverse plane; (B) coronal planes. For the patient described in Case 3, two magnetic resonance images reveal the small,  $5 \times 10$  mm midurethral diverticulum just left of the midline axis.

Physical exam revealed a tender urethra with a small cystic mass deviating the meatus. Therefore, a urethral MRI was ordered (*see* Fig. 3). This demonstrated a 5 × 10 mm midurethral diverticulum just left of midline. Given the relatively small size of this lesion, we opted to try conservative management for 4 wk. However, because her symptoms were not much improved, operative urethral diverticulotomy was performed. This offered significant relief of her lower urinary tract symptoms. However, the patient does understand that a symptomatic diverticulum may recur in the future.

## REFERENCES

1. Hey W. *Practical Observations in Surgery*, Humphreys, Philadelphia, 1805, p. 303.
2. Davis HJ, Cian LG. Positive pressure urethrography: a new diagnostic method. *J Urol* 1956; 75:753–757.
3. Routh A. Urethral diverticula. Obstetrical Society of London. *BMJ* 1890;1:361–362.
4. Johnson CM. Diverticula and cysts of the female urethra. *J Urol* 1938;39:506–516.
5. Huffman JW. The detailed anatomy of the paraurethral ducts in the adult human female. *Am J Obstet Gynecol* 1948;55:86–101.
6. Hoffman MJ, Adams WF. Recognition and repair of urethral diverticula: a report of 60 cases. *Am J Obstet Gynecol* 1965;92:106–109.
7. Kim B, Hricak H, Tanagho EA. Diagnosis of urethral diverticula in women. Value of MR imaging. *AJR* 1993;161:809–815.
8. Leach GE, Sirls LT, Ganabathi K, et al. LNSC3: a proposed classification system for female urethral diverticula. *Neurourol Urodyn* 1993;12:523–531.
9. Lang EK, Davis HJ. Positive pressure urethrography: a roentgenographic diagnostic method for urethral diverticula in the female. *Radiology* 1959;108:401–405.
10. Ginsburg D, Genadry R. Suburethral diverticulum: classification and therapeutic considerations. *Obstet Gynecol* 1983;61:685–688.
11. Leng WW, McGuire EJ. Management of female urethral diverticula: a new classification. *J Urol* 1998; 160:1297–1300.
12. Davis BL, Robinson DG. Diverticula of the female urethra: assay of 120 cases. *J Urol* 1970;104:850–853.
13. Andersen FJF. The incidence of diverticula in the female urethra. *J Urol* 1967;98:96–98.
14. Fortunato P, Schettini M, Gallucci M. Diverticula of the female urethra. *BJU* 1997;80:628–632.
15. Romanzi LJ, Groutz A, Blaivas JG. Urethral diverticulum in women: diverse presentations resulting in diagnostic delay and mismanagement. *J Urol* 2000;164:428–433.
16. Gerrard ER, Lloyd LK, Kubricht WS, Kolettis PN. Transvaginal ultrasound for the diagnosis of urethral diverticulum. *J Urol* 2003;169:1395–1397.
17. Jacoby K, Rowbotham RK. Double balloon positive pressure urethrography is a more sensitive test than voiding cystourethrography for diagnosing urethral diverticulum in women. *J Urol* 1999;162:2066–2069.
18. Rufford J, Cardozo L. Urethral diverticula: a diagnostic dilemma. *BJU* 2004;94:1044–1047.
19. Ganabathi K, Leach GE, Zimmern PE, Dmochowski R. Experience with the management of urethral diverticulum in 63 women. *J Urol* 1994;152:1445–1452.
20. Davis HJ, Telinde RW. Urethral diverticula: an assay of 121 cases. *J Urol* 1958;80:34–39.
21. Wang AC, Wang CR. Radiologic diagnosis and surgical treatment of urethral diverticulum in women: a reappraisal of voiding cystourethrography and positive pressure urethrography. *J Reprod Med* 2000; 45:377–382.
22. Golumb J, Leibovitch I, Mor Y, Morag B, Ramon J. Comparison of voiding cystourethrography and double-balloon urethrography in the diagnosis of complex female diverticula. *Eur Radiol* 2003; 13:536–542.
23. Lee TC, Keller FS. Urethral diverticulum: diagnosis by ultrasound. *AJR* 1977;128:691–691.
24. Siegel CL, Middleton WD, Teefey SA, Wainstein MA, McDougall EM, Klutke CG. Sonography of the female urethra. *AJR* 1998;170:1269–1274.
25. Chancellor MB, Liu JB, Rivas DA, Karasick S, Bagley DH, Goldberg BB. Intraoperative endo-luminal ultrasound evaluation of urethral diverticula. *J Urol* 1995;153:72–75.
26. Lorenzo AJ, Zimmern P, Lemack GE, Nurenberg P. Endorectal coil magnetic resonance imaging for diagnosis of urethral and periurethral pathologic findings in women. *Urology* 2003;61:1129–1133.
27. Kim B, Hricak H, Tanagho EA. Diagnosis of urethral diverticula in women: value of MR imaging. *AJR* 1993;161:809–815.

28. Neitlich JD, Foster HE, Glickman MG, Smith RC. Detection of urethral diverticula in women: comparison of a high resolution fast spin echo technique with double balloon urethrography. *J Urol* 1998; 159:408–410.
29. Blander DS, Rovner ES, Schnall MD, et al. Endoluminal magnetic resonance imaging in the evaluation of urethral diverticula in women. *Urology* 2001;57:660–665.
30. Daneshgari F, Zimmern P, Jacomides L. Magnetic resonance imaging detection of symptomatic non-communicating intraurethral wall diverticula in women. *J Urol* 1999;161:1259–1261.
31. Kim SH, Kim SH, Park BK, et al. CT voiding cystourethrography using 16-MDCT for the evaluation of female urethral diverticula: initial experience. *AJR* 2005;184:1594–1596.
32. Chou CP, Huang JS, Yu CC, Pan HB, Huang FD. Urethral diverticulum: diagnosis with virtual CT urethroscopy. *AJR* 2005;184:1889–1890.
33. Ellik M. Diverticulum of the female urethra. A new method of ablation. *J Urol* 1957;77:243–246.
34. Mizrahi S, Bitterman W. Transvaginal, periurethral injection of polytetrafluoroethylene (polytef) in the treatment of urethral diverticula. *Br J Urol* 1988;62:280.
35. Lapidus J. Transurethral treatment of urethral diverticula in women. *J Urol* 1979;121:736–738.
36. Spence HM, Dukett JW. Diverticulum of the female urethra: clinical aspects and presentation of a simple operative technique for cure. *J Urol* 1970;104:432–437.
37. Roehrborn CG. Long term follow-up study of the marsupialization technique for urethral diverticula in women. *Surg Gynecol Obstet* 1988;167:191–196.
38. Hyams JA, Hyams MN. A new operative procedure for the treatment of diverticulum of the female urethra. *J Urol* 1939;43:573–577.
39. Morre TD. Diverticulum of female urethra: an improved technique of surgical excision. *J Urol* 1952; 68:611–616.
40. Gilber C, Cintron F. Urethral diverticula in the female: review of the subject and introduction of a different surgical approach. *Am J Obstet Gynecol* 1954;67:616–627.
41. Rovner ES, Wein AJ. Diagnosis and reconstruction of the dorsal or circumferential urethral diverticulum. *J Urol* 2003;170:82–86.
42. Hamilton JD, Leach WB. Adenocarcinoma in a diverticulum of the female urethra. *Arch Pathol* 1951; 51:90–97.
43. Clayton M, Siami P, Guinan P. Urethral diverticular carcinoma. *Cancer* 1992;70:665–670.
44. Awakura Y, Nonomura M, Itoh N, Maeno A, Fukuyama T. Adenocarcinoma of the female urethral diverticulum treated by multimodality therapy. *Int J Urol* 2003;10:281–283.
45. Rajan N, Tuddi P, Mallouh C, Choudhury M. Carcinoma in female urethral diverticulum: case reports and review of management. *J Urol* 1993;150:1911–1914.



---

# 1

---

## Recurrent Stress Urinary Incontinence

---

A 45-yr-old woman with pure stress urinary incontinence underwent a synthetic midurethral sling. Postoperatively, she continued to have significant incontinence requiring six heavy pads per day. A bulking agent was tried without any improvement. Valsalva leak-point pressure is 38 cm H<sub>2</sub>O. She had minimal urethral mobility.

How would you proceed with management of this patient? Any thoughts on why she may have failed the initial procedures?

### COMMENTARY BY JERRY BLAIVAS, MD

This woman has significant incontinence, as evidenced by saturating six heavy pads a day. She has a low leak-point pressure (38 cm H<sub>2</sub>O), indicative of severe sphincteric incontinence and minimal urethral hypermobility.

First, to dispense with the necessities, treatment of incontinence is elective, and after two failed procedures, the patient might elect to use pads or adopt behavioral techniques specifically designed to improve the incontinence. They may suffice but will not cure the condition.

In our judgment, treatment of persistent stress incontinence depends as much (or more) on the experience and expertise of the surgeon as it does on the underlying pathophysiology of the incontinence. What we recommend is based on our personal experience, not the literature. We do some things better than the literature reports; we do other things worse, so we try to do what we do best.

For patients with little or no urethral hypermobility and low leak-point pressure, we believe that slings work much better than all other procedures. So, we would do another sling, and in our hands, it would be an autologous rectus fascial sling. We harvest the sling through a 6- to 8-cm skin incision just below the pubic hairline. The resulting scar is usually invisible (to all except those who shave their pubic hair).

The sling should be about 2 cm wide and long enough so that both ends are well into the retropubic space (usually about 8 cm). We place the sling at the bladder neck with no tension, and even in a patient like this, we expect to get two fingers between the rectus fascia and the suture, tying the two ends of the sling together over the fascia; we do not try to make the sling tighter than usual just because she has failed two procedures. We test bladder neck mobility by pulling up on the sutures attached to either end of the sling, and if there is restricted mobility, we do a partial (posterior and lateral) urethrolysis. We do not routinely look for or incise the synthetic sling unless it is in the way of the surgery. Of course, cystoscopy and vaginal inspection should be routinely performed; if there is urethral or vaginal erosion, as much as possible of the synthetic sling should be removed.

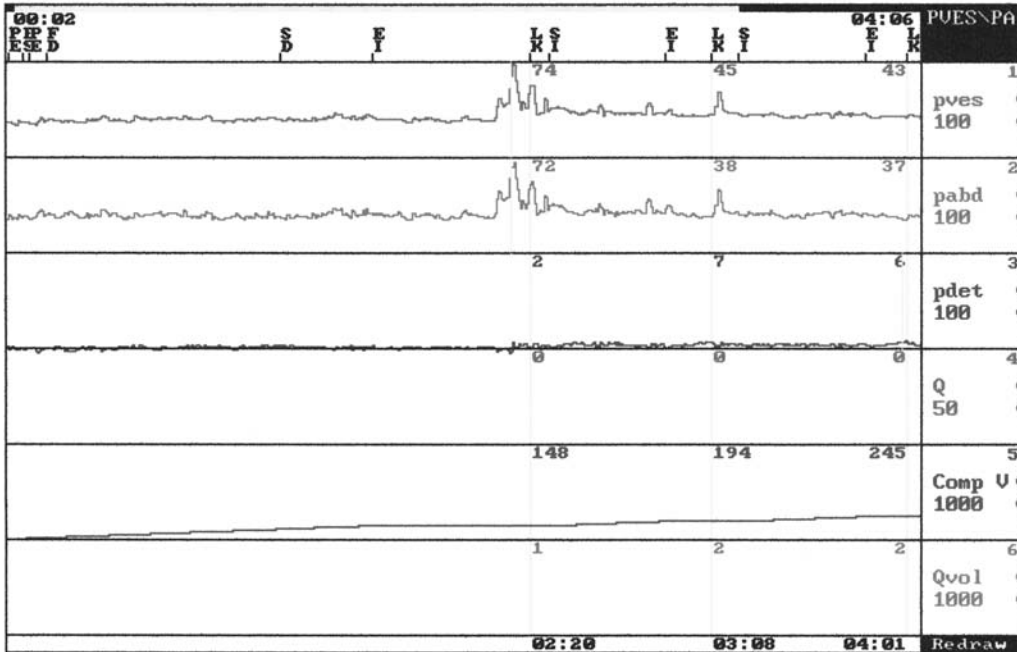


Fig. 1.

Can another synthetic sling be done instead? I suppose so, but not by us.

### SOURCES

- Blaivas JG, Groutz A. Bladder outlet obstruction nomogram for women with lower urinary tract symptomatology. *Neurourol Urodyn* 2000;19:553–554.
- Chaikin DC, Rosenthal J, Blaivas JG. Pubovaginal fascial sling for all types of stress urinary incontinence: long-term analysis. *J Urol* 1998;160:1312–1316.

### EDITOR'S COMMENTS BY HOWARD B. GOLDMAN, MD

There are a number of different ways that treatment for this patient can be approached, but my personal approach would be similar to that of Dr. Blaivas. One has to wonder what degree of mobility and intrinsic sphincteric deficiency this patient had before the original midurethral synthetic sling was placed. There is evidence that the success rates of midurethral synthetic slings decrease with less urethral mobility. On the other hand, there have been some reports showing equivalent outcomes in patients with hypermobility and those without. Whichever side of that debate one wants to take and though it may have been reasonable to try a midurethral sling the first time, probably at this point with significant intrinsic sphincter deficiency and minimal mobility a different procedure would be advised. I believe that an autologous fascial sling remains the gold standard and is what I would do as well in this case.

---

## 2 Recurrent Urinary Tract Infections and Pelvic Organ Prolapse

---

A 65-yr-old woman presents with a history of chronic urinary tract infections (UTIs) for the past 8 mo. As soon as appropriate antibiotics are stopped, she gets another UTI. Antibiotic prophylaxis has not helped. She also notes recent onset of some urge incontinence and straining to void. On exam, she has significant atrophic vaginitis and a cystocele to the introitus with strain. There is a question of some apical prolapse as well. Postvoid residual (PVR) is 180 cc.

How would you evaluate and manage this woman?

### COMMENTARY BY JENNIFER TAKACS, MD AND PHILIPPE ZIMMERN, MD

In the evaluation of this patient, additional information needs to be extrapolated from her history regarding possible mechanisms for her chronic UTIs. Key history items include presence of general risk factors for recurrent UTI, such as diabetes mellitus, immunosuppression, or any apparent neurological conditions that could either affect bladder function and contribute to her PVR or render her more susceptible to a UTI and to its recurrence. Localized risk factors such as a history of prior gynecological or incontinence procedure or both are also important, not only for developing a differential diagnosis, but also for planning surgical intervention.

Because it is common for patients to be vague regarding the nature and extent of a prior pelvic or anti-incontinence procedure, it is best to retrieve the operative notes and review them carefully for undisclosed bladder injuries, types of sutures used (absorbable vs non-absorbable), and possible synthetic material (e.g., polypropylene sling, prior cystocele repair with mesh interposition). In a prospective study to evaluate the presence and association of risk factors in postmenopausal women referred to an infectious disease clinic for evaluation of recurrent UTI and compared to age-matched controls, PVR, reduced urine flow, history of urogynecological procedures, incontinence, and cystocele were associated with recurrent UTIs (1). Finally, in this patient with a large residual, it is also important to inquire about medications that could reduce detrusor contractility such as anticholinergic drugs or antidepressants. Cessation of these medications could improve voiding.

Based on the reported physical examination, we assume that this patient has not undergone prior incontinence or gynecological procedures. If she had such procedures, then location of vaginal scars and degree of urethral mobility would be particularly important to assess. In this patient with prolapse to the introitus with strain, the bulging vaginal wall must be carefully inspected for mucosal ulcerations because such finding may preclude the use of a synthetic mesh for repair. Ulcerations and atrophic vaginal

tissue changes can be improved by topical estrogen replacement therapy prior to surgical repair (2).

Although uncommon, large multiloculated urethral diverticuli or urethral leiomyoma can distort the anterior vaginal wall to the point of mimicking a cystocele. Therefore, palpation for a mass, tenderness, or expression of purulent material is recommended.

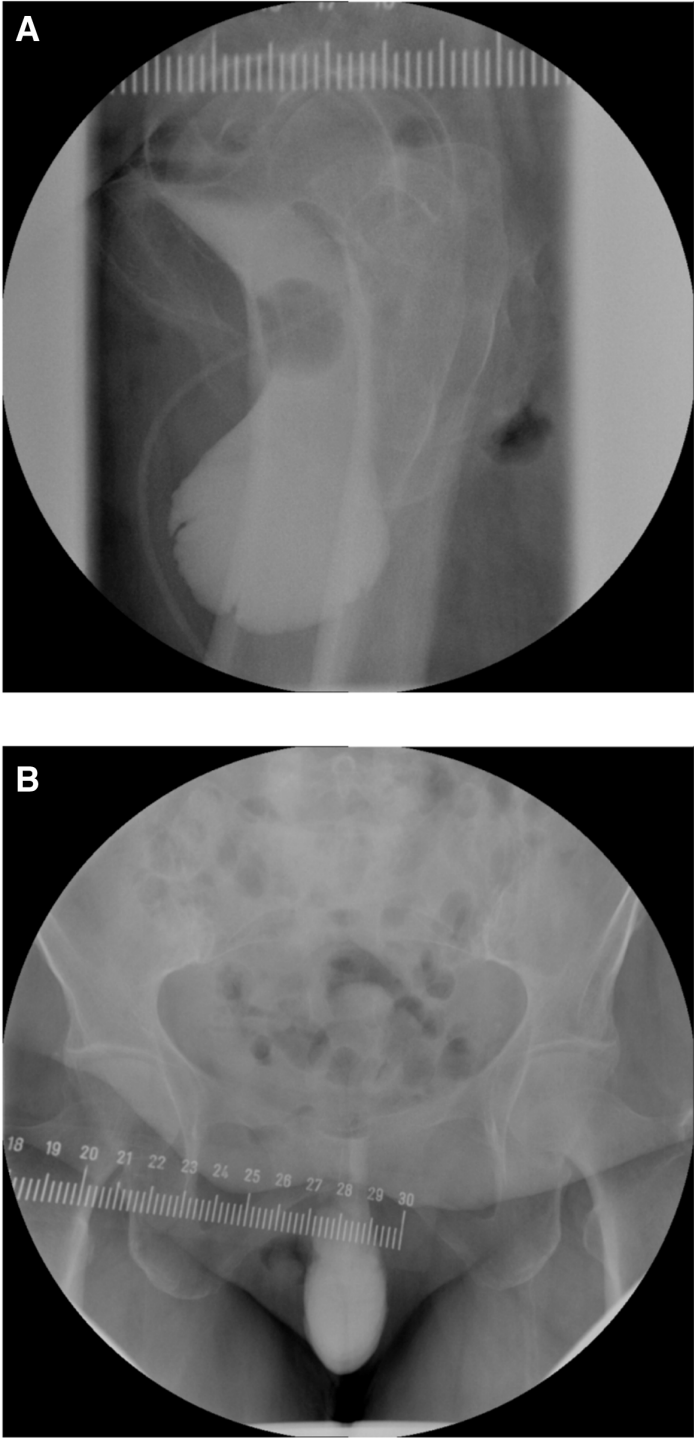
The examination would be completed by Pelvic Organ Prolapse Quantification measurements and possibly using a handheld mirror to allow the patient to visualize her prolapse.

At the initial visit, we would obtain a urine culture and initiate low-dose antibiotic prophylaxis during the coming weeks to prevent another UTI while the patient is undergoing further testing. If atrophic vaginitis was the sole etiology for her recurrent UTIs, then topical estrogens might decrease the number of recurrences (3). However, in this patient with straining to void, a cystocele with apical prolapse, and a large PVR, this would not be sufficient, and further testing is warranted, including a complete urological work-up and a more focused assessment of the prolapse as a possible etiology of this patient's recurrent UTIs.

Routine evaluation of recurrent UTIs includes upper tract imaging (i.e., renal ultrasound or intravenous pyelogram) and lower tract evaluation with cystoscopy. Renal ultrasound will exclude an unsuspected upper tract pathology (tumor, stone) or some element of hydronephrosis. Uni- or bilateral hydronephrosis has been reported with a large (Baden Walker grade 4 or stage IV) cystocele, but its clinical degree here seems insufficient to explain such a finding, therefore continued evaluation to identify the etiology would be recommended. Cystoscopy will evaluate the urethra for inflammatory polyps at the bladder neck or areas of pus or urethritis; specific attention should be paid to identification of a diverticular os or glandular secretions, which may be enhanced by palpation and milking of the anterior vaginal wall. Then, the bladder wall will be inspected for presence of bladder wall trabeculations, tumor, stone, foreign body, or areas of cystitis. Urine cytology may be indicated if carcinoma *in situ* is suspected. Discovery of a bladder calculi or tumor would require standard urological intervention.

Assuming no prior surgery, a normal neurological examination, no general risk factors, and a completely negative urological work-up of the upper and lower urinary tracts, further evaluation of the cystocele as a possible source for these recurrent UTIs would be pursued and could include pelvic ultrasound, standing cystogram (voiding cystourethrography [VCUG]), or a urodynamic study (UDS) with and without prolapse reduction. Pelvic ultrasound is important to evaluate the size, appearance, and position of the uterus and ovaries. This establishes whether there are abnormalities of these organs that could influence the decision and approach to corrective surgery of this cystocele and apical prolapse.

The VCUG may identify reflux, define the bladder contour and degree of trabeculations, and discover a urethral diverticulum on the voiding or postvoid views. In addition, the VCUG will provide objective documentation regarding the degree of bladder prolapse in the standing position, comparing lateral views at rest and with straining and the same for the urethral support. This patient with prolapse to the level of the introitus would likely have a grade II cystocele on VCUG, with a bladder base descent at 2–5 cm below the inferior ramus of the pubic symphysis (4) (Fig. 1). Around 6 mo postoperatively, a repeat VCUG may be helpful to document correction of the cystocele, adequate urethral support, and improved bladder emptying, especially in a woman with continuing UTIs for whom the concern may be that the repair was not successful (5).



**Fig. 1.** Voiding cystourethrography demonstrating a grade 2 cystocele (grade 1: 0–2cm; grade 2: 2–5cm; grade 3: >5 cm<sup>5</sup>). (A) Lateral view with straining at capacity. (B) AP view of post-voidal residual.

Because this patient has new onset of urge incontinence and straining to void, UDS may assist in determining the etiology of her lower urinary tract symptoms and the mechanism for her PVR. In this situation, the goals of UDS are to unmask stress incontinence by cough or Valsalva maneuvers, detect detrusor overactivity during filling, and then assess detrusor contractility during voiding. Cystocele reduction is recommended to undo the mechanical kinking at the urethrovesical junction. To limit patient interference during the test, we have used a vaginal pack gauze but pessary, sponge-stick, hand, or speculum reductions have all been reported.

The importance of knowing the contractile state of the bladder is critical in managing the urethral outlet, especially if stress urinary incontinence is unmasked by prolapse reduction. In the presence of a hypo- or acontractile bladder or in a Valsalva voider, increasing urethral resistance with a sling would place the patient at high risk for permanent urinary retention postoperatively. Obstruction, as suggested by a high detrusor pressure at peak flow with an associated low flow rate (6), should resolve once the bladder and urethra are surgically returned to a more normal anatomic position. Detrusor overactivity is often undetected during conventional UDS without triggering maneuvers. However, its detection linked to urge incontinence should serve in preoperative counseling as it may indicate some permanent bladder wall changes that may or may not improve after bladder repair.

After review of some or all of these tests, and assuming that the cystocele is the presumed source of her UTIs by inducing chronic retention, that she has normal detrusor parameters on UDS and no abnormal uterine or ovarian findings on pelvic ultrasound, we would discuss with this patient a hysterectomy and bilateral salpingo-oophorectomy by our gynecology team, followed by an anterior vaginal wall suspension (7) and vault support repair. We recognize that there are a number of different techniques that could be used to correct her anatomic defects, including transvaginal, laparoscopic, and abdominal approaches alone or with a variety of tissue interposition; their advantages and risks are beyond the scope of this case discussion.

Postoperatively, this patient's PVR should be carefully monitored. Straining to void could contribute to prolapse recurrence and should be avoided. In rare instances when UTIs continue despite a successful repair of the cystocele, no urinary incontinence, no or limited PVR, and a normalized voiding pattern, a complete reassessment may be needed. Some patients who were bothered by the cystocele preoperatively may have subsequently returned to sexual activity. If a relationship between UTI and intercourse is noted, then coital prophylaxis should be considered. When urgency and urge incontinence persist despite an adequate cystocele repair, anticholinergic medications can be useful, but in this older woman PVR should be monitored at regular intervals to confirm adequate bladder drainage.

## REFERENCES

1. Raz R, Gennesin Y, Wasser J, et al. Recurrent urinary tract infections in postmenopausal women. *Clin Infect Dis* 2000;30:152–156.
2. Klutke JJ, Bergman A. Hormonal influence of the urinary tract. *Urol Clin North Am* 1995;22:629.
3. Raz R, Stamm W. A controlled trial of intravaginal estriol in postmenopausal women with recurrent urinary tract infections. *N Engl J Med* 1993;329:753–756.
4. Zimmern PE. The role of voiding cystourethrography in the evaluation of the female lower urinary tract. *Problems Urol* 1991;5:23–41.
5. Showalter PR, Zimmern PE, Roehrborn CG, Lemack GE. Standing cystourethrogram: an outcome measure after anti-incontinence procedures and cystocele repair in women. *Urology* 2001;58:33–37.

6. Defreitas G, Zimmern P. The role of urodynamics in women with stress urinary incontinence. *EAU Update Series* 2003;1:135–144.
7. Wilson TS, Zimmern PE. Anterior vaginal wall suspension. In: *Female Urology, Urogynecology, and Voiding Dysfunction* (Vasavada SP, Appell RA, Sand PK, Raz S, eds.), Dekker, New York: 2005, p. 283.

#### EDITOR'S COMMENTS BY SANDIP P. VASAVADA, MD

Dr. Takacs and Dr. Zimmern have nicely discussed a variety of potential evaluations as well as therapeutic options for a patient with prolapse in the setting of incomplete emptying and recurrent UTIs. It is often difficult to evaluate a patient who has mild-to-moderate prolapse, and is not emptying the bladder well. We should always remember that a spot or a single postvoid residual measurement may not be completely indicative of the entire situation for a patient's voiding dysfunction. Therefore, the residual urine should often be retested to ensure that this is truly the case, such as in this patient's situation for which she had a 180-cc residual. Certainly, this can be impacted by her prolapse; however, one must also be certain to eliminate other causes, including detrusor hypocontractility or certainly upper tract causes, as was nicely reviewed by the discussants. It seems that when conservative measures fail, operative intervention may be required, and the patient should be appropriately counseled that she may still have problems in the future but she should empty better once the prolapse is corrected. It should help reduce the likelihood of continued infections as well.

---

## 3 Mixed Incontinence

---

A 57-yr-old woman presents with significant mixed incontinence requiring six heavy pads per day. She says both aspects of the incontinence (stress urinary incontinence [SUI] and urge incontinence [UI]) are equally bothersome. She has failed pelvic floor exercises and multiple anticholinergics. Physical exam reveals no prolapse, but she does have some urethral hypermobility. No other testing has been done.

How would you proceed with your evaluation and treatment?

### COMMENTARY BY WACHIRA KOCHAKARN, MD, FACS

This patient presents with mixed incontinence, and both of the symptoms (stress and urge) are equally bothersome. Both pelvic floor exercises and anticholinergic medications have failed to improve her symptom complex. To improve her quality of life and keep her dry, further investigation and treatment will be needed. Surgical treatment, in particular cystourethropexy, should be considered. The pubovaginal sling is my preference because many studies have shown acceptable results with long-term follow up (1). Morgan and colleagues treated 247 patients with mixed incontinence and reported an 88% continence rate, with more than 90% having a high degree of satisfaction after 4 yr of follow-up (2). Schrepferman et al. (3) also reported a success rate of 91.3% after cystourethropexy for mixed incontinence as well as with motor urge with low-amplitude detrusor overactivity.

The mechanisms of mixed incontinence are unclear, but we find that 35–65% of patients with stress incontinence have subjective urgency or abnormal detrusor contractions during conventional urodynamic testing (4). Petros and Ulmsten (5) found a sudden decrease in urethral pressure following the onset of urge symptoms with a rising detrusor pressure. They concluded that supporting the urethra with a sling could improve urge symptoms in this group of patients. However, the tension-free vaginal tape (TVT) or other minimally invasive procedure with a similar mechanism did not work well in the patients with mixed incontinence. Farrell and Halifax reported a high failure rate of 81.2% after TVT procedure in the patients who had mixed incontinence (6).

Biologic pubovaginal slings can be harvested from autologous rectus fascia or fascia lata. Cadaveric fascia is commercially available and can be used depending on the patient's preference and the surgeon's expertise. However, in my hands, I almost always use autologous rectus fascia as the sling material and have had minimal complications (7).

Before the procedure is performed, routine laboratory tests, including urine examination to check for infection or hematuria, should be performed. Abdominopelvic ultrasonography is another test that should be included, and a postvoid residual urine volume can



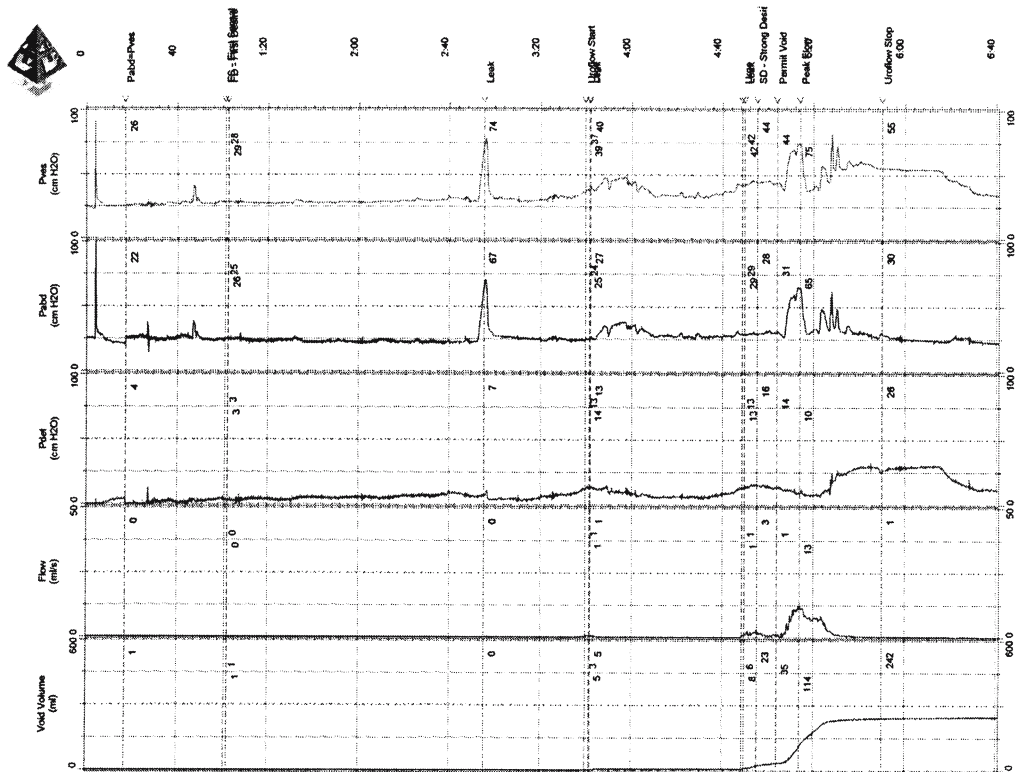


Fig. 1.

be estimated. Significant residual urine (more than 100 mL) may result from other pathology, such as neuropathic bladder dysfunction, that mimics symptoms similar to those of mixed incontinence (8).

A multichannel urodynamic study should be done, and abdominal leak-point pressure measurement should be recorded. Many studies have shown that leak-point pressure and presence or absence of abnormal detrusor contractions are two important factors that predict the outcome after treatment (3,4). The patients with low-amplitude detrusor overactivity showed higher success rates than those with high-amplitude detrusor overactivity (3,4). Regarding leak-point pressures, some surgeons have reported using alternative techniques, such as bladder neck suspension or a TVT procedure, if urodynamic testing shows high leak-point pressures (greater than 90 mL H<sub>2</sub>O) (9). However, we do not have long-term results of TVT in this specific (mixed) group of patients and thus must have a fully informed discussion with the patient, weighing pros and cons of a TVT or similar procedure in such a setting.

Overall then, my preference for a patient with mixed incontinence who has already failed conservative therapy for the urge component is to proceed with an autologous rectus fascial sling to treat the SUI with the knowledge that a significant number of these patients will also note a diminution in their urge problem after such surgery.

## REFERENCES

1. Chou E, Flisser A, Panagopoulos G, Blaivas J. Effective treatment for mixed urinary incontinence with pubovaginal sling. *J Urol* 2003;170:494–497.
2. Morgan TO, Westney OL, McGuire EJ. Pubovaginal sling: 4-yr outcome analysis and quality of life assessment. *J Urol* 2000;163:1845–1848.
3. Schrepferman CG, Griebing TL, Nygaard IE, Kreder KJ. Resolution of urge symptoms following sling cystourethropexy. *J Urol* 2000;164:1628–1631.
4. Heslington K, Hilton P. The incidence of detrusor instability by ambulatory monitoring and conventional cystometry pre and post colposuspension. *Neurourol Urodyn* 1995;14:416–417.
5. Petros PE, Ulmsten U. Bladder instability in women: a premature activation of the micturition reflex. *Neurourol Urodyn* 1993;12:235–239.
6. Farrell SA, Halifax NS. Tension-free vaginal tape (TVT) procedure. *J Obstet Gynecol Can* 2003;25:692–694.
7. Kochakarn W, Leenanupunth C, Ratana-Olarn K, Roongreungsilp U, Siripornpinyo N. Pubovaginal sling for the treatment of female stress urinary incontinence: experience of 100 cases at Ramathibodi Hospital. *J Med Assoc Thai* 2001;84:1412–1415.
8. Milleman M, Langenstroer P, Guralnick ML. Post-void residual urine volume in women with overactive bladder symptoms. *J Urol* 2004;172:1911–1914.
9. Osman T. Stress incontinence surgery for patients presenting with mixed incontinence and a normal cystometrogram. *BJU Int* 2003;92:964–968.

## COMMENTARY BY GARY E. LEACH, MD

This patient is not unusual in that about 60% of the women we have operated on for SUI have some component of urgency (mixed incontinence) with a predominance of stress symptoms. The difficult aspect of this situation is that she states that her symptoms are evenly “split” between both urge incontinence and stress incontinence. In recent studies (in press), we have found that the urge component resolves in about 70% of women following a sling procedure, with 30% having continued urgency following the sling. Also, when we have examined the “predictors” of failure following a sling procedure, the only preoperative variable that clearly correlated with a less-than-satisfactory postoperative outcome was the presence of preoperative urge incontinence.

Given these findings, I would clearly prefer to control this patient’s urge symptoms as the initial step in management, followed by treatment of the stress incontinence (if necessary) once the urgency is controlled. Before embarking on treatment, I would also perform a detailed multichannel urodynamic study to clearly define the causes of her incontinence (i.e., demonstrate SUI, evaluate the presence of detrusor instability [DI], and evaluate the patient’s ability to empty her bladder). However, many patients have complaints of urgency and urge incontinence with a totally stable bladder on urodynamic evaluation (UDE). The stable bladder on the UDE does not mean the patient does not have DI, it just means that the DI was not seen during the study. When the patient has major complaints of urge or urge incontinence, the presence or absence of DI on the urodynamic study does not influence our treatment recommendations.

*Control of Urgency/Urge Incontinence*

In addition to standard oral anticholinergic medications, there is a variety of additional treatments that can help control the urgency and frequency symptoms. These treatments include dietary modification (i.e., avoiding foods/drinks that tend to irritate the bladder, limiting fluid intake); computer-assisted pelvic floor training/biofeedback; vaginal estrogen cream in those women with atrophic vaginitis; and following a timed voiding

program. When these additional measures in combination with standard anticholinergic therapy do not control the urgency symptoms, we frequently add a second medication (10 or 25 mg imipramine three times a day) to the treatment program. When this program is not effective, consideration is given to a trial of the Interstim bladder pacemaker device.

The Interstim device is placed initially as a test stimulation with the tined lead placed under fluoroscopic control adjacent to the S3 nerve root as an outpatient procedure under local anesthesia. The patient wears an external stimulation device attached to the tined lead for 7–10 d to gage the response to neurostimulation with a voiding/incontinence diary. When the patient returns in 1 wk, the response to the Interstim is evaluated.

When the patient has significant improvement in her urgency symptoms with neurostimulation (seen in approx 70%), the Interstim generator is implanted as a second-stage outpatient procedure under local anesthesia. Should the patient have complaints of significant residual SUI following the Interstim procedure, the UDE would be repeated to document the presence of SUI and adequate bladder volume with a stable bladder.

Should the patient not respond to the first-stage Interstim trial, the stimulation electrode is removed, and a trial of Botox injection (200–300 U) into the bladder wall could be considered. In our experience, approx 50% of patients respond to the Botox, with a maximum response time of 6 mo and with a small risk of short-term post-Botox retention.

### *Treatment of Stress Urinary Incontinence After Control of Urgency Symptoms*

Commonly, the degree of residual SUI following control of the urge symptoms is a minimal problem and frequently well tolerated by the patient who is experiencing significant improvement in quality of life. When the residual SUI with urethral hypermobility is a significant problem for the woman, our surgical procedure of choice is a sling procedure. We have had extensive experience with the CATS procedure (transvaginal sling with bone anchors and nonfrozen cadaveric fascia lata). With maximum follow-up of more than 6 yr, the SUI recurrence rate is 11%. More recently, we have utilized the transobturator synthetic sling with early encouraging results.

### *Summary*

When urge symptoms either predominate or are equivalent to the stress symptoms in the woman with mixed incontinence, control of urgency symptoms before treatment of SUI is prudent to avoid patient dissatisfaction with the surgical result because of continued or exacerbated postoperative urgency. When the SUI symptoms predominate, a sling procedure is performed with a 70% chance that the urge symptoms will be improved postoperatively. Should the patient be in the 30% group and need postsling treatment for her urge symptoms, the previously described options are offered.

### **EDITOR'S COMMENTS BY HOWARD B. GOLDMAN, MD**

Typically, if one type of incontinence—either the stress or urge—predominates, it is relatively simple to know how to proceed. We try to treat the one that is most bothersome. However, the fact that this patient finds her stress and urge incontinence equally troubling makes the decision a little more difficult. Although, as Dr. Kochakarn points

out, many patients who have a sling will have resolution of the urge symptoms after the sling, as Dr. Leach eloquently states those who do not have resolution will frequently feel that their sling procedure was not effective.

In my practice, I would attempt to treat the urge component in a similar fashion as Dr. Leach. However, if the stress component seems particularly significant, I would consider doing a sling prior to proceeding with Interstim, with the patient understanding that there is a high likelihood that she will need an Interstim after the sling. In some cases, if the urge component resolves after the sling, that is all that needs to be done. In the other cases when they have continued urge symptoms, we proceed with the Interstim within a few months of the sling.

Occasionally, if someone has significant stress incontinence it can make it hard to interpret the results of the test stimulation with the Interstim as they are still having significant leakage and wearing a significant number of pads because of the SUI and may not fully realize the benefit of the Interstim. Therefore, by taking care of the stress incontinence, one may be able to have a more accurate idea of whether the Interstim will ultimately be beneficial for the urge incontinence.

---

## 4 Urinary Tract Infections and Pelvic Pain

---

A 34-yr-old woman presents with a history of having had her first urinary tract infection (UTI) 6 mo ago. Since that time, she has had multiple UTI recurrences, dysuria, pelvic pain, and dyspareunia. Physical exam reveals an area of tenderness along the distal anterior vaginal wall.

How would you evaluate and treat this patient?

COMMENTARY BY SUZETTE E. SUTHERLAND, MD

### *Step 1: Physical Exam and Labs*

With this history, the suspicion for a symptomatic urethral diverticulum is high. The differential diagnosis for a suburethral anterior vaginal wall mass can be seen in Table 1. The first step, however, is to ensure the accuracy of the recurrent UTI diagnosis through a review of all typical and atypical urine cultures in the last 6 mo. Following this, a thorough physical exam should be telling.

Along with tenderness, palpation of the anterior vaginal wall may also reveal a mass, soft or hard, from which purulent material or urine can be expressed through the meatus. A direct compression of the mass and underlying urethra. Full bimanual pelvic exam with assessment of baseline tonicity of the pelvic floor musculature is an important adjunct to possible understanding of the associated development of chronic pelvic pain in this woman. Repeat pelvic insults (i.e., UTIs, painful intercourse attempts, persistent inflamed mass) can result in chronic spasticity of the levator muscle complex, resulting in referred chronic pelvic pain, irritative bladder and bowel symptom, and vaginismus-related dyspareunia. If all such symptoms are not relieved following surgical correction of urethral diverticulum, then pelvic floor rehabilitation with biofeedback and manual manipulative techniques should be considered.

### *Step 2: Office Cystourethroscopy*

Office flexible cystourethroscopy can help document the presence and location of a urethral ostium, with most located posterolaterally. Concomitant compression of the anterior vaginal wall mass may aid in ostium localization through direct visualization of expressed fluid from the opening of the diverticulum. Viewed transvaginally, the mass may also enlarge during urethral infusion of fluid, thereby confirming the diagnosis of a communication between the urethra and the mass.

### *Step 3: Diagnostic Imaging*

There are multiple imaging modalities available today to confirm the diagnosis of urethral diverticulum (see Table 2). Although voiding cystourethrography (VCUG)

**Table 1**  
**Differential Diagnosis for a Suburethral Anterior Vaginal Wall Mass**

---

Urethral diverticulum
Gartner's duct cyst
Skene's gland infection
Solid vaginal wall mass (leiomyoma, schwannoma)
Urethral neoplasm
Mucosal prolapse
Urethral caruncle
Ectopic ureter

---

**Table 2**  
**Diagnostic Studies for Urethral Diverticulum**

---

Cystourethroscopy
Voiding cystourethrogram
Positive pressure urethrography
Transvaginal ultrasonography
Intravenous pyelogram
Pelvic MRI

---

has traditionally been the initial imaging technique of choice in terms of sensitivity, specificity, availability, patient comfort, and cost—it does not always provide definitive anatomical information. Retrograde positive pressure urethrography (PPU) with a double-balloon catheter has been used for diagnosis since the 1950s and is more sensitive than VCUG, but it can be uncomfortable for the patient (1,2). Transvaginal ultrasonography provides a quick, noninvasive means for diagnosis and can help distinguish multiple diverticula from a single, large, loculated diverticulum. With significant tenderness of the anterior vaginal wall, a comfortable evaluation via ultrasound may not be possible (3). If an ectopic ureter is suspected, then an intravenous pyelogram is certainly indicated (4).

Owing to its degree of definitive anatomical detail, pelvic magnetic resonance imaging (MRI) has become the new gold standard for documenting urethral diverticula (5). A distinct advantage of pelvic MRI is an appreciation for the extent and complexity of the diverticulum about the urethra. Not only does it aid in surgical planning, but it provides more information to guide preoperative patient counseling concerning the likelihood of possible postoperative complications (such as urinary incontinence with large proximal diverticula). Although rare, preoperative visualization of concomitant intradiverticular pathology (i.e., tumors, stones) is likewise useful (6). For anything other than a simple, small distal urethral diverticulum that is readily appreciated on physical exam and office cystourethroscopy, pelvic MRI is my imaging modality of choice for definitive diagnosis and preoperative planning.

#### ***Step 4: Treatment***

Total diverticulum excision offers the best long-term outcome in those patients who are good surgical candidates. A variety of techniques have been described, but the ultimate surgical goal is complete excision of the diverticular neck and ostium, followed by a

watertight urethral closure, complete excision or obliteration of the diverticular sac, and a multilayer closure of the periurethral fascia and vaginal mucosa in as nonoverlapping suture fashion as possible. Marsupialization provides another viable option for a distal diverticulum with associated abscess, for which excision would be fraught with considerable difficulty because of the extent of peridiverticular and periurethral inflammation.

## REFERENCES

1. Davis JH, Cian LF. Positive pressure urethrography: a new diagnostic method. *J Urol* 1956;75:753-757.
2. Wang AC, Wang CR. Radiologic diagnosis and surgical treatment of urethral diverticulum: a reappraisal of voiding cystourethrography and positive pressure urethrography. *J Reprod Med* 2000;45:377-382.
3. Fontana D, Porphiglia F, Morra I, et al. Transvaginal ultrasonography in the assessment of organic diseases of the female urethra. *J Ultrasound Med* 1999;18:237-241.
4. Blacklock AR, Shaw RE, Geddes JR. Late presentation of ectopic ureter. *Br J Urol* 1982;54:106-110.
5. Blander DS, Rovner ES, Schnall MD, et al. Endoluminal magnetic resonance imaging in the evaluation of urethral diverticula in women. *Urology* 2001;57:660-665.
6. Applewhite JC, Hall MC, McCullough DL. Urethral carcinoma in women. In: *Adult and Pediatric Urology, 4th ed.* (Gillenwater J, Grayhack JT, Howards SS, Mitchell ME, eds.), Lippincott, Williams, and Wilkins, Philadelphia, 2002, pp. 1800-1804.

## EDITOR'S COMMENTS BY SANDIP P. VASAVADA, MD

Dr. Sutherland correctly points out the salient diagnostic choices in a patient with a likely urethral diverticulum. As such, MRI is rapidly emerging as the gold standard not only to diagnose the diverticulum, but also to evaluate its extent. This second point is important in that certain diverticula may be amenable to simple excision and closure, whereas diverticula with more extensive proximal or superior extent (horseshoe or saddlebag) may require more complex reconstructions with or without addition of Martius flaps or even pubovaginal slings. Still, half the battle is getting to the proper diagnosis prior to embarking on therapy.

---

## 5 Multiple Sclerosis and Voiding Dysfunction

---

A 42-yr-old woman with a 10-yr history of multiple sclerosis presents with worsening voiding complaints. For the past 3 yr, she has had increasing frequency, which was treated successfully with anticholinergics. Recently, she has noticed worsening urgency and has also begun to have hesitancy and straining to void. Physical exam is normal. Postvoid residual (PVR) is 240 cc. Urodynamics demonstrates detrusor overactivity and detrusor-sphincter dyssynergia (DSD). She voids with a detrusor pressure of 37.7 cm H<sub>2</sub>O with a maximum flow of 5.4 cc/s.

How would you evaluate and treat this patient?

### COMMENTARY BY E. JAMES WRIGHT, MD

Management of patients with multiple sclerosis and the wide spectrum of symptoms and voiding dysfunction this disease can cause is a challenge. I think it is helpful to stratify the type and site of dysfunction to organize treatment strategies and to follow progress and therapy effects. Multiple sclerosis presents a “moving target” in terms of voiding dysfunction, and one should remain vigilant and flexible in assessment and treatment planning. Employing the simple 4 × 4 matrix with headings for bladder, outlet, storage, and emptying is useful for directing diagnosis and intervention.

In addition to urinary tract assessment, attention in multiple sclerosis should be paid to bowel function. Difficulties with fecal urgency, fecal incontinence, constipation, and impaction can be a source of poor quality of life and exacerbation of lower urinary tract symptoms. Improvement in bowel evacuation and relief of fecal incontinence can assist the management of voiding complaints.

In this case of a 42-yr-old woman with recent progression of voiding complaints, the finding of DSD documented on urodynamic testing warrants further evaluation and therapy. This should include a renal ultrasound study and serum creatinine to ensure safety of the upper tracts. A 72-h frequency and volume voiding diary may also be helpful. The patient has difficulty with both urine storage and emptying, and both the bladder and outlet are involved. The bladder is overactive with the appearance of adequate contractility but fails to empty efficiently in light of a 240-cc residual volume. Regarding the urethra and bladder outlet, storage function appears satisfactory. Emptying is impaired because of DSD. In this context, therapy should be directed at maximizing bladder storage and reduction of outlet resistance. The dilemma facing this goal is therapies to improve urine storage often require a trade-off regarding emptying.

Voiding by Valsalva should be discouraged in this patient as it may lead to compromise of renal function and further deterioration of bladder function. An empiric trial of an  $\alpha$ -blocker is reasonable in an effort to decrease outlet resistance and lower voiding pressures. Although evidence is anecdotal, I have seen improvement in both symptoms



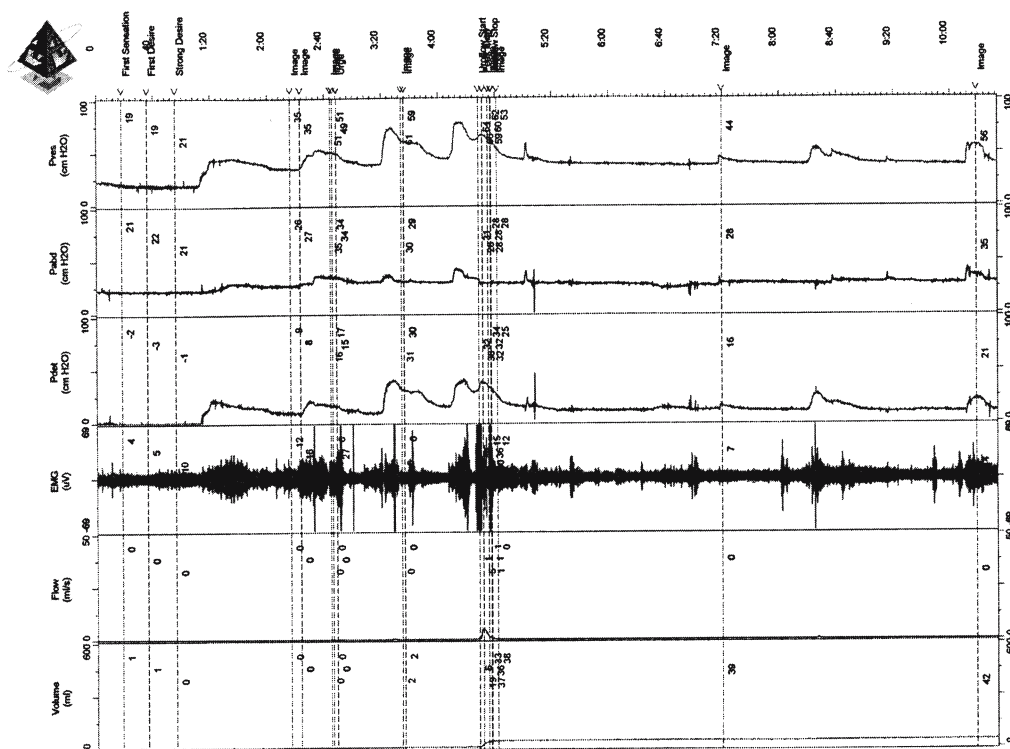


Fig. 1.

and urodynamic parameters with  $\alpha$ -blockade. When helpful, hesitancy and emptying efficiency may improve as well as PVR and additional concerns of cystitis and urgency symptoms.

In progressing along a treatment algorithm, the patient should be told of the difficulty in restoring completely normal function. When pushed to the side of urine storage, the balance of voiding function is often most comfortable. A trial of self-catheterization (SIC) may show that elimination of PVR and voiding against a resistant outlet yields improvement in bothersome urgency, frequency, and hesitancy. This could be done on a twice-daily (morning and evening) regimen with increased frequency as necessary to assess effectiveness. A program of SIC can also be combined with a repeat trial of anticholinergic medication without concern for worsening the emptying side of the equation.

When SIC is undesirable, unfeasible, or ineffective, the intensity of intervention can be increased. Application of botulinum toxin injection into the external sphincter has yielded improvement in voiding function for some patients with multiple sclerosis and DSD. Neuromodulation may also have some benefit for this patient as a way to decrease the sensory bother from urgency and frequency. Temporary placement of a sacral stimulation lead can allow a therapeutic trial to assess possible benefit.

In conclusion, there is no “one size fits all” in the approach to patients with multiple sclerosis and resultant voiding dysfunction. Therapy should be tailored to the needs and abilities of the patient. Preservation of the upper tracts, satisfactory continence, an effective mechanism for bladder emptying, independence, and a satisfactory quality of life

Table 1  
Event Summary

<i>Annotation</i>	<i>Time</i>	<i>Pves</i>	<i>Pabd</i>	<i>Pdet</i>	<i>EMG</i>	<i>EMGR</i>	<i>Flow</i>	<i>Volume</i>
First sensation	17.9	19	21	-2	4	1	0	1
First desire	35.9	19	22	-3	5	4	0	1
Strong desire	55.6	21	21	-1	10	5	0	0
Image	2:15.9	35	26	9	12	-1	0	0
Image	2:23.1	35	27	8	16	4	0	0
Image	2:44.3	51	35	16	16	9	0	0
Image	2:45.7	51	34	17	8	1	0	0
Urge	2:48.7	49	34	15	27	3	0	0
Image	3:33.9	61	30	31	6	1	0	2
Image	3:35.8	59	29	30	6	0	0	2
Uroflow start	4:28.4	64	31	32	49	20	1	5
Peak flow	4:31.1	66	28	38	8	5	5	19
Image	4:34.8	62	28	34	15	10	1	33
Uroflow stop	4:36.7	60	28	32	36	35	1	36
Image	4:37.2	59	28	32	30	17	1	37
Image	4:41.4	53	28	25	12	3	0	38
Image	7:19.5	44	28	16	7	-2	0	39
Image	10:18.7	56	35	21	14	5	0	42

#### Uroflow Summary

Maximum flow:	5.4 mL/s	Dev (Female)	****
Average flow:	4.1 mL/s		****
Voiding time:	8.4		****
Flow time:	7.5		
Time to peak flow:	2.8		****
Voided volume:	31 mL		
Flow at 2 seconds:	4.9 mL/s		
Acceleration:	1.5 mL/s/s		
Pressure at peak flow:	37.7 cm H <sub>2</sub> O		
Flow at peak pressure:	4.9 mL/s		
Mean Pressure:	35.6 cm H <sub>2</sub> O		
PVR:	92 mL		

\*, moved event.

are the goals of therapy. The principles of managing neurogenic voiding dysfunction remain the same, but the “recipe” is often unique.

#### EDITOR’S COMMENTS BY HOWARD B. GOLDMAN, MD

As Dr. Wright notes, patients with multiple sclerosis and bladder dysfunction can represent a moving target as things can change. In this patient with overactive bladder and DSD, evaluation and monitoring of the upper tract is important. If the patient has good manual dexterity and is not opposed to intermittent catheterization, then trying to put the bladder to rest and instituting intermittent catheterization may be the easiest

approach. If that is unsuccessful or the patient does not desire intermittent catheterization, then Botox injection into the external sphincter may allow resumption of relatively normal voiding. Interstim sacral neuromodulation can be useful in this sort of situation, but it is important to discuss with the patient that she may have difficulties obtaining magnetic resonance imaging in the future as the presence of an Interstim or similar device is currently a contraindication to magnetic resonance imaging. In severe cases for which nothing else works, different types of diversion (e.g., an ileal vesicostomy) have proven useful for these types of patients.

---

## 6 *De novo* Overactive Bladder Symptoms After a Sling

---

A 45-yr-old woman with pure stress urinary incontinence (SUI) undergoes a sling procedure. Preoperatively, she had no irritative voiding symptoms and no voiding complaints. After the sling is done, she notes some mild increase in her urinary frequency. At her 6-wk follow-up visit, she complains of onset of urge incontinence requiring two pads per day. She has no SUI. She notes her stream has slowed a bit since the surgery.

How would you evaluate and treat this patient? Is there really such a thing as *de novo* overactive bladder (OAB)?

### COMMENTARY BY VICTOR W. NITTI, MD, FACS

This woman is experiencing new-onset urge incontinence, which was preceded by increased urinary frequency 6 wk after sling surgery for SUI. An additional new symptom is a somewhat slowed urinary stream. *De novo*, or newly acquired, OAB symptoms are reported in all types of incontinence surgery, including slings (pubovaginal and midurethral). *De novo* OAB symptoms have been reported in 0–14% of sling procedures (1), but the occurrence of the symptoms appear to be at the lower end for tension-free vaginal tape (TVT) and other similar procedures. When one considers these symptoms that did not appear to exist prior to surgery, there are four possible explanations:

1. The symptoms actually did exist before but were masked by the more predominant stress symptoms. Now that the stress incontinence is cured, the OAB symptoms and urge incontinence are obvious to the patient.
2. The OAB symptoms truly are *de novo* and occurred after the operation or even as a result of the operation. Possible explanations for this include:
  - a. Surgery, or surgical manipulation, of the lower urinary tract has caused changes (perhaps based on neurological innervation) that are responsible for the symptoms.
  - b. Surgery has caused a more obvious problem, such as bladder outlet obstruction, known to be associated with OAB symptoms. Obstruction requiring intervention has been reported in about 2–3% of cases of pubovaginal slings and midurethral synthetic slings (2–4). Erosion of the sling into the bladder or urethra can also cause *de novo* OAB symptoms.
3. The apparent urge incontinence is actually persistent SUI but may appear different in some way to the patient, and thus history is not an accurate representation of the underlying cause of the symptoms.
4. The OAB symptoms are caused by an acute problem such as a urinary tract infection (UTI).

In this particular case, voiding has changed slightly, so the suspicion of obstruction is raised, although many clinically unobstructed patients will complain of a stream that has slowed a bit. Nevertheless, the suspicion is raised.

As in all cases of incontinence, the evaluation of this patient starts with a good history and physical exam. Every effort should be made to characterize the new storage and voiding symptoms and temporal association with surgery. If questionnaires were given preoperatively that assessed these, then now is a good time to repeat them. Physical exam should assess for bladder distension, vaginal healing, and prolapse that may have been missed or become apparent after surgery. A urine analysis should be done to rule out infection.

Another standard postoperative test is a postvoid residual (PVR). If bladder emptying is significantly impaired from preoperatively, then this will raise the suspicion of obstruction. In this case, even if the PVR is in an acceptable range (similar to preoperative), a noninvasive uroflow can be considered because of the patient's voiding complaints. With these simple tests, history, and physical exam, we are armed to make our first decisions regarding further evaluation or treatment.

Anything obvious, such as a UTI, should be treated and the patient reevaluated. If there is a problem with healing of the vaginal incision, then this should raise the suspicion of a problem, such as a vaginal extrusion (especially if synthetic material was used) or even erosion into the urinary tract. Significant hematuria in the absence of an infection or recurrent UTIs early in the postoperative period should also raise the suspicion of an erosion, and cystourethroscopy should be done.

If there are no obvious abnormalities on physical exam and urine analysis, then the PVR becomes the most important factor in determining how to proceed.

If PVR is significantly elevated (e.g.,  $\geq 50\%$  of bladder capacity) and this is new, then obstruction must be suspected. As the possibility of obstruction is just recognized, a period of drainage (preferably with intermittent self-catheterization) is warranted. Symptoms and PVR can then be followed for a period of time (usually 2–6 wk) if necessary. Only if self-catheterization is not possible should an indwelling catheter be placed. If after adequate time has passed the patient continues to be symptomatic and emptying is still impaired, then consideration to take down the sling by simple incision or urethrolisis (if necessary) is warranted. Both procedures have been effective for all types of slings (4–10). If one has a definite understanding of the patient's pre-sling voiding and emptying status and it has clearly changed for the worse, then there is little utility for urodynamic studies (UDS).

We prefer the simpler sling incision or lysis to formal urethrolisis whenever possible (i.e., the sling can be clearly identified) as it is less invasive and has comparable results. For synthetic slings, we feel that the sling must be cut to relieve obstruction whether or not a formal urethrolisis is done as well. In the early postoperative period, it is often possible to loosen a midurethral synthetic sling by pulling it down; however, after 10–14 d this is usually not possible, and the tape must be cut. There are not many data on the effectiveness of conservative therapy for OAB and, in particular, anticholinergics, in the face of obstruction after incontinence surgery. In our experience, it does not seem particularly effective if obstruction is not relieved.

If PVR is minimally elevated or unchanged, then uroflow may help to raise or lower the suspicion of obstruction and proceed with aggressive treatment. However, unless there are gross changes in uroflow, it is reasonable to treat the OAB symptoms with a variety of conservative measures (e.g., pelvic floor exercises, anticholinergics, and so on)

if they are bothersome. It is also reasonable to consider watchful waiting if acceptable to the patient. In many cases, OAB symptoms will resolve over time. If they do not or if conservative therapy fails, then workup with UDS and cystoscopy is warranted.

It is in those cases for which obstruction is not obvious that UDS probably has its highest yield. Although it is sometimes difficult to definitively rule in obstruction (e.g., the patient cannot void or has low-pressure/low-flow voiding dynamics), it can be ruled out (e.g., the patient has low-to-normal pressure and normal-to-high-flow voiding dynamics). Urethrolisis and sling incision have been effective in relieving symptoms when obstruction is suspected but not urodynamically documented. However, there are insufficient data regarding the outcomes of such procedures in patients who are unequivocally unobstructed on UDS. If OAB symptoms persist after successful treatment of obstruction, then the standard OAB treatments mentioned can be tried.

When OAB symptoms persist despite treatment with appropriate conservative measures, and obstruction/recurrent obstruction, other treatable causes of OAB, and recurrent SUI have been excluded (e.g., sling erosion), then second-line therapies such as neuromodulation, botulinum type A toxin, and even bladder augmentation can be considered depending on severity and degree of bother.

## REFERENCES

1. Smith ARB, Daneshgari F, Dmochowski R, et al. Surgery for urinary incontinence in women. In *Incontinence (Edition 2005) Third International Consultation on Incontinence* (Abrams P, Cardozo L, Khoury S, Wein A, eds.), Health, Plymouth, UK, 2005, pp. 1297–1370.
2. Chaikin DC, Rosenthal J, Blaivas JG. Pubovaginal fascial sling for all types of stress urinary incontinence: long-term analysis. *J Urol* 1998;160:1312–1316.
3. Morgan TO, Jr, Westney OL, McGuire EJ. Pubovaginal sling: 4-yr outcome analysis and quality of life assessment. *J Urol* 2000;163:1845–1848.
4. Klutke C, Siegel S, Carlin B, Paszkiewicz E, Kirkemo A, Klutke J. Urinary retention after tension-free vaginal tape procedure: incidence and treatment. *Urology* 2001;58:697–701.
5. Amundsen CL, Guralnick ML, Webster GD. Variations in strategy for the treatment of urethral obstruction after a pubovaginal sling procedure. *J Urol* 2000;164:434–437.
6. Nitti VW, Carlson KV, Blaivas JG, Dmochowski RR. Early results of pubovaginal sling lysis by midline sling incision. *Urology* 2002;59:47–52.
7. Goldman HB. Simple sling incision for the treatment of iatrogenic urethral obstruction. *Urology* 2003;62:714–718.
8. Rardin CR, Rosenblatt PL, Kohli N, Miklos JR, Heit M, Lucente VR. Release of tension-free vaginal tape for the treatment of refractory postoperative voiding dysfunction. *Obstet Gynecol* 2002;100:898–902.

## COMMENTARY BY CARL G. KLUTKE, MD AND TRAVIS L. BULLOCK, MD

The majority (30–60%) of women who present with complaints of urinary incontinence are found to have mixed stress and urge incontinence. The true incidence of isolated SUI in the general population is estimated to be between 10 and 20% (1,2). The pathophysiology of SUI is not well understood; consequently, the surgical treatment of this condition has undergone significant changes over many decades. In the last 100 yr, more than 150 different surgical procedures have been described (2). All of these various procedures have one thing in common: Voiding dysfunction is a commonly reported and troublesome complication.

The idea of using a biological urethral sling for the surgical correction of SUI was first proposed in 1910. Over the last several decades, the various sling procedures have become among the most common and efficacious incontinence procedures performed,

with long-term success rates reported to be between 70 and 95% (3). In 1996, Ulmsten first described the TVT. With the advent of this procedure, there was a paradigm shift in the surgical treatment of SUI, with the placement of the sling moved more distally into the midurethra in a tension-free manner (4). According to the original theory, leakage is prevented when the urethra comes in contact with the mesh during periods of stress. The procedure is attractive to both physicians and patients because of its effectiveness, simplicity, short learning curve, minimally invasive nature, and low rates of intraoperative complications and postoperative morbidity.

When a patient presents with complaints of new-onset frequency, urgency, urge incontinence, or difficulty voiding after an antiincontinence procedure, it is of paramount importance to first rule out obstruction, usually by determination of PVR urine and occasionally by urodynamics. The incidence of true urinary retention after pubovaginal sling and TVT is reported to be between 4 and 15% and between 2.5 and 19.7%, respectively (1,3,5–7). Many of these cases resolve with either temporary clean intermittent catheterization or short-term indwelling catheterization, but reoperation is sometimes required in the form of loosening or cutting of the sling and in some cases formal urethrolisis. In a series by Klutke et al., 2.8% of patients who underwent TVT required reoperation to loosen or cut the sling. All voided freely without obstruction 24 h after the procedure, and continence was maintained in 94% (8).

Once obstruction is effectively ruled out, one is left with *de novo* instability as the likely cause of a patient's complaints of urgency and urge incontinence. Postoperative OAB symptoms following urethral sling surgery are historically unpredictable and often lead to patient dissatisfaction. Urgency symptoms may worsen, resolve, or remain unchanged. Voiding dysfunction, particularly *de novo* urgency or urge incontinence after pubovaginal sling and TVT, range from 5 to 24% and from 4.3 to 12%, respectively (2,4,9). This lower incidence of detrusor instability in the TVT literature as compared to traditional sling procedures is thought to be primarily because of the tension-free placement of the tape.

There are several theories to explain why sling procedures may lead to new-onset OAB symptoms. Placement of the sling may lead to bladder mucosal irritation or a foreign body reaction. The procedure may also cause autonomic dysfunction within the nerves to the pelvic floor, especially when the sling is placed in the neurologically important bladder neck area. Others believe that changes in paraurethral collagen metabolism or sclerosis around the tape may be involved in *de novo* voiding dysfunction. Postoperative detrusor instability may also stem from excessive urethral compression, leading to partial outflow obstruction, or increased outflow resistance may lead to the unmasking of existing detrusor overactivity (2,5,10).

In a series of 62 women undergoing TVT, Haab et al. noted *de novo* OAB symptoms in 4 patients (6.5%). Videourodynamics performed in these patients revealed an open bladder neck at rest and during stress without evidence of obstruction. Based on these findings, the researchers proposed that *de novo* urgency was related to the activation of the voiding reflex by stimulation of afferent fibers in the proximal urethra (11). Similar videourodynamic findings were found by Fulford et al., in a series of 85 patients undergoing pubovaginal sling; 41% of patients with urge symptoms had an open bladder neck at rest (12). These two studies did differ, however, in that the TVT group showed normal pressure/flow parameters on urodynamics, and the pubovaginal sling cohort showed a significant degree of outflow obstruction (11,12).

Treatment of *de novo* OAB after urethral sling surgery should be managed similarly to idiopathic OAB. Principle treatment options include fluid restriction, timed voiding,

pelvic floor exercises, physical therapy, and medications, specifically the antimuscarinic family of drugs. Cross et al., reported a 19% incidence of *de novo* urgency in a series of 150 women undergoing pubovaginal sling with autologous rectus fascia. In all but four (3%) of these women, postoperative OAB symptoms resolved within 3 mo with timed voiding and anticholinergic medications (13).

In the TVT literature, Segal et al., reported a 9.1% incidence of *de novo* urge incontinence and a 4.3% incidence of new-onset OAB symptoms. In this series, only 8.7% of patients required anticholinergic medication for symptom relief (2). In marked contrast, Jeffry et al., reported a 25.9% incidence of *de novo* urge symptoms in 112 consecutive women undergoing TVT. Anticholinergic medications only provided effective symptom relief in 51.7% of patients. Of the women developing OAB symptoms, only 37.9% reported subjective cure of their stress incontinence, likely because of their new-onset urge incontinence (14). Reports like this have led some to advocate sling release in an attempt to relieve any component of underlying obstruction in all patients complaining of *de novo* urgency (C. G. Klutke, personal communication, June 2005).

In conclusion, *de novo* OAB is a commonly reported and distressing complication of sling procedures for the surgical correction of SUI. It often leads to patient dissatisfaction with surgery and a decrease in subjective cure rates. It is of utmost importance to counsel women preoperatively regarding the likelihood of new-onset urgency and its various treatment options. Continued research is needed to elucidate the true etiology of *de novo* urgency after sling surgery and to predict which patients are at risk for its development.

In this particular case, with *de novo* urgency accompanied by evidence of outlet obstruction because of elevated residuals and suggestive symptoms, we would advocate sling release in an attempt to relieve any component of underlying obstruction. If *de novo* symptoms persist, then a course of behavioral and pharmacological therapy would be instructed; if no improvement was evident in 3–6 mo, then a test of sacral nerve stimulation would be performed.

## REFERENCES

1. Abouassaly R, Steinberg JR, Lemiux M, et al. Complications of tension-free vaginal tape surgery: a multi-institutional review. *BJU Int* 2004;94:110–113.
2. Segal JL, Vassallo B, Kleeman S, Silva A, Karram MM. Prevalence of persistent and *de novo* overactive bladder symptoms after the tension-free vaginal tape. *Obstet Gynecol* 2004;104:1263–1269.
3. Minassian VA, Al-Badr A, Drutz HP, Lovatsis D. Tension-free vaginal tape, Burch, and slings: are there predictors for early postoperative voiding dysfunction? *Int Urogyn J* 2004;15:183–187.
4. Wang KH, Neimark M, Davila GW. Voiding dysfunction following TVT procedure. *Int Urogyn J* 2002;13:353–358.
5. Gateau T, Faramarzi-Roques R, Normand LL, Glemain P, Buzelin JM, Ballanger P. Clinical and urodynamic repercussions after TVT procedure and how to diminish patient complaints. *Eur Urol* 2003;44:372–376.
6. Levin I, Groutz A, Gold R, Pauzner D, Lessing JB, Gordon D. Surgical complications and medium-term outcome results of tension-free vaginal tape: a prospective study of 313 consecutive patients. *Neurourol Urodyn* 2004;23:7–9.
7. Miller EA, Amundsen CL, Toh KL, Flynn BJ, Webster GD. Preoperative urodynamic evaluation may predict voiding dysfunction in women undergoing pubovaginal sling. *J Urol* 2003;169:2234–2237.
8. Klutke CG, Siegel S, Carlin B, Paszkiewicz E, Kirkemo A, Klutke JJ. Urinary retention after tension-free vaginal tape procedure: incidence and treatment. *Urology* 2001;58:697–701.
9. Karram MM, Segal JL, Vassallo BJ, Kleeman SD. Complications and untoward effects of the tension-free vaginal tape procedure. *Obstet Gynecol* 2003;101:929–932.



10. Deval B, Jeffry L, Al Najjar F, Soriano D, Darai E. Determinants of patient dissatisfaction after tension-free vaginal tape procedure for urinary incontinence. *J Urol* 2002;167:2093–2097.
11. Haab F, Sananes S, Amarenco G, et al. Results of the tension-free vaginal tape procedure for the treatment of type II stress urinary incontinence at minimum follow-up of 1 yr. *J Urol* 2001;165:159–162.
12. Fulford SC, Flynn R, Barrington J, Appanna T, Stephenson TP. An assessment of the surgical outcome and urodynamic effects of the pubovaginal sling for stress incontinence and the associated urge syndrome. *J Urol* 1999;162:135–137.
13. Cross CA, Duane CR, McGuire EJ. Our experience with pubovaginal slings in patients with stress urinary incontinence. *J Urol* 1998;159:1195–1198.
14. Jeffry L, Deval B, Birsn A, Soriano D, Darai E. Objective and subjective cure rates after tension-free vaginal tape for treatment of urinary incontinence. *Urology* 2001;58:702–706.

### EDITOR'S COMMENTS BY SANDIP P. VASAVADA, MD

Drs. Nitti, Klutke, and Bullock have done an extremely nice job highlighting all of the salient issues in this case. Certainly, a diagnosis of OAB in the setting of potential bladder outlet obstruction is challenging at times. They have stated well that often the temporal relationship of the symptoms to the patient's previous surgery may be the most telltale indication of the sling or bladder outlet procedure as the likely cause. Nonetheless, urodynamics may play some role in helping elicit the proper diagnosis, and ultimately sling incision may be the procedure of choice to manage this patient initially. Correctly, they have stated that some cases, especially ones that have long-standing obstruction, may require adjuvant therapies, including neuromodulation, botulinum toxin injections, or rarely bladder augmentation.

The overall incidence of *de novo* urge incontinence in the setting of recent TVT procedures is overall low. Nonetheless, one should be prepared to manage these complicated situations as they may, even though infrequent, be problematic. It should be understood that patients who have undergone TVT procedures in which they eventually developed *de novo* symptoms, quality of life was diminished. Furthermore, this adverse effect on quality of life persisted if physicians prolonged the time to intervention in cases of suspect bladder outflow obstruction. Accordingly, one should clinically follow patients with suspect obstruction very closely and perhaps consider early evaluation to avoid long-term detriment to quality of life.

---

# 7

## Recurrent Pelvic Organ Prolapse

---

A 56-yr-old sexually active woman presents with a bothersome, large vaginal bulge. She had a hysterectomy and cystocele repair 5 yr earlier. She voids well and does not complain of incontinence. On exam, she has total procidentia. She desires treatment.

How would you evaluate her, and what are the treatment options—pros and cons? How would you counsel her?

COMMENTARY BY CHRISTOPHER C. ROTH, MD  
AND J. CHRISTIAN WINTERS, MD

This case of a sexually active woman who has developed procidentia following an anterior colporrhaphy presents interesting diagnostic and therapeutic considerations. One must understand the impact of this condition on her quality of life and identify all anatomic defects and any present (or potential) pelvic floor dysfunction. Finally, treatment options with the associated risks and benefits of these interventions must be discussed openly with the patient.

A careful history and physical exam should target bowel, bladder, and sexual function, as well as the patient's goals and expectations of treatment. Widely available validated questionnaires can provide input into the patient's specific voiding or prolapse problems and the effects on quality of life. In this scenario, there is no mention of urinary, bowel, or sexual dysfunction.

A systematic pelvic exam, including inspection of urethral, anterior, apical, and posterior support, is done with the prolapse reduced. Urethral mobility is determined by observation or Q-tip test. A basic assessment of continence is performed by having the patient Valsalva and observing for any leakage per urethra. Although the posterior compartment is reduced, the anterior compartment is assessed for both central and lateral defects. The anterior compartment will be reduced to evaluate the posterior support. Careful inspection of the apex will determine location of the vaginal cuff and any associated enterocele. A rectal exam will determine anal sphincter tone and may help in the diagnosis of enterocele. A clinical classification of the defects, for example, the Pelvic Organ Prolapse Quantification system, can be useful to the clinician to compare the severity of prolapse in each of the respective compartments.

Prior to repair, voiding function needs to be well understood. Obstructive symptoms caused by prolapse should be carefully evaluated. Likewise, occult stress incontinence can be seen once the prolapse is reduced. Urodynamics will provide the most information and should be done with and without reduction of the prolapse via vaginal packing or pessary. We assume that occult stress urinary incontinence was determined on urodynamic testing, and the patient voids normally with the prolapse reduced without coexisting fecal control abnormalities.

In the scenario of a middle-aged sexually active woman, aggressive management of her condition will be needed. Pessaries are the mainstay of nonsurgical management. Although not likely applicable in this scenario, patients should be informed of this nonsurgical option. Surgical management is likely to provide this patient with the best results. This particular patient has recurrent prolapse following anterior colporrhaphy at the time of hysterectomy and is likely going to be concerned with rates of future recurrence. Counseling this patient will largely center on a careful discussion of the various surgical techniques and their associated risks and benefits.

Either a vaginal or an abdominal approach can be considered. In general, vaginal approaches offer less morbidity than abdominal approaches regarding hospital stay and overall convalescence. In addition to supporting the apex, concomitant incontinence procedures and measures to restore anterior and posterior support can be done through the same approach. However, we disclose that, in our experience, the most durable and successful correction of apical prolapse is achieved with an abdominal sacral colpopexy. Even though a combined approach may be needed, the colpopexy ensures the most definitive correction of the apical prolapse and enterocele, which is the major contributing cause to the patient's complex problem. In addition, we disclose that the vaginal axis and length are consistently better following colpopexy. Ultimately, the patient chooses the approach after reviewing the risks and benefits of each.

Our preference in the transvaginal approach to restoring apical support in this scenario is the uterosacral ligament suspension. This procedure restores the apical anatomy by reapproximating the vaginal cuff with proximal remnants of the uterosacral ligaments. In this patient, who undoubtedly has a large enterocele, the enterocele sac is reduced and ligated. In the same operative setting, an anterior-posterior repair and transobturator sling procedure will be performed. The pubocervical and pararectal fascia are included in the sutures that secure the apex of the vagina to the uterosacral ligament. This provides an anatomically sound vagina, restoring adequate depth and axis. Disadvantages of this technique include difficulty in identifying the proximal uterosacral ligaments and the concern of reattaching the apex to an already-deficient structure.

Despite these limitations, we have been satisfied with this approach. The rate of recurrence of apical prolapse after this procedure is approx 11% (1). Rates of sexual dysfunction have been similar for vaginal and abdominal prolapse procedures, with an incidence of 20% (2). However, our experience, as well that of others, points toward increasing rates of dyspareunia with increasing numbers of vaginal procedures (3).

It is for these reasons that we prefer an abdominal sacral colpopexy and enterocele repair. This technique restores apical vaginal support by fixing the vaginal cuff to the sacral promontory with synthetic mesh. We are now performing this procedure laparoscopically, and this has eliminated the abdominal incision and shortened hospitalization. This procedure can easily be performed in conjunction with a midurethral sling procedure. A limitation of this approach is the ability to correct distal pubocervical, pararectal, and perineal body defects.

Some report completing all of the vaginal procedures prior to the colpopexy; however, we have adopted a different approach. We initially perform the abdominal sacral colpopexy and enterocele repair, followed by an assessment of the distal defects. If these defects are not significant, then we have not been repairing them—particularly the anterior compartment. In this particular patient, it is likely that the abdominal surgery will be followed by a posterior and perineal body repair and a transobturator tape procedure because in patients with total procidentia the levator hiatus is often severely

widened and needs correction. With this selective approach, success rates of 97.5% are achieved in correcting the apical defects and enterocele. Distal defects may occur as often as 40% of the time, but most of these defects are minor, and over 80% of the patients are satisfied with their outcome (4).

Thus, we would combine a laparoscopic abdominal sacral colpopexy and enterocele repair with a posterior repair and TOT procedure. An anterior repair would be performed if necessary after reduction of the apex.

## REFERENCES

1. Sze EHM, Karram MM. Transvaginal repair of vault prolapse: a review. *Obstet Gynecol* 1997;89:466.
2. Maher CF, Qataweh AM, Dwyer PL, Carey MP, Cornish A, Schluter PJ. Abdominal sacral colpopexy or vaginal sacrospinous colpopexy for vaginal vault prolapse: a prospective randomized study. *Am J Obstet Gynecol* 2004;190:20–26.
3. Nygaard IE, McCreery R, Brubaker L, et al. Abdominal sacralcolpopexy: a comprehensive review. *Obstet Gynecol* 2004;104:805–823.
4. Blanchard K, Vanlangendonck R, Winters J. Abdominal sacral colpopexy and abdominal enterocele repair for the correction of vaginal vault prolapse. *J Urol* 2005;174:V497(A).

## EDITOR'S COMMENTS BY HOWARD B. GOLDMAN, MD

Drs. Roth and Winters have given us a review of the various surgical treatment options for total procidentia. Current outcomes data would seem to agree with their approach as an abdominal sacrocolpopexy seems to have the fewest reoccurrences. From the vaginal approach, another option besides the uterosacral ligament suspension would be a sacrospinous fixation of the apex. There are data that show a higher rate of cystocele formation, probably because of the change in the vaginal axis.

In the last few years, the number of transvaginal procedures utilizing nonnative materials to supplement the prolapse repair has increased. There have been relatively good outcomes utilizing cadaveric fascia for that purpose, and there have been a number of procedures described using synthetic mesh for this purpose. With use of the synthetic mesh, one has theoretically a permanent material that may help prevent recurrence. This mesh can be used to treat both anterior and posterior components as well as the apex. At this point, most seem to favor the use of a large-pore polypropylene-type material for these types of procedures. Although there are some potential risks with this, including mesh extrusion and infection, to date these have not been too significant. The outcomes data and the follow-up on these patients are minimal at this point, and certainly although many have adopted this approach, more follow-up data are required before one can adequately compare it to the existing procedures.

---

## 8 Recalcitrant Urinary Frequency and Urgency

---

A 36-yr-old woman presents with a 7-yr history of worsening urgency and frequency. She voids 20 times a day and awakens 5 times at night to void. She says that the force of her stream is normal. Her physical exam is normal. Fluid diary reveals an average volume of 60 cc per void. She has failed the standard anticholinergic treatments.

How would you evaluate and treat this woman? What are her treatment options?

### COMMENTARY BY MICHAEL CHANCELLOR, MD

Although the general history and physical exam are reported as normal, I would ask the patient again for specific symptoms that may suggest an occult neurological condition. Specific questions include change in vision, numbness or weakness of the lower extremities, changes in sexual function such as erectile dysfunction or vaginal numbness, and change in bowel function such as new onset of constipation. Essentially, I want to be sure that she does not have an occult lumbosacral radiculopathy or multiple sclerosis. If I am still not convinced, then I will refer her to a neurologist, who I trust would facilitate a workup of occult neurological conditions.

Before discussing treatment with the patient, I will make sure she has a normal urinalysis and not be at risk for bladder carcinoma.

To try to help this patient, I would first offer the option of double-, or rarely triple-, dose antimuscarinic agents. I have had good success using a double dose of antimuscarinic agents such as 30 mg oxybutynin every 24 h or adding 15 mg oxybutynin and 4 mg tolterodine or 40 mg tropsium every 24 h. For refractory cases, I often see improved efficacy with greater dosage of overactive bladder (OAB) medications without doubling side effects. With the “black box” labels slapped on all antidepressants, I do not recommend imipramine anymore as a second- or third-line therapy. I would also recommend pelvic floor biofeedback if she has not done this already, although I doubt biofeedback alone will resolve the refractory OAB.

If an oral agent and biofeedback do not work, then I will offer sacral neuromodulation or off-label use of bladder botulinum toxin injection. In my experience, when cost is not an issue, most patients will choose cystoscopic botulinum toxin injection over the invasive sacral stimulator implantation. In my personal experience, bladder botulinum toxin has worked better than sacral neuromodulation. I have stopped performing bladder augmentation in nonneurogenic detrusor overactivity as the results have not been as satisfactory as in true neurogenic detrusor overactivity, and the patients often are not willing to trade off frequency and incontinence with a big operation that can result in retention and self-catheterization.

If the patient chooses bladder botulinum toxin injection and gives informed consent, I typically use 200 U botulinum type A toxin (BTX-A; Allergan, Irvine, CA) dissolved in 20 mL sterile saline. I have mostly used a flexible cystoscope technique and a 27-French Olympus flexible cystoscopy injection needle. Through a urethral Foley catheter, I first instill 30–50 cc of 1% lidocaine anesthesia and leave the catheter clamped in the bladder for approx 10 min. I focus on placing most of the injection directly into the bladder base, and I have not avoided the trigone. I make a 1.0-cc submucosal bleb raised at each site to maximize horizontal spread of BTX-A within the tissue.

I tell the patients that, in addition to the usual cystoscopic risks, the BTX-A bladder injection is an off-label use of an agent approved by the Food and Drug Administration (FDA) for muscle spasticity, and that unanticipated events may occur, and there is a risk of urinary retention that may last weeks to months. Usually, patients will notice an improvement, not immediately, but after about 1 wk, and then the efficacy will further improve to a maximum at about a month. In my hands, the duration of response is commonly 6 mo. Most interesting and a nice observation is that subsequent injection lasts longer than the first one. So, if the first injection lasts 6 mo, subsequent injections may last 8 mo or longer.

#### COMMENTARY BY GAMAL M. GHONIEM, MD, FACS

This patient has chronic and refractory OAB. Her condition is consistent and progressive, requiring careful evaluation. Her bladder capacity while awake is small and probably true because of her nocturia; she may have a true contracted bladder. Another differential diagnosis may include neurogenic bladder. Approximately 10% of idiopathic OAB patients show neurological symptomatology in 3–5 yr. A common finding with our patient's scenario is multiple sclerosis. Neurological evaluation is recommended.

#### *Evaluation*

Evaluation includes quality-of-life questionnaires like the short form of the Urogenital Distress Inventory (UDI-6) and discussions with the patient about her expectations. The patient is often frustrated at this point because of the long duration of her progressive and severe symptoms in spite of previous anticholinergic treatments, which are significantly interfering with her life. I would perform the following tests:

1. *Urine*: Urinalysis, including microscopic examination to rule out infection and microhematuria, is the first step. Urine culture and urine cytology will be the second step if the urine is positive. Special culture for acid-fast bacilli (to rule out tuberculosis) and urine examination for ova and parasites (to rule out schistosomiasis) should be considered if there is pyuria, microhematuria, or history of foreign travel.
2. *Urodynamics*: Multichannel fluorourodynamics is indicated in this patient. Expected abnormalities could be all or any combination of the following: small bladder capacity, low bladder compliance, detrusor overactivity with early involuntary contractions, detrusor-sphincter dyssynergia, bladder trabeculations, diverticuli, and vesicoureteral reflux.
3. *Cystoscopy*: Cystoscopy is performed to look for bladder tumor, carcinoma *in situ*, bladder calculi, or foreign bodies. It is preferable to do cystoscopy under anesthesia to determine the anesthetic bladder capacity and to perform a biopsy if needed.
4. Upper tract studies may be required with any abnormality. I like to use computed tomography with genitourinary three-dimensional reconstruction.

### *Treatment Options*

If the patient was previously treated with anticholinergic medications, combinations and maximum tolerable dosage are less likely to help. Biofeedback and bladder retraining behavioral technique may help to a small extent. Before considering aggressive surgical options, I would recommend the following:

1. *Intravesical injection of botulinum toxin A (Botox®)*. I use 200–300 U in an office procedure. Botox is injected into the detrusor muscle, not submucosally. This treatment has shown efficacy for treatment of either neurogenic detrusor overactivity or idiopathic OAB in many publications, especially from Europe. At present, it is not FDA approved for urological use.
2. *Neuromodulation*: Implantation of a unilateral S3 quadripolar lead for sacral stimulation has shown efficacy up to 70% in refractory OAB. It is an FDA-approved device for select indications, including frequency of urination. Because I suspect that this patient may have a truly small bladder, I would do a staged implant. Approximately 2 wk after the first stage, her bladder diary and quality of life are reviewed, and if there is significant improvement, she will undergo the second stage; otherwise, the lead is removed.

Urinary diversion is considered if the evaluation and the first-line interventions support this decision, especially if her bladder is end stage (small contracted bladder). Augmentation cystoplasty or even continent diversion would also be valid options.

### **EDITOR'S COMMENTS BY SANDIP P. VASAVADA, MD**

Drs. Chancellor and Ghoniem have demonstrated the evaluation as well as therapeutic options for a patient who has what sounds to be severe overactive bladder. They have both appropriately indicated the need to rule out occult neurological disease in many of these patients. Certainly, minimally invasive therapy would include medications, but often when this fails the patient may need more advanced therapy. Botulinum toxin injections, although considered currently off-label use in the United States, is an option and certainly one of the less-invasive refractory options for management of a patient such as this. We do not know the long-term effects of Botox injections; however, the patient needs to understand, especially at such a young age, that she is likely to require this management for many years. Accordingly, one may consider neuromodulation as first-line therapy in the refractory state of overactive bladder; however, this is a bit more invasive. Neuromodulation may, however, give better single-treatment, long-term management of her problem.

---

## 9 Difficulty Voiding and Overactive Bladder Symptoms

---

A 23-yr-old woman presents with slow onset over the course of 2 yrs of worsening hesitancy and slowing of urinary stream and recent onset of urgency and frequency. Her physical exam is normal. Postvoid residual (PVR) is 100 cc. Urodynamics reveal a detrusor pressure at maximum flow of 28 cc H<sub>2</sub>O and a peak flow of 4 cc/s. Electromyography (EMG) of the external sphincter is normal (not shown on urodynamic studies tracing). Magnetic resonance imaging (MRI) of the pelvis is normal.

How would you treat this patient? What else would you do to evaluate her?

### COMMENTARY BY MICHAEL J. KENNELLY, MD, FACS

When meeting a patient on the initial visit, I have the patient verbalize not only which specific issue they are trying to resolve but also their expectations. The response is critical to the workup and evaluation. An elevated voiding pressure of 28 cm H<sub>2</sub>O and 100 cc residual on an isolated urodynamic study does not warrant further evaluation unless the patient is symptomatically bothered. Assuming that the patient would like to improve her voiding stream and reduce her overactive bladder symptoms, I would begin an orderly evaluation of female bladder outlet obstruction (BOO).

History would include questioning the time-course of symptoms with association of any change in mobility, neurological function, bowel dysfunction, and psychosocial issues. Complete medication review would look for agents that decrease detrusor function (anticholinergics) and agents that increase urethral tone ( $\alpha$ -agonist, norepinephrine/serotonin reuptake inhibition). Past surgical history, including urological and obstetrical history, would be reviewed specifically to look for potential effects on the lower urinary tract.

Beyond the stated physical exam findings, a focused neurourological exam of the S2 through S4 segments of the spinal cord provides insight into lower urinary tract dysfunctions. Various techniques would be done to ascertain if reflex activity, sensation, and volitional control are present. Bulbocavernosus reflex, digital anal reflex, anocutaneous reflex, pinprick and light touch sensation testing of S2–S4 dermatomes, and volitional control of the external anal sphincter would be tested. Cutaneous abnormalities of the lumbosacral back (dermal sinus tract, deep skin pimples, hairy tufts, and hemangiomas) are often present in occult spinal dysraphism. In our office, urinary residual assessment is typically performed with ultrasound. An elevated PVR would prompt urethral catheterization to obtain a true PVR and rule out a urethral stricture. The patient would be asked to complete a 3-d frequency/volume diary to objectively document her symptoms.

Based on the clinical information, the patient appears to have BOO with etiologies that can be neurogenic or nonneurogenic in origin.



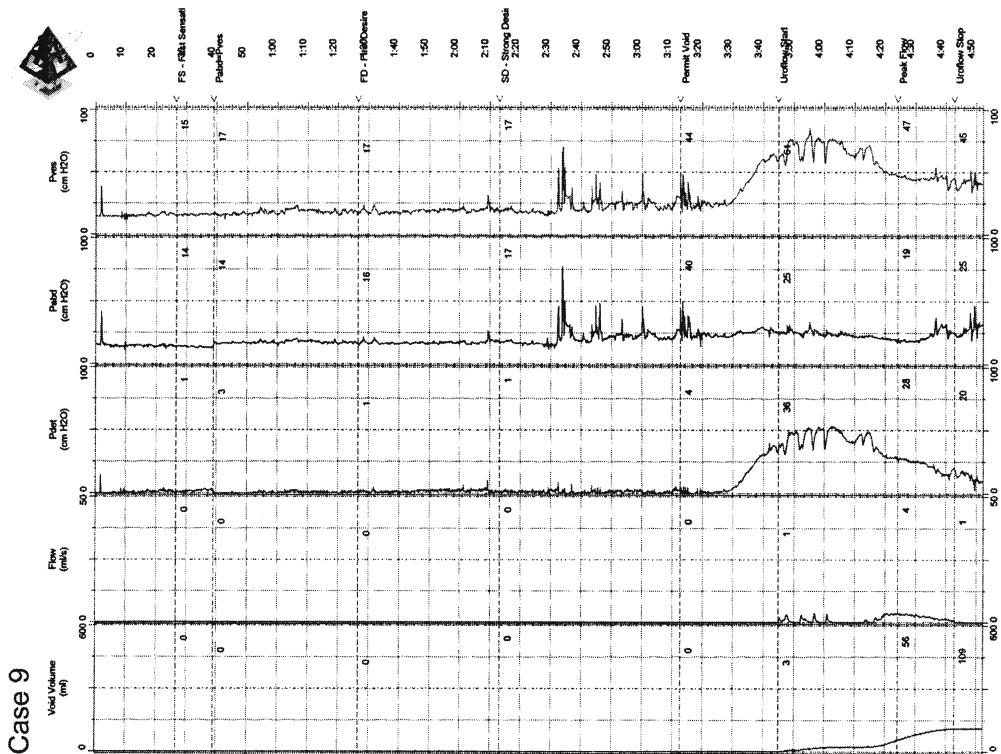


Fig. 1.

### Neurogenic

Positive neurological findings on the exam may indicate a neurogenic etiology for her symptoms, such as multiple sclerosis, unrecognized occult spinal dysraphism, or development of spinal cord pathology.

If I had a heightened suspicion for neurological etiology (despite a normal EMG), I would order an MRI of the central nervous system and refer the patient to a neurologist for evaluation. A patient with multiple sclerosis can have a variety of lower urinary tract dysfunction, including detrusor overactivity, detrusor areflexia, and detrusor external sphincter dyssynergia (DESD). In this patient, BOO may be secondary to DESD. Patients with DESD are evaluated at least annually, monitoring the status of multiple sclerosis, lower urinary tract symptoms, and PVR. Genitourinary complications (repeated urinary tract infections, urinary incontinence, hematuria, and so on) warrant an upper urinary tract (renal ultrasound or computed tomographic urogram) and lower urinary tract (urodynamics and cystoscopy) investigations as appropriate.

### Nonneurogenic

A normal physical exam and MRI of the pelvis ruled out many anatomic etiologies, including an anterior vaginal wall cyst, Mullerian duct remnant, urethral diverticulum, large ovarian cyst, uterine fibroids, and bladder foreign body.

If the patient has had prior lower urinary tract surgery/instrumentation or there is difficulty in urethral catheterization, then cystoscopy would be performed. Urethroscopy allows

visual assessment, localization, and treatment implications of urethral fibrosis/stricture if present. My initial management of a female urethral stricture would be cystoscopy and coaxial dilation. Periodic follow-up office visits (initially 3–6 mo, then annually) would monitor symptoms and PVR. Recurrent strictures would be managed with dilation and self-obturation (less likely) vs urethral reconstruction, which has a more durable effect.

With neurological etiologies excluded, videourodynamics would be performed specifically looking for primary bladder neck obstruction and dysfunctional voiding (nonrelaxation of the pelvic floor). The voiding cystourethrography part of the videourodynamics study is critical in this patient to identify the specific anatomic area of obstruction. Video images reveal a nonopening of the bladder neck in primary bladder neck obstruction (i.e., smooth muscle dyssynergia). Nonrelaxation of the pelvic floor demonstrates intermittent contraction along the midurethra area that may be missed on EMG. Because of confounding variables (patient and catheter), the voiding cystourethrography part of the study would be performed with and without a urethral catheter. Voiding without a catheter often allows improved visualization of the obstruction site. Although no absolute urodynamic criteria exist for differentiating BOO in women, most agree that urodynamics are essential. Important urodynamic parameters are detrusor pressure at peak flow, maximum flow rate (instrumented and uninstrumented), PVR, and radiographically localizing obstruction. According to the Blaivas-Groutz nomogram (1), this patient has mild obstruction (Zone 1) with a detrusor pressure at maximum flow of 28 cm H<sub>2</sub>O and a peak flow of 4 cc/s.

In this patient, whether she had neurogenic or nonneurogenic etiologies of her voiding dysfunction, urological management would be similar. Initially, multimodal conservative management with behavioral therapy and medications would be prescribed. Our Continence Care Center employs specialists who are experts in lower urinary tract function. The behavioral methods they would utilize for this patient would include pelvic physiotherapy, biofeedback, and emptying maneuvers (pelvic tilt, double void, and deep breathing). The focus would be on identification and subsequent relaxation of the pelvic floor muscles to assist in bladder emptying. Electrical stimulation would be used to fatigue the muscle and assist in pelvic floor reeducation. In addition, they would teach urge suppression techniques to help her overactive bladder symptoms.

Medications offered this patient may include  $\alpha$ -adrenergic blocking agents (prazosin [Minipress<sup>®</sup>], terazosin [Hytrin<sup>®</sup>], tamsulosin [Flomax<sup>®</sup>], and alfuzosin [Uroxatrol<sup>®</sup>]) and antispasticity agents (baclofen [Lioresal<sup>®</sup>], tizanidine hydrochloride [Zanaflex<sup>®</sup>], and diazepam [Valium<sup>®</sup>]). In my experience,  $\alpha$ -blockers are effective first-line therapy and seem to be well tolerated. Recalcitrant patients would be offered botulinum toxin injection (Botox<sup>®</sup>) into the external/internal sphincter or neuromodulation of the sacral nerves with Interstim<sup>®</sup> or tibial nerve stimulation. My anecdotal experience with botulinum toxin injections has been promising. Unfortunately, the desired effect on the bladder neck/pelvic floor (skeletal muscle) seems to taper off after 3–4 mo, unlike the usual 6- to 9-mo duration of effect on detrusor smooth muscle injections. Patients with primary bladder neck obstruction who respond to botulinum toxin injection are offered bladder neck incision, which has provided a more durable response.

## REFERENCE

1. Blaivas JG, Groutz A. Bladder outlet obstruction nomogram for women with lower urinary tract symptomatology. *Neurourol Urodyn* 2000;19:553–564.

## COMMENTARY BY DEBORAH LIGHTNER, MD

Her voiding dysfunction evaluation is incomplete without objective evidence of the symptom impact beyond her subjective history. The symptoms should be further quantified by a bladder diary. The AUA symptom index, initially developed for male voiding dysfunction, can also help evaluate the degree of bother and effect on quality of life that these voiding symptoms cause in women (1).

A review of symptoms is critical in determining if she has other system complaints often associated with voiding dysfunction. Many have a history of pelvic trauma; questions regarding sexual abuse are most appropriate. Given the common association of voiding symptoms with other pelvic organ dysfunction, particular attention to bowel and sexual function, prolapse symptoms, and a neurological review of systems is also appropriate.

The physical examination includes an examination of sacral nerve roots, of light touch sensation over the medial thigh and labia, of the patient's ability to identify and contract the pelvic floor, with palpation of the urethra for cysts, other masses, tenderness, or expressible discharge; palpation of the levators; and Valsalva maneuver to briefly assess that there is no high-grade prolapse. The rectal examination evaluates rectal tone, anal wink, and a bulbocavernosus reflex, particularly important as the differential includes several neurological diseases. This tailored brief exam then tailors the radiographic and urodynamic evaluations. For example, the pelvic MRI is an expensive test with low yield, particularly if the history and examination raise suspicions for a neurological lesion, but it rules out extrinsic urethral compression and extraluminal pathology (2). Appropriate cultures for sexually transmitted disease are important in this initial consultation.

The most helpful and cost-effective urodynamic test, not supplied to us, would be uninstrumented free urinary flow, including the contour, peak, and average flow rates. An uninstrumented free flow greater than 15 mL/s, a voided volume of greater than 100 cc with a low PVR volume would have been good screening evidence of no obstruction. Here, we are given the results of the more expensive gold standard test: Her pressure flow study reveals both a decrease in the flow rate (less than 15 mL/s is suspicious for outlet obstruction) and an increase in the maximum voiding pressure (>20 cm H<sub>2</sub>O water is highly suspicious); by all female pressure flow nomograms, the high-pressure/low-flow combination is diagnostic of a degree of BOO. With a detrusor capable of compensating, she remains able to empty adequately. Assuming that these urodynamics values are obtained appropriately with the urodynamics catheter size sufficiently small to reduce catheter artifact and that a multichannel system is used to adequately subtract the influences of changing intraabdominal pressures, adding fluoroscopy to the urodynamic study could be helpful in determining any possible anatomic sites of obstruction.

Most urodynamic equipment is equipped only for patch electrode EMG studies; hence, this screening patch EMG reported as normal does not rule out the possibility of either a pseudodyssynergic or truly dyssynergic voiding pattern; both remain high in the differential of a young woman with BOO.

A cystoscopic examination with careful attention to urethral distortion by compression or intraluminal pathology and to bladder neck is necessary. Retroflexion of the cystoscope to view the bladder neck should be included.

Treatment is predicated on the etiology of the outlet obstruction, which in this case may still be either functional or anatomic. BOO occurs in the setting of voiding symptoms in

8% (3) to 23% (4). Studies of BOO in females suggest that voiding dysfunction, particularly in a young patient, is the most likely; anatomic causes, such as cystocele (unlikely without high-grade prolapse on examination) and primary bladder neck obstruction account for the majority of women who have not had prior antiincontinence surgery. If she proves to have a dysfunction outlet on video studies, then she may report dyspareunia and have inducible pelvic floor spasm on physical examination. Again, all women with these complaints should be queried regarding risk for sexually transmitted diseases or history of instrumentation or abuse. A truly dyssynergic outlet should be ruled out, with careful determination if the patient has other signs or symptoms of a neurological disease.

Completion of this examination may necessitate a formal neurological evaluation. Parenthetically, the presence of an overactive bladder and BOO are presumptive evidence of a neurological lesion. However, detrusor overactivity on the urodynamic study is not reported here. Hence, although there is nothing in provided urodynamic information is highly suggestive of neurological etiology, noting that a patch EMG is not reliable evidence for the lack of a dyssynergic outlet. Assuming a normal neurological examination (no occult cord lesion or evidence of a demyelinating disorder), a normal videourodynamic study and cystoscopy (e.g., no delayed or incomplete opening of the bladder representative of primary bladder neck obstruction, no strictures), we are left with the presumptive diagnosis of dysfunctional voiding and hold discordant information that the presumably abnormally high tone of the pelvic floor leading to the BOO and dysfunctional voiding could not be detected by the high false-negative patch EMG.

Pelvic floor muscle relaxation and biofeedback may be helpful in patients with isolated pelvic floor dysfunction. Often associated with a traumatic history or dysfunctional bowel and sexual symptoms, these patients respond well to treatment of associated constipation, pelvic floor relaxation exercises, biofeedback, and even physical therapy (5). Urethral dilation plays no role in voiding dysfunction without a demonstrable anatomic stricture; this form of BOO is uniquely rare in women. The use of  $\alpha$ -adrenergic antagonists is described, but the results are unimpressive in my hands. Failing these conservative and less-costly treatments, the use of sacral neuromodulation can be curative of the voiding dysfunction (6,7). Botulinum toxin injected into the external sphincter can also be temporarily curative, clinching both the diagnosis and an effective therapy (8).

## REFERENCES

1. Scarpero HM, Fiske J, Xue X, Nitti VW. American Urological Association Symptom Index for lower urinary tract symptoms in women: correlation with degree of bother and impact on quality of life. *Urology* 2003;61:1118–1122.
2. Neitlich JD, Foster HE Jr, Glickman MG, Smith RC. Detection of urethral diverticula in women: comparison of a high resolution fast spin echo technique with double balloon urethrography. *J Urol* 1998; 159:408–410.
3. Blaivas JG, Groutz A. Bladder outlet obstruction nomogram for women with lower urinary tract symptomatology. *Neurourol Urodyn* 2000;19:553–564.
4. Nitti VW, Tu LM, Gitlin J. Diagnosing bladder outlet obstruction in women. *J Urol* 1999; 161:1535–1540.
5. Weiss JM. Pelvic floor myofascial trigger points: manual therapy for interstitial cystitis and the urgency-frequency syndrome. *J Urol* 2001;166:2226–2231.
6. Spinelli M, Bertapelle P, Cappellano F, et al. Chronic sacral neuromodulation in patients with lower urinary tract symptoms: results from a national register. *J Urol* 2001;166:541–545.
7. MaLossi J, Chai TC. Sacral neuromodulation for the treatment of bladder dysfunction. *Curr Urol Rep* 2002;3:61–66.
8. Frenkl TL, Rackley RR. Injectable neuromodulatory agents: botulinum toxin therapy. *Urol Clin North Am* 2005;32:89–99.

---

**EDITOR'S COMMENTS BY HOWARD B. GOLDMAN, MD**

The treatment of women with bladder obstruction without an obvious anatomic site of obstruction can be challenging. Our reviewers have summed up the basic evaluation and management of women with such problems. For those who have primary bladder neck obstruction, Botox or neuromodulation can be effective, but they can also be expensive. A transurethral incision of the bladder neck is fairly easy with high efficacy rates and only a small risk of stress incontinence; it should be discussed with the patient in that setting.

---

# 10 Post-Hysterectomy Incontinence

---

A 54-yr-old woman presents for a second opinion concerning her urinary incontinence, which started after an abdominal hysterectomy. She notes increased leakage with cough, sneeze, and laugh but notes that she seems to have leakage even when still and at night in bed. She cannot recall any time that she is actually completely dry. On exam, she has urine in the vaginal vault but does leak per urethra with straining. She has significant urethral hypermobility. An intravenous pyelogram is normal. A cystogram shows contrast entering the vagina. Cystoscopy shows two small ostia in the bladder base away from the ureteral orifices.

How would you proceed?

## COMMENTARY BY COURTENAY K. MOORE, MD

With the history, the suspicion for a vesicovaginal fistula is extremely high. On physical examination, the patient also has reproducible stress urinary incontinence *per urethra*. The cystogram confirmed evidence of contrast entering the vagina, which confirms a fistulous track at the apex of the vagina. Cystoscopy also confirmed the diagnosis, demonstrating two small ostia at the bladder base. A pyridium pad test or methylene blue instillation in the bladder and confirming evidence of blue dye effluxing the apex of the vagina would also be suggestive of a vesicovaginal fistula. The intravenous pyelogram was done to confirm the integrity of the upper urinary tracts, ruling out the possibility of a coexistent ureterovaginal fistula. In the differential diagnosis, peritoneovaginal fistula should be considered. A peritoneovaginal fistula could present with similar symptoms and physical exam; however, both the pyridium pad test and cystogram would be negative.

Therapeutic options should then be discussed with the patient and may include initial conservative management with urethral catheter if the leakage is minimal. Although there are reports using fibrin glue and electrocauterization of the fistulous tract, these are small series, and the data are inconclusive. Assuming that the leakage does not resolve after a prolonged period of time (2 wk) of Foley catheter drainage, definitive surgical correction (vaginal or abdominal) should be discussed. The time of repair remains somewhat controversial. Some surgeons will attempt to repair the fistula several days to a few weeks after the injury. However, early intervention should not be attempted in the face of active inflammation or infection.

The main determination of when and how to repair the fistula appears to be based on surgeon comfort and anatomy. If there are one or two small adjacent ostia accessible vaginally, a vaginal approach is desirable. Given the fistula is accessible vaginally, I would perform a transvaginal vesicovaginal fistula repair with a peritoneal-based vascularized-interposition graft covering the entire repair. Contraindications to performing a transvaginal procedure would be active inflammation, obvious infection, evidence of healing early

in the postoperative period, and markedly diminished bladder capacity secondary to radiation or other changes within the bladder. It is important to remember that the patient also had evidence of leakage per urethra. One can contemplate a vaginal sling at the time of the fistula repair. If a sling is done simultaneously, then it should be a tension-free sling to minimize the risk of postoperative complications, such as postoperative urinary retention. After performing a good apical vaginal fistula closure, one would not want to place the repair under undue tension or stress, like voiding against a higher degree of urethral resistance. Alternatively, the stress incontinence could be done in a staged approach at a later date.

An abdominal approach to the vesicovaginal repair with interposition of either perivesical or omental fat is another option. In these cases, it is best to bivalve the bladder through the fistula tract, followed by closure of both the vagina and bladder. The bladder is closed using interrupted sutures near the fistula tract, followed by a standard running closure of the remainder of the bladder. At the time of an open abdominal vesicovaginal fistula repair, it is important to identify the ureters. Intraoperative placement of 5-French feeding tubes allows identification of the ureters to avoid iatrogenic injury.

Postoperative care in both cases involves a urethral Foley and suprapubic tube. The urethral catheter can be removed prior to discharge, leaving the patient with a suprapubic catheter to minimize postoperative bladder spasms. The use of postoperative anticholinergics and antibiotics is prudent to prevent bladder spasms and infections, respectively. A cystogram is obtained 2 wk postoperatively to confirm closure of this fistula site. The suprapubic tube is removed if the cystogram is negative.

#### EDITOR'S COMMENTS BY SANDIP P. VASAVADA, MD

Dr. Moore thoroughly describes the treatment approaches for repair of a vesicovaginal fistula. Ultimately, as noted, the timing of the repair as well as the approach are based on both patient factors and surgeon preference. Treatment of the patient's stress urinary incontinence can be done at the same time as the fistula repair; however, as noted by Dr. Moore, it is particularly important in a case like this not to cause outlet obstruction. If one were to do an abdominal repair of the fistula, a Burch procedure certainly could be considered, whereas with a vaginal approach, a nonobstructing midurethral sling, which would be well away from the area of repair, would be a good choice.

---

# 11 Severe Incontinence After Multiple Prior Procedures

---

A 72-yr-old active woman presents for evaluation of incontinence. She leaks with any sort of activity and wears 11 pads per day. She rarely goes to the bathroom as the bladder rarely fills—it all leaks out. The only time the bladder fills and she has the urge to void is at night in bed, and as soon as she gets the urge, the bladder completely empties before she even stands up. She has had an autologous fascial sling at the bladder neck and four treatments with a bulking agent, all with minimal improvement. On exam, she has no prolapse or urethral hypermobility. Urodynamics show no detrusor overactivity, a capacity of 245 cc, and a Valsalva leak-point pressure of 41 cm H<sub>2</sub>O.

Would you do anything else to evaluate her? What are the treatment options?

## COMMENTARY BY ROGER DMOCHOWSKI, MD, FACS

The woman with mixed urinary incontinence (MUI) represents probably the most common clinical scenario for women with bothersome incontinence who seek therapy. This presentation is often confounded by prior surgical intervention for stress incontinence, as in the case presented here for discussion.

No single paradigm can completely address the clinical evaluation and therapeutic management in this scenario; however, several caveats and options do exist. It is our preference to evaluate this woman as completely as possible. A subjective and objective assessment of incontinence is crucial, as is a one-item assessment of the woman's bladder condition (PPBC). We prefer a combination of quality-of-life estimation, a PPBC, and an assessment of those symptoms most bothersome to the individual. It is often difficult for women to segregate their symptoms, but an early estimate of degree and magnitude of stress and urge symptoms can at least frame the patient presentation.

From an objective standpoint, clinical evaluation should include history and physical (with emphasis on vaginal examination to identify hypersuspension of the proximal urethra, concomitant anterior vaginal compartment prolapse, and any other associated vaginal compartment prolapse), and testing. We would perform urodynamic studies (UDS) in this circumstance given the prior interventions and their associated failure. UDS are crucial for identifying not only urethral dysfunction, but also associated storage abnormalities (detrusor overactivity, bladder compliance abnormalities, and sensory changes, such as either loss of or delay in normal sensation or, in contradistinction, sensory overactivity) and pressure/flow aberrancies (low pressure or poorly sustained detrusor contractions, or high-pressure/low-flow voiding, possibly indicating outlet obstruction).

We also feel that cystoscopy is a valuable adjunctive diagnostic tool. Cystoscopy will exclude bladder pathologies such as foreign bodies and assist in the identification



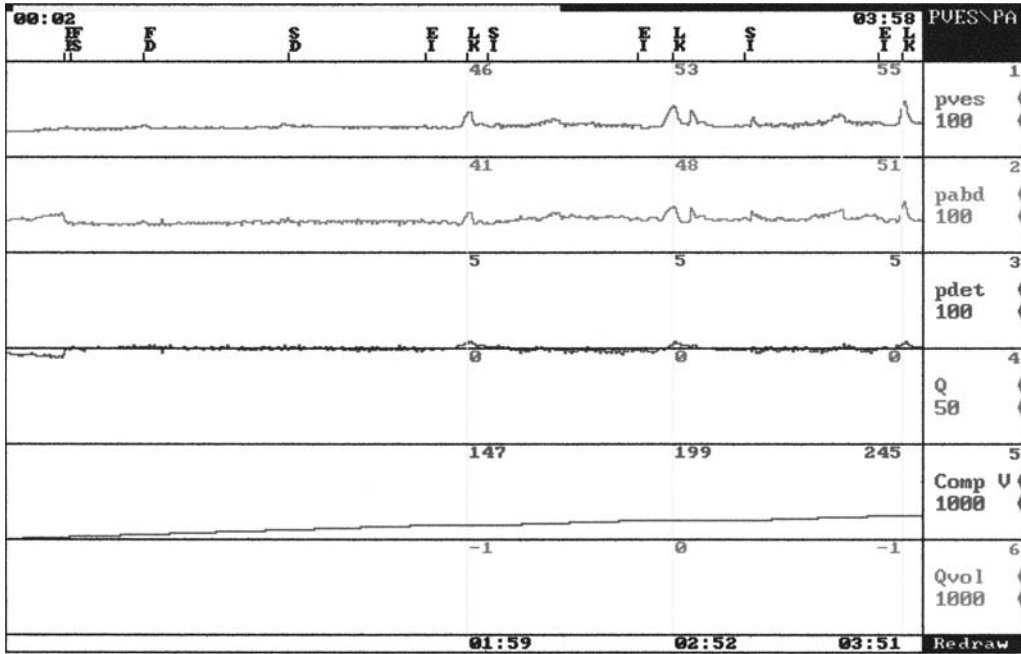


Fig. 1.

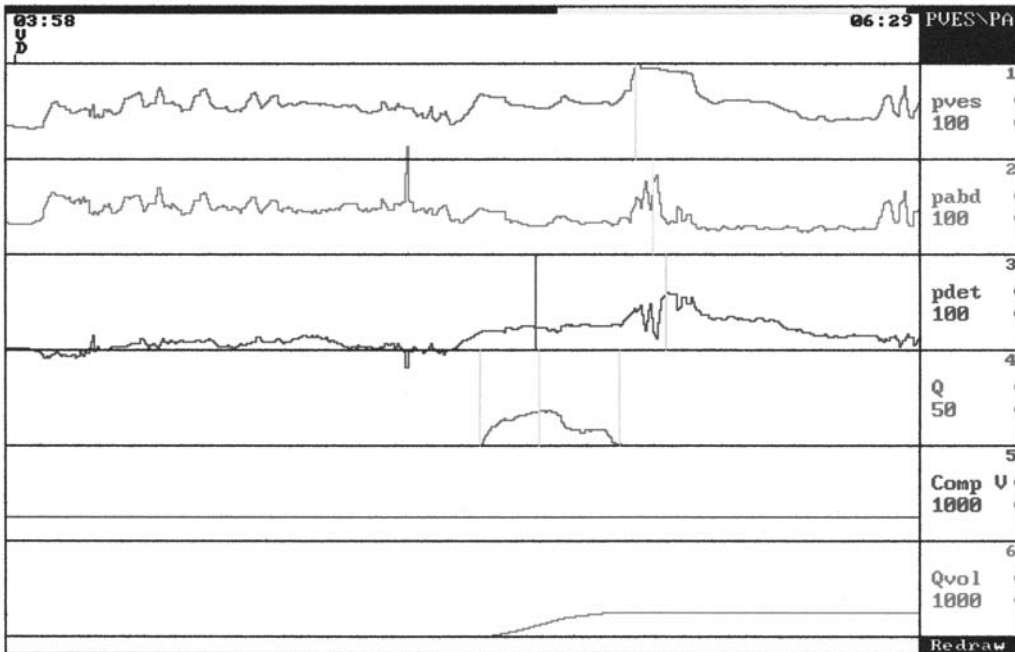


Fig. 2.

of subtle urethral obstruction (acute angulation of the urethra in relation to the bladder). A bladder diary may be particularly beneficial for women with significant urgency and frequency. We tend not to use pad testing but occasionally will do so in persistently problematic diagnostic scenarios.

At this juncture, a reappraisal of the varying contributions of stress and urgency symptoms is important, as is a frank discussion regarding patient expectations for therapy. We prefer to frame the therapeutic discussion in the context of the degree and relative contributions of MUI and realistic outcomes for the particular individual. The importance of conveying the concept of symptomatic improvement as opposed to resolution cannot be overestimated during this discussion.

Assuming a substantial urgency component, a presumptive trial of anticholinergic agents is reasonable and would be an early option in our paradigm. A degree of improvement may be predictive of the need for these agents after intervention for any outlet dysfunction. In the circumstance of predominant urgency, this trial will dictate further interventions aimed at improving bladder storage abnormalities.

In those women with pure mixed symptoms (relative equal contributions) or with stress-predominant MUI, outlet therapy almost certainly will be dictated to achieve symptomatic improvement. In the scenario of this patient, we would offer either bulking therapy or a sling. Many would also consider behavioral or pelvic floor exercise regimens, and certainly this should be mentioned to the patient; however, in the case of prior surgical failure, it is our impression that the overall benefit of these therapies is somewhat less than in the woman who has not undergone prior therapies. Bulking offers a reasonable option and often is our first treatment, especially if there is relatively depressed urethral function, as measured by leak-point pressure evaluation (with or without urethral hypermobility). It can also be used sequentially with secondary surgical therapy.

Surgical therapy for this case would be founded on some type of sling. Often, in our hands, an autologous pubovaginal sling is used when surgical failure has occurred with one of the newer sling modalities (i.e., alternative material or midurethral placement). We will occasionally use a secondary midurethral tape if persistent hypermobility is present, but in the circumstance of an immobile urethra or relative urethral fixation, we prefer the autologous sling as the optimal salvage procedure.

We often find that this paradigm provides reasonably successful outcomes and patient satisfaction. However, there is no substitute for patient education and a clear delineation of patient expectations and reasonability of outcomes in the circumstances of prior failed interventions.

#### EDITOR'S COMMENTS BY HOWARD B. GOLDMAN, MD

The patient with severe incontinence who has already failed multiple treatments is a challenging problem for the clinician. The patient in this case who goes through 11 pads a day and has already has a bladder neck sling and treatment with bulking agents is one such patient. During urodynamic evaluation, detrusor overactivity was noted; however, given the severity of the stress incontinence, one cannot be totally sure how the bladder will function when it is allowed to fill without almost continuous leakage because of an incompetent sphincter. The fact that the patient does not leak while in bed at night and only leaks on standing up gives some indication that it may not be abnormal detrusor overactivity that is causing her problem. In this case, treatment of the bladder outlet first would certainly be an appropriate option; however, the patient would need to understand

that treatment for overactive bladder symptoms may be necessary once she has adequate sphincteric competence.

Certainly, another trial with a bulking agent is a good way to start treatment of this patient; however, given that she has already failed multiple other bulking agent treatments, the likelihood of success is perhaps diminished. She had already failed one autologous fascial sling, although some of the failure may have been because of technical issues, and one could try another fascial sling. However, another option that may give the best chance of achieving adequate sphincteric resistance would be a synthetic midurethral “wraparound” sling. These slings, which have recently been described and shown to be effective, are formed by taking a long strip of synthetic mesh, then dissecting around the urethra and passing the ends of the sling to the contralateral side above the urethra and up and out through a prepubic incision. The success rates with these have been relatively good; however, there certainly is a risk of requiring long-term intermittent catheterization. Once the stress incontinence is addressed, any further issues related to overactive bladder symptoms can be dealt with in the standard fashion.

---

# 12 Urinary Frequency and Pelvic Pain

---

A 41-yr-old woman complains of urinary frequency and pelvic pain. Three years earlier, she began to have “recurrent urinary tract infections.” Cultures were always negative. Since then, she has developed significant urinary frequency and pelvic pain that seems to intensify when she needs to void. She also has significant dyspareunia and says this is ruining her life. She has had a normal office cystoscopy, normal pelvic magnetic resonance imaging (MRI), and urodynamic studies that show early sensation of need to void but no detrusor overactivity or emptying problems. She has been on Elmiron, Atarax, multiple anticholinergics, amitriptylene, and occasionally narcotics for the pain—all without any significant improvement. On exam, she has no prolapse but does have diffuse tenderness throughout the vagina and appears to have a tense pelvic floor by palpation.

How would you proceed with this patient?

## COMMENTARY BY E. ANN GORMLEY, MD

Ideally, when a patient with this case history makes an appointment, they are asked to send us all office notes from their primary care provider, other urologists, or gynecologists and the results of all diagnostic tests pertaining to the diagnosis. The urodynamic tracings and films are also obtained. After receiving and reviewing the appropriate records, a 30-min visit is booked. With the information confirmed from our review of the correspondence, the purpose of the first visit is to obtain more information from the patient and to begin to treat the patient’s symptoms. In some cases, after a review of the records, additional testing may need to be performed or repeated.

When the patient is first seen, a more detailed history is obtained. The following questions are asked to add to the information that we already have:

1. Is her pain episodic or constant?
2. Does she have good days and bad days? How many bad days does she have per month?
3. How often does she void? What is the longest she can hold urine during the day and at night when she is having a relatively good day?
4. Are her pain and or frequency at all related to her menstrual cycle?
5. More details are asked about previous treatments. Specifically, how long did she take Elmiron and amitriptylene? Did she notice any improvement, and if so, was it her pain or frequency or both that improved? Has she tried taking nonsteroidal antiinflammatory drugs for the pain, and if so, have they helped?
6. Are her symptoms at all affected by diet, and if so, what foods are aggravating?

The physical exam is repeated to assess the patient’s ability to relax her pelvic floor. This is done by asking the patient during the pelvic or rectal exam to first tighten and then relax her pelvic floor.

The diagnosis is then explained to the patient. She is told that urinary tract infections, urethral diverticulum, ovarian pathology, and bladder cancer have all been ruled out by negative cultures and normal MRI and office cystography. The patient is told that the most likely diagnosis is interstitial cystitis (IC). It is explained that the diagnosis is based on her symptoms, the urodynamic finding of sensory urgency, and the lack of other diagnosis. IC is described to the patient as a chronic inflammatory disease affecting the lining of the bladder that waxes and wanes and that is rarely progressive. The patient is advised that the goal of therapy is to control her symptoms, and like many chronic diseases, the optimum treatment is long-term multimodality therapy. Further explanation regarding what is and is not known about the disease is also provided. Written patient information on the disease and treatment options, including the IC Association patient education brochures on diet and sex, are also provided.

Treatment, based on the patient's symptoms, is then prescribed. If she has noted that her symptoms are affected by diet, the IC diet, published by the IC Association, is reviewed.

If the patient is unable to relax her pelvic floor, then she is offered a referral to physical therapy to learn to relax her pelvic floor. Because pain is significant in this patient, she is advised to take nonsteroidal antiinflammatory drugs daily, with 200 mg feldene twice daily or 200 mg ibuprofen three times daily generally prescribed. If ibuprofen is used, then additional ibuprofen, for a total of 800 mg three times a day, may be taken during flares.

If amitriptyline was not tried for a minimum of 8 wk and was not given throughout the day, then the patient is advised to try it again. Amitriptyline, with its anticholinergic and antiinflammatory properties as well as its effect on neuropathic pain, is prescribed to help pain, frequency, and sleep. Initially, 10 mg amitriptyline three times daily is prescribed with a warning regarding severe fatigue for the first 2 wk. Patients who have not tolerated the fatigue in the past are started with 10 mg at bedtime and then instructed to titrate the drug by 10 mg when they are no longer tired. Once the patient has been on 10 mg three times daily for 8 wk without adequate symptomatic relief, they are increased to 25 mg three times a day.

If the patient fails amitriptyline as prescribed here, then neurontin is started. The starting dose is 100 mg three times daily, and then the dose is titrated every 1–2 wk until a maximum dose of 800 mg three times a day is reached.

Elmiron is restarted if the patient did not try it for at least 6 mo. Patients are advised that Elmiron may take 6–12 mo before the full benefit is noted. Elmiron instillations, consisting of 100 mg Elmiron mixed with a vial of sodium bicarbonate and a vial of lidocaine, are used during flares for patients who describe good days and bad days, or they may be used in patients who have chronic pain. Instillations are generally given three times per week for 2 wk, and patients can be taught to do their own instillations.

A cystoscopy and hydrodistention under anesthesia are only performed when the outcome will affect treatment or if the patient is going to undergo an anesthetic for some other reason. Previously, hydrodistention was felt to be therapeutic; however, it rarely is, and when it is, the results are often short-lived. A hydrodistention is often done prior to considering dimethyl sulfoxide instillations or performing neuromodulation. The most valuable piece of information that is obtained from the hydrodistention is the bladder capacity. A good bladder capacity under anesthesia, more than 500–600 cc, bodes well for the patient because long term if her pain can be controlled, then her frequency will ultimately be controlled. Conversely, a poor bladder capacity under anesthesia (<200 cc)

is a poor prognostic sign because the patient will likely always have frequency even once her pain is managed.

Bladder capacity can also be inferred by history and confirmed by having the patient do a voiding diary in which she is asked to measure her output. The potassium sensitivity test is not used because it is painful. The PUF score is administered at all office visits to evaluate response to treatment.

Once patients are started or restarted on any or all of the drugs mentioned, plans are made to see the patient in 3 mo. Patients are told to call prior to that if they would like to consider Elmiron instillations or if their pain is poorly controlled. Patients who do not get relief of pain with nonnarcotics are referred to a pain clinic prior to starting long-term narcotic usage. If a patient has failed all of the behavioral and medical treatments mentioned, sacral nerve stimulation may be considered. Patients are advised that sacral neuromodulation with a sacral stimulator can be effective for patients with pain and frequency from IC; however, little is known about the durability of the response. Pudendal nerve stimulation has been shown to have an even greater improvement in frequency and urgency than sacral nerve stimulation in IC patients, but even less is known about durability. Dimethyl sulfoxide is offered to patients who have failed oral therapy prior to consideration of sacral neuromodulation.

In conclusion, this patient with symptoms of IC would be offered combination behavioral and medical therapy with a variety of drugs either alone or in combinations. Efforts would be made to control her frequency and pain. She would be offered oral therapies as well as intravesical agents before being offered neuromodulation. She would be followed at 3-mo intervals both subjectively and objectively, with the final goal control of symptoms so that she can lead a reasonably normal life.

#### EDITOR'S COMMENTS BY SANDIP P. VASAVADA, MD

Dr. Gormley has demonstrated well her evaluation as well as therapeutic options for a patient with potential IC. She has correctly stated that numerous therapies have been used and work in small series; however, no single treatment algorithm seems to have been able to manage the majority of patients in this situation. Refractory therapies, neuromodulation, and intravesical therapy have been only moderately successful. She is correct in her statement that most patients will require some combined form of behavioral and medication therapy as well as potentially other more invasive therapeutic options for ultimate management so they can resume a reasonable quality of life.

#### EDITOR'S NOTE

How would you manage this differently if the patients pain was not related to voiding?

#### COMMENTARY BY JEFFREY P. WEISS, MD

The history and evaluation presented is significant for having narrowed the long list of possibilities of female pelvic pain to a disorder known as pelvic floor dysfunction (PFD). Negative urine cultures rule out chronic cystitis; normal cystoscopy militates against carcinoma *in situ*, although I would like to see normal urinary cytologies and urine for acid-fast bacilli. Urethral swabs for chlamydia would be appropriate in the course of the workup of this woman. An upper tract study to rule out hydronephrosis or hydrocalyx should accompany the workup to exclude genitourinary tuberculosis.

High-pressure/neurogenic voiding dysfunction is excluded by the normal urodynamic studies; the neurourologic exam was presumably normal.

Diffuse, as opposed to focal, vaginal tenderness plus a normal pelvic MRI and absence of infection are taken to exclude the diagnosis of urethral diverticulum, which are commonly associated with female lower urinary tract symptoms and dyspareunia. IC often presents with pain relieved by voiding, which is not the case in our 41-yr-old, who in any case did not respond to Elmiron. A 24-h voiding diary would be useful to evaluate the typical volume of her voids and whether bladder capacity is better during hours of sleep than day. If that were the case, then a functional as opposed to physical explanation for her symptoms would exist. Urodynamic demonstration of a stable detrusor, albeit with early sensation to void, along with diary evidence for small volume voids suggest a diagnosis of sensory urge voiding dysfunction. However, the constellation of detrusor hypersensitivity, pelvic pain/tenderness, and dyspareunia all point to the diagnosis of PFD.

The pathogenesis of PFD is thought to be related to discoordination and excessive tone of the pelvic floor musculature (PFM). Elements of PFM include the pubovaginalis, puborectalis, iliococcygeus, as well as related anal sphincter, obturator internus, and piriformis muscles. The PFM forms a hammock in the pelvis and acts as a sling for the rectum, vagina, and urethra. Owing to the complex relationship between the various components of these pelvic structures, it is not surprising that on occasion there is failure of appropriate contraction and relaxation, as exemplified by inappropriate contraction of the vaginal sling muscles during intended intercourse, at which point contraction of both the urethral and anorectal hammocks is appropriate.

A theory regarding the etiology of pelvic pain has been proposed as caused by excessive tension in relatively short pelvic floor muscles, the *short pelvic floor*. Related lower urinary tract symptoms and dyspareunia may be treated by pelvic floor reeducation techniques, which involve biofeedback-mediated recognition of pelvic muscle function/contraction as well as local physiotherapy of the involved muscle bellies and their tendinous insertions. These structures may be identified as excessively tense by experienced urologists and physical therapists and may respond to therapy that emphasizes myofascial release of trigger points identified during digital rectovaginal examination.

Administration of low-dose benzodiazepines (e.g., diazepam) as well as warm baths may be useful adjuncts to massage-related therapy. Constipation should be identified and treated in the standard fashion. Instructing patients to relax during micturition and defecation will thwart the tendency to further tense pelvic floor structures, which have a primary function of maintenance of continence. Transrectal administration of low-intensity electrical stimulation is useful in patients who are not excessively sensitive to such stimuli and can help create an awareness of their voluntary pelvic floor muscles to teach contraction/relaxation, with emphasis on the latter. Bladder hydrodistension and instillations, topical hormone creams, urethral dilatation, anticholinergics, and  $\alpha$ -blockers have not generally been helpful in treatment of these patients.

In summary, the emphasis in treatment of PFD is pelvic floor muscle relaxation to match pelvic muscle tightness and spasm as its suspected pathophysiology.

## REFERENCES

1. Fitzgerald MP, Kotarinos R. Rehabilitation of the short pelvic floor. I: Background and patient evaluation. *Int Urogynecol J* 2003;14:261–268.

2. Fitzgerald MP, Kotarinos R. Rehabilitation of the short pelvic floor. II: Treatment of the patient with the short pelvic floor. *Int Urogynecol J* 2003;14:269–275.
3. Weiss JM. Pelvic floor myofascial trigger points: manual therapy for interstitial cystitis and the urgency-frequency syndrome. *J Urol* 2001;166:2226–2231.
4. Butrick CW. Discordant urination and defecation as symptoms of pelvic floor dysfunction. In: *Pelvic Pain. Diagnosis and Management* (Butrick CW, ed.), Lippincott, Williams, and Wilkins, Philadelphia, 2000.

#### EDITOR'S COMMENTS BY SANDIP P. VASAVADA, MD

Dr. Weiss has touched on a common issue that I think is often overlooked in the majority of general urologic as well as female urological care and that is pelvic floor dysfunction (PFD). One must realize that patients with PFD may present with a variety of symptoms and complaints, and he has appropriately isolated this. In our experience one should have access to a good physical therapist or other specialist to help in evaluating and managing these patients as often this is our first line of therapy and can be successful. It seems that many patients have never been treated appropriately for this, and I believe that once this continues long term they do not respond quite as well to the simple therapeutic measures that he has described. In these cases, selectively they may require more invasive management, including neuromodulation, as the next step in management.



---

# 13 Pelvic Organ Prolapse

---

A 55-yr-old woman presents with significant apical and anterior vaginal wall prolapse. She had a hysterectomy 5 yr earlier and a cystocele and rectocele repair and uterosacral vault suspension 2 yr ago. Currently, she is bothered by the prolapse, has difficulty voiding, and has a postvoid residual (PVR) of 200 cc. She does not note any incontinence. She is not interested in a pessary.

What further work-up is required? How would you treat her?

## COMMENTARY BY SHLOMO RAZ, MD AND MATTHEW P. RUTMAN, MD

A new patient presenting with voiding symptoms and prolapse would undergo a complete evaluation. This would include a routine history and physical examination. History should document any prior anti-incontinence procedure. Pelvic examination would be evaluated by the Pelvic Organ Prolapse Quantification grading system. Urinalysis and PVR would be checked.

With a history of previous surgery and elevated PVRs, this patient would undergo evaluation with videourodynamics, magnetic resonance imaging (MRI) for prolapse, and cystoscopy. Urodynamics evaluation would evaluate the patient for stress incontinence, detrusor instability, obstructive voiding, and demonstrate the grade of cystocele with the patient in standing position. In our experience, performing urodynamics is critical in patients with prior surgery or voiding complaints. The MRI study provides excellent anatomic pictures of the anterior, apical, and posterior vaginal wall and often shows more prolapse than that seen on pelvic examination. Patients with severe anterior wall prolapse develop obstructive uropathy in up to 5% of cases, and MRI includes upper tract imaging. MRI also rules out any concomitant pelvic pathology, such as ovarian disease. Cystoscopy is performed in patients with voiding symptoms and prior surgery and is important to document absence of suture or foreign body.

Based on the patient's desire to avoid a pessary, we would recommend surgical correction. In a patient with significant apical and anterior vaginal wall prolapse, it is rare not to have posterior wall and perineal body descent. If the patient has not had a prior anti-incontinence procedure, then we place a prophylactic sling along with cystocele repair. In our series of over 600 distal urethral polypropylene slings, no patients are in retention. It is a 20-min procedure that adds no morbidity. No anti-incontinence procedure is done if the patient had a prior bladder neck procedure and is obstructed clinically or urodynamically.

Based on prior experience with failures of slings and cystocele repair without surrogate materials, we now advocate total mesh reconstruction. This is based on the premise that sewing attenuated tissues together will not provide a durable repair. This

mesh reconstruction includes a mesh sling, paravaginal mesh repair for the cystocele, and a mesh reconstruction for vault/enterocele/rectocele, even in patients with no prior failures.

The patient is placed in the lithotomy position and prepped in standard sterile fashion. Intravenous antibiotics are administered, and a ring retractor is positioned. A distal urethral polypropylene sling is placed as previously reported.

Attention is now turned to repair of the grade IV cystocele. The cuff of the vagina is marked. A vertical incision is made from the bladder neck to the cuff of the vagina. Dissection is performed around the perivesical fascia laterally to expose the obturator fascia and distally to the bladder neck. Proximally, the enterocele sac is identified and freed completely from the rectal wall posteriorly and bladder anteriorly. Two laparotomy pads are inserted into the peritoneal cavity, and the bladder is retracted anteriorly. A soft Prolene mesh in the shape of a T is prepared. The center segment is  $3 \times 7$  cm with two lateral segments of  $4 \times 1$  cm.

To repair the vaginal vault, a 1-0 Vicryl suture is placed through the vaginal wall in the area of the cuff. It is then passed into the peritoneal cavity, between the levator and rectal wall, incorporating the perirectal fascia and the origin of the sacrouterine ligament 1–2 cm from the sacrum. After incorporating a strong bite of tissue, the transverse arm of the mesh is included, and a second purchase of the sacrouterine ligament is taken. The needle is brought out the vaginal wall 1 cm from the original entrance. The same maneuver is performed on the contralateral side.

The enterocele sac is now closed. Two 1-0 Vicryl sutures are placed in a purse-string fashion to incorporate prerectal fascia, the transverse segment of the mesh, lateral peritoneum, and perivesical fascia. The laparotomy pads are removed, and the purse-string sutures are secured and left tagged. Attention is now turned to repair of the grade IV cystocele. Interrupted sutures of 3-0 Vicryl are used to approximate the central defect. This helps reduce the central defect to assist in the repair but does not provide strength and durability. The obturator fascia is identified bilaterally, and 2-0 Vicryl sutures are placed, incorporating a strong bite of the fascia on the side.

Cystoscopy is performed after injection of indigo carmine, and good excretion from both ureters is confirmed. Suprapubic catheter position is confirmed, and bladder and urethral injury are excluded. The central defect sutures are tied. A  $5 \times 5$  cm disk of soft Prolene mesh is prepared. The base of the mesh is approximated to the area of the sacrouterine ligament (enterocele suture). Laterally, the mesh is approximated to the obturator fascia and distally to the bladder neck. The vault suspension sutures are tied, providing depth and support to the vaginal cuff. The excess vaginal wall is excised, and the anterior vaginal wall closed with runs of 3-0 and 2-0 Vicryl suture. Prior to closure, the vertical segment of mesh is transferred to the posterior vaginal wall.

The rectocele is now repaired as previously reported. Dissection is carried out on the prerectal fascia to the opening of the mesh at the vaginal cuff. A 1-cm rectangular strip of posterior vaginal wall is excised to expose the prerectal fascia. The mesh is applied over the prerectal area. The rectocele is repaired by incorporating anterior vaginal wall and perirectal fascia with running and interrupted sutures. Interrupted sutures of 2-0 Vicryl approximate the perineal membrane and the levator plate in the midline in the distal 4 cm of the vagina, obtaining significant elevation and restoration of the normal vaginal axis. A vaginal packing soaked with antibiotic is inserted in the vagina, and the patient is discharged the following day.

## COMMENTARY BY KATHLEEN C. KOBASHI, MD

*History*

Some aspects of the history should be clarified. Understanding of the patient's symptomatology can be important in directing proper counseling so that the patient has appropriate expectations postoperatively.

How, specifically, is she bothered by the prolapse?

What would she like to have "fixed" or "changed" by undergoing surgery?

What specific difficulties is she having with voiding? Urgency? Frequency? Decreased force of stream? Hesitancy? Sensation of incomplete voiding?

Any trouble with urinary tract infections?

*Physical Examination*

A physical examination should be performed to assess the following:

Components of prolapse.

Degree of pelvic prolapse.

Estrogen status.

Presence or absence of overt or occult stress urinary incontinence (SUI) (examination with and without reduction of prolapse).

Position of urethra and urethral mobility.

*Urodynamics*

To obtain as much information as possible to facilitate proper counseling of the patient about reasonable postoperative expectations, urodynamics should be performed to evaluate the following:

1. Bladder function/stability/compliance.

Those patients who are found to have instability or decreased compliance should be counseled on the possibility that they may experience no improvement or even exacerbation of symptoms related to these findings (i.e., urinary frequency, urinary urgency/urge incontinence). They may require further therapy or need to continue preoperative therapy (e.g., medications, dietary or behavioral modification, bladder training, and so on) to address these symptoms if they should persist or arise.

2. Bladder capacity.

Patients should be counseled that bladder capacity may or may not be affected by pelvic floor reconstruction. For instance, in the patient who is experiencing symptoms of urgency/frequency as a manifestation of mechanical bladder outlet obstruction caused by kinking of the urethra secondary to the prolapse, reduction of the prolapse may effectively increase bladder capacity by decreasing the obstructive urinary symptoms. Conversely, in those who have primary symptoms of frequency/urgency (unrelated to the prolapse), reconstruction may have no effect.

3. Bladder emptying.

With concomitant sling placement, subsequent incomplete bladder emptying or complete urinary retention is always a possibility. In those who have baseline retention of any degree, emptying ability may or may not be affected by reduction of the prolapse.

4. Presence or absence of SUI with and without reduction of the prolapse.

Whether to place a sling concomitant with anterior compartment reconstruction regardless of whether SUI is demonstrated is controversial. It is my practice to proceed with sling even in those patients in whom SUI is not demonstrated in light of the literature that suggests a relative and not insignificant risk of postoperative SUI even when SUI is not demonstrated preoperatively (1). There are always exceptions to this rule, and one must treat each patient on a case-by-case basis. One exception to this practice includes the patient with a well-supported urethra from previous antiincontinence surgery and no objective SUI or complaints of SUI, such as in this case.

At my institution, Valsalva leak-point pressure (VLPP) measurements are used somewhat to guide the choice of sling material, sling placement technique/approach, and sling tension. How VLPP affects the outcomes of various slings is currently under evaluation.

5. Pressure flow analysis.

This measure can be somewhat difficult to interpret in women as females tend to void with low detrusor pressures. It is important to note, for instance, the patient who has low flow and low voiding detrusor pressures with or without baseline elevated PVRs. This patient is at risk for postoperative urinary retention, perhaps requiring intermittent self-catheterization, and she needs to be counseled on this preoperatively.

### *Cystoscopy*

Cystoscopy should be performed to evaluate for

*Trabeculation/cellules:* The presence of trabeculation and cellules indicates some functional pathology, such as detrusor overactivity or bladder outlet obstruction.

*Other pathology* (e.g., bladder tumors, stones): These findings must be addressed before proceeding with pelvic floor reconstruction.

*Foreign body* (e.g., suture from previous surgery): Foreign body can contribute to irritative voiding symptoms.

### *Treatment*

Assuming that the patient is healthy, I would counsel her on the following options:

1. Open abdominal sacrocolpopexy (ASCP) with concomitant cystocele repair with or without sling.

ASCP is considered by many to be the current gold standard for repair of vault prolapse. It restores the vault with excellent depth and position without deviation of the vagina to one side or another as seen with the sacrospinous ligament fixation. Success rates reported in the literature are high (2,3), although the ASCP does involve the morbidity of an abdominal incision and the prolonged recovery period associated with transperitoneal surgery. I use soft polypropylene mesh fashioned into a Y configuration and sacral bone anchors to secure the repair to the sacrum.

Regardless of the graft material used to suspend the vault to the sacrum, there have been reports of transvaginal extrusion of the material (4). In many cases, this requires complete removal of the mesh and puts the patient at risk for failure of the repair and intra-abdominal infection.

2. Laparoscopic sacrocolpopexy with concomitant cystocele repair with or without sling. In the case presented here, assuming the patient has not undergone multiple abdominal surgeries, laparoscopic sacrocolpopexy would be my choice. In my experience, patients are typically discharged on postoperative day 1 (23-h observation). This patient should be counseled on the risks of laparoscopic surgery, including possible conversion to open surgery, in addition to the risks of infection or vaginal extrusion of the mesh and infection or inflammation of the bone anchors, possibly requiring removal.

3. Transvaginal repair using levator myorrhaphy with concomitant cystocele repair with or without sling.

This is an excellent option in those patients who do not wish to undergo abdominal surgery or who are not candidates for such surgery. The success rate is not as high as that seen with the sacrocolpopexy (5), but the transvaginal approach affords the patient advantages over that seen with abdominal surgery, whether open or laparoscopic. In this case, I would use a segment of cadaveric fascia for the cystocele repair, which would be secured apically by the levator myorrhaphy stitches prior to their passage through the vaginal wall to provide reinforcement of the repair both apically and anteriorly.

4. A recently introduced technique for a synthetic graft-reinforced transvaginal vault suspension (6) is also an option.

This technique involves placement of a T-shaped polypropylene graft from the sacroureterine cardinal ligament complex to just above the perineal body to support the vault and the pelvic floor. The technique is new and is not currently employed at my institution, with our biggest concern being placement of a considerable size synthetic mesh intraperitoneally for the vault suspension and adjacent to the rectum for the rectocele repair as described (although in this case a significant rectocele is not presented). The concern is the risk of visceral adhesions prompted by the polypropylene mesh and rectal erosion of the graft.

My current technique of choice for anterior compartment repair is a variation on the CaPS technique (7), which incorporates a single piece of solvent-dehydrated, nonfrozen cadaveric fascia lata in a simultaneous cystocele repair with sling. In my institution, this technique has evolved to involve a polypropylene mesh sling placed pubovaginally, transvaginally, or via the transobturator approach with concomitant fascial reinforcement of the anterior compartment reconstruction. We continue to use cadaveric fascia for the cystocele repair despite recent reports of less-than-optimal outcomes with cadaveric fascial slings as our outcomes with the anterior compartment reconstruction have continued to be favorable with continued follow-up.

This particular case presents a potential exception to my general practice to proceed with a sling concomitant with repair of a large cystocele. In light of the fact that the patient has undergone previous surgical repair of prolapse (although it is unclear regarding whether she underwent a concomitant anti-incontinence procedure or what the current position of the urethra is on physical examination) and that she is experiencing incomplete bladder emptying and “difficulty voiding,” consideration of a concomitant sling poses somewhat of a dilemma. Urodynamics, specifically the pressure flow analysis, should be helpful in making this decision. In addition, further questioning regarding what she means by difficulty voiding would be useful.

If the pressure flow analysis indicates outlet obstruction even with reduction of the prolapse, then I would not proceed with sling and would counsel the patient that

she may likely continue to experience voiding difficulty and incomplete emptying postoperatively despite repair of the prolapse. Unfortunately, she is also at risk for development of SUI, although this may be less likely if she does not demonstrate any change in her voiding or the presence of SUI with prolapse reduction.

If, on the other hand, she demonstrates SUI and complete bladder emptying with reduction of the prolapse, then concomitant sling placement would be performed. The method by which I currently determine sling material and technique is undergoing evaluation to determine its validity, but in short, if the VLPP is high, then she would be offered a polypropylene sling placed transvaginally with bone anchors, pubovaginally, or by the transobturator approach. If the VLPP is moderate to low, then the transobturator approach would not be considered. If the VLPP is excessively low, then she would also be counseled on autologous fascia pubovaginal sling.

If SUI is seen in the face of a fixed urethra, concomitant partial (lateral) urethrolysis may be considered to render the urethra “compressible” enough to benefit from a sling.

Detailed conversation regarding risks, benefits, and alternatives is imperative to ensure that the patient’s expectations are realistic. In a patient with baseline retention, exacerbation of the retention requiring intermittent catheterization is clearly a risk. In addition, the risk of postoperative SUI, urgency, frequency, and slow stream, as well as the risks inherent in placement of a foreign body (urinary tract erosion, vaginal extrusion, infection, or inflammation of the mesh or bone anchors, if used) should be presented. Finally, if she undergoes an autologous fascial sling, I would preferentially choose rectus fascia over fascia lata to minimize morbidity. However, if she has reason to have poor rectus fascia, such as pelvic radiation, steroids, multiple abdominopelvic surgeries, and so on, then fascia lata would be considered. The risks associated with harvesting at the selected site would be reviewed in detail with the patient.

## REFERENCES

1. Gallentine ML, Cespedes RD. Occult stress urinary incontinence and the effect of vaginal vault prolapse on abdominal leak point pressures. *Urology* 2001;57:40–44.
2. Maher C, Baessler K, Glazener CM, Adams EJ, Hagen S. Surgical management of pelvic prolapse in women. *Cochrane Database Syst Rev* 2004;(4):CD004014.
3. Nygaard IE, McCreery R, Brubaker L, et al. Pelvic Floor Disorders Network: abdominal sacrocolpopexy: a comprehensive review. *Obstet Gynecol* 2005;104:805–823.
4. Begley JS, Kupferman SP, Kuznetsov DD, et al. Incidence and management of abdominal sacrocolpopexy mesh erosions. *Am J Obstet Gynecol* 2005;192:1956–1962.
5. Lemack GE, Blander DS, Margulis V, Zimmern PE. Vaginal vault fixation and prevention of enterocele recurrence by high midline levator myorrhaphy: physical examination and questionnaire-based follow-up. *Eur Urol* 2001;40:648–651.
6. Rutman MP, Deng DY, Rodriguez LC, Raz S. Repair of vaginal vault prolapse and pelvic floor relaxation using polypropylene mesh. Abstract presented at: SUFU 2005; Orlando, FL.
7. Kobashi KC, Mee SL, Leach GE. A new technique for cystocele repair and transvaginal sling: the cystocele repair with sling (CaPS): *Urology* 2000;56(suppl 6):9–14.

## EDITOR’S COMMENTS BY HOWARD B. GOLDMAN, MD

The authors have done an excellent job summarizing the evaluation and treatment for a patient with recurrent pelvic organ prolapse. It is debatable whether an MRI of the pelvis is necessary in all patients, as it can significantly add to the cost of the evaluation at most centers but may not ultimately change the operative approach or outcomes.

---

It does, however, benefit the surgeon in revealing occult defects and give additional preoperative information. Concerning the treatment, both authors discussed the possibility of doing a transvaginal technique utilizing a synthetic mesh. There are now commercially available kits that can facilitate such a technique; however, the costs of the kits are significantly higher than cutting one's own mesh, as described by these authors. Long-term outcomes are still not available.

---

# 14

## Recurrent Pelvic Organ Prolapse After Colpocleisis

---

A 72-yr-old woman presents with total pelvic prolapse. She also notes occasional incontinence when she sneezes. She had a colpocleisis 3 yr ago. She is bothered by the prolapse. Exam reveals a significant vault prolapse with an introitus that easily admits four fingers.

How would you proceed?

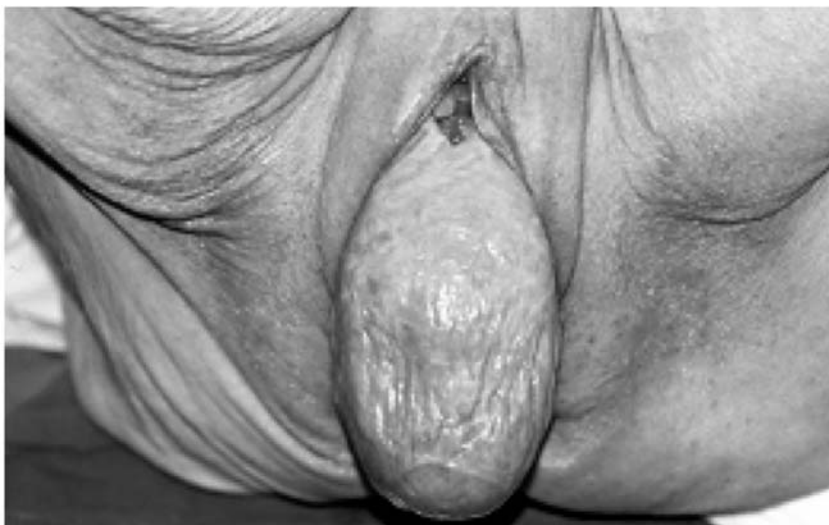### COMMENTARY BY RAYMOND RACKLEY, MD

For this 72-yr-old woman who chose a previous surgical intervention consisting of a vaginal obliterative procedure in the past, the option of a pessary or total vaginal length restoration as part of her pelvic prolapse repair are less likely to match her needs and expectations.

The finding of the pelvic organ prolapse recurrence in the setting of a large vaginal hiatus suggests that a likely reason for failure of the previous colpocleisis was the failure to provide a robust perineal body reconstruction, which often includes a distal rectocele repair at the time of colpocleisis. Thus, a repeat colpocleisis procedure using a biodegradable or absorbing synthetic mesh interposition with high perineal body repair and distal rectocele repair with tension-free midline approximation of the levator muscle surrounding the vaginal hiatus would be an excellent first choice for a reconstructive option. If during the procedure the surgeon was not pleased with the quality of the tissue for colpocleisis repair, then a unilateral sacrospinous fixation procedure with the same attention to high perineal body and rectocele repair with levator approximation would be an excellent second option as enough vaginal depth to reach the sacrospinous ligament is suggested by the finding of recurrent “total” pelvic organ prolapse. A third choice includes the use of the newer transvaginal tape procedures for vault suspensions, which would provide adequate apical stabilization of the vagina, but poor vaginal depth. However, vaginal depth is not needed in this case, but there is no extensive reported experience in performing these vaginal tape procedures for failed pelvic organ prolapse reconstruction.

In light of the symptoms of stress incontinence, urodynamic testing should confirm the presence of the signs of the symptoms and determine the leak-point pressure that guides the optimal sling intervention (platform transobturator sling for a high leak-point pressure or low voiding detrusor pressure vs a suspending sling for low leak-point pressure in the setting of normal voiding detrusor pressure). The timing of the chosen sling procedure should precede the pelvic organ prolapse repair as exposure to the midurethra and bladder neck will be limited after a robust posterior repair.





**Fig. 1.**

While waiting to perform the reconstructive procedure, the patient's vaginal tissue may be optimized for the surgical repair by instituting topical vaginal estrogen replacement therapy for several months.

#### **EDITOR'S COMMENTS BY SANDIP P. VASAVADA, MD**

The finding of a 72-yr-old postcolpocleisis with recurrent prolapse is certainly rare. Dr. Rackley has demonstrated that the appropriate type of repair usually is not simply resuspending or support of the apical vaginal segments, but a robust distal vaginal reconstruction in the form of the rectocele and perineal body to prevent further descent. Furthermore, in our experience, it seems to be that many of these patients will require some form of anti-incontinence procedure, and often they are subject to having voiding dysfunction for which they may require longer term catheterization, or in many cases we will simply place a suprapubic tube as the voiding dysfunction may be persistent for some time. It becomes even more challenging to manage a patient with bladder outlet obstruction that may be *de novo* after placing a sling in a colpocleisis patient as often the vaginal canal is obliterated. Accordingly, one should be careful in placing sling tension in these complex patients.

---

# 15

## Stress Incontinence and Straining to Void

---

A 45-yr-old woman presents with stress urinary incontinence (SUI). On questioning, she notes the need to strain to fully empty. A pressure flow study shows straining during voiding but a  $Q_{\max}$  of 21 mL/s. SUI is present on cystometrics with a Valsalva leak-point pressure of 120 cm H<sub>2</sub>O. Exam shows a Q-tip test of 0–40° and no prolapse.

Is any further evaluation necessary? What would you recommend for treatment of her SUI?

### COMMENTARY BY STEVEN SIEGEL, MD

This case presentation demands an exploration of possible bladder outlet obstruction (BOO) in conjunction with the presenting complaint of SUI. Although BOO in women is relatively rare, the most common causes include iatrogenic obstruction from a prior incontinence or prolapse repair, factors related to simultaneous pelvic prolapse, and pelvic floor muscle spasticity with dysfunctional voiding. Less-common causes include primary BOO, urethral stricture, malignancy, diverticulum, ectopic ureterocele, and Fowler's syndrome or pseudomyotonia of the external urethral sphincter.

Although the patient admits she must strain to empty, the history does not include mention of any irritative voiding complaints. One would usually expect to find them in women with BOO. There is no prior history of prolapse repair or antiincontinence surgery. The physical exam indicates a degree of urethral hypermobility, but there is no prolapse identified, which probably rules out prolapse as the cause. Finally, the urodynamic exam demonstrates a normal filling phase, except for SUI with a relatively high leak-point pressure. During the voiding phase, she develops a strong detrusor contraction augmented by abdominal straining, a peak flow rate that is relatively normal, and evidence of near-complete bladder evacuation. Is she obstructed? If so, what is the cause? How do the answers impact the plan for treatment of her SUI?

First, is she obstructed? My gut sense is yes. I would rely on my clinical judgment here and be careful to document the behavior of the pelvic floor musculature (PFM) on physical exam. Does she relax adequately and contract efficiently, indicating a normal range of motion of the PFM, or is there spasticity and tenderness even at rest, with limited ability to isolate or further increase the muscles or effect the tone on command? If these things were documented and a cystoscopy showed no visual evidence of an obstruction, then I think I would not be tempted to do any additional evaluation and would recommend a course of PFM electromyographic biofeedback to her, with the expectation that she could learn to void with relaxed PFM, and that the improved range of motion from relaxation to coordinated contraction would be enough to resolve both the voiding dysfunction and the SUI. If only the voiding dysfunction were to be improved, then the treatment of the SUI would be greatly simplified.

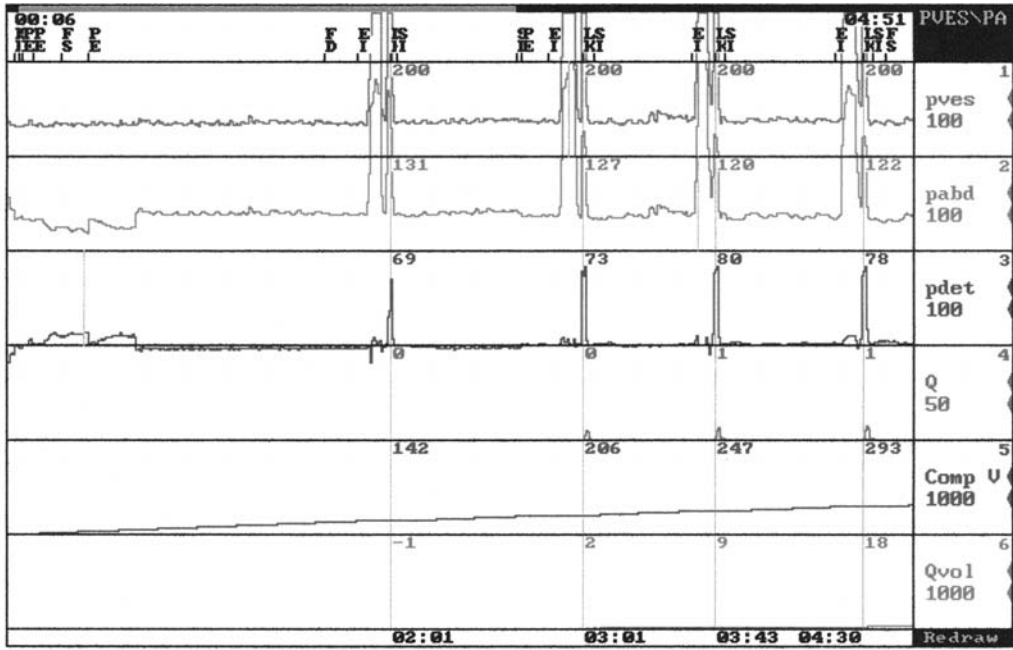


Fig. 1.




Fig. 2.

Beyond clinical intuition, the objective determination of BOO in women is hard to know. Using the Blaivas and Groutz nomogram (1), a  $Q_{\max}$  of 21, and  $P_{\det}$  at  $Q_{\max}$  of 45 puts her in the mildly obstructed zone. Nitti et al. (2) suggested that simultaneous video imaging and pressure flow studies greatly aids the evaluation and diagnosis of BOO. This is less likely to be true when there is adequate detrusor contractility, as in this example. Radiographic imaging in the form of a videourodynamic study or fluoro-voiding cystourethrography would be helpful to assess this complaint further if there was no clear evidence of PFM dysfunction. An upright rest-stress cystogram would also be helpful to rule out a significant degree of cystocele in the unlikely event that it was missed on physical exam. In addition, the voiding phase of such a study may also elucidate a diverticulum that was not otherwise identified. Finally, cystoscopy is essential to rule out a local factor responsible for obstruction.

If a specific cause of obstruction were identified, then it would need to be resolved prior to or as a part of her SUI management. I would be reluctant to recommend surgical treatment for her SUI complaint unless the voiding dysfunction or other cause for her emptying complaint is resolved because a midurethral sling is likely to compound the difficulty whether done via a transobturator or retropubic route. An abdominal retropubic bladder neck suspension such as a Burch procedure may offer less risk of obstruction, but it is also less reversible should it prove unsatisfactory.

## REFERENCES

1. Blaivas JG, Groutz A. Bladder outlet obstruction nomogram for women with lower urinary tract symptomatology. *Neurourol Urodyn* 2000;19:553–554.
2. Nitti VW, Lefkowitz G, Ficazzola M, et al. Lower urinary tract symptoms in young men: videourodynamic findings and correlation with noninvasive measures. *J Urol* 2002;168:135–138.

## EDITOR'S COMMENTS BY HOWARD B. GOLDMAN, MD

Dr. Siegel reviews all the pertinent points dealing with a woman with stress incontinence who also may have BOO. The maximum flow rate of 21 cc/s, however, makes one wonder the degree of obstruction, if any, that really exists. Care must be taken in this subgroup of patients to ensure that one does not do anything that could potentially increase the degree of obstruction. A midurethral transobturator sling may prove useful in this case if she continues to have stress incontinence after various pelvic floor relaxation and other potential treatments have been tried. There is some early evidence that indicates that there may be less risk of urethral obstruction given the relatively flatter position of the obturator slings than with the standard retropubic-type slings. Nevertheless, good counseling of the patient at all steps of her evaluation and treatment is crucial in a case like this.

---

# 16 Male With Post-Prostatectomy Incontinence

---

A 64-yr-old man is 2 yr postradical retropubic prostatectomy for prostate cancer. He currently leaks and uses two to three thick pads per day. He does not leak at night while in bed and can sleep through the night without needing to urinate. Prostate-specific antigen is undetectable.

What workup is necessary? What are the treatment options? What would you recommend?

## COMMENTARY BY CRAIG V. COMITER, MD

This gentleman suffers from postprostatectomy incontinence (PPI), which may be caused by bladder or outlet dysfunction. Bladder causes of incontinence include detrusor overactivity (DO), diminished vesical compliance, and overflow incontinence caused by a noncontractile bladder. Outlet causes of leakage include intrinsic sphincter dysfunction (ISD), and outflow obstruction (usually because of anastomotic stricture), which may lead to DO or overflow incontinence. Because he is 2 yr out from surgery, his symptoms are unlikely to improve spontaneously.

History and physical examination may not lead to a definitive diagnosis. Although ISD is the most common finding in men with PPI (especially stress incontinence), bladder dysfunction (detrusor overactivity or underactivity, diminished vesical compliance) is also common. In addition, significant bladder outlet obstruction (BOO) should be ruled out prior to consideration of pharmacological or surgical therapy. It is therefore essential to evaluate patients suffering from PPI with multichannel urodynamics. Filling cystometry is used to assess sensation, compliance, and the presence of unstable contractions. Measurement of leak-point pressure (antegrade or retrograde) is useful for quantifying the degree of ISD. Pressure flow study allows the examiner to rule out significant BOO. Cystoscopy is indicated to rule out anastomotic stricture and urethral foreign body (suture or clip).

DO is best treated with a combination of behavioral modification (pelvic floor exercises, fluid restriction, timed voiding) and pharmacotherapy (antimuscarinic medication). BOO, if significant, may be managed by dilatation or incision of any strictured area of the vesical-urethral anastomosis, although this can result in new or worse stress incontinence. ISD is often initially managed with a trial of pelvic floor exercises, fluid restriction, and timed voiding. Unfortunately, evidence that pelvic floor exercises have any efficacy for PPI outside the immediate postoperative period is generally lacking. In patients such as this man, who is 2 yr out from his prostatectomy, surgery is usually required for the successful treatment of significant stress incontinence.

The lack of supine leakage and absence of nocturia supports a diagnosis of ISD without significant bladder dysfunction. One of the most important aspects of the management of PPI caused by ISD is to set realistic expectations of treatment outcome. For milder cases of ISD, periurethral bulking agents may suffice. With more severe leakage, injection therapy is unlikely to lead to a satisfactory outcome. Carbon-coated zirconium beads in  $\beta$ -glucan gel (Durasphere, Boston Scientific, Natick, MA) and bovine glutaraldehyde crosslinked collagen (Contigen, Bard, Covington, GA) are the most popular injectable agents for stress urinary incontinence caused by ISD in men. Cure rates with transurethral retrograde collagen injection have generally been low for PPI, ranging from 5 to 20%. Antegrade injection may be associated with slightly higher success rates. Polydimethylsiloxane (Macropastique, Uroplasty, Minneapolis, MN) is a newer agent that has been shown to have moderate benefit for treating PPI, with success rates of 40% at 1 mo but diminishing to 26% at 12 mo. In general, periurethral bulking agents fail to provide satisfactory continence more than half the time.

The most successful surgical treatments for the management of PPI caused by ISD are artificial urinary sphincter (AUS) surgery and male sling surgery. For the past three decades, the AUS has proven to be the most effective long-term solution for male stress urinary incontinence caused by ISD, with success rates between 75 and 90% in most modern series and patient satisfaction rates of 85–95%, despite the frequent necessity for surgical revision. Because of the circumferential compression of the urethra, the corpus spongiosum invariably atrophies, and revision rates range from 17 to 21% at 5 yr to 65 to 80% at 10 yr. Complications requiring immediate reoperation (infection, erosion) are generally less than 5% but can be as high as 10% in radiated or reoperative patients.

Sling surgery has emerged as a viable alternative to AUS surgery, with similar satisfaction rates and a lower incidence of infection and erosion. Based on the Berry prosthesis described in 1961, multiple incarnations of the perineal sling have come in and out of vogue. Such devices included the Kaufman prostheses from the 1970s and the Northwestern abdominal-perineal sling from the 1990s. Perhaps the most significant innovation affecting male sling surgery has been the use of bone screws. Bone fixation obviates the abdominal incision, has transformed the surgery into a minimally invasive outpatient procedure, and has led to a substantial reduction in perineal pain when compared to suprapubic/rectus fascial fixation. Synthetic slings are associated with a substantially higher success rate than are organic slings, with patient satisfaction and continence rates generally as high as those achieved with AUS surgery.

Occasionally, certain patient factors dictate surgical therapy. If a patient lacks adequate manual dexterity, then he may not be able to operate the AUS scrotal pump. On the other hand, a patient must have adequate detrusor contractility to overcome the fixed resistance of the perineal sling. In addition, in patients after full-course external beam radiation therapy, AUS surgery is associated with more predictably favorable outcomes than is sling surgery. Finally, in those who have had previous AUS implantation, revision or reoperative AUS placement is more likely to succeed than is sling surgery.

In this particular patient, if the urodynamics support the diagnosis of ISD with a relatively normal bladder, I would recommend sling surgery. Although there is currently insufficient data to support the superiority of one approach over the other, the bone-anchored perineal sling is associated with fewer complications than the AUS, and the revision rate for sling surgery is less than that for AUS surgery. In addition, unsuccessful

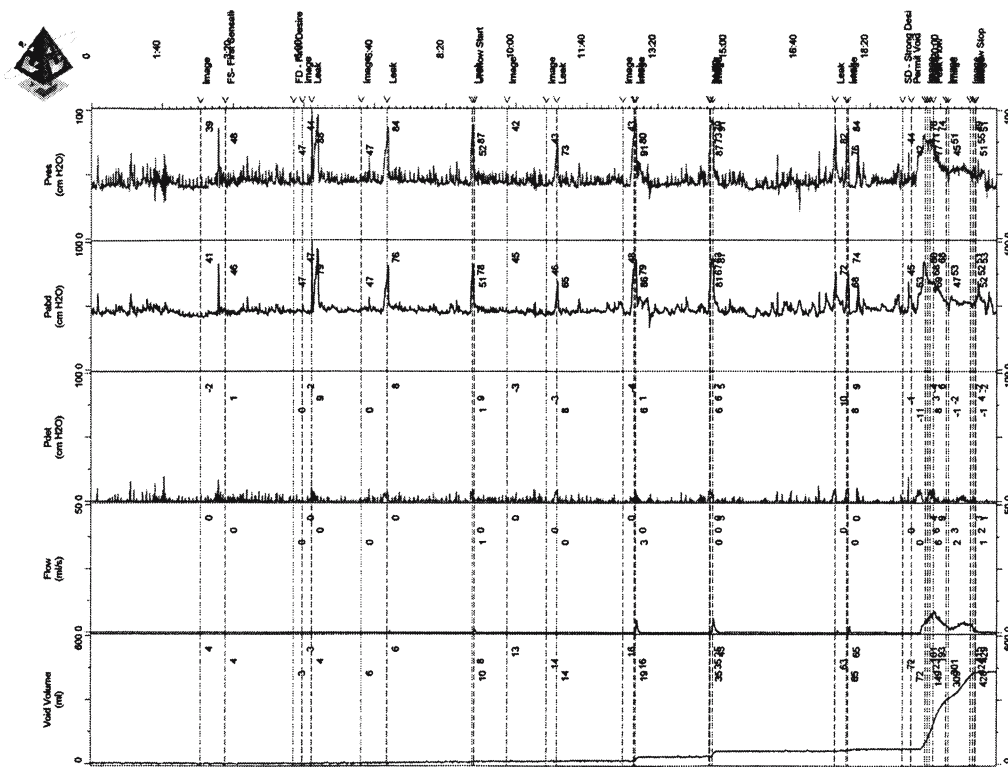


Fig. 1.

sling surgery does not alter the difficulty or success rates of subsequent AUS placement. On the other hand, failed AUS surgery may lead to urethral fibrosis, which may preclude sling surgery in the future.

**COMMENTARY BY FRED E. GOVIER, MD**

As with most medical problems, we must begin with the history of present illness. I would first want to know the timeline of the urinary leakage. Was leakage severe after the prostatectomy, slowly improved, and now has not changed over the past year, or was the leakage a lot better at some point after surgery and is now getting worse? What is the character of the leakage? Is it stress incontinence, urge incontinence, or incontinence without his knowledge? When he first arises in the morning, can he make it to the toilet, or does he leak on the way? Once he gets to the toilet, is there any problem starting the stream, does he have to use abdominal straining, how forceful is his stream, and does he feel that he empties his bladder? Has he had radiation therapy, or has he had any anastomotic strictures dilated since the prostatectomy?

Because erectile dysfunction is also common after this operation, I would want to know about his function before the operation and at present. If the patient is not functional now, what are his desires in the future? If he is not functional now and desires therapy, then I would discuss which prior treatment options he has explored and the results he has achieved.

Looking at his past medical history, I would want to know about any significant medical or surgical issues that would affect placement of a male sling, AUS, or inflatable penile prosthesis.

During the physical examination, I would conduct a brief neurological exam to ensure he had the dexterity and strength to manipulate a sphincter. I would want to know about any abdominal wall or inguinal hernias, any lymphadenopathy or rectal masses, and whether the condition of the skin around the genitalia was healthy.

In my practice, this patient would undergo videourodynamic testing. I would start by looking at his flow rate and urinalysis to rule out a urinary tract infection or hematuria. Next, I would examine his flow characteristics and residual urine. I would look at his bladder capacity, his compliance and rule out detrusor overactivity. In most cases, I would be able to reproduce his incontinence, know what type of detrusor pressures he generated with voiding, and whether he used abdominal straining during the voiding phase. Finally, I would get a dynamic, visual picture of the anastomosis and urethra. If there were any concerns about the outlet or he had hematuria, I would perform cystoscopy.

If I was considering him for a male sling, I believe a pressure flow study is mandatory to rule out an areflexic bladder with abdominal straining. If I am considering him only for an AUS, his health history was completely straightforward, and all of the above questions had been answered to my satisfaction, then I do not believe a urodynamic study is mandatory, and a flow rate, urinalysis, residual urine, and cystoscopy would be an acceptable workup.

The history given to us appears straightforward for anatomic sphincteric incontinence, and unless something unexpected is discovered in the patient's history, physical examination, or testing, he should be an excellent candidate for therapy. There is no effective medical therapy, and I do not offer injection therapy to males. Therefore, we would be considering a male sling or AUS, either of which may be done in conjunction with an inflatable penile prosthesis (IPP). Before offering the patient a simultaneous IPP, I would want to have explored other, less-invasive options for his erectile dysfunction, if not done previously. Although I do an occasional male sling, my overall experience with this procedure has been less than satisfactory, and my experience mirrors the report by Castle et al. (1). The male sling in my practice is offered primarily to those patients with less incontinence, who have satisfactory voiding pressures and who desire a less-complicated but in my hands a less-successful option. In those instances, I use only permanent mesh products with bone anchors as opposed to allografts or xenografts.

My recommendation to this patient would be an AUS placed as far proximally on the bulbar urethra as possible through a perineal incision. I would use a single cuff with a 61- to 70-cm pressure balloon filled with 24 cc of saline placed through a second lower midline abdominal incision. The cuff would be sized so that it was snug but would rotate with minimal tension around the urethra. Assuming the patient's characteristics are straightforward as presented, I would council him that he should expect to have a 50% chance of getting out of pads completely and an additional 40–45% chance of getting down to one small pad a day. The patient would understand that, at 64 yr of age, he would most likely require one or more revisions in his lifetime. In the unusual event that the urethra was too small for adequate occlusion with a single cuff, we were not placing an IPP, and he was impotent, he would be counseled preoperatively that I would place a second cuff transcorporally. If we could not get occlusion with a single cuff and he were potent or we were placing a simultaneous IPP, then I would place a second cuff more



distally in the bulb. He would understand that simultaneously placing two cuffs would carry up to a 10.5% risk of urethral erosion (2).

Placement of an AUS through a penile scrotal incision is a relatively straightforward approach that saves a small amount of time and a second incision. The tradeoff is that the cuff placement is more distal; therefore, the cuff is virtually always 4 cm, which limits options later for dealing with atrophy. I use this approach only when I am placing a combined AUS/IPP in an older individual with a limited life expectancy who is not physically active. In the combined placement, I believe there is significant time-saving, and the entire operation can be done through a single incision, both of which should theoretically lower the infection rate. I believe these advantages outweigh the downside of the smaller, more distal cuff in selected individuals.

As with all surgery, the key to good results and satisfied patients is to counsel the patient realistically about expected results, complications, and any commonly encountered contingencies. For the surgeon, the time to plan for contingencies is before the operation commences and not at the time one encounters an unexpected problem in the operating room.

## REFERENCES

1. Castle EP, Andres PE, Itano N, Novicki D, Swanson SK, Ferrigni RG. The male sling for post-prostatectomy incontinence: mean follow-up of 18 mo. *J Urol* 2005;173:1657–1660.
2. Kowalczyk JJ, Spicer DL, Mulcahy JJ. Erosion rate of the double cuff AMS800 artificial urinary sphincter: long-term follow-up. *J Urol* 1996;156:1300–1301.

## EDITOR'S COMMENTS BY SANDIP P. VASAVADA, MD

Both Dr. Comiter and Dr. Govier have demonstrated the evaluation as well as management options, albeit the limited ones, that we have for a gentleman with PPI of a mild-to-moderate nature. As many of us know, there is no good, sure way to quantitate how severe incontinence is in most of our patient populations. We have used surrogate markers of pad usage as well as sometimes pad weights to evaluate these patients pre-operatively. Nonetheless, we are still in need of some form of a severity scale to help us evaluate and follow patients before and after any interventions. I certainly agree with all of the commentaries made about options, including the most definitive options of male sling procedures as well as AUSs. Eventually we will obtain longer term data that may give us more information so we are able to counsel our patients appropriately regarding the success rates with the male sling. We certainly have these data with the AUS, and patients certainly need to understand this as they are counseled on ultimate treatment approaches to their problem.

---

# 17 Mixed Incontinence in an Elderly Woman

---

A 79-yr-old active woman complains of symptoms of mixed incontinence requiring four thick pads per day. Exam reveals no prolapse, a postvoid residual (PVR) of 170 cc and a Q-tip test of 0–30°. Urodynamics demonstrates a Valsalva leak-point pressure of 52 cm H<sub>2</sub>O, detrusor overactivity, and poor detrusor contraction during voiding.

Is further evaluation necessary? What are the treatment options?

## COMMENTARY BY TOMAS L. GRIEBLING, MD, FACS FGSA

Mixed urinary incontinence in the elderly female patient can present a considerable therapeutic challenge. This patient complains of significant mixed incontinence, which can have major negative impacts on her physical activity, social interactions, and overall quality of life.

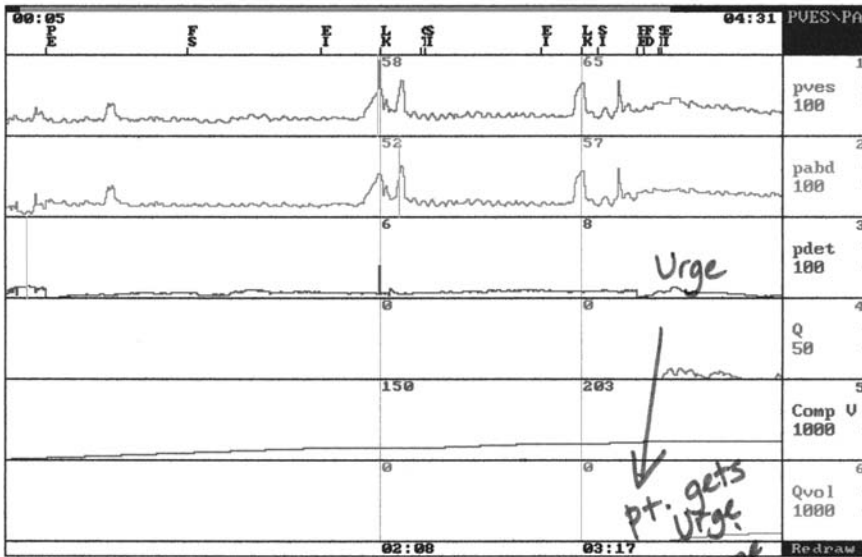
The physical examination reveals no pelvic organ prolapse and no significant urethral hypermobility (Q-tip test 0–30°). This information, combined with the positive leak-point pressure of 57 cm H<sub>2</sub>O on pressure flow urodynamics, supports a diagnosis of intrinsic sphincter deficiency (ISD) as the etiology of her stress incontinence.

However, her complaints of urinary urgency and urge incontinence complicate the clinical situation. The filling cystometrogram reveals low-pressure detrusor overactivity with associated urge sensations and urge incontinence at a volume of approx 200 mL. This study was performed with a relatively fast infusion rate (80 mL/min), which could artificially exacerbate involuntary detrusor contractions. Repeating the filling portion of the study at a slower rate that more closely matches physiological parameters might help to diminish potential artifact. However, in this particular case, the patient reports she experiences urinary urgency and urge incontinence on a regular basis. This historical information suggests that the observed urodynamic finding is clinically significant and is more than just an artifact of the filling rate.

The clinical situation is also complicated by the poor detrusor contractility identified on the pressure flow portion of the study and the elevated PVR volume of 170 mL. These results, combined with the findings from the filling cystometrogram, support a diagnosis of detrusor hyperactivity with impaired contractility (DHIC). This is a relatively common disorder in older adults that presents as a combination of incomplete bladder emptying and urinary urgency or urge incontinence (Griffiths et al., 2002; Malone-Lee, 1992).

Additional evaluation would include upper tract imaging and an assessment of renal function. Some patients with detrusor overactivity and elevated postvoid residuals can develop clinically significant hydronephrosis as a long-term complication. This can lead to renal insufficiency in some cases. Renal ultrasonography and measurement of serum urea nitrogen and creatinine would be useful in this patient. Videourodynamics or a voiding cystourethrogram could also be considered to rule out associated vesicoureteral

⊕ leak = stress, ⊕ = Urge  
leak



Urge  
Pt. gets Urge  
+ Urine pours out.  
Pt. cannot stop leakage

Fig. 1.

Voluntary Void

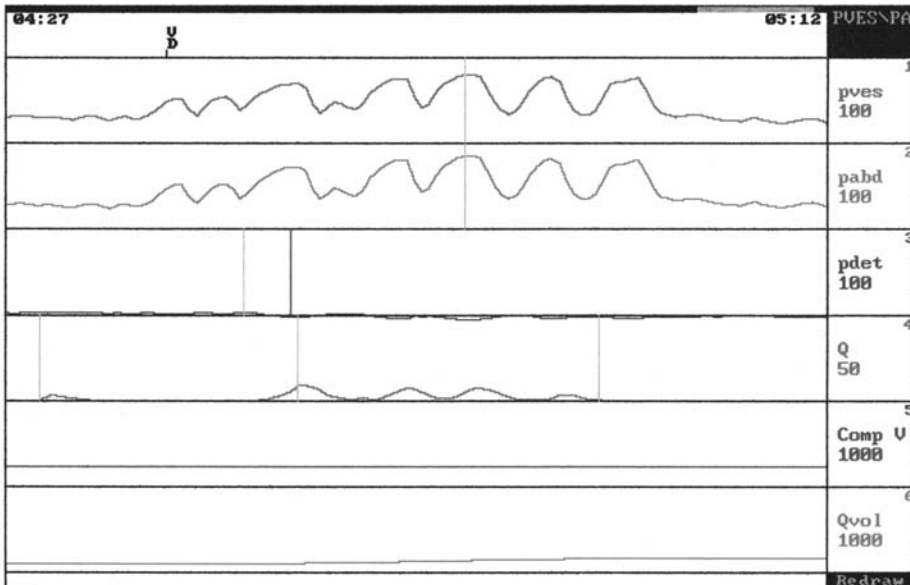


Fig. 2.

reflux or a bladder diverticulum. A voiding diary with measurement of PVR volumes would also be helpful in this patient. Although her PVR was elevated at 170 mL on the urodynamic study, this measurement represents a single point in time. If the patient is willing and able to perform intermittent self-catheterization, then measurements of PVR over several days could provide useful information. If the patient does have consistently elevated PVR volumes, then intermittent self-catheterization might also provide some therapeutic relief of her urgency and frequency symptoms.

The choice of treatment options in this patient with combined ISD and DHIC presents a significant clinical challenge. Combination therapy will likely be required given her combined diagnoses. Because of her large-volume leakage (four thick pads daily), some type of treatment will be needed to address the open bladder neck. However, many common treatments for this condition may worsen her urgency or retention. In some cases, intentional creation of urinary retention with subsequent institution of a self-catheterization regimen may be preferred over urinary incontinence. In this case, therapies can be targeted to maximally treat both the stress and the urge components without concern for the risk of retention.

Conservative therapies could help both the urge and stress components of her incontinence. Dietary modification should be recommended. Avoidance of known dietary irritants, such as caffeine, carbonated beverages, artificial sweeteners, acidic foods, and alcohol, may help diminish her urinary urgency and urge incontinence. Timed voiding and double voiding may also be helpful. Many patients only experience urinary urgency near bladder capacity. Timed voiding may help to preempt this occurrence by preventing the bladder from reaching this volume. Double voiding might help reduce her overall PVRs, which could also improve urinary frequency.

Pelvic floor muscle exercises may be helpful in this case, particularly in terms of the patient's urgency and urge incontinence. Targeted pelvic floor exercises may help to reduce the duration and intensity of involuntary detrusor contractions. This could provide additional time to reach the toilet and help alleviate urge incontinent episodes. Biofeedback therapy may help to localize muscle contractions correctly and enhance exercise efficiency. Improved pelvic floor muscle tone may help with her stress incontinence, although the improvement in patients with ISD will likely be less pronounced compared to patients with urethral hypermobility.

Treatment of the stress incontinence component will be somewhat more difficult in this patient because she also has DHIC. Many treatments for her stress incontinence may worsen her urinary urgency or retention. Surgical therapy could be considered, including either injection of periurethral bulking agents or a pubovaginal sling cystourethropexy. Because the patient has ISD with no significant urethral hypermobility, a traditional bladder neck sling would be preferable over a midurethral sling. However, both injection therapy and sling cystourethropexy may worsen this patient's urinary urgency and urinary retention. A sling would likely provide better durability compared to injection therapy, particularly if she requires intermittent self-catheterization.

Anticholinergic therapy could be considered for treatment of the urinary urgency and urge incontinence. This may worsen urinary retention, which could necessitate intermittent self-catheterization. The potential clinical benefits must also be balanced with associated pharmacological side effects, including dry mouth, constipation, visual changes, and confusion. The incidence of these side effects may be somewhat higher in elderly patients.

Sacral neuromodulation may also be useful in this patient to help treat both urinary retention and urgency with associated urge incontinence. One benefit of this therapy is

that it can be tested in a staged fashion using an external generator prior to implantation of the programmable generator. If the test is unsuccessful, then the lead is removed.

Treatment of combined ISD and DHIC in the elderly female patient can be challenging. Therapeutic choices must be tailored carefully with input from the patient about her specific desires and preferences. Successful treatment can lead to substantial improvements in overall quality of life.

## REFERENCES

1. Malone-Lee J. A re-examination of detrusor hyperactivity with impaired contractile function. *Neurourol Urodyn* 1992;11:298–300.
2. Griffiths DJ, McCracken PN, Harrison GM, Gormley EA, Moore KN. Urge incontinence and impaired detrusor contractility in the elderly. *Neurourol Urodyn* 2002;21:126–131.

## EDITOR'S COMMENTS BY HOWARD B. GOLDMAN, MD

Dr. Griebing correctly notes the potential presence of DHIC in this patient and the difficulties that can ensue when trying to treat someone with this conditions. A trial of conservative measures combined with anticholinergics may help reduce the bladder overactivity, perhaps without impacting her ability to void. It is important to highlight that one measurement of an elevated PVR does not necessarily mean that it is the usual status of her bladder. Frequently, on a first visit to the doctor or perhaps under a testing situation, patients may not empty as well as in their natural setting. For the stress incontinence, a bulking agent would probably be a less-morbid and a potentially less-obstructing treatment for this woman and is likely an appropriate first-line therapy given her relatively low leak-point pressure.

---

# 18 Male With Post-Prostatectomy Incontinence

## *Status Post-removal of Eroded Artificial Sphincter*

---

A 58-yr-old active man is 18 mo postradical retropubic prostatectomy for prostate cancer, 6 mo post-artificial urethral sphincter placement for stress urinary incontinence, and 3 mo postsphincter removal (all components) for cuff erosion and infection. He is currently totally incontinent, requiring 10 thin pads per day. Cystoscopy shows no urethral strictures and no bladder neck contracture. His prostate-specific antigen (PSA) has started to rise. Metastatic evaluation is negative. No radiation is planned. Hormonal ablation was discussed and may be instituted in the future if the PSA continues to rise. The patient states that the incontinence is ruining his life.

How would you proceed with evaluation and treatment?

### COMMENTARY BY AJAY SINGLA, MD, FACS, FRCS, FICS

This is a 58-yr-old gentleman who is 18 mo postradical retropubic prostatectomy for prostate cancer who developed urinary stress incontinence and underwent an artificial urinary sphincter placement. He developed cuff erosion 3 mo later, and the artificial urinary sphincter was removed. The patient is currently totally incontinent, requiring 10 pads a day. Cystoscopy showed no urethral stricture and no bladder neck contracture. The patient did not receive radiation or any hormonal treatment. The PSA has started to rise slightly. The patient is currently bothered by severe urinary incontinence. He is requesting further treatment.

A detail urological history is taken from the patient to determine his urinary habits; urinary frequency; any urge incontinence; whether the incontinence is caused by pure stress; his voiding habits, which would include any history of incomplete bladder emptying as well as history of any obstructive symptoms. I also ask if the patient's incontinence was resolved after the first artificial urinary sphincter placement and if the patient was satisfied with this device. A past medical history will also be obtained, which will include a neurological history, any history of diabetes, and any prior surgeries. A complete physical examination, which will involve examination of genitalia, scrotum, and a digital rectal examination as well as a focused neurological examination, will be carried out. I will also order the operative report from his previous artificial urinary sphincter implantation to check on a cuff size and measurement of the urethra.

A urinary analysis will be ordered, and I would also like to check his postvoid residual.

I will counsel the patient in detail regarding the need for the videourodynamic evaluation to assess the detrusor function, to rule out any poor compliance, and to check his bladder capacity as well as any uninhibited detrusor overactivity. This will also help to

rule out any bladder outlet obstruction. After the urodynamic evaluation is completed, I will have a detailed discussion with the patient regarding the treatment plan. If the detrusor function is stable on the urodynamic evaluation, then I will discuss all the treatment options in detail, which will include (1) role of bulking agent, (2) option of male sling, and (3) a repeat implantation of artificial urinary sphincter.

Because this patient has severe urinary incontinence, he would be a good candidate for artificial urinary sphincter placement, and it would provide him the best chances of success. Based on our experience, I would counsel this patient that male sling can be performed in this particular situation even though chance of complete continence is low. The patient may have some improvement, but chances of failure would be high. Similarly, the bulking agent would have no role in patients with severe urinary incontinence and has almost zero success in patients who use 10 pads a day. If the patient agrees to have a repeat implantation of artificial urinary sphincter, then I will inform him that the artificial urinary sphincter is the only procedure that would provide him the highest satisfaction and either complete dryness or significant improvement in his urinary incontinence. There are reports in the literature that the male sling has not performed well in cases of severe urinary incontinence (*1*). If the patient agrees with this approach, I will proceed with a repeat artificial urinary sphincter implantation using either a single cuff or a tandem cuff.

#### REFERENCE

1. Onur R, Singla A, Rajpurkar A. New perineal bone-anchored male sling. Lessons learned. *Urology* 2004;64:58–61.

#### EDITOR'S COMMENTS BY SANDIP P. VASAVADA, MD

This patient is unlikely to respond well to either bulking agents or a male sling to manage his, what sounds to be, severe urinary incontinence. He has certainly failed a single artificial urinary sphincter alone in that he has developed cuff erosion and ultimately explantation of this device. He should be counseled about other diversionary options to manage his situation as he is at risk of developing complications from a subsequent sling. One may consider a distal placement of the cuff or tandem cuff placements as well. Others have considered these types of patients ideal candidates for transcorporeal cuffs in a distal location. Nonetheless, he should be counseled that he is certainly a high-risk patient for failure, and additional therapies may be required to manage him appropriately.

# Index

---

## A

A-adrenergic agonists, 89–90, 93  
Abscesses  
    from slings, 168–169  
    transvaginal repair and, 312  
Abdomen, examination of, 34  
Abdominal leak-point pressure, 42–45, 98, 99  
A-blockers, mechanism of action, 28, 29  
Acetylcholine  
    in bladder control, 20, 24, 25, 180, 198  
    inhibition of, 209  
ACT<sup>®</sup>, 105  
Actinomycosis, 169  
Active continence, mechanism of, 11  
A $\delta$  fibers, 199  
Adrenergic agonists, 28  
Adrenergic antagonists, 28  
B3-Adrenergic receptor ( $\beta$ 3-AR), 20  
B<sub>2</sub>-Adrenoceptor agonists/antagonists, 90  
Alcohol as bladder irritant, 65  
Amitriptyline, 392  
Anogenital stimulation, 221–222  
Anterior colporrhaphy  
    complications, 371–373  
    outcomes, 270–273  
    surgical techniques, 267–268  
Anterior wall vaginal prolapse. *See* Cystoceles  
Antibiotics and VVF, 312  
Anticholinergic medications, 126, 179, 187–191, 260. *See also* specific drug by name  
Antidiuretic hormone, 88  
Antimuscarinic agents, 22, 177, 179–187. *See also* specific drugs by name  
Anus  
    anatomy, 16  
    EMG sensors, 73  
    sphincter, examination of, 285  
Aorta, 7  
Apical prolapse. *See* Enteroceles  
Arcus tendinous fascia pelvis (ATFP), 5  
Artificial sweeteners as bladder irritant, 65–66  
Artificial urinary sphincter surgery, 412, 422  
Aspartame as bladder irritant, 65–66  
ATP in bladder control, 22–23, 25  
Atrium, 117  
Atropine sulfate (DL-hyoscyamine), 180  
Augmentation cystoplasty

    alternatives to, 252  
    cecum, 252–253, 256  
    complications, 257–258  
    ileocecal segment, 253, 255  
    ileum, 252, 256  
    indications/contraindications, 251–252  
    jejunum, 252  
    overview, 251, 258  
    port sites, 254  
    results, 256–257  
    sigmoid colon, 253  
    stomach, 253  
    surgical technique, 252–256  
Autologous fat, 97  
**B**  
Bartholin gland anatomy, 16  
Behavioral treatments described, 63  
Benign prostatic hyperplasia,  $\alpha$ -blocker treatment of, 28  
Biofeedback therapy, 73–74, 373  
Bion<sup>®</sup> microstimulator  
    described, 223–225  
    procedure, 229–232  
Bladder  
    anatomy, 10  
    botulinum toxin injection techniques, 213, 214  
    in continence, 12  
    examination of, 34  
    function, neurophysiological control  
        afferent pathway, 24–27  
        efferent pathway, 20–24  
        micturition/storage, 26–29  
        overview, 19–20, 30  
    histology, 19  
    injuries  
        augmentation cystoplasty, 258  
        by slings, 153, 161–163  
    innervation  
        afferent, 199  
        efferent, 198  
        overview, 12, 14  
    overactivity, radiation-induced, 54, 56  
    sensory processing neurotransmitters, 25  
    uroepithelium, anatomy/function, 198  
Bladder neck slings  
    complications, 132, 150–153



- history, 131–132
- incisions, 148
- material selection
  - autologous rectus fascia, 139, 159
  - bovine collagen-injected polyester, 147
  - cadaveric dermis/acellular collagen matrix, 144–145, 159
  - cadaveric fascia lata, 144, 159
  - fascia lata, 139–140, 144, 159
  - overview, 138, 159
  - polyethylene terephthalate, 117, 118, 147
  - polypropylene mesh (*See* Polypropylene mesh)
  - polytetrafluoroethylene (PTFE; Gore-Tex) (*See* Gore-Tex); Polytetrafluoroethylene (PTFE)
  - porcine dermis, 145, 159
  - porcine small intestinal submucosa, 145–146, 159
  - silicone-coated polyester, 147, 168
  - synthetic materials, 146–147, 159
- method of suspension
  - bone anchors, 124, 148, 169
  - sutures, 147–148
- outcomes, 149–152
- patient selection, 132–133
- surgical technique
  - fascia lata harvest, 140, 148
  - postoperative care, 137–138
  - pubovaginal slings (autologous rectus fascia), 133–137, 139–141, 267
  - pubovaginal slings (urethral diverticula repair), 137, 138
  - vaginal wall sling, 140–141
  - variations, 142–143
- suture selection, 147
- tension, 148, 152
- VVF and, 313
- Bladder outlet obstruction (BOO)
  - case studies, 379–384, 405–407
  - c-fiber activation in, 25
  - neurophysiologic pathways, 24, 54, 58
  - treatment, 24, 411
- Bladder retraining (BT)
  - described, 68, 69
  - rationale, 63
  - recommendations, 64, 65
- Bleeding/hematoma complications, 160, 257
- Bone anchors, 124, 148, 169
- Bony pelvic anatomy described, 3–5
- BOO. *See* Bladder outlet obstruction (BOO)
- Botox®. *See* Botulinum toxin
- Botulinum toxin (Botox®, Dysport®, MyoBloc®, NeuroBloc®)
  - contraindications, 215
  - described, 192–193, 209
  - for DO, 252
  - injection techniques
    - bladder, 213, 214
    - urethra, 213–214
  - mechanism of action, 209–210
  - for OAB, 373–375
  - vs.* resiniferatoxin, 205
  - side effects, 215
- Bowel
  - complications, augmentation cystoplasty, 258
  - function regularity, 66
  - injury, by slings, 162
- Broad ligaments, 13
- Bulbocavernosus muscles, 16
- Bulking agents
  - complications, 103–104
  - contraindications, 99
  - Durasphere, 104–105
  - GAX (*See* Glutaraldehyde crosslinked (GAX) collagen)
  - history, 97–98
  - injection technique, 100–102
  - overview, 107
  - patient selection, 98–100
  - results, 102–103
  - Tegress®, 105–107
- Burch procedure, 112, 115
- C**
- Cadaveric dermis/acellular collagen matrix
  - in bladder neck slings, 144–145, 159
  - in rectocele repair, 293
- Cadaveric fascia lata, 144, 149
- Caffeine
  - consumption statistics, 65
  - management, 66
  - and OAB/UI, 34, 65
- Calcium in bladder control, 23
- Caliculi formation, augmentation cystoplasty, 258
- Capsaicin
  - administration, 205
  - c-fiber blockage by, 25
  - chemical structure, 200
  - clinical results, 202–203
  - complications, 205
  - for OAB, 193–194, 197–198
  - pharmacology, 199–202
- Cardinal ligament anatomy, 6, 8, 13
- Case studies
  - bladder outlet obstruction, 379–384, 405–407
  - cystoceles, 371–373
  - interstitial cystitis, 391–395
  - MS/voiding dysfunction, 361–364
  - MUI, 351–352, 385–388, 417–420

- overactive bladder, 236–237, 245, 365–370, 373–375
- pelvic pain, 355–357, 391–395
- post prostatectomy incontinence, 411–415, 421–422
- prolapse, 343–346, 371–373, 397–404
- sexual dysfunction, 391–395
- SUI, 343–344, 383–384, 405–407
- urethral diverticula, 331–334, 355–357
- UTI/pelvic pain, 355–357
- UTI/prolapse, 343–346
- VVF, 383–384
- Cecum, in augmentation cystoplasty, 252–253, 256
- Cervix anatomy, 13
- C fibers, 25, 199, 201
- Childbirth, 283
- Children, botulinum toxin treatment, 210–211
- Chronic constipation, 66
- Clenbuterol, 90, 93
- Clitoris, 10, 16
- Coaptite®, 105
- Coccygeus muscle, 5
- Coccyx anatomy, 16
- Cognitive impairment, antimuscarinic agents, 180, 186
- Colpectomy, 296
- Colpocleisis, 296, 403–404
- Colporrhaphy
  - anterior
    - complications, 371–373
    - outcomes, 270–273
    - surgical techniques, 267–268
  - posterior, technique, 287–288
- Common iliac arteries, 7
- Complications
  - anterior colporrhaphy, 371–373
  - augmentation cystoplasty, 257–258
  - bleeding/hematoma, 160, 257
  - bulking agents, 103–104
  - capsaicin, 205
  - cystoceles, 273–274
  - enteroceles, 274
  - GAX collagen, 103–104
  - prolapse, 274
  - rectoceles, 274
  - resiniferatoxin, 205
  - sacral neuromodulation, 244–245
  - SPARC technique, 122, 124, 160, 164–165, 168
  - tined quadripolar leads, 244–245
  - TVT, 121–126, 160, 164, 166–168
  - VVF, 323–325
- Complications, sling surgery
  - bladder neck slings, 132, 150–153
  - bladder perforation, 161–163
  - bleeding/hematoma, 160
  - bowel perforation, 162
  - fascia lata slings, 124
  - infection/abscess, 124, 166, 168–169
  - overview, 159–160, 169–170
  - polypropylene mesh slings, 123, 124, 161–168
  - retropubic midurethral slings, 121–122, 124, 165
  - transobturator midurethral slings, 122–123, 161, 165, 168
  - urethral erosions, 123–124, 153, 165–168
  - urge incontinence, 153, 163–165
  - urinary retention, 153, 163–164
  - vaginal erosions, 123–124, 153, 165–168
  - vaginal extrusion, 168
  - voiding disturbance, 124–125, 162–165
- Computed tomographic (CT), 328
- Conjugated equine estrogens (CEE), 87
- Conservative therapy
  - biofeedback therapy, 73–74
  - bladder irritants, influence of, 65–66
  - bladder retraining, 63–65, 68, 69
  - bowel function regularity, 66
  - fluid management, 64, 65
  - lifestyle/behavior modifications, 63–67
  - overview, 63
  - PFES, 75
  - PFMT, 63, 64, 69–75
  - recommendations, 64
  - smoking and, 64, 66
  - toileting programs, 63, 67–69
  - urethral diverticula, 328
  - vaginal weights, 74–75
  - VVF, 311–312
- Constipation, therapeutic reduction of, 66
- Contigen®, 105
- Continence, mechanism of, 11–14, 20, 84–86
- Cooper's (pectineal) ligament, 3, 4
- Cough UPP, 46, 47
- CRF in bladder control, 28
- Cymbalta (Duloxetine), 29, 90–93
- Cystoceles
  - case studies, 371–373, 397–403
  - complications, 273–274
  - evaluation, 266–267, 344, 345
  - formation of, 6
  - mesh/tissue graft repair, 267–269
  - outcomes
    - anterior colporrhaphy, 270–273
    - paravaginal defect repair, 272–274
  - overview, 265
  - surgical techniques
    - anterior colporrhaphy, 267–268
    - overview, 267
    - paravaginal defect repair, 269–272
- Cystometrograms, 24, 35

- Cystoscopy, 36, 163, 267, 385–386  
 Cystourethrography (video urodynamics), 53
- D**
- Darifenacin, 183–186  
 daVinci robot, 298  
 Defecating proctography, 285  
 Depression and urge incontinence, 28  
 Detrusor contractions, tibial nerve stimulation, 220–221  
 Detrusor leak-point pressure (DLPP), 41–42  
 Detrusor overactivity (DO)  
   botulinum toxin treatment of, 210–211  
   case study, 361–364  
   refractory, 210–211, 252  
   tibial nerve stimulation, 219–221  
   urodynamic evaluation of  
   nonneurogenic findings, 54–57  
   nonphasic, 55  
   phasic, 58  
   protocol, 53–54  
 Detrusor smooth muscle signaling in bladder control, 20–24  
 Detrusor-sphincter dyssynergia (DSD)  
   botulinum toxin for, 211–212  
   case study, 361–364  
   neurogenic OAB and, 57–59  
 Dexon, 117, 118  
 Dicyclomine hydrochloride, 190  
 Diverticula, urethral. *See* Urethral diverticula  
 Diverticulectomy, endoscopic, 329  
 Dondren, 97  
 Duloxetine (Cymbalta), 29, 90–93  
 Duraderm™, 117, 145  
 Durasphere, 104–105  
 Dynamic MRI, 285, 286. *See also* Magnetic resonance imaging (MRI)  
 Dynamic UPP, 46, 47  
 Dyspareunia. *See* Sexual dysfunction  
 Dysport®. *See* Botulinum toxin
- E**
- Edema, fluid management, 65  
 Elderly patients  
   bladder contractility in, 22  
   detrusor instability in, 98  
   fluid management, 65  
   midurethral slings, 114, 115  
   MUI in, 417–420  
 Electrical stimulation, anogential, 221–222  
 Electromyography (EMG), 73  
 Elmiron, 392  
 Endometrium anatomy, 13  
 Endopelvic fascia, 6  
 Enteroceles  
   case studies, 397–403  
   complications, 274  
   nonsurgical management, 296  
   observation management, 295  
   overview, 293, 301  
   physical examination, 295  
   predisposing factors, 294  
   preoperative evaluation, 293–295  
   vs. rectocele, 285  
   surgical management  
   laparoscopic sacrocolpopexy, 298–301  
   overview, 296  
   transabdominal sacrocolpopexy, 297–298  
   transvaginal repairs, 296–298, 372  
   uterosacral ligament suspension, 296, 372  
   symptoms, 294–295  
 Ephedrine, 89  
 Erosions  
   midurethral slings, 123–124, 153, 165–168  
   rectocele repair, 293  
 Estrogens, 194–195, 260. *See also* Hormone replacement therapy (HRT)  
   for VVF, 311  
 Excision technique, urethral diverticula, 329–330  
 External iliac artery, 7, 9  
 External pudendal artery, 8  
 External sphincter, 11  
 External urethral sphincter (rhabdosphincter), 19, 28–29
- F**
- Fascia lata slings  
   cadaveric, 144, 149  
   complications, 124  
   described, 139–140  
   disadvantages of, 159  
   history, 131  
   types of, 117  
 Femoral artery, 7–8  
 Fibrin therapy, for VVF, 312  
 Fistulas  
   augmentation cystoplasty, 257  
   bladder neck, 312  
   complex, 319  
   fulguration of, 312  
   infratrigonal, 312  
   perineovaginal, 383  
   radiation-induced, 319  
   from slings, 166, 167  
   supratrigonal, 312  
   ureterovaginal, 310, 311  
   urethrovaginal, 330  
   VVF (*See* Vesicovaginal fistula (VVF))  
 Flavoxate hydrochloride, 190–191  
 Fluid management, 64, 65

- Foods as bladder irritant, 65–66
- Frequency-urgency syndrome  
  case studies, 236  
  pudendal neurostimulation, 225  
  sacral neuromodulation, 238, 242, 243  
  tibial nerve stimulation, 220
- Fulguration, of fistulas, 312
- G**
- Genitals, examination of, 34
- Genuine stress incontinence (GSI), 36
- Glutamate, 85
- Glutaraldehyde crosslinked (GAX) collagen  
  complications, 103–104  
  described, 98  
  injection technique, 100–102  
  patient selection, 98–100  
  results, 102–103
- Gore-Tex, 117, 118, 146, 293
- H**
- Habit training described, 67, 68
- Heart and Estrogen/Progestin Replacement Study, 87
- Hematoma complications, 160
- Hormone replacement therapy (HRT)  
  for OAB, 194–195  
  in postmenopausal women, 195  
  for SUI, 86–88, 93
- Hydrodistention, 392–393
- Hyalgel<sup>®</sup>, 105
- Hypersensitivity disorders, 202–203
- Hypogastric nerve  
  in bladder innervation, 20, 24, 29, 84  
  in pelvic anatomy, 12, 14
- I**
- IC. *See* Interstitial cystitis (IC)
- Idiopathic detrusor overactivity, 52
- Idiopathic nonobstructive urinary retention.  
  *See* Bladder outlet obstruction (BOO)
- Ileocecal segment, in augmentation cystoplasty,  
  253, 255
- Ileum, in augmentation cystoplasty, 252, 256
- Iliococcygeus muscle, 5, 6
- Ilioinguinal nerve, 10
- Imipramine  
  for OAB, 191  
  for SUI, 88–89, 93
- Infections  
  augmentation cystoplasty, 257  
  midurethral slings, 124, 166, 168–169  
  sacral neurostimulation, 244  
  transvaginal repair and, 312
- Inferior anal nerves, 10
- Inferior epigastric artery, 8, 9
- Inferior epigastric vein, 9
- Inferior vesical artery, 9
- IntePro<sup>™</sup> graft, 299, 300
- Internal iliac artery, 7–9, 13
- Internal pudendal vessels, 9
- Internal urethral sphincter, 19, 29
- Interstitial cystitis (IC)  
  ATP response, 23, 25  
  augmentation cystoplasty, 251  
  bladder afferent activity, clinical measures, 26  
  botulinum toxin for, 213  
  case study, 391–395  
  c-fiber activation in, 25  
  sacral neuromodulation, 238, 243  
  tibial nerve stimulation, 220, 221  
  vanilloid treatment of, 202, 204
- Intravaginal slingoplasty (IVS), 112, 168
- Intravenous pyelography, 36
- Intrinsic sphincter deficiency (ISD)  
  case study, 411–415  
  described, 98, 99  
  treatment, slings, 132  
  vaginal wall slings, 141  
  VLPP readings, 133
- IPG implantation procedure, 241–243
- Ischial spines, 4, 9
- Ischiocavernosus muscles, 16
- Ischiopubic ramus, 3, 9
- ISD. *See* Intrinsic sphincter deficiency (ISD)
- J**
- Jejunum, in augmentation cystoplasty, 252
- K**
- Kegel exercises described, 70–73
- Knack described, 71
- L**
- Latzko operation, 318
- Lead migration, 244, 245
- Leak-point pressures (LPPs)  
  abdominal, 42–45, 98, 99  
  DLPP, 41–42  
  overview, 41  
  VLPP, 42–45, 132–133  
  vs. URP, 48
- Levator ani group (LAG)  
  anatomy of, 5–6, 8  
  in biofeedback therapy, 74  
  in continence control, 12, 84
- Levator hiatus, 6, 7
- Lower urinary tract symptoms (LUTS)  
   $\alpha$ -blocker treatment of, 28, 29  
  urodynamic evaluation, 51, 52
- LPP. *See* Leak-point pressures (LPPs)

**M**

Macroplastique<sup>®</sup>, 105  
 Magnetic resonance imaging (MRI), 285, 286, 327, 328, 332–334, 356  
 Male sling surgery, 412, 422  
 Manometry described, 74  
 Marlex, 117, 118, 146, 293  
 Marshall-Marchetti-Krantz procedure, 112, 115  
 Martius flap, 16  
 Martius grafts, 319–320  
 MAUDE database statistics, 160, 162  
 Maximum urethral closure pressure, 46, 48, 133  
 Mayo culdoplasty, 296  
 Medroxyprogesterone acetate, 87  
 Menopause, 86, 195  
 Menstruation, 86  
 Mersilene, 117, 118, 147  
 Methoxamine, 90  
 Micturition/storage, CNS control of, 26–29, 198  
 Middle rectal artery, 9  
 Midurethral slings  
   anesthetic requirements, 115  
   complications  
     bladder perforation, 161–163  
     intraoperative, 121–123  
     overview, 121, 159–160  
     postoperative, 123–126  
   history/background, 111–114  
   materials, 117–118  
   for MUI/SUI, 261  
   overview, 111, 126  
   patient selection, 114  
   percutaneous  
     outcomes, 120–121  
     technique, 116–117  
   retropubic  
     complications, 121–122, 124, 165  
     described, 112–113  
     outcomes, 118–120  
     technique, 115–116  
   techniques, 115–117  
   transobturator  
     complications, 122–123, 161, 165, 168  
     described, 112–113  
     outcomes, 120  
     technique, 116  
   VVF and, 313  
 Mixed urinary incontinence (MUI)  
   assessment, 259–262  
   behavioral/pharmacological therapy  
     outcomes, 260  
   case studies, 351–352, 385–388, 417–420  
   clinical presentation, 259–260  
   defined, 259

    overview, 259  
     surgical outcomes, 261  
 Monarc slings, 168  
 Movement disorders and DO, 57–58  
 MRI (magnetic resonance imaging), 285, 286, 327, 328, 332–334, 356  
 MUI. *See* Mixed urinary incontinence (MUI)  
 Multidetector CT (MDCT), 328  
 Multiple sclerosis (MS), 57, 203, 222, 361–364  
 Muscarinic agonists, 24  
 Muscarinic receptors in bladder control, 20–25  
 MyoBloc<sup>®</sup>. *See* Botulinum toxin

**N**

NeuroBloc<sup>®</sup>. *See* Botulinum toxin  
 Neurogenic detrusor overactivity  
   capsaicin, 203  
   resiniferatoxin, 204–205  
 Neurological examination described, 34–35  
 Neuromodulation, nonsacral  
   electrical stimulation, anogential, 221–222  
   overview, 219, 232  
   sacral (*See* Pudendal nerve electrical stimulation; Sacral neuromodulation)  
   tibial nerve stimulation, 219–221  
 Nocturia, 65  
 Nocturnal polyuria, 65  
 Nonneurogenic detrusor overactivity, 205  
 Norepinephrine, 29, 85, 88  
 NS-49, 90

**O**

OAB. *See* Overactive bladder (OAB)  
 Obesity, 67, 114  
 ObTape sling, 113, 116, 166, 168  
 Obturator artery, 9  
 Obturator canal, 8  
 Obturator foramen, 3, 4, 8  
 Obturator muscle, 84  
 Obturator nerve, 8–9  
 O’Conor technique, 317–318  
 Onuf’s nucleus, 26, 85  
 Osteitis pubis, 153  
 Osteomyelitis, 124, 153, 169  
 Ovarian artery, 12  
 Overactive bladder (OAB)  
   apical prolapse and, 294  
   caffeine and, 34  
   case studies, 236–237, 245, 365–370, 373–375  
   compliance loss in, 55  
   conservative therapy (*See* Conservative therapy)  
   described, 197, 235  
   electrical stimulation, anogential, 221–222  
 fluid management, 65

- intravesical treatment  
 capsaicin (*See* Capsaicin)  
 overview, 197–198, 205–206  
 resiniferatoxin (*See* Resiniferatoxin)
- midurethral slings, 125–126, 164–165 (*See also* Midurethral slings)
- pathophysiology, 22
- pharmacological therapy  
 anticholinergic agents, 126, 179, 187–191, 260  
 antimuscarinic agents, 22, 177, 179–187  
 atropine sulfate (DL-hyoscyamine), 180  
 botulinum toxin, 192–193, 205  
 capsaicin (*See* Capsaicin)  
 darifenacin, 183–186  
 dicyclomine hydrochloride, 190  
 estrogens, 194–195  
 flavoxate hydrochloride, 190–191  
 imipramine (*See* Imipramine)  
 organ specificity, 179  
 overview, 177–178, 195, 197  
 oxybutynin chloride (*See* Oxybutynin chloride)  
 propantheline bromide, 180–181  
 resiniferatoxin (*See* Resiniferatoxin)  
 solifenacin, 183, 184, 186–187  
 tolterodine tartrate, 181–184, 187, 189, 190, 373  
 tricyclic antidepressants, 191–193  
 trospium chloride, 182–184, 373  
 uroselectivity, 178–179
- refractory, 236–237, 373–375
- sacral neuromodulation therapy, 242–243 (*See also* Pudendal nerve electrical stimulation; Sacral neuromodulation)
- stress-induced, 54, 56
- tibial nerve stimulation, 220
- urodynamic evaluation  
 components of, 53–54  
 neurogenic findings, 57–58  
 nonneurogenic findings, 54–57  
 overview, 51  
 patient selection, 52–53
- Oxybutynin chloride  
 intravesical, 197–199  
 overview, 53, 181, 183, 184, 187–189, 373  
 transdermal, 189–190
- P**
- Paraffin, 97
- Paravaginal defect repair  
 outcomes, 272–274  
 retropubic approach, 269–271  
 vaginal approach, 271–272
- Parity, 7
- Passive continence, mechanism of, 11
- Pectineal line, 3
- Pelvic anatomy  
 bony, 3–5  
 circulation, 7–10  
 lower urinary tract, 10–12  
 lymphatic drainage, 9  
 musculature/fascia, 5–8, 70, 71  
 nerves, 10  
 overview, 3, 282–283
- Pelvic diaphragm, 5
- Pelvic floor electrical stimulation (PFES), 75
- Pelvic floor muscle exercises (PFMEs), 70–73
- Pelvic floor muscle rehabilitation or training (PFMT)  
 vs. clenbuterol, 90  
 described, 69–75  
 vs. duloxetine, 92  
 rationale, 63  
 recommendations, 64
- Pelvic nerve, in bladder innervation, 24, 29, 84
- Pelvic Organ Prolapse Quantification (POP-Q) system, 285
- Pelvic pain  
 botulinum toxin for, 212–213  
 case studies, 355–357, 391–395  
 diverticula and, 325  
 sacral neuromodulation, 238, 243
- Percutaneous midurethral slings  
 outcomes, 120–121  
 technique, 116–117
- Periaqueductal gray (PAG), 26
- Perineal body, 14, 285
- Perineal membrane, 5
- Perineal membrane (urogenital diaphragm)  
 anatomy, 14
- Perineum anatomy, 14–17
- Peripheral nervous system, 84–86
- Peritoneum anatomy, 10, 11
- Periurethral fascia, 8
- Perivesical fascia, 8
- Phenylpropanolamine (PPA), 89, 90
- Polyethylene terephthalate, 117, 118, 147
- Polypropylene mesh slings  
 bone anchors, 148  
 complications, 123, 124, 161–168  
 described, 146  
 types of, 117, 118
- Polytetrafluoroethylene (PTFE; Gore-Tex), 117, 118, 146, 293
- Pontine micturition center (PMC), 26, 28
- Porcine dermis slings, 145, 159
- Porcine small intestinal submucosa slings, 145–146, 159
- Positive pressure urethrography (PPU), 323, 326–327, 356
- Posterior colporrhaphy technique, 287–288
- Posterior triangle anatomy, 16

- Post prostatectomy incontinence (PPI), 411–415, 421–422
- Pre-/pararectal fascia plication/levator reconstruction, 288–290
- Pressure transmission ratio, 47
- Procidencia, 371–374
- Prolapse
  - anterior vaginal wall (*See* Cystoceles)
  - apical (*See* Enteroceles)
  - case studies, 343–346, 371–373, 397–404
  - complications, 274
  - examination of, 34
  - posterior vaginal wall (*See* Rectocele)
  - vaginal, urodynamics, 266–267, 343–346, 397
- Prolene, 117, 118, 146
- Prompted voiding (PV) described, 67, 68
- Propantheline bromide, 180–181
- Propranolol, 90
- ProteGen® sling, 147, 166, 167
- Provocation test, 35
- Pseudodiverticula, 324, 330
- Pseudoephedrine, 89
- PTFE (polytetrafluoroethylene; Gore-Tex), 117, 118, 146, 293
- Pubic symphysis, 4
- Pubocervical fascia (vesicopelvic ligament), 6
- Pubococcygeus muscle, 5, 6
- Puborectalis muscle, 5, 6
- Pubourethral ligaments, 6, 11
- Pubovaginal slings. *See also* Midurethral slings
  - overview, 111
  - surgical technique
    - autologous rectus fascia, 133–137, 139–141, 267
    - urethral diverticula repair, 137, 138
- Pudendal nerve
  - anatomy, 5, 9, 223
  - in bladder innervation, 24, 28, 29, 85
  - in continence, 12
- Pudendal nerve electrical stimulation. *See also* Sacral neuromodulation
  - bion® microstimulator
    - described, 223–225
    - procedure, 229–232
  - devices, 223–225
  - overview, 222
  - patient selection, 224–225
  - timed quadripolar lead
    - complications, 244–245
    - described, 223–224
    - procedure, 225–229
    - test stimulation, 240–241
- P2X3/P2X2 purinergic receptors in bladder control, 25
- Pyramidalis slings, 131
- R**
- Radiation-induced bladder overactivity, 54, 56
- Radiation-induced fistulas, 319
- Rectoceles
  - case studies, 397–404
  - causes, 281, 283
  - complications, 274
  - defecating proctography, 285
  - diagnosis, 283–286
  - dynamic MRI, 285, 286
  - grading, 285
  - natural history of, 281
  - overview, 294
  - rectovaginal septum breaks in, 17
  - risk factors, 281
  - surgery, indications, 286–287
  - surgery, techniques
    - laparoscopic, 293–294
    - posterior colporrhaphy, 287–288
    - pre-/pararectal fascia plication/levator reconstruction, 288–290
    - repair, defect-directed, 284, 290–292
    - repair with mesh, 292–293
  - symptoms, 283, 286
  - ultrasound, 285–286
- Rectovaginal septum, 16–17
- Rectum, 6, 282–283
- Renal transplantation, augmentation cystoplasty and, 251
- Repliform™, 117, 145
- Resiniferatoxin
  - administration, 205
  - c-fiber blockage by, 25
  - chemical structure, 200
  - clinical results, 202–205
  - complications, 205
  - described, 194
  - pharmacology, 199–202
- Retropubic midurethral slings
  - complications, 121–122, 124, 165
  - described, 112–113
  - outcomes, 118–120
  - technique, 115–116
- Retropubic urethral suspensions, surgical landmarks, 3, 4
- Rho-rho-kinase pathway in bladder control, 23
- Ro 115–1240, 90
- S**
- Sabre sling, 161
- Sacral neuromodulation. *See also* Pudendal nerve electrical stimulation
  - complications, 244–245
  - for DO, 252

- history, 237
  - indications, 238, 239
  - IPG implantation procedure, 241–243
  - mechanism of action, 237–238
  - for OAB, 373, 375
  - overview, 235, 245–246
  - results, 241–244, 373
  - test procedure, 238–241
  - Sacrocolpopexy
    - laparoscopic, 298–301
    - transabdominal, 297–298
  - Sacrospinous ligaments, 4–5, 9
  - Sacrum, 3, 4
  - Sampson's artery, 12
  - Scheduled toileting described, 67, 68
  - Sensory urgency. *See* Detrusor overactivity (DO)
  - Serotonin, 29, 85, 88
  - Sexual dysfunction
    - case study, 391–395
    - diverticula and, 325
    - midurethral slings, 126
    - post-rectocele repair, 288, 291
    - vaginal prolapse, 266, 372
  - Sigmoid colon, in augmentation cystoplasty, 253
  - Silastic, 146
  - Silicone-coated polyester slings, 147, 168
  - Silicone elastomer slings, 146
  - Simultaneous cystourethrography (video urodynamics), 53
  - Slingsurgery, male, 412, 422
  - Smoking and UI/OAB/SUI, 64, 66
  - Sodium morrhuate, 97
  - Solifenacin, 183, 184, 186–187
  - Sonography, 327
  - SPARC. *See* Suprapubic arc (SPARC) technique
  - Spinal cord injury (SCI)
    - botulinum toxin treatment, 210–212
    - DSD and, 59
    - tibial nerve stimulation, 219–220
  - Spino-bulbo-spinal pathway issues, 58, 59
  - Stomach, in augmentation cystoplasty, 253
  - Stratasis, 117
  - Stress urinary incontinence (SUI)
    - anogenital stimulation, 222
    - apical prolapse and, 294, 296
    - bladder neck slings (*See* Bladder neck slings)
    - bulking agents (*See* Bulking agents)
    - case studies, 343–344, 383–384, 405–407
    - causes of, 84, 265, 266
    - described, 83
    - diverticula management, 330
    - midurethral slings (*See* Midurethral slings)
    - patient history, 34
    - PFES, 75
    - PFMT, 64
    - pharmacologic treatment
      - $\alpha$ -adrenergic agonists, 89–90, 93
      - $\beta_2$ -adrenoceptor agonists/antagonists, 90
      - HRT, 86–88, 93
      - imipramine, 88–89, 93
      - overview, 93
      - serotonin/norepinephrine reuptake inhibitors, 90–92
    - post-prolapse surgery, 273
    - surgical management guidelines, 41
    - type II, 99
    - type III, 98, 99, 132
    - urodynamic testing
      - LPPs, 41–45, 48
      - overview, 36, 53
      - role of, 48–49
      - UPP, 45–48
      - URP, 46
    - vaginal weights, 74–75
    - VVF and, 313
    - xenografts, 118
  - Substance P in bladder control, 24
  - SUI. *See* Stress urinary incontinence (SUI)
  - Superior vesical arteries, 9
  - Suprapubic arc (SPARC) technique
    - complications, 122, 124, 160, 164–165, 168
    - described, 112, 113
    - outcomes, 119
    - technique, 115–116
- T**
- Teflon, 117
  - Tegress<sup>®</sup>, 105–107
  - Tension-free vaginal tape (TVT)
    - anesthetic requirements, 115
    - complications, 121–126, 160, 164, 166–168
    - described, 112–114, 161
    - materials, 117
    - outcomes, 118–121, 365
    - patient selection, 114
    - technique, 115–116
  - Terminal detrusor overactivity, 54, 57
  - Thigh nerves, 10
  - Tibial nerve stimulation, 219–221
  - Tined quadripolar lead
    - complications, 244–245
    - described, 223–224
    - procedure, 225–229
    - test stimulation, 240–241
  - Toileting programs described, 63, 67–69
  - Tolterodine tartrate, 53, 181–184, 187, 189, 190, 373
  - Transobturator midurethral slings
    - complications, 122–123, 161, 165, 168
    - described, 112–113



- outcomes, 120
- technique, 116
- Transobturator procedure, pelvic anatomy points, 9
- Transurethral suture cystorrhaphy, 318
- Tricyclic antidepressants, 191–193
- Trospium chloride, 182–184, 373
- Tutoplast, 117
- TVT. *See* Tension-free vaginal tape (TVT)
- U**
- Ultrasonography, 37, 285–286
- Umbilical artery, 9
- Uratape sling, 113, 116, 166
- Urecholine, 24
- Ureteropelvic ligaments, 6, 12
- Ureters
  - anatomy, 10–12
  - obstruction of, post-prolapse surgery, 274
- Uretex slings, 168
- Urethra
  - afferent pathway, 29
  - anatomy, 11
  - botulinum toxin injection techniques, 213–214
  - efferent pathway, 28–29
  - erosions, from slings, 123–124, 153, 165–168
  - examination of, 34
  - function, neurophysiological control
    - overview, 19
  - histology, 13
  - innervation, 12, 14
  - neural control of, 85
  - pelvic support of, 6–8
  - resistance, characterizing, 45
  - in SUI etiology, 84
- Urethral closure pressure profile (UCPP), 46–48
- Urethral diverticula
  - case studies, 331–334, 355–357
  - classification, 324
  - conservative therapy, 328
  - etiology, 323–324
  - glandular sources of, 11
  - incidence, 325
  - overview, 323, 331
  - pathology, 330–331
  - presentation/evaluation, 325–328
  - pseudodiverticula, 324, 330
  - surgical techniques
    - complications, 330
    - endoscopic diverticulectomy, 329
    - excision, 329–330
    - incision and drainage with packing, 328
    - open marsupialization, 329
    - pubovaginal slings, 137, 138
- Urethral pressure profile (UPP), 45–48
- Urethral retroresistance pressure (URP), 46
- Urge incontinence
  - anticholinergic therapy, 189–190
  - apical prolapse and, 294
  - case studies, 236
  - HRT, 194
  - oxybutynin *vs.* tolterodine, 181
  - post-prolapse surgery, 273
  - post-sling surgery, 153, 163–165
  - pudendal neurostimulation, 225
  - sacral neuromodulation, 238, 241–243
  - tibial nerve stimulation, 220
- Urinary incontinence (UI)
  - complicated, 35
  - conservative therapy (*See* Conservative therapy)
    - described, 83
    - DO symptoms in, 54
    - economic impact of, 83
    - etiologies, 98
    - fluid management, 65
    - HRT, 194–195
    - laboratory evaluation
      - fluid intake/voiding diary, 34, 52
      - laboratory tests, 35
      - overview, 33
      - patient history, 33–34
      - physical examination, 34–35
      - urodynamics, multichannel, 35–37
    - post-prolapse surgery, 273
- Urinary retention
  - botulinum toxin for, 212
  - post-prolapse surgery, 273
  - post-sling surgery, 153, 163–164
  - pudendal neurostimulation, 225
  - sacral neurostimulation, 243
  - tibial nerve stimulation, 220
- Urinary system regulation, 12
- Urinary tract imaging, 36
- Urinary tract infections (UTIs)
  - case studies, 343–346, 355–357
  - diverticula and, 325, 331–332
  - fluid management, 65
- Urination. *See* Micturition/storage
- Urodynamics
  - OAB, 51–58
  - overview, 51
  - SUI, 36, 41–49, 53
  - urinary incontinence, 35–37
  - vaginal prolapse, 266–267, 343–346, 397
  - video, 53
- Uroepithelium, anatomy/function, 198
- Urogenital triangle anatomy, 16
- Urothelial afferent signaling in bladder control, 25–27
- Uroville®, 105

- Uterine arteries, anatomy, 9, 12, 13  
 Uterosacral ligament, 6  
 Uterosacral ligament suspension, 296, 372  
 Uterus anatomy, 6, 12–13, 15
- V**
- Vagina  
 anatomy, 6–8, 13, 15, 265, 282–283  
 anterior wall prolapse (*See* Cystoceles)  
 closure, Martius flap, 16  
 EMG sensors, 73  
 erosions  
   from rectocele mesh repair, 293  
   from slings, 65–168, 123, 153  
 examination of, 34  
 posterior wall prolapse (*See* Rectocele)  
 suburethral wall mass, differential diagnosis, 356  
   VVF (*See* Vesicovaginal fistula (VVF))
- Vaginal artery, 9, 12  
 Vaginal weights, 74–75  
 Valsalva leak-point pressure, 42–45, 132–133  
 Valsalva UPP, 46, 47  
 Vanilloid pharmacology, 199–202. *See also*  
   specific drugs by name  
 Vanilloid-receptor subtype 1, 194  
 VCUG (voiding cystourethrography), 37, 326–328,  
   344, 345, 355–356  
 Vesica™, 148  
 Vesicovaginal fistula (VVF)  
   case study, 383–384  
   complex, 319  
   conservative management, 311–312  
   diagnosis, 311  
   etiology, 309–310  
   operative management  
     complications, 323–325  
     full-thickness labial flap, 322, 323  
     gluteal skin flaps, 322  
     laparoscopic, 318–319  
     Latzko operation, 318  
     Martius graft, 319–320  
     myocutaneous gracilis flap, 322–324  
     O’Conor technique, 317–318  
     omental interposition, 321–322  
     outcomes, 324  
     peritoneal flap, 320–321  
     preoperative considerations, 312–313  
     transabdominal repair, 316–317  
     transurethral suture cystorrhaphy, 318  
     transvaginal repair, 312–316, 324  
   overview, 309, 325  
   prevention, 310  
   radiation-induced, 319  
   symptoms/signs, 310–311
- Vicryl, 117, 118  
 Voiding, CNS modulation of, 85–86  
 Voiding cystourethrography (VCUG), 37,  
   326–328, 344, 345, 355–356  
 Voiding dysfunction  
   assessment of, 53, 266  
   botulinum toxin for, 212  
   case study, 361–364  
   midurethral slings, 124–125  
   pudendal neurostimulation, 225  
   sacral neurostimulation, 252  
   slings generally, 162–165  
   tibial nerve stimulation, 219–221  
 VVF. *See* Vesicovaginal fistula (VVF)
- W**
- Women’s Health Initiative, 87–88
- X**
- Xenografts in slings, 118, 131, 145–146
- Z**
- Zuidex®, 105