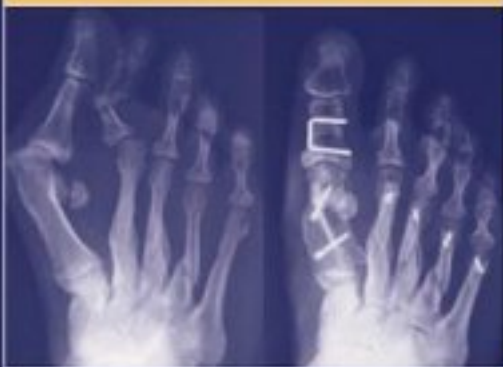

Louis Samuel Barouk

# Forefoot Reconstruction

Second edition



LS Barouk



**Springer**

*Paris*

*Berlin*

*Heidelberg*

*New York*

*Hong Kong*

*London*

*Milan*

Louis Samuel Barouk

# **Forefoot Reconstruction**

## **Second edition**

 Springer

Dr Louis Samuel Barouk  
Polyclinique de Bordeaux  
147, rue du Tondu  
33000 Bordeaux  
France

ISBN-10: 2-287-25251-7 Springer Paris Berlin Heidelberg New York  
ISBN-13: 978-2-287-25251-8 Springer Paris Berlin Heidelberg New York

© Springer-Verlag France, Paris, 2005  
Printed in France

© Springer-Verlag France, 2003 (for the first edition)  
Springer-Verlag France is a member of Springer Science + Business Media

Apart from any fair dealing for the purposes of the research or private study, or criticism or review, as permitted under the Copyright, Designs and Patents Act 1998, this publication may only be reproduced, stored or transmitted, in any form or by any means, with the prior permission in writing of the publishers, or in the case of reprographic reproduction in accordance with the terms of licenses issued by the copyright. Enquiry concerning reproduction outside those terms should be sent to the publishers.

The use of registered names, trademarks, etc, in this publication does not imply, even in the absence of a specific statement, that such names exempt from the relevant laws and regulations and therefore free for general use.

Product liability: the publisher can give no guarantee for information about drug dosage and application thereof contained in this book. In every individual case, the user must check its accuracy by consulting other pharmaceutical literature.

SPIN: 11404781

*Cover design: Nadia OUDDANE*

# Foreword of the second edition

by Marc Myerson

Dr. Samuel Barouk is a true renaissance man. It is reflected not only in his personality and his lifestyle but also magnificently in his surgery and this text book. Concepts embodied in his surgeries are not only based on biomechanics and a knowledge of forefoot anatomy but joint preservation, retaining mobility and, wherever possible, an understanding of the aesthetic components of the surgery.

I have always been fascinated by the differences in the approach to surgery, and in particular to forefoot reconstruction in Europe and the United States. The reconstructive message proposed by Dr. Barouk in this textbook has been embodied in his teachings for the past two decades and should be viewed in the light of his experience, his patients and the deformities that he encounters. I think that we should consider this a holistic approach to forefoot reconstruction. The tendency in the United States is to ignore the aesthetic and cosmetic requirements as well as the shoe wear needs of many patients. This is not to imply that doctors in the United States do not take these points into consideration but these are certainly not emphasized on this continent.

The surgical procedures are beautifully presented and illustrated in this textbook. Concepts are well explained, based on anatomic principles, and superbly illustrated. For the surgeon who is either an expert footcare, or practices general orthopaedic surgery and has a more peripheral interest in the foot, this book is going to be immensely helpful. It is very well illustrated, and the reader is taken “step by step” through each surgery in a logical manner.

Dr. Barouk is to be commended. He has generously given his time, energy and expertise to others. It is a credit to him that he has been able to pursue all of his interests and continue with his teaching and writings which are well embodied in this excellent book. It is my privilege to consider Dr. Samuel Barouk a friend and colleague. I am certain that this book will find an enthusiastic readership worldwide.

Mark Myerson, MD

Director,

Institute for Foot and Ankle Reconstruction at Mercy

President,

American Orthopedic Foot and Ankle Society.

# Foreword of the first edition

Andrea Cracchiolo, III, M. D.  
Professor of Orthopaedic Surgery  
UCLA Medical Center  
10833 Le Conte, Room 76-139  
Los Angeles, CA 90095-6902

When reviewing a book, I consider two questions: a) Why did the author write the book, and b) Why should I select it for my library? The answers for this book are simple. First, Dr. Barouk wanted to synthesize his vast experience with forefoot pathology and share with us his methods of treatment. Secondly, the book contains important surgical procedures that as yet have not been widely documented in the literature. For this reason, the combination of text plus CD-ROM is most important; the CD-ROM is beautifully illustrated and appears to be well integrated with the text. Therefore, any surgeon specializing in foot surgery will find this book and the CD to be an important reference.

Most medical books are compiled by editors and various chapters are written by different authors. However, *Forefoot Reconstruction* is the work of a single surgeon, Dr. Barouk, and like all surgeons he has developed techniques that will work well in his hands. So it is important to carefully read not only about a relatively new procedure like the Scarf osteotomy but also about older procedures like the osteotomy of the great toe. Originally described as a medial closing wedge osteotomy, Dr. Barouk (instead) uses various osteotomies and describes a shortening of the proximal phalanx. Another concept that the reader must examine is the treatment of metatarsalgia. A long history of performing a variety of osteotomies for this condition exists and most have been discarded. However, Barouk enthusiastically and aggressively utilizes the Weil and the BRT osteotomies to shorten or elevate the metatarsal. Thus, he adopts a global approach to the treatment of forefoot abnormalities and he emphasizes the use of internal fixation in performing these procedures. Here Dr. Barouk has developed various implants like

the threaded head cannulated screw, the memory staple and the twist off screw and he gives us the specific usage indications for each.

Readers may wonder why Dr. Barouk uses these surgical techniques, all of which include a learning curve and are only easily done if one incorporates them frequently into his or her surgical armamentarium. Having visited Bordeaux, I was truly amazed at the vast numbers of women who present with major forefoot deformities which are far more severe than I see here in Southern California. These patients want their painful feet corrected. More importantly they want to be able to wear the fashionable shoes that may have contributed to their pathology and return to their former lifestyles, which have been interrupted by their foot pathology. Dr. Barouk accepts this challenge, which has molded his surgical philosophy. Therefore after reading about these various procedures, each of us must reflect on the types of patients we treat and the extent of the patients forefoot deformities. Only then perhaps we can select the surgical techniques which will help our patients. For example, it is not important to adopt the Scarf osteotomy if our own type of metatarsal osteotomy is providing satisfactory results. Personally, I would emphasize the options: a) of conservative surgery and dealing with the symptomatic complaints or b) a more global approach (that Barouk favors) of attempting to remodel the entire house. Which approach is best will remain to be seen but certainly one can benefit from the various adjunctive forefoot techniques such as central metatarsal shortening and elevation osteotomies; procedures of the hallux, Akin, shortening osteotomy; and capsule tendon balancing procedures of the metatarso-phalangeal joints.

Although these techniques may benefit by the sophisticated instrumentation and fixation recommended by Dr. Barouk, almost all can be performed using standard K-Wires which may be necessary in countries where the economics of medicine and orthopaedic implants is under financial pressures. Dr. Barouk stresses, in his postoperative management, the critical role of the physiotherapist. One cannot disagree, but in practicality, shouldn't the patient take the lead role in being sufficiently motivated to enthusiastically participate in self-therapy in order to achieve the success of the surgical procedures performed on the forefoot? Are those patients, who fail to demonstrate this motivation, poor

candidates for reconstructive and cosmetic realignment of the forefoot? Therefore, it is important to understand whether your patients are sufficiently motivated to withstand the long convalescence associated with forefoot reconstruction.

Lastly, it is refreshing to see that Dr. Barouk has given extensive credit to the other surgeons whose techniques he has adopted and in some cases modified. Samuel Barouk is truly a Renaissance man; he is a cultured man, participates in and enjoys the fine arts, and is even an oenologist. All of these factors can be seen in his surgical procedures, in which both science and art are embraced.

## Preface

Beams, chevrons, scarf, mortises and tenons, arcs and vaults... All these architectural terms find their meaning in anatomical studies of the foot, the superbly crafted mechanism which enables humans to stand upright on just a few square inches.

But it only takes one axis to be misaligned, one rafter slightly off-beam, and the remarkable construction will shift, bringing down the edifice.

This is why, as opposed to some of past practices, forefoot surgery should be designed and applied in respect to the overall architecture of the foot. We must constantly bear in mind what direct or subsequent consequences surgery will have on a specific part of the foot; in terms of its static and biomechanical future in the medium to long-term.

This is why we talk about *forefoot reconstruction*, even for seemingly isolated deformities. Reconstruction means using special tools and techniques. In this context, we started out 28 years ago by studying the deformities of the great toe joint and their corresponding surgeries. But then we were lucky enough to meet L. S. Weil in 1991, who showed us the Scarf Osteotomy of the first metatarsal and, in 1992, his lateral metatarsal osteotomy. Since 1992, we have also studied and developed the soft tissue release and balancing procedures on the forefoot, hindfoot and leg. Recently, with P. Rippstein (Zurich) and E. Toullec, my associate, we developed a new basal oblique metatarsal osteotomy (the BRT osteotomy). At last, we sought to improve the first MTP and Lisfranc joint fusions. In combination with these techniques, we used a number of specific implants along with their instrumentation, adapted to forefoot reconstruction surgery.

All these techniques are based on a release, both in the transversal and the sagittal planes,

where we achieve a harmonized / balanced *transversal and longitudinal decompression* of the forefoot. It's because of this "release" that these techniques are now practically painless for the patient.

Indeed, the *patient* has always been at the center of our studies on forefoot reconstruction. We have developed a complete patient-support system that begins with the first consultation when we give patients a guidebook explaining all the stages of our footcare approach, through the surgery and the postoperative care using a footwear system that we have designed and developed. This has enabled our patients to recover their autonomy and be self-sufficient in just a few days after their operation.

In this forefoot reconstruction, the *functional and esthetic aspects* are also a major concern. *Functional*, because the techniques of the Scarf, Weil and BRT osteotomies extend joint conservation surgery to its present day limits. *Esthetic*, because we're lucky enough to operate on French women who are extremely demanding about the esthetic of their feet, as they are for their footwear and general appearance. This means we must rebuild their feet to slip into elegant, high-heeled shoes. For many years we have studied women's footwear, even building shoes ourselves, to better understand these specific problems.

Since 1990, I have had the pleasure of presenting regular, forefoot surgery, training courses in Bordeaux. As a result of these training sessions, I have had the opportunity to appreciate and assess what the orthopaedic surgeon needs to learn regarding the performance of functional and rehabilitative forefoot surgery.

*This book is not based on theory, but is rather a direct result of my day-to-day current practice of forefoot surgery, research and collaboration*



with my colleagues. I took special care to give to my colleagues an easy, practical and simple work tool. The pictures are from my own experience in the surgical theater and my office. All the postoperative pictures have a minimum of one year follow-up.

The book and the CD-ROM have been designed to be user-friendly.

*The book is above all an atlas:* The text itself is very condensed, and the pictures are grouped in plates with a small legend.

The book is divided in three chapters.

1. *Description of the procedures used.* This is based on extensive experience of more than 3,000 procedures during the past 10 years. The history, indications, techniques, advantages and drawbacks are fully described.

2. *Application of these procedures to the main forefoot pathologies;* including the main aspects of each pathology I have observed, their respective causes, their evolution, and what we can expect from the above mentioned techniques.

3. *At last a chapter on the therapeutic management.* This chapter first *highlights* the main points of the two previous ones and gives a *more practical light* on how to deal with the *examination* of the foot, the *assessment* of its disorders, and presents examples of the *surgical management*.

What are the main points of this new edition?

1) On the BOOK

– *Improvement of the general presentation:*

The text remains succinct emphasising the main points. In fact the pictures are essential: this book may be read like a “strip cartoon”.

– *Emphasis on several topics:*

- great toe proximal phalanx osteotomy, notably shaft osteotomy with the memory staple;
- revision after failed bunionectomy, notably joint preservative surgery;
- joint preservative surgery in the treatment of severe forefoot disorders – including rheumatoid forefoot. Emphasis of the “ms” point for and accurate and effective metatarsal shortening;
- gastrocnemius proximal release.

– *Bringing additional or new procedures*

- in claw and Hammer toe surgery: there is three significant improvements : Percutaneous procedure, and, above all, PIP plantar release, and surgery of the middle phalanx;
- Weil osteotomy of the first metatarsal in hallux limitus and in single shortening.

2) On the CD-rom

The CD-ROM is an *animation of the book’s pictures, drawings and graphic illustrations;* some of which are presented in three dimensions; *Videos* are taken directly from the surgical theater.

The CD illustrates only the first part of the book (the procedures).

– Furthermore, on a second Disk there are *Available Pictures:* they include all the computerized pictures of the CD-rom, including AVI in 3 D. These Pictures may be used Copyright Free for presentations or Articles.

If “*Forefoot reconstruction*” helps you to share my passion for foot surgery and for its continual improvement, it will have more than fulfilled its mission.

L.S. Barouk

# Forefoot Reconstruction

# Table of Contents

<b>I. THE PROCEDURES</b> .....	19
<b>Scarf and Great Toe Osteotomies in the Treatment of Hallux Valgus</b> .....	19
<b><i>The Lateral Release of the Metatarso-Sesamoidal Phalangeal Complex (MSPC)</i></b> .....	20
<i>Local Anatomy</i> .....	20
<i>Technique and Result</i> .....	21
Approach .....	21
The Release .....	21
<b><i>Scarf Osteotomy of the First Metatarsal</i></b> .....	25
<i>Definition</i> .....	25
<i>History</i> .....	28
<i>Local Anatomy as Applied to the Scarf Osteotomy</i> .....	29
<i>First Metatarsal Medial Approach</i> .....	32
<i>The Scarf Cuts</i> .....	34
Longitudinal Cut .....	34
The Transverse Cuts .....	39
<i>The Displacements</i> .....	40
The Versatility of the Scarf Osteotomy .....	40
Transverse Lateral Shift .....	40
Lateral Rotation .....	44
DMAA (or PASA) Correction: Medial Rotation .....	44
Lowering .....	49
Elevation .....	56
Lengthening .....	57
Shortening of the First Metatarsal .....	58
Axial Rotation .....	66
Combination of Different Displacements .....	67
<i>Scarf Fixation</i> .....	68
Distal Fixation .....	70
Proximal Fixation .....	72
<i>Medial Distal Resection</i> .....	73
<b><i>Medial Soft Tissue Tightening (Capsulorrhaphy)</i></b> .....	74
<b><i>The Great Toe First Phalanx Osteotomy</i></b> .....	78
<i>Basal Osteotomy</i> .....	79
<i>Shaft Osteotomy</i> .....	81
Fixation .....	82
<i>Conclusion</i> .....	88

<b>Check Tests to be Performed During the Hallux Valgus Surgery</b> .....	88
<i>The Load Simulation Test</i> .....	88
<i>The Other Tests</i> .....	90
<b>Postoperative Period after Hallux Valgus Surgery</b> .....	91
<i>Walking and Postoperative Footwear</i> .....	91
<i>Functional Recovery</i> .....	92
<b>Drawbacks with this Type of Hallux Valgus Surgery</b> .....	94
<i>Fractures with the Scarf Osteotomy</i> .....	94
<i>Under or Overcorrection of the Deformity</i> .....	96
<b>Undercorrection</b> .....	96
<b>Overcorrection</b> .....	99
<i>Incorrect Sagittal Position of the First Metatarsal Head</i> .....	102
<i>First Metatarsal Head Necrosis</i> .....	103
<i>MTP Stiffness</i> .....	104
<i>Drawbacks with the Great Toe First Phalanx Osteotomy</i> .....	105
<i>P1 Basal Osteotomies</i> .....	105
<i>P1 Shaft Osteotomy</i> .....	105
<b>Advantages of this Type of Hallux Valgus Surgery</b> .....	106
<b>The Weil first metatarsal decompression osteotomy</b> .....	111
<i>Two indications</i> .....	111
<i>Technique</i> .....	111
<b>Displacement of the head</b> .....	111
<b>Fixation</b> .....	111
<b>Combined procedures</b> .....	113
<i>Specificities for hallux limitus</i> .....	113
<b>Indications</b> .....	113
<b>Results</b> .....	113
<b>In conclusion</b> .....	113
<i>Specificities for simple shortening</i> .....	114
<b>Indication</b> .....	114
<b>Results</b> .....	114
<b>The Weil Lesser Metatarsal Osteotomy</b> .....	115
<b>History, Definition</b> .....	115
<b>Surgical Anatomy</b> .....	116
<b>Technique</b> .....	120
<b>Indications</b> .....	129
<i>Metatarsalgia</i> .....	129
<i>Indications in Claw Toe and MTP Dislocation (Longitudinal Decompression)</i> .....	129
<b>Hammer Toe or Claw Toe</b> .....	129
<b>MTP Dislocation</b> .....	129
<i>Excess of Lesser Metatarsal Length</i> .....	130
<i>Indications in Overlapping and Wind-Swept Toes (Transverse Displacement)</i> .....	130

<i>Weil Osteotomy: Drawbacks</i> .....	132
<i>MTP Stiffness after Weil Osteotomy</i> .....	133
<i>Long-Term Results</i> .....	138
<b>The BRT Proximal Metatarsal Osteotomy</b> .....	139
<i>History, Definition</i> .....	139
<i>Local Anatomy as Applied to the BRT Osteotomy</i> .....	140
<i>Bone Aspects</i> .....	140
<i>Vascular Aspect</i> .....	140
<i>Technique</i> .....	141
<i>Osteotomy of the Three Central Metatarsals</i> .....	141
<i>Osteotomy of the First Metatarsal</i> .....	143
<i>Osteotomy of the Fifth Metatarsal</i> .....	144
<i>Combined Procedure</i> .....	144
<i>Postoperative Period</i> .....	144
<i>Drawbacks</i> .....	145
<i>Advantages</i> .....	145
<i>Indications and Results</i> .....	146
<i>BRT Osteotomy in Metatarsalgia</i> .....	146
<i>BRT Osteotomy in Emerging MTP Subluxation</i> .....	149
<i>BRT Osteotomy in Pes Cavus</i> .....	149
<i>BRT Osteotomy in Iatrogenic Forefoot</i> .....	152
<i>Conclusion</i> .....	154
<b>Soft Tissue Procedures in Forefoot Surgery</b> .....	155
<i>In Hallux Valgus Correction</i> .....	155
<i>In Lesser Toes Deformity Correction</i> .....	156
<b>Gastrocnemius Proximal Release (GPR)</b> .....	158
<i>Definition, History</i> .....	158
<i>Local Anatomy</i> .....	159
<i>Patient Examination for Gastrocnemius Shortness</i> .....	160
<i>Consequences of Gastrocnemius Shortness</i> .....	161
<i>Technique of Proximal Release</i> .....	162
<i>Results</i> .....	165
<i>Forefoot and GPR</i> .....	165

<b>Use of the “20” Memory Staple in Osteotomies of Fusions of the Forefoot</b> .....	168
<i>Definition, History, Generalities</i> .....	168
<b>Indications and Results</b> .....	168
<i>Basal Metatarsal Osteotomies</i> .....	168
<i>First Metatarso Phalangeal Joint Fusion</i> .....	171
<i>Lisfranc’s Fusion</i> .....	171
<i>Hindfoot Arthrodesis</i> .....	173
<i>Conclusion</i> .....	173
<b>The Button Temporary Spacer</b> .....	174
<i>Definition, History</i> .....	174
<i>Technique</i> .....	175
<i>Results</i> .....	175
<b>II. THE MAIN FOREFOOT PATHOLOGIES</b> .....	179
<b>The Different Types of Hallux Valgus Deformity</b> .....	179
<i>Mild or Emerging Hallux Valgus</i> .....	179
<i>Juvenile Hallux Valgus</i> .....	181
<i>Arthritic Hallux Valgus</i> .....	187
<i>Hallux Valgus in Spastic Foot</i> .....	193
<i>Hallux Valgus in Elderly Patients (more than 80)</i> .....	197
<i>Failed Bunionectomy</i> .....	199
<i>Undercorrection</i> .....	199
<i>Overcorrection</i> .....	201
<i>Impaired MTP Joint: Joint Preservative Surgery</i> .....	204
<i>Very Impaired MTP Joint, or Loss of Great Toe Ground Contact</i> .....	204
<b>Hammer and Claw Toe of the Lesser Rays</b> .....	205
<i>Main Causes and Chronology of Hammer and Claw Toes</i> .....	205
<i>Soft Tissue Procedure in Hammer Toe Deformity</i> .....	206
<i>The PIP Surgery</i> .....	208
<i>Middle Phalanx Osteotomies</i> .....	211
<i>Weil Osteotomy and Toe Deformity</i> .....	214
<b>Metatarsalgia</b> .....	217
<i>The Main Causes</i> .....	218
<i>Insufficiency of the First Ray</i> .....	218
<i>Excess of Metatarsal Plantar Slope or Head Protuberance</i> .....	219

<i>Vertical Position of the First Phalanx</i> .....	220
<i>Metatarsal Excess of Length in Dorso-Plantar X-Ray View in Standing Position</i> .....	220
<i>Metatarsal Excess of Length in the Medial Oblique X-Ray View</i> .....	223
<i>Stance and Propulsive Phase Metatarsalgia</i> .....	224
<i>Stance Phase Metatarsalgia (SPM)</i> .....	224
<i>Propulsive Phase Metatarsalgia (PPM)</i> .....	224
<i>Equinism</i> .....	225
<b><i>The Surgical Treatment of Metatarsalgia</i></b> .....	226
<i>The Principles of Surgical Treatment</i> .....	226
<i>The Procedures we Used to Relieve Metatarsalgia</i> .....	227
<i>Weil Osteotomy for metatarsalgia</i> .....	227
<i>Basal Metatarsal Chevron Osteotomy</i> .....	231
<i>The BRT Osteotomy</i> .....	231
<b><i>Clinical Types of Metatarsalgia and their Treatments</i></b> .....	233
<i>Hallux Valgus and Metatarsalgia</i> .....	233
<i>Solutions for Metatarsalgia with Excessive Length of Lesser Metatarsals</i> .....	237
<i>Solutions for the Correction of Vertical Position of the First Phalanx and Recovery of a Correct Ground Contact</i> .....	238
<i>Equinism Correction</i> .....	239
<i>Iatrogenic Metatarsalgia</i> .....	240
<i>Metatarsalgia and Pes Cavus</i> .....	241
<i>Conclusion</i> .....	242
<b>MTP Joint Dislocation of the Lesser Rays</b> .....	243
<b>Impairment of the Lesser MTP Joints (Excluding Rheumatoid Lesion)</b> .....	251
<b>Lesser Toes Transverse Deformity</b> .....	255
<b><i>Overlapping Second Toe</i></b> .....	255
<i>Technique and Results in Mild, Moderate or Severe Deformity</i> .....	257
<i>The Problem of Footwear</i> .....	262
<b><i>Lateral Wind-Swept Toes Deformity</i></b> .....	263
<i>Generalities</i> .....	263
<i>Surgical Treatment</i> .....	263
<i>MTP Release on the Lesser Rays Combined with Toe Surgery and Hallux Valgus Correction</i> .....	263
<i>Weil Lesser Metatarsal Osteotomy</i> .....	265
<b><i>Diverging Toes</i></b> .....	268
<b>The Second Ray Pathology</b> .....	269
<b><i>Hammer or claw toes</i></b> .....	269
<b><i>Metatarsalgia</i></b> .....	273
<b><i>MTP Dislocation</i></b> .....	275

<b>Some Pathologies of the Fifth Ray</b> .....	279
<i>Hammer or Claw Toe</i> .....	279
<i>Intercommissural Keratosis</i> .....	280
<i>Overlapping Fifth Toe</i> .....	281
<i>Taylor's Bunion</i> .....	282
<b>Lesser Metatarsal Aplasia (Congenital Brachi Metatarsal)</b> .....	290
<b>Severe Forefoot Disorders</b> .....	291
<i>Postoperative Aspects</i> .....	296
<i>Application to the Main Types of Forefoot Severe Disorders</i> .....	297
<i>Limits, Problems and Long-Term Result of Such Joint Preservative Surgery</i> .....	301
<b>Rheumatoid Forefoot</b> .....	305
<i>Conclusion</i> .....	312
<b>Some Aspects of Surgery for Hallux Limitus</b> .....	313
<i>Weil 1st Metatarsal decompression osteotomy</i> .....	313
<i>MTP Fusion</i> .....	313
<i>Button Prosthesis</i> .....	313
<b>III. SURGICAL MANAGEMENT IN FOREFOOT RECONSTRUCTION</b> .....	315
<b>Preoperative Management</b> .....	315
<i>Examination</i> .....	315
<i>Decision-Making in the Main Pathologies</i> .....	324
<i>In Hallux Valgus Deformity</i> .....	324
<i>In Relieving Metatarsalgia</i> .....	326
<i>In Hammer or Claw Toe Correction</i> .....	328
<i>In MTP Dislocation on Lesser Rays</i> .....	332
<i>In Severe Forefoot Disorders Treatment</i> .....	333
<i>In the Iatrogenic Forefoot</i> .....	336
<b>Intraoperative Management</b> .....	339
<i>Specific Tools</i> .....	339
<i>Operative General Tactics</i> .....	341



<b><i>Management in the Different Main Pathologies Encountered</i></b> .....	342
<i>Hallux Valgus Correction</i> .....	342
<i>Management on the Lesser Rays</i> .....	346
<i>Management in Severe Forefoot Disorders</i> .....	352
<b>Postoperative Management</b> .....	354
<b>Revision in Forefoot Surgery</b> .....	358
<b>IV. EIGHT PRINCIPLES OF FOREFOOT RECONSTRUCTION</b> ....	359
<b>First Principle.</b> The post operative period .....	359
<b>Second Principle.</b> Where to focus the surgery. (Law of the most impaired ray).....	359
<b>Third Principle.</b> The metatarsal parabola .....	365
<b>Fourth Principle.</b> The generous shortening of the metatarsals.....	366
<b>Fifth Principle.</b> Single ray pathology .....	370
<b>Sixth Principle.</b> Relationships between forefoot, rear foot and lower limb .....	371
<b>Seventh Principle.</b> Keep the toes long .....	374
<i>Keep the Toes Long</i> .....	374
<i>Obtain a Square Type Foot</i> .....	374
<b>Eighth Principle.</b> Obtain a foot which fits to elegant shoes	375
<b>References</b> .....	383
<b>Acknowledgements</b> .....	389

# I. THE PROCEDURES

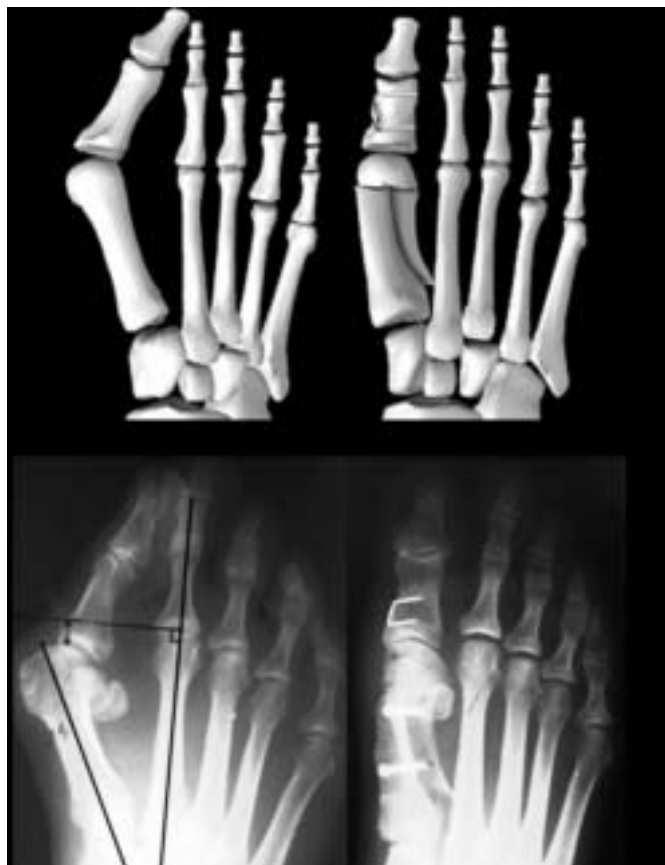
## Scarf and Great Toe Osteotomies in the Treatment of Hallux Valgus

The SCARF, first metatarsal osteotomy, is most often combined with the FIRST PHALANX (P1) great toe osteotomy for *hallux valgus correction*. This is why these two procedures are described

in the same chapter. Nevertheless, the scarf and the P1 osteotomy may also be used separately for other indications, such as hallux limitus.

In fact, *hallux valgus deformity correction* may be divided into four chronological steps (Fig. 01b) we describe successively:

- 1) The lateral release of the Metatarso-Sesamoid Phalangeal Complex (MSPC);
- 2) The scarf first metatarsal osteotomy;
- 3) The medial soft tissue tightening;
- 4) The first phalanx great toe osteotomy (performed in most cases).



**Fig. 01a.**  
1st metatarsal scarf  
and great toe  
1st phalanx  
osteotomies  
in hallux valgus  
correction.

After this description, we will study:

- The check tests to be performed during hallux valgus surgery;
- The postoperative period;

- The drawbacks of this procedure;
- The advantages encountered with this procedure.

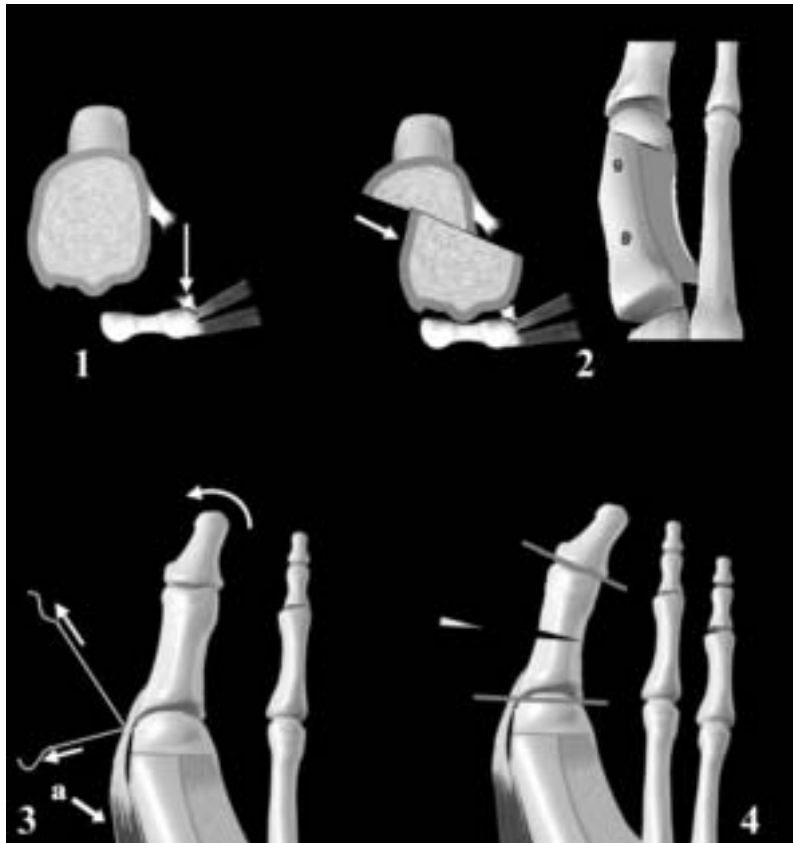


Fig. 01b. The four chronological steps for hallux valgus correction.

### ***The Lateral Release of the Metatarso-Sesamoidal Phalangeal Complex (MSPC)***

The MSPC lateral release is the first step of hallux valgus correction. We perform it in each case, because we have observed that, even for mild deformities, the correction may be inadequate when the MSPC release is not performed.

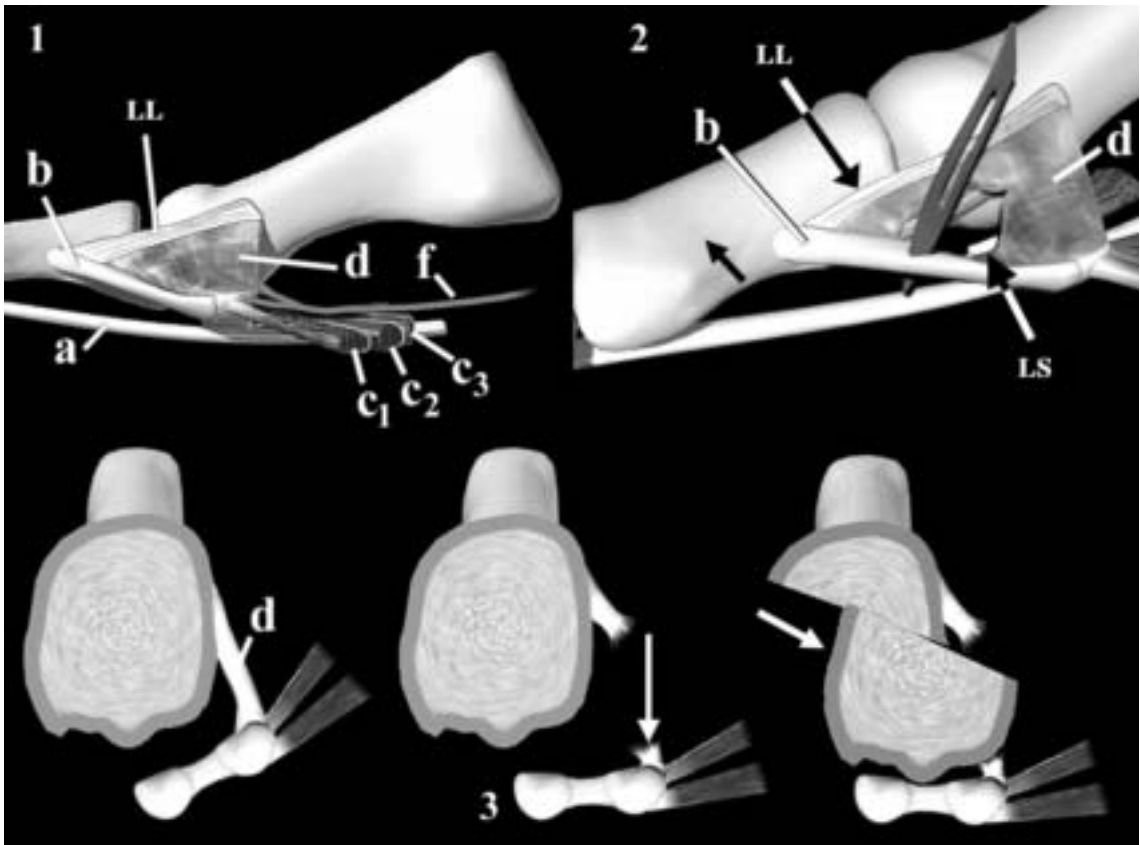
The lateral release has *two goals* (Fig. 02a):

1. To release the sesamoids from the head of the metatarsal, so that after the head is displaced laterally it will lie in its correct position above the sesamoids, which should still be in their original position.

2. To perform the first step of hallux valgus correction by sectioning the phalangeal insertional band – without severing the metatarso-phalangeal collateral ligament –, in order to avoid over correction of the deformity.

### ***Local Anatomy***

Fig. 02a shows the local anatomy that has to be considered when accurately performing the lateral release.



**Fig. 02a. Lateral release: anatomy, the two goals.**

1. *Anatomy of the Metatarso-Sesamoidal Phalangeal Complex (MSPC).*

a: flexor hallucis longus tendon.

b: Phalangeal Insertional Band (PIB).

c: C1 C2 adductor muscles and tendons.

C3 lateral head of the flexor hallucis brevis.

d: metatarsal sesamoidal suspensory ligament.

LL: metatarsal phalangeal collateral ligament.

2. The scalpel first divides the suspensory ligament (d), then cuts the PIB (b): This is the first step of the hallux valgus correction and the *first goal* of the lateral release.

3. The total section of the suspensory sesamoid ligament (d) allows the lateral sesamoids to move plantarward, and allows the metatarsal head to lie above the sesamoids when this head is laterally displaced. This is the *second goal* of the lateral release.

## Technique and Result

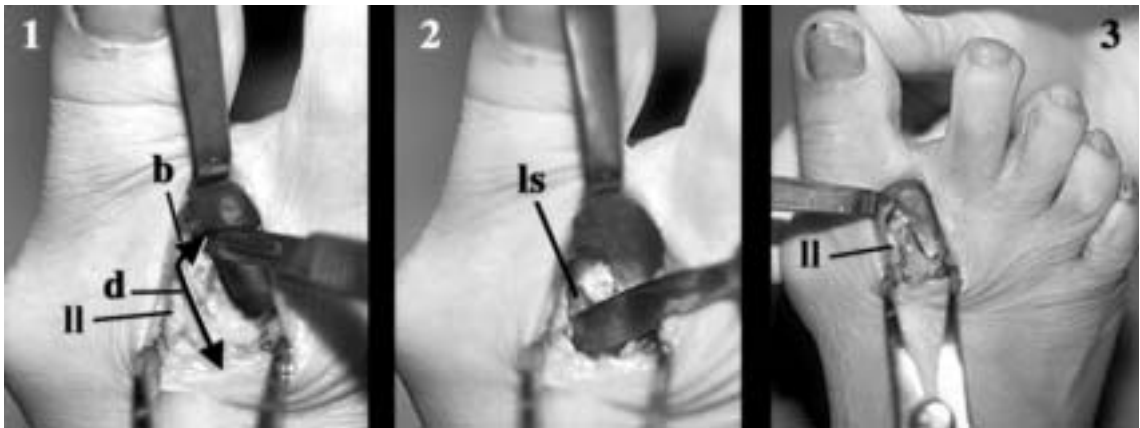### Approach

Lateral mobilisation can be achieved using a medial approach, and it can be performed working either below and occasionally above the head. I prefer using a *lateral intermetatarsal approach*. It is easy, harmless, accurate and it allows easy access to the second metatarsal if necessary and eventually sectioning of the intermetatarsal ligament.

### The Release

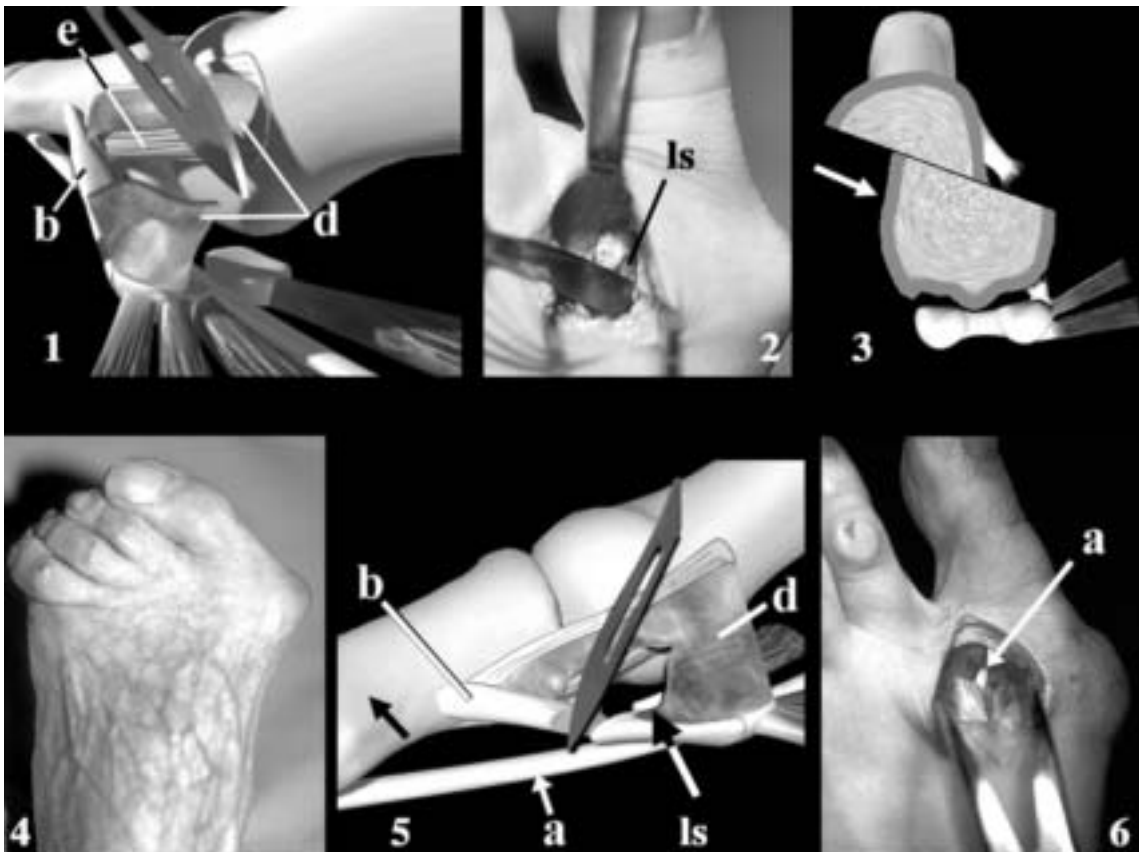
The *metatarso-phalangeal collateral ligament* is *preserved* in almost every case. I believe that the valgus of the toe is a result of muscular unbalance. So cutting the Phalangeal Insertion Band (PIB) is sufficient when performing the lateral release.

Usually, *the adductor tendon does not have to be completely detached from the basis of the phalanx*. The head of the first metatarsal will lie in the correct superior relation with the sesamoids. On the



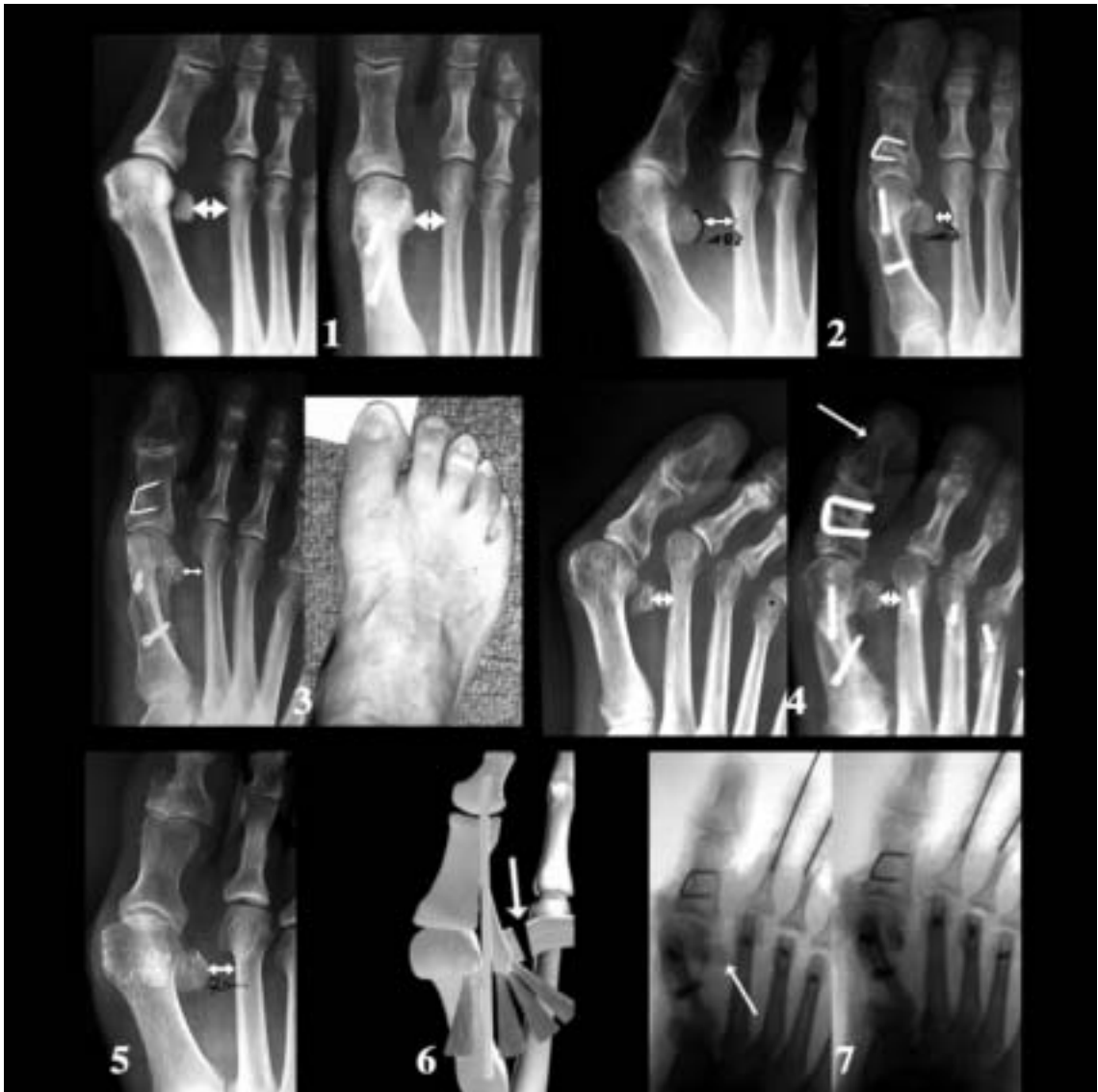**Fig. 02b. Lateral release. Operative views.**

1. Section of the sesamoid suspensory ligament (d) and of the phalangeal insertional band (b).
2. Checking the lateral release: ls: lateral sesamoid.
3. No overcorrection because of the preservation of the metatarsal phalangeal ligament (ll).



**Fig. 02c. Lateral release in mild or severe deformity.**

- 1, 2, 3. In *mild* deformity: The scalpel just divides the suspensory ligament (d) in order to release the sesamoids, which allows the metatarsal head to move laterally and to lie above the sesamoids. The PIB (b) remains preserved.
- 4, 5, 6. In *severe* deformity: The phalangeal insertional band (b) has to be released as far as the flexor hallucis longus (a), the tendon, becomes visible.



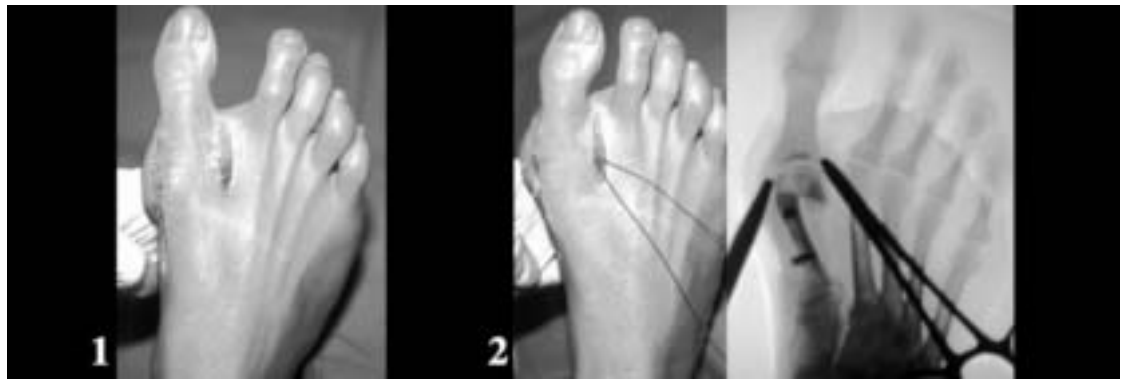**Fig. 02d. The importance of the lateral release.**

1. Usually (P. Diebold) the distance between the lateral sesamoid and the 2nd metatarsal does not change after the deformity correction. If the lateral release is incomplete (2), the lateral sesamoid moves laterally with the lateral shift of the head: Sometimes this does not affect the correction (3) but generally it is a factor of *undercorrection* (4). 5, 6, 7. Preoperatively, the lateral sesamoid is sometimes too close of the 2nd metatarsal. In this case, release of the intermetatarsal ligament is necessary (in this location this ligament is joining the 2nd metatarsal to the lateral sesamoid). This may also be useful after the metatarsal head lateral shift (7).

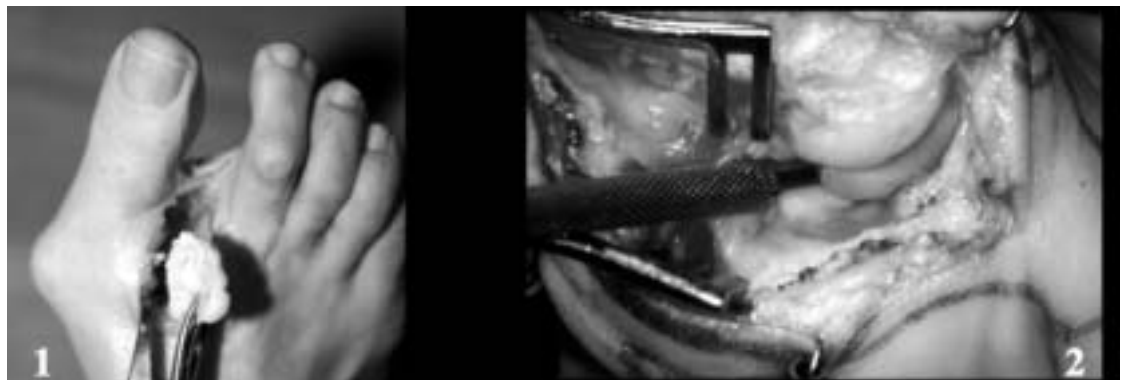other hand, it has been observed (P. Diebold, AFCP\* 4th annual meeting, Paris 1998) that whatever the method used in hallux valgus correction, the preoperative standing dorsal plantar radiographs show that the distance between the

lateral sesamoid and the second metatarsal remains unchanged in most cases. However in preoperative cases in which the lateral sesamoid is too close to the second metatarsal, the same intermetatarsal incision allows easy release of the first deep intermetatarsal ligament which, in this location, extends between the second metatarsal and the lateral sesamoid.

\* AFCP : Association Française de Chirurgie du Pied (belonging to the SOFCOT).



**Fig. 02e.** An excessive lateral release, generally resulting from the complete release of the metatarsophalangeal collateral ligament, results in overcorrection; repairing this ligament is then necessary (2).



**Fig. 02f.** Lateral release – Lateral sesamoid – Medial approach.

1. Sometimes the lateral sesamoid is hypertrophied, impaired or arthritic and cannot be adequately released; in this case (B. Baudet, L. S. Weil), it may be removed.

2. The lateral release can also be made by a medial approach (L. S. Weil) with exposure between the 1st metatarsal head and sesamoids. It may be somewhat more difficult to perform and provides less exposure than the intermetatarsal approach (ex.: for the 2nd ray approach).

*In very mild deformity*, the PIB may almost be preserved, but the suspensory ligament must always be cut.

*In large deformities*, the PIB has to be entirely cut, as far as the long flexor hallucis tendon is clearly visible in the bottom of the exposure

and the lateral metatarso-phalangeal ligament may also be divided but only on its plantar part, as recommended by A. Cracchiolo.


Sometimes an hypertrophied and arthritic lateral sesamoid may be removed (B. Baudet, Toulouse), which increases the MTP dorsal flexion.

## Scarf Osteotomy of the First Metatarsal

### Definition

Scarf is a carpentry term, meaning “a joint made by bevelling two beams to correspond”. The aim is to set the two beams end-to-end in order to make a longer beam, providing a longer bearing surface. The join – or the cut – is similar to a flash of lightning, on a thunder sky. This is why it is called in France: “*trait de Jupiter*” (in Spain “*rayo de Jupiter*”); in France Jupiter is Zeus.


The name “scarf” was given in 1984 by Lowell Scott Weil to this first metatarsal osteotomy in regard to its cuts. However, in this osteotomy, instead of end-to-end lengthening, the plantar beam which includes the first metatarsal head, shifts laterally to the dorsal beam that is stable throughout its length. This displacement can be not only lateral, but also in several directions, resulting in a great versatility, to adapt to the different hallux valgus deformities. Furthermore, the stability is notable, resulting from a large fragment area contact and from the double chevron shaped cut – proximal and distal – (Fig. 03a).



**Fig 03a1. The scarf term.**

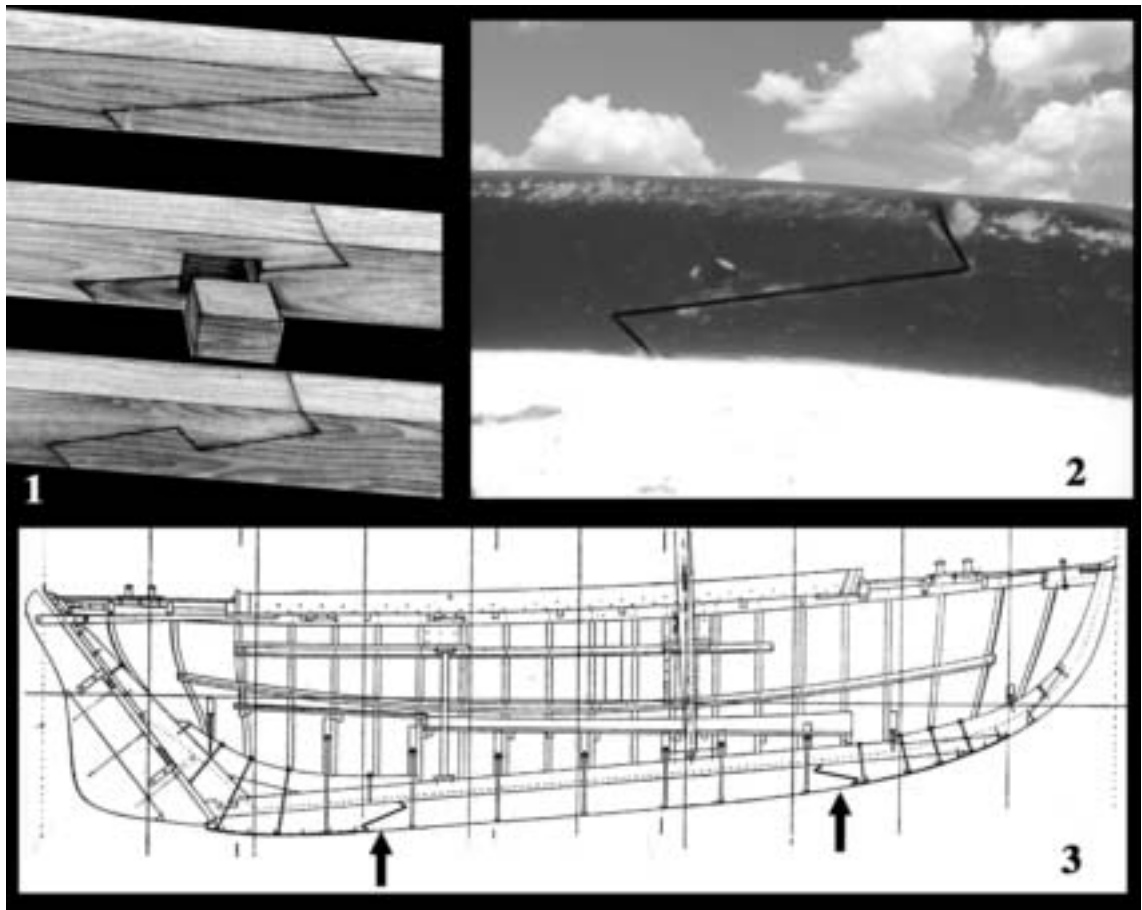
The scarf term comes from the French term “*trait de Jupiter*” (Jupiter is the Roman name of the Greek god: Zeus); it certainly comes from lightningning observed in a thunder sky. In Spanish it is called “*Rayo de Jupiter*”. English people talk about “Jupiter cut” or “scarf”. It was first applied to the carpentry (to lengthen a beam) then to the forefoot surgery, particularly to the first metatarsal. L. S. Weil gave the name scarf to this osteotomy.





**Fig. 03a2. Scarf, a carpentry term.**

Scarf, or “*trait de Jupiter*”, in an old market – picture communicated by B. Baudet (Toulouse, France). The two beams are joined by a “*trait de Jupiter*” cut.

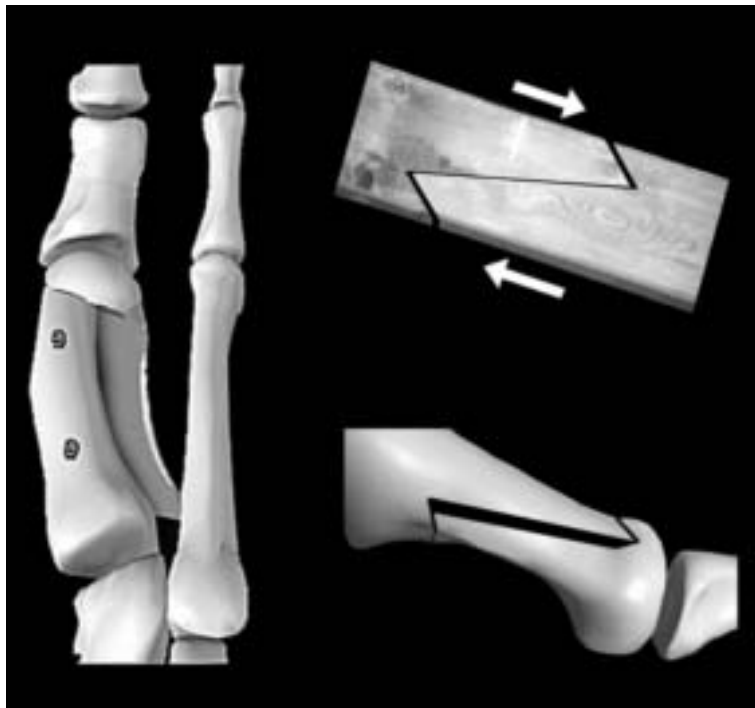


**Fig. 03a3. Ship's carpentry.**

1. Scarf cuts, with and without lock piece (picture provided by E. Maceira, Madrid).

2. Scarf in a ship's sheathing.

3. Scarf in a ship's keel is necessary to have both a sufficient length and to follow the changing keel direction.



**Fig. 03a4. Scarf cut in carpentry and in forefoot surgery.**

In the 1st metatarsal, the scarf cut is the same as in carpentry, but its aim is not end-to-end lengthening of the two fragments, but rather to displace only the plantar one, primarily in lateral shifting – but also in several directions, resulting in great versatility. The large fragment area is an important factor of stability of this osteotomy.

## History

1973 J. M. Burutaran [29] described a cut almost similar to the scarf cut, though not chevron-ended, and which was used to lengthen the first metatarsal.

1983 Charles Gudas and K. H. Z. Zygmunt [102] began to perform “z bunionectomies” with lateral shift of the plantar / distal fragment, including the metatarsal head.

1984 L. S. Weil [8, 26, 128, 129] gave the name “scarf” to this osteotomy (see above definition). With A. H. Borrelli, they studied the blood supply regarding this osteotomy, modified the scarf cuts, increased the length of the osteotomy, and made the first important clinical study, particularly with a long follow-up.

I met L. S. Weil in Chicago eleven years ago (February 1991) and since this moment I have begun to perform the scarf osteotomy. During these years I have performed more than

3,000 scarf osteotomies of the first metatarsal for hallux valgus. My personal contribution to the procedure has been: study of the first metatarsal anatomy [3], describing and emphasizing the displacements of the osteotomy, in particular the lowering of the first metatarsal head (in collaboration with B. Valtin\*); the shortening of the first metatarsal (in collaboration with M. Maestro\*\*); the use of a specially designed bone clamp, the internal fixation using a threaded head screw, placing the distal screw into the head to offer additional support to the osteotomy, and placing of scarf osteotomy in the global surgical management of static forefoot disorders [4-8, 15]. Many authors have already written about the scarf procedure [23, 24, 26, 29, 30, 31, 33, 34, 35, 38, 40, 41, 45-48, 53-57, 61, 62, 63, 64, 66, 70, 77-79, 82, 85, 87, 90, 91-96, 100-

\* Bernard Valtin, Paris – France.

\*\* Michel Maestro, Nice – France.



**Fig. 03b. Surgical scarf story.**

1. 1973 J. M. Burutaran (San Sebastian, Spain).
2. 1983 Ch. Gudas (Charleston, USA).
3. 1984 L. S. Weil (Chicago, USA).

102, 104, 109, 110-112, 122, 124, 127-129, 131] (Fig. 03b).

### *Local Anatomy as Applied to the Scarf Osteotomy*

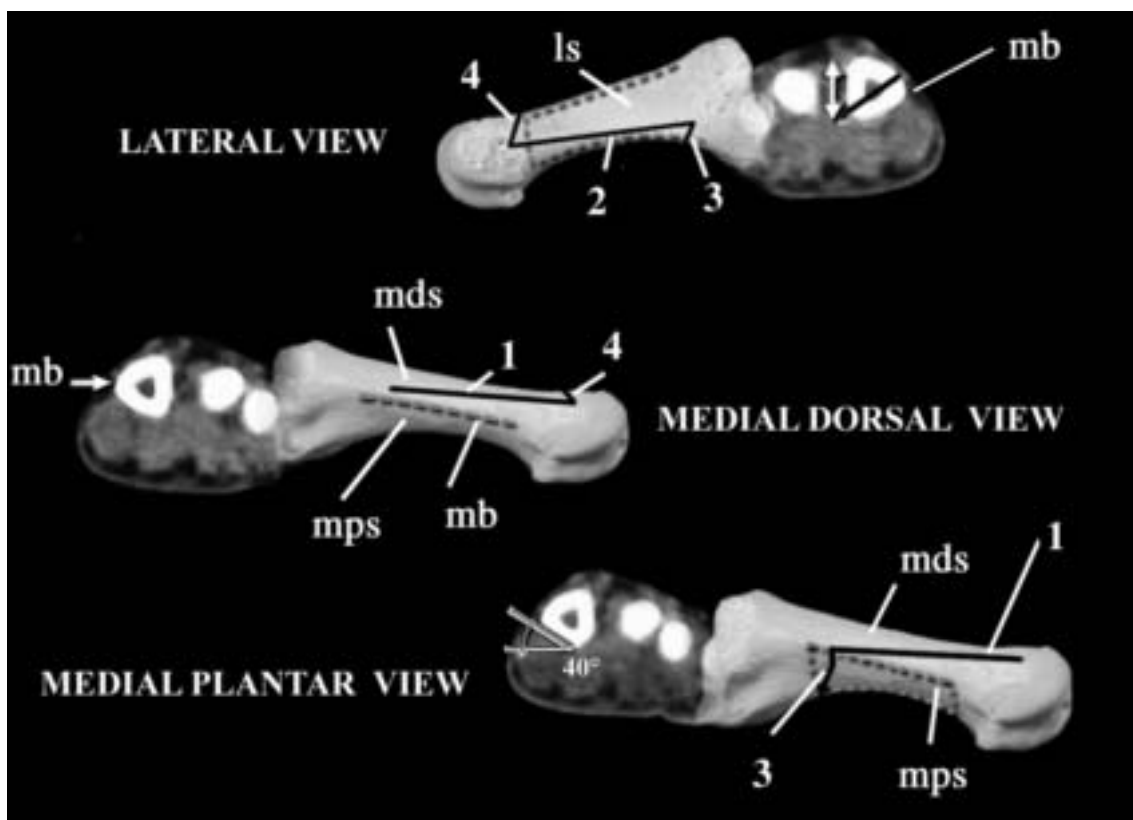
– The *first metatarsal bone* is described in Fig. 04a; it shows that M1 is closely adapted to the scarf osteotomy; the cuts are extended from the distal to the proximal cancellous bone; the obliquity of the medial plantar surface is also adapted to the scarf osteotomy, as described further.

– The *blood supply* of the 1st metatarsal head (Fig. 04b). This study results from cadaver findings (5 feet with injection of the vessels) made in

collaboration with Pr. Dominique Ligoro (CHU Bordeaux) [3], from the literature [58, 73, 107], but mainly from my operative and postoperative findings. We observed that the blood supply of the 1st metatarsal head can be entirely preserved; firstly, by the approach, lateral when performing the lateral release, medial when performing the medial approach, secondly by the cuts and the displacements of the scarf osteotomy.

– The *Proximal Plantar Exposure* (Fig. 05b) is performed proximal to the plantar neck vascular bundle; it is a “no man’s land” allowing the osteotomy, the displacement and the fixation to be performed accurately and harmlessly.

– The local anatomy is more detailed in the enclosed CD-ROM.



**Fig. 04a. First metatarsal anatomy and scarf cuts.**

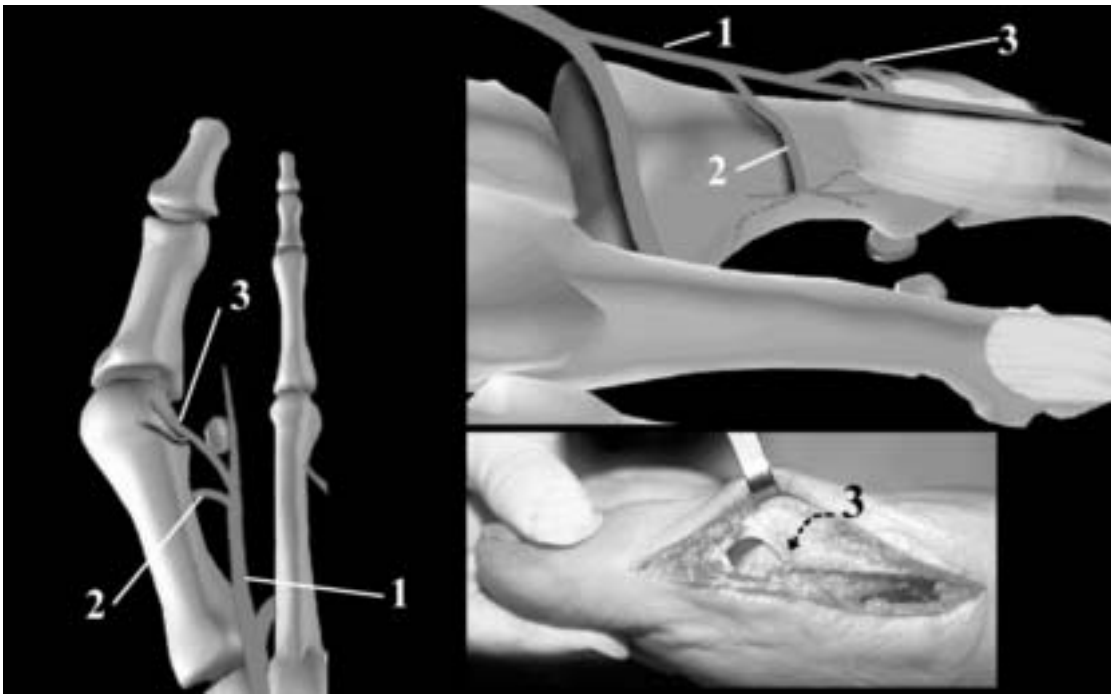
*The first metatarsal anatomy is closely adapted to the scarf osteotomy (specimen bones and CT scan).*

**Lateral view 2.** The longitudinal cut reaches the lateral surface (ls) in its plantar part, thus preserving almost the entire lateral surface which works as a strong beam.

**3, 4.** Proximal and distal transverse cuts.

**Medial dorsal view.** The medial border (mb) is an important landmark to perform the longitudinal cut (1) on the medial dorsal face. The distal transverse cut (4) is directed backwards, making a chevron with the longitudinal cut.

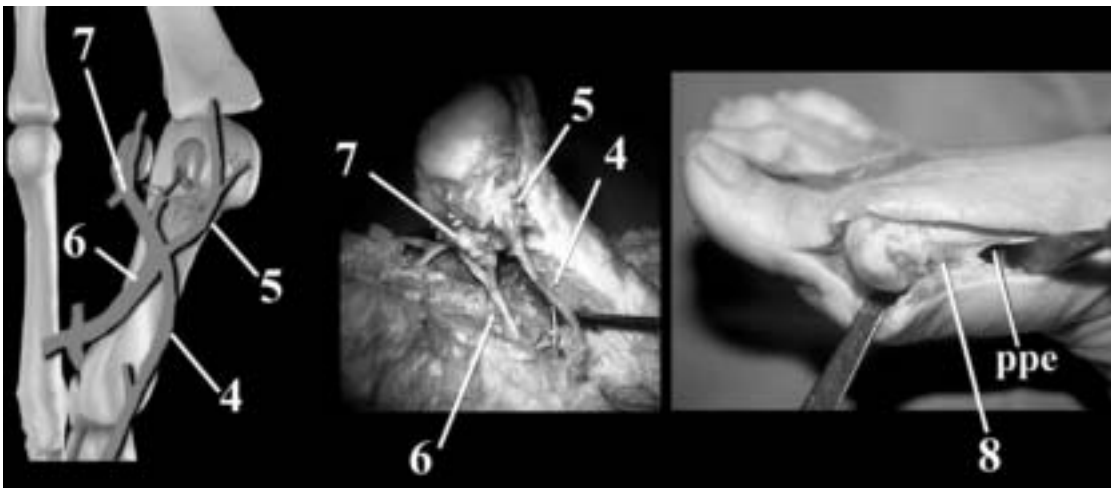
**Medial plantar view.** This view reveals that the medial plantar surface (mps) is about 40° inclined from the horizontal plane. The scarf proximal transverse cut (3) is located on this face and is directed backwards.



**Fig. 04b1. First metatarsal distal blood supply.**

#### 1. Dorsal

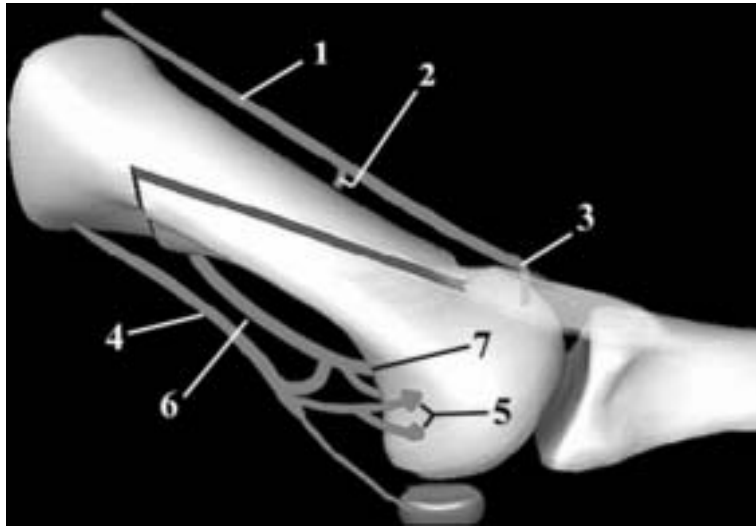
The *dorsalis pedis artery* (1) is in fact dorsal-lateral, and it branches off to a nutrient artery (2) which is not constant. Then it supplies a fine branch, the *metaphyseal capital dorsal branch* (3) which penetrates the head through the dorsal capsule. Both the scarf approach and distal cut can respect this blood supply which nevertheless cannot alone adequately supply the metatarsal head: The main head blood supply is plantar.



**Fig. 04b2. First metatarsal distal blood supply.**

#### 2. Plantar

The *medial plantar artery* (4) runs on the dorsal aspect of the abductor muscle. It anastomoses with the first intermetatarsal plantar artery. The *first intermetatarsal artery* (6) is the main artery regarding the first metatarsal head, blood supply. It is created by the union of the deep plantar arch and the first perforating artery. It runs on the dorsal aspect of the lateral head of the flexor hallucis brevis muscle. In the scarf osteotomy, both of these arteries are preserved as a result of the Proximal Plantar Exposure (ppe). These arteries create an arch and join themselves under the metatarsal neck; this junction provides two *metaphyseal capital branches: medial* (5) and *lateral* (7) and similarly a branch to the medial and lateral sesamoids. The junction under the arch and the metaphyseal capital arteries are included in the *plantar vascular bundle* (8) which is also preserved both by the approach and the cuts of the scarf osteotomy. The plantar blood supply is the primary one of the 1st metatarsal head.



**Fig. 04b3. Scarf and 1st metatarsal head blood supply.**

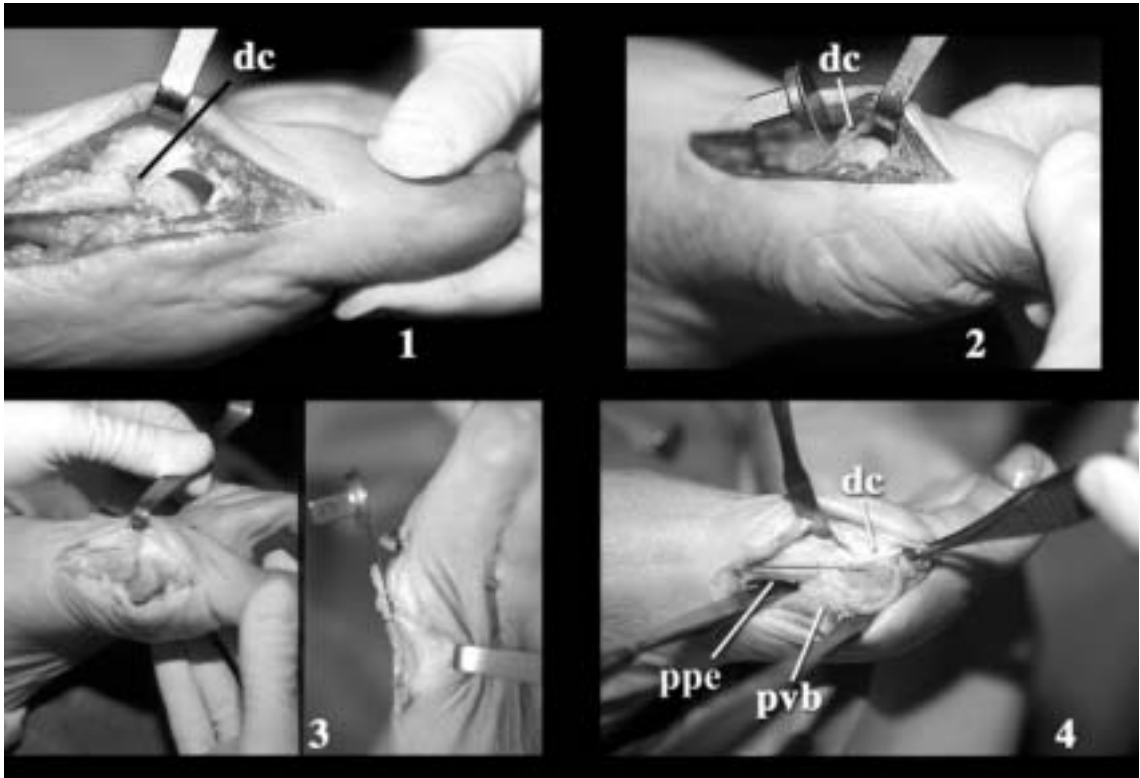
The scarf cuts preserve both the dorsal and the plantar metatarsal head blood supply.

### *First Metatarsal Medial Approach*

We emphasize the following points:

- *Preservation of the MTP dorsal capsule* to keep the distal cut just proximal thus extra articular while preserving the dorsal blood supply.

- Preservation of the *plantar vascular bundle*.
- The *proximal plantar exposure (ppe)* is really the best approach to guarantee an accurate and harmless longitudinal cut and proximal transverse cut. The proximal fixation and the M1 shortening resection are easily performed through this approach.



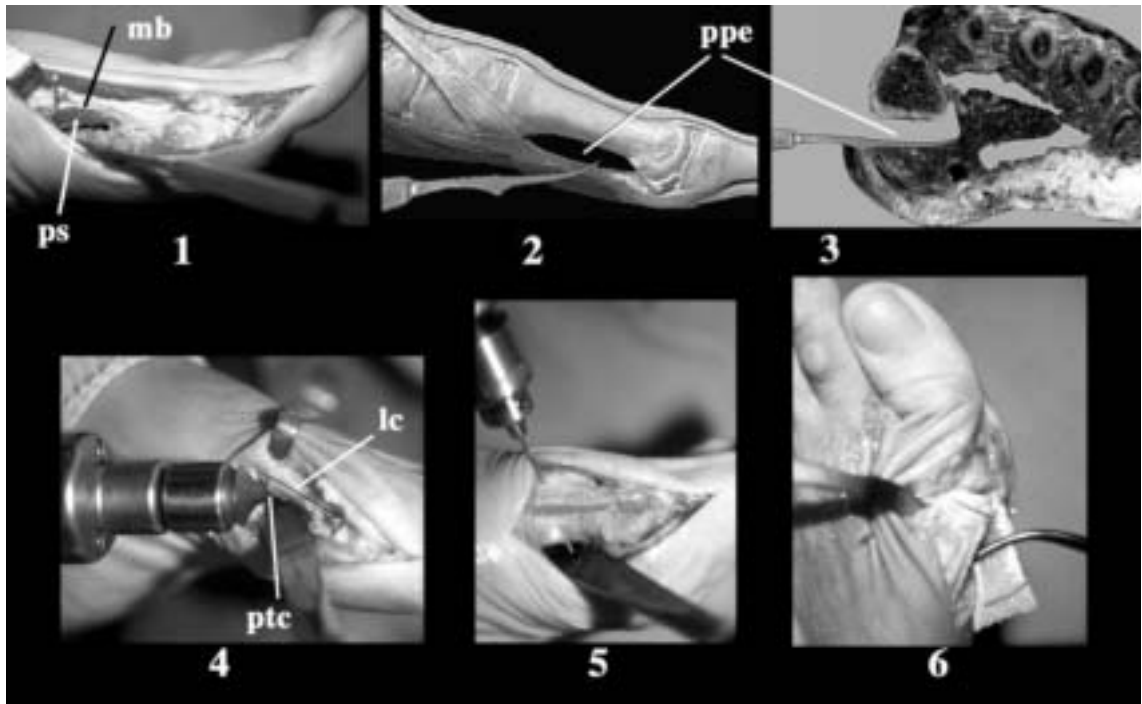
**Fig. 05a. Scarf osteotomy: the medial approach – 1. Distally.**

1, 2. *The medial approach* must preserve the dorsal capsule (dc) to preserve the dorsal blood supply and to keep the distal cut extra articular (2).

3. Minimal exostosis resection, in line with the medial border, just enough to facilitate the medial longitudinal scarf cut.

4. The plantar vascular bundle (pvb) must also be preserved, located between the distal approach and the proximal plantar exposure (ppe).





**Fig. 05b. Scarf osteotomy medial approach – 2. Proximally: The Proximal Plantar Exposure (ppe).**

1.5 centimeter proximally from the metatarsal head medial cartilage, the scalpel divides the thin septum joining the abductor muscle to the medial border (mb), enabling the ppe which is an important landmark for the scarf osteotomy. The spatula easily separates plantarly from the plantar metatarsal surface (ps), the abductor and the medial head of the flexor hallucis brevis muscles as well as the plantar arteries. There are *four advantages of the ppe*:

1. To *point out the medial border (mb)* of the 1st metatarsal, which is an important landmark to perform the longitudinal cut on the medial face.
2. To *see the plantar surface of the metatarsal*, ensuring first to perform the longitudinal cut (lc) parallel and located just above the metatarsal plantar surface, secondly to make an accurate and safe proximal transverse cut (ptc).
3. To *see and control the exit of the K wire* for the proximal fixation (5).
4. To *pull easily and harmlessly the plantar fragment* for 1st metatarsal shortening (6).

### *The Scarf Cuts*

The osteotomy is designed to separate a proximally based dorsal fragment, which must be handled carefully, especially on the lateral side, and a plantar fragment, which comprises the plantar surface and the metatarsal head. The longitudinal cut is then followed by two transverse cuts.

### **Longitudinal Cut**

*The longitudinal cut is first performed on the M1 medial aspect, with accurate specificities following the type of displacement osteotomy requires.*

*Then the longitudinal cut is made transversally across the metatarsal.*

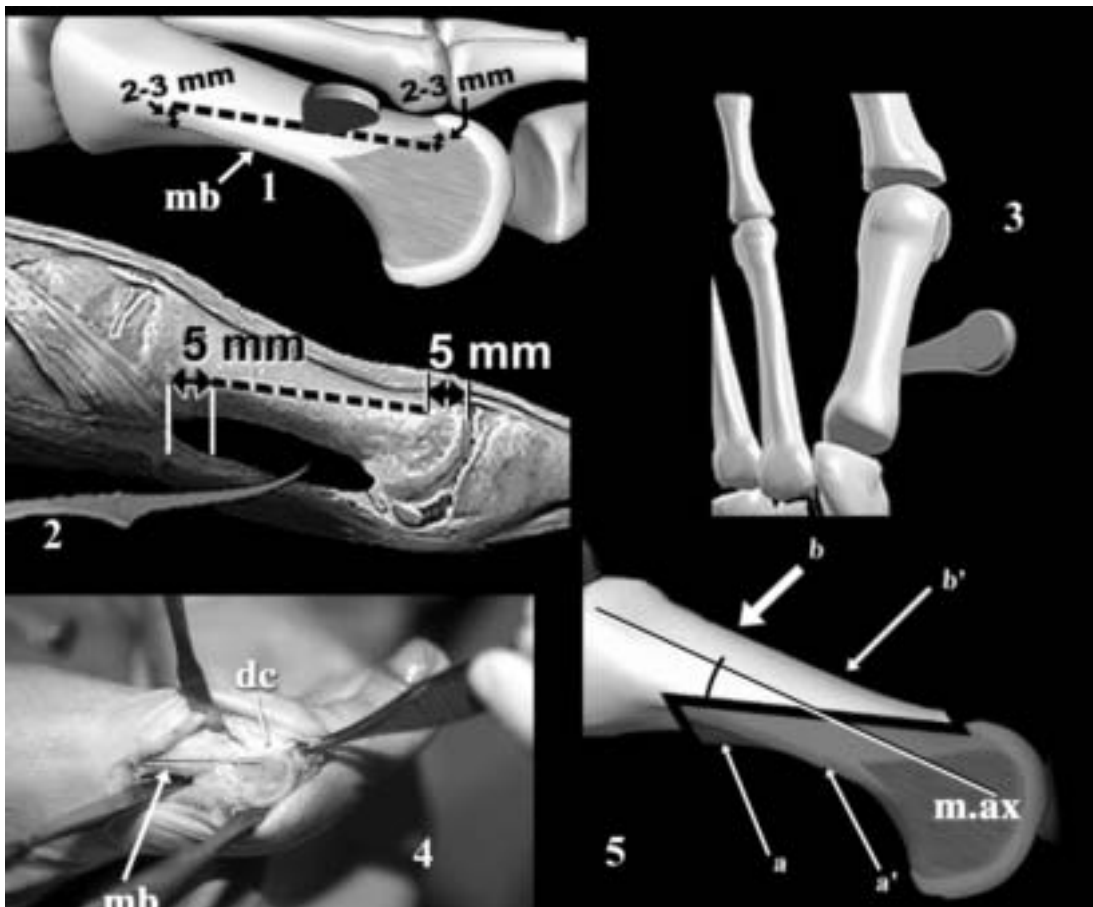
The proximal plantar exposure enables this cut to be performed parallel to and located just

above the medial plantar surface, therefore isolating the plantar cortex. This cut is oblique laterally and plantarward; it reaches and cuts the lateral surface near its plantar border. This has two results: (1) *Lowering* of the plantar head fragment when it is laterally displaced; and (2) *preservation of the lateral surface*, which acts as a strong sagittal strut which allows a *large lateral shift* of the plantar fragment.

The length of the longitudinal cut.

I know that some authors, like L. S. Weil, adapt the cut length to the degree of de-

formity, making a short cut (middle shaft) in mild hallux valgus, and a long cut in case of advanced hallux valgus or osteoporotic bones. I also make this distinction, but I prefer *reserving the short cut only for very mild deformity in young patients with a strong bone*, particularly to avoid secondary fractures. It is not more invasive to perform a 1 or 1.5 cm longitudinal cut, thus I prefer to reach proximally the cancellous bone of the proximal metaphyseal, for having two strong pillars, both distal and proximal [131].



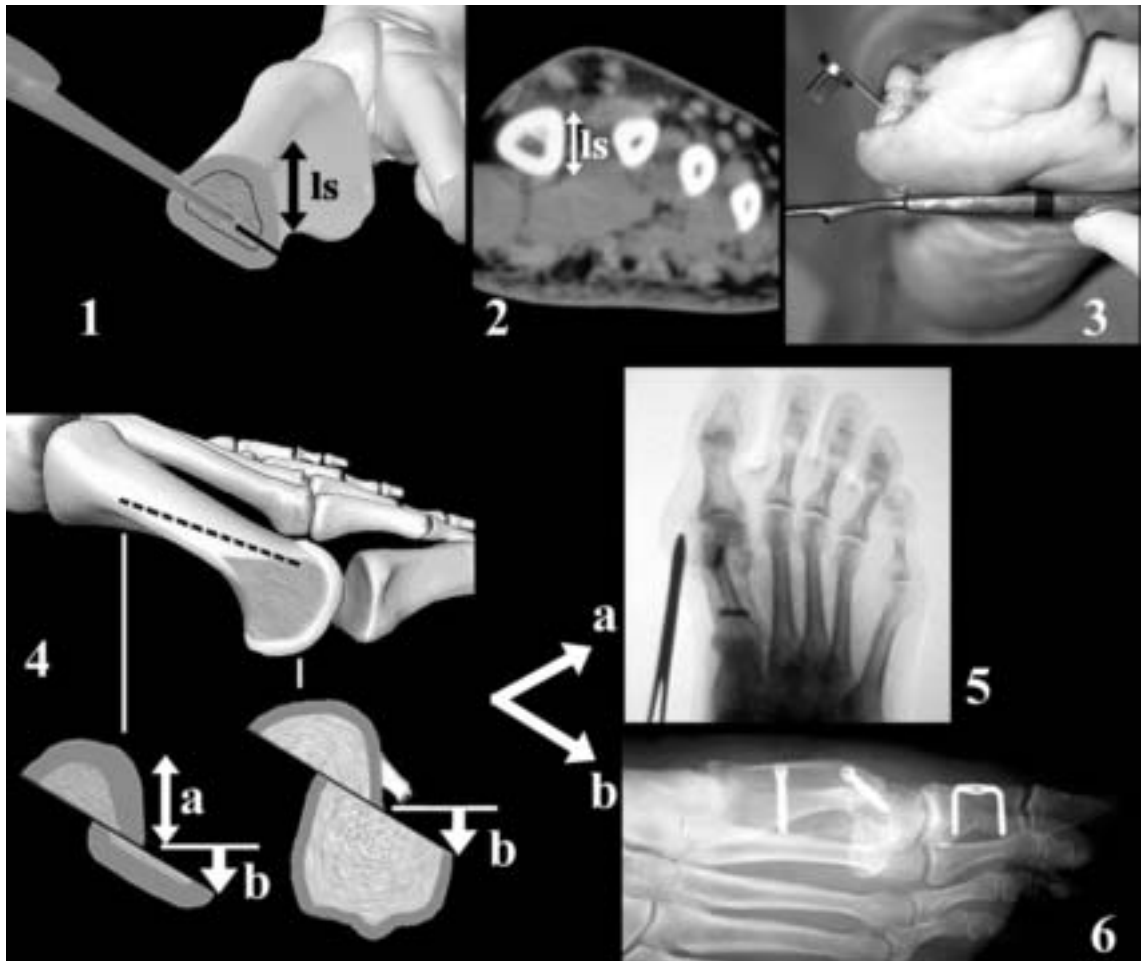
**Fig. 06a1. Longitudinal cut on the medial surface.**

The longitudinal cut is first performed on the medial surface. There are two important landmarks to perform this cut: 1, 4. The *medial border* (mb) – correctly pointed out by performing the proximal plantar exposure – and the *medial surface of the metatarsal head* after performing an economic exostosis resection.

2. Location, proximal and distal ends of the longitudinal cut performed on the medial dorsal surface.

3. The saw blade has a slight proximal direction.

5. Regarding the metatarsal axis (m.ax) the longitudinal cut is oblique so that the solidity of the dorsal fragment is preserved and the cut is longitudinal (so that there is no elevation when shortening; see Fig. 07f5).



**Fig. 06a2. Longitudinal cut crossing the metatarsal transversally.**

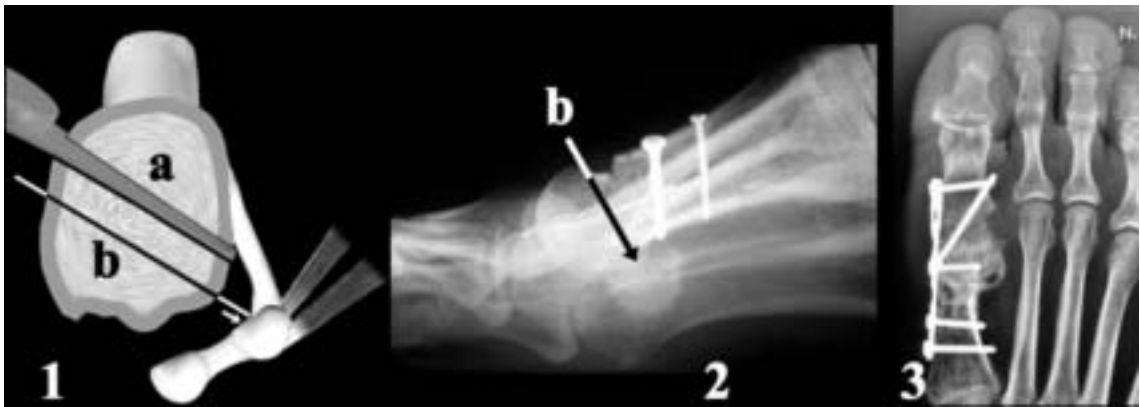1, 2, 3. The *ppe* allows to perform this cut accurately. It has to be parallel to the very oblique plantar surface, and located just above. This has *two consequences*:

Almost the entire lateral surface (*ls*) is preserved and this strong beam enables *a large lateral shift* of the plantar fragment while preserving the solidity (*a*).

The plantar obliquity of the cut results in *metatarsal head lowering* (*b*) when laterally displaced.

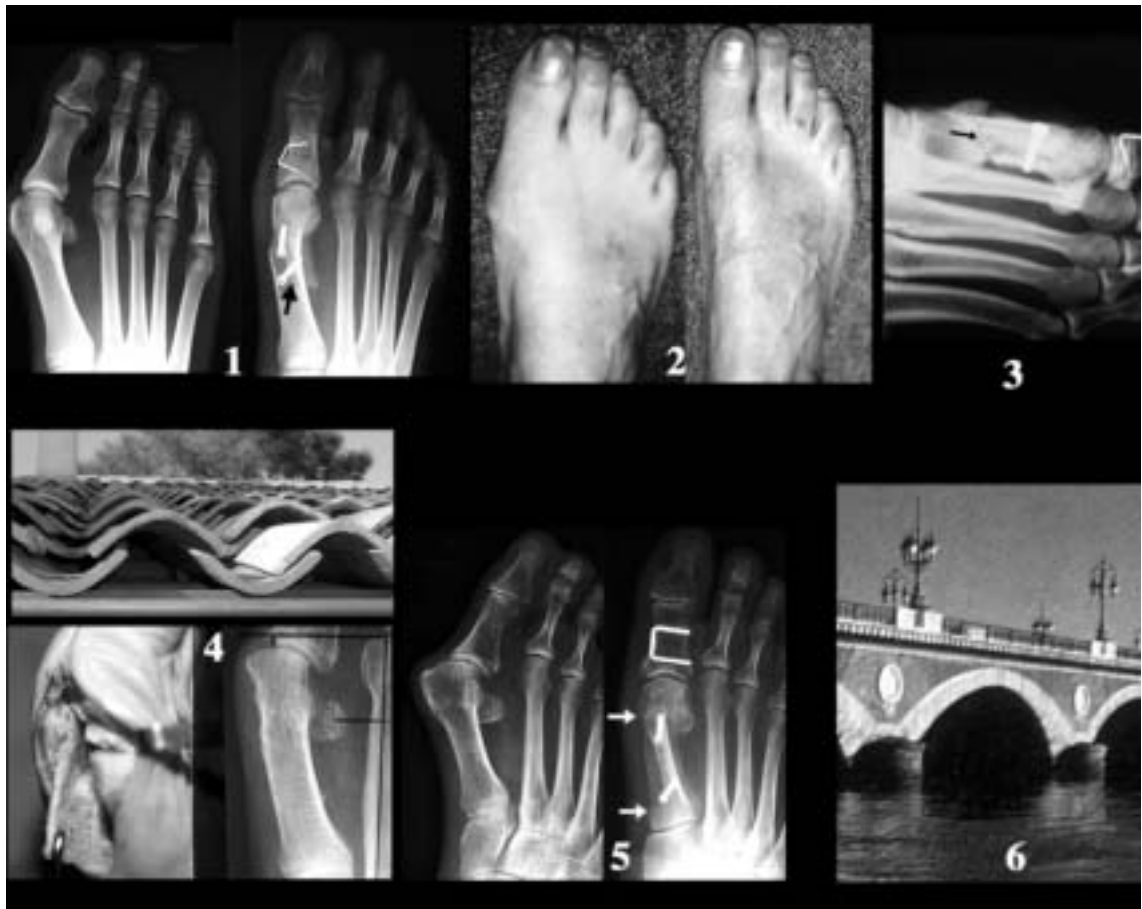For this reason, I don't agree with a short osteotomy when it is performed in every case by certain authors like Zygmunt *et al.*, Day *et al.*, Reed, Glickman and Zahari [63], Maestro *et al.*, though the

short scarf should be preferable to a long cut distal chevron osteotomy, because the short scarf has two chevrons, proximal and distal, which provides more stability than only a distal one.



**Fig. 06a3. Longitudinal oblique cut. Particular aspect.**

Since the longitudinal cut is very oblique plantarly, care has to be taken not to begin this cut distally in the middle part of the medial surface of the head (b). This may jeopardize the plantar and lateral surface of the MTP > joint and the lateral sesamoid leading sometimes to a MTP fusion (2, 3): pictures communicated by P. Rippstein, Zurich. *We must begin the cut very dorsally on this medial aspect (a).*



**Fig. 06a4. Longitudinal cut: long or short cut?**

1, 2, 3. A *short cut* is almost only indicated for young patient with mild deformity. For moderate or large deformity this cut weakens the osteotomy by being placed at a stress riser and could result in a stress fracture (3). It is also indicated just for DMAA correction (without lateral shift).

4, 5. Only a *long cut* allows to have two solid fragmental contacts in both the distal and the proximal cancellous bone of the 1st metatarsal. This avoids particularly the “channel effect” in an osteoporotic shaft. In fact, we preserve too strong pillars located in the distal and the proximal cancellous bone of the metatarsal, like in the Bordeaux “Pont de Pierre” (6).

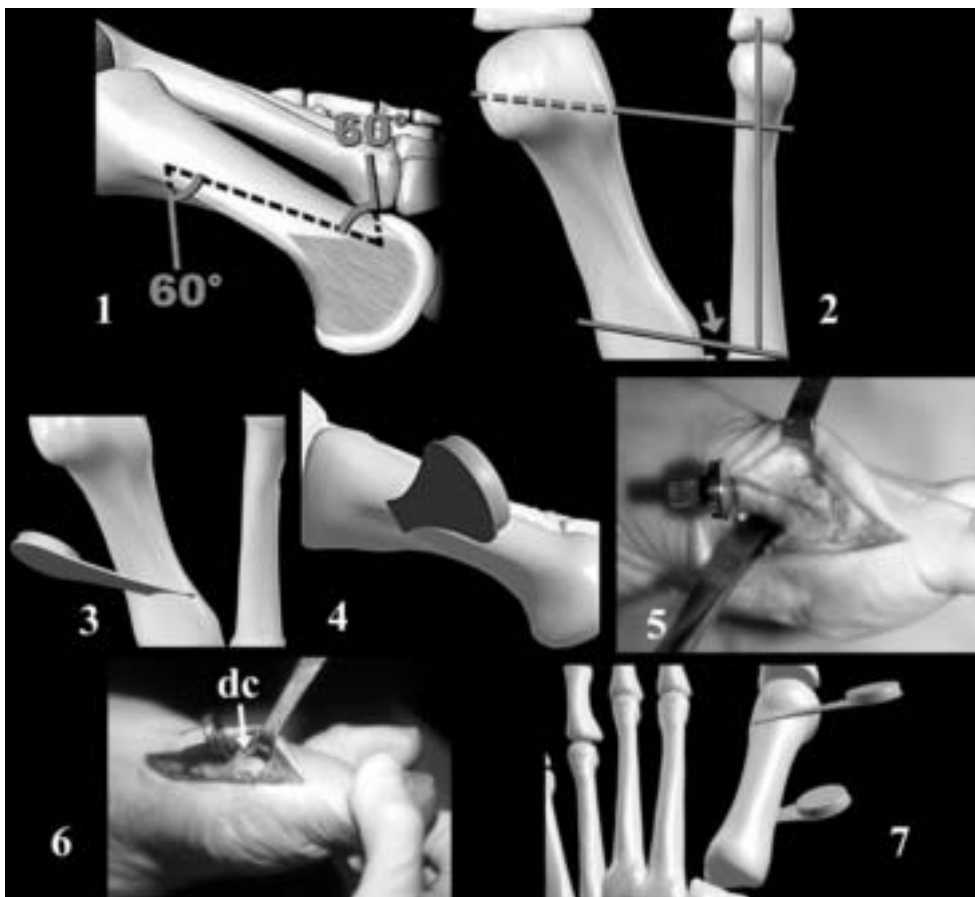
### The Transverse Cuts

They are chevron shaped,  $60^\circ$  to the longitudinal cut. Both cuts are directed proximally to allow easier lateral displacement. The proximal cut is performed first in order not to jeopardize the distal fragment when performing the proximal cut.

The *proximal cut* is accurately and harmlessly performed thanks to the PPE. The *distal cut* is

directed less proximally than the proximal cut to obtain good distal contact between the two fragments; it is performed just proximally to the dorsal capsule, thus remaining extra articular.

Once the cuts are performed, the two fragments become separated. If they are not, we recommend to cross over the saw cut and gently lever the proximal transverse cut with a spatula (Fig. 06b).



**Fig. 06b. Transverse cuts.**

*The scarf is a bi-chevron osteotomy.* So the transverse cuts form an angle of about  $60^\circ$  with the longitudinal cut (1). Both cuts are directed backwards, but the proximal one is slightly more inclined in order to ensure the distal fragments good contact (2).

– *Proximal cut:* (3, 4) direction and inclination of the saw blade. The proximal cut is easily performed and checked thanks to the ppe, which also allows protection of the soft tissue (5).

– *Distal cut:* (6, 7) this cut is just proximal to the dorsal capsule (dc), thus remaining extra articular. This is important for preserving both the MTP range motion and the dorsal blood supply.

## The Displacements

### The Versatility of the Scarf Osteotomy

The scarf technique allows a considerable choice of final positions of the fragments. The main displacements, however, are in the transverse plane, mainly lateral shift and if necessary with medial rotation (DMAA or PASA correction). In the frontal plane, lowering, and in the sagittal plane, shortening can be performed if required.

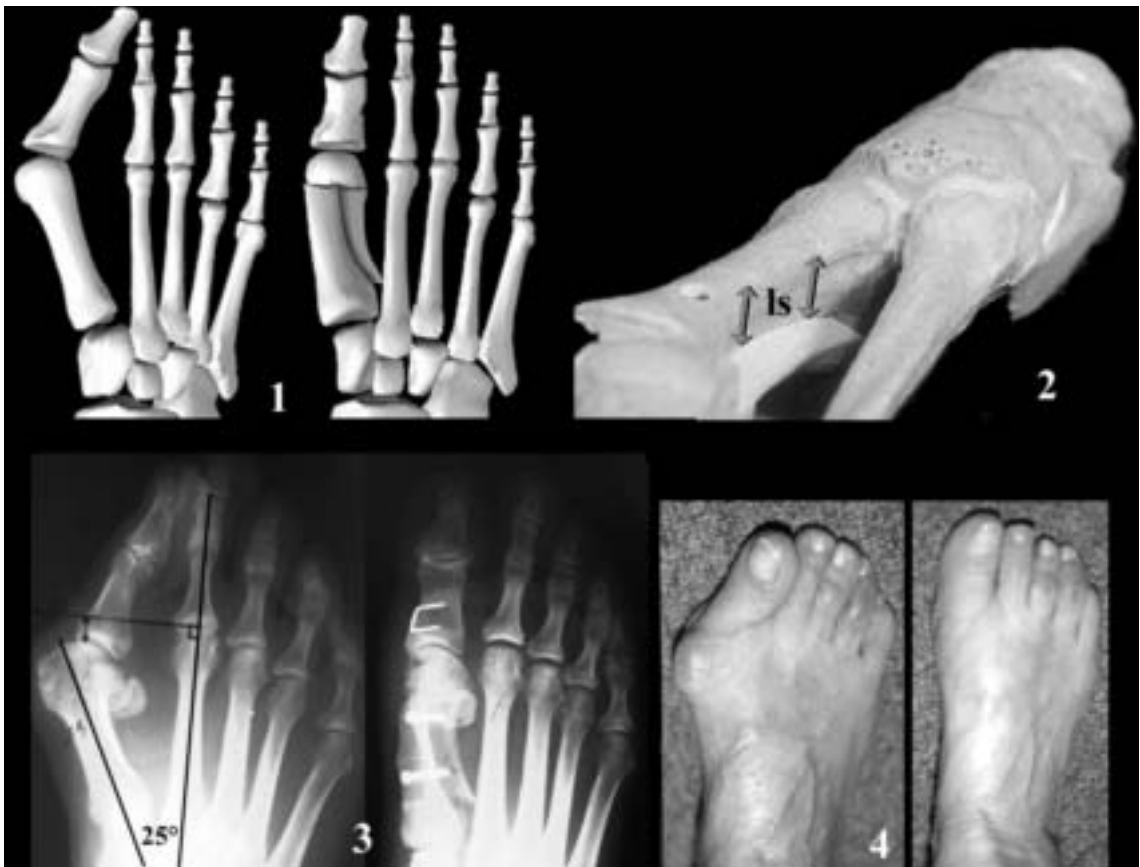
### Transverse Lateral Shift

There can be a *considerable amount of lateral shift* (two-thirds to three-fourths of the surface), because a strong lateral strut is preserved. This

is what differentiates the scarf technique from other osteotomies.

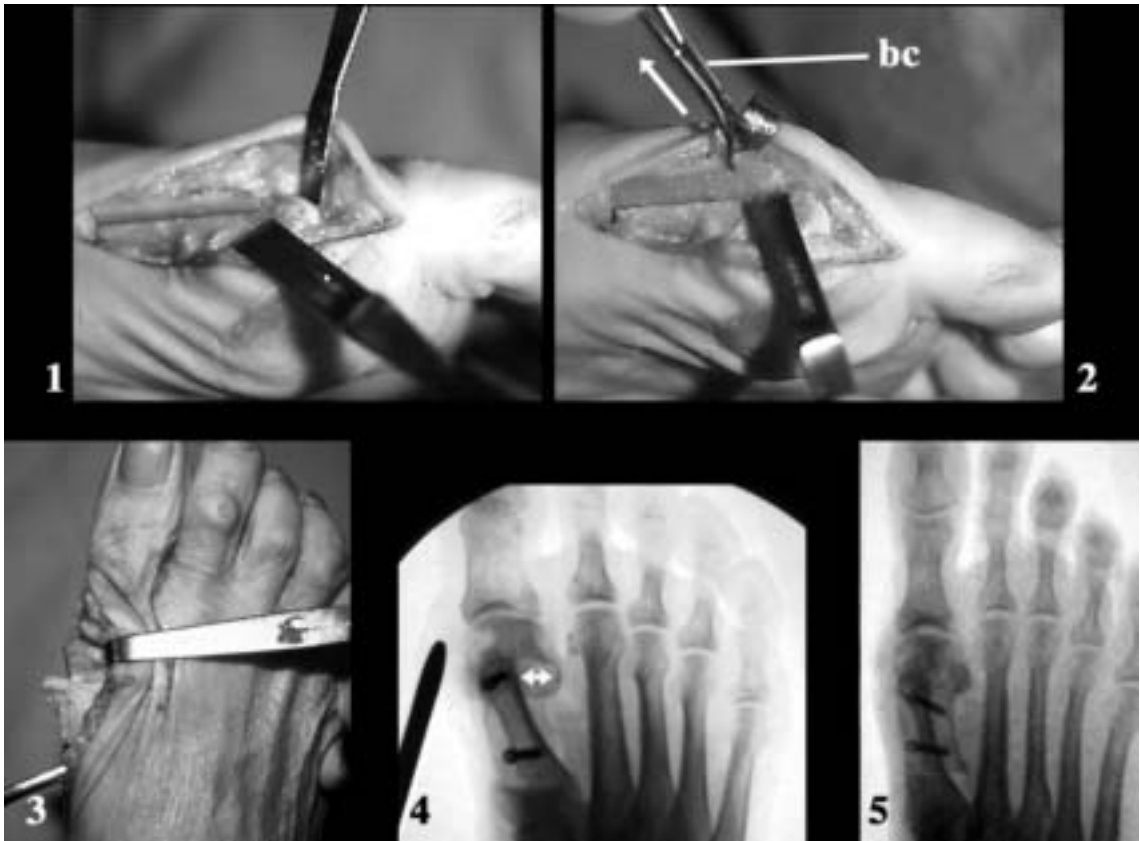
To obtain such a large lateral shift, simply pushing the plantar head fragment is insufficient. To “*pull and push*” is necessary, combining the pushing of the plantar fragment with the medial pulling of the dorsal fragment using a Backhaus clamp (one of the ancillary instruments). The amount of lateral shift depends on the degree of deformity, although the exact amount of the displacement cannot be determined preoperatively.

The lateral shift is the common denominator of the scarf osteotomy for hallux valgus correction. To improve this correction, however, it has to be combined with other displacements.



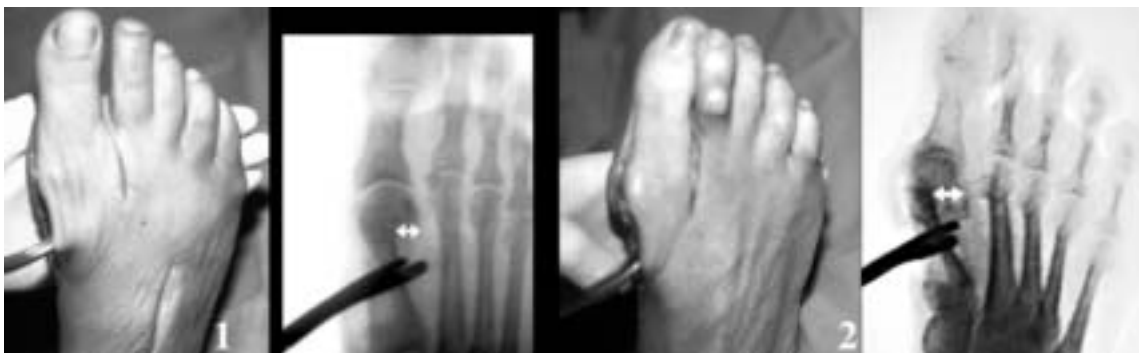**Fig. 07a1. Scarf lateral shift: generalities.**

Thanks to the preservation of the lateral surface (ls), the scarf enables a very large lateral shift of the plantar fragment while preserving the solidity. This is a significant improvement for the correction of a large hallux valgus deformity.



**Fig. 07a2. Scarf lateral shift : operative views.**

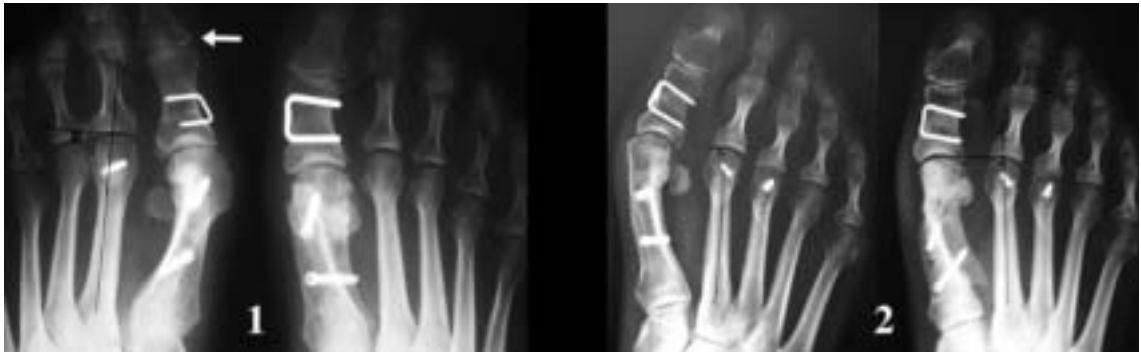- 1, 2. “Pull and push”. 1. Pushing the plantar fragment laterally is not sufficient to achieve a large displacement.
2. The use of a Backhaus clamp (bc) is often necessary to pull the dorsal fragment while pushing the plantar one. This is the “pull and push” motion.
- 3, 4, 5. We can have more than “half a head” lateral shift and it can be performed not only when the metatarsal is large (4) but also when it is narrow (5).



**Fig. 07a3. Is the lateral shift sufficient to correct the deformity?**

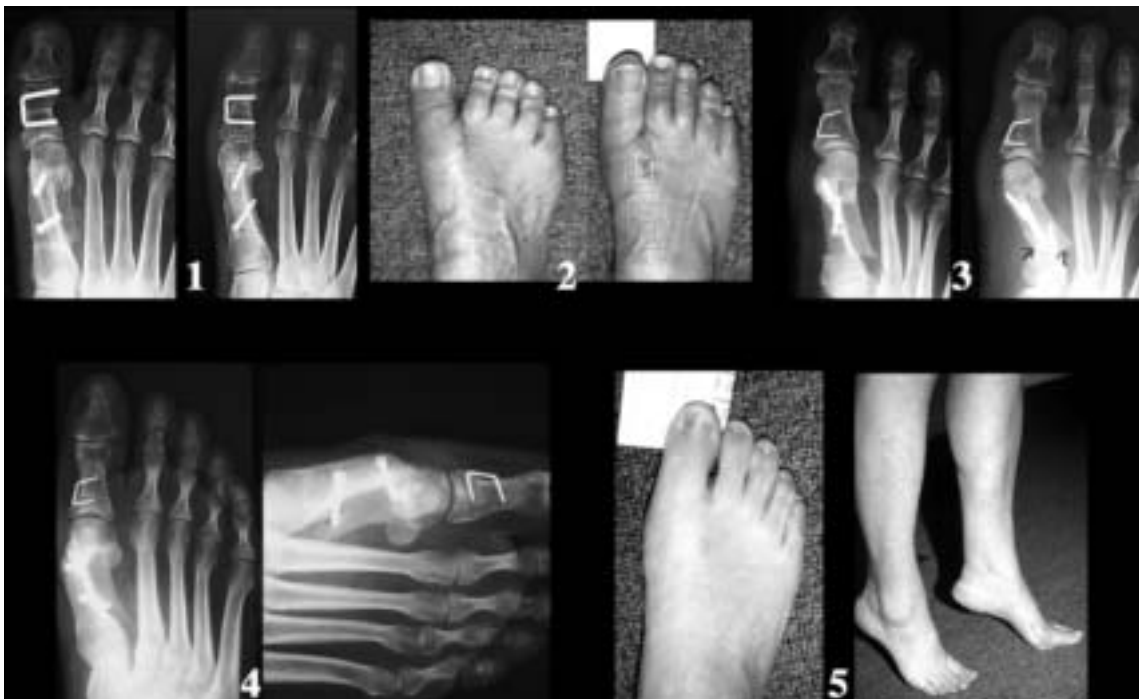1. In mild or moderate deformity the lateral shift is sufficient.
2. In advanced deformities, in spite of large lateral shift, the medial soft tissue tightening (capsulorrhaphy) is necessary.





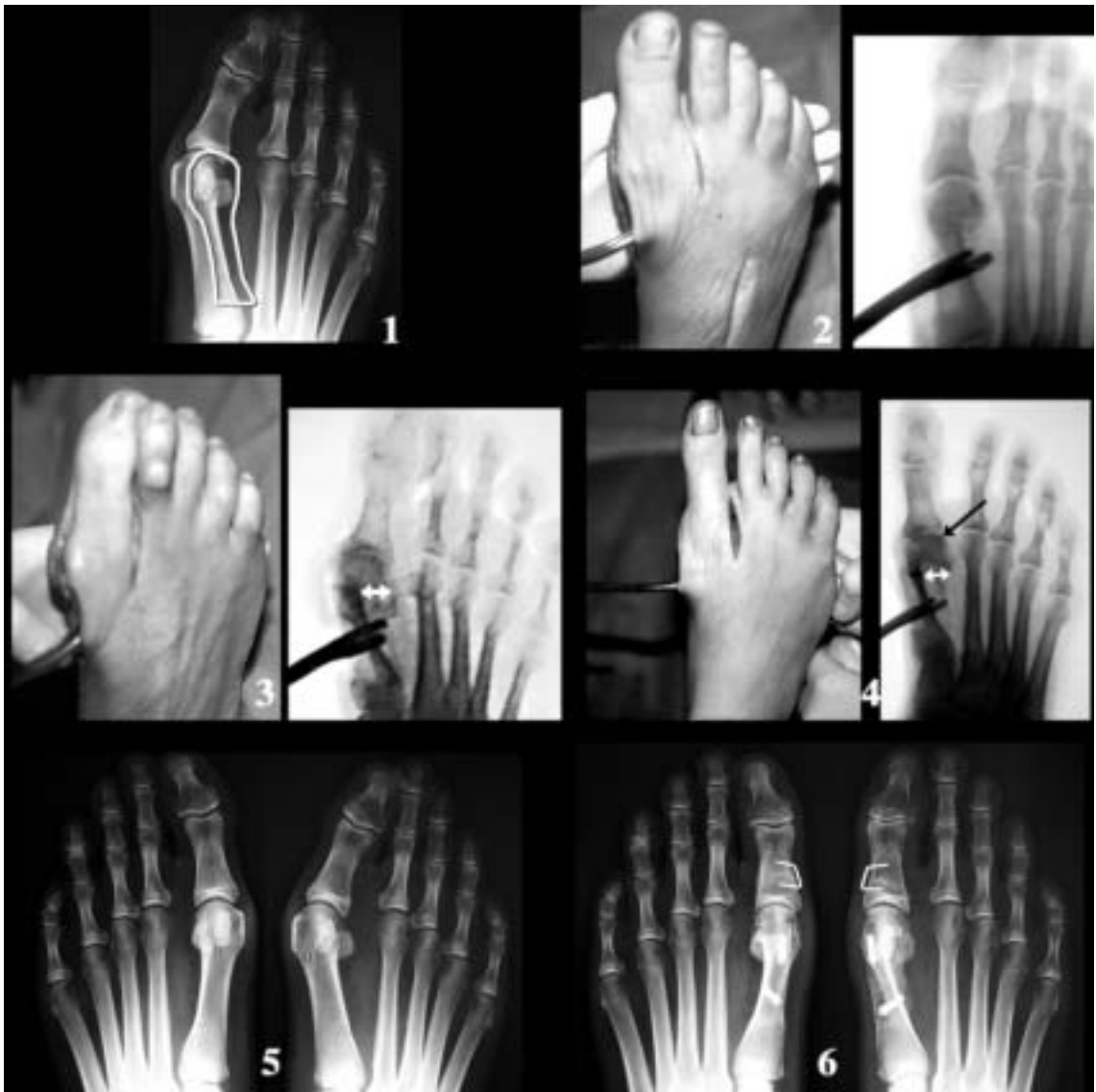
**Fig. 07a4. Insufficient lateral shift results in undercorrection.**

1. In this case only the foot with a large lateral shift has a good correction.
2. Secondary lateral shift for undercorrection is possible and successful.



**Fig. 07a5. Excessive lateral shift.**

- 1, 2. Excess of lateral shift leads to overcorrection, which in this case needed revision to be corrected.
3. Very exceptionally, an excessive lateral shift provides stress secondary fracture.
- 4, 5. Ordinarily we can have a very large lateral shift without a risk of fracture. But in this case, it is preferable to use the heel support shoe for one month after the operation instead of the 15 days usually prescribed.



**Fig. 07a6. Adaptation of lateral shift to the deformity.**

1. *Preoperative planning is not sufficient.* In fact, only the intraoperative check is accurate, by performing the load simulation test (2) before screwing. This is a very useful test.

In this plate, there are *three examples*:

2. The lateral shift is *sufficient*.

3. It is *insufficient*, needing more lateral release, medial tightening and / or P1 osteotomy.

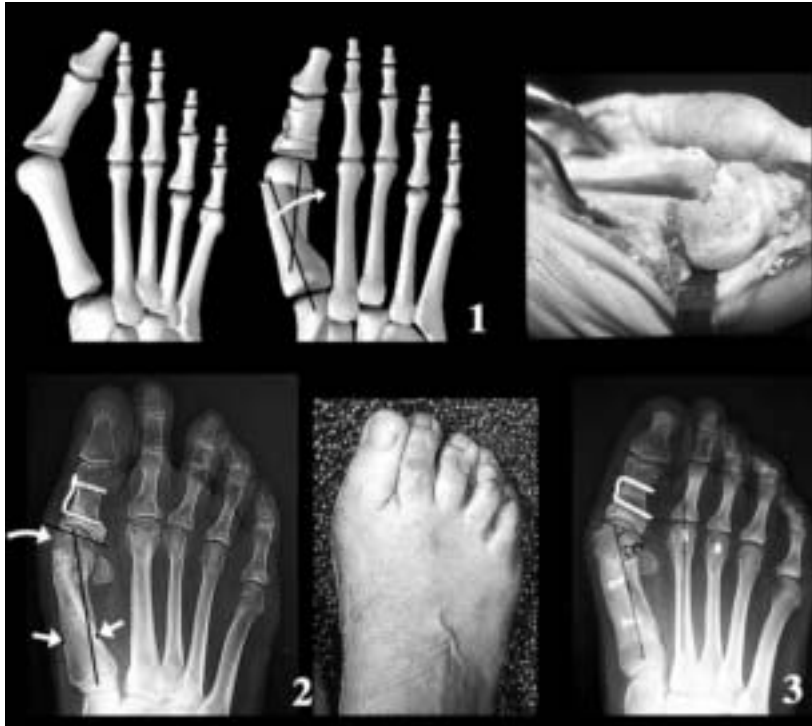
4. It is *excessive*: We must return to less displacement.

5, 6. Lateral shift was required to be more important on the right foot than on the left one.

### Lateral Rotation

Lateral rotation is possible but should be avoided because it increases the lateral inclination of

the articular cartilage (*i.e.* the DMAA or the PASA) on the contrary. The DMAA has to be corrected in many cases, especially in congenital, juvenile hallux valgus (Fig. 07b1).



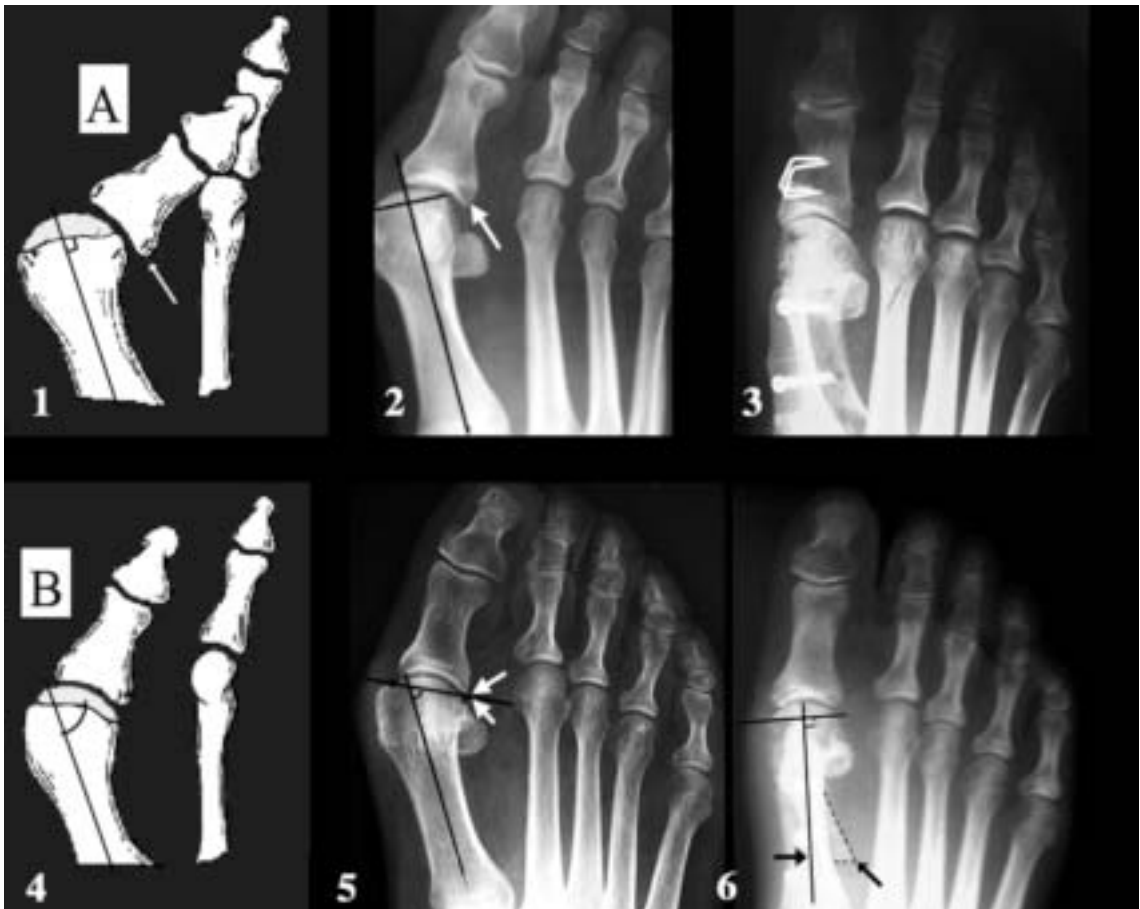**Fig. 07b1. Lateral rotation of the head 1.**

1. It is obtained by pushing the plantar fragment more distally than proximally.  
2, 3. Since the metatarsal surface remains oblique laterally, this results in undercorrection.

### DMAA (or PASA) Correction: Medial Rotation

The lateral inclination of the articular cartilage of the head can be corrected by medial rotation of the head and the plantar fragment as emphasized by authors like Bonnel [23], Cassagnaud [31], Chi [33], Coughlin [37], Delmi [45], Diebold [49, 50], Lau [79] and many others. The three main indications are in juve-

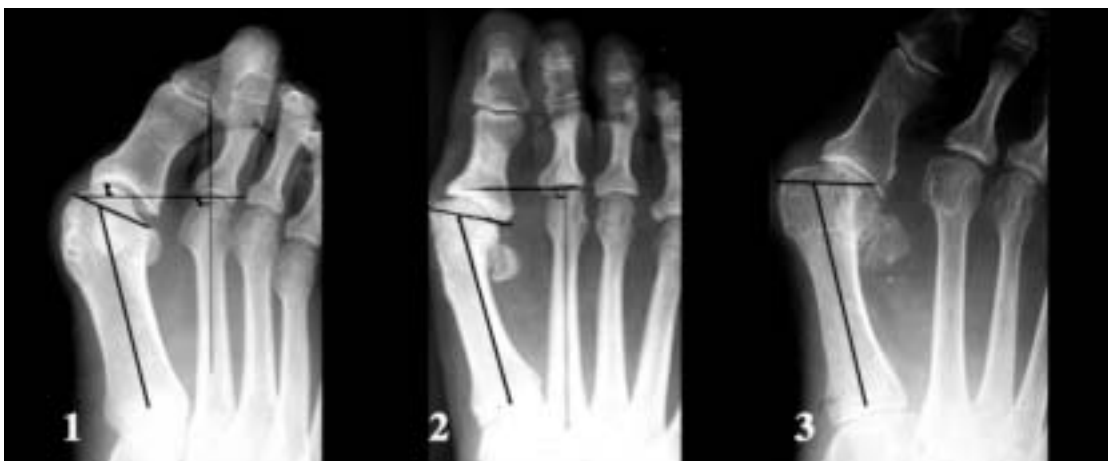nile, arthritic, and iatrogenic hallux valgus. As a rule, I now make this rotation in almost every case but just of a few degrees. With the scarf osteotomy, more than 20° of medial rotation cannot be made to preserve the proximal contact between the two fragments. I found that 20° are sufficient in almost every cases in which DMAA correction is indicated.



**Fig. 07b2. DMAA (or PASA) decreased or not? (Drawings from M. Delmi, Geneva – Switzerland). We can distinguish two types in hallux valgus deformity:**

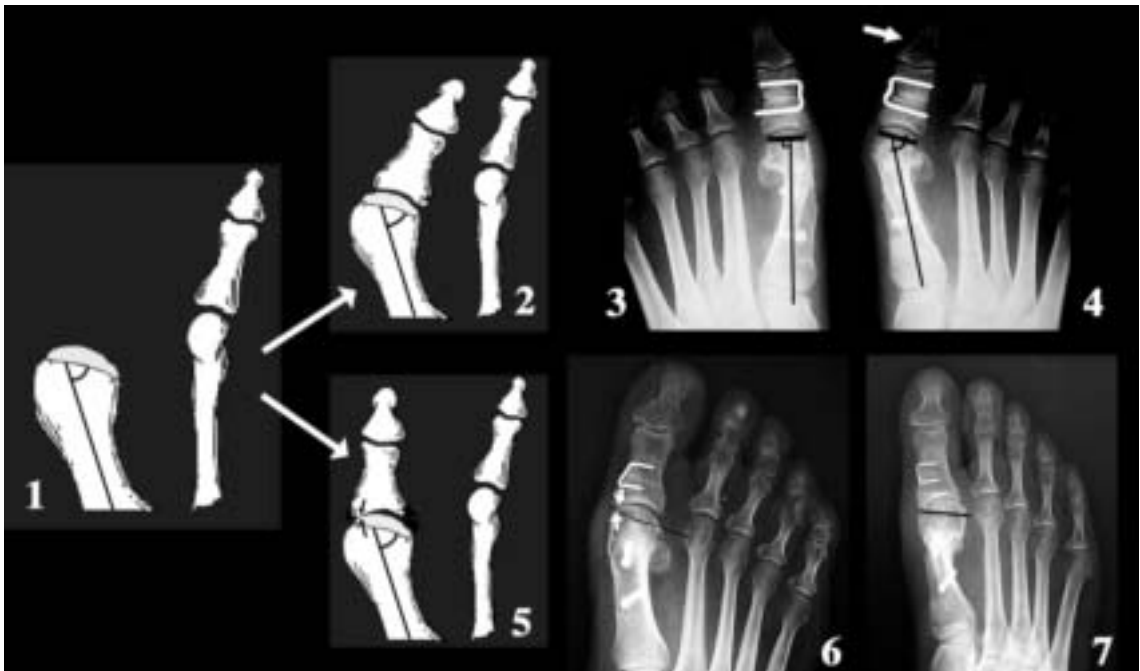
A. The DMAA is not decreased: The MTP is laterally subdislocated (2). In this case, the correction is obtained by a mere lateral shift (3).

B. The DMAA is decreased: There is a good congruence of the MTP joint (5) but the correction of DMAA is necessary (6).



**Fig. 07b3. DMAA decreased: the three causes.**

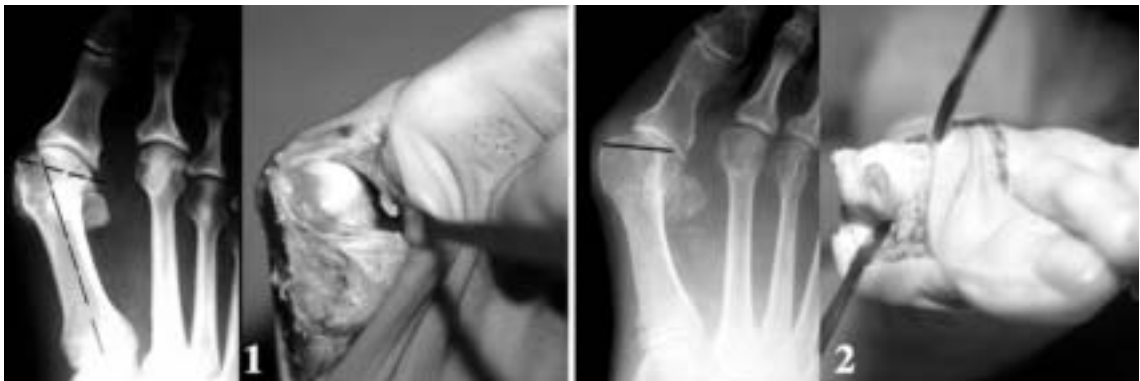1. Juvenile hallux valgus.
2. Iatrogenic hallux valgus.
3. Arthritic hallux valgus.



**Fig. 07b4. The two consequences of lack of DMAA correction (1)** (Drawings from M. Delmi, Geneva – Switzerland).

2, 3, 4. Ordinarily lack of DMAA correction results in undercorrection (bilateral case, right forefoot).

5, 6, 7. Sometimes the correction may be obtained without DMAA correction but with pinching the medial part of the cartilage, with pain and stiffness.



**Fig. 07b5. DMAA operative findings.**

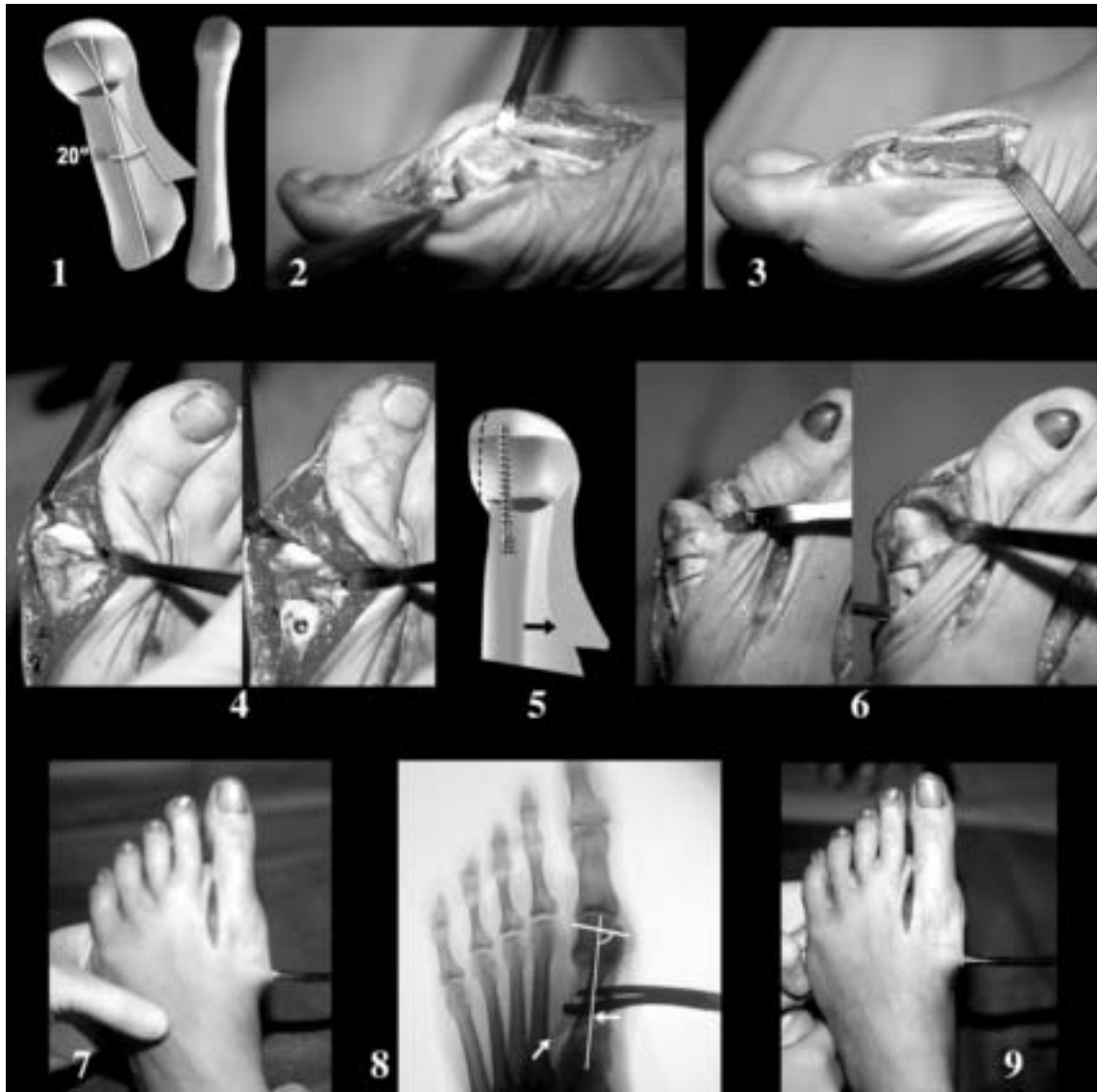
1. Ordinarily the assessment of the DMAA is the same on preoperative X-rays and operative findings.

2. In arthritic hallux valgus, preoperative X-ray is insufficient to assess the DMAA; only the operative view (same case) shows clearly the lateral location of the head cartilage, needing correction.

In case of severe hallux valgus deformity, DMAA correction has to be combined with an important lateral shift. Some authors think that the scarf is not the best procedure in such a case. My experience reveals that the contact area of the two fragments is narrow proximally, but

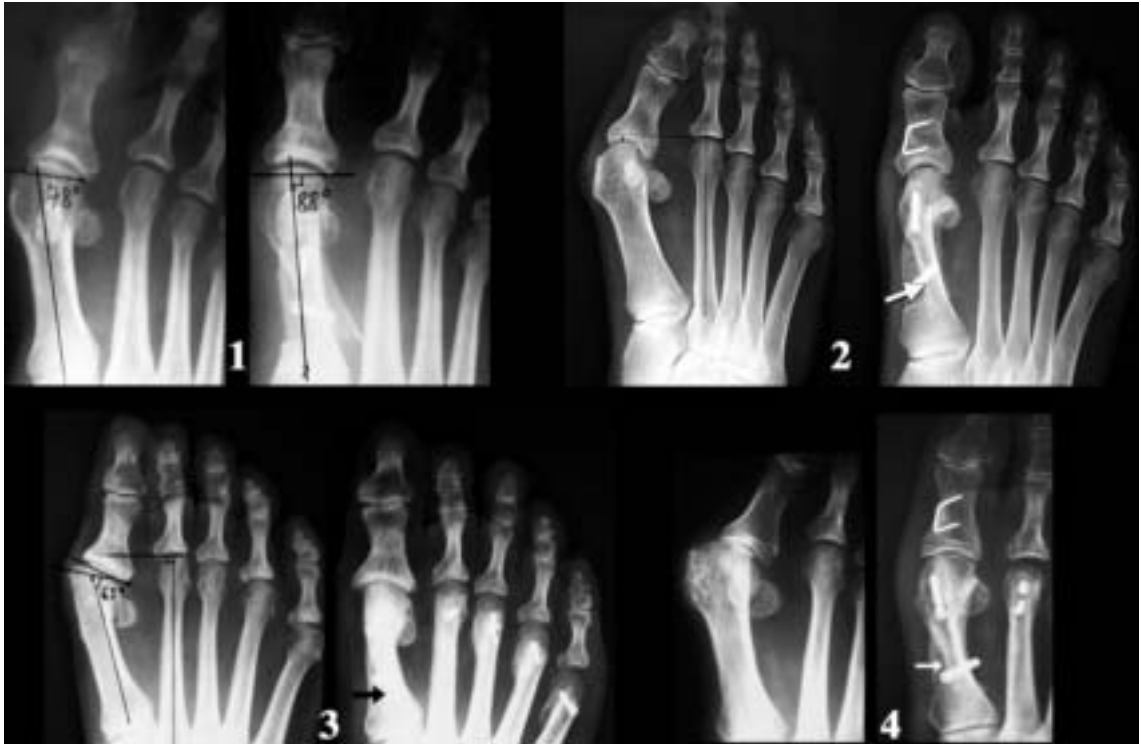the global contact is sufficient, because of the length of the osteotomy.

In cases in which the DMAA has to be corrected more than 20°, the short scarf, however, is perhaps preferable.



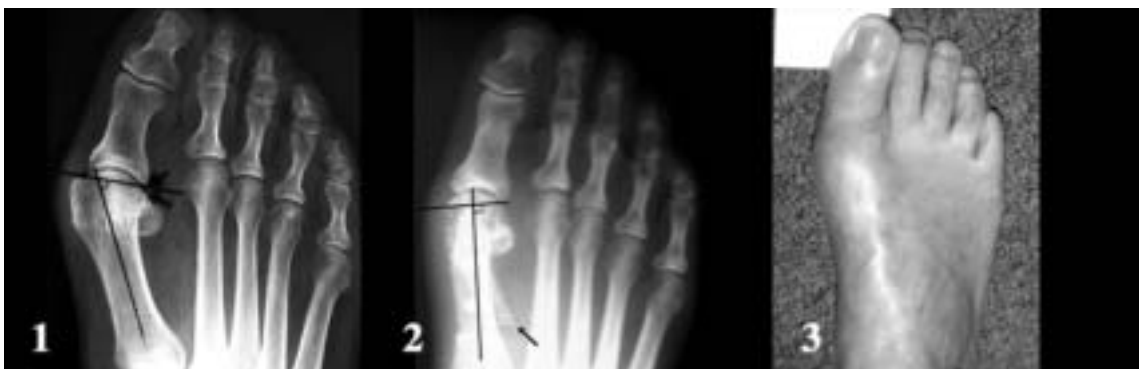**Fig. 07b6. DMAA correction: operative technique.**

1. The scarf allows DMAA correction as far as 20°.
- 2, 3. The DMAA correction is obtained by pushing more laterally the proximal part of the plantar fragment. This can be isolated (2) or mostly combined lateral shift (3). In this case, the proximal interfragmental contact is almost lost, but contact remains sufficient in the head and in the shaft to ensure the healing.
4. Intraoperative correction of the cartilage obliquity.
5. Medial location of the distal screw, to maintain the DMAA correction.
6. DMAA correction combined with M1 shortening.
7. Sometimes, there is an intraoperative excess of DMAA correction: In this case, the Load Simulation Test is useful, but the real assessment is made by X-ray (or fluoroscopy) (8). At this stage, the correction is easy (9).



**Fig. 07b7. DMAA correction: indications and results.**

1. In usual case.
2. In juvenile hallux valgus.
3. In iatrogenic deformity.
4. In arthritic hallux valgus. The improvement of the X-ray aspect of the joint, as well as the MTP range motion, are both due to small shortening (harmonized with Weil 2nd metatarsal osteotomy) and to the DMAA correction.



**Fig. 07b8. DMAA correction: the limits.**

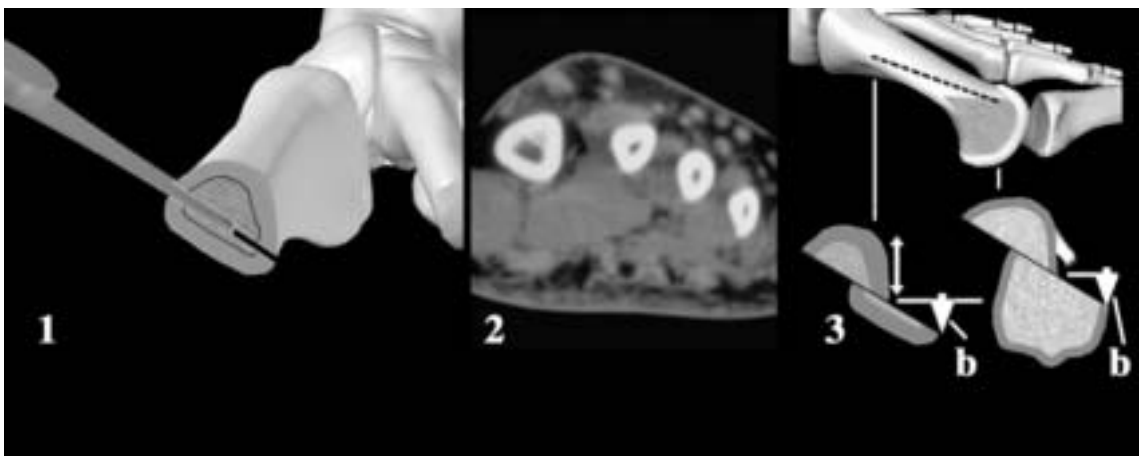
The DMAA correction is insufficient to achieve the correction of hallux valgus deformity. In this case, the medial soft tissue tightening and a great toe first phalanx osteotomy are necessary.

**Lowering**

The lowering of the head of the first metatarsal follows automatically as a result of the direction of the longitudinal cut, parallel to the oblique medial plantar surface, combined with the lateral shift. Normally more lateral shift leads to more lowering. The lowering can however be increased by more lateral-plantar inclination. In this case, the longitudinal cut on the medial surface has to end distally in the very dorsal part of the exostosis resection (i.e. in the medial

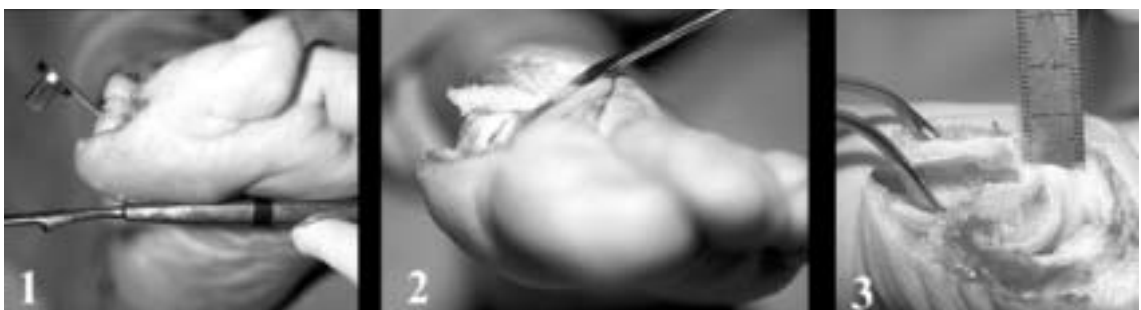dorsal edge) so the inclination does not create problems with the lateral sesamoid. Thanks to the use of a distal oblique screwing, the lowering of the 1st metatarsal head is not decreased by screwing (Fig. 07c3).

Lowering of the head is one of the main advantages of the scarf osteotomy, for it is easy and can be large, up to 7 mm. Furthermore, *lowering by scarf is not a plantar declination but a plantar translation of the head, which keeps its cartilage in a frontal plane* (Fig. 07c3). The first



**Fig. 07c1. The first metatarsal anatomy and the scarf lowering.**

It is a great advantage to have the first metatarsal with a *medial plantar surface plantarly inclined*. The longitudinal cut, which is located just above and *parallel* to this plantar face is thus very oblique plantarly and *this obliquity, combined with the lateral shift, results in lowering the plantar fragment (b)*. So M1 lowering by scarf can be large: It is one advantage of this osteotomy.



**Fig. 07c2. Operative views of lowering by scarf.**

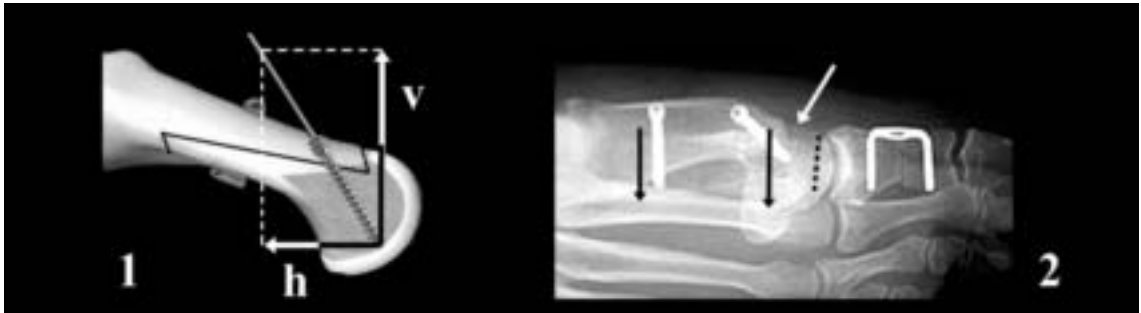
1. The saw blade plantar declination.
2. Same declination is observed when the head is laterally shifted.
3. The amount of lowering: It can be up to 6 mm.



indication for lowering is metatarsalgia of the second ray. I progressively diminished the number of osteotomies of the second metatarsal for metatarsalgia, reserving the osteotomy only for severe metatarsalgia or for significant excess of length ( $> 5$  mm) of the second metatarsal. However, too much lowering may result in overpressure on the metatarsal head. This is why pre-

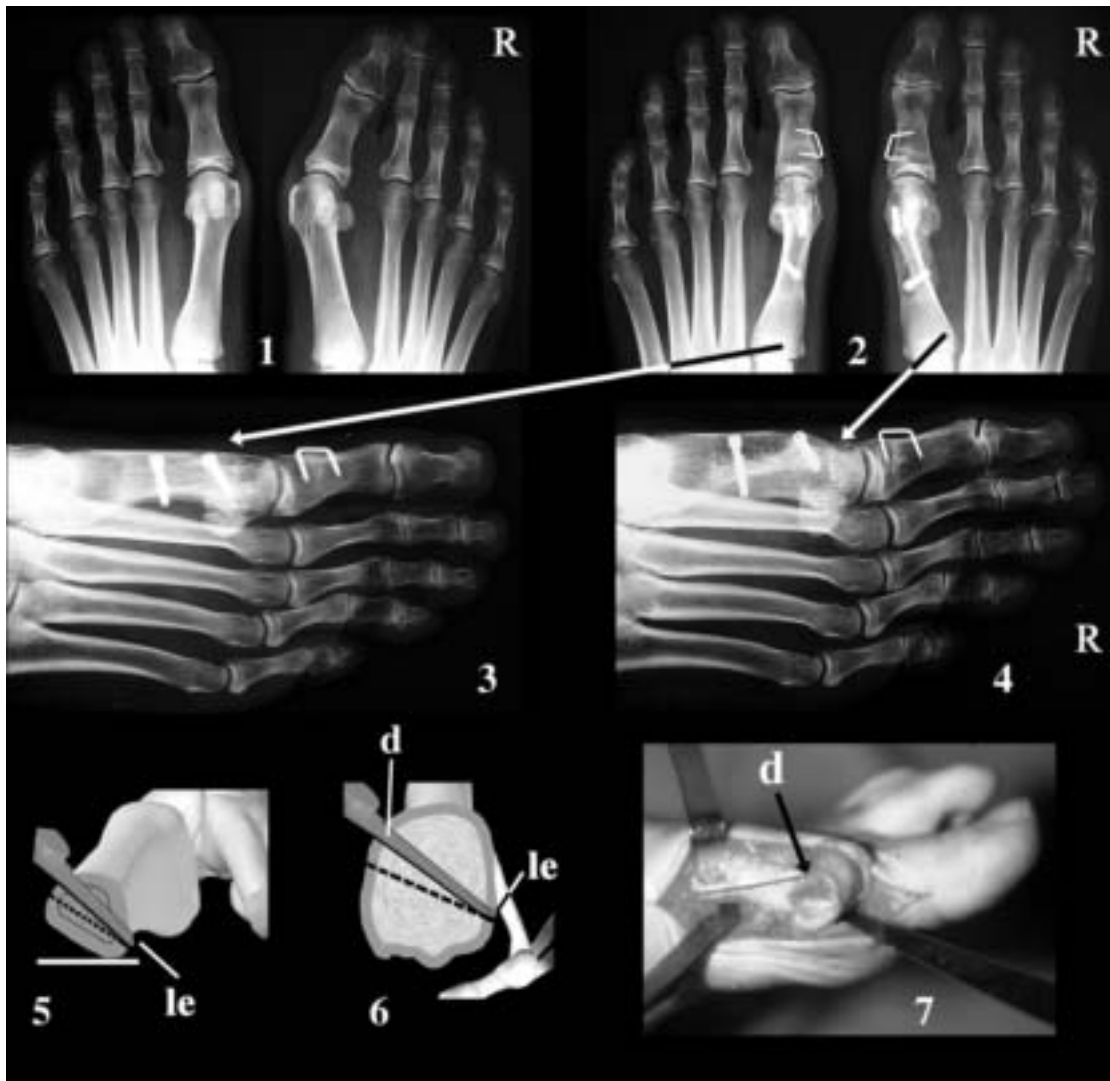
sently, in case of metatarsalgia of the second ray combined with hallux valgus, we perform a combined BRT osteotomy on the second metatarsal (or M2 Weil for a long 2nd metatarsal).

In the *supinated forefoot*, scarf lowering can bring such a good correction that now I reserve the Lapidus procedure only for an arthritic first tarso metatarsal joint.



**Fig. 07c3. Two specifics of lowering by scarf.**

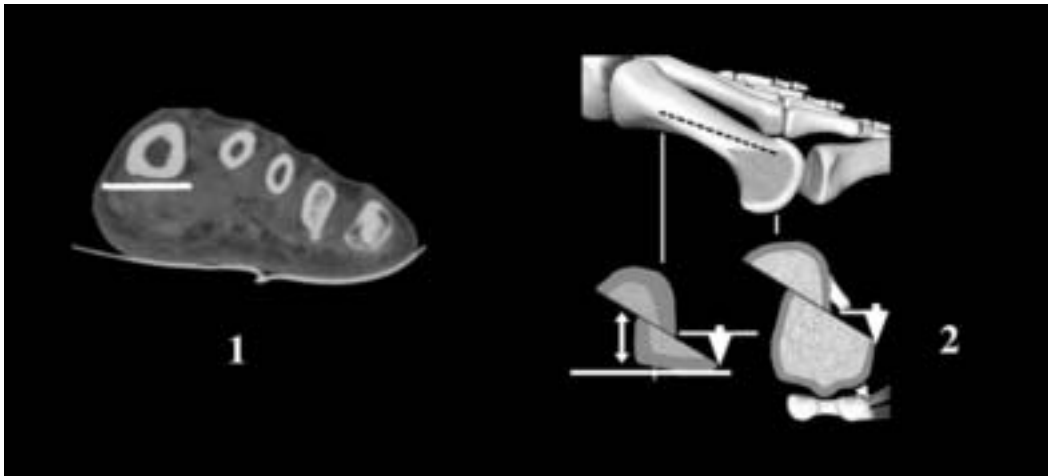
1. The oblique, distal, screwing compression forces can be split in two vectors: A *vertical* vector but also an *horizontal* one, that diminishes the fragments dorso plantar impaction while screwing.
2. One important specificity of lowering by scarf is that there is no plantar flexion of the plantar fragment: On the contrary, the lowering is a *plantar translation* of the entire plantar fragment, which remains parallel to the dorsal fragment. Thus the M1 head cartilage remains in the same sagittal and frontal plane.



**Fig. 07c4. Lowering by scarf and lateral shift.**

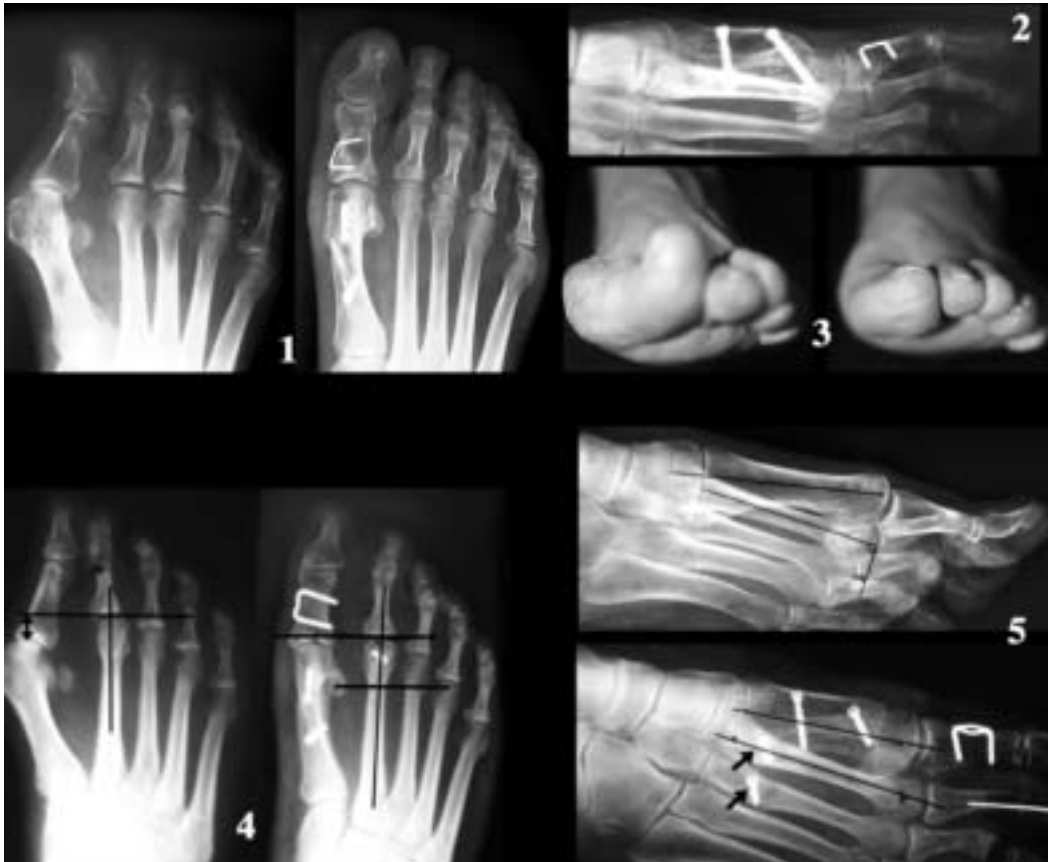1, 2, 3, 4. Usually the plantar fragment lowering is *dependent on the lateral shift*. In this case, more lateral shift was needed on the right foot, thus more lowering (4).

5, 6, 7. In cases where the lateral shift is not large enough, we have to give a *more plantar direction* to the longitudinal cut. Thus, the cut has to begin more dorsally on the medial surface (d) but the cut has to reach the lateral face on the same level as in usual cases (le).



**Fig. 07c5. Lowering by scarf when the M1 plantar surface is not oblique plantarly.**

This case is particularly encountered in *arthritic hallux valgus* and in *hallux limitus*. In this case, the lowering by scarf is obtained by a cut which is not parallel to the plantar face.

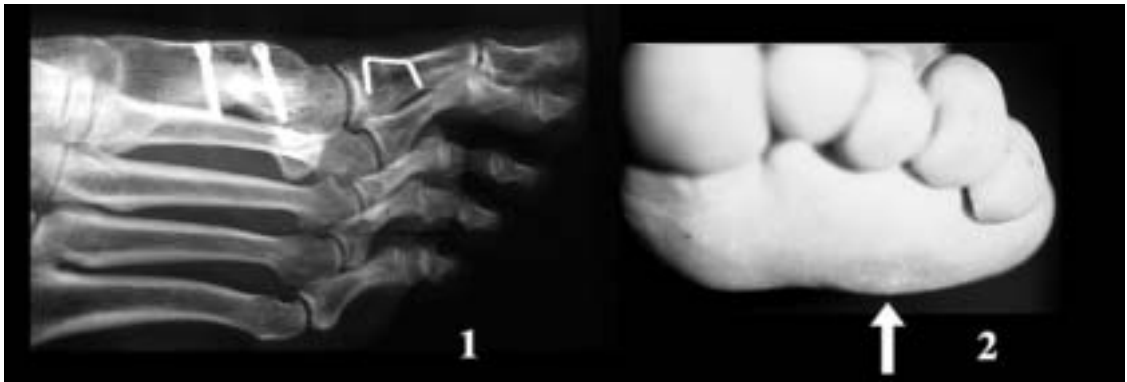


**Fig. 07c6. Lowering by scarf and metatarsalgia of the 2nd ray: the three main cases encountered.**

1, 2, 3. Usually, lowering by scarf is sufficient to correct the 2nd ray metatarsalgia. It is currently observed (same case, clinical and radiologic aspects, 1 year follow-up).

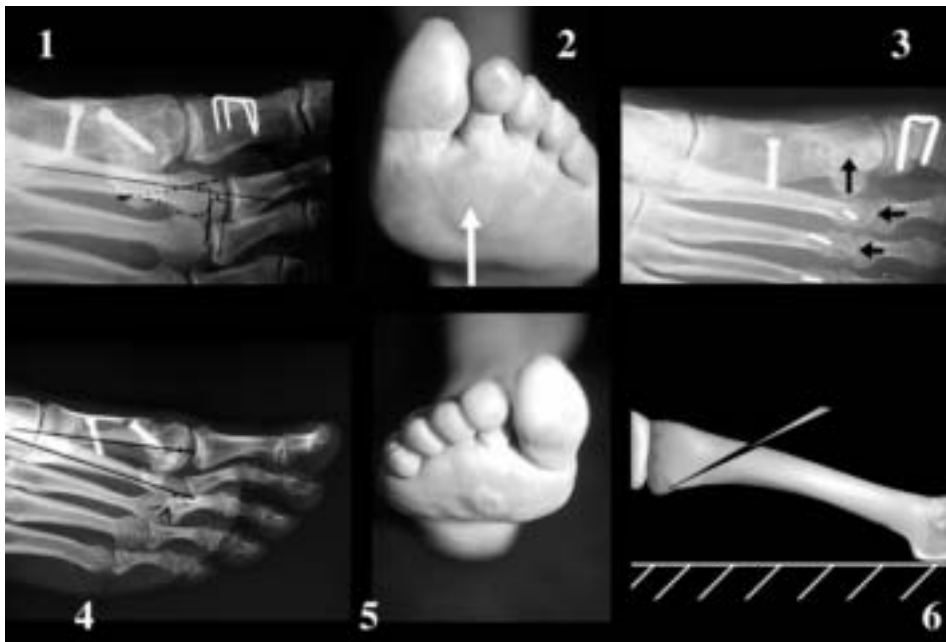
4. When the first metatarsal is preoperatively shorter than the second, lowering by scarf is not sufficient and has to be combined with a *Weil 2nd metatarsal osteotomy*.

5. Sometimes a *basal elevation osteotomy* of the 2nd or 3rd metatarsal (BRT) has to be combined with the scarf osteotomy.



**Fig. 07c7. Limit of lowering by scarf regarding the 4th ray metatarsalgia.**

Lowering by scarf can correct metatarsalgia on the 2nd ray, sometimes also on the 3rd one, but never on the 4th metatarsal. In this case, we have to add a separate lesser ray surgery (ex.: M4 BRT osteotomy of the 4th metatarsal).

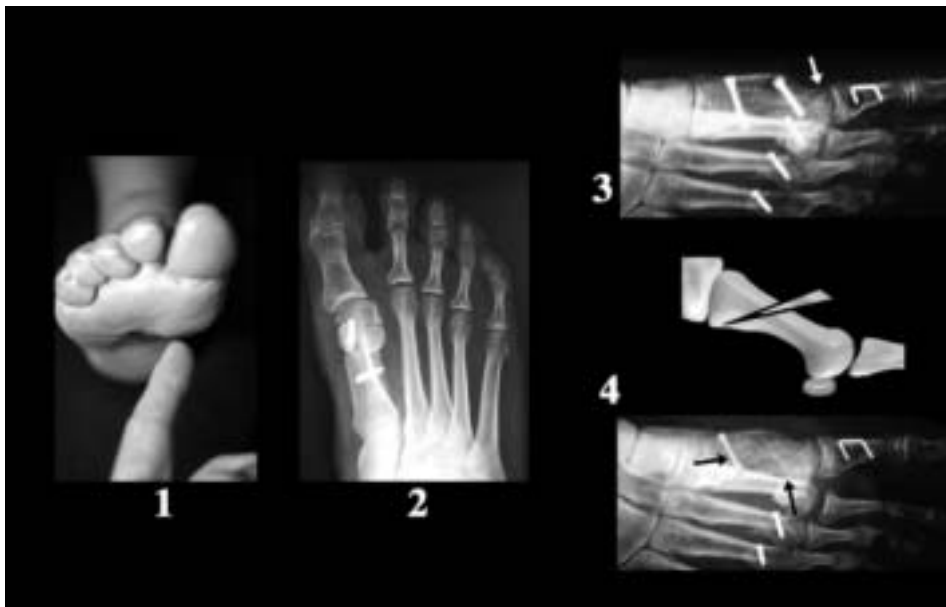


**Fig. 07c8. Insufficiency of M1 lowering by scarf.**

1, 2. In an *early experience*, we did not make the longitudinal cut in a plantar direction which resulted in the lack of M1 lowering (1) and therefore in remaining or transfer metatarsalgia on the 2nd ray.

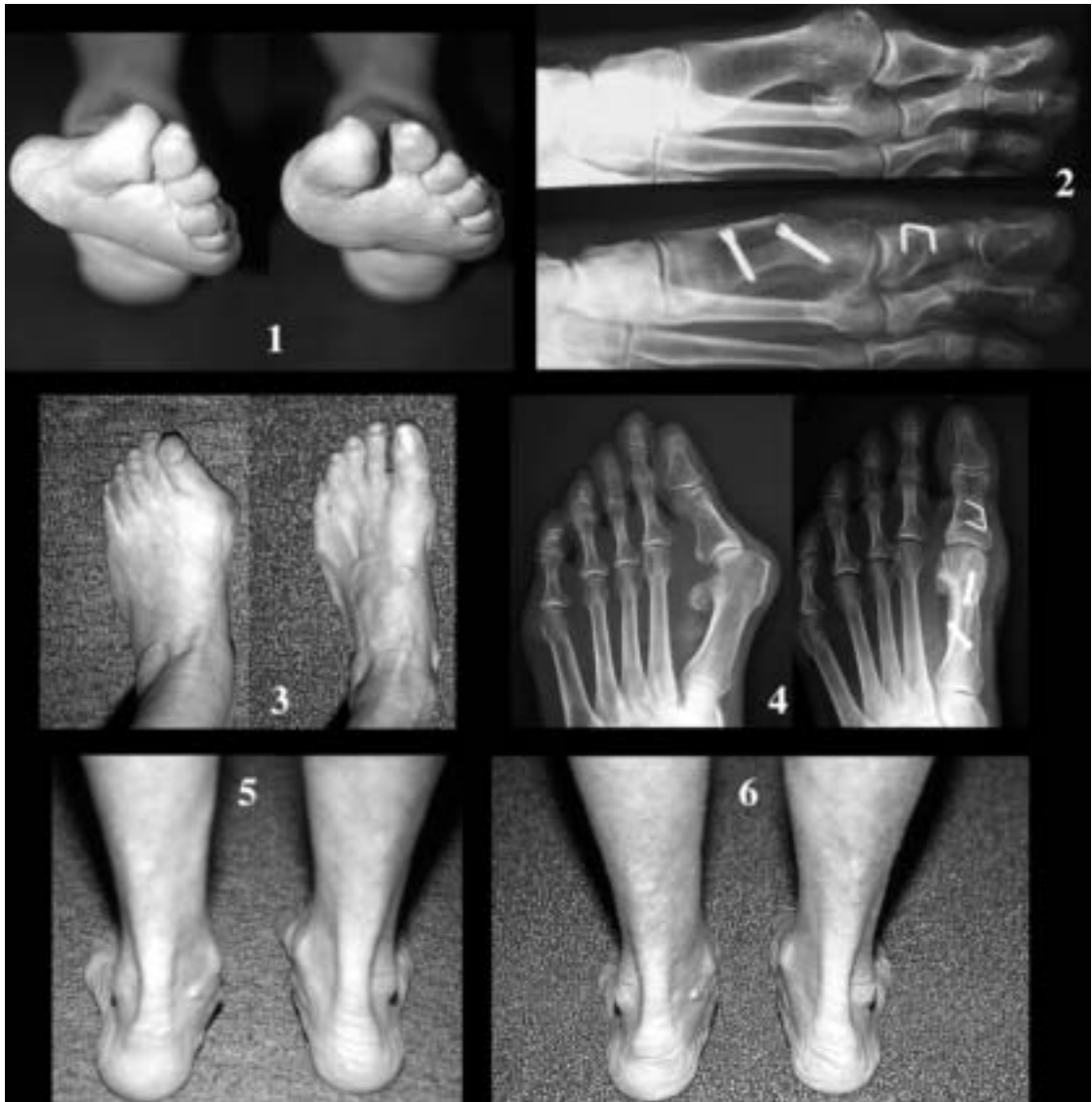3. In this case, *the lesser metatarsals were too long* comparatively to the 1st one, so the solution was a secondary *Weil osteotomy* of the lesser metatarsals.

4, 5, 6. In this case, the lesser metatarsals were *not too long*, the *BRT osteotomy* was the solution to relieve this type of transfer metatarsalgia.



**Fig. 07c9. Excess of M1 lowering by scarf.**

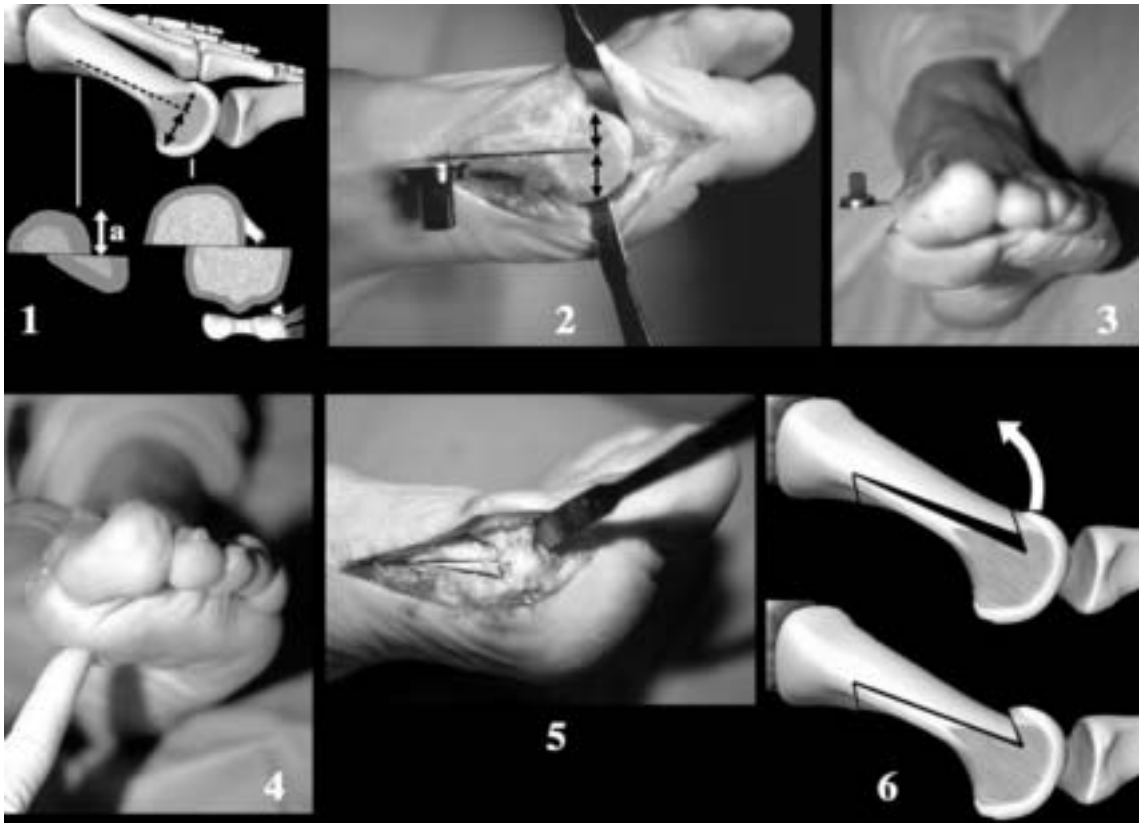
1. It results in an *overpressure and metatarsalgia on the 1st ray*.
2. It is sometimes combined with a small overcorrection of the sesamoids.
- 3, 4. The solution is the BRT elevation osteotomy performed in the base of M1, it is preferable to fix this osteotomy with the “20” memory staple, combined if required with the first MTP joint release.



**Fig. 07c10. In a supinated forefoot or an hypermobile 1st ray, does the scarf replace the Lapidus procedure?**

1, 2. We observed that each time we have a sufficient M1 lowering (large intermetatarsal angle), this lowering is sufficient to ensure both the long-lasting hallux valgus correction (3, 4) and to significantly improve the hindfoot valgus (5, 6). All these pictures are from the same patient with 2 years follow-up, left foot.

When there is too much foot valgus, additional rearfoot procedures have to be performed (see Fig. 43V1b).



**Fig. 07d1. First metatarsal elevation by scarf.**

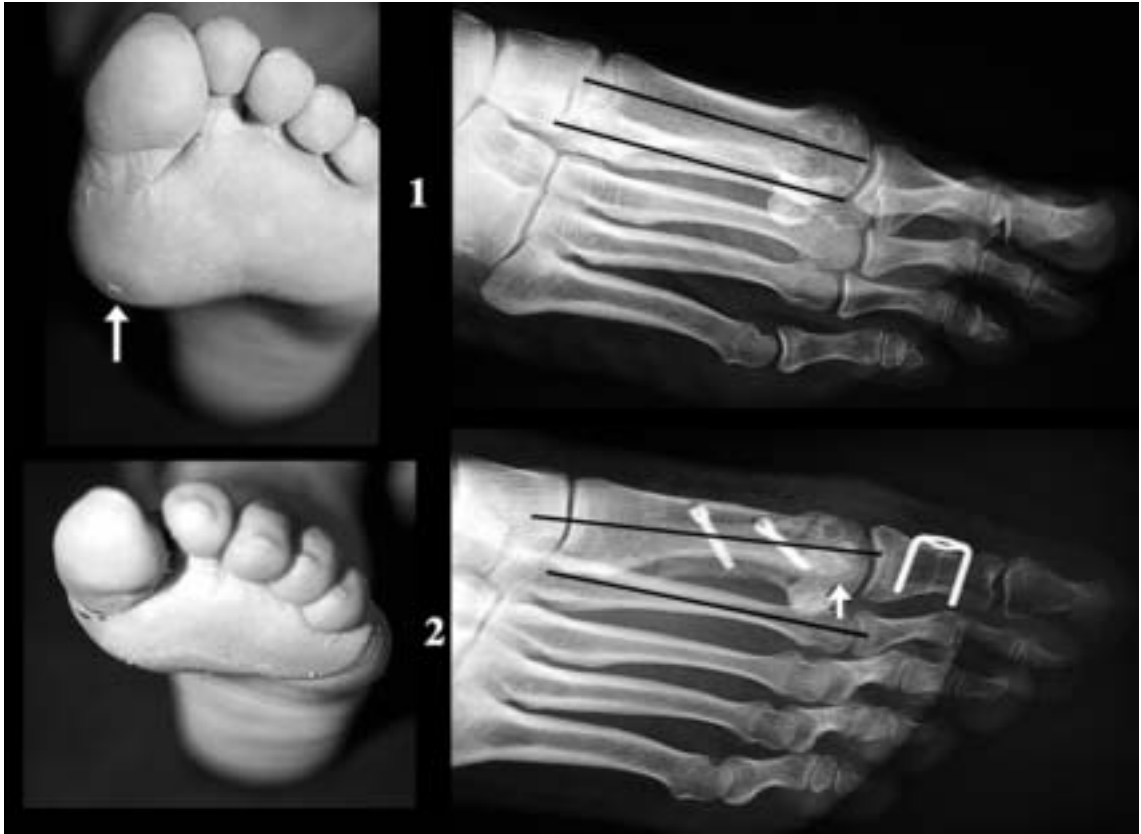1, 2, 3. First of all, *no M1 lowering* is obtained performing the longitudinal cut horizontally. In this case, its distal end is on the center of the medial aspect of the head. But care has to be taken not to fragilize the lateral beam (a).

4, 5, 6. If we want *elevation*, we have to perform a *distal closing wedge*, the bone is mainly removed on the dorsal fragment. However, if a large wedge is removed, the resulting elevation will modify the orientation of the head articular surface, sometimes resulting in insufficiency of MTP plantar flexion.

### Elevation

Elevation is indicated when the hallux valgus is associated with a cavus foot or when the first metatarsal has too much plantar slope, resulting in a metatarsalgia of the first metatarsal head. Elevation is first obtained by a longitudinal cut horizontally instead of dorsally inclined

and, above all, by a long distal edge resection. Elevation may result in a dorsal inclination of the cartilage, which leads to a slight decrease in the great toe's ground contact. So, the scarf elevation is reserved for severe first ray metatarsalgia or cavus foot with hallux valgus deformity.



**Fig. 07d2. Result of M1 elevation by scarf.**

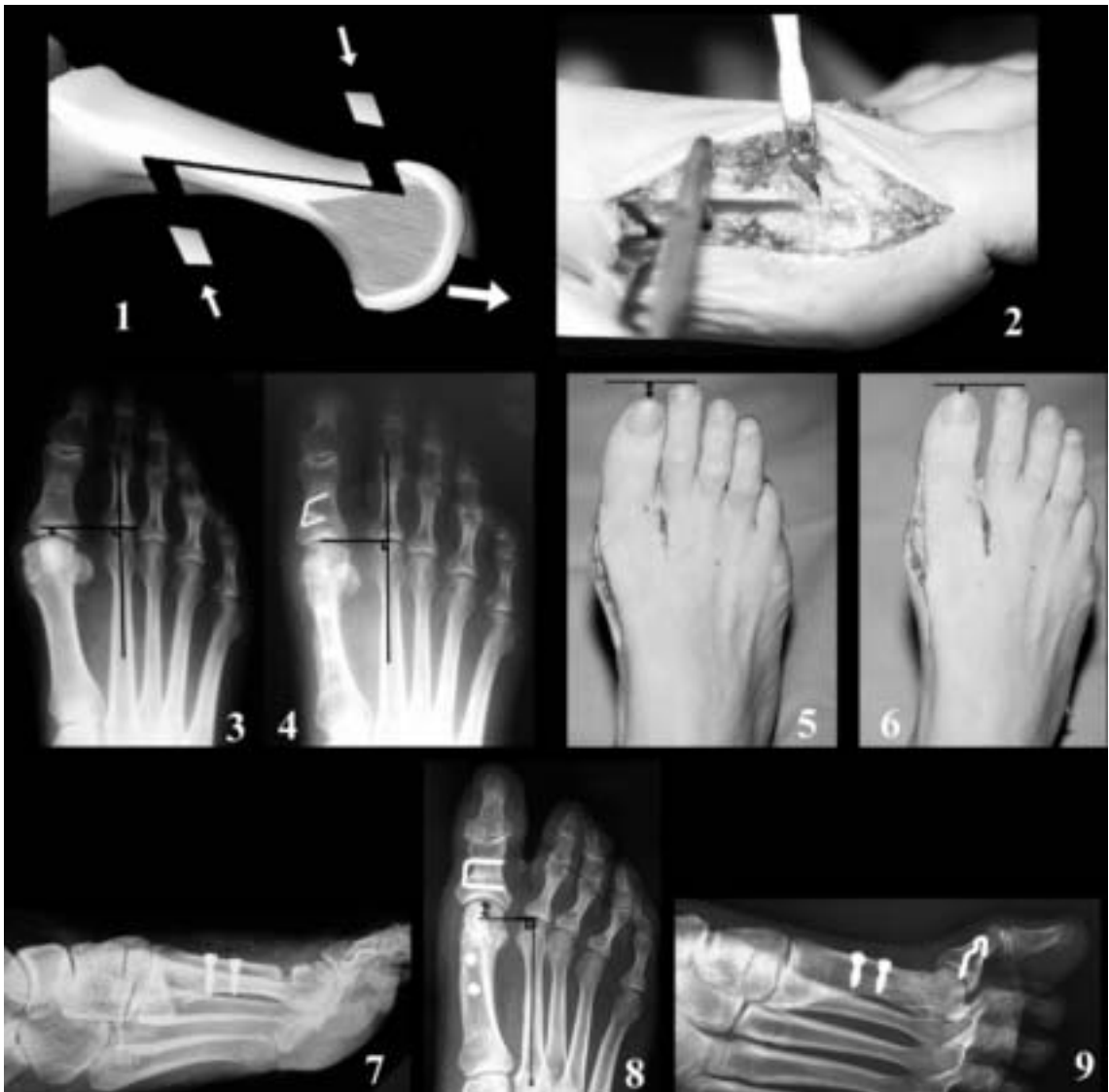
Same patient before the operation and one year after. Clinical and radiological aspects. Care has to be taken with elevation because the lateral surface is not so strong after the distal wedge removal.

### Lengthening

Burutaran [29] performed the scarf procedure as a lengthening of the metatarsal. Lengthening, however, makes the lateral shift more difficult and increases the longitudinal pressure, which may

result in impairment of the first MTP joint or in decrease of its range of motion. Although lengthening is possible and easy with the scarf procedure, it should be reserved for young patients with normal first MP joints as suggested by Weil.





**Fig. 07e. First metatarsal lengthening by scarf.**

1, 2. Performed initially by Burutaran, the scarf lengthening uses two bone grafts, distal and proximal.

3, 4, 5, 6. A *small* lengthening may be performed in young patient with a good preoperative MTP radiological aspect and range motion.

7, 8, 9. But lengthening may result in 1st MTP stiffness, under or overcorrection. Here is one example of lengthening resulting in too long M1 and over MTP dorsal flexion: Care has *to be taken with M1 lengthening*.

### Shortening of the First Metatarsal

Shortening by scarf presents the following specificities:

– It can be obtained by *increasing the proximal inclination of the transverse cuts*, reserved in my experience for shortening of less than 3mm, but L. S. Weil obtains more shortening with

more oblique cut. Nevertheless, the shortening is principally provided by *proximal and distal resection*. Proximal resection is easy and accurate thanks to the PPE, which reveals the “no man’s land” area from which the plantar fragment may be pulled and resected easily. The distal resection sometimes resulted in overcor-

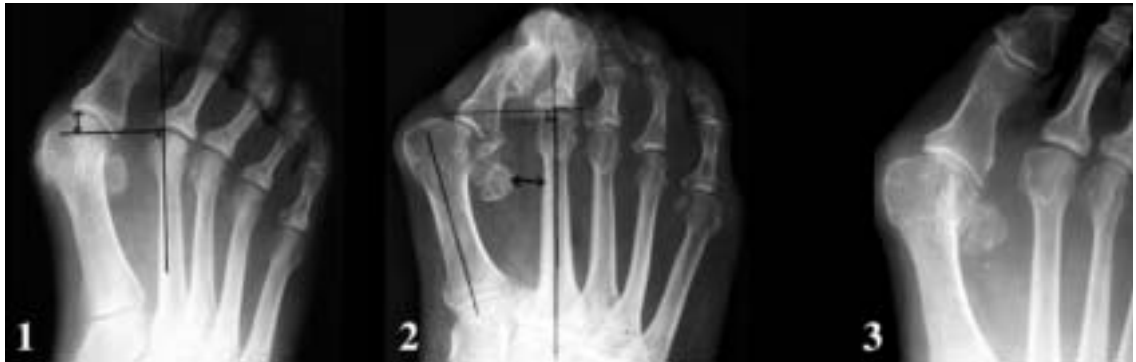recession (hallux varus), which is now avoided by the *Maestro distal cut* (Fig. 07f2).

– It is easy and accurate.

– *Shortening by scarf does not result in elevation.* Firstly, because the longitudinal cut has a proximal plantar inclination from the metatarsal axis, thus being almost horizontal. Secondly, because the shortening is generally

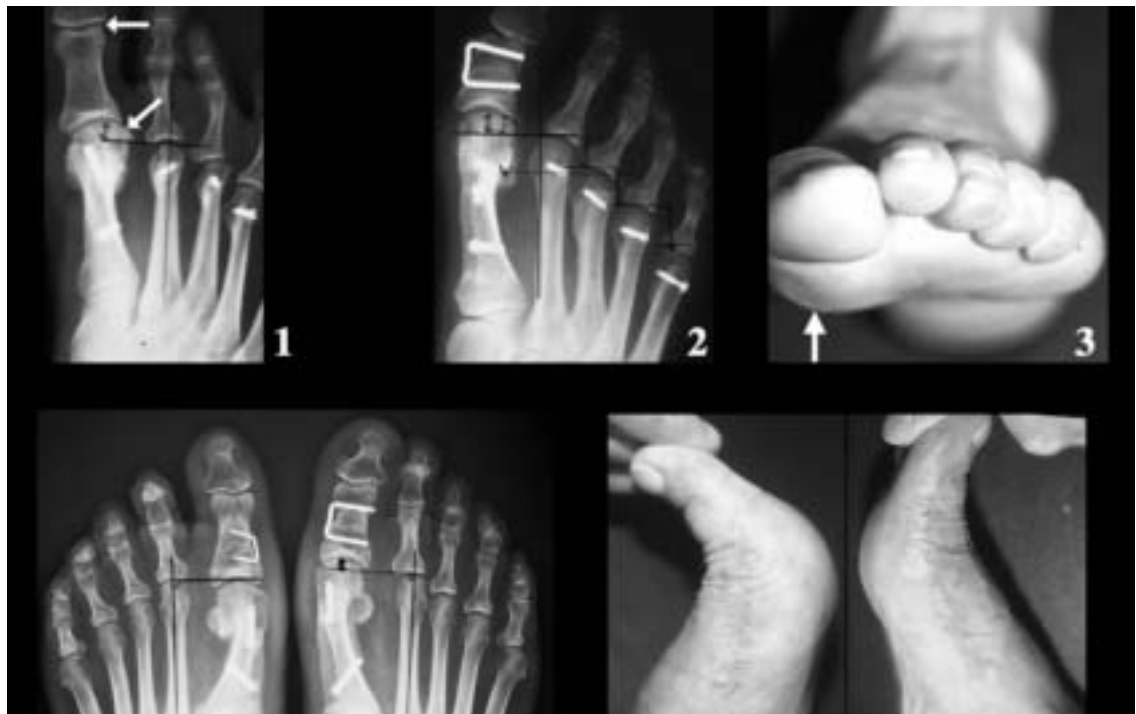combined with lowering that can be as generous as when the osteotomy is performed without shortening (Fig. 07f5).

– In a dorsal plantar radiograph, the sesamoid bones are in a distal position in respect to the MTP joint but only for 2 to 5 weeks. After this period, radiographs show them to be moving backward, returning to their normal position.



**Fig. 07f1a. Three main indications of M1 shortening.**

1. Congenital excess of M1 length.
2. Severe deformity.
3. Arthritic hallux valgus.



**Fig. 07f1b. Problems occurring when the first metatarsal remains too long.**

1. Overcorrection of the deformity.
- 2, 3. Same patient: *Overpressure* and metatarsalgia on the 1st ray.
- 4, 5. Same patient: MTP *less dorsal flexion* on the side where M1 remains too long (right foot).

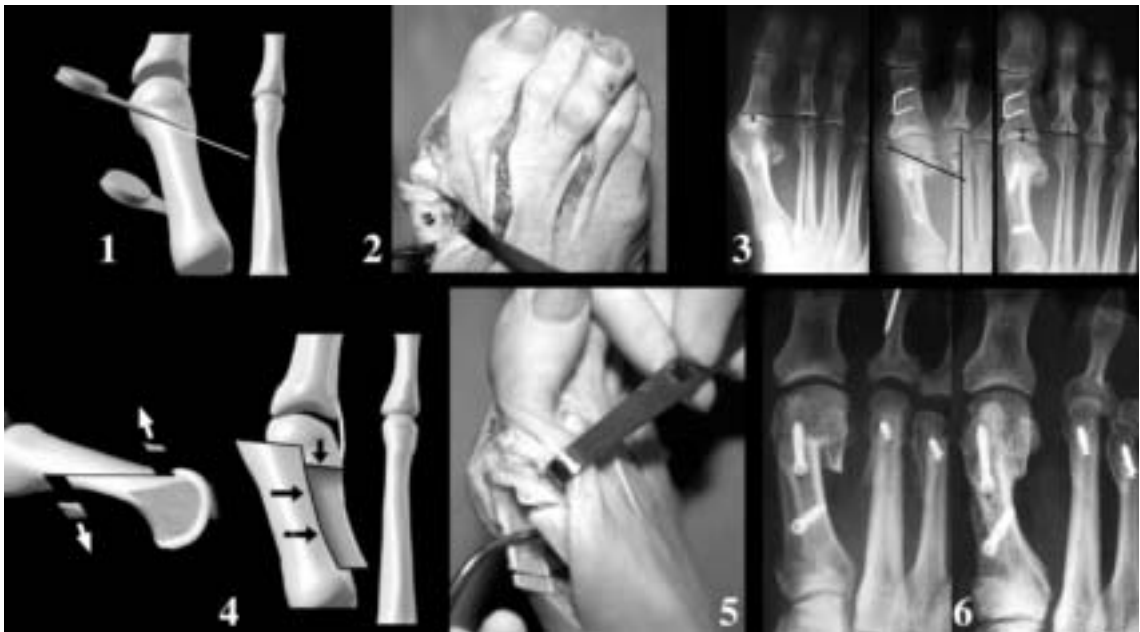– Nevertheless, the first metatarsal can only be shortened up to 5 mm less than the second metatarsal, in spite of combined lowering of the first metatarsal head. The *harmony of the metatarsal curve* has to be preserved. In this case, shortening of the lesser metatarsal by Weil osteotomy is indicated.

– *The amount of predictable shortening* depends on the preoperative examination. *Clinically* by the MTP dorsal flexion test, *radiographically* by taking into consideration the proximal location of the 1st phalanx basis. It is the *ms point*. But the real magnitude of M1

shortening is finally determined intraoperatively (Fig. 07f4).

– *Shortening enables preservation of the MTP joint as far as possible, reducing the indications for MTP arthrodesis. The main effect of shortening is the longitudinal decompression of the MP joint and the first ray, which has two consequences:*

- 1) Improving the dorsal MTP flexion, notably by a relative lengthening of the flexor brevis;
- 2) expanding the indications up to impaired MTP joints with advanced arthrosis, very large hallux valgus deformity and generally severe forefoot disorder, including the rheumatoid forefoot.

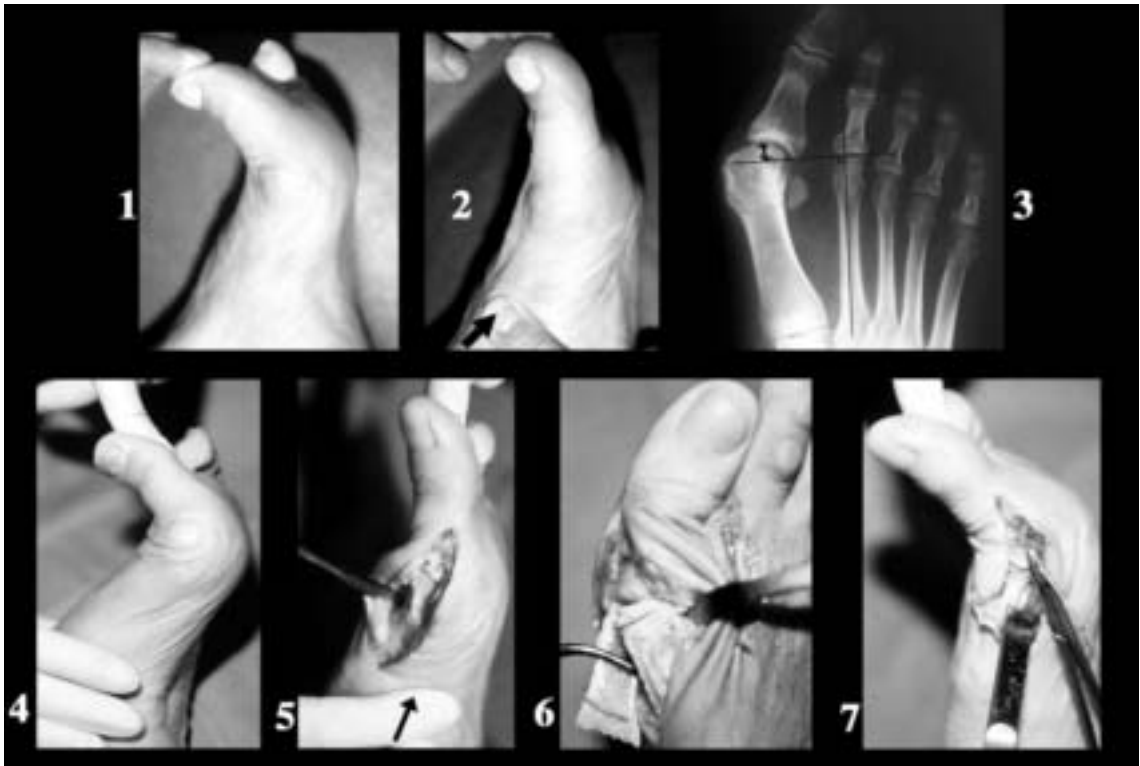


**Fig. 07f2. Technique of first metatarsal shortening by scarf.**

1, 2, 3. Usual shortening by *increasing the proximal obliquity* of the transverse cuts does not shorten more than 3 mm. However, L. S. Weil performs a 45° proximally directed cut: In this case, the metatarsal will shorten of the same number of millimetres as it will laterally translate towards the 2nd metatarsal, *i.e.* 6-7 mm of both shortening and lateral displacement.

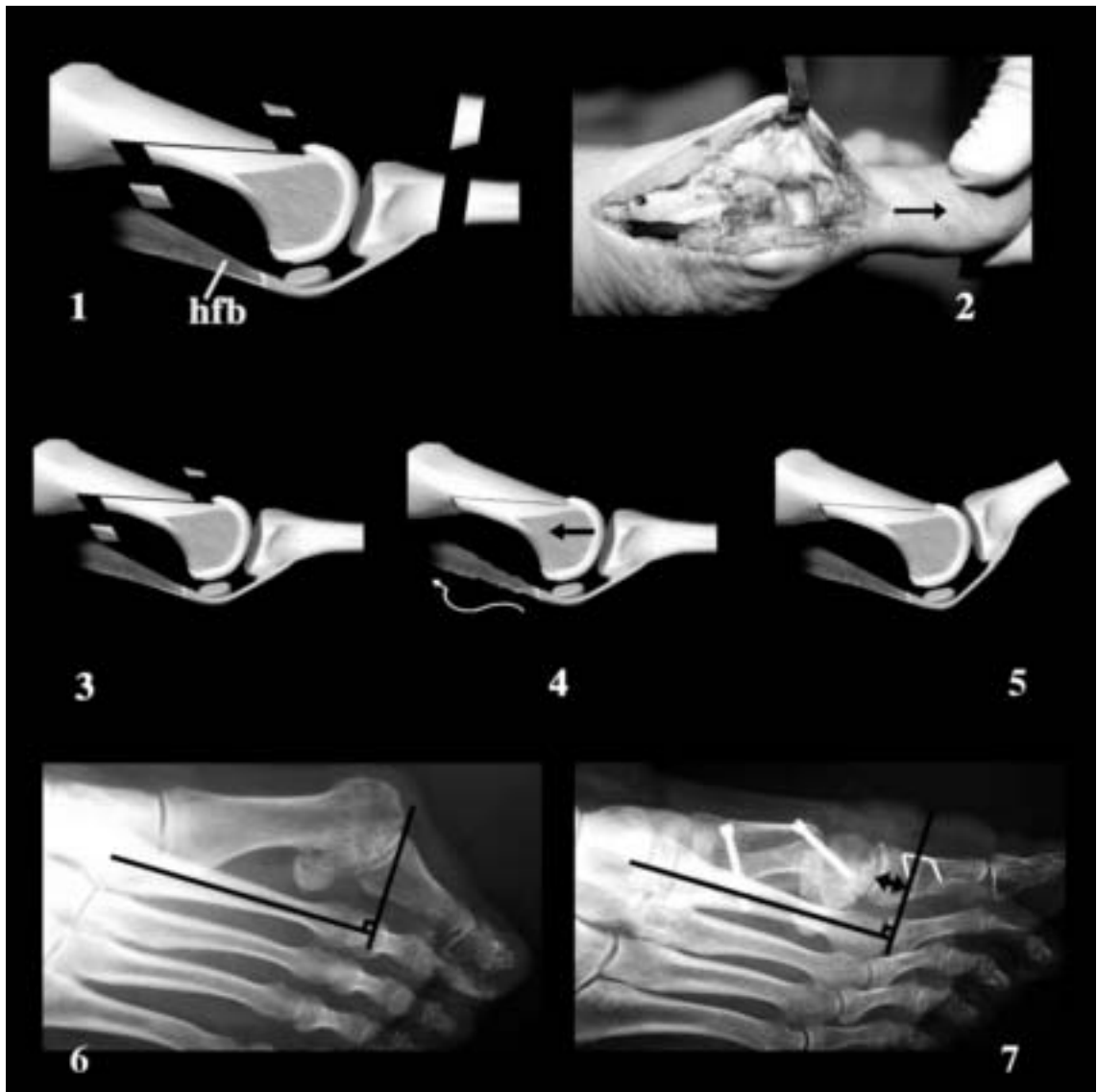4, 5. Shortening by *resection*. Significant shortening is obtained by performing the Maestro (Nice, France) distal cut, which furthermore increases the fragmental contact area and preserves the MTP lateral ligament. Then, thanks to the ppe, the plantar fragment is easily and harmlessly pulled out medially to make the proximal resection.

6. X-ray aspect just after and one postoperative year with such a shortening.



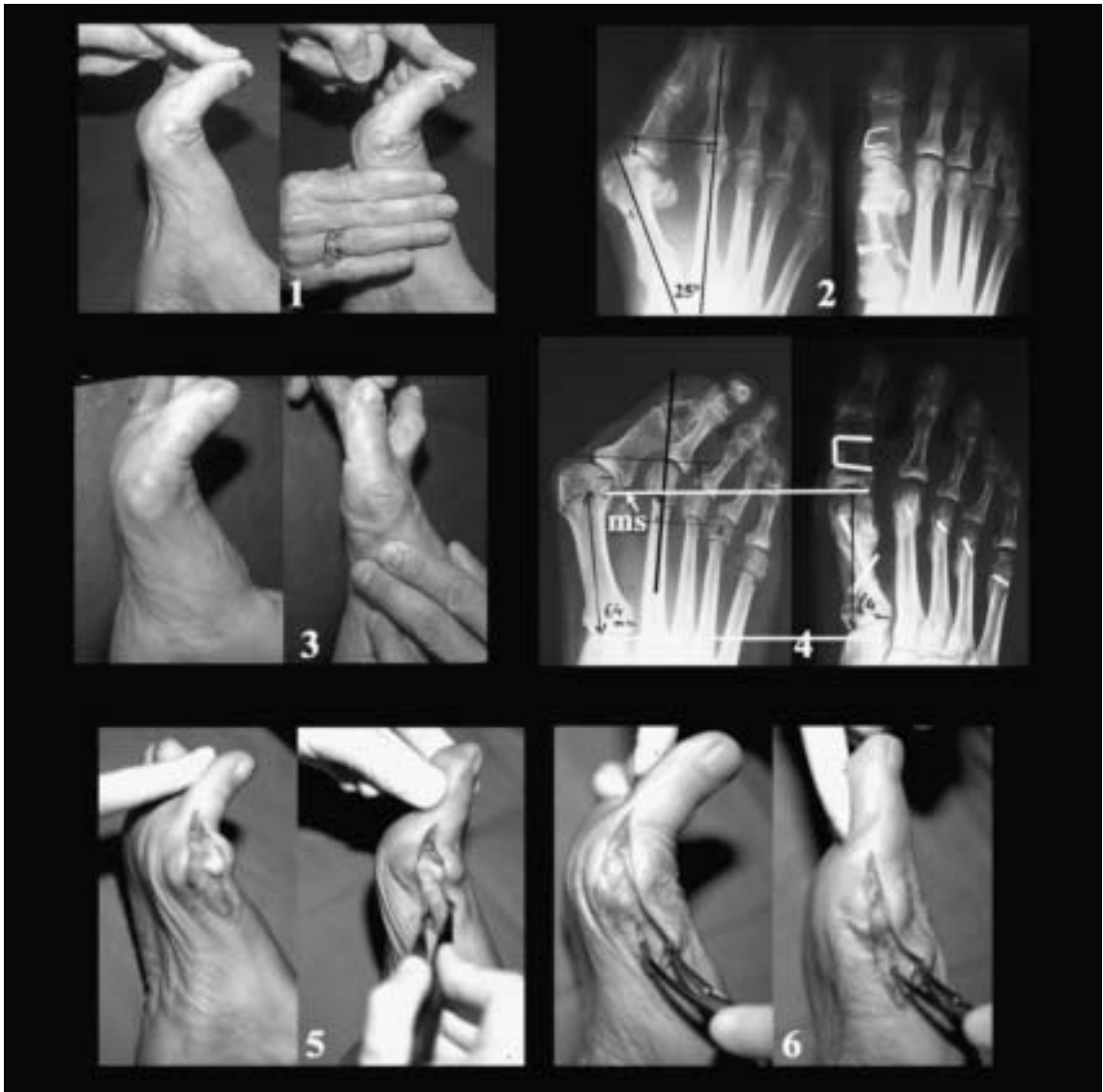**Fig. 07f3a. The M1 shortening increases the MTP dorsal flexion (1).**

- 1, 2. Preoperative dorsal flexion is diminished when the examiner attempts a passive correction of the deformity: X-ray shows a too long M1.
- 4, 5. Intraoperative same foot: Same decreased dorsal flexion with passive correction of the deformity.
6. M1 shortening.
7. Same foot: The dorsal flexion is recovered.



**Fig. 07f3b. M1 shortening and MTP dorsal flexion (2): M1 shortening versus P1 shortening.**

1. Only 1st metatarsal shortening increases the MTP dorsal flexion since the flexor hallucis brevis (fhb) and plantar fascia are relaxed. The P1 shortening cannot have the same effect since it is distal from the fhb phalanx insertion.
2. MTP longitudinal decompression after M1 shortening.
- 3, 4, 5. The mechanism of MTP dorsal flexion increasing with M1 scarf shortening.
- 6, 7. Same foot before and after M1 shortening by scarf.



**Fig. 07f4. Assessment of need and amount of first metatarsal shortening.**

**1 to 4.** Preoperative assessment.

**1, 2.** In this case, the MTP dorsal flexion is not decreased with the correction of intermetatarsal angle and hallux valgus: No need of M1 shortening.

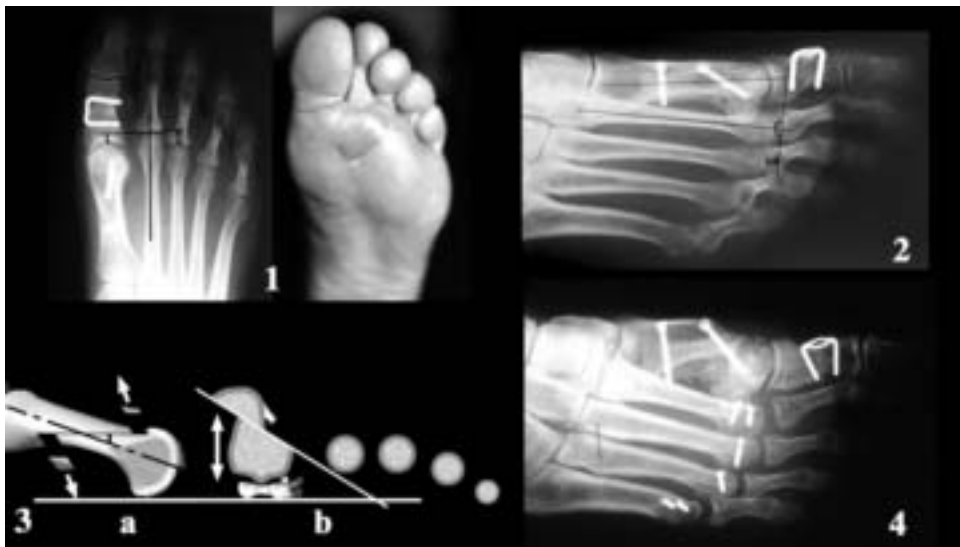
**3.** In this case, the MTP dorsal flexion is decreased with the same correction: Need of M1 shortening.

**4.** The *amount of metatarsal shortening*: As far as the **ms point** (the more proximal part – lateral – of the 1st phalanx basis).

**5, 6.** *Intraoperatively* we always check the dorsal MTP flexion after performing the lateral release and medial approach of the first metatarsal (M1).

**5.** No need of M1 shortening.

**6.** Need of M1 shortening.

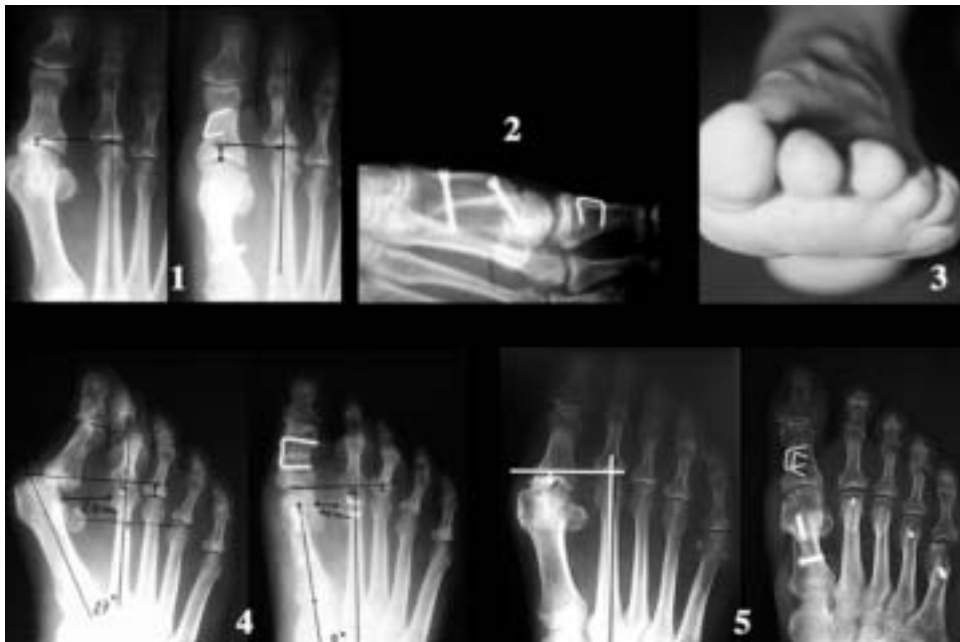

**Fig. 07f5. Relationships between M1 shortening and M1 lowering.**

1, 2. Shortening *without* lowering may result in 2nd ray transfer metatarsalgia (scarf early experience).

3. a: The longitudinal cut does not follow the axis of the 1st metatarsal, so that the 1st metatarsal shortening by scarf does not provide elevation. b: Thanks to the plantar obliquity of the longitudinal cut, M1 lowering by scarf is automatically combined with the lateral shift.

4. This lowering should compensate the shortening but does not cancel the necessity to harmonize the metatarsal parabola. On this example, Weil osteotomy on the lesser metatarsals is combined.

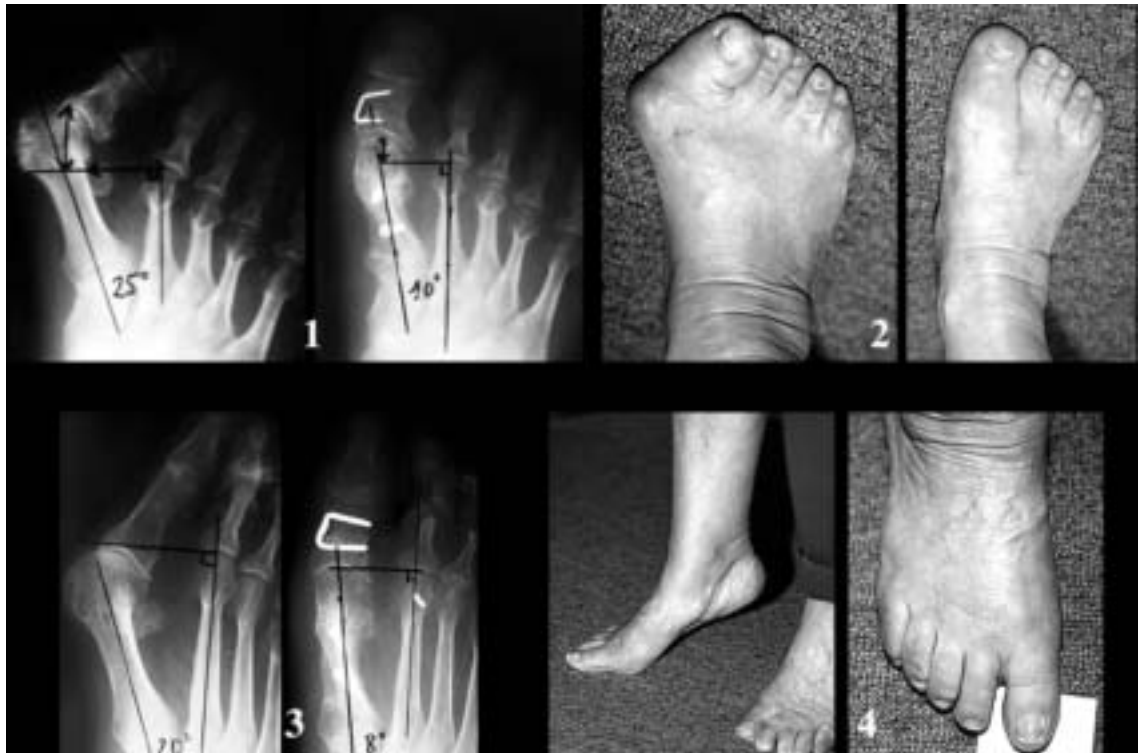

**Fig. 07f6. Scarf M1 shortening: Relationships with the lesser metatarsals.**

1, 2, 3. *Arthritic hallux valgus*: The M1 shortening is compensated by lowering. But this example is a limit: If the correction is longer than 8 mm we also have to shorten the 2nd metatarsal.

4. Shortening was needed to correct 27° of IM angle, while preserving correct MTP range motion; in this case, combination of Weil M2 shortening.

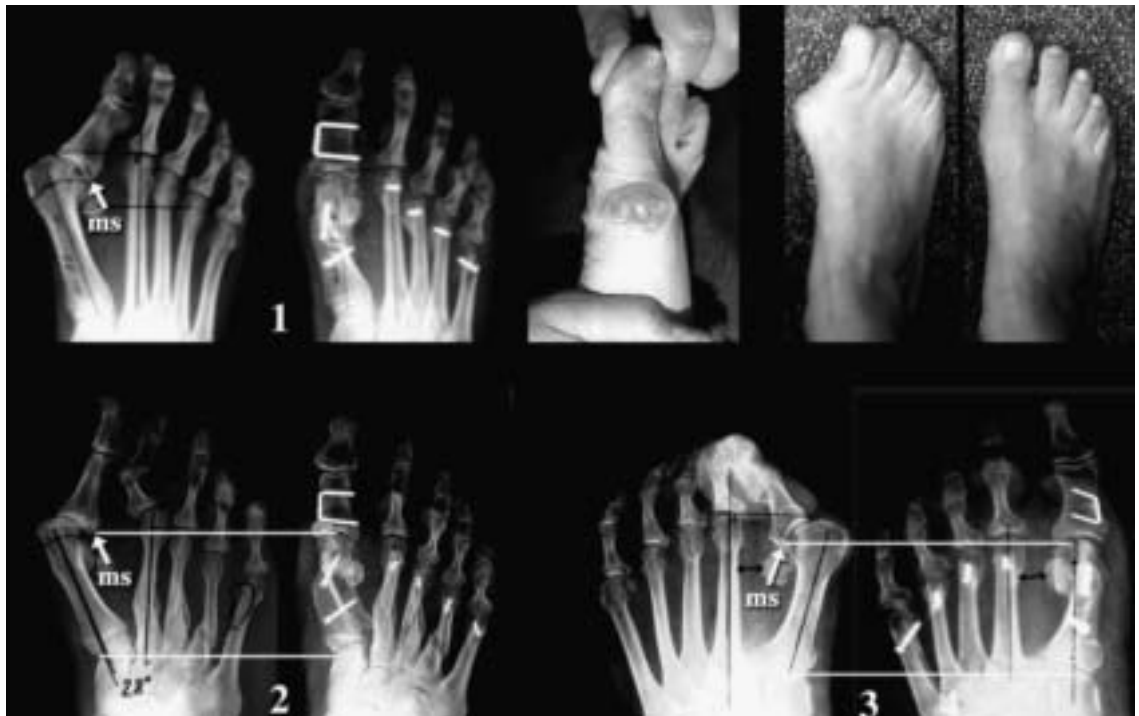
5. *Shortening of M1 already shorter than M2*. Since there was metatarsalgia on the lesser rays and the 1st MTP joint was painless, a joint preservative solution was adapted. Shortening of M1 and harmonized shortening of the lesser metatarsals.



**Fig. 07f7a.** Three main indications and results for M1 shortening.

1, 2. *Congenital excess of M1 length.*

3, 4. *Arthritic hallux valgus.*



**Fig. 07f7b.** Three main indications and results for M1 shortening.

1, 2, 3. *Severe forefoot deformity, three cases.*

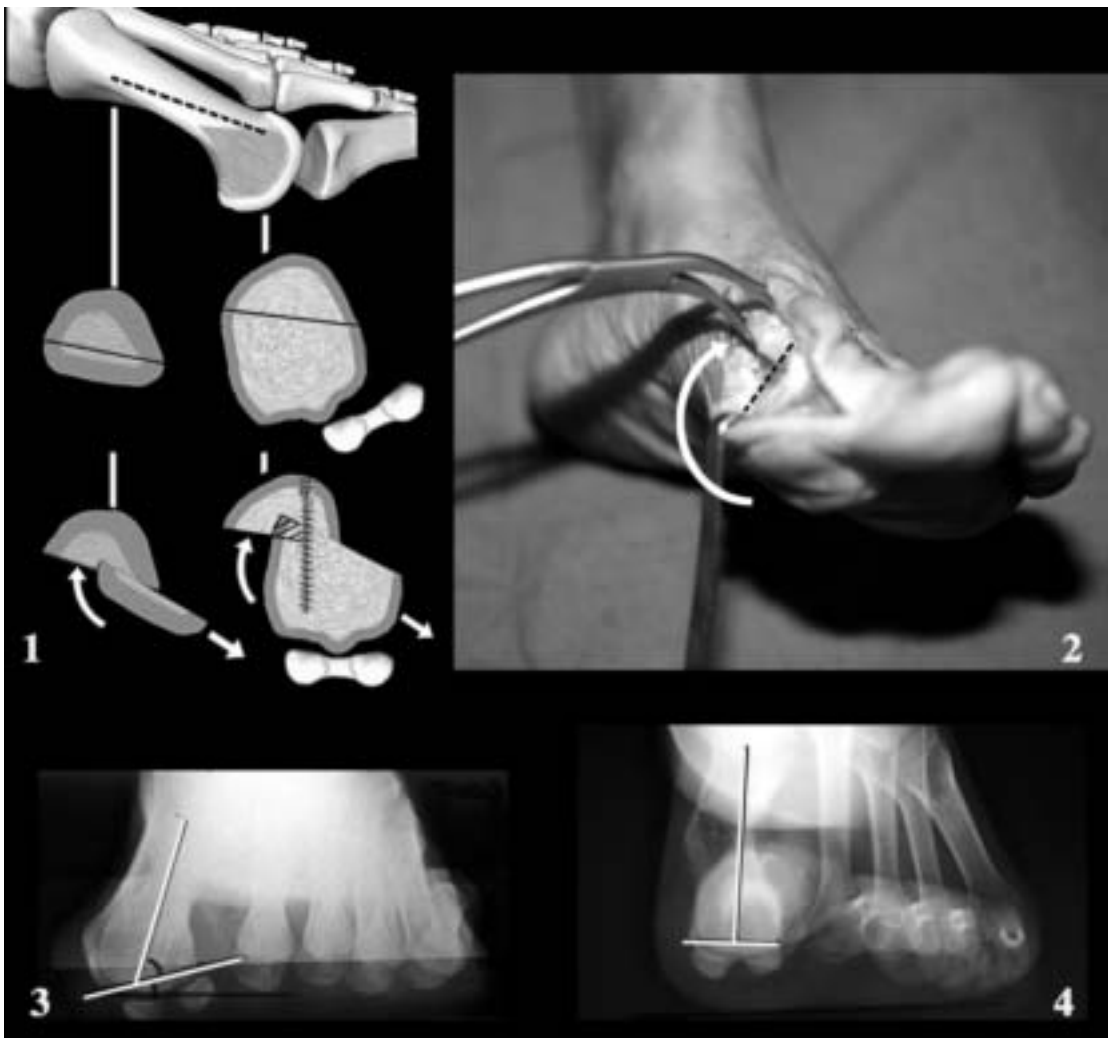
In each example, note that the appropriate metatarsal shortening was determined by the location of the basis of the 1st phalanx (*ms point*). This shortening not only increases the MTP dorsal flexion but also ensures the deformity correction whatever its grade.



### Axial Rotation

Usually, performing the scarf osteotomy results automatically in an axial rotation which corrects the pronation of the 1st metatarsal. We can increase the supination by removing a small piece in the distal part of the plantar fragment, but it is rarely necessary. There are relationships between DMAA and axial rotation of the first metatarsal (Fig. 40a8b).

The Bernard and Mortier incidence (see Fig. 40a8a) is accurate in the assessment of the 1st metatarsal axial rotation. In case where the pronation of the first metatarsal is severe, the Mortier-Bernard oblique plane osteotomy (TRADE) is a good procedure to correct this deformity (AFCP, Annual Meeting, 1998, Paris). However the healing is longer than with the scarf (basal osteotomy).



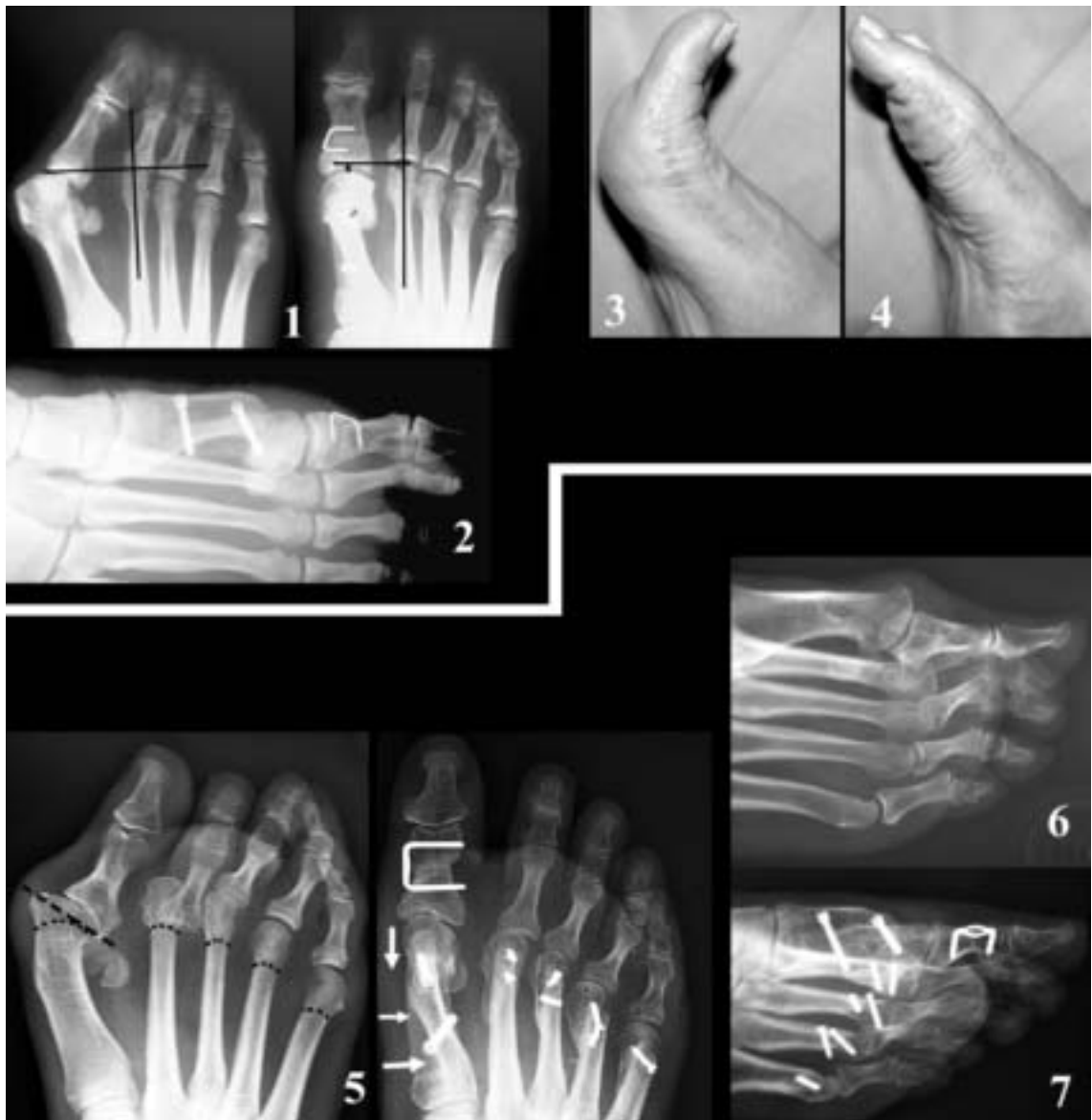**Fig. 07g. Scarf and correction of first metatarsal axial rotation.**

- 1, 2. Usually, performing the scarf osteotomy results automatically in an axial rotation which corrects the pronation of the 1st metatarsal. We can increase the supination by removing a small piece (a) in the distal part of the plantar fragment, but it is rarely necessary.
3. The Bernard and Mortier incidence (see Fig. 40a) is accurate in the assessment of the 1st metatarsal axial rotation.
4. Same case, after scarf osteotomy, correction of the 1st metatarsal pronation with the scarf osteotomy.

**Combination of Different Displacements**

Obviously, different displacements can be combined and this versatility is not only very large but also very easy to perform. The only problem is to determinate preoperatively and intraoperatively the combination to be perfor-

med by the clinical examination, the preoperative X-ray and the intraoperative findings. Several authors, like Stephens and Borton [27] emphasize the necessity of combined displacements in a first metatarsal osteotomy for hallux valgus correction.



**Fig. 07h. Two examples of combination of displacements by scarf osteotomy.**

1. Combination of lateral shift and small shortening compensated by lowering (2). This shortening ensures a good MTP articular range motion (3, 4).

5. In this case, DMAA correction is combined with lateral shift and shortening resulting in a good correction of the deformity and in correct MTP joint mobility. The lesser metatarsal shortening was according to the needed parabola.

6, 7. Same foot on the medial oblique view.

### Scarf Fixation

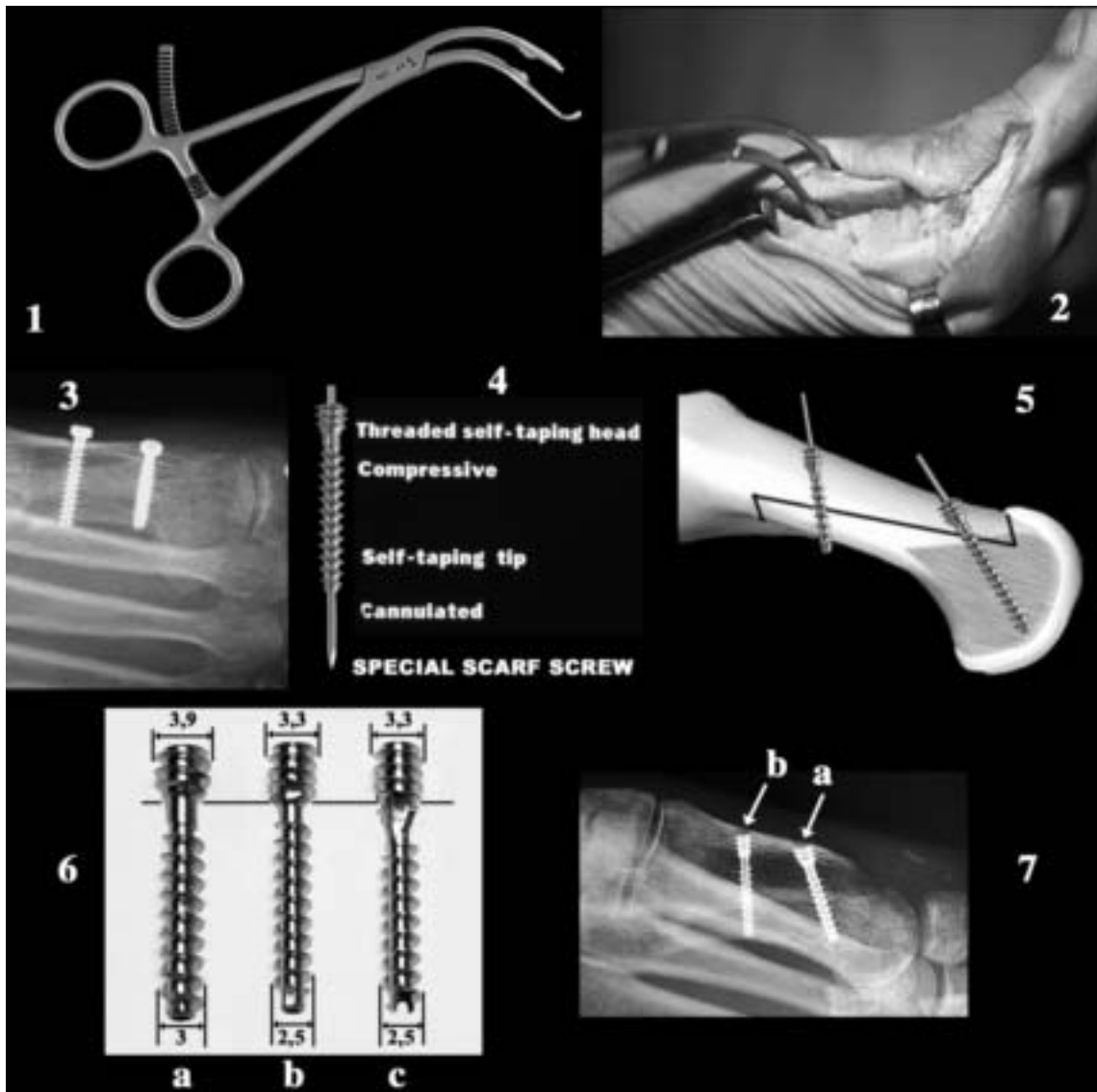
A *strong fixation* is necessary, not only to make secure the location of the plantar distal fragment once displaced, but also to have a strong osteosynthesis allowing early and harmless functional recovery. Several authors emphasized the quality of fixation [2, 123].

First, I designed a special clamp to hold the fragments for fixation. The length of the fragments allows the use of two well separated screws, which achieve easy and reliable fixation: The evolution of the scarf screws I designed in collaboration with the engineers from DePuy Company, is later described.

We have designed and developed a *specific scarf screw*. It has a threaded head, provides sufficient compression but avoids elevation of the metatarsal head, is self tapping, has a long distal

threaded part, and is cannulated. This last feature allows the use of two fine K-wires (1 mm) that are placed (and replaced if necessary) between both fragments with less potential damage than it could result from primary drilling. The setting of the K-wires is critical. The last improvement of scarf screw is now made in collaboration with L. S. Weil: It is the FRS screw, which has new features, such as a longer head allowing more compression and, above all, is self cutting in the distal and proximal threads. Therefore, the use of a countersink is not necessary except in very hard bone (young patients). Furthermore a low profile screw is now available (core 2.5 mm with a special low profile head).

L. S. Weil uses a 2 mm threaded pin instead of K-wire and cannulated drill, and then takes the screw measurement with a standard depth gauge.



**Fig. 08a. M1 scarf fixation.**

1, 2. The *special clamp* to hold the displaced fragments.

3. The *head of a normal screw* may provide problems.

4. Features of the *special scarf screw* (DePuy).

5. The distal screw is oblique in the head, the proximal is bicortical. This screw is cannulated, which allows to use first a thin K-wire. Furthermore, it may be set and set again until it is in the accurate and correct location.

6. *Evolution of the scarf screw*: a) 3 mm diameter, original scarf screw. b) 2.5 mm scarf screw with a low profile and longer head. c) the new self cutting screw: It is the FRS screw, designed by L. S. Weil, myself and the Foot + group.

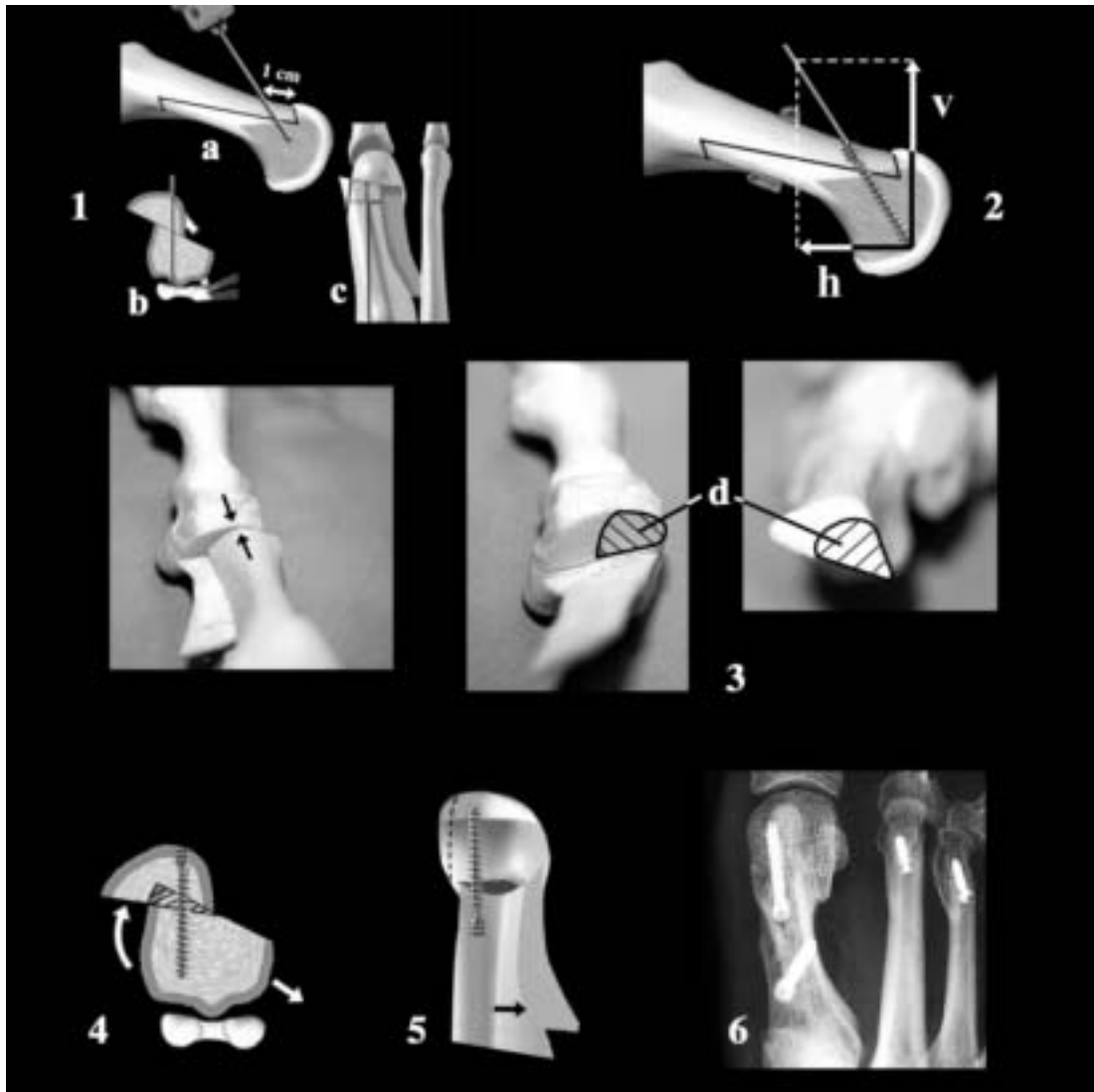
7. Proximally the 2.5 mm screw (b, or the FRS screw) allows to fix very displaced fragments and avoid the risk of proximal secondary fracture.

### Distal Fixation

Since 1995, I have been using an oblique fixation through the metatarsal head, which does not decrease the lowering and ensures good longitudinal compression. This is useful because the two fragments have a large area in contact in a distal frontal plane. The location of the screw allows the DMAA and the axial rotation

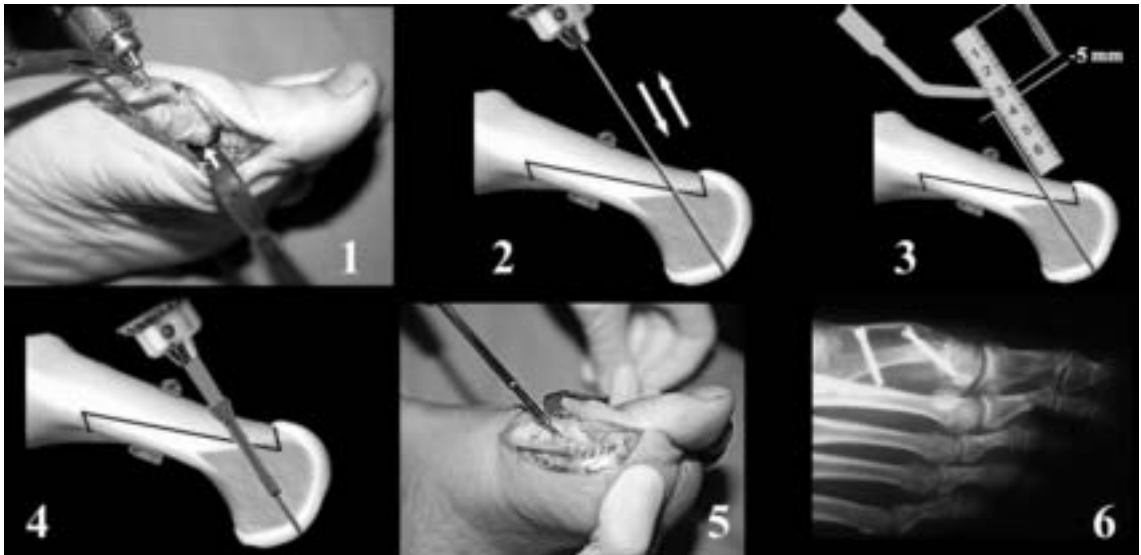
corrections. The setting of the K-wire has to be accurate; it is described on Fig. 08b2.

One point of distal fixation is not sufficient to allow early weight bearing, so a proximal screw is added, ensuring the fixation. Double fixation ensures such a strong osteosynthesis that functional recovery is immediate; this is one of the main advantages of this procedure.



**Fig. 08b1. M1 scarf distal fixation 1) the screw location.**

1. The introduction of the K-wire has to be in a correct location: 1 cm proximally from the head cartilage, near of the lateral border (b, c) and in a sagittal direction (b).
2. Oblique distal screwing in order to ensure the distal compression of the fragment and also to avoid elevation of the head.
3. The distal surfaces in contact (d) are in a correct longitudinal compression thanks to the distal screw obliquity (vector h).
- 4, 5, 6. The sagittal direction and the medial location of the screw in the metatarsal head fix both the head axial rotation and the DMAA correction.

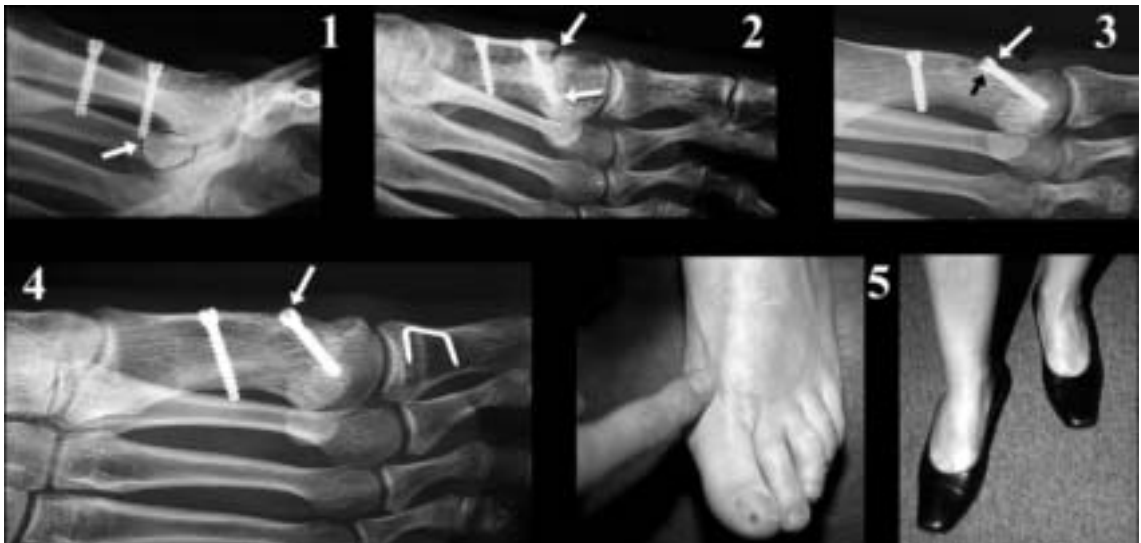

**Fig. 08b2. M1 scarf distal fixation 2) setting the screw.**

1, 2. Setting a thin diameter K-wire in a forward and backward motion until positioned at level of head cartilage.

3. Direct measure of screw length on a graduated ruler (which has the same length than the K-wire). We have to remove 5 mm to have the screw tip distal 3 mm from the cartilage and its head countersunk in the dorsal fragment.

4, 5, 6. Setting the special scarf drill and the screw around the same K-wire (now the FRS screw avoids the use of a drill with countersink).



**Fig. 08b3. Problems with scarf distal fixation.**

1. Without oblique screwing, the distal end of the screw may result in plantar problems.

2. Not enough obliquity leads to lack of longitudinal compression of the fragments.

3. Too much obliquity generates problems with the screw head.

4, 5. In spite of a correct location, the screw head must be deeply introduced in the dorsal fragment in order to avoid problems when a woman wears shoes.

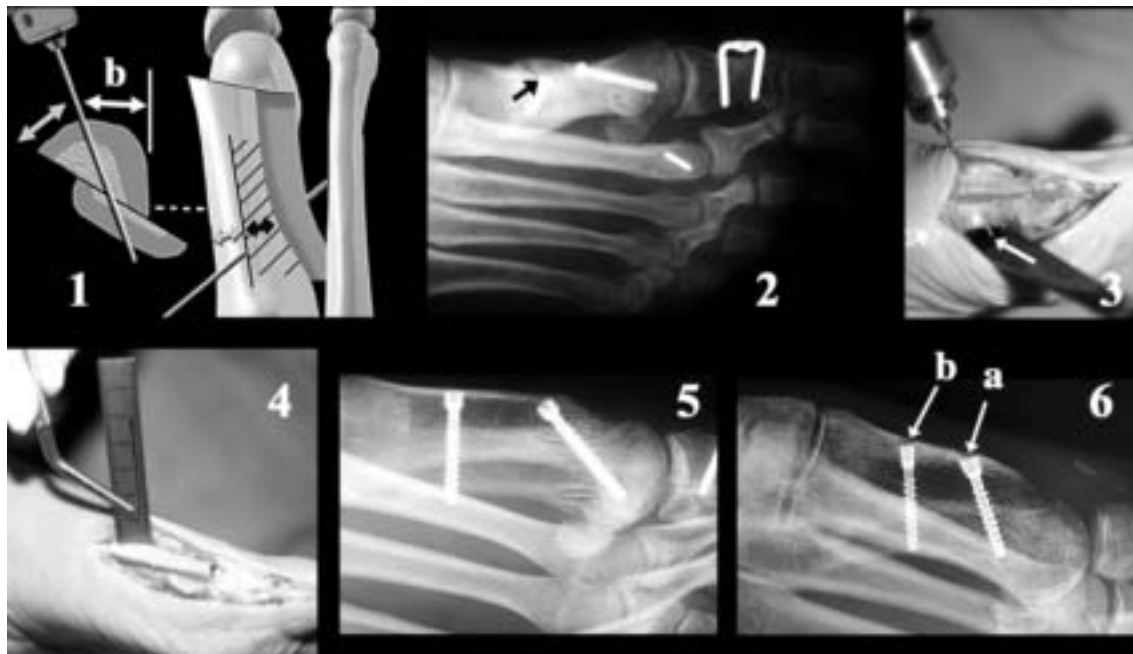
### Proximal Fixation

We have to preserve the lateral part of the dorsal fragment to avoid the risk of a secondary stress fracture. The proximal wire is set in the midline or, preferably, slightly medial of this line.

The K-wire (or the threaded pin) is placed in an oblique direction, lateral plantar and distal, to reach the plantar cortex in a stronger part of the shaft and to ease fixation in case of DMAA correction.

The exit of the K-wire or of the Weil threaded pin can be accurately controlled through the ppe. Then, a measurement is taken with the same graduated ruler. In this way, the drill and the screw can be set around the K-wire easily and accurately. The proximal screw must include the plantar cortex. The usual scarf screw has a 3 mm diameter. For smaller metatarsals, the 2.5 mm low-profile screw is preferable.

Now the self cutting FRS screw is only used: This is a great improvement in the scarf fixation.



**Fig. 08c. Scarf M1 proximal fixation.**

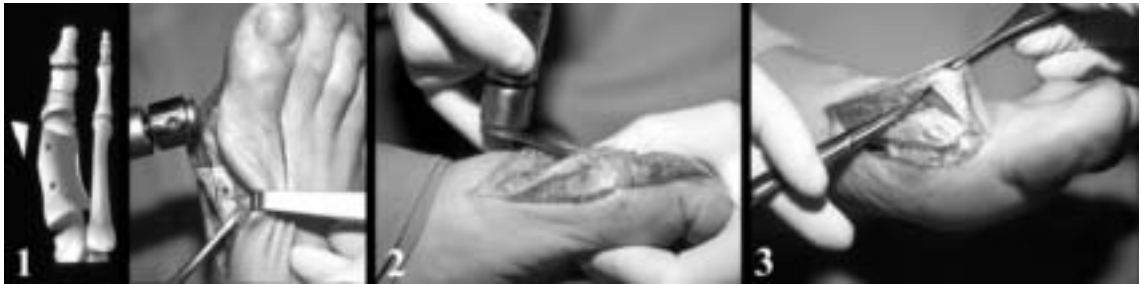1. Introduction of the K-wire: It is important to respect the lateral part of the dorsal fragment (b) to avoid the risk of a secondary stress fracture (2).
3. The K-wire is set in an oblique direction, lateral plantar and distal, to reach the plantar cortex in a stronger part of the shaft and closer to the lateral part. The exit of the K-wire can be accurately controlled through the ppe.
4. Screw measurement: The length is directly seen of the graduate ruler.
5. Screwing with 3 mm diameter screw.
6. The 2.5 mm diameter screw (b) is preferable especially for the proximal fixation.

### *Medial Distal Resection*

Bone excess at the medial distal aspect of the dorsal fragment is resected obliquely. This can be done without risk to the distal screw because

it pierces the dorsal fragment near the lateral border.

Similarly, the distal dorsal end is rounded, this is necessary when lowering is large.



**Fig. 09. Medial distal resection and release of the dorsal medial nerve.**

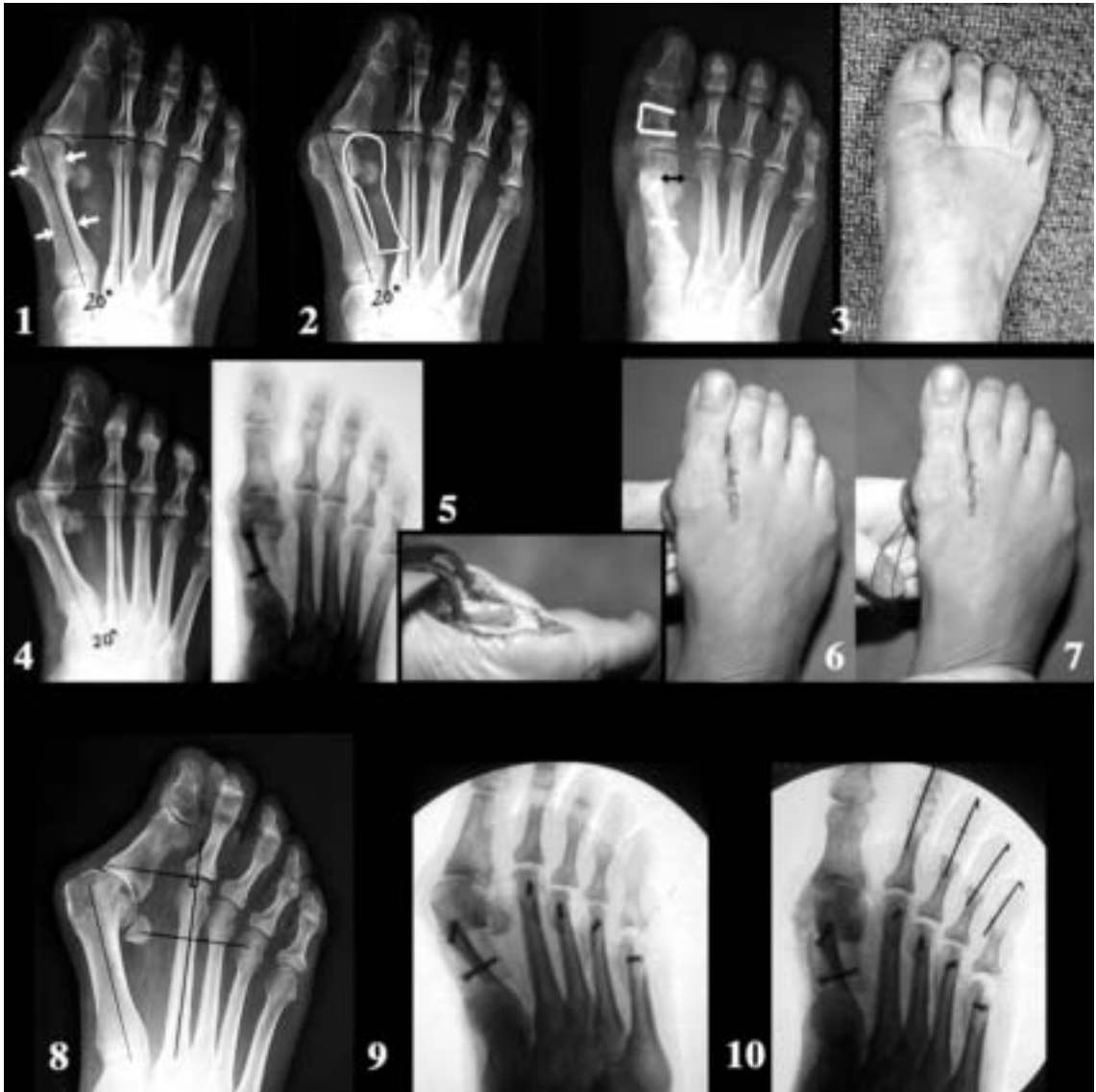1. *Bone excess* at the medial distal aspect of the dorsal fragment is resected obliquely. This can be done without risk regarding the distal screw because it pierces the dorsal fragment near the lateral border.
2. Similarly, *the distal end of the dorsal fragment is smoothed*; this is useful above all after lowering of the plantar fragment.
3. *Release of the dorsal medial nerve*, to put it more lateral. We do not forget that a painful bunion is above all a problem with this nerve, located between the bunion and the shoe.



## Medial Soft Tissue Tightening (Capsulorrhaphy)

First, the **dorsal medial sensory** nerve is isolated and positioned more laterally, an important step in the procedure (Fig. 9). Medial capsular closure is a key step in all corrective surgery for hallux valgus.

The **necessity of performing the capsulorrhaphy** is exposed Fig. 10a: In fact, we have to distinguish the cases – rarely encountered – where there is a mild deformity, for which the capsulorrhaphy is just a medial closure, from the other cases – the majority – for which the capsulorrhaphy is a **medial tightening**. In these last cases, we prefer using the term “tightening”



**Fig. 10a. Soft tissue medial tightening: the necessity.**

- 1, 2. In this case, the M1 lateral shift should be such as the two fragments loose their contact (2).
3. Same case operated on: We see the lateral shift (black arrow). The correction is also due to the MTP lateral release, the medial tightening, the great toe osteotomy.
- 4, 5, 6. Same case before and after the scarf osteotomy: In spite of a large lateral shift (5) the Load Simulation Test shows that the medial tightening is necessary (6). Result after medial tightening (7).
- 8, 9, 10. Same foot. 8: before surgery; 9: after MTP lateral release and large lateral shift; 10: finally after medial tightening.

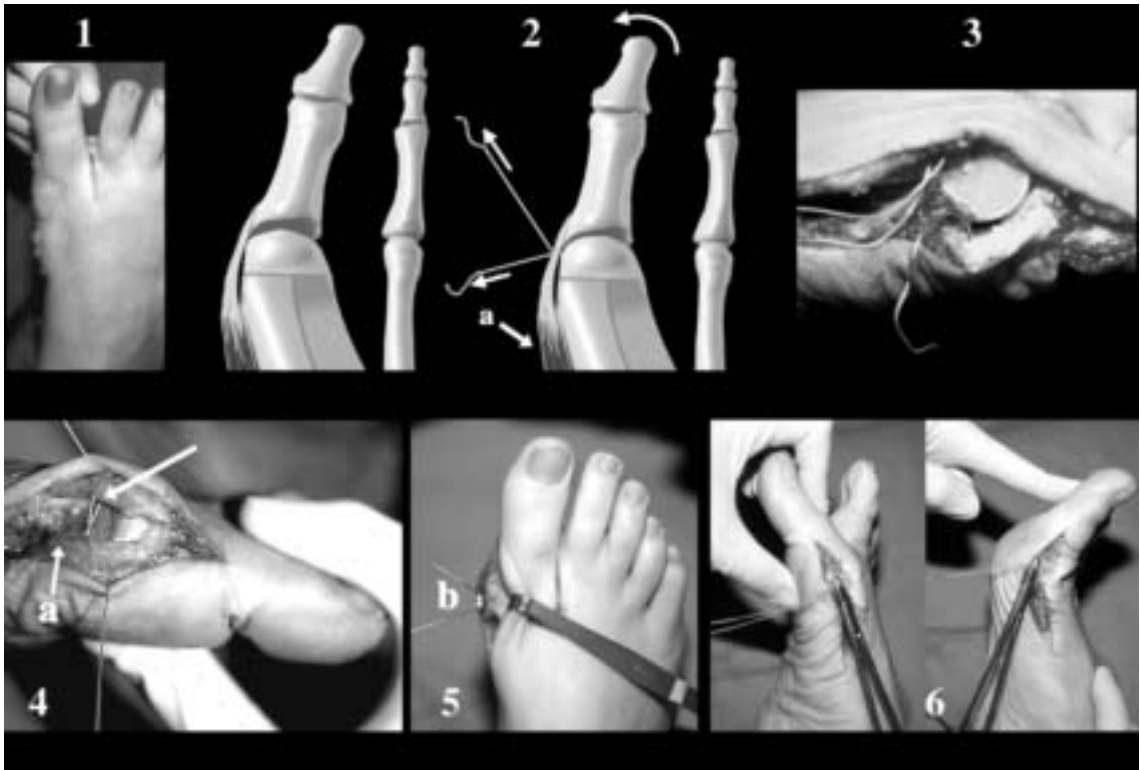
instead of capsulorrhaphy, because through the suture all the medial tissues are tightened, particularly the abductor muscle, which is repositioned medially and tied.

This suture should insure a good repositioning of the sesamoid complex. Medial capsulorrhaphy is particularly useful in cases of severely deformed hallux valgus.

The **technique** is described **Fig. 10 b1**: we emphasize two points: 1) To perform only one suture located at the level of the head centre, in

order not to decrease the MTP mobility: It is the “rotation point” pointed out by A. Lahm\*;  
2) To perform this suture while the great toe is held in plantar flexion to increase postoperative great toe ground contact;  
3) The long extensor tendon has to remain straight, not curved medially in order not to decrease the MTP plantar flexion and to decrease the risk of over-correction.

\* Andreas Lahm, Freiburg, Germany.



**Fig. 10b1. Soft tissue medial tightening: operative technique.**

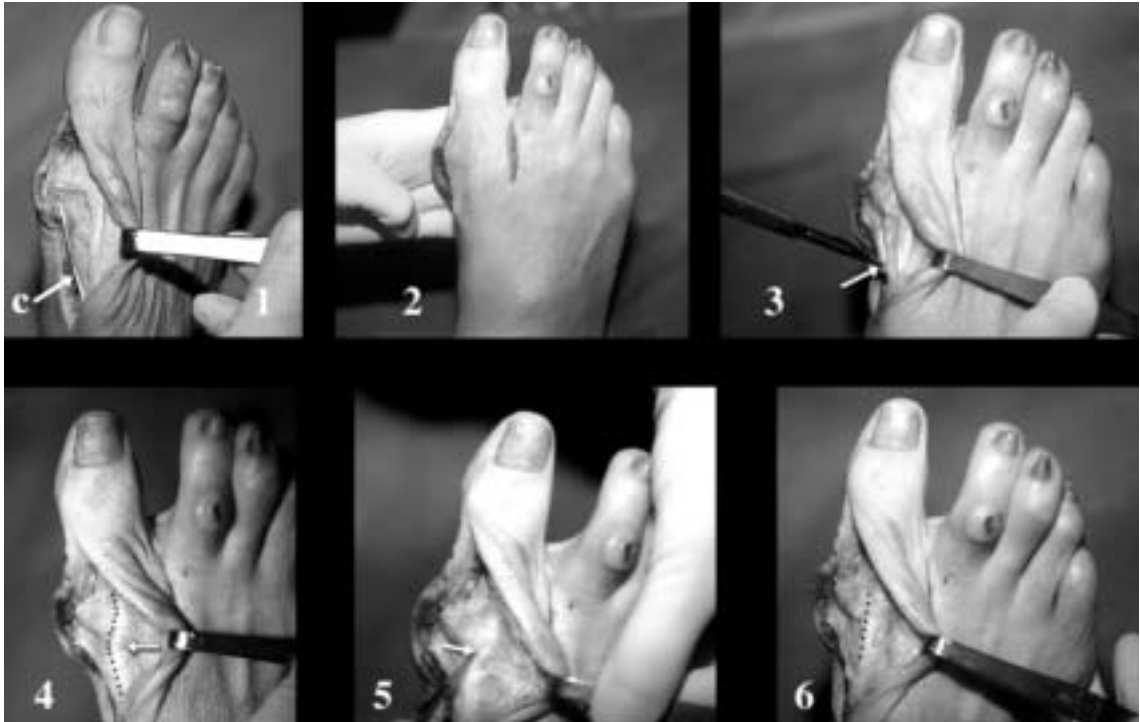
1. Abduction test (to assess the amount of the tightening which should be necessary).

2, 3, 4. The medial tightening does not only consist of capsulorrhaphy but above of all the medial reposition and tightening of the abductor muscle (a). This is performed in its distal end, through the medial capsule, without necessity to approach the muscle itself.

3, 4. We perform only one suture in a crossed fashion. The two plantar threads cross the medial capsule near the medial border of the medial sesamoid, the great toe held in a plantar flexion (4) to increase the postoperative great toe ground contact.

5. The exit holes for this suture on the medial plantar surface should be separated (b) as much as the hallux valgus remaining after the scarf osteotomy.

6. Since the suture it is located on the level of the metatarsal head centre, it constitutes a “rotation point” as pointed out by A. Lahm (Germany).

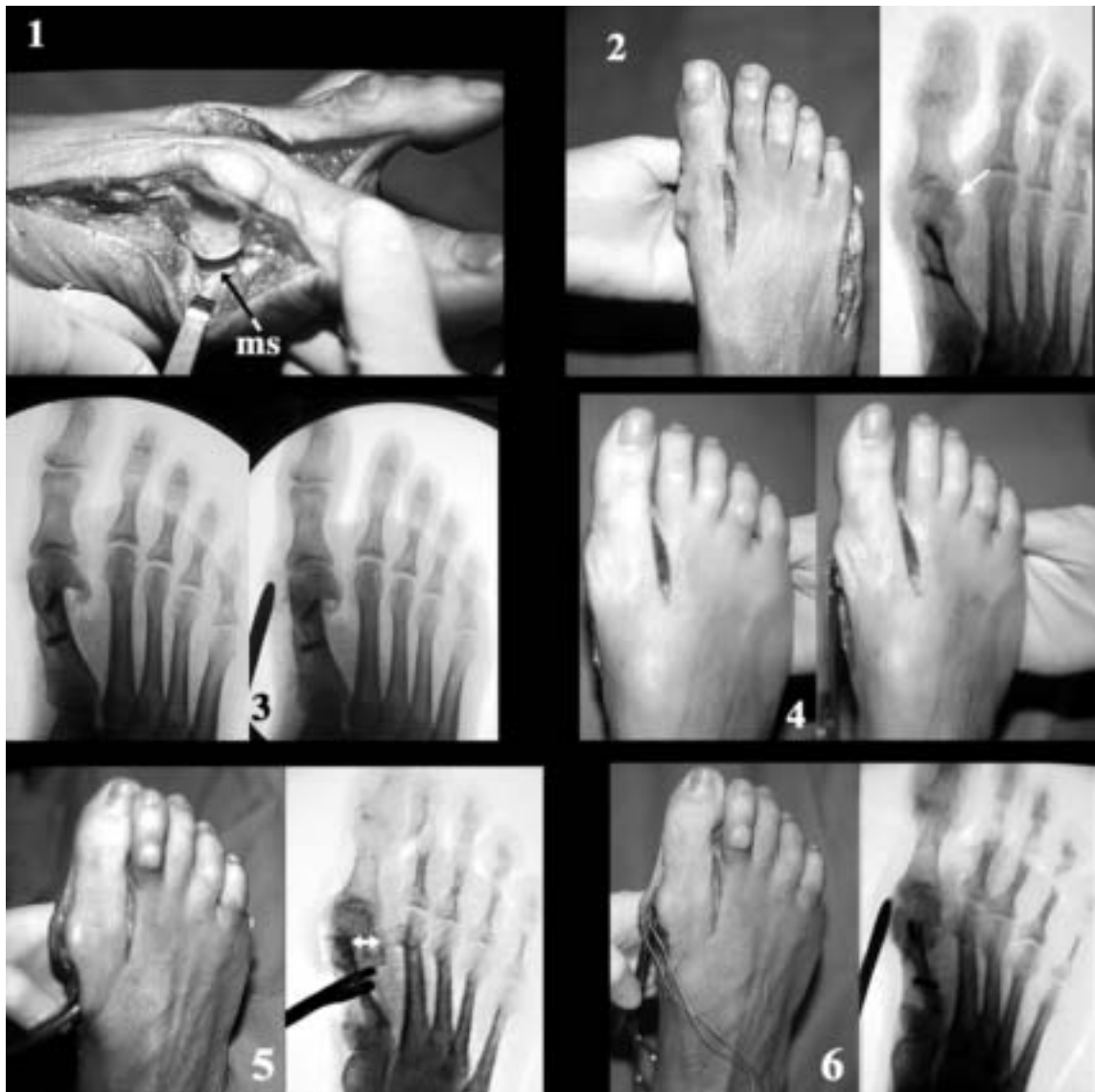


**Fig. 10b2. Medial tightening: about the extensor tendons.**

1, 2, 3. Role of the extensor accessory tendon (c).

1. In cases where the medial soft tissue is of bad quality, this tendon brings a significant help. On the contrary, in cases where it seems to have an overcorrection (2), the proximal section of this tendon should be necessary (3).

4, 5, 6. *Hallucis extensor longus*: This tendon should be retracted medially by the medial soft tissue tightening. In this case, the tendon release is required (5) to result in straight direction of this tendon (6). Furthermore, this tendon has sometimes to be lengthened on the surgery last step.



**Fig. 10c. The four cases encountered for medial tightening.**

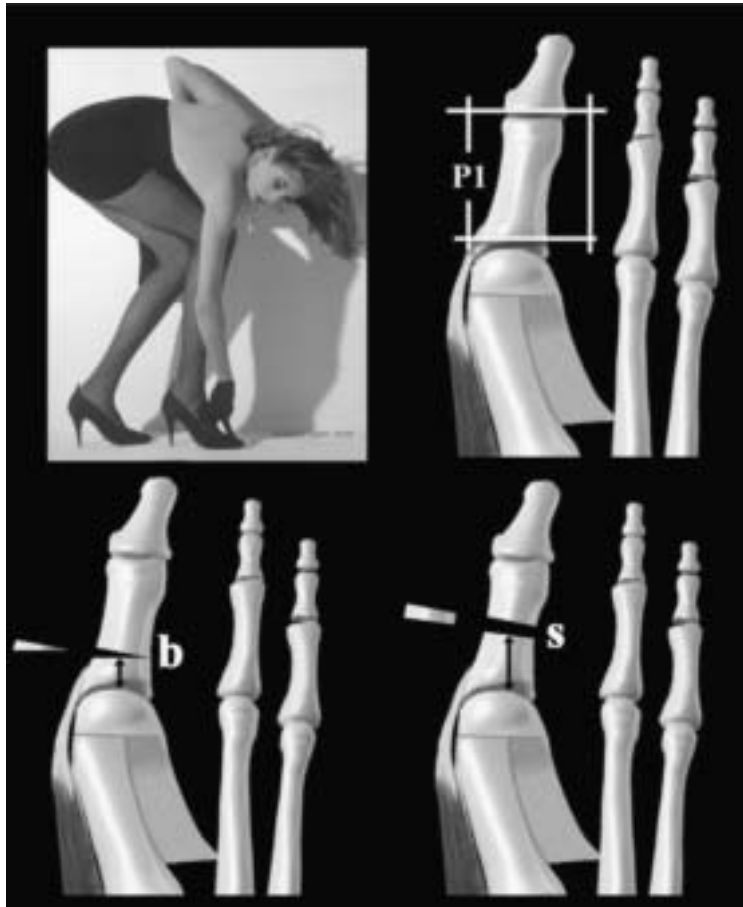
1. The medial border of the medial sesamoid is correctly located after the scarf osteotomy: Now we have just to perform the medial capsule closing, without tightening.
2. Overcorrection after too much medial tightening. We have to make another suture.
- 3, 4. In spite of correct lateral shift, the correction is not complete (LST) and needs the medial tightening.
5. In the 4th case, in spite of correct lateral shift (5) and medial tightening (6), the great toe P1 osteotomy is required to complete the correction.

## The Great Toe First Phalanx Osteotomy

This osteotomy, initially described by Akin, is popular in Europe, particularly in France, as indicated by Baudet *et al.* [25], by Delagoutte [43], by R. Viladot [30] and by myself [9, 10, 12, 15]. The great toe first phalanx osteotomy

is most often combined with the scarf osteotomy, Jarde [47]. In more than 80% of cases we combine this procedure with a scarf osteotomy. There are two locations of P1 great toe osteotomy: basal and shaft.

There are **two types** of P1 osteotomy, which have separated indications and technique: the **basal** osteotomy and the **shaft** osteotomy.



**Fig. 11a. Great toe osteotomy 1. The two locations of P1 great toe osteotomy.**

What is the interest of this picture (from Wilford Coe)? Certainly that this girl shows her great toe which needs some correction!

Basal osteotomy (b). These two locations require separated technique and have distinct indications.  
Shaft osteotomy (s).

### Basal Osteotomy

– It is indicated when the great toe is not long enough (Greek or square type foot).

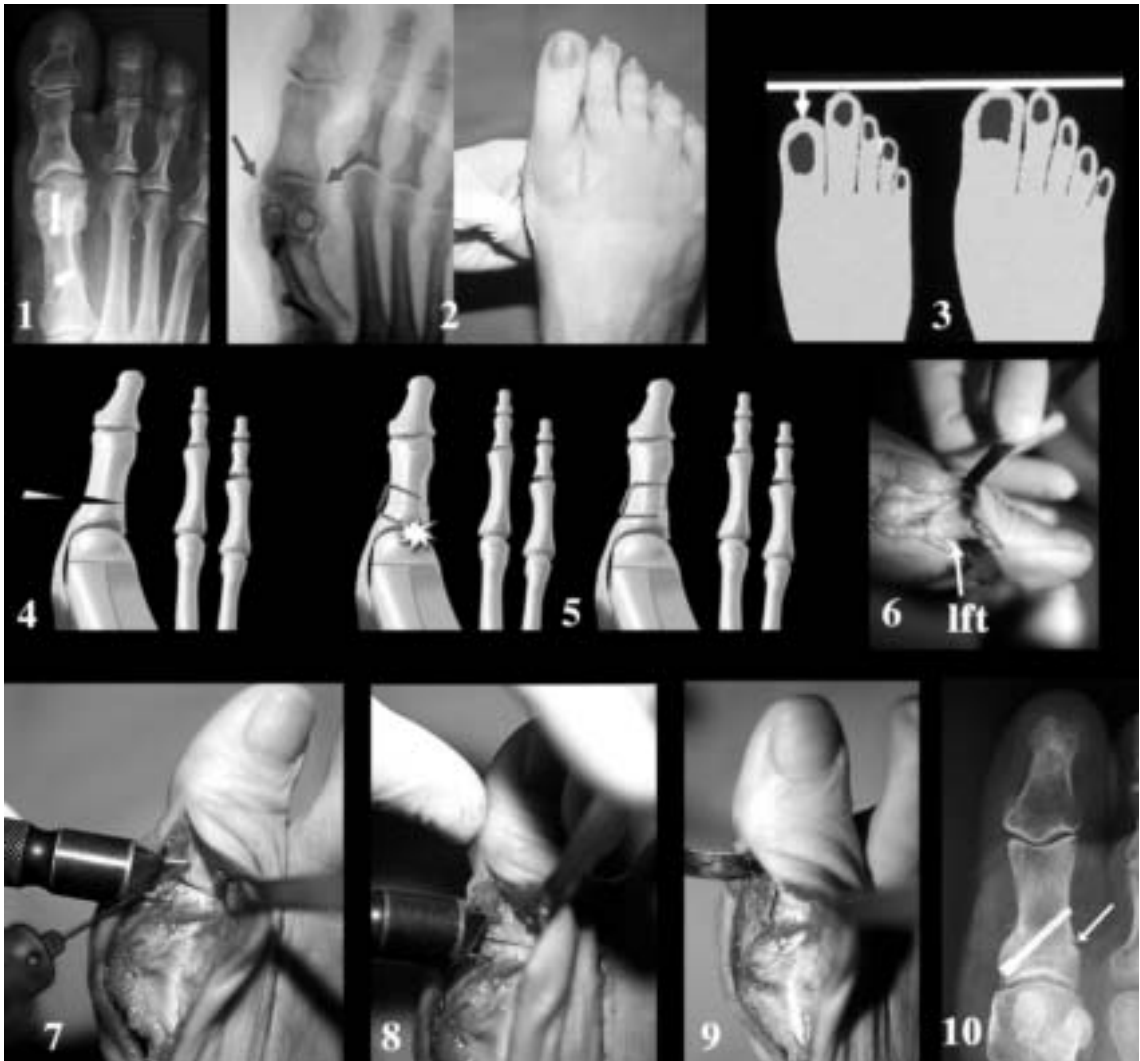
– It is performed on the proximal P1 metaphysis in cancellous bone, without healing problems.

– It preserves a lateral hinge located on the lateral cortex.

– Its fixation is easy thanks to a *special small staple*.

We distinguish two kinds of basal osteotomy.

**a) Variation osteotomy** (medial closing wedge) (Fig. 11b1-b2)



**Fig. 11b1. Great toe 1st phalanx basal variation.**

1. Without great toe osteotomy, some overcorrection should be observed when the great toe variation is not performed.
2. In spite of correct MTP congruence and sesamoid location, the great toe variation is required to achieve the correction (revealed by the LST).
3. Indication of great toe variation without shortening: Greek or square forefoot type.
4. Preservation of a lateral cortical hinge.
5. Use of a special 27° oblique staple (DePuy) instead of a straight one (90°).
6. Care has to be taken to preserve the long hallucis flexor tendon (lft).
- 7, 8, 9. Operative views. 7. Presentation of the staple, and introduction of a 1 mm K-wire only in the distal fragment. 8, 9. Setting of the staple.
10. In case of rupture of the lateral cortex, a scarf screw use is required.

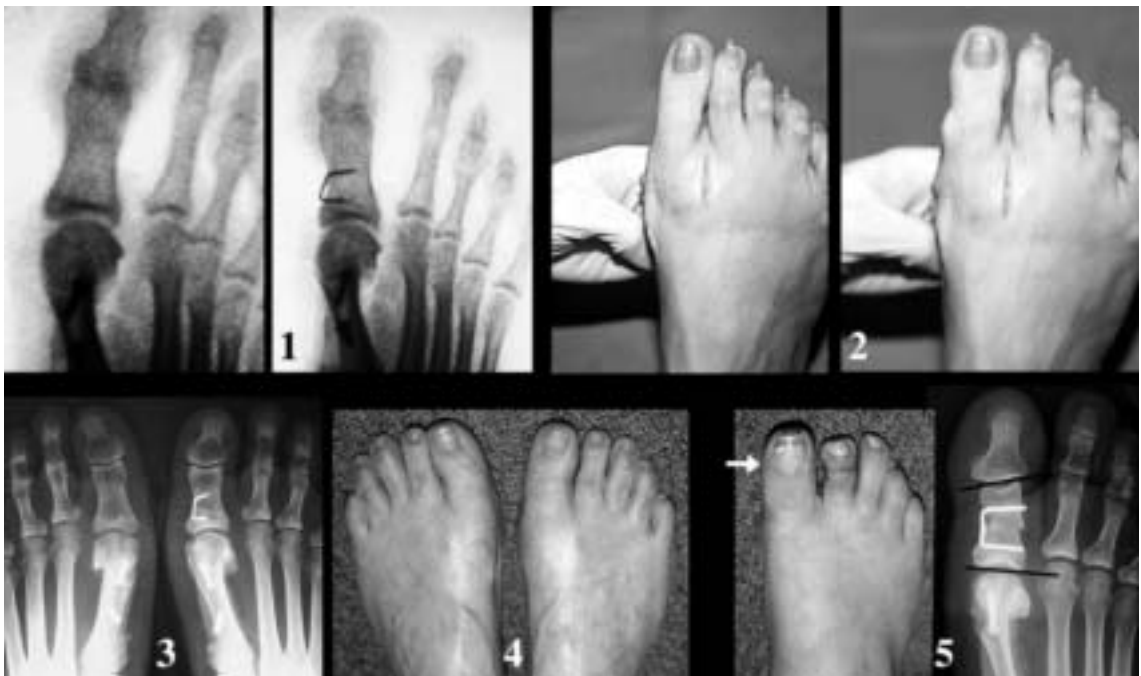The interest of performing proximally this osteotomy is to provide a large distal medial displacement in spite of removing a small medial wedge, because of the long distal lever arm.

**b) Varisation combined with derotation** (Fig. 11b4)

It is an oblique / plane osteotomy, indicated by P. Diebold (Nancy, France). This osteotomy is very useful for completing the hallux valgus correction, but the lateral hinge is more fragile.

The *fixation* with the special oblique stainless steel staple is detailed on Figures 11b.

When the previous surgery steps for hallux valgus correction are made, resulting in a congruent 1st MTP joint, basal osteotomies are very easy to perform and fix. They are also harmless and at last extremely effective in completing the hallux valgus correction. But they are limited to Greek or square feet. When large varisation, derotation or shortening are necessary, we prefer to do shaft osteotomy, therefore to use the special memory staple.

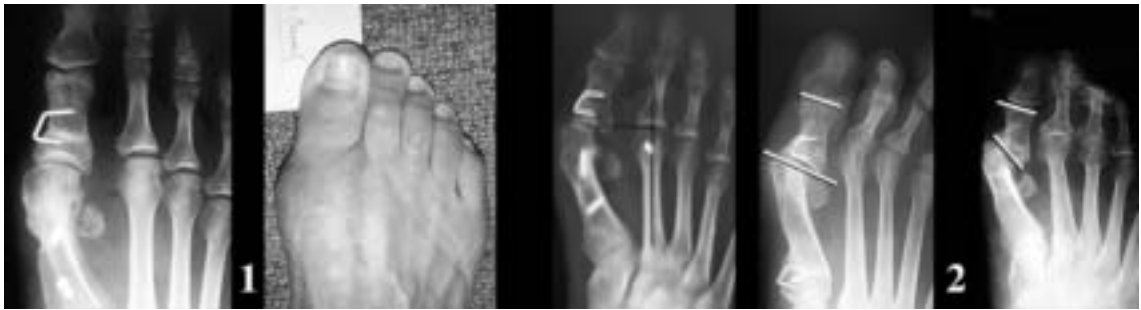


**Fig. 11b2. Great toe 1st phalanx basal varisation: results.**

1, 2. Radiological and clinical results of great toe P1 basal varisation.

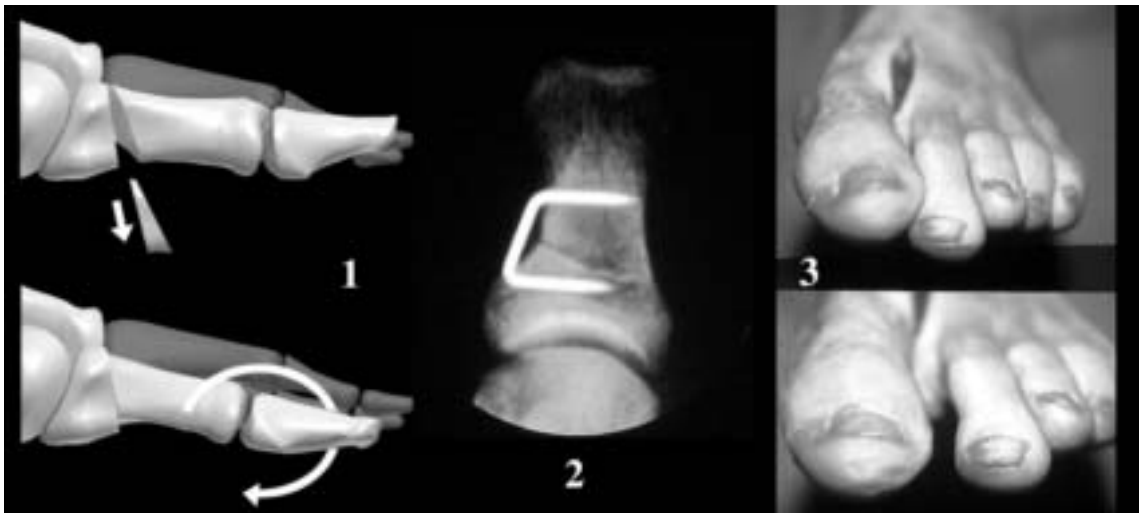3, 4. Better correction on the side with P1 varisation: When during the operation we hesitate to do – or not – a varisation, I think we have to do it! I have regretted many not having done P1 varisation in many similar cases.

5. However, excess of varisation (IP joint medially inclined) should result in shoe conflict (white arrow).



**Fig. 11b3. Insufficiency of P1 varisation.**

1. P1 varisation is extremely useful to complete the correction but on the condition to have already almost a good correction. 2. When the correction is really insufficient with MTP incongruence, the great toe osteotomy is unable to make complete correction: On the contrary, an excess of varisation may increase the deformity.



**Fig. 11b4. P1 basal varisation combined with derotation**

1. It is an oblique-plane osteotomy, initially described by M. d'Aubigné for the hip, and adapted to the great toe first phalanx by P. Diebold (Nancy, France). The wedge removed is medial and plantar. The lateral hinge is more fragile.  
 2. Fixation by the same oblique staple than the varisation.  
 3. Result. This osteotomy is extremely useful for completing the result.

### Shaft Osteotomy

– It is performed with a cut perpendicular to the shaft, so that it allows a large range of correction.

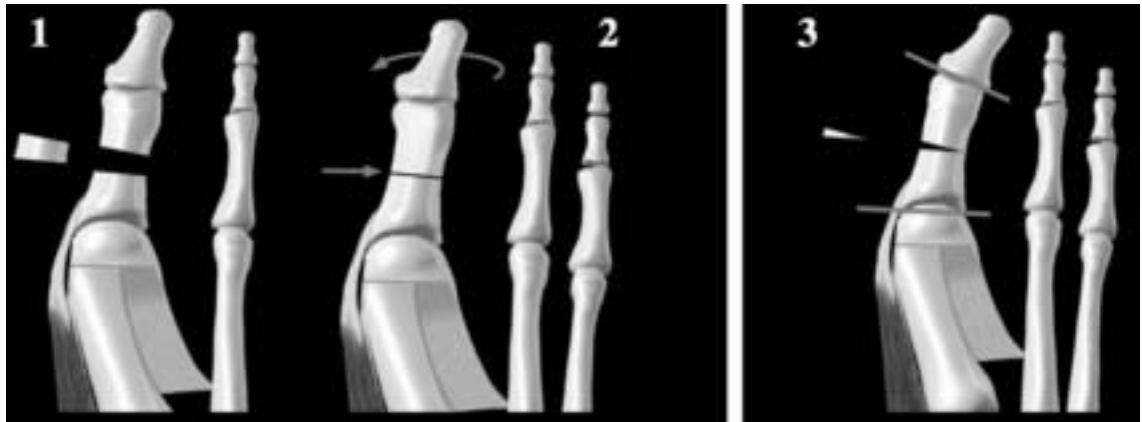
– It is less stable than the basal osteotomy, needing a stronger fixation. We distinguish

three kinds of shaft osteotomy: shortening, derotation, shaft varisation.

#### *a) Shortening osteotomy*

It is indicated when the great toe is too long (Egyptian type foot). The P1 shortening improves the correction by reducing the phalangeal arm (bowstring effect), and reducing the dorsi flexion





**Fig. 11c1. P1 shaft osteotomy**

There are 3 types of shaft osteotomy:

1. Shortening.
2. Derotation.
3. Shaft variation.

angle on the toe off phase during the gait. It will also cancel the longitudinal pressure provided by the shoe, the type forefoot becoming square (equality of the two first toes length).

**b) Derotation osteotomy**

It is indicated when moderate or large lateral rotation remains on the great toe, and also when there is only need of derotation, without variation.

**c) Shaft variation osteotomy**

Two indications:

1. Variation for large deformity or osteoporotic bone.
2. Interphalangeus hallux valgus: in this case, the cut is slightly more distal.

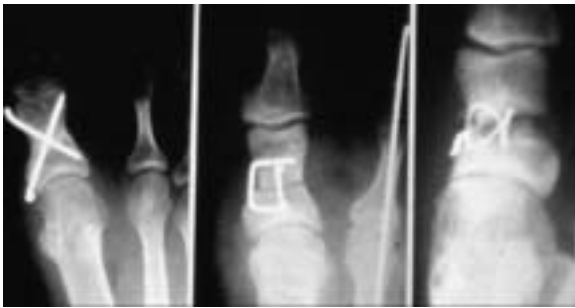**Fixation**

1) **Scarf screw:** We may fix this osteotomy with a scarf cannulated screw or better with the FRS screw. However, the screw has to be located

accurately in the lateral distal part of distal epiphysis; this often needs an intraoperative X-rays control.

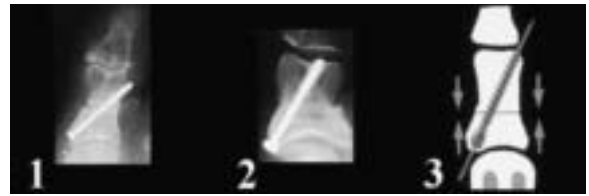
2) **Special memory staple** [9, 10, 11, 12]: We devised this staple 15 years ago. The oval part (R) which unites the two prongs was devised by M. Bertholet (France). The characteristics, the operative technique and the results are detailed in Figures 11c. The distance between the two prongs are 12mm, which is enough for the great toe 1st phalanx, the main indication of this staple. The only problem was too much lateral pinching (in the end of the prongs) in spite of the compressive oval part, this problem occurs only in cases of shortening in osteoporotic bone: in this case, fixation by screw is preferable.

– Part this case, the “12” memory staple provides an easy and reliable fixation of the shaft osteotomy of the great toe 1st phalanx.

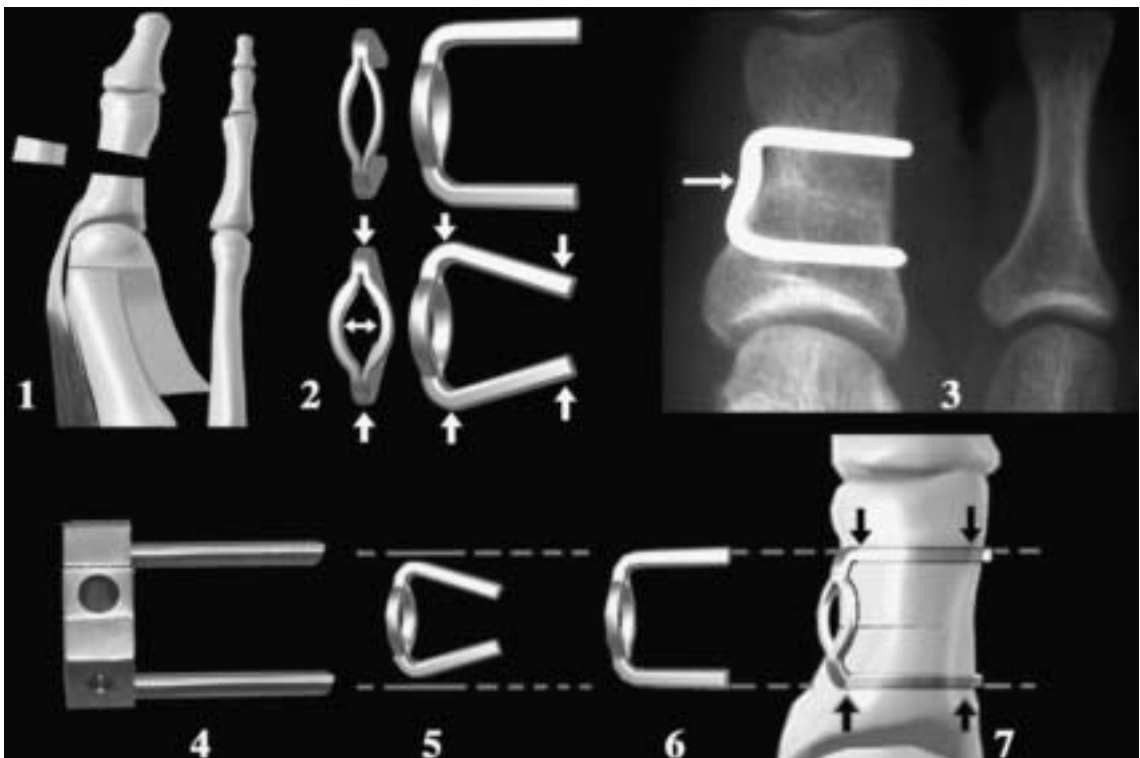


**Fig. 11c2. P1 Shaft osteotomy is more unstable than for basal location.**

It requires strong fixation: Some result of unsatisfactory fixation in our early experience.



**Fig. 11c3. P1 screw fixation is technical demanding.** 1, 2, 3. The screw location has to be very accurate (1). 4. The use of a K-wire guide improves the screw setting. Therefore the scarf screw may be used for P1 fixation.



**Fig. 11c4. Use of the special memory staple (DePuy) in fixation of shaft osteotomy. Generalities.**

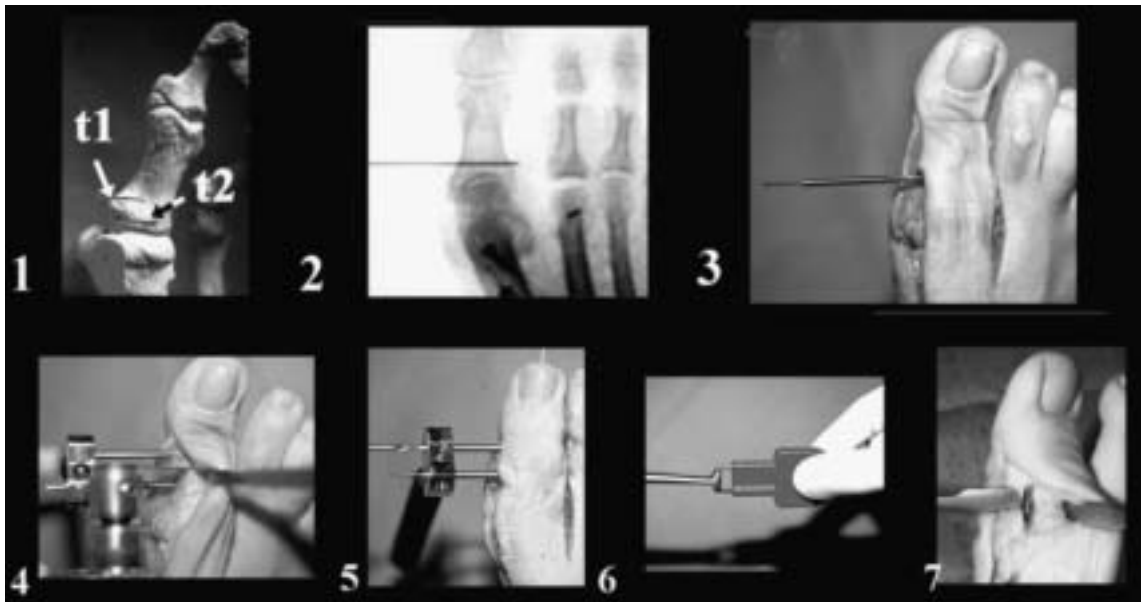
2. This memory staple provides bicortical compression: Lateral on the prong extremities, medial on the oval part.

3. Anatomical adaptation of the oval part on the medial surface.

4, 7. Principles of setting the memory staple.

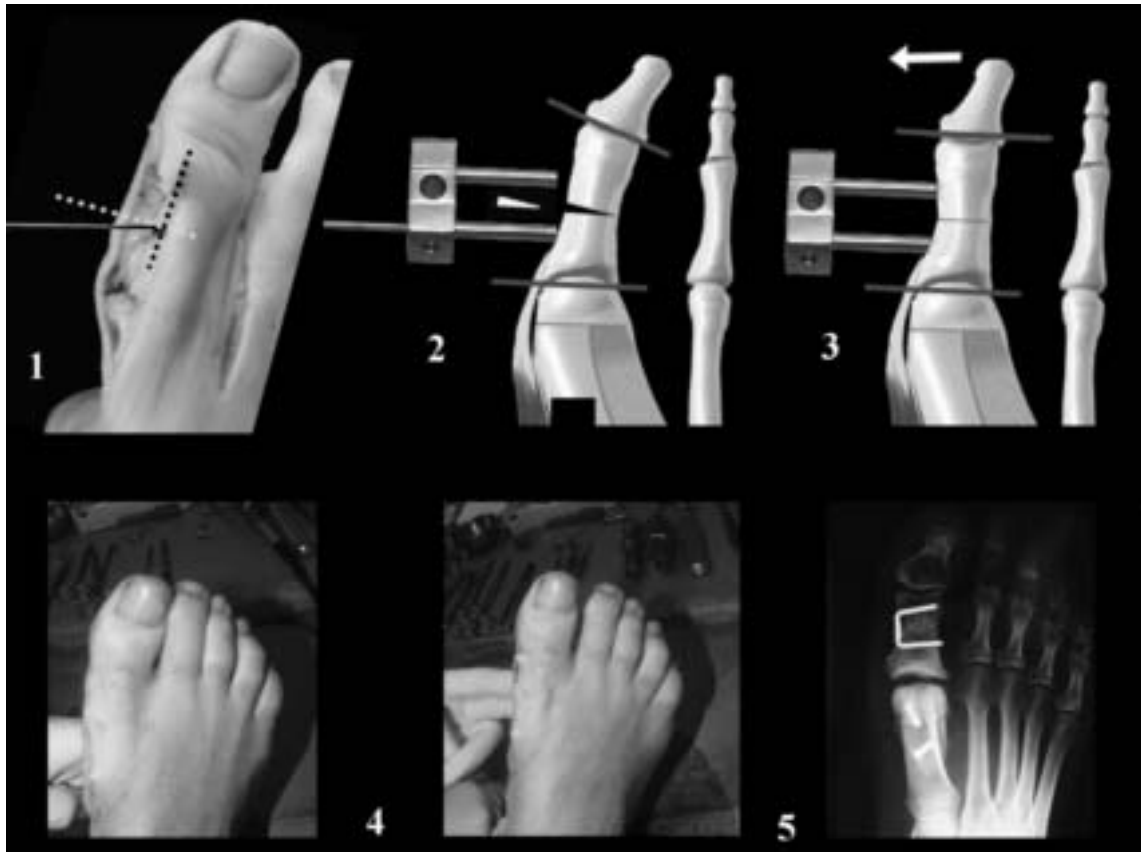
4. The guide.

5, 6. The staple can be shaped when it is cool; (7) bicortical compression at the body temperature.



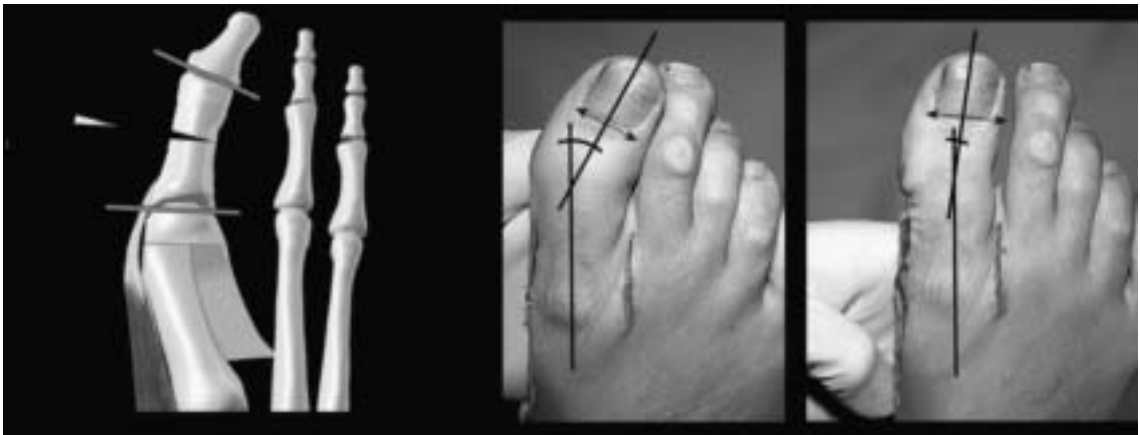**Fig. 11c5. Use of the special memory staple (DePuy) in fixation of shaft osteotomy: Technique.**

- 1, 2. First : setting the proximal K wire, between the two medial and proximal tubercles.
3. Around the K wire, the cannulated drill.
4. Around the canulated drill, we set the guide ; the saw is located at an equal distance of the two guide drills.
5. Setting the distal drill, after performed the osteotomy.
- 6, 7. Setting of the staple.



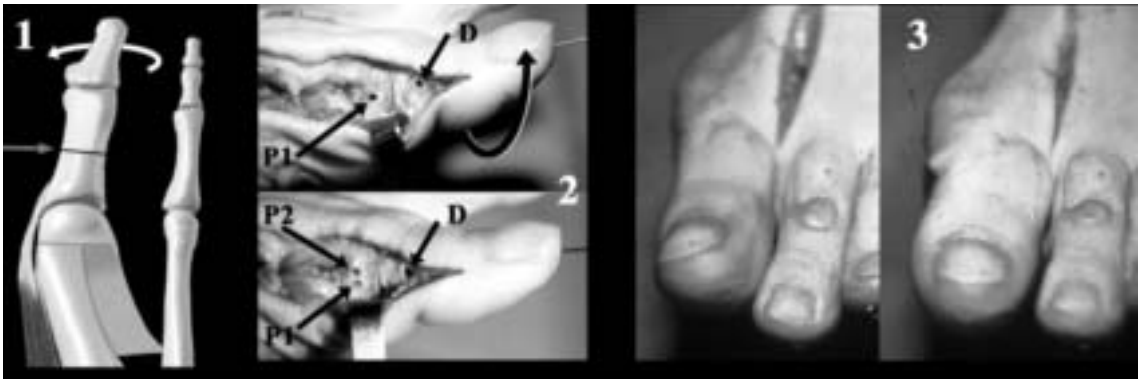
**Fig. 11c6a. Variation with the memory staple.**

1. The K wire is directed distally an laterally.
- 2, 3. Around the K wire, the cannulated drill, then the guide : the distal prong of the guide has to be 2 or 3 mm separated from the medial face of the bone, in order to be applied after variation.
- 4, 5. Clinical and radiological aspects before and after variation.



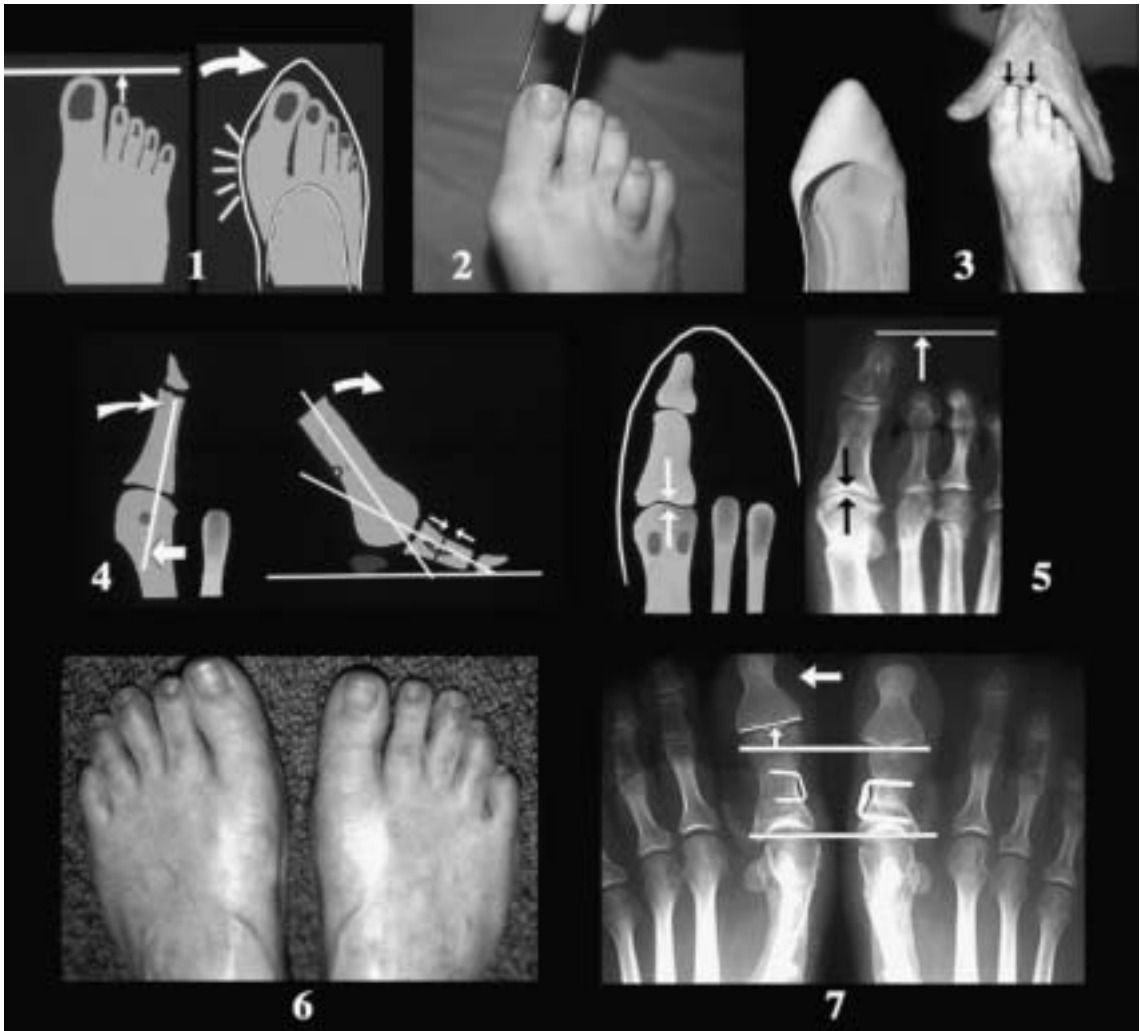
**Fig. 11c6b. Variation in case of hallux valgus interphalangeus.**

In this case, the cut (and the staple) are located in the middle of the shaft. *i.e.* slightly more distal than for usual variation.



**Fig. 11c6c. Shaft osteotomy for derotation.**

Derotation : great toe derotation is accurately performed with a diaphyseal cut perpendicular to the shaft. After derotation, the distal prong should be too much dorsal (D). Therefore the proximal drill has already to be set more dorsally (P2). Derotation result (3).



**Fig. 11c6d1. Why shorten the great toe?**

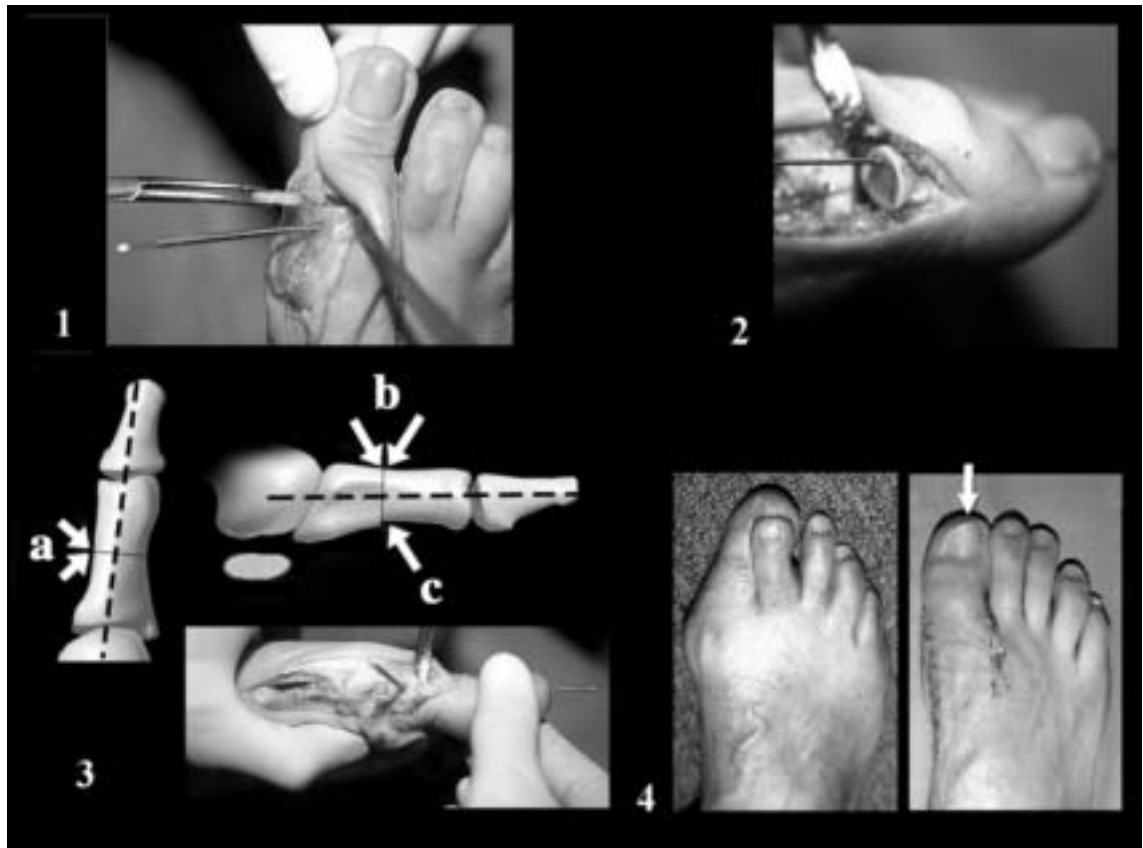
1, 2. Egyptian type foot as well as too large big toe increase the rate of hallux valgus deformity or recurrence with ladies shoes.

3. This test is an assessment of the forefoot shape which is compatible with ladies footwear: We note that the great toe doesn't have to be Egyptian.

4, 5. Egyptian type foot and hallux rigidus (or arthritic hallux valgus). 4. Decreasing the sagittal lever arm by P1 shortening increases the global dorsal flexion on the great toe.

5. Egyptian type foot remaining increases the longitudinal pressure in the MTP joint (shoe longitudinal pressure). However, the first metatarsal shortening provides much more longitudinal decompression of the MTP joint (Scarf with shortening weil of the first metatarsal).

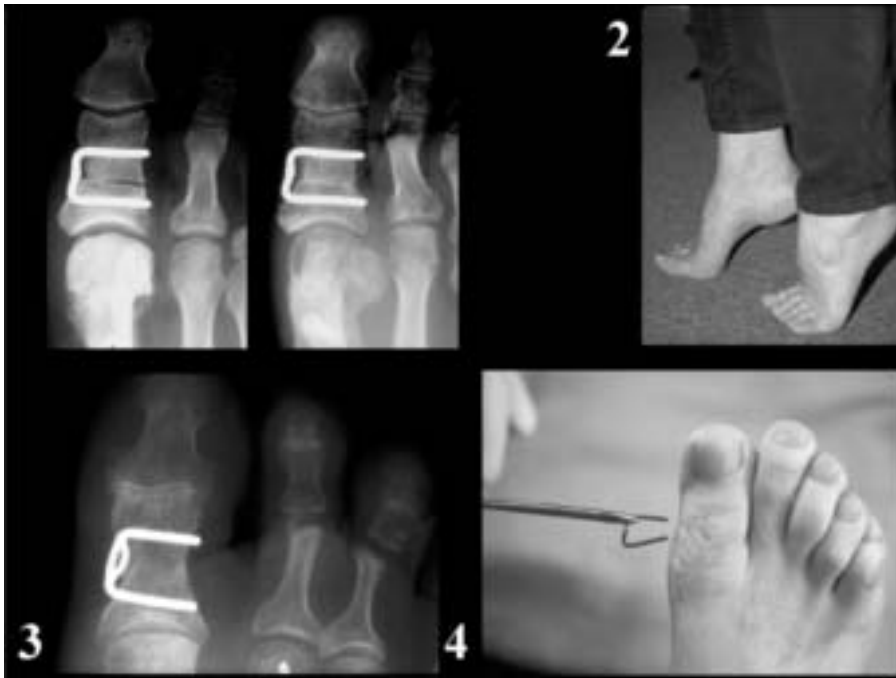6, 7. Undercorrection of hallux valgus on the foot with Egyptian type remaining.



**Fig. 11c6d2. Shaft osteotomy for shortening.**

1. Longitudinal K wiring is required, close to the dorsal cortex, not to disturb the prongs setting.
2. Care has to be taken to have both dorsal and medial fragment congruence.
3. Note the operator thumb location under the metatarsal head.
4. Result of the great toe shortening.

*The fixation may be performed by the "12" memory staple, but, for osteoporotic bone, fixation by an oblique screw is preferable.*



**Fig. 11c7. Shaft osteotomy with memory staple: General results.**

1. Immediate aspect and one month postoperative: The bicortical compression with memory staple.
2. The strong fixation allows early functional recovery.
3. Good tolerance (five years follow-up).
4. Elasticity remaining when removing the staple six years after setting.

### Conclusion

The great toe 1st phalanx osteotomies are very helpful, particularly as a complementary procedure to reduce hallux valgus deformity. The location, the technique and the indication have to be accurate to provide the required displacement and early functional recovery.

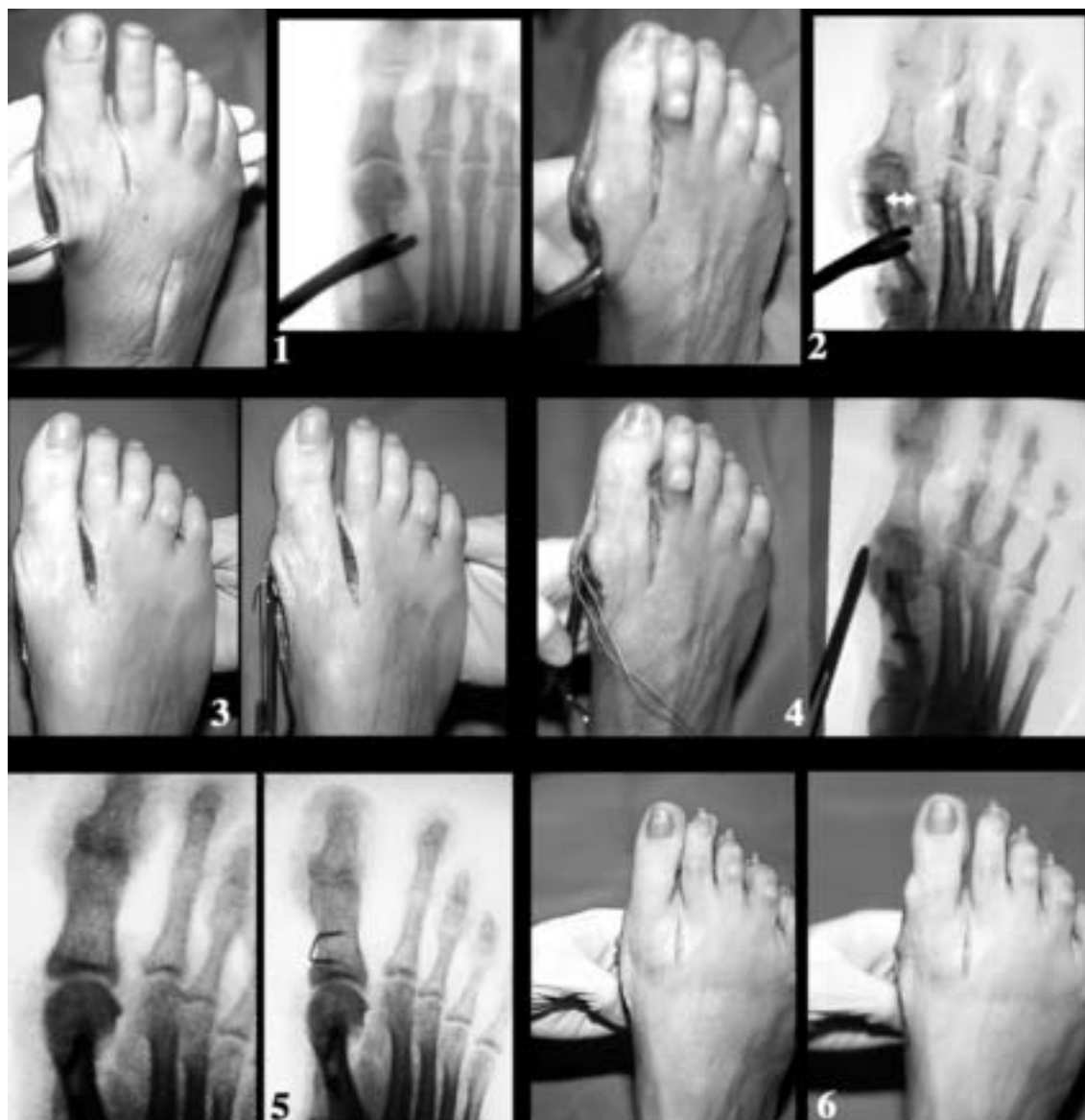Shaft osteotomies with fixation by the special memory style, are powerful in completing the hallux valgus correction. The rate of respective

basal or shaft osteotomies is 40% for basal and 60% for shaft.

### **Check Tests to be Performed During the Hallux Valgus Surgery**

#### *The Load Simulation Test*

The load simulation Test was so named by K.-H. Kristen\* (AFCP, International Summer Meeting,



**Fig. 12a. Intraoperative tests for bunion surgery 1. The Load Simulation Test (LST).**

This test was pointed out by H. Kristen (Vienna, Austria).

1, 2. After scarf osteotomy and before fixation: Assessment of correction. 1: The osteotomy is sufficient for correction. 2: In spite of large lateral shift, need of medial tightening and perhaps P1 osteotomy.

3, 4. During medial tightening. 3: The LST emphasizes the need of medial tightening and checks the correction after tightening. 4: In spite of good MTP correction, the LST assesses the need of P1 osteotomy.

5, 6. During P1 osteotomy. Clinical aspect before and after P1 basal variation: Once again the LST emphasizes the necessity of P1 osteotomy – or not – and checks the final correction aspect.

Bordeaux, 2000). Performing this test during the procedure is extremely useful. It reproduces the standing position. The deformity has to be controlled at several phases of correction. The Load Simulation Test (LST) is particularly useful in the following situations (Fig. 12a).

\* Karl-Heinz Kristen, Wien, Austria.

– After the displacement of the plantar fragment and before setting the screws, while the fragments are held by a special clamp. Complete correction or a slight undercorrection of the hallux valgus has to be obtained but never overcorrection. At this point, lateral displacement, DMAA correction, or shorte-



ning, lowering or elevation can still be modified.

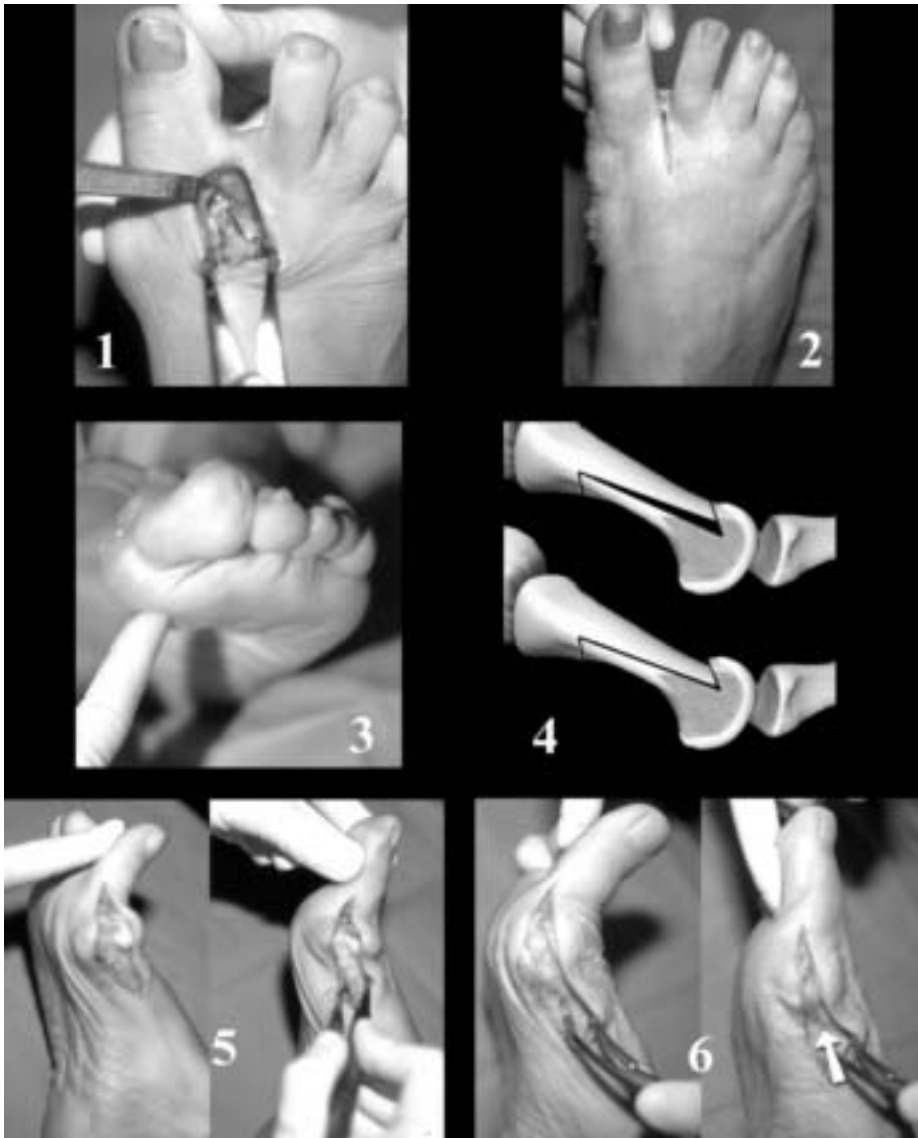– After the medial capsulorrhaphy and in order to determine if the medial suture has to be tightened or loosened.

– To evaluate the type of great toe osteotomy that may be required.

### The Other Tests

– *Hallux valgus correction test*, during the MTP lateral release, during the medial capsulorrhaphy,

– Assessment of the *plantar location of the metatarsal head*.



**Fig. 12b. Intraoperative tests for bunion surgery 2. Other tests.**

1, 2. *Hallux valgus passive correction test*: 1. during the lateral MTP release. 2. before the medial tightening.

3, 4. Assessment of *plantar location of the 1st metatarsal head IP*. In this case, it is too plantar, which is an indication of M1 elevation (4).

5, 6. Assessment of *MTP passive dorsal flexion with and without passive correction of intermetatarsal angle (IMA)*. 5: No significant difference: There is no need of M1 shortening. 6: The MTP dorsal flexion is significantly decreased with IMA correction: there is need of M1 shortening.

– Assessment of the *MTP passive dorsal flexion* particularly useful for determining the necessity and the importance of the M1 shortening (Fig. 12b).

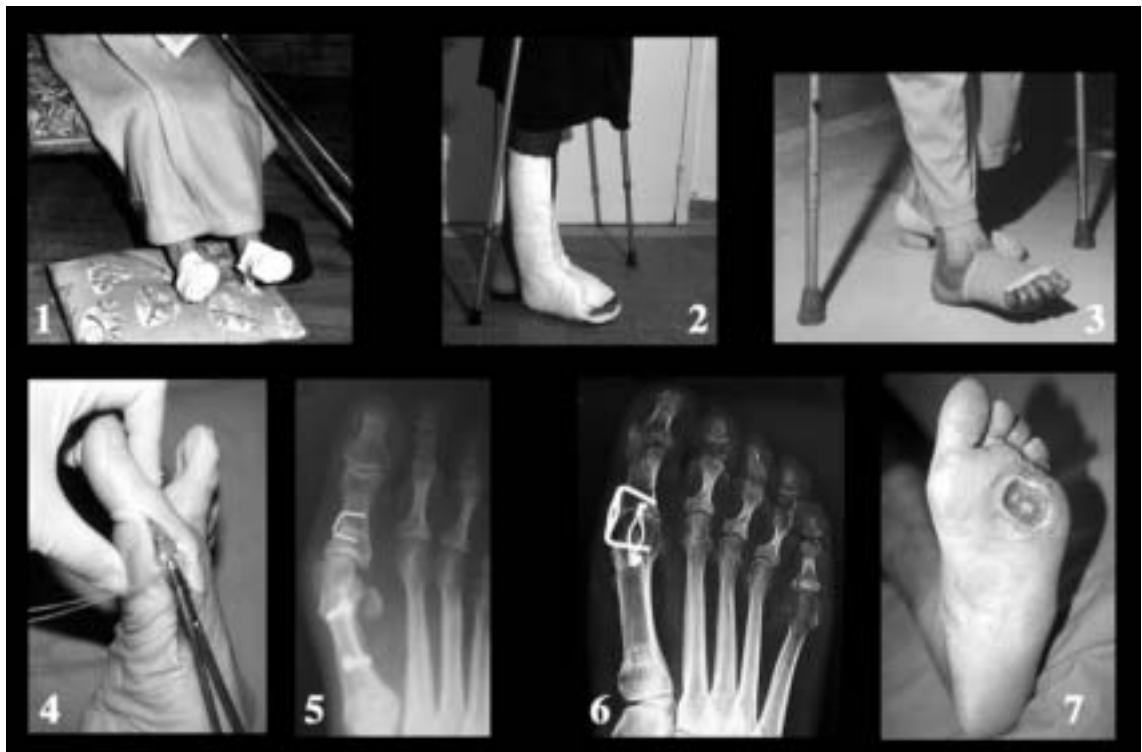
## Postoperative Period after Hallux Valgus Surgery

### Walking and Postoperative Footwear

Although some authors, like Graff [64] recommend full weight bearing on the forefoot immediately after surgery, we think it is more reliable and also more comfortable to wear the heel

support shoe during the 3 or 4 postoperative weeks.

Patients can wear these special shoes that only allow weight-bearing on the heel (Type I). We designed and developed these shoes [20, 21], so walking can start on the day after the operation, with a relatively normal gait. It is therefore possible to operate both feet at the same time, and to walk without the use of a crutches (Fig. 12). Weight-bearing on the forefoot can start on approximately the 30th day. If the foot is still swollen four weeks postoperatively, the patient should wear Type II shoes with variable volume, also allowing correct positioning of the great toe (Fig. 13a). All these postoperative shoes were made in collaboration with Romans Industrie CD (Romans, France), which distributes these shoes.



**Fig. 13a1. Postoperative footwear.**

1, 3. We observed that walking after forefoot surgery was difficult: 1. sometimes using a cast, 2. sometimes resulting in a long-time without walking, 3. above all walking on the heel.

4, 7. Postoperative walking on the heel is necessary in the following cases:

4. For the first ray surgery to protect the medial capsular tightening which is a soft tissue procedure.

5. Immediate weight-bearing should result in undercorrection.

For combined procedures MTP K-wiring, MTP fusion (6) or plantar ulcers (7).

### Functional Recovery

We observe that such a hallux valgus surgery generally provides by far the earliest functional recovery. Even when both feet are operated,

patients can return to work four to eight weeks postoperatively and return to wear ladies shoes two to three months postoperatively. This is one of the main advantages of this technique (Fig. 13b).

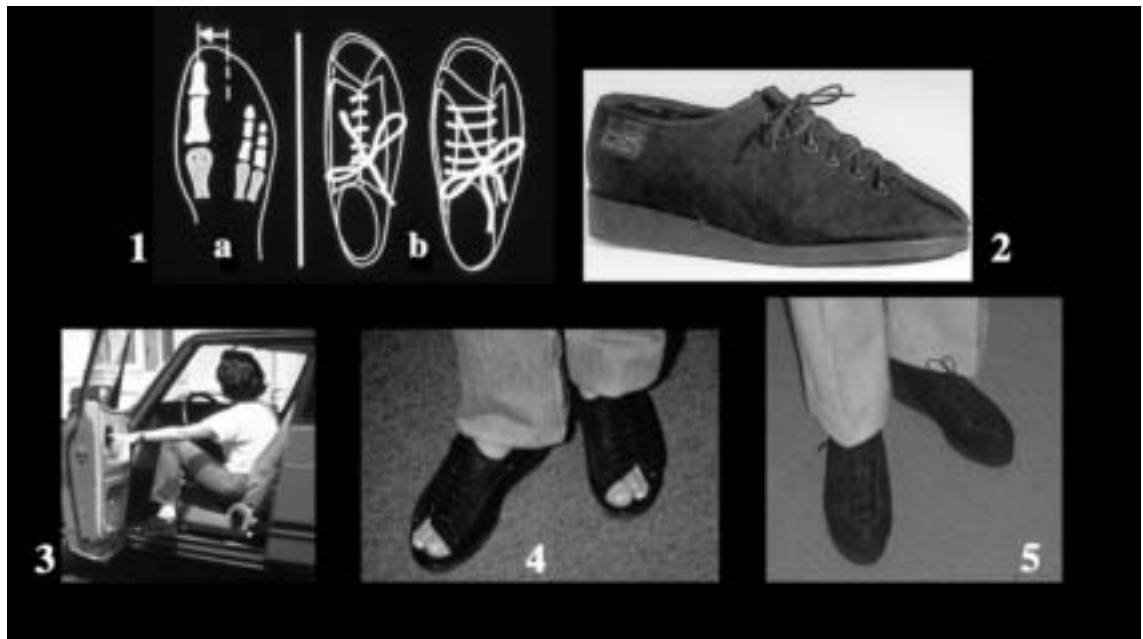

**Fig. 13a2. The heel support shoe.**

1, 2, 3. The first heel support shoe I devised in 1981 only protected the forefoot for weight-bearing but there were problems with the distal end of the sole and this shoe did not protect the forefoot at all against distal shocks.

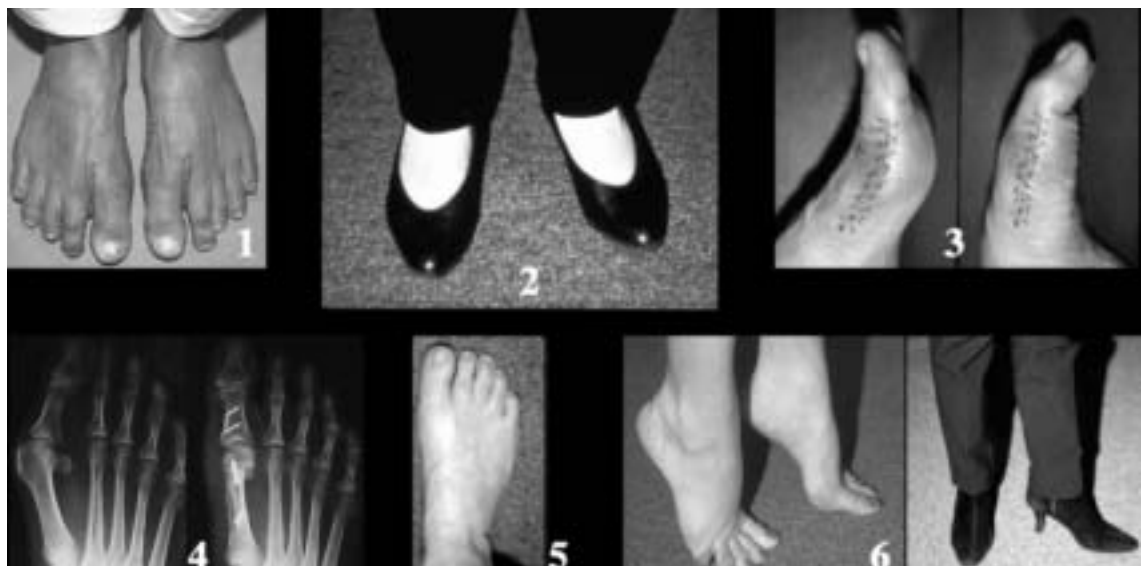Since 1986, I have devised the present heel support shoe Type I\* with a special last (4), a special sole with ABS plate resulting in a progressive compression resistance (5) which allows to walk easily (7) and to early return to normal activities (8).

\* Made by Romans Industrie (France), as well as the Type II shoes.



**Fig. 13a3.** These shoes (Romans Industrie, Romans, France) are adapted to the post operative différent phases. Their sole is medially rotated for preserving this correction of hallux valgus. Their volume is variable, allowing the adaptation to the different phases of the post operative oedema, including the phase where there is a bandage.

2. The shoe “Alba” is certainly one of the best type II shoe.
3. These shoes allow an early function recovery.
4. There shoe “Morphee” for spring and summer.
5. A type III shoe “Cyclo”, return to normal life with a very variable volume shoe.



**Fig. 13b.** The early functional recovery.

With scarf and P1 osteotomy, we observe, by far in our experience, *the earliest functional recovery we can have in forefoot surgery.* 15th postoperative day (1, 3).

2. Five months: normal footwear (2).
3. Five postoperative months usual result (4, 5, 6).

## ***Drawbacks with this Type of Hallux Valgus Surgery***

In this book, if you compare the place (text, volume and number of illustrations) of the respective drawbacks and advantages of this procedure for hallux valgus correction, you see that the drawbacks volume is more important. In fact, this is not the current reality since we now avoid most of the drawbacks. In the light of our experience, we have emphasized the possible drawbacks, to study their causes, their treatments and to avoid them.

Generally we observe that the drawbacks are mainly due to the *technical problems* and we emphasize that the surgery of hallux valgus is composed of several steps, from the lateral release to the great toe osteotomy, and that we have to assess and to check the correction on every chronological step. I think there is a *learning curve* – minimum of 15 cases – for performing this procedure accurately and reliably.

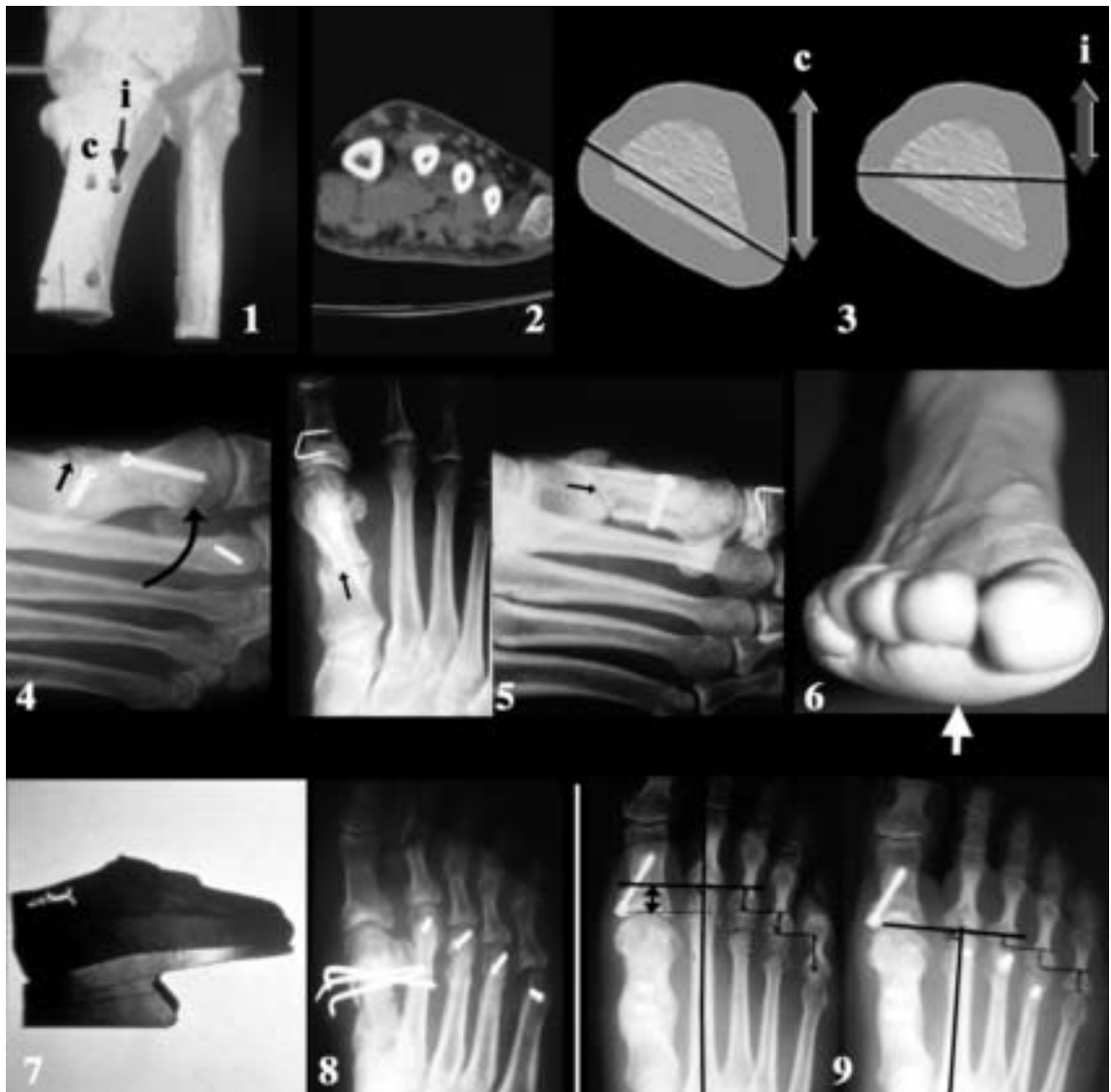
Regarding our personal experience, we distinguish a first period – early experience – from 1991 to 1994, in which we observe the main drawbacks, then a second period from 1996 to 1998, when we brought the main appropriate solution both to avoid and to repair these drawbacks. At the present time, this technique proves to be extremely reliable.

## ***Fractures with the Scarf Osteotomy***

We observed a fracture rate of about 6% in 1994.

*Three main causes:* 1) incorrect cut; 2) incorrect location of the proximal screw; both of these fail to preserve the dorsal lateral strut; 3) short longitudinal cut, which also weakens the dorsal fragment. There are *secondary stress fractures*, occurring generally one to two months postoperatively. These fractures did not result in hallux valgus recurrence but in elevation of the first metatarsal, giving a transfer metatarsalgia to the lesser rays. Healing was obtained through Type I heel support shoes and removal of the screw. In two cases intermetatarsal pinning was used as indicated by P. Diebold. The treatment of the transfer metatarsalgia to the lesser rays was successfully performed by Weil metatarsals osteotomies.

In a study of 920 cases performed from 1996 to 1998, we observed only 1% of fractures (nine cases). We believe that this complication has been virtually eliminated by the more medial placement of the proximal screw, by respecting the lateral surface (plantar oblique longitudinal cut, located just above the plantar surface), and by using an oblique distal screw that stabilizes the distal chevron part of the osteotomy. Now the self cutting low profile FRS screw appears to be a great contribution in avoiding the first metatarsal fractures. No fractures were observed in cases of very large displacement, because the cut is oblique plantarly. I believe therefore, physicians should not be afraid of performing a large lateral shift when performing the scarf: Just as a precaution in very large lateral shift, the heel support shoe is worn during one month.



**Fig. 14a. Scarf drawbacks: Secondary stress fracture, the three main causes.**

1. *First cause:* Incorrect (i) location of the proximal screw, which fragilizes the dorsal fragment (c = correct location).

2, 3. *Second cause:* Incorrect (i) longitudinal cut in a transverse plane leaving insufficient lateral surface (c = correct location).

4. Result of such fragilization of the dorsal fragment: Proximal fracture.

5. *Third cause:* Short longitudinal cut.

6. *The result of such fracture* is rarely recurrence of hallux valgus, but M1 shortening and elevation resulting in transfer metatarsalgia.

*Fracture treatment.*

7. Type heel support shoe during one month.

8. When the displacement is too important, intermetatarsal K-wiring as indicated by P. Diebold.

9. Sometimes, the first metatarsal shortening requires a secondary shortening of the lesser metatarsals by Weil osteotomy.

## Under or Overcorrection of the Deformity

### Undercorrection (Fig. 14 b)

The **main cause** of undercorrection is a lack of pre- and intraoperative management, particularly technical insufficiency, *i.e.* lack of MTP lateral release, of lateral shift, of DMAA correction, emphasized by Diebold [49, 50], and M. Delmi (Figs 07b2 and 07b4).

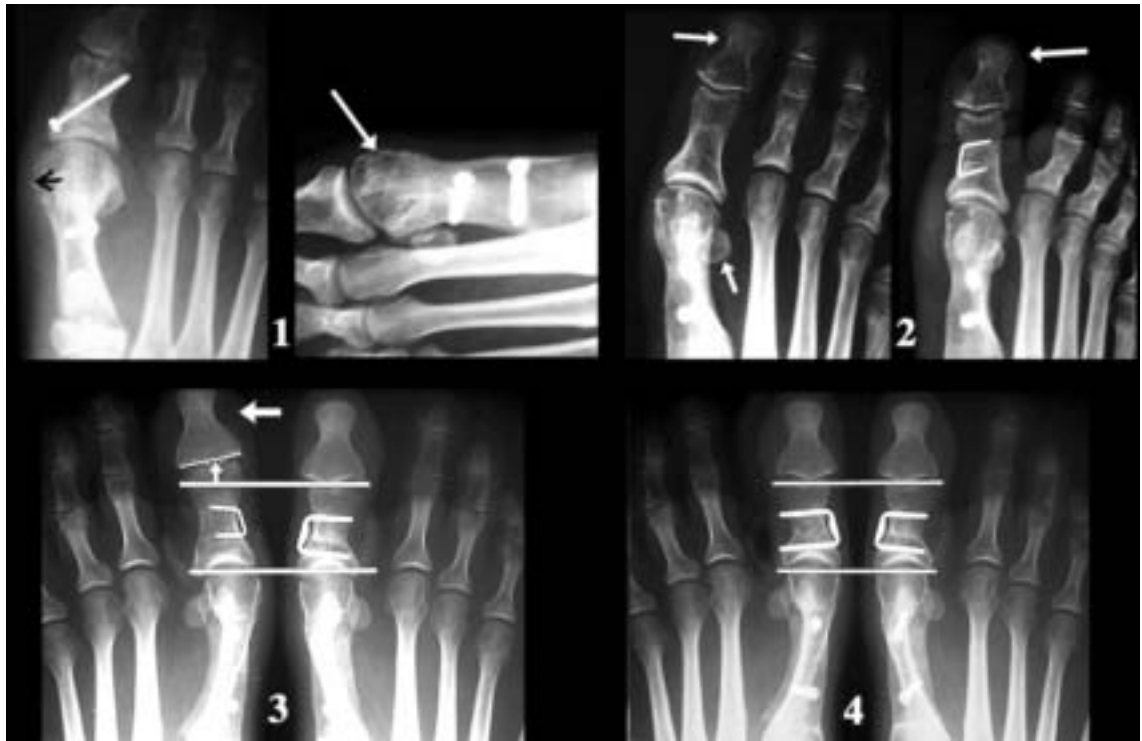
**Mild** undercorrection results from an incomplete lateral release, insufficient exostosis resection, both medial and dorsal (as pointed out by B. Valtin) and lack of P1 osteotomy.

**Severe deformity** is absolutely not a cause of undercorrection, since we can always achieve a reasonable congruence of the MTP joint and good correction of hallux valgus, thanks particularly to the shortening of the first metatarsal.

For **recurrent deformity**, it is always possible to perform another scarf osteotomy with good results (see later chapter “iatrogenic hallux valgus”). In the 920 scarf osteotomies study (performed from 1996 to 1998), we observe that only five cases (0.55%) required revision surgery for undercorrection.



Fig. 14b. Under or overcorrection...

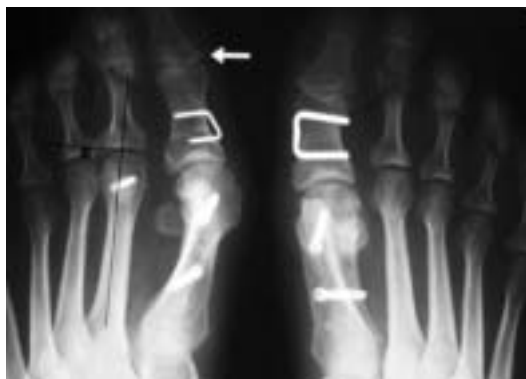

**Fig. 14b1. Scarf drawbacks: Mild or moderate undercorrection.**

1. No recurrence of deformity, but *insufficient exostosectomy*, both medial and dorsal, as pointed out by B. Valtin (Paris).

2. *Insufficient MTP lateral release* leaves the lateral sesamoid not corrected and too close of M2: On the right, revision with lateral release, medial soft tissue tightening and P1 osteotomy.

3, 4. The great toe first phalanx remain too long: Treatment by P1 shortening.



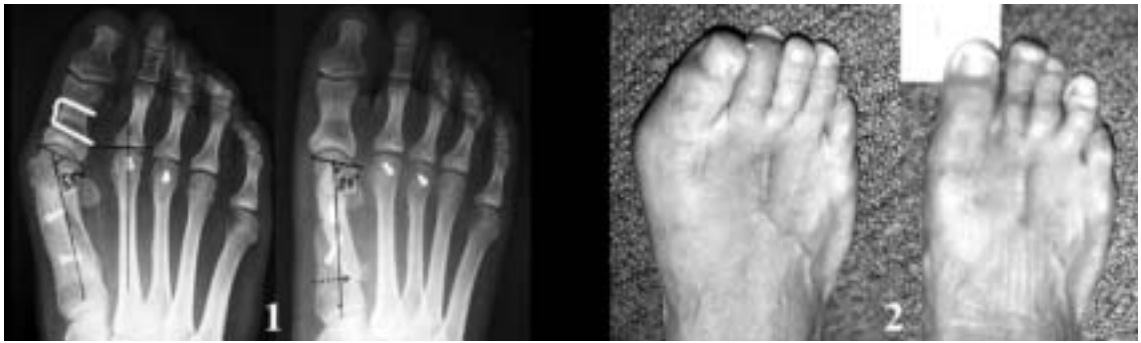**Fig. 14b2. Scarf drawbacks:**

**The three main causes of undercorrection.**

**1. Insufficiency of lateral shift.**

Same patient: Undercorrection on the side where the lateral shift was insufficient.

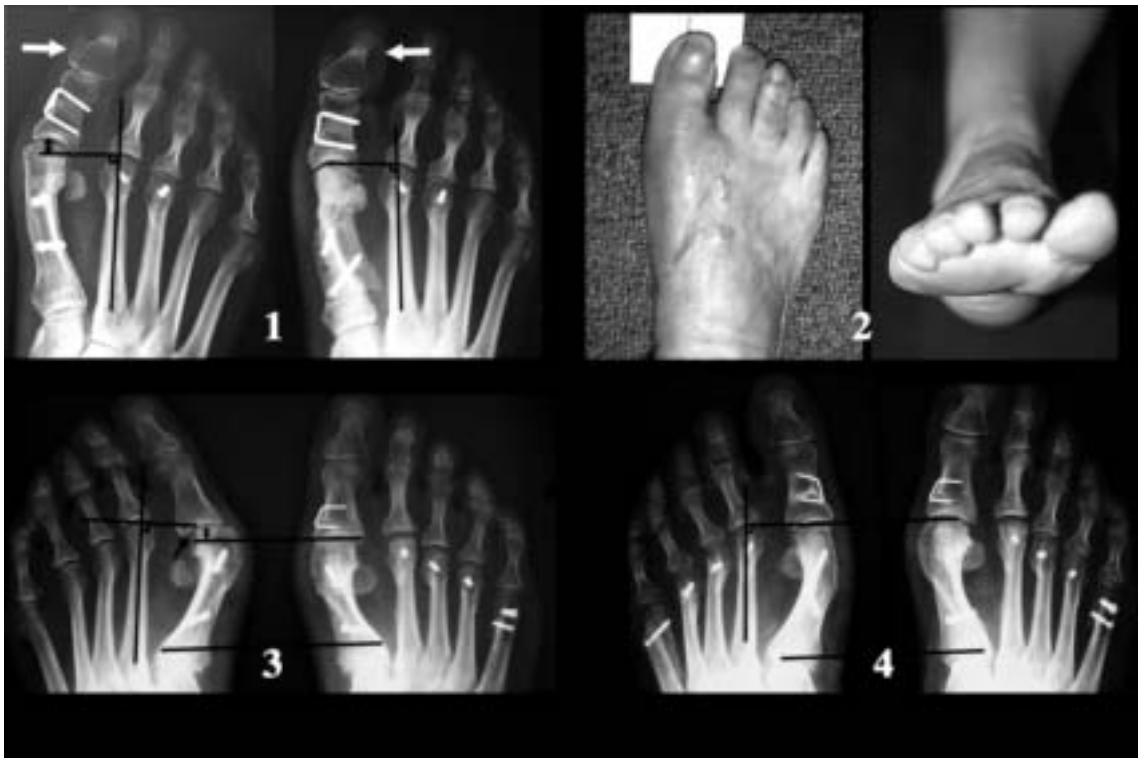



**Fig. 14b3. Scarf drawbacks: The three main causes of undercorrection.**

**2. Lack of DMAA correction.**

1, 2. Another usual cause of undercorrection is the lack of DMAA or PASA correction. Revision with DMAA correction.



**Fig. 14b4. Scarf drawbacks: The three main causes of undercorrection.**

**3. Insufficiency of M1 shortening.**

1, 2. The third main cause is the lack of M1 shortening. In this case, it is associated with insufficient lateral shift. Revision by shortening and lateral shift of M1.

3, 4. Bilateral case: Undercorrection on the foot without shortening (3); the revision results in equality of length of the two first metatarsals and, since M1 was not too long, by the lesser metatarsals shortening (4).

## Overcorrection

Thanks to the preservation of the lateral ligament during the MTP lateral release, and the use of the P1 osteotomy, the overcorrection is very rare (revision surgery for overcorrection accounted for less than 1% in our 920 cases study). *Intraoperative clinical and radiological checks and tests can really avoid overcorrection.* Contrarily to the appearances, the interphalangeal valgus does not diminish the rate of overcorrection. On the contrary, it increases the deformity. Furthermore, when 1st metatarsal

shortening is performed, the Maestro distal cut (see chapter about scarf shortening) avoids the overcorrection since it preserves the lateral metatarso-phalangeal ligament.

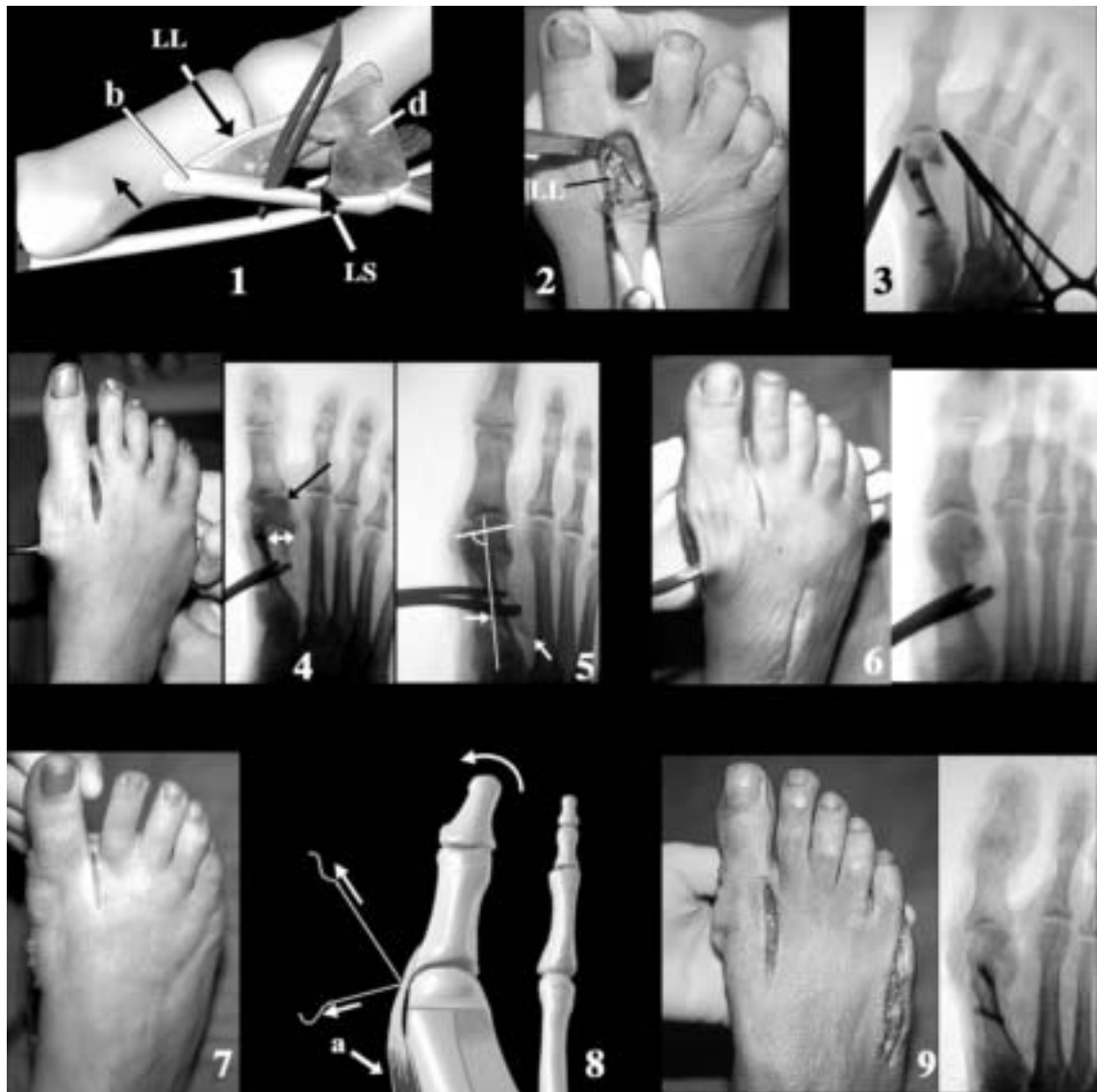When revision is necessary, articular preservative treatment can be used for moderate deformity: It includes the *proximal metatarsal varisation osteotomy* as indicated by A. Denis for reestablishment of a correct intermetatarsal angle (Fig. 14c3). For severe overcorrection, MTP arthrodesis is indicated (in our experience, two cases out of 3,000 scarf osteotomies).



**Fig. 14c1. Scarf drawbacks: 1. Overcorrection.**

1, 2. Overcorrection after scarf is often *moderate and correctible*, compatible with normal footwear.

2. Furthermore, it should diminish after a few months (one year in this case).



**Fig. 14c2. Scarf drawbacks: 2. Intraoperative prevention of overcorrection by LST and X-rays control.**

This prevention has to be done in the following three steps of the hallux valgus correction.

1, 2. During the MTP lateral release.

1, 2. By preserving the metatarsal phalangeal lateral ligament (LL).

3. In case of excessive lateral release, repairing of LL is possible.

4. During the scarf osteotomy: Excessive lateral shift emphasized by LST and X-rays controls: It is possible to come back to less displacement.

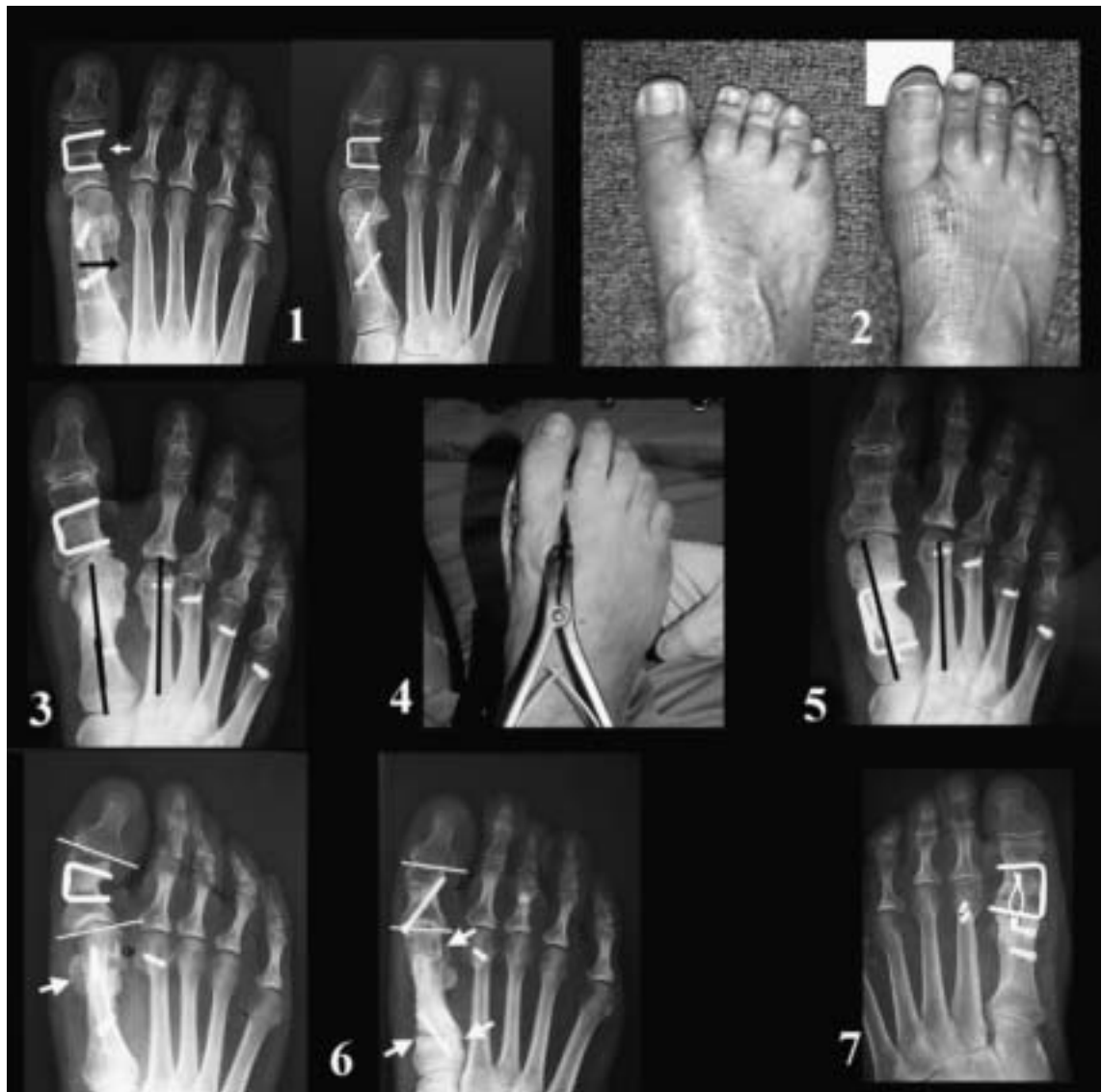
5. Same, we can control an excess of DMAA correction.

6. Both LST and X-rays controls are satisfying.

7, 8, 9. During the medial tightening.

7. Checking the risk of overcorrection (before the suture) while adjusting the tightening (8).

9. Checking the correct final position.



**Fig. 14c3. Scarf Drawbacks: Treatment of Over correction.**

1, 2. Excessive lateral shift. Early revision to come back to less displacement X rays and clinical results.

3, 4, 5. The first intermetatarsal (IM) angle is too closed : 4 same case with a hinge distractor to recover a correct IM angle: correction of the deformity (load simulation test). 5: same case after medial closing base wedge osteotomy of the 1st metatarsal.

6. Hallux valgus interphalangeus increases the over correction: this needs a varisation osteotomy of the phalanx.

7. When there is a severe and long lasting over correction, MTP fusion may be required.

### *Incorrect Sagittal Position of the First Metatarsal Head*

**Too much** plantar translation may be observed after lowering the plantar fragment. However, it rarely results in metatarsalgia or in sesamoid problems, often seen when the medial sesamoid is too close to the medial aspect of the head.

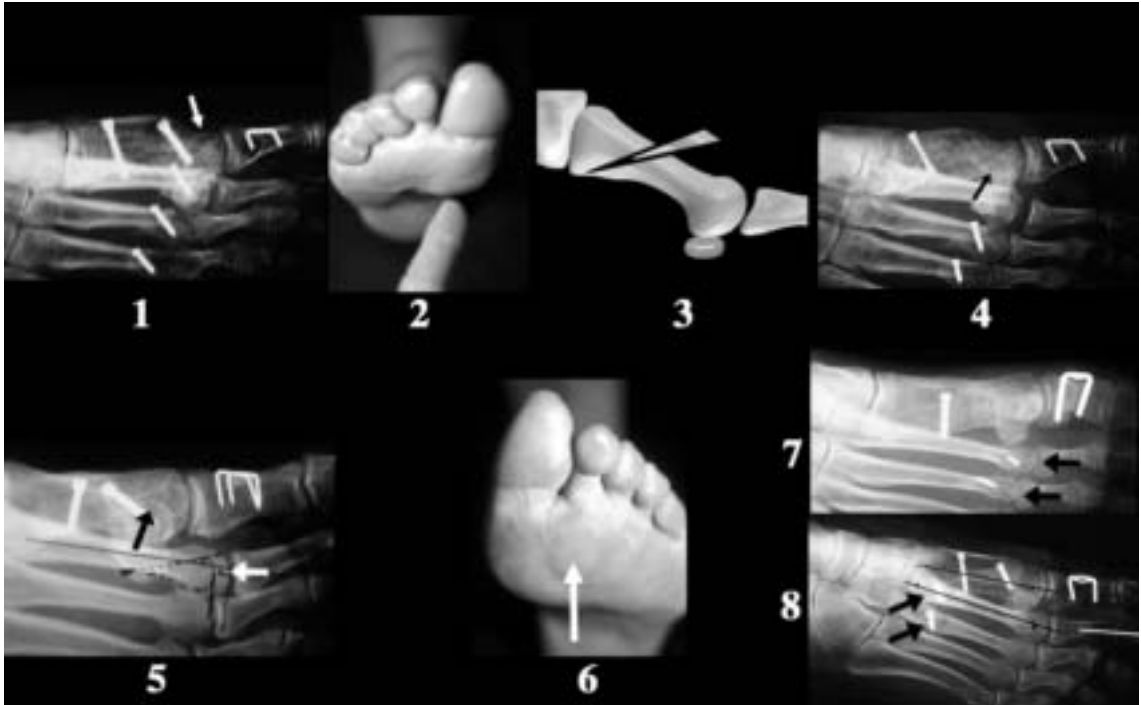
Generally we avoid too much lowering in the correction of arthritic hallux valgus.

Regarding the *2nd ray metatarsalgia*, since 1994 we have performed a large lowering of the first metatarsal head which is very effective for relieving this metatarsalgia location: However, this

lowering was sometimes excessive. Now we can perform less lowering since we use either Weil osteotomy on the 2nd metatarsal, when it is too long, or BRT 2nd metatarsal basal elevation when it is not too long. In both cases we can avoid too much lowering of the first metatarsal head.

**Insufficient** plantar head location was observed before we made large lowering with the scarf (1992-1994). Revision surgery is in this case either Weil or BRT osteotomies on the lesser metatarsal, as required.

In spite of a correct sagittal position, we may observe a *temporary* thickening of the medial part of the foot, with some problem for this footwear.

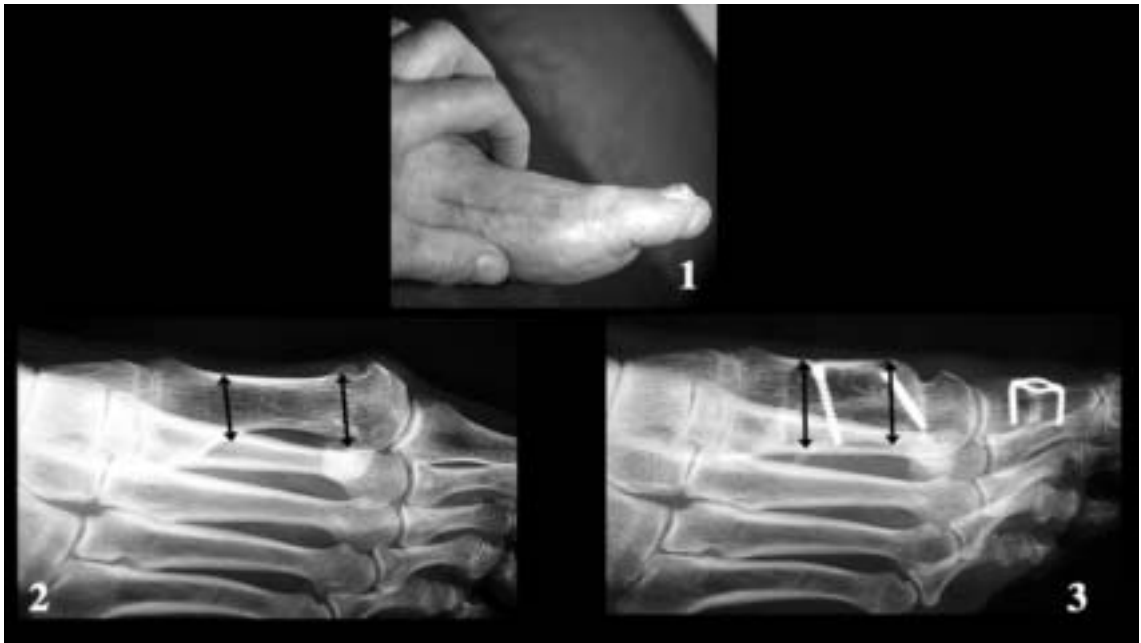

**Fig. 14d. Scarf drawbacks: Head location in sagittal plane.**

1, 2. Excess of M1 lowering: M1 plantar overpressure.

3, 4. Revision by BRT M1 osteotomy.

5, 6. Insufficiency of M1 lowering results in transfer metatarsalgia on M2. Revision by lesser metatarsal Weil shortening osteotomy (7) or BRT osteotomy (8).



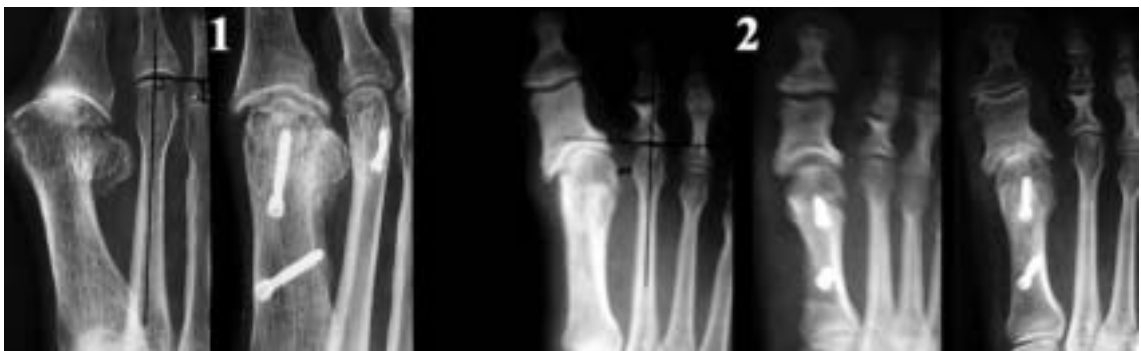**Fig. 14e. Thickening of the medial part of the foot after lowering by scarf.**

This may result in problems to fit narrow shoes. However this problem disappears after one year postoperative.

### *First Metatarsal Head Necrosis*

This complication rarely occurs in scarf osteotomy, since it preserves both plantar and dorsal metatarsal head blood supply. In fact, the rare head necroses are observed in two specific cases:

- 1) For *severe arthritic* hallux valgus correction;
  - 2) For *iatrogenic hallux valgus overcorrection*.
- This necrosis is well tolerated: In our experience, up to now only one case requires secondary MTP fusion.



**Fig. 14f. Scarf drawbacks: M1 head necrosis.**

Head necrosis is extremely rare after M1 scarf osteotomy, it only occurs in two cases:

1. *Arthritic* hallux valgus correction.
2. *Scarf* for hallux valgus overcorrection.

In these cases until now, no MTP fusion was necessary in our personal experience since these necroses were painless, except in one case where we plan to make a fusion (2).

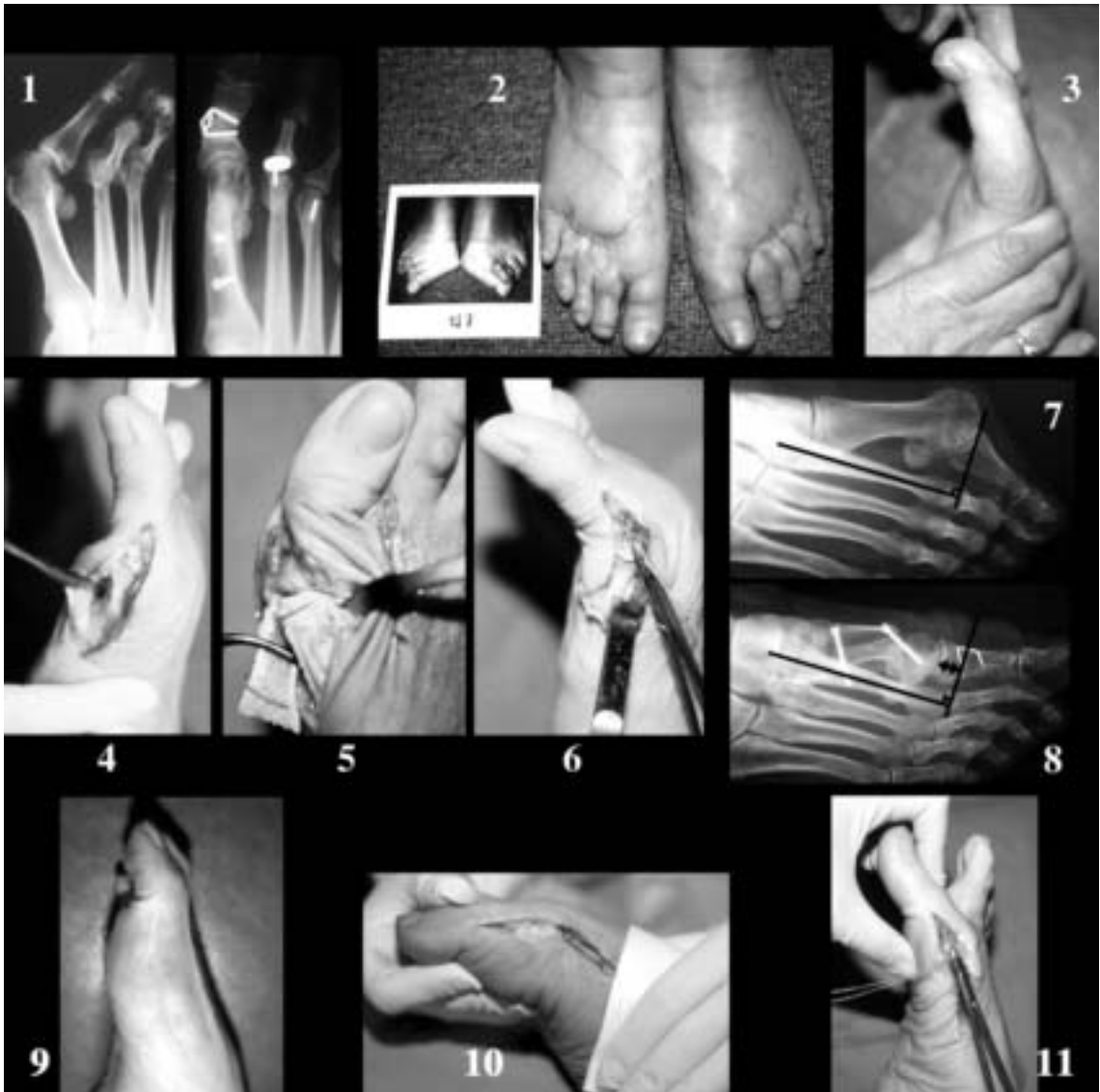**MTP Stiffness**

Stiffness may result from severe Sympathetic Dystrophy Reflex Syndrome, it very rarely occurs in isolated scarf osteotomy.

Most MTP stiffness was observed in our early experience *when we did not shorten the first metatarsal*. We can easily avoid MTP stiffness by checking the *dorsal flexion* per operati-

vely and performing the appropriate M1 shortening.

Concerning the lack of MTP *plantar* flexion, we can also avoid it when performing the medial capsulorrhaphy and if necessary make secondary MTP dorsal release after one year post operative; it is a simple surgery performed when necessary while removing the distal screw when there is some problem with ladies shoes.



**Fig. 14g. Scarf drawbacks: MTP stiffness.**

1, 2, 3. Generally MTP global stiffness is only observed when the correction of hallux valgus is performed *without M1 shortening*.

4, 5, 6, 7, 8. The stiffness (*mainly loss of dorsal flexion*) is usually completely avoided by performing M1 shortening, which is easy with the scarf osteotomy.

9, 10. *Lack of plantar flexion* is easily treated by MTP1 dorsal release after one postoperative year.

11. However it is avoided by performing the medial tightening suture while the great toe is held in plantar flexion.

## Drawbacks with the Great Toe First Phalanx Osteotomy

### P1 Basal Osteotomies

– Basal varisation: During the closing of the medial wedge or during the staple setting, the lateral cortex may not be preserved. This results in instability of the osteotomy; to set a second staple may be a solution, but we prefer making the fixation with the scarf cannulated screw (now, FRS screw).

– Varisation combined with derotation: The same drawback should occur, because the lateral cortex is more fragilized with the combined derotation (same remark concerning the fixation).

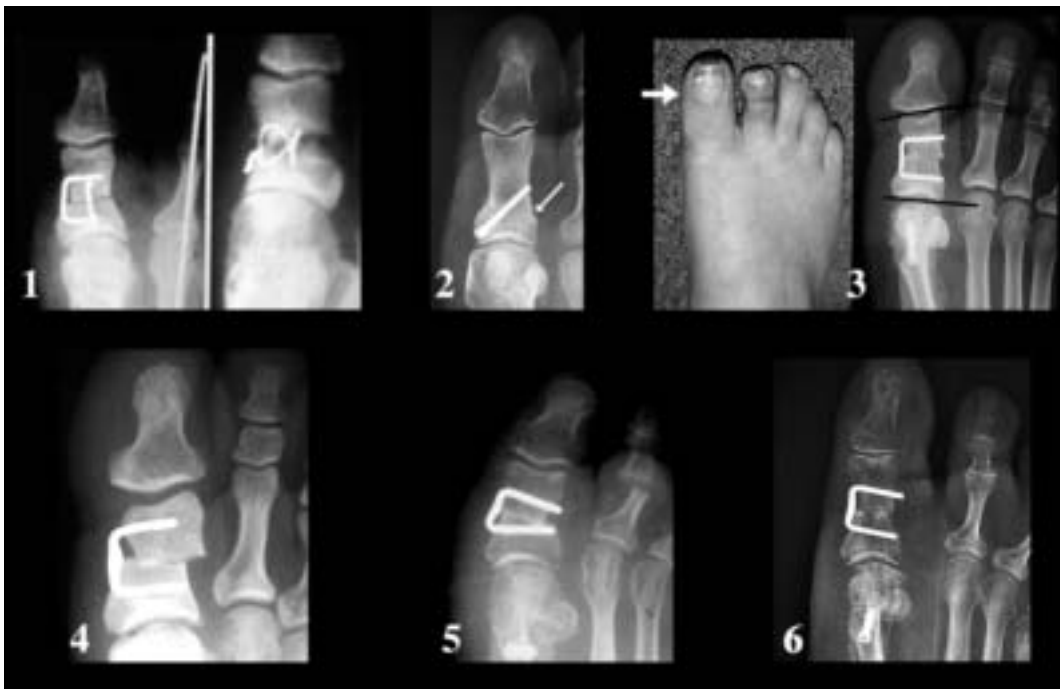– Too much varisation should be observed with a conflict between the medial part of the great toe and the shoe.

### P1 Shaft Osteotomy

Fixation by screw has to be very accurate. The screw should not be too oblique with an insufficient fixation or too straight and too long: So we prefer the fixation by memory staple. Two drawbacks may be observed:

– Without temporary axial K-wiring, displacement of the fragment when setting the staple.

– Too much pinching of the lateral part, by the prongs extremities: We have remedied to this problem with the new *tepid memory staple* which allows to adapt its strength to the bone quality.



**Fig. 14h. Drawbacks in great toe 1<sup>st</sup> phalanx osteotomy.**

1. Problems of osteosynthesis observed before the use of the special implants for P1 fixation.

2. Basal varisation: When the lateral cortex breaks, it is preferable to fix it with a scarf screw.

3. Excess of varisation (rarely observed).

4-5. Drawbacks observed in shortening using the memory staple: they are particularly observed in osteoporotic bone: in this case, fixation by screw is preferable.

6. These drawbacks are not observed in case of varisation without shortening, whatever the quality of bone.



## Advantages of this Type of Hallux Valgus Surgery

1. As a result of extremely strong internal fixation, *early functional recovery* occurs and *simultaneous bilateral operations* can be performed.

2. Its *versatility*, made possible by the variety of possible displacements. The lateral shift can be extremely large. DMAA correction is sufficient in almost all cases. The head can be lowered by up to 7 mm. If required, shortening is accurate, does not result in elevation of the head, and can be as ample and predictable (no secondary shortening) as required.

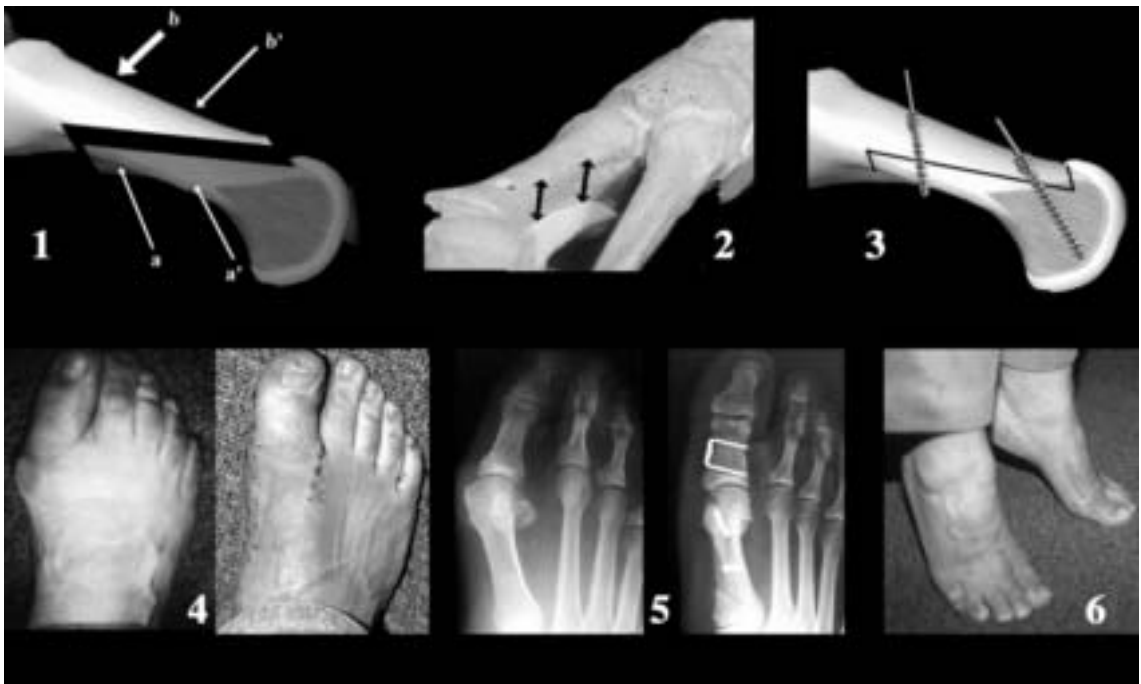
3. This procedure is suitable for *old patients*. The Keller's procedure is not performed any more.

4. *The preservation of the first MTP joint as far as possible*, reducing notably the necessity of the MTP fusion.

5. As a result of these upper advantages, there is an extremely *wide range of indications*, from emerging deformity up to the most deformed hallux valgus including all severe forefoot disorders.

6. *Long-term results* highlight the technique's *long-term reliability*. Borelli and Weil reviewed more than 1,000 cases over 1.5 to 12 years [26]. In my experience (Fig. 13), since February 1991, almost no long-term deterioration of results has been observed. I have now more than 500 cases with over five years of follow-up. Our findings and those of Valtin [124] confirm Borrelli and Weil's study.

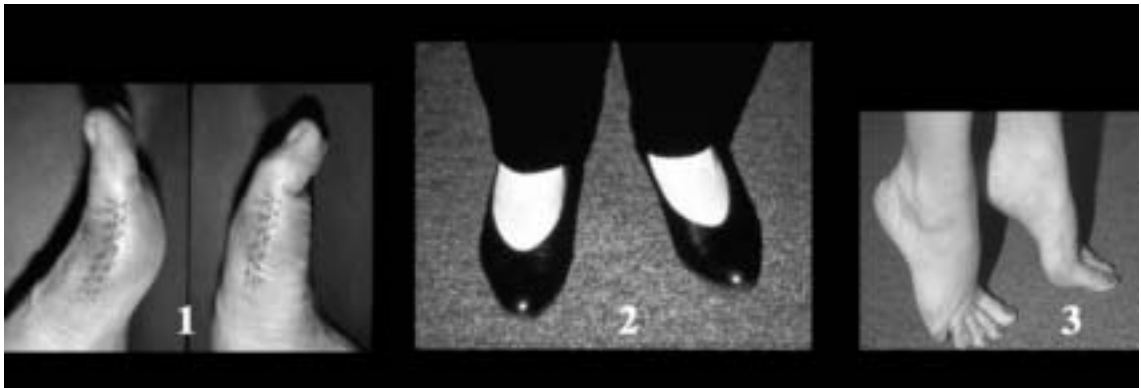
**In conclusion**, such a fixation, a versatility, a reliability lead us to perform scarf and great toe osteotomy in every case of hallux valgus, except extremely rare cases of MTP joint fusion for very old patients or rare cases of extremely impaired or stiff MTP joint.



**Fig. 15a.** Advantages of the scarf and great toe osteotomies: 1. *strong fixation*.

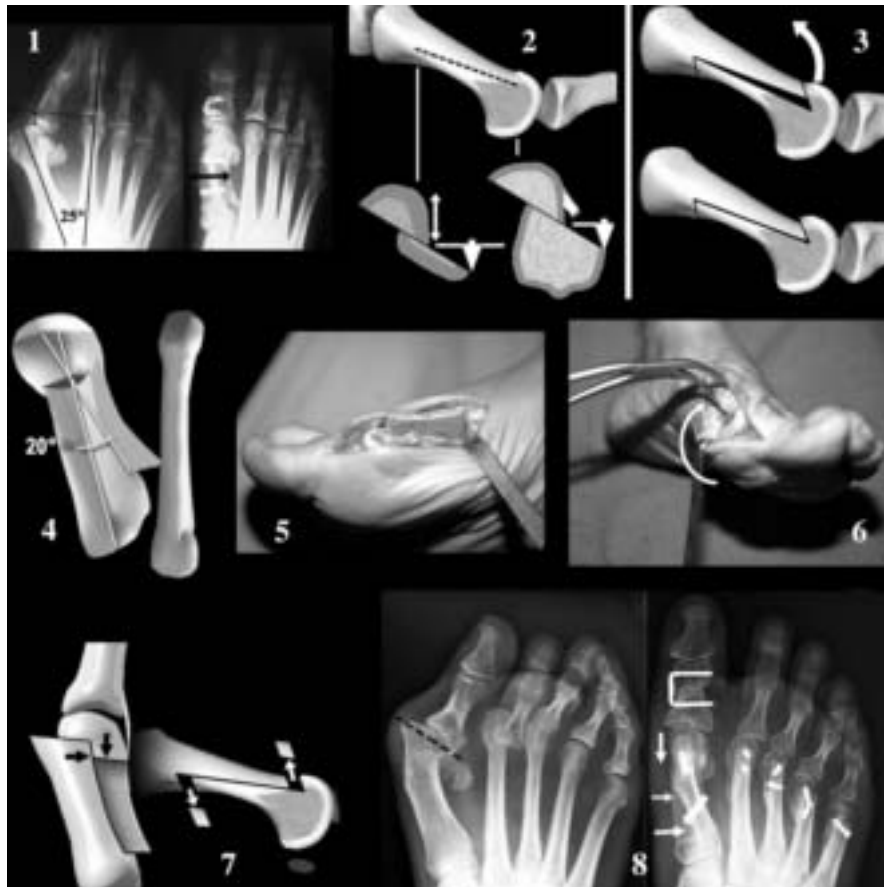1, 2, 3. Strong osteotomy and fixation thanks to the preservation of the dorsal fragment, particularly of its lateral surface (2) and thanks to the twin screws fixation.

4, 5, 6. Even in case of trophic troubles or for old or heavy patients (in this picture a 125 kg man), strong fixation allows function recovery and good correction.



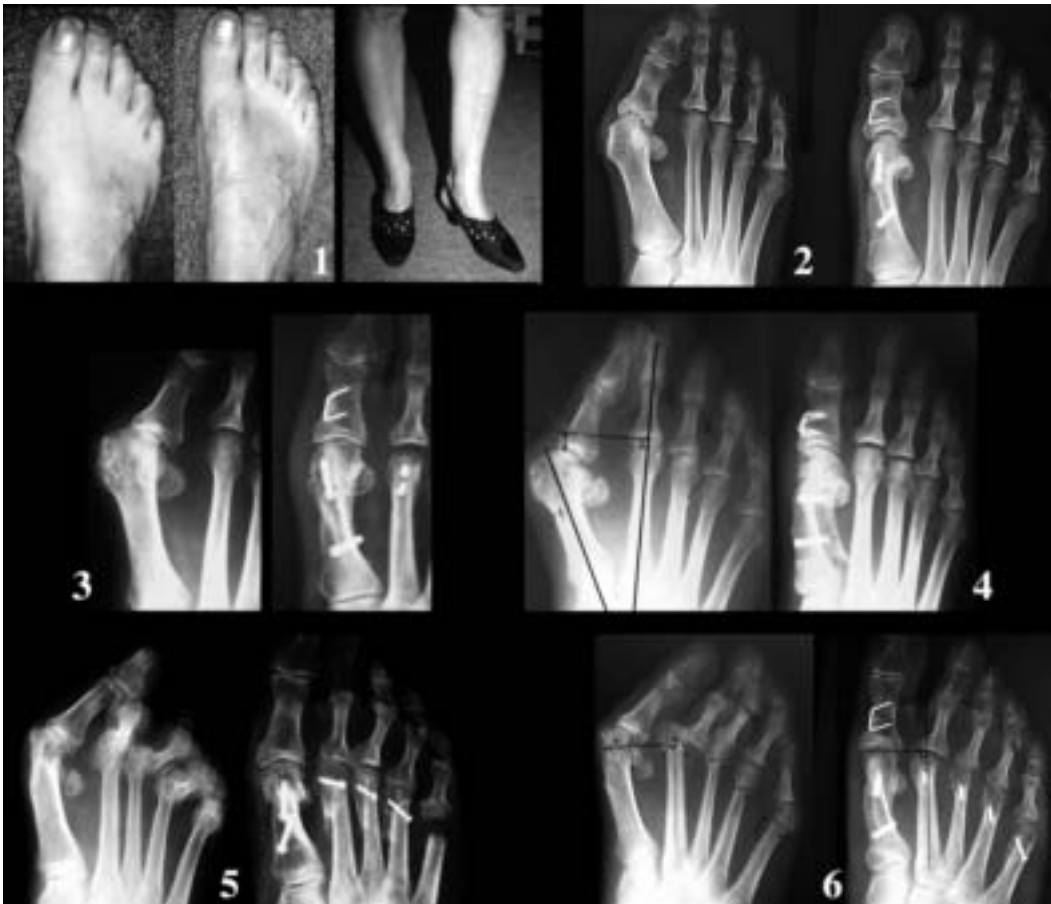**Fig. 15b. Scarf and great toe osteotomies advantages: 2. very early function a recovery.**

1. 15th postoperative day: The MTP active range motion.
2. Two months postoperative.
3. Three months postoperative.

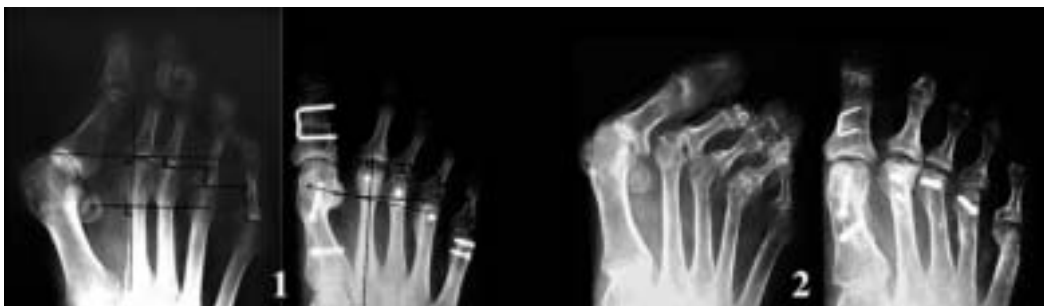

**Fig. 15c1. Scarf advantages: 3. versatility.**

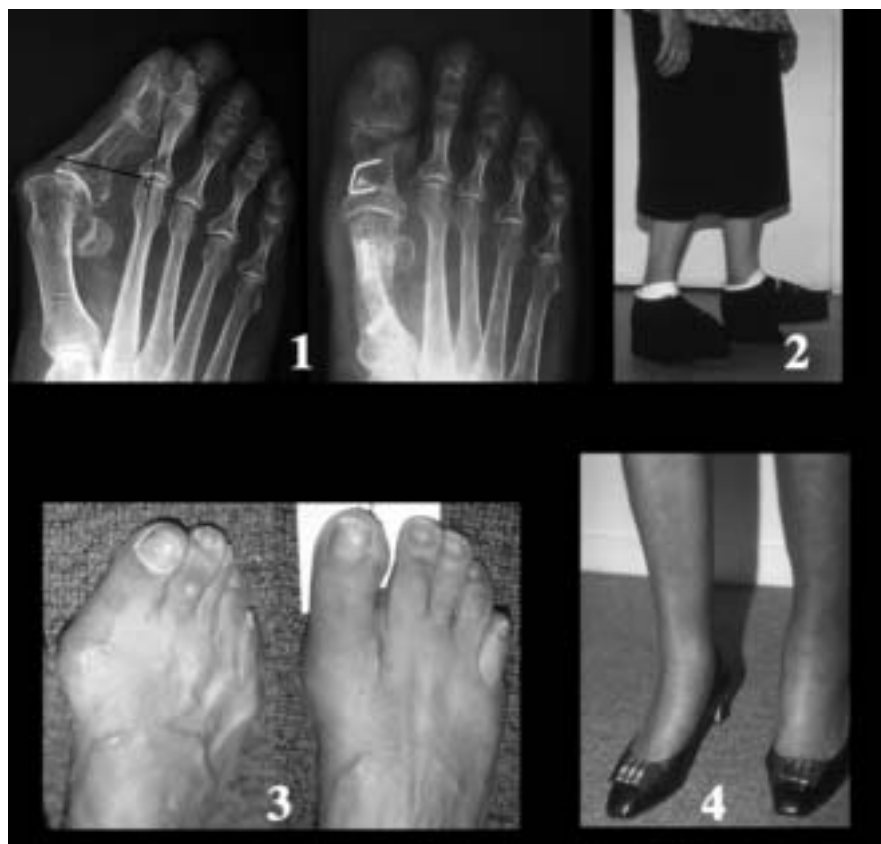1. Very large lateral shift for advanced hallux valgus.
  2. Lowering.
  3. Elevation.
  4. DMAA correction.
  5. Lateral shift combined with DMAA correction.
  6. Axial rotation for correction of M1 pronation.
  7. Large and harmless shortening.
  8. Easy combination of various displacements: In this case lateral shift, shortening, DMAA correction, lowering.
- This versatility allows the *largest field of indications for hallux valgus correction.*



**Fig. 15c2. Scarf advantages: 4. the large field of indications resulting from the scarf versatility.**  
 1. In *emerging or mild* hallux valgus, the scarf provides both security in the correction and early functional recovery.  
 2. In *juvenile* hallux valgus the scarf can adapt its versatility.  
 3. In *arthritic* hallux valgus, correction thanks to M1 shortening and DMAA correction.  
 4. In *large deformity*, correction thanks to large lateral shift.  
 5. In *rheumatoid* hallux valgus M1 shortening allows to preserve as far as possible the 1st MTP joint.  
 6. In *severe or iatrogenic* hallux valgus, joints preservative surgery.  
 In the Figs. 5 and 6 the M1 shortening is combined with the Weil lesser metatarsal osteotomy.



**Fig. 15d. Scarf and great toe osteotomies advantages 5. two examples of the MTP I preservation.**  
 1. In *advanced arthritic* hallux valgus (follow-up 3 years).  
 2. In *rheumatoid* forefoot (follow-up 2 years).



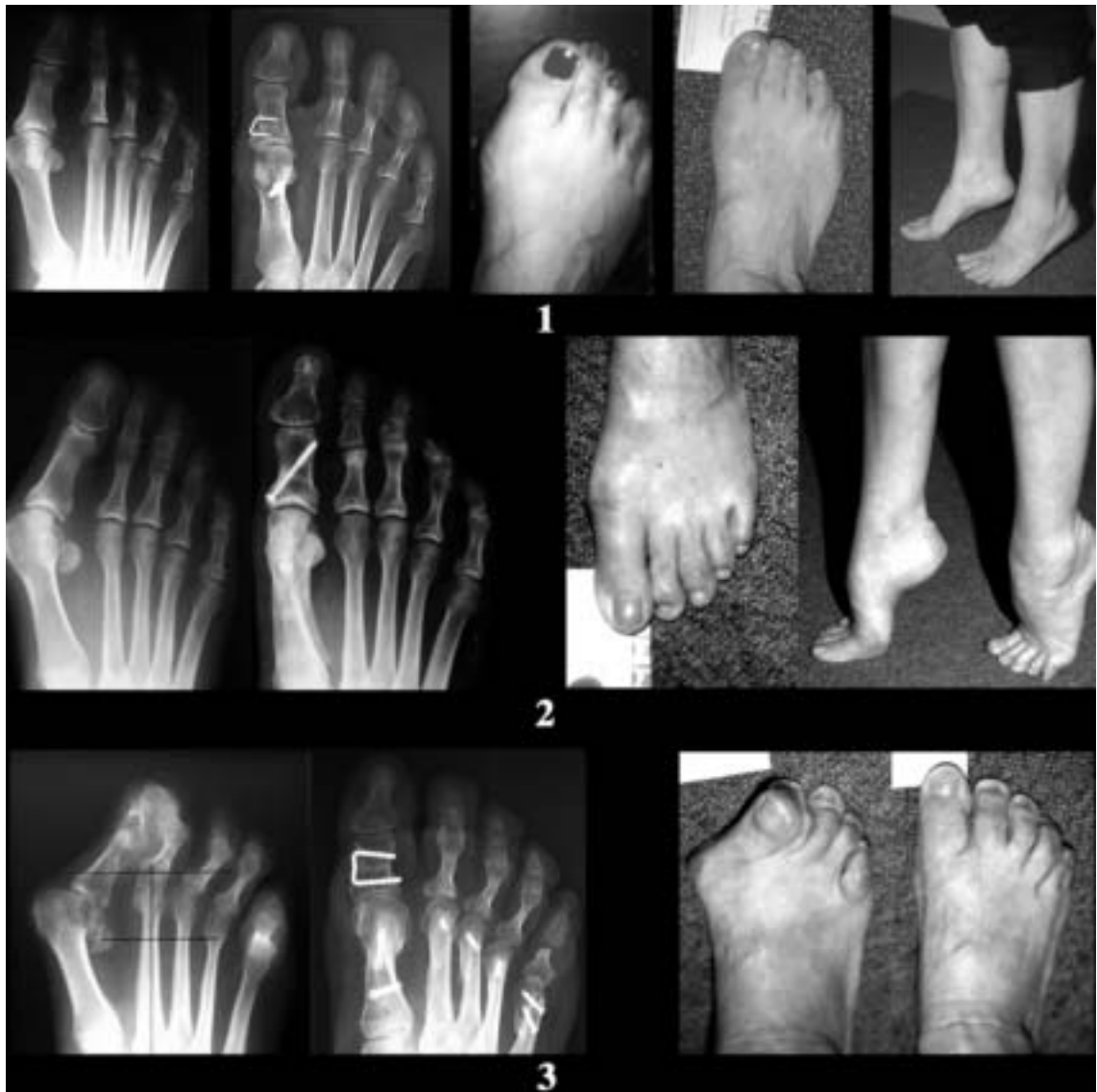**Fig. 15e. Scarf and great toe osteotomies advantages 6. for old patients.**

For more than 80 year-old patients scarf also provides excellent results

1. Note the long cut, in order to reach both distal and proximal cancellous bones and, to avoid shaft channel effect.

2. The heel support shoe has been worn for one month.

3, 4. Clinical result, same patient. Thus, we think there is no more indications for Keller procedure.



**Fig. 15f.** Scarf and great toe osteotomies advantages 7. *long-term results.*

1. One of our early cases (April 1991). Patient reviewed in April 2001: ten years follow-up.
2. Eight years follow-up.
3. Five years follow-up in severe deformity.

## **The Weil first metatarsal decompression osteotomy**

This osteotomy is similar than the Weil osteotomy performed in the lesser metatarsals; however indications and technique are different.

### *Two indications:*

- 1) Hallux limitus.
- 2) Shortening of the first metatarsal as an additional procedure.

### *Technique* (Fig. 16b-c)

(Common technique for hallux limitus or for simple shortening)

- Medial approach.
- The plantar vascular bundle is preserved; the proximal plantar exposure (see Fig. 05b) is performed in order to check the proximal end of the cut.

- The dorsal capsula is not preserved.
- The cut begin distally at the upper part of the head cartilage (1 to 3 mm of the cartilage may be removed).
- Direction of the cut: oblique proximally and plantarly. Too short as well as too long cut have to be avoided.

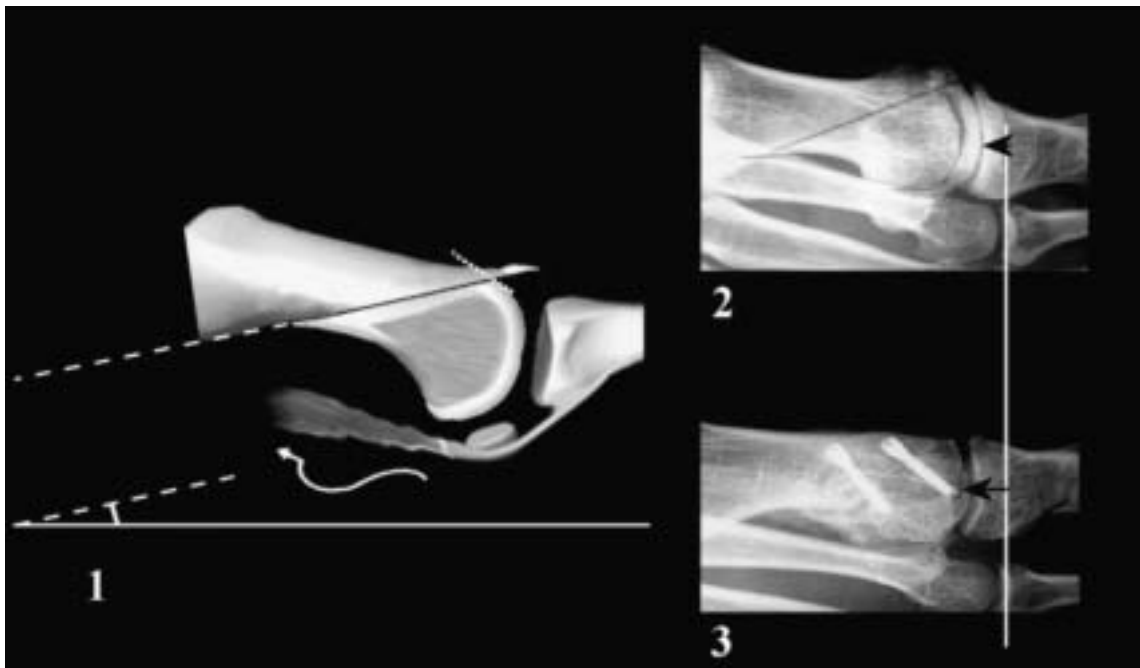
### **Displacement of the head**

The shortening is generally accompanied with a small lowering, even in case of metatarsus elevatus, (observed in hallux limitus).

DMAA correction is easy to perform, as well as lateral shift, but when large lateral shift is required, we prefer to perform the scarf osteotomy (Fig. 07f2).

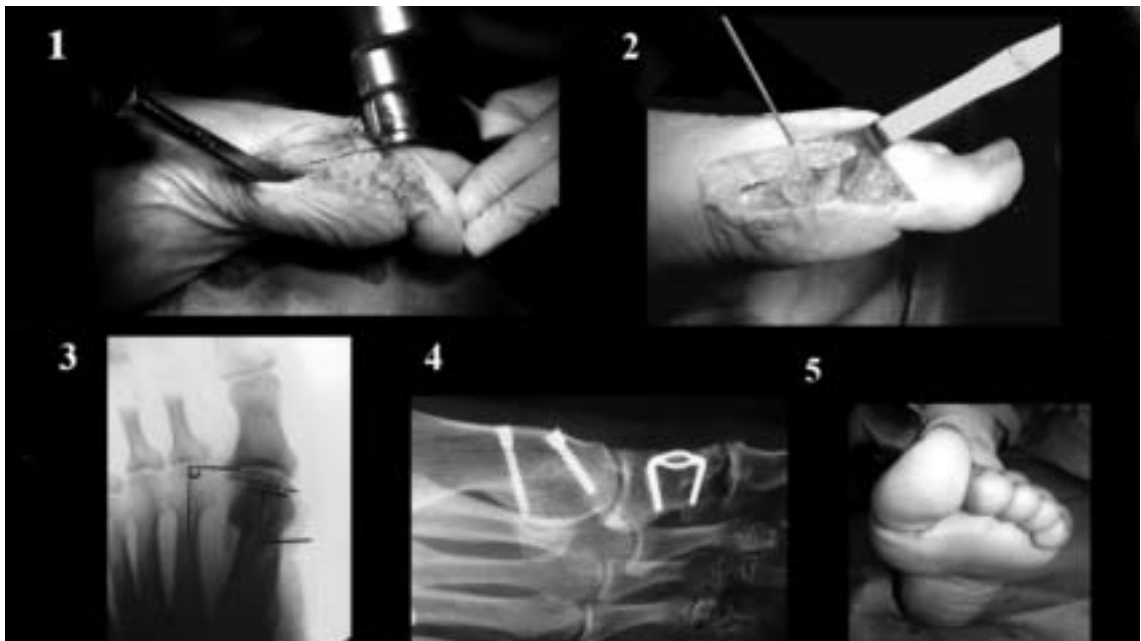
### **Fixation**

Two scarf screws, or preferably two FRS screws are set obliquely in a distal and pantar direction from the dorsal cortex to the metatarsal head.



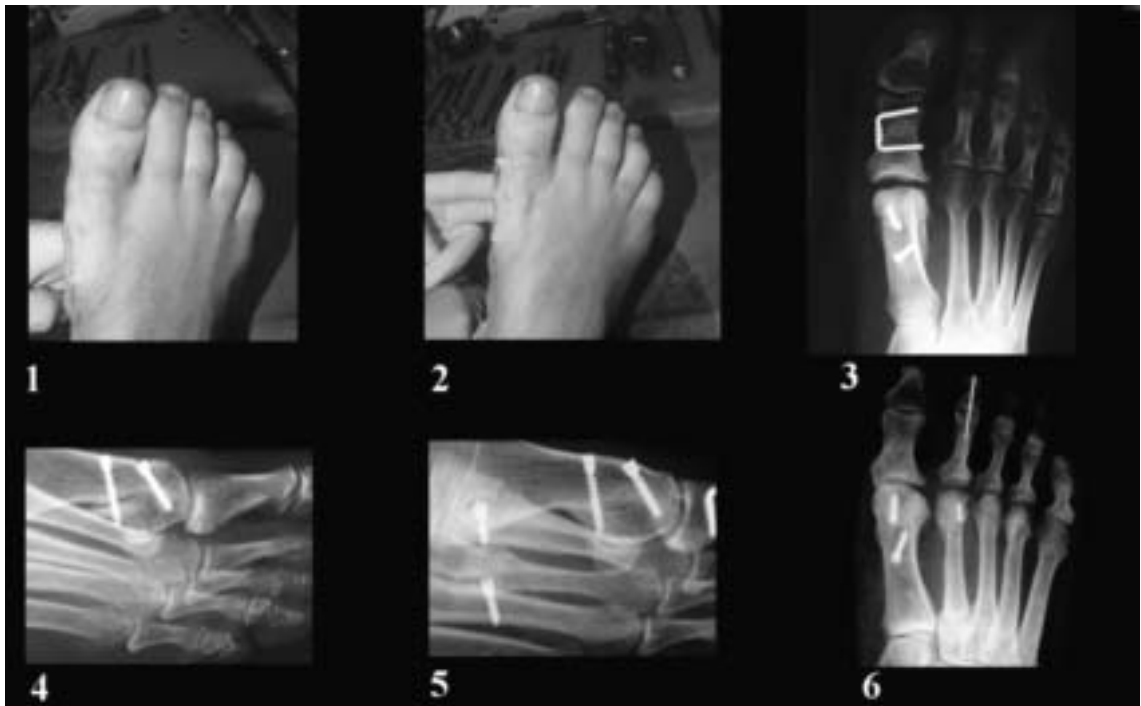
**Fig. 16a.** The Weil 1st metatarsal decompression osteotomy.

1. The cut crosses the horizontal plane, resulting in metatarsal head lowering, even in case of metatarsus elevatus.
- 2, 3. *Hallux limitus*. Medial view: pre operative and one year post operative (fixation : 2 scarf or FRS screws).



**Fig. 16b. 1st metatarsal weil osteotomy. Intra operative views.**

1. The cut: its proximal end, located on the proximal plantar exposure, preserves the plantar vascular bundle.
2. Proximal sliding of the metatarsal head, before resection of the peak.
3. Intra operative x ray control: in this case, the excess of DMAA correction will be corrected.
4. Strong fixation by two cannulated screws (FRS).
5. The first metatarsal head is lowered, avoiding transfer metatarsalgie.



**Fig. 16c. 1st metatarsal weil osteotomy additional procedures.**

- 1, 2, 3. Variation of the proximal phalanx, fixation by memory staple (3).
- 4, 5. Secondary additional BRT osteotomy of the lesser metatarsals.
6. In this case, the 2nd metatarsal was already too long preoperatively, requiring additional weil osteotomy.

**Combined procedures**

Great toe proximal phalanx osteotomy.

BRT or Weil osteotomies on the lesser metatarsals.

Grade 1 to 2, but sometimes grade 3, when the motion of the MTP joint is more than 45° and with moderate pain.

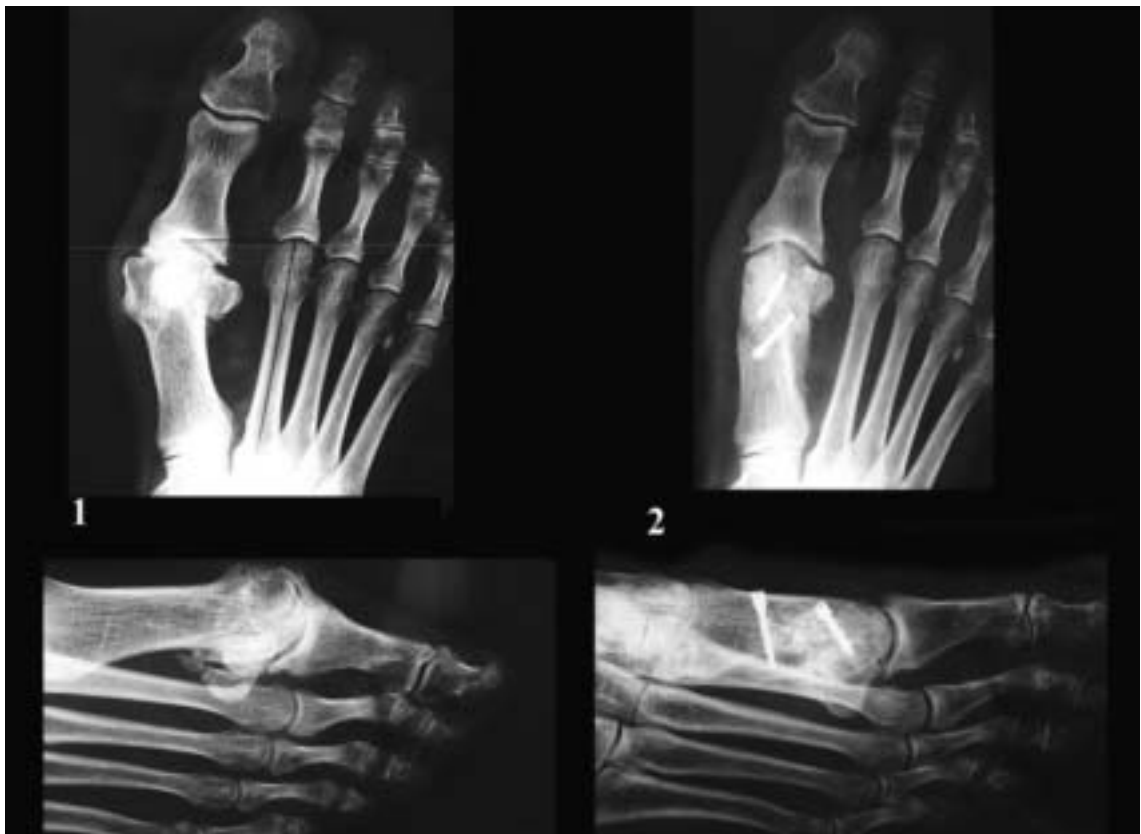**Results** (see p. 311)

**Specificities for hallux limitus****Indications**

Metatarsal index: first metatarsal longer than the second, or with same length.

**In conclusion**

We are very confident in this osteotomy, which is easy to perform, and which avoid in many cases more invasive procedure, such as prosthesis or fusion.



**Fig. 16d.** 1st metatarsal weil osteotomy: *hallux limitus*.

Result in a grade III.

1. Pre operative.

2. 6 months post operative.



*Specificities for simple shortening***Indication**

When shortening of the lesser metatarsals is required, care has to be taken not to leave a too long first metatarsal, so that the first metatarsal shortening is indicated.

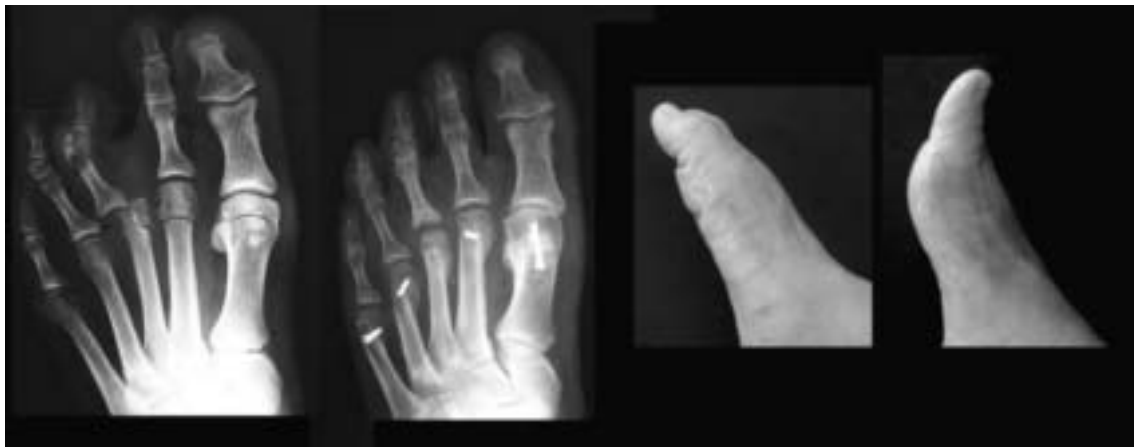Two cases are encountered

- 1) Hallux valgus deformity: perform scarf with shortening.
- 2) No hallux valgus deformity: perform 1st metatarsal weil osteotomy.

Contra indication: apart hallux valgus, pes cavus is a contra indication because of the lowering of the first metatarsal (always associated with the 1st metatarsal weil osteotomy).

**Results**

- Post operative period: no pain, early functional recovery.
- No healing problems, excellent MTP range notion.



**Fig. 16e. Weil osteotomy. Other indication, shortening of the first metatarsal.**

In this case (rhumatoïd forefoot) the required shortening of the third metatarsal needs, the combined shortening of the other metatarsals, including the first metatarsal: the weil osteotomy is chosen instead of a scarf osteotomy, because only shortening is required.

## The Weil Lesser Metatarsal Osteotomy

### History, Definition

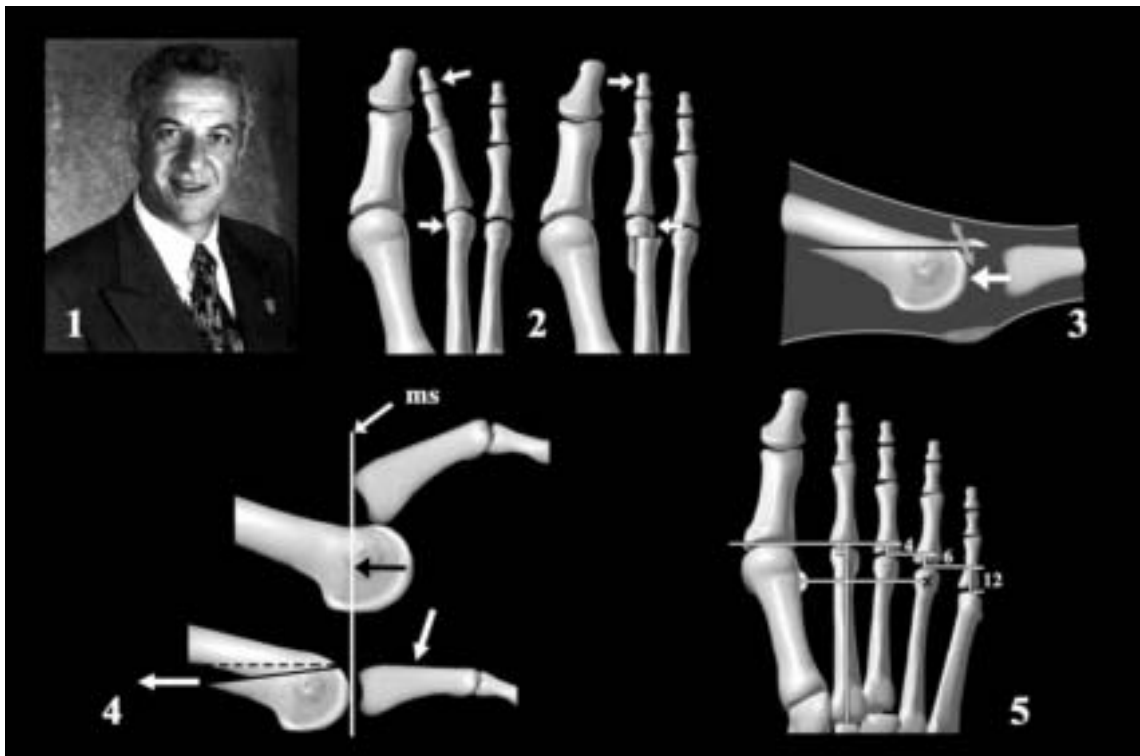
The Weil osteotomy on the lesser metatarsal has been performed since 1985 by L. S. Weil (Chicago). It is a distal metatarsal oblique osteotomy, performed on the metaphysis and the metatarsal neck, which principally results in a proximal translation of the head, providing a **longitudinal decompression**; it can also provide a **transverse displacement**, medial or lateral.

In 1992, L. S. Weil came to Bordeaux to collaborate with me on modifications to the Scarf

bunionectomy and, in a live surgery, performed the first case of a Weil osteotomy in Europe. During that time, I got used to the Weil osteotomy performing and studying this osteotomy, which is now very popular all around the world. It provides a great improvement in its specific indication in forefoot surgery. These indications are mainly those of a longitudinal decompression which is accurate, controlled and taking into account the harmony of the anatomical metatarsal curve.

The main drawback of this osteotomy was MTP stiffness in plantar flexion. We have now overcome these problems and this drawback is now significantly diminished thanks to the choice of indications, the improvement of the technique and the postoperative management.

Many authors wrote about this procedure [13-15, 30, 48, 66-85, 86-90, 92-122, 126].



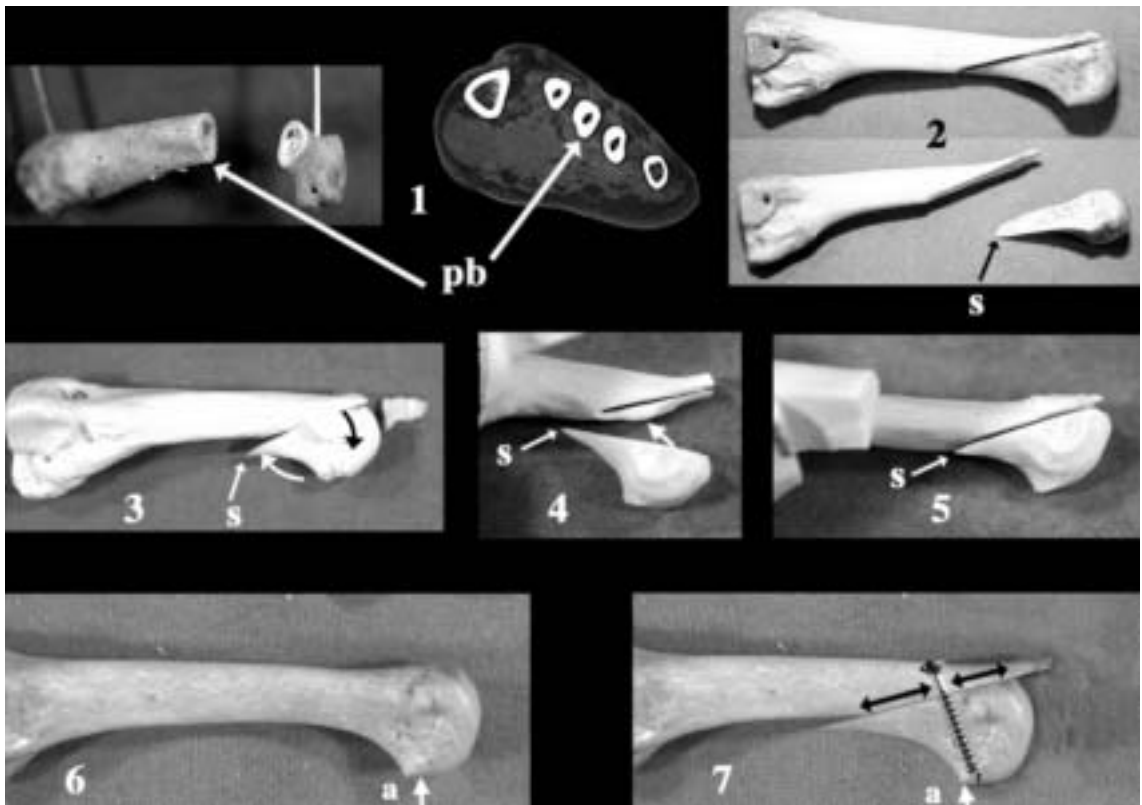
**Fig. 17a1. The Weil lesser metatarsal osteotomy.**

This procedure provides a significant improvement in the treatment of transverse lesser toes deformities (2), of metatarsalgia (3) MTP dislocation (4) and generally of any disorder needing a longitudinal MTP decompression. We note that the second layer is necessary in most cases, as well as the respect of the metatarsal parabola (5).

## Surgical Anatomy

We studied the **surgical anatomy** of the distal part of the metatarsal and its relationships with the Weil osteotomy. The blood supply was studied by B. Valtin and Th. Leemrijse (Paris). In regards to the muscles, and as already noted by E. Pisani, and T. Leemrijse, we have to remark that the 2nd metatarsal has only *dorsal* interosseous muscles and not *plantar* (Fig. 17a7). In

this study we pointed out the relationships with the **metatarsal plantar slope**, notably with the studies of B. Valtin, Th. Leemrijse, and M. Benichou (Montpellier). We can combine Benichou's and Valtin's studies to emphasize that there is generally no lowering for the 2nd metatarsal when it is shortened less than 3mm. This was also observed by L. S. Weil and W. Graff, as a result of a geometrical study. The 3rd metatarsal can be horizontally displaced but a slight lowering may be observed and, in this case, the tarso-

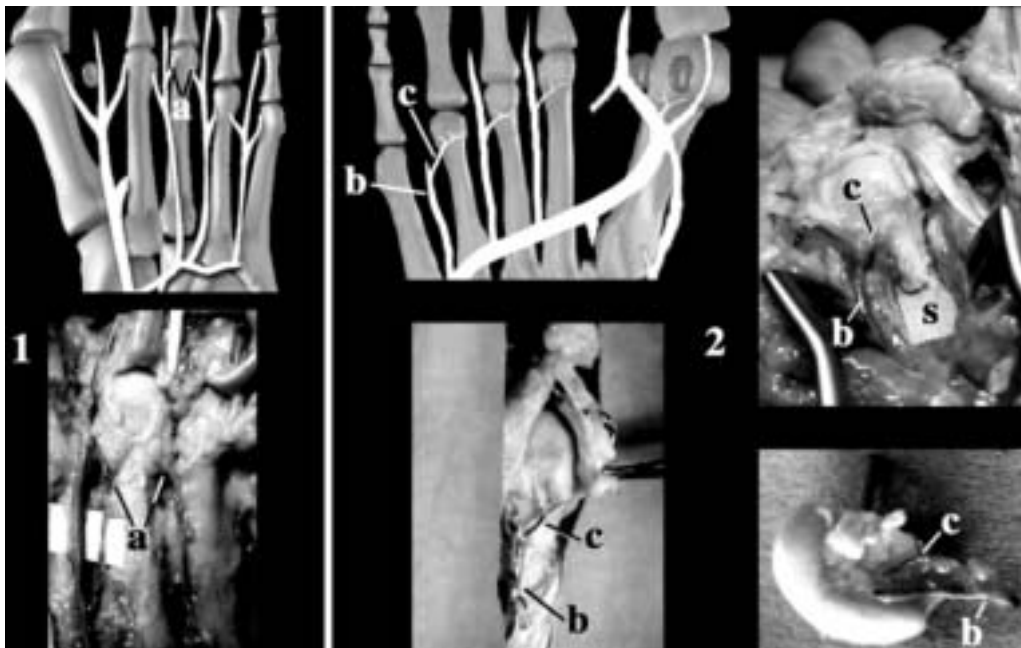


**Fig. 17a2. Weil osteotomy: Surgical anatomy of the lesser metatarsal distal part.**

1. A cross section on the neck level shows that the plantar border (pb) is sharp.
- 2, 3. Therefore performing Weil osteotomy results in leaving a sharp proximal spike (s) of the distal fragment. Furthermore it might exist an instability between the two fragments (rocking motion).
- 4, 5. Both to eliminate the spike and to improve the stability, a second layer is necessary in large displacements.
- 6, 7. In a sagittal plane the deeper part of the head is on its proximal part (a); this leads to set the screw in this proximal part and not more distally, both to have more bone thus more solidity, to avoid rocking motion of the plantar fragment, and to have the screw located at an equal distance of the two ends of the distal fragment.

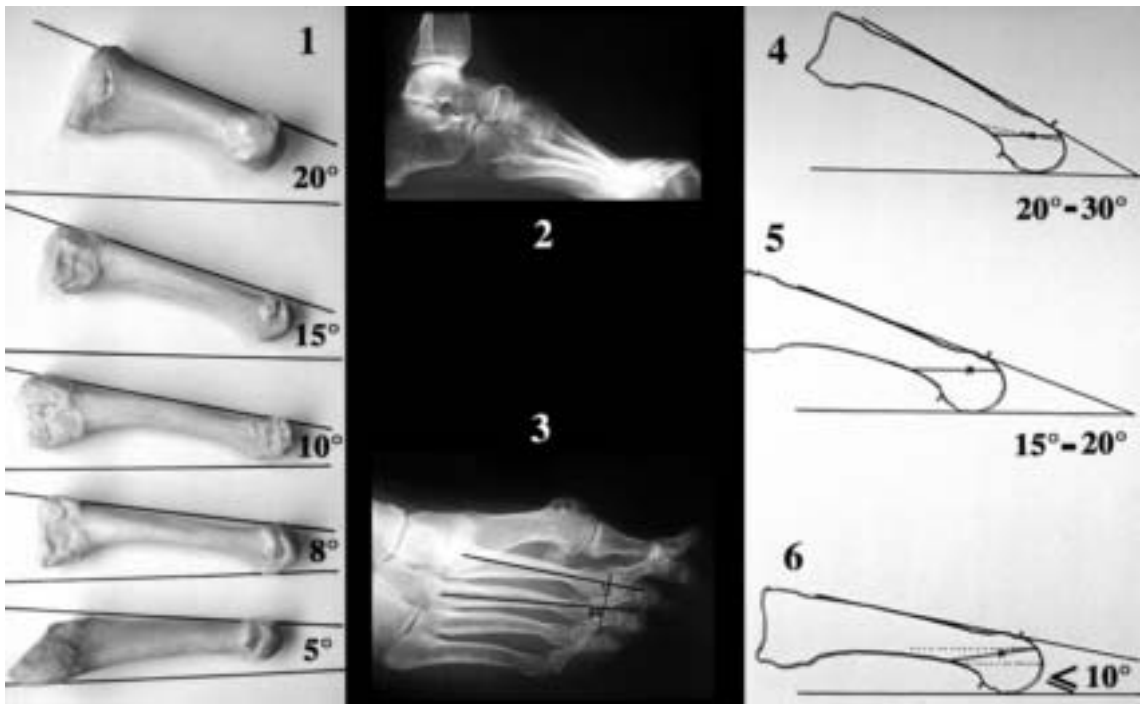
metatarsal joint is unable to compensate this lowering. Lowering may be observed in the two lesser metatarsals but the cuboido-metatarsal joint may provide the appropriate compensation. The medial oblique X-rays views is helpful to assess the plantar slope of the lesser metatarsals.

In the transverse plane, the **metatarsal parabola** was also studied by Tanaka [117] and Maestro, Ragusa and Besse [83]. Both the transverse and the sagittal planes have to be taken into account in the assessment and the management of the Weil osteotomy, as indicated in Figs. 17.



**Fig. 17a3. Blood supply of lesser metatarsal heads.**

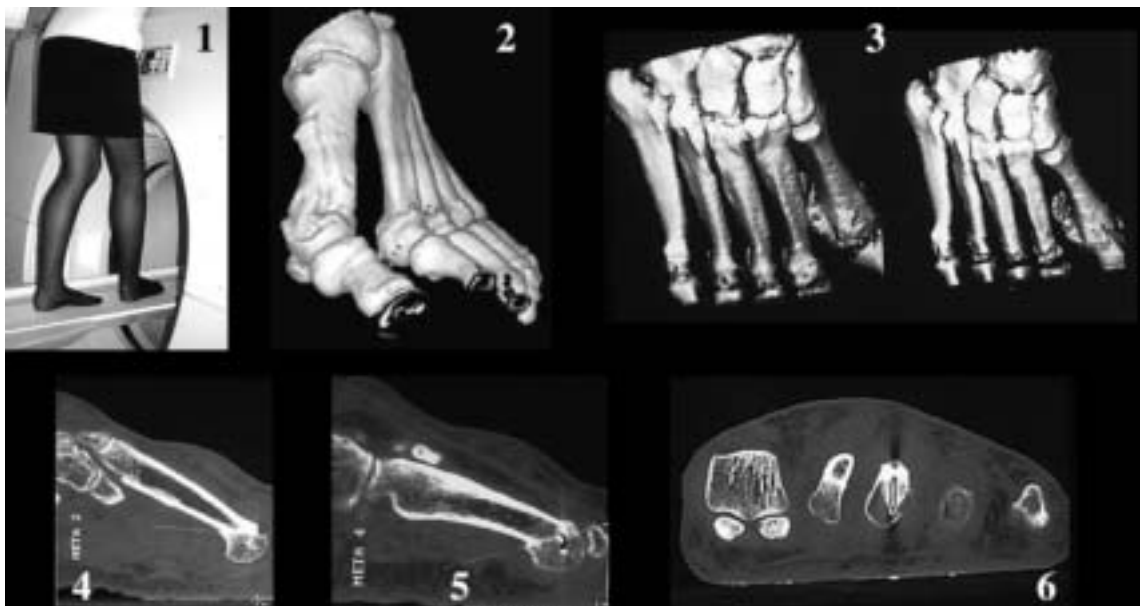1. *Dorsal aspect*: the *dorsalis pedis* arteries give small metaphyseal capital arteries (a).
2. *Plantar aspect*: in fact, the main blood supply is a special plantar metaphyseal capital artery (c), one for each metatarsal head, which arises from the corresponding intermetatarsal artery (b). This special artery penetrates the head in its lateral aspects, through the capsule. The Weil osteotomy (saw blade S) does not jeopardize this special artery and this is certainly why head necrosis doesn't occur in this osteotomy. This blood supply was studied by B. Valtin and T. Leemrijse (Paris), who provided these pictures. The study was carried on seven specimen feet, after latex artery injection.



**Fig. 17a4. Weil osteotomy: relationships with metatarsal plantar slope 1.**

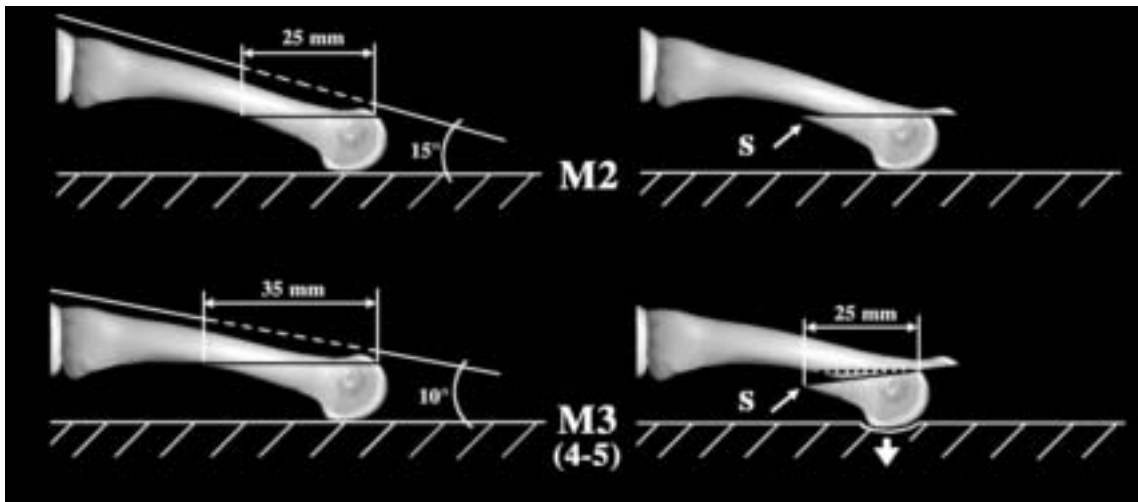
M. Benichou (Montpellier, France) who provided these pictures, studied the plantar slope average of the metatarsals (1) and the relationships with the usual Weil osteotomy cut (4, 5, 6): The cut (20 to 25 mm long) can be horizontal for the 2nd metatarsal but it has a plantar inclination for metatarsals with less plantar slope, *i.e.* the three last metatarsals.

2. The standing sagittal X-rays view can assess the plantar slope for the first metatarsal but not for the lesser ones: For these metatarsals the *medial oblique X-rays view* (3) can not assess the absolute plantar slope, but the relative slope between each metatarsal.



**Fig. 17a5. Weil osteotomy: relationships with metatarsal plantar slope 2: TDM aspect slope.**

Study made by B. Valtin and T. Leemrijse (Paris) with 3D CT scan shows the Weil osteotomy cut in the different metatarsals. On the 2nd and the cut is horizontal, or slightly dorsal inclined (4). On the 3rd, 4th, 5th ones it is plantar inclined (5).

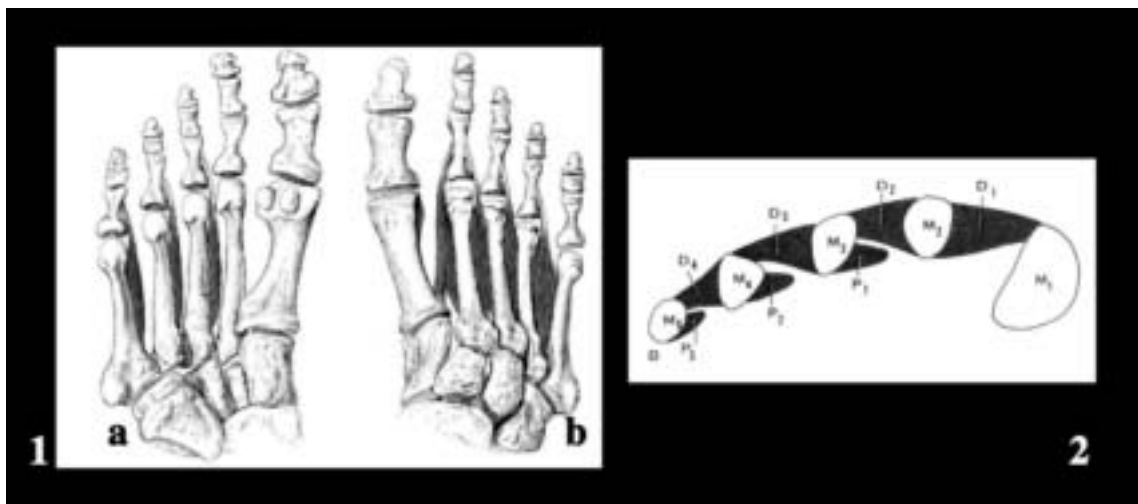


**Fig. 17a6. Weil osteotomy: relationships with metatarsal plantar slope 3.**

– For M2 the 25 mm long saw blade can be horizontal and entirely cuts the metatarsal but the plantar fragment presents a proximal sharp spike(s).

– For M3, M4 and M5, since the plantar slope is  $10^\circ$  or less, the saw blade should be 35 mm long to remain in an horizontal plane. The 25 mm long usual saw blade entirely cuts the metatarsal but with a plantar inclination which results in lowering the metatarsal head and increasing the spike prominence(s).

These last three Figures. (16 a4, a5, a6) emphasize the need to perform a second layer in most cases of Weil osteotomy. This second layer, combined with a large shortening, reduces the insufficiency of MTP plantar flexion described by Trnka and Myerson (54).



**Fig. 17a7. Interosseous muscles on the forefoot.**

1. Picture from the *Sobota Anatomy* book.

a) The interosseous *plantar* muscles are located only on the 3rd, 4th and 5th metatarsals.

b) The interosseous *dorsal* muscles are located on the four lesser metatarsals.

2. Picture from the *Sarrafian foot anatomy* book (83). Some observation on the plantar and dorsal interosseous: these observations explain why the active plantar flexion is more difficult for the 2nd toe than for the more lesser toes.

## Technique

**Approach.** Although several authors, like L. S. Weil, use a transverse incision (for multiple osteotomies), we prefer performing the Weil osteotomy through longitudinal skin incisions, one incision for adjacent metatarsals. The metatarsal approach is located between the longus and the brevis extensor tendons.

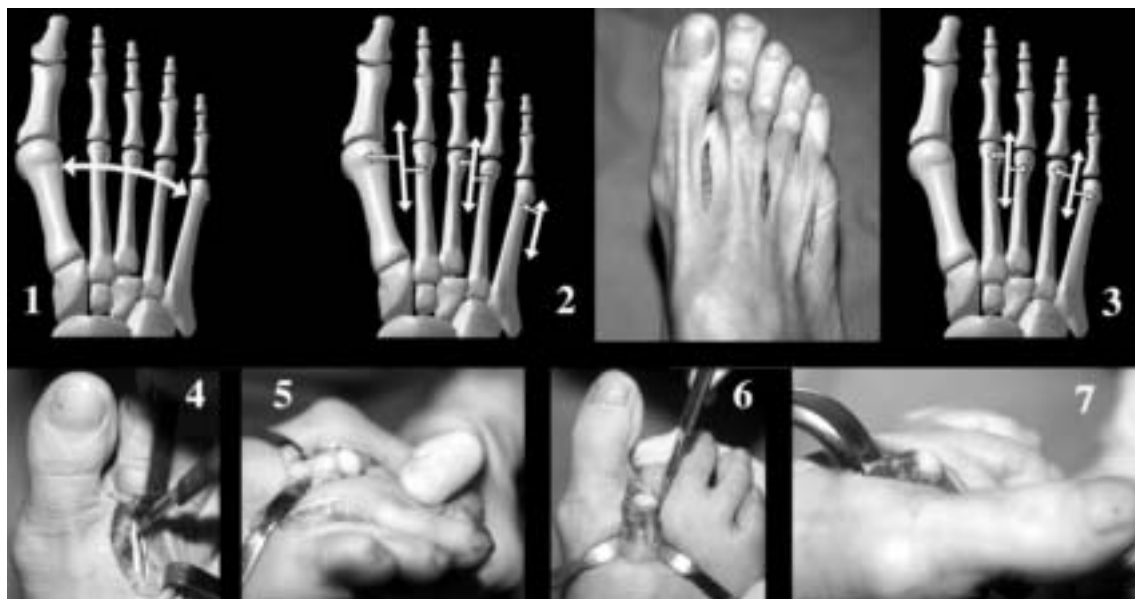**Osteotomy.** The type of osteotomy cut depends on the number of metatarsals and the degree of shortening. A long horizontal cut to shorten the metatarsal upper part of the metatarsal head avoids injury to the joint. A *double layer* is most often performed. The soft tissues are respected as far as possible. The relative metatarsal lengths are determined not with the heads but with the proximal fragment, except for the M1-M2 relationship.

The Maceira “3 steps” modified weil osteotomy (Fig. 17b4b) [102] is completely extra articular and shortens the metatarsal following his longitudinal axis, thus without any head lowering.

However, the fragmental area surface is relatively small; this technique seems to be reserved for small to medium displacements, although Maceira use it whatever the magnitude of the shortening.

**Fixation** is achieved by the *special twist-off screw* we developed with the French *Pied Innovation Group*\*. It is compressive, self-tapping and flat-headed. It may be combined with the *Weil and Schwartz Snap Of Compression Pin* (S.O.C.Pin), which may also be used alone.

\* M. Augoyard (Lyon), L. S. Barouk, M. Benichou (Montpellier), M. Maestro (Nice), J. Peyrot (Lyon), M. Ragusa (Grenoble), B. Valtin (Paris).



**Fig. 17b1. Weil lesser metatarsal osteotomy: technique. The approach.**

1. Although a transverse approach is used by several authors, even by L. S. Weil himself, we use a longitudinal approach (2, 3), generally one incision for adjacent metatarsals, notably in order to avoid skin problem, and to facilitate the surgery in case of large metatarsal shortening.

2. Approach with hallux valgus correction.

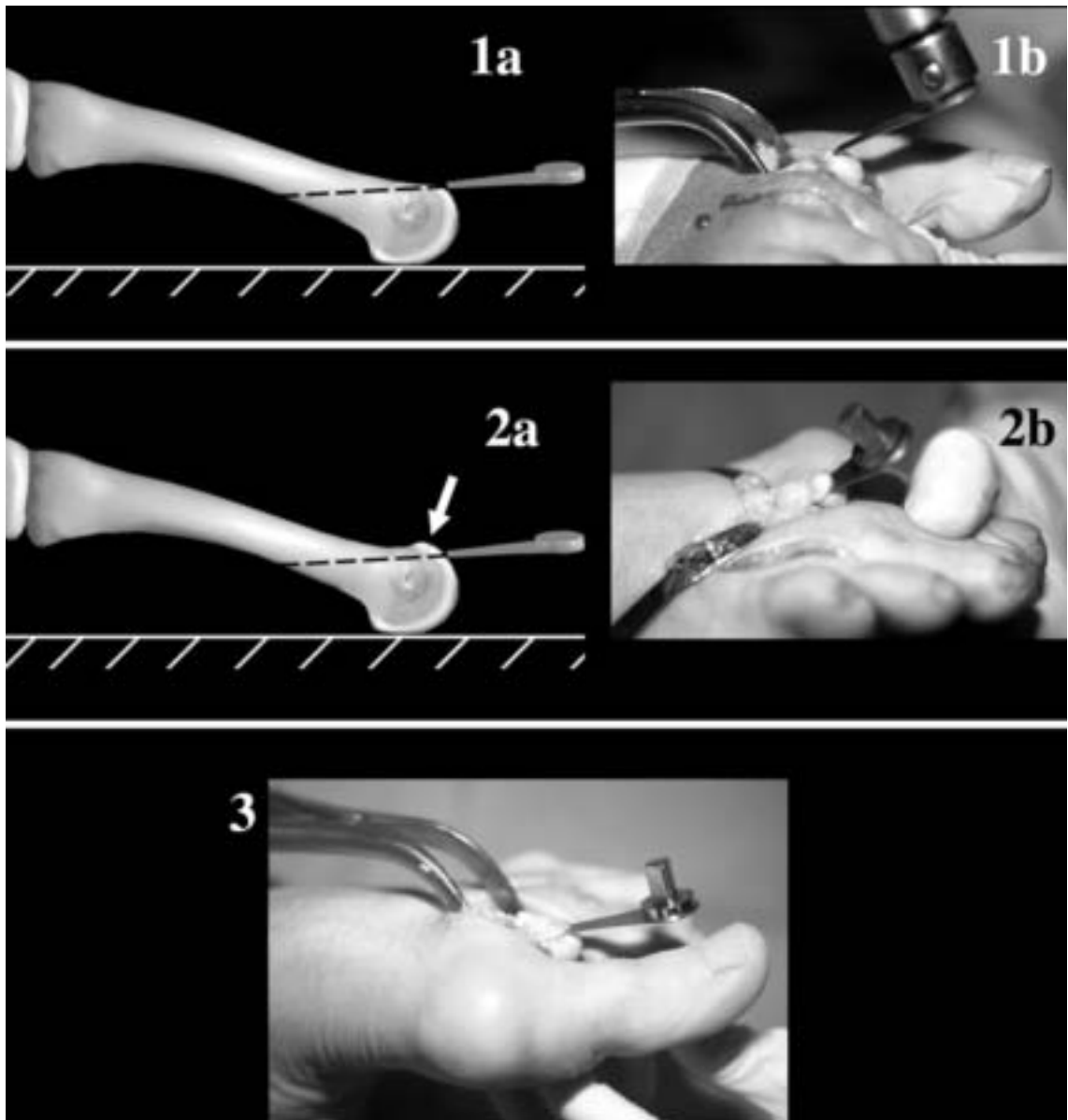
3. Approach without hallux valgus correction.

4. Metatarsal approach between the longus and the brevis extensor tendons (5), setting two Hohmann retractors (5), cutting in most cases the lateral ligaments (6) and setting a special hinge retractor to protect the soft tissues (7).

5. Setting two Hohmann retractors (5).

6. Cutting the lateral ligaments (6).

7. Setting a special hinge retractor (7).



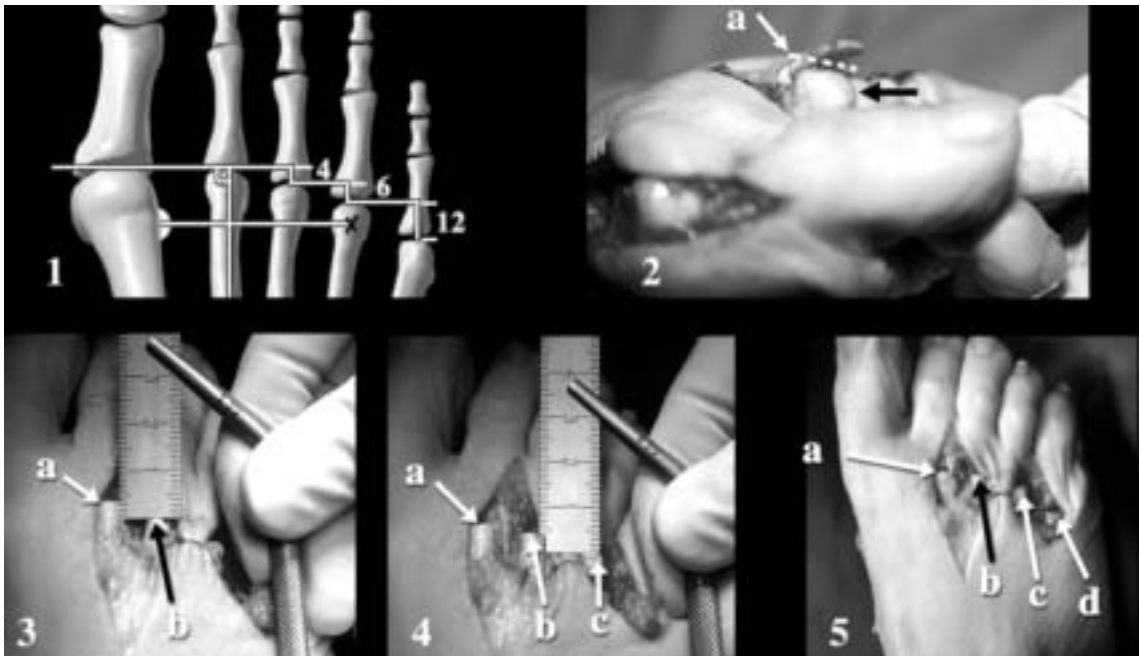
**Fig. 17b2. Weil osteotomy technique: *The cut.***

1. **a-b.** In case of flat dorsal aspect of the head, the cut can be almost extra articular.
2. **a-b.** In case of round dorsal head, small removal of the head is necessary.
3. In all cases, the cut has to be the most horizontal as possible in order to shorten the metatarsal without lowering.

An X-ray control is necessary both to check the metatarsal length and the head rotation. At last, soft tissue surgery is performed as required

on extensor or flexor tendon and on MTP joint, notably to correct remaining sagittal inclination.






**Fig. 17b3. Metatarsal parabola: shortening of the metatarsals.**

1. This is the metatarsal parabola that has to be respected: Equality of the two first metatarsals – the 2nd metatarsal may be slightly longer but never the first –, then as a rule, 4, 6 and 12 mm decreasing length (studies of Tanaka, Maestro, Ragusa, Besse).

2. We have to *respect* in most cases the *spontaneous proximal translation of the head*, then to cut the peak on this level (a).

3, 5. Since the metatarsal length assessment is difficult when looking at the heads, we prefering making the resection on *the proximal metatarsal fragment*.

3. The 3rd metatarsal (b) is cut for having 4mm less than the 2nd one (a). 4. The 4th metatarsal (c) must be 6 mm less than the 3rd one. 5. The 5th metatarsal must be 12 mm less than the 4th one.



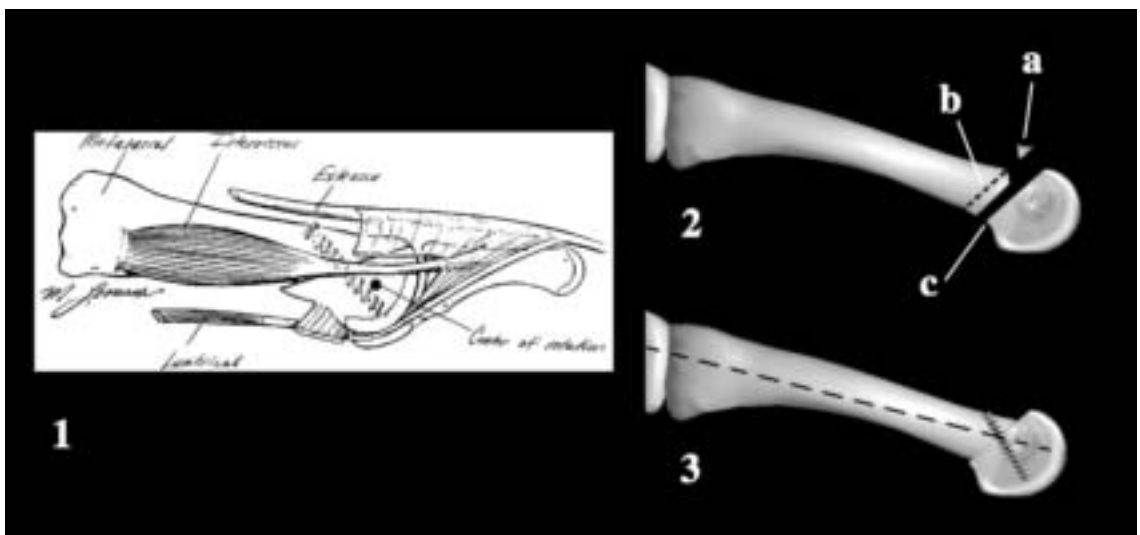
**Fig. 17b4a. Weil osteotomy technique: the 2nd layer.**

1, 4, 5. It is necessary to expose the plantar aspect of the proximal fragment in order to assess the top of the angulation made by the osteotomy cut (e). Then two cases are encountered:

1. The peak is thin, we only make a proximal closing wedge.

2. The peak is too thick: Bone removal both proximal and distal.

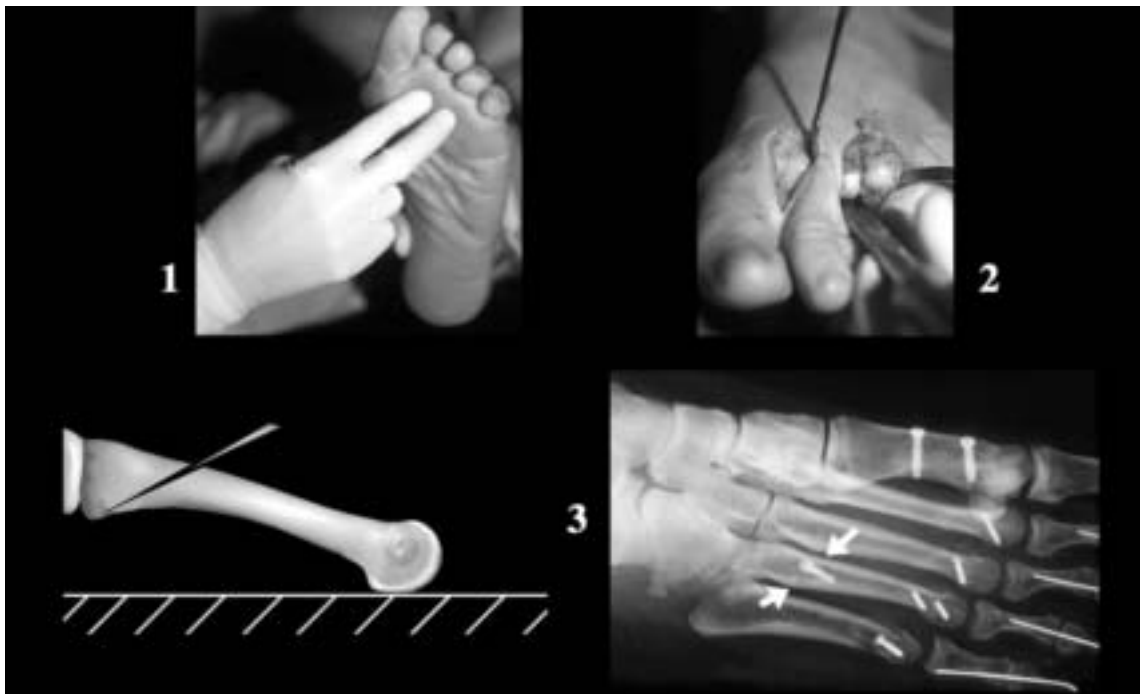3. Final result: The spike prominence(s) has disappeared, the head is elevated and also well rotated, which increases the toe ground contact and enlarges the plantar head cartilage area. At last, the fragmental contact is correct.



**Fig. 17b4b. Trnka, Myerson and Maceira observations and technique modification.**

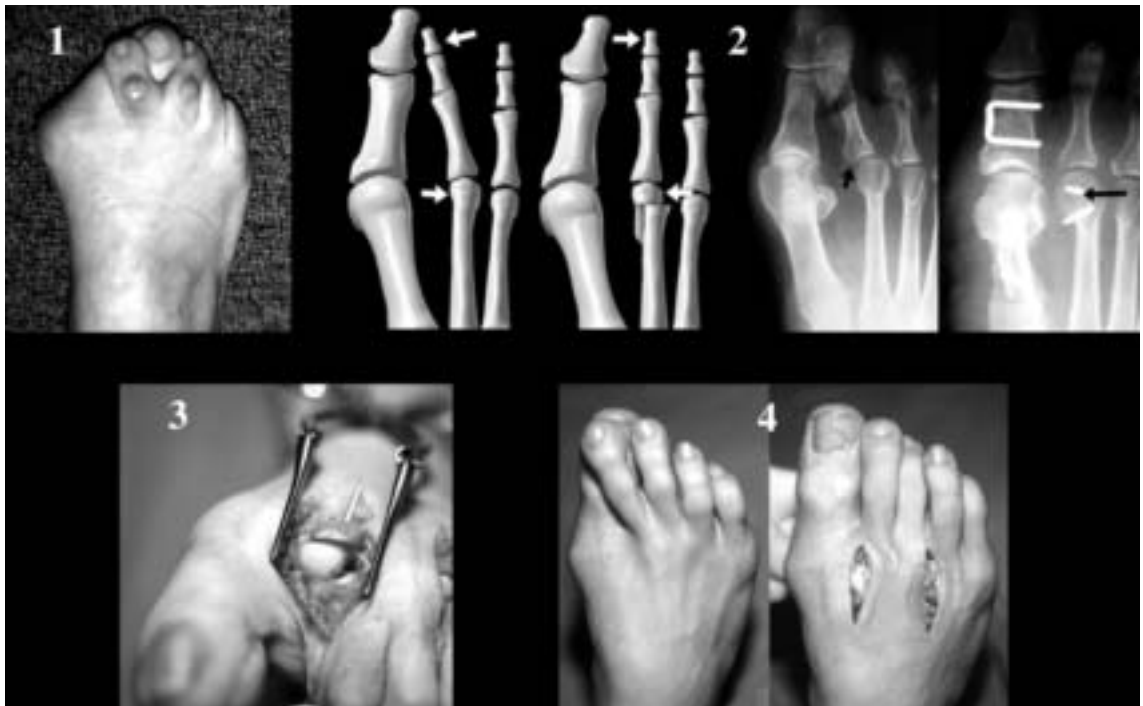
1. Trnka and Myerson (93) observed that after Weil osteotomy, the metatarsal head center is located among the interosseous muscle so that the active plantar flexion of the proximal phalanx is not possible: however, this observation does not take into account the Weil osteotomy performed with a second layer.

2. The Maceira “3 steps” osteotomy, following the Trnka and Myerson observation, is a shortening of the metatarsal following its longitudinal axis thus it does not need a second layer. However, the fragmental contact area is not so large than in our Weil technique and the cut is oblique, this resulting in a less strong osteosynthesis.



**Fig. 17b5. Weil osteotomy technique: final assessment of the plantar head location.**

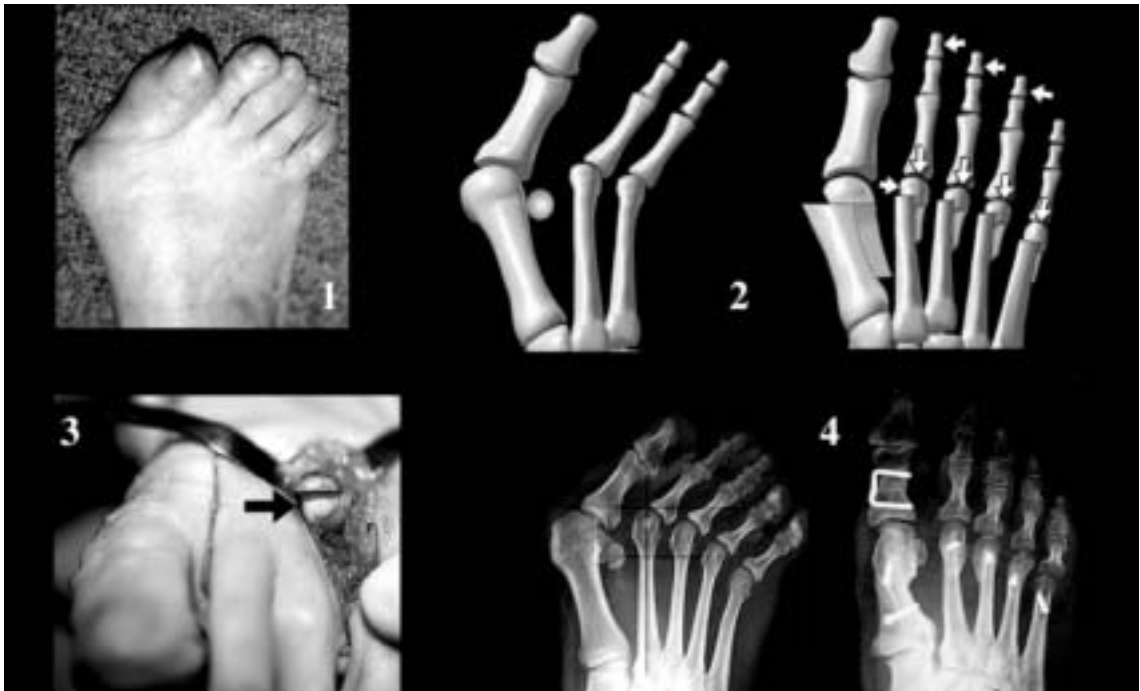
It is mostly made by palpation or by looking directly at the heads (1, 2). If one head is too low (2), we have to perform a basal dorsal wedge BRT osteotomy (3) (see later).



**Fig. 17b6. Weil osteotomy. Head transversal displacement for crossover 2nd toe.**

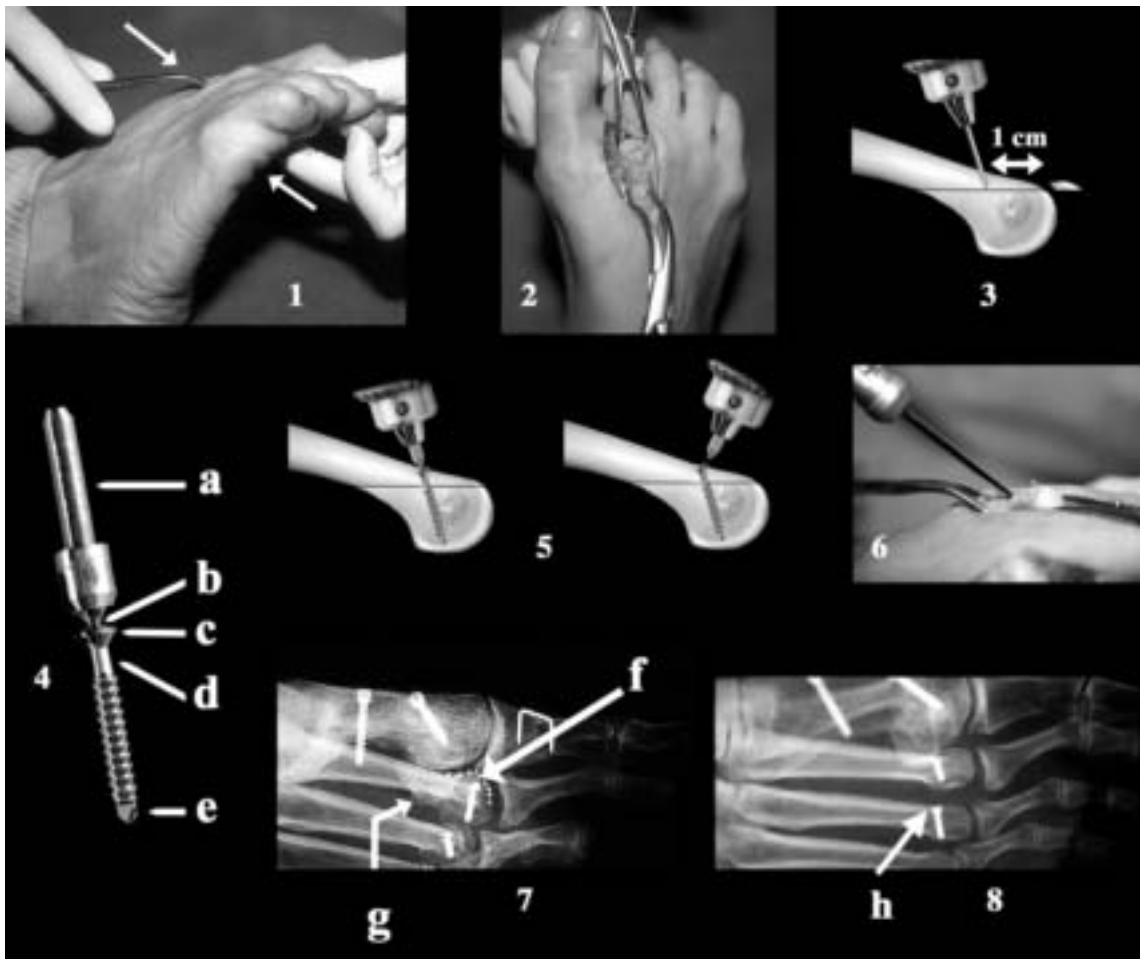
1, 2, 3. In overlapping 2nd toe, the 2nd metatarsal head is in a lateral location and has to be medially displaced.

4. Operative view before and just after the Weil osteotomy: The medial head shift is spontaneous and is sufficient to correct the deformity. We just have to fix the head, avoiding any transversal rotation (X-ray control).



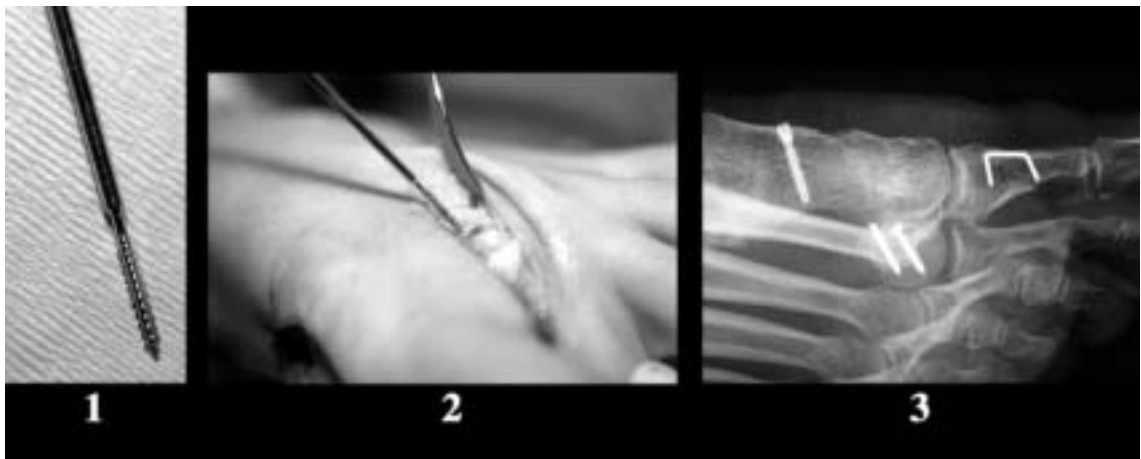
**Fig. 17b7. Weil osteotomy. Head transverse displacement for lateral wind-swept toe.**

In this deformity, the head has to be shifted laterally but *above all proximally*, to ensure the reliability of the correction.



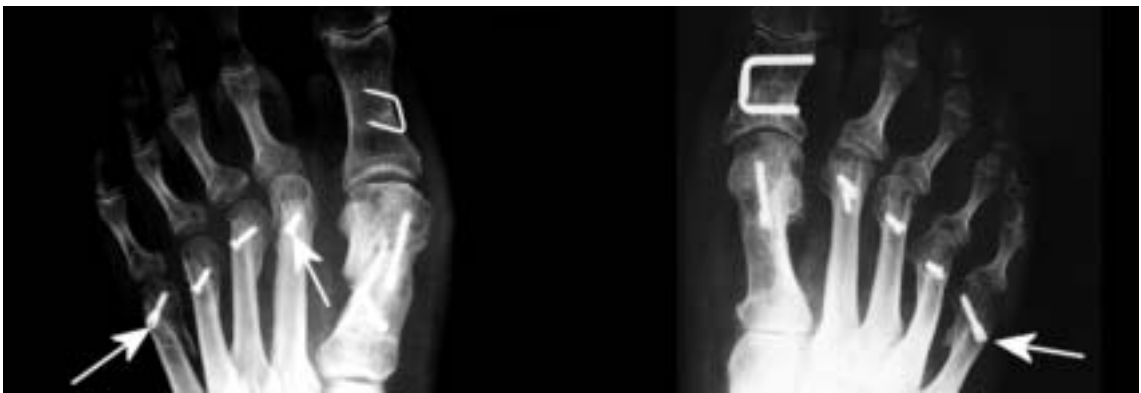**Fig. 17b8. Weil osteotomy technique. Fixation by the twist-off screw (DePuy).**

1. The best way to coaptate the fragments is a plantar pushing of the head with a finger while maintaining the dorsal fragment (Banaleck clamp).
2. Then the operator holds the metatarsal head with a small clamp and with the other hand makes a pre-drill with a thin K-wire *just in the dorsal fragment* (3). Then the special twist-off screw is set with a slow motion motor, as far as the screw head be in bone contact.
5. At this moment, breaking the support is performed by a forward motion (not by continuing the screw rotation). For this it is recommended *not* to have a speed motor rotation. We use preferably the Aesculap motor.
6. The fixation is always finished with the screw driver.
4. The *twist-off* screw is then above all a *snap-off* screw. It is composed of a support (a) with a thin attach to facilitate the rupture (b). The head is flat (c). There is a no threaded part to provide compression (d). Self perforation tip (e). The use of thin K-wires is nevertheless recommended to have more time to break the support.
7. f-g. Incorrect position of the screw (too distal) resulting in MTP stiffness.
8. h. Correct location of the screw (1 cm from the top of the metatarsal head).



**Fig. 17b9.** Weil osteotomy technique: *fixation by the SOC pin.*

The SOC pin is devised by L. S. Weil and N. Schwartz. It also provides fragment compression and has a self rupture of the support. We use thin pin in complement to the twist-off screw, particularly in osteoporotic bones (3).



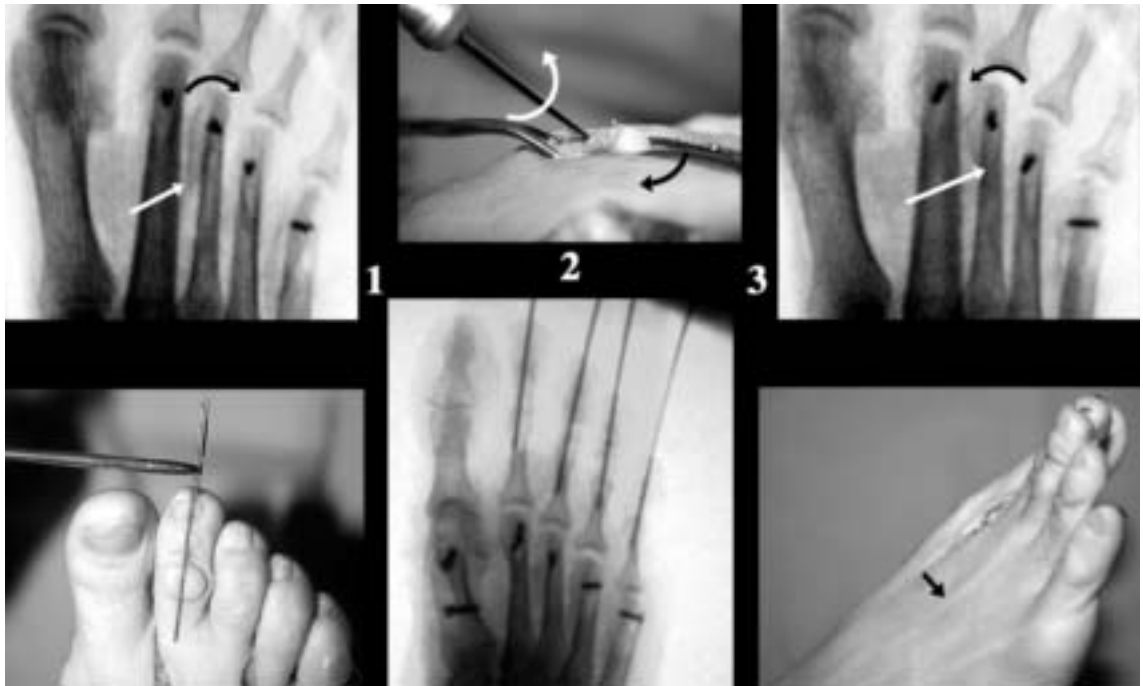
**Fig. 17b10.** In the second and in the fifth metatarsals, the FRS 2.5 screw may be used instead of the twist off screw ; in the fifth metatarsal, we use almost only the FRS screw, because of secondary problem between the head of the twist off screw and the shoe. In the second metatarsal, and eventually in the others, we use the FRS screw only in case of insufficiency of fixation by the twist off screw.



**Fig. 17b11.** Weil osteotomy technique. *Peak smoothing.*

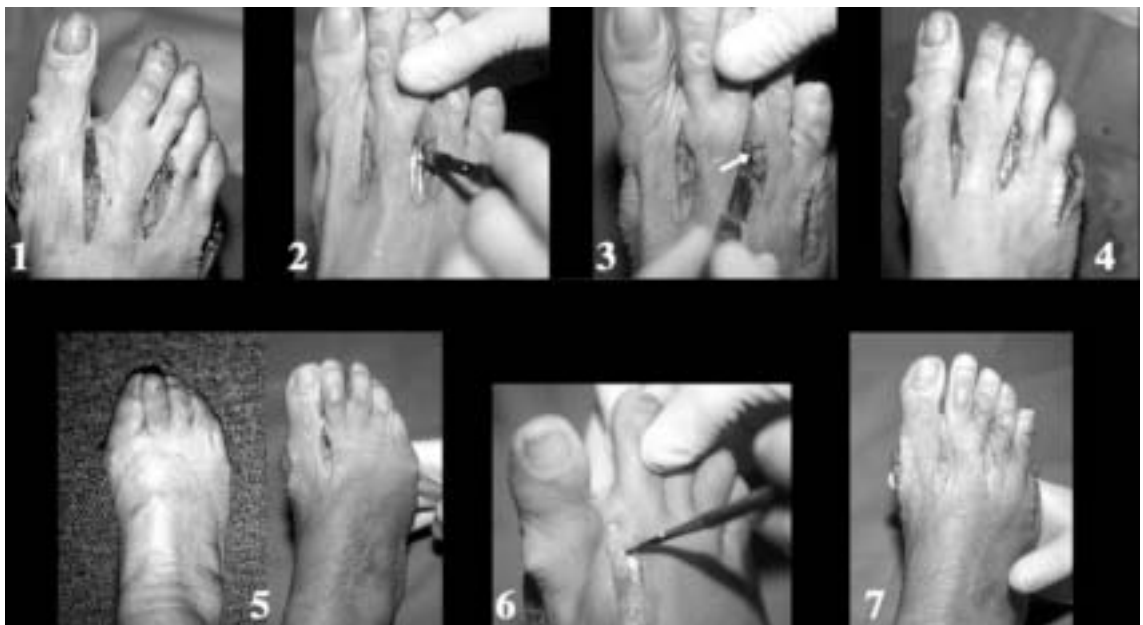1. Generally the peak is thin and smoothing is not necessary.

2. Nevertheless, we have sometimes to smooth it. In this case, we add some bone wax.



**Fig. 17b12. Weil osteotomy technique. Metatarsal head rotation check; toe K-wiring.**

- 1, 2, 3. It is difficult to assess the rotation head clinically. So we use an X-ray control. The white arrow indicates a lateral 3rd head rotation. Then we make a little unscrewing, we turn the head with a small clamp and we finish the screwing.
- 4, 5. We set a K-wire which does not cross the MTP joint, for ensuring the hammer toe correction when necessary.
6. Once the K-wiring is made, we can assess the necessity to perform extensor tendon lengthening.



**Fig. 17b13. Weil osteotomy technique. Correction of remaining toe transverse inclination.**

- 1 to 4. In case of toe *lateral* inclination remaining, we perform medialisation of extensor brevis tendon (2) and lateral MTP release (3). Same foot: result (4).
- 5, 6. Medial inclination in case of toe *medial* inclination remaining.
7. Final checking by LST.

## Indications

### Metatarsalgia

Recurrence of metatarsalgia is almost never observed in a more proximal location, but we must respect the following points:

1) To respect the relative length of the metatarsals, both in the transverse and in the sagittal plane.

2) To perform second layer and remove a small (1-3 mm) piece of bone in most cases.

These points will be detailed in the chapter about metatarsalgia.

Single metatarsalgia of the 2nd ray is detailed in the chapter on 2nd ray pathology.

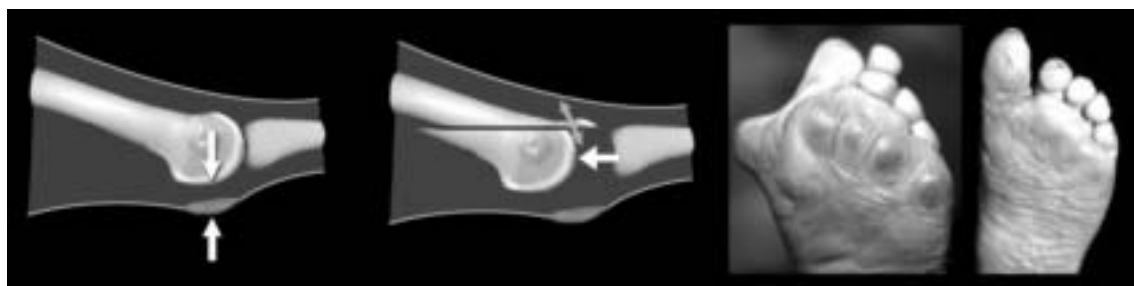
### Indications in Claw Toe and MTP Dislocation (Longitudinal Decompression)

#### Hammer Toe or Claw Toe

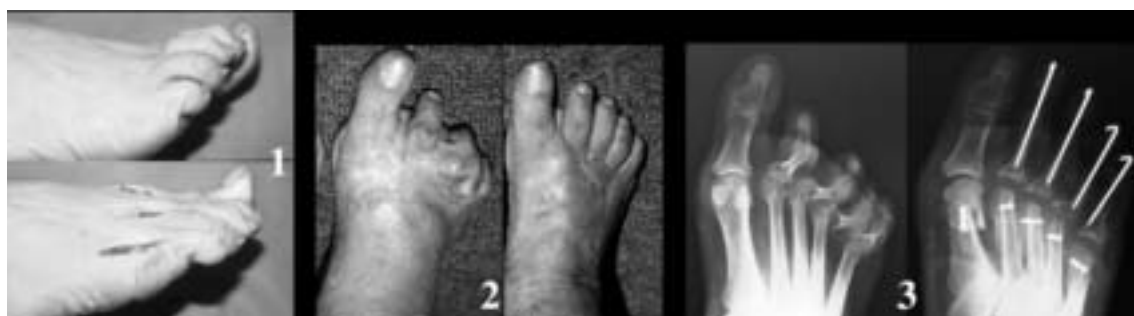The Weil osteotomy is very effective in the correction of hammer or claw toe. Thanks to this procedure, the toe deformity can be corrected without PIP arthroplasty or fusion, but with toe K-wiring for one month. The indications are detailed in the chapter hammer toe deformity.

#### MTP Dislocation

The Weil osteotomy is by far the best technique for correction of MTP dislocation. It is detailed in the chapter about MTP dislocation.



**Fig. 17c1. Weil osteotomy indications 1) proximal translation of the metatarsal head for metatarsalgia.** Almost no proximally recurrence of metatarsalgia was observed after Weil osteotomy, which is an excellent treatment for metatarsalgia with metatarsal length excess (see later: metatarsalgia), but at the condition to perform a second layer.



**Fig. 17c2. Weil osteotomy indications 2) longitudinal decompression.**

#### a) Hammer toe correction

1. Intraoperatively, hammer toe deformity correction is automatically resulting from the Weil osteotomy: Same foot before and just after the Weil osteotomy.

2, 3. Some foot = Clinical and radiological result after Weil osteotomy and K-wiring. Neither fusion nor arthroplasty on the lesser toes were necessary.



*Excess of Lesser Metatarsal Length*

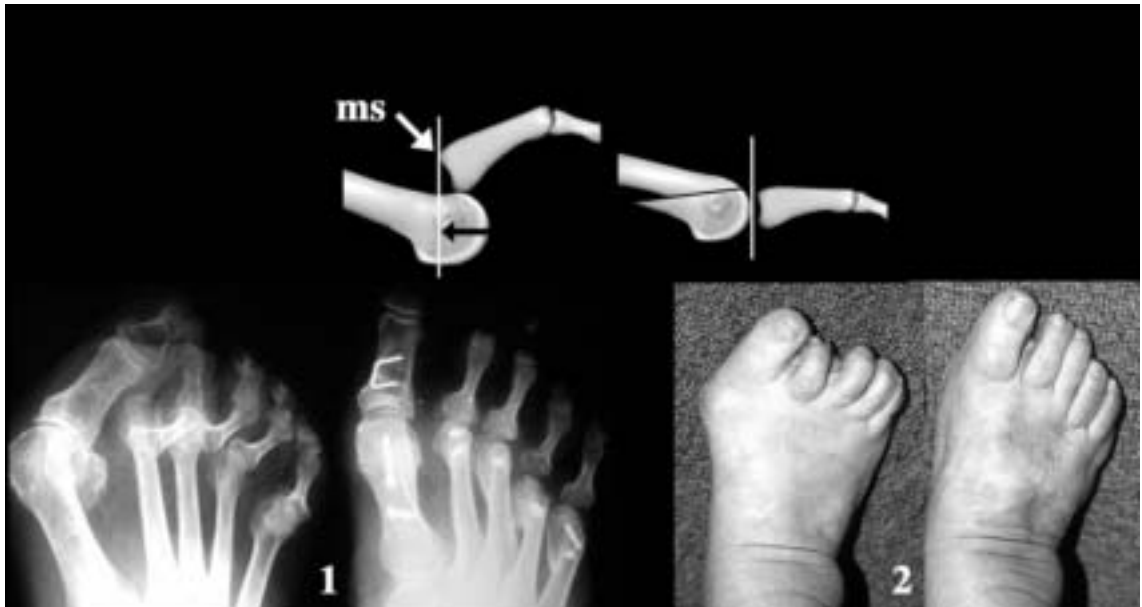In this indication, the Weil osteotomy not only allows shortening of the metatarsal as far as necessary, but also allows to adjust this shortening very accurately. This shortening may be necessary in primitive or iatrogenic excess of the lesser metatarsal length.

*Indications in Overlapping and Wind-Swept Toes (Transverse Displacement)*

See also the corresponding chapters.

*Medial shift of the head* is indicated in cross-over 2nd toe or in 5th metatarsal bunionette.

*Lateral shift of the head* is indicated in lateral wind-swept toe deformity or in diverging toe deformity.

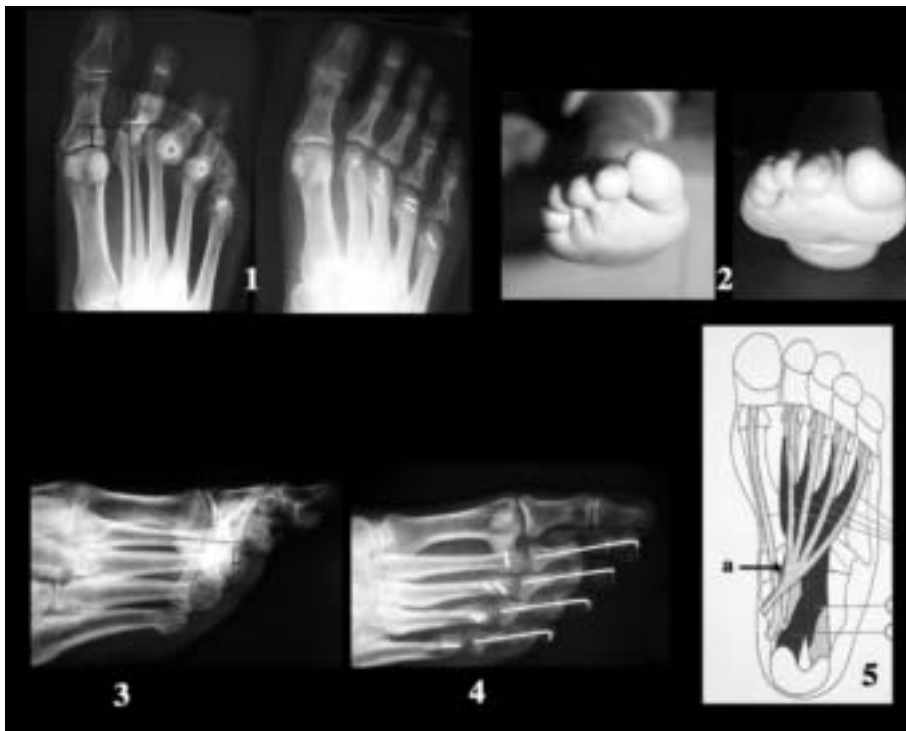


**Fig. 17c3. Weil osteotomy indications 2) longitudinal decompression.**

*MTP dislocation*

The proximal head translation has to be on the minimum at the frontal level of the basis of the phalanx, to ensure the correction (ms point).

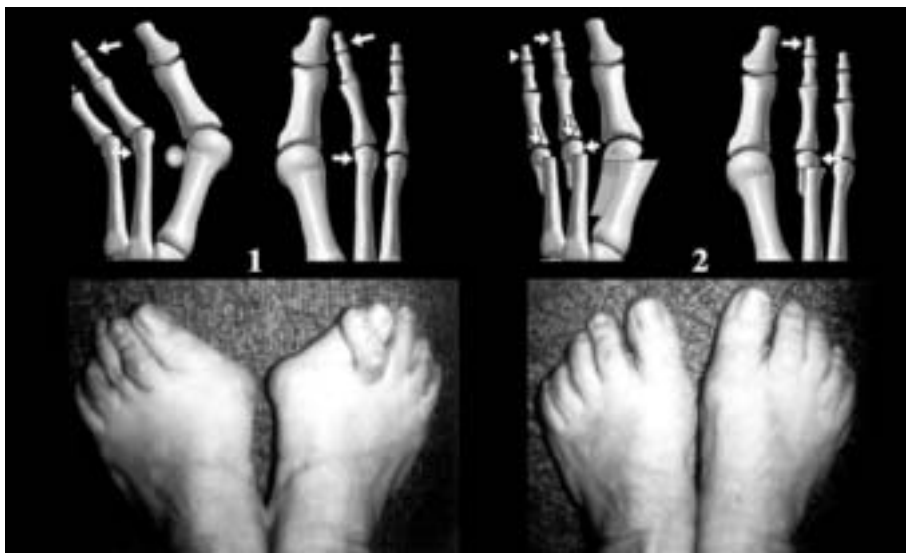
1, 2. The Weil osteotomy allows to correct MTP dislocation whatever its importance.



**Fig. 17c4. Weil osteotomy indications 3) excessive length of the lesser metatarsals.**

Weil osteotomy provides accurately the appropriate shortening. 1, 2. Preoperative aspects and one year postoperative follow-up. 3, 4. Same foot: Medial view. Note the MTP dorsal flexion correction and the combined temporary K-wiring.

5. Care has to be taken in claw toe resulting from lesser rays large shortening without shortening of the first metatarsal: In this case, release of the attachment between the first and second flexor tendon should be sometimes necessary (picture provided by P. Diebold).



**Fig. 17c5. Weil osteotomy indication 4) Transverse deformity.**

1. Preoperative aspect. Right foot, overlapping 2nd toe. Left, wind-swept.

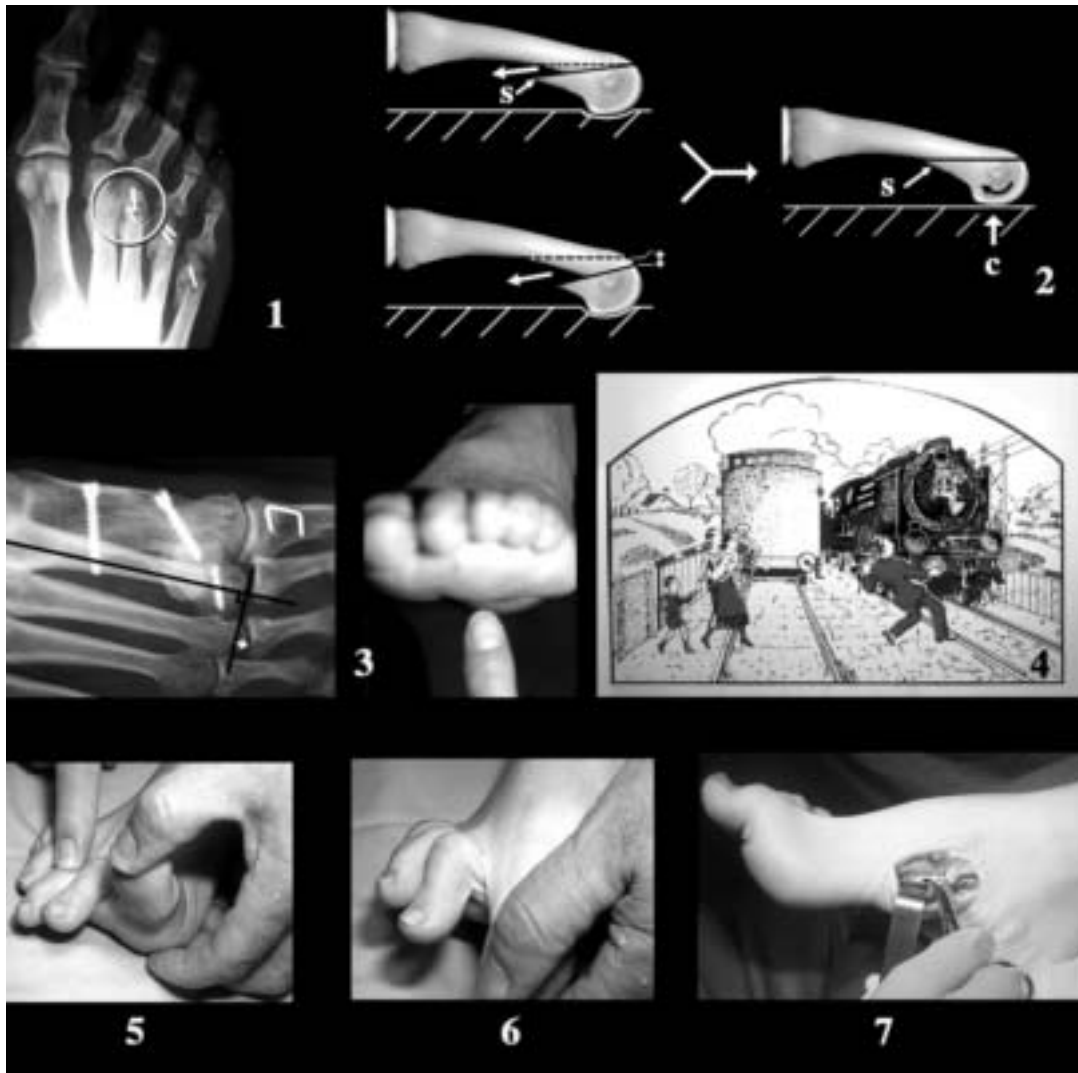
2. Postoperative, same patient. Correction was obtained by adapted lateral or medial shift of the metatarsal head.

### Weil Osteotomy: Drawbacks

Secondary malunion or metatarsal head necrosis are almost not observed with this procedure.

Transfer metatarsalgia can be avoided by respecting the metatarsal relative lengths, both in a

dorso-plantar and in a medial oblique view. At last, care has to be taken to respect the relative length between the first and the lesser metatarsals; the combined first metatarsal shortening may be performed if required. On the other hand, the double layer is extremely useful to avoid most of the drawbacks.



**Fig. 17d.** Weil osteotomy drawbacks.

1. *Secondary malunion* can be avoided by better fragmental contact provided by the second layer (2) and a strong fixation (one screw, one soc pin).

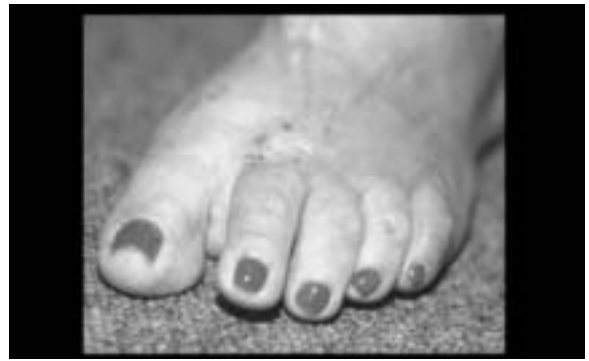3. When a single metatarsal osteotomy is performed, the fixation has to be particularly strong, to avoid secondary proximal sliding, which results in transfer metatarsalgia. Anyway, an isolated shortening of one metatarsal is often delicate. To illustrate this, a notice picked out from a level crossing in France: The text is “don’t cross without looking in the two directions: a *train could hide another one*” (4).

5, 6, 7. If the first ray is not shortened (or not enough), loss of toe ground contact or remaining claw toe may be observed, mainly because of the anastomosis between the flexor *hallucis longus* and the common flexor *digitarum* tendon. This test allows to explain and to assess the necessity of cutting this anastomosis by a separated medial foot approach (pictures by courtesy of P. Diebold). In France it is called “*syndrome de l’attelage*”.

## **MTP Stiffness after Weil Osteotomy**

Generally, after the first cases were performed with enthusiastic results, surgeons observed some MTP stiffness, generally loss of plantar flexion, notably of the second ray. This is a second step; we observed the same chronology. However we have worked to analyze the causes, and adapted specific techniques and postoperative management.

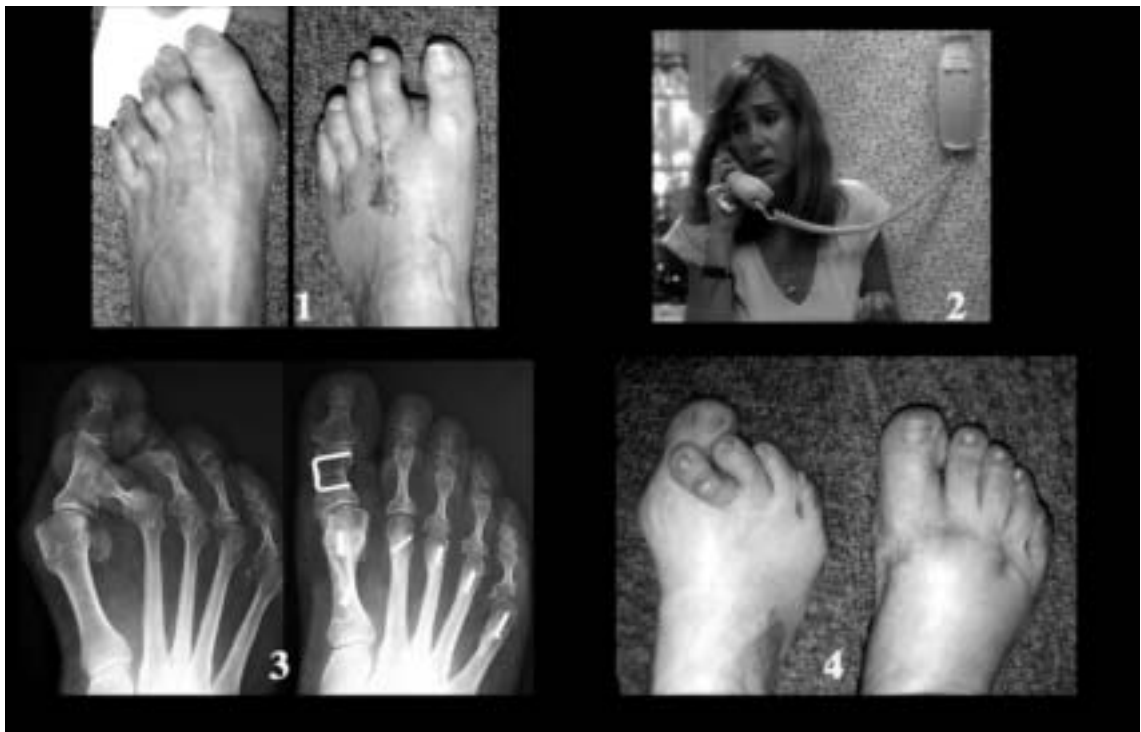Now we can write that we have virtually eliminated this complication, thanks to the respect of the pre, per and postoperative specific points.



**Fig. 17e1. Weil MTP stiffness**

When this problem occurs, it is mainly on the 2nd ray and with loss of the ground contact.

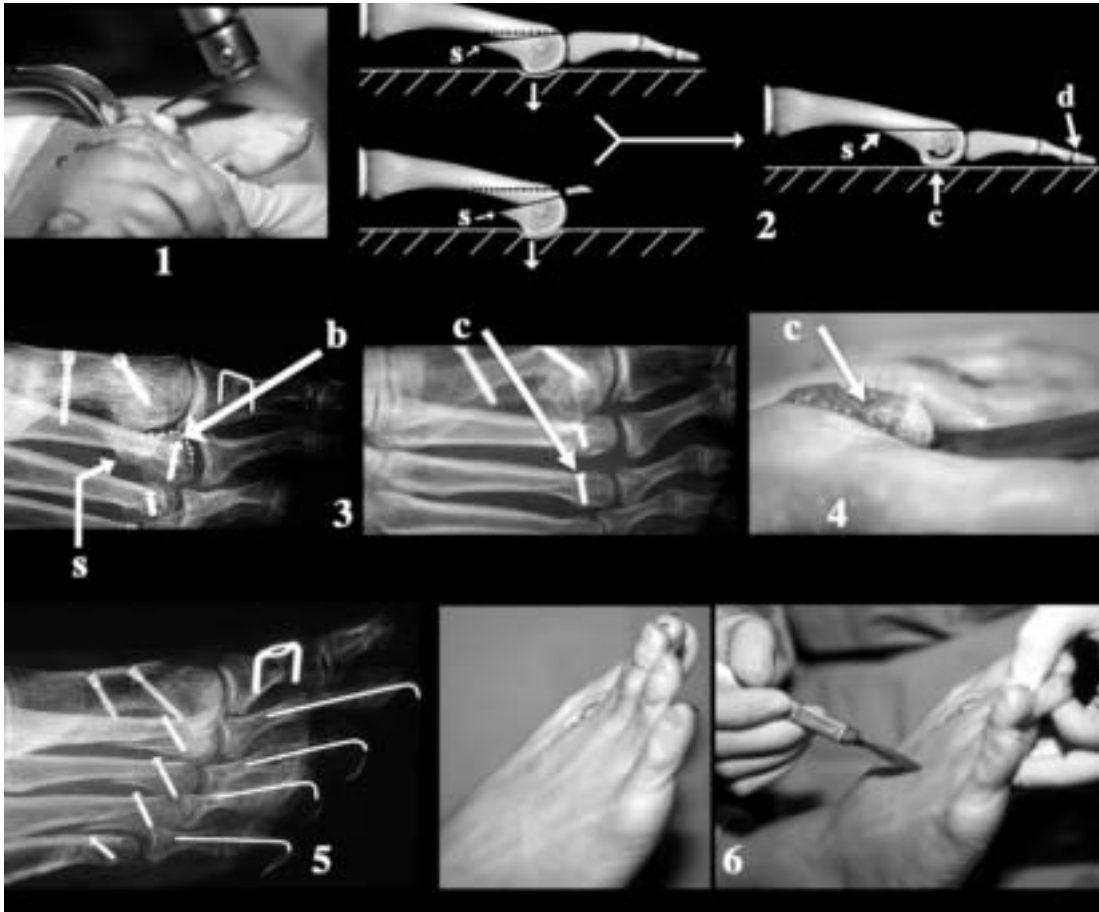
Now the MTP stiffness is very rare thanks to the prevention we detail on the following plates.



**Fig. 17e2. Weil MTP stiffness prevention – preoperative aspects.**

1. Contraindications of Weil osteotomy are trophic troubles with cold foot, very thin foot or cheloid scar tendency, or very anxious and young patient (2).

3, 4. Warning to the patient: “You have an advanced deformity: We must perform an invasive surgery which includes some postoperative care: Your participation is highly required for postoperative self-training of your toes”.



**Fig. 17e3. Weil MTP stiffness prevention: *intraoperative aspects.***

1. Preserving the head cartilage as far as possible.
2. Performing a second layer to eliminate the spike (s) and provide plantar rotation of the toe (d).
3. Not setting the screw too distal but more proximally.
4. Preserving the soft tissue as far as possible (setting the screw without impairing the soft tissue).
5. Toe K-wiring excluding the MTP joints.
6. Correction of dorsal MTP flexion, notably by required lengthening of the extensor tendons.

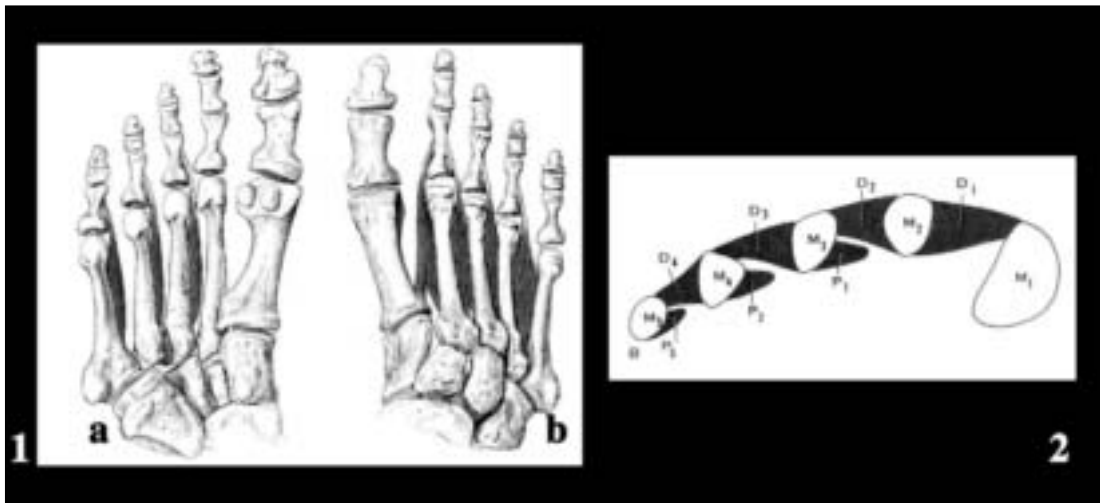
*Preoperatively*, contraindications are **trophic troubles** like *cold feet* or *too thin feet*, very anxious patients (CRPS syndrome), or *mild deformity* or mild pain (except for the 2nd metatarsal).

*Intraoperatively*, by *respecting soft tissue*, performing a *double layer* in most cases, a strong fixation, the lengthening of the extensor tendons and the accurate *respect* of relative metatarsal length.

*Postoperatively*, accurate toe strapping in plantar flexion, self-training notably for plantar motion of the MTP joints.

Apart from a case of a 2nd metatarsal osteotomy, we now perform a *large shortening of the metatarsals by Weil osteotomy*, which is the *more reliable way to avoid MTP stiffness*.

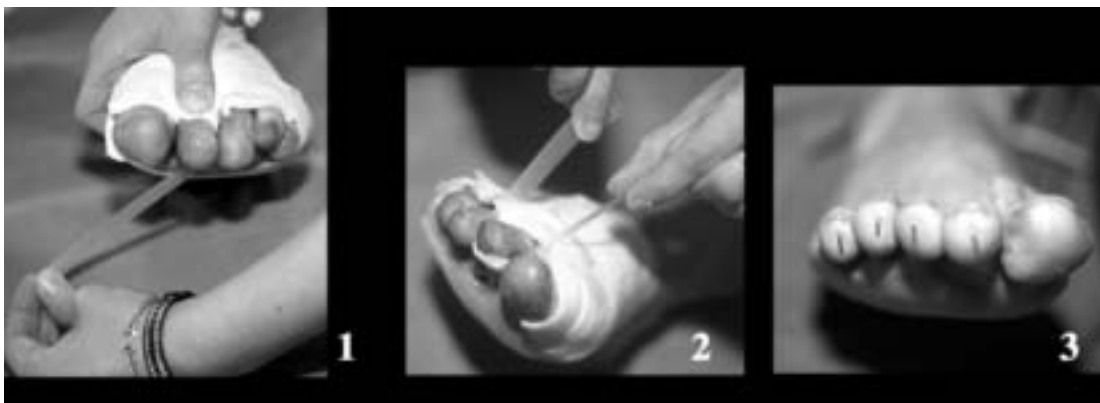
When the stiffness remains, after one post operative year, the MTP release provides usually good results (Fig. 17e5c). In this case, the *percutaneous* or *mini invasive MTP release* is a great improvement.



**Fig. 17e4. Decreased 2nd toe active ground contact.**

This picture to remind that there are no plantar interossei muscles on the 2nd metatarsal, that explains why the 2nd toe ground contact is more difficult, in this location, whatever the used procedure.

(Pictures from the *Sobota* and the *Sarrafian* Anatomy books)

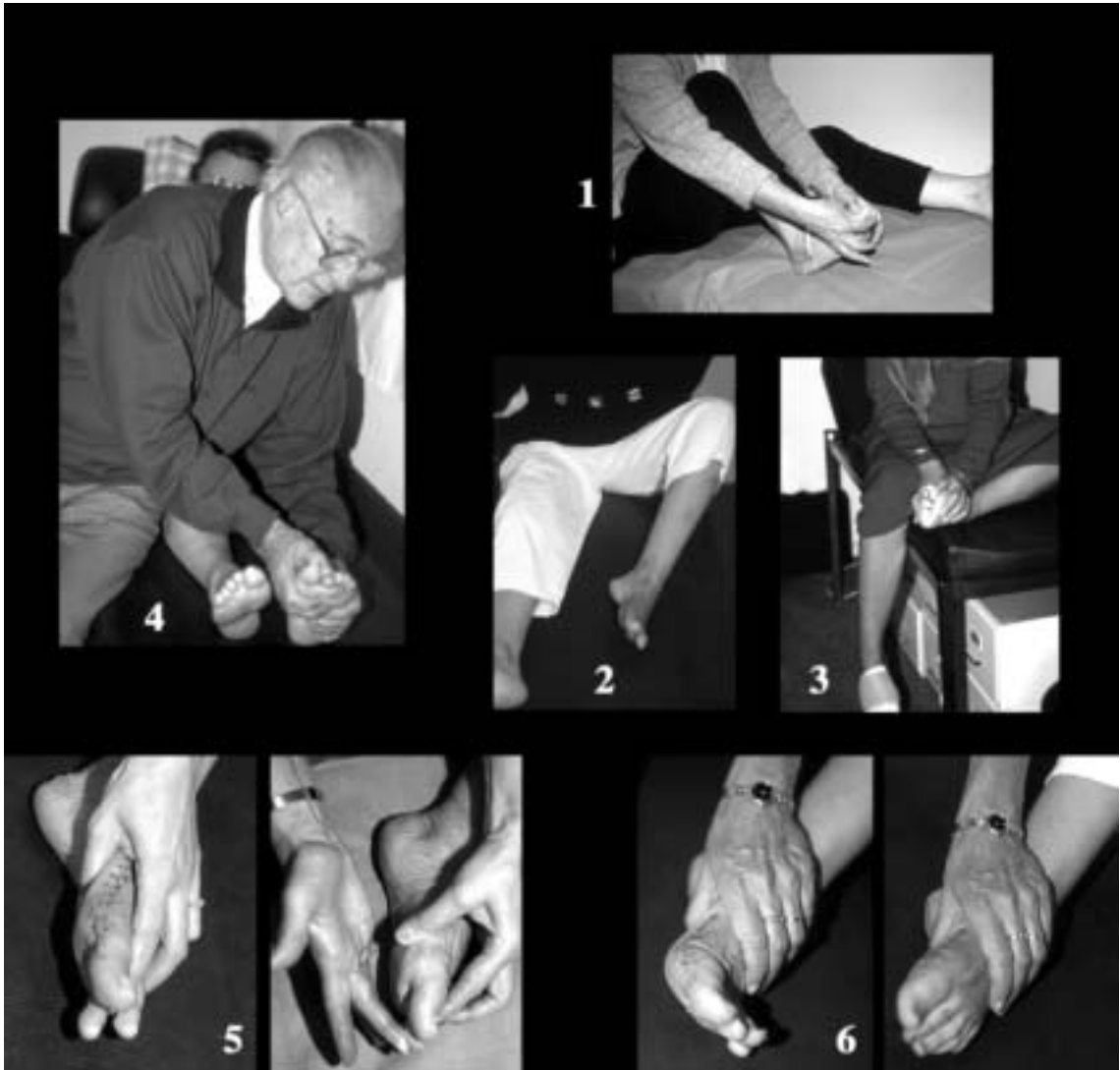

**Fig. 17e5a. MTP stiffness prevention: postoperative aspects 1.**

1. Strapping in MTP plantar flexion.

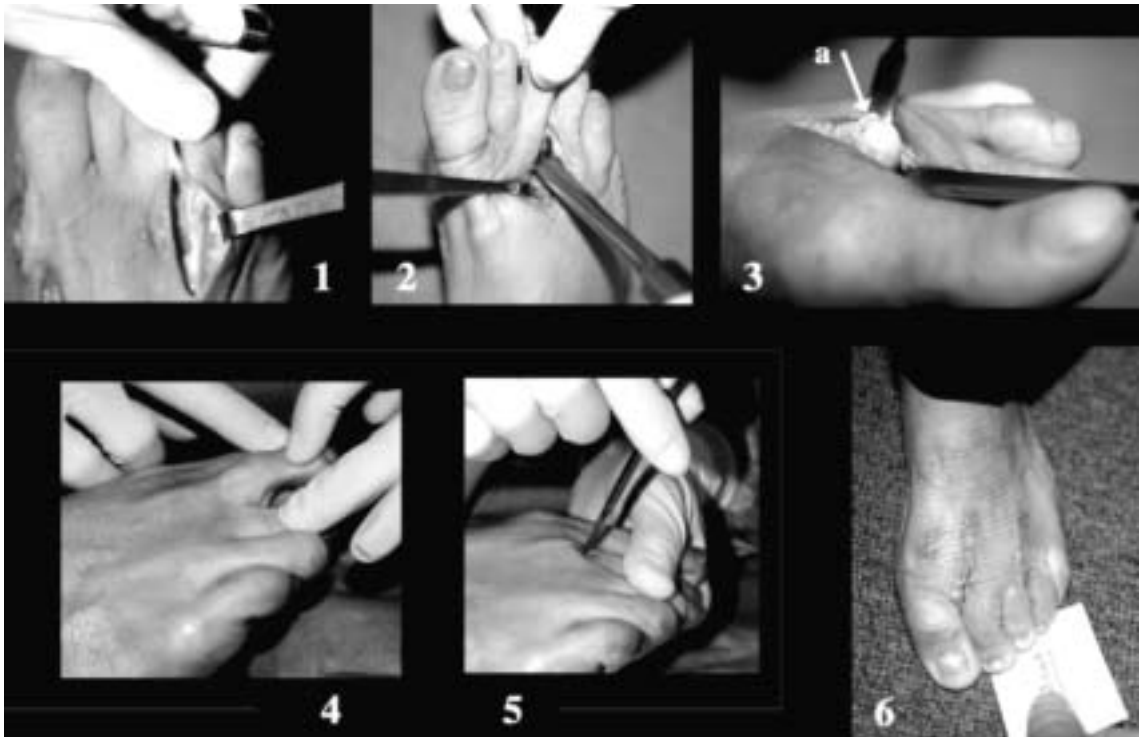
2. When there is no K-wire, we have to make a DIP dorsal flexion strapping.

3. When there is a K-wire, strapping is easier (no DIP strapping).



**Fig. 17e5b. Self-training: postoperative aspects 2.**

1. Incorrect position since it is difficult not to contract the toe extensor muscles.
2. Correct position: The foot is relaxed and can be easily reached with the hand.
3. Better position: The contra-lateral knee is flexed.
4. Sometimes another person may be useful and effective for this training (here, the husband).
5. Plantar MTP flexion made by the index finger while the thumb make a still support. While maintaining this position DIP dorsal flexion is made with the other hand.
6. Toes are more easily self-moving in the knee flexed position and when the foot is held by the corresponding hand.

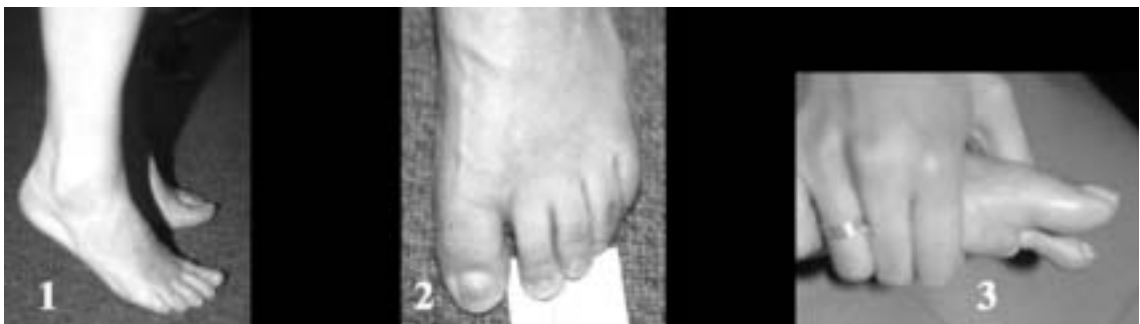

**Fig. 17e5c. MTP stiffness treatment: infraoperative aspects 4.**

After one postoperative year, if required (now very rarely), MTP surgical release is very successful. The metatarsal approach may be a bit difficult between the extensor tendons, through the fibrous tissue. A smooth “*ciseau de Cauchoix*” (DePuy set) is introduced in the MTP joint, as far as required: Bone excess and fibrous tissue are generally observed when the screw is too much distal.

4, 5. But same results are obtained by *percutaneous* or *mini invasive* MTP release: this is the procedure we use currently.

6. Excellent results are observed early, notably toe ground contact recovery.

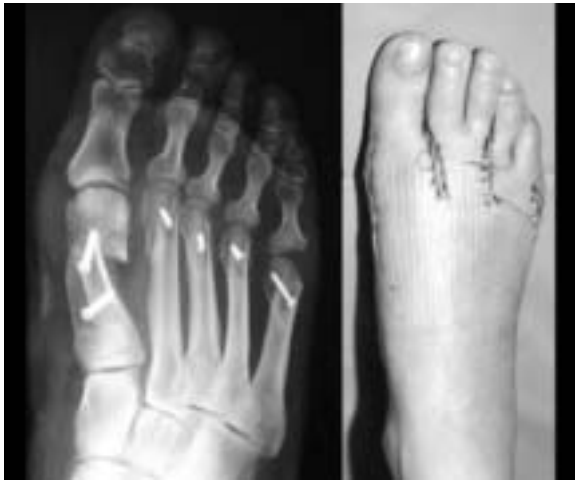

**Fig. 17e5d. MTP stiffness prevention: postoperative aspects 3.**

1, 2. Tiptoes and toe ground contact training as soon as possible.

3. If required (now extremely rarely), MTP mobilisation under general or local anaesthesia on the 3rd postoperative month.

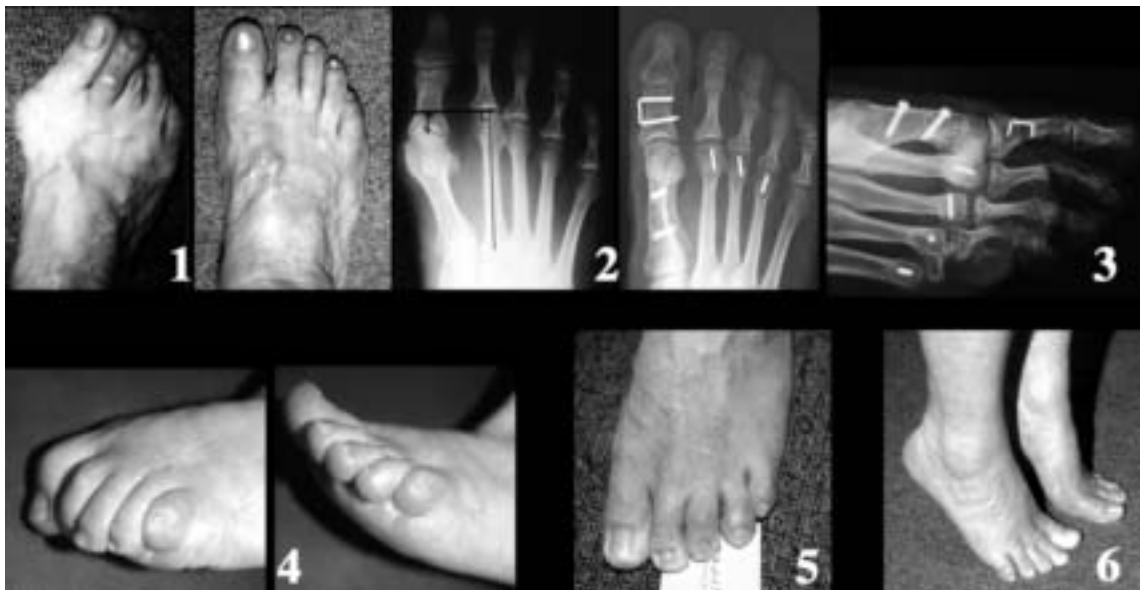



### Long-Term Results

Neither MTP joint deterioration was observed with long follow-up, nor head necrosis, and the MTP motion was always increased (comparatively to the postoperative MTP motion) so that the Weil osteotomy, with an accurate technique and adapted indications and management, is a *versatile and reliable procedure*.

**Fig. 17f.** Weil osteotomy stiffness?  
*The best way to eliminate MTP stiffness is a large and harmonised shortening of the metatarsals with Weil osteotomy (and if necessary with M1 shortening by scarf, as in this picture).*



**Fig. 17g.** Long-term results of the Weil osteotomy: *Improvement of the results, notably functional aspects.*  
 1, 2, 3. One case preoperative and with five years follow-up: Clinical and radiological results.  
 4. MTP stiffness is progressively decreasing: Aspect on 4 years follow-up.  
 5, 6. Other functional aspects, notably recovering of the toe ground contact and of tiptoes.

## The BRT Proximal Metatarsal Osteotomy

Basal elevation osteotomies of the metatarsals performed in patients with metatarsalgia or *pes cavus* have given unpredictable results. We have devised a new oblique proximal osteotomy which is immediately accurate and stable post-operatively, resulting in a significant improvement of this kind of osteotomy.

### History, Definition

Since several years, we have performed oblique proximal metatarsal osteotomies for metatar-

salgia. P. Rippstein fixed these osteotomies by AO screw but with some problems notably with the screw head. L. S. Barouk and E. Toullec fixed these osteotomies by staples with some similar fixation problems. In March 2000, we met each other at Schulthess Clinic in Zurich and we decided to join our experiences of this osteotomy, to define and improve both the cut and the fixation, and at last to make a prospective study.

This metatarsal osteotomy is a dorsal closing wedge. Its cut is very oblique ( $60^\circ$ ) providing long fragment contact area. Therefore it is not only basal but also proximal. This osteotomy is almost on an horizontal plane. A proximal hinge is carefully preserved, in a cancellous part where the bone cannot break.



**Fig. 18a1.** The BRT\* lesser metatarsal osteotomy.

**BRT:** Barouk Rippstein Toullec. From the left to the right: L. S. Barouk (Bordeaux), P. Rippstein (Zurich), E. Toullec (Bordeaux).

1. The BRT oblique osteotomy for metatarsal elevation provides a good stability because a proximal plantar hinge is preserved, and it is solidly secured with a FRS (or scarf screw) (2).

\* Barouk (Bordeaux), Rippstein (Zurich), Toullec (Bordeaux).

These elements still provide a primary stability. However we perform the fixation with the scarf screw. The screw is set perpendicularly to the osteotomy cut; it provides a strong fixation. The use of the new FRS self-cutting screw is another improvement for producing predictable and reliable results.

### Local Anatomy as Applied to the BRT Osteotomy

The proximal part of the metatarsals:

#### Bone Aspects

- The plantar edge is plantarally curved, provi-

ding favorable conditions for an oblique proximal and plantar cut.

- The articular and intermetatarsal surfaces are located partly the dorsal part, and therefore preserved from the osteotomy cut.

- The fifth metatarsal has a flattened proximal part where the osteotomy is more delicate to perform.

- The first metatarsal has a particularly voluminous proximal plantar part.

#### Vascular Aspect

- The dorsal and plantar vascular arches are not a problem for performing this osteotomy. The only problem arises from the perforating arteries: Each one must be protected when performing the cut, particularly the first perforating artery.

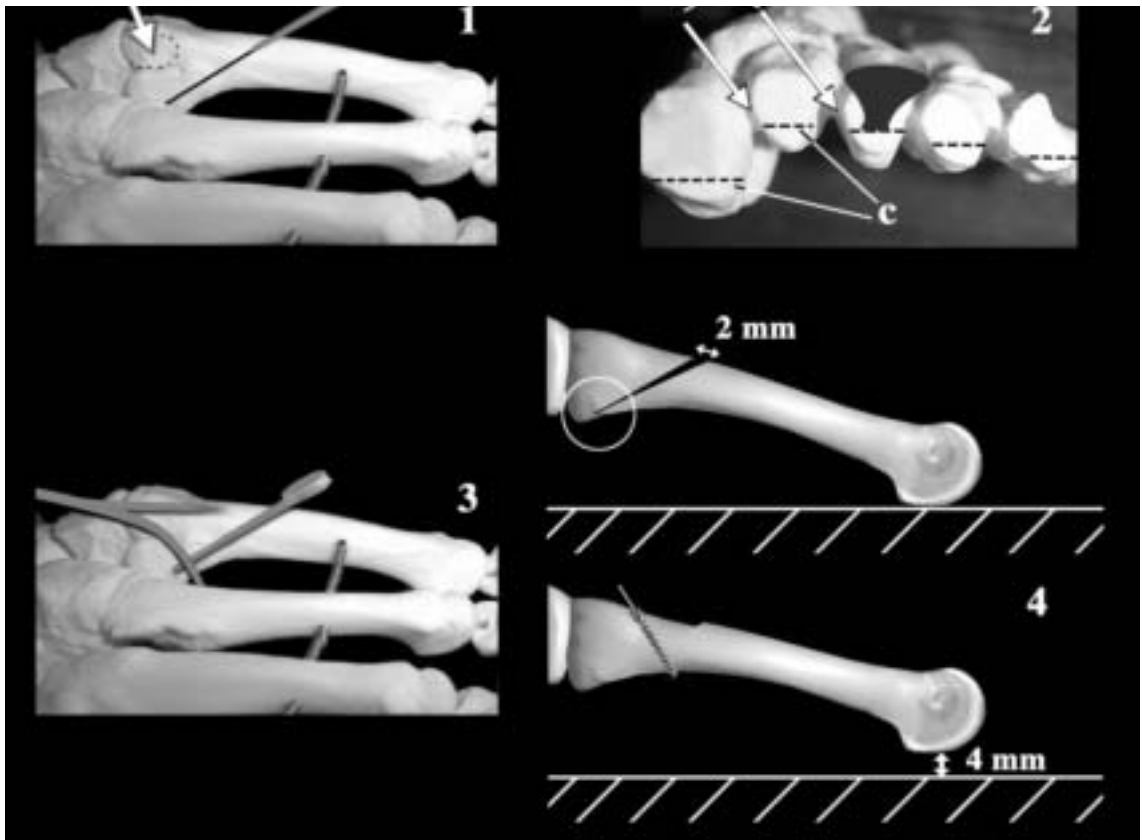


Fig. 18a2. BRT osteotomy. Anatomy.

- 1, 2. This osteotomy is extra-articular, its cut is located plantarly from the intermetatarsal joints.
3. Care has to be taken not to jeopardize the perforating arteries, notably the first perforating one.
4. The dorsal wedge has to be very thin: a 2 mm large wedge elevates the metatarsal head of 4 mm.

## Technique

### Osteotomy of the Three Central Metatarsals

– *Approach.* Skin incision: Dorsal, one incision for one or three metatarsals. The proximal intermetatarsal edge is checked with the scarf graduated ruler.

– *The osteotomy* begins dorsally at 1.5cm from this edge. It is 60° plantar and proximal directed, respects the intermetatarsal articular surfaces and reaches the proximal and plantar parts of the metatarsal in a part where the can-

cellous bone and the cortex provide favorable conditions to preserve the proximal hinge with sufficient elasticity when closing the osteotomy.

– *A second cut* may be performed but it is better to enlarge the first one instead of performing a second cut, in order to avoid too much elevation.

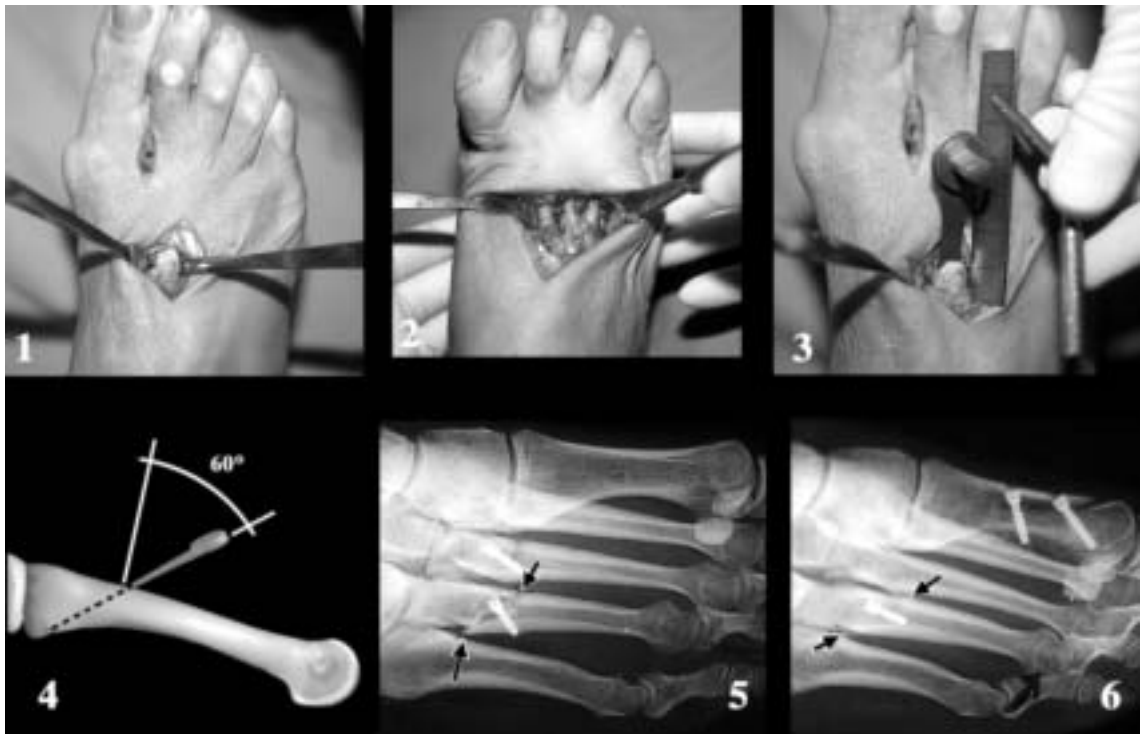
*Three rules for this osteotomy:*

a) To have sufficient obliquity in order to reach the very plantar aspect proximally and to have a long cut.

b) To carefully preserve the proximal hinge.

c) Not to elevate the metatarsal too much.

– *The amount of metatarsal elevation, i.e. the size of the bony wedge* which will be removed,



**Fig. 18b1. BRT osteotomy. Operative technique 1.**

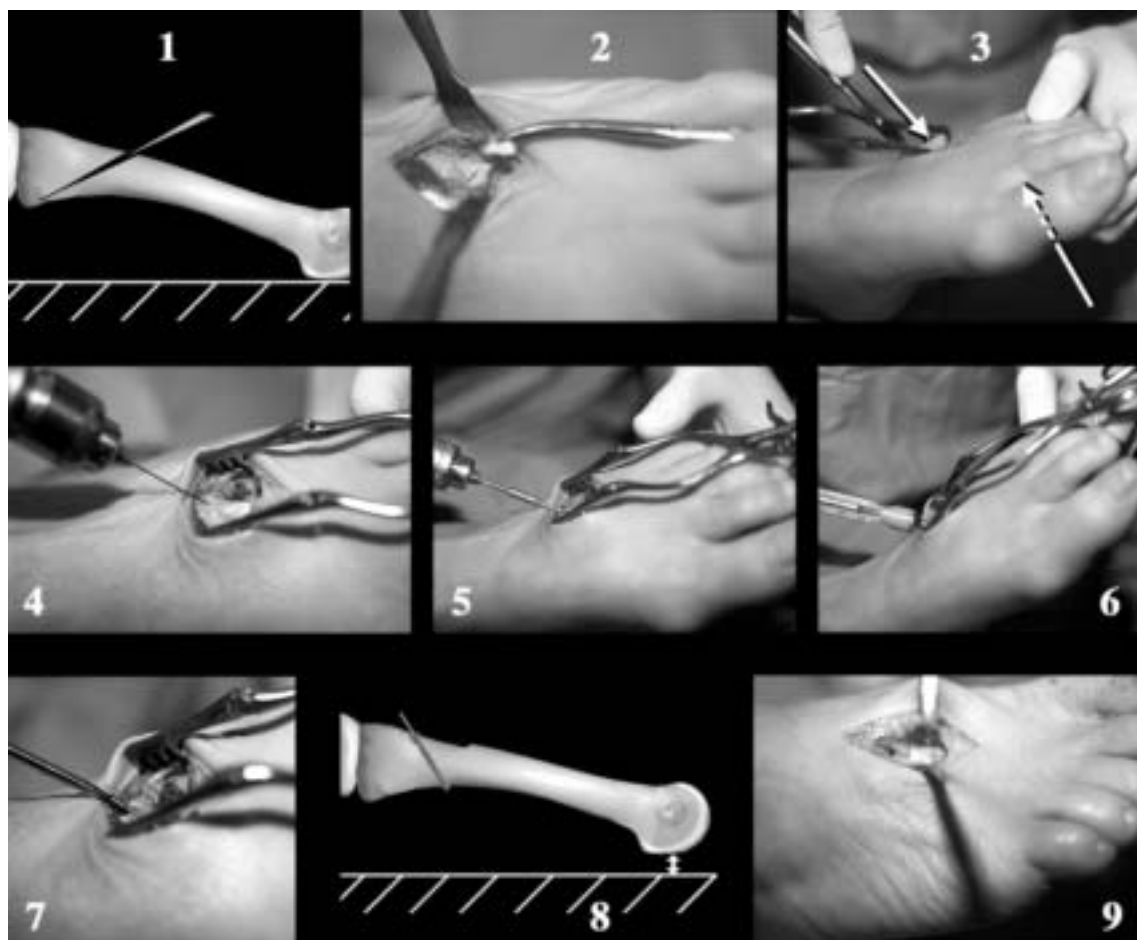
1, 2. Approach through a longitudinal incision for one or for the three median metatarsals.

3. The cut begins on the dorsal metatarsal aspect 1 to 1.5 centimetre from the intermetatarsal proximal edge.

4. The cut has a 60° plantar and proximal oblique direction.

5. Cut not enough oblique: Rupture of the plantar cortex.

6. Correct obliquity of the cut: The proximal hinge is preserved.



**Fig. 18b2. BRT osteotomy. Operative technique 2.**

Removing of the dorsal distal wedge (1, 2).

Coaptation of the fragments (3).

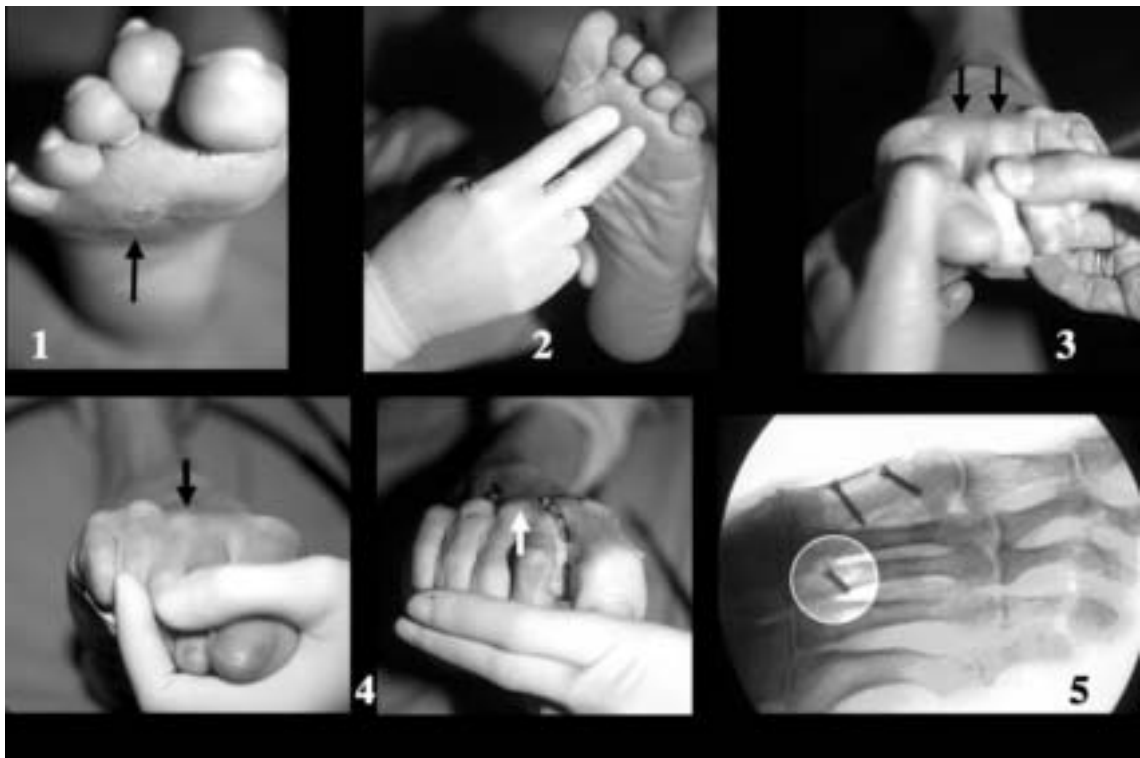4, 5. Firstly K-wiring, then setting of the cannulated drill.

6. Screw measuring with a depth gauge.

7, 8, 9. Setting of the screw which ensures the fragmental contact.

has to be clinically assessed during the surgery, above all by palpating the metatarsal heads, which is common for all osteotomies without exposure of the metatarsal heads. We can also assess this elevation amount by plantar flexion of the MTP, which indicates the position of the metatarsal heads (Fig. 18b3). At last, the oblique X-ray view (or fluoroscopy) may also be useful. Only 2mm distance between the two fragments in the dorsal aspect elevates the metatarsal head up to 4mm.

– *The fixation:* After closing the osteotomy wedge, the distal fragment is held in a dorsal position while the dorsal fragment is maintained. A Kirchner wire is first set, then a cannulated drill (or directly a threaded pin). Then we measure screw to be placed with a depth gauge. The screw is a threaded head, preferably the FRS self-cutting screw, set around K-wire. We observe the good coaptation of the fragment due to the screw compression effect.



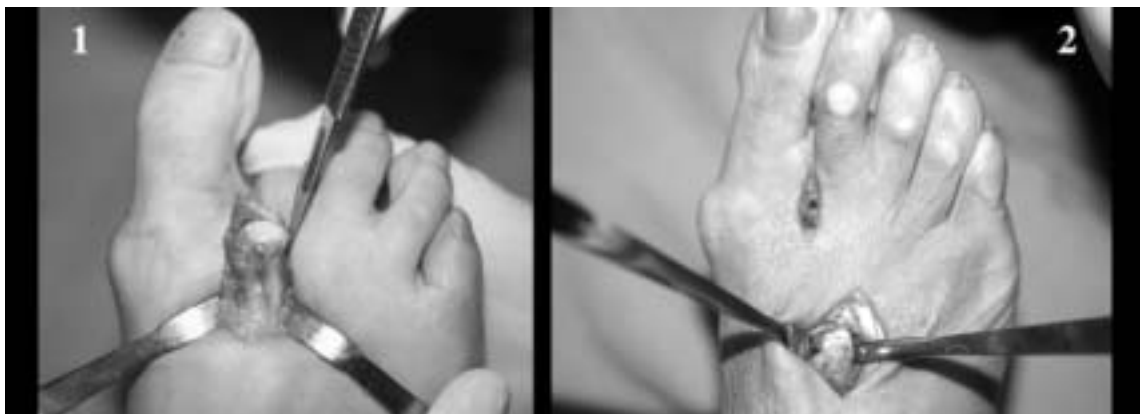**Fig. 18b3. BRT osteotomy. Operative technique 3.**

1, 2. Since this osteotomy is clinically assessed, the callus has to be previously removed.

3. Another clinical assessment of the metatarsal head position in a sagittal plane is made by plantar MTP flexion.

4. In this position, pre and postoperative aspects of the same foot.

5. The medial oblique X-ray view can also help to assess the metatarsal sagittal position. *Care has to be taken not to elevate too much the metatarsal.*



**Fig. 18b4. BRT osteotomy. Operative technique 4.**

1, 2. When MTP joint release is necessary, it is performed through another incision.

### *Osteotomy of the First Metatarsal*

A medial incision can be used. When it is extended forwards, we easily reach the MTP joint. Generally, the wedge to be removed has

to be longer, because the first metatarsal is shorter ones and than the other, more plantar sloped. The elevation has to be large, above all in medial *pes cavus* surgery. The preservation of the proximal hinge is therefore more deli-

cate but is important. Fixation has to be strong. Preferably we use one or two “20” memory staples.

### *Osteotomy of the Fifth Metatarsal*

The proximal part is flattened comparatively to the other lesser metatarsals so that the osteotomy has to be more horizontal to carefully preserve the proximal hinge.

Remark: actually, I have modified the BRT technique for the 1st ray: I perform a less oblique cut and I use the 20 memory staple which ensures a very strong fixation. Some remark for the 5th ray.

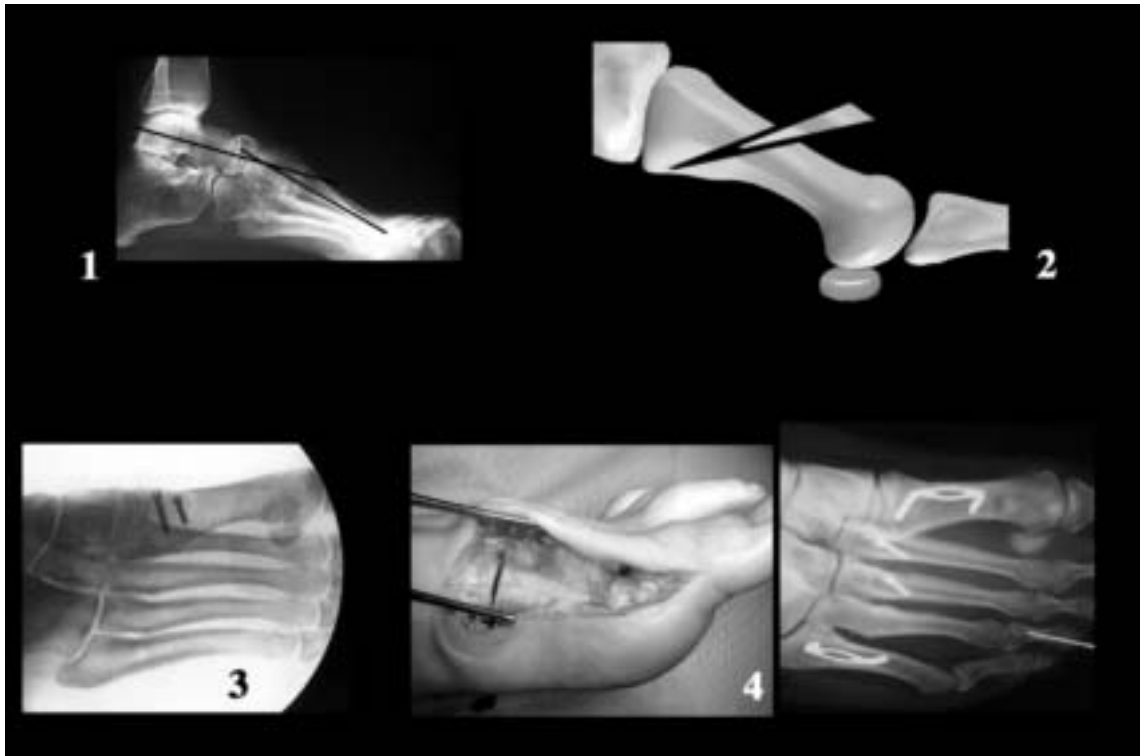
### *Combined Procedure*

MTP surgery is performed through a separated incision, except sometimes for the first metatarsal.

### *Postoperative Period*

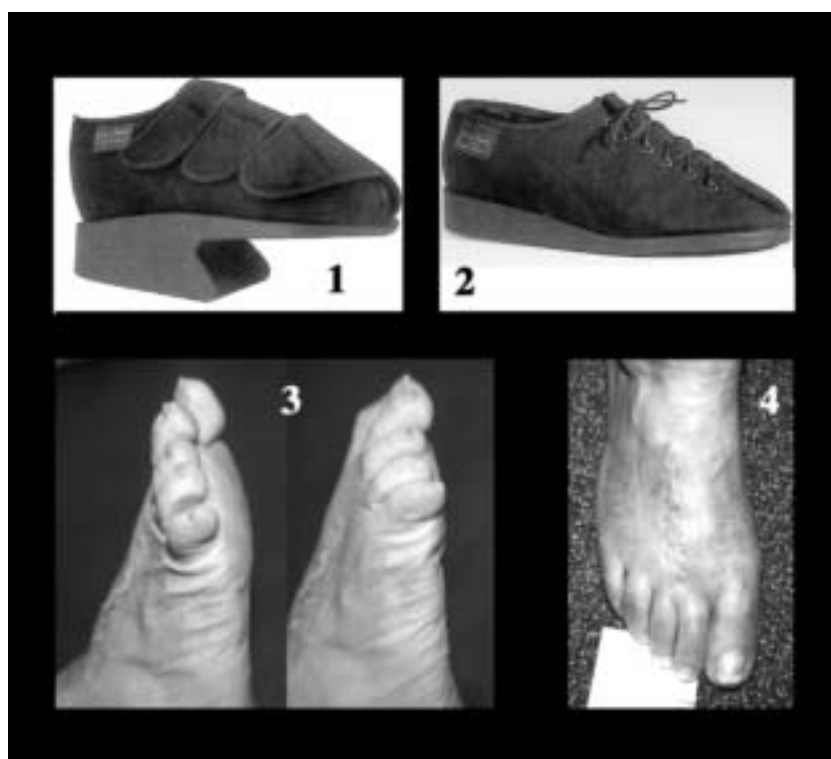
– Only two weeks with heel support shoes are sufficient.

– Thanks to the strong fixation we observe no significant edema nor pain. The MTP joint motion is notably preserved. Full weight bearing is allowed after two weeks; we immediately observe that metatarsalgia is relieved without transfer on the adjacent metatarsals.



**Fig. 18b5. BRT osteotomy. Technique for the first metatarsal.**

The first metatarsal is performed through a medial incision which furthermore allows to reach the first MTP joint for releasing. The wedge to be removed should be thicker than for the lesser metatarsals, above all in the *pes cavus* correction. The proximal hinge is more fragile: One or preferably two FRS screws are necessary to ensure the fixation or, preferably, the use of the “20” memory staple (preferably use two staples) but in this case with a *more vertical cut*. Some observation for the 5th metatarsal.



**Fig. 18c1.** BRT osteotomy. *Postoperative aspects.*

1. Heel support shoe to be worn only for the first 15 days postoperative, then comfort shoe for one month (2), here Type II shoe (Alba).

3, 4. One month postoperative: Active MTP motion and toes ground contact.

## Drawbacks

- Perioperative injury of perforating artery, without significant consequence.

- The breaking of proximal hinge can be easily avoided with respect of the operative technique (long and horizontal cut). However, in the three encountered cases, the screw fixation avoided too much elevation.

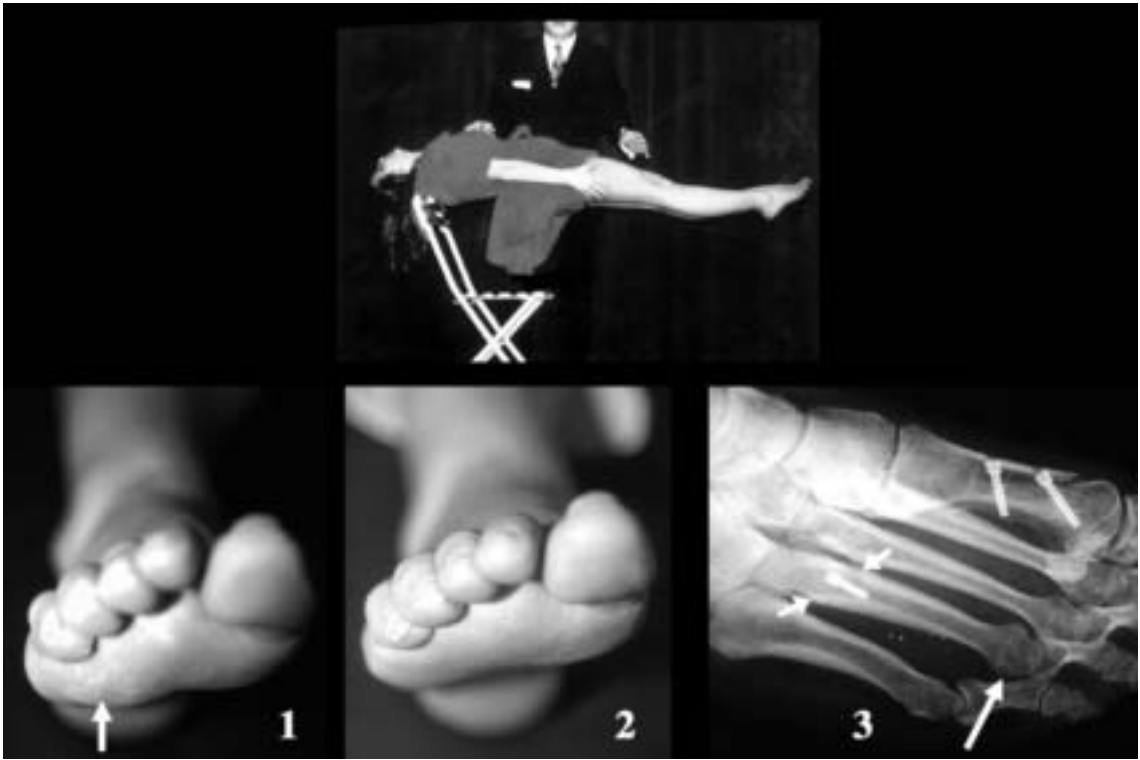
- Recurrence of metatarsalgia: We observed it only once due to insufficiency of correction.

- Transfer metatarsalgia: Since our rule is not to elevate the metatarsal too much and thanks to strong fixation, no secondary displacement was observed. So, transfer metatarsalgia is due to our assessment of the elevation amount. In fact, it very rarely occurs in the BRT osteotomy.

## Advantages

The BRT osteotomy is very easy to perform, accurate, predictable as far as the surgeon can assess and check the amount of metatarsal elevation. The MTP range motion is not decreased, local edema, pain or fibrous tissue problem are almost never observed. The strong fixation allows very early functional recovery. We do not have long-term results at the moment, but we think that they will not change since there is no secondary displacement. BRT osteotomy is only devised for *metatarsal* elevation but it can be combined with other procedures for hammer or claw toe correction or *pes cavus*.





**Fig. 18c2. BRT osteotomy. Isolated head pressure (of a metatarsal).**

1. Isolated plantar keratosis is an excellent indication for this osteotomy.
2. The same foot two months after the osteotomy.
3. Medial X-ray oblique view of the same foot.

## Indications and Results

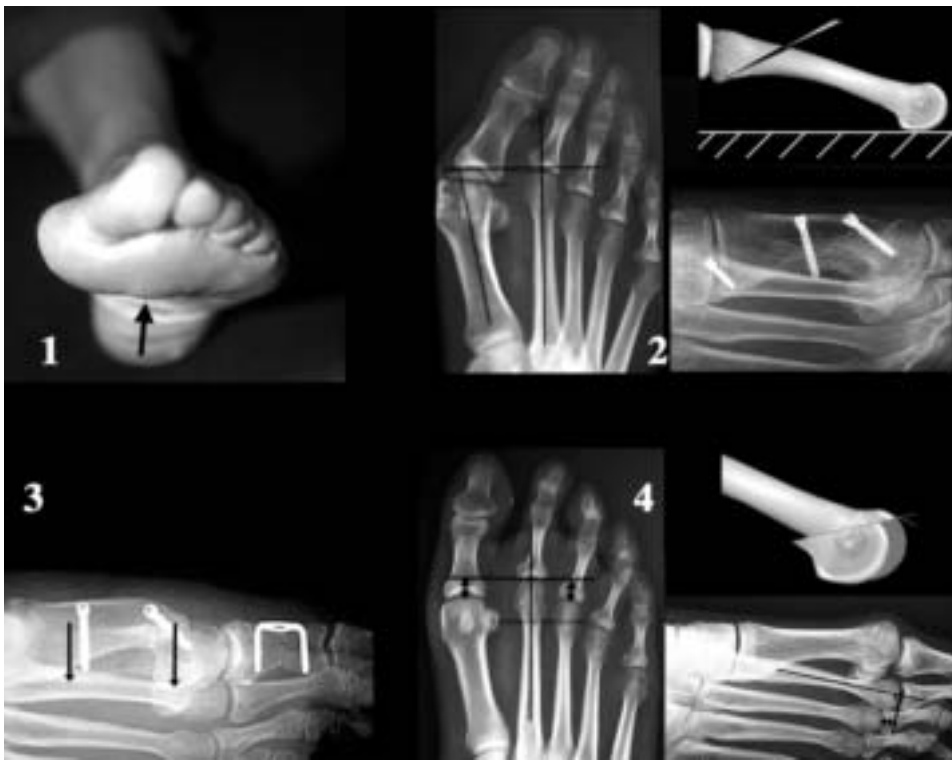
*The BRT osteotomy is only devised for metatarsal elevation.* So its indication are metatarsalgia and pes cavus.

### *BRT Osteotomy in Metatarsalgia*

*Isolated plantar callus* is an excellent indication for BRT osteotomy of the corresponding metatarsal.

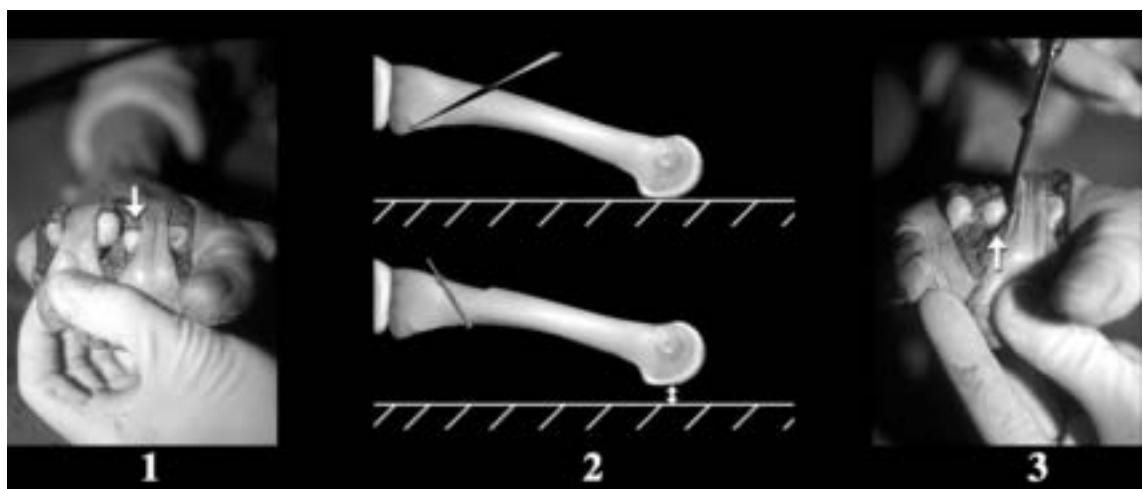
Similarly, the BRT osteotomy can relieve metatarsalgia on several rays.

2nd ray metatarsalgia with hallux valgus deformity can be treated either by M1 scarf lowering for mild deformity without excess of 2nd metatarsal length, or by Weil osteotomy of the 2nd metatarsal when it is too long. At last, BRT 2nd metatarsal osteotomy is indicated when the metatarsalgia is moderate or severe but without excess of length of the 2nd ray and without possibility to lower the 1st metatarsal – *i.e.* small first intermetatarsal angle.



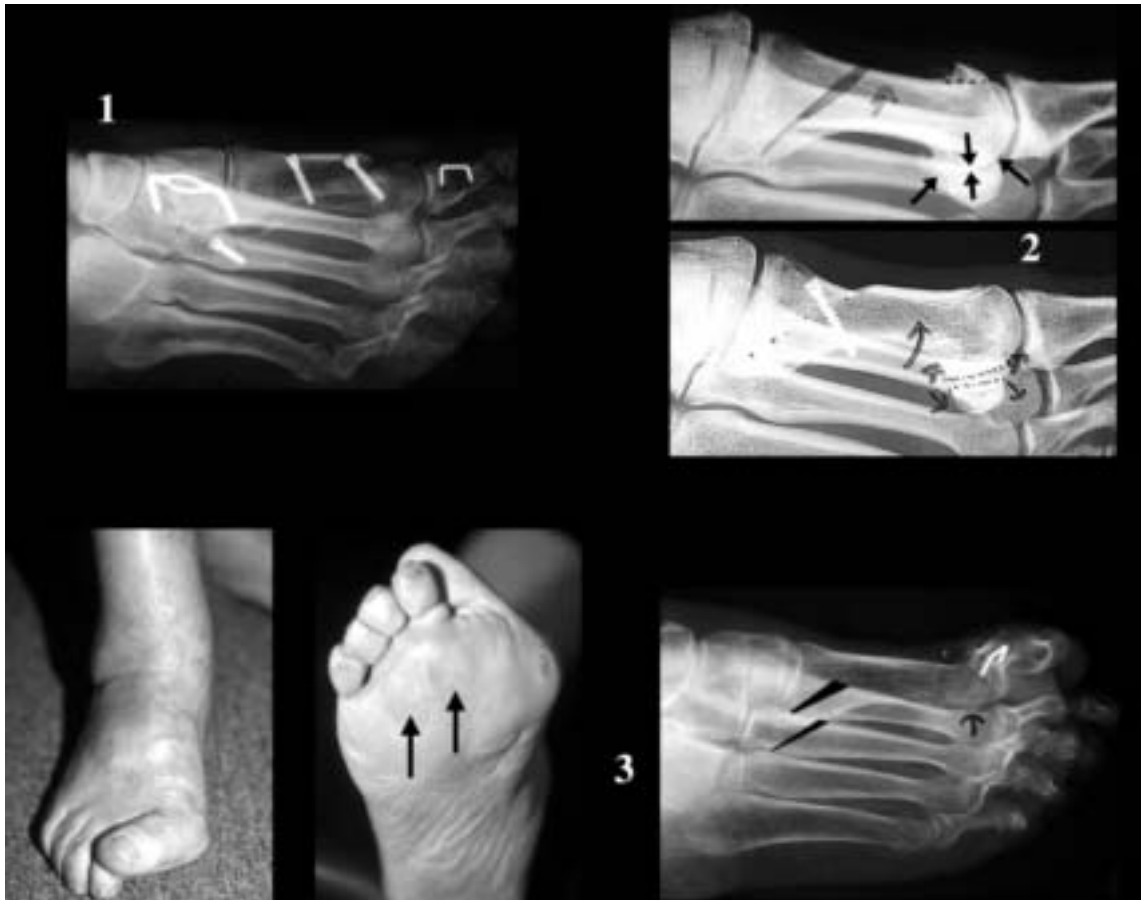**Fig. 18c3.** Place of the BRT osteotomy for 2nd ray metatarsalgia combined with hallux deformity.

2. The *BRT osteotomy* is indicated when the hallux valgus correction does not allow to lower enough the first metatarsal (small intermetatarsal angle).
3. With a large intermetatarsal angle, the *scarf osteotomy* provides a large lowering of the first metatarsal which is enough for 2nd ray metatarsalgia relieving.
4. When the 2nd metatarsal is very long comparatively to the 1st and the 3rd metatarsals, both in a dorso-plantar and a medial oblique X-ray view, the *Weil osteotomy* has to be performed instead of the BRT osteotomy.



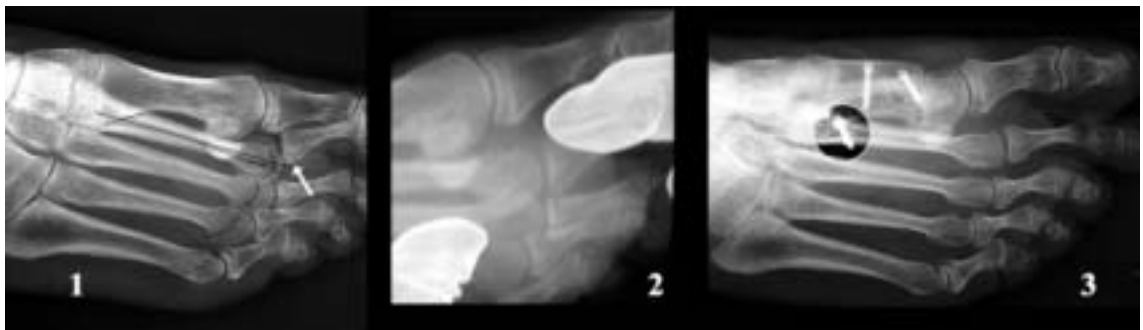
**Fig. 18c4.** BRT osteotomy in addition to Weil osteotomy.

It is performed when a metatarsal head remains too low. This case is rarely encountered.



**Fig. 18c5. BRT osteotomy. Other indications for metatarsalgia.**

1. The 3rd metatarsal osteotomy is combined to 2nd cuneo-metatarsal fusion.
2. BRT osteotomy for metatarsalgia with sesamoidal metatarsal arthritis.
3. Indication of BRT osteotomy on the 2nd and 3rd metatarsals for metatarsalgia with trophic troubles and hallux valgus.



**Fig. 18c6. BRT osteotomy. Emerging MTP subluxation.**

It seems to be an indication of this osteotomy, but we have to take care of incomplete correction.

### *BRT Osteotomy in Emerging MTP Subluxation*

This is perhaps a place to this procedure in this indication, in combination with the corresponding MTP toe surgery.

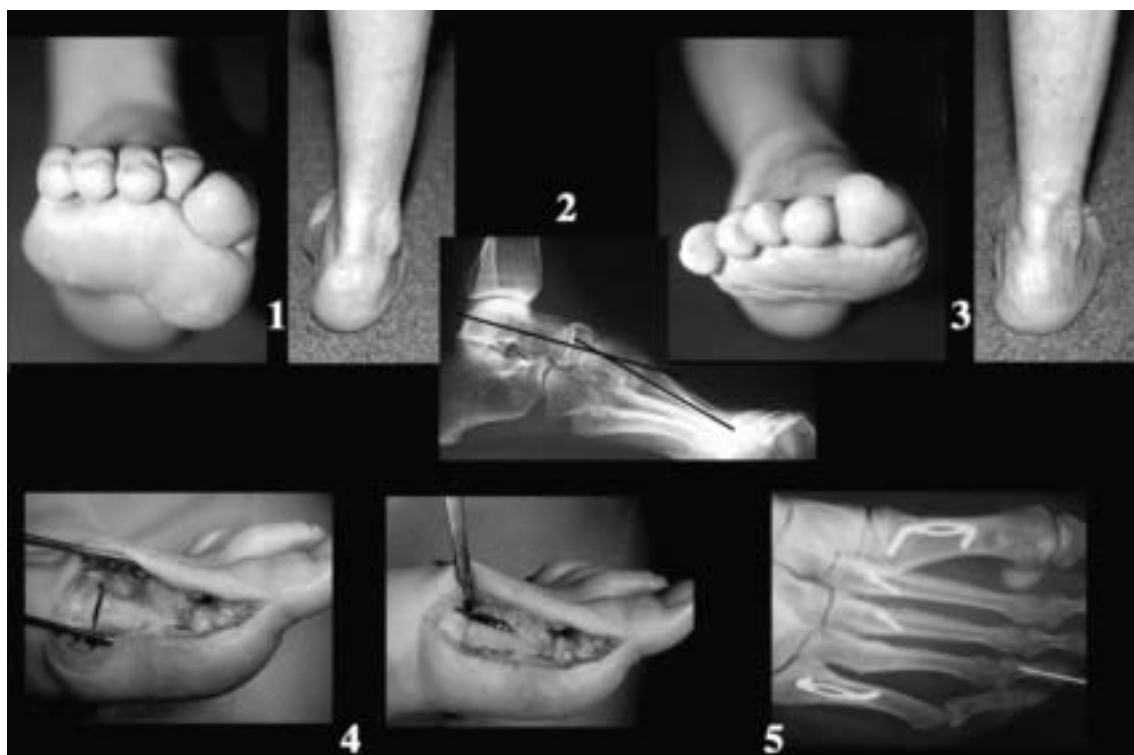### *BRT Osteotomy in Pes Cavus*

Initially we performed only basal elevation osteotomy in the 1st metatarsal and we observed the limits of this procedure – *i.e.* some transfer metatarsalgia on the 2nd and 3rd ray, or on the contrary, insufficiency of M1 elevation. However we observe the good results with this osteotomy regarding notably the correction of the rear foot varus; since we can now easily perform basal osteotomy elevation in the lesser

metatarsals, we can elevate the 1st metatarsal as far as necessary, and combine with BRT osteotomy on the lesser metatarsal as required.

The combined procedures we use are the equinus correction by Achilles tendon lengthening or gastrocnemius proximal desinsertion. The *calcaneum osteotomy* can be performed, this kind of extra-articular surgery was recently emphasized by J. Sammarco. For mild and moderate *pes cavus* – *i.e.* the main cases encountered – the calcaneum osteotomy combined with BRT osteotomy and distal extra-articular correction of claw toe (mainly by soft tissue procedure and K-wiring of the toe) appear to be an excellent solution of the problems of *pes cavus*.

The Weil lesser metatarsal osteotomy is a reliable solution only in *pes cavus* with severe claw toe. For the other cases, the BRT osteotomy gives good results: the two procedures may be also combined.



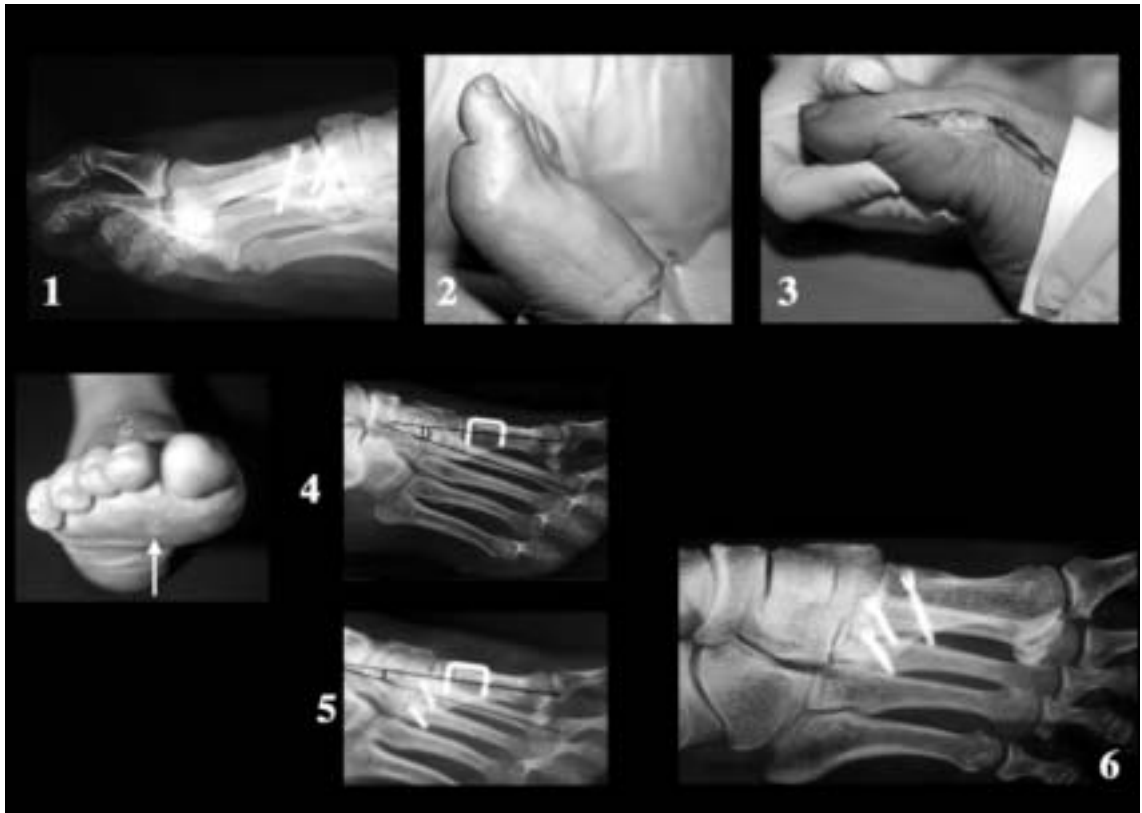
**Fig. 18d1.** *Pes cavus* BRT osteotomy of the 1st metatarsal.

1, 2, 3. The excess of plantar slope of the 1st metatarsal, which contributes to give a rear foot varus, can be corrected by the BRT osteotomy, as a consequence of correction of the forefoot supination.

4. Intraoperative aspects. We note that the wedge to be removed is larger than for the lesser metatarsals.

5. Post operative ray with fixation by the “20” memory staple (use of two staples is preferable).

This staple may be also used in the fifth metatarsal.



**Fig. 18d2. Pes cavus and BRT osteotomy 2.**

Some problems resulting for *isolated* 1st metatarsal osteotomy.

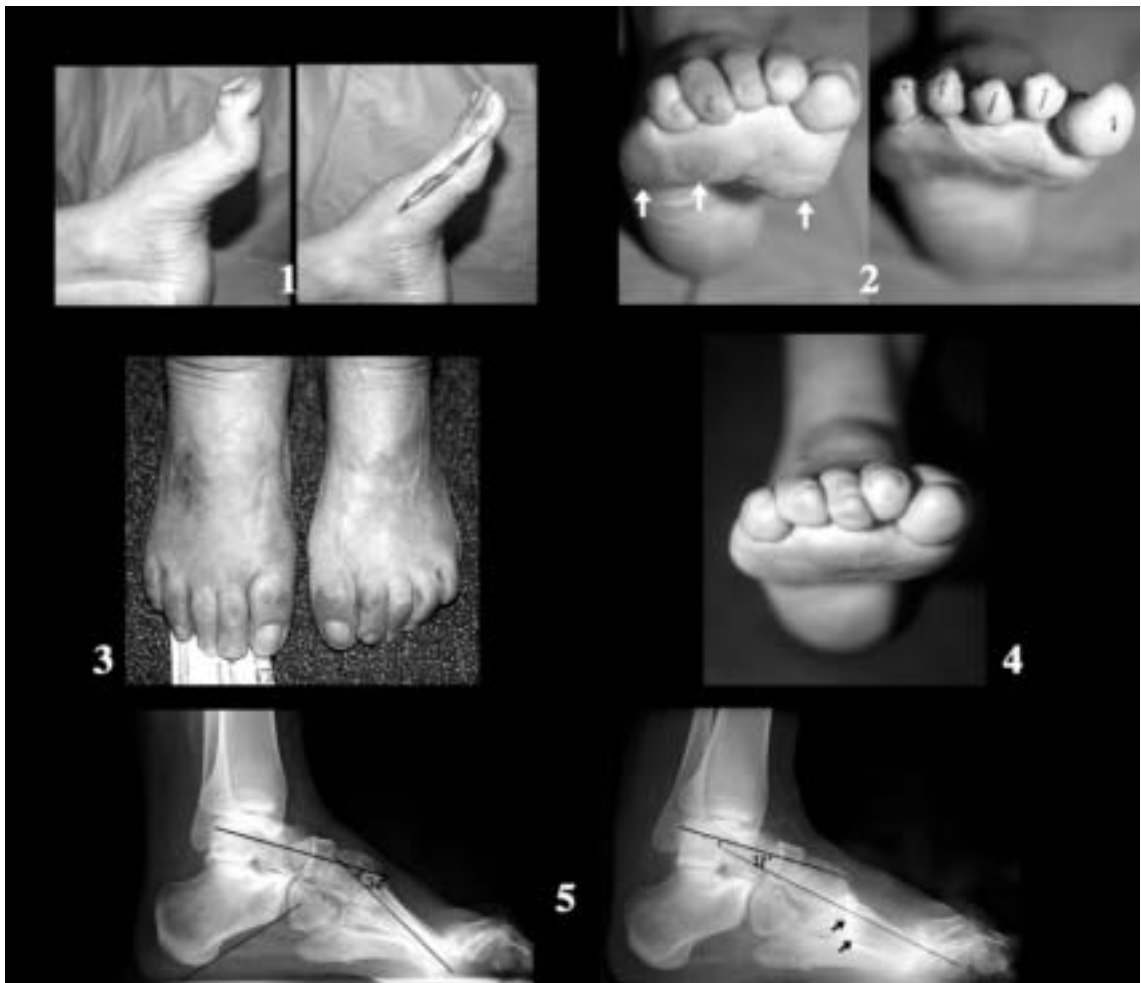1, 2. Excess of MTP dorsal flexion.

3. Correction by secondary MTP surgical release (1 year).

4. Too much elevation of the 1st metatarsal: Transfer metatarsalgia on the 2nd ray.

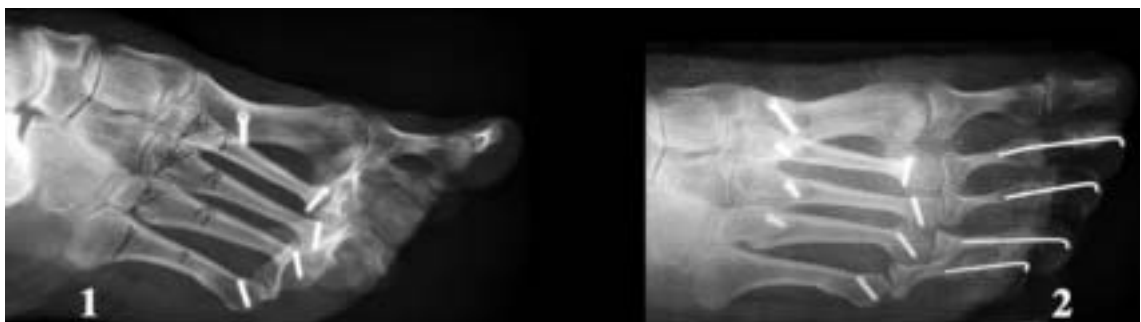
5. Good result after performing BRT osteotomy on the 2nd and 3rd metatarsals.

6. Now, in case of large elevation of the 1st metatarsal, we perform in the same time the required elevation of the lesser metatarsals.



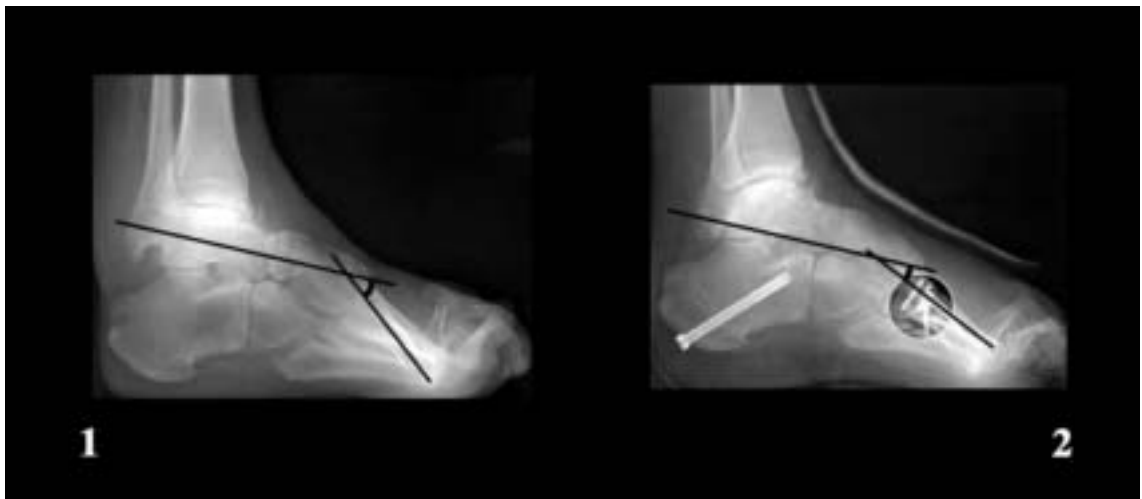**Fig. 18d3. Pes cavus and BRT osteotomy. Treatment of metatarsalgia and claw toes in pes cavus.**

- 1, 2. Operative views: We perform BRT osteotomies as required on the corresponding metatarsals, combined with tendons lengthening (extensor, flexor tendons) and toes K-wiring.
- 3, 4. The same foot four months after the operation (right foot operated on).
5. Standing sagittal X-ray preoperative and four months after the operation.



**Fig. 18d4. Pes cavus and BRT osteotomy. Revision after Weil osteotomy.**

1. Sometimes, *pes cavus* is not a good indication of single Weil lesser metatarsal osteotomy.
2. Same foot, correction of recurrent hammertoe and metatarsalgia by BRT osteotomy. In severe claw toe observed in *pes cavus*, the best way is to combine Weil and BRT osteotomy.



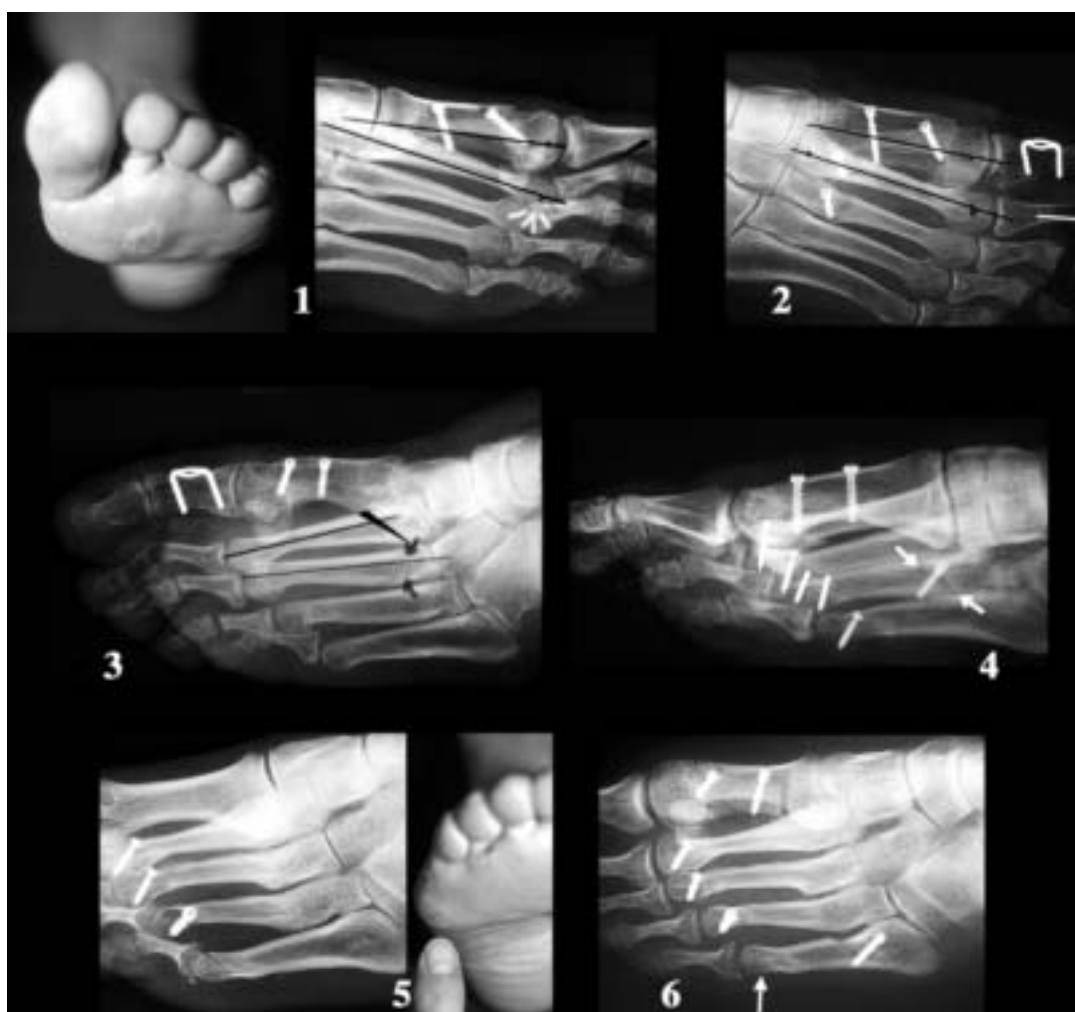
**Fig. 18d5. Pes cavus: BRT osteotomy combined with calcaneum osteotomy.**

Instead of Lisfranc's osteotomy for *pes cavus* correction, combination of calcaneum osteotomy (Myerson) and BRT osteotomy is an extra-articular effective solution.

### *BRT Osteotomy in Iatrogenic Forefoot*

Iatrogenic problems require reliable solution for patients: When recurrence or transfer

metatarsalgia occurs, the BRT osteotomy is a good and accurate solution, furthermore it is a "light" surgery, not followed by pain nor edema.



**Fig. 18e1. BRT osteotomy and iatrogenic metatarsalgia 1.**

1. Transfer metatarsalgia on the 2nd ray after scarf for hallux valgus.

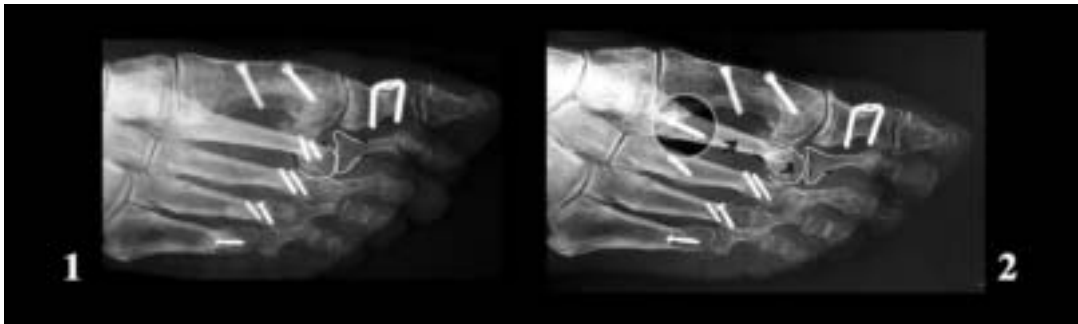
2. Revision by BRT osteotomy on the 2nd and 3rd metatarsals.

3. Basal chevron osteotomy on the 3rd metatarsal: Transfer metatarsalgia on the 2nd ray: Indication for BRT 2nd metatarsal osteotomy.

4. BRT osteotomy performed for remaining metatarsalgia on the 4th ray.

5, 6. Weil osteotomy not performed on the 5th ray: Remaining metatarsalgia relieved by BRT osteotomy.





**Fig. 18e2.** BRT osteotomy and iatrogenic metatarsalgia 2: revision in remaining subluxation on the 2nd MTP joint.

In this case, neither the Girdlerstone – Taylor’s procedure –, nor the double layer Weil osteotomy was performed, so that there were remaining 2nd ray metatarsalgia and MTP subluxation: Revision by soft tissue and BRT osteotomy with: good results.

### Conclusion

As compared to previous oblique metatarsal osteotomies, *BRT osteotomy is accurate and solidly secured by the screw fixation*; its results are predictable as far as the surgeon can assess the amount of metatarsal elevation – *i.e.* that

there is no secondary displacement of the osteotomy. It is indicated in treating:

- 1) Primary or iatrogenic metatarsalgia without MTP incongruence.
- 2) *Pes cavus*.

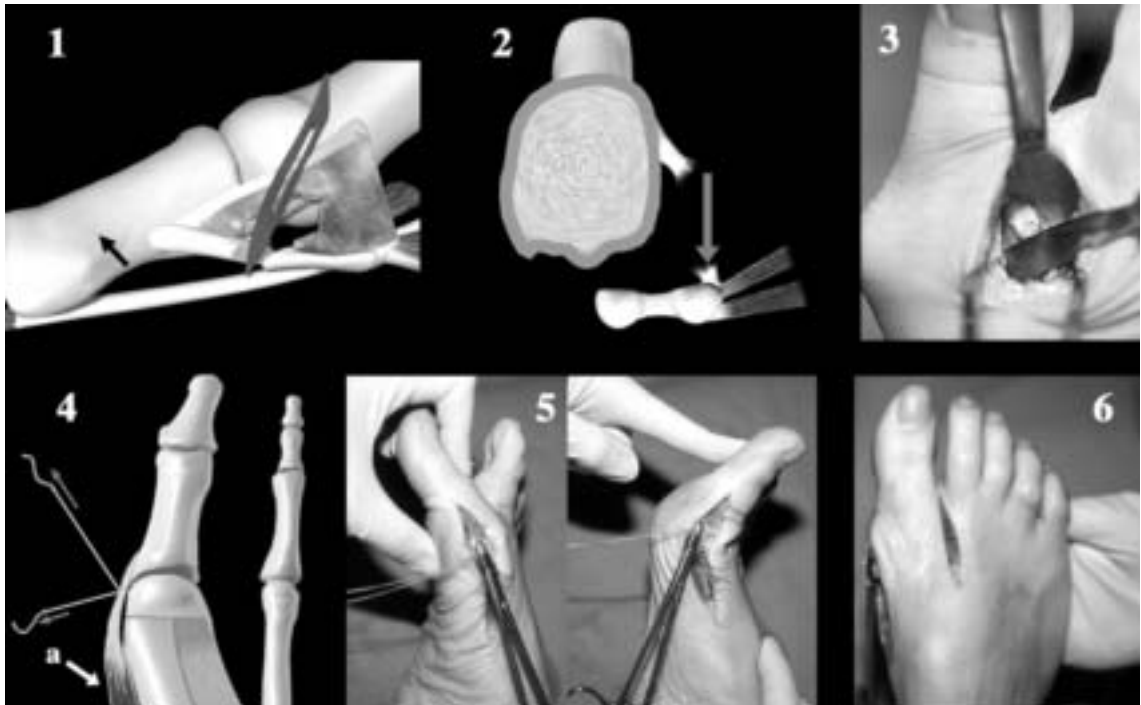
At last, it perfectly completes the Weil osteotomy.

## Soft Tissue Procedures in Forefoot Surgery

Therefore, we perform in almost each case an additional MTP lateral release and medial soft tissue tightening (Fig. 19a).

### *In Hallux Valgus Correction*

We observed that the osteotomies are not sufficient to provide a good hallux valgus correction:



**Fig. 19a. Soft tissue procedures in hallux valgus correction.**

1, 2, 3. The release of the metatarso-sesamoidal phalangeal complex (MSPC) is necessary in almost all cases.

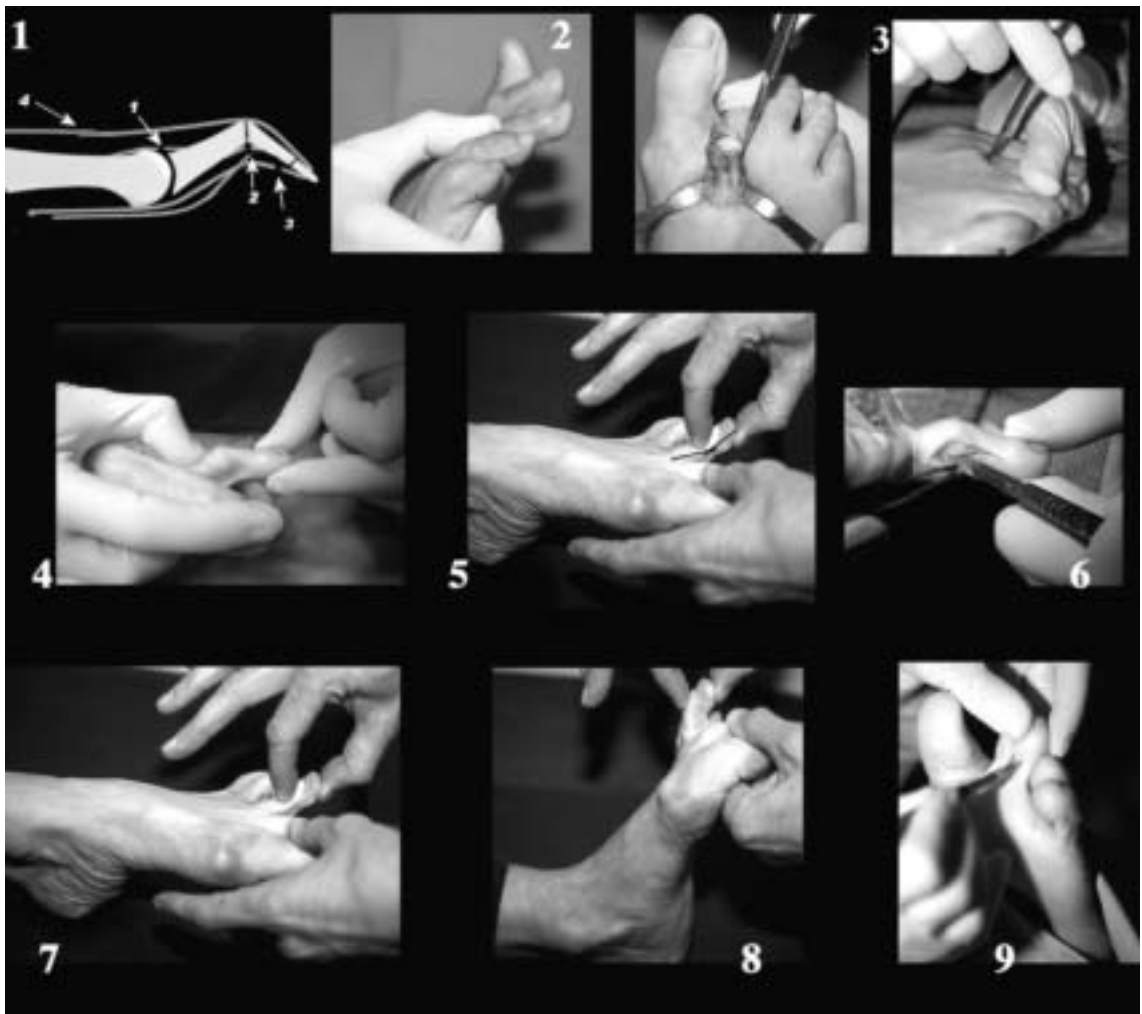4, 5. The medial capsuloraphy is also necessary in almost all cases, in fact it is a *medial soft tissue tightening* (a: including the abductor muscle). It is rarely a simple closure of the MTP medial aspect.

6. In each case, the Load Simulation Test (LST) is the only test for assessing the correction after medial tightening.

### In Lesser Toes Deformity Correction

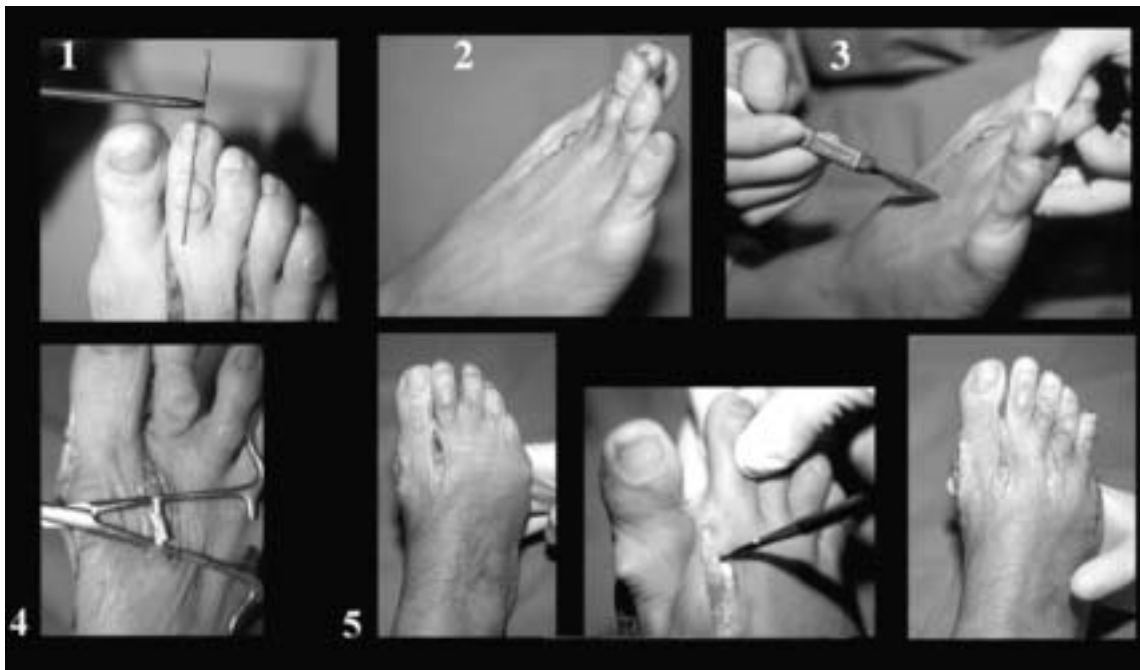We observed that *most of hammertoe or claw toe deformities can only be corrected by soft tissue procedure*. This correction has to be insured in most cases by *temporary K-wiring excluding the MTP joint* (for four weeks), the K-wire is only 1mm diameter. Removing such K-wiring is painless, ordinary made when removing the bandage. The different soft tissue procedures are

described Fig. 19b. However, even when toe arthroplasty condylectomy or fusion is necessary, soft tissue procedures are highly recommended to insure the correction. On the lesser rays, whatever the procedure performed, the last step is certainly a soft tissue surgery: *Most of soft tissue procedure can be performed by mini invasive or percutaneous surgery* (Fig. 19d).



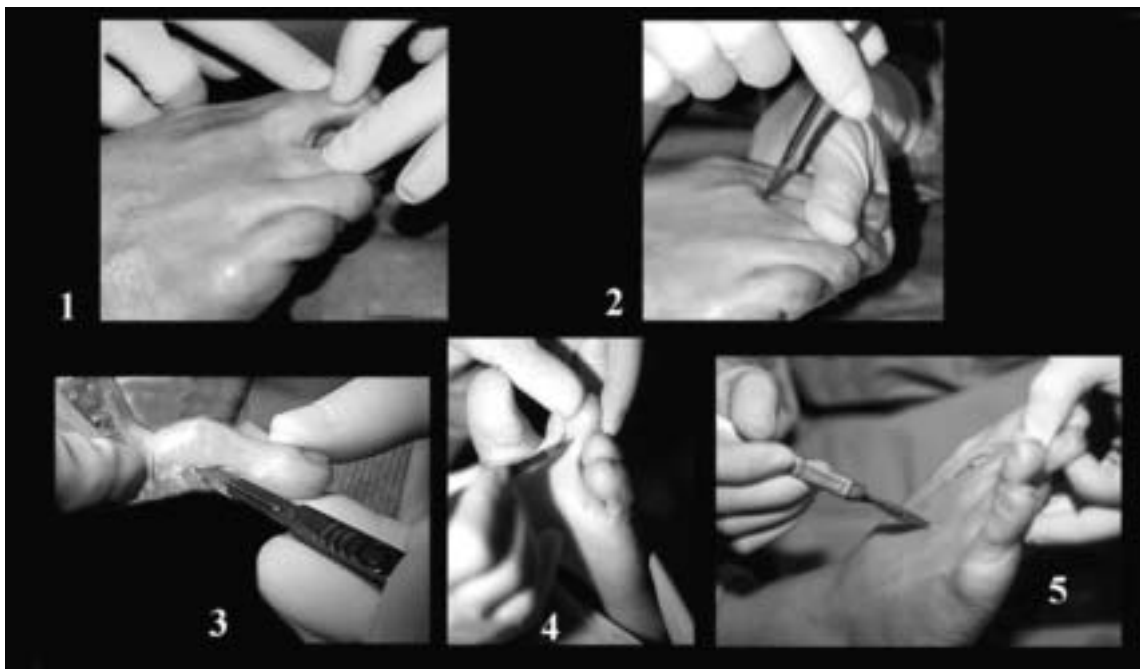**Fig. 19b.** Soft tissue procedure in hammer or claw toe correction. *Chronological steps: 1.*

1. Chronological steps.
2. The MTP passive plantar flexion is correct, nothing more to do in the MTP.
3. MTP dorsal release (one by per cutaneous procedure).
4. The PIP seems to be rigid.
5. PIP dorsal flexion obtained by manipulation: no more thing to do on the PIP, except temporary axial K-wiring.
6. PIP plantar release (this may be also performed by per cutaneous procedure).
- 7, 8. Assessment of the need of long flexor tendon lengthening.
9. Distal section of the long flexor tendon.



**Fig. 19c. Soft tissue procedures in hammer toe correction. Chronological steps: 2.**

1. Toe K wiring, excluding the MTP joint, is often required to ensure the correction with soft tissue.
2. The K wiring emphasizes the need of the extensor tendons lengthening.
3. Percutaneous lengthening of the extensor tendon.
4. Lengthening with the green procedure.
5. Need of medial MTP release (this should be lateral release if required).
6. Final correction assessed by the load simulation test.



**Fig. 19d. percutaneous surgery for soft tissue.**

- 1, 2. MTP release for loss of plantar flexion.
3. PIP plantar release for hammer or claw toe.
4. Cut of flexor tendons.
5. Cut of extensor tendons.

## Gastrocnemius Proximal Release (GPR)

### Definition, History

The GPR has a special place in our foot surgery; we have to distinguish on one hand *permanent equinism*, which is present either with knee extended or knee flexed, and on the other hand, *gastrocnemius shortness*, where equinism disappears when the knee is flexed (Fig. 20a2).

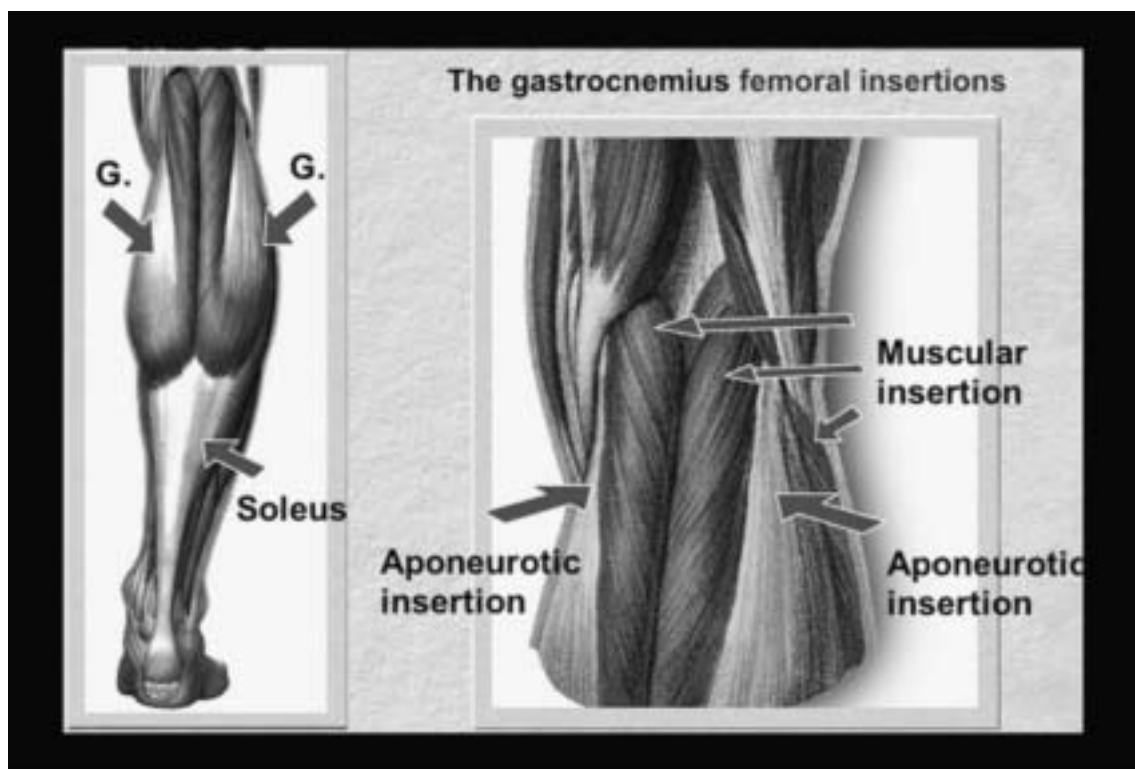
The permanent equinism is rare. The gastrocnemius shortness is frequently observed –

*i.e.* in our experience in almost 10% of forefoot disorders – some of these cases do not need gastrocnemius proximal release, for example when patients are more than 65 years or when gastrocnemius shortness does not have any obvious clinical consequences.

The clinical *consequences of gastrocnemius shortness* are those of equinism (see later).

The Gastrocnemius Proximal Release (GPR) is a harmless and effective procedure, which provides a significant improvement in the equinism depending on the gastrocnemius shortness.

**Historically**, we began to perform PGR in *spastic* children [18] in 1972, with J. Cadoux in Bordeaux. Initially we performed *Vulpinus* distal



**Fig. 20a1. Gastrocnemius shortness and its correction by proximal release. Anatomy.** (Original drawings from Bourgerly and Jacobs [28].) **Femoral attachment of the gastrocnemius.**

*Medial attachment:* The muscular fiber attachment is central. The aponeurotic attachment is medial, deeply located and thick (in fact, it is a strong tendon). Its medial border is near the 1/2 membranous tendon. It sometimes exists a bursitis between these two tendons.

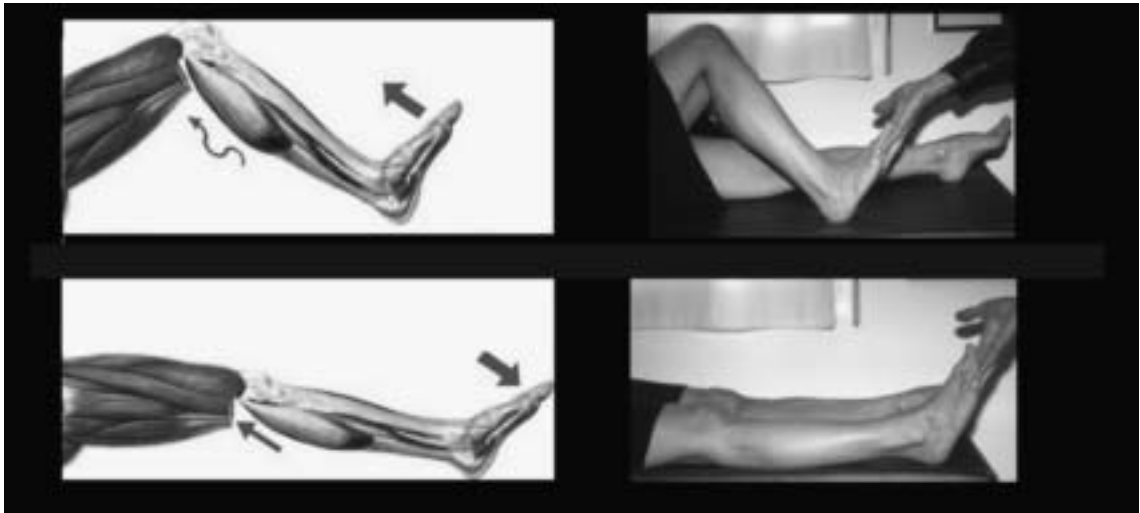
*Lateral attachment:* The muscular fiber insertion is also central. The aponeurotic insertion is lateral, but there are three differences with the medial insertion. (1) Aponeurotic fibers are less large than for the medial insertion. (2) They are less deep (facilitating their sections, fortunately because of the cpn). (3) They are less peripheral, *i.e.* there are some muscular fibers more laterally.

gastrocnemius lengthening, but we were not satisfied with the results (scar problems, recurrence of shortness). After GPR we didn't observe significant loss of the triceps surae strength. The GPR was sufficient in 20% of spastic children to correct the equinism for those who only had a mild spasticity (little disease or mild hemiplegia). For moderate or severe spasticity, the GPR was combined with Achilles lengthening but either performed secondarily (7 years old or often at the end of growth) or in the same time for severe deformity. In each case, the Achilles surgery was performed with a minimum tendon lengthening resulting in less diminution of the triceps strength.

For *static troubles* we began to perform the gastrocnemius desinsertion in 1983, and we progressively extend our indications. We realized that several foot troubles were increased by the gastrocnemius shortness, and some troubles were only due to the gastrocnemius shortness. The GPR was found to be a very easy and harmless procedure.

### **Local Anatomy**

**Anatomically** and regarding the patho-physiology, the gastrocnemius muscles belong to the



**Fig. 20a2. Clinical assessment of the gastrocnemius shortness 1.**

When the knee is flexed, the gastrocnemius is slack: This results in dorsal flexion of the foot. When the knee is extended, the gastrocnemius is tight, so that the foot is in plantar flexion.

suro-achilleo plantar system: This aponeurotic muscular system is composed of the triceps surae, the Achilles tendon, the calcaneum, and the plantar fascia.

Our aim is to release the tension resulting from gastrocnemius shortness by cutting the tendinous or aponeurotic fibers in their proximal part. The Fig. 19a1 shows the local anatomy of the gastrocnemius proximal part.

### **Patient Examination for Gastrocnemius Shortness**

– Active motion is only an indication for correct assessment of gastrocnemius shortness, only the *passive motion* is required.

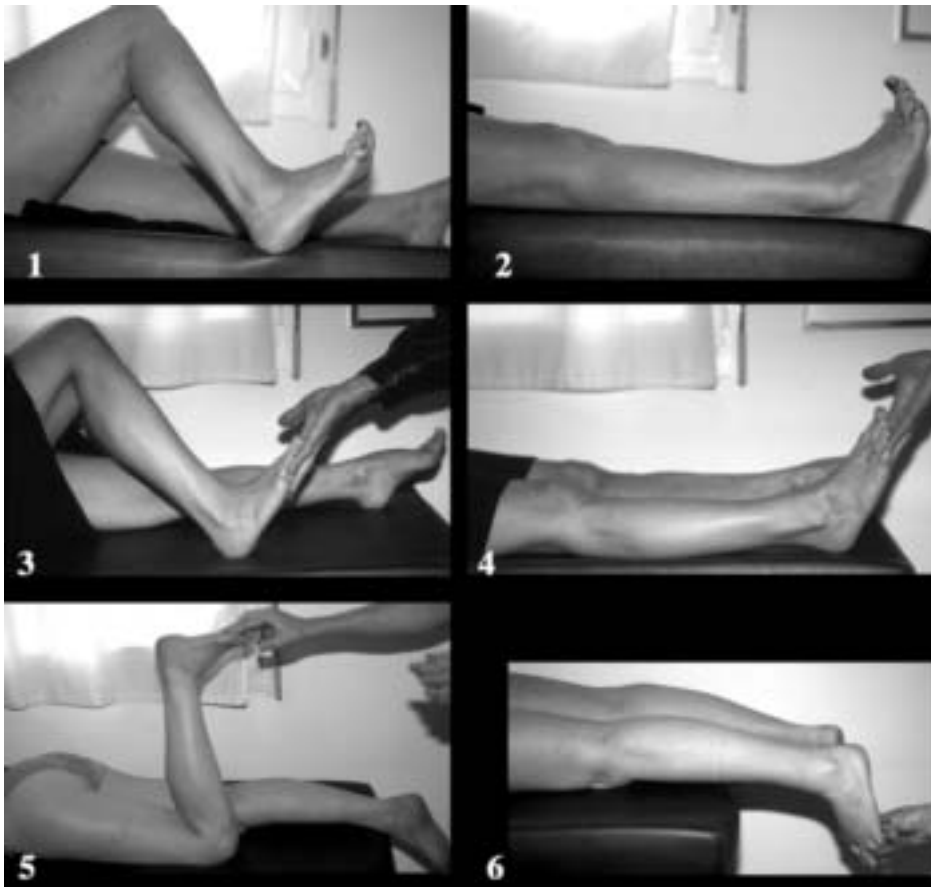
– The patient doesn't have to contract the ankle dorsal flexor muscles during the examination.

– The foot valgus has to be corrected passively.

– The hand of the examiner is applied on the foot *without strength*. This is an important point to respect.

– The ankle dorsal flexion is assessed with and without flexed knee.

– We consider there is a gastrocnemius shortness when the ankle passive dorsal flexion is negative in the extended knee position and when it is positive (or 90° angle) with a flexed knee position (more than 15° difference).



**Fig. 20a3. Clinical assessment of the gastrocnemius shortness 2.**

1, 2. Active motion with flexed and not flexed knee is not sufficient for gastrocnemius shortness assessment.

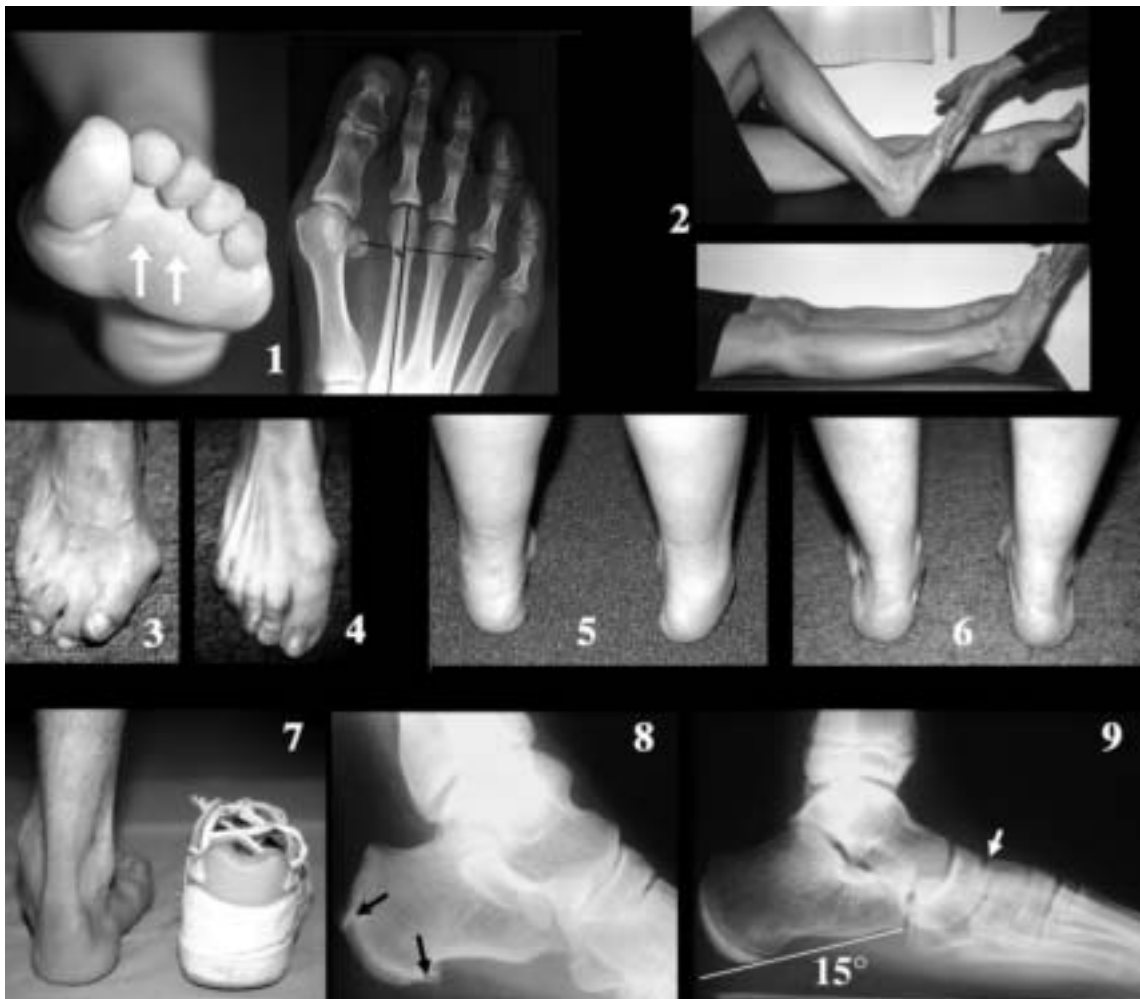4. Passive ankle dorsal flexion with and without flexed knee is the only test to assess the gastrocnemius shortness: But care has to be taken for the patient not to contract the tibialis anterior during this test, above all when the knee is flexed.

5, 6. Sometimes examination is easier in ventral decubitus.

## Consequences of *Gastrocnemius Shortness*

It first results in overpressure on the forefoot, isolating or increasing any forefoot disorder. There is also congruence on the midfoot and the rearfoot, similarly increasing a deformity,

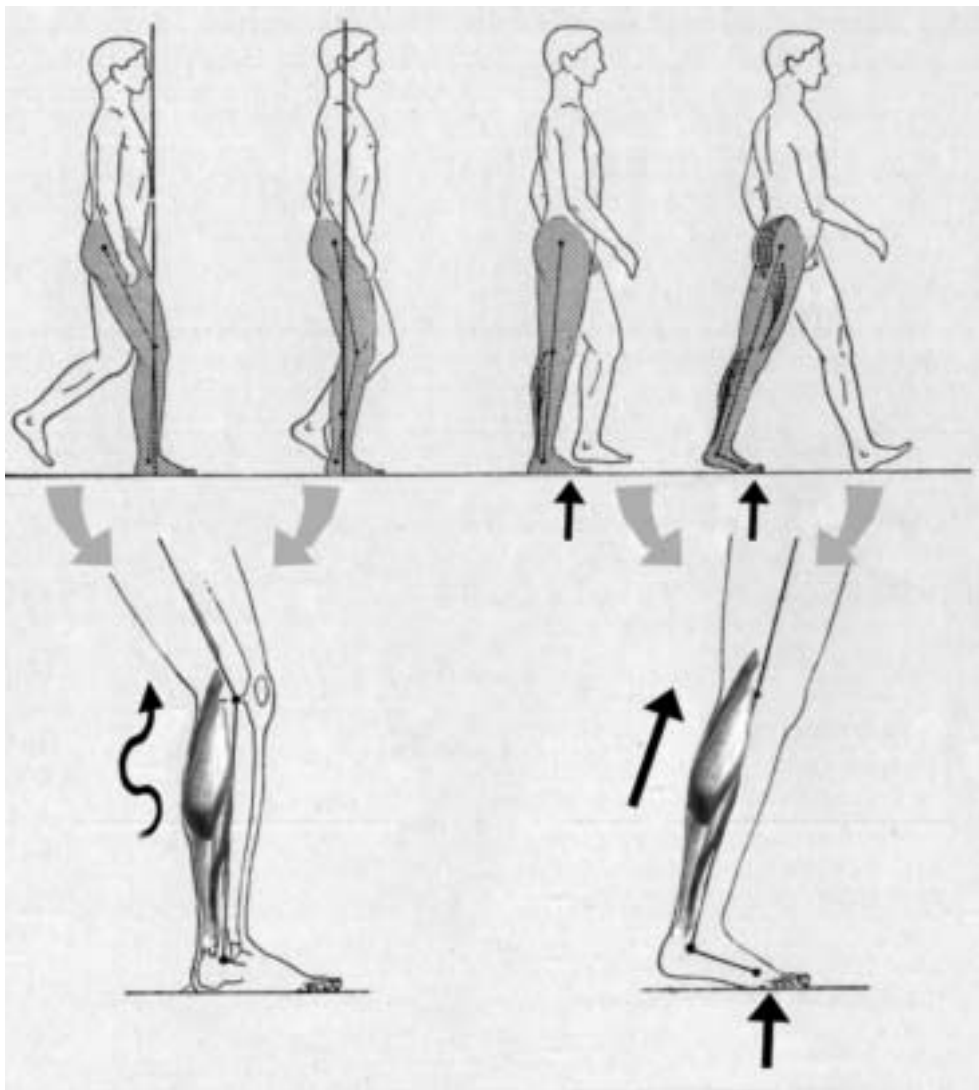
like varus or valgus, ankle instability, or increasing a plantar fasciitis or calcaneum spurs. These foot consequences are also well described by Di Giovanni [54] and above all by C. Kowalski, who studied the gastrocnemius shortness [32, 75]. Kowalski treats this shortness by physiotherapy. I find more reliable *long-term* result in doing the *Gastrocnemius Proximal Release (GPR)*.



**Fig. 20a4a. Gastrocnemius Proximal Release (GPR). The effects of the *gastrocnemius shortness*.**

1. In this case, there are not enough foot disorders to explain the metatarsalgia: The explanation is given by observation of an equinism (2) which depends on gastrocnemius shortness (GPR).
- 3, 4. The equinism increases the hammer or claw toes and the hallux valgus deformity.
5. Increasing hind foot varus.
6. Increasing hind foot valgus.
7. The hind foot is valgus but the shoe has a varus deformity: It is also due to an equinism (ankle instability).
8. Increasing calcaneum spurs by tightening of the suro-achilleo plantar system.
9. This calcaneum angle is less than  $15^\circ$  which is a sign of equinism. We have to clinically determine if this equinism depends on the gastrocnemius shortness.





**Fig. 20a4b. Role of the gastrocnemius on the forefoot ground pressure: pictures from Ducroquet [55].**

- In the first two steps, the knee is flexed, so that the gastrocnemius do not interfere in the forefoot ground pressure.
- In these following two steps, the knee is extended so that the gastrocnemius are tight. Furthermore, the repartition of the load is displaced on the forefoot. So that the gastrocnemius shortness increases the load on the forefoot in these last two steps.

### ***Technique of Proximal Release***

It is described in Fig. 19b1-2. The patient is in ventral decubitus, under general anesthesia. Through a transverse incision located in the hollow of the knee, reaching the gastrocnemius muscle hind aspect is very easy. Then you must reach the white aponeurotic peripheric fibers (white) and cut them. The cpn may be easily

identified and preserved but usually this is not necessary since the cpn is more lateral than the lateral gastrocnemius. As soon as they are cut, passive dorsal flexion of the ankle is applied and we see the gastrocnemius attachment moving distally.

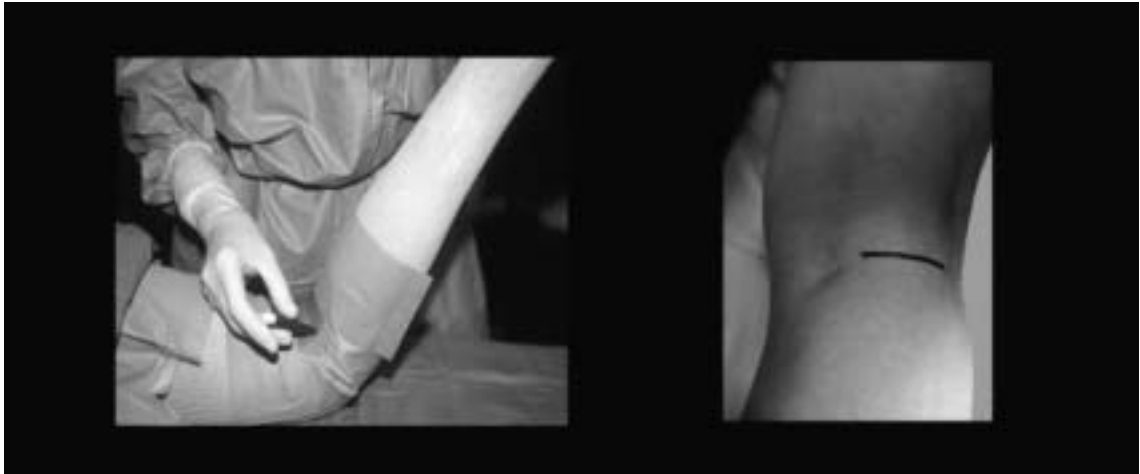
We check the complete release, but we avoid to disinsert the muscular fibers (red), because it may result in a bad cosmetic appearance. Furthermore, we observed it is without

consequence for the final result, which is equality of ankle dorsal flexion with or without knee extended. Intradermic absorbable suture closure is performed.

Postoperative aspects: Weight bearing below the knee, *cast or splint*, has been applied with slight ankle dorsal flexion for *only two days*.

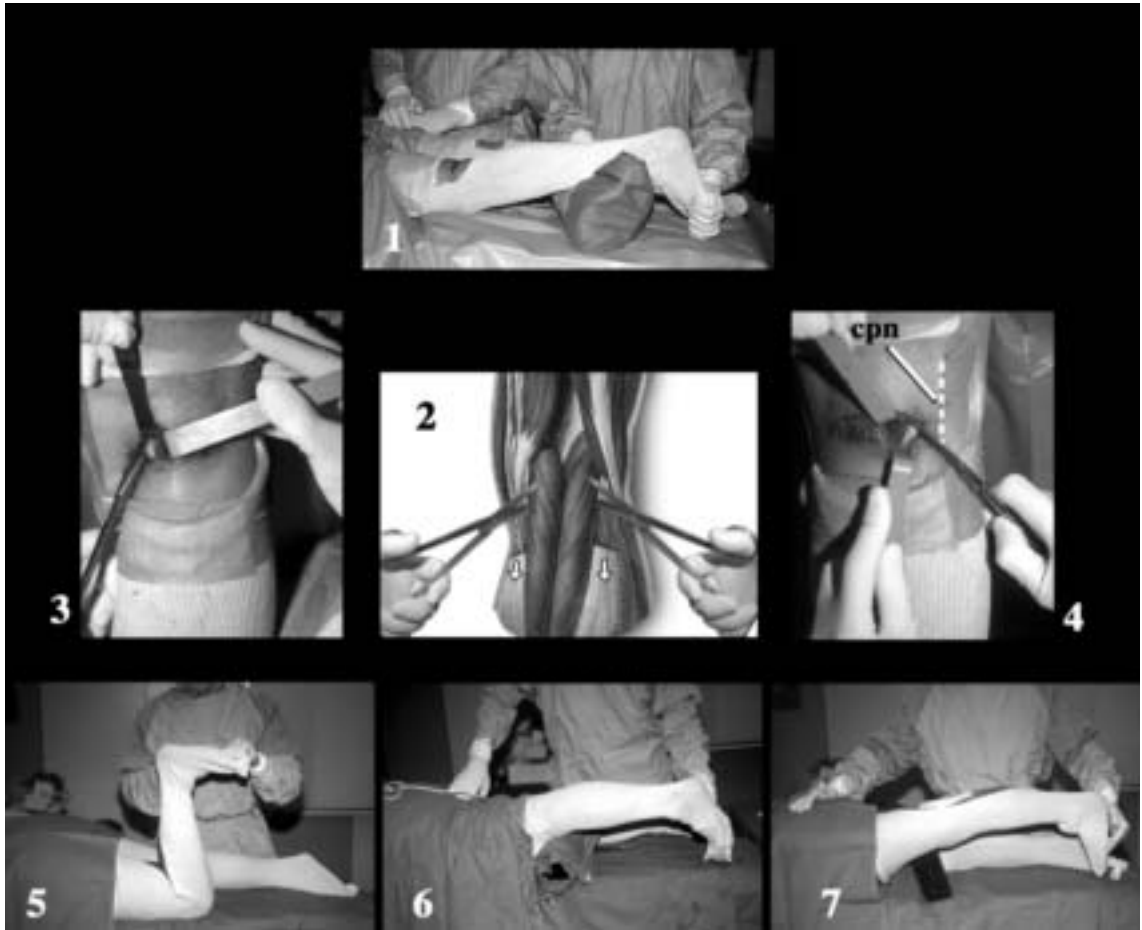
Then the *heel support shoe*, *i.e.* walking with ankle dorsal flexion, is worn during the three next weeks.

In a unilateral case, GPR may be performed at the same time as the forefoot surgery. In a bilateral case, GPR is first performed, then forefoot bilateral surgery one week later.



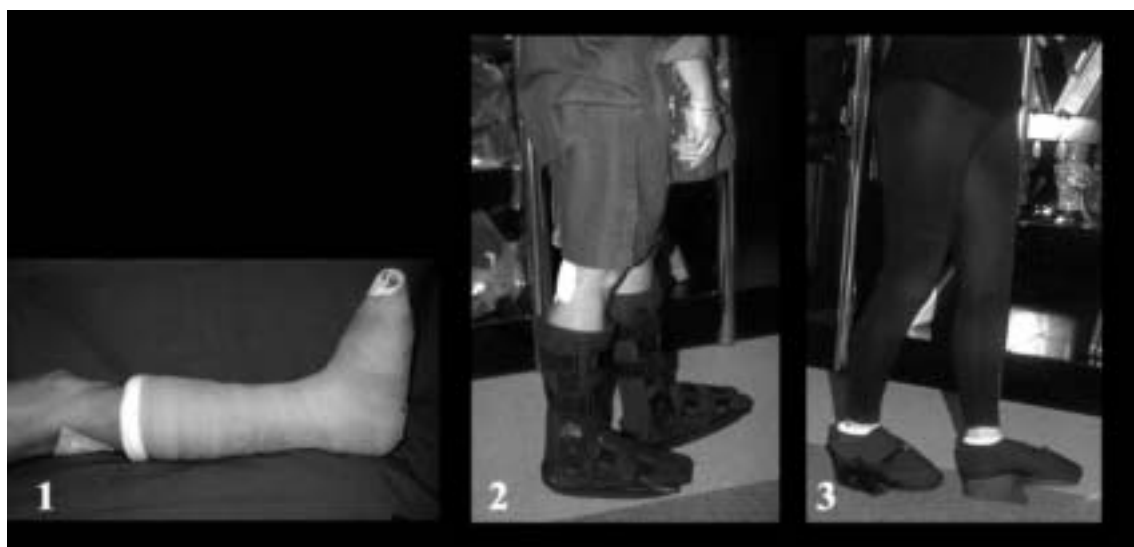
**Fig. 20b1. Gastrocnemius proximal release. Technique 1.**

Transverse incision in the flexion cutaneous pleat: First, we draw the incision with a marker when the knee is flexed. Its length is 5 cm. Its medial end is located 1.5 cm from the medial cutaneous fovea.



**Fig. 20b2. Gastrocnemius proximal release. Technique 2.**

1. Surgery leg position allowing to make ankle dorsiflexion and to release the cpn.
- 2, 4. The incision only cuts the aponeurotic or tendinous fibers of the gastrocnemius, first medial, then lateral.
3. The cpn should be seen but it is not necessary to perform its release. It is more lateral than the lateral gastrocnemius, and there is no risk if we follow closely the gastrocnemius muscle.
- 5, 6. Before GPR: Difference with and without knee flexed.
7. No difference after release.



**Fig. 20c. Gastrocnemius release. Postoperative aspects.**

1. Foot and leg cast have been applied with 90° flexed ankle, for only two postoperative days.
2. We can now use just a splint which maintains this position night and day (walking splint).
3. Walking with heel support shoe at one week postoperative and during three weeks. This maintains the gastrocnemius in a distal position.

## Results

We did not observe any drawbacks in the GPR, particularly, no decreasing of the triceps strength, no pain, no cosmetic problem since we make a longitudinal scar with intradermic suture, and no problem on the cpn.

First of all, patients recover comfort in foot and leg in standing position or in other functional aspects, due to the decreasing of the triceps surae tightness. The instability of the ankle disappears. The heel ground contact increases with easier walking without shoes or with flat heel shoes. GPR also improves the result of plantar fasciitis or calcaneum spurs treatment (including achillis insertion problem).

### Forefoot and GPR

Regarding the forefoot, the *excess of load pressure decreases significantly*, so that mild or

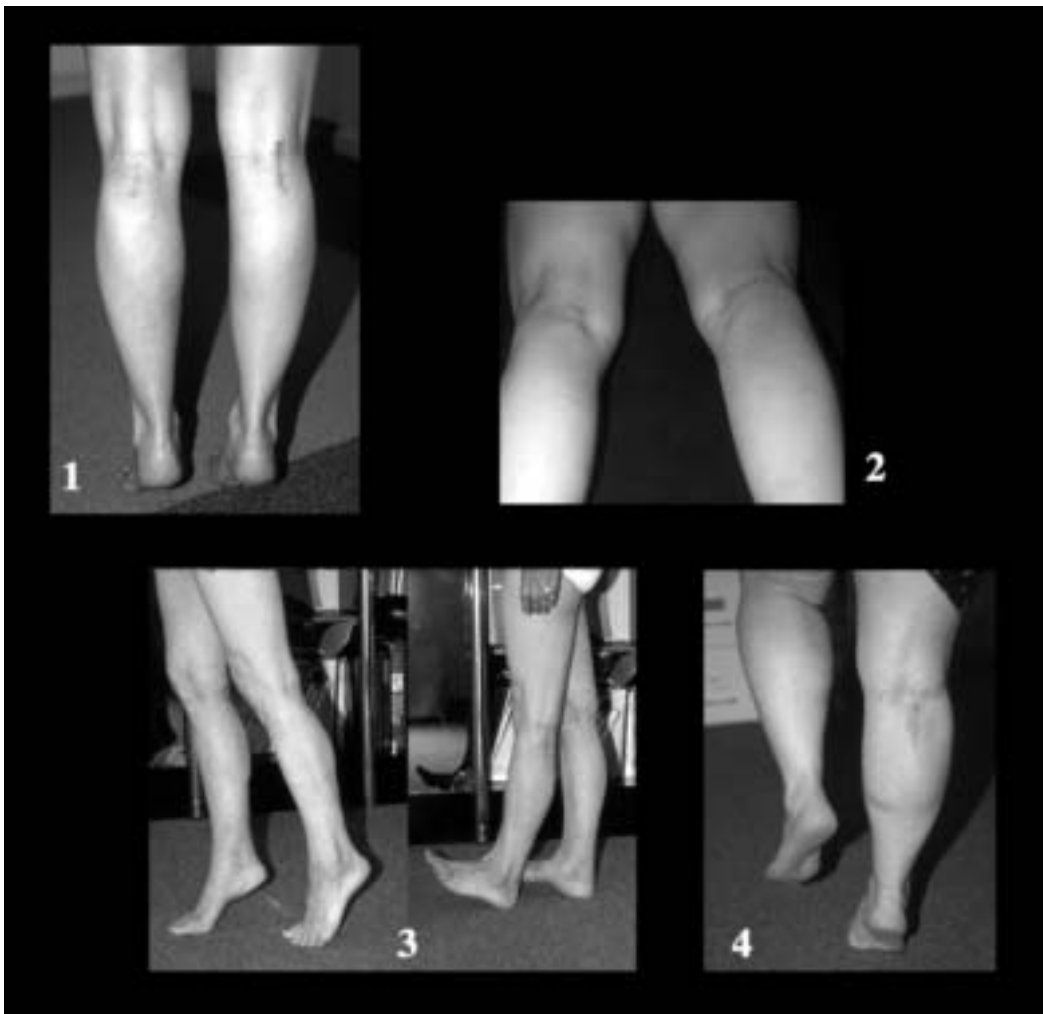
moderate metatarsalgia may be relieved just by the GPR. In every case, the forefoot local surgery results are improved and secured, notably for hallux valgus or claw toe correction and for relieving metatarsalgia.

– The load on the forefoot is certainly not decreased with or without GPD when a high heel shoe is worn.

– But when GPR is not performed, the forefoot load pressure remains when walking without high heel shoes.

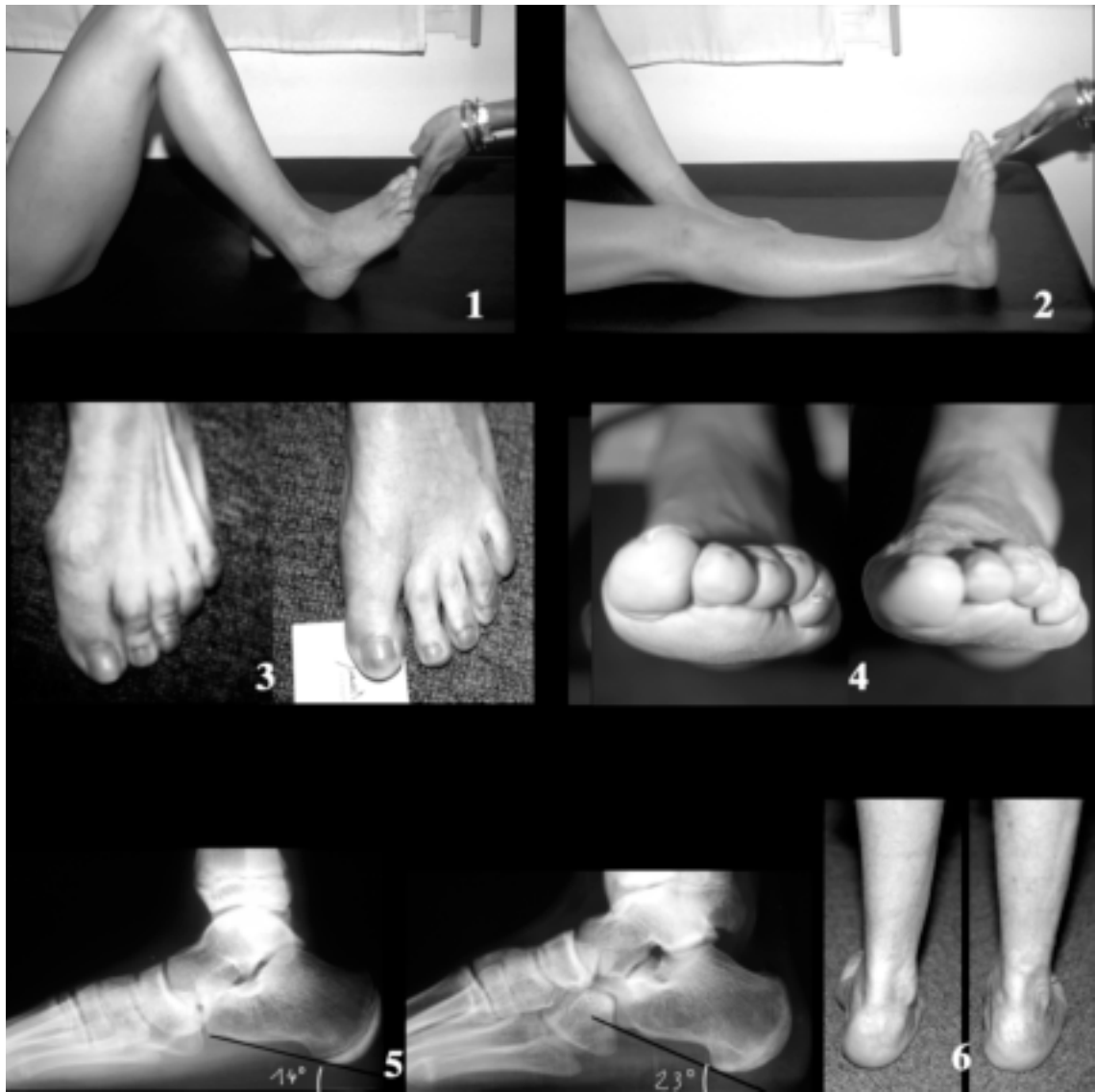– Many old people certainly suffer from equinism because they have worn high heel shoes all their life, and in this case, we do not perform GPR. When equinism is important we prefer performing Achilles tendon lengthening.

But now, more and more women wear shoes with flat or moderate high heel. High heel shoes still exist but are worn more temporarily than in the past: for these patients, who are the most numerous, GPR is useful for significantly decreasing overpressure on the forefoot and its consequences.



**Fig. 20d1. Gastrocnemius proximal release (GPR) Results 1.**

1. The triceps strength is not diminished after GPR: Tiptoes two months after the operation.
2. Transverse incision ten weeks after the operation: We have used this incision since October 2000. It is by far better looking than the longitudinal incision we used during the ten last years.
3. Both tiptoe and heel walking three months after gastrocnemius release.
4. We note that this procedure is sometimes used for patients with voluminous triceps.



**Fig. 20d2. Gastrocnemius release. Results 2.**

1, 2. Postoperative aspect after GPR. The ankle dorsal flexion is correct and similar when the knee is flexed or extended.

3, 4. Foot aspect after forefoot surgery and GPR. Both the forefoot disorders and the equinism are corrected.

5. Increased calcaneus angle after GPR.

6. Recovering of correct hind foot position after GPR and first metatarsal BRT proximal elevation in medial *pes cavus*.

## Use of the “20” Memory Staple in Osteotomies of Fusions of the Forefoot

### Definition, History, Generalities

*This staple first provides a permanent compression both in the prongs extremities and in the oval part which unites the two prongs.*

During the last fifteen years, we have used a memory staple in one indication: The shaft osteotomy of the great toe first phalanx. It is the memory staple “12” – *i.e.* 12 mm distance between the two prongs – but it was neither strong enough nor large enough to have indications other than the great toe P1 osteotomy. So, we devised a *stronger and larger staple (20 mm)* for the other indications in foot surgery, *i.e.*: *fusion of the first MTP joint, of the Lisfranc’s joint, osteotomies of the metatarsals, and osteotomy or fusion of the hindfoot.*

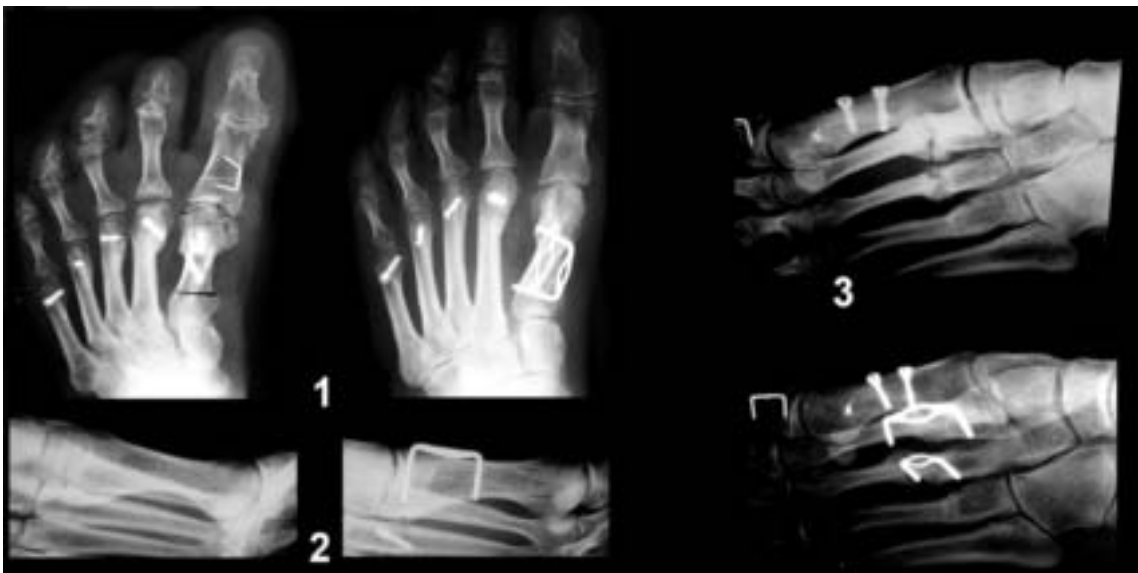Once osteotomy has been made, or the resection for fusion has been carried out, temporary fixation is performed. Then the guide determines the position of the two drills, then the length of the prongs is measured. Finally the staple is easily introduced. One or two staple are used following the indication.

### Indications and Results

#### Basal Metatarsal Osteotomies

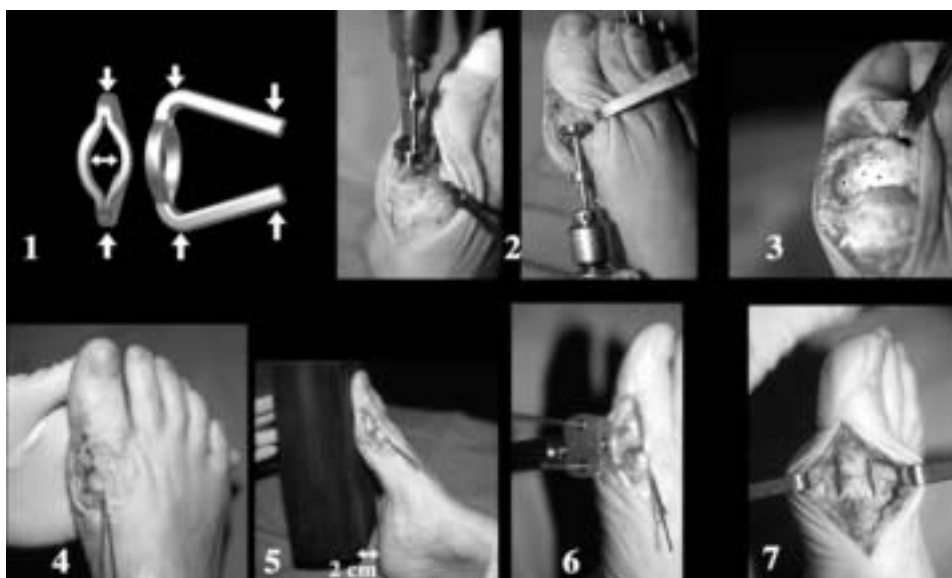
(Fig. 21a)

Principally it is the *first metatarsal* osteotomy, notably the elevation osteotomy, or the varisation osteotomy. For the other metatarsals, we use only the “20” memory staple in case of non union after any osteotomy.



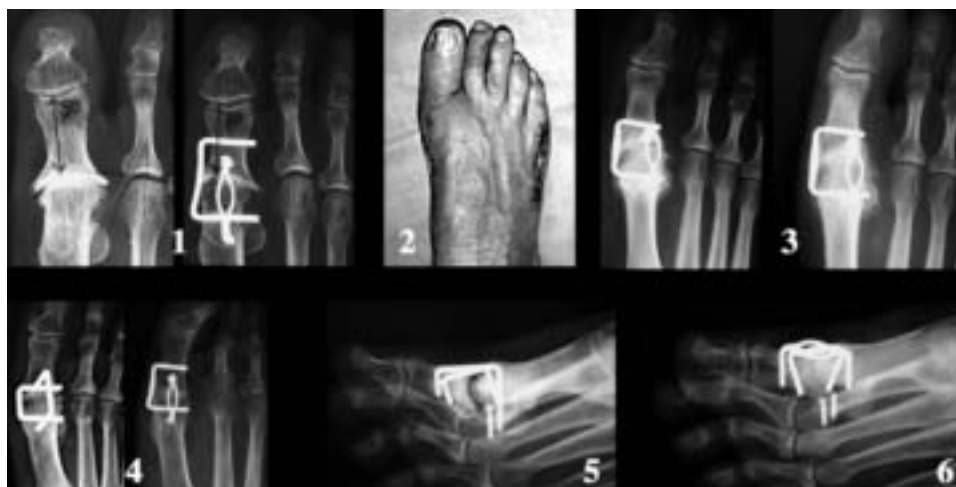**Fig. 21a. Basal osteotomies of the first metatarsal.**

1. *Variation* osteotomy for correction of introgenic hallux varus (see Fig. 14c3).
2. *Elevation* osteotomy for correction of over pressure under the first metatarsal osteotomy or for pes cavus.
3. Treatment of a *non union* of metatarsal osteotomy.



**Fig. 21b1. The “20” memory staple in the 1st MTP fusion: 1. Technique.**

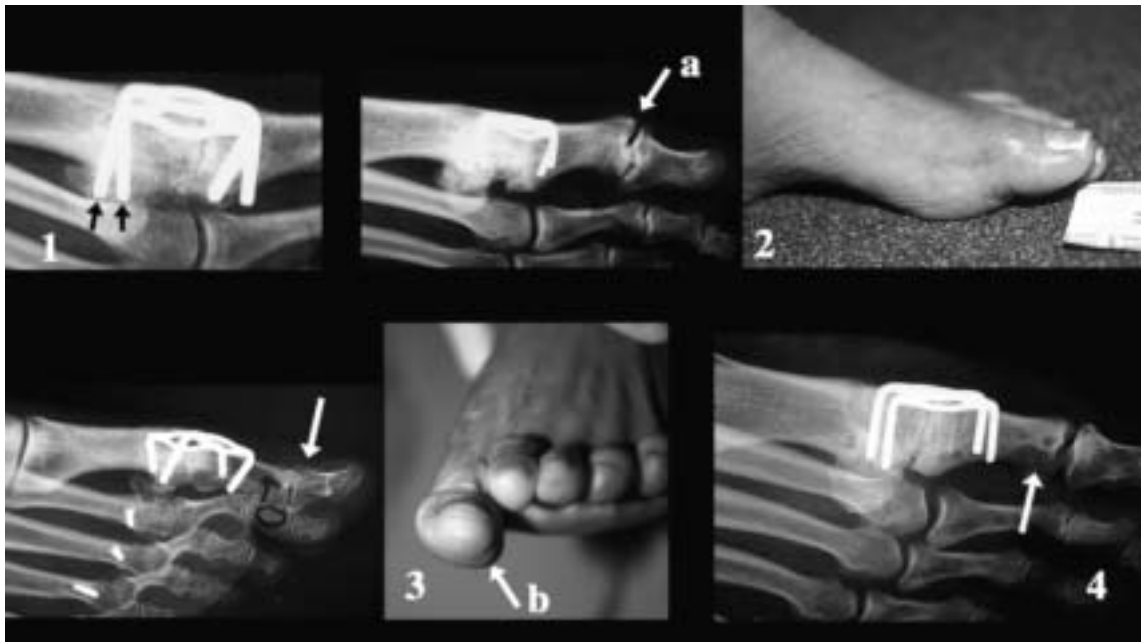
1. The principles of the “20” memory staple are the same than the “12” inter axis staple, *i.e.* bilateral compression – both on the oval part and on the prongs extremities – and permanent elasticity but the inter axis is up to 20 mm and is adapted with strong nesses.
2. Removal of the cartilage to reach the subchondral bone, avoiding to reach the cancellous bone.
3. Pride perforation if required.
- 4, 5. Temporary double K-wiring and checking of the correct great toe position in both horizontal and sagittal planes. Our rule: Not too much MTP dorsal flexion, (*i.e.* 2 cm between the heel and the board) and a slight MTP valgus, assessed by the Load Simulation Test.
- 6, 7. The two staples are set.
6. The first staple in a transverse plane, through the medial cortex.
7. The second one in a sagittal plane, through the dorsal cortex, is set slightly proximally comparatively to the transverse staple.



**Fig. 21b2. The “20” memory staple in the first MTP1 fusion. Advantages.**

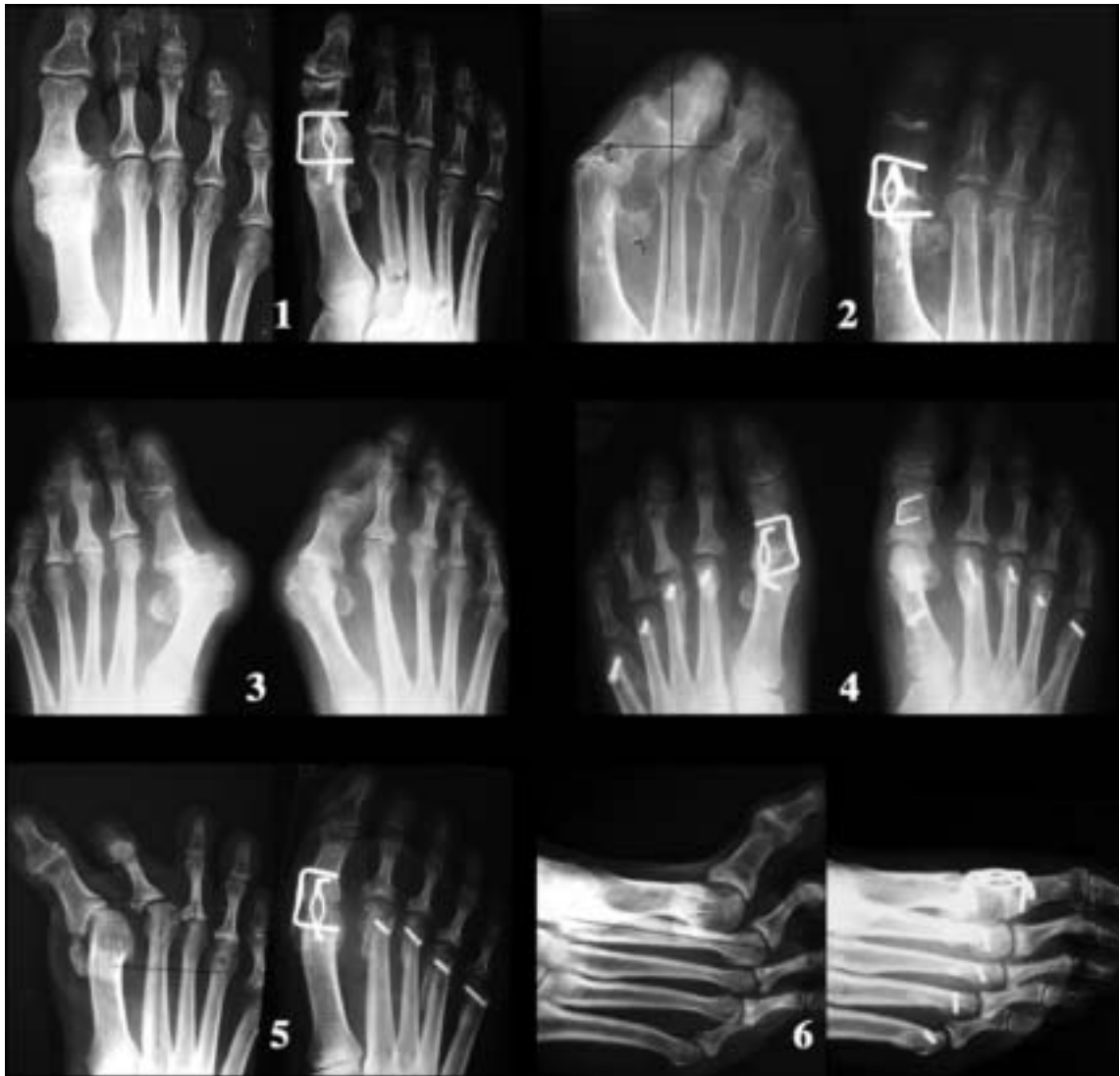- 1, 2. Very small resection of the fragment extremities allowing to keep as far as possible the great toe length.
3. Permanent compression allowing good healing in spite of inter fragmental resorption.
- 4, 5, 6. In case of non-union of previous fusion attempt, good results with only removal of the osteosynthesis implants and setting of the memory staple.





**Fig. 21b3. The “20” memory staple in the first MTP1 fusion. Drawbacks.**

1. The sagittal proximal prongs are too long.  
Incorrect position of the fragments.
2. Too much *dorsal* flexion: Keratosis in dorsal IP part. It is difficult to repair (plantar flexion osteotomy).
3. Too much *plantar* flexion (and incorrect toe rotation).
4. Repairing is easier with an oblique dorsal distal closing wedge. Fixation with the “20” memory staple.



**Fig. 21b4. First MTP fusion with “20” memory staple. Indications.**

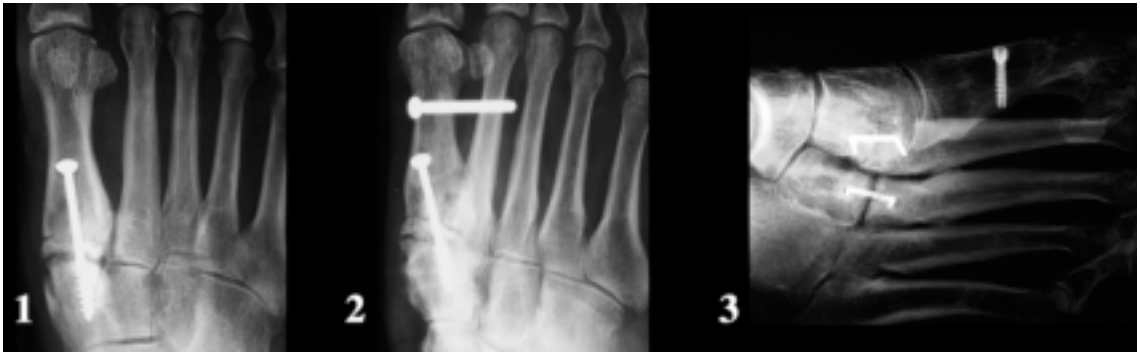1. Hallux limitus.
- 2, 3, 4. Extremely impaired MTP joint.
2. With hallux valgus.
- 3, 4. Rheumatoid forefoot (note the possibility of preserving one side with M1 scarf shortening).
- 5, 6. Severe hallux valgus overcorrection.

### *First Metatarso Phalangeal Joint Fusion*

Two staples are used in perpendicular planes. With this staple, the fusion is remarkably easy and reliable. Very few cases of non union were observed, and in four cases of non union after any fixation, the fusion was obtained without bone grafting, with only removing the previous fixation and using two “20” memory staples.

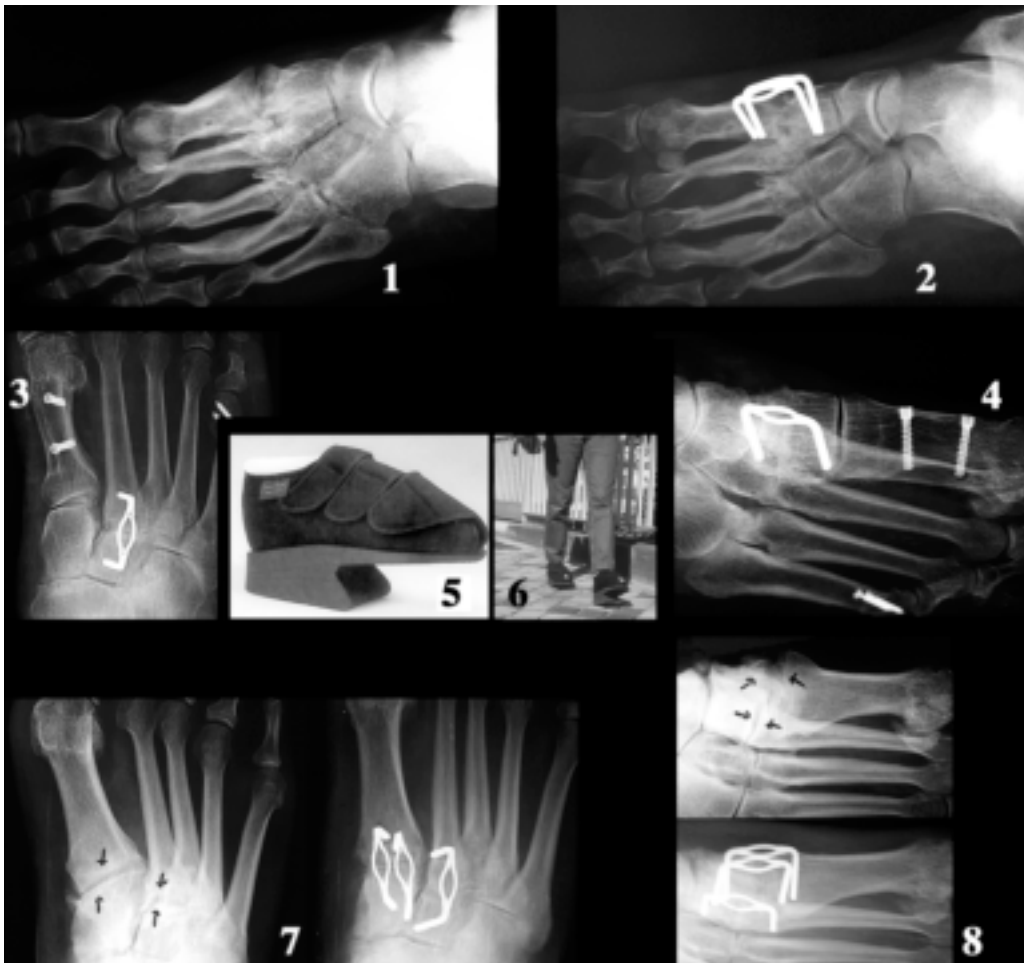### *Lisfranc’s Fusion*

We know the difficulty to obtain fusion in this location with traditional fixation. On the contrary in this indication, the permanent compression of the memory staple is very useful, *providing a reliable fusion in all cases.*



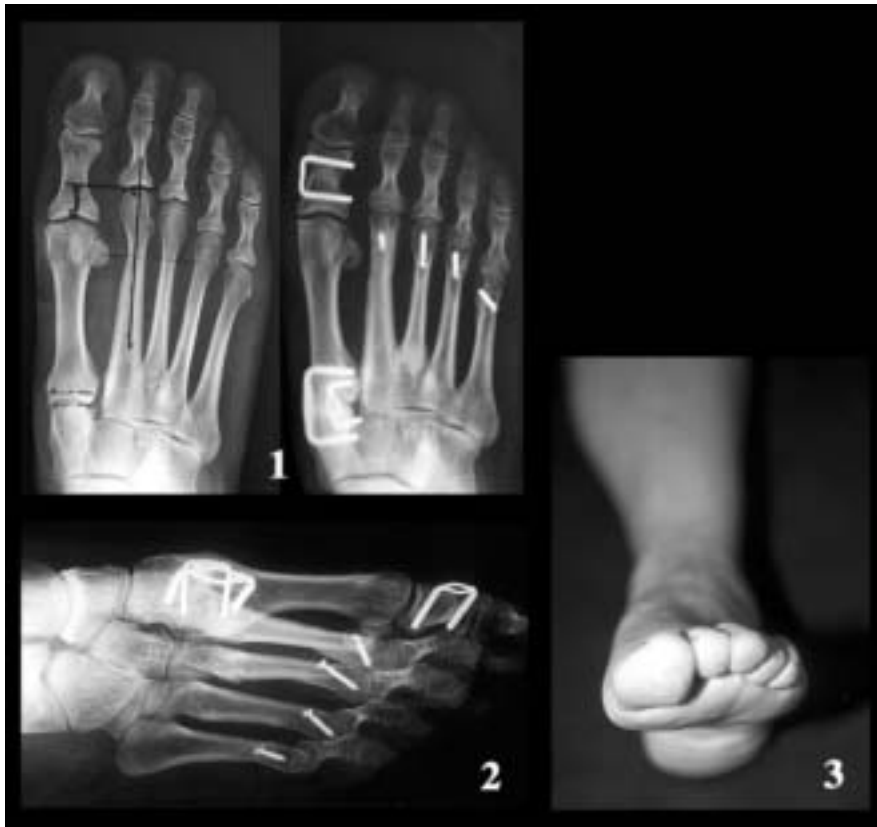**Fig. 21c1. Lisfranc's fusion. Problems occurring with usual fixation.**

- 1, 2. Fusion is sometimes difficult in the first ray even when using two screws.
- 3. Fusion is also difficult in the second and third cuneo-metatarsal joints.



**Fig. 21c2. Lisfranc's fusion with the "20" memory staple.**

- 1, 2. Fusion in posttraumatic first cuneo-metatarsal joint.
- 3,4. Isolated fusion in second cuneo-metatarsal joint.
- 5,6. With these staples, there is no need of postoperative cast but only the use of heel support shoe for six weeks.
- 7,8. Fusion for Lapidus procedure (indication: hallux valgus with *arthritic* cuneo-metatarsal joints).



**Fig. 21c3. Combination of first cuneo-metatarsal fusion and Weil lesser metatarsals osteotomy.**

To balance the shortening of the lesser rays, the first MTP fusion is not enough. So we perform the first phalanx great toe shortening.

### *Hindfoot Arthrodesis*

Indication in calcaneal cuboidal fusion or above all in *talo navicular* fusion where the fusion is ordinary difficult to achieve.

### *Conclusion*

The “20” memory staple may be used on the first or secondary time after non-union. We observe an extremely reliable fusion of the various arthrodesis or osteotomies of the foot.

The only restriction of this staple use is that it provides permanent compression, so that its use is not recommended for fusion in cancellous bone when additional bone graft is set between the two fragments.

*The use of the 20 memory staple provides a significant improvement in its indications, notably for first MTP fusion or Lisfranc’s fusion, and for basal first metatarsal osteotomy.*

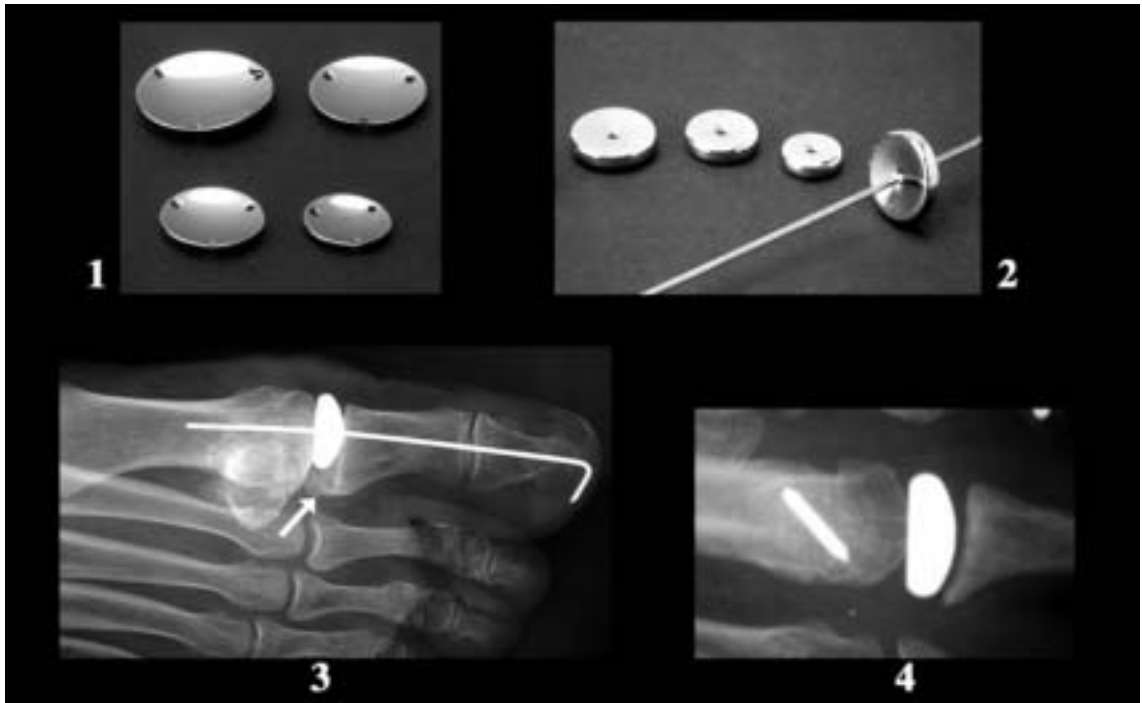
## The Button Temporary Spacer

### Definition, History

We were interested in the polyethylene cup described by B. Regnaud in 1975 [98, 99]. This cup provided good results particularly in hallux rigidus surgery. With B. Regnaud we first replace the polyethylene by stainless steel for providing better surrounding soft tissue and increasing the local tolerance. These cups were held by peripheral small holes. Then we devised the button prosthesis or button spacer [16]. It is thicker than the Regnaud's cup and it has a central hole allowing the primary fixation by an axial K-wiring (one

month). This spacer has to be removed from six months to one year postoperative. Later we replaced the stainless steel by Zirconium for it provides more mobility and better quality surrounding soft tissue. However the Zirconium cup has absolutely to be removed before one year postoperative, since the long-lasting implanting results in abrasion of both the resected phalanx bases and the metatarsal head cartilage. Since there is more abrasion with Zirconium than with stainless steel, we now only use stainless steel cup following the recommendations of M. Ragusa.

\* M. Ragusa, Grenoble, France.



**Fig. 22a1. The temporary button spacer 1. Generalities.**

1. From the Regnaud's cup, made in polyethylene, we first developed a stainless steel cup, with B. Regnaud. Fixation by peripheral holes.
2. The button is in stainless steel. Fixation by temporary K-wiring.
3. The button in the first MTP joint: Note the preservation of the plantar part of the first phalanx base, to keep the flexor brevis insertion, as indicated by M. Ragusa (Grenoble, France).
4. Button in lesser MTP joint.

## Technique

First ray: *MTP joint*, respect of the metatarsal head cartilage (osteophytes resection only) and resection of the base of the phalanx trying to preserve a part of the flexor brevis insertion (M. Ragusa).

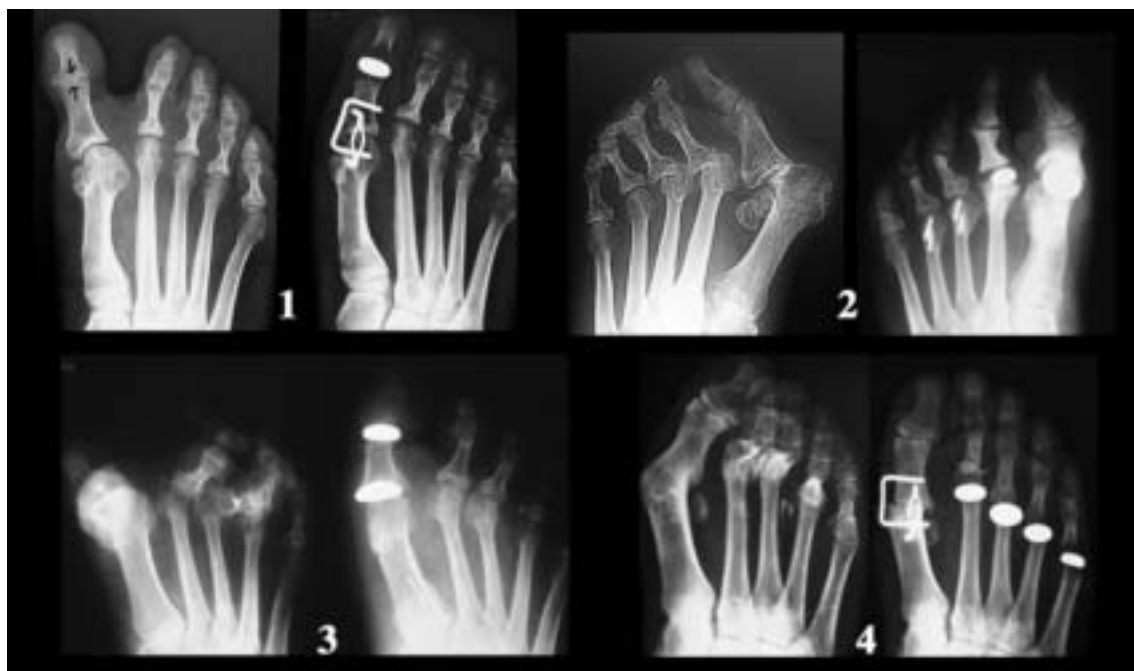*IP joint*: Respect of the basis of the second phalanx and resection of the first phalanx head.

Lesser rays: *MTP joint*, respect of the phalanx base and minimum resection of the metatarsal head. Axial K-wiring (1.2mm) to be removed one month after wards.

## Results

Secondary displacements of the cup may occur but it is painless and ordinarily without consequences. However, a long-lasting incorrect position may provide oblique abrasion and secondary deviation of the joint, which indicates an earlier removal of

the cup. The mobility of the joint is good and painless and the radiological aspect of the joint is correct. We used a lot of these spacers from 1985 to 1992, but we progressively stopped because of reliable osteosynthesis in first MTP fusion thanks to the “20” memory staple. Above all we had the possibility of MTP joint preservation on the first ray thanks to the easy first metatarsal shortening with scarf osteotomy on the lesser rays using the Weil metatarsal osteotomy. Both of these osteotomies provide such a longitudinal decompression that the MTP joint is opened very far. On the other hand, in the first MTP joint, the resection of the basis of the first phalanx (even when we try to preserve the flexor brevis insertion), results in diminishing the strength of the great toe ground contact. For this reason we now reserve the use of this cup for patients who do not want MTP fusion or in case of degenerative change in the corresponding interphalangeal joint. O. Jarde [72] devised a similar cup but with a small insertion in the phalanx base, providing more stability. Its main indication is impaired first MTP joint.

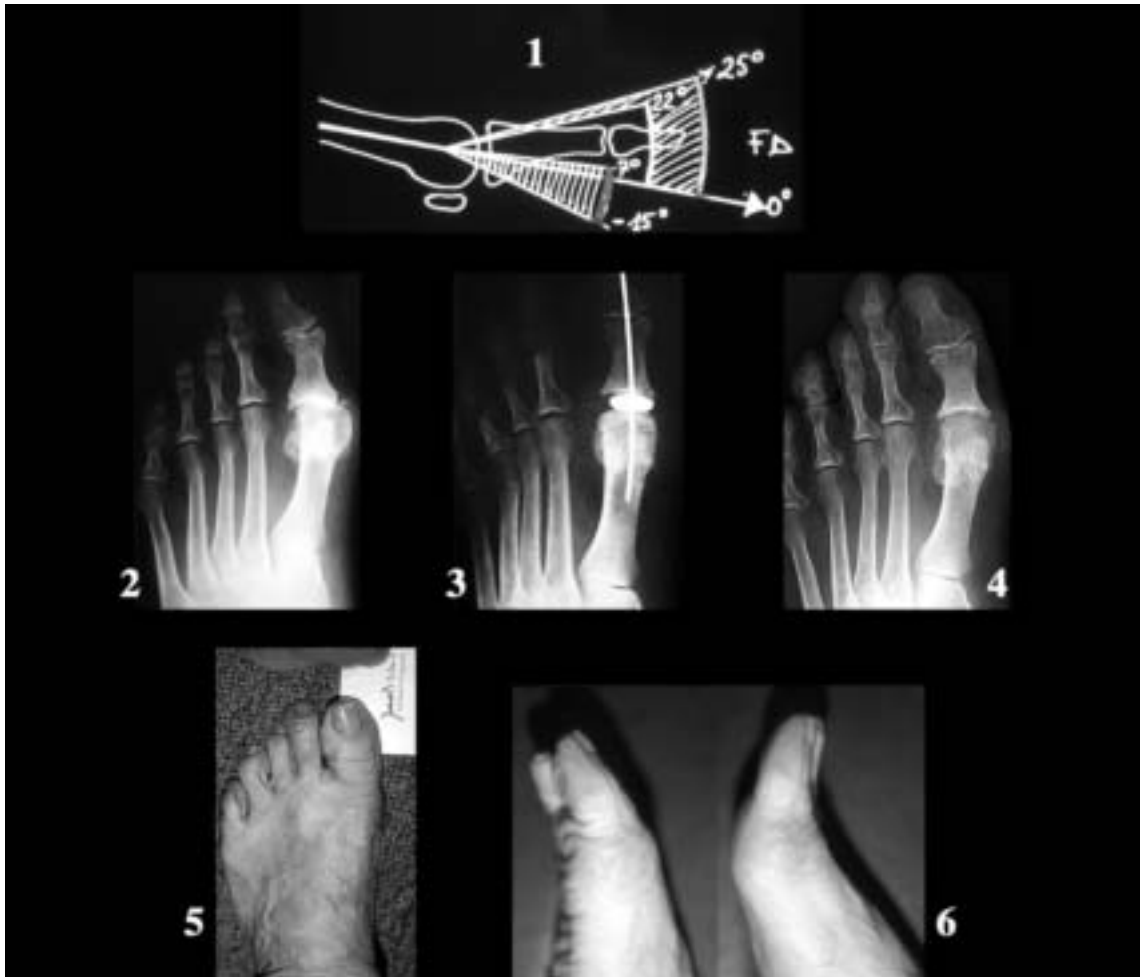

**Fig. 22a2. The temporary button spacer 2. Indications and results.**

1. A good indication on the great toe: Impaired IP joint combined with necessity of MTP fusion.
2. Long-time implantation results in abrasion of the fragments. The problem is that patients doesn't feel any discomfort and must be convinced to have the implant removed.
3. Buttons in MTP and IP joints.
4. Indications in lesser MTP joints. For a spondyloarthropathy forefoot, with MTP spontaneous fusion.

The best indication of the button prosthesis is one of the interphalangeal joint of the great toe for arthritic changes or rheumatoid lesion (Fig. 22d). However in very impaired meta-

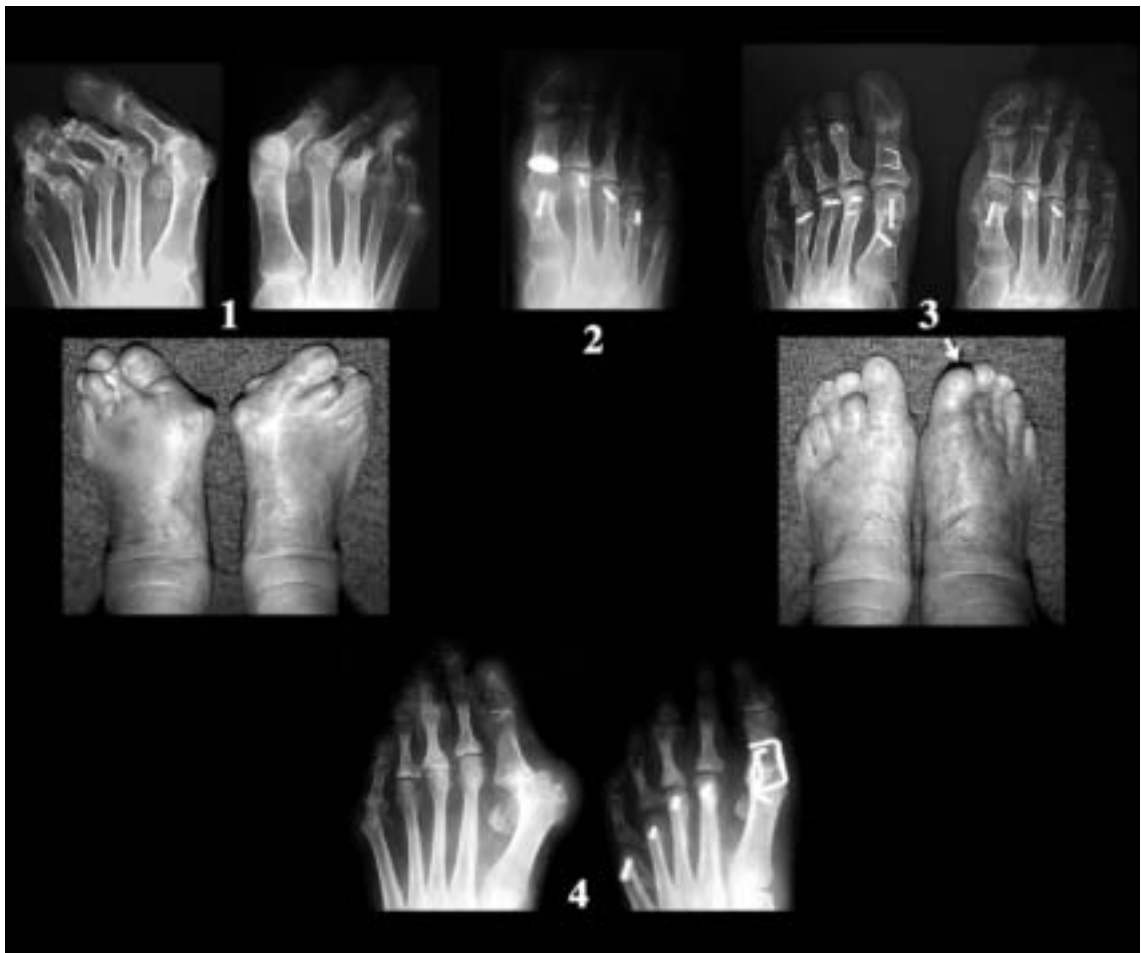
tarso-phalangeal joints on lesser rays or in spontaneous MTP fusion, as observed in some rheumatoid foot, the use of this button spacer is indicated.



**Fig. 22b. The button temporary spacer in hallux limitus.**

1. Pre and postoperative MTP range motion with hallux limitus treated by button setting.
- 2, 6. Hallux limitus: Treatment by button Zircone spacer.
2. Before operation.
3. With K-wiring (one month).
4. MTP joint aspect two years after removing the button.
- 5, 6. Same case, two years follow-up.

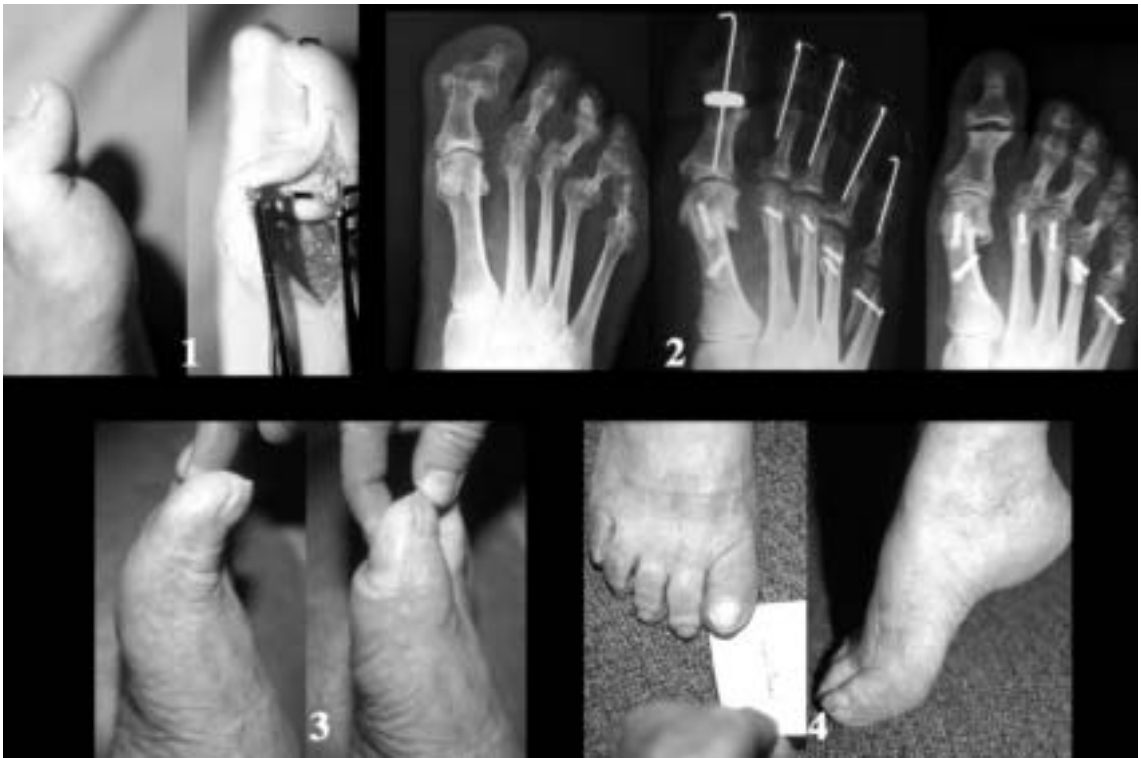However, the toe ground contact is sometimes decreased (however better than after Keller procedure) and we may observe some remaining discomfort.



**Fig. 22c. The button spacer in hallux valgus with MTP impaired joint – Comparative aspects with and without MTP preservation:** In the left foot preservation thanks to M1 scarf shortening, in the right foot MTP1 button.

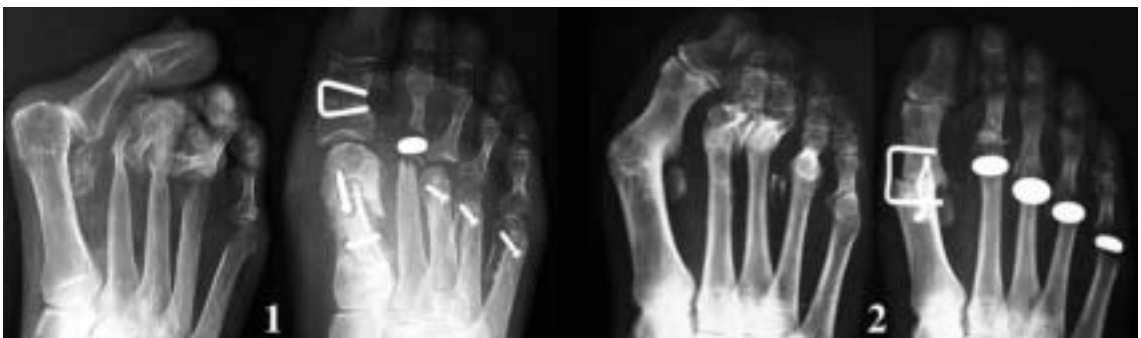1. Preoperative X-ray and clinical aspect.
2. The right foot with MTP button.
3. One year postoperative aspect (X-ray and clinical aspect when the button is removed). We note that the great toe ground contact is not correct in the right foot (with button).
4. So now we reserve the button spacer for patients who do not want to have a MTP fusion or when the IP joint is too much impaired. For other cases, MTP fusion is indicated.





**Fig. 22d. The button spacer in first IP joint.**

In impaired or stiff first IP joint, the button spacer gives good results, avoiding in most cases to perform IP fusion. In this plate one case of rheumatoid forefoot before surgery and one year after removing the button. When the first IP joint is only stiff, we always perform a plantar soft tissue release, which is sufficient in most cases.



**Fig. 22e. Button spacer in lesser MTP joints.**

It is rarely indicated. But here are two cases of good indications:

1. In iatrogenic forefoot severe disorder.
2. In rheumatoid forefoot with spontaneous lesser MTP joint fusion.

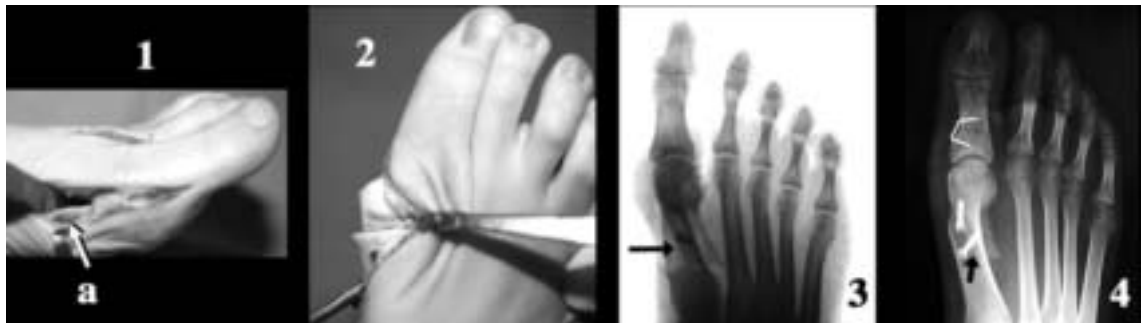
## II. THE MAIN FOREFOOT PATHOLOGIES

### The Different Types of Hallux Valgus Deformity

#### *Mild or Emerging Hallux Valgus*

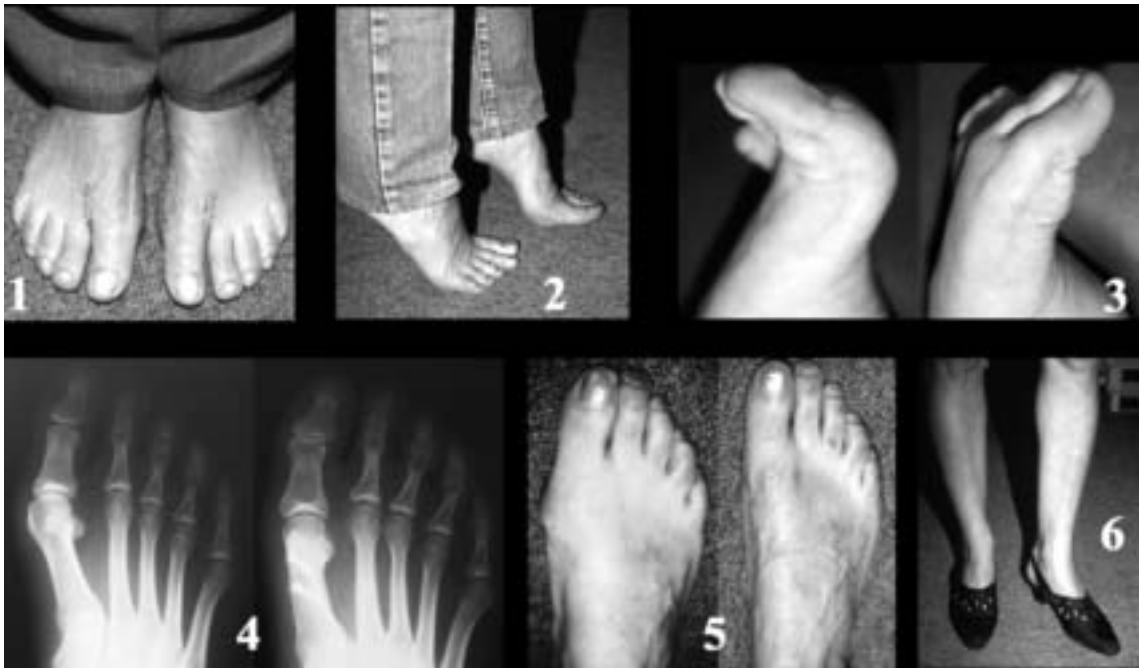We continue to use the M1 scarf osteotomy even for mild deformity, because in this case,

the very strong fixation allows an extremely early recovery and the long term results are very reliable. We observe generally a “restituto ad integrum” of the forefoot. The specificities of this procedure in such case are a small lateral displacement, sometimes a cut shorter than in moderate or severe deformities.



**Fig. 23a. Mild or emerging hallux valgus correction generalities.**

1. in this case, the abductor muscle is visible as soon as the medial incision is made, since it is not yet laterally shifted.
2. The lateral displacement of the distal fragment has to be minimum.
3. DMMA correction if required.
4. In this case, and in the case of a young patient, a short cut may be performed.



**Fig. 23 b. Mild or emerging hallux valgus correction – Results with scarf osteotomy.**

In mild hallux valgus, certainly other procedures such as distal chevron can provide good correction.

However, the scarf osteotomy has the following advantages:

1, 4. To provide a consistent and a reliable correction.

2, 3. The strong fixation allows a very early functional recovery, without pain or edema.

4, 6. The long term results – in this case – 4 years follow up: are excellent and stable.

For these advantages we continue to perform scarf osteotomy for mild hallux valgus.



**Fig. 24a1. Juvenile hallux valgus – Chronological phases.**

1. The juvenile hallux valgus may occur in the very early age (*photograph by the “Frères Lumière”*).
2. But it generally occurs at the age of puberty (*photography by David Hamilton*).
3. Juvenile hallux valgus without surgery certainly provides the worst deformities in advanced stage.

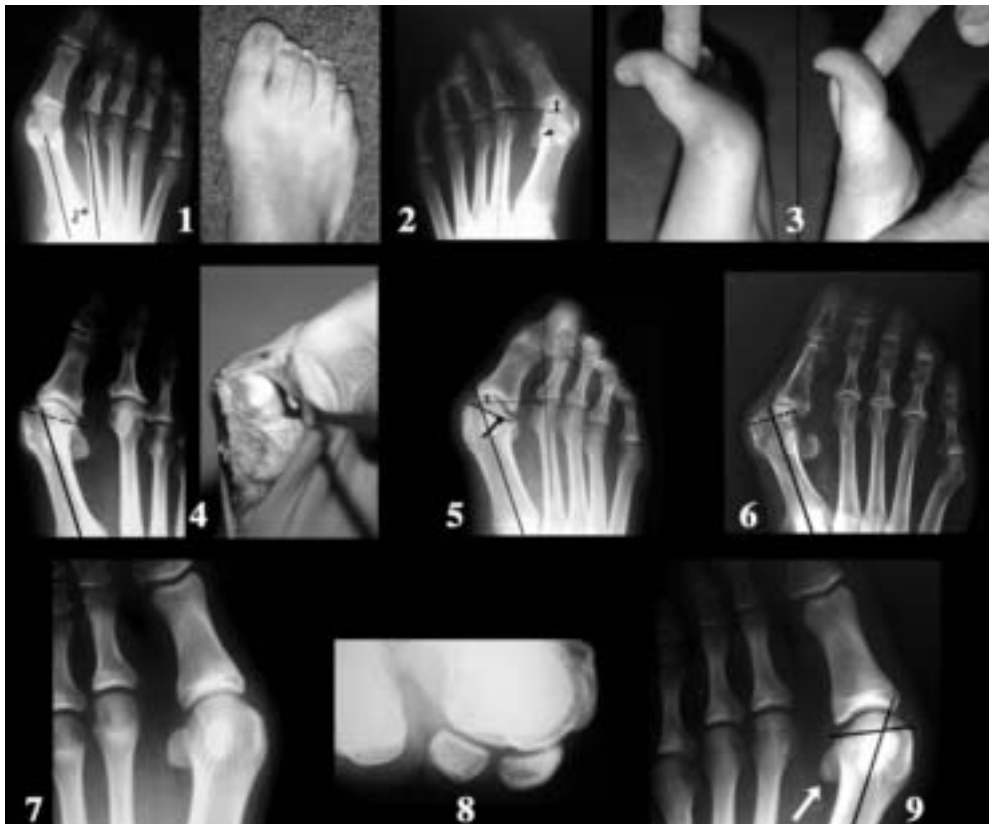## ***Juvenile Hallux Valgus***

We have a particular interest for this kind of hallux valgus above all since the 1990 Bordeaux SFMCP\* annual meeting where we directed, with P. Diebold, a symposium on this topic [17]. Like other authors, particularly Coughlin [45] we have observed and assessed the clinical and radiological characteristics of the juvenile bunion (Fig. 24a2) which are very particular. This type of deformity leads to a

worse deformity after 50 years if there is no treatment (Fig. 24a1 & a3).

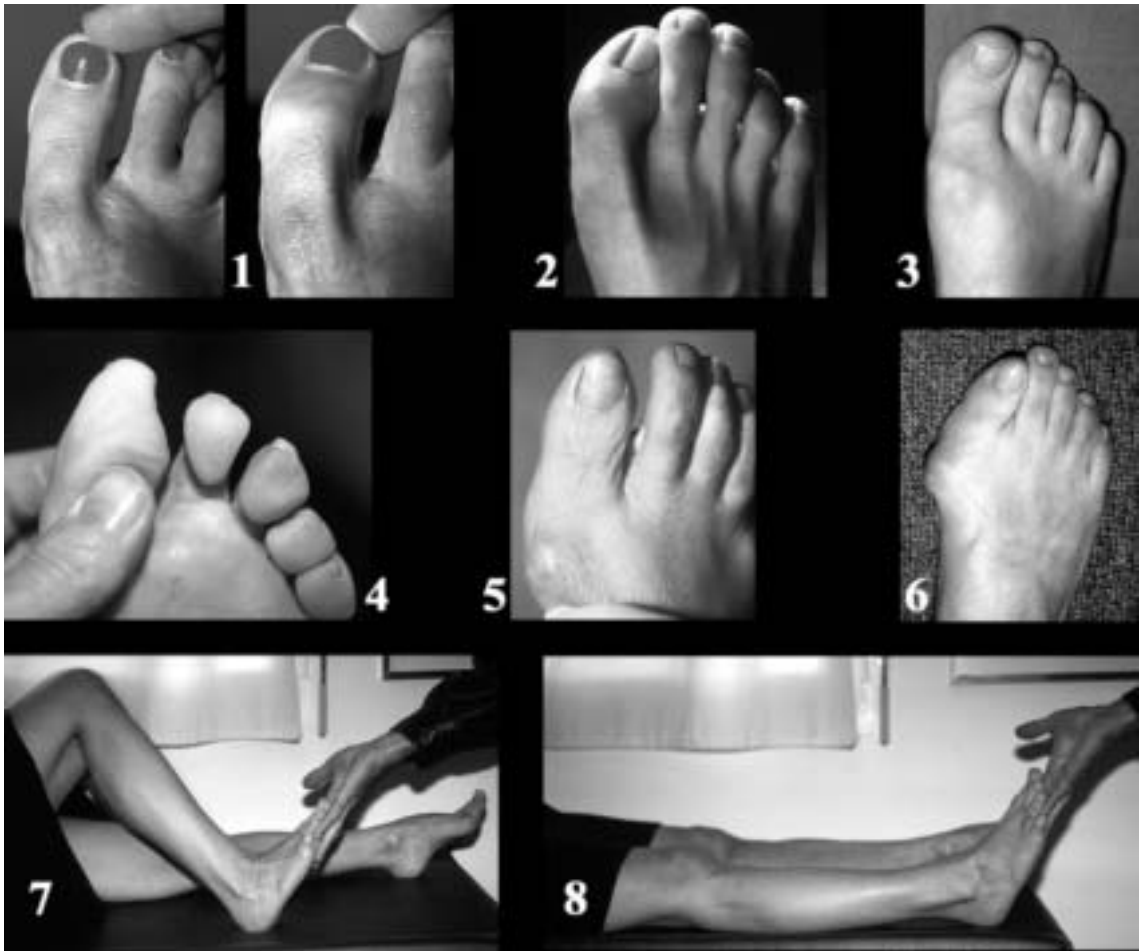*The 1<sup>st</sup> metatarsal scarf osteotomy is particularly adapted to the juvenile hallux valgus deformity* thanks notably to the possibility of DMAA or PASA correction of M1 shortening and to the great toe 1<sup>st</sup> phalanx osteotomy which completes this correction. So, the results are extremely reliable for surgery performed as soon as the forefoot growth has terminated, as showed in Fig. 24b1; furthermore, thanks to additional procedures like the Weil lesser metatarsals osteotomy, the correction can be obtained whatever the stage and the importance of the deformity and with articular preservation.

\* S.F.M.C.P. Société Française de Médecine et Chirurgie du Pied.



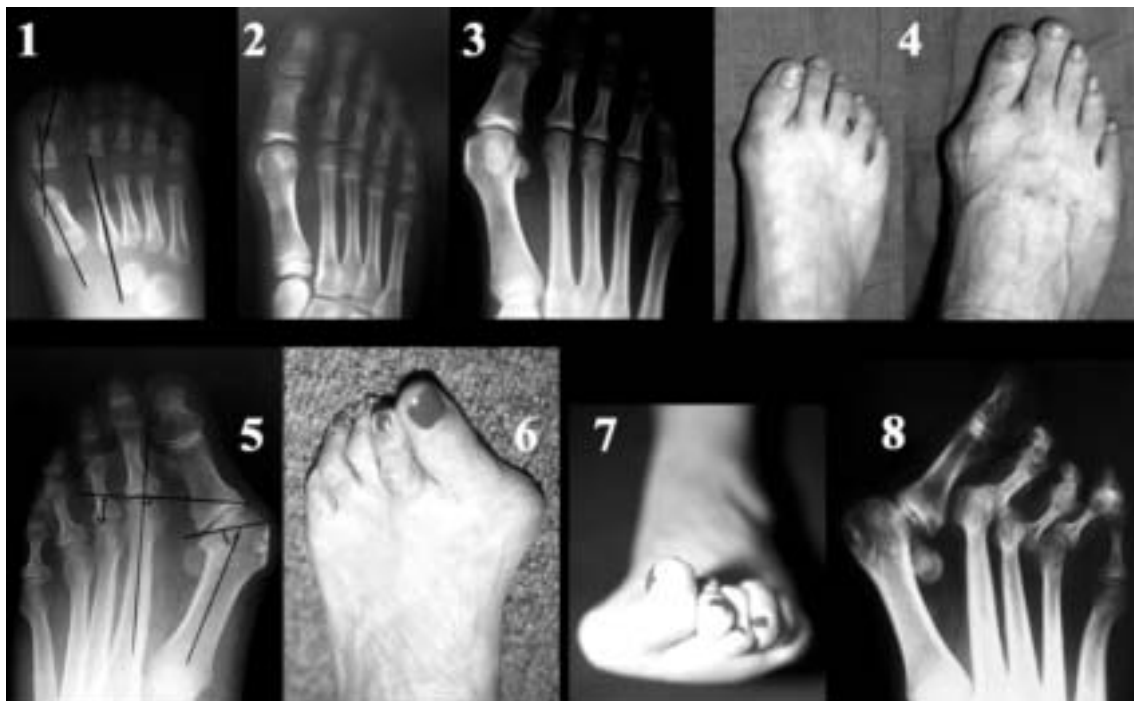**Fig. 24a2. Juvenile hallux valgus – Anatomical characteristics 1.**

1. Frequently, the intermetatarsal angle is not increased, it seems to be only a hallux valgus deformity.
2. We observe an index plus (first metatarsal longer than the second) metatarsal formula more often than in usual acquired hallux valgus.
3. The dorsal flexion of the MTP joint may be diminished.
- 4, 5. The DMMA angle is often modified.
6. However, we also observe normal DMAA angle (in this case, incongruent joint). Furthermore, a chevron shaped head may be observed (5).
7. The head is more rounded than in usual hallux valgus.
8. The metatarsal sesamoidal crest is often not visible.
9. Hypotrophic lateral sesamoid.



**Fig. 24a3. Juvenile hallux valgus – Anatomical characteristics 2.**

1. An usual observation is an interphalangeal or distal hallux valgus just when this joint is plantar flexed; this is due to the obliquity of the IP joint. It is different from a permanent interphalangeal (IP) hallux valgus.
2. IP hallux valgus is generally not combined with juvenile bunion, but the combination sometimes occurs (3).
- 4, 5, 6. We often observe a *sharp distal end of the great toe*, visible on the plantar and on the dorsal aspects.
- 7, 8. More often than for adult acquired hallux valgus, the gastrocnemius muscles are short.



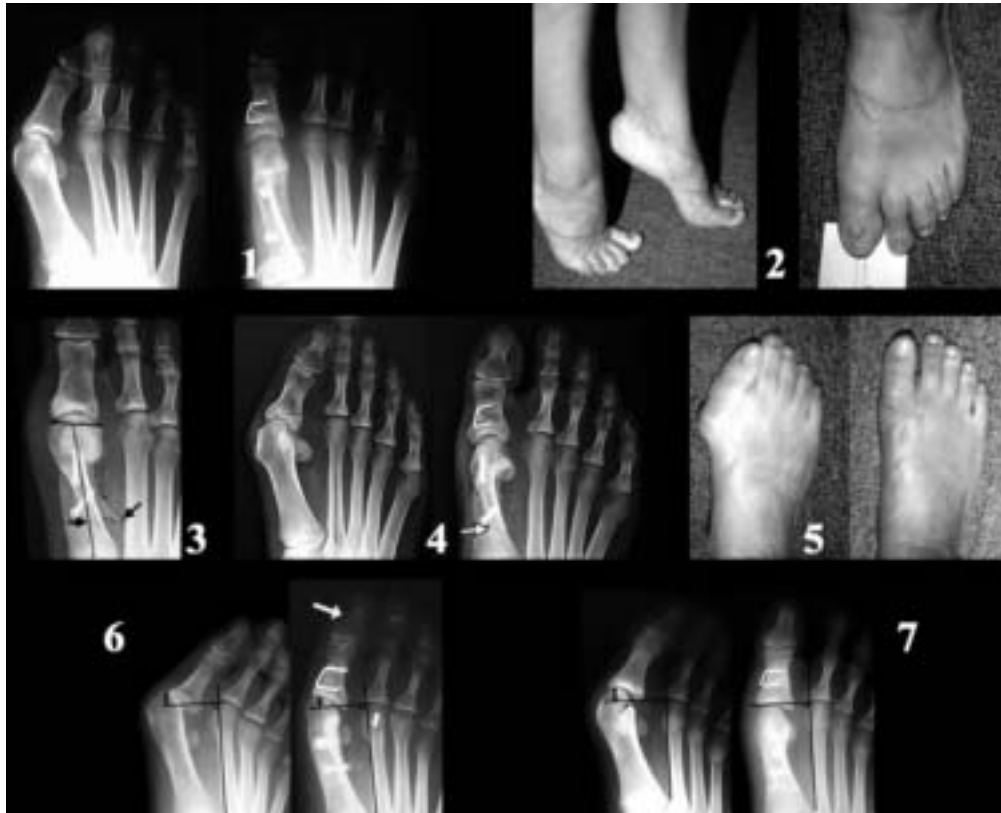
**Fig. 24a4. Juvenile hallux valgus: Chronological evolution.**

1. Early X-ray deformity is rarely observed: Picture provided by courtesy of C. Themar-Noël (Paris) who particularly studied the juvenile hallux valgus in its early stage.

2, 3. Same foot at 13 and 17 years.

4. A girl and her father (13 and 45 years): Same deformity, Greek type foot.

5, 6, 7, 8. After 50 years, the juvenile hallux valgus knows a bad evolution, resulting in severe forefoot disorders. Fortunately, the surgery is now reliable and possible as soon as the growth is finished, thanks notably to the scarf osteotomy, and generally such severe deformities are avoided.



**Fig. 24b1. Juvenile hallux valgus – Correction with M1 scarf osteotomy.**

1, 2. 18 year-old adolescent radiographic and clinical results.

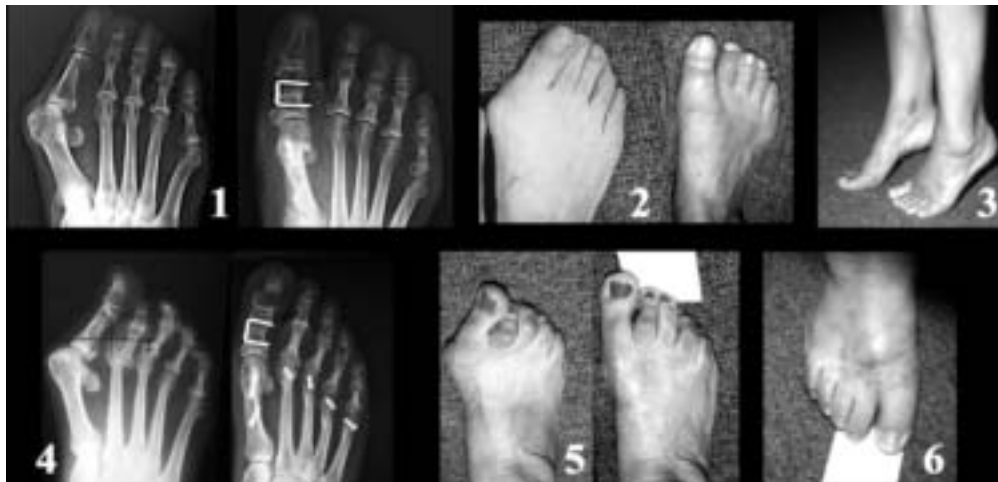3. The correction of DMAA is necessary in almost all cases.

4, 5. Radiographic and clinical results in chevron-shaped metatarsal head. DMAA correction.

6. Insufficient correction of an excessive M1 length, and insufficiency of DMAA correction, lead to undercorrection.

7. Excess of the first metatarsal length and its correction with scarf M1 shortening.





**Fig. 24b2. Juvenile hallux valgus – Correction in later stages.**

1, 2, 3. Radiographic and clinical results in moderate hallux valgus (45 years).

4, 5. Advanced “juvenile” bunion (60 years) requires shortening of the metatarsals with scarf and Weil osteotomies. 2,5 years follow-up.

6. This procedure keeps a functional toe ground contact.

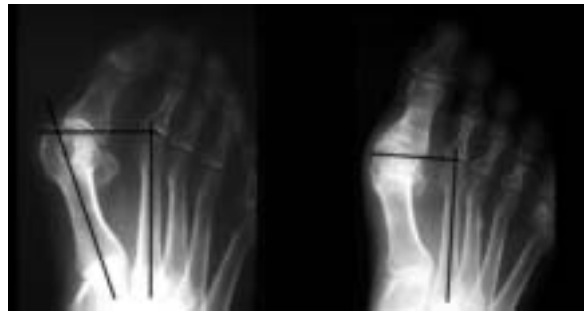## Arthritic Hallux Valgus

First of all, soft tissue procedures such as MacBride procedure cannot be adapted (Fig. 25a1).

On the contrary, the M1 scarf osteotomy allows preservation and large correction of the MTP joint while providing good deformity correction and articular mobility.

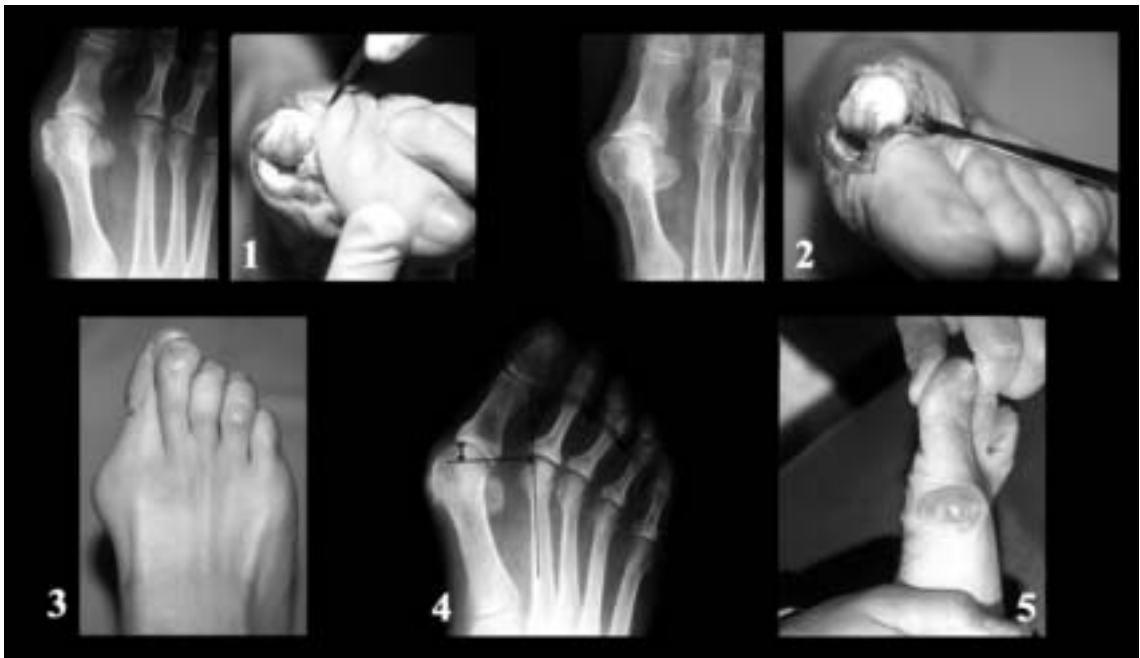In fact, when hallux valgus is combined with MTP arthritic changes, we observe some specifications leading to adapt the surgery.

– In *mild* deformities, the *lateral shift of the metatarsal head* works like a MacMurray procedure in the hip, and provides good results (Fig. 25b1).



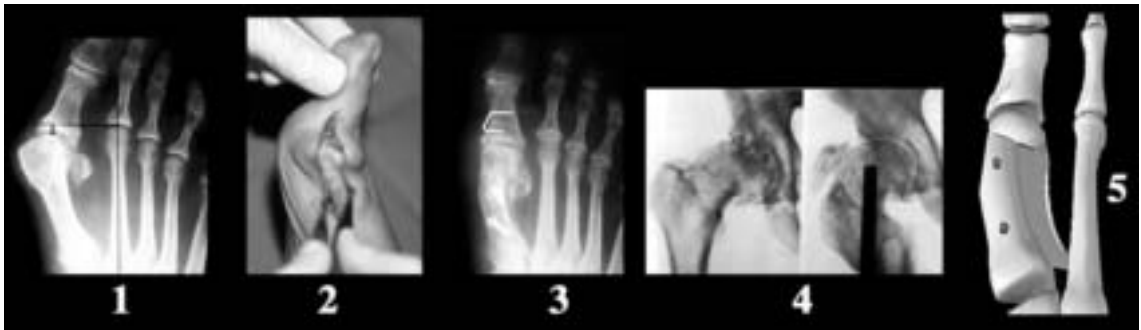**Fig. 25a1. Arthritic hallux valgus correction. Soft tissue procedures.**

Only with soft tissue procedure (in this case, MacBride), arthritic lesions may be remaining. Arthritic hallux valgus needs transverse and longitudinal decompression which is obtained by the metatarsal osteotomies.

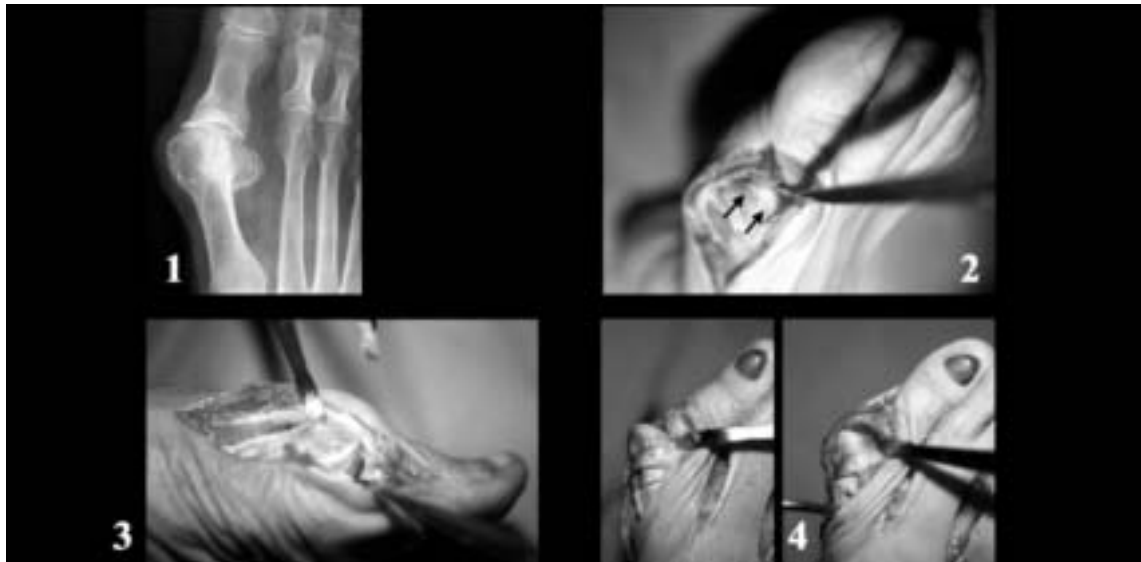


**Fig. 25a2. Arthritic hallux valgus – Main characteristics: Surgical consequences.**

1. Sometimes a *central lesion* exists: Its treatment is the 1st metatarsal shortening.
2. However, *the remaining good metatarsal head cartilage is in most cases only on the lateral aspect*. This cannot be assessed on preoperative X-ray, it is only a peroperative finding. This is an important characteristic of the arthritic hallux valgus, leading to medial head rotation like for DMMA correction.
- 3, 4. *Excess of first ray length*, that may be located on the 1st metatarsal or on the great toe (Egyptian type foot); this leads to an appropriate shortening.
5. Decrease of dorsal MTP range motion.



**Fig. 25b1. Arthritic hallux valgus – (1) The lateral shift of the 1st metatarsal.**  
 The scarf, like other transverse shift osteotomies, works like the MacMurray procedure for arthritic hip, providing MTP joint decompression. Only lateral shift is indicated when the cartilage is not laterally located, when there is a correct preoperative MTP dorsal flexion and a not too long 1st metatarsal.



**Fig. 25b2. Arthritic hallux valgus – (2) The DMAA or PASA correction.**  
 1. In most cases, the remaining cartilage is only located in the lateral part of the head, this cannot be assessed preoperatively, as showed by the presented X-ray, the accurate assessment is an *intraoperative finding*.  
 2. Correction by medial rotation of the head (DMAA correction).  
 3. Operative view.  
 4. DMAA correction combined with M1 shortening.

– A notable specificity of arthritic hallux valgus is the preservation of correct cartilage on the lateral part of the metatarsal head. This leads to correct the DMAA.

– The *first metatarsal shortening*: In most cases, we observe a decreasing dorsal flexion in

the MTP joint, needing the M1 shortening which is easy and accurate with the scarf osteotomy. The dorsal flexion decreasing is assessed preoperatively by examination of the dorsal flexion with passive correction of the hallux valgus deformity. The M1 shortening significantly

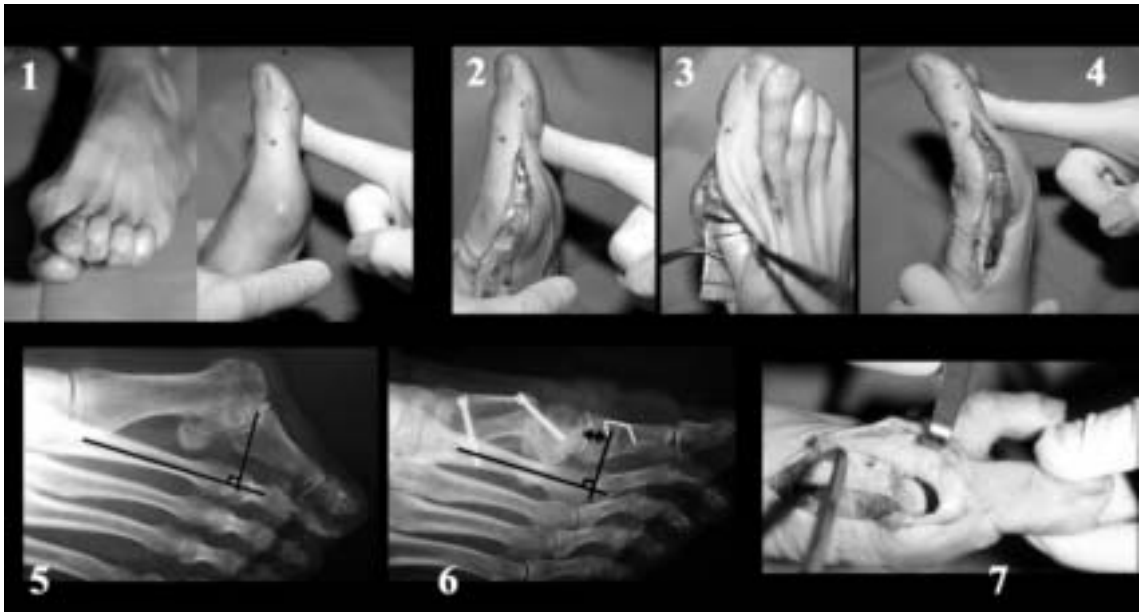improves the MTP dorsal flexion. The M1 shortening also significantly improves the MTP joint radiographic aspect. However, in arthritic hallux valgus, we cannot compensate too much the M1 shortening by its lowering because of the arthritic changes in the metatarso-sesamoid joint. So that we have to shorten the lesser metatarsals if required (Fig. 25b4) to harmonize the forefoot parabola.

– Another possibility both to shorten and to lower the first metatarsal is the first metatarsal Weil osteotomy [125]. It is one of the third metatarsal osteotomies described by Weil for the treatment of hallux limitus and arthritic

hallux valgus: It gives excellent results on condition that the first metatarsal is preoperatively very long.

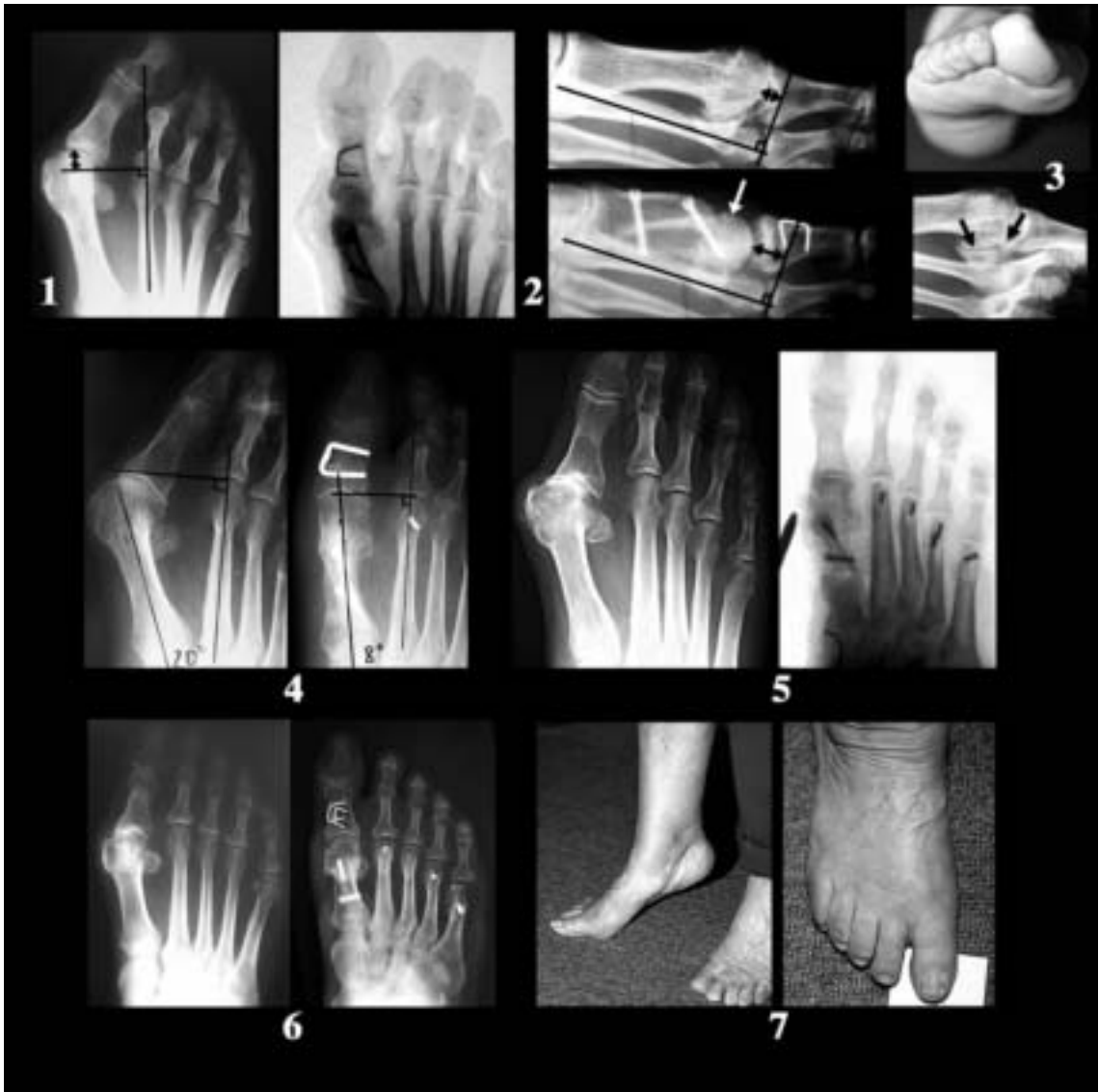– The *great toe osteotomies* must also be performed in most cases (Fig. 25b6), either to complete the correction or to shorten the first phalanx in order both to improve the toe position in the gait and to avoid longitudinal pressure with the shoes.

– With the scarf, great toe and Weil osteotomies, *the limits of articular preservation are significantly very far*: We can now write that *the MTP fusion for arthritic hallux valgus is rarely necessary*.



**Fig. 25b3. Arthritic hallux valgus – 3) The shortening of the first metatarsal – a) for recovering the dorsal flexion in the MTP joint.**

1. The loss of dorsal flexion is preoperatively observed with passive correction of the intermetatarsal angle.
- 2, 3, 4. Intraoperatively (same foot), same observation: The M1 shortening by scarf allows to recover a correct dorsal flexion.
- 5, 6. Medial oblique view showing both the correction of the plantar flexion and the improvement of radiographic aspect of the MTP joint (same foot).
7. The M1 shortening is the best way to provide *longitudinal decompression*, notably thanks to the release of the flexor brevis hallucis (see above Fig. 07f3b).



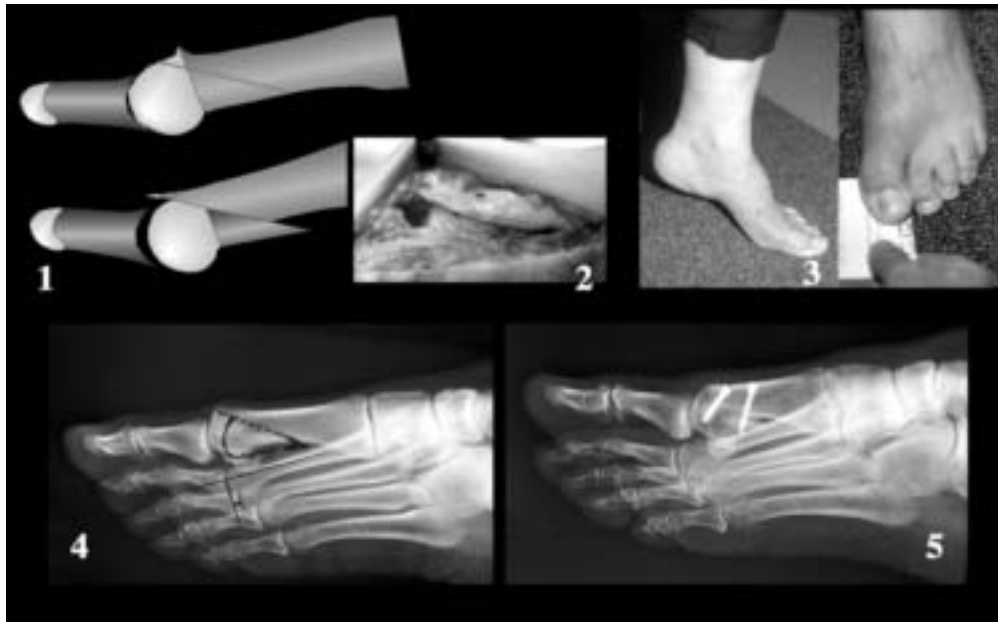
**Fig. 25b4. Arthritic hallux valgus – (3) The shortening of the first metatarsal – b) relationships between the M1 shortening and the lesser metatarsals.**

1. In case of too long first metatarsal, it is easy to reestablish an index plus minus metatarsal, while providing sufficient longitudinal decompression.

2, 3. When the first metatarsal is not too long, we compensate the M1 shortening by its lowering – but not too much lowering in order not to increase the arthritic problem with the sesamoids.

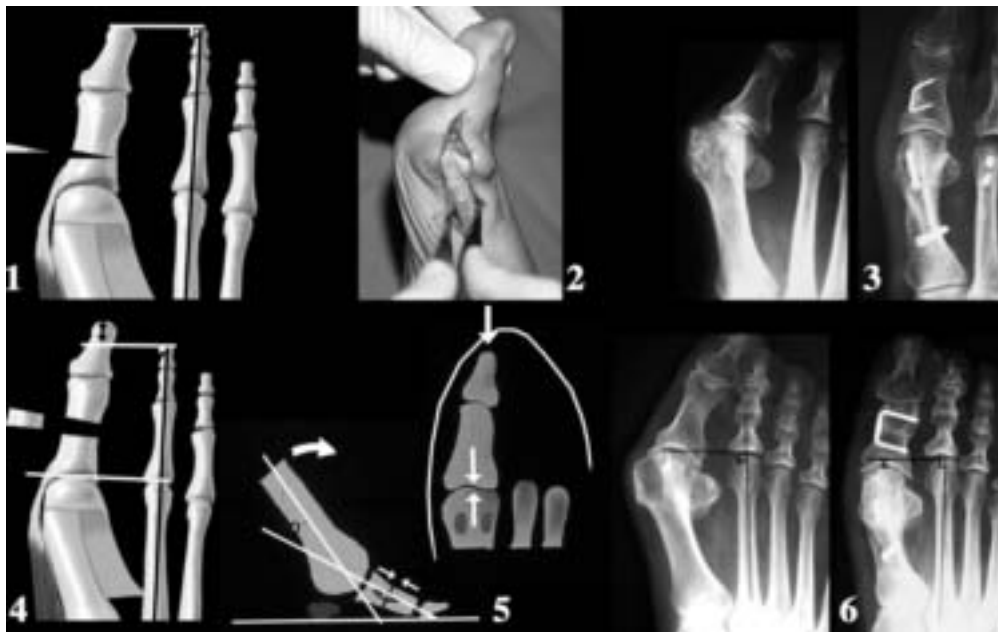4, 5. Combined shortening of the lesser metatarsals: The shortening of the first metatarsal has to be performed by the second metatarsal (4) or on several metatarsals (5), if required.

6, 7. Same foot: Such a long-term result (three years) with the five metatarsal shortening is regularly observed, with a significant improvement of both radiographic and clinical signs.



**Fig. 25b5. Arthritic hallux valgus – (3) The shortening of the first metatarsal – c) by the Weil osteotomy.**

Among the three osteotomies described by L. S. Weil for hallux limitus, one is particularly adapted to arthritic hallux valgus, above all when the first metatarsal is too long. 1, 2. B. Valtin (Paris) pictures. The cut is usually directed 30° plantarwards to decompress and moreover, plantar displace. 3. Clinical result. 4, 5. Radiographical aspects.



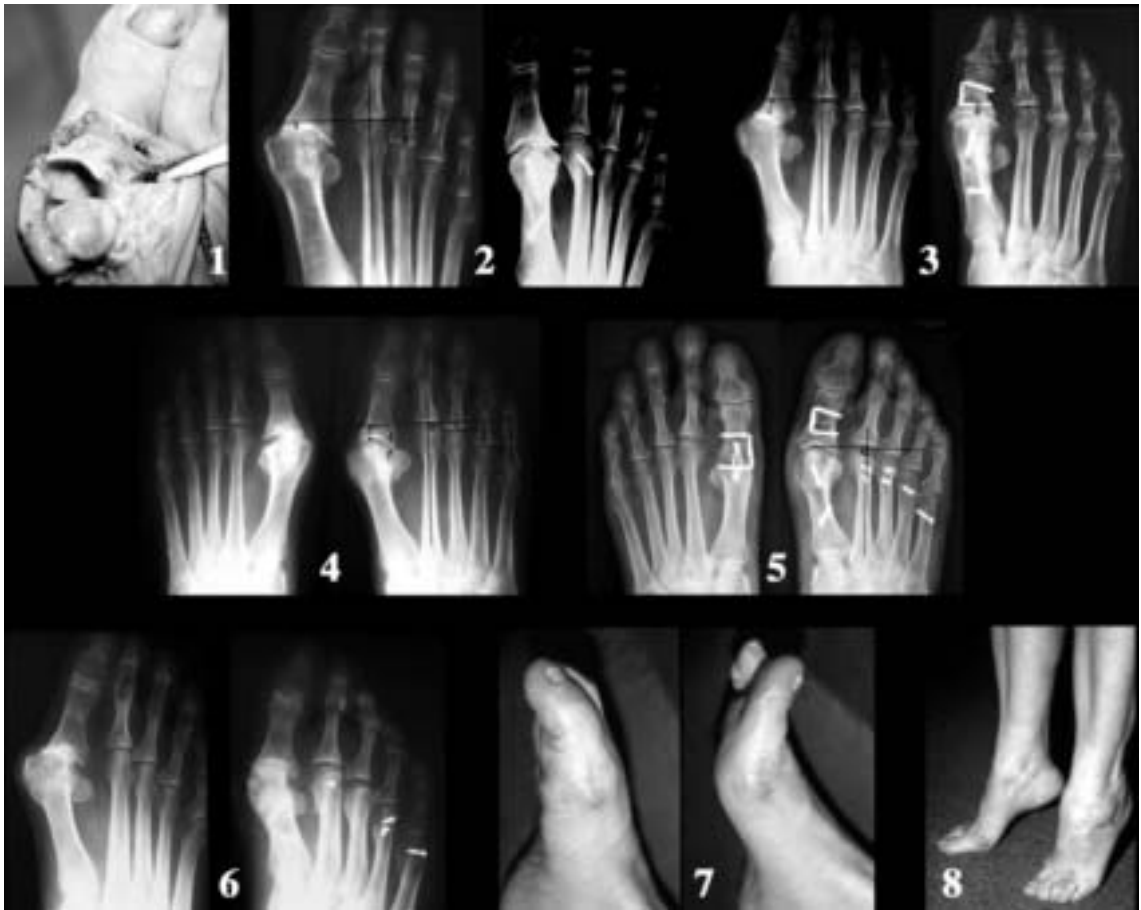**Fig. 25b6. Arthritic hallux valgus – (4) The great toe first phalanx osteotomy.**

1, 2, 3. Basal varisation is performed on Greek or square type foot and correct dorsal flexion of the MTP joint.

4. First phalanx shortening is performed on Egyptian foot remaining after eventual M1 shortening.

5. The P1 shortening first increases the toe amplitude on the gait and diminishes the axial pressure determined by the contact between the shoe and the distal end of the great toe.

6. X-rays aspect.



**Fig. 25c. Arthritic hallux valgus – The limits of MTP joint preservation. Long-term results.**

1, 2. Three years follow-up of a very impaired MTP joint: Excellent clinical results in spite of slight overcorrection and slight head necrosis. The rare cases of head necrosis with scarf are observed in arthritic hallux valgus or in revision of overcorrected hallux valgus.

3. Two years follow-up with the same good clinical results.

4, 5. In this case, the left foot was not only very impaired but also with a radiologic aspect of hallux limitus; furthermore the MTP was *painful*: In this case, fusion was performed. In the right foot a true arthritic hallux valgus, articular preservation thanks to metatarsals shortening.

6, 7, 8. Five years follow-up: Excellent radiographic and clinical result with articular preservative surgery.

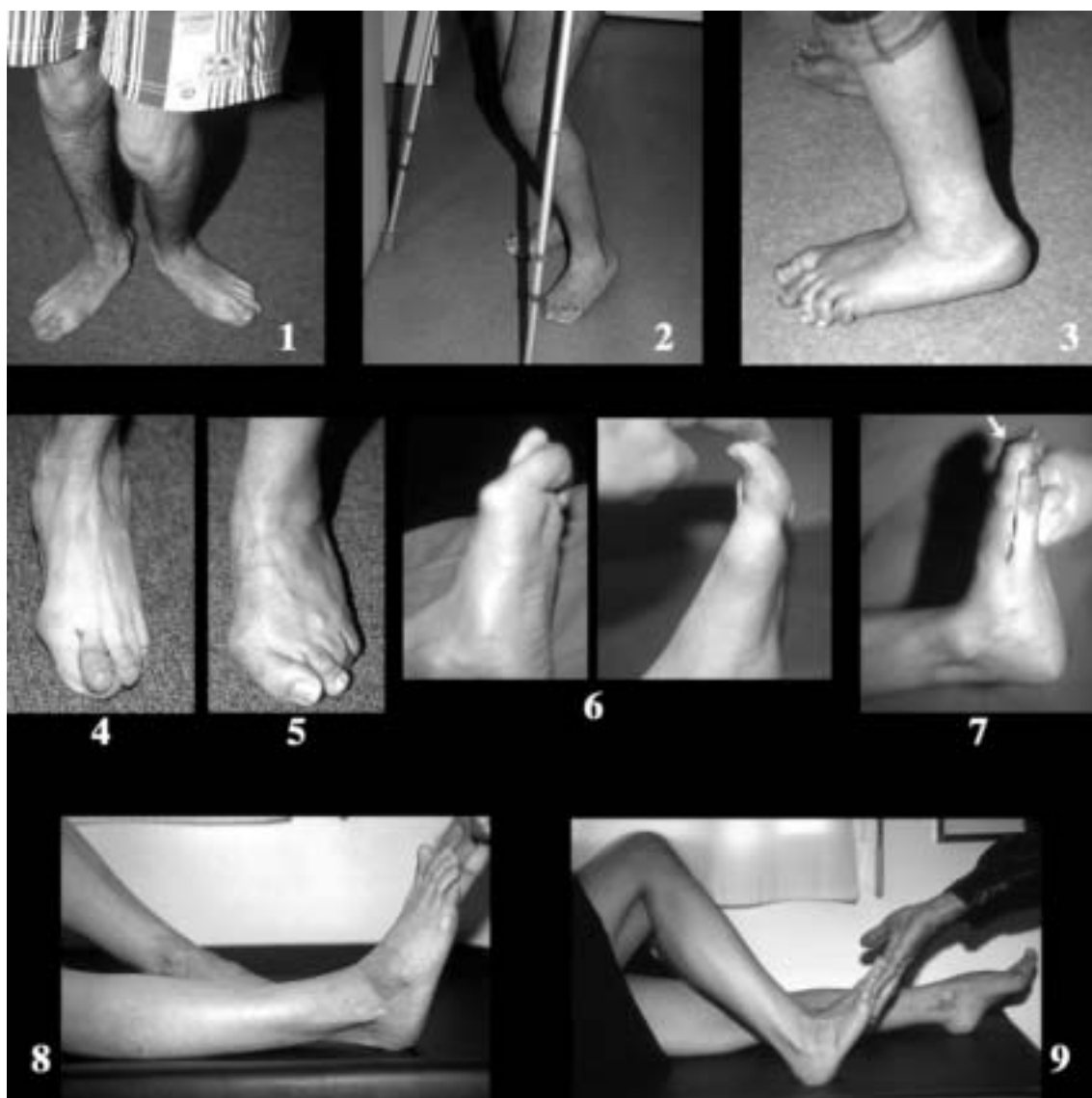*Until now, no secondary first MTP fusion was necessary.* So that preservative surgery has to be performed in almost every case of arthritic hallux valgus.

So we think that we have to reserve the MTP fusion to extremely impaired joint, with high stiffness, when the first metatarsal is already too short, and above all when the first MTP joint is painful.

## ***Hallux Valgus in Spastic Foot***

There are static conditions that increase or emphasize the hallux valgus deformity in spastic lower limbs: Genu flexum, lateral rotation of the foot, foot valgus, forefoot supination and

shortness of the posterior muscles and tendons. Nevertheless, the hallux valgus has to be treated and since we have used the scarf osteotomy, we observe a great improvement in the reliability of the correction.



**Fig. 26a.** Hallux valgus in spastic foot – *The conditions of increasing the forefoot deformities.*

1, 2. The medial plantar overpressure and the foot valgus are conditions increasing the hallux valgus deformity.

3. Spastic claw toes.

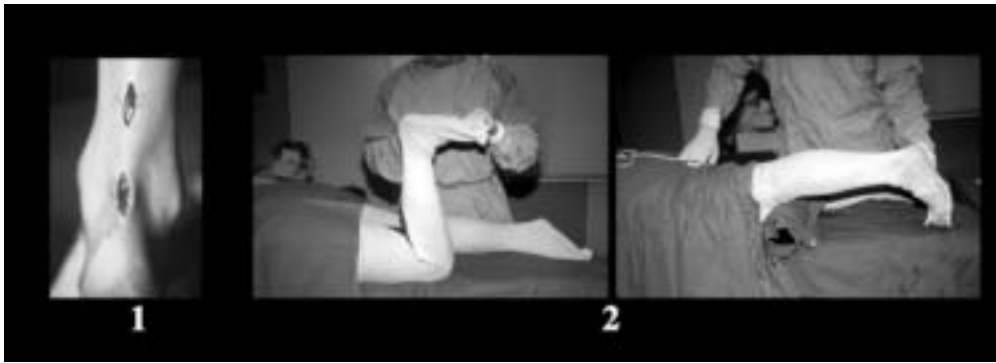4. There is often an appearance of crossover second toe, but it is in fact a *crossunder great toe*, due to the contraction of the flexor hallucis tendons (both the brevis and the longus flexor tendons).

5. Wind-swept toes deformity.

6, 7. Long flexor tendon shortness: The toe flexion is increased with dorsal flexion of the ankle (7).

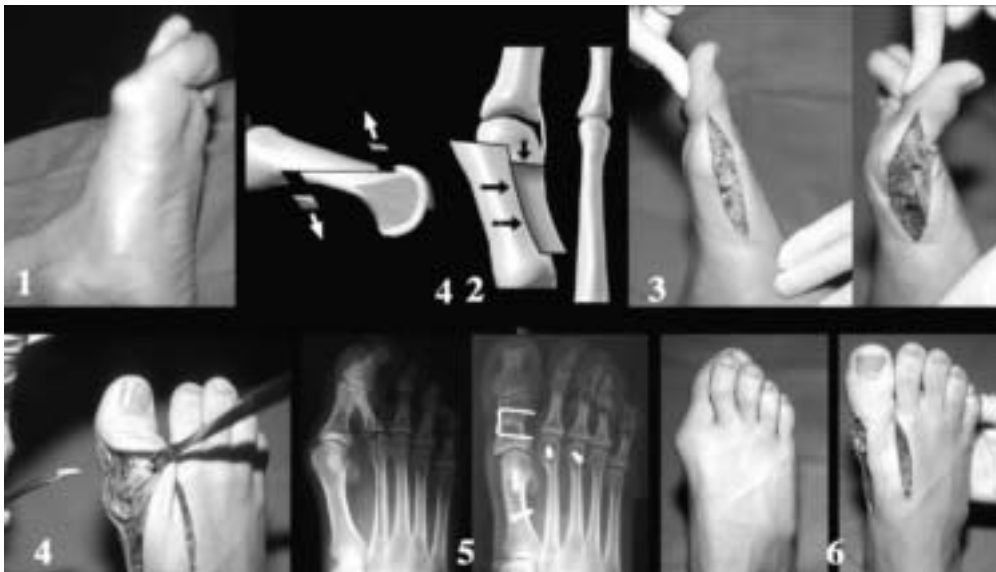8, 9. Equinism is always present and increases the deformity; assessment of gastrocnemius shortness.





**Fig. 26b1. Hallux valgus in spastic foot – Operative views 1.**

We first have to correct equinism, either by Achilles tendon lengthening (green procedure) (1) or/and by gastrocnemius proximal release (GPR) (2).

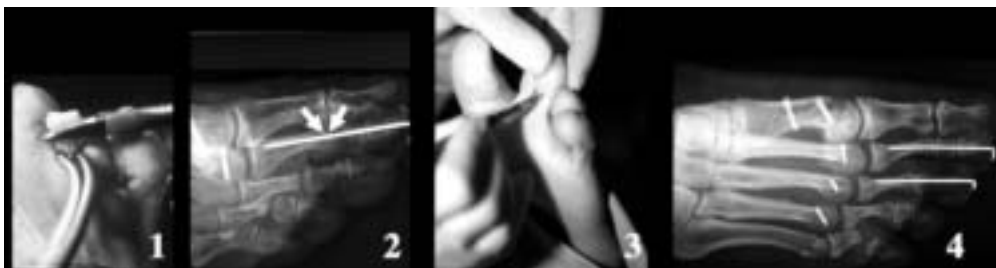

**Fig. 26b2. Hallux valgus in spastic foot – Operative views 2.**

1, 2, 3. The great toe plantar flexion is corrected by the M1 shortening by scarf (release of both longus and brevis flexor tendons), and by the Hallucis long flexor lengthening (retro malleolus incision).

4, 5. In *crossunder first toe*, shortening of the first phalanx (4); shortening of the first metatarsal (but also medial displacement) shortening of the second and third metatarsals (5).

6. Clinical aspect.

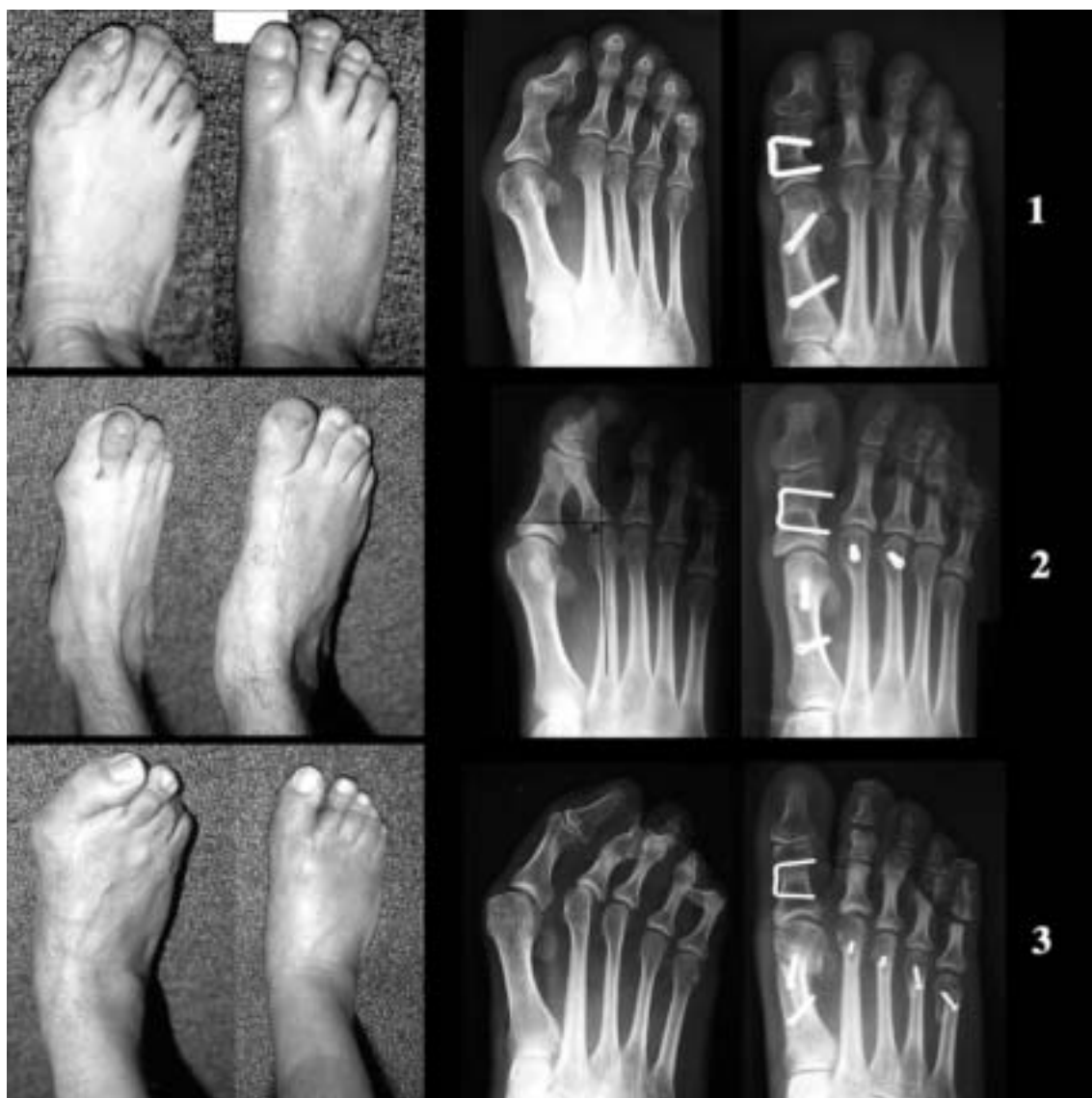

**Fig. 26b3. Hallux valgus in spastic foot – Operative views 3. Claw toe correction.**

1. Arthroplasty by resection of the distal end of the first phalanx is not a good procedure. IP fusion has to be preferred (2).

3. In many cases, we have to cut the long flexor tendon, distally.

4. The toe K-wiring has to be performed whatever the procedure applied.



**Fig. 26c1. Hallux valgus in spastic foot – Results.**

(All results at minimum one year postoperative.)

1. Usual hallux valgus treated by scarf and great toe osteotomies.
2. Crossunder great toe treated by scarf, great toe and Weil osteotomies.
3. Wind-swept toes treated by shortening of the five metatarsals, of the great toe, IP fusion on the second and 3rd PIP toes joints, PIP resection arthroplasty on the 4th and 5th toes.

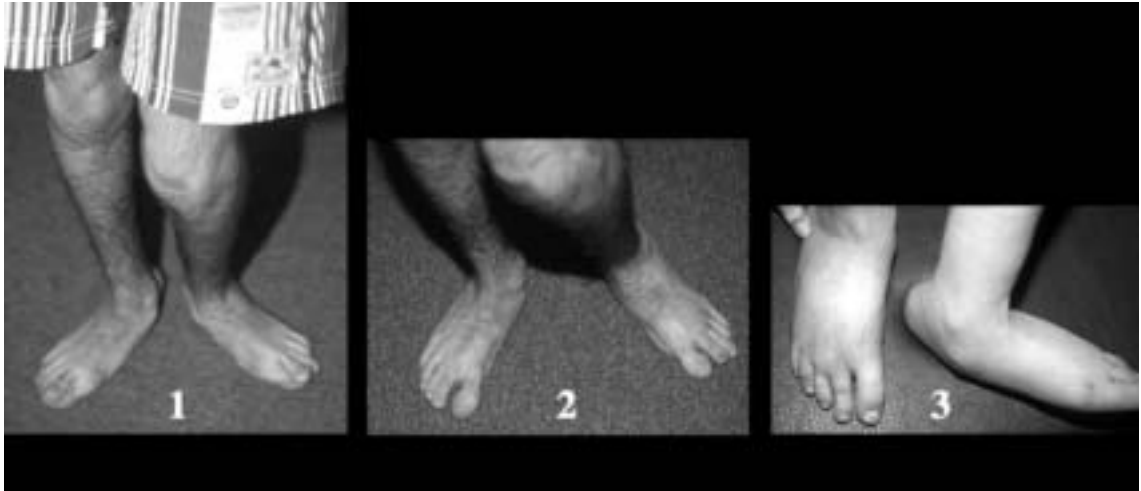The valgus of the great toe is rarely isolated. It may be combined with a wind-swept lateral deviation of the toe, or a *cross-under* great toe deformity, which is not the same regarding the treatment that the crossover second toe presents. The crossunder great toe is due to the shortness of the plantar and posterior muscles.

**Surgery:** Once the upper disorders (knee, rear foot) are corrected and even if these disorders are not completely corrected, the forefoot surgery has to be performed: Scarf M1 osteotomy, in most cases with shortening and, if required, Weil osteotomy on the lesser metatarsals. On the lesser toes we avoid PIP resection arthroplasty except for the 4th or 5th toes.

Generally, a soft tissue procedure is enough, with the addition of a K-wiring, but PIP fusion is sometimes necessary on the 2nd and 3rd toes.

Tendon surgery has to be widely combined [14], above all the lengthening of the posterior tendons, either on the retro-malleolar level, or preferably on the toes (except on the great toe).

The results of this surgery are good and significantly stable in spite of remaining rear foot valgus or slight genu flexum. Sometimes we observed some overcorrection in hallux valgus surgery (one case of secondary MTP fusion). This should be avoided regarding the disorders of the foot and the lower limbs.



**Fig. 26c2. Hallux valgus in spastic foot: Taking into account the whole foot and the legs.**

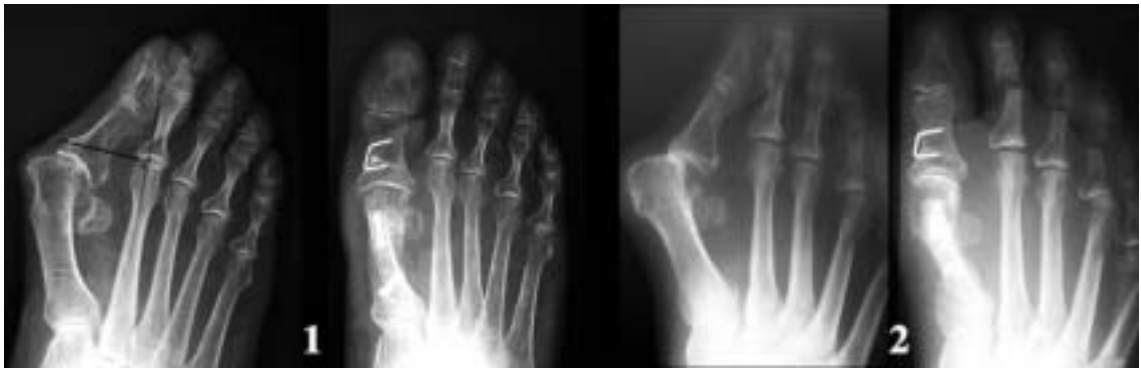1, 2. The medial overpressure, which may continue to be applied in spite of surgery of the lower limbs, contributes both to the emerging of hallux valgus (1) and to the tendency to hallux *overcorrection* after surgery (2).

3. It is also necessary to treat the rear foot, where by slight or moderate deformity may remain, although only slightly affecting the result.

### ***Hallux Valgus in Elderly Patients (more than 80)***

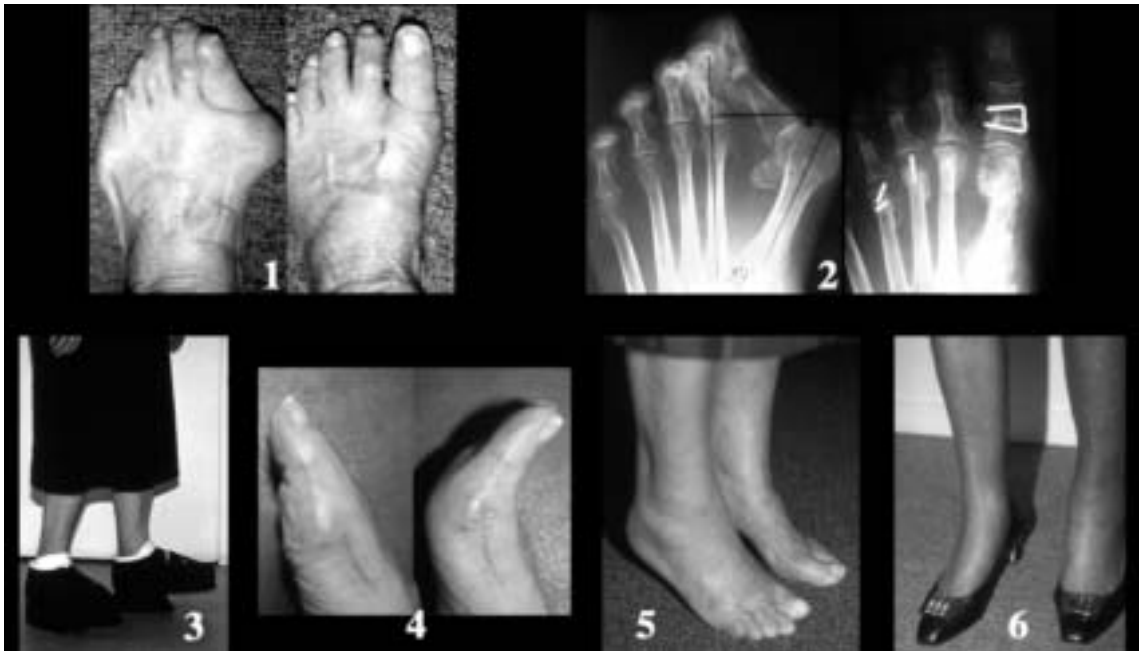Although it is easy and reliable to perform MTP fusion, we observed that the scarf osteotomy provides such good results, that, even for old patients, we make articular preservative surgery, scarf osteotomy of course, with great toe osteotomy and once again Weil lesser metatarsal

osteotomy if necessary. This surgery is by far really better than Keller procedure and we think that this procedure has no more to be used even for very old patients. This was recently observed by other authors, like A. Wagner [127]. Now we know that old women want to keep the footwear elegance, above all in France and in Europe and we now have the appropriate conservative procedure to carry out their wishes.



***Fig. 27a. Hallux valgus surgery in elderly patients (more than 80 years old).***

1, 2. Whatever the bone osteoporosis and the importance of deformity, the scarf osteotomy regularly provides good results in more than 80 years old patients.



**Fig. 27b. 1, 2.** In this case of severe hallux valgus with metatarsalgia, the shortening of the metatarsals is very effective even in old patients. The only contraindication is arthritic severe lesion (in this case, first MTP fusion).

3. The heel support shoe is generally stable enough, but crutches may be used sometimes.

4, 5. We observe in most cases early and correct functional recovery.

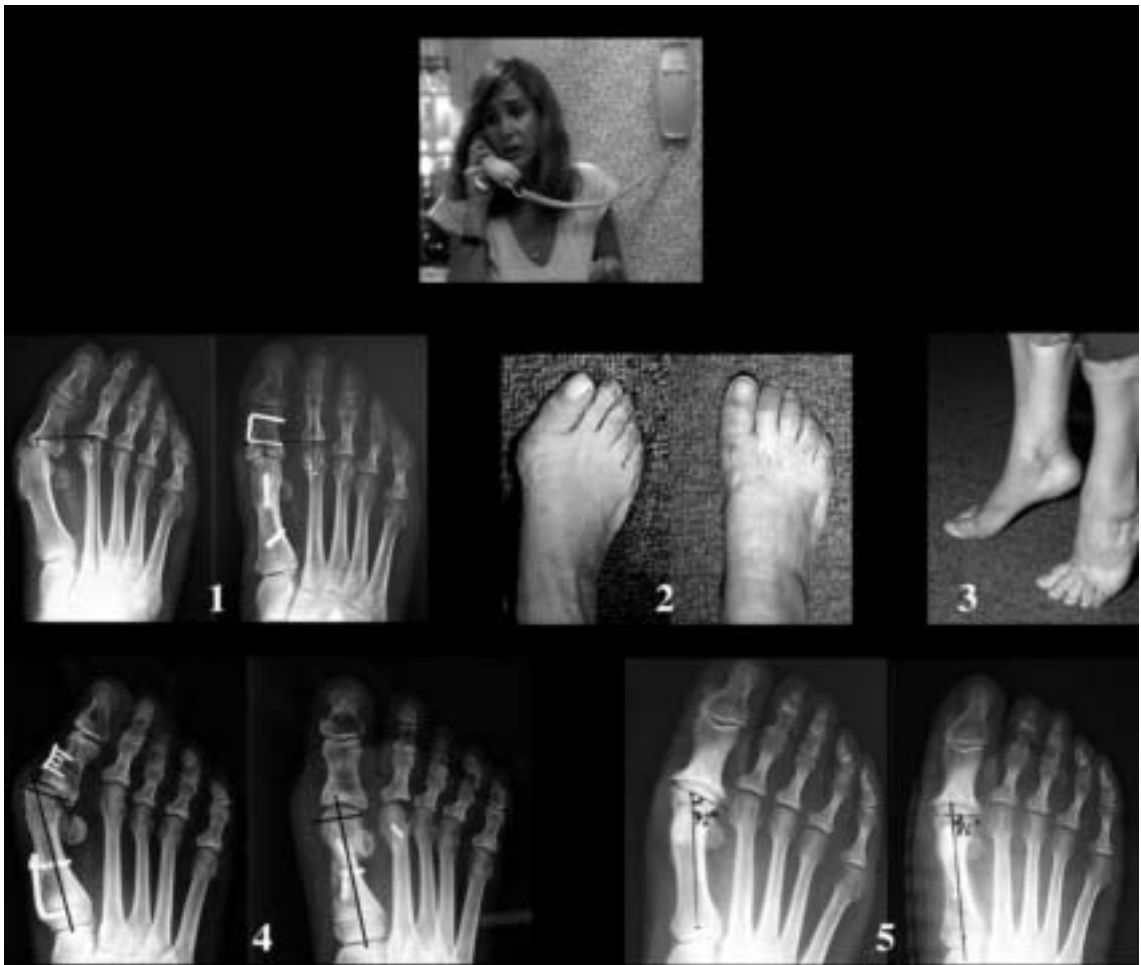6. The cosmetic appearance has not to be underestimated, and with this articular conservative surgery we can carry out the wishes of elegant footwear.

## Failed Bunionectomy

Scarf, great toe and Weil osteotomy provide a large versatility which allows the adaptation in almost every case of failed bunionectomy.

## Undercorrection

– *Mild or moderate* undercorrection are an excellent indication for the scarf and great toe osteotomies since they can adapt to any deformity: Lateral shift, DMAA correction, shortening, lowering, etc.



**Fig. 28a1. Failed bunionectomy (undercorrection): Mild or moderate deformity.**

We first have to take into account the anxiety (or the aggressivity) of the patient already operated on and to propose the most reliable solution.

1, 2, 3. Pre and one year postoperative aspects of a moderate undercorrection treated by scarf and great toe osteotomies.

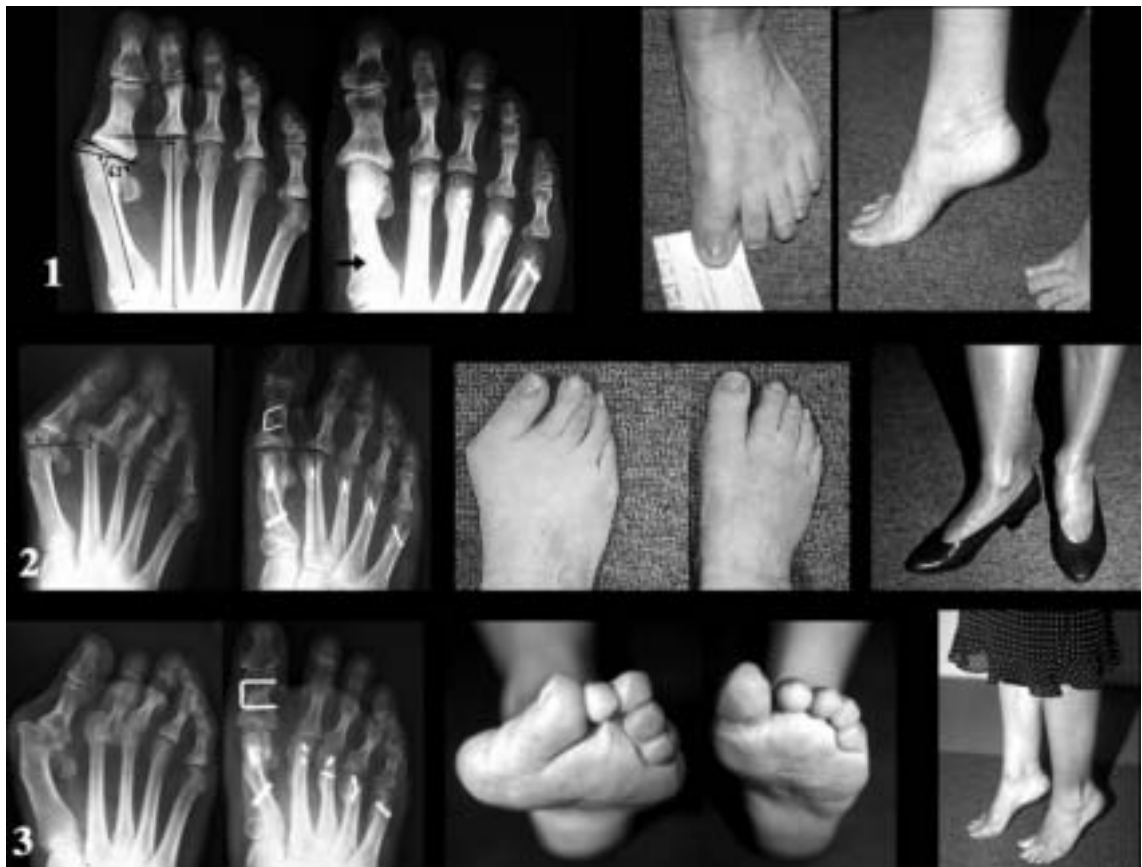
4. Revision by DMAA correction and M1 shortening by scarf (note the shortening of the 2nd lesser metatarsal (Weil)).

5. DMAA correction in a failed bunionectomy by Keller procedure: Since the MTP range motion was preserved and not painful, we may preserve the joint.

– *Severe* undercorrection requires the same osteotomies on the first ray, combined in many cases with the shortening of the other rays by Weil osteotomy: We observe extremely reliable results with the harmonized metatarsal shortening. The only problem is the shortening of one foot when we do not have to shorten the other

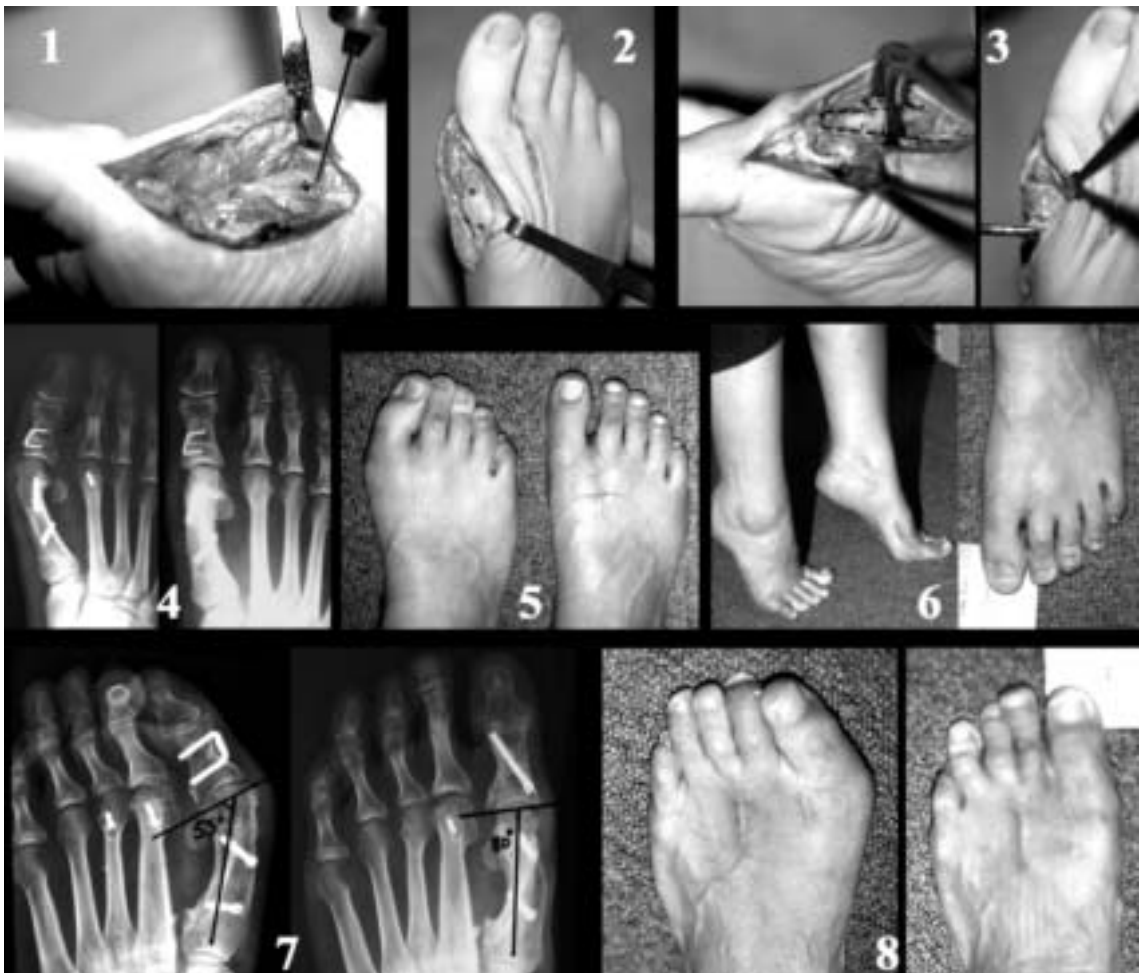one: We are lucky when we can mainly shorten the great toe (Egyptian foot).

– When there is undercorrection after scarf, another scarf may be performed. Care has to be taken to use the same dorsal holes for screwing when it is possible. The healing is a little bit longer.



**Fig. 28a2. Failed bunionectomy (undercorrection): Severe deformity.**

1. Revision by DMAA correction M1 shortening, one year follow-up. Note the combined shortening of the lesser metatarsals (Weil).
2. Same foot preoperative and 2.5 years postoperative aspects. Scarf and Weil osteotomies. Note the five metatarsals shortening and the correction of the MTP dislocation.
3. Same foot preoperative and 1 year postoperative aspects. On the first ray, lateral shift, shortening and DMAA correction, on the lesser rays Weil osteotomies.



**Fig. 28a3. Failed bunionectomy (undercorrection): Scarf on previous scarf.**

1, 2. Intraoperative characteristics: 1) Removing the screw may be delicate: K-wiring carefully around the screw or using a specific screw removing instrument (DePuy) in order to use the same dorsal hole for revision screwing. This is important to avoid secondary fracture by weakness of the dorsal fragment.

3. Note the large lateral shift performed, in such a case, Type I heel support shoe: 1 postoperative month follow-up.

4, 5, 6. Same foot as on the fig. 1, 2, 3. Preoperative and one year postoperative aspects.

7, 8. Same foot preoperative and one year postoperative aspects. DMAA correction and derotation osteotomy of the 1st phalanx.

### Overcorrection

Overcorrection can be corrected by reverse scarf (medial displacement). However, some drawbacks may occur: M1 elevation (the solution is a more horizontal cut), and metatarsal head necrosis (no reliable solution at the moment). However, we didn't observe head necrosis when

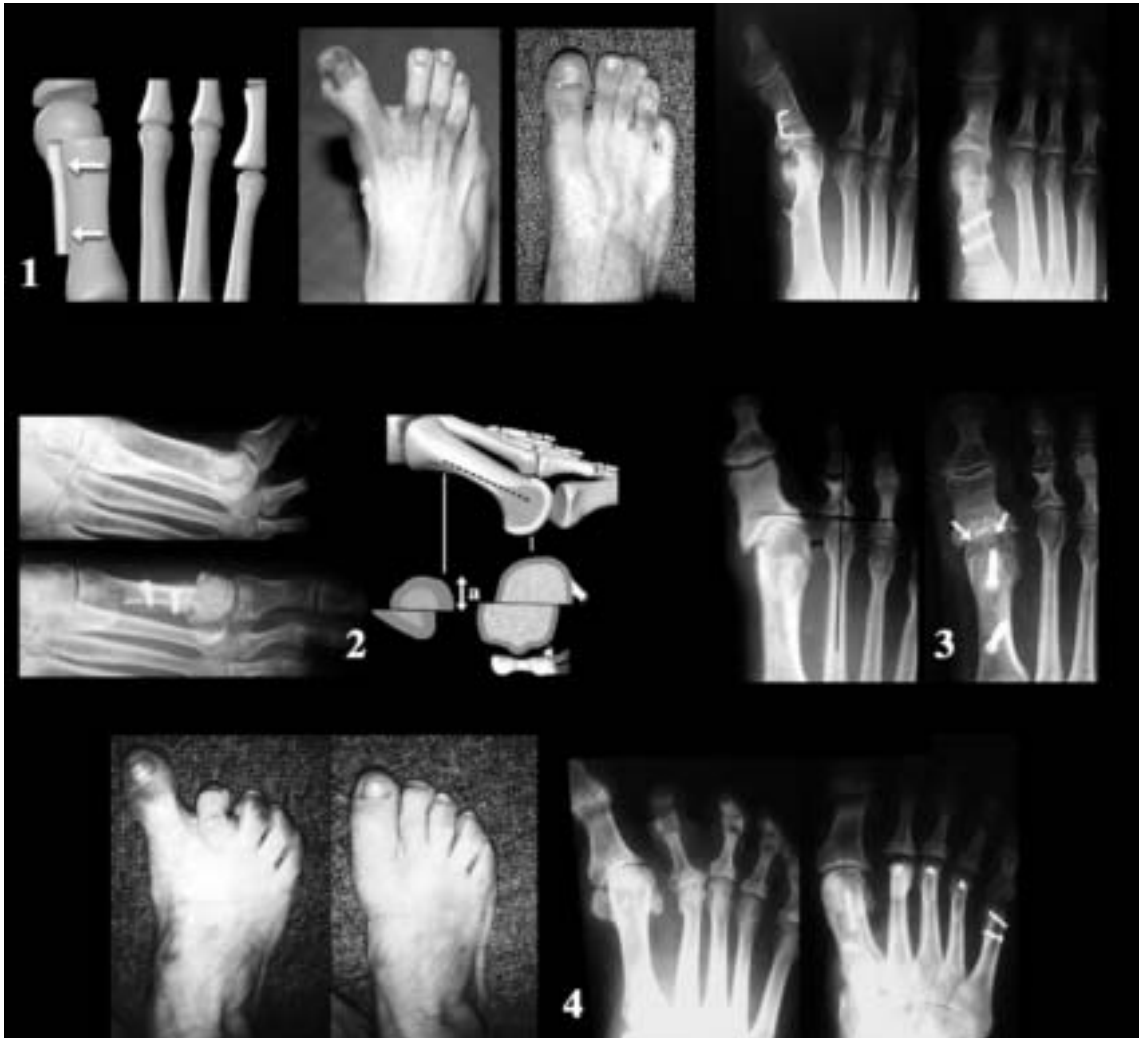we performed the shortening of the five metatarsals, but this may be done when there is a whole forefoot deformity.

Another surgical procedure to treat overcorrection is very reliable: It is a *medial* closing wedge osteotomy, as described by A. Denis [69], and paradoxically, a *lateral* closing wedge osteotomy of the great toe first phalanx (Fig. 14c3).



When overcorrection is severe – long-lasting or combined with a severe dorsal flexion of the MTP joint – the MTP fusion is our choice, combined as required with the Weil lesser metatarsal osteotomies. This provides in one time (the patient would like it to be the last time!) a reliable solution.

Overcorrection with scarf osteotomy is now extremely rare because it *is almost entirely avoidable with the operative management*, at each operative step.

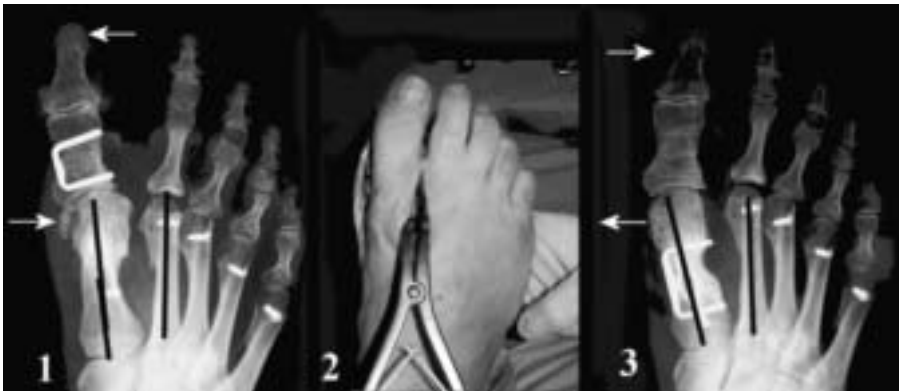


**Fig. 28b1. Failed bunionectomy (overcorrection): Joint preservative surgery.**

1. Medial shift can be obtained by reverse scarf osteotomy; in this case it is combined with small shortening. Two years postoperative results.

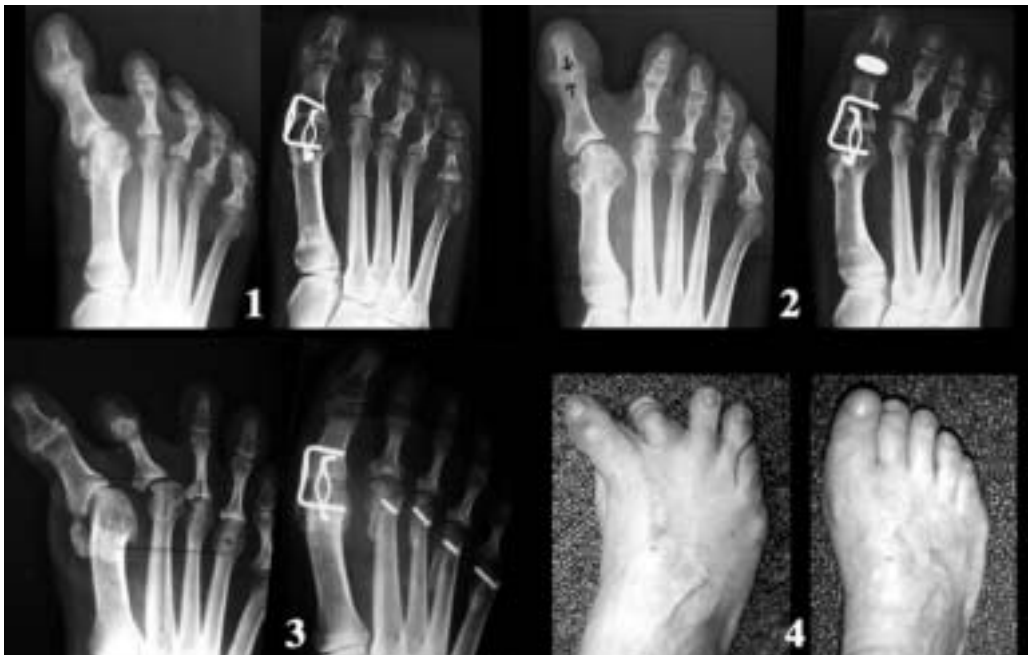
2, 3. Drawbacks with such a reverse scarf: 2) Elevation of the first metatarsal. To avoid it, take care to have an horizontal cut, but this may fragilize the lateral strut (this needs longer time with the type I heel support shoe). 3) Metatarsal head necrosis. This necrosis is painful and will certainly need an MTP fusion. It should be the fusion after head necrosis and scarf osteotomy that we observed. Note: In our experience of M1 scarf osteotomy we only observe head necrosis in cases of arthritic hallux valgus and in revision for overcorrection. 4. However, joint preservative surgery can be made with good results in overcorrected bunionectomy but at the cost of performing the shortening of the five metatarsals, like in this case: Two years follow-up.

NB: Another procedure that proves to be successful is shown on the Fig. 14c3: It is a first metatarsal basal closing wedge sometimes combined with a great toe lateral closing wedge.



**Fig. 28b2. Hallux valgus over correction treated by the Denis osteotomy.**

1. In over correction, the first inter metatarsal angle is too much closed.
2. After medial and metatarsal release, a hinge distractor is set in order to assess the required correction.
3. The medial closing wedge osteotomy (Denis) is fixed by 2 memory staple “20”.



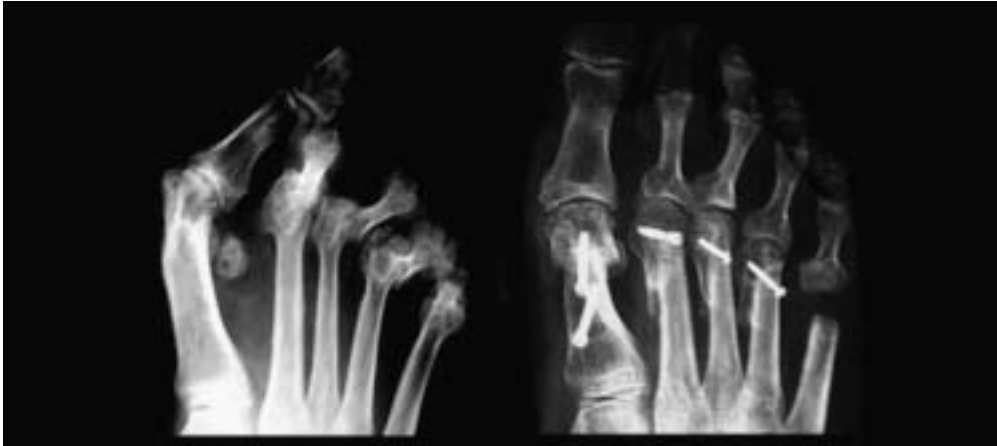**Fig. 28b3. Failed bunionectomy (overcorrection): MTP joint fusion.**

1. When there is a severe or / and long-lasting overcorrection, the MTP fusion is the best solution. The “20” memory staples ensure the fixation.
2. In this case, stiffness and pain on the IP joint. This is treated by *button spacer* combined with MTP fusion.
- 3, 4. Radiographic and clinical results after MTP fusion combined with Weil osteotomy. A very reliable way of treatment in such severe overcorrection.

*Impaired MTP Joint: Joint Preservative Surgery*

*Moderate impairment of the MTP joint, with correct great toe ground contact. In this*

case, the correction of the deformity with scarf procedure with shortening of the first metatarsal. Allows to *preserve the MTP joint.*



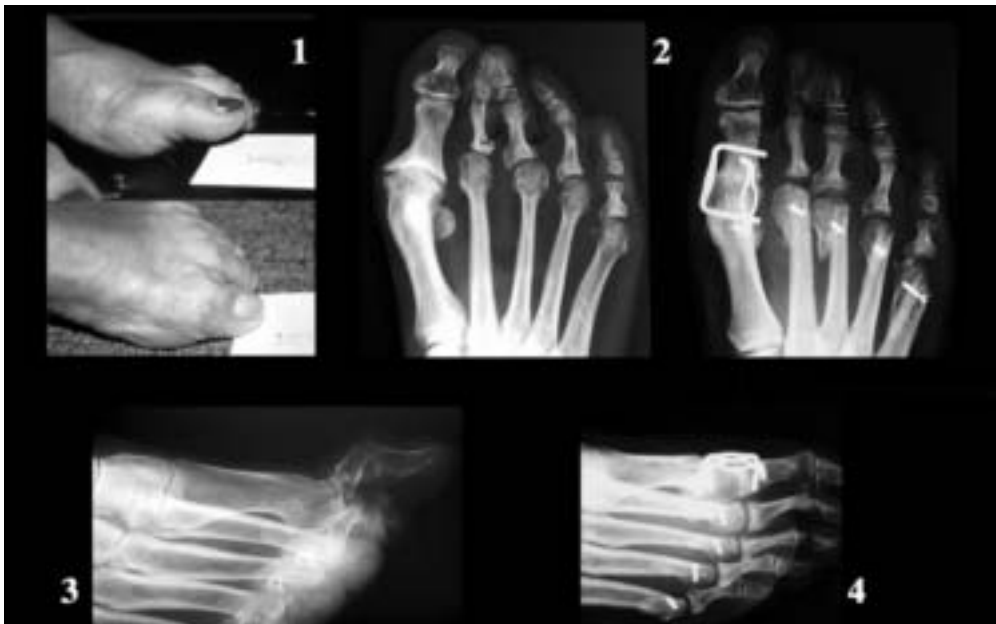**Fig. 28c1. Failed bunionectomy with impaired MTP joint: joint preservative surgery.**

Pre operative and 2.5 years follow up post operative aspect. This result is obtained thanks to the metatarsal shortening.

*Very Impaired MTP Joint, or Loss of Great Toe Ground Contact*

This is an indication for MTP fusion which provides reliable results.

In conclusion, we can be very effective in revision for failed bunionectomy, in most cases with articular preservation, thanks to the scarf, great toe and Weil osteotomy and, if required, with MTP fusion.



**Fig. 28c2. Failed bunionectomy. Very impaired MTP joint, or loss of great toe ground contact.**

1. Impaired MTP joint after Keller procedure with loss of great toe ground contact and resection of the first phalanx basis of the second toe. Good result with MTP fusion and Weil osteotomy.

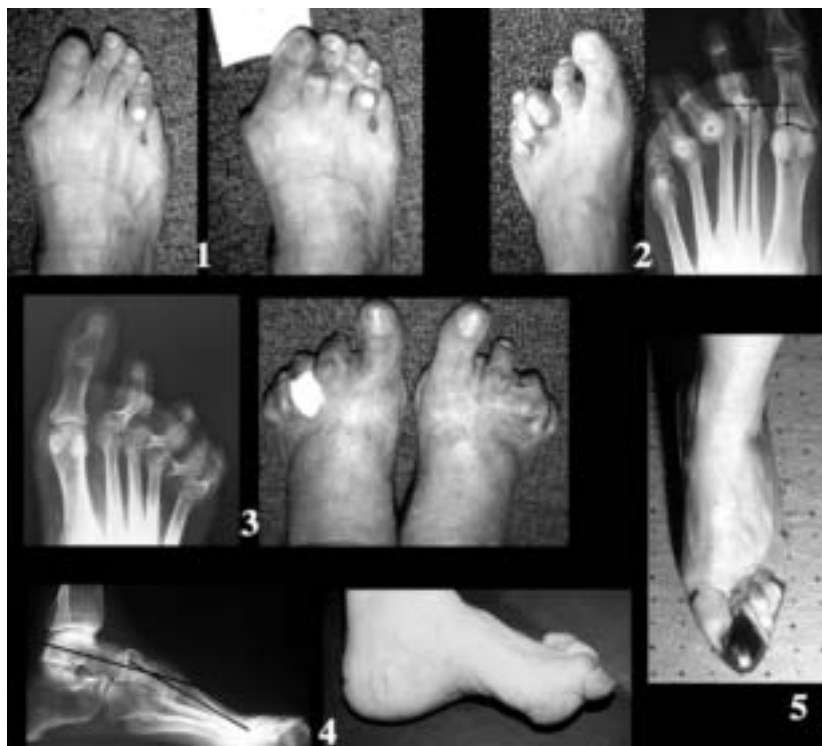3, 4. Another case of good result by first MTP fusion and Weil osteotomy on the lesser metatarsals.

## Hammer and Claw Toe of the Lesser Rays

Clinically and therapeutically, the boundary between hammer and claw toe is often uncertain. So we prefer to distinguish these two deformities only when they have to be examined or treated differently.

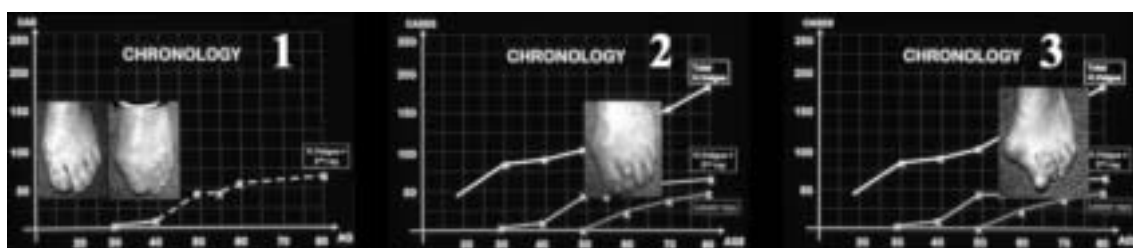## Main Causes and Chronology of Hammer and Claw Toes

Apart the congenital deformity, hammer or claw toe deformity is in most case secondary to foot problems which are detailed Fig. 29a1. We also observed the chronology of the emerging of hammertoe in the hallux valgus deformity.



**Fig. 29a1. Hammer and claw toe deformity; main causes.**

1. Same foot: The Bristol test emphasizes the role of hallux valgus in producing hammertoe deformity.
2. Excess of lesser metatarsal length.
3. Same patient: MTP dislocation.
4. Cavus forefoot.
5. A lady shoe!



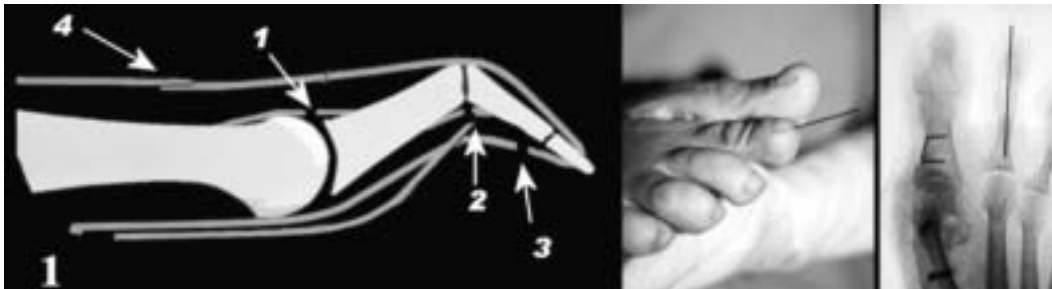
**Fig. 29a2. Hammertoe chronology after hallux valgus deformity.**

1. Almost no secondary hammertoe before 40 years.
2. Emerging of hammer toe after 40 years; generally on the second toe, followed by the other ones.
3. Final stage: Extended hammer toe deformities.

### Soft Tissue Procedure in Hammer Toe Deformity

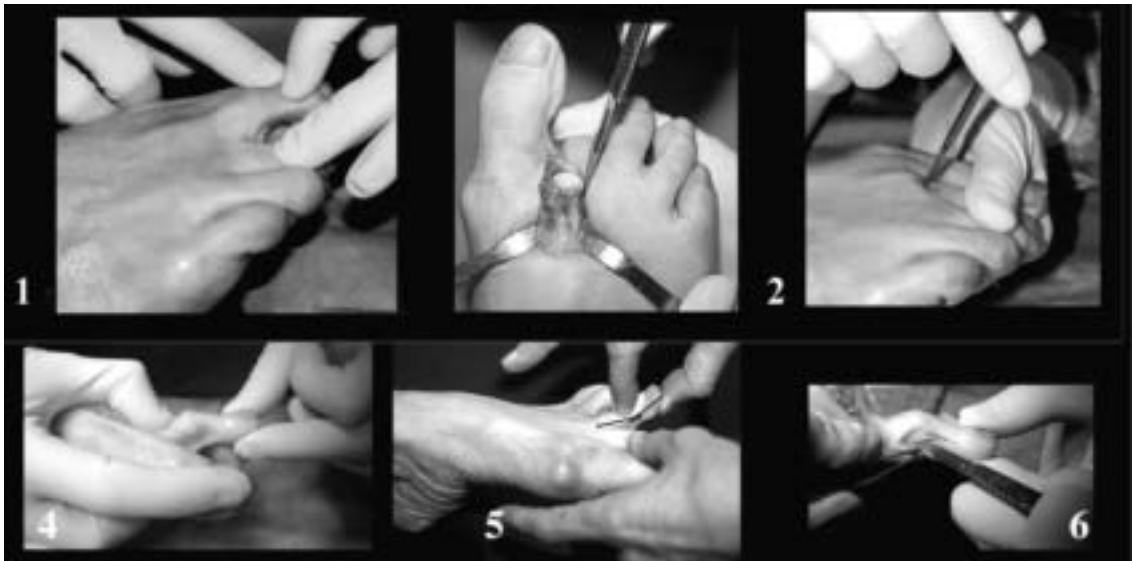
We think that soft tissue procedures have to be emphasized because in most cases they are a reliable joint preservative treatment with the follo-

wing conditions: 1) To have flexible deformity on the pre or intraoperative assessment. 2) To perform the different steps in a chronological order. 3) To be secured by toe K-wiring (during one month). 4) To have a postoperative period with accurate bandage, strapping and self-training.



**Fig. 29b1. Hammertoe correction. Soft tissue procedure. Generalities**

1. Chronology of the surgery steps in hammertoe correction.
2. In many cases we use a temporary (one month) toe K-wiring: It ensures the correction.

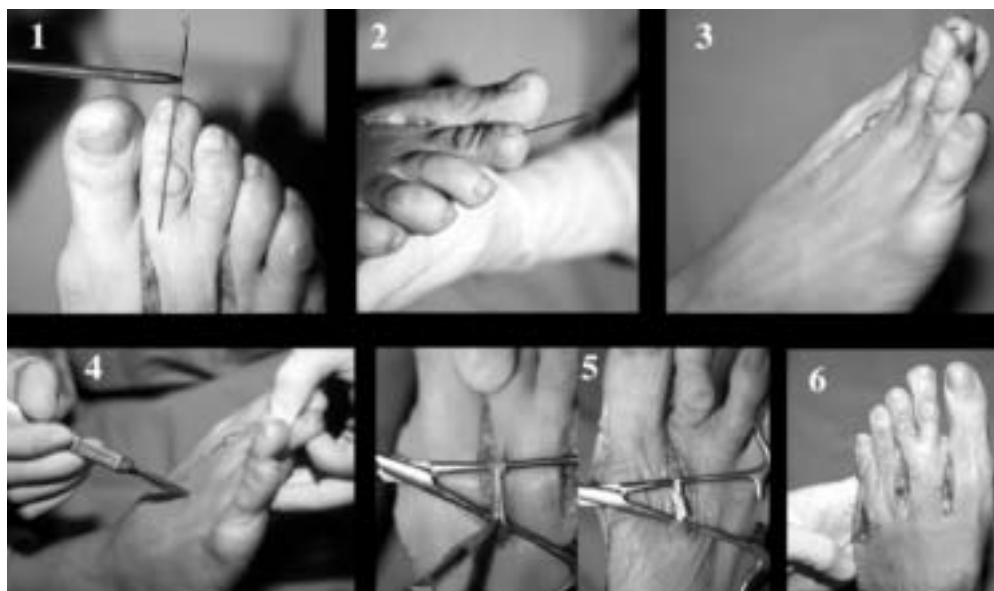


**Fig. 29b2. Hammer or claw toe correction. Soft tissue procedures: MTP and PIP Joints.**

- 1, 2, 3. *MTP Joint* 1 loss of Plantar Flexion: need of MTP dorsal release 2 MTP release by usual procedure.
3. Per cutaneous MTP release.
- 4, 5, 6. *PIP Joint* 1 The PIP seems to be rigid : in fact the deformity may be corrected in most cases:
5. By manipulation: but the dorsal flexion must be free up to 45°.
6. By PIP plantar release (open or percutaneous procedure).



**Fig. 29b3. Hammer or claw toe correction. Soft tissue procedures: Long flexor tendon distal section.**  
1, 2. *Indication:* Hammer toe correctible when the ankle is in Plantar Flexion.  
3. Percutaneous Long flexor distal section.



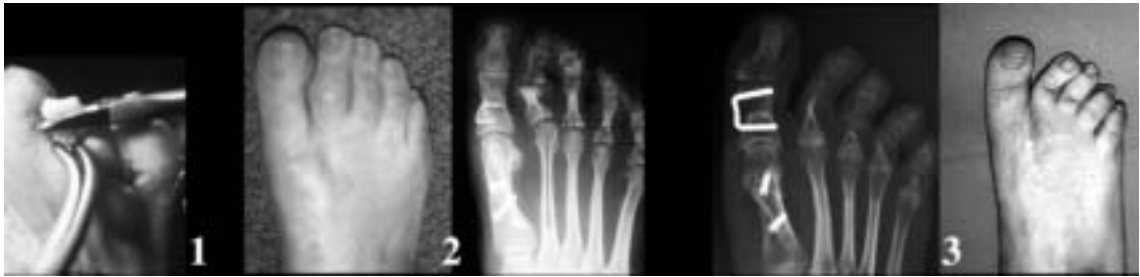**Fig. 29b4. Hammertoe correction. Soft tissue procedure. Last surgical steps.**  
1, 2. Toe K-wiring in often necessary (excluding the MTP joint).  
3. The K-wiring emphasizes the need of extensor tendon lengthening.  
4, 5. Extensor tendon lengthening: 4. Percutaneous, 5. Green procedure.  
6. Final load simulation test, to check the correction.

## The PIP Surgery

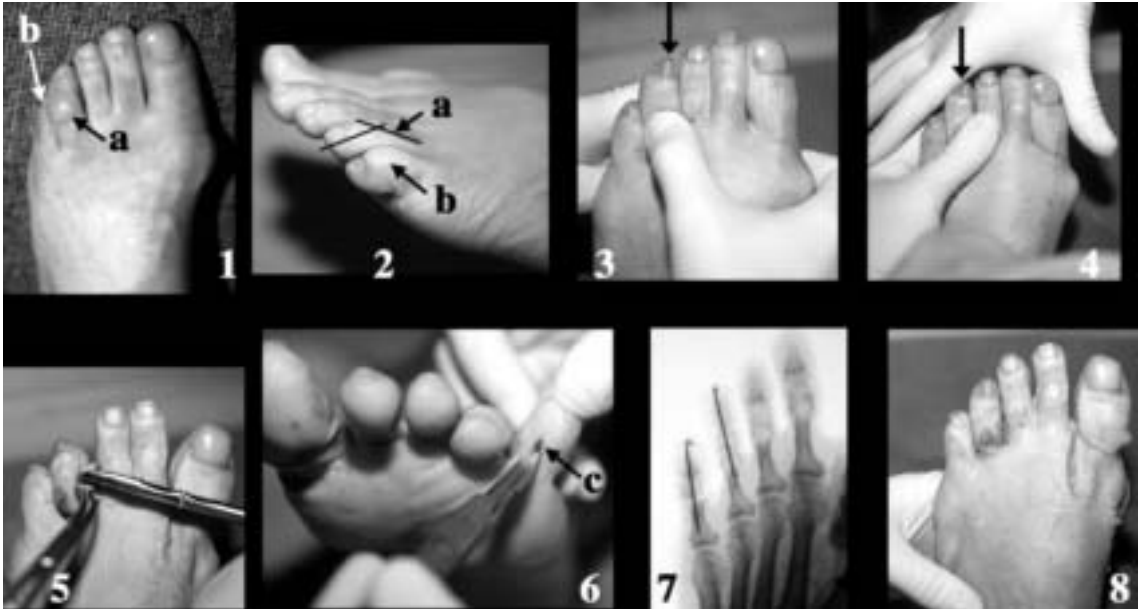
The PIP resection is a common surgery which gives a good result but on the condition that it is limited to the 4th and 5th toes. In this location, care has to be taken not to leave too much plantar flexion of the adjacent toe, particularly the 5th one.

The PIP fusion has to be economically performed both in the magnitude of the resection and in the indication: *We have to reserve PIP fusion to the 2nd ad 3rd rigid hammertoes.*

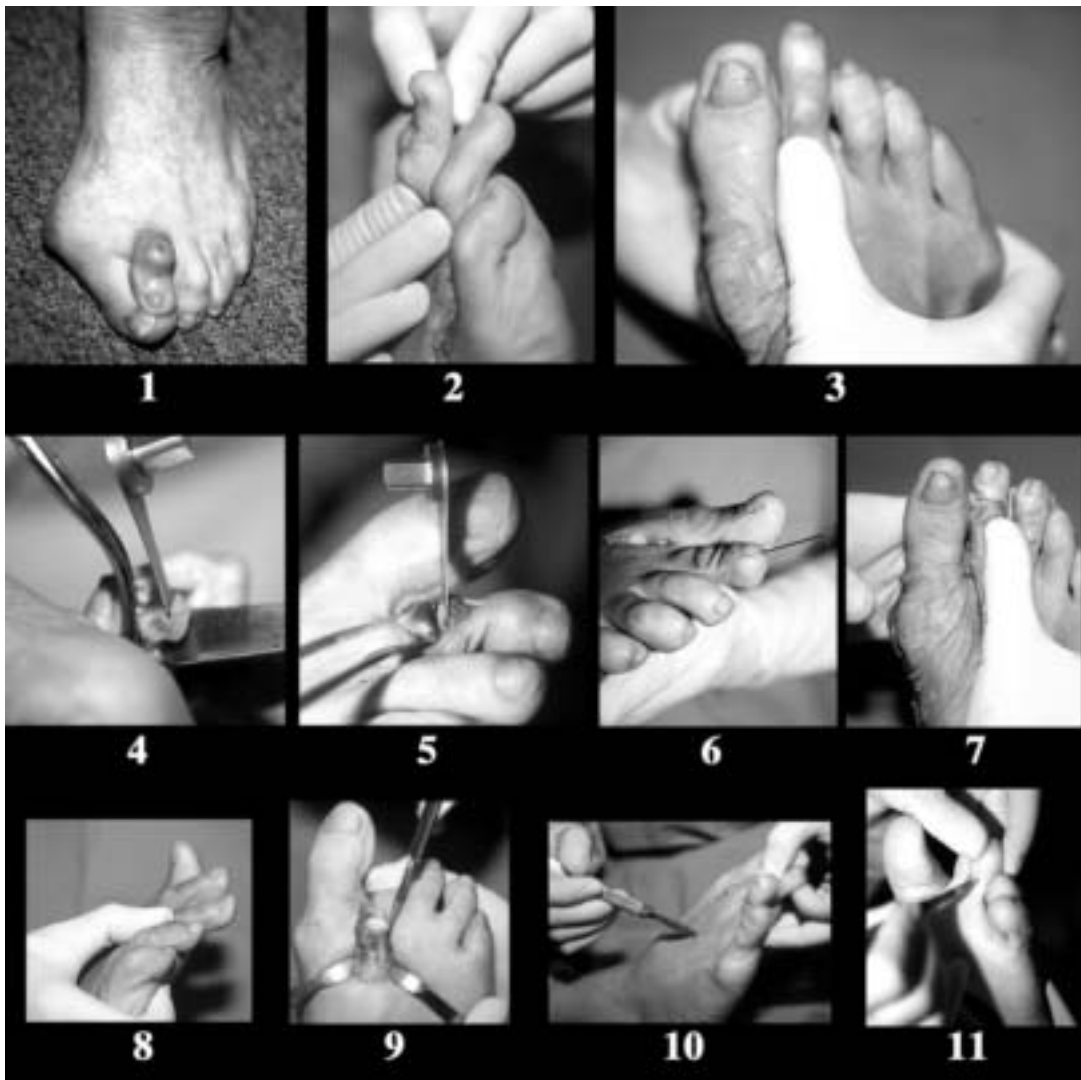But in fact, very few cases need a PIP resection of fusion, because the only PIP *plantar release* usually provides the correction (Fig. 29d3). Through a medial approach, the plantar capsule of the PIP is cut, and the flexor brevis tendon is detached (medial and lateral attachments). This is an opportunity to thanks Paul Golano (lab. Anatomy, Barcelone) for his excellent protographs of specimens.



**Fig. 29c1. Hammertoe correction – PIP resection arthroplasty: An unreliable solution for the 2nd and 3rd toes.** It is an unreliable solution for the 2nd and the 3rd toes, since it first results in long swollen and painful postoperative period (2), and secondly its long term results are unpredictable (3).



**Fig. 29c2. Hammertoe correction – PIP resection arthroplasty: A good solution only for the 4th and 5th toes.**  
 1, 2. In the 4th toe deformity (a) we have to assess the role of “crossunder” 5th toe, which has often flexible hammertoe deformity due to the long flexor tendon shortness (b).  
 3, 4. Assessment of the excess of the 4th toe length. With my right hand, I assess the toe length corresponding to a woman shoe. In this case, the 4th toe is too much long.  
 5. Distal resection of the 1st phalanx of the 4th toe.  
 6. Distal section of the long flexor tendon (c) of the 5th toe.  
 7, 8. K-wiring and final aspect of the 4th and 5th toes.



**Fig. 29d1. Hammertoe correction – PIP fusion for rigid deformity on the second and third toes.**

1, 2, 3. A really rigid hammertoe is a *good indication* for PIP fusion above all in cases of a very long corresponding toe. However, PIP fusion has to be mainly performed on the *second and third toes*.

4. Distal section of the first phalanx.

5. Proximal section of the second phalanx. Both economic resections performed with the saw, and preferably in cancellous bone.

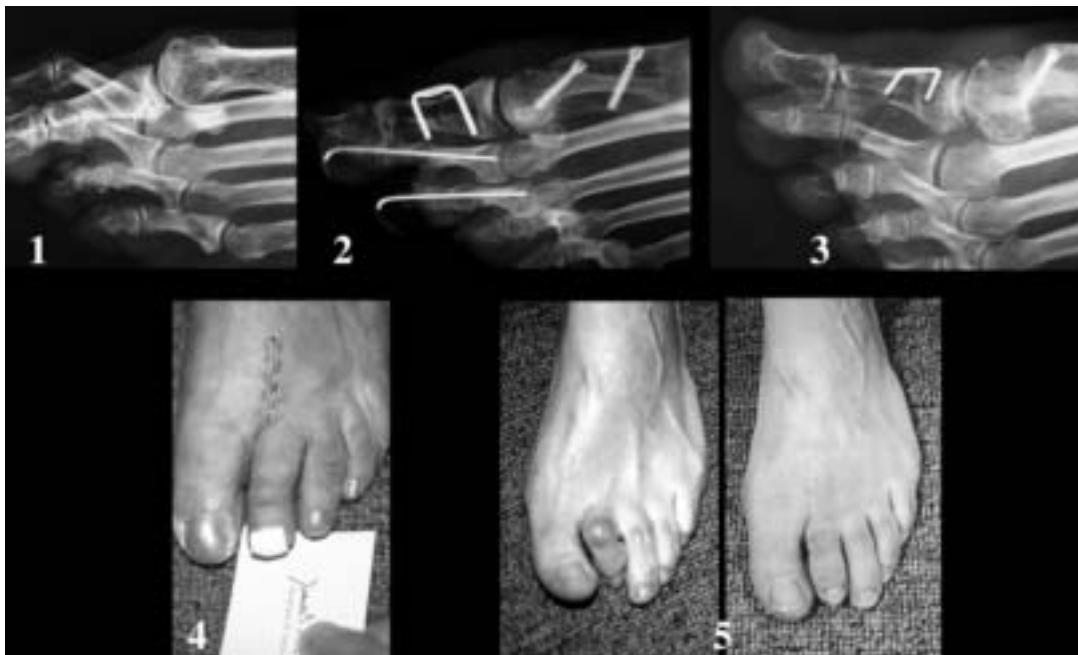6, 7. K-wiring excluding the MTP joint, and checking the toe correct length.

8, 9. If required, MTP dorso-lateral release.

10. If required (in most cases), extensor tendon lengthening.

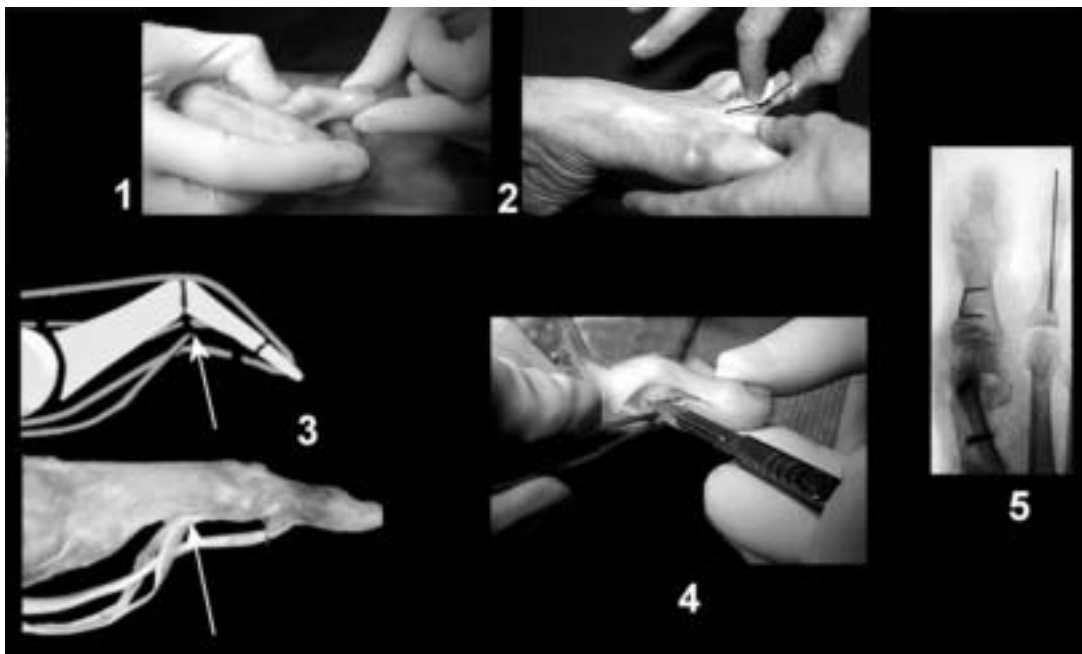
11. If required, long flexor tendon distal section. Note: This is rarely necessary for the second toe, which has a tendency not to have a good ground contact postoperatively, whatever the surgery performed.





**Fig. 29d2. Hammertoe correction – PIP fusion. Results.**

- 1, 2, 3. The K-wire is removed one month after the operation. We note that the fusion healing may be incomplete (3) without any problem in most cases.
- 4. Result after removing the K-wire (one postoperative month).
- 5. Result of PIP fusion: Care has to be taken not to shorten the toe too much.



**Fig. 29d3. Hammer or claw toe correction: the PIP plantar release: The best solution in almost all cases.** Both the two attachments of the flexor brevis (lateral and medial) must be detached. 1. The PIP seems to be rigid. 2. In case of easy dorsal flexion only by manipulation, the PIP plantar release is not required: make only K wiring 3, 4. PIP plantar release is made by a medial approach: cut of the PIP plantar capsula and disinsertion of the flexor brevis from the middle phalanx. This is an opportunity to thanks Paul Golano (Lab-Anatomy Barcelona) for his excellent photographs of specimens. 5. Temporary K wiring (weeks) excluding the MTP joint. NB : if this dorsal flexion is not easy, make a PIP fusion (Fig. 29d1).

### Middle Phalanx Osteotomies

1) We have to distinguish: The distal Resection-*Distal Interphalangeal (DIP) arthroplasty*.

2) The *Shaft resection*.

The two procedures have the following common points:

1) They are only a *partial* resection of the middle phalanx, performed through a medial approach and followed by a temporary K. wiring.

2) Indication: excess of the toe length, once corrected the deformities of the MTP and the PIP joints.

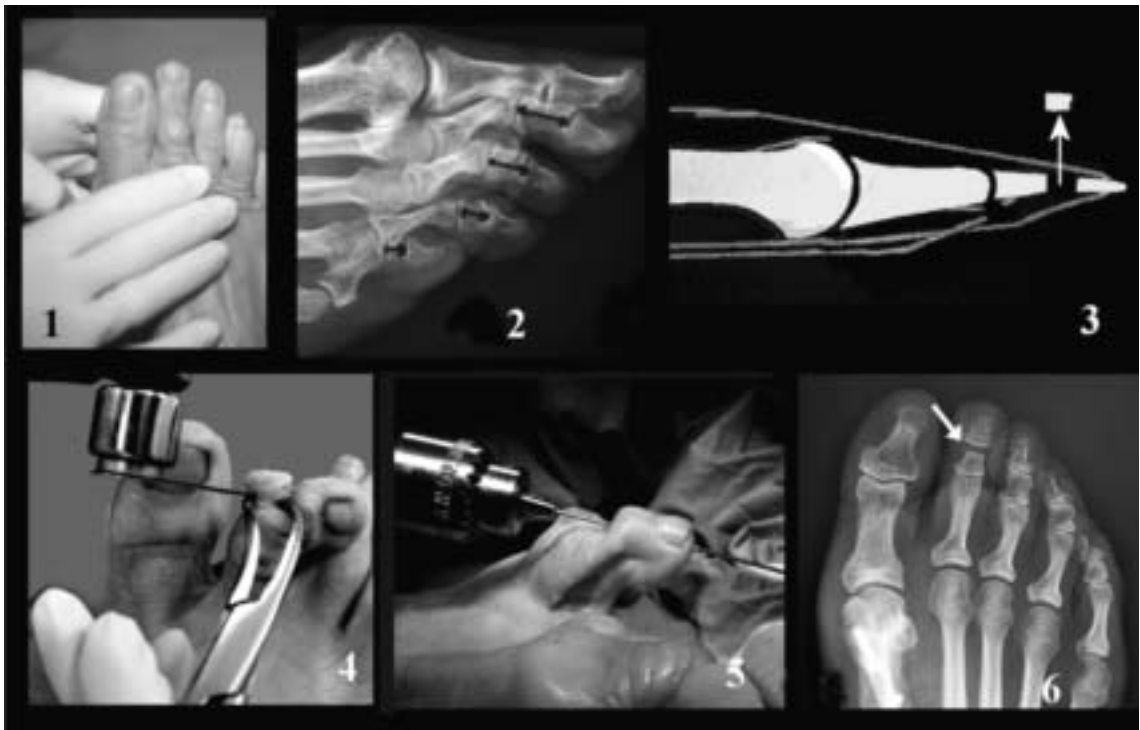
3) The distal lever arm is shorter than for proximal phalanx or PIP surgery

1 – *DIP arthroplasty*: indication: mallet finger, stiff or impaired DIP joint. we use this procedure for 5 years. It gives excellent results, but at the condition to respect several condition:

1. Disinsertion of the collateral ligaments (to avoid lateral deviation particularly medial).

2. Removal of the distal part of the middle phalanx, with a proximal cut stricly perpendicular to the shaft (avoiding secondary medial deviation). Therefore cutting with a saw and use of a banaleck clamp.

3. Not to leave any fragment in the joint, nor any excess of the toe length.



**Fig 29e1. Hammer or claw toe correction: the DIP arthroplasty.**

1. Once corrected the deformity on the PIP joint, the toe may be too long.

2. The principle is the resection of the distal part of the middle phalanx: this is allowed only when this phalanx is long enough, principally on the 2nd 3rd toes.

3, 4. Resection of the distal part of the middle phalanx (preferably with a saw).

5. K. wiring: the K wire is introduced through the dorsal skin: this facilitates its location: in the middle of the 3rd phalanx basis, and axially directed.

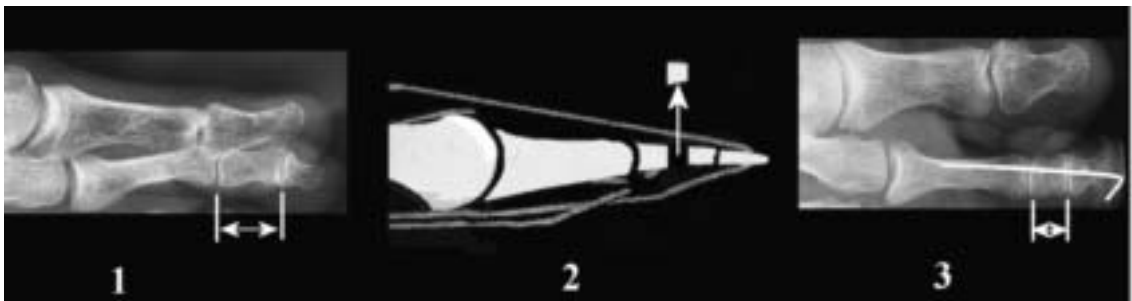
6. One year after surgery: x ray and clinical aspect.

*Shaft Resection of the Middle Phalanx (SRMP).*

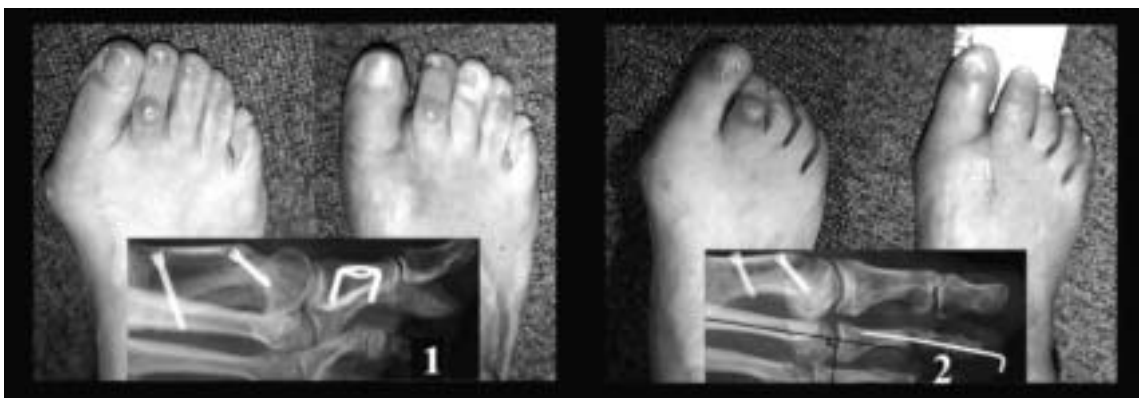
Indication: when the middle phalanx is long enough; advantage of this procedure: it preserves totally the joints. However, the K wire has to be set

for one month to ensure the healing. Contrarily to the shaft resection of the proximal phalanx, the two fragments have sufficient cancellous bone to ensure a correct healing, and the distal lever arm is shorter.

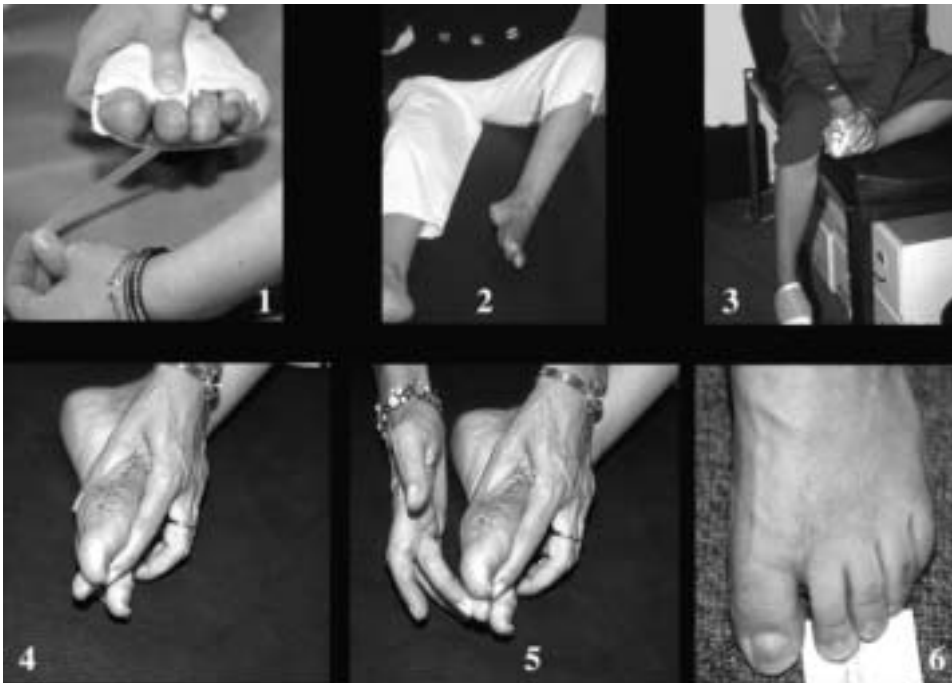In both procedures, temporary K wiring (one month), post operative bandage, and self training.



**Fig. 29e2. Hammer or claw the correction. The shaft resection of the middle phalanx (SRMP).** It is an excellent procedure for single shortening of the toe: contra indication = impaired or fixed DIP joint (ex: mallet finger), and not long enough the middle phalanx.



**Fig. 29f. Hammer or claw the correction: the role of temporary K wiring in claw toe correction without.** No K wiring leads often to insufficiency of correction. The k wiring ensures the correction, once performed whatever required procedure.



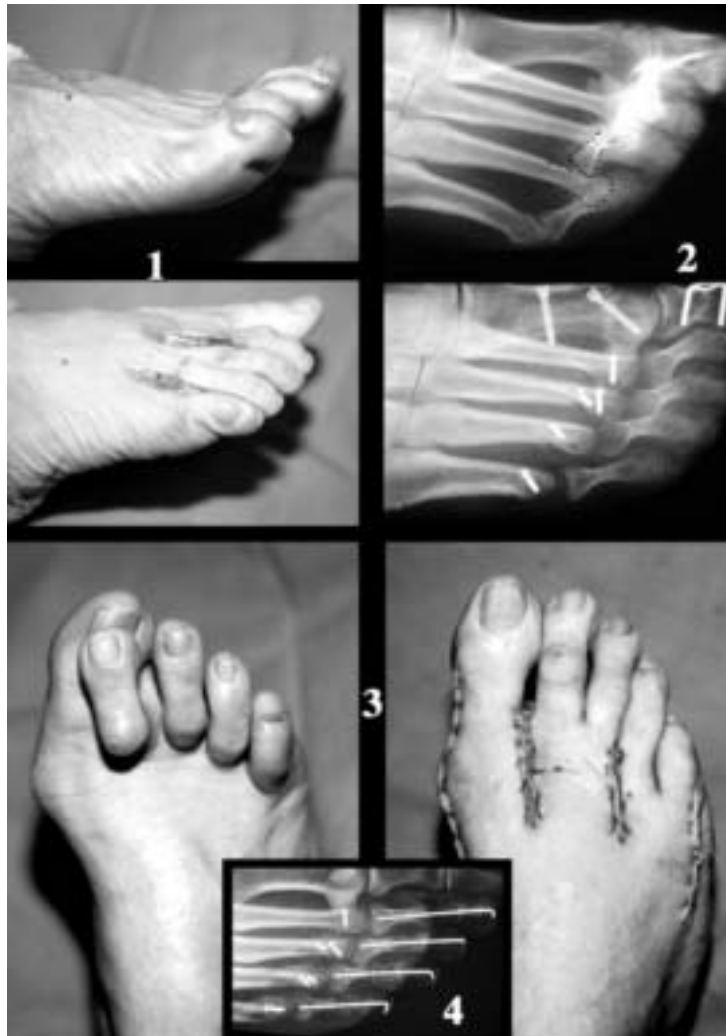**Fig. 29g. Strapping and self-training after claw or hammertoe correction.**

1. Strapping in MTP plantar flexion.
- 2, 3. Leg position to easily reach the foot with the hands (preferably position in Fig. 3).
- 4, 5. Plantar MTP flexion, and dorsal IPP flexion.
6. Standing exercise.

## ***Weil Osteotomy and Toe Deformity***

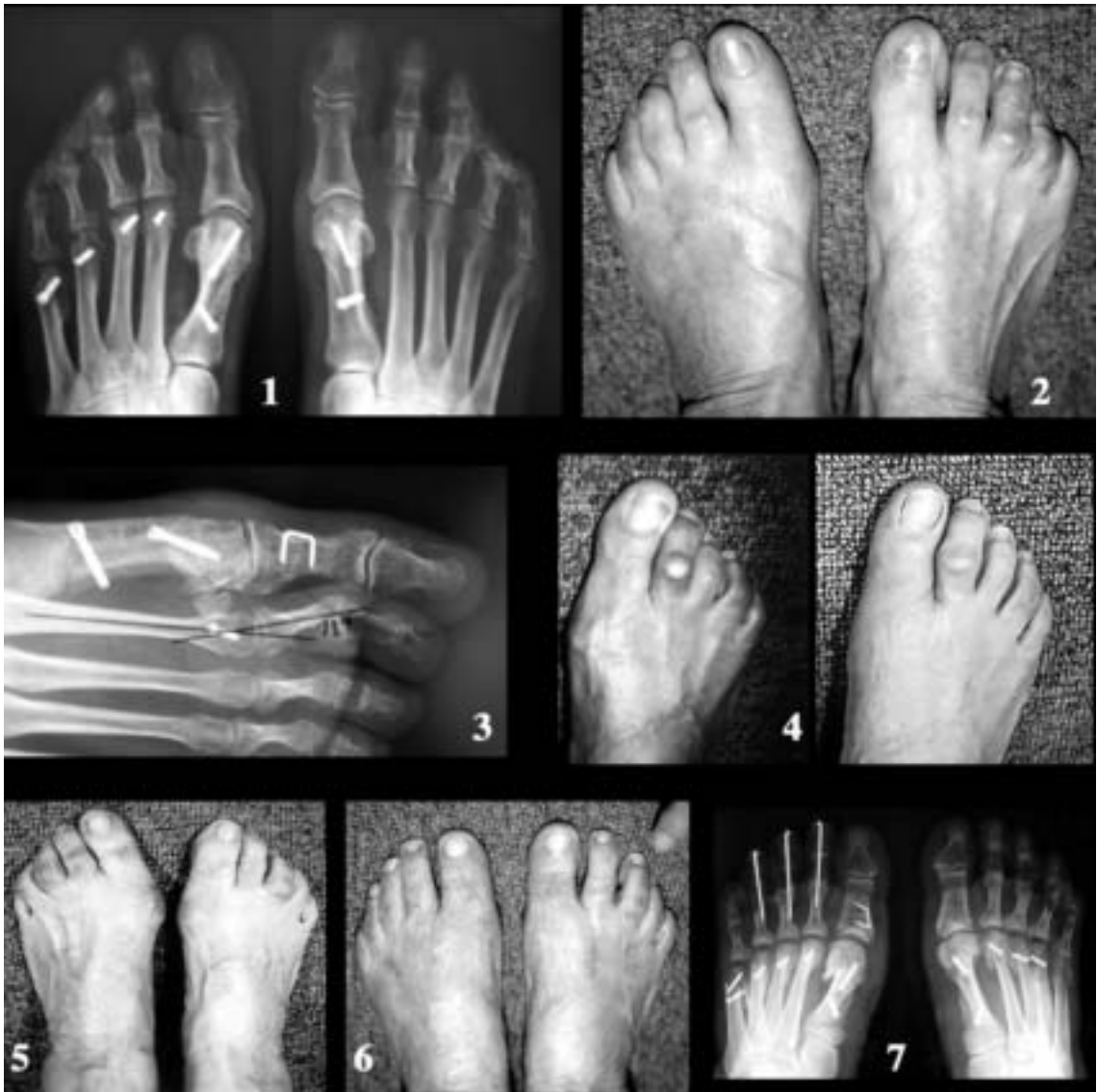When lesser metatarsal Weil osteotomy is performed, we observe a significant correction of hammer or claw toe deformity. We just generally do (after Weil osteotomy) a toe manipulation and we observe that many toe deformities, which seemed to be rigid in the preoperative assessment, were in fact flexible after the longi-

tudinal decompression provided by the Weil osteotomy. After that, we just have to set a thin K-wire in the toe, excluding the MTP joint: In moderate or severe hammertoe deformity, we observe a significant difference with and without K-wiring, so that we now perform additional K-wiring when necessary. So, when the Weil osteotomy is indicated, as showed in the Fig. 29f, it is a reliable procedure to correct hammertoe deformity.



**Fig. 29h1. Hammertoe correction. Weil osteotomy 1.**

1. We observe an immediate correction of the hammertoe deformity after Weil osteotomy (and toe manipulation).
2. Radiological aspect.
3. Hammertoe correction with respect of toe length and joints (just K-wiring).
4. Note the combined K-wiring (one month).



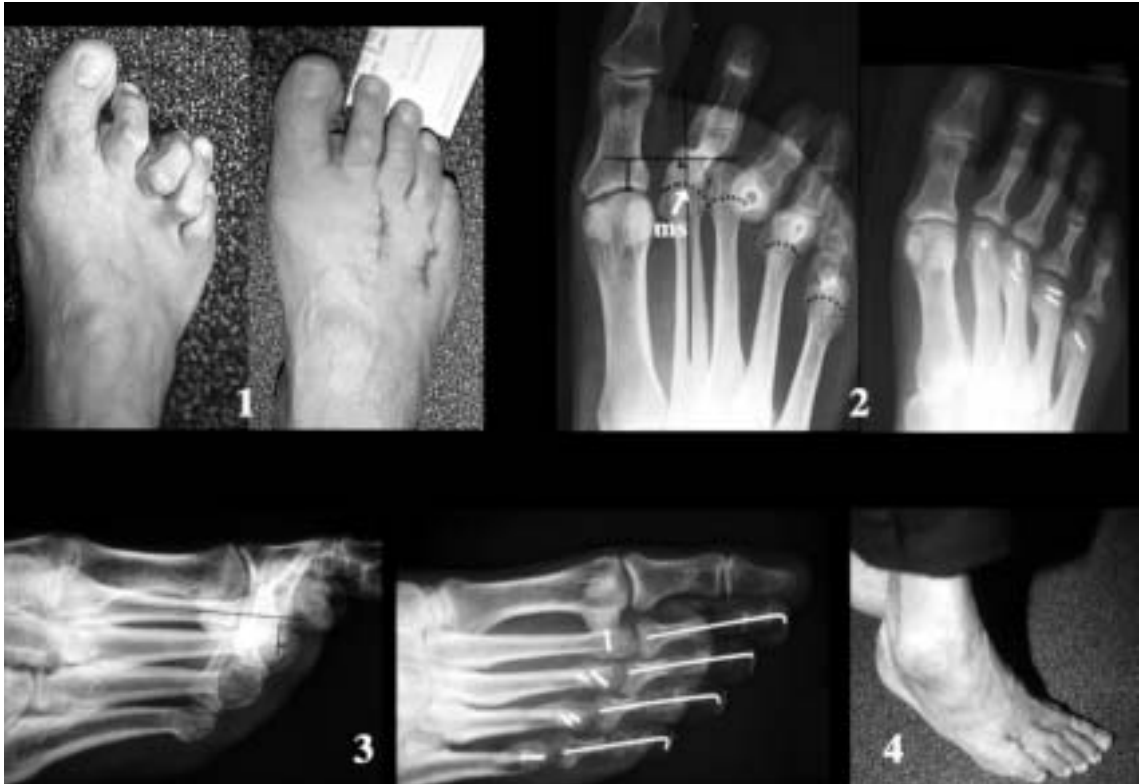**Fig. 29h2. Hammertoe correction: Weil osteotomy. 2**

1, 2. Same patient: on the foot with Weil osteotomy (left), the hammer toe correction is better

3, 4. Weil osteotomy without toe K wiring may result in incomplete correction of hammertoe deformity (2nd toe)

5, 6, 7. Same patient: on the foot with additional K wiring (left), the hammertoe correction is better, in spite of more severe pre operative deformity.

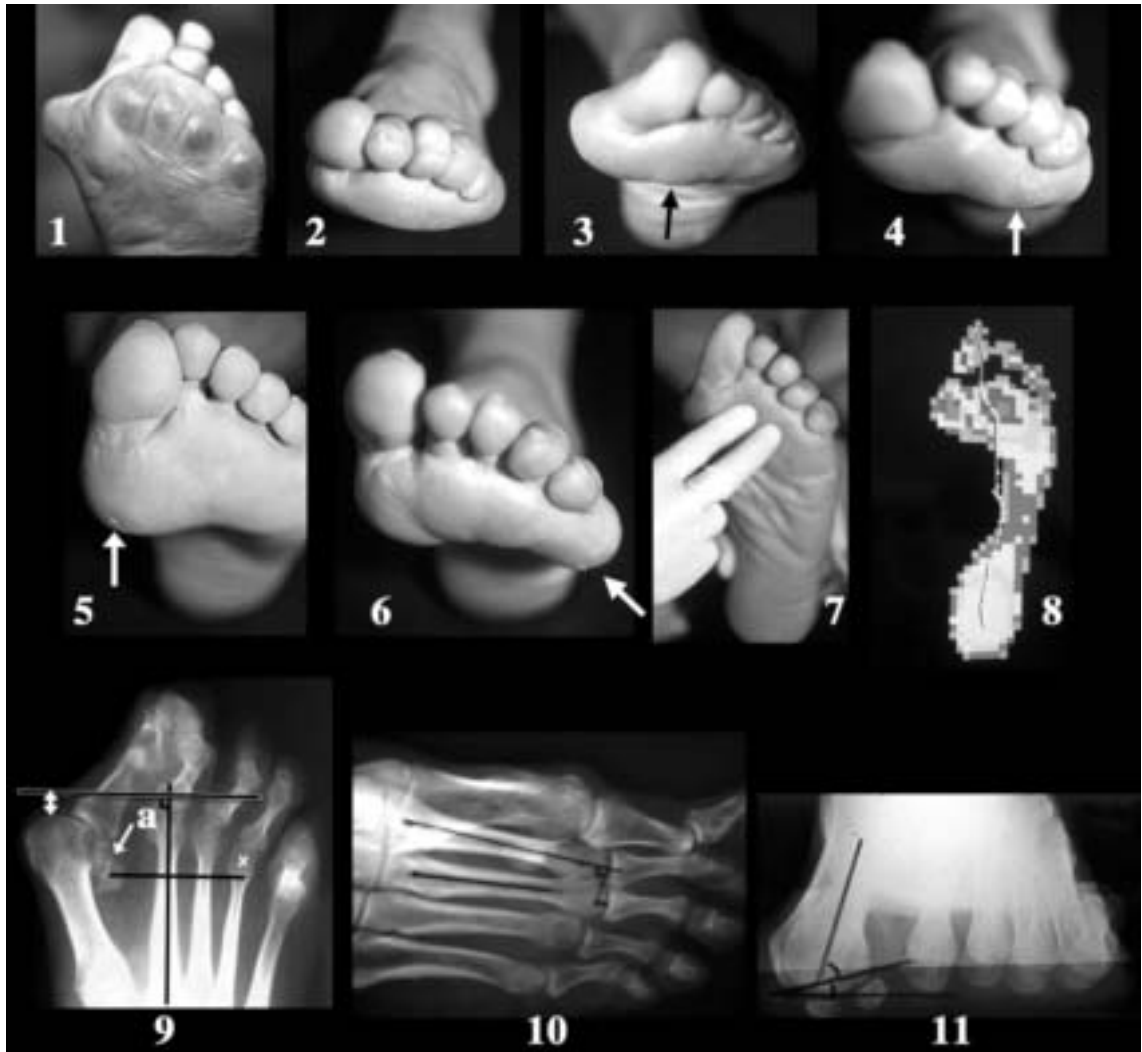*This emphasises the role of Weil osteotomy with additional toe K wiring as a reliable procedure for hammertoe correction*



**Fig. 29h3. Hammertoe correction. Weil osteotomy 3. In excessive metatarsal length. Same patient.**

In excessive length of the lesser metatarsals, hammertoe correction with MTP preservation. This result is obtained by Weil osteotomy with additional toe surgery. Note the *ms point*, indicating the required metatarsal shortening. This level corresponds to the length equality of M1 and M2. Since the first ray does not have to be shortened, care has to be taken to avoid problems with the first two flexor tendons possible anastomosis (however, in this case, it was not necessary to do resection of the retinaculum between the first two flexor tendons).

## Metatarsalgia



**Fig. 30a1. Metatarsalgia: The different aspects.**

1. Plantar callosities on the central rays. 2. Central metatarsalgia “round forefoot”. 3, 4. Callosities on a single ray. 5. Plantar overpressure on the first ray. 6. Plantar overpressure on the fifth ray. Clinical (7) and pedobarometric (8) assessment of plantar overpressure. 9, 10, 11. The main radiographic assessment is made on a dorso-plantar view in standing position (9) on a medial oblique view (10), at last on an axial (11) radiography.

The term metatarsalgia was used to describe many conditions including metatarsal head pain, forefoot neuroma, intractable plantar keratosis, metatarsal joint instability or dislocation, synovitis and inflammatory or degenerative arthritis of the metatarso-phalangeal joint.

In this book, we limit the meaning of metatarsalgia to *metatarsal head pain in its plantar aspect, in a standing position*. The other aspects of painful MTP joint are described in other chapters.

Metatarsalgia is a frequent patient complaint



in first examination for forefoot pathology. It is a complex problem that requires considerable discussion. We therefore elected to divide this chapter into these three subchapters:

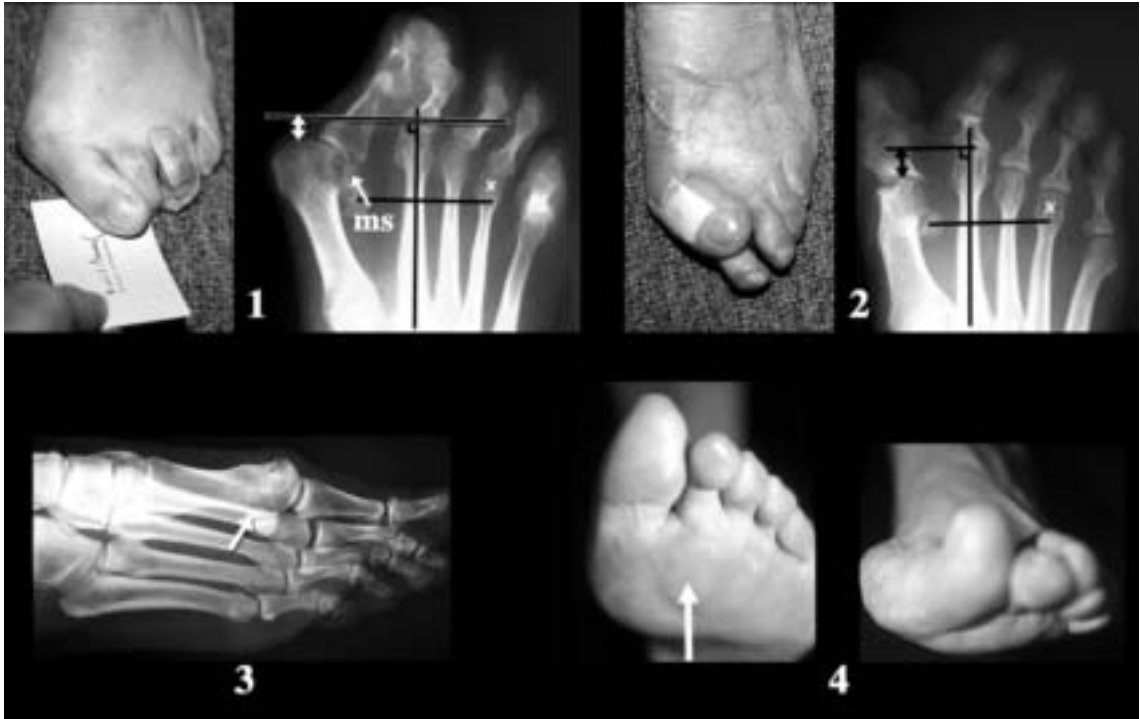
1. Study of the *causes* of metatarsalgia.
2. The *surgical procedures* we use for relieving metatarsalgia, with their techniques, advantages, limits.
3. Study of the *different clinical types* and their appropriate *surgical treatment*.

## *The Main Causes*

We can distinguish the *following main causes*.

### *Insufficiency of the First Ray*

It can only be a *functional insufficiency*, principally the incorrect ground contact of the great toe, with loss of strength and toe rotation and



**Fig. 30a2. Metatarsalgia – Main causes: (1) Insufficiency of the first ray.**

1, 2. *Functional insufficiency of the first ray*: Insufficiency of the great toe ground contact, lateral sesamoid too far proximal (Maestro line passing proximally from the center of the metatarsal head). Lesser metatarsals are too long comparatively to the first one.

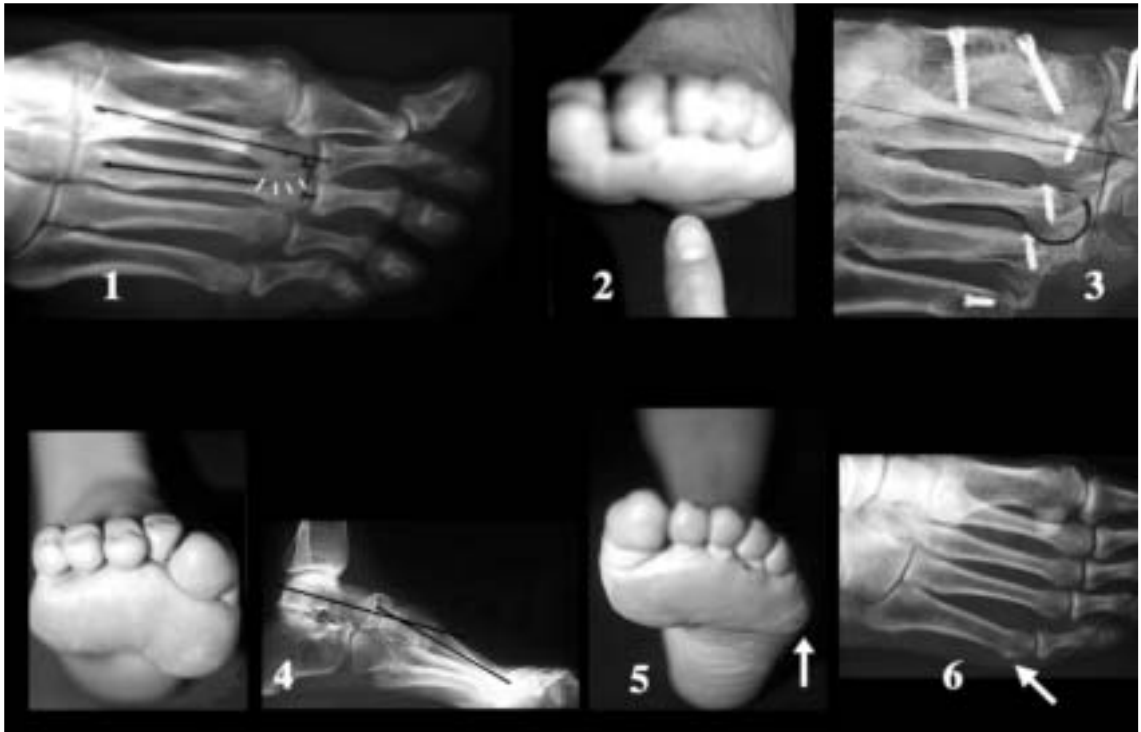
3. *Elevation of the first metatarsal* after osteotomy.

4. This leads to second ray metatarsalgia or to central metatarsalgia.

apparent proximal position of the lateral sesamoid (in fact due to the lateral position of the first phalanx). It can also be *shortness, hypermobility or elevation of the first metatarsal* (Fig. 30a2).

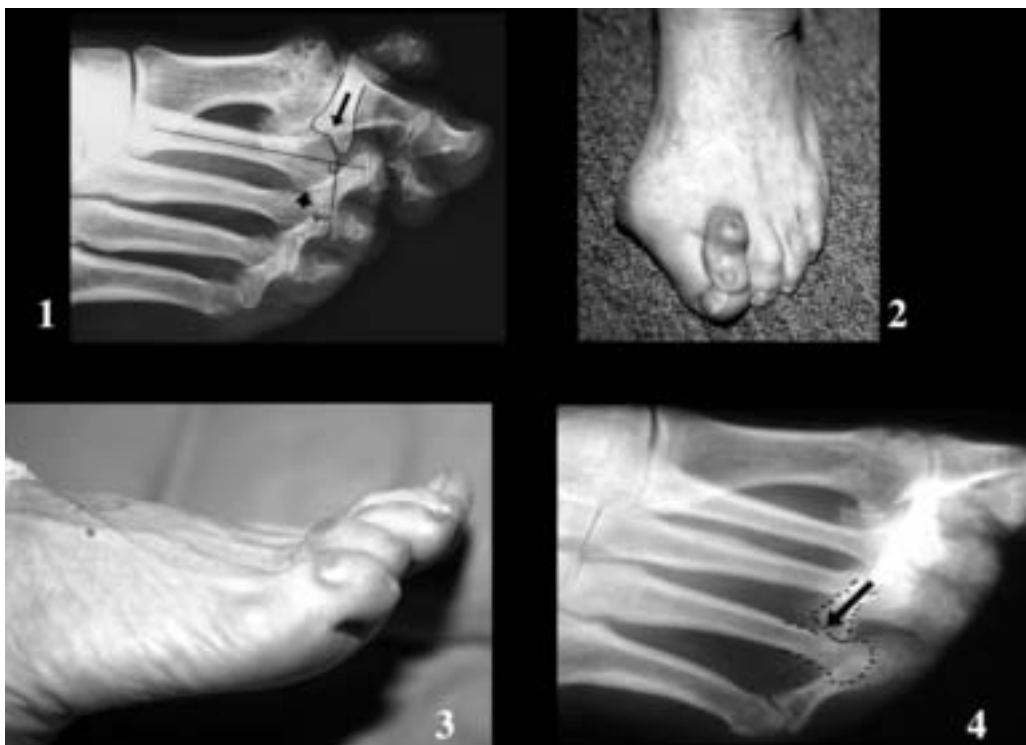*Excess of Metatarsal Plantar Slope or Head Protuberance*

This is assessed on weight bearing X-ray for the first ray, on the medial oblique view for the lesser rays (Fig. 30a3).



**Fig. 30a3. Metatarsalgia – Main causes : (2) Excess of metatarsal plantar slope or protuberance.**

- 1. Excess of metatarsal plantar slope (comparatively to the other metatarsals). This is well assessed on a medial oblique view.
- 2, 3. Excess of metatarsal head plantar protuberance on the third metatarsal and the corresponding X-ray (3).
- 4. Excess of plantar slope of the first metatarsal in *pes cavus*.
- 5, 6. Excess of plantar slope of the fifth metatarsal in bunionette.



**Fig. 30a4. Metatarsalgia – Main causes: (3) Vertical position of the first phalanx, that pushes down the metatarsal head.**

1, 2. Dorsal flexion of the first phalanx resulting from severe hammer or claw toe.  
3, 4. MTP dislocation.

### *Vertical Position of the First Phalanx*

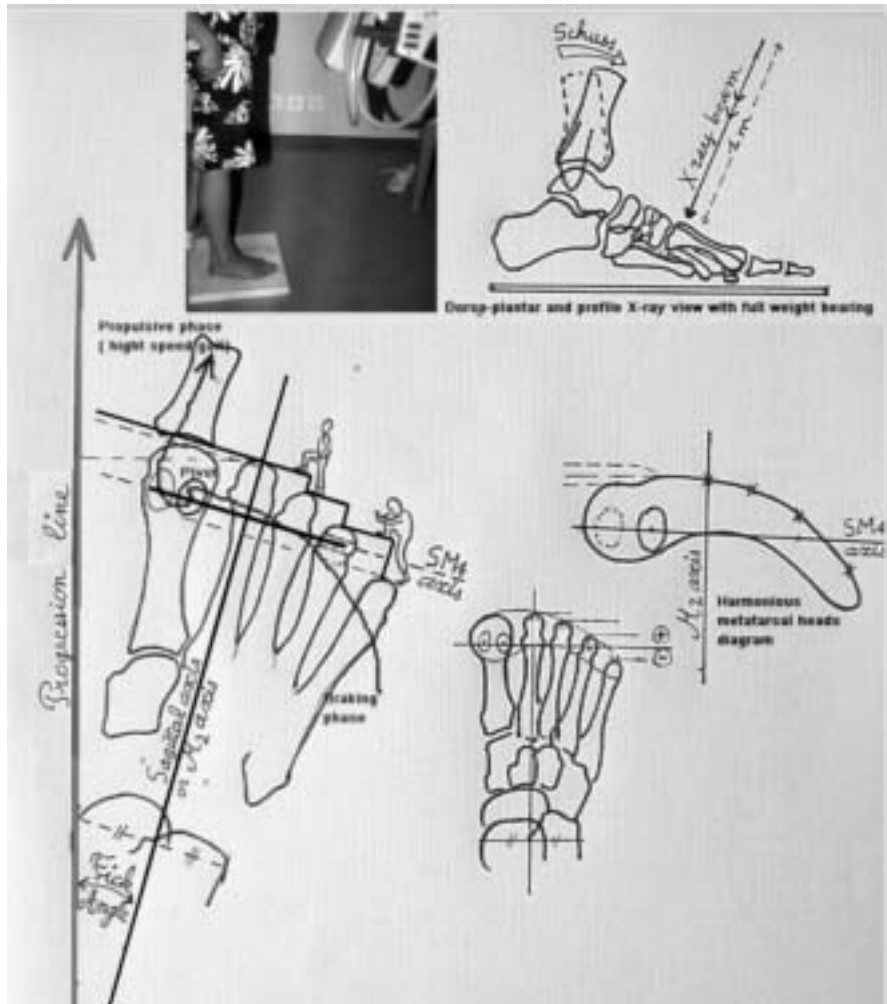
This position pushes down the metatarsal head. This is encountered in advanced hammertoe deformity or in MTP dislocation (Fig. 30a4).

### *Metatarsal Excess of Length in Dorso-Plantar X-Ray View in Standing Position*

The incidence in producing metatarsalgia was studied and clarified by the studies of Maestro and Ragusa [41] as well as Tanaka [51]. These authors studied the average of the relative metatarsal lengths (metatarsal parabola), bringing more precisions than the previous authors and determining a forefoot morphotype. Recently (Nov. 2000, French AFCP annual meeting), a more complete study was made by Maestro, Besse and Ragusa confirming the previous results (Fig. 30a5a). Figures 30a5b shows that

we have to assess *this metatarsal relative length in dorso-plantar standing position*. M. Maestro considers the lateral sesamoid of the first MTP joint as a pivot in his gait's analysis. He also emphasizes the longitudinal axis of the second metatarsal: The line passing in the center of the lateral sesamoid and perpendicular to the M2 longitudinal axis has to pass in the center of the fourth metatarsal. After forefoot reconstruction, if the *Maestro line* crosses the fourth metatarsal center, or if this line is slightly distal from the M4 head center, there is no more metatarsalgia. On the contrary, a *Maestro line* passing proximally to the fourth metatarsal head center is generally accompanied by remaining metatarsalgia after forefoot reconstruction.

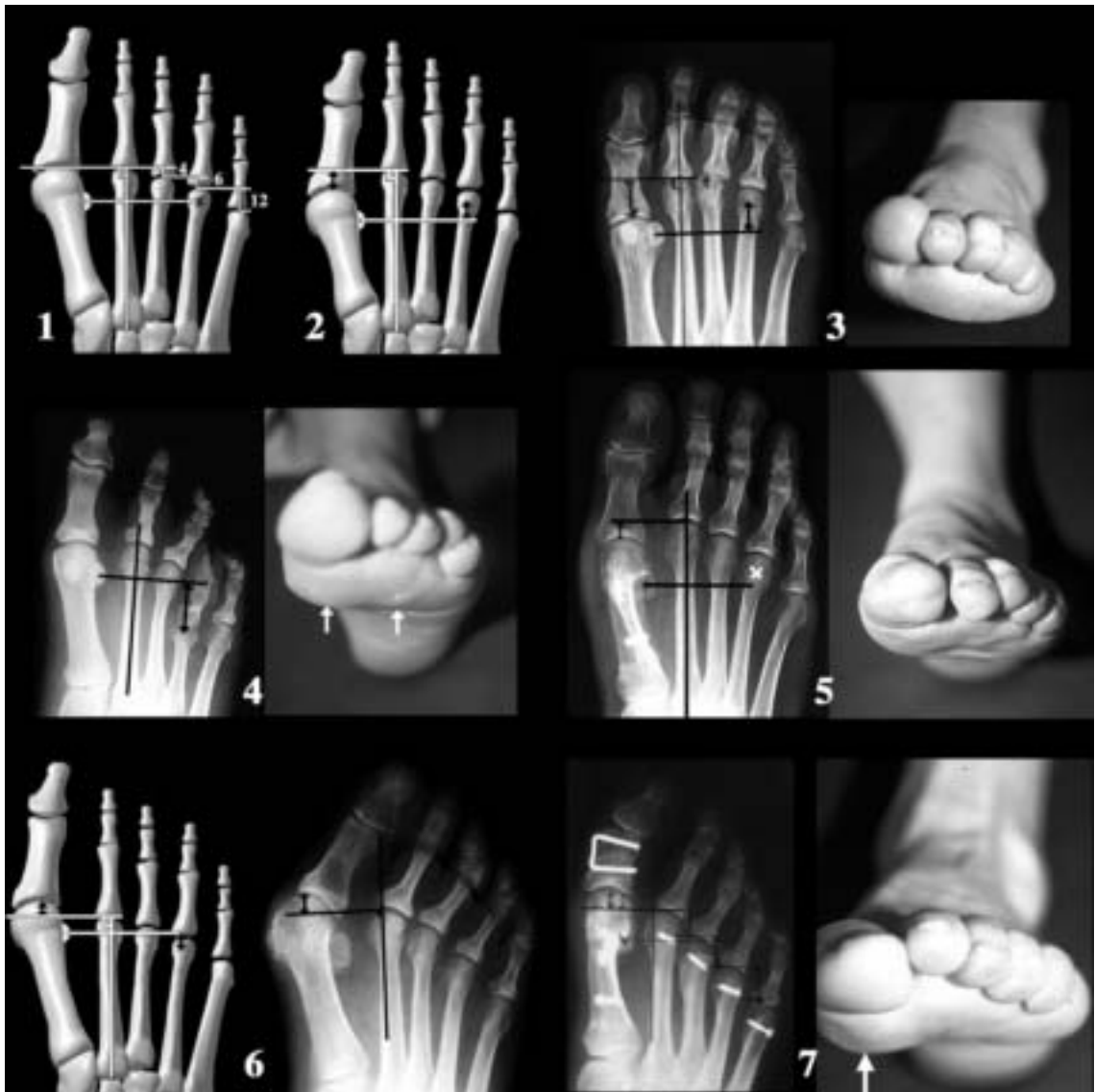On the other hand, *the excess of the first metatarsal length* is usually not well tolerated and has to be carefully avoided, as indicated by several authors like L. S. Weil, M. Ragusa and myself.



**Fig. 30a5a. Metatarsalgia – Main causes: 4) Metatarsal excess of length a1) In dorso-plantar X-ray in standing position.**

These pictures are provided by M. Maestro (Nice, France), who studied in particular the relative metatarsal length of the metatarsals and its relationships with metatarsalgia.

The M2 axis is drawn and we have to assess the comparative metatarsal length. On the other hand we have to draw the Maestro line (see also Fig. 30a5b).



**Fig. 30a5b. Metatarsalgia – Main causes: (4) Metatarsal excess of length  $a_2$  In dorso-plantar X-ray in standing position.**

1. The normal relative length of the metatarsal is:

- Equality of the first two metatarsals.
- Decreasing length of the metatarsals as indicated in this fig. (4-6-12 mm).
- Maestro line, which passes in the center of the lateral sesamoid and is perpendicular to the M2 axis. Normally this line passes by the center of the fourth metatarsal head.

2, 3. Conditions encountered in metatarsalgia:

- Lesser metatarsals comparatively longer than the first one.
- Maestro line passing distally from the fourth metatarsal head center.

4. Brachi congenital metatarsal on the fourth ray: Disharmony of metatarsal length results in metatarsalgia of the three medial metatarsals.

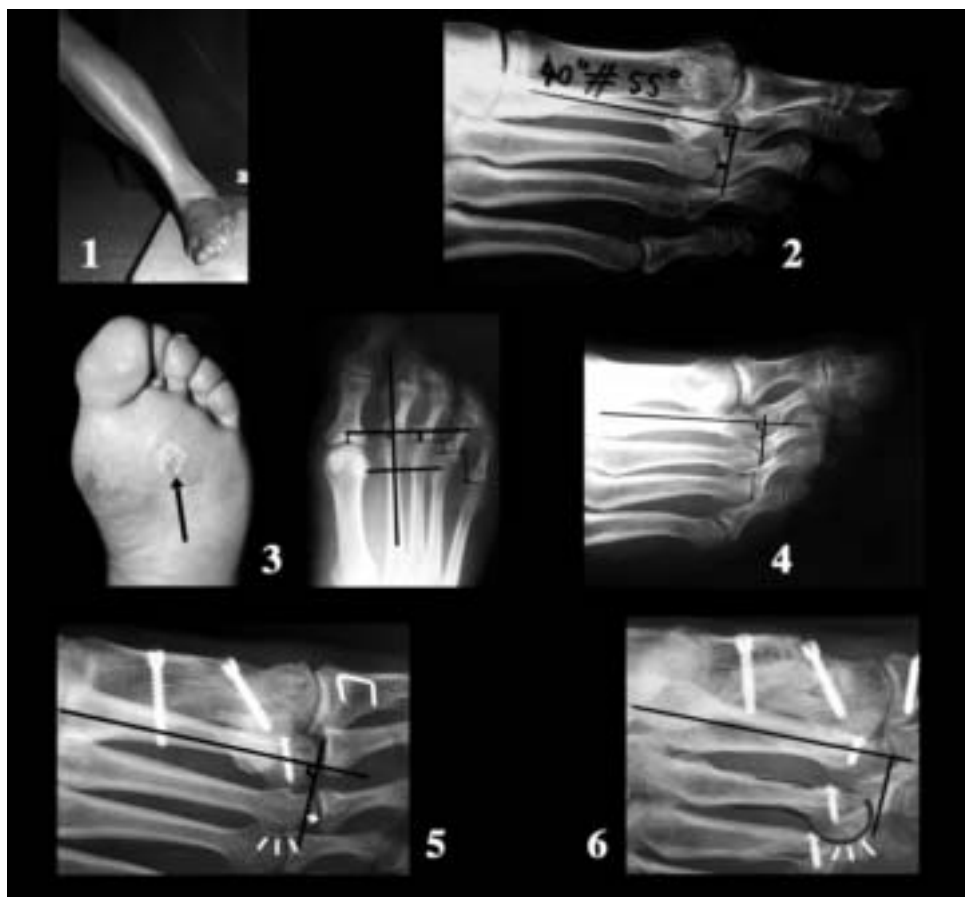
5. However, if there is preoperatively no problem with the lesser rays, we should respect the metatarsal formula without secondary problems.

6. The excess of the first metatarsal length is rarely well tolerated: Degenerative MTP joint changes (longitudinal compression), overpressure on the first metatarsal head, over or undercorrection of the deformity. So, in forefoot reconstruction we have to provide equality of the two metatarsal lengths or a slightly excessive length of the second metatarsal ( $< 3$  mm), but never the first metatarsal must never be longer than the second one.

### Metatarsal Excess of Length in the Medial Oblique X-Ray View

In this incidence, we cannot assess the relationships between the first two metatarsals, but we can accurately assess the relationships between the lesser metatarsals, particularly between the second, third and fourth ones. First we draw a line on the longitudinal axis of the second metatarsal, then a perpendicular line on the distal end of this

metatarsal and we appreciate the position of the third, fourth and fifth metatarsals with respect to this perpendicular line. There is a close relation between metatarsalgia and the relative length of the metatarsals in this incidence. The medial oblique view is essential for the preoperative therapeutic planning, in combination with the dorso-plantar view. It is also critical to explain a recurrent or transfer metatarsalgia after surgery (Fig. 29a5c).



**Fig. 30a5c. Metatarsalgia – Main causes: (4) Metatarsal excess of length b) In a Medial X-ray oblique view.**

1. This X-ray view is essential for the preoperative therapeutic management. Note the foot position for taking the X-ray.
2. There is no significant difference with 40° or 55° oblique inclination of the foot.
- 3, 4. In the same foot: Metatarsalgia on the third ray with a correct dorso-plantar X-ray view but with an excess of the third metatarsal length on the medial oblique view.
5. Excess of the third metatarsal length resulting in metatarsalgia, emphasized by medial oblique view after single second metatarsal Weil osteotomy.
6. The medial oblique view also points out a protruding head of the third metatarsal, resulting in metatarsalgia in this location.

### Stance and Propulsive Phase Metatarsalgia

L. S. Weil emphasizes the distinction between stance and propulsive metatarsalgia in relation with the relative length of the metatarsals (Fig. 30a6).

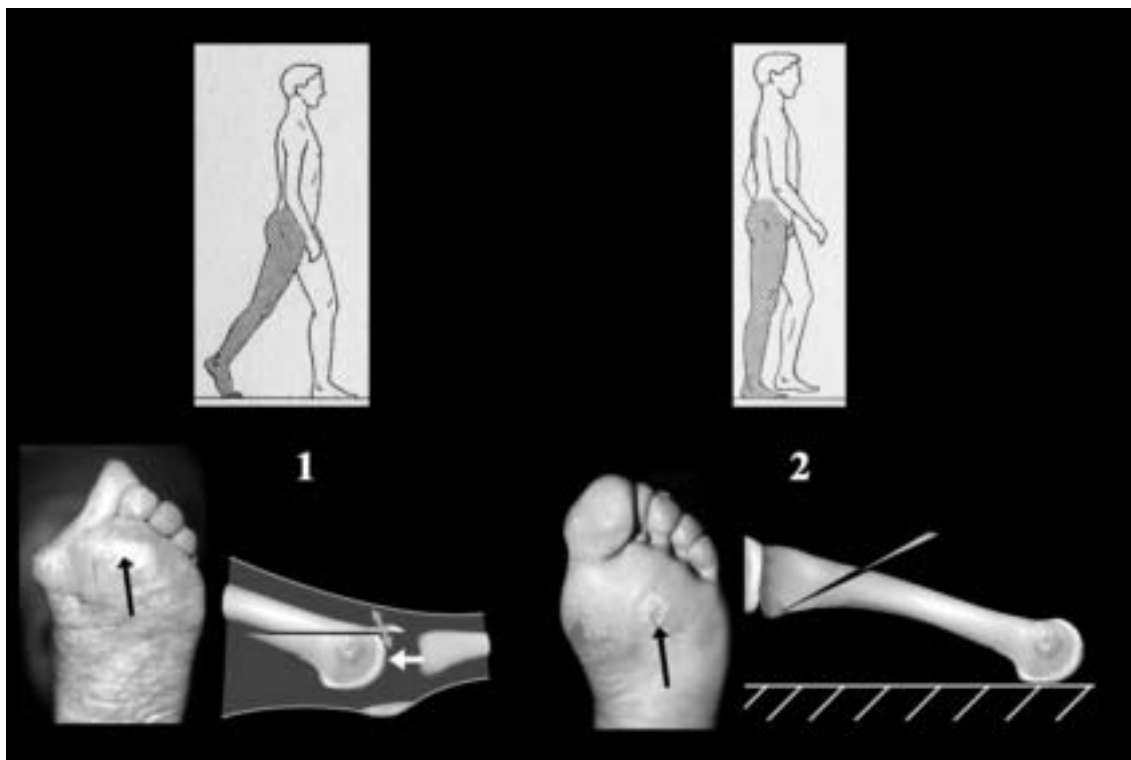
#### Stance Phase Metatarsalgia (SPM)

This condition is caused by an overload directly beneath the metatarsal head and initially causes pain in that area. Later, a callosity may develop and eventually an intractable plantar keratosis may emerge. Axial radiographs will often demonstrate an abnormal weight bearing position of the metatarsal heads with one lying in a more plantar position than the adjacent metatarsal. The exact cause can be congenital, from a prior stress fracture or surgery to the adjacent

metatarsal, or from insufficient loading of the first metatarsal secondary to the deformity or prior surgery. Following conservative treatment failure, the treatment of SPM is an elevation osteotomy such the BRT, which is certainly the more accurate and reliable osteotomy.

#### Propulsive Phase Metatarsalgia (PPM)

This condition is the more common type and is characterized by abnormal metatarsal length pattern especially noted when it is compared to the contra-lateral foot. Even an increase in length of 2 mm can be enough to increase the time/load force under the distal metatarsal head, leading the capsulitis, joint effusion, subluxation and digital contracture (Cavanaugh). Following a careful analysis of the lesser metatarsal length pattern (Maestro formula), a Weil metatarsal osteotomy may prove valuable for relieving the submetatarsal pain.



**Fig. 30a6. Metatarsalgia – Main causes: (5) In stance or propulsive phase of the gait.**

Although it should be difficult for the patient to report the painful phase (propulsive or stance), the examination clearly assesses the difference between *propulsive phase* metatarsalgia (distal callus), which indicates Weil osteotomy, and *stance phase* metatarsalgia (proximal callus), which indicates metatarsal elevation (like BRT osteotomy).

Although it is difficult for the patient to distinguish between stance or propulsive metatarsalgia during the clinical examination, the stance phase generates a proximal callosity or pain preoperative, while propulsive phase metatarsalgia generates distal pain and a linear type callosity.

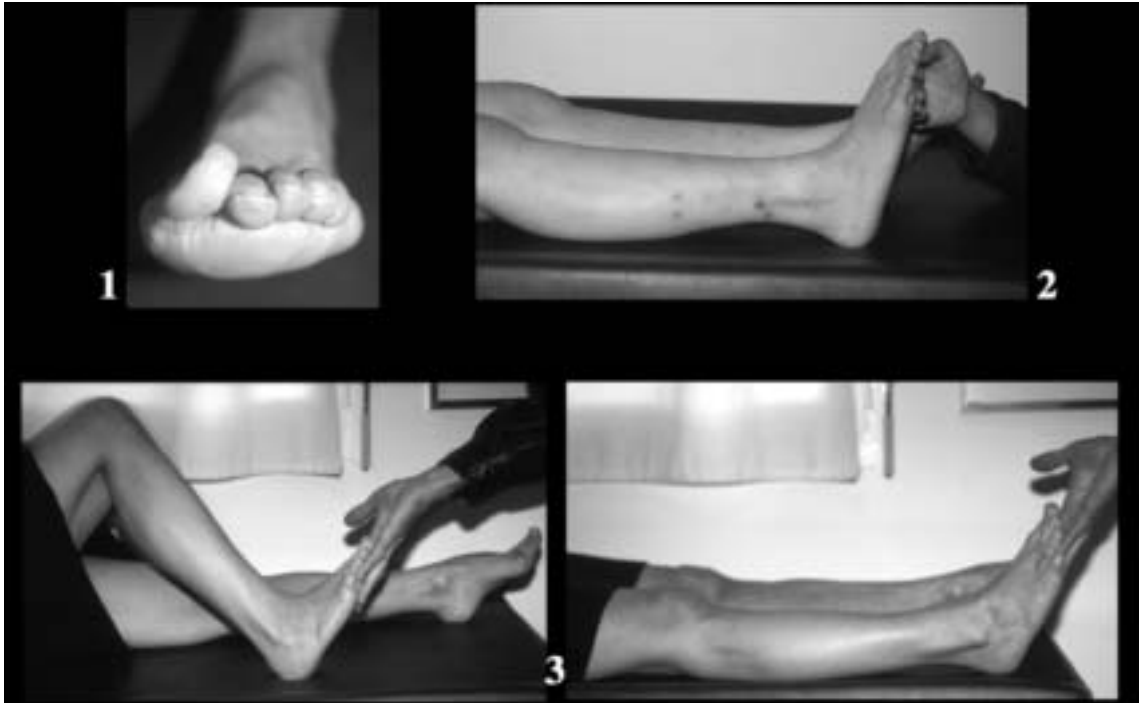
### Equinism

Equinism can result in metatarsalgia by itself (*i.e.* without forefoot disturbance). Furthermore, equinism increases metatarsalgia caused

by any forefoot disorder. So we have to carefully assess equinism: We distinguish *permanent equinism* from *gastrocnemius equinism* which disappears when the knee is flexed.

*Gastrocnemius equinism* is frequently encountered in forefoot pathology. When it is notable we have to perform its treatment – *i.e.* the gastrocnemius proximal release (see above) – which is an harmless and reliable procedure.

The *permanent equinism* is less frequently encountered, fortunately because the Achilles tendon lengthening is a small procedure but followed by a long recovery time and decreased triceps surae strength (Fig. 30a7).



**Fig. 30a7. Metatarsalgia – Main causes : 5) Equinism.**

1, 2. Equinism is not the only cause of metatarsalgia, but in every case equinism increases the metatarsalgia whatever another cause existing in the forefoot.

3. Preoperative examination has to assess the part of gastrocnemius shortness in equinism, because the gastrocnemius proximal release is much more harmless than Achilles tendon lengthening.



## ***The Surgical Treatment of Metatarsalgia***

### *The Principles of Surgical Treatment*

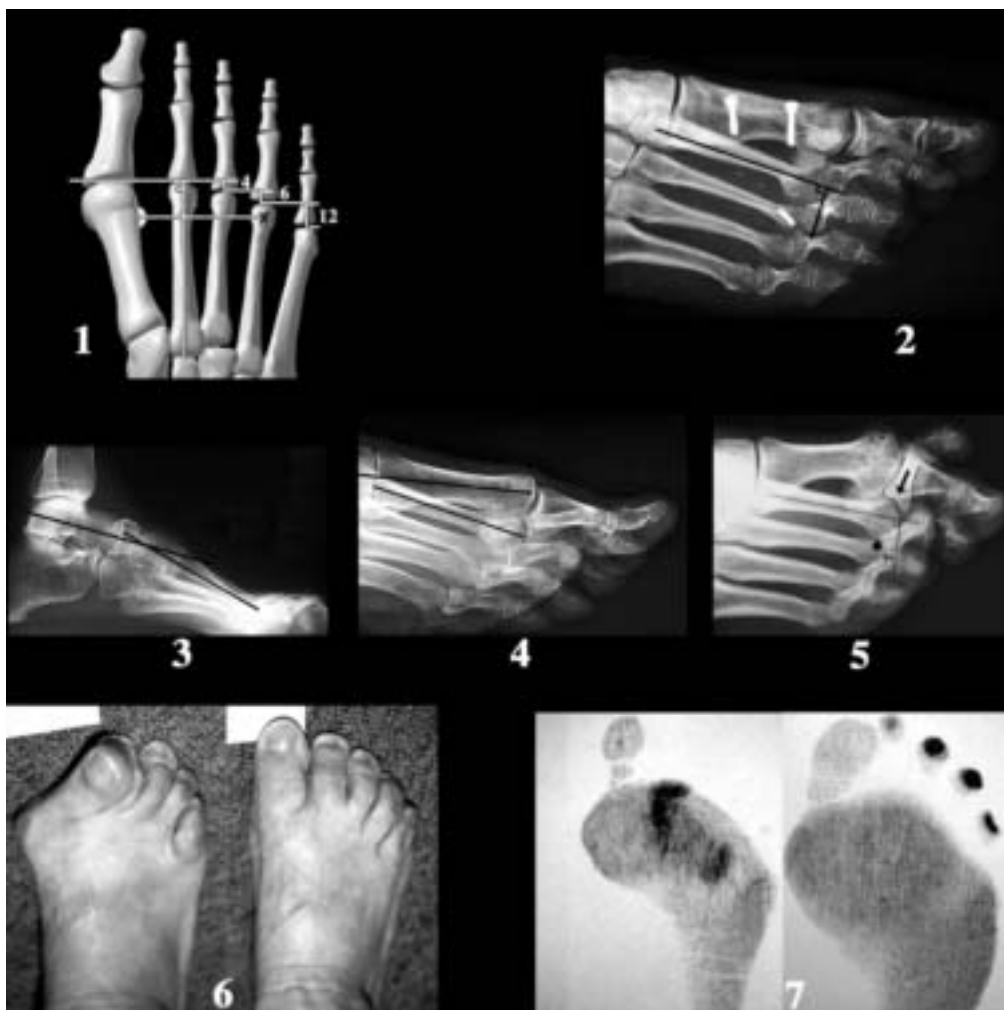We have to follow the four main principles:

1) Respect or reestablishment of the relative metatarsal length both in the dorso-plantar and in medial oblique X-rays views.

2) Reestablishment of a correct metatarsal plantar slope.

3) Recovering of the first ray correct anatomy and physiology.

4) Reestablishment of the lesser toes correct ground contact.



**Fig. 30b1. Metatarsalgia: main principles of surgical treatment**

1, 2. Recovery or respect of the relative metatarsal length both in dorso plantar (1) and in medial oblique X ray views (2)

3, 4. Decrease of the metatarsal plantar slope or protuberance (first ray sagittal standing view (3) lesser rays medial oblique view (4))

5. Correction of the vertical position of the first phalanx

6. Recovery of first ray anatomy and physiology (particularly the strength of the great toe ground contact)

7. Recovery of the lesser toes ground contact

### *The Procedures we Use to Relieve Metatarsalgia*

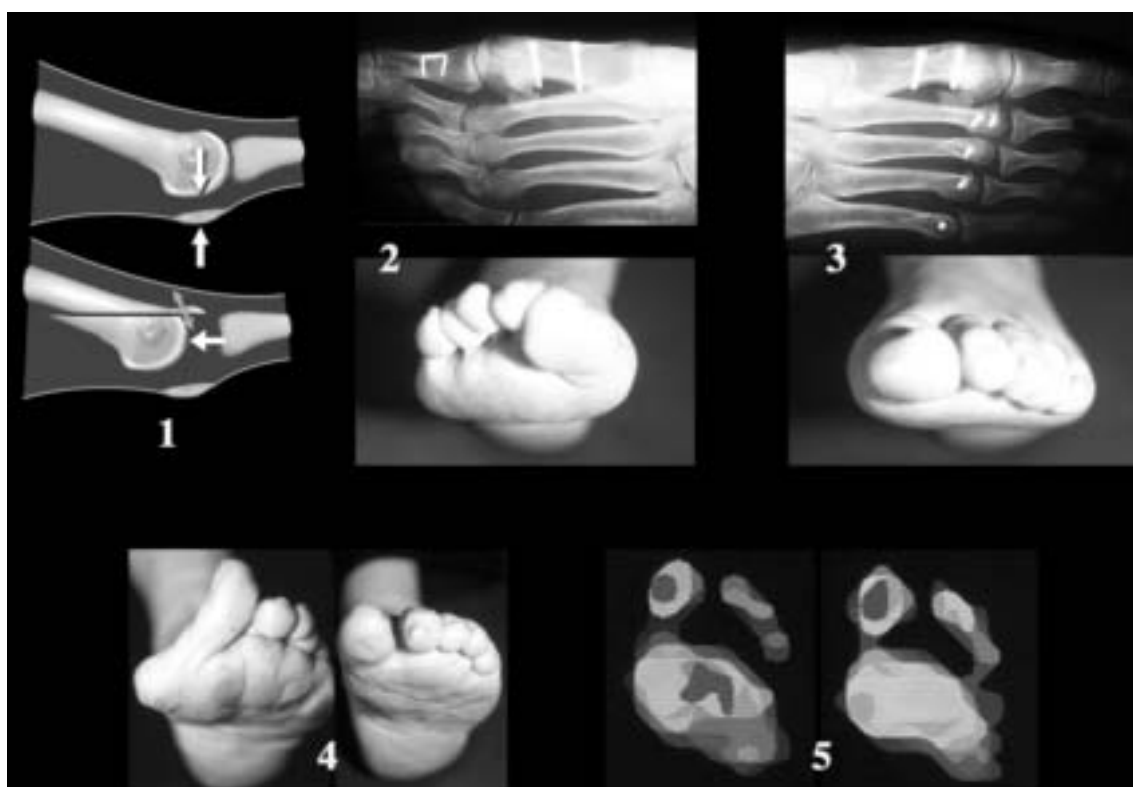
The Weil lesser metatarsal osteotomy, the BRT osteotomy, the insufficiency of the first ray, notably the hallux valgus correction are successively studied in the following plates.

#### **Weil Osteotomy for metatarsalgia**

The main specific aspects of the Weil osteotomy regarding metatarsalgia are detailed in the follo-

wing plates. Notably, the management of the lesser metatarsal relative length, the role of the metatarsal plantar slope in the final position of the metatarsal head, and the double layer osteotomy to be performed.

The Weil osteotomy has to be accurate and well managed. But on these conditions, this procedure is extremely effective for relieving metatarsalgia, as observed by many authors (cf. references).



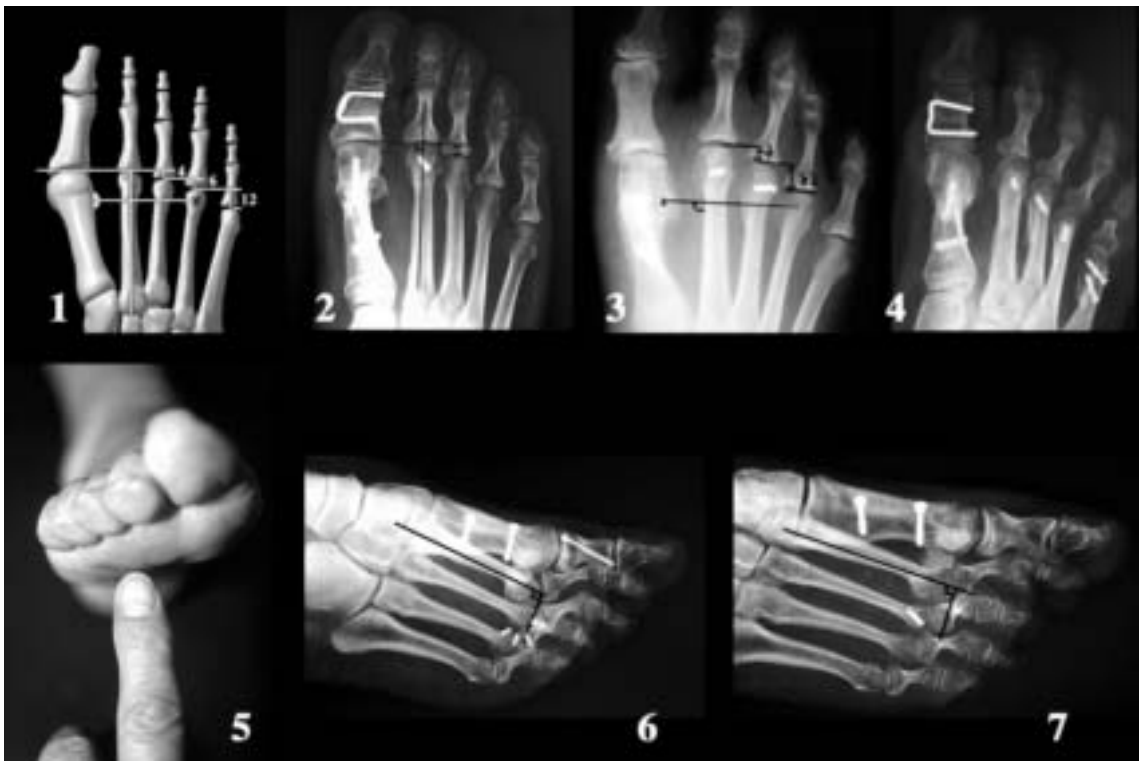
**Fig. 30b2a. Metatarsalgia and Weil osteotomy. (1) Effect of the proximal translation of the metatarsal head.**

1. The accurate proximal translation provided by the Weil osteotomy places the head proximally from the callus and the metatarsalgia is relieved almost in every case.

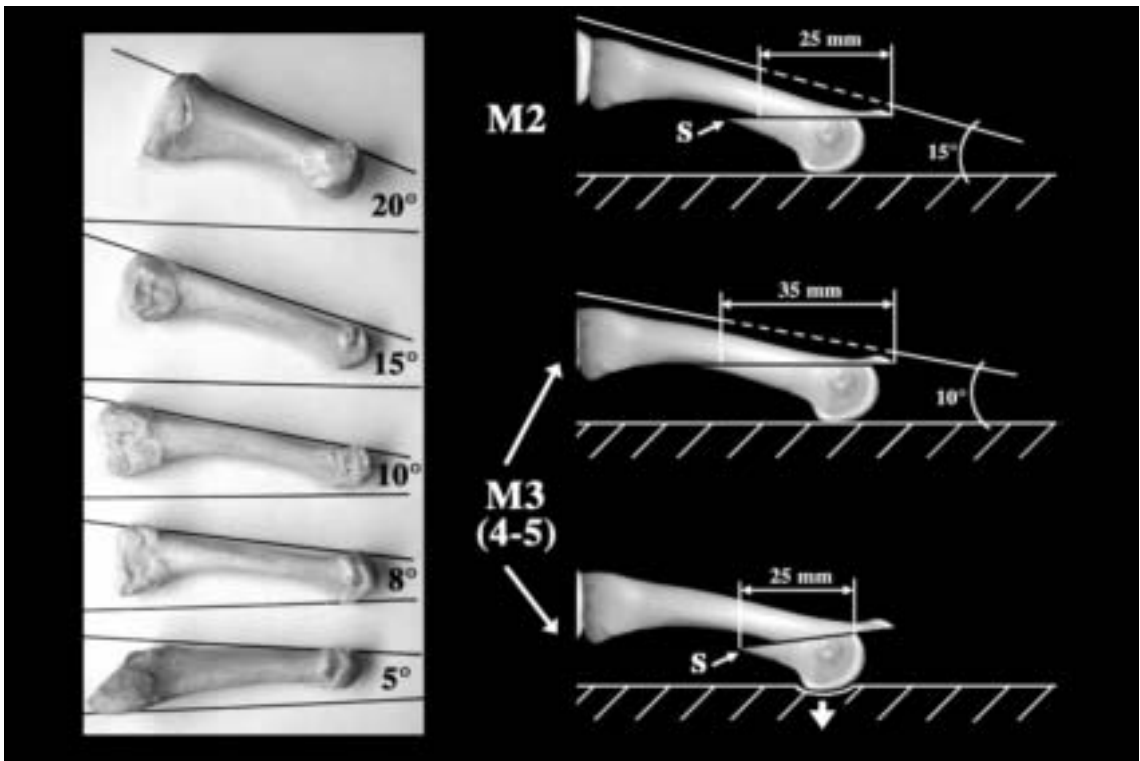
2, 3. Same patient: In the right foot (2), incomplete relieved metatarsalgia without Weil osteotomy. In the left foot (3), complete relieved metatarsalgia with Weil osteotomy.

4. Six years long-lasting relieving of the metatarsalgia after Weil osteotomy.

5. Plantar prints before and after Weil lesser metatarsals osteotomy (picture provided by L. S. Weil).



**Fig. 30b2b. Metatarsalgia and Weil osteotomy. (2) Management of lesser metatarsal relative length.**  
 1, 2, 3, 4. *In dorso-plantar view*, this metatarsal curve has to be reproduced as far as possible. This needs Weil osteotomy on the second (2), third and fourth (3) or on the four lesser metatarsals (4) as required.  
 5, 6, 7. *In medial oblique view*, same foot: 5-6 transfer metatarsalgia on the third metatarsal which is too long comparatively to the second one. Metatarsalgia relieved by the third metatarsal secondary shortening (7).

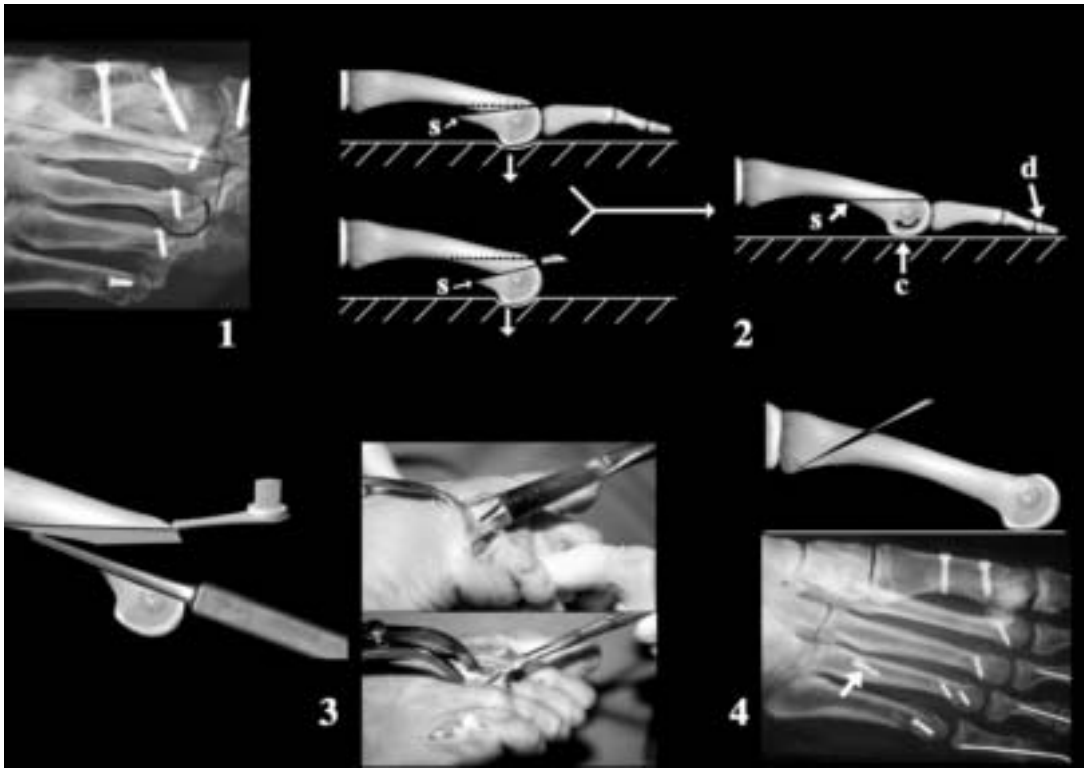


**Fig. 30b2c. Metatarsalgia and Weil osteotomy. (3) Role of the metatarsal plantar slope in final sagittal position of the metatarsal head.**

On the left, picture from M. Benichou, Montpellier, France.

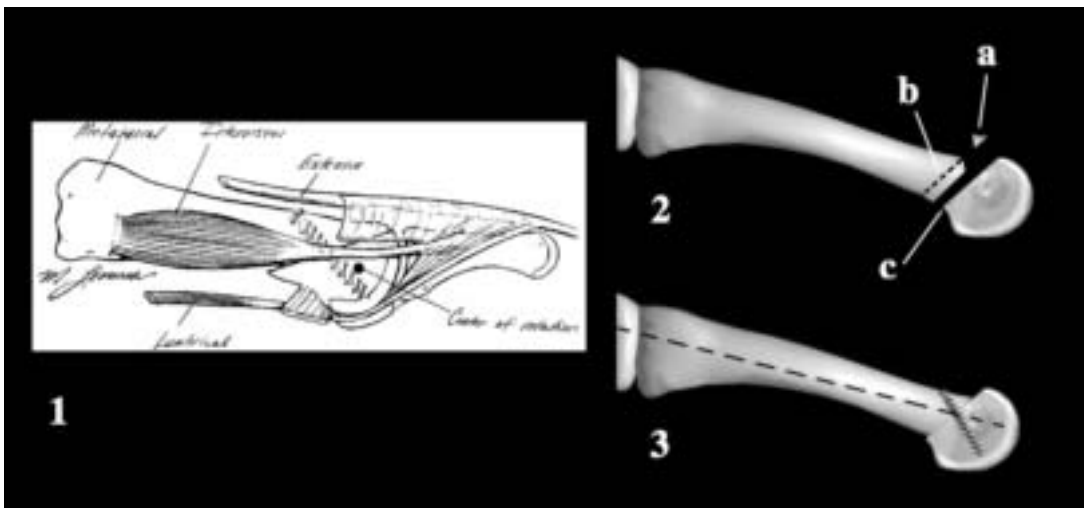
From M2 to M5, take care to the acute spike “s”.

From M3 to M5, take care to a slight lowering of the head with an usual saw blade 25 mm length. Solution: Double layer osteotomy.



**Fig. 30b2d. Metatarsalgia and Weil osteotomy. 4) The double layer.**

- 1, 2. In order both to *elevate the head* – notably on the third metatarsal, which has poor compensation in the tarso-metatarsal joint –, and to *remove the spike “s”*, the double layer is necessary. Two cases are encountered:
  - The peak is not too thick: Single proximal wedge removing.
  - The peak is too thick: Removing both distally and proximally.
2. This double layer being in each case more important proximally, this results in head rotation such as the spike “s” disappears, and the toe is more in ground contact (d).
3. Operative view.
4. If the double layer is insufficient, elevation by BRT osteotomy should be necessary.



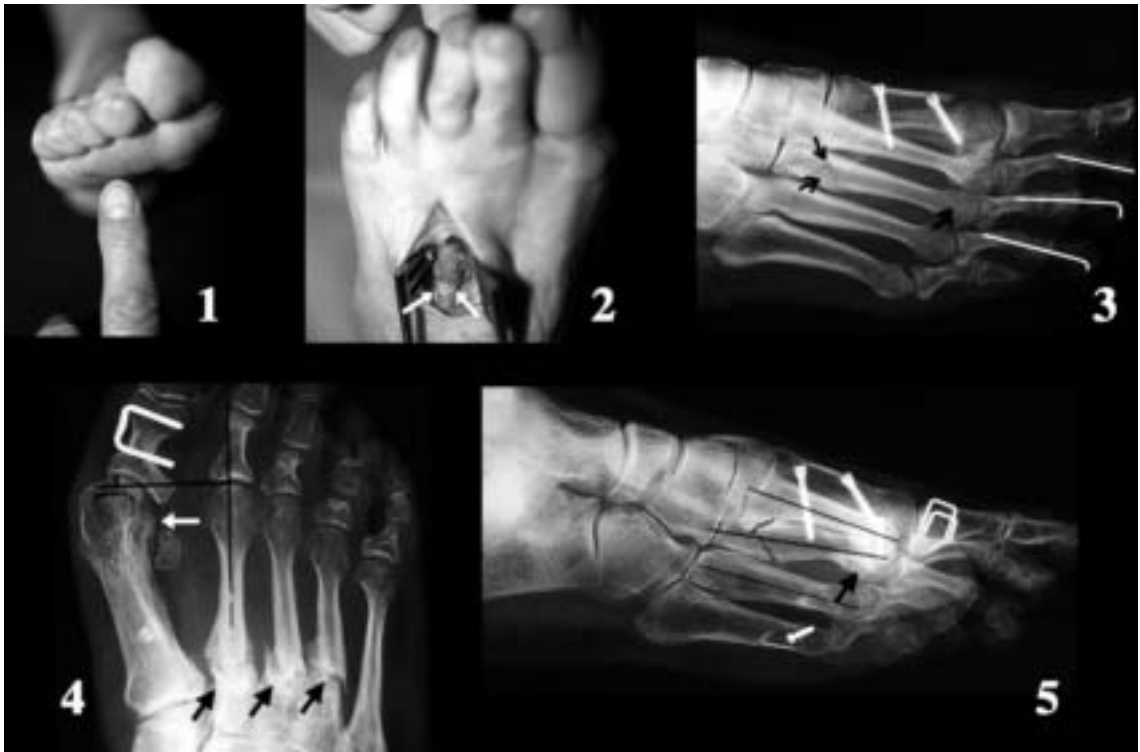**Fig. 30b2e. The Maceira “3 steps” Weil modified osteofied osteotomy.** Following the observations of Trnka and Myerson, E. Maceira performs this osteotomy which shorten the metatarsal without any head lowering. This is above all useful for mild to moderate deformities.

### Basal Metatarsal Chevron Osteotomy

We have performed this osteotomy for many years; we sometimes observed good results but in fact this osteotomy is unpredictable regarding the final elevation of the metatarsal and the healing is

sometimes not perfect, resulting in local problems such as shortening of the central metatarsals.

As a result of these difficulties, we devised the BRT osteotomy.



**Fig. 30b3. Metatarsalgia and metatarsal basal elevation osteotomy. (1) Chevron.**

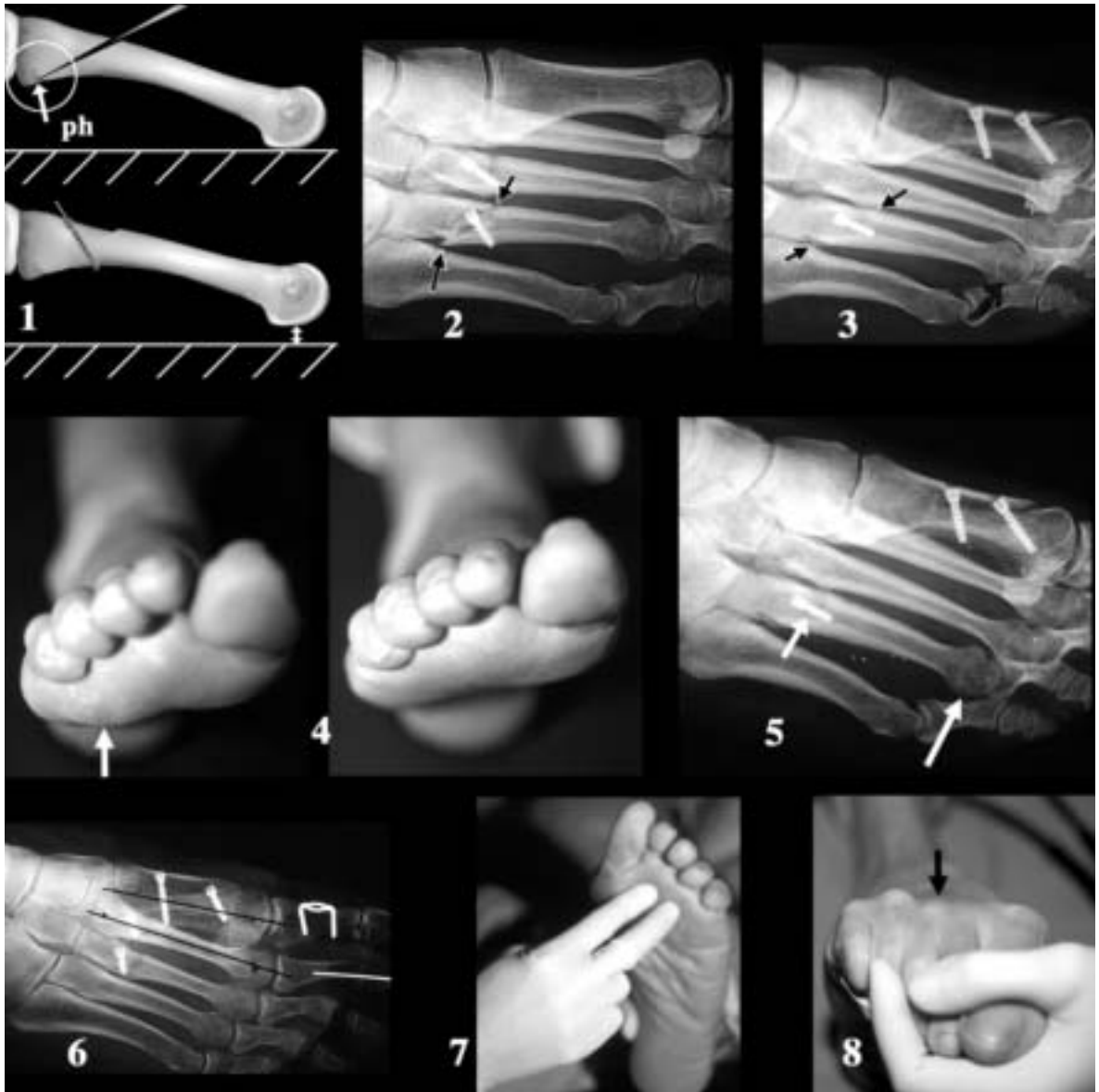1, 2. We performed this kind of osteotomy during many years, with sometimes appropriate elevation of the metatarsal (3), but also sometimes *healing problems*, with shortening of the lesser metatarsals, resulting in *increasing hallux valgus deformity*, and also unpredictable metatarsal elevation (5), resulting in *transfer metatarsalgia*. So we no longer perform this osteotomy, and we perform now in every case the BRT osteotomy when metatarsal elevation is required.

### The BRT Osteotomy

This osteotomy is almost exclusively consecrated to relieving metatarsalgia since it is a metatarsal elevation osteotomy. It is predictable and accurate. We don't observe any secondary displacement if the cut and the osteotomy are correctly performed. The only problem is to assess the

amount of elevation, mainly clinically or by the medial oblique X-rays view, but in fact the rule is not to elevate too much, not to provide transfer metatarsalgia.

For metatarsalgia in *pes cavus*, the BRT osteotomy is extremely effective and may be combined with a calcaneum osteotomy.



**Fig. 30b4. Metatarsalgia and metatarsal basal elevation osteotomy. (2) BRT osteotomy.**

1. The BRT osteotomy (Barouk, Rippstein, Toullec) is a long oblique proximal osteotomy, which preserves a proximal plantar hinge (ph), and which is firmly fixed by a compressive threaded-head screw (2.5 mm FRS screw).
2. The only problem is a too distal osteotomy with no preservation of the proximal hinge.
3. Correct osteotomy.
4. The main indication is a single metatarsalgia where the BRT provides excellent results.
5. Same foot: X-rays aspect.
6. BRT osteotomy may be combined with scarf osteotomy and with BRT osteotomy on other lesser metatarsals. However, the amount of metatarsal elevation is assessed above all clinically by palpation of the metatarsal head (7), or, when the foot is not too thick, by passive MTP plantar flexion (8).

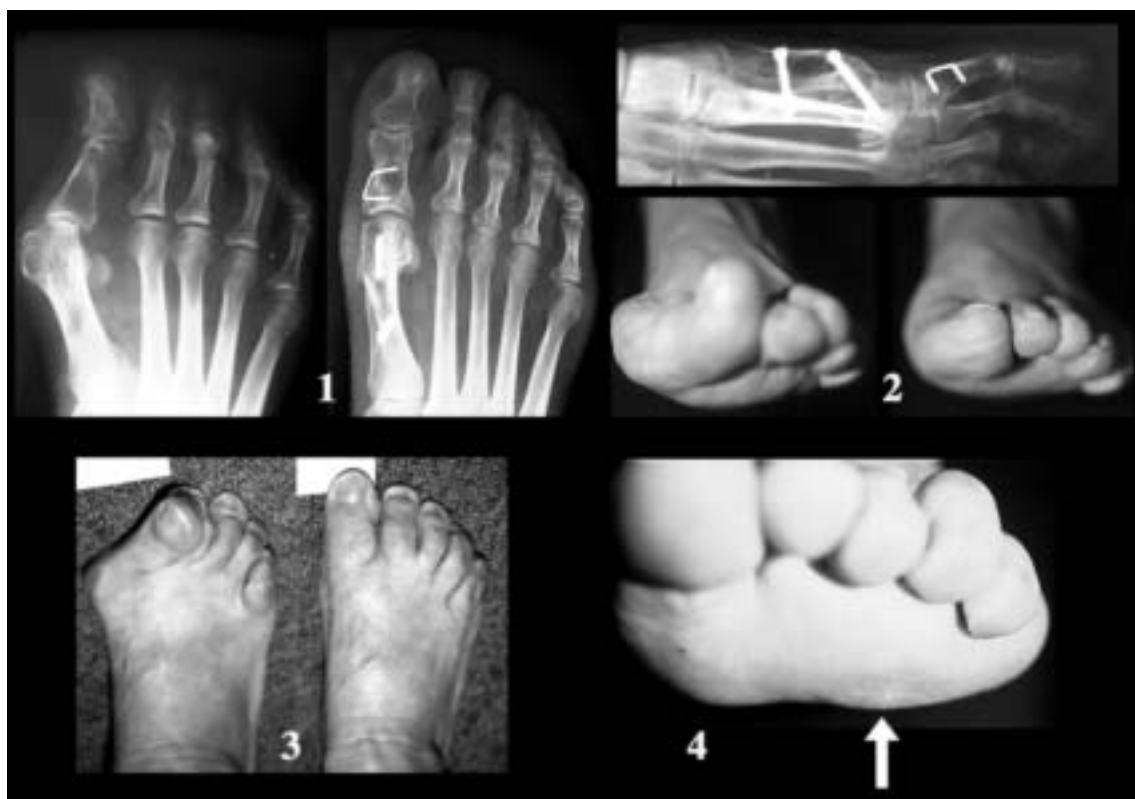
## Clinical Types of Metatarsalgia and their Treatments

### Hallux Valgus and Metatarsalgia

Reestablishing of an anatomically correct first ray with good function is critical for relieving metatarsalgia. The appropriate aspects of scarf

and great toe osteotomies regarding metatarsalgia are detailed.

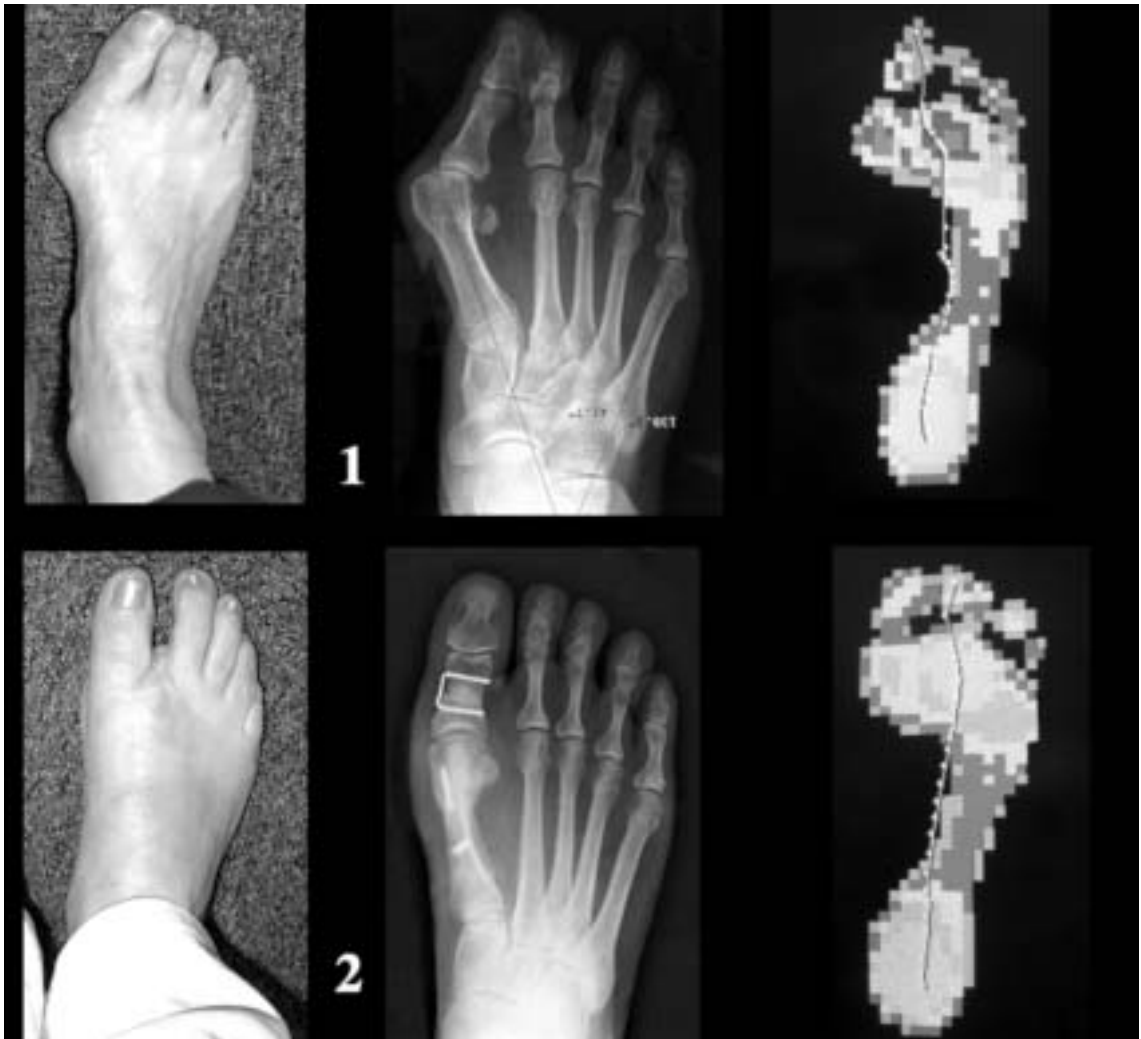The common problem of *second ray metatarsalgia* accompanying hallux valgus is studied with the different required solutions as well as central metatarsalgia with hallux valgus in severe disorders and overpressure on the first metatarsal head combined with hallux valgus deformity.



**Fig. 30c1a. Metatarsalgia and hallux valgus correction (1).**

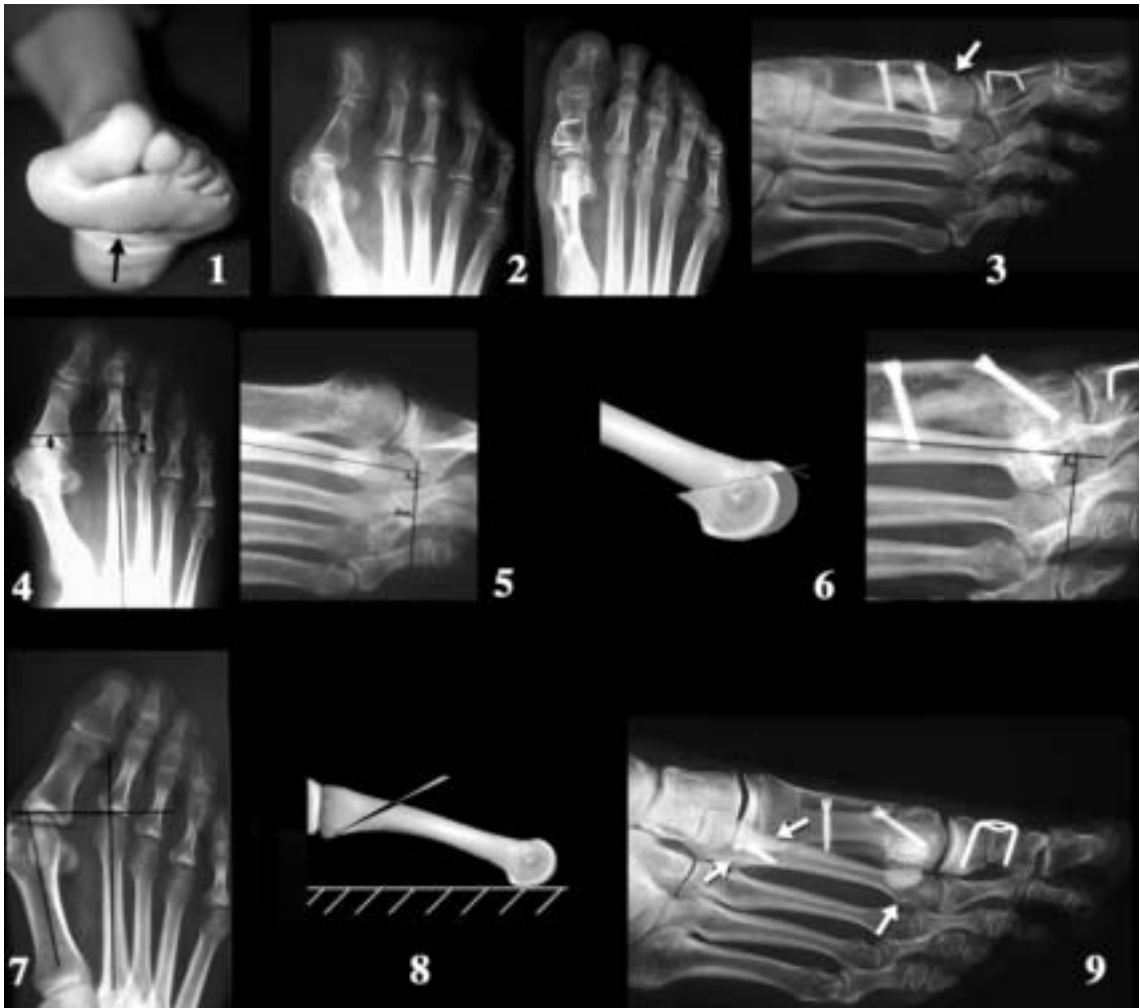
1. Hallux valgus correction with *scarf and great toe osteotomy* results in recovering the anatomy and the physiology of the first ray.
2. The scarf M1 osteotomy *lowers* the first metatarsal, for recovery of the correct forefoot distal transverse arch. This is suitable for mild or moderate metatarsalgia on the *second and third ray*. Furthermore, a correct great toe ground contact is recovered (3).
4. However, the scarf and great toe osteotomies are less effective for metatarsalgia on the *fourth ray*, which needs local surgery (principally BRT osteotomy).





**Fig. 30c1b. Metatarsalgia and hallux valgus correction (2).**

One example of central metatarsalgia relieved by scarf and great toe osteotomies (picture provided by E. Toullec, Bordeaux).



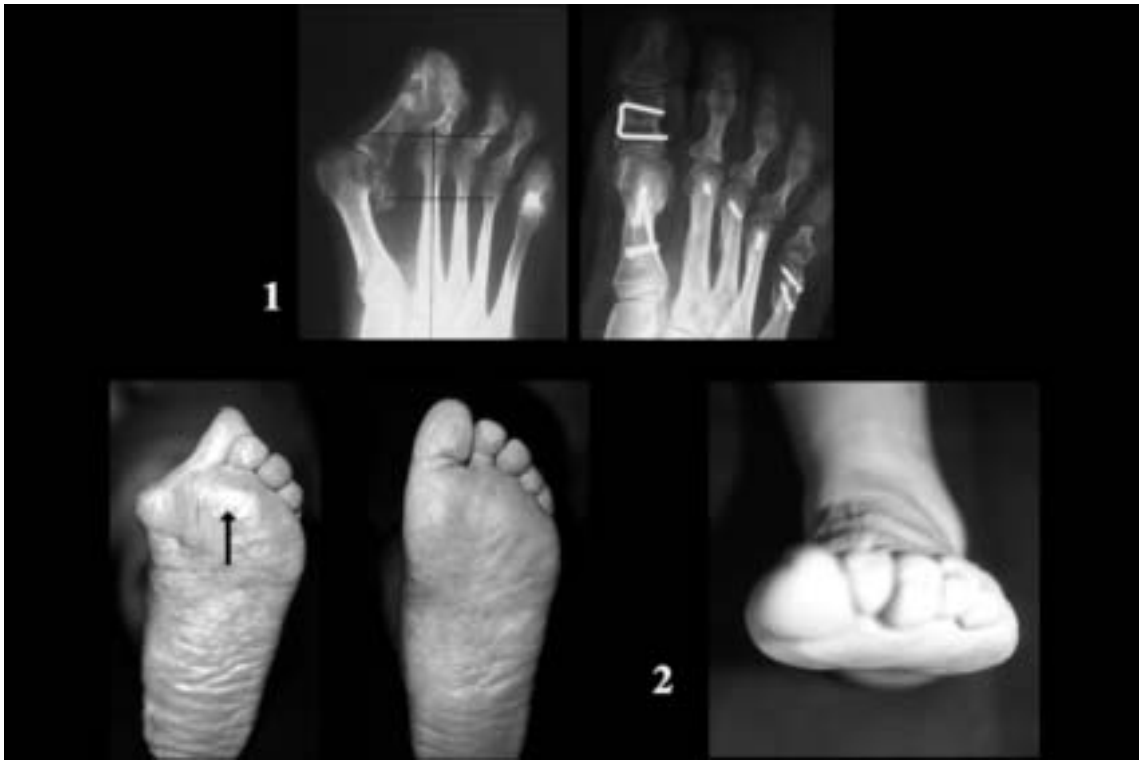**Fig. 30c1c. Metatarsalgia and hallux valgus correction. (3) Metatarsalgia on the second ray, a common problem.**

Three solutions for relieving second ray metatarsalgia associated with hallux valgus (1).

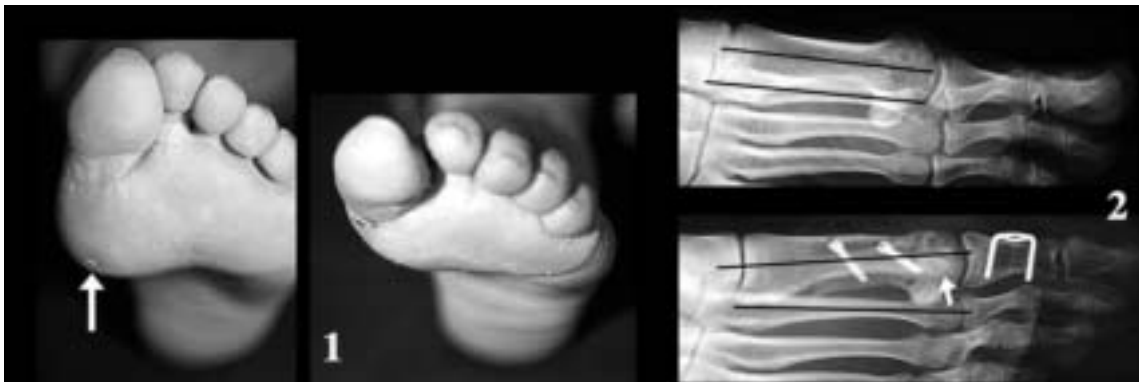**2, 3. Scarf lowering.** When it is possible to sufficiently lower the first metatarsal with the scarf osteotomy – *i.e.* when the intermetatarsal angle is large. Mild or moderate second ray metatarsalgia is regularly relieved.

**4, 5, 6. Weil osteotomy.** When the second metatarsal is too long, both on dorso-plantar (4) and in medial oblique X-ray view (5), the single second metatarsal Weil osteotomy is the good solution (6). Care has to be taken not to shorten too much, and also to perform a plantar directed cut in order to avoid transfer metatarsalgia on the third ray. Once again, the medial oblique view is helpful to assess the length relationships between the second and the third metatarsals (7).

**7, 8, 9. BRT osteotomy.** When intermetatarsal angle is not large, the possibility of lowering the first metatarsal head by scarf is decreased. When the second metatarsal is not too long, the Weil osteotomy is not indicated. The solution is then the BRT second metatarsal elevation osteotomy combined with hallux valgus correction (8, 9).



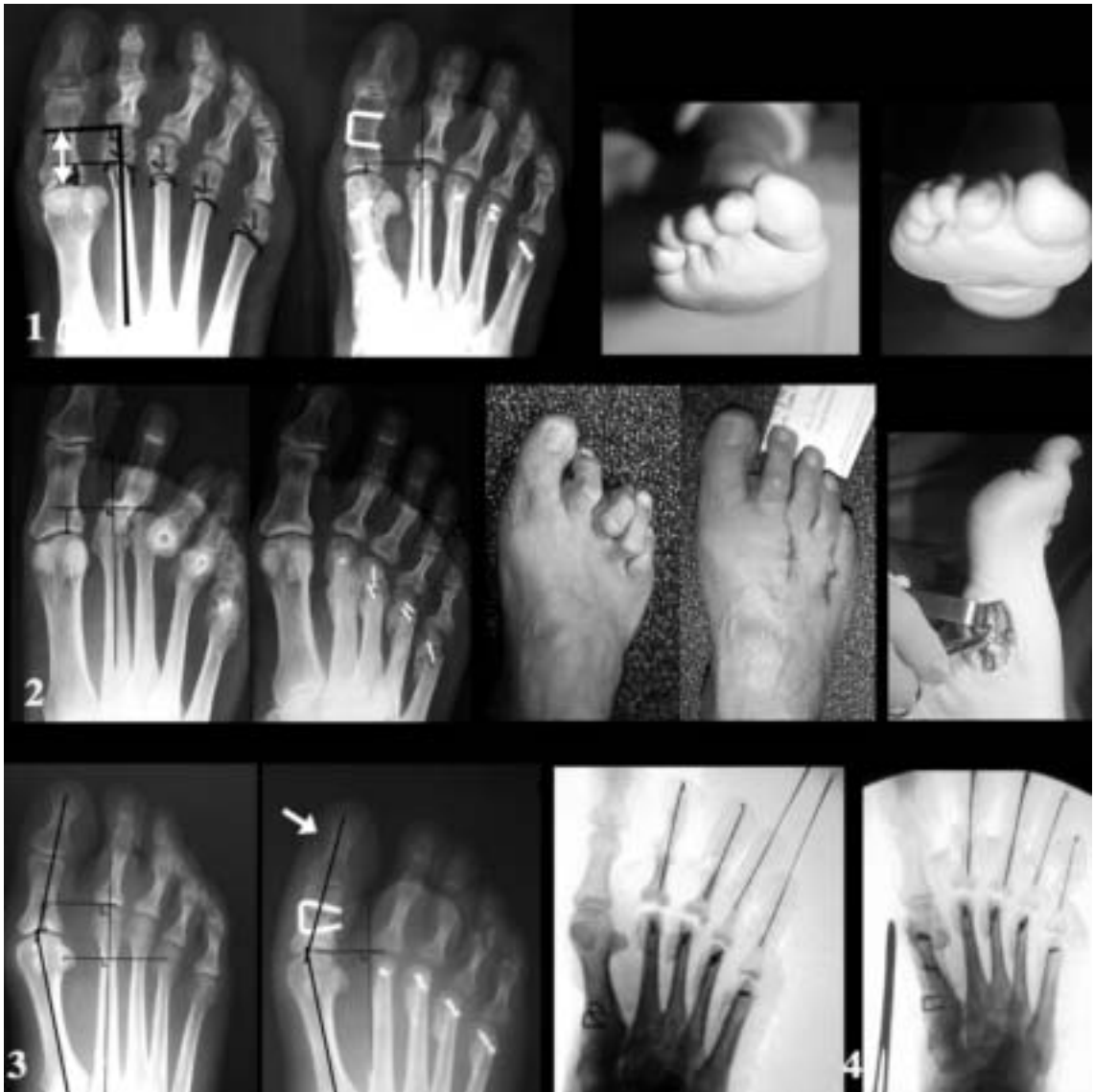**Fig. 30c1d. Metatarsalgia and hallux valgus correction. (4) Severe forefoot deformity.** Scarf, great toe and Weil osteotomies provide a regular and reliable solution for relieving metatarsalgia in severe forefoot disorders, thanks notably to *the large and harmonized shortening of the metatarsals*.



**Fig. 30c1e. Metatarsalgia and hallux valgus correction. (5) Overplantar pressure on the first metatarsal head.** If required, the first metatarsal elevation is provided by the scarf osteotomy. However the distal wedge may fragilize the lateral strut, needing to wear longer time type I heel support shoe.

*Solution for Metatarsalgia with Excessive Length of the Lesser Metatarsals*

The appropriate shortening by Weil osteotomy has to be performed, taking care not to increase or to result in hallux valgus deformity, as well as not to result in claw toe (“syndrome de l’attelage”).

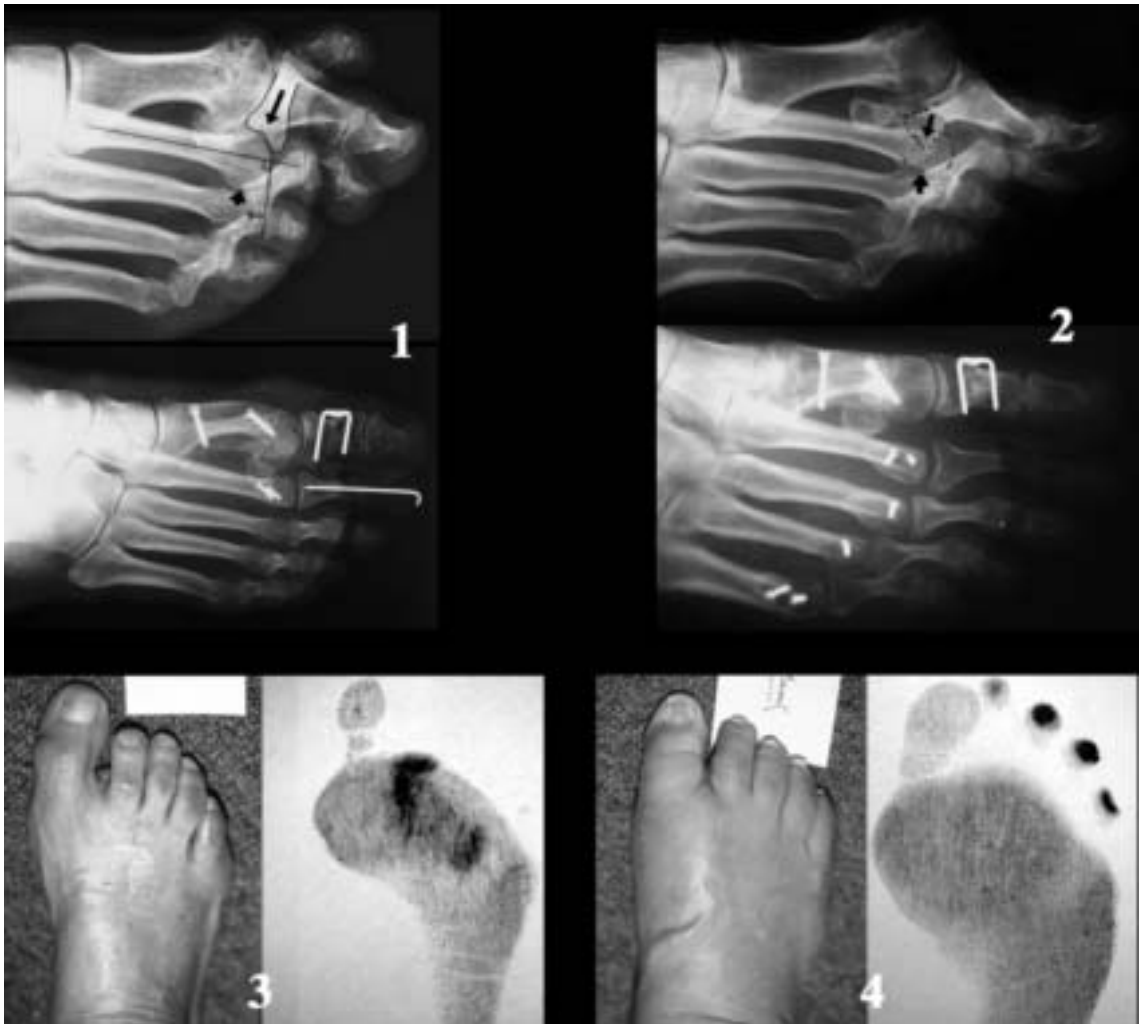

**Fig. 30c2. Metatarsalgia by excess of lesser metatarsal length: The Weil osteotomy.**

1. Radiographic and clinical aspects, preoperative and at one year follow-up.
2. Another case. Metatarsalgia is principally relieved by shortening the metatarsals, but also by correcting the claw toe (Weil osteotomy and toe K-wiring). If necessary section on the reticulanum between the first two flexor tendons.
- 3, 4. Care has to be taken not to increase or to create a hallux valgus deformity (3), which should occur after only lesser metatarsal shortening, so that we have to correct this first ray deformity at the same time that Weil osteotomy on the lesser rays (4).

*Solutions for the Correction of Vertical Position of the First Phalanx and Recovery of a Correct Ground Contact*

This is critical for relieving metatarsalgia.



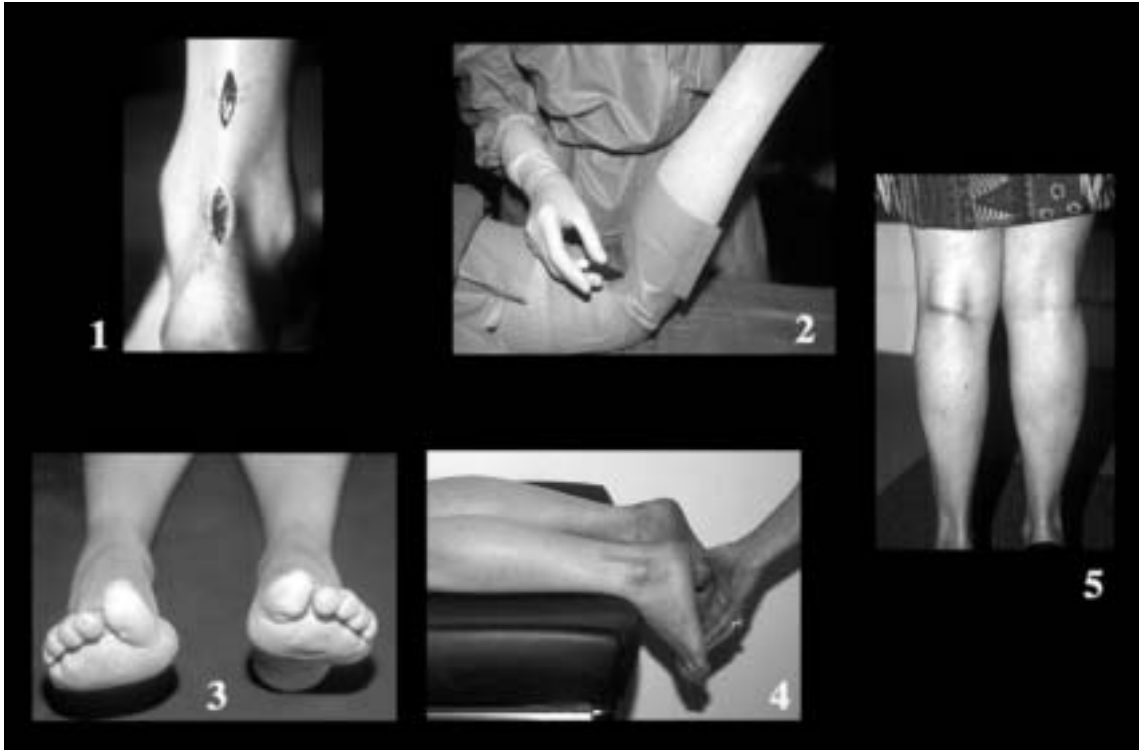
**Fig. 30c3.** Correction of the vertical position of the first phalanx and recovery of a correct toe ground contact.

1. Correction by Weil osteotomy and toe K-wiring after soft tissue procedures.
2. In MTP dislocation, the generous proximal translation of the metatarsal head ensures the correction, as well as, in most cases shortening of the five metatarsals.
3. No toe ground contact increases or causes the metatarsalgia.
4. The recovery of the toe ground contact is helpful for relieving metatarsalgia.

*Equinism Correction*

Overload on the forefoot was not enough taken in consideration in forefoot surgery, notably for the metatarsalgia surgery. Once

again we emphasize the significant results observed when, in addition to forefoot surgery, we correct the equinism, notably by the harmless Gastrocnemius Proximal Release, when it is indicated.



**Fig. 30c4. Equinism correction for metatarsalgia relief.**

1. Achilles tendon lengthening is easy to perform but the consequences are heavy: Long postoperative rehabilitation and at last decreasing of the calf strength.

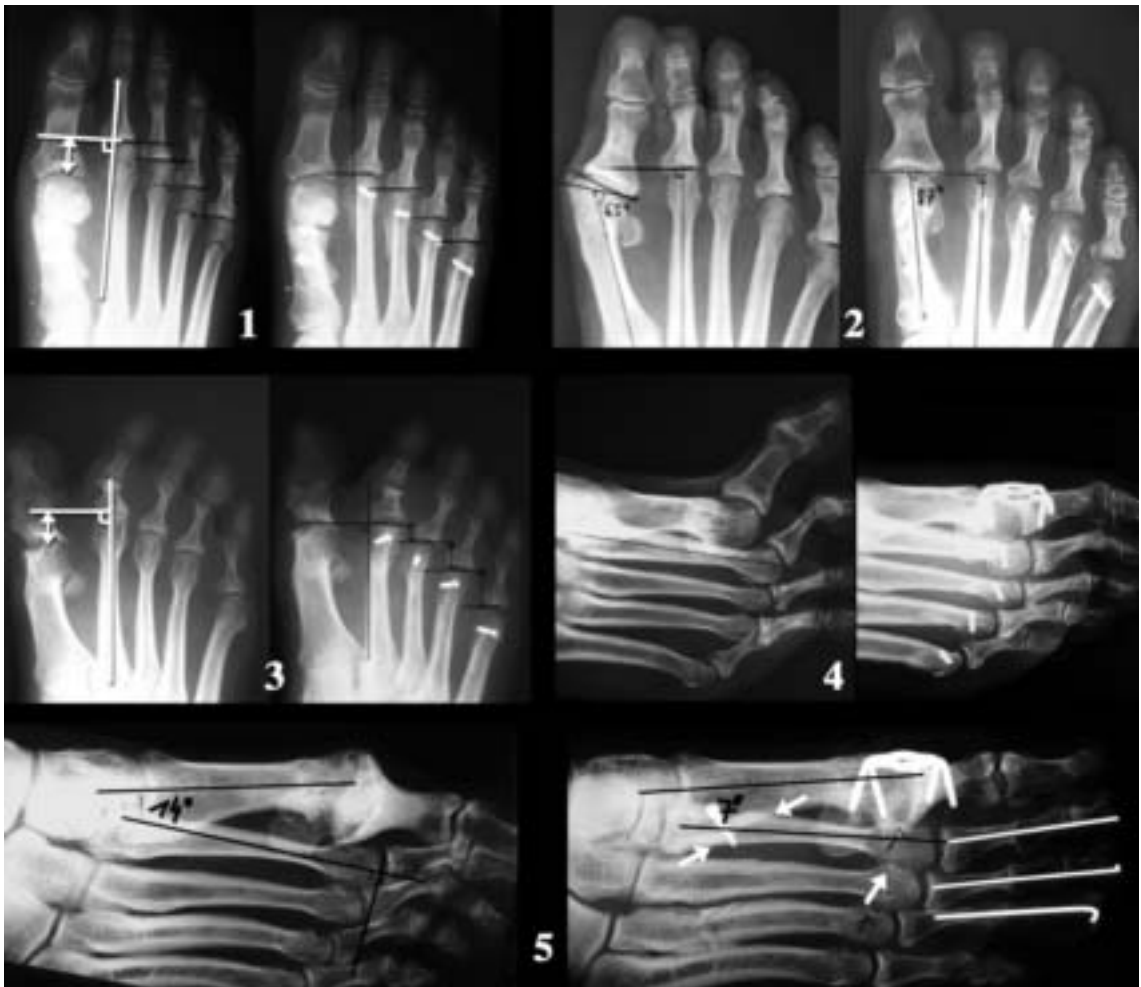
2, 5. The gastrocnemius proximal release (GPR), when it is indicated, is extremely harmless, reliable and does not decrease the triceps strength; the GPR is very helpful for decreasing the load pressure on the forefoot and is more reliable whatever the forefoot surgery performed.

3, 4, 5. In this case, GPR is performed on the left foot.

*Iatrogenic Metatarsalgia*

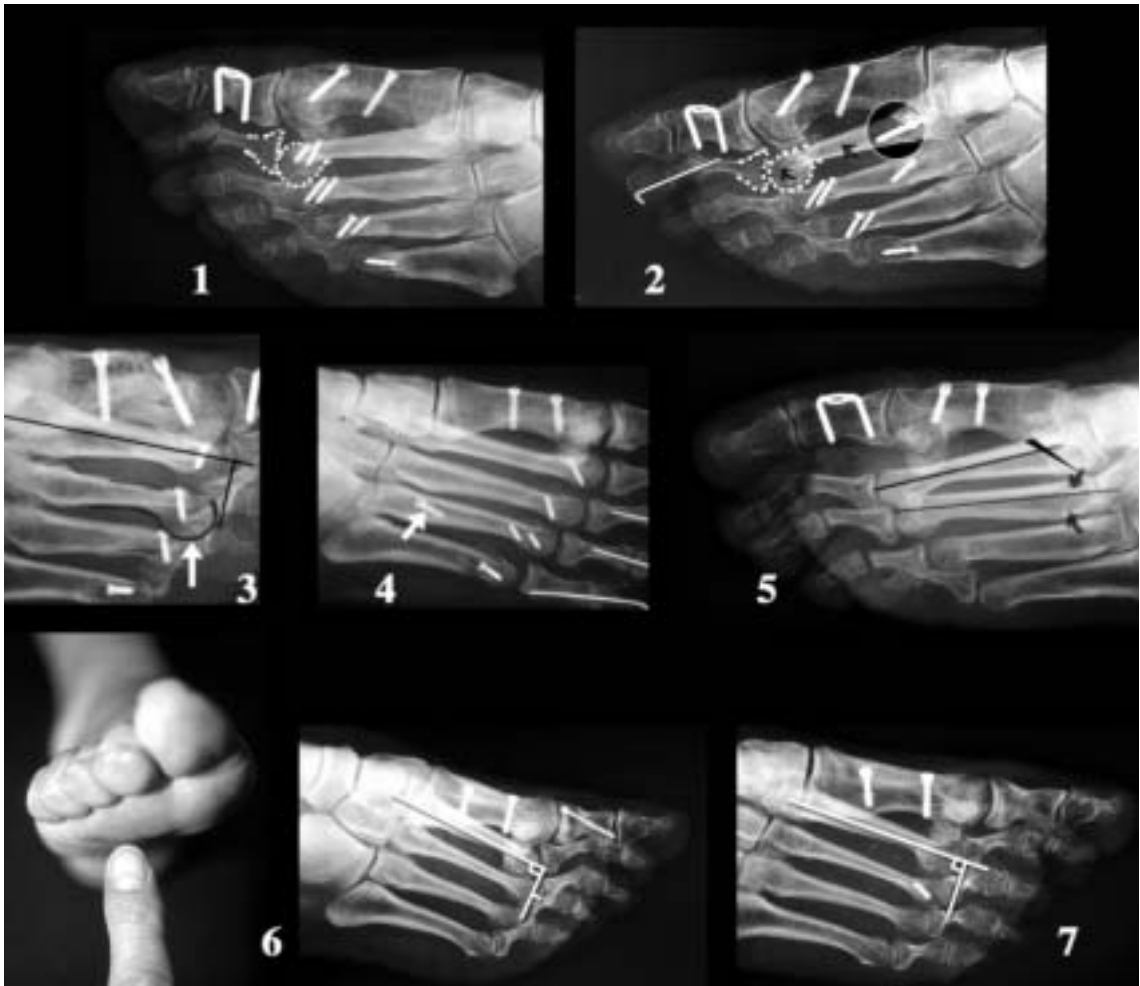
This problem can also be treated by surgery, the insoles being in our practice either temporary or reserved to the rare contraindications of surgery (notably very old patients).

We distinguish iatrogenic metatarsalgia in failed bunionectomy and in failed surgery of the lesser metatarsals.



**Fig. 30c5a. Iatrogenic metatarsalgia. (1) In failed bunionectomy.**

1. M1 shortening after secondary stress fracture two months after a scarf osteotomy. Correction by Weil osteotomy of the lesser metatarsals.
2. Functional and anatomical insufficiency of the first ray in a failed bunionectomy: Weil osteotomy in lesser metatarsals combined with a first metatarsal scarf osteotomy.
3. Insufficiency of the first ray after Keller procedure: Weil osteotomy on the lesser rays.
4. Overcorrection and rigid dorsal flexion of the MTP joint after Petersen procedure: First MTP fusion and lesser metatarsals Weil osteotomy.
5. Isolated second ray metatarsalgia after Keller procedure: First MTP fusion and BRT second metatarsal osteotomy.



**Fig. 30c5b. Iatrogenic metatarsalgia. (2) In failed surgery of the lesser metatarsals.**

1, 2. Remaining subluxation of the second MTP joint, with plantar prominence of the metatarsal head: Revision by BRT metatarsal elevation combined with MTP release.

3. Plantar prominence of the third metatarsal head: Indication for BRT osteotomy more than for condylectomy.

4. BRT osteotomy for recurrent metatarsalgia on the fourth ray.

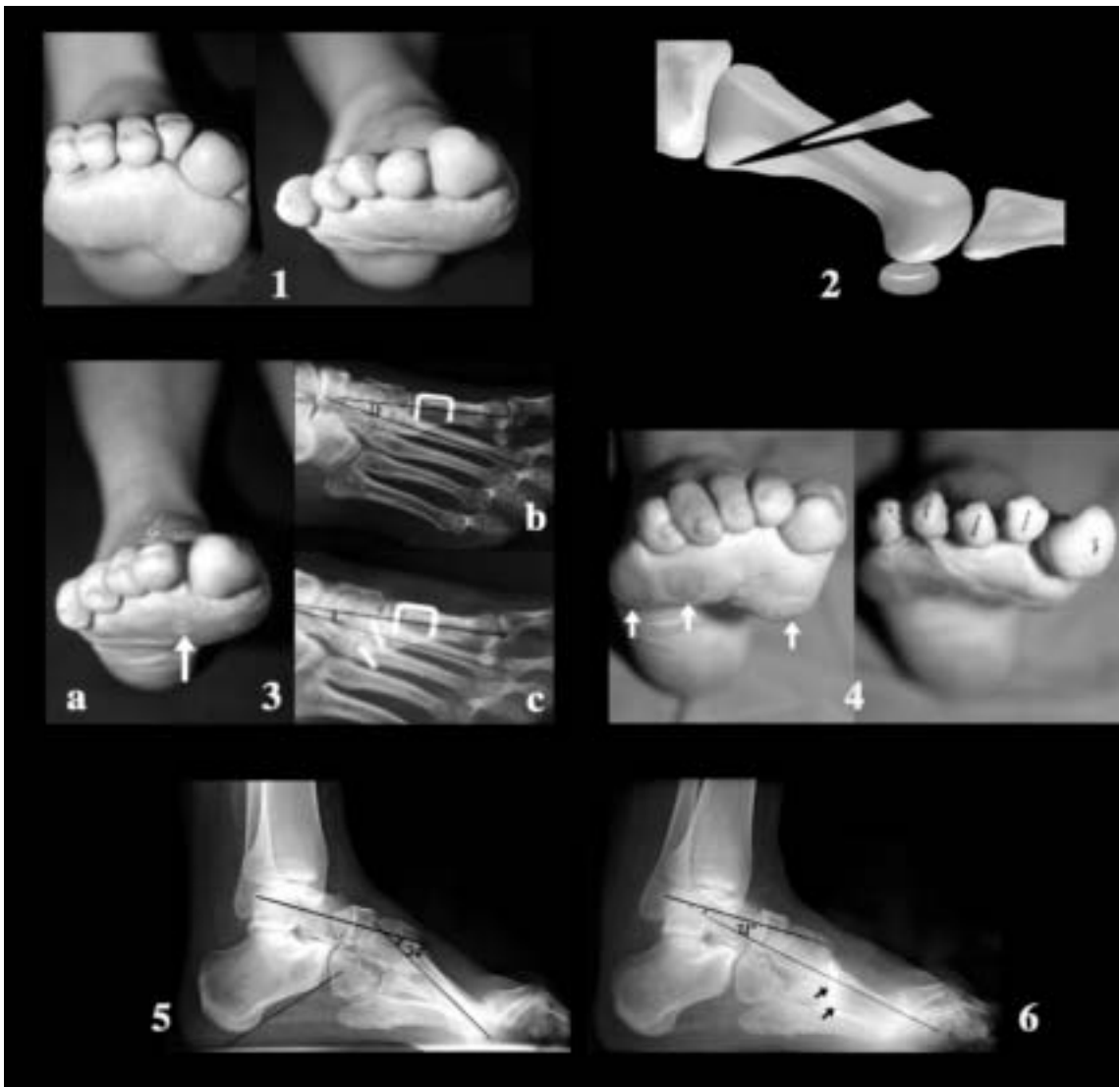5. Basal chevron osteotomy on the third metatarsal: Too much elevation; indication of BRT osteotomy on the second ray for relieving the transfer metatarsalgia.

6. A too long third metatarsal in medial oblique view after single Weil osteotomy on the second ray. Secondary Weil osteotomy on the third ray (7).

### *Metatarsalgia and Pes Cavus*

The patient complaints concerning forefoot are generally metatarsalgia and claw toe, much more observed than problems of dorsal apex of the deformity.





**Fig. 30c6. Metatarsalgia in *pes cavus*. Decreasing the plantar slope of the metatarsals.**

1, 2. BRT osteotomy is suitable to elevate as far as necessary the first metatarsal, decreasing the forefoot pronation as required (thus the hindfoot supination).

3a. However in some cases elevating only the first metatarsal results in metatarsalgia in the lesser metatarsals, needing secondary elevation (3b), so that we now performed the BRT osteotomy on several metatarsals if required (3c).

4. Of course, metatarsalgia in *pes cavus* also results from the claw toe; so we make this correction in the same time as the BRT osteotomy (generally soft tissue procedure and toes K-wiring).

5. Pre and postoperative standing X-ray.

These procedures are often performed in contribution with the correction of equinism.

### Conclusion

The causes of metatarsalgia cannot be resumed to a disharmony of the metatarsal relative length, or to a first ray insufficiency; in fact, a complete clinical and radiological examination allows to determine the causes, in which several factors may be combined.

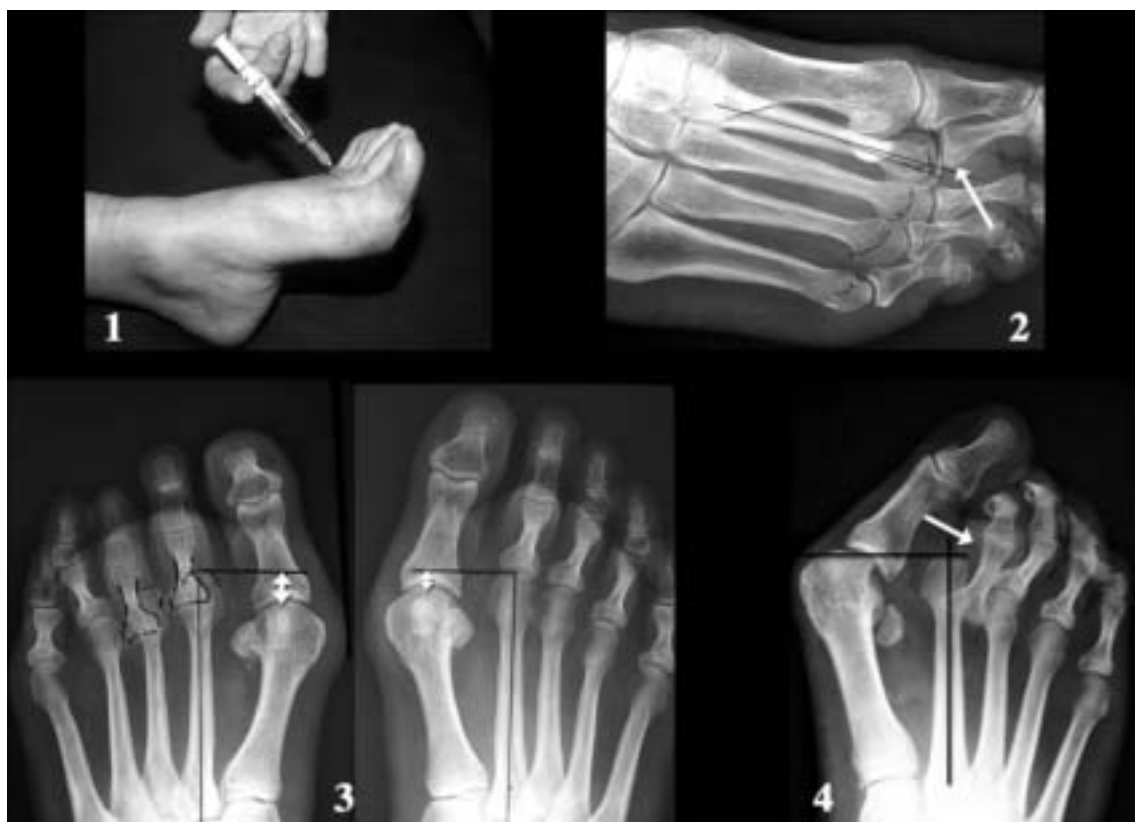This analysis allows to apply the appropriate surgical solution: We think that there is a very small place for insole (apart temporary) for relieving metatarsalgia, since we now have reliable surgical procedures to treat this problem entirely.

## MTP Joint Dislocation of the Lesser Rays

First, we studied the *main causes* of dislocation, then the *principles of surgical correction*. The *technique* of correction is important: We observe that the **Weil osteotomy** is a great improvement in the correction of the MTP dislocation but on the condition to perform a large proximal sliding of the metatarsal head. The *ms point* is critical to

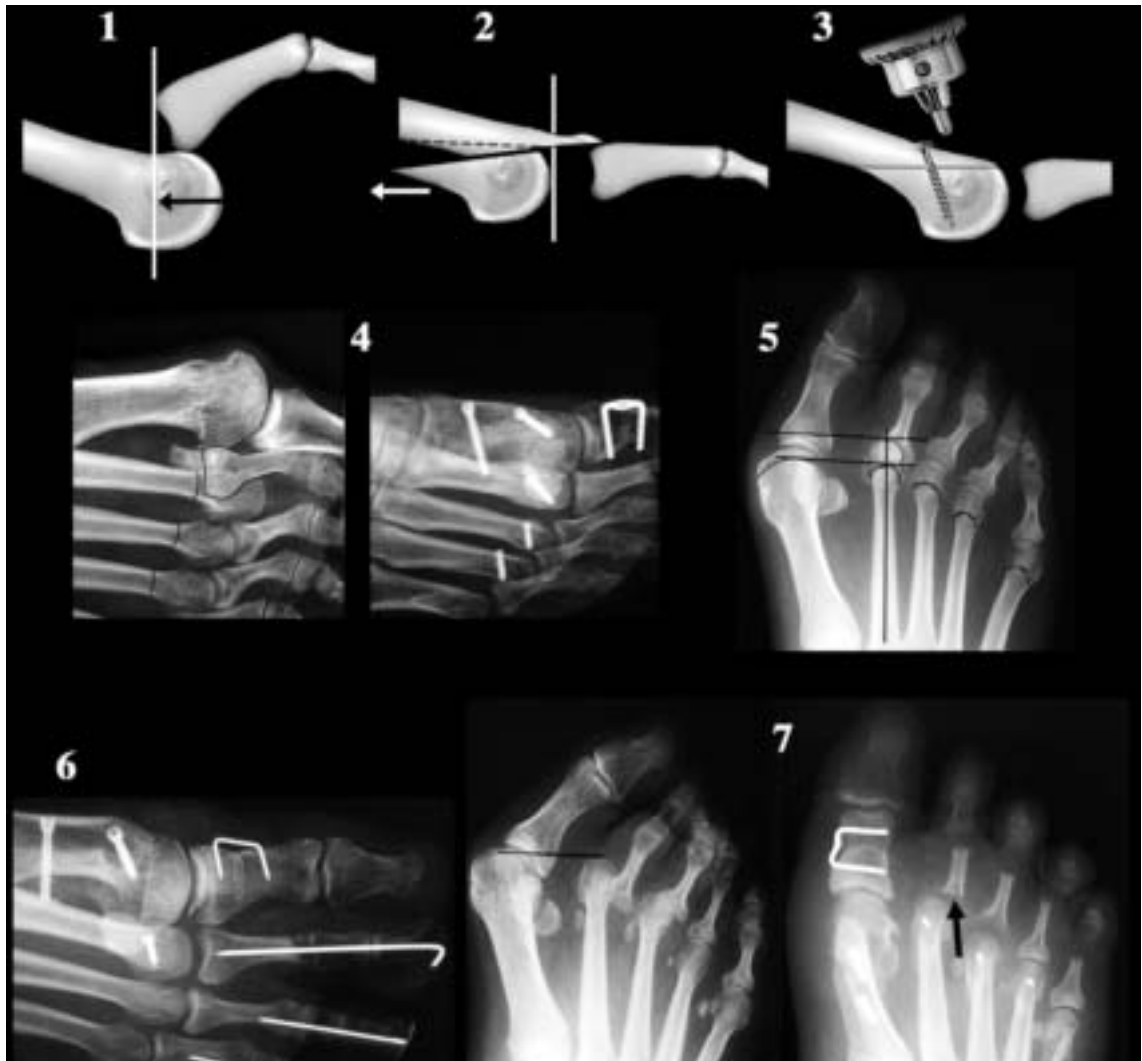
assess the amount of the metatarsal shortening. The adjacent metatarsals, as well as the whole metatarsal parabola, have to be taken into account. For completing the correction, the Girdlerstone-Taylor procedure may be helpful, as emphasized by P. Rippstein [103]. This procedure is certainly more effective than the difficult and unpredictable suture of the plantar plate.

Many authors emphasize the reliability and effectiveness of the Weil osteotomy in the correction of MTP dislocation, recently, Hart (66), Jarde (69), Okane (92), Melamed (85), Podsknba (95), Trnka (122), Vandeputte (124).



**Fig. 31a.** MTP dislocation – Some causes.

1. Corticoid injection certainly provides MTP dislocation (as emphasized by W. Benton-Weil, Chicago), above all when there is already a predislocation stage with anatomic conditions which promote the dislocation.
2. 3. Excess of lesser metatarsal length.
4. Hallux valgus deformity (above all for the second MTP joint).



**Fig. 31b1. MTP dislocation – Principles of surgical correction.**

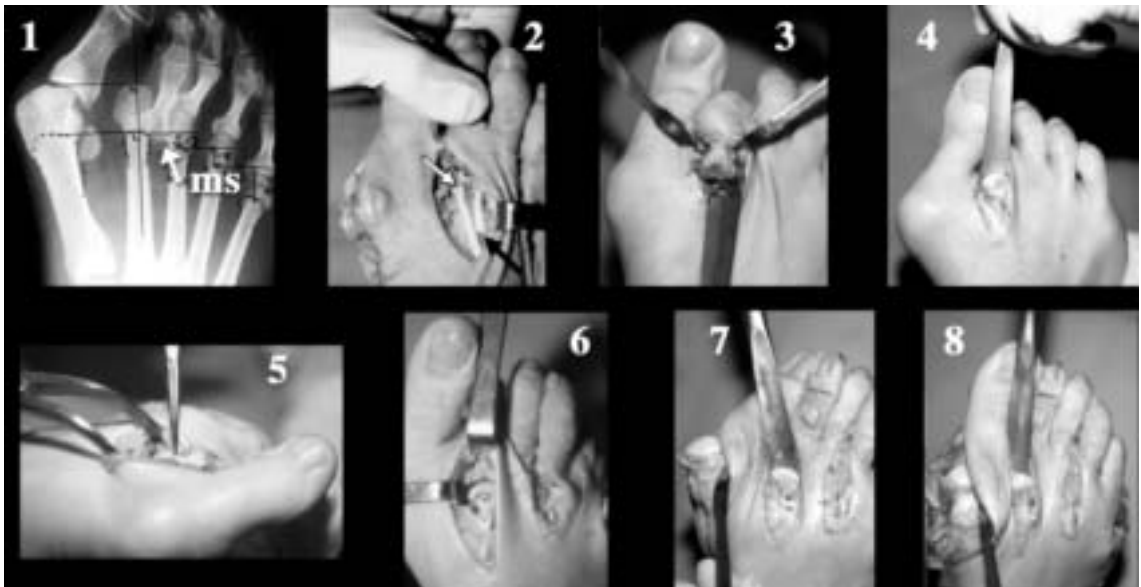
1, 2, 3. The best solution is the Weil osteotomy on the condition to have a large shortening (1 or 2 mm more than the phalanx overriding).

4. The head proximal translation is accurately assessed in the medial oblique view, above all when overriding is not large.

5. The corresponding shortening of the *first metatarsal* has to be assessed on the dorso-plantar view.

6. Toe K-wiring has to be made in most cases. This avoids PIP fusion, preserves as far as possible the first length and the foot elegance (long toes).

7. The resection of the proximal phalanx is not a good solution.



**Fig. 31b2. MTP dislocation – Technique 1.**

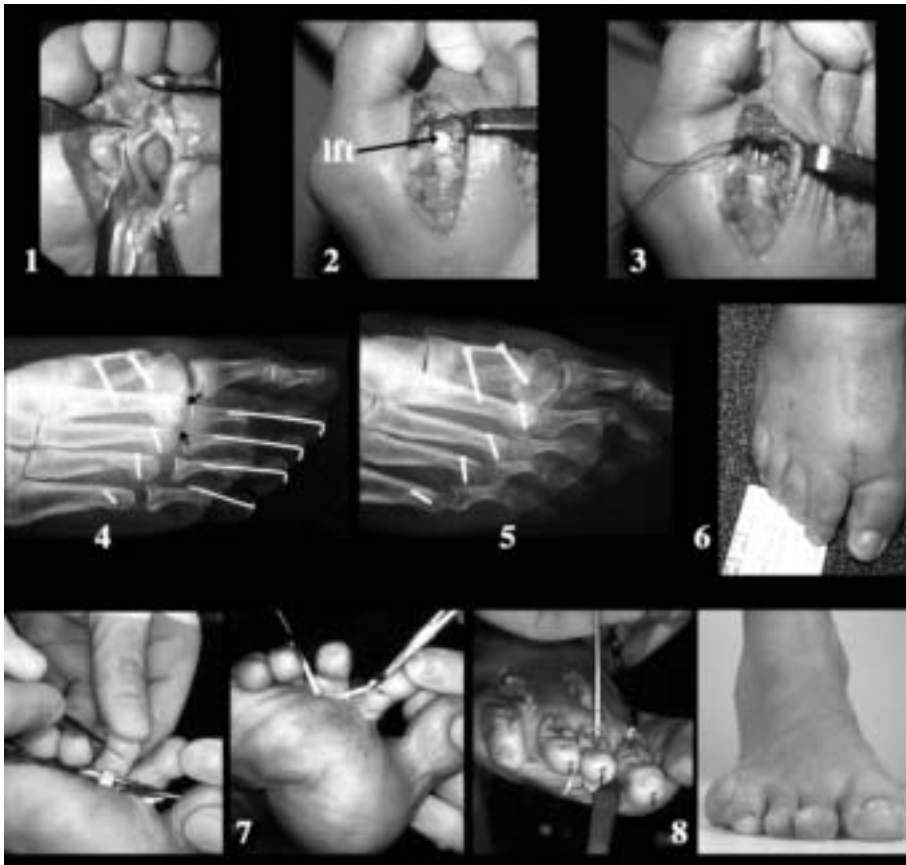1. In this case the proximal translation has to be important, so that it can be assessed on the dorso-plantar X-ray view (ms point).

2. MTP joint approach: Distal section of the long extensor tendon, proximal section of the extensor brevis tendon.

3, 4. Correction of MTP dislocation by soft tissue procedure and at last by the “ciseau de Cauchoix”, with its smoothed end.

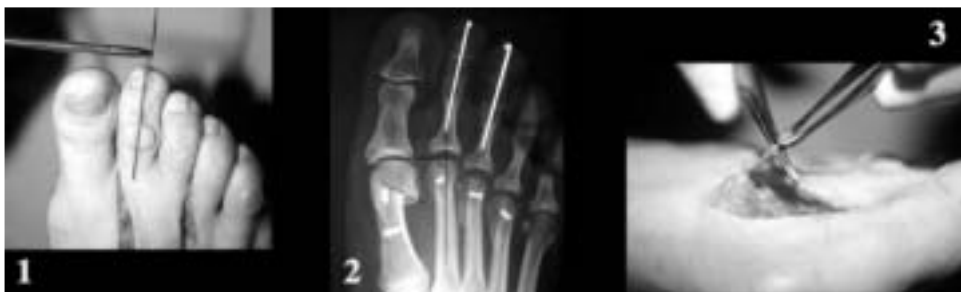5, 6. We pointed out the overriding point on the dorsal aspect of the metatarsal, but *the real proximal translation of the head is spontaneous*, as far as the base of the phalanx is well located without any tension.

7, 8. The first metatarsal shortening is performed to obtain equality of the two first metatarsal lengths.



**Fig. 31b3.** MTP dislocation – *Technique 2.* Reparation of the *plantar plate* rupture and Girdlerstone-Taylor's procedure.

1. A specimen view showing this rupture (picture communicated by Pr J. P. Delagoutte, Nancy).
2. Dorsal view of the rupture (the flexor tendons are visible in the bottom ) (lft).
3. The *suture of the plantar plate* is often difficult, and is to make preferably before the metatarsal head fixation.
4. Immediate postoperative view after correction of dislocation and plantar plate suture.
- 5, 6. Postoperative aspect at the 3rd month.
- 7, 8. Another solution is the *Girdlerstone-Taylor procedure* (picture provided by P. Rippstein, Zurich) which provides the correction of the remaining dislocation. It is certainly a good solution, *but it cannot avoid the Weil osteotomy*, and it may be avoided by a large proximal sliding of the metatarsal head.

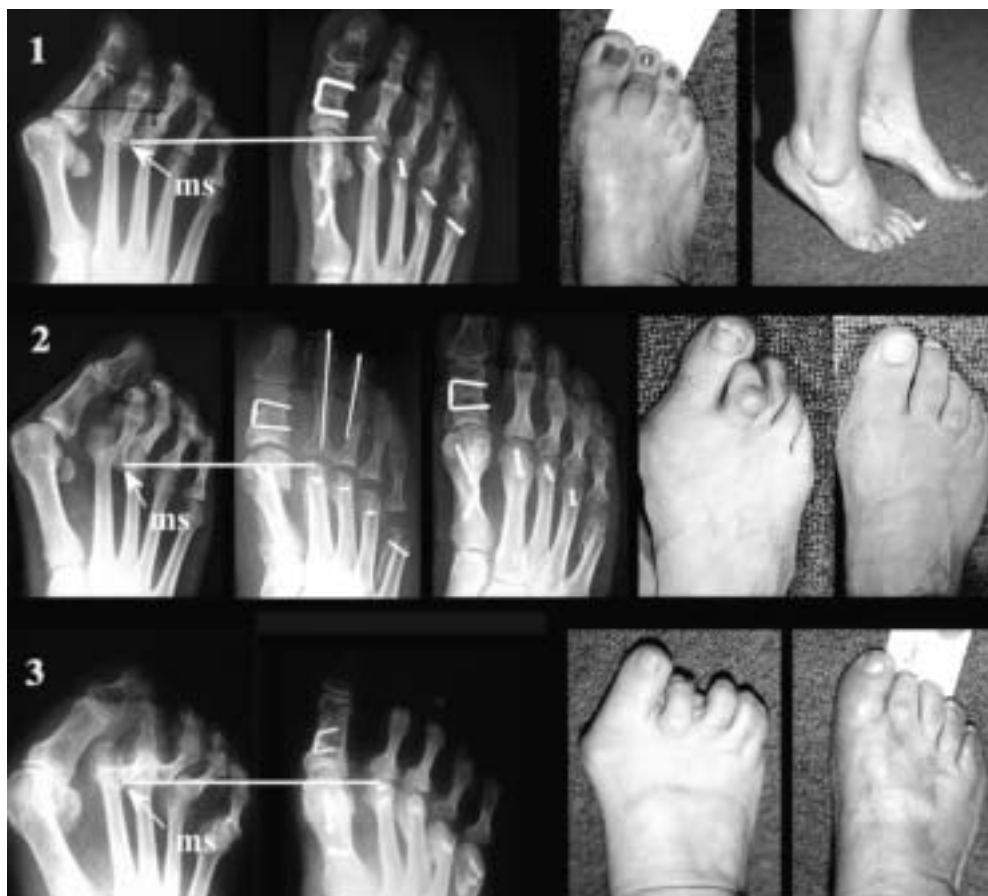

**Fig. 31b4.** MTP dislocation – *Technique 3.*

- 1, 2. The toe K-wiring allows the toe joints preservation.
3. Suture of the long and brevis extensor tendons with the pulver taff procedure.

The results clearly show that only a sufficient proximal sliding of the metatarsal head (ms point), combined with the respect of the metatarsal parabola, makes reliable the correction of the dislocation; this is shown both

in dorso-plantar and in the medial oblique view. The problem of remaining subluxation after surgery is mentioned as well as the problem of MTP subluxation observed in the first time.

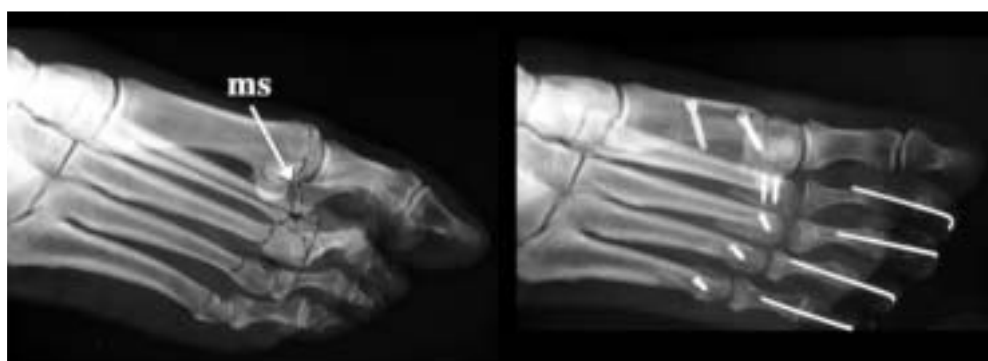

**Fig. 31c1. MTP dislocation – Results 1. On dorso-plantar X-rays view.**

1. Same foot: Clinical and radiological results (one year follow-up).

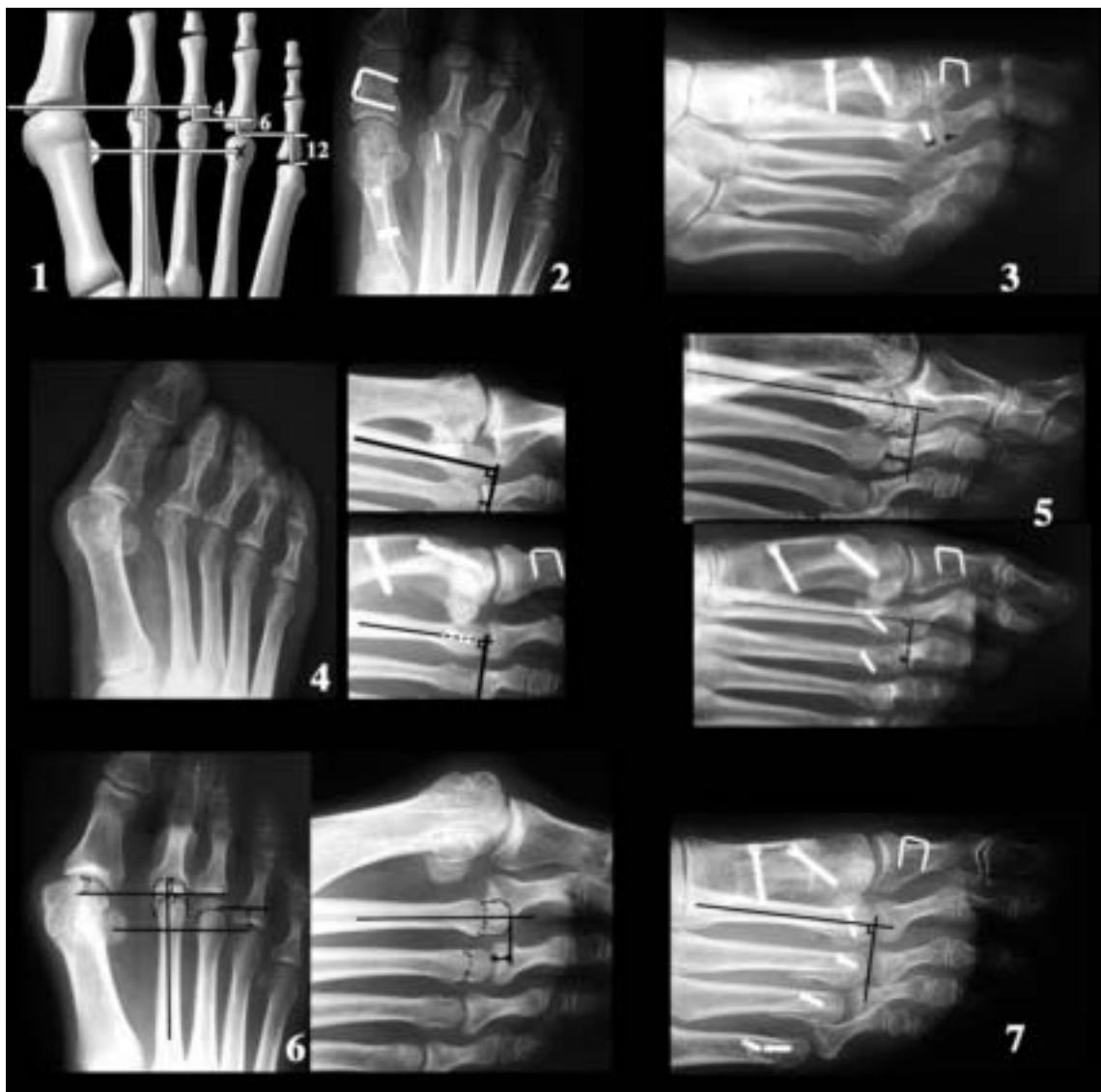2. Same foot that in Fig. 30 b2: Note the correction of both the MTP dislocation and the hammertoe deformity with articular preservation of the MTP and toe joints. Metatarsal shortening: up to the *ms point*, located on the basis of the proximal phalux

3. Another case before and one year after articular preservative surgery. So the Weil osteotomy with additional K-wiring is an extremely reliable solution for MTP dislocation.



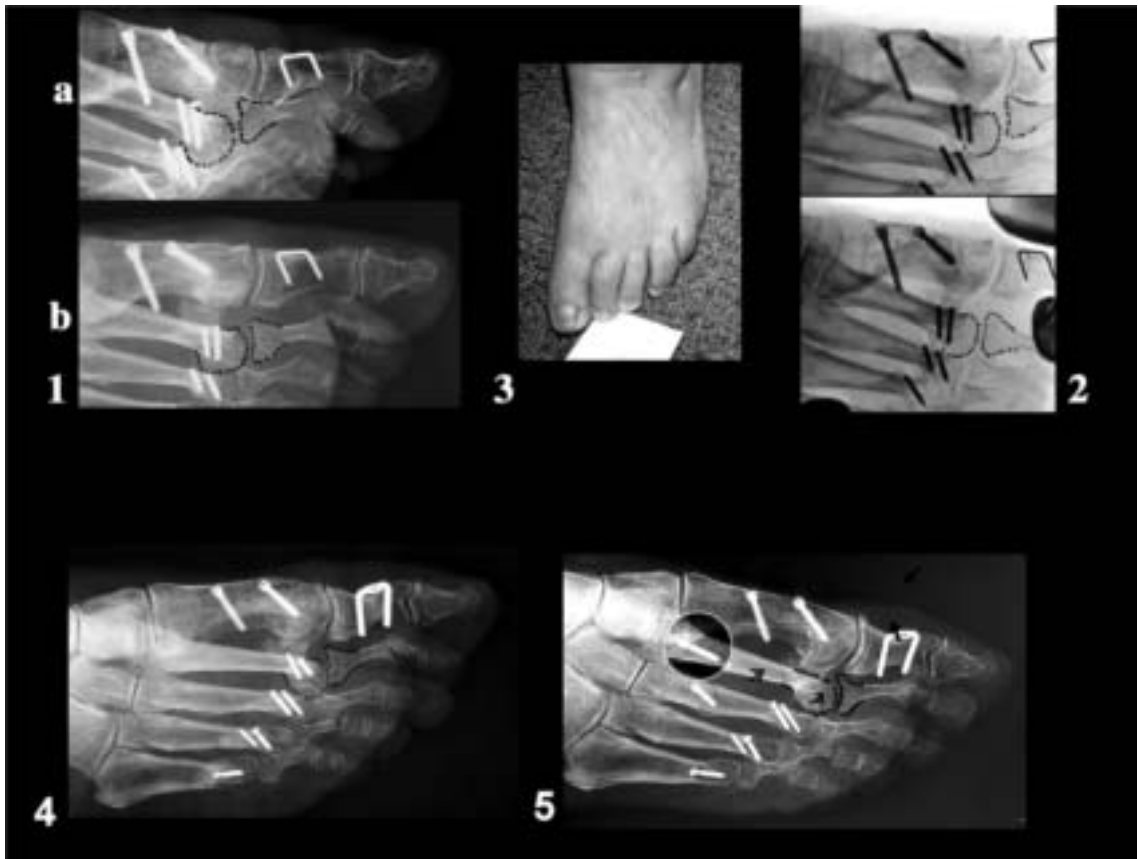**Fig. 31c2. MTP dislocation – Results 2. On medial oblique view.**

Note the required metatarsal shortening, assessed by the *ms point*.



**Fig. 31c3.** MTP dislocation – *The correct amount of the metatarsal head proximal translation by the Weil osteotomy.*

1. The amount of metatarsal shortening on the *dorso-plantar X-ray*: As a rule, we have to follow this metatarsal curve.
2. *Single Weil osteotomy on the second ray*: Insufficient correction of the MTP subluxation results in a too long third metatarsal.
3. The *medial oblique view* clearly shows that in this case, *single Weil osteotomy* was performed without enough proximal translation: Stiffness and pain on the MTP joint.
4. In this case, the second metatarsal was really too long both on the dorso-plantar and on the medial oblique views, so that a *single second metatarsal Weil osteotomy* can respect the metatarsal curve.
5. In this case, Weil osteotomy was necessary *in the second and the third metatarsals*: It is more frequent.
- 6, 7. Same foot: Pre and postoperative aspect. *Shortening of the four lesser metatarsals*: It is the usual surgery we have to do in case of MTP dislocation.

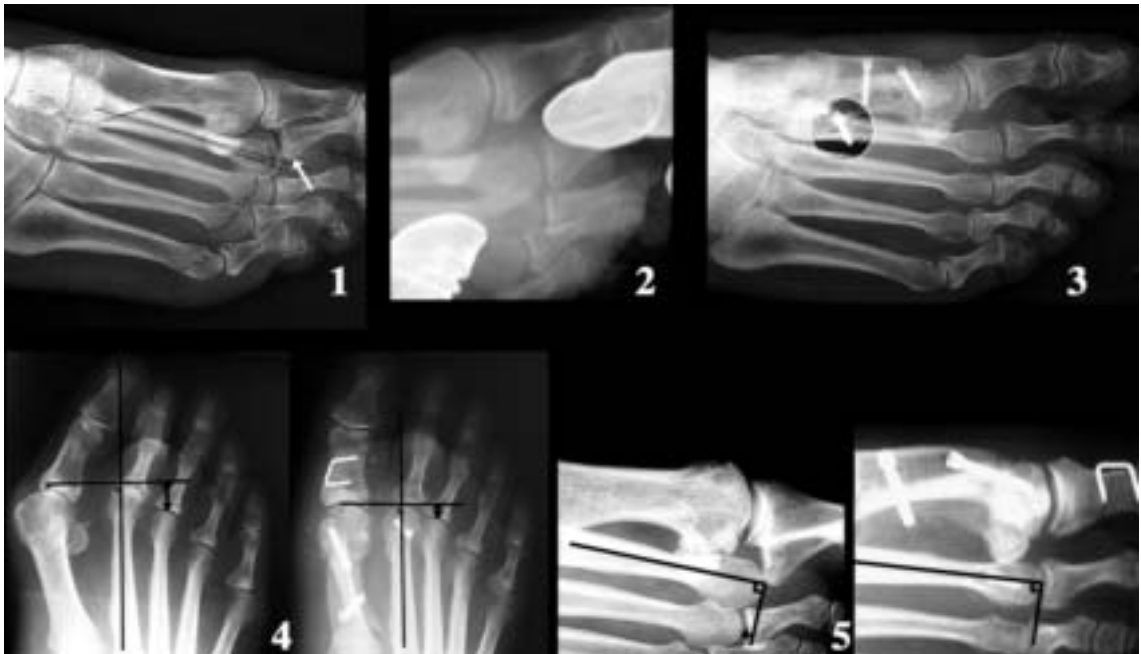


**Fig. 31c4. MTP dislocation – The remaining MTP subluxation after Weil osteotomy.**

1. Without suturing the plantar plate, or without the Girdlestone-Taylor procedure, we sometimes observed MTP incongruence (a), which nevertheless usually decreased with longer follow-up (b).
2. A more detailed test shows the correctibility of this incongruence.
3. This incongruence was generally painless and a slight ground contact of the toe is observed.
- 4-5. When this remaining subluxation is not tolerated, we can make a revision with MTP release and BRT osteotomy on the corresponding metatarsal, sometimes combined with the Girdlestone-Taylor procedure.

*A good way to avoid such remaining subluxation is a large proximal sliding of the metatarsal head. The best way to avoid such remaining subluxation is a large proximal sliding of the metatarsal head.*





**Fig. 31d.** MTP subluxation – *The two recommended procedures.*

1. In emerging deformity, the *BRT osteotomy* may be performed with good results.

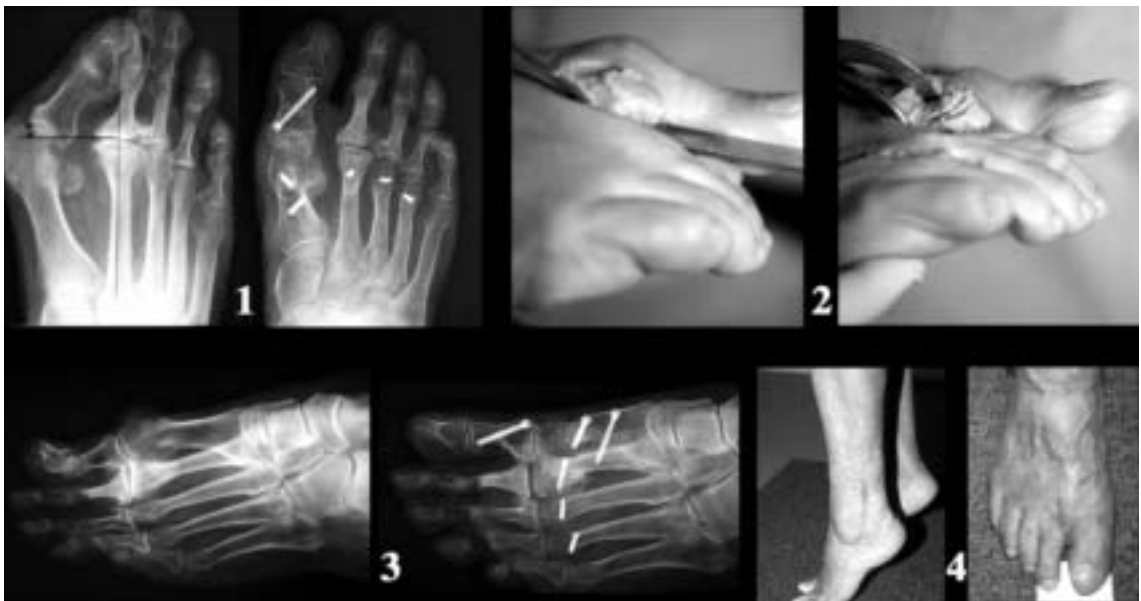2. However, if the corresponding metatarsal is too long, both in dorso-plantar and medial oblique X-ray views, the solution is a single *Weil osteotomy*.

Both of these procedures have to be combined with MTP dorsal release and to the correction of the hammer or claw toe deformity.

## Impairment of the Lesser MTP Joints (Excluding Rheumatoid Lesion)

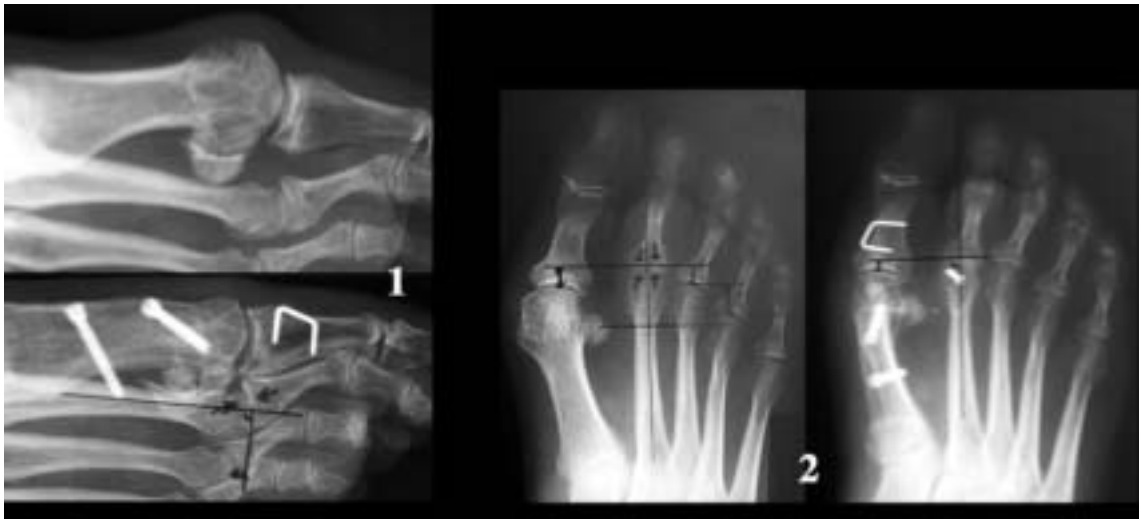Then, the other types of MTP joint impairment are also reported, with samely the large and harmonized Weil osteotomy, which is the only solution for providing reliable and long-lasting result.

First, we report our experience of the Frieberg-Koelher advanced stage treatment by Weil osteotomy, which is a reliable solution.



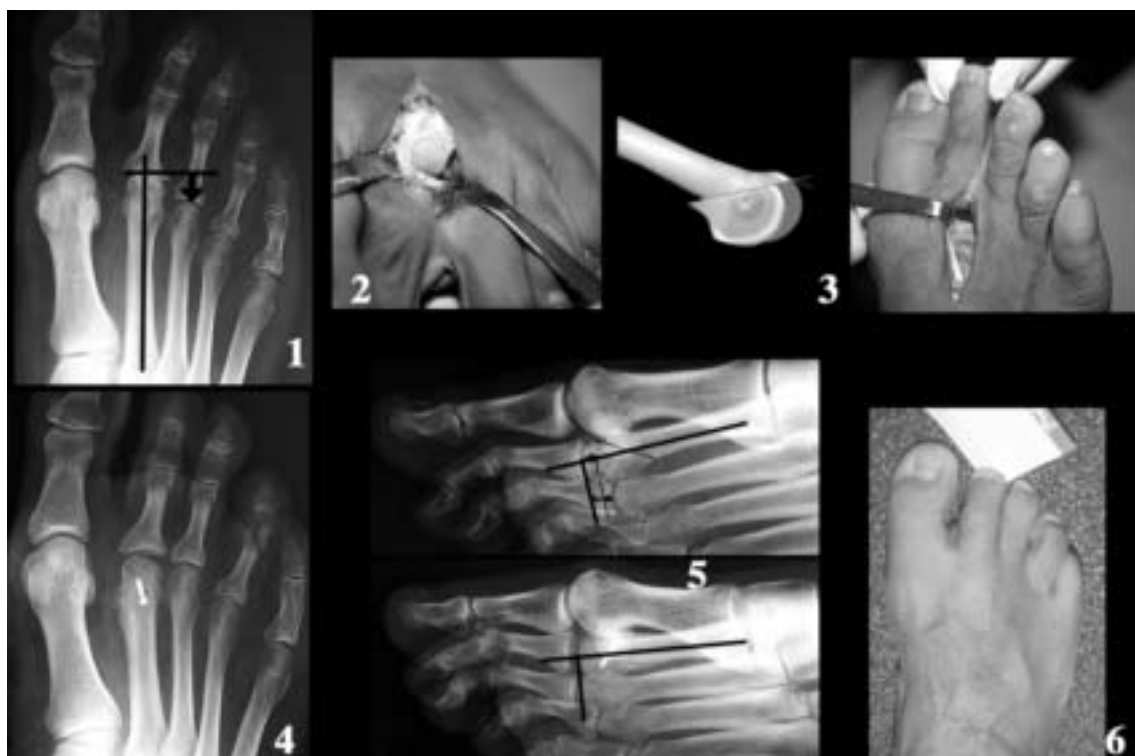**Fig. 32a.** MTP impairment – *Frieberg-Koelher and Weil osteotomy.*

In advanced Frieberg-Koelher disease, a dorsal-distal edge has to be removed, as recommended by A. Gauthier (Lyon, France). However, we recommend not to remove a large edge, but to *decompress* the MTP joint with a combined *metatarsal shortening*. In this case, the first metatarsal was already too long, so that the good result showed here was obtained by the shortening of the five metatarsals.



*Fig. 32b1.* MTP impairment (excluding rheumatoid lesion).

1. Surgery without Weil osteotomy usually does not provide good result.
2. The Weil osteotomy with small proximal sliding is usually not sufficient.



**Fig. 32b2.** MTP impairment (excluding rheumatoid lesion) – *Single Weil osteotomy in a very long corresponding metatarsal.*

Same case in all figures of this plate.

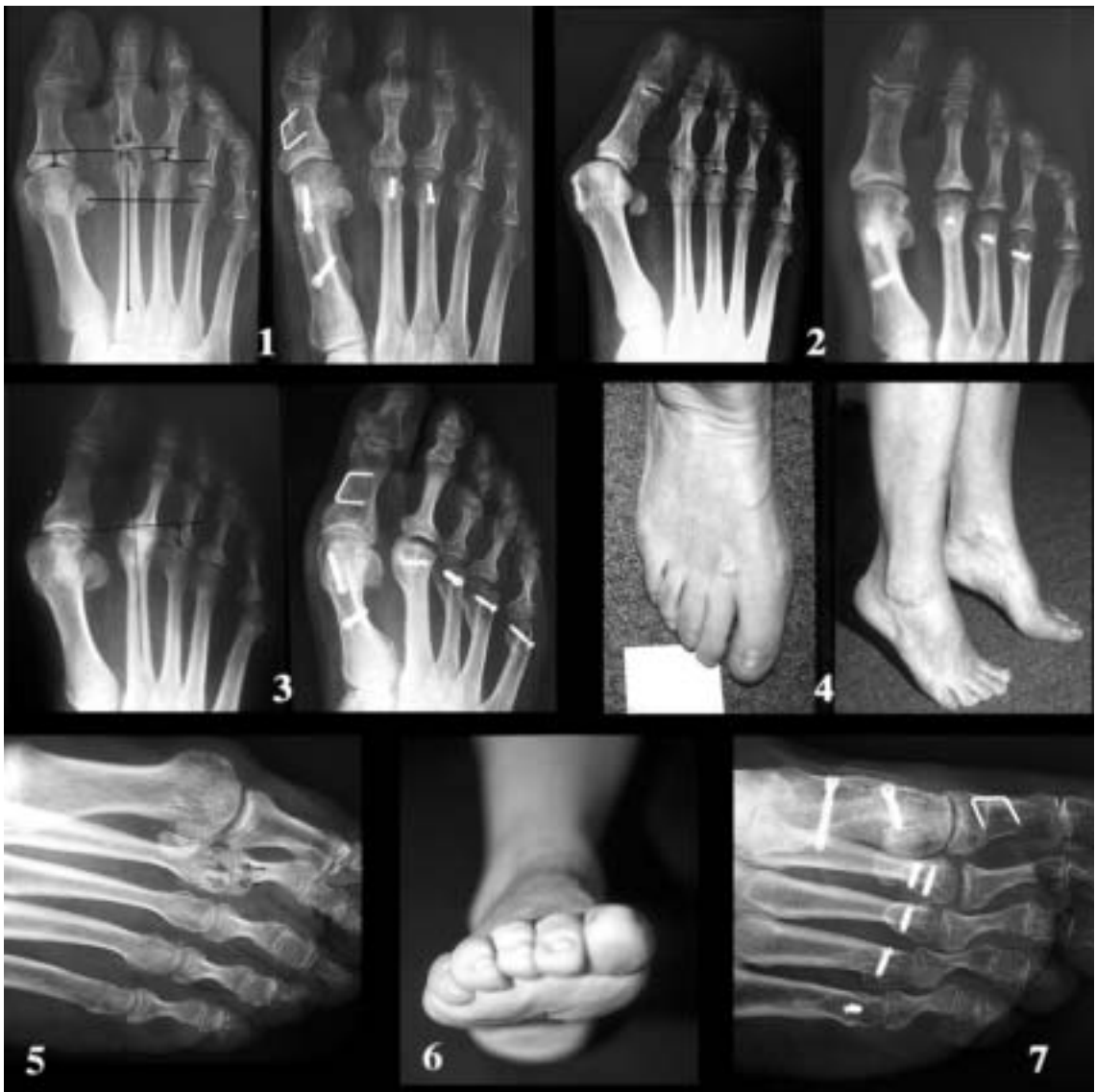1, 5. This excessive length has to be assessed both on the dorso-plantar and the medial oblique X-rays views.

2, 3. Operative views.

2. The metatarsal head with its impaired cartilage.

3. Weil osteotomy. Resulting MTP longitudinal decompression.

4, 5, 6. One year follow-up: Good result, in spite of M1 remaining slightly too long, but preserving a correct length relationship between M2 and M3.



**Fig. 32b3.** MTP impairment (excluding rheumatoid lesion) – *Necessity of large proximal sliding by Weil osteotomy.*

1. Weil on the second and third metatarsals.

2. Weil on the second, third and fourth metatarsals.

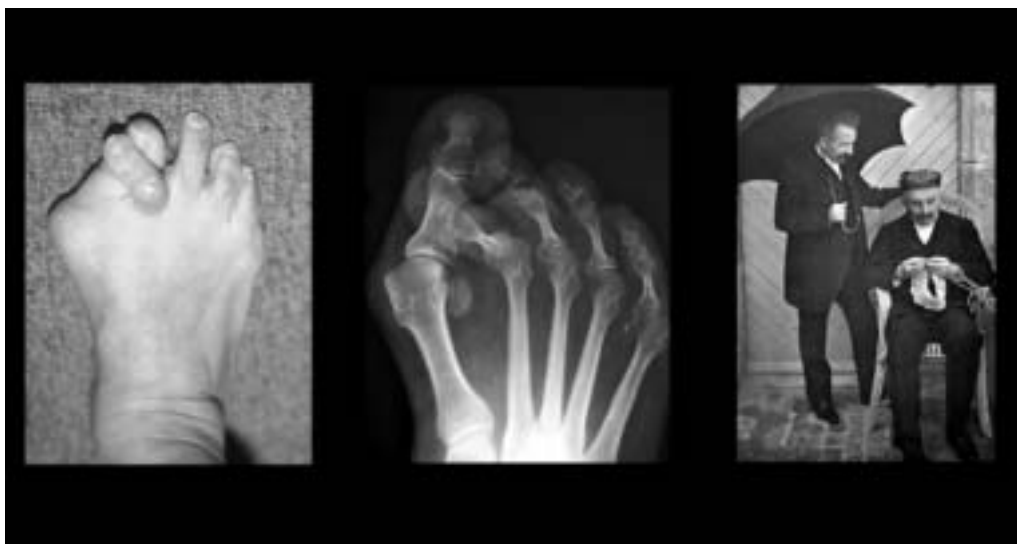3, 4. Severe impairment: Shortening of the five metatarsals: Excellent radiologic and clinical results, two years follow-up.

5, 6, 7. Another similar case, one year follow-up.

*The large metatarsal shortening is certainly the best way to treat such lesions.*

## Lesser Toes Transverse Deformity

There are the *overlapping second toe*, *wind-swept toe* and *diverging toe* deformities (the transverse deformities of the fifth ray are reported later).



**Fig. 33a1. Overlapping second toe. Introduction.**

The “Frères Lumière” (photographed in 1900) are knitting a more harmless layette than the overlapping second toe foot deformity !

### *Overlapping Second Toe*

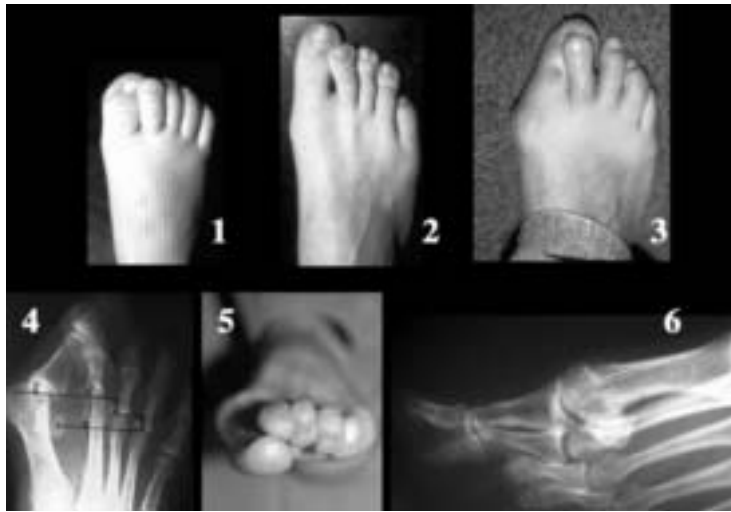This deformity has *two main causes*: First, congenital, then arthritic hallux valgus which is in fact a crossunder first toe.

We studied the *characteristics with their consequences*, leading to a specific surgery, which has to be mainly performed on the first ray and second MTP, but also, if necessary, on the whole forefoot. We observe that soft tissue procedures provide unpredictable correction of the overlapping second toe. On the contrary, the Weil medial shift osteotomy as described by J. B. Johnson, is extremely reliable taking care not to result

in transfer lesions. But the shortening of the other lesser metatarsals is easy and often performed. We have also to take care of the remaining medial deviation of the lesser toes, notably the third toe and to perform the appropriate correction.

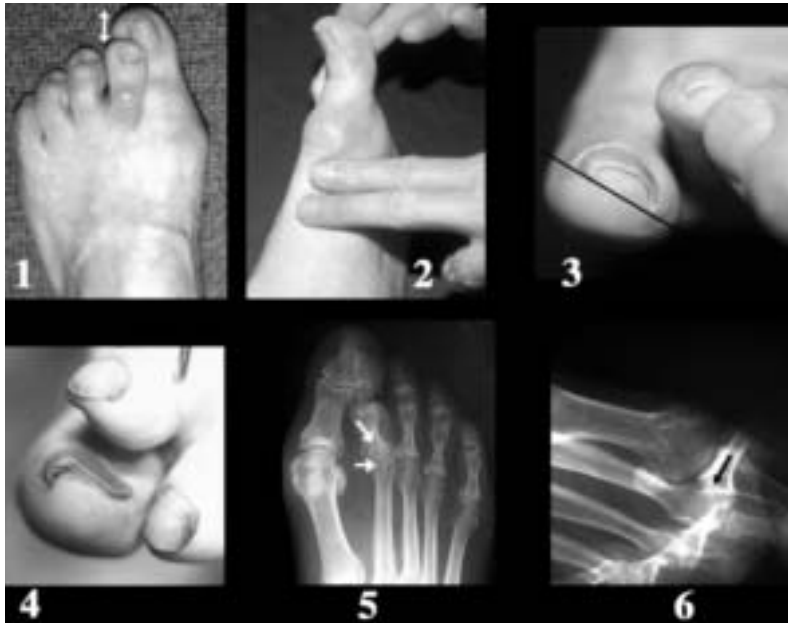#### *Medial wind-swept toes* deformity.

The deformity is often encountered: In this case, the surgery has to be performed on several rays, particularly to avoid the *cross under* third or fourth toes. This can be performed on soft tissues (notably long flexor tendon) or preferably by Weil Osteotomy on the 4 lesser metatarsals.



**Fig. 33a2. Overlapping second toe – Main causes.**

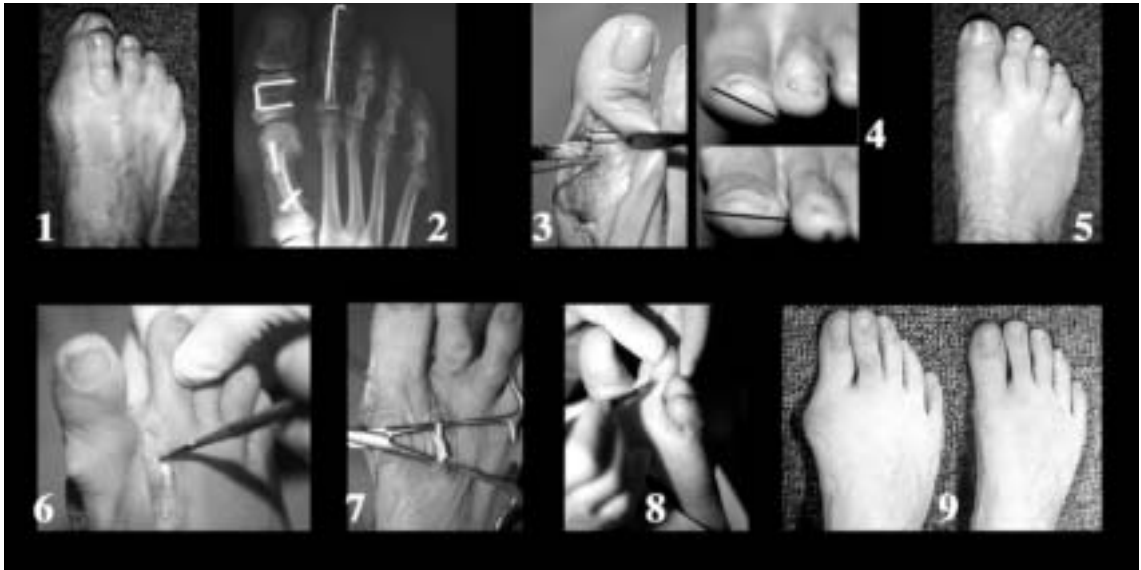1. In most cases, the deformity is juvenile (congenital), emerging very early (one year). Picture by courtesy of Christine Themar-Noël (Paris), who particularly studied the juvenile hallux valgus.
2. The deformity during adolescence.
3. In adult age.
- 4, 5, 6. Second cause: Arthritic hallux valgus, with plantar flexed TP joint. In this case it is a *crossunder great toe deformity*.



**Fig. 33a3. Overlapping second toe – Main specificities encountered.**

1. Egyptian type foot.
2. Loss of dorsal flexion of the first MTP joint.
3. Medial rotation of the great toe.
4. Great toe nail deformity caused by the second toe pressure.
5. Second metatarsal in a lateral inclination, due to the first phalanx second toe pressure.
6. Dorsal flexed second MTP joint; this results in metatarsalgia in the second ray.

*Technique and Results in Mild,  
Moderate or Severe Deformity*



**Fig. 33b. Overlapping second toe – Surgical treatment: Mild deformity.**

**1. to 5.** *On the first ray.*

1, 2, 3. The combined hallux valgus is corrected by scarf and great toe shortening osteotomies.

4. Lateral axial rotation is performed in the great toe osteotomy.

5. Result (same foot): Note the foot type: From Egyptian to square foot.

**6 to 8.** *On the second and lesser rays.*

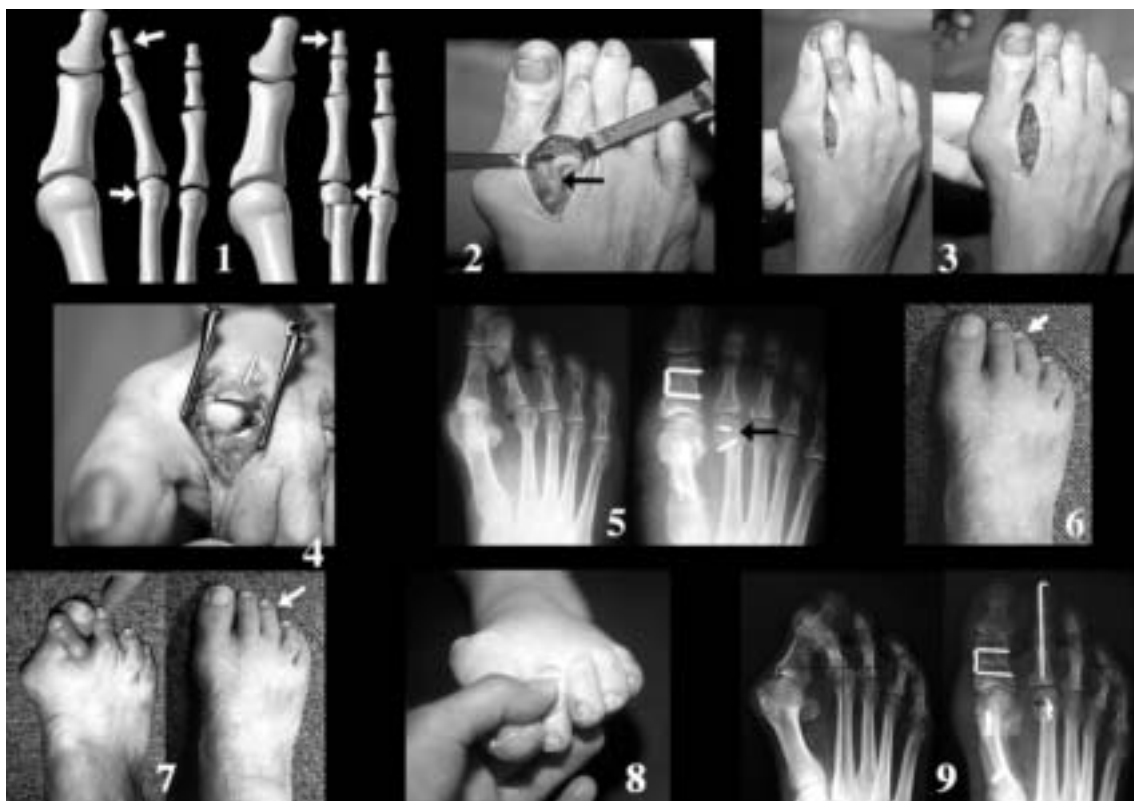6. Medial release of the second MTP joint.

7. Extensor tendon lengthening.

8. Long flexor tendon section in the third and fourth toes.

9. In spite of correct soft tissue procedure in the lesser rays, it may remain some medial wind-swept deformity of the toes. *So that this procedure is less reliable than with additional Weil osteotomy, as showed in the next plate.*





**Fig. 33c. Overlapping second toe – Surgical treatment: Moderate deformity. The Weil second metatarsal osteotomy.**

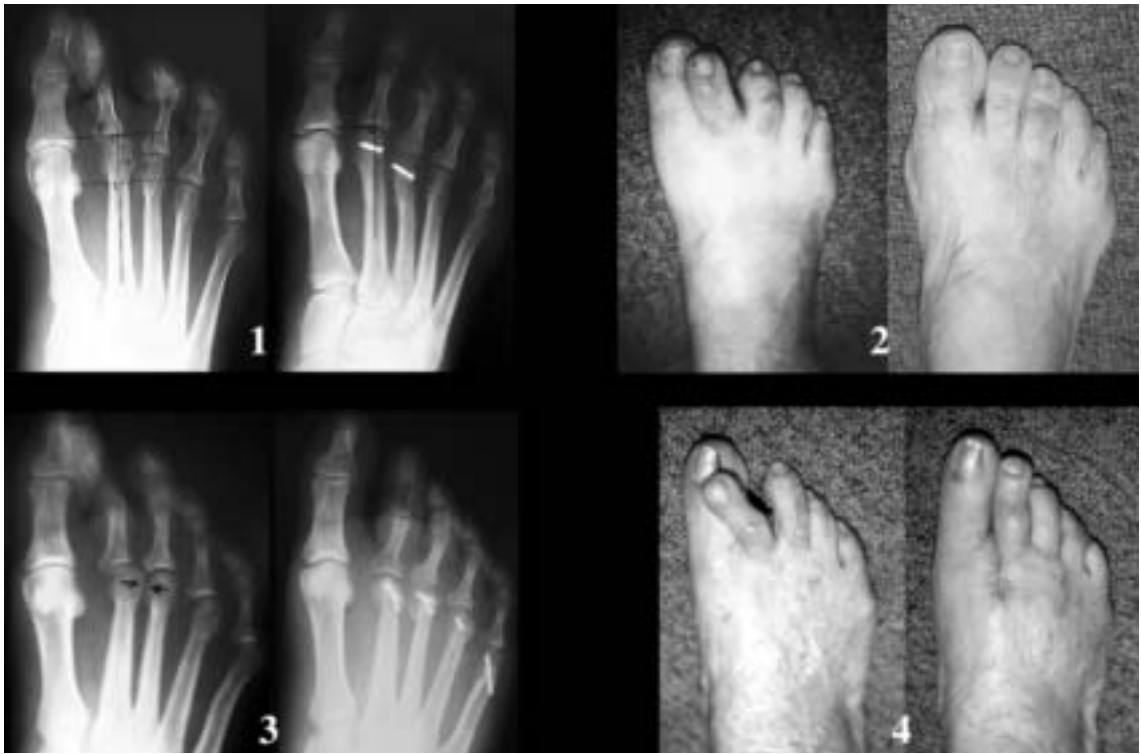1, 2, 3. As soon as the osteotomy is made, we observe the medial displacement of the metatarsal head which automatically results in the correction of the toe deformity.

4. Fixation of the head in its medial displacement. Care has to be taken to just have a *medial shift* of the head and not a *medial rotation*.

5. Radiographic result.

6. Take care of the remaining *medial crossunder third toe*. Solution: Distal section of the long flexor tendon.

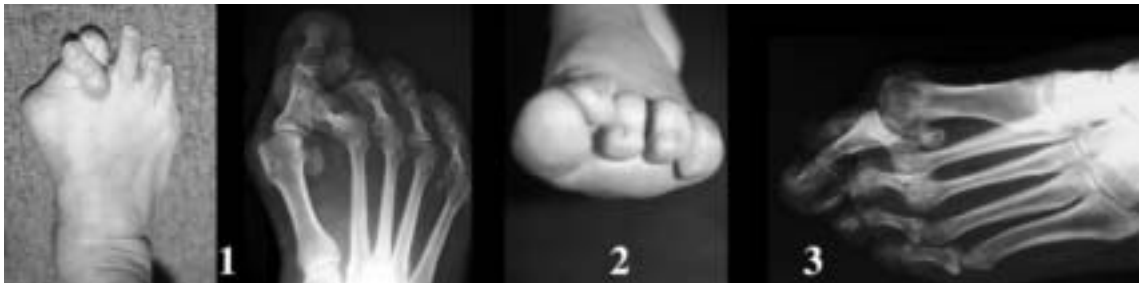7, 8, 9. Same foot: In spite of large deformity, the Weil osteotomy may be limited to the second metatarsal because the deformity is correctible in the preoperative examination (notably good MTP plantar flexion). But take care to the tendency to crossunder third toe (white arrow)!



**Fig. 33d. Overlapping second toe with a normal first ray – Surgical treatment.**

1, 2. Same foot: Weil osteotomy on the second and third metatarsals.

3. A more important deformity needs Weil osteotomy on the lesser four rays.

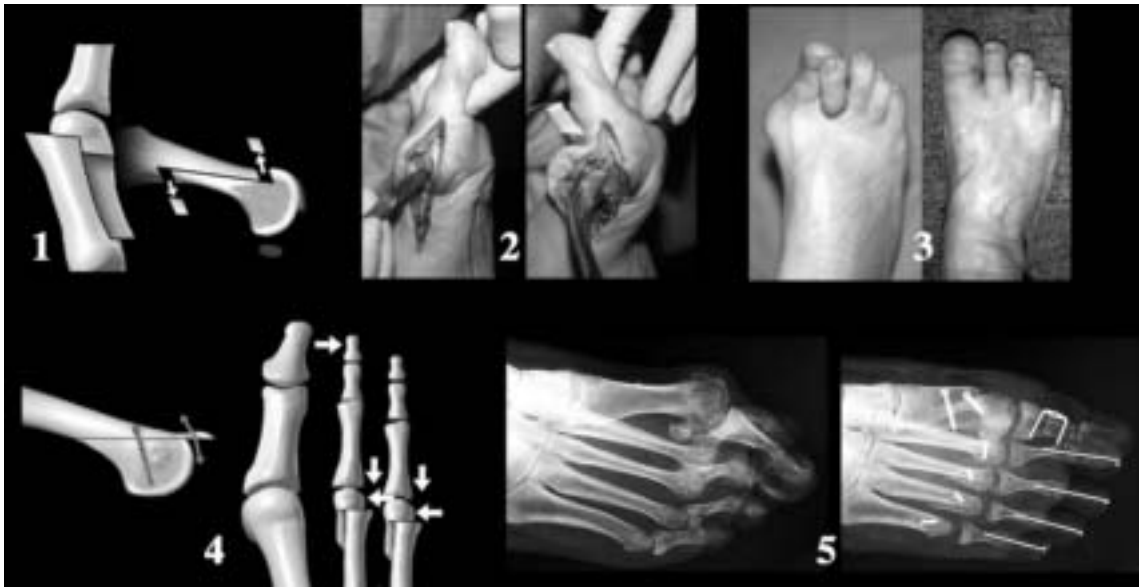

**Fig. 33e1. Overlapping second toe – Severe deformity. Specificities.**

1. Severe clinical deformity.

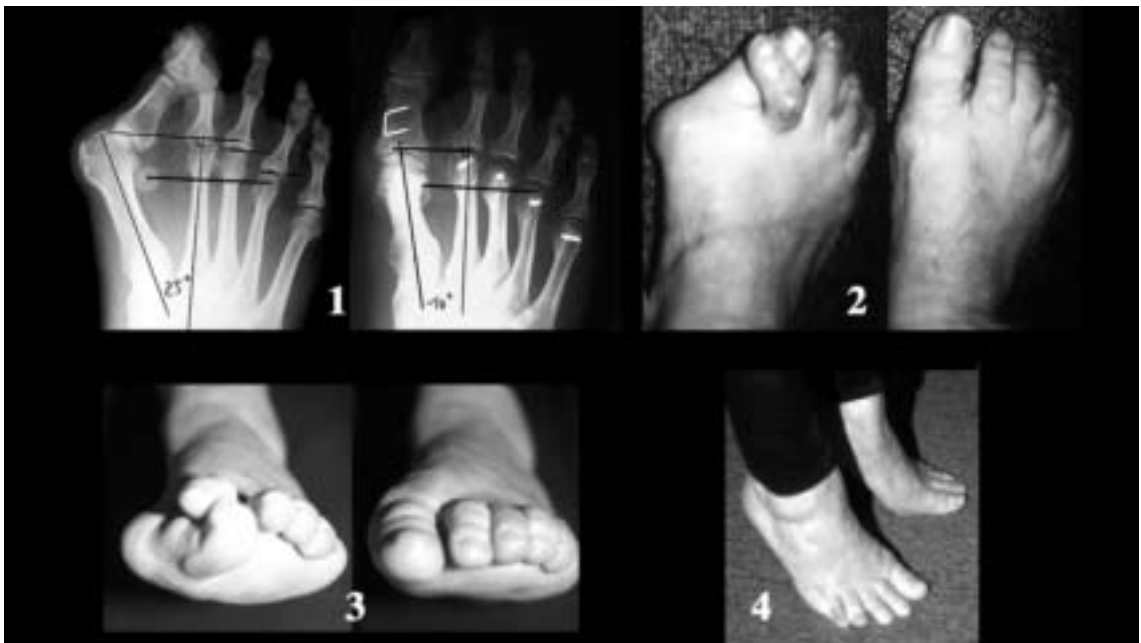2. Metatarsalgia is more extended than only in the second ray.

3. Severe and not flexible *dorsal* flexion of the second MTP joint and *plantar* flexion of the first MTP joint. These severe deformities require the shortening of the five metatarsals.



**Fig. 33e2. Overlapping second toe – Severe deformity. Surgical correction.**

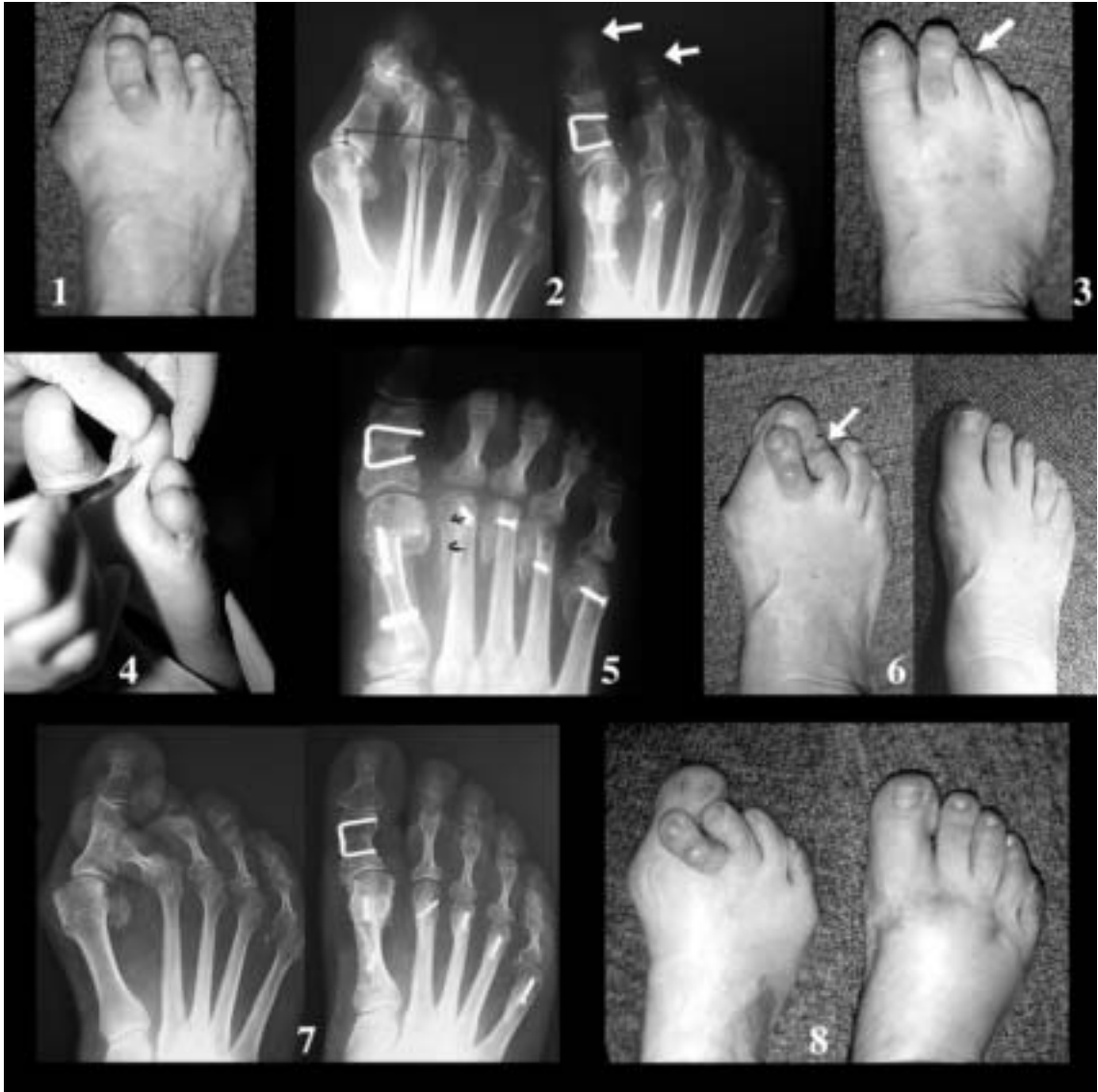- 1, 2, 3. Shortening of the first metatarsal by scarf, to recover a correct dorsal flexion and correct the hallux valgus deformity.
4. Weil osteotomy of the second metatarsal but also in most cases of the other lesser metatarsals.
5. Radiographic aspect on a medial oblique view. The lengthening of the tendons are performed as required; note the K-Wiring of the toes.



**Fig. 33e3. Overlapping second toe – Severe deformity. Results.**

Same case for all figures of this plate.

This case is a *four years follow-up* result of severe deformity correction, thanks to transverse displacement of the metatarsal combined to the whole metatarsal shortening. We note the preservation of all forefoot joints, the metatarsalgia relieving and the good functional aspect.



**Fig. 33f. Overlapping second toe – Medial wind-swept toes.**

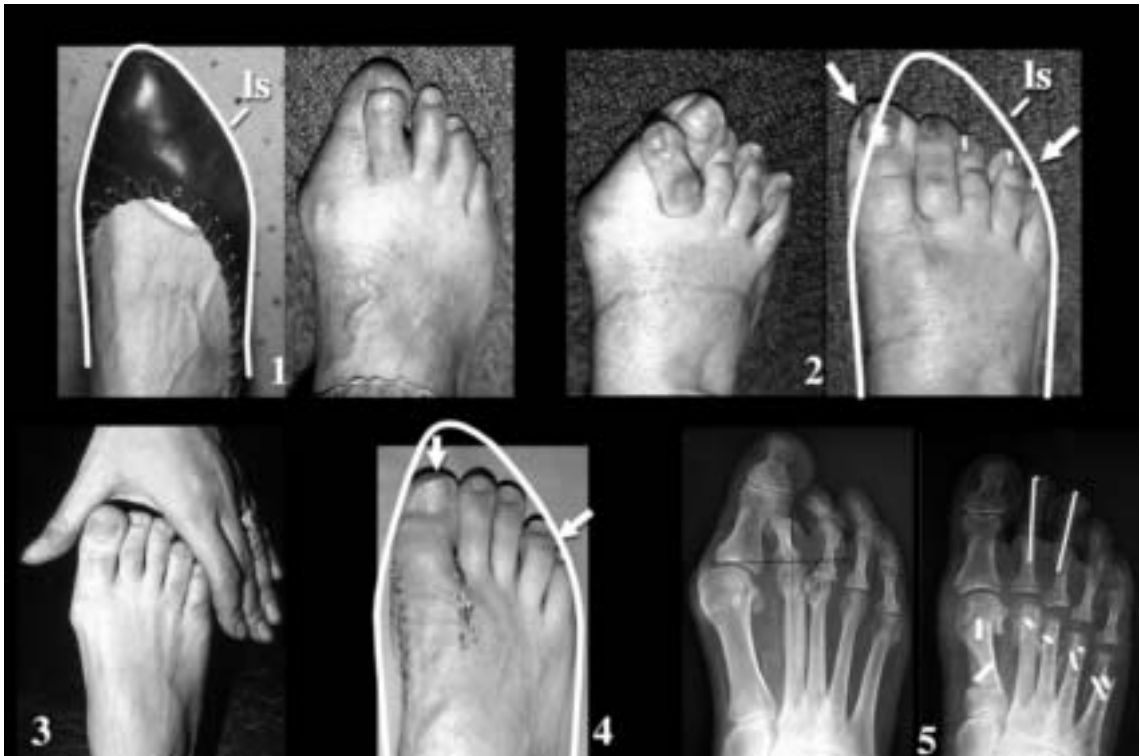1, 2, 3. We observed that the crossover second toe is sometimes combined with a medial inclination of the other lesser toes. *Lack of the whole deformity correction* results in *crossunder of the third toe* but also in *overcorrection of the hallux* which is *medially pushed* by the lesser toes.

4. The first additional procedure to resolve this problem is the distal section of the long flexor tendon in the third, fourth and fifth toes. It is only suitable for mild deformity.

5, 6. For severe wind-swept toes deformity, medial and proximal metatarsal head displacement of the lesser metatarsals, combined to shortening of the first metatarsal, is the most reliable solution which preserves MTP and toes joints.

7, 8. Radiographic and clinical results (same foot).

*The Problem of Footwear*



**Fig. 33g. Overlapping second toe and footwear.**

1. Before surgery, there is painful problems but the foot still enters into a feminine shoe.
2. After surgery the problems on the bunion and on the second toe disappear, but the forefoot is too large to easily enter in the shoe (particularly the too large and too long great toe, and the last lesser toes).
3. This test reproduces the shape the forefoot has to have to easily enter in a feminine shoe.
4. Correct shape of an operated foot.
5. The corresponding X-ray: Since we have to perform lesser metatarsal Weil osteotomy, it is preferable to perform the shortening of the fifth metatarsal instead of a resection of the fifth toe first phalanx.

**In conclusion,** soft tissue procedures are not reliable to correct overlapping second toe: In fact, scarf, great toe first phalanx and Weil osteotomies are the pillars for supporting reliable correction of the overlapping second toe deformity.

## **Lateral Wind-Swept Toes Deformity**

### *Generalities*

In most cases, this deformity is combined with hallux valgus deformity as well as hammertoe. The wind-swept toes will remain even after correction of hallux valgus. Furthermore, the wind-swept toes are mostly combined with excessive length of the lesser metatarsals.

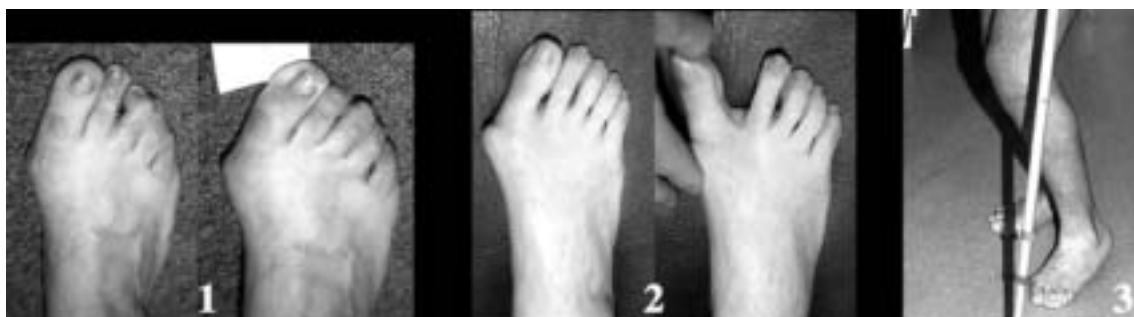To assess the necessity of performing lesser rays specific surgery, we perform a check test, (passive hallux valgus correction) which in main cases shows that the wind-swept devia-

tion remains in spite of the great toe correction.

### *Surgical Treatment*

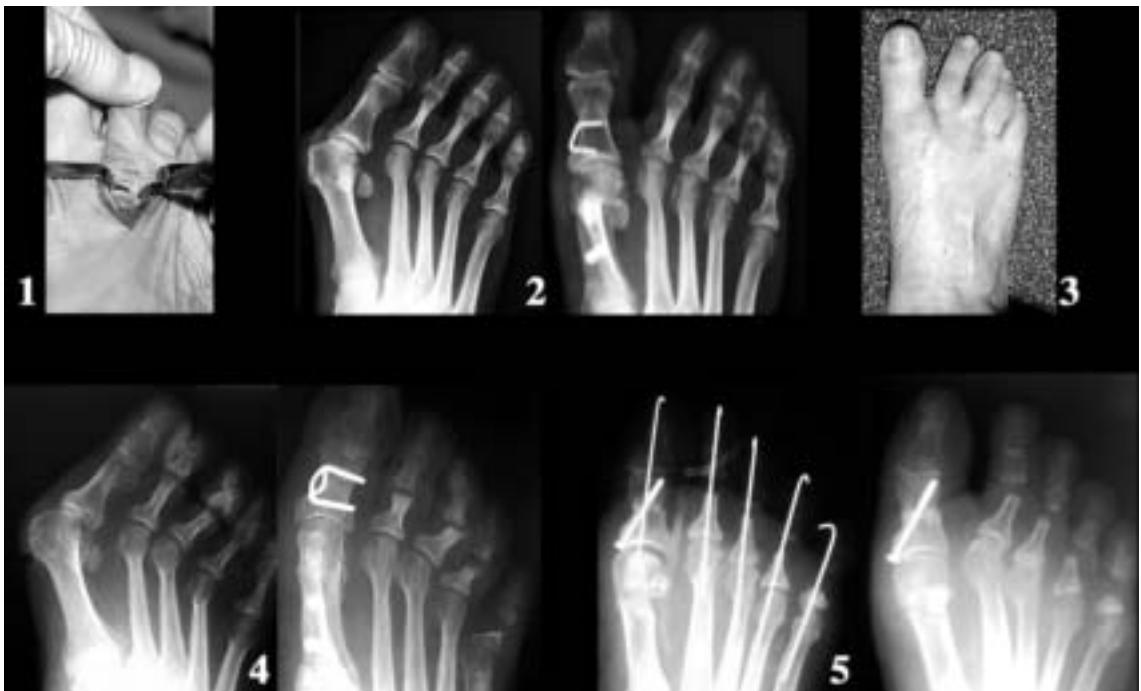#### **MTP Release on the Lesser Rays Combined with Toe Surgery and Hallux Valgus Correction**

We have performed tendon lengthening, MTP lateral release, PIP fusion or resection arthroplasty. Except in very emerging or mild deformity, we were disappointed by the results: Ordinarily the valgus of the toe remains almost the same, or, in a case where we performed PIP resection arthroplasty, valgus occurs in the PIP joint.



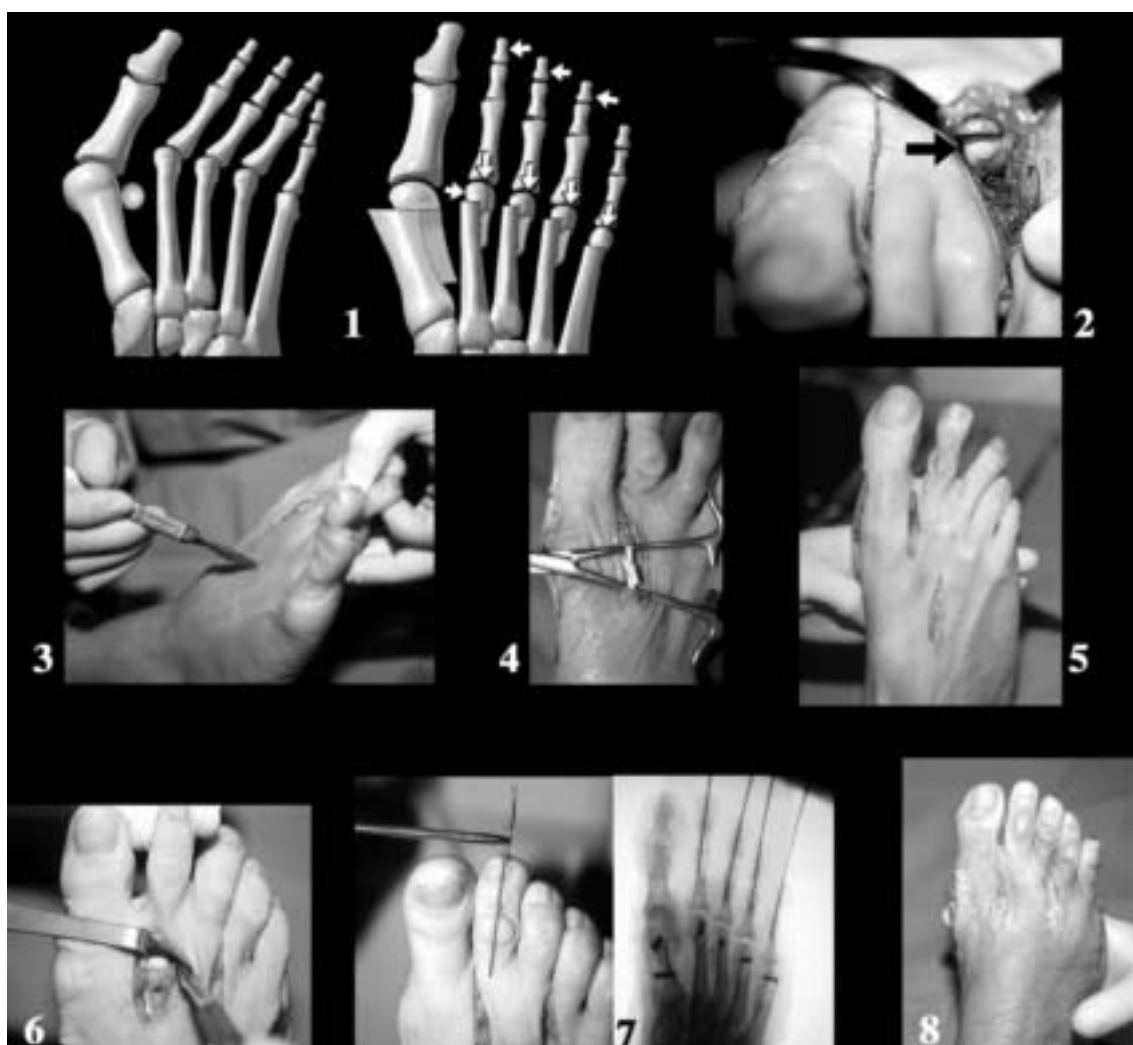**Fig. 34a. Lateral wind-swept toes deformity – Generalities.**

1. The *valgus of the great toe* increases the wind-swept toe deformity.
2. *Check test*: Active toes ground contact while the valgus of the great toe is maintained: If there is still a wind-swept deformity of the lesser toes, the soft tissue procedure should not be sufficient to the deformity correction.
3. The wind-swept deformity should be increased by the *foot valgus* and the *lateral rotation* of the forefoot – but *does not directly result from them*.



**Fig. 34b1. Lateral wind-swept toe correction – Only soft tissue procedure should be insufficient.**

1. Soft tissue procedure: Additionally to extensor or flexor tendons lengthening, MTP lateral release.
2. Same foot before and after scarf osteotomy and soft tissue procedure. X-ray: In spite of good correction of the hallux valgus deformity, the wind-swept appearance of the toes remains.
3. Same foot: Clinical insufficiency of the correction.
4. Another case of undercorrection with soft tissue procedure. We note the medial deviation in the PIP joint.
5. Same remark in this case, in spite of MTP axial K-wiring and PIP resection arthroplasty.



**Fig. 34b2. Weil osteotomy for lateral wind-swept toe deformity correction.**

1. Principle. *Lesser metatarsals*: Above all, *shortening*, combined with a *slight lateral shift* of the metatarsal heads. *1<sup>st</sup> ray*: Correction of hallux valgus deformity and harmonization of the metatarsal parabola ( $M1 = M2$ ).
2. Operative view of the head displacement resulting from the Weil osteotomy.
3. Percutaneous section of the extensor tendons.
4. Green procedure for extensors tendons lengthening.
5. Assessment of remaining lateral deviation of the toes.
6. MTP lateral release for final correction of the lateral deviation.
7. Toe K-wiring as required, excluding the MTP joint.
8. Final check of the correction, with the Load Simulation Test.

### Weil Lesser Metatarsal Osteotomy

The Weil osteotomy has two effects.

1) First the *longitudinal MTP decompression* provided by the proximal translation of the metatarsal head.

2) The *lateral shift of the head*, which works like the medial shift for medial toe deviation (overlapping second toe or medial wind-swept toes, J. B. Johnson).

Although the Weil osteotomy provides the correction once performed, this correction is



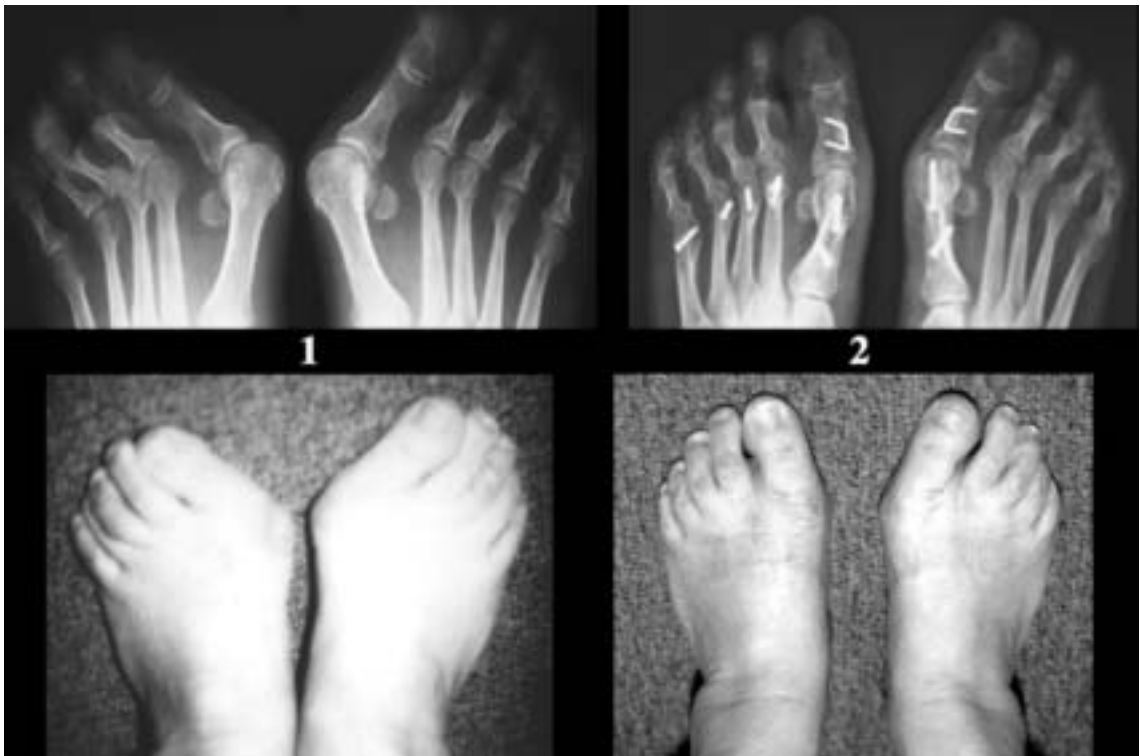not complete and needs K-wiring of the toe, lengthening of the extensor tendons and MTP lateral release. With this additional procedure, the Weil osteotomy provided good and reliable results in the wind-swept toes deformity correction.

Compared with soft tissue and toe surgery, the performance of the Weil osteotomy shows a clear advantage.

However, we observed that the *proximal sli-*

*ding of the metatarsal head has to be generous* to ensure complete and long-lasting correction. This metatarsal shortening is more effective than the lateral shift of the head in providing such good results.

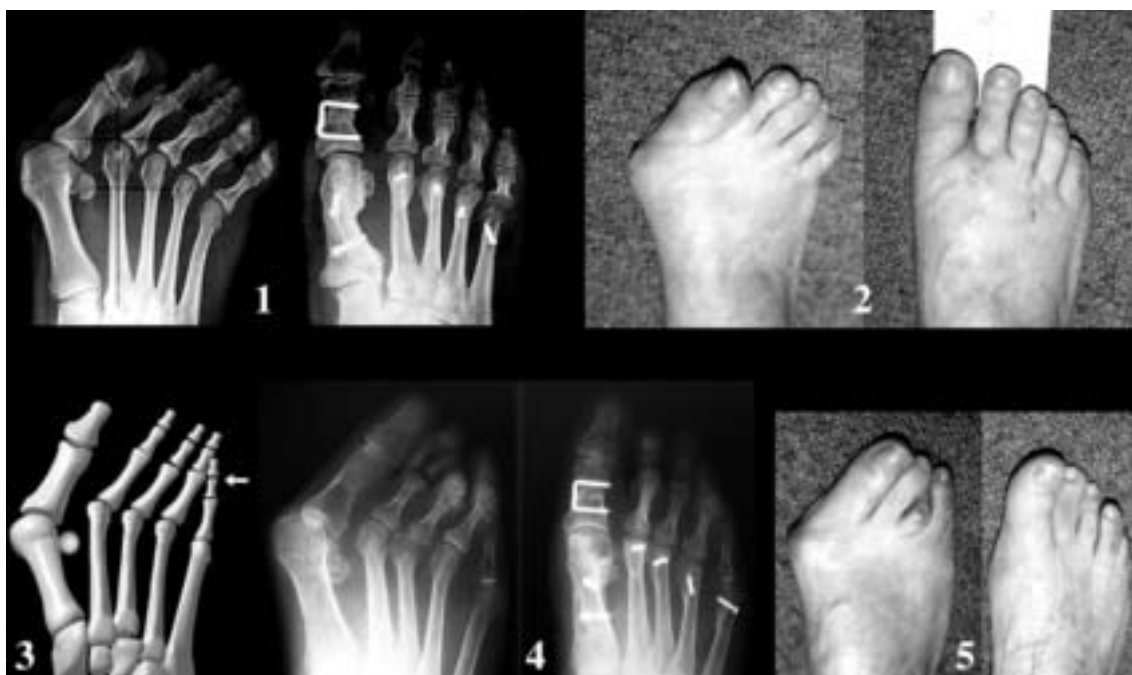Furthermore, in order to *harmonize the metatarsal parabola*, the lesser metatarsals shortening leads in some cases to shorten the first metatarsal. This is easy with the scarf osteotomy, which also provides the hallux valgus correction.



**Fig. 34c1. Weil osteotomy versus soft tissue surgery in lateral wind-swept toe deformity.**

1. Clinical and radiological preoperative aspects. On the left foot, more advanced deformity: We decide to make Weil osteotomy only on this foot.

2. Clinical and radiological results: Same patient, on the left foot, better correction with Weil and scarf osteotomies, in spite of preoperative more advanced deformity on this side.



**Fig. 34c2. Weil osteotomy for lateral wind-swept toe deformity – The reliable solution.**

1, 2. Radiological and clinical results of wind-swept toe deformity correction by Weil osteotomy. The required shortening of the lesser metatarsals leads to also shorten the first metatarsal by scarf osteotomy.

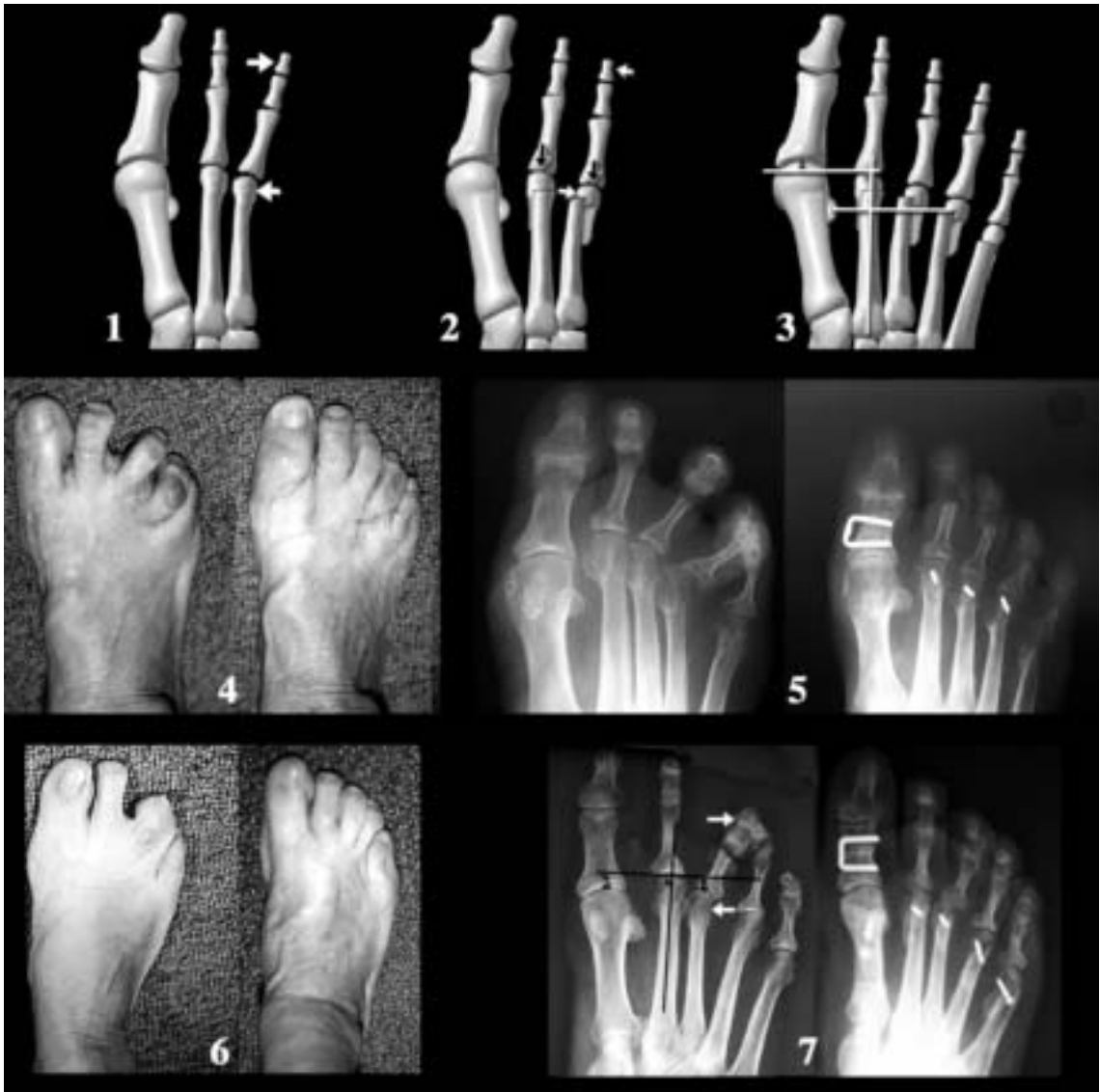3, 4, 5. In case where the wind-swept deformity does not affect the fifth metatarsal, the required shortening of the metatarsal head leads to also shorten the fifth metatarsal. Same case: Complete correction of the deformity.

### Diverging Toes

In fact, diverging toe deformity seems to be only the lateral deviation of one toe.

This deformity is generally combined with an

excessive lesser metatarsal length. Once again, the Weil osteotomy of the corresponding metatarsals regularly provides the correction, but sometimes with such an amount of shortening that the other metatarsals also have to be shortened.



**Fig. 35. Diverging toes. Diverging toe is in fact a lateral deviation of one or two toes only.**

It is generally combined with an excess of length of the corresponding metatarsals.

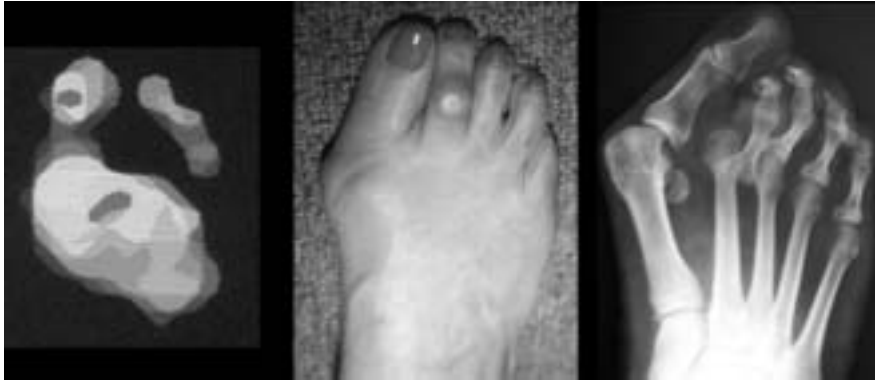1, 2, 3. Diverging toe is a combination of lateral toe inclination and of the corresponding metatarsal medial deviation: The Weil osteotomy provides the required metatarsal head lateral displacement. This displacement is not sufficient, needing the shortening of one or several metatarsal, respecting the metatarsal curve.

4, 5. Clinical and radiological results.

6, 7. Better result in this case, where the shortening of the five metatarsals was performed.

## The Second Ray Pathology

We distinguish three kinds of second ray pathology: *claw or hammertoe, metatarsalgia, MTP dislocation*.



**Fig. 36a1. Second ray pathology – The three types of second ray pathology: Metatarsalgia – Hammertoe – MTP dislocation.**

### *Hammer or claw toe*

Except in a congenital deformity, the cause of this deformity is usually hallux valgus. We made a study on 200 feet showing that secondary hammertoe due to hallux valgus does generally not appear before 40 years. In fact, we distinguish four phases in the hallux valgus chronology.

First, there is a *painful bunion*.

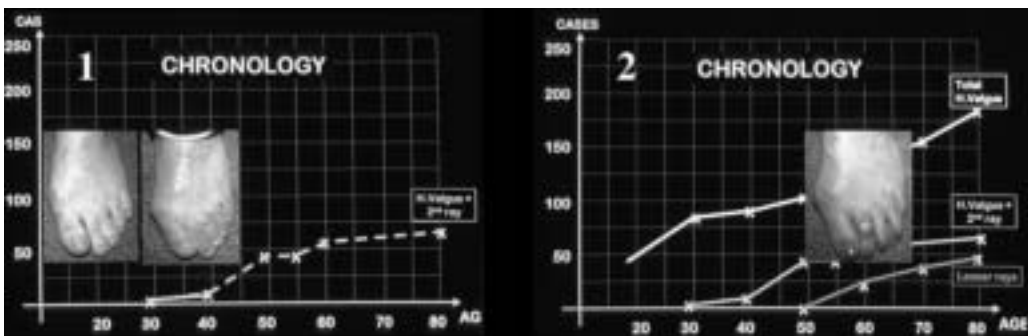
Secondly, the *bunion is less or not painful*, because of the medial displacement of the head which leaves the medial dorsal nerve laterally.

Thirdly, patients consult for *secondary effects of the bunion*, in most cases hammertoe, or metatarsalgia. This phase occurs between 40 and 60 years.

*The correction of hallux valgus does not change the hammertoe deformity, so that we have to perform a local treatment.*

In most cases the *soft tissue procedure* combined with axial K-wiring of the toe ensures the hammertoe correction. The chronological surgery steps are detailed Fig. 19b-c-d, and Fig. 36b2, b3, b5.

*PIP surgery:* Resection arthroplasty has to be avoided because of the painful postoperative period and unpredictable long-term results.



**Fig. 36a2. Second ray pathology – Chronology of hammertoe deformity combined with hallux valgus. Study on emerging second hammertoe in the hallux valgus evolution (200 feet).**

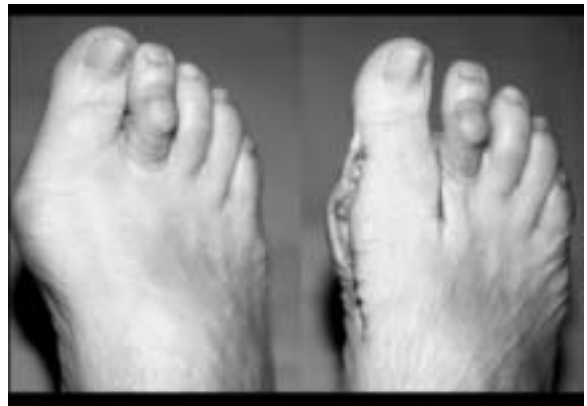1. Before 40 years, almost no hammertoe.
2. Emerging of the hammertoe after 40 years.

When the hammertoe is rigid, PIP fusion is a good solution. But in fact, in most cases we can correct the deformity with PIP joint preservation (Fig. 36b3). *It is the PIP plantar release.*

*Middle phalanx osteotomies:* when the toe is too long, a good solution is the middle phalanx osteotomies. We use either the *distal resection* (mallet finger, impaired DIP joint) ie DIP arthroplasty or, preferably, the *shaft resection* i.e. (SRMP), which preserves the joints (Fig. 36b4): only point required: the middle phalanx has to be long enough.

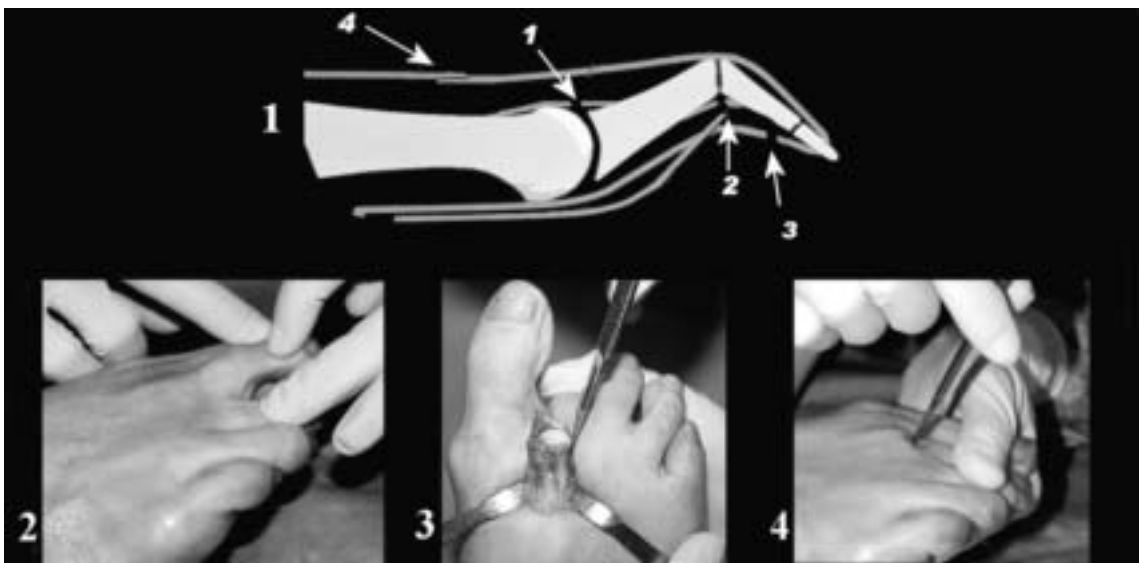
*Weil osteotomy:* Single second metatarsal osteotomy may be performed when the condition is an elongated second metatarsal compared to the first metatarsal (dorso-plantar X-ray view) and to the third metatarsal (medial oblique X-ray view). In other types, we *have to perform also the Weil osteotomy in the third and sometimes the other lesser rays.*

In every case, the correction of a hammertoe needs a temporary toe, axial K-wiring and extensor lengthening.



**Fig. 36b1. Second ray pathology – Hammertoe and hallux valgus correction.**

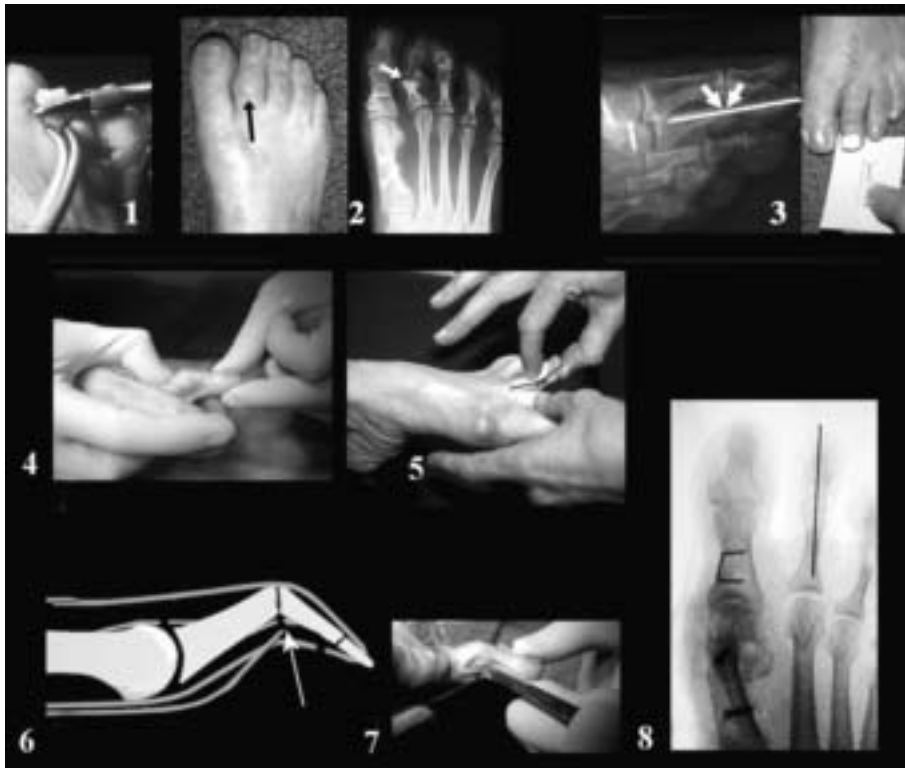Even if the second hammer claw toe is due to the hallux valgus deformity, the correction of hallux valgus does not change the hammertoe which needs a *special surgery.*



**Fig. 36b2. Second ray pathology – Hammer/claw toe correction: Chronological steps MTP Joint.**

1. Chronological steps.

2, 3, 4. MTP release 2: the loss of passive MTP plantar flexion requires MTP release. 3. Release by open procedure. 4. Per cutaneous release.



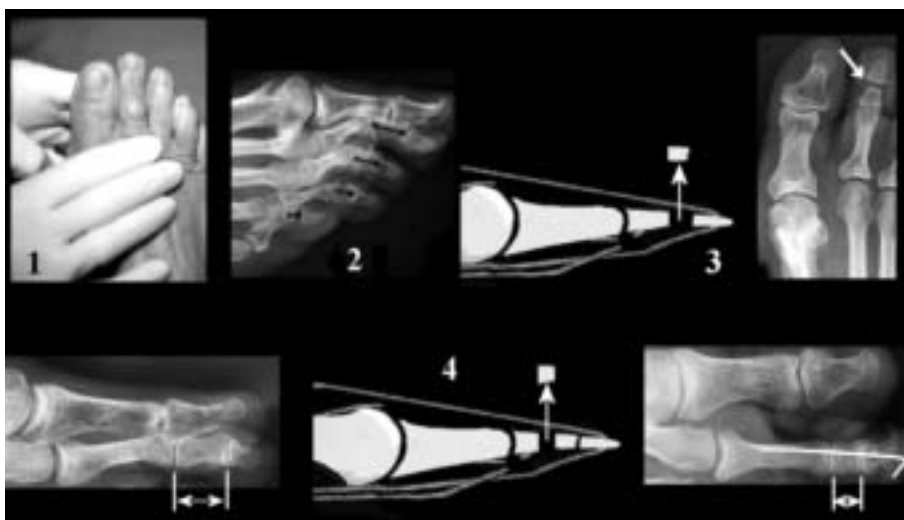
**Fig. 36b3. Second ray pathology – Hammer/claw toe: Proximal interphalangeal (PIP) surgery.**

1, 2. The resection arthroplasty is not a reliable procedure for the second toe. The toe remains swollen and painful for a long time. Long term results are sometimes a disaster.

3. When the deformity is strongly fixed, PTP fusion is a good solution. Fixation by temporary K wiring (one month).

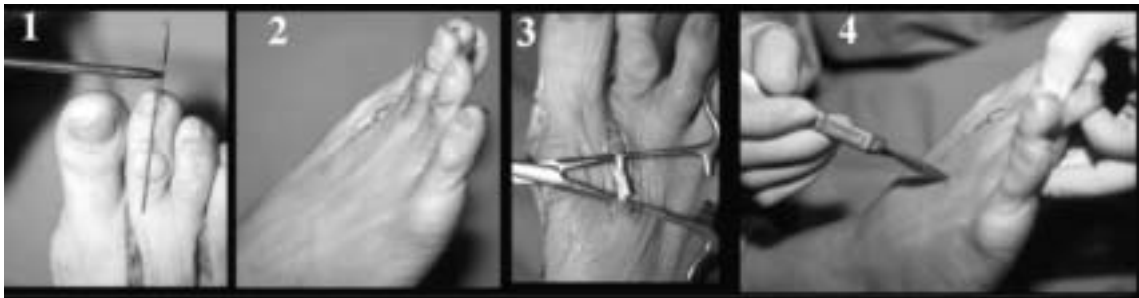4, 5, 6, 7. The PIP joint seems to be rigid: in fact, *in most cases* the correction may be made with joint preservation: (4) Correction by only manipulation: the dorsal flexion must be free up to 45°. 6, 7 correction by PIP plantar release which is a very good procedure.

8. Temporary K wiring.



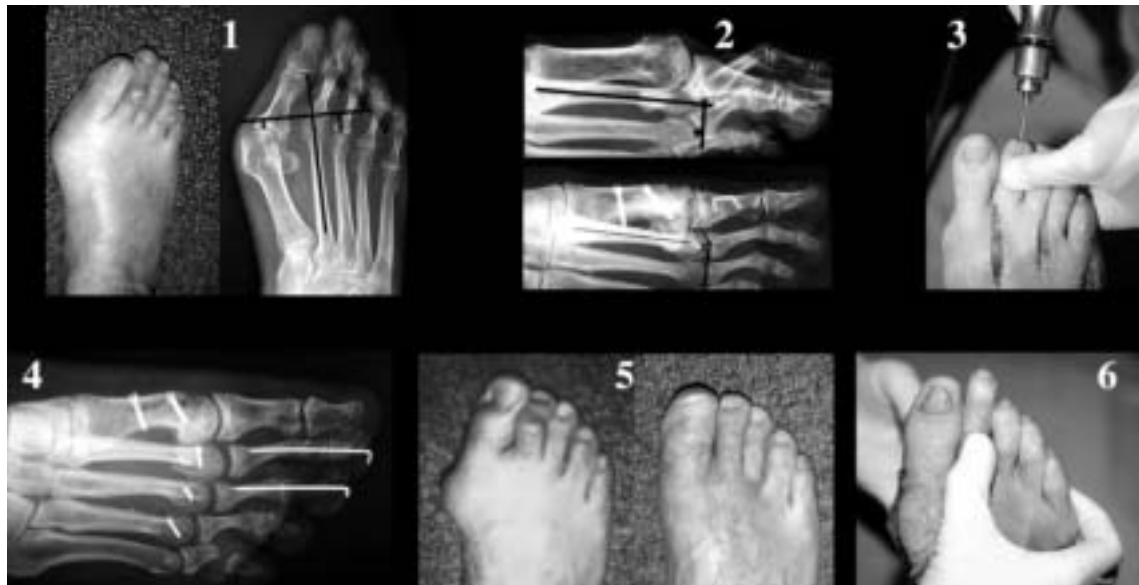**Fig. 36b4. Second ray pathology – Hammer/claw toe correction: middle phalanx surgery.**

1. The toe is too long. 2. Assessment of the middle phalanx length. 3. Distal resection (DIP arthroplasty), see also Fig. 29e1. 4. Shaft resection (SRMP), see also Fig. 29e2.



**Fig. 36b5. Second ray pathology – Hammer/claw toe correction: Lengthening of the extensor tendon.**

- 1, 2. The axial K-wiring emphasizes the need to perform the extensor tendons lengthening.
3. Lengthening by open procedure.
4. Percutaneous lengthening (as soon as possible).



**Fig. 36b6. Second ray pathology – Hammer / claw toe: Weil metatarsal osteotomy.**

- 1, 2. Single Weil osteotomy is indicated if there is an excess of the second metatarsal length both on dorso-plantar (1) and the medial oblique (2) X-ray views. The shortening of the second metatarsal has to be assessed preferably on the medial oblique view: After the surgery, the third metatarsal must not be too long, but we have to avoid generally this isolated weil osteotomy.
3. The Weil osteotomy has to be combined with the toe K-wiring.
- 4, 5. If the excess of the second metatarsal length is *not significant* (comparatively to the third metatarsal) on the *medial oblique view*, the Weil osteotomy has to be made on the other lesser metatarsals. This is our preferred method.
6. If there is an important excess of the second toe length, the toe itself has to be shortened (see Fig. 36b4), *in addition* to the Weil osteotomy, because a too long second toe remaining is not well tolerated.

## **Metatarsalgia**

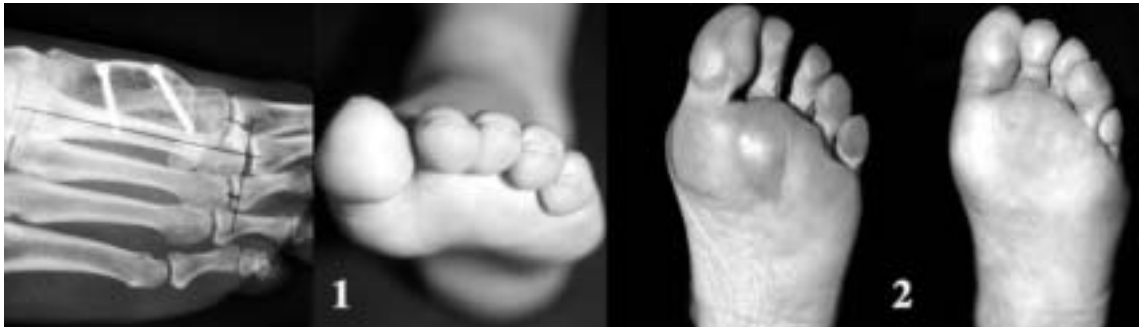To relieve the *second ray metatarsalgia* we have three solutions :

1. Lowering the first metatarsal, which is possible with scarf osteotomy when the inter - metatarsal angle is sufficient.

2. Shortening the second metatarsal by Weil

osteotomy: The same conditions are necessary as for second hammertoe. In both cases, the proximal sliding has to be slight, so as not to result in transfer metatarsalgia to the third ray.

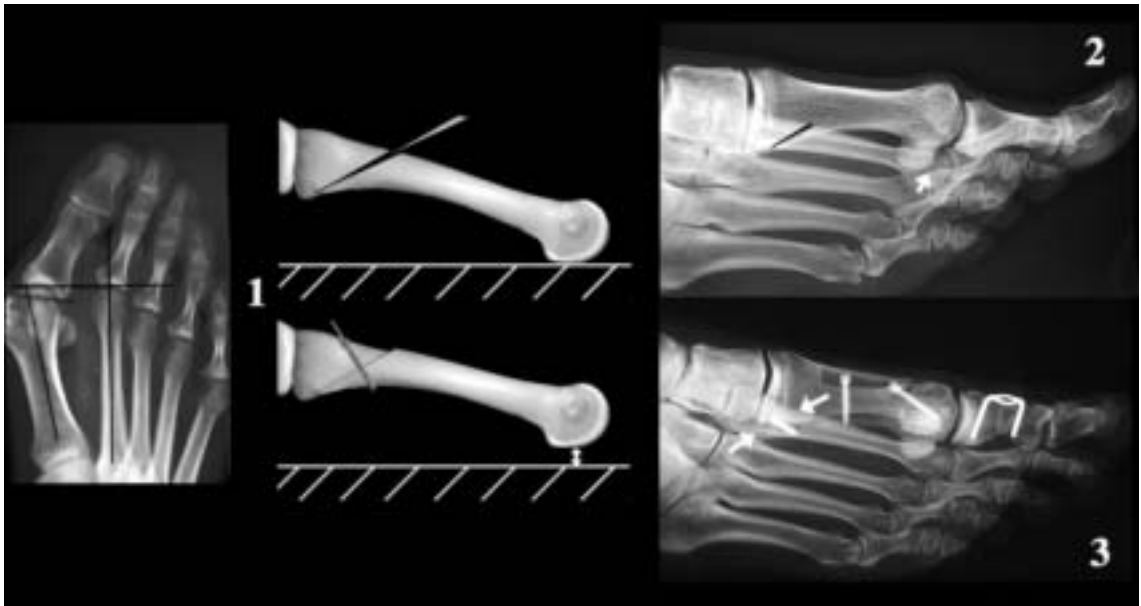
3. BRT second metatarsal elevation osteotomy, in cases where there is no indication nor possibility of lowering the first metatarsal or of Weil osteotomy on the second ray.



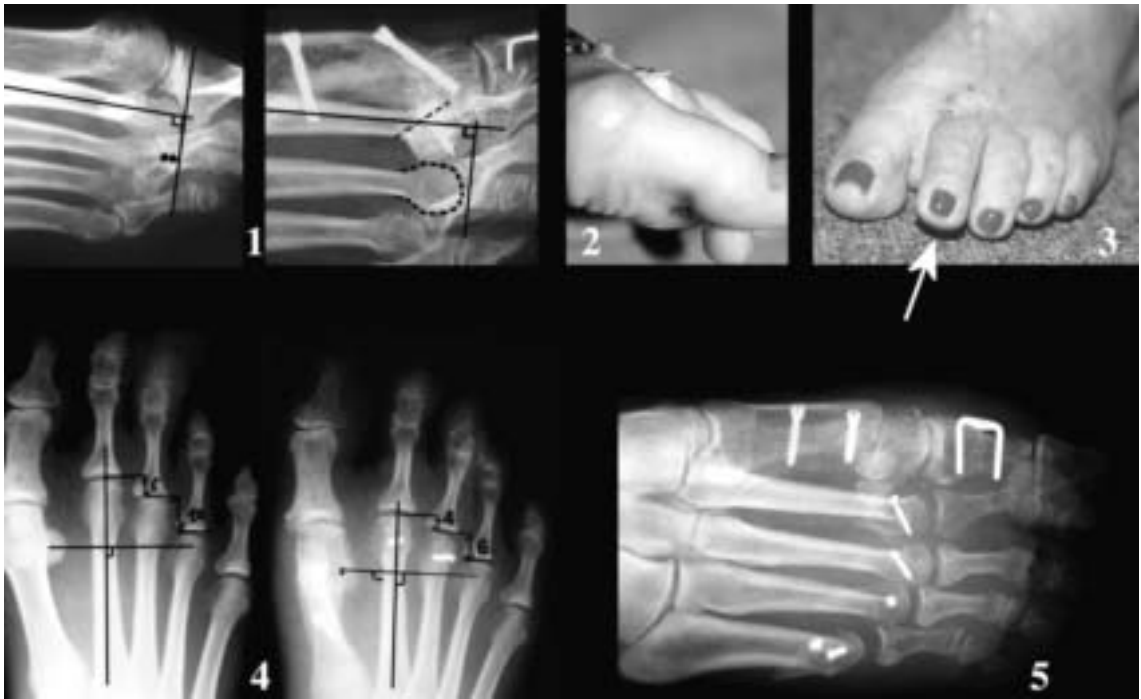**Fig. 36c1. Second ray pathology – Metatarsalgia: (1) lowering of the first metatarsal.**

1. When the intermetatarsal angle is large, we can have a large lowering with the scarf osteotomy, thanks to the lateral plantar obliquity of the cut. So we can relieve *mild or moderate second ray metatarsalgia* only by first metatarsal lowering by scarf (2).





**Fig. 36c2. Second ray pathology – Metatarsalgia:** (2) *elevation of the second metatarsal by BRT osteotomy.*  
 1. When *intermetatarsal angle is not large*, we cannot lower the first metatarsal enough. In this case, *if the second metatarsal is not too long*, the BRT osteotomy (2) (3) is a good solution to relieve the second ray metatarsalgia.



**Fig. 36c3. Second ray pathology – Metatarsalgia:** (3) *Weil osteotomy.*

1, 2. When *the second metatarsal is too long* comparatively to the first one (dorso-plantar X-ray) and to the third one (medial oblique view), we have to perform a Weil osteotomy on the second metatarsal: Care has to be taken not to shorten too much. The third metatarsal has to remain shorter or equal to the second in the medial oblique view.

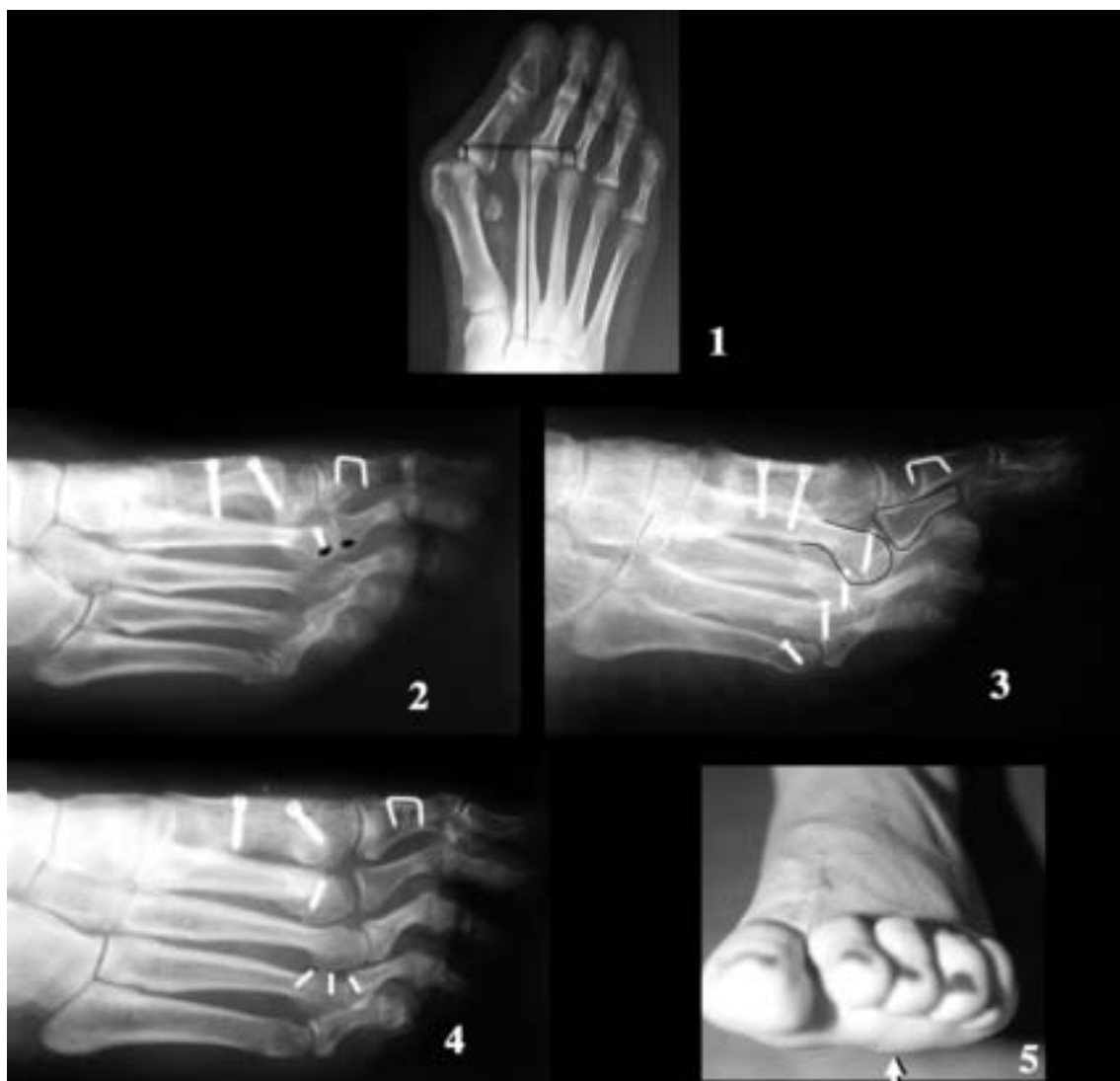
3. Single second metatarsal Weil osteotomy sometimes results in decreasing the second toe ground contact. Postoperative training is very important to avoid this problem.

4, 5. Preferably, we perform Weil osteotomy also on the third and, if necessary, on the other lesser metatarsals.

## MTP Dislocation

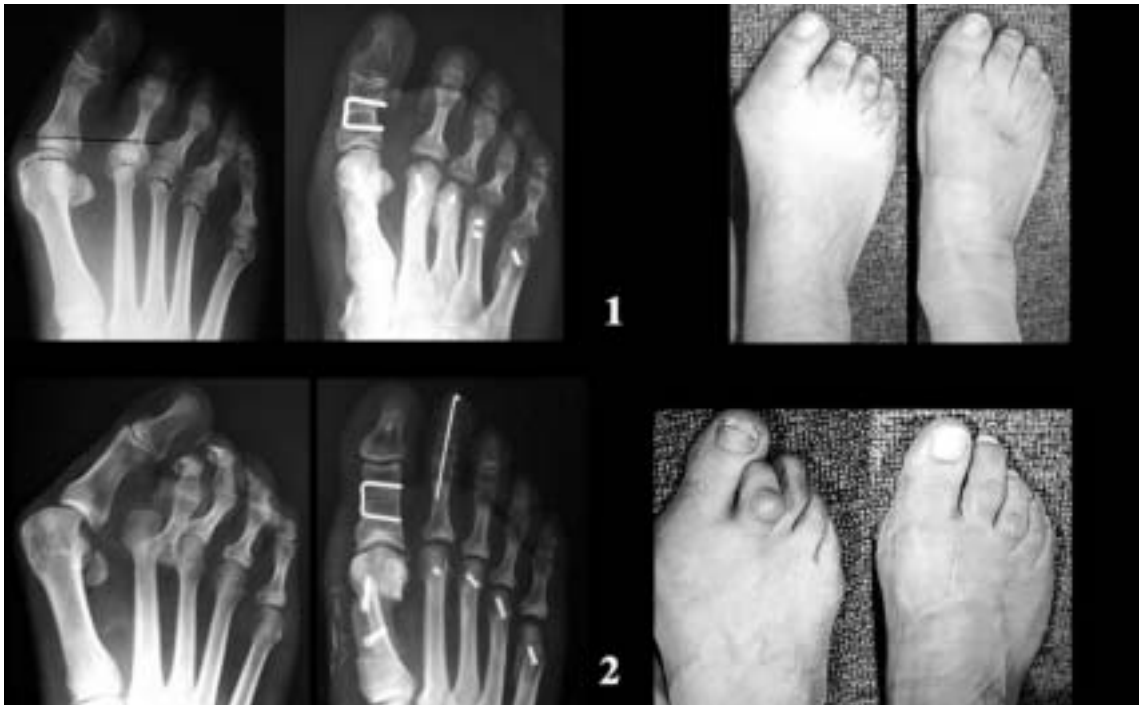In our experience, the best results are observed by far with the shortening of the corresponding metatarsal by the Weil osteotomy. Emerging dislocation may be treated by a single Weil osteotomy, if the second metatarsal is too long. The best results are observed when *the shortening of the metatarsal is generous* – avoiding deformity, recurrence, stiffness or pain, so that single second ray osteotomy is rarely performed.

Generally the shortening concerns several lesser metatarsals, as far as the four last metatarsals. A more delicate problem is the correction of the MTP subluxation: The BRT osteotomy can provide good results while additionally performing a Girdlerstone-Taylor I procedure. But in fact, in MTP dislocation, or even subluxation, which is in fact an early case of dislocation, the second metatarsal is usually too long, so that the Weil osteotomy is the most useful correction of this deformity.

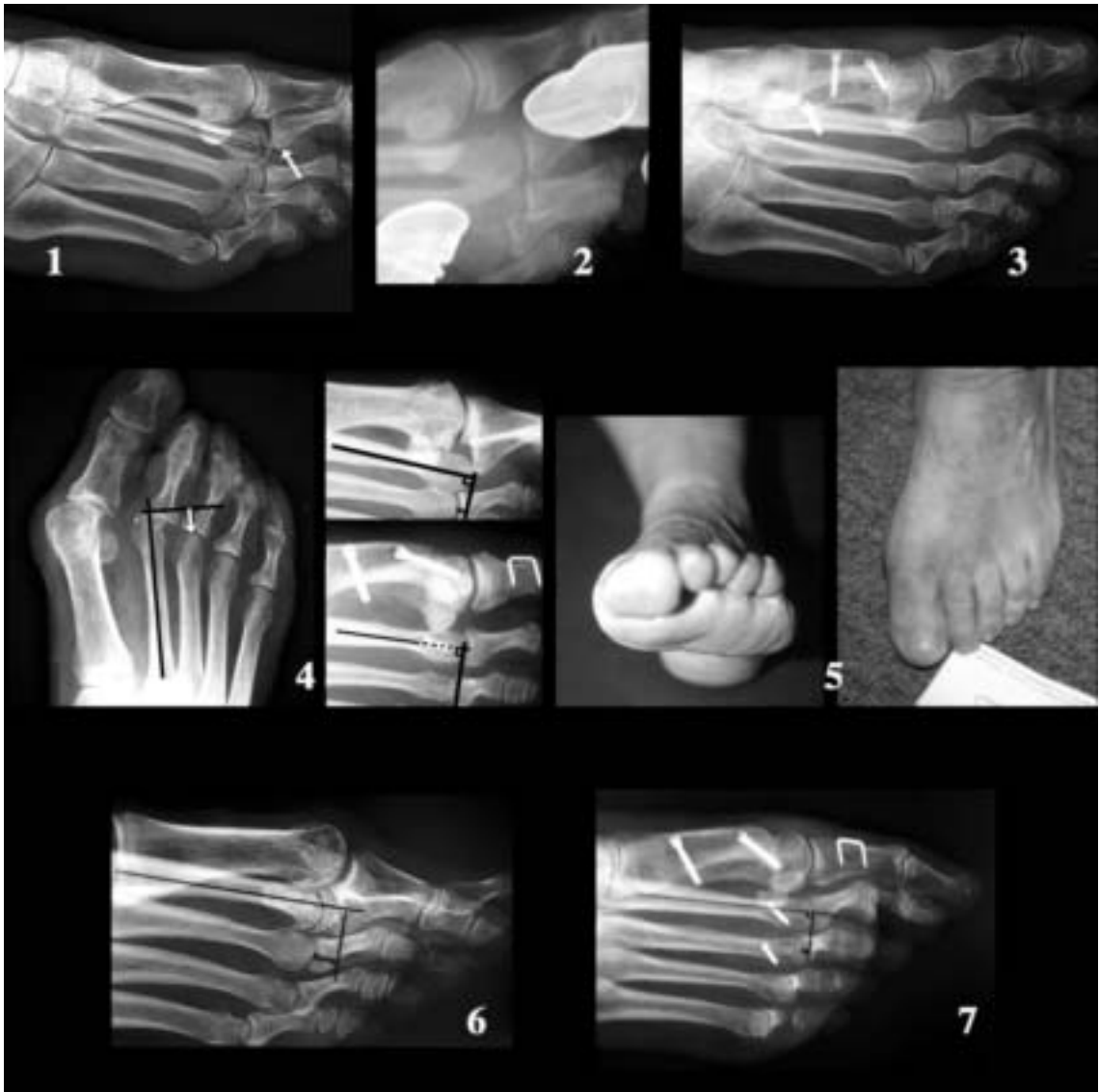

**Fig. 36d1.** Second ray pathology – MTP dislocation: (1) *The necessity of sufficient M2 shortening by Weil osteotomy.*

In MTP second ray dislocation (1), insufficient M2 shortening may result in painful and stiff MTP joint (2) and remaining subdislocation (3); 4, 5. In this case, the M2 shortening is correct, but the excess of M3 length on the medial oblique view explains the transfer metatarsalgia.



**Fig. 36d2. Second ray pathology – MTP dislocation: (2) The large shortening is effective.**  
1, 2. The large shortening is the best way to have a reliable correction of large or long-lasting MTP dislocation. In these two cases, note the complete forefoot joint preservation (including the second toe).



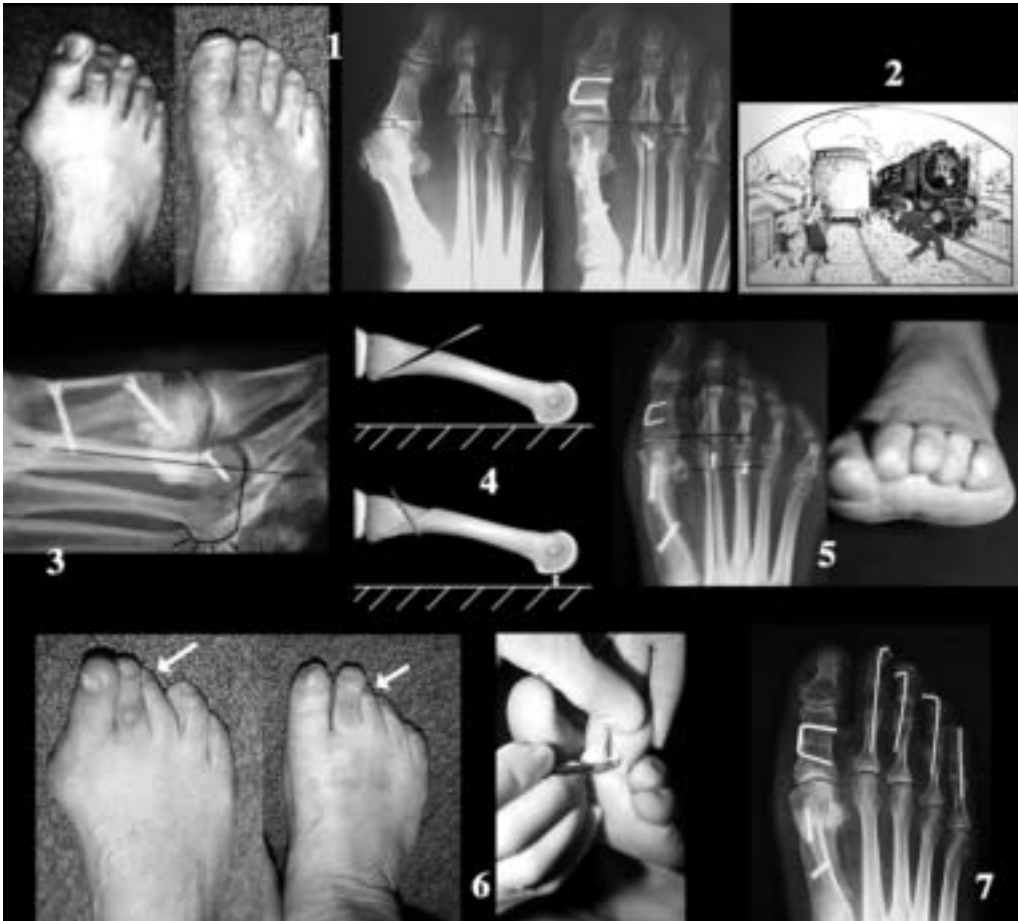**Fig. 36d3. MTP Second ray pathology – MTP subluxation: Respective place of the BRT and the Weil osteotomies.**

1, 2, 3. *BRT osteotomy.* The indication of this procedure is limited to *emerging MTP subluxation* clinically correctible, without too long second metatarsal. On this condition, the BRT osteotomy gives good results, combined to hammertoe correction.

4, 5. *Weil osteotomy.* When there is an emerging MTP dislocation (subdislocation, passively correctible on the foot examination), and when the *second metatarsal is too long both in dorso-plantar and above all in the medial oblique view*, we may perform Weil osteotomy just in the second metatarsal with a good result.

6, 7. *The shortening has to be assessed on the medial oblique view:* In this case, shortening of M2 is not sufficient: We also have to perform the shortening of the third metatarsal.

Anyway, *isolated second ray pathology is exceptional*: We have to take into account the disorders of the other rays.



**Fig. 36e. Second ray isolated pathology?**

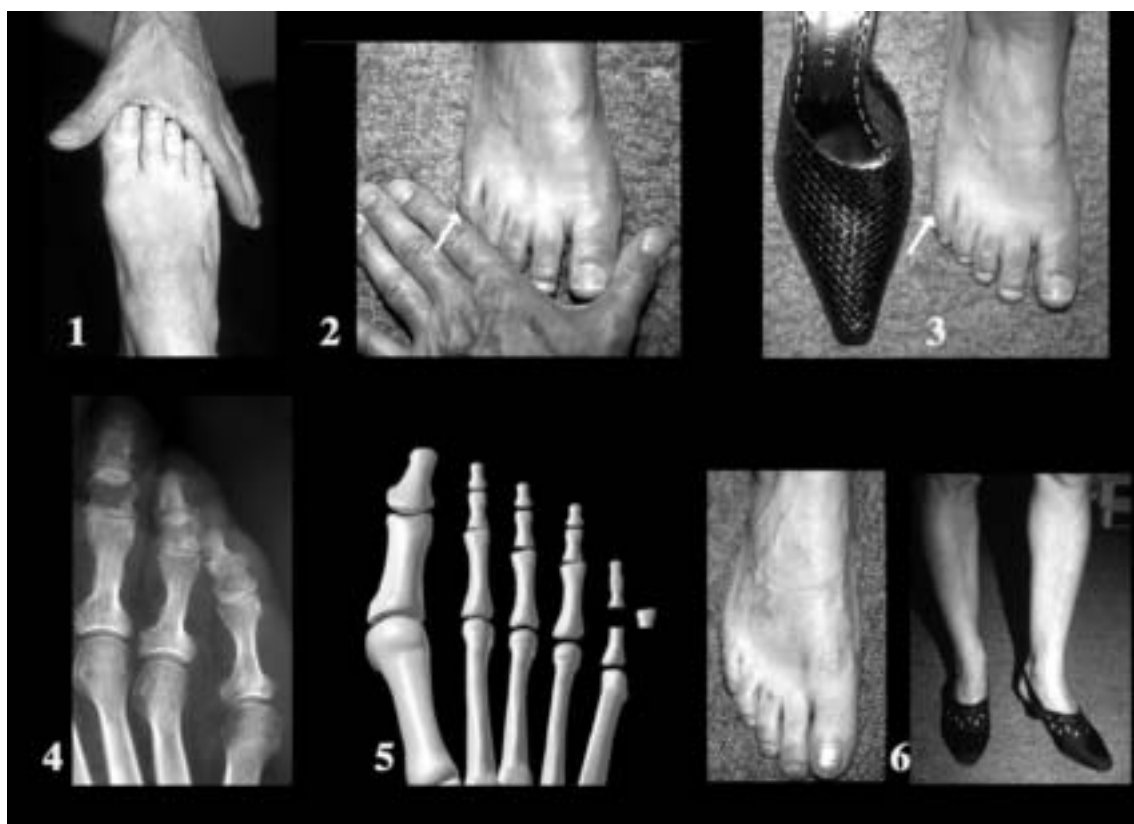
1. In most cases the second ray pathology is certainly not isolated, but combined with first ray pathology.
2. We have to take care to the adjacent rays (*a train may hide another one!*) because of transfer metatarsalgia, particularly on the third ray (3). To avoid this, we can perform BRT osteotomy (4) or extend the Weil osteotomy on the third metatarsal (or even more) (5).
6. We also have to take care to the remaining plantar flexion of the third toe (one solution is the distal long flexor section).
7. Example of K-wiring with soft tissue procedure of not only the second but also the others lesser toes.

## Some Pathologies of the Fifth Ray

French ladies are concerned by this fifth ray pathology because they like narrow shoes, and we observe that a narrow shoe is mainly obtained by narrowing the last and the sole on their lateral part.

### *Hammer or Claw Toe*

When the fifth toe is too long, it has no place in ladies shoes, so that the hammertoe has to be corrected and the fifth toe reduced. But the relationships with the fourth toe has to be taken into account, notably the long flexor tendon shortness.



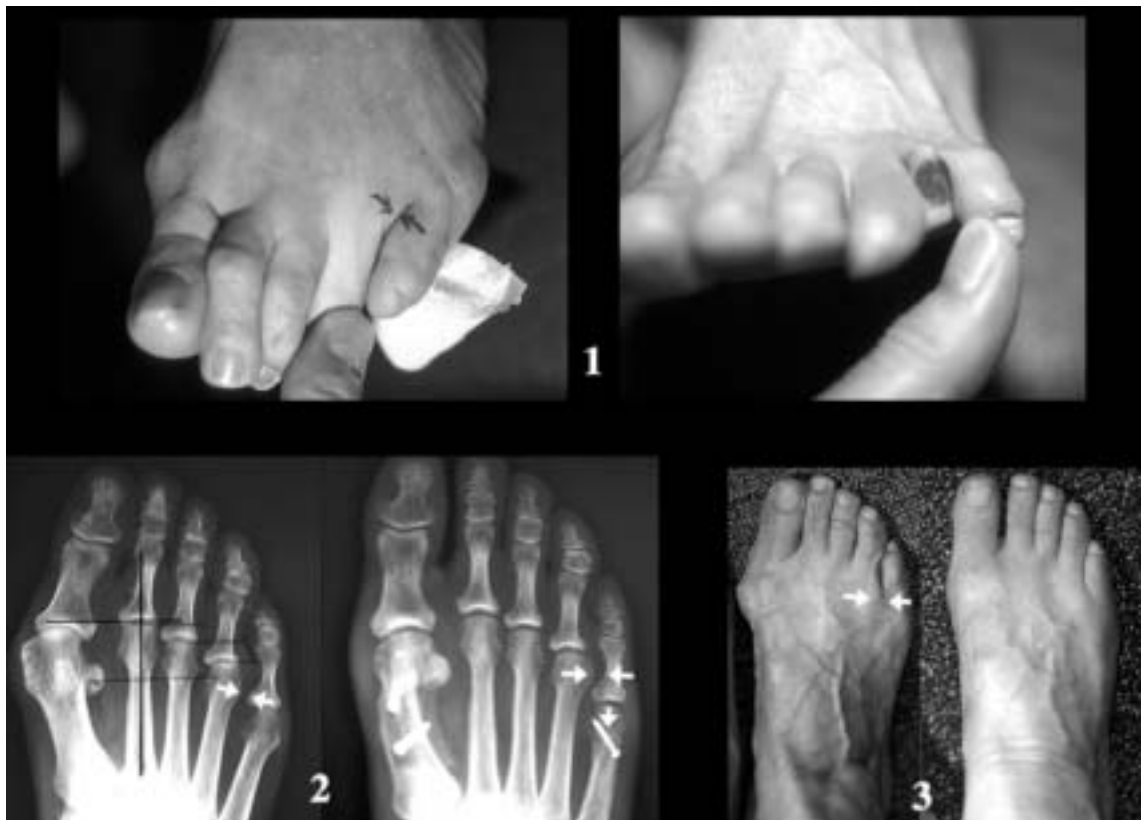**Fig. 37a. Some pathologies of the fifth ray – (1) Hammer or claw toe.**

1. The assessment of correct lateral shape (thus of the corresponding toe shortening) of the forefoot is made by this test.
- 2, 3. When the fifth toe is too long, it has no place in ladies shoes. This results in hammer or claw toe we have to correct while reducing the toe length.
4. In such hammertoe, we often observe that there are only *two phalanges* on the fifth toe.
5. We perform a distal resection of the first phalanx combined or not with a long flexor distal section and if necessary with extensor tendon lengthening. Sometimes we also have to correct the combined fourth toe deformity.
6. Our aim: The possibility for our patients to fit this type of shoe.

### ***Intercommissural Keratosis***

In this painful lesion, which is almost only located on the fourth interdigital proximal edge, we

observe that the main cause is an incorrect relationship between the last two metatarsal and phalanx, leading to a specific surgery.



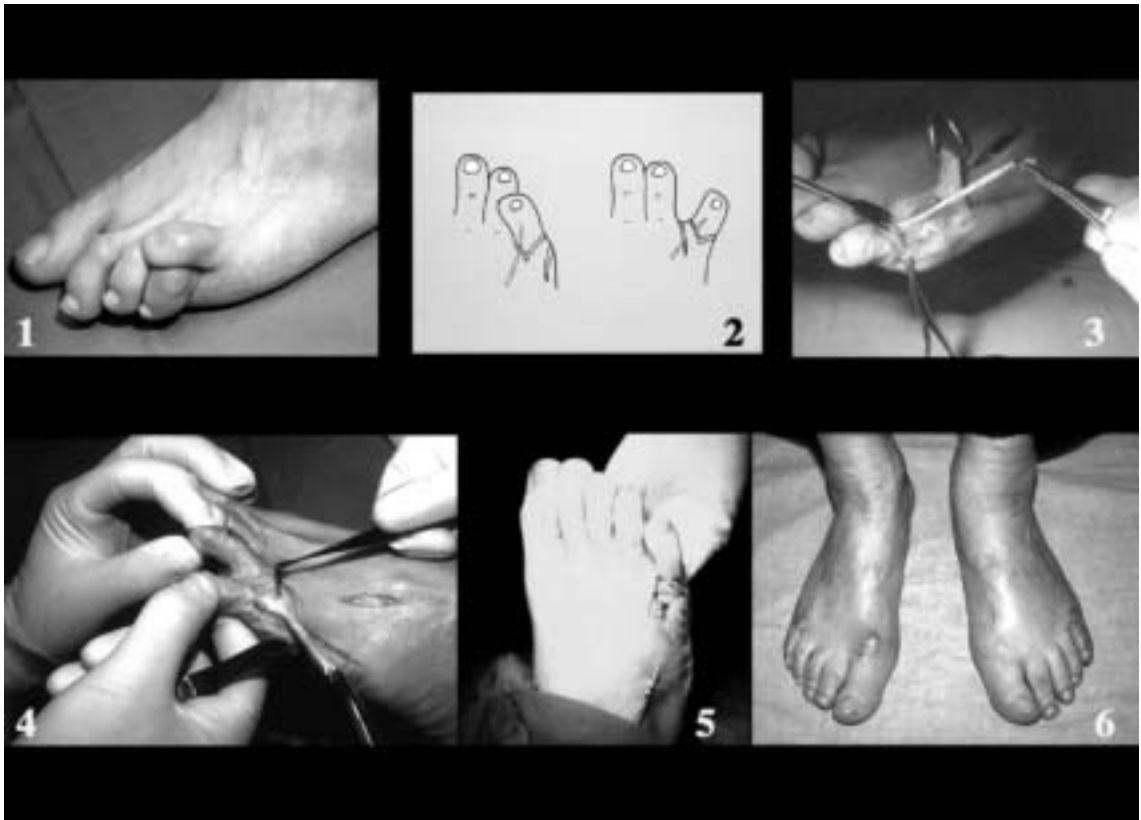**Fig. 37b. Some pathologies of the fifth ray – (2) Intractable intercommissural keratosis.**

1. This painful lesion may be explained in the dorso-plantar X-ray view (2). The lateral aspect of the fourth metatarsal head (sometimes too protuberant) has a too close contact with the medial aspect of the first phalanx of the fifth toe.

2, 3. The solution is a small shortening of the fourth metatarsal by scarf or Weil osteotomy (in this case, Weil).

## Overlapping Fifth Toe

The Lapidus procedure is a good solution for correcting this deformity, as indicated by P. Diebold (Nancy) [49] who provided the picture of this plate.



**Fig. 37c. Some pathologies of the fifth ray – (3) Overlapping fifth toe.**

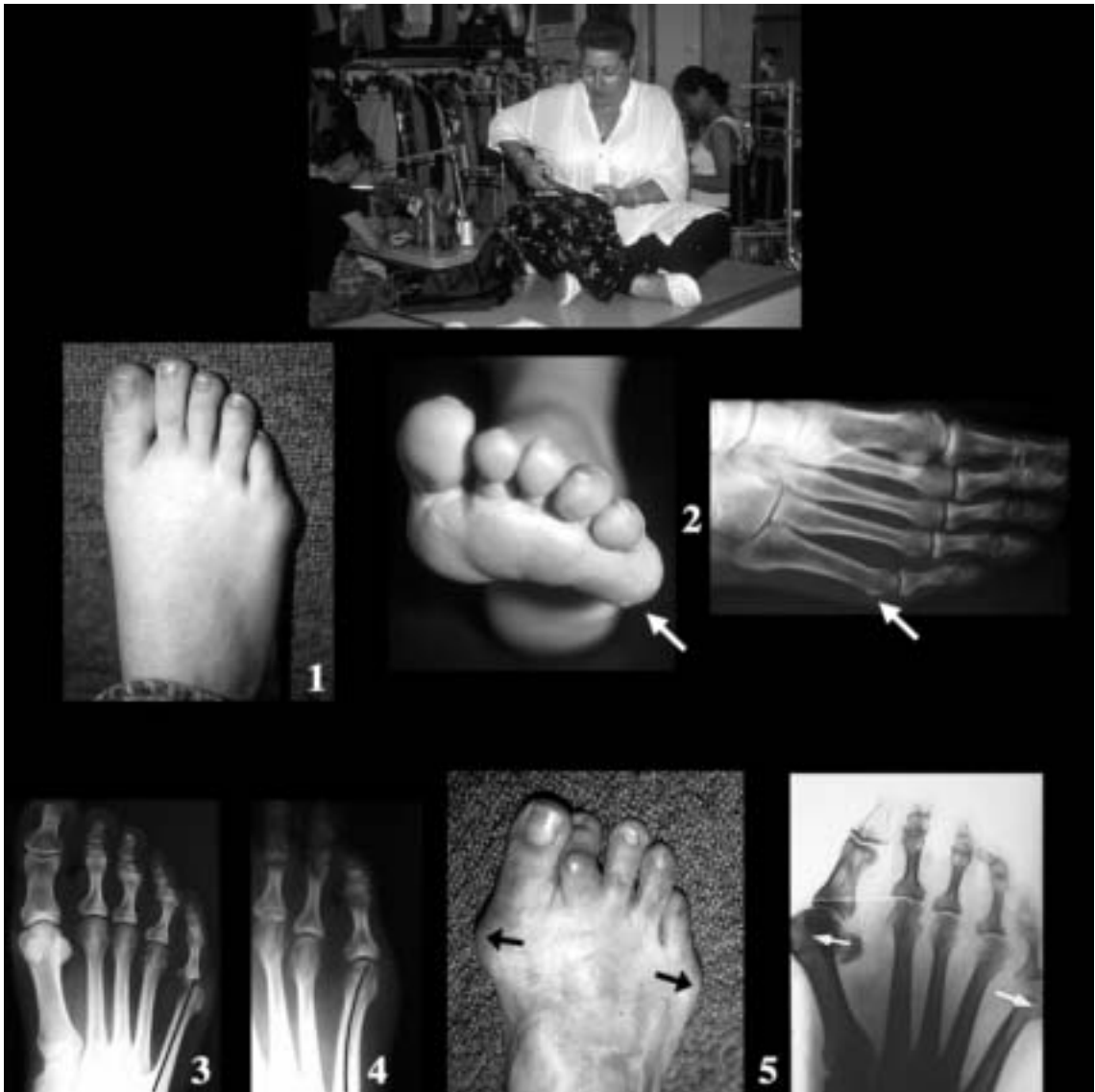*Lapidus procedure:* Pictures provided by courtesy of P. Diebold (Nancy, France).

1. Aspect of the deformity.
2. Skin flap to be performed.
3. Extensor tendon is cut proximally; it remains distally attached.
4. The tendon is passed through the phalanx basis, from dorsal to plantar face, then it is laterally and plantarly pulled and attached to the lateral capsule.
- 5, 6. Result.



## Taylor's Bunion

This interesting deformity presents some *anatomical specificities* we have studied. This led to a specific surgery.



**Fig. 37da. Some pathologies of the fifth ray. Taylor's bunion. Generalities.**

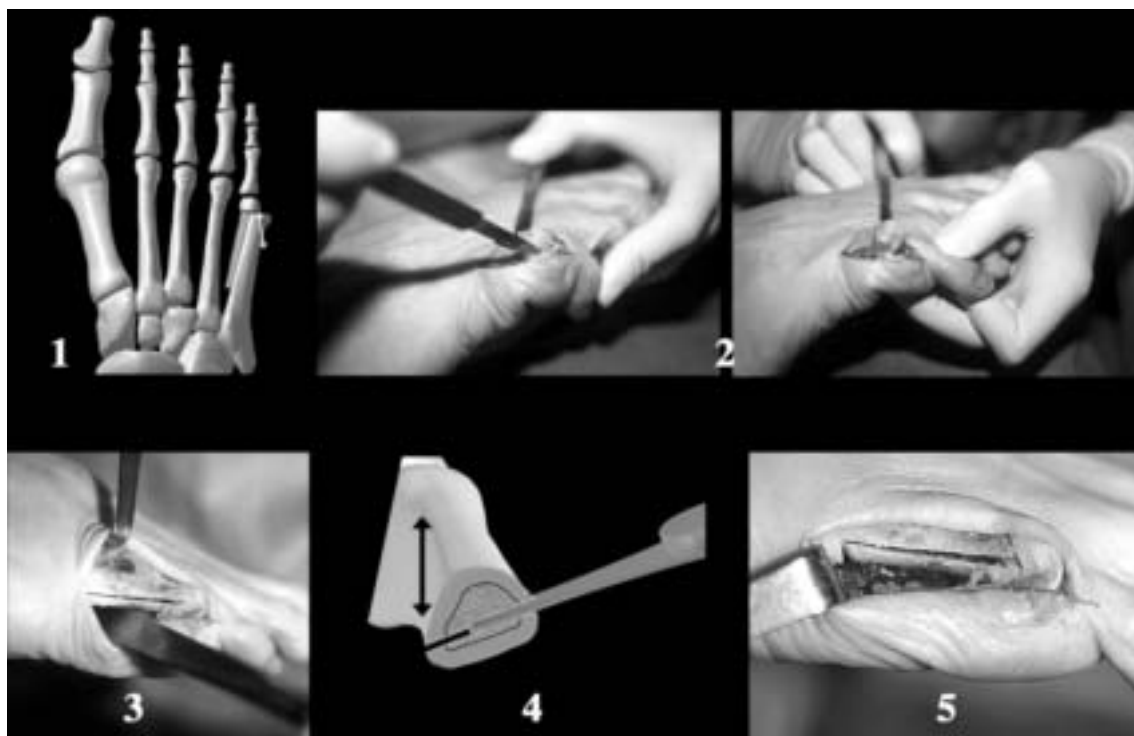
The Taylor's position (in the past) increased or provided the Taylor's bunion deformity.

1. The lateral part of the fifth metatarsal head is prominent, either by itself, or mainly as the top of the metatarso-phalangeal angulation.
2. In some cases, the prominence is also plantar.
- 3, 4. Two kinds of metatarsal shapes have to be distinguished:
3. Straight metatarsal. 4. Curved metatarsal "lame de sabre".
5. Diverging first and fifth metatarsals.

We think that, like for the first ray, *we have to keep the metatarsal head cartilage in a frontal plane*, so that we do not use osteotomies creating rotation of this head. Elevation or shortening are sometimes required in combination with the medial shift of the head. We use the *scarf* or *Weil* osteotomy with different indications, which are reported. The technique and the results for each procedure are detailed. In each of these techniques, section of the collate-

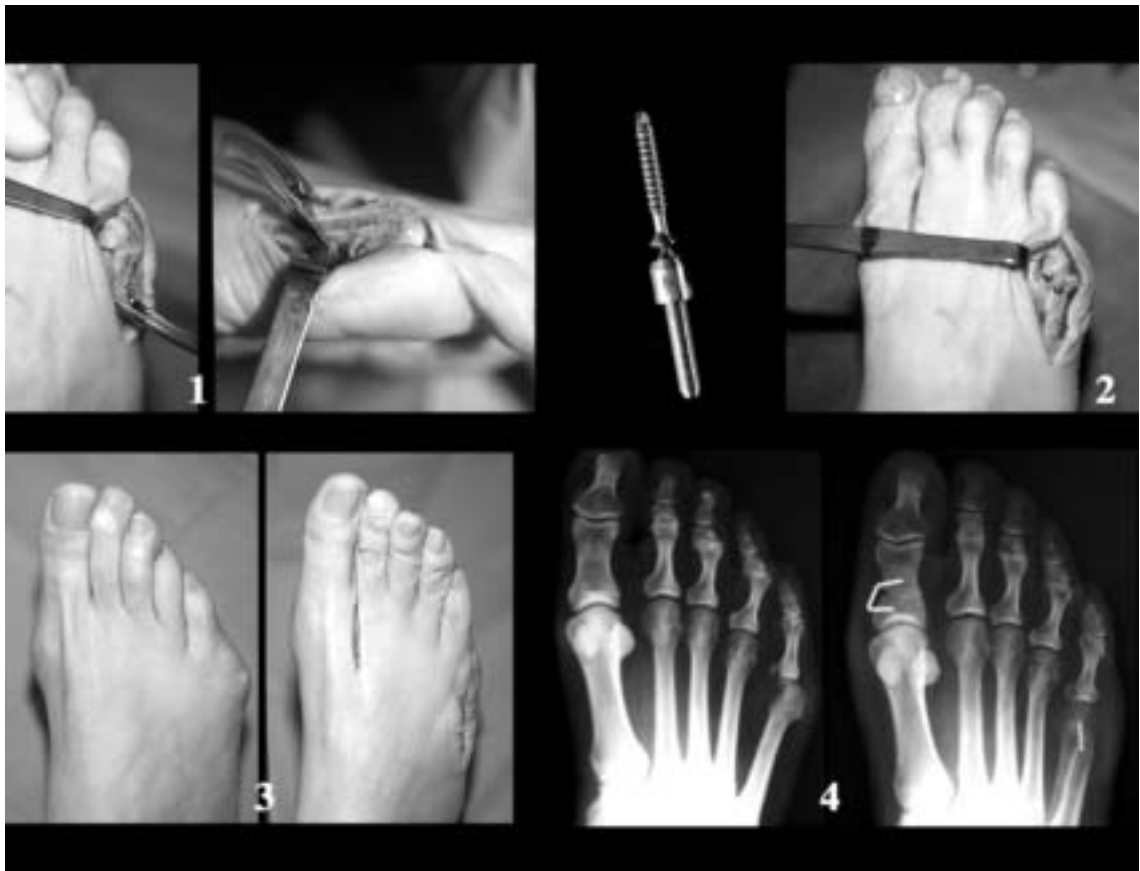ral ligaments is critical in making the approach to preserve a correct ground contact of the fifth toe. For isolated deformity, the scarf osteotomy is indicated. We reserve the Weil osteotomy when the fifth metatarsal osteotomy is combined with the other lesser metatarsal osteotomies.

The *fifth metatarsal scarf osteotomy*: An accurate technique allows to avoid drawbacks and provides reliable results.



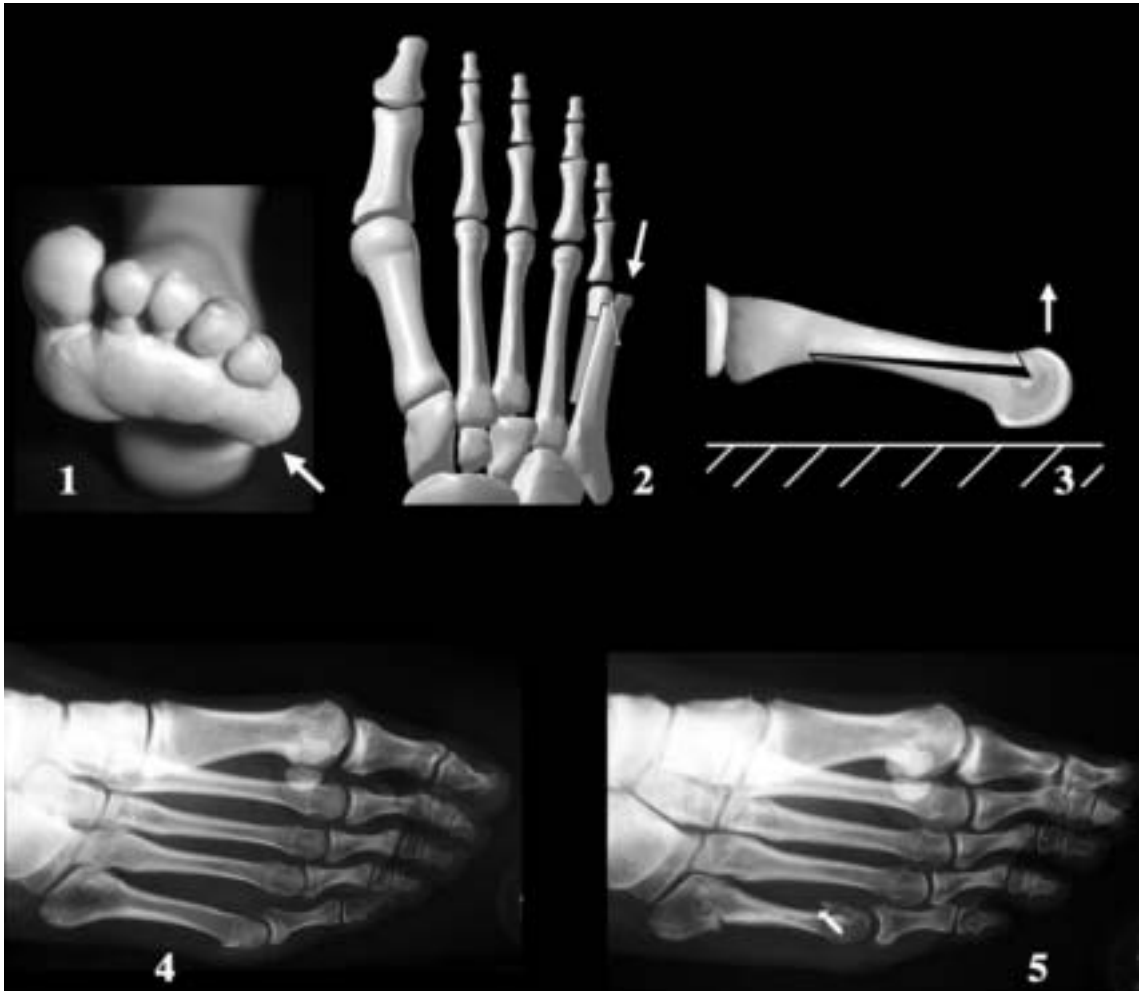
**Fig. 37db1. Taylor's bunion correction – (1) Scarf osteotomy. First steps.**

1. The long scarf osteotomy of the fifth metatarsal allows a large medial shift while keeping stability.
2. Section of the MTP collateral ligaments is necessary to avoid postoperative excessive dorsal flexion of the first phalanx.
- 3, 4. As for the first ray, the PPE (Proximal Plantar Exposure) allows to perform the longitudinal cut close to the plantar surface, so preserving the medial surface which works as a strong longitudinal beam, useful in large displacements. The large "ciseau de cauchoix" also allows to protect the soft tissue and to control the sawing for the proximal transverse cut.
5. Transverse cuts, chevron shaped, to increase the osteotomy stability. Nevertheless, screw fixation is useful.



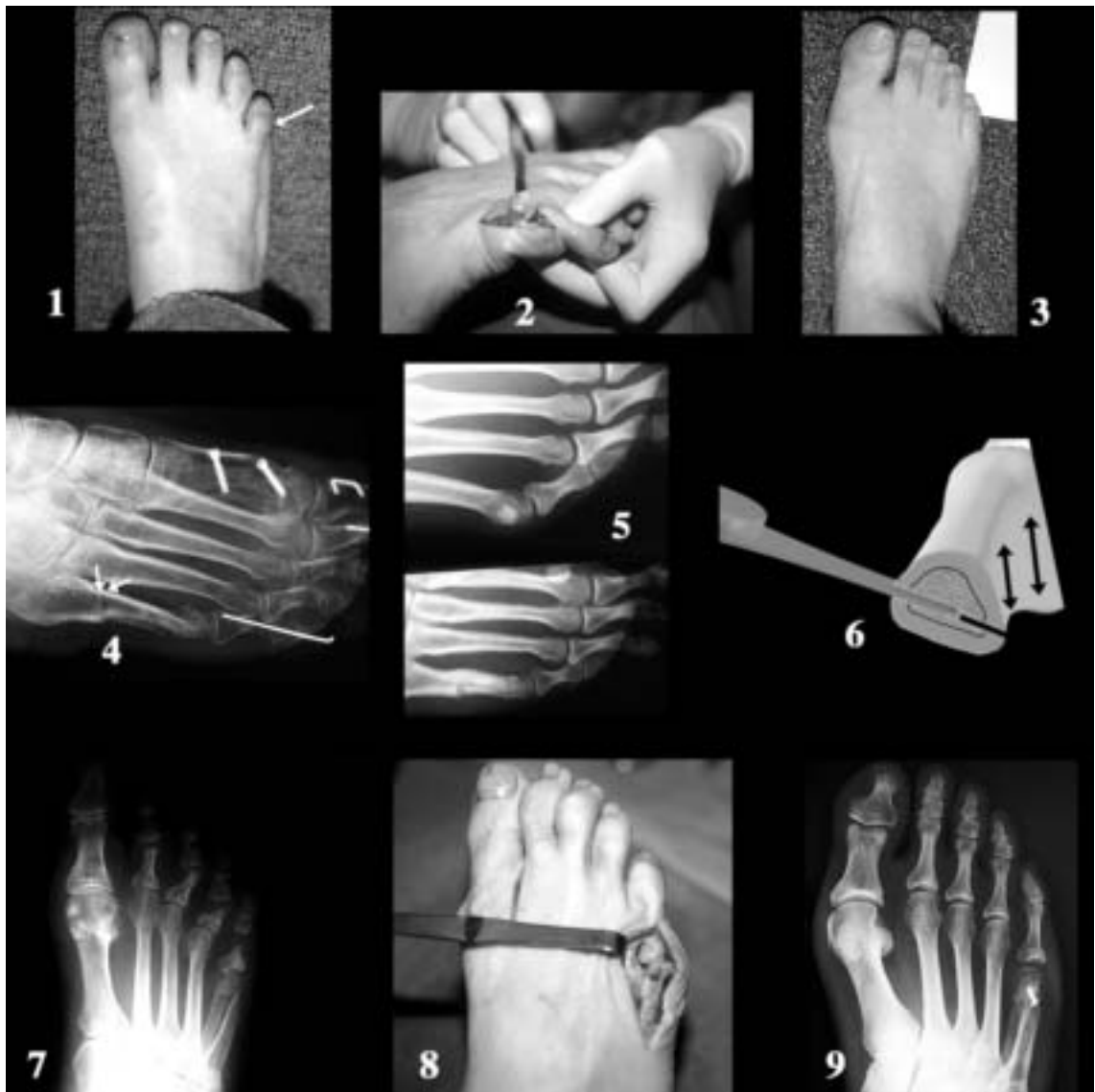**Fig. 37db2. Taylor's bunion correction – Scarf osteotomy. Lateral shift: Fixation.**

1. Medial displacement by lateral shift it is *not a medial rotation*, not to result in medial obliquity of the MTP joint. The plantar fragment can be pushed as far as two third of the surface.
2. The *twist-off screw* (DePuy) ensures strong fixation; its distal obliquity increases both the dorso-plantar and the longitudinal congruence of the fragments.
- 3, 4. Clinical and radiographic results.



**Fig. 37db3. Taylor's bunion correction – Scarf osteotomy. Shortening, elevation.**

1. Both lateral and plantar prominence.
2. Shortening with the Maestro cut.
3. A distal closing wedge is performed from the dorsal fragment; in order not to fragilize this fragment, the longitudinal cut has to reach the head in its central aspect (not too much dorsally).
4. Radiographic aspect of the fifth metatarsal elevation (here combined with shortening).



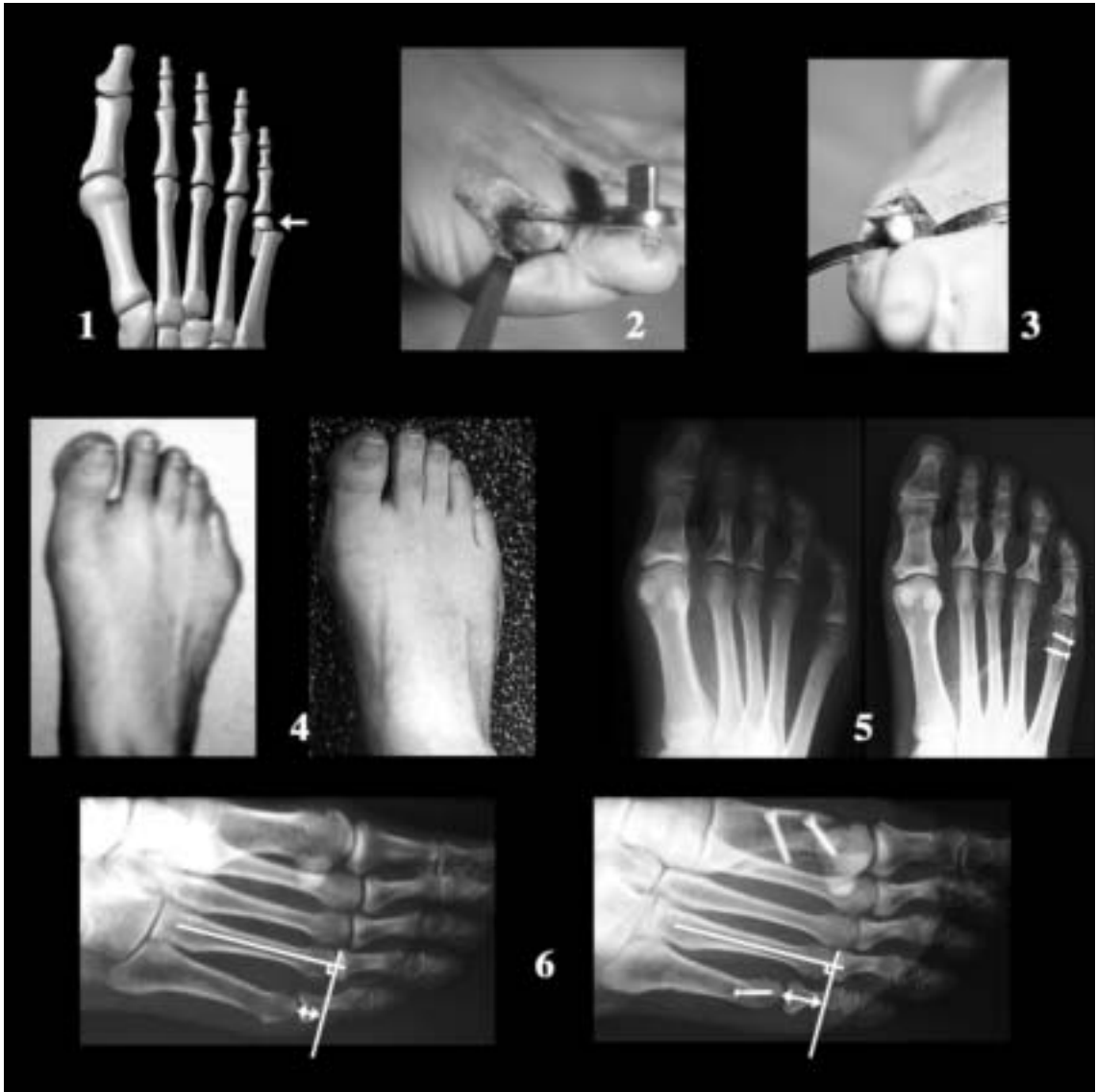**Fig. 37db4. Taylor's bunion correction – Scarf osteotomy. Drawbacks to avoid.**

1, 2, 3. Postoperative remaining hammertoe or claw toe is avoided by the collateral ligament section performed during the surgery.

4, 5, 6. Fracture of the dorsal fragment is observed at the level of the transverse proximal cut. The PPE allows to avoid this drawback by performing under sight control a longitudinal cut very close to the plantar fragment and the transverse cut which is not too generous (not on the dorsal fragment).

7, 8, 9. Overcorrection results from excessive medial shift of the plantar fragment. It can easily be avoided by the distal screwing.

The **Weil fifth metatarsal osteotomy**: We distinguish the single metatarsal and the osteo-  
tomy performed in combination with the other  
lesser metatarsal osteotomies.



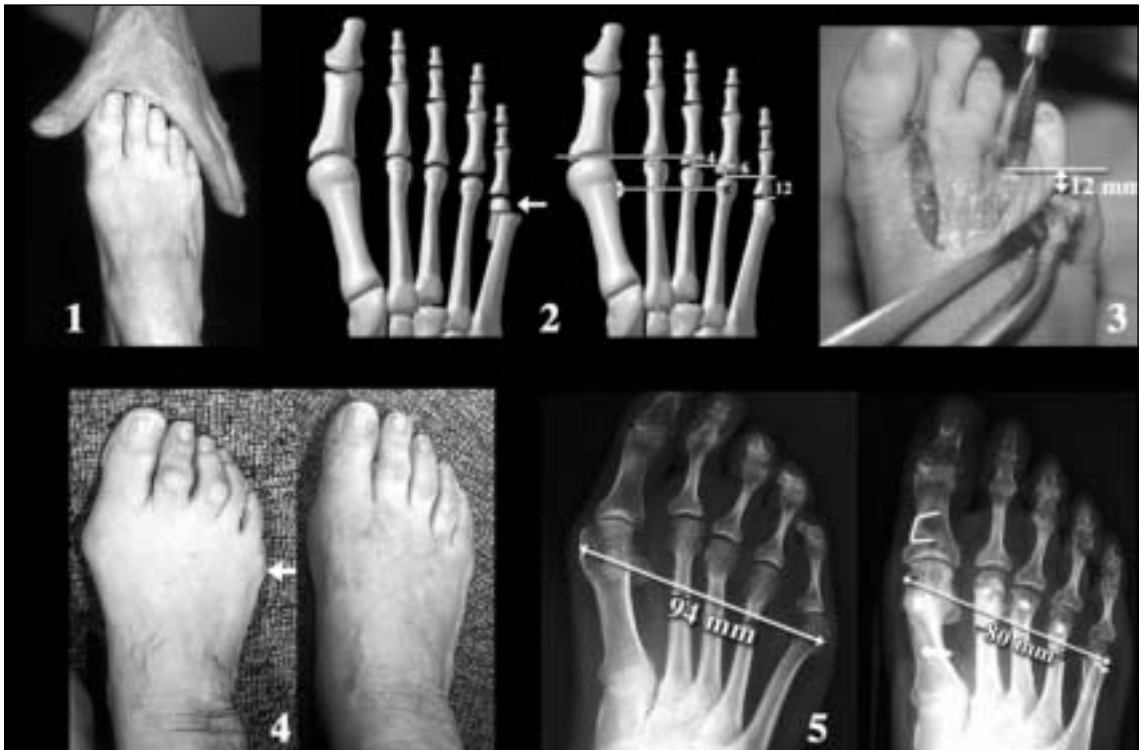**Fig. 37dc1. Taylor's bunion correction – Weil osteotomy. 1. Single metatarsal osteotomy.**

1. Medial head displacement by Weil osteotomy corrects the deformity.

2, 3. Operative view.

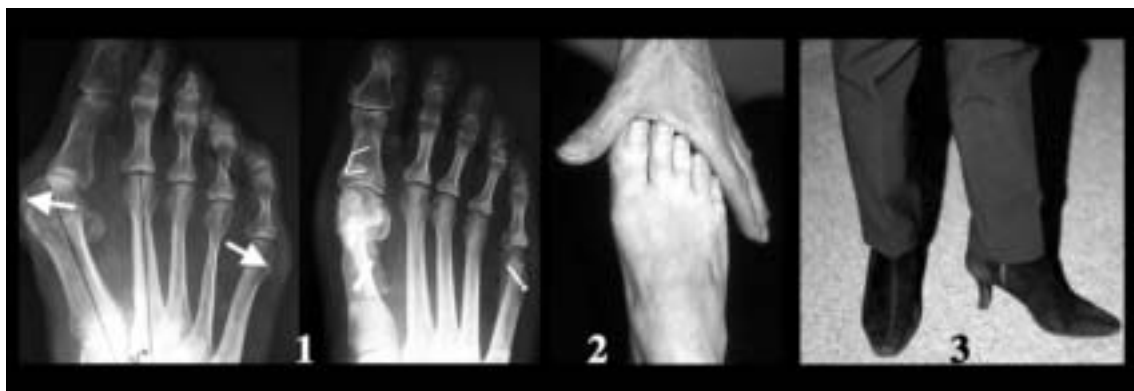4, 5. Clinical and radiological results.

6. Care has to be taken not to shorten excessively the fifth metatarsal which must not be 12 mm shorter than the fourth metatarsal.



**Fig. 36dc2. Taylor's bunion correction – Weil osteotomy. 2. Included in a whole lesser metatarsal shortening.** When Weil osteotomy is indicated on the four lesser metatarsals, it is easy to include a medial displacement of the fifth metatarsal head, to correct the combined Taylor's bunion, respecting the relative length of the metatarsals.  
4, 5. Clinical and radiological results.

The *aim of the tailor's bunion surgery* is not only to relieve the pain but also to narrow this lateral part of the foot that is critical for wearing elegant and narrow shoes.



**Fig. 37dc3. Taylor's bunion correction. Lady's footwear.**

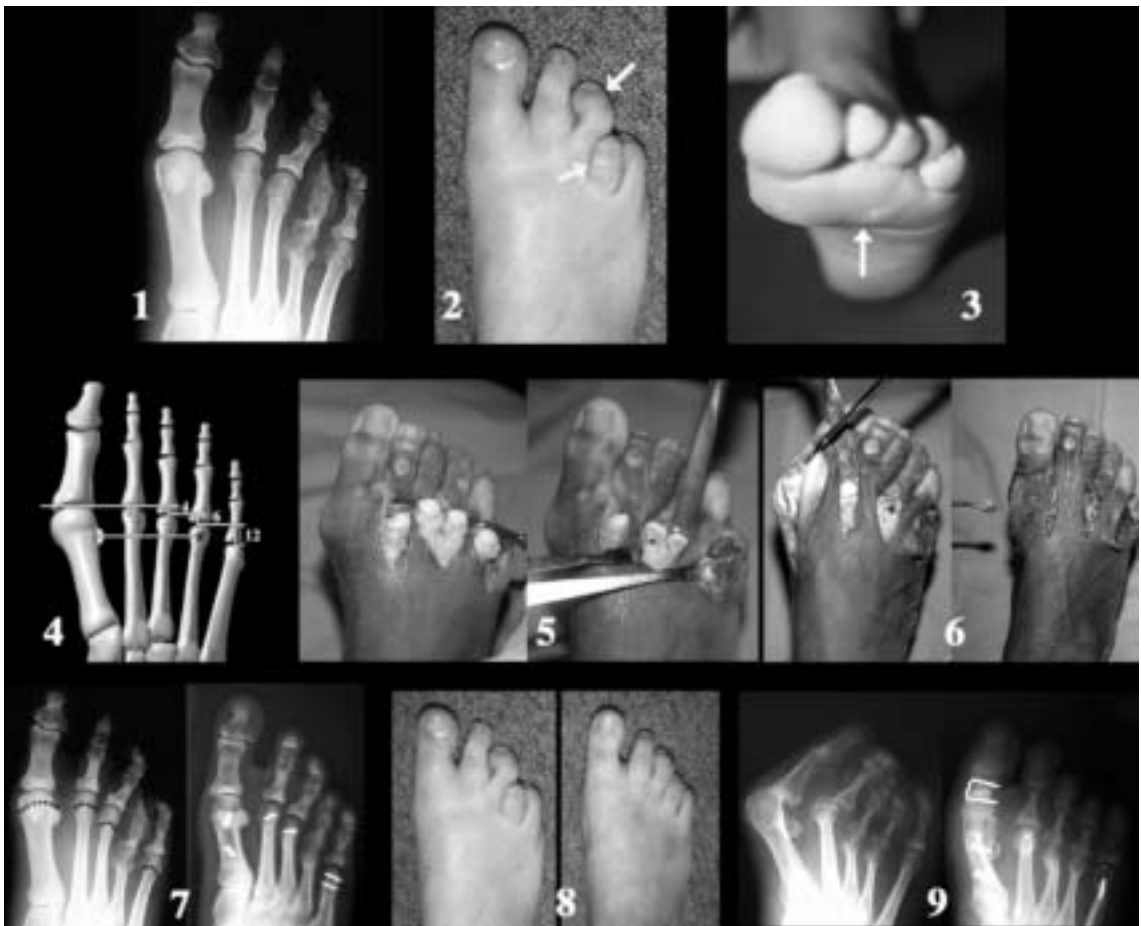1. Diverging first and fifth metatarsal can be corrected by scarf osteotomies on these two metatarsals: X-ray aspect.
2. Clinical aspects. In France women like narrow shoes (as well as in other countries!).



## Lesser Metatarsal Aplasia (Congenital Brachi Metatarsal)

We only have experience of this deformity for adult patients. This deformity may be painful not only on the corresponding short ray but also on adjacent metatarsals that have a relative

excessive length. In adults, lengthening of the brachi metatarsal is not a good solution. We prefer to shorten the other rays not quite as far as the short metatarsal, but trying to get a compromise which respects the rules of a correct metatarsal relative length and metatarsal parabola. This technique will relieve pain, preserve the cosmetic appearance and take into account the length of the contra-lateral foot for foot-wear.



**Fig. 38a. Congenital brachi metatarsal 1.**

1, 2, 3. This deformity may be painful on the corresponding short ray (dorsal flexion of the toe, painful MTP joint) or mostly on the adjacent rays: In this example metatarsalgia on the third ray. Since our cases are not adults, we do not lengthen the short metatarsal. On the contrary it is easy and harmless to shorten the other metatarsals.

4. Our aim is to reestablish as far as possible the metatarsal parabola.

5, 6. One example of brachi metatarsal on the second ray: We shorten the four other metatarsals: Excellent result.

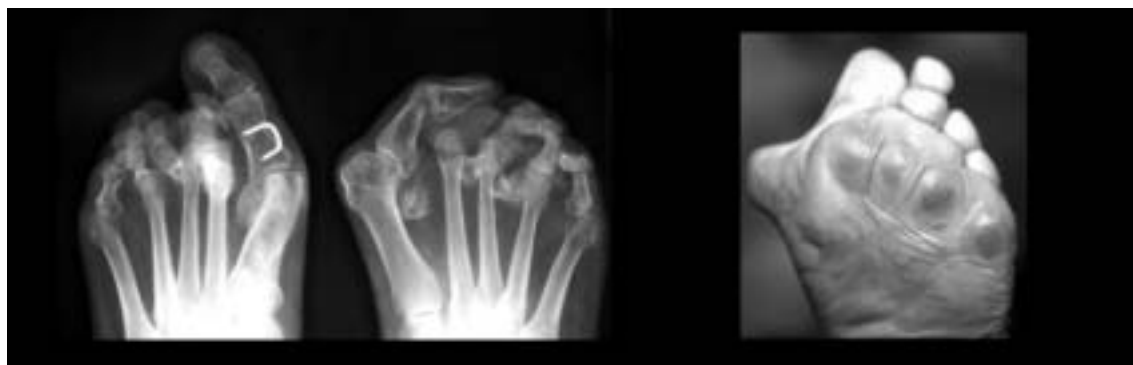7, 8. Brachi metatarsal on the fourth ray and the treatment.

9. Shortening of three rays.

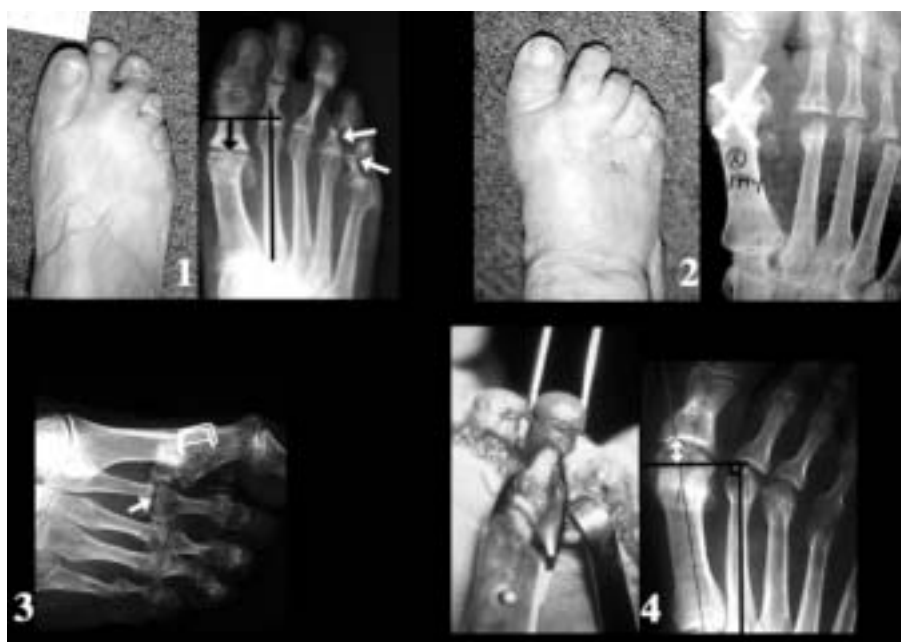## Severe Forefoot Disorders

joint preserving surgery instead of traditional joint sacrificing procedures.

In the majority of severe cases of forefoot deformities it is possible to carry out successful



**Fig. 39a1.** Severe forefoot disorders – *Current radiological and clinical aspects.*



**Fig. 39a2.** Severe forefoot disorders. *Some current procedures which can be avoided now.*

1. Keller procedure or first MTP prosthesis, PIP resection arthroplasty on the lesser toes.
2. “Systematic” first MTP fusion and lesser metatarsal resection (we perform these procedures but in limited indications).
3. Disorders resulting from anarchic metatarsal head resections.
4. Among these procedures, we have to distinguish the *Regnaud's* technique (that we made before the Weil osteotomy), which can provide good result while preserving the lesser metatarsal heads (enclavement). However it is unpredictable concerning the blood supply of the metatarsal heads, and on the other hand the shortening of the first metatarsal was not performed (only the first phalanx shortening). So this procedure was indicated above all in case of index minus metatarsal formula.

Ten years ago, we were perplexed when a patient came in consultation with painful severe forefoot disorders. Now, we are not only embarrassed, but we can offer our patients joint preservative solutions, with a painless postoperative period and notable functional recovery. So, faced with the anxiety of such patients, often already operated several times, we can now bring a peaceful and confident glance for both reassure the patients and treat correctly its severe forefoot disorders.

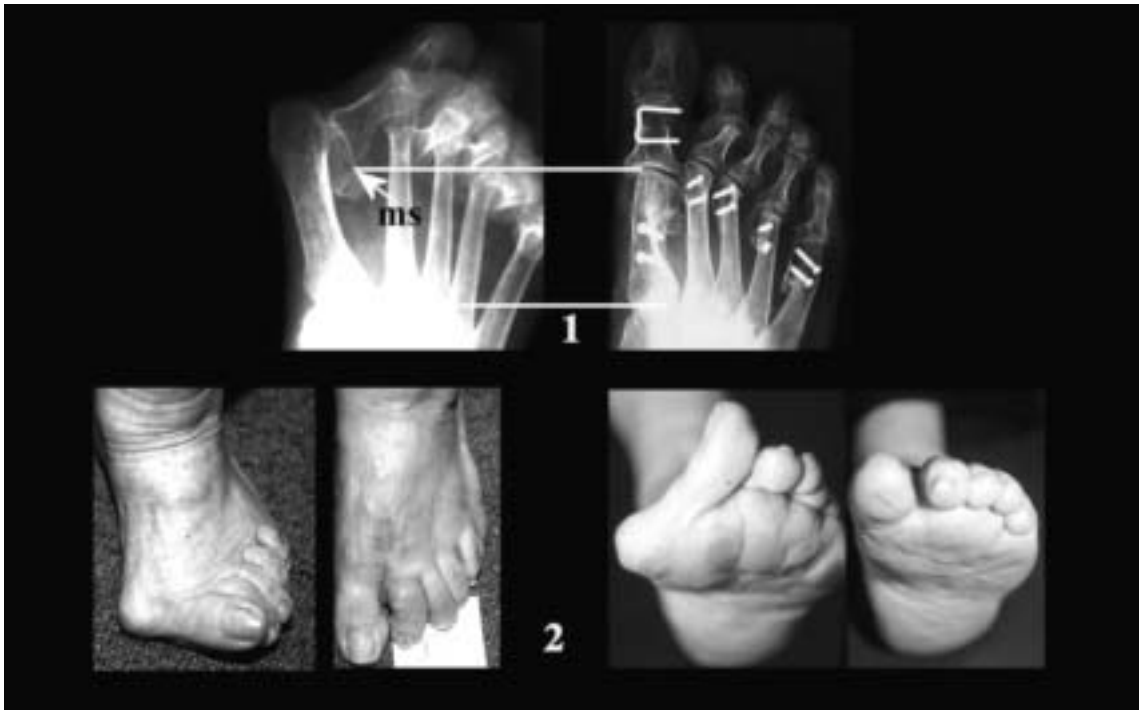Our decisive case was performed in October 1993 (Fig. 39a3). We were surprised when we observed the good results, first immediately in the postoperative period, then year by year and at last with six years follow-up. This case encouraged us to continue in this therapeutic way. ***The key to the severe forefoot disorders treatment is certainly the longitudinal decompression provided by the large and harmonized metatarsal shortening.***

***The amount of metatarsal shortening*** is assessed clinically and radiologically.

*Clinically*, this is above all reliable *in the first ray*, notably by the observation of the first

MTP passive dorsal flexion with a maneuver trying to correct the intermetatarsal angle and the hallux valgus deformity. *In case of loss of MTP dorsal flexion, the first metatarsal shortening is indicated:* However, a more accurate assessment is made *intraoperatively* after MTP lateral release and M1 medial approach. *We usually observed that 1/2 cm M1 shortening increases the MTP dorsal flexion up to 30°.*

*Radiographically*, we observed that both good correction of the hallux valgus deformity and improvement of the MTP are obtained when shortening is up to the X-ray level of the most proximal part of the first phalanx: It is the ***ms point*** noted in many pictures of this book. In cases where the shortening is less, the result is insufficient. This is reliable *whatever the considered ray (first ray, lesser rays)*. This may be assessed on dorso-plantar X-ray views but also in the medial oblique view. This ms point is useful for the assessment of metatarsal shortening in the following cases: MTP dislocation, severe hammer or claw toes, or lateral deviation such as lateral wind-swept toes deformities as well as advanced hallux valgus deformity.

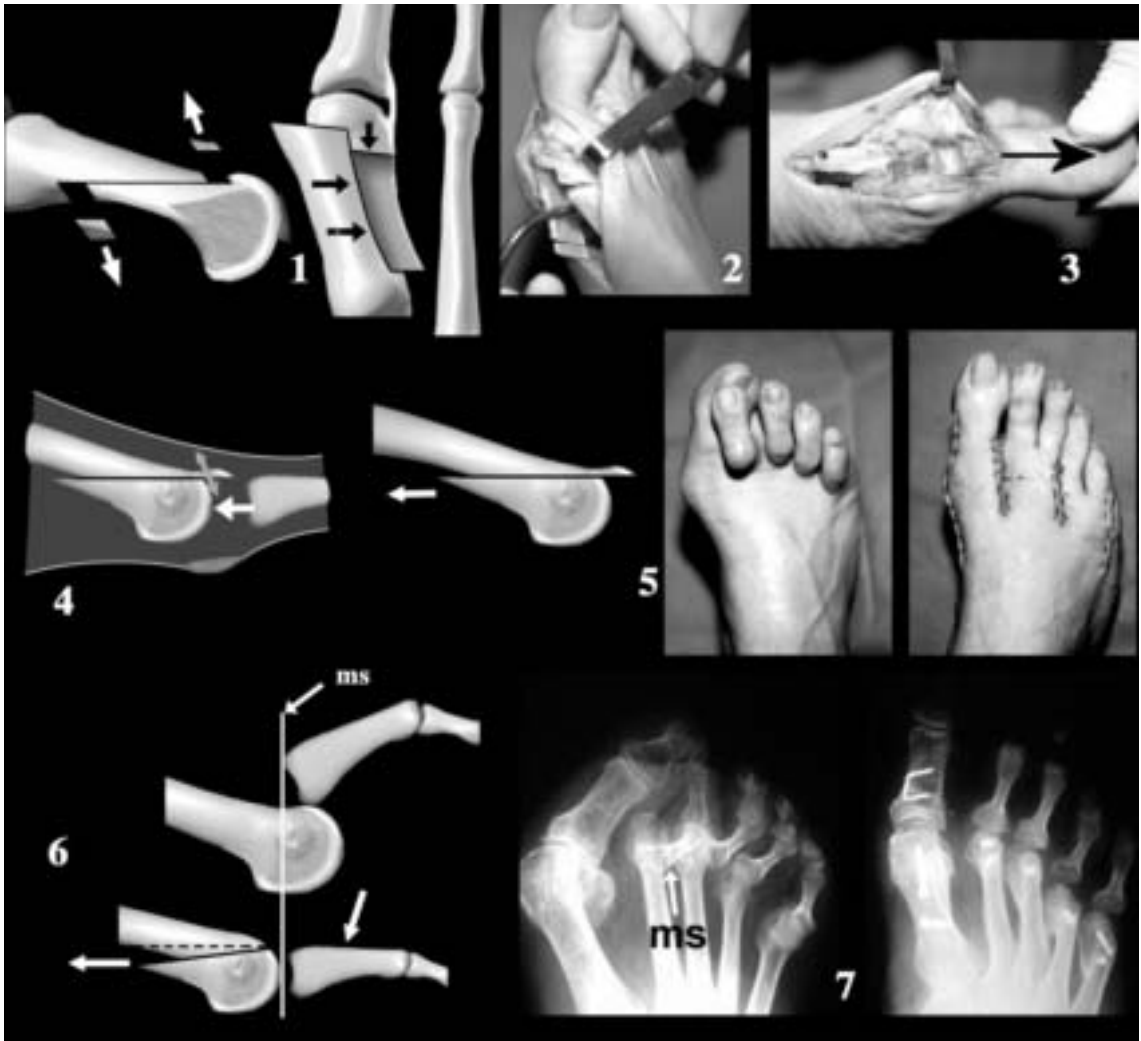


**Fig. 39a3. Our deciding case to preserve MTP joints in severe forefoot disorders.**

In October 1993, I attempted for the first time to correct this severe forefoot disorder, while preserving the MTP joints, thanks to the shortening of the metatarsals (scarf and Weil osteotomies). In this picture we show the results six years after this procedure (October 1999). This case was deciding to carry on such joint preservation in severe forefoot disorders.

We observe that this result is obtained with the following amount of shortening: the remaining first metatarsal length is located on the basis of the proximal phalanx of the great toe in the P reoperative X-ray: this is the *ms* (Metatarsal Shortening) *point*.

In this case, we observed that the hallux valgus correction is stable as well as the correction of the MTP dislocation of the lesser rays. Nevertheless, we also observe that the second metatarsal remains too long: Secondary we performed PIP resection arthroplasty on the second toe, which is not a good procedure. We also observe that the great toe remains too long: Now we avoid these problems.



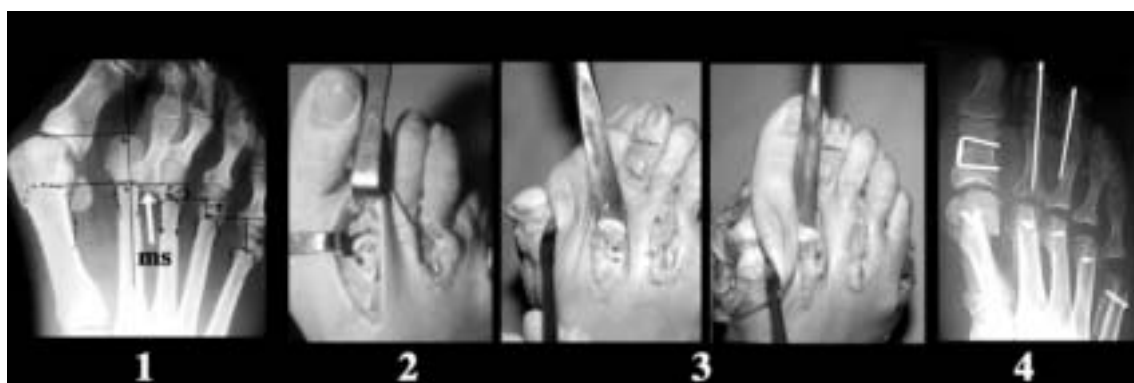**Fig. 39b1. Severe forefoot disorders – Longitudinal decompression by shortening of the metatarsals: Surgical principles.**

1, 2, 3. First metatarsal shortening by *M scarf osteotomy* with the Maestro technique, which increases the fragmental contact and preserves the TP lateral ligament. This results in longitudinal decompression of the MTP joint (3) which allows the correction of both severe hallux valgus and impaired MTP joint.

4, 5. *Weil lesser metatarsal osteotomy* provides a predictable and reliable shortening of the metatarsals while preserving the head with its blood supply. The resulting longitudinal decompression allows relief of metatarsalgia as well as correction of any toe deformity.

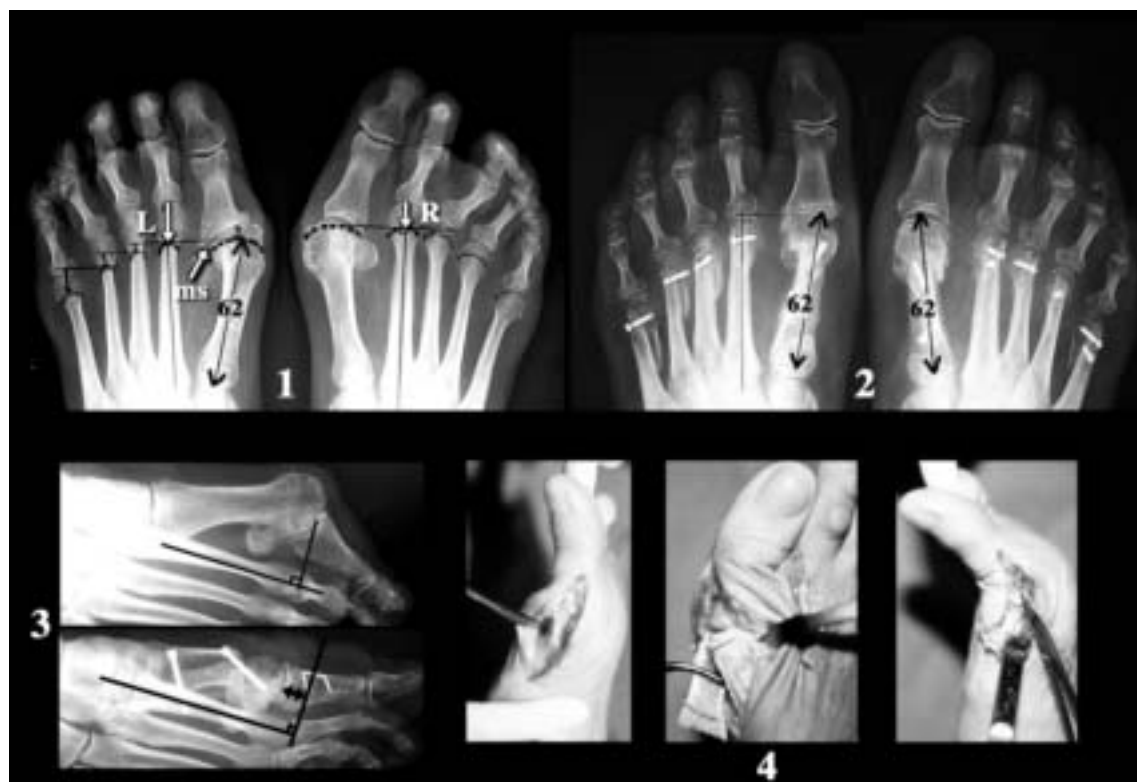
6, 7. In *MTP dislocation*, the proximal sliding has to be as large as the *metatarsal phalangeal over riding (ms point)*.

*We observe that the best results were obtained with these two conditions: Large and harmonized shortening of the metatarsals.*



**Fig. 39b2a. Severe forefoot disorders – Management when the lesser rays are the most impaired.**

1. In this case, the most impaired or deformed ray is the second one.
2. So we focus the surgery on this ray (it is the most common impaired ray): Shortening as far as to obtain the correction of the MTP dislocation (Weil osteotomy).
- 3, 4. Then harmonizing the other metatarsals (in this case particularly the first one).



**Fig. 39b2b. Severe forefoot disorders – Management when the first ray is the most impaired.**

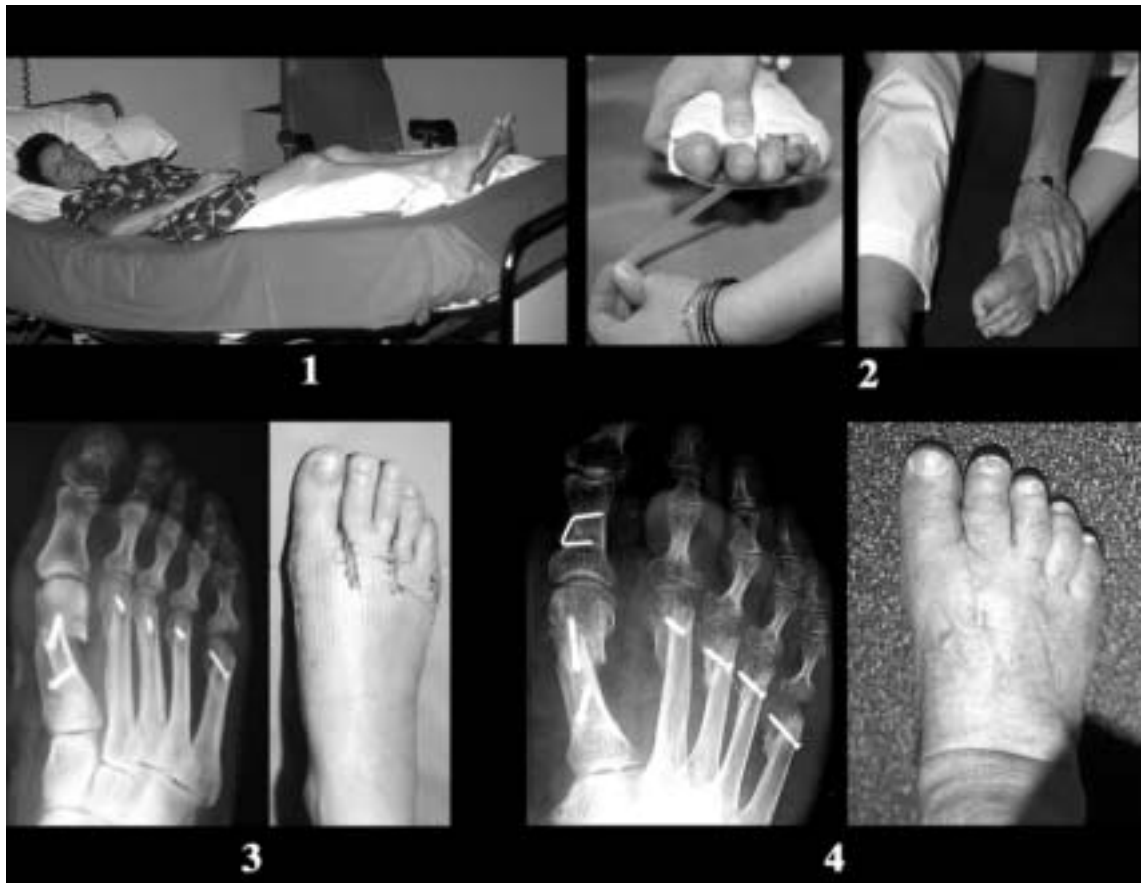- 1, 2. The amount of shortening (ms point) is determined from the first metatarsal of the *left* foot, but is *applied on contra-lateral* foot: We observe that this shortening, which allows preservation of the MTP joint, is finally almost the same as for the MTP fusion of this joint; good result with this amount of shortening.
- 3, 4. Recovering of the MTP dorsal flexion needs to shorten the first metatarsal.

## Postoperative Aspects

Certainly, surgery of severe forefoot disorders is more invasive than for single bunion. Two days at the hospital are recommended instead of one day. However, we observe that both postopera-

tive edema and pain are minimum, but on the condition to perform a large shortening of the metatarsals.

This large shortening is also a solution to decrease or to avoid the Reflex Sympathetic Syndrome (RSDS).



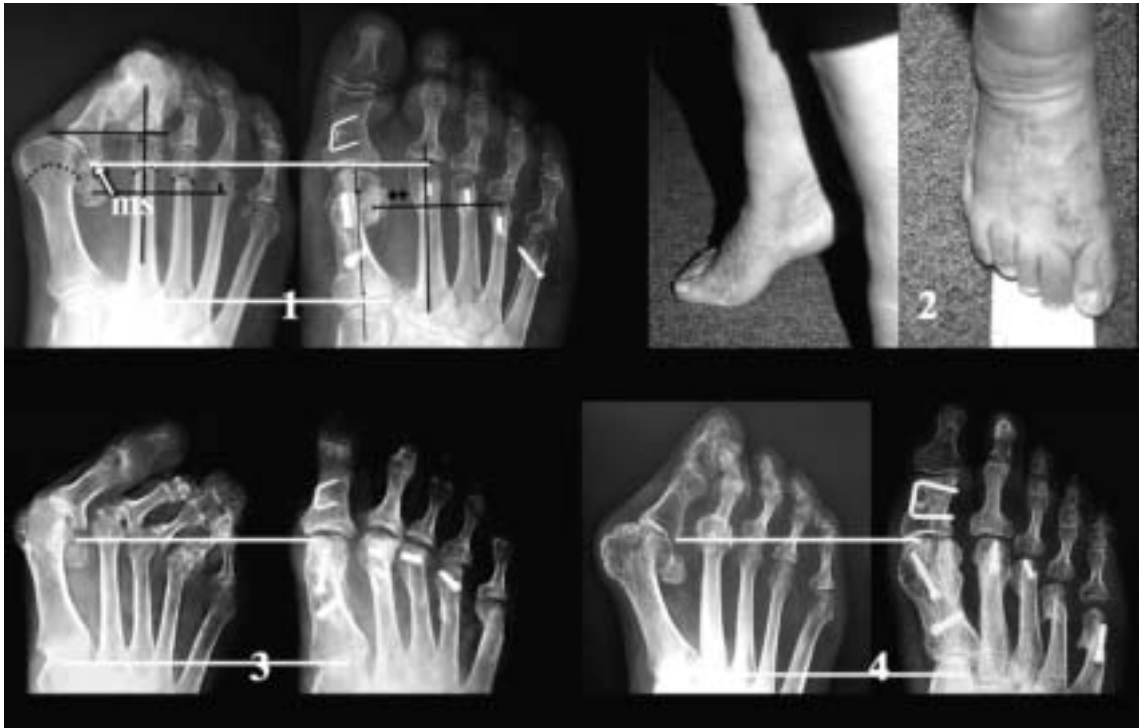
**Fig. 39b3. Severe forefoot disorders – Postoperative aspects.**

1. Elevation of the foot is a rule to diminish edema. So, in this case, a minimum of “two days surgery” instead of “one day surgery”.
2. Toes strapping and self-training are also essential.
3. With large metatarsal shortening, no pain and minimum swelling of the foot in postoperative period.
4. Complex Regional Pain Syndrome (CRPS) occurs more often than for less invasive surgery, but it is usually relieved by Thyrocalcitonin injections without retaining too much stiffness. However, *CRPS is now much more seldom since we make a larger shortening of the metatarsals.*

**Application to the Main Types of Forefoot Severe Disorders**

main severe static troubles of the forefoot: for example, advanced and iatrogenic hallux valgus, MTP dislocation or severe metatarsalgia and claw toes.

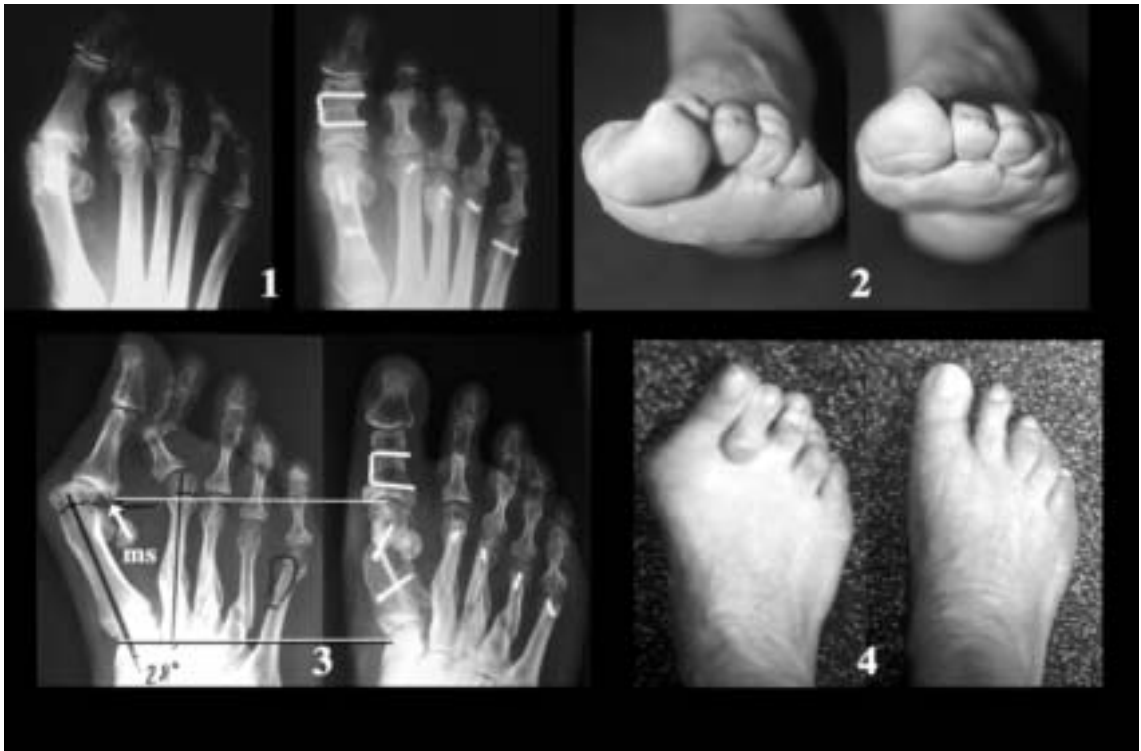In the following plates, we find the application of this metatarsal shortening procedure in the



**Fig. 39c1a. Severe forefoot disorders – *Advanced hallux valgus deformity.***

1, 2, 3. There is no more problem to obtain a reliable correction whatever the deformity but, once again, with large shortening of the metatarsals. (1, 2. Same case). These three cases: two years follow-up.

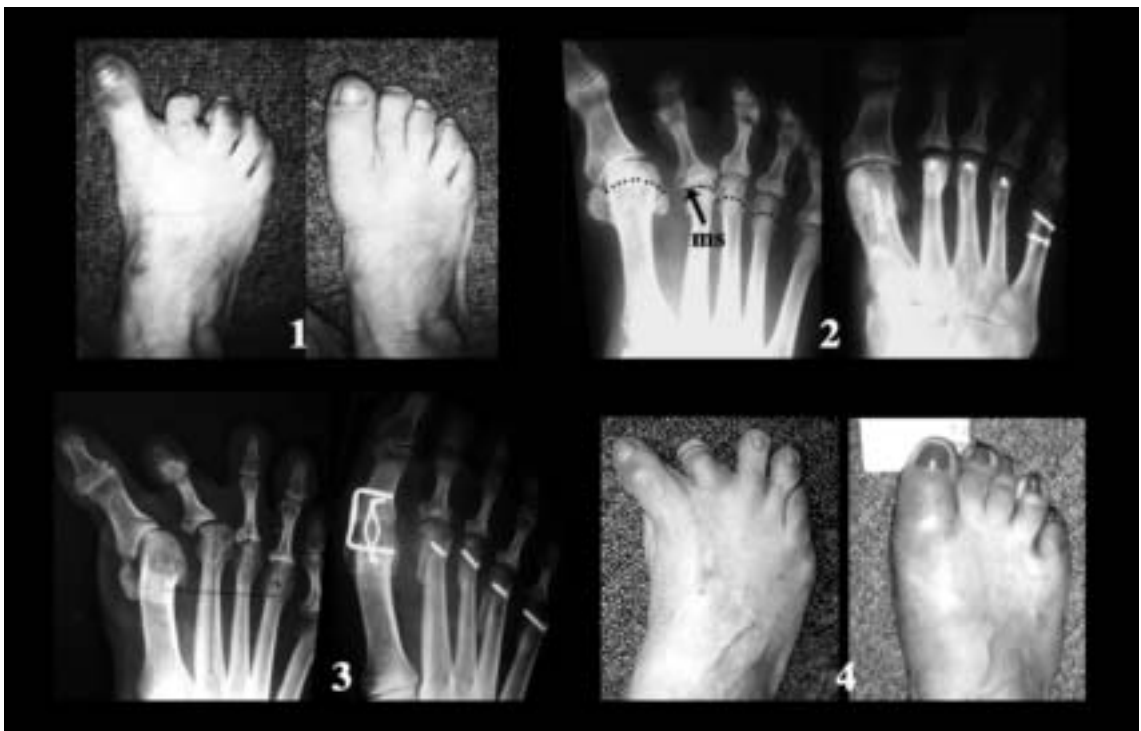



**Fig. 39c1b. Severe forefoot disorders – Failed bunionectomy: Joint preservative treatment.**

1, 2. It is easy to correct this failed bunionectomy with the shortening of the metatarsals.

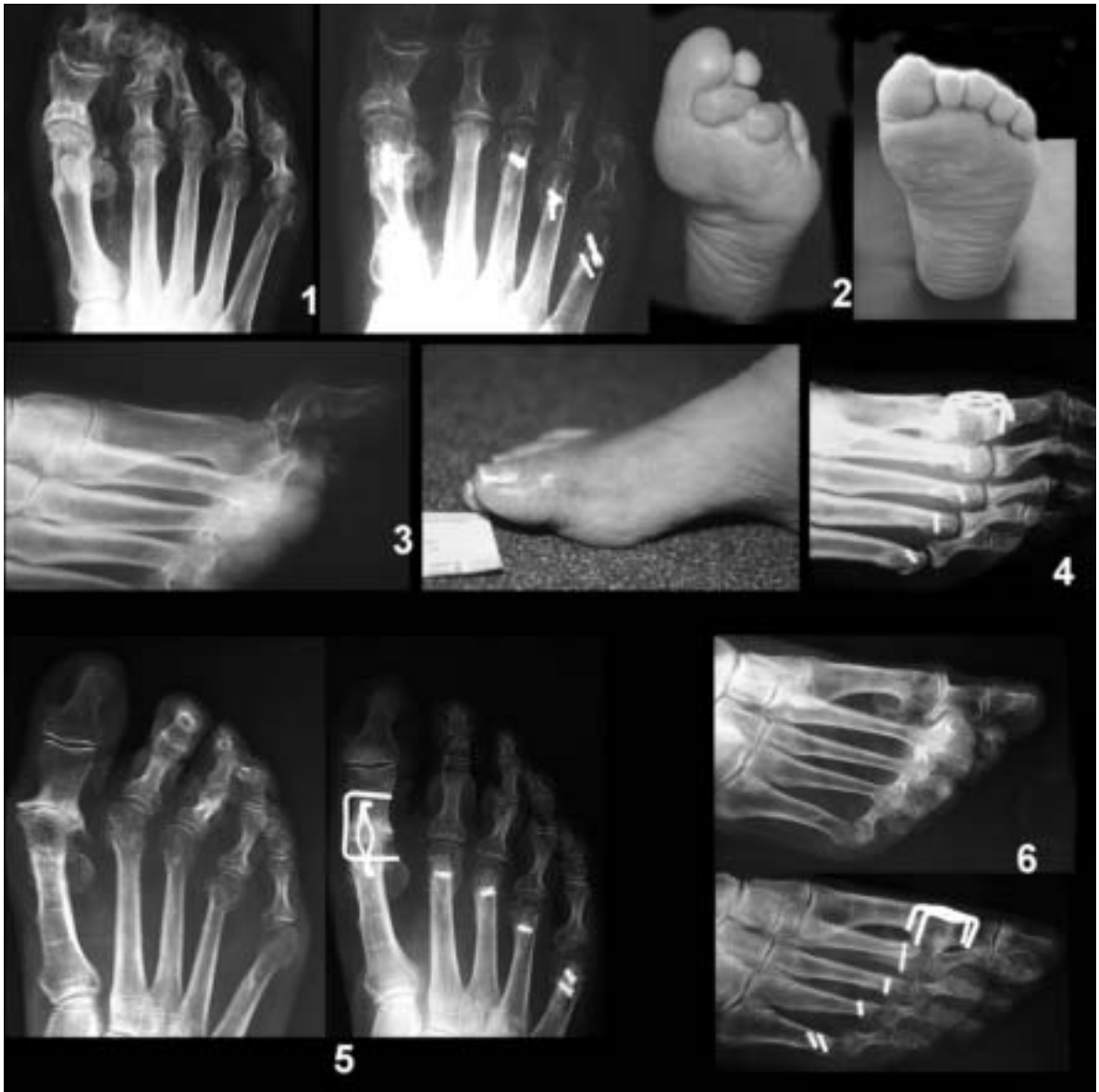
3, 4. Other example of severe failed bunionectomy; *ms*: Metatarsal shortening level.



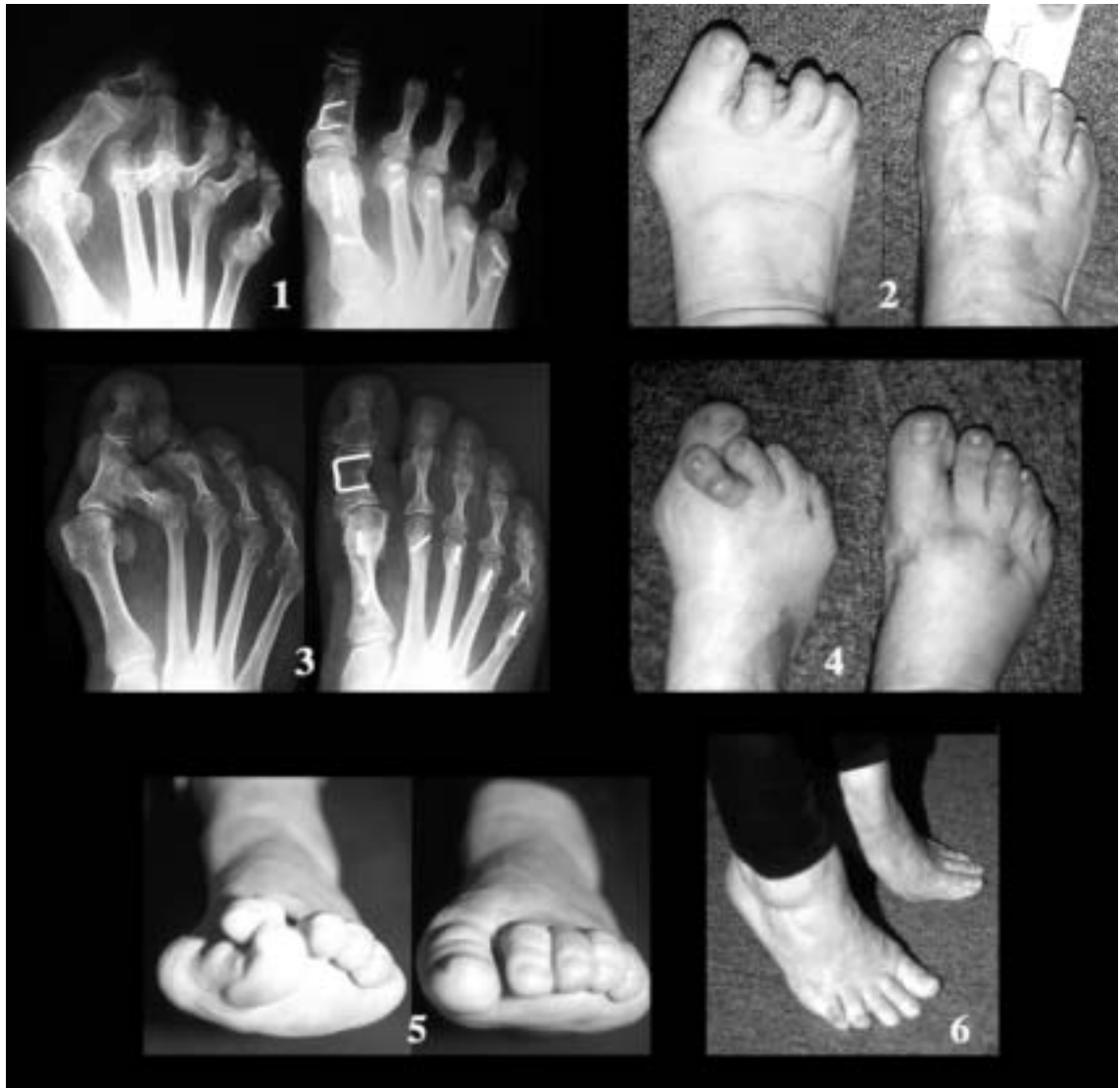**Fig. 39c1c. Severe forefoot disorders – Failed bunionectomy: Overcorrection.**

1, 2. Overcorrection is also well corrected, with *joint preservation*, but we have to take care to the possibility of first metatarsal head necrosis (rare when the metatarsal shortening is performed).

3, 4. In *severe* and long-lasting overcorrection, the most reliable treatment is first MTP *joint fusion* and Weil osteotomy on the lesser metatarsals.



**Fig. 39c1d. Severe forefoot disorders – Failed bunionectomy: After Keller procedure.**  
 Articular preservation 1-2 in this case where there is sufficient active MTP motion and not too much pain, articular preservation by scarf osteotomy (and combined Weil osteotomy if necessary) is a good solution.  
 MTP fusion and weil osteotomy of the lesser rays: it is an excellent solution in the following cases : 3-4 after Keller procedure followed by loss of great toe ground contact. 5-6 Keller followed by painful and stiff MTP joint and lesser rays metatarsal.



*Fig. 39c2. Severe forefoot disorders – Some examples of correction with joint preservation.*

1, 2. MTP dislocation: Correction with complete joint preservation thanks to harmonized metatarsal shortening.

3, 4. Medial wind-swept toes: Same remarks.

5, 6. Metatarsalgia relieving and good function.

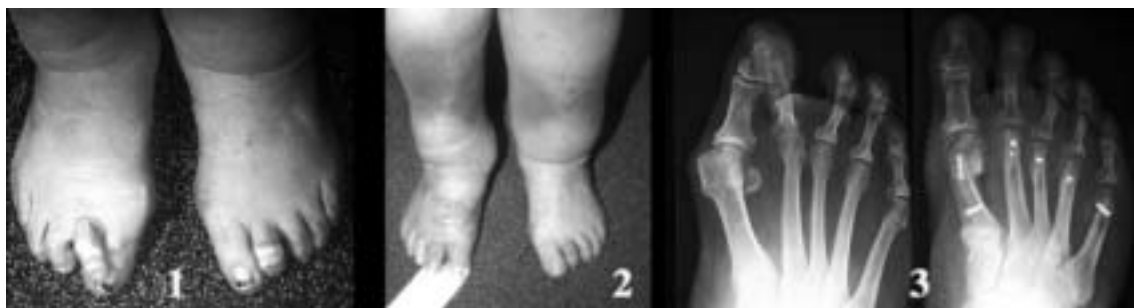### **Limits, Problems and Long-Term Result of Such Joint Preservative Surgery**

Our questions were: Are trophic troubles a real contraindication to this joint preservative surgery? What about the foot length diminution?

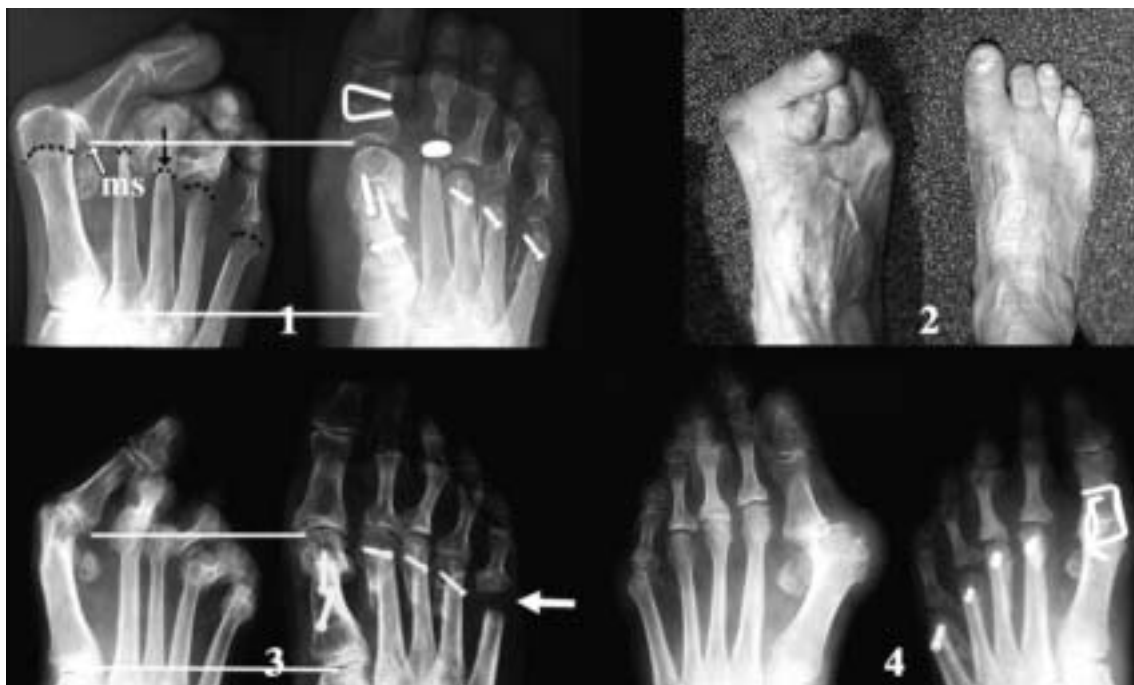Certainly, joint preservation has *limits*, but these limits are now far away. So that we still

perform the traditional first MTP fusion and metatarsal head resection, but only when it is necessary – *i.e.* rarely. On the last feet with severe deformity operated on, the average rate was: Head preservation 88%, head resection 12%.

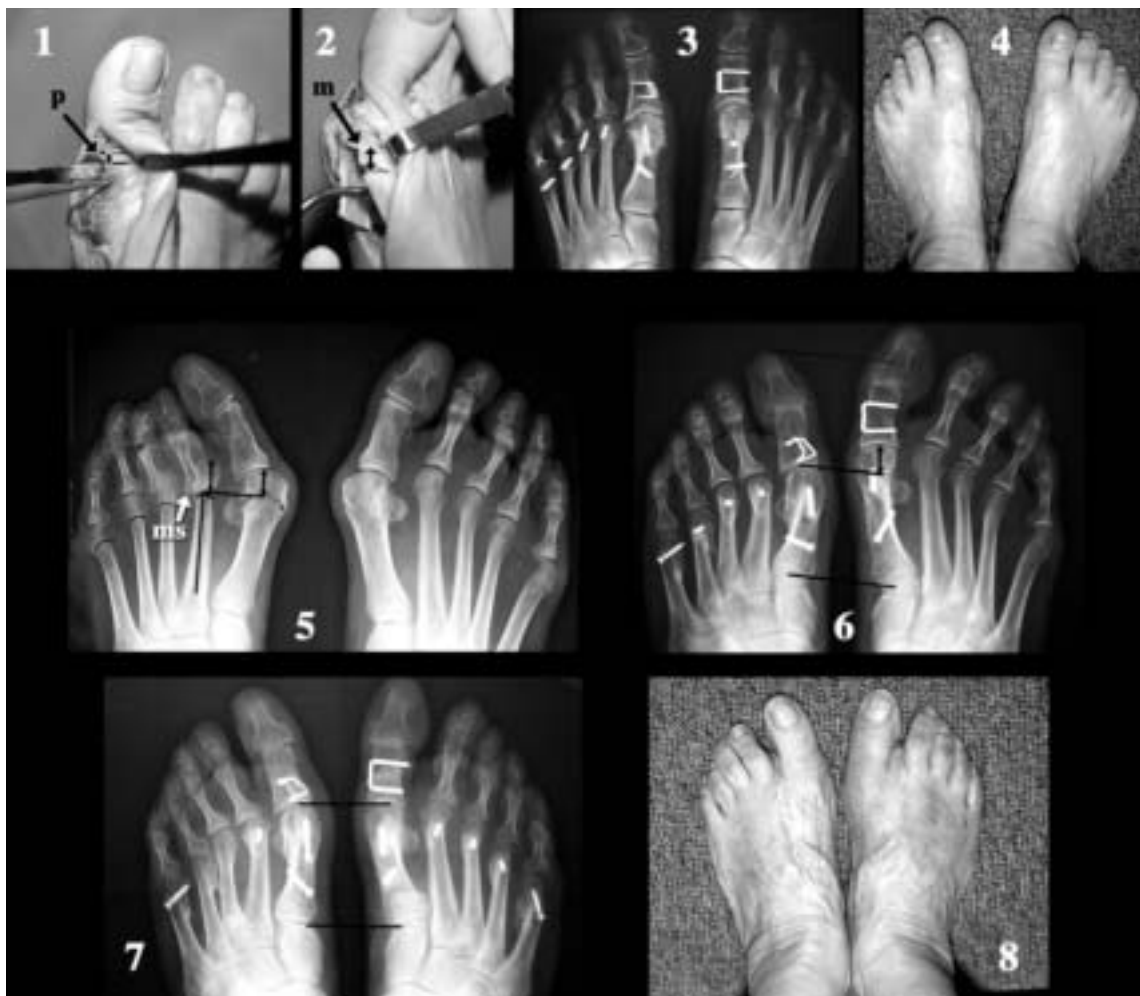At last, we show some examples of long-term results: Our follow-up is not more than seven years, but until now we don't observe any deterioration of the result with such a follow-up; this emphasizes the reliability of this procedure.



**Fig. 39c3a. Severe forefoot disorders – Limits of joint preservation: Trophic troubles?**  
*Trophic troubles are not a limit for joint preservation in severe forefoot disorder, but once again on the condition to make a large shortening of the metatarsals.*



**Fig. 39c3b. Severe forefoot disorders – Limits of correction with joint preservation: Some examples.**  
 1, 2. Preoperative and one year follow-up: All joints preserved, except second ray (there was no more head!). Note the M1 shortening up to the lateral basal location of the first phalanx (ms point).  
 3. Preoperative and two years follow-up rheumatoid foot: Just one metatarsal head resection.  
 4. In this case, with dislocated first MTP joint with a *first metatarsal which is already short*, fusion of the first MTP joint and Weil osteotomy on the lesser metatarsals.



**Fig. 39c4. Severe forefoot disorders – The relative shortening of the foot.**

Regarding the footwear, we have to remark that the *shortening of the first ray is by far the most significant one* (lesser rays shortening does not change the shoe size).

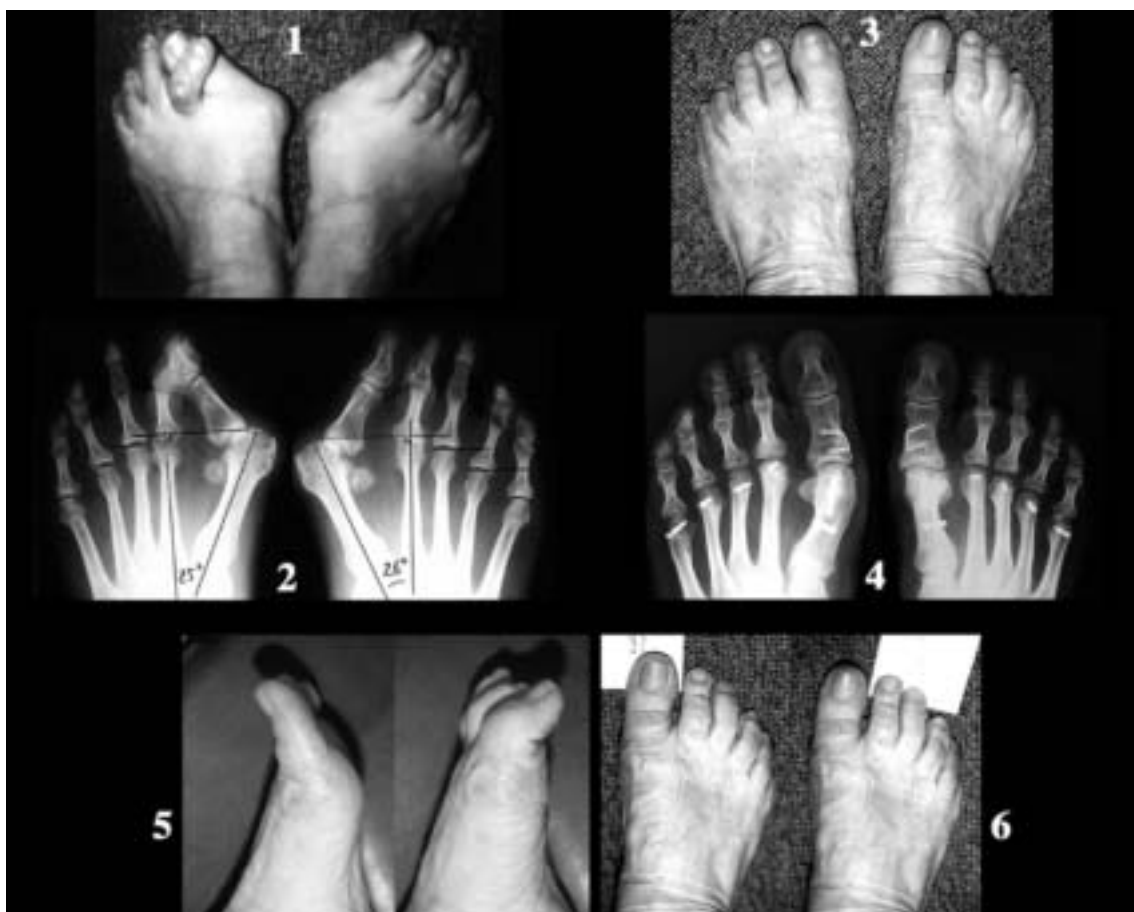1, 2. The shortening of the first metatarsal (m) can be larger than the first phalanx shortening (p): *But how compensate this shortening on the other foot?*

3, 4. Sometimes the *shortening of the great toe first phalanx* is sufficient.

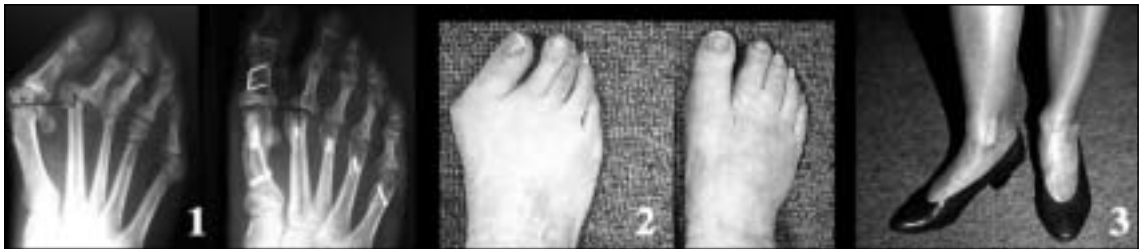5, 6. In this case, the required shortening was large, focused on the second ray MTP dislocation (ms) but the patient did not withstand the shortening of the right foot: she lost her court shoes!

7. So we were obliged to secondarily shorten this foot *by shortening of the metatarsals*.

8. One year follow-up: Good result, the patient continues to wear her court shoes. This emphasizes the harmonized metatarsal shortening as a harmless procedure.

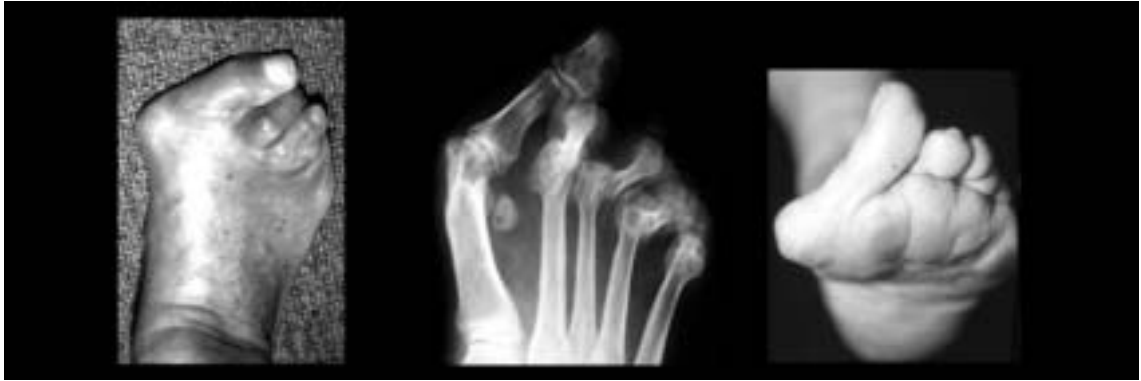

**Fig. 39c5a.** Severe forefoot disorders – Long-term result: *One example of five years follow-up of bilateral case of joint preservative surgery.*  
*The shortening of the five metatarsals significantly widen the indications of joint preservation in the treatment of severe forefoot disorders.*

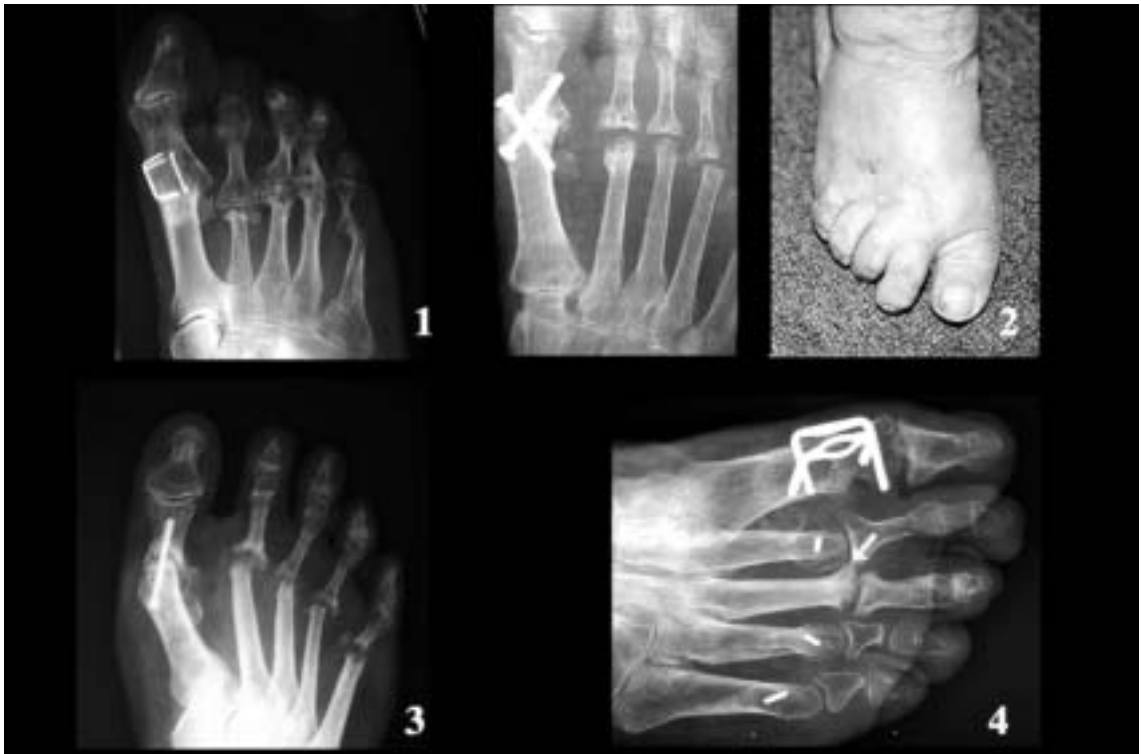

**Fig. 39c5b. Severe forefoot disorders – Long-term result: Articular preservation in failed bunionectomy.** Another example: three years follow-up. The five metatarsals shortening with preservation of the toes length leave a foot which looks well and *is able to fit elegant shoes.*

## Rheumatoid Forefoot



*Fig. 40a1.* Rheumatoid forefoot – Radiological and clinical aspects.



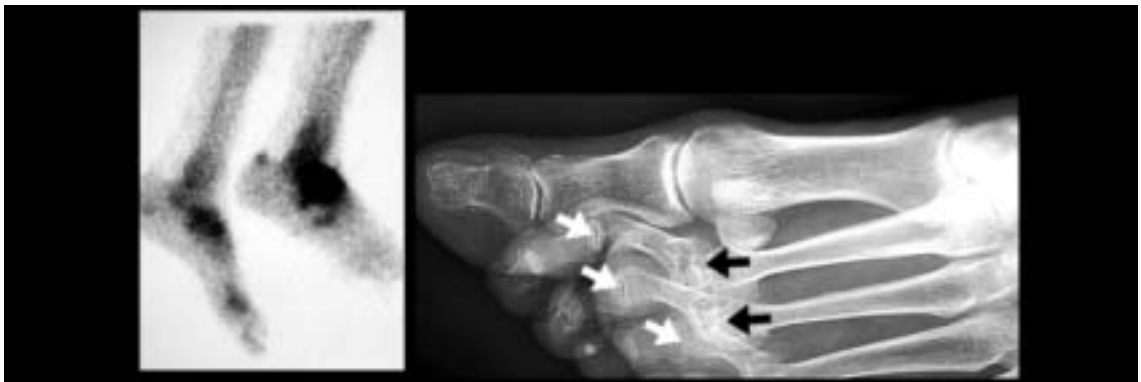
*Fig. 40a2.* Rheumatoid forefoot – *Traditional surgery.*

1. First MTP fusion and metatarsal head resection may result in such a disaster when not well performed. Even when the surgery is well performed (2) some problems may remain.
3. Problem of first MTP fusion.
4. Problem of remaining spurs of the metatarsal resection (white arrow).



Ordinarily, when patients come at orthopedic surgeon consultation, it is at an advanced stage, so that there is also no more inflammatory evolution as shown by bone scan. On the other

hand, small joints like lesser toe interphalangeal do not seem to have a rheumatoid lesion: This is a reason to preserve these joints.



**Fig. 40a3. Rheumatoid forefoot – Some observations leading to joint preservative surgery.**

1. Usual findings in rheumatoid forefoot bone and joints impairment. In this forefoot, as usually in long-lasting rheumatoid lesions, the inflammation disappears (bone scan is almost negative on the forefoot).
2. Usually, lesions are located on the metatarsal heads and the MTP joints (black arrow), and almost do not affect the interphalangeal joints (white arrows) except in the great toe. This is a reason to *preserve these toe joints*, performing as far as possible toe soft tissue procedures so keeping the toes long. But the *metatarsal heads* can also be preserved thanks to metatarsal shortening, our aim being to preserve the joints as far as possible.

*In the first ray:* The first MTP joint fusion was mainly common because of recurrence of hallux valgus. In fact, we observed so *reliable results in hallux valgus correction with scarf osteotomy* (notably thanks to M1 shortening), that *we now reserve the first MTP fusion for extremely impaired lesions*: The average rate of fusion was 22% in the last cases operated on, i.e. 78% of first MTP joint preservation.

*In the lesser rays:* Some metatarsal heads are extremely impaired and cannot be preserved. However, **most of the heads and joints can be preserved**: In our experience 72% of preserved

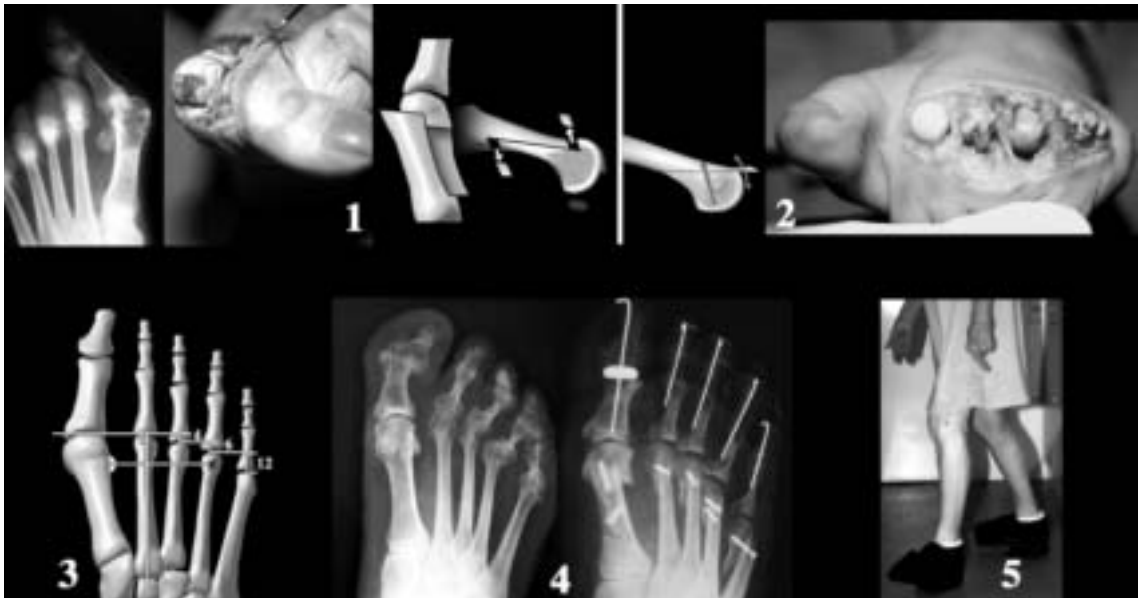heads, 28% of head resections, but on **two conditions**:

1) **To change the nature of the bone thanks to a osteotomy.**

2) **To provide a longitudinal decompression.**

The Weil osteotomy and the M scarf with shortening fulfill these conditions. Removing as far as possible the rheumatoid nodules and performing a synovectomy is certainly helpful.

On the following plates, the *results* of this type of joint preservative surgery is detailed, first on the first ray, then on the lesser rays.



**Fig. 40b1. Rheumatoid forefoot – Joints preservation. Generalities: Surgical principles.**

1. *On the first ray*, we can now preserve and improve both the metatarsal head radiological aspect and the MTP joint thanks to the *scarf M1 shortening*.

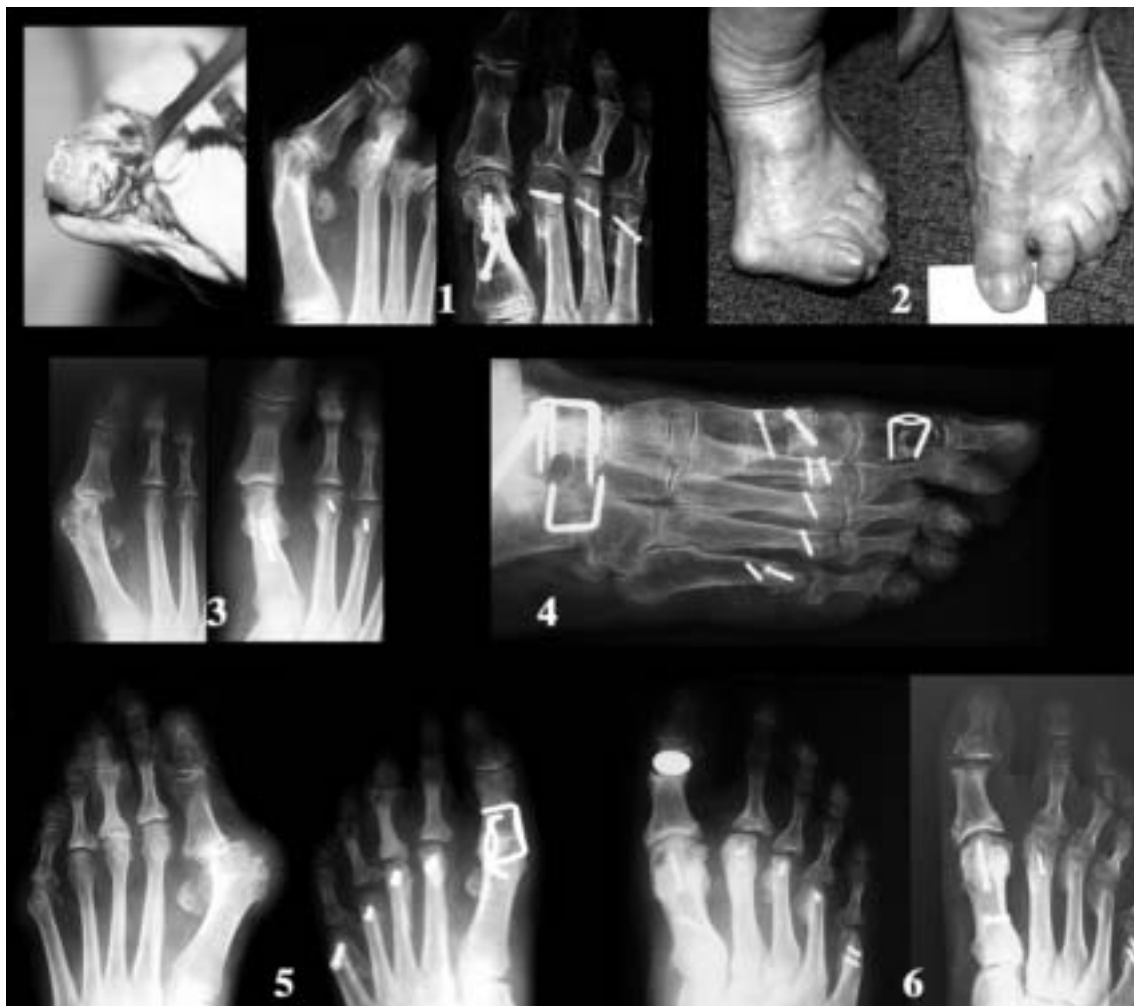2. *On the lesser rays*, the *Weil osteotomy* allows us to preserve and to improve the metatarsal heads and the MTP joint.

The effect of these metatarsal osteotomies is not only to provide a *longitudinal decompression* but also to *change the nature of the bone*: Thanks to the osteotomy itself. This, in addition to the usual synovial resection.

3. The metatarsal osteotomies have to reach a *correct metatarsal parabola*.

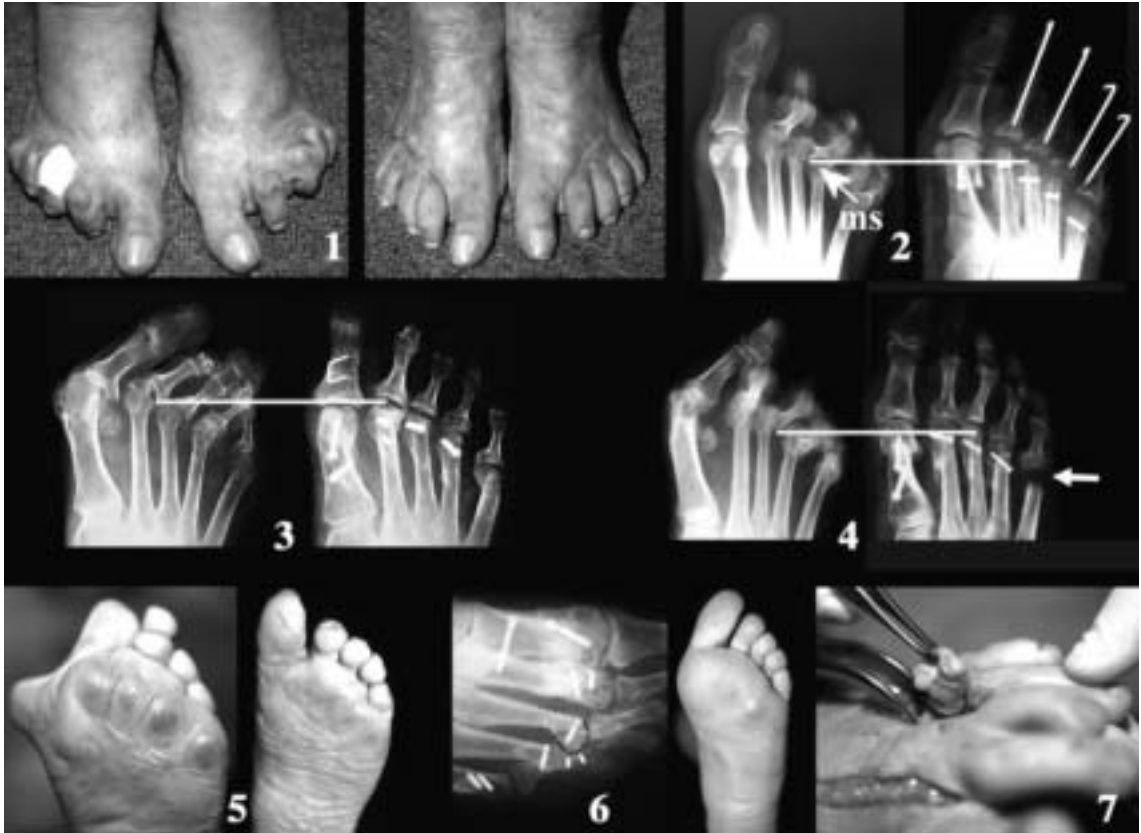4. *On the great toe IP joint*, the temporary button prosthesis is a good indication. *On the lesser toes* the preservation of the interphalangeal joints is now possible thanks to the metatarsal Weil osteotomy.

5. Patient walking three days after bilateral forefoot surgery, with the heel support type I shoes.



**Fig. 40b2. Rheumatoid forefoot – Joint preservation. First ray.**

1. In spite of impaired metatarsal head including its cartilage, *improvement of both the head and the MTP joint radiological aspects* at two years postoperative follow-up.
- 1, 2, 3. We observe the reliability of the hallux valgus correction, even with a long follow-up.
4. Preservation of the first MTP joint is useful when we know the possibility to have a hind foot or / and ankle fusion.
- 5, 6. Limits of first ray joints preservation.
5. Fusion in extremely impaired and MTP joint is dislocated with first metatarsal already very short (note the additional Weil osteotomy on the lesser rays).
6. Button prosthesis on the great toe IP joint. Result at two years postoperative.



**Fig. 40b3. Rheumatoid forefoot – Joint preservation. In lesser rays.**

1, 2. Same case. Correction of both MTP dislocation and claw toes deformity with Weil osteotomy and lesser toes temporary K wiring, with preservation of interphalangeal and MTP joints.

3. Pre and 2.5 years post operative aspect with preservation of every metatarsal head.

4. In this case (2 years follow up) only the fifth metatarsal head was removed.

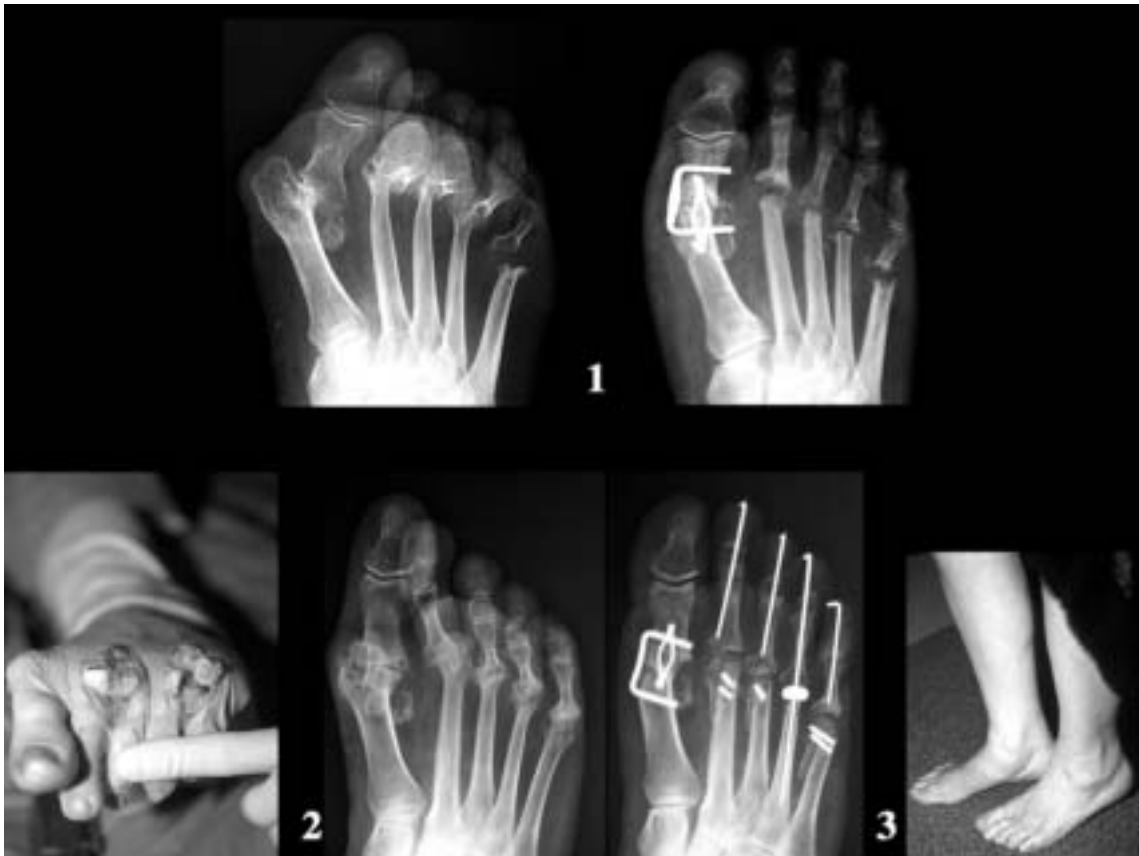5, 6. *Metatarsalgia and plantar problems.*

5. *Metatarsalgia and callosities disappear after Weil osteotomy (six years follow-up).*

6, 7. When *metatarsalgia* recurrence occurs (5% of case only), it may be due to technical insufficiency (in this case the double layer for the third metatarsal head was not performed) or to remaining rheumatoid nodule (7).

The *limits of the joint preservation* are mentioned.

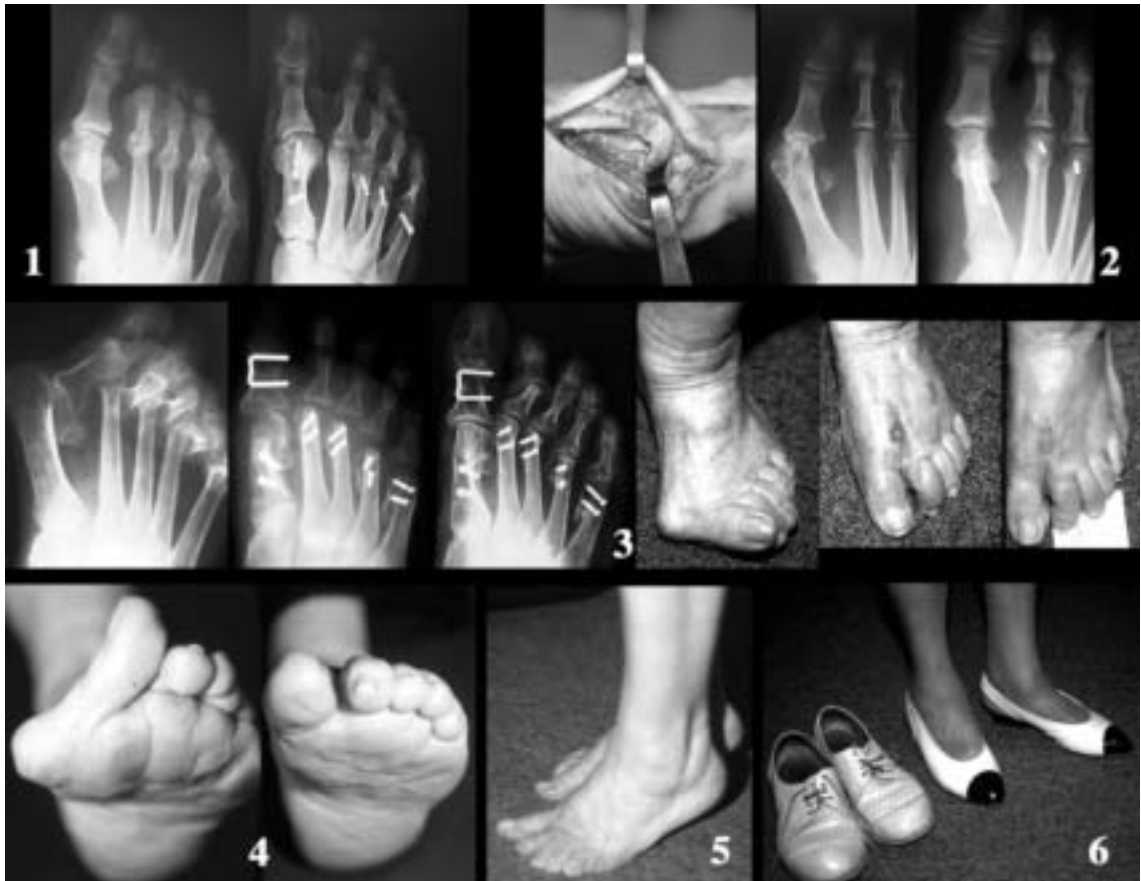At last, *particular cases*, notably surgery on early stage, are reported.



**Fig. 40c. Rheumatoid forefoot – Limits of joint preservation.**

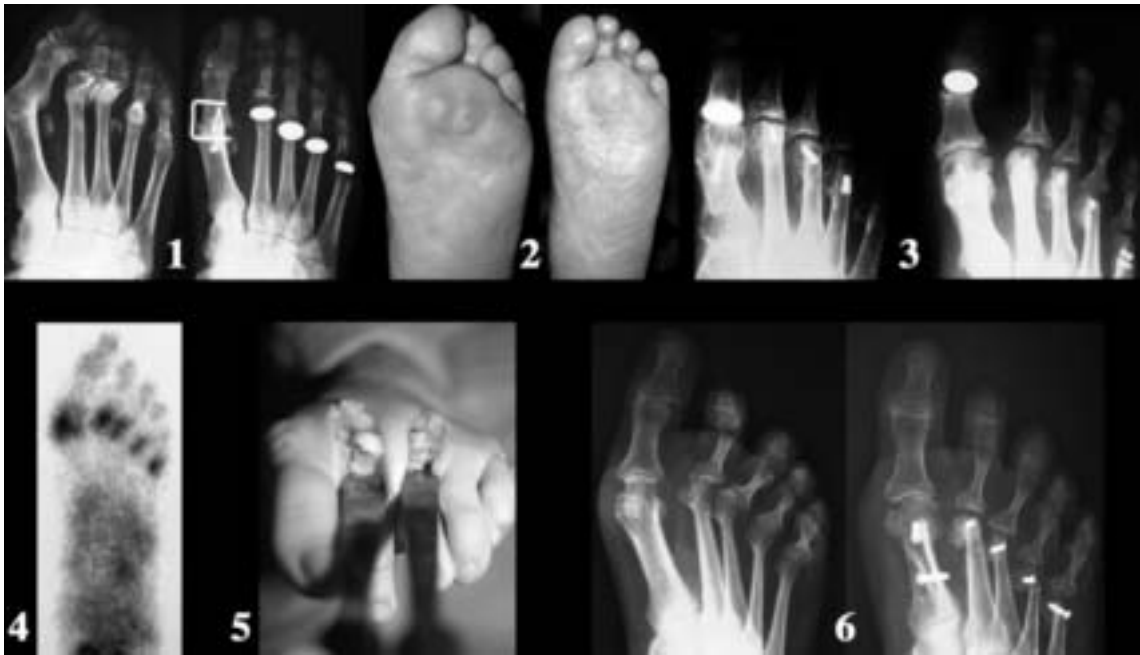1. When the metatarsal heads are too much impaired, resection is the only solution.

2, 3. Same foot. Preservation of three heads, included the third one, which is very impaired. First MTP fusion, and button prosthesis on the fourth MTP.



**Fig. 40d. Rheumatoid forefoot – Joint preservation. Long-term results**

1. 4 years follow up result. Preservation of every forefoot joint
2. Pre operative cystic head – 4 post operative years: X-ray aspect
3. Pre operative, immediate post operative and 6 years post operative. Radiological and clinical aspects
- 4, 5, 6. Same foot. Plantar aspect, functional aspect, and improvement of the footwear



**Fig. 40e. Rheumatoid forefoot – Particular cases**

1. Spontaneous MTP fusion of three MTP joints: correction of the great toe position, and setting of *button prosthesis* in the lesser MTP joints (radiographic and clinical results).
2. Button prosthesis in the first MTP joint: we think that in this location, fusion is preferable
3. Button prosthesis in great toe IP joint: it is a good location in case of lesion in this location
- 4, 5, 6. Rheumatoid forefoot operated “early” – *i.e.* in inflammatory period. Bone scan is positive, the metatarsal heads are impaired. 1.5 year follow up: good clinical and radiographic results. We do not have an long follow up on rheumatoid forefoot operated on early stage yet.

## Conclusion

This experience, with now a *follow up of 10 years* (average 4 years) allows me to be confident in this **new way** for the treatment of rheumatoid forefoot which proved that **joint preservative surgery** has to be done in most cases and fusion or resection surgery, always useful but in limited cases.

We have to remark that until now, very few authors, like Diebold, Rippstein [102] and Maceira, have a similar experience of this type of surgery in rheumatoid forefoot. However, we think that more and more surgeons will adapt this conservative surgery and we are interested to see what will happen in the next 5 or 10 years.

## Some aspects of surgery for hallux limitus

Our purpose is *just to point out the three procedures we use* to perform the treatment of hallux limitus: the *Weil* 1st metatarsal decompression osteotomy, the *button* prosthesis, the 1st MTP fusion with memory staple.

### *Weil* 1st metatarsal decompression osteotomy

(see also p. 111)

Indications: 1st metatarsal longer than the 2nd or with the same length. Hallux limitus grade 2 or even grade 3 in case of not too much painful the MTP joint and 45° of average range motion pre operatively. This procedure is very easy to perform by a medial approach. The fixation is strong thanks the two Scarf or FRS screws. Results 45 cases follow up 1 to 4 years: post operative period, no pain, early functional recovery. Average range motion: 60°: 10° plantar, 50° dorsal, pre and post operative improvement

average: 25°. Pain: moderate 2 cases, no pain: 43 cases. Head necrosis: 2 cases (moderate, MTP fusion not required at the moment).

The results are so good that the indication of the other procedures we use have notably decreased.

### *MTP fusion*

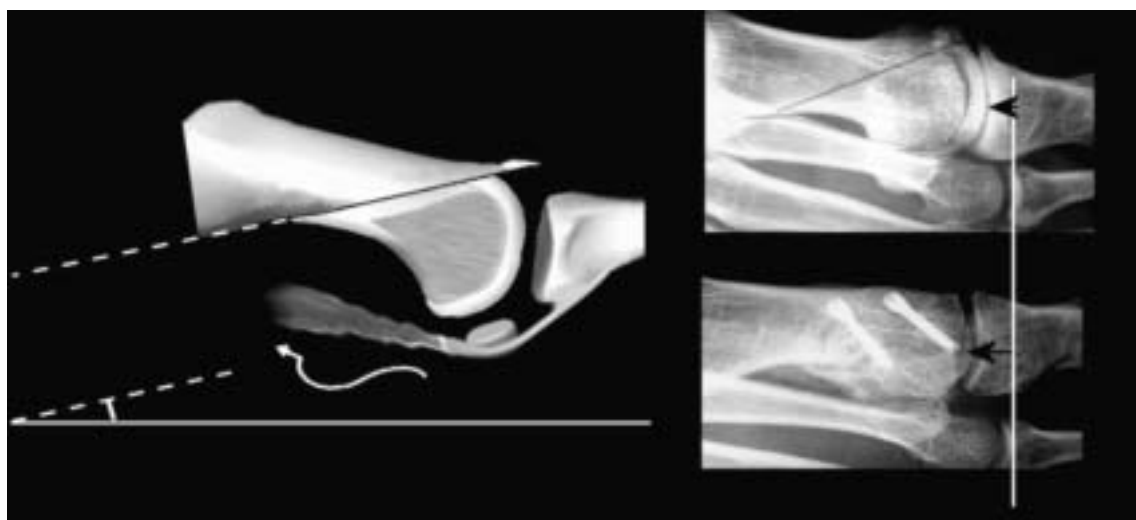
(see also p. 168)

Indications: grade 3 or 4 and very painful MTP joint, with less than 45° average range motion. The fixation is very easy and reliable with the special “20” memory staple, this fixation allows to do successful revision surgery without bone graft in case of non union with previous surgery.

### *Button prosthesis*

(see also p. 174)

Indications of this temporary spacer are grade 3 or 4; so the same indications that for MTP fusion but when the patient does not want a fusion. The results are good but actually we perform preferently the *Weil* osteotomy or the MTP fusion.

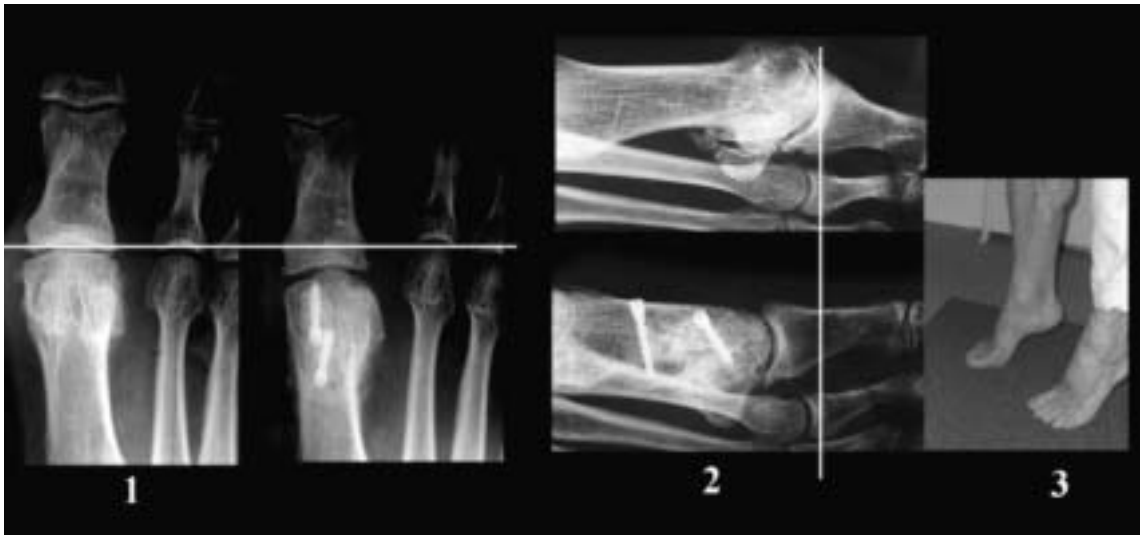

**Fig. 41a1. Weil first metatarsal decompression osteotomy.**

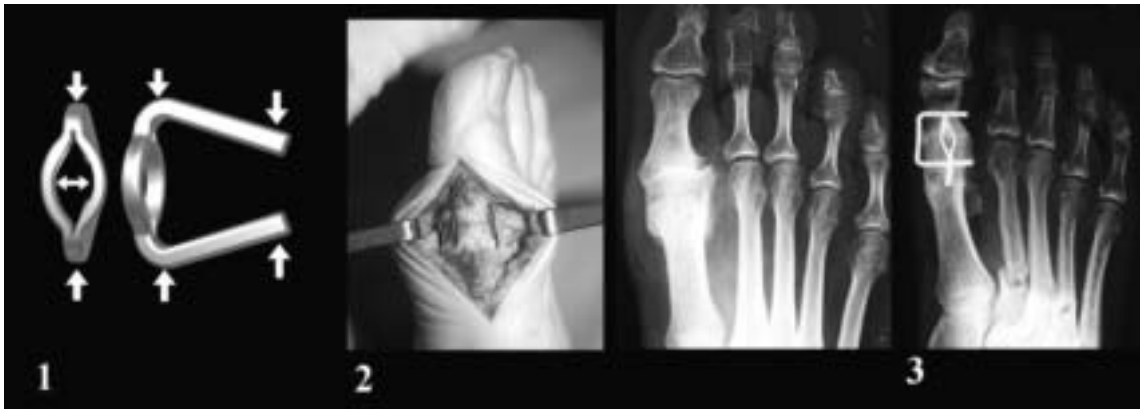The proximal sliding of the metatarsal head is combined with lowering, even in case of first metatarsal elevatus observed in case of hallux limitus.

This explain that we do not observe transfer metatarsalgia, even in case of post operative too short the first metatarsal. The clinical and radiological results are directly due to the MTP longitudinal decompression.

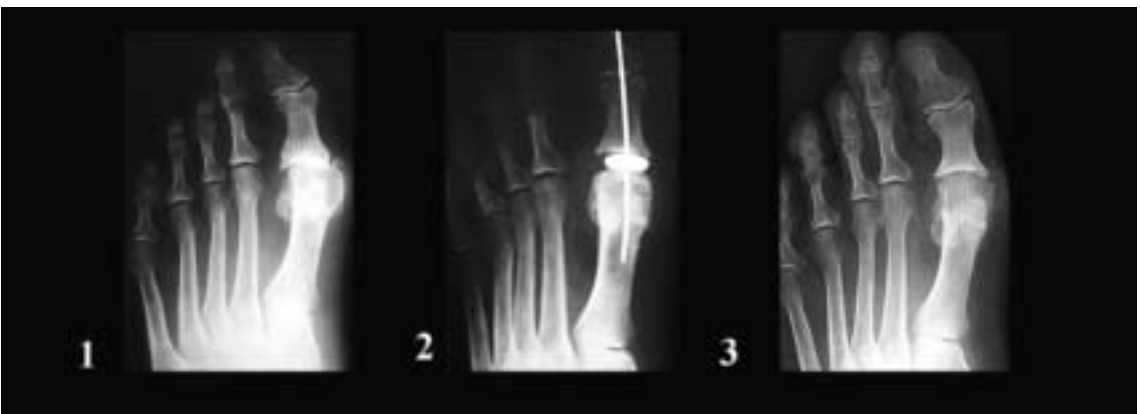



**Fig. 41a2.** Weil first metatarsal decompression osteotomy.  
Hallux limitus grade 2 – result one year post operative.  
2, 3. Grade 3: one year post operative.



**Fig. 41b.** Hallux limitus: MTP fusion by the “20” memory staple.  
A reliable procedure, and easy to perform.



**Fig. 41c.** Hallux limitus. Use of the “button” temporary spacer, temporary K. wire.  
One month: removing the button.  
One year: result 5 years post operative.

### III. SURGICAL MANAGEMENT IN FOREFOOT RECONSTRUCTION

The main points of this chapter are the components, that, according to us, make up the forefoot surgical management. We successively consider the *preoperative*, *intraoperative*, and *postoperative* management.

#### Preoperative Management

##### *Examination*

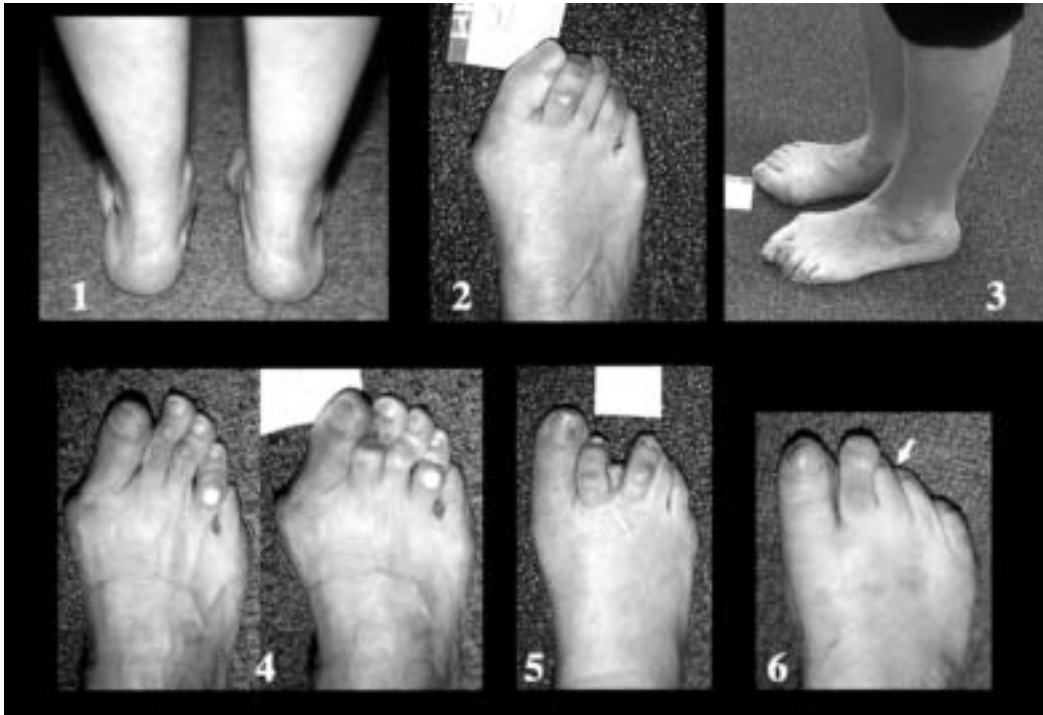There is no synthesis without analysis. So the *preoperative* clinical and radiographical examination is critical. That is why I emphasize precision about the main – or the most useful – steps of preoperative examination for assessment of the forefoot troubles.

Among the different documents which are necessary to assess the foot deformities, the **photography with dorsal view in a standing position is critical**. Why? First because it shows

the foot and the toes with their true functional aspects. A video would certainly be better but the picture is sufficient, above all if we ask the patient to be in a slight ankle dorsal flexion position. In this picture, claw or hammertoe deformities are emphasized and clearly assessed as apposed to X-rays which cannot, so easily, provide us this information. We have to take this strongly into account in our therapeutic decision making (Fig. 40a2). This photography is taken by a *digital camera* of good quality. Pictures can be stocked in our computer and a paper copy is given to the patient: I also take another picture at one postoperative year. I also give it to the patient, who can see the difference in the appearance of the foot (it is also a challenge for me).

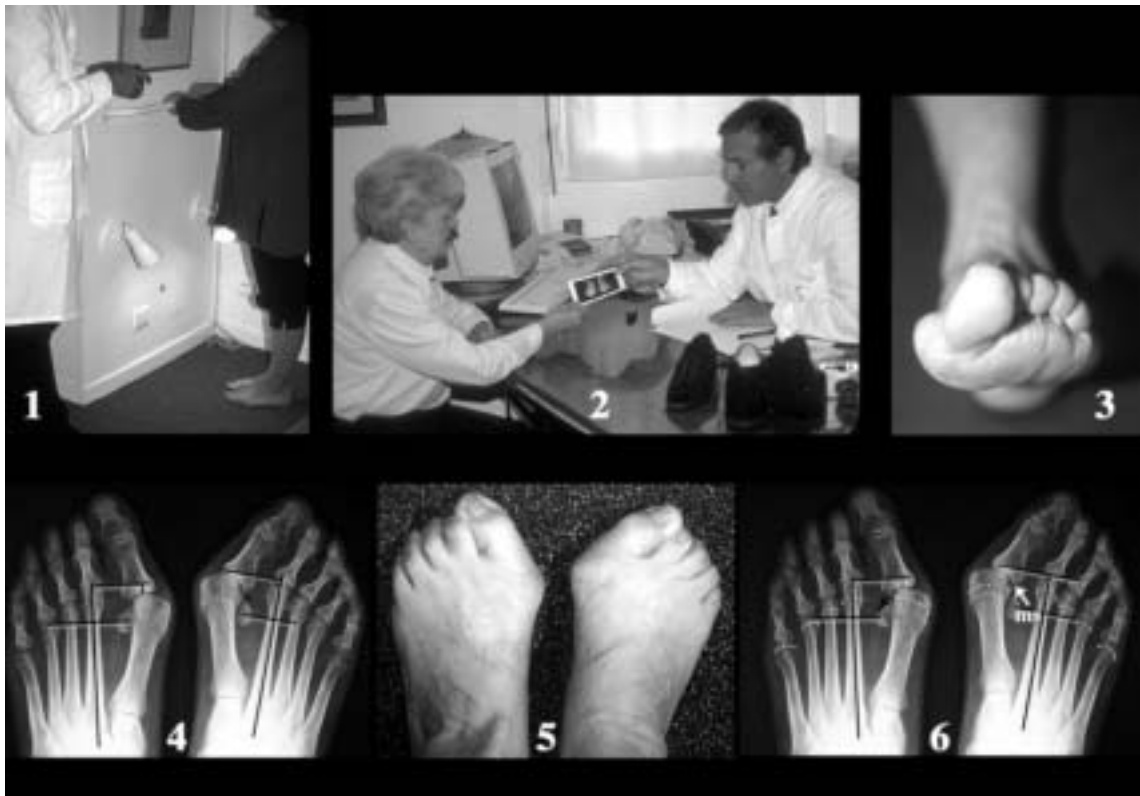Additionally, a picture of the rearfoot is made and, if required, of the plantar aspect of the foot (showing the forefoot axial rotation, like supination, pronation and the plantar callosities).

Of course, **clinical examination** is made step by step, as shown in the following plates.



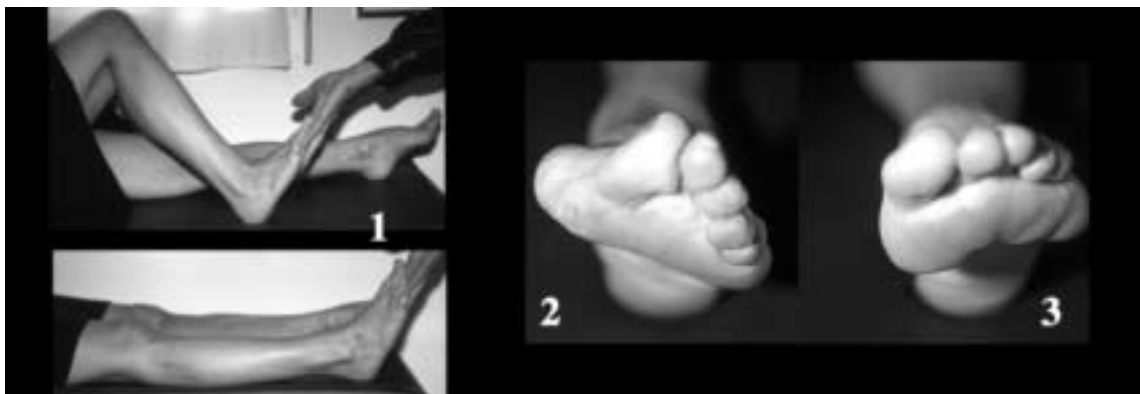**Fig. 42a1. Preoperative management – Clinical assessment 1: In a standing position.**

1. Rearfoot in a standing position.
2. Valgus and axial rotation of the great toe are emphasized by the Bristol test.
3. Decrease or loss of toe ground contact, also pointed out by the Bristol test.
4. The *Bristol test* emphasizes both the hallux valgus and the hammer lesser toes deformities.
5. Assessment of lesser toes ground contact.
6. Assessment of lateral or medial tilt of the toes in a standing position.



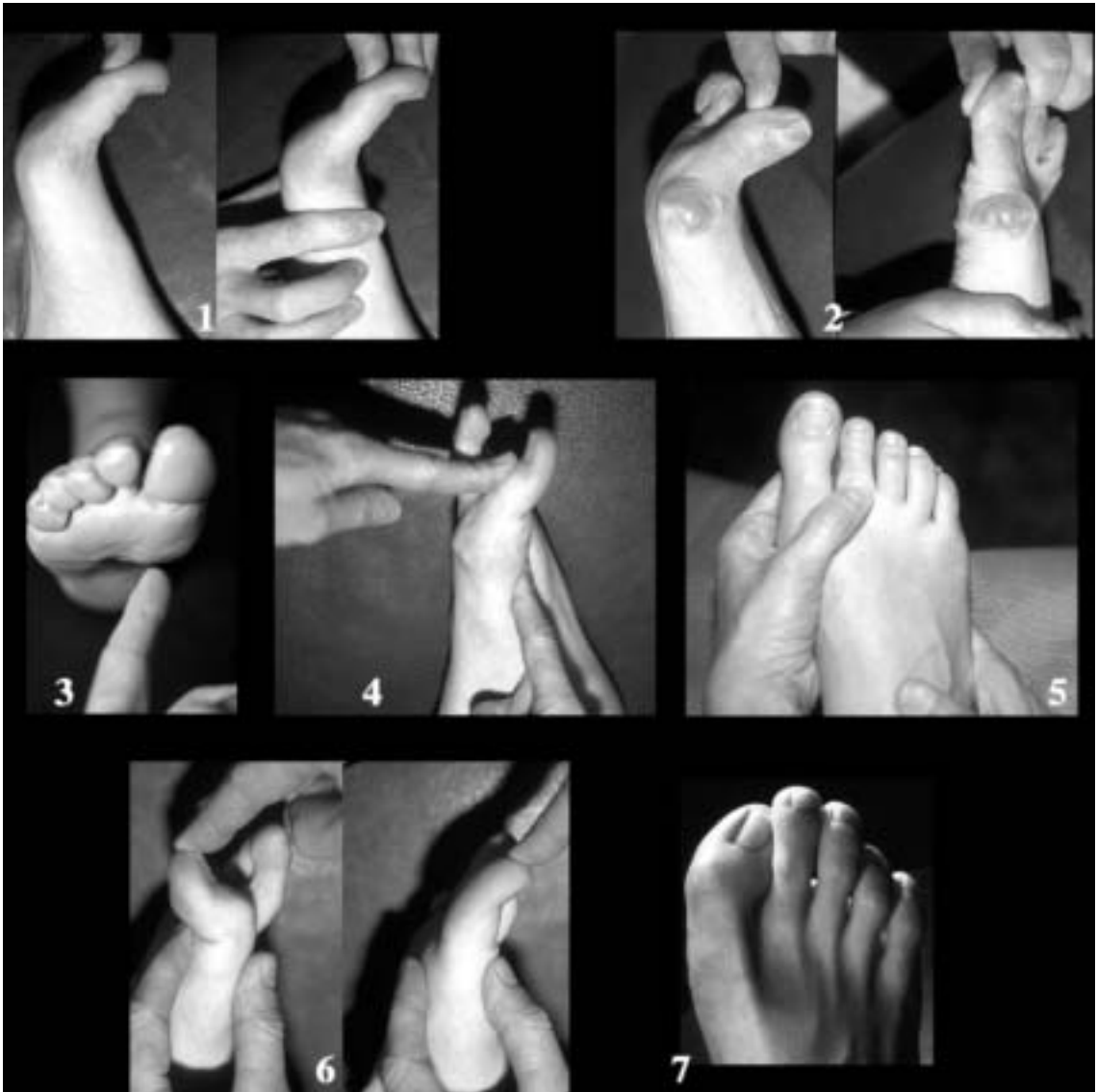**Fig. 42a2. Preoperative management – The importance of the photography.**

1. With a digital camera, I always take a foot photography, during the first consultation.
2. I give this picture to the patient. I will take another one at one postoperative year.
3. When necessary, a plantar view photography is also taken and given to the patient.
- 4, 5, 6. Importance of the photography.
4. If we only see this X-ray, we plan to perform a single surgery on the first ray, for hallux valgus correction.
5. Same patient: The photography reveals the magnitude of the first ray deformity as well as the severe claw toe deformity and the plantar callosities. This leads to perform a global shortening of the metatarsals to ensure a reliable correction.



**Fig. 42a3. Preoperative management – Clinical assessment 2.**

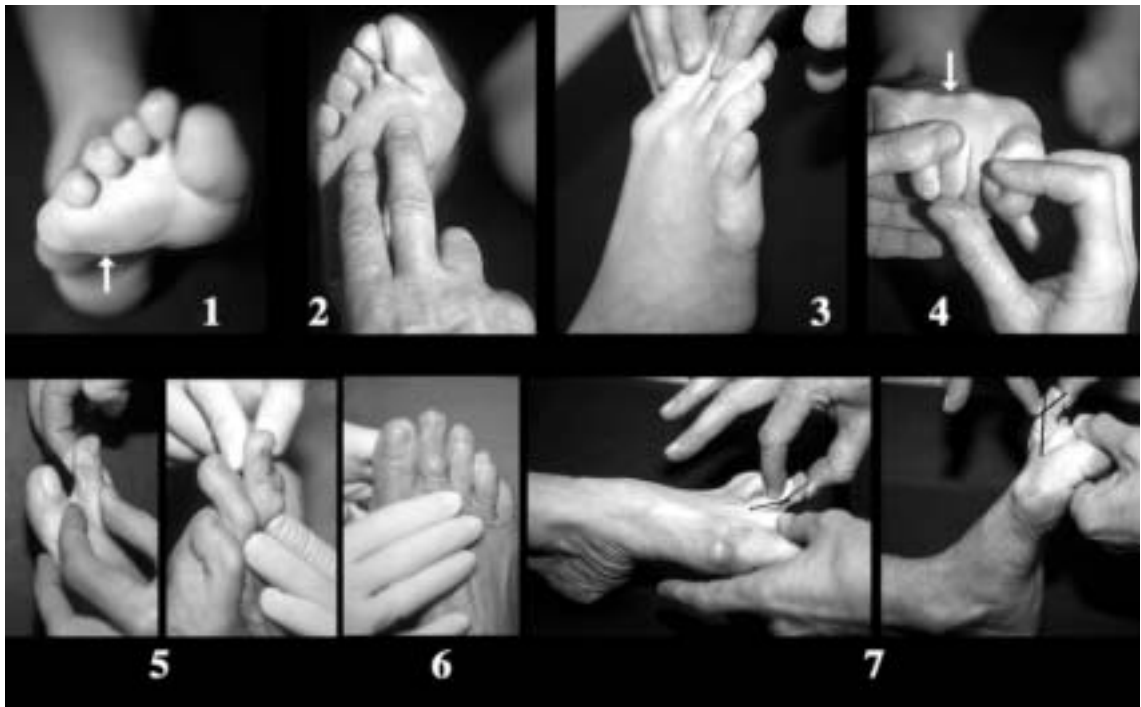1. Equinus and gastrocnemius shortness.
2. Assessment of supination or pronation of the forefoot.



**Fig. 42a4. Preoperative management – Clinical assessment 3: First ray.**

1, 2. Assessment of the MTP passive dorsal flexion with and without passive correction test of the intermetatarsal angle and of the valgus of the great toe:

- 1) The dorsal flexion is not decreased: We may preserve the first metatarsal length.
- 2) The dorsal flexion is decreased: We have to shorten the first metatarsal.
3. Assessment of plantar protuberance of the first metatarsal head, comparatively to the second one.
4. MTP plantar flexion.
5. Foot type: In this case, Egyptian.
6. Assessment of IP passive motion.
7. Interphalangeal hallux valgus.



**Fig. 42a5. Preoperative management – Clinical assessment 4: Lesser rays.**

1. Plantar callosities.
2. Metatarsal head palpation assesses the location of metatarsalgia. *Distal*: Propulsive phase metatarsalgia: Indication of Weil osteotomy. *Proximal*: Stance phase metatarsalgia: Indications of BRT osteotomy (see Fig. 30a6).
3. Assessment of MTP passive plantar flexion.
4. In a slim enough foot, assessment of the metatarsal head level, in a sagittal plane: In this case, the third metatarsal head is lowered.
5. Assessment of the passive hammertoe correction.
6. Assessment of the comparative length of the toes.
7. The long flexor tendon shortness is emphasized when the ankle is held in dorsal flexion.

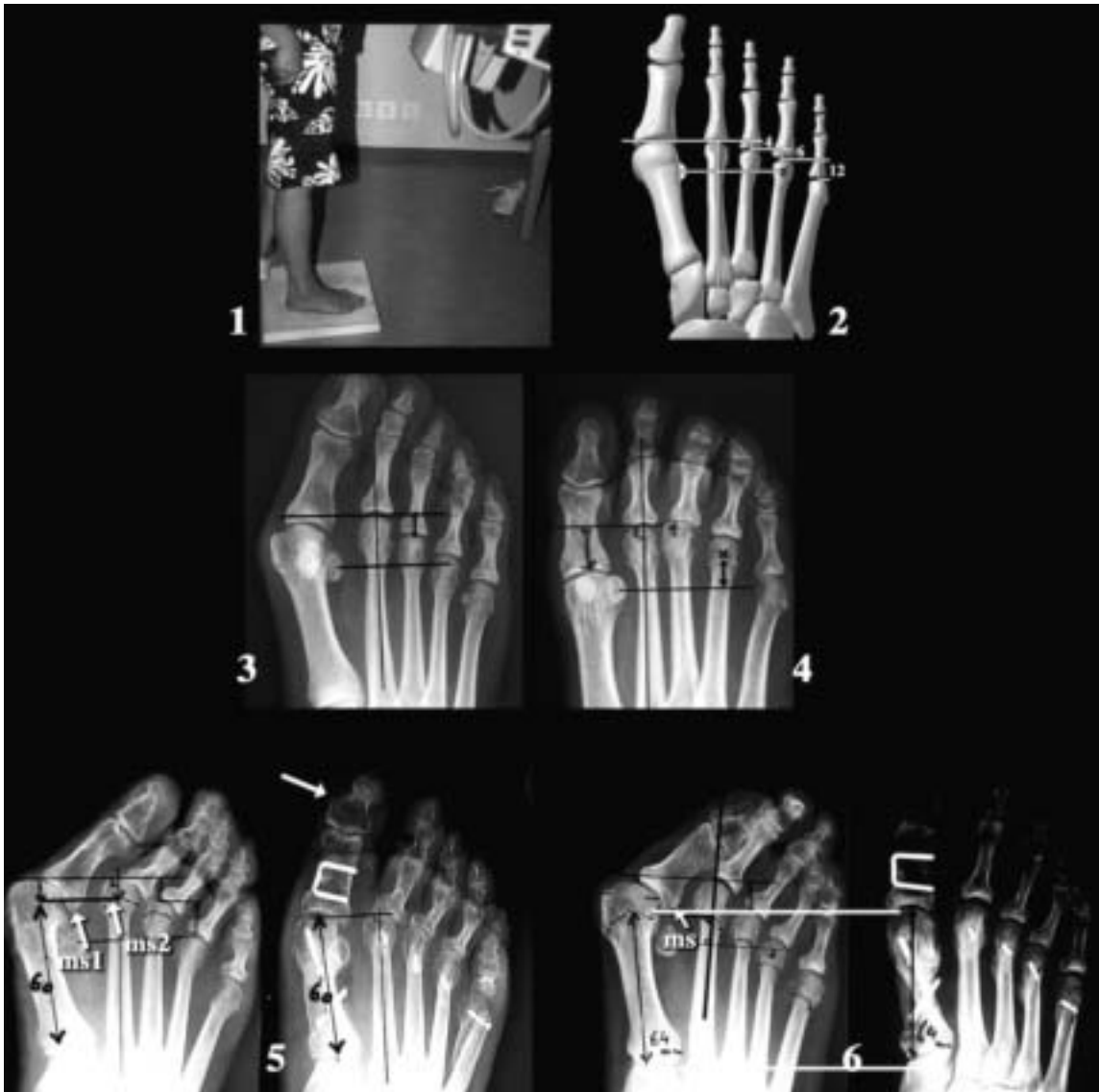
We think that it is critical that radiologists are especially trained for forefoot surgery, performing X-rays first in coordination with the surgeon, then always making the same angles of incidence so that the results can be appreciated comparatively. This is an opportunity to thank the radiologist team of the Polyclinique de Bordeaux-Tondu. Furthermore, for this book, they sometimes had to make good pictures in spite of patients having trophic troubles, important edema or porotic bones!

**The X-rays information** are also critical. Two views are essential: 1) **Dorso-plantar** in a standing position. 2) **Medial oblique** view: We

show in the plates what can be expected from these X-rays views.

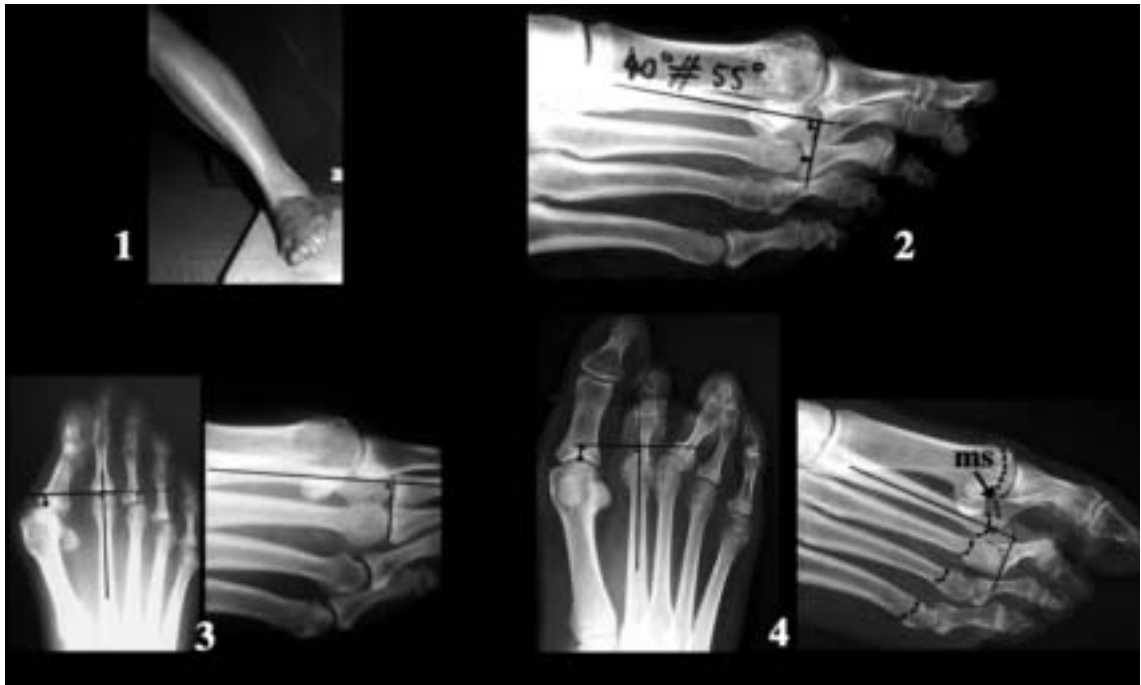
Anyway, the reliability of the preoperative radiological information may be not perfect, as emphasized by several authors, like Cassagnaud [31], Condon [35] Coughlin [39], Schneider [109]. So that the *intra operative* assessment is very useful.

The **pedo barometric evaluation** may also be useful, notably to assess the relationships between rearfoot and forefoot, as emphasized by E. Toullec (Bordeaux), R. Abboud [1], M. Stephens [27], G. Dereymaeker [48] and Vandeputte [126].



**Fig. 42a6. Preoperative management – Radiological forefoot assessment in a dorso-plantar view.**

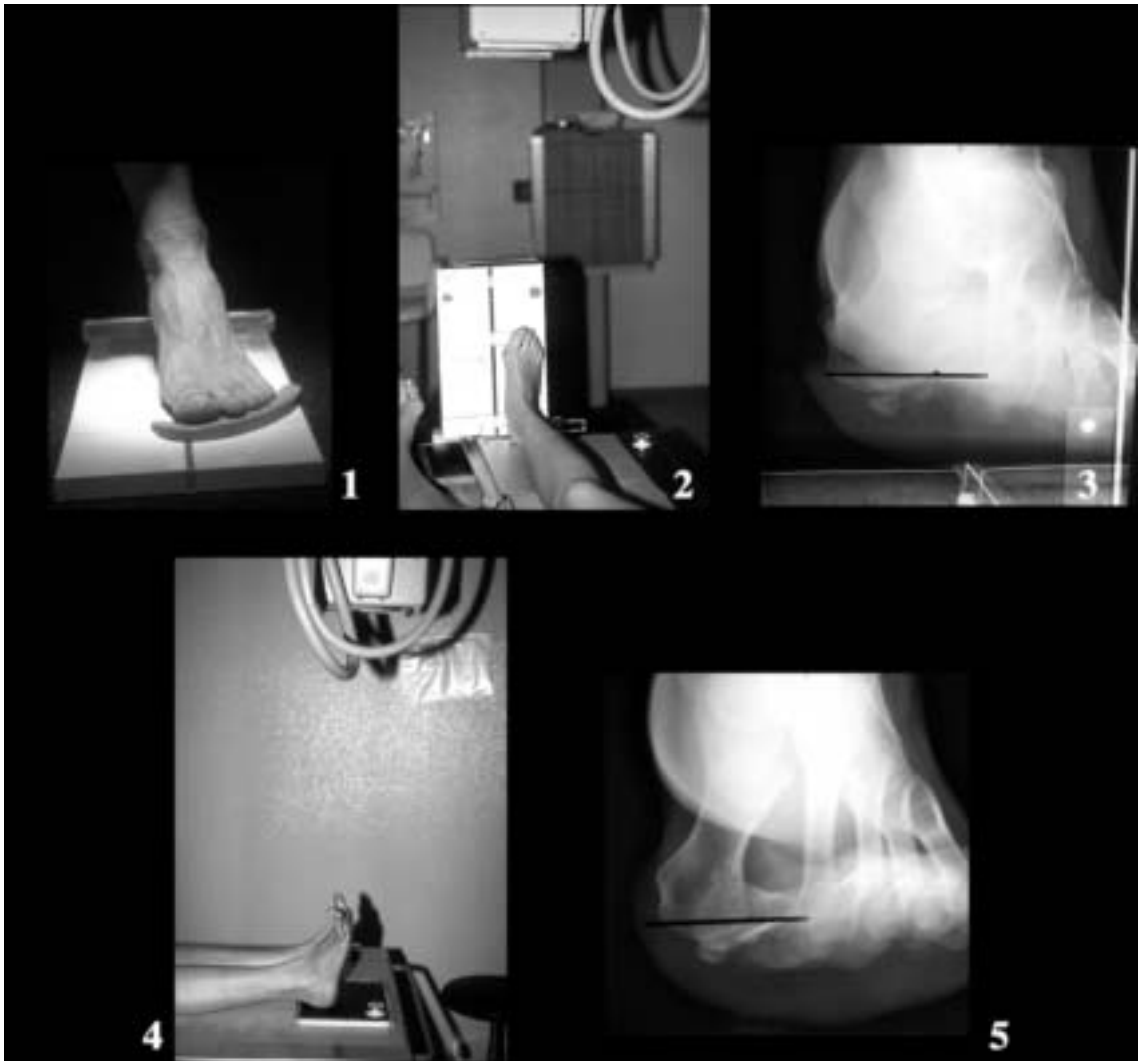
1. Radiography in standing position, preferably with slight “schuss” position (the ankle in a slight dorsal flexion).
2. We have to respect – or to reach – such metatarsal parabola, *i.e.*: Equality of M1/M2 length, M2/M3 = – 4 mm, M3/M4 = – 6 mm, M4/M5 = – 12 mm. The Maestro line (passing by the centre of lateral sesamoid and perpendicular to M2 axis) runs in the centre of M4 head.
3. This metatarsal parabola is still correct or tolerable, *i.e.*: The second metatarsal is slightly longer than the first one, and the Maestro line is slightly distal from the M4 head centre.
4. This metatarsal parabola has to be corrected: Excessive length of the lesser metatarsals and Maestro line proximal.
5. The first metatarsal length: Insufficient shortening of M1: M1/M2 line passing distally from the first phalanx basis (shortening based on ms2 instead of ms1). This results in undercorrection.
6. Correct shortening (line passing by the lateral proximal edge of the phalanx on the most impaired ray, ms point), good correction.



**Fig. 42a7. Preoperative management – Radiological forefoot assessment in a medial oblique view.**

1. Foot position during the radiography.
2. No significant difference of the lesser metatarsal length from 40° to 55° of obliquity foot position during the radiography.
3. *The medial oblique view assesses accurately the comparative length of M2, M3 and M4:* In this example, on the dorso-plantar view, M2 is longer than M3. In fact, same length in the medial oblique view. As a consequence, we have to manage the metatarsal shortening of M2, M3 and M4 preferably on the medial oblique view; the dorso-plantar view is however essential to assess the comparative length between M1 and M2.
4. Same foot: The amount of phalangeal/metatarsal overriding (ms point) is accurately assessed by the medial oblique view, preferably to the dorso-plantar view.



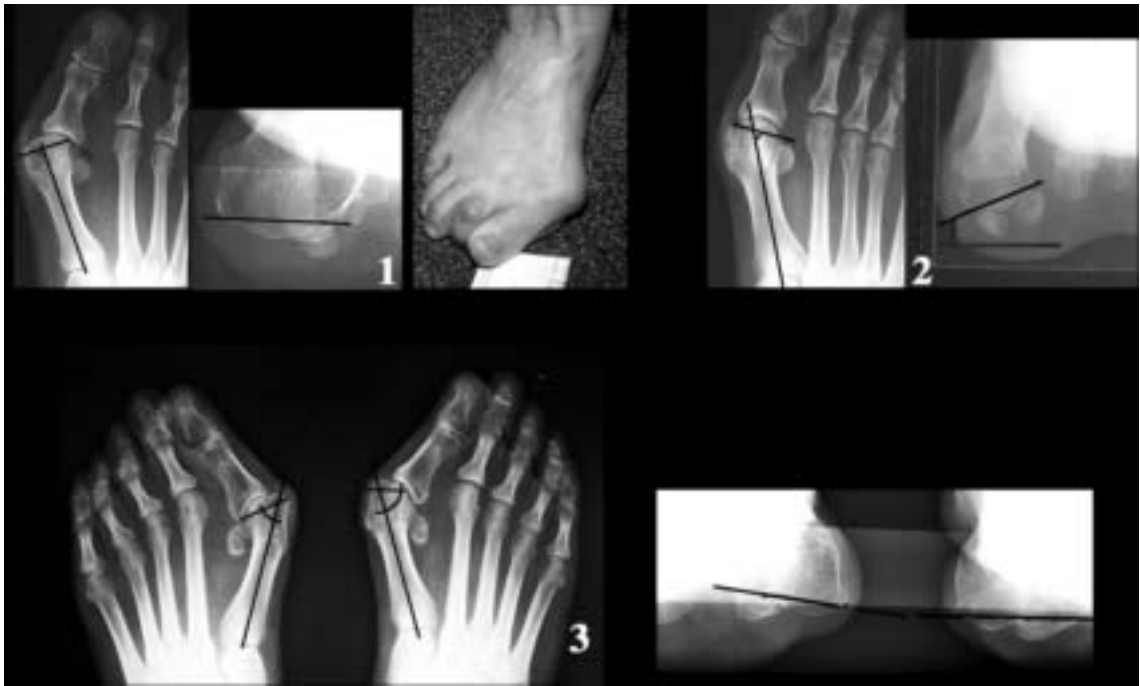

**Fig. 42a8a.** Preoperative management – Radiological forefoot assessment of axial rotation of the first metatarsal. 1).

1, 2. Bernard and Mortier (Paris) apparatus to assess the M1 axial rotation: M1 has to be parallel to the drawn line. This radiography has to be taken in propulsion or with the sole firmly pushed on this apparatus.

3. Assessment of the head rotation: The problem is the difficulty to appreciate the limits of the metatarsal cartilage.

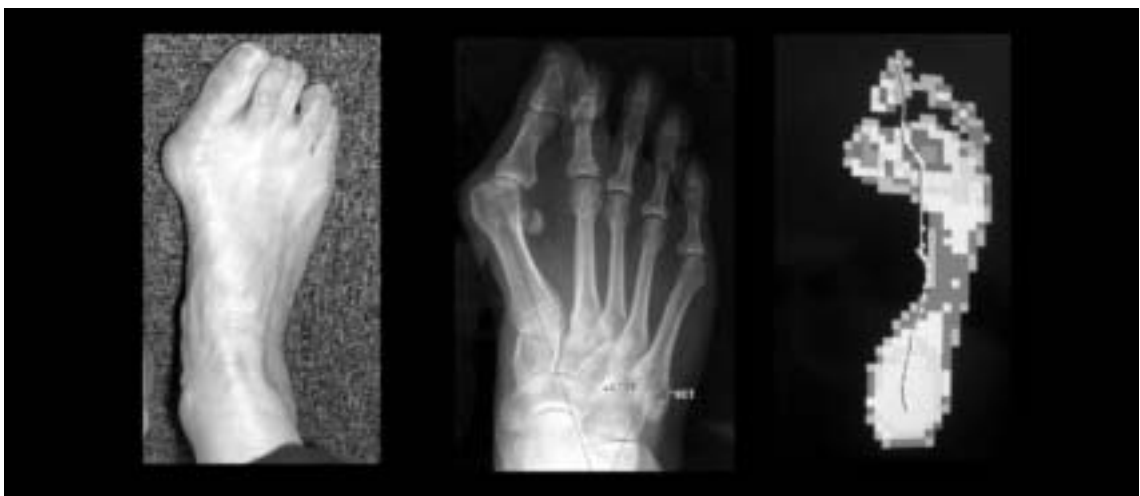4, 5. Without this apparatus, but with the same position of the first metatarsal, the assessment of the axial rotation seems to be easier.



**Fig. 42a8b. Preoperative management – Radiological forefoot assessment of axial rotation of the first metatarsal. 2).**

*Relationships between the axial rotation and the DMAA angle.*

1. Normal DMAA angle: No axial rotation.
2. Decreased DMAA: Axial rotation of M1 (pronation).
3. Axial rotation (pronation) in the side where DMAA is decreased.



**Fig. 42a9. Preoperative management – Podo barometric pressure evaluation.**

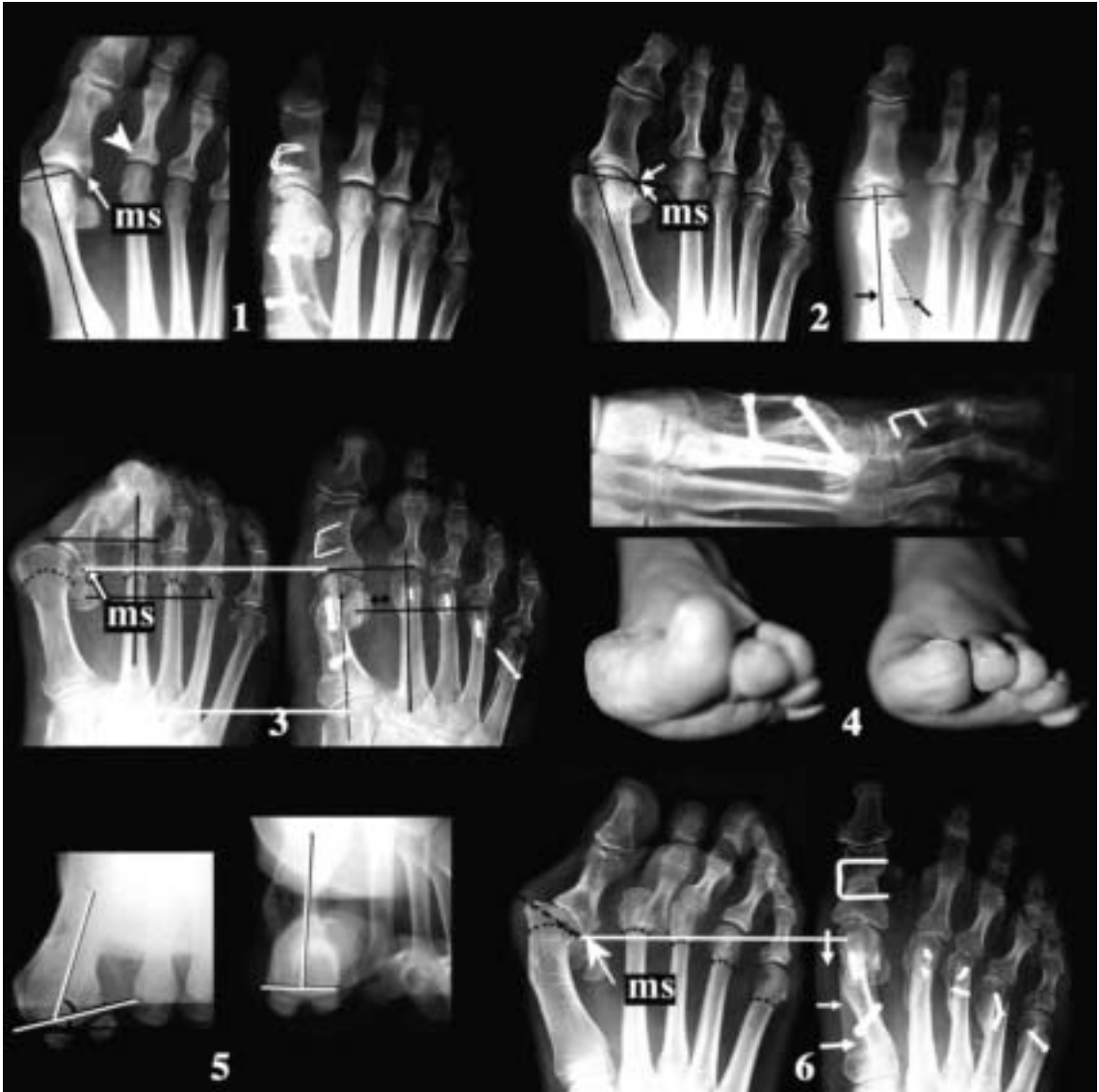
(Pictures from E. Toullec, Bordeaux.) This technique is useful to assess the forefoot pressure locations and pressure not only in a standing position but also during the gait. It also assesses the whole forefoot in its plantar aspect, notably the relationships between forefoot and rearfoot.

## Decision-Making in the Main Pathologies

We reached the “*decision-making*” in the different main pathologies encountered.

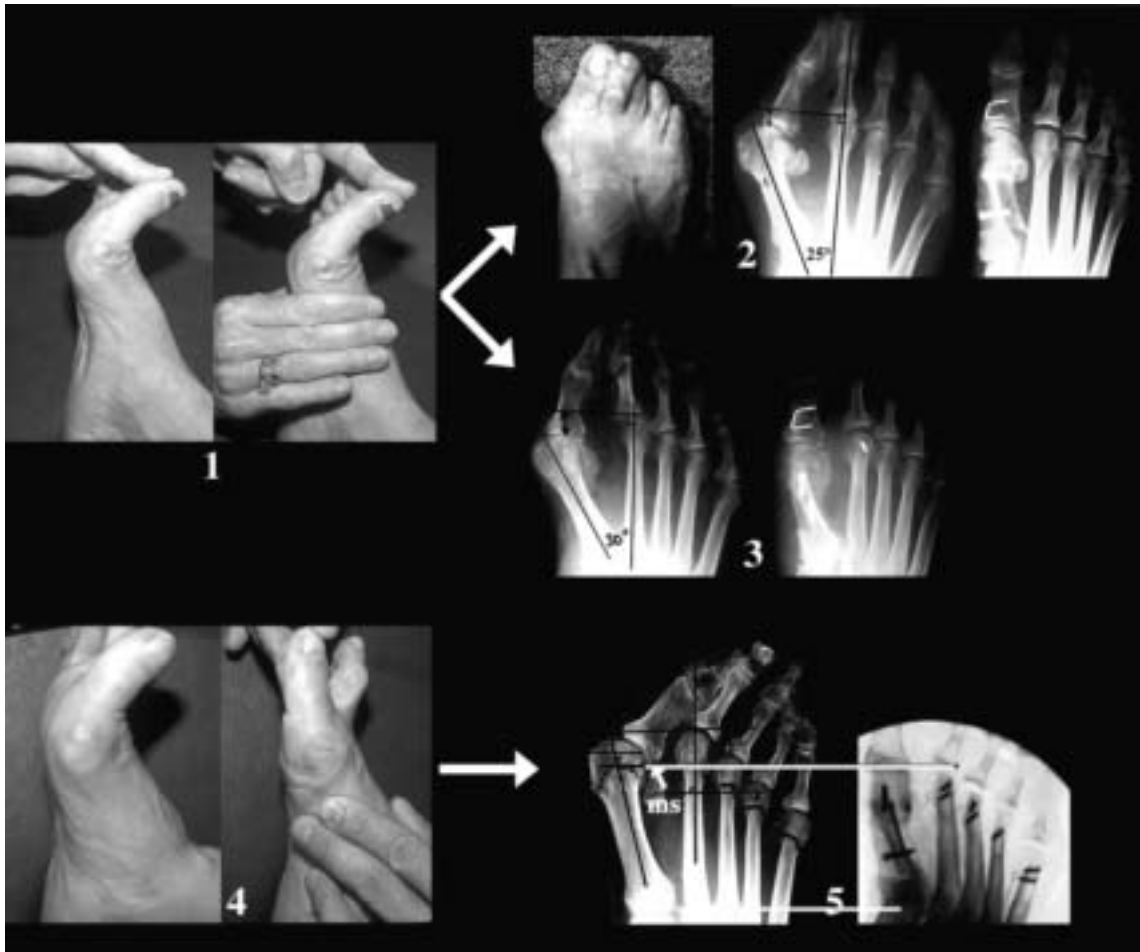
### In Hallux Valgus Deformity

Our choice was: What kind of metatarsal displacement do we have to create in the scarf osteotomy, particularly to which extent do we have – or not – to shorten the first metatarsal?



**Fig. 42b1. Preoperative management. 1) Decision-making on hallux valgus. a) The appropriate displacement to perform with the scarf osteotomy.**

1. Incongruent MTP joint: Lateral shift.
2. Congruent MTP joint but decreased DMAA: Correction of DMAA (combined with lateral shift if required).
3. Severe hallux valgus: Shortening up to the base of the first phalanx (white arrow).
4. Second ray metatarsalgia but with large intermetatarsal angle: M1 lowering.
5. First metatarsal pronation: Correction by M1 axial rotation (supination).
6. Iatrogenic hallux valgus: Combined displacements: Shortening, lateral shift, DMAA correction (white arrows).



**Fig. 42b2. Preoperative management. 1) Decision-making on hallux valgus. b) Shortening – or no shortening – of the first metatarsal.**

1, 2, 3. Since the passive MTP dorsal flexion is not decreased with passive reduction of intermetatarsal angle and hallux valgus, the hallux valgus correction does not need M1 shortening:

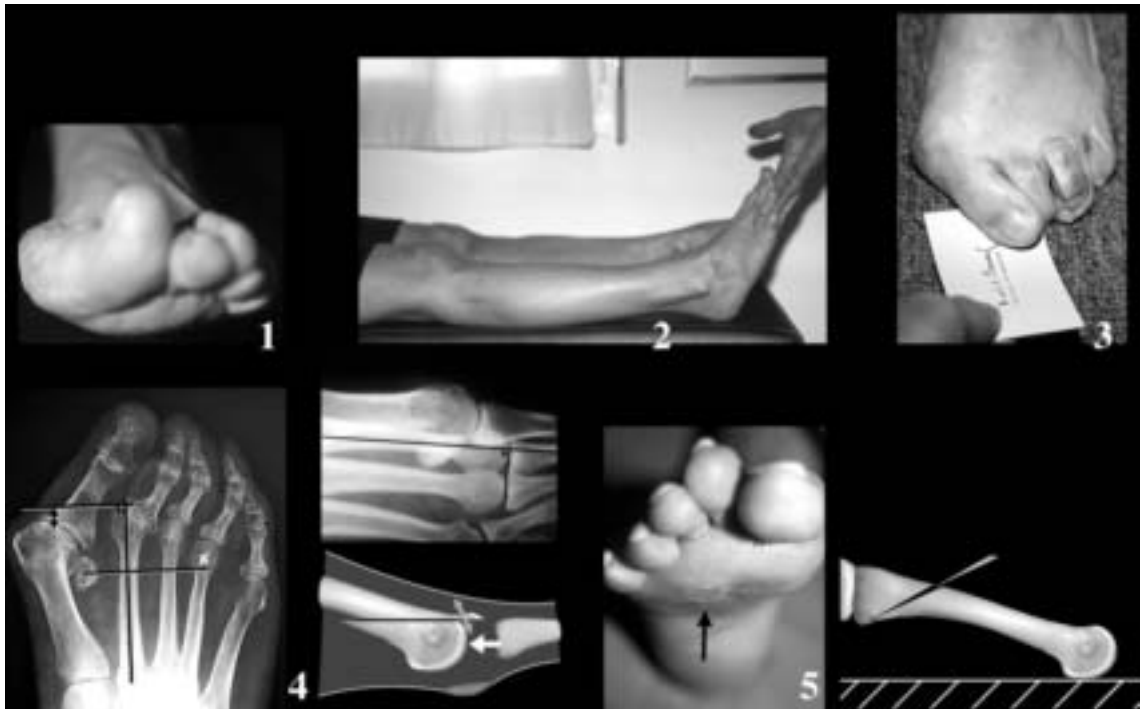
2. In this case, just lateral shift.

3. In this case, just additional M2 shortening by Weil osteotomy.

4, 5. Dorsal flexion decreased with passive correction of the deformity: The first metatarsal has to be shortened, to obtain both a long-lasting correction and a correct MTP articular range motion. What is the predictable necessary first metatarsal (M1) shortening? As a rule (resulting from the observation of our results), the amount of shortening has now to be located on the *ms* point (proximal point of the first phalanx).

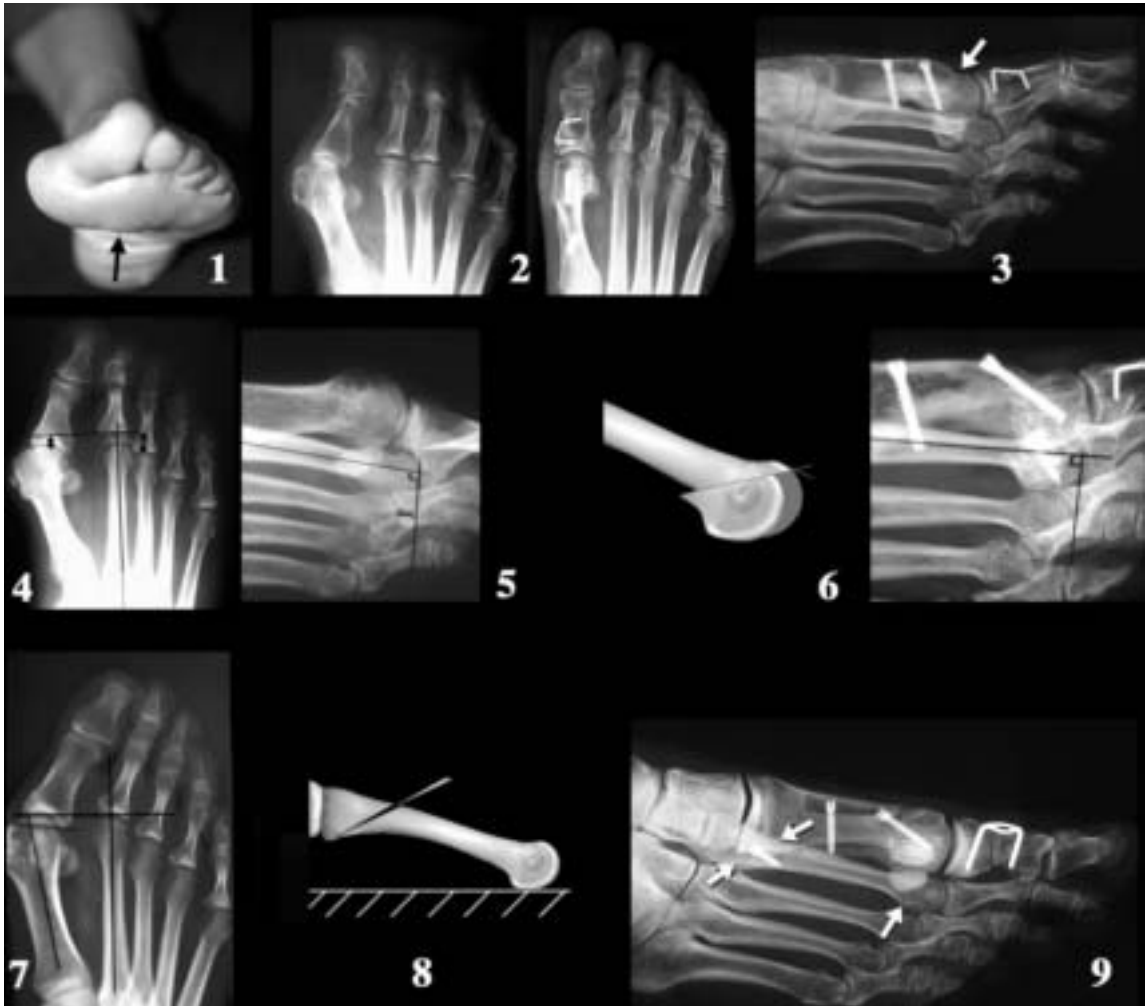
*In Relieving Metatarsalgia*

- In general, central metatarsalgia,
- Regarding the particular and common case of the second ray metatarsalgia.



**Fig. 42c1. Preoperative management. 2) Decision-making in relieving metatarsalgia. Generalities.**

1. Central metatarsalgia.
2. First we have to correct equinism, in this case fortunately just from the gastrocnemius shortness.
3. First ray disorders, notably hallux valgus, have to be corrected, to reach a correct great toe ground contact.
4. Large and harmonized shortening of the metatarsals (Weil osteotomy, additional scarf shortening if required) to reach a correct metatarsal parabola in dorso-plantar view as well as in medial oblique view.
5. In isolated or single ray metatarsalgia, indication of metatarsal basal elevation (BRT osteotomy).



**Fig. 42c2. Preoperative management. 3) Decision-making in relieving second ray metatarsalgia combined with hallux valgus deformity.**

2, 3. When *intermetatarsal angle* is sufficient, the scarf osteotomy provides sufficient lowering to relieve mild or moderate second ray metatarsalgia.

4, 5, 6. The *second metatarsal is too long*:

- Comparatively to the first metatarsal (dorso-plantar view).
- Comparatively to the third metatarsal (medial oblique view).

In this case, the Weil osteotomy is indicated to be performed only on the second metatarsal on the two following conditions.

- 1) No excessive proximal sliding.
- 2) Plantar inclined cut: This avoids transfer metatarsalgia.

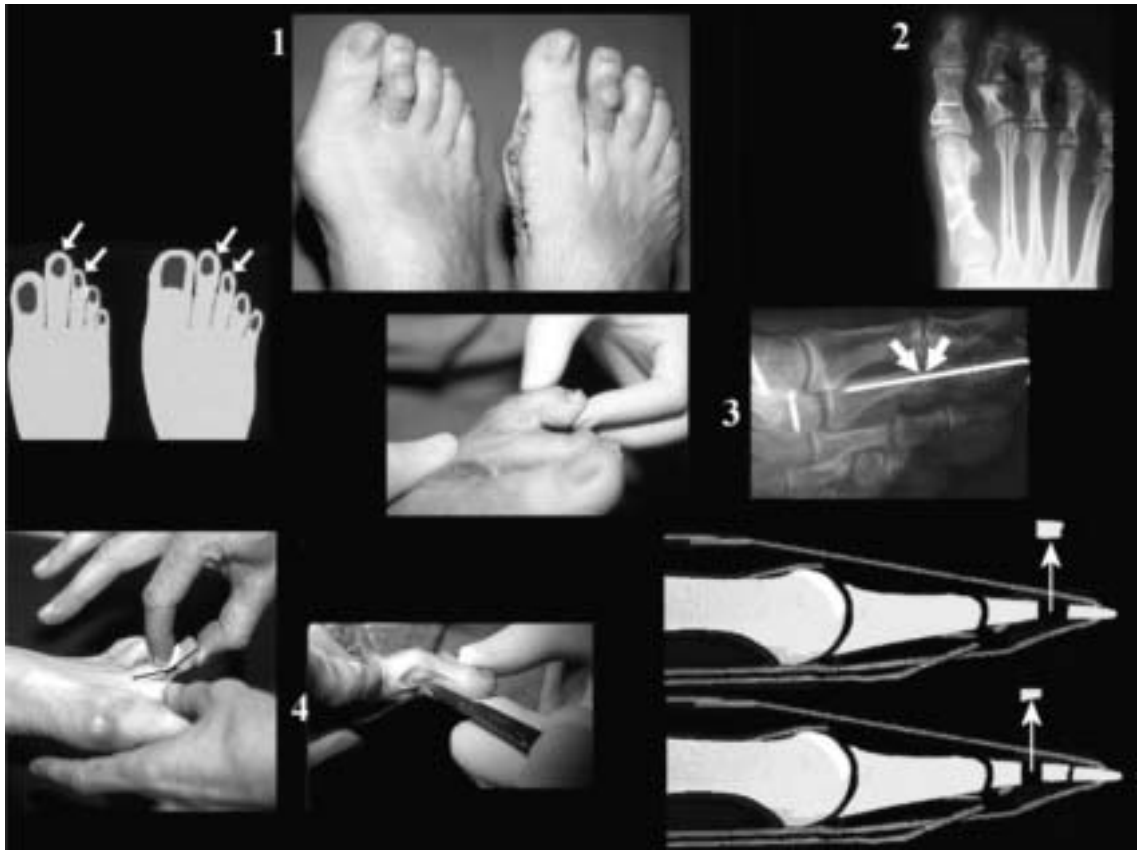7, 8, 9. In this case, the *first intermetatarsal angle* is not large enough to allow sufficient lowering by scarf osteotomy. Furthermore, the second metatarsal is not too long. This is an indication for a BRT osteotomy to be performed on the second metatarsal, in combination with M1 scarf osteotomy.

*In Hammer or Claw Toe Correction*

On the corresponding pictures, we bring precisions about the folkway points.

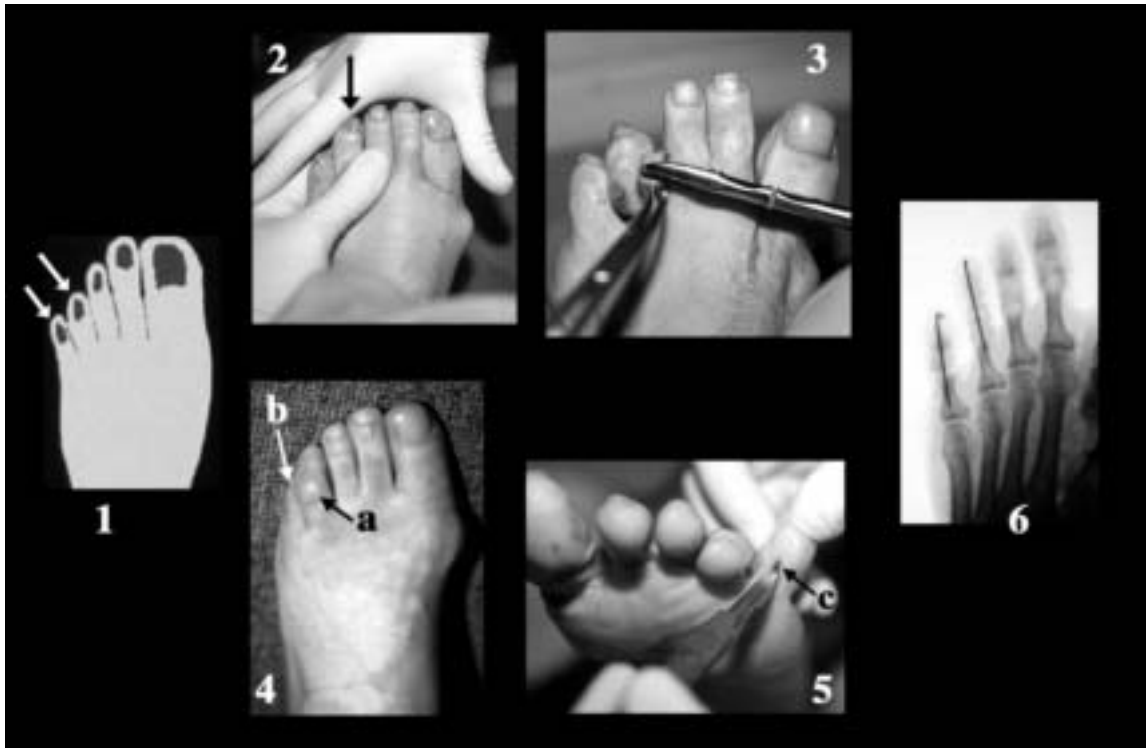
– In the second and third toes.

- In the fourth and fifth toes.
- What are the indications of Weil osteotomy for correcting hammer or claw toe.
- Indications of soft tissue procedure for this correction.



**Fig. 42d1. Preoperative management. 4 decision making in Hammer and claw toe. Second and third toes surgery.**

1. Hallux valgus correction does not cure the 2nd toe deformity.
2. The traditional first phalanx distal resection is only good for the surgeon: not for the patient!
3. The PIP joint fusion has to be reserved to *really* fixed deformity (rare).
4. The PIP flexion deformity is correctible in most cases: we can preserve this joint by manipulation or by PIP plantar release.
5. In case of too long the toe, shortening by DIP arthroplasty (resection of the distal part of the middle phalanx) or, by Shaft Resection of the Middle Phalanx (SRMP).



**Fig. 42d2. Preoperative management – Decision-making in hammer or claw toe. Fourth and fifth toes surgery.**

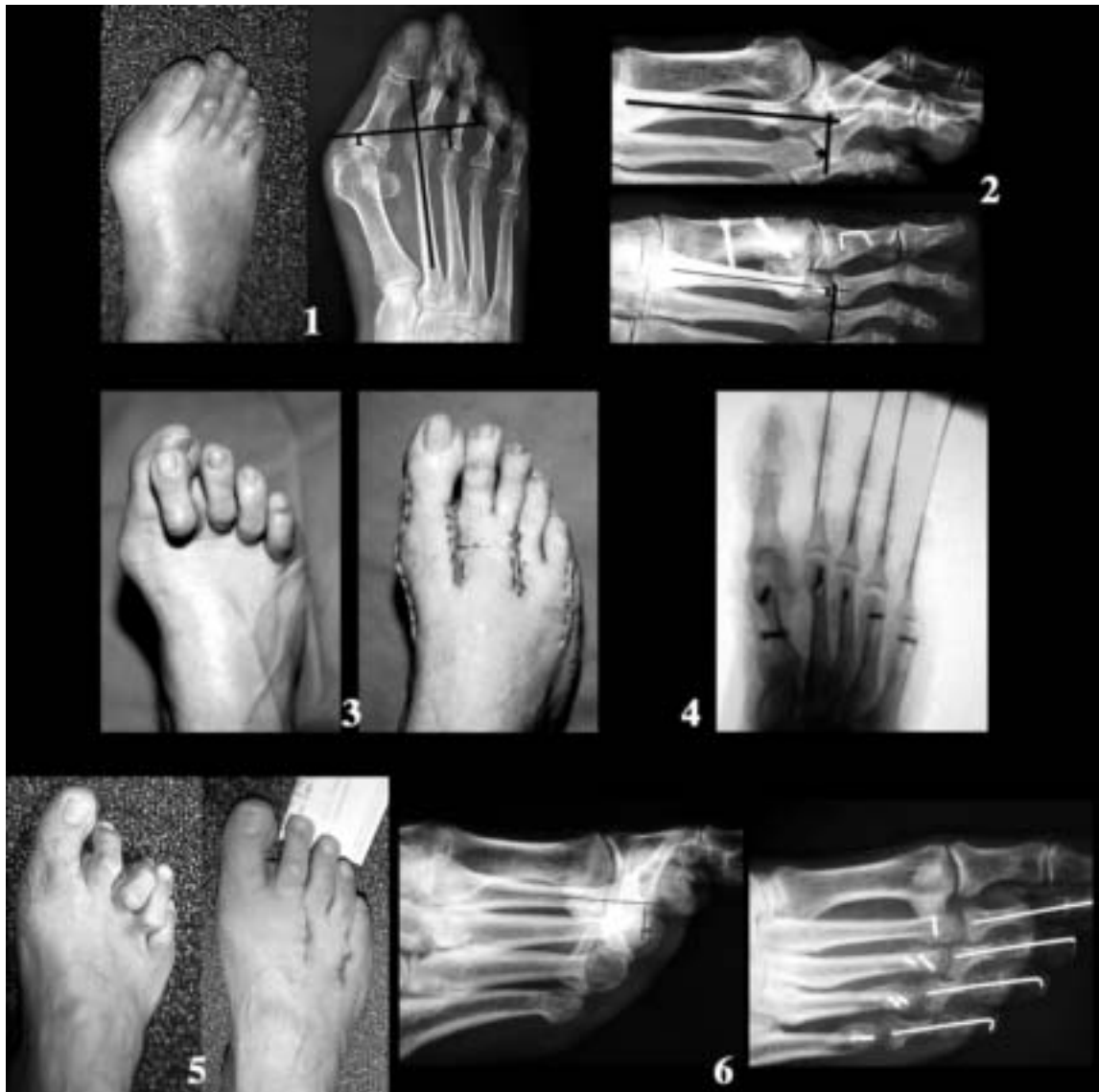*In this location, joint fusion is not necessary; furthermore, the second phalanx is already too short to be shortened again. Two reliable solutions:*

**2, 3.** *The toe is too long* (here the fourth one): In this location, the distal resection of the first phalanx gives good results.

**4, 5.** *The toe is not too long* but it is plantar flexed (here the fifth one) (**b**); the resulting claw toe increases the deformity of the adjacent toe (**a**). So that we have to cut the long flexor tendon near of its distal insertion (**c**).

**6.** In each case, the K-wiring excluding the MTP joint ensures the fixation.





**Fig. 42d3. Preoperative management – Decision-making in hammer or claw toe. Role of the Weil osteotomy.**

This procedure is a great help for the deformity correction whatever the location of hammer or claw toe.

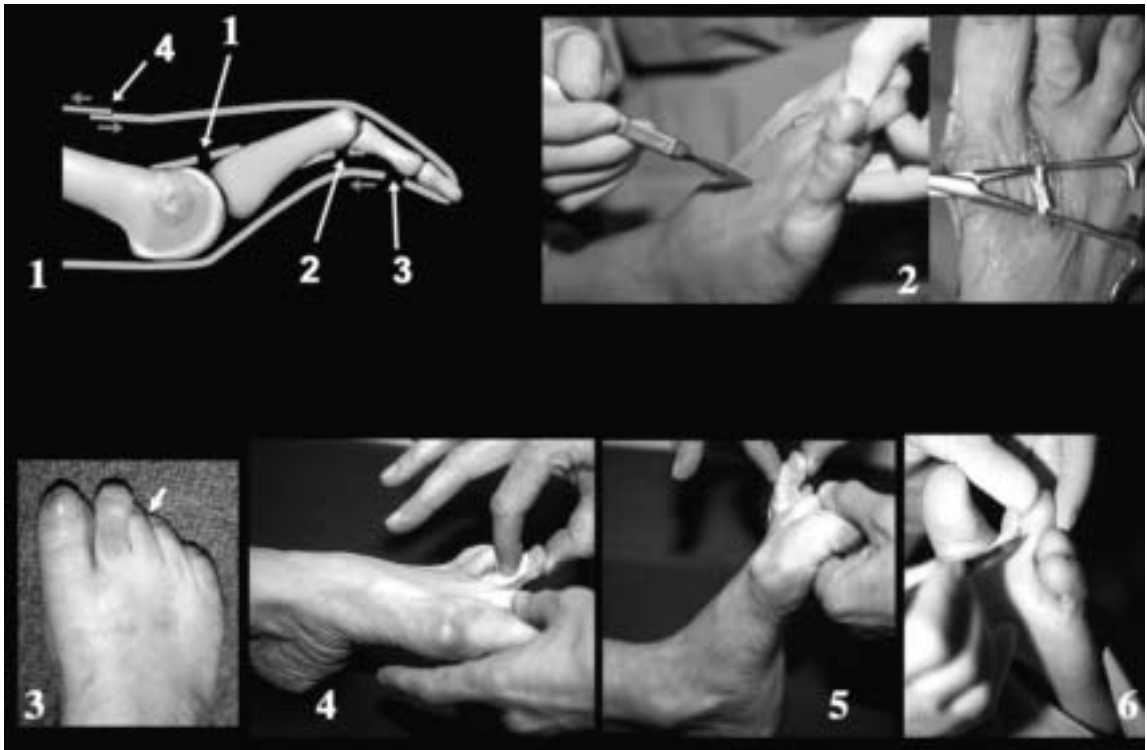
**1, 2.** Single metatarsal excess of length (both in dorso-plantar and in medial oblique view): Indications of single Weil osteotomy.

**3, 4.** Severe hammertoe deformity: Correction by Weil osteotomy (often extended to the four lesser metatarsal) and toes K-wiring.

**5, 6.** Same foot.

**5.** Excessive length of the lesser metatarsals.

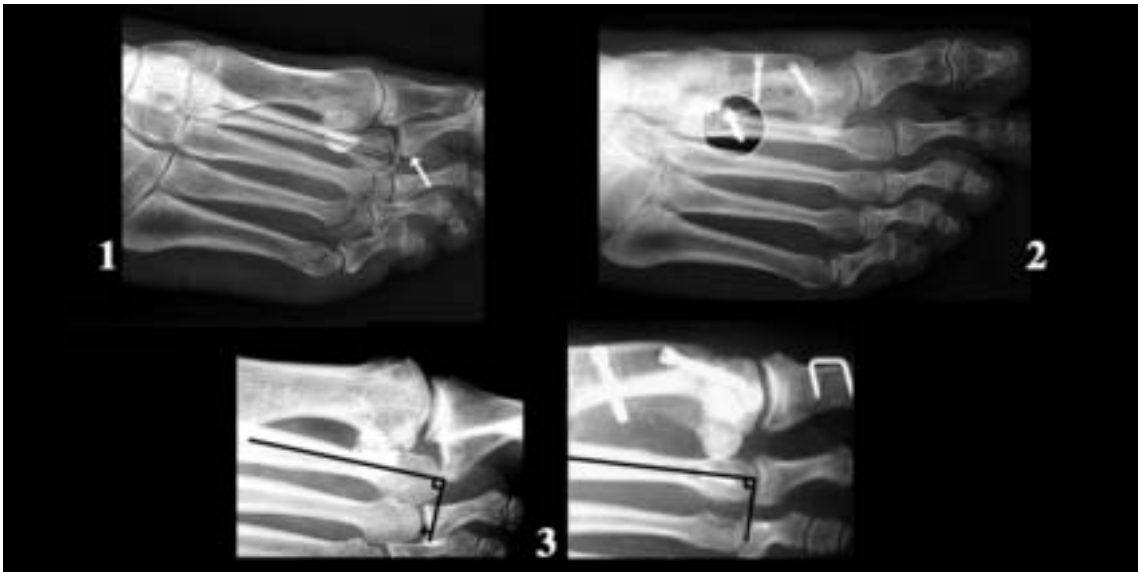**6.** Medial oblique view. Correction by Weil osteotomy.



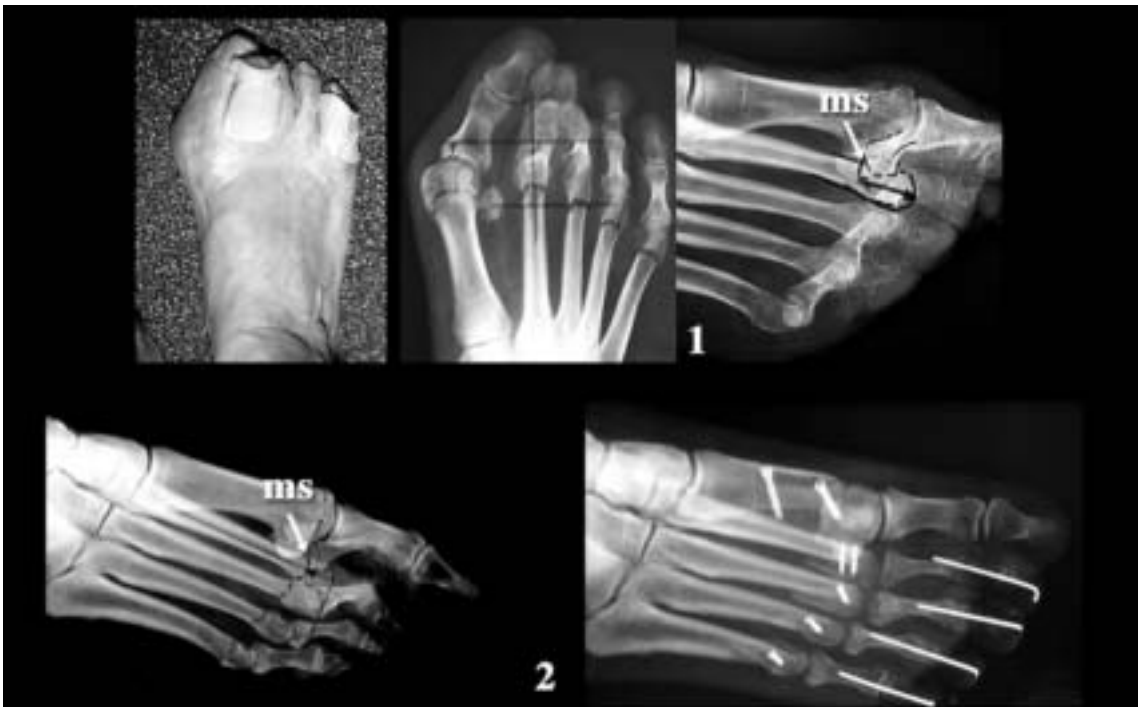**Fig. 42d4.** Preoperative management – Decision-making in hammer or claw toe. *Additional soft tissue procedure to be performed.*

1. If the MTP passive plantar flexion is not sufficient, we have to perform its dorsal release.
2. The extensor tendons often have to be lengthened in many cases.
- 3 to 6. Need of flexor tendon release. Distal section.

*In MTP Dislocation on Lesser Rays*



**Fig. 42e1. Preoperative management. 5) Decision-making in MTP dislocation of the lesser rays. 1) Subluxation.** 1-2. Subluxation without excessive second metatarsal length: Indication of BRT osteotomy.  
 3. Subluxation of the second MTP joint and excessive length of the second metatarsal: This is an indication to perform a single second metatarsal Weil osteotomy. This case rarely occurs. Usually Weil osteotomy is necessary on several metatarsals.

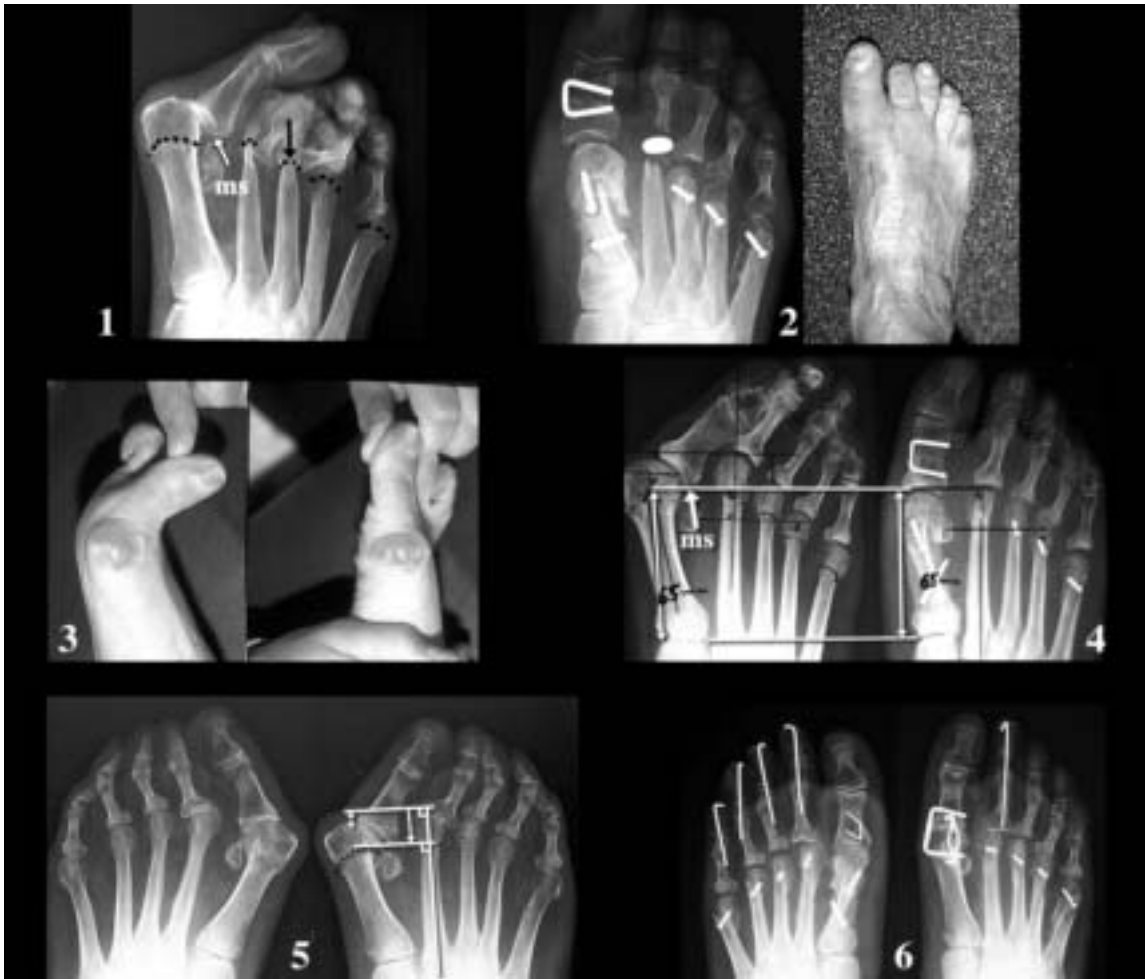


**Fig. 42e2. Preoperative management. 5) Decision-making in MTP dislocation of the lesser rays. 2) MTP dislocation.** 1. *MTP dislocation:* The amount of proximal sliding of the corresponding metatarsal is assessed on the medial oblique view. The metatarsal shortening is focused on the ray with MTP dislocation and the metatarsal parabola is harmonized from this ray, both in dorso-plantar and medial oblique views.  
 2. In this other case, result of this type of surgery: We note the additional toe K-wiring, usually correcting the hammertoe deformity without PIP fusion or resection.

*In Severe Forefoot Disorders Treatment*

We must have a whole forefoot overview, focused on the most affected ray but harmonizing

the forefoot – around the correction of this ray. This is an opportunity to thank B. Regnaud, who was one of the first surgeons to emphasize this aspect of taking in charge the whole foot.

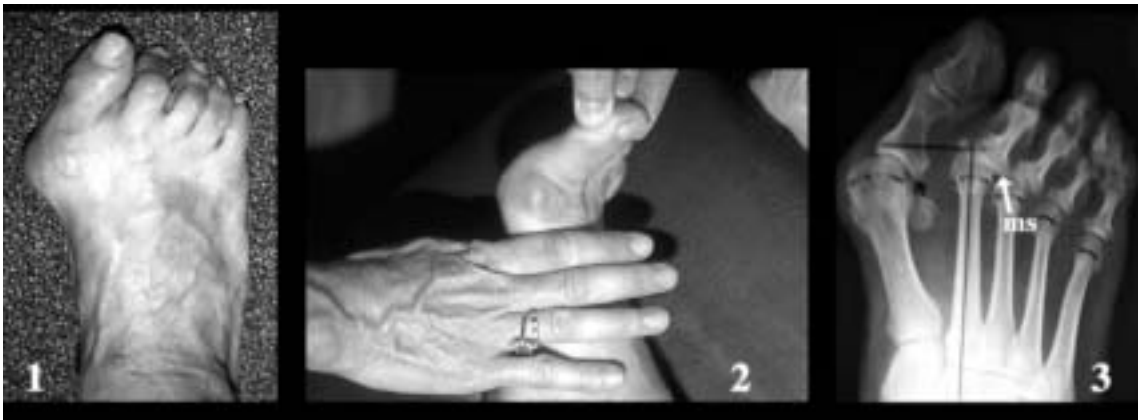

**Fig. 42f1. Preoperative management. 6) Decision-making in severe forefoot disorders. a) The first ray is the most impaired.**

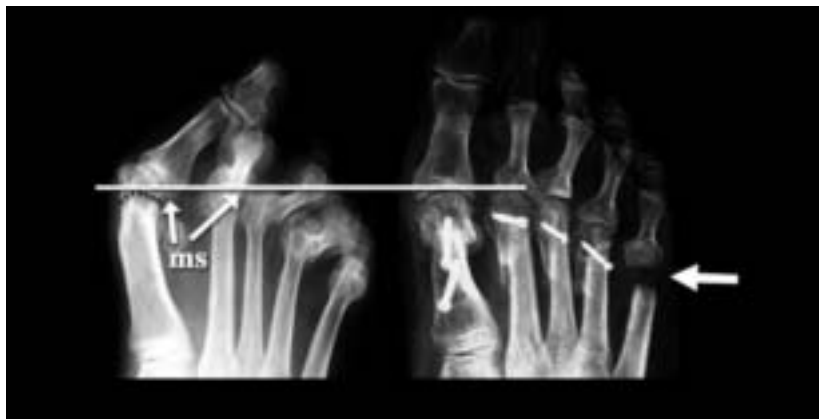
1, 2. In spite of this severe deformity, this patient has a good and painless first MTP joint mobility. In the preoperative examination the joint preservative surgery has to be indicated. The amount of M1 shortening is determined thanks to the ms point. We note the button prosthesis on the second metatarsal on which the head had already disappeared.

3, 4. In this case, in the preoperative examination, taking into account the radiological aspect and the loss of preoperative first MTP dorsal flexion, the shortening had to be generous, as indicated on this picture (ms point): We did it and the postoperative aspect showed that the planned remaining length of the first metatarsal was correct (65 mm).

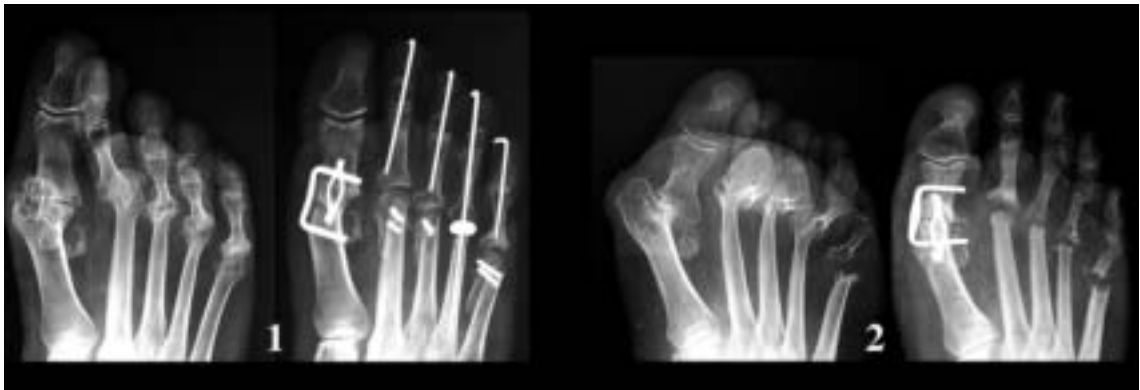5, 6. On the left foot, joint preservative surgery was indicated and easily performed. On the right foot, the first metatarsal was already too short, the MTP joint already stiff, so that the shortening to be performed should be excessive. As a consequence we preferred to make a MTP fusion.



**Fig. 42f2. Preoperative management. 6) Decision-making in severe forefoot disorders. b) The lesser rays are the most impaired.**  
 The metatarsal shortening is focused on the second ray (ms point), since the first MTP joint has correct dorsal flexion. Nevertheless, M1 has to be shortened to follow the M2 shortening and this is a security to both correction and MTP mobility.

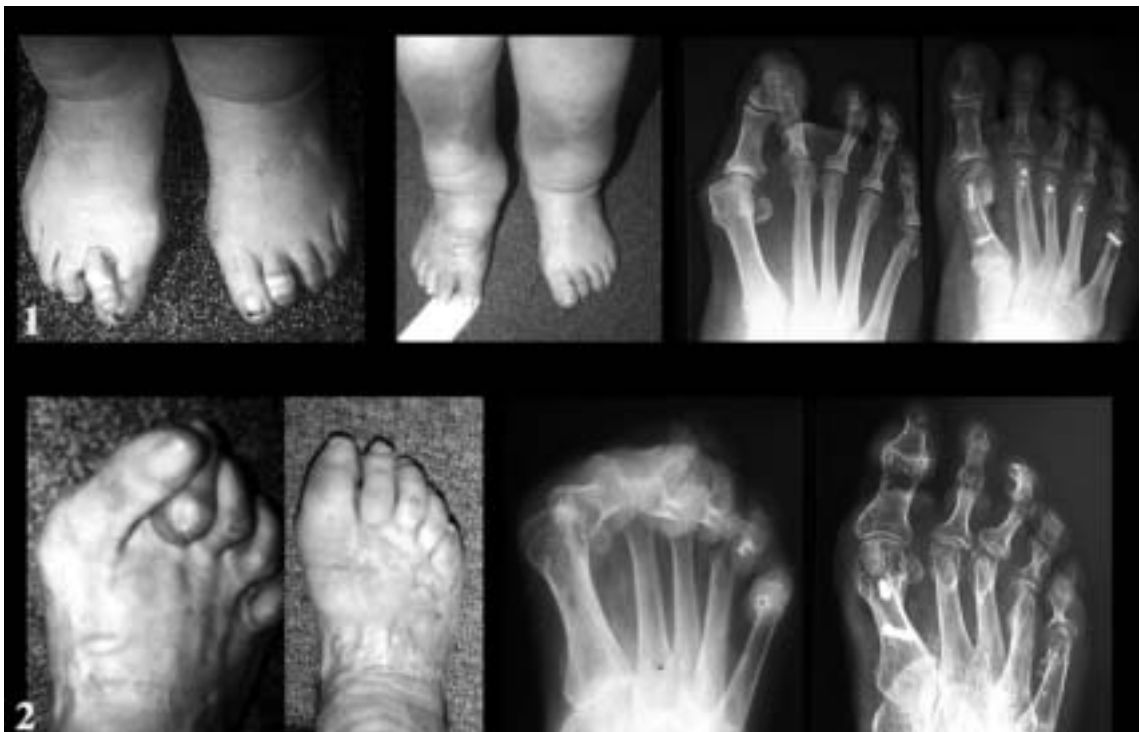

**Fig. 42f3. Preoperative management. 6) Decision-making in severe forefoot disorders. c) Metatarsal shortening focused on both the first and second rays.**  
 A case of rheumatoid forefoot: Preservation of every joint with only resection of the fifth metatarsal head. Note the required metatarsal shortening, focused both on the first and second rays (ms points).



**Fig. 42f4. Preoperative management. 6) Decision-making in severe forefoot disorders. d) Limits of joint preservation.**

1. Preservation of three metatarsal heads: Button prosthesis only on the fourth MTP joint.
2. The lesser metatarsal head resection must be reserved for extremely impaired metatarsal heads, as showed in this case.

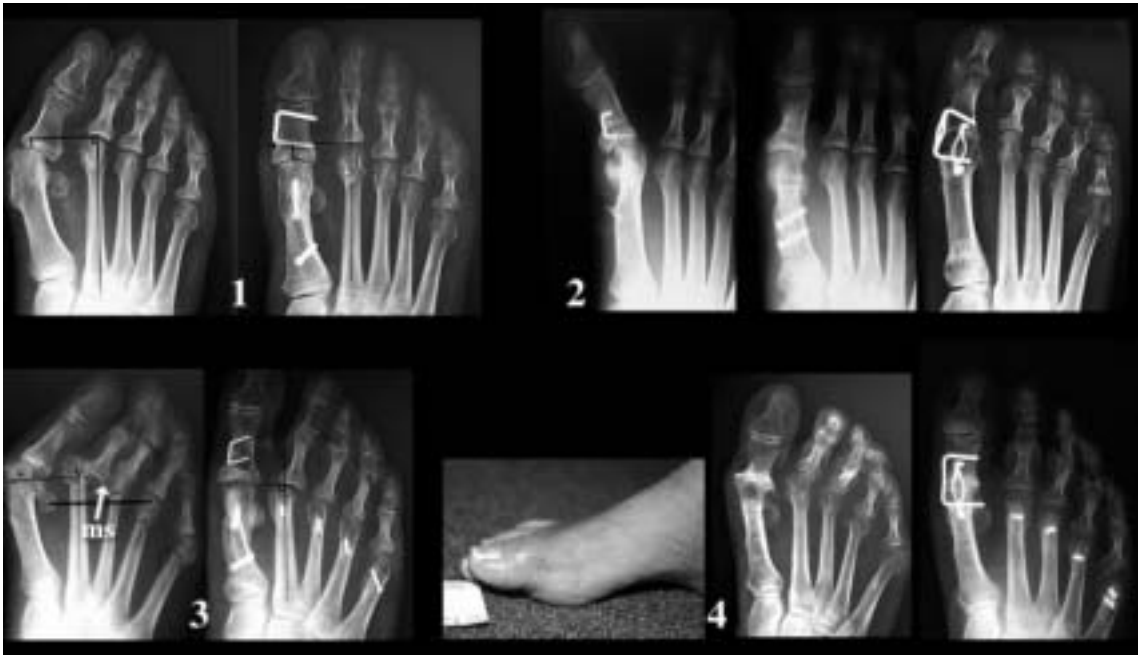

**Fig. 42f5. Preoperative management. 8) Decision-making in forefoot surgery with severe trophic troubles.**

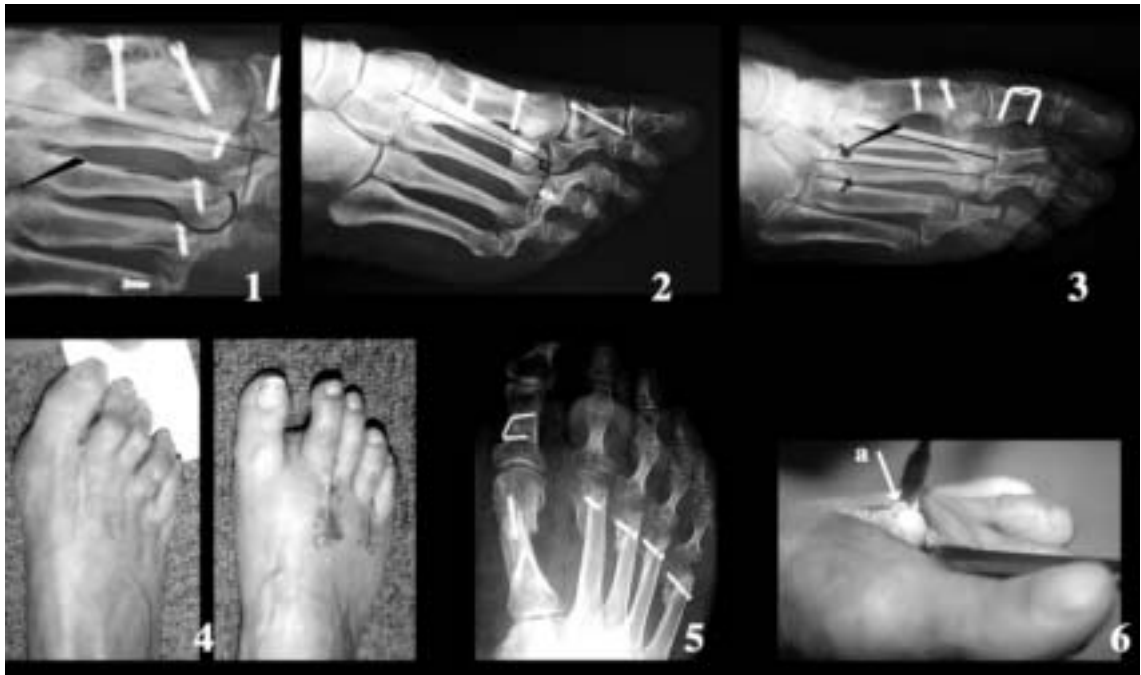1. Joint preservative forefoot surgery is not contraindicated in the case of severe trophic troubles.
2. Clinical and radiological aspect of forefoot with important deformity and such osteoporosis that the Weil osteotomy was only fixed by vinyl suture. Result at one postoperative year.

*In the Iatrogenic Forefoot*

- In failed bunionectomy,
- In lesser ray iatrogenic pathology.



**Fig. 42g1. Preoperative management. 7) Decision-making in iatrogenic forefoot. a) Failed bunionectomy.**  
 1. Undercorrection in M1 scarf combined with great toe osteotomies regularly provides the correction.  
 2. In overcorrection the reverse scarf should be performed, but with a risk of metatarsal head necrosis, so that in advanced cases we prefer either the large shortening of the five metatarsals, which does not result in necrosis or directly MTP fusion.  
 3. In advanced or long-lasting undercorrection, the shortening of the metatarsal allows in almost all cases to obtain a reliable correction – note that the metatarsal shortening (ms) is focused on the second ray.  
 4. In case of failed bunionectomy after Keller procedure, MTP fusion is indicated with lesser metatarsal Weil osteotomy.

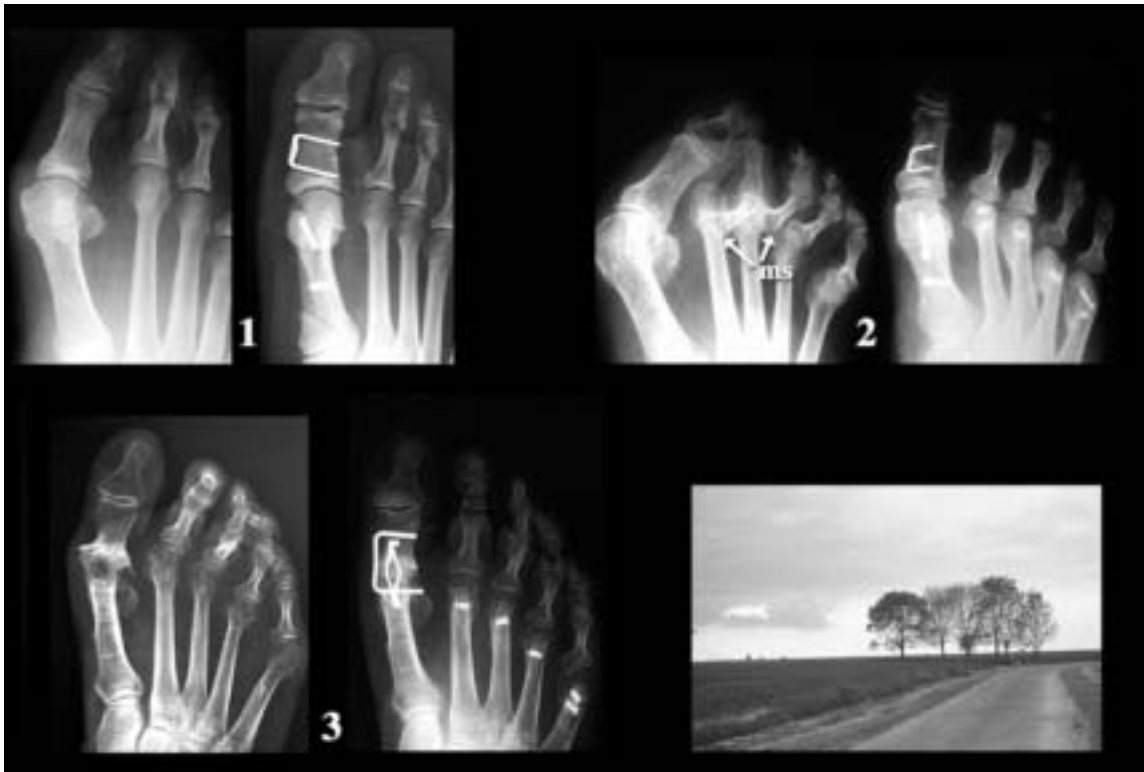


**Fig. 42g2. Preoperative management. 7) Decision-making in iatrogenic forefoot. b) On lesser rays.**

1. Double layer osteotomy not performed in Weil osteotomy (third ray): Remaining metatarsalgia. This is an indication for BRT osteotomy on the corresponding metatarsal.
2. Excessive length of the third metatarsal emphasized by the medial oblique view: Transfer metatarsalgia on the third ray. We have to secondarily perform a Weil osteotomy on the third ray.
3. Too much elevation of the third metatarsal after basal chevron osteotomy (black arrows): Transfer metatarsalgia on the second ray. This is an indication for BRT second metatarsal osteotomy.
4. In failed lesser rays surgery by trophic troubles (SDRS followed by MTP stiffness) the MTP surgical release (6) has to be widely indicated but at least one year after the operation.



Fig. 42i shows *three easy cases* for surgical management, *i.e.* cases where there is no discussion of what we have to do to provide a reliable correction.



**Fig. 42i. Preoperative management. 9) Three easy cases for decision-making.**

1. Acquired hallux valgus and moderate deformity: Scarf and great toe osteotomies.
2. Severe forefoot disorder: Large and harmonized shortening of the metatarsals, with amount of shortening focused on the second ray (ms point): Preservation of the joints.
3. After Keller procedure, first MTP is impaired and painful, metatarsalgia and claw toes appear on the lesser rays. First MTP fusion and lesser metatarsal Weil osteotomy.

## Intraoperative Management



Fig. 43a1. Intraoperative management – The aim: *Balancing the surgery for a well balanced foot.*

### Specific Tools

The ancillary instruments, the motors, the implants have to be specific to forefoot surgery.

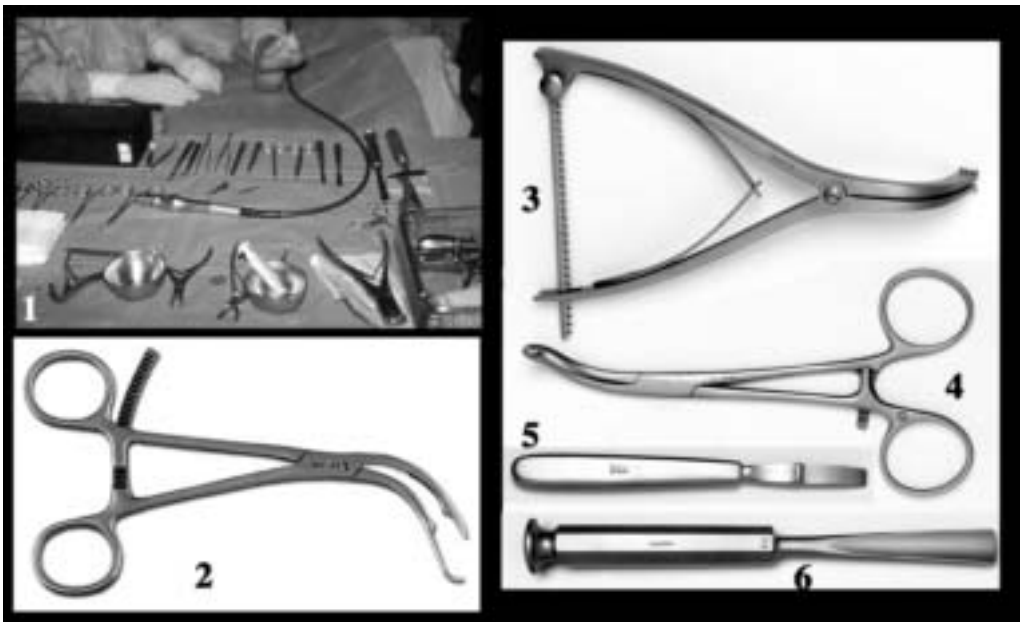
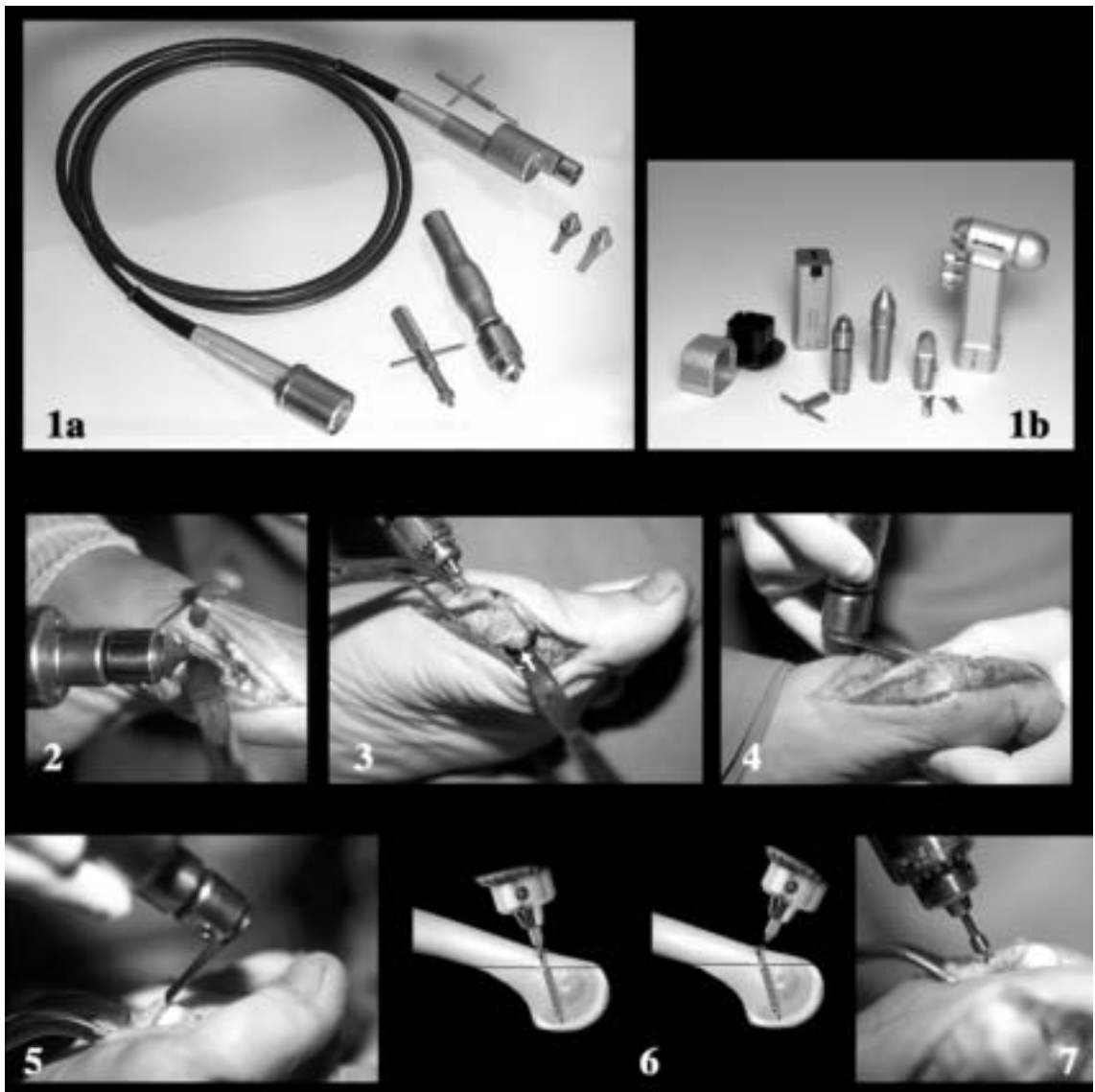

Fig. 43a2. Ancillary set in forefoot surgery.

1. The table with the DePuy instruments and the Aesculap motor.
2. The special scarf clamp.
3. The modified hinge retractor (for MTP lateral release and for Weil osteotomy).
4. The banaleck clamp (very often useful).
5. Small rigne 5mm, curve (for checking the first MTP lateral release and for toe surgery).
6. Ciseau de Cauchoix 17mm, useful for soft tissue protection in the ppe (scarf osteotomy), for lesser MTP joints release and for performing a second layer in lesser metatarsal Weil osteotomy.



**Fig. 43a3. The Aesculap motor.**

**1. a.** The *elan ec*: Barouk configuration.

**b.** The *Acculan mini*.

**2, 3, 4.** Applications in scarf osteotomy.

**2.** Scarf proximal cut.


**3.** Distal fixation.

**4.** Distal resection.

**5, 6, 7.** Applications in Weil osteotomy.

**5.** Osteotomy cut.

**6, 7.** The *twist-off* screw, thanks to the *low motion* of the Aesculap motor, becomes a *snap-off* screw, which secures the fixation (to be finished by screw driver).



**Fig. 43a4. Usual implants in forefoot surgery (DePuy).**

1. Evolution of the scarf screw: From the 3.0 diameter (a) to the 2.5 mm diameter long head (b) and the self cutting FRS screw (c).
2. Implants for Weil osteotomy: d) the twist off screw, e) the soc pin.
3. The two sizes of memory staples: f) 12 mm (great toe first phalanx), g) 20 mm (MTP, Lisfranc or rear foot joint fusions).
4. The variation staple (great toe first phalanx).
5. The Tiflex staple (first MTP and rear foot fusion).
6. The button temporary spacer (stainless steel or Zirconium).

## Operative General Tactics

First, whatever the decision taken preoperatively, **we have to adjust** – and eventually to modify – the surgery following the **intraoperative findings**.

Secondly, we think that there is a **chronological order** to follow for performing surgery and each step is an opportunity to assess and to control what we are doing. I think that forefoot surgery, perhaps more than any other location of orthopaedic surgery, has to be made with a *very trained assistant*, always the same. Actually there are many things to do in a short time,

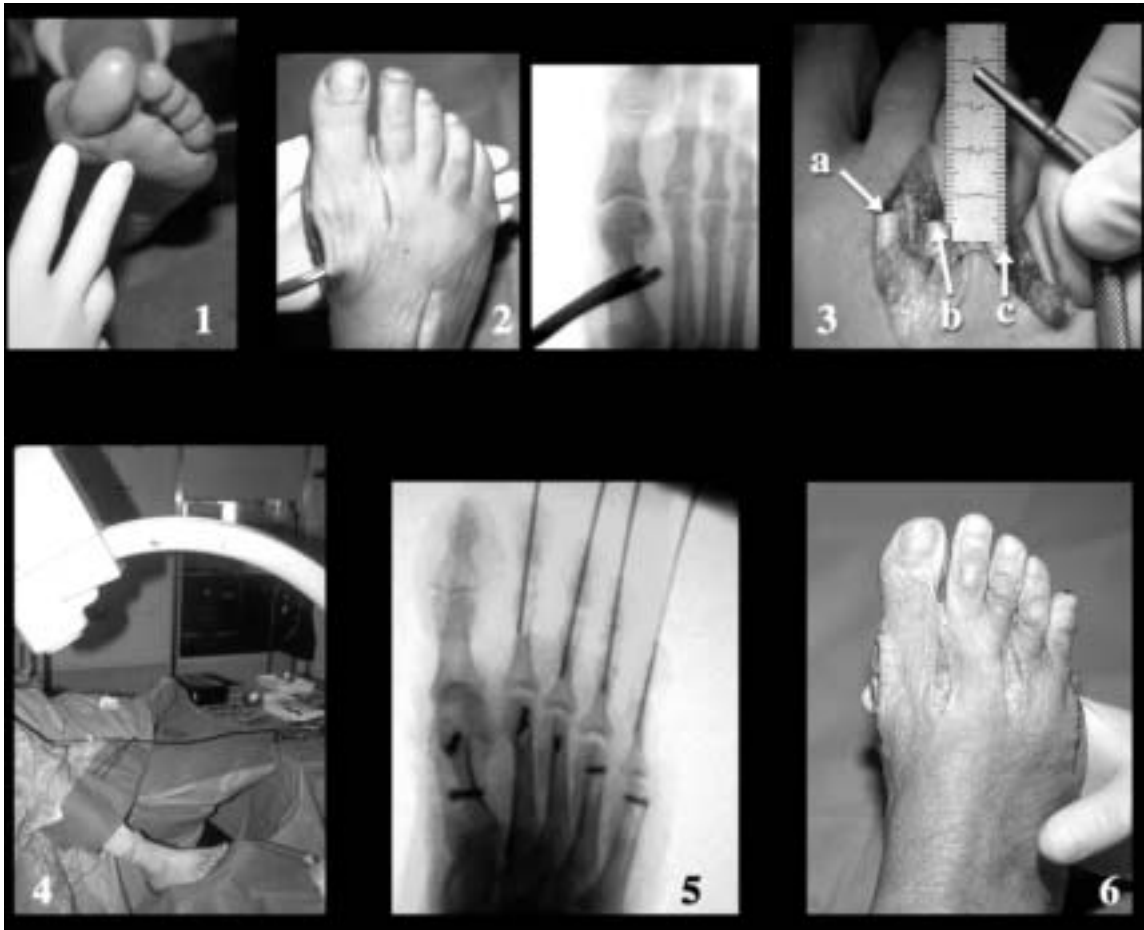
above all if the two feet are operated on the same time. Furthermore, it is better to look at the foot from a different location. This is one example: If we look at a right foot while sitting on the right side of the operative table, we have tendency to see too much length of the big toe, but this is the contrary if we sit on the left side.

This is an opportunity to thank Viviane Coste, my nurse and assistant on forefoot surgery for 25 years, for her help and patience. We also have to remember that women are perhaps more finicky than men and that forefoot surgery needs to be made with a great accurateness.

Thanks also to my second nurse Françoise Lebrun.

Concerning the *anesthesia* I know that local anesthesia is now very popular. It can be made by peripheric blocks, as emphasized very accurately by A. Delbos (Toulouse) [44]. However, since we

make in many cases bilateral surgery, we usually make surgery with general anesthesia, which is also now very improved, becoming both “light”, reliable, safe and comfortable for the patient. This is an opportunity to thank Dr C. Izquierdo, my very effective and patient anesthetist.



**Fig. 43a5. Intraoperative main assessment tests.**

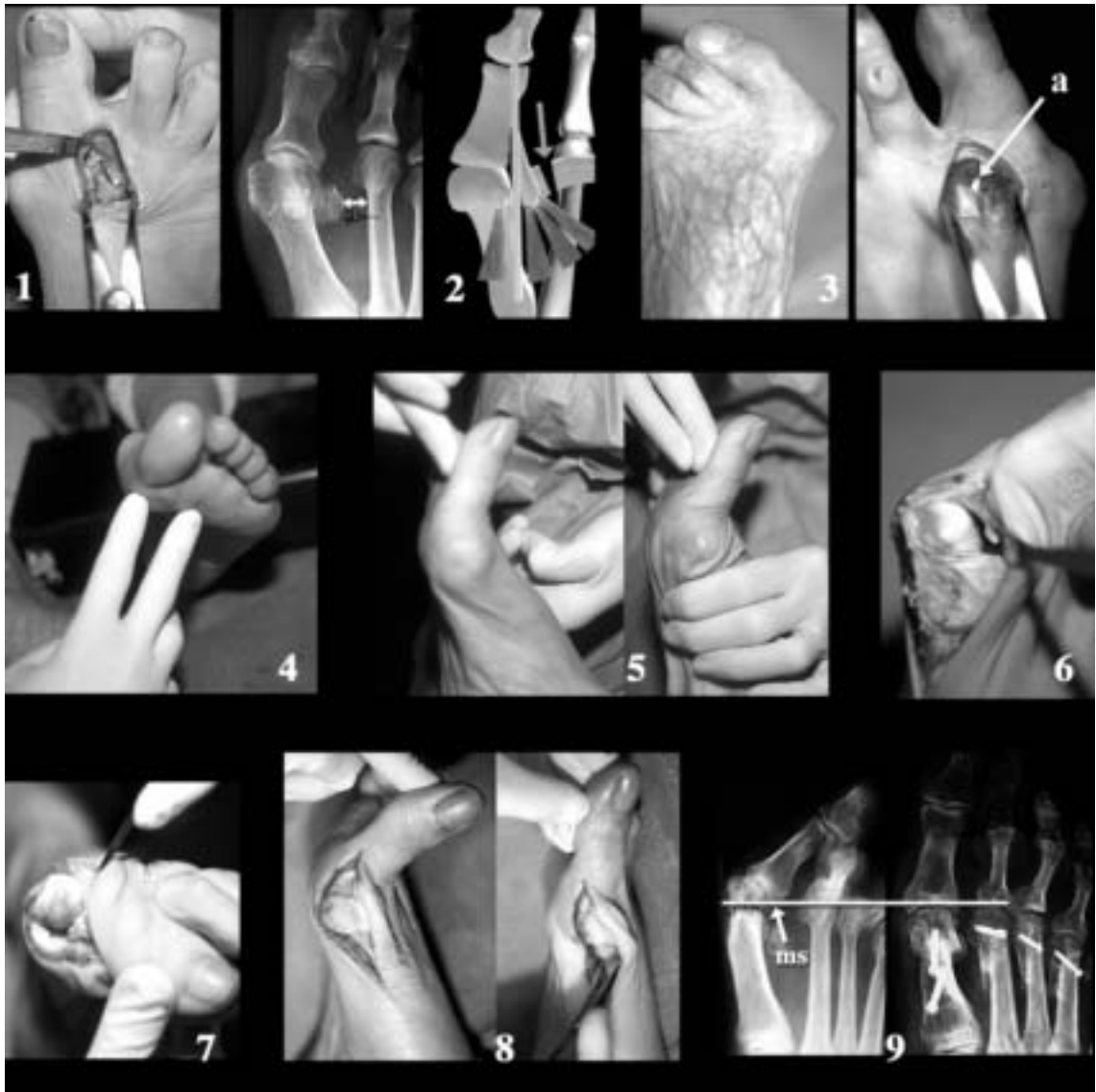1. Assessment of the plantar position of the metatarsal heads.
2. The Load Simulation Test (LST) and its corresponding intraoperative X-ray views.
3. Assessment and control of the relative length of the metatarsals in Weil osteotomy.
- 4, 5. Final X-ray control (X-ray amplifier or fluoroscop).
6. Final control by LST.

### ***Management in the Different Main Pathologies Encountered***

This intraoperative management is also an opportunity to sum up the technique of the used procedures that we describe successively.

### ***Hallux Valgus Correction***

The different steps.



**Fig. 43b1. Intraoperative management – Hallux valgus correction. a) First steps.**

1, 2, 3. *Lateral release.*

1. After lateral release, checking of the MTP lateral ligament preservation to avoid overcorrection.

2. Lateral sesamoid too close to the second metatarsal: Indication of first intermetatarsal ligament section.

3. Very large hallux valgus deformity: Complete section of the phalangeal insertional band, as far as the flexor hallucis longus tendon becomes visible.

4. *Assessment of the plantar location of the first two metatarsal heads*, for indication of lowering or elevation of the first or the second metatarsal additional surgery.

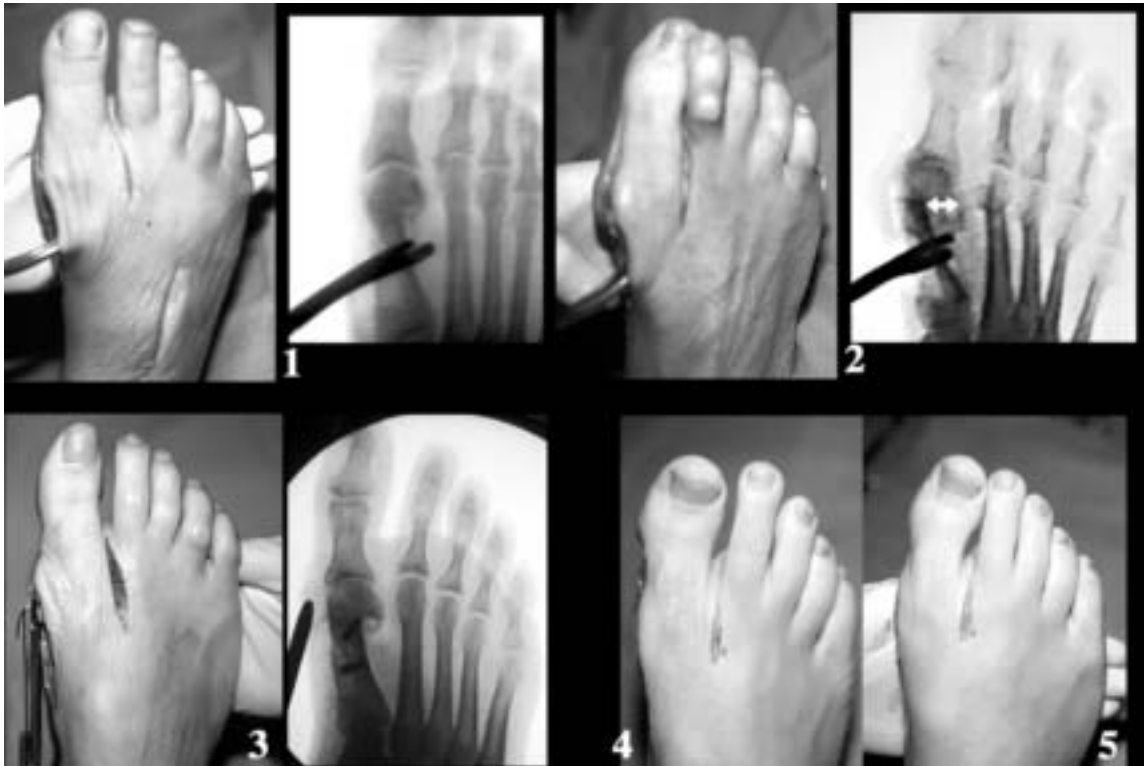5. Hallux valgus correction handling: After lateral release, the hallux valgus may be corrected and the intermetatarsal angle diminished (left hand). The assessment of the remaining MTP dorsal flexion is accurate and reliable. In this case, the dorsal flexion is preserved and there is *no indication of first metatarsal shortening*.

6. Assessment of the location of cartilage: In this case, it is laterally located, this is an indication for DMAA correction.

7, 8. In this case, impairment of the metatarsal head cartilage, and loss of dorsal flexion with the hallux valgus correction handling: This is an *indication to first metatarsal shortening*.

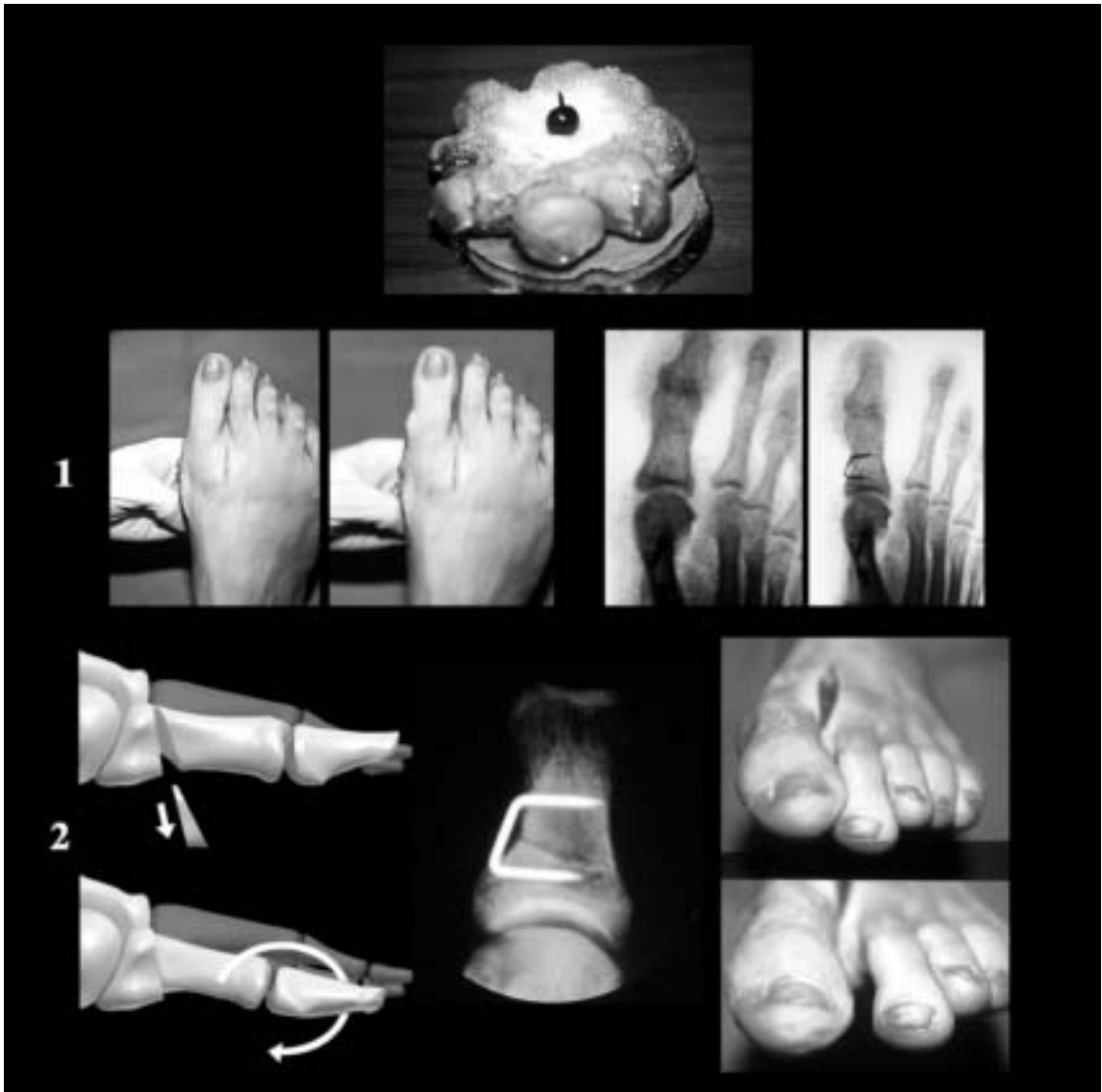
9. One year postoperative radiological result in case of rheumatoid forefoot (same foot that Fig. 7).

Shortening as far as *ms* point.



**Fig. 43b2. Intraoperative management – Hallux valgus correction. b) Following steps.**

- 1, 2. After scarf osteotomy, before screwing, Load Simulation Test (LST) and if required fluoroscopy checking.
1. Good correction.
2. Large deformity: More lateral shift is not allowed. This indicates more DMAA correction, and, after screwing, medial soft tissue tightening and great toe osteotomy.
- 3, 4. After medial tightening.
3. Good correction: The osteotomy of the great toe is not necessary.
4. It seems to be a good correction, but the LST reveals the need of great toe first phalanx osteotomy to complete the correction.

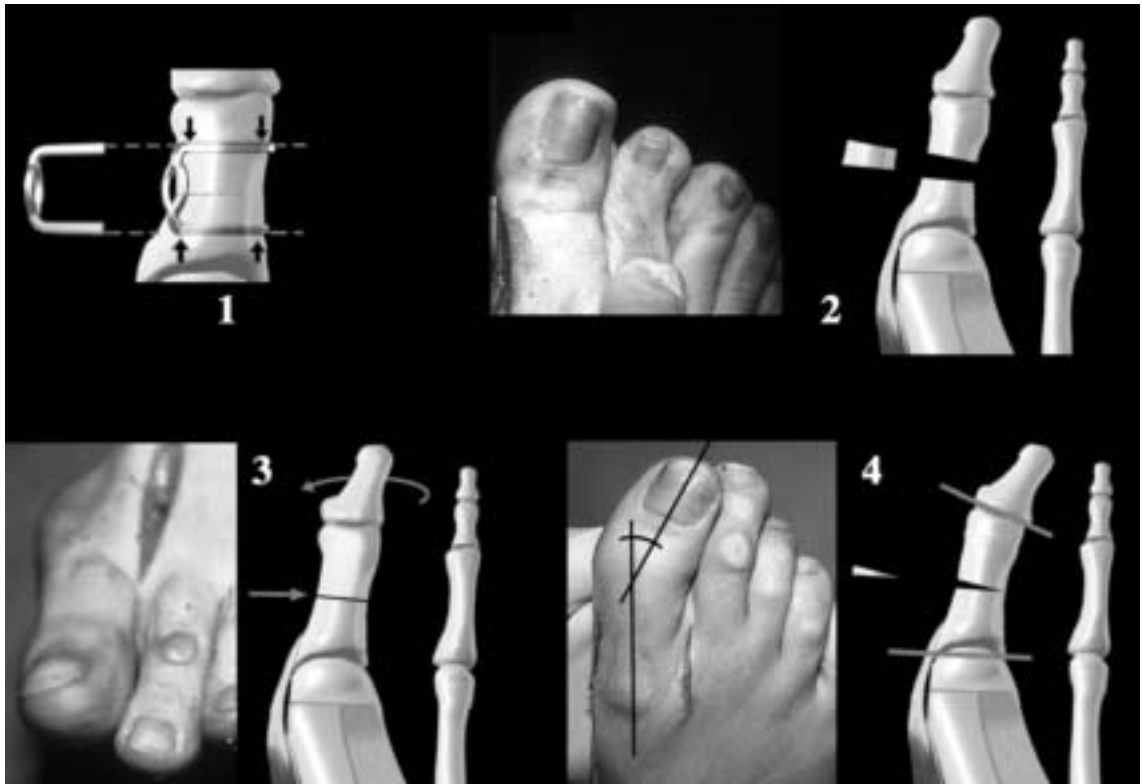

**Fig. 43b3. Intraoperative management – Hallux valgus correction. c) Last step: First phalanx basal osteotomies.**

... As a cherry on the cake: But if the cake is bad, the cherry cannot save it (remark of Pr Groulier, Marseille, France).

1. The basal varisation osteotomy completes the correction: LST before and after osteotomy and X-ray aspect.
2. Varisation combined with derotation (P. Diebold, Nancy, France). When required, this osteotomy perfectly completes the correction: However, care has to be taken to preserve the dorso-lateral cortical hinge.





**Fig. 43b4.** Intraoperative management – Hallux valgus correction. *c) Last step: First phalanx shaft osteotomy.*

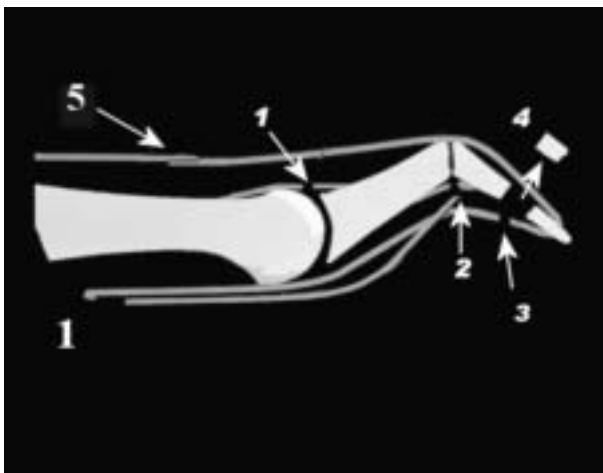
1. This osteotomy is easy thanks to the special memory staple in the three following osteotomies:
2. Shortening for Egyptian type foot remaining.
3. Derotation which may also be useful.
4. Shaft varisation for residual valgus of the toe or for interphalangeal hallux valgus.

*Management on the Lesser Rays*

See the pictures and their legends respectively:

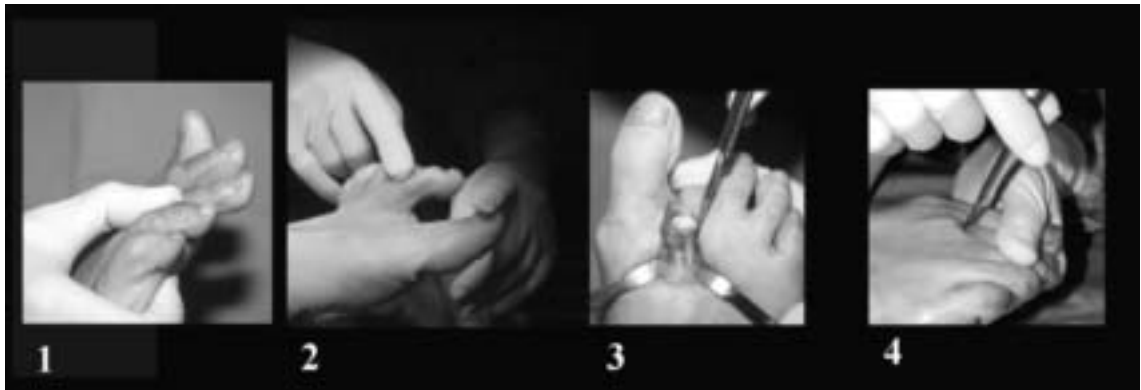
– **Hammer or claw toe operative management.**

- **BRT osteotomy** technique.
- **Weil osteotomy:** Technique in making a single ray osteotomy, then in making several rays osteotomies.



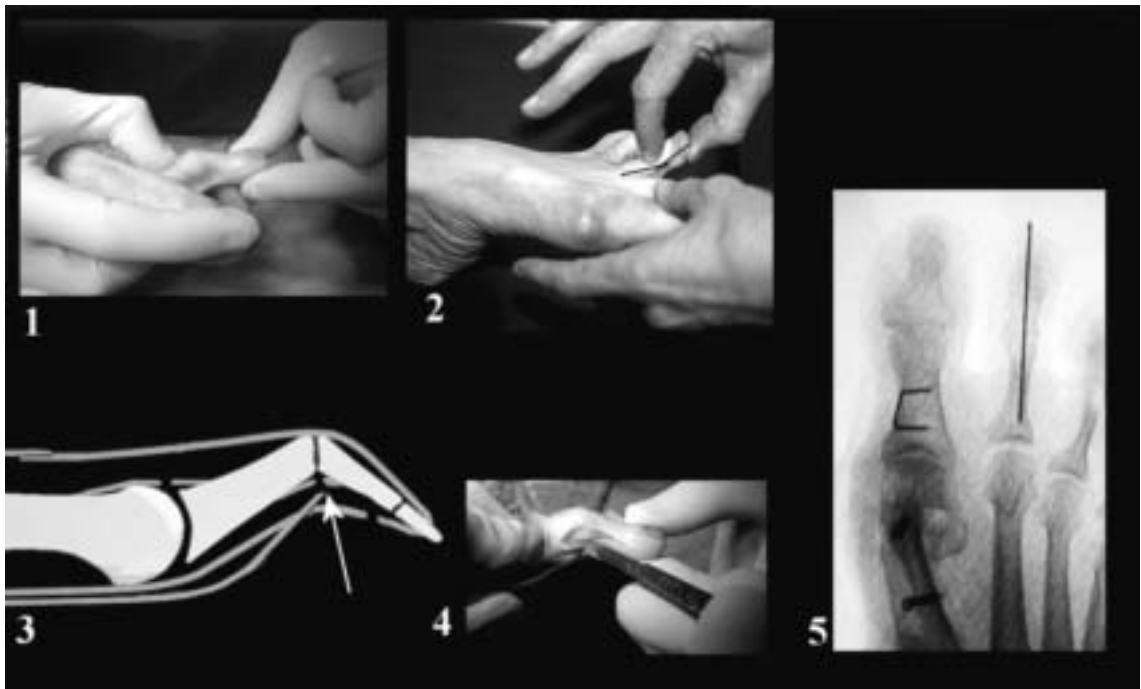
**Fig. 43c1.** Intra operative management. Chronological steps for hammer or claw toe correction.

1. MTP dorsal release.
1. PIP plantar release.
- 3, 4. Distal section of the long flexor tendon. in case of too long the toe, DIP arthroplasty by middle phalanx distal resection.
5. Long flexor tendon lengthening.



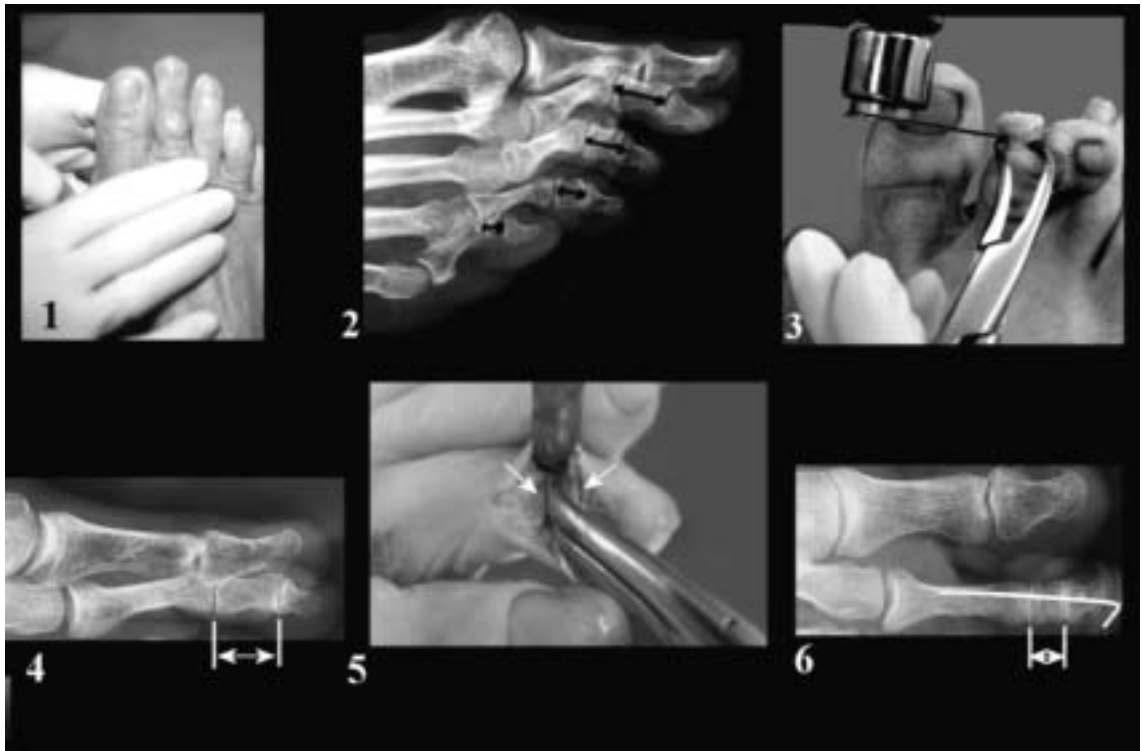
**Fig. 43c2. Intraoperative management – Chronological steps for hammer or claw toe correction.**  
**1st step: MTP release.**

1. Correct plantar flexion of the MTP: no anything more to do in the MTP.
2. Loss of MTP plantar flexion: need to dorsal release of the MTP.
- 3-4. Dorsal MTP release (one percutaneous).



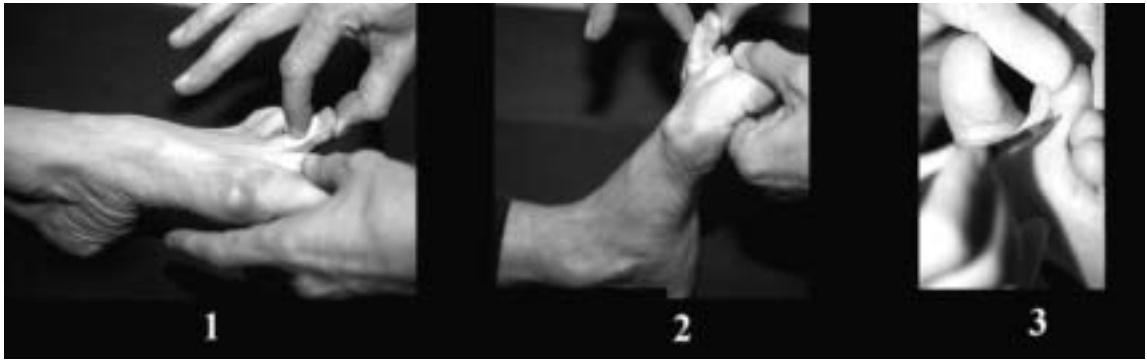**Fig. 43c3. Intraoperative management – Chronological steps for hammer or claw toe correction.**  
**2nd step: PIP plantar release.**

- PIP seems to be rigid.  
 PIP correction only by *manipulation*: the dorsal flexion has to be easy up to 30° or 45° dorsal flexion.  
 If required, *PIP plantar release* (section of the plantar capsula and desinsertion of the flexor brevis).  
 Temporary K-wiring (one month).

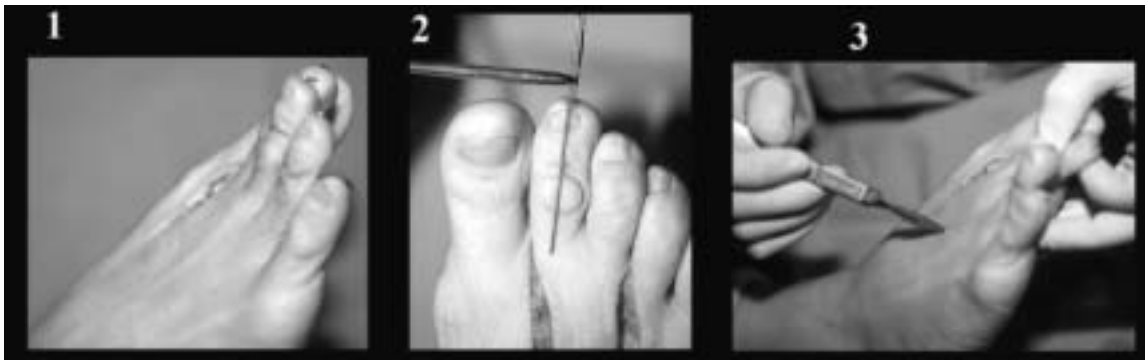


**Fig. 43c4. Intraoperative management – Chronological steps for hammer or claw toe correction.**

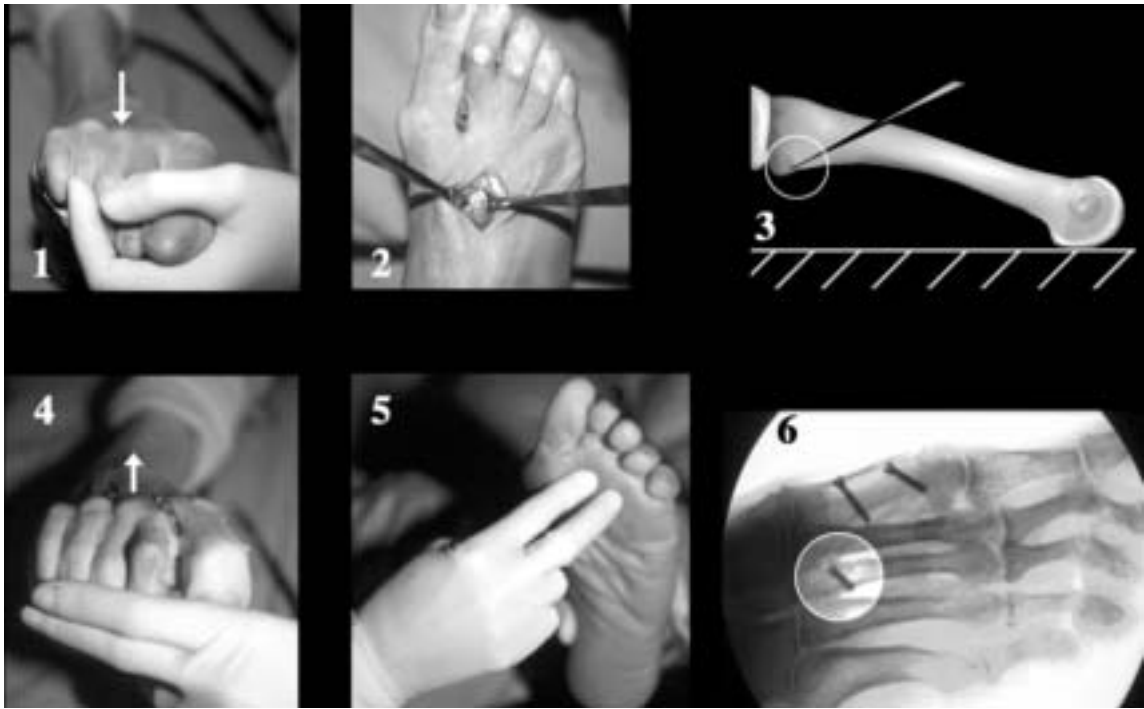
1. **3rd step: toe shortening.** The toe is too long.
2. Assessment of the possibility of the middle phalanx shortening in the pre operative medial oblique view. (This may be done also in the dorso plantar view. In this case, when the claw toe is not severe.)
3. Middle phalanx surgery : distal resection (DIP arthroplasty). The cut of the middle phalanx: thanks to the Banaleck clamp, the saw blade can be perpendicular to the shaft.
- 4, 5, 6. shaft resection of the middle phalanx (SRMP); 4. drawing of the shaft resection; 5. the two cuts around the Banaleck clamp; 6. post operative X-ray control.



**Fig. 43c5. Intraoperative management – Chronological steps for hammer or claw toe correction.**  
*4th step: long flexor tendon lengthening.*  
1, 2. Assessment of the long flexor tendon shortness.  
3. Percutaneous section of the tendon.

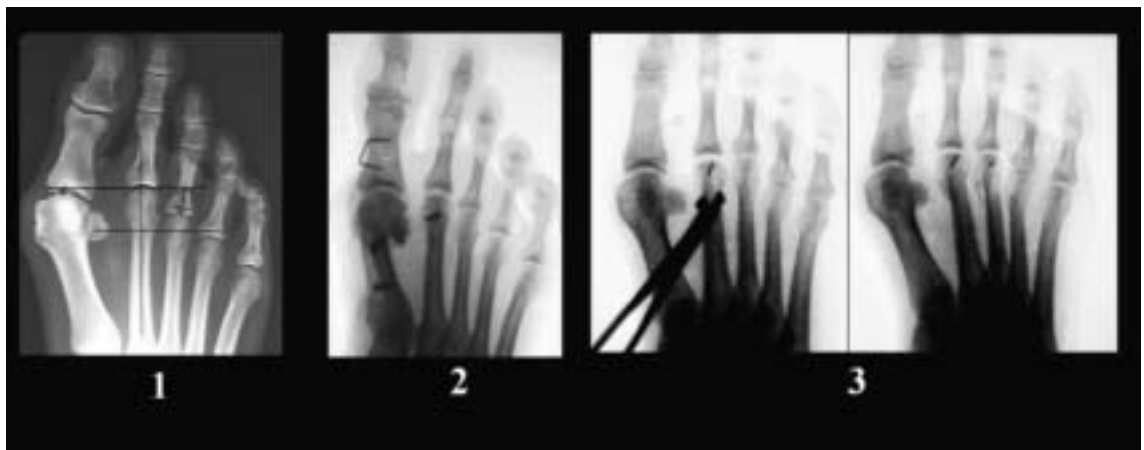

**Fig. 43c6. Intraoperative management – Chronological steps for hammer or claw toe correction.**  
1, 2. The longitudinal K-wiring of the toe emphasizes the need to lengthen the extensor tendons.  
3. Percutaneous section of the extensor tendons.



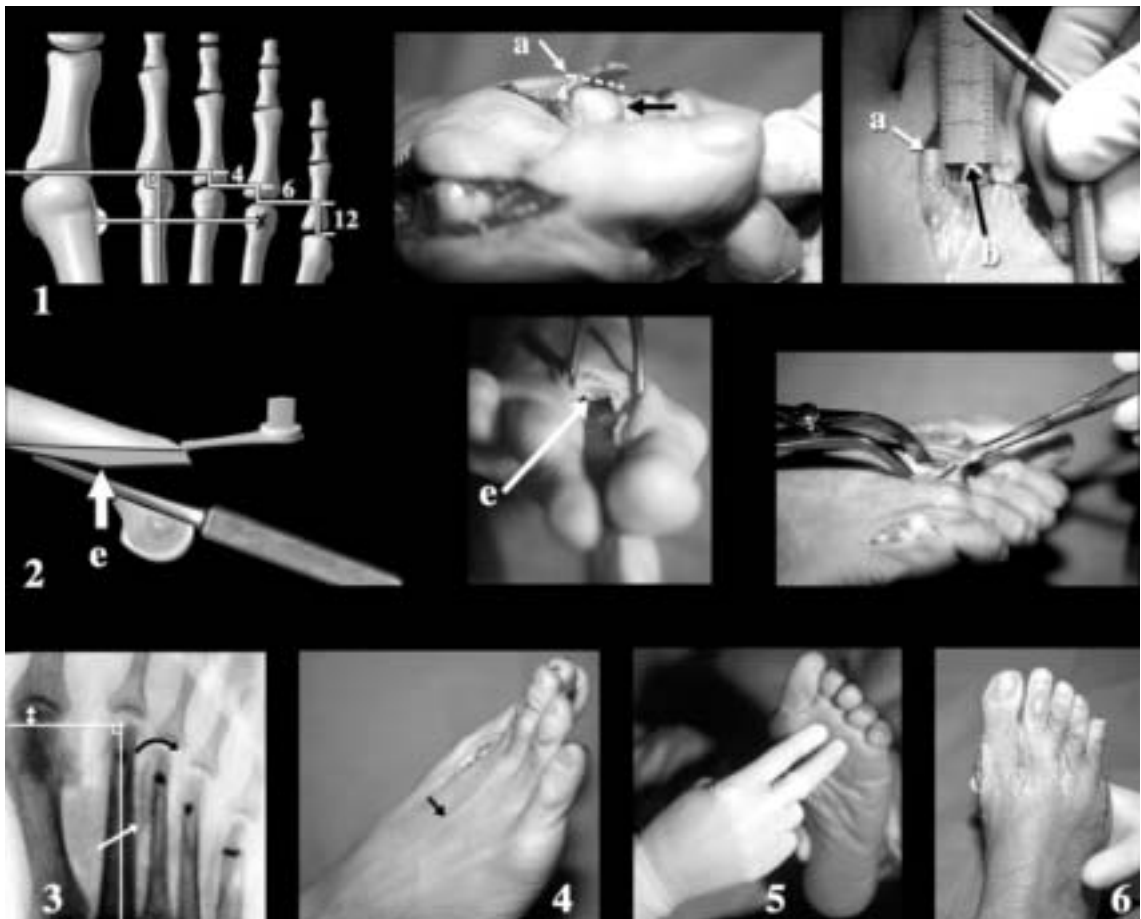**Fig. 43d1. Intraoperative management – Lesser rays. BRT osteotomy for single metatarsalgia.**

1. MTP plantar flexion test, to assess the low position of the corresponding metatarsal head (the third one): This is significant only for slim foot.
2. Local approach.
3. The osteotomy.
4. Same foot as on Fig. 1: The head is elevated.
5. Checking the metatarsal head plantar protuberance comparatively to the other rays.
6. X-ray checking in medial oblique view. Take care not to elevate too much, to avoid transfer metatarsalgia.



**Fig. 43d2. Intraoperative management. Weil osteotomy on the second and on the third metatarsals.**

1. The 2nd metatarsal is too long.
2. The isolated weil osteotomy on the 2nd metatarsal has to be very rarely performed
3. In most cases weil osteotomy has to be performed on the second and on the third metatarsals: this ensures a better result.



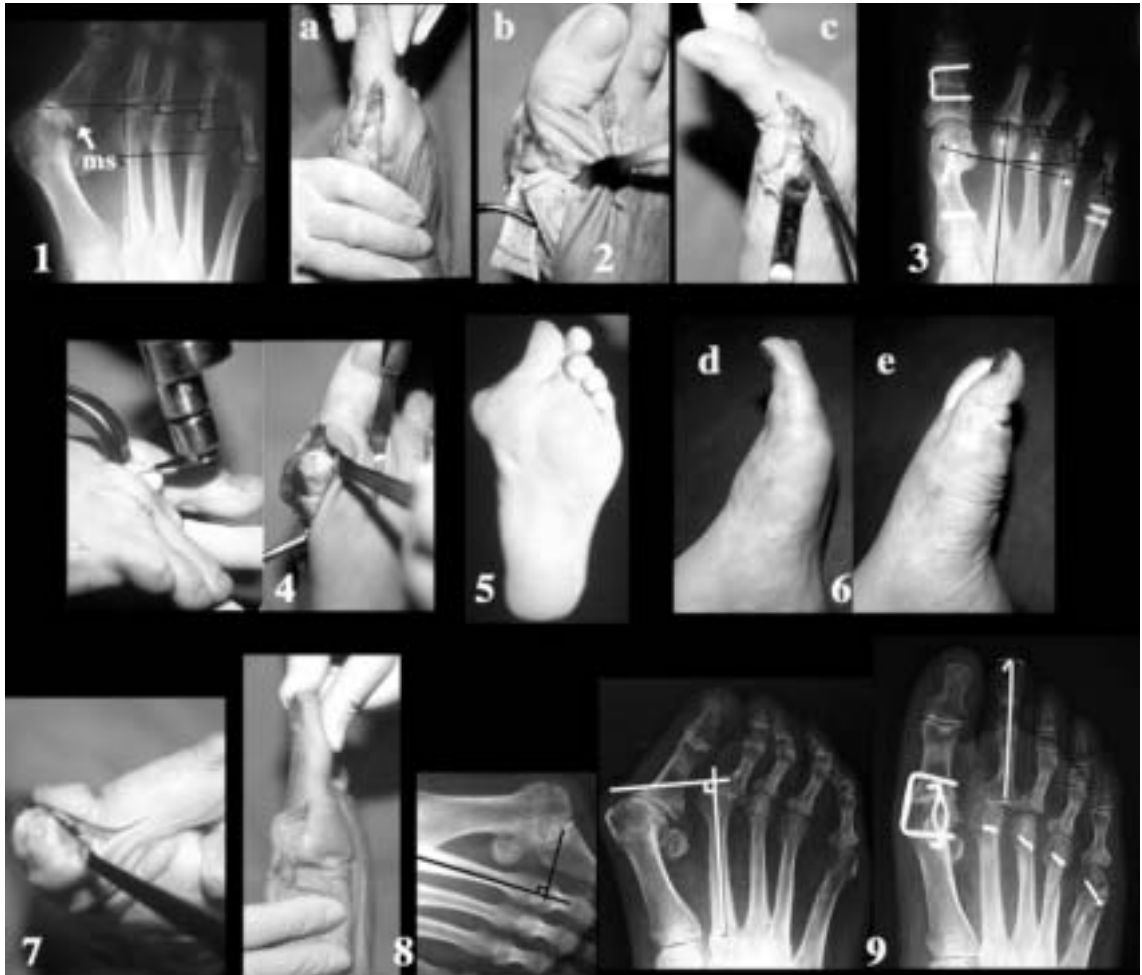**Fig. 43d3. Intraoperative management – Lesser rays. Weil osteotomy. On several rays.**

1. *Metatarsal parabola* to be reached: We observe the spontaneous proximal sliding on the ray with the largest deformity; section of the pick (a) and determination of the metatarsal length from the dorsal / proximal fragment instead of from the metatarsal heads.
2. *Double layer* for better congruence of the fragment, elevation and suppression of the proximal spike.
3. Amplifier or fluoroscopic checking of the correct length of the metatarsals and the remaining head rotations.
4. *After the K-wiring*, extensor tendon lengthening or percutaneous section.
- 5, 6. Last checking of the plantar head aspect, and of the final aspect, with the *Load Simulation Test*.

*Management in Severe Forefoot Disorders*

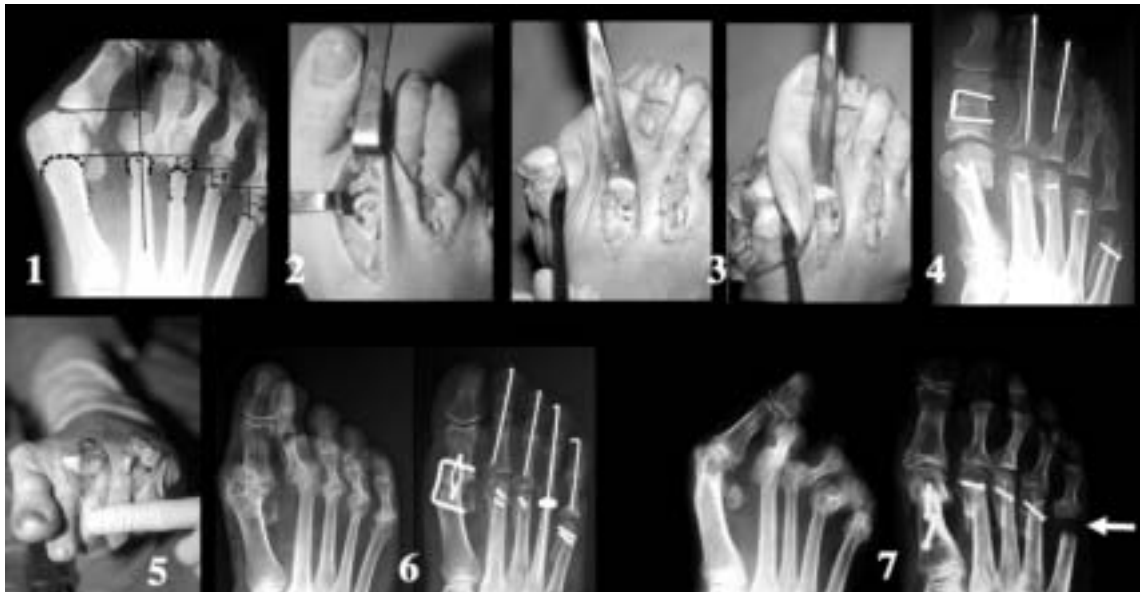
– Successively the first ray, then the lesser ray.

– **Management in Severe Forefoot Disorders,**  
 focused on the most affected ray.



**Fig. 43e1. Intraoperative management – Severe forefoot disorders. a) Focused on first ray (the most impaired one).**

1. Preoperative aspect.
2. M1 shortening: MTP dorsal flexion recovery.
- 3, 6. Same foot 2.5 years postoperative: Note the correction, the MTP joint improvement and the mobility of the first MTP joint.
- 4, 5. Same foot. To harmonize the forefoot, and also because there was metatarsalgia (5), Weil osteotomy of the lesser metatarsals.
- 7, 8, 9. In this case, M1 already too short, loss of cartilage, loss of dorsal flexion: The shortening of the lesser metatarsal would be much too large. So that we performed first MTP fusion and Weil on the lesser metatarsals.



**Fig. 43e2. Intraoperative management – Severe forefoot disorder. b) Focused on lesser rays (the most impaired ones).**

**1 to 4. Surgery focused on the second ray.**

**1.** Preoperative aspect: To obtain stable correction of the second MTP dislocation, note the shortening we have to do, focused on the second ray; after wards, we have to harmonize the metatarsal parabola around this second ray shortening.

**2.** The Weil is performed on the second ray: The correction of the dislocation is made.

**3.** Of course M1 is now too long: Shortening as far as  $M1 = M2$ .

**4.** Postoperative aspect; note the complete preservation of the joints; this man recovered normal activity.

**5 to 7. Limits of joint preservation.**

**5, 6.** When the head disappeared or when it is too much impaired, its resection is preferable (in this case, on fourth ray).

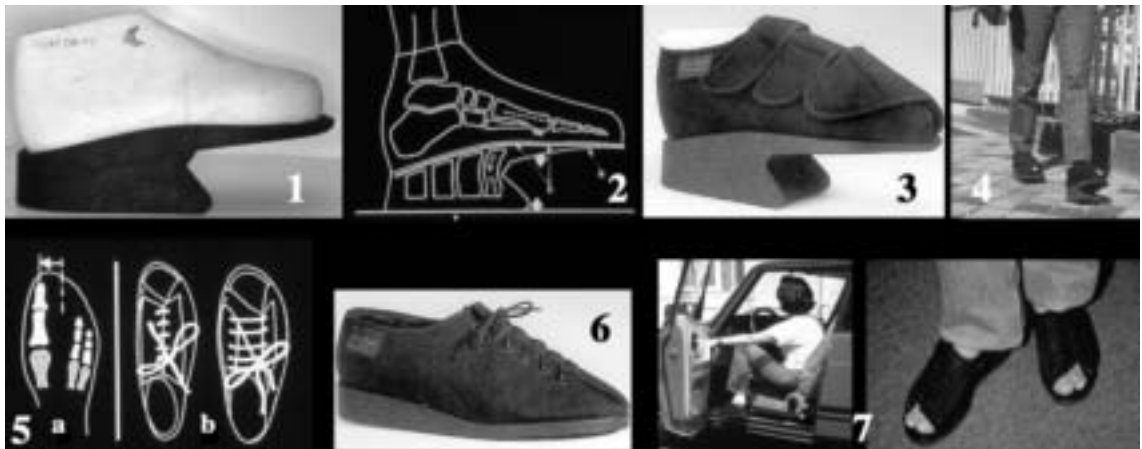
**7.** Rheumatoid forefoot: Only resection of the fifth metatarsal head.



## Postoperative Management

First, as we use special instruments and implants for forefoot surgery, we have to use special postoperative footwear. All our patients wear the heel support postoperative shoe, which not only

preserves the operative results, but also allow immediate postoperative walking. Similarly, our postoperative Type II and Type III system allow an early functional recovery and return to social activities [20, 21]. This is an opportunity to thank Romans Industrie (Romans, France) which manufactures these shoes.



**Fig. 44a.** Postoperative management 1) *Special footwear.*

1. Sole and last of the *Type I heel support shoe.*
2. Elasticity of the distal part of the sole allowing to have correct gait. Note that the metatarsal heads are out of support.
- 3, 4. The shoe: Walking one week postoperative.
- 5, 6. Specifications of postoperative *variable volume shoe (Type II)*: Correct place for the great toe and adaptable top.
7. At 15th postoperative day.

The postoperative period has to be taken in charge and completely **controlled by the surgeon himself**, because he knows better than anyone the foot operated and what we have to expect from the performed surgery. I particularly think that the surgeon has to apply the bandage and strapping himself and has to control the foot “self-training” of the patient [15, 129].

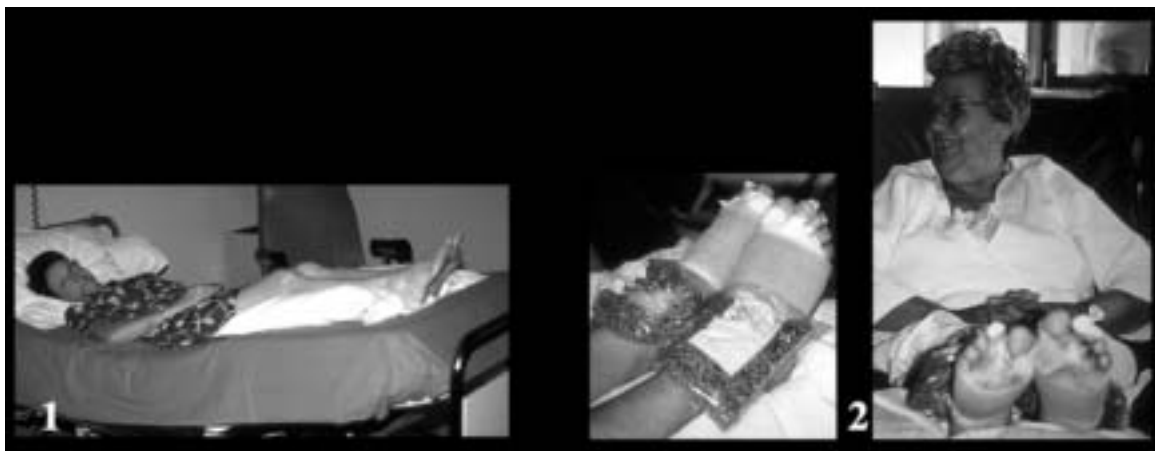This is an opportunity to emphasize the **role of the patient in the success of the surgery** and to write that foot surgery is not like hip surgery which is low demanding from the patient in the postoperative period. On the contrary, the role of the patient is critical in the post foot surgery period: The patient has to be disciplined. During the first postoperative days, he must elevate his foot and stay in this position for a long time. The foot must not just lay on a chair while sitting, but must be upper than the heart in a decubitus position. The patient must also perform **self-training that is accurate** with foot and leg position and handlings for several weeks and every day particularly in case of invasive

forefoot surgery (moderate hallux valgus corrected by scarf osteotomy is not demanding from the patient).

The role of the **physiotherapist** is also critical. The first postoperative days, he has to massage the entire lower limbs to decrease the oedema. He must also show the patient exercises to increase the blood circulation, at last he teaches and controls the patient self-training. I thank my physiotherapists team A. Zandi, A. and T. Gouzland.

The RSDS is more frequent in invasive surgery like the five rays osteotomies: However, it is significantly decreased or avoided by the large shortening of the metatarsal. When it occurs, the Thyrocalcitonin injections are a good solution.

At last, what about **insoles**? I think that in most cases the surgery can resolve the problems to give final results without insoles. However, there are *two indications* of insole. The first one is temporary: This may be in the preoperative period, or in the postoperative one. Secondly, there are some cases where surgery is contrain-

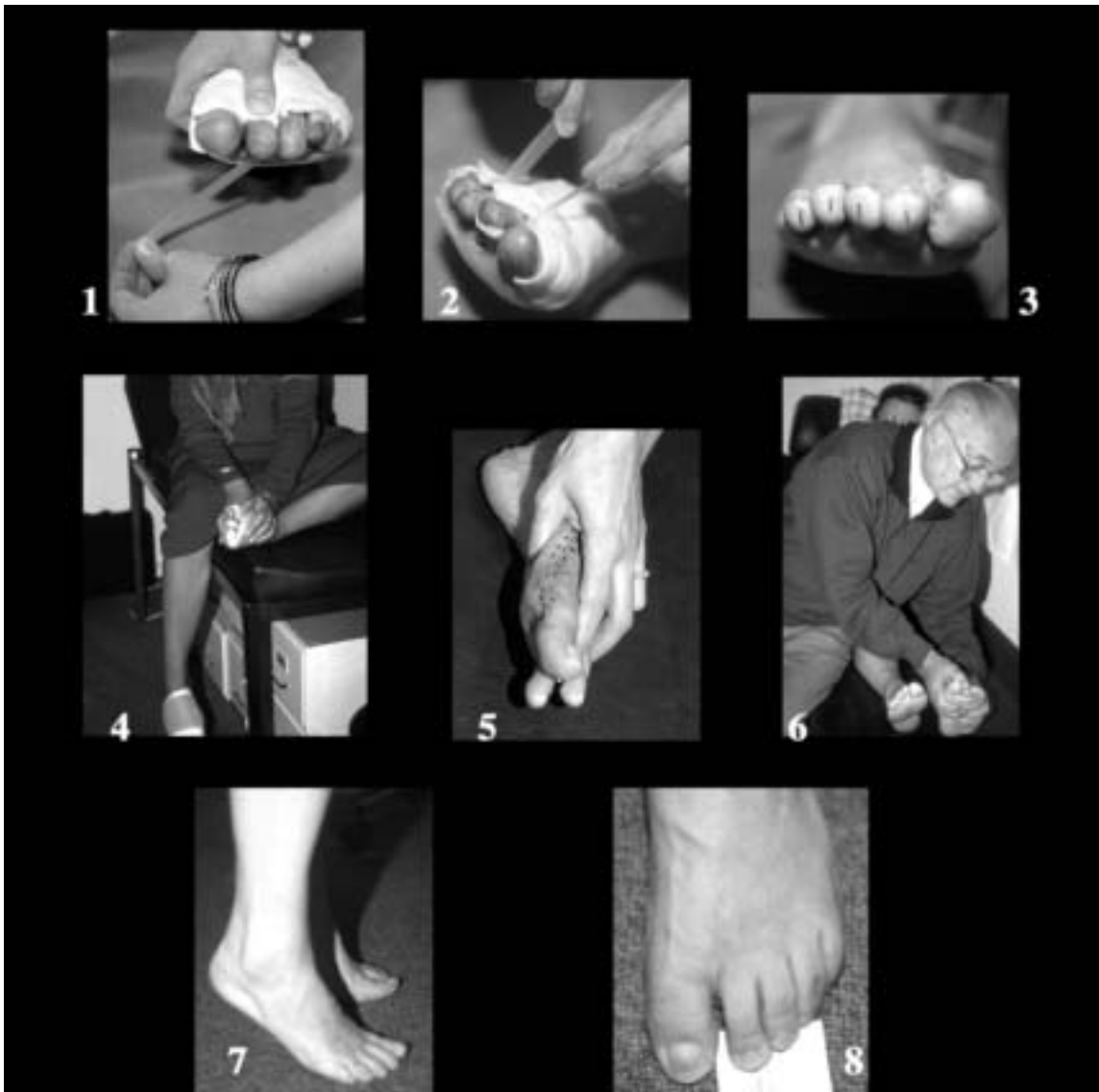

**Fig. 44b. Postoperative management 2) Avoiding edema.**

1. Foot must be elevated during the 48 postoperative hours. It is necessary to stop the edema. In our practice, both feet operated on the same day, and two days staying with elevated feet.
2. Once back home, 500gr of frozen green *garden peas* is certainly the best means to cool the foot! Set on the dorsal part of the ankle and of the middle foot, it is long-lasting cool (> 2 hours) and takes the correct shape around the foot, thus it is stable from the beginning. It is easy to take another bag. This is for only three days postoperative.

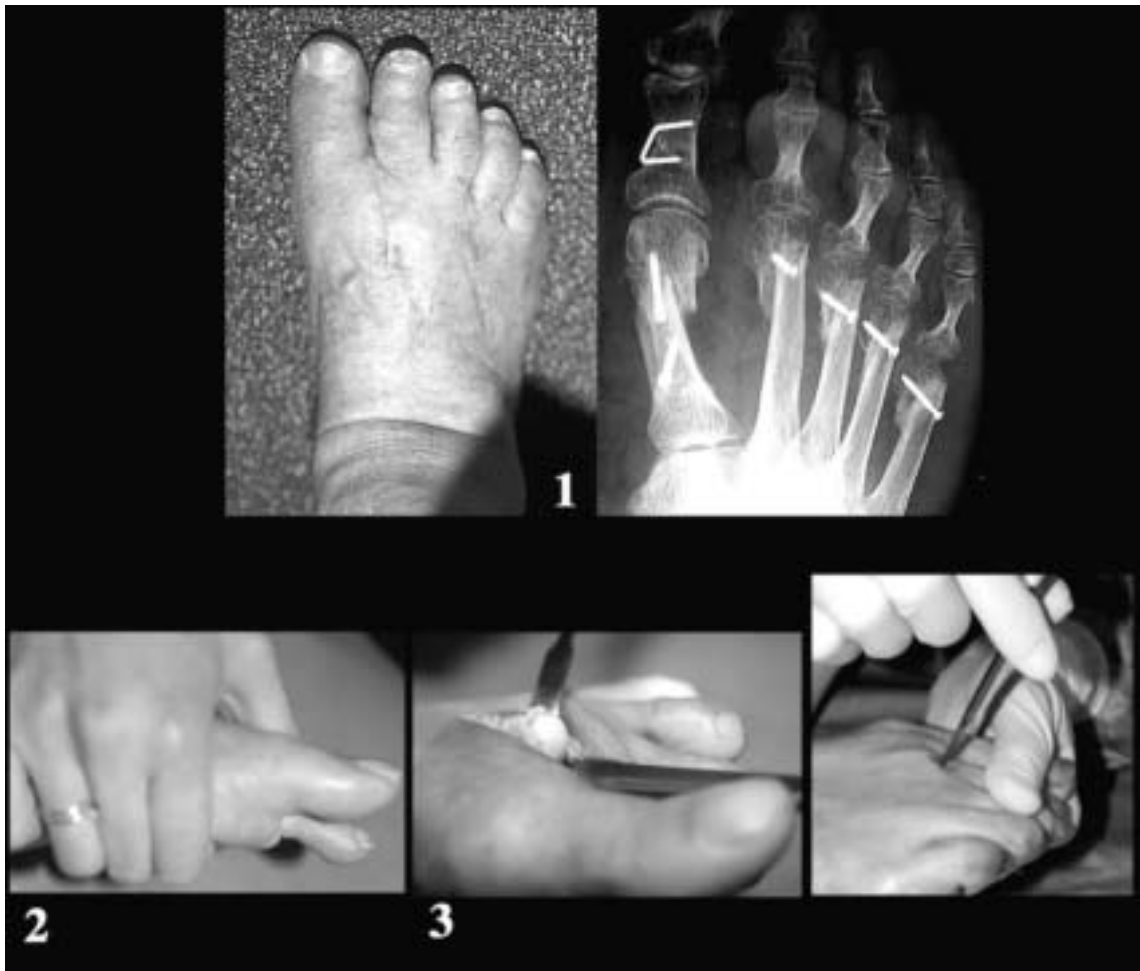dicated. In these cases, the role of insoles is critical. However, insole has to be in the shoe and not in the cupboard! So that insoles have first to be the most simple and the less invasive, in

order to leave place for the foot in the shoe. It is an opportunity to thank my chiropodist F. Langlois who makes thin and effective soles (which stay in the shoes!).



**Fig. 44c. Postoperative management 3) Toes strapping and mobility recovering (training).**

1. Toes strapping in MTP plantar flexion (3 or 4 weeks postoperative).
2. When there is no K-wiring, strapping of the DIP in dorsal flexion. This is not necessary in case of toe K-wiring (3).
4. The best position to reach the foot with the hands and to make self-training.
5. Plantar flexion of the MTP joints (passive and active).
6. The husband should be useful too!
7. Tiptoes and training of toe ground contact (after one postoperative month).



**Fig. 44d. Postoperative management 4) Problems occurring in invasive surgery.**

1. Reflex Sympathetic Dystrophy Syndrom (RSDS) is more frequent for such invasive surgery with local previous trophic troubles and with anxious patients. It usually occurs after one postoperative month. It is usually well treated by Thyrocalcitonine injections. However, this syndrome may be diminished or avoided by large and harmonized metatarsal shortening and the precautions we mentioned above in the postoperative period.

2, 3. Treatment of remaining postoperative stiffness.

2. Manipulation under anaesthesia: To be performed at 2.5 or 3 postoperative months.

3. If necessary, at 1 postoperative year, MTP surgical release regularly provides good results if there is only stiffness and no remaining static or anatomic problems. Percutaneous or mini invasive MTP release or/and section of the tendons is extremely effective in revision for stiffness. Once again, stiffness now rarely occurs since we perform large harmonized shortening in severe forefoot disorders.

*These problems (CRPS, stiffness) rarely occur for the single first ray surgery (scarf and great toe osteotomy).*

## Revision in Forefoot Surgery

All along this book, we studied revision surgery in the different chapters of the two parts: The procedures, the main forefoot pathologies. It means that **revision in forefoot surgery is not exceptional. To decrease** the number of revision cases, we have:

1. To be *accurate* in the *preoperative* assessment of the forefoot disorders and in the preoperative *decision-making*.

2. To *adapt intraoperatively* the preoperative decisions (ex.: Thanks to the true assessment of the first MTP dorsal flexion). To take care not to leave any deformity without treatment. I mean a preoperative deformity or a problem resulting from the surgery itself, like noted in a level crossing advice “a train should hide another one”.

3. To accurately manage the *postoperative period*.

4. In general to *consider the forefoot in its*

*whole aspect*, contrarily to a too common attitude which limits the treatment to a single ray (or one toe!).

In spite of these precautions, there are cases where initial good postoperative results become not so good secondarily: So that I make some revisions in my own forefoot surgery practice. Sometimes, this revision is made for ***cases of failed surgery***, but in most cases it is for ***improvement of the results***, our aim being to provide a foot:

- With preserved joints as far as possible,
- With correct functional recovery,
- Without the need of any insole or splints,
- With good cosmetic appearances, notably allowing elegant footwear (high heel shoes, if this is the expectation of the patient).

***So, we don't have to be afraid to make revision in forefoot surgery:*** Finally when I consider the orthopaedic surgery in its whole, forefoot surgery is certainly one of the fields where revision may be made, but also one field where revision can *improve* the results, until providing the best result as possible – relatively to the case encountered.

## IV. EIGHT PRINCIPLES OF FOREFOOT RECONSTRUCTION

### First Principle

#### The post operative period

*Our first principle is to make a surgery followed by painless postoperative period and early functional recovery (Fig. 45a1-2):* Thanks to the improvement of the surgical technique, we can be less invasive by the respect of soft tissue, by strong fixation of the osteotomies, and generally by accurate surgery respecting the forefoot architecture. Furthermore, a local, long-lasting anesthesia injection is made (ex.: naropeine).

*Postoperative period* is also carefully managed with the *foot elevated* at least for two days following the surgery. The physiotherapy and the *self-training* are critical and need discipline from the patient which has to be strongly concerned in the successful achievement of this foot surgery.

### Second Principle

#### Where to focus the surgery (law of the most impaired ray)

*The second principle is to focus the surgery on the most affected ray, and to harmonize the foot (and the contra-lateral foot) from or around the correction of this focused ray (Fig. 45b1).*

This is particularly useful when shortening of this ray (mainly metatarsal) is necessary. Since we now have very reliable and harmless procedures to shorten the metatarsals, we must not be afraid to shorten as far as required. The pictures illustrate some examples of this management. As a rule now, the *metatarsal shortening* has to be up to the *proximal bases of the first phalanx*, on the first ray in severe hallux valgus, on the lesser rays in MTP dislocation or transversal inclination of the toes.

## IV. EIGHT PRINCIPLES OF FOREFOOT RECONSTRUCTION

### First Principle

#### The post operative period

*Our first principle is to make a surgery followed by painless postoperative period and early functional recovery (Fig. 45a1-2):* Thanks to the improvement of the surgical technique, we can be less invasive by the respect of soft tissue, by strong fixation of the osteotomies, and generally by accurate surgery respecting the forefoot architecture. Furthermore, a local, long-lasting anesthesia injection is made (ex.: naropeine).

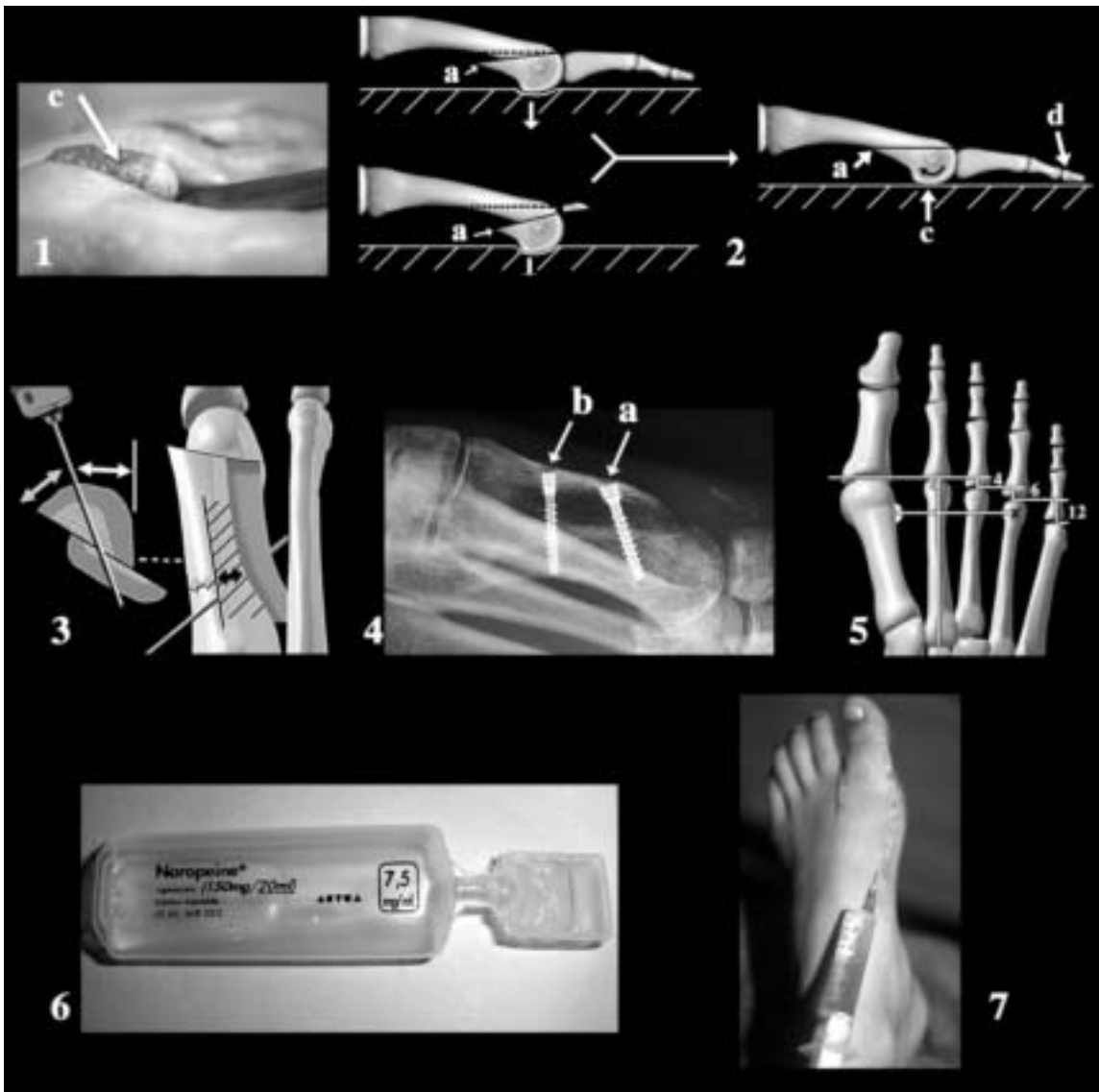
*Postoperative period* is also carefully managed with the *foot elevated* at least for two days following the surgery. The physiotherapy and the *self-training* are critical and need discipline from the patient which has to be strongly concerned in the successful achievement of this foot surgery.

### Second Principle

#### Where to focus the surgery (law of the most impaired ray)

*The second principle is to focus the surgery on the most affected ray, and to harmonize the foot (and the contra-lateral foot) from or around the correction of this focused ray (Fig. 45b1).*

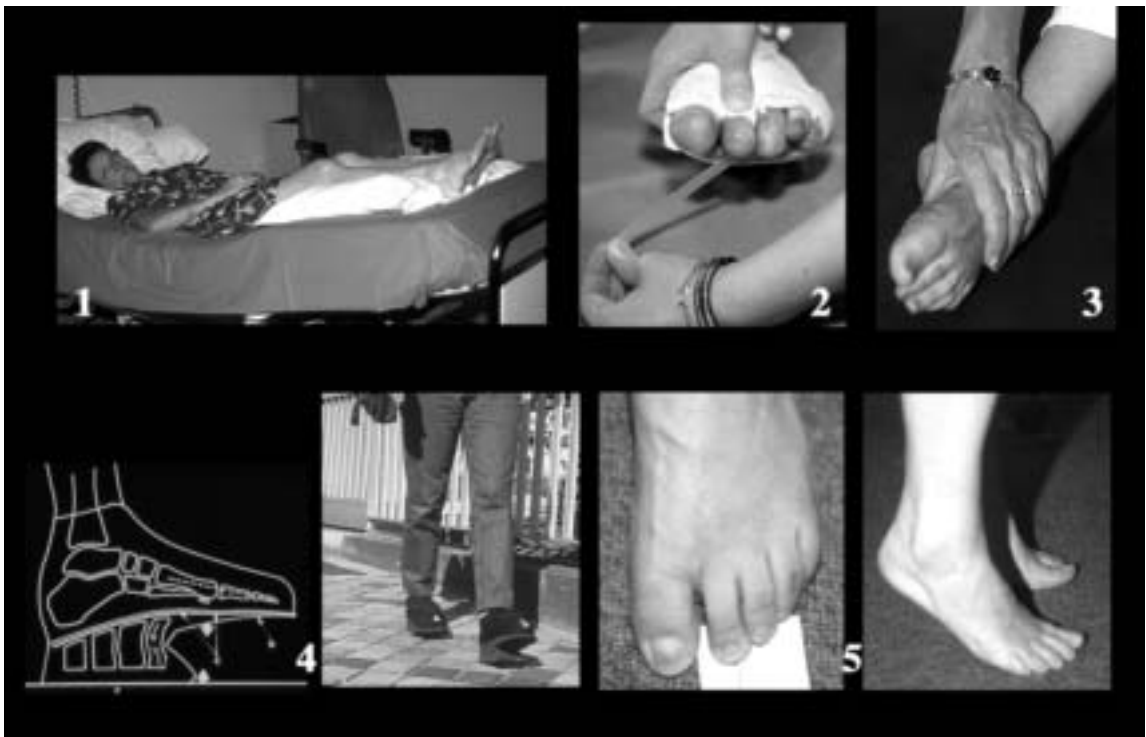This is particularly useful when shortening of this ray (mainly metatarsal) is necessary. Since we now have very reliable and harmless procedures to shorten the metatarsals, we must not be afraid to shorten as far as required. The pictures illustrate some examples of this management. As a rule now, the *metatarsal shortening* has to be up to the *proximal bases of the first phalanx*, on the first ray in severe hallux valgus, on the lesser rays in MTP dislocation or transversal inclination of the toes.



**Fig. 45a1. Principle I – Make a surgery followed by painless postoperative period and early functional recovery. a) The surgery itself.**

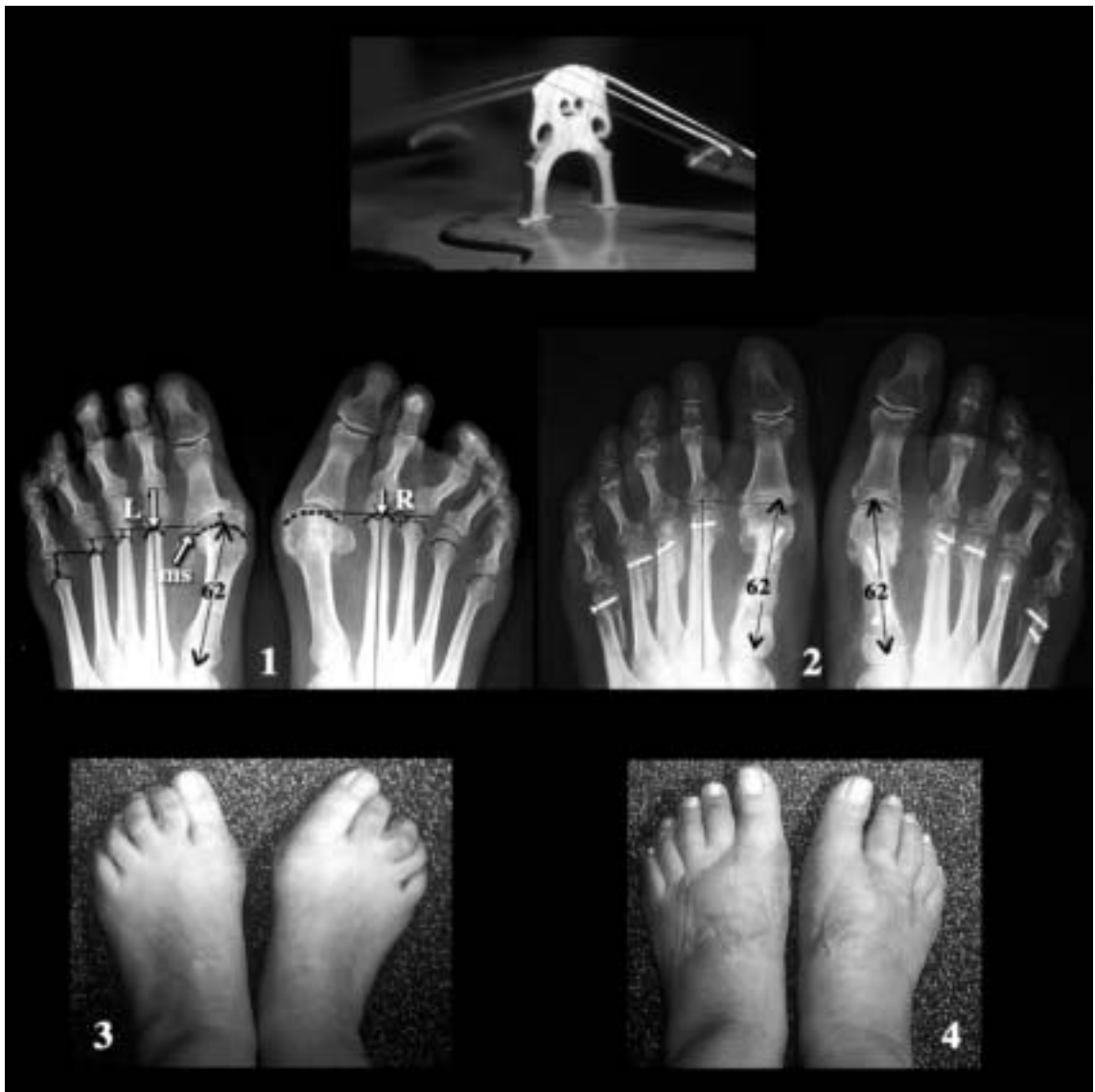1. *Respect of the soft tissue.* Ex.: Keep the soft tissue on the *dorsal surface of the metatarsal* during Weil osteotomy and fixation.
2. *Accurate surgery.* Ex.: Double layer in Weil osteotomy both to leave out the protruding spike “a”, to elevate the metatarsal head and to turn the head for better toe ground contact.
- 3, 4. *Accurate and strong fixation* of the osteotomies, which allows early functional recovery.
5. *Well balanced forefoot*, particularly respecting the relative length of the metatarsals.
- 6, 7. *Préoperative bloc injection* of a *long-lasting anaesthetic* (Naropeine).





**Fig. 45a2. Principle I – Painless postoperative period and early functional recovery. b) Postoperative precautions.**

1. *Foot elevated almost non stop during the first two days* is the best way not to have postoperative edema. That's why we prefer "two days surgery" instead of one day surgery (and three days for severe forefoot disorders surgery).
2. *Toes strapping* (I make the strapping myself, three times during the first postoperative month). It is extremely important during the first three weeks because no strapped toes (particularly the lesser toes) should remain not so well corrected.
3. *Self-training* three times a day is also essential to complete the correction. The husband should be helpful.
4. The *Type I heel support shoe* effectively protects the surgery correction of the deformities and allows immediate and painless walking.
5. After one month, *tiptoe and toe ground contact training*.



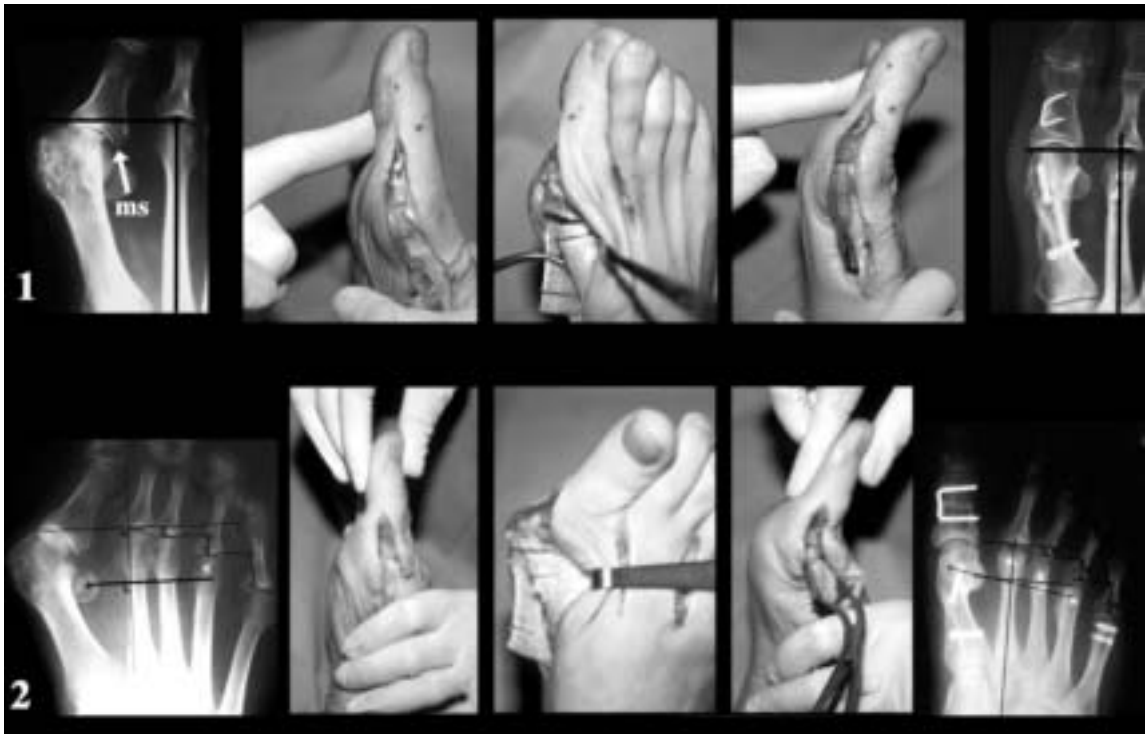**Fig. 45b1. Principle II – Harmonizing the forefoot around the correction of the most impaired ray.**

**a) Generalities.**

We have to play on several strings/rays.

**1, 3. Bilateral problems:** If we only consider the *right foot*, the shortening should be “R”. But we have to focus on the amount of shortening on the *most impaired ray* which is the first one ray of the *left foot*: Note that for this first MTP joint, fusion or preservation result in the same resection. This first MTP joint being preoperatively painless and mobile, our choice was preservation. But the amount of shortening was “L” and this was reported on the right foot.

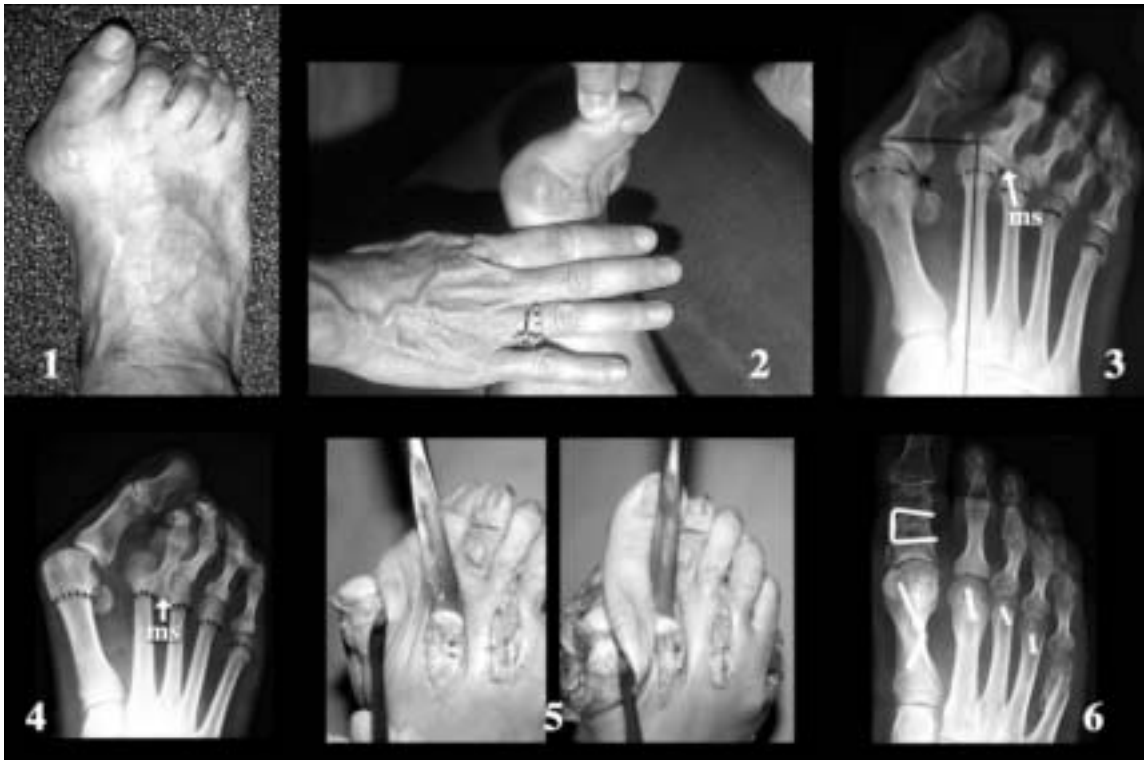**2, 4.** Radiological and clinical result (two months postoperative).



**Fig. 45b2. Principle II – Harmonizing the forefoot around the correction of the most impaired ray. b) The first ray is the most impaired.**

1. Arthritic hallux valgus: Recovering of MTP dorsal flexion thanks to M1 shortening. But since preoperatively  $M1 = M2$ , we had to make additional Weil second metatarsal osteotomy.

2. Another case of arthritic hallux valgus: The amount of M1 shortening to obtain correct dorsal flexion leads to shorten the four lesser metatarsals. But there was metatarsalgia which justified this shortening. Radiological results 2.5 years postoperative (bottom, right).



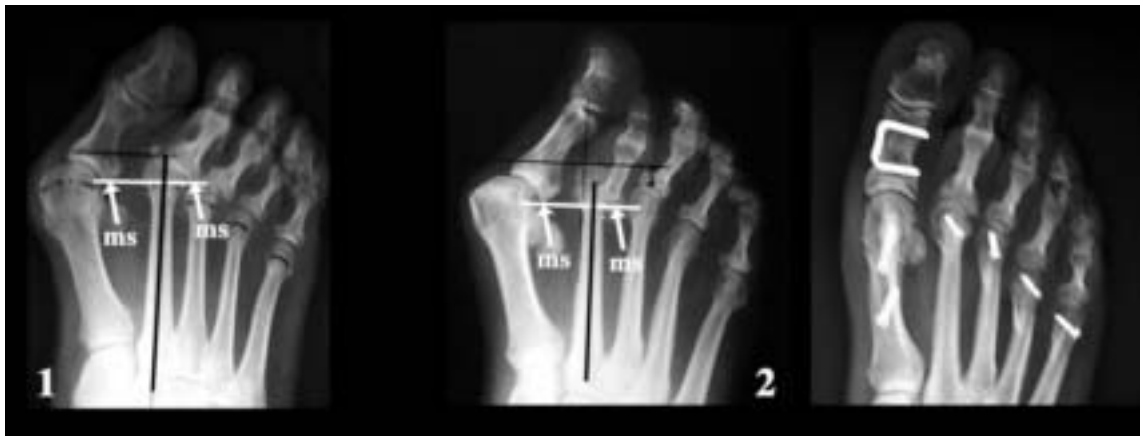**Fig. 45b3. Principle II – Harmonizing the forefoot around the correction of the most impaired ray.**  
*c) Lesser rays are the most impaired.*

1, 2, 3. In spite of severe hallux valgus, first MTP dorsal flexion is preserved so that the shortening is focused on the *second metatarsal*.

4, 5, 6. Second ray MTP dislocation.

5. Stable correction is obtained with this shortening.  $M1$  shortening to obtain  $M1 = M2$ .

6. One year postoperative radiological aspect.



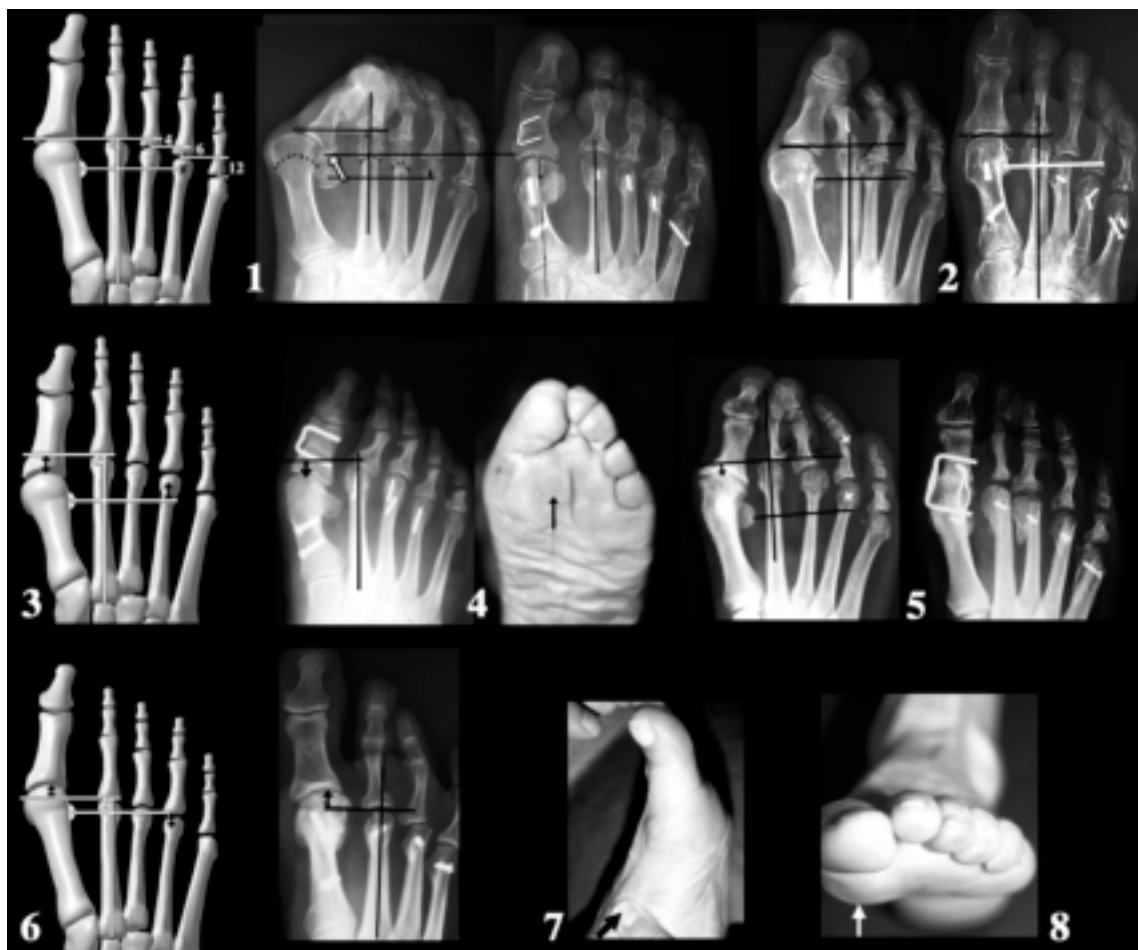**Fig. 45b4. Principle II – Harmonizing the forefoot around the correction of the most impaired ray.**  
*d) Surgery focused both on the first and second rays.*

## Third Principle

### The metatarsal parabola

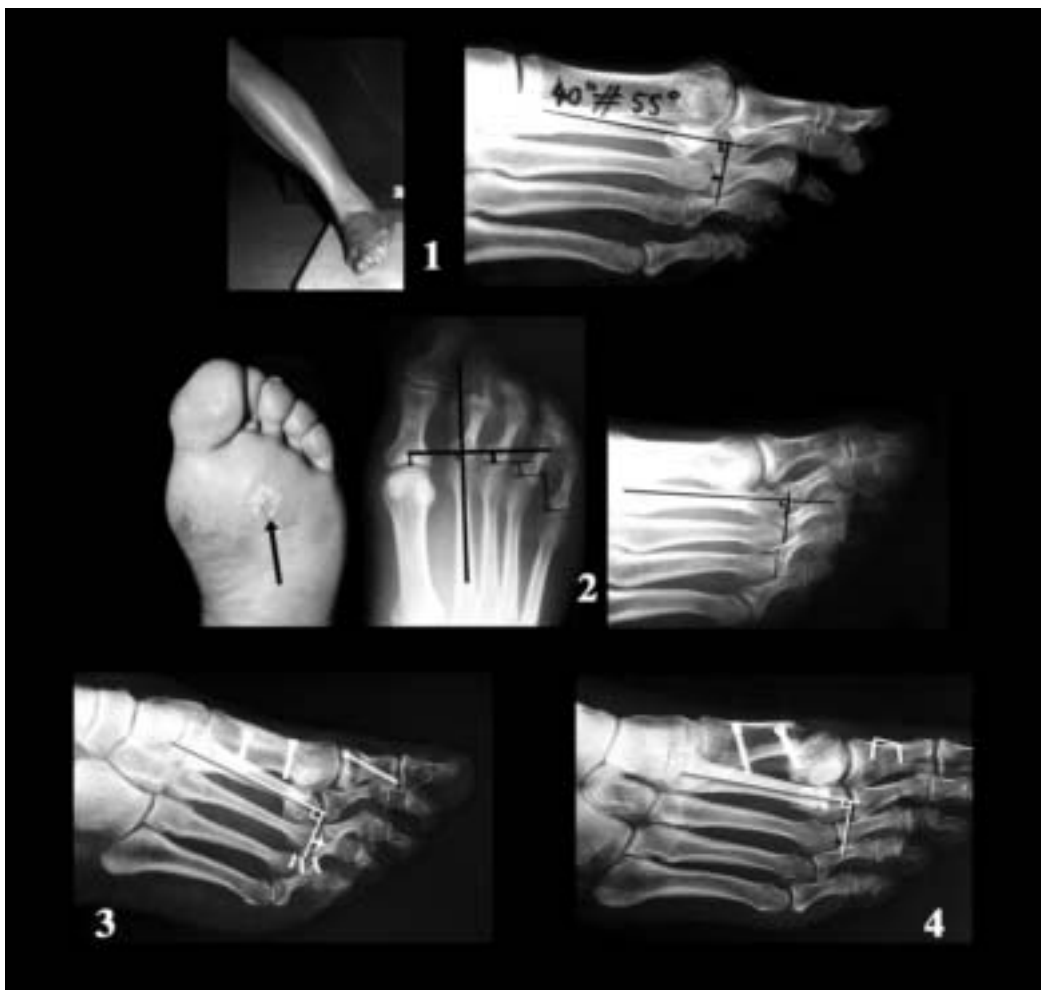
This has to be achieved not only on the *dorso-plantar view*, but also on the *medial oblique view*.

*The third principle is to reach a correct relative length of the metatarsals – i.e. the metatarsal parabola (Fig. 45c1-2).*



**Fig. 45c1. Principle III – To reach or to respect a correct relative length of the metatarsals (metatarsal parabola). a) In the dorso-plantar view.**

1. The *ideal metatarsal parabola* to be reached.
2. However, this parabola is also good – with a slight index minus metatarsal index and a Maestro line distally passing from the centre of the fourth metatarsal head.
3. *Metatarsal parabola leading to central metatarsalgia*: Second metatarsal longer than 3mm and maestro line proximally passing from the center of the fourth metatarsal.
4. Too long second metatarsals: Metatarsalgia on this ray.
5. Too long lesser metatarsals, both metatarsals index and Maestro line proximal to the fourth metatarsal head: Postoperative X-rays.
- 6 to 8. *Excessive length of the first metatarsal has absolutely to be avoided* because it results in unstable correction (under or over correction of hallux valgus), in MTP stiffness (loss of dorsal flexion), and in first ray metatarsalgia.



**Fig. 45c2. Principle III – To reach a correct relative length of the metatarsals (metatarsal parabola). b) In the medial oblique view.**

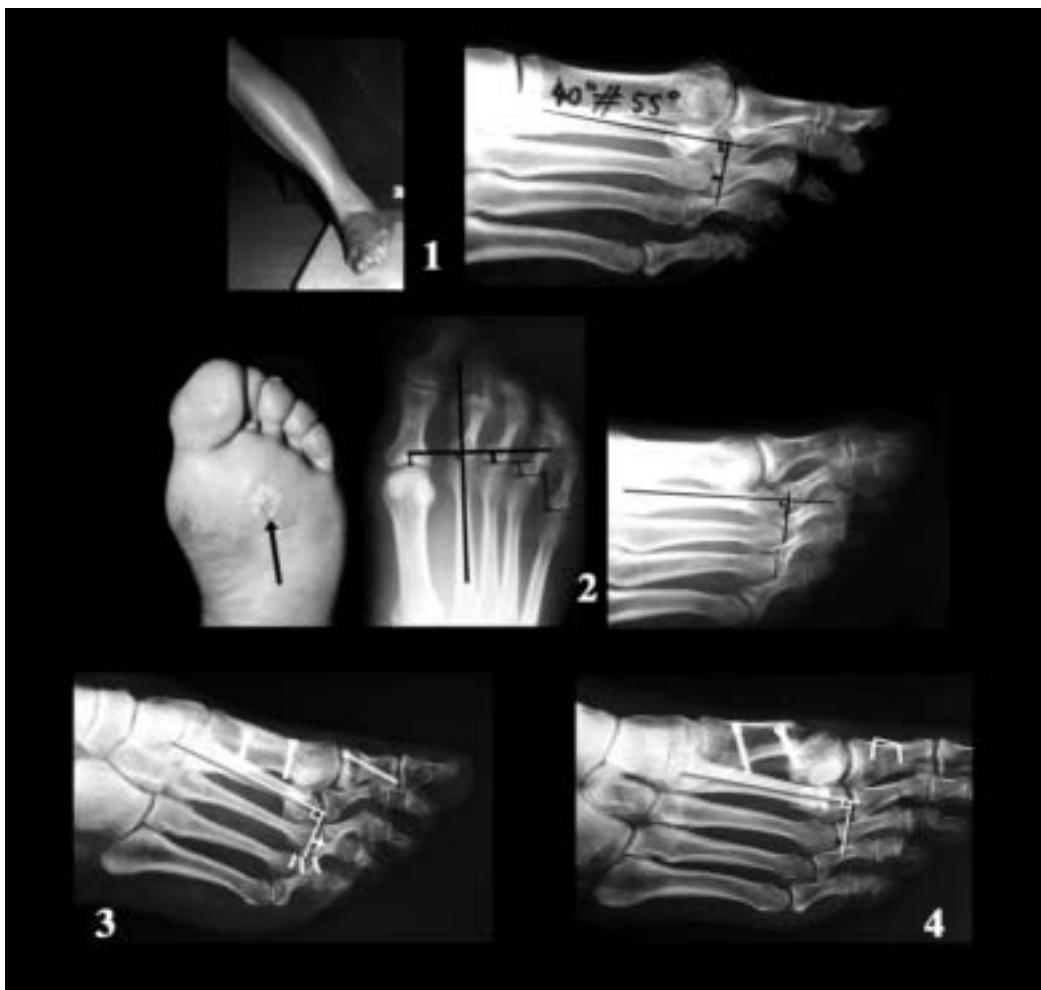
1. The medial oblique view.
2. *Metatarsalgia on the third ray*: Same foot on dorso-plantar view. The third metatarsal has a correct length comparatively to the second one. The Maestro line is correct. The explanation of this metatarsalgia location is provided by the medial oblique view, which shows the relative excess of length of the third metatarsal.
3. *Single second metatarsal osteotomy*, resulting in excessive length of the third metatarsal. The corresponding transfer metatarsalgia was relieved by a secondary Weil osteotomy.
4. *Single second metatarsal well managed osteotomy*: The second metatarsal remains slightly longer than the third one. There is no transfer metatarsalgia.

## Fourth Principle

### The generous shortening of the metatarsals

*The fourth principle is to give more place to a generous shortening of the metatarsals (Fig. 45d1-2-3-4), resulting in a significant widening of joint preservation.*

*This is certainly a point which is more difficult to assimilate because first, previous techniques of shortening were unpredictable, harmful, invasive and because surgeons generally think that the “less is the best”. In spite of this, my observations and critique of the results show clearly, strongly, obviously that the generous shortening of the metatarsals provides a painless, harmless, reliable and elegant solution to any severe deformity of the forefoot.*



**Fig. 45c2. Principle III – To reach a correct relative length of the metatarsals (metatarsal parabola). b) In the medial oblique view.**

1. The medial oblique view.
2. *Metatarsalgia on the third ray*: Same foot on dorso-plantar view. The third metatarsal has a correct length comparatively to the second one. The Maestro line is correct. The explanation of this metatarsalgia location is provided by the medial oblique view, which shows the relative excess of length of the third metatarsal.
3. *Single second metatarsal osteotomy*, resulting in excessive length of the third metatarsal. The corresponding transfer metatarsalgia was relieved by a secondary Weil osteotomy.
4. *Single second metatarsal well managed osteotomy*: The second metatarsal remains slightly longer than the third one. There is no transfer metatarsalgia.

## Fourth Principle

### The generous shortening of the metatarsals

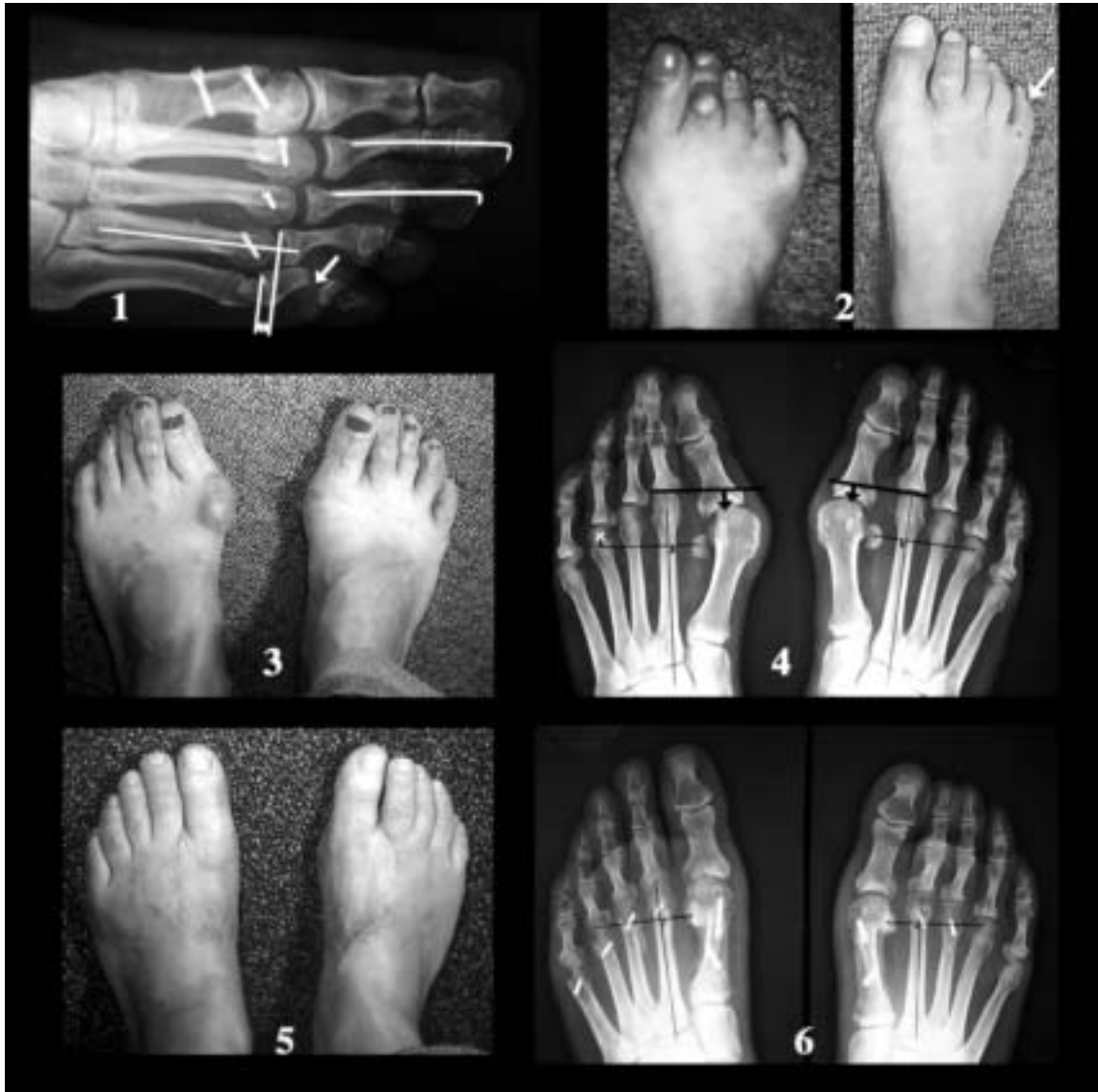*The fourth principle is to give more place to a generous shortening of the metatarsals (Fig. 45d1-2-3-4), resulting in a significant widening of joint preservation.*

*This is certainly a point which is more difficult to assimilate because first, previous techniques of shortening were unpredictable, harmful, invasive and because surgeons generally think that the “less is the best”. In spite of this, my observations and critique of the results show clearly, strongly, obviously that the generous shortening of the metatarsals provides a painless, harmless, reliable and elegant solution to any severe deformity of the forefoot.*

All along this book, we already brought precisions about the **amount of the required metatarsal shortening**, clinically notably on the first ray, by the MTP dorsal flexion, radiologically thanks to the **ms point** (metatarsal shortening),

which is the most proximal part of the first phalanx bases, whatever the considered ray.

This amount of metatarsal shortening for severe forefoot problems was determined not by a prospective study, but by the observation of



**Fig. 45d1. Principle IV – The place of a generous shortening of the metatarsals. a) In large deformities.**

1, 2. In such forefoot deformity we regret not to have shortened the fifth metatarsal, for two reasons:

1) The correction (hallux valgus and hammertoes) should certainly be better because the shortening of the metatarsals should be larger.

2) Some problems remain in the fifth toe in spite of its distal resection.

3, 6. *Bilateral problem.*

3, 4. We decided to make a larger shortening on the left foot because it was more deformed and because the lesser metatarsals were longer (M2/M1 and Maestro line proximal from the fourth metatarsal center).

5, 6. Result for the same patient: On the left foot, where the shortening of the metatarsals was larger, both postoperative period, deformity correction and joints mobility were significantly better than for the right foot.



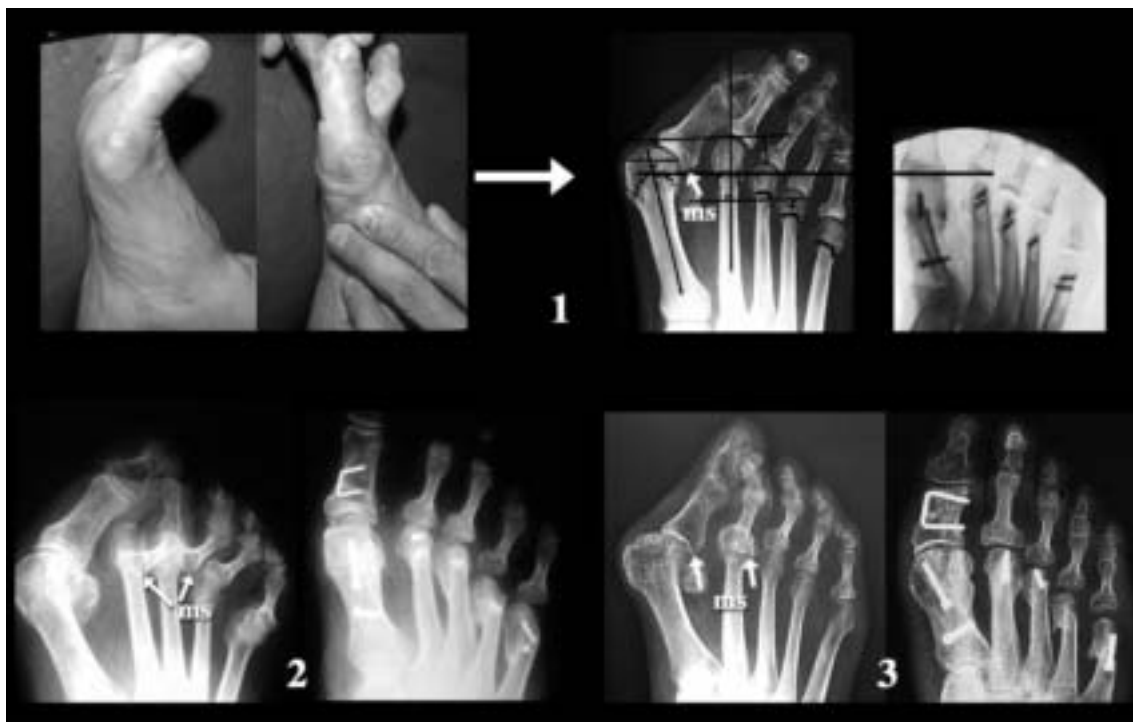
the results. Reliable and good results are significant according to this amount of shortening: Less metatarsal shortening may be attractive and is usually made by surgeons (and was made by myself in my earlier experience) but the results are significantly less and incomplete.

Additionally the **metatarsal shortening allows to preserve the length of the toes and the toe joints** so that the global foot length is not diminished very much and the foot remains elegant: **It is another way to approach the forefoot problem, above all the severe disorders.**

The **frontier between moderate and severe deformity** is sometimes easy to delimit but sometimes uneasy: In this case, we can say that this frontier is much closer than what is usually considered. In other words, when we are hesitating, the balance swings in the generous metatarsal shortening versus soft tissue and toes sur-

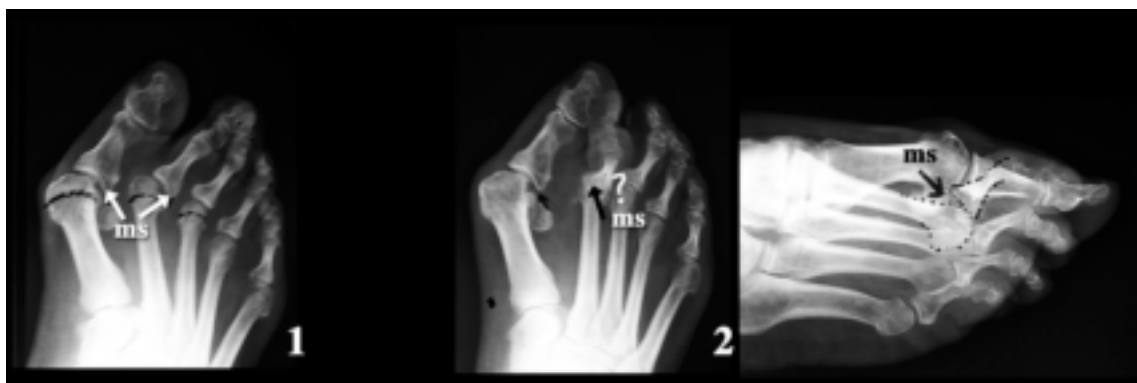gery. We now have sufficient bilateral cases (one example Fig. 45 IVa) to be sure of this.

Regarding this principle, the *trophic troubles* or the patient age are also interesting: We usually considered not to be invasive in such cases. Now, on the contrary, we do a generous shortening of the metatarsal even in these cases and the result is excellent whatever the local troubles, the deformity, the age. *For me it is a radical change in my attitude.* The result clearly shows that it is in fact a significant improvement in the approach of such severe deformities. The **key of this generous metatarsal shortening** is, as called by L. S. Weil, **the longitudinal decompression** notably of the MTP joints, allowing a much better joint preservation than traditionally. Of course, this articular preservation has **limits** and in this case, we do an MTP fusion or head resection. We do this less than usually, it is all!



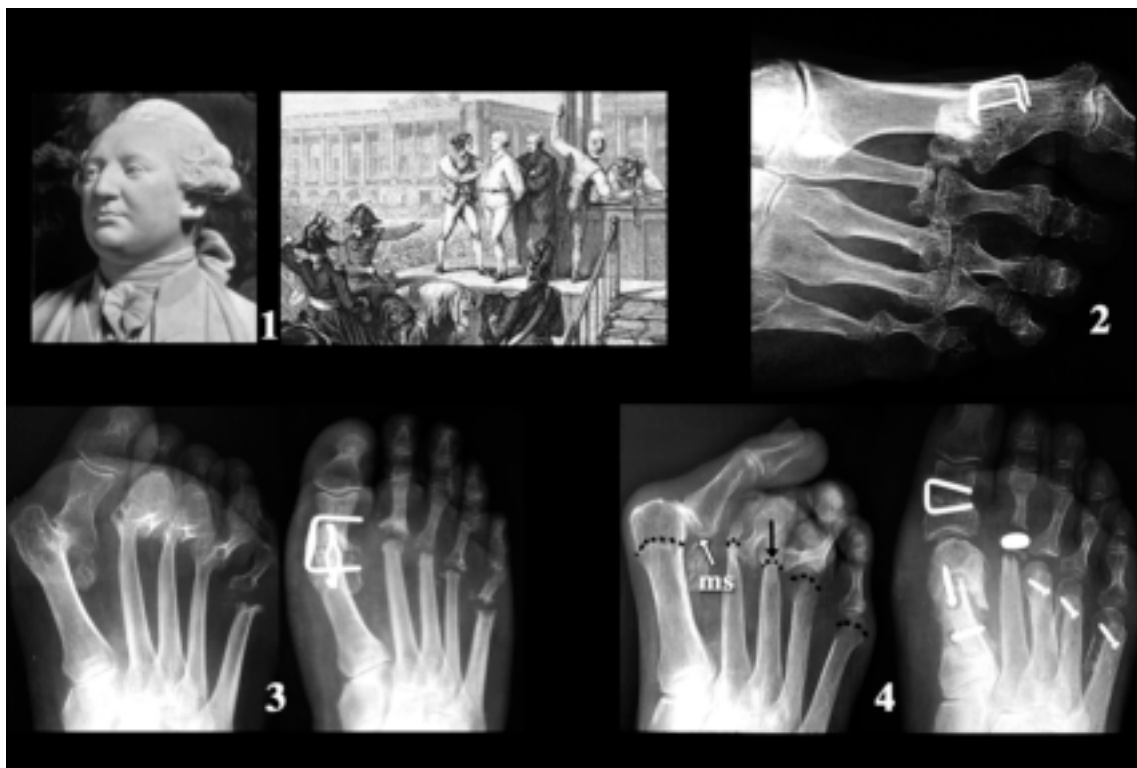
**Fig. 45d2a. Principle IV – The place of a generous shortening of the metatarsals. b) In severe forefoot disorders. 1) The amount of shortening on the dorso-plantar X-ray view.**

1. Focus on the first ray. Loss of MTP dorsal flexion in the correction handling and lateral subluxation of the first phalanx which indicates the required shortening (*ms* point).
2. Focus on the lesser rays. *Ms* point located on the proximal part of the phalanx (on the most dislocated ray).
3. Focused both on first and lesser rays (*ms* point).



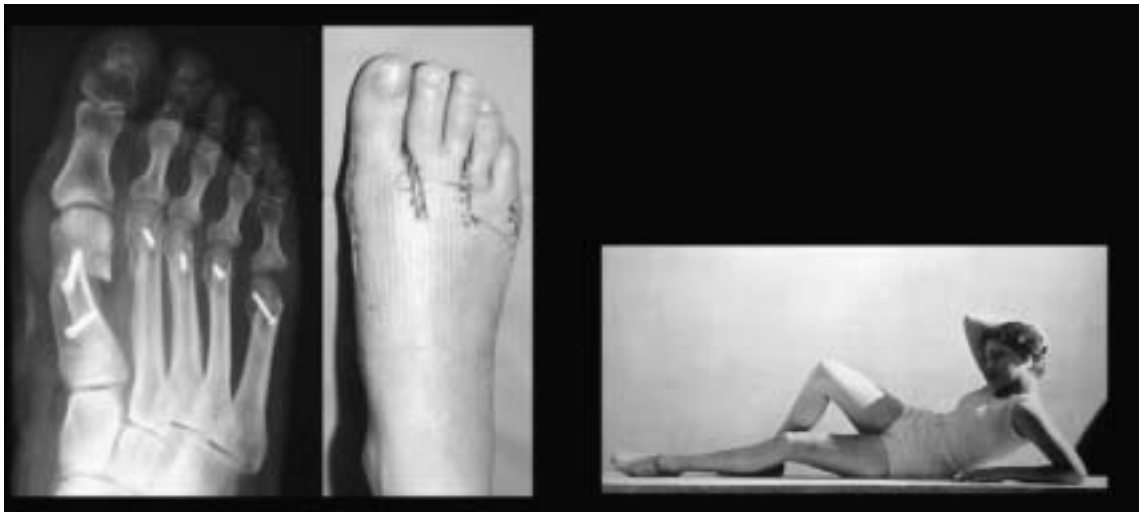**Fig. 45d2b. Principle IV – The place of a generous shortening of the metatarsals. b) In severe forefoot disorders. 2) The amount of shortening on the medial oblique view.**

For this patient, the metatarsal shortening is well assessed on the right foot (*ms*). On the left foot, the *ms* point is uncertain and in this case, the medial oblique view is useful to accurately determine the *ms* shortening point (overriding of the first phalanx).



**Fig. 45d3. Principle IV – The place of a generous shortening of the metatarsals. c) Preservation of the metatarsal heads.**

1. Louis XVI, before and during his beheading: Did his head deserve this treatment?
2. In the same way, did this foot really deserve the head resections? (Sometimes replacing monarchy by anarchy... Unfortunately, L. S. Weil born is 1.5 century too late!)
3. It is certain that in this foot the MTP joints could not be preserved, nor the metatarsal heads.
4. But, in this case, we preserved 4/5 of the heads. Is it not preferable, as far as we can do it?

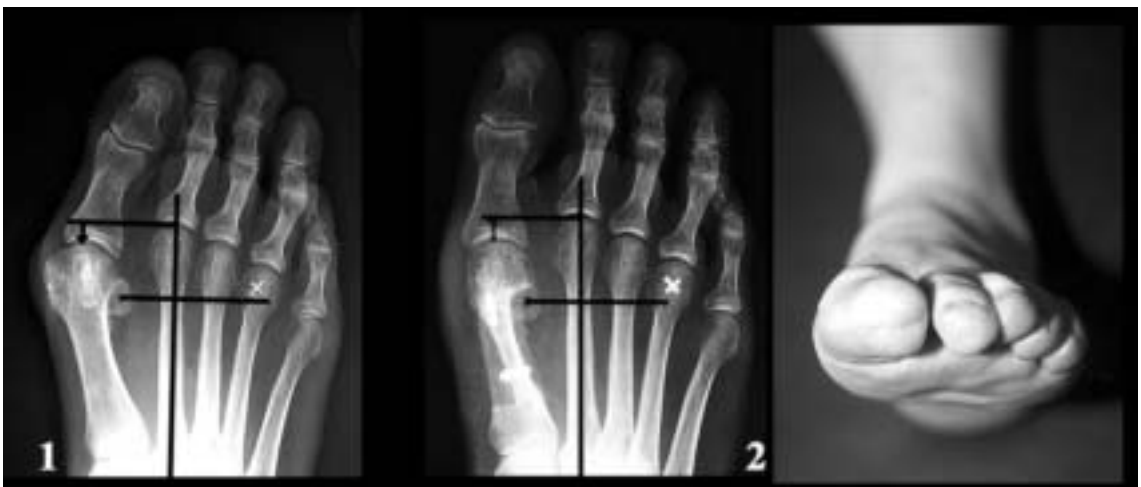

**Fig. 45d4. Principle IV – The place of a generous shortening of the metatarsals. c) Postoperative aspects.** The foot is not very swollen, it is painful. The mobility is early recovered. The foot is relaxed and the patient too!

## Fifth Principle Single ray pathology

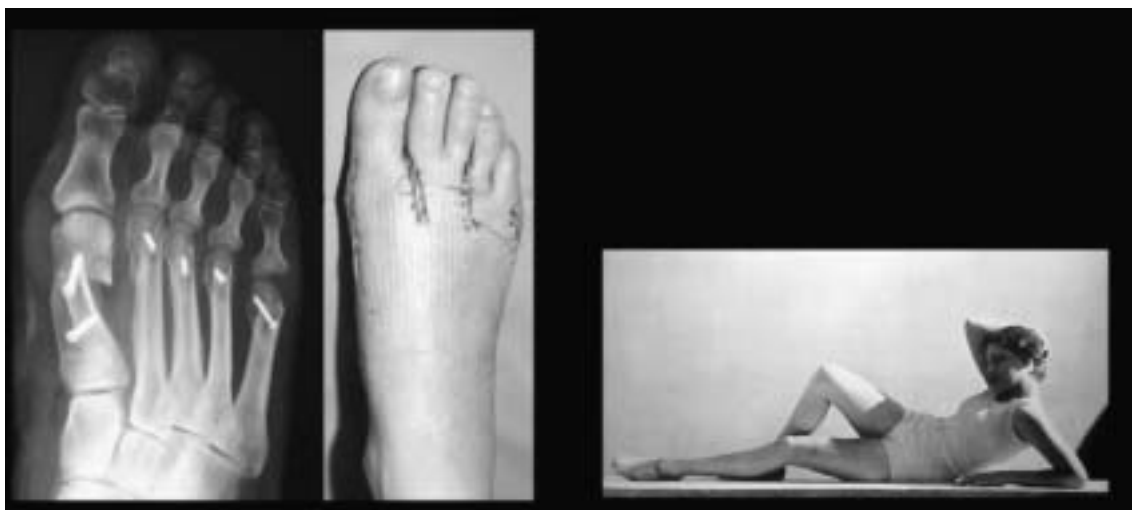*The fifth principle is, when the pathology only affects one ray and the surgery doesn't have to jeopardize the other rays, to perform surgery only on this ray! (Fig. 45e)*

The only point we would like to emphasize is to be sure that this one ray surgery will really not really compromise the other rays (transfer lesion). Once again, remember the level crossing notice “a train should hide another one”.



**Fig. 45e. Principle V – Nevertheless when there is no previous forefoot pathology, we have to respect the preoperative anatomy.**

In this example, there is an excessive length of the lesser metatarsal but without clinical signs: We firstly performed a scarf osteotomy (but with M1 lowering).

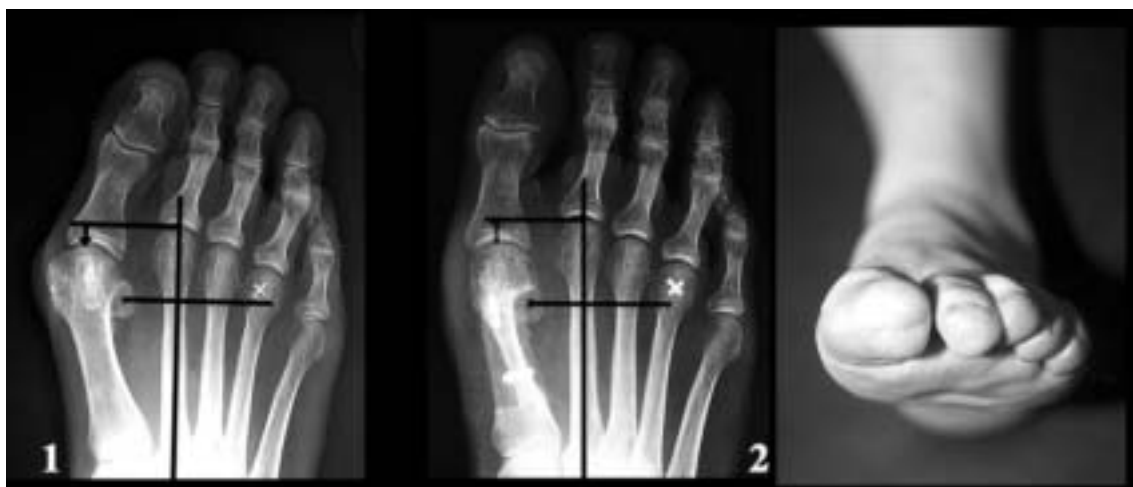

**Fig. 45d4. Principle IV – The place of a generous shortening of the metatarsals. c) Postoperative aspects.** The foot is not very swollen, it is painful. The mobility is early recovered. The foot is relaxed and the patient too!

## Fifth Principle Single ray pathology

*The fifth principle is, when the pathology only affects one ray and the surgery doesn't have to jeopardize the other rays, to perform surgery only on this ray! (Fig. 45e)*

The only point we would like to emphasize is to be sure that this one ray surgery will really not really compromise the other rays (transfer lesion). Once again, remember the level crossing notice “a train should hide another one”.



**Fig. 45e. Principle V – Nevertheless when there is no previous forefoot pathology, we have to respect the preoperative anatomy.**

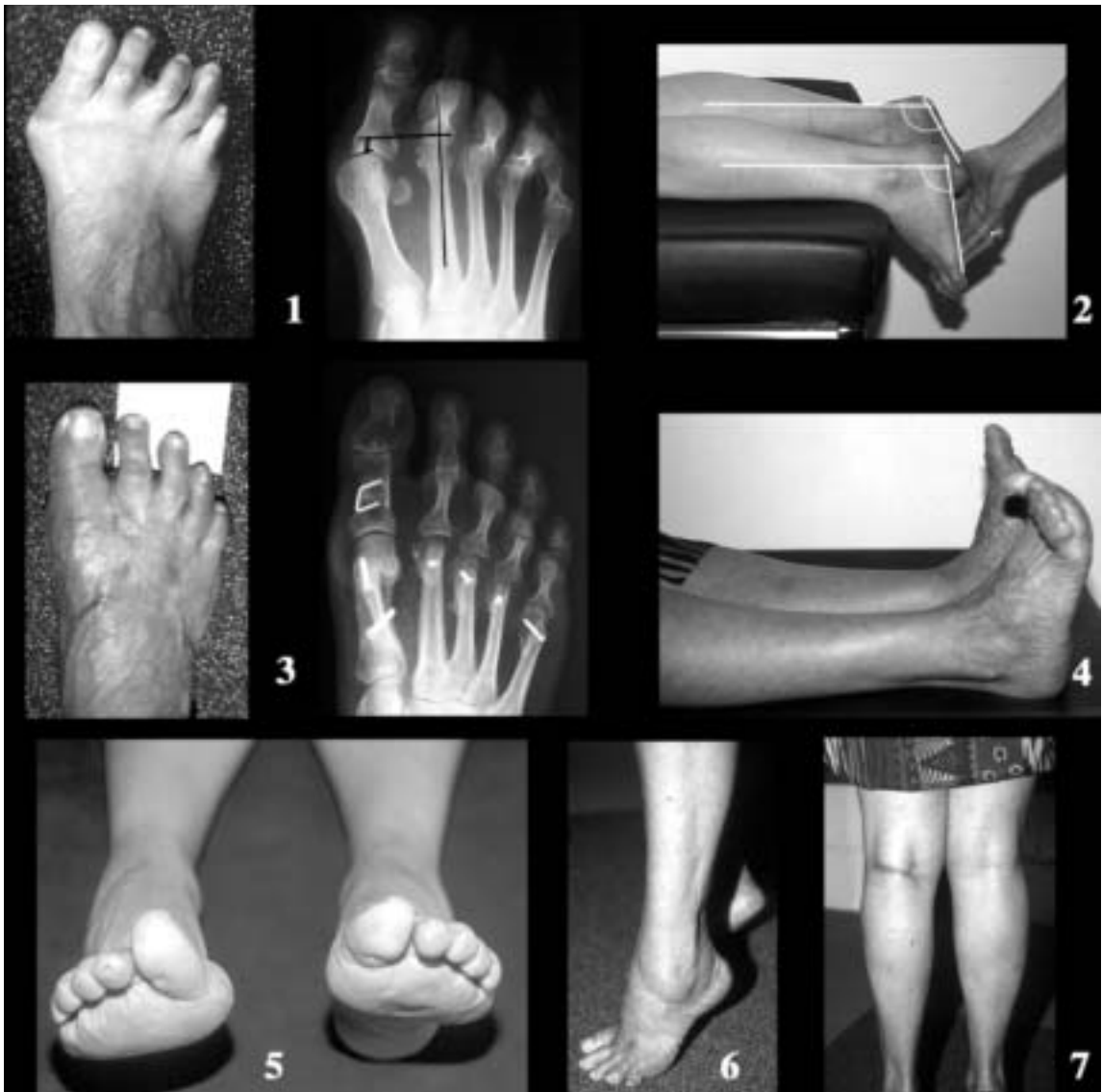In this example, there is an excessive length of the lesser metatarsal but without clinical signs: We firstly performed a scarf osteotomy (but with M1 lowering).

## Sixth Principle

### Relationships between forefoot, rear foot and lower limb

*The sixth principle is to take into account the relationship between the forefoot and the rear-foot (and the lower limb). We emphasize this combination with three examples.*

1) *The gastrocnemius shortness* (Fig. 45f1) has a close relationship with the forefoot, in most cases, by increasing the forefoot deformities so that the security in forefoot surgery is to perform in the same session (or preferably few days before) the gastrocnemius release as required. Sometimes the forefoot deformity, particularly overload (metatarsalgia) or claw toes deformity, have their main cause in the gastrocnemius shortness so that in this case, the forefoot sur-



**Fig. 45f1 – Principle VI – Take into account the relationship between the rearfoot and the lower limb. a) The gastrocnemius shortness (in all this figure, the same patient).**

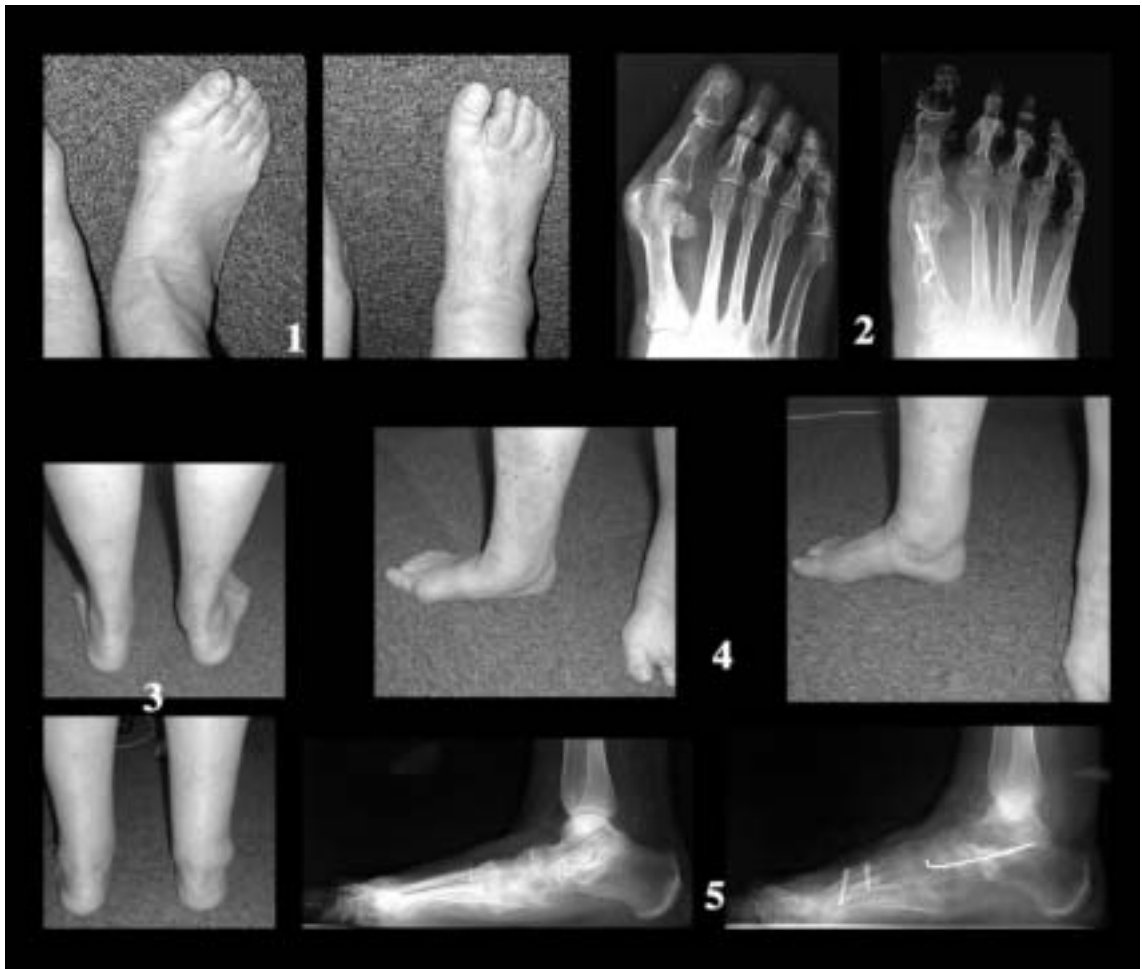1. Severe forefoot deformity. 2. Same patient, left foot: Shortness of the gastrocnemius.

3 to 7. Postoperative aspects two months after metatarsal osteotomies (small shortening) and proximal gastrocnemius release. 3. The correction. 4, 5. On the corresponding foot, normal dorsal flexion (more than in the not operated right foot). 5. Plantar callosities have disappeared. 6. The patient can be on tiptoes and says that she feels better on this leg than on the right one.

gery is limited and the main surgery is the gastrocnemius release.

2) *Pes valgus*. In this case, the forefoot surgery is additional but very useful in achieving the correction. We met some significant cases of Evan's calcaneum osteotomy combined with a scarf first metatarsal osteotomy with lowering.

3) *In cavus foot* (Fig. 45f3), the BRT basal metatarsal elevation osteotomy can be successfully combined with a calcaneum osteotomy like the M. Myerson osteotomy, to offer an alternative to the Lisfranc dorsal resection. This association of extra-articular osteotomies was recently emphasized by J. Sammarco [107].

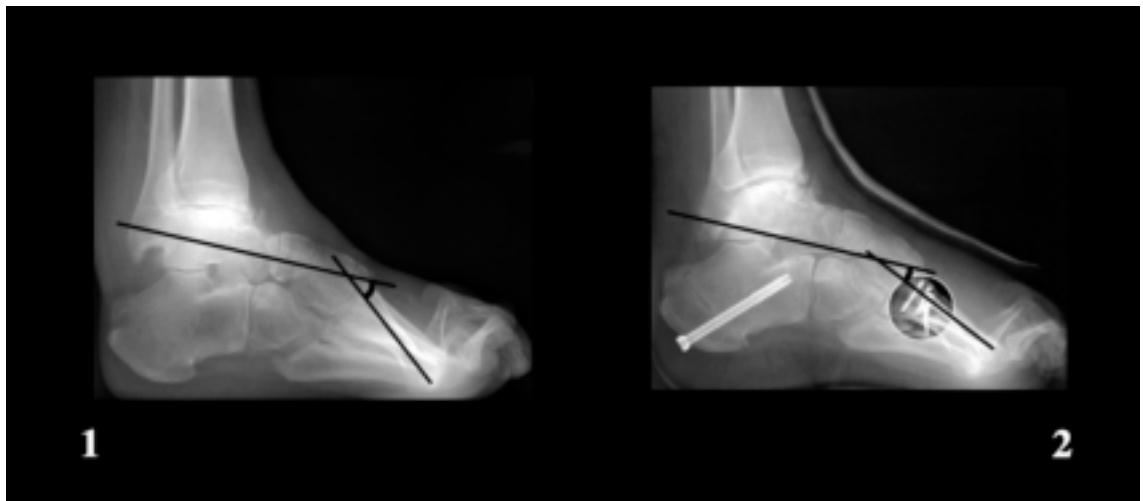

**Fig. 45f2. Principle VI – Take into account the relationship between the rear foot and the lower limb.**  
**b) Pes valgus.**

Pictures from E. Toullec, Bordeaux.

Pes planus / valgus combined with hallux valgus deformity: Evan's calcaneum osteotomy and scarf first metatarsal osteotomy with lateral shift and lowering. Pre and postoperative (months) aspects.

- 1, 2. Dorso-plantar clinical and radiological aspects.
3. The rear foot view.
4. Medial aspect.
5. Weight bearing sagittal X-rays, before removing the K-wire.



**Fig. 45f3. Principle VI – Take into account the relationship between the rear foot and the lower limb.**

**c) Pes cavus.**

As an *alternative* to the traditional *Lisfranc* osteotomy and according to other authors, like J. Sammarco, we think that the *calcaneum* osteotomy should be *combined* with the *metatarsal basal* osteotomy; so we use the BRT osteotomy.

## Seventh Principle Keep the toes long

*The seventh principle is to take care of the toes.*

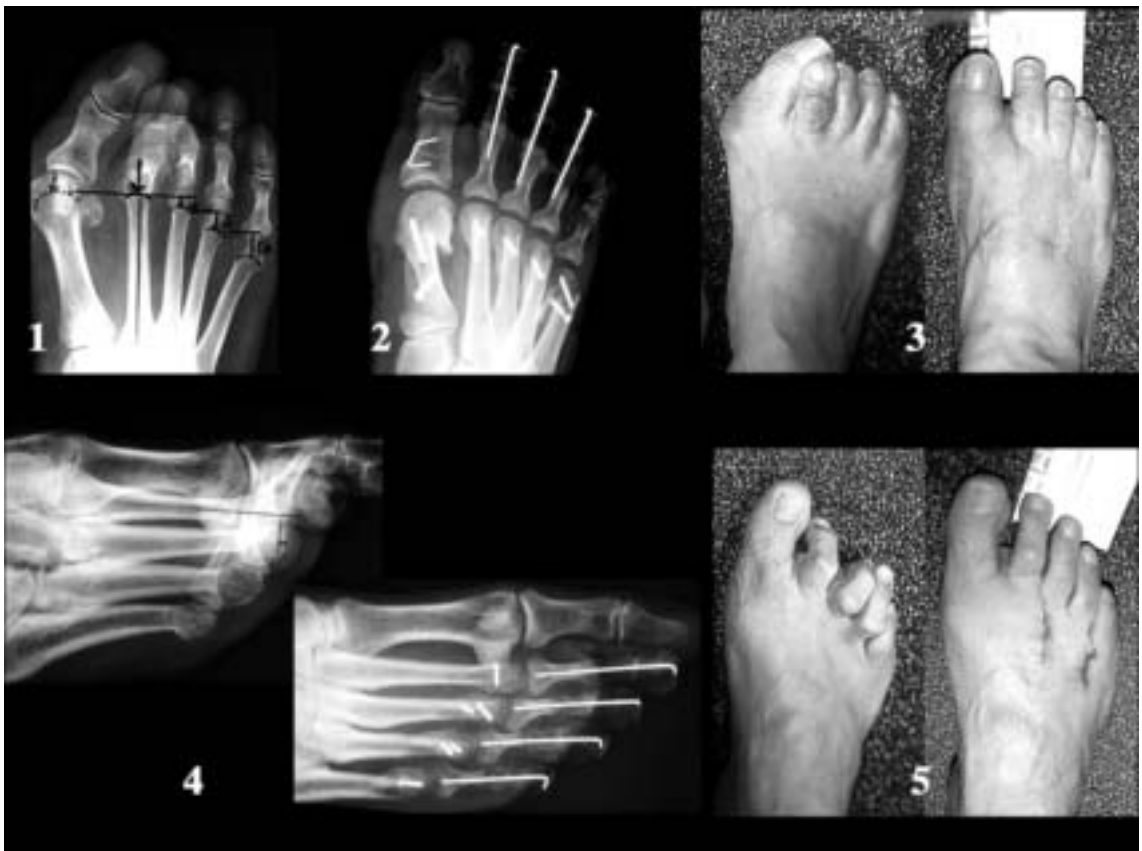
### **Keep the Toes Long** (Fig. 45g1)

– *i.e.* without joint resection or fusion. This is possible thanks to the longitudinal decompression provided by the metatarsal shortening. It is useful but it also preserves the cosmetic appearance of the forefoot, which has to be emphasized.

### **Obtain a Square Type Foot** (Fig. 45g2)

– *Egyptian type foot*: We know that many people have a preference for Egyptian type foot and it is true that it is as well as more elegant sign of a certain strength of the foot; at last, perhaps a sexual signification... But we also know that we cannot leave the Egyptian foot in a case of first MTP arthritic changes and generally to secure the hallux valgus correction. So we can leave a slight Egyptian foot in a young person or when there is no arthritic changes.

– *Greek type foot*: This is not a good type! First because we observe that it is not well tolerated, providing also hallux valgus deformity and second toes problems, secondly because

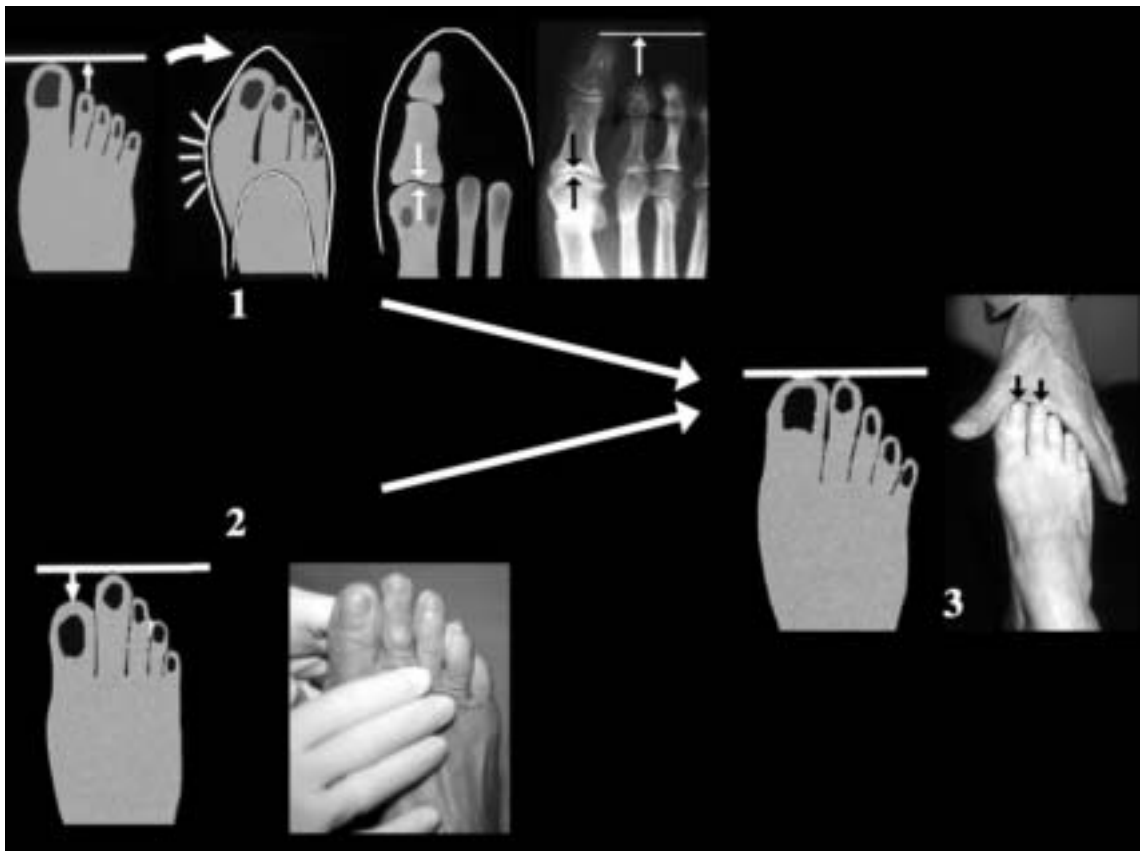


**Fig. 45g1. Principle VII – The toes. a) Keep the lesser toes long.**

1, 2, 3. The correction of this deformity is obtained only by the shortening of the metatarsals: The toes are corrected by soft tissue procedure and toe K-wiring. The toes remain long and more effective in the ground contact strength. The foot cosmetic aspect is preserved notably by keeping the toes long.

4, 5. Other example of the toe length preservation.





**Fig. 45g2. Principle VII – The toes. b) To obtain a square type foot.**

1. An *Egyptian* type foot remaining may result in recurrence of deformity or in longitudinal overpressure notably in the MTP joint. However a slight excess of the grant toe length is well tolerated.

2. A *Greek* type foot is *not well tolerated* if a second *hammertoe* deformity previously exists.

3. So we have to obtain a *square* type foot which is the best tolerated by footwear (above all by ladies footwear).

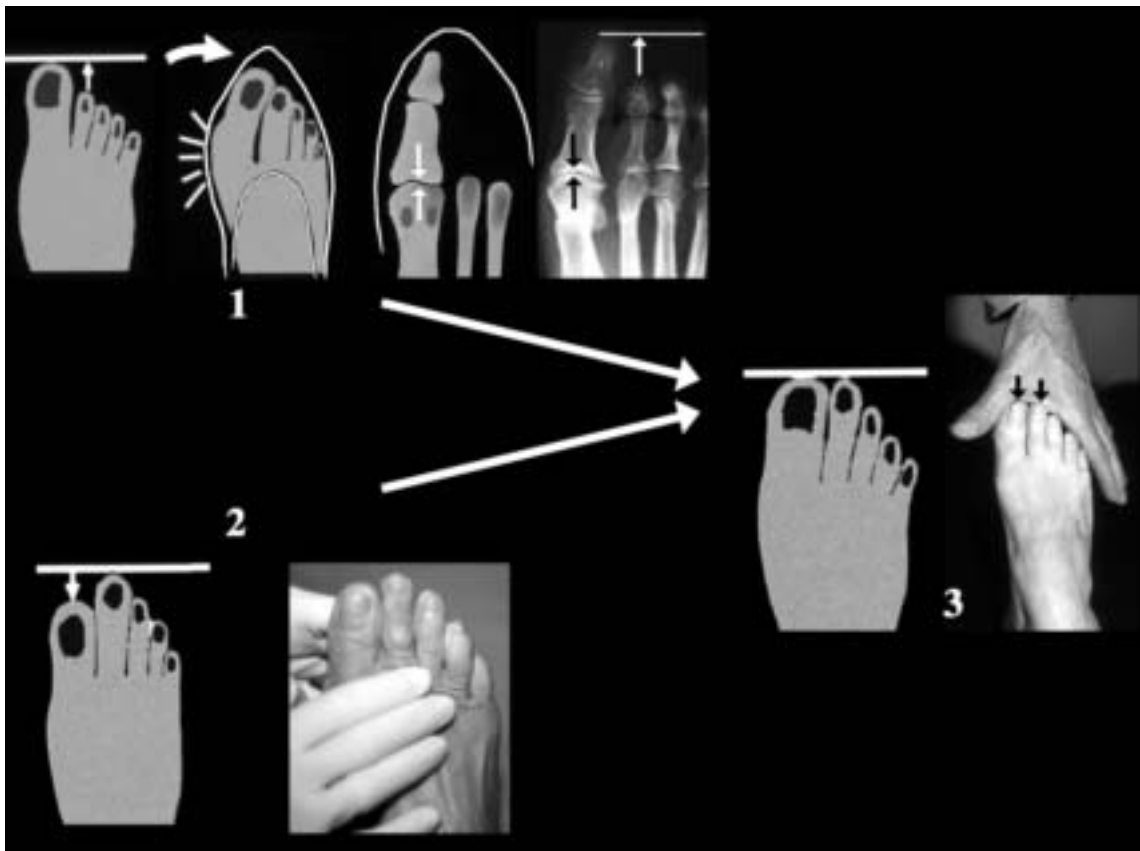
hallux valgus is more difficult to treat, thirdly because the second toe excessive length is often accompanied by the corresponding metatarsal excess of length.

– *Square type foot*: The security is to reach a square type foot, which is not only an elegant foot, but also very well tolerated regarding the footwear. This introduces the eighth and last principle.

## **Eighth Principle** Obtain a foot which fits to elegant shoes

*The eighth principle is to obtain a foot which fits to elegant shoes (Fig. 45h1-2-3-4-5).*

First, a few words about *my experience as a “shoemaker”*. Since 1981, I have studied feminine shoes with designers and also technicians and *last* manufacturers. From 1985 to 1995 I was additionally a shoemaker. I made myself the lasts, trying to combine comfort and elegance. Twice a year, I launched a collection “Spring/Summer” and “Autumn/Winter”. It was a very exciting period in which I learned a lot of things about shoes, comfort, fashion... and the foot. I wrote some papers on this subject [19]. Unfortunately a medical surgeon is not a businessman and this period finished in 1995. However, the same year, I met L. Piclet and Ph. Alberola, who created a society for medical and comfort shoes (*Romans Industrie*) which actually make the Type I heel support shoe, the Type II and at last some models of Type III which are good-looking.



**Fig. 45g2. Principle VII – The toes. b) To obtain a square type foot.**

1. An *Egyptian* type foot remaining may result in recurrence of deformity or in longitudinal overpressure notably in the MTP joint. However a slight excess of the grant toe length is well tolerated.
2. A *Greek* type foot is *not well tolerated* if a second hammertoe deformity previously exists.
3. So we have to obtain a *square* type foot which is the best tolerated by footwear (above all by ladies footwear).

hallux valgus is more difficult to treat, thirdly because the second toe excessive length is often accompanied by the corresponding metatarsal excess of length.

– *Square type foot*: The security is to reach a square type foot, which is not only an elegant foot, but also very well tolerated regarding the footwear. This introduces the eighth and last principle.

## Eighth Principle

### Obtain a foot which fits to elegant shoes

*The eighth principle is to obtain a foot which fits to elegant shoes (Fig. 45h1-2-3-4-5).*

First, a few words about *my experience as a “shoemaker”*. Since 1981, I have studied feminine shoes with designers and also technicians and *last* manufacturers. From 1985 to 1995 I was additionally a shoemaker. I made myself the lasts, trying to combine comfort and elegance. Twice a year, I launched a collection “Spring/Summer” and “Autumn/Winter”. It was a very exciting period in which I learned a lot of things about shoes, comfort, fashion... and the foot. I wrote some papers on this subject [19]. Unfortunately a medical surgeon is not a businessman and this period finished in 1995. However, the same year, I met L. Piclet and Ph. Alberola, who created a society for medical and comfort shoes (*Romans Industrie*) which actually make the Type I heel support shoe, the Type II and at last some models of Type III which are good-looking.

Regarding the shoes which were made 20 years ago, the general concept of shoes has changed: The lasts have been improved, as well as generally the comfort of the shoes, even if the high heel ladies shoes still remain, fortunately for the elegance.

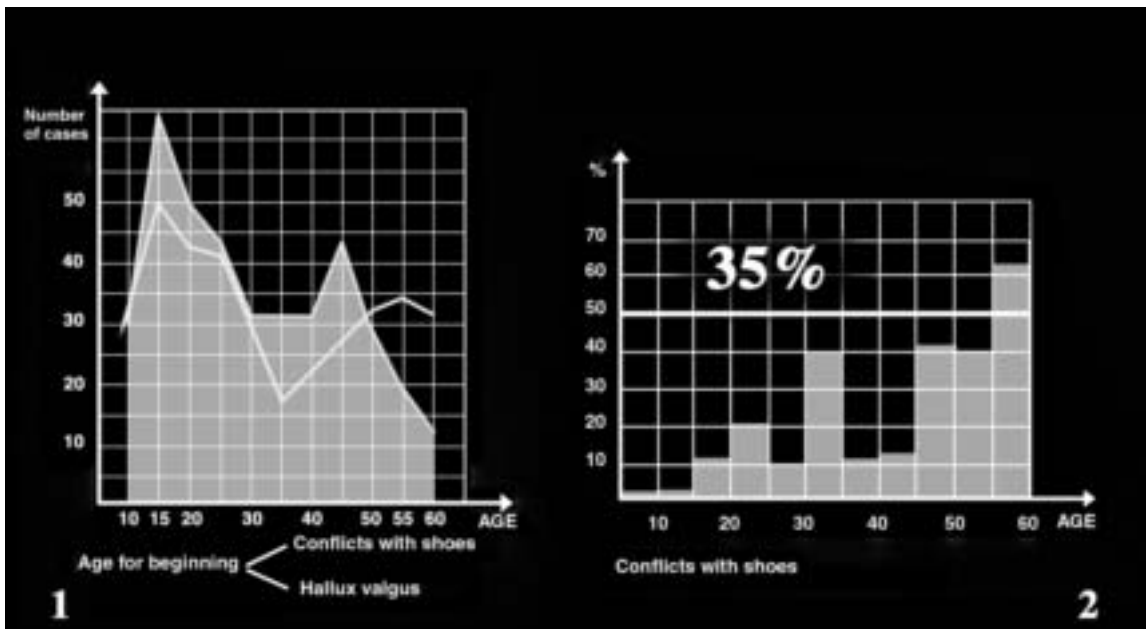
Let's come back to forefoot surgery and the eighth principle : "to obtain a foot which fits to

*elegant shoes*". This is unusual when we read books about foot surgery. On the contrary, I emphasize this dimension: Certainly, we first have to obtain a painless foot, but 95% of our forefoot patients are women and they are more and more younger current, since they come earlier to surgery, thanks to the reliability of the current procedures. We just have to look at *the*



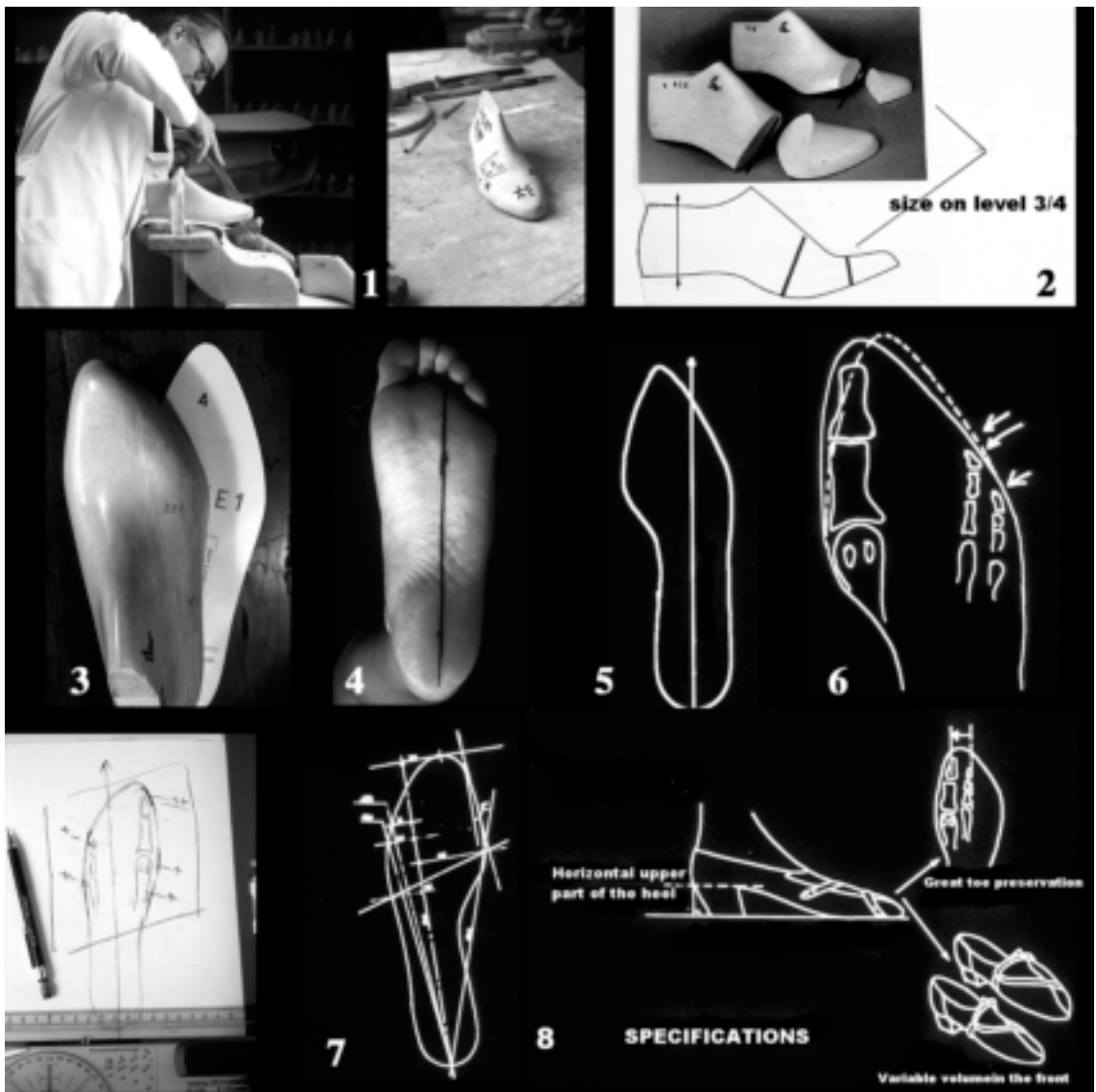
**Fig. 45h1. To obtain a foot which fits to elegant shoes. a) The conflicts forefoot/shoes 1.**

1. "Doctor, I am coming because I cannot wear shoes any more!" This sentence is more used than "it hurts" or "it is painful". So that the forefoot surgery has to deal closely with the footwear.
- 2, 3. Problem: "What could I wear today?" (among dozen of shoes). In these ones I feel good! Finally her choice is old slippers...
- 4, 5. The resulting pressure on the forefoot, due to the first high heel shoes (court shoe) in France in the fifties, with the fashion designer Jacques Fath.
- 6, 7. I studied the compromise between the height of the heel and tolerable pressure on the forefoot: 5.8 cm is correct.



**Fig. 45h2. To obtain a foot which fits to elegant shoes. a) The conflicts forefoot/shoes 2.**

1. I performed a study on 1,300 women in 1985. Average rate of *emerging conflicts with the shoes* (c sh.) and *emerging hallux valgus deformity* (HV): Conflicts appeared as soon as the girls wear shoes. (At this time the footwear was more feminine than today.) Hallux valgus appeared in most cases around 15 years – so juvenile – but this was not painful, and the second pick was towards 50 years.
2. Study of *average rate of conflicts foot / shoe*. Note an average of 35% but we observe the three peaks: A small in the twenties, a more important in the thirties, and a big one from the fifties.



**Fig. 45h3.** To obtain a foot which fits to elegant shoes. *b1) My experience of shoemaker (1985/1995).*

- 1, 2. Final works on the last, to add or to remove material in order to follow the good anatomy.
3. The width at the level 3/4 I found to be the most important for the toes.
4. A last and its sole.
5. The importance of the “axe d’emboitage” (axis from the rear part of the sole). Where does it pass on the fore part?
6. The problem is to provide enough place for the toes while keeping narrow tip shoes.
7. Drawings sole studies.
8. This is the result of the sole study I made: With this sole, the problem is almost resolved, but we have to make a compromise with this and the shoe cosmetic appearance.
9. In a nutshell, the main schedule of conditions of the shoe line I devised during these years.

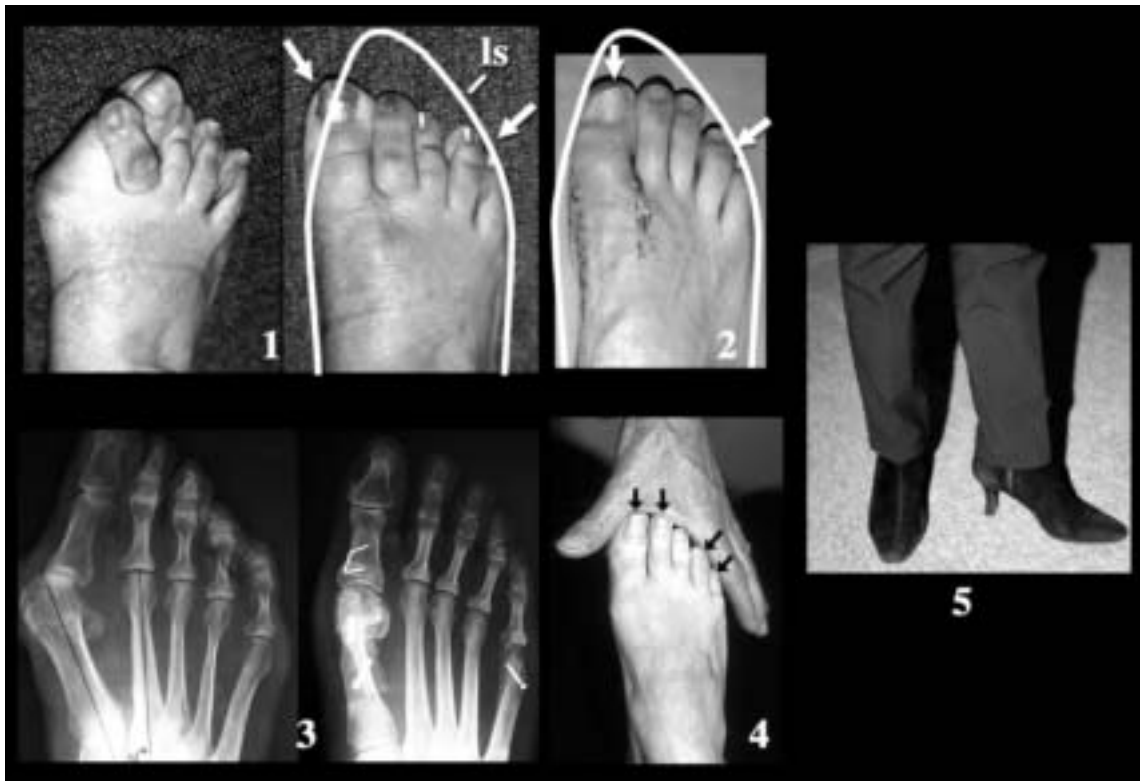


**Fig. 45h4.** Principle VIII – To obtain a foot which fits to elegant shoes. *b2: my experience of shoemaker*  
*c) Some examples of the LSB shoes: Collection 1993.*

1. The lasts used in 1993.

2, 3, 4. Some shoes of the collection *Automne/Hiver 1992/1993*.

5, 6. Some shoes of the collection *Printemps/Été 1993*.



**Fig. 45h5. Principle VIII – To obtain a foot which fits to elegant shoes. c) The corresponding surgery.**

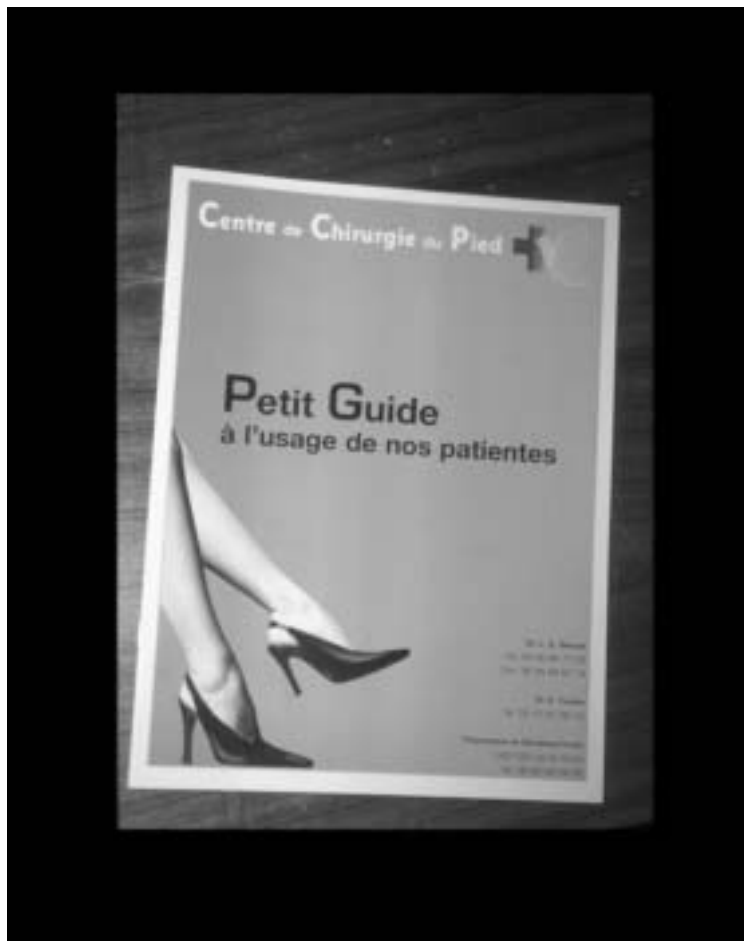
1. This operated foot is not compatible with usual women's footwear: The great toe is too long and too large. Too long the fourth and fifth toes.
2. This foot can fit to women shoe with a square type foot and no problem with the two last rays. We must obtain such a foot.
3. Example of foot for which we obtained a correct shape.
4. This test reproduces the forefoot aspect to be obtained. With the techniques we presented all along this book, we can do it.
5. One of our patient: 3.5 postoperative month. All our patients are not like her but this is what we would like to achieve everytime!

*foot that must fit to elegant shoes* to make the appropriate “forefoot reconstruction”.

So, coming back to the title of this book, we know that a house to be built must be comfortable. It is better if this house is also elegant! In our present “petit guide” we give our patients on the first consultation, there is a picture of high heel and acute tip shoes. We say to our patients:

“We want to allow you to wear this shoe after surgery if you want and not to forbid it.”

So if we can offer to our feminine patients the opportunity to choose their shoes not only following the comfort but also following the cosmetic appearance and the fashion, I think we have fulfilled our goals in forefoot reconstruction.





# REFERENCES

1. Abboud RJ, Rowley DI (1996). *Foot Pressure Measurement. History and Development. Surgery of Disorders of the Foot and Ankle*. Helal B, Rowley DI, Cracchiolo III A, Myerson MS, Édition Martin Dunitz, London, 123, 138.
2. Acevedo JI (2000). *Fixation of Metatarsal Osteotomies in the Treatment of Hallux Valgus, Foot and Ankle*. Myerson MS, Cracchiolo III A, Saunders, 451-68.
3. Barouk LS (1994). *Éléments d'anatomie chirurgicale du premier métatarsien*. Méd. Chir. Pied. Expansion Scientifique Française, Paris 2, 76-82.
4. Barouk LS (1992). *Notre Expérience de l'Ostéotomie « scarf » des Premier et Cinquième Métatarsiens*. Méd. Chir. Pied. Expansion Scientifique Française, Paris 8, 2: 67-84.
5. Barouk LS (1993). *The First Metatarsal Scarf Osteotomy Associated with the First Phalanx Osteotomy in the Hallux Valgus Treatment*. In: *Médecine et chirurgie du pied. Premier congrès européen d'Orthopédie. Journée des spécialités du pied* (sous la direction de Benamou P et Montagne J). Masson, Paris, 133-60.
6. Barouk LS (2000). *Scarf Osteotomy for Hallux Valgus Correction*. Foot and Ankle clinics, editors Myerson M, Cracchiolo III A, vol. 5, n° 3, Saunders, 525-58.
7. Barouk LS (1995). *Scarf Osteotomy of the First Metatarsal in the Treatment of Hallux Valgus*. Foot diseases II, 1, 35-48.
8. Barouk LS, Weil LS (1994). *La osteotomia « scarf » associada a la osteotomia de la phalange en el tratamiento del hallux valgus, sistemas de fijacion possibilades e indicaciones*. Revista de Medicina y cirugía del pie, tomo III, n° 1, 33-43.
9. Barouk LS (1994). *Great Toe Osteotomies in the Hallux Valgus. Personal Experience. Therapeutic Proposition*. Foot Diseases I, 1, 79-89.
10. Barouk LS (1993). *Le raccourcissement du gros orteil : intérêt de l'agrafe à mémoire spécifique*. In: *Actualités en médecine et chirurgie du pied*. 8<sup>e</sup> série. Masson, Paris, 93-105.
11. Barouk LS (1998). *Hallux Valgus. Proximal Phalangeal Osteotomy, Atlas of Foot and Ankle Surgery*. Wulker N, Stephens M, Cracchiolo III A, Martin Dunitz, London, 1-6.
12. Barouk LS, Barouk P, Baudet B, Toullec E (2005). *The great toe proximal phalanx osteotomy : the final step of the bunionectomy*. Foot Ankle Clin. Elsevier-Saunders.
13. Barouk LS (1994). *L'ostéotomie cervico-céphalique de Weil dans les métatarsalgies médianes*. Méd. Chir. Pied. Expansion Scientifique Française, Paris 1, 23-33.
14. Barouk LS (1996). *Die Metatarsalosteotomie nach Weil zur Behandlung der Metatarsalgie*. Orthopäde 25, 338-44.
15. Barouk LS (1997). *New Osteotomies in the Forefoot and their Therapeutic Roles. Forefoot Surgery*. Edited by Valtin B. Expansion Scientifique Française, Paris 49-76.
16. Barouk LS (1992). *Utilisation de la prothèse bouton au niveau du premier rayon. Médecine et Chirurgie du pied*. Expansion Scientifique Française, Paris 8, 3: 125-36.
17. Barouk LS, Diebold P, Chiappara P, Goldcher A, Maestro M, Themar-Noël C (1991). *Hallux valgus congénital, symposium*. Médecine et chirurgie du pied. Expansion Scientifique Française, Paris 7-23.
18. Barouk LS (1984). *Les Brièvetés Musculaires Postérieures du Pied de l'Infirmes Moteur Cérébral (IMC)*. Suppl II, rev. Chir. Orthop. 70, 10-3.
19. Barouk LS (1988). *La femme et sa chaussure*. Monographie de podologie, n° 9, Masson, Paris, 47-62.

20. Barouk LS (1988). *Évolution de la chaussure post-opératoire sans appui sur l'avant-pied*. Monographies de podologie, n° 9, Masson, Paris, 4-5.
21. Barouk LS (1986). *Use of a Postoperative Shoe without Forefoot Support, Comparative Statistical Study*. Actualités de médecine et chirurgie du pied XVI, 57-69.
22. Bock P, Kristen KH, Engel A (2004). *Hallux valgus an cartilage degeneration in the first metatarsophalangeal joint*. J. Bone Joint Surg. Br. 86-B, n° 5, 669-73.
23. Bonnel I, Canovas F, Poiree G, Dusserre F, Vergnes C (1999). *Évaluation de l'ostéotomie scarf pour hallux valgus en fonction de l'angle articulaire distal métatarsien. Étude prospective sur 79 cas opérés*. Revue de chirurgie orthopédique, Masson 85, 381-6.
24. Bonnel F, Largey A, Faline A, Roussane Y (2003). *Lésions dégénératives de l'articulation métatarso-sésamoïdienne dans le cadre de la correction des hallux valgus (étude prospective continue; à propos de 18 cas)*. Réunion annuelle de l'AFCP sous l'égide de la SOFCOT.
25. Bonneville P, Baudet B, Mansat M, Gay R (1986). *Place de l'ostéotomie phalangienne dans la cure chirurgicale de l'hallux valgus*. In: *Actualités en médecine et chirurgie du pied*. 1<sup>re</sup> série. Expansion Scientifique Française, Paris 29-33.
26. Borrelli AH, Weil LS (1991). *Modified Scarf Bunionectomy: Our Experience in More Than 1,000 Cases*. J. Foot Surg. 30, 609.
27. Borton D, Stephens M. *Basal Metatarsal Osteotomy for Hallux Valgus*. Journal of Bone and Joint surgery 76b, 204-9.
28. Bourguery JM, Jacob NH. *Traité complet de l'anatomie de l'homme*. 1831-51. Paris CA Delaunay-Édit.
29. Burutaran JM (1976). *Hallux valgus y corteada anatomica del primer metatarsano (correccion quirurgica)*. Actual. Méd. Chir. Pied, XIII, 261-6.
30. Carranza A, Maceira E, Viladot R, De Prado M (2000). *Estado Actual de la cirugía del hallux valgus*. Cursos de Actualizacion SECOT. 5-21. Madrid.
31. Cassagnaud X, Barouk P, Baudson H, Maynou C, Mestdach H (2003). *Mesure radiographique du DMAA : étude de reproductibilité et de validité*. In Chirurgie de l'avant-pied, Symposium de la SOFCOT, 2002. Rev. Chir. Orthop. 89 (Suppl. n° 5), 94-6.
32. Cornu JY, Kowalski C, Daum B, Guyot J (1999). *Analyse clinique de l'extensibilité du couple suro-achilléen – le tendon d'Achille et sa pathologie*. Sauramps, 34-46.
33. Chi TD, Davitt J, Younger A, Holt S, Sangeorzan BJ (2002). *Intra and inter-observer reliability of the distal metatarsal articular angle in adult hallux valgus*. Foot and Ankle Int. August, vol. 22, n° 8, 722-6.
34. Coetzee JC (2003). *Scarf osteotomy for hallux valgus repair: the dark side*. Foot and Ankle Int. Vol. 24, n° 1, 29-33.
35. Condon F, Kaliszer M et coll. (2002). *The first intermetatarsal angle in hallux valgus: an analysis measurement reliability and the error involved*. Foot and Ankle Int. Vol. 22, n° 8, 717-21.
36. Coughlin MJ (1995). *Juvenile Hallux Valgus: Etiology and Treatment*. Foot Ankle Int. 16, 682-97.
37. Coughlin MJ (1997). *Hallux Valgus in Men: Effect of the Distal Articular Angle on Hallux Valgus Correction*. Foot Ankle Int. 18 (8): 463-70.
38. Coughlin MJ, Shurnas PS (2003). *Hallux valgus in men part II: First ray mobility after bunionectomy and factors associated with hallux valgus deformity*. Foot and Ankle Int. Vol. 14, n° 1, 73-8.
39. Coughlin MJ, Freund E (2001). *The reliability of angular measurements in hallux valgus deformities*. Foot and Ankle Int. Vol. 22, n° 5, 369-79.
40. Crevoisier X, Mouhsine E, Ortolano V, Udin B, Dutoit M (2001). *The Scarf Osteotomy for the Treatment of Hallux Valgus Deformity: A review of 84 Cases*. Foot Ankle Int. 22: 970-6.
41. Day Mardon R, White S, Dejesus JM (1987). *The Z Osteotomy versus the Khalish Osteotomy for the Correction of Hallux Abducto Valgus Deformities: A Retrospective Analysis*. J. Foot and Ankle Surgery. Vol. 36, n° 1, 44-50.
42. De Doncker E, Kowalski C (1970). *Le pied normal et pathologique*. 183 pages, Acta Orthopaedica Belgica.
43. Delagoutte JP, Becker JP (1986). *Traitement de l'hallux rigidus par ostéotomie d'accourcisse-*

- ment phalangien. In: *Podologie*. Expansion Scientifique Française, Paris 117-21.
44. Delbos A, Eisenach J, Narchi P, Brasseur L (1998). *Peripheral Nerve Blocks in Upper and Lower Limbs*. CD rom Lippincott Raven.
45. Delmi M (1999). Chirurgie de l'avant-pied. *Méd. Hyg* 57 : 2, 398-406.
46. De Prado M, Ripoll P., Golano P (2003). *Cirurgia per cutanea del pie*. Masson-Barcelona.
47. Dereymaeker G (1996). *Management of Hallux Valgus and Metatarsalgia. A Comparative Study of Various Surgical Procedures for Hallux Valgus, Based on Clinical and Radiographic Assessment and Gait Analysis Thesis*. Katholieke Universiteit Leuven Faculty of Medicine, Department of Surgical and anaesthesiological science, HNC agency, Medical Publishing Cat, GDW01-001.
48. Dereymaeker G (2000). *Scarf Osteotomy for Correction of Hallux Valgus. Surgical Technique and Results as Compared to Distal Chevron Osteotomy*. *Foot Ankle Cli*. 5 (3): 513-24. Review.
49. Diebold PF (1997). *Distal Chevron Osteotomy of the First Metatarsal*. In: *Cahiers d'enseignement de la SOFCOT n° 60*. Forefoot surgery. Expansion Scientifique Française, Paris 76-81.
50. Diebold PF (2000). *Chevron Akin Double Osteotomy for Correction of Hallux Valgus after the Age of 60 Years. A Ten Years Follow up. Proceeding of the 30<sup>th</sup> Annual Meeting AOFAS 18.03*. Orlando.
51. Diebold PF, Daum B, Delagoutte JP (1988). *A propos du traitement du quintus supraductus*. In: *Podologie*. Expansion Scientifique Française, Paris 59-62.
52. Diebold PF, Bejjani FJ (1987). *Basal Osteotomy of the Fifth Metatarsal with Intermetatarsal Pining: A New Approach to Tailor's Bunion*. *Foot Ankle* 8: 40-5.
53. Diebold PF (1998). *Y a-t-il une vie après le Scarf ?* *Maîtrise Orthopédique* n° 77, 6-9.
54. Di Giovanni CW, Kuo R, Tejawani N, Price R, Hansens S, Cziernecki J, Sangeorzan BJ (2002). *Isolated gastrocnemius tightness*. *J. Bone Joint Surg*. Vol. 84-A, n° 6, 962-70.
55. Ducroquet R, J, Pb (1965). *La marche et les boiteries*. Masson, Paris.
56. Dutoit M (1998). *Hallux Valgus. Diaphyseal First Metatarsal Osteotomy. An Atlas of Foot and Ankle Surgery*. Editors Wulker N, Stephens M, Cracchiolo III A, Martin Dunitz, London 29-33.
57. Duke HF (1982). *Rotational Scarf (2) Osteotomy Bunionectomy for Correction of High Intermetatarsal Angles*. *J. Am Pédiatr. Méd. Association* 83, 352-60.
58. Edward EA (1960). *Anatomy of the Small Arteries of the Foot and Toes*. *Acta Anat*. 41, 81-96.
59. Gautier C (1986). *Physiopathologie de l'hallux valgus*. In: *Actualités en médecine et chirurgie du pied*. Sous la direction de Claustre J et Simon L, 20-4. Masson, Paris.
60. Faber F, Kleinrensink GL, Mulder P, Verhaar JA (2001). *Mobility of the first tarsometatarsal joint in hallux valgus patients: a radiographic analysis*. *Foot Ankle Int*. Vol. 22, n° 12, 965-9.
61. Ferrari J, Malone-Lee J (2002). *The shape of the metatarsal head as a cause of hallux abductovalgus*. *Foot and Ankle Int*. Vol. 23, n° 3, 236-42.
62. Gayet LE, Vaz S, Muller A, Vedekian J, Pries P, Clarac JP (1986). *L'ostéotomie scarf dans le traitement de l'hallux valgus*. *Méd. Chir. Pied* 12, 85-91.
63. Glickman S, Zahari DT (1986). *Short Z Bunionectomy*. *J. Foot Surgery* 25, 304-6.
64. Graff W (2003). *Reprise d'appui complet immédiat après ostéotomie Scarf du premier métatarsien : étude prospective de 224 cas*. Journées de l'AFCP, Marseille.
65. Groulier P (2001). *Échecs de la chirurgie du premier rayon*. *Cahiers d'enseignement de la SOFCOT*. Conférences d'enseignement 257-74.
66. Hart R, Janecek M, Bucek P (2003). *The weil osteotomy in metatarsalgia*. *Z Orthop. Ihre Grenzgeb*, 141 (5): 590-4 German.
67. Helal B (1975). *Metatarsal Osteotomy for Metatarsalgia*. *J Bone joint surg*. 57 b 87-192.
68. Helal B (1996). *Principles of patient care. Surgery of Disorders of the Foot and Ankle*. Martin Dunitz, London 593-6.
69. Huber-Levernieux C, Denis A, Goutalier D (1987). *Hallux varus iatrogène. Correction par ostéotomie de varisation de la base du premier métatarsien*. *Actualités en médecine et chirurgie du pied*. 2<sup>e</sup> série, sous la direction de Claustre J et Simon L. 87-90 Masson, Paris.

70. Jarde O, Trinquier JL, Gabrion A, Ruzic JC, Vives P (1999). *Hallux valgus traité par une ostéotomie de scarf du premier métatarsien et de la première phalange associée à une plastie de l'abducteur*. Revue de chirurgie orthopédique 85, 374-80.
71. Jarde O, Hussenot D, Vimont E, Barouk LS, Ferré B, Abi Raad G (2001). *L'ostéotomie cervico-capitale de Weil dans les métatarsalgies médianes – étude de 70 cas*. Acta orthopaedica Belgica 67, 2, 139-48.
72. Jarde O, Nable E, Havel E, De Lestang M, Rives L (2001). *Prothèse métallique d'interposition dans l'hallux rigidus*. Revue de Chirurgie Orthopédique 87, 67-72.
73. Javorek TE (1973). *The Intrinsic Vascular Supply to the First Metatarsal. Surgical Considerations*. J. Am. Pediatr. Med. Assoc. 63, 11, 555-62.
74. King DM, Toolan BC (2004). *Associated deformities and hypermobility in hallux valgus: an investigation with weightbearing radiographs*. Foot Ankle Int. Vol. 25, n° 4, 251-5.
75. Kowalski C (2000). *Le petit livre rouge du pied*. Podo. 3000, 117 pages, éd. IPL, Liège.
76. Kowalski C, Diebold P, Pennecot GF (1999). *Le tendon d'Achille court*. Encyclopédie médico-chirurgicale 27-060-A-60, 18 pages. Elsevier Editor.
77. Kramer J, Barry LD, Heffman DN, Mehmert JA, Pokrifcak (1992). *The Modified Scarf Bunionectomy*. J. Foot Surg. 31, 360-7.
78. Kristen KH, et al. (2002) *The Scarf Osteotomy for the Correction of Hallux Valgus Deformities*. Foot and Ankle Inter. Vol 23, n° 3, 221-9.
79. Lau JT, Daniels T (1999). *Effect of Increasing Distal Medial Closing Wedge Osteotomies on the Distal Metatarsal Articular Angle*. Foot Ankle Int. 20 (12): 771-6.
80. Maceira E. *Osteotomia triple de Weil/3-step Weil osteotomy*. Revista de la Asoc. Esp. De M. & C. del Pie.
81. Maceira E, Farinas F, Tena J, Escobar R, Baltés JL (1988). *Análisis de la Rídidéz Metatarso-falangica en las Osteotomias de Weil*. Rev. Med. Cir. Pie. Vol XII, n° 2, 35-40.
82. Maceira E (2001). *Osteotomias múltiples instrumentadas en el Antepied para el Tratamiento de los síndromes de Insuficiencia del primer Radio*. Clinica Osteoarticular, vol. 4, n° 1, 7-14.
83. Maestro M, Augoyard M, Barouk LS, Benichou M, Peyrot J, Ragusa M, Valtin B (1995). *Biomécaniques et repères radiologiques du sésamoïde latéral de l'hallux par rapport à la palette métatarsienne*. Méd. Chir. Pied. Expansion Scientifique Française, Paris 11, 3: 145-54.
84. Maestro M, Augoyard M, Barouk LS, Benichou M, Perot J, Ragusa M, Valtin B (1997). *Arthrodèse de la première articulation métatarsophalangienne. Ostéotosynthèse au titane pur T40. À propos de 272 cas d'arthrodèses de première intention*. Médecine et chirurgie du pied. Expansion Scientifique Française, Paris 1, 41-9.
85. Melamed EA, Shon LC, Myerson MS, Parks BG (2002). *Two modifications of the weil osteotomy : analysis on sawbone*. Foot Ankle Int. 23 (5) : 400-5.
86. Miguez A, Slullitel G, Bilbao F, Carroasco M, Solari G (2004). *Floating-toe deformity as a complication of the weil osteotomy*. Foot Ankle Int. 25 (9): 609-13.
87. Miller JM, Stuck R, Santori M (1994). *The Inverted Z Bunionectomy, Quantitative Analysis of the Scarf and Inverted Scarf Bunionectomy Osteotomies in Fresh Cadaveric Matched Pair Specimens*. J. Foot Surgery, vol. 33, n° 5, 455-62.
88. Muhlbauer M, Trnka HJ, Zembsch A, Ritschl P (1999). *Short-term Outcome of Weil Osteotomy in Treatment of Metatarsalgia*. Z. Orthop. Ihre Grenzgeb. 137 (5): 452-6, German.
89. Nexman AS, Negrine JP, Zecovic M, Stanford P, Walsh WR (2000). *A biomechanical comparison of the Z step-cut and basilar crescentic osteotomies of the first metatarsal*. Foot Ankle Int. Vol. 21, 584-7.
90. Numez-Samper-Pizarroso M, Llanos Alcazar LF, Viladot Perice R (2003). *Técnicas quirúrgicas en cirugía del pie*. Masson-Barcelona.
91. Nyska M (2001). *Principles of First Metatarsal Osteotomies*. Foot ankle Clin. 6(3): 399-408. Review.
92. Okane C, Kilmartin TL (2002). *The surgical management of central metatarsalgia*. Foot Ankle Int. 23 (5): 514-9.
93. Perugia D, Basile A, Gensini A, Stopponi M, Simeonibus AU (2003). *The Scarf osteotomy for severe hallux valgus*. Int. Orthop. 27 (2): 103-6.
94. Petersen W, Seide HW (2000). *Early Outcome of Correction of Hallux Valgus with the*

- Scarf Osteotomy. *Z. orthop. Ihre Grenzgeb.* 138 (3): 258-64, German.
95. Podskubka A, Stedry V, Kafunek M (2002). *Distal shortening osteotomy of the metatarsals using the weil technique: surgical treatment of metatarsalgia and dislocation of the metatarsophalangeal joint.* *Acta Chir. Orthop. Traumatol. Cech* 69 (2): 79-84. Czech.
96. Reed TH (1998). *Allofix Freeze-dried Cortical Bone Pins as an Alternative to Synthetic Absorbable Polymer Pins: A Preliminary Study in Short Z Bunions.* *J. Foot and Ankle Surgery*, vol. 38, n° 1, 14-22.
97. Regnauld B (1974). *Techniques chirurgicales du pied.* Masson, Paris.
98. Regnauld B (1986). *Le pied.* Springer Verlag, Berlin, 383-7.
99. Regnauld B (1986). *Le pied.* Monographie. Springer Verlag, Berlin, 635-8.
100. Rippstein P, Zund T (2000). *Klinische und radiologische mittelfristige Resultate von 73 Scarf-Osteotomien zur Behandlung der Hallux-Valgus-Deformität.* Schweizerische medizinische
101. Rippstein P, Zund T (2001). *The Scarf Osteotomy for the Correction of Hallux Valgus.* *Orthop. Traumatol.* 9: 101-12.
102. Rippstein P, Zund T (2001). *Die scarf Osteotomie bei Hallux Valgus.* *Operat. Orthop. Traumatol.* 13, 107-20.
103. Rippstein P. *Rheumatoid Forefoot Deformities. Surgical Technique in Orthopaedics and Traumatology* 55-680-B-10, 200.
104. Rippstein P (2001). *Aktuelle Lösungen von Hallux-beschwerden.* *Hospitalis* 368-9.
105. Rochwerger A, Launay F, Piclet B, Curvale G, Groulier P (1998). *Static Instability and Dislocation of the 2<sup>nd</sup> Metatarsophalangeal Joint. Comparative Analysis of 2 Different Therapeutic Modalities.* *Rev. Chir. Orthop. Reparatrice App. Mot.* 84 (5): 433-9, French.
106. Salmeron F, Sales de Gauzy, Galy C, Darodes P, Cahuzac JP (2001). *Traitement de l'hallux valgus de l'enfant et de l'adolescent par ostéotomie de Scarf.* *Rev. Chir. Orthop.* 87, 706-11.
107. Sammarco G. James, Taylor Roos (2001). *Cavo Varus Foot Treated with Combined Calcaneus and Metatarsal Osteotomies.* *Foot and Ankle International*, vol. 22, n° 1, 19-30.
108. Sarrafian SK (1983). *Anatomy of the Foot and Ankle.* Philadelphia, J.B. Lippincott Company.
109. Schneider W, Csepan R, Knahr K (2003). *Reproductibility of the radiographic metatarsophalangeal angle in hallux surgery.* *J. Bone Joint Surg. Am.* Vol. 85-A, n° 3, 494-9.
110. Schwartz N, Groves ER (1987). *Long Term Follow up of Internal Threaded Kirschner – Wire Fixation of the Scarf Bunions.* *J. Foot Surg.* 26, 313-6.
111. Seide HW, Petersen W (2001). *Taylor's Bunion: Result of a Scarf Osteotomy for the Correction of an Increased Intermetatarsal IV/V angle. A Report on Ten Cases with a 1 Year Follow-up.* *Arch. Orthop. Trauma. Surg.* 121 (3): 166-9.
112. Smith A, Alwan T, Davies MS (2003). *Perioperative complications of the Scarf osteotomy.* *Foot Ankle Int.* Vol. 24, n° 3, 222-7.
113. Solana Carne J, Alvarez Goenaga F, Viladot Pericé R (1998). *Osteotomia de Weil en la metatarsalgia. Revision de los primeros 50 casos.* XXXV Congreso Nacional SECOT, Santander, 30.
114. Sorto LA Jr., Balding MG, Weil LS, Smith SD (1992). *Hallux Abductus Interphalangeus. Etiology, X-ray Evaluation and Treatment.* 1975. *J. Am. Podiatry. Med. Assoc.* 82 (2): 85-97.
115. Staquet V. *Facteurs anatomo-cliniques influençant les résultats de l'ostéotomie scarf dans le traitement chirurgical de l'hallux valgus.* A propos de 125 cas revus. Thèse, décembre 2004. Université du droit et de la santé, Lille II, France.
116. Steck JK, Ringstrom JB (2001). *Long Z-Osteotomy: A Review and New Modification to Correct Troughing.* *J. Foot Ankle Surg.* 40 (5), 305-10.
117. Tanaka Y, Takakura Y, Kuma T, Samoton, Tamai S (1995). *Radiographic Analysis of Hallux Valgus.* *J. Bone Joint Surg. (jm)* 77, 205-13.
118. Themar-Noël C (1995). *Proposition d'un traitement orthopédique de l'hallux valgus de l'enfant.* *Podologie. Expansion Scientifique Française*, Paris 148-52.
119. Themar-Noël C, Jehanno P, Bensahel H (1993). *Étude radiographique des pieds présentant un hallux valgus chez l'enfant.* *Actualités en Médecine et Chirurgie du pied.* 8<sup>e</sup> série sous la

- direction de Herisson C et Simon L, Masson, Paris, 172-5.
120. Trnka HJ, Muhlbauer M, Zetti R, Myerson MS, Ritshi P (1999). *Comparison of the Results of the Weil and Helal Osteotomies for the treatment of Metatarsalgia Secondary to Dislocation of the Lesser Metatarso Phalangeal-Joints*. Foot and Ankle international, vol. 20, n° 2.
121. Trnka HJ, Nyska M, Parks BG, Myerson MS (2001). *Dorsiflexion Contracture after the Weil Osteotomy: Results of Cadaver Study and Three-dimensional Analysis*. Foot Ankle Int. 22 (1): 47-50.
122. Trnka HJ, Gebhard C, Muhlbauer M, Ivanic G, Kitschl P (2002). *The weil osteotomy for treatment of dislocated lesser metatarsophalangeal joints : good outcome in 21 patients with osteotomies*. Acta Orthop. Scand. 73 (2): 190-4.
123. Trnka HJ, Parks BG, Ivanic C, Chu IT, Easley ME, Schon LC, Myerson MS (2000). *Six First Metatarsal Shaft Osteotomies: Mechanical and Immobilization Comparisons*. Clin. Orthop. (381): 256-65.
124. Valtin B (1994). *Quelle ostéotomie pour quel hallux valgus ? Table ronde sur « les ostéotomies de premier métatarsien dans le traitement chirurgical de l'hallux valgus »*. Méd. Chir. Pied. Expansion Scientifique Française, Paris 10 (2): 121-8.
125. Valtin B (1997). *Les ostéotomies métatarsiennes*. In: *Traitement chirurgical de l'hallux valgus*. Table ronde. SOFCOT réunion annuelle nov. 96. Suppl. III, rev. Chir. Orthop. Masson, Paris, 83, 34-5.
126. Vandeputte G, Dereymaeker G, Steenwerckx A, Peeraer L (2000). *The Weil Osteotomy of the Lesser Metatarsals: A Clinical and Pedobarographic Follow-up Study*. Foot Ankle Int. 21 (5): 370-4.
127. Wagner A, Fuhrmann B, Abramoski I (2000). *Early Results of Scarf Osteotomies Using Differentiated Therapy of Hallux Valgus*. Foot Ankle Surg. 6: 105-12.
128. Weil LS (2000). *Scarf Osteotomy for Correction of Hallux Valgus. Historical Perspective, Surgical Technique and Results*. Foot Ankle Clin. 5 (3): 559-80. Review.
129. Weil LS Jr, Benton-Weil W (1998). *Postoperative Hallux Valgus Exercises*. J. Foot Ankle Surg. 37 (4): 355.
130. Wulker N, Stephens M, Cracchiolo A (1998). *An Atlas of Foot and Ankle Surgery*. Martin Dunitz, London.
131. Zygmunt KHZ, Gudas CJ, Laros GS (1989). *Bunionectomy with Internal Screw Fixation*. J. Am. Pédiatr. Méd. Assoc.

# Acknowledgements

Over the last 25 years, I have learned and shared many ideas and tips from my surgeon friends, I thank notably for their great contribution to this book, P. Diebold, P. Rippstein, M. Delmi, the members of Pied Innovation Group\*, and also B. Baudet, H. Kristen, O. Jardé, E. Maceira, B. Regnaud who was my master in foot surgery, R. Viladot, M. Stephens and many others who in the main are mentioned in the different chapters of this book. My sincere thanks to them for sharing their experience and knowledge. Thanks also to K. S. Sarafian for allowing me to reproduce some pictures from its accurate book on foot anatomy.

At last, I would not have been able to write this book without the support – and the patience – of my surgical team, the radiologists and the physiotherapists of the Polyclinique de Bordeaux-Tondu.

Thanks to my son Pierre, first for his contribution to our common works, and for developing and improving the techniques and their management in the foot surgery.

Thanks to E. Toullec, for his significant contribution to our common studies.

Thanks also to the engineers of DePuy Orthopaedics for their effective collaboration and to Romans Industrie Company for its collaboration in making the postoperative shoes.

Thanks to R. Watelet: He has been making videos and pictures with me for more than 10 years, very effectively. Thanks to Anne, my daughter for making a special music for the video surgery.

Thanks to Adelaïde, the company which has made not only the CD-ROM but which has also improved the quality of the pictures, made the

drawings, the layout of the book's plates and the animations of the CD, thanks notably to A. Delbos and S. Bergantin, for their great contribution and patience.

Talking of patience, the editor Springer Verlag has been waiting a long time before I give the definitive version, in fact three years, during which I did not waste my time because I brought a significant improvement in clarifying and making more complete my forefoot reconstruction philosophy, and the practical details for applying it.

Thanks to Andrea Cracchiolo who knows first hands the work needed by writing a book about foot surgery and who accepted to make the preface of this book, and to Lowell Scott Weil, not only for his critical contribution to the foot surgery, and his understanding during the collaboration with me but also for correcting my English text while keeping the “French flavour”.

Thanks also to Mark Myerson, current president of AOFAS, who kindly agreed to write the forward for the second edition. For many years, he has been at the forefront of foot surgery because his thoughts are clear, his observations accurate and his techniques effective. I am grateful to him for his kindness and availability. Furthermore, he is very fond of Bordeaux wine!

Above all, I want to express my thanks and love to my wife Edith, who took a great part in the redaction of this book but, more importantly, has supported my passion for excellence in foot surgery, travelling to many distant countries to present papers, and endless hours of work to complete this publication.

Thanks to Tony Hillsmith (Anglomedica) for his advices, his kindness and for giving his voice to the CD-ROM.

---

\* M. Augoyard and P. Peyrot, M. Benichou, M. Maestro, M. Ragusa, B. Valtin.