

Diana Weedman Molavi

The Practice of Surgical Pathology

A Beginner's Guide
to the Diagnostic Process

Second Edition

 Springer

The Practice of Surgical Pathology

The Practice of Surgical Pathology

A Beginner's Guide to the Diagnostic Process

Second Edition

Diana Weedman Molavi, MD, PhD
Sinai Hospital, Baltimore, Maryland

Diana Weedman Molavi, MD, PhD
Department of Pathology
Sinai Hospital of Baltimore Pathology
Baltimore, MD, USA

ISBN 978-3-319-59210-7 ISBN 978-3-319-59211-4 (eBook)
DOI 10.1007/978-3-319-59211-4

Library of Congress Control Number: 2017944372

© Springer International Publishing AG 2008, 2018

This work is subject to copyright. All rights are reserved by the Publisher, whether the whole or part of the material is concerned, specifically the rights of translation, reprinting, reuse of illustrations, recitation, broadcasting, reproduction on microfilms or in any other physical way, and transmission or information storage and retrieval, electronic adaptation, computer software, or by similar or dissimilar methodology now known or hereafter developed. The use of general descriptive names, registered names, trademarks, service marks, etc. in this publication does not imply, even in the absence of a specific statement, that such names are exempt from the relevant protective laws and regulations and therefore free for general use.

The publisher, the authors and the editors are safe to assume that the advice and information in this book are believed to be true and accurate at the date of publication. Neither the publisher nor the authors or the editors give a warranty, express or implied, with respect to the material contained herein or for any errors or omissions that may have been made. The publisher remains neutral with regard to jurisdictional claims in published maps and institutional affiliations.

Printed on acid-free paper

This Springer imprint is published by Springer Nature
The registered company is Springer International Publishing AG
The registered company address is: Gewerbestrasse 11, 6330 Cham, Switzerland

Dedicated to
Rameen, Claire,
and Annelise

On This Book

Welcome to pathology. If you are reading this book, it is likely that you are either in pathology training or considering pathology as a specialty. This book is an attempt to bridge a gap between the way pathology is taught to medical students and the way you must learn to practice it as a resident. In medical school, with tacit acknowledgment that most students are not going to become pathologists, we teach pathology as it intersects with pathophysiology and pharmacology. Robbins and Cotran's *Pathologic Basis of Disease* is the most prominent example of this approach and is an excellent and comprehensive text for this purpose. However, this book does not teach the more practical aspects of pathology practice, such as differential diagnoses, special stains, biopsy interpretation, the assessment of margins, and tumor grading and staging. These are the nuts and bolts of pathology practice, the countless subtleties, shades of gray, and conventions of semantics that go into creating a patient's diagnosis. For this, the resident must turn to the huge volume of literature for practicing pathologists, from the general surgical pathology texts such as *Sternberg's Diagnostic Surgical Pathology* and *Rosai and Ackerman's Surgical Pathology* to the highly detailed organ-system texts. For the beginner, not yet fluent in the foreign dialect that is pathology, these professional-level texts are simply too much, too soon. This book, inspired by my own rocky and somewhat prolonged learning curve, is an attempt to create an intermediate step.

This book is intended to be a crash course in the basic facts that you are expected to know when you begin your surgical pathology rotations. In this book, you will find organ-based chapters that describe the approach to specimens, descriptions of common diagnoses, pitfalls, practical pearls, differential diagnoses, and key requirements of written diagnoses. The goal is for you to be able to read a chapter in 20 min and come away knowing enough about a specimen to hold an intelligent conversation with the attending at the microscope. Early in training, you do not have to get the diagnosis right to get credit—you just need to demonstrate a sound thought process and some background knowledge. If you already know the language, you can focus on asking the really practical questions, such as “How do you know it is X and not Y?” and “How do you handle this if you cannot show definite invasion?” These are the conversations that will enable you to function independently when you are finally out in the real world.

This book will also be useful to medical students rotating through pathology. Many students are given the opportunity to preview cases like a resident but will quickly find their second-year pathology course does not really help in formulating a diagnosis. This book is written at a level that should be accessible to students, enabling them to get more out of their pathology rotation by understanding the more interesting diagnostic challenges involved in even routine specimens.

On What This Book Is Not

- Complete or comprehensive: This book is a very oversimplified view of pathology and, in the interests of brevity and clarity, is deliberately scant on details in many areas. Some advanced topics have been omitted entirely.
- An atlas: Photographs have been chosen to complement some of the specimen descriptions, but you will get more out of this book if you have a good thick illustrated text, atlas, or online image database to supplement your learning.
- A grossing manual: For many organs, this chapter deals with either the biopsy or the organ resection, but not both, depending on which specimen type is more common or more illustrative. Therefore, while some grossing tips are included, this book complements, rather than replaces, your grossing manual.
- A board review book: While you do need to know just about everything in this book to pass the boards, this text is in no way sufficient for that. However, many senior residents have commented that it was a good way to begin their study, to identify any small gaps that existed in their big-picture views.

On Learning Pathology

In pathology resident education, there are two main categories of knowledge. One is factual knowledge, and the second is experiential knowledge. To understand the difference, think about how a child learns her colors. The rote question “What is the color of the sky?” and its answer “Blue!” can be taught to a child as soon as she learns to talk. She may know the colors of apples, grass, or bananas purely by repetition and games. However, when you pick up a blue block and ask her to identify the color, she may not actually know the answer. You can tell her, “This is blue,” but she does not yet understand what particular quality you are pointing out. Is it the shape of the block or the texture? Is it the wood it is made from or the letter on the side? It takes many, many repetitions of pointing out different blue things (a towel, a crayon, a book) before she finally understands the quality of blue, the thing that is similar across all those different-looking items. In the same way, an intern may know that “hyperchromatic” and “atypical” are indicators of malignant cells. However, he or she will need to see countless examples of what the professionals call atypical to really understand what qualities of the cell they are identifying. To that end, the more glass you see during your training, the better your eye will be. No book can give you that kind of experiential knowledge.

On the other hand, you can have the best eye in the world and misinterpret what you are seeing for lack of factual knowledge. Part of the goal of this book is to give you a head start on the factual knowledge. There are many examples in this book of very basic principles that are more or less assumed to be common knowledge and so are rarely, if ever, explicitly taught. I had multiple head-smacking moments in my own residency, when I thought in exasperation, “Why didn’t anyone tell me that in the beginning?” My hope is that getting these company secrets up front will smooth the learning curve for future residents.

On Teaching Pathology

This book began over the course of a 2-year experiment at the Johns Hopkins Hospital. In my fourth year of residency, I started a weekly microscope-based slide session for interns. Each session was accompanied by a handout and approximately 20 glass slides representing the most common diagnoses in that organ. The conferences were designed purely for the interns, with the intent of creating a protected didactic environment in which no question was too basic, no prior knowledge was expected, and “zebras” (unusual or exotic diagnoses) were ignored. Sitting around a large multihead scope, we began with normal histology and the mental approach to the biopsy or resection and then covered the array of non-neoplastic entities or changes that could simulate cancer. Finally, we looked at common tumor types and

their variants, comparing and contrasting normal with tumor, low grade with high grade. This book is a compilation of those handouts, with the addition of illustrations.

The intern conference was passed to a group of fourth-year residents committed to teaching and has become a self-sustaining tradition at Johns Hopkins. With the curriculum written, and the focus on common entities seen at hospitals of all sizes, this conference could easily be duplicated at other programs, either by faculty or by senior residents.

On Practicing Pathology

After 10 years in practice, including some smart moments and some very dumb moments, I have accumulated a few general guidelines on practicing pathology. Here are some suggestions for surviving the first years of practice. If you begin these habits now, in training, they will be automatic when you begin signing out cases on your own.

- Always cross-check the names and numbers on the slide with the paperwork. Make this a reflex, the first thing you do on every case.
- Look at all the levels on the slide, at least at low power.
- When looking for metastases in a lymph node, scan the slide at low power first to look for big mets and save yourself some time. But if they aren't obvious, look at every lymph node at 10 \times . The whole thing. Even the fatty extranodal stuff. Really.
- Write on your slides. Circles and arrows and notes and dots are really useful when you or your colleagues have to present that case at tumor board next month.
- Never make a first-time diagnosis without backup. In other words, if you personally have never signed out that particular tumor, have your diagnosis blessed by another pathologist or, if it's a real zebra, an expert. If you haven't seen it before, you may not recognize some essential feature that is incompatible with that diagnosis.
- Don't decide a strange tumor is benign or malignant until you have a name for it. There are malignant things that look benign and vice versa.
- Don't order the stain if you don't have a plan for interpreting it.
- Leave a train of thought for the next pathologist; write your thought processes down in your diagnoses, comments, or microscopic descriptions. For example, "Although the tumor has some lobular features, an e-cadherin stain is strongly positive." Or "The endometrial and ovarian tumors are considered synchronous primaries and are staged accordingly." Future reviewers of your case may agree or disagree with your interpretation, but they will not be able to say "What were you thinking?"
- Microscopic descriptions are very helpful in cases with unusual morphology. You should be able to describe a tumor well enough that a future pathologist, when presented with a new metastasis, can read your report and say, "Yeah, sounds like the same tumor."
- Pay attention to any sense that the case is "off," even if you can't put your finger on what is bothering you. Sleep on it, look at it again the next day, read the history, and show it around.
- If you can't recite the key differential diagnoses and cardinal features of an entity from memory, look it up. (Is it supposed to be well-circumscribed? Is a neutrophilic infiltrate typical? Does it ever occur in children? Does it frequently get mistaken for something else? Do I need a stain?) Yes, you may look up 20 things a day, but it will save you from rookie errors.
- You are going to make a mistake. More than one, actually. You will miss something, or see a cat and call it a dog. Everybody does, so don't let it destroy your confidence. Be transparent about your mistakes; own up to them, learn from them, and let your colleagues learn from them.

Checklist for a new malignancy

- Clerical check (name, numbers, gross description match).
- Someone else has seen it and agrees.
- Clinical picture is reasonable (demographics, radiology, etc., make sense).
- Mimickers have been excluded/lineage confirmed.
- The clinician knows about it.

Checklist for a recurrent malignancy

- Clerical check.
- The old histology matches or the new workup matches.
- Occam was only right 75% of the time—sometimes the simplest answer (a recurrence) is not the right answer (a new primary).

Checklist for a finding that seems discordant with the clinical information

- Clerical check.
- Is the gross description and number of pieces right?
- Does the printed label match what was handwritten on the slide?
- Does the tissue match the block?
- Was the clinical information presented correctly? Call the clinician.
- Were there any other (liver, breast, prostate) biopsies grossed that day that are also discordant? Could they have been switched?
- Could it be a floater? As a last resort, DNA fingerprinting may be able to establish an identity mismatch.

On the Second Edition

The second edition is a 10-years-on update. I have now been in general practice for 10 years, at a midsize community hospital, where I see everything from Pap smears to autopsy and where my time is split between AP and CP. There have been many advances in nomenclature, classification, and our understanding of tumor progression over the last 10 years, and many aspects of the book were desperately in need of an update. In addition, the thymus and spleen finally got some coverage, and bone and soft tissue tumors each got their own expanded chapters. The potential downside of an update was that my fund of knowledge is no longer cutting edge, as I no longer sit at the scope daily with the leaders of the field. I now have to rely on conferences and the literature, as well as my colleagues, to keep me current. My role as jack-of-all-trades is still a useful perspective in pathology education, I hope, but it is nerve-wracking to publish as a master-of-none. If I have slipped up and included outdated nomenclature or concepts in this edition, please let me know. This book continues to be an experiment in teaching, and feedback is welcome.

Diana Weedman Molavi
Baltimore, MD, USA
diana.molavi@gmail.com

Acknowledgments

The existence of a second edition of this book is due in large part to the support, mentorship, and patience of my current and former colleagues at Sinai Hospital: Drs. Dean Nuckols, Deepa Dutta, Fred Gilkey, Christian Hansen, Theresa Nicol, Michael O'Malley, Vidya Sathiyamoorthy, and Robert Van Wesep, as well as the larger group behind us, HCT Pathology. Wherever you end up working, make sure it is with people who are smarter than you are, and who will happily look at your cases, no matter how trivial. In the long run, you are only as smart as the people around you.

I am indebted to the friends and colleagues that were willing to be a second set of eyes on chapters in this edition. They are Drs. Albert Aboulafia, Justin Bishop, Jasreman Dhillon, Charles Eberhart, Olga Ioffe, Karen Matsukuma, Dean Nuckols, Kristin Olson, Anne Herdman Royal, Josh Wisell, Riyam Zreik, and my good friend and guest author Natasha Rekhman. Never underestimate the value of a second set of eyes.

I remain grateful to the former Johns Hopkins residents who lent such invaluable support in the creation of the first edition, including Drs. Natasha Rekhman, Janis Taube, Terina Chen, and Alex Hristov. The original book would never have gotten off the ground without the support and assistance of a handful of faculty, including Drs. Pete Argani, Ralph Hruban, and Bill Westra, as well as those who donated their time to help me with content, including Drs. Fred Askin, Mike Borowitz, Charles Eberhart, Jonathan Epstein, Hongxiu Ji, Ed McCarthy, Elizabeth Montgomery, George Netto, Mike Torbenson, and Russell Vang. However, I've been away from Johns Hopkins for 10 years now, so any errors in this edition are 100% my fault.

Contents

Preface	vii
Acknowledgments	xi
Chapter 1 Using the Microscope	1
Chapter 2 Descriptive Terms in Anatomic Pathology	6
Chapter 3 Infection and Inflammation	16
Chapter 4 Interpreting the Complex Epithelium	28
Chapter 5 Ditzels	38
Chapter 6 Esophagus	54
Chapter 7 Stomach and Duodenum	62
Chapter 8 Colon and Appendix	74
Chapter 9 Liver	86
Chapter 10 Pancreas	97
Chapter 11 Prostate	108
Chapter 12 Bladder	120
Chapter 13 Kidney	129
Chapter 14 Testis	144
Chapter 15 Ovary	153
Chapter 16 Cervix and Vagina	165
Chapter 17 Uterus	177
Chapter 18 Placenta	189
Chapter 19 Breast	198
Chapter 20 Bone Marrow	210
Chapter 21 Lymph Node and Spleen	222
Chapter 22 Lungs and Pleura	239
Chapter 23 Thymus and Mediastinum	253

Chapter 24	Thyroid	260
Chapter 25	Salivary Gland.	271
Chapter 26	Neuroendocrine Neoplasms Natasha Rekhtman	279
Chapter 27	Brain and Meninges	286
Chapter 28	Skin	301
Chapter 29	Soft Tissue.	322
Chapter 30	Bone	345
Chapter 31	A Primer on Immunostains	360
Chapter 32	So You Want to Get a Job	370
Appendix	376
Bibliography	377
Index	379

1 Using the Microscope

Using the Microscope

Upon arriving in the pathology department, you will most likely be given a microscope of your own. Learning to operate the microscope effectively is the prerequisite to everything else in this book. We will begin with the basics: how not to hurt yourself.

Ergonomics

Many pathology residents have acquired new and painful musculoskeletal complaints after a few months at the microscope. Here are the general principles to avoid injury.

- A neutral neck: When looking through the eyepieces, your neck should be in a neutral position, meaning no active muscle tension is required to maintain the position. Your eyes should be pointed directly forward or slightly downward. Bad positions are those that involve flexing your neck (dropping your chin to your chest), jutting your chin forward, or turning your neck left or right. Tilt-head microscopes are optimal for this positioning, but three-ring binders under the microscope can also adjust the tilt. Your eyepieces should make no more than a 30° angle with the desk surface.
- A straight back: Your mom was right about your posture, a straight back is better than a slouch, but you will need some help in the form of a chair with a supportive back. Your chair should hold you upright so that your head and neck can sit comfortably on top of your spine, without having to crane your neck forward. This can be accomplished by either adjusting your chair back to a more vertical position or adding a support pillow. Always sit directly in front of your microscope; having it off to one side to make more room on your desk will quickly cause back and neck pain.
- Supported elbows: You will be using two hands all the time, one to drive the slide and one to focus. Either job can be done with either hand, but both elbows need to be supported on the desk. Leaving your elbows floating in space while doing fine movements with your hand will lead to a nasty parascapular back spasm. Therefore, your chair should be high enough that you can place your forearms flat on the desk in front of you, with your upper arms perpendicular to the floor and flat against your torso. This may create a new problem for your neck (see the first point) if your microscope is not tall enough to meet your eyes. A good thick book or two under the microscope should fix this problem. Shorter people may also require a footstool to maintain this chair height.
- A padded surface: Your driving hand will probably rest on its elbow, while your focusing hand will lay flat on the desk. For both arms, the point of contact with the table should be padded to avoid a compression neuropathy (often the ulnar nerve). Possible solutions involve pieces of rug or bathmat, sponges, mouse pads, or commercial gel pads designed for desk users.

- Pay attention: When something starts to hurt, take a moment to critically analyze your posture and position. Focus on which muscle group is hurting you and what action relieves it and jury-rig a way to achieve the more comfortable position. You cannot “push through” the pain; you will only end up with a chronic repetitive motion injury that will be with you for months or years. Once the cycle of pain and muscle spasm has begun, it can be very difficult to reverse it, short of taking a few months away from the microscope.

The Parts of a Microscope

Figure 1.1 shows an Olympus BX40 microscope. The exact positions of the various knobs and rings may vary by microscope, but all of these elements should be present.

1. Light source: light from the bulb at the back of the microscope is directed upward by a mirror, hidden within the microscope base.
2. Field diaphragm: the width of this diaphragm is controlled by the knurled ring. Closing this diaphragm reduces the visible circle of light illuminating the image. A glass neutral density filter, optional and removable, sits atop this diaphragm.
3. Screws to center substage condenser, one on each side.
4. Focus knobs, coarse and fine.
5. Knob to raise and lower condenser, focusing the light to achieve Köhler illumination.
6. Flip knob to move the condenser out of the light path for viewing at lowest power.
7. Eyepieces with diopter adjustment ring.
8. Objectives.
9. Stage for the slide: the slide holder has been removed, allowing free movement of the slide, which is preferred by many pathologists.
10. Aperture diaphragm of the substage condenser: the knurled ring controls the size of the cone of light reaching the specimen, and adjusting it causes changes in image contrast and quality. (The substage condenser itself is the conical lens housing that sits on top of the diaphragm, hidden by the stage in this view.)




FIGURE 1.1. Diagram of the parts of a microscope. See the text for a description of the parts.

11. Knobs to move the stage, which allow for controlled X- and Y-axis movement when the slide holder is in place.
12. Light intensity adjustment (not seen): the voltage, or brightness, of the light is controlled by a knob or sliding bar.

A Review of Optics

There are excellent Web sites and books out there for a thorough technical review of Köhler illumination in microscopes. This is not one of them. However, the essence is that light is passed up through the microscope and focused down to a point image or spread into a wide cone through the use of lenses and diaphragms. The light originates at the light bulb at the back of the microscope, is redirected upward by a mirror, and is first shaped by the field diaphragm at the base of the microscope. Like a spotlight, this diaphragm directs a column of light up toward the slide. This column of light is concentrated into a tighter beam of light by the condenser, which results in illumination of the specimen with an even, bright, flat light.

When an image or beam of light is sent through a lens, there is a point on the other side of the lens at which the light rays converge to a point and the image is in sharp focus. In the eye, ideally, this point is at the retina, but if the eye is too long or too short relative to the lens, corrective lenses are required. In the modern microscope, there are many lenses and diaphragms in series, but there are essentially two light paths, and each one is in focus (converging to a point) at multiple different levels of the microscope.

One path is the image of the tissue. There are four points within the microscope where, if you placed a tiny projector screen, you would see a focused image of your tissue; these are called the *conjugate planes*. The conjugate planes of the image path are (1) the field diaphragm, (2) the slide or specimen, (3) the fixed diaphragm within the eyepiece (at the bottom of the removable eyepiece), and (4) a point above the microscope where you put your retina or your camera. Note that if you are trying to take a photo with a smartphone camera, to get a focused image, you need to pull the camera lens away from your eyepiece until the lens is approximately where your retina would be.

The second path is the image of the light bulb filament. At certain points along this path, a tiny projector screen would show an image of the light source; this path is designed to have different conjugate planes than your tissue image, because, at the level of your tissue, you want a wide *unfocused* source of light. The conjugate planes of the light source are (1) the light bulb itself, (2) the condenser's aperture diaphragm, (3) the back focal plane of the objective (inside the objective), and (4) the "eye point" immediately above the microscope that corresponds to about where your cornea should be.

To achieve Köhler illumination is to align all of these lenses and diaphragms such that the conjugate planes are exactly where they should be, creating the best image your microscope is capable of. Fortunately, it is possible to learn this technique without fully understanding the physics behind it. You can certainly use the microscope without knowing how to do this, but the image quality will not be great, and neither will your photography.

Achieving Köhler Illumination

- Place a slide on the stage. Adjust the eyepieces so that they are the correct distance apart for your eyes.
- Focus on a slide using your 10× objective. For microscopes with only one adjustable eyepiece, close the adjustable eye, and focus using the regular focusing knob. For microscopes with two adjustable eyepieces, either eye can be used first.
- Once the fixed eyepiece is in focus, shut that eye and focus the other eye with the eyepiece ring. The scale on the eyepiece ring shows the diopter adjustment; the positive direction is analogous to reading glasses, so it is easier on the eye.
- Make sure your aperture diaphragm on the substage condenser is completely open (this may be clockwise or counterclockwise, depending on the microscope).
- Close down the field diaphragm until you see a small circle or octagon of light. It should be in the center of your field of view and have a crisply focused edge. If not, you can center it using the small screws on the condenser and focus it by raising or lowering the condenser.

- Open the field diaphragm back up so that light completely fills your field of view.
- For most work, this is sufficient to give optimal viewing conditions. However, for viewing translucent (unstained) structures, or for photography, you also need to optimize the aperture diaphragm. Notice that closing it down dims the light and creates a three-dimensional quality to the image, whereas opening it up creates a flatter, brighter image. The optimal diaphragm size closes down the light path to match the diameter of the objective so that the light rays coming up from below make a straight, parallel column of light into the objective, minimizing scatter. This size is different for each objective. To find it, you must remove an eyepiece and look down into the eye tube. You will see a circle of light; close the aperture diaphragm (the ring on the condenser) until the outer one fourth of the field is black. Replace the eyepiece.

Becoming Parfocal

Parfocality means that if an image is focused at 40 \times , you should be able to switch to 4 \times and still be in focus. It is not the same as Köhler illumination. You can achieve true parfocality only on a microscope with two adjustable eyepieces; it is most important on multiheaded microscopes, when the observers at the additional heads need to be in sync with the person controlling the focus. The beginning of a session with multiple users on a multihead microscope should always start with this focusing ritual.

- Start by adjusting the eyepieces on the main microscope head to the neutral position, or zero diopters. The person driving the microscope should first adjust for Köhler illumination, as above, and then go to 40 \times and focus on the slide. (If using a camera that projects to a TV or screen, focus the microscope such that the TV is in focus.) While the driver adjusts his or her own eyepieces, all observers should also adjust their own eyepieces to optimal focus.
- Now go to 4 \times without moving the slide or touching the main focus knob. While at 4 \times , the driver and all observers should readjust their eyepieces to be in focus. Now the screen and each individual should be in focus at each objective, or parfocal.
- If one objective is slightly “out,” make sure it is tightly screwed in to the objective carriage. Sometimes one objective just cannot be made perfectly parfocal, but if the above procedure is followed, at least the observers will be in sync with the driver, who can make corrections using the main focus knob.

Cool Microscope Tricks

Some things on slides do not pick up stain and therefore appear transparent or translucent on the slide. Good examples are calcium oxalate and suture material. They can be essentially invisible during normal viewing but will glow under polarized light. However, most residents' microscopes do not have polarizers. A quick and easy substitute is to flip the condenser out of the light path, just like you do when viewing at 2 \times . This will cause refractile material to “pop out” and be easily visible.

The knowledge of different paths of light being focused at different planes can be useful. For example, if you are looking at a slide and see debris or dust in sharp focus, that debris must be located in one of the same planes in which the image path is focused: on the surface of the field diaphragm, on the slide itself, or at the fixed eyepiece diaphragm. This diaphragm is located at the bottom of the eyepiece, in the tube, and is not usually exposed to dirt. The eyepiece diaphragm is the position where an ocular micrometer sits to superimpose a tiny ruler on your image. On the other hand, if the debris is out of focus when the image is focused, it is more likely to be on the condenser or the top of the eyepiece.

Sometimes, at a multihead microscope session, you would like to give everyone a very low-power view of a slide, even lower than the 2 \times objective. The slide itself can be placed directly on the field diaphragm at the base of the microscope. This focal plane is in sync with that of a slide on the stage, so you will actually get a reasonably focused image of the entire slide. This trick also works with Kodachrome slides.

If your slide stubbornly refuses to come into sharp focus at high power, it is probably one of two problems: either the slide is upside down (coverslip on the bottom) or the objective is dirty

(either a fingerprint or oil from the 100×). A dirty 40× is hard to clean, so many residents avoid ever using oil immersion on their own microscopes. If you do have a rotation that requires use of the 100×, consider arranging the objectives so that the 100× and the 40× are not next to each other, reducing the chances that you will drag the 40× through a puddle of oil. The lower power objectives are usually far enough from the slide that they pass above the oil slick.

Eyeglasses

For your average moderately nearsighted scholar, it is better to use the microscope without corrective lenses (glasses or contacts) in place. The microscope eyepieces can correct for mild to moderate vision problems, and it is easier on your eyes without an additional lens in the way. However, for more severe vision problems, or for those with astigmatism, it may be necessary to work with corrective lenses on. If you must wear glasses, there are special “high eye point” eyepieces that can be purchased. These account for the fact that because of the glasses on your face, your eye is farther from the eyepiece than if you were not wearing glasses. The eyepieces are usually labeled with an “H” or a spectacles icon. They can also be used comfortably by non-eyeglass wearers, as in fact the field of view is slightly wider.

Mechanical Stage Guides

The mechanical stage is the set of brackets that fix the slide to the stage and enable controlled movement in the x- and y-axes. They are very useful in cytology, when you are screening a slide at 10× and want to make sure you sweep in perfect parallel lines, not missing any of the slide by drifting off at an angle. However, most pathologists find that for everyday use, the slide brackets just get in the way. With practice your muscles get a precise feel for how much movement is required to get from one edge of the tissue to the other, enabling you to quickly navigate around your specimen. In addition, many microscopes still allow you to move the entire stage in the y-axis by using the stage knobs, allowing you to make parallel vertical sweeps of the slide at high power even without slide brackets. Learning to move the slide smoothly without a mechanical stage takes several months to perfect, due to the inverted image, so do not give up on this skill.

Motion Sickness

There are some unfortunate individuals out there who are very sensitive to vestibular–ocular mismatches. If you are not one of them, you may disregard this section. Having a moving image that fills most of your field of view while your body is motionless can trigger, essentially, car sickness. As in cars, this phenomenon is usually only a problem when someone else is “driving,” or moving the slide around, but as a resident you do quite a bit of observing while the attending drives. Some drivers are better than others; the habit of constantly moving the slide, as opposed to quick movements with long pauses, is particularly nauseating for the susceptible. Here are some suggestions to get through this unpleasant experience:

- Be reassured that you will quickly get your sea legs. Most people have to battle with this for only a few weeks before their vestibular systems adjust.
- If the experience is really bad, consider medication. There are over-the-counter medicines for this. Meclizine, sold as Bonine®, does not cause as much drowsiness as Dramamine® (dimenhydrinate).
- If you have an unexpected episode and you are stuck at the microscope for an indefinite period of time, you need to reduce the amount of moving images hitting your eyes. If you are in a conference with the microscope hooked to a TV monitor, watch the monitor instead. Another option is to let your head sink down just enough that the images hit your eyelids, not your eyes; this is subtle, and you can straighten back up when the attending asks, “What do you think of this?” You can also close your eyes while the slide is moving, but this is a little more obvious. Studying your paperwork, looking up the patient history on the computer, answering a page, or going to get the old biopsy material can all give you momentary breaks. In desperate times, you just do what you can.

2 Descriptive Terms in Anatomic Pathology

The ability to speak the language is essential to effective learning in pathology. This chapter covers the approach to defining and describing an unknown tumor or lesion and defines histologic terms commonly used in pathology.

Common Prefixes and Suffixes and Their Definitions (a Very Short List)

Prefix or suffix	Definition	Example
angio-	Vessels (usually blood vessels)	Angiosarcoma
-blast	A precursor	Lipoblast
chol-	Bile	Cholangitis
chondro-	Cartilage	Chondroma
-cyte	Cell	Erythrocyte
dys-	Bad or improper	Dysplasia
ecto-	Outside	Ectocervix
-ectomy	Resection	Appendectomy
endo-	Inside	Endobronchial
epi-	Upon or in addition	Epidermis
exo-	Outside	Exogenous
extra-	Outside of, beyond	Extravasated
hist-	Tissue	Histology
hyper-	Above, beyond	Hyperchromatic
hypo-	Under, below	Hypopharynx
-iform	Resembling, but not the same as	Kaposiform
inter-	Between	Intercellular
intra-	Within, inside	Intrathoracic
-itis	Inflammation	Meningitis
leiomyo-	Smooth muscle	Leiomyoma
lipo-	Adipose tissue	Lipoblast
macro-	Large	Macroscopic
mega-	Very large	Megakaryocyte
meso-	Middle	Mesothelium
meta-	After, beyond, or accompanying	Metaphysis
micro-	Small	Microscope

(continued)

(continued)

Prefix or suffix	Definition	Example
myxo-	Mucus	Myxoid
neo-	New	Neoplasia
-oid	Resembling, but not the same as	Sarcomatoid
-oma	Tumor or mass	Hemangioma
olig-	Few, small	Oligodendrocyte
-osis	Indicating a pathologic state	Diverticulosis
osteo-	Bone	Osteophyte
-otomy	To cut into	Laparotomy
-ous	Forming an adjective	Mucinous
para-	Next to	Paravertebral
-plasia	Growth	Hyperplasia
pseudo-	False	Pseudocyst
rhabdomyo-	Skeletal muscle	Rhabdomyosarcoma
trich-	Hair	Trichobezoar

Interface with the Surrounding Normal Tissue

Term and definition	Appearance	Example
Circumscribed: well-delineated lesion	Well-defined border between normal tissue and the lesion	Fibroadenoma
Encapsulated: surrounded by a fibrous capsule	Thick pink border surrounding the lesion	Follicular adenoma, thyroid
Infiltrative: invading into and among the surrounding normal cells	No clear border between tumor and normal tissue	Prostate carcinoma
Lobular: in architecture, refers to a generally circumscribed or anatomic distribution	Circumscribed, rounded nodules of cells; simulates a normal anatomic unit	Lobular capillary hemangioma
Pushing border: expanding into and compressing the surrounding tissue	Can create the appearance of a capsule	Medullary carcinoma, breast

Cellularity (Low to High) and Mitotic Rate

Note the cellularity (by *cellularity* we often mean how blue it is or how densely packed the nuclei are). Cellularity ranges from *hypercellular*, also called *cellular*, to *hypocellular* or *paucicellular*. Also look for mitoses on high power. High mitotic rate may be an indicator of malignancy. Atypical mitoses (tripolar or worse) are strongly suggestive of malignancy. Estimate how many mitoses are seen per high-power field (40× objective).

Architectural Pattern

Term and definition	Appearance	Example
Alveolar: resembling alveoli or little cells, sacs, or nests	Nested—there is structure to the lesion but no glands or ducts	Paraganglioma (Figure 2.1a)
Basaloid: resembling basal cell carcinoma	A blue, nested tumor (often poorly differentiated squamous) with tightly packed nuclei and palisading around the edge of the nest	Basal cell carcinoma (Figure 2.1b)
Biphasic: having components of two cell lineages	Spindled cells with islands of epithelial cells or glands	Synovial sarcoma
Cribriform: perforated, like a colander	Crisp round holes within a glandular structure	Adenoid cystic carcinoma (Figure 2.1c)
Discohesive: falling apart into single cells	No common borders among cells	Lobular carcinoma in situ

(continued)

(continued)

Term and definition	Appearance	Example
Epithelioid: composed of round to oval cells with abundant cytoplasm	Cells look plump and have clear cell borders; the opposite of sarcomatoid	Ductal carcinoma, breast (Figure 2.1d)
Fascicular: composed of fascicles	Bundles of elongated, spindly cells streaming in parallel arrays	Leiomyoma (Figure 2.1e)
Glandular: forming gland structures with lumens	True glands should have polarized cells radiating around a lumen	Adenocarcinoma
Glomeruloid: resembling the glomerulus	A coiled tangle of vessels, capillaries, or glands	Vascular proliferations in glioblastoma (GBM)
Herringbone: resembling a pattern of tweed fabric	A variant of fascicular that shows bundles alternating in a zigzag array	Fibrosarcoma (Figure 2.1f)
Hobnailed: resembling a large-headed nail once used in shoes	Epithelial or endothelial cells that round up and protrude into the lumen as little humps	Angiosarcoma (Figure 2.1g)
“Indian file”: cells infiltrating through the tissue in single-file lines	Lines may be only three to four cells long and run parallel to stromal planes	Lobular breast carcinoma
Microcystic: scattered small cystic spaces that are not ducts, tubules, or glands	Microcysts lack polarized epithelial linings and are haphazard; nuclei touch the lumen	Mammary analogue secretory carcinoma (Figure 2.1h)
Micropapillary: papillary-shaped epithelial projections without true fibrovascular cores	Can have a medusa-head appearance (serous carcinoma) or lollipop projections into a duct (micropapillary DCIS)	Micropapillary serous carcinoma, ovary (Figure 2.1i)
Nested: see <i>alveolar</i>		
Pagetoid spread: single malignant cells scattered throughout a benign epidermis	Cells standing out at low power as not belonging in the epithelium	Paget's disease
Palisading: resembling a fence made of sharp stakes	Parallel arrays of nuclei catching your eye at low power as a dark border	Basal cell carcinoma (see Figure 2.1b)
Papillary: an exophytic growth pattern with fibrovascular cores supporting proliferative epithelium	Cauliflower- or coral-shaped structures with branching fibrovascular cores	Papilloma, breast (Figure 2.2a)
Polarized: epithelial cells that have a uniform nuclear position, either apical (lumen side) or basal (basement membrane side)	Polarized cells surrounding a true lumen should show a distinct ring of cytoplasm surrounding the lumen, if the nuclei are basal	Cribiform DCIS
Pseudopapillary: a papillary pattern caused by cell die-off in between fibrovascular septa	Looks papillary but there is evidence of solid or nested growth in some areas	Solid pseudopapillary neoplasm, pancreas
Reticular: resembling a network or netlike array	Microcystic or honeycomb appearance	Yolk sac tumor, testes (Figure 2.2b)
Rosettes: a group of non-epithelial cells that are clustered around a common center	Pseudorosettes are rosettes around a vessel; true rosettes surround a lumen or a fibrillary core	Ependymoma (Figure 2.2c) and other neuroglial and neuroendocrine lesions
Sarcomatoid: resembling a sarcoma, but not one	Sheets or bundles of tumor cells without epithelial structures or clear cell borders	Sarcomatoid carcinoma
Spindled: composed of elongated cells with fusiform nuclei	Sheets or fascicles of fusiform cells; suggests a lesion is either a soft tissue neoplasm or a sarcomatoid variant of something else	Leiomyoma
Staghorn vessels: gaping, branching vessels with thin walls, scattered throughout a lesion	Vessels should strike you as prominent at low power; the shape is unusual, and the walls are disproportionately thin for the diameter	Hemangiopericytoma (Figure 2.2d)
Storiform: having a cartwheel pattern—spindle cells with elongated nuclei radiating from a center point	A cellular spindled lesion with short whorls of cells as opposed to long parallel fascicles	Dermatofibrosarcoma protuberans (Figure 2.2e)
Syncytial: having apparent cytoplasmic continuity between adjacent cells	Looks like a collection of nuclei without recognizable cell borders	Meningioma
Tissue culture pattern: a loose aggregate of stellate (star-shaped) cells	Cells have delicate tentacles of cytoplasm	Nodular fasciitis (Figure 2.2f)
Trabecular: cord-like arrays separated by fibrous septa	Long nests and cords of cell groups	Oncocytoma (Figure 2.2g)

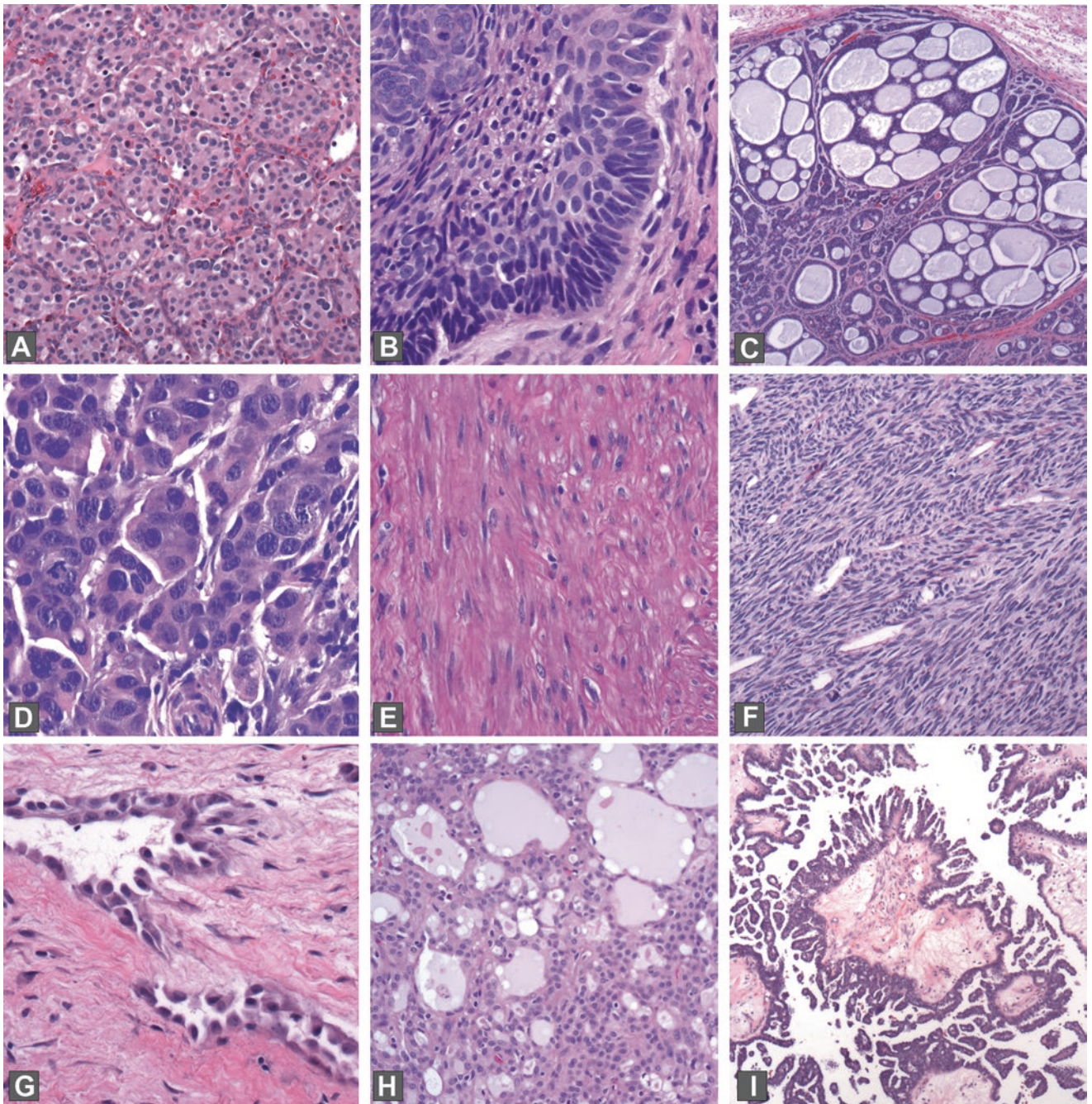


FIGURE 2.1. (a) Alveolar pattern, paraganglioma; (b) basaloid pattern and palisading, basal cell carcinoma; (c) cribriform pattern, adenoid cystic carcinoma; (d) epithelioid cells, breast carcinoma; (e) fascicular pattern, leiomyoma; (f) herringbone pattern, fibrosarcoma; (g) hobnail cells, angiosarcoma; (h) microcystic pattern, mammary analogue secretory carcinoma; (i) micropapillary architecture, serous carcinoma of the ovary.

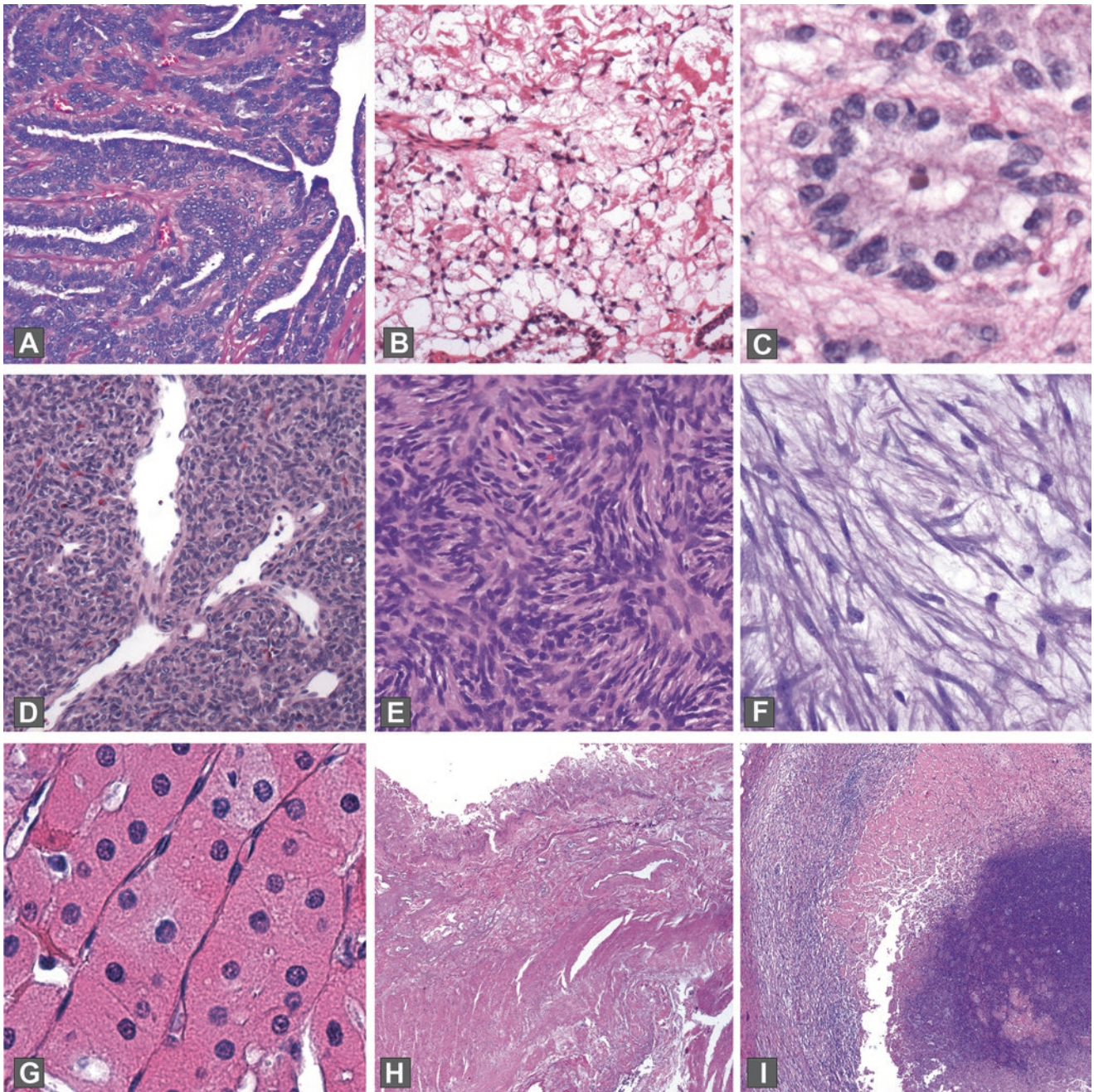


FIGURE 2.2. (a) Papillary architecture, papilloma of breast; (b) reticular pattern, yolk sac tumor of the testis; (c) rosette, ependyoma; (d) staghorn vessels, hemangiopericytoma; (e) storiform pattern, dermatofibrosarcoma protuberans; (f) tissue culture cells, nodular fasciitis; (g) trabecular pattern and oncocytes, oncocytoma; (h) coagulative necrosis, ischemic bowel; (i) caseating necrosis in a granuloma, tuberculosis.

Presence or Absence of Necrosis

Term and definition	Appearance	Example
Coagulative necrosis	Cells appear mummified; architecture is preserved, but there is no basophilia or cell detail	Ischemia (Figure 2.2h)
Caseating necrosis	Total loss of cellular structure and architecture; basically degenerates into pink soup	Tuberculosis (Figure 2.2i)
Fibrinoid necrosis	Vessels with replacement of wall by pink amorphous material	Vascular necrosis (Figure 2.3a)
Fat necrosis	Grossly hard and chalky white; microscopically the fat cells are disrupted and collapsed, with foamy macrophages and giant cells	Biopsy site changes in breast (Figure 2.3b)
Geographic necrosis	Describes large confluent “continent-shaped” patches of necrosis	Kikuchi’s disease
Necrobiosis or gangrenous necrosis	Has a granular and blue look, with lots of fibrin deposition; loss of cellular and architectural detail	Gangrene (Figure 2.3c)

Cell Shape and Size and Cytoplasm

Term and definition	Appearance	Example
Amphophilic: having an affinity for both acid and basic dyes	Has a unique color character, almost an iridescent purple that is hard to capture on film	Pheochromocytoma (Figure 2.3d)
Foamy macrophages: macrophages (histiocytes) stuffed with lipid	Macrophages have a small dark eccentric nucleus; the lipid vacuoles give a glittery granular appearance	Papillary renal cell carcinoma (Figure 2.3e)
Granular: containing granules or tiny vacuoles	Color may vary, but granular texture is visible especially with lowered condenser	Granular cell tumor
Hof: a perinuclear clear zone corresponding to the Golgi apparatus	Looks like a pale spot hugging the nucleus	Plasma cells
Keratinized: keratin-producing	Keratin has a very pink and dense appearance on H&E stain	Squamous cell carcinoma (Figure 2.3f)
Mucous (adj.): mucinous or producing mucus (n.); also called <i>colloid</i>	Mucin (mucus) appears clear after processing but can be stained with mucicarmine or PAS-AB	Adenocarcinoma
Oncocytic: large cells with cytoplasm that is granular and eosinophilic due to the presence of abundant mitochondria	Oncocytes are usually cytologically bland (uniform small dense nuclei) and look pink on H&E, mahogany on gross examination	Oncocytoma (see Figure 2.2g)
Plasmacytoid: like plasma cells	Round cells with abundant cytoplasm and an eccentric round nucleus	Plasmacytoma (Figure 2.3g)
Rhabdoid: refers to a specific malignant tumor that resembles rhabdomyosarcoma or used to describe a tumor with similar histology	Large tumor cells with eccentric nuclei, prominent nucleoli, and globules of pink cytoplasm	Rhabdoid tumor of the kidney
Signet ring: having the shape of a jeweled ring, with a flattened nucleus compressed by a cytoplasm stuffed with mucin	Can be very hard to see on low power; on high power, the cell is a droplet of mucin with a faint cell wall and a nucleus pushed to one side	Signet-ring cell carcinoma (Figure 2.3h)

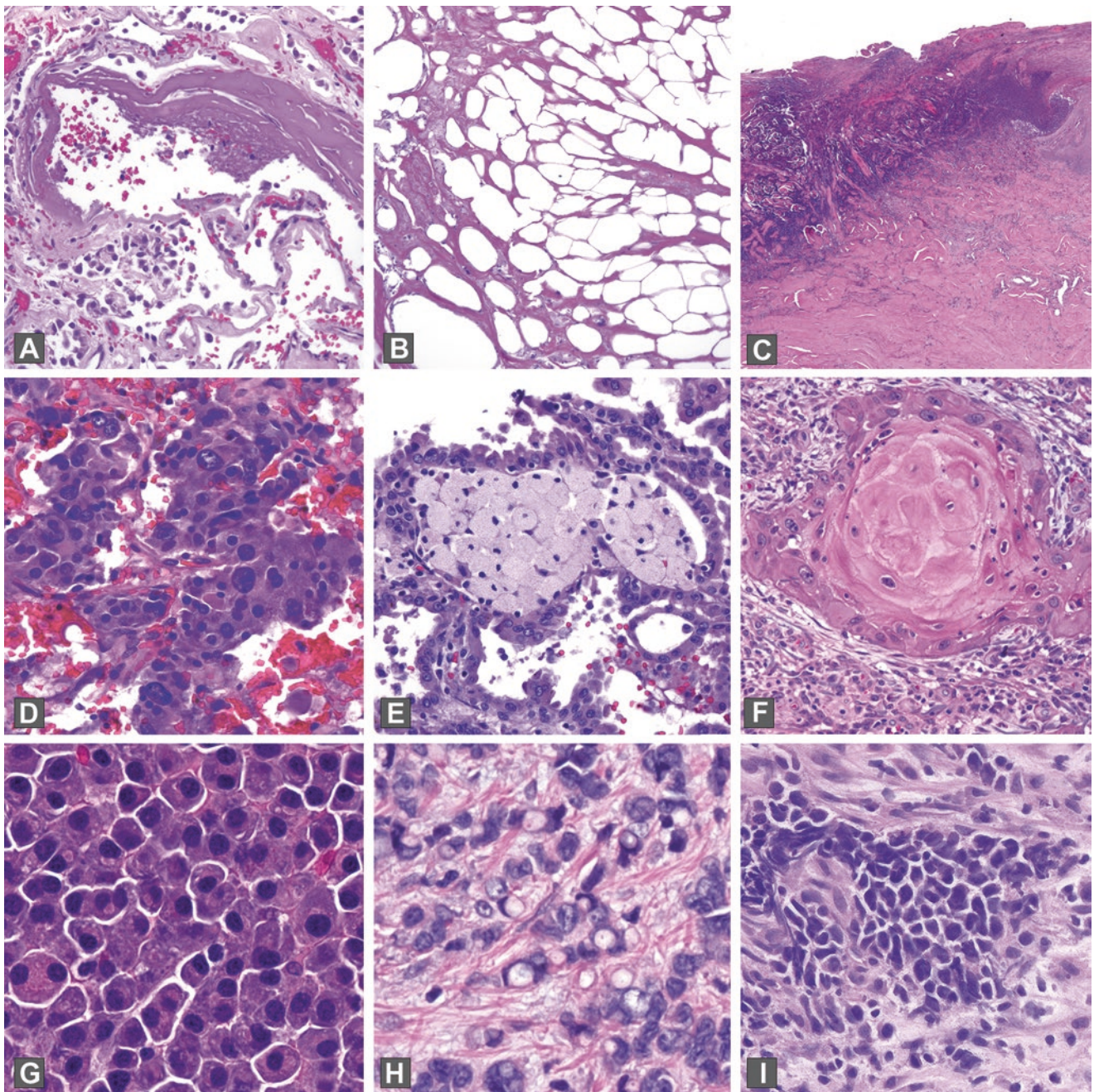


FIGURE 2.3. (a) Fibrinoid necrosis, pulmonary vessel; (b) fat necrosis, breast; (c) gangrenous necrosis, toe wound; (d) amphophilic cytoplasm, pheochromocytoma; (e) foamy macrophages, papillary renal cell carcinoma; (f) keratin, squamous cell carcinoma; (g) plasmacytoid morphology, plasmacytoma; (h) signet-ring cells, breast carcinoma; (i) nuclear molding, small cell carcinoma.

Nucleus

Let's take a moment to talk about the nucleus. If you are beginning your pathology residency, you will spend the next 4 years learning to read nuclei. The H in H&E stands for hematoxylin, which stains nucleic acids, and therefore nuclei, purple; the eosin highlights everything else.

A large chunk of pathology can be boiled down to recognizing nuclear changes that suggest malignancy. The nucleus is the genetic center of the cell, and surprisingly, molecular changes that disconnect the cell from normal feedback mechanisms (i.e., cancer) can often be detected by actual physical changes in the nucleus. For example, changes in the nuclear membrane, changes or irregularities in the nuclear size and shape, alterations in the chromatin pattern and density, or abnormally prominent nucleoli all prompt the pathologist to look more closely. Part of what makes pathology so challenging is that different organs play by different rules, so that what is a “normal” nucleus in one organ represents dysplasia in another. As you learn pathology, above all you must get a feel for which nuclei should make you worry, and the way to do this is to ask your mentors to describe exactly what they are seeing when they use the single most overused and least specific word in our field: atypical.

Atypical: literally, not typical or outside the norm of a certain class of cells When a pathologist uses the term, however, it means “nuclear changes which concern me.” The exact nuclear alterations which warrant the *atypical* label vary by tissue type. On the clinical side, *atypical* is read to mean “the differential diagnosis includes benign and malignant,” and it often ends up punting the question the biopsy was intended to answer. Although it is sometimes unavoidable, try to minimize the use of “atypical” in your diagnoses.

Variants:

Reactive atypia: nuclear changes which might concern me if it weren’t for this blazing inflammation.

Degenerative atypia: nuclear changes which would concern me if I wasn’t 100% sure this was a benign tumor.

Marked atypia: nuclear changes which are so pronounced I’m almost certain this is cancer, but if it turns out to be reactive atypia instead, you can’t sue me.

Mild atypia: nuclear changes which are so trivial I’m almost certain this is benign, but if it turns out to be dysplasia instead, you can’t sue me.

We see this: not atypical.

Making the interpretation of nuclei more complicated is the fact that changes in fixation, staining intensity, crush artifact, cautery, desiccation, and other variables can make the same tumor look very different. Part of the learning process is determining which nuclear features are truly part of the tumor and which are due to artifact. One way is to calibrate using the non-tumor nuclei in the tissue, such as normal epithelial or endothelial nuclei. This is similar to the process by which your brain learns to identify “blue” in all different lighting conditions, by comparing the actual color signal (which may not be blue at all) to the color signals of other known objects, like skin tone or white paper. Some nuclear artifacts become signatures of the tumor type, like the cleared-out chromatin of papillary thyroid carcinoma. Vesicular nuclei, however, while associated with malignancy, can also be a consequence of delayed fixation.

There are some general categories of nuclear changes that you should be able to recognize, which are listed below. Large and hyperchromatic nuclei often indicate an instability of karyotype (literally too much chromatin) that is seen in certain malignancies, whereas large but euchromatic nuclei are commonly seen in benign reactive cells. Irregular nuclear membranes (folds, crenations, corners, asymmetry) are usually not found in benign cells. A prominent nucleolus indicates an active nucleus, but does not equal malignancy. Normal myeloid blasts, for example, have prominent nucleoli, and reactive epithelial cells often have multiple small nucleoli. However, the presence of a large and reddish (protein-rich) nucleolus in a tumor is characteristic of certain tumor types, including carcinoma, melanoma, angiosarcoma, and some lymphomas (e.g., Hodgkin lymphoma). Very finely speckled chromatin is typical of neuroendocrine tumors, which generally do not show a nucleolus. Finally, primitive cells, such as small round blue cell tumors and fetal cells, have a characteristic homogeneous dispersed evenly blue chromatin, as though the undifferentiated cell has yet to sort out what genes are relevant and has all of them spread out in anticipation of starting the filing system. (As a pathologist, you will begin to anthropomorphize individual cells. This is not atypical.)

Other Nuclear Adjectives

Term and definition	Appearance	Example
Clock face: evenly distributed clumped chromatin	Looks like a soccer ball	Plasma cells
Eccentric: displaced to one side	Nucleus on one side, cytoplasm on the other	Plasma cells, rhabdoid cells
Molding: nuclei that press together and indent each other due to the near absence of cytoplasm	Has a mosaic appearance and usually seen in conjunction with small dense blue nuclei	Small cell carcinoma (Figure 2.3i)
Neuroendocrine: having finely speckled or salt-and-pepper chromatin	Nuclei should be round, pale, and smooth, without nucleoli, but with occasional chromatin "chunks" or speckles	Carcinoid (Figure 2.4a)
Pleomorphic: multiple sizes and shapes	Usually refers to nuclei and implies a very irregular mix of sizes and shapes	Embryonal carcinoma, testis
Vesicular: a nucleus in open phase, in which the chromatin is expanded (as opposed to compact and condensed)	A nucleus that is swollen and distorted by apparent bubbles in the chromatin	Various malignant neoplasms

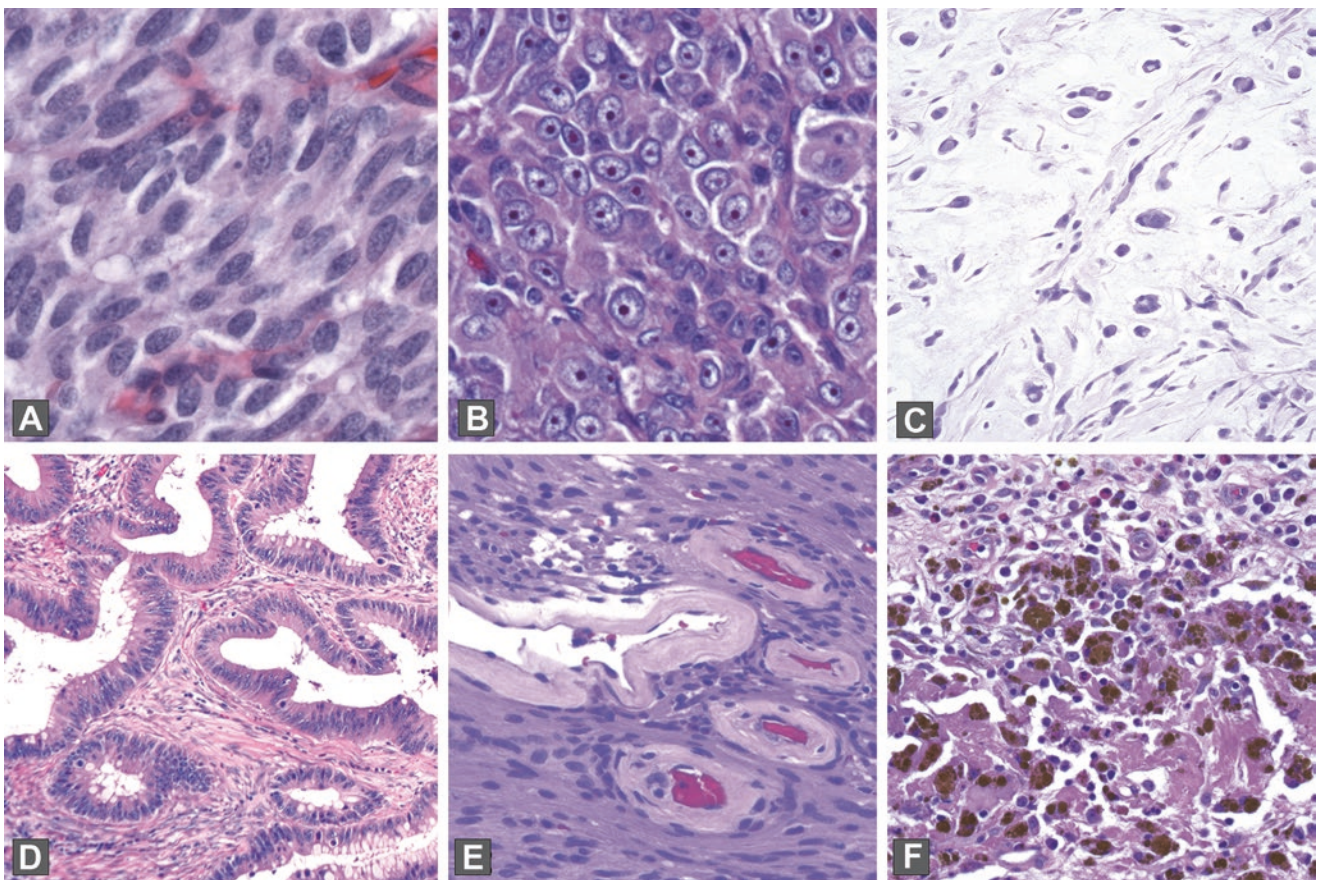


FIGURE 2.4. (a) Neuroendocrine nuclei, carcinoid tumor; (b) cherry-red nucleolus, melanoma; (c) myxoid stroma, myxofibrosarcoma; (d) desmoplastic stroma, colon cancer; (e) hyaline deposits, vessels in schwannoma; (f) hemosiderin, nasal polyp.

Nucleolus

Cherry red: implies a malignant-looking nucleolus	An enlarged, solid nucleolus with a refractile red tinge due to increased protein content	Melanoma (Figure 2.4b)
---	---	------------------------

Cell Membrane

Ciliated: having cilia	If the cilia are not visible, sometimes the terminal bar is enough	Respiratory mucosa
Intercellular bridges: desmosomes	The prickles or spines between squamous cells	Normal skin, especially visible if edematous

Stroma of Lesion, If Present

Term and definition	Appearance	Example
Chondroid: resembling, or made of, cartilage	Bluish-gray stroma with small cells suspended in lacunae (open spaces)	Normal cartilage
Desmoplastic: causing edema and fibrosis in the stroma next to a neoplasm	Alternating layers of pink fibrosis and clear edema surrounding malignant glands; overall appears pale at low power	Adenocarcinoma, pancreas or colon (Figure 2.4d)
Edematous: waterlogged	Water is clear on H&E so appears as lots of cleared-out space	Granulation tissue
Fibrotic/sclerotic: replaced by collagen (fibrosis)	Collagen is pink and opaque on H&E and usually streams in parallel fibers	Sclerosed intraductal papilloma
Hyaline: clear, transparent, homogeneous	Glassy-pink appearance	Characteristic vessel walls in schwannoma (Figure 2.4e)
Myxoid: resembling mucus, but usually associated with a soft tissue lesion and hyaluronic acid	Appears as a faint pink to bluish-gray background, with a stringy mucous look	Myxofibrosarcoma (Figure 2.4c)

Other Noncellular Entities

Term and definition	Appearance	Example
Amyloid: protein deposited in a β -pleated sheet molecular structure	Appears glassy pink, stains salmon-pink with Congo red, and fluoresces apple green	Medullary carcinoma, thyroid
Anthracotic pigment	Very black, very dense fine granules	Pulmonary lymph nodes
Calcium and psammoma bodies	Purple and granular, with hard edges; psammoma bodies are concentrically laminated	Papillary thyroid carcinoma
Colloid: refers to a mucin-producing neoplasm <i>or</i> the pink substance in thyroid follicles	Thyroidal colloid is a thin homogeneous pink	Thyroid tissue
Hemosiderin	Has a glittery golden-brown refractile appearance with the poor man's polarizer (waving your finger above the light source)	Old blood in any lesion (Figure 2.4f)
Lipofuscin	Appears yellowish brown and globular	Seminal vesicle
Melanin	Unlike hemosiderin, is <i>not</i> refractile; may be brown to gray	Melanoma
Tattoo pigment	Similar to anthracotic pigment, may be multicolored	Skin with tattoos

3 Infection and Inflammation

Let's review the types of inflammatory responses you may see. It seems very basic, but learning to differentiate inflammatory changes from dysplastic ones is a fundamental goal in pathology training.

Acute Inflammation

Acute changes are the result of recent tissue damage, either from trauma, ischemia, toxins, or infection. Features include the following:

- Vascular congestion
- Edema
- Fibrinous exudate
- Tissue damage and/or necrosis
- Neutrophils (or polymorphonuclear leukocytes, often shortened to “polys”)

Note that when a pathologist says “acute inflammation,” it is synonymous with neutrophils and does not necessarily imply an acute clinical time course. Acute injury can be followed by resolution (healing), fibrosis or scar, abscess formation (Figure 3.1), or a chronic inflammatory stage. Evidence of recent damage and reparative changes includes granulation tissue, hemosiderin, lipid-laden macrophages, and fibroblast proliferation.

Granulation tissue has a characteristic look of a watery or myxoid background with sparse fibroblasts floating in it and a proliferation of inflammatory cells (all types) and capillaries (Figure 3.2). The endothelial cells of the capillaries can become quite plump and prominent, resembling epithelial cells or glands.

Biopsy site changes, a term often used to indicate evidence of a recent procedure, includes fibroblast proliferation (early scar), foreign-body-type giant cells, suture material, foamy macrophages, fat necrosis, and inflammation. It has a more solid look than granulation tissue (Figure 3.3). Scar tissue implies that a dense thick collagen has replaced the normal structures. In the skin, a dermal scar is evidenced by a homogeneous pink layer of collagen and absence of adnexal structures (Figure 3.4).

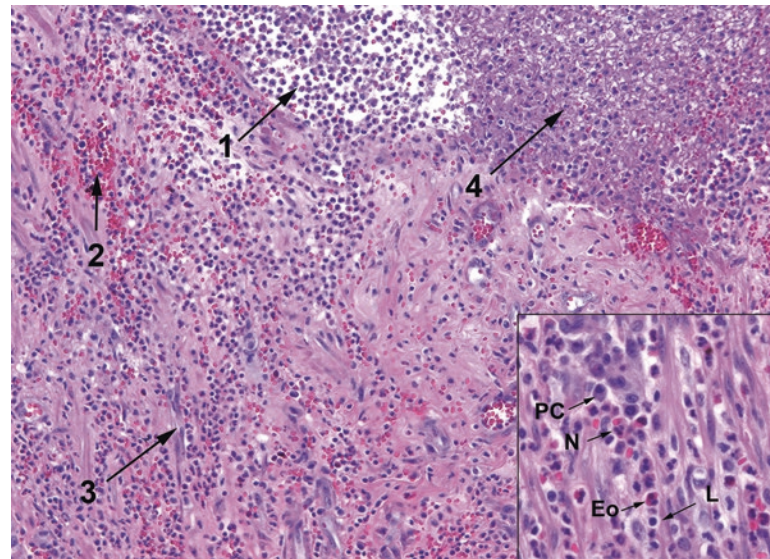


FIGURE 3.1. Acute inflammation and abscess formation. This example of the acute inflammatory response shows collections of neutrophils (abscess formation, 1), extravasated blood (2), prominent capillaries (3), and fibrin accumulation (4). Inset: the mixed inflammatory infiltrate includes plasma cells (PC), neutrophils (N), eosinophils (Eo), and lymphocytes (L).

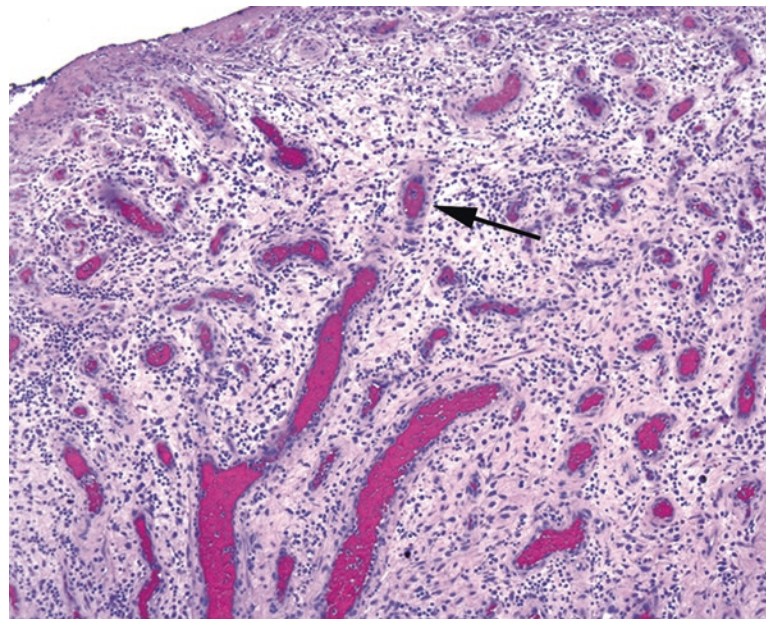


FIGURE 3.2. Granulation tissue is characterized by a loose myxoid background with fibroblasts and inflammatory cells and by prominent capillaries with plump endothelial cells and thick walls. The stroma appears condensed and thickened around the capillaries, giving them a pink halo (arrow).

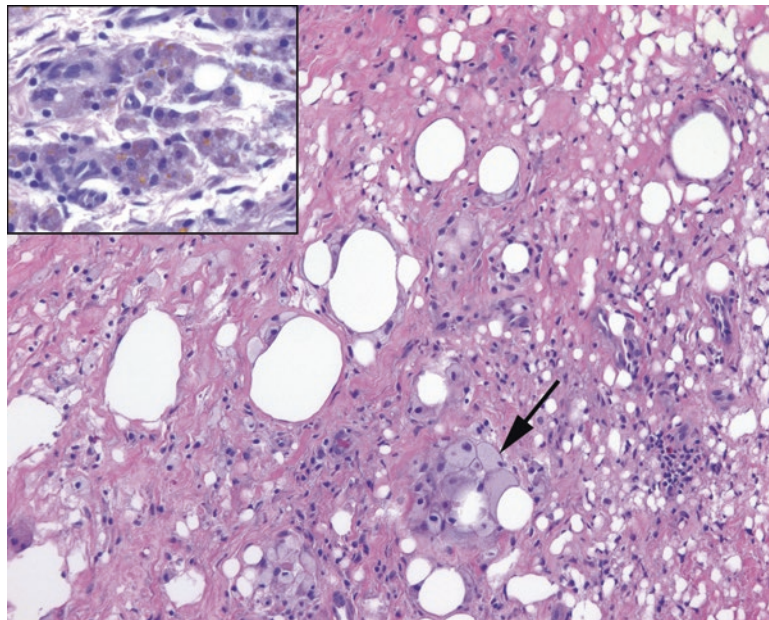


FIGURE 3.3. Biopsy site changes. In this subcutaneous specimen, collagen has replaced most of the fat cells, and foamy histiocytes can be seen ingesting some residual fat (*arrow*). *Inset:* Hemosiderin in macrophages (*golden yellow to brown granules*) can be seen in sites of prior trauma or bleeding.

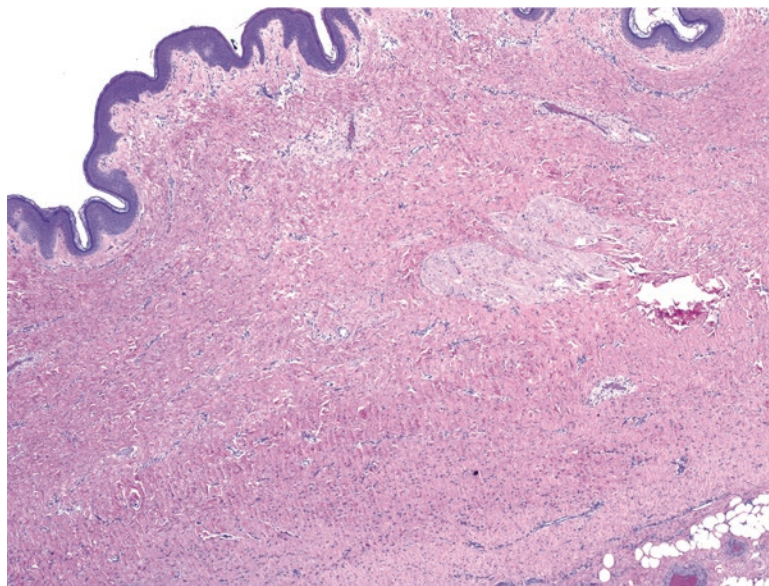


FIGURE 3.4. Dermal scar. Dense pink collagen has replaced the adnexal structures and displaced the subcutaneous fat in this biopsy site.

Chronic Inflammation

Chronic changes are the result of repetitive or sustained tissue damage due to trauma, ischemia, toxins, infection, or autoimmune processes. Features include the following:

- Increased vascularity and/or fibrosis (attempts to heal)
- Tissue destruction or obliteration of normal structures
- Lymphocytes, macrophages*, plasma cells, eosinophils

*What is a *macrophage*? The precursor is a circulating monocyte, part of the myeloid lineage of blood cells (*myeloid* generally refers to cells in the granulocyte and monocyte groups, although it can also mean all cells that mature in the bone marrow, i.e., the opposite of lymphoid). The monocyte leaves the circulation and becomes a tissue macrophage. It can differentiate into organ-specific resident macrophages, such as microglia, Kupffer cells, and alveolar macrophages. It can also go to an area of inflammation and become activated, participating in the immune response. Activated macrophages are also called *histiocytes* and may be “epithelioid,” as in a granuloma, and “foamy,” as in lipid-laden (xanthomatous), hemosiderin-laden, or full of mucin or melanin. Finally, macrophages can acquire multiple nuclei to become a Langerhans giant cell (ring of nuclei) or a foreign-body-type giant cell (scattered nuclei).

Histologically, histiocytes have a bland and fade-into-the-background look to match their name (literally, “tissue cell”). They have pale-pink granular cytoplasm, sometimes with chunky phagocytosed bits of material, and indistinct cell borders (Figure 3.5). The nuclei are pale with crisp outlines, oval in shape, and often grooved. In tissue, a collection of histiocytes appears as an ill-defined pink area that is easy to miss. The nuclei often stream in a circular pattern like fish swimming in a barrel. Foamy macrophages are stuffed with lipid debris or organisms and can have an almost signet-ring appearance.

We usually refer to the presence of lymphocytes as *chronic inflammation*. Lymphocytes plus neutrophils equals acute and chronic inflammation. In the gastrointestinal tract, instead of *acute* we use *active*, such as active chronic gastritis or active chronic inflammatory bowel disease. *Inactive* disease in the gastrointestinal tract means increased lymphocytes and plasma cells but no neutrophils. Eosinophils, which are grouped under chronic inflammation, have a bilobed nucleus and big red granules. They are usually an indication of an immune/IgE response, such as allergy or parasites.

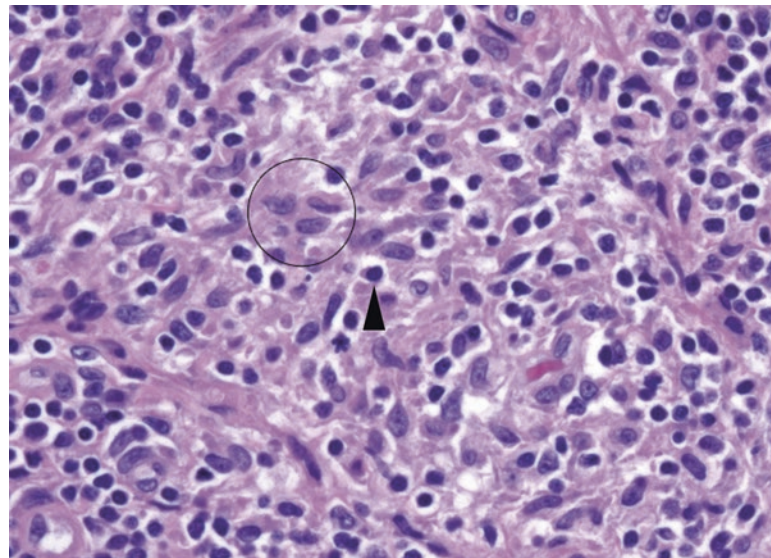


FIGURE 3.5. Histiocytes appear as pale folded nuclei within an area of inflammation; the cell borders are indistinct, but the nuclei are surrounded by light pink cytoplasm (*circle*). Compare the pale chromatin to that of the neighboring lymphocyte (*arrowhead*).

Granulomatous Inflammation

A granulomatous appearance indicates a specific type of chronic inflammation with a limited differential; it can indicate mycobacterial infection (plus a few other bacteria), fungal infection, autoimmune disease, some toxins or irritants, and sarcoidosis. Granulomas are divided into necrotizing (usually infectious) and non-necrotizing. Caseating granulomas are synonymous with necrotizing granulomas, named after the cheese-like gross appearance of the necrosis, and usually implying tuberculosis.

The histologic appearance of a granuloma is a microscopic aggregate of histiocytes, with surrounding lymphocytes and plasma cells. The appearance ranges from tiny collections of histiocytes (as in Crohn's disease; Figure 3.6) to large well-circumscribed whorls of cells (sarcoidosis; Figure 3.7), to a layer of histiocytes surrounding a pool of necrotic debris (tuberculosis, fungus; Figure 3.8). Giant cells are helpful but not essential. Old granulomas can become hyalinized and acellular (Figure 3.9).

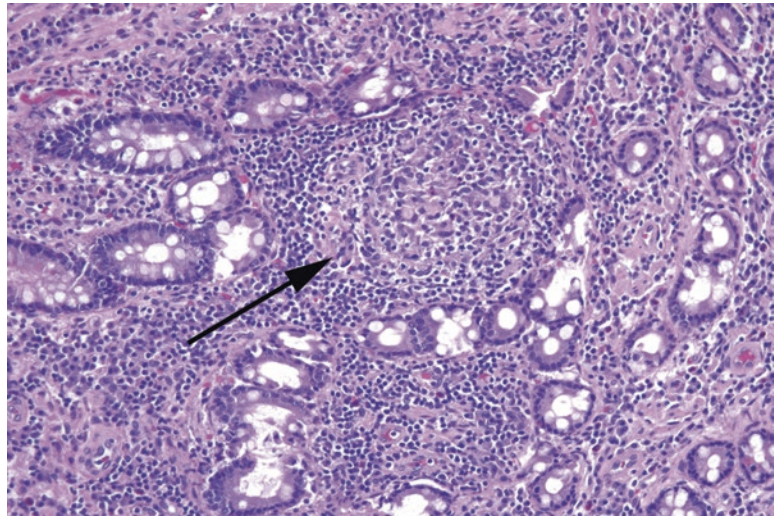


FIGURE 3.6. Granulomas in Crohn's disease. These granulomas of the colon are subtle (*arrow*), and the pale histiocytes may be seen only on high power. A surrounding collar of lymphocytes is common.

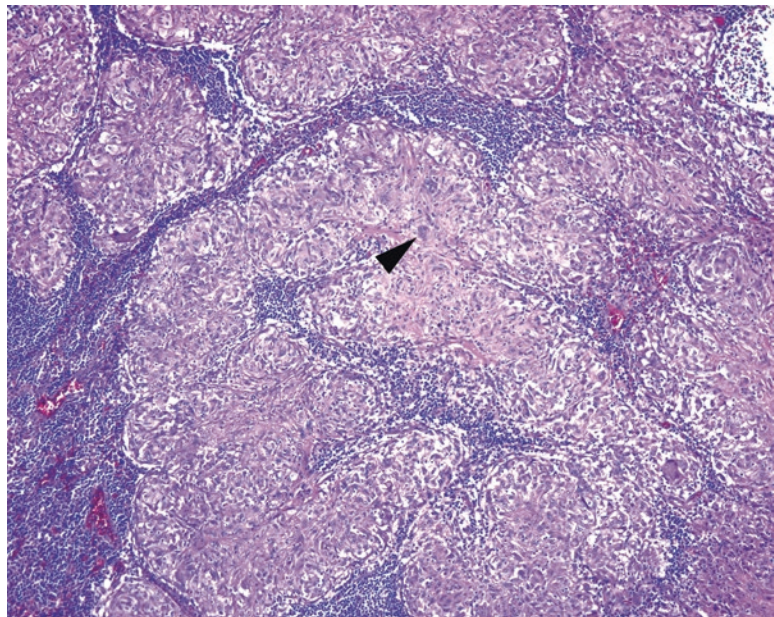


FIGURE 3.7. Granulomas in sarcoid. These granulomas are often more substantial and more easily recognized than those in Crohn's disease. They appear as well-defined masses of pink histiocytes. Occasional multinucleated giant cells (*arrowhead*) are present.

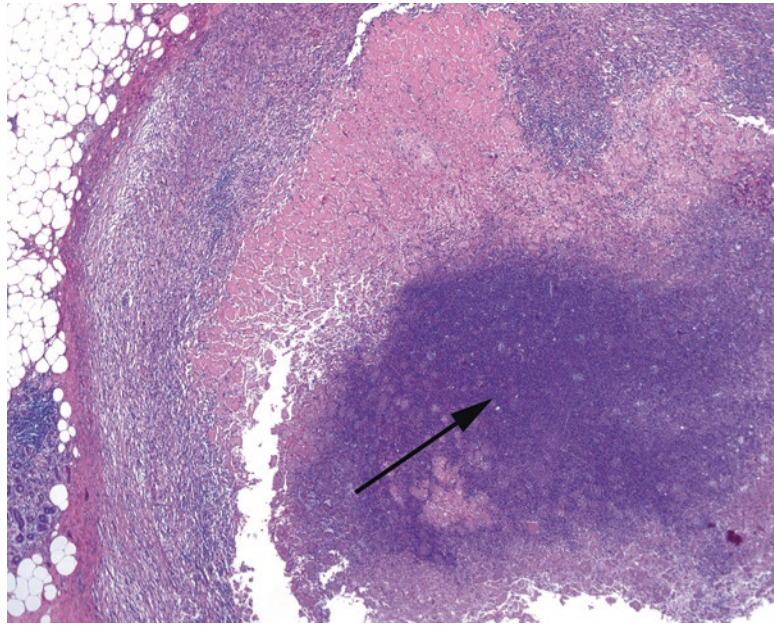


FIGURE 3.8. Caseating or necrotizing granulomas in tuberculosis. The histiocytes in these granulomas are visible only at the periphery, as the center is a mass of necrosis and cellular debris (*arrow*).

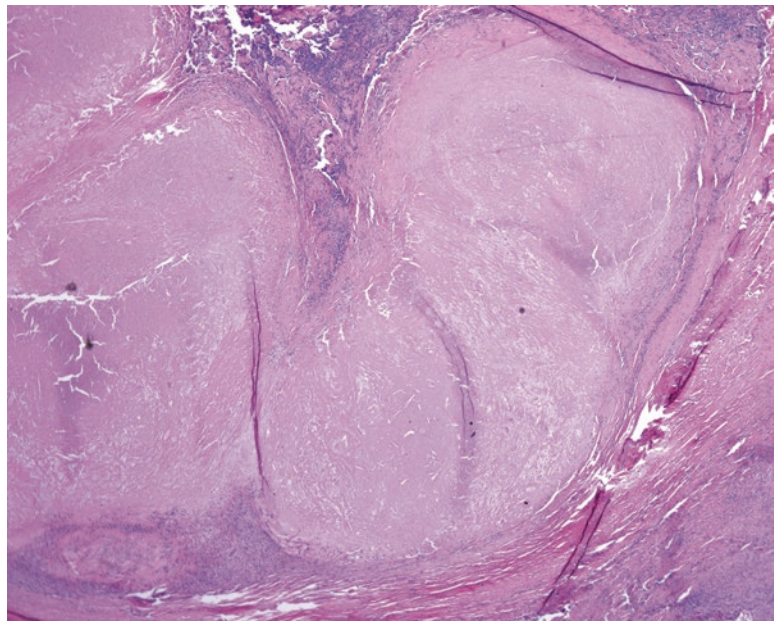


FIGURE 3.9. Hyalinized granuloma. The amorphous area of hyalinized collagen likely represents old, burned-out necrosis.

Specific Organisms and Their Stains

Fungi

Fungal organisms stain bright pink on periodic acid-Schiff (PAS) stain and black on Gomori's methenamine silver (GMS) stain. For most of these organisms, it is important to identify not just the presence and morphology of the organism but whether it is invading viable tissue or colonizing necrotic debris. Size can be helpful in identifying the various yeasts (Figure 3.10).

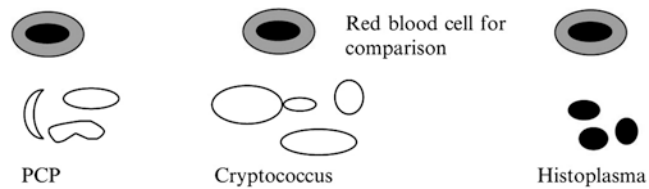


FIGURE 3.10. Relative size of yeasts compared to an RBC (an RBC is approximately 7 μ m).

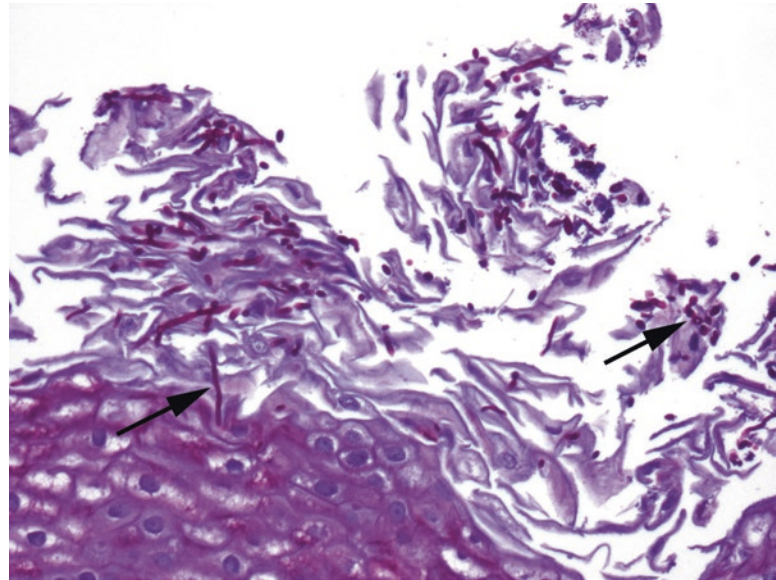


FIGURE 3.11. *Candida*. This example from the esophagus shows magenta pseudohyphae and yeasts (arrows, PAS stain).




FIGURE 3.12. *Aspergillus*. A forest of branching hyphae is visible by GMS stain.

Candida are visible on H&E as round-to-oval yeast forms and pseudohyphae (segmented and nonbranching). They are often found in the debris at the epithelial surface (Figure 3.11). *Aspergilli* are visible on H&E as long, thin hyphae with 45° branching and septations. They may appear as a solid fungal ball or as single hyphae in the tissue (Figure 3.12). Treated *Aspergilli* may have different morphology.

Mucor and zygomycetes have irregular and wide nonseptate hyphae and have the appearance of gnarled tree branch outlines with wide branch points (Figure 3.13). On H&E, they can be almost invisible, as they are essentially wide hollow spaces in the tissue. These are the bread molds and are typically seen only in very neutropenic patients or in sinusitis in a patient with ketoacidosis.

Histoplasma are tiny intracellular yeast forms with narrow-based budding, often seen in macrophages. On H&E and Giemsa stain, these are delicate 2- μm forms in macrophages. In a hyalinized granuloma, however, a silver stain shows distinct yeasts that are nearly the size of red cells (about 5 μm ; Figure 3.14). *Cryptococcus* are usually encapsulated yeast forms with narrow-based budding; some may be in macrophages but are often free in the tissue; on GMS the sizes are variable, and some may collapse into squashed balls (Figure 3.15). This variability in size is actually a key indicator of *Cryptococcus*. Stains for the capsule of *Cryptococcus* can differentiate it from other yeasts, including mucicarmine and Fontana-Masson. However, be aware that *Cryptococcus* can occasionally lose the capsule.

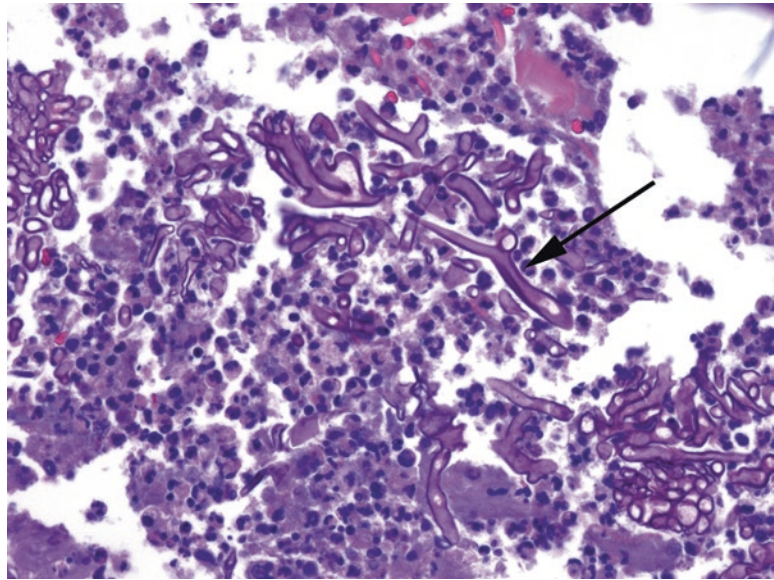


FIGURE 3.13. *Mucor*. A PAS stain shows the thick, hollow, irregular outlines of *Mucor* (arrow).

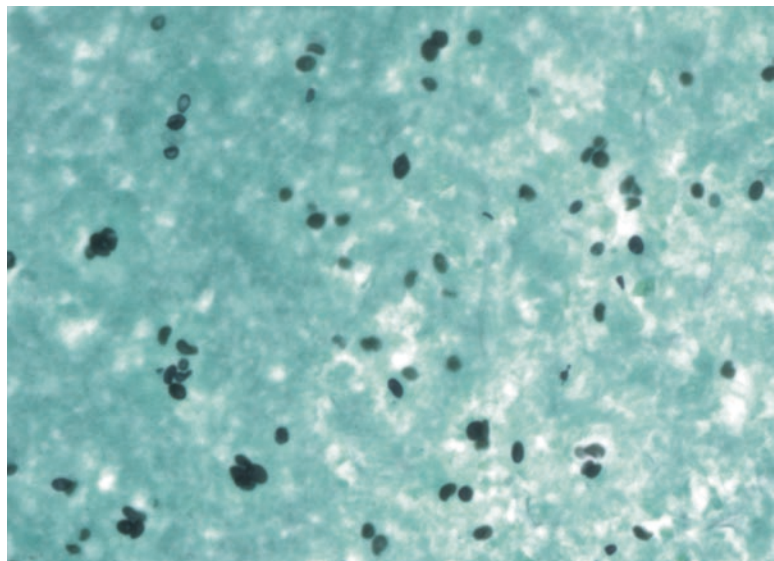


FIGURE 3.14. *Histoplasma*. Tiny yeasts are visible on GMS stain (40 \times objective).

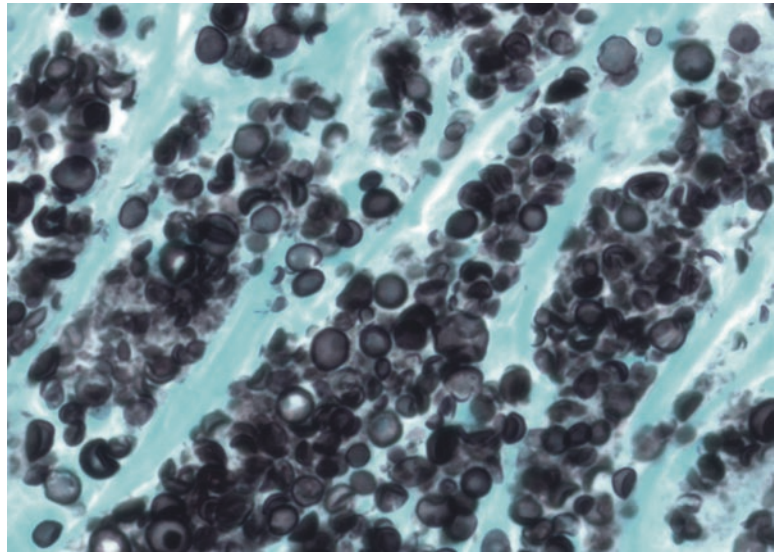


FIGURE 3.15. *Cryptococcus*. This photograph is taken at the same magnification as Figure 3.14. The organisms are significantly larger and show a range of sizes and shapes on GMS stain.

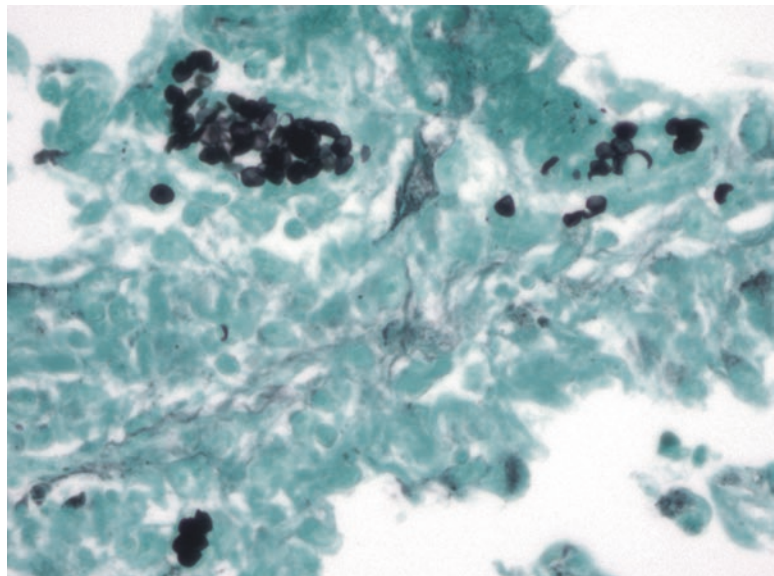


FIGURE 3.16. *Pneumocystis*. This photograph in the lung is taken at the same power as Figures 3.14 and 3.15. The organisms are stained with GMS stain.

Pneumocystis jirovecii, formerly known as *Pneumocystis carinii*, is a yeast and therefore black on GMS. They are flattened contact-lens-shaped organisms found in the alveoli (Figure 3.16). They are not visible on H&E but are usually accompanied by a foamy pink exudate.

Bacteria

Most bacteria are not found by, or identified with, stains. This is because there is little more we could say than “Gram-positive cocci in clusters,” for example, which is pretty unhelpful without a culture. There are a few that are hard to culture and are best identified by stains.

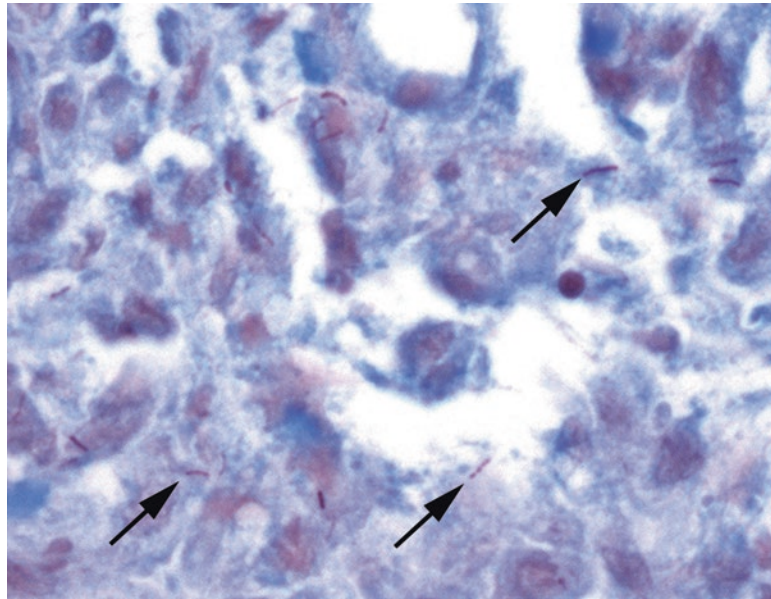


FIGURE 3.17. Mycobacteria on AFB stain. In this example, tiny wine-red rods are visible within the tissue (arrows) under the 40× objective.

Necrotizing granulomas are histologic evidence of *Mycobacterium* (causing tuberculosis and other diseases). The organisms are not seen on H&E and may be very sparse in an immunocompetent patient. The conventional stain is the acid-fast bacilli (AFB) stain, which leaves the tissue unstained, with occasional pink blush in some cell types, but stains mycobacteria a bright wine red (Figure 3.17). These are tiny scattered bacilli; you need to be at 20×, at least, to spot them. Scanning the entire slide at 40× for red lint is painful but necessary to rule out infection. If clinical suspicion is high but an AFB is negative, an auramine-rhodamine is a more sensitive fluorescent stain for tuberculosis, but requires a fluorescent microscope for viewing.

Mycobacterium avium-intracellulare (MAI) causes infection in an immunocompromised patient. In these patients, the mycobacteria are eaten by macrophages and then multiply like crazy within the cells, giving the appearance of foamy macrophages. In the duodenum, this can look just like Whipple's disease, but a PAS stain will differentiate the two (histiocytes stuffed with cranberries in Whipple's disease but with fine rods in MAI infection). An AFB stain will also be positive in MAI.

Helicobacter pylori is the most common cause of gastric ulcers. Histologically you should see a chronic inflammatory infiltrate in the stomach, with a little activity here and there (neutrophils). Infection is more common in the antrum. On Diff-Quik or Giemsa stain, look in the areas of activity. If present, *H. pylori* will be in the pit lumens or at the surface in clusters of tiny (barely visible at 20×) seagull-shaped bacilli (Figure 3.18).

Actinomyces, causing a puffed bacterial colony, is completely unremarkable in the tonsil but significant in endometrium, especially in the setting of an intrauterine device. The H&E appearance is a granular grey-purple cloud, sometimes filamentous, with no identifiable cells or structures (Figure 3.19).

Viruses

As an interesting generalization, DNA viruses (HSV, CMV, varicella, adenovirus, JC and BK virus, HPV, and the poxviruses) tend to cause visible viral cytopathic effects on the cell nucleus. The RNA viruses do not.

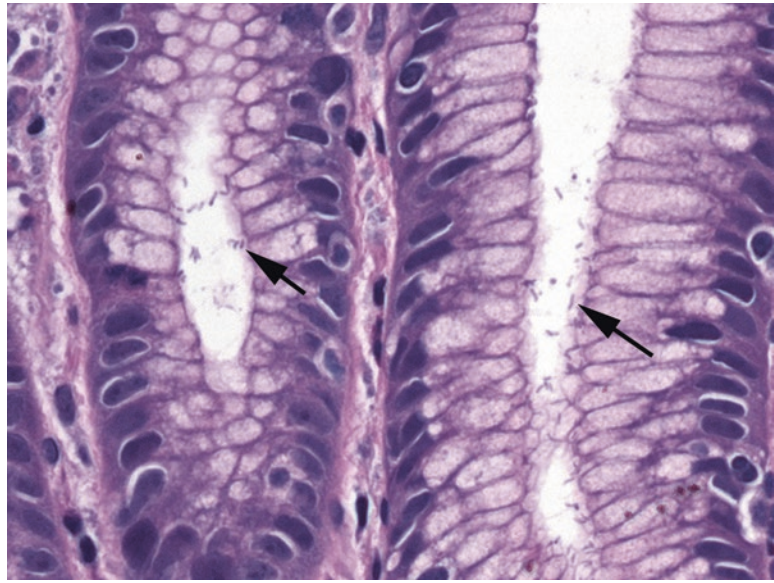


FIGURE 3.18. *Helicobacter pylori*. The bacilli may be visible on H&E stain, as seen here (arrows), in the pits of the gastric mucosa.

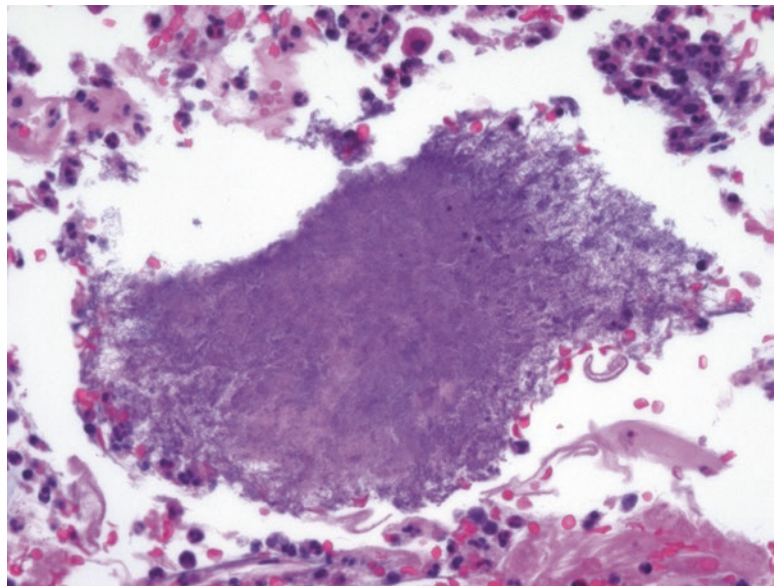


FIGURE 3.19. *Actinomyces*. This filamentous ball of organisms is easily overlooked, as it resembles fibrin.

Herpes simplex virus (HSV) tends to cause extensive tissue damage and ulcers. It infects the epithelium, so look in the cells immediately adjacent to the ulcer. The cells become multinucleated, with the transformed nuclei molding into each other. The chromatin is entirely displaced by glassy nuclear inclusions (viral proteins), outlined by a dark rim of residual chromatin, as though the nucleus is being digested from the inside (Figure 3.20).

Cytomegalovirus (CMV) can also cause ulcers but may infect tissue without obvious localizing damage. It infects epithelial, endothelial, and mesenchymal cells. In the case of an ulcer, look in the ulcer bed, not the periphery. The virus causes enlarged cells with large nuclei. The nuclei have a very characteristic inclusion; a dark dense round/oval inclusion surrounded by a pale halo, all within the nuclear membrane (Figure 3.21). The pale halo is not always entirely visible, so finding large smudgy dark nuclei in a group of non-neoplastic cells should prompt you to consider CMV. Immunostains help.

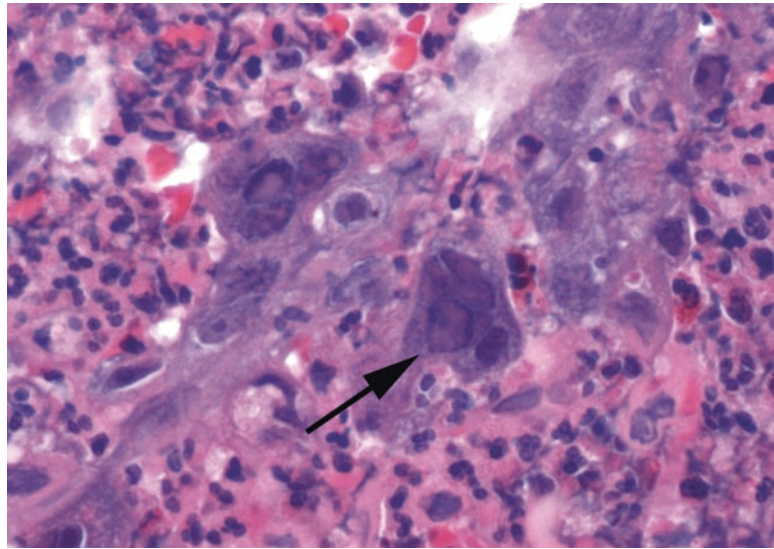


FIGURE 3.20. Herpes infection. The classic nuclear changes include multiple molded nuclei with a peripheral rim of chromatin and a glassy inclusion nearly replacing the chromatin (*arrow*).

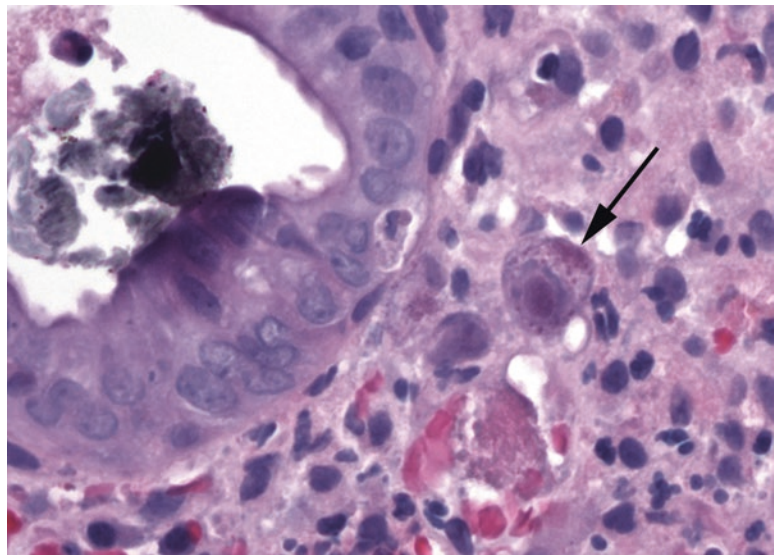


FIGURE 3.21. CMV infection. This endothelial cell in the gastrointestinal tract (*arrow*) shows the typical nuclear changes of CMV, with a central reddish dense nuclear inclusion, surrounded by a clear halo and a rim of purple chromatin.

Parasites

Giardia is a duodenal parasite that looks a little like a flounder with a long tail: It is kite shaped when viewed from above but a flat crescent from the side (refer to Figure 7.14). It is found at the luminal surface of the villi and may not cause much inflammation. The parasites look very much like debris, but in a fortuitous cut you may see the “eyes,” which identify it. You will not see *Giardia* unless you look for it. It is related to *Trichomonas*, which you will see on pap smears.

Cryptosporidium is another duodenal parasite that mainly infects the immunocompromised. The tiny round parasites line up along the brush border like clinging bubbles, considerably smaller than an epithelial cell’s nucleus.

4 Interpreting the Complex Epithelium

Complex, or multilayered, epithelia (squamous and urothelial) may progress through a spectrum of changes, from benign hyperplasia and/or metaplasia to inflamed reactive changes, to dysplasia, to carcinoma in situ (CIS), and to invasive carcinoma (crossing the basement membrane). The progression is not inevitable or consistent, and some lesions will regress. However, true dysplasia is generally regarded as a premalignant condition. Carcinoma in situ is one step from invasive cancer and therefore treated aggressively. Some lesions are easily monitored clinically, such as those in the cervix and oral cavity, and therefore each phase of change can be seen, biopsied, and followed. Others, such as in the nasopharynx, are generally not noticed until they are fairly large and/or symptomatic. This chapter will touch on basic principles that these epithelial layers have in common and introduce some organ systems that are covered in greater detail later in the book.

Approach to the Epithelium: General Principles

On low power (4×), look for the following:

- Type of epithelium: Is it squamous, columnar, or ciliated?
- Architecture: Is it an exophytic structure, such as a verrucous lesion or a papilloma? Is there downward growth, as in an inverted papilloma or invasive lesion?
- Keratinization: Is keratinization present or absent? Hyperkeratosis? Parakeratosis? Mounds or church spires of keratin (as in a wart)?
- Thickness of the epithelium: Is the epithelium thickened and irregular (hyperplastic) or thin and flat (atrophic)? A markedly thickened epithelium may indicate irritation and hyperplasia but not necessarily dysplasia.
- Architectural orderliness: Is there a clear difference between the basal layer and the superficial layer? Are the rows of cells orderly (Figure 4.1)? Are the nuclei lined up, either parallel to the surface or perpendicular to it?
- General color: What color is it? Although it is hard to compare one slide to another, within a single slide, differences in color can make a dysplastic or inflamed area stand out as dark or blue. Islands of bright pink, on the other hand, may indicate deep keratinization, which is a feature of invasion.

On high power, look for the following:

- Architectural orderliness and polarity: Try to find a well-oriented fragment, not a tangential cut. In a benign, even reactive epithelium, all of the nuclei should appear to “know which way is up.”

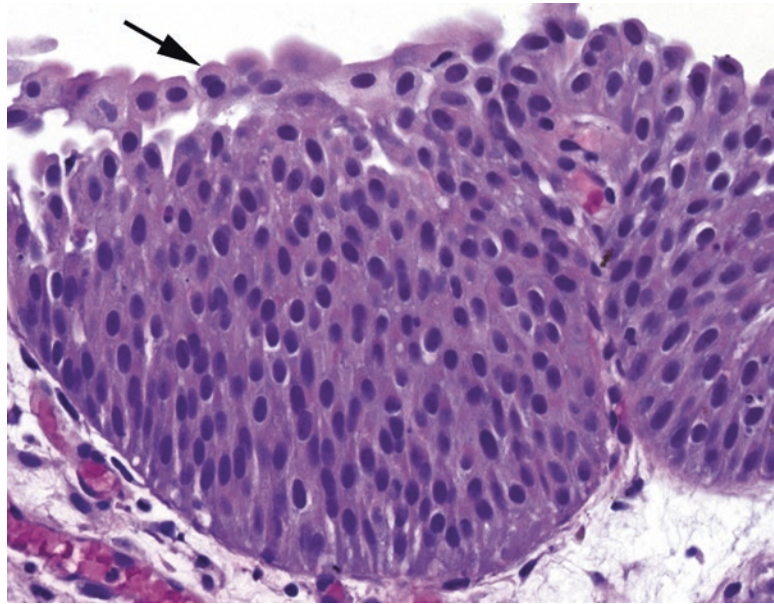


FIGURE 4.1. Polarity in an epithelium. In this section of urothelium, although it is thickened relative to normal, all of the nuclei can be seen to be roughly perpendicular to the surface; they “know which way is up.” Plump umbrella cells are visible at the surface (*arrow*).

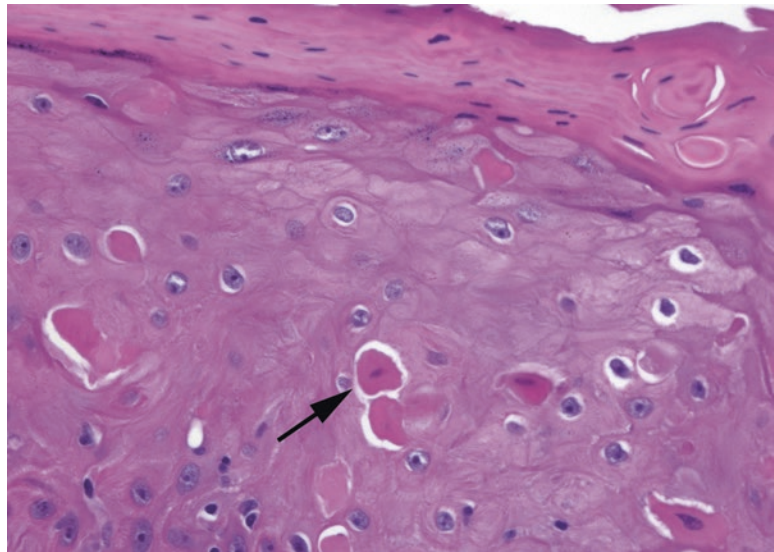


FIGURE 4.2. Dyskeratotic cells in the epidermis. These cells are essentially mummified; their nuclei are dying, and they have lost their connections to other cells. Their dense pink keratin stands out relative to the neighboring cells (*arrow*). Note the surface parakeratosis.

- Mitotic figures: Although a few mitoses near the basal layer are acceptable, mitoses higher in the epithelium are not. As above, a well-oriented fragment is very helpful.
- Dyskeratotic cells: Small, intensely pink, shriveled round cells that have detached from their neighbors (Figure 4.2) can be a feature of dysplasia.
- Inflammation: Look for neutrophils, plasma cells, and lymphocytes. Keep a high threshold for dysplasia in the setting of intense acute inflammation.

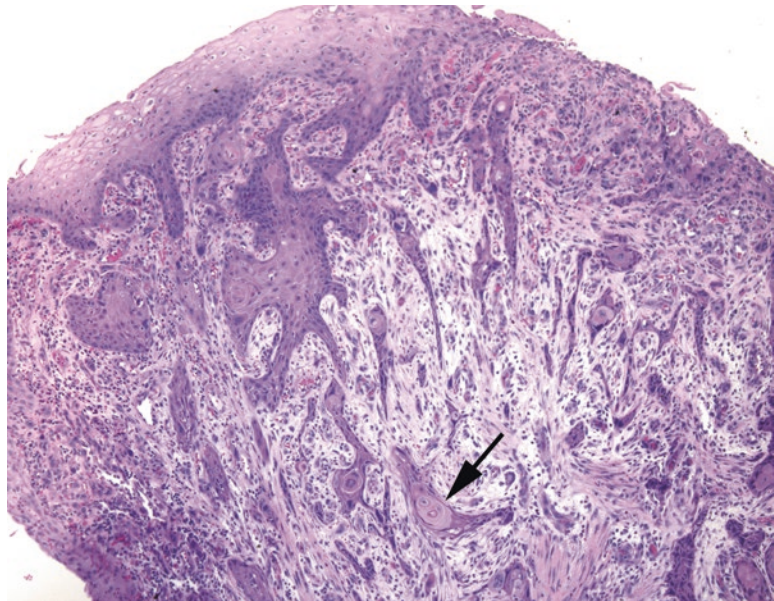


FIGURE 4.3. Invasive squamous cell carcinoma. Irregular nests and spicules of cells invade down into the stroma from the surface (*top*). Although single infiltrating cells are not visible at this magnification, the deep aberrant keratinization (*arrow*), in which a deep nest of cells takes on the color and texture of the normal surface keratin, is highly suspicious for invasion.

- Invasion: Stromal invasion is a sure sign of cancer but is not always obvious. Pseudoepitheliomatous hyperplasia (see “Definitions of Terms”) and tangential sectioning are the main mimickers. Features that suggest true invasion include deep aberrant keratinization (pinking up) and single infiltrating cells with atypical nuclei (Figure 4.3). The basement membrane border should appear ragged and discontinuous in invasion. Well-differentiated squamous cell carcinoma can acquire prominent nuclei (usually not seen in CIS) and mimic reactive nuclei, but it should have the architectural features of invasion.

Nuclear Changes: It’s All About the Nucleus, Remember?

- Nuclei, eggs versus boulders (Figure 4.4): Reactive nuclei may enlarge but stay smooth and round to oval, and their chromatin condenses into several small nucleoli or speckles, like a bird’s egg. The chromatin may have an overall grey-blue look, and the nuclear membrane is often indistinct. Dysplastic or immature nuclei, however, appear to have too much chromatin. They are large and tend to be angulated with irregular nuclear membranes (like boulders), and the chromatin is uniformly dense and dark, like it was drawn with charcoal. Nuclear membranes may also appear thicker and more prominent.
- Nucleoli: Prominent nucleoli are actually a feature more suggestive of reactive changes than of dysplasia. A prominent nucleolus in a background of fine pale chromatin, in a smoothly rounded nucleus, is likely benign. Squamous carcinomas usually do not acquire large dark nucleoli until they become invasive.
- Nuclear to cytoplasmic (N/C) ratios: The N/C ratio is normally high in the basal layer (meaning mostly nucleus and minimal cytoplasm) but should fall off as the cells mature and move to the surface. A high N/C ratio at the surface, especially in the setting of “boulder” nuclei, is very worrisome. This creates the impression of blueness at low power.

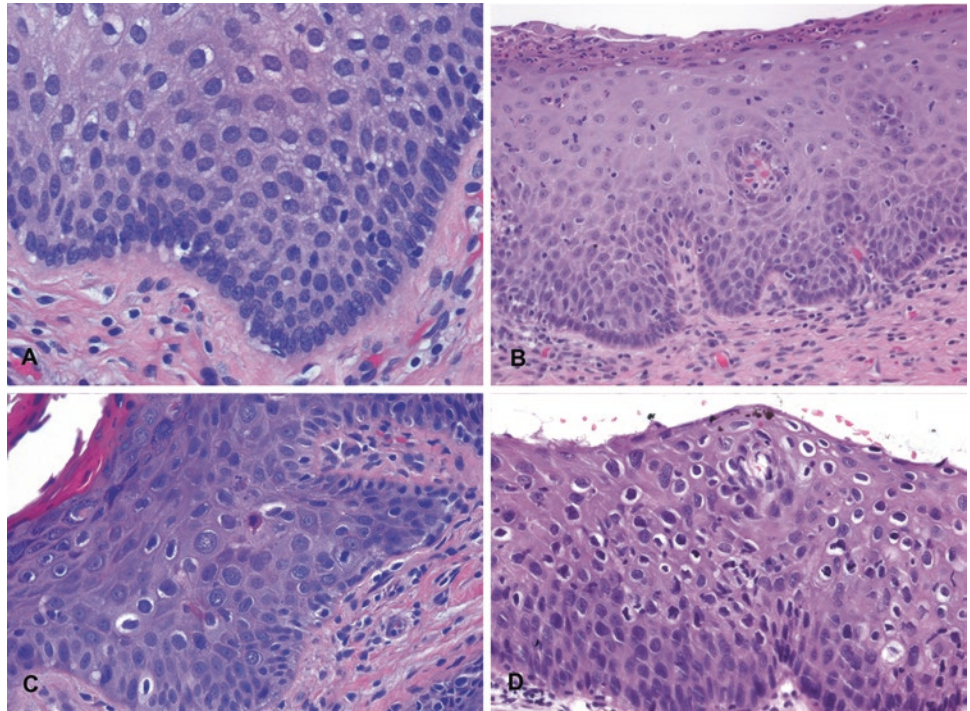


FIGURE 4.4. Examples of reactive, benign nuclei (**a, b**) and dysplastic nuclei (**c, d**). In reactive conditions (*upper panels*), the nuclei may be enlarged and have visible nucleoli, but the N/C ratios are still low (abundant cytoplasm), there is nuclear polarity relative to the surface, the chromatin is not too dark, and the nuclear membranes are smooth and oval. Maturation is visible in that as cells get closer to the surface, the nuclei get smaller and the cytoplasm more abundant. In dysplasia (*lower panels*), the nuclei are significantly darker, the N/C ratios are higher, there is more disorder to the epithelium, and the nuclei (being more closely packed) may take on irregular shapes to fit more closely together, similar to boulders in a rock wall.

Definitions of Terms

Acanthosis: thickening of the epithelium, usually referring to a keratinized epidermis.

Hyperkeratosis: too much keratin, which sits on the epithelial surface in a thick pink layer, often accompanied by parakeratosis.

Orthokeratosis: “normal” anucleate keratin, found on the skin, with a basket weave pattern.

Parakeratosis: the retention of small pyknotic nuclei in surface keratin (see Figure 4.2).

Papilloma: exophytic growth of finger-like, arborizing projections with fibrovascular cores, lined by squamous epithelium (Figure 4.5).

Inverted papilloma: endophytic (inward) growth of islands of benign squamous epithelium. The nests should be surrounded by stroma, and fibrovascular cores are not seen. Each nest is bordered by a smooth continuous basement membrane. It is essentially an inside-out papilloma.

Pseudoepitheliomatous hyperplasia: a benign reactive condition that simulates invasive squamous cell carcinoma. It has a very characteristic look, as though someone dragged the epithelium down into the stroma with a toothpick, like marbling a cake (Figure 4.6). The individual nuclei should look reactive, not dysplastic. There should not be deep keratinization. Granular cell tumors are notorious for provoking an intense pseudoepitheliomatous reaction.

Verrucous: warty; an exophytic growth pattern with prominent hyperkeratosis (Figure 4.7) and an appearance described as “church spire” (pointy projections) or “cauliflower” (rounded projections).

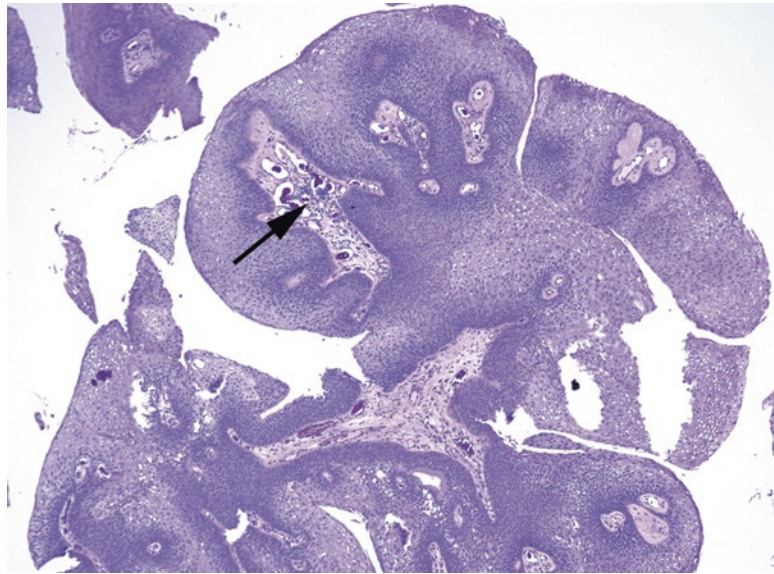


FIGURE 4.5. Papilloma. The squamous papilloma is defined by a squamous epithelium overlying branching fibrovascular cores (*arrow*).

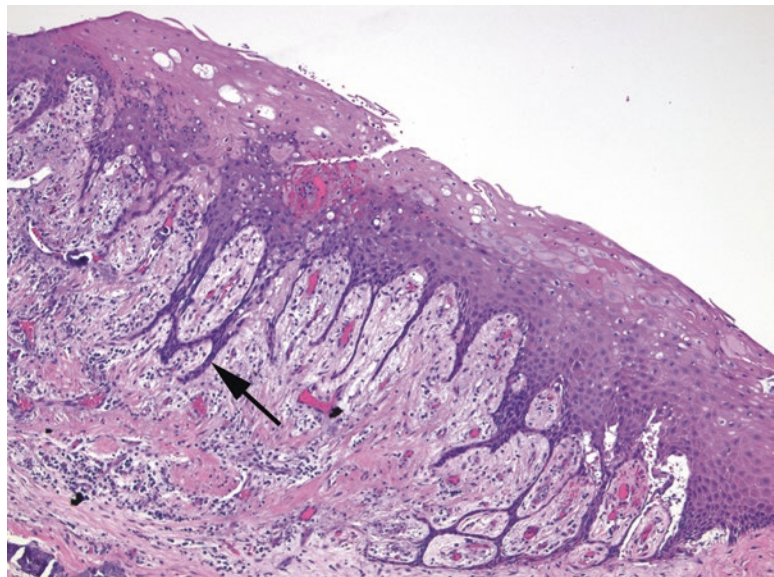


FIGURE 4.6. Pseudoepitheliomatous hyperplasia. In this reactive condition, thin strands of epithelium (*arrow*) are pulled down into the underlying dermis or lamina propria. However, the strands should not expand out into nests or show deep keratinization (compare to Figure 4.3).

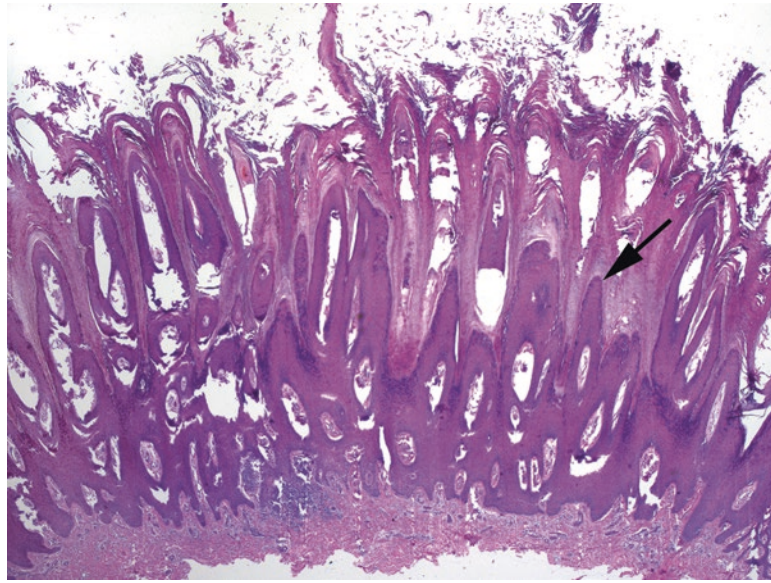


FIGURE 4.7. Verrucous pattern in a wart. Verruca vulgaris is characterized by prominent exophytic spires of the epidermis (*arrow*), with overlying hyperkeratosis and parakeratosis.

Cervix and the Anogenital Mucosa

The cervix (discussed in detail in Chapter 16) is the prototypical mucosal squamous epithelium. It can be visualized and easily biopsied, and the changes of dysplasia are well documented and well understood. Dysplastic changes in the cervix are nearly all HPV related, whereas reactive changes and squamous metaplasia are so common that they are considered normal. Dysplastic changes are grouped into low and high grade, with high-grade squamous intraepithelial lesions (HSIL) encompassing cervical intraepithelial neoplasia (CIN) grades 2 and 3. The low-grade squamous intraepithelial lesions (LSILs) show predominantly viral-type changes in the superficial epithelium and can regress. The high-grade lesions show significant dysplasia rising up from the basal layer and overtaking part or all of the epithelium. They are less likely to regress and are treated aggressively.

Low-Grade Squamous Intraepithelial Lesions

- Koilocytic (viral) changes, characterized by ballooned cells with enlarged and raisinoid nuclei, are present. Beware glycogenated normal cells, which are also ballooned but have small nuclei (Figure 4.8).
- The basal layer is disorganized, with mitoses in the lower one third of the epithelium.
- Condylomas have the same changes but a verrucous architecture.

High-Grade Squamous Intraepithelial Lesions

- Undifferentiated, immature cells occupy >50% of the epithelium (Figure 4.9).
- Mitoses occur above the lower one third of the epithelium.
- Overlying koilocytes or adjacent LSIL may be present.
- Cells can be deceptively bland-looking without prominent mitoses, but nuclei should still be enlarged with high N/C ratios.
- Beware immature squamous metaplasia, which can look like HSIL at low power.

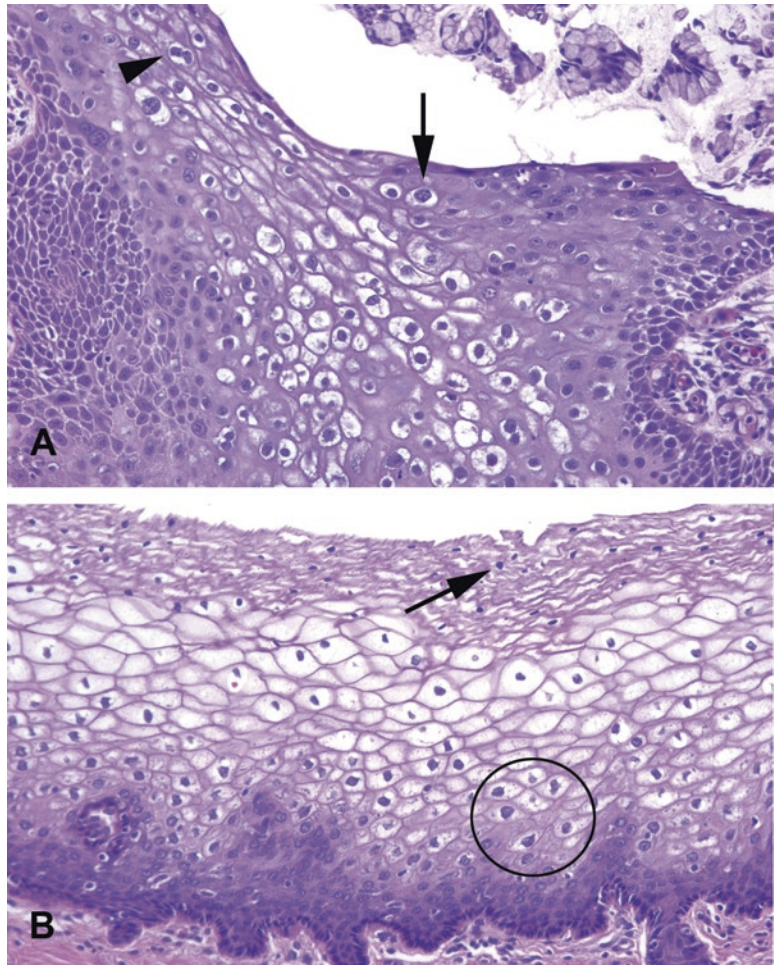


FIGURE 4.8. Viral or koilocytic atypia versus glycogen. (a) In this low-grade cervical lesion (LSIL), koilocytes are visible as large cells with prominent, crinkled, dark nuclei and perinuclear halos (*arrow*). Nuclei that get larger as you approach the surface are an indicator of dysplasia. Binucleate cells are suggestive of LSIL (*arrowhead*). (b) Normal glycogenated cervical epithelium can appear to have prominent nuclear halos, but the nuclei at the surface should be tiny and pyknotic (*arrow*). Larger cells may be seen near the basal layer (*circle*).

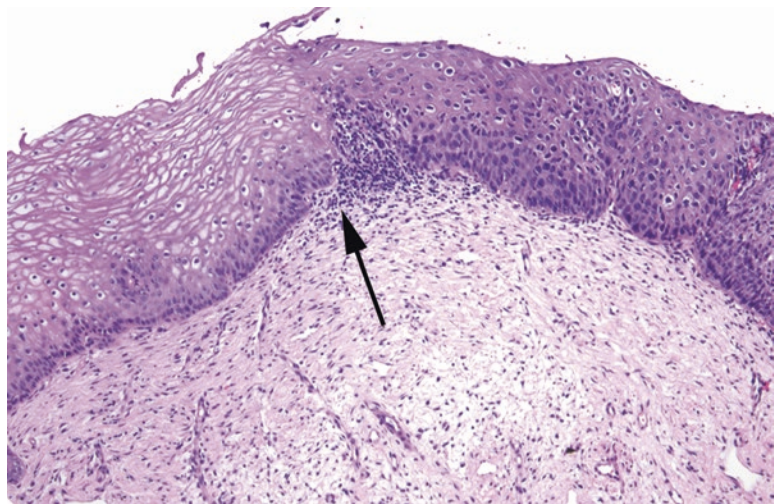


FIGURE 4.9. High-grade squamous intraepithelial lesion. An abrupt transition (*arrow*) is visible between normal (*left*) and dysplastic (*right*) epithelium. The epithelium at the right shows a persistence of immature cells (large nuclei and high N/C ratios) up to the surface. Compare this to the clear distinction between basal cells and maturing cells seen at left.

Urothelium

The benign urothelium (discussed in detail in Chapter 12) is five to seven cells thick, with an umbrella cell layer. Reactive changes look similar to those in other organs, and squamous metaplasia, dysplasia, or carcinoma can also occur.

Carcinoma arising in the urothelium can follow two pathways: flat or papillary. Flat lesions are those that progress from dysplasia to CIS to invasive carcinoma without making an exophytic lesion; these are similar to epithelia in other sites. Papillary lesions, however, break the rules of nomenclature and are graded as benign (papilloma), borderline (papillary urothelial neoplasm of low malignant potential), or cancer (low- and high-grade papillary urothelial carcinoma). Although papillary cancers are often technically *in situ*, by convention papillary cancers are simply divided into invasive or noninvasive. *Carcinoma in situ* refers only to flat lesions. The term *dysplasia* is also not applied to papillary lesions.

Do not be fooled by the von Brunn's nests. These are invaginated folds of normal urothelium, which can simulate invasion.

Features of urothelial carcinoma include the following:

- Increased number of cell layers (mainly in papillary lesions)
- Loss of polarity (loss of parallel arrays of nuclei)
- Increased mitoses, above the basal layer
- Enlarged, irregular, or hyperchromatic nuclei
- Discohesive cells or partially denuded epithelium

Oropharynx, Larynx, and Tongue

Viral squamous papillomas are relatively common in the larynx. Features of benign papillomas include hyperkeratosis (para- or ortho-), basal layer hyperplasia, abnormal mitoses, and koilocytic changes (HPV change). They should *not* have significant atypia, high-grade dysplasia, or warty architecture (church-spire keratosis). The mouth and larynx are lined by a nonkeratinized squamous epithelium, like the cervix. Unlike the cervix, however, the oral mucosa tends to keratinize in dysplasia. This leads to a different pattern of dysplasia called *severe keratinizing dysplasia*. In severe keratinizing dysplasia, the dysplasia does not have to be full thickness to behave like CIS, so it is a more insidious lesion. The criteria for grading dysplasia are much more subjective than in the cervix.

Features of squamous dysplasia in the mouth include the following:

- Loss of polarity of the basal layer and maturation arrest (basal-type cells above the basal layer)
- Dyskeratosis (abnormal keratinization), hyperkeratosis, and acanthosis
- Increased mitoses and/or mitoses above the basal layer
- Cellular and nuclear pleomorphism (unlike at many other sites, dysplastic nuclei tend to show prominent nucleoli and nuclear membranes, like an invasive carcinoma; Figure 4.10).
- Variable N/C ratios (in keratinizing dysplasia, there may be abundant pink cytoplasm)
- Not necessarily full-thickness involvement, even in severe dysplasia

Nasopharynx

Schneiderian (sinonasal) papillomas are characterized by the following:

- They are lined with a nonkeratinizing squamous or transitional epithelium, 5–30 cells thick, and may have a ciliated or mucous lining (Figure 4.11). Neutrophils are common.
- They may be fungiform (exophytic, septal) or inverted (inward growing).
- They should have only mild atypia, orderly cells, and few mitoses.

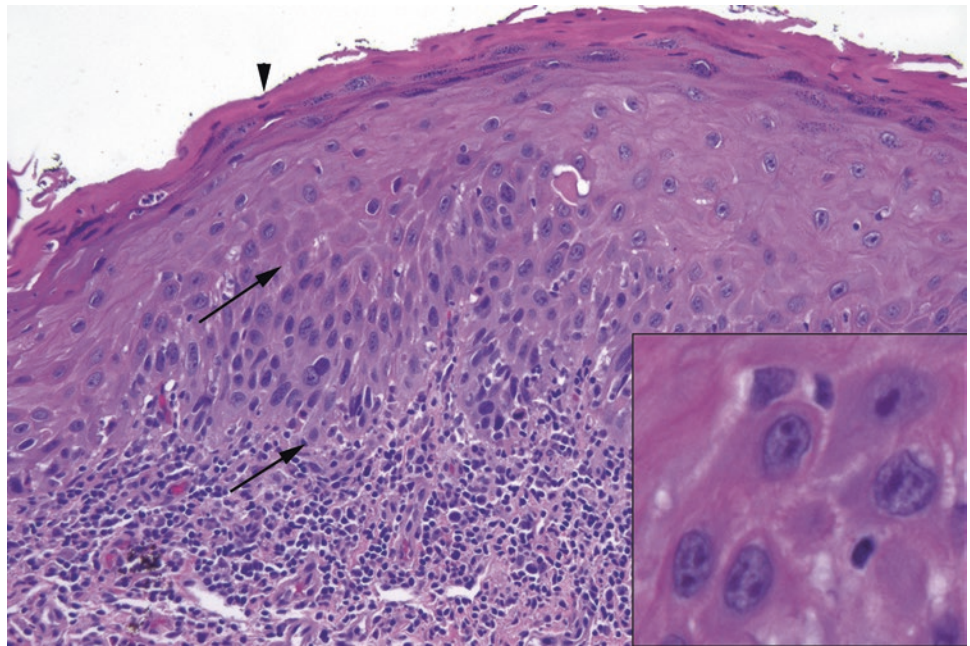


FIGURE 4.10. Squamous dysplasia in the mouth. In the area between the *arrows*, dysplastic cells with high N/C ratios and hyperchromatic, irregular nuclei can be seen occupying the lower half of the epithelium. The surface shows parakeratosis (*arrowhead*), which clinically will appear as a *white plaque*. *Inset*: Unlike in cervical dysplasia, prominent nucleoli are often seen in keratinizing dysplasia of the oral cavity. Notice the irregularly shaped, dark nuclear membranes.

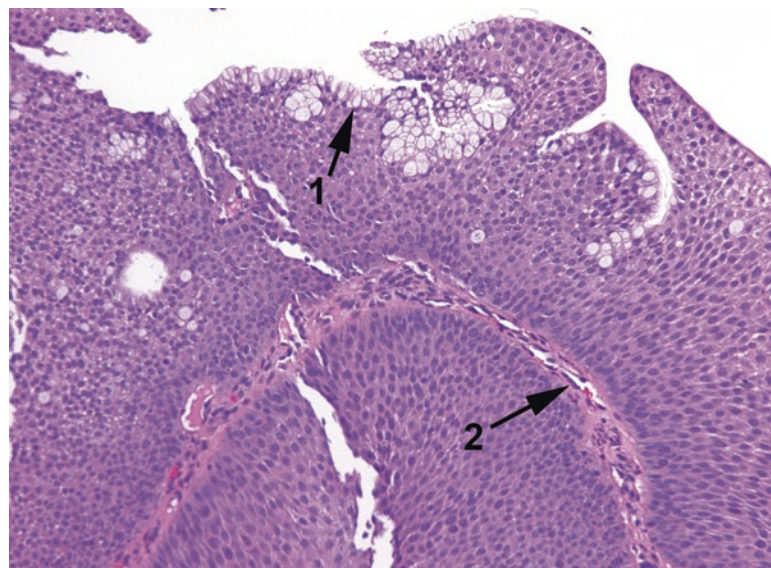


FIGURE 4.11. Schneiderian papilloma. The typical features are a squamous or respiratory epithelium with goblet cells (*1*) and neutrophils (not seen at this power). As in any papilloma, there are fibrovascular cores (*2*).

The differential diagnosis for an inverted papilloma includes an invasive squamous carcinoma. Atypia and pleomorphism, increased mitotic activity, and cells invading as nests and cords suggest a carcinoma.

Esophagus

In the esophagus (which is discussed in detail in Chapter 6), the squamous mucosa is not usually the bad actor; dysplasia is more often glandular, seen in the setting of Barrett esophagus. Mild reactive changes are very common and correspond to reflux changes. More intense reactive changes can be seen in infection. Squamous dysplasia is not often caught on biopsy, as it is asymptomatic. Squamous carcinoma looks similar to that found in other sites.

Skin

The skin is a keratinizing epithelium and is discussed in more detail in Chapter 28. Actinic keratosis, seen on sun-damaged skin, is a common form of squamous dysplasia in the epidermis. Carcinoma in situ is the most severe form of dysplasia in the skin, and the cues used in determining whether foci of invasion are present are similar to other sites.

Ditzel (slang): A word used to describe any part of the body that is not ordinarily appropriate for everyday conversation. “Susan is always walking down the hall with her ditzels hanging out” (<http://www.urbandictionary.com/>).

Ditzels are small specimens with limited educational potential. For the purposes of this chapter, these are all specimens with no suspicion or history of malignancy. They often have about three possible diagnoses and a reduced billing charge because of their limited complexity. Until you get experience with them, they slow you down inordinately at the grossing bench and at the microscope as you struggle to get the “right” wording and obsess over whether what you see is pathologic or normal. After all, it is really embarrassing to get a ditzel *wrong*. What follows is a list of typical features, things not to miss, and a suggested wording for unremarkable specimens. However, diagnosis style may vary across institutions, so take your cues from your own attendings.

Amputated Limbs

Grossing: It is gross, all right. Document the extent of gangrene, ulcers, venous stasis, trauma, etc., as well as the level of amputation and the viability of the margin. In vascular or infectious disease, identify and section the vascular margin. Take representative sections from the worst area (soft tissue) and margin. Tissue from the bony margin is usually not necessary, but softened bone under an ulcer should be sampled.

Histology: Look for gangrenous necrosis (Figure 5.1), ulceration, scar, granulation tissue, and inflammation. Evaluate vessel for atherosclerotic disease and thrombus, and bone for osteomyelitis.

Rule out: Invasive fungal disease in a neutropenic patient (requires more extensive sampling of the margin).

Sample sign-out: Left foot (amputation)—*Foot with gangrenous necrosis. Atherosclerotic vessels with thrombus and 90 % occlusion. Surgical margin appears viable.*

Appendix

Grossing: The first section should be a cross section of the proximal margin, inked or otherwise marked as margin. Then cut off the tip and take a longitudinal section (U shaped). Breadloaf the remainder, and take one to two cross sections. Look for nodules, fecaliths, hemorrhage, and pus.

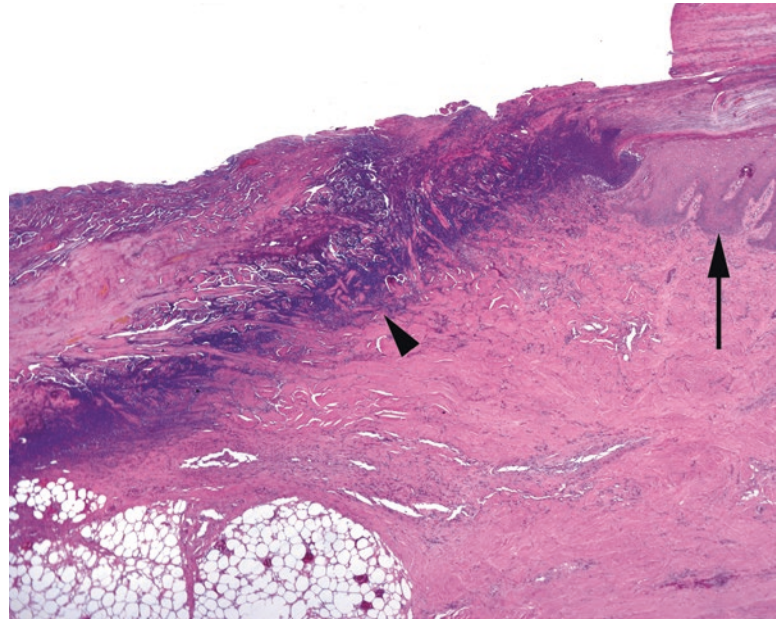


FIGURE 5.1. Gangrene. In this gangrenous ulcer of the toe, the epidermis is visible to the right (*arrow*), while the ulcer bed to the left shows an obliteration of epidermis and dermis, with a dense blue line of debris representing dying bacteria and cells (*arrowhead*).

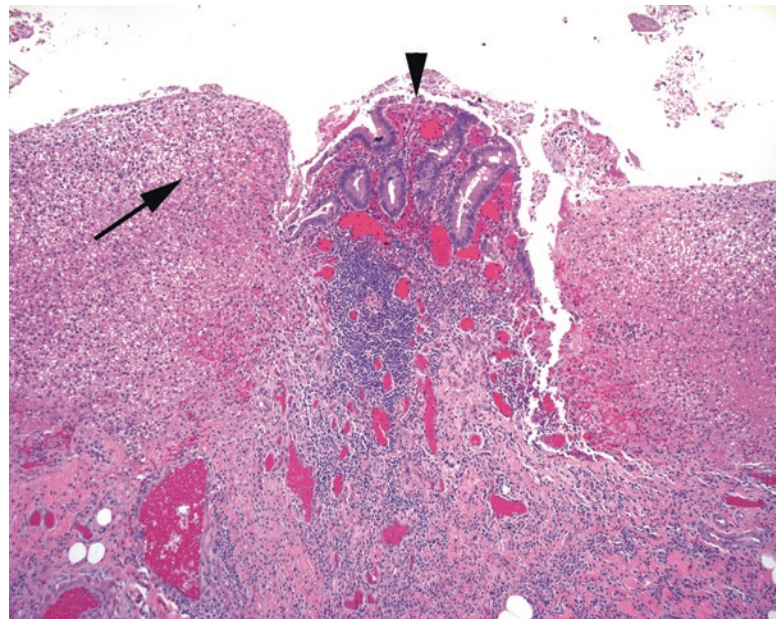


FIGURE 5.2. Appendicitis. In this close-up view, a small amount of residual colonic-type mucosa is visible (*arrowhead*), surrounded by mounds of fibrinopurulent debris (*arrow*).

Histology: Normal histology is colonic mucosa with abundant lymphoid aggregates. Chronic inflammation is not significant, but neutrophils are, whether in the mucosa, wall (transmural inflammation; Figure 5.2), or serosa (serositis). Serositis without transmural inflammation suggests another abdominal source.

Rule out: Carcinoid in the tip; pools of mucin in the wall, indicating a mucinous neoplasm. See Chapter 8 for a more detailed discussion of mucinous tumors.

Sample sign-out: Appendix (appendectomy)—*Acute transmural appendicitis with serositis* or *histologically unremarkable appendix*.

Carotid and Femoral Plaques

Grossing: Specimen is essentially a cast of the artery lumen. Take one block of representative cross sections; this usually requires light decalcification.

Histology: The inner layer of the elastic arterial wall has a variable amount of atherosclerotic debris, calcification, and/or thrombus (Figure 5.3).

Sample sign-out: Carotid artery, right (endarterectomy)—*Calcified atherosclerotic plaque.*

Chalazion of Eyelid

Grossing: Entirely submit; usually a small piece of tissue.

Histology: Lipogranulomas in the soft tissue, with giant cells and acute and chronic inflammation (Figure 5.4).

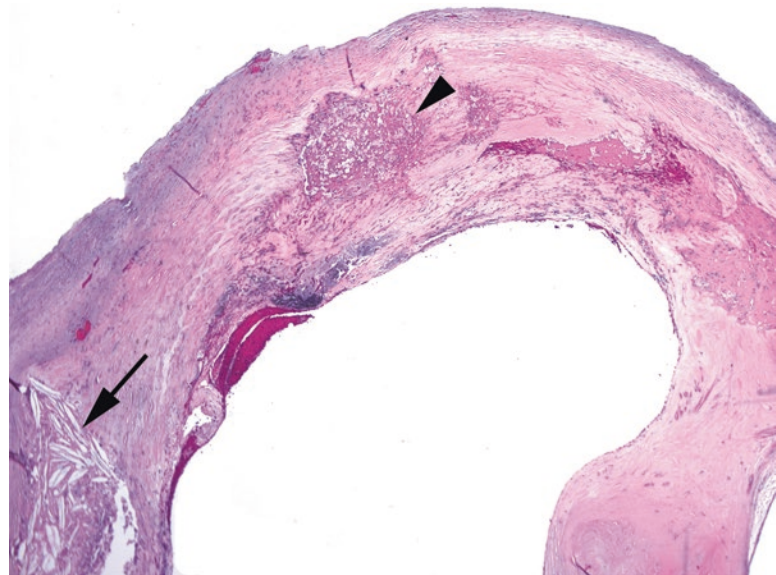


FIGURE 5.3. Carotid plaque. This represents the intimal surface of the artery, in which there may be calcification, foamy macrophages (*arrowhead*), cholesterol clefts (*arrow*), or inflammatory debris.

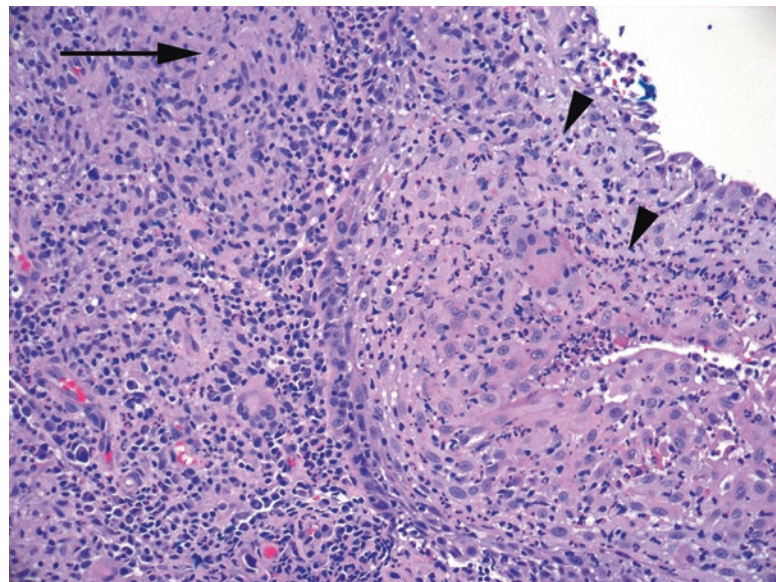


FIGURE 5.4. Chalazion. The squamous mucosa is inflamed (*arrowheads*), and the stroma shows granulomatous inflammation (*arrow*), and abundant inflammatory cells.

Rule out: Carcinoma, which can resemble the chalazion clinically. Stains for microorganisms are not necessary in routine cases.

Sample sign-out: Right upper eyelid (excision of mass)—*Chalazion* or *conjunctival epithelium with lipogranuloma consistent with chalazion*.

Cholesteatoma of Middle Ear

Grossing: A small, whole specimen is usually submitted.

Histology: A cyst is formed by keratinizing epithelium and filled with flaky keratin. Other features can include inflammation, cholesterol clefts, and foreign body giant cells (Figure 5.5).

Rule out: Differential diagnosis of a middle ear mass includes inflammatory polyp, paraganglioma, middle ear adenoma, meningioma, and schwannoma.

Sample sign-out: Left middle ear (excision)—*Cholesteatoma* or *fragments of keratinaceous debris (clinical cholesteatoma)*.

Cornea

Grossing: Cut the corneal button into cross sections using a fresh blade, and submit in tissue paper or biopsy bag.

Histology: The normal cornea consists of an outer squamous epithelium, a hyalinized layer under that called the Bowman layer, a thick layer of paucicellular pink stroma, another hyalinized layer called the Descemet membrane, and thin endothelium (Figure 5.6). There may be disruptions or inflammatory changes to these components depending on the disease process. Bumps on the Descemet membrane are called guttae and are seen in Fuchs dystrophy and some other conditions.

Rule out: In the presence of acute inflammation or ulceration, rule out infectious organisms, including bacteria, *Acanthamoeba*, or herpes virus.

Sample sign-out: Left cornea (excision)—*Descemet membrane with guttae consistent with the clinical history of Fuchs disease*.

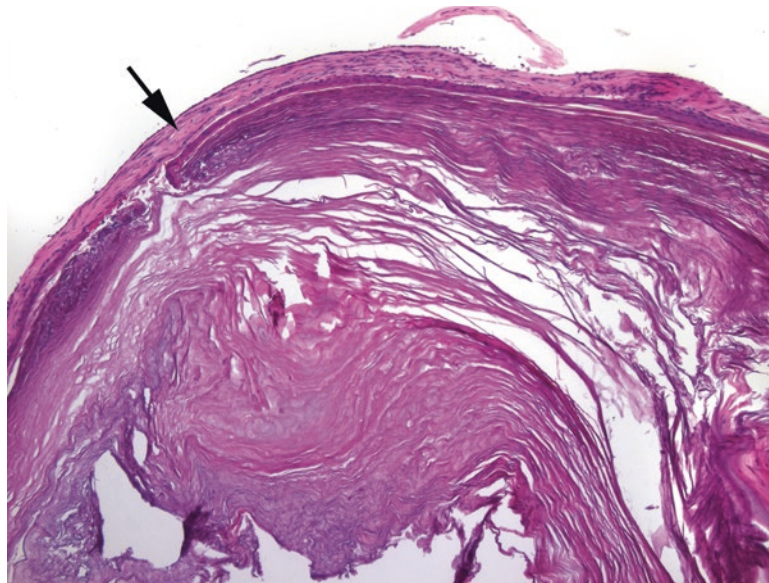


FIGURE 5.5. Cholesteatoma. The specimen is dominated by layers of pink keratin; the thin epithelium can be seen surrounding the keratin nodule (*arrow*).

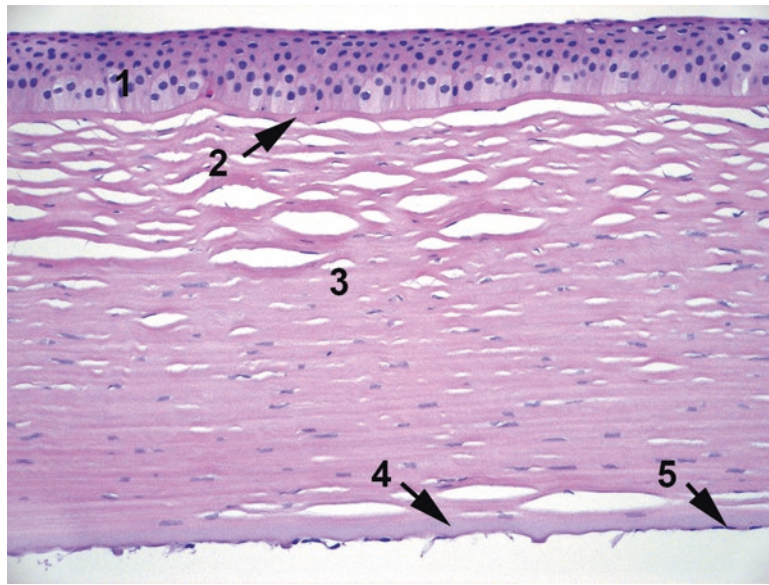


FIGURE 5.6. Cornea. The normal layers of the cornea are (1) an outer squamous epithelium; (2) an acellular Bowman layer; (3) stroma, shown here with some cracking artifact; (4) the slightly bluish acellular Descemet membrane; and (5) nuclei of the thin endothelium.

Cysts of the Jaw (Odontogenic)

Grossing: The specimen usually consists of curettings; submit entirely.

Histology: Odontogenic cysts may be non-neoplastic, in which case they are named by their clinical location and presentation, including the common periapical cyst (an inflammatory cyst at the tooth root) and dentigerous cyst (a fluid inclusion cyst associated with an impacted tooth). These are lined by squamous or enamel epithelium with or without inflammation. Small islands of odontogenic epithelium may be seen in a dentigerous cyst. A cyst lined by a stellate reticulum-like epithelium, however, brings ameloblastoma into the differential, which is beyond the scope of this chapter.

Rule out: The *keratocystic odontogenic tumor (KOT)*, formerly odontogenic keratocyst, is a neoplasm and should not be missed. This differs from the non-neoplastic cysts in that the squamous epithelium is flat at the base (no rete) and undulating at the surface, with parakeratosis (Figure 5.7).

Sample sign-out: Mandible (excision of cyst)—*Squamous mucosa with extensive acute and chronic inflammation (clinical periapical cyst).*

Debridement

Grossing: One or two representative sections should suffice. Submit bone fragments if included.

Histology: You may see gangrenous necrosis, ulcerated skin or mucosa, abscess, granulation tissue, or fat necrosis.

Rule out: It is not necessary to do bacterial or fungal stains in most cases. However, in the case of extensive skin necrosis, examine the deep subcutaneous vessels for angioinvasive fungal hyphae (visible on H&E) or calciphylaxis (calcification of the vessel walls). Rule out osteomyelitis in bone fragments. Acute osteomyelitis should show sheets of neutrophils (not as part of normal hematopoiesis), bone necrosis, and granulation tissue within the marrow space. Chronic osteomyelitis may show granulation tissue or fibrosis and lymphoplasmacytic inflammation. Bone remodeling (new viable bone laid down on top of dead bone) may be visible.

Sample sign-out: Sacrum (debridement)—*Ulcerated skin and subcutaneous fat with gangrenous necrosis. Features of acute suppurative osteomyelitis are not identified.*

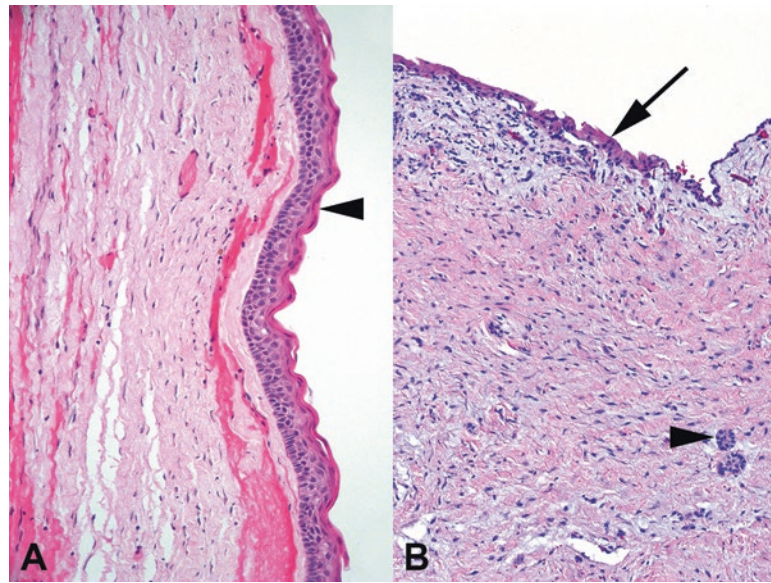


FIGURE 5.7. (a) Keratocystic odontogenic tumor of jaw. The squamous epithelium has a flat basal layer without rete and a corrugated surface with parakeratosis (*arrowhead*). (b) In contrast, the dentigerous cyst shows a flat nonkeratinized squamous epithelium (*arrow*) with underlying islands of odontogenic epithelium (*arrowheads*).

Eyelids (Plastic Repair)

Grossing: One representative section from each tissue fragment.

Histology: Unremarkable skin with hair follicles and often solar elastosis of the dermis; specimens of the eyelid itself may have nonkeratinized conjunctival epithelium.

Rule out: Any unexpected neoplasms will be pretty obvious.

Sample sign-out: Bilateral upper eyelids (revision)—*Benign skin with mild chronic inflammation and solar elastosis.*

Femoral or Humeral Head, Knee Bones

Grossing: Use a bone saw to cross-section the bone and get a 2 mm slice. Describe eburation (absence of cartilage), osteophytes, femoral neck (fracture vs. surgical), infarcts, and subchondral cysts. Sample the articular surface, plus the margin or fracture site in fracture cases. Submit for routine decalcification.

Histology: Healthy bone has a thick cartilage layer with a smooth articular surface and marrow between the trabeculae. Look for the following:

- Osteoarthritis: uneven and ragged or absent cartilage, clonal nests of chondrocytes, dual tide-line, thickened and sclerotic subchondral bone, subchondral cysts, fibrosis, and granulation tissue within marrow (Figure 5.8).
- Osteonecrosis: loss of basophilia and nuclei in the marrow, fat cells, and osteocytes; fat necrosis; hemorrhage (Figure 5.9).
- Osteopenia: markedly thinned trabeculae.
- Metastatic carcinoma: epithelial cells in an area of fracture. Sometimes the only visible evidence of a metastasis is dense fibrosis, so do a keratin immunostain if you see this. Melanoma and lymphoma can also cause a pathologic fracture but should not be subtle.

Sample sign-out: Right femoral head (arthroplasty)—*Femoral head with osteonecrosis and fracture or bone and cartilage with degenerative changes or just osteoarthritis.*

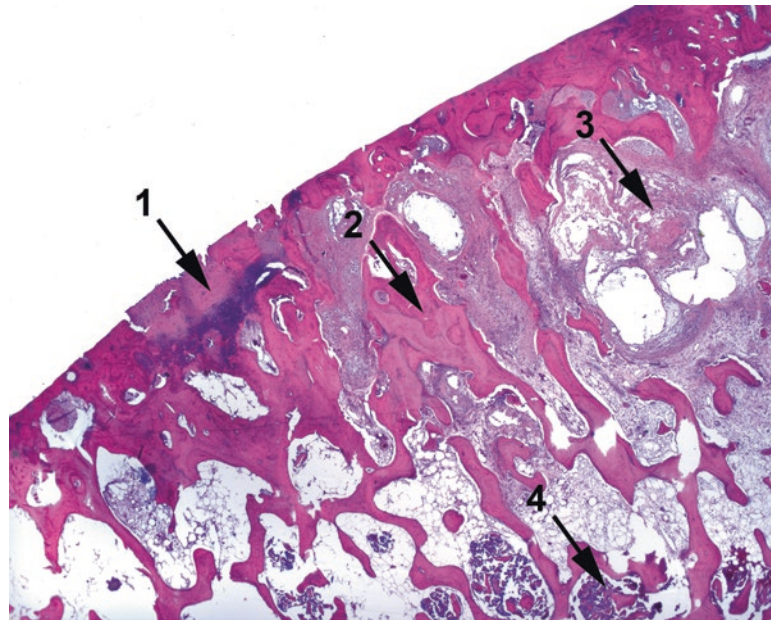


FIGURE 5.8. Osteoarthritis. Features include (1) eroded cartilage, in this case nearly absent, and irregular mineralization of the cartilage, seen here as a dark purple stain; (2) thickening of the subchondral bony trabeculae; (3) myxoid degeneration of the subchondral bone, forming cyst-like spaces; and (4) some residual hematopoietic marrow.

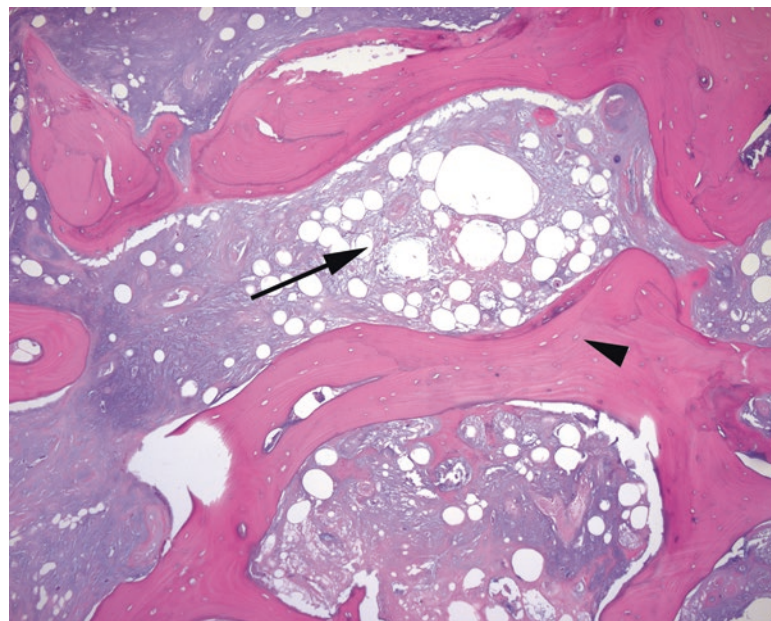


FIGURE 5.9. Osteonecrosis. The necrotic marrow is the most eye-catching feature (*arrow*), showing fat necrosis and an absence of marrow elements. On close examination, the osteocytes within lacunae are also dead or missing (*arrowhead*).

Gallbladder

Grossing: The first section should be a cross section of the cystic duct margin. Open the gallbladder, look for stones, and take two sections of the wall. Note the wall thickness and describe the mucosa. All three fragments can go in one cassette.

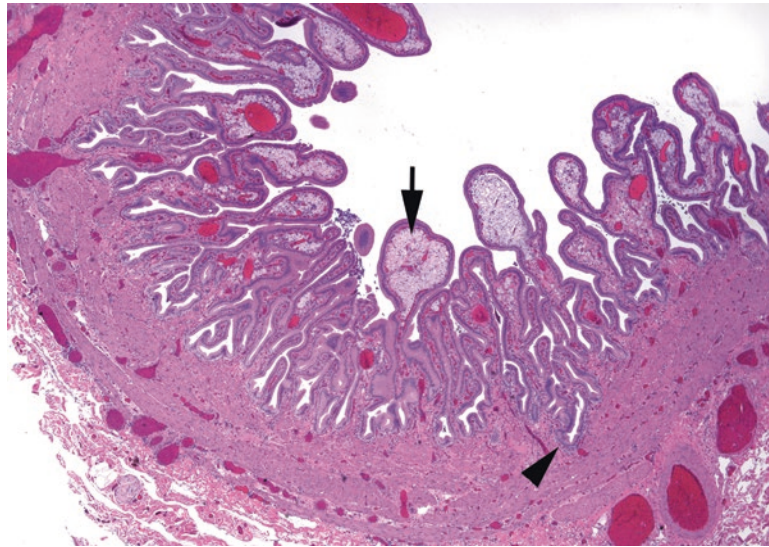


FIGURE 5.10. Gallbladder with cholesterolosis. The mucosal folds are distended with foamy macrophages (*arrow*), called cholesterolosis. Inflammation is minimal in this example. Rokitsky–Aschoff sinuses can penetrate deeply into the gallbladder wall (*arrowhead*).

Histology: The gallbladder is lined by a single layer of columnar epithelium in folds, overlying a fibromuscular layer that sometimes contains Rokitsky–Aschoff sinuses (infolded mucosa) or ducts of Luschka. Cholecystitis can range from mild lymphoplasmacytic inflammation to transmural acute inflammation. Cholesterolosis is the accumulation of foamy macrophages (Figure 5.10).

Rule out: Dysplasia or carcinoma is rare in an isolated cholecystectomy. If you find dysplasia, go back for more sections.

Sample sign-out: Gallbladder (cholecystectomy)—*Chronic cholecystitis, cholelithiasis, and cholesterolosis or acute and chronic cholecystitis.*

Ganglion Cyst

Grossing: Submit the entire specimen, usually.

Histology: The ganglion cyst is not a true cyst, so there is no epithelium, but there may be synovial cells lining a cavity. More often the cyst is just myxoid degeneration of the soft tissue (Figure 5.11).

Rule out: A giant cell tumor of tendon sheath or a fibroma may occasionally be mistaken clinically for a ganglion cyst.

Sample sign-out: Left wrist (excision of cyst)—*Ganglion cyst or fibrous tissue with myxoid degeneration consistent with ganglion cyst.*

Heart Valves

Grossing: There is much information to be gained in grossing. Review your grossing manual for details. Note the presence of vegetations, commissural fusion, calcification, and redundancy.

Histology: Look for myxoid degeneration, calcification, and adherent vegetations (Figure 5.12).

Rule out: Use Gram and GMS stains on vegetations to rule out bacteria or fungus.

Sample sign-out: Aortic valve (excision)—*Valve with myxoid degeneration and calcification or valve with adherent fibrinopurulent debris. Numerous Gram-positive cocci are seen on Gram stain.*

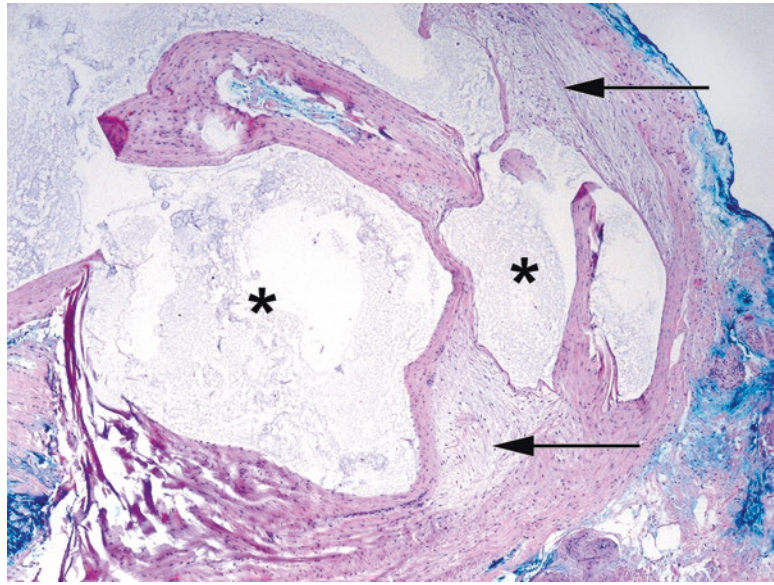


FIGURE 5.11. Ganglion cyst. The soft tissue shows myxoid degeneration (*arrows*) with serous fluid collecting in irregular cystic spaces (*asterisks*). There is no epithelial lining.

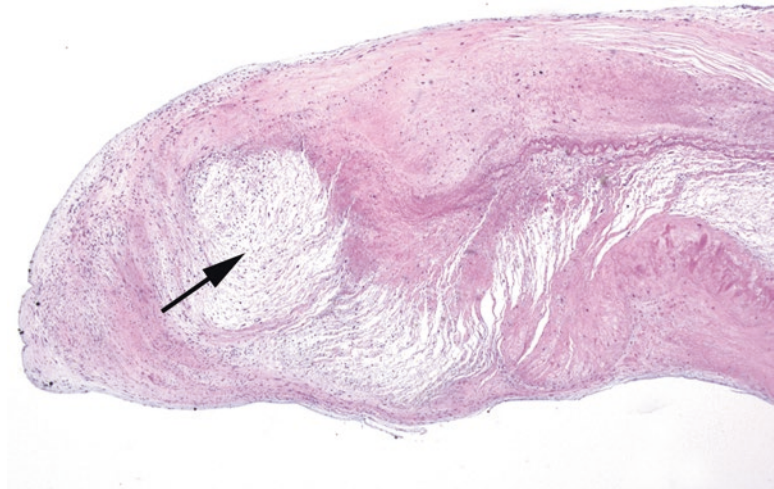

FIGURE 5.12. Myxoid degeneration, heart valve. In the free end of this heart valve, there is an attenuated pale area of myxoid degeneration (*arrow*). Calcifications and vegetations may also be seen.

Hernia Sac

Grossing: Submit a representative section.

Histology: A pouch of fibroadipose tissue is lined with mesothelium, which can be reactive or proliferative (Figure 5.13).

Rule out: A piece of the vas deferens (warrants an immediate call to the surgeon), incarcerated bowel, or metastatic tumor (especially incisional hernias).

Sample sign-out: Soft tissue, right inguinal (herniorrhaphy)—*Hernia sac* or *fibrovascular tissue (clinical hernia sac)*.

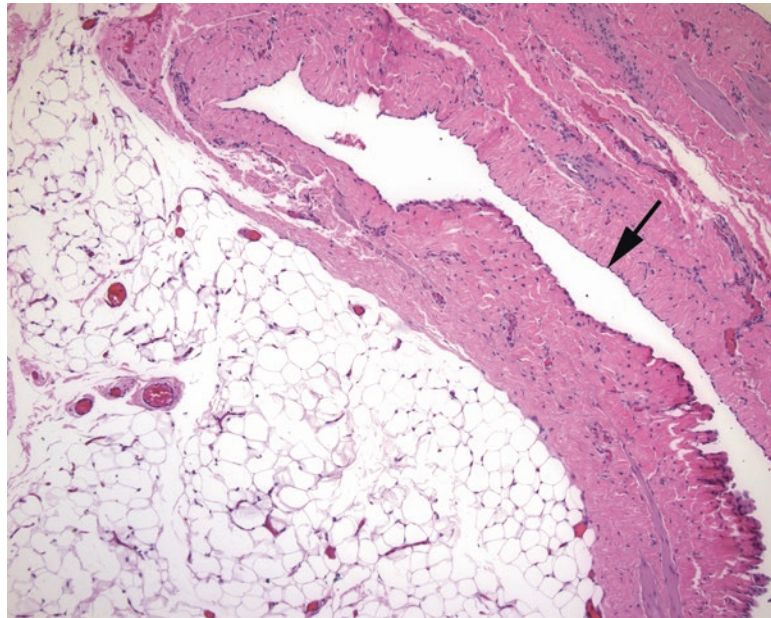


FIGURE 5.13. Hernia sac. Thick fibrous tissue and fat characterize the typical hernia sac. In this section, the delicate mesothelial lining (*arrow*) is visible.

Intervertebral Disc

Grossing: Submit one block of representative or total material.

Histology: Fibrocartilage and pulpy myxoid gel (the nucleus pulposus), possibly with fragments of bone (Figure 5.14), are present.

Rule out: Tumors, inflammation.

Sample sign-out: Cervical disc (excision)—*Fragments of disc material.*

Lipoma

Grossing: Measure it. It never hurts to ink it. Submit thin slices (one per centimeter), and give them a nice long fixation time. Sample areas that are fibrous, fleshy, hemorrhagic, or otherwise nonfatty.

Histology: The definition of a lipoma is a neoplasm of mature fat cells. Small septa of fibrous tissue are okay, but a second cell type (such as smooth muscle cells or spindle cells) may indicate a lipoma variant.

Rule out: Exclude atypical lipomatous tumor (well-differentiated liposarcoma). Clinical features that are suspicious include a large deep-seated circumscribed mass in the skeletal muscle, retroperitoneum, or scrotum of an adult. Histologic features include thick fibrous bands with atypical cells (large hyperchromatic nuclei) and lipoblasts (Figure 5.15). More details on liposarcomas are given in Chapter 29.

Sample sign-out: Soft tissue, left flank (excision)—*Lipoma (12 cm) or mature adipose tissue (clinical lipoma).*

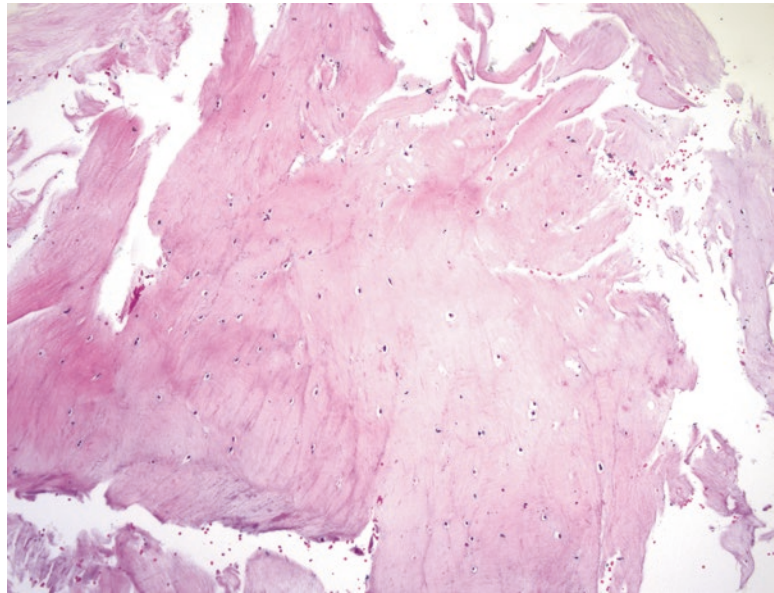


FIGURE 5.14. Intervertebral disc. The disc substance is paucicellular, with a homogeneous translucent stroma (ranging from myxoid to collagenous).

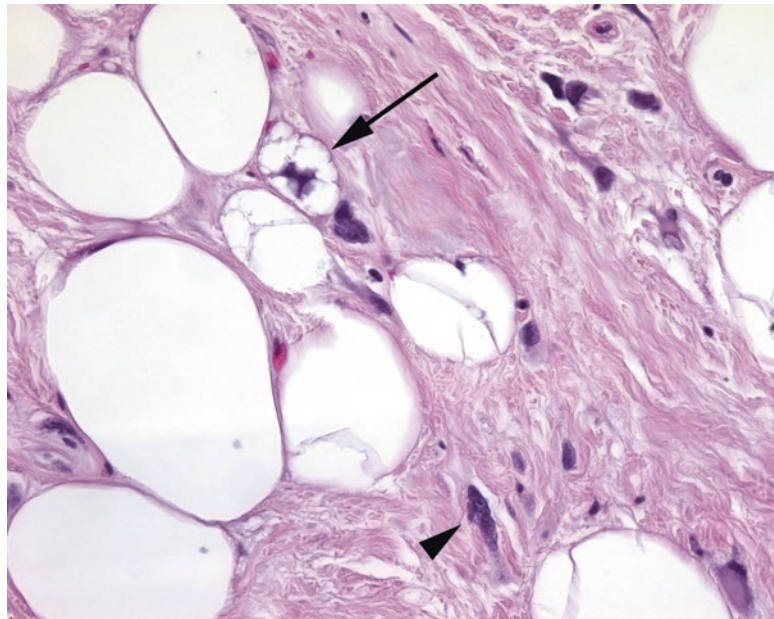


FIGURE 5.15. Lipoblast in an atypical lipomatous tumor. What you do not want to see in your lipoma—lipoblasts (*arrow*), with small fat vacuoles indenting the nucleus and atypical hyperchromatic cells within the fibrous stroma (*arrowhead*).

Neuroma

Grossing: Submit the entire thing, usually.

Histology: A neuroma is a tangle of small nerve fibers in a fibrous background, usually associated with a prior surgery (Figure 5.16). The Morton neuroma is fibrosis and degeneration of the nerves of the feet, not related to trauma.

Rule out: A true neoplasm, such as a peripheral nerve sheath tumor.

Sample sign-out: Right hand (excision of mass)—*Traumatic neuroma*.

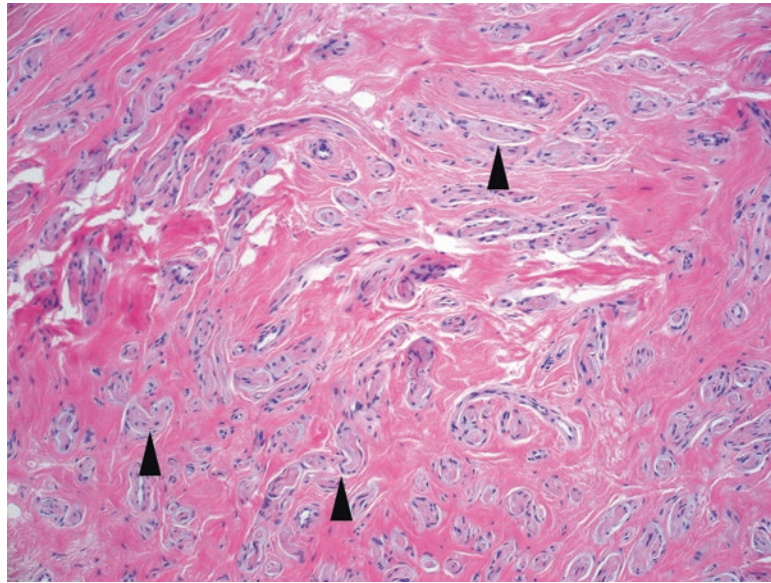


FIGURE 5.16. Neuroma. Tiny disorganized nerve twigs (*arrowheads*) are set in a background of dense pink fibrosis.

Parathyroid

Grossing: *Weigh it.* Submit it in its entirety.

Histology: Features include monotonous round neuroendocrine cells with clear cytoplasm (chief cells) or abundant pink cytoplasm (oxyphil cells). Normal weight is around 50 mg; adenomas are usually >300 mg. *Adenoma* is a clinical diagnosis requiring evidence of normalized parathyroid hormone level after surgery. Hyperplasia and adenoma may look the same on the slide (Figure 5.17).

Rule out: Carcinoma is very rare, but dense fibrotic bands and nuclear atypia are suggestive. The diagnosis of carcinoma requires capsular or vascular invasion.

Sample sign-out: Left superior parathyroid (excision)—*Cellular parathyroid tissue (250 mg).*

Pyogenic Granuloma

Grossing: This is often a small skin biopsy which can be entirely submitted.

Histology: The other name for this entity is a lobular capillary hemangioma, which is a better descriptive name. At low power the pyogenic granuloma should have a rounded contour, usually with a surface of ulcerated skin or squamous mucosa (Figure 5.18). The stroma within the polypoid lesion resembles granulation tissue, with capillaries, acute and chronic inflammation, and edema. It is neither granulomatous nor pyogenic, sadly.

Rule out: An ulcerated skin tumor.

Sample sign-out: Lip (biopsy of mass)—*Ulcerated squamous mucosa with granulation tissue, consistent with pyogenic granuloma, or just pyogenic granuloma.*

Scar Revision

Grossing: Breadloaf and take one to two representative sections through the scar. Note that this does not apply to re-excision of a skin cancer or melanoma, which must usually be entirely submitted.

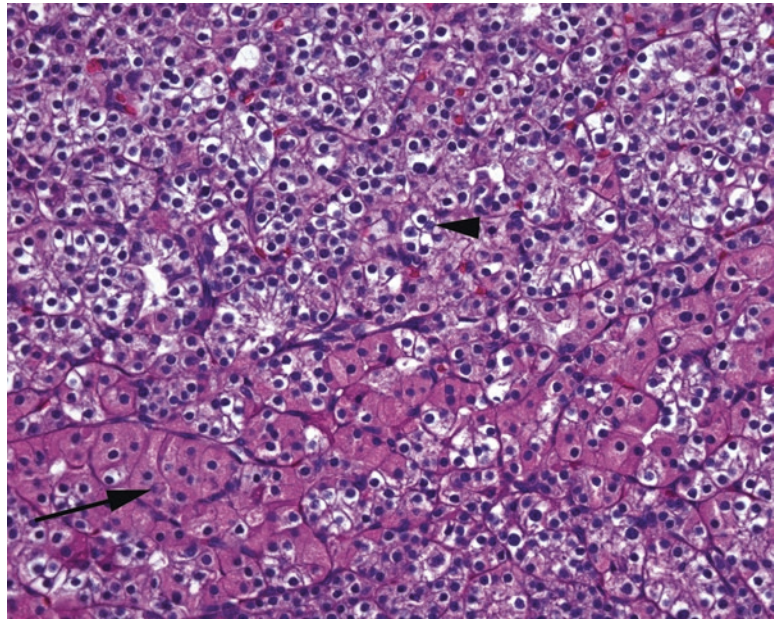


FIGURE 5.17. Parathyroid tissue. Normal parathyroid has two cell populations, the chief cells (*arrow-head*) and oxyphil cells (*arrow*).

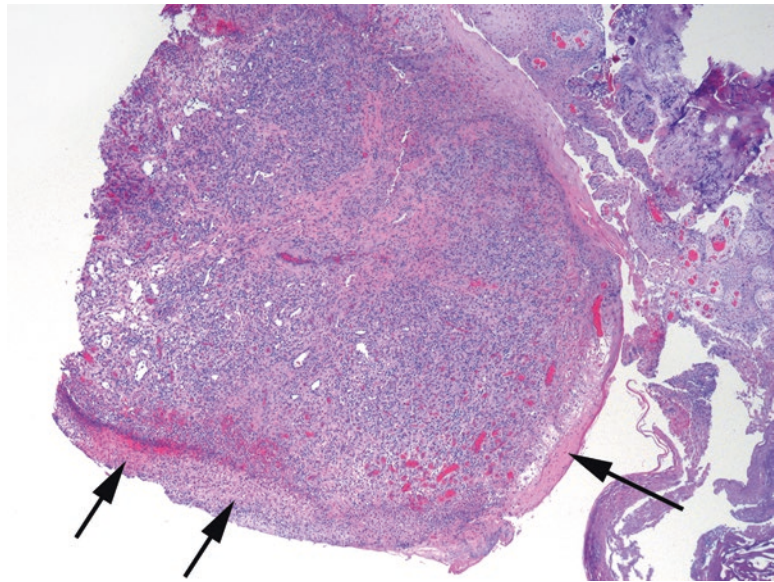


FIGURE 5.18. Lobular capillary hemangioma (pyogenic granuloma). The surface is covered by an ulcerated squamous epithelium (*arrows*), but the center of the polyp consists of small capillaries, granulation tissue, and acute and chronic inflammation.

Histology: Dermal scar has dense fine pink collagen, no appendages, and thin epithelium (Figure 5.19). Recent injury or surgery will show hemorrhage, foamy macrophages, inflammation and granulation tissue, suture material, and foreign body-type giant cells.

Rule out: Exclude tumor, if there is a history of tumor, and abscess.

Sample sign-out: Left abdominal wall (scar revision)—*Skin with dermal scar, negative for tumor, or skin with biopsy site changes and suture material.*

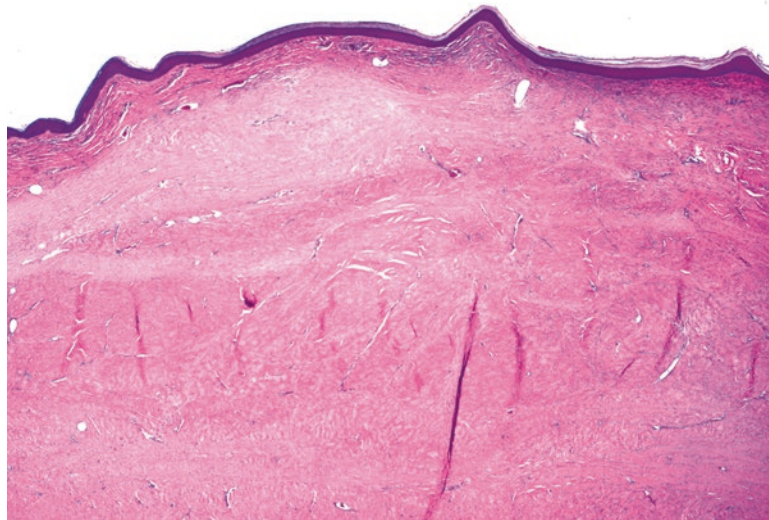


FIGURE 5.19. Dermal scar. Pale and homogeneous collagen underneath the epidermis, with obliteration of adnexal structures, is typical of scar formation.

Sinus Contents

Grossing: Aspirate sent in a nylon bag. Submit one to two blocks, depending on volume. Use biopsy bags in cassettes.

Histology: Normal components include fragments of bone, respiratory and squamous mucosa, and mucous glands.

- Chronic sinusitis: edema, acute and chronic inflammation
- Allergic fungal sinusitis: sheets of allergic mucin (Figure 5.20) and Charcot–Leyden crystals

Rule out: If allergic mucin is present, get a PAS or GMS stain to rule out fungus; other sinus lesions include polyps, papillomas, and unusual tumors.

Sample sign-out: Right and left sinus contents (aspiration)—*Chronic sinusitis* or *fragments of respiratory mucosa with chronic inflammation* or *allergic fungal sinusitis (a PAS stain highlights fungal organisms within the mucin)*.

Temporal Artery

Grossing: The small segment of artery must be thinly cross-sectioned and submitted entirely, but may all be in one block; multiple levels are required to find focal lesions.

Histology: The normal temporal artery has a loose outer adventitia, a muscular media, and an intima, with endothelium as the innermost layer. There is an undulating internal elastic lamina (best seen on elastin stain) between the intima and media. Normal aging changes include medial calcification, intimal thickening, and reduplication and small breaks in the elastic lamina.

Rule out: The point of the biopsy is to look for giant cell arteritis (temporal arteritis). Technically, this is an important diagnostic biopsy, not a ditzel, but it is included here for convenience. Giant cell arteritis may be acute or resolving (Figure 5.21). In the acute phase, there is chronic inflammation with or without giant cells, centered on the elastic lamina, which is disrupted by the process. In a healing or treated lesion, the inflammation may have subsided, but you will see fibrosis and destruction of the elastic layer.

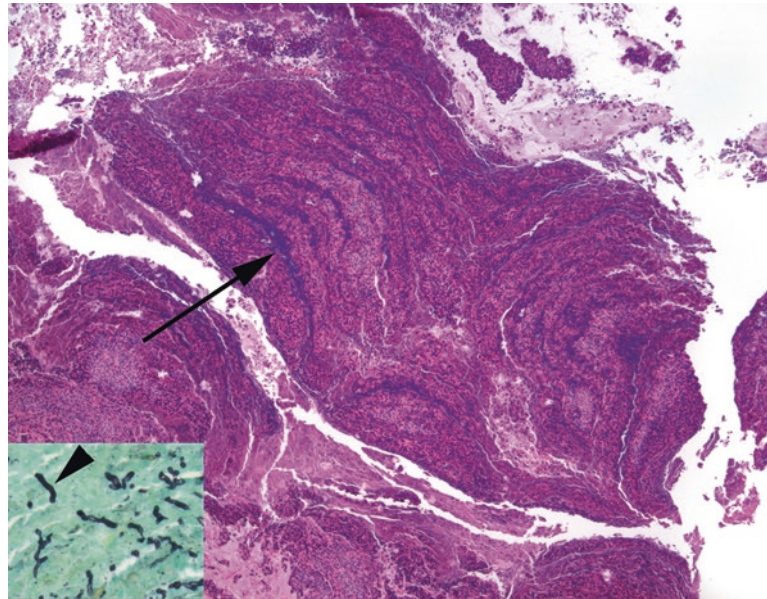


FIGURE 5.20. Allergic mucin in sinusitis. The allergic mucin takes on a characteristic tiger-striped appearance (*arrow*) as layers of eosinophils, mucin, and cell debris accumulate. *Inset:* A GMS stain shows *black* fungal hyphae (*arrowhead*).

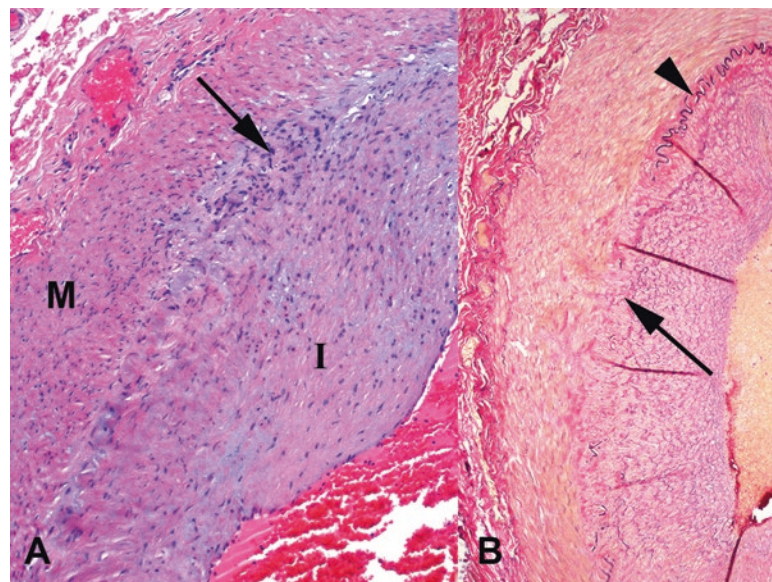


FIGURE 5.21. Giant cell arteritis. (a) There is a small, subtle collection of inflammatory cells and giant cells (*arrow*) at the interface between the media (*M*) and the thickened intima (*I*). (b) An elastin stain highlights the destruction (*arrow*) of the internal elastic lamina (seen intact at the *arrowhead*).

Sample sign-out: Right temporal artery (biopsy)—*Segment of muscular artery with no significant inflammation; no evidence of temporal arteritis or, if positive, chronic inflammation and giant cells with destruction of the internal elastic lamina, consistent with arteritis.*

Tonsils and Adenoids

Grossing: One or two cross sections from each tonsil or adenoid fragment are sufficient.

Histology: The tonsils have large lymphoid follicles with overlying nonkeratinizing squamous epithelium; this epithelium is normally infiltrated with lymphocytes (Figure 5.22). Clumps of filamentous *Actinomyces* in the crevices are not worthy of mention. Verify that the germinal centers are benign (see Chapter 21 for the hallmarks of benign follicles) and that the squamous epithelium is not malignant.

Rule out: Follicular lymphoma or another lymphoma in an adult; squamous carcinoma in an adult.

Sample sign-out: Tonsils and adenoids (tonsillectomy)—*Chronic inflammation and lymphoid hyperplasia.*

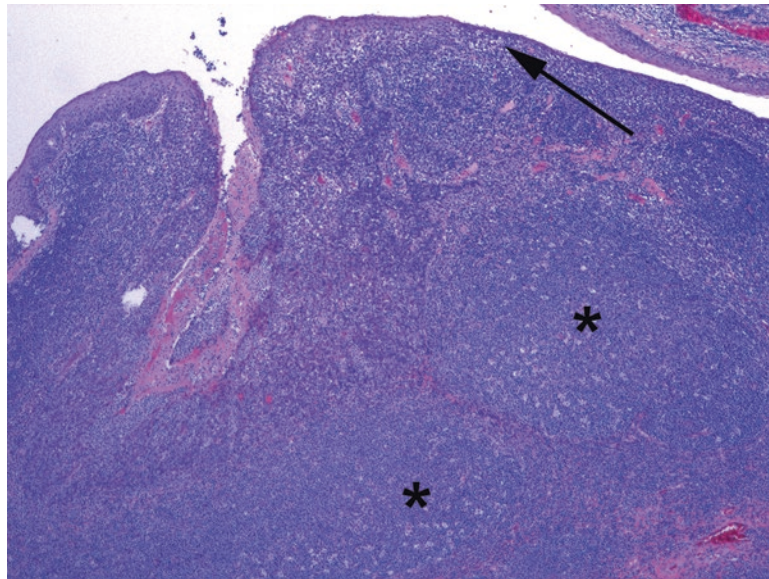


FIGURE 5.22. Tonsil. The squamous mucosa is densely infiltrated with lymphocytes (*arrow*). There are large lymphoid follicles underneath the mucosa (*asterisks*).

The esophagus is composed of a nonkeratinized squamous epithelium overlying a thin lamina propria and muscularis mucosa. Beneath that, the submucosa contains lymphatics and mucous glands with cuboidal-lined ducts running up to the luminal surface. Under the submucosa is muscularis propria (skeletal muscle proximally, smooth muscle distally), surrounded by the adventitia, which is continuous with mediastinum.

Most esophageal biopsies are performed on patients with symptoms of reflux or dysphagia, and often the goal is to rule out Barrett's esophagus, a glandular metaplasia that puts the patient at increased risk for adenocarcinoma. Other common findings include reflux changes in the squamous epithelium, ulcers, or infection. Squamous dysplasia is uncommon.

Approach to the Slide

On low power, survey the epithelium. A normal biopsy specimen (Figure 6.1) will have a bland pink squamous epithelium and scant underlying lamina propria; muscularis mucosa is usually not present. Occasional lymphocytes in the epithelium are typical (so-called squiggle cells because of their stretched-out appearance). The epithelium should not be interrupted or undermined by gastric-type glands, although salivary-like mucous glands are okay.

Within the squamous epithelium, look for the following:

- Basal cell hyperplasia (an increase over the normal three-cells-deep layer). Basal cells are the deepest layer of squamous cells and are the regenerative cell layer. They are defined by their closely packed nuclei: if you cannot squeeze a new nucleus between two existing nuclei, they are basal cells.
- Elongated vascular papillae (into the upper third of the epithelium).
- Balloon cell change of epithelium (excess clear glycogen in the cytoplasm).
- Intraepithelial neutrophils or eosinophils.
- Erosions, fibrinopurulent exudate, granulation tissue.
- Columnar cell mucosa or glands.
- Squamous debris which has been sloughed from the epithelium.

Eosinophils

Eosinophils are not a normal component of the esophageal epithelium, and the presence of even a single eosinophil should prompt you to look for other features of reflux esophagitis. *Reflux esophagitis*, secondary to gastroesophageal reflux disease (GERD), is a common condition which is associated with the first four features in the preceding list (Figure 6.2a).

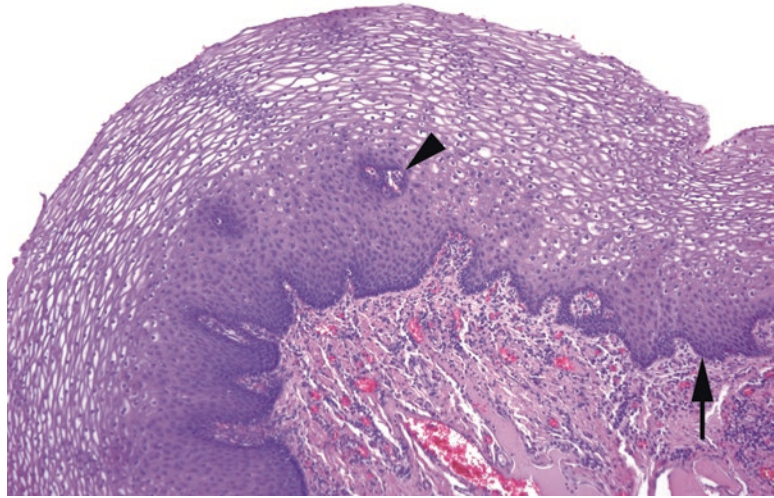


FIGURE 6.1. Normal esophageal mucosa. The basal layer (*arrow*) is seen as a crowded and *blue layer* at the base. The cells mature into flat nonkeratinizing squamous cells with small nuclei; the clear cytoplasm seen here is glycogen. Vascular pegs penetrate into the epithelium (*arrowhead*). The vascular lamina propria is visible below the basal layer.

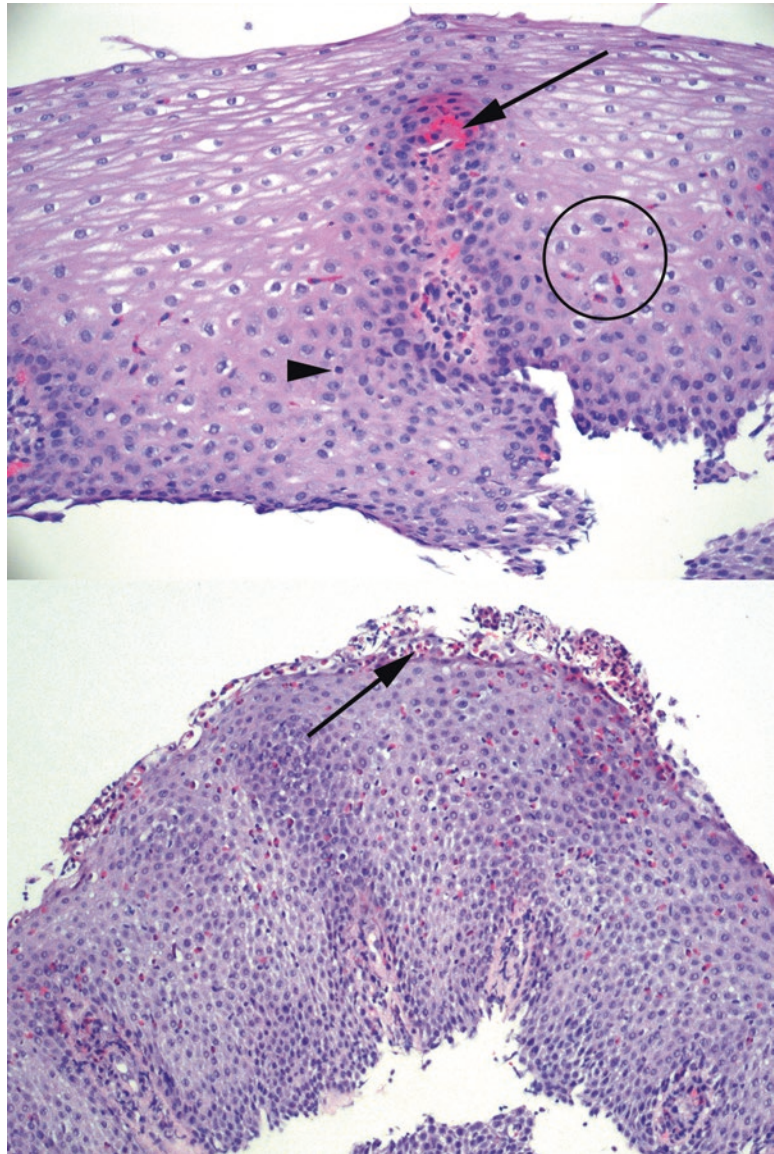


FIGURE 6.2. (*Top*) Reflux esophagitis. There are inflammatory cells scattered throughout, including eosinophils (*circle*) and lymphocytes (*arrowhead*). The vascular peg (*arrow*) extends nearly to the surface. (*Bottom*) Eosinophilic esophagitis, low power. The epithelium is very blue due to the high N/C ratio of the reactive squamous cells, and there are dense clusters of eosinophils, including microabscesses at the surface (*arrow*).

Not all features need be present in every case and typically are not. Severe cases may progress to erosions and ulcerations. The inflammation in reflux is mainly lymphocytic, but the presence of scattered eosinophils supports the diagnosis. In reflux esophagitis, the damage is most noticeable distally, close to the gastroesophageal junction.

In contrast, there is a distinct condition called *eosinophilic esophagitis* which shows increasing involvement as you move proximally in the esophagus. Eosinophilic esophagitis is mainly an allergy-induced pediatric disease, and although it shares histologic features with reflux, the eosinophils tend to:

- Be more numerous (usually >15 per high power field)
- Be grouped into microabscesses (clusters of >4 eosinophils)
- Show degranulation of contents
- And be clustered at the surface of the epithelium (Figure 6.2b)

Stylistically, as the changes seen in GERD are not specific (nor are they seen in all cases of documented reflux), the diagnosis is often descriptive, such as “reactive epithelial changes of the type seen in reflux esophagitis.” Similarly, there is no magic number of eosinophils that indicates eosinophilic esophagitis over reflux, so clinical findings must always be taken into consideration.

Neutrophils

A prominent neutrophilic infiltrate points more to an infection or acute injury than to reflux. A PAS stain can help to find *Candida* organisms (pseudohyphae and yeast forms in the epithelium or exudate; Figure 6.3). They may be very numerous or extremely scanty. Luminal squamous debris is another hint to look closely for *Candida*. Candidal infection is typically associated with a superficial neutrophilic infiltrate and parakeratosis (surface squames that are keratinized and have retained nuclei); however, some cases have almost *no* inflammation and few epithelial changes.

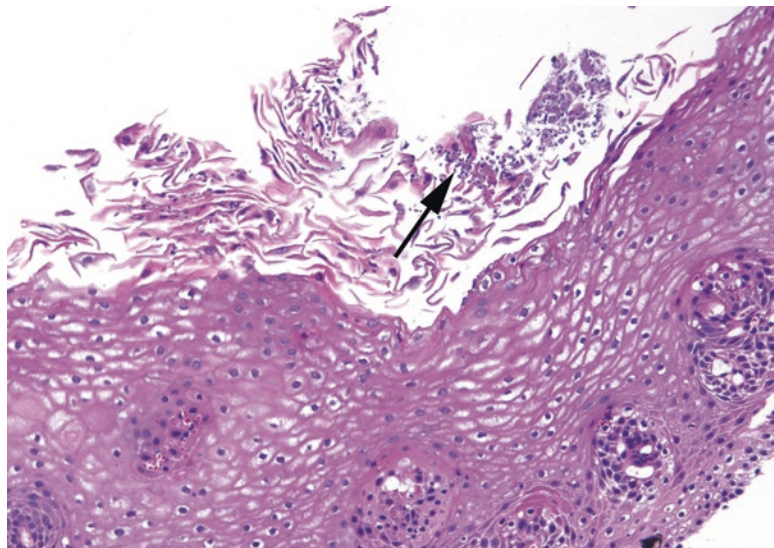


FIGURE 6.3. *Candida*. Tiny purple yeasts and pseudohyphae (arrow) are seen among the squamous debris at the surface of the epithelium. This is an H&E stain; the yeasts are magenta on PAS stain. Note that sometimes there is not a significant neutrophilic response.

Ulcers

Ulcers can be caused by severe reflux or chemical injury (especially pill esophagitis; polarize to look for pill fragments), radiation (should be accompanied by necrosis and bizarre atypia), or infection, or they can be idiopathic (particularly in HIV-AIDS). Viral esophagitis is rare but more common in the immunosuppressed. Herpes simplex virus (HSV) and cytomegalovirus (CMV) cause inflamed, punched-out ulcers.

- HSV infects epithelial cells. This is best seen on intact squamous mucosa adjacent to the ulcer, typically causing multinucleation with nuclear molding and glassy chromatin.
- CMV infects mesenchymal cells (fibroblasts, endothelial, etc.) at the ulcer base. CMV infection usually manifests with intranuclear and cytoplasmic red/purple inclusions that render the cells gigantic (*cyto-megalo-virus*), and thus 10× is a good objective with which to find them. Inclusions can be seen in both intact mucosa and ulcer eschar.

The H&E slide is the best place to find the inclusions, but immunostains may help if clinical suspicion is high and H&E is not definitive (refer to Figures 3.20 and 3.21 for images of viral inclusions).

Columnar Epithelium

Collections of submucosal mucous glands resembling salivary glands or Brunner's glands of duodenum are occasionally seen in mucosal biopsy material. It is more common to see the ducts from these glands. Gastric-type epithelium (foveolar surface epithelium and underlying specialized gastric glands, usually oxyntic) in an "esophagus" biopsy specimen may be metaplastic but may also represent tissue inadvertently taken from proximal stomach or hiatal hernia. The presence of gastric mucosa should be noted but does *not* equal a diagnosis of Barrett's esophagus (see later discussion). Collections of pink-purple acinar cells beneath the epithelium, resembling normal pancreas, may in fact be normal pancreas (called *pancreatic metaplasia* or *heterotopia*); pancreatic metaplasia is a common finding in long-standing reflux esophagitis.

Goblet Cells

In the tubular esophagus, the presence of goblet cells, which are bulbous mucinous cells that are indigo-blue on PAS/alcian blue (PAS-AB) stain, and clear-to-pale-blue on H&E (Figure 6.4), in metaplastic glandular mucosa is known as *intestinal metaplasia* or *Barrett's esophagus*. In the USA and in most countries, goblet cells are required for a diagnosis of Barrett's esophagus, due to a risk of progression to adenocarcinoma that is not seen in patients with simple columnar metaplasia. The second requirement for a diagnosis of Barrett's is an endoscopically visible lesion.

There are two caveats to be considered. First, intestinal metaplasia can also occur in the true cardia of the stomach as a response to inflammation. Therefore, if the location that was biopsied is not entirely clear, some pathologists will sign out apparent Barrett's as "consistent with Barrett's mucosa if the biopsy was taken from tubular esophagus." Second, not all that stains blue with PAS/AB is a goblet cell. Some gastric-type foveolar cells, especially at the squamo-columnar junction, will stain blue (so-called tall blues), so, to be a genuine goblet, it has to stain blue *and* have goblet cell morphology (bulbous outline of goblet cells vs. the elongated narrow foveolar cells).

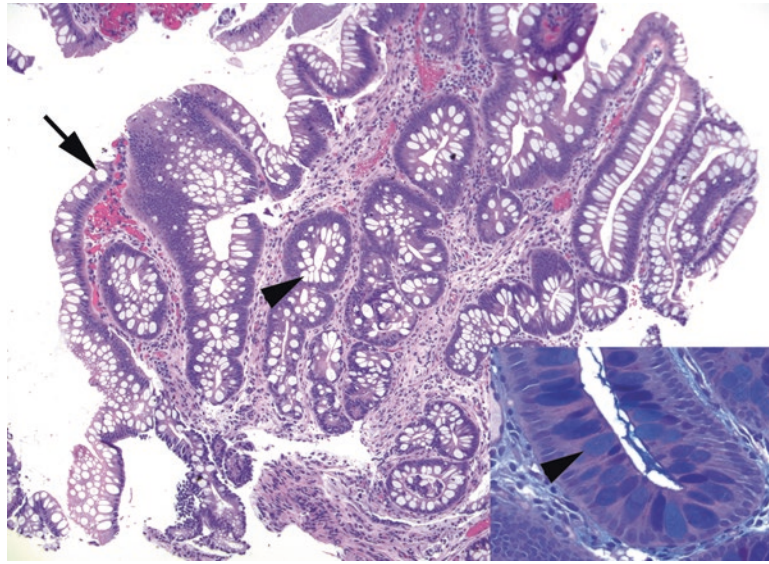


FIGURE 6.4. Goblet cells in Barrett's esophagus. The presence of columnar epithelium with goblet cells indicates Barrett's esophagus. Goblet cells are round cells that appear clear on H&E stain and are typically flanked by the purplish absorptive-type cells. Back-to-back mucinous cells resembling a row of teeth are more likely to be gastric foveolar epithelium. Goblet cells may be present at the surface (*arrow*) or in deep glands (*arrowhead*). *Inset:* A PAS/AB stain confirms the goblet cells, which stain indigo blue (*arrowhead*).

Dysplasia Within Barrett's Esophagus

Like any gastrointestinal glandular mucosa, Barrett's mucosa can progress through dysplasia, intramucosal carcinoma, and invasive adenocarcinoma. Barrett's is a high risk lesion by definition and is regularly screened for dysplasia by biopsy. Any diagnosis of Barrett's must include a comment on the presence or absence of dysplasia.

Dysplasia in Barrett's mucosa initially begins to look like a tubular adenoma of the colon (it gets blue). The cells in low-grade dysplasia have the following characteristics:

- Increased nuclear hyperchromatism and pleomorphism
- High N/C ratio
- Loss of mucin vacuoles
- Crowding and pseudostratification
- Loss of polarity

True dysplasia should extend *all the way to the surface epithelium*, just like in a tubular adenoma of colon (Figure 6.5). Use caution if the surface has been disrupted, such as tissue that has been previously biopsied, or in the case of surface re-epithelialization (so-called buried dysplasia). Features that should make you favor reactive changes over dysplasia include surface maturation (crypt base looks bad, but surface looks fine), big grey-purple nuclei with prominent nucleoli, and pronounced inflammation. The phrase "indefinite for dysplasia" is sometimes used to indicate changes which are suggestive of dysplasia but are accompanied by inflammation, so which *may* be reactive. Note that "indefinite for dysplasia" should not be a catch-all bucket for every biopsy that looks a bit off!

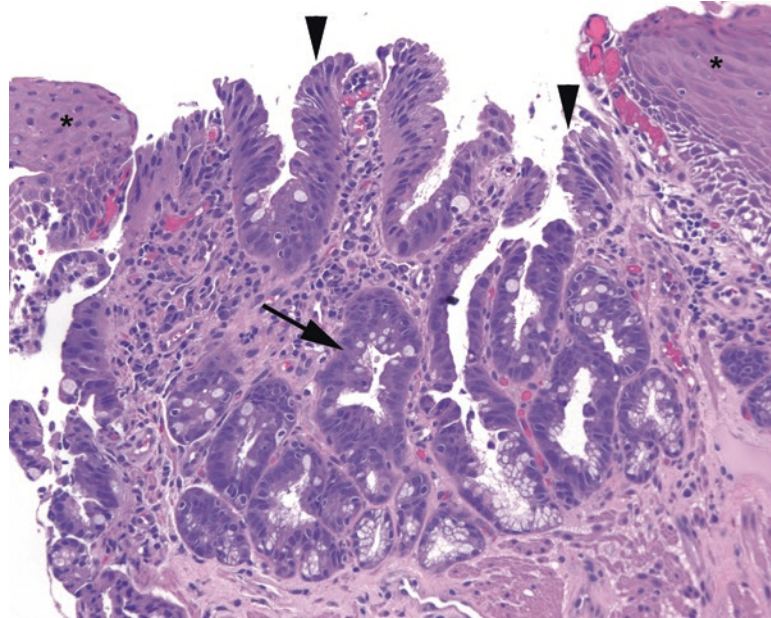


FIGURE 6.5. Low-grade dysplasia in Barrett's esophagus. The cells begin to lose polarity and organization, with nuclei becoming more pleomorphic and lifting up off the basement membrane (*arrow*). The changes must extend to the surface (*arrowheads*) to count. Compare with the nondysplastic epithelium shown in Figure 6.4. Adjacent squamous epithelium can be seen on either side (*asterisks*).

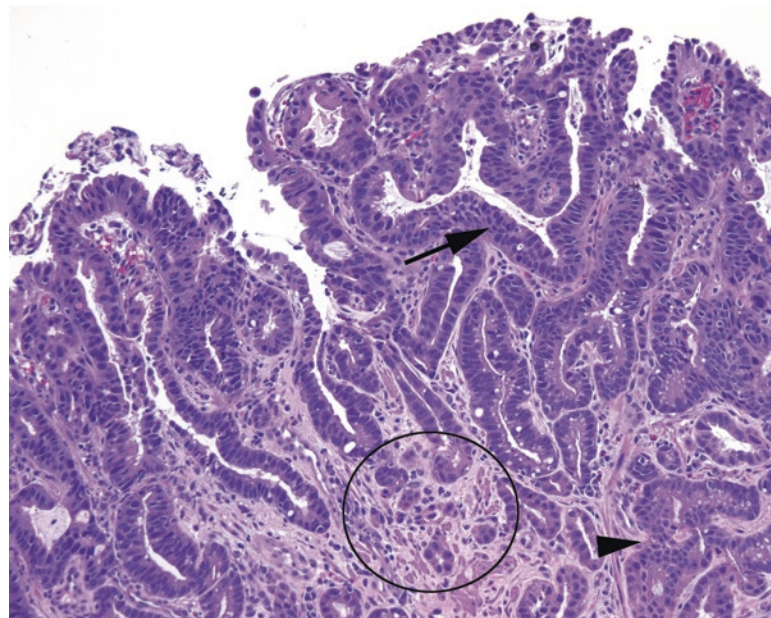


FIGURE 6.6. High-grade dysplasia. Nuclei here show marked hyperchromasia, pleomorphism, and disorganization (*arrow*), and the glands are beginning to show cribriform growth (*arrowhead*). There is a focus suspicious for invasion highlighted in the *circle*.

Progression to high-grade dysplasia (Figure 6.6) includes increasing atypia (loss of polarity, nuclei that begin to look like boulders: large with irregular outlines), mitotic activity (although mitoses alone are not worrisome), and architectural dysplasia (glands that are crowded and complex: budding, branching, cribriform, papillary, or villiform). High-grade dysplasia tends to be diagnosed in situations in which you are worried about invasive carcinoma but cannot prove it. Think of high-grade dysplasia as synonymous with carcinoma in situ.

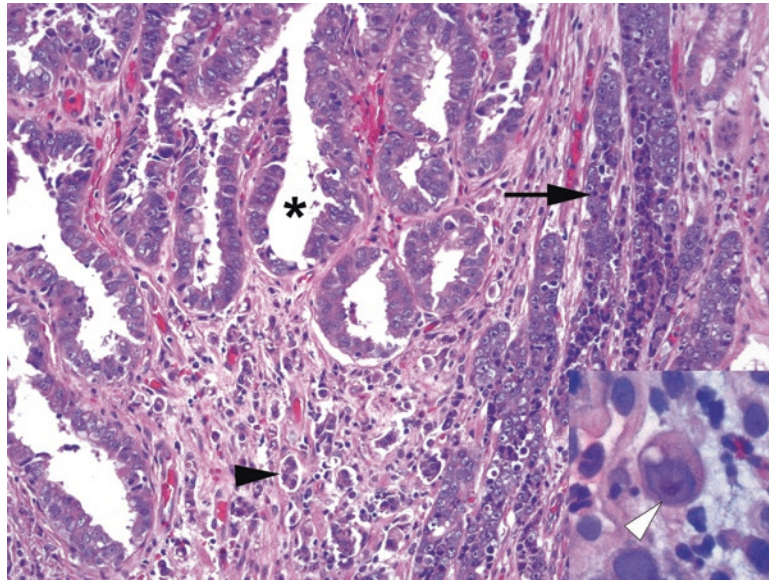


FIGURE 6.7. Invasive adenocarcinoma. The carcinoma can be seen invading the stroma as glands (*asterisk*), cords (*arrow*), and single cells (*arrowhead*). Inset: Invasive cells may acquire a prominent nucleolus (*white arrowhead*).

The next step along the malignancy progression is invasive carcinoma (Figure 6.7). As in other organs, clues to invasion include a ragged basement membrane border, single cells infiltrating the lamina propria, and a desmoplastic stromal response. The cells in invasive carcinoma often acquire prominent nucleoli. Note that in the esophagus, unlike in the colon, intramucosal carcinoma (invasive adenocarcinoma confined to the lamina propria) is thought to have metastatic potential and thus is considered a “T1” lesion (not “Tis”) in the TNM (tumor, node, metastasis) staging classification. This is due to the presence of lymphatics in the lamina propria of the esophagus.

Squamous Dysplasia

Within the squamous epithelium, dysplasia, carcinoma in situ, and invasive squamous cell carcinoma are diagnosed by criteria similar to those for the cervix. Dysplastic changes include enlarged, pleomorphic nuclei, increased N/C ratio (a general blueness at low power), mitoses above the basal layer, and loss of order and polarity. Prominent nucleoli are more consistent with reactive/repairative changes. Dysplasia begins at the base and progresses to the surface. If the changes persist all the way to the surface, it is carcinoma in situ. Invasion can be hard to identify; a deep pushing front is not necessarily invasion. Look for deep aberrant keratinization (pink up) and single cells trailing off as a clue to invasive carcinoma. Also beware the granular cell tumor, a bland tumor of the submucosa which can provoke a very alarming pseudoepitheliomatous hyperplasia (see Figure 29.21).

Polyps

A reasonable differential for a polypoid structure in the esophagus includes the following:

Benign

- Inflammatory fibroid polyp: vascular, inflamed, fibrous stroma covered by benign squamous epithelium, may be ulcerated; looks like granulation tissue
- Fibrovascular polyp: fibrovascular core covered by benign squamous epithelium, plus or minus fat

- Squamous papilloma: fibrovascular core covered by hyperplastic, but benign, squamous epithelium
- Submucosal nodules such as leiomyoma (which can be stained for actin and desmin) and granular cell tumor (which can be stained for S100)

Malignant

- Verrucous squamous cell carcinoma
- Other carcinomas

Neoplasms in the Esophagus

One way to create a differential of neoplasms within an organ is to list all of the normal cell types and then think about what tumors can arise from each one. In the esophagus, the whopping majority of cancers arise from the epithelium and therefore are squamous or adenocarcinoma, but soft tissue tumors, although unusual, can occur. These include leiomyoma, granular cell tumor, hemangioma, angiosarcoma, and others.

7 Stomach and Duodenum

Stomach

The stomach is composed of several anatomic zones. Moving proximal to distal, like a piece of food, you pass (1) the gastroesophageal junction, (2) the cardia, (3) the fundus and body, (4) the antrum, and (5) the pylorus (Table 7.1 and Figure 7.1). For the pathologist, there are essentially two types of mucosa in the stomach (Figure 7.2): antral (mucinous or protective) and oxyntic (secretory). The entire stomach epithelium is composed of pits (invaginations from the surface) and glands (deep to the pits). The surface and pits are lined by columnar mucinous epithelium (called *foveolar type*) which stains bright pink with PAS/AB. The regions of the stomach are divided by the type of underlying glands:

Antral mucosa (found at the borders of the stomach—the cardia, antrum, and pyloric regions): the glands are loosely packed and mucinous and occupy about half of the epithelial thickness (meaning the other half are the pits from the surface).

Oxyntic mucosa (found in the digestive regions of the stomach—the fundus and body): the glands are tightly packed, contain granular parietal (pink, acid-secreting) and chief (purple, enzyme-secreting) cells, and occupy three fourths of the mucosal thickness.

Transitional mucosa: An overlap zone where features of both antral and oxyntic are present.

It is important to note what kind of epithelium is present in the biopsy tissue because there are certain processes that differentially affect mucosal types; clarifying the type of epithelium involved may change the differential.

Endocrine cells occur singly in the glands. In the body, they are mainly enterochromaffin-like (ECL) cells, while in the antrum they are mixed gastrin-, enterochromaffin-, and somatostatin-producing cells. A chromogranin stain highlights all endocrine cells. A gastrin stain should be positive only in the antrum.

The Approach to the Biopsy

Survey the glandular epithelium at low power:

- Note what kind of mucosa you have and whether it correlates with what the endoscopist thought.
- Assess the color of the biopsy specimen. A healthy stomach is a fairly pale pink, overall. If your general impression is blue, this probably indicates inflammation in the stroma, such as in gastritis (Figure 7.3). If your impression is that of a pink stroma with unusually dark and distinct glands, you may be looking at chemical gastritis.

	Histology	Endocrine cells	Common pathology
Esophagus	Squamous	None	Reflux esophagitis Eosinophilic esophagitis Barrett esophagus
Cardia	Mucinous (antral)		Reflux carditis <i>H. pylori</i> gastritis
Body and fundus	Oxyntic	Enterochromaffin-like	Autoimmune gastritis
Antrum	Mucinous (antral)	Gastrin, somatostatin, enterochromaffin	<i>H. pylori</i> gastritis Chemical gastritis
Pylorus	Antral to duodenal		Chemical gastritis

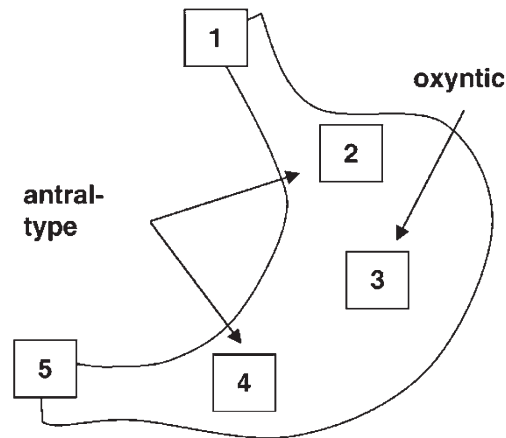


FIGURE 7.1. Localization of anatomic regions within the stomach: (1) the gastroesophageal junction, (2) the cardia, (3) the fundus and body, (4) the antrum, and (5) the pylorus. Antral-type (mucinous) mucosa is seen in the cardia, antrum, and pylorus.

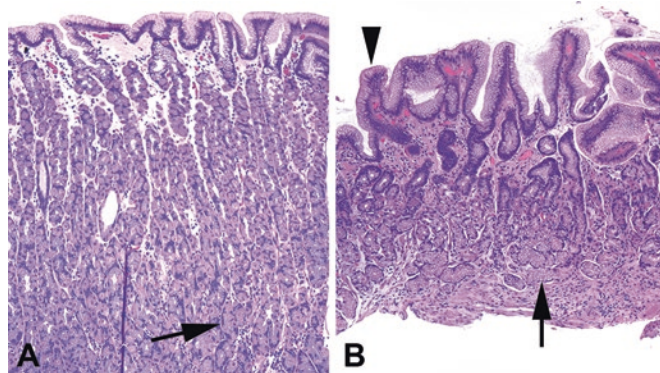


FIGURE 7.2. Antral and oxyntic mucosa. (a) Oxyntic mucosa is relatively thick, with most of the mucosa occupied by secretory cells (*arrow*), the parietal and chief cells. The surface is composed of mucinous foveolar epithelium. (b) Antral mucosa is thinner, and the glands are mucinous instead of secretory (*arrow*). However, the surface is still composed of foveolar epithelium (*arrowhead*).

- Look for intestinal metaplasia, or goblet cells, a marker of chronic irritation in the stomach. Goblet cells are usually visible from low power, especially on a PAS/AB stain (as indigo-blue, bulbous cells). Remember that true goblet cells are usually interspersed among non-mucinous pink cells (absorptive). A row of back-to-back tall mucinous cells, even if blue on PAS/AB, is unlikely to be actual intestinal metaplasia.
- Look for areas of exudate, neutrophils, debris, and ragged-looking glands that indicate an erosion or ulcer.

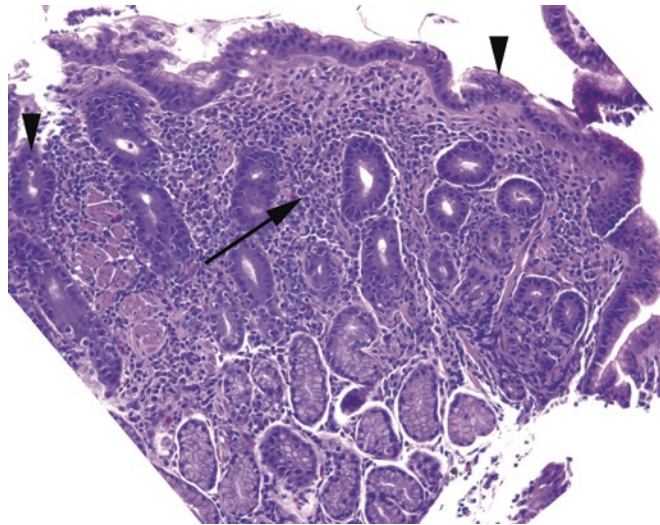


FIGURE 7.3. *Helicobacter pylori* gastritis, antrum. In this disease, the low-power impression is that of a “blue” biopsy due to the dense inflammatory infiltrate in the lamina propria (arrow). There are lymphocytes, plasma cells, and neutrophils. Neutrophils in the glandular or surface epithelium (arrowheads) indicate an active component to this gastritis. *H. pylori* organisms are pictured in Chapter 3.

On higher power, assess the inflammation:

- A few lymphocytes, plasma cells, and rare eosinophils are okay in the lamina propria of the stomach, especially in the antrum, where there is more space between glands. However, back-to-back lymphocytes and plasma cells pushing aside or crowding the glands indicate *chronic gastritis*.
- Neutrophils in the epithelium indicate *activity* (by convention, *active inflammation* is used instead of *acute*). If you have only mononuclear cells, you have *inactive chronic gastritis*, but if there are any neutrophils embedded in the surface or glandular epithelium, you have *active chronic gastritis*.
- Eosinophils can be a normal component, but dense sheets of eosinophils in the lamina propria may indicate allergic or *eosinophilic gastritis*.
- How many lymphocytes does it take to diagnose *lymphoma*? The answer is *a lot*. See the section on lymphoma, below.
- How about lymphocytes in the surface epithelium? Extensive intraepithelial lymphocytes in the stomach may be seen in patients who also have celiac disease and/or lymphocytic gastritis/colitis.

Active chronic gastritis and lymphoid follicles are usually indicative of *Helicobacter pylori* infection. The tiny rods are visible on H&E stain (see Chapter 3) but are better seen on Diff-Quik or Giemsa (immunohistochemistry for *H. pylori* is helpful if organisms are sparse). They should be visible at 40× as tiny discrete seagull-shaped rods in the pit lumens or on the surface, mainly in the antrum, unless there is intestinal metaplasia, a hostile mucosa for these bugs. If you have no significant inflammation, do not work too hard looking for *H. pylori*.

Another cause of unexplained active or inactive chronic gastritis is inflammatory bowel disease, especially Crohn’s disease (see Chapter 8). Think of Crohn’s if you find granulomas in the stomach, or an unexplained active chronic gastritis in a child.

Foveolar Hyperplasia and Chemical Gastritis

Especially in the antrum, the stomach is vulnerable to bile reflux. Bile and other sources of chemical irritation, such as nonsteroidal anti-inflammatory drugs, cause a process called *foveolar hyperplasia*. The surface mucin cells proliferate, giving the surface a papillary appearance and the pits a corkscrew profile. The mucinous cells lose mucin, and the cytoplasm becomes

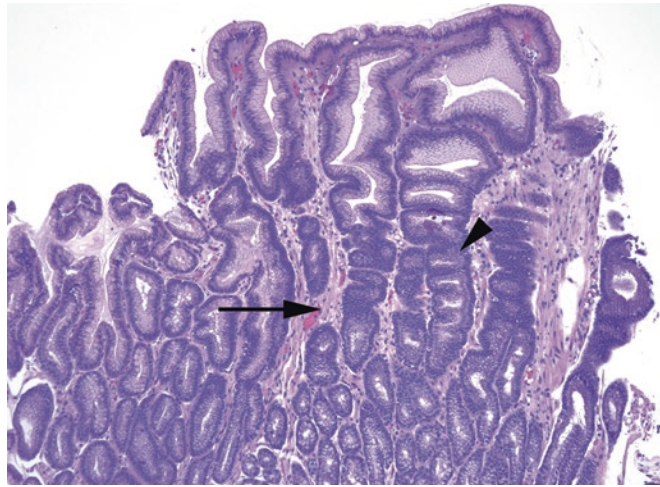


FIGURE 7.4. Chemical gastritis, antrum. In chemical gastritis, the lamina propria shows very little inflammation, unlike in *H. pylori* gastritis. The lamina propria is pale and sometimes edematous such that the dark reactive nuclei of the glands stand out sharply in contrast. The corkscrew profile of the hyperplastic glands is a second classic feature (*arrowhead*), as is the presence of thin strands of smooth muscle between the glands (*arrow*).

more dark or opaque; the nuclei also may become hyperchromatic, adding to the dark look (Figure 7.4). Smooth muscle fibers proliferate and can be seen stranding up between the pits. Inflammation in the stroma is not a prominent feature, so the lamina propria is often fairly pale, even edematous. This appearance is called *chemical gastritis* or *chemical gastropathy*, and it is very common.

Atrophy and Intestinal Metaplasia

The loss of glands in the stomach, in any region, is called *atrophy*. Atrophy can be difficult to assess on any given biopsy specimen, as badly oriented sections, a healing ulcer, or dense inflammation can all lead to the appearance of loss of glands. Regardless of the cause, true atrophy, as an end-stage response to severe chronic damage, should be accompanied by intestinal metaplasia and inflammation (Figure 7.5). The two principal types of atrophy are the following:

- *Multifocal atrophic gastritis* is secondary to *H. pylori* infection, primarily affects the antrum, and involves loss of glands in the setting of active chronic gastritis and intestinal metaplasia. You may also see lymphoid follicles and pit abscesses (pits full of neutrophils).
- *Autoimmune metaplastic atrophic gastritis (AMAG)*, a result of the autoimmune destruction of the parietal cells in the body, shows loss of oxyntic glands in the setting of chronic inflammation and intestinal metaplasia. This ultimately causes pernicious anemia through the loss of intrinsic factor and the resulting vitamin B12 deficiency. It is associated with a compensatory antral gastrin-cell response and hypergastrinemia, which in turn stimulates the ECL cells in the body. Those ECL cells proliferate and may even progress to microcarcinoids or tumorlets. In AMAG, you should not typically see activity or lymphoid follicles.

In severe autoimmune gastritis, the body of the stomach comes to resemble the antrum due to the atrophy of the secretory glands. It can therefore be difficult to decide if it is antrum or “antralized” atrophic oxyntic mucosa. A gastrin stain, which will stain only true antrum, will help.

Lymphoma

Although diffuse large B cell lymphoma is the most common lymphoma in the stomach, and should be considered if you see sheets of very ugly single cells, differentiating it from normal inflammation is not usually a problem. Low-grade lymphomas, however, are tricky, especially

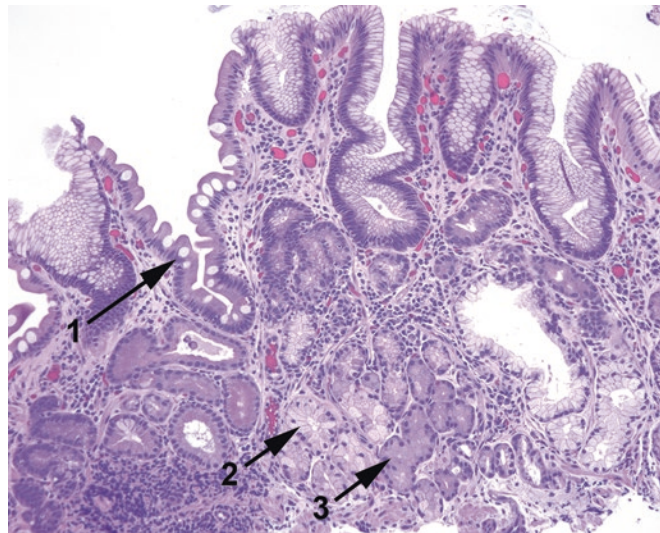


FIGURE 7.5. Autoimmune gastritis. This biopsy specimen from the gastric body shows several features of atrophy. The surface shows goblet cells, which are indicative of intestinal metaplasia (1); deep to this there is inflammation and replacement of the secretory glands by mucinous, antral-type glands (2). Some residual oxyntic cells are also visible (3).

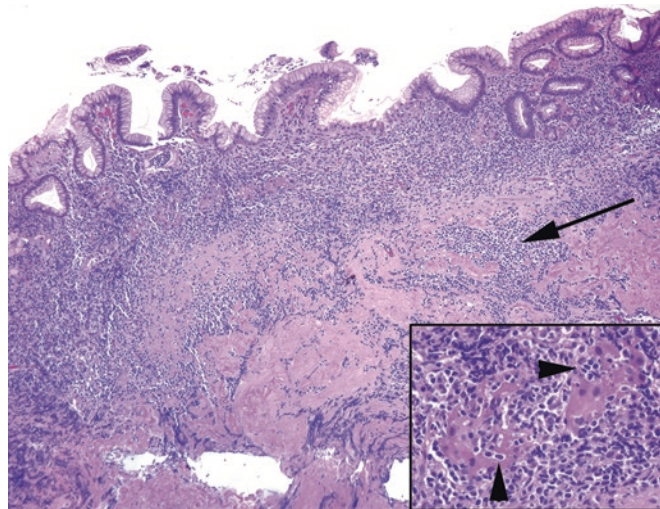


FIGURE 7.6. Mucosa-associated lymphoid tissue lymphoma. There are sheets of lymphocytes under the epithelium and dissecting into the muscularis mucosa (arrow). Inset: lymphoepithelial lesions are typical, in which residual glands (seen here as little more than islands of pink cytoplasm) are infiltrated and destroyed by lymphocytes (arrowheads).

given that most arise in the setting of chronic *H. pylori* gastritis. In lymphoma, but not in chronic gastritis, you may see lymphoepithelial lesions, which are collections of lymphocytes that appear to be eating glands (Figure 7.6), as well as sheets of mature lymphocytes. The most common low-grade lymphoma in the stomach is mucosa-associated lymphoid tissue (MALT) lymphoma and is usually of the marginal zone type, which is monocytoid in appearance (fried-egg-like cells, with small round nuclei surrounded by a halo of clear cytoplasm).

Immunostains are often used to establish the diagnosis. In a MALT lymphoma, the majority of the cells should be B cells (CD20⁺) that also stain for CD43. Normal T cells may also stain for CD43, so you must mentally subtract out the background T cells (shown by CD3 stain). Helpfully, in chronic gastritis, most of the lymphocytes are T cells.

Amyloid

Systemic amyloidosis often involves the GI tract. Dense glassy pink deposits in the stomach wall, especially around vessels, should be stained with Congo red or your favorite amyloid marker.

Ulcers

An ulcer is a full-thickness defect of the epithelium down to muscularis mucosa; an erosion is more superficial. It is accompanied by fibrinopurulent exudate and/or granulation tissue, plus reparative glands. Search the periphery for the reason for the ulcer, including *H. pylori*, chemical gastritis, and adjacent cancer. Reparative glands appear as small, angulated glands with little mucin, and the lamina propria around them may be fibrotic. This can be difficult to distinguish from invasive carcinoma. However, reparative glands should have small or reactive nuclei and should have an overall streaming parallel arrangement, as they all want to orient to the surface (Figure 7.7).

Polyps

A reasonable differential for a polypoid structure in the stomach includes the following:

- Fundic gland polyps: Fundic gland polyps look like oxyntic mucosa but with cystically dilated glands (Figure 7.8). They are common in older people. Multiple polyps occur in familial adenomatous polyposis.
- Hyperplastic polyps: Polyps are hyperplastic, elongated, or cystic foveolar pits with mild inflammation (Figure 7.9). They are usually associated with background gastritis and can have intestinal metaplasia.
- Adenomas: These are neoplastic and dysplastic nodules that can be either gastric type (foveolar or mucinous) or intestinal type (with goblet cells). By definition they have at least low-grade dysplasia, similar to a tubular adenoma of colon and should be studied carefully to look for high-grade dysplasia. They are usually associated with surrounding stomach pathology, especially atrophic gastritis.

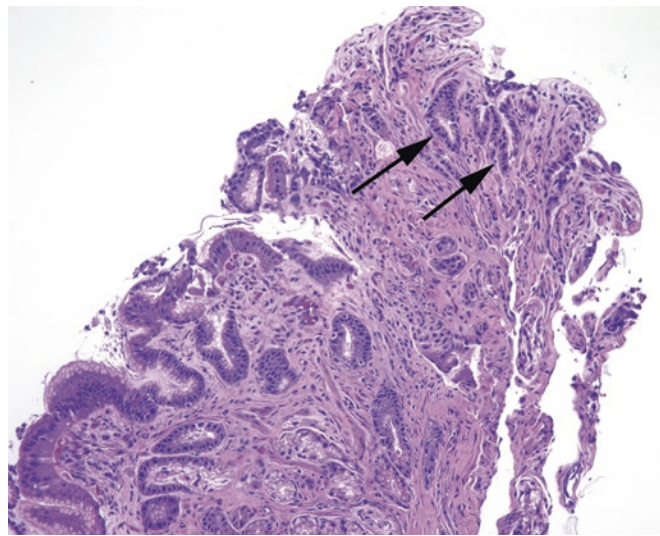


FIGURE 7.7. Reparative changes next to an ulcer. The tip of this fragment has a collection of poorly formed glands with an infiltrative look and minimal cytoplasm, giving the appearance of a high N/C ratio (*arrows*). However, the nuclei are of about the same size and shape as the rest of the gastric glands, and these small glands stream in parallel toward the surface, consistent with regenerative or reparative glands.

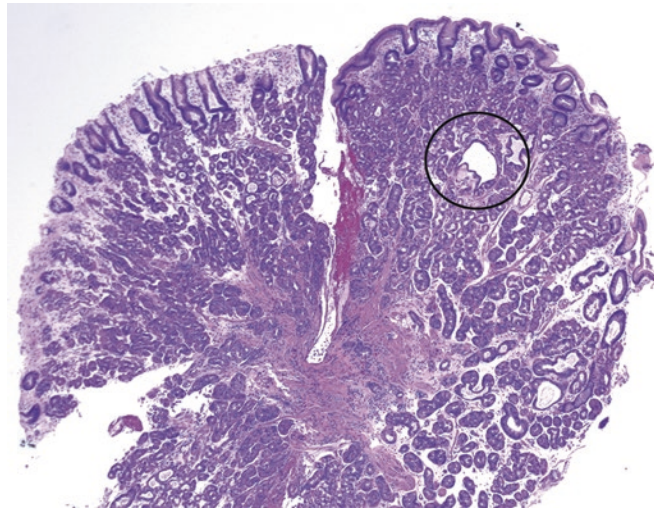


FIGURE 7.8. Fundic gland polyp. This polypoid fragment shows oxyntic- or fundic-type glands, with occasional dilated glands (*circle*).

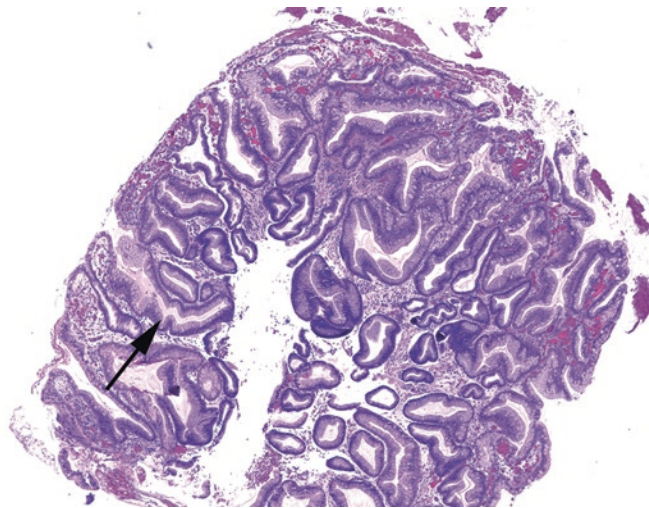


FIGURE 7.9. Hyperplastic polyp. This polyp is reminiscent of chemical gastritis, with corkscrew glands (*arrow*) and hyperplastic foveolar epithelium. Inflammation and intestinal metaplasia may be present.

Dysplasia and Carcinoma

By convention, a polypoid dysplastic lesion will be classified as an adenoma, but if no polyp was identified, simply grade the dysplasia. Dysplasia in the stomach is assessed similarly to dysplasia in Barrett's esophagus (see Chapter 6). As in Barrett's esophagus, intestinal metaplasia is an abnormal finding but by itself is not dysplasia. Dysplasia in gastric mucosa initially begins to look like a tubular adenoma of the colon (it gets blue). The nuclei show increased hyperchromasia and pleomorphism, high N/C ratio, loss of mucin vacuoles, crowding and pseudostratification, and loss of polarity. High-grade dysplasia tends to be diagnosed when invasive carcinoma is suspected but cannot be proven. *Carcinoma in situ* is not used in this situation; think of high-grade dysplasia as synonymous.

Invasive adenocarcinoma comes in two types in the stomach: intestinal type (which looks like colon cancer, hence the name) and diffuse. The intestinal type is fairly easy to spot; it is usually associated with atrophy and intestinal metaplasia. The diffuse type is the poorly

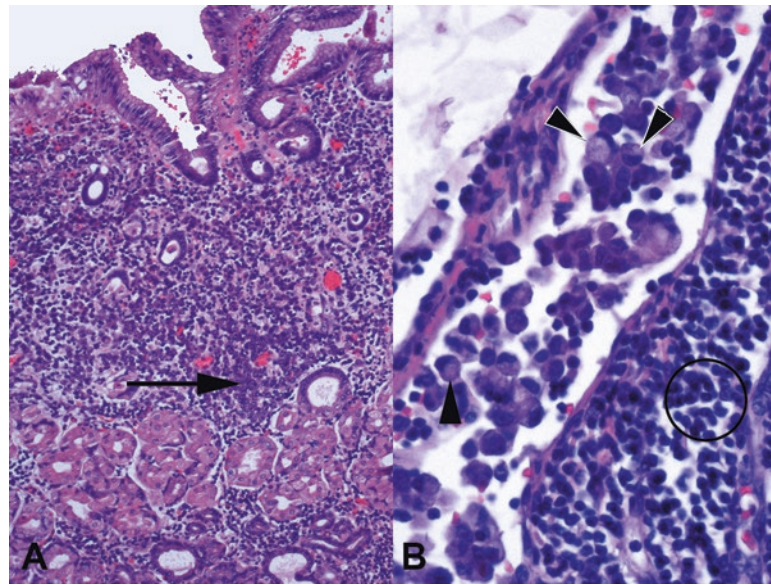


FIGURE 7.10. Signet-ring cell carcinoma. (a) At low power, this sneaky tumor may be visible as little more than a slightly busy or cellular lamina propria. The tumor cells here do not display prominent signet ring features (*arrow*) but are still present as individual tumor cells. (b) These tumor cells in a lymph node show the characteristic single large mucin vacuoles (*arrowheads*). The signet-ring cells differ from fat cells by having large dark nuclei that protrude up from the surface of the central vacuole. Compare their size to the lymphocyte nuclei (*circle*).

differentiated, often signet-ring, infiltrative cancer that can creep through the entire stomach and cause linitus plastica. Signet-ring cell carcinoma gets its name from the single vacuolated cells with displaced and indented nuclei (Figure 7.10). They can look like foamy macrophages, and they can blend almost imperceptibly into the stroma. Every stomach biopsy specimen should get a once-over at high power, such as 20 \times , to scan the lamina propria for signet rings. When they are there, often you will see the first one and then realize there are hundreds of them.

The Submucosa

The submucosa is not always included in a biopsy specimen. It lies below the thin muscularis mucosa. However, there are some things that are more often found in the submucosa, including the following:

- Heterotopic pancreas, which is a nodule of acinar pancreatic tissue.
- Gastrointestinal stromal tumors (GIST), which arise from the interstitial cells of Cajal. These are spindle-cell neoplasms that should stain for c-kit (CD117) and DOG1 proteins (Figure 7.11). Their malignant potential is assessed using size, location, and mitotic rate.
- Leiomyomas, arising from smooth muscle cells. Leiomyoma is the second entity in the differential for a spindle-cell neoplasm. It stains for smooth muscle markers but not c-kit.
- Schwannoma, a nerve sheath tumor, the third spindle-cell lesion of the submucosa; it will stain for S100.
- Well-differentiated neuroendocrine tumors (WD-NET; carcinoid) may be mucosal or submucosal; they have similar morphology to WD-NETs elsewhere. These may be sporadic, they may arise in multinodular form in response to autoimmune gastritis, or they may be associated with multiple endocrine neoplasia (MEN) syndromes. See Chapter 26 for more information on the nomenclature of NETs.

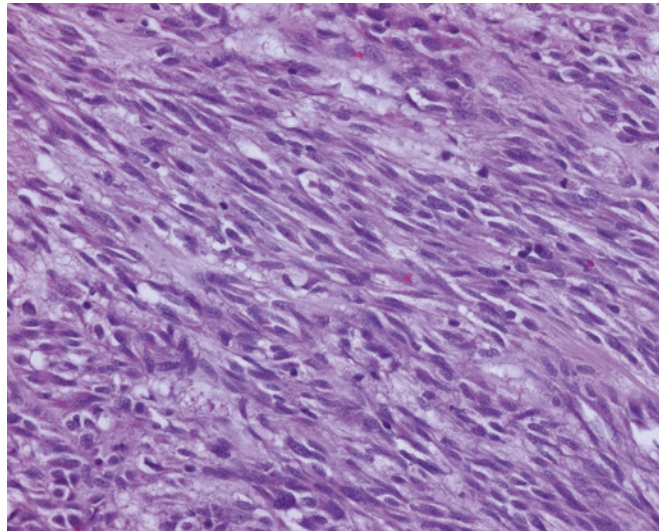


FIGURE 7.11. Gastrointestinal stromal tumor (GIST). This example shows spindle cell morphology, with occasional paranuclear vacuoles suggestive of smooth muscle. GISTs may also resemble schwannoma, with nuclear palisading, or may be epithelioid.

Duodenum

Duodenum is included here as duodenal biopsies often accompany upper GI in biopsy specimens, and the pathology in some cases is continuous. A duodenal biopsy may be performed because of combined gastritis and duodenitis, with or without peptic ulcer disease; to investigate suspected malabsorption syndromes, such as celiac disease; or to diagnose a mass lesion.

Normal duodenal mucosa is approximately 1 mm thick and is characterized by narrow villi that project above the mucosal surface, and between the villi, tube-like crypts which invaginate down into the mucosa. The epithelium is intestinal type, which means goblet cells are interspersed among the absorptive cells. Lymphocytes, plasma cells, and eosinophils are normal inhabitants of the lamina propria. A few intraepithelial lymphocytes may be seen, although they should be rare at the tips of the villi. Under the muscularis mucosa are collections of mucous glands called Brunner glands, which stain bright pink on PAS/AB. The proximal duodenum may be distinguished from the more distal duodenum by the Brunner glands present within the mucosa, in addition to the submucosa. The distal-most duodenum (as well as jejunum and ileum) will be devoid of Brunner glands.

The Approach to the Biopsy

At low power:

- Assess the height of the villi. In a well-oriented specimen, they should be greater than three times as tall as the crypts are deep. *Villous blunting* or *villous atrophy* are terms used to describe short and stubby villi. Technically, however, the villi do not get shorter, rather the crypts and surrounding mucosa get deeper; the total thickness of the mucosa remains the same.
- Look for areas of epithelium that are darker than the surrounding mucosa, suggesting dysplasia, or any mass lesions.

On higher power:

- Look for intraepithelial lymphocytes in the tips of the villi, which may indicate celiac disease.
- Neutrophils in the epithelium and gastric (foveolar type) metaplasia can be seen in peptic duodenitis (see below).

- Are there plasma cells in the lamina propria? There should be. Their absence may suggest an immunodeficiency state.
- Critter check – look for the fallen leaves of *Giardia* or the clinging dark bubbles of *Cryptosporidium*, both easy to miss. *Strongyloides* is hard to miss.
- Are there abundant stuffed histiocytes in the lamina propria? Some microorganisms are primarily found inside histiocytes.

Chronic Peptic Duodenitis

In severe gastritis, the inflammation and increased acid secretion may spill into the duodenum. In response to the lowered pH, the duodenum may “turn itself into stomach” or acquire gastric-type metaplasia. This shows up as metaplastic mucinous cells lining the villi (Figure 7.12) and is very obvious on PAS/AB stain because of the pink color of the gastric-type mucin. Other changes include Brunner gland hyperplasia, which is a mucosal (as opposed to a submucosal) proliferation of Brunner glands, and increased inflammation in the lamina propria. Advanced cases may ulcerate. *H. pylori* organisms may be seen here as well.

Don't be confused by gastric heterotopia, which is a nodule of misplaced gastric tissue within the duodenum and may present as a polyp. Helpfully, this almost always consists of oxyntic-type glands, not foveolar mucinous epithelium as is seen in peptic duodenitis.

Celiac Disease

Although celiac disease (also called gluten-sensitive enteropathy or sprue) is not very common, requests to rule it out are frequent. The classic picture of advanced celiac disease is that of a completely flattened mucosa, with total loss of villi, such that the duodenum mimics colon (Figure 7.13). The absorptive epithelium loses its brush border and flattens into a low cuboidal layer, hence the resulting malabsorption. Evaluating villous blunting can be difficult in a poorly oriented or mangled mucosal fragment, though. The earliest and most subtle change is prominent intraepithelial lymphocytes (IELs) at the tips of the villi, even before there is noticeable villous blunting. Over 40 IELs/100 enterocytes (with a single villus being approximately equal to 100 enterocytes) is considered diagnostic of a malabsorption pattern. Also keep in mind that the differential for these histologic findings is long and is only diagnostic of celiac disease if the serology and clinical picture agrees.

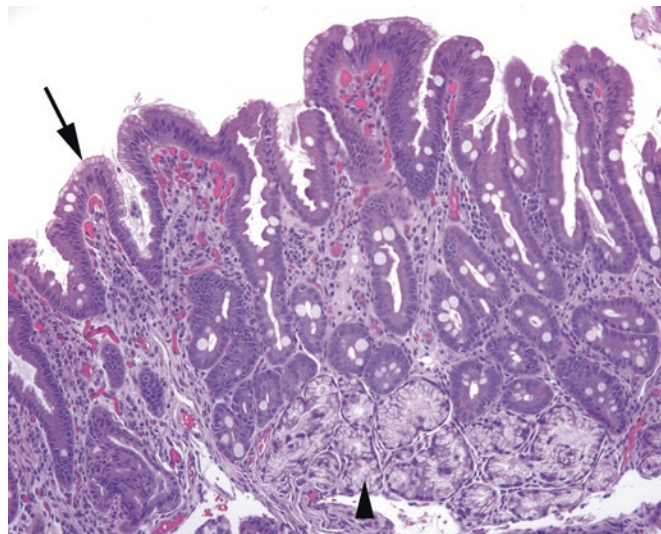


FIGURE 7.12. Chronic peptic duodenitis. At the surface, there is a subtle metaplastic change (*arrow*), where the normal absorptive and goblet cells are replaced by mucinous, foveolar-type cells, similar to those seen in antrum. There is increased chronic inflammation in the lamina propria and Brunner gland hyperplasia (*arrowhead*).

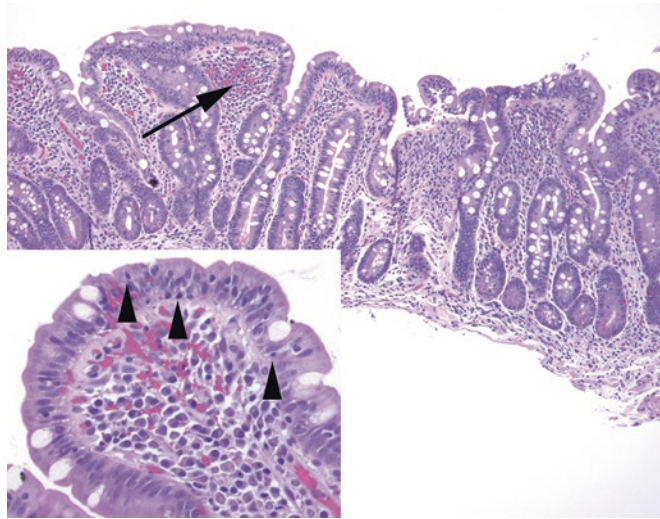


FIGURE 7.13. Celiac disease. The normal villi are blunted almost out of existence, with the duodenal mucosa resembling colon. There is chronic inflammation within the lamina propria (*arrow*). Inset: Increased numbers of intraepithelial lymphocytes are present (*arrowheads*).

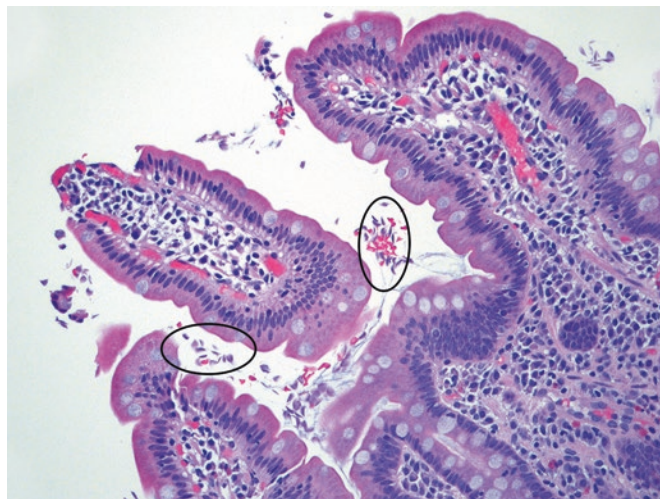


FIGURE 7.14. *Giardia*. Small pink flattened organisms resembling sloughed cells (in *ovals*) are present in the lumen, loosely associated with villi. There is no significant inflammatory response.

Infections

Infections of the duodenum include those caused by *H. pylori*, which can rarely occur in the setting of gastric mucin cell metaplasia, giardiasis, and others. *Giardia* is very sneaky, as the organisms hide in the luminal debris and do not cause inflammatory changes. If you notice tiny pink fallen leaves floating just outside the mucosa (Figure 7.14), those may be *Giardia*, so look more closely for the diagnostic “eyes” and kite tail. A worm nesting in the duodenal crypts is most likely *Strongyloides* (Figure 7.15). In the immunocompromised, collections of foamy histiocytes stuffing the lamina propria may represent *Mycobacterium avium-intracellulare* (MAI) infection, which will be evident on an AFB stain. However, the differential for stuffed macrophages also includes Whipple’s disease, in which the macrophages are filled with PAS-positive granules. *Cryptosporidium* (often nicknamed “crypto,” which is unfortunate as it shares a nickname with the fungus *Cryptococcus*) is a parasite that clings to the luminal surface of the mucosa as tiny dark spheres.

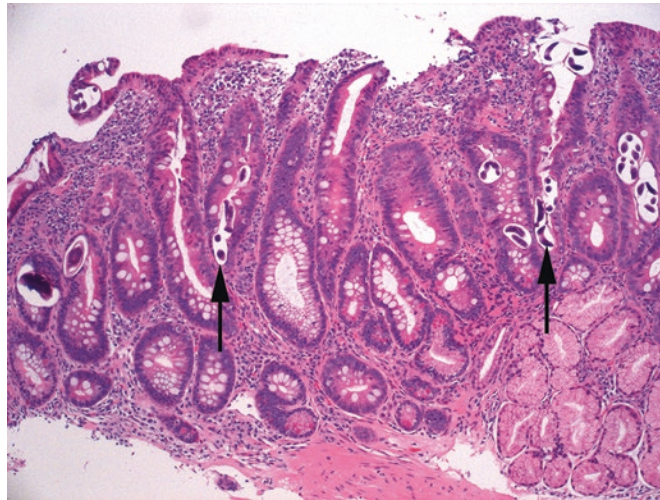


FIGURE 7.15. *Strongyloides*. Tiny worm bodies are visible nested in the duodenal crypts (*arrows*).

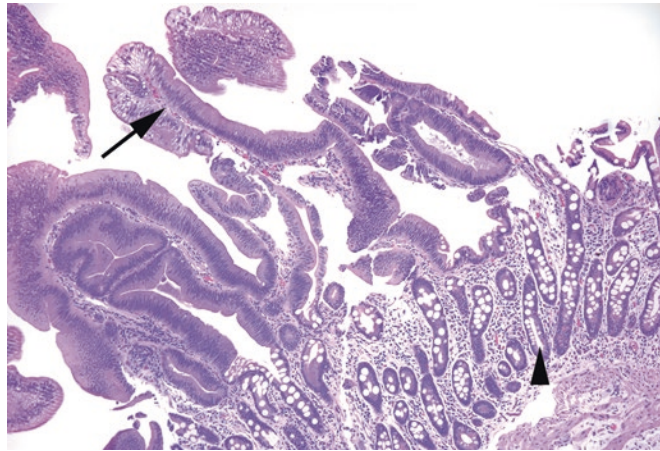


FIGURE 7.16. Duodenal adenoma. As in the colon, the tubular adenoma is characterized by low-grade dysplasia, showing crowded and elongated nuclei and loss of mucinous differentiation (*arrow*). Residual duodenal mucosa is seen underneath the adenoma (*arrowhead*).

Neoplasms

Neoplasms of the duodenum are unusual, but the most common of these are tubular adenomas (Figure 7.16), carcinoid tumors, and lymphoma (usually MALT type), all of which are also described in the sections on stomach and colon. Remember the intimate association of the duodenum to the pancreas and common bile duct; an adenocarcinoma found in duodenum may be originating in any of these organs.

8 Colon and Appendix

Colon biopsies are most often performed for one of three reasons:

1. To evaluate a polyp or mass in the setting of screening or obstruction
2. To diagnose inflammatory bowel disease and monitor dysplasia
3. To look for an explanation for diarrhea or bleeding

The history is very important; you should not be diagnosing a tubular adenoma when the endoscopist did not see a polyp. Assuming that you have at least a succinct history or description from the endoscopist, therefore, your approach to the biopsy depends on what you are looking for.

Normal Histology

Normal colonic mucosa should have a flat surface and nicely parallel crypts, like “test tubes in a rack.” The crypts are lined with goblet cells, endocrine cells, and precursor cells. Paneth cells, which are red granular cells with basal nuclei, are normal in the ascending and transverse colon but abnormal in the left colon. Immediately under the epithelium is the lamina propria, which is separated from the underlying submucosa by the muscularis mucosa (Figure 8.1). Normal constituents of the lamina propria include lymphocytes, plasma cells, and eosinophils. How many lymphocytes are too many? In general, they are assumed to be physiologic unless there is clinical or histologic evidence of chronic damage to the mucosa. Lymphoid aggregates are common and unremarkable.

Deep to the submucosa is the thick muscularis propria. Beyond this layer lies the serosal fat. In biopsy or polypectomy tissue, seeing adipose tissue and thick muscularis propria is *not* normal and means the endoscopist may have taken a full-thickness specimen, in other words, perforated the colon. This should prompt an immediate courtesy call. However, keep in mind that fat can be seen in the submucosa, so just seeing fat without the thick muscular layer of propria is usually not significant.

Polyps and Masses

Adenomas

An adenoma (at least in the tubular-to-villous family) is defined as a polyp with low-grade dysplasia. Low-grade dysplasia in the colon indicates a cytologic change and stands out from the normal colon as looking blue on the slide. The cells lining the crypts and the surface become

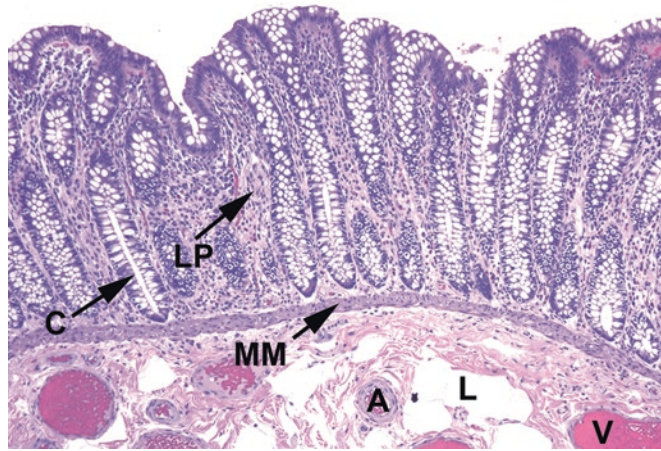

FIGURE 8.1. Normal colon. Section through colonic mucosa showing parallel crypts (C), lamina propria (LP), muscularis mucosa (MM), and submucosal arteries (A), veins (V), and lymphatics (L).

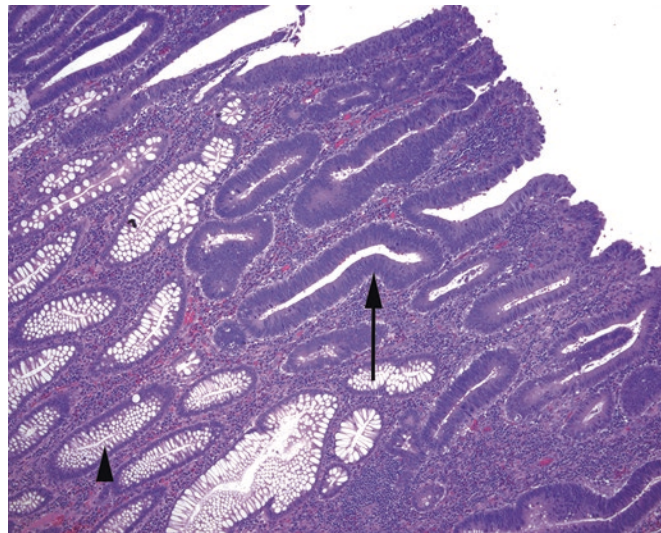


FIGURE 8.2. Tubular adenoma. This section shows an early tubular adenoma in which low-grade dysplasia is seen in the surface glands (arrow) while the deeper glands are uninvolved (arrowhead). The adenomatous epithelium is dark due to crowded and hyperchromatic nuclei and loss of mucinous goblet cells. Mitotic activity and neutrophils are common in adenomas but may also be seen in benign epithelium.

tall and dark (because of depleted mucin) and have cigar-shaped and/or pseudostratified hyperchromatic nuclei (Figure 8.2). Mitoses may be present but are generally confined to the base of the crypts.

The dysplasia must extend all the way to the surface epithelium to qualify as an adenoma; if the epithelium shows signs of maturing (progressing to more normal-appearing nuclei) as it ascends, it is more likely to be reactive changes.

Adenomas are subdivided by their architecture. The most common type is the *tubular adenoma*, which has a smooth surface and parallel crypts, similar to normal epithelium. A *villous adenoma* is covered in fingerlike projections, whereas a *tubulovillous adenoma* has features of both. These are soft and subjective distinctions, in practice.

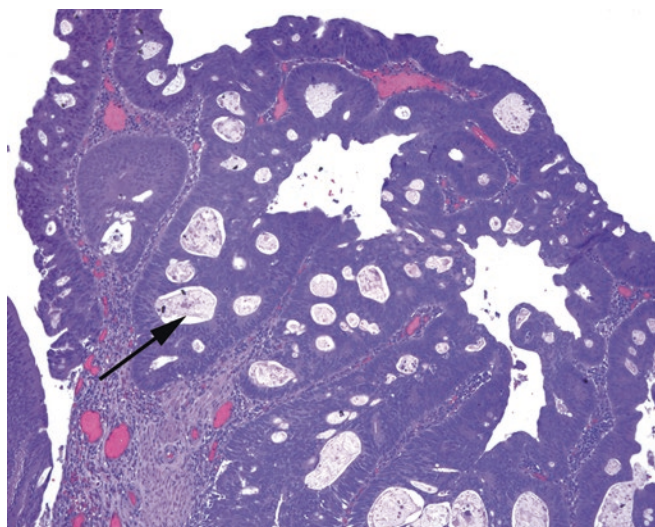


FIGURE 8.3. High-grade dysplasia in an adenoma. The diagnosis is largely based on architectural features, such as cribriform growth (*arrow*).

Important considerations for sign-out include the following:

- **Margins:** When an entire polyp is plucked off the colon, ideally it is cross-sectioned so that you can see the stalk. Ink on the stalk is helpful, but cautery also identifies your margin. If there are identifiable margins, mention whether or not the adenomatous epithelium extends to the margin.
- **Dysplasia:** By definition, low-grade dysplasia is present and need not be mentioned. However, *high-grade dysplasia* is equivalent to carcinoma in situ and must be noted. The diagnosis of high-grade dysplasia is made on the basis of architecture AND cytology. The glands become cribriform, fused, or back to back (Figure 8.3). High-grade architecture is also usually accompanied by ugly cytology: total loss of nuclear polarity, significant pleomorphism, atypical mitoses, and large nucleoli. Often the diagnosis of high-grade dysplasia is reserved for areas that look so complex you are worried about carcinoma but cannot put your finger on invasion.
- **Carcinoma:** All adenomas are considered at least premalignant lesions; sometimes you will find carcinoma arising in a polyp on biopsy. To diagnose carcinoma (as opposed to high-grade dysplasia), you must demonstrate cancer crossing the basal lamina, that is, into the lamina propria. Clues to invasion include a jagged interface with the lamina propria, individual infiltrating cells, desmoplastic response, and a pinking up of the invasive cells (Figure 8.4).
- **Invasion:** Invasion into the lamina propria alone is called *intramucosal carcinoma*. This may happen in a large polyp, and excision is still curative if negative margins can be identified. Within the lamina propria, colon cancer has no metastatic potential. However, once malignant cells cross the muscularis mucosa into the submucosa, there is risk of metastasis. The extent of invasion must be noted in the diagnosis, to the degree that it can be assessed on a biopsy.

The Serrated Polyps Family

Hyperplastic polyps are those in which the epithelial cells, although benign, begin to outgrow their available space. The glands have an increased number of goblet cells and therefore look pale or cleared out next to normal epithelium, and there tends to be a thickened or “sclerotic-appearing” basement membrane under the neoplastic cells. Furthermore, because the surface area is outgrowing the lamina propria, hyperplastic polyps take on a distinctive frilly (like a skirt) or lacy appearance (Figure 8.5). An imaginary cast of the inside of the crypts might look like a flaring fluted vase, narrow at the base. Crypts cut in cross section have a distinctive star-shaped lumen, and this architecture is called “serrated.”

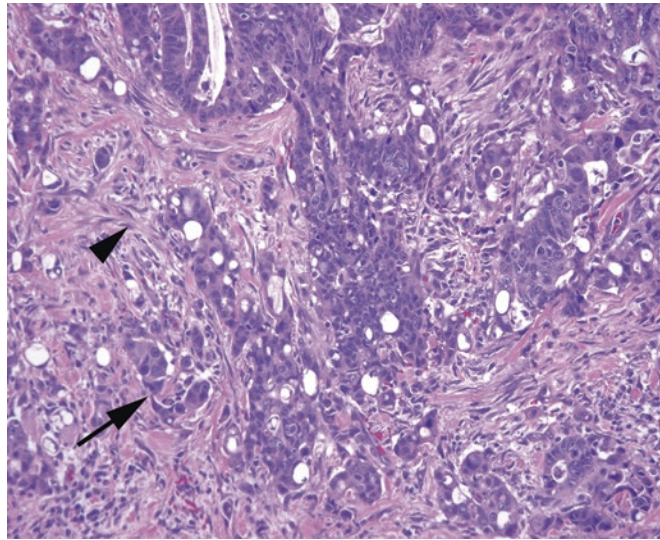


FIGURE 8.4. Invasive adenocarcinoma. Poorly formed glands and single cells (*arrow*) infiltrate through a desmoplastic stroma (*arrowhead*). Cells show marked pleomorphism and prominent nucleoli.

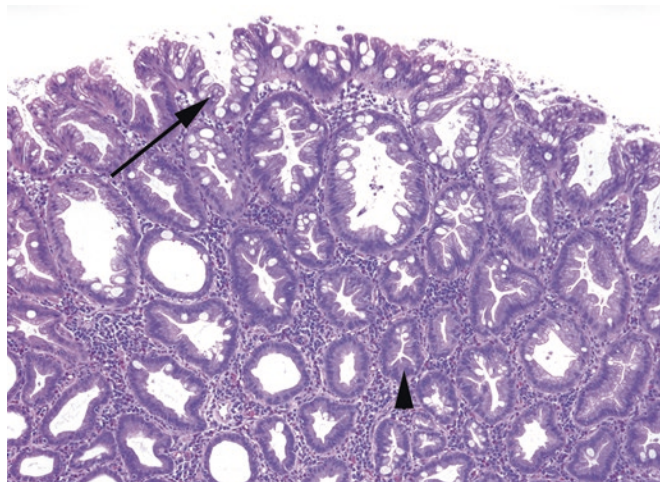


FIGURE 8.5. Hyperplastic polyp. The surface of the polyp shows a characteristic “frilly” appearance (*arrow*), with hyperplastic mucinous epithelium and prominent goblet cells. Deeper crypts (*arrowhead*) show star-shaped lumens.

A polyp with adenomatous-looking cells at the base of the crypts, and frilly hyperplastic cells at the surface, is still a hyperplastic polyp. Remember that surface maturation is not consistent with a tubular adenoma. However, a true adenoma with a serrated surface profile may be in the serrated adenoma category, below.

Historically, a “serrated adenoma” was a polyp with low-grade dysplasia extending to the surface, as seen in tubular adenoma, but with serrated architecture. Now a subset of what were once lumped in with hyperplastic polyps, especially in the right colon, are recognized as a distinct type of polyp with malignant potential, associated with the microsatellite instability (MSI) cancer pathway. These polyps, often broad and sessile, are called either *sessile serrated adenomas* (SSA) or *sessile serrated polyps* (SSP). The crypts have characteristic widening and horizontal branching at the base (“duck feet”), and the epithelial cells may be more eosinophilic (less mucin) and pseudostratified than the usual hyperplastic polyp (Figure 8.6). In addition, the thickened basement membrane seen near the surface in hyperplastic polyps is absent in SSAs. However, mature goblet cells and the serrated profile are still evident.

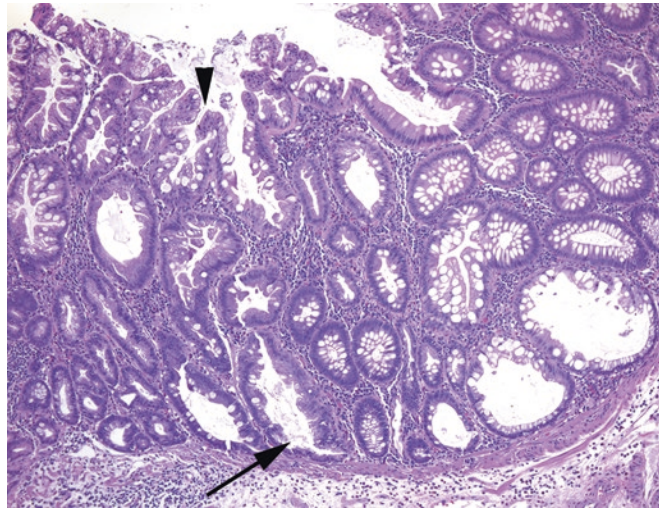


FIGURE 8.6. Sessile serrated adenoma. The surface looks similar to a hyperplastic polyp (*arrowhead*), but the base shows sideways branching of crypts (*arrow*) caused by proliferation at the base of the lesion.

The difference is in the depth of proliferation: hyperplastic polyps show mostly surface hyperplasia and expansion, whereas the SSA is hyperplastic right down to the base. These are important to recognize, because they should be treated clinically like an adenoma, not just a hyperplastic polyp.

The phrase *traditional serrated adenoma* is now reserved for the rare polyps, usually left sided, that have diffuse low-grade dysplasia but also a serrated architecture. In contrast, a recognizable SSA/P with a focus of low- or high-grade dysplasia is signed out just that way, “SSP with ___-grade cytologic dysplasia.” Dysplasia in SSAs is thought to progress to MSI-type carcinomas, at least in sporadic cases. See below for further discussion on the genetics of cancer.

Inflammatory Pseudopolyps

Inflammatory pseudopolyps are polypoid structures that consist of either granulation tissue (when adjacent to an ulcer) or inflamed lamina propria with distorted crypts. Given the inflammation, there can be severe reactive changes in the crypts, resembling dysplasia. However, surface maturation should be visible. These are common in inflammatory bowel disease. A polyp that looks like an inflammatory polyp but occurs without background inflammatory disease may be a *juvenile polyp*, a diagnosis that can be made in a patient of any age.

Prolapse-Type Lesions

Mucosal prolapse is like a tiny focus of intussusception; a protruding bulge of mucosa gets pulled, twisted, generally battered in the breeze, suffers ischemia and trauma, and begins to look fairly weird as it tries to repair itself. Features include extension of the muscularis mucosa into the lamina propria as disorganized fibers, crypt distortion and dilation with diamond-shaped crypts, hemosiderin, and edema and inflammation with reactive atypia (Figure 8.7). This lesion may be called a *polypoid prolapsing mucosal fold* in the colon, *solitary rectal ulcer syndrome* in the rectum, or *inflammatory cloacogenic polyp* at the anorectal junction.

Carcinoma

Molecular medicine changes so quickly that any discussion of the molecular definition of tumors firmly cements the document in the year in which it was written. However, the molecular pathways of colon carcinoma have become too central to pathology to skim over.

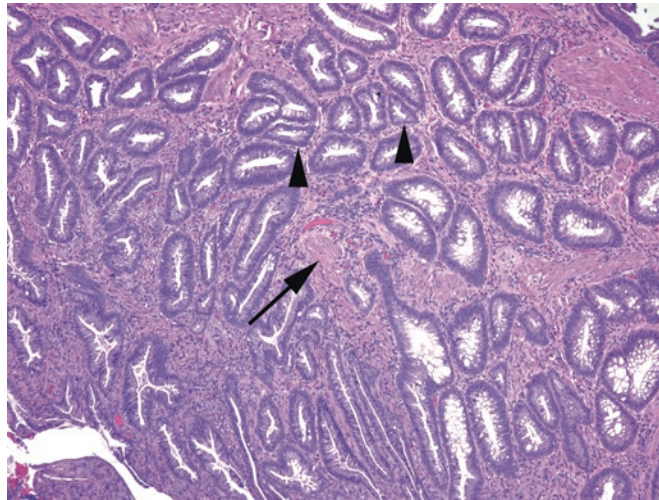


FIGURE 8.7. Prolapse lesion. The center of this prolapse-related polyp shows typical features, including angulated or diamond-shaped crypts (*arrowheads*) and smooth muscle growing between crypts (*arrow*).

TABLE 8.1. A somewhat oversimplified breakdown of the categories of tumor progression.

Epigenetic changes	Genetic changes	Precursor lesion	Adenocarcinoma phenotype	Approx. %
(None)	APC gene inactivation with subsequent KRAS or BRAF mutations (includes both sporadic and FAP patients)	Tubular adenoma or villous adenoma	Conventional adenocarcinoma	60
(None)	Germline mutation of MMR genes with resulting MSI (Lynch syndrome)	Tubular adenoma or villous adenoma	MSI-high-type adenocarcinoma ^a	5
CIMP				
Promoter methylation of TSG	Secondary downregulation of TSG and resulting activating mutations	Traditional serrated adenoma (postulated)	Conventional adenocarcinoma	20
Promoter methylation of MLH1 gene	Secondary downregulation of MMR genes with resulting MSI	Sessile serrated adenoma	MSI-high-type adenocarcinoma ^a	15

CIMP CpG island methylator phenotype, *MMR* mismatch repair, *MSI* microsatellite instability, *TSG* tumor suppressor gene

^aMSI-high features include right-sided location; mucinous, medullary, or signet-ring variants; and prominent lymphocytic infiltrate

Adenocarcinoma of the colon follows principally three lines of tumorigenesis, which can be grouped into:

- The APC or *chromosome instability* pathway, in which the tumor suppressor APC gene is inactivated, resulting in increasing numbers of mutations within the tumor cells, including p53, KRAS, or BRAF mutations.
- The *microsatellite instability* (MSI) pathway, in which there is inactivation of genes that repair DNA mismatch in areas of repeated sequences (microsatellites), leading to instability in these regions and malignant transformation.
- The *epigenetic instability* or CpG island methylator phenotype (CIMP) pathway, in which methylation of promoters inactivates tumor suppressor or mismatch repair genes. The resulting tumors may therefore mimic the phenotype of either the APC-type or the MSI-type carcinomas (Table 8.1).

Distinction of the processes is important because they respond to different regimens of chemotherapy and have different prognoses. While there are histologic clues to subtyping the tumor, in practice most are definitively tested now using ancillary methods.

About 5% of colon cancers are hereditary, most of them autosomal dominant syndromes which also carry a risk of cancer in other organs. The most well known of these syndromes were described long before the molecular signatures were known: familial adenomatous polyposis (FAP) and hereditary non-polyposis coli (HNPCC). FAP is caused by a germline mutation in the *APC* gene, such that the remaining functional allele is vulnerable to somatic mutations. Knockout of both genes leads to adenoma formation. These patients have thousands of tubular adenomas and inevitably progress to adenocarcinoma. *p53* mutation is involved in this same pathway, but as a late event in the progression from adenoma to carcinoma. The resulting adenocarcinoma is of the garden variety, indistinguishable from sporadic adenocarcinoma.

HNPCC syndrome is divided into Lynch syndrome and the “other” bucket. Lynch syndrome patients have germline mutations of DNA mismatch repair genes (*MLH1*, *MSH2*, *MSH6*, or *PMS2*). As above, these genes are vulnerable to the “second hit” somatic mutation, which leads to microsatellite instability. Although cancers are still thought to arise from tubular adenomas in this group, not SSAs, their adenocarcinomas are more often medullary, mucinous, or signet-ring cancers, usually right sided.

Medullary carcinoma of the colon is a distinct and rare variant with an associated dense lymphocytic reaction (like medullary carcinoma of the breast) but a bland, almost neuroendocrine cytology (like medullary carcinoma of the thyroid), although there is probably no connection among these entities. In the colon, medullary carcinoma suggests Lynch syndrome or a sporadic MSI-type tumor. Other types of carcinoma often associated with MSI include mucinous and signet ring.

Neuroendocrine (Carcinoid) Tumors

The most common locations for gastrointestinal neuroendocrine tumors (NETs) are the appendix and small bowel, with rectum and colon further down the list. Often submucosal, NETs may present as a mass on endoscopy or cause obstruction. The carcinoid syndrome (skin flushing, diarrhea, abdominal pain) does not occur until and unless the tumor metastasizes to the liver. Well-differentiated NETs are characterized by uniform neuroendocrine-type cytology and trabecular, spindly, or rosette-like architecture (Figure 8.8). Most of the time, NETs are clearly identifiable, but if you are about to diagnose an adenocarcinoma that seems to have unusually bland and homogeneous nuclei, consider that you may be looking at a NET with pseudo-gland formation.

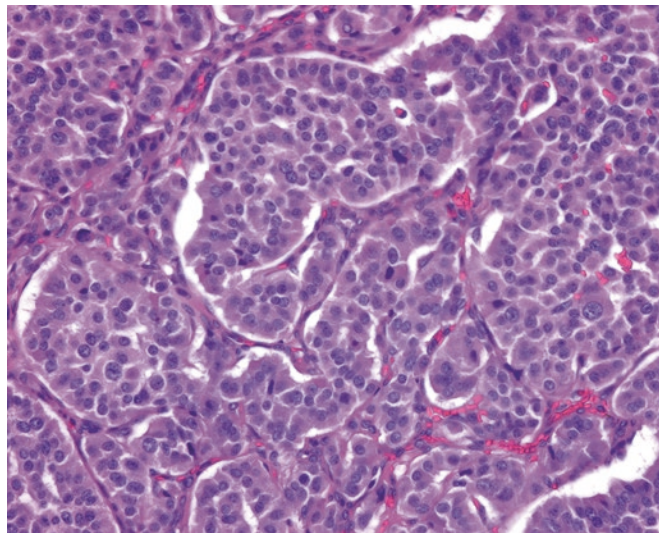


FIGURE 8.8. Carcinoid tumor. Nests and ribbons of cells separated by delicate fibrovascular septa are classic, as are the round and regular nuclei with finely speckled chromatin.

As in other sites, NETs are graded by their proliferative index into grade 1 and grade 2 NETs or grade 3 neuroendocrine carcinomas (NECs). As in other sites, a well-differentiated grade 1 tumor may still metastasize. Neuroendocrine tumors are covered in more depth in Chapter 26.

The Dreaded Appendiceal Mucinous Neoplasms (supply your own acronym)

Although the appendix is usually a ditzel, there are few things more painful than the giant distended mucinous appendix, which must be submitted entirely and then leads you into the swampy quagmire of mucinous neoplasm nomenclature. Fortunately, experts have recently begun to agree on what to call these entities and their frequent sidekicks, the mucinous peritoneal lesions.

First, deal with the appendix. If an epithelial lesion is confined to the mucosa (does not cross the muscularis mucosa), then you may choose to call it a serrated polyp, a tubular adenoma, or a villous adenoma, with or without high-grade dysplasia, just as you would in the colon. A mucinous epithelial neoplasm that distends the appendix and compresses the lamina propria out of existence, however, joins the appendiceal mucinous neoplasm family. *Low-grade appendiceal mucinous neoplasms* (LAMNs) are tumors with bland or low-grade cytology, and they may extravasate mucinous epithelium, or just mucin, into the wall of the appendix and all the way to the serosa. The extent of the spread of mucin determines the stage of the tumor, even in the absence of stromal invasion. High-grade tumors (HAMNs) are those that have high-grade dysplasia, but like the LAMN seem to be pushing expansively through the wall, without stromal invasion. The term *mucinous adenocarcinoma* is reserved for those tumors that show usual colonic-type invasion with a desmoplastic stromal response.

After categorizing the appendix, move on to the peritoneum or other sites within the belly. Even without stromal invasion, these tumors can perforate the appendix and fill the belly with mucin, which is clinically called *pseudomyxoma peritonei*. Histologically, the disease is classified by the tumor cells producing it. If there is free mucin in the belly, without any visible tumor cells floating in the mucin, this can be described as just acellular mucin. If, however, there are identifiable epithelial cells (Figure 8.9), the disease is called *mucinous carcinoma peritonei*, either low grade or high grade depending on the degree of atypia. (All of this nomenclature is still evolving and may change; in addition, some institutions may have preferred synonyms.)

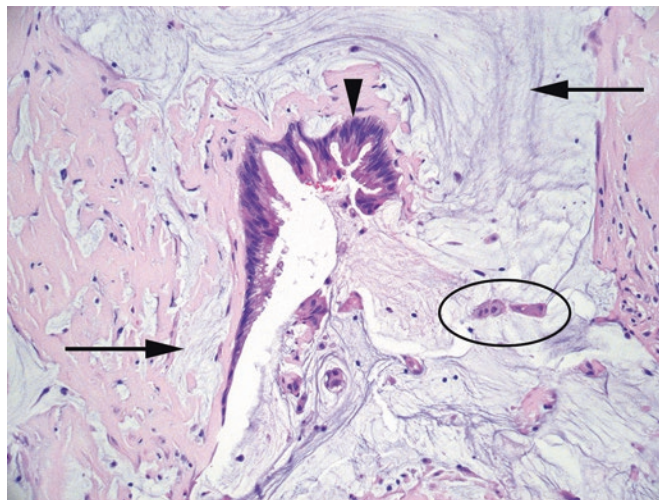


FIGURE 8.9. Mucinous carcinoma peritonei. In this specimen from the peritoneum, there is abundant extracellular mucin (*arrows*), but the mucinous tumor cells are also visible, both as partial glands (*arrowhead*) and as floating clusters (*oval*).

Inflammatory Bowel Disease

Inflammatory bowel disease (IBD) is an idiopathic chronic inflammatory disease affecting the colon and consists primarily of ulcerative colitis and Crohn's disease. A definitive diagnosis of IBD must include changes indicating activity AND chronicity. A simple active colitis without chronic changes may be due to infection, ischemia, drugs, or bowel preparation, as well as early IBD.

Features of active colitis (Figure 8.10) include the following:

- Neutrophils in the crypt epithelium = cryptitis.
- Neutrophils in the crypt lumen = crypt abscesses.
- Erosions and ulcers and pus are also consistent with active lesions.

Features of chronicity are architectural and include the following (Figure 8.11):

- Crypt distortion (branching, tortuous, or sideways crypts)
- Crypt loss (crypts missing)
- Crypt atrophy (crypts too short)
- Basal plasmacytosis (crypts pushed up by a dense layer of chronic inflammation)
- Paneth cell metaplasia (Paneth cells in the left colon, where they don't belong)

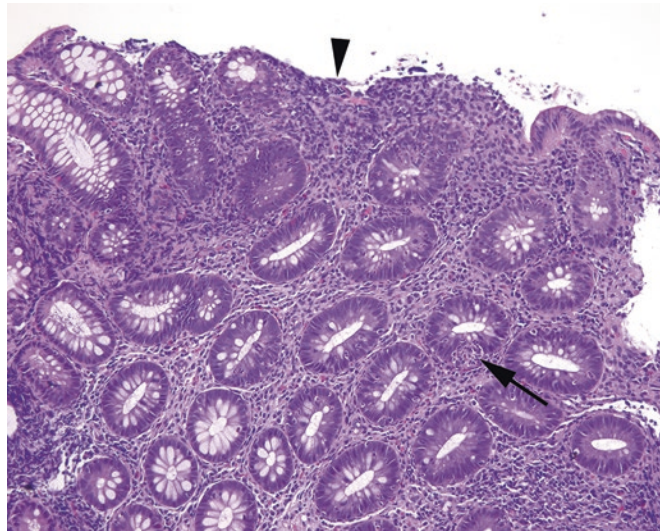


FIGURE 8.10. Active colitis. Neutrophils are seen in the epithelium of the crypts (*arrow*), and the surface is ulcerated (*arrowhead*).

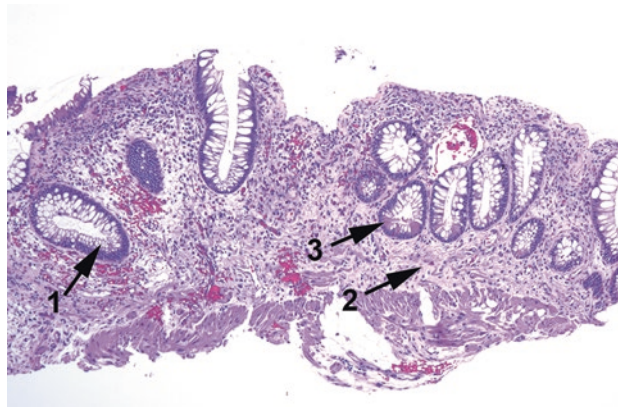


FIGURE 8.11. Chronic inflammatory disease. This biopsy specimen shows a loss of crypt density (atrophy); crypt distortion (*1*); elevation of crypts off of the muscularis mucosa (*2*), often accompanied by a dense basal lymphocytic infiltrate (not seen here); and Paneth cell metaplasia (*3*).

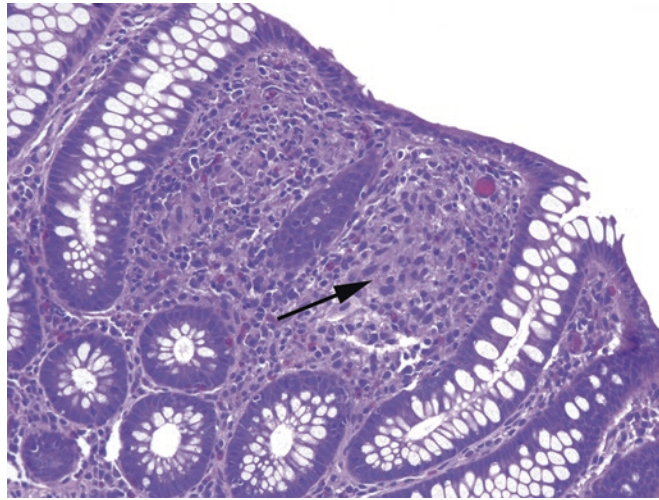


FIGURE 8.12. Granuloma in Crohn's disease. The granulomas in Crohn's are small and subtle. This image, taken at 40 \times , shows a small collection of histiocytes (*arrow*) between crypts.

Chronic inflammatory disease is usually qualified as either active (having neutrophils) or inactive. The differentiation between Crohn's disease and ulcerative colitis can be difficult on biopsy; a more definitive diagnosis is made on colectomy (should it come to that). However, there are features that suggest one or the other, and the endoscopic distribution of disease alone may favor one over the other before you even see the slides. Remember that you must first see chronic changes to consider making the diagnosis of IBD (at least at the time of initial diagnosis). In a patient with known IBD and a sudden exacerbation, look for CMV hiding in the ulcers.

Features favoring Crohn's disease:

- Patchy mucosal involvement with skip areas (including patchy involvement within the same biopsy)
- Involvement of the terminal ileum
- Non-necrotizing, poorly formed granulomas (Figure 8.12)
- On colectomy, transmural or submucosal inflammation, cobblestoning, fissures, fistulas, and creeping fat

Features favoring ulcerative colitis:

- Predominantly distal involvement or pancolonic (no skip areas)
- Diffuse mucosal inflammation, many neutrophils
- Dense basal plasmacytosis

Note, however, that once a patient has begun treatment, ulcerative colitis may appear patchy in activity.

Dysplasia in Inflammatory Bowel Disease

Once diagnosed, IBD must be followed both to monitor activity (response to therapy) and to look for dysplasia. The constant inflammation puts the patient at high risk for developing cancer. Therefore, the presence or absence of dysplasia should be noted in every IBD surveillance biopsy specimen. If an area of dysplasia is grossly visible to the gastroenterologist, simple excision may be curative, but "invisible dysplasia" (invisible to the endoscope, at any rate) will require more intensive follow-up study.

Diarrhea

Microscopic Colidities: Lymphocytic and Collagenous Colitis

Microscopic colidities are defined by having no abnormal endoscopic findings; they are only diagnosable under the microscope. The symptoms include chronic watery diarrhea, abdominal pain, fatigue, and weight loss. The two types are *lymphocytic colitis* and *collagenous colitis*. Both are characterized by the following:

- A lack of chronic changes (no crypt distortion, no basal plasmacytosis)
- A predominantly top-heavy lymphocytic infiltrate in the lamina propria
- Intraepithelial lymphocytes, especially at the surface
- Evidence of damage to the surface epithelium (loss of cells)

Just those four features are sufficient for a diagnosis of lymphocytic colitis. Collagenous colitis has, in addition, a distinct thickened collagen band along the basement membrane under the surface epithelium. This band must be irregular and blurred into the lamina propria, not just thick, typically with entrapped capillaries. A trichrome stain confirms the diagnosis (Figure 8.13).

In the setting of a dense lymphoplasmacytic infiltrate, pay attention to whether the blueness is top-heavy (more prominent under the surface) or bottom-heavy (more prominent at the base of the crypts). Inflammatory bowel disease tends to be bottom-heavy and the microscopic colidities more top-heavy. This is a soft feature rather than a rule.

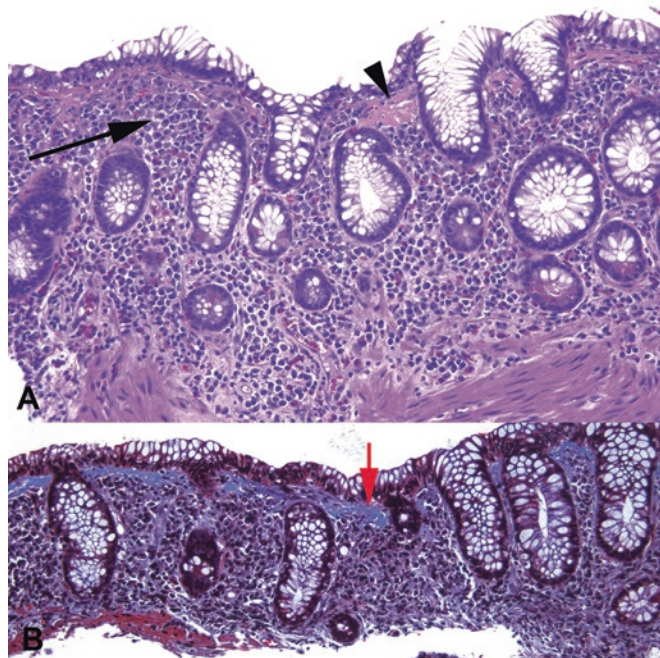


FIGURE 8.13. Collagenous colitis. (a) The H&E stain shows a top-heavy lymphoplasmacytic infiltrate (*arrow*) accompanied by dense pink material just under the surface epithelium (*arrowhead*). (b) A trichrome stain confirms the thickened collagen table (*blue on this stain, red arrow*), which has an irregular border and entraps nuclei within the lamina propria.

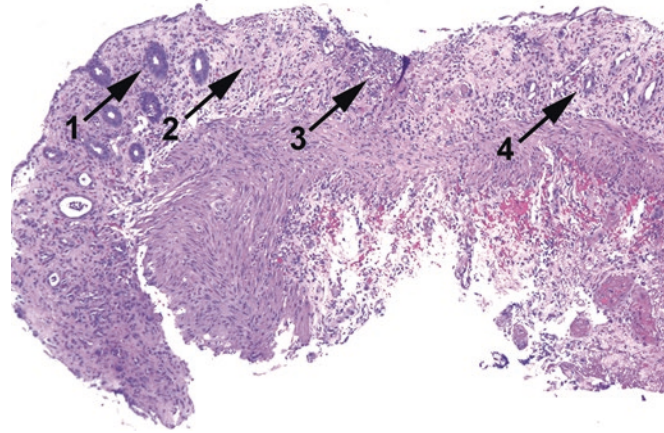


FIGURE 8.14. Ischemic colitis. Features include small dark regenerative crypts (1), hyalinization and fibrosis of the lamina propria (2), ulceration (3), and crypt dropout (4).

Other Colidities

Ischemic colitis may have many appearances, from focal active colitis to diffuse pseudomembranous colitis mimicking *C. difficile* colitis. Acute or transient ischemia appears as damage to the superficial surface of the mucosa, with hemorrhage and coagulative necrosis. Prolonged ischemia causes fibrosis of the lamina propria and a top-down atrophy of the crypts: they appear collapsed at the surface and regenerative at the base (Figure 8.14). *Infectious colitis* is not often biopsied because of its usually self-limited course. It may range from no pathologic findings to a severe active colitis. *Diversion colitis* is a special entity associated with a Hartmann pouch, which is a blind-ended rectal cavity disconnected from the fecal stream. The loss of normal colonizing flora causes a nonspecific colitis, which may be mistaken for inflammatory bowel disease. Both drugs and the bowel preparation process may cause transient active colitis. Acute inflammation in the absence of chronic changes is nonspecific and should not be overinterpreted.

Liver biopsies are usually needle core biopsies. The most common reasons for a biopsy include monitoring disease progression in hepatitis, evaluating a transplanted patient for rejection or graft-versus-host disease (GVHD), investigating elevated liver function tests (LFTs), or diagnosing a radiographic mass. At many institutions, all non-neoplastic liver biopsy specimens are stained with trichrome (to evaluate fibrosis) and an iron stain (to reveal abnormal stores of iron in the tissue).

Anatomy

Blood comes into the liver via the portal vein (from the gut) and the hepatic artery (from the aorta). These vessels ramify into the small veins and arteries within the portal tracts. Blood gets from the terminal portal vessels to the outgoing central veins via the sinusoids—the long channels lined by hepatocytes. Once in the central vein, blood exits the liver via the hepatic veins, which drain into the inferior vena cava (resulting in a mingling of blood from the liver and lower extremities).

Bile is created by the hepatocytes and is secreted into the bile canaliculi, which eventually coalesce into ductules and ducts in the portal tracts. The bile then exits the liver via the common hepatic duct, which joins the cystic duct (from the gallbladder) to form the common bile duct.

Normal Histology

The liver is composed of three main components—the *hepatocytes*, the *biliary system*, and the *blood vessels*. Hepatocytes are large pink polygonal cells with dense round nuclei. Nucleoli, nuclear size variation, and occasional binucleate cells are okay. The hepatocytes are organized into plates that are one hepatocyte thick and lined by reticulin. Between these plates are the sinusoids for blood. Running perpendicular to the sinusoids, and essentially invisible to light microscopy, are the *bile canaliculi*: tiny intercellular channels between the hepatocytes.

Bile from the canaliculi makes its way to the bile ducts. The bile ducts are tubular structures with a low cuboidal epithelium (Figure 9.1). They are found in the *portal tracts*, which also contain branches of the hepatic artery and portal vein. These three components are also called the *portal triad*. Blood in both vessels is flowing *into* the liver; bile is flowing *out*. The portal tract also contains a small amount of connective tissue, which makes it stand out on a trichrome stain. The hepatocytes immediately surrounding the portal tract are called the *limiting plate*. The portal tract is usually the hotspot for inflammatory processes in the liver and so is important to identify on biopsy.

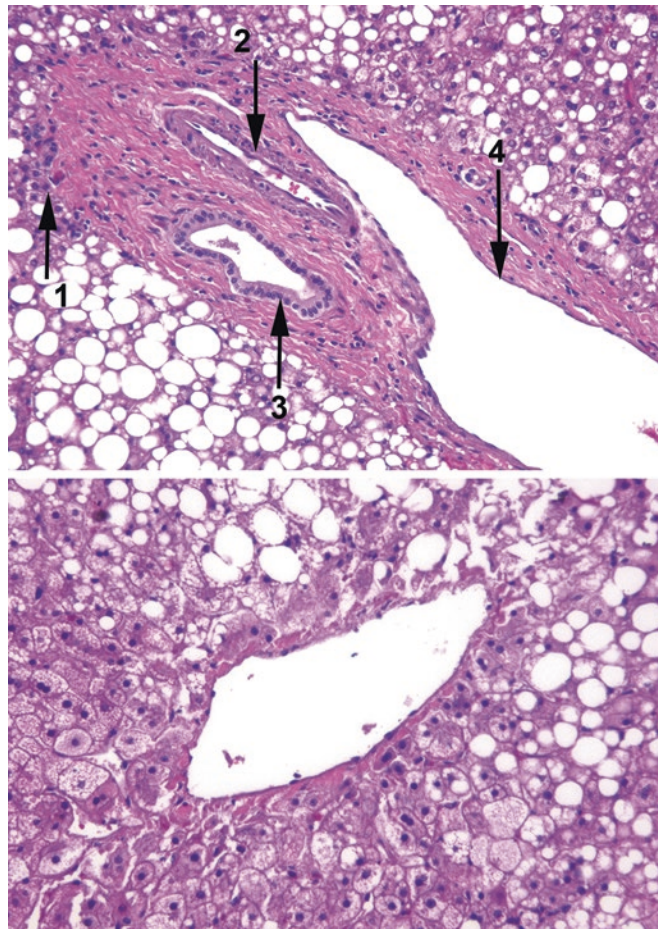


FIGURE 9.1. Portal tract and central vein. The *upper* panel shows a typical portal tract surrounded by the limiting plate of hepatocytes (1) and containing a branch of the hepatic artery (2), bile ductule (3), and portal vein (4). The *lower* panel shows a central vein from the same liver. Both panels show extensive macrovesicular steatosis.

The third vessel in the liver unit is the *central vein* or *terminal venule*. This is a thin-walled vessel surrounded by hepatocytes and nothing else (see Figure 9.1). It contains blood on its way *out* of the liver.

The *lobule* is an architectural unit with the central vein as its center and portal tracts at the periphery. *Centrilobular* refers to a process surrounding the central vein, as opposed to being centered on the portal triad. The lobule is the most easily visualized anatomic unit (Figure 9.2).

The *acinus* is a functional triangular unit with the portal tracts at the base (as the source of blood flow) and the central vein at the apex. In this model, the hepatocytes closest to the source of blood and oxygen are in zone 1, the base, and the most peripheral hepatocytes are in zone 3, the apex at the central vein. Ischemia and toxic insults affect the zones differently. The acinus is more of a physiologic unit and is used when describing liver findings that vary by zone.

Non-neoplastic or Inflammatory Disease Categories

It is helpful to think of the different liver compartments separately, because histologic findings can often be grouped according to the involved compartment:

- Diseases of hepatocytes: viral hepatitis, autoimmune hepatitis, nonalcoholic and alcoholic fatty liver disease, drug toxicity, and metabolic/storage diseases

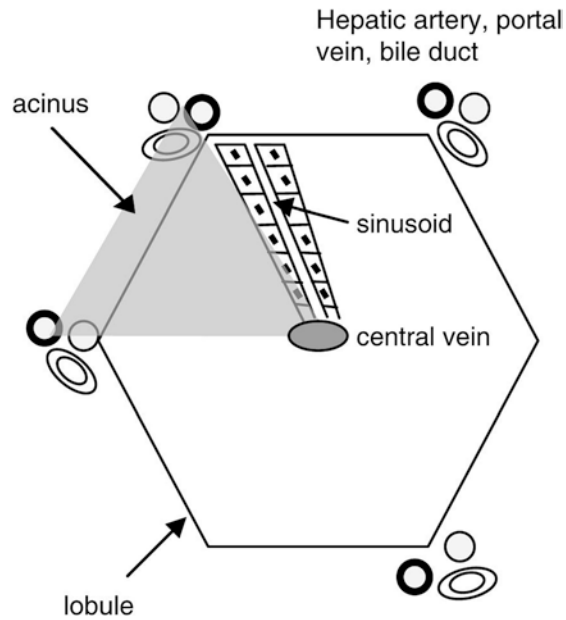


FIGURE 9.2. Liver organization. The acinus is a triangular, physiologic unit, while the lobule is a hexagonal anatomically based unit.

- Diseases of the biliary system: autoimmune biliary diseases (primary sclerosing cholangitis and primary biliary cirrhosis), obstruction, atresia, transplant rejection, GVHD, and drug-induced injury
- Diseases of the vasculature: transplant rejection, GVHD, and systemic vasculitides

The portal tract represents a convergence of all three compartments. Therefore, inflammation of the portal tract can be found in all of these diseases.

Pathologic Findings

The liver has only so many ways to respond to an insult or injury. An acute injury in the liver looks similar to that in any other organ: widespread edema, acute and chronic inflammation, and/or necrosis. Subacute or chronic injury generally has mainly mononuclear inflammatory cells as well as individual hepatocyte necrosis or degeneration. The final result of chronic injury from many causes is cirrhosis or end-stage liver disease. Therefore, many diseases in the liver have histologic overlap, and, in the case of cirrhosis, often you cannot tell what the original disease process was. The most important skill in interpreting the liver biopsy is recognizing injury to the different compartments. To attach a diagnosis to this collection of findings (wait for it), *clinical correlation is required*. Since that is an absolute given in liver pathology, don't feel the need to include that phrase in your diagnosis. Instead, learn to look for clues in the chart and create a differential diagnosis that accounts for both clinical and histologic findings, with the help of a focused liver textbook. The most common patterns of injury are the following:

Hepatocellular Compartment

- Portal inflammation: Inflammatory cells within the portal tract. In viral hepatitis and autoimmune disorders, the infiltrate is predominantly mononuclear. Eosinophils suggest a drug reaction, while plasma cells are often seen in autoimmune hepatitis.

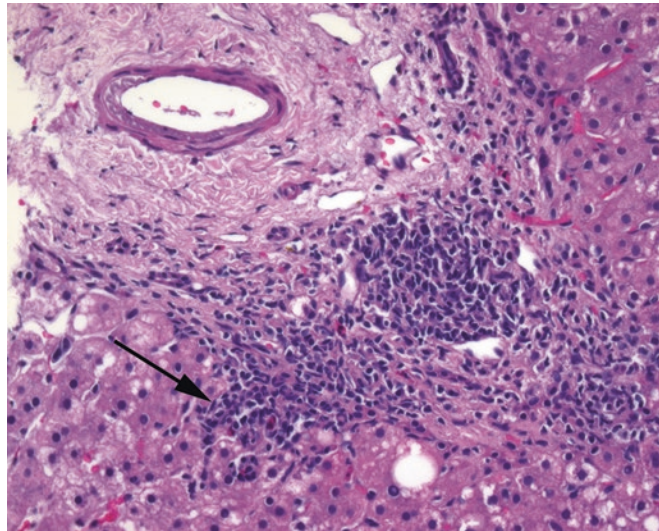


FIGURE 9.3. Portal inflammation. This is an example of chronic viral hepatitis. Lymphocytes in the portal tract spill out into the limiting plate of surrounding hepatocytes (*arrow*).

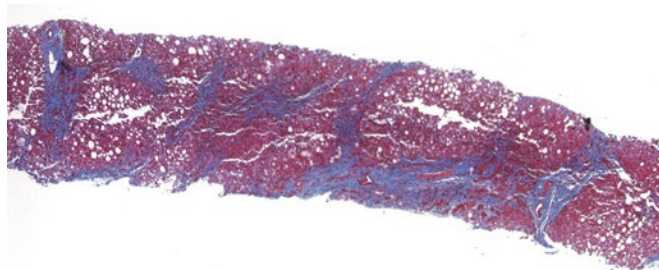


FIGURE 9.4. Cirrhosis in a biopsy specimen. In this trichrome stain, collagen is blue, while hepatic parenchyma is red. Collagen can be seen outlining the lobules of regenerative hepatocytes, bridging the portal tracts and creating a nodular pattern.

- Interface activity (periportal hepatitis, piecemeal necrosis): Inflammation, usually lymphocytic, occurring in the limiting plate and damaging the hepatocytes along that boundary. This looks like portal inflammation spilling out into the hepatocytes (Figure 9.3). Note that the word *activity* when describing something in the liver does not necessarily mean neutrophils.
- Lobular inflammation: Inflammation, often accompanied by hepatocyte necrosis, farther out from the portal tracts. *Spotty necrosis* is characterized by little clusters of lymphocytes and/or macrophages destroying individual hepatocytes in the lobules. Do not count lymphocytes in the sinuses, as they are physiologic.
- Vacuolar degeneration (balloon cell change, or ballooning degeneration): One way in which hepatocytes become injured and die. The cell swells and the cytoplasm becomes feathery and pale to clear.
- Acidophilic bodies: Another way in which hepatocytes die. These cells are similar to dyskeratotic cells in the skin; they are bright pink and shriveled up, with pyknotic nuclei.
- Fibrosis: A general term indicating too much collagen. Fibrosis usually begins as an increase in collagen around the portal tract (portal fibrosis) and eventually spreads to connect adjacent portal tracts or central veins by thin webs of collagen (bridging fibrosis). The end stage of the process is cirrhosis, which is the division of the liver into individual nodules of regenerative hepatocytes separated by thick bands of fibrosis (Figure 9.4).

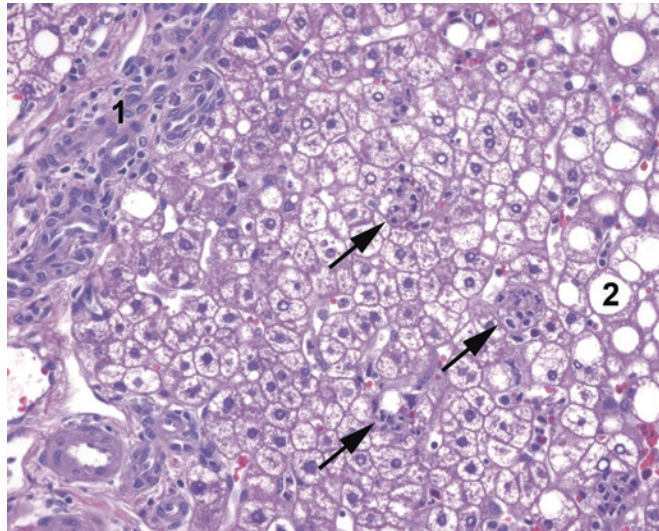


FIGURE 9.5. Steatohepatitis. An adjacent portal tract (1) shows minimal mononuclear inflammation. In the lobule, there is macrovesicular steatosis (2) and collections of neutrophils attacking individual hepatocytes (arrows).

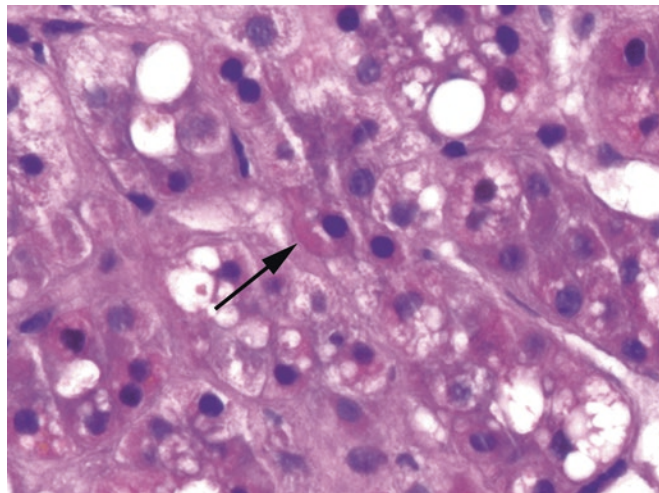


FIGURE 9.6. Mallory's hyaline. In the background of steatosis and inflammation, a pink refractile wormlike structure in the hepatocyte (arrow) is evidence of cytoskeletal collapse and condensation.

- Steatosis: Fat (triglycerides) in the hepatocytes. Steatosis can be physiologic in small amounts (<5%). Involvement of 5–33% of hepatocytes is mild steatosis, 33–66% of hepatocytes is moderate steatosis, and more than 66% of hepatocytes is marked or severe steatosis. Macrovesicular steatosis describes large lipid vacuoles in each hepatocyte and is typical of alcoholic and nonalcoholic fatty liver disease. Pure microvesicular steatosis looks like foamy cytoplasm and is characteristic of mitochondrial injury, such as in Reye's syndrome.
- Steatohepatitis: Steatosis with inflammation (usually lobular) and/or hepatocyte injury. Neutrophils are not necessary for the diagnosis, but some evidence of hepatocyte injury is (Figure 9.5). This includes hepatocyte necrosis, balloon cells, pericellular/perisinusoidal fibrosis, and Mallory's hyaline (see below). Lipogranulomas consisting of lipid-containing macrophages and lymphocytes suggest previous episodes of steatohepatitis.
- Mallory's hyaline (Mallory bodies): Irregular wormlike pink blobs of condensed cytoskeleton in the cytoplasm, especially within balloon cells (Figure 9.6). They are associated with steatohepatitis and alcoholic disease in particular.

- Megamitochondria: Markedly enlarged mitochondria that look like red blood cells entrapped in the hepatocyte cytoplasm.
- Iron accumulation: Abnormal iron deposits detected with either H&E or iron stain. When severe, iron accumulation may indicate hemochromatosis. Mild to moderate iron deposition (hemosiderosis) can also occur from frequent blood transfusions or hemolytic anemia; typically, the iron deposition is predominantly within macrophages (Kupffer cells).
- Other storage diseases: Special stains or immunohistochemistry may be required to detect abnormal copper deposits (Wilson disease), α_1 -antitrypsin globules in α_1 -antitrypsin deficiency (in this disease, the enzyme is deficient *in the serum* because it is trapped in the hepatocytes as globules after being produced), Gaucher disease (positive on PAS-diacetate), or the glycogen storage diseases (negative on PAS-diacetate).

Biliary Compartment

- Cholestasis: The backup of bile in the liver, visible as yellow globs or chunks in hepatocyte cytoplasm, bile canaliculi, or (less commonly) bile duct lumina. Cholestasis may be caused by extrahepatic obstruction to flow, intrahepatic biliary disease, or impaired excretion by the hepatocytes themselves.
- Bile duct proliferation (ductular reaction): An increase in the number of bile duct profiles/ductules in each portal tract beyond the typical one or two per tract. Many of the new ductules are small, peripheral, and poorly formed with compressed or inconspicuous lumina. Bile duct proliferation occurs as a response to obstruction to flow. Other findings in obstruction include visible bile in hepatocytes or canaliculi, edema and inflammation (especially neutrophils) in the portal tracts, eventual loss of ducts, and finally, widespread fibrosis (Figure 9.7).
- Bile duct injury: Identified by lymphocytes in the bile duct epithelium and vacuolar degeneration or dropout of the epithelial cells. The end stage is ductopenia. Injury to the bile ducts can indicate a biliary-centric disease, including autoimmune disease (such as primary biliary cirrhosis) or transplant rejection. Bile duct injury is usually patchy, so multiple portal tracts must be examined.
- Ductopenia: Loss of bile ducts, which is an indicator of chronic damage to the biliary system. Recognizing ductopenia, a diagnosis of absence, requires a conscious effort to look for bile ducts in each portal tract. If bile ducts are present in fewer than 80% of the portal tracts, that suggests ductopenia. A CK7 immunostain can help with bile duct identification.

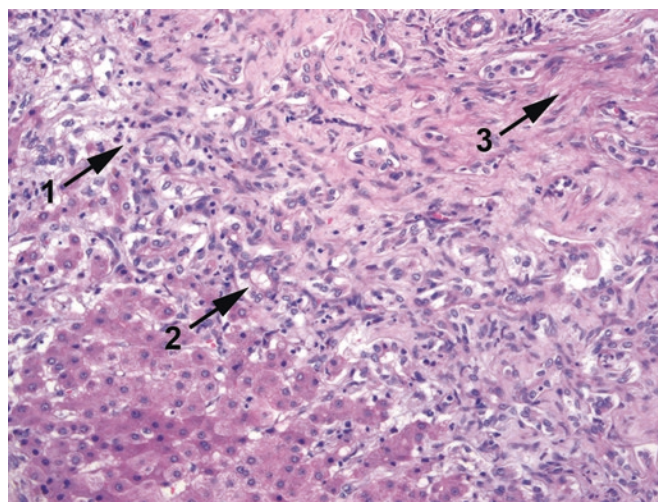


FIGURE 9.7. Bile stasis. In this example of congenital biliary atresia, the downstream obstruction to flow creates the triad of acute inflammation (1), a proliferation of poorly formed bile ductules (2), and the accumulation of golden globs of bile (not seen here). This will progress to fibrosis (3) and eventually loss of ductules.

Vascular Compartment

- Venulitis (endotheliitis): Damage to the endothelium of the portal or central veins by inflammatory cells. The endothelial cells tend to round up and become more prominent. Venulitis is usually an indication of rejection or GVHD.
- Extramedullary hematopoiesis: Hematopoietic precursors (megakaryocytes are the most distinctive) in the liver sinuses. It is generally an indication of bone marrow disease, but is physiologic in fetuses and infants.

Chronic Hepatitis

Biopsies in chronic hepatitis are done to track disease progression or exacerbation, with the ultimate endpoint of the disease being cirrhosis. Sign-out of a hepatitis biopsy specimen should include three key diagnostic and prognostic factors: *etiology* (if known), *grade* (degree of inflammation and necrosis), and *stage* (extent of fibrosis), plus any other disease process present (such as steatohepatitis).

There are many different scoring systems used to quantify grade and stage, as all clinicians love a number. However, most numeric scoring systems can be translated to or from adjectives, which convey the same information (e.g., scores 0–4 correspond to none, minimal, mild, moderate, or severe inflammation; and none, portal, periportal, bridging, or cirrhotic fibrosis). Calibrating these levels takes some experience, and thresholds and systems will vary by institution.

The changes in viral hepatitis are nonspecific. The differential includes most other hepatocellular diseases.

Transplant Biopsy for Rejection or Graft-Versus-Host Disease

The changes seen in cellular rejection and GVHD are histologically similar; one occurs in the setting of a liver transplant and the other after a bone marrow transplant. Both can be divided into acute and chronic. (Hyperacute rejection implies an antibody response and is rare and immediate and not usually diagnosed by biopsy.)

- Acute cellular rejection: Acute rejection usually occurs 5–30 days after transplant, but can be longer. Changes include the following:
 - Mixed portal tract inflammation, including lymphocytes, neutrophils, and eosinophils
 - Venulitis
 - Bile duct inflammation and damage (Figure 9.8)
- Chronic rejection: Chronic rejection usually occurs after more than 1 year.

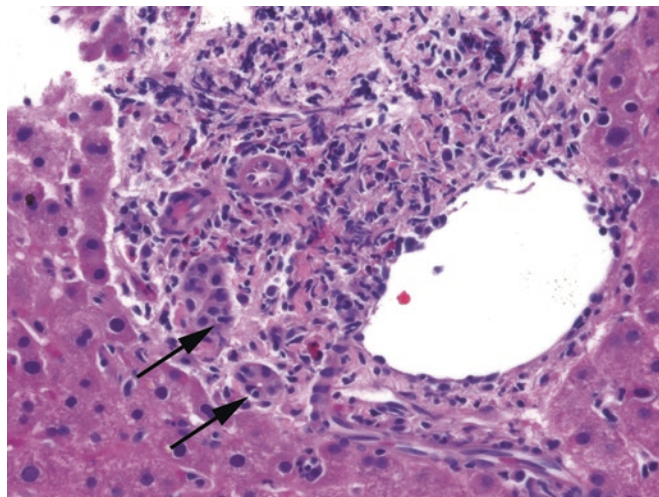


FIGURE 9.8. Acute rejection. Acute rejection refers to the attack on the bile ducts and venules by lymphocytes, which are seen invading the duct epithelium (*arrows*). Note how plump the endothelial cells are as well.

Changes are primarily those of ductopenia and fibrosis.

Note that the changes of rejection must be differentiated from recurrent hepatitis C, an inevitable occurrence in patients who lost their first liver to hepatitis C (occurs from 3 to 9 months after transplantation).

Primary Biliary Cirrhosis, Primary Sclerosing Cholangitis, and Autoimmune Hepatitis

The autoimmune disorders are hard to keep straight. The bullet version is as follows:

Primary biliary cirrhosis, PBC (occurs much more often in women than in men and never in children):

- PBC is a chronic destructive *intrahepatic* cholangitis (inflammation of the intrahepatic bile ducts).
- Cirrhosis is an end-stage feature.
- It is associated with anti-mitochondrial antibody.
- Findings are nonspecific and patchy but include portal inflammation and predominantly granulomatous injury to the bile ducts, followed by ductular proliferation and cholestasis, and then eventually ductopenia and cirrhosis (Figure 9.9).
- The etiology is direct autoinflammatory damage to bile duct epithelium.

Primary sclerosing cholangitis, PSC (occurs more often in men than in women):

- PSC is an inflammatory disease of the *extrahepatic* (and large intrahepatic) ducts.
- It leads to patchy stricturing lesions, visible on cholangiogram.
- It is associated with inflammatory bowel disease (especially ulcerative colitis) and p-ANCA.
- The histologic picture is also nonspecific but dominated by ductular proliferation and cholestasis due to downstream obstruction; with luck, an involved portal tract with mixed portal inflammation, bile duct injury, and “onion skin” concentric periductal fibrosis may be sampled.
- The etiology is likely multifactorial and autoinflammatory with resultant fibrosis of the connective tissue surrounding the bile ducts, causing secondary stricture and damage.

Autoimmune hepatitis, AIH (occurs much more often in women than in men):

- AIH is an inflammatory disease attacking the hepatocytes themselves.
- It leads to chronic hepatitis with portal and lobular inflammation, interface activity, and prominent plasma cells.
- It is associated with antinuclear antibodies (ANA) and anti-smooth muscle antibodies (SMA).

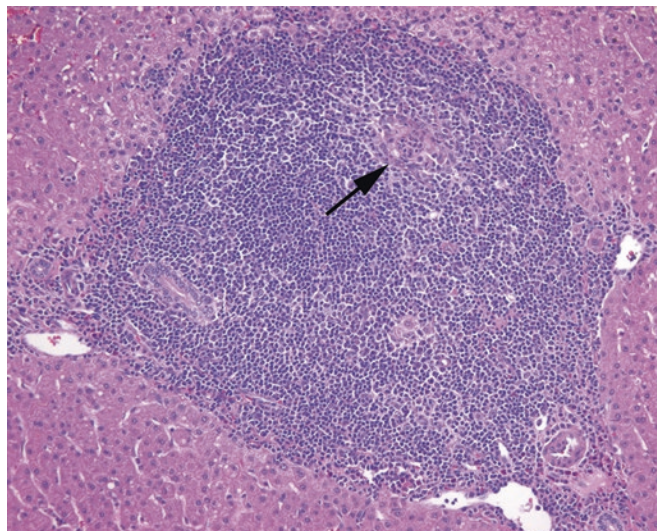


FIGURE 9.9. Primary biliary cirrhosis. There is a mononuclear and granulomatous inflammation of the portal tract, with destruction of a bile ductule (arrow).

Mass Lesions (Neoplasms)

The most common cause of mass lesions in the liver is metastatic tumor. However, there are primary neoplasms of all three components of the liver: hepatocytes, biliary epithelium, and vessels. Within each category, it can be difficult to differentiate neoplastic from non-neoplastic and benign from malignant on resection, let alone on biopsy. However, here is a brief list of features that favor one over the other.

Hepatocellular Neoplasms and Mimickers

- **Focal nodular hyperplasia:** Essentially an “island of cirrhosis” occurring in the background of a noncirrhotic liver. This is not a clonal process, so there is more than one cell type present; in addition to hepatocytes, you will see bile ducts and fibrous septae. There is no capsule, but sometimes a central scar is evident. The lesion is composed of hepatocyte nodules divided by bands of fibrosis and thick-walled vessels.
- **Adenoma:** Benign clonal neoplasms. They occur mainly in noncirrhotic livers of adult women taking oral contraceptive pills. Adenomas are circumscribed, partially encapsulated masses of uniform, bland-looking hepatocytes with no central veins or bile ducts (although there are diffuse, prominent arterioles often termed “orphan arteries” or “naked arteries”). The cells may be pale due to steatosis or glycogen or discolored with entrapped bile. When visualized with the reticulin stain, the hepatocyte plates are still only one to two cells thick (every cell touches reticulin). Adenomas have been classified into four groups based on molecular changes, including steatotic adenomas (mutated HNF1 α), inflammatory (telangiectatic) adenomas, β -catenin-activated adenomas, and “none-of-the-above” adenomas.
- **Well-differentiated hepatocellular carcinoma (HCC):** Low-grade malignant neoplasm. HCC can be very difficult to distinguish from an adenoma histologically. However, HCC generally occurs in the setting of cirrhosis, unlike the adenoma. As with an adenoma, there are no bile ducts or central veins, and you may see intracellular bile (Figure 9.10). Nuclei may be large, hyperchromatic, and irregularly contoured. Pseudo-acinar formation is a mimic of gland formation which may suggest adenocarcinoma. A reticulin stain shows a breakdown in architecture, with plates three or more cells in thickness, unlike the adenoma. Note that you may sometimes hear HCC referred to as a hepatoma, which is a terrible name because it sounds like an hepatic adenoma.
- **Poorly differentiated HCC:** High-grade malignant neoplasm which can be very pleomorphic and hard to identify as hepatic. The presence of bile, if any, is still a giveaway. Immunostains can help.

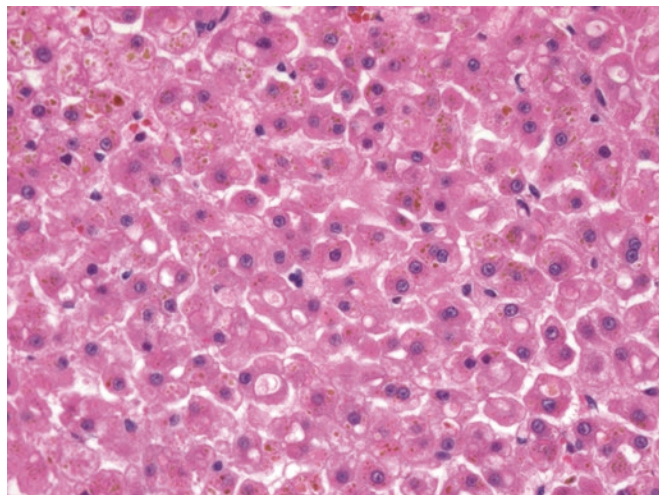


FIGURE 9.10. Well-differentiated hepatocellular carcinoma. Golden bile can be seen in the tumor cells, as well as pseudo-acinar formation. Portal tracts are absent.

- **Fibrolamellar HCC:** A variant of well-differentiated HCC occurring in children and young adults. It consists of oncocytic cells with prominent nucleoli in a dense fibrotic stroma.

Biliary Neoplasms and Mimickers

- **Bile duct adenoma:** Often sampled on frozen section during cancer resections, the bile duct adenoma is usually <1 cm and subcapsular, with a well-circumscribed tangle of small simple tubules, with or without inflammation and fibrosis. It may produce mucin but not bile. Think of this as a benign biliary epithelial neoplasm (Figure 9.11) similar in appearance to the previously described ductular reaction, and always think to exclude it when sampling a small bump on the liver.
- **Bile duct hamartoma:** Also called von Meyenburg complex, a bile duct hamartoma is also usually <1 cm and subcapsular. However, it generally shows more dilated and angular tubules separated by a loose connective tissue stroma, and the tubules often contain bile. Think of this as a disordered reduplication of the portal tract. The consequences of confusing the hamartoma with the adenoma are negligible; it is okay to call it “benign bile duct proliferation” when the subtype is unclear.
- **Mucinous cystic neoplasm:** a large cyst lined with (usually) bland mucinous epithelium over an ovarian-type stroma. These tumors are mostly seen in women.
- **Cholangiocarcinoma:** A primary malignancy of the bile ducts that appears as a nondescript adenocarcinoma infiltrating the liver. There is no definitive way to distinguish it from a metastatic lesion except by history; immunostains are of limited help. Although bile is not present in a cholangiocarcinoma, mucin is common, as is an intense desmoplastic response (Figure 9.12).

Vascular Neoplasms and Mimickers

- **Cavernous hemangioma:** Benign vascular tumors with large lakes of blood and flat, small endothelial cells lining the channels.
- **Epithelioid hemangioendothelioma:** Vascular tumor of low malignant potential. The textbook appearance is that of plump (i.e., epithelioid) endothelial cells in a dense pink stroma. While the tumor does not make well-formed vascular channels, some tumor cells create their own tiny vascular lumens with red blood cells inside (see Figure 29.26).

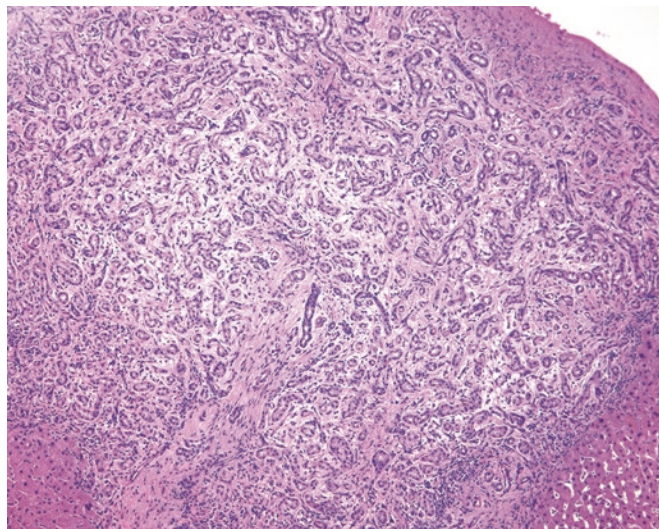


FIGURE 9.11. Bile duct adenoma. This is a benign, well-circumscribed tangle of proliferating bile ducts with associated edema, which may mimic desmoplasia. Bile is absent, and there is no significant cytologic atypia.

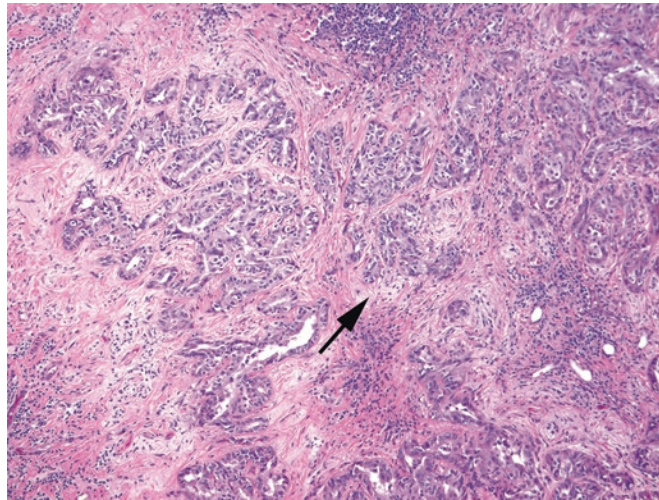


FIGURE 9.12. Cholangiocarcinoma. Although this is a generic adenocarcinoma without unique features, cholangiocarcinoma produces an intense desmoplastic response in the stroma (*arrow*; the pale swirling fibrosis surrounding the malignant glands).

- Angiomyolipoma can occur in the liver, but you can read about it in Chapter 13 (kidney).
- Angiosarcoma: A high-grade vascular malignancy that can have a wide array of morphologies. Although it can be positive for keratin immunostains (a treacherous pitfall), it will also be positive for vascular markers if you remember to order them.

The Normal Pancreas

The normal pancreas is a large mixed exocrine and endocrine gland, with acinar cells arranged around ducts in lobular units. The acinar cells secrete digestive enzymes in precursor form, which travel to the duodenum via the ducts. Normal ducts are low cuboidal epithelium, and the acinar cells are wedge-shaped granular pink and purple cells (Figure 10.1). Scattered among them are the islets of Langerhans, which show typical neuroendocrine cytology and are arranged in little nests. The pancreas is shaped like a J, with the head forming the base of the J and the uncinata process the hook. The head is nestled in the curve of the duodenum near the major papilla. The distal common bile duct runs through the head of the pancreas and joins the main pancreatic duct to form the ampulla just before entering the duodenum (Figure 10.2).

The Whipple Procedure

The Whipple procedure is, at minimum, a *pancreaticoduodenectomy*, which may or may not also include pylorus of the stomach and the gallbladder. In the pylorus-preserving Whipple, the simplest version, you receive the segment of duodenum from just past the pylorus to about 20 cm beyond the ampulla of Vater. Usually it is only the head of the pancreas that accompanies the Whipple specimen; if the tail is also involved by tumor, you may get the total pancreas and spleen. A resection of only the tail is a *distal pancreatectomy* and comes with attached spleen but no duodenum.

Margins are the most complicated element of the Whipple specimen, so a word on general margin strategy and nomenclature is in order. In any specimen, not just the pancreas, there are two principal types of margin: shave (also called tangential or en face) and perpendicular. If you consider a loaf of bread, with the inked margin represented by the crust, a *shave margin* would be the heel of the loaf, in which one entire surface is covered with crust. This type of margin is sectioned parallel to the inked surface, and therefore the entire block is a margin; the presence of any tumor, regardless of ink, is a positive margin. The shave margin is best used when: (1) you need to evaluate the entire margin, not just a representative cross section, and (2) the presence of tumor within 1 mm of the ink is considered a positive margin, even if the tumor doesn't actually touch the inked surface. The ends of hollow structures, like the colon, stomach, ureter, etc., are almost always sampled by shave margin, as you can see the entire circumference of the ring on one or two slides.

The *perpendicular margin*, on the other hand, is represented by a slice of bread in the middle of the loaf. In this slice, there is only crust around the edge of the bread. In a perpendicular margin, the margin is only positive if tumor extends to the ink; tumor away from the

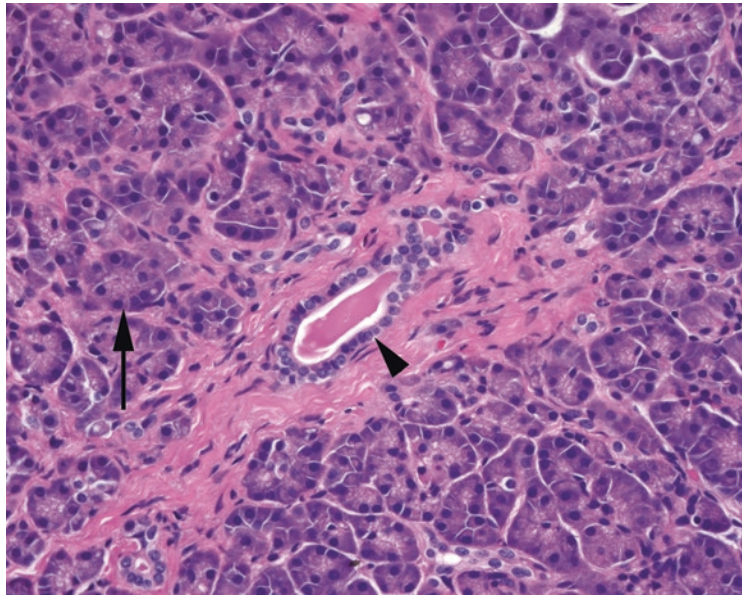


FIGURE 10.1. Normal pancreatic lobule. The duct is seen at the center (*arrowhead*), with surrounding acini of secretory cells (*arrow*).

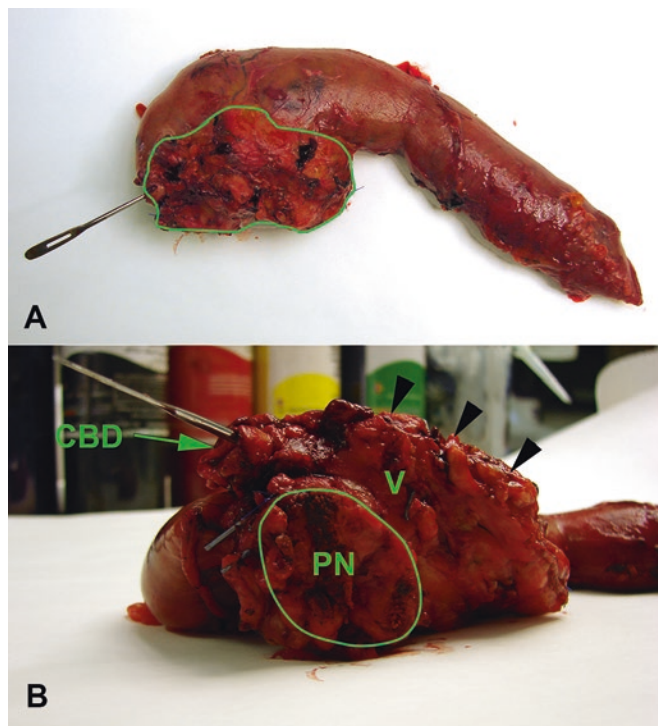


FIGURE 10.2. Whipple specimen. (a) From the top, the duodenum can be seen curled around the pancreatic head (outlined). Stomach, if present, would be to the left; distal duodenum is to the right. The probe is in the distal common bile duct. (b) From the side, the flat, cauterized pancreatic neck margin faces you (*PN*), and the dilated common bile duct is at top left (*CBD*), both of which are taken as shave margins. The vascular groove (*V*) and retroperitoneal (uncinate) soft tissue margin are at right (*arrowheads*).

inked surface is irrelevant. A related concept is the *radial margin*, in which you slice a round specimen into pizzalike slices, and only the outer rim of pizza crust is a true margin. The perpendicular margin is used if you want to get a precise measurement of how close the tumor is

to the margin, as you can see the relationship of tumor to ink on the slide. Edges that are very close to solid tumors are usually sampled by perpendicular margin. The downside is that like a single slice of bread, a perpendicular margin is only a representative sample, unless you are submitting the entire tumor. Therefore, you are relying on your ability to grossly identify the point at which the tumor is closest to the margin.

Because the interpretation of the margin slide depends on whether the margin was a shave or a perpendicular, *always be explicit about this* in your gross description.

Now back to the Whipple. There are five principal margins that are usually sampled on frozen section (Figure 10.2). The first is the pancreatic margin, called the *pancreatic neck* (where the pancreas is transected). This is usually taken as a shave margin. There is no neck margin on a total pancreatectomy. The second margin is the *common bile duct margin*, which is a shave of the bile duct stump. This ensures that cancer is not tracking up the bile duct toward the liver. The third is the *uncinate (retroperitoneal) margin*. This is the edge of the short end of the J, and it represents the place where the pancreas sits against the retroperitoneum. This surface is inked, and you take one representative perpendicular margin. Cancer on the slide is okay, as long as it does not touch ink. As this tissue abuts major vessels and nerves, the surgeon often cannot resect additional tissue if this is positive, but it has prognostic and therapeutic implications. The fourth and fifth margins are the *proximal* and *distal duodenal margins*, taken as shave margins. It is rare for these sections to contain tumor.

Most Whipple procedures are performed for a pancreatic mass seen radiologically. There may be no prior biopsy of tumor available. For this reason, it is useful to include a slide of tumor, often adjacent to the uncinata margin, at the time of frozen section so that you can compare funny looking cells on the margins to the morphology of the tumor itself.

Chronic Pancreatitis Versus Ductal Adenocarcinoma

Chronic pancreatitis is a common finding in a resected pancreas. The damage done to the pancreas by chronic obstruction, as with a mass, causes diffuse fibrosis, atrophy of the acinar units, reactive changes, and disruption of the normal architecture, all of which can mimic carcinoma. One of the hardest tasks (especially on frozen section) is differentiating reactive pancreatic ducts from well-differentiated infiltrating adenocarcinoma, the most common pancreatic malignancy. Some tips include the following:

- Helpful but subjective
 - On low power, chronic pancreatitis has a lobular architecture, with large central ducts surrounded by smaller peripheral ones. Cancer is haphazard, with random and irregular distribution of glands (Figure 10.3).
 - Incomplete lumina, in which the luminal spaces are not symmetrically surrounded by nuclei, and luminal necrosis both point to a diagnosis of pancreatic cancer (Figure 10.4).
 - Cellular pleomorphism. In general, cancer tends to have hyperchromatic and irregularly shaped nuclei, mitoses, and necrosis (see Figure 10.4). You will hear the “4:1 rule,” which states that if, in one gland, one nucleus is four times the size (area) of another, it favors cancer. However, chronic pancreatitis can lead to some more subtle atypia, and it does take some experience to tell the difference between a 4:1 ratio and a 3:1 ratio. Also, you will sometimes see well-differentiated pancreatic carcinoma with uniform nuclei.
- Not helpful
 - The fibrosis of chronic pancreatitis can mimic the desmoplastic stromal response of infiltrating carcinoma. However, the pale edematous fibrosis can accentuate the lobular architecture of chronic pancreatitis, which is helpful.
 - Every intern dots all the benign islets of Langerhans on a pancreatic neck, usually missing the sneaky invasive stuff. In chronic pancreatitis, islets are essentially all that remain of the withered parenchyma, and therefore they look crowded, infiltrative, and haphazard (Figure 10.5). As is true for any endocrine cell, these cells can have some pleomorphism,

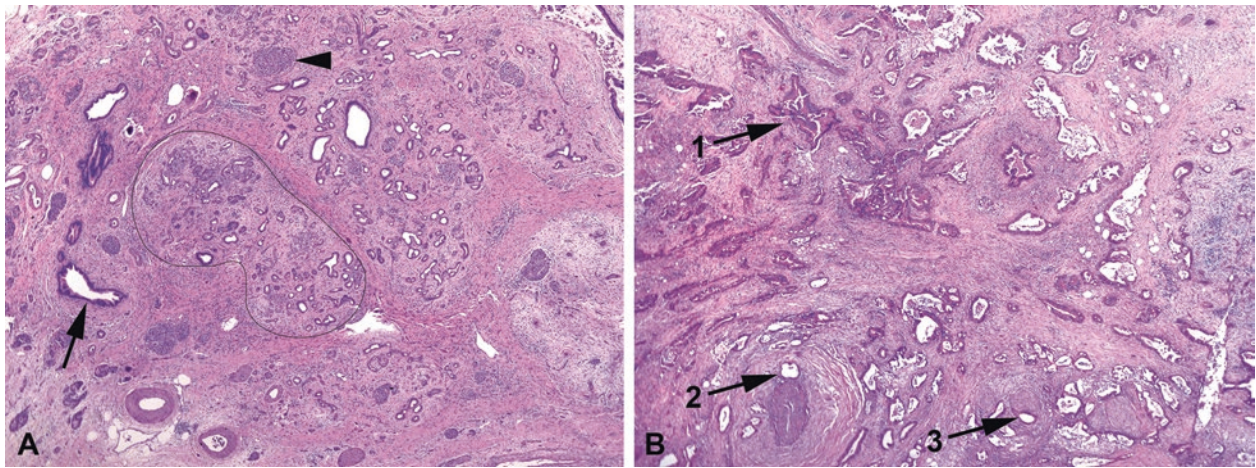


FIGURE 10.3. Chronic pancreatitis versus cancer, low power. (a) In chronic pancreatitis, the large ducts may show marked reactive changes, appearing blue and prominent (*arrow*), but they should still be located between lobules of acini. Islets are prominent (*arrowhead*). The acini show marked atrophy and fibrosis such that only the small ducts remain and appear infiltrative; however, the lobules retain a circumscribed outline (*black line*). (b) In adenocarcinoma, large, prominent, irregularly shaped ducts are scattered throughout, without respect to normal architecture (*1*). Large ducts next to vessels (*2*) or nerves (*3*) are virtually diagnostic of cancer.

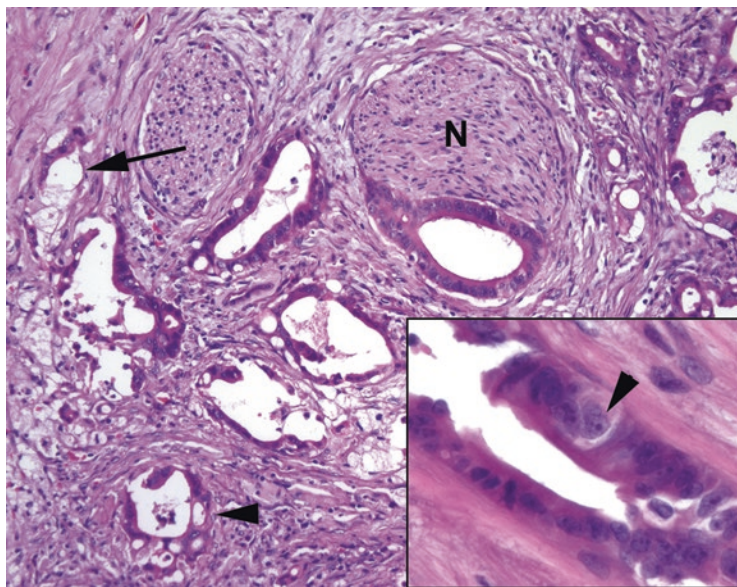


FIGURE 10.4. Adenocarcinoma. On high power, the infiltrative glands show incomplete gland walls (*arrow*), cribriform growth pattern (*arrowhead*), and perineural invasion (*N*). Inset: marked variation in nuclear size supports a diagnosis of cancer. Note the large nucleus with prominent nucleolus (*arrowhead*) across the gland from nuclei less than one fourth of its size.

and in some cases they can involve perineural spaces. Fortunately, the chromatin still looks neuroendocrine, so try to ignore them even though they really do look a little like lobular breast carcinoma.

- Freebies (even the beginner can interpret them).
 - Glands in a nerve, or perineural invasion, always indicate cancer.
 - Large ducts running next to a large muscular vessel almost always indicate cancer (Figure 10.6).
 - Ducts leaving the pancreas to infiltrate the duodenum always indicate cancer.

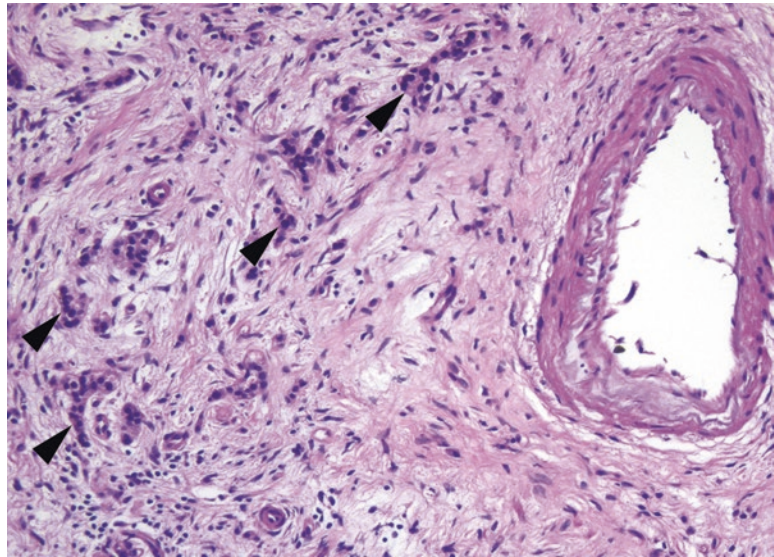


FIGURE 10.5. Residual islets of Langerhans. Neuroendocrine cells are among the last to go in chronic pancreatitis and appear to infiltrate through the fibrotic stroma (*arrowheads*). However, their small, round, dense, regular nuclei do not resemble pancreatic adenocarcinoma.

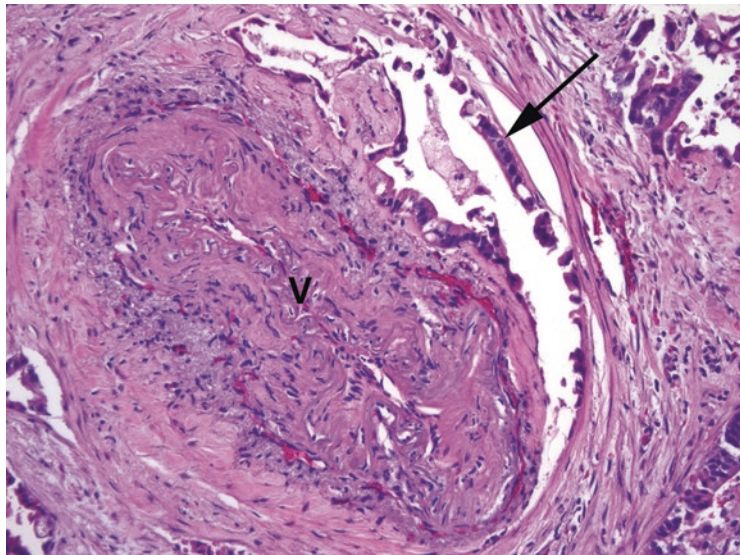


FIGURE 10.6. Adenocarcinoma next to a vessel. Large duct-like structures (*arrow*) next to a large-caliber vessel (*V*) are almost certainly cancer, even if deceptively well differentiated.

Dysplasia in the Pancreas

The pancreas is not an organ that can be evaluated with serial biopsies, and thus the natural history and malignant potential of dysplastic lesions are not as well understood as in, say, the colon. However, there are recognized grades of dysplasia within the duct system, called pancreatic intraepithelial neoplasia (PanIN). This ranges from PanIN-1, which may overlap with hyperplastic or reactive changes, to PanIN-3, which is carcinoma in situ. A lesion should always be graded by the highest level of dysplasia seen.

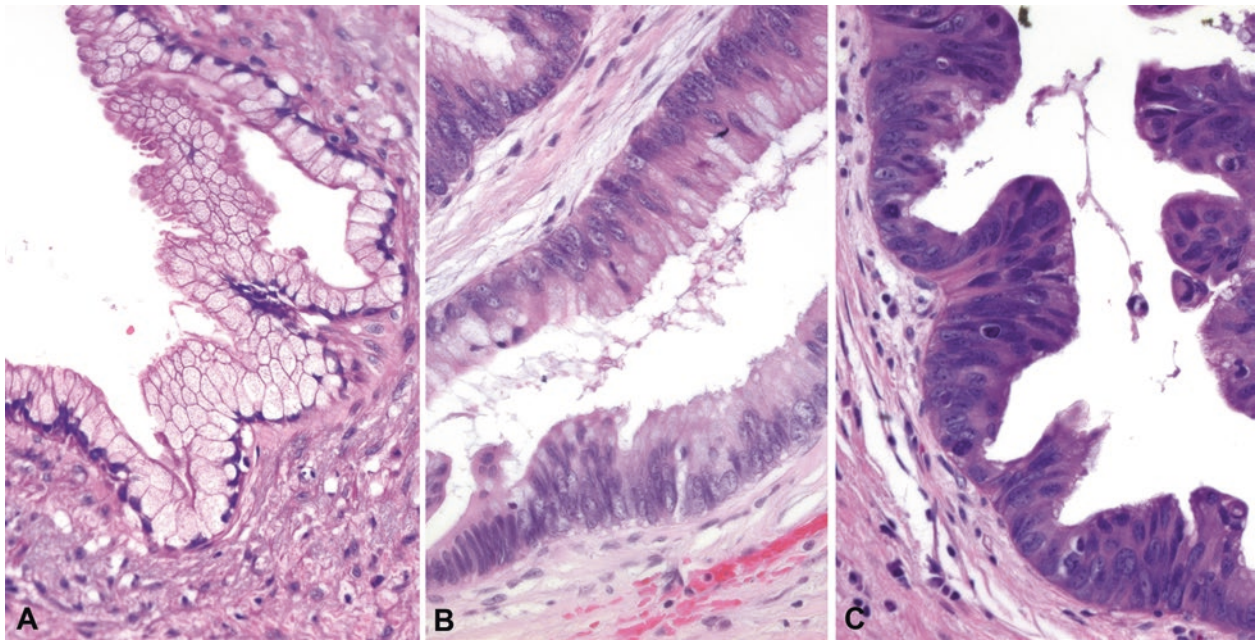


FIGURE 10.7. The grades of pancreatic intraepithelial neoplasia (PanIN). (a) PanIN-1 shows tall mucinous cells resembling endocervix. (b) PanIN-2 shows increasing nuclear crowding, enlargement, and atypia, similar to a tubular adenoma of the colon. (c) PanIN-3 shows high-grade nuclei with loss of polarity, frequent mitoses, and loss of mucinous differentiation.

PanIN-1 has a flat layer of tall columnar cells with basally oriented nuclei, apical mucin, and no atypia. The cells are similar to normal endocervical glands (Figure 10.7a).

PanIN-2 is flat or papillary but with nuclear abnormalities, including nuclear crowding and enlargement, stratification, hyperchromasia, and sometimes basal mitoses. This epithelium should remind you of a tubular adenoma in the gastrointestinal tract (Figure 10.7b). PanIN-1 and PanIN-2 are grouped together as simply *low-grade PanIN*.

PanIN-3 is carcinoma in situ or *high-grade PanIN*. You may see cribriform (like anastomosing glands), papillary, or micropapillary architecture or necrosis. Cytologic features include large ugly nuclei with prominent nucleoli, total loss of polarity, atypical mitoses, and maloriented goblet cells (upside down)—essentially the same criteria you would use for high-grade dysplasia in other gastrointestinal epithelia (Figure 10.7c).

Invasive carcinoma arising out of high-grade PanIN is well documented. However, remember that PanIN is a common incidental finding in a pancreas. It is not visible radiologically, it does not make a mass, and it does not cause obstruction. If you have a clinical mass lesion, you should be looking for an invasive carcinoma or intraductal papillary mucinous neoplasm (IPMN; see next section). Also, do not worry too much about the PanINs. With the exception of high-grade PanIN, they are of no proven clinical significance; margins with low-grade PanIN can safely be called negative.

Intraductal Papillary Mucinous Neoplasm (IPMN)

An IPMN is defined as a mucin-producing neoplasm arising in either the main pancreatic duct or a secondary (side-branch) duct. The ducts are usually dilated because they are full of the neoplasm and abundant mucin. The main lesion to consider in the differential diagnosis is the mucinous cystic neoplasm (discussed later). If you have a mucin-producing cystic neoplasm in the pancreas, always grossly probe the main duct to see if the cysts are connected to it (an IPMN) or not (a mucinous cystic neoplasm). Essentially it is a gross diagnosis and may even be an endoscopic one; if mucin was seen coming out of the ampulla, the cysts must be connected

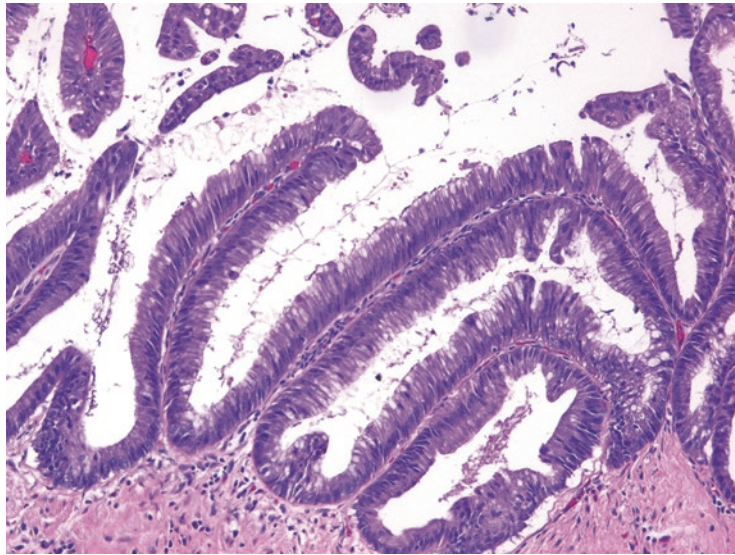


FIGURE 10.8. Papillary projections, low-grade IPMN. These tall papillary fronds are covered with mucinous cells showing features similar to PanIN-2.

to the pancreatic ducts, and the lesion is more likely to be an IPMN. However, once you have identified an IPMN grossly, you must look microscopically to evaluate the level of atypia and look for an associated invasive carcinoma (which occurs in approximately 30 % of IPMNs).

IPMNs are divided into two grades based on nuclear atypia and architectural complexity.

- IPMN, low grade: IPMNs in this category can have either low-grade dysplasia (cytologically bland, minimal architectural complexity, similar to PanIN-1) or intermediate-grade dysplasia (increasing nuclear abnormalities, some architectural complexity, similar to PanIN-2).
- IPMN, high grade: IPMNs in this category are cytologically malignant, like PanIN-3 or high-grade dysplasia elsewhere in the GI tract. Any IPMN with high-grade dysplasia must be carefully scrutinized, and usually entirely submitted, to rule out associated invasive carcinoma.

A typical sample sign-out for an IPMN might be:

Pancreas and duodenum (Whipple resection): Intraductal papillary mucinous neoplasm, low grade, intestinal type, involving the main duct (4.5 cm). OR,

Pancreas and duodenum (Whipple resection): Invasive moderately differentiated adenocarcinoma arising in association with an intraductal papillary mucinous neoplasm.

A common question is: how can I tell the difference between PanIN in a largish duct and IPMN in a smallish duct? Generally, lesions smaller than 5 mm are PanIN, and those over 1 cm are IPMNs. In the gray zone in between, features that favor an IPMN include the following:

- Long papillae or fingerlike projections with fibrovascular cores (Figure 10.8)
- Blue mucin in the lumen of the duct
- Continuity with one of the main pancreatic ducts
- Grossly or radiologically visible

When it comes right down to it, identifying the grade of the lesion is much more important than distinguishing between an IPMN and PanIN.

Invasive Adenocarcinoma (Ductal)

The most common form of infiltrating adenocarcinoma in the pancreas is ductal type. It usually arises in the head and often invades adjacent structures before coming to clinical attention. The histologic features of ductal adenocarcinoma have been described earlier in the chapter.

Once you have established the diagnosis of carcinoma, look carefully at all sections of duodenum, peripancreatic fat, and extrapancreatic bile duct to see if the carcinoma invades those regions (corresponding to an increase in tumor stage). The common bile duct and ampullary region have numerous benign glands branching off them, but remember that the benign glands will have a lobular and symmetric look at low power. Variants of ductal adenocarcinoma include adenosquamous, colloid (mucinous), hepatoid, medullary, signet ring cell, undifferentiated (anaplastic), and undifferentiated with osteoclast-like giant cells.

Other Cystic Lesions of the Pancreas

Mucinous Cystic Neoplasm (MCN)

The mucinous cystic neoplasm almost always occurs in middle-aged women, usually in the tail of the pancreas. This mucinous neoplasm produces multilocular cysts that do not communicate with the main duct system. Neoplastic epithelium lines the cysts, and they have, by definition, a rim of ovarian stroma (Figure 10.9), similar to the mixed epithelial and stromal tumor of the kidney. The pancreatic MCN has just two grades, which are based on epithelial atypia and architectural complexity, and these grades conveniently parallel the grades of the IPMN:

- MCN, low grade: This category of MCNs can have either low-grade dysplasia (no atypia, like PanIN-1) or intermediate-grade dysplasia (nuclear atypia and/or architectural complexity, like PanIN-2).
- MCN, high grade: This category of MCNs has high-grade dysplasia (marked nuclear atypia and architectural complexity, like PanIN-3), equivalent to carcinoma in situ.

Approximately one-third of mucinous cystic neoplasms have an associated invasive carcinoma, which would be called *invasive adenocarcinoma arising in association with a mucinous cystic neoplasm*.

Serous Cystadenoma

Serous cystadenomas of the pancreas, unlike the serous cystadenomas of the ovary, are almost always microcystic. Grossly, they have a central scar and, radiating from it, small, clear fluid-filled cysts, like the cross section of a lime. Microscopically, the cysts are lined by cuboidal cells with clear cytoplasm (glycogen) and dark, small, uniform, round nuclei (Figure 10.10). Areas of more solid or trabecular (network of thin bands) growth may look much like metastatic renal cell carcinoma. Serous cystadenocarcinomas exist but are extremely rare.

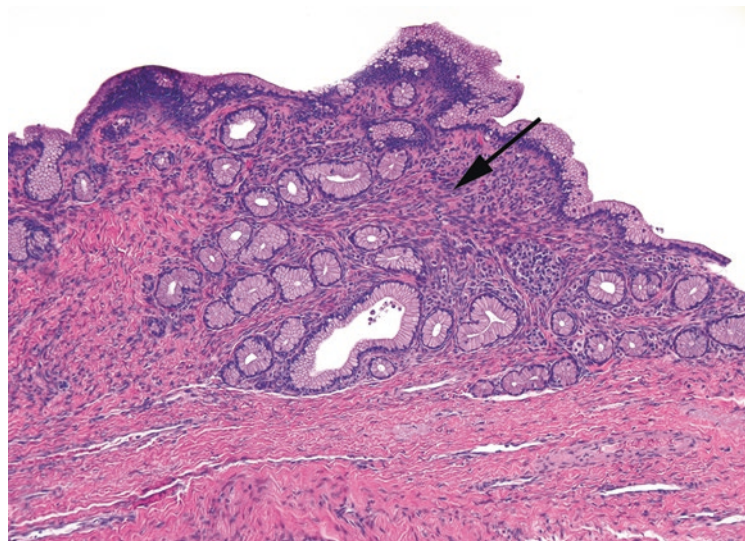


FIGURE 10.9. Mucinous cystic neoplasm. The cyst lining is composed of mucinous cells, with low-grade dysplasia in this example, and underlying blue spindly ovarian-type stroma (*arrow*).

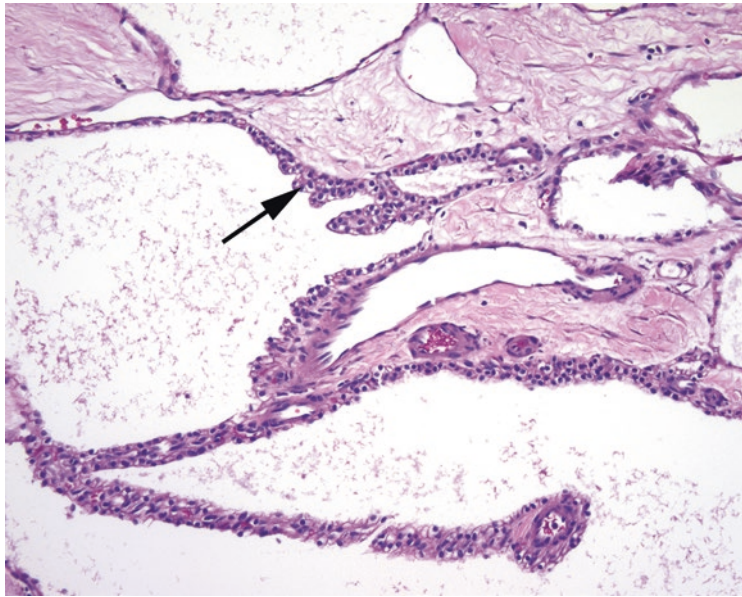


FIGURE 10.10. Serous cystadenoma, high power. The cells lining the multilocular cyst are small, with dense round nuclei and clear cytoplasm (*arrow*).

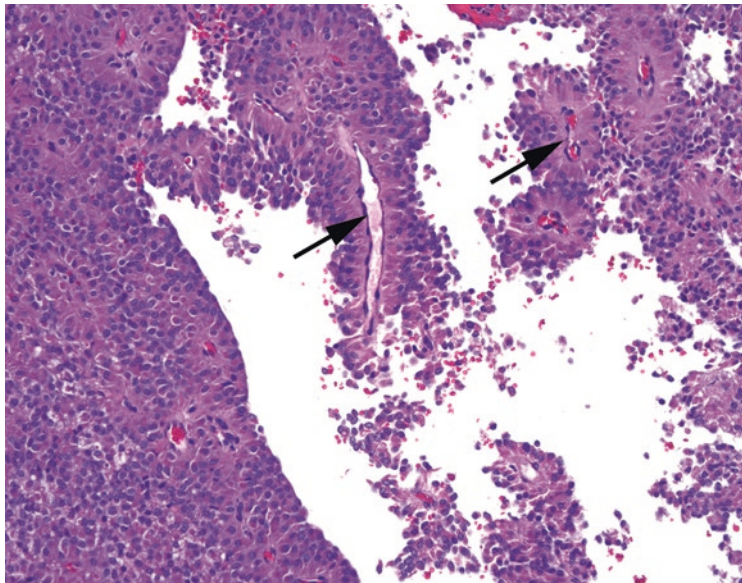


FIGURE 10.11. Solid-pseudopapillary neoplasm. The small plasmacytoid (abundant eosinophilic cytoplasm and eccentric nucleus) cells with neuroendocrine-type chromatin could be mistaken for islet cell tumor or acinar cell carcinoma. However, this growth pattern, with rosette-like (pseudopapillary) growth around fibrovascular cores (*arrows*) and dropout of the intervening cells, is typical of solid-pseudopapillary neoplasm.

Solid-Pseudopapillary Neoplasm

Solid-pseudopapillary neoplasms are unusual and distinctive tumors in the differential diagnosis of cystic lesions in young women. They are malignant but typically indolent. The cell of origin is not known, and so the neoplasm is named based on its appearance. These neoplasms start out solid but may undergo central necrosis and therefore may appear at least partially cystic on imaging (despite the name). The cells are characteristically poorly cohesive, and when individual cells undergo degeneration, only the tumor cells along fibrovascular septa remain intact, resulting in a pseudopapillary growth pattern. The nuclei are small, oval, bland, and grooved (Figure 10.11).

The differential diagnosis for this neoplasm includes well-differentiated pancreatic neuroendocrine tumor and acinar cell carcinoma. Immunohistochemical labeling is very helpful, as solid-pseudopapillary neoplasms are CD10 positive and, more importantly, show nuclear labeling for β -catenin.

Pseudocyst

The definition of a pseudocyst is “lacking an epithelial lining.” This is a walled-off area of fat necrosis and granulation tissue containing high levels of pancreatic enzymes that is not usually mistaken for a malignancy, clinically or microscopically. Remember that most pseudocysts are actually extrapancreatic.

Other Solid Tumors in the Pancreas

There are only two pancreatic cell types not yet discussed (not counting soft tissue elements such as vessels and nerves): the acinar cells (exocrine secretory) and the islet cells (endocrine/neuroendocrine). Neoplasms composed of these cells are important to remember because they can release enzymes or hormones, causing dramatic clinical presentations. These tumors can also show considerable histologic overlap and may require special stains to distinguish.

Acinar Cell Carcinoma

Acinar cell carcinomas are rare tumors of older adults, usually male. The usual appearance is that of nodules and sheets of densely packed amphophilic (purple) cells with uniform round nuclei. Growth may be trabecular, nested, or acinar (arranged around tiny lumina). Prominent nucleoli are often seen and are a clue to the diagnosis. Like the benign acinar cells, these tumors are usually positive for trypsin and chymotrypsin.

Pancreatic Neuroendocrine Neoplasms

Pancreatic neuroendocrine neoplasms are divided into two groups:

- Well-differentiated pancreatic neuroendocrine tumors (WD-NET): These tumors have had many synonyms (i.e., islet cell tumors), but they are just the carcinoid-like neuroendocrine tumors of the pancreas. These tumors are usually well circumscribed and cellular, and the neoplastic cells tend to form nests or trabeculae. The cells are like those of a WD-NET in any other site (Figure 10.12), with smooth round to oval nuclei, finely speckled chromatin, and pink-to-purple cytoplasm. Some are *functional* in that they produce clinical symptoms directly related to expression of hormones such as insulin, glucagon, and somatostatin. However, most pancreatic neuroendocrine tumors are *nonfunctional*. Lack of atypia is not an indication of good behavior, and a bland tumor may look just as bland when you later find it in the liver. Instead, the prognosis depends on the tumor's proliferative activity (e.g., mitotic rate), which separates these neoplasms into low grade and intermediate grade.
- High-grade neuroendocrine carcinoma: These are much more aggressive neoplasms, with a very high proliferative rate, but fortunately they are very rare. They can be either the small-cell or large-cell variety.

Pancreatic neuroendocrine neoplasms express neuroendocrine markers (synaptophysin, chromogranin, CD56) as well as any peptides they may be producing. A nonfunctional pancreatic neuroendocrine tumor less than 0.5 cm is a microadenoma and is generally regarded as a benign tumor.

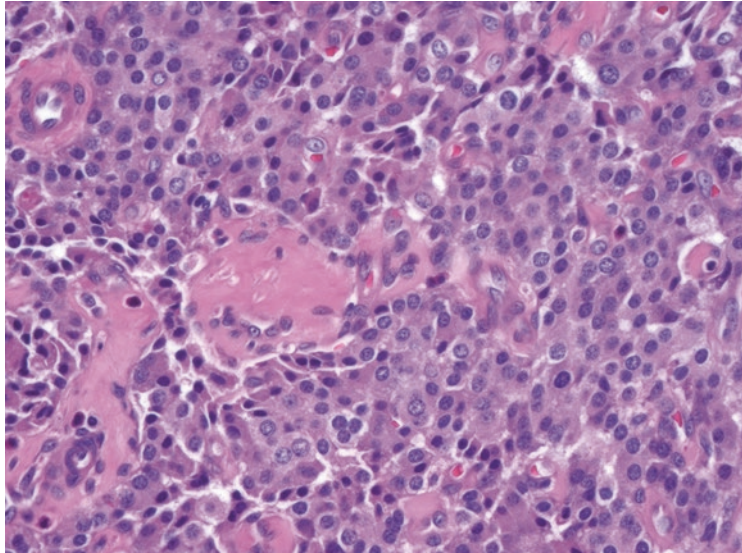


FIGURE 10.12. Well-differentiated pancreatic neuroendocrine tumor, high power. This resembles neuroendocrine tumors in other body sites, with round, well-spaced nuclei and speckled neuroendocrine-type chromatin.

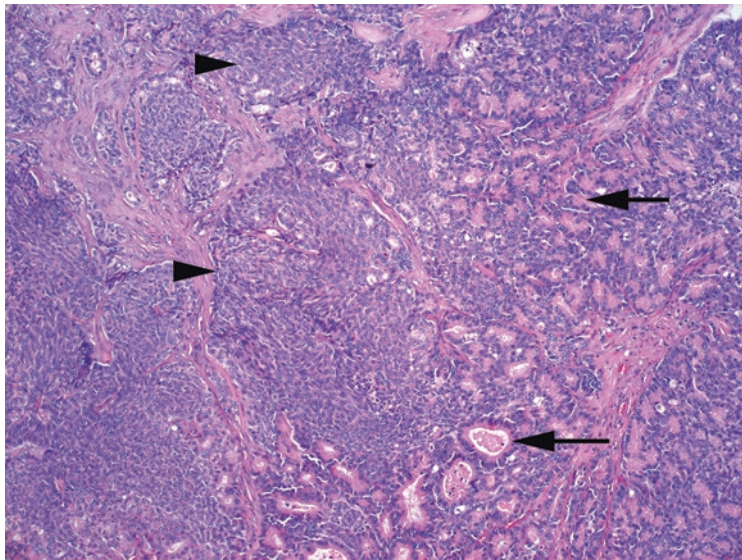


FIGURE 10.13. Pancreatoblastoma. Well-formed acinar structures (*arrows*) are adjacent to squamoid nests (*arrowheads*) in a fibrous stroma.

Pancreatoblastoma

Despite the *-blastoma*, the pancreatoblastoma is not a small round blue cell tumor. It is, however, usually a pediatric tumor. The pancreatoblastoma is histologically very similar to the acinar cell carcinoma, except with the addition of squamous nests and occasionally a neuroendocrine component. The presence of the squamous (or squamoid) nests (Figure 10.13) is a defining feature of this tumor, so if you see squamous differentiation in what appears to be an acinar cell carcinoma in an adult, think of the pancreatoblastoma.

Most biopsies are performed for an elevated prostate-specific antigen (PSA) level, a palpable nodule, or a history of an abnormal biopsy. In the prostate, you are generally looking only for carcinoma and other rare malignancies, as opposed to non-neoplastic processes.

A typical sextant biopsy are cores from left apex, mid, and base and right apex, mid, and base. Increasingly, urologists sample from the lateral aspect of the gland as well, generating 10–12 different cores or containers. Each container is processed and reported separately.

Approach to the Core Biopsy

On 4× to 10×, scan the length of the core looking for glands that stand out and look different.

Low-power features of prostate cancer (Figure 11.1):

- Small individual glands infiltrating among groups of larger benign glands (low-grade cancer).
- Crowded glands.
- Cribriform glands.
- Sheets of cells, or an unusually cellular infiltrate (individual cells of high-grade cancer).
- A different color or texture to the glands (cancer cytoplasm may appear a denser pink or more blue; the exact alteration varies by histology lab).
- Blue mucin, crystalloids, or dense pink secretions in the lumen.
- Absence of desmoplastic response.

Low-power features of benign glands (Figure 11.2):

- Irregularly shaped glands with papillary infoldings (a “frilly” look)
- Glands with a modest amount of intervening stroma
- Corpora amylacea

At high power (20× – 40×), examine any suspicious areas. Look for *features of carcinoma*:

- Large, often cherry-red nucleoli (Figure 11.3).
- Straight, crisp luminal borders to the glands.
- Enlarged and/or hyperchromatic nuclei (however, pleomorphism is minimal).
- Lack of basal cell layer (can be confirmed by immunostains).

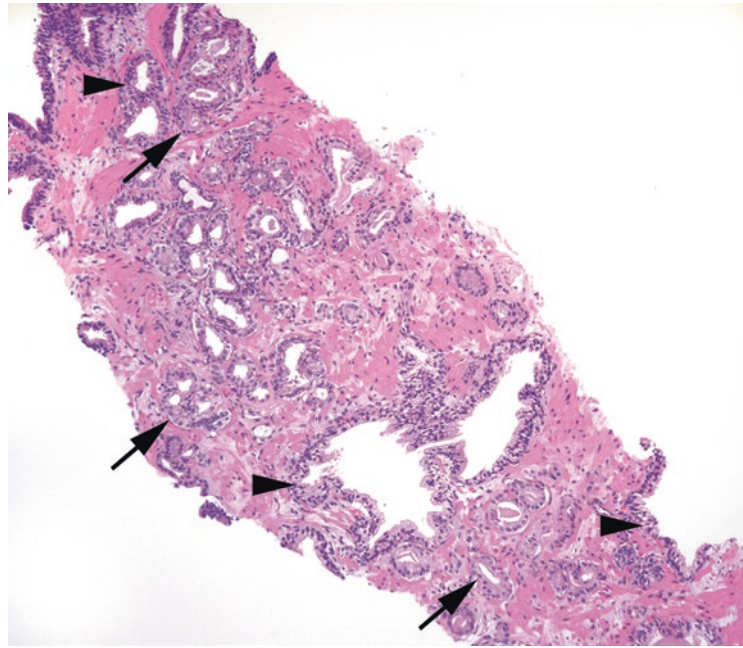


FIGURE 11.1. Low-power features of carcinoma. Adenocarcinoma (*arrows*) is seen infiltrating throughout benign glands (*arrowheads*) in this core biopsy specimen. The malignant glands are often back to back and have relatively denser cytoplasm, no basal layer, and straight luminal borders.

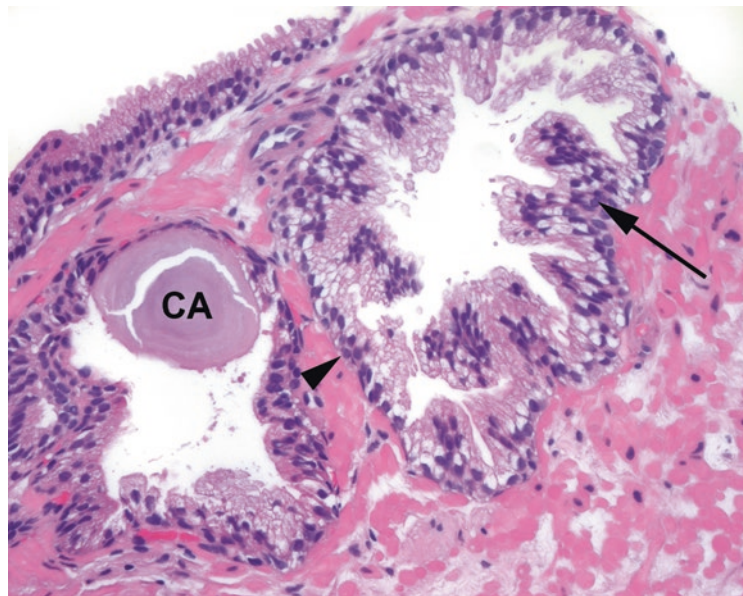


FIGURE 11.2. Benign prostate glands. These glands have a distinct basal cell layer underlying the epithelial cells (*arrowhead*) and papillary fronds in the lumen (*arrow*). Corpora amylacea (*CA*) are concentrically laminated concretions associated with benign glands.

Although none of these findings is completely sensitive and specific for cancer, having more malignant than benign features is a pretty good indication. There are three features that, although uncommon, are only seen in cancer:

1. Perineural invasion: the nerve appears as a discrete oval profile with wavy parallel stripes, and the malignant gland must be within the nerve sheath to count as perineural invasion (Figure 11.4). Often the gland will fill up the nerve sheath circumferentially, so the nerve appears to be floating in a gland.

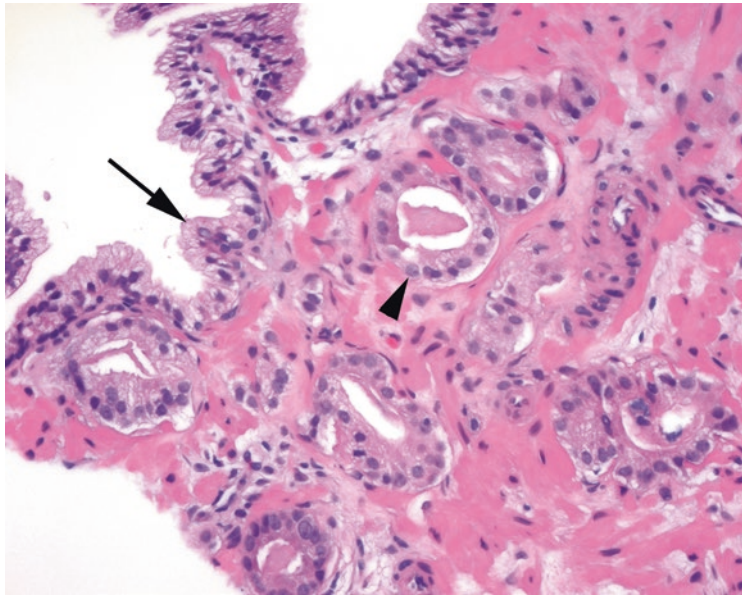


FIGURE 11.3. High-power features of carcinoma. Malignant glands show distinct nucleoli (*arrowhead*), sharp luminal borders, and an absence of basal cells. Benign glands are seen adjacent to the cancer (*arrow*).

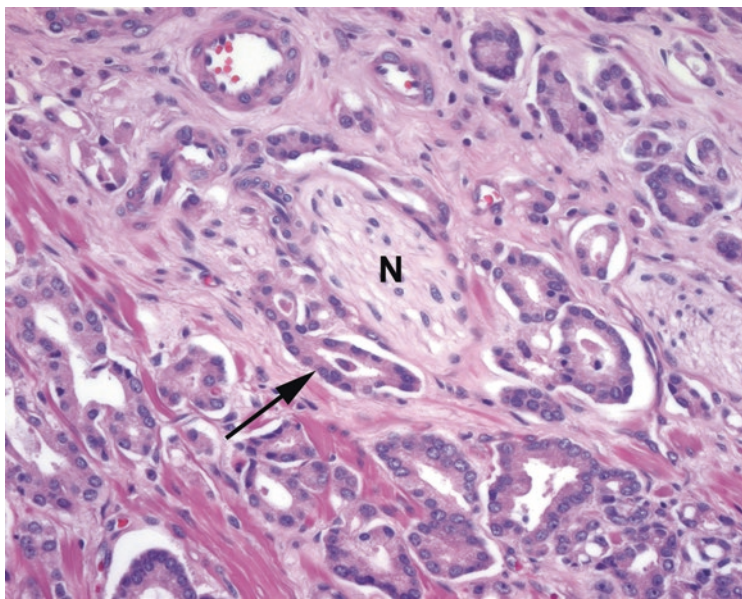


FIGURE 11.4. Perineural invasion. A nerve (*N*) is identified by the undulating axons and nerve sheath nuclei. Malignant glands are seen nearly surrounding the nerve (*arrow*).

2. Mucinous fibroplasia: hyalinized whorls of organized mucin in the lumen; sometimes the surrounding gland epithelium may be compressed and indistinct. This is analogous to collagenous spherulosis in the breast.
3. Glomeruloid forms: proliferative tangles of cells project into the larger gland lumen, resembling a glomerulus.

Gleason Grading

Once you have identified adenocarcinoma, you must give it a histologic score. Prostatic adenocarcinoma is graded by the Gleason system, which is based on architectural pattern. Cytology (nuclear morphology) is pretty monotonous in prostate cancer and therefore does not affect grade. Historically there were five patterns of adenocarcinoma, from 1 to 5, with 5 being the least differentiated. However, in practice, patterns 1 and 2 have fallen out of use, such that pattern 3 is synonymous with well-differentiated carcinoma and pattern 5 is poorly differentiated. The first and second most prevalent patterns are combined to create the Gleason score, which runs from 6 to 10 (combinations of 3, 4, or 5). A pure pattern 3 tumor would be a $3+3=6$; a mixture of 3 and 4 could be signed out as $4+3=7$ or $3+4=7$, depending on the prevalence of each pattern.

The patterns are as follows:

- 3: Well differentiated, with well-formed glands. Pattern 3 should have discrete and individual gland profiles such that you can draw a circle around each gland (Figure 11.5).
- 4: Moderately differentiated, with at attempt at gland formation. Pattern 4 includes fused or ill-defined glands, sheets of cribriform glands, or poorly formed lumens (Figure 11.6).
- 5: Poorly differentiated, with a complete absence of glandular differentiation. Pattern 5 tumors may have solid sheets of single cells or cords of cells (Figure 11.7).

What if all three patterns are present? The guiding principle is that the highest pattern present **MUST** be worked into the score, as those tumors will be more aggressive. On a biopsy, your Gleason score is comprised of the most common pattern + the highest pattern. For example, a tumor with mostly pattern 3, a bit of 4, and a tiny bit of 5 would be graded $3+5=8$. On a radical prostatectomy, the Gleason score is the first and second most prevalent patterns, and if there is a minor or third component of higher grade, that is assigned a tertiary pattern. In this case, that same tumor would be classified as $3+4=7$ with tertiary pattern 5.

To add a new wrinkle, there is now a tertiary level of prognostic information called the grade group. So you combine two Gleason *patterns* into one Gleason *score*, which then corresponds to one of five *groups*. These groups divide prostate cancer into distinct categories with different mortality rates, from Group 1 ($3+3=6$, excellent prognosis) to Group 5 (Gleason scores 9 and 10, poor prognosis). This system may eventually supplant the Gleason score, but the need to recognize these three histologic patterns is unlikely to change.

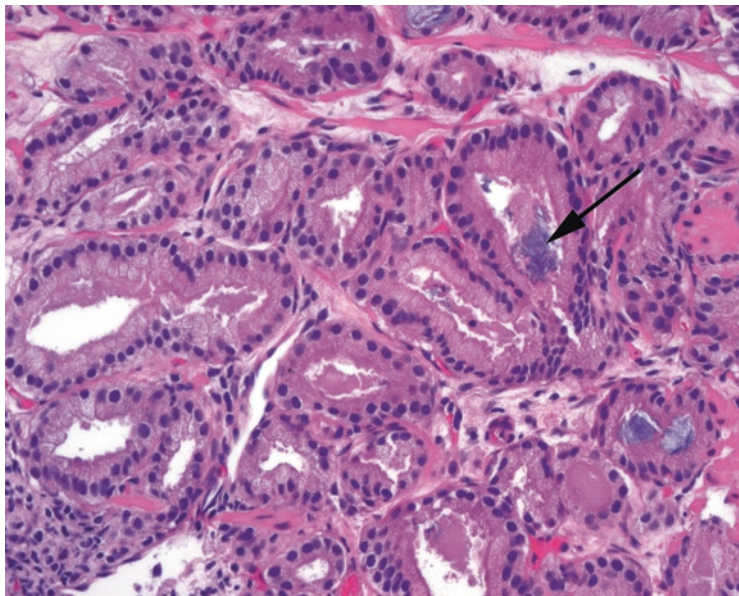


FIGURE 11.5. Gleason pattern 3. Individual, well-formed malignant glands make up pattern 3 cancer. Blue mucin, often associated with carcinoma, is present (*arrow*).

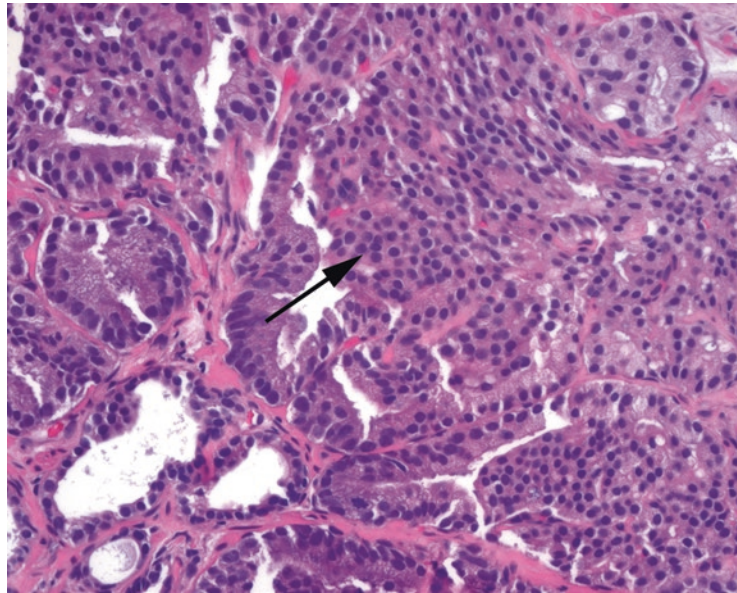


FIGURE 11.6. Gleason pattern 4. The area of cribriform growth (*arrow*) and adjacent fused glands is typical of pattern 4.

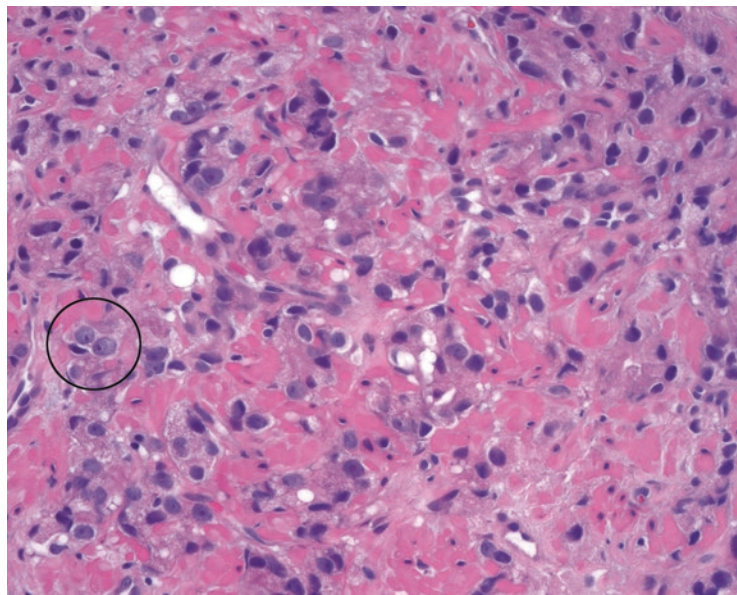


FIGURE 11.7. Gleason pattern 5. Individual malignant cells, without evidence of gland formation, are typical of pattern 5. The individual cells still cytologically resemble well-differentiated carcinoma, with round nuclei and prominent nucleoli (*circle*).

Features of Prognostic Importance

The following features should be mentioned in any cancer diagnosis for biopsies and reported separately for each container:

- Gleason score: discussed above.
- Number of involved cores, as well as the total examined (e.g., *1 of 1 core* or *2 of 4 cores*).
- Percent involvement: note the approximate percentage involvement on each core (e.g., *involving 2 of 4 cores [30%, 60%]*) or as a percent of the total tissue. Small foci of cancer (<5% of a core) can be described as *small foci*.

- Linear extent: some centers use linear extent of tumor in mm, out of the total core length. Either linear extent or percent involvement is acceptable.
- Perineural invasion: the presence of perineural invasion in a biopsy specimen has adverse prognostic significance.
- Extraprostatic extension: rarely, a core biopsy will go through the capsule of the prostate and into the fat beyond. An extremely lucky shot may show malignant glands trickling into the fat, which is diagnostic of extraprostatic extension. This upstages the tumor.

Prostatic Intraepithelial Neoplasia

Prostatic intraepithelial neoplasia (PIN) occupies a slightly uncertain place in pathology. It is considered to be a precursor to cancer and to demonstrate a generally increased risk of cancer, but, unlike precursor lesions such as high-grade squamous intraepithelial lesions (cervix) or ductal carcinoma in situ (breast), it does not warrant an immediate rebiopsy or excision. It is more analogous to atypical lobular hyperplasia (ALH) in the breast, in that it indicates a higher risk for coexisting carcinoma. For this reason, PIN in the setting of prostate carcinoma is not terribly relevant, but PIN in the absence of carcinoma may lead to closer follow-up of that patient. Only high-grade PIN is notable; don't worry about trying to identify low-grade PIN. Features of high-grade PIN include the following:

- Glands are large with prominent papillary or micropapillary luminal surfaces, similar to benign architecture. Cribriform PIN can be seen, but back-to-back glands are not PIN.
- At low power, glands appear darker and more blue than surrounding glands (Figure 11.8).
- Nuclei are enlarged, elongated, and hyperchromatic, and by definition nucleoli are visible at 20 \times .
- The basal cell layer is usually still present, yet often patchy; immunostains show this nicely.

Mimickers of Prostate Cancer

There are some benign entities that may catch your eye and stand out in a biopsy specimen but that are definitely not carcinoma.

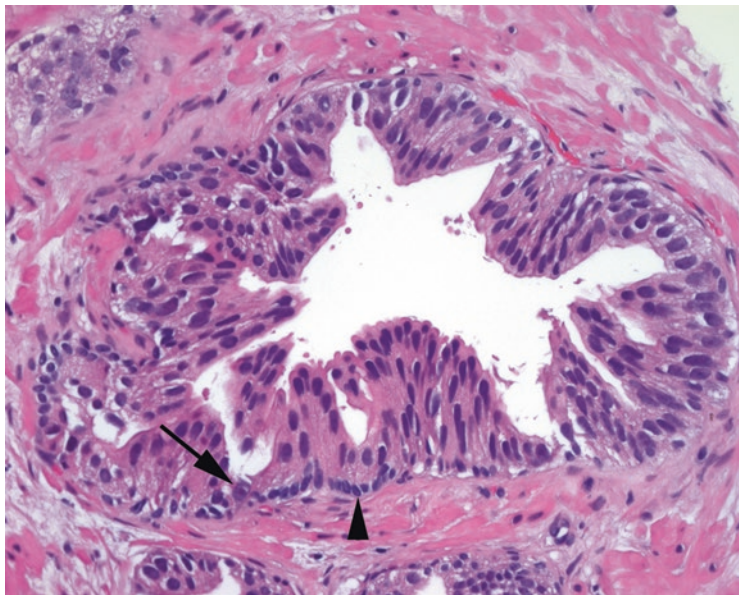


FIGURE 11.8. High-grade prostatic intraepithelial neoplasia. Although the papillary infoldings resemble benign prostate, the nuclei are larger and darker and show occasional prominent nucleoli (*arrow*). Basal cells are still present (*arrowhead*).

Adenosis

Adenosis literally means a proliferation of glands. Adenosis is a hyperplastic lesion, not a neoplastic one. It consists of a *lobular group* of crowded glands, which may include small suspicious-looking glands among them. The morphology of the small glands, however, should overlap with the intermixed larger, benign-looking glands; there should be a spectrum so that you cannot point to definite malignant versus benign glands. Adenosis may have visible small nucleoli (how unfortunate) but by definition has a basal layer (visible by immunostains if not by H&E).

Atrophy

Atrophy is the shrinkage of the cells forming the glands. The cytoplasm shrivels down, leaving essentially rows of nuclei outlining the lumens (Figure 11.9). At low power, these atrophic glands can look small and irregular, which may be suspicious. However, the lumens have an angular, almost staghorn look to them. Small- to medium-sized nucleoli may be seen, but the lack of cytoplasm should be a red flag against diagnosing cancer. Immunostains highlight a basal cell layer.

Basal Cell Hyperplasia

The basal cells that underlie the glandular cells are not usually well visualized. When they are noticeable, you can see them as sort of denim-blue, oval, regular nuclei surrounding the more purple glandular nuclei (Figure 11.10). The tricky part is that they may have nucleoli. In basal cell hyperplasia, the basal layers may proliferate and create several layers of worrisome-looking cells in the glands. The key is in recognizing the dual population; sometimes you can still see the glandular cells floating on top of the basal hyperplasia. Stains help.

Cowper's Glands

Cowper's glands are normal glands (distal to the prostate, secreting directly into the urethra, and normally not sampled on needle biopsy) that consist of mucous-filled secretory glands surrounding a coil of ducts. They are lobular in architecture and have small bland nuclei. Their abundant mucin will stain with periodic acid–Schiff, and they are usually negative for the prostate markers prostate-specific antigen (PSA) and prostate-specific acid phosphatase (PSAP).

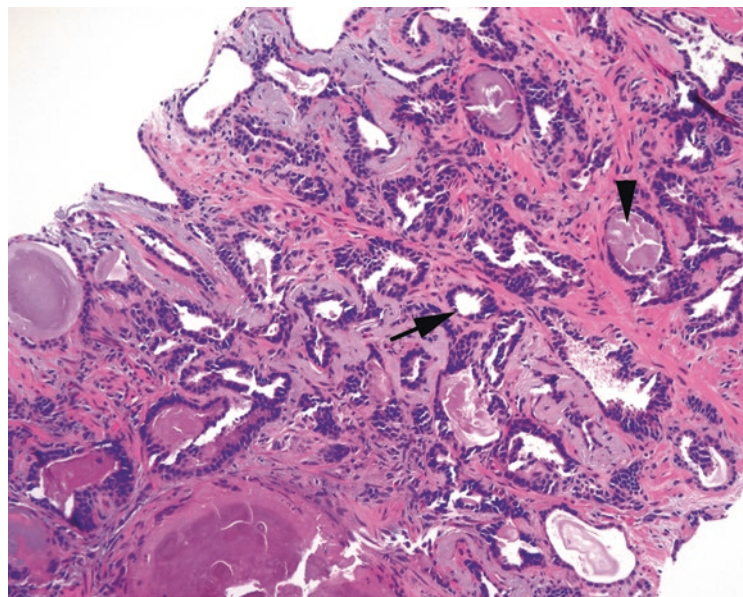


FIGURE 11.9. Atrophy. These glands appear hyperchromatic and infiltrative. However, the low cuboidal cells with attenuated cytoplasm (*arrow*) and angular gland profiles are typical of benign atrophy. Corpora amylacea are present (*arrowhead*).

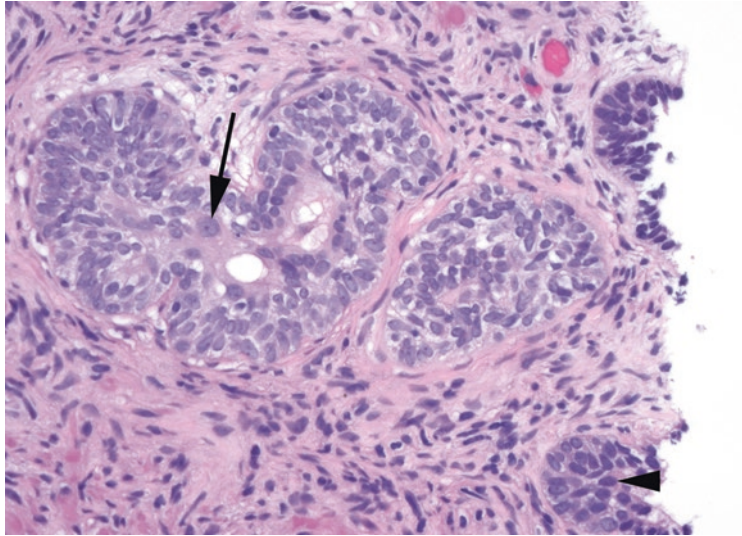


FIGURE 11.10. Basal cell hyperplasia. This proliferation of cells, some with prominent nucleoli (*arrow*), is actually an expanded basal cell layer. Comparison with benign epithelium (*arrowhead*) shows the relatively pale and grayish nuclei of the basal cells.

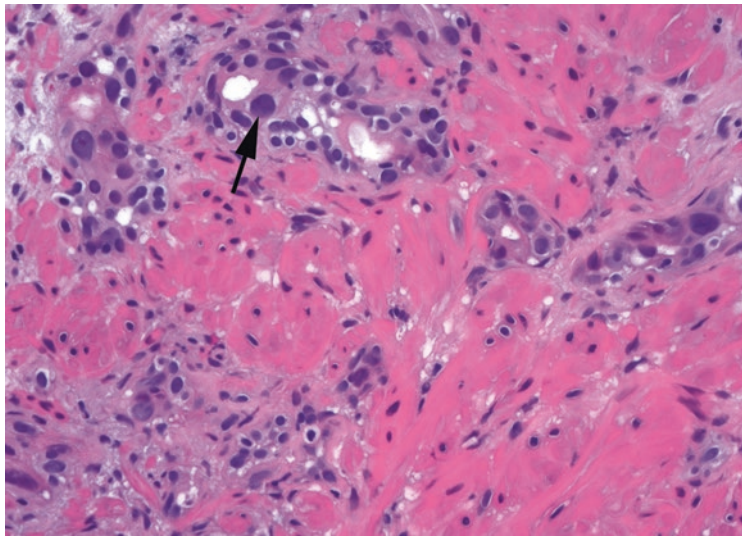


FIGURE 11.11. Radiation atypia in benign prostate. There is scattered and random nuclear pleomorphism (*arrow*). Enlarged nuclei classically have dense, uniform, smudgy chromatin.

Radiation Changes

Radiation atypia has a characteristic look which you will come to recognize. The nuclei are *too* pleomorphic to be cancer, especially when compared with the relatively uniform nuclei of prostate cancer. Radiated benign glands show atrophic cytoplasm and wildly pleomorphic nuclei mixed in with normal nuclei (Figure 11.11). The nuclei may be very large, with angular shapes, and tend to have a dense smudgy chromatin without nucleoli. Identifying residual cancer in the radiated prostate is a diagnosis made largely on architecture (many individual cells with ample vacuolated cytoplasm and nuclei that ironically are often not as pleomorphic as the benign radiated nuclei).

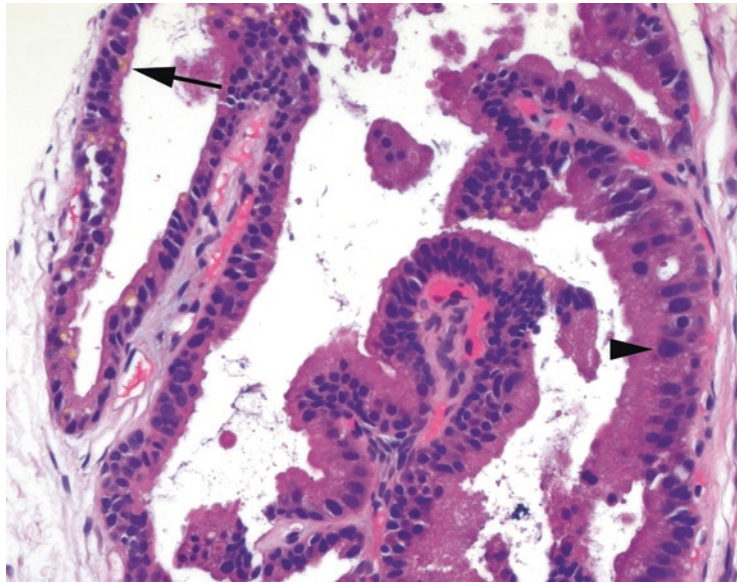


FIGURE 11.12. Seminal vesicle in a biopsy specimen. There are scattered large, hyperchromatic, and crowded nuclei in this gland (*arrowhead*). However, golden pigment is visible in the cytoplasm (*arrow*), identifying this as seminal vesicle.

Seminal Vesicle

The nuclei of the seminal vesicles have very pleomorphic nuclei, not unlike radiation atypia. They will definitely stand out in a needle biopsy specimen and can be very concerning based on cytology. However, remember that prostate cancer is usually not pleomorphic, and look for the telltale golden globs of lipofuscin to identify it as seminal vesicle (Figure 11.12).

Sclerosing Adenosis

Sclerosing adenosis is seen best in transurethral resection specimens. It is a hyperplastic and proliferative lesion that is complicated by a hypercellular stroma. The appearance is that of crowded glands and individual cells (which may have prominent nucleoli) in a background of cellular stroma. Remember that prostate cancer *does not* induce a stromal reaction.

Atypical Glands and Stains

It is not uncommon, in a needle core biopsy specimen, to stumble across one or two isolated glands that make you very nervous. However, unless several features of carcinoma are evident, most pathologists will be reluctant to make the diagnosis of cancer in that setting. One option is to sign it out as a focus of atypical glands. In the absence of definitive cancer, it will usually generate a repeat biopsy.

Immunostains may help in the diagnosis of these tiny lesions or with larger groups of glands that have some but not all of the features of cancer. Stains for the basal layer (CK903/high molecular weight keratin and p63) should highlight the basal cells in all benign glands and show loss of staining in malignant glands. Racemase is a marker that preferentially stains the cytoplasm of cancer. However, there are false-positive and false-negative results with all three of these antibodies, and so each case is interpreted in the context of the H&E appearance (the best approach for all immunostains).

Approach to the Radical Prostatectomy Specimen

For the radical prostatectomy specimen, the prostate is inked and bread loafed from apex (nearest the penile urethra) to base (nearest the bladder neck). A colored stripe down one side of the gland is helpful in determining left from right should you happen to drop the slices on the floor while grossing (purely a hypothetical). Each slice is cut into four quadrants to fit them into cassettes. The margins are taken first:

1. Right and left vas deferens, shaves: these represent the true surgical margins of the vas deferens. Positive vas deferens margins are very rare, and some pathologists do not even submit them.
2. Apical, or distal, margin: this is where the prostate meets the penile urethra. It is cut off as a thick tangential shave and then turned 90°, sliced, and submitted as a series of perpendicular margins that are parallel to the urethra. The presence of malignant glands is acceptable, as long as they do not touch the inked apical surface.
3. Bladder neck margin: this is where the prostate meets the bladder; it is a soft tissue margin, not a urethral margin. The urethra itself retracts back into the prostate at surgery and may not be seen on the slide. This may be a shave margin, in which the presence of any malignant glands is considered a positive margin. It can also be treated like the apical margin, however, and sectioned perpendicularly.

After evaluating the margins, systematically examine each section of the prostate. Each full slice of prostate is halved into left and right sides. If the entire hemisection cannot fit into one block (usually it cannot), it is subdivided into anterior and posterior quadrants. Orienting the isolated quadrant on the slide can be tricky. For posterior sections, the true posterior surface should be flatter than the lateral surface. The neurovascular bundles, which sometimes come out with the prostate, are located at the posterolateral corners. For anterior sections, the anterior tip should have many smooth muscle bundles and a very poorly defined perimeter. The verumontanum of the urethra (the bump on the posterior urethra) points anteriorly (Figure 11.13).

Examination of the edge of the prostate is prognostically important. There is no true organ capsule but rather the outer limit or edge of the prostate, which is best recognized posteriorly and posterolaterally as packed muscle bundles of the prostate. Extension of the cancer beyond the edge indicates extraprostatic extension (EPE) and increases the stage of the tumor. Intraprostatic incision (IPI), where the surgeon has cut across the organ and left some prostate in the patient, becomes very important if there is cancer in the area. Malignant glands near big vessels or among skeletal muscle are not necessarily EPE, but cancer in fat is “out” by definition (Figure 11.14), as there is no intraprostatic fat. However, if you wait to diagnose EPE until seeing tumor in fat, you will miss some EPE. As cancer extends beyond the border of the

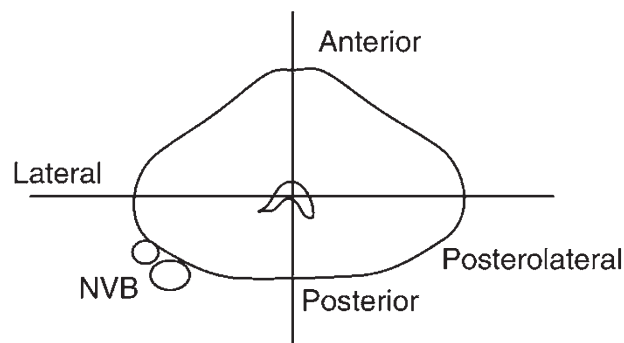


FIGURE 11.13. Low-power view of radical prostatectomy sections. Each cross section of prostate is cut into quadrants to fit into cassettes. The neurovascular bundles (NVB) are found at the posterolateral border of the prostate. The verumontanum points anteriorly.

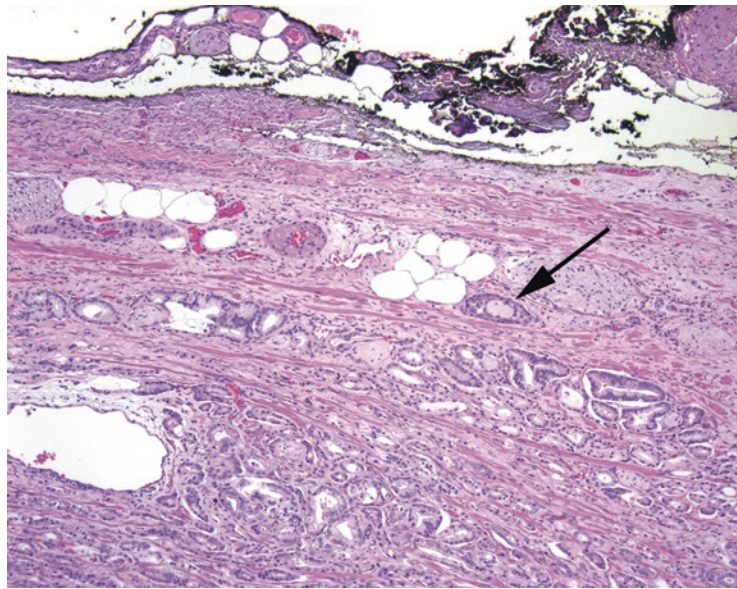


FIGURE 11.14. Extraprostatic extension. Malignant glands are seen wrapping around a nerve (*arrow*) adjacent to extraprostatic fat, diagnostic of focal extraprostatic extension. The margin, seen as the ink at the top of the photograph, is negative.

prostate, it is often associated with a fibrotic response to the tumor, wiping out the fat. This type of EPE is better appreciated at low power by following the contour of the edge of the prostate and looking for a bulge of tumor. Anteriorly, the muscle bundles are loose and disorganized, so it is difficult to recognize EPE except by seeing tumor in or beyond the plane of adjacent fat.

Although calling it “out” changes the tumor stage, it does not necessarily mean a positive margin. To call a positive margin, you must have glands not just really, really close to ink but actually transected by ink. The threshold is very high. In a positive margin, you must also decide “why” it is positive—by noting if it occurs in an area of IPI or in an area of EPE. A positive margin is almost always going to be considered EPE in the anterior prostate, because the prostatic border is so poorly defined.

Perineural invasion is a big deal in a biopsy specimen but is taken for granted in a radical. It is not worth mentioning in the diagnosis. You only have to Gleason grade the one or two biggest nodules, and each big nodule is given its own grade, as long as the highest grade present is mentioned in the diagnosis.

The seminal vesicles are examined by sampling the seminal vesicle at the point where it meets the prostate. Seminal vesicle invasion, if present, is seen on this section. Microscopically, you need to see tumor in the parenchyma of the seminal vesicle, not just next to it.

Other Prostate Neoplasms

Ductal adenocarcinoma is a variant type of prostatic adenocarcinoma that is characterized by tall, stratified columnar cells making papillary or cribriform structures (Figure 11.15). They may grow into the urethra as exophytic masses, or they may arise from more peripheral ducts in the prostate. It may be found in conjunction with conventional adenocarcinoma. It is considered a pattern 4 tumor unless comedonecrosis is present, which makes it pattern 5.

Other types of carcinoma include mucinous carcinoma, squamous cell carcinoma, urothelial carcinoma, sarcomatoid carcinoma, basal cell carcinoma, and small cell carcinoma. The more difficult-to-recognize variants of usual prostate cancer are pseudohyperplastic carcinoma (a sneaky variant that mimics the papillary architecture of benign hyperplasia),

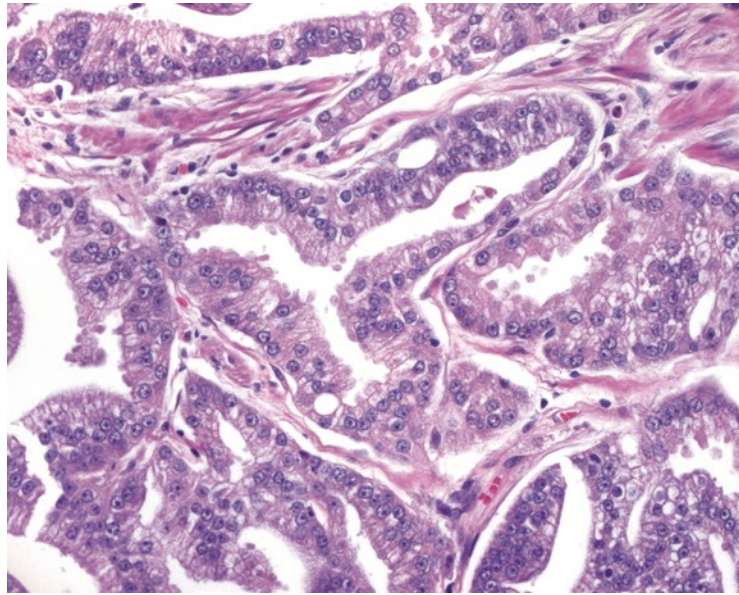


FIGURE 11.15. Ductal adenocarcinoma. In this variant, the tumor cells have tall columnar morphology. The nuclei still resemble conventional prostatic adenocarcinoma.

atrophic cancer (mimicking benign atrophy), and foamy gland cancer (with abundant xanthomatous appearing cytoplasm and tiny nuclei). You will be relieved to learn that these variants almost always show up in association with usual type adenocarcinoma, not as a pure tumor.

Spindle cell lesions may arise in the prostate. Stromal lesions arising from the unique stroma of the prostate range from benign stromal nodules, to stromal tumors of uncertain malignant potential (STUMP), to stromal sarcomas. The most common prostatic sarcoma in adults is leiomyosarcoma. Rhabdomyosarcomas occur mainly in children.

Bladder biopsy specimens are usually submitted to rule out a urothelial neoplasm. The procedure may be indicated because of hematuria, abnormal urine cytology, a history of urothelial neoplasm, or a lesion seen on cystoscopy. The cystoscopic impression is important, and you usually do not diagnose a papillary lesion if none was seen by the urologist. The bladder biopsy specimen is typically a tiny tissue fragment, so you should look at each level carefully.

The normal urothelium consists of a stratified nonsquamous epithelium, also called *transitional cell epithelium*. It consists of a five- to seven-cell-thick layer of uniform cells that do not significantly mature as they reach the surface (unlike squamous epithelium) and that tend to have oblong nuclei oriented perpendicular to the surface (Figure 12.1). The nuclei are about two to three times the size of lymphocytes. Mitoses are usually seen only at the basal layer, but in the presence of inflammation and reactive changes, they may be seen throughout. At the surface is a specialized cell layer called the *umbrella cells*, large pillowy cells that are wider than the underlying urothelial cells. Umbrella cells may have atypical nuclei and should be ignored when assessing the urothelium for dysplasia.

Underneath the urothelium lies the lamina propria, a connective tissue layer that has vessels, lymphatics, occasional smooth muscle fibers, and even occasional fat. Deep to this is the thick muscularis propria, also known as the *detrusor muscle*. Beyond the muscular wall is either adventitia or, where the bladder lies against the peritoneum, peritonealized serosa.

Normal Variants

Some changes in the bladder are so common that they are essentially normal. One of these changes is the formation of *von Brunn's nests*, which are downward invaginations of the urothelium into the lamina propria (Figure 12.2). These can look alarmingly like a urothelial neoplasm that is invading the bladder, but they should have bland urothelium that looks just like normal urothelium (see below for a description of neoplastic urothelium) and have a smooth rounded border. As these nests progress, they may acquire a dilated central lumen (*cystitis cystica*), columnar cell metaplasia (*cystitis glandularis*; see Figure 12.2), and even intestinal metaplasia with mucin production. They are still benign. However, just as high-grade squamous intraepithelial lesions can involve endocervical glands, in situ urothelial carcinoma can grow down into von Brunn's nests, mimicking invasion. Another normal variant is the formation of squamous metaplasia, especially in the trigone area of the female bladder.

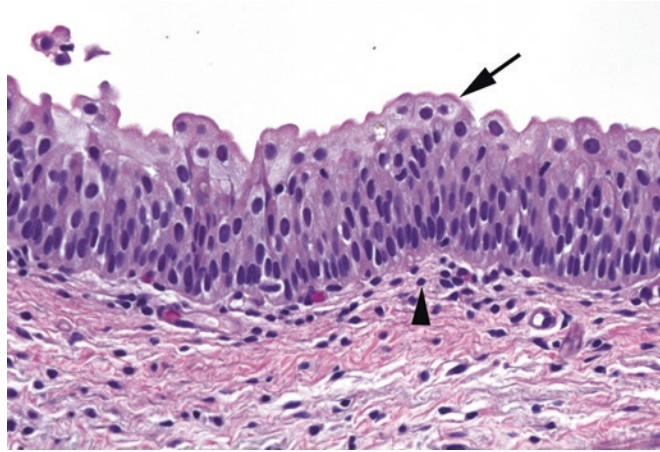


FIGURE 12.1. Normal urothelium. The urothelial cells form a layer five to seven cells thick, with large umbrella cells sitting on top (*arrow*). The urothelial nuclei are generally polarized and oriented perpendicular to the surface, with the exception of the umbrella cells. The nuclei are two to three times the size of a lymphocyte (*arrowhead*).

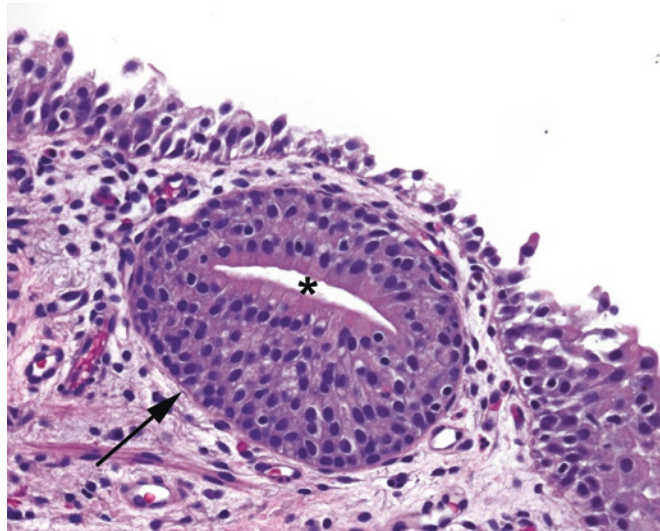


FIGURE 12.2. Von Brunn's nest and cystitis glandularis. The normal urothelium has invaginated down into the lamina propria, forming a rounded von Brunn's nest (*arrow*). The center of the nest has acquired a lumen and columnar cell metaplasia (*asterisk*), which is known as cystitis glandularis.

Inflammation (Cystitis)

There are several types of inflammatory disease that you may see. One is *granulomatous cystitis*, which once was largely caused by tuberculosis but is now more likely to be secondary to bacillus Calmette-Guerin (BCG) therapy—a topical chemotherapy for urothelial carcinoma. The intravesical injection of BCG causes an intense inflammatory response that may wipe out the carcinoma.

Parasitic infection, most commonly by *Schistosoma* species, is still common in undeveloped countries but rare in the United States. The inflammatory response is actually not caused by the organisms but by their eggs, which are extruded into the bladder wall and cause intense foreign body reaction. The eggs themselves are dark purple oval bodies with single spines,

large enough to be seen at 4×. *Polypoid cystitis* is similar to an inflammatory polyp of the bladder and is associated with any process that injures the bladder (e.g., indwelling catheters, calculi, fistula from the colon). *Interstitial cystitis* is a poorly understood disease that is mainly a cystoscopic diagnosis and more a diagnosis of exclusion for the pathologist.

Malakoplakia is one of those mysterious rare entities that most residents do not see, think about, or understand until they are studying for boards. It is a descriptive name for the yellow plaques seen on cystoscopy, which are formed by sheets of epithelioid histiocytes sporting characteristic round inclusions called Michaelis-Gutmann bodies (they look like archery targets). It is caused by a defective macrophage response to infection.

Urothelial Neoplasms

Urothelial neoplasms are categorized into two cancer pathways: *flat* and *papillary*. Both can lead to invasive carcinoma, but the terminology is different. About 90% of bladder carcinomas are urothelial, so this will be the focus of this chapter.

Flat neoplasia does not form an exophytic lesion but may still be visible on cystoscopy as a red area. It progresses through dysplasia (rarely diagnosed) to carcinoma in situ. Flat urothelial carcinoma in situ is just known as *carcinoma in situ* (CIS) and can go on to deeply invasive carcinoma without ever making an exophytic lesion, so always scrutinize the urothelium at high power, especially in denuded areas. Features of CIS include the following:

- Urothelial cells with increased nuclear size. A helpful hint is that the worst nuclei of CIS should be four to five times the size of lymphocyte nuclei (Figure 12.3).
- Hyperchromatic nuclei with irregular (“boulder-like”) outlines.
- Urothelium that is falling apart, appearing denuded, with a few clinging cells.
- Full-thickness involvement is *not* a requirement to diagnose CIS (even scattered malignant cells with the above features justify a diagnosis of CIS).

If a lesion has atypia that you think is neoplastic (i.e., not reactive) yet the cells are not bad enough to call CIS, then the diagnosis of dysplasia is appropriate. However, the options are limited: you should not call mild dysplasia, as urologists do not treat it, nor should you call severe dysplasia, which is the same as CIS. True dysplasia (meaning moderate dysplasia falling just short of CIS) is an uncommon diagnosis, with most bladder biopsies of flat lesions signed out as benign, CIS, or reactive.

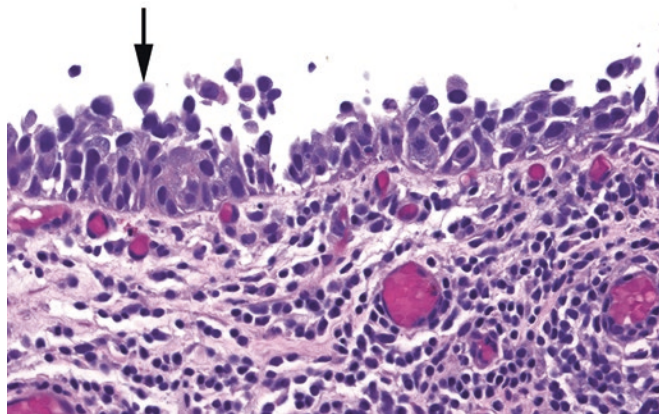


FIGURE 12.3. Flat carcinoma in situ. The urothelium is partially denuded (stripped of cells), but the cells that remain show enlarged, round, hyperchromatic nuclei appearing to pop off the surface (*arrow*). Compare the nuclear size to the underlying lymphocytes.

Papillary neoplasia has a much wider spectrum of disease, from benign papilloma to high-grade carcinoma. The papillary lesions are unusual in nomenclature, however, in that despite being in situ lesions, they are conventionally just called *noninvasive papillary urothelial carcinoma*, either low or high grade. If you use the word in situ to refer to papillary lesions, urologists think you mean flat CIS. Once these cancers invade, they are called *invasive papillary urothelial carcinoma* and are typically high grade.

Papillary lesions all have in common a branching architecture with delicate fibrovascular cores, and they can get quite large, even filling the bladder. The classification is determined by the cytology of the urothelial lining.

Papilloma

Papillomas are defined by having a normal urothelial lining (normal thickness, well-organized and polarized, and small nuclei, often with nuclear grooves, without mitoses; Figure 12.4). They tend to be small lesions. There is no risk of malignant transformation. Do not be fooled by papillary hyperplasia, which is an undulating wavelike urothelium without true fibrovascular cores.

Papillary Urothelial Neoplasm of Low Malignant Potential

“Papillary urothelial neoplasm of low malignant potential” (PUNLMP) is a category for those proliferative neoplasms that are larger and fuller than papillomas but do not look malignant. Their behavior is intermediate between a papilloma and a low-grade papillary carcinoma, like any “LMP” lesion. The urothelial lining is increased in thickness but still appears well organized, with all nuclei streaming in parallel, and has near-normal N/C ratios (Figure 12.5). Mitoses should be exceedingly rare and confined to the basal layer, as in normal urothelium.

Low-Grade Papillary Urothelial Carcinoma

Low-grade papillary urothelial carcinomas (Figure 12.6) have the following features:

- The urothelial lining is increased in thickness and is still in general fairly organized (the cells are still mostly polarized with respect to the surface).
- There is scattered subtle nuclear atypia consisting of random slightly enlarged darker nuclei, in contrast to PUNLMP, in which every nucleus looks the same.
- Mitoses are uncommon, but typically you will see some of them, in contrast to PUNLMP.

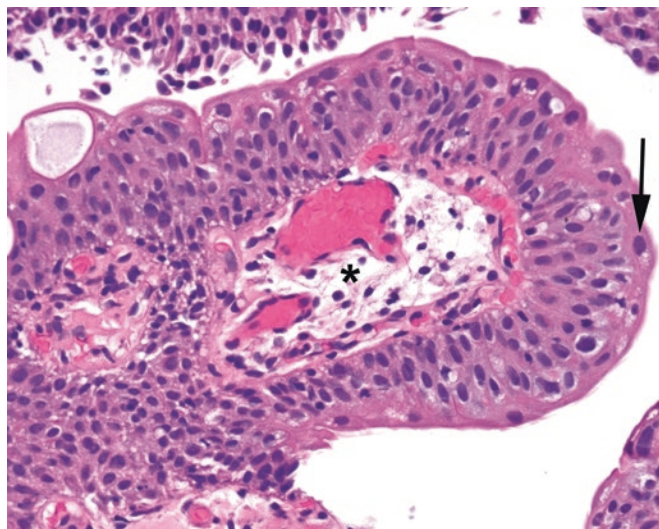


FIGURE 12.4. Papilloma. There is a prominent fibrovascular core (*asterisk*), and the urothelium resembles normal urothelium both in thickness and in bland cytology. Some large umbrella cells are visible (*arrow*).

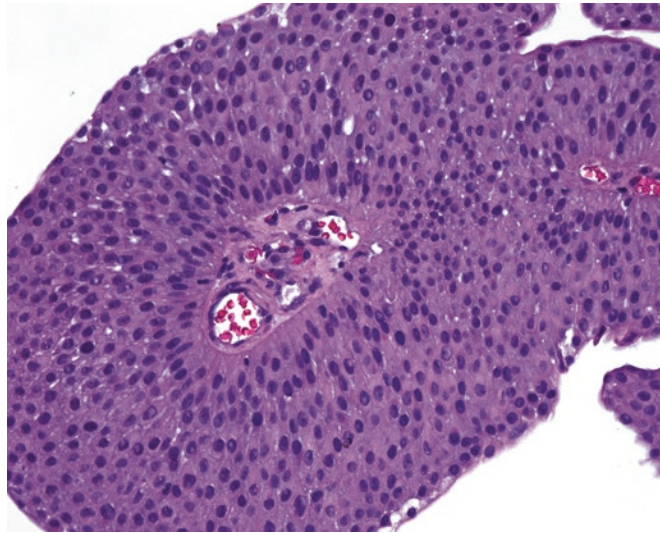


FIGURE 12.5. Papillary urothelial neoplasm of low malignant potential. This papillary lesion shows an increased thickness relative to normal urothelium, but the cells remain uniform and organized.

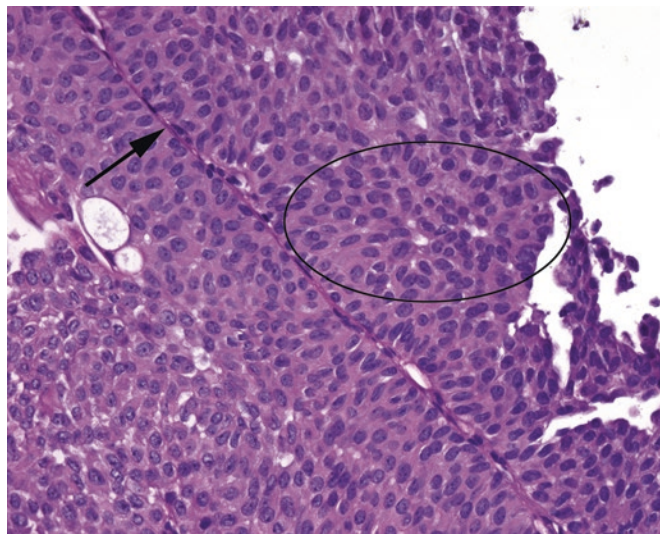


FIGURE 12.6. Low-grade papillary urothelial cancer. The fibrovascular cores (*arrow*) are lined by urothelium that is thicker than normal, increasingly disorganized (*circle*), and with enlarged nuclei.

High-Grade Papillary Urothelial Carcinoma

High-grade papillary urothelial carcinoma lesions are lined by cells that look like CIS. They can be noninvasive, but you have to look carefully for associated invasion, which is often present.

- The urothelium is very disorderly, with little nuclear orientation to the surface.
- Nuclei are enlarged, hyperchromatic, and pleomorphic and may have nucleoli (Figure 12.7).
- Mitoses are seen at all levels of the epithelium (in a well-oriented fragment).
- Focal non-urothelial differentiation (squamous or glandular) is possible.
- A small amount of high-grade characteristics (>5%) generally defines the entire lesion as high grade.

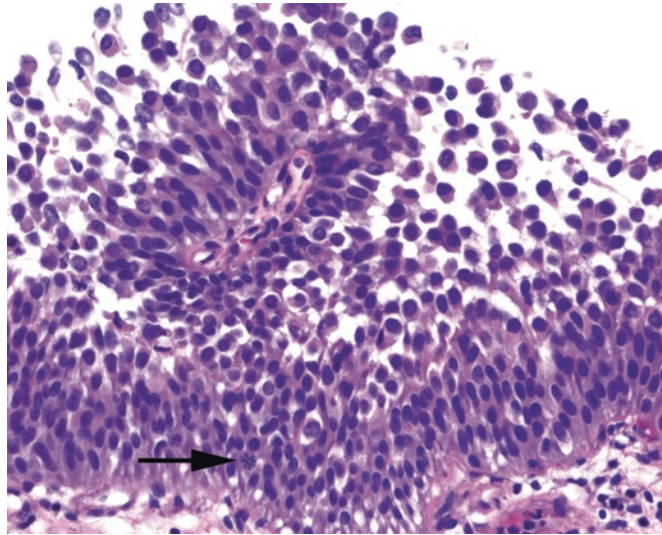


FIGURE 12.7. High-grade papillary urothelial cancer. This papillary lesion shows large, dark, pleomorphic nuclei popping off the surface, similar to carcinoma in situ (see Figure 12.3). A large mitotic figure is visible (*arrow*).

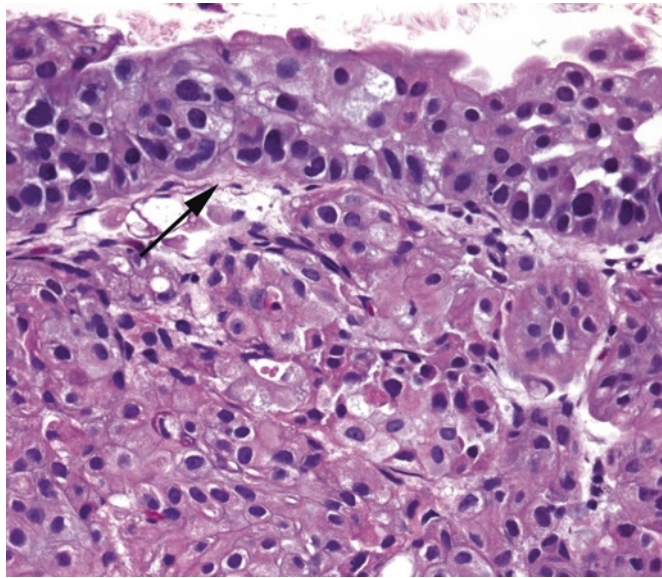


FIGURE 12.8. Invasive urothelial carcinoma. In this case, the carcinoma is arising out of flat carcinoma in situ, seen above the basement membrane (*arrow*). The nests of tumor in the lamina propria appear more pink than the surface carcinoma in situ, corresponding to paradoxical differentiation.

Invasive Urothelial Carcinoma: The Tumor Formerly Known as “Transitional Cell Carcinoma”

Most invasive carcinomas arise in the setting of either high-grade papillary urothelial carcinoma or CIS. Identifying invasion into the lamina propria relies on similar cues as found in other organs:

- Irregular tongues of cells or single cells pushing into the lamina propria
- “Paradoxical differentiation”: the deep invasive cells acquire increased pink cytoplasm, mimicking maturing surface cells (Figure 12.8)
- Retraction artifact: the cracking of the stroma away from tumor nests
- Desmoplastic response of stroma (however, often not present)

Identifying the *muscularis propria* (detrusor muscle), and whether the tumor invades it, is critically important. Superficial carcinomas that do not invade the muscularis propria may be treated conservatively by transurethral resection (TURBT) or topical chemotherapy. Invasion of the detrusor buys the patient a cystectomy. Therefore, any diagnosis of invasive carcinoma should state whether the detrusor is (1) present on the biopsy or (2) involved. Remember that wisps of smooth muscle (the discontinuous muscularis mucosae) may be found in the lamina propria, so do not overcall detrusor invasion on that basis. The detrusor is a big slab of muscle, relatively speaking (Figure 12.9).

Also, as mentioned earlier, ugly urothelium that invades the lamina propria in broad round nests may actually be growth of CIS into von Brunn's nests or an inverted growth pattern of a noninvasive papillary urothelial carcinoma (see the following list). The difference is that in these mimickers of invasion, the nests are round and even without ragged borders, and they appear basophilic, often with crowding or palisading of the outermost layer of cells.

- Conditions that look like cancer but are not:
 - Inverted papilloma: As in the nose (Schneiderian papilloma), a papilloma can occasionally grow down and in, instead of up and out, creating an inside-out or inverted papilloma that is buried in stroma but does not cross the basement membrane. Like von Brunn's nests, the urothelium should look benign.
 - Reactive changes in urothelium: As in other organs, reactive changes tend to create enlarged but euchromatic nuclei; the chromatin should be evenly blue gray and the nuclear contour smooth and oval, yet nucleoli may be prominent (Figure 12.10). You should raise your threshold for CIS in the presence of extensive inflammation.
 - Nephrogenic adenoma: Nephrogenic adenoma is a benign proliferative neoplasm that can take on many appearances, including cuboidal cells lining papillary fronds; hobnail cells lining vessel-like structures (Figure 12.11); small infiltrative-looking tubules, sometimes with thyroid-like accumulations of colloid; and small tubules mimicking signet-ring cell carcinoma. In all cases, these differ from urothelial lesions by being a single-layered epithelium, so you must think of nephrogenic adenoma when you see a tumor lacking the usual stratified nuclei of urothelium. There may be focal large dark nuclei, but they should have uniform dense chromatin and no mitoses.

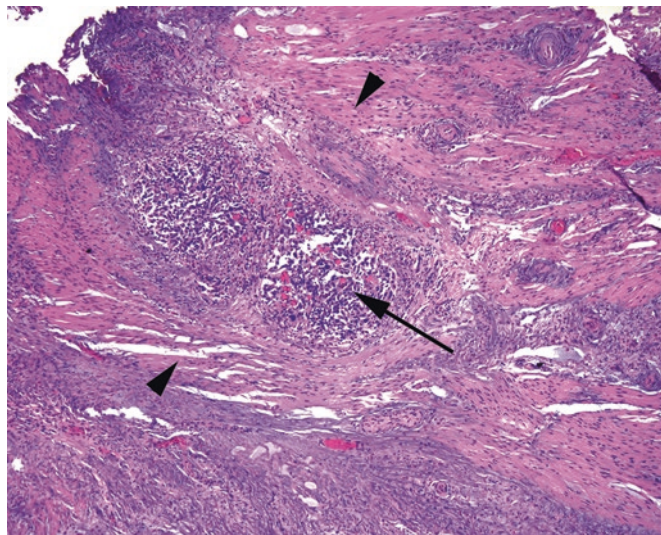


FIGURE 12.9. Carcinoma in detrusor muscle. Thick bands of muscle (*arrowheads*) are seen on either side of a nest of tumor cells (*arrow*).

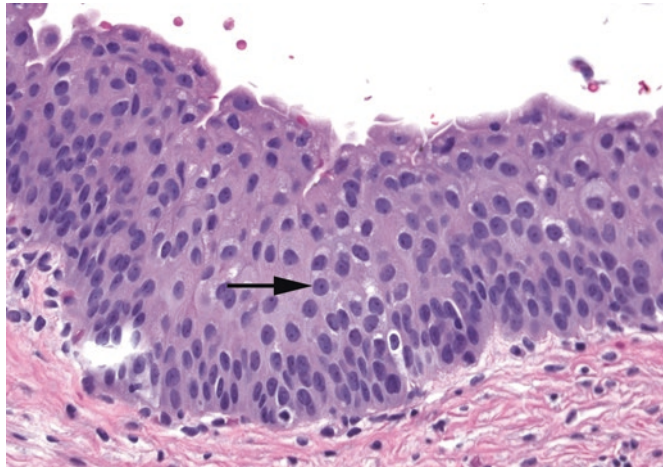


FIGURE 12.10. Reactive nuclei. These urothelial nuclei are somewhat enlarged and have prominent nucleoli (*arrow*) but retain a smooth nuclear outline and pale, even chromatin. They are benign.

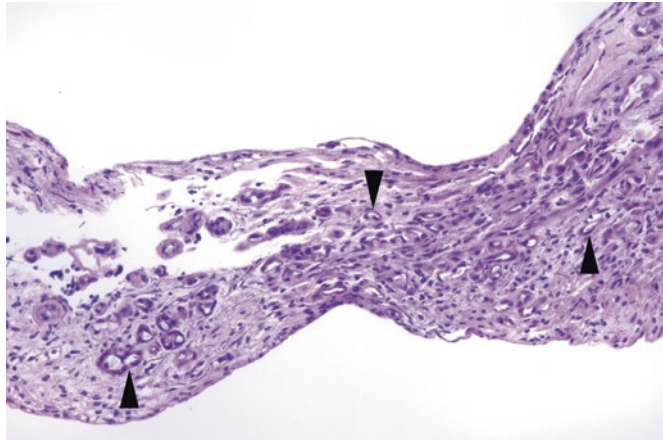


FIGURE 12.11. Nephrogenic adenoma. In this bladder biopsy specimen, there are multiple tiny tubules in the lamina propria (*arrowheads*) with prominent dark nuclei. The urothelium is not seen here.

- Inflammatory pseudotumors (postoperative spindle cell nodule and inflammatory myofibroblastic tumor): These myofibroblastic proliferations may mimic a sarcoma or sarcomatoid carcinoma. The reactive postop spindle cell nodule arises, by definition, after a urinary procedure, while the inflammatory myofibroblastic tumor is thought to be a true neoplasm. Both can have myxoid stroma, a tissue culture-like pattern, inflammatory cells, and frequent mitoses; unfortunately, they can also be deeply infiltrative and occasionally stain for keratins! However, like in related reactive lesions such as nodular fasciitis, the nuclei are pale with smooth round contours and nucleoli, very unlike the typical sarcoma nucleus (see Chapter 29 for further discussion).
- Conditions that look benign but are not:
 - Nested transitional cell carcinoma: This is an invasive urothelial carcinoma made of small, bland nests in the lamina propria that, despite looking like von Brunn's nests, is actually an aggressive carcinoma. Great, right? Features suggestive of this lesion include an infiltrative pattern at the base of the lesion as well as an architecturally complex pattern of closely packed small nests.

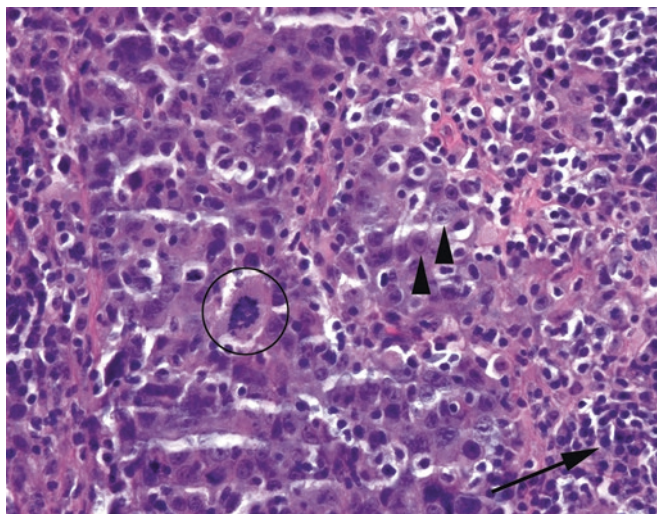


FIGURE 12.12. Lymphoepithelial-like carcinoma. The malignant cells (*arrowheads*) are almost obscured by the background of lymphocytes (*arrow*). Atypical mitoses are present (*circle*).

- Lymphoepithelial-like carcinoma: While this certainly does not look like normal bladder, lymphoepithelial-like carcinoma can be very sneaky to the pathologist in training. The overall impression is that of raging inflammation and tissue destruction, with sheets of lymphocytes, but the actual carcinomatous cells tend to fade into the background on H&E stain. The nuclei tend to be large and bubbly but not particularly hyperchromatic or carcinoma like, and the cytoplasmic borders are very indistinct, almost syncytial (Figure 12.12). A cytokeratin stain is helpful.

Neoplasms

The kidney is primarily composed of glomeruli, tubules, stroma, and vasculature. However, unlike in some other organs, the neoplasms of the kidney do not faithfully reflect or recapitulate their cells of origin. Therefore, recognizing a lesion is not so much a systematic process as a recognition of patterns. However, there are certain features to notice in evaluating any kidney mass, as they will help narrow the differential diagnosis in tough cases:

- Circumscription and/or encapsulation
- Presence of stroma within the tumor
- Vascular or capillary pattern
- Architectural pattern (solid, acinar, trabecular, tubular, papillary, pseudopapillary, cystic)
- Cellular pleomorphism (ranging from monotonous to bizarre)
- Mitotic activity
- Cytoplasm (clear to granular pink to densely eosinophilic, perinuclear halos)
- Nuclear size and contour (shape, and whether the membrane is smooth or wrinkled)
- Nucleoli

When studying the kidney grossly, many details crucial to staging are identified (or lost) at the bench. Key prognostic factors include the following:

- Tumor invading into the renal sinus fat at the hilum
- Tumor extending through the kidney capsule and into the perirenal fat
- Tumor invading adrenal gland (always note whether the adrenal is even present)
- Gross tumor in the renal vein, both at the margin and in the renal pelvis (always open the renal vein)
- Tumor growing through Gerota's fascia (the very delicate membrane surrounding the perirenal fat; this is actually fairly uncommon but indicates stage T4 disease)

Other helpful gross features include the following:

- Circumscription and presence of multiple lesions
- If cystic, multilocular versus unilocular, the presence of mural nodules, the relationship to renal pelvis
- If solid, the homogeneity and the color(s)—yellow gold, mahogany brown, areas of hemorrhage, necrosis, fibrosis (gristle gray), or possible sarcomatoid foci (dense white)
- Site of origin (cortex vs. medulla or pelvis), if you can tell

Now that you have the key identifying features of your tumor, let us look at the differential diagnosis for tumors *in the adult*. In the decade since the first edition of this book was published, a host of new entities has been described, and, unfortunately, the names for renal tumors read like they were generated by pulling kidney-related terms out of a bag (like the world's smallest magnetic poetry kit). There is a lot of overlap of syllables and words. Take “nephro” as an example. A *metanephric* adenoma is a benign tumor of the kidney, discussed below. A *nephrogenic* adenoma is a benign lesion of the bladder (see Chapter 12). *Mesonephric* refers to the Wolffian duct in embryos and can be used to describe vestigial remnants in the female cervix or vanishingly rare carcinomas of the cervix. *Cystic nephroma* actually describes two different tumors of the kidney (see below), and *nephroblastoma* is a synonym for Wilms tumor, but a *congenital mesoblastic nephroma* is a rare stromal tumor of infants. Some new adjectives would be very helpful in this field.

Cystic Lesions

Simple Cyst

Simple cysts are a very common finding, even at autopsy. The simple cyst is essentially a dilated tubule and will have a low cuboidal or flattened pink epithelial lining (Figure 13.1). It is usually unilocular. If multilocular, the septa dividing the cysts should be unremarkable stroma with no epithelial islands or nodules. *There should be no clear cells.*

Cystic Nephroma/Multilocular Cyst

The term “cystic nephroma,” when used in the adult, falls in the category of “one of those ectopic-ovarian-stroma-lesions found mainly in women” and is related to the *mixed epithelial and stromal tumor (MEST)*, discussed below. (In the pediatric population, however, the term indicates a benign tumor on the nephroblastoma spectrum.) This is a multilocular cyst with a background of ovarian-type stroma: fairly blue, cellular, spindly, and estrogen and progesterone receptor positive (Figure 13.2). The cyst lining is cuboidal to hobnailed. *There should be no clear cells.*

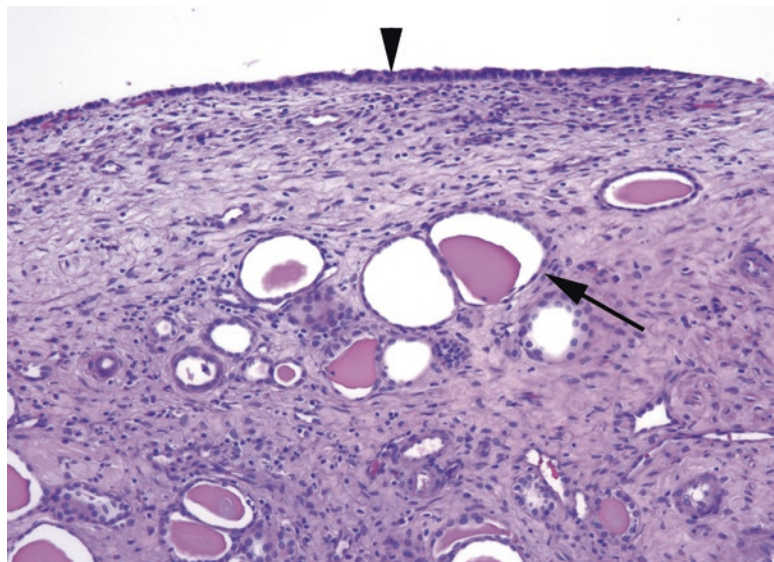


FIGURE 13.1. Simple cyst. The cyst lining (*arrowhead*) consists of a *thin* layer of cuboidal cells. Below the cyst, dilated tubules filled with proteinaceous fluid are visible (*arrow*).

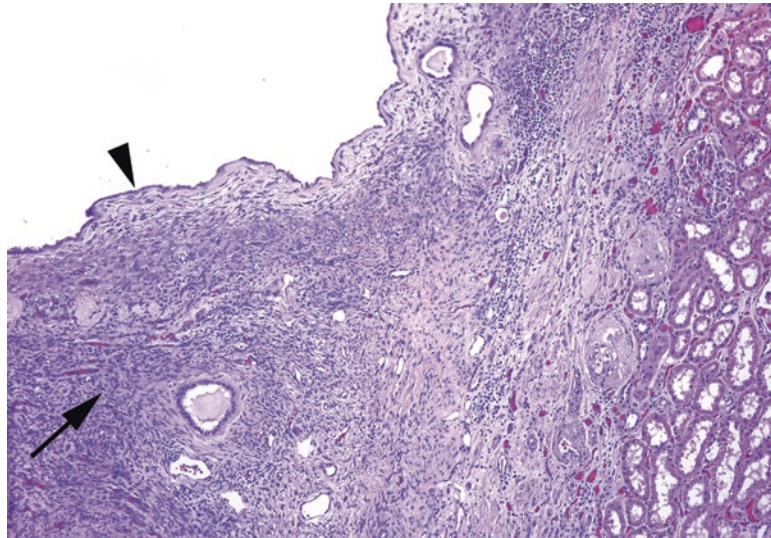


FIGURE 13.2. Cystic nephroma. Like the simple cyst, this cyst is lined with bland epithelial cells (*arrowhead*). However, there is adjacent spindle stroma, similar to ovarian stroma (*arrow*). Kidney parenchyma is seen at the *right*.

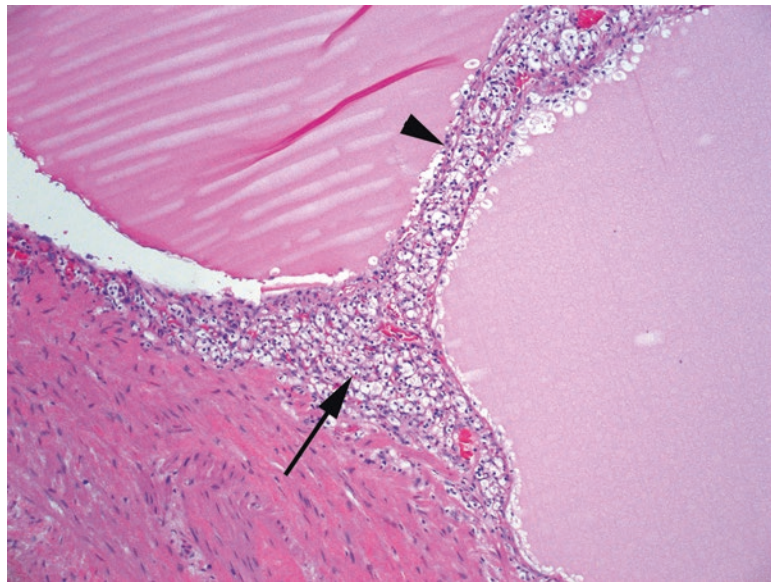


FIGURE 13.3. Multilocular cystic renal neoplasm of low malignant potential. The cyst lining and fibrovascular septa (*arrowhead*) are composed of clear cells with small dark nuclei (*arrow*); compare these cells to conventional renal cell carcinoma (see Figure 13.6).

Clear Cell Renal Cell Carcinoma

Clear cell renal cell carcinoma (RCC) can present as a cyst in several ways. First, it can arise in the wall of a preexisting simple cyst. Second, a solid tumor mass can undergo cystic degeneration. Third, and most sneaky, it can occur purely as a cyst lining, usually in a multilocular cyst: this is called *multilocular cystic renal neoplasm of low malignant potential*, due to its extremely indolent behavior. The main indicator is the presence of clear cell aggregates and nests in the cyst walls (Figure 13.3). The cyst walls may be denuded of epithelium, though, so careful sampling and hunting are essential.

Lesions with Multiple Cell Populations

Angiomyolipoma

The angiomyolipoma is, at first, a difficult lesion to recognize, because it looks like just a mishmash of normal soft tissue components. From the name, you know that it must have vessels, smooth muscle, and fat, but then so do most organs of the body. Also working against you is the fact that these lesions can have one or two components predominating, so all you see is a mass of plump spindly cells with a vessel here and there and maybe a couple of fat cells. The key to recognizing an angiomyolipoma is knowing that you have a mass lesion and appreciating the unusual vessels that are the hallmark of this tumor.

This tumor is benign. The usual histologic features include the following:

- Large, tangled, tortuous, thick-walled, hyalinized vessels
- Smooth muscle cells (pink to clear and spindly) that seem to spin off of, or be continuous with, the vessel walls (Figure 13.4)
- Mature fat cells without atypia or lipoblasts
- Pushing borders but not encapsulated
- HMB-45 and Melan-A positive. This tumor is in the perivascular epithelioid cell tumor (PEComa) family, all of which stain for melanoma markers but not for S100.

Mixed Epithelial and Stromal Tumor (MEST)

The MEST, although rare, is simple in concept: it is the renal version of an adenofibroma, or a fibroadenoma, or any other benign mixture of stromal and epithelial elements. Because it can be cystic, it is also included in the differential diagnosis of cystic lesions. The histologic findings include a population of cytologically benign tubules of varying shapes and sizes set in a background of bland spindled stroma, which may consist of smooth muscle, fibroblasts, or myofibroblasts. This may also be in a spectrum with adult cystic nephroma (discussed earlier), because it also has estrogen and progesterone receptor-positive stroma.

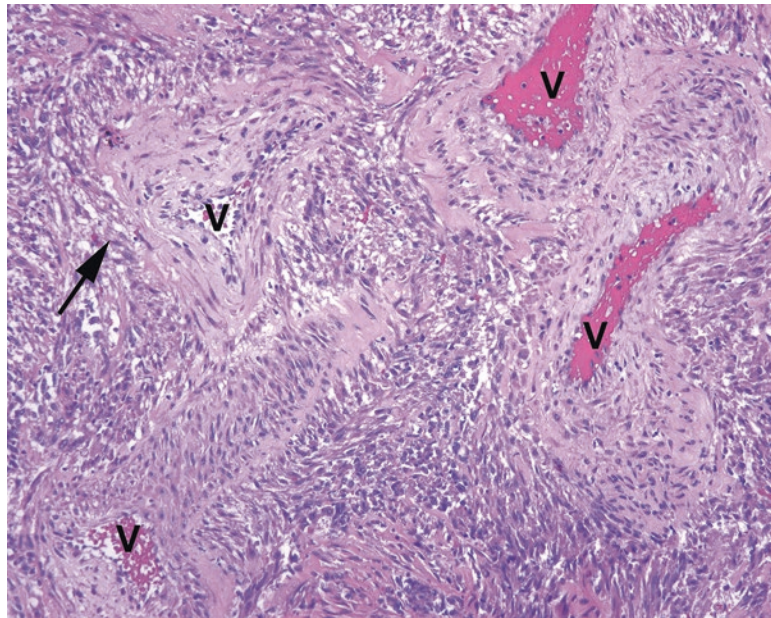


FIGURE 13.4. Angiomyolipoma. This example does not show the fatty component, but the prominent vessels (V) and smooth muscle components here are classic. In angiomyolipoma, the spindle cells seem to merge with, or spin off from, the thick-walled vessels (*arrow*).

Solid Neoplasms

Tumors with Clear Cells

The presence of clear cells in a renal tumor immediately puts renal cell carcinoma at the top of the differential. For all practical purposes, there are no clear cell adenomas. A 3 mm clear cell focus is still a clear cell carcinoma, albeit a fairly nonthreatening one. *Note:* Avoid the big, embarrassing, novice mistake number 1—mistaking the normal adrenal cortex for a clear cell tumor. The adrenal cell should have visible vacuoles that indent the nucleus, giving it a stellate outline (Figure 13.5).

Clear Cell Renal Cell Carcinoma

Clear cell renal cell carcinoma is a common tumor that is grossly a granular, golden-yellow-orange, well-circumscribed tumor, with a color and texture similar to normal adrenal cortex. It may get quite large and have areas of necrosis, hemorrhage, cystic degeneration, and fibrosis. All different looking areas should be sampled, especially the firm solid white-to-gray areas, which could indicate sarcomatoid transformation.

Histologically, the tumor may be solid with an acinar pattern, pseudopapillary (which is an acinar pattern with central dropout), or cystic. Areas of sheeting, spindly, sarcomatoid growth will bump up the tumor to grade IV. Identifying features include the following:

- A netlike array of delicate capillaries, dividing cells into packets (“acinar” pattern)
- Clear cytoplasm, at least focally if not diffusely (Figure 13.6)
- Delicate, distinct cell membranes
- Lack of desmoplasia (although sclerosis of burned-out tumor is common)

Clear cell RCC is graded cytologically according to *ISUP nucleolar grade*. Low-grade tumors have clear cytoplasm, polygonal cells, and round nuclei. Higher-grade tumors may acquire pink cytoplasm and pleomorphic nuclei. Grade criteria, with a 10× objective (Figure 13.7), are as follows:

- Grade I: nuclei resemble lymphocytes, no nucleoli
- Grade II: nuclei still small, +/- tiny nucleoli, but with open chromatin
- Grade III: easily recognizable nucleoli, larger nuclei
- Grade IV: pleomorphic and hyperchromatic nuclei with big nucleoli

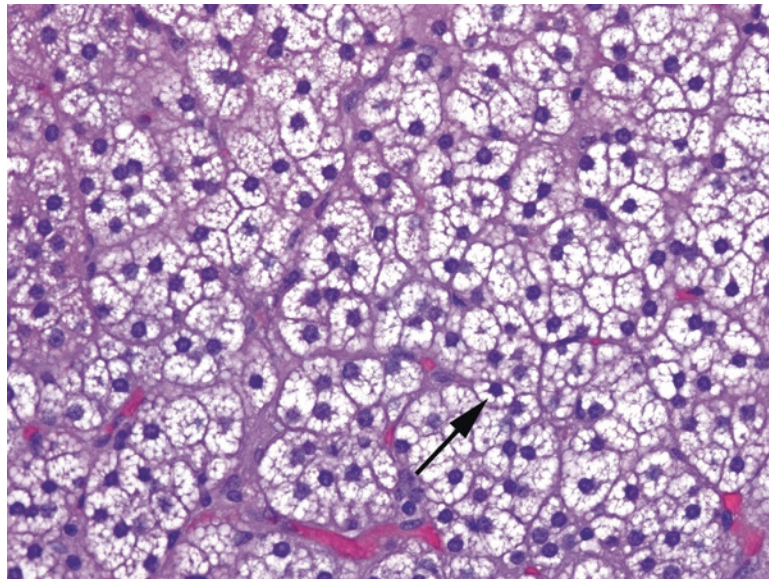


FIGURE 13.5. Normal adrenal cortex. Unlike clear cell carcinoma, the cells of the adrenal cortex have discrete cytoplasmic vacuoles that indent the nuclei, creating a stellate outline around the nucleus (*arrow*).

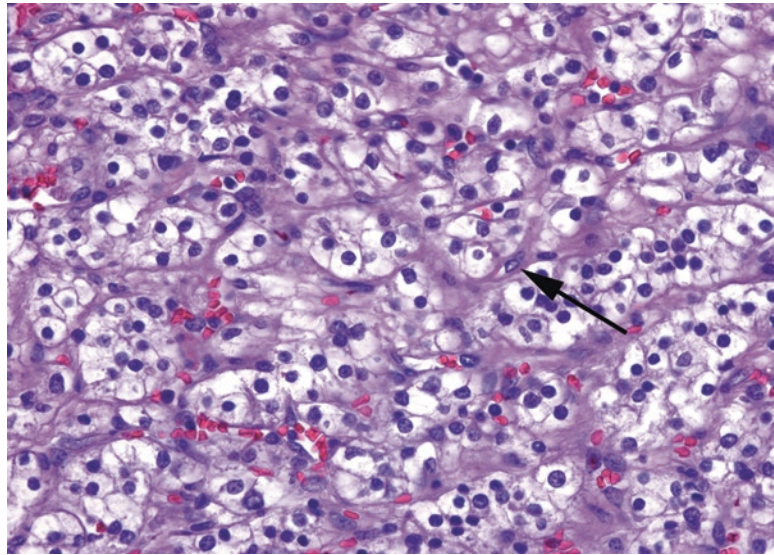


FIGURE 13.6. Clear cell renal cell carcinoma. The tumor is composed of packets of clear cells, divided by delicate fibrovascular septa (*arrow*). These septa are characteristic of renal cell carcinoma and are seen even in high-grade or metastatic tumors. The nuclei in this example are enlarged, but nucleoli are visible only at high power, consistent with ISUP grade II.

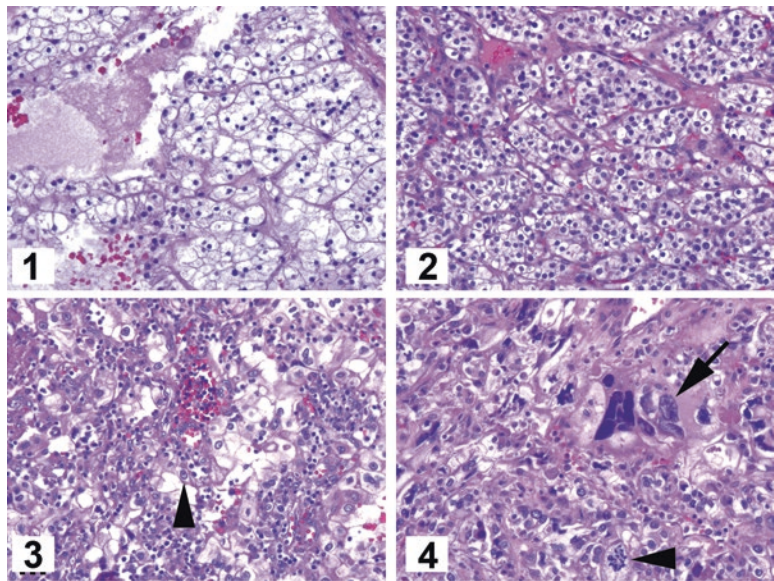


FIGURE 13.7. ISUP grades shown at 10x. 1 Grade I: Nuclei are small and dense, resembling lymphocyte nuclei. 2 Grade II: Nuclei are larger, but no nucleoli are visible at this power. 3 Grade III: Nuclei are even larger, now with some visible nucleoli (*arrowhead*). 4 Grade IV: Nuclei are frankly anaplastic (*arrow*) with large atypical mitoses (*arrowhead*). All images are taken at the same magnification.

Chromophobe Renal Cell Carcinoma

Chromophobe RCC is usually pale pink under the microscope. The cytoplasm ranges from clear to feathery pink to deep oncocytic pink. It is not encapsulated, and it grows as a solid to papillary mass. Features include the following:

- Distinct cell membranes that give the tumor a three-dimensional texture, like alligator skin or plant cells (Figure 13.8)
- Cells of varying sizes and shapes
- Pink, granular, wispy cytoplasm, often with a perinuclear clearing
- Nuclei that vary in size and shape and are crinkly, like koilocytes (see Figure 13.8)
- Can transform to sarcomatoid morphology

The *eosinophilic variant of chromophobe* can look at low power like an oncocytoma, but the nuclei should still have a koilocytic flavor, unlike the very round and regular nuclei of an oncocytoma.

Clear Cell Papillary (or Tubulopapillary) Renal Cell Carcinoma

This new addition to the renal family (which truly deserves a more distinctive name) looks pretty much as the name would suggest. It is a low-grade clear cell neoplasm with papillary or tubular architecture. Features include:

- Clear cells with small, dense, dark nuclei, often oriented with the nucleus on the luminal surface, and the cytoplasm toward the base (“upside down”; Figure 13.9).
- Cells are arranged on delicate fibrovascular cores or in small closely packed tubules.
- May show cystic degeneration.
- Small tumors, well circumscribed, and often encapsulated.

Be aware that on small samples, like a needle core, clear cell papillary RCC can mimic clear cell RCC and vice versa. Like the multilocular cystic renal neoplasm of low malignant potential, this tumor is extremely indolent and may be reclassified as a tumor of low malignant potential.

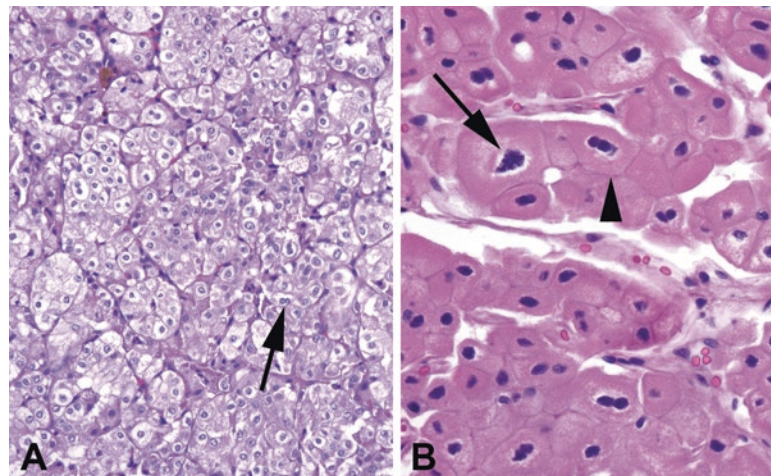


FIGURE 13.8. Chromophobe renal cell carcinoma. (a) Low power view of chromophobe, showing packets of cells with clear-to-pink cytoplasm, perinuclear halos, and occasional binucleate cells (*arrow*). The cell membranes are distinct, giving the tumor a cobblestone or alligator skin texture. (b) High power view of a chromophobe carcinoma, eosinophilic variant. Although the granular pink cytoplasm resembles an oncocytoma (see Figure 13.12), the nuclei are distinctly koilocytic, with crinkly outlines and perinuclear halos (*arrow*). In addition, the fine cellular membranes are preserved (*arrowhead*).

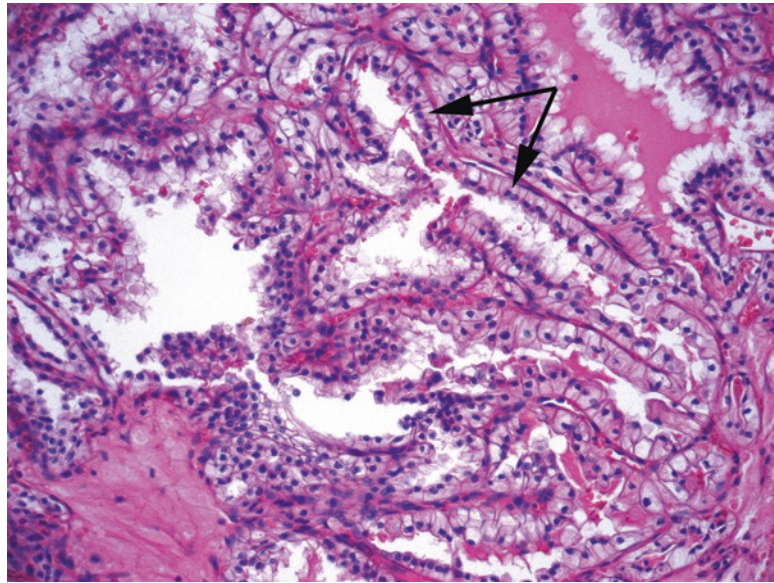


FIGURE 13.9. Clear cell papillary renal cell carcinoma. There are clear cells arranged on fibrovascular cores, creating a papillary pattern. The small dark nuclei are classically lined up at the luminal surface of the clear cells, rather than at the base (*arrows*).

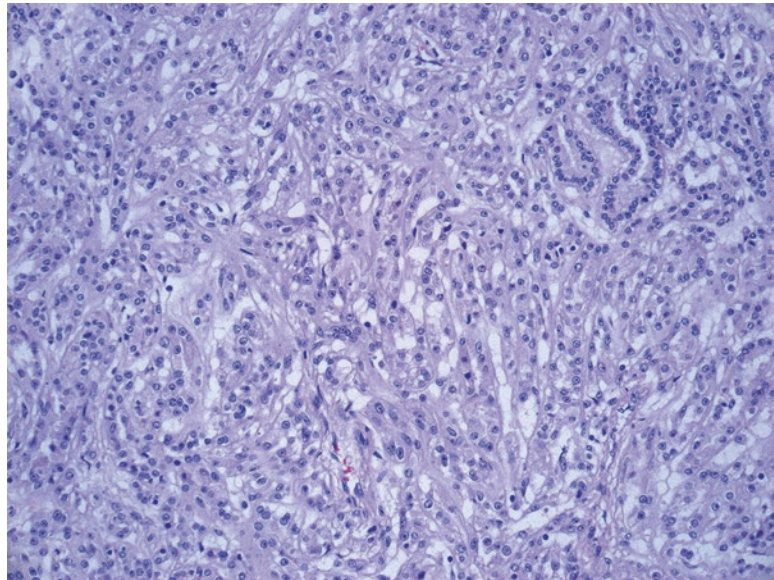


FIGURE 13.10. Mucinous tubular and spindle cell carcinoma. In an overall pale tumor, the nuclei are small and euclromatic and arranged in long tubules and areas of spindling.

Mucinous Tubular and Spindle Cell Carcinoma

The mucinous tubular and spindle cell carcinoma is a rare entity which may not, despite the name, jump out at you as a mucinous neoplasm. Overall the tumor is pale and bland, with extracellular mucin which may not be prominent. Features include:

- Long arrays of narrow tubules, which may remind you of renal medulla at low power (Figure 13.10).
- Clear cells with indistinct cell boundaries that may fuse into spindle cell areas.
- Nuclei are small, round, and pale, sometimes with pinpoint nucleoli.

Translocation Tumors

At least two different translocation tumors are grouped under the larger heading of *MiT family translocation RCCs*. The MiT family includes transcription factors TFE3, TFEB, MiTF, and others. Renal carcinomas resulting from translocations of these genes include (so far) the t(6;11) RCC and the Xp11 RCC. As with most translocation tumors, these tend to be seen in younger patients. Their histology is a mix of patterns that can easily be mistaken for other tumor types.

Xp11 translocation RCC: Typically a tumor with plump clear cells, large nuclei, papillary architecture, and psammoma bodies.

t(6;11) RCC: The unique feature of this tumor is a dual cell population, with nests of large clear or granular pink cells interspersed with aggregates of small compact cells which can be mistaken for lymphocytes at low power (Figure 13.11). Oddly, this carcinoma will stain for HMB-45 and Melan-A, but not keratin, which could lead to confusion with epithelioid angiomyolipoma.

Tumors with Pink Cells

If the cells are not clear, your differential diagnosis includes eosinophilic variants of chromophobe or clear cell renal cell carcinoma, as well as the following:

Oncocytoma

Oncocytoma is a benign tumor resembling oncocytes (or Hurthle cells) in other organs. Grossly, it is mahogany brown and well circumscribed but not encapsulated. There may be a stellate scar (a nonspecific sign of slow growth). The oncocytes are arranged in nests or cords of cells in a hypocellular stroma. The cells are round with dense pink cytoplasm and very regular, round nuclei (Figure 13.12). This regularity should strike you at low power, very different from a chromophobe. The oncocytoma is not graded. Features incompatible with this diagnosis include mitoses, papillary architecture, clear cells, and grossly identified vascular invasion.

Papillary Renal Cell Carcinoma

Papillary renal cell carcinoma is a cellular tumor of pink-to-blue cells (low nuclear grade Type 1 tumors tend to be blue at low power, and high nuclear grade Type 2 tumors tend to be pink) that may be arranged in papillary formations (helpful), solid sheets, or trabecular cords. The classic image is that of a fibrovascular core packed with foamy macrophages and lined by

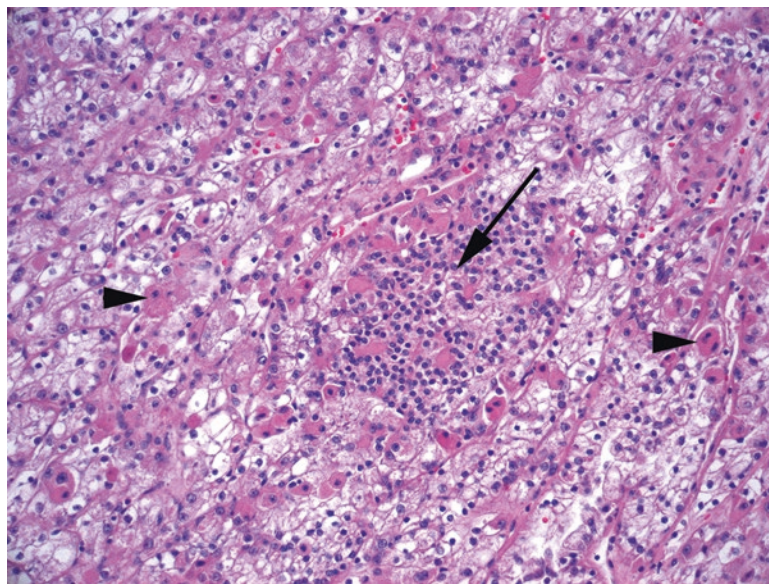


FIGURE 13.11. t(6;11) carcinoma. There are large clear or granular pink cells (*arrowheads*) interspersed with aggregates of small compact cells (*arrow*).

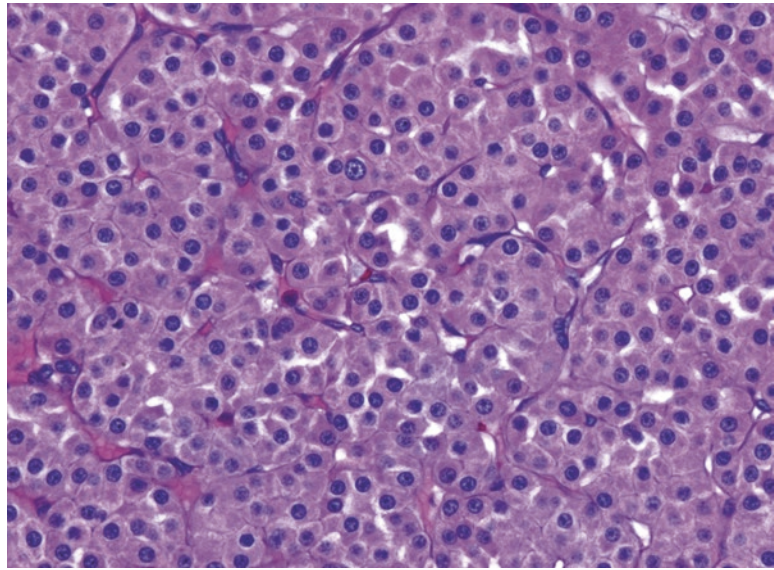


FIGURE 13.12. Oncocytoma. The nuclei are typically very round, uniform in size, and evenly spaced. Nucleoli may be seen, but there are no perinuclear halos. The cytoplasm is pink and granular, similar to oncocytic neoplasms elsewhere in the body.

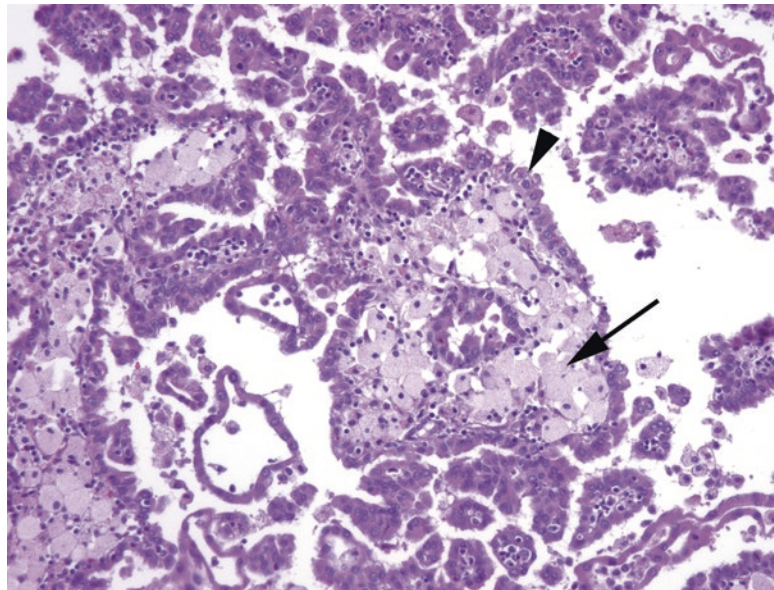


FIGURE 13.13. Papillary renal cell carcinoma, Type 1. The tumor cells are pink, not clear, and range from cuboidal to columnar (*arrowhead*). This tumor may grow as solid sheets and tubules, but finding papillary structures with central cores packed with foamy histiocytes (*arrow*) is diagnostic. Although the tumor in this example is of low nuclear grade, the cells have a relatively high N/C ratio, and therefore this would be somewhat blue on low power.

cuboidal cells with round nuclei (Figure 13.13). This image is so pathognomonic that if you find it, you are basically done. You may also see psammoma bodies, hemosiderin-laden cells, and focal clear cells.

Papillary Adenoma

By definition, a papillary adenoma is a papillary and *non-clear cell* neoplasm of low nuclear grade and ≤ 15 mm in diameter.

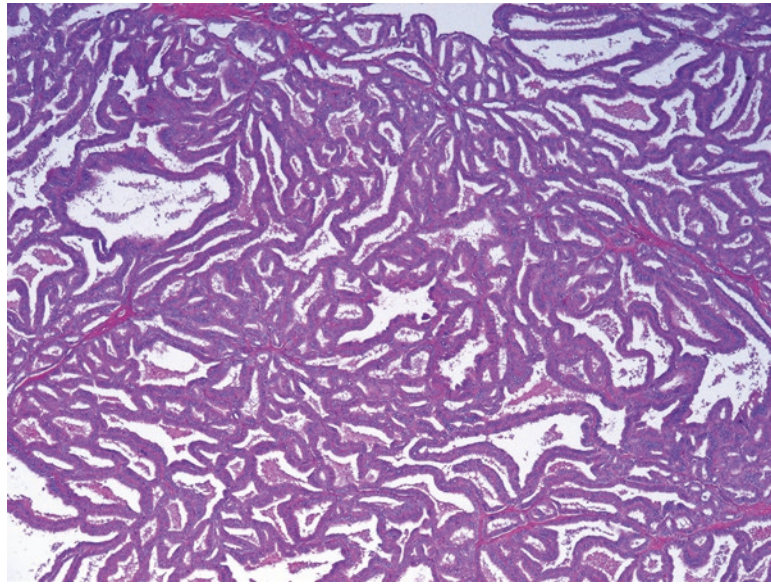


FIGURE 13.14. Tubulocystic carcinoma. This tumor consists of a spongy collection of dilated tubules lined by plump pink apocrine-looking cells with round nuclei.

Tubulocystic Carcinoma

This rare tumor is best described as a spongy collection of dilated tubules lined by fat pink apocrine-looking cells (Figure 13.14).

Collecting Duct Carcinoma

A collecting duct carcinoma is a high-grade tumor that arises in the medulla. It looks and acts much like an adenocarcinoma. The cytology is clearly malignant, there is a desmoplastic response, and it may stain for mucin and carcinoembryonic antigen. However, it is rare. Rarer still is the variant of collecting duct carcinoma found in sickle cell trait patients, the *medullary carcinoma*.

Acquired Cystic Kidney Disease-Associated RCC

Found in end-stage kidneys, this tumor is a grungy mix of oncocyctic cells with a bubbly microcystic architecture, hemorrhage, necrosis, and oxalate crystals.

Tumors with Blue Cells

When the tumor looks blue to the naked eye, the differential diagnosis includes the following:

Metanephric Adenoma

Metanephric adenoma is usually a 1× diagnosis (blue, indigo blue, lymph node blue). It is a circumscribed but nonencapsulated tumor of monotonous, small, tightly packed, dense blue cells (Figure 13.15). It has little or no cytoplasm. The patterns range from tiny tubules to serpiginous gland-like structures. If this looks like a Wilms tumor to you, you are an astute observer. The benign metanephric adenoma may be essentially a differentiated (mature) form of a pure epithelial Wilms tumor.

Wilms Tumor

Wilms tumors are unusual in adults. See the following discussion of the pediatric population.

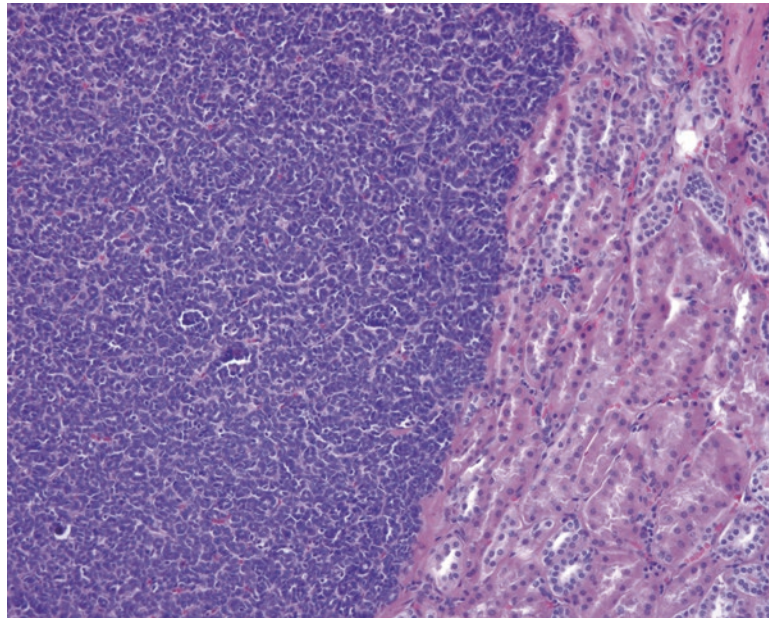


FIGURE 13.15. Metanephric adenoma. This benign tumor is the bluest of them all because of the very high N/C ratio of the cells. Here you can see tiny primitive blue tubules on the *left*, adjacent to the normal kidney on the *right*.

A Brief Introduction to the Pediatric Kidney

The most common pediatric renal tumor is Wilms tumor, or nephroblastoma, one of the small round blue cell tumors of childhood.

Definition of Key Terms in Nephroblastoma

- Nephrogenic rests: abnormally persistent foci of embryonal cells (small, round, and blue) that may develop into Wilms tumor, although most do not
- Blastema: sheets of undifferentiated embryonal cells in a Wilms tumor or the prototypical small round blue cells
- Anaplasia: unfavorable histology in a Wilms tumor, defined by large, hyperchromatic nuclei and abnormal mitotic figures (such as tripolar)

Wilms Tumor

Wilms tumor is defined by triphasic histology, which means you should see three components (Figure 13.16): blastema (undifferentiated, very blue), stroma (generally less cellular, more pink), and epithelium (blue like blastema but organized into tubules). One component may predominate. The tumor should be encapsulated; infiltration of the surrounding kidney suggests a hyperplastic nephrogenic rest. Histology is defined as favorable or unfavorable, based on the presence of anaplasia. Finding foci of anaplasia requires extensive sampling and eye-grinding hunting. A Wilms tumor may arrive at your bench post-chemotherapy. Chemotherapy changes include massive necrosis, fibrosis, histiocytes, and maturation of the immature elements. One common finding is maturation to skeletal muscle cells.

Wilms tumor, like renal cell carcinoma, can grossly resemble a multilocular cyst. This is called a *cystic partially differentiated nephroblastoma*. The three components are the same.

Other Pediatric Tumors

Congenital mesoblastic nephroma is a low-grade sarcoma that can resemble fibromatosis (classic type) or fibrosarcoma (cellular type). *Metanephric stromal tumor* is a spindle cell tumor that infiltrates and entraps native elements such as tubules and blood vessels. Other

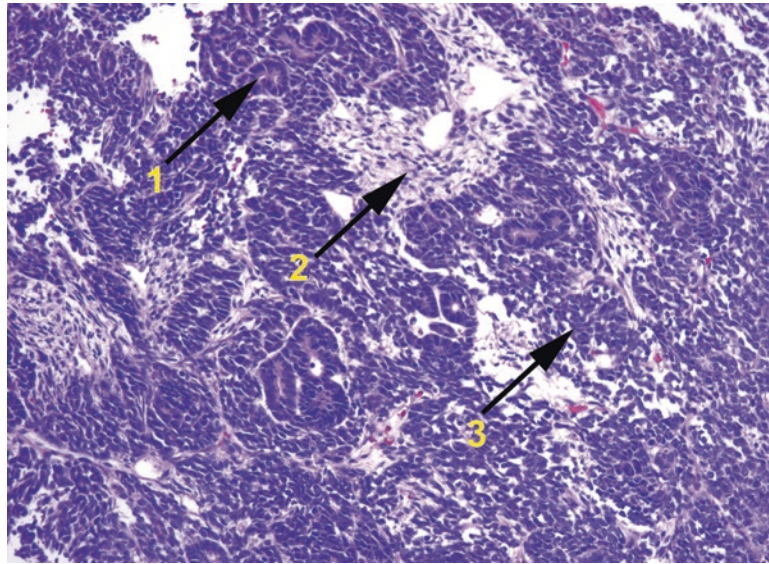


FIGURE 13.16. Wilms tumor. This small round blue cell tumor classically has three components: 1 epithelium, in which the cells form primitive tubules; 2 stroma, the mesenchymal component; and 3 blastema, the most primitive and undifferentiated component. Ratios may vary by tumor.

more aggressive tumors include *clear cell sarcoma* and *rhabdoid tumor*. Clear cell nomenclature, which is actually somewhat less than clear, is summarized below.

A Note on Clear Cell Features: In General (Adults and Children)

You know about *clear cell renal cell carcinoma* (classically positive for cytokeratins and EMA). Now you also know about the *Xp11 translocation carcinoma of the kidney*, which is clear cells on a papillary core and which is caused by translocations of the *TFE3* gene and will stain for TFE3. This same gene can be translocated in the soft tissues, in which case you get the TFE3+ *alveolar soft part sarcoma*, which may or may not be clear but does resemble renal cell carcinoma because of its delicate capillary network and alveolar architecture (hence the name). This soft tissue tumor may be confused with the *clear cell sarcoma of soft tissue*, formerly known as *melanoma of soft parts*. Like alveolar soft part sarcoma, it has an alveolar pattern and clear cells; however, it stains for the melanoma markers (S100, Melan-A, and HMB45). This tumor should not be confused with the pediatric *clear cell sarcoma of the kidney*, which looks like but is totally unrelated to the clear cell sarcoma of soft tissue and is negative for most markers, including S100, cytokeratin, and EMA. However, if you are in the kidney and you have a spindle cell lesion that is staining for HMB45 and Melan-A, you are most likely looking at an *angiomyolipoma*, which is a benign tumor having nothing to do with melanocytes but which does stain for the melanoma markers. Is this clear?

Medical Kidney (Non-neoplastic)

The subspecialty of medical kidney includes electron microscopy and immunofluorescence, methods that are beyond the scope of most surgical pathology practice. As a result, this chapter does not go into great detail on these non-neoplastic entities, except to put them into the very big picture. However, keep in mind that as a surgical pathologist, you will be expected to assess the background kidney in nephrectomy specimens for tumor. While you are not expected to go into as much detail as a nephropathologist, you need to be able to recognize common renal diseases. After all, when a patient is down one kidney, it becomes quite important to know if they have a systemic renal disease that may limit the function of the remaining kidney.

The four main compartments of the non-neoplastic kidney are the glomeruli, the tubules, the interstitium, and the vessels. The compartments are differentially affected by systemic diseases, toxins, and other insults. When evaluating kidney, you are looking for the following:

- In the glomeruli: the percentage of globally sclerosed glomeruli, hypercellularity (mesangial vs. endocapillary), inflammatory cells, the thickness of mesangial matrix, segmental sclerosis, hyalinosis, crescents, thrombi, and changes in the basement membrane of the capillary loops (especially by PAS and silver stains)
- In the tubules: acute and chronic inflammation in the epithelium or lumen, injury (epithelial vacuolization, necrosis, or sloughing), cellular or hyaline casts, Tamm-Horsfall protein accumulation, atrophy (dropout)
- In the interstitium: inflammation, fibrosis (especially by trichrome stain), edema
- In the arteries and arterioles: intimal thickening, hyaline deposits, emboli, thrombotic microangiopathy (fibrin thrombi, red blood cell fragments in capillary walls, fibrinoid necrosis)

Acute and Chronic Damage Patterns

Nephritic Presentations

Acute injury to the glomerulus (usually immune mediated) leads to a picture of *acute glomerulonephritis* (hematuria, proteinuria, oliguria, azotemia, edema, hypertension). Histologically, the glomerulus responds with increased cellularity, which includes mesangial cells, endothelial cells, and inflammatory cells. This is a *proliferative glomerulonephritis*, and in this setting you will also see an interstitial response (edema and inflammation) and red cell casts in the tubules. Causes of this acute injury include postinfectious glomerulonephritis, IgA nephropathy, and lupus.

Severe acute injury causes an even more proliferative response in the form of *cellular crescents*. These are collections of epithelial and inflammatory cells in Bowman's space, hugging the glomerulus, and they are an indication of severe glomerular injury. You may also see necrosis of the glomeruli, fibrin deposition, and disruption of the basement membrane. Clinically, this appears as a *rapidly progressive glomerulonephritis* (which is the symptoms of glomerulonephritis plus acute renal failure), and causes include anti-glomerular basement membrane nephropathy (Goodpasture's syndrome), vasculitis, and anything that can cause a proliferative glomerulonephritis (see above).

Most of the above diseases are *immune complex mediated*, so classification of the location and type of immune complex is key to subclassifying the disease. Immune complexes can be seen by electron microscopy as electron-dense areas, and their location with respect to the basement membrane is important. Immunofluorescence utilizes individual stains for IgG, IgM, IgA, and complement (C1q, C3), and their distribution also helps narrow the diagnosis. Most immune complex diseases have granular immunofluorescence staining, with the exception of anti-glomerular basement membrane disease, which has linear staining of the basement membrane.

Nephrotic Presentations

Injury that is limited to the *glomerular basement membrane* or the *podocytes* can produce a much more subtle picture. Destruction of the foot processes of the podocytes, which line the basement membrane, or disruption of the basement membrane itself, can lead to a leaky glomerulus that just shows up as proteinuria. Severe proteinuria and the subsequent edema and hypertension are called the *nephrotic syndrome*. Diseases in this category include minimal change disease, focal segmental glomerulosclerosis, membranous glomerulonephritis, and membranoproliferative glomerulonephritis. Many other nonprimary renal diseases can also produce this picture, including diabetes, amyloid, lupus, drugs, and infections.

Of the four primary renal diseases listed earlier, two (minimal change and focal segmental glomerulosclerosis) are not immune complex mediated. They have little or no increase in cellularity and no immunofluorescence findings. You should see evidence of foot process damage by electron microscopy but no deposits. However, membranous and membranoproliferative glomerulonephritis, which are immune mediated, show thickened and disrupted basement membranes, granular immunofluorescence staining, and ultrastructural deposits. Membranoproliferative glomerulonephritis also has an inflammatory cellular component, so it has an added hypercellular (*hyperproliferative*) picture as well as clinical evidence of inflammation (a nephritic picture in addition to the proteinuria).

Chronic injury to the kidney produces more of a sclerotic and scarring response, as in other organs. Chronically injured glomeruli become globally sclerotic and look like whorled amorphous pink blobs in the cortex. Chronically injured tubules become flattened, sparse, and dilated, surrounded by interstitial fibrosis and chronic inflammation. When these changes are extensive, you have end-stage kidney and chronic renal failure, and it can be impossible to figure out what the original injury was.

Most of the diagnoses listed earlier are *patterns of injury*. While they can be primary renal processes, they can also represent the kidney's response to systemic diseases. Infection, drugs, and lupus are all examples of systemic diseases that can cause more than one type of kidney damage.

Diabetes and *hypertension* are common, and both are hard on the kidney. Diabetic nephropathy includes thickened basement membranes and increased mesangial matrix; it is not immune complex mediated. The hemodynamic alterations of diabetes also predispose the kidney to glomerulosclerosis, which may be nodular (the Kimmelstiel-Wilson bodies) or eventually global (end-stage kidney disease). Hypertension causes vascular changes in the kidney, including intimal fibrosis of arteries and hyaline deposits in arterioles.

Tubular diseases include acute interstitial nephritis and acute tubular necrosis. Acute interstitial nephritis is reversible damage secondary to drugs and is often associated with eosinophils. Acute tubular necrosis is acute and severe damage to the tubules causing acute renal failure. It may be caused by ischemia or a toxin.

Transplant rejection occurs in at least three forms: acute humoral, acute cellular, and chronic. Each form has specific criteria and an associated grading system. The features to look for include the following:

- In humoral rejection: glomerulitis, tubular injury, margination of neutrophils, and C4d staining in the peritubular capillaries
- In acute cellular rejection: glomerulitis, interstitial inflammation, tubulitis, and intimal arteritis
- In chronic rejection: glomerulopathy (double contours in basement membrane), mesangial matrix increase, tubular atrophy, interstitial fibrosis, intimal thickening of arteries, and hyaline thickening of arterioles

These types of rejection need to be separated from recurrence of the original disease process, preexisting donor disease (often vascular), and cyclosporine toxicity (tubular injury).

The testis is not a common specimen. Resections in children or young adults may be due to a non-neoplastic condition such as torsion, which produces the relatively nonspecific picture of hemorrhage and/or ischemic necrosis. Occasionally in young children, undescended (cryptorchid) testes are removed because of an increased risk of developing germ cell tumors. There are also a few tumors that typically only occur in children. Most testicular tumors occur in men in their 20s–40s, although they can also occur in the elderly.

Normal Histology

The testis is composed of a tightly packed collection of tubules. In the prepubertal testis, the tubules are lined with spindly, radially arranged Sertoli cells and rare spermatogonia. After puberty, spermatogenesis begins, and the tubules are dominated by the developing spermatocytes. Maturation is completed near the lumen of the tubules, where you can see tiny sesame-seed-like spermatids (which grow tails to become spermatozoa). Polygonal pink Leydig cells in the interstitium produce testosterone (Figure 14.1).

Sperm leaves the testis via the rete testis (Figure 14.2), a collection of epithelial-lined slit-like channels at the hilum of the testis, which lead into the epididymis, which eventually feeds into the vas deferens. The epididymis is lined by a pseudostratified and ciliated epithelium (Figure 14.3).

Orchiectomy in Infants and Children

In the setting of an undescended testis, the testis may be removed to prevent the development of a germ cell neoplasm. The typical *cryptorchid testis* shows small atrophic seminiferous tubules, fibrosis, and widened interstitial spaces (Figure 14.4). A related finding is the “vanishing testis syndrome” in which, upon surgical retrieval of the undescended testis, there is nothing but a nub of fibrosis and dystrophic calcification attached to an epididymal remnant. These conditions are generally signed out descriptively.

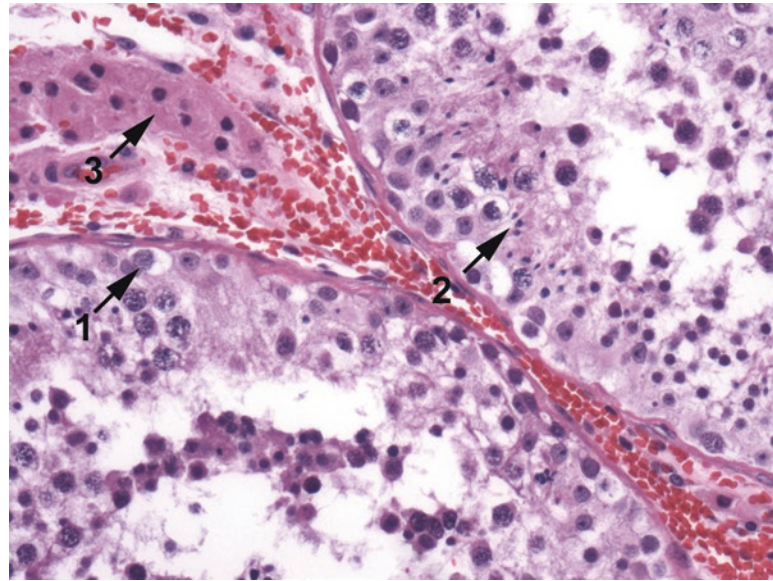


FIGURE 14.1. Normal seminiferous tubules. Large spermatogonia with clear cytoplasm are present at the tubule periphery (1). The developing spermatocytes have a wide range of morphologies, ending with the tiny spermatids (2), a marker of successful spermatogenesis. Plump pink Leydig cells are seen in the interstitium (3).

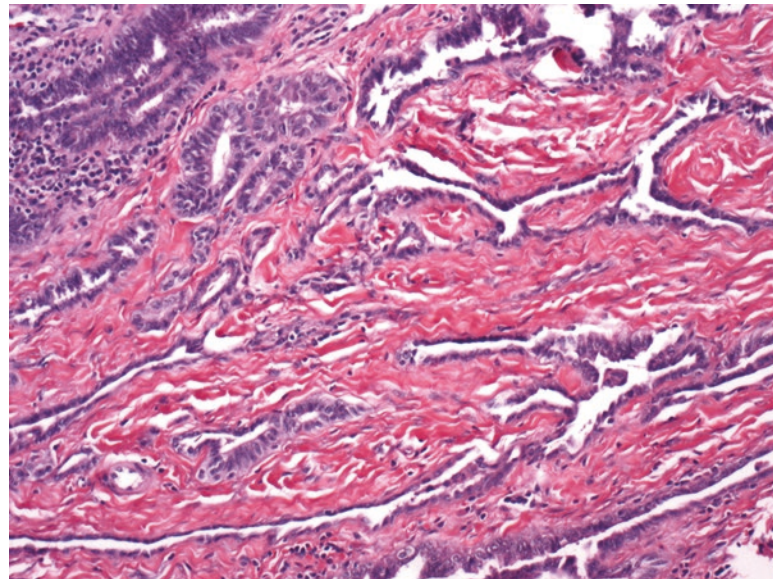


FIGURE 14.2. Normal rete testis. Slit-like spaces with cuboidal epithelium.

Infertility

A testis biopsy may be indicated in the workup of a persistent low sperm count (male infertility). From the pathologists' perspective, the options are the following:

- Aplasia (or Sertoli-only syndrome, a total lack of germ cells; Figure 14.5)
- Hypospermatogenesis (decreased spermatogenesis in most tubules)
- Maturation arrest (when there is partial maturation but no spermatids produced)
- “End-stage testis” (global sclerosis and atrophy, no functioning tubules)
- Normal spermatogenesis (implying a distal obstruction)

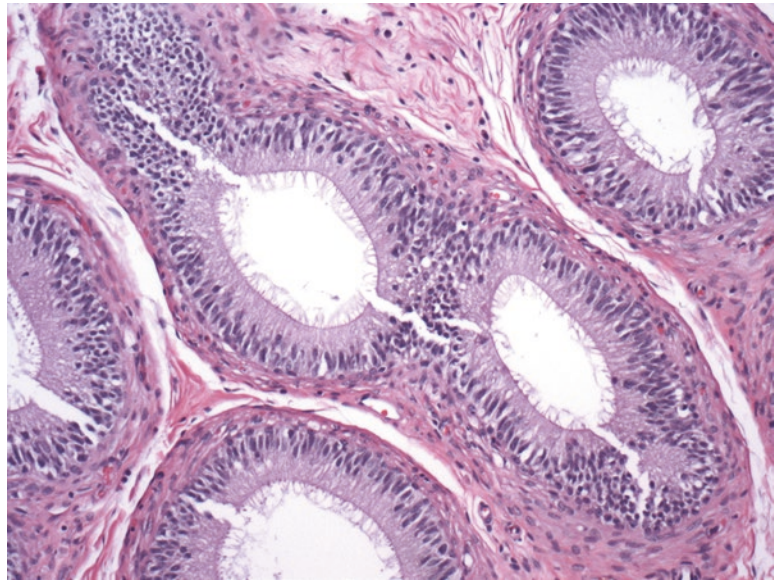


FIGURE 14.3. Normal epididymis. Columnar epithelium with cilia. This epithelium continues into the vas deferens.

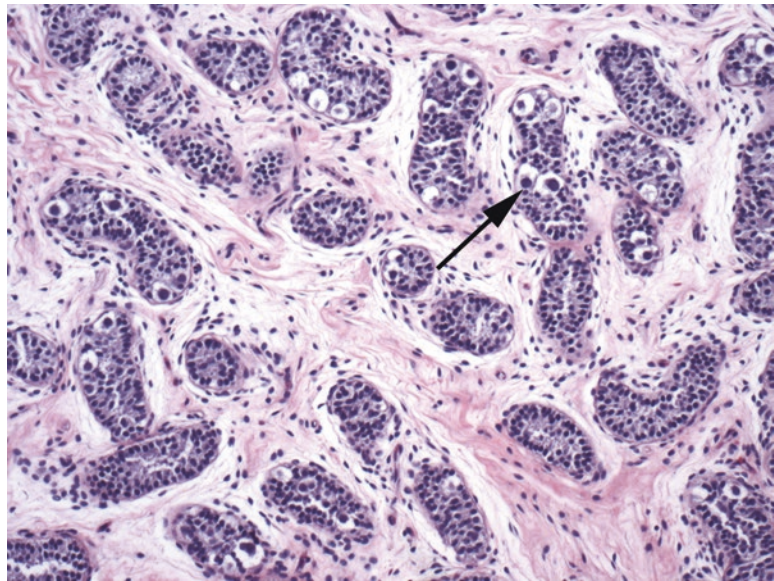


FIGURE 14.4. Cryptorchidism. In the infant testis, large dark spermatogonia are visible (*arrow*).

Tumors

Tumors of the testis are staged by their extent of invasion beyond the testis. If you imagine the testis as a lime, the outer green rind is the tunica vaginalis. Like the pleura, this is a mesothelial layer that has both a visceral side, on the testis, and a parietal side, lining the scrotal wall. As in the lime, which has a white pith underneath the green rind, under the tunica vaginalis is a fibrous layer called the tunica albuginea (“white membrane”). It is important to sample tumor that appears to erode into these layers.

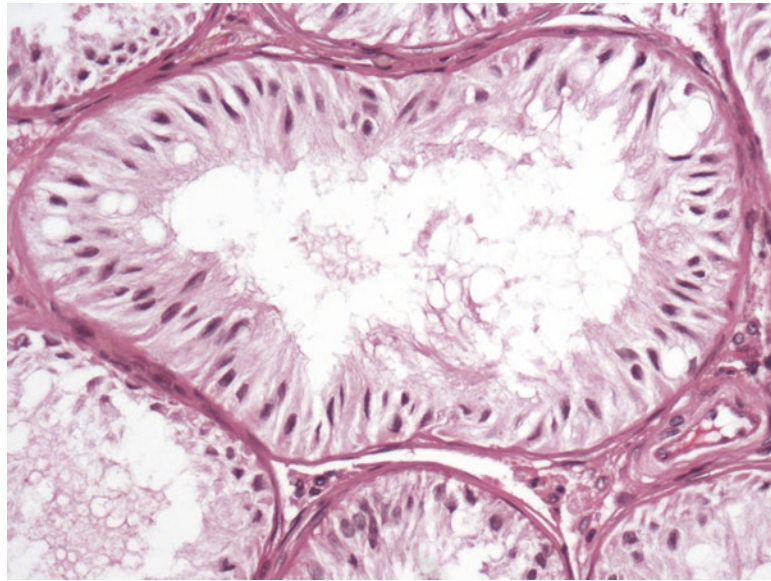


FIGURE 14.5. Sertoli-only syndrome in an adult. The tubules are lined with spindly Sertoli cells, and no germ cells are visible.

Infants and children	Young adults and adults	Older adults
Yolk sac tumor	Seminoma	Spermatocytic tumor
Teratoma, prepubertal type	Embryonal carcinoma	Lymphoma
	Choriocarcinoma	Sex cord stromal tumors
	Teratoma, postpubertal type	Seminoma
	Mixed germ cell tumor	

The vast majority of testicular tumors are of germ cell origin (Table 14.1). The remainder, aside from lymphoma, are tumors of mesothelial, epithelial, or connective tissue origin which will not be covered here.

Germ Cell Tumors

Germ cell tumors, which include seminoma, teratoma, yolk sac tumor, choriocarcinoma, and embryonal carcinoma, can all occur as pure tumors in and of themselves, but they do have a tendency to collide in adults, with the resulting mixture called a *mixed germ cell tumor* (MGCT). Here, they will be described individually, but remember that for any adult neoplasm you are trying to identify and quantify every component present.

These neoplasms are notorious for their ability to nearly completely regress in the testis, leaving behind mainly a fibrotic scar. This does not, however, mean that they have not already metastasized.

Seminoma

The seminoma is the most common germ cell neoplasm in adults, and the most likely to appear in pure form. It is usually a large nodular mass in the testis. Microscopically, it is poorly circumscribed and infiltrates in between tubules at the periphery. The histologic features (Figure 14.6) include the following:

- An array of large, round, coarse nuclei, non-overlapping and non-molding, suspended in a network of delicate cell membranes
- One to two prominent central nucleoli

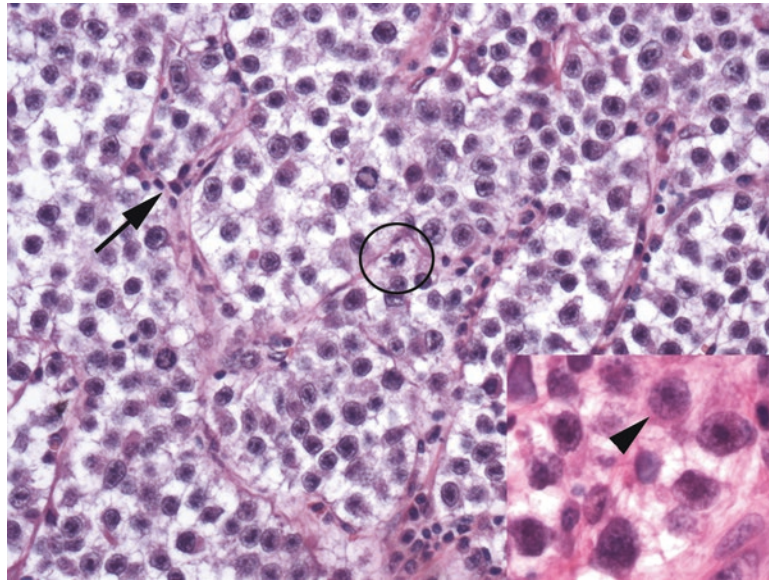


FIGURE 14.6. Seminoma. Delicate fibrovascular septae divide the cells into packets (*arrow*); collections of lymphocytes can be seen along the septae. The nuclei are widely spaced, with clear cytoplasm. Mitoses are common (*circle*). Nuclei have distinct nuclear membranes and prominent nucleoli (*arrowhead*).

- Associated inflammation, especially lymphocytes, granulomas, and fibrosis
- Delicate branching fibrovascular septa
- Surrounding germ cell neoplasia in situ (see below)

Seminoma has fairly monomorphic cells; at low power this uniformity can be deceptively bland. It may occur in pure form, but all tumors should be carefully sampled for other germ cell components (in which case it becomes an MGCT).

Germ Cell Neoplasia in Situ

Germ cell neoplasia in situ (GCNIS, also known as intratubular germ cell neoplasia) is essentially seminoma in situ, confined to the seminiferous tubules. It is actually very hard to identify for a beginner, as normal spermatogenesis creates some strange-looking cells. The easiest way to find GCNIS is to slowly scan the tubules at 4 \times , looking for areas that stand out as having scattered dark, or large, or fried egg-type cells. Another approach is to study the seminomatous cells in the main tumor and look for similar cells in the adjacent tubules. GCNIS may be as subtle as a few big cells in the tubule, spreading in pagetoid fashion, or as obvious as a lumen packed with malignant cells (Figure 14.7). GCNIS is associated with most germ cell tumors in the adult but is not seen in prepubertal teratoma, prepubertal yolk sac tumor, or spermatocytic tumor. Due to differences in behavior and genetics, the tumors associated with GCNIS (all of which are malignant) are grouped together in the WHO classification system.

Features that help distinguish spermatogonia from GCNIS are summarized in Table 14.2.

Spermatocytic Tumor

Many organ systems have low-grade, indolent, or better-differentiated versions of their neoplasms. This tumor, formerly named “spermatocytic seminoma” is the indolent seminoma in that it does not metastasize. It occurs in older men and has seminoma-like cells, except in three cell sizes: small, medium, and large. This tumor also lacks inflammation and PLAP positivity. It is not found in mixed germ cell tumors nor is it associated with GCNIS.

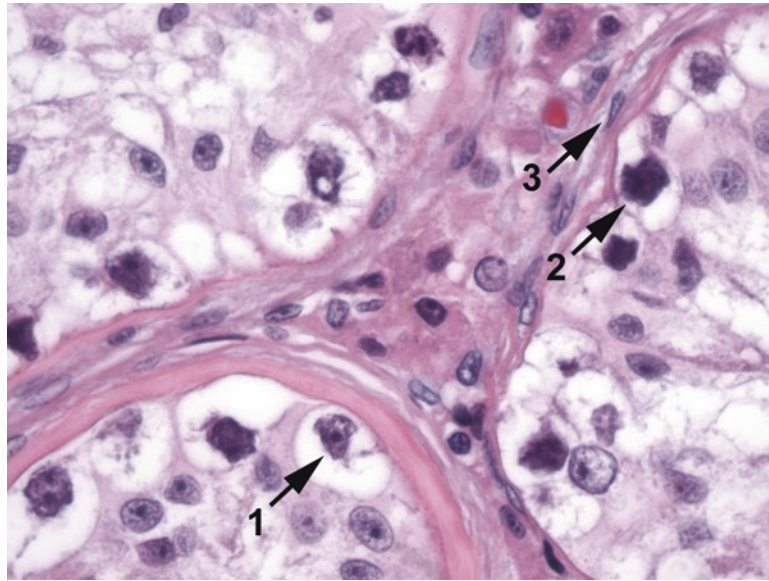


FIGURE 14.7. Germ cell neoplasia in situ. Large cells with clear halos of cytoplasm and prominent nucleoli are seen at the tubule perimeter (1). Other malignant nuclei appear hyperchromatic and solid (2). Compare the malignant cells to the euchromatin of nearby endothelial cells (3).

Spermatogonia	Germ cell neoplasia in situ
Clear cytoplasm	More abundant clear cytoplasm
Fine-grained chromatin (spermatogonia) or visibly condensed chromosomes (spermatocytes)	Coarse chunky chromatin
Smooth nuclear membrane, if any	Irregular nuclear membrane
Tiny nucleolus, if any	Prominent nucleolus
Mature into spermatids	Little to no maturation
Placental alkaline phosphatase (PLAP) negative	c-kit, OCT3/4, and (often) PLAP positive

Embryonal Tumor

Rare as a pure tumor, embryonal tumors are a common component of MGCT. Remember embryonal as the ugly one. The cells are very pleomorphic, with hyperchromatic, angular, overlapping, or molding nuclei and large nucleoli (Figure 14.8). It looks epithelioid, like a carcinoma, and is in fact keratin positive, treacherously. Fortunately it also stains for germ cell markers. The architecture is solid, glandular, or papillary.

Yolk Sac Tumor

Yolk sac tumor is the most common testicular neoplasm in children (in pure form), but in adults it is mostly only seen as a component of MGCT. In children, or in the prepubertal type, the tumor is not associated with GCNIS and tends to be less aggressive. Postpubertal-type tumors occur in postpubertal patients.

Yolk sac tumor, whether pre- or postpubertal, is famous for its many forms, especially microcystic and reticular (net-like). The pathognomonic finding is the Schiller-Duval body, a little glomeruloid form, but these are not always seen. The nuclei tend to be somewhat smaller and a little more regular than embryonal carcinoma yet more atypical than seminoma (Figure 14.9). When found next to embryonal carcinoma, these areas look hypocellular and myxoid in comparison to the large epithelioid embryonal cells.

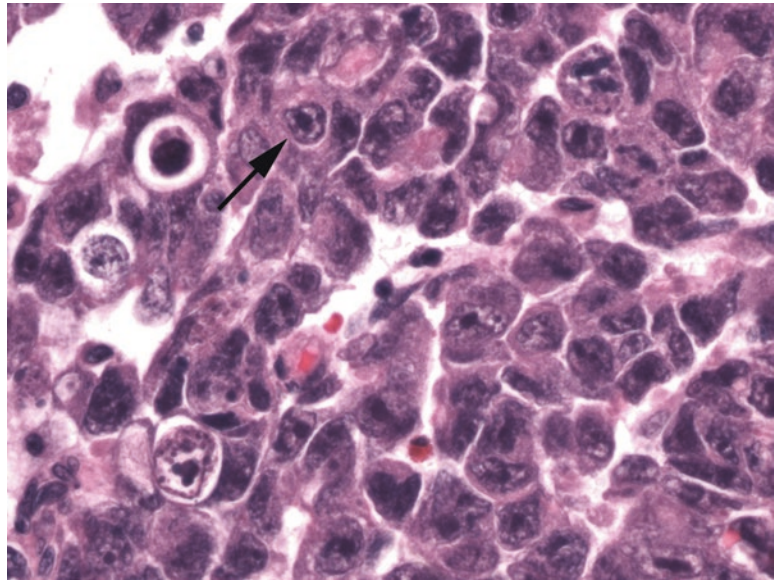


FIGURE 14.8. Embryonal carcinoma. Large epithelioid cells with pleomorphic nuclei grow in sheets. Unlike in seminoma, the cytoplasm is dense, and the nuclei have irregular shapes and sizes, some showing nuclear molding. Many have coarse chromatin with dark nuclear membranes and prominent nucleoli (*arrow*).

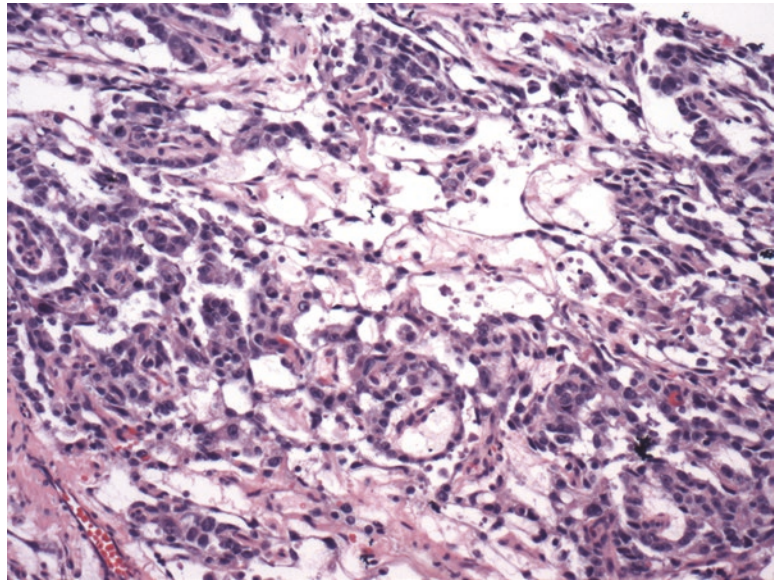


FIGURE 14.9. Yolk sac tumor. The cells of yolk sac tumor often appear more bland than other germ cell tumor types. The cells are cuboidal, with pink cytoplasm, and have a tendency to pull apart into a microcystic pattern (shown here).

Choriocarcinoma

Choriocarcinoma is a rare tumor, especially in pure form. Like the placental tumor, it is characterized by two cell types (cytotrophoblast and syncytiotrophoblast), lots of blood, and human chorionic gonadotropin (hCG) production. Also like the placenta, this tumor is very good at invading blood vessels, and widespread metastases are common. Syncytiotrophoblasts, the multinucleated giant cells that stain for hCG, can show up in other germ cell tumors; this does not make them choriocarcinomas. The cytotrophoblasts resemble embryonal carcinoma, but the nuclei are smaller and not quite so pleomorphic, and the cytoplasm is pale.

Teratoma

A teratoma (from the Greek for “monster tumor”) is a neoplasm composed of elements of the three primitive germ layers: ectoderm (skin, central nervous system), mesoderm (cartilage, bone), and endoderm (gut, viscera). Not all layers must be present, and tumors limited to the ectodermal component, either with keratinized skin or skin plus hair and adnexal glands, are types of benign “monodermal” teratomas called *epidermoid* or *dermoid cyst*, respectively.

Prepubertal-type teratomas are those found primarily in kids and do not have GCNIS, atypia, or a germ cell tumor component. Prepubertal teratomas are always considered benign, even if immature elements are present (unlike in teratomas in females). In contrast, in postpubertal males, teratomas are almost always malignant, regardless of the presence of mature or immature tissues, and are usually seen in the context of mixed germ cell tumors. Rarely, teratomas can develop secondary cancers, such as carcinomas, sarcomas, or small round blue cell tumors.

Sex Cord Stromal Tumors

The sex cord stromal tumors include Sertoli cell and Leydig cell tumors. They are not germ cell neoplasms and are usually benign. They resemble their normal counterparts, so a tumor of oncocytic pink cells with very round nuclei is likely to be a Leydig cell tumor (Figure 14.10), and a collection of primitive tubules lined with spindly cells and oval nuclei is likely to be a Sertoli cell tumor (Figure 14.11). In both tumors, approximately 10 % behave badly, but there are no hard criteria by which to predict malignancy. The usual rules apply: atypia, mitotic rate, necrosis, vascular invasion, and invasion beyond the testis all suggest poor prognosis.

Lymphoma

While uncommon in the testis, lymphoma is always in the differential diagnosis when sheets of discohesive malignant cells are present. Lymphoma can look like seminoma, yet the cells are not as homogeneous. The usual type is diffuse large B cell lymphoma, which is CD20-positive cells with large nuclei, often with vesicular chromatin and large nucleoli (Figure 14.12). Lymphoma occurs in an older age group than seminoma and should not have any GCNIS.

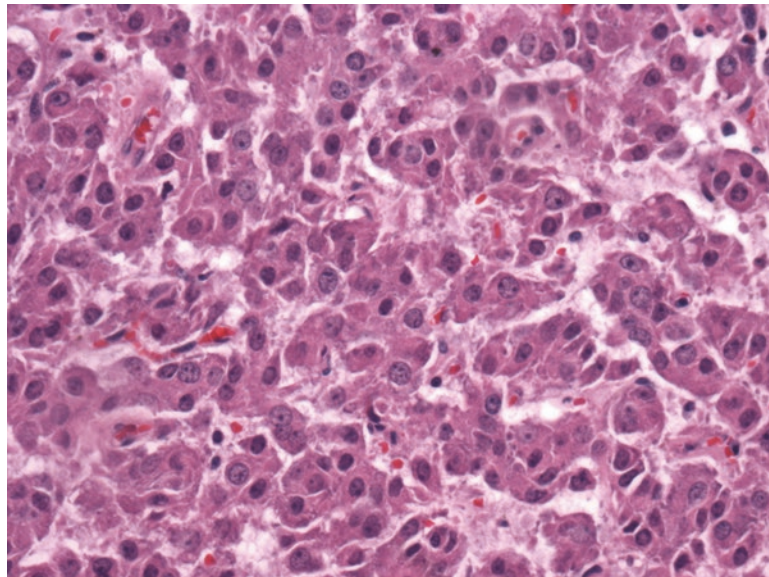


FIGURE 14.10. Leydig cell tumor. These neoplasms are reminiscent of oncocytomas in other sites. Most are benign.

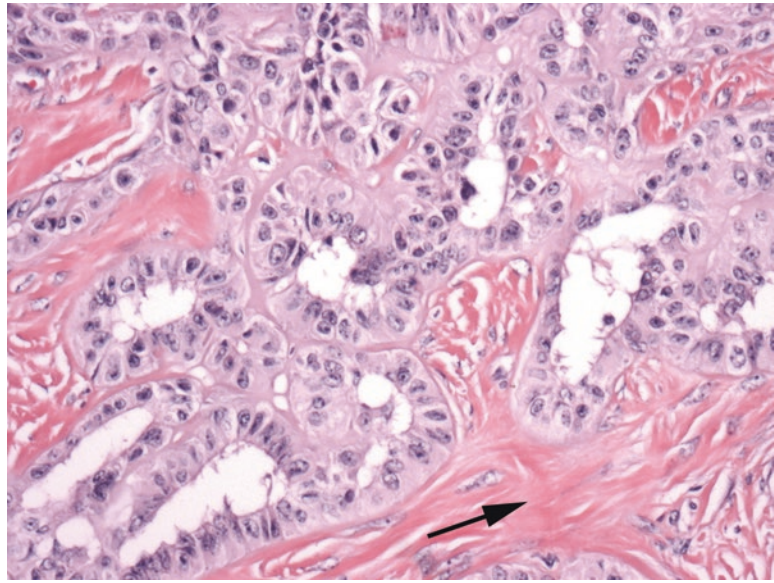


FIGURE 14.11. Sertoli cell tumor. This tumor attempts to recreate the seminiferous tubules. The stroma may become hyalinized (*arrow*).

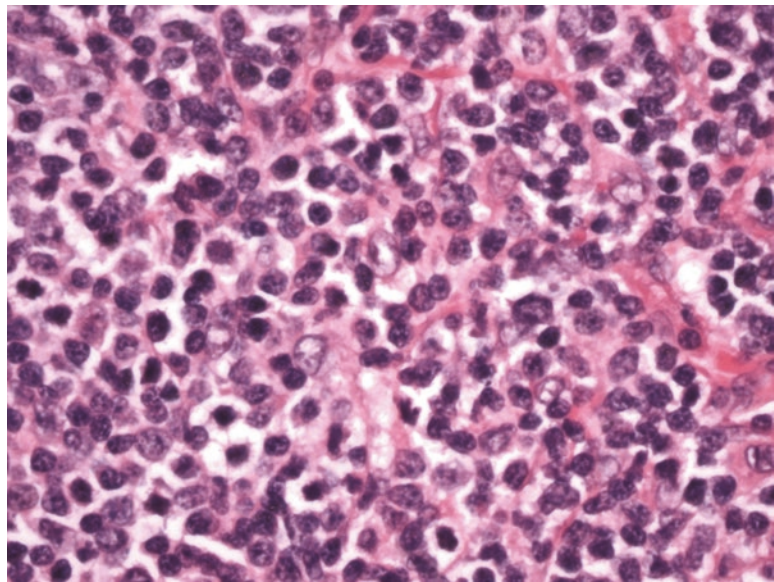


FIGURE 14.12. Diffuse large B cell lymphoma. The main histologic feature is sheets of discohesive tumor cells. Nuclear chromatin is chunky.

North of the Testis

All of the germ cell tumors can also arise outside of the testis in midline sites (i.e., sacrum, mediastinum, skull base, or pineal gland). A germ cell tumor in the brain is called a *germinoma*. These neoplasms can also occur in the female ovary. A seminoma occurring in the ovary is called a *dysgerminoma*. Yolk sac tumors, embryonal carcinomas, and teratomas can occur in ovary. Choriocarcinoma is more commonly associated with placental tissue in women but can also arise in the ovary. Sex cord stromal tumors also arise in women, usually of the thecoma and granulosa cell groups, but Sertoli and Leydig cell tumors can also develop. Strangely, you can also rarely see granulosa cell tumors in the testis. In fact, when presented with a tumor in the testis or ovary that looks like nothing you recognize, the sex cord stromal tumors are a good place to start.

The ovary is a fairly straightforward organ as far as the pathologist is concerned. Find tumor; identify tumor. No messing around with non-neoplastic pathology, margins, depth of invasion, reactive lesions, and so on. If it looks malignant, it probably is.

Normal Histology and Definitions

Surface epithelium: essentially a mesothelial lining. It is easily rubbed off the surface, so you do not always see it.

Stroma: the ovarian stroma is blue and spindly, with short, crisscrossing fascicles. Most of the cells in the stroma are fibroblasts (Figure 15.1).

Sex cord cells: the hormone-secreting supporting cells of the ovary, the thecal cells and granulosa cells. The thecal cells, under luteinizing hormone (LH) stimulation, secrete androgens, and the granulosa cells, under follicle stimulating hormone (FSH) control, convert androgens to estrogen. Together they nurture an oocyte to ovulation. These cells are analogous to Sertoli and Leydig cells in the testis.

Follicles: characterized by a halo of thecal cells outside a ring of granulosa cells (Figure 15.1), all surrounding the giant oocyte (germ cell). In developing follicles, the granulosa cells form Call–Exner bodies, rosettes of granulosa cells surrounding pink globules.

Luteinized: similar to “decidualized,” luteinized indicates cells that have become plump with abundant pink cytoplasm.

Corpus luteum: a newly ovulated follicle (Figure 15.2). The capsule of luteinized granulosa cells collapses in on itself, becoming undulating, and there is associated hemorrhage. The corpus luteum produces progesterone until (and if) the placenta takes over. If there is no pregnancy, it involutes.

Corpus albicans: the former corpus luteum ultimately hyalinizes to form cloud-shaped pink islands in the ovary, the scars of old follicles (Figure 15.2).

Walthard rests: benign nests of transitional (urothelial)-type epithelium in the ovary and fallopian tube.

Rete ovarii: analogous to the rete testis, rete ovarii are rudimentary gland spaces located in the hilum of the ovary. They are angulated, slit-like spaces with a low cuboidal epithelium (Figure 15.3). Do not mistake them for cancer.

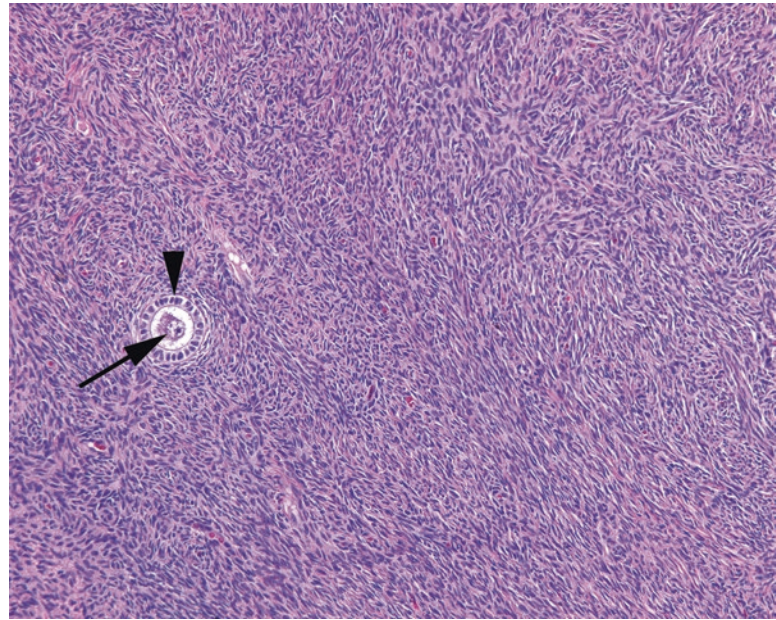


FIGURE 15.1. Ovarian stroma with follicle. Typical ovarian stroma is blue and cellular, with a vaguely fascicular or storiform pattern. A small primary follicle is seen with the central oocyte (*arrow*) and a ring of granulosa cells (*arrowhead*).

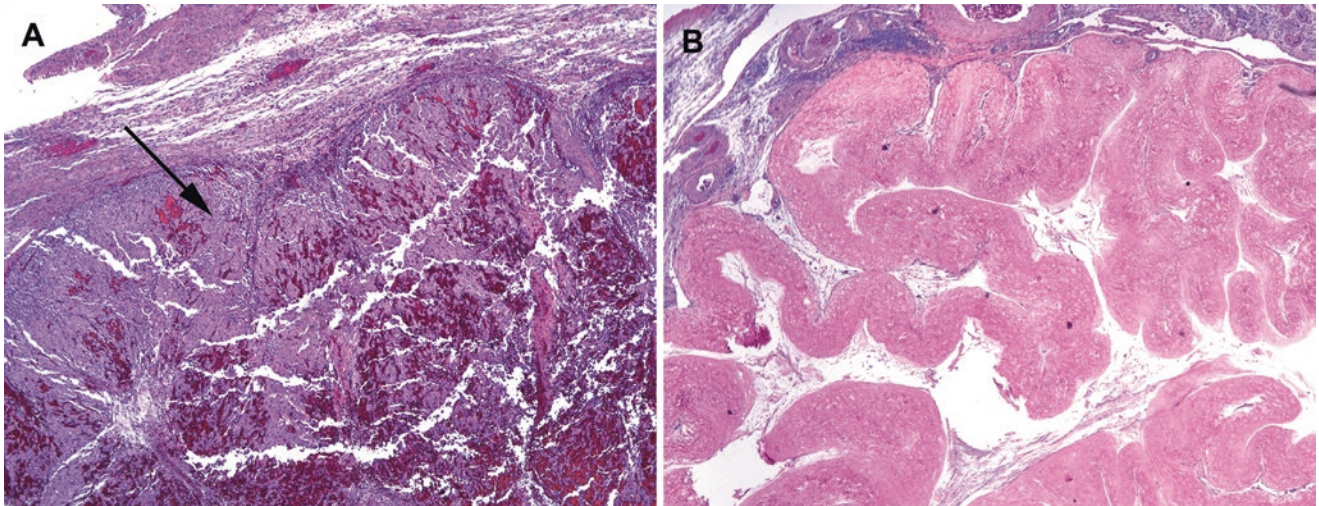


FIGURE 15.2. (a) Hemorrhagic corpus luteum, with undulating layers of luteinized granulosa cells (*arrow*) and associated blood. (b) A corpus albicans, the remnant of a prior corpus luteum.

Follicle cyst: a cyst lined with the normal components of the follicle, the granulosa cells, and the thecal layer (Figure 15.4). A similar lesion is the hemorrhagic corpus luteum cyst, which is a blood-filled corpus luteum.

Inclusion cyst: a simple cyst lined with a cuboidal, columnar, or ciliated epithelium, often budding inward from the ovarian surface (Figure 15.4). When small, these can be called surface inclusion cysts. However, if they are large, they are best referred to as serous cystadenomas (see below).

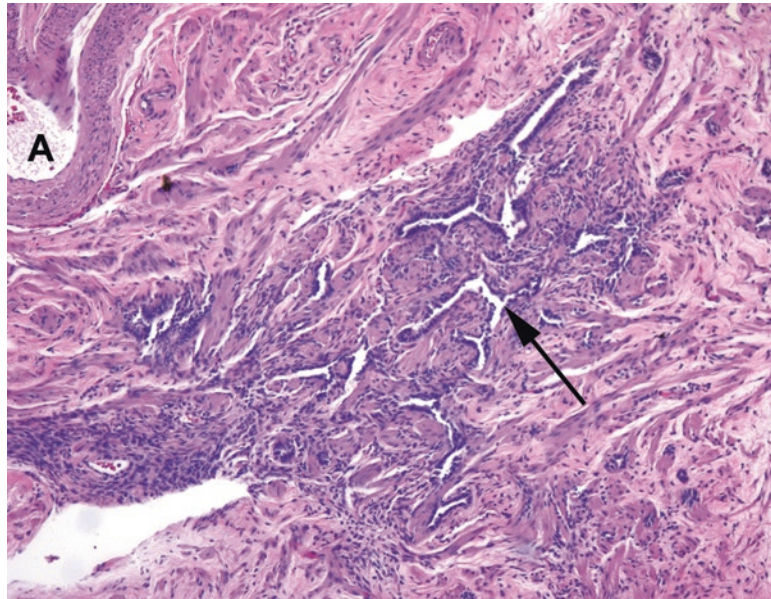


FIGURE 15.3. Rete ovarii. This vestigial structure is found at the hilum of the ovary, adjacent to large arteries (A) and veins. The rete consist of slit-like channels with a cuboidal cell lining (*arrow*).

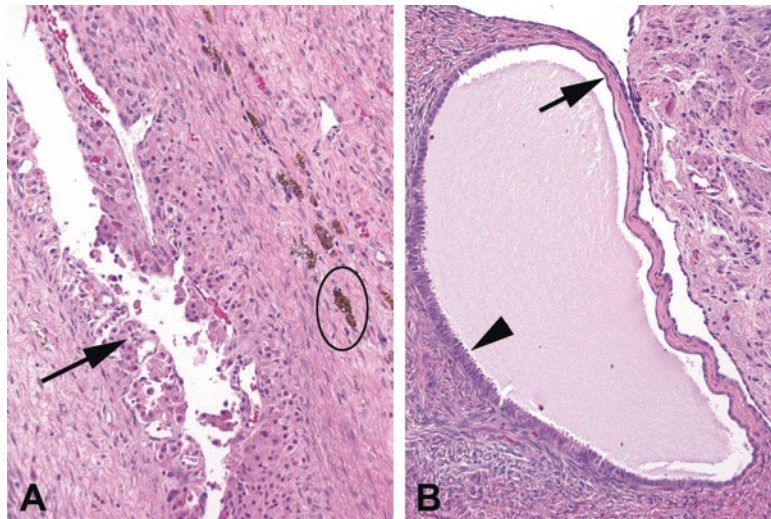


FIGURE 15.4. Follicular cyst versus inclusion cyst. (a) A follicle cyst is lined by luteinized cells, similar to those seen in the corpus luteum (*arrow*). There is adjacent hemosiderin (*oval*). (b) An inclusion cyst may be lined by an attenuated epithelium, similar to the surface epithelium (*arrow*), or may show tubal metaplasia (*arrowhead*).

Neoplasms

For each cell type defined above (and then some), there are families of neoplasms that can arise. Table 15.1 lists the broad categories of neoplasms that occur in the ovary. Those in shaded boxes are rare enough that we will not talk about them here.

TABLE 15.1. Neoplasms of the ovary.

Surface epithelial tumors	Germ cell tumors	Sex cord stromal	Metastases
Serous	Teratoma	Fibroma	Gastrointestinal
Mucinous	Dysgerminoma	Thecoma	Pancreatic
Endometrioid	Yolk sac	Granulosa cell tumor	Breast
Clear cell	Choriocarcinoma	Sertoli cell tumor	Others
Brenner	Embryonal carcinoma	Leydig cell tumor	
		Sertoli–Leydig cell tumor	

Shaded entries are rare tumors that are not discussed in this chapter. See Chapter 14 for illustrations of the germ cell neoplasms

TABLE 15.2. Five types of epithelial neoplasms. Within each column, the approximate frequency of benign, borderline, and malignant is listed.

	Serous	Mucinous	Endometrioid	Clear cell	Brenner
Benign	60%	80%	Rare	Rare	>90%
Borderline	15%	15%	Rare	Rare	Rare
Malignant	25%	<5%	>95%	>95%	5%

Epithelial Neoplasms

Epithelial neoplasms are by far the most common tumors of the ovary and come in three strengths: benign, borderline, and malignant. Benign tumors do not metastasize, malignant ones do, and borderline tumors may recur, spread intraperitoneally, or rarely metastasize. The nomenclature is as follows:

Adenoma: an adenoma is a benign epithelial proliferation. When cystic, as they often are, it is a *cystadenoma*. If biphasic with a secondary fibrous stromal component, it is an *adenofibroma*. If all three, it can be called a *cystadenofibroma*. Histologically, the cystadenomas are simple or multilocular cysts with a simple monolayered epithelial lining.

Borderline tumor (atypical proliferative tumor): borderline lesions have an increasing epithelial complexity over the adenomas. Their epithelium begins to ruffle up in papillary fronds and may “ruffle down” into the stroma in a way that looks similar to invasion. However, they do not cross the basement membrane, do not invade the stroma, and do not induce a desmoplastic reaction. Serous borderline tumors can shed cells into the peritoneum, which may stick onto other organs and begin to grow. However, if they do not actually invade, they are called implants, not metastases. True invasion indicates a metastasis, not an implant.

Carcinoma: carcinomas commonly present as combination cystic/solid tumors. You may hear cystic tumors called *cystadenocarcinomas*, but there is not a significant clinical difference between calling something a carcinoma and a cystadenocarcinoma, so the latter term is falling out of use. These can be divided into low- and high-grade carcinomas, but all types can metastasize.

Carcinosarcoma: a carcinosarcoma is a carcinoma with a sarcomatous stroma—it is a true biphasic malignancy. In the gynecologic tract, these are also called *malignant mixed Mullerian tumors* or MMT. An *adenosarcoma* would be a benign epithelial neoplasm in a sarcomatous stroma, which is rare.

Within the surface epithelial group, there are five flavors of epithelial neoplasms. Each type can be subdivided into benign, borderline, or malignant, as shown in Table 15.2.

Serous Tumors (most common: now divided into low grade and high grade)

Serous tumors are those in which the epithelial lining consists of cuboidal or columnar cells with pink nonmucinous cytoplasm; ciliated tubal-type epithelium may be seen as well. The fluid in a cystic tumor will be watery, or serous, hence the name. Low-grade serous carcinomas (LGSC) are neoplasms which progress along a slow pathway to carcinoma, from

adenoma to borderline tumor to carcinoma. They have KRAS or BRAF mutations, but not p53 mutations. Their genotype is fairly stable. As a result, their nuclei are fairly uniform, which is part of what distinguishes LGSC from high-grade serous carcinoma (HGSC). They likely arise from inclusions of the ovarian surface epithelium.

High-grade serous carcinomas, on the other hand, are genetically, clinically, and histologically distinct from LGSC. These aggressive tumors appear to arise from fallopian tube epithelium, and generally present at a high stage due to their tendency to spread from even tiny tumors. These carcinomas have p53 mutations and marked genetic instability and show significant nuclear atypia. They are associated with BRCA mutations, and in fact, in prophylactic removal of the tubes and ovaries in BRCA patients, the entire fallopian tubes and fimbria must be submitted to exclude tiny foci of serous tubal intraepithelial carcinoma (STIC).

Cystadenoma: cystadenomas are simple or multilocular cysts lined by a tubal-like epithelium with columnar and/or ciliated cells. They can become huge, but the lining remains simple. Serous cystadenofibromas are also common.

Borderline tumor (atypical proliferative serous tumor): borderline tumors have increasingly complex papillary fronds, looking grossly granular, resembling cauliflower. The papillary pattern is characterized by treelike branching of papillae with fibrovascular cores (Figure 15.5). However, the epithelium lining the papillae is usually a thin layer, without significant atypia. When the papillae acquire secondary epithelial proliferations, which are fingers of epithelial cells not supported on a fibrovascular core, this is called *micropapillary pattern* (the medusa head look; Figure 15.6). Over 5 mm of confluent micropapillary pattern upgrades this to a noninvasive LGSC.

Noninvasive low-grade serous carcinoma: this is a tumor characterized by the micropapillary growth pattern of LGSC, but confined to the cystic cavity, without stromal invasion. This perplexing concept of a noninvasive carcinoma is somewhat like the papillary urothelial carcinomas of the bladder or the papillary carcinomas of the breast. Psammoma bodies are common.

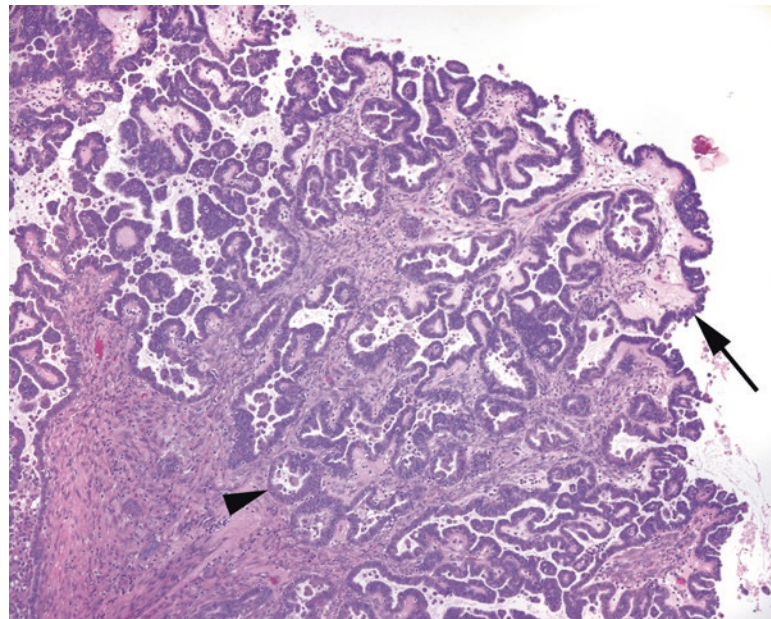


FIGURE 15.5. Borderline serous tumor. The epithelial lining is composed of serous, or nonmucinous, cells (*arrow*). The overall architecture is quite complex, with papillary branching and invaginated folds that should not be mistaken for invasion (*arrowhead*). However, the epithelial component is mostly a monolayer.

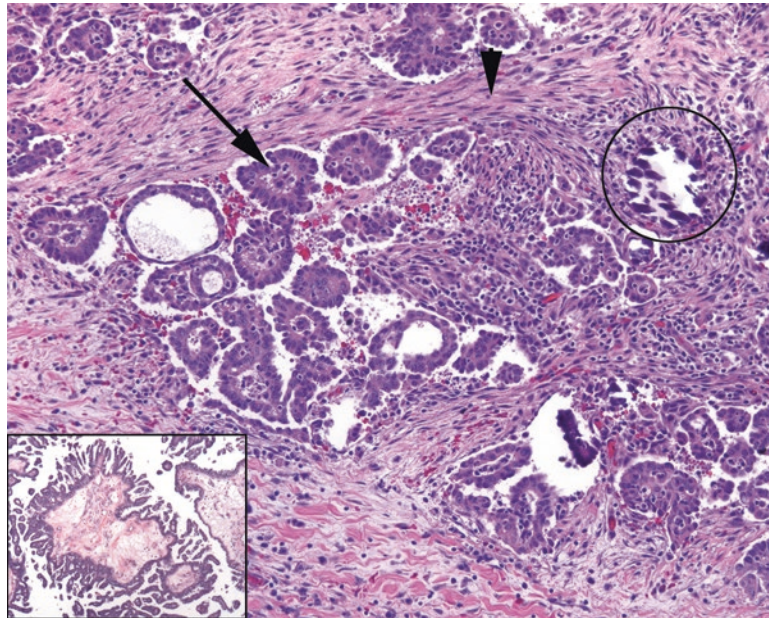


FIGURE 15.6. Micropapillary serous carcinoma. When invasive, micropapillary serous carcinoma looks like tiny florets of cells (*arrow*) in a desmoplastic stroma (*arrowhead*). Psammoma bodies are common (*circle*). *Inset:* the medusa head, or micropapillary, pattern is indicative of micropapillary serous carcinoma. Compare the epithelial micropapillae to the simple epithelium of the borderline tumor (see Figure 15.5).

Low-grade serous carcinoma: the presence of stromal invasion, either in a borderline tumor or a noninvasive LGSC, upgrades the tumor to simply LGSC. True invasion into the stroma can be identified by the micropapillary invasion pattern: small nests of tumor cells with their nuclei pointing outwards like flower petals, sitting in an unlined cleft in the stroma (Figure 15.6).

Implants: implants are the presence of serous tumor foci outside of the ovaries, such as in the omentum. By definition, an implant is not a metastasis, and it should not show evidence of stromal invasion as it is defined above. However, the presence of implants will increase the stage of the tumor (paradoxically, ovarian borderline tumors are given a T stage, despite not qualifying as an actual carcinoma). If stromal invasion is present, the “implant” is actually a metastasis, and the “borderline” graduates to a LGSC.

High-grade serous carcinoma: this tumor has no known premalignant form. The “in situ” lesion in the fallopian tubes, the STIC, is not really a carcinoma in situ as it is capable of widely disseminating in the belly. The tumor is typically solid with slit-like spaces, although papillary architecture mimicking the LGSC is also common. The nuclei are mitotically active, apoptotic, pleomorphic, and dark (Figure 15.7).

Mucinous Tumors

Mucinous tumors are those with mucinous and/or intestinal-type cytoplasm, such as what you might see in the endocervix, stomach, or colon. Note that in the ovary, the diagnosis of mucinous carcinoma does *not* imply nests of epithelial cells floating in extravasated mucin, as it does in other organs. In the ovary, mucinous simply describes the type of cell found in the tumor. Mucinous carcinomas are notorious for showing a full spectrum of grades, from areas that look like cystadenoma to areas that are clearly carcinoma. For this reason, extensive sampling is mandatory in mucinous tumors.

Cystadenoma: cysts (often multilocular) are lined with fairly flat mucinous epithelium, although simple tubules and papillae are acceptable.

Borderline tumor (atypical proliferative tumor): like in serous tumors, a mucinous tumor graduates to borderline when it acquires a more complex epithelial lining, with pseudostratified nuclei and papillary architecture (Figure 15.8). The cells may be gastric foveolar type,

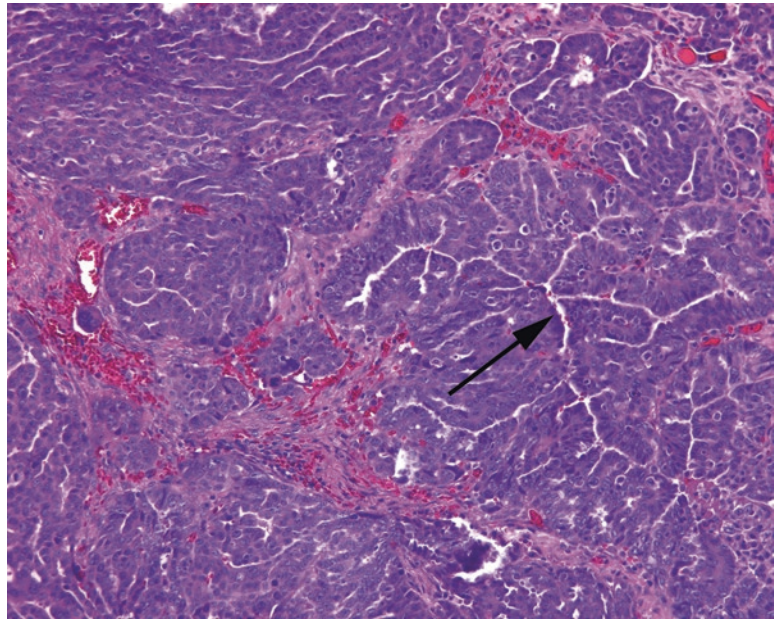


FIGURE 15.7. High-grade serous carcinoma. This tumor is shown invading the stroma. The cells are pleomorphic and dark, with prominent nucleoli, and grow in solid nests with slit-like spaces (*arrow*).

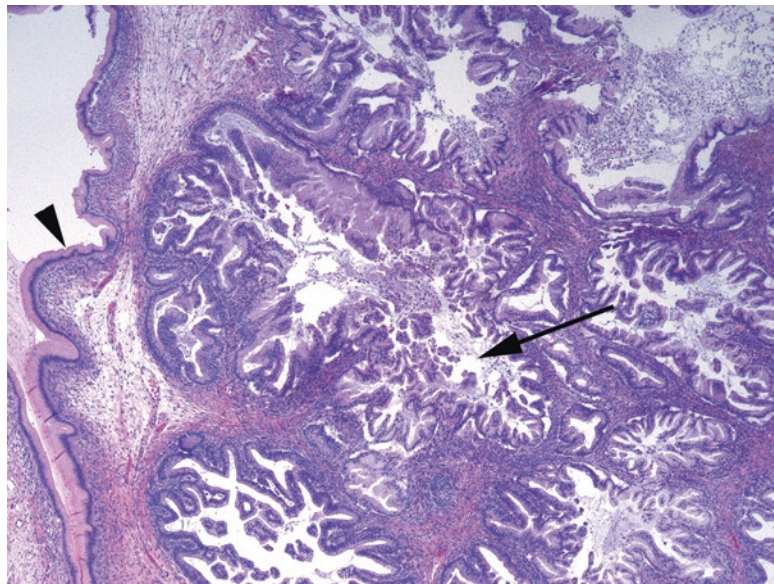


FIGURE 15.8. Borderline mucinous tumor. Although parts of the tumor resemble cystadenoma (*arrow-head*), the adjacent epithelial proliferation shows complexity and epithelial tufting (*arrow*). As with the borderline serous tumor, invaginations into the stroma are not necessarily invasion.

intestinal type with goblet cells, or even Paneth cells. Like the serous borderline tumor, it is possible to have intraepithelial carcinoma without stromal invasion. However, remember that metastases to the ovary can masquerade as borderline tumors.

Carcinoma: primary mucinous carcinoma of the ovary is uncommon. As mucinous tumors are usually unilateral and low stage, the presence of bilateral disease strongly implies a metastasis from elsewhere. Immunohistochemistry can help.

Endometrioid Tumors

Endometrioid tumors are those which replicate endometrial glands. In practice, you will likely only see endometrioid carcinomas, as the benign and borderline tumors are rare. Carcinomas are histologically identical to, and graded using the same FIGO three-tiered system as, the endometrioid carcinomas of endometrium.

Adenoma: Q—how is endometrioid adenoma different from endometriosis? A—it has no endometrial stroma. Also, these adenomas are rare. Endometriosis is common.

Carcinoma: Endometrioid carcinomas, like those in the uterus, have tubular to cribriform glands and villous structures (Figure 15.9). They may arise within endometriosis, or be found along with endometriosis, and a concurrent endometrial carcinoma is not uncommon. High-grade endometrioid carcinomas may be difficult to separate from high-grade serous.

Clear Cell Tumors

Carcinoma: clear cell carcinomas consist of clear cells with marked nuclear atypia. The tumor cells may be arranged in small tubules, dilated glands, nests, or papillae, but unlike serous carcinoma, they tend to appear in a monolayer, without the stratification of nuclei seen in other high-grade tumors (Figure 15.10). These are by definition high grade and, like endometrioid carcinoma, are also associated with endometriosis.

Brenner Tumors

Adenomaladenofibroma: a Brenner tumor is an adenoma of urothelial-type epithelium, possibly arising from Walthard rests. It is characterized by nests of urothelial epithelium in a fibrous stroma (Figure 15.11). There may be a mucinous layer surrounding a central lumen in each nest. Brenner tumors may also be found within a mucinous tumor.

Malignant Brenner tumors: malignant Brenner tumors are invasive urothelial or squamous carcinomas which arise in association with a benign Brenner tumor (which excludes a metastasis).

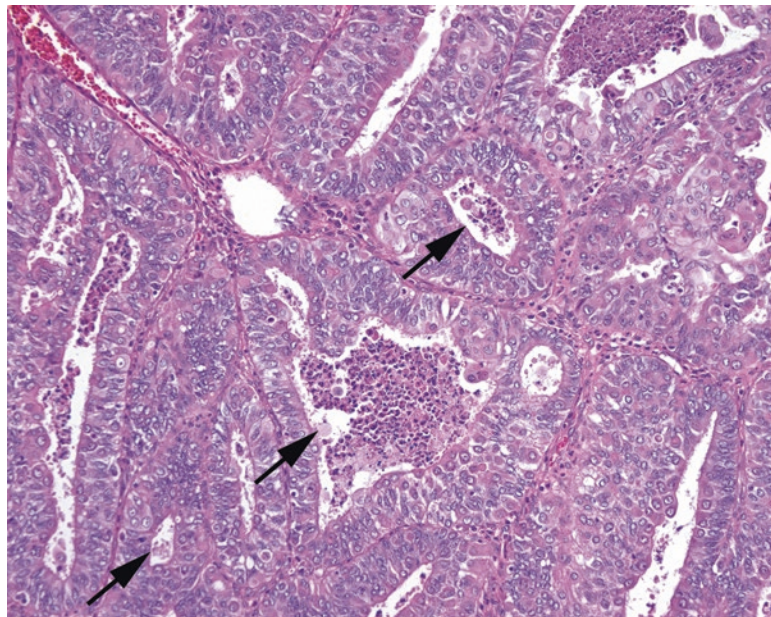


FIGURE 15.9. Endometrioid carcinoma. The nuclei are cleared out and pleomorphic, like endometrioid carcinoma of the endometrium. Distinct glandular spaces are visible (*arrows*), some with central necrosis.

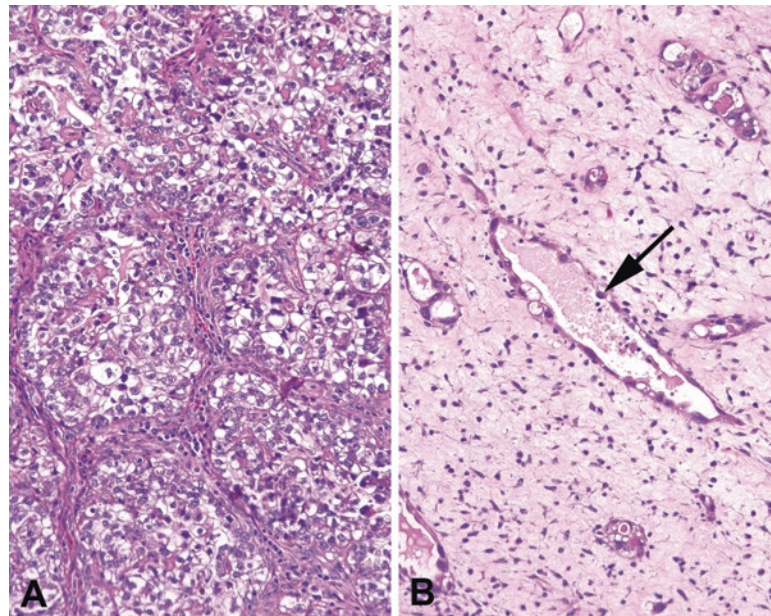


FIGURE 15.10. Clear cell carcinoma. (a) In this field, nests of clear cells are seen separated by fibrovascular septa. (b) A less cellular area of the same tumor shows vessel-like spaces lined by atypical cells that protrude into the lumen in hobnail fashion (*arrow*).

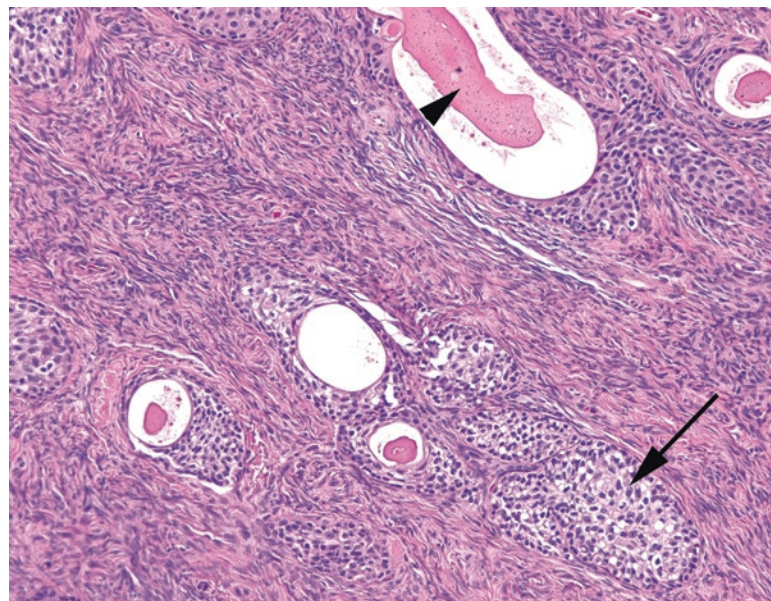


FIGURE 15.11. Brenner tumor. Nests of urothelial-type epithelium (*arrow*) in a fibrotic stroma are typical. Some form gland-like spaces with pink secretions (*arrowhead*).

See Table 15.3 for a summary of histologic clues to tumor type. Note that the presence of papillary structures is completely nonspecific, as most epithelial tumors can acquire papillary architecture (Figure 15.12).

TABLE 15.3. The surface epithelial tumors can have overlapping features.

If you see...	Think of...
Clear cells with very atypical nuclei	Clear cell
Clear cells with bland nuclei	Endometrioid or Brenner
Hobnail cells lining glands or papillae	Clear cell
Intestinal-type cells	Mucinous
Mucinous cells with papillary fronds	Mucinous
Intracytoplasmic mucin	Mucinous or endometrioid
Papillary fronds	Any tumor (see Figure 15.12)
Micropapillary pattern	Serous
Sheets of high-grade nuclei	Serous
Solid growth with slit-like spaces	Serous
Squamous-like nests of cells	Brenner
Squamous metaplasia in glands	Endometrioid
Round gland lumens	Endometrioid
Tall villi	Endometrioid or mucinous

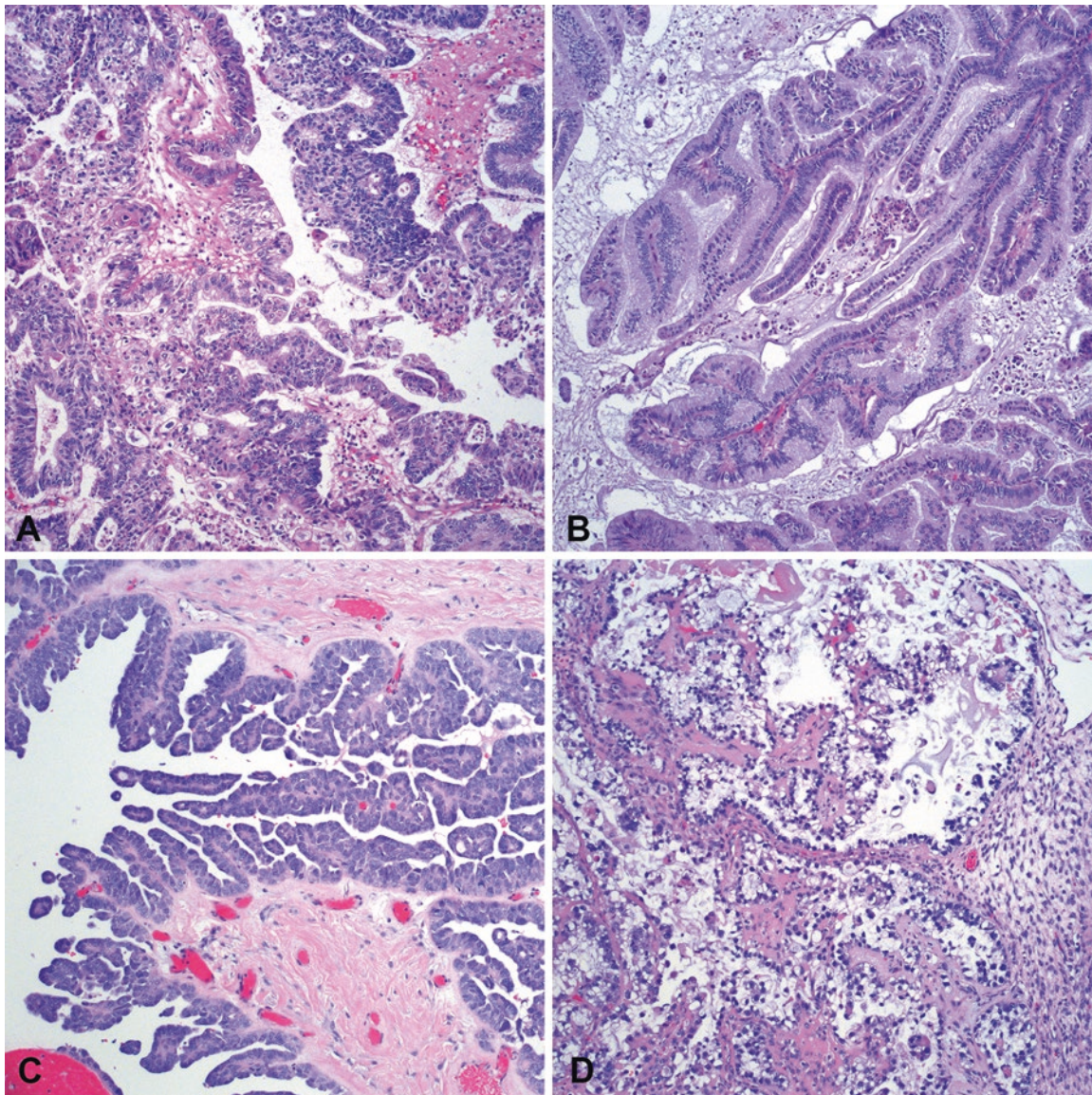


FIGURE 15.12. Papillary architecture is completely nonspecific. Compare the papillae which can be found in (a) endometrioid carcinoma, in which fibrovascular cores are lined by columnar endometrial-type cells; (b) mucinous carcinoma, in which papillae are lined by tall cells with apical mucin; (c) serous carcinoma, in which there are both papillae and micropapillae with jumbled, high N/C ratio nuclei; and (d) clear cell carcinoma, in which there is a single layer of cuboidal clear cells with very atypical nuclei. All photos are taken at the same magnification.

Non-epithelial Neoplasms

For the purposes of this chapter, we will gloss over the germ cell and sex cord stromal neoplasms, except for the most common entities.

Germ Cell Neoplasms

Anything that can occur in the testis can occur in the ovary. The most common germ cell neoplasm in the ovary is the teratoma, but you can also see dysgerminoma (seminoma), yolk sac tumor, choriocarcinoma (arising unrelated to gestational trophoblastic disease), and embryonal carcinoma. Each looks similar in the testis and ovary.

Teratomas are usually composed of at least two of three embryonic derivatives: ectoderm, endoderm, and mesodermal cells. They are often cystic and may grow to a large size. Common elements include squamous epithelium, skin adnexal structures, hair, fat, cartilage, thyroid, brain and nerve tissue, gut epithelium, and respiratory epithelium. Teratomas in females are most often benign but may be malignant in one of three ways, regardless of age or puberty status: (1) by developing a secondary malignancy from a tumor component, like lymphoma or thyroid carcinoma, (2) by being associated with a malignant germ cell tumor, or (3) by having an immature component, usually neural. After a few products-of-conception (POC) specimens or fetal autopsies, you should recognize fetal brain—dark blue cells in a myxoid, clear background (Figure 15.13).

Sex Cord Stromal Neoplasms

Sex cord stromal neoplasms include all of the fibrous and steroid-hormone-cell tumors. The most common tumors are the fibroma/thecoma group. Granulosa cell tumors are also not uncommon. However, many of the weird and paradoxical ovarian lesions (Sertoli–Leydig?) fall into this group. As in the testis, if you cannot begin to imagine what kind of tumor you are looking at, start with the sex-cord-stromal chapter.

The fibroma/thecoma group is a spectrum of lesions from the pure fibroma, to the common mixed fibrothecoma, to the pure thecoma. Grossly fibromas look like leiomyomas, which are actually rare in the ovary. On cross section, the thecoma areas in mixed tumors are butter-colored and stand out from the gray-white fibroma. Histologically the tumors are also similar to leiomyomas but have more of a sheetlike pattern with bland, spindled cells (Figure 15.14).

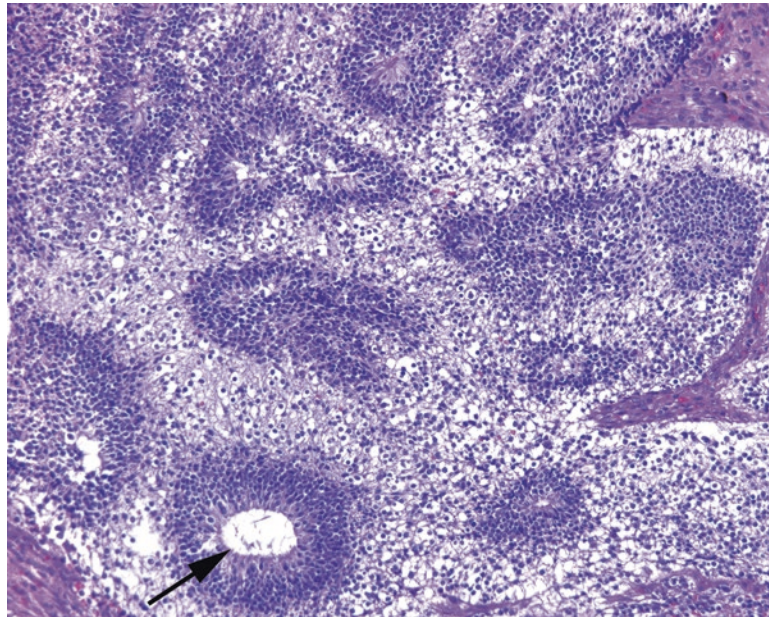


FIGURE 15.13. Immature neural tissue, teratoma. The combination of hypocellular areas and dense small round *blue* cell areas is suggestive of fetal brain. Rosettes (*arrow*) may also be seen. Finding this histology in a teratoma indicates an immature component.

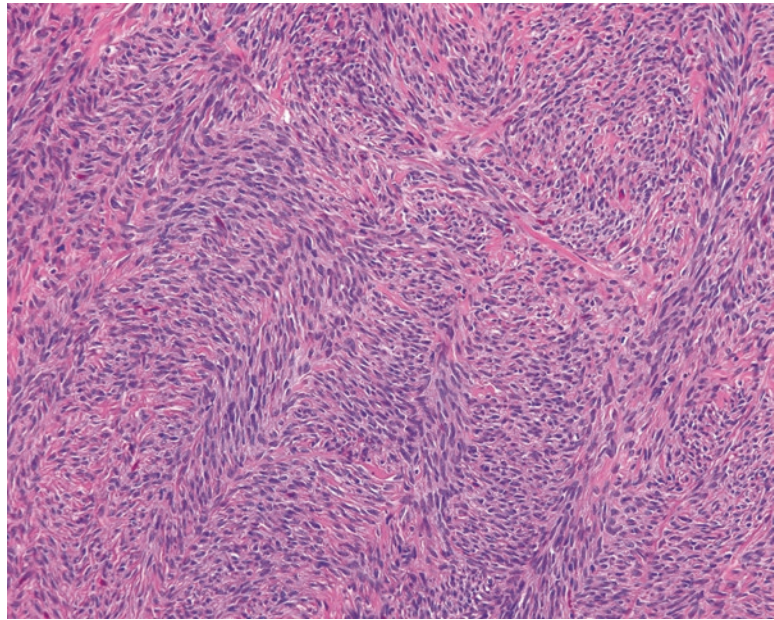


FIGURE 15.14. Fibrothecoma. This specimen shows mainly the fibroma component, with fascicles of bland spindled cells.

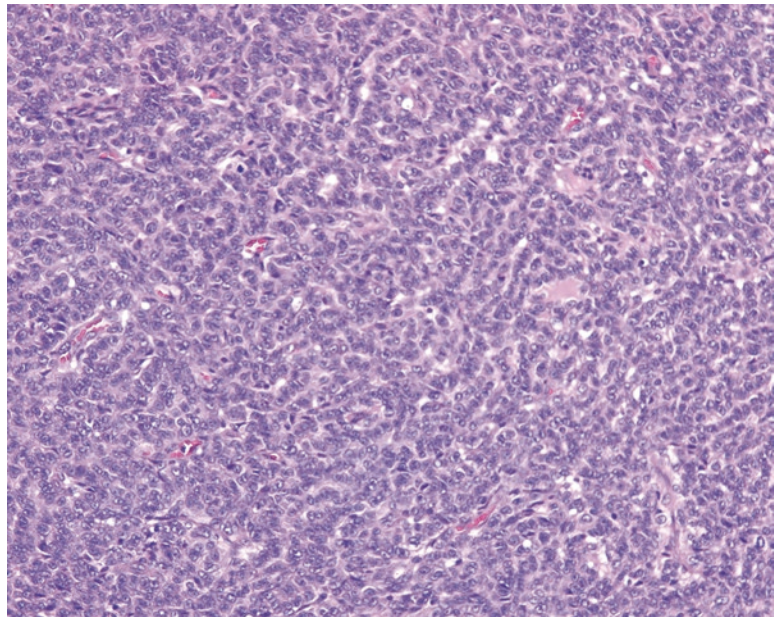


FIGURE 15.15. Granulosa cell tumor, low power. This section shows the characteristic cords and rows of granulosa cells, creating a pattern like watered silk, or (for those not frequenting fabric stores) a topographic map.

The tiny lipid vacuoles that identify the thecoma component are hard to see on H&E stain. These are benign tumors.

Granulosa cell tumor cells appear similar to the normal granulosa cells in the ovary but have more distinctive oval folded or angulated nuclei with a longitudinal groove (the “coffee bean” nuclei). In a tumor, these cells may become more closely packed, almost giving the impression of nuclear molding, but they are not as blue, hyperchromatic, or crowded as small cell carcinoma. At low power, the cells are arranged in rows, with a zigzag “watered silk” pattern (think of a topographic map; Figure 15.15). The cells appear very uniform throughout. Rarely, you may see the pathognomonic Call–Exner bodies as seen in the developing follicle. These are malignant but indolent and tend to recur after many years.

16 Cervix and Vagina

Cervical biopsies are common and nearly always performed for the purpose of evaluating squamous or glandular dysplasia. Usually the patient will have a history of an abnormal Pap test or a prior abnormal biopsy finding. Correlation with prior pathology is nice, but lesions can be focal and/or transient, so perfect agreement is not required.

There are several types of specimens. The smallest is usually the endocervical curettage. This is meant to be a sampling of the endocervix and so should contain endocervical (columnar) mucosa. These tissue scrapings may have tiny and maloriented fragments, and the tissue can be spread out over a wide area on the slide.

If a lesion is seen by the clinician on colposcopy, there may be a cervical biopsy performed, which is a crescent-shaped chunk taken out of the cervix. This tiny specimen is uninked and unoriented. A high-grade lesion requires a cone biopsy, where the transition zone is taken out in a conical fragment with the goal of completely excising the lesion. The cone biopsy may be done with cautery (loop electrosurgical excision procedure, LEEP) or blade (cold-knife cone). The proximal/endocervical margin should be identified and inked to make sure the lesion is not extending up into the canal where it cannot be seen or sampled. The ectocervical margin is also inked, but a positive ectocervical margin is unusual.

Normal Histology of Cervix

The cervix is covered by a nonkeratinized squamous epithelium that merges into the surrounding vaginal wall. The squamous cells may be full of glycogen and have a plump cleared-out cytoplasm (refer to Figure 4.8). In postmenopausal women, the epithelium may become thin and atrophic, with an immature look.

The transition zone represents an abrupt transition to mucous-secreting columnar and glandular epithelium and may be located at the os or within the endocervical canal. Irritation or inflammation at the transition zone may lead to acute and/or chronic inflammation and squamous metaplasia overlying the glandular mucosa. This state is so universal that “chronic cervicitis and squamous metaplasia” is synonymous with normal. Squamous metaplasia, by definition, can only occur at or above the transition zone (Figure 16.1), and so mentioning it confirms that the transition zone was sampled. If you see no endocervical component at all, you may phrase it as “benign squamous mucosa.”

Endocervical glands are branching and complex glands that are pale with a dark outline due to the large cytoplasmic mucin vacuole pushing aside a small crescent-shaped nucleus (Figure 16.2). Fragments of glands on endocervical curettage may have a papillary or inside-out look, which is not significant. Squamous metaplasia or dysplasia may fill up and replace glands and must be distinguished from invasive cancer. Crowding of otherwise benign-looking glands is not a feature of concern, as it is in the endometrium.

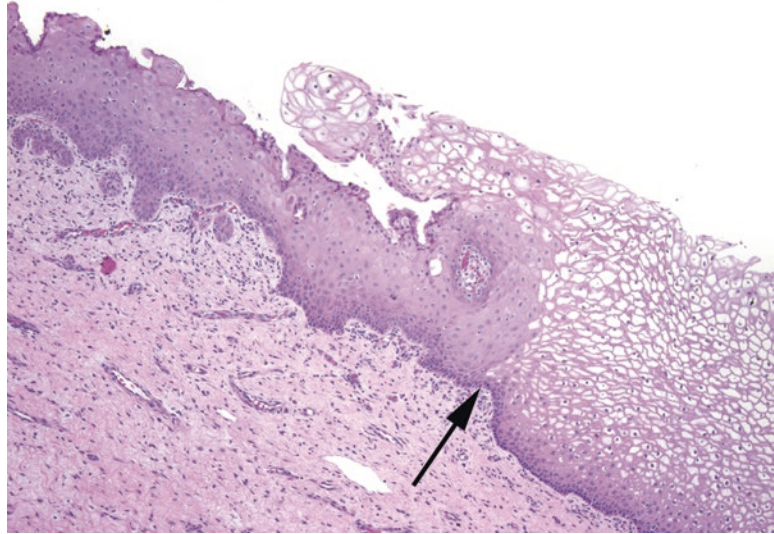


FIGURE 16.1. Squamous metaplasia at the transition zone. Mature squamous epithelium is seen to the *right* of the *arrow*, and squamous metaplasia is seen to the *left*. In squamous metaplasia, the nuclei may be larger and more immature-appearing and the cytoplasm more dense.

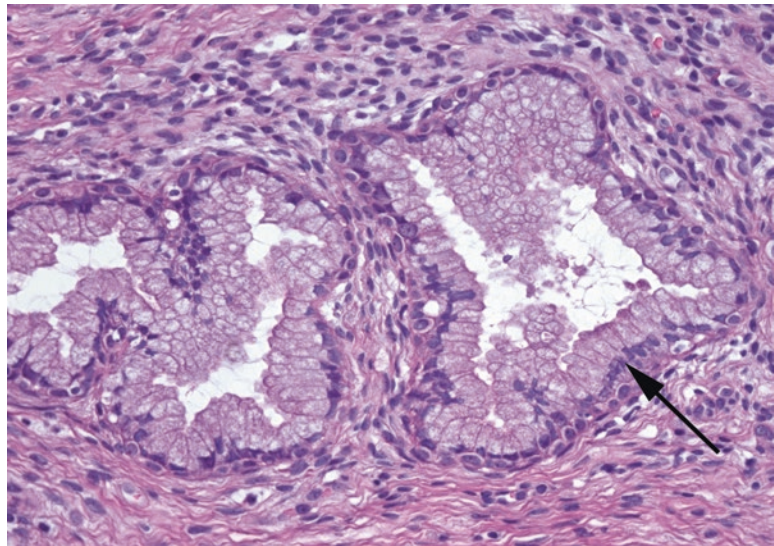


FIGURE 16.2. Endocervical glands. Normal endocervical glands are composed of tall columnar cells with apical mucin and small basal nuclei (*arrow*).

The cervical stroma is very fibrotic (as you will find when cutting through one), so it looks pink and spindly. There are a variety of normal cysts and glandular proliferations that may occur within the stroma.

The Approach to the Endocervical Curettage

First look at the slide on the tray, and circle a single level of the tissue, so you don't miss cells at the periphery. At low power, look for fragments of squamous epithelium and endocervical glands. The presence or absence of each is noted in the diagnosis. There may be a fair amount of background mucus (stringy pale pink amorphous substance) and inflammation. At higher power, at least 10 \times , concentrate on the actual epithelial fragments, if there are any. A smear of scattered endocervical cells (columnar cells with apical mucin) may be all you get, but ideally there are

fragments of squamous epithelium to evaluate. These are evaluated by the same criteria as the biopsy, described next. Endometrial malignancies may also extend into the endocervical canal, so fragments of adenocarcinoma are not necessarily of endocervical origin.

The Approach to the Biopsy

On low power, first survey the squamous epithelium and the endocervical glands to look for areas that stand out as being more disorganized, darker, denser, or more inflamed than other areas. This applies to the squamous epithelium as well as to individual endocervical glands. Any suspicious area should be studied at higher magnification to look for dysplasia. The old three-tier system for classifying dysplasia has been condensed into a two-tier system that reflects the Bethesda system for cytology; this applies to biopsy material from the entire anogenital tract. What was once called CIN-1 (or VIN-1, or VaIN-1, or AIN-1) is now called *LSIL* (*low-grade squamous intraepithelial lesion*) and represents the viral cytopathic changes of HPV infection. LSIL lesions may contain either low-risk or high-risk HPV subtypes. Exophytic LSIL lesions may also be called condyloma.

On the other hand, the moderate and severe categories of CIN 2 and CIN 3 are now grouped into *HSIL* (*high-grade squamous intraepithelial lesion*) and reflect a true dysplastic transformation as a result of HPV infection. These lesions are nearly always associated with high-risk HPV subtypes.

Squamous Lesions

LSIL

- A viral cytopathic effect that affects primarily the upper cell layers of the epithelium.
- The cells have pleomorphic, wrinkled, hyperchromatic nuclei with a perinuclear cleared halo; these are called *koilocytes*. Binucleation is common (Figure 16.3).
- The N/C ratio remains low, despite the marked atypia of the nuclei. The degree of nuclear atypia alone does *not* upgrade the lesion to HSIL.
- It can look haphazard at low power, but the basal layer should be maintained as a discrete layer, and mitoses should not be higher than the lower one third.

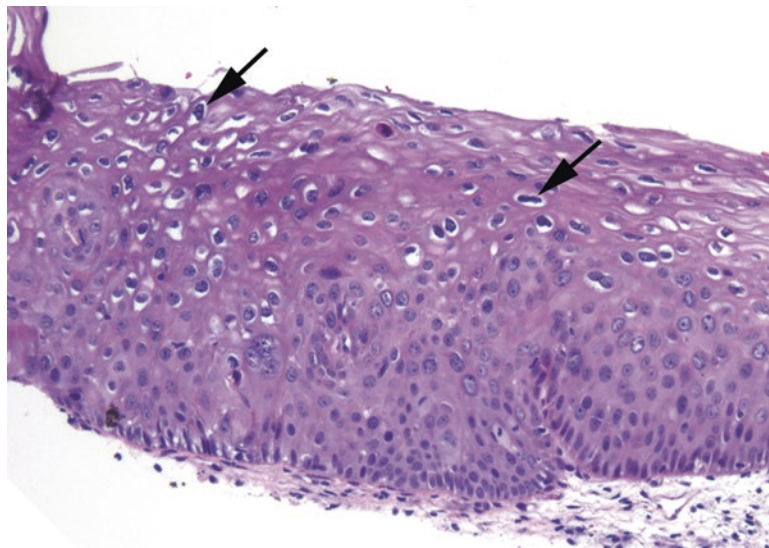


FIGURE 16.3. LSIL. The hallmark of LSIL is the koilocyte, which is a squamous cell with HPV viral cytopathic effect. The nuclei are hyperchromatic (dark) and raisinoid (crinkly; see *arrows*), with a surrounding clear halo in the cytoplasm. Other good features include superficial nuclei that are larger than the nuclei below them, and binucleated cells.

HSIL

- A persistence of immaturity along with dysplastic changes. Essentially, the basal cells are becoming “immortalized,” like a cancerous cell, and are not maturing and differentiating as they should. Therefore, the basal cell appearance persists up into higher levels of the epithelium.
- The overall impression is of a denser and darker epithelium due to high N/C ratios. The high N/C ratio is the same feature that allows these cells to be identified on Pap smear.
- Atypia is seen in all cell layers, from the bottom up. The nuclei may not be as large or as bizarre as LSIL but are uniformly crowded, enlarged, and hyperchromatic with clumped chromatin and irregular membranes (boulder nuclei), and mitoses are present in the upper two thirds (Figure 16.4).
- CIN 2 may show maturation at the surface or overlying LSIL, versus CIN 3, which shows full-thickness immaturity and atypia. The distinction is only significant in some subpopulations in which CIN 2 may be treated more conservatively.
- HSIL can grow into endocervical glands, which should be mentioned in the diagnosis.

Do not confuse HSIL with *immature squamous metaplasia*, which has the following characteristics:

- Well-defined cell borders and low N/C ratios
- The “boiling mud” look (Figure 16.5)
- Pinker than HSIL, due to having more cytoplasm
- Bird egg nuclei (smooth, round, with even chromatin)
- Surface mucin or columnar layer

Ancillary Tests

p16 is an indirect marker for high-risk HPV infection, and high-grade lesions should have strong full-thickness nuclear and cytoplasmic staining for this marker. It is unreliable in LSIL, though, as not all LSIL have high-risk HPV, and not all high-risk HPV lesions are HSIL. The use of p16 is recommended only in situations when you are trying to rule out uncertain HSIL (e.g., HSIL vs. atrophy or CIN 2 vs. CIN 1). p16 should not be used to try to differentiate LSIL from benign nor should it be used to second-guess cases that are clearly LSIL or HSIL on histologic grounds.

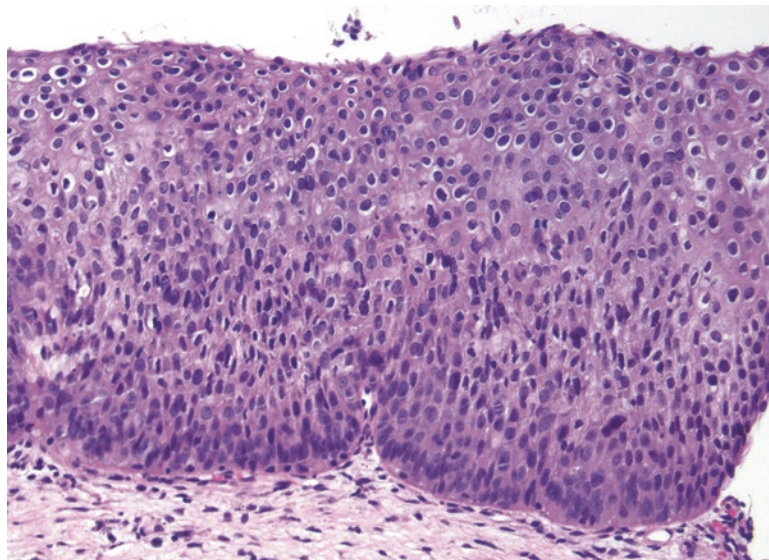


FIGURE 16.4. HSIL. In a high-grade lesion, paradoxically, the nuclei may not look as abnormal as in LSIL. The hallmark of HSIL is a persistence of immature-appearing cells throughout the epithelium. The nuclei are hyperchromatic and may have slightly irregular nuclear outlines, but the most striking feature at low power is the high N/C ratios present from top to bottom.

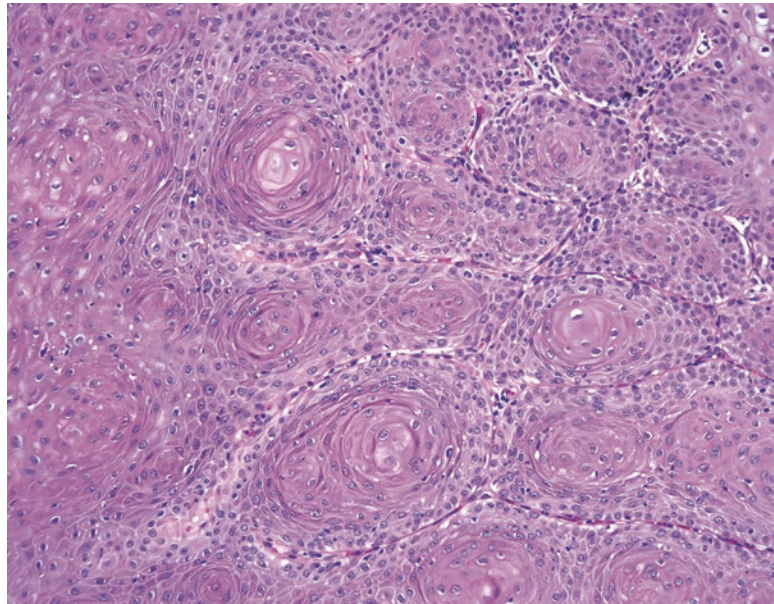


FIGURE 16.5. Immature squamous metaplasia. A tangential cut of squamous metaplasia can look like a lesion. However, this pattern of concentric whorls of cells with central pools of pink cytoplasm (resembling the boiling mud puddles of Yellowstone) is typical of benign squamous metaplasia.

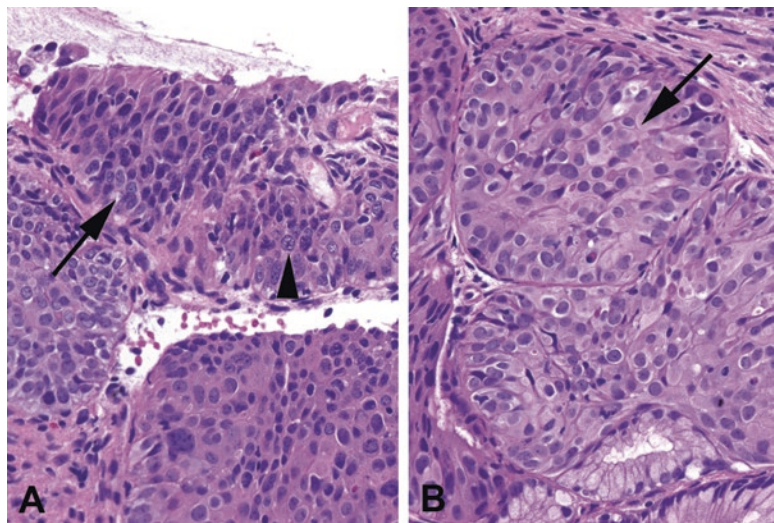


FIGURE 16.6. Dysplasia versus reactive changes. (a) In this example of HSIL, the dysplastic nuclei are irregularly shaped and appear to interlock together like stones in a wall (*arrow*). The quality of the chromatin is characteristic as well; it is dark and granular. Occasional nucleoli are visible (*arrowhead*), but they are surrounded by clumpy chromatin within the nucleus. (b) In reactive changes, the nuclei may be enlarged, but each nucleus remains smooth and oval in shape. The chromatin has a fine, even texture and is pale in color compared to the dysplastic cells in HSIL. Small dense nucleoli are visible in many of the cells (*arrow*).

Reactive Changes

Be wary of calling an SIL in the context of extensive acute inflammation (neutrophils). Reactive changes include the following:

- Regularly spaced nuclei with prominent nucleoli, homogeneous size, and smooth contours (Figure 16.6)
- Maturing upper layers without atypia
- Spongiotic edema (increased water spaces between squamous cells)

Invasive Squamous Cell Carcinoma

In the case of extensive HSIL (which is functionally carcinoma in situ), you should carefully search for evidence of invasion. As with squamous carcinoma in the skin or oropharynx, identifying invasion can be difficult and depends on multiple features. Features of invasion are similar to those in other sites:

- Deep keratinization
- Large nucleoli
- Blurred or sawtooth interface between epithelium and stroma (Figure 16.7)
- Loss of the regular palisading basal layer
- Desmoplastic response within stroma

In the cervix, invasion to a depth of less than 3 mm is considered microinvasion and has a better prognosis. Review the current criteria for microinvasion before diagnosing it; however, as like any staging system, these periodically change and differ for different gynecologic sites.

The differential diagnosis for invasion includes pseudoepitheliomatous hyperplasia (see Chapter 4), glandular involvement by HSIL, and placental site nodules. HSIL has a tendency to crawl down into endocervical glands, much like squamous metaplasia does. Although this is important and should be mentioned, it must be differentiated from invasion. Clues include remnants of columnar epithelium, a smooth rounded contour to the gland, and the lack of individual cells in the stroma.

A *placental site nodule* is a remote remnant of pregnancy—aggregates of intermediate trophoblastic cells that have large single nuclei that can look atypical, found in hyaline nodules. Their pink cytoplasm and atypical cells may remind you of deep invasive keratinizing cells (Figure 16.8). However, the cell borders should be less well defined than squamous nests, and the nuclei show bizarre degenerative atypia—large, dark, and smudgy nuclei (no chromatin detail) without nucleoli.

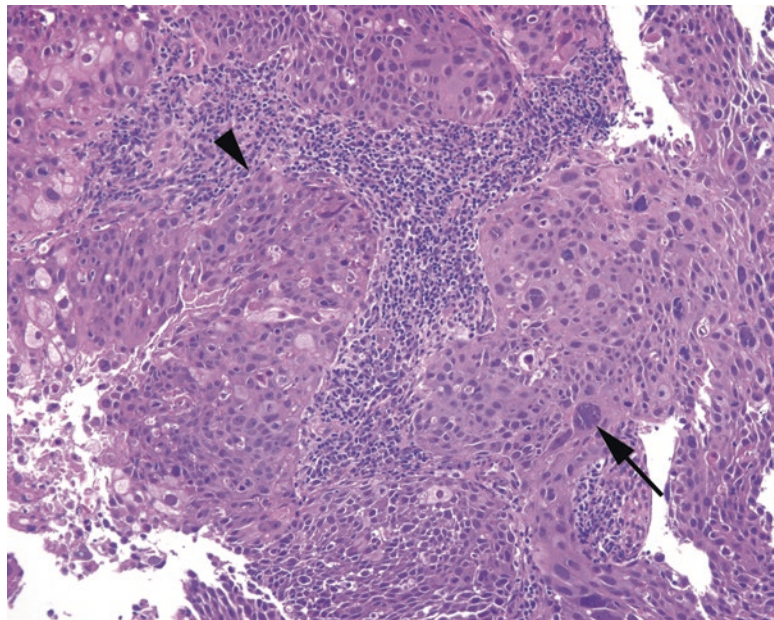


FIGURE 16.7. Invasive squamous cell carcinoma. Broad fronts of cells push into the stroma of the cervix, and at the leading edge, there is a ragged border with individual infiltrating cells (*arrowhead*). Occasional huge and pleomorphic cells are visible (*arrow*).

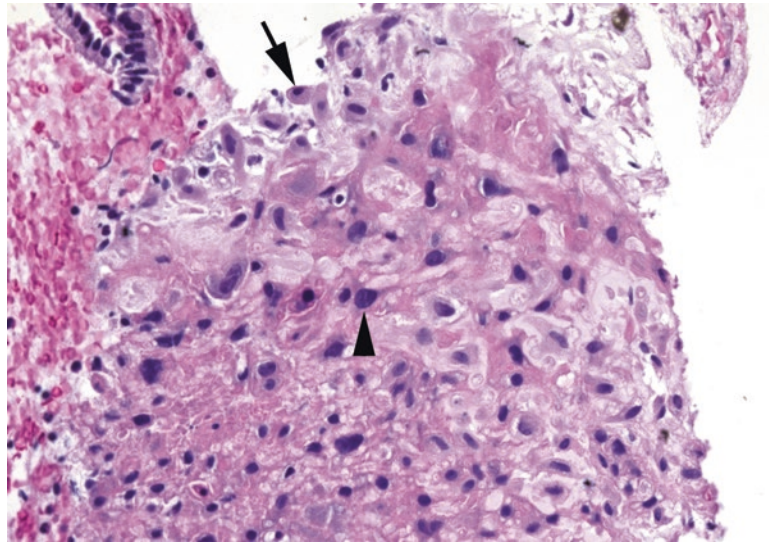


FIGURE 16.8. Placental site nodule, cervix. Although the dark nuclei and pink cytoplasm are concerning for squamous cell carcinoma, the nuclei are predominantly small and oval, with a few large nuclei visible (*arrowhead*). These large cells have dark but smudgy (blurred or indistinct) chromatin, without the chunky texture seen in HSIL (see Figure 16.6), and do not have the nuclear membrane irregularity of invasive squamous cell carcinoma (see Figure 16.7). The final clue is what appears to be a decidualized cell at the periphery (*arrow*).

Miscellaneous Benign Entities

Endocervical polyps have fibrotic (spindly) stroma with a polypoid shape and normal endocervical glands or epithelium. They may have cysts, inflammation, or tubal metaplasia (luminal cilia). *Nabothian cysts* are large dilated mucous-filled glands, lined with columnar epithelium. *Tunnel clusters* are lobular groups of complex branching glands (cystic or tubular), with benign columnar epithelium.

Microglandular hyperplasia is associated with oral contraceptive pills. It looks like a proliferation of small back-to-back glands lined with cuboidal or mucinous columnar cells with squamous cells (Figure 16.9). The low-power impression is that of a cribriform architecture, but the glands should still appear overall pale and pink, in contrast to the dark blue adenocarcinoma in situ (AIS) (discussed later). Unlike in the endometrium, the presence of crowded glands here does not indicate neoplasia. Some pathologists are reluctant to put this diagnosis in a report, out of fear that the word “hyperplasia” may be misinterpreted as cause for concern.

Endometriosis appears as dense blue palisaded columnar glands without mucin, surrounded by edematous endometrial-type stroma. The dark glands can be very eye catching and can even show mitoses, so recognizing the stroma is the key to making the diagnosis (Figure 16.10). The presence of extravasated red blood cells or hemosiderin is very helpful.

Glandular Lesions

Most pathologists do not diagnose “endocervical dysplasia” and only recognize the two ends of the spectrum, reactive atypia and *adenocarcinoma in situ* (AIS), for atypical noninvasive glandular lesions. Glands with AIS should stand out as being distinctly different from their benign neighbors, as they look much darker. Recognizing these glands requires a conscious effort to look for them, however, because the eye tends to focus on the squamous epithelium, and AIS can be subtle at scanning magnification.

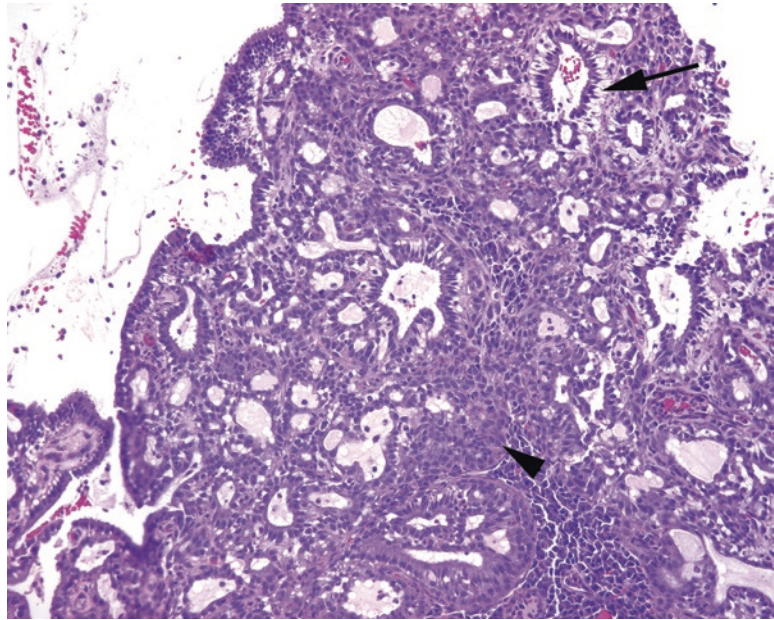


FIGURE 16.9. Microglandular hyperplasia. These endocervical glands show a very cellular proliferation composed of mucinous cells (*arrow*) and squamous metaplasia (*arrowhead*) and a cribriform pattern of lumens. This is benign.

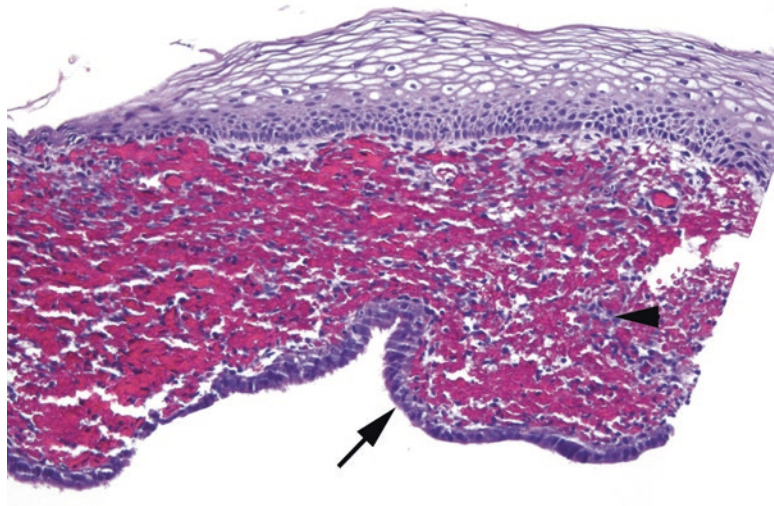


FIGURE 16.10. Endometriosis. This cervical biopsy specimen shows a squamous epithelium overlying stroma with hemorrhage. At the bottom of the fragment, there is a dark cuboidal lining (*arrow*) resembling endometrial epithelium. The telltale endometrial stroma (*arrowhead*) is mostly obscured by blood.

Features of AIS include the following:

- Close clusters of dark glands may resemble intestinal crypts or a tubular adenoma (Figure 16.11).
- Nuclei are tall and pseudostratified, enlarged, and hyperchromatic.
- Nucleoli may be present.
- Mitoses and apoptotic bodies are common.
- Papillary or cribriform architecture may be present and, if confluent, should raise the possibility of stromal invasion.

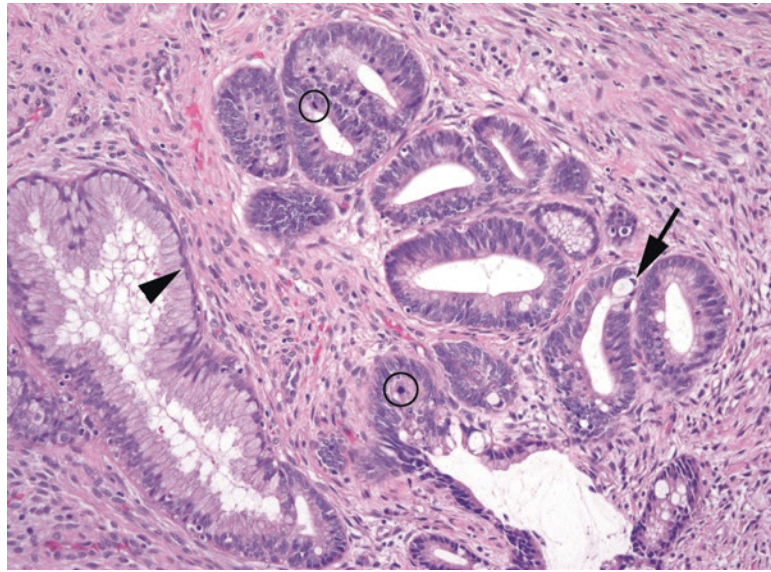


FIGURE 16.11. Adenocarcinoma in situ (AIS). This field shows some residual normal endocervical glands (*arrowhead*) adjacent to a very abnormal population with dark, elongated, crowded, and stratified nuclei representing AIS. Occasional intestinal-type goblet cells (*arrow*) and mitoses (*circles*) are present.

- Mucin may be present as scattered vacuoles or as discrete goblet cells (intestinal type).
- p16 staining should be diffusely positive (AIS is an HPV-associated lesion). However, do not rely solely on p16, as tubal metaplasia can mimic AIS and can also stain for p16. The ciliated cells of tubal metaplasia can help to differentiate the two.

Invasive Adenocarcinoma

The most common variant of invasive adenocarcinoma is the endocervical (usual) type, which is an invasive form with the morphology seen in AIS. Features of invasion include the following:

- Glands with AIS features that are too crowded, with cribriform growth or back-to-back glands
- Cell clusters diving off into the stroma, as with squamous cell carcinoma
- Desmoplastic response
- Glands that are significantly deeper into the stroma than the benign glands (on perpendicular section)

Endocervical adenocarcinoma may be hard to distinguish from endometrial adenocarcinoma. However, the endocervical variety should be diffusely p16 positive, whereas the endometrial type is usually estrogen- and progesterone-receptor positive.

The dreaded and rare “adenoma malignum,” or *minimal deviation adenocarcinoma*, is a very well-differentiated adenocarcinoma in which the individual malignant glands are nearly indistinguishable from normal endocervical glands. They do not produce a desmoplastic response and are not positive for p16. They are identified (in the most subtle cases) by their tendency to invade more deeply into the cervical stroma than normal endocervical glands should. Kind of a rotten trick, isn’t it?

Vulvar Epithelium

HPV can cause similar lesions in the vagina and vulva. As in the cervix, the lesions are grouped into LSIL and HSIL (Figure 16.12). As in the cervix, these lesions can progress to invasive squamous cell carcinoma. Unlike in the cervix, however, the vulva is a keratinized epithelium, and the manifestation of HPV lesions is slightly different. Although condylomas are common,

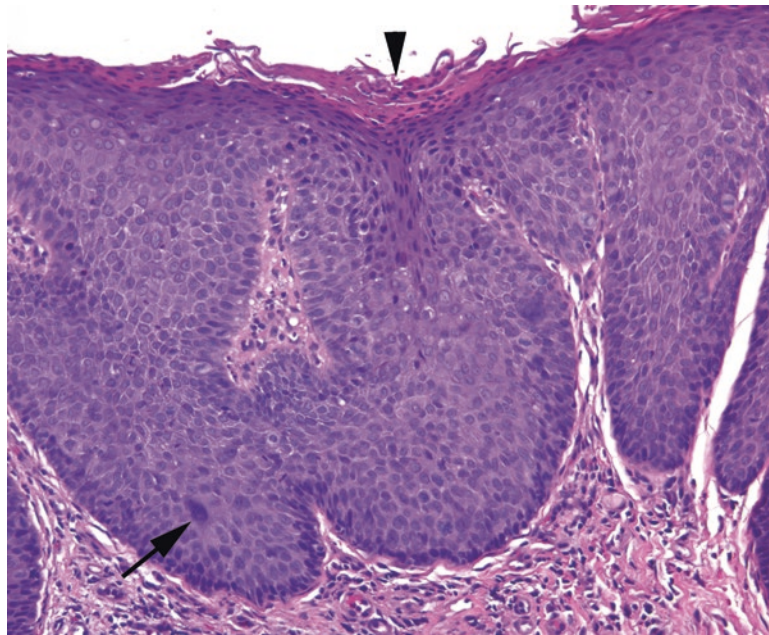


FIGURE 16.12. Vulvar HSIL (VIN3). This biopsy specimen shows hyperkeratosis and parakeratosis (arrowhead) overlying a very blue squamous epithelium. Although the nuclear changes are not as obvious as in high-grade cervical lesions, there is loss of polarity and high N/C ratios in the superficial epithelium. Occasional large atypical cells (arrow) are visible.

flat LSIL is somewhat uncommon in the vulva. HSIL can be more subtle than in the cervix as well, such that HSIL areas will stand out at low power as thickened and darker patches of epithelium, but on high power the nuclear atypia is not as convincing as you might wish. A good way to calibrate your eye is to compare the darker area to an adjacent fragment that is clearly benign, and the cytologic differences will be more apparent. In addition, mitotic activity high in the epithelium also supports HSIL.

Papillary Lesions

An exophytic viral lesion with LSIL-type changes is called *condyloma acuminatum*. The LSIL features are somewhat subtler in a condyloma, and the nuclei may not be as obviously koilocytic. However, the presence of a verrucous (papillary, hyperkeratotic, and parakeratotic) lesion is virtually diagnostic of a condyloma (Figure 16.13). Non-HPV-related squamous papillomas also occur, usually in the vestibule, but without evidence of viral changes or hyperkeratosis. Finally, if the lesion is composed of more stroma than epithelium, it is most likely a *fibroepithelial polyp* (skin tag).

Inflammatory Skin Conditions

Lichen sclerosus appears as a flat, white, shiny patch clinically and in developed form looks like a bland pale swath of collagen (homogenous hyalinization) just beneath a thinned and flattened epidermis (Figure 16.14). *Lichen simplex chronicus*, on the other hand, is related to chronic spongiotic dermatitis and is characterized by epidermal thickening and hyperkeratosis over chronic inflammation in the dermis. It is a diagnosis of exclusion; you should first rule out fungal infection and squamous dysplasia.

Paget's disease, extramammary type, is not an inflammatory skin disorder but may be mistaken for one clinically. Unlike in the breast, it does not always indicate an underlying adenocarcinoma. However, in other respects, it is analogous to mammary Paget's, with large atypical carcinomatous cells percolating through a benign epidermis (Figure 16.15). *Melanoma*, vulvar type, must always be in your differential diagnosis when you see pagetoid cells. A simple immunopanel will differentiate the two.

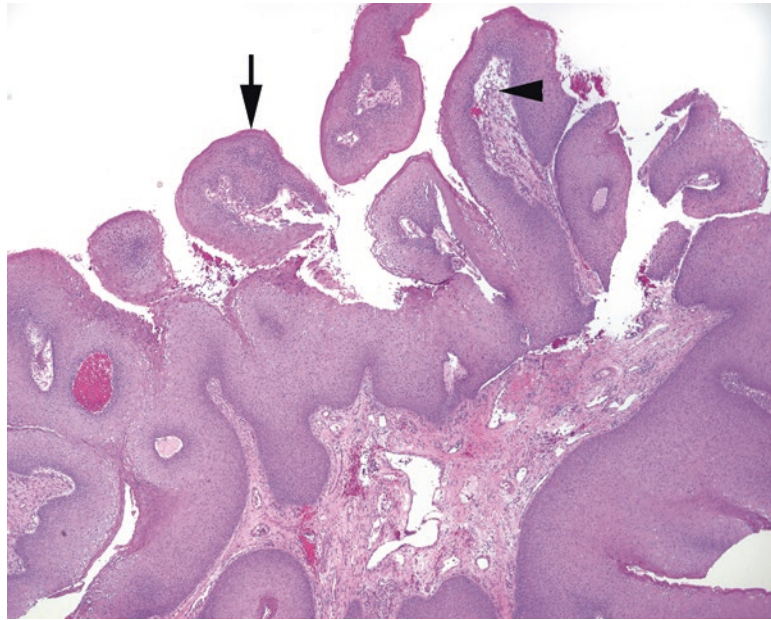


FIGURE 16.13. Condyloma. This exophytic lesion has prominent fibrovascular cores (*arrowhead*) underlying a thickened and hyperkeratotic squamous epithelium (*arrow*). Koilocytic or LSIL-type changes are not always obvious in condylomas.

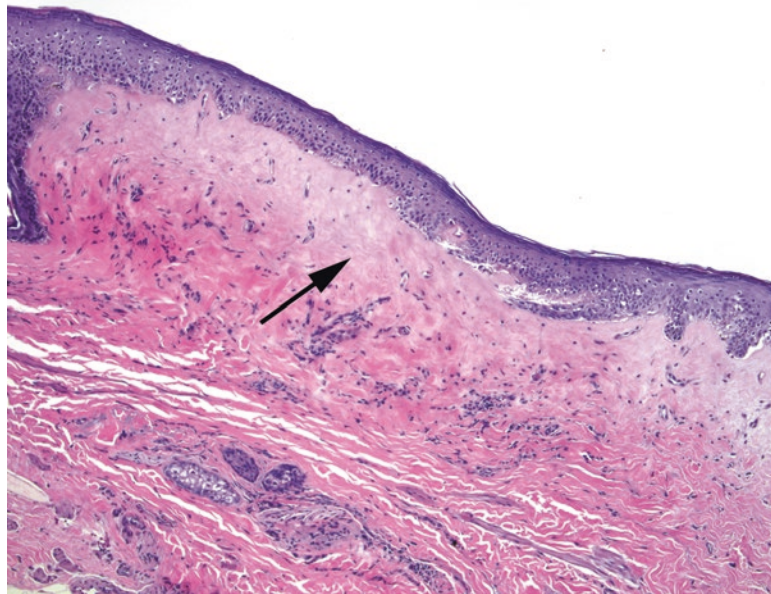


FIGURE 16.14. Lichen sclerosus. The epithelium is thin and atrophic, and the collagen underneath is pale, dense, and homogenized in texture (*arrow*). The dermal–epidermal junction is flattened, with an absence of rete.

Squamous Carcinoma of the Vulva

Squamous carcinoma in the vulva can take a variety of patterns, including keratinizing, nonkeratinizing, and basaloid (resembling basal cell carcinoma). One particularly well-differentiated form of keratinizing squamous carcinoma may arise in older women with a history of lichen sclerosus or other inflammatory conditions. This type, which is *not* related to HPV, is associated with a sneaky type of dysplasia called differentiated vulvar intraepithelial neoplasia (*differentiated VIN*). Differentiated VIN does not display the nuclear changes we associate with HPV and may therefore be invisible to cytologic screening. The cells have abundant pink cytoplasm and

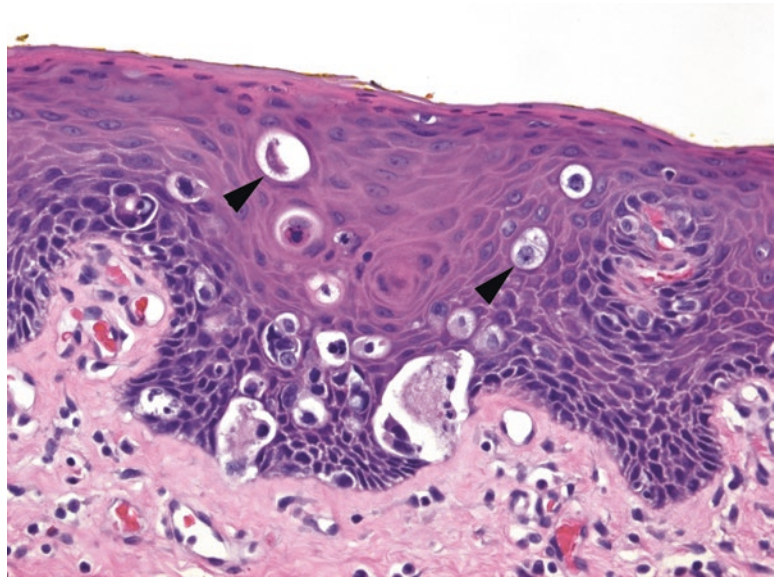


FIGURE 16.15. Paget's disease. Several nonsquamous cells (*arrowheads*) are visible within the squamous epithelium.

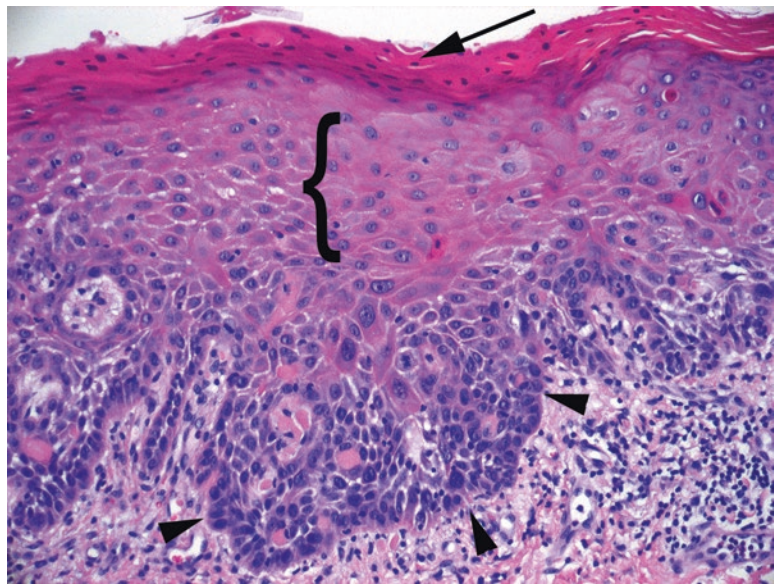


FIGURE 16.16. Differentiated VIN. In this type of dysplasia, there are misshapen and atypical nuclei clustered along the base (*arrowheads*), but the overlying cells appear to be maturing (*bracket*), and the upper nuclei are small, round, and regular. There is parakeratosis on the surface (*arrow*).

large cleared-out nuclei with prominent nucleoli (Figure 16.16). It is similar in appearance to the keratinizing dysplasia of the oropharynx, in which the nuclear atypia may be limited to the lower half of the epithelium and still qualify as severe dysplasia. Because of this paradox, differentiated VIN is not graded by the usual HSIL/LSIL criteria, and it is important to realize that it essentially disobeys all of the rules that you have learned in cervix and vulva.

For Further Study

At the time of publication, there is an excellent WHO online atlas for cervical specimens, both cytologic and histopathologic. This atlas has hundreds of images with explanations and a statistical breakdown of what alternate diagnoses were also considered by viewers.

See images at: <http://screening.iarc.fr/atlashisto.php>

The endometrium is a cycling glandular and stromal layer overlying the myometrium of the uterus. The appearance varies widely across different phases of the menstrual cycle, pregnancy, and menopause. Common reasons for performing an endometrial biopsy include the following:

- Abnormal vaginal bleeding
- A “thickened endometrial stripe” found on ultrasound, suggesting hyperplasia or carcinoma
- Part of an infertility workup
- Follow-up study for women with a history of hyperplasia who have been conservatively treated with hormones

The reason for the biopsy will influence your approach to the slide. Regardless of history, start by differentiating between atrophic, inactive, proliferative, secretory, and hormone-treated endometrium. On low power, survey the epithelium to get a feel for the glands and stroma:

- *Atrophic* endometrium (typically postmenopausal) has a low gland-to-stroma ratio, and the glands are thin, with an almost cuboidal epithelium, and no mitoses. In biopsy specimens, they tend to come off in thin strips that look like hair pins (Figure 17.1).
- *Proliferative* endometrium has a fuller, blue look to the stroma and a gland-to-stroma ratio of about 1:1. The glands are simple tubular structures that stand out as dark blue “donuts” with pseudostratified nuclei (slight variation in nuclear location, but predominantly basal) and columnar epithelium (Figure 17.2). Mitoses should be readily visible in the glands. A similar architecture with an absence of mitoses indicates an inactive endometrium.
- *Secretory* endometrium has prominent spiral arterioles and variably edematous stroma so that the stromal cells look like naked nuclei floating in water. The glands are notable for cytoplasmic secretory vacuoles and secretions in the lumen (Figure 17.3). Late-cycle secretory stroma begins to get decidualized (acquires pink cytoplasm), and the glands lose their vacuoles and show low cuboidal pink cells, ragged luminal edges, and a tortuous spiral shape. You should not see mitoses in secretory glands.
- *Progestin-treated* endometrium, like gestational endometrium, has a very decidualized stroma (plump pink cells with visible cytoplasm) but is paired with attenuated, flattened gland epithelium (Figure 17.4). These changes are due to the unopposed progesterone exposure. Unopposed estrogen, on the other hand, has a proliferative effect and tends to promote hyperplasia or carcinoma. Tamoxifen, paradoxically, acts as an estrogen agonist in the endometrium.

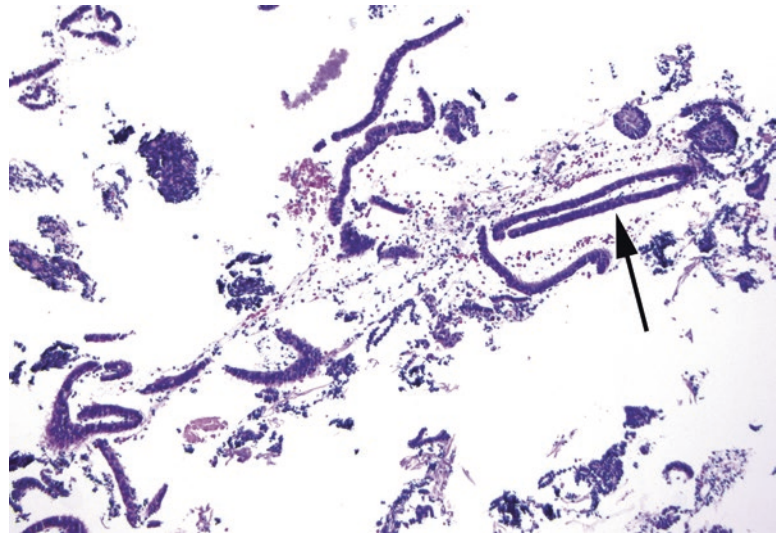


FIGURE 17.1. Atrophic endometrium. When curetted, the epithelium typically comes off in thin strips resembling hairpins (*arrow*). The specimen is also scant.

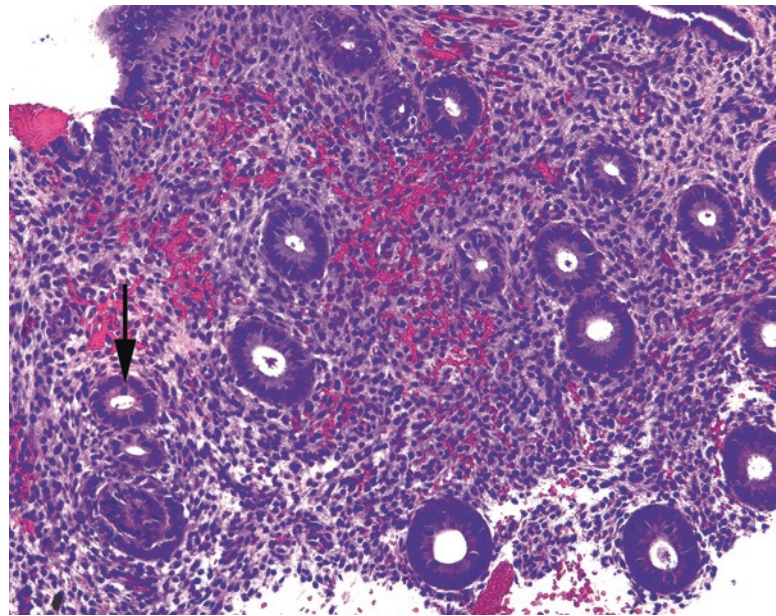


FIGURE 17.2. Proliferative endometrium. Multiple donut-shaped glands are visible, with dark oblong nuclei and frequent mitoses (*arrow*).

Why are the endometrial characteristics important? Secretory endometrium, almost by definition, is not hyperplastic. Once you have identified secretory phase, you (usually) do not need to agonize over crowded glands. Because progesterone pushes the endometrium toward secretory change, it is used as treatment for hyperplasia; if you can prod the endometrium to complete the cycle and shed, the hyperplasia may go away.

Next, within the biopsy fragments, look for possible causes of bleeding:

- *Benign endometrial polyp*: Benign endometrial polyps are composed of fibrotic (pink and spindly) stroma, thick-walled vessels, and usually nonfunctional (atrophic) and/or cystically dilated glands (Figure 17.5).

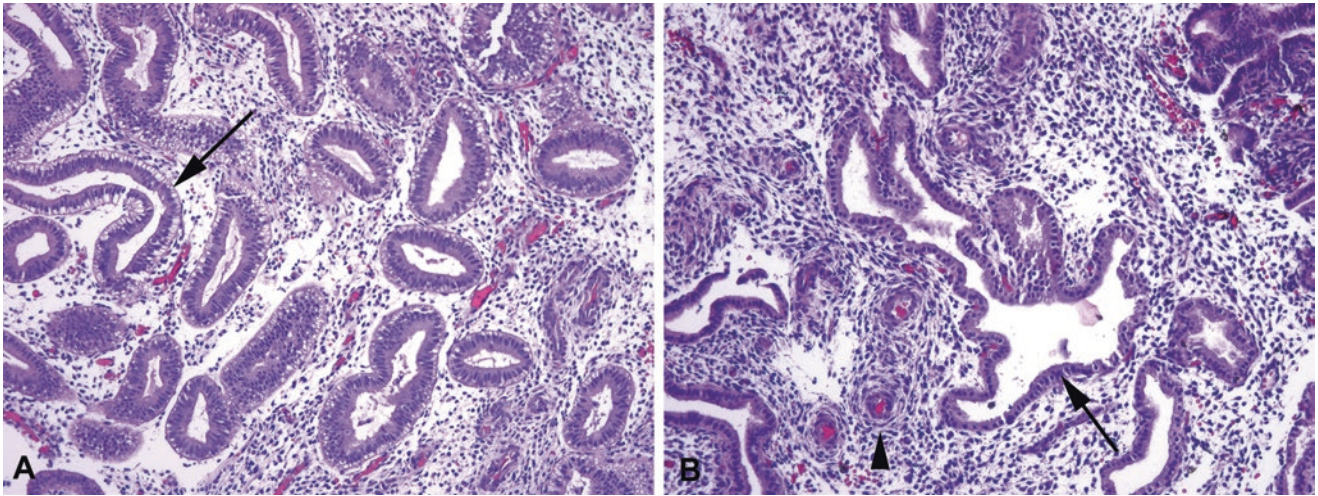


FIGURE 17.3. Secretory endometrium, various phases. (a) In early secretory endometrium, the glands have become tortuous in shape, and prominent cytoplasmic vacuoles are present (subnuclear, in this example; *arrow*). (b) Later in the secretory phase, the cytoplasmic vacuoles are gone, and the epithelium is more cuboidal in shape, with small round nuclei (*arrow*). The stroma is edematous, and early decidualization (accumulation of pink cytoplasm) is beginning around the spiral arteries (*arrowhead*).

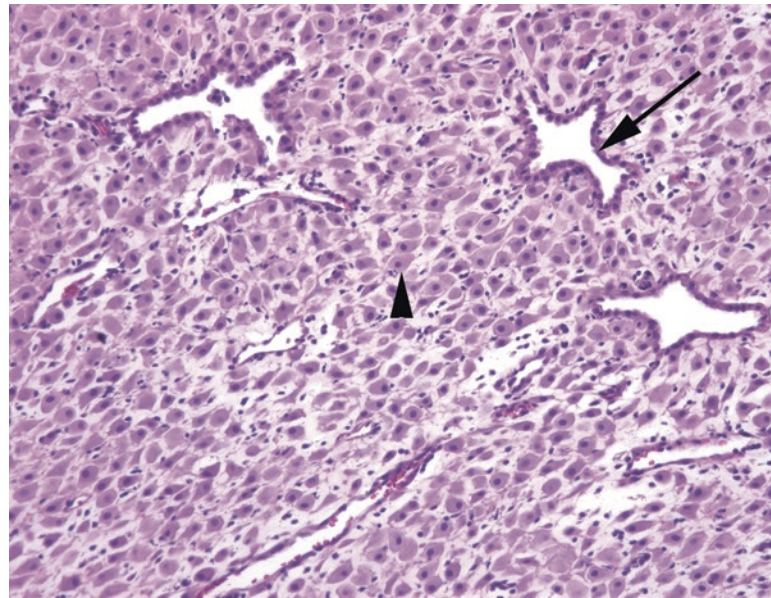


FIGURE 17.4. Progestin-treated endometrium. The glands are still tortuous in shape, like secretory endometrium, but the epithelium is markedly thinned (*arrow*). The stromal cells are decidualized (*arrowhead*), which means they have plump pink cytoplasm and distinct cell borders.

- *Endometrial stromal breakdown:* At the end of the secretory phase, the stroma takes on a blurry blue look as it condenses into small dense aggregates (“blue balls”). The associated surface epithelium shows eosinophilic metaplasia, becoming almost oncocytic in appearance. Fibrin thrombi in vessels and neutrophils are also common features (Figure 17.6). The background endometrium may be end-secretory (in normal menstrual bleeding) or proliferative (in dysfunctional bleeding).

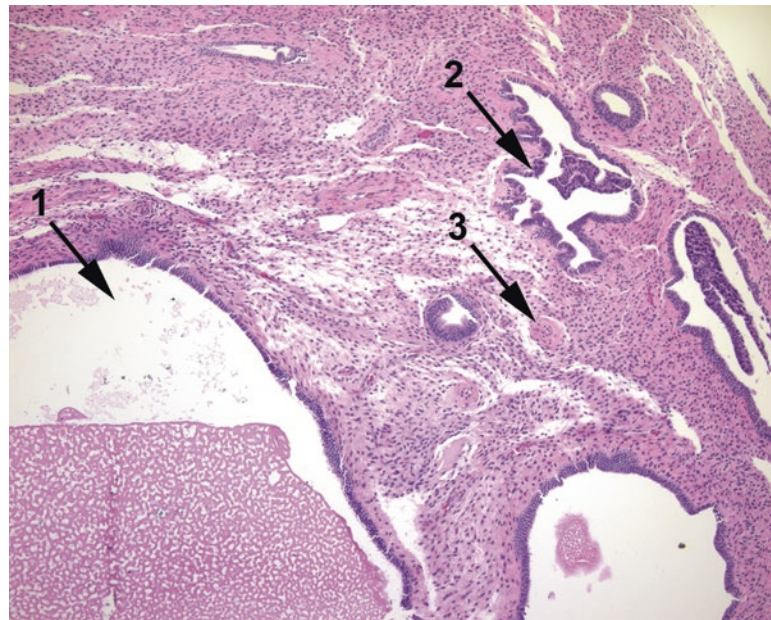


FIGURE 17.5. Benign endometrial polyp. This polyp shows cystic dilation of glands (1), secretory-type epithelium (2), and thickened arteries (3). The stroma is also pink, indicating a high collagen content.

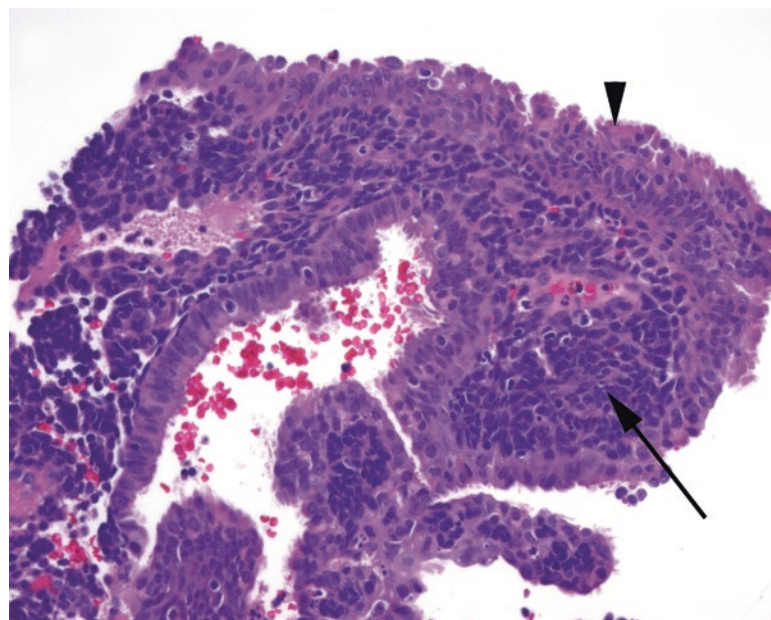


FIGURE 17.6. Endometrial stromal breakdown. The stroma is condensed into an extremely blue mass of tightly packed cells (arrow). The overlying epithelium is expanded into papillary tufts of pink cells, some with cilia, which is a metaplastic change (arrowhead).

- Endometritis: The diagnosis of *acute endometritis* requires microabscesses and epithelial destruction; the presence of neutrophils alone may just indicate normal menstrual breakdown. *Chronic endometritis* is diagnosed by the presence of plasma cells, which are not found in normal endometrium. In general, the stroma takes on a blue spindly look, and there are increased numbers of lymphocytes; these features should prompt you to crawl around at 20× looking for plasma cells (Figure 17.7).

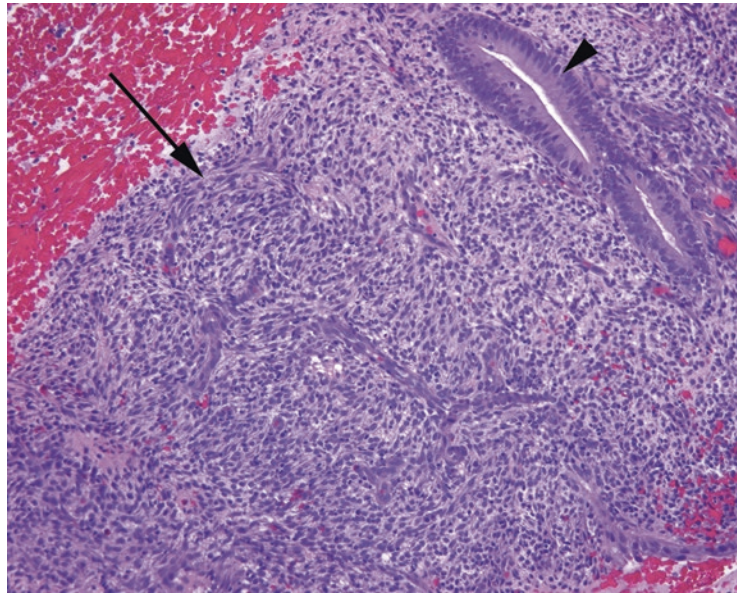


FIGURE 17.7. Chronic endometritis. At low power, the diagnostic plasma cells are not visible, but the spindly, swirling blue stroma (*arrow*) should be a clue to look more closely. The epithelium here is proliferative (*arrowhead*).

- *Disordered proliferative endometrium*: This is a diagnosis used when there is some glandular crowding that falls short of a diagnosis of hyperplasia. It is a mixture of cystically dilated, budding, and tubular glands in a proliferative setting. It typically occurs during anovulatory cycles.
- *Atrophy*: Atrophy, described earlier, is responsible for about half of all cases of abnormal postmenopausal bleeding.

Hyperplasia

Hyperplasia is defined as an increase in the gland-to-stroma ratio, and you will notice it as “crowded glands” in a proliferative setting (Figure 17.8). Endometrial hyperplasia has been classified as simple vs. complex and atypical vs. non-atypical, but it appears to be only the presence of atypia that has prognostic significance, so it is acceptable (and easier) to simply classify it as either *hyperplasia without atypia* or *atypical hyperplasia*. The terms *dysplasia* and *carcinoma in situ* are not applied to endometrium.

The definition of atypia varies among organs. In the endometrium, the *normal* proliferating gland has hyperchromatic, pseudostratified, elongated nuclei and frequent mitoses. This appearance in other organs, such as the colon, may make you think of low-grade dysplasia (such as a tubular adenoma). In endometrial *atypia*, the nuclei become round and pale or vesicular because of the chromatin clumping up and migrating to the nuclear membrane (Figure 17.9). Nucleoli may be prominent. The nuclei lose polarity and are seen at all levels of the epithelium (stratified). Nuclei are larger and show increased variability in size and shape. The cytoplasm becomes more eosinophilic than in non-atypical glands. As a result, a focus of atypical hyperplasia may look more pale than the surrounding glands, and it is this contrast from normal that is the most reliable indicator of atypical hyperplasia. Atypia is not graded.

Atypical hyperplasia (also called *endometrial intraepithelial neoplasia* or EIN) is due to unopposed estrogen stimulation and is a precursor to endometrioid adenocarcinoma. EIN is in fact on a spectrum with well-differentiated endometrioid adenocarcinoma, in that an increasingly complex architecture pushes the diagnosis from EIN up to carcinoma. The line between the two is subjective, and experts may disagree on a tweener case. However, the

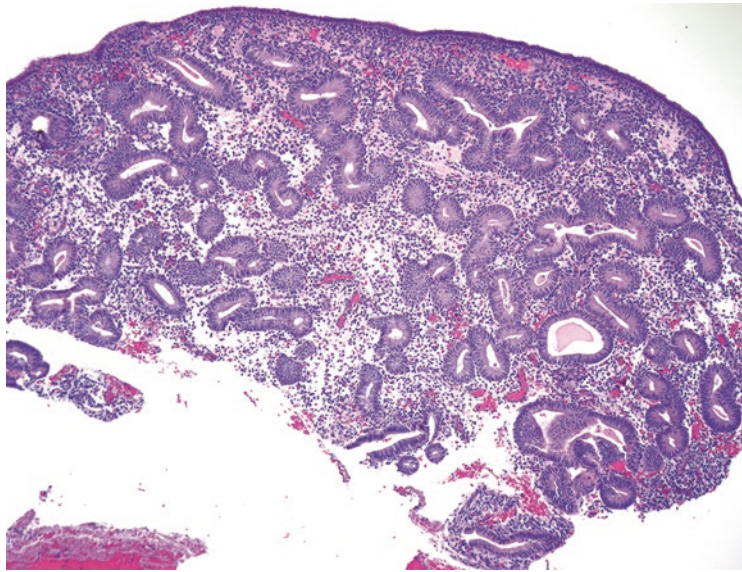


FIGURE 17.8. Hyperplasia without atypia. In this biopsy specimen, the glands appear proliferative and are too crowded (the gland-to-stroma ratio is greater than 1). The cells resemble normal endometrium and are not atypical.

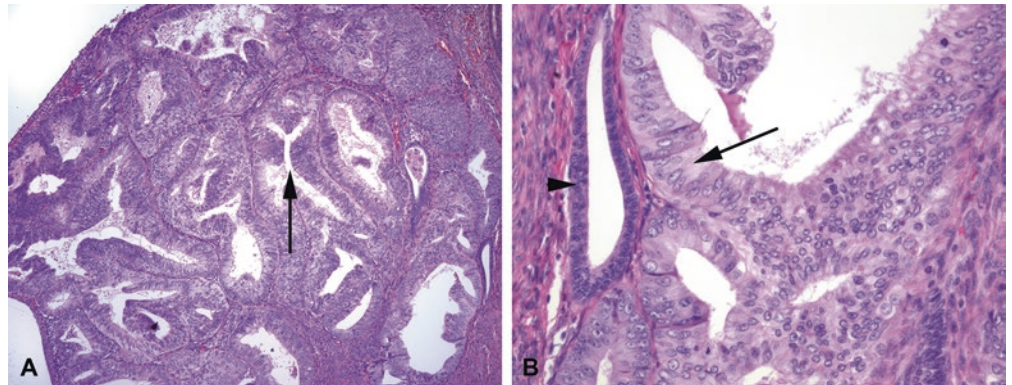


FIGURE 17.9. Atypical hyperplasia. (a) At low power, the glands are very crowded, even back to back, and the gland lumens have become branching and irregular (*arrow*). (b) At high power, comparing the hyperplastic epithelium (*arrow*) with normal residual glands (*arrowhead*), the hyperplastic cells have round nuclei and pale, vesicular chromatin with prominent nucleoli, diagnostic of atypia.

treatment is not significantly different, so an expression of uncertainty (“florid atypical hyperplasia bordering on well-differentiated endometrioid adenocarcinoma”) is an acceptable diagnosis.

Do not be fooled by artifactual crowding in a biopsy. When glands are scraped out of the uterine cavity, they may clump together and look crowded. You need to find an intact piece of endometrium to evaluate the gland-to-stroma ratio. Also, beware of calling hyperplasia in the setting of an endometrial polyp (they are often crowded) or secretory endometrium.

Dating the Endometrium

Proliferative endometrium, in the first half of the 28 day cycle, cannot be dated. The first secretory change occurs, on average, on day 16 or so. This change is the appearance of clear secretory vacuoles at the base of the epithelial cells, below the nuclei. When you see just a few

of these in a generally proliferative endometrium, it is called *interval endometrium*. Beyond that point, histologic criteria are as follows:

Early secretory endometrium (days 16–18; indicates ovulation): distinct subnuclear vacuoles in endometrial glands

Mid-secretory endometrium (days 19–23): supranuclear-to-exhausted vacuoles; orderly row of nuclei, no mitoses; peak secretions in the lumen and ragged luminal border; significant stromal edema

Late secretory endometrium (days 24–28): exhausted glands with a serrated profile; periarteriolar cuffing with predecidua (stromal cells around the arteries begin to get plump pink cytoplasm, creating a pink halo around the vessels)

After day 28 there is prominent necrosis, hemorrhage, clumping, and stromal breakdown consistent with menstrual epithelium.

Changes of Pregnancy

Gestational endometrium is a solid sheet of decidua. Decidual cells are plump polygonal cells with pink to lavender cytoplasm and small oval nuclei. The glandular epithelium becomes almost papillary in nature with a hypersecretory appearance.

Well-formed glands with ballooning, cleared-out cytoplasm, and very pleomorphic nuclei are characteristic of the Arias-Stella reaction, a normal reaction to pregnancy (Figure 17.10). The changes can be focal. The lack of mitoses or infiltration differentiates this from clear-cell carcinoma, as does the age of the patient (clear cell is usually postmenopausal) and the surrounding gestational changes.

In a patient with a history of pregnancy, you may see a placental site nodule: aggregates of intermediate trophoblastic cells, which have scattered large nuclei that look atypical, within hyaline nodules. Placental site nodules should be well-circumscribed. They are the benign remnants of old implantation sites (refer to Figure 16.8).

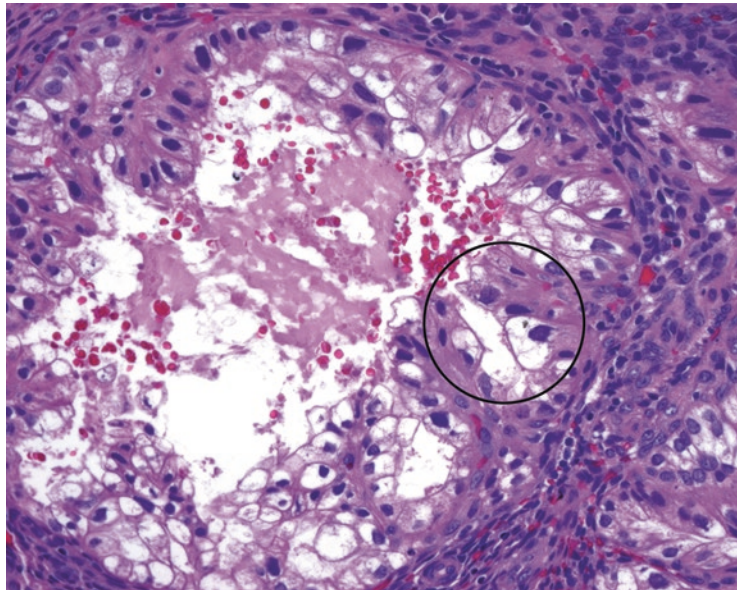


FIGURE 17.10. Arias-Stella reaction. Glands in the gestational endometrium can show bizarre cytology, including cleared-out cytoplasm and large hyperchromatic irregular nuclei (*circle*).

Types of Metaplasia

Metaplasia by itself is a benign process; however, metaplasia is often accompanied by hyperplasia. Still, it is important to recognize these cell varieties and not call them cancer. The less ominous-sounding word *change* may be used instead of *metaplasia*. Cell types include the following:

- Tubal metaplasia: luminal cilia in an epithelium that looks slightly plumped up and cleared out (if you overlook the cilia, the nuclei may worry you).
- Squamous metaplasia: swirling islands of immature squamous cells and, rarely, keratinization.
- Mucinous metaplasia: mucinous, endocervical-type cells.
- Eosinophilic metaplasia: increased eosinophilic cytoplasm; cells can proliferate in glands to the point of looking papillary, but the nuclei remain bland.

Endometrial Malignancies

The endometrium has two cell types that can transform: glandular and stromal. Glandular cells give rise to several types of adenocarcinoma, including endometrioid, serous, and clear cell. The stromal cells give rise to stromal sarcomas; these are entirely different from the leiomyosarcomas of the myometrium.

Endometrioid carcinoma is the most common type of endometrial cancer. It usually occurs in postmenopausal women (80% of cases), like its precursor lesion, atypical hyperplasia. Be cautious about diagnosing either type in a young woman, although it can happen. Endometrioid carcinomas may be associated with microsatellite instability (sporadic or hereditary).

Endometrioid carcinoma, in its well-differentiated form, closely resembles atypical endometrial glands. Architecturally, the glands are fused and complex and cover large areas without intervening stroma (Figure 17.11). The overall pattern may appear cribriform or villoglandular (like a villous adenoma of colon). The tumor may be limited to endometrium or

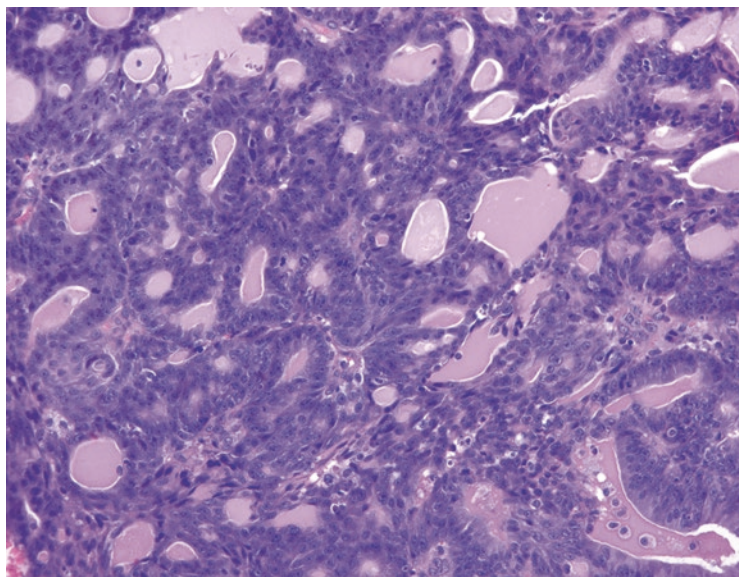


FIGURE 17.11. Endometrioid adenocarcinoma. Foci of well-differentiated endometrioid adenocarcinoma can be difficult to distinguish from atypical hyperplasia. However, the complicated proliferation of fused and cribriform glands in this biopsy specimen is diagnostic of carcinoma. The nuclei in this example resemble those of atypical hyperplasia.

may invade myometrium or adjacent organs; the extent determines *stage*. The assessment of the depth of invasion into myometrium can be difficult, as it is not always clear where native endometrium ends and myometrium begins, especially in areas of *adenomyosis* (islands of endometrial glands and stroma deep in the myometrium).

The *grade* is determined by cytology and architecture. High-grade tumors are equivalent to “poorly differentiated.”

FIGO (International Federation of Gynecology and Obstetrics) grade 1: The tumor is <5% solid, where *solid* means sheets of cells that have lost their glandular differentiation. Areas of squamous metaplasia (common) are not counted as solid areas.

FIGO grade 2: The tumor is 6–50% solid growth pattern.

FIGO grade 3: The tumor is >50% solid growth pattern.

Significant nuclear atypia (one of those features that require experience to judge) can raise the grade by one level unless the tumor is already grade 3. Variants of endometrioid carcinoma include those with squamous differentiation, a villoglandular variant, a secretory variant, and a ciliated cell variant. These variants are identified only when the majority of the tumor takes on that morphology.

Mucinous carcinomas can occur in the endometrium and must be composed of over 50% mucinous cells to qualify. Like endometrioid carcinomas, they are primarily glandular and may have squamous differentiation.

Serous carcinoma is a separate tumor pathway, leading to a distinct type of carcinoma. Serous carcinoma is not associated with hormonal exposure or endometrial hyperplasia. It is considerably more aggressive than endometrioid carcinoma and tends to be diagnosed in older women. It is, by definition, high grade and therefore is not graded.

Histologically, it resembles serous carcinoma of the ovaries. Its hallmark is papillary architecture, although this is not required for diagnosis. The papillae have broad or fine fibrovascular cores with complex branching (Figure 17.12). The cells are notable for extreme atypia, including cherry-red nucleoli, bizarre mitoses, and multinucleated cells.

The precursor lesion is believed to be *serous endometrial intraepithelial carcinoma* (serous EIC), a transformation of the surface epithelium, especially in polyps in older women. Serous EIC is not quite analogous to carcinoma in situ, because EIC itself has metastatic potential. Like serous carcinoma, it is often associated with a *p53* mutation leading to overexpression. An immunostain for *p53* is sometimes used to confirm the diagnosis. Histologically, serous

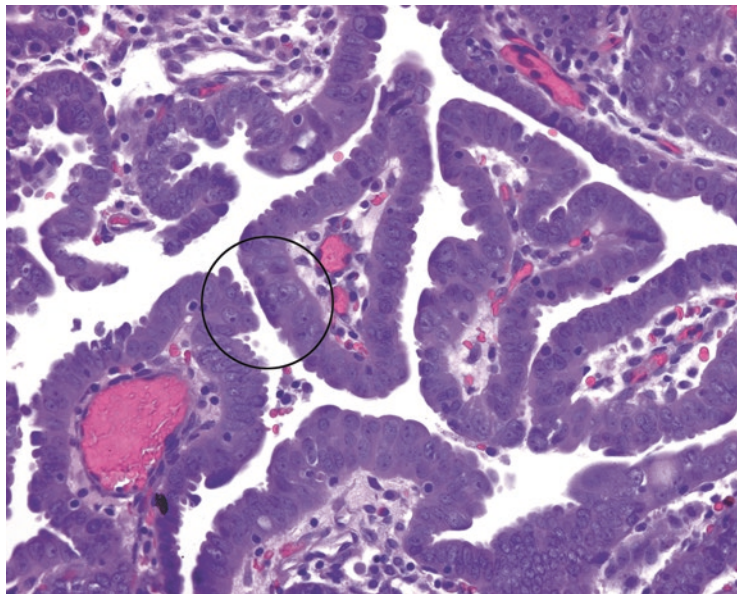


FIGURE 17.12. Serous carcinoma. Papillary structures are lined by atypical nuclei with prominent nucleoli (*circle*).

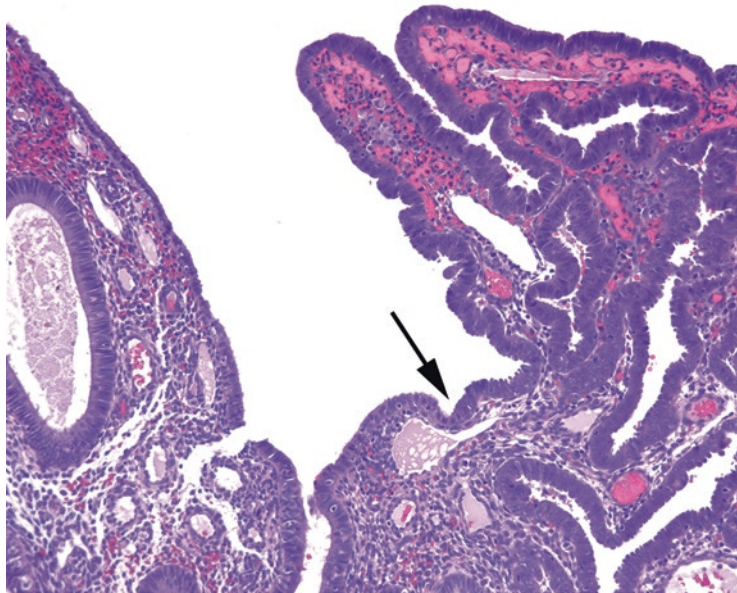


FIGURE 17.13. Serous endometrial intraepithelial carcinoma. There is an abrupt transition (*arrow*) from normal surface epithelium (*left*) to malignant cells (*right*). The cells resemble those of serous carcinoma.

EIC appears as an abrupt transition on the surface from benign atrophic epithelium to pleomorphic, enlarged, atypical, mitotically active cells (Figure 17.13).

High-grade endometrioid carcinoma and serous carcinoma may be difficult to distinguish. Features favoring serous carcinoma, like in ovary, include solid growth with slit-like spaces, papillary structures, and diffuse p53 positivity by immunostain. Note that a dead-negative p53 stain also indicates a mutation and suggests serous carcinoma.

Clear-cell carcinoma, like serous carcinoma, occurs primarily in older women, has no relation to hormone exposure or hyperplasia, and has a poor prognosis. Histologically, it may remind you of clear-cell neoplasms in other organs (such as renal cell). The cytoplasm is glycogen-rich and clear, the cell borders are distinct, and the architecture can be tubular, papillary, or solid. However, be aware that clear cytoplasm can occur in endometrioid carcinomas, so clear cells alone do not make a clear-cell carcinoma. A true clear-cell carcinoma must have significant nuclear atypia, and the architectural features seen in ovarian clear cell (such as hobnailing) support the diagnosis. Like serous carcinoma, this tumor is high grade by definition. Other rare types of carcinoma include squamous, transitional cell, undifferentiated, and small cell carcinoma.

Endometrial stromal sarcoma is a rare malignancy of the endometrial stromal cells. A benign tumor called an endometrial stromal nodule is a circumscribed nodule of endometrial stroma, without glands. The difference between a benign stromal nodule and a *low-grade endometrial stromal sarcoma* (LGESS) is in the interface with the surrounding tissue—sarcomas are infiltrative. These sarcomas have minimal atypia and few mitoses, as well as a prominent plexiform vascular proliferation (like the normal spiral arteries gone wild). At the more malignant end of the spectrum are the *high-grade endometrial stromal sarcoma* (HGESS), a somewhat monotonous round cell neoplasm with a defining translocation, and the *undifferentiated uterine sarcoma* (UUS), a catchall category of high-grade sarcomas with significant nuclear pleomorphism. Distinguishing a UUS from other sarcomas, such as leiomyosarcoma and carcinosarcoma, requires immunostains. (In 2003, the term “high-grade stromal sarcoma” went away for a while, as all of the high-grade tumors were lumped in together as “undifferentiated endometrial sarcomas.” Upon the discovery of a distinct translocation-related subtype of high-grade tumor, the lumpers lost this battle and were forced to reintroduce HGESS in 2014 to cover the new entity, thus rendering everyone who hadn’t been paying attention for a decade more or less current again.)

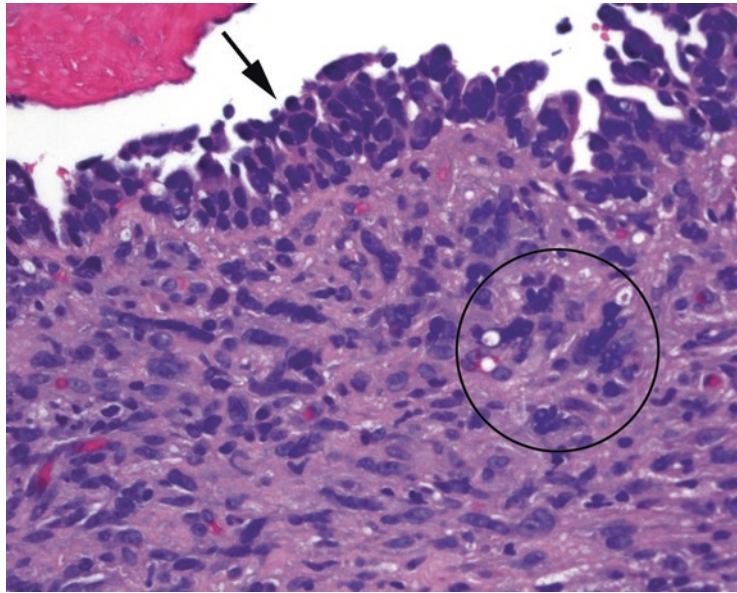


FIGURE 17.14. Malignant Mullerian mixed tumor. This tumor is defined by the presence of carcinomatous cells in the epithelium (*arrow*) and sarcomatous cells in the stroma (*circle*). The carcinoma cells are hyperchromatic and crowded; elsewhere in this biopsy specimen, there were malignant glands. The sarcomatous cells are hyperchromatic, large, and irregular in shape, similar to those found in other sarcomas (see Chapter 29).

Malignant Mullerian mixed tumor (carcinosarcoma) is a biphasic tumor consisting of malignant glands in a sarcomatous stroma. It appears as a recognizable carcinoma, often serous type, with adjacent sarcomatous cells (large pleomorphic nuclei without distinct cell membranes) in the stroma (Figure 17.14). Other soft tissue elements, like skeletal muscle or cartilage, may also show up.

In contrast, an *adenosarcoma* is a neoplasm with benign glands and a malignant stroma. An *adenofibroma* is benign glands with benign stroma. These tumors are similar to the phyllodes tumor of the breast, which can range from malignant to benign stroma.

Myometrium

The most common neoplasm of the uterus is the *leiomyoma* or “fibroid,” a benign smooth muscle tumor of the myometrium. These tumors can be huge, multiple, myxoid, even necrotic, and still benign. Although benign, many are removed for symptomatic relief. When sampling these at the grossing bench, what you are looking for are areas that are different in texture from the typical rubbery dense consistency; areas of necrosis, hemorrhage, or dense white foci should be sampled.

The classic leiomyoma is a spindle cell lesion with intersecting fascicles of elongated cells, typically intersecting at right angles (Figure 17.15). The nuclei are long and thin with fine pale chromatin and small nucleoli. You may also see “corkscrew” nuclei, which are characteristic of smooth muscle. The stroma may be fibrotic, edematous, myxoid, or even hemorrhagic; these are all permissible degenerative changes in the absence of nuclear atypia or a high mitotic rate.

Leiomyosarcoma tends to present as a large, solitary mass and is not thought to arise from preexisting leiomyomas. It may resemble the fascicular leiomyoma, but mitotic activity must be high, over 10 per 10 high-power fields, and cytologic atypia should be prominent (Figure 17.16). As in soft-tissue sarcomas, atypia takes the form of large dark nuclei with crisp, irregularly shaped nuclear borders, usually without nucleoli. The third required feature is tumor necrosis, which must be distinguished from the more innocuous infarct-type necrosis, a common feature of leiomyomas. The threshold for diagnosing leiomyosarcoma is quite high

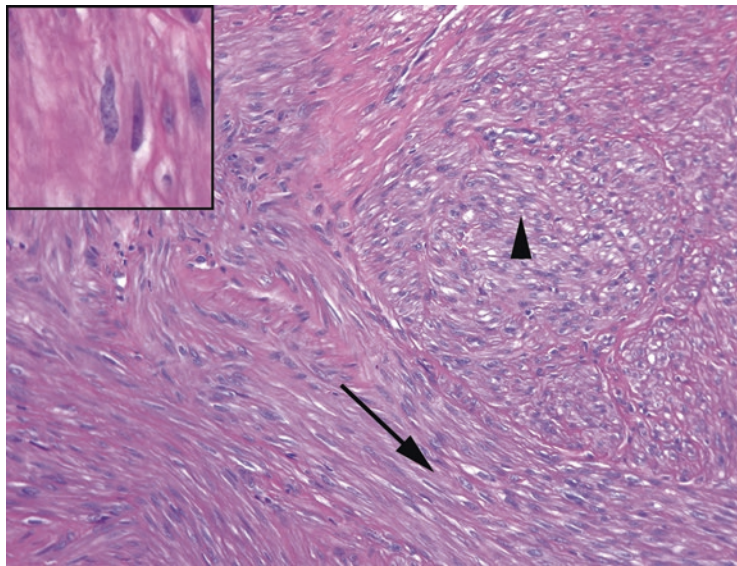


FIGURE 17.15. Leiomyoma. The low-power impression is that of fascicles or bundles of cells, some parallel to the slide (*arrow*) and some coming out at right angles (*arrowhead*). *Inset*: The nuclei are tapered and pale, with occasional paranuclear vacuoles, and sometimes show “corkscrew” morphology, as though the nucleus was twisted longitudinally. (Dog owners may liken this lumpy shape to something else).

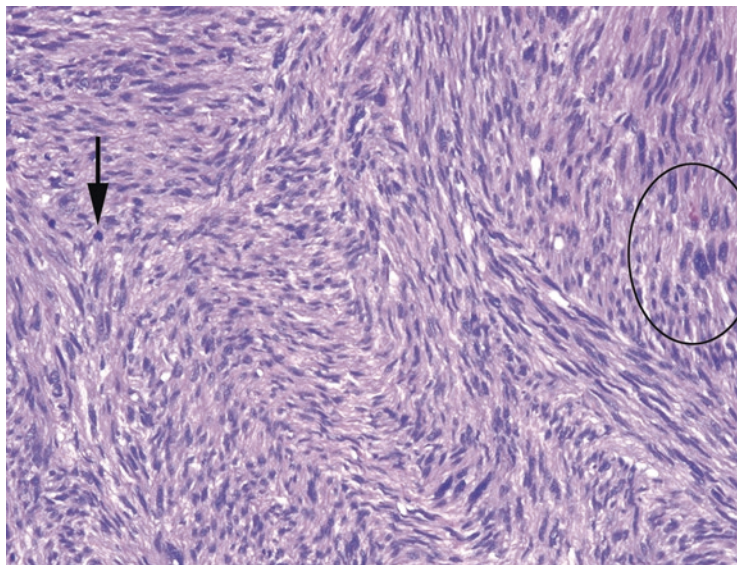


FIGURE 17.16. Leiomyosarcoma. The threshold for diagnosing leiomyosarcoma in the uterus is high. This lesion should be much more cellular than the leiomyoma, with mitoses (*arrow*), atypical and pleomorphic cells (*circle*), and necrosis (not seen here).

in the uterus, unlike a leiomyomatous lesion found in the soft tissue or retroperitoneum, for example. In the uterus, atypia without mitotic activity, or mitoses without atypia, should discourage you from calling a sarcoma.

Adenomatoid tumor is a benign proliferation of mesothelial origin. It usually occurs on the serosal surface of the uterus, resembling a leiomyoma both grossly and microscopically. The mesothelial tumor cells induce a smooth muscle proliferation that is probably often mistaken for leiomyoma. However, on close inspection, you will see small clefted spaces between the muscle bundles, lined by cuboidal cells forming gland-like or angiomatoid lumens. The cells can appear epithelial by histology and in fact would stain for cytokeratins. Accidentally missing it and calling it a leiomyoma does no harm to the patient; mistaking it for metastatic adenocarcinoma would be disastrous, however. Unlike adenocarcinoma, it should stain for calretinin.

The gestational sac begins as a spherical structure, with the fetus surrounded by an *amnion*, a *chorion*, and placental *villi*. One surface of the gestational sac implants into the endometrium and becomes the placenta; the villi on the opposite surface degenerate. When you look at placental slides, you can see the layers of the amnion and chorion, both in the membrane section (Figure 18.1) and on the fetal surface. In both locations, amnion is on the fetal side and chorion on the maternal side. The two membranes can be peeled apart grossly, because there is no tissue connection between the two. As an aside, the inner membrane is also called the amniotic membrane (not amniotic), and the fluid is called amniotic fluid.

The villi are fetal structures; they grow downward from the fetal surface in a branching architecture, like the roots of a tree. Vessels and cells inside the villi are fetal. There should not be any maternal vessels in the placenta itself. The spiral arteries of the decidua (endometrium), invaded and opened by trophoblastic cells, spray maternal blood into the space between the villi.

Immature villi have an open and pale appearance (Figure 18.2); they are large compared with the terminal villi of the full-term placenta (when surface area is most required). They are lined by two cell layers, an outer syncytiotrophoblast and an inner cytotrophoblast layer. Very early villi may have a large heaped-up trophoblastic proliferation on the surface, but it should be polar (only on one surface; for a mental image, google Don King's hair). Circumferential proliferation is suspicious for hydatidiform mole. Mature villi acquire syncytial knots and perivillous fibrin (like hyaline membranes lining the villi). They are tiny—just large enough to hold a few capillaries (see Figure 18.2).

Twin placentas are divided into categories based on how many cell layers they share. Two separate eggs fertilized by two sperm will always form two separate placentas, although they may mash into each other. With two placentas you will see two chorionic plates and two complete sets of membranes (Figure 18.3); this is called diamniotic-dichorionic (di-di). An ovum that splits very early can also produce two entirely separate placentas, so a di-di placenta may be either monozygotic or dizygotic twins.

An ovum that splits a little later, after it has already formed a chorion, will produce two separate amnions and two fetuses; this is a diamniotic-monochorionic placenta (di-mo). An even later split produces two fetuses in the same amniotic sac or monoamniotic-monochorionic (mo-mo). If the split occurs any later than this, conjoined twins will develop.

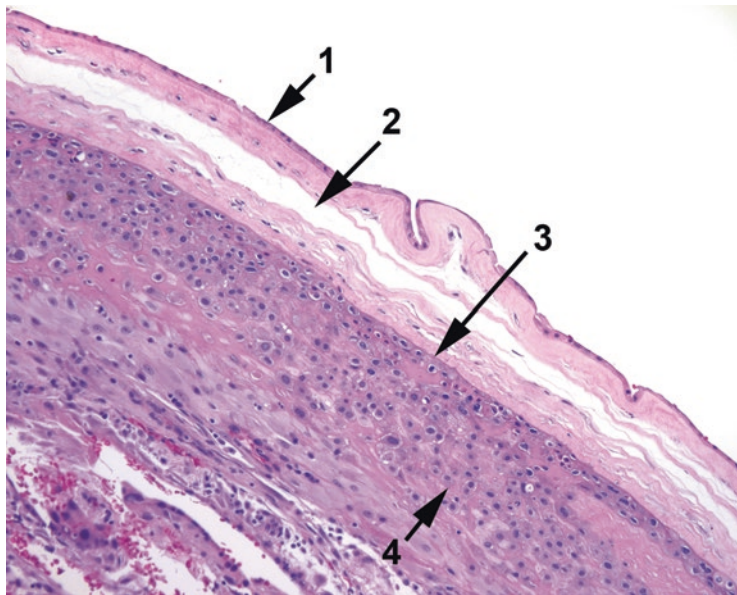


FIGURE 18.1. Placental membranes. In the membrane section, you can see amniochorion (1), an artificial space (2) between amniochorion and chorion (3), and underlying decidua (4).

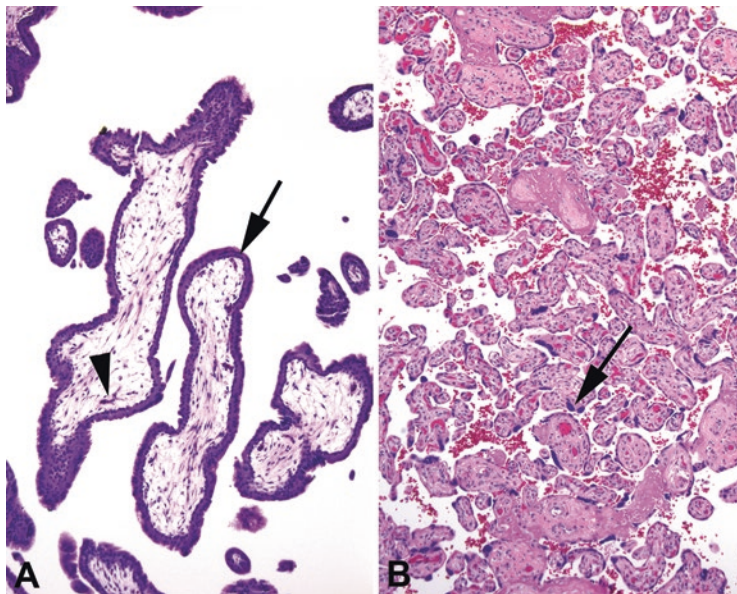


FIGURE 18.2. Immature villi versus terminal villi. (a) Villi at around 8–10 weeks are large in diameter and have a double layer of cells lining the surface (arrow). Tiny fetal capillaries have nucleated red blood cells inside (arrowhead). (b) Taken at the same magnification as A, this shows mature villi at approximately 38 weeks. The villi are much smaller, the fetal capillaries are more prominent, and the cytotrophoblasts have pulled away from the gas-exchange surface into syncytial knots (arrow). Maternal blood and fibrin are visible between villi.

Approach to the Slides

In the *umbilical cord*, look at the vessels on low power (Figure 18.4). There should be two arteries (thick walls and constricted lumens) and a vein (open lumen, or the mouth on the surreal Mr. Bill faces that are found on the walls of most histology laboratories) suspended in the myxoid Wharton's jelly or stroma. The number of vessels is always noted on sign out, because a two-vessel cord may indicate a fetal abnormality.

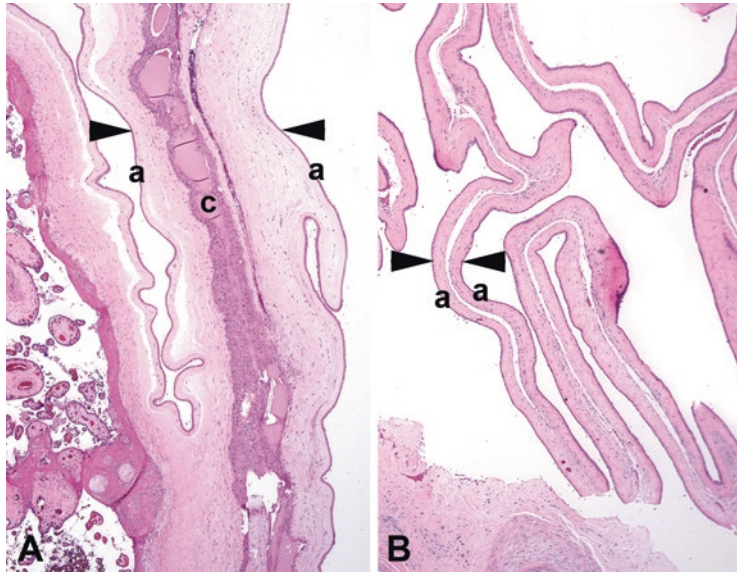


FIGURE 18.3. Twin placentas. (a) In a diamniotic–dichorionic placenta, the dividing membrane is captured here between the arrowheads. Amnion is seen on both surfaces (a), and a double layer of chorion is sandwiched in the middle (c). (b) In a diamniotic–mono chorionic placenta, no chorion is present between the layers (arrowheads) of amnion (a).

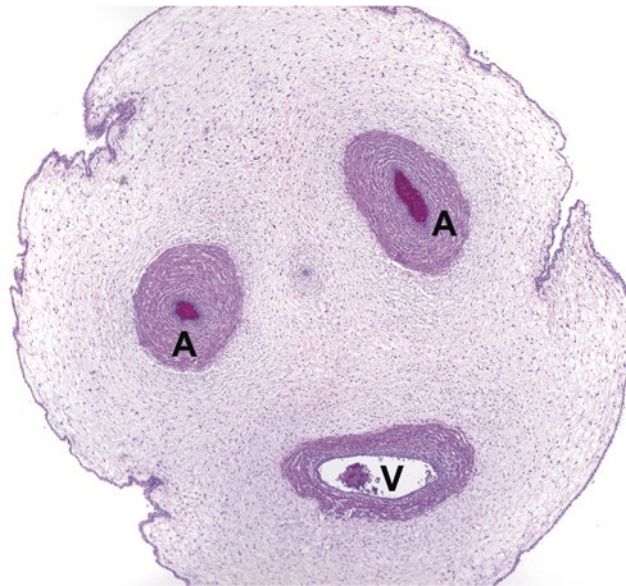


FIGURE 18.4. An umbilical cord in cross section, showing two arteries (A) and one vein (V).

Study the muscular wall of each vessel to look for neutrophils. Umbilical phlebitis, or neutrophils migrating into the vein wall, is an indicator of early funisitis (a fetal inflammatory response). More advanced funisitis involves the arteries (arteritis), and the most severe cases show neutrophils in the Wharton's jelly (Figure 18.5).

The *membrane roll* is evaluated for the following:

- **Chorioamnionitis:** Look for neutrophils invading the chorion and/or amnion. Neutrophils in the decidua (below the chorion) are okay (Figure 18.6). Table 18.1 summarizes staging and grading of chorioamnionitis. Inflammation may also result in a very reactive (tall, papillary) amnion. Unlike funisitis, this is a maternal response.

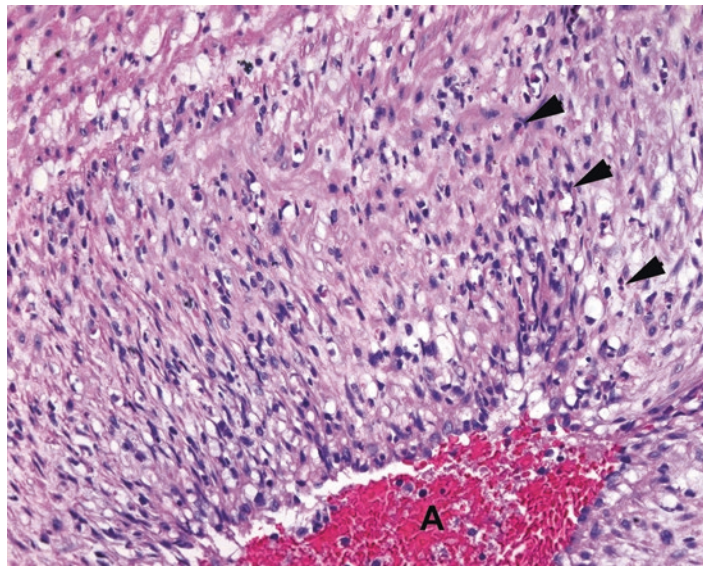


FIGURE 18.5. Funisitis. Neutrophils (*arrowheads*) can be seen squeezing through the muscular layer of an umbilical artery (*A*). This migration is a fetal response to infection.

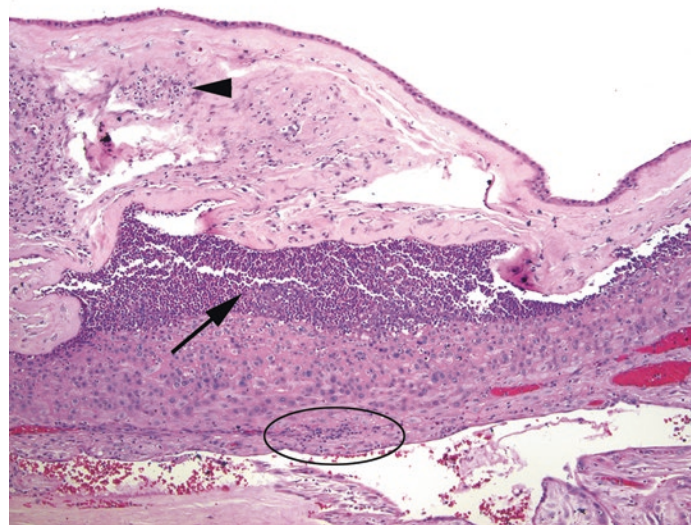


FIGURE 18.6. Chorioamnionitis. A collection of neutrophils (pus) has formed between the amnion and chorion (*arrow*). Neutrophils can also be seen beneath the amnion (*arrowhead*). Inflammation in the decidua (*oval*) may be physiologic and is not sufficient to diagnose chorioamnionitis. This is a maternal response to infection.

TABLE 18.1. Criteria for staging of acute chorioamnionitis and funisitis.

Stage	Maternal response	Fetal response (funisitis)
1	Subchorionitis and chorionitis: <i>maternal neutrophils</i> line up beneath the chorionic surface of either the chorionic plate or membranes	Chorionic plate vasculitis and umbilical phlebitis: <i>fetal neutrophils</i> marginate through the vessel wall
2	Chorioamnionitis: neutrophils cross the basement membrane into the connective tissue between chorion and amnion	Umbilical arteritis: neutrophils in the arterial wall
3	Necrotizing chorioamnionitis: sheets of neutrophils below the amnion, reactive or necrotic amnion, thickened amniotic basement membrane	Umbilical perivasculitis: neutrophils spread out from the vessels into Wharton's jelly

Grade 1 focal disease, *grade 2* extensive disease

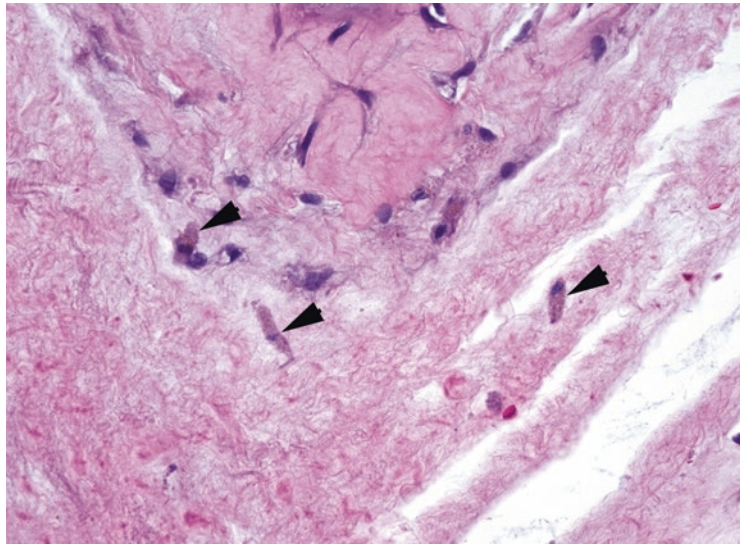


FIGURE 18.7. Meconiophages between the amnion and chorion, with deposits of brown pigment (*arrowheads*).

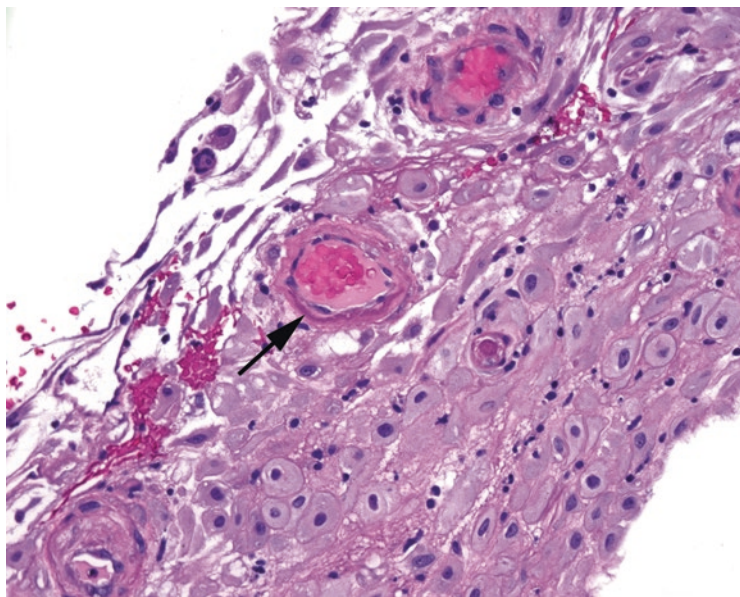


FIGURE 18.8. Fibrinoid necrosis. The dark pink condensation of the wall of this small artery (*arrow*) is an early sign of fibrinoid necrosis, which may be seen in preeclampsia.

- Meconium staining: If, on low power, the amnion has a flat and autolyzed look, with edema separating amnion from chorion, look closely for meconiophages (Figure 18.7). These are histiocytes eating meconium pigment (fetal bile), and they appear granular and brown-gold. The attenuated look of the amnion is due to the caustic nature of the meconium, just as gallbladders look when they have been sitting around for a day or so.
- Decidual vasculopathy: The membrane roll usually shows a nice lining of decidua, where you will find maternal vessels. Evaluate these for fibrinoid necrosis, a finding suggestive of preeclampsia (Figure 18.8).

On the *fetal surface*, look for the following:

- Subchorionitis: This is the earliest manifestation of chorioamnionitis (a maternal response). Neutrophils line up in the fibrin layer below the chorionic plate (*see* Table 18.1 for staging and grading).

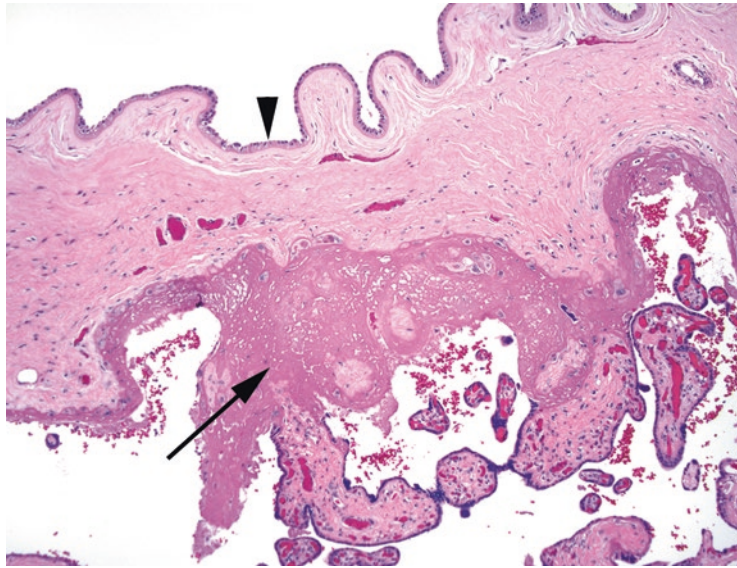


FIGURE 18.9. Fibrin, subchorionic. Subchorionic deposits of fibrin (*arrow*) are normal in a term placenta and should not be mistaken for infarct. The amnion lies atop the fetal surface (*arrowhead*).

- Fetal vasculitis: The vessels that coalesce to become the umbilical vessels arborize on the fetal surface, sandwiched between the amnion and chorion. This is another place to look for a fetal inflammatory response.
- Subchorionic fibrin: This is normal, and you may see large deposits in full-term placentas (Figure 18.9). Do not call it an infarct.

Below the fetal surface and above the maternal surface, you will find the villi, the massive gas- and nutrient-exchange surface area of the placenta. In very early villi, such as in spontaneous or elective abortion, look for changes suggestive of a *hydatidiform mole* (Figure 18.10). A complete mole is a diploid gestation with two paternal genomes, and by definition has no fetus, and large abnormal villi. A partial mole is triploid, with one maternal and two paternal copies, and has a fetus, as well as two distinct populations of villi: normal and abnormal. The villous changes include large swollen villi with no internal fetal vessels, central “cisterns” of proteinaceous fluid, circumferential and atypical trophoblast proliferation, and an irregular scalloped outline similar to a map of a rocky coastline. An incidentally discovered early partial mole can be very subtle and hard to distinguish from the hydropic degeneration of normal villi.

In a more mature placenta, evaluate the *villi* for the following:

- Villous maturity: A full-term placenta should have a dense mass of tiny terminal villi, each full of capillaries and lined with syncytial knots. A preterm placenta (<32 weeks or so) should have more immature villi, with larger contours, few syncytial knots, and myxoid stroma. The presence of terminal villi and knots on a preterm placenta is considered accelerated villous maturation and may indicate ischemia.
- Fibrin: Perivillous fibrin, which looks like hyaline membranes outlining the villi, increases with maturity, especially around the larger stem villi. Massive deposition may look like an infarct.
- Inflammation: Villitis is inflammation within the villi, while intervillitis is inflammation between the villi; the inflammation can be acute, chronic, or granulomatous. An increase in chronic inflammation within the villi may indicate a viral or syphilis infection. Neutrophils or abscesses in the intervillous space are unusual but indicate maternal sepsis, such as from *Listeria*. Often no organism can be found, in which case it is *villitis of uncertain etiology (VUE)*.

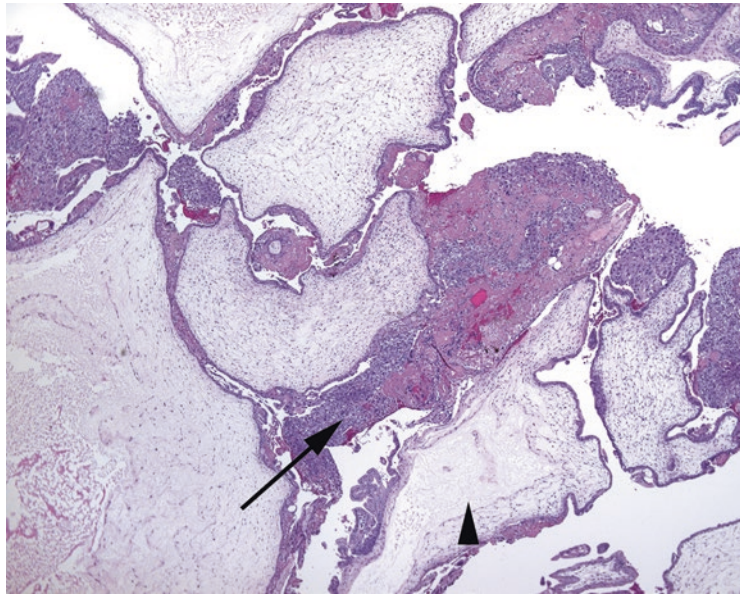


FIGURE 18.10. Molar villi. The villi are markedly enlarged, some with central cavities or cisterns (*arrowhead*). Dense trophoblastic proliferation is visible (*arrow*); on higher power, the cells may be very pleomorphic. This is a complete mole, so there are no fetal capillaries within the villi. Note the irregular coastline-like outlines of the villi.

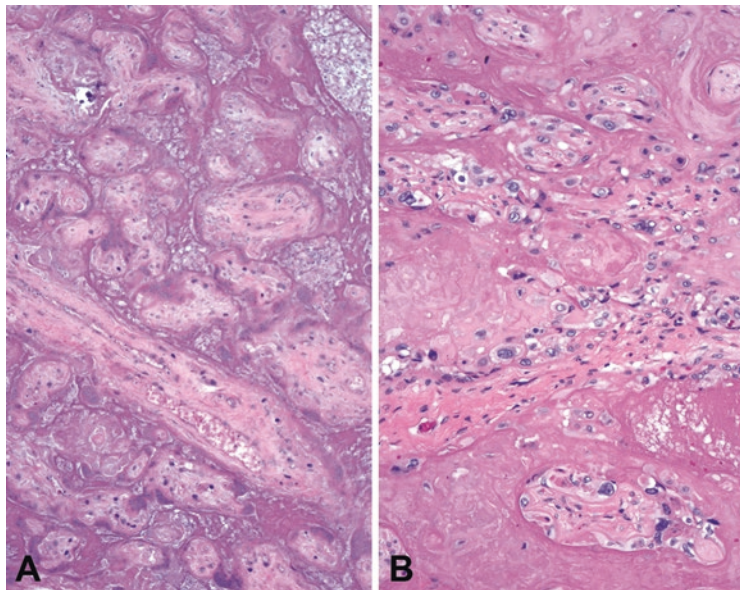


FIGURE 18.11. Infarct versus perivillous fibrin. (a) In an infarct, there is loss of basophilia and cellular detail with residual apoptotic bodies, as in coagulative necrosis elsewhere. (b) In a mass of perivillous fibrin, while the low-power impression is a sheet of consolidated pink, on high power you can see the villi remain viable, with good nuclear detail.

- Infarct: Usually visible grossly as dense white patches, a true infarct has the look of coagulative necrosis (loss of nuclei and cell structure) with the mummified villi touching each other (Figure 18.11). Do not confuse this with perivillous fibrin deposition, in which fibrin encases a wide area of villi, and the encased villi still show nuclear detail and are separated by abundant surrounding fibrin.

- Hematoma: A large acellular mass of fibrin, complete with lines of Zahn, is evidence of a prior hemorrhage. The hematoma may be subchorionic, intraplacental, or retroplacental (clinical abruption).
- Fetal capillaries: After prolonged death in utero or a thrombosis, these capillaries collapse and the villi become avascular and fibrotic. Also look for nucleated red blood cells, which are abnormal in third trimester placentas.

The *maternal surface* shows a layer of decidua, with implantation site changes. Trophoblasts invade the maternal muscular arteries, dissolving their muscular wall to create wide-open pipes (Figure 18.12). This invasive but normal process leaves behind a fibrinous layer—do not mistake this for fibrinoid necrosis or vasculopathy. True fibrinoid necrosis is best seen on the small maternal vessels in the membrane roll and also has an inflammatory component. However, in the maternal surface of the placenta, the persistence of muscular spiral arteries *is* a form of maternal vasculopathy, because it means the trophoblasts did not do their job, and the placenta may be ischemic. This is another component of preeclampsia.

A *maternal floor infarct* is not really a true infarct but a dense rind of fibrin encasing all of the villi along the maternal surface. *Placenta accreta* is the implantation of trophoblastic cells directly into myometrium. Histologically you may see placental villi very close to smooth muscle, with no intervening decidua. Accreta is a cause of postpartum hemorrhage.

Just as the inflammatory response can be divided into maternal pattern (chorioamnionitis) and fetal pattern (funisitis), vascular lesions also divide into maternal and fetal vasculopathies. *Maternal vascular malperfusion* is associated with preeclampsia and intrauterine growth restriction, and the pathological findings include things discussed above, including infarcts, retroplacental hemorrhage, accelerated villous maturation, and decidual vasculopathy, as well as low placental weight for gestational age. It is also important to remember that sometimes there are no pathologic findings in clinical preeclampsia.

Fetal vascular malperfusion, on the other hand, corresponds to lesions of the cord, thrombosis of fetal vessels, and fetal cardiac abnormalities. The findings here include thrombosis of fetal vessels, avascular villi, and karyorrhexis within the terminal villi. Similar changes can be seen in fetal death in utero, so determining if fetal vascular changes are the cause or effect of a fetal death can take experience.

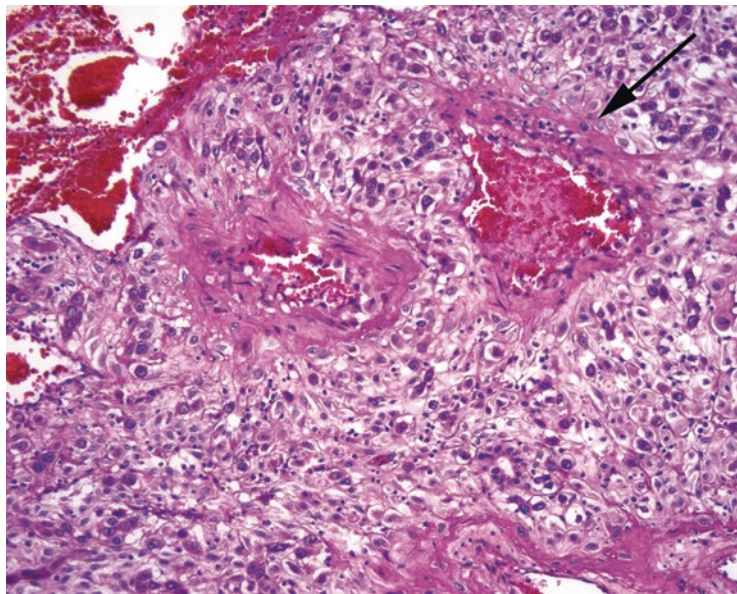


FIGURE 18.12. Trophoblasts in vessels. Intermediate trophoblasts (*arrow*) invading the wall of the maternal arteries. This is a normal process, opening firehoses of blood to supply the placenta.

Gestational Trophoblastic Disease

Lesions of trophoblasts range from the completely benign *placental site nodule*, which is a small island of trophoblasts left over from a remote pregnancy, to the aggressive and malignant choriocarcinoma. In between are the poorly understood entities of *exaggerated placental site*, which is often associated with a complete mole, and the very rare *placental site trophoblastic tumor* and *epithelioid trophoblastic tumor*. These latter two are mass-forming lesions of intermediate trophoblasts, which are the large pleomorphic smudgy nuclei seen invading blood vessels in the normal placenta, so they are not likely to be overlooked in a biopsy. The challenge is more in correctly identifying which tumor type you see. A quick nonscientific survey reveals that nine out of ten general surgical pathologists prefer to send trophoblastic tumors to an expert for diagnosis.

Breast biopsy specimens come in several sizes. There is the core biopsy, which is a large-bore needle biopsy, and the excisional biopsy, which is like a small lumpectomy. Some institutions perform cytologic studies (fine-needle aspirations), but their usefulness is limited, as many breast diagnoses are more architectural than cytologic. Biopsies are performed, with few exceptions, to rule out malignancy; there are almost no other disease processes that require tissue monitoring. A biopsy specimen with carcinoma or carcinoma in situ will trigger either a lumpectomy, in which a portion of the breast is removed (a partial mastectomy, breast-conserving therapy), or a mastectomy. The mastectomy itself may include sentinel lymph nodes or an entire axillary dissection. Biopsies and most lumpectomy specimens are entirely submitted, and anything that is oriented is inked with four to six colors so we can identify all of the margins later. Mastectomies have only two margins, deep and superficial, and are representatively sampled by quadrant.

Normal Histology

The breast is sort of a giant specialized sweat gland, and so it has secretory glands (acini or lobules), arranged like grapes, and ducts, like the grape stems. A single bunch of grapes is a terminal duct lobular unit (TDLU; Figure 19.1). The ducts from these TDLUs all converge on the nipple, which has multiple large ducts and smooth muscle for ejecting the milk. The breast of a child or male will have ducts but no lobules. During lactation, the lobules fill up with fatty vacuoles of milk, giving them a very characteristic look usually called *secretory* or *lactational change*.

Each lobule and duct is composed of two cell types, the outer myoepithelial layer and the inner epithelial cells (see Figure 19.1). This is an important feature that can separate an in situ lesion (two cell types) from an invasive one (one cell type). The whole structure is bounded by a basement membrane, which is the boundary between in situ and invasive cancers. While there are unusual myoepithelial tumors, in this chapter we will only cover epithelial lesions.

Approach to the Biopsy Specimen

When signing out a core biopsy, there are certain things that should be included in the diagnosis. For malignant lesions, in situ or invasive, it is helpful to give an indication of how differentiated the tumor is, or the *grade*. Some institutions do not formally grade a core, but you should at least note the nuclear grade (for ductal carcinoma in situ [DCIS]) or whether it is well/moderate/poorly differentiated (for invasive cancer). These three tiers of differentiation correspond roughly to the three Elston grades.

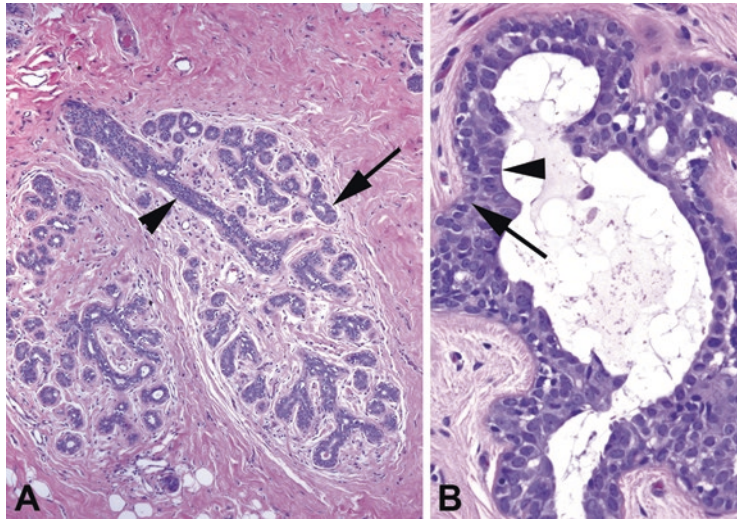


FIGURE 19.1. Normal breast. (a) The terminal duct lobular unit (TDLU) is arranged like a cluster of grapes, with the duct (*arrowhead*) as the stem and secretory lobules (*arrow*) as the grapes. The rounded and circumscribed border of the TDLU is a key feature of noninvasive lesions. (b) The benign breast always has two cell layers, the outer myoepithelial cells (*arrow*) and the inner epithelial cells (*arrowhead*). In situ lesions also have two cell layers.

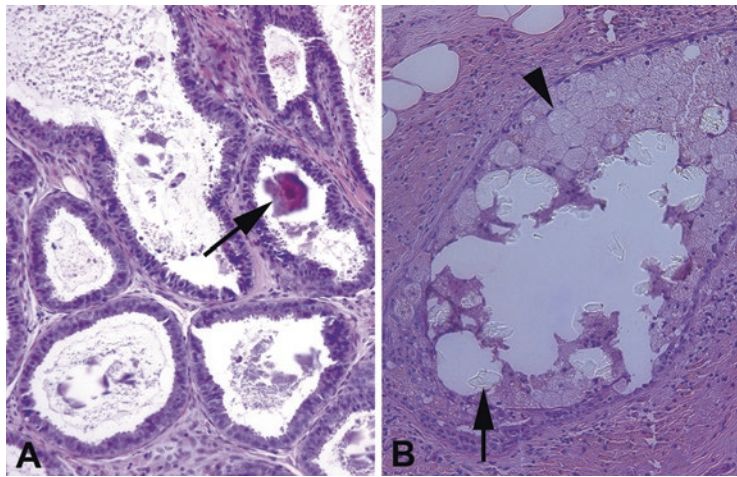


FIGURE 19.2. Calcifications. (a) Microcalcifications in this columnar cell lesion appear as tiny purple rocks (*arrow*), which may shatter and drag through the tissue, creating telltale scratches in the H&E stain. (b) Calcium oxalate does not pick up hematoxylin and therefore is only visible with a polarizer or when the condenser is flipped down, as in this photograph. The oxalate crystals (*arrow*) are seen in a duct space, surrounded by foamy macrophages (*arrowhead*).

Second, if microcalcifications were seen on mammography, you must note whether they are present in the specimen and in what context (such as “in association with usual duct hyperplasia”). Failure to find the microcalcifications leads to x-raying the block, calling the radiologist, and cutting deeper levels. Microcalcifications usually are gritty and dark purple, like calcification in other tissues, but occasionally take the sneaky form of calcium oxalate, clear refractile crystals best seen with polarized light (or flipping the condenser down; Figure 19.2).

Finally, your goal should be to identify the mass or radiographic abnormality the clinicians have detected. If there is no malignancy, you should be looking for some explanation for their findings. Aside from microcalcifications, which do explain a mammographic lesion, you should be looking for anything that could cause a palpable mass, such as fibrosis, cysts or cyst wall, fat necrosis, and benign tumors such as fibroadenomas.

Fibrocystic Changes

Fibrocystic changes are very common in young women, and many palpable lumps turn out to be nothing more than fibrocystic change. These may be signed out as “Benign breast tissue with fibrocystic changes, including...” and then a list of the features. These features include the following:

- Fibrosis: dense pink collagen among the lobules.
- Cysts: often visible grossly, thin walled, and full of clear fluid (Figure 19.3).
- Usual duct hyperplasia: described in detail in a later section.
- Adenosis (too many glands or lobules) or sclerosing adenosis: This is a big pitfall because the lobules can look very crowded and worrisome. This is especially true of sclerosing adenosis, in which the proliferative lobules are squeezed together by fibrosis, making them look small and infiltrative (Figure 19.4). The reassuring myoepithelial cell layer can be hard to see. However, sclerosing adenosis should have an overall lobular (circumscribed and rounded) architecture, and myoepithelial cells should be visible in some glands.
- Apocrine metaplasia: Breasts are just big sweat glands, remember? Apocrine metaplasia means the epithelial cells lining the ducts look like apocrine glands (Figure 19.5); they acquire a lot of bright pink cytoplasm, can get a hobnail profile protruding into the lumen, and have enlarged nuclei with prominent nucleoli (not unlike Hurthle cell change in the thyroid). It is important to recognize this entity as a metaplastic, not a dysplastic, change.
- Fibroadenomas: A biphasic (two cell types) proliferative lesion. The ducts are proliferating (adenoma), as is the stroma (fibro-). (A similar lesion in the ovary is called an *adenofibroma*.) This benign tumor has thin, branching ducts set in a sparsely cellular fluffy pink stroma (Figure 19.6). The ducts often have a myxoid pale halo around them, and the proliferative stroma compresses the ducts into slits. Old fibroadenomas may become hyalinized and calcified. Fibroadenomas can occur alone or in association with fibrocystic changes.

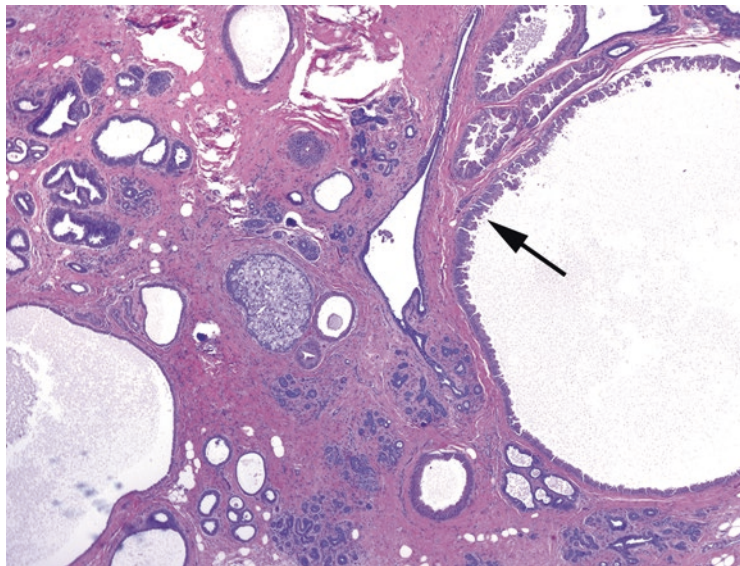


FIGURE 19.3. Fibrocystic disease. In this example, large dilated duct spaces are visible, some with a lining of apocrine metaplasia (*arrow*). The stroma is dense and fibrotic (pink).

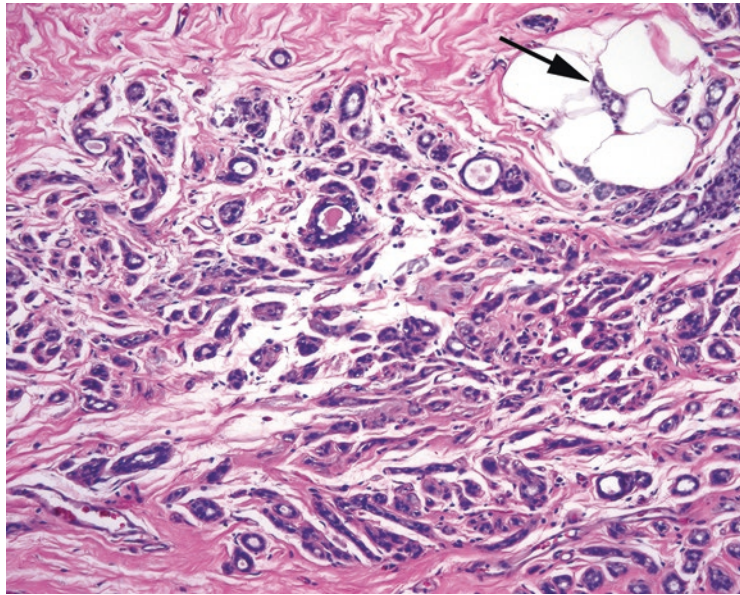


FIGURE 19.4. Sclerosing adenosis. On high power, this benign lesion looks infiltrative. Tiny tubules are entrapped in a fibrotic stroma, and some tubules are even seen among fat (*arrow*). Because of the compression, myoepithelial cells are not visible. Clues to the diagnosis include a circumscribed lesion at low power, the lack of desmoplastic reaction, and an intact myoepithelial cell layer seen on immunostains.

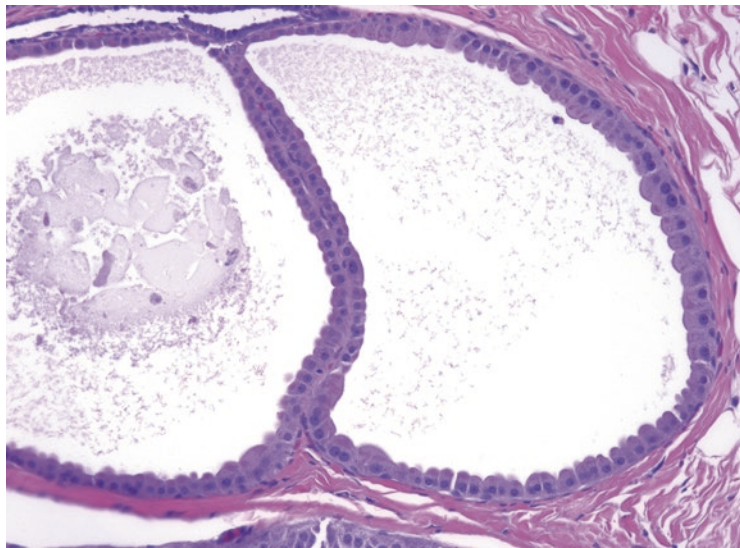


FIGURE 19.5. Apocrine metaplasia in fibrocystic disease. The epithelial cells lining the dilated duct are large and plump, with abundant dark pink cytoplasm, and round nuclei with prominent nucleoli. Secretions (the granular schmutz in the lumen) are common.

The *phyllodes tumor* is another biphasic lesion, which has a similar appearance but a much more cellular stroma than a fibroadenoma. The phyllodes (*leaf-like*) tumor is graded based on how aggressive the stromal growth pattern is and ranges from benign to malignant. This leaf-like pattern is often indicative of biphasic tumors with a proliferative stroma and is seen in biphasic tumors of other organs.

Fat necrosis is evidence of a prior biopsy or other trauma. It can be hard, painful, calcified, or discolored. By clinical examination it may be suspicious for malignancy. It is also very

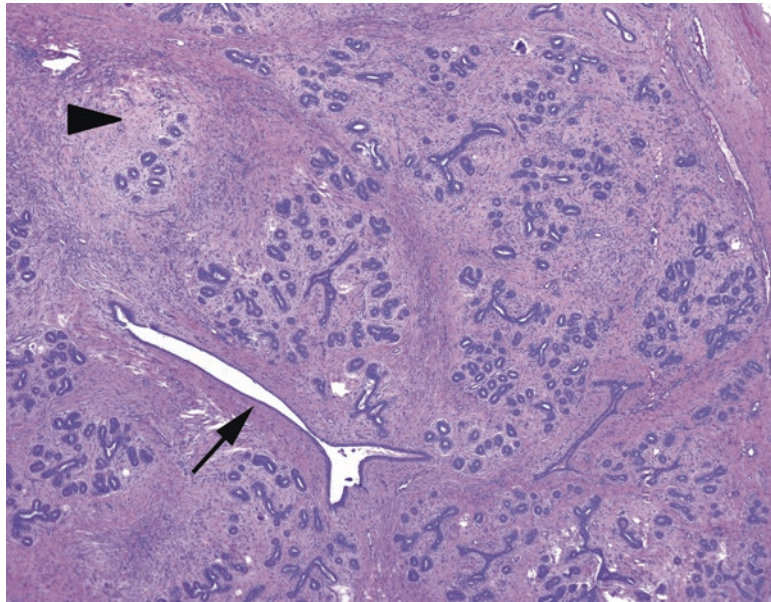


FIGURE 19.6. Fibroadenoma. At low power, the fibroadenoma is a well-circumscribed nodule (the perimeter is not shown here). Within the lesion, the secretory lobules stand out in slightly edematous (pale) stroma (*arrowhead*), and the ducts are compressed into slit-like spaces (*arrow*) by the proliferative stroma.

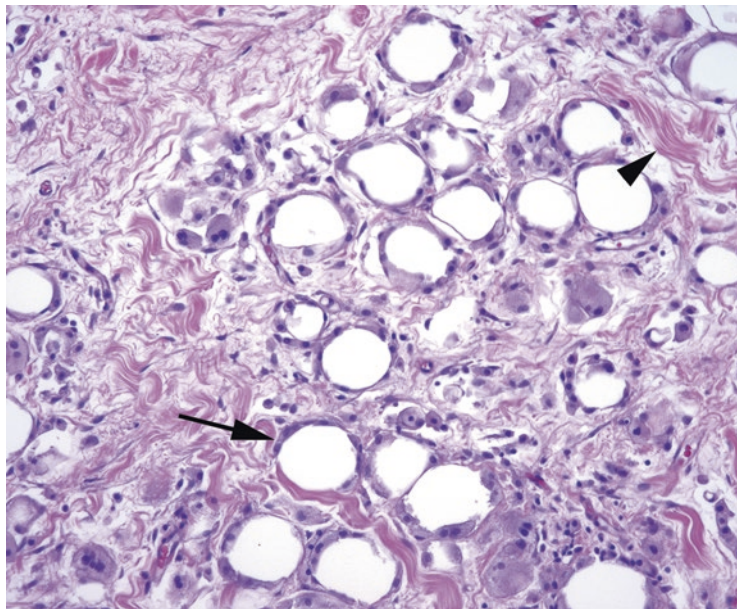


FIGURE 19.7. Fat necrosis. In an area of fat necrosis, secondary to trauma or surgery, the fat cells die but the globes of lipid remain. Foamy macrophages ring each dead fat cell (*arrow*), digesting the lipid; the spaces between the fat cells are filled in by fibrosis (*arrowhead*).

distracting in interpreting re-excision biopsies, where the prior surgery has left extensive fat necrosis. The key features (Figure 19.7) are as follows:

- Disrupted and irregular fat cells
- Foamy macrophages and giant cells
- Edema and hemosiderin
- Acute inflammation
- Fibrosis and calcification (in older lesions)

Intraductal Papilloma

The papilloma is composed of proliferative but benign secretory and myoepithelial cells lining a branching arbor of fibrovascular cores (Figure 19.8). The lesion is usually found in the large central ducts and can become fibrotic (sclerosing papilloma) or calcified with age. Rarely, carcinoma can arise in a papilloma.

Ductal and Lobular Proliferative Lesions

Before we go any further, it is important to understand that deciding whether a lesion is ductal or lobular has nothing to do with whether you find it in a duct or a lobule. Lobular carcinoma in situ (LCIS) can fill a duct, and DCIS can invade a lobule, so there is no need to struggle to identify which structure you are looking at. Instead, *ductal* and *lobular* refer to *distinct morphologic patterns of in situ or invasive carcinoma*. They probably represent cancer pathways arising from a common cell type by two different mechanisms, analogous to the two cancer pathways in colon, but there are plenty of examples of “tweener” lesions (features of both) that are signed out as “mixed mammary carcinoma.”

Benign hyperplasia of ductal-type epithelium (usual ductal hyperplasia) is common, whereas benign hyperplasia of lobular-type epithelium is not a thing. However, both cell types can occur in an atypical hyperplastic lesion (atypical ductal or lobular hyperplasia [ADH or ALH]), carcinoma in situ (DCIS and LCIS), and invasive carcinoma (invasive ductal or invasive lobular).

Usual ductal hyperplasia refers to a proliferation of cells within the ducts. The usual monolayer of cuboidal cells heaps up into mounds or even fills the ducts. Features of usual ductal hyperplasia include the following:

- The cells have an overall pale look; they are normochromic.
- Cells appear jumbled, overlapping, or streaming and almost syncytial (Figure 19.9).

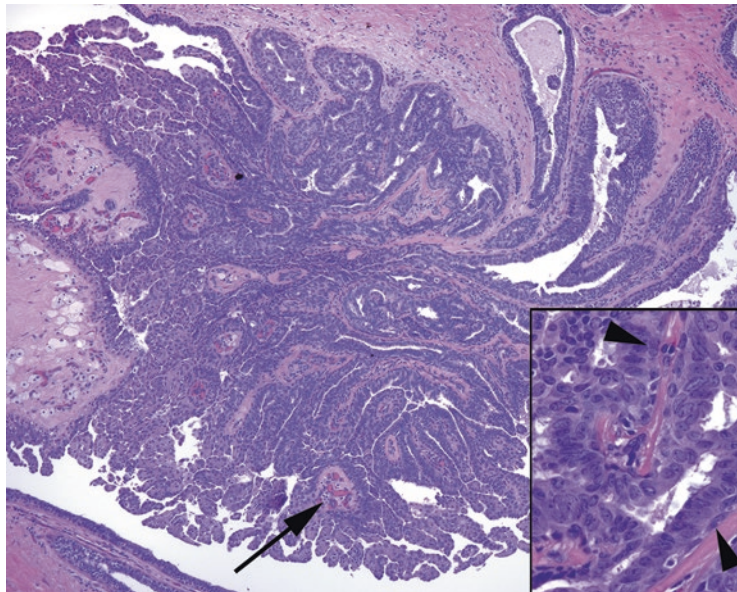


FIGURE 19.8. Intraductal papilloma. The branching structure fills a subareolar duct; smaller, more distal examples may be called micropapillomas. Although there is florid usual ductal hyperplasia, resulting in fusion of multiple branches of the papilloma, distinct fibrovascular cores are still visible (*arrow*). *Inset:* along each fibrovascular core, you should still see myoepithelial cells (*arrowheads*), which differentiates this from a papillary carcinoma.

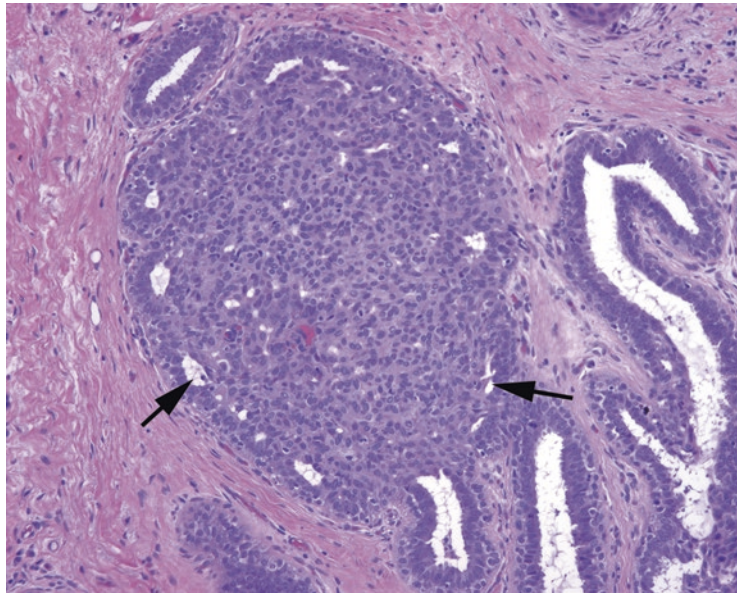


FIGURE 19.9. Florid usual ductal hyperplasia. The cellular proliferation entirely fills this duct, but the cell population is swirly and heterogeneous, with randomly overlapping nuclei. The peripheral ring of slit-like spaces (*arrows*), as though this clot of cells floated into the duct and stuck there, is classic for usual ductal hyperplasia.

- Heterogeneity (not to be confused with pleomorphism) is present. The nuclei, all bland with even chromatin and smooth nuclear membranes, range slightly in size and shape as though they were drawn by a lazy artist.
- Ducts may be filled with cells and may even have a cribriform look at low power, but on higher power, the nuclei should be streaming, flowing parallel to the lumens, as opposed to polarizing perpendicularly (radially) around the lumen. Luminal spaces should be slit-like or irregular, not round, and may be “fuzzy” (due to apocrine secretions).

Ductal carcinoma in situ may be low grade, which is a homogeneous population of cells, or high grade, which is a pleomorphic population of cells. Low-grade DCIS (nuclear grade 1) takes some getting used to, because it is in fact *more* homogeneous and regular than the normal breast tissue, a feature not normally associated with atypia. It is also recognized more by architecture than by nuclear features. You should get the impression that there is a monotonous, clonal population of cells, with evenly spaced dark nuclei and distinct cell borders. High-grade DCIS (nuclear grades 2–3) is more similar to what we recognize elsewhere as cellular atypia. It should still have discrete nonoverlapping cells; it also may get very pink. Irregular nuclear borders, enlarged nuclei, and nucleoli are common.

Architectural patterns of DCIS include the following:

- Cribriform: sharply punched-out round holes in the mass of cells, with cells lined up around the lumens like rosettes (Figure 19.10)
- Solid: a solid sheet of monotonous cells filling the duct space
- Micropapillary: top-heavy lollipop protrusions into the lumen, without true fibrovascular cores; must also have cellular monotony as above
- Comedo: a rim of malignant, usually high grade, cells with central necrosis (see Figure 19.10)

Remember that DCIS by definition has not crossed the basement membrane, and the outer myoepithelial layer remains intact. The intact myoepithelial layer can be highlighted by immunostains, which is useful in situations in which it is hard to distinguish in situ disease from invasive. DCIS is treated as a precursor to malignancy, and the treatment goal is total excision. Therefore, on anything but a core biopsy, you must document its distance *from each margin*.

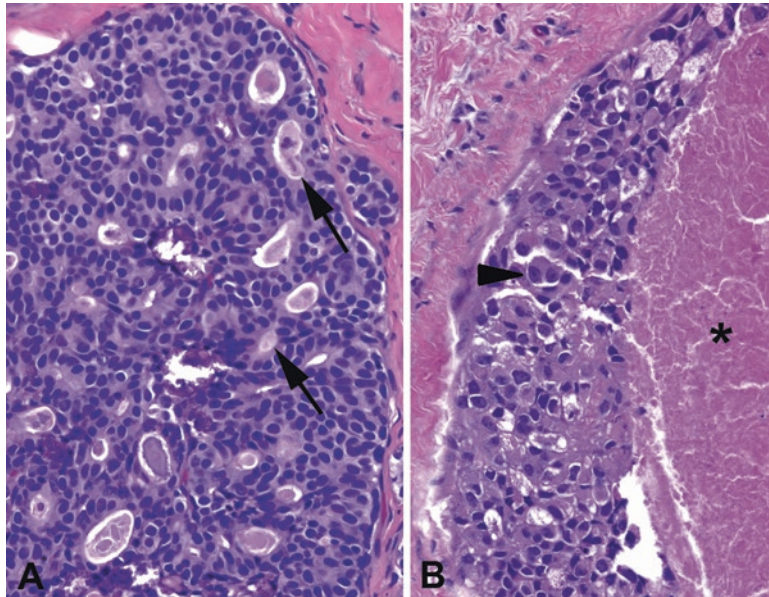


FIGURE 19.10. Ductal carcinoma in situ (DCIS). (a) In low-grade DCIS, the cells are monotonous, uniform, and largely nonoverlapping, and they form cribriform duct spaces with the cells polarized around the tiny lumens (arrows). (b) In high-grade DCIS, the cells have lost their monotony and are instead pleomorphic, some with prominent nucleoli (arrowhead). At the center of the dilated duct, there is necrosis (asterisk), indicating comedo-type DCIS.

Do not expect to get comfortable with the diagnosis of *atypical ductal hyperplasia* until you have mastered usual ductal hyperplasia and low-grade DCIS. Atypical ductal hyperplasia falls somewhere in between and has no definitive criteria other than “has some but not all of the features of low-grade DCIS.” This diagnosis is also used in the setting of a single focus of apparent low-grade DCIS measuring less than 2 mm or involving only a single duct profile. In a core biopsy, atypical ductal hyperplasia is interpreted as “get me more tissue.” The usual therapy for DCIS is excision +/- radiation, so there is some reluctance to overcall it on a core biopsy. In an excision, however, if there is DCIS present, this trumps ADH, and the ADH component need not be mentioned.

Invasive ductal carcinoma is invasive carcinoma arising from a DCIS lesion, and therefore the cells of invasive ductal carcinoma look similar to those you see in DCIS. In its most common form, invasive ductal carcinoma is the cancer formerly known as *scirrhous*, so-called because of the dense desmoplastic reaction generated. High-grade ductal carcinoma is eye-catching even to the untrained eye, as a cellular lesion with irregular ducts and nests of cells, radiating outward in a stellate and decidedly un-TDLU-like shape (Figure 19.11). The cells are large, with large pleomorphic nuclei and substantial pink cytoplasm. Necrosis and mitoses are common. Nests of tumor cells can imitate ducts or tubules in the stroma or acquire large necrotic centers like comedo-DCIS. For this reason it is sometimes hard to tell invasive carcinoma from DCIS or even benign tubules. Stains for myoepithelial borders are helpful here: invasive cancer does not have any.

Variants of ductal carcinoma include the following:

- Tubular: a very well-differentiated cancer composed entirely of cytologically bland small angular tubules; may coexist with lobular carcinoma (Figure 19.12).
- Mucinous or colloid: characterized by pools of mucin and floating fragments of neoplastic epithelium (Figure 19.13).
- Medullary: a well-circumscribed yet ugly group of cells, with a dense lymphocytic infiltrate.
- Micropapillary: a histologic subtype in which florets of tumor cells are seen floating in a cleft in the tissue, similar to micropapillary serous carcinoma of ovary or the micropapillary pattern of lung adenocarcinoma. The presence of micropapillary architecture is a poor prognostic sign.

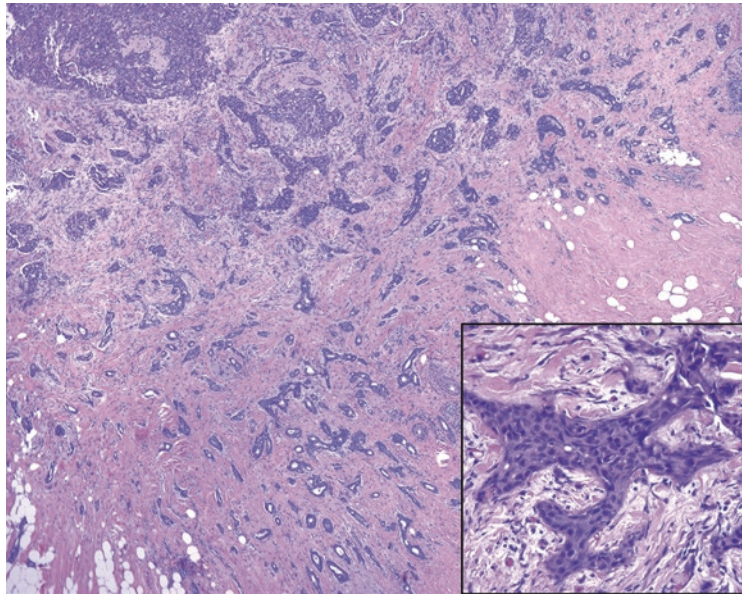


FIGURE 19.11. Infiltrating ductal carcinoma. At low power, the irregular border of the lesion is evident, with small angular tubules radiating outward into the fat. Grossly, this lesion would have a stellate appearance, and the dense stromal reaction would make the lesion very hard. *Inset:* the irregularly shaped nests of tumor cells create a desmoplastic stromal reaction, which is a combination of edema (white space) and fibrosis (pink collagen).

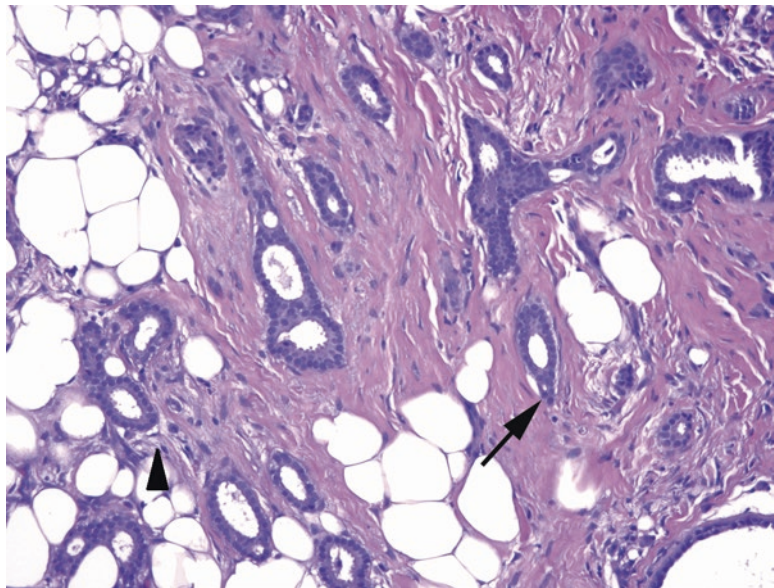


FIGURE 19.12. Tubular carcinoma. Well-formed tubules with pointed ends (*arrow*) and round, monotonous cells infiltrate through the stroma and fat. The myoepithelial layer is absent, both on H&E stain and by immunostain, and there is a subtle desmoplastic reaction around some of the tubules (*arrowhead*).

- Adenoid cystic carcinoma: a biphasic tumor of epithelial and myoepithelial cells, identical to the salivary gland tumor of the same name.
- Metaplastic: a tumor in which there is a squamous, mesenchymal, or spindle-cell component, such as cartilage, bone, or frank sarcoma, with prognosis depending on grade.

In *lobular carcinoma in situ (LCIS)*, lobular cells, when they begin to proliferate, take on a characteristic appearance. They are homogeneous, like low-grade DCIS cells, but they have a round fried-egg shape, with a pale cytoplasm, discrete borders, and a central round nucleus

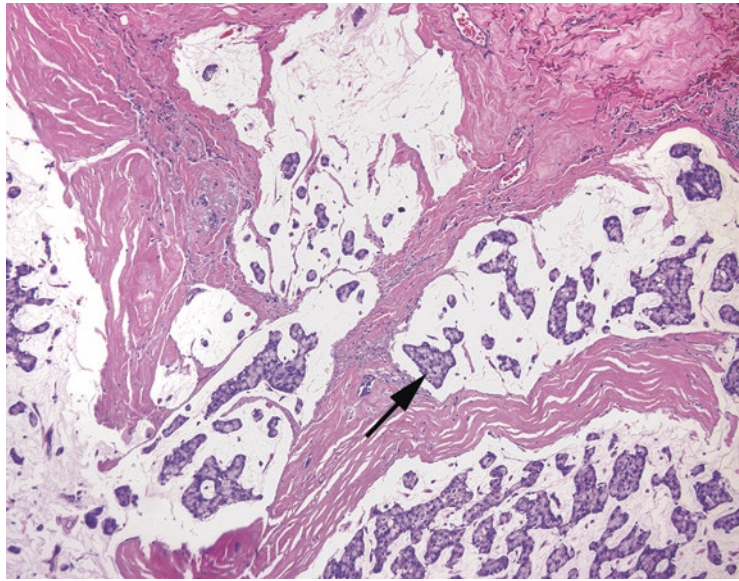


FIGURE 19.13. Mucinous carcinoma. Pools of extruded mucin dissect into the stroma. Although this can occur in benign mucocele-like lesions, the presence of floating clumps of cells (*arrow*) is diagnostic of mucinous, or colloid, carcinoma.

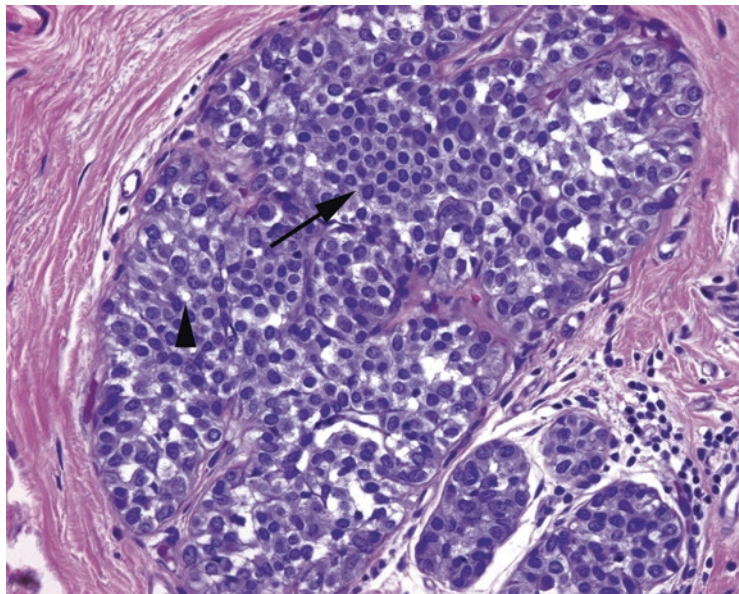


FIGURE 19.14. Lobular carcinoma in situ. The lobule is distended by a population of monotonous cells with distinct cellular borders and small round nuclei (*arrow*). As the lesion expands, the noncohesive cells will begin to fall apart. Cytoplasmic vacuoles (*arrowhead*) are typical of lobular carcinoma cells, both in situ and invasive.

(Figure 19.14). Intracytoplasmic vacuoles, even signet-ring cells, are also common. In LCIS, these cells fill and expand the lobules, appearing at low power like a very circumscribed stippled space (such as the texture of newspaper photos under a magnifying glass). LCIS retains its bland cytology right through to invasive carcinoma.

LCIS is often multifocal and bilateral, and its progression to cancer is not considered inevitable or predictable. As a result, excision is not the goal of treatment, and so its presence at a margin is not usually noted. LCIS is an incidental finding. It does not form masses or calcify

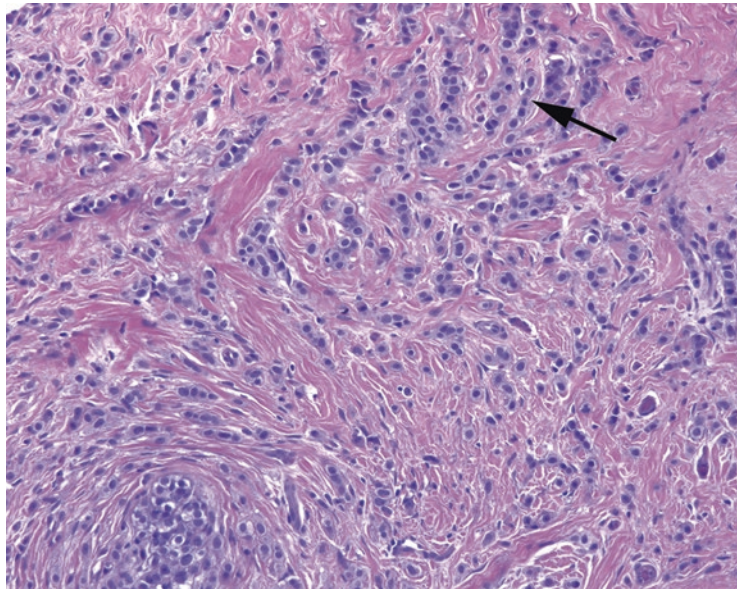


FIGURE 19.15. Invasive lobular carcinoma. The same cells as in Figure 19.14 are seen here invading through the stroma. They often form single file lines (*arrow*) but may also be seen as single cells or concentric circles around a duct. In some cases there is little to no desmoplastic stromal reaction, making the lesion difficult to palpate or detect.

(usually). *Atypical lobular hyperplasia* is generally translated as “I’m really worried about LCIS but cannot quite get there.” Like atypical ductal hyperplasia, ALH does not have consistently agreed-upon criteria.

E-cadherin is a cell surface molecule that helps cells stick together. Lobular lesions lose expression of e-cadherin and therefore become very discohesive. You can imagine that this nonsticky surface enables the invasive lobular cells to slip through the stroma as single cells and that is exactly what they do. Stains for e-cadherin can help to sort out lobular processes (negative) from ductal (positive).

The cells of *invasive lobular carcinoma* look similar to those of LCIS. They are small uniform cells with bland round nuclei, pale cytoplasm, and a sometimes plasmacytoid shape with an eccentric mucin vacuole. Because of their normochromic nuclei and lack of malignant cytology, they are identified by the way they slip through the stroma. They line up as single file lines or as concentric rings around ducts and do not cause an appreciable desmoplastic response (Figure 19.15). They are sneaky and scary, and you have not ruled out lobular until you have looked closely at 10× or 20×. A cytokeratin stain can highlight the individual cells, as everything else in the stroma should be negative.

Invasive epithelial carcinomas must be given an *Elston grade* (a.k.a. Nottingham grade or Elston-Ellis modification of Scarff-Bloom-Richardson) when diagnosed in a lumpectomy or mastectomy. The Elston grade is the pathologic assessment of the tumor’s aggressiveness; the stage is diagnosed separately by features such as size and local extent. The Elston grade takes into account three prognostic factors:

- Tubule formation (1–3 points; the less tubule formation, the higher the score)
- Mitotic rate (1–3 points; the more mitoses, the higher the score)
- Pleomorphism (1–3 points; the more pleomorphic the nuclei, the higher the score)

Each characteristic is scored, and then all are added, to give you a range of 3–9. Grade 1 tumors are those that range from 3 to 5 points, Grade 2 corresponds to scores 6–7, and Grade 3 is tumors that are 8–9 points. For more details on scoring, including how to adjust your own mitotic count thresholds for your scope field diameter, see your favorite surgical pathology text. In the beginning, just learn to look for these three features. Pleomorphism, especially, is a fairly subjective criterion that takes some experience to judge.

Every breast carcinoma must be stained by IHC for three prognostic markers, as the expression profile will determine therapy. The rules for quantitation of ER, PR, and Her2 expression are precise and rigorously controlled, to ensure that breast carcinomas in all laboratories are scored on the same scale. Another way to subdivide carcinomas, both ductal and lobular, is by gene-expression profile. Luminal-type tumors are those that express estrogen receptor (ER) and progesterone receptor (PR), with or without expression of Her2 (luminal A tend to be Her2-negative grade 1 tumors with a low proliferation index, and luminal B tend to be higher grade, higher proliferative index, and may be Her2-positive). A third group are the Her2 tumors, which are ER and PR negative but overexpress Her2. The final group is the “triple negative” or basal-like carcinomas that are negative for all three markers.

Papillary Nomenclature

Papillary lesions in the breast are a confusing area. Here is the nutshell.

A *papilloma* is a benign lesion with papillary architecture. The fibrovascular cores, and the surrounding duct, are lined by myoepithelial cells. Within a papilloma, you can get usual or atypical ductal hyperplasia or DCIS, all of which are diagnosed as “arising in a papilloma.” You should still have myoepithelial cells around the perimeter.

Within the DCIS family, there are several architectural types: *micropapillary* (epithelial projections *without* fibrovascular cores), *papillary* (epithelial projections *with* fibrovascular cores), and *solid papillary* (a solid ball of cells with residual entombed fibrovascular cores). None of these necessarily has anything to do with a papilloma. All usually have intact myoepithelial cells around the outside. All may be multifocal processes in the breast.

Papillary carcinoma is a specific type of carcinoma with a papillary architecture, homogeneous columnar cells, and a circumscribed profile, as though it once grew in a duct. It should be a single discrete lesion. The fibrovascular cores have no myoepithelial cells. The myoepithelial stains may also be negative around the perimeter, but it is still not really considered a true invasive carcinoma. It may be called *intracystic* or *encysted* papillary carcinoma to get this point across and is typically staged as an in situ lesion.

The Many Faces of Metaplastic Carcinoma

Numerous morphologies get lumped under the term *metaplastic carcinoma* and hence the struggle to learn to recognize it. You may see this diagnosis applied to the following entities:

- Squamous carcinoma: a ductal carcinoma with prominent squamous differentiation (and technically a form of metaplastic carcinoma).
- Low-grade spindle-cell carcinoma: very difficult to identify; can masquerade as a hypercellular stroma, but the spindle cells should stain for cytokeratins (especially high-molecular-weight cytokeratins such as CK903).
- High-grade carcinoma with spindle-cell features: should also be cytokeratin positive.
- Any carcinoma with coexisting sarcoma, such as chondrosarcoma or osteosarcoma. The carcinoma component will be cytokeratin positive, the sarcoma usually will not. In another organ this would be called a carcinosarcoma.

The differential diagnosis for entities that are spindly and malignant also includes malignant phyllodes tumor and primary or metastatic sarcoma.

Normal Histology

The marrow biopsy specimen is usually taken from the iliac bone. It consists of bony trabeculae surrounded by a mixture of fat and hematopoietic cells. The percent cellularity (nonfat) should be roughly [100 – the patient’s age]. The components of normal trilineage hematopoiesis are (1) megakaryocytes, (2) erythroid precursors, and (3) myeloid precursors. There may also be assorted plasma cells, lymphocytes, and histiocytes. The bone marrow is considered a reflection of what is in the peripheral blood, so *disorders of marrow affect blood counts*. Lymphomas can involve the marrow, but generally the primary malignancies of the marrow are the leukemias.

The nomenclature is slightly confusing. *Myelo-* means bone marrow (or sometimes spinal cord, but that’s not relevant here). Technically, all three of the marrow-based hematopoietic lines (megakaryocytes, erythroids, and granulocytic cells) are of the *myeloid lineage*, in contrast to the *lymphoid lineage* (B and T cells), because they mature in the marrow. The *myeloproliferative neoplasms* and *myeloid* leukemias refer to this broad classification. However, the word *myeloid*, as used to describe individual components of the marrow, generally refers to those cells in the granulocyte/monocyte pathway only.

This chapter will discuss the morphologic approach to the specimen and will focus on the findings under the microscope. However, in reality, hematopathology, more than any other discipline, is becoming driven primarily by genetic classification of diseases. The recent WHO classification has defined many leukemias by their cytogenetic abnormalities, which can be identified by molecular testing and which supersede the histologic impression. However, the histology is still valuable in providing a preliminary impression of the diagnosis, as well as determining the significance of the molecular finding. In myelodysplastic syndrome, for example, the presence of genetic abnormalities in the absence of recognizable dysplasia is significantly less worrisome than those same abnormalities *with* extensive dysplasia. For the time being at least, histology is still relevant to hematopathology.

Megakaryocytes are the most easily identified cells, with their lakes of pink cytoplasm and multilobated nuclei (Figure 20.1). Erythroid precursors have a distinct rim of clear cytoplasm and centrally located, perfectly round nuclei; as they mature, the nuclei become small and dense such that erythroid islands in the marrow look like handfuls of buckshot (see Figure 20.1). Myeloid cells make up almost everything else. Myeloid precursors have more open chromatin than the red cell precursors, more cytoplasm, and more convoluted nuclei as they mature. Mature neutrophils and eosinophils should be present in normal marrow. Blasts, the most primitive hematopoietic cells, can be difficult to identify on H&E stain. Lymphoid cells, especially immature, should generally not be found in the marrow, with the exception of hematogones (nonneoplastic B cell precursors), which can be markedly increased in children.

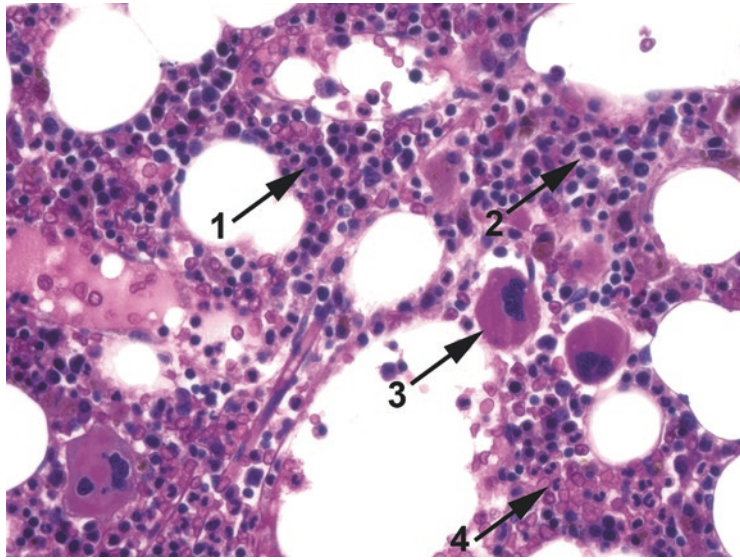


FIGURE 20.1. Normal megakaryocytes, erythroids, and myelocytic precursors. In this H&E-stained core biopsy specimen, there are erythroid precursors (1), myeloid precursors (2), megakaryocytes (3), and maturing neutrophils (4).

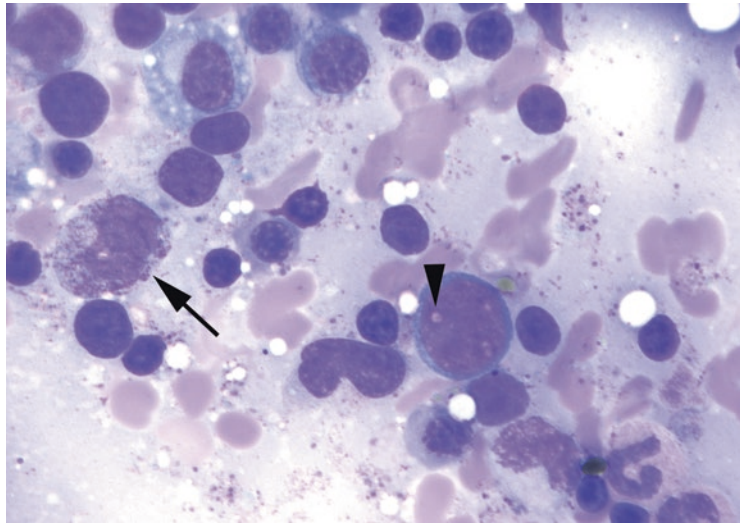


FIGURE 20.2. Blast on aspirate, Wright-Giemsa stain. The key to identifying a blast is the high N/C ratio and immature chromatin pattern, which consists of very finely grained, uniform chromatin with several nucleoli that show up as negative images on this stain (*arrowhead*). The immature cell nearby is a promyelocyte, which has the same nuclear qualities as a blast but has abundant cytoplasm with granules (*arrow*).

Usually an aspirate smear will be submitted with the biopsy specimen. The aspirate is stained with the Wright-Giemsa stain, which highlights nuclear detail. Blasts, and the successive stages of maturation, are best seen on an aspirate. The blasts are large cells with a thin rim of cytoplasm and a characteristic nucleus (Figure 20.2). The blast nucleus is large and round with a very finely textured chromatin pattern and a nonstaining nucleolus that shows up as a “hole” in the chromatin. The more differentiated precursors, such as promyelocytes and myelocytes, may have a similarly immature nucleus but acquire cytoplasmic features such as granules and a “hof” (the cleared-out Golgi zone in the cytoplasm, as in a plasma cell; see Figure 20.2).

On the aspirate, a myeloblast (as seen in acute myeloid leukemia) cannot always be distinguished from a lymphoblast (as seen in acute lymphoblastic leukemia) on histology alone. However, the presence of granules or Auer rods identifies a blast as myeloid. Erythroblasts have royal blue cytoplasm and very round nuclei. Monocyte precursors tend to have grayer cytoplasm and a folded or creased nucleus. Flow cytometry is performed on the aspirate as well and helps to confirm the lineage.

Approach to the Biopsy Specimen

A full evaluation of the specimen requires an H&E-stained core biopsy, a Wright–Giemsa-stained aspirate, and a peripheral smear. Beginning with the biopsy:

On low power (4×):

- Assess the cellularity of the marrow (Figure 20.3). A hypo- or hypercellular marrow will guide your differential diagnosis.
- Estimate the cellularity as a percentage range (i.e., 30–40%), as clinicians follow the cellularity to monitor response to therapy.

On medium power (10×):

- Survey the marrow for trilineage hematopoiesis. You should see megakaryocytes, erythroid islands, and myeloid cells. Look to see if each line matures to completion: you should see mature neutrophils and red cells. Estimate the ratio of myeloid to erythroid cells (M/E ratio), which is normally about 2–4 to 1.
- Look for things that do not belong in the marrow in large populations or aggregates, such as blue areas (lymphocytes), pink areas (histiocytes, plasma cells), or islands of nonheme cells (metastases). Look for fibrosis, which gives the marrow a streaming texture (Figure 20.4).

On high power (20× and 40×):

- Look at the individual cells, especially megakaryocytes. Small megakaryocytes with single nuclei are a feature of myelodysplasia and are also seen in chronic myeloid leukemia (Figure 20.5). Giant-clustered megakaryocytes are a feature of myeloproliferative disorders. A few atypical megakaryocytes are not unusual, but a large population is significant.

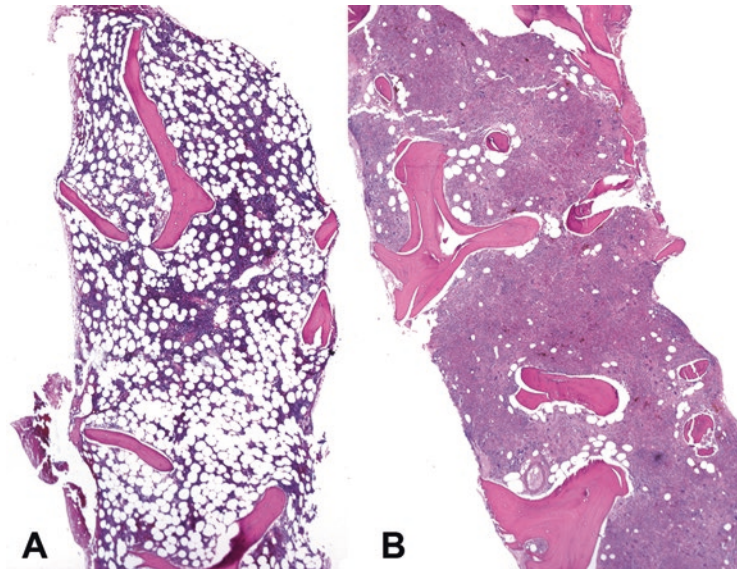


FIGURE 20.3. Marrow cellularity. (a) Normocellular marrow for a middle-aged adult; this cellularity is approximately 30%. (b) Hypercellular marrow for an adult; this cellularity is about 95% and is taken from a case of acute myeloid leukemia.

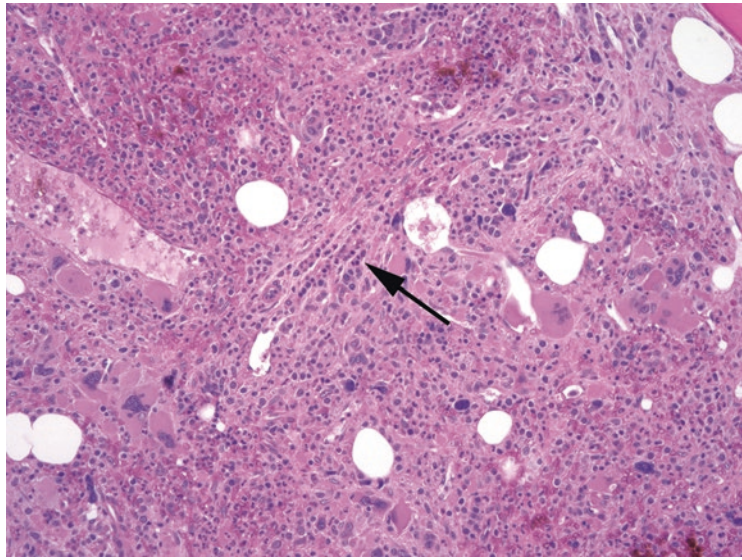


FIGURE 20.4. Marrow fibrosis. On H&E stain, the marrow has a streaming texture (*arrow*), indicative of strands of collagen separating the hematopoietic cells into nests and channels.

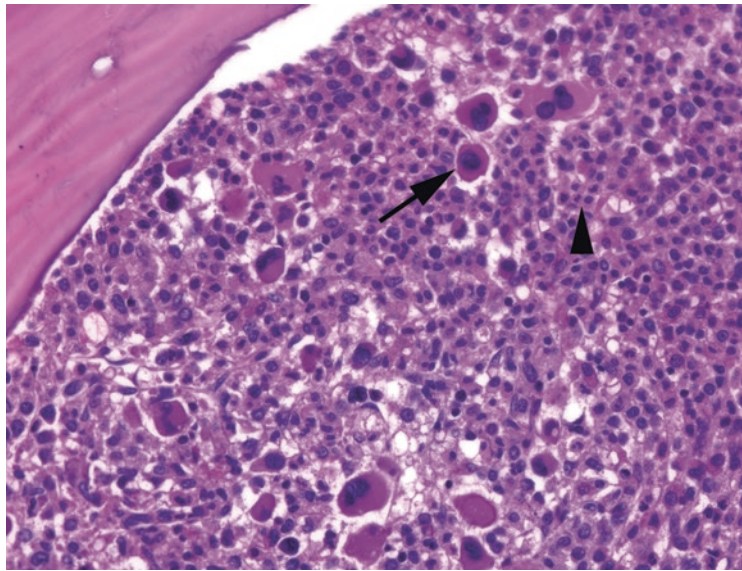


FIGURE 20.5. Chronic myeloid leukemia. This hypercellular marrow is full of small, hypolobated megakaryocytes (*arrow*) and maturing and mature neutrophils (*arrowhead*).

- Look for neutrophils. A packed marrow with numerous neutrophils may indicate chronic myeloid leukemia (see Figure 20.5), whereas numerous myeloid precursors with few neutrophils indicates a left shift in maturation. Sheets of immature myeloid cells could represent anything from acute myeloid leukemia to infection; the aspirate needs to be evaluated for blasts (see next section).

Next, look at the aspirate. Hold it up to the light; an adequate aspirate will have little chunks in it (spicules) that are foci of stromal elements. Scan the slide for an optimal area of the smear. Cells should be spread out in a monolayer, with intact cytoplasm and distinct nuclei. “Naked” nuclei, which have been stripped of cytoplasm, are not evaluable. You have already

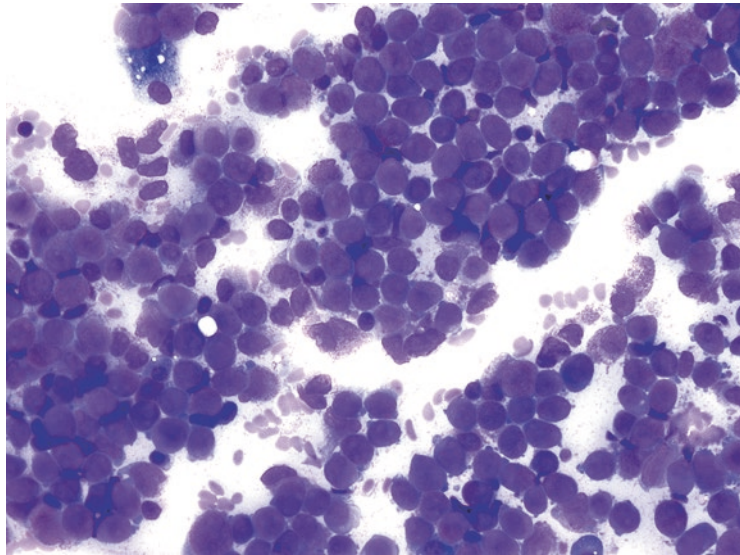


FIGURE 20.6. Monomorphic aspirate in acute leukemia. This aspirate is composed of sheets of blasts, identified by high N/C ratios and immature chromatin.

evaluated the megakaryocytes, so with the aspirate, focus on erythroid and myeloid cells. On high power (20× to 100×, with oil if necessary):

- Assess the heterogeneity of the marrow. A healthy aspirate should be a random mosaic of all different cell types at all levels of maturity. Sheets of uniform cells is a bad, bad sign (Figure 20.6).
- Look for blasts. You should be able to find scattered blasts but not clusters of them. Clumps of immature-looking cells are more commonly promyelocytes and myelocytes, as identified by their granules and cytoplasmic hofs. If you do find lots of blasts, note the shape of the nuclei, the color of the cytoplasm, and the presence of Auer rods. The presence of greater than 5% blasts is abnormal; they should be quantified by a systematic cell count of 200–500 nucleated cells. Flow cytometry will also provide a blast count.
- Evaluate the red cell precursors for dysplasia. Dyserythropoiesis shows up as binucleated red cells and red cell precursors with irregular nuclear membranes (Figure 20.7). Megaloblastoid change is a softer sign and looks like large “sliced salami” nuclei within mature (pale gray) cytoplasm. Dysplasia is subjective and may be subtle; it is one of those things that only comes with seeing many examples.
- Dysgranulopoiesis (in neutrophils) appears as abnormalities in nuclear lobation (“Pelgeroid,” which is bilobed like spectacles) and granules (absence of granules or occasionally coarse basophilic granules). Hypersegmented neutrophils can be seen in megaloblastic anemia.
- Plasma cells are easy to spot on the aspirate, with their bright blue cytoplasm and eccentric nucleus. Too many plasma cells (more than 5–10%) may indicate a plasma cell dyscrasia.

Iron stains are performed on marrow smears to evaluate the iron stores. Hemosiderin (stainable storage iron) is found in reticuloendothelial cells and also in granules in normoblasts (developing red cell precursors). Normoblasts with iron granules in the cytoplasm are called *sideroblasts*. Sideroblasts are decreased in iron-deficiency anemia but increased in sideroblastic anemia, especially in the form of ringed sideroblasts, which have iron granules surrounding the nucleus in a ring.

After the aspirates, look at the peripheral blood film. Assess the white count, get a very rough differential, look for circulating blasts, and estimate the platelet count. (This chapter will not go into detail on peripheral smear interpretation.) Hypersegmented, hyposegmented, or hypogranular neutrophils are considered evidence of dysgranulopoiesis on the smear.

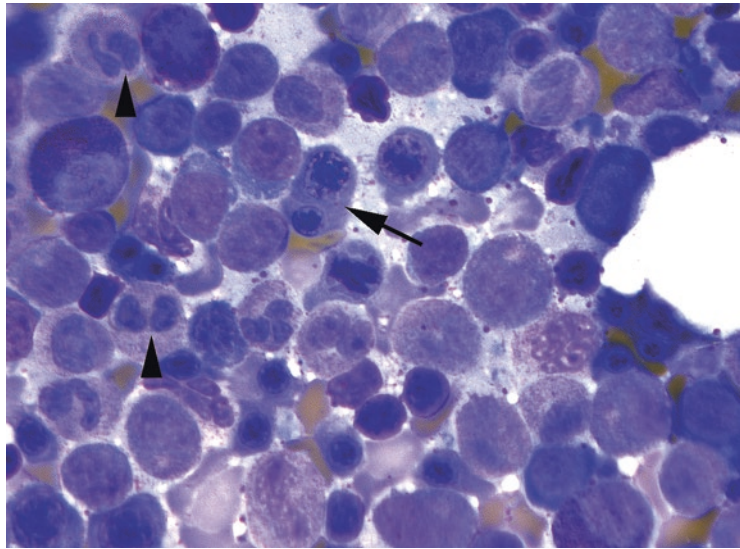


FIGURE 20.7. Dyserythropoiesis and dysgranulopoiesis. Binucleated erythroid precursors (*arrow*) and bilobed neutrophils without granules (*arrowheads*) are indicative of dysplasia.

Differential Diagnosis

Once you have looked at everything, gather your facts to generate a differential diagnosis:

Hypercellular or hypocellular? (See marrow cellularity.)

Dysplasia of any cell lines? (See myelodysplastic syndrome.)

A prominent excess of any one cell line? (See myeloproliferative disorders.)

Too many blasts? (See acute leukemia.)

Lots of plasma cells? (See plasma cell dyscrasias.)

Lymphocytes? (See lymphocytes.)

Marrow Cellularity

With hypercellular marrow, the differential diagnosis includes the following:

- Physiologic response to anemia, especially hemolytic anemia, or infection (no dysplasia, no increase in blasts)
- Ineffective hematopoiesis (such as megaloblastic anemia, human immunodeficiency virus)
- Myelodysplasia (dysplastic hematopoiesis in any cell line, <20% blasts)
- Myeloproliferative disorders (chronic myeloid leukemia, polycythemia vera, essential thrombocythemia, myelofibrosis)
- Acute leukemia (>20% blasts, with or without dysplasia)
- Other neoplasms (lymphoma, metastatic disease)

With hypocellular marrow, the differential diagnosis includes the following:

- Aplastic anemia
- Chemotherapy
- Infection
- Hypocellular forms of myelodysplastic syndrome or acute myeloid leukemia (but blasts are still increased)

Myelodysplastic Syndrome

Myelodysplastic syndrome (MDS) encompasses those diseases with *dysplasia of at least one cell line AND with blasts <20% in the marrow*. Myelodysplastic syndrome may progress to acute myeloid leukemia, which by definition is >20% blasts. *Each dysplastic cell line has a corresponding peripheral cytopenia*, as it represents a dysfunctional hematopoiesis. MDS tends to have an erythroid predominance in the marrow (decreased M/E ratio), as the body struggles to compensate for the anemia. MDS is characterized by how many lineages are affected (single or multiple) and by whether ringed sideroblasts, excess blasts, or a defining mutation is present. The most minor disease is *MDS with single lineage dysplasia* (MDS-SLD, formerly refractory anemia), which presents with anemia and shows erythroid dysplasia (see Figure 20.7). Blasts are not increased (<5% by definition). The finding of $\geq 15\%$ ringed sideroblasts on an iron stain indicates *MDS with ringed sideroblasts*.

Dysplasia and cytopenias in two, or more usually three, cell lines bump you to *MDS with multilineage dysplasia* (with or without ringed sideroblasts). The dysplasia must be seen in >10% of a given cell line to be significant. Blasts are still not increased.

Once the blast percentage begins to increase, you get to *MDS with excess blasts* (MDS-EB), -1 or -2 for marrow blasts 5–9% and 10–19%, respectively. MDS-EB-2 is otherwise known as high-grade MDS and usually indicates a high risk of progression to acute myeloid leukemia. The presence of an Auer rod in the setting of MDS, regardless of the percentage of blasts, indicates MDS-EB-2. Similarly, the presence of >5% circulating or peripheral blasts indicates MDS-EB-2.

Myeloproliferative Neoplasms

The *myeloproliferative neoplasms*, in contrast to myelodysplasia, show a super-hematopoiesis. There is little or no dysplasia, and the *peripheral counts of the involved cell line(s) are high*. In *chronic myeloid leukemia* (CML), the most common neoplasm, the neutrophils are pushed out of the marrow so fast that they are not fully mature, so there are immature as well as mature granulocytes in circulation. Unlike MDS, there is an increased M/E ratio in the marrow. Like MDS, though, the marrow is hypercellular and the blast percentage is low. The gradual replacement of the bone marrow usually leads to cytopenias of the uninvolved cell lines (although CML usually comes with a thrombocytosis), as well as extramedullary hematopoiesis and organomegaly.

Myeloproliferative neoplasms can affect any of the myeloid (nonlymphoid) cell lines: granulocytic (chronic myeloid leukemia), megakaryocytic (essential thrombocythemia), and erythroid (polycythemia vera). Primary myelofibrosis involves both the megakaryocytic and granulocytic lines. The myeloproliferative neoplasms can have overlapping features and be difficult to separate, with the exception of chronic myeloid leukemia, which is defined by unique cytogenetics (t 9;22, *BCR-ABL1*).

Myelodysplastic/Myeloproliferative Disorders

Of course there would be an overlap among the myelodysplastic and myeloproliferative diseases. The MDS/MPN category has features of both. The most common disorder in this category is chronic myelomonocytic leukemia (CMML). It has the dysplasia, anemia, and thrombocytopenia of MDS, a proliferation of monocytes (monocytosis), <20% blasts, and no Philadelphia chromosome.

Acute Leukemia

Acute leukemia is defined as $\geq 20\%$ blasts in the blood or marrow, but it is not uncommon to see >90% blasts in an initial presentation (Figure 20.8). *Acute lymphoblastic leukemia* (ALL) is the leukemic counterpart to acute lymphoblastic lymphoma and is primarily a disease of children in which immature lymphocyte precursors fill the marrow. Most commonly the cells are B cell precursors (pre-B ALL), although T cell ALL can also involve the marrow. Acute lymphoblastic leukemia can be very difficult to distinguish from acute myeloid leukemia on routine stains, as the lymphoblasts look very similar to myeloblasts. However, the diagnosis is easily confirmed by immunostains or flow cytometry.

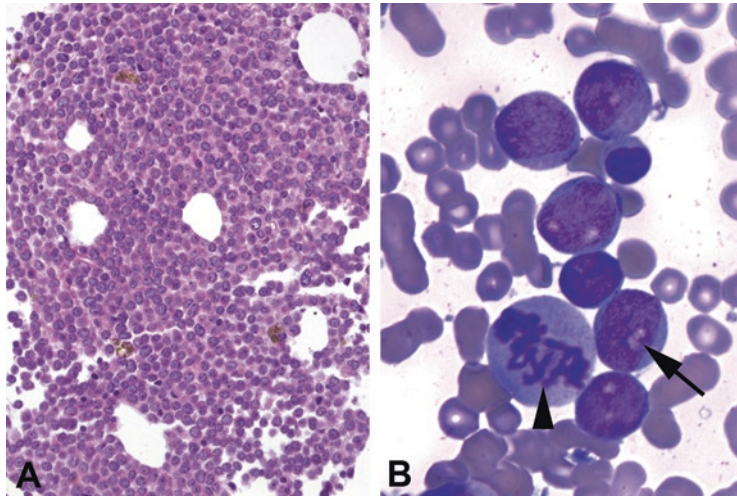


FIGURE 20.8. Acute myeloid leukemia. (a) The marrow biopsy material shows sheets of immature cells, with little or no background hematopoietic elements. Nucleoli appear dark on H&E stain. (b) The aspirate shows clusters of myeloblasts with clear nucleoli (arrow). A large mitosis is visible (arrowhead); this in itself is not an unusual finding in the marrow.

TABLE 20.1. The 2016 WHO acute leukemia classification (partial list).

WHO classification	Proliferating cell type	Histologic hallmark
<i>AML with recurrent genetic abnormalities</i>		
AML with t(8;21)	Myeloblast with neutrophilic differentiation	Blasts with blue cytoplasm and granules, plus the immature “sunset” cells
AML with t(15;17)	Promyelocyte	Promyelocytes with blue granules and Auer rods
AML with inv.(16)	Blast with myeloid and monocytic features	Features of monocytic differentiation plus lots of eosinophils
AML with t(9;11)	Blast with myeloid and monocytic features	Features of monocytic differentiation (gray cytoplasm, folded nuclei)
AML with t(6;9)	Myeloblast	Dysplasia and marrow basophilia
AML with MDS-related changes	Myeloblast	Background of multilineage dysplasia
Therapy-related AML	Myeloblast	Background of multilineage dysplasia
<i>AML NOS (by histologic criteria)</i>		
AML with minimal differentiation	Blast	Primitive blasts
AML without maturation	Blast	Primitive blasts
AML with maturation	Myeloblast	Granules, Auer rods, or myeloid markers
AMML	Blast with myeloid and monocytic features	Features of monocytic differentiation
Acute monoblastic leukemia	Monoblast	Monoblasts, promonocytes, and monocytes
Pure erythroid leukemia	Erythroblast	Erythroblasts and erythroid precursors
Acute megakaryoblastic leukemia	Megakaryoblast	Megakaryoblasts with marrow fibrosis

Note: AML acute myeloid leukemia, AMML acute myelomonocytic leukemia, MDS myelodysplastic syndrome

Acute myeloid leukemia (AML) spans a wide array of diseases. The classification of AML was by morphology for many years, based on identifying the type of blast that was proliferative. However, the classification system used since 2001 is the World Health Organization (WHO) classification, which relies more on cytogenetic, molecular, and immunophenotypic features (Table 20.1). In this system, many AML types are defined by their cytogenetics, and those that can be associated with a distinct genotype fall under the heading “AML with recurrent genetic abnormalities.” These include AML with t(8;21), AML with t(15;17)

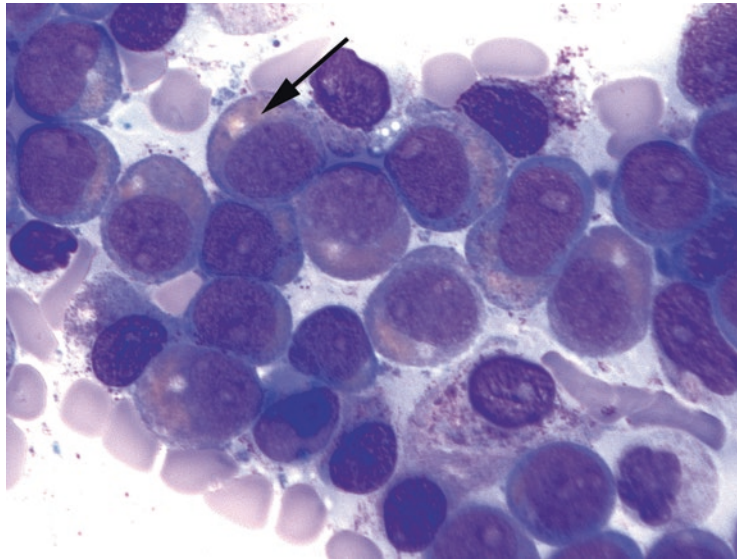


FIGURE 20.9. AML with t(8;21). A population of the blasts have pink cytoplasm with pale hof, a peripheral blue rim, and pink granules (*arrow*).

(formerly acute promyelocytic leukemia), and AML with inv.(16). While many of these do have characteristic morphologic features, the identification now relies on molecular studies. These subtypes are more likely to arise de novo and have a better prognosis. AML arising from MDS, however, has a poor prognosis and often deletions of chromosomes 5 and 7. Similar cytogenetics and poor prognosis may be found in chemotherapy-related AML. The remaining AML subtypes (now relegated to the NOS bucket) include those leukemias which have no molecular signature; this category will likely continue to shrink.

Histologically, AML usually presents as a hypercellular marrow mostly replaced by blasts. The differentiation of the blasts (and therefore the subclassification of the AML) is identified by morphology on the aspirate, flow cytometry, and cytogenetics. Some unique findings of the different subtypes include the following:

- AML with t(8;21): This subtype consists of a population of blasts with blue cytoplasm and granules, plus immature myeloid cells with salmon-pink granules, a pink cytoplasm with hof, and a peripheral blue rim. These look like a little sunset to some observers (Figure 20.9).
- AML with inv.(16): This subtype has both granulocytic and monocytic differentiation (bluish gray cytoplasm and folded or convoluted nuclei) plus a high number of eosinophils in the marrow (Figure 20.10). Some of the eosinophils may have large abnormal blue granules (like basophils).
- AML with t(15;17), or *PML-RARA*: Technically there is not an increase in blasts but in promyelocytes. The nuclei are large with blast-like chromatin but are folded (kidney-shaped), and the cytoplasm has large and numerous blue granules or Auer rods.

Plasma Cell Dyscrasias

A normal marrow should have 1–2% plasma cells, scattered in a perivascular distribution. Aggregates of plasma cells and atypical forms (large nucleoli, binucleate forms) are abnormal. The diagnosis of a plasma cell myeloma requires a marrow plasmacytosis with evidence of clonality (either by flow cytometry or by expression of kappa or lambda light chains). The marrow plasmacytosis in myeloma is typically >30% but can be as little as 10% if there are also lytic bone lesions or certain other criteria (refer to the International Myeloma Working Group criteria). A single localized plasma cell lesion without the defining features of multiple myeloma is a plasmacytoma.

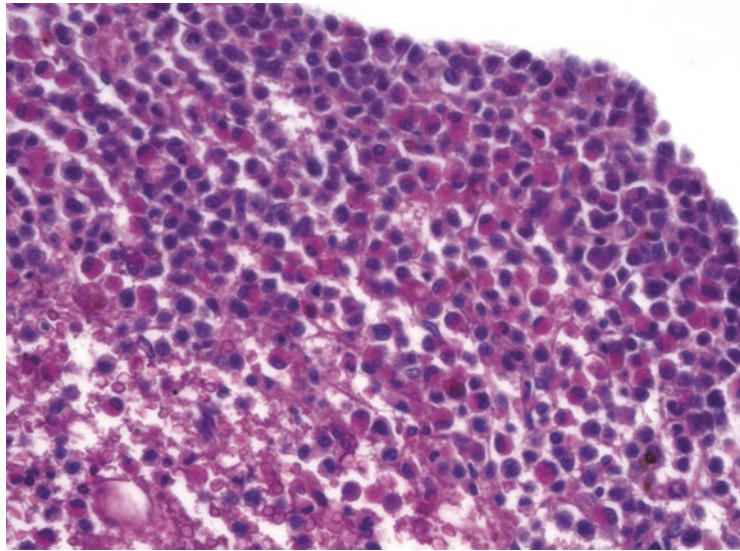


FIGURE 20.10. AML with *inv(16)*. The marrow shows sheets of immature myeloid cells (the aspirate showed blasts) and numerous eosinophils.

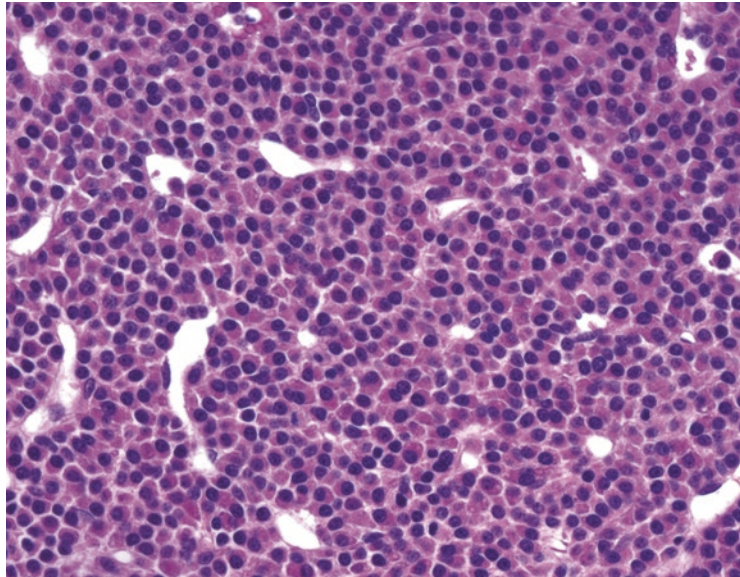


FIGURE 20.11. Myeloma. The marrow is replaced by sheets of plasma cells. Although the section is thick and the chromatin appears very dark, some nuclei show the distinct soccer ball chromatin of plasma cells. The eccentric nucleus and abundant pink cytoplasm are also characteristic.

Sheets of plasma cells are recognizable on H&E stain (Figure 20.11), but it is difficult to pick out a subtle interstitial plasmacytosis. CD138 can be used to help estimate the percentage. In situ hybridization for light chains kappa and lambda can identify an abnormally restricted (all kappa or all lambda) population, confirming a clonal process. Flow cytometry tends to underestimate the number of plasma cells.

Lymphocytes

Lymphocytes in the bone marrow can be a normal or reactive finding. They can also be an indication of lymphoma involvement. History is important, as the marrow is an unlikely place for a presentation of occult lymphoma (i.e., without lymphadenopathy). However, non-Hodgkin lymphoma has a 30–50% chance of involving the marrow at the time of diagnosis.

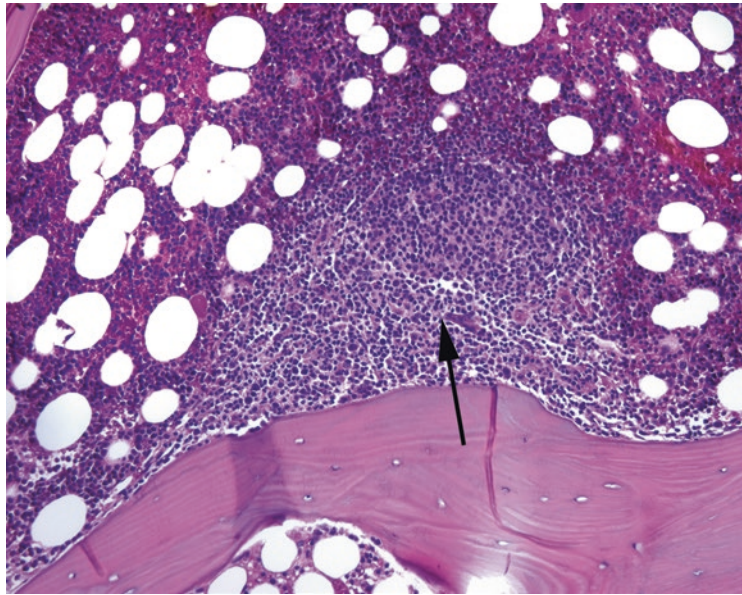


FIGURE 20.12. Paratrabeular aggregate. The arrow points to the center of this lymphoid aggregate, which appears more blue, relatively, than the surrounding marrow. One surface of the aggregate is plastered down to the bony trabecula.

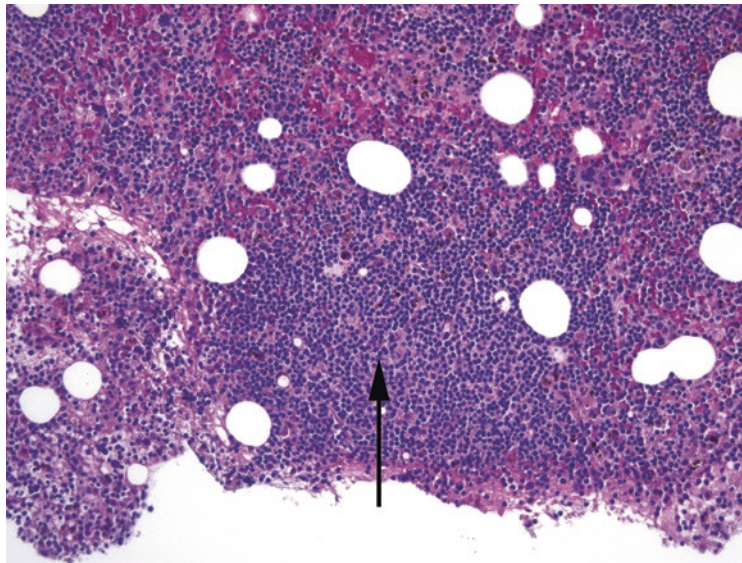


FIGURE 20.13. Nonparatrabeular aggregate in chronic lymphocytic leukemia. The arrow here points to the center of a free-floating, rounded lymphoid aggregate.

The subtypes most likely to go to marrow are follicular, small lymphocytic lymphoma/chronic lymphocytic leukemia (SLL/CLL), mantle cell, lymphoblastic, Burkitt, and peripheral T cell lymphomas. Diffuse large B cell is less likely.

Lymphoid infiltrates can come in four basic patterns:

- Paratrabeular: This is a collection of lymphocytes that hugs the bony trabeculae. This pattern favors follicular lymphoma (Figure 20.12).
- Nonparatrabeular: This is a lymphoid aggregate that is not closely associated with a trabecula. Benign lymphoid aggregates (discussed further below) are common in elderly patients, but SLL/CLL can also have this pattern (Figure 20.13).

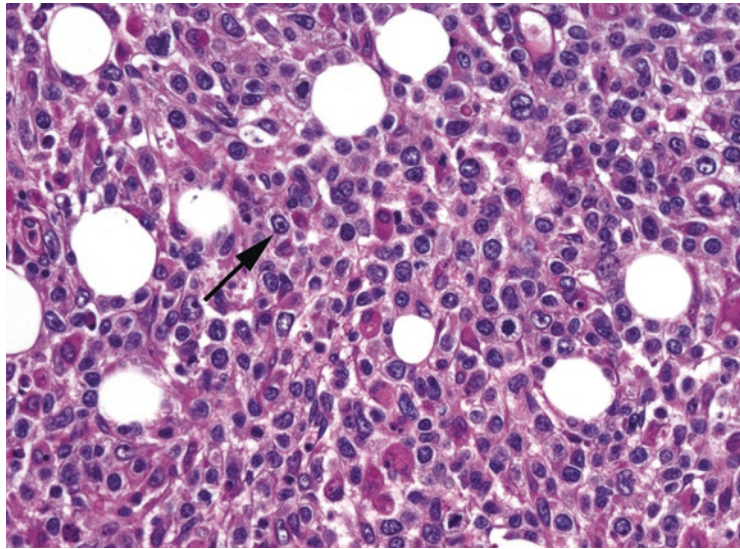


FIGURE 20.14. Diffuse large B cell lymphoma in the marrow. The marrow is infiltrated by large atypical cells with prominent nucleoli, thick nuclear rims, abundant cytoplasm, and irregular nuclear membranes (*arrow*). This is suggestive of involvement by diffuse large B cell lymphoma or carcinoma.

- **Interstitial:** This implies a scattered collection of lymphocytes in and among the marrow elements. It can be hard to pick out on H&E stain, because single lymphocytes will blend into the hematopoietic soup. Mantle cell and SLL/CLL tend to have this pattern, often in conjunction with nonparatrabeular aggregates.
- **Diffuse:** This means sheets of lymphocytes replacing the marrow (Figure 20.14) and is more typical of aggressive lymphomas such as Burkitt lymphoma, diffuse large B cell lymphoma, or advanced SLL/CLL.

Features of a *benign lymphoid aggregate* include a nonparatrabeular site; heterogeneous mixtures of lymphocytes, plasma cells, and histiocytes; well-demarcated borders; germinal centers; and older patient age. Immunostains can also help. A benign aggregate should be a mixture of B and T cells (CD20 and CD3). Beware the CD20 stain in a patient who is taking Rituximab, though, as this drug targets and eradicates CD20 expression. Use another B cell marker such as CD22, CD79a, or PAX5.

Hodgkin lymphoma in the marrow can be extremely subtle, as the defining trait is a mixed infiltrate with scattered neoplastic (Reed–Sternberg) cells. Focal fibrosis or granulomatous inflammation may be all that is seen initially; immunostains can often pick out the rare neoplastic cells.

21 Lymph Node and Spleen

Normal Histology of the Lymph Node

The normal or benign lymph node is composed of a collection of follicles and interfollicular areas surrounded by sinuses (spaces mostly filled with histiocytes), vessels, and sometimes fat. Lymph flows from the subcapsular sinuses, through the medullary sinuses in the lymph node, and out the hilum. The follicles represent areas of maturing B cells (CD20⁺), whereas the interfollicular areas are mostly mature T cells (CD3⁺).

Follicles begin as primary follicles or aggregates of antigen-naïve B cells. As they mature into secondary follicles, they acquire germinal centers, which are visible as targetoid nodules within the follicles (Figure 21.1). The dark outer rim of the follicle is the displaced remains of the primary follicle and is called the mantle zone, still composed of antigen-naïve B cells. Once exposed to antigen, the B cells move to the germinal center and become centroblasts, large cells with primitive-looking nuclei. From there they either mature into centrocytes or die through apoptosis. Finally, B cells leave the germinal center genetically altered to circulate as memory B cells, which may ultimately differentiate into plasma cells if they meet their antigen.

Other normal germinal center components include the supporting follicular dendritic cells and tingible body macrophages, which clean up the apoptotic debris. These macrophages appear as relatively clear cells within the germinal center, with visible “dust specks” in the cytoplasm (Figure 21.2). Germinal centers may be found in any hotbed of lymphocyte activity outside the lymph nodes, but the morphology and staining pattern are preserved.

The paracortex, or interfollicular area, may occupy most of the lymph node in some cases. This absence of obvious follicles is not necessarily a reason for concern. The benign paracortex should have a mottled appearance due to the scattered pale histiocytes among the T cells.

Lymphoma, Conceptually

The word *lymphoma* means a malignancy of the lymphoid system and usually implies a solid tumor mass, whether it is in the lymph nodes or an extranodal site. However, remember that many of the lymphomas can have an associated liquid phase, or leukemia, in which the neoplastic cells invade the bone marrow and enter the peripheral blood (Table 21.1). Among the myeloid leukemias, discussed in Chapter 20, solid tumor disease is uncommon but exists (such as the chloroma or granulocytic sarcoma).

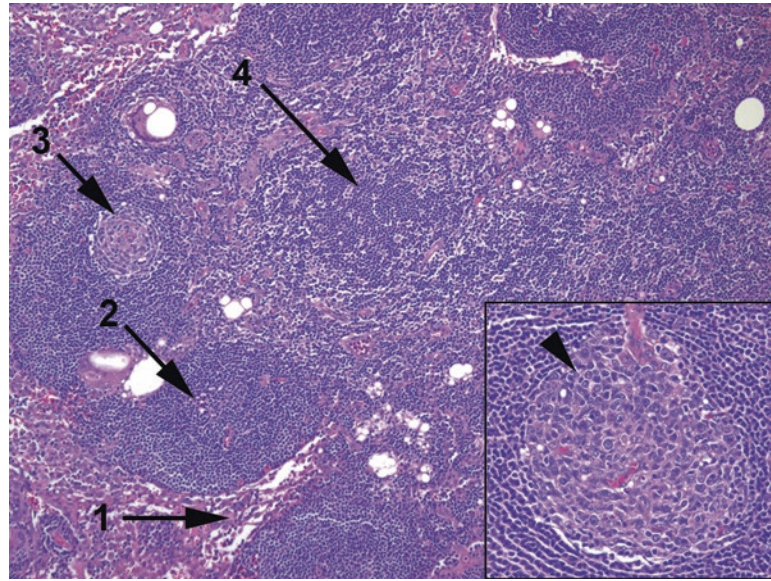


FIGURE 21.1. Normal lymph node. The sinuses are visible mainly as loose collections of histiocytes (1). Primary follicles (2) are collections of B cells lacking germinal centers. Secondary follicles contain germinal centers (3). The space between the follicles, or paracortex (4), is composed of T cells and shows a characteristic spotted or mottled appearance. *Inset:* A normal germinal center should be polarized, with large centroblasts clustered at one side of the follicle (*arrowhead*), creating a lopsided appearance.

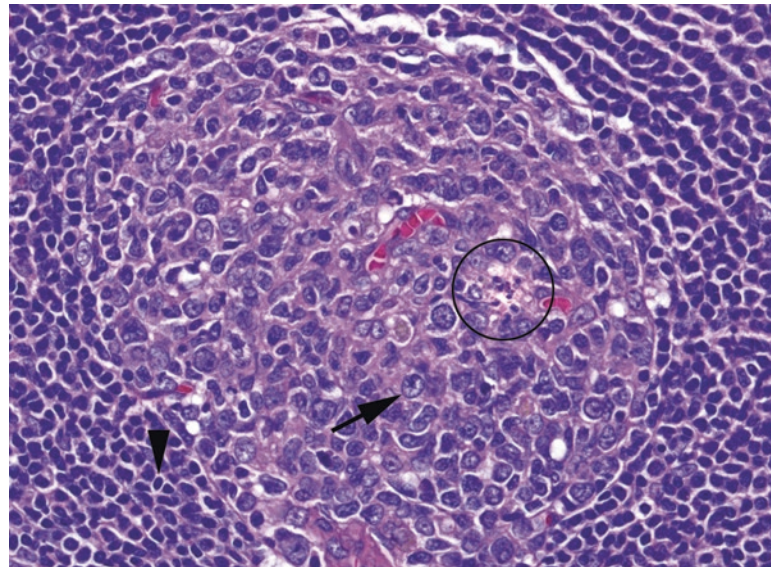


FIGURE 21.2. Germinal center. Other components of a benign germinal center include tingible body macrophages (*circle*) and large centroblasts with prominent nucleoli (*arrow*). The germinal center is surrounded by the mature B cells of the mantle zone (*arrowhead*).

This chapter covers several major categories of lymphomas:

- High-grade (aggressive) lymphomas: neoplasms of activated B cells and T cells (activated means exposed to the target antigen) or that resemble activated cells.
- Low-grade B cell lymphomas (neoplasms of mature B cells): Like the chronic leukemias, these are indolent and simmering and are diseases of adults.

TABLE 21.1. Lymphomas and associated leukemias.

Cell of origin	Myeloid line		Lymphoid line	
	Solid tumors	Leukemias	Lymphomas	Leukemias
Blasts	Myeloid sarcoma	AML	B lymphoblastic lymphoma T lymphoblastic leukemia	B lymphoblastic leukemia T lymphoblastic lymphoma
Mature cells	Myeloid sarcoma	CML and other myeloproliferative disorders	Follicular SLL Mantle cell Marginal zone Mycosis fungoides Plasmacytoma	CLL Hairy cell leukemia Sezary syndrome Myeloma
Activated cells			DLBCL ALCL	

Leukemias, by definition, involve the marrow and peripheral blood, while lymphomas are solid tumors. In many cases a single malignancy may be either solid or leukemic

ALCL anaplastic large cell lymphoma, *AML* acute myeloid leukemia, *CLL* chronic lymphocytic leukemia, *CML* chronic myeloid leukemia, *DLBCL* diffuse large B cell lymphoma, *SLL* small lymphocytic lymphoma

- Lymphoblastic lymphoma (neoplasms of precursor cells or lymphoblasts): These cells resemble myeloblasts and are the solid tumor counterpart to the acute lymphoblastic leukemias (ALLs).
- Hodgkin lymphomas: As a group, these are neoplasms in which the neoplastic cells are a minority population, with a variable mixed inflammatory background. The prototypical tumor cell is the Reed–Sternberg cell, of which there are many variants.
- Others include T cell neoplasms and non-B, non-T cell types.

Many of the lymphomas can be placed into categories by nuclear morphology, and learning to recognize the “look” of each group is important, although actual diagnosis is primarily by flow, immunohistochemistry (IHC), and molecular studies. The lymphoblastic lymphomas have immature chromatin, which means the texture is very fine grained, with small nucleoli and an indistinct nuclear membrane, much like the myeloblasts in acute myeloid leukemia. On H&E stain, they may be mistaken for small cell carcinoma or a primitive sarcoma. The low-grade neoplasms resemble normal lymphocytes, with small condensed nuclei. The high-grade lymphomas show very carcinoma-like nuclei: they are large (compared with lymphocytes) and pleomorphic, with prominent nucleoli and coarse nuclear membranes. Hodgkin lymphomas are the hardest to identify, usually, as the diagnostic cells (Reed–Sternberg cells and variants) may be few and far between. However, Reed–Sternberg cells do resemble high-grade nuclei in their chromatin pattern.

Recognizing a lymphoma in an extranodal site, especially a tumor of unknown origin, takes practice. Clues to lymphoma include a relatively homogeneous, sheet-like growth of malignant cells; a lack of cell-to-cell cohesiveness or architecture; nuclei that are highly irregular in shape or contour; and an accentuation of cell density around vessels (especially in the brain, Figure 21.3). Most should stain for CD45, the common leukocyte antigen, or for specific B or T markers. Positive staining for melanoma markers or cytokeratins rules out lymphoma. Sarcoma markers should be used with caution, though, as many of the familiar stains (CD117, CD34, etc.) also stain hematopoietic elements.

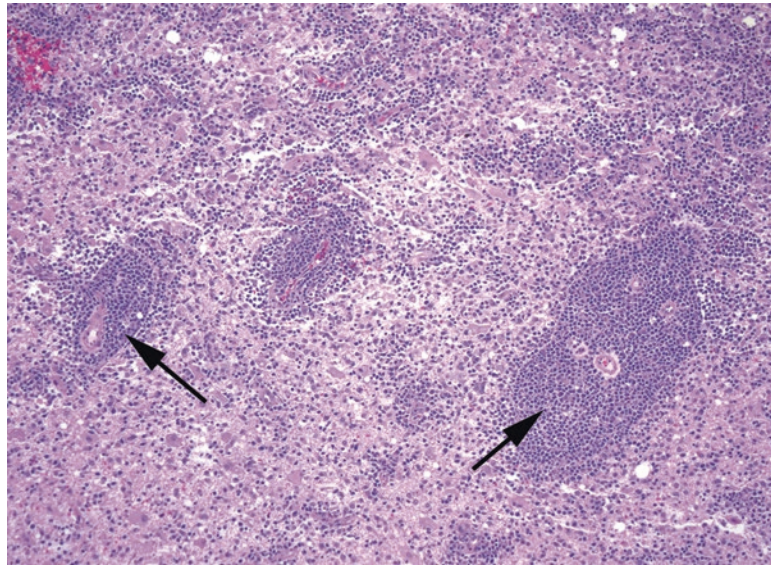


FIGURE 21.3. Diffuse large B cell lymphoma in the central nervous system. The tendency of the malignant cells to cluster around blood vessels (*arrows*) is typical of lymphoma within the brain.

Diffuse Large B Cell Lymphoma

As the most common lymphoma, you will see *diffuse large B cell lymphoma* (DLBCL) frequently. DLBCL is essentially a final common pathway in lymphoma; although it can arise spontaneously, it can also arise from the setting of any other low-grade B cell lymphoma or from Hodgkin lymphoma. The “diffuse” is used here as an opposite of follicular or nodular, and it implies the sheet-like growth. The “large” should be interpreted with caution—what is large in hematopathology may still be fairly small next to a squamous cell.

DLBCL is not usually mistaken for a benign entity; the nuclei are too abnormal. However, it may be mistaken for other types of malignancy, especially given its tendency to crop up in extranodal sites. As described earlier, the nuclei are very irregular in contour, with cleared-out or vesicular chromatin leaving a prominent nucleolus and thick nuclear rim (Figure 21.4). Folded, or cleaved, nuclei are common. The cells may have more cytoplasm than lymphocytes and therefore a lower N/C ratio.

Although DLBCL was formerly a single category in the World Health Organization classification, the splitters are gaining on it. One division is between those DLBCLs that are of germinal center cell origin, such as a follicular lymphoma gone bad, and those of activated B cell (or non-germinal center) origin. The latter have the worse prognosis; the distinction is through an IHC staining algorithm. Other subtypes of DLBCL are the so-called double- and triple-hit lymphomas, which are identified through their rearrangements of the *MYC*, *BCL2*, and/or *BCL6* genes. Such lymphomas are now called high-grade B cell lymphomas (HGBL), with the genetic rearrangements specified. Additional variants of DLBCL are identified based on unique molecular events and/or viral associations; this list grows longer each year.

Burkitt Lymphoma

Burkitt lymphoma is a distinct type of high-grade B cell lymphoma that is identified by its high mitotic rate (Ki67 index of nearly 100%) and its population of medium-sized, densely packed lymphocytes with intermixed macrophages and apoptotic bodies (Figure 21.5). The scattered macrophages on a blue background give rise to the “starry sky” analogy. The individual cells are atypical enough that they would not be mistaken for normal mature lymphocytes, however. Burkitt lymphoma is EBV-associated in some cases, and most cases involve a *MYC* translocation.

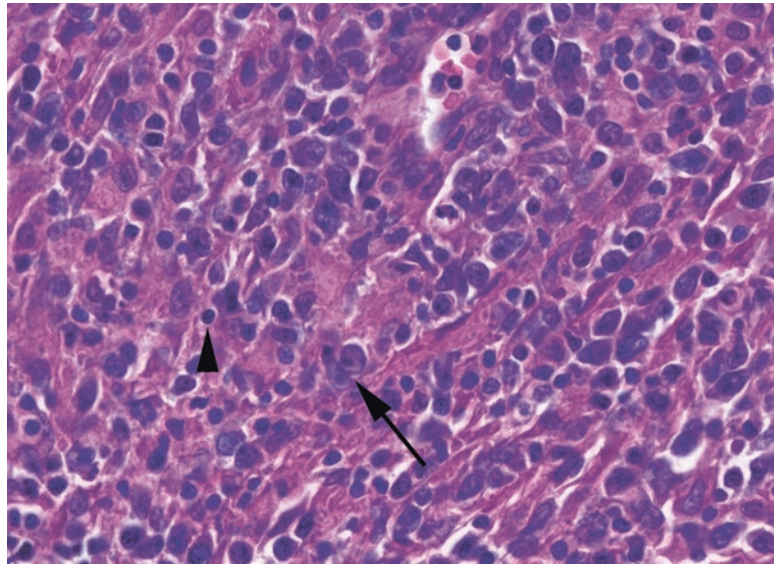


FIGURE 21.4. Diffuse large B cell lymphoma. The usual appearance is that of sheets of discohesive cells that do not form any recognizable architectural patterns (such as glands or trabeculae). The cells typically have large nuclei, irregular and prominent nuclear membranes, and nucleoli (*arrow*). Compare the cell size to a background lymphocyte (*arrowhead*).

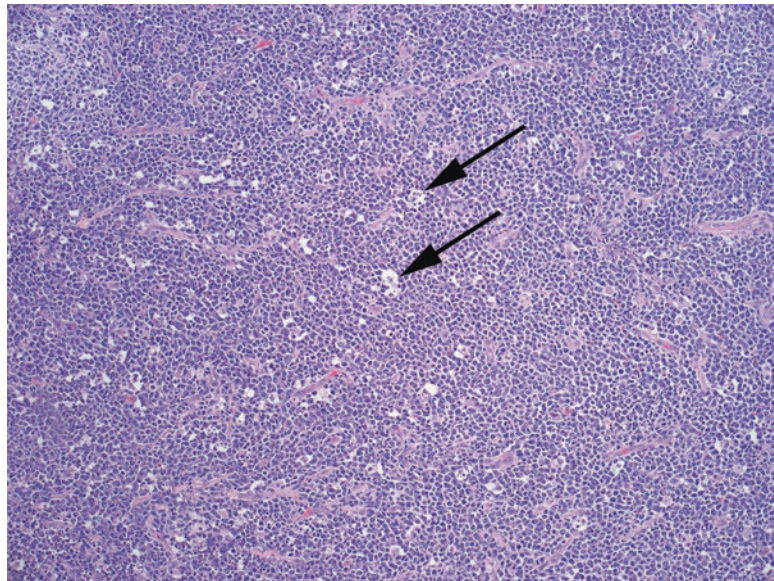


FIGURE 21.5. Burkitt lymphoma. This low-power view shows the typical “starry sky” pattern of Burkitt lymphoma, which is a densely packed tumor with scattered tingible body macrophages (*arrows*).

Follicular Lymphoma

Follicular lymphoma is the second most common non-Hodgkin lymphoma. Together DLBCL and follicular lymphoma account for over half of non-Hodgkin lymphomas. Follicular lymphoma is defined by a translocation in which *BCL2* (an antiapoptotic factor) is abnormally upregulated. *BCL2* usually turns *off* in germinal centers, making the

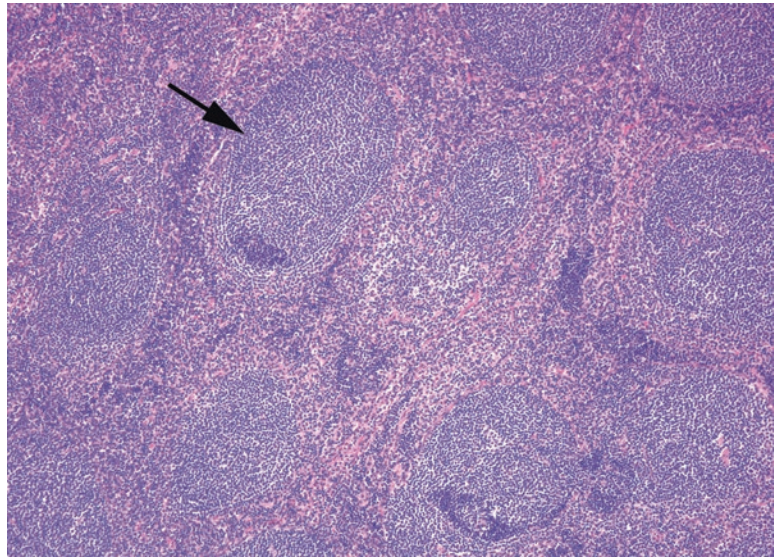


FIGURE 21.6. Follicular lymphoma. The lymph node is replaced by malignant follicles (*arrow*), which lack the mantle zones, polarization, and cell heterogeneity of germinal centers.

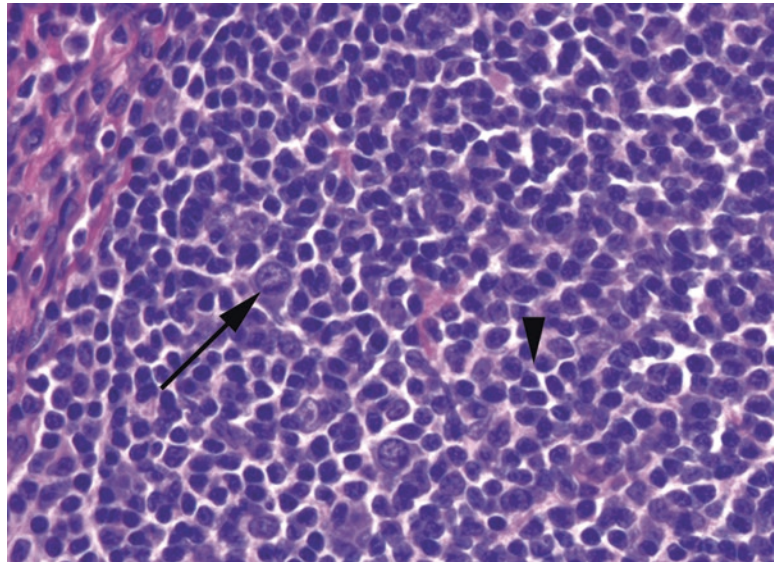


FIGURE 21.7. Follicular lymphoma, high power. The malignant follicles contain a mixture of small cleaved centrocytes (*arrowhead*) and large centroblasts (*arrow*).

centroblasts and centrocytes susceptible to apoptosis. Abnormal retention of *BCL2* leads to cells that do not die, more or less, hence the malignancy. Follicular lymphoma appears as a nodular proliferation of back-to-back neoplastic follicles that fill the lymph node (Figures 21.6 and 21.7). Within these follicles are a mixture of neoplastic centrocytes (smaller) and centroblasts (larger); the relative proportion determines the grade of the lymphoma. Follicular lymphoma can also have areas of diffuse growth (the opposite of nodular), can spread to the marrow, and can transform to DLBCL. When circulating as a leukemia, the folded (cleaved) centrocyte nucleus has been compared to a “baby’s butt.”

The diagnostic dilemma is that benign, reactive lymphoid hyperplasia can also present as a nodular collection of follicles in an enlarged node. How to distinguish the two? The following are features of *benign follicular hyperplasia*, not seen in follicular lymphoma (see Figures 21.1 and 21.2):

- Germinal centers of variable sizes and cuffed by mantle zones (as opposed to back to back)
- Polarity of germinal centers in which the centroblasts and centrocytes tend to take up opposite positions in the follicle, creating an asymmetry
- Tingible body macrophages
- “Open” sinuses (which are not seen as open, really, but full of histiocytes)
- Abundant mitoses and apoptoses

These features should weed out the most straightforward cases. However, in very tough cases, stains help. The neoplastic follicles of follicular lymphoma will stain for BCL2; benign follicles should be negative.

Other Mature B Cell Neoplasms

The other three common lymphomas of mature B cells, small lymphocytic lymphoma, marginal zone lymphoma, and mantle cell lymphoma each make up less than 10% of non-Hodgkin lymphomas. While the first two are considered low-grade, mantle cell lymphoma is more aggressive. For these, and actually for most non-Hodgkin lymphomas, flow cytometry is critical in the diagnosis. Flow cytometry can establish two things:

1. There is a monoclonal population present. All B cells express either kappa or lambda light chain, so a significant predominance of one or the other implies a large genetically identical population (a neoplasm). A similar test can be done for T cell neoplasms (T cell receptor rearrangement studies) but not by flow cytometry.
2. There are cells with an abnormal phenotype. The power of flow cytometry is that individual cells can be simultaneously tested for multiple markers, for instance, abnormal coexpression of CD20 and CD5. Doing this with immunohistochemistry is much less precise; you can estimate that the CD5⁺ cells outnumber the normal T cells (identified by CD3) and that they are clustered in areas of B cells (identified by CD20), but you cannot see two markers on a single cell.

The interpretation of flow cytometry is beyond the scope of this chapter (and this pathologist), but the major learning point is that saving tissue for flow cytometry will make your life much easier, so set some fresh tissue aside in appropriate media for any lymphadenopathy workup or possible extranodal lymphoma. Formalin-fixed tissue cannot be sent for flow cytometric studies.

In mature B cell lymphomas, the low-power feature that rings alarm bells is the *effacement of the lymph node*. This means that the normal architecture, the follicles and sinuses and interfollicular areas, have been blurred out or replaced by a rather uniform population of cells. This takes some experience to judge; fortunately, every carcinoma resection comes with some bonus lymph nodes, so take the time to notice what normal looks like.

Small Lymphocytic Lymphoma

Small lymphocytic lymphoma (SLL) is the solid-phase manifestation of chronic lymphocytic leukemia (CLL), and the two are often seen in concert. In lymphoma form, SLL appears at 1× as a very homogeneous, very blue lymph node. At low power, the follicles, paracortex, and sinuses are replaced by a sheet of what look like normal lymphocytes. There may be a vague suggestion of nodularity, called *pseudofollicles*, containing proliferating cells (Figure 21.8). On high power, the SLL cells usually have chromatin that may remind you of a plasma cell; they look like soccer balls. The nuclei are small, round, regular, and without nucleoli. SLL cells abnormally express CD23 and CD5.

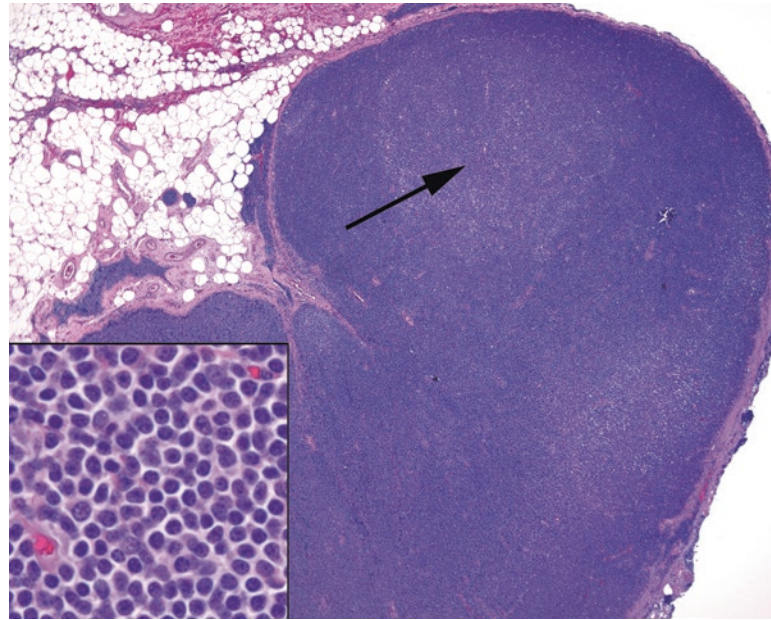


FIGURE 21.8. Small lymphocytic lymphoma. The lymph node, at low power, is an unnatural flat blue, without the variegation of normal sinuses and follicles. Subtle pale pseudofollicles (*arrow*) may be seen. *Inset:* The cells are small and nuclei are round and dense, like normal lymphocytes, except the chromatin has a chunky soccer ball pattern, similar to a plasma cell.

Marginal Zone Lymphoma

The marginal zone of the lymph nodes is named after the more prominent and identifiable marginal zone in the spleen. In the lymph nodes, it is barely visible as a slightly lower-density zone surrounding the mantle. The cells in this zone have a prominent rim of clear cytoplasm, giving them almost a fried-egg appearance, and a pale look at low power. This morphology is called *monocytoid*. This cell type can give rise to at least three distinct lymphomas: *splenic marginal zone lymphoma (MZL)*, *nodal MZL*, and *extranodal mucosa-associated lymphoid tissue (MALT) lymphoma* of the gut, salivary glands, and other mucosal sites.

MALT lymphoma is discussed in Chapter 7. Like MALT lymphoma, the cells of MZL are monocytoid in appearance and grow in sheets or clusters, mainly in the interfollicular areas (Figure 21.9). They are negative for most of the markers that identify other lymphomas but may sometimes abnormally express CD43.

Mantle Cell Lymphoma

Mantle cell lymphoma (MCL), although it is in the histologic differential diagnosis for the low-grade lymphomas, actually behaves more aggressively than the others in this group. On low power it is reminiscent of SLL, with sheets of small lymphocytes effacing the node. In a not-entirely-replaced node, you may be able to tell that the mantle zones are expanding to engulf the germinal centers. Hyalinized vessels are typical. On high power, the cells of MCL have a chunky dark chromatin similar to the cells of SLL, but the nuclear membranes are more crinkled or angular, with more size variation (Figure 21.10). Cyclin D1 is an IHC marker for MCL, which correlates with the translocation that defines the tumor.

Markers

Although the mature B cell lymphomas do have histologic features that distinguish them, few pathologists would sign them out without confirming flow cytometry or immunostains. Although this book does not otherwise focus on immunostains, it is impossible to discuss the lymphomas without them. The standard panel includes CD markers 3 and 20, 5 and 10, and

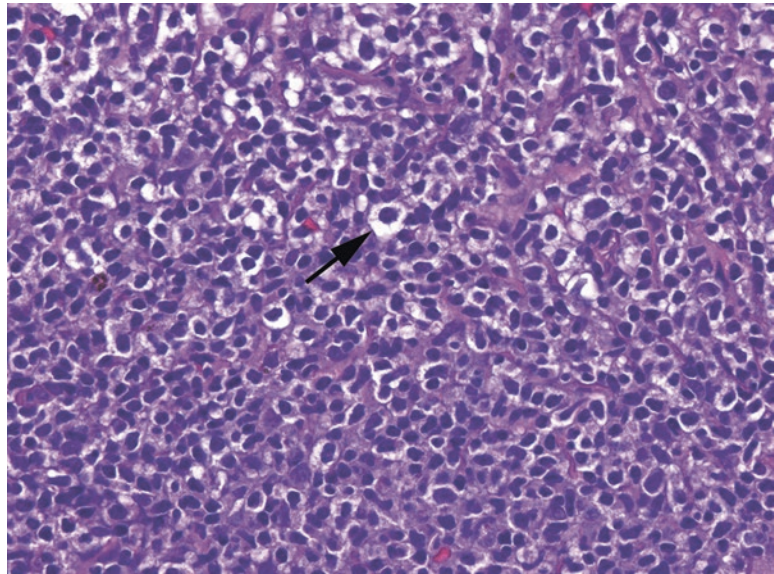


FIGURE 21.9. Marginal zone lymphoma. The marginal zone cells classically have a monocytoid appearance, meaning there is a distinct thin halo of clear cytoplasm (*arrow*).

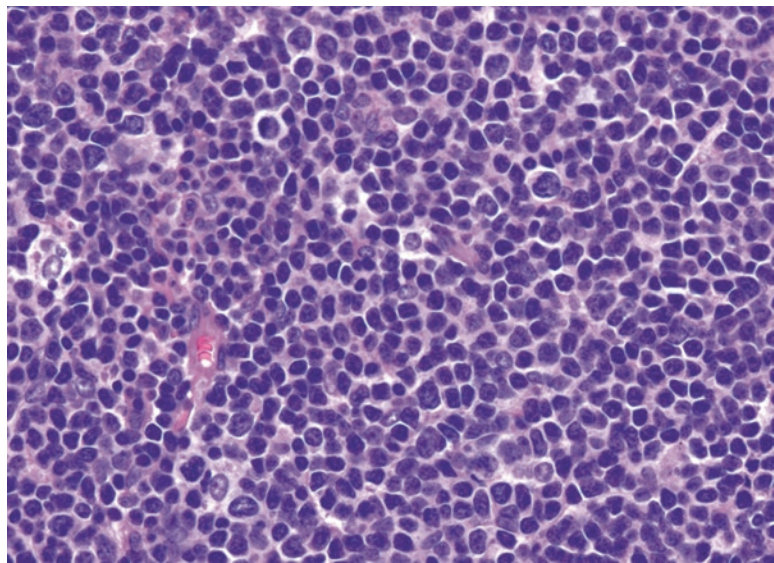


FIGURE 21.10. Mantle cell lymphoma. The neoplastic cells in mantle cell tend to be more irregular in shape than those of small lymphocytic lymphoma, with slightly angular nuclei. The chromatin pattern, with the soccer ball splotches, is similar to small lymphocytic lymphoma.

43, as well as some specific markers discussed earlier. CD3 identifies T cells, and CD20 identifies B cells. The expression of either CD5 or CD43 (T cell markers), or CD10 (an immature B cell/germinal center marker), in mature B cells is abnormal and guides your differential.

Lymphoblastic Lymphoma

The *lymphoblastic lymphomas* are not usually diagnosed in lymph nodes. The B cell type more commonly presents as a leukemia (B-ALL), whereas the T cell type is most often found as a mediastinal mass (remember the immature T cells are found in the thymus; Figure 21.11).

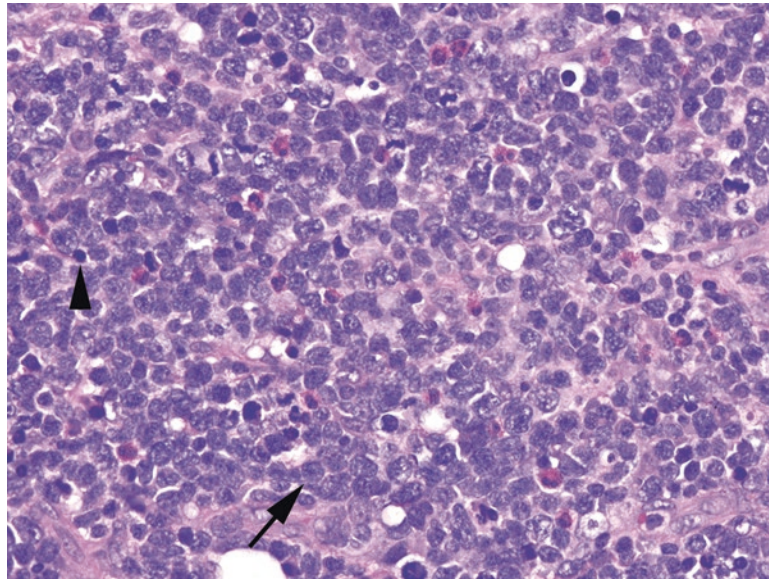


FIGURE 21.11. Acute lymphoblastic lymphoma. The nuclei (*arrow*) are larger than a normal lymphocyte (*arrowhead*), and the chromatin is very immature (meaning widely dispersed throughout the nucleus). Unlike large B cell lymphoma, there are no prominent nucleoli or thick nuclear membranes.

Most ALLs are now defined by cytogenetics, but they also stain for the blast markers TdT and CD34. As CD45, the usual screening immunostain, is not reliably expressed in these tumors, be aware that a negative CD45 in a pediatric small round blue cell tumor may still be lymphoma. Finally, what looks like a low-grade B cell lymphoma in a child is much more likely to be a lymphoblastic lymphoma.

Hodgkin Lymphoma

Hodgkin lymphoma is common, comprising 30–40% of all lymphomas. It is divided into two large groups, *classic* (several types) versus *nodular lymphocyte predominant* (NLPHL). Both groups share the histologic features of a dense and effacing mixed inflammatory infiltrate with scattered Reed–Sternberg (or Reed–Sternberg-like) cells. Because of the high benign background population, flow cytometry is not effective in detecting Hodgkin lymphoma. Making the diagnosis requires either seeing the diagnostic tumor cells or demonstrating them by immunostain. In classic Hodgkin lymphoma, the Reed–Sternberg cells are CD30 and CD15 positive, while negative for CD45 and CD20. In NLPHL, the tumor cells stain exactly the opposite (45/20⁺, 30/15⁻). In this sense, NLPHL is really analogous to DLBCL with an associated inflammatory response.

The subtypes of classic Hodgkin lymphoma include nodular sclerosing, mixed cellularity, and the less common lymphocyte-depleted and lymphocyte-rich. All should have some variety of the Reed–Sternberg cells, which in classic form have at least two nuclear lobes, each with a prominent, cherry-red nucleolus and thick nuclear membrane (Figure 21.12). However, variants with single or multilobed nuclei may be seen.

In *nodular sclerosing Hodgkin lymphoma*, at low power, the node is “cirrhotic,” with nodules of mixed inflammation divided by broad fibrous bands (Figure 21.13). The node is usually also encapsulated. The Reed–Sternberg cells take the form of lacunar cells, which means the diagnostic nuclei are suspended in a retracted space or halo.

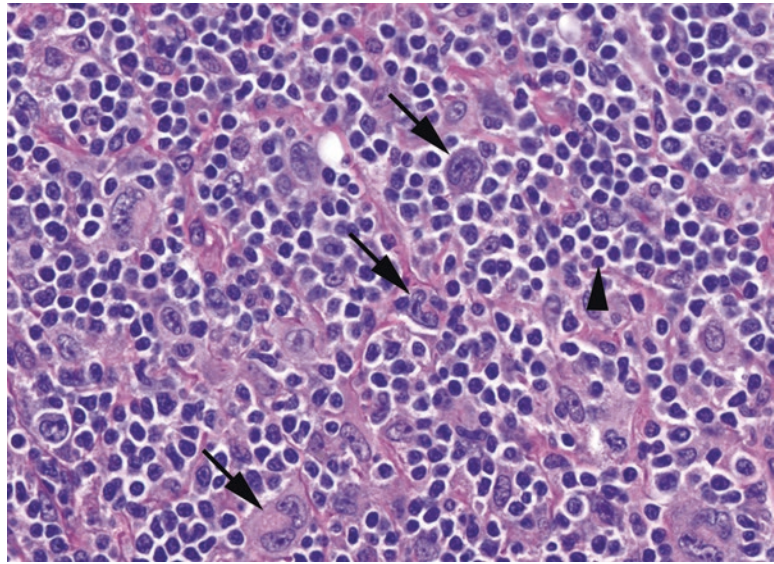


FIGURE 21.12. Hodgkin lymphoma. The malignant Reed–Sternberg cells (*arrows*) are spread out among a background of non-neoplastic inflammatory cells, especially lymphocytes (*arrowhead*).

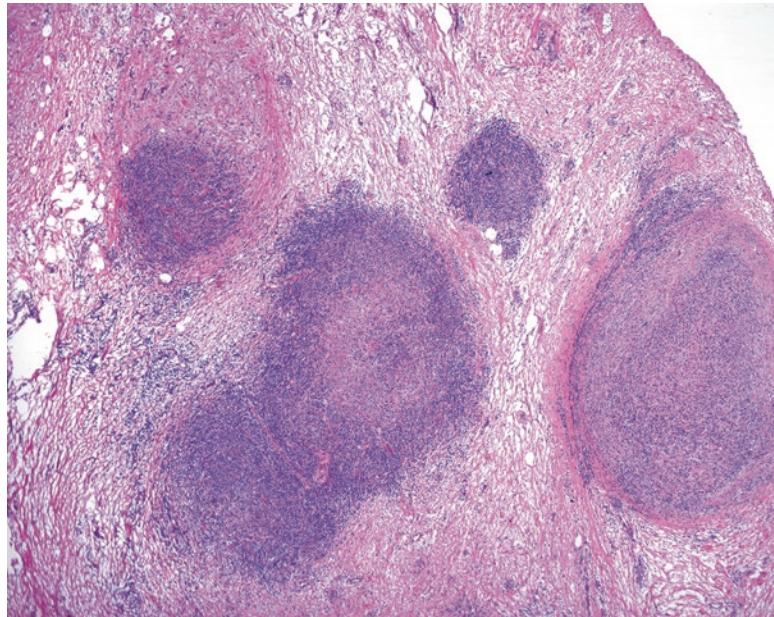


FIGURE 21.13. Nodular sclerosing Hodgkin lymphoma. The aggregates of Reed–Sternberg cells and inflammation are separated by broad bands of fibrosis.

At low power, *mixed cellularity Hodgkin lymphoma* appears pink because of the abundant histiocytes and eosinophils found in the background infiltrate (Figure 21.14). Plasma cells and lymphocytes are also common. Very subtle cases may present as granulomatous inflammation.

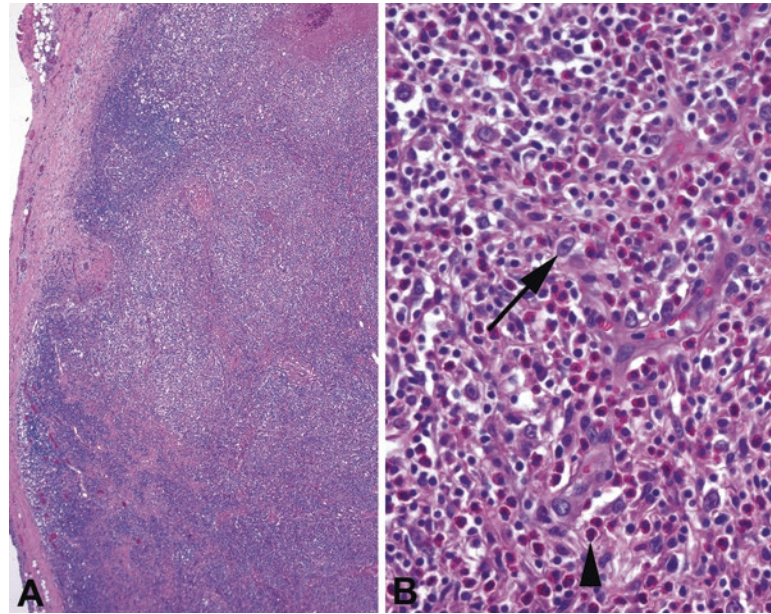


FIGURE 21.14. Mixed cellularity Hodgkin lymphoma. (a) At low power, the lymph node appears to be effaced by a heterogeneous population, giving a slightly pink color to the node (compare to small lymphocytic lymphoma in Figure 21.7). (b) The Reed–Sternberg variants are few and far between (*arrow*), with a dominant population of eosinophils (*arrowhead*).

T Cell Lymphomas

The incidence of T cell neoplasms is much lower than that of B cell lymphomas. The most common T cell lymphoma is *peripheral T cell lymphoma NOS*, a neoplasm of mature T cells, which is in fact subdivided into some specified types. *Angioimmunoblastic T cell lymphoma* (AITL) is another neoplasm of mature T cells that is notable for an accompanying proliferation of capillaries and dendritic cells within the node.

Anaplastic large cell lymphoma (ALCL) is the T cell equivalent of DLBCL, in that it is comprised of large pleomorphic activated-type tumor cells. It is characterized by large, atypical, elaborately folded nuclei, described as *cerebriform*, but still must be identified by T-specific markers, as well as CD30. It may present as a cutaneous or a systemic disease. In general, skin involvement by a lymphoma suggests a T cell process. A cutaneous mature T cell neoplasm is *mycosis fungoides/Sezary syndrome* (the solid and circulating phases, respectively).

Non-neoplastic Entities

Inflammation in a lymph node? It is only abnormal if it is granulomatous, acute, or necrotizing. Granulomatous inflammation may be nonnecrotizing in sarcoid or caseating in tuberculosis or fungal infection. Both of the latter should have positive findings on microorganism stains. Other infectious entities include infectious mononucleosis and cytomegalovirus, which can both cause dramatic follicular hyperplasia; cat scratch disease, causing an acute lymphadenitis with neutrophils; and *Toxoplasma*, which causes a follicular hyperplasia with ill-defined granulomatous inflammation. An unusual disease, called *Kikuchi's lymphadenitis*, resembles a granulomatous response, with large swaths of geographic necrosis, but on high power, the necrotic areas are paradoxically devoid of neutrophils, showing only apoptotic nuclear debris.

See Table 21.2 for a summary of diagnostic features in the lymph node.

TABLE 21.2. Diagnostic features.

In summary, if you see...	Think of...
Diffuse sheet of small mature lymphocytes	Small lymphocytic, mantle cell, or marginal zone lymphoma
Prominent nodular pattern	Follicular lymphoma vs. reactive lymph node
Diffuse sheet of large atypical cells	Diffuse large B cell lymphoma or anaplastic large cell lymphoma
Mitotically active, primitive cells resembling small cell carcinoma	Lymphoblastic lymphoma or Burkitt lymphoma
A pink and/or granulomatous mixed infiltrate	Mixed cellularity Hodgkin lymphoma
Fibrous bands dividing the node	Nodular sclerosing Hodgkin lymphoma

Spleen

The spleen, having no clearly identifiable gross or microscopic architecture, was a somewhat mysterious organ for much of medical history. Many pathologists still do not get farther than “negative for tumor” when examining a spleen. To understand the components of the spleen, you should start with the function. The first function is that of blood filtration or more specifically filtration of the cellular components of blood. Blood entering via the splenic artery travels to capillaries which end abruptly in the *red pulp*, a sort of jelly-like interstitium that fills up with blood like a sponge. The blood cells must traverse the macrophages in the red pulp before collecting in the sinuses, which coalesce into the outgoing splenic vein. In the red pulp, cells are literally (littorally) sorted and cleaned, removing fragments and particles, as well as antibody-coated cells or microorganisms. The presence of Howell–Jolly bodies, or nuclear remnants, in red cells is an indication of splenectomy or a nonfunctioning spleen, as these are normally plucked out in the red pulp. Because the red pulp is in direct continuity with the bloodstream, neoplasms of the marrow or peripheral blood (such as leukemias) will also extend to the red pulp.

The *white pulp*, on the other hand, is a network of lymphoid tissue distributed throughout the spleen, and it carries out the second main function of the spleen, which is that of antigen presentation. On fresh-cut section, the white pulp appears as faint pale speckles in a background of dark red pulp. On H&E, however, the white pulp appears purple, just like a lymph node (Figure 21.15). The white pulp generally follows the arterioles as a sleeve, with all of the normal components of a lymph node (primary follicles +/- germinal centers, and mantle, marginal, and perifollicular zones; Figure 21.16). Disease processes that involve the lymph nodes elsewhere, such as lymphomas, will preferentially expand the white pulp, to the point of being grossly visible as mottled white patches.

Due to the thick organ capsule and the extraordinary amount of blood in a spleen, it is somewhat difficult to fix properly. A spleen specimen should be sliced at thin intervals and fixed overnight. Take care to make some nice splenic preparations when you get a distal pancreatectomy/splenectomy, because autopsy spleens are usually severely autolyzed.

Reasons for splenectomy (and it is essentially never biopsied, because of the inability to sew it back up) include hypersplenism, in which the spleen is too aggressively destroying blood cells; immune thrombocytopenia (ITP), in which it is specifically destroying platelets; sequestration crisis in sickle cell anemia (Figure 21.17); and hematopoietic diseases that cause splenomegaly (including leukemia, lymphoma, or extramedullary hematopoiesis). In addition, the spleen may be removed for traumatic rupture or as part of a carcinoma resection. Metastases to the spleen are very rare, as there are no afferent lymphatics to the spleen, but capsular involvement by peritoneal carcinomatosis is not uncommon. One peculiar feature of spleen is the tendency for small nodules of splenic tissue to grow elsewhere in the abdomen. These self-contained *accessory spleens* or *splenules* may arise after splenectomy or may be present despite a normal spleen. More than once a biopsy of a suspicious nodule in the abdomen has turned out to be nothing but a splenule.

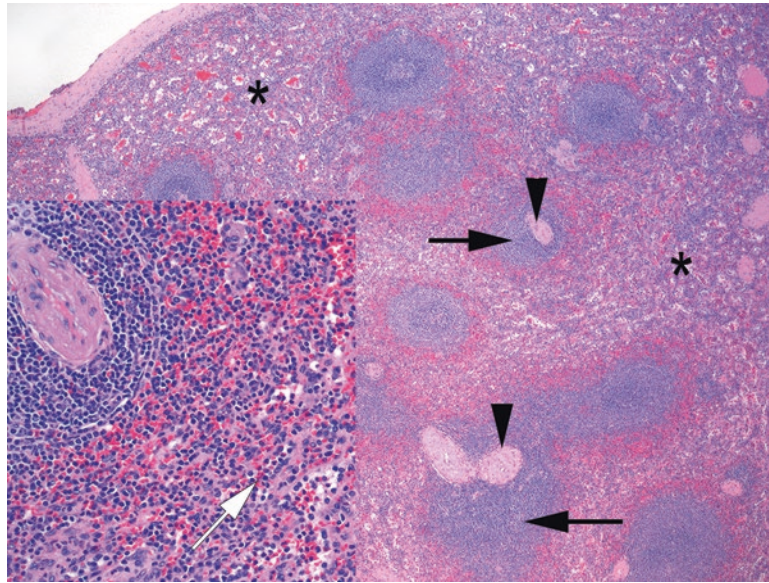


FIGURE 21.15. Normal spleen. The spleen consists of prominent lymphoid follicles or white pulp (*black arrows*) adjacent to arterioles (*arrowheads*), embedded in a network of sinusoids that comprise the red pulp (*asterisks*). (*Inset*) At high power, the capillaries of the red pulp are indistinct, but open sinuses full of red and white blood cells are visible (*white arrow*).

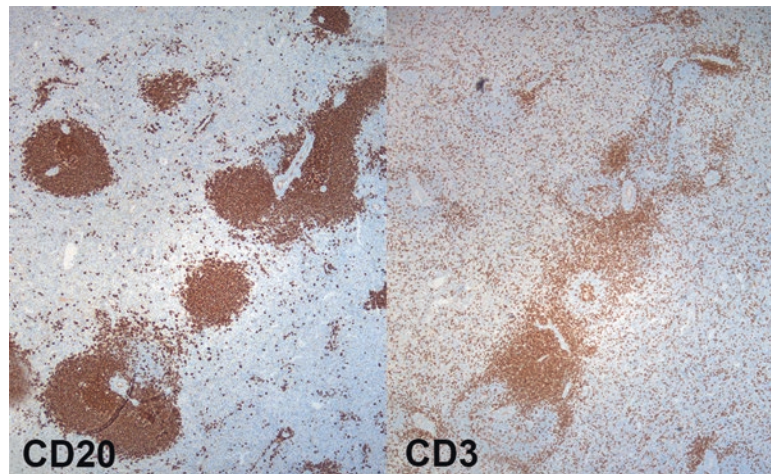


FIGURE 21.16. B and T cells. (*Left*) A stain for CD20 highlights B cells, clustered tightly around the arterioles and in lymphoid follicles. (*Right*) A stain for CD3 in the same area shows T cells in the perifollicular zone of the white pulp.

Lymphomas Involving the Spleen

Any lymphoma can involve the spleen, but it is rare for the spleen to be the primary or presenting site of involvement. As a result, it is unusual to work up an unknown lymphoma in the spleen, but if you had to, the workup would be the same as for a nodal or extranodal site. Lymphomas commonly encountered in the white pulp include SLL, MCL, MZL, and DLBCL, as well as T cell lymphomas and Hodgkin lymphomas in the periarteriolar T cell zones.

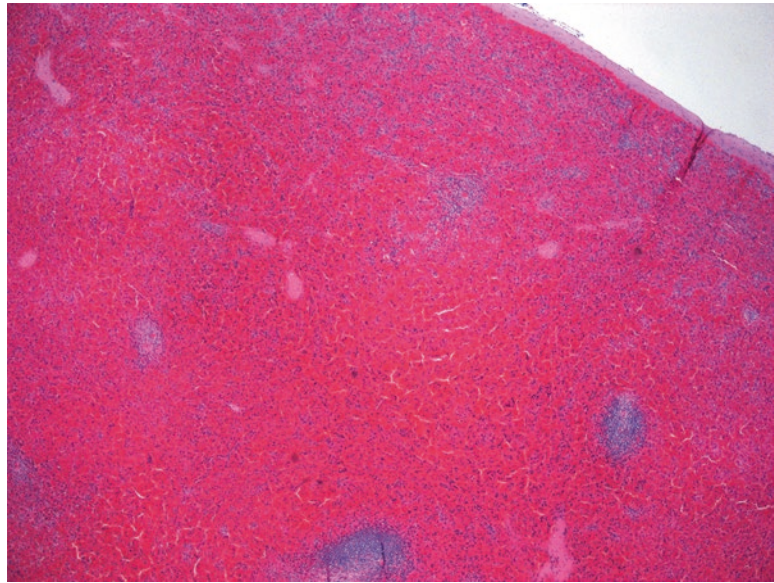


FIGURE 21.17. Sickle cell sequestration crisis. The red pulp is congested and expanded with red blood cells; the white pulp is nearly obliterated. On high power the red cells were sickled (not visible here).

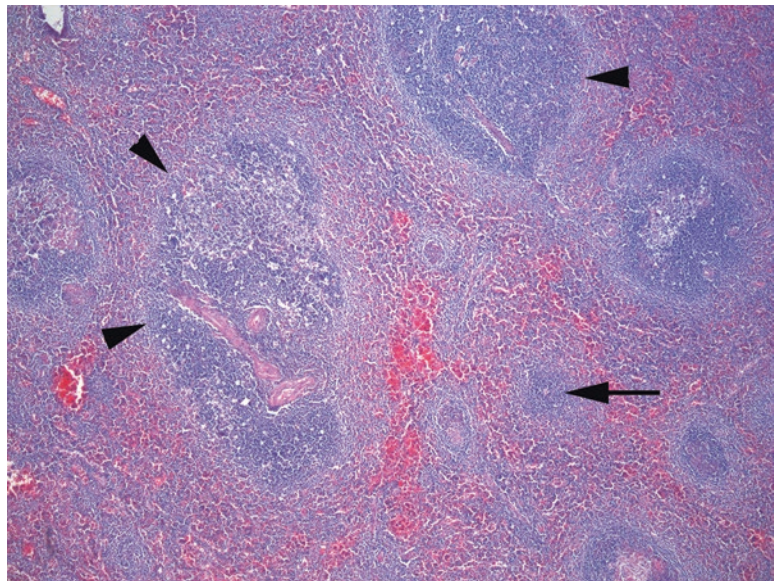


FIGURE 21.18. Splenic marginal zone lymphoma. Large irregular neoplastic follicles are lined by a pale layer of monocytoid cells (*arrowheads*). Tumor cells are also present in the intervening red pulp, visible as areas of purple between the follicles (*arrow*).

Lymphomas Originating in the Spleen

Splenic marginal zone lymphoma is a primary splenic lymphoma arising from the B cells of the marginal zone. Like extranodal MZL and MALT lymphoma, the neoplastic cells are monocytoid in appearance and are negative for most of the markers that define the other mature B cell lymphomas. Splenic MZL expands the white pulp, with characteristic prominent pale marginal zones surrounding enlarged follicles, but also involves the red pulp, with tumor cells invading sinuses (Figure 21.18). *Hepatosplenic T cell lymphoma* is a rare lymphoma of mature T cells

that involves the liver and spleen, leading to massive hepatosplenomegaly in adolescents and young adults. It also involves the bone marrow, so despite being a lymphoma, it localizes to the red pulp.

Leukemias of the Spleen

The leukemias, characterized by circulating tumor cells, will preferentially involve the red pulp. These include the acute and chronic leukemias covered in Chapter 20 but also lymphomas with a leukemic component, such as CLL and hairy cell leukemia. *Hairy cell leukemia* is a tumor of B lymphocytes, but it involves mainly the bone marrow and spleen, with a small number of circulating cells. The cells are named for the fine filamentous cytoplasmic projections seen on peripheral smear, but these “hairs” are not seen on H&E. Instead, they are identified by their rings of pale cytoplasm and small oval nuclei (Figure 21.19). The low N/C ratio leads to an overall pink and decidedly nonlymphoid appearance, but the diagnosis can be confirmed by immunostains. Hairy cell leukemia, like the other leukemias, primarily expands the red pulp, often in the form of sheets of tumor cells with scattered “lakes” of red blood cells.

Primary Neoplasms

There are only a handful of non-hematopoietic cell types in the spleen, so the primary tumors of the spleen fall mainly into two categories: vascular and dendritic cells. Of the vascular tumors, while you may see hemangiomas, lymphangiomas, and angiosarcomas, the tumor that is unique to the spleen is the *littoral cell angioma*. The littoral cells are the endothelial cells that line the sinuses of the red pulp and that express both vascular and histiocytic cell markers. The low-power appearance of the littoral cell angioma is that of a cavernous hemangioma, but on higher power, the plump littoral cells can be seen lining the spaces and filling the lumens like alveolar macrophages in the lungs (Figure 21.20).

The dendritic cells of the spleen consist of the *interdigitating dendritic cells* and the *follicular dendritic cells*, both of which play supportive roles similar to those in the lymph nodes. Neoplasms of these cells (interdigitating dendritic cell sarcoma and follicular dendritic cell sarcoma) can arise in any lymphoid site, including the spleen, but are extremely rare.

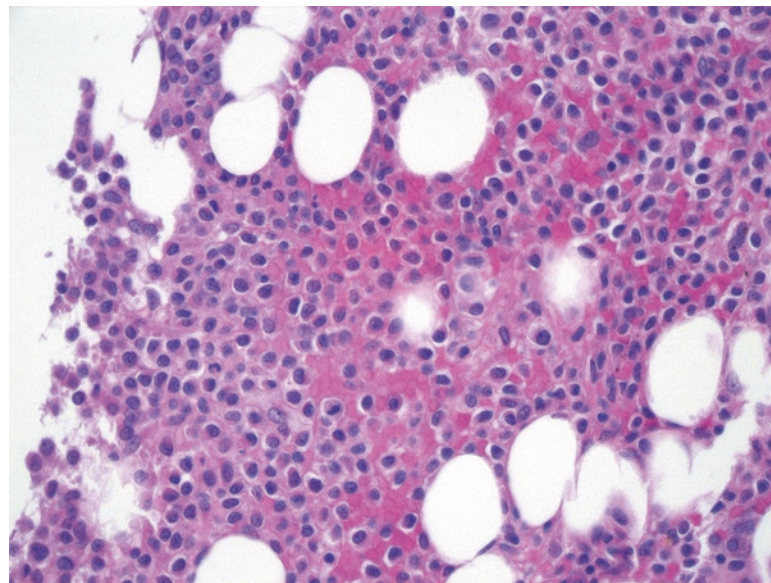


FIGURE 21.19. Hairy cell leukemia, bone marrow. The tumor cells have more pink cytoplasm than is generally seen in lymphocytes, and the nuclei are oval and folded, with lighter chromatin than a mature lymphocyte.

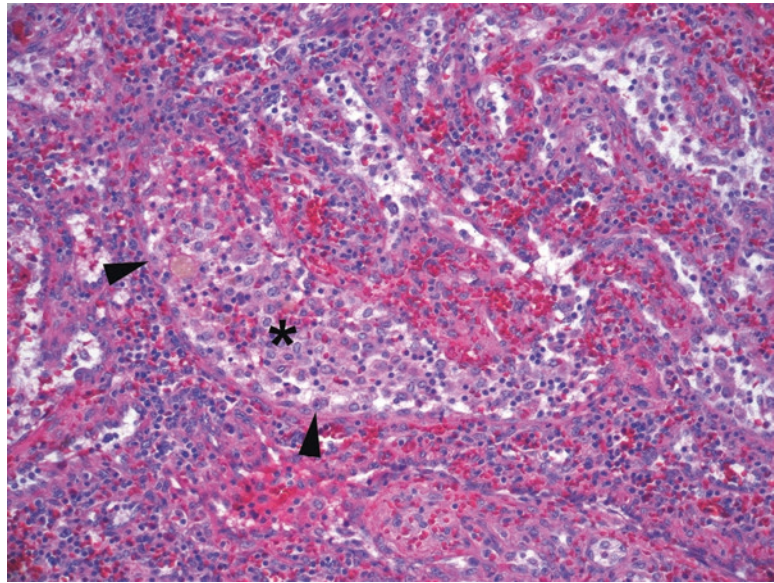


FIGURE 21.20. Littoral cell angioma. The irregular vascular spaces and channels are lined with plump pink cells, the littoral cells (*arrowheads*). They have a tendency to slough into the sinus spaces like pulmonary macrophages (*asterisk*).

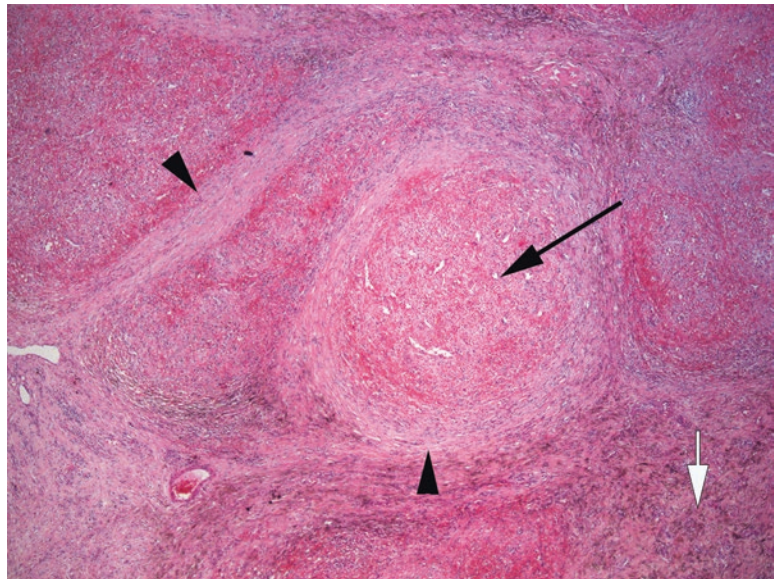


FIGURE 21.21. Sclerosing angiomatoid nodular transformation (SANT). A large nodule can be seen at the center (*black arrow*) surrounded by sweeping cords of collagen (*arrowheads*) that divide the red pulp into nodules. There is a background of red blood cells and hemosiderin (*white arrow*).

Non-neoplastic Processes

The spleen may be involved by all of the non-neoplastic processes that involve lymph nodes, including reactive lymphoid hyperplasia, granulomas, or infections. One unique splenic lesion is *sclerosing angiomatoid nodular transformation* (SANT). This non-neoplastic entity may present as a mass lesion of the spleen, visible by radiology. Under the microscope, it is a hyperplasia of the stroma of the red pulp, leading to tumor-like or angiomatoid nodules of red pulp surrounded by sclerosis, almost like cirrhosis of the spleen (Figure 21.21).

Normal Histology

The lungs consist of principally four compartments: the large airways (bronchi), small airways and airspaces (bronchioles and alveoli), interstitium, and vessels. As in most organs, inflammatory processes tend to preferentially involve one or two compartments, so identifying the most affected area is key to the differential diagnosis. Normal histologic features include the following:

- **Bronchi:** The bronchi are lined with ciliated or columnar epithelium with scattered goblet cells. Goblet cell metaplasia is an indication of irritation, such as in bronchitis or asthma. Squamous cell metaplasia is common in smokers. Under the epithelium you should find seromucinous (salivary-type) glands, cartilage, smooth muscle, and branches of the bronchial arteries (Figure 22.1).
- **Bronchioles:** The bronchioles should have a cuboidal epithelium without goblet cells (Figure 22.2). The club (Clara) cells are secretory and reserve cells, but they are difficult to see. There is no cartilage.
- **Alveoli:** The alveoli are the terminal air sacs and therefore have extremely thin walls (see Figure 22.2); in atelectasis, a common biopsy artifact, it is difficult to pick out the collapsed airspaces. Normally they are lined by nearly invisible flat type I epithelium. The presence of a cuboidal epithelium indicates type II hyperplasia (surfactant and reserve cells, which are normally sparse), seen in chronic inflammation or repair. Alveolar macrophages are often scattered throughout, but macrophages packing the alveoli are pathologic (see later discussion of desquamative interstitial pneumonia).
- **Vessels:** The pulmonary arterioles run with bronchioles and have two elastic layers on Movat's stain (train track appearance). The veins run in the interlobular septa and have one irregular elastic lamina. The lymphatics run with the arteries and veins in the pleura and interlobular septa.

Movat's stain is a standard supplemental stain for non-neoplastic lung. On this pentachrome stain, you will see elastic laminae highlighted as black fibers (useful for identifying pleural involvement by tumors as well), hyaluronic acid or mucin in aqua blue, mature collagen in yellow, smooth muscle in dull red, and fibrinoid necrosis (in vessels) as bright red (Figure 22.3). This stain is very useful for identifying fibroblast foci in organizing pneumonia (discussed later) because they stand out as turquoise swirls on low power. Established interstitial fibrosis will be yellow.

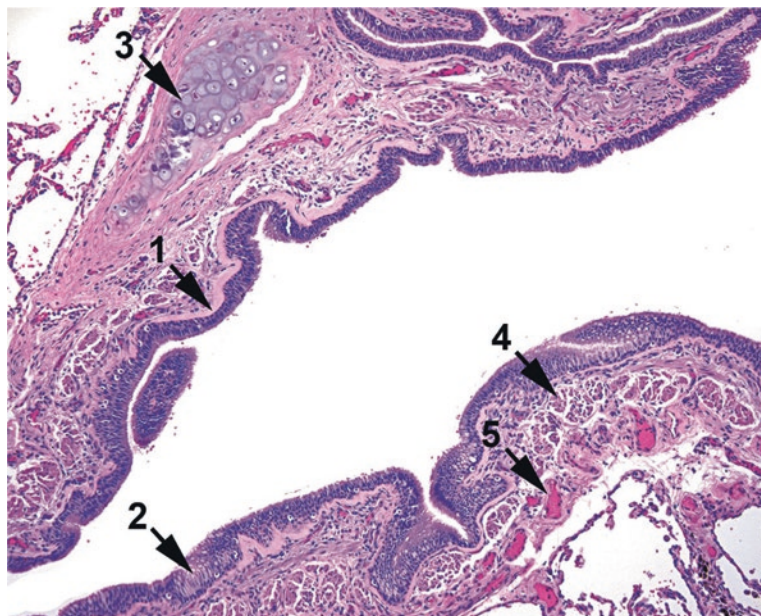


FIGURE 22.1. Normal bronchus. The bronchus is lined by ciliated columnar epithelium (1), foci of goblet cells (2), cartilage (3), and smooth muscle (4). The small arteries seen here (5) are branches of the bronchial artery, which carries oxygenated blood from the left ventricle.

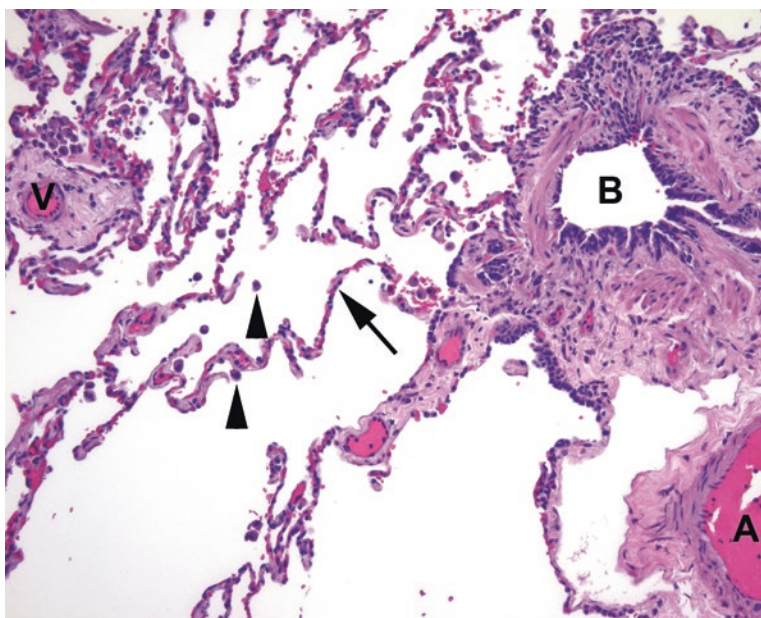


FIGURE 22.2. Bronchioles and alveoli. The small bronchiole (B) seen here is lined by a cuboidal epithelium and smooth muscle. The large adjacent arteriole (A) is a branch of the pulmonary artery. The veins or venules (V) run in septa. The alveolar walls (arrow) are normally lined with flat type I epithelium, of which only the nuclei are visible. Alveolar macrophages (arrowheads) are common.

A Brief Introduction to Non-neoplastic Lung

In non-neoplastic lung, within each of the four compartments, you are usually looking for something that does not belong. Examples of things that do not belong include heavy mononuclear cell infiltrates (lymphocytes and macrophages), neutrophils (other than in capillaries), eosinophils, granulomas, fibrosis, and fibroblast foci and substances such as amyloid, edema fluid, and asbestos. Table 22.1 lists differential diagnoses organized by what you see and in which compartment.

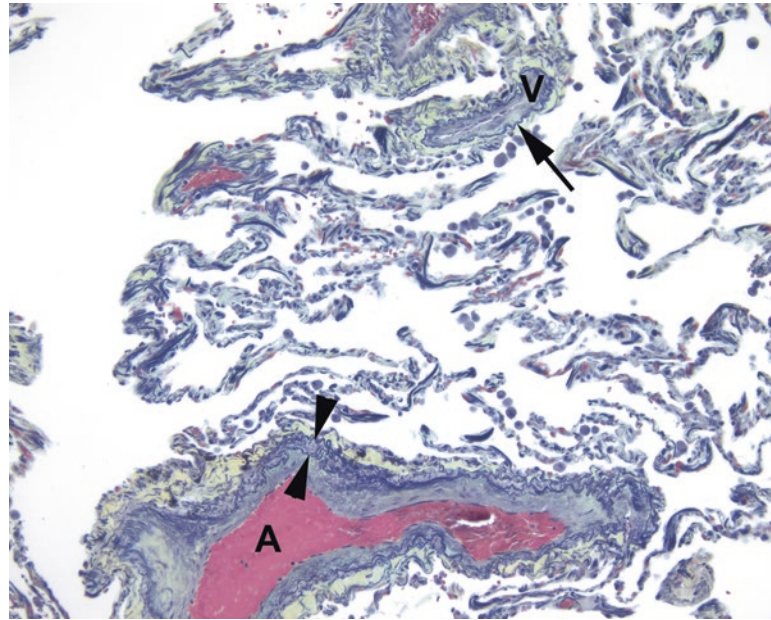


FIGURE 22.3. Movat's stain. The pulmonary arteries (A) have two elastic layers (*arrowheads*), while the veins (V) have one (*arrow*). The collagen lining the vessels is pale yellow-green in this stain.

TABLE 22.1. Differential diagnoses in non-neoplastic lung, by compartment.

Infiltrate	Large and small airways	Alveoli	Interstitialium/septa	Vessels
Lymphocytes and mononuclear cells	Atypical/viral pneumonia CHP Respiratory bronchiolitis (macrophages)	Atypical/viral pneumonia CHP Desquamative interstitial pneumonia (macrophages)	CHP DAD LCH (histiocytes) LIP NSIP Systemic CTD UIP	
Neutrophils	Bronchopneumonia Bronchocentric granulomatosis	Bronchopneumonia		Wegener's granulomatosis
Eosinophils	ABPA Asthma Bronchocentric granulomatosis Chronic eosinophilic pneumonia	Chronic eosinophilic pneumonia Churg–Strauss syndrome Loeffler syndrome	Chronic eosinophilic pneumonia LCH	Churg–Strauss syndrome
Granulomas	TB and fungus Bronchocentric granulomatosis	TB and fungus	CHP (poorly formed) Sarcoidosis Rheumatoid nodules	Churg–Strauss syndrome Invasive aspergillosis Sarcoidosis Wegener's granulomatosis Pulmonary hypertension
Fibrosis and fibroblast foci	Organizing pneumonia Constrictive bronchiolitis	Organizing pneumonia	DAD (late or organizing) DIP Pneumoconioses Sarcoidosis Systemic CTD UIP and NSIP	
Other substances (mucus, exudates, etc.)	Asthma Chronic bronchitis	Early DAD (HM) Goodpasture's syndrome (heme) Pulmonary alveolar proteinosis (exudate) <i>Pneumocystis</i> pneumonia (foamy material)	Lymphangioliomyomatosis (smooth muscle) Pneumoconioses (refractile material)	Amyloidosis DAD (fibrin thrombi)

ABPA allergic bronchopulmonary aspergillosis, *CHP* chronic hypersensitivity pneumonitis, *CIP* chronic interstitial pneumonia, *CTD* connective tissue disease, *DAD* diffuse alveolar damage, *HM* hyaline membranes, *LCH* Langerhans cell histiocytosis, *LIP* lymphocytic interstitial pneumonia, *NSIP* nonspecific interstitial pneumonia, *TB* tuberculosis, *UIP* usual interstitial pneumonia

Response to Injury in the Lung

Part of what makes the non-neoplastic lung so challenging is that there are a finite number of histologic patterns of injury, and each pattern can be caused by up to dozens of etiologies. In addition, a single etiology can cause more than one pattern. For this reason, you can only get so far on histology alone, and after that you need a pretty strong grasp of the clinical differential, radiology, and history. What follows is largely a discussion of patterns rather than the clinical nomenclature. Note that most of these are not diagnoses that can be made on a core or transbronchial biopsy; they require the larger context of a wedge biopsy.

It is useful to think of the three phases of injury response in the lung: acute, subacute, and chronic. *Acute injury*, which may be from infection, trauma, toxins, drugs, or a transfusion reaction, manifests as *diffuse alveolar damage* (DAD). This pattern correlates with the clinical entity *acute respiratory distress syndrome* (ARDS). Idiopathic DAD, when no known precipitating factor can be identified, is called *acute interstitial pneumonia* (AIP). The histologic picture is a nonspecific indication of injury and includes interstitial edema and hemorrhage, hyaline membrane formation, type II hyperplasia, fibrin thrombi, and fibrin extravasation into alveolar spaces (Figure 22.4). There should be a uniform and diffuse appearance throughout the field of view (although it may be patchy grossly). Acute bronchopneumonia, on the other hand, is the accumulation of neutrophils in the alveolar spaces, on top of the nonspecific findings of acute injury.

When the initial injury begins to resolve, you see the organizing or *subacute phase*, which consists of new fibroblast foci forming in the alveoli and bronchioles. These are the swirling nodules of stellate fibroblasts that appear myxoid on H&E stain and aqua on Movat's stain (Figure 22.5). This pattern is called *organizing pneumonia* (OP), and it can represent the healing phase of nearly any lung injury. It can be impossible to distinguish a primary OP from a resolving acute injury without the clinical context. It is also seen as a component of many other disease processes, but as a primary idiopathic disease, it is simply *cryptogenic organizing pneumonia* (COP). *Constrictive bronchiolitis* is a related lesion that is thought to be immune mediated and includes the clinical entities of *obliterative bronchiolitis* (seen in lung transplant rejection) and *bronchiolitis obliterans syndrome* (seen in graft-versus-host disease).

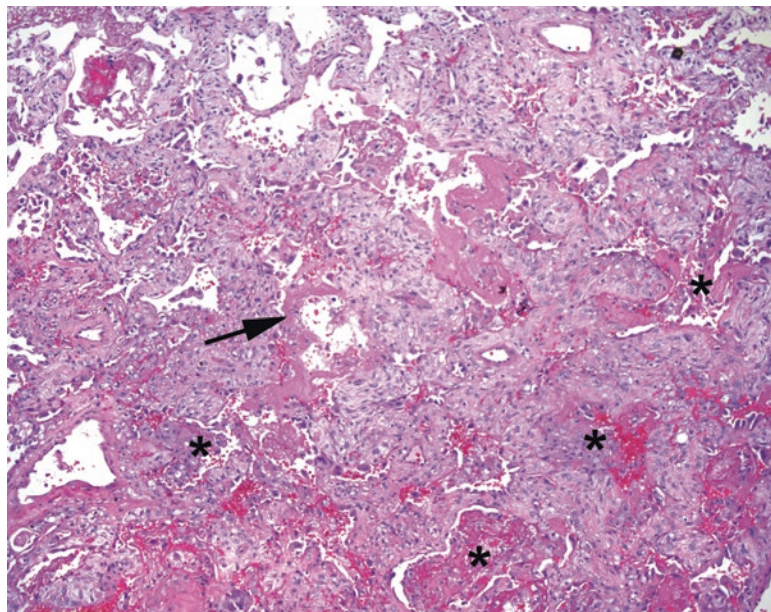


FIGURE 22.4. Diffuse alveolar damage. The alveolar spaces are full of fluid and blood (*asterisk*), which in some areas are beginning to coalesce into thick pink hyaline membranes (*arrow*). The interstitial spaces are thickened due to edema.

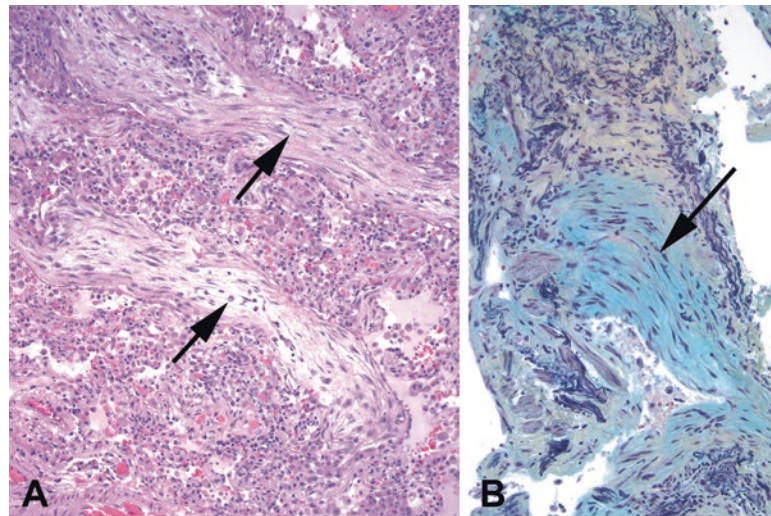


FIGURE 22.5. Fibroblast foci. (a) By H&E stain, these myxoid swirls of new fibroblasts are pale and streamy (arrows). (b) On Movat's stain, they are turquoise (arrow).

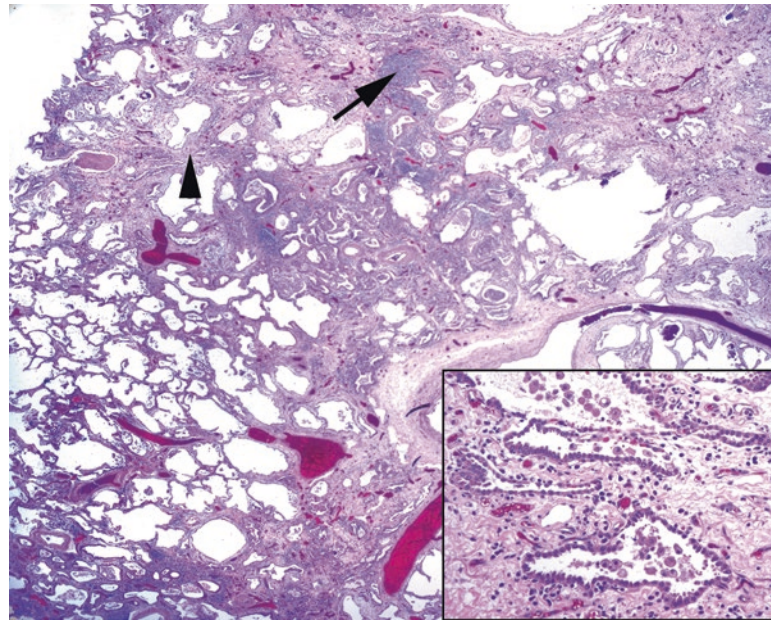


FIGURE 22.6. Usual interstitial pneumonia. The interstitial spaces are thickened and fibrotic (arrowhead), and there is abundant chronic inflammation (arrow). *Inset:* The scarred-down, irregularly shaped, residual alveolar spaces are lined with type II pneumocytes, which protrude into the lumen and may have atypical nuclei.

Chronic and repetitive injury to the lung is like a scab on the skin that gets repeatedly picked off; there are multiple cycles of damage and repair, and the end result is chronic inflammation and fibrosis. The final common pathway of many diseases or end-stage lung is called honeycomb lung, named for the thick-walled open airspaces visible grossly. One specific histologic pattern of chronic injury is *usual interstitial pneumonia (UIP)*. While UIP is a nonspecific pattern, if there is no identifiable etiology, it is labeled *idiopathic pulmonary fibrosis (IPF)*. UIP should be temporally and spatially heterogeneous, which means you should see evidence of all stages of injury (acute, subacute, and chronic), and areas of fibrosis should be interspersed with normal-looking lung. There is prominent interstitial fibrosis, which outlines large and angular distorted airspaces (Figure 22.6), but there should also be fibroblast foci

(unlike in OP, these involve primarily the interstitium rather than airspaces). The airspaces are lined by plump, reactive, and scary-looking type II pneumocytes. There is chronic inflammation, as well as pockets of acute inflammation.

The second major pattern of chronic injury is the *nonspecific interstitial pneumonia* (NSIP) pattern. NSIP is, in contrast to UIP, a temporally and spatially uniform process. Instead of the chaotic remodeling seen in UIP, NSIP looks like a diffuse even thickening and fibrosis of the alveolar walls and septa, with or without an inflammatory component. There should be no fibroblast foci. *Idiopathic NSIP* is called simply that.

Interstitial Lung Disease

The clinical term “interstitial lung disease” refers to a group of diseases with diffuse lung damage resulting in impaired pulmonary function. It can include pneumonias or pneumonitis caused by infection, drugs, autoimmune and connective tissue diseases, toxic exposures, smoking, or medications. If there is no known precipitating cause, the disease will be classified as an *idiopathic interstitial pneumonia* (IIP), with the specific disease entity determined by histologic pattern. There are six major categories of IIP: two are acute/subacute (AIP and COP, above), two are chronic (IPF and NSIP, above), and two are smoking-related (RB-ILD and DIP, below). Allergic diseases have their own classification system.

Allergic Disease

There are two forms of allergic response in the lung: IgE-mediated disease and cell-mediated hypersensitivity reactions. Diseases in the first category include asthma, allergic bronchopulmonary aspergillosis, bronchocentric granulomatosis, and the eosinophilic pneumonias.

The prototypical cell-mediated hypersensitivity disease is *hypersensitivity pneumonia* or *extrinsic allergic alveolitis*. It can have many causes and many appearances. This includes all the “dirty-job’s lung” and “(exotic-pet) fancier’s lung” diseases (i.e., cheese-washer’s lung). Eosinophils do *not* feature prominently in hypersensitivity pneumonia. The classic histologic triad includes (1) patchy interstitial chronic inflammation, especially peribronchiolar; (2) poorly formed small non-necrotizing granulomas; and (3) organizing pneumonia. As a chronic disease, however, hypersensitivity pneumonia can lead to either UIP or NSIP patterns.

Diseases of Smokers

Smokers get a spectrum of interstitial lung diseases, including *desquamative interstitial pneumonitis* (DIP), *respiratory bronchiolitis*, and *Langerhans cell histiocytosis* (LCH). They also get obstructive lung disease, which includes chronic bronchitis and emphysema. Respiratory bronchiolitis is an increase in pigmented macrophages within the alveolar spaces, whereas DIP is a more extreme presentation in which the macrophages pack the alveoli; it is usually associated with smoking, but both patterns may be seen in other processes as well.

Note that LCH, also called *eosinophilic granuloma*, does not have traditional granulomas and may not always have prominent eosinophils. What it does have is collections of Langerhans cells, identified by their pale nuclei with folds and creases (or by immunostains for S100 and CD1a). This disease may occur systemically in the pediatric population, but in adults (which are 50% of cases) it is an isolated and reversible pulmonary disease of smokers (refer to Figure 30.14 for an image of LCH in bone).

Neoplastic Lung

Precursor Lesions

There are at least three types of epithelium that are typically seen in the lungs, respiratory (ciliated columnar), alveolar, and squamous (metaplastic). In bronchial respiratory epithelium, the presence of cilia is a reassuring sign that all is well, even in the presence of reactive atypia

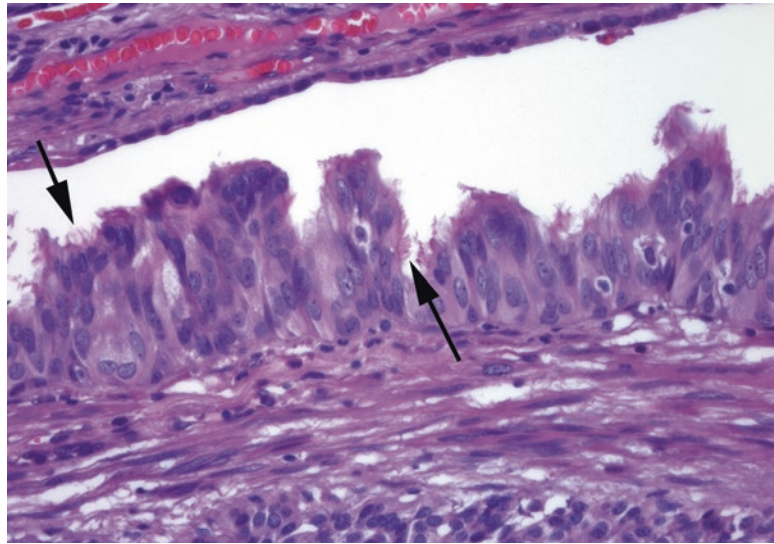


FIGURE 22.7. Reactive bronchial epithelium overlying a carcinoid tumor. Although the epithelium is very proliferative and has enlarged and crowded nuclei, the presence of cilia (*arrows*) indicates that these cells are benign.

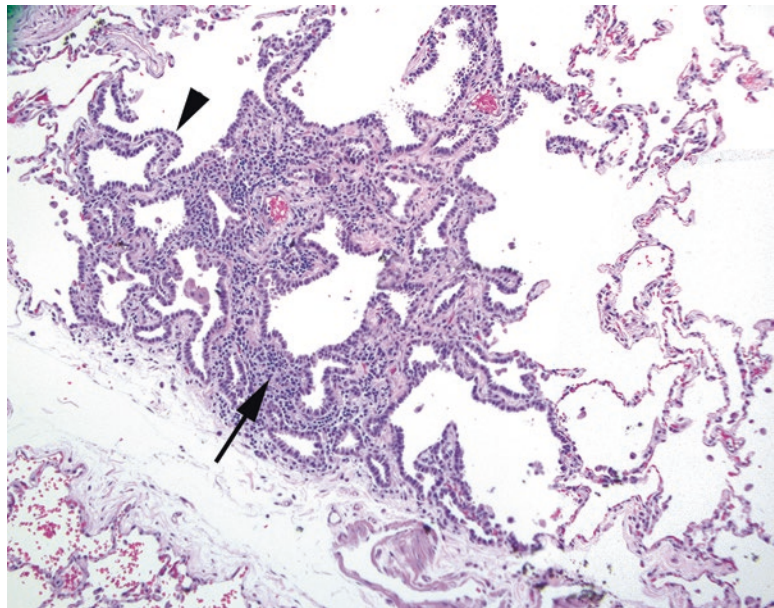


FIGURE 22.8. Atypical adenomatous hyperplasia. In this tiny, limited focus, there is interstitial inflammation (*arrow*) and prominent type II hyperplasia (*arrowhead*). The adjacent alveolar walls are unremarkable.

(Figure 22.7). The alveolar epithelium is normally so thin as to be invisible. However, chronically injured or irritated airspaces can show type II cell hyperplasia. On the slide, this appears as plump cuboidal to columnar eosinophilic cells with enlarged nuclei, lining the airspaces. In the absence of an inflammatory background to explain reactive hyperplasia, a small focus (<0.5 cm) of prominent, mildly atypical pneumocytes is called *atypical adenomatous hyperplasia* (Figure 22.8). This lesion is usually incidental, not mass-forming, and is analogous to dysplasia in other epithelia. Like dysplasia in other organs, it can be multifocal and progress to *adenocarcinoma in situ* (AIS). AIS may be visible radiographically and histologically takes the

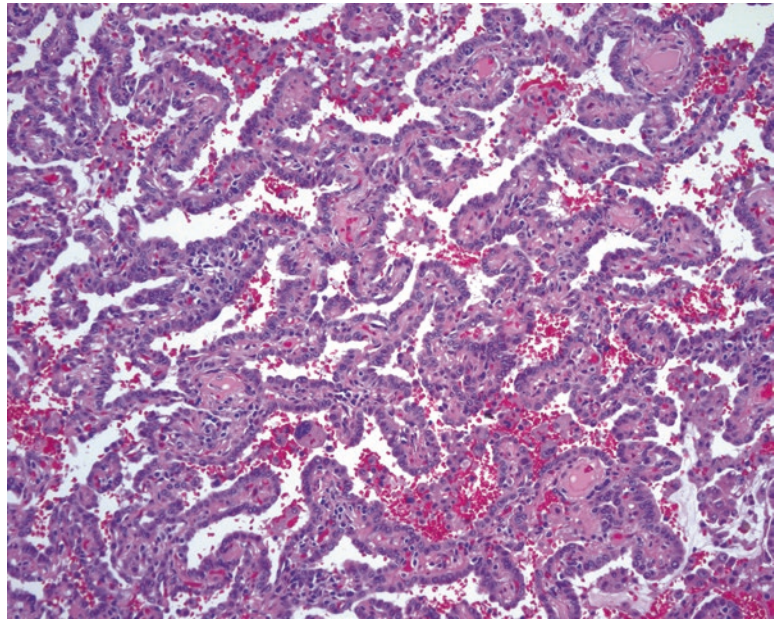


FIGURE 22.9. Adenocarcinoma in situ. The malignant cells line the alveolar walls but do not invade the stroma.

form of cuboidal/columnar and usually eosinophilic cells growing along the alveolar walls, outlining the structure of the airspaces (Figure 22.9); the line between atypical adenomatous hyperplasia and AIS is a subjective one. The cells are usually nonmucinous, but mucinous types also occur. By definition, there must not be evidence of stromal invasion (irregularly shaped back-to-back glands, single cells, or desmoplasia). AIS in a lepidic pattern is often found at the periphery of invasive tumors, so this diagnosis should not be made on a biopsy specimen or frozen tissue until the entire tumor has been sampled. This rule applies to most “improved-prognosis variant” tumors in pathology: you had better not label something as a good-prognosis tumor unless the entire lesion is of that type.

For squamous epithelia, although squamous dysplasia exists and is analogous to other organs, in practice it is not often caught on biopsy. Similarly, squamous carcinoma in situ exists in the bronchi just as in the larynx or oropharynx but is usually seen at the periphery of squamous cancers instead of as the sole finding in a biopsy specimen.

Carcinoma

Most lung biopsies in the neoplastic category are performed because a mass lesion was detected on radiology. Other than granulomatous processes or organizing pneumonia, most masses are neoplastic. The most common lesions are discussed in this chapter. There are some diagnostic entities that have been retired from the nomenclature. One is “bronchioloalveolar carcinoma” (BAC), which described a noninvasive lepidic pattern of adenocarcinoma. Currently, however, a noninvasive adenocarcinoma is just called adenocarcinoma in situ, like in other organs. The second nearly archived term is “non-small cell lung carcinoma” (NSCLC). Originally this was a catchall term for adeno- and squamous carcinomas. However, given the divergent clinical treatments for the two types of carcinomas, these days it is essential to fit a carcinoma into one category or the other, with large cell carcinoma (in resection specimens) and NSCLC (in biopsy specimens) covering the rare tumors that express no squamous or glandular differentiation at all. These historic terms are quite solidly entrenched in the clinical literature, however, so it is still important to know what they meant.

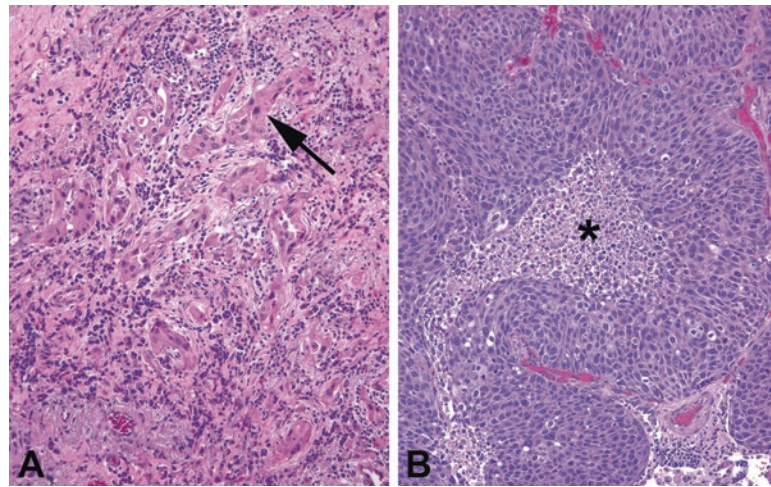


FIGURE 22.10. Squamous cell carcinoma. (a) Moderately differentiated squamous cell carcinoma, with irregular nests of cells with highly pleomorphic nuclei and bright pink, dense cytoplasm (*arrow*). Keratin pearls may also be seen in more well-differentiated tumors. (b) Basaloid squamous cell carcinoma, with rounded nests of very blue tumor cells with high N/C ratio and a high mitotic rate. Central necrosis (*asterisk*) is common.

Squamous carcinoma arises from squamous metaplasia, often in the major bronchi, and therefore is often central or hilar. The most recognizable form is the keratinizing variety, with its pink, dense cytoplasm, keratin whorls, and distinct cell borders (Figure 22.10). It is graded on the typical well, moderately, or poorly differentiated scale. However, there are trickier variants, including *nonkeratinizing* and *basaloid*. *Basaloid squamous cell carcinoma* is nonkeratinizing and mimics the HPV-related squamous carcinomas of head and neck, with densely packed, molded blue nuclei and peripheral palisading around large round nests, often with central necrosis (Figure 22.9). However, it is not HPV-associated and should not stain for HPV markers. All squamous carcinomas should stain with the immunohistochemical marker of squamous differentiation, p40 (which has largely replaced p63 as a squamous marker), and this can be especially helpful in identifying the nonkeratinizing tumors.

Adenocarcinoma is by definition a tumor with glandular or mucinous differentiation. The classification for adenocarcinomas of the lung now includes adenocarcinoma in situ (described above), minimally invasive adenocarcinoma (strictly defined by size criteria), and invasive adenocarcinoma with histologic pattern subtypes. Most of the adenocarcinomas will stain for the lung marker TTF-1, and this in conjunction with p40 is used on most biopsy specimens to confirm the type of tumor. In addition, adenocarcinomas must be further classified on the basis of molecular alterations, as the presence of mutations or rearrangements of KRAS, EGFR, ALK, or other genes has therapeutic significance.

Minimally invasive adenocarcinoma is a tumor that is 3 cm or less in total, with a predominantly in situ pattern, and no more than 5 mm of stromal invasion. Like AIS, it cannot be diagnosed on a core biopsy, because the diagnosis depends on evaluating the entire tumor. *Invasive adenocarcinoma* is any lesion that surpasses these size cutoffs. Invasive adenocarcinomas of the lung are usually a mixture of different histologic patterns, and these patterns should be identified and roughly quantified. The patterns are *acinar*, *lepidic*, *solid*, *papillary*, and *micropapillary* (Figure 22.11). While any adenocarcinoma can have intracytoplasmic mucin, a tumor which appears to be composed largely of mucin-filled goblet cells, usually in a lepidic pattern, is called a *mucinous adenocarcinoma* (Figure 22.12). Many of the tumors that were once called mucinous BAC would now be classified as invasive mucinous adenocarcinoma, as most have foci of invasion if you look hard enough. Finally, a tumor with actual pools of mucin containing floating tumor cells is called a *colloid carcinoma*.

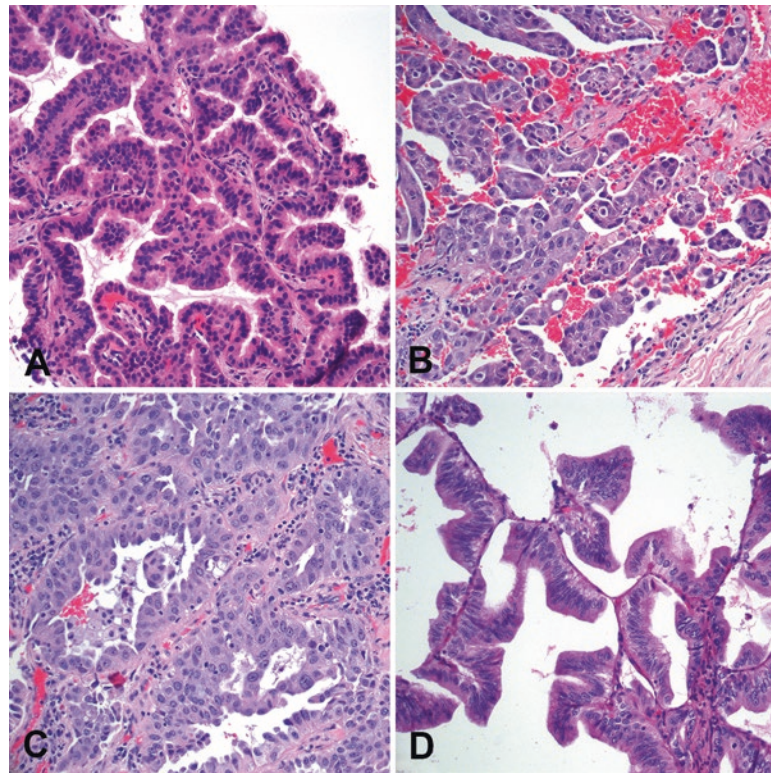


FIGURE 22.11. Adenocarcinoma. Patterns include (a) papillary (tumor cells on fibrovascular cores), (b) micropapillary (rounded fingers and florets of tumor without fibrovascular cores), (c) acinar (gland forming), (d) lepidic (growing along alveolar walls), and solid (not shown).

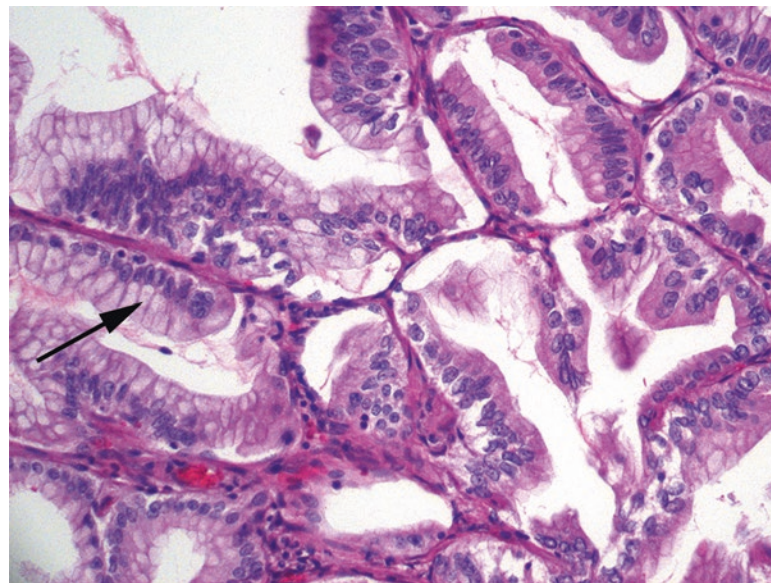


FIGURE 22.12. Mucinous adenocarcinoma. The tumor cells resemble goblet cells, with uniform basal nuclei and fat drops of mucin at the apical surface (*arrow*). This field also shows a lepidic pattern.

Large cell carcinoma, as mentioned above, is basically a non-small cell carcinoma with no recognizable glandular or squamous features, either by histology or by IHC. This is distinct from a large cell neuroendocrine carcinoma, discussed below.

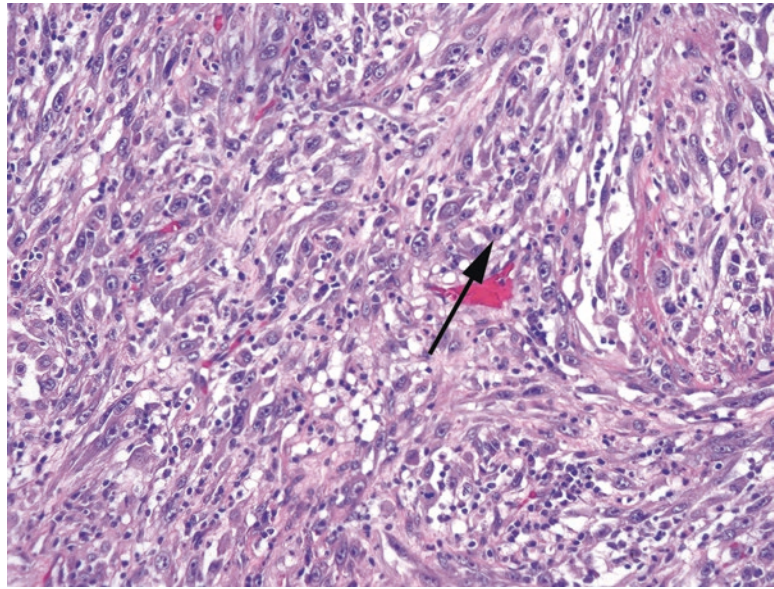


FIGURE 22.13. Sarcomatoid carcinoma. Sheets of spindled cells with large nuclei and prominent nucleoli are visible. Mitoses (*arrow*) are common. These cells should be positive for cytokeratin stains, confirming their epithelial origin.

Spindle cell or *sarcomatoid carcinoma* is a tumor that mimics a sarcoma (Figure 22.13) but is demonstrably keratin-positive. However, keratin expression in sarcomatoid carcinomas can be extremely weak and focal and particularly in small biopsies may appear negative. Remember that sarcomas usually do not have prominent nucleoli, while sarcomatoid carcinomas often do, so this feature should help tip you off. A *carcinosarcoma*, on the other hand, is a biphasic tumor with a malignant epithelial component as well as a separate keratin-negative, recognizable sarcoma (such as chondrosarcoma or osteosarcoma). The lung also has a peculiar category of “pleomorphic carcinoma” which is used for combined tumors in which there is a recognizable conventional carcinoma (adeno- or squamous) plus a spindle cell or giant cell component.

Neuroendocrine Tumors

The neuroendocrine spectrum of tumors contains the well-differentiated neuroendocrine tumors and the high-grade tumors. The lung and thymus are the only body sites that retain the older terms of carcinoid and atypical carcinoid (for low-grade and intermediate-grade neuroendocrine tumors, respectively) and small cell and large cell neuroendocrine (for high-grade tumors). Neuroendocrine differentiation in the lung may be identified by histology, especially for the carcinoids and for small cell carcinoma, but a diagnosis of large cell neuroendocrine carcinoma requires confirmation by immunostain (such as with synaptophysin, chromogranin, and CD56).

- *Typical carcinoid*: A well-differentiated (but not benign) neoplasm with classic neuroendocrine features, including epithelial-to-spindled architecture, regular round or oval nuclei with fine-speckled chromatin, a low mitotic rate, and no nucleoli (Figure 22.14). Despite the bland appearance, carcinoids can metastasize to lymph nodes, and in rare cases, distally.
- *Atypical carcinoid*: Carcinoids with increased mitoses, 2–10 per 2 mm², or necrosis. Their behavior is more aggressive than typical carcinoids.
- *Small cell carcinoma*: A high-grade neuroendocrine neoplasm with small cell morphology, including hyperchromatic, dense indigo-blue nuclei, no nucleoli, syncytial appearance with nuclear molding, frequent mitoses and apoptosis/necrosis, and streaming crush artifact (Figure 22.15). Small cell carcinoma may be found in combination with other carcinomas.

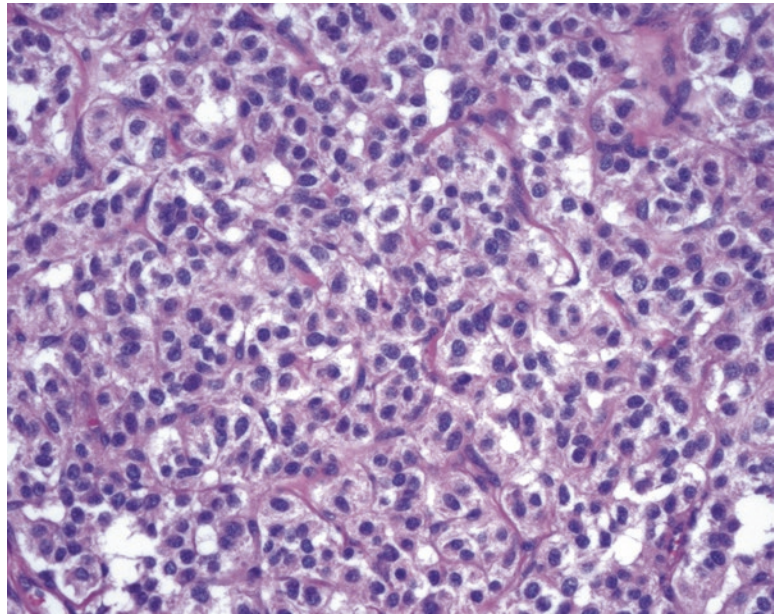


FIGURE 22.14. Carcinoid. This high-power view of an intrabronchial carcinoid shows a nested and trabecular pattern of cells with oval nuclei and typical “neuroendocrine” chromatin, meaning finely textured and speckled, without nucleoli or prominent nuclear membranes.

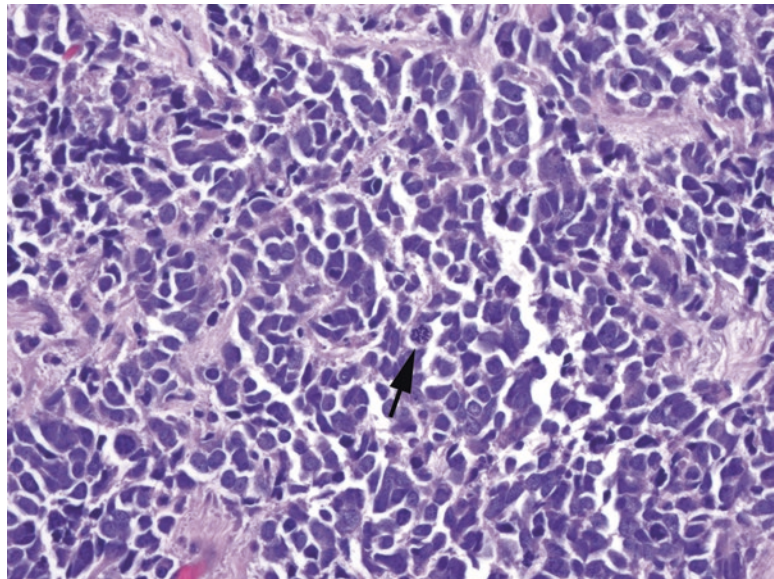


FIGURE 22.15. Small cell carcinoma. Sheets of nuclei appear molded together with interlocking shapes due to the near absence of cytoplasm. The dense chromatin is uniform and lacks nucleoli. Necrosis and mitoses (*arrow*) are common.

- *Large cell neuroendocrine carcinoma:* A high-grade neuroendocrine neoplasm with some neuroendocrine features, either architectural or nuclear, and positive neuroendocrine immunostains. Note that the “large cell” refers to the presence of cytoplasm and/or prominent nucleoli, not larger nuclei per se.

Other Lesions (An Incomplete Listing)

- Hamartoma: A tumorlike mass composed of a disorganized mixture of the normal elements found in that organ. In the lung, these are often masses of cartilage, fat, smooth muscle, and epithelium.
- Salivary neoplasms: The seromucinous glands around the bronchi can give rise to any of the traditional salivary gland neoplasms (see Chapter 25).
- Pulmonary blastoma: A form of carcinosarcoma in adults in which the epithelial component resembles fetal lung and the stromal component may be composed of adult-type sarcomas or immature mesenchymal tissue.
- Pleuropulmonary blastoma: An embryonal-type sarcoma of infancy, which may have cartilage and rhabdomyoblastic elements but not a carcinoma component.

Pleura

The lung surface is lined by a mesothelial layer, the visceral pleura. This is separated from a matching mesothelial layer on the inside of the chest wall, called the parietal pleura, by a potential space and pleural fluid. The pleura must be assessed in staging lung carcinomas, as invasion into the pleura can affect the stage. The easiest way to visualize the pleural layer overlying a carcinoma is with an elastin stain, which highlights the elastic lamina just under the mesothelium.

Mesothelial cells may acquire some fairly dramatic reactive changes under conditions of infection or persistent inflammation. The cytology of pleural effusions is one of the most challenging differentials, and even once you have proven that an atypical cell population is mesothelial (by IHC), you really can't make a diagnosis of mesothelioma without seeing the tissue invasion on a slide; the spectrum of reactive changes is just too wide.

A "pleural peel" is a section of thickened pleura removed during surgery, and it may consist of anything from simple acellular fibrin to dense fibrosis to organizing granulation tissue. The presence of acute inflammation indicates an empyema or purulent effusion. Stains for microorganisms are not usually very high yield, as culture is the preferred method to identify a bacterial infection and fungal infections are very rare. Prominent eosinophils are common in pneumothorax, but may also be seen in allergic reactions to drugs or parasites. Reactive mesothelial cells may have large nuclei and nucleoli, as well as piled-up areas of proliferation, and still be benign. The diagnosis of mesothelioma requires evidence of mesothelial cells invading tissue, but be careful not to overcall a stratum of mesothelial cells buried in layers of fibrin and granulation tissue. It is not uncommon for a layer of reactive mesothelium to be entombed in an inflammatory process in this way (this is true in the peritoneum as well), so a linear or planar layer should make you hesitate before calling invasion.

Mesothelioma

Mesothelioma, or malignant mesothelioma, is a malignant neoplasm of mesothelial cells. The most well-known cause of mesothelioma is asbestos exposure, so be aware that any mesothelioma specimen is likely to attract the attention of the legal system through no fault of the pathologists. Mesothelioma in its most common form, epithelioid, consists of malignant mesothelial cells invading into the lung or the fat and muscle of the chest wall and almost always forming a mass or plaque. The architectural patterns include tubules, papillary structures, or solid masses (Figure 22.16). The nuclei, however, are often fairly bland and uniform, unlike an adenocarcinoma. The presence of spindled areas indicates a sarcomatoid component, which must be quantified and reported, as it negatively impacts the prognosis.

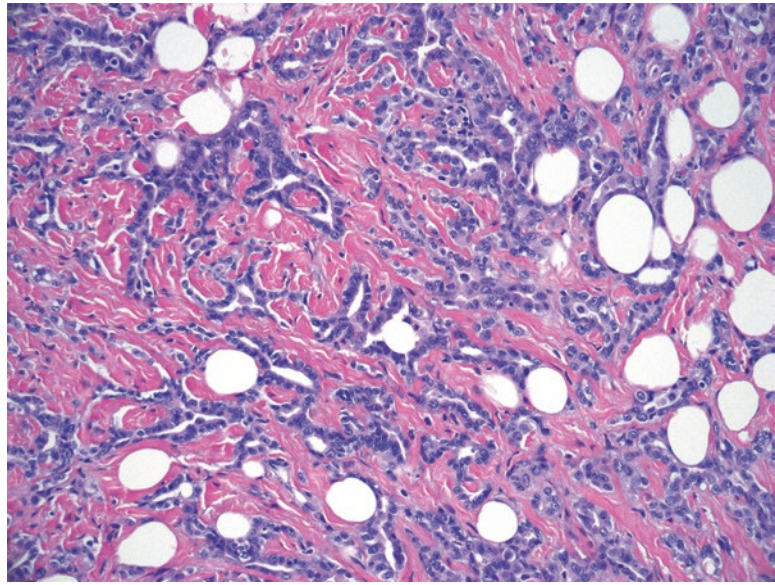


FIGURE 22.16. Mesothelioma. Small angular tubules are seen invading fat and fibrous tissue. The nuclei, however, are smaller and more uniform than a typical adenocarcinoma.

23 Thymus and Mediastinum

The thymus is a lymphoepithelial organ in the anterior mediastinum and is the site of maturation for T cells, serving a similar function as lymph nodes for B cells. Unlike lymph nodes, however, the thymus has a prominent epithelial component. It is these epithelial cells that give rise to the tumors called thymomas and thymic carcinomas. Lymphomas can also arise within the thymus, as can tumors of other cell types that are found in smaller numbers in the thymus, such as nerves, fat, smooth muscle, and even germ cells. While lymphomas, germ cell tumors, and soft tissue tumors are familiar to us from other sites, the thymomas are unique to the thymus, are rarely seen, and suffer from a particularly opaque classification system, making them a pretty inaccessible subject. But thymomas, as it turns out, are not so bad once you get to know them.

Normal Histology

The thymus is a lobulated organ, as you will see best in examples of fetal autopsy thymus. Each lobule is made up of an outer cortex (the darker, more densely lymphocytic area) and an inner medulla (pale due to lower cellularity). Embedded invisibly within these areas is an extensive epithelial network, which is only noticeable on H&E as the squamous nests within the medulla called Hassall's corpuscles (Figure 23.1) but can be nicely highlighted by staining for cytokeratins. The epithelial cells within the cortex and medulla differ in their antigen profile and are presumed to give rise to different varieties of thymoma.

The lymphocytes within the thymus are a mix of B and T cells. The T cells begin life as lymphoblasts at the subcapsular perimeter of the thymus (Figure 23.2); like other lymphoblasts they are positive for the blast marker TdT by immunostain. As they mature and become exposed to antigens, they migrate inward through the cortex and to the medulla, finally leaving the thymus from the medullary vessels as mature T cells. Before maturity these immature T cells are called *thymocytes*. The B cells are not undergoing maturation but may organize into germinal centers as they do everywhere else in the body. The presence of lymphoid follicles and germinal centers is not, by itself, pathologic, but the autoimmune disease *myasthenia gravis* is associated with follicular hyperplasia within the thymus.

The thymus gradually involutes throughout life, which is to say the lymphoepithelial structure is gradually replaced by fat. In an adult, all that may remain is a mass of fat in the mediastinum with microscopically visible nests of lymphocytes and Hassall's corpuscles. It is the recognition of these corpuscles that enables you to definitively identify the tissue as the thymus. Most thymomas occur in adults, so evidently the involution is not protective against neoplastic transformation. The thymus may also be found anywhere along the anterior mediastinum, as far up as the thyroid, so always think of it when you see tiny squamous whorls within lymphoid tissue—interpreting ectopic thymus as metastatic carcinoma would be particularly egregious.

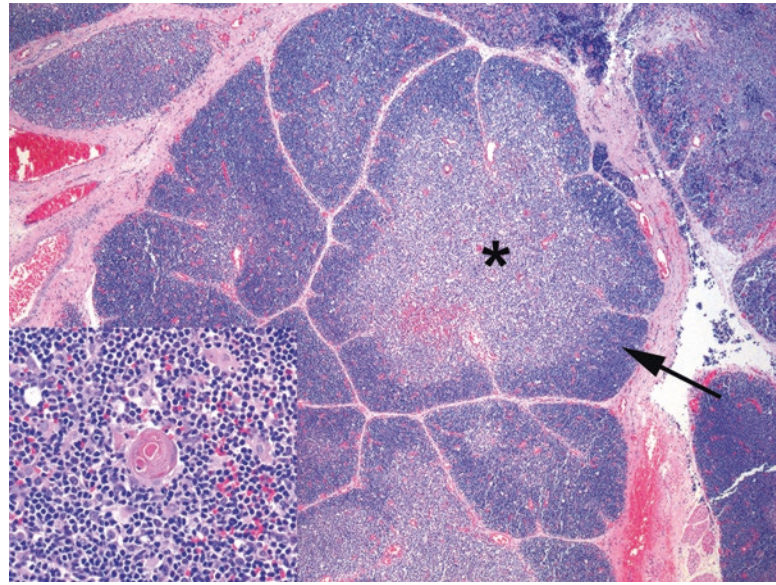


FIGURE 23.1. Normal fetal thymus. The lobular organization of the thymus is visible here, with darker outer cortical areas (*arrow*) and pale inner medulla (*asterisk*). Delicate fibrous bands separate the lobules. *Inset:* Hassall's corpuscles are small pink squamoid nests.

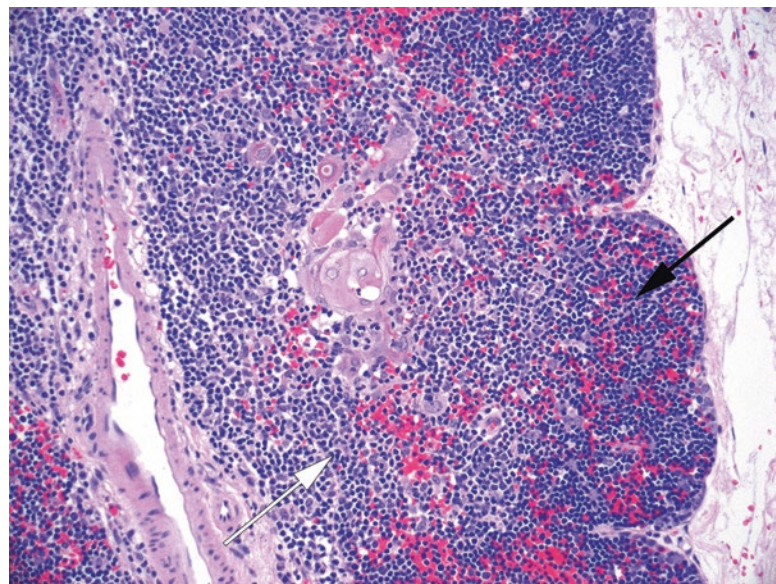


FIGURE 23.2. Normal thymic T cells. T cells begin as immature T cells with a high N/C ratio at the periphery of the outer cortex (*black arrow*) and migrate inward toward the medulla (*white arrow*) where they mature and exit the thymus.

Thymic hyperplasia is more of a clinical diagnosis than a pathologic one, as the thymus appears histologically normal, but simply weighs more than it should for age. True thymic hyperplasia is not associated with prominent lymphoid follicles and may be unrelated to autoimmune disease. *Thymic lymphoid hyperplasia* (also called thymic follicular hyperplasia or thymic germinal center hyperplasia), on the other hand, is characterized by prominent germinal centers and is often associated with myasthenia gravis. The weight or size of the thymus may be normal.

Neoplasms

The term *thymoma* refers to tumors of thymic epithelium. Many types of thymoma also have a lymphocytic component, but the lymphocytes are polyclonal bystanders; thymomas are not lymphomas. Lymphomas do occur in the thymus but most are the familiar varieties covered in other chapters (Hodgkin disease, T cell lymphoblastic lymphoma, anaplastic large cell lymphoma, etc.) and will not be discussed here. Of the thymomas, there are three basic categories (Table 23.1): thymomas presumably arising from medullary epithelium (called type A, usually indolent), thymomas presumably arising from cortical epithelium (type B), and a mixed type called Type AB. What used to be called a “Type C” thymoma is now designated thymic carcinoma. The carcinomas are often squamous but may take the morphology of almost any other carcinomas found elsewhere in the body. The thymomas, however, are unique to the thymus.

Type A thymomas are easily recognizable as tumors. They are encapsulated solid masses, often with thick fibrous bands, comprised of pure populations of spindled to epithelioid cells that clearly do not belong in normal thymus (Figure 23.3). The cells are bland, however, with

TABLE 23.1. Thymomas.

Type A thymoma	Type B thymoma			Thymic carcinoma
	B1	B2	B3	
	Type AB			
Good prognosis		→ Increasingly worse prognosis →		Poor prognosis
Medullary (spindle/ovoid) epithelium		Cortical epithelium		Many subtypes
EMA +, CK5/6 –		EMA –, CK5/6 +, some CD5 +		CD5 + or –
No atypia		→ Increasing epithelial atypia →		Atypical cells
Mature T cells		Immature T cells which are TdT +		N/A
Minimal lymphoid component	Dense lymphocytic component	Intermediate lymphoid component	Minimal lymphoid component	Minimal or no lymphoid component
Often spindled but many possible morphologies	Resembles normal thymus	Increasing epithelial cells	Sheets of epithelial cells	Sheets of malignant cells
Encapsulated (usually)		Encapsulated → to → infiltrative		Infiltrative

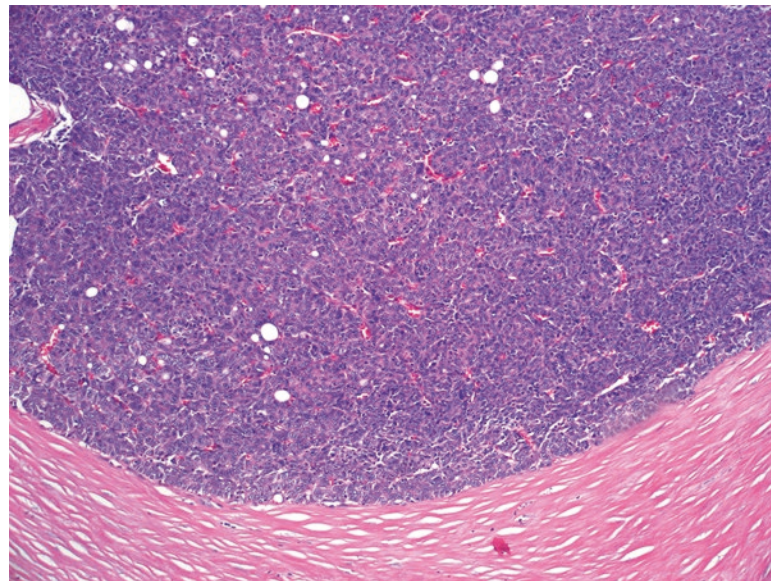


FIGURE 23.3. Type A thymoma. The cells are spindled and jumbled, with pale nuclei and overlapping cells. The dense fibrous capsule is typical. Lymphocytes are scarce. The architectural patterns in Type A thymoma can vary widely, however.

pale chromatin and no significant atypia or mitotic activity. Adjacent compressed thymus may be visible around the tumor; advanced stage or extension beyond the thymus is not common in this subtype. What makes the Type A's tricky is that they may take on many different architectural patterns, including storiform, fascicular, hemangiopericytoma-like, rosetting, or cribriform. However, immunostains and their location in the thymus are usually enough to establish the diagnosis.

The *Type B thymomas* are lymphoepithelial tumors. Unlike the relatively pure epithelial populations of Type A thymomas and carcinomas, the Type B group recruits immature T cells to the tumor, which can mask the underlying neoplastic epithelium. The Type B thymomas are subdivided based on the relative proportion of lymphocytes and tumor cells, from B1 (lymphocyte-rich, so they look blue) to B3 (predominantly epithelium, so they look pink). The B1 thymomas are, in fact, so lymphocyte-rich that they may be mistaken for normal thymus or lymphoma (Figure 23.4). Like normal thymus, they may have pale areas of medulla with Hassall's corpuscles. Ideally they have a distorted architecture and thickened fibrous capsule that sets them apart from normal thymus. The B2 thymomas are not divided from B1 by strict criteria, but instead show increasing proportions of epithelial cells, now distinctly visible as nests and aggregates (Figure 23.5). Unlike in the Type A thymomas, the tumor cells in the Type B thymomas are somewhat atypical, with large vesicular nuclei and nucleoli. The background T cells, also unlike the Type A tumors, are immature and will stain for the blast marker TdT.

The B3 thymomas are the most aggressive of the Type B group. As above, there is not a strict cutoff between a cellular B2 and a B3, but the B3 thymomas are predominantly made up of atypical epithelial cells, with a sparse background of immature T cells (Figure 23.6). They frequently invade through the capsule and are more likely to present at high stage, with invasion into mediastinal structures. Unlike carcinoma, there should not be a desmoplastic stromal response.

The *Type AB thymoma* represents a collision or hybrid between a spindle-cell Type A and a lymphocyte-rich Type B (usually B1 or B2) tumor. The areas of each tumor type appear as discrete nodules (Figure 23.7) or intimately intermixed, and the cells within each component stain as would be expected in a pure tumor of that type (e.g., immature T cells in the Type B component). Remember that a Type A thymoma should not have a significant lymphocytic population, so the presence of lymphoid foci within a Type A may be enough to classify it as a Type AB. This is differentiated from the rare *micronodular thymoma*, in which small islands of spindled epithelioid cells are suspended in a background of predominantly mature B cells and germinal centers.

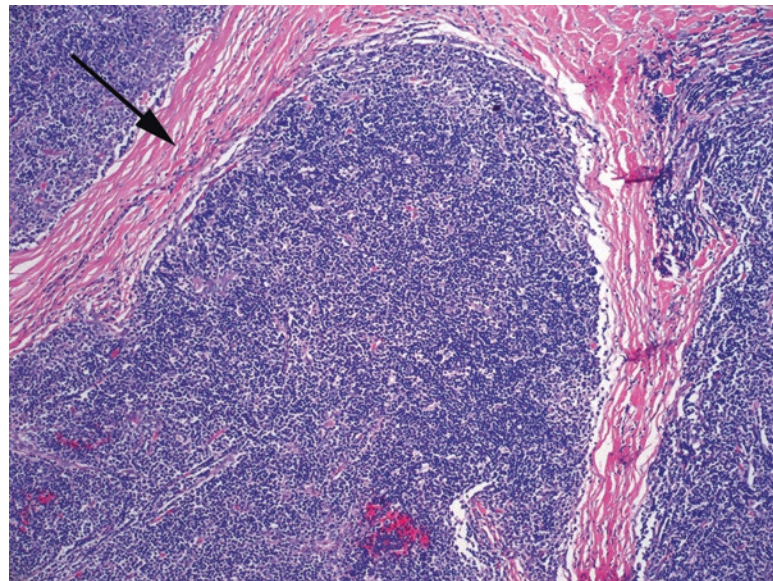


FIGURE 23.4. Type B1 thymoma. The tumoral epithelial cells are not even visible here due to the dense sheet of T cells, resembling normal thymus. The presence of thick sclerotic bands (*arrow*) helps to identify it as a tumor.

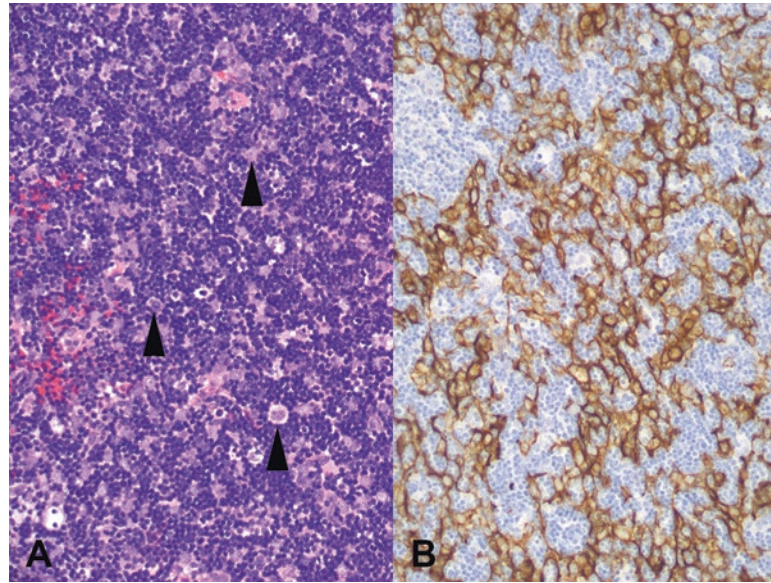


FIGURE 23.5. Type B2 thymoma. (a) In this example, there are identifiable epithelial tumor cells (*arrowheads*) in a background of lymphocytes. (b) A cytokeratin stain highlights the epithelial cells.

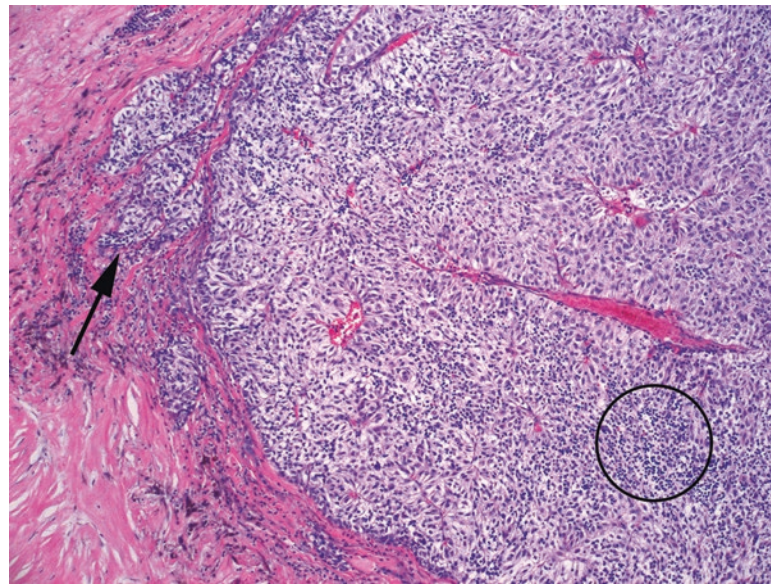


FIGURE 23.6. Type B3 thymoma. There is a population of spindled or epithelial cells with scattered lymphocytes (*circle*) and an infiltrative border (*arrow*). Unlike the spindled Type A thymoma, these cells show atypia and would stain for CK5/6, not for EMA.

Thymic carcinoma is a heterogeneous group of carcinomas that, while they arise in the thymus, are classified according to the conventional morphologic classifications found elsewhere in the body. A squamous cell carcinoma, therefore, may be keratinizing or nonkeratinizing and will stain for the usual markers of squamous differentiation. The two markers that are unique to thymic squamous carcinomas are CD5 and CD117 (c-kit), although neither is completely sensitive or specific. Other varieties of thymic carcinoma include lymphoepithelioma-like, mucoepidermoid (like the salivary tumor), basaloid, and carcinomas with NUT rearrangement (see next section). Adenocarcinomas do exist but are rare. Primary neuroendocrine tumors of the thymus are named as per the convention in the lung: carcinoid, atypical carcinoid, large cell neuroendocrine carcinoma, and small cell carcinoma, of which atypical carcinoid is by far the most common.

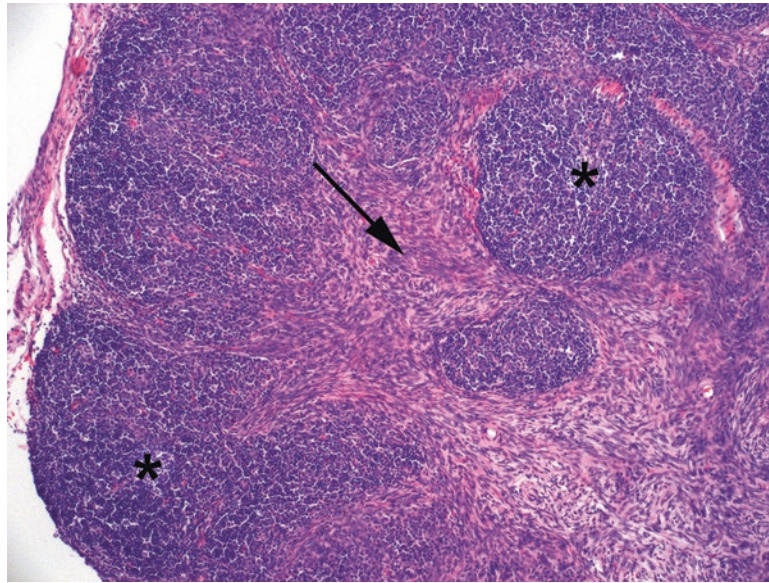


FIGURE 23.7. Type AB thymoma. This tumor has admixed features of the Type A (bland spindle cells, *arrow*) and Type B1 (lymphocytic areas, *asterisks*) thymomas.

Cysts

Thymic and mediastinal cysts include:

- Thymic cyst—an inclusion cyst within thymic tissue, lined by cuboidal, non-ciliated epithelium. May be uni- or multilocular and may have acute and chronic inflammation.
- Bronchogenic cyst—occurs anywhere in the anterior mediastinum. Lined with ciliated epithelium and resembling bronchus; may contain smooth muscle and cartilage.
- Enteric cyst—developmental anomaly from the gut, may occur in anterior or posterior mediastinum. Lined with squamous, columnar, or glandular mucosa.
- Esophageal duplication cyst—a pouch adjacent to but not connecting with the esophagus; lined with squamous mucosa and smooth muscle.
- Dermoid cyst—a type of teratoma, lined by keratinizing squamous epithelium and adnexal structures.

Other Tumors of the Mediastinum

The differential diagnosis for tumors of the anterior mediastinum includes thymic tumors, teratomas/germ cell tumors (arising from the germ cells embedded in the thymus), and lymphomas, as covered above, but also ectopic thyroid tissue (goiter or tumors). In the posterior mediastinum, a tumor is most likely to be of neural origin, such as a peripheral nerve sheath tumor or a paraganglioma. Chordomas, which are tumors of notochordal remnants, can also arise in the posterior mediastinum. A relatively new entity called *NUT midline carcinoma* arises in midline locations such as the head, neck, or mediastinum and is named after rearrangements in the *NUT* gene. This tumor is an extremely aggressive, poorly differentiated malignancy with somewhat paradoxically homogeneous tumor cells (Figure 23.8, a feature of many translocation-related tumors) and often shows areas of well-differentiated squamous carcinoma. The appearance of a poorly differentiated carcinoma in a young person would provoke an extensive workup, but in an older person, it might be mistaken for another more common entity such as poorly differentiated squamous carcinoma; the only way to identify it is through FISH or IHC for the NUT protein.

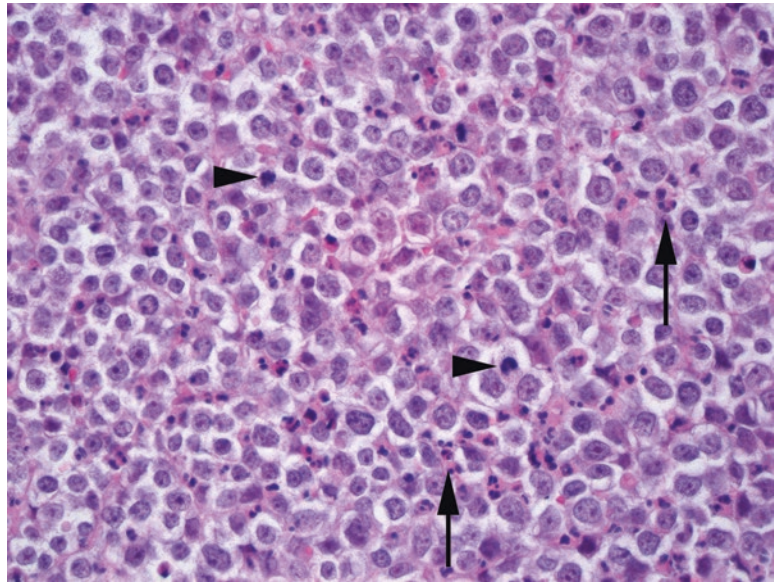


FIGURE 23.8. NUT midline carcinoma. This relatively uniform cell population shows medium-sized cells with clumpy chromatin and nucleoli and pale cytoplasm. Background neutrophils are common (*arrows*), as are mitotic figures (*arrowheads*).

The thyroid has two basic cell types: the follicular epithelium (TTF-1, PAX8, and thyroglobulin positive) and the C cells (TTF-1, neuroendocrine marker, and calcitonin positive, thyroglobulin negative). Normal follicular epithelium is low cuboidal. The stroma or interstitium is scant but highly vascular. The thyroid epithelium encloses small cystic spaces called follicles, which are filled with gelatinous thyroglobulin, the raw material used to make thyroid hormone. On the slide, the thyroglobulin is called colloid and is pink and thick.

Inflammatory diseases of the thyroid are not commonly sent to surgical pathology, with a few exceptions detailed in this chapter. Conceptually, they can be classified by type of response:

- Acute inflammation and necrosis: acute thyroiditis (usually infectious)
- Foreign body giant cells, histiocytes, and lymphocytes, diffuse: subacute or granulomatous thyroiditis (de Quervain disease)
- Histiocytes, lymphocytes, and rare giant cells, focal: palpation thyroiditis (a reaction to physical trauma, not a primary inflammatory disease)
- Lymphocytic infiltrate with germinal centers: lymphocytic thyroiditis or Hashimoto thyroiditis
- Dense fibrosis and chronic inflammation: sclerosing Hashimoto thyroiditis versus fibrosing thyroiditis (Riedel thyroiditis, one of the IgG4-related sclerosing disorders)

Lymphocytic thyroiditis is a descriptive term implying a generalized lymphocytic infiltrate. The term *Hashimoto thyroiditis* refers to an autoimmune process attacking the thyroid, and it is characterized by the following:

- Prominent lymphoplasmacytic infiltrate with germinal center formation (Figure 24.1)
- Small, atrophic follicles with Hürthle cell change (oncocyctic change)

Scattered nuclear atypia may be seen in this setting, including large hyperchromatic Hürthle cell nuclei, as well as areas of nuclear clearing and pleomorphism that can simulate papillary carcinoma. Therefore, be cautious about diagnosing papillary carcinoma in the setting of lymphocytic thyroiditis. *However*, these patients can also get papillary carcinoma.

Graves disease (diffuse toxic hyperplasia) is a hyperplastic, hyperthyroid condition in which autoantibodies stimulate the thyroid-stimulating hormone receptor to produce excess thyroid hormone. In treated form, more commonly seen in pathology, the follicles are large and distended, with prominent papillary infoldings (Figure 24.2). The papillary architecture can become florid, but the nuclear features are not those of papillary carcinoma (discussed later). Scalloping of the colloid is prominent. In untreated Graves disease, on the other hand, the thyroid is highly cellular with minimal colloid.

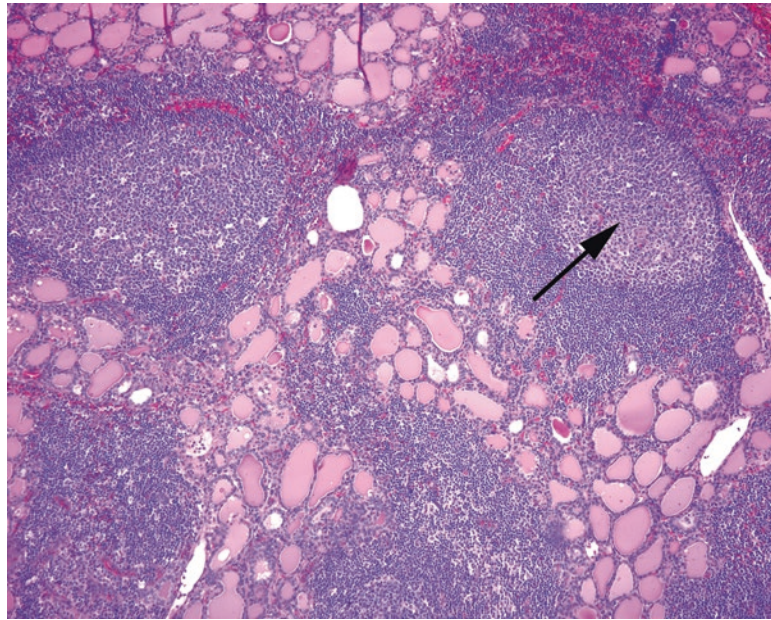


FIGURE 24.1. Hashimoto thyroiditis. The thyroid follicles are displaced by germinal centers (*arrow*).

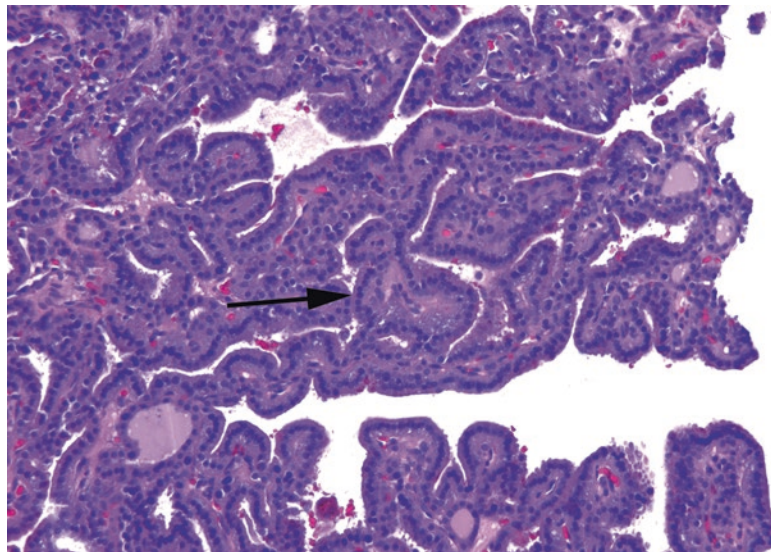


FIGURE 24.2. Graves disease with papillary hyperplasia. These papillary formations are due to hyperplasia of the follicular epithelium. The follicular cells are round and fairly evenly spaced and have dark uniform chromatin (*arrow*), similar to normal follicles.

Goiter is a nonspecific term for enlargement (hyperplasia) of the thyroid but is often used to refer to the nodular enlargement of the thyroid due to iodine deficiency or enzyme defects. *Multinodular hyperplasia* may be sampled by fine-needle aspiration (FNA) if a single nodule becomes dominant and suspicious, or the whole gland may be removed for cosmetic or physiologic reasons. The nodules usually fall on the colloid nodule-to-follicular-adenoma spectrum.

The thyroid neoplasms can be broken down into several large categories. The first two categories arise from follicular epithelium but are separated based on cytologic and nuclear features. The first category is made up of follicular-type cells that resemble normal thyroid follicular epithelium. This includes Hürthle cells, which can be found in non-neoplastic thyroid. The second category is papillary carcinoma, of which there are many variants; they have in

TABLE 24.1. Summary matrix of architectural and cytologic features of thyroid neoplasms.

Cytology	Macro- or normofollicular nodule	Microfollicular nodule	Papillary pattern	Solid or nested growth
“Follicular” nuclei	Hyperplastic nodule or follicular adenoma	Follicular adenoma/ carcinoma	Graves disease	Follicular carcinoma
Hürthle cells	Hürthle cell adenoma	Hürthle cell adenoma/ carcinoma	Oncocytic variant of papillary carcinoma	Hürthle cell adenoma/ carcinoma
“Papillary” nuclei	Follicular variant of papillary carcinoma	Follicular variant of papillary carcinoma	Papillary carcinoma	Hyalinizing trabecular tumor
Pleomorphic or squamoid cells				Anaplastic carcinoma
Neuroendocrine nuclei				Medullary carcinoma

common a set of diagnostic nuclear features. The third category of neoplasms arises from the *neuroendocrine* or C cell component of the thyroid; medullary carcinoma is the main entity in this group. Table 24.1 summarizes the architectural and cytologic features of thyroid neoplasms.

Follicular-Type Lesions

Follicular-type cells are notable for their uniformity. The nuclei tend to be round and monotonous, although they may be enlarged in neoplasms. The overall impression is that of a regular array of cells, without crowded, overlapping, or irregular nuclei (Figure 24.3). The cells should respect each other's personal space, so to speak. The chromatin should be even and smooth, not cleared out, coarse, or chunky.

Colloid nodule, *adenomatoid nodule*, and *follicular adenoma* all describe a spectrum of hyperplastic to neoplastic lesions composed of a nodular cluster of follicular epithelium. This area is somewhat confusing as the same lesion may get different names depending on whether it is seen by FNA or on resection. A *colloid nodule* is a hyperplastic nodule of large distended follicles in which the ratio of colloid to cells is high (a key finding on FNA). A *follicular adenoma* is defined as a solitary encapsulated nodule with compression of the surrounding thyroid and is usually composed of small microfollicles with scant colloid (a low colloid to cell ratio; Figure 24.4). This lesion, seen on FNA, is called a *follicular neoplasm*, as follicular adenoma and carcinoma cannot be distinguished by FNA alone. Finally, there is the *adenomatoid nodule*, a hyperplastic lesion that has some features of adenoma but usually lacks a well-defined capsule.

Before calling an encapsulated lesion a follicular adenoma, however, you must submit and examine the entire capsule. Follicular carcinoma may appear histologically similar to adenoma but for the focal diagnostic capsular or vascular invasion. This is why you cannot make the distinction by FNA alone. You should also exclude the follicular variant of papillary carcinoma.

Hürthle cell adenoma is very similar to a follicular adenoma in concept except the cells are large pink oncocytes with round nuclei (Hürthle cell change; Figure 24.5). Nucleoli may be prominent, and the nuclei may appear very enlarged or irregular in shape, unlike in follicular adenoma.

The defining feature of a *follicular carcinoma* is the presence of capsular or vascular invasion, so examination of the capsule is critical. Atypia and necrosis, while seen in some follicular carcinomas, are not sufficient to make the diagnosis.¹ Capsular invasion is a somewhat subjective

¹*Random pearl:* In this, the thyroid is like most other neuroendocrine organs, including parathyroid, adrenal, and pituitary. The diagnosis of malignancy is not based on atypia, which can be seen in hyperplastic conditions, but on capsular/vascular invasion or metastases.

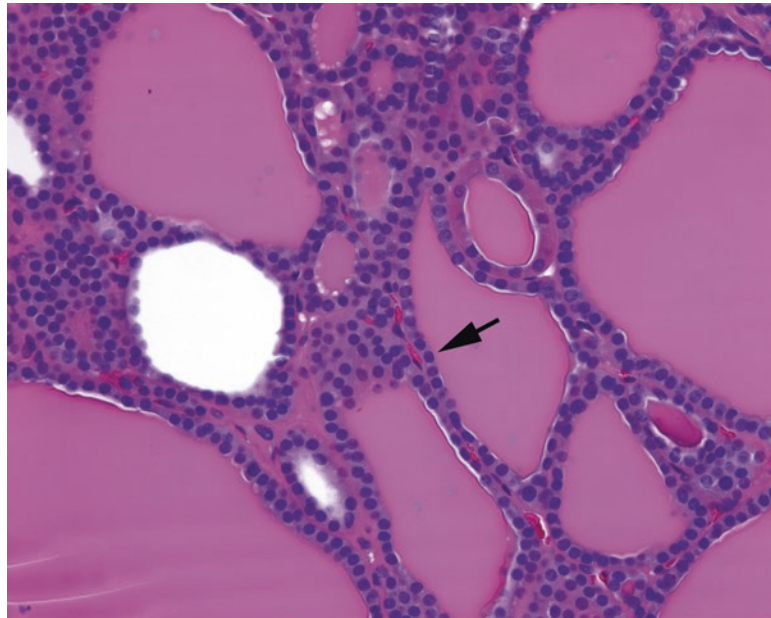


FIGURE 24.3. Follicular cells. Normal follicular epithelium has round uniform nuclei that tend not to overlap or crowd each other (*arrow*). This field is a combination of large and small follicles full of colloid and could represent normal thyroid, nodular hyperplasia, or a follicular neoplasm.

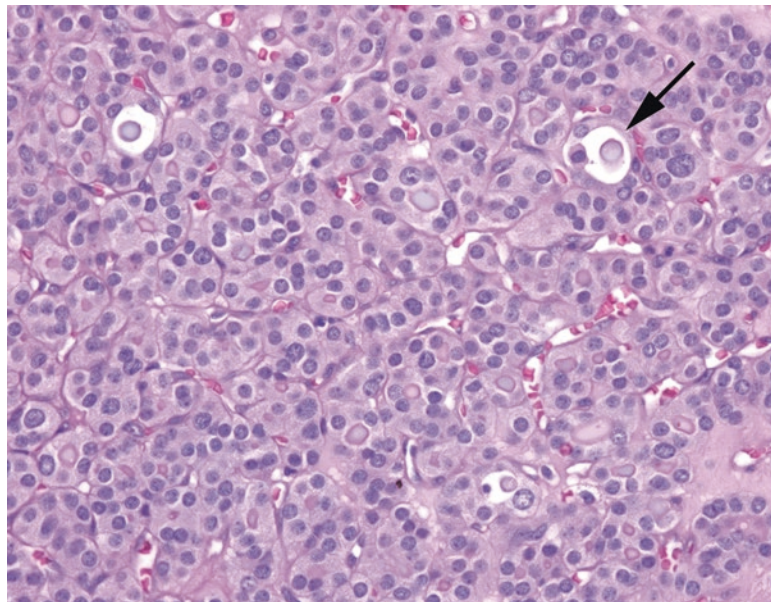


FIGURE 24.4. Follicular adenoma. This field shows a microfollicular pattern in a follicular adenoma. The capsule is not seen here. The neoplasm is composed of tightly packed small follicles (*arrow*) with round nuclei that, like normal follicular epithelium (compared to Figure 24.3), tend not to overlap or crowd. There are scattered enlarged nuclei, some with pale chromatin that should not be mistaken for true nuclear clearing.

area, and experts disagree on the exact criteria that define it; however, a mushrooming growth of tumor through the capsule is accepted by most. Vascular invasion must be found within the capsule itself or outside the capsule. The tumor deposit should be visibly attached to the vessel wall (Figure 24.6). Hürthle cell carcinomas are diagnosed by the same criteria.

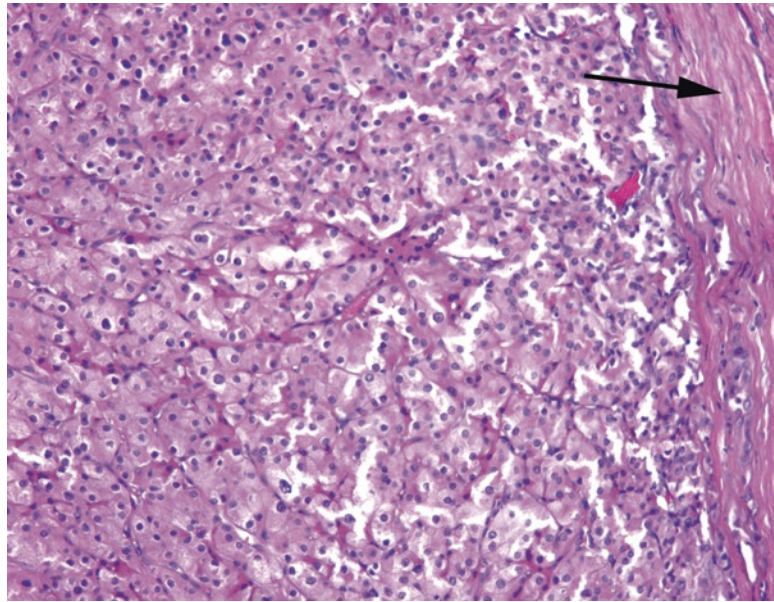


FIGURE 24.5. Hürthle cell adenoma. Like follicular adenomas, there is a thick fibrous capsule surrounding the neoplasm (*arrow*). In a Hürthle cell adenoma, the cells have abundant pink cytoplasm, and although the nuclei are still overall round and nonoverlapping, there is increased nuclear atypia in the form of some prominent nucleoli and irregular nuclear shapes.

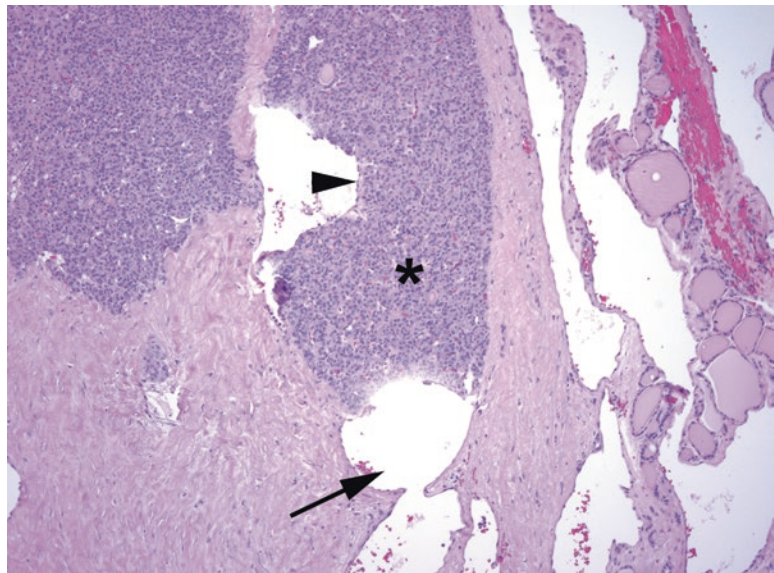


FIGURE 24.6. Follicular carcinoma. The neoplasm here resembles a follicular adenoma at low power, with a dense microfollicular pattern and a thick capsule. However, there is vascular invasion in the capsule, diagnostic of follicular carcinoma. A tumor plug (*asterisk*) is seen in the lumen of a large vessel (*arrow*). The surface of the tumor plug becomes endothelialized (*arrowhead*).

Follicular carcinoma comes in two strengths: minimally invasive (where invasion is limited to the capsule and you may have to struggle to find the diagnostic vascular invasion) and widely invasive (where there is no more capsule and you have to dissect it off the adherent neck structures). For minimally invasive types, the number of foci of invasion is important: follicular carcinomas with >5 foci of invasion do worse (confusingly, “minimally invasive” follicular carcinomas can have a lot of invasion, but it is confined to the capsule). It is not associated with radiation or thyroiditis, unlike papillary carcinoma. It spreads via the blood to the lung and bone.

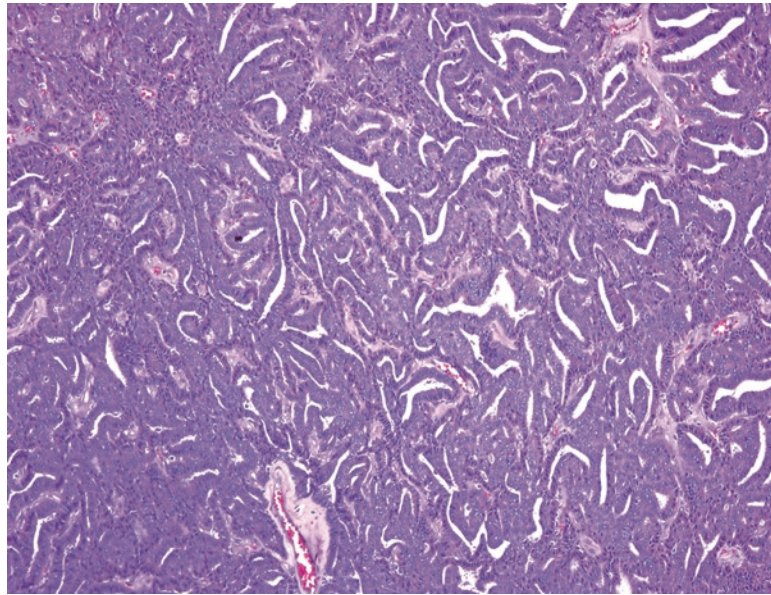


FIGURE 24.7. Poorly differentiated carcinoma. Instead of microfollicles, the tumor has acquired a pattern of ribbons, cords, and slit-like spaces.

Poorly differentiated thyroid carcinoma refers to a tumor in the follicular family with a high mitotic rate and necrosis; it is significantly more aggressive than follicular carcinoma, but less so than anaplastic carcinoma. Tumor cells may grow in sheets, nests, and cords instead of follicles (Figure 24.7) but on high power resemble the round and uniform cells of follicular carcinoma.

Papillary Carcinoma

Papillary carcinoma (there is no papillary adenoma), despite the name, may come with or without the papillae. The diagnosis actually rests on the nuclear features, which are consistent across variant types. The nuclear features are as follows:

- Chromatin is cleared out (often compared to the somewhat creepy eyes of the 1930s comic strip Little Orphan Annie). This imparts a characteristic low-power look to the lesion; the cells stand out as crisp and pale, almost glittery or glassy (Figure 24.8). It is an artifact of formalin, so is not seen in frozen section or cytology.
- Nuclei are overlapping, crowded, and pleomorphic. They often appear boxy and angular at low power, and you get the impression that too many nuclei have been stuffed into a single row (Figure 24.9); some are squeezed up and out of the row.
- Nuclear grooves are present, creating a coffee-bean appearance.
- Nuclear pseudoinclusions (indentations of cytoplasm) are present.

Note that prominent nucleoli are not a feature of papillary carcinoma. Psammoma bodies are fairly specific for papillary carcinoma but are generally seen only in the context of papillary architecture. True psammoma bodies are dark purple, ringed like a tree, and usually found in the interstitium, not in follicles (Figure 24.10). There are several variants of papillary carcinoma.

- Papillary microcarcinoma: Although histologically identical to papillary carcinoma, papillary microcarcinomas are, by definition, <1 cm and incidentally discovered and, if solitary, are considered clinically benign. A clinically discovered carcinoma is *not* a microcarcinoma, though, regardless of size.

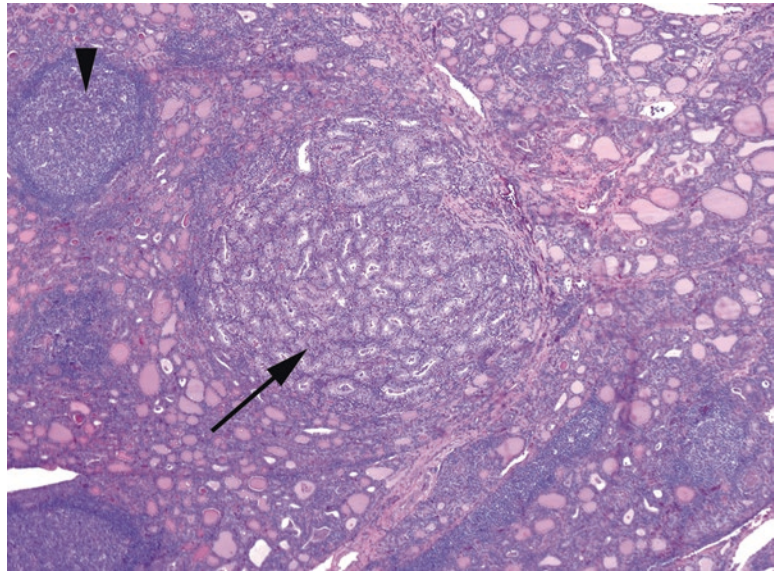


FIGURE 24.8. Papillary carcinoma, low power. The nuclear features of papillary carcinoma are eye-catching even at low power, as the clear nuclei give a translucent or glassy appearance to the tumor nodule (*arrow*). This is an example of an incidental microcarcinoma, arising in Hashimoto thyroiditis (note germinal centers, *arrowhead*).

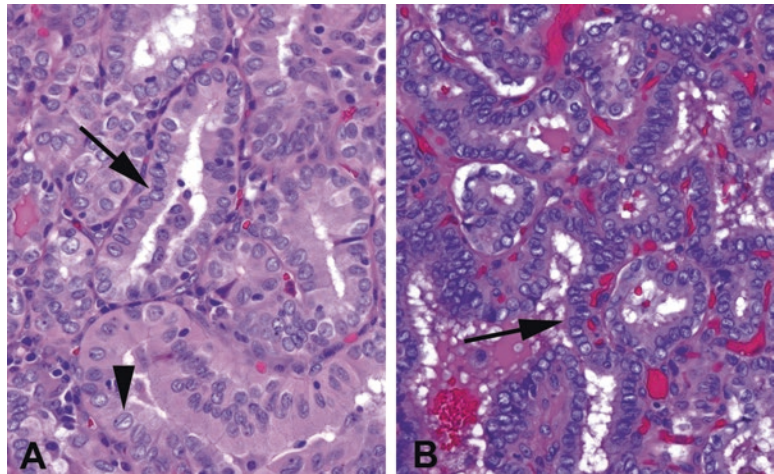


FIGURE 24.9. Papillary nuclei. (a) In this example, although the nuclear clearing is not striking, the presence of oval nuclei crowded into a row (*arrow*) suggests papillary carcinoma, as does the presence of nuclear grooves (*arrowhead*). Compare these nuclei to those of follicular epithelium; see Figure 24.3. (b) In this lesion the nuclear clearing is much more evident. However, the nuclei are still oval in shape and crammed together such that they mold to each other, popping up and out of their crowded rows (*arrow*).

- Follicular variant of papillary thyroid carcinoma (FVPTC): A lesion with follicular architecture (no papillae) and papillary nuclei (Figure 24.11). If it is unencapsulated and infiltrative, it behaves like a papillary carcinoma and is signed out as one. If it is encapsulated and invades the capsule, like a follicular carcinoma, it behaves like a follicular carcinoma. However, if the neoplasm is surrounded by an intact capsule, it behaves in a benign fashion and is classified as a *noninvasive follicular thyroid neoplasm with papillary-like nuclear features* (NIFTP). Just as with follicular carcinomas, the entire capsule must be examined.

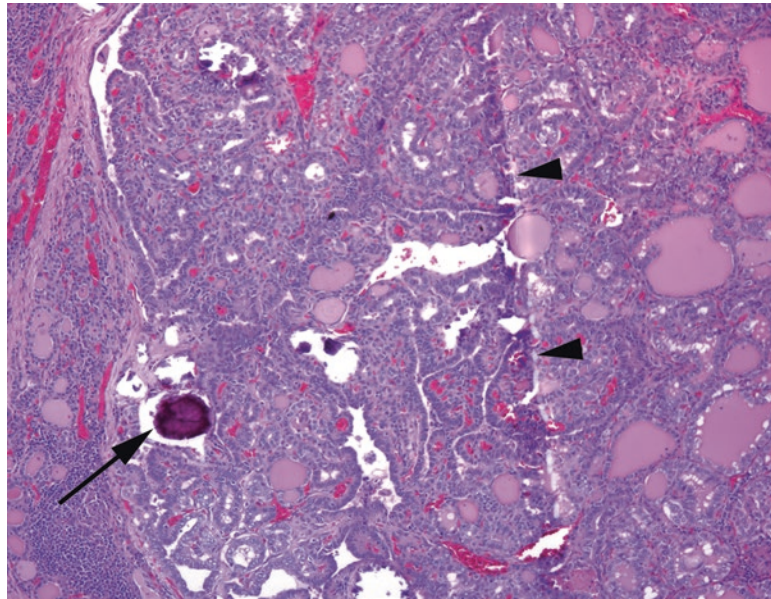


FIGURE 24.10. Psammoma body. This dense purple laminated calcification (*arrow*) is virtually diagnostic of papillary thyroid carcinoma in the thyroid or in a neck lymph node. Telltale scratches in the tissue section (*arrowheads*) often show where a psammoma body was dragged across the block during sectioning.

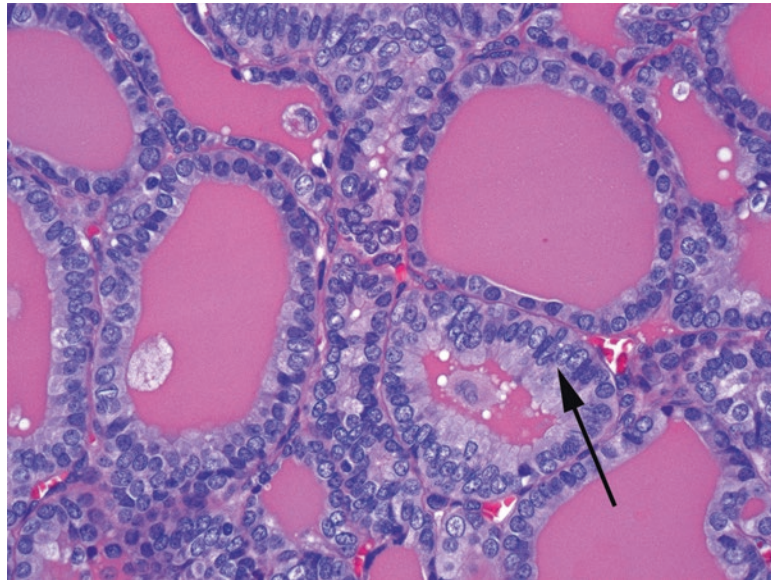


FIGURE 24.11. Follicular variant of papillary carcinoma. The architecture is that of a follicular adenoma, but the nuclei, oval in shape and crowded together (*arrow*), are those of papillary carcinoma. The presence or absence of a capsule, and invasion, determines how this lesion would be classified.

- Diffuse sclerosing variant: Although rare, this variant is important to recognize because of its worse prognosis. This variant is widely infiltrative, as opposed to discrete and mass-forming, and more aggressive. The features include a desmoplastic or sclerotic stroma, squamous metaplasia, tons of psammoma bodies, a dense lymphocytic infiltrate, and extensive lymphovascular invasion.

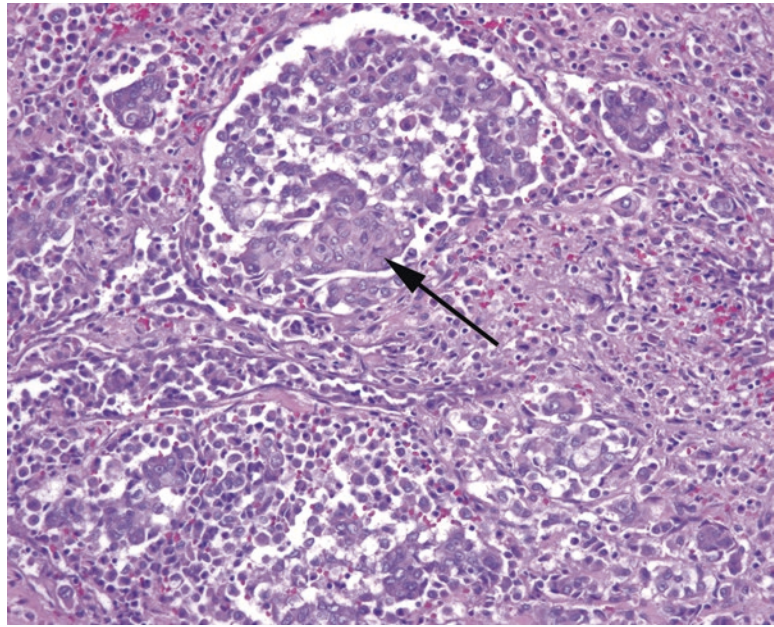


FIGURE 24.12. Anaplastic carcinoma. Nests and sheets of poorly differentiated carcinoma, some areas with a squamoid appearance (*arrow*).

- Tall cell variant: The cells in tall cell PTC are at least two times as tall as they are wide and have pink, oncocytic-like cytoplasm. This tumor also carries a worse prognosis.
- Other uncommon variants include oncocytic, clear cell, cribriform–morular, columnar, and solid.

Anaplastic carcinoma is a high-grade tumor that probably arises from the dedifferentiation of a papillary or follicular carcinoma (Figure 24.12). The tumor cells may appear as sheets of pleomorphic cells (truly undifferentiated), as nonkeratinizing squamous cell carcinoma (squamoid differentiation), or sarcomatoid. They usually lose their TTF-1 and thyroglobulin expression, but should retain PAX8 staining. They are typically widely invasive, high stage, and lethal.

The most important lessons of the papillary variants are: not all papillary lesions are papillary carcinoma (e.g., Graves disease), and not all papillary carcinomas have papillary architecture (e.g., follicular variant). Also, not all cleared-out nuclei are papillary carcinoma. Beware fixation artifact that can give patchy nuclear clearing in benign thyroid epithelium and have a very high threshold for papillary carcinoma in the setting of lymphocytic (Hashimoto) thyroiditis. A carcinoma arising in Hashimoto thyroiditis should stand out sharply from its neighbors, as in an uninfamed thyroid (see Figure 24.8). Varying degrees of nuclear clearing that come and go across the section are likely to be insignificant, especially if the nuclei are not crowded or grooved.

Hyalinizing trabecular tumor is a perplexing lesion with textbook papillary nuclei, including beautiful grooves and inclusions (Figure 24.13), but the architecture is more similar to medullary carcinoma: a well-circumscribed nodule of nests and cords (trabecular) set in a dense pink stroma (hyalinized). It is benign.

Papillary carcinomas are associated with radiation and (possibly) thyroiditis as risk factors; unlike follicular carcinoma, they spread to lymph nodes. The prognosis is usually excellent. Age is the most important prognostic factor (younger is better).

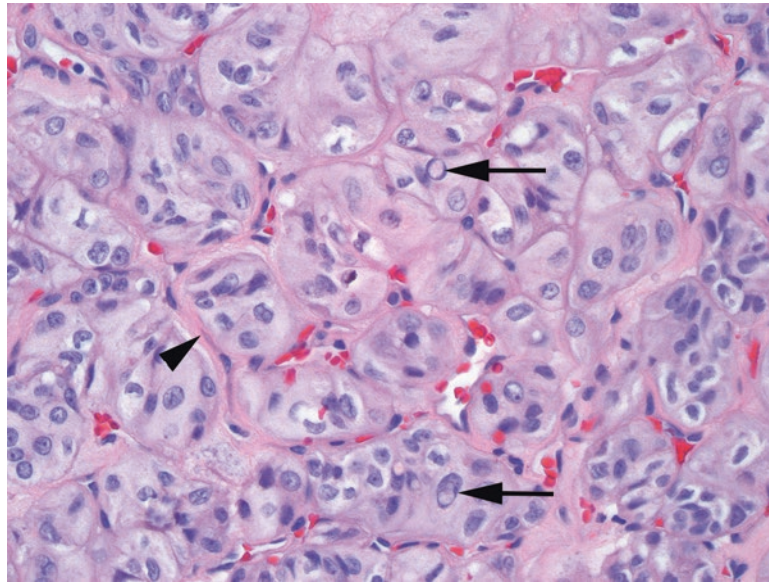


FIGURE 24.13. Hyalinizing trabecular tumor. This tumor shows nests and cords of pale, sometimes spindly cells with a background of dense pink amyloid-like stroma (*arrowhead*). The nuclei may be mistaken for papillary carcinoma, as grooves and nuclear inclusions are prominent (*arrows*).

Neuroendocrine Lesions

Medullary carcinoma has features common to other neuroendocrine tumors; the growth may be nested or trabecular, and the cells range from epithelioid to spindled, with uniform finely speckled nuclei (Figure 24.14). At low power, or with poor histology, the sheetlike growth may simulate an anaplastic carcinoma. However, nuclear features or immunohistochemistry should easily tell the difference (calcitonin and neuroendocrine marker positive). Medullary carcinomas produce prominent amyloid, which is Congo red positive.

Thymus-Like Lesions

There are at least two thyroid tumors which are thought to arise from thymic tissue remnants entrapped in the thyroid. These are the *spindle epithelial tumor with thymus-like elements* (SETTLE) and the *carcinoma showing thymus-like elements* (CASTLE). The “thymus-like” is probably a misnomer, as these are arising from actual thymic cells and resemble their thymic counterparts, so “ectopic thymoma” and “ectopic thymic carcinoma” are probably better ways to remember them, conceptually.

Cystic Non-neoplastic Lesions of the Neck

While not thyroid lesions, cystic non-neoplastic lesions of the neck are included here as they are commonly seen in surgical pathology and are sometimes mistaken clinically for a thyroid nodule. Such lesions include the following:

- Thyroglossal duct cyst: a midline cyst between the thyroid and the tongue, lined by ciliated epithelium and thyroid follicles
- Branchial cleft cyst: an anterolateral structure (as are the branchial clefts, the gill-looking things in the embryo) that looks somewhat tonsillar: squamous, columnar, or ciliated epithelium with a dense underlying lymphocytic infiltrate. Not to be confused with bronchial (refers to the lung) or brachial (refers to the arm). This is a congenital developmental abnormality.

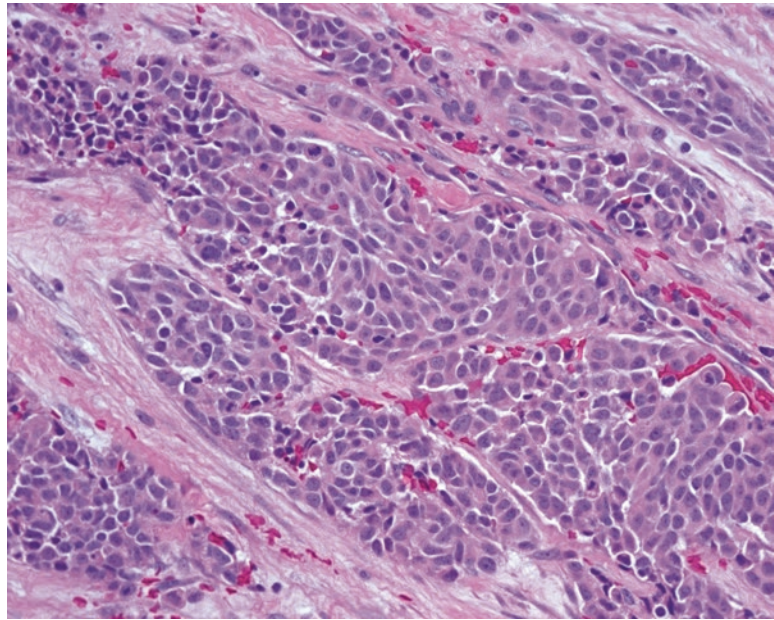


FIGURE 24.14. Medullary carcinoma. Although the pattern of infiltrative nests of cells may resemble anaplastic carcinoma, the nuclei are much more bland, with pale, finely speckled, neuroendocrine-type chromatin.

With the exception of pleomorphic adenoma, salivary gland neoplasms are rare, so you may not see many during residency training. To make matters worse, there is a great deal of morphologic overlap in some of the tumors, and immunostains are not usually helpful in distinguishing them. Your goal, early in your training, should be to recognize the more classic forms of the major tumors and also to be able to create a short differential diagnosis for any given tumor. In this organ, with all the mimics and variants, it is extremely important to approach a specimen with the question, “What *else* could this be?”

Biopsies of the salivary gland are occasionally performed in search of Sjögren syndrome; this is a complex diagnosis with specific criteria that must be met (see your favorite pathology textbook for that). Inflammatory lesions can also create a mass, such as chronic sialadenitis or a lymphoepithelial cyst. Necrotizing sialometaplasia is a known pitfall in the salivary glands, as this reactive condition shows intense inflammation, squamous metaplasia, and reactive atypia in the salivary ducts and may form a mass. The key to recognizing this condition is that, like chronic pancreatitis, the low-power architecture retains lobular contours and normal anatomic organization, with large ducts at the centers of the lobules.

Anatomy and Histology

There are three major and innumerable minor pairs of salivary glands. The largest, on the cheek, is the parotid, where most neoplasms arise. The smaller major glands are the sublingual and submandibular, under the tongue and jaw. In general, the smaller the gland, the higher the proportion of its neoplasms that are malignant. Salivary neoplasms can arise in virtually any part of the sinonasopharyngeal system.

The first major cell type is the *secretory cell*. The salivary glands are composed of serous and mucinous secretory units and ducts (Figure 25.1). *Serous* cells are wedge-shaped (like pie slices) and arranged in acini around ducts. They are full of blue to purple granules. *Mucinous* cells have basal nuclei and apical mucin, like goblet cells; these are also arranged in acinar formations. The parotid is primarily serous, the submandibular is mixed, and the sublingual is primarily mucinous.

The second major cell type is the *duct cell*. The duct system has three types of ducts: the terminal or intercalated ducts, the intermediate-sized striated ducts, and the interlobular large ducts. Each has a different epithelium and is theoretically associated with different tumor types. The *intercalated ducts* are small profiles with low cuboidal epithelium, similar to a bile ductule (Figure 25.2). *Striated ducts* are more proximal and are larger, with pink columnar cells full of mitochondria and striated basal borders (hard to see). *Interlobular* or *excretory ducts* have pseudostratified columnar epithelium with or without goblet and squamous metaplasia.

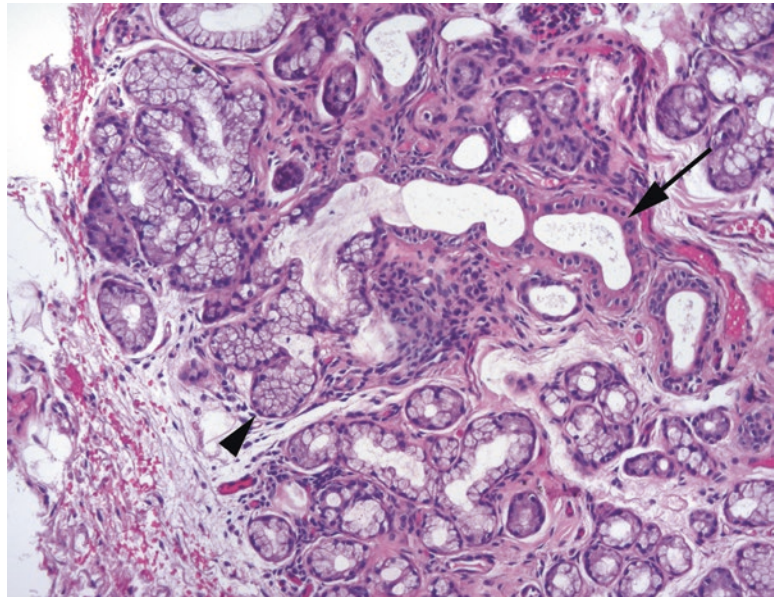


FIGURE 25.1. Normal salivary gland. In this example of mucinous salivary gland, the columnar secretory cells (*arrowhead*) form acini arranged around salivary ducts (*arrow*). Myoepithelial cells are not particularly visible on H&E stain.

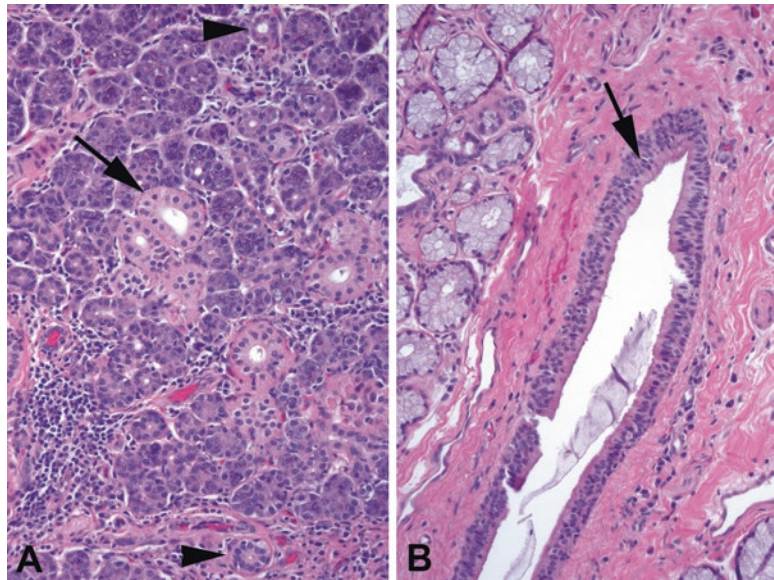


FIGURE 25.2. Types of ducts. (a) In the parotid, which has mainly serous glands, the terminal or intercalated ducts are visible as small tubules lined by cuboidal epithelium (*arrowheads*). The medium-sized striated ducts are more oncocytic in appearance, with abundant pink cytoplasm (*arrow*). (b) The large interlobular ducts have pseudostratified columnar epithelium (*arrow*), with occasional goblet cells, and become squamous at their junction with the gingival mucosa.

Different tumors have some morphologic similarity to these different ducts, which may help you keep the neoplasms straight.

The third major cell type is the *myoepithelial cell*. These cells, as in breast, surround acini and ducts. They are normally pale stellate cells with small nuclei and are very hard to identify in normal salivary gland. However, many neoplasms arise from the epithelial–myoepithelial cell line or, more specifically, from cells that can differentiate into either line. This creates a diagnostic nightmare, because the myoepithelial cells alone can take four different forms:

TABLE 25.1. Basic categories of the most common neoplasms.

Common neoplasms	Probable cells of origin
<i>Benign adenomas</i>	
Pleomorphic adenoma (mixed tumor) and its end-of-the-spectrum variant, myoepithelioma	Epithelial–myoepithelial
Basal cell adenoma	Epithelial–myoepithelial
Warthin tumor and oncocytoma	Striated duct cells
<i>Low grade, malignant</i>	
Mucoepidermoid carcinoma (low grade)	Interlobular duct cells, translocation related
Polymorphous adenocarcinoma	Epithelial–myoepithelial
Acinic cell carcinoma	Serous acinar cells
Secretory carcinoma	Terminal duct cells, translocation related
<i>Intermediate to high grade, malignant</i>	
Mucoepidermoid carcinoma (intermediate to high grade)	Interlobular duct cells, translocation related
Adenoid cystic carcinoma	Epithelial–myoepithelial
Salivary duct carcinoma	Striated duct cells
Adenocarcinoma not otherwise specified (wastebasket of those adenocarcinomas that do not show specific differentiation)	Ducts

spindled, plasmacytoid, epithelioid, and clear. Therefore, you must recognize any of these variants as myoepithelial (their immunologic profiles change with their form, unfortunately) and lump some very different-looking tumors into the same basket. Table 25.1 lists the most common neoplasms.

Note that, in general, benign lesions are encapsulated, whereas malignant tumors are infiltrative, either as pushing fronts or as tendrils of cells (although mucoepidermoid carcinoma and acinic cell carcinoma can be deceptively well circumscribed). The first thing you should do when evaluating a salivary neoplasm is to study the periphery or capsule.

Neoplasms

This section describes the common neoplasms in order of how likely you are to see them, beginning with the most common.

Pleomorphic Adenoma: Benign Mixed Tumor

Pleomorphic adenoma is a biphasic tumor with epithelial–myoepithelial components in a stromal background. It can occur anywhere but is very common in the parotid. The two key features to recognizing this lesion are a circumscribed, usually encapsulated tumor, and a stromal component in the background (Figure 25.3). The stroma is often myxoid but may be chondroid or even osseous. The epithelial component can range from obviously epithelial to myoepithelial, so you may see well-defined ductular structures or pink to clear myoepithelial cells (in any of their four morphologies)—hence the designation *pleomorphic*. The individual cells, however, are notably *not* pleomorphic and in fact should be very bland (small, oval, pale nuclei). It would be more accurate to call it a multi-morphic adenoma.

The lesion not to miss is the *polymorphous adenocarcinoma*, which can look very similar but has an infiltrative periphery. You should also examine the tumor for cytologically malignant cells, which may represent a *carcinoma ex-pleomorphic adenoma* (a pleomorphic adenoma gone bad).

The *myoepithelioma* is one end of the pleomorphic adenoma spectrum, with very little stromal component and no ductular differentiation. As with a pleomorphic adenoma, it should be encapsulated and circumscribed. Immunostains can help you here, as myoepitheliomas should be positive for S100, cytokeratin, glial fibrillary acidic protein (GFAP), and actin. *Basal cell adenoma* is also analogous to a pleomorphic adenoma, with no stromal component, but with a pure population of basaloid cells (hence its other name, *monomorphic adenoma*).

Rule of thumb: If it is an encapsulated solid lesion in the parotid, it probably fits into this category somehow.

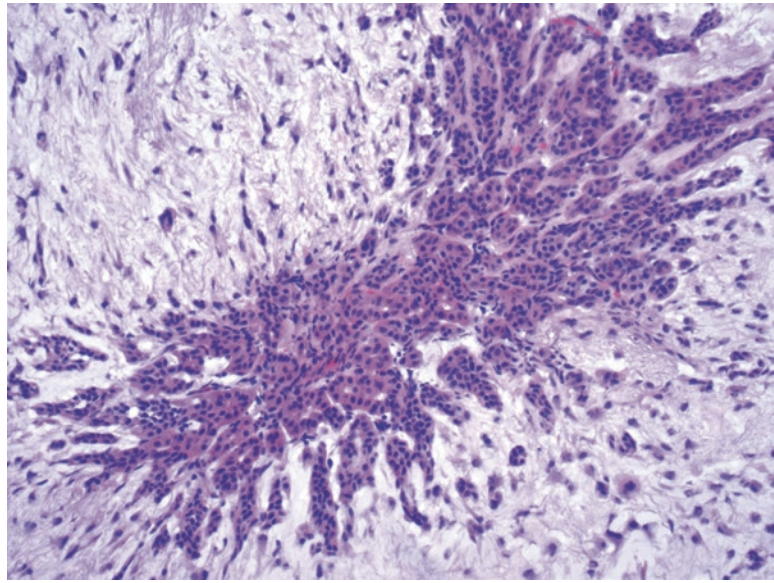


FIGURE 25.3. Pleomorphic adenoma. A cluster of cells is visible within the bluish myxoid stroma of a pleomorphic adenoma. The epithelial cells are small and cytologically benign, and they appear as small cords and tubules set within the stroma. The proportion of epithelial cells to stroma can vary widely.

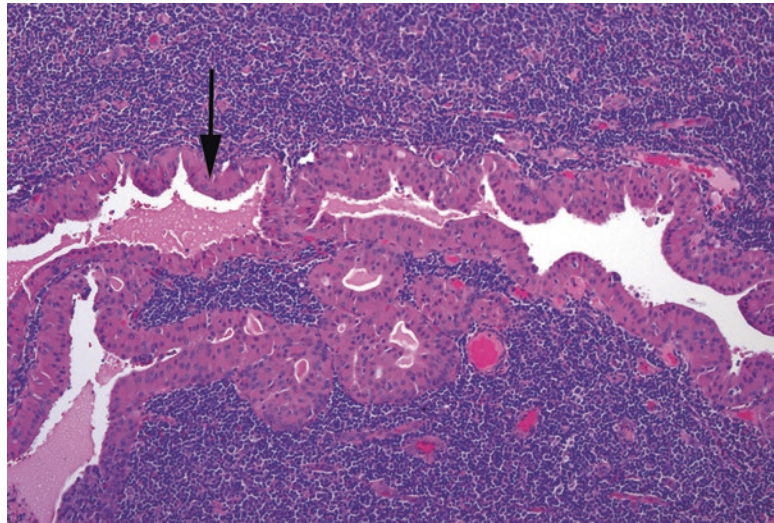


FIGURE 25.4. Warthin tumor. This cyst is lined by a double layer of oncocytic cells (*arrow*) overlying a dense lymphoid infiltrate.

Warthin Tumor

Warthin tumor is a papillary and cystic lesion lined by a double layer of oncocytic cells on top of a prominent lymphoid infiltrate with germinal centers (Figure 25.4). This usually occurs only in the parotid, but it can be bilateral. It is a low-power, 5-second diagnosis. This neoplasm may arise from striated ducts passing through intraparotid lymph nodes. The striated ducts are mitochondria-rich, which explains the oncocytic nature of the lesion. This is different from the *lymphoepithelial cyst*, a common lesion in patients with HIV that has a thin ragged epithelial lining instead of an oncocytic one. A related oncocytic lesion is the *oncocytoma*—a lesion composed of oncocytes that looks similar to a Hürthle cell nodule in thyroid or an oncocytoma in the kidney.

Mucoepidermoid Carcinoma

Mucoepidermoid carcinoma is the most common malignant tumor of salivary gland; most are associated with a translocation, although molecular analysis is not required for diagnosis. Mucoepidermoid carcinoma (often abbreviated “muco-epp”) has a wide range of cellularity, from cystic to solid. It can be low grade to high grade, depending on five factors: percentage of cystic component, tumor necrosis, mitoses, anaplasia, and neural invasion. The neoplasm is a mixture of squamous cells, cuboidal epithelial cells, and clear mucinous cells. However, when one cell type dominates, it can be difficult to tell this tumor from other tumors such as squamous cell carcinoma or clear cell carcinoma. In these cases, recognizing intracellular mucin is the key to the diagnosis, so a PAS or mucicarmine stain may be used.

The periphery should be infiltrative, not encapsulated, although the low-grade tumors may be fairly well circumscribed. This tumor may arise from the interlobular ducts (the big excretory ducts), and you will notice that an inflamed or metaplastic duct does not look that different from a little focus of low-grade mucoepidermoid carcinoma (Figure 25.5).

A low-grade cystic mucoepidermoid carcinoma must be distinguished from a mucin-containing salivary duct cyst, usually by carefully examining the cyst wall. As mentioned earlier, an intermediate- to high-grade mucoepidermoid carcinoma may be confused with metastatic or primary squamous cell carcinoma or clear cell carcinoma.

Adenoid Cystic Carcinoma

Adenoid cystic carcinoma is the prototypical cribriform tumor. It is blue, very cellular, with high N/C ratios and fairly dense, angulated nuclei. It can be solid or tubular, but cribriform is the classic presentation, which makes it often instantly identifiable (Figure 25.6). Like the pleomorphic adenoma, it has two cell populations, myoepithelial cells (which predominate) and ducts (which may be invisible on H&E). Another classic feature is the hyaline material found in the cribriform lumens, which consists of basement membrane material secreted by the myoepithelial tumor cells. Adenoid cystic carcinoma is highly infiltrative and loves nerves. Although intermediate grade at baseline, if solid growth predominates, this can be a high-grade tumor.

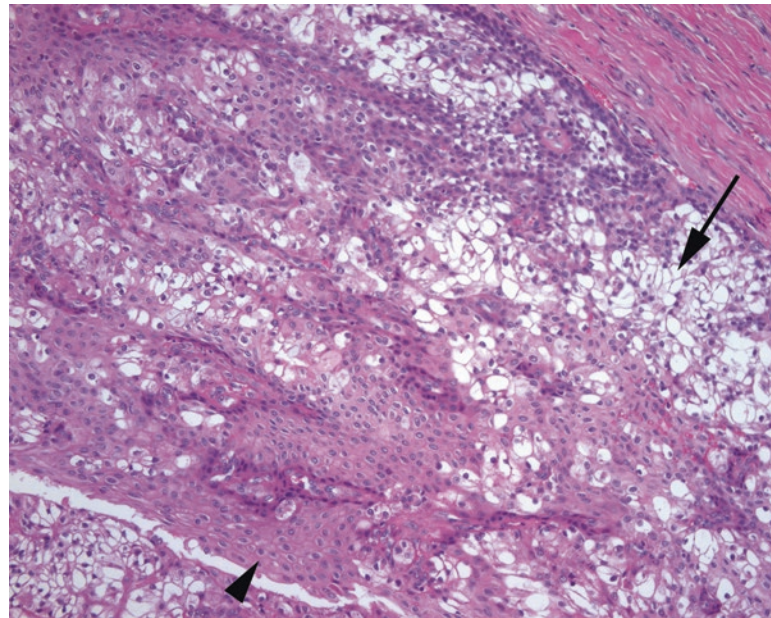


FIGURE 25.5. Mucoepidermoid carcinoma, low grade. This tumor resembles the metaplastic epithelium within an interlobular duct and is composed predominantly of clear goblet-like mucinous cells (*arrow*) and squamous cells (*arrowhead*).

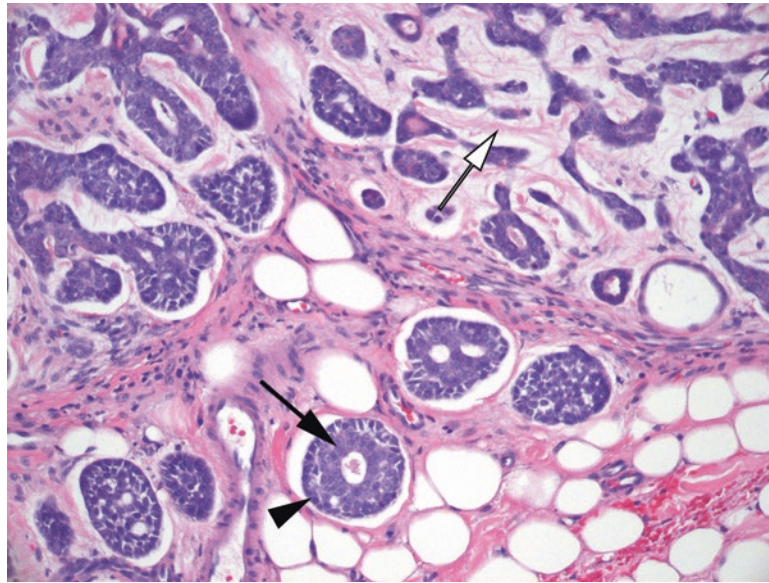


FIGURE 25.6. Adenoid cystic carcinoma. Although the nuclei are small, the nuclear to cytoplasmic ratio is high, making the tumor appear blue at low power. The architecture is classically cribriform, with sharply punched-out spaces full of pink secretions. There are actually two cell populations, the ductal cells (*black arrow*) and the slightly darker myoepithelial cells (*arrowhead*). The pink basement membrane material is visible between cell nests (*white arrow*).

The presence of squamous areas favors a *squamous cell carcinoma*, which is in the differential diagnosis, although much more likely to be a metastasis than primary. Adenoid cystic carcinoma is very similar to cylindroma of the skin, which can be in the differential around the ear (where there are both skin adnexa and tail of the parotid). Finally, if occurring in the lip or palate, rule out polymorphous adenocarcinoma, which can sometimes mimic an adenoid cystic. If you have a tumor that is cribriform and reminds you of an adenoid cystic, but is encapsulated or well circumscribed, think instead of one of the adenomas, such as a basal cell adenoma.

Acinic Cell Carcinoma

Acinic cell carcinoma is a tumor of the granular blue serous acinar cells, and in its most differentiated form, it looks quite similar to normal parotid, except without the ducts (Figure 25.7). Acinic cell is invasive but as pushing borders rather than single cells. The tumor may be solid, cystic, or microcystic, but it is the serous cells with their hallmark blue granules that really identify the tumor. There can be other nonserous cell types present, too, including clear cells, vacuolated cells, and ductal cells. This tumor category used to contain a variant without these diagnostic serous cells, but those have been split off now into the category of *secretory carcinoma*. (Note the pronunciation: it is ass-inic like *acini*, not ax-inic like *access*.)

Tumors Related to the Breast

The salivary glands are ontogenetically related to the female breast, and there is some overlap of tumor types between the two organs, as well as protein expression. Two salivary tumors in particular are dead ringers for breast carcinomas and in fact will also stain for the breast markers GCDFP-15 and mammaglobin (although not for ER, PR, or Her2). The first of these mimics the secretory carcinoma of breast and is named the *mammary analogue secretory carcinoma* (MASC), or just *secretory carcinoma*. This tumor type was once contained completely within the acinic cell family, and in fact older literature will show photos of secretory carcinoma labeled as acinic cell (including the first edition of this book; Figure 25.8).

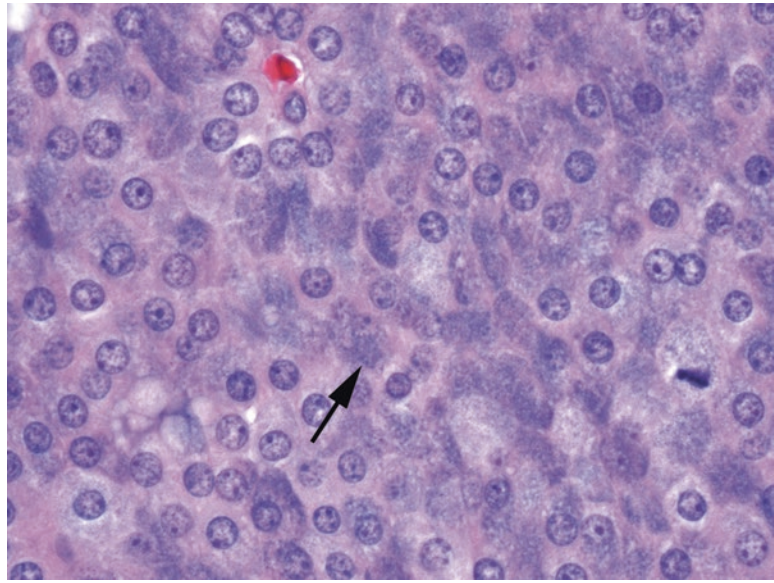


FIGURE 25.7. Acinic cell, solid pattern. The cells in acinic cell carcinoma replicate those of serous acini, with blue granular cytoplasm (*arrow*).

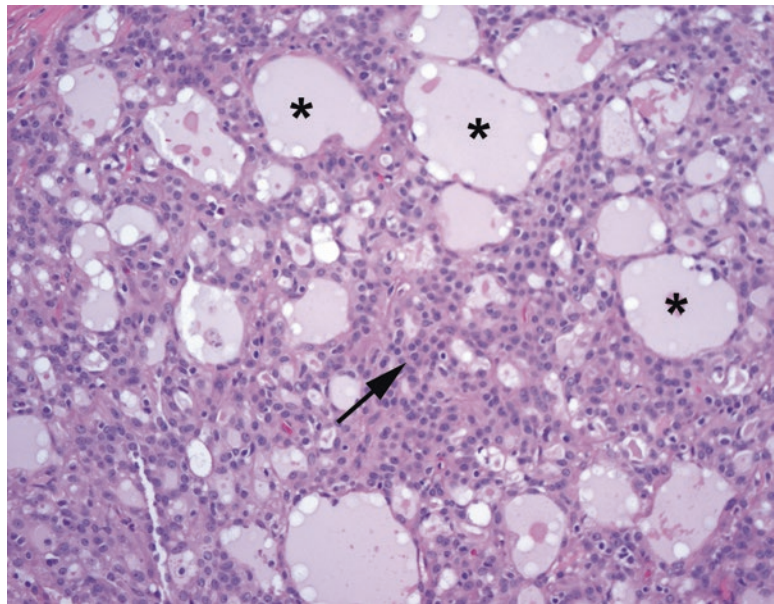


FIGURE 25.8. Secretory carcinoma. The cells are pink (*arrow*) and lack the telltale blue granules of acinic cell. The microcystic pattern, in which cells appear to be pushed apart by expanding pockets of fluid (*asterisks*), is typical. Compare these microcysts to the sharp cribriform spaces in adenoid cystic carcinoma (see Figure 25.6).

This tumor is defined by a translocation and was probably grouped with acinic cell due to its microcystic appearance (a pattern that can also be seen in acinic cell). In secretory carcinoma, however, there are no blue granules. The microcystic pattern is an array of little holes, but they are irregular holes that look as though the tissue has been pushed apart by expanding bubbles, very different from the rigid punched-out holes of adenoid cystic. Adjacent holes may be separated by the thinnest of epithelial strands, with the cell nuclei pushing into the hole. There should be no cytoplasmic mucin (unlike in mucoepidermoid carcinoma), and the nuclei are

uniform and well spaced (either small and dense or medium-sized and very round with small nucleoli), similar to the follicular thyroid lesions. The secretory carcinoma stains for both mammaglobin and S100, an unusual combination.

The second breast-like tumor is the *salivary duct carcinoma*, an aggressive tumor that is usually found in men, and in fact is almost always positive for androgen receptors by IHC. This carcinoma may be intraductal, in which case it mimics DCIS of the breast, cribriform or comedo patterns, but it is more typically invasive. Apocrine-like cells are common, like apocrine metaplasia of the breast. Salivary duct carcinoma is the most common carcinoma to arise from a pleomorphic adenoma.

Polymorphous Adenocarcinoma

Importantly, *polymorphous adenocarcinoma* (also known as *polymorphous low-grade adenocarcinoma* or PLGA) occurs almost exclusively in the intraoral minor salivary glands (lip and palate), so do not agonize over a funny-looking pleomorphic adenoma in the parotid! The polymorphous adenocarcinoma looks very similar to a pleomorphic adenoma in terms of the epithelial component, and like a pleomorphic adenoma, the cells are very bland. The key is in the margin of the tumor, which in a polymorphous adenocarcinoma is infiltrative (Figure 25.9). The cells tend to spiral out of the central mass like a hurricane and may remind you of lobular carcinoma of the breast (its former name, incidentally). Polymorphous adenocarcinoma can also sometimes be cribriform in appearance, mimicking an adenoid cystic, but unlike the adenoid cystic has only a single cell type.

Miscellaneous Malignant Neoplasms

Many of the benign adenomas described here have malignant counterparts, although they are rare. They include myoepithelial carcinoma, epithelial–myoepithelial carcinoma, basal cell adenocarcinoma, and oncocytic carcinoma. In general, features that favor malignancy include an infiltrative periphery, cellular pleomorphism, mitoses, or necrosis. Adenocarcinoma NOS is a shrinking category for any ductal-derived carcinoma without other distinguishing features.

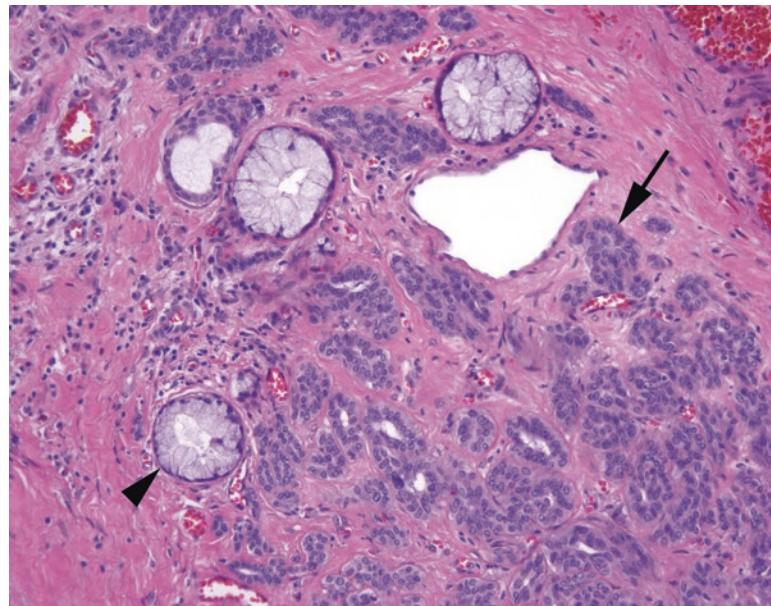


FIGURE 25.9. Polymorphous adenocarcinoma. Small tubules of bland cells (*arrow*) creep between benign mucinous glands (*arrowhead*). On high power, these infiltrative cells resemble those of the pleomorphic adenoma, but unlike that benign tumor, the polymorphous adenocarcinoma infiltrates surrounding tissues. It may also invade as single-file lines, like lobular breast carcinoma.

26 Neuroendocrine Neoplasms

Natasha Rekhtman, MD, PhD*

The subject of neuroendocrine neoplasms, starting with the definition of what *neuroendocrine* means, may be thoroughly confusing to the beginner. Although these tumors are mentioned in many other chapters in this book, this chapter will focus on the general concepts and definitions pertaining to this subject.

Let us start with a definition of *neuroendocrine*. As the term implies, there are two components: “neuro” and “endocrine.” The “endocrine” quality refers to the secretory nature of neuroendocrine cells: they produce and secrete peptides and amines. The “neuro” quality refers to their ultrastructural similarity to neurons: neuroendocrine cells store their secretory products in granules (i.e., dense-core granules), which bear resemblance to synaptic vesicles. Neuroendocrine cells are different from neurons structurally (no processes) and by the fact that the secretory mode is paracrine rather than synaptic. Also note that not all that secretes is neuroendocrine: for example, thyroid and adrenal cortex are not neuroendocrine because their cells do not possess neurosecretory granules; they are simply endocrine. Thus, at the most basic level, neuroendocrine cells are defined by the presence of neurosecretory granules in non-neurons. However, in practice, neuroendocrine neoplasms are recognized based on distinctive morphology and expression of neuroendocrine markers, which we will review.

Neuroendocrine Cells and Neoplasms

What are the tissues that qualify as neuroendocrine? In addition to neuroendocrine organs (adrenal medulla and paraganglia), the neuroendocrine system includes the so-called diffuse neuroendocrine system. The term *diffuse neuroendocrine system* refers to neuroendocrine cells dispersed singly or in clusters throughout the body, including the pancreas (islets of Langerhans), thyroid (C cells), lungs (Kulchitsky cells), skin (Merkel cells), gastrointestinal tract (many types), and so forth. In fact, neuroendocrine neoplasms may arise in any organ (e.g., prostate, breast, thymus, others). The broad definition of neuroendocrine cells also includes parathyroid and anterior pituitary glands. The only endocrine (peptide-secreting) organs excluded as clearly non-neuroendocrine are the thyroid gland, adrenal cortex, and steroid-producing cells of testes and ovaries. Table 26.1 summarizes the major neuroendocrine cell types and their corresponding neoplasms. However, it is worth noting that expression of various hormones is not considered to be specific for the site of origin of neuroendocrine tumors and is generally not used for this purpose diagnostically (e.g., lung carcinoids can express calcitonin).

*Department of Pathology, Memorial Sloan Kettering Cancer Center, 1275 York Ave, New York, NY 10065, USA
e-mail: rekhtman@mskcc.org

TABLE 26.1. Major neuroendocrine cell types and corresponding neoplasms.

Location	Neuroendocrine cell type (secreted product)	Corresponding neoplasm	Cytokeratin expression
Intestine and appendix	EC cell (serotonin); D, L cells; others	WD-NET	Positive
Gastric fundus	ECL cell (histamine)	WD-NET	Positive
Gastric antrum, duodenum	G cell (gastrin)	WD-NET	Positive
Lung	Kulchitsky cell	Carcinoid	Positive
Pancreatic islets of Langerhans	α -Cell (insulin)	WD-NET	Positive
	β -Cell (glucagon)		
	δ -Cell (somatostatin)		
Thyroid	C cell (calcitonin)	Medullary carcinoma	Positive
Skin	Merkel cell	Merkel cell carcinoma	Positive
Anterior pituitary	Acidophil (PRL, GH)	Pituitary neoplasms	Positive
	Basophil (ACTH, TSH, FSH/LH)		
Parathyroid	Parathyroid cells (PTH)	Parathyroid neoplasms	Positive
Adrenal medulla and paraganglia	Sympathetic neural cells (epinephrine, norepinephrine)	Pheochromocytoma	Negative
		Paraganglioma	
Adrenal medulla and other sites	Neuroblast (catecholamines, variable)	Neuroblastoma	Negative

ACTH adrenocorticotropic hormone, *EC* enterochromaffin, *ECL* enterochromaffin-like, *FSH* follicle-stimulating hormone, *GH* growth hormone, *LH* luteinizing hormone, *PRL* prolactin, *PTH* parathyroid hormone, *WD-NET* well-differentiated neuroendocrine tumor (carcinoid)

Neuroendocrine Markers

In the past, neurosecretory granules were identified by electron microscopy and special stains. Currently those methods have been completely replaced by several immunohistochemical markers. These are called *neuroendocrine markers*, and they include synaptophysin (SYN), chromogranin A (CHR), CD56 (neural cell adhesion molecule), and neuron-specific enolase (NSE). NSE is widely known to be highly nonspecific and is not generally used in practice. SYN and CHR specifically recognize dense-core granules. An emerging neuroendocrine marker is insulinoma-associated protein 1 (INSM1), which at the time of writing is promising to be more sensitive and specific than the conventional markers.

Neuroendocrine Morphology

Morphologically, there is no single feature that defines neuroendocrine neoplasms as a group. Instead, *neuroendocrine morphology* is defined by a constellation of several cytologic and architectural features. When someone says a tumor “looks neuroendocrine,” they are implying these features:

- Neuroendocrine cytology
 - Overall nuclear uniformity/monotony with smooth nuclear contours (unlike typical adenocarcinomas or squamous carcinomas).
 - Evenly dispersed, finely speckled “salt-and-pepper” nuclear chromatin without prominent nucleoli (Figure 26.1).
 - Cytoplasmic granularity (corresponding to “neurosecretory granules,” which are only variably present).
- Neuroendocrine architecture
 - Formation of nests, rosettes, and ribbons/trabeculae. Nesting in neuroendocrine tumors is conventionally called “organoid” pattern.
 - Prominent vascularity (in keeping with their secretory nature).

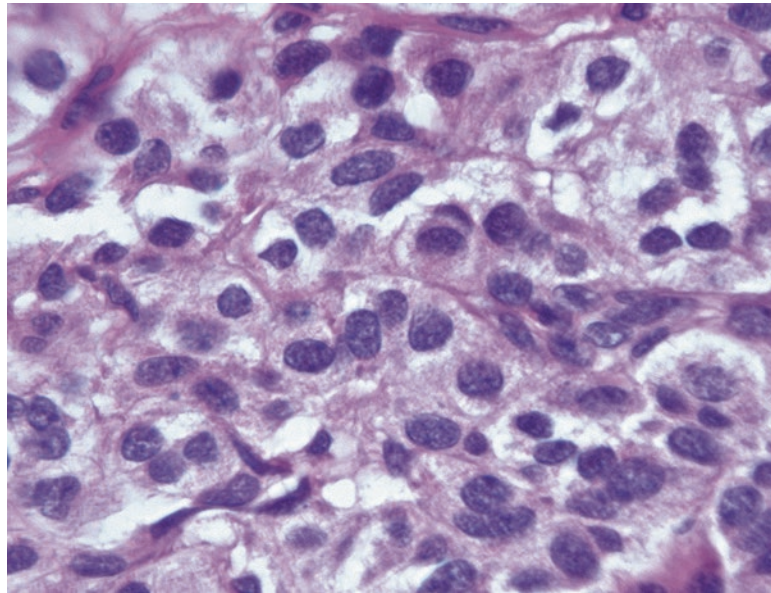


FIGURE 26.1. Classic neuroendocrine nuclei, with smooth *oval* nuclear borders, chromatin that is finely speckled throughout (“salt and pepper”), and no nucleoli.

The appearance may be thought of vaguely recapitulating the normal neuroendocrine structures. Recall that nesting is a feature of normal adrenal medulla, and subtle trabecular/ribbonlike structures are present in the islets of Langerhans. The presence of rosettes is not easily explained by resemblance to normal neural/neuroendocrine structures in the adult, but such structures can be seen in the developing neural tube, and many neuroglial tumors also form rosettes.

One of the challenges with neuroendocrine tumors is that this family includes tumors with quite different morphology and behavior, spanning from well-differentiated tumors (such as lung carcinoids) to highly aggressive, poorly differentiated carcinomas (such as small cell carcinoma). Whereas the defining neuroendocrine features are usually very obvious in well-differentiated neoplasms, they may be quite subtle to barely detectable in poorly differentiated carcinomas. Nevertheless, even in the latter tumors, the overall uniformity and dispersed finely granular chromatin should be preserved, and at least a hint of neuroendocrine architecture (in the form of nesting, rosettes, or ribbons) is usually present. Therefore, diagnosis frequently hinges on recognition of subtle morphologic clues and confirmation with immunostains. Below is the brief summary of prototypical neuroendocrine neoplasms.

Well-Differentiated Neuroendocrine Tumors (i.e., Lung Carcinoid)

These tumors have all of the features listed earlier as the hallmarks of neuroendocrine differentiation, including finely speckled chromatin with *no* prominent nucleoli (though there can be dramatic exceptions), uniform (monotonous) round nuclei with smooth nuclear membranes, and frequently a plasmacytoid appearance (eccentrically placed nucleus). The architecture may be nests, rosettes, ribbons, or trabeculae. Delicate fibrovascular septae are characteristic. Neuroendocrine markers are usually strongly expressed.

Note that tumors in this family may occasionally display random nuclear atypia, that is, *neuroendocrine-type atypia* or pleomorphism. Atypical nuclei are large, with smudgy chromatin, and have bizarre shapes. Such atypia is degenerative in nature, probably owing to the slow growth rate of these neoplasms, and has no correlation with malignant potential. Do not mistake this for a feature of high-grade malignancy.

Recently tumors of this type in the pancreas (formerly *islet cell tumors* or *pancreatic endocrine neoplasms*) and the bowel (formerly bowel carcinoids) have been renamed under the cumbersome term of *well-differentiated neuroendocrine tumor* (WD-NET) in order to have a single designation for this family of tumors. In the lung, the same tumor is still a carcinoid. In a later section, we will cover the grading within the well-differentiated category.

Poorly Differentiated Neuroendocrine Carcinoma (i.e., Small Cell Carcinoma)

Small cell carcinoma has some features in common with NETs. The chromatin is finely speckled but is also very dark/hyperchromatic, which may obscure the “salt-and-pepper” quality in a surgical specimen (refer to Figure 22.15). As in other neuroendocrine neoplasms, there are no prominent nucleoli. Despite the name, diagnosis is not based purely on cell size, but the nuclei are generally less than three lymphocytes in diameter. The unique features include nuclear molding, high N/C ratio with very scant cytoplasm, numerous mitoses and apoptotic bodies, and frequent crush artifact with DNA streaming and incrustation of blood vessels by liberated dark blue DNA material (known as the *Azzopardi phenomenon*). Nests, trabeculae, and rosettes are uncommon in biopsies but are commonly seen at least focally in resections (though this tumor, particularly in the lung, is rarely resected because it is almost always metastatic at presentation).

Most tumors stain for SYN and/or CHR, but nearly 20% stain for CD56 only. In fact, the time-honored teaching is that if morphology is classic, expression of neuroendocrine markers is not required for the diagnosis of small cell carcinoma, provided that you exclude the mimics, particularly lymphoma, basaloid squamous cell carcinoma, and, in younger patients, various small round blue cell tumors. Small cell carcinoma can arise virtually in any organ, but it is by far most common in the lung in heavy smokers. Other much less common sites include the esophagus, cervix, and bladder. Although small cell carcinoma is the best-known example in this category, there are large cell variants as well.

A Note on Terminology

A quick note on the subtle difference in the use of the terms neuroendocrine neoplasm (NEN) vs. neuroendocrine tumor (NET): by current terminology, NET is a term replacing pancreatic islet cell tumors and gastrointestinal carcinoids, whereas NEN is an umbrella term for NE neoplasms in general, including the poorly differentiated neuroendocrine neoplasms, which are by convention called neuroendocrine carcinomas (NECs). So simply put, NENs = NETs + NECs.

You may see in some older literature the use of the term “low-grade neuroendocrine carcinoma” in place of WD-NET or carcinoid tumor. Although indeed these tumors are epithelial and malignant (all NETs are by definition at least a low-grade malignancy), currently, the term *tumor* is considered standard. The main reason is to draw a clear distinction between these tumors and true epithelial carcinomas, such as pancreatic adenocarcinoma, which behave in a much more aggressive fashion than any neuroendocrine tumor. After all, carcinoid, literally translated, originally meant “looks like a carcinoma, but isn’t.”

Historic Terminology

As a final comment on terminology, there are a number of terms that have been applied to neuroendocrine cells over the years. These terms are rarely in routine use today, but they may be encountered in the literature, so feel free to skip this section until you encounter an unfamiliar term in an older publication:

- *Amine precursor uptake and decarboxylase* (APUD) cells and *diffuse neuroendocrine system* are the terms for neuroendocrine cells scattered throughout the body (like enterochromaffin-like cells in the stomach). An *APUD-oma* is an old term for carcinoid tumor.
- *Chromaffin* is a term applied to adrenal medulla because of its property to stain brown with chromic salts.
- *Enterochromaffin* refers to neuroendocrine cells of the intestine with similar properties, hence “entero” (gut).
- *Enterochromaffin-like* refers to histamine-secreting neuroendocrine cells of the gastric fundus.
- *Argentaffin* and *argyrophil* refer to the property of neuroendocrine cells to take up silver stains without or with a pretreatment step, respectively. Pretreatment gets more cells to stain. Fontana–Masson is a type of argentaffin stain (it also stains melanin), and Grimelius is a type of argyrophil stain. These stains are of historic interest only, because they have been entirely replaced by immunostains in current practice.

Cytokeratin Expression in Neuroendocrine Neoplasms

A potentially confusing issue with neuroendocrine neoplasms is their status as neural versus epithelial. In the recent past, all neuroendocrine cells were erroneously thought to be neural (neural crest) derived; this is probably what you learned in medical school. However, currently it is thought that at least some high-grade neuroendocrine carcinomas may arise from epithelial precursors rather than from cells of the diffuse neuroendocrine system. It appears that NETs actually fall into two groups: the “truly neural” group (pheochromocytoma/paranglioma) and the endoderm-derived “epithelial” group (carcinoid, pancreatic NETs, small cell carcinoma, others). The former group is cytokeratin negative, whereas the latter is typically cytokeratin positive (though note important exception, ~20% of lung carcinoids are keratin negative).

Grading of Neuroendocrine Neoplasms

Predicting clinical behavior in WD-NETs has been a long-standing challenge. Some WD-NETs are indolent, while others can metastasize and grow relentlessly. Currently, the best predictor of aggressive behavior in these tumors is proliferation rate, which is the key parameter in the grading system. In recent years, the Ki67 (MIB1) marker of proliferation rate has become a standard part of grading of GEP-NETs. Note that at the time of writing, lung carcinoids are still graded based on mitotic counts per 10 HPF (2 mm²). In addition to Ki67, the site of origin of WD-NET is also significant associated with prognosis: for example, appendiceal tumors are almost always indolent, whereas those arising in the pancreas are metastatic in the majority of cases.

As summarized in Table 26.2, neuroendocrine neoplasms are generally graded in a three-tier system: grade 1 (low), grade 2 (intermediate), and grade 3 (high). High grade traditionally has been applied only to small cell and large cell neuroendocrine carcinomas. Note that WD-NETs do not progress to small cell carcinoma—these are completely unrelated diseases. Inclusion of these tumors in a single grading system is a bit misleading may imply “progression,” which in fact does not occur. In essence, grading is only truly relevant for WD-NETs/carcinoids, whereas small cell and large cell neuroendocrine carcinomas are by definition high grade. Up until recently, WD-NETs were only graded as grades 1 and 2 (see Table 26.2 for mitotic and MIB1 criteria). However, the existence of a highly proliferative variant of WD-NETs is now well established, particularly in the pancreas. So grade 3 now includes a mixture of neuroendocrine carcinomas and highly proliferative WD-NETs, which should be designated accordingly in the sign out.

The method of scoring MIB1 is another evolving area. Currently, for GEP tumors, scoring of the so-called hotspots (20× fields with the highest MIB1 rate) in a total of 500 cells is recommended.

TABLE 26.2. Corresponding categories and grading criteria for thoracic vs. gastro-entero-pancreatic neuroendocrine neoplasms.

Grade	Gastro-entero-pancreatic	Lung and thymus
Low	WD-NET, grade 1 <2 mits/10 HPF and <3% Ki67	Typical carcinoid <2 mits/10 HPF and no necrosis
Intermediate	WD-NET, grade 2 2–20 mits/10 HPF and/or 3–20% Ki67	Atypical carcinoid 2–10 mits/10 HPF and/or necrosis
High	WD-NET, grade 3 ^a >20 mits/HPF and/or >20% Ki67 Small cell and large cell neuroendocrine carcinoma	Stay tuned (category of carcinoids with elevated proliferation rate is starting to emerge) Small cell and large cell neuroendocrine carcinoma

HPF high-power fields, WD-NET well-differentiated neuroendocrine tumor

^aNote: Poorly differentiated neuroendocrine carcinomas (small cell and large cell) are always grade 3

Other Select Neuroendocrine Neoplasms

Neuroendocrine neoplasms can occur in any organ and, in general, are named by the conventions above (WD-NETs vs. neuroendocrine carcinomas), regardless of their site of origin. There are a few special types that retain their own names, however.

Merkel Cell Carcinoma of Skin

The cytology and architecture of Merkel cell carcinoma overlaps with small cell carcinoma (refer to Figure 28.22). As in small cell carcinoma, nuclear molding, crush artifact, and necrosis are usually present, with numerous mitoses and apoptotic bodies (although Merkel cell carcinoma often shows less molding than small cell carcinoma). Stains are usually required to distinguish the two. In addition to neuroendocrine markers, Merkel cell carcinoma stains for Merkel cell viral protein and neurofilament (normally a neuronal marker) and CK20 (in classic punctate perinuclear dots). In contrast, small cell carcinoma is negative for those markers but is positive for TTF-1.

Medullary Carcinoma of Thyroid

Neuroendocrine cytology is as described for carcinoid; speckled chromatin may not be evident in surgical slides due to hyperchromasia but should be more apparent in cytology preparations (refer to Figure 24.14). Plasmacytoid cytology is common. Neuroendocrine architectural features may be present. A common feature is the presence of amyloid and tendency to form large cellular islands. These tumors are positive for calcitonin, which helps distinguish them from thyroid follicular neoplasms (but remember that other neuroendocrine neoplasm can stain for calcitonin, though generally serum levels are not nearly as high).

Large Cell Neuroendocrine Carcinoma

Large cell neuroendocrine carcinoma is one of the neuroendocrine neoplasms that you would not guess had a neuroendocrine nature based on cytology (nuclei can be vesicular, not salt and pepper, and have a single prominent nucleolus). Neuroendocrine classification is based on a neuroendocrine architecture (rosettes, organoid nesting, and nuclear palisading) and expression of neuroendocrine markers, which (unlike in small cell carcinoma) is required for this diagnosis. Although most common in the lung, this tumor can occur in virtually any organ. Recent molecular data show a heterogeneous composition of tumors falling under the term of large cell neuroendocrine carcinoma, with some tumors related to small cell and others to non-small cell carcinoma. So the diagnostic approach for this entity may evolve in the future. Stay tuned.

Pheochromocytoma (Adrenal)/Paraganglioma (Extra-adrenal)

Paragangliomas are considered to represent a type of extra-adrenal pheochromocytomas, so the morphology of these tumors is similar (refer to Figure 29.23). In terms of cytologic features, some nuclei are carcinoid-like in that they are uniform, round, and finely speckled, but many nuclei are more neuron-like by virtue of large size and a single prominent nucleolus. The cytoplasm is abundant, granular, and “amphophilic” (lavender). Nuclear pseudoinclusions (cytoplasmic invaginations) are present in 30% of cases. Hyaline globules are common and, if present, distinguish pheochromocytomas from other adrenal neoplasms. Random nuclear atypia is common and does not correlate with aggressive behavior. The consistent clue to neuroendocrine nature in these tumors is their nested architecture—the so-called *zellballen* pattern, which in German literally means *cell balls*. The nests are surrounded by the so-called *sustentacular* (supportive) cells, which can be highlighted by S100 stain (sustentacular cells are not visible on H&E stain). Neuroendocrine markers are positive in the nests. Unlike all other neuroendocrine neoplasms (e.g., carcinoid), these tumors are always cytokeratin negative.

Neuroendocrine Differentiation in Other Types of Carcinoma

In addition to conventional neuroendocrine neoplasms described above, there are three settings in which neuroendocrine differentiation/component can be encountered:

First, expression of neuroendocrine markers may be detected incidentally in an otherwise entirely non-neuroendocrine neoplasm (morphologically), such as a classic adenocarcinoma or squamous cell carcinoma. In most organs, this is thought to represent a type of occult differentiation with no clear clinical significance. These lesions may be signed out as *carcinoma with neuroendocrine differentiation by immunohistochemistry*. Generally, performing neuroendocrine stains on otherwise conventional carcinomas is not recommended.

This scenario is different from finding small cell carcinoma as a component of another type of carcinoma, such as adenocarcinoma or squamous cell carcinoma. The latter situation is considered to be a form of dedifferentiation to a more primitive phenotype, which does carry a worse prognosis and a need for specific therapy. Such cases are signed out as *mixed (or combined in the lung) adenocarcinoma/small cell carcinoma* or *adenocarcinoma with small cell component*.

The third setting is somewhat analogous to the one above, but rather than representing a de novo combined carcinoma, small cell carcinoma can develop from preexisting non-small cell carcinoma as a result of certain systemic therapies and is thought to represent a mechanism of treatment evasion by the tumor cells (acquired resistance). This is called small cell transformation, and this can occur in prostate carcinoma after androgen deprivation therapy and lung adenocarcinoma after EGFR-targeted therapy. It is important to watch out for this possibility in patients who are biopsied during the progression of these diseases.

27 Brain and Meninges

The pathology of the central nervous system (CNS) is an intimidating area for pathologists. In part this is because we have virtually no role in the gross examination, just processing shreds of gray pulp on gauze, and in part because of the feeling that “it could be anything at all,” including a long list of exotic zebras that look just like the common things except behave completely differently. The fact that we are often asked to make our diagnoses on frozen section does not help matters. However, even in the brain, the list of likely diagnoses is still reasonably short if you have three pieces of key information: the age of the patient, the location, and the radiographic appearance of the tumor. Table 27.1 lists differential diagnoses that should at least put you in the right ballpark.

The most important first step is to start by asking if your “lesion” could be normal tissue (i.e., the surgeon has missed). To answer this question you have to know a little normal histology (Figures 27.1 and 27.2). Pay attention to autopsy brain specimens to get a sense for the normal cellularity and cellular components of brain tissue. Second, you should ask if your lesion is neoplastic or non-neoplastic. The non-neoplastic lesion that pathologists worry most about is the demyelinating lesion, which can look like a tumor by radiology. Abundant foamy macrophages, and an absence of obvious malignant cells, should make you think of a possible demyelinating lesion or infarct (Figure 27.3). Gliosis, a reactive proliferation of astrocytes, can also simulate a glioma (glial tumor) histologically (Figure 27.4). However, once you have decided you have a neoplasm, the real work begins.

General Principle I

First, as in any organ, there are a finite number of cell types in the brain, and each cell type can give rise to a spectrum of neoplasms. In the brain, the cells and their common neoplasms are summarized in Table 27.2. Neurons, which are thought to be nondividing terminally differentiated cells, are a pretty rare source of tumors, so most CNS tumors arise from the supporting cell types of the brain.

General Principle II

There is a broad grading system used for CNS neoplasms, the World Health Organization (WHO) tumor grade, which ranges from 1 (most indolent) to 4 (most aggressive). In this system, grade 1 is equivalent to “benign” and curable by resection, but in the CNS something otherwise benign may be clinically devastating depending on where it is growing. Conversely, while grade 4 tumors are often lethal and are considered “malignant,” they do not metastasize throughout the body. For this reason, CNS tumors are not described as benign versus malignant

TABLE 27.1. Differential diagnoses of CNS neoplasms, the most common entities.

Location	Infants and young children	Adolescents and young adults	Adults to elderly
Cerebellum (infratentorial)	Medulloblastoma Pilocytic astrocytoma	Ependymoma Medulloblastoma Pilocytic astrocytoma	Astrocytoma Hemangioblastoma Metastases
Cerebellopontine angle (cranial nerves)			Meningioma Schwannoma
Cerebrum (supratentorial)	Neuroblastoma (although rare in this location, more often an abdominal tumor)	Astrocytoma Ependymoma Pilocytic astrocytoma Pleomorphic xanthoastrocytoma	Astrocytoma and glioblastoma Lymphoma Meningioma Metastases Oligodendroglioma
Sella	Craniopharyngioma	Craniopharyngioma Germ cell tumors Pituitary adenoma	Craniopharyngioma Pituitary adenoma
Pineal	Pineoblastoma	Germ cell tumors Pineal tumors/cysts Pineoblastoma	Pineal tumors/cysts
Ventricles (in or adjacent to)	Choroid plexus papilloma/ carcinoma	Choroid plexus papilloma Ependymoma Pilocytic astrocytoma Neurocytoma Subependymal giant cell astrocytoma	Subependymoma
Dural-based			Meningioma Solitary fibrous tumor/ hemangiopericytoma

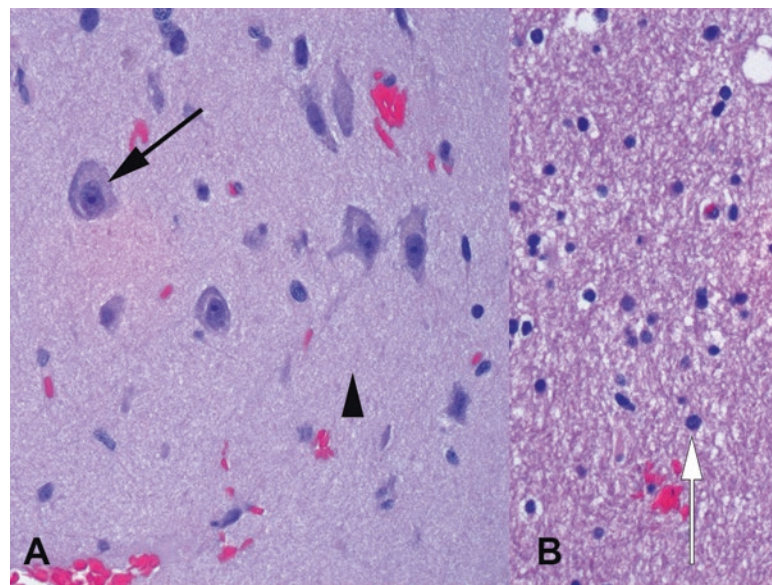


FIGURE 27.1. Normal cerebral cortex. (a) In the gray matter, there is a fine fibrillary background of neuropil (*arrowhead*), with glial nuclei in the background. Neurons are unmistakable, with their plump cell bodies and prominent nucleoli (*arrow*). (b) The white matter has a coarser texture, as it is made up of myelinated axons, and the glial nuclei are visible as small dense dots (*white arrow*).

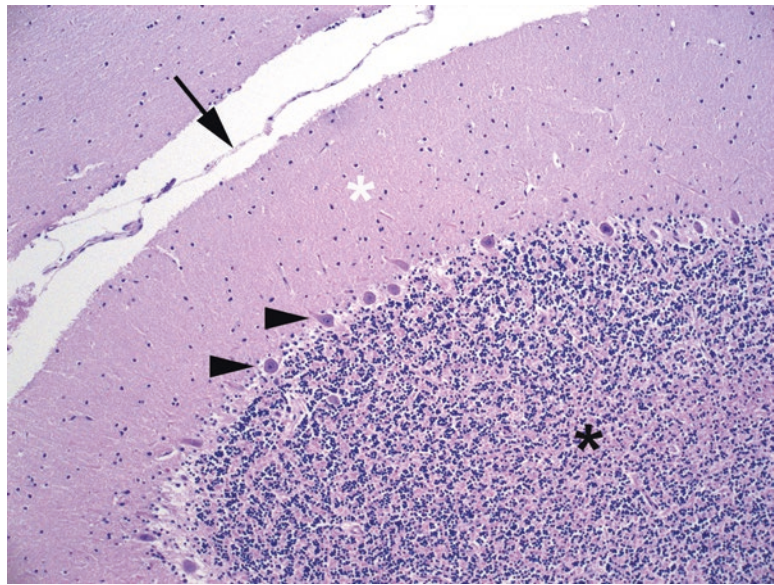


FIGURE 27.2. Normal cerebellum. The tiny nuclei of the granule cell layer are seen at the bottom left (*black asterisk*), underlying a layer of large neurons called Purkinje neurons (*arrowheads*). The Purkinje cells send their dendrites up into the molecular layer (*white asterisk*). The arachnoid layer is seen between folds of the cerebellum (*arrow*).

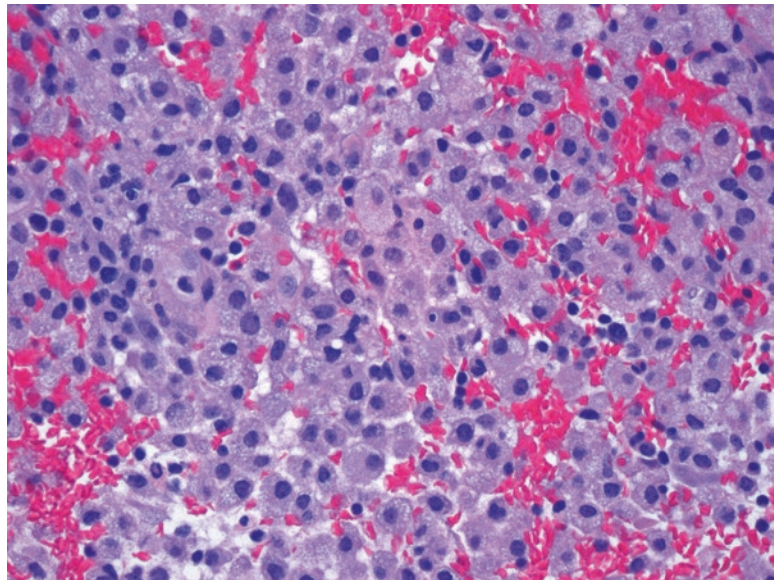


FIGURE 27.3. Infarct. The presence of sheets of histiocytes or macrophages, with their round contours and bubbly cytoplasm, should be a flag to consider an infarct or demyelinating lesion.

but are graded according to the WHO scale, which predicts prognosis. The grade 1 and 2 tumors are referred to as “low grade,” whereas grade 3 and 4 lesions are considered “high grade.” There is no TNM staging for primary brain tumors; margin status and tumor size are also not usually determined by the pathologist.

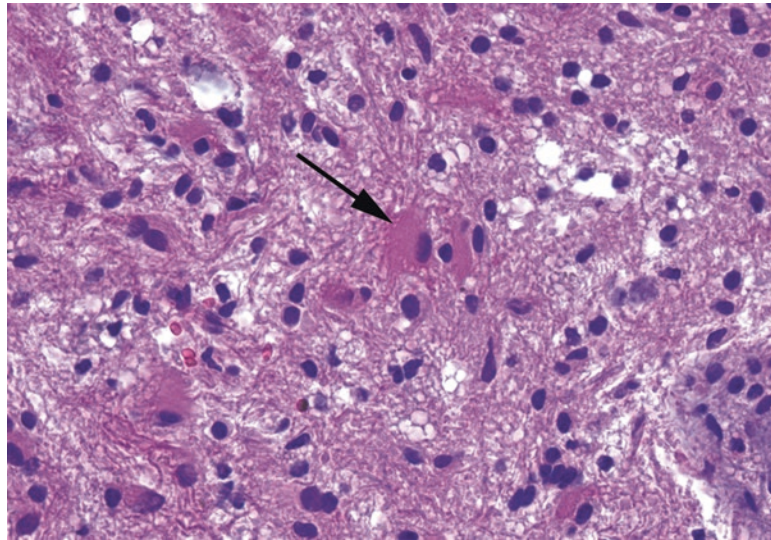


FIGURE 27.4. Reactive astrocytes in gliosis. Normal resting astrocytes generally do not have visible cytoplasm. When responding to inflammation or injury, they become compact in shape, with dense pink cytoplasm and stubby processes (*arrow*).

Native cells	Tumors	
Astrocytes	Astrocytoma and variants	} Gliomas, collectively
Oligodendroglia	Oligodendroglioma	
Ependymal cells	Ependymoma and variants	
Neurons and precursors	Neurocytoma and gangliocytoma	
Meninges (arachnoid cells)	Meningioma and variants, hemangiopericytoma	
Choroid plexus cells	Choroid plexus papilloma/carcinoma	
Pituitary cells	Pituitary adenoma	
Schwann cells (in nerves)	Schwannoma	
Stromal or vascular cells	Hemangioblastoma	
Embryonal (immature) cells	Medulloblastoma, neuroblastoma, others	
Pharynx remnants ^a	Craniopharyngioma, Rathke's cleft cyst	
Germ cell remnants ^a	Germinoma, teratoma, etc.	
Notochord remnant ^a	Chordoma	

^a*Remnants* are those cell lines that do not anatomically belong in the brain but sometimes get left behind in a developmental fluke. They create midline tumors.

Most neoplasms are assigned to a grade by definition, but some tumor families have a spectrum of grades based on certain histologic features. For these tumors, the following features are used to assign a higher grade to the lesion:

- Cytologic atypia (a subjective observation requiring some experience)
- Increasing cellularity relative to lowest-grade tumor (again, subjective)
- Increasing numbers of mitoses (usually quantitative)
- Microvascular proliferation (objective: either present or absent)
- Necrosis (objective: either present or absent)

These features need to be assessed in every tumor (Table 27.3). Note that tumors with an “anaplastic” qualifier are grade 3, while tumors with a “blastoma” in the name are grade 4 (hemangioblastoma not included).

TABLE 27.3. Morphologic features of glial tumors in increasing order of concern (from left to right).

EGBs or RFs	No atypia	No mitoses	Atypia	High cellularity	High mitoses	MVP	Necrosis
							Occ. in pilocytic astrocytoma, grade 1
		Astrocytoma, grade 2		Anaplastic astrocytoma, grade 3			Glioblastoma, grade 4
		Oligodendroglioma, grade 2			Anaplastic oligodendroglioma, grade 3		
		Ependymoma, grade 2			Anaplastic ependymoma, grade 3		
		Subependymoma, grade 1					

EGBs eosinophilic granular bodies, *MVP* microvascular proliferation, *Occ* occasionally, *RFs* Rosenthal fibers

General Principle III

CNS tumors are usually sent for frozen section to guide intraoperative management and ensure a diagnostic biopsy and should also be evaluated with a smear or touch preparation, along with the frozen. The smear highlights some features that also narrow your differential diagnosis; on a smear it is easy to detect the fibrillary processes that identify most glial tumors, and nuclear detail is preserved. You can also get a feel for how cohesive (cell-to-cell adhesion) the tumor cells are, from very cohesive tumors (usually metastasis, schwannoma, or meningioma) to very noncohesive tumors (lymphoma, pituitary adenoma, and oligodendroglioma).

The general aim of the frozen section diagnosis is to verify that lesional tissue is present, classify the tumor into a major category (such as glioma vs. meningioma vs. carcinoma), and approximate a grade (low or high). It is often difficult and/or unwise to get more specific than this at the time of frozen.

Overall, the tumors discussed in this chapter are organized based on location and age. However, astrocytomas, oligodendrogliomas, and meningiomas are discussed first, as they are so common and can arise almost anywhere along the neural axis. These are mainly tumors of adults. Note that metastases are actually the most common brain tumors in adults but are often diagnosed clinically (no biopsy, no pathologist required).

Astrocytoma

Astrocytes, in their non-neoplastic form, are stellate cells with long processes that support the neurons. A resting astrocyte is barely more than a naked nucleus in the neuropil, by H&E. Tumors of astrocytes are called *astrocytomas*, of which there are several variants. A major split in categorization is between diffuse or infiltrating types and circumscribed variants. Infiltrating astrocytomas creep out into the surrounding brain so subtly that it is hard to tell where tumor ends and reactive brain begins. They come in three WHO grades: *diffuse astrocytoma* (2), *anaplastic astrocytoma* (3), and *glioblastoma* (4). The distinction is by the criteria listed in Table 27.3. Hypercellularity and mitoses bump the tumor to grade 3, while the presence of microvascular proliferation or necrosis is diagnostic of a glioblastoma (formerly called glioblastoma multiforme, hence the common nickname “GBM”).

Histologically, the cells of a diffuse astrocytoma are scattered in and among the normal cells of the brain, with no visible architecture or cell borders (Figure 27.5). The key is in recognizing (1) that there are too many nuclei, distributed too unevenly, and (2) that many of the nuclei are large, hyperchromatic, coarse in texture, and irregularly shaped. In this sense, the astrocytomas follow the rules of other organs—you just have to learn to recognize the features of a “bad nucleus.”

The higher the grade of tumor, the more obvious it becomes. Finding significant numbers of mitoses will push you to grade 3. The glioblastoma, while classically shown with pseudopalisading necrosis (tumor cells lining up around a necrotic focus, Figure 27.6), can be diagnosed

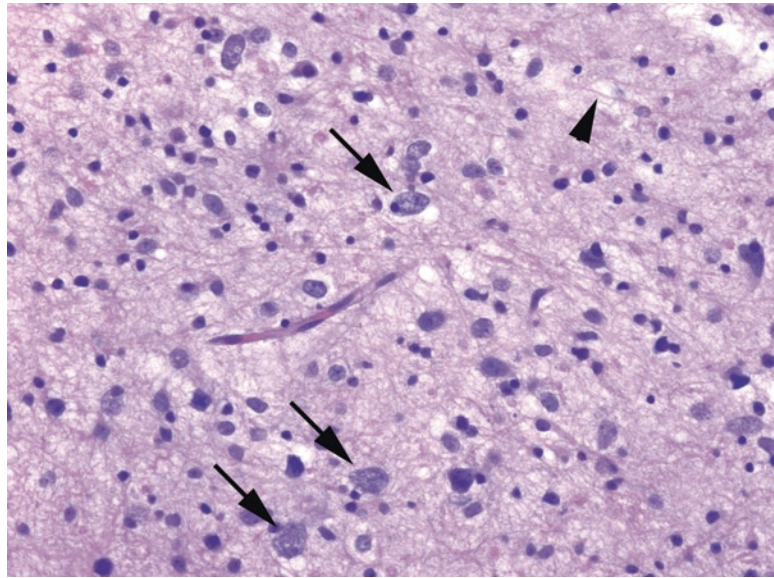


FIGURE 27.5. Astrocytoma, grade 2. This field of tissue is hypercellular relative to normal brain. There are scattered large nuclei with irregular shapes and coarse chromatin (*arrows*); these are malignant astrocytes. The background is fibrillary (*arrowhead*), meaning there is a diffuse network of native neuropil and the processes of the malignant astrocytes.

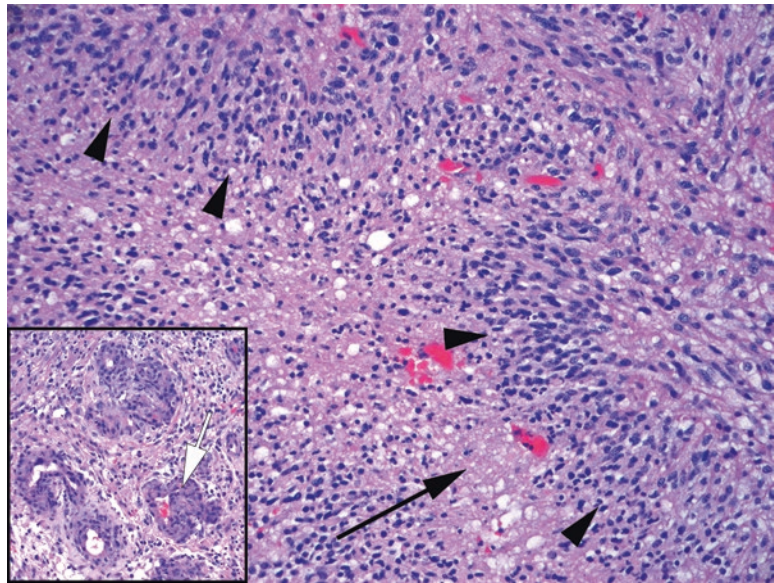


FIGURE 27.6. Glioblastoma. In this example, there is both necrosis (*arrow*) and palisading of large hyperchromatic cells (*arrowheads*). *Inset:* The microvascular proliferation is a characteristic tangle of plump purple capillaries (*white arrow*).

just by identifying a combination of malignant astrocytes plus necrosis and/or microvascular proliferation, which is a characteristic expanding capillary population. Diffuse gliomas, aside from grade, are also subdivided by mutation status into *IDH mutant* and *IDH wild type*, as this has significant prognostic impact. Tumors for which IDH status cannot be determined, including cases in which molecular testing was inconclusive or not possible, are labeled “NOS” (not otherwise specified). While most grade 2 and grade 3 gliomas are IDH mutant, the majority of glioblastomas are not. Finding an IDH mutation in a glioblastoma suggests that it arose from a precursor lower-grade tumor.

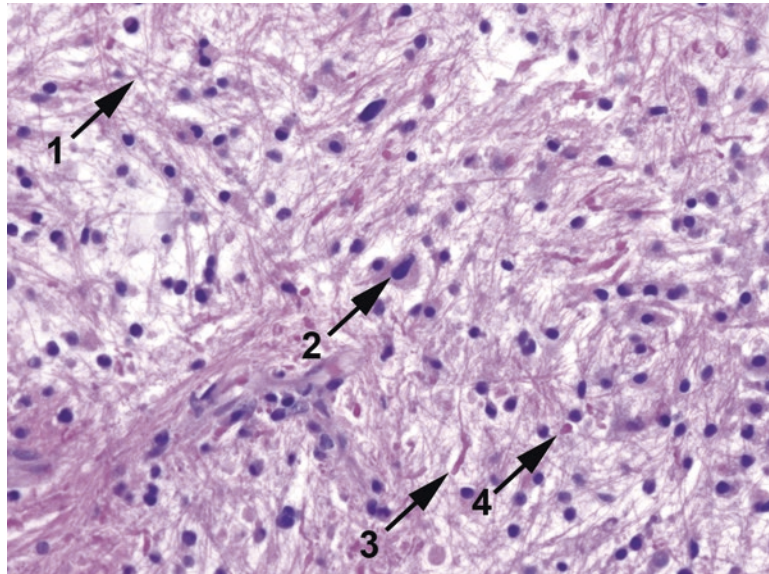


FIGURE 27.7. Pilocytic astrocytoma. The classic features shown here are a fibrillary or hairlike background (1), scattered large dark nuclei (2), Rosenthal fibers (3), and eosinophilic granular bodies (4).

A circumscribed (nondiffuse) and very indolent form of astrocytoma is *pilocytic astrocytoma* (grade 1). It occurs in children and young adults and is usually associated with the cerebellum, optic nerve, hypothalamic region, or ventricles. The “pilo” means hair, because the fine processes create a matted hairlike background (Figure 27.7). These tumors also show the hallmarks of a slow-growing glial process: Rosenthal fibers and eosinophilic granular bodies, which are both types of pink deposits seen among the tumor cells. Other, more rare, circumscribed astrocytic lesions include *pleomorphic xanthoastrocytoma*, a seizure-causing tumor of young adults often found in the superficial cerebral cortex, and *subependymal giant cell astrocytoma* (SEGA) of tuberous sclerosis. The SEGA is a tumor of the lateral ventricles consisting of very large cells with a somewhat ganglionic appearance.

Astrocytes can become reactive, in which their processes shorten and become more clearly visible, emphasizing their stellate shape (Figure 27.4). This nonspecific reaction to injury is called *gliosis*, and it can make non-neoplastic brain appear hypercellular. The key differential is with a diffuse astrocytoma, which can also resemble a subtle hypercellularity, especially around the edges. However, although some astrocytomas can develop a prominent “gemistocytic” or abundant pink cytoplasm, they usually lack the multiple well-defined processes of reactive astrocytes. *Other features that favor glioma over gliosis include the following:*

- Microcystic pattern
- Calcifications
- Mitoses
- Clustering of glial cells around neurons or vessels or below the pia (satellitosis)
- Irregular distribution and crowding of glial cells

Oligodendroglioma

Oligodendroglioma is a diffuse glioma, typically arising in the frontal/temporal lobes of adults. Usually it is a grade 2 tumor, although vascular proliferation, mitotic activity, and necrosis can push it to grade 3. Histologically, it is characterized by a population of tumor cells that look like normal oligodendroglia: small round nuclei surrounded by clear halos (a retraction artifact seen only in formalin-fixed tissues). The chromatin is a little clumpy, like a plasma cell, but overall it is uniform (Figure 27.8). Architecturally, they tend to cluster around

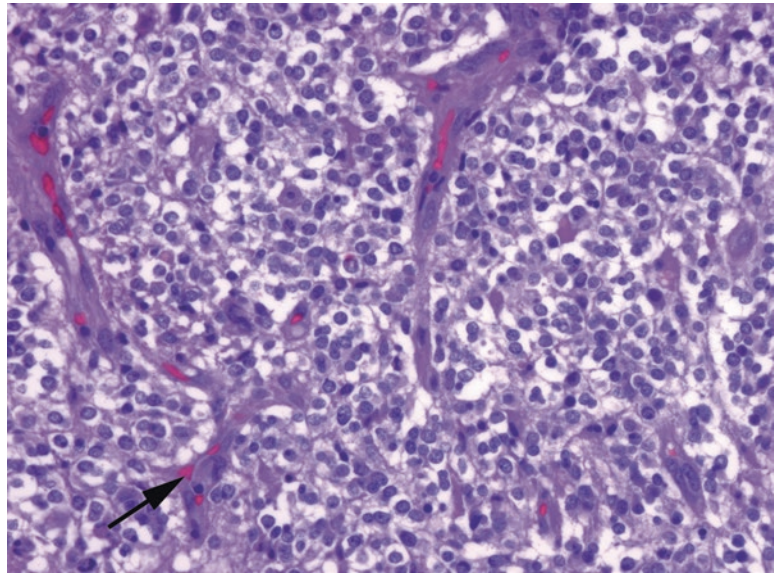


FIGURE 27.8. Oligodendroglioma. This is a very cellular example of an oligodendroglioma. The closely packed oligodendroglia have very round nuclei which are surrounded by clear halos. The tumor cells are suspended in a network of fine capillaries (*arrow*).

existing neurons (satellitosis). Other helpful features include a netlike capillary array, a microcystic pattern (as though torn apart by expanding bubbles), and calcifications. On a smear, these cells are not fibrillary like the astrocytoma but instead sheet out as discohesive round cells. Although the histology is important, in reality the oligodendroglioma is evolving into a molecular diagnosis, characterized by a chromosomal deletion of 1p and 19q, as well as an IDH mutation.

Meningioma

The meningioma arises from arachnoid-type cells associated with the dura and is therefore almost always dural based, which may include tumors on the cerebral convexities, tumors of the falx, or tumors around the brain stem or spinal cord. It is common in adults and rare in children. The usual meningioma is a grade 1 tumor, but certain features or subtypes can raise the grade to 2 (atypical) or 3 (anaplastic).

Histologically, meningioma is one of the most protean tumors in the CNS. It has over a dozen subtypes, few of which have clinical significance, but variants must be recognized for their benign selves and not called carcinoma or sarcoma. For this reason, before you start trying to learn subtypes, become very comfortable with the basic cytologic features of meningotheelial cells, as these do not vary much across types. The classic meningotheelial cell occurs in a syncytium with its neighbors, so cell borders are invisible. The nuclei are small, oval, and regular, with a very fine powdery chromatin, and they tend to stream in parallel in their syncytial groups (Figure 27.9). Nuclear inclusions may be seen. Meningiomas of all types often have whorls, which are spiral-shaped streams of nuclei, similar to the whorl of a fingerprint. Psammoma bodies are frequently present.

The “classic” grade 1 meningioma is called the *syncytial type*, but it can differentiate along more mesenchymal lines (fibrous, angiomatous) or more epithelial lines (secretory, clear cell). Important subtypes which are automatically upgraded are as follows:

- *Clear cell* (grade 2): glycogen-filled cells, which therefore lose their syncytial appearance, resembling instead a clear cell carcinoma (Figure 27.10)
- *Chordoid* (grade 2): resembles a chordoma, with a myxoid background and cords of cells

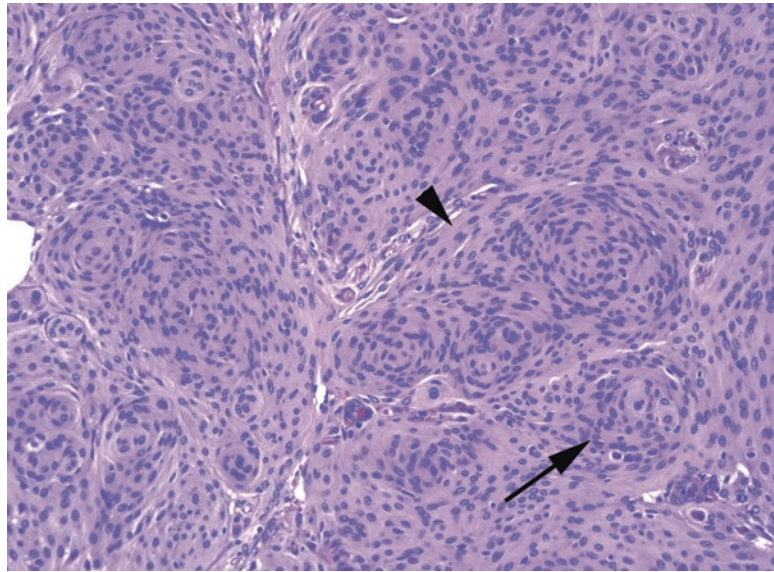


FIGURE 27.9. Meningioma. The meningioma nuclei are small and oval and tend to cluster in syncytial groups (*arrowhead*) without visible cell borders or make whorls (*arrow*).

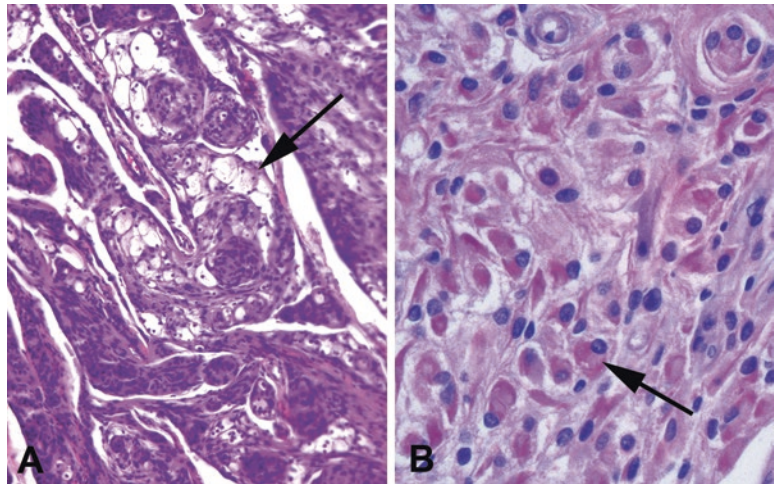


FIGURE 27.10. Aggressive variants of meningioma. (a) Clusters of distended clear cells (*arrow*) are visible in this meningioma, indicative of clear cell meningioma. (b) Rhabdoid meningioma has plump eosinophilic cells (*arrow*) with eccentric nuclei.

- *Rhabdoid* (grade 3): plump pink cells with eccentric nuclei, similar to rhabdomyoblasts (Figure 27.10)
- *Papillary* (grade 3): syncytial meningothelial cells on arborizing fibrovascular cores

A meningioma can also be upgraded to grade 2 based on histological criteria, including hypercellularity, sheetlike growth, spontaneous (not treatment-related) necrosis, increased mitotic rate (4 or more per 10 high-power fields), or brain invasion (true infiltration into brain parenchyma, not a pushing mass effect). Grade 3 tumors have a very high mitotic rate (20 or more per 10 high-power fields), anaplasia, or are one of the malignant subtypes above. Skull invasion, on the other hand, does *not* affect the tumor grade, although invasion of the skull base can be surgically problematic.

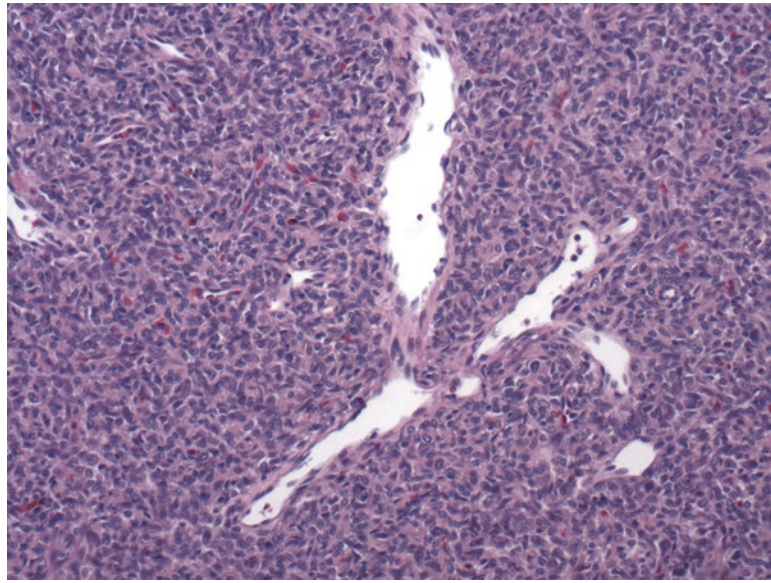


FIGURE 27.11. Solitary fibrous tumor/hemangiopericytoma. A typical staghorn vessel in a background of small blue cells that are somewhere between epithelioid and spindled.

A much less common lesion is *solitary fibrous tumor/hemangiopericytoma*. Like meningiomas, these are also dural-based, enhancing, well-circumscribed lesions. However, the SFT/HPC is a blue and cellular tumor with prominent and stereotypical gaping vessels called *staghorn vessels* (Figure 27.11). The nuclei are oval but have nucleoli and coarser chromatin than the meningioma.

Lesions of the Posterior Fossa (Infratentorial)

The main structure of the posterior fossa is the cerebellum. Never forget where you are; the granule cells of the cerebellum look tumorlike on smear if you are not expecting them (Figure 27.2). Within the cerebellum of adults, your differential usually includes gliomas, metastases, and hemangioblastoma. Infratentorial tumors are much more commonly seen in children, and in this age group the big players are low-grade gliomas (*pilocytic astrocytoma* and *ependymoma*) vs. *medulloblastoma*: fortunately difficult to mix up on frozen section.

Hemangioblastoma (not an embryonal tumor, not a grade 4) is an uncommon tumor often associated with von Hippel–Lindau syndrome (VHL). It looks a little like a renal cell carcinoma, with packets of lipidized clear tumor cells surrounded by a delicate capillary network (Figure 27.12). This is unfortunate, because VHL patients also get renal cell carcinoma metastases. Oil Red O (a stain for fat performed only on frozen sections) and immunostains can sort out the ambiguous cases.

Pilocytic astrocytomas are described above in the section on astrocytomas. *Ependymomas* (also from the ventricle) are described below, with other periventricular tumors.

A special infratentorial location is along the eighth nerve, the most common site of *schwannoma* in adults. Named the *acoustic neuroma* because of its position on the auditory nerve, the schwannoma is a peripheral nerve sheath tumor, made up of the myelinating nonneural Schwann cells. It is a benign fibrillary tumor consisting of streaming, elongated, syncytial nuclei (Figure 27.13). It often has alternating areas of high and low cellularity (Antoni A and B areas) and tends to make little palisaded arrays called Verocay bodies. Hyalinized, thick, pink vessels are common.

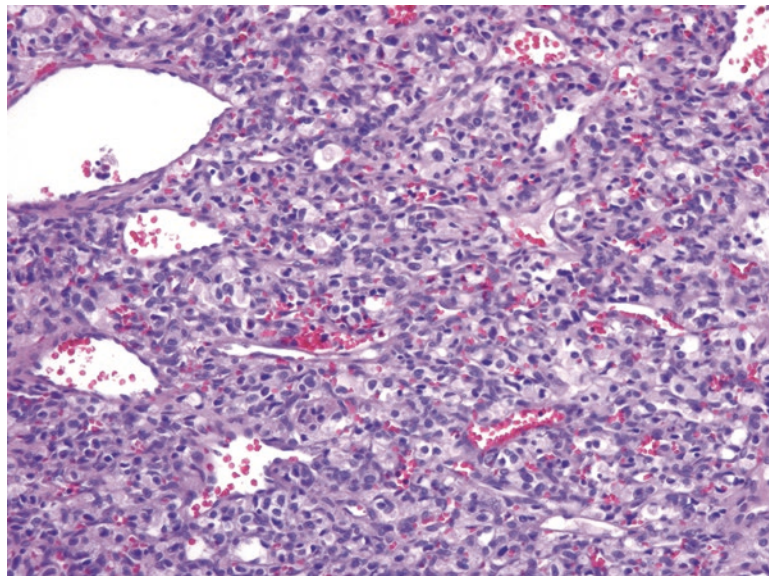


FIGURE 27.12. Hemangioblastoma. Clear (lipidized) cells with bland nuclei in a background of interlacing and dilated capillaries.

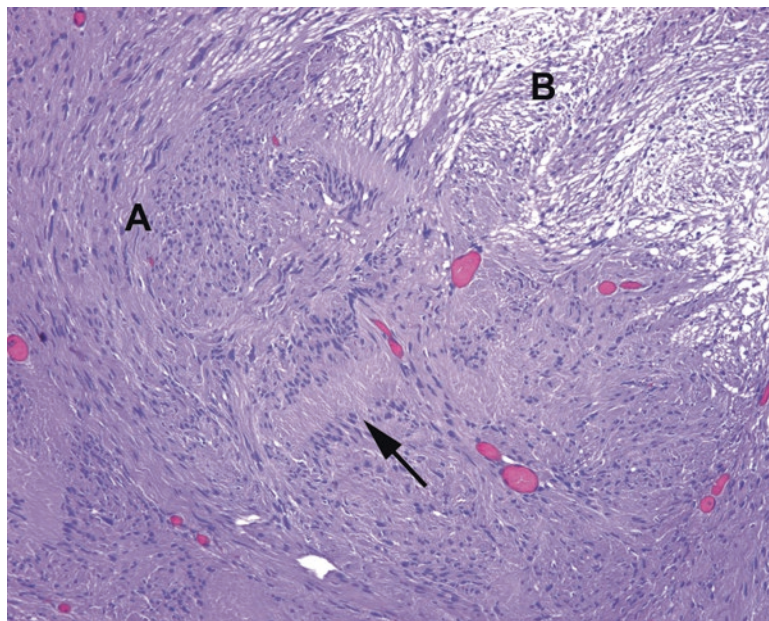


FIGURE 27.13. Schwannoma. This lesion shows alternating areas of high and low cellularity, called Antoni A (a) and B (b) areas. The elongated Schwann cells tend to stream in parallel groups and form opposing parallel arrays, called Verocay bodies (*arrow*).

Lesions of the Midline

Tumors arising from embryologic remnants usually occur in the midline. *Germ cell tumors* include the *germinoma*, which is essentially a primary CNS seminoma, and the *teratoma*, more often found in a sacrococcygeal location than in the head. Other germ cell tumors, such as yolk sac tumor and choriocarcinoma, are rare but do occur in the CNS.

Craniopharyngioma and Rathke's cleft cyst both derive from pharyngeal tissues occurring in the sellar region. The craniopharyngioma, most common in young people, classically has an "adamantinomatous" appearance, meaning it looks like a developing tooth. The nests of cells are bounded by dark palisaded cells, with central areas of stellate cells in a myxoid stroma (Figure 27.14). There is also keratin and debris. Adults, when they get craniopharyngiomas, more often get the papillary type, resembling a nonkeratinizing squamous papilloma.

Chordomas are tumors of the notochord remnant, hence the name; note that they have nothing to do with "chondroid" or cartilage. They are most often found at the top and bottom of the spine—the clivus and the sacrum. Like intervertebral disks, another notochord remnant, they have a bluish, mucinous background. The tumor cells are typically full of clear bubbles and grow in cords.

Other sources of midline tumors include the pituitary and pineal. *Pituitary adenoma* is a common tumor of the sella. Remember that the pituitary is a very heterogenous mass of cell types, arranged in lobular nests. Therefore, cellular monotony and loss of the normal pattern of small nests of cells are the key to differentiating between an adenoma and normal pituitary (Figure 27.15). The pituitary adenoma looks similar to a neuroendocrine tumor in other sites, both cytologically and architecturally. The *pineocytoma* is the pineal adenoma. It can be very difficult to tell a pineal tumor from normal pineal, mainly because so few pathologists have actually seen a normal pineal. *Pineoblastomas* are more primitive-appearing "embryonal" tumors which arise in this region. Tumors that are midline because they are associated with the third or fourth ventricle are discussed in the next section. *Diffuse midline glioma, H3K27M mutant*, is a grade 4 infiltrating astrocytic tumor which arises from the brain stem, spinal cord, or thalamus, generally in children.

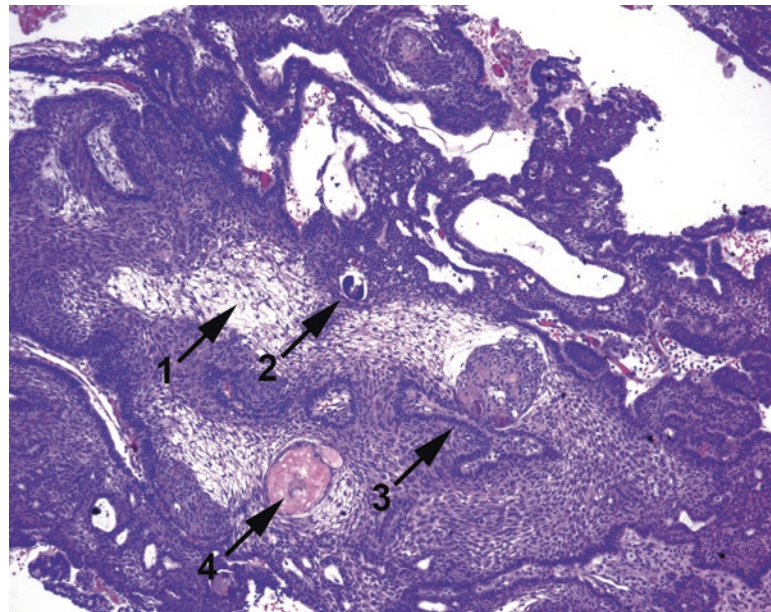


FIGURE 27.14. Craniopharyngioma, adamantinomatous type. There are areas of stellate reticulum (1), calcification (2), peripheral palisading (3), and accumulated "wet" keratin (4).

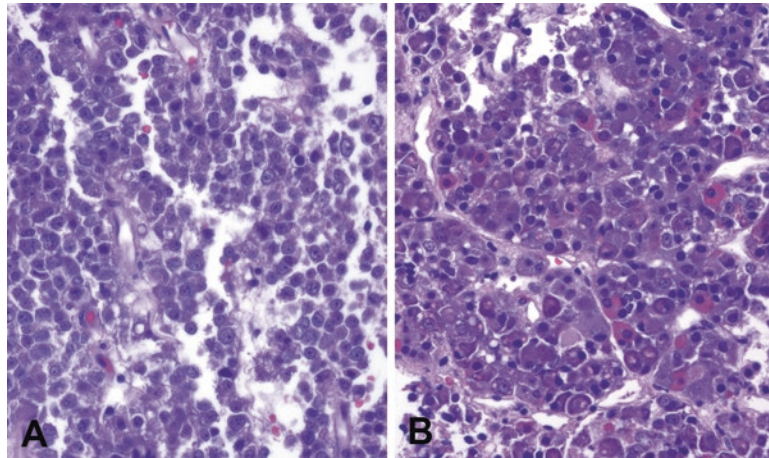


FIGURE 27.15. Pituitary adenoma versus normal. (a) In a pituitary adenoma, there is a monomorphic population of neuroendocrine-type cells. A collagen or reticulin stain would show sheets of cells no longer encircled by reticulin. (b) Normal pituitary is a mix of many different cell types, both eosinophilic and basophilic, and a reticulin stain would show the tissue divided into small discrete nests.

Lesions of the Ventricular/Periventricular Areas

Ependymoma

Ependymoma is a usually low (grade 2) lesion of children and young adults. Grade 3 anaplastic ependymomas also exist, but this pathologic distinction is not consistently defined. It arises from a population of cells that line the ventricles, called *ependymal cells*. When they become neoplastic, they retain this affinity for making boundaries or lumens and tend to encircle vessels.

Histologically, this is a circumscribed lesion composed of cells with pale oval nuclei that align themselves around blood vessels, sending processes down to the vessel like spokes of a wheel (Figure 27.16). The resulting structure is called a *pseudorosette*. When the cells make an array around a tiny open lumen, it is called a *true rosette*. These rosettes are the signature feature of the ependymoma.

A special type of ependymoma is the *myxopapillary ependymoma*, occurring almost exclusively at the filum terminale of the spinal cord. It has a myxoid background and ependymal cells radiating off of papillary structures, so it was well named (Figure 27.17). A *subependymoma* is an even lower-grade lesion (grade 1) which typically occurs as a nodule on the ventricular wall. Remember that this is distinct from the subependymal giant cell astrocytoma, though, which is astrocytic.

Other Tumors

SEGAs, covered above, are commonly associated with ventricles, especially in children. Central neurocytoma is a low-grade lesion of neural origin, typically occurring in the lateral/third ventricle area. Like other neuronal tumors, it is uncommon and mainly occurs in children and young adults. It may be mistaken for an ependymoma or oligodendroglioma. *Choroid plexus papilloma* is an intraventricular tumor of young children and can even be congenital. It resembles normal choroid plexus but grows in large arborizing fronds to make a mass. The bland columnar cells form a single-to-pseudostratified layer on the fibrovascular cores. When these tumors become more solid, mitotically active, and invasive, they are known as *choroid plexus carcinomas*.

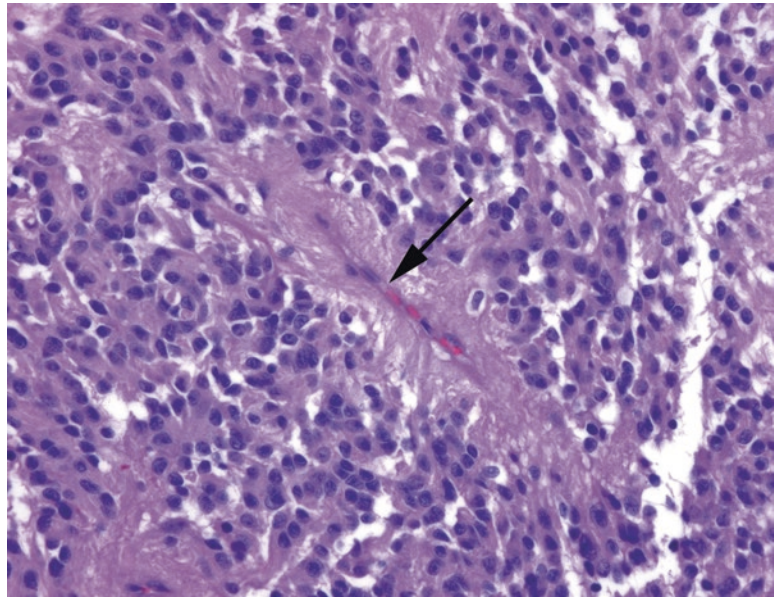


FIGURE 27.16. Ependymoma. There is a fibrillary background and a tendency for the cells to line up around vessels (*arrow*), with the ependymal cell processes extending to the vessel and the nuclei around the perimeter. This is actually an example of a pseudorosette; true rosettes have a lumen, not a vessel, at the center.

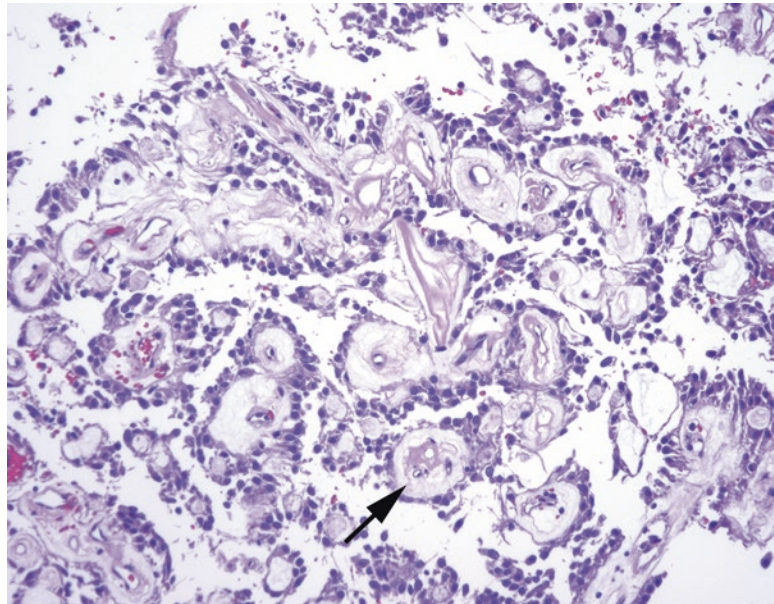


FIGURE 27.17. Myxopapillary ependymoma. The tumor is a papillary neoplasm with vascular cores surrounded by a myxoid stroma (*arrow*) and lined by ependymal cells.

Embryonal Tumors

Embryonal tumors are the small round blue cell tumors of infancy and childhood, high grade and aggressive. They arise from immature stem cells. A feature they have in common is the tendency to form rosettes, similar to fetal neural tissue. *Medulloblastoma* is the most common

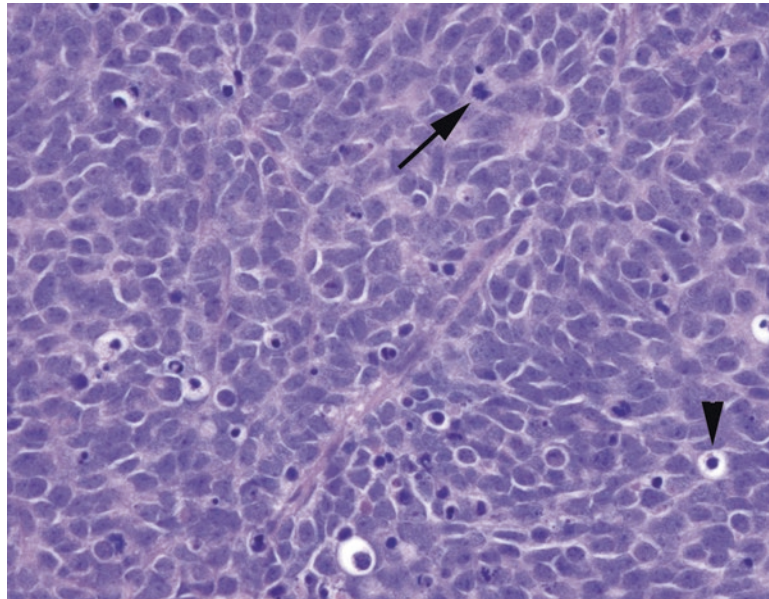


FIGURE 27.18. Medulloblastoma. A small round blue cell tumor composed of cells that are not actually round but more wedge-shaped or even spindly. The chromatin is very fine in texture, and there are frequent apoptoses (*arrowhead*) and mitoses (*arrow*).

of these tumors. The tumors are sheets of small blue cells of high N/C ratio, high mitotic rate, and necrosis (Figure 27.18). The chromatin of the cells is fine and granular like small cell carcinoma, but the nuclei tend to be somewhat wedge or carrot shaped, especially when molded into rosettes. Unlike small cell carcinoma, there is often a fibrillary background due to the neural lineage of this tumor. Like neural stem cells, these tumors retain the ability to differentiate into neurons and glia, so these more differentiated cellular elements may be seen in the tumor. Multiple medulloblastoma variants are recognized, defined either by genetic or histologic criteria.

Other tumors in this category, all rare, all grade 4, include pineoblastoma, neuroblastoma, and atypical teratoid/rhabdoid tumor. Neuroblastoma is typically an abdominal neoplasm arising in the adrenal, but it can occur in the CNS as well. *Atypical teratoid/rhabdoid tumor* (AT/RT) is a tumor of childhood which was named for its resemblance to the rhabdoid tumor of kidney as well as its varied epithelial and mesenchymal components (teratoid or teratoma-like), but is now defined by loss of INI1 expression. This category does not include olfactory neuroblastoma (a sinonasal tumor of adults, arising from the olfactory membrane, unrelated to other things called neuroblastoma).

Other Tumors

Metastases to the brain are fairly common, typically from the lung, breast, skin (melanoma), kidney, or colon, but tend to be biopsied only when the primary is not yet confirmed or known. Lymphomas may present first in the CNS, and the initial diagnostic clue may be the clustering of markedly atypical round nuclei around the blood vessels (refer to Figure 21.3). A skull mass with prominent eosinophils should make you consider Langerhans cell histiocytosis, whereas Rosai–Dorfman disease, usually dural-based, may not look like a tumor at all, just lymphocytes and plasma cells.

The discussion of the skin will be divided into three subsections: melanocytic tumors, non-melanocytic tumors, and inflammatory disorders. Skin biopsies are usually performed because the clinician sees a lesion, such as a mass, a rash, or a macule. However, skin biopsies are also sometimes used to diagnose systemic conditions. Usually the history is enough to direct you to one of the major three categories. Inflammatory and systemic conditions are not usually diagnosed by the general surgical pathologist, but a working knowledge of their classification can be very helpful. Melanocytic lesions are also more and more the exclusive domain of dermatopathologists, but any surgical pathologist should at least be able to tackle the most benign and most malignant ends of the spectrum.

The grossing of skin biopsy specimens varies a bit by the shape, size, and purpose of the excision, but for diagnostic specimens of tumors, the margins must be entirely examined in perpendicular cuts. See your grossing manual, and consult with your attending, for the best way to cut in a specimen.

Melanocytic Lesions

Melanocytes are specialized cells in the epidermis and elsewhere that are derived from neural crest cells. They have a neuralish, dendritic morphology and stain with S100 and Sox10, like peripheral nerve cells. They also produce melanin pigment, which is exported from the cell and taken up by surrounding epidermal cells. Normal melanocytes do not have much visible pigment; in fact, the cytoplasm is clear, as the pigment leaves the cell (Figure 28.1). Densely pigmented cells along the basal layer of the epidermis are usually basal keratinocytes, not melanocytes. It is this pigment distribution that creates shades of skin color.

Abnormal melanocytes can accumulate pigment, and this can be a useful clue in identifying dysplastic melanocytes (discussed below) or identifying an unknown metastasis as melanoma. However, there are plenty of melanomas with no melanin to be found, so do not rely on that. Also beware of the melanophage, spindly macrophages in the dermis full of chunky globs of melanin—they are eating it, not making it (Figure 28.2).

Become familiar with the melanocyte; spend a few seconds looking for them when you encounter normal skin. Melanoma is a treacherous area precisely because there are no strict diagnostic rules about when something is malignant and when it is not, and much of the diagnosis (in subtle cases) relies on recognizing atypical melanocytes that are up to no good. The only way to learn this skill is to see lots of normal melanocytes.

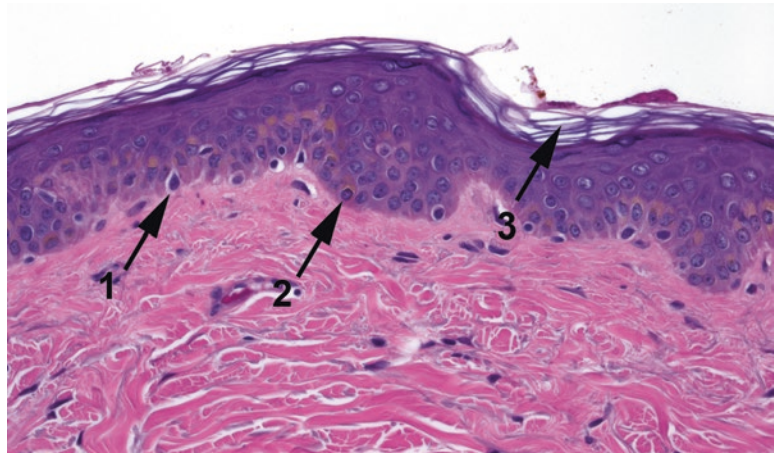


FIGURE 28.1. Normal melanocyte and skin. A normal melanocyte (1) stands out within a clear halo of cytoplasm. The pigmented component of the skin is actually the basal keratinocytes (2), which absorb the melanin. Typical basket weave or orthokeratin is present (3).

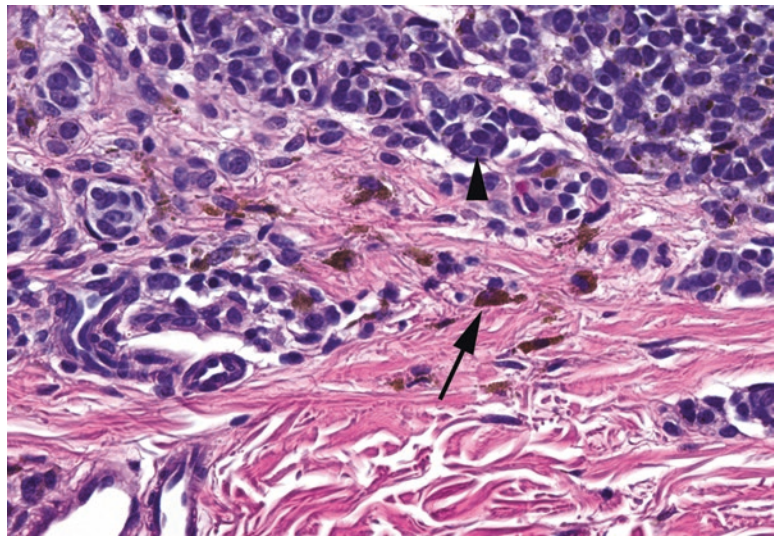


FIGURE 28.2. Melanophages in an intradermal nevus. The nevus cells (arrowhead) have focal small specks of pigment, but the macrophages digesting the excess melanin (arrow) stand out.

Terminology

As a pathologist, you now know that a “mole” is a type of gestational trophoblastic disease, and you are sophisticated enough to refer to a bump on the skin as a nevus. However, the word *nevus* really does mean just a *bump on the skin*, and there are things called *nevus* that have nothing to do with melanocytes. In this chapter, we will just be discussing the melanocytic nevi.

A melanocytic nevus is a proliferation of benign melanocytes. It begins along the basal layer of the epidermis, where melanocytes live, and the very earliest manifestation of this is an increased number of melanocytes along the dermoepidermal junction (DEJ) in a single layer. This produces a dark patch on the skin, and the lesion is called a *lentigo simplex* (Figure 28.3). The word *lentigo* or *lentiginous* refers to “along the DEJ” and is used in several different contexts.

The next step in the life cycle of a nevus is the proliferation of melanocytes into little nests, or *theques*, along the DEJ. These are technically intraepidermal, although it is sometimes hard to appreciate that. This lesion is called a *junctional nevus*, and it appears as little clusters of bland melanocytes hanging from the DEJ.

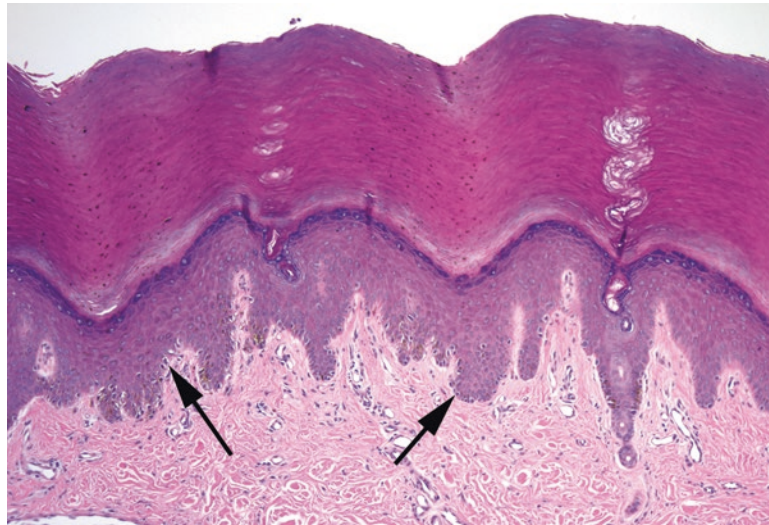


FIGURE 28.3. Lentigo simplex in acral skin. The dense thick keratin seen here is typical of acral skin (palms and soles). There is a linear proliferation of single benign melanocytes along the dermoepidermal junction (*arrows*).

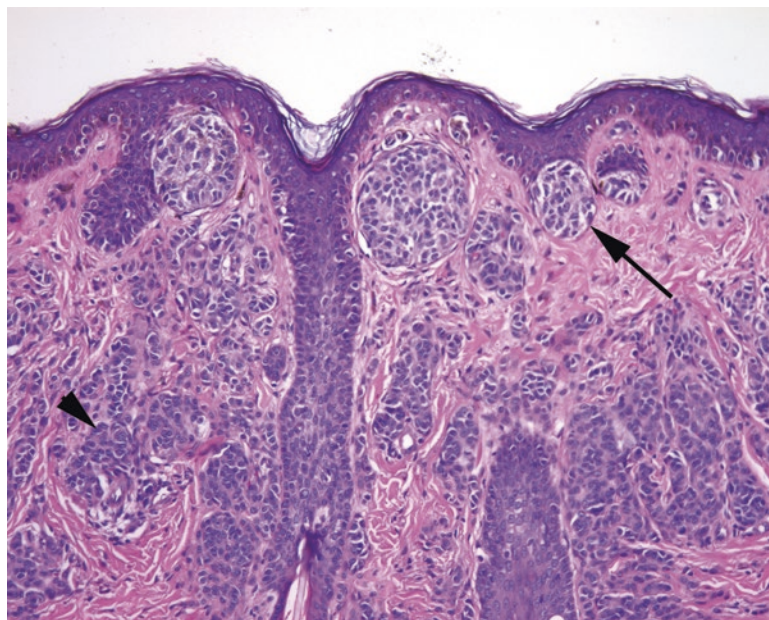


FIGURE 28.4. Compound nevus. This nevus shows nests of nevocellular (melanocytic) cells attached to the dermoepidermal junction (DEJ) (*arrow*). A nevus with only DEJ nests would be a junctional nevus. In this example, as there are also nevus cells dropping down into the dermis (*arrowhead*), this is a compound nevus. In a compound nevus, the cells at the deepest point should appear slightly smaller and more bland than those at the DEJ (“maturation”).

From there, the melanocytes may begin to proliferate down into the dermis. They do so as small nests, sheets, or single cells, and they grow in a lobular pattern. Cytologically they are bland, round, clear cells, and they tend to “mature” (become smaller and more bland) the deeper into the dermis they progress. They become so numerous that they make a little nodule in the skin, forming the classic “mole.” Most adults have 10–20 of them. A nevus with a dermal component plus a junctional component is called a *compound nevus* (Figure 28.4). Eventually, with age, the junctional component regresses, and you are left with just an *intra-dermal nevus* (Figure 28.5). These can be pedunculated, hyperkeratotic, or hair bearing. Fortunately, melanoma arising in a benign intradermal nevus is vanishingly rare.

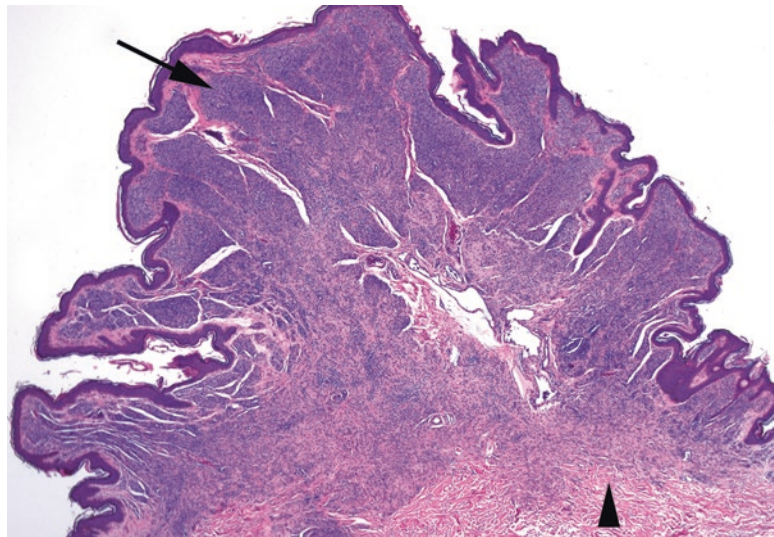


FIGURE 28.5. Intradermal nevus. This exophytic nevus has only dermal nests of nevus cells (*arrow*). The lesion is roughly symmetric, and the cells are smaller and more mature at the base (*arrowhead*).

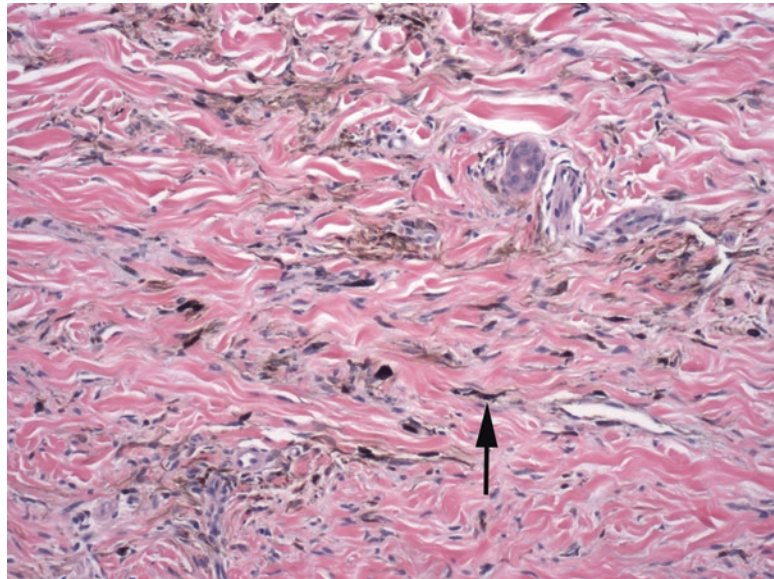


FIGURE 28.6. Blue nevus. Small, indistinct, pigmented cells are scattered throughout the dermal collagen (*arrow*). The cells are elongated and fusiform or stellate and do not make rounded nests like typical nevus cells. Some of the larger cells with chunky pigment are likely melanophages.

Histologic features that suggest a benign nevus:

- Symmetry
- Size <3 mm in diameter
- Lateral borders defined by nests, not individual trailing melanocytes
- Lack of atypia in the melanocytes (nuclei are no larger than a keratinocyte nucleus and have small dense nucleoli, if any; multiple nuclei are okay)
- Maturation into the dermis
- Chunky brown-black pigment

Other Benign Nevi

The common *blue nevus* consists of a diffuse scattering of pigmented, dendritic (stellate), single melanocytes in the dermis (Figure 28.6). They are mixed in with melanophages.

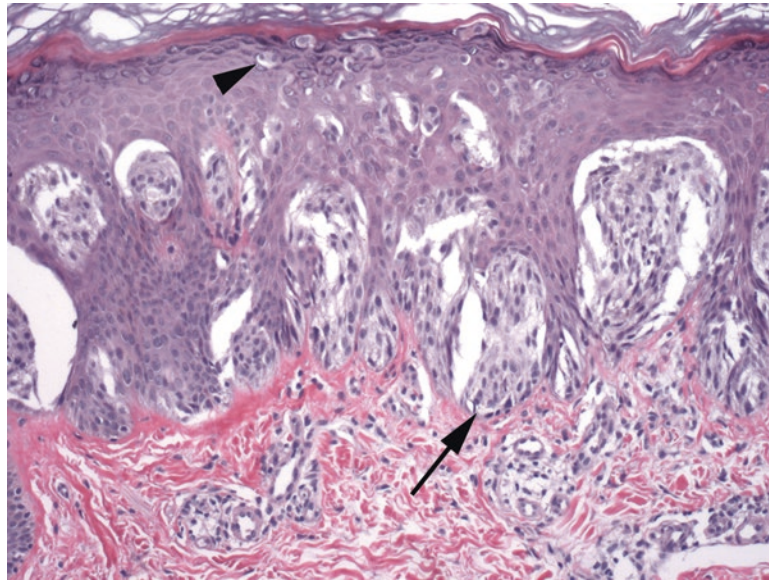


FIGURE 28.7. Spitz nevus. This nevus in a child shows nests of large, spindly melanocytes at the dermo-epidermal junction (*arrow*) and rare melanocytes spreading up through the epidermis (*arrowhead*). In an adult, this pattern would be very worrisome.

The *Spitz nevus* is usually found on the head and neck of children and adolescents. At low power, it is circumscribed and symmetric, and large nests of melanocytes are found between skinny elongated rete (Figure 28.7). Eosinophilic globules may be seen at the DEJ. The reason this lesion is so troublesome is that the melanocytes may be large, spindled, pleomorphic, or atypical and they may even show rare mitoses and pagetoid spread, all of which suggests melanoma. The distinction of Spitz nevus from rare pediatric melanoma, however, (or the variants of atypical Spitz nevus and spitzoid melanoma) is best left to the experts.

Acral and genital nevi—nevi of the hands and feet, genital regions, and breasts—are allowed some atypical features. They may have more irregular placement of melanocytic cells and can even have occasional ascending cells mimicking pagetoid spread. However, they should not have cytologic atypia.

Most nevi are acquired during childhood to early adulthood, but some are congenital. To have *congenital features* means that the dermal melanocytes tend to track down the adnexal structures and along neurovascular bundles.

Dysplastic Nevi

There are some nevi that begin to show some features more commonly associated with melanoma. These nevi are clinically distinct looking, and although they are not considered actual precursors to melanoma, patients with multiple dysplastic nevi are at significantly higher risk of developing melanoma. However, “dysplastic nevus” is a clinical diagnosis, and as pathologists, we merely describe the features we see. There are two components to dysplasia in this context: architectural disorder and atypia. These lesions are signed out as, for example, *compound nevus with architectural disorder and severe cytologic atypia*. (However, in some texts, you will find this entity listed as lentiginous melanocytic nevus or Clark’s nevus.)

There are four features of *architectural disorder*: architectural disorder is not graded but is simply present or absent.

- Lentiginous spread of atypical melanocytes (along the DEJ in a creeping line)
- Shouldering (the lentiginous component is wider than the dermal component)
- Bridging of rete (nests attached to adjacent rete ridges fuse; Figure 28.8)
- Fibroplasia (a feathering of the dermal collagen that looks like pink cotton candy)

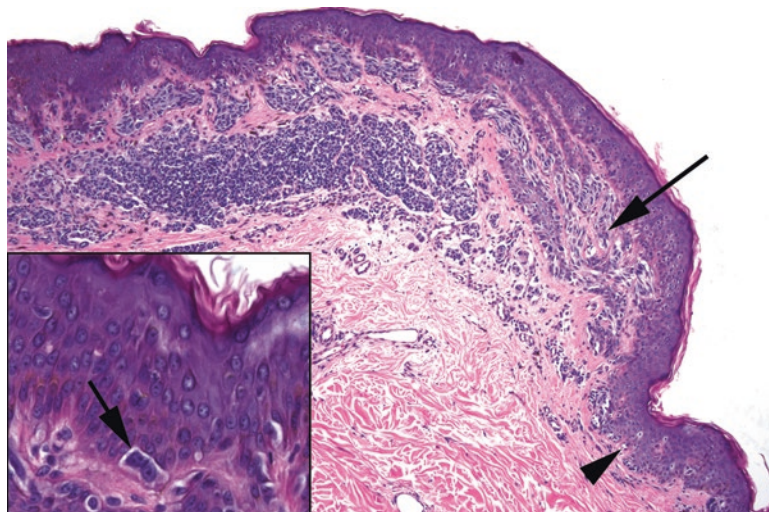


FIGURE 28.8. Dysplastic nevus. At low power, elongated nests of spindly melanocytes are seen bridging across adjacent rete (*arrow*), and single melanocytes trail off to the lateral edge of the lesion (*arrow-head*). These are features of architectural disorder. *Inset*: atypical melanocytes with large nuclei and nucleoli are seen at the dermoepidermal junction.

The features of *cytologic atypia* include the following:

- Hyperchromatic nuclei, increased nuclear to cytoplasmic ratio
- Large red nucleoli
- Accumulation of dusty gray-brown melanin (see Figure 28.8)
- Atypical mitoses

Atypia is graded as mild, focally severe, or severe. In general, these nevi tend to be suspicious enough that you must take a few moments to prove to yourself that they are *not* melanoma.

Melanoma

The best way to think about melanoma is the presence of malignant melanocytes. Because melanocytes can proliferate in many ways and still be benign, it takes considerable experience to decide if a melanocyte is malignant or not. However, setting that aside for a moment, the types of melanoma include the following:

- *Melanoma in situ (MIS)*: malignant melanocytes along the DEJ *and* percolating up through the epidermis in a pagetoid fashion (something benign melanocytes do not do)
 - *Lentigo maligna*: a subtype of MIS in which malignant melanocytes proliferate only along the DEJ
- *Invasive melanoma*: malignant melanocytes along the DEJ, pageting through the epidermis *and* invading the dermis
 - *Superficial spreading melanoma*: melanoma in a “horizontal growth phase,” meaning it is spreading laterally along the DEJ but also involves the dermis (clinically, this is a macular lesion [flat])
 - *Nodular melanoma*: melanoma with a “vertical growth phase,” meaning that it is primarily growing down into the dermis (almost like an intradermal nevus, but with malignant cells), producing a raised lesion
 - *Lentigo maligna melanoma*: invasive melanoma that has arisen in the setting of lentigo maligna

Most melanomas have both a horizontal and a vertical component, which is the classic irregularly shaped dark macule with a central raised or ulcerated papule.

Features of Malignancy

Unfortunately there is no single feature that can rule melanoma in or out. As with many types of neoplasia, there are certain features that suggest malignancy, and the presence of enough of them can convince you of the diagnosis. Many of these criteria are subjective and require experience, which is why dermatopathology is such a booming subspecialty these days.

On low power, look for the following:

- Asymmetry
- Poorly circumscribed, pleomorphic, discohesive nests of melanocytes
- Shouldering (lateral spread) of atypical melanocytes
- Pagetoid spread through the epidermis (Figure 28.9)
- Associated lymphocytes, especially band-like

On high power, look for the following:

- Atypia, as described earlier
- Lack of deep maturation (for dermal component)
- Mitoses or atypia in the dermis (see Figure 28.9)
- Melanocytic necrosis

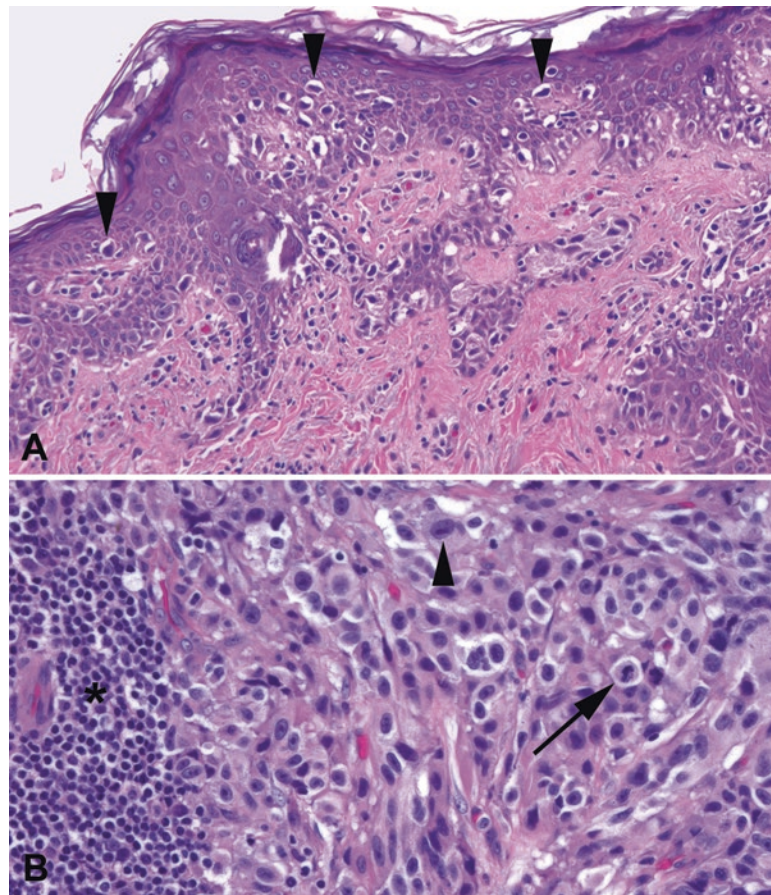


FIGURE 28.9. Melanoma. (a) Large, dark, irregular melanocytes can be seen infiltrating upward through the epidermis (*arrowheads*) in pagetoid fashion. If there were no dermal component, this would qualify as melanoma in situ. (b) Invasive melanocytes deep in the dermis. Large atypical nuclei with large nucleoli (*arrowhead*) plus the presence of mitoses (*arrow*) are diagnostic of invasive melanoma. Adjacent lymphocytes (*asterisk* left side of the field) are common.

Sign-Out Criteria

All diagnoses of invasive (into the dermis) melanoma must include certain prognostic features. The first is the depth of invasion. This is called Breslow's thickness and is the depth (to the hundredth of a millimeter) of invasion from the top of the epidermal granular layer to the deepest malignant cell. Measurement at that resolution requires an ocular micrometer in the eyepiece (typically at 10× the bar represents 1 mm). Depth is proportional to stage; the deeper the invasion, the poorer the prognosis. Clark's level is a related concept but is based on the histologic layers or levels of the dermis, not the absolute depth.

The second key prognostic feature is the presence or absence of ulceration, which also determines stage. The third is the mitotic rate, counted per square millimeter. Knowing how many high-power fields make up 1 mm² is important but will vary by scope and requires calculating the area of your circle of view. In addition, there are different names for multiple foci of tumor: microscopic satellites (at least 0.3 mm from the main tumor), clinical satellites (up to 2 cm from the tumor), and in-transit metastases (>2 cm away, within the same lymph node drainage area).

Special Types of Melanoma

In *desmoplastic* and *spindle-cell melanoma*, melanocytes can become very spindly and sarcomatoid. With an unidentified spindle-cell lesion in the dermis, you must always rule out melanoma. The scariest and most subtle form is the desmoplastic melanoma, which is not only spindly but often sparsely cellular in a background of dense collagen; in other words, it looks just like a scar. A useful tip-off to a lurking desmoplastic melanoma is, aside from a slightly "busy" dermis, the presence of bands or clumps of lymphocytes (Figure 28.10).

Another type of melanoma is *acral lentiginous*. *Acral* refers to the distal extremities. Like the benign acral nevus, this lesion is characterized by prominent lentiginous growth. It can be very difficult to distinguish from an acral nevus, and clinicopathologic correlation can help more with this type of melanoma than the others.

Metastases can look like anything at all; they can be spindly, epithelioid, rhabdoid, small cell, etc. However, stereotypical features of metastases include alveolar (nested) architecture, large pink-to-violet cells with big nuclei and red nucleoli, and occasional melanin pigment. As a rule of thumb, if you don't know what it is, consider melanoma.

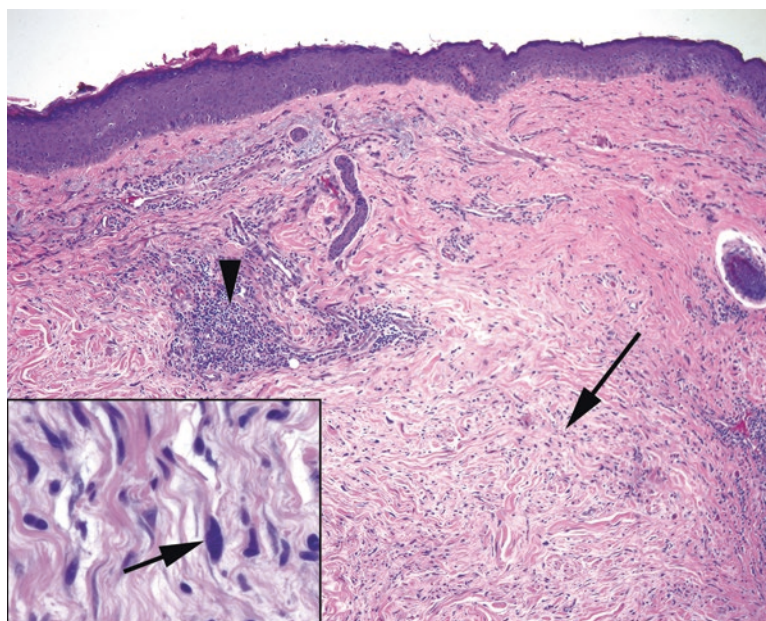


FIGURE 28.10. Desmoplastic melanoma. At low power, there appears to be a hypocellular scar in the dermis (arrow). The clue to melanoma lies in the collection of lymphocytes (arrowhead). Inset: on higher power, there are enlarged and hyperchromatic cells (arrow) in the "scar." These would be positive for S100, unlike fibroblasts.

Re-excision of Melanomas

When a melanoma is diagnosed on excisional biopsy, it is nearly always given a wide re-excision. You will see these large ellipses on surgical pathology. Pathologists differ in how much of the re-excision to submit, but at the least, the entire biopsy scar, to the lateral margins, should be submitted. Carefully scan not just the epidermis but also the dermis deep to the biopsy site.

Special Stains

S100 has historically been the workhorse stain for melanoma, as it stains all types, but it is seeing significant competition from Sox10 in recent years as the latter does not label Langerhans cells in the skin. HMB-45, Melan-A, and tyrosinase are also melanoma markers, but notably do not stain spindle or desmoplastic melanomas. Remember that there is a whole family of tumors that are HMB-45-positive but not melanoma (angiomyolipoma and the perivascular epithelioid cell tumors). MitF is yet another melanocytic marker, and like SOX10, it stains melanocyte nuclei. There are, unfortunately, no stains that can differentiate a benign nevus from a malignant melanoma. However, in general, HMB-45 should only stain the most superficial cells in a nevus, as the deeper maturing component loses the antigen. Similarly, Ki67, a proliferation marker, should only be positive at the surface of a nevus, not deep.

Sentinel nodes for melanoma, if negative by H&E, are stained at most institutions by some combinations of the markers discussed above. There are inherent S100-positive cells in lymph nodes, so many avoid it for this purpose.

Nonmelanocytic Lesions

This section will address the lesions, both neoplastic and hyperplastic, which are not made of melanocytes. These include squamous lesions, cysts, adnexal tumors, and miscellaneous common soft tissue tumors of the dermis.

Sun Damage

The first major category of tumors is the spectrum of disease seen in sun-exposed skin, typically the face, neck, and arms of adults. A general marker of sun exposure is *solar elastosis*, which is an accumulation of gray wispy damaged elastin in the dermis (Figure 28.11). Ironically, it represents a loss of elasticity (wrinkles). One of the benign changes seen in the

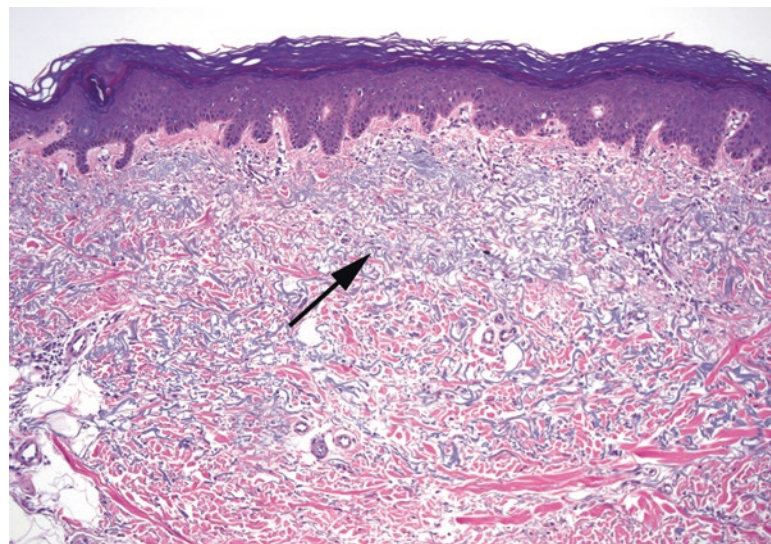


FIGURE 28.11. Solar elastosis. This is the typical microscopic appearance of sun-damaged skin. The collagen is replaced by wispy gray-blue strands of elastin (*arrow*).

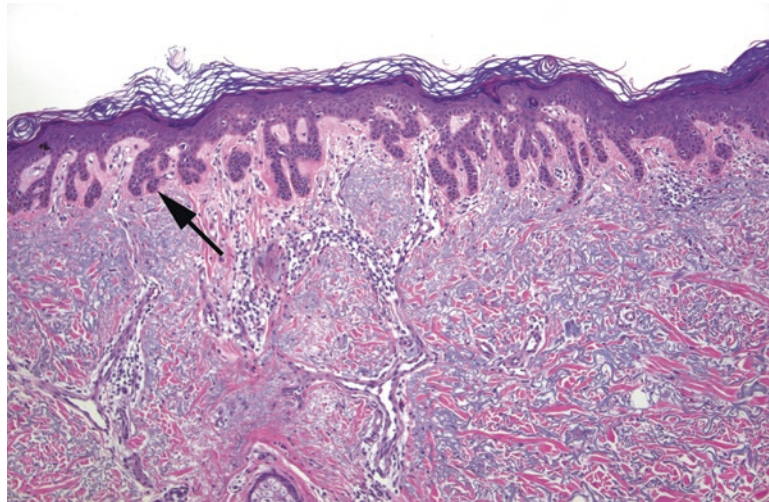


FIGURE 28.12. Solar lentigo. Prominent rete is growing down from the epidermis (*arrow*), with increased basal pigmentation (not clearly visible at this power). Notice the underlying solar elastosis. Compare this lesion to the lentigo simplex (see Figure 28.3), which, in contrast, shows a proliferation of melanocytes.

context of sun exposure is the *solar lentigo* (lentigo senilis, age spot), which appears as a fingerlike proliferation of hyperpigmented rete growing down from the epidermis (Figure 28.12). Keratinocytes, not melanocytes, are the pigmented cells.

The solar lentigo may then develop into a dysplastic lesion called an *actinic keratosis* (AK). Actinic keratoses have a wide variety of appearances, from very thin with subtle atypia to very hypertrophic with full-thickness atypia. However, the defining features of an AK should include the following:

- Squamous atypia of varying thickness, often noticeable only in comparison to the surrounding uninvolved epidermis (Figure 28.13)
- Alteration of the keratinization to become pink and parakeratotic
- Sparing of the keratin above the hair follicles, classically resulting in alternating columns of parakeratosis and orthokeratosis
- Underlying solar elastosis

AK is regarded, conceptually, as a form of carcinoma in situ, but its natural history is unpredictable. It can (rarely) invade before reaching full-thickness atypia, unlike squamous lesions of the cervix. However, when the atypia does reach full thickness (assuming no invasion), these lesions may be called *Bowenoid actinic keratosis* or just *squamous cell carcinoma in situ* to emphasize the severity of the lesion.

Carcinoma in situ is a simple concept in other organs, but in the skin, it is a source of great debate. Most dermatopathology chapters are littered with the phrase “we use the term...”—meaning each camp has their own philosophy and style. Part of the problem is that the path from dysplasia to invasive carcinoma looks more like a metro subway map than a straight line. However, the basic idea is that carcinoma in situ has not yet crossed the basement membrane and that there is some degree of epidermal dysplasia. Entities that fall under the category of carcinoma in situ include the following:

- AK (as discussed earlier) and Bowenoid AK
- Bowen’s disease—often used as a synonym for carcinoma in situ but actually describes a particular clinical presentation that occurs on non-sun-damaged skin and does not spare the hair follicles, unlike the actinic keratosis family
- Bowenoid papulosis—an HPV-related lesion of genital sites

Invasive squamous cell carcinoma is most likely to arise from the sun-damaged, AK-type pathway and hence is usually seen in the background of solar elastosis and AK-like changes.

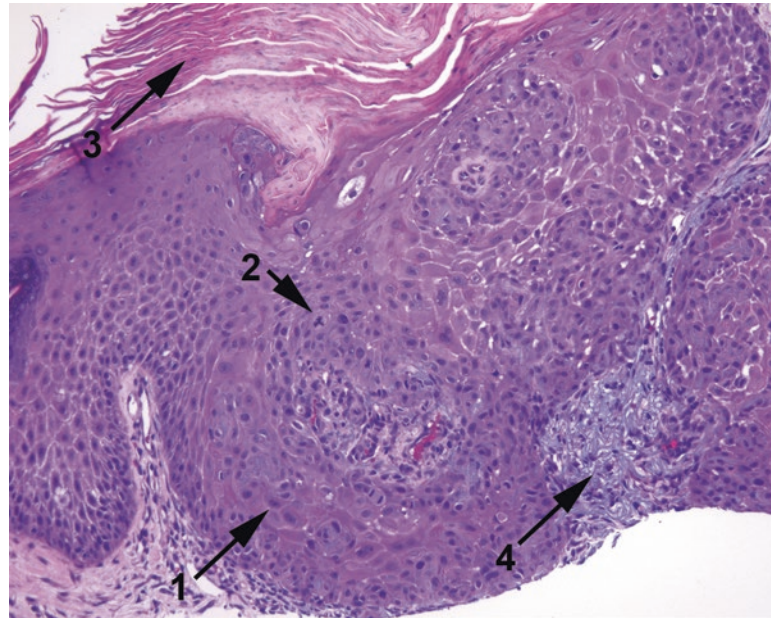


FIGURE 28.13. Actinic keratosis. This example shows an area of disorganized and enlarged nuclei (1) with prominent and atypical mitoses (2), consistent with dysplasia. There is overlying hyperkeratosis and parakeratosis (3) and underlying solar elastosis (4). This is a slightly tangential cut through the skin, making the lesion appear very thick.

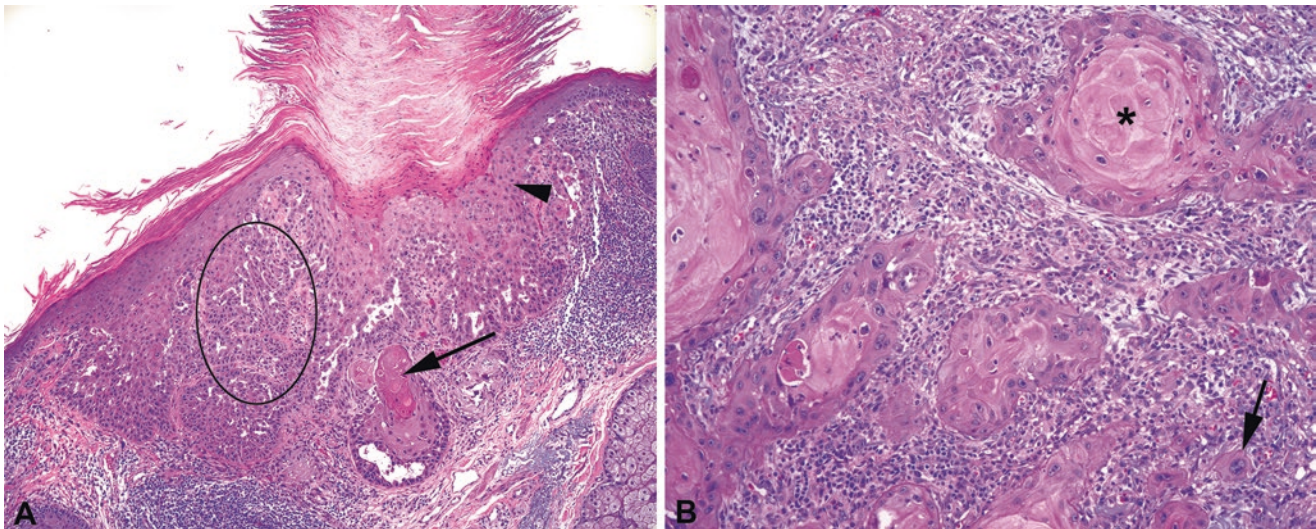


FIGURE 28.14. Squamous cell carcinoma. (a) Superficially invasive squamous cell carcinoma, showing the paradoxical deep keratinization (arrow), indicating an invasive nest. Actinic keratosis-type changes are seen in the overlying epidermis (arrowhead), including hyperkeratosis. In one area, the pattern of thin cords of cells infiltrating the stroma (oval) is too complex to be explained by a funny plane of section and is another pattern of invasion. (b) Higher-power view of invasive squamous cell carcinoma, showing keratin pearls (asterisk) and infiltrating single cells (arrow).

Features that suggest invasion include penetration of nests deep into the dermis, accompanied by an aberrant deep keratinization (pinking up). Finding single cells invading the dermis is fairly conclusive (Figure 28.14). The appearance of squamous cell carcinoma is similar to that found in other sites.

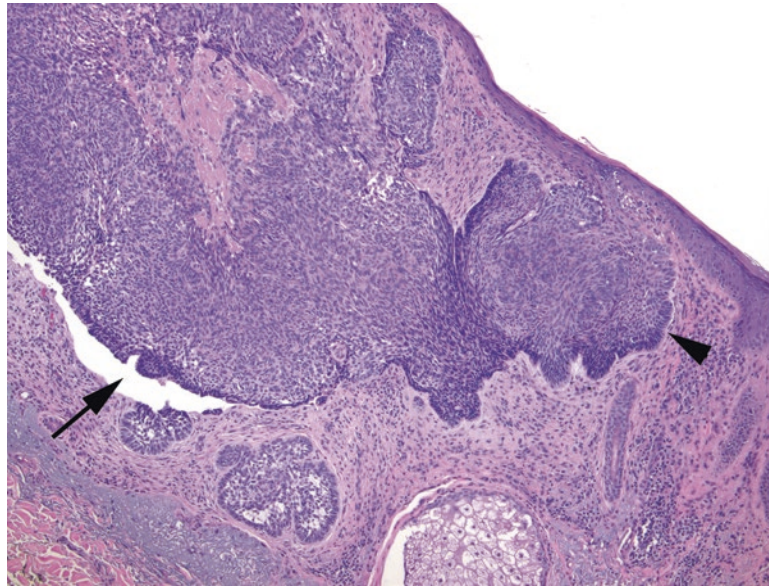


FIGURE 28.15. Basal cell carcinoma. Blue nests of cells appear to drop down from the epidermis. There is prominent palisading of the basal cells at the periphery of the nests (*arrowhead*) and clefting of the tumor cells away from the stroma (*arrow*).

Basal cell carcinoma is another of the common sun-related tumors. It is the most common cutaneous malignancy and, despite its reputation as a sort of ho-hum and uninteresting tumor, has a very wide range of appearances. There is also some overlap between basal cell carcinoma and benign adnexal tumors; the latter are probably often missed. Features of basal cell carcinoma include the following:

- Lobules of small, blue, basal-type keratinocytes with peripheral palisading (picket fence) arrays of oblong nuclei (Figure 28.15)
- Formation of clefts (cracks) between the tumor nests and the stroma
- Sometimes (not always) desmoplasia, focal keratinization, or mucin production

At low power, the basal cell carcinoma nests can look similar to adnexal structures, making margins challenging. However, basal cell carcinoma tumor cells should have darker chromatin, more apoptosis and mitoses, and paler cytoplasm than the hair follicles.

Special types of basal cell carcinoma include *nodular* (the usual type), *superficial*, and *sclerosing*. The superficial form tends to hang off the epidermis like stalactites, without forming a mass, and can have the appearance of skip areas. The sclerosing form shows a prominent desmoplastic response. There are up to 20 more subtypes; a large dermatopathology atlas will show the many faces of basal cell carcinoma. Many of the subtypes don't have clinical significance, but seem to exist largely to aid the pathologist in recognizing them as a basal cell carcinoma.

Other Hyperkeratotic but Non-neoplastic Lesions

Seborrheic keratoses are very common, benign lesions that have many, many forms, but the usual picture is a hyperkeratotic, orthokeratotic lesion with a markedly thickened epidermis. It often forms a raised plaque on the skin; on the slide, the epidermis looks as though it was accidentally cut en face, with convoluted, confluent cords of epidermis. Horn cysts, which are entrapped whorls of orthokeratin, are common (Figure 28.16). (These are quite different from the squamous pearls of carcinoma, which are pink and parakeratotic.) Pigment and inflammation may be seen; atypia is not. These are not necessarily associated with sun damage.

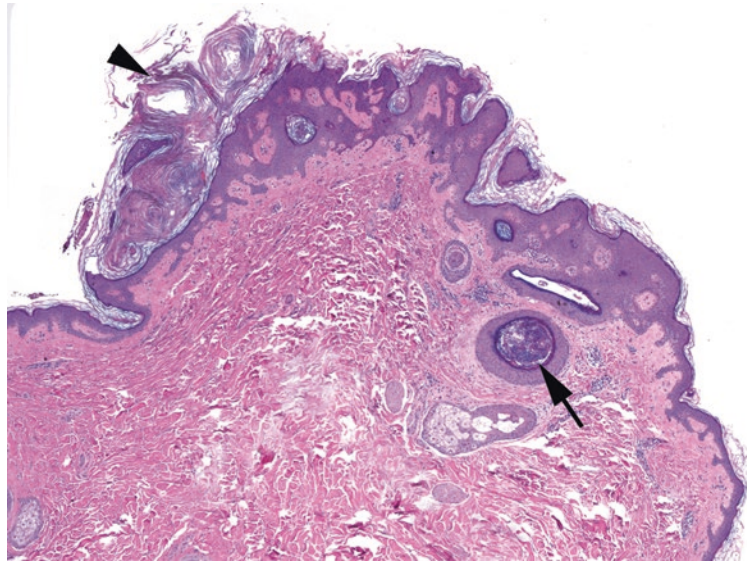


FIGURE 28.16. Seborrheic keratosis. This exophytic lesion shows hyperkeratosis (*arrowhead*) but not parakeratosis (no visible nuclei in the keratin). The epidermis takes on a complicated pattern of intertwining rete, and in some areas, foci of keratin are trapped within the lesion, forming horn cysts (*arrow*). Compare these blue, acellular, lamellated balls of keratin with the pink keratin pearls of squamous cell carcinoma (see Figure 28.14).

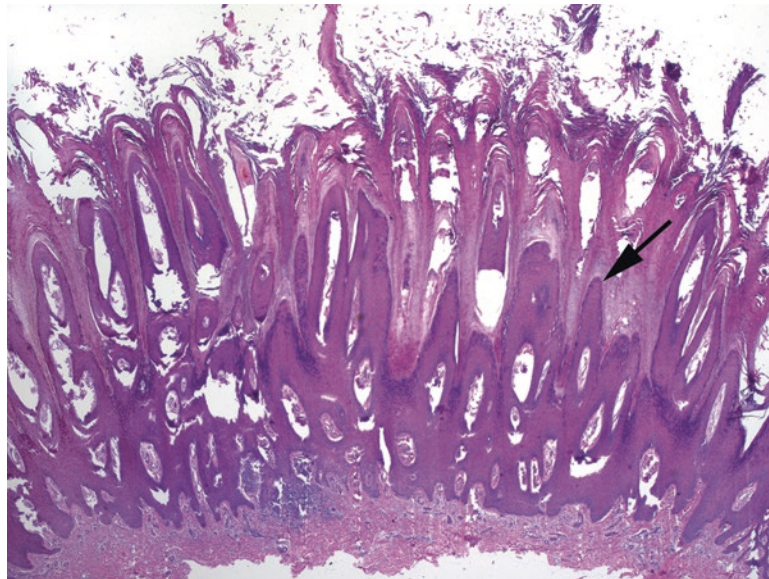


FIGURE 28.17. Verruca vulgaris. The epidermis in this wart is thrown up into sharply pointed spires, which are topped by hyperkeratosis and parakeratosis.

Verruca vulgaris (the common wart) is a virally induced circumscribed lesion, usually on the hands or feet, which shows a striking epidermal proliferation (“church spires”) with overlying hyperkeratosis (Figure 28.17). The tips of the spires are often topped by parakeratosis, which can lead to a striped effect. Koilocytes (review the description of this viral change in Chapter 16) may be hard to identify. Related lesions are the planar (flat) and plantar (endophytic) warts, as well as the condylomata (genital).

If you cannot quite tell if a lesion is a seborrheic keratosis or a wart, compromise and call it a verruciform keratosis. Verrucous carcinoma, a deceptively innocuous cancer, is not usually in the differential diagnosis for skin: it is mainly seen on mucosal and genital sites.

Adnexal Tumors

Adnexal tumors are a large, mystifying, shape-shifting group of lesions encompassing follicular, eccrine, apocrine, and sebaceous lesions. Some of the more readily identifiable tumors are listed here. Most of these are benign, although carcinomas do exist. Of the carcinomas, many are similar to those found in breast or salivary gland (similar embryologic origin), such as adenoid cystic carcinoma, mucoepidermoid carcinoma, and ductal adenocarcinomas.

The *eccrine poroma/acrospiroma/hidradenoma* groups are tumors of the sweat ducts and get different names depending on where in the dermis or epidermis they arise. They are composed of cells that look similar to keratinocytes but that try to form ducts (usually tiny lumens in a sheet of cells). The cells are streamy, pale, and disorganized, not unlike usual ductal hyperplasia in the breast (Figure 28.18).

Eccrine spiradenomas are “blue cannonballs in the dermis.” Tumor balls consist of two basaloid cell lineages (often hard to separate) and have noticeable cords and droplets of hyaline basement membrane substance running through them (Figure 28.19). A related lesion is the *cylindroma*. The *cylindroma* (“jigsaw puzzle”) also has basaloid (blue) nests in the dermis, also with two cell populations and basement membrane matrix. However, the tumor nests are mosaic in shape.

The *syringoma* is a collection of round, dilated tubules in the dermis with characteristic comma-like or tadpole tails (Figure 28.20). *Trichoepithelioma* is a benign tumor of hair follicle differentiation that looks a lot like a basal cell carcinoma except with horn cysts, hair formation, little abortive follicles, fibrotic stroma, and a lack of clefting. *Microcystic adnexal carcinoma* (sclerosing sweat duct carcinoma), although rare, is the malignant one you do not want to miss. It looks similar to syringoma, with tubules and cords of bland cells, and also has horn cysts (Figure 28.21). What differentiates it from syringoma is the deep infiltration of the dermis, so dermatopathologists like to see the base of an adnexal lesion.

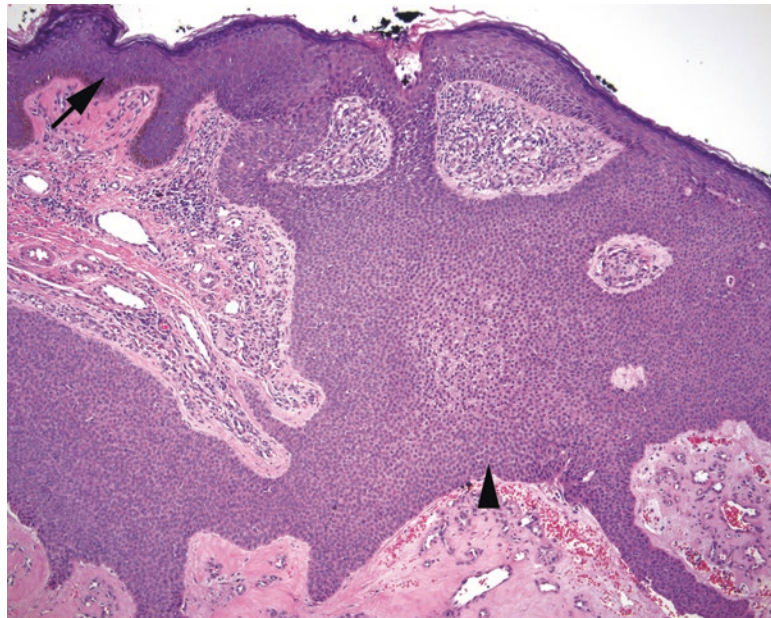


FIGURE 28.18. Poroma. This eccrine tumor is continuous with the epidermis, which can be seen at the left (*arrow*). The tumor cells (*arrowhead*) are uniform, small, round, and pale and in some areas may form rudimentary duct spaces.

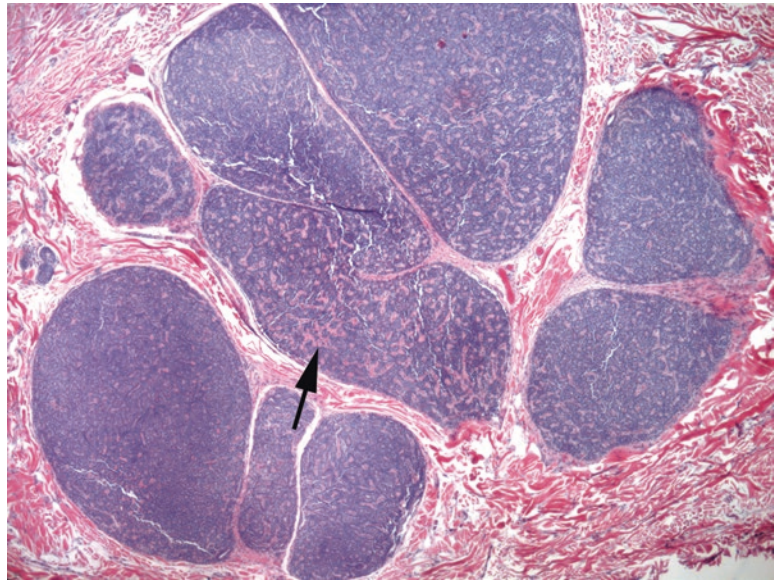


FIGURE 28.19. Eccrine spiradenoma. “Cannonballs in the dermis” is the catch phrase for this tumor. Like the poroma, the cells are small and bland. Cords of hyaline pink basement membrane material are seen throughout the tumor (*arrow*).

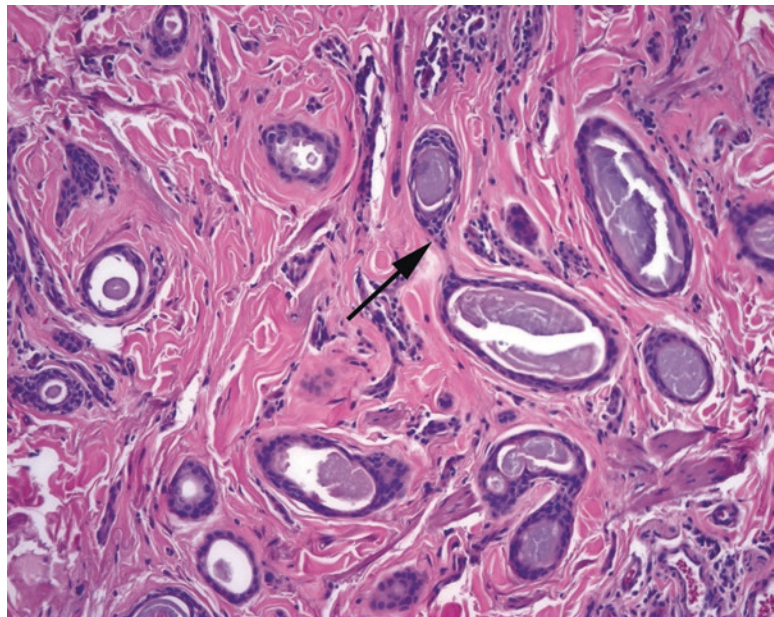


FIGURE 28.20. Syringoma. Small tubules with comma-like pointed tails within the dermis (*arrow*).

Merkel Cell Carcinoma

Merkel cell carcinoma is the primary neuroendocrine carcinoma of the skin, similar to small cell carcinoma. The nuclei are small and round, but larger than lymphocytes, with primitive, finely textured chromatin and a deep blue color due to the absence of cytoplasm (Figure 28.22). Merkel cell carcinoma has a unique dot-like staining pattern when stained with CK20, which can help to identify it.

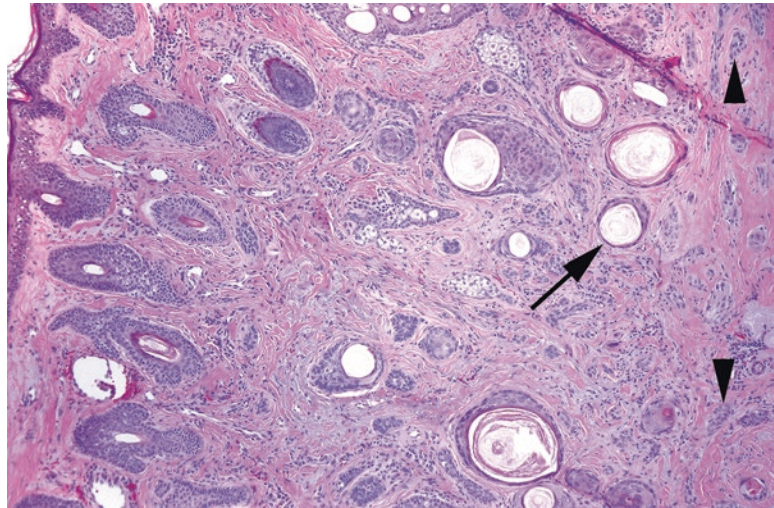


FIGURE 28.21. Microcystic adnexal carcinoma. A collection of small pale nests of cells can be seen in the dermis, some of them forming horn cysts (*arrow*). The feature that separates this from a benign lesion is the small nests that are infiltrating deeply into the base of the lesion at right (*arrowheads*). This small carcinoma has infiltrated into the subcutaneous fat (not seen here).

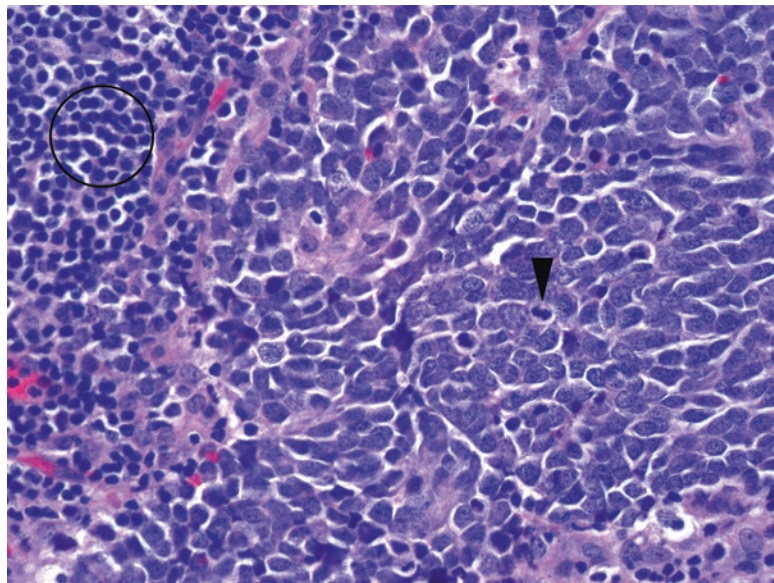


FIGURE 28.22. Merkel cell carcinoma in a lymph node. The tumor cells are on the right side of the field and show nuclei with primitive, fine-grained chromatin and virtually no cytoplasm. Mitotic figures are frequent (*arrowhead*). Compare the nuclei with the lymphocytes at the left (*circle*).

Cysts

The most common cysts you will see are the *epidermoid cyst* (often casually referred to as epidermal inclusion cyst by clinicians) and the *trichilemmal* or *pilar cyst* (Figure 28.23). The epidermoid cyst is lined by mature squamous epithelium with a granular layer and filled with layers of flaky keratin. The pilar cyst is lined by plump pillowy keratinocytes with no granular layer and is filled with dense compact keratin.

Dermal Tumors

The three most common benign soft tissue tumors of the dermis are the dermatofibroma, the neurofibroma, and the hemangioma. More information about soft tissue tumors can be found in Chapter 29.

Dermatofibromas appear as an ill-defined blue haze in the dermis. On higher power, the blue haze is made up of tiny swarming nondescript cells that infiltrate the collagen and tend to packet it into thick bundles (Figure 28.24). The overlying epidermis may be hyperpigmented and hypertrophic (hence its presentation as a brown nodule). *Dermatofibrosarcoma protuberans* (DFSP) is the malignant counterpart of this lesion and is more deeply infiltrative, wrapping around the subcutaneous fat in a characteristic pattern (Figure 28.25); most DFSPs are associated with a translocation.

Neurofibromas more often appear as a pale or gray nodule in the dermis, more defined than the dermatofibroma. It displaces the dermis rather than infiltrating it. The individual cells have wavy nuclei and wavy collagen, like overstretched elastic (Figure 28.26).

Hemangiomas are a proliferation of well-formed, dilated capillaries in the dermis (Figure 28.27). There are many variants. The malignant counterpart, angiosarcoma, is more cellular and has anastomosing channels lined by plump cells. Early Kaposi's sarcoma is so subtle it is basically invisible to the inexperienced and is not likely to simulate a hemangioma (Figure 28.28); nearly all of these will be positive for human herpes virus 8 (HHV8). Pyogenic granuloma, or lobular capillary hemangioma, is a common benign lesion that may be very cellular and inflamed but is identified as benign due to its rounded and circumscribed periphery (refer to Figure 5.18).

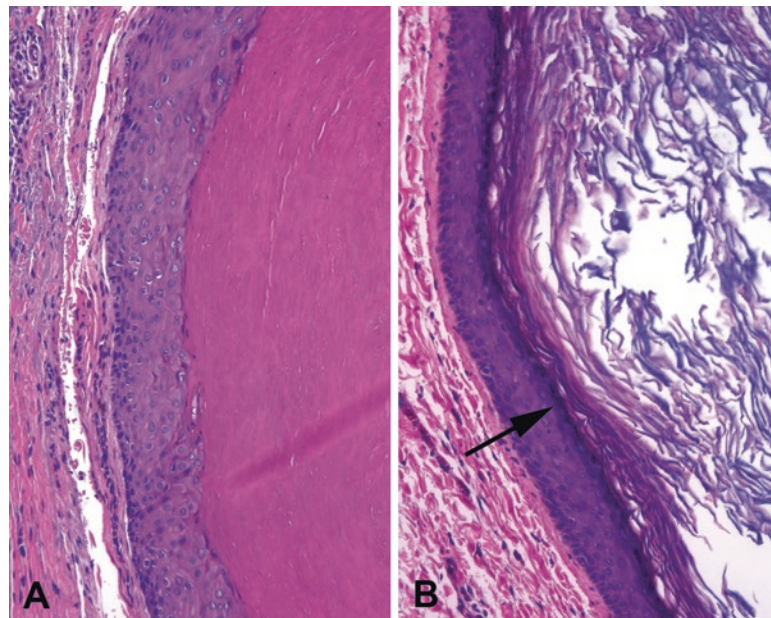


FIGURE 28.23. Cysts. (a) The trichilemmal cyst has no granular layer, with large pink puffy cells showing an abrupt transition to dense “wet” appearing keratin. (b) The epidermoid cyst more closely resembles epidermis, with a granular layer (*arrow*) and layers of “dry” flaky keratin.

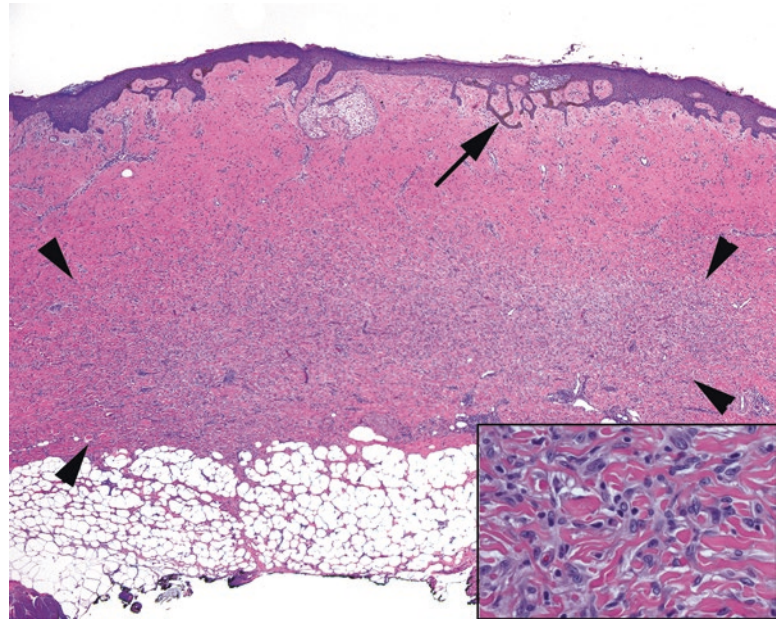


FIGURE 28.24. Dermatofibroma. This poorly circumscribed tumor creates a blue haze in the dermis (outlined by *arrowheads*), and the epidermal rete above it may become pigmented and prominent (*arrow*). The lesion mainly stops at the subcutaneous fat. *Inset:* the cells infiltrate between collagen bundles but have small pale round-to-oval nuclei.

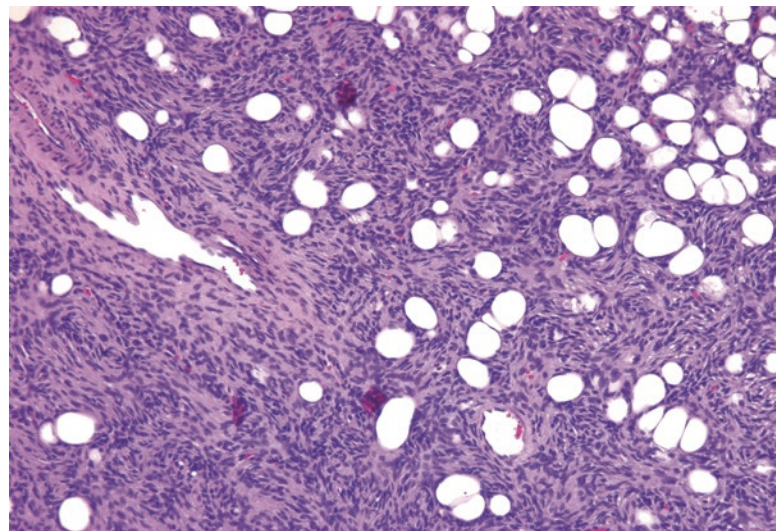


FIGURE 28.25. Dermatofibrosarcoma protuberans (DFSP). The DFSP is more cellular than the dermatofibroma and shows a prominent storiform pattern of spindled cells infiltrating between fat cells.

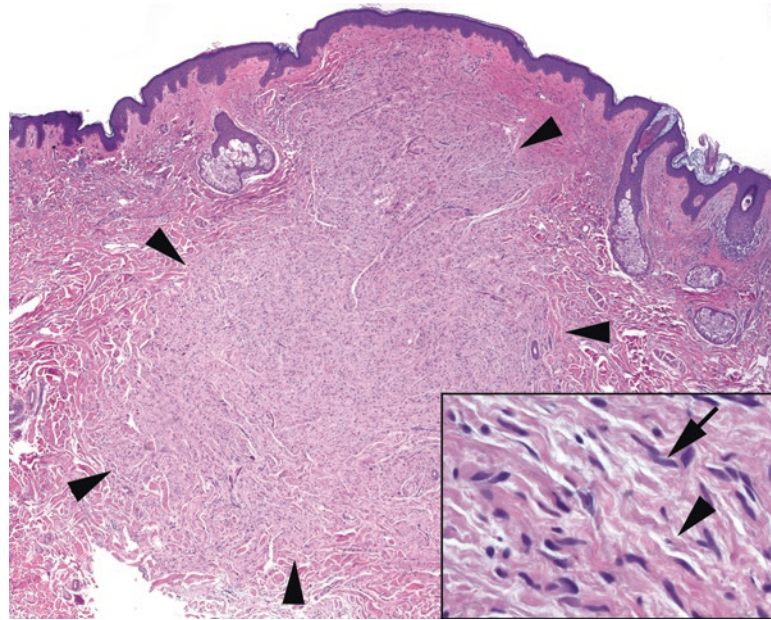


FIGURE 28.26. Neurofibroma. Like the dermatofibroma, this diffuse neurofibroma is a poorly defined dermal tumor (*arrowheads*), but unlike the dermatofibroma, it tends to appear more pale than the surrounding dermis. *Inset:* on higher power, the tapering, undulating nuclei (*arrow*) are visible, as is the background of wavy collagen fibers (*arrowhead*).

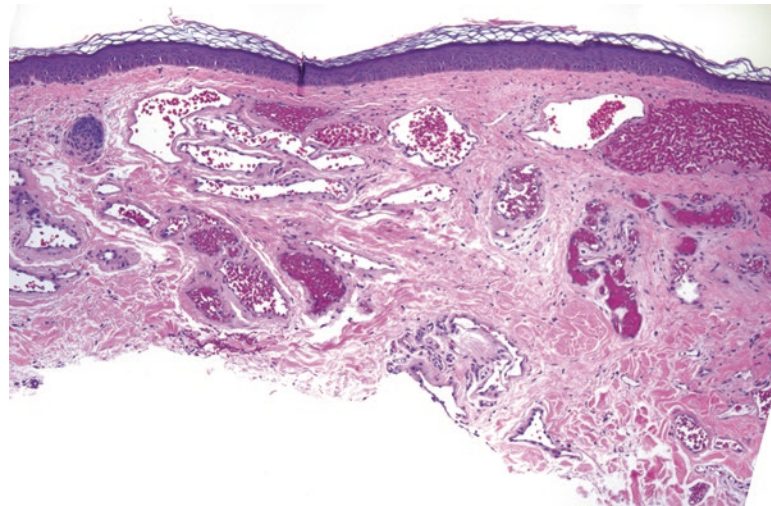


FIGURE 28.27. Capillary hemangioma. There is a collection of discrete, well-formed, dilated capillaries under the epidermis.

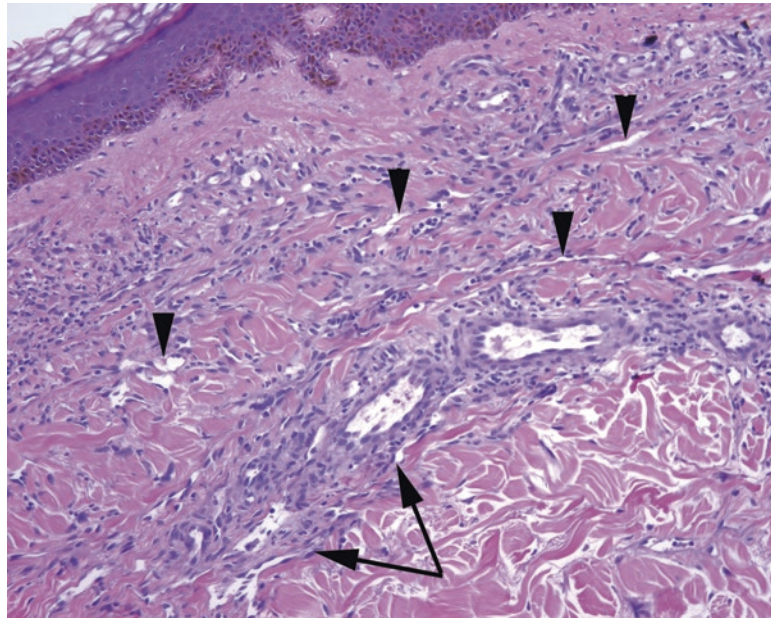


FIGURE 28.28. Kaposi's sarcoma. The subtle cellularity to the dermis is actually composed of slit-like vascular spaces with bland endothelium (*arrowheads*). The slit-like spaces are accentuated around existing capillaries (*arrows*), the "promontory sign".

A Brief Introduction to Non-neoplastic Skin: Patterns of Inflammation and Injury

This section is simply a primer on the terminology and classification of the inflammatory skin diseases; the details are beyond the scope of this chapter. These diagnoses are heavily influenced by the clinical presentation, so the goal here is to understand the histologic families of disease. The ultimate diagnosis of many inflammatory skin conditions is based largely on the clinical findings with the histologic findings providing only one piece to the puzzle.

Injury to the Epidermis

1. The epidermis can become acutely damaged or inflamed. The result is edema, or *spongiosis*. This is seen as an accentuation of the spaces between keratinocytes. Severe edema can cause intraepidermal vesicles to form (i.e., poison ivy), which have to be distinguished from other vesicular diseases (see later).

If this process continues for a while, the epidermis becomes less edematous and more hyperplastic as it responds to the chronic insult. The hyperplasia is in the form of thickening of the epidermis and elongation of the rete and is called *acanthosis*, usually accompanied by *hyperkeratosis* (a protective thickening of the keratin layer).

These changes make up the spectrum of *acute to chronic spongiotic dermatitis*, clinically eczema, and there is a large differential. Usually the pathologist signs the biopsy out descriptively, and the dermatologist combines that with the clinical features to diagnose it. *Psoriasis* fits in here, as it has histologic overlap with chronic spongiotic dermatitis, especially when partially treated.

2. Some inflammatory processes attack the basal layer of keratinocytes. This pattern is called *interface dermatitis*. Interface dermatitis has two predominant patterns that may overlap. One is an intense lymphocytic infiltrate at the DEJ, which is called *lichenoid* inflammation or dermatitis. The second is a vacuolar degeneration of the basal cells, or *vacuolar dermatitis*.

Both of these patterns result in a ragged DEJ, dyskeratotic or necrotic basal cells trapped in the epidermis (colloid bodies), and a cleavage plane along the DEJ if the damage is severe enough. This can be mistaken for a bullous disease, which is a different process.

The prototypical lichenoid dermatitis is *lichen planus*. Vacuolar dermatitis has a wider differential, including *acute graft-versus-host disease*, *lupus erythematosus*, and *erythema multiforme*.

3. A third pattern is the dissolution of the intercellular bridges that link the keratinocytes. The cells break apart and round up into individual cells, a process called *acantholysis*. This process is often antibody mediated, so immunofluorescence on fresh tissue is important. The acantholysis can coalesce into large spaces within the epidermis, or *bullae*. Different diseases cleave the skin within different planes of the epidermis.

This group includes the inflammatory bullous diseases, such as *pemphigus vulgaris*, *bullous pemphigoid*, and *dermatitis herpetiformis*. A noninflammatory bullous disease is *porphyria cutanea tarda*. There is also familial acantholytic disease (*Hailey–Hailey* and *Darier diseases*), transient acantholytic disease (*Grover’s disease*), and focal acantholytic lesions (*warty dyskeratoma*).

Inflammation of the Dermis

The patterns of injury discussed in this section are limited to the dermis, usually with a fairly unremarkable epidermis. Many diseases begin with a nonspecific pattern of *perivascular lymphocytic inflammation* in the dermis. It is the first sign that the skin is upset. Some diseases never declare themselves beyond this stage, such as *polymorphous light eruption* and *urticaria*. If the inflammation progresses to involve neutrophils and actual damage to the vessels, the disease is called a *vasculitis*. *Leukocytoclastic vasculitis*, in which the vessels show fibrinoid necrosis and nuclear debris (karyorrhexis), has a wide clinical differential diagnosis.

Inflammatory infiltrates of the dermis are classified based on the type of infiltrate. A dense neutrophilic infiltrate is a *neutrophilic dermatosis*, such as *Sweet’s syndrome*. Granulomatous inflammation may indicate infection, foreign body response, sarcoidosis, or *granuloma annulare*. *Mycosis fungoides* and other cutaneous lymphomas can have numerous appearances, so a dense lymphocytic infiltrate should trigger a workup for lymphoma.

Some diseases involve alteration of the collagen of the dermis. These include scar, keloid, *scleroderma* or *morphea*, and *lichen sclerosus*. *Chronic graft-versus-host disease* can look like scleroderma as well.

Inflammation of the Deep Subcutaneous Tissue (Panniculitis)

Panniculitis is divided into septal, where the inflammation is mostly in the fibrous septae between fat lobules, and lobular, where the fat itself is involved. The classic septal panniculitis is *erythema nodosum*. *Lupus profundus*, or deep lupus, is a lobular panniculitis.

Tumors of soft tissue are among the most challenging in surgical pathology. There are several reasons for this: they are rare, so you see few in training; they are overlapping in morphology; they do not always obey the principles that help you to identify malignant potential in carcinomas; and each entity has at least three names, four variants, and seven mimickers. However, this chapter covers some of the names you will hear most commonly. The tumors are broken down into lines of differentiation, with the caveats that there are some tumors that do not differentiate along any known lineage (grouped separately) and that many soft tissue tumors dedifferentiate into the same final common malignant pathway, undifferentiated pleomorphic sarcoma (the entity formerly known as *malignant fibrous histiocytoma* or MFH). The good news is, once it is that high grade, the origin becomes sort of academic.

One overarching principle is that there are roughly three categories of sarcomas. The first is the well-differentiated or low-grade sarcoma, which closely resembles its tissue of origin and is sometimes difficult to identify as malignant. The second large category is the high-grade sarcoma with an unstable karyotype, of which *undifferentiated pleomorphic sarcoma* (UPS) is the textbook example (Figure 29.1). The unstable karyotype leads to a marked nuclear irregularity and pleomorphism that is readily identifiable as malignant. These are usually tumors of older adults or postradiation. The third category is the translocation sarcoma, of which most are high grade. These tumors, usually found in children to young adults, are not histologically linked to any particular normal tissue, as they represent a uniquely transformed stem cell (presumably). In addition, because they actually have a homogeneous genome, they tend to have *monomorphic* nuclei which are quite distinct from the *pleomorphic* sarcomas.

Another general principle is that sarcomas are often very well circumscribed (angiosarcoma being an exception). They tend to grow in an expansile and pushing fashion, sometimes with a surrounding pseudocapsule. Therefore, you cannot rely on infiltrative growth at the periphery to identify malignancy.

A third principle is that mitotic figures are sometimes relevant and sometimes not. Nodular fasciitis, for example, a benign neoplasm, can have a rip-roaring mitotic rate. In a soft tissue leiomyoma, however, you really don't want to see any mitoses at all. Therefore, a high mitotic rate, in isolation, is not significant until you have identified the tumor and know the tolerance for mitoses in that tumor.

When diagnosing a soft tissue lesion, especially in its initial presentation, you must always walk yourself through the mental game of "what else could this be?" It is a good habit for any organ system but especially in the field of sarcomas and spindle-cell lesions. For lesions that are cellular and spindled, you must always consider a sarcoma mimicker, such as nodular fasciitis. For lesions with bizarre and huge nuclei, despite the malignant look, you must rule out benign entities with degenerative atypia, such as ancient schwannoma or pleomorphic

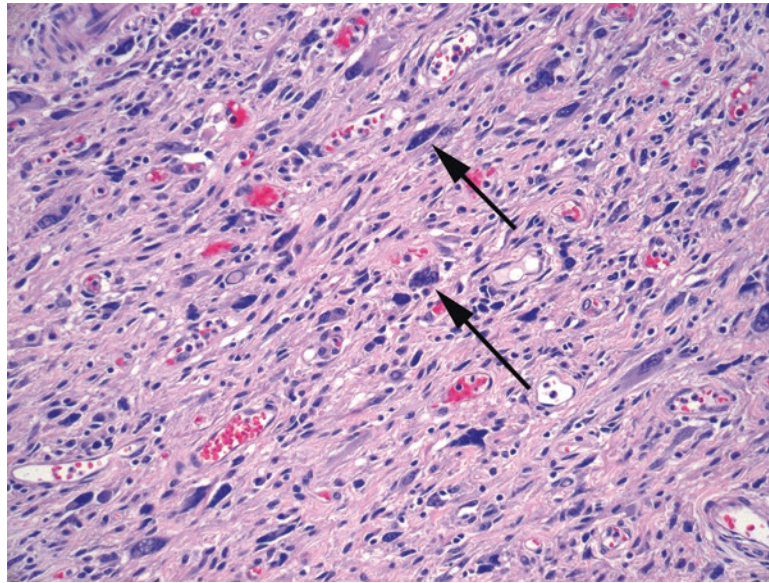


FIGURE 29.1. Undifferentiated pleomorphic sarcoma (UPS). There are scattered large dark nuclei with bizarre shapes (such as those at *arrows*) in a background of hyperchromatic spindle cells and a fibrous pink stroma. The most striking feature of the UPS is the nuclear pleomorphism. The nuclei lack nucleoli or distinct nuclear membranes, however.

TABLE 29.1. Characteristics of tumor families.

Lipomatous (“lipo”)	Fat cells intermixed with other elements; fat cells are identified by their crescent-shaped nuclei hugging large clear vacuoles
Fibrous (“fibro”)	Fibroblasts and myofibroblasts are typically fusiform or stellate cells with pale nuclei in a collagenous (pink) matrix
Smooth muscle (“leiomyo”)	Smooth muscle cells are elongated cells that run in parallel bundles, intersecting at right angles. The nuclei may be cigar or corkscrew shaped and often have paranuclear vacuoles
Skeletal muscle (“rhabdomyo”)	Skeletal muscle may show either rhabdoid cells, which are plump round cells with eccentric nuclei and pink cytoplasm, or strap cells, like individual elongated myocytes with cytoplasmic cross-striations
Nerve sheath (neurofibroma, schwannoma)	Nerve sheath tumors may show delicate spindle cells with wavy nuclei in a myxoid background with thin curly tendrils of collagen, as in a neurofibroma. They may also show the dense nuclear palisading and fibrillar background of a schwannoma
Vascular (“hemangio,” “angio”)	Vascular tumors are characterized by a network of irregular vascular spaces, often with admixed blood. Malignant endothelial cells tend to protrude into the lumens with a hobnail appearance

lipoma. For lesions in or near an organ, such as in visceral sites, you must always ask if it could be a carcinoma masquerading as a sarcoma. For spindle-cell lesions anywhere, you must prove it is not melanoma. Some of these questions require immunostains to answer, some just a skeptical eye.

The second question to ask, once you have ordered the cytokeratins and melanoma markers, is “what family of soft tissue does it belong to?” Table 29.1 lists some stereotypical features of different tumor families, seen best in low-grade (well-differentiated) lesions. If there is a well-differentiated tumor component adjacent to a high-grade sarcoma, the high-grade component is often referred to as *dedifferentiated*. The well-differentiated areas may not be obviously tumor, so you need to ensure the tumor is well sampled and search for the well-differentiated areas at the periphery.

High-Grade Sarcomas

Once sarcomas become high grade, they may take on any number of appearances, regardless of line of differentiation. Some classic visual patterns are described in Table 29.2. The herringbone pattern is classically ascribed to fibrosarcoma, but in truth, fibrosarcoma is exceedingly rare, and most things that look like fibrosarcoma are not. A similar pattern is the leiomyosarcomatous pattern, which also has long bundles of tumor cells. A high-grade tumor with a myxoid stroma is usually a myxofibrosarcoma (once called “myxoid MFH”). A tumor with large pink cells with eccentric nuclei may be called rhabdoid (when used as an adjective, this means resembling a rhabdomyosarcoma), and in fact sarcomas of all types may develop foci of true rhabdomyosarcoma. If, however, the sarcoma has none of these patterns, and no differentiation can be identified through immunostains, history, or the low-grade remnants of another tumor found at the periphery, the diagnosis of exclusion is an undifferentiated pleomorphic sarcoma (UPS).

A reliable clue to a high-grade sarcoma is the presence of malignant nuclei. A pleomorphic sarcoma nucleus has some reproducible features across many tumor types. The nucleus has an irregularly shaped border and has dark, dense, granular chromatin that is fairly evenly distributed throughout the nucleus (Figure 29.2). Unlike carcinoma nuclei, prominent nucleoli and nuclear membranes are *not* a usual feature. Learning to recognize this sort of atypia is critical in identifying some of the sarcomas.

Fibrosarcomatous	A hypercellular, fascicular tumor with a “herringbone” pattern (see Chapter 2). Atypia may not be significant. May be seen in fibrosarcoma, malignant peripheral nerve sheath tumor, synovial sarcoma, and others
Leiomyosarcomatous	A fascicular tumor with bundles of cells intersecting at right angles, a high mitotic rate, and significant cytologic atypia, although not as pleomorphic as the UPS. Non-smooth muscle tumors may occasionally show this pattern
Myxofibrosarcomatous	A tumor with a myxoid or edematous background containing highly pleomorphic cells, frequent mitoses, and characteristic arcing vessels
Rhabdoid	A tumor with large eosinophilic cells with eccentric nuclei. May occur as a component of other high-grade sarcomas
Undifferentiated pleomorphic sarcoma (UPS)	A cellular tumor with bizarre nuclear atypia, including giant cells and highly pleomorphic and hyperchromatic nuclei. Very mitotically active, often with necrosis. A common tumor that is occasionally still referred to as “MFH”

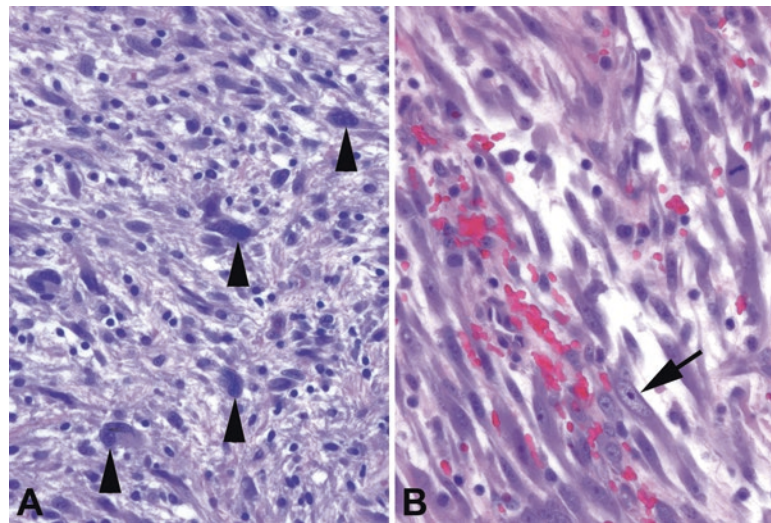


FIGURE 29.2. The sarcoma cell vs. the benign cell. (a) Malignant cells in a UPS or other high-grade sarcoma show large nuclei with irregular shapes and very dark chromatin with a coarse texture (*arrowheads*). It is as though (in fact, it is likely) the nucleus has way too many chromosomes, and the nucleus is swollen and dark with the extra chromatin (truly hyperchromatic). Nucleoli are not usually prominent. (b) Tumor cells in nodular fasciitis have large nuclei and prominent nucleoli that stand out against a pale nucleus (*arrow*). The nuclear membrane is smooth and oval.

Tumors of Fat

Throughout this chapter, you will find tables listing some of the more common entities, grouped by clinical behavior. Table 29.3 lists some of the common tumors of fat. There are no specific immunostains for fatty tumors, although MDM2 is a marker that is often expressed in well-differentiated liposarcomas (and negative in lipomas).

The most common soft tissue tumor is the *lipoma*. A lipoma is defined as a neoplasm of mature fat. It is histologically indistinguishable from ordinary fat; to tell the difference, you must know it appeared clinically as a discrete lobular mass. There are many histologic variants of lipoma, classified based on what additional soft tissue component is present, such as *angiolipoma*, *myolipoma*, *myelolipoma*, etc. A *hibernoma* is a lipoma of brown fat, in which the fat cells are full of innumerable tiny vacuoles. The *lipoblastoma*, despite the alarming name, is a benign pediatric tumor of mature fat and benign lipoblasts.

There is a lot of fuss about *lipoblasts*. They are immature fat cells in which the nucleus is star shaped or scalloped, due to being indented on multiple sides by small bubbles of fat (Figure 29.3). They are often associated with liposarcomas, but they can also appear in the benign lipoblastoma, and they are not necessary for a diagnosis of liposarcoma. Note that normal adipocytes are not mitotically active cells, so mitoses are generally seen only in high-grade liposarcomas.

TABLE 29.3. Common neoplasms of fat.

Benign	Malignant but indolent	Malignant and aggressive
Lipoma, including	Well-differentiated liposarcoma/ atypical lipomatous tumor	Dedifferentiated liposarcoma
Angiolipoma	Myxoid liposarcoma	Myxoid liposarcoma with round cell morphology
Myolipoma		Pleomorphic liposarcoma (no relation to pleomorphic lipoma)
Hibernoma		
Lipoblastoma (children)		
Myelolipoma		
Spindle-cell/pleomorphic lipoma		

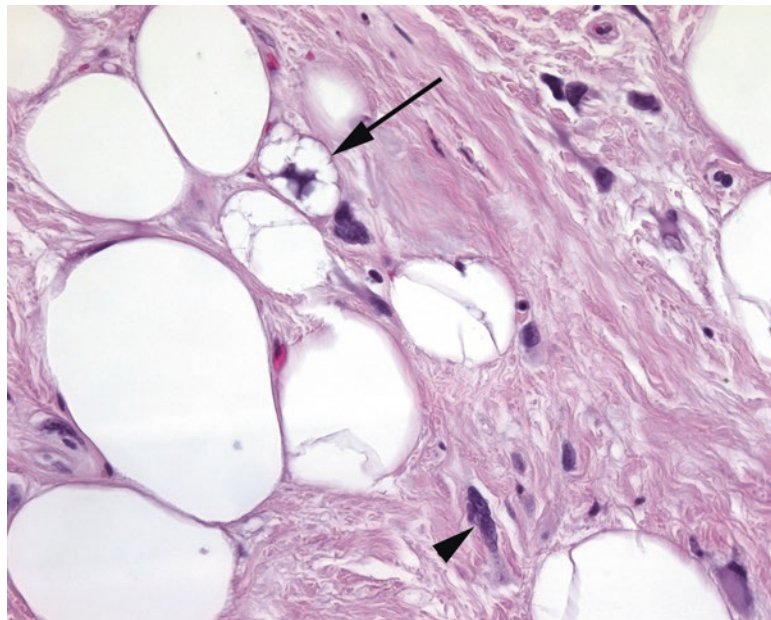


FIGURE 29.3. Lipoblast. Small fat vacuoles indent the nucleus of this lipoblast (*arrow*), seen in a well-differentiated liposarcoma. Other cells within the fibrous septa (*arrowhead*) have the look of sarcoma cells, with irregular, large, dark nuclei.

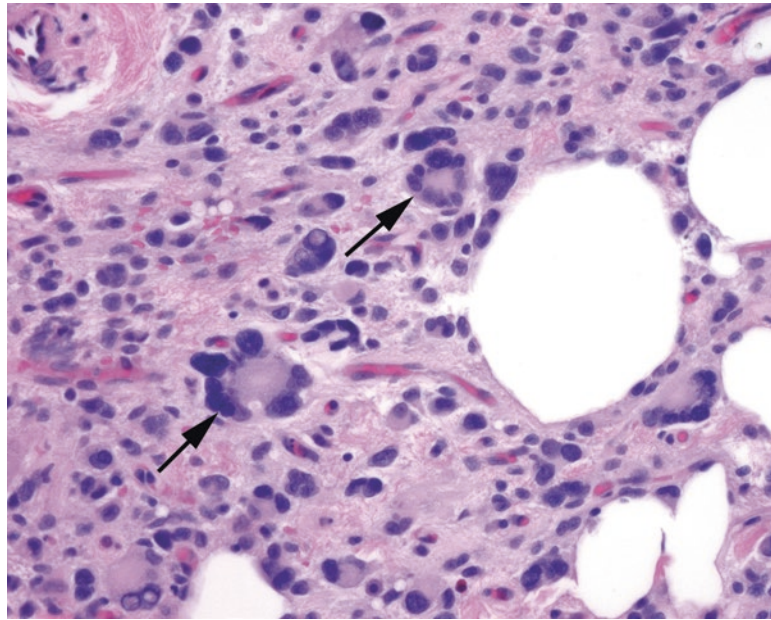


FIGURE 29.4. Pleomorphic lipoma. This type of benign lipoma is known for having very bizarre stromal cells that mimic sarcoma. The classic cell is the floret cell, with a circular wreath of nuclear lobes (arrows). Their presence suggests the diagnosis of pleomorphic lipoma.

One type of lipoma is notable for unusual cytologic features. *Spindle-cell/pleomorphic lipoma* is usually found on the back or neck of elderly men and may be fibrous and nonfatty on low power. Pleomorphic lipoma and spindle-cell lipoma represent two ends of a morphologic spectrum. Spindle-cell lipoma has areas of nondescript spindle cells and collagen and may remind you of a nerve sheath tumor if there is not much fat in the lesion. Pleomorphic lipoma is similar but with the addition of giant cells and floret cells (hyperchromatic wreath-shaped nuclei). These giant cells (Figure 29.4) are an example of a benign lesion simulating malignant atypia; clinical information is helpful in not mistaking these for liposarcomas.

Well-differentiated liposarcoma (WDLS) is a tumor of adults. It looks similar to a lipoma on low power except for an increase in fibrous “interstitium” between fat cells and fibrous bands (Figure 29.5). A close examination of the fibrous areas reveals hyperchromatic, irregularly shaped nuclei; these are usually large and dark enough to be visible at 4 \times . Finding a lipoblast is a bonus. A softer feature is an assortment of differently sized fat cells, unlike the monomorphic benign lipoma, but this feature can be unreliable as it is seen in benign entities as well. WDLS is so named when it occurs in a nonresectable location, such as the retroperitoneum. By definition, when it occurs on an extremity, it is called an *atypical lipomatous tumor* (ALT), as the prognosis in these sites is excellent with simple resection.

When WDLS has been around for a while, especially in a recurrent or occult retroperitoneal lesion, there is a risk of the tumor transforming into a high-grade pleomorphic sarcoma. When this happens, you will see a tumor with WDLS areas and an abrupt transition to a high-grade tumor (storiform, spindled, pleomorphic, or even rhabdoid or leiomyosarcomatous). Regardless of morphology, this is called a *dedifferentiated liposarcoma*, and the key to diagnosis is recognizing adjacent WDLS. Because a retroperitoneal sarcoma is a dedifferentiated liposarcoma until proven otherwise, if you are grossing such a tumor, be sure to sample anything near the tumor that looks like normal fat: it may be the well-differentiated component.

Myxoid liposarcoma is unrelated to the WDLS; it is actually a translocation tumor. It is not clearly fatty on gross examination, but may have a myxoid or gelatinous cut surface. The low-power impression is that of a gelatinous tumor with scattered fat cells and a stereotypical capillary network that has been compared to chicken wire (Figure 29.6). These vessels are very delicate, and, unlike normal capillaries, they have little substance to their walls; they

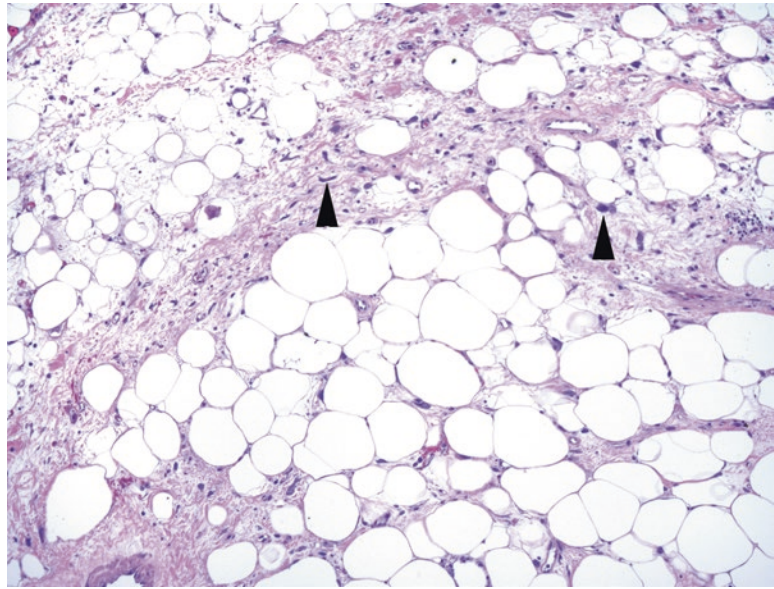


FIGURE 29.5. Well-differentiated liposarcoma. There is an increased amount of fibrous interstitium between fat cells, and atypical cells stand out at low power (*arrowheads*).

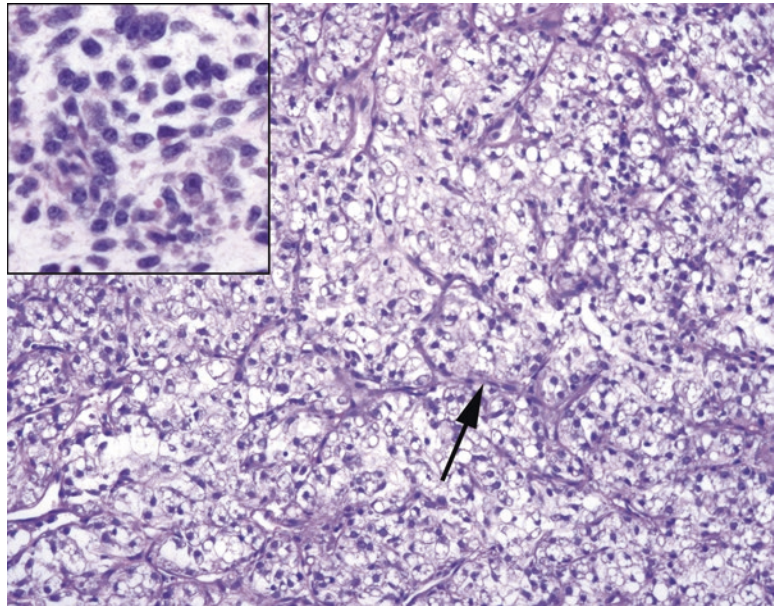


FIGURE 29.6. Myxoid liposarcoma. The fatty component may be very subtle in myxoid liposarcoma; the vessels are more often the tip-off. The vasculature is composed of a delicate network of very thin capillaries with three- and four-way branch points, similar to chicken wire (*arrow*). The cell population is composed of small cells, which may have fat vacuoles in them, and a myxoid background. Large atypical cells should not be present. *Inset*: areas of closely packed small cells are indicative of round cell differentiation.

appear as a naked sleeve of endothelium stretched through the tumor. The vessels are arborizing or branching and often take on Y-shapes. The tumor cells themselves are small regular rounded cells and single-vacuole lipoblasts, without the large atypical cells of WDLS. (This, remember, is in keeping with the translocation tumors.) Correct identification of myxoid liposarcoma on biopsy is essential, as it can be treated presurgically with radiation.

Myxoid liposarcoma can also transform into a higher-grade lesion. When the small uniform cells become very densely packed and obscure the vascular pattern, it is indicative of *round cell morphology*, a poor prognostic sign. Remember to always give the estimated round cell component when signing out this type of tumor.

The rare *pleomorphic liposarcoma* describes a high-grade tumor with extremely bizarre pleomorphic lipoblasts. It does not arise from WDLS or from a pleomorphic lipoma; conceptually you may think of it as a high-grade sarcoma that happens to have lipoblastic differentiation.

Fibrous Tumors and Myxoid Tumors

The fibroblast and the myofibroblast are ubiquitous cells in charge of the reparative changes that take place in every part of the body. In resting state, they are fusiform-to-stellate cells with oblong pale nuclei, and they lay down a collagen matrix. Their job is to proliferate, and therefore mitotic activity is not unusual in fibroblastic tumors. Although myofibroblasts may stain for actin (and are occasionally mistaken for smooth muscle), in general immunostains are not helpful in this tumor family (Table 29.4).

Nodular fasciitis, once thought to be a reactive lesion (hence the -itis), is now recognized as a clonal (translocation-associated) neoplasm. It is classically a rapidly growing lesion, sometimes associated with known trauma, sometimes not. On low power, it is a somewhat circumscribed but unencapsulated lesion with a hypercellular periphery. On high power the fibroblasts show a “tissue culture” appearance (fusiform-to-stellate with distinct cytoplasmic processes), and they float in a myxoid background with surrounding red blood cells and lymphocytes (Figure 29.7). Older lesions may become more dense, collagenized, and pink and may resemble a fibromatosis with chronic inflammation. There should be no nuclear atypia, but you will see mitotic activity. The biggest pitfall in nodular fasciitis is misinterpreting the patchy high cellularity and mitotic activity for a sarcoma. The clinical history is helpful, as is recognizing that the nuclear features are not that of a sarcoma (something that takes practice).

Proliferative fasciitis is a subcutaneous reactive fibroblastic proliferation that resembles nodular fasciitis but with the addition of large pink ganglion-like cells (Figure 29.8). *Proliferative myositis* is the same lesion but in an intramuscular location. *Myositis ossificans* is a variant of proliferative myositis that shows reactive bone formation. The bone formation shows a distinctive zonation with the peripheral bone being more mature and mineralized than the central bone, which is visible on x-ray.

Inflammatory myofibroblastic tumor has gone by many names (inflammatory pseudotumor, inflammatory fibrosarcoma, plasma cell granuloma, others), but in this chapter, it will be shortened to IMT. Like nodular fasciitis, it was long considered a reactive lesion, but is now regarded as a neoplasm. It is a neoplasm mainly of young people, often arising in the abdominal cavity, consisting of a proliferation of plump fibroblasts with abundant associated inflammation, especially plasma cells. IMT is very similar in appearance to nodular fasciitis in that there are tissue culture-like fibroblasts in a myxoid, granulation tissue-like background

TABLE 29.4. Fibrous and myxoid neoplasms.

Benign	Malignant but indolent	Malignant and aggressive
Fibromatosis	Low-grade fibromyxoid sarcoma	Fibrosarcoma (rare)
Palmar/plantar (superficial)	Malignant solitary fibrous tumor	Myxofibrosarcoma, high grade
Desmoid tumor (deep)	Myxofibrosarcoma, low grade	
Solitary fibrous tumor		
Intramuscular myxoma		
Nodular fasciitis and inflammatory myofibroblastic tumor		

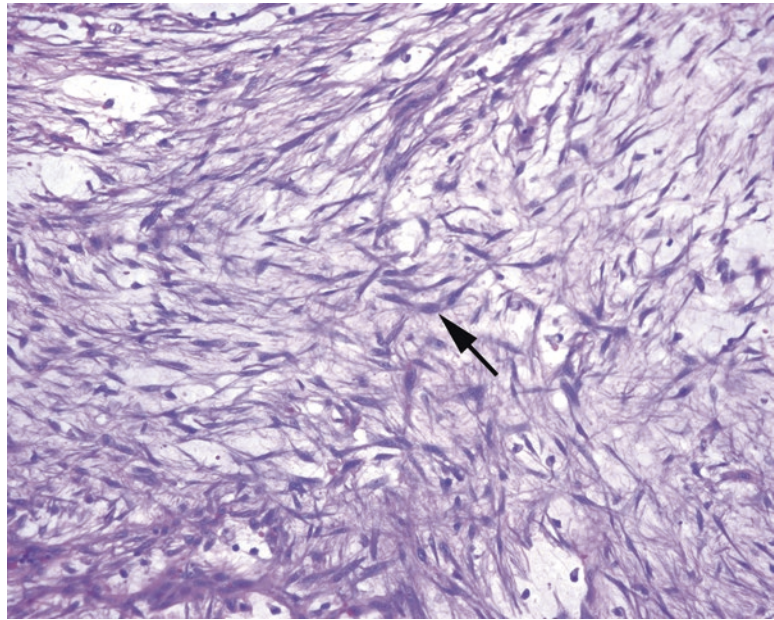


FIGURE 29.7. Nodular fasciitis. In this field the inflammatory component is not prominent, but the “tissue culture” pattern is seen clearly, with fusiform and stellate fibroblasts stretching delicate processes through the myxoid background (*arrow*).

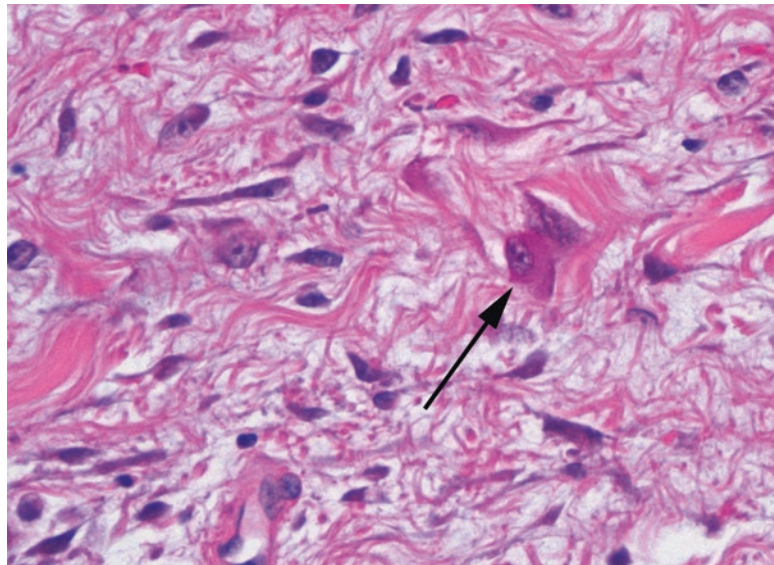


FIGURE 29.8. Ganglion-like cells in proliferative fasciitis. Ganglion-like cells, which have abundant cytoplasm, large nuclei, and large nucleoli (*arrow*), resembling neural ganglion cells, are seen in proliferative fasciitis and myositis and are a clue to the reactive nature of the tumor.

(Figure 29.9). It differs by its visceral location and prominence of plasma cells (not seen in nodular fasciitis). The hypercellularity may be very worrisome for a high-grade sarcoma. However, while the nuclei may be enlarged, with prominent nuclear membranes or large nucleoli, you should not see the irregularly shaped hyperchromatic nuclei of pleomorphic sarcomas. Many cases show immunoreactivity for ALK.

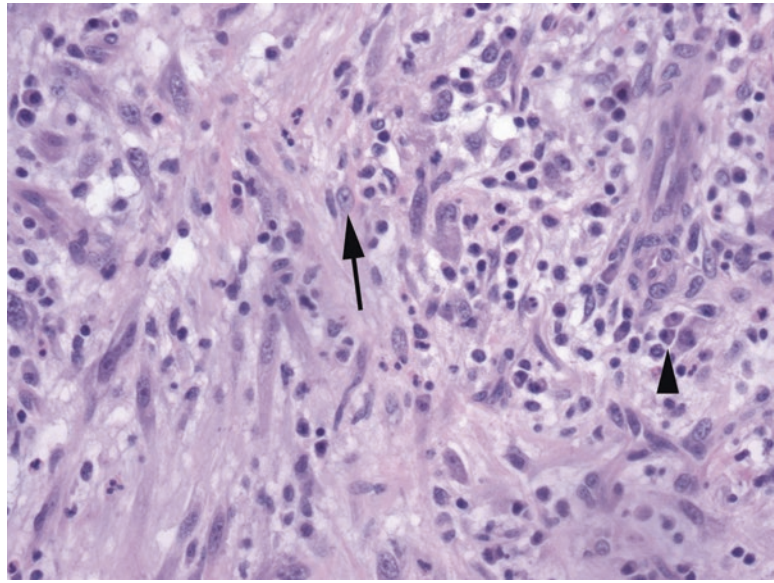


FIGURE 29.9. Inflammatory myofibroblastic tumor. The tumor is composed of a network of reactive-looking fibroblasts (*arrow*), capillaries, and inflammation, especially plasma cells (*arrowhead*).

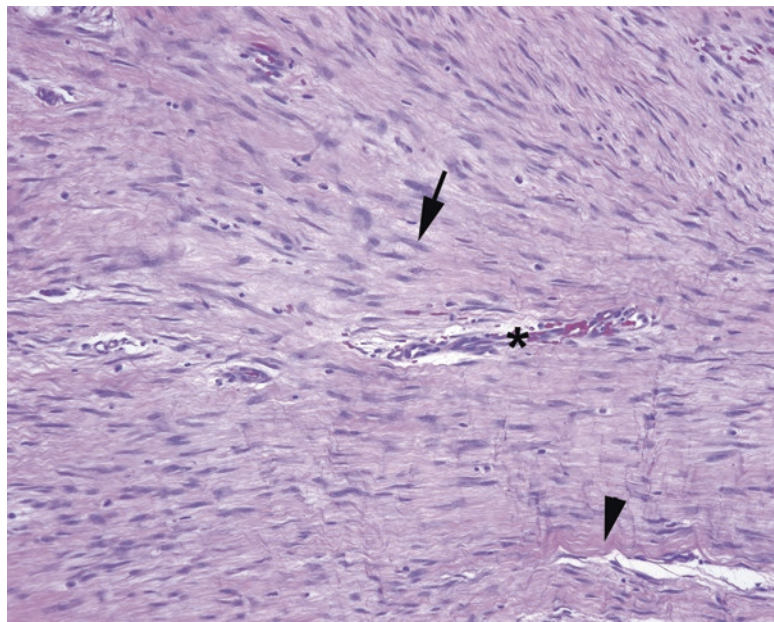


FIGURE 29.10. Fibromatosis. The cells in this lesion are pale and indistinct, with small wavy nuclei (*arrow*) noticeably hypochromatic relative to the endothelial cells of the nearby capillary (a good internal control; *asterisk*). There is abundant collagen in the stroma (*arrowhead*). At low power the stroma is slightly more grayish purple than the surrounding normal tissue.

The most subtle fibroblastic lesion is *fibromatosis*. This is a bland and indistinct benign tumor composed of normal-looking fibroblasts: fascicles of pink cells with pale tapering nuclei in a collagenous background (Figure 29.10). The very pale nuclei make the capillaries stand out and appear dark in comparison. It is very infiltrative around the edges, much like a normal scar. Superficial fibromatoses can occur on the palm (palmar fibromatosis, Dupuytren's contracture), sole (plantar, Ledderhose disease), or penis (Peyronie's disease), where they are benign but can recur. Axial or deep fibromatoses, such as on the chest wall or mesentery, are typically more aggressive in their expansion and are called desmoid tumors. Desmoid tumors are characterized by a specific immunohistochemical trait, the accumulation of β -catenin in nuclei.

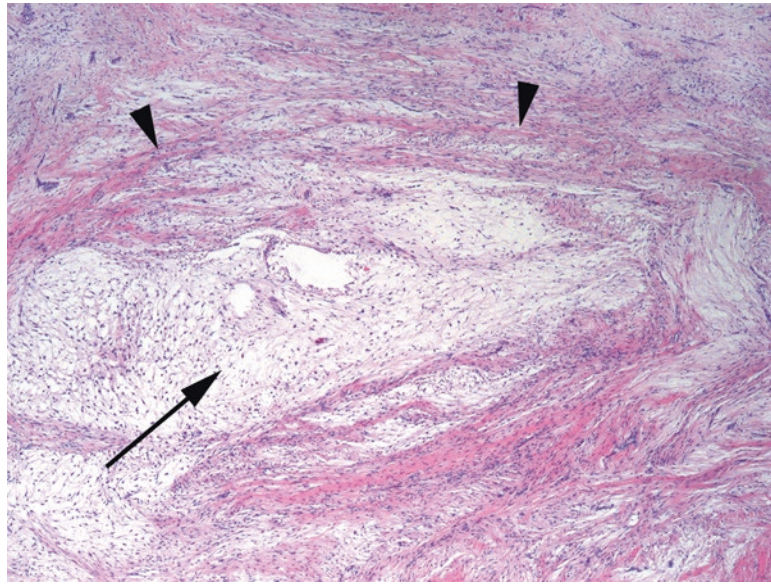


FIGURE 29.11. Low-grade fibromyxoid sarcoma. This tumor has areas that resemble desmoid tumor, with a high collagen content and sweeping fascicles (*arrowheads*), but the distinct feature at low power is the presence of alternating pale myxoid areas (*arrow*). Atypia is insignificant.

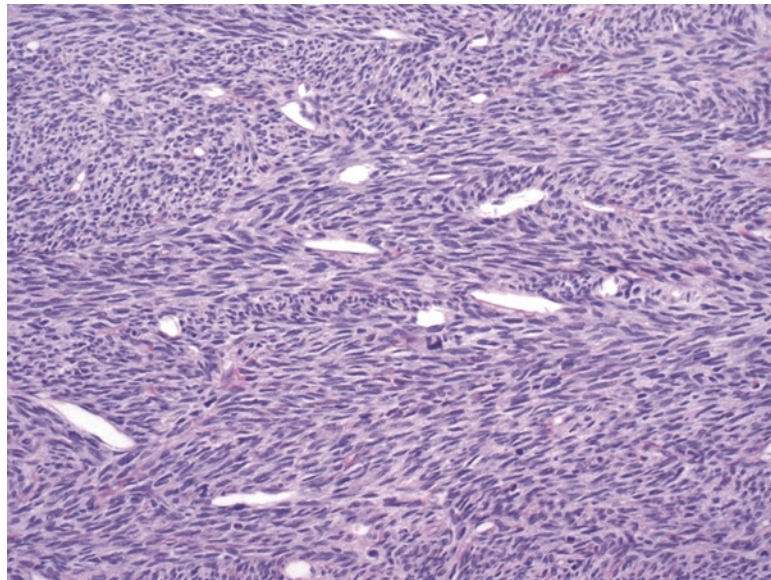


FIGURE 29.12. Fibrosarcoma. This field shows the typical herringbone pattern of fibrosarcoma, with zigzagging bands of spindle cells. Many other tumors can have this pattern.

Low-grade fibromyxoid sarcoma (Evans tumor) is one of those most troublesome entities; it simulates a benign lesion (fibromatosis) yet has metastatic potential. At low power it is often mottled pink and white, with hypocellular myxoid zones and collagenous pink nodules that resemble the desmoid tumor (Figure 29.11).

Fibrosarcoma is the high-grade endpoint of this spectrum of lesions. It is the classic pure “herringbone” lesion, with fascicles alternating in a zigzag pattern. There is no significant collagen or inflammation to speak of. It has a high mitotic rate, but the cells are not particularly atypical: the nuclei tend to be monomorphic, oval, and euchromatic (Figure 29.12). It is mainly the cellular density and mitotic activity that set this lesion apart as malignant. However, true fibrosarcoma is quite rare, while its imitators, especially malignant peripheral nerve sheath tumor and synovial sarcoma, are more common. Therefore, fibrosarcoma is a diagnosis

of exclusion. The most common scenario in which to see fibrosarcoma is in association with dermatofibrosarcoma protuberans (DFSP). DFSP is a superficial sarcoma that occurs in the subcutaneous tissue of younger patients and is composed of somewhat bland-appearing fibroblasts arranged in a storiform pattern (refer to Figure 28.25). When DFSP progresses to a higher-grade malignancy, it takes the form of fibrosarcoma and is called fibrosarcomatous transformation of DFSP. This higher-grade tumor will have areas of malignant cells arranged in fascicles with increased mitotic activity, as opposed to the storiform pattern of DFSP.

Solitary fibrous tumor (SFT) is included here because of its resemblance to fibroblastic tumors, but in truth the type of differentiation is not known. SFT has a unique staining pattern (CD34, CD99, and bcl-2) and typically arises from serosal surfaces. Because of its association with the pleura, it was once called “benign mesothelioma.” On low power, the tumor is described as having a patternless pattern, which evidently means non-storiform–non-herringbone–non-fascicular. The swirling mass of uniform cells is reminiscent of ovarian stroma, but appears more pink due to abundant collagen (Figure 29.13). Collagen is laid down in parallel bundles, and the cellularity varies from one field to the next. The vessels are of the “staghorn” type, meaning they are gaping, branching vessels without an appreciable wall thickness: the tumor appears to extend right up to the endothelium. There are some features of concern (a mitotic rate of more than 4 per 10 hpf, necrosis, atypia) that suggest a malignant solitary fibrous tumor, but in reality it is difficult to predict their behavior.

Myxoid Tumors

The myxoid lesions included here are those that are not myxoid variants of other tumor types (such as myxoid liposarcoma). Many different lesions may converge on the myxoid phenotype, however. What we call *myxoid* is really the accumulation of hyaluronic acid, a gel-like substance that is essentially a form of solid water in the body (as seen in tissue edema). It may appear clear to a very pale blue on routine stains. A myxoid differential diagnosis would include myxoma, neurofibroma, and nodular fasciitis (all benign) and myxofibrosarcoma, myxoid liposarcoma, myxoid chondrosarcoma, myxoid leiomyosarcoma, and low-grade fibromyxoid sarcoma (all malignant). You would also need to exclude tumors that may appear myxoid but are not, including chordoma, cartilaginous tumors, and epithelial mucinous tumors.

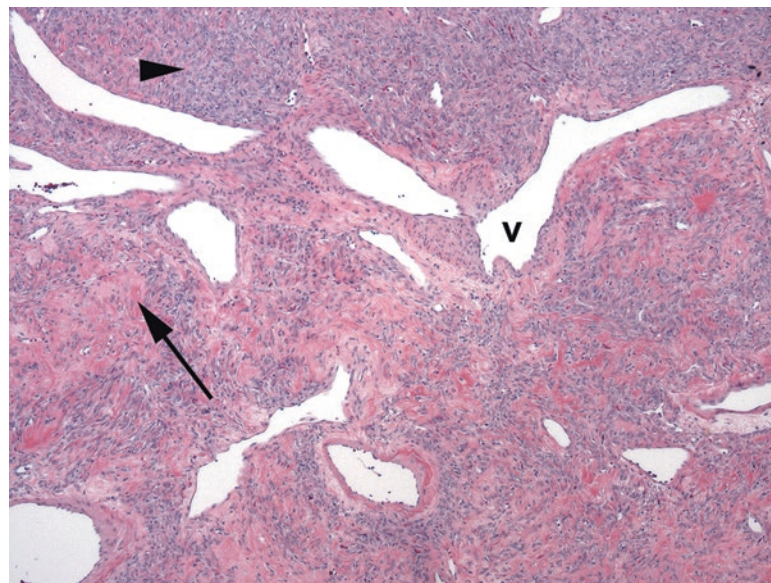


FIGURE 29.13. Solitary fibrous tumor. The most noticeable features at low power are the staghorn vessels (v), which this tumor shares with the related hemangiopericytoma. The tumor is composed of areas of small nondescript spindle cells (arrowhead) and collagenous stroma (arrow). The pattern of the spindle cells is described as “patternless,” meaning somewhat chaotic.

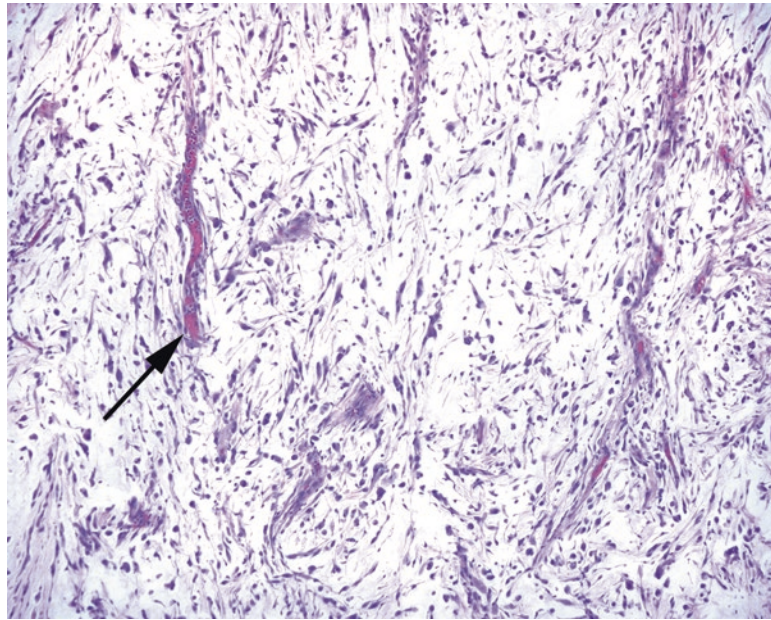


FIGURE 29.14. Myxofibrosarcoma. Although the cells here resemble those of UPS, the stroma is myxoid, and the vessels are unique (*arrow*). They appear as short arcs or segments, unlike the complex branching vessels of myxoid liposarcoma, and the tumor cells are intimately associated with the vessels, like wax dripping down the side of a candle.

Intramuscular myxoma is a benign and nearly acellular lesion that presents as a gelatinous mass within a muscle, usually in women. There are rare small stellate cells without atypia. What separates the benign myxoma from other more worrisome lesions is its virtual lack of capillaries, and the few capillaries that are present should be delicate.

Myxofibrosarcoma is not to be confused with low-grade *fibromyxoid* sarcoma. Myxofibrosarcomas are tumors that are prominently myxoid but that have an increasing cellularity, nuclear pleomorphism, and mitotic rate compared to myxoma. Because of prominent vessels and bubbly cells (pseudolipoblasts), they may be mistaken for myxoid liposarcoma. However, the vessels are different. Myxofibrosarcoma vessels are “curvilinear,” which means they make short thick arcs in the tumor, and the tumor cells appear to drip off of them like wax from a candle (Figure 29.14). Compare these to the delicate branching capillaries of the myxoid liposarcoma (see Figure 29.6). The nuclei of myxofibrosarcoma also set them apart; they are hyperchromatic and pleomorphic, unlike the uniform nuclei of myxoid liposarcoma. Subcutaneous myxofibrosarcomas may extend microscopic tentacles of tumor along fascial planes in all directions, making these tumors particularly difficult to excise.

Smooth Muscle

Smooth muscle neoplasms (Table 29.5) may be positively identified by immunoreactivity to actin and desmin but may sometimes show spurious cytokeratin or EMA staining.

Leiomyoma should be familiar, as it is identical to the uterine tumor. It can occur as a primary neoplasm in cutaneous, gastrointestinal, and other sites. However, unlike in the uterus, in these body sites, there is a very low threshold for bumping the lesion up to leiomyosarcoma. In general, greater than 1 mitosis per 10 hpf is worrisome. Leiomyomas are characterized by long parallel bundles of smooth muscle cells that intersect at right angles, such that some are seen longitudinally and some cut in cross section. The nuclei are pale, elongated, and blunt-ended in shape. You may also see corkscrew nuclei, which appear twisted about themselves and are associated with the contracted state. Paranuclear vacuoles are common (Figure 29.15).

TABLE 29.5. Smooth muscle neoplasms.

Benign	Malignant but indolent	Malignant and aggressive
Leiomyoma	Cutaneous leiomyosarcoma	Leiomyosarcoma, retroperitoneal or soft tissue

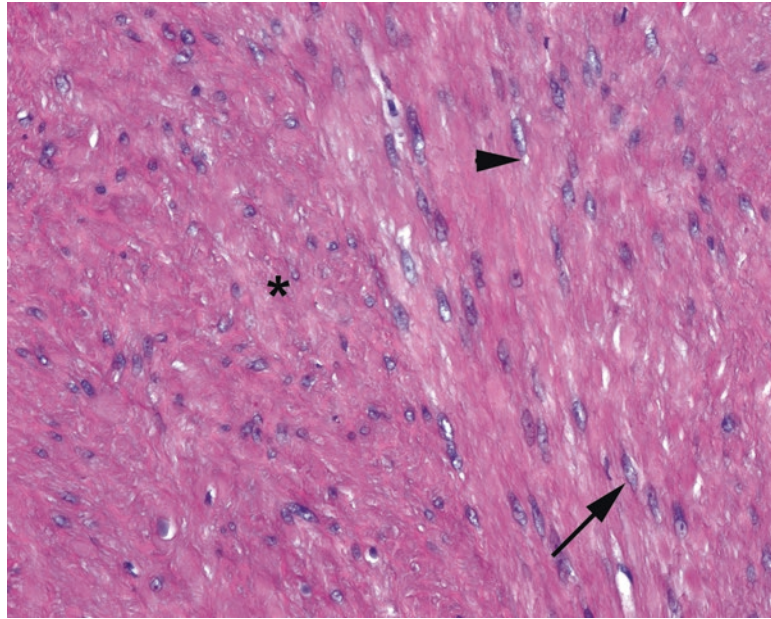


FIGURE 29.15. Leiomyoma of the colon. As in the leiomyoma of the uterus, there are smooth muscle cells in bundles running parallel to and perpendicular to (*asterisk*) the slide. The features of benign smooth muscle include elongated pale nuclei with paranuclear vacuoles (*arrowhead*) and occasional corkscrew nuclei in which the nuclei appear twisted (*arrow*). Wavy pink muscle fibers are usually visible between the nuclei.

Leiomyosarcomas range in appearance from something very similar to leiomyoma to a densely cellular and hyperchromatic tumor with scattered highly atypical nuclei (Figure 29.16). They can occur in the skin, where they are relatively indolent, or in the retroperitoneum, soft tissues, or any organ with the smooth muscle, where they are more aggressive.

In a smooth muscle-like lesion arising anywhere near the gastrointestinal tract, you should consider *gastrointestinal stromal tumor* (GIST) in the differential diagnosis. The cells of origin are the interstitial cell of Cajal, the pacemaker cell of the stomach, and, like this cell, GIST stains for c-kit, DOG1, and CD34, but not for smooth muscle markers. GIST may be spindled, resembling leiomyoma or schwannoma, or may be epithelioid with a wide range of morphology (refer to Figure 7.11). Clinical behaviors range from benign to malignant, depending on site and histologic factors.

Skeletal Muscle

Tumors of skeletal muscle are uncommon, and, as a terminal cell type with no stem cells or regenerative activity (like neurons), they are mainly seen in children or young adults (Table 29.6). They all get the rhabdo- prefix and should all stain with actin and desmin, plus special skeletal muscle markers myogenin and MyoD1. Other unrelated tumors in other sites sometimes are described as “rhabdoid”; remember that the -oid suffix means “looks like, but is not.” Therefore, the rhabdoid meningioma or rhabdoid tumor of the kidney is not of muscle origin but simply displays similar cell shape and appearance.

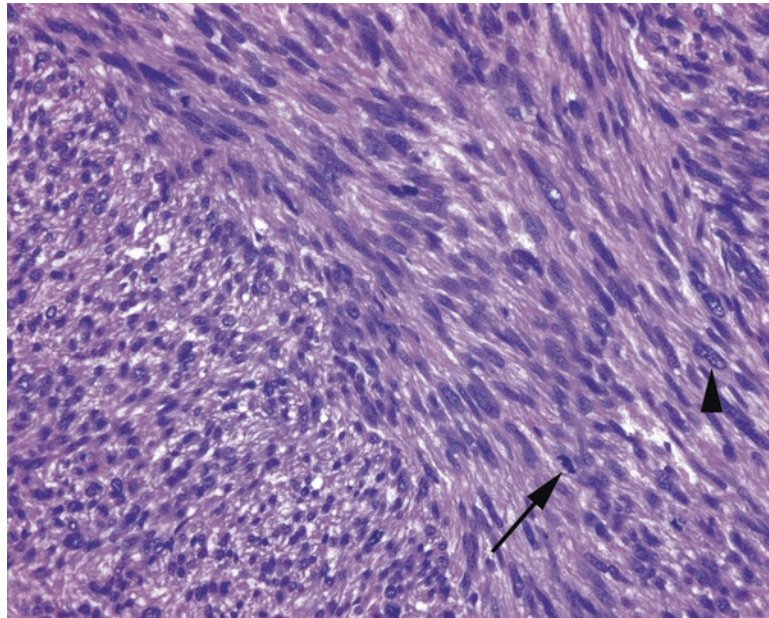


FIGURE 29.16. Leiomyosarcoma. A malignant version of the leiomyoma, this tumor has the architectural pattern and nuclear morphology of its benign cousin but with much higher cellularity, hyperchromatic nuclei, frequent mitoses (*arrow*), and large atypical cells (*arrowhead*).

TABLE 29.6. Skeletal muscle neoplasms.

Benign	Malignant but less aggressive	Malignant and aggressive
Rhabdomyoma	Embryonal rhabdomyosarcoma	Alveolar rhabdomyosarcoma
Fetal		Pleomorphic rhabdomyosarcoma
Adult (head and neck)		
Genital		

Rhabdomyoma is a rare benign neoplasm of primitive skeletal muscle cells. *Fetal rhabdomyoma* generally occurs in children, typically in the head and neck, and resembles embryonal rhabdomyosarcoma but without the atypia and mitoses. In adult men, *adult rhabdomyoma* usually arises in the head and neck. In this variant, the cells are rhabdoid in shape, with small peripheral nuclei, and pink clumps of myofilaments in the cytoplasm, not unlike mature muscle cut in cross-section. The third variant, *genital*, occurs in adult women. This variant is predominantly composed of strap cells (elongated pink cells with cytoplasmic cross-striations), again without atypia or mitoses.

Rhabdomyosarcoma is the most common sarcoma of children and is rare in adults. Remember that any adult high-grade sarcoma can acquire partial rhabdo- differentiation, however. Pure rhabdomyosarcomas can be grouped into three main subtypes (although other subtypes exist): embryonal, alveolar, and pleomorphic.

Embryonal rhabdomyosarcoma comprises about 80% of cases and has a significantly better outcome than the alveolar type. It is composed of sheets of varying proportions of hyperchromatic small round blue cells, nonspecific spindled cells, rhabdomyoblasts (plump and eosinophilic with large eccentric nuclei), and strap cells resembling primitive muscle fibers (Figure 29.17). The botryoid subtype of embryonal rhabdomyosarcoma refers to tumors occurring in a mucosal site, such as the genital tract. *Alveolar rhabdomyosarcoma*, a translocation tumor, is a very aggressive variant. In this type, fibrous septa divide the tumor into packets,

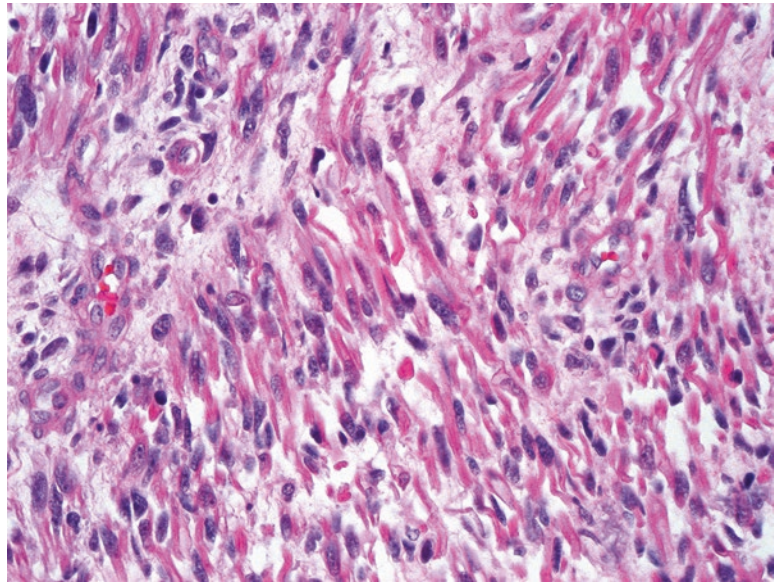


FIGURE 29.17. Embryonal rhabdomyosarcoma. The background is myxoid, and many of the tumor cells resemble primitive muscle fibers, with elongated tapering pink cytoplasm in which cross-striations may be visible (below the resolution of this photo, however). These are called strap cells.

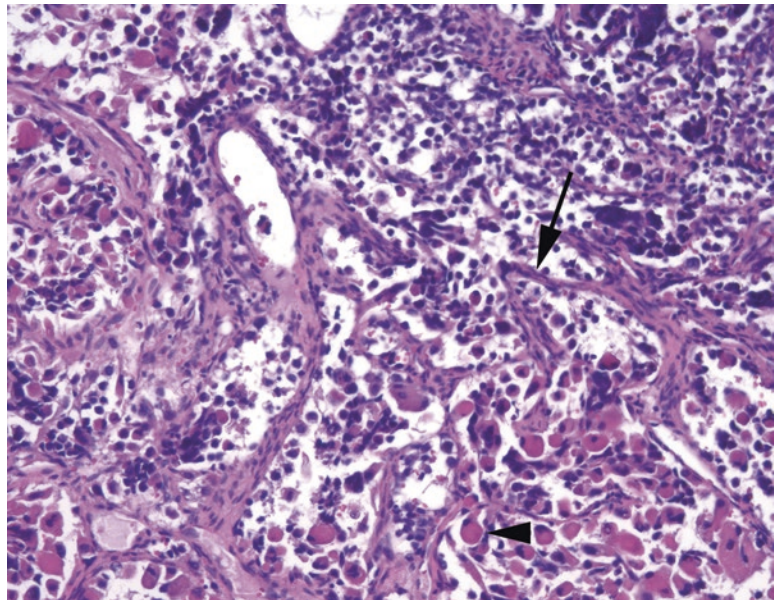


FIGURE 29.18. Alveolar rhabdomyosarcoma. The alveolar pattern is outlined by fibrovascular septa (*arrow*), and the tumor cells tend to fall out of the centers of their nests. This example shows prominent rhabdomyoblast differentiation (*arrowhead*), with large cells full of dense pink cytoplasm and eccentric nuclei. Other specimens may show only a small round blue cell phenotype.

mimicking lung alveoli, but the discohesive cells tend to fall apart in the middle of the packets (Figure 29.18). Similar to other translocation tumors, the cells of alveolar rhabdomyosarcoma tend to be more uniform than the cells of embryonal rhabdomyosarcoma. The solid variant may be indistinguishable from other small round blue cell tumors. *Pleomorphic rhabdomyosarcoma* is, like other pleomorphic sarcomas, a high-grade tumor of adults with marked nuclear pleomorphism, and has skeletal muscle differentiation. It is very rare.

Peripheral Nerve/Neuroectodermal

Nerves, as the axonal processes of terminally differentiated neurons around the spinal cord, do not actually form tumors. However, the cells associated with the nerve sheath do commonly produce neoplasms, including schwannoma and neurofibroma. Other tumors of neuroectodermal origin are included here as well.

The benign peripheral nerve sheath tumors include schwannoma and neurofibroma (Table 29.7). Both of these lesions are S100 positive. Both can undergo malignant transformation into malignant peripheral nerve sheath tumor, although this is much less common in the schwannoma. However, the nerve sheath lesions, just like the pleomorphic lipoma, may occasionally acquire bizarre cytology that by itself does not indicate malignancy. This degenerative atypia is called *ancient change*.

The *schwannoma* is an encapsulated lesion that arises from a peripheral nerve and can therefore be found anywhere in the body. It usually shows alternating hypercellular (Antoni A) and myxoid (Antoni B) areas, as well as characteristic parallel arrays of palisading cells called *Verocay bodies* (Figure 29.19). The cells themselves have euchromatic, fusiform nuclei that stream in parallel within a pink fibrillary background. Thick-walled, hyalinized vessels are typical, which look as though they have a layer of amyloid replacing the vessel wall. Foamy macrophages are common within this tumor, and cystic degeneration may simulate necrosis. The *cellular variant* of schwannoma is still benign but can get quite hypercellular and mitotically active (up to 10 mitoses per 10 hpf). The capsule and hyaline vessels should help to point you toward schwannoma.

TABLE 29.7. Nerve-related neoplasms.

Benign	Malignant
Schwannoma, neurofibroma	Malignant peripheral nerve sheath tumor
Granular cell tumor	Malignant granular cell tumor (rare)
Paraganglioma	Paraganglioma (a subset)

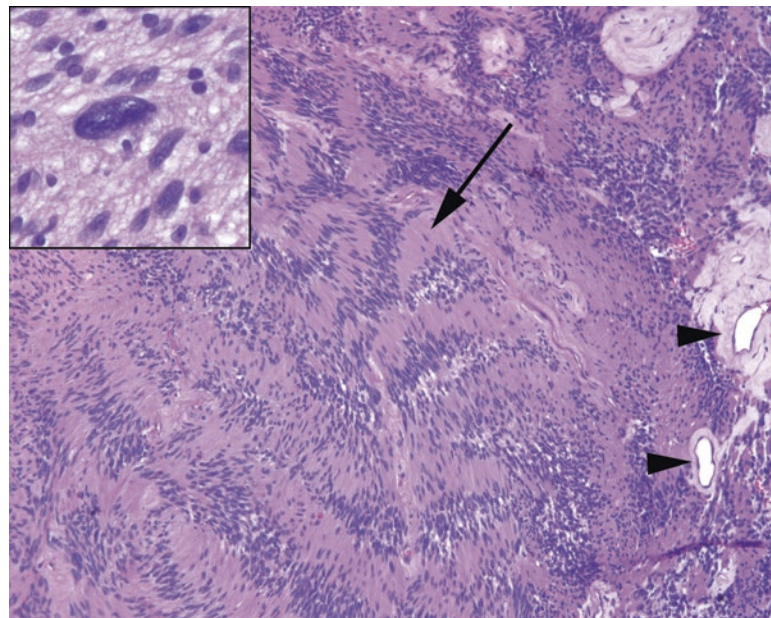


FIGURE 29.19. Schwannoma. In this spindle-cell neoplasm, the long tapered nuclei tend to clump together and form arrays called Verocay bodies (*arrow*). Hyalinized vessels (*arrowheads*) are common. *Inset*: occasional large atypical cells indicate ancient change, not malignancy.

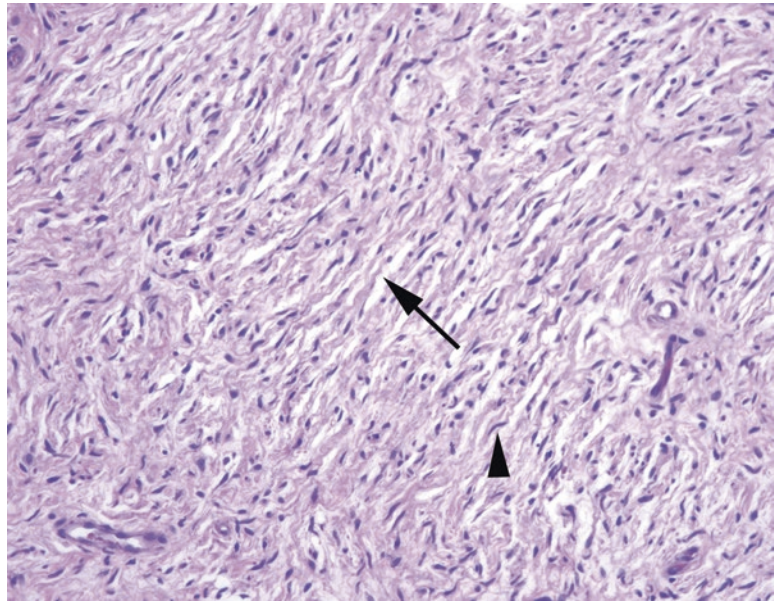


FIGURE 29.20. Neurofibroma. The nuclei tend to be thin and wavy (*arrowhead*), much like in a normal nerve. The tumor is usually paucicellular, with a myxoid background and delicate curly strands of wispy collagen (*arrow*).

The *neurofibroma*, in contrast, is an unencapsulated lesion that may appear as a nodule, a poorly circumscribed tumor, or a plexiform (“bag of worms”) tangle. It is pale to pink at low power, with a myxoid background and thin curly tendrils of collagen between the cells (Figure 29.20). The nuclei are pale, thin, and slightly undulating, as in a normal nerve, and there should be no mitoses. Unlike in the schwannoma, special stains may reveal axons trapped within the lesion. There should be almost no mitoses.

Malignant peripheral nerve sheath tumor (MPNST) is usually a high-grade sarcoma and often takes the morphology of the fibrosarcoma. It may retain some nerve sheath features, such as the wavy nuclei, nuclear palisading, or hyalinized vessels, but tends to lose most of its S100 reactivity (Figure 29.21). Mitoses should be present, unlike in a neurofibroma. Patients with neurofibromatosis Type 1 have a high lifetime risk of MPNST; however, it is otherwise a rare tumor.

Granular cell tumor is a benign tumor that shows neural differentiation but that resembles a collection of foamy macrophages (Figure 29.22). It is often associated with striking pseudoepitheliomatous hyperplasia in mucosal sites. These epithelial changes may be mistaken for squamous cell carcinoma if the subtle underlying diagnostic granular cells are overlooked. *Paraganglioma* is actually a neuroendocrine tumor but is included here as it sometimes presents as a soft tissue mass. It is a (usually) benign tumor with neuroendocrine-type nuclei, arranged in an alveolar pattern (Figure 29.23).

Vascular Tumors

Reactive lesions of capillaries are very common, as an inherent part of the healing process is the formation of new vasculature. Granulation tissue, which fills in a defect in the body tissues, has very prominent capillaries with large endothelial cells (refer to Figure 3.2). The capillaries of granulation tissue are plump and round, with at least two cell layers (endothelium and pericytes), and may be crowded but do not appear interconnected. Neoplastic vessels, on the other hand, are often lacking the pericyte component and typically form anastomotic channels and slit-like spaces with sharp angular profiles. Extravasated or free-floating blood cells are common in vascular neoplasms. The immunohistochemical markers for the vascular tumors are CD31 and CD34.

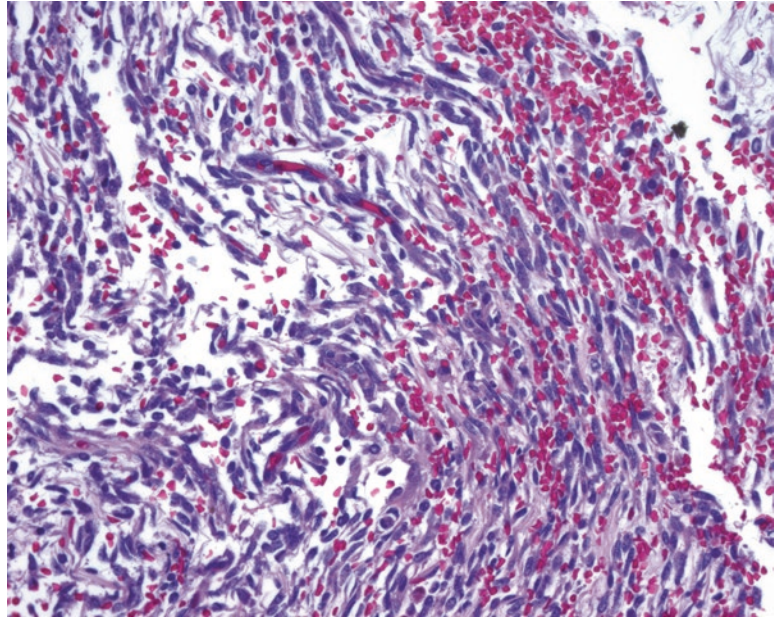


FIGURE 29.21. Malignant peripheral nerve sheath tumor. Although the malignant peripheral nerve sheath tumor sometimes resembles a fibrosarcoma, in this example it is more reminiscent of a neurofibroma, which was probably the origin in this case. There is a myxoid background and wavy collagen, but the cells are much more hyperchromatic and atypical than in neurofibroma.

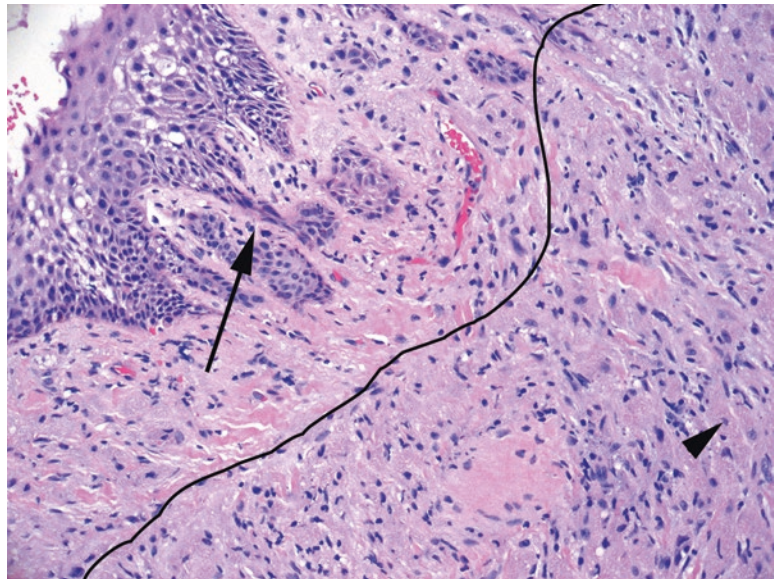


FIGURE 29.22. Granular cell tumor. This is a particularly subtle example, but the *right side* of the photo (*outlined*) contains the amphophilic granular cells. Individual cells may merge into a mass, but occasional distinct cells with their small oval nuclei are visible (*arrowhead*). The cytoplasm is granular at high power. This tumor is famous for provoking pseudoeplitheliomatous hyperplasia over the tumor (*arrow*), which may lead to a mistaken diagnosis of squamous cell carcinoma.

Papillary endothelial hyperplasia is a pattern of organizing thrombus that may occur within a vessel or hematoma. It may be seen incidentally in a surgical specimen or represent a symptomatic small mass by itself, in which case it is called a *Masson's tumor*. It is composed of tiny fibrin papillae covered by thin endothelium (Figure 29.24).

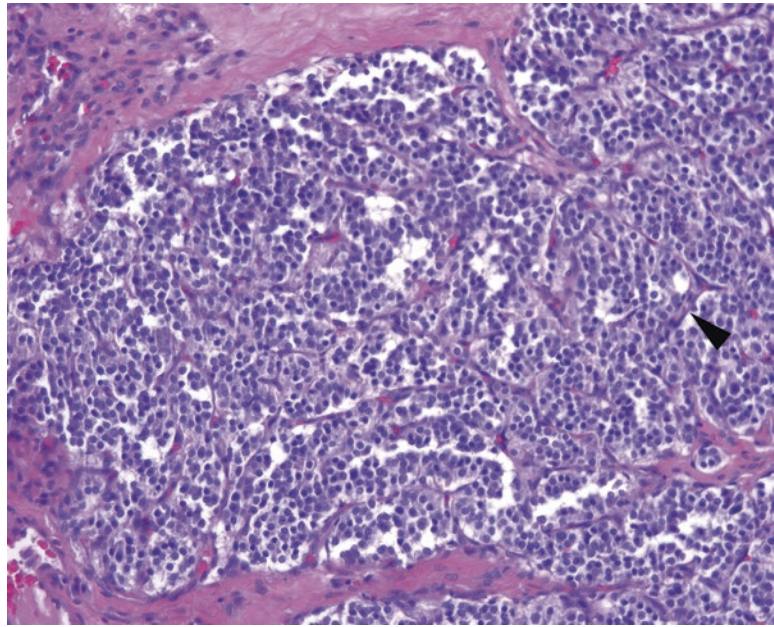


FIGURE 29.23. Paraganglioma. Fibrovascular septa (*arrowhead*) divide the neoplasm into small balls of cells (the “zellballen” pattern). The cells have small, perfectly round nuclei with neuroendocrine chromatin. Despite the paraganglioma’s classification as an extra-adrenal pheochromocytoma, it resembles the carcinoid tumor more closely than the pheochromocytoma.

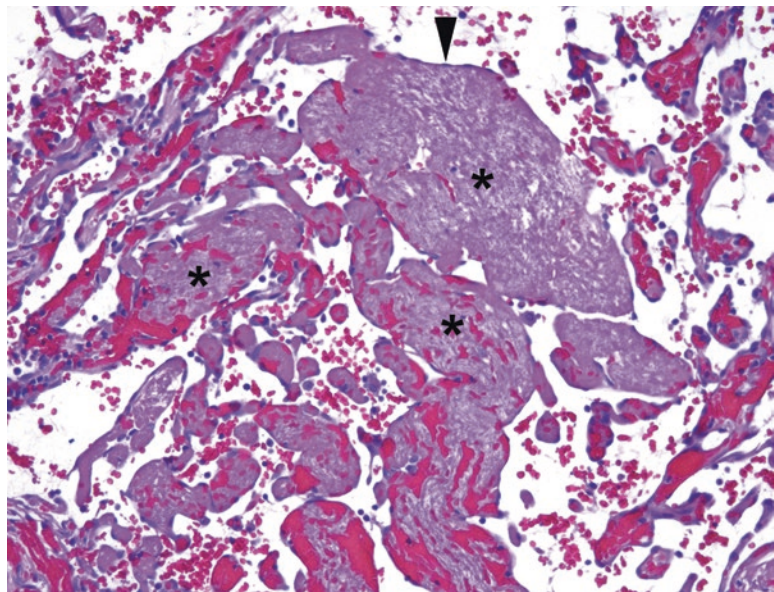


FIGURE 29.24. Papillary endothelial hyperplasia. Fingers of fibrin and red blood cells (*asterisks*), not true fibrovascular cores, are lined by bland endothelial cells (*arrowhead*).

A *hemangioma* is a benign neoplasm of vascular elements, and there are many subtypes, including the common capillary hemangioma, cavernous hemangioma, and juvenile capillary hemangioma (Table 29.8). Capillary hemangiomas generally have round, nonbranching vessels, although they may be very crowded or dilated, and the capillaries are surrounded by a pericyte layer, whereas cavernous hemangiomas are an interconnected mass of dilated vessels (Figure 29.25). The low-power lobular appearance (circumscribed with rounded contours) is key to identifying a vascular tumor as benign, as angiosarcoma is not well circumscribed.

In general, for every category of endothelial lesions, there is an epithelioid variant, in which the endothelial cells acquire a lot of cytoplasm, becoming plump and epithelial-looking, often

TABLE 29.8. Vascular neoplasms.

Benign	Malignant but indolent	Malignant and aggressive
Hemangioma variants	Hemangioendothelioma	Angiosarcoma
Perivascular tumors, PEComa	Kaposi's sarcoma	
Glomus tumor	Malignant perivascular or glomus tumors (rare)	

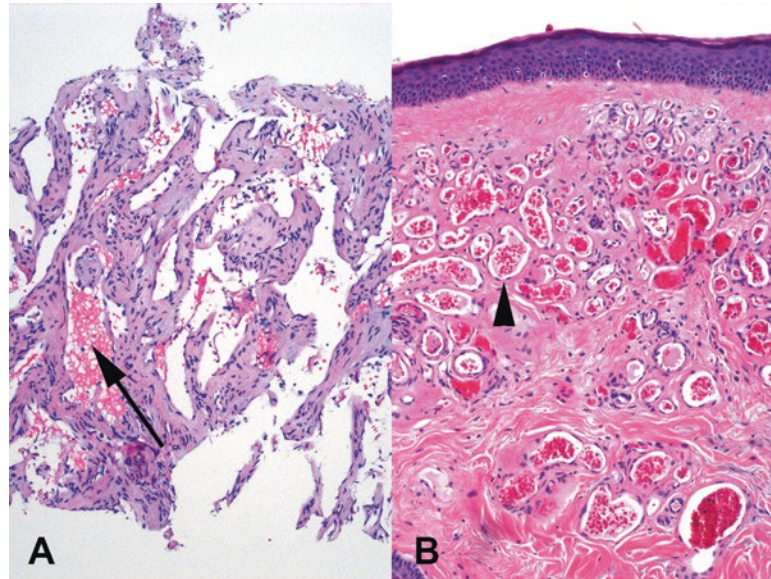


FIGURE 29.25. Hemangiomas. (a) This cavernous hemangioma of liver shows broad anastomosing vascular channels (*arrow*), some of which may form cystic spaces. At low power it is well circumscribed. (b) A capillary hemangioma of the skin consists of a cluster of small round well-formed capillaries (*arrowhead*). This is also well circumscribed.

with cytoplasmic lumina that are their attempts at vessels. These variants are challenging because they may not look particularly vascular. Negative epithelial markers (cytokeratins, EMA) would be helpful, but unfortunately epithelioid vascular neoplasms may express some keratins.

The low-grade sarcomas of endothelium are called *hemangioendotheliomas*, of which there are many subtypes. *Epithelioid hemangioendothelioma* is a sclerosing lesion with cords of vacuolated cells, some of which may contain red blood cells within the vacuoles, a diagnostic feature (Figure 29.26). It can be very difficult to distinguish from carcinoma without stains. *Kaposi's sarcoma*, a virally induced (HHV Type 8) low-grade sarcoma seen primarily in patients with HIV, has several stages and appearances, ranging from the most subtle of slit-like spaces in the dermis (see Chapter 28) to a dense spindle-cell lesion. Because of the many variants, and a considerable array of “kaposiform” mimickers, the differential diagnosis is beyond the scope of this chapter.

Angiosarcoma is the high-grade endothelial tumor, and it too has many variants. It can occur in organs, such as the liver or breast, especially after exposure to toxins or radiation. However, it can also arise in soft tissues *de novo*. Lymphedema is a recognized risk factor. Angiosarcoma classically shows branching, anastomotic irregular spaces with bulbous atypical cells lining the spaces (the hobnail pattern; Figure 29.27). Pericytes are typically absent, and at the periphery the tumor infiltrates into the surrounding tissue. This infiltrative border is very helpful in identifying malignant vascular lesions.

Epithelioid angiosarcoma may look like a generic “very bad tumor” composed of sheets of plump cells with large nuclei and prominent nucleoli, having almost no vascular differentiation. This sort of tumor may be identified only after a large battery of stains; as a rule, an undifferentiated epithelioid tumor with large red nucleoli should always get a CD34 or CD31 to exclude angiosarcoma.

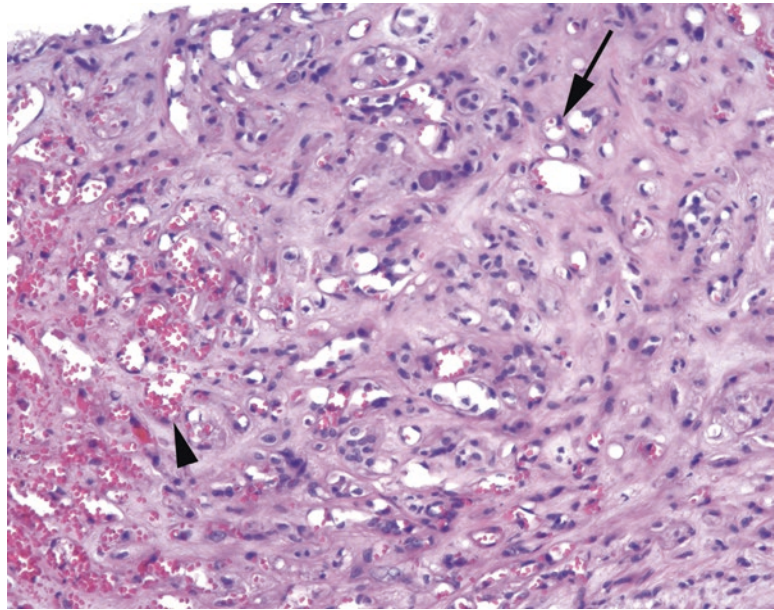


FIGURE 29.26. Epithelioid hemangioendothelioma. A rare but distinctive tumor, the epithelioid hemangioendothelioma is characterized by a dense fibrotic or sclerotic background, with small capillary spaces (*arrowhead*) and single cells with intracytoplasmic lumens complete with red blood cells (*arrow*).

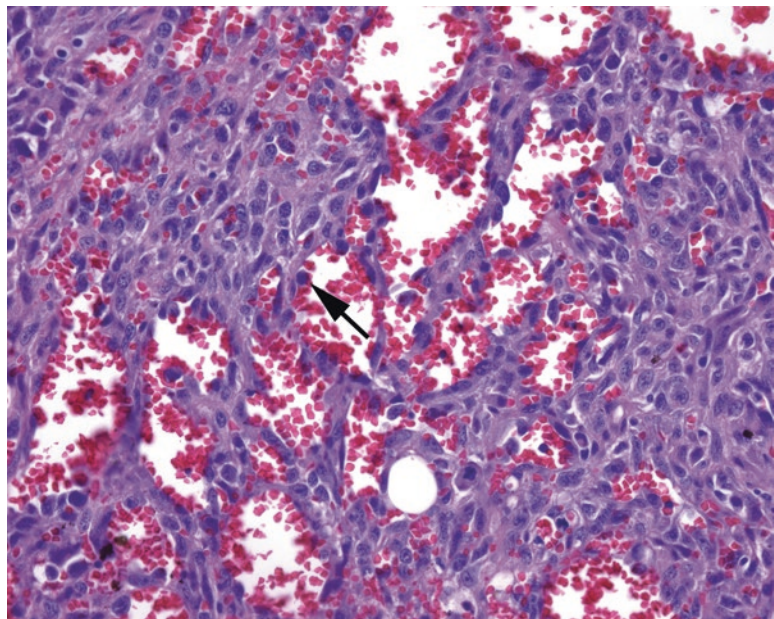


FIGURE 29.27. Angiosarcoma. In some areas the tumor cells have begun to grow as a solid sheet, but there are still blood-filled vascular spaces visible. Large and hyperchromatic malignant cells protrude into the lumina (*arrow*) in a hobnail pattern. The tumor cells also show prominent nucleoli.

There are several tumors with *pericyte* differentiation, those cells that surround and support the endothelial cells. They are not exactly smooth muscle cells and have their own phenotype and immunostaining profile. The *glomus tumor* is one such lesion. The perivascular epithelioid cell tumor family of lesions (*PEComas*) are a unique group of neoplasms that share immunoreactivity for the melanoma markers HMB45 and Melan-A. This group includes the angiomyolipoma, covered in more detail in Chapter 13.

Malignant Tumors of Unknown Differentiation

The following malignant tumors of unknown differentiation are all high grade by definition and mostly occur in younger people, adolescents to people in their 30s. Most are defined by translocations, which may explain why they do not particularly look or stain like other mesenchymal elements we are familiar with.

Synovial sarcoma, despite the name, is neither synovial in origin nor found in joint spaces. It is a translocation associated sarcoma, and the most recognizable form is the biphasic synovial sarcoma, in which packets of cytokeratin-positive, gland-forming, epithelial cells are scattered in a monomorphic spindle-cell background (Figure 29.28). Not much else looks like that. However, synovial sarcoma more commonly presents in monophasic form, which is just the spindle-cell component. It is a blue and hypercellular tumor, with a monomorphic population of nondescript spindle cells arranged in fascicles, and it should be in the differential diagnosis for fibrosarcomatous or storiform tumors.

Epithelioid sarcoma is easy to miss, as it does not look much like a sarcoma. It presents as ulcerated nodules on the extremities of young men and at low power resembles a large granulomatous reaction with central geographic (continent-shaped) necrosis. On higher power the tumor cells range from monomorphic spindle cells to large epithelioid cells with pink cytoplasm (Figure 29.29). Epithelioid sarcoma is unusual in that it shows reactivity to both vimentin, a mesenchymal marker, and cytokeratin, an epithelial marker. Because epithelioid sarcoma is easy to miss, it is wise to order a cytokeratin stain when working up granulomatous soft tissue lesions in young patients.

Alveolar soft part sarcoma is a translocation tumor involving the *TFE3* gene. It is divided into small packets of cells by a capillary network, similar to a renal cell carcinoma, and in fact looks somewhat carcinoma-like. The cells are large and eosinophilic with round nuclei and prominent nucleoli.

Clear cell sarcoma of soft tissue is one of several translocation tumors linked to the *EWSR1* gene. It used to be called *melanoma of soft parts*, as it stains with melanoma markers and may even produce melanin. Another *EWS*-related tumor is the visceral *desmoplastic small round cell tumor*, which like it sounds is a small round blue cell tumor in a sclerotic background. The third tumor in this group is Ewing sarcoma, which is discussed with bone tumors.

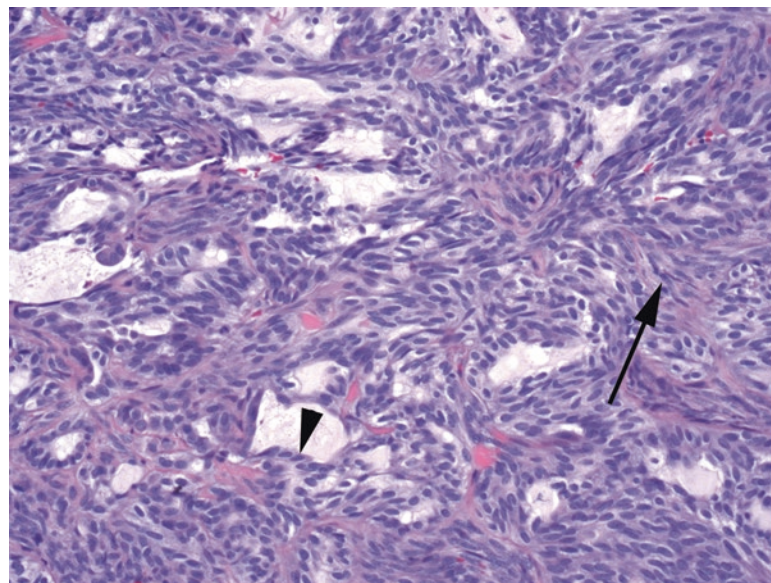


FIGURE 29.28. Biphasic synovial sarcoma. There are gland-like spaces surrounded by epithelial cells (*arrowhead*), set in a background of spindle cells (*arrow*). Monophasic synovial sarcoma lacks the epithelial component and can resemble fibrosarcoma.

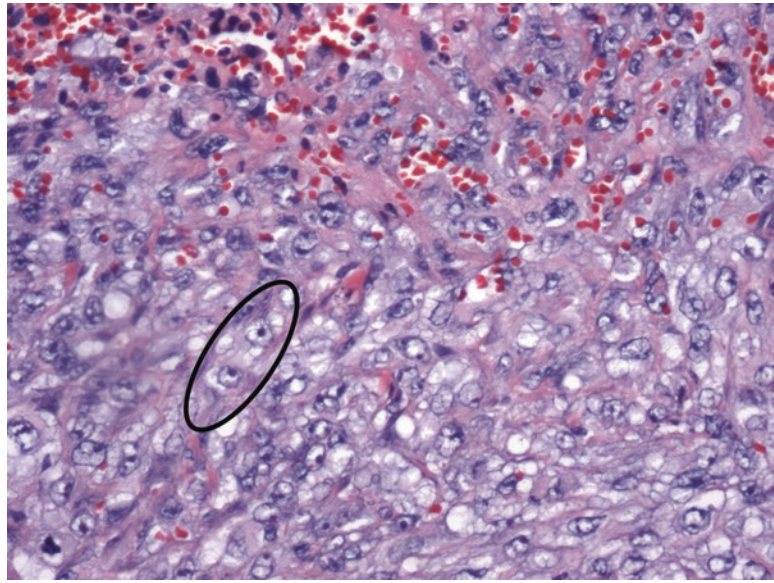


FIGURE 29.29. Epithelioid sarcoma. This tumor often has vesicular nuclei with prominent nucleoli (*oval*), distinct from most sarcomas. You can see how these cells might not stand out in a background of inflammation and necrosis.

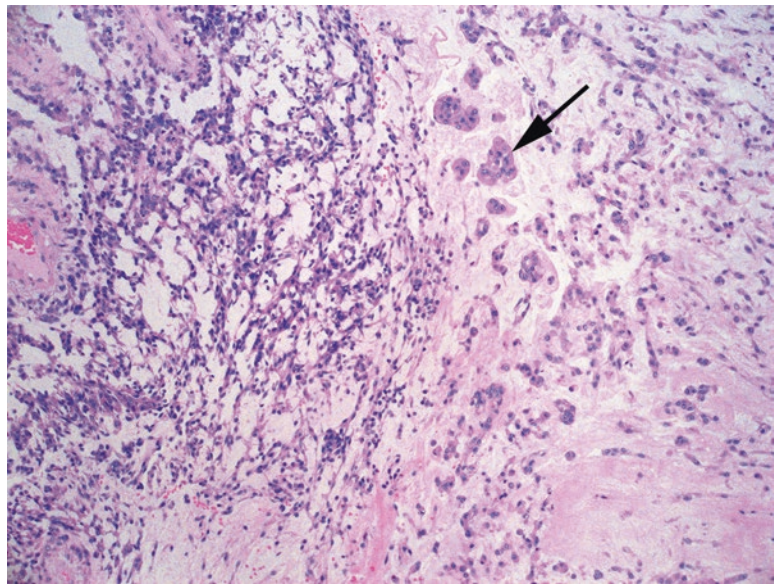


FIGURE 29.30. Extraskeletal myxoid chondrosarcoma. There is variable cellularity in a myxoid background. Small clusters (*arrow*) or cords of very bland cells are diffusely spread throughout the tumor. The cells have small round nuclei with a small amount of pink cytoplasm. The myxoid stroma may look chondroid at low power, but there is no actual cartilage.

Extraskeletal myxoid chondrosarcoma is grouped here, as it is more of a soft tissue tumor than a chondrosarcoma. It is a translocation tumor, like those above, and despite the name (due to a resemblance to chondroblasts), there is no cartilaginous differentiation. The myxoid is the key part of the name, as it has a prominent myxoid stroma without prominent vessels, and within it cords and nests of small round cells (Figure 29.30). These cells are very bland, though, so this is not a tumor which is obviously malignant on the slide, despite its aggressive clinical behavior.

For tumors of the bone, involving the bone, or simulating the bone, the radiograph is the gross examination. Just as in vascular lesions, a well-differentiated neoplasm may be classified as benign or low-grade malignant largely by the degree to which it infiltrates or invades the surrounding tissue or bone. In the bone, this infiltration of the periphery is best assessed by a radiologist or an experienced bone pathologist. General features are:

- Benign and slow-growing lesions tend to be clearly defined, well circumscribed, and walled off by a layer of reactive bone (a thin dense sclerotic rim on x-ray). Benign things also tend to evoke a thick and smooth periosteal reaction (thickening of the cortex). Note that some benign processes can still make large tumor masses that dramatically expand the bone—aneurysmal bone cyst, for example.
- Aggressive lesions, which include infectious or malignant lesions, tend to be poorly circumscribed, reflecting their infiltration of surrounding marrow. Aggressive lesions tend to produce an onionskin, spiculated, or discontinuous periosteal reaction. They may also erode through the cortex of the bone and spill into the soft tissue.

The second major principle is that primary bone tumors are rare and mainly occur in young adults and kids. For any patient over 50, the first three things in the differential for a bony lesion are metastasis, metastasis, and metastasis. Number four is a hematopoietic malignancy such as multiple myeloma. Metastatic carcinoma to the bone may consist of very rare tumor cells in a background of fibrosis, so dense fibrosis in the marrow space should always be screened with a cytokeratin stain.

The third major principle is that *lytic* (radiolucent) lesions, as described radiologically, just mean that something is replacing or destroying the bone. That something may be fluid, as in a simple cyst, or granulation tissue in infection, or a benign or malignant non-bone-forming tumor. *Blastic* lesions are radiodense and imply that the bone is being added to the lesion, either by tumor (a bone-forming tumor) or as a reaction (such as in metastatic prostate carcinoma or in Paget's disease of the bone). The terms lytic and blastic/sclerotic refer to changes seen on x-ray or CT scan, which are the preferred modalities for seeing calcified or ossified tissues. MRI is preferable for visualizing soft tissues, while a bone scan can highlight other skeletal lesions that may be involved by the same process.

As a side note, when grossing any bone specimens, before automatically placing it in decalcification solution, it is important to know the clinical situation. Was this biopsy performed to diagnose a suspected metastatic carcinoma in a patient with a history of carcinoma, or is this a workup of a primary bone tumor? If it is for a metastatic workup, will any molecular/FISH testing be needed for potential treatment (i.e., EGFR, ALK, ROS1 in lung cancer or Her2 in breast cancer)? Bone biopsies that have been decalcified in acid solution may be unsuitable for molecular studies. Gentler decalcification methods are available, although slower.

Starting with some basic histology, how does the bone form? In the fetus, the main pathway is by endochondral ossification, in which new bone is laid down on the cartilage scaffolding. You can see this process at any growth plate, as the edge of the cartilage plate ossifies into a layer of the bone. However, in the membranous bones of the skull and in the adult at sites of repair, the first step is the synthesis of *osteoid* (a salmon-pink acellular matrix) by osteoblasts and its subsequent mineralization with calcium hydroxyapatite. This immature bone has a disorganized collagen framework and is called woven bone (Figure 30.1). Continuing development and remodeling produces the bone with organized layers or lamellae of collagen visible as parallel seams within the trabeculae or cortex; this mature configuration is called lamellar bone (Figure 30.1). Polarization, or even lowering the condenser, can highlight the contrast between mature and woven bone. Neoplastic or reactive bone is almost always woven-type; fragments of lamellar bone within a lesion are entrapped native bone.

Second, how do we look at the bone on the slide? Most histologic sections of the bone are decalcified, so the pink fragments of the “bone” you see are the osteoid left behind. Calcium salts are dark purple on H&E. In lesions with osteoid formation, which may include anything from reactive metaplastic bone to fibrous dysplasia to osteosarcoma, the osteoid (pink) can be differentiated from collagen or amyloid (also pink) by the process of mineralization, seen as a purple tinge within the seams of osteoid. Dystrophic calcification in soft tissue, such as tumoral calcinosis, is not the same as bone formation. Heterotopic bone formation, such as in myositis ossificans, is true bone, but is not neoplastic.

The trickiest thing about bone tumors is that quite a lot of them lay down reactive bone as part of the process, yet are not true bone-forming tumors: the bone is just a bystander. Determining whether you are looking at reactive bystander bone versus a tumor-forming bone is critical and difficult. A basic rule of thumb is that malignant osteoid is fairly distinctive and defines the tumor as an osteosarcoma. Every other pattern is nonspecific and may be seen in benign or malignant or reactive processes, so context is key.

Malignant osteoid pattern:

- A lacelike deposition of osteoid surrounding atypical and malignant-appearing spindle cells (Figure 30.2). The cells should appear to be secreting little moats of osteoid that surround them and coalesce into lacelike islands of osteoid, which in turn may mineralize.
- Finding this in the context of a high-grade sarcoma = osteosarcoma.

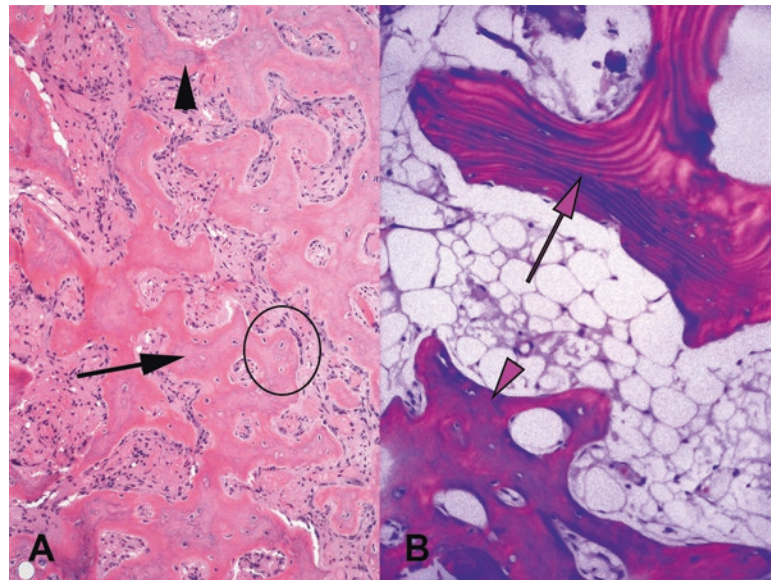


FIGURE 30.1. Types of bone. (a) Woven bone is laid down in thick primitive trabeculae (arrow) of osteoid, which undergoes mineralization and acquires a purple tinge (arrowhead) which may vary depending on the extent of tissue decalcification. Osteocytes (within the osteoid seams) and osteoblasts (lining the seams) can be seen in the oval. (b) Lamellar bone, seen here under polarized light, has parallel arrays of collagen (purple arrow) indicating mature bone. Immature woven bone (arrowhead) shows no organization of the collagen.

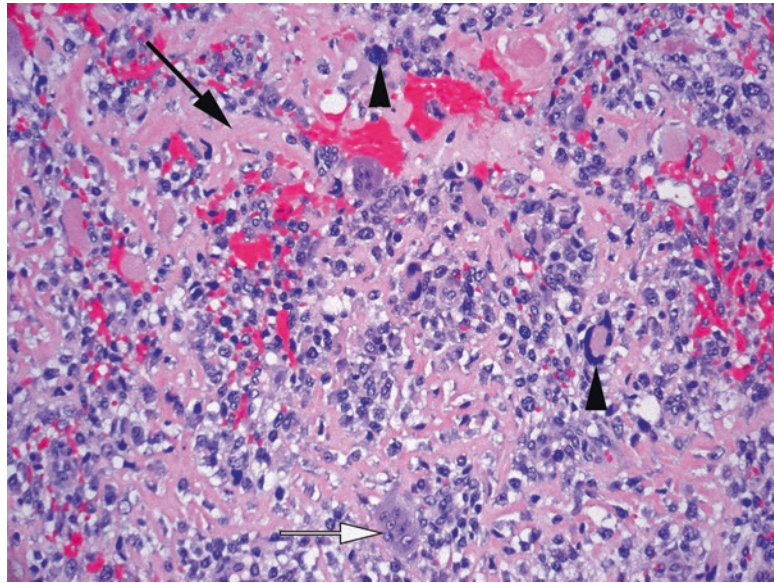


FIGURE 30.2. Malignant osteoid. The osteoid is visible as pink soup among the tumor cells (*arrow*), which are secreting it in a haphazard fashion without trabecular organization. Pleomorphic tumor cells identify this as malignant (*arrowheads*), which makes this an osteosarcoma. Note the completely irrelevant giant cell (*white arrow*), which can be seen in any bone tumor.

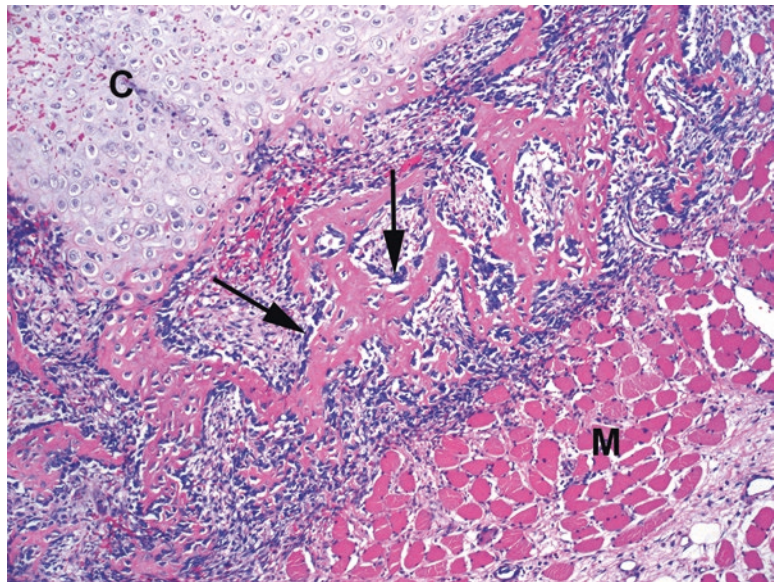


FIGURE 30.3. Osteoblastic rimming in heterotopic ossification. Between layers of cartilage (*C*) and muscle (*M*), there is a layer of woven bone with prominent osteoblastic rims (*arrows*) outlining the seams. This often indicates reactive bone formation.

Nonspecific osteoid patterns:

- Well-formed, mature, lamellar bone (almost always benign)
- Interlacing fingers of woven bone with prominent osteoblastic rimming and minimal atypia (usually benign; Figure 30.3)
- Little islands of osteoid in the context of either of the first two, without cellular atypia

Any of these three patterns may be seen in non-bone-forming tumors (like giant cell tumor of the bone), in fracture repair, in an inflammatory response, in benign bone-forming tumors (like an osteoma), and in very low-grade osteosarcomas (e.g., parosteal osteosarcoma). Therefore, they are nonspecific, and you'll need other information to help you make the diagnosis.

Definitions

Epiphysis: the end of the long bone, adjacent to the joint surface

Physis: another term for the cartilaginous growth plate

Metaphysis: the "shoulder" of the bone between epiphysis and shaft

Diaphysis: the shaft of the bone

Cortical or *compact bone*: the dense structural outer layer of the bone

Medullary cavity: the inner core of the diaphysis, with marrow

Trabecular or *cancellous bone*: mature spicules of bone, "spongy" bone

Lamellar bone: mature bone, with concentric or layered architecture

Woven bone: immature seams of bone

Bone-Forming Tumors (Table 30.1)

Osteoid osteoma is a common benign bone-forming neoplasm characterized by a small (<1.5 cm) radiolucent nidus of woven bone rimmed by prominent osteoblasts and surrounded by a dense sclerotic zone (Figure 30.4). The nidus is the source of intense bone pain. It is rarely seen on a slide these days, as radiofrequency ablation is an effective treatment. *Osteoblastoma* is essentially the same lesion histologically but is larger (>1.5 cm). The osteoblasts within these lesions are plump and amphophilic, and the pattern of osteoid deposition may be alarming at high power, but there should not be any atypia.

At the other end of the spectrum lies *osteosarcoma*. Conventional osteosarcoma is the stereotypical high-grade osteogenic sarcoma that classically arises in the femur or tibia of a young person. It is a heterogeneous malignant bone-forming tumor composed of (1) malignant cells (spindle cell, round cell, or pleomorphic) and (2) malignant osteoid (Figure 30.5). High-grade osteosarcomas have multiple morphologic variants, including osteoblastic (bone forming), chondroblastic (cartilage forming), and fibroblastic (predominantly fibrous), telangiectatic (a very aggressive variant with prominent blood lakes), and small cell (very hard to distinguish from Ewing sarcoma). The osteoid is laid down in a lacelike pattern, the classic malignant osteoid as described above. The relative amount of osteoid and nonspecific sarcoma varies by case; sometimes the osteoid is very focal. The unifying and defining feature is the production of osteoid by tumor cells, as immunostains are not usually helpful. Resections of osteosarcoma are usually done post-chemotherapy, at which time the goal is quantifying the amount of viable tumor that remains. Rarely, a high-grade soft tissue or visceral sarcoma will show osteosarcomatous differentiation; the histologic appearance is the same.

TABLE 30.1. Bone-forming tumors.

Benign	Malignant but indolent	Malignant and aggressive
Osteoma	Parosteal osteosarcoma	Osteosarcoma, conventional type
Osteoid osteoma		Osteoblastic
Osteoblastoma		Chondroblastic
		Fibroblastic
		Periosteal osteosarcoma
		Telangiectatic osteosarcoma
		Small cell osteosarcoma

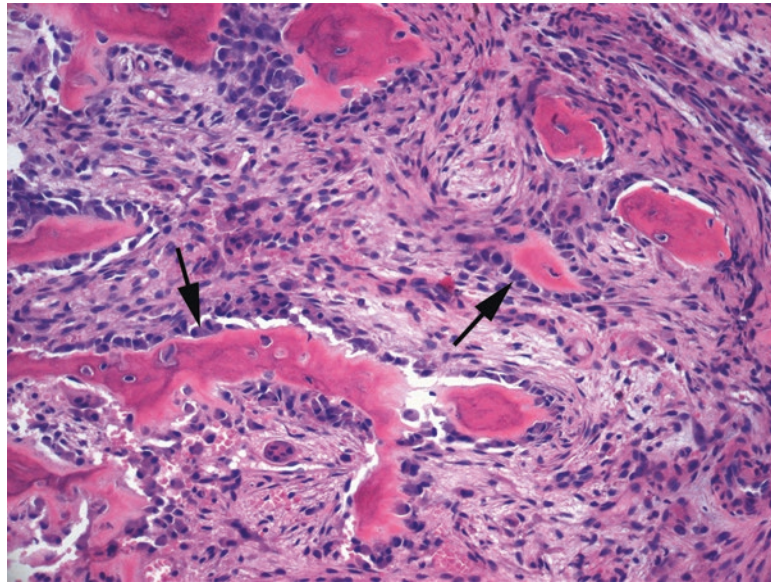


FIGURE 30.4. Osteoid osteoma or osteoblastoma (depending on size). At the nidus of the lesion, osteoid is laid down in seams by benign osteoblasts (*arrows*). The hyaline pink substance can be identified as osteoid by the dark purple tinge of mineralization.

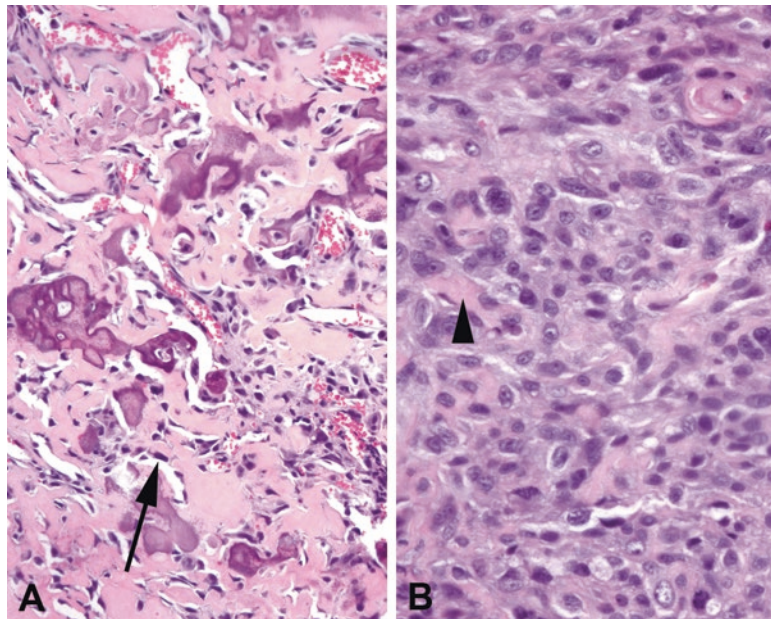


FIGURE 30.5. Osteosarcoma. (a) Some tumors may show extensive osteoid, with small tumor cells that are difficult to identify as sarcoma (*arrow*). The lacelike osteoid deposition helps to make the diagnosis. (b) A poorly differentiated tumor can be difficult to identify as osteosarcoma because of the focal and subtle production of osteoid (*arrowhead*).

Some variants of osteosarcoma are more indolent. The low-grade *parosteal osteosarcoma* occurs on the surface of the bone, usually behind the knee of a young adult. Histologically it is a bland spindle-cell neoplasm with minimal atypia and very mature, even trabecular, bone (Figure 30.6). The bony trabeculae often show a parallel arrangement. The key to recognizing it, aside from the radiologic appearance, is the substantial fibrous stroma between the trabeculae. The similarly named but quite different *periosteal osteosarcoma* is also a surface osteosarcoma, but is primarily chondroblastic, and consists of a spindle-cell population with cartilage formation.

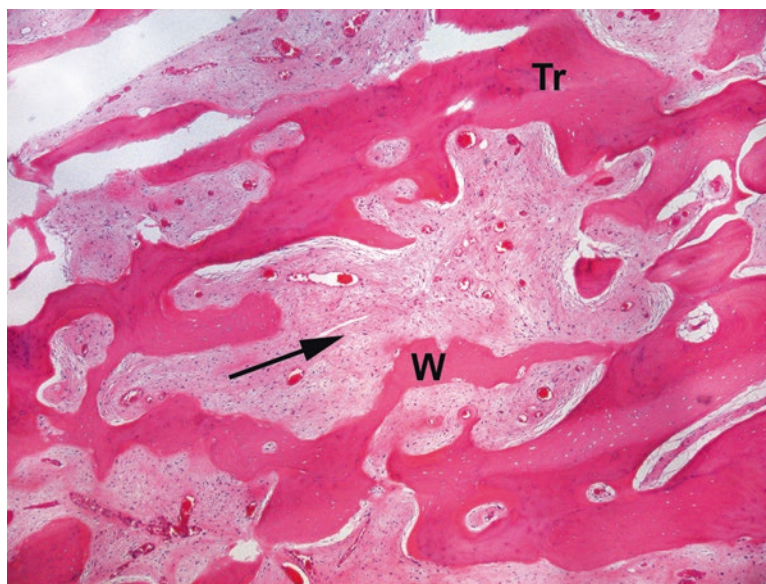

FIGURE 30.6. Parosteal osteosarcoma shows alarmingly mature trabeculae (*Tr*) mixed with immature woven (*W*) bone. The tip-off (in addition to radiology) is a dense collagenized pink stroma (*arrow*) from which the woven bone is arising.

Cartilage-Forming Tumors (Table 30.2)

Cartilage-forming tumors produce a characteristic fluffy or concentric ring pattern of calcification on x-rays. The *osteochondroma* is almost diagnosable by x-ray alone, as it stands out from the bone surface like a mushroom. Histologically, it is a bony stalk in continuity with the main marrow space, capped by mature cartilage, looking very much like a duplicated joint surface (Figure 30.7). Osteochondromas carry a tiny risk of transformation to chondrosarcoma, which presents as a dramatic increase in size and cartilage cap thickness.

Enchondroma is an island of benign, hypocellular, mature cartilage occurring within the marrow space of the bone. It is usually asymptomatic and incidentally discovered in long bones, but may be symptomatic in the small bones of the hands and feet, where it leads to a visible swelling. The tumor consists of mature cartilage, which is a pale blue matrix with varying amounts of calcification (purple), and single chondrocytes sitting in bubble-like lacunae (Figure 30.8). The lobules of cartilage often show ossification at their leading edge, replicating the enchondral ossification seen at the growth plate.

Chondroblastoma is also benign (despite the -blastoma suffix) and is notable for a peculiar pattern of calcification which rings the chondroblasts, creating a chicken-wire or honeycomb effect (Figure 30.9). It presents as a lytic lesion by x-ray, not as a cartilage-containing one. *Chondromyxoid fibroma* is rare but is in the differential for a well-differentiated cartilage lesion in the bone. It has both a fibrous component and a cartilaginous component.

Chondrosarcoma is typically a mass of atypical but recognizable cartilage, ranging from the grade 1 chondrosarcoma (histologically resembling enchondroma) to the grade 3 chondrosarcoma (Figure 30.10) based on cellularity, pleomorphism, and mitotic activity. It may be located on the surface of the bone (periosteal or juxtacortical) or in the medullary cavity. Features that separate the low-grade chondrosarcoma from benign enchondromas include erosion (or scalloping) of the cortex of the bone, entrapment of mature trabeculae, myxoid change, and a tendency to involve the axial skeleton. Chondrosarcomas are tumors of adults (those in their 30s to 50s). An apparent chondrosarcoma in a young person is more likely a chondroblastic osteosarcoma. An apparent chondrosarcoma in the little bones of the hands and feet is more likely an enchondroma.

TABLE 30.2. Cartilage-forming tumors.

Benign	Malignant but indolent	Malignant
Osteochondroma	Grade 1 chondrosarcoma	Grade 2–3 chondrosarcoma
Enchondroma	Clear cell chondrosarcoma	Dedifferentiated chondrosarcoma
Chondroblastoma		Mesenchymal chondrosarcoma
Chondromyxoid fibroma		

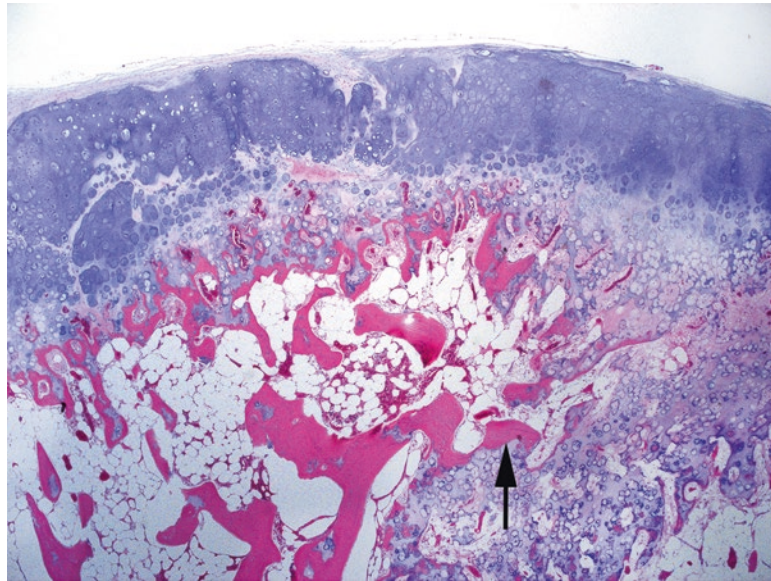


FIGURE 30.7. Osteochondroma. Like a miniature joint surface, this tumor has a hyaline cartilage cap with the underlying bone and marrow. Seams of cartilage are seen ossifying into the bone (*arrow*).

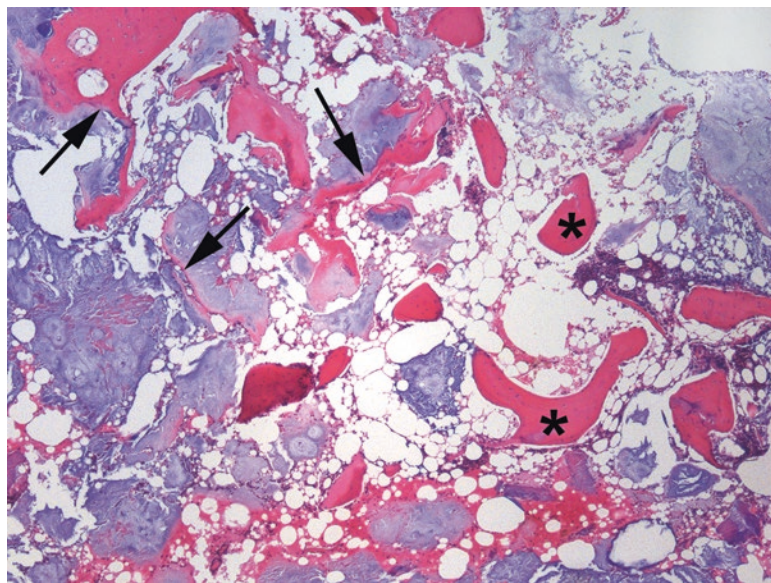


FIGURE 30.8. Enchondroma. A typical biopsy consists of curetted fragments of the bone and mature cartilage. Lobules of cartilage may ossify at their periphery (*arrows*), which should not be mistaken for osteoid formation. Fragments of mature trabeculae (*asterisks*) are present and surrounded by marrow fat.

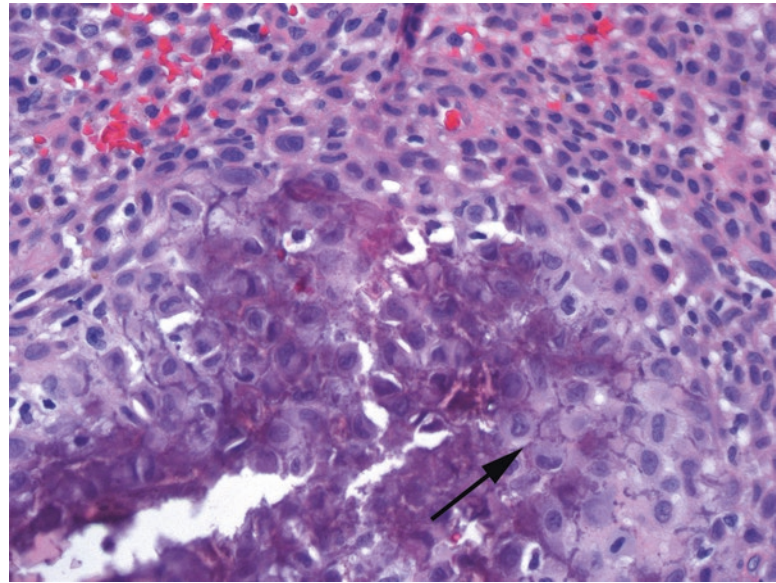


FIGURE 30.9. Chondroblastoma. The pericellular calcification (*arrow*) leads to a distinctive chicken-wire pattern. The individual cells are small with delicate nuclear membranes and eosinophilic cytoplasm.

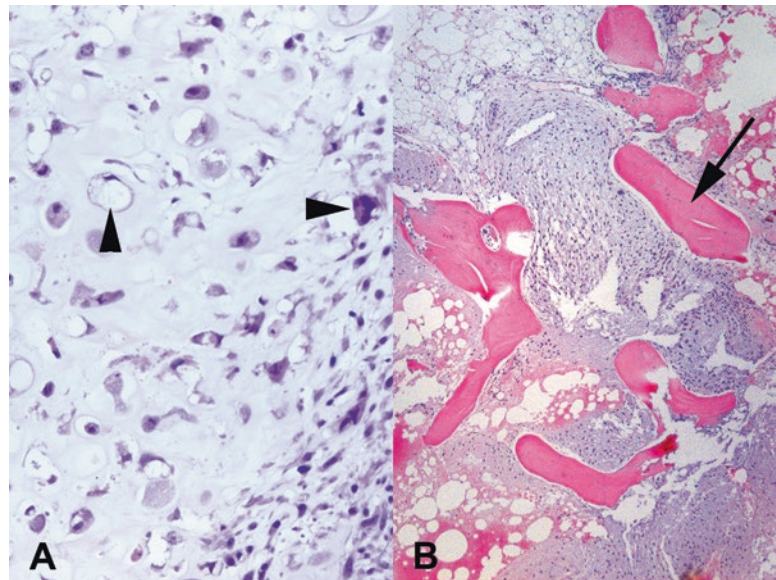


FIGURE 30.10. Chondrosarcoma. (a) Even high-grade chondrosarcoma is still fundamentally recognizable as cartilage, although with atypical nuclei (*arrowheads*). (b) In grade 1 chondrosarcoma, the cytologic features overlap with enchondroma, but the tumor envelops and entraps native trabeculae (*arrow*) like molten wax. Compare to the enchondroma (Figure 30.8), in which trabeculae are not surrounded by cartilage.

Chondrosarcomas, even high-grade ones, do not typically have a spindle-cell component. A low-grade chondrosarcoma with an abrupt transition to high-grade sarcoma (of any pattern) is most likely a *dedifferentiated chondrosarcoma*. As in the liposarcoma family, this diagnosis relies on seeing the previous or adjacent well-differentiated chondrosarcoma. However, a tumor that shows a gradual transition from high-grade cartilaginous areas to high-grade spindle-cell areas is more likely a chondroblastic osteosarcoma.

This raises a question: osteosarcomas often form cartilage (“chondroblastic”), and chondrosarcomas may mineralize into the bone. How do we identify the primary nature of the neoplasm? Chondrosarcoma is a neoplasm of recognizable cartilage without a spindle-cell sarcoma component, and the bone formation is through the direct mineralization or ossification of the cartilage, not by osteoid deposition. A cartilage-forming osteosarcoma, on the other hand, should have areas of spindle cells that are producing osteoid. A spindle-cell neoplasm intermixed with cartilage, even if the osteoid is not obvious, is more likely to be in the osteosarcoma family. This is an important clinical distinction, as osteosarcomas respond to chemotherapy and chondrosarcomas usually do not.

Fibrous and Miscellaneous Tumors in Bone (Table 30.3)

Fibrous dysplasia is a lytic and fibrotic lesion (originally believed to be a developmental abnormality, but now known to be associated with a genetic mutation) seen mainly in long bones and craniofacial bones. The lytic holes in the bone are described as having a “ground glass” (frosted glass) appearance on x-ray. Microscopically, the lesion consists of a bland spindle-cell population in which thin trabeculae of woven bone are laid down in curved irregular shapes, resembling letters of the alphabet (Figure 30.11). Unlike the typical reactive bone in an inflammatory lesion, osteoblasts are not visible surrounding the trabeculae.

TABLE 30.3. Fibrous and miscellaneous tumors in the bone.

Benign	Malignant
Fibrous tumors	Malignant fibrous histiocytoma
Fibrous dysplasia	Fibrosarcoma
Osteofibrous dysplasia	Metastatic carcinoma/others
Non-ossifying fibroma	Lymphoma/myeloma
Desmoid fibromatosis	Ewing sarcoma
Other tumors	Adamantinoma
Giant cell tumor of bone (benign but can be locally aggressive)	

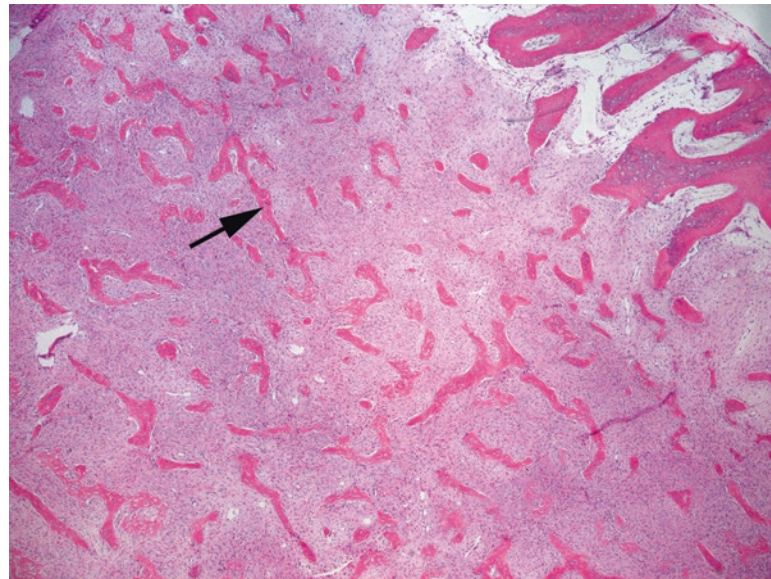


FIGURE 30.11. Fibrous dysplasia. Within a dense fibrous stroma, thin seams of osteoid (*arrow*) are laid down without significant osteoblastic rimming (compare to Figure 30.3) and without maturation.

Osteofibrous dysplasia is a very similar lesion that occurs in the shins (tibia, fibula) of very young children; only osteofibrous dysplasia *does* show prominent osteoblastic rimming. Finally, we have *non-ossifying fibroma*, another lytic lesion which occurs during childhood or young adulthood and tends to arise in the lower extremities. Non-ossifying fibroma is composed of fibroblastic cells arranged in a storiform pattern and may have quite a few giant cells present, but differs from the giant cell tumor by having a spindle-cell background, as well as a different radiologic presentation. Some soft tissue tumors can occur rarely in the bone as well, including desmoid fibromatosis, vascular tumors, pleomorphic undifferentiated sarcoma (still called malignant fibrous histiocytoma in the bone), and fibrosarcoma.

Giant cell tumor of bone is a lytic, destructive lesion seen at the ends of long bones in adults (skeletally mature with closed growth plates). It is composed of a mixture of osteoclast-like giant cells, often with over 50 nuclei, mixed with a background population of mononuclear cells, which are the true neoplastic component (Figure 30.12). Mitoses may be seen, but atypia is not. Giant cells, however, are not a unique feature, as they can be seen in almost any bony lesion. What makes a giant cell tumor unique is that the nuclei of the tumor cells exactly match the nuclei of the giant cells in size, shape, and color.

Adamantinoma is a rare malignancy of the tibia that may be composed of squamous, fibrous, or adamantinomatous (see discussion of craniopharyngioma in Chap. 27) cells. The main reason to know about it is to avoid calling it metastatic carcinoma, as it is keratin positive.

Ewing sarcoma is a small round blue cell tumor of adolescents and young adults. Like most primitive-type tumors, the cells have hyperchromatic, round, blue nuclei without prominent nucleoli, high N/C ratios with scant cytoplasm, and prominent necrosis and apoptosis (Figure 30.13). It is classically positive for CD99 and has a diagnostic translocation. The differential diagnosis includes metastases from other small round blue cell tumors, lymphoma/leukemia, and the small cell variant of osteosarcoma.

Langerhans cell histiocytosis (LCH) forms a lytic lesion that may clinically mimic sarcoma in children. Histologically it resembles LCH at any other site, with abundant eosinophils in a background of pale oval grooved Langerhans cells (Figure 30.14).

Paget's disease of bone is a disorder of accelerated formation and destruction of the bone. It can present as either lytic or sclerotic lesions, depending on which process dominates. The key finding is the jigsaw puzzle like intersecting tide lines in the trabeculae, which mark the point at which the osteoclasts stopped their destructive advance (Figure 30.15). Polarizing the bone can help enhance this finding.

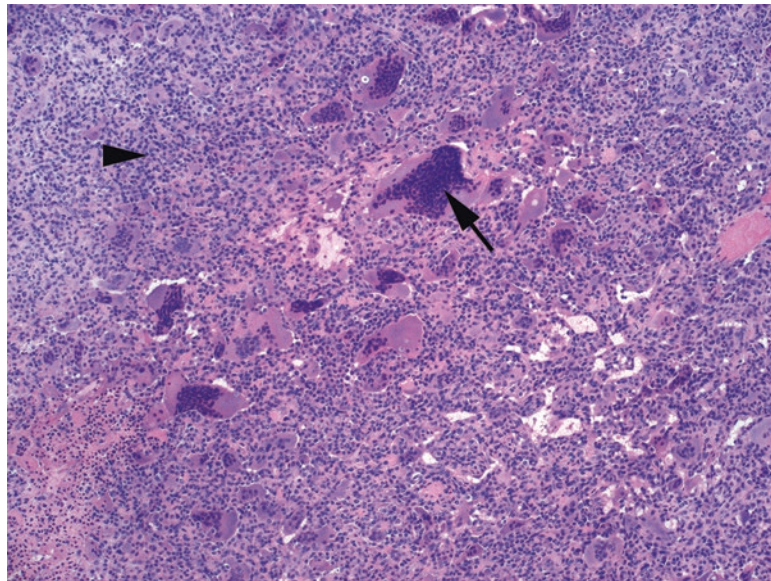


FIGURE 30.12. Giant cell tumor. This cellular tumor is composed of giant cells, occasionally enormous (*arrow*) in a background of mononuclear tumor cells (*arrowhead*).

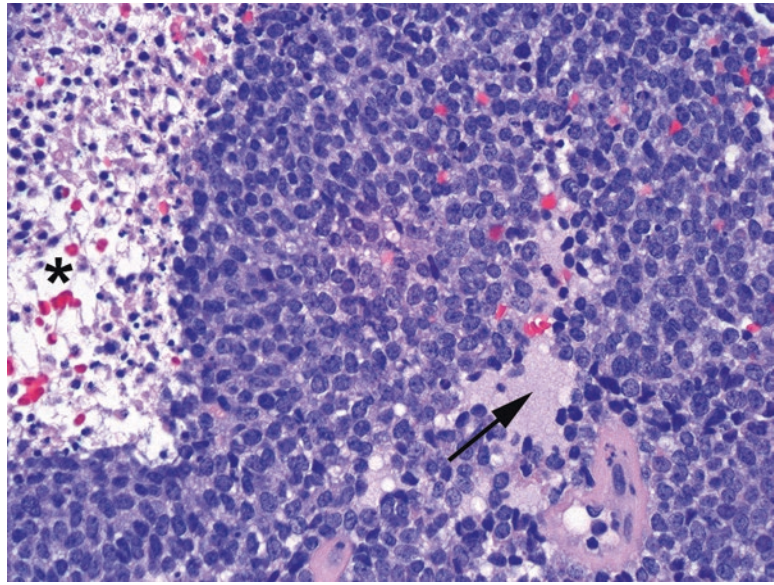


FIGURE 30.13. Ewing sarcoma. This small round blue cell tumor is very monomorphic and primitive. Small islands of neuropil (*arrow*) and necrosis (*asterisk*) are visible.

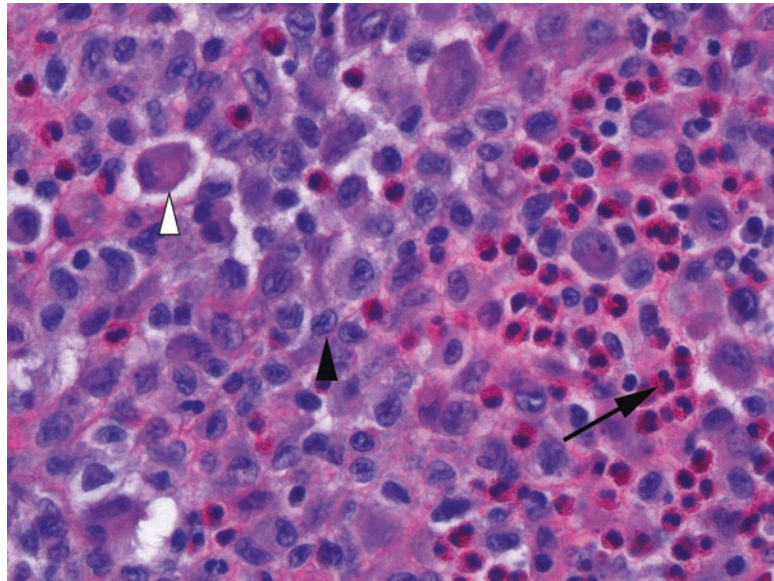


FIGURE 30.14. Langerhans cell histiocytosis is composed of Langerhans cell histiocytes, S100 and CD1a-positive cells with small, pale, cleaved, coffee-bean-like nuclei (*arrowhead*) and purple cytoplasm (*white arrowhead*). A background of eosinophils may be the most eye-catching feature (*arrow*).

Bones may acquire *simple* or *unicameral bone cysts*, a fluid-filled space often lined by a hyaline-membrane-type layer. The *aneurysmal bone cyst* (ABC) is a neoplasm characterized by multilocular cysts filled with blood that may dramatically distort and expand the bone, simulating malignancy. The stroma of the ABC somewhat resembles granulation tissue, with abundant giant cells and spindle cells (Figure 30.16); the most important tumor not to miss here is the telangiectatic osteosarcoma.

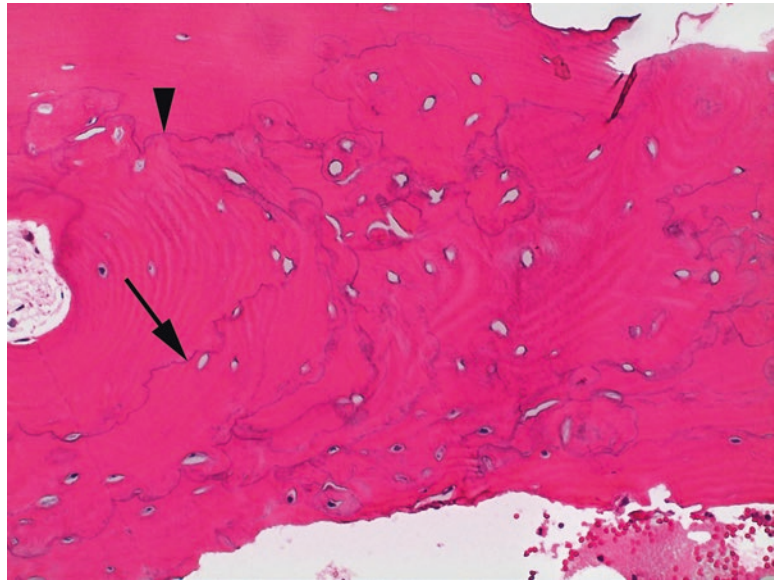


FIGURE 30.15. Paget's disease. This condition is characterized by chaotic remodeling, which is reflected in the jumbled and scalloped tide lines within trabeculae (*arrow*). Tide lines intersecting at right angles (*arrowhead*) are abnormal.

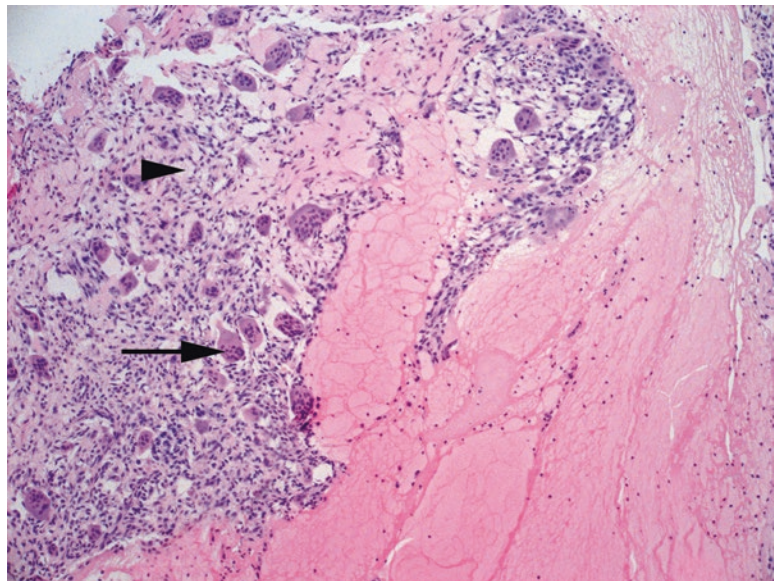


FIGURE 30.16. Aneurysmal bone cyst. There are abundant lakes of blood (*right side*, here mostly fibrin) separated by seams of spindly granulation tissue (*arrowhead*) containing giant cells (*arrow*). This can be a primary lesion or may arise as a secondary component of other tumors.

Joint Tumors (Table 30.4)

Synovial chondromatosis is one of the few true tumors of the joint space. It is characterized by the accumulation of nodules of benign cartilage in the synovium. *Pigmented villonodular synovitis* (PVNS) is another one of the few lesions that involve the joint space. It is composed of a villous or papillary mass of small bland cells, multinucleated giant cells, and foamy macrophages (Figure 30.17). There are prominent clefted spaces at low power and sometimes pigment (hemosiderin).

TABLE 30.4. Joint lesions.

Benign	Malignant
Pigmented villonodular synovitis	Malignant giant cell tumor (rare)
Synovial lipoma	
Synovial chondromatosis	

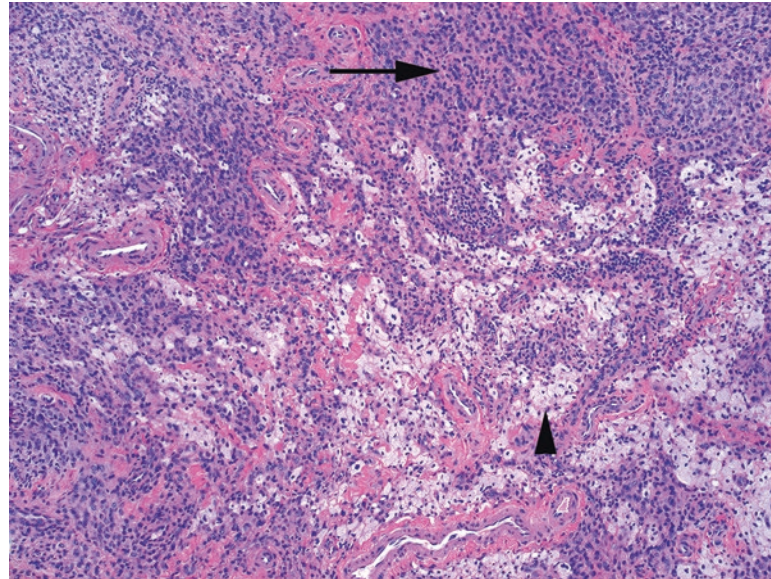


FIGURE 30.17. PVNS. The main cell types are mononuclear cells (*arrow*), foamy histiocytes (*arrowhead*), and giant cells (not seen here). Hemosiderin is common. This field of view could represent PVNS or localized tenosynovial giant cell tumor.

The term *giant cell tumor of tendon sheath* actually describes two entities: PVNS, which is multinodular and diffuse, and the single-nodule form of the same tumor, *localized tenosynovial giant cell tumor* or *nodular tenosynovitis*. Aside from presenting as a nodule on a tendon, its appearance is very similar to PVNS. The lesion is composed of bland mononuclear cells, giant cells, foamy histiocytes, cleft-like spaces, and hemosiderin, all set in a collagenous stroma. Both of the giant cell tumors of tendon sheath are distinguished from the giant cell tumor of the bone by their immunoreactivity to CD68, a histiocyte marker, as well as by their clinical presentation. However, they do resemble each other on H&E.

Radiologic and Histologic Differential Diagnoses (Table 30.5)

As discussed at the beginning of the chapter, x-ray findings offer significant information about the differential diagnosis. As in dermatopathology, in which the clinical impression and the histological differential ideally form a Venn diagram with a single entity in the overlap, many times you cannot make a diagnosis in the bone without the radiologic findings. So, although you would not attempt to interpret radiographs without a radiologist, a working familiarity with some basic differentials is helpful.

TABLE 30.5. Differential diagnoses.

Radiologic finding	Differential diagnosis and clues
Well-defined lytic lesion of the epiphysis, extending to the joint surface	Giant cell tumor (skeletally mature patients) Chondroblastoma (can span an open physis)
Well-defined lytic lesion of the long bones, metaphysis or diaphysis (often incidentally discovered, usually young patients)	Fibrous dysplasia (ground glass appearance) Non-ossifying fibroma (eccentric, cortical defect) Simple (unicameral) cyst Chondromyxoid fibroma
Expansile, lytic lesion	Giant cell tumor of bone (extends to the epiphysis) Aneurysmal bone cyst (fluid-fluid levels are classic) Giant cell tumor of bone Osteosarcoma, especially telangiectatic Osteoblastoma, especially in vertebral bodies
Blastic or sclerotic lesion	Metastatic carcinoma, classically prostate or carcinoid Treated metastatic carcinoma from any site Paget's disease Osteosarcoma
Mixed lytic and sclerotic lesion, often with periosteal reaction	Osteosarcoma (aggressive lesion) Osteoid osteoma/osteoblastoma (sclerotic rim)
Aggressive lesions (poorly circumscribed, infiltrative, with a permeative pattern)	Infection Osteosarcoma Ewing sarcoma Lymphoma, metastases, myeloma Langerhans cell histiocytosis
Surface (cortical or protruding) lesions	Osteochondroma (mushroomlike) Parosteal osteosarcoma Periosteal osteosarcoma (chondroblastic) Juxtacortical chondroma Myositis ossificans (technically outside the bone)
Central (medullary) lesions	Fibrous dysplasia Enchondroma Simple cyst
Eccentric lesions	Giant cell tumor of bone Non-ossifying fibroma Aneurysmal bone cyst Chondromyxoid fibroma
<i>Histologic patterns</i>	
Small round blue cell tumor	Ewing sarcoma Lymphoma Metastasis
Giant cell-rich lesions (Figure 30.18)	Small cell osteosarcoma Giant cell tumor of bone Aneurysmal bone cyst Non-ossifying fibroma Chondroblastoma
Blood-filled lesion	Aneurysmal bone cyst Telangiectatic osteosarcoma Hemangioma or other vascular tumors Metastatic carcinoma, especially renal cell carcinoma
Woven bone formation and osteoid deposition, poorly organized	Fracture repair Giant cell tumor of bone Aneurysmal bone cyst Osteoid osteoma/osteoblastoma Osteosarcoma
Woven bone formation and osteoid deposition, distinct trabeculae	Fracture repair Fibrous dysplasia Ossifying fibroma Parosteal osteosarcoma

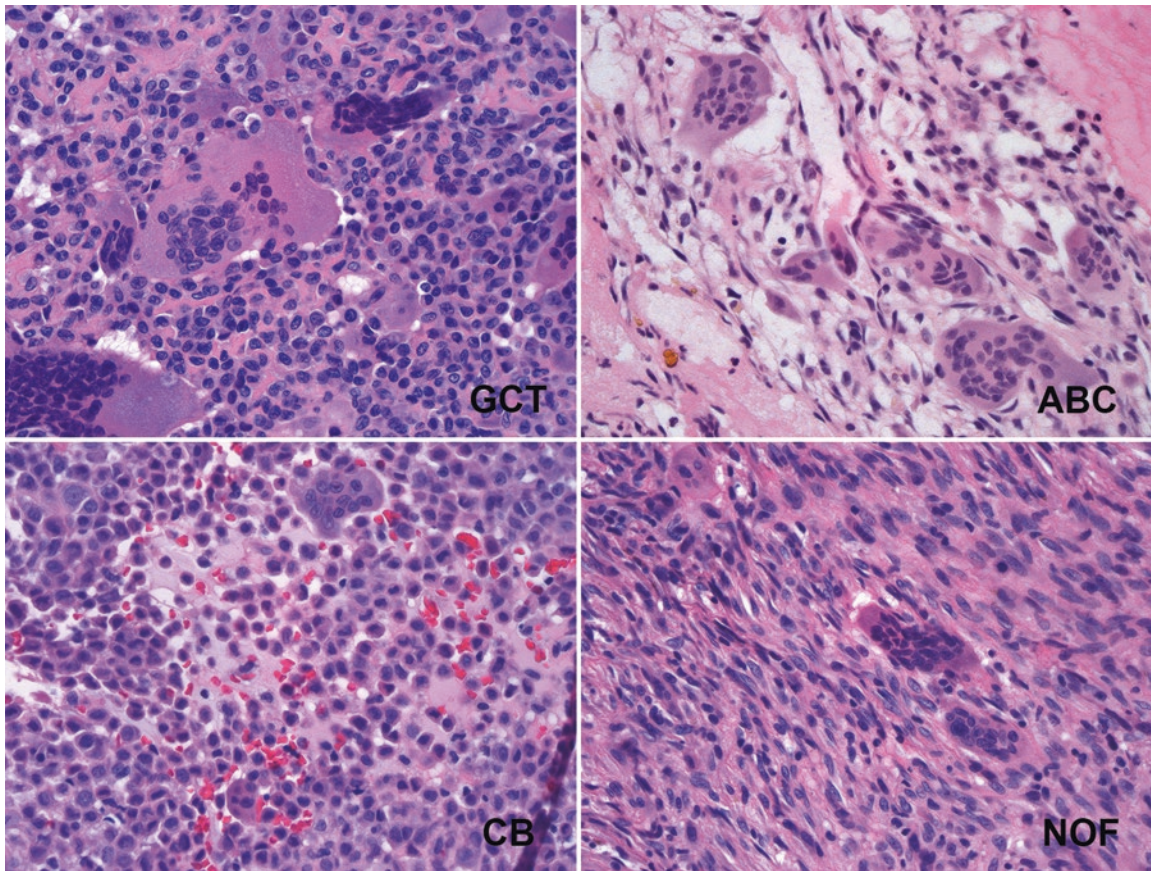


FIGURE 30.18. Giant cell-rich tumors. (*GCT*) Giant cell tumor is identified by the syncytial mass of tumor nuclei which exactly mirror the nuclei inside the giant cells. (*ABC*) Aneurysmal bone cyst has giant cells set in a loose background resembling granulation tissue. (*CB*) Chondroblastoma cells are plump pink round cells which, like decidualized cells in endometrium, have discrete cell outlines. (*NOF*) Non-ossifying fibroma is a spindle-cell lesion which may also have abundant giant cells.

31 A Primer on Immunostains

The use of immunostains is a highly complex field in and of itself and one that is changing so rapidly that no printed text can really keep up. This chapter is meant as an introduction to the most commonly used stains so that you can at least follow the thread of conversation when the acronyms begin to fly. Stains are organized by the organ system in which they are most often used. A much more comprehensive reference is Rekhtman and Bishop's *Quick Reference Handbook for Surgical Pathologists*.

TABLE 31.1. Blood vessels (endothelium).

Antibody	Normal tissues stained	When it is used
CD31	Endothelial cells and megakaryocytes (cytoplasmic and membranous), also macrophages	To identify endothelial differentiation or angiosarcoma; most specific endothelial marker
CD34	Endothelial cells, fibroblasts, and hematopoietic blasts (cytoplasmic and membranous)	To identify vascular sarcomas, Kaposi sarcoma, solitary fibrous tumor, DFSP, epithelioid sarcoma, plus some other soft tissue tumors. Synovial sarcoma is negative
D240	Lymphatic endothelium (cytoplasmic)	To identify vascular differentiation or lymphatics; also marks mesothelium
FVIII	Endothelial cells, megakaryocytes, platelets (cytoplasmic)	To identify endothelial differentiation, specific but not very sensitive

DFSP dermatofibrosarcoma protuberans

TABLE 31.2. Brain and meninges.

Antibody	Normal tissues stained	When it is used
EMA	Epithelial, perineural, meningothelial cells (cytoplasmic or membranous)	To identify meningioma, perineuroma, chordoma. Germ cell tumors (excluding some teratomas) are negative
GFAP	Glial cells (cytoplasmic)	To identify astrocytoma and ependymoma; also myoepithelial tumors of salivary gland
IDH1	None: antibody stains mutant IDH1 (cytoplasmic)	To subclassify glial tumors (IDH1 mutated)
INI1	All normal cells (nuclear)	To identify atypical teratoid/rhabdoid tumor (loss of staining)
NSE (neuronal-specific enolase)	Neuroectodermal and neuroendocrine cells (cytoplasmic)	To identify neural differentiation but not very specific (<i>not</i> the same as nonspecific esterase, an enzyme assay for heme path). Sensitive for neuroblastoma
S100	Glial cells, Schwann cells, dendritic and Langerhans cells, melanocytes, and other mesenchymal cells (nuclear and cytoplasmic)	To identify cellular schwannoma, astrocytomas, granular cell tumor, chordoma, ependymoma, MPNST, and melanocytic lesions (all types)
Synaptophysin	Neuroendocrine cells (cytoplasmic)	To identify neuroendocrine tumors, paraganglioma, pheochromocytomas, small cell carcinoma, neuroblastoma, and others. Differentiates neural differentiation (positive) from glial (negative)

MPNST malignant peripheral nerve sheath tumor

TABLE 31.3. Breast.

Antibody	Normal tissues stained	When it is used
CK903 (CK5/6 is similar)	Myoepithelial cells (cytoplasmic and membranous) and usual duct hyperplasia	To differentiate usual ductal hyperplasia (positive) from ductal carcinoma in situ (negative). Also stains metaplastic carcinoma
E-cadherin	Normal ductal and lobular cells (membranous)	Loss of staining identifies lobular carcinoma (in situ and invasive); ductal lesions are positive
ER and PR	Estrogen receptor (nuclear) and progesterone receptor (nuclear)	For breast cancer prognosis (predicts response to tamoxifen) and to identify metastatic breast cancer, some gynecologic tumors, and others
GATA3	Breast epithelium (nuclear)	To identify breast differentiation in carcinoma; sensitive but not specific
GCDFP	Apocrine metaplasia of the breast and apocrine sweat glands (cytoplasmic)	To identify breast differentiation in carcinoma, also sweat and salivary gland carcinoma
Her2	Growth factor receptor that is only weakly expressed in normal epithelial cells (membranous)	To evaluate breast carcinomas (overexpression is a poor prognostic sign but can be treated with Herceptin)
Mammaglobin	Normal breast tissue (cytoplasmic)	To identify breast differentiation in carcinoma, also sweat and salivary gland carcinoma
<i>Stains that identify myoepithelial cells to rule out invasive carcinoma</i>		
Calponin	Myoepithelial cells (cytoplasmic)	To delineate myoepithelial layer
p63	Tumor suppressor gene (nuclear)	Stains myoepithelial cells but not endothelium and fibroblasts. Also stains metaplastic carcinoma
Smooth muscle myosin heavy chain (SMMHC)	Myoepithelial cells, blood vessels, myofibroblasts (cytoplasmic)	To delineate myoepithelial layer
Smooth muscle actin (SMA)	Smooth muscle: myoepithelial cells, blood vessels, myofibroblasts (cytoplasmic)	To delineate myoepithelial layer; also stains myofibroblasts

TABLE 31.4. Cytokeratins.

Antibody	Normal tissues stained	When it is used
AE1–AE3 (pankeratin)	Wide panel of keratins stains most epithelial cells (cytoplasmic), except cytokeratins 8 and 18	To identify carcinomas in general; used in conjunction with cam 5.2 to screen for carcinoma
EMA	Epithelial, perineural, meningothelial cells (cytoplasmic or membranous)	To identify meningioma, many carcinomas, plus some sarcomas (synovial sarcoma, epithelioid sarcoma), and plasma cell neoplasms. Germ cell tumors (excluding some teratomas) are negative
<i>Entities that are EMA-positive, keratin-negative: meningioma, perineuroma, plasma cell myeloma</i>		
High-molecular-weight keratins		
CK5/6	High-molecular-weight keratins, mainly in squamous and urothelial epithelia (cytoplasmic)	To differentiate squamous cell carcinoma (positive) or mesothelioma (positive) from adenocarcinoma (negative)
CK903 (34BE12)	High-molecular-weight keratins, mainly in squamous and urothelial epithelia (cytoplasmic and membranous)	To identify prostatic basal cells (loss of staining indicates carcinoma) and urothelial carcinoma (positive); also metaplastic breast carcinoma
Low-molecular-weight keratins		
CK7	A specific low-molecular-weight cytokeratin (cytoplasmic, membranous)	CK7 and CK20 are used in combination to narrow the differential of carcinoma of unknown origin. CK7 is generally positive in above-the-diaphragm carcinomas (see below on CK7 and CK20)
CK20	A specific low-molecular-weight cytokeratin (cytoplasmic, membranous)	Generally positive in below-the-diaphragm carcinomas and in Merkel cell carcinoma (see below on CK7 and CK20)
cam 5.2	Low- and intermediate-molecular-weight keratins 8, 18, and 19, in nonsquamous epithelia (cytoplasmic)	Used in conjunction with AE1/AE3 to screen for carcinoma. Also to identify hepatocellular carcinoma, some adrenal cortical tumors, and some carcinomas that are negative for other keratins (undifferentiated carcinoma)
7/20 matrix	CK20⁺	CK20⁻
CK7⁺	Urothelial carcinoma Pancreatic carcinoma Ovarian mucinous carcinoma	Breast carcinoma Lung carcinoma, non-small cell Ovarian serous carcinoma Endometrial carcinoma Epithelial mesothelioma Thymoma
CK7⁻	Colorectal carcinoma Merkel cell carcinoma	Hepatocellular carcinoma Renal cell carcinoma, clear cell type Prostate carcinoma Neuroendocrine small cell carcinoma Squamous cell carcinoma

TABLE 31.5. Germ cell and testis.

Antibody	Normal tissues stained	When it is used
β-hCG	Human chorionic gonadotropin β-chain (cytoplasmic) in syncytiotrophoblasts	To identify choriocarcinoma and germ cell tumors, some adenocarcinoma
CD30	Activated lymphocytes (cytoplasmic)	To identify embryonal carcinoma, Hodgkin lymphoma, and ALCL
c-kit (CD117)	Germ cells, mast cells, interstitial cells of Cajal (cytoplasmic or membranous)	To identify seminoma (membranous) and mature teratoma, plus GIST in the stomach
OCT3/4	Developing brain and stem cells (nuclear)	To identify seminoma, embryonal carcinoma, and GCNIS
PLAP	Placenta (cytoplasmic)	To identify germ cell tumors, GCNIS
SALL4	Fetal tissues, germ cells (nuclear)	To identify germ cell tumors (sensitive but not specific)
SOX2	Stem cells (nuclear)	To identify embryonal carcinoma; also stains squamous carcinomas

ALCL anaplastic large cell lymphoma, GCNIS germ cell neoplasia in situ, GIST gastrointestinal stromal tumor

TABLE 31.6. Gynecologic.

Antibody	Normal tissues stained	When it is used
Actin, desmin	Smooth muscle cells, myometrium (cytoplasmic)	To identify leiomyomas or leiomyosarcomas
β -hCG	Syncytiotrophoblasts (cytoplasmic)	To identify choriocarcinoma and germ cell tumors
CD10	Endometrial stroma (cytoplasmic)	To identify endometrial stroma and stromal sarcoma
ER, PR	Ovarian and endometrial tissues (nuclear)	To differentiate between some carcinomas and to identify treatment responsiveness
Inhibin	Granulosa cells, Sertoli cells, and others (cytoplasmic)	To identify sex cord stromal tumors (granulosa, Sertoli, and Leydig cells) and hydatidiform moles, choriocarcinomas, fibrothecomas, and adrenal cortical tumors
Napsin A	Pneumocytes, lung (cytoplasmic)	To identify clear cell carcinoma of the ovary, as well as lung carcinomas
PAX8	Renal and Mullerian tissues (nuclear)	To identify nonmucinous tumors of GYN origin, also stains renal and thyroid tumors
p16	Cells infected by HPV (nuclear), also benign tubal metaplasia	To identify HSIL and HPV lesions of the cervix and to differentiate between endocervical (positive) and endometrial (negative) adenocarcinoma; serous carcinoma also positive
p53	Tumor suppressor gene variant that should be absent in normal cells (nuclear)	To identify serous carcinoma of endometrium or the ovary, to identify STIC
p57	Expressed in trophoblastic cells (nuclear)	To confirm complete hydatidiform mole (negative); only expressed in maternally derived chromosomes
WT-1	Tumor suppressor gene in developing nephrons (nuclear)	To identify ovarian serous carcinoma; endometrial serous carcinoma is usually negative

HPV human papillomavirus, *HSIL* high-grade squamous intraepithelial lesion, *STIC* serous tubal intraepithelial carcinoma

TABLE 31.7. Heme path.

Antibody	Normal tissues stained	When it is used
ALK	Fusion protein expressed in tumor cells (cytoplasmic)	Stains a subset of ALCL and DLBCL. Hodgkin lymphoma is negative
bcl-2	Inhibits apoptosis and normally turns <i>off</i> in a germinal center (membranous and cytoplasmic stain)	To differentiate follicular lymphoma (positive) from reactive follicles (negative). Also stains mantle cell lymphoma. Burkitt lymphoma should be negative
bcl-6	Germinal center cells (cytoplasmic)	To identify lymphomas of follicular origin and subclassify DLBCL
CD1a	Thymocytes (immature T cells) and Langerhans cells (membranous)	To identify Langerhans cell proliferations, T-LBL
CD3, 4, 5, 7, 8	T cells	To identify T cell lymphomas and leukemias; CD4 is also dimly positive in monocytic/histiocytic lesions
CD10	Precursor B and T cells, granulocytes (membranous)	To identify ALL, LBL, Burkitt lymphoma, and CML; to subclassify DLBCL; MALTomas are negative
CD20	B cells (cytoplasmic and membranous)	Used as a pan-B cell marker; stains B cell lymphomas, but plasmacytomas are negative
CD15 (LeuM1)	Granulocytes and macrophages (membranous and dot-like perinuclear)	To identify RS cells, some large T cell lymphomas, and mycosis fungoides
CD23	B cells, IgE receptor (membranous)	To identify SLL/CLL; mantle cell lymphomas are negative
CD30	Activated B and T cells, immunoblasts, and other nonheme cell types (cytoplasmic, membranous)	To identify RS cells, ALCL, large B and T cell lymphomas; also stains embryonal carcinoma

(continued)

TABLE 31.7. (continued)

Antibody	Normal tissues stained	When it is used
CD34	Hematolymphoid blasts, fibroblasts, and endothelial cells (cytoplasmic and membranous)	To identify blasts in the marrow in acute leukemias
CD45 (LCA)	Lymphocytes, granulocytes, and histiocytes, but not plasma cells (cytoplasmic, membranous)	To identify neoplasms of hematopoietic origin
CD56	NK cells (membranous)	To identify NK/T cell lymphomas
CD68	Histiocytes/macrophages/monocytes, granulocytes, and others (cytoplasmic, membranous)	To identify histiocytic origin; also stains some soft tissue tumors
CD79a	B cells and plasma cells (membranous)	To identify B cell neoplasms negative for other B cell markers, especially in the context of Rituxan treatment; stains B-ALL and B lymphomas, myelomas
CD138	Plasma cells (membranous), epithelial cells	To identify plasma cell neoplasms
Cyclin D1	Nuclear stain in mantle cell lymphoma	To identify mantle cell lymphoma
EBV EBER	EBV RNA in infected B cells (nuclear)	To identify EBV-related tumors, including nasopharyngeal carcinoma, posttransplantation/HIV lymphomas
FVIII (vWF)	Stains megakaryocytes, platelets, and endothelial cells, (cytoplasmic)	To identify megakaryocytic leukemias
Kappa and lambda	Light chains of immunoglobulins in plasma cells and B cells (cytoplasmic)	Restricted kappa or lambda staining indicates a monoclonal population of B or plasma cells
Ki67	Any proliferating cell (nuclear)	To gauge mitotic activity and identify Burkitt lymphoma (100 % positivity)
MPO	Enzyme granules in myeloid lineage cells (cytoplasmic)	To identify AML and myeloid sarcoma (chloroma)
MUM-1	Lymphocytes at certain phases of differentiation (nuclear, cytoplasmic)	To subclassify DLBCL into germinal center or non-germinal center types
TdT	Immature lymphocytes (nuclear)	To identify LBL and ALL

ALCL anaplastic large cell lymphoma, *ALL* acute lymphocytic leukemia, *AML* acute myeloid leukemia, *CML* chronic myeloid leukemia, *DLBCL* diffuse large B cell lymphoma, *EBV* Epstein-Barr virus, *HIV* human immunodeficiency virus, *LBL* lymphoblastic lymphoma, *MALT* mucosa-associated lymphoid tissue, *NK* natural killer, *RS* Reed-Sternberg, *SLL/CLL* small lymphocytic lymphoma/chronic lymphocytic leukemia

TABLE 31.8. Kidney and bladder.

Antibody	Normal tissues stained	When it is used
CAIX	Nonrenal tissues (membranous)	To identify renal cell carcinoma, especially clear cell type
CK7	A specific low-molecular-weight cytokeratin (cytoplasmic, membranous)	To differentiate chromophobe carcinoma (strongly positive) from oncocytoma (patchy positive or negative)
GATA3	Breast and renal epithelium (nuclear)	To differentiate urothelial (positive) from renal (negative) neoplasms
HMB-45	Melanocytes (cytoplasmic)	To identify angiomyolipoma; also stains melanoma
Melan-A	Melanocytes (cytoplasmic)	To identify angiomyolipoma; also stains melanoma and adrenal cortical tumors
PAX8	Renal and Mullerian tissues (nuclear)	To identify renal differentiation in tumors
RCC	Proximal renal tubules (cytoplasmic)	To identify renal differentiation in tumors (older marker, less sensitive)
TFE3	Transcription factor (nuclear)	To identify Xp11-translocation RCC and alveolar soft part sarcoma
TFE3B	Transcription factor (nuclear)	To identify t(6:11) renal cell carcinoma
Thrombomodulin	Both endothelial (cytoplasmic) and mesothelial (membranous) cells	To identify urothelial carcinoma, mesothelioma, and some vascular tumors
WT-1	Tumor suppressor gene in developing nephrons; nephrogenic rests and adult glomerular podocytes (nuclear)	To identify Wilms tumor; also mesothelioma, desmoplastic small round cell tumor

RCC renal cell carcinoma

TABLE 31.9. Liver, pancreas, and gastrointestinal.

Antibody	Normal tissues stained	When it is used
AFP	Fetal tissues (granular cytoplasmic)	To identify hepatocellular tumors and yolk sac tumors. May also stain other carcinomas
Arginase	An enzyme in the urea cycle, found in the liver (cytoplasmic)	To identify hepatocellular tumors (very sensitive)
C-reactive protein	Acute phase reactant in hepatocytes (cytoplasmic)	To subtype hepatic adenomas (stains telangiectatic adenomas)
CDX-2	A transcription factor in intestinal epithelium (nuclear)	To identify GI origin (especially lower GI) in adenocarcinoma
c-kit (CD117)	Mast cells, interstitial cells of Cajal (cytoplasmic and membranous)	To identify GIST
DOG-1	Interstitial cells of Cajal (cytoplasmic and membranous)	To identify GIST (more sensitive than c-kit)
DPC-4 clone B8	Most normal tissues (cytoplasmic)	To identify pancreatic carcinoma (55% of in situ or invasive cancers exhibit loss of staining)
Glypican-3	Fetal liver and trophoblasts (cytoplasmic)	To identify HCC; should be negative in adenoma and FNH
HepPar1 (OCH1E5)	Mitochondria in normal hepatocytes (granular cytoplasmic stain)	To identify hepatocellular tumors
pCEA	Fetal tissues and adenocarcinomas (cytoplasmic)	A canalicular pattern in HCC (not seen with mCEA); also stains lung, colon, pancreatic carcinoma
Trypsin, chymotrypsin	Enzymes in acinar cells of the pancreas (cytoplasmic)	To identify acinar cell carcinoma, pancreas
α_1 -Antitrypsin	Histiocytes and reticulum cells (cytoplasmic)	To highlight globules of α_1 -antitrypsin disease in the liver; not specific to a tumor
β -Catenin	APC-binding protein present in most cells (only nuclear staining is significant; indicates a mutation in APC or β -catenin)	To subtype hepatic adenomas, also stains abdominal fibromatosis and solid pseudopapillary tumor of the pancreas

APC activated protein C, *FNH* focal nodular hyperplasia, *GIST* gastrointestinal stromal tumors, *HCC* hepatocellular carcinoma, *mCEA* monoclonal carcinoembryonic antigen

TABLE 31.10. Lungs, pleura.

Antibody	Normal tissues stained	When it is used
<i>Markers of mesothelium</i>		
Calretinin	Various neural and epithelial cells (cytoplasmic and nuclear)	To differentiate epithelial mesothelioma (positive) from carcinoma (negative)
D2-40 (podoplanin)	Mesothelium (membranous)	To differentiate epithelial mesothelioma (positive) from carcinoma (negative)
WT-1	Mesothelium (nuclear)	To differentiate epithelial mesothelioma (positive) from carcinoma (negative)
<i>Markers of adenocarcinoma</i>		
BerEP4	Epithelial cells (membranous)	To differentiate mesothelioma (negative) from adenocarcinoma (positive)
mCEA and pCEA	Fetal tissues and mucin-secreting glandular tissues (cytoplasmic)	To differentiate mesothelioma (negative) from adenocarcinoma (positive)
MOC-31	Epithelial cells (membranous)	To differentiate mesothelioma (negative) from adenocarcinoma (positive)
Napsin A	Pneumocytes (cytoplasmic)	To identify adenocarcinoma of the lung
p40 (also p63)	Transcription factor in squamous epithelium (nuclear)	To identify squamous differentiation in lung carcinoma
PD-L1, PD-1	Proteins overexpressed in some tumors (membranous)	To predict response to specific therapeutic antibodies
TTF-1	Transcription factor in the lung and thyroid (nuclear)	To differentiate nonsquamous carcinoma of lung origin (including adenocarcinoma, small cell, and neuroendocrine: all positive) from non-pulmonary (negative)

TABLE 31.11. Melanoma.

Antibody	Normal tissues stained	When it is used
HMB-45	Immature melanocytes (cytoplasmic)	To identify epithelioid melanoma, metastatic melanoma, angiomyolipoma, clear cell sarcoma, perivascular epithelioid cell tumors, and others
MART-1	Melanocytes (cytoplasmic)	To identify melanoma (mainly epithelioid), more sensitive than HMB-45. Recognizes the same protein as Melan-A antibody
Melan-A (A103 clone)	Melanocytes (cytoplasmic)	To identify melanoma (mainly epithelioid), more sensitive than HMB-45; also angiomyolipoma. Unlike MART-1, labels steroid cell tumors (adrenocortical tumors, Sertoli and Leydig cell tumors)
MitF	Melanocytes (nuclear)	To identify melanoma and melanocytic tumors, also angiomyolipoma
S100 protein	Melanocytes, glial cells, dendritic and Langerhans cells, and other mesenchymal cells (nuclear and cytoplasmic)	To identify nevi and melanoma (all types, most sensitive), cellular schwannoma, granular cell tumor, glial neoplasms. Not used to screen lymph nodes, as normal dendritic cells are positive
SOX10	Melanocytes, nerves, and some glandular tissues (nuclear)	To identify melanoma; also stains other neural tumors and tissues

TABLE 31.12. Neuroendocrine and endocrine.

Antibody	Normal tissues stained	When it is used
CD56	Some neural cells, NK cells (membranous)	To identify neuroendocrine differentiation, especially in small cell carcinoma
Chromogranin	Neurosecretory granules (cytoplasmic, granular) in endocrine tissues and neurons	To differentiate pheochromocytoma (positive) from adrenal cortical carcinoma (negative) or to identify carcinoids and small cell, Merkel cell, and islet cell tumors
Inhibin	Adrenal cortical cells (cytoplasmic)	To identify adrenal cortical tumors, stromal sex cord tumors (granulosa, Sertoli, and Leydig cells)
Melan-A	Melanocytes (cytoplasmic) and adrenal cortex	To identify adrenal cortical tumors, stromal sex cord tumors (granulosa, Sertoli, and Leydig cells)
Synaptophysin	Neuroendocrine cells (cytoplasmic), neuromuscular junction, Merkel cells	To identify carcinoids, paragangliomas, pheochromocytomas, small cell carcinoma, medullary carcinoma of the thyroid, neuroblastoma, islet cell tumors, and others
Various hormones	Cells that produce insulin, somatostatin, gastrin, glucagon, parathyroid hormone, etc. (cytoplasmic)	To identify products of neuroendocrine tumors, such as islet cell tumors and others

TABLE 31.13. Prostate.

Antibody	Normal tissues stained	When it is used
AR	Androgen-receptive tissues, prostate (nuclear)	To identify metastatic prostate cancer
CK903 (34BE12)	High-molecular-weight keratin (cytoplasmic and membranous) in basal cells	To identify prostatic basal cells (loss of staining indicates carcinoma) and urothelial carcinoma (positive)
p63	Prostatic gland basal cells (nuclear)	To identify basal cells (loss of staining indicates carcinoma)
Prostein (p501s)	Prostatic epithelium (cytoplasmic)	To identify metastatic prostate cancer (very sensitive)
PSA	Prostatic epithelium (cytoplasmic), also salivary gland	To identify metastatic prostate cancer. Seminal vesicle is negative
PSAP (PAP)	Prostatic epithelium (cytoplasmic)	To identify metastatic prostate cancer; also stains rectal carcinoids
PSMA	Prostatic epithelium (cytoplasmic)	To identify metastatic prostate cancer (very sensitive)
Racemase (p504s)	Prostatic carcinoma	To confirm prostate carcinoma in prostate biopsies; also stains nephrogenic adenoma of the bladder

TABLE 31.14. Soft tissue.

Antibody	Normal tissues stained	When it is used
α -Actin	Smooth muscle actin (cytoplasmic)	To identify smooth muscle differentiation, leiomyoma, and leiomyosarcoma; rhabdomyosarcoma is usually negative
Actin (HHF-35)	Smooth, skeletal, and cardiac muscle, myoepithelial cells (cytoplasmic)	To identify muscle differentiation
β -Catenin	APC-binding protein present in most cells (only nuclear staining is significant; indicates a mutation in APC or β -catenin)	To identify desmoid fibromatosis
c-kit (CD117)	Mast cells, interstitial cells of Cajal (cytoplasmic and membranous)	To identify GIST, also seminoma, mature teratoma, and leukemias
CD34	Fibroblasts, endothelial cells, and hematopoietic blasts (cytoplasmic and membranous)	To identify SFT, DFSP, and vascular sarcomas plus other soft tissue tumors
CD99 (O13)	A variety of mesenchymal cells (membranous)	To identify PNET/Ewing sarcoma, lymphocytes in thymoma, plus other sarcomas and hematologic tumors. Neuroblastoma is negative
Desmin	Intermediate filaments in smooth, striated, and cardiac muscle (cytoplasmic)	To identify muscle differentiation, including rhabdomyosarcoma, some leiomyosarcomas, and others
EMA	Epithelial, perineural, meningeal cells (cytoplasmic or membranous)	To identify some sarcomas (synovial sarcoma, epithelioid sarcoma) plus chordoma, meningioma, mesothelioma, perineural tumors, and plasma cell tumors
HMB-45	Immature melanocytes (cytoplasmic)	To identify angiomyolipoma, clear cell sarcomas, PEComas, and others; also epithelioid and metastatic melanomas
Myogenin	Regenerating, but not normal, skeletal muscle (cytoplasmic)	To identify rhabdomyosarcoma
Pankeratin	Epithelial cells (membranous, cytoplasmic)	To identify epithelioid sarcoma, also stains epithelioid vascular tumors
S100	Glial cells, melanocytes, dendritic and Langerhans cells, and other mesenchymal cells (nuclear and cytoplasmic)	To identify cellular schwannoma, granular cell tumors, MPNST, chondrosarcoma, melanomas (all types), and astrocytoma
Vimentin	Most mesenchymal cells (cytoplasmic), including fibroblasts, endothelium, smooth muscle	As an internal control for immunoreactivity and antigen preservation (the "pankeratin" of soft tissue)
WT-1	Tumor suppressor gene in developing nephrons; nephrogenic rests and adult glomerular podocytes (nuclear)	To identify desmoplastic small round cell tumor, also Wilms tumor

DFSP dermatofibrosarcoma protuberans, *GIST* gastrointestinal stromal tumor, *MFH* malignant fibrous histiocytoma, *MPNST* malignant peripheral nerve sheath tumor, *PEComa* perivascular epithelioid cell tumor, *PNET* primitive neuroectodermal tumor, *SFT* solitary fibrous tumor

TABLE 31.15. Thyroid.

Antibody	Normal tissues stained	When it is used
Calcitonin	C cells of the thyroid (cytoplasm and extracellular material)	To identify medullary carcinoma of the thyroid
PAX8	Renal and Mullerian tissues (nuclear)	To identify anaplastic carcinoma of thyroid and other thyroid carcinomas
Thyroglobulin	Thyroid follicles (cytoplasmic)	To identify metastatic thyroid carcinoma
TTF-1	Transcription factor in the lung and thyroid (nuclear)	To identify thyroid carcinoma, including follicular, papillary, and medullary; also nonsquamous carcinoma of the lung (adenocarcinoma and small cell)

TABLE 31.16. Gotcha! Stains that you thought were only associated with one tumor type, and the surprise non-specificity that will lead you down the rabbit hole.

Antibody	Famous for staining	But <i>also</i> stains
ALK	Anaplastic large cell lymphoma	Some lung adenocarcinomas Inflammatory myofibroblastic tumor
CD138	Plasma cells	Some carcinomas and epithelial cells
CD34	Blood vessels	Myeloid blasts, many soft tissue tumors
CD56	Small cell carcinoma	NK/T cell lymphomas, sex cord stromal tumors
CD68	Histiocytes	Melanoma
CD99	Ewing sarcoma	ALL, synovial sarcoma, melanoma, and many others
CDX-2	GI carcinomas	Some lung carcinomas with intestinal differentiation
c-kit/CD117	GIST	Seminoma, AML, and others
Cyclin D1	Mantle cell lymphoma	Undifferentiated uterine sarcoma Plasma cell myeloma, some carcinomas
D2-40	Mesothelium, lymphatics	Germ cell tumors
E-cadherin	Epithelial cell membranes	RBC precursors in the marrow
ER	Breast and GYN tumors	Some NETs
GATA-3	Breast and urothelial carcinomas	Mesothelioma, cutaneous adnexal carcinoma, squamous cell carcinoma, pancreatic carcinoma, paraganglioma, and some T cell lymphomas
Glypican-3	Hepatocellular carcinoma	Some squamous and ovarian carcinomas, melanoma
HepPar	Hepatocellular carcinoma	Many other adenocarcinomas, sporadically
HMB-45 and Melan-A	Melanoma	Angiomyolipoma and PEComas Alveolar soft part sarcoma Adrenal cortical or sex cord stromal tumors (Melan-A)
Keratins	Carcinoma	Angiosarcoma, myeloma
Mammaglobin, GCDFP	Breast tumors	Cutaneous adnexal tumors
Napsin A	Lung carcinoma	Clear cell carcinoma of the ovary Papillary thyroid carcinoma, renal cell carcinoma
p16	HPV-associated carcinoma	Many other high-grade carcinomas Benign tubal metaplasia in the cervix
p63, p40	Squamous carcinoma	Urothelial carcinoma, myoepithelial/basal cells, B cell lymphomas, plasma cells (p63) Giant cell tumor of the bone (p63)
PAX8	Kidney and GYN carcinomas	Thyroid tumors NET of the pancreas and duodenum
SOX10	Melanoma	Nerve sheath tumors, breast carcinoma Cutaneous adnexal tumors, salivary gland
TTF-1	Lung and thyroid carcinomas	Almost anything else, sporadically Cytoplasmic staining in the liver
WT-1	Wilms tumor and serous carcinoma of the ovary	Mesothelial cells

AML acute myeloid leukemia, *ALL* acute lymphoblastic lymphoma, *NETs* neuroendocrine tumors, *PEComa* perivascular epithelioid cell tumors

32 So You Want to Get a Job

Congratulations! You've survived residency and you are looking for a job. If you want to stay in academia, you probably have a pretty good idea of what your job will look like, and you have lots of mentors you can talk to about life in an academic hospital. But what if you are considering private practice? Private practice jobs may entail anything from subspecialty sign-out at a large reference lab to a one-person show at a tiny community hospital. Your best source of information will be other pathologists; social media makes this networking really easy now, which is a good thing, as many jobs are advertised purely by word of mouth. Pathology is a small field, so you probably know someone who knows someone who can introduce you to just about any practice in the country. Keep in touch with former graduates, and find out what they learned from their job searches.

Starting Your Search

While in residency, if you have an idea of what city or area you might like to work in, use your time on consult services to take note of the practices in that area that are sending consults. Letterheads may list the pathologists in the practice, as well as contact information. Talk to peers and faculty who may be from that area to find out about the practice climate there. Once you have some names, it's not unreasonable to start calling these practices. Find out if they anticipate hiring in the next few years, if they know what type of subspecialty training or CP expertise they might be looking for, and if you can send them a CV. Try to find out which hospitals might fall under the same group or corporate umbrella.

If you don't have a geographic preference, you may instead prefer a certain type of practice. If you are looking at subspecialty practice, track down previous graduates from your fellowship to try to narrow down what features you are looking for in a job and what part of the country has the practice climate you are looking for. Keep watching the jobs boards at Pathology Outlines (pathologyoutlines.com), journals, and professional societies to see how often your desired job description comes up and where.

Am I Marketable?

Once you've decided what you want, you may wonder who is going to want you. New graduates bring cutting-edge training to the practice, as well as enthusiasm and a willingness to learn new skills (usually!), so private practices are willing to invest time in bringing a newbie up to speed in order to get these benefits. New graduates may also be cheaper to employ than seasoned professionals, so a practice may be happy to replace a retiring senior pathologist with a brand new one.

In addition, practices are looking for:

- Someone who can get along with colleagues and with client clinicians
- Someone who can get the work done with reasonable efficiency and accuracy
- Someone who can sign out most cases independently within the first month
- Someone who is likely to stick around and be loyal to the group
- Someone who is professional, ethical, and hardworking

More specifically, community hospitals often need someone who is AP/CP certified to take over some medical directorship duties. A subspecialty fellowship may not be necessary; this is where you need to do your research in advance to find out what the needs are in your target area. If all of the local prostate biopsies go to GU-R-Us, having a GU fellowship would not bring much value to a hospital in that area (but may be just what GU-R-Us are looking for). General surgical pathology fellowships are always useful, though, especially if they give you sign-out experience that will enable you to hit the ground running.

Some Definitions

There are some definitions and concepts you should know about private practice. One is that there are two basic ways a pathology group can be organized: as employees of a larger organization (hospital or lab) or as an independent contractor. Independent contractors are privately owned practices (or, rarely, individual pathologists) that may work within a hospital setting but are paid for their services by the hospital (as opposed to being employees of the hospital). What's the difference?

Employee: The hospital/lab pays the pathologist a salary and is responsible for benefits, withholding taxes, hiring and firing, job expectations, malpractice insurance coverage, etc. The hospital bills and collects for the professional services of the pathologist.

Pros:

- A steady salary with hospital benefits
- Clear relationship to non-MD staff
- No share of financial risk
- No requirement for business acumen

Cons:

- Salary may not be linked to productivity.
- MDs are at the mercy of the administration.
- Duty obligations, hours, responsibilities, and workload are determined by the hospital.

Independent contractor: The hospital pays for the services of a privately managed group or individual. The group or individual bills for their own professional services but also must cover benefits, salary, taxes, insurance, etc. A group may be just a cohort of physicians, or they may have some overhead expenses or capital investments (office space, equipment, computer systems) and non-MD staff (transcription, pathology assistants [PAs], techs, couriers). In addition, some independent contractors may outsource their billing right back to the hospital (called reassigning) and negotiate a percentage, per diem, per discharge, or per member (capitation) reimbursement from the hospital.

Pros:

- The group determines salary, bonuses, vacation time, coverage, etc.
- Autonomy and a buffer from the policy or budget decisions of administration.
- Revenue is linked to productivity (group or individual).
- The business can grow beyond the hospital.

Cons:

- No clear relationship to, or control over, hospital and lab staff.
- All billing, collections, insurance, benefits, and business logistics must be covered and administered by the group (or outsourced).
- Business may fluctuate with hospital volume; there is financial risk.

Billing

Billing is a huge and complex topic that varies by state (and by year, as regulations change). There are some generalities about Medicare payments that are important to understand. Hospital services provided by pathologists that are paid for under Medicare Part A include all non-billable services (teaching, conferences, medical directorship, autopsies, committee work, etc.). Only a hospital can be paid for Part A services. Part A compensation for non-Medicare patients is different with every hospital—it may be handled just like Medicare or not. The hospital may pay an independent group a fixed annual fee that covers Medicare Part A services, or it may be linked to patient or test volume, productivity, or lab revenues.

Part B is billable work—whatever has a CPT code—and can be AP or CP. Part B includes a pro fee (the MD or professional fee) plus a technical fee (the work done by the lab). Pro fee + tech component = global fee. Part B can be billed to the patient/insurer by the pathologist or by the hospital on behalf of the pathologist. In addition, outpatient charges, which are usually billed per service, are handled differently from inpatient charges. Inpatient services may be reimbursed under the DRG payment (diagnosis-related group), which covers nearly all lab testing and the technical component of AP for a flat fee determined by diagnosis, or they may be covered on the basis of population health payment models, which give hospitals a fixed overall budget for services.

The reason any of this matters to you is that, especially if you are looking at an independent contractor arrangement, the way your services are paid for is your bottom line. You need to understand the basics of payment well enough to be able to ask salient questions when evaluating a job. One possible arrangement is that a practice is contracted by a hospital, which pays the practice a flat annual fee to cover Part A work (for which the hospital is reimbursed from Medicare), and the practice runs its own histology lab so it can bill global fees (professional and technical). In this scenario the risk of fluctuating volumes or reimbursement rates rests entirely on the practice, *but* if the practice has a really good year, they keep all the revenue. Another arrangement may be a practice that uses the hospital's histology lab and lets the hospital bill for technical services while the practice bills only the professional component. A third possibility is a practice that is not affiliated with a hospital at all and only does outpatient work, for which they bill global fees directly. As a new graduate, you will not be expected to be fluent in these things, but once you get to the stage of a job interview, you must get the practice to explain it to you in sufficient detail that you have some idea of the potential strengths and weaknesses of the arrangement.

Contracts and Compensation

In many private groups, there are different levels of employment. New hires are usually employees, with a fixed salary, benefits, and limited voice in the company, similar to a hospital employee. After a certain number of years, employees may be eligible to become partners or shareholders, with some stake in the company. Partnership usually comes with a buy-in, which is an initial payment for your “share” of the group's assets. If the group has a lot of capital investments, this can be substantial. On leaving a group, though, you should get that buy-in back. Partnership also comes with an increase in salary, but things that the company once covered for the employee (like CME and benefits) may now come out of your salary, as now you *are* the company. Practices differ in their ratio of partners to employees, the criteria for

getting to partnership, how compensation is determined, and whether there are year-end bonuses or an accumulation of profits from year to year.

All of these details must be spelled out in a contract. Don't seriously consider any job offer on a verbal or back-of-the-napkin basis. A contract (which may be different for employees and for partners) should spell out everything: compensation, benefits, opportunity for partnership, expectations, vacation and leave policy, conditions of termination or departure, malpractice insurance (including tail coverage, which is the insurance that covers you after you leave a group), retirement plans, and so on. The more details, the better. Have a lawyer familiar with physician contracts review it for you for red flags or omissions. If you are geographically restricted, you may end up in a take-it-or-leave-it situation, but even then, it's still important to know what you are signing up for. No practice or contract is perfect, but you must be able to make an educated choice based on known quantities, and that includes knowing how you might get out of a practice if it turns out to be a bad fit. Watch for noncompete clauses, which can bar you from taking another job within a certain radius of your old hospital.

Comparing Practices

The following 100 questions are the types of things you should know about a potential job before signing on. There is a lot of information here; some you may be able to determine from internet research, some from the interview process, and some from follow-up conversations. These are the factors that determine what your life will be like in a practice. There is no one right answer for any of these questions, but there is probably a preferred answer for you.

About the position

1. What are they looking for in a pathologist?
2. What do they see as the advantages and disadvantages of hiring a new trainee?
3. What are they hoping I will bring to the group?
4. When would they need me?
5. Am I replacing someone, or is the practice growing?
6. If a pathologist has just left, what was the reason?

About the hospital/lab

7. Is this the only hospital or facility I will be working in?
8. Is this hospital/lab under a larger corporate umbrella or independent?
9. What is the subspecialty makeup of the surgery, oncology, and medical staff?
10. How much of the hospital is devoted to oncology?
11. Does it participate in clinical trials or perform transplants?
12. Does the group get OB or pediatrics specimens?
13. Is there an active faculty research program?
14. Are there residents, fellows, or students?
15. Is there a medical library and journal access?
16. Is the administration of the hospital/lab MD driven or MBA driven?
17. What effects have they seen from the recent changes in healthcare policy?
18. How active are the pathologists on hospital committees?
19. What role do they play in determining resource usage or testing guidelines for the hospital/lab?
20. Am I required to live within a certain distance of the hospital?

About the group

21. What is the employment structure—employees or contracted group?
22. Does the pathology group own any of the lab, either AP or CP?
23. Do they have any part-time pathologists?
24. Is there a partnership track within the group, and what is the time course?
25. How many partners vs. employees are there?

26. What is the buy-in amount for partnership?
27. Is the partnership process clearly laid out in the contract?
28. Does the practice employ any support staff?
29. Do they seem to like each other, get along, and communicate well?
30. Does the group seem to make decisions democratically or by seniority?
31. How do they divide call, weekend, and holiday coverage?
32. What are the vacation, holiday, and conference/CME allowances?
33. Is there a sign on bonus, or do they cover relocation expenses?
34. Is the compensation a fixed salary, or is linked to productivity?
35. How are increases in compensation determined?
36. Is there an annual bonus, and does it apply to employees or only partners?
37. Is there reimbursement for CME, subscriptions, professional memberships, or books?
38. Is moonlighting permitted?
39. Who covers the malpractice insurance?
40. Do they provide health insurance coverage, disability insurance, dental, or vision?
41. Is there a noncompete clause or restrictive covenant? How long and what radius?
42. How is malpractice tail coverage handled if I leave for any reason?
43. Are the benefits clearly stated in the contract?
44. Are there provisions for short-term disability, family or maternity leave, etc.?
45. Is there a 401 K retirement plan, with or without employer contribution?
46. Does the group encourage going to national meetings, like USCAP or CAP?
47. Does the group subscribe to any CME programs, like PIPs or CheckSamples?
48. Do they seem to be up on current terminology and classification? (Remember—in the long term, you can only be as smart as the people around you. Choose wisely.)

About the job

49. What is the annual specimen volume and the breakdown of biopsies vs. surgical cases vs. cytology?
50. How many autopsies per year, and who does them; is there diener support? Do they do forensic autopsies as well?
51. How does the per MD workload compare to other hospitals in the area?
52. Have they been affected by pod labs, or by GU, GI, or derm practices retaining their biopsy work?
53. How much of the practice's volume comes from outreach/outpatients?
54. Does every pathologist sign-out every specimen type?
55. How are the cases divided up on a daily basis?
56. What about specialty cases like peripheral smears, marrows, skins, medical liver, medical kidney, muscle and nerve biopsies, etc.?
57. Will I need to perform bone marrow biopsies or FNAs?
58. Do they have PAs and/or ever need to do grossing?
59. Do they have a microscope and/or camera for me, or will I need to provide my own?
60. How are frozen sections handled during working hours or after hours?
61. What are the hours pathologists are expected to be on-site?
62. Do they seem to have flexibility for things like doctor's appointments and sick kids or other things that may require me to occasionally miss part of the workday?
63. What are the on call responsibilities—AP, CP, autopsy, and radius of travel?
64. What is a typical call weekend like?
65. What sorts of CP calls come in after hours?
66. Will I be signing out transfusion reactions, serum protein electrophoresis, hemoglobin electrophoresis, or coagulation work-ups?
67. Are there routine AP sign-outs, rushes, or autopsies on weekends?
68. Are any support staff available on weekends?
69. Is there a formal process for intradepartmental consultations? A daily meeting?
70. For difficult cases and outside consultations, is there a preferred local expert or tertiary medical center?

71. Are there in-group experts that will look at cases?
72. How do they handle internal disagreements about diagnoses?
73. What are the weekly tumor boards or conferences? What format?
74. Are there additional teaching responsibilities?
75. Will medical directorship of a laboratory section be part of the job?
76. Is the lab accredited by CAP, Joint Commission, or other?
77. Are pathologists required to maintain licensure in more than one state?
78. How is my performance evaluated within the group?

About the billing

79. Is the MD responsible for assigning CPT and ICD-10 codes?
80. Is there a billing agency that does the administrative work of billing and collection and takes care of rejected claims?
81. How does the group recover Part A revenue and Part B billables?
82. Are there periodic audits on coding accuracy and HIPAA compliance?
83. Does the practice participate in the CMS Quality Measures incentive programs (PQRS, MACRA, etc.)?
84. Are employment/promotion/compensation linked to billing or collections?
85. Is there any financial disincentive to sending consults?

About the support

86. Is there adequate transcription and clerical staff?
87. How effective are the lab managers and administration?
88. Is the lab given adequate resources to stay modern, safe, and efficient?
89. How long has the group (or these employees) been at this hospital?
90. Has there been a lot of staff turnover?
91. Is the tissue processing on-site?
92. How is the quality of the slides?
93. What IHC and special stains are in house? FISH or molecular testing?
94. What is the average TAT for cases? How strict are the expectations?
95. Do they have automated specimen tracking or barcoding?
96. What do their cancer checklists look like?
97. Who is in charge of updating them, as CAP makes updates?
98. How do they enter diagnoses—transcription, voice recognition, and typing?
99. Is there LIS access from home?
100. How user friendly is the LIS?

The information in this chapter represents the author's experiences in community practice, as well as accumulated information from the job searches and experiences (both good and bad) of friends and colleagues. As a result, it is somewhat anecdotal. However, a comprehensive survey of what employers report they are looking for in new graduates was published in 2017 and is essential reading for job applicants [1].

Reference

1. Post MD, Johnson K, Brissette MD, Conran RM, Domen RE, Hoffman RD, et al. Employer expectations for newly trained pathologists: report of a survey from the graduate medical education committee of the College of American Pathologists. *Arch Pathol Lab Med.* 2017;141(2):193–202.

A list of common abbreviations used throughout this book and in pathology in general, often without explanation.

AFB	Acid-fast bacilli stain
CD	Markers of cellular differentiation (i.e. CD3, CD20 stains)
CIS	Carcinoma in situ
CK	Cytokeratin (stain)
CMV	Cytomegalovirus
CT	Computed tomography (scan)
DNA	Deoxyribonucleic acid
EBV	Epstein–Barr virus
GI	Gastrointestinal
GMS	Grocott (or Gomori) methenamine silver stain
GU	Genitourinary
GYN	Gynecologic
H&E	Hematoxylin and eosin stain
HIV	Human immunodeficiency virus
HPF	High-power field (40×)
HPV	Human papillomavirus
HSIL	High-grade squamous intraepithelial lesion
HSV	Herpes simplex virus
IHC	Immunohistochemistry
LSIL	Low-grade squamous intraepithelial lesion
N/C	Nuclear to cytoplasmic (ratio)
NET	Neuroendocrine tumor
PAS	Periodic acid–Schiff stain
PAS/AB	Periodic acid–Schiff and Alcian blue stain
RBC	Red blood cell
RNA	Ribonucleic acid

Bibliography

The following is a list of textbooks that were used in the writing of this book and that were generally helpful during my residency training or since. This is by no means a complete listing of recommended books. (Editions and dates have been updated).

General Surgical Pathology and Grossing Texts

Differential Diagnosis in Surgical Pathology. Paolo Gattuso, Vijaya Reddy, Odile David, Daniel J. Spitz, and Meryl Haber. Philadelphia: Saunders; 3rd ed., 2014.

Histology for Pathologists. Stacey E. Mills. Philadelphia: Lippincott Williams & Wilkins; 4th ed., 2012.

Manual of Surgical Pathology. Susan Lester. Philadelphia: Elsevier; 3rd ed., 2010.

Quick Reference Handbook for Surgical Pathologists. Natasha Rekhman and Justin Bishop. New York: Springer; 2011.

Rosai and Ackerman's Surgical Pathology. John Goldblum, Laura Lamps, Jesse McKenney, and Jeffrey Myers. Philadelphia: Elsevier; 11th ed., 2017.

Sternberg's Diagnostic Surgical Pathology. Stacey Mills, Joel Greenson, Jason Hornick, Teri Longacre, and Victor Reuter. Philadelphia: Wolters Kluwer; 6th ed., 2015.

Surgical Pathology Dissection: An Illustrated Guide. William H. Westra, Ralph H. Hruban, Timothy H. Phelps, Christina Isacson, and Fred Askin. New York: Springer; 2nd ed., 2009.

Organ- or System-Specific Texts

Blaustein's Pathology of the Female Genital Tract. Robert J. Kurman, Lora Hendrick Ellenson, and Brigitte M. Ronnett. New York: Springer; 6th ed., 2011.

Diagnostic Pathology: Placenta. Amy Heerema-McKenney, Edwina J. Popek, and Monique E. DePaepe. Philadelphia: Elsevier; 2015.

Enzinger and Weiss's Soft Tissue Tumors. John R. Goldblum, Andrew L. Folpe, and Sharon W. Weiss. Philadelphia: Elsevier; 6th ed., 2013.

Practical Thoracic Pathology: Diseases of the Lung, Heart, and Thymus. Allen Burke, Marie-Christine Aubry, Joseph Maleszewski, Borislav Alexiev, and Fabio Tavora. Philadelphia: Wolters Kluwer; 2017.

Rosen's Breast Pathology. Syed A. Hoda, Edi Brogi, Frederick C. Koerner, and Paul Peter Rosen. Philadelphia: Wolters Kluwer; 4th ed. 2014.

Surgical Pathology of the GI Tract, Liver, Biliary Tract, and Pancreas. Robert Odze and John Goldblum. Philadelphia: Elsevier; 3rd ed., 2014.

Pathology Series

The following books are all parts of larger series, and consist of individual organ-based volumes. These books are probably more than you will need in residency, although it would be nice to have them around in a departmental library. However, once in practice, these are indispensable

for the organ systems you deal with most commonly. Explore the different series, as each presents information in a slightly different format, and you may find you are drawn to one over the other. The WHO series is recognized as an international standard in nomenclature, so try to collect those at the very minimum.

WHO/IARC Classification of Tumours Series, 4th edition (the “black-cover series”). Lyon: IARC Press.

Volumes in the 4th Edition include:

WHO Classification of Tumours of Haematopoietic and Lymphoid Tissues (WHO/IARC Classification of Tumours, 4th Edition, Volume 2). Edited by Swerdlow SH, Campo E, Harris NL, Jaffe ES, Pileri SA, Stein H, Thiele J, Vardiman JW. Lyon: IARC Press; 2008.

WHO Classification of Tumours of the Digestive System (WHO/IARC Classification of Tumours, 4th Edition, Volume 3). Edited by Bosman FT, Carneiro F, Hruban RH, Theise ND. Lyon: IARC Press; 2010.

WHO Classification of Tumours of the Breast (WHO/IARC Classification of Tumours, 4th Edition, Volume 4). Edited by Lakhani SR, Ellis IO, Schnitt SJ, Tan PH, van de Vijver MJ. Lyon: IARC Press; 2012.

WHO Classification of Tumours of Soft Tissue and Bone (WHO/IARC Classification of Tumours, 4th Edition, Volume 5). Edited by Fletcher CDM, Bridge JA, Hogendoorn PCW, Mertens F. Lyon: IARC Press; 2013.

WHO Classification of Tumours of Female Reproductive Organs (WHO/IARC Classification of Tumours, 4th Edition, Volume 6). Edited by Kurman RJ, Carcangiu ML, Herrington CS, Young RH. Lyon: IARC Press; 2014.

WHO Classification of Tumours of the Lung, Pleura, Thymus and Heart (WHO/IARC Classification of Tumours, 4th Edition, Volume 7). Edited by Travis WD, Brambilla E, Burke AP, Marx A, Nicholson AG. Lyon: IARC Press; 2015.

WHO Classification of Tumours of the Central Nervous System (WHO/IARC Classification of Tumours, 4th Edition Revised, Volume 1). Edited by Louis DN, Ohgaki H, Wiestler OD, Cavenee WK. Lyon: IARC Press; 2016.

WHO Classification of Tumours of the Urinary System and Male Genital Organs (WHO/IARC Classification of Tumours, 4th Edition, Volume 8). Edited by Moch H, Humphrey PA, Ulbright TM, Reuter VE. Lyon: IARC Press; 2016.

WHO Classification of Head and Neck Tumours (WHO/IARC Classification of Tumours, 4th Edition, Volume 9). Edited by El-Naggar AK, Chan JKC, Grandis JR, Takata T, Slootweg PJ. Lyon: IARC Press; 2017.

AFIP Atlas of Tumor Pathology, Series 4 (the “Fascicles”). Washington, DC: ARP Press. The series begins with Volume 1:

Tumors of the Kidney, Bladder, and Related Urinary Structures. Edited by William Murphy, David Grignon, and Elizabeth Perlman. Washington, DC: ARP Press; 2004.

And at the time of publication has 24 distinct organ-system volumes.

AFIP Atlas of Nontumor Pathology, Series 1. Washington, DC: ARP Press. The series, which is one of the most in-depth publications you will find on inflammatory and non-neoplastic pathology, begins with Volume 1:

Endocrine Diseases. Edited by Ricardo Lloyd, Bruce Douglas, and William Young. Washington, DC: ARP Press; 2002.

And at the time of publication has 10 distinct organ-system volumes.

Atlases in Diagnostic Pathology Series (multiple volumes). Philadelphia: Elsevier. This large-format series includes multiple volumes (Atlas of Gynecologic Surgical Pathology, Atlas of Orthopedic Pathology, etc.) with a focus on photographs and key diagnostic information presented in largely bullet-point format.

Biopsy Interpretation Series (multiple volumes). Series edited by Jonathan Epstein. Philadelphia: Wolters Kluwer. These are small-format organ-based volumes that are more didactic than the WHO and AFIP tumor series.

- A**
- Acantholysis, 321
 - Acanthosis, 31
 - Acid-fast bacilli (AFB) stain, 25
 - Acinar cell carcinoma, 106–107
 - Acinic cell, 277
 - Acinic cell carcinoma, 276
 - Acquired cystic kidney disease-associated RCC, 139
 - Acral lentiginous, 308
 - Actinic keratosis, 311
 - Actinomyces, 25, 26
 - Acute chorioamnionitis and funisitis, 192
 - Acute inflammation, 16–19
 - Acute interstitial pneumonia (AIP), 242
 - Acute lymphoblastic leukemias (ALLs), 216, 224
 - Acute lymphoblastic lymphoma, 231
 - Acute myeloid leukemia (AML), 217, 218
 - Acute respiratory distress syndrome (ARDS), 242
 - Adamantinoma, 353, 354
 - Adenocarcinoma, 100, 247, 248
 - Adenocarcinoma in situ (AIS), 171, 173, 245, 246
 - Adenofibroma, 156, 187, 200
 - Adenoid cystic carcinoma, 7, 9, 275, 276
 - Adenoids, 53
 - Adenoma, 74–81
 - Adenomatoid nodule, 262
 - Adenomatoid tumor, 188
 - Adenosarcoma, 156, 187
 - Adult rhabdomyoma, 335
 - Aggressive lesions, 345, 358
 - AIN-1, 167
 - Allergic disease, 244
 - Allergic mucin in sinusitis, 52
 - Alveolar rhabdomyosarcoma, 335, 336
 - Alveolar soft part sarcoma, 343
 - Amine precursor uptake and decarboxylase (APUD), 282
 - Amniotic fluid, 189
 - Amniotic membrane, 189
 - Amputated limbs, 38
 - Amyloid, 67
 - Anaplasia, 140
 - Anaplastic carcinoma, 268
 - Anaplastic large cell lymphoma (ALCL), 233
 - Anatomic pathology
 - normal tissue, 7
 - prefixes and suffixes, 6–7
 - Aneurysmal bone cyst (ABC), 355
 - Angioimmunoblastic T cell lymphoma (AITL), 233
 - Angiomyolipoma, 96, 132, 141
 - Angiosarcoma, 8, 9, 96, 341, 342
 - Antinuclear antibodies (ANA), 93
 - Antral mucosa, 62, 63
 - Apocrine metaplasia, 201
 - Appendicitis, 39
 - Architectural pattern, 7–8
 - Argentaffin, 282
 - Argyrophil, 282
 - Arias-Stella reaction, 183
 - Aspergilli, 22
 - Aspergillus, 22
 - Astrocytes, 289
 - Astrocytoma, 290–292
 - Atrophic endometrium, 178
 - Atrophy, 65, 66, 68, 70
 - Atypical adenomatous hyperplasia, 245
 - Atypical ductal hyperplasia, 205
 - Atypical glands and stains, 116
 - Atypical hyperplasia, 182
 - Atypical lobular hyperplasia (ALH), 113, 208
 - Atypical teratoid/rhabdoid tumor (AT/RT), 300
 - Autoimmune gastritis, 63, 66
 - Autoimmune hepatitis (AIH), 93
 - Autoimmune metaplastic atrophic gastritis (AMAG), 65
 - Azzopardi phenomenon, 282
- B**
- Bacteria stain, 24, 25
 - actinomyces, 25
 - Helicobacter pylori*, 25
 - Mycobacterium avium-intracellulare*, 25
 - Barrett's esophagus, 54, 57–59
 - Basal cell carcinoma, 7, 9, 312, 314
 - Basaloid squamous cell carcinoma, 247
 - Benign endometrial polyp, 180
 - Benign glands, 108
 - Bile duct adenoma, 95
 - Bile duct hamartoma, 95
 - Bile stasis, 91
 - Billing, 372
 - Biopsy, 167
 - Biopsy site changes, 16
 - Bladder neck margin, 117
 - Blastema, 140
 - Blastic lesions, 345
 - Blue cells
 - metanephric adenoma, 139
 - Wilms tumors, 139
 - Blue nevus, 304
 - Bone marrow
 - aspirate, 211
 - biopsy, 212
 - differential diagnosis
 - acute leukemia, 216–218
 - lymphocytes, 219–221
 - marrow cellularity, 215
 - MDS, 216
 - myelodysplastic/myeloproliferative disorders, 216
 - myeloproliferative neoplasms, 216
 - plasma cell dyscrasias, 218–219
 - erythroid precursors, 210
 - fat and hematopoietic cells, 210
 - hematopathology, 210
 - high power (20× and 100×), 214
 - high power (20× and 40×), 212
 - medium power (10×), 212
 - myeloid and lymphoid lineage, 210
 - myeloid cells, 210
 - trilineage hematopoiesis, 210
 - Bone tumors, 345, 346, 348
 - Bone-forming tumors, 348–350
 - Borderline mucinous tumor, 159
 - Borderline serous tumor, 157
 - Bowenoid actinic keratosis, 310

- Brain
 demyelinating lesion/infarct, 286
 midline, 297–298
 neoplastic or non-neoplastic, 286
 Principle I, 286
 Principle II, 286–290
 Principle III, 290
- Branchial cleft cyst, 269
- Breast biopsy
 Elston grades, 198
 mass/radiographic abnormality, 200
 mastectomy, 198
 microcalcifications, 199
 outer myoepithelial layer and inner
 epithelial cells, 198
 small lumpectomy, 198
 sweat gland, 198
- Breast carcinoma, 8, 9
- Brenner tumors
 adenoma/adenofibroma, 160
 malignant Brenner tumors, 160
- Bronchiolitis obliterans syndrome, 242
- Bronchioloalveolar carcinoma (BAC), 246
- Bronchogenic cyst, 258
- Burkitt lymphoma, 225–226
- C**
- Candida, 22
- Capillary hemangioma, 319
- Carcinoid, 14, 250
- Carcinoid tumor, 80
- Carcinoma, 68–69, 76, 78–80
- Carcinoma in situ (CIS), 28, 122
- Carcinoma showing thymus-like elements
 (CASTLE), 269
- Carcinosarcoma, 156
- Carotid and femoral plaques, 40
- Carotid plaque, 40
- Cartilage-forming tumors, 350–353
- Cavernous hemangioma, 95
- CD56 (neural cell adhesion molecule), 280
- Celiac disease, 71
- Cell membrane, 15
- Cellular variant, 337
- Cellularity, 7
- Central nervous system (CNS), 286
- Centrilobular, 87
- Cerebellum, 288
- Cerebral cortex, 287
- Cervix, 165–166
- Chalazion, 40
- Chalazion of eyelid, 40–41
- Cholangiocarcinoma, 95, 96
- Cholestasis, 91
- Cholesteatoma, 41
- Chondroblastoma, 350–352, 358, 359
- Chordomas, 297
- Chorioamnionitis, 191, 192
- Choriocarcinoma, 150, 152
- Choroid plexus carcinomas, 298
- Choroid plexus papilloma, 298
- Chromaffin, 282
- Chromogranin A (CHR), 280
- Chromophobe renal cell carcinoma, 135
- Chronic endometritis, 181
- Chronic gastritis, 64–66
- Chronic inflammation, 19
- Chronic injury, 143
- Chronic lymphocytic leukemia (CLL), 220, 228
- Chronic myeloid leukemia (CML), 213, 216
- Chronic myelomonocytic leukemia
 (CMML), 216
- Chronic sialadenitis, 271
- Chronic sinusitis, 51
- CIN-1, 167
- Clear cell carcinoma, 161, 186
- Clear cell papillary renal cell carcinoma, 136
- Clear cell papillary/tubulopapillary renal cell
 carcinoma, 135
- Clear cell renal cell carcinoma, 134
 adrenal cortex, 133
 chromophobe, 135
 clear cell papillary/tubulopapillary, 135
 cyst walls, 131
 features, 133
 grade, 133
 mucinous tubular and spindle cell
 carcinoma, 136–137
 sarcomatoid transformation, 133
 translocation tumors, 137
- Clear cell sarcoma, 140
- Clear cell sarcoma of soft tissue, 343
- Clear cell tumors, 160
- Clear cells, 133
- CNS neoplasms, 287
- CNS tumors, 289
- Collecting duct carcinoma, 139
- Colloid, 11, 260
- Colloid carcinoma, 247
- Colloid nodule, 262
- Colon biopsies, 74
 normal histology, 74
- Columnar epithelium, 57
- Compound nevus, 303, 305
- Condyloma, 175
- Condyloma acuminatum*, 174
- Cone biopsy, 165
- Congenital mesoblastic nephroma, 130, 140
- Constrictive bronchiolitis, 242
- Contracts and Compensation, 372–373
- Cornea, 41
- Corpora amylacea, 114
- Corpus albicans, 153, 154
- Corpus luteum, 153
- Cortical or compact bone, 348
- Craniopharyngioma, 297
- Cryptococcus*, 23, 24
- Cryptogenic organizing pneumonia (COP), 242
- Cryptorchid testis, 144
- Cryptorchidism, 146
- Cryptosporidium, 27, 71, 72
- Cystadenocarcinomas, 156
- Cystadenofibroma, 156
- Cystadenoma, 156
- Cystic nephroma, 130, 131
- Cystic nephroma/multilocular cyst, 130–131
- Cystic non-neoplastic lesions, neck, 269
- Cystic partially differentiated
 nephroblastoma, 140
- Cystitis cystica, 120
- Cystitis glandularis, 120
- Cysts of the Jaw (Odontogenic), 42
- Cytokeratin expression, 283
- Cytologic atypia, 305, 306
- Cytomegalovirus (CMV), 26, 57
- Cytoplasm, 11
- D**
- Debridement, 42
- Decidual vasculopathy, 193
- Dermal scar, 18, 51
- Dermatofibromas, 317, 318
- Dermatofibrosarcoma protuberans (DFSP), 8,
 10, 317, 318, 332
- Dermis inflammation, 321
- Dermoepidermal junction (DEJ), 302, 305,
 306, 320, 321
- Dermoid cyst, 258
- Desmoplastic melanoma, 308
- Desquamative interstitial pneumonitis (DIP), 244
- Detrusor muscle, 120
- Diamnionic-dichorionic (di-di), 189
- Diaphysis, 348
- Diarrhea, 84–85
 microscopic colidities, 84
 other colidities, 85
- Differentiated VIN, 176
- Diffuse alveolar damage (DAD), 242
- Diffuse large B cell lymphoma (DLBCL), 152,
 221, 225, 226
- Diffuse neuroendocrine system, 279, 282
- Diffuse sclerosing variant, 267
- Distal pancreatectomy, 97
- Ditzels, 38
- Double- and triple-hit lymphomas, 225
- Dreaded Appendiceal Mucinous Neoplasms,
 81–82
- DRG payment, 372
- Duct cell, 271
 intercalated ducts, 271
 interlobular or excretory ducts, 271
 striated ducts, 271
- Ductal adenocarcinoma, 118, 119
- Ductal carcinoma, 205
- Ductal carcinoma in situ (DCIS), 198, 204, 205
- Ductopenia, 91
- Duodenal adenoma, 73
- Duodenum
 approach to biopsy, 70–71
 celiac disease, 71–72
 chronic peptic duodenitis, 71
 infections, 72–73
 neoplasms, 63, 73
- Dyserythropoiesis, 214, 215
- Dysgerminoma, 152
- Dysgranulopoiesis, 214, 215
- Dyskeratotic cells, 29
- Dysplasia, 68–69, 76, 78, 83
- Dysplasia versus reactive changes, 169
- Dysplastic nevus, 306
- E**
- E-cadherin, 208
- Eccrine spiradenomas, 314, 315
- Elston grade, 208
- Embryonal carcinoma, 150
- Embryonal rhabdomyosarcoma, 335, 336
- Embryonal tumors, 149, 299–300

- Employee, 371
 Enchondroma, 350, 351, 358
 Endocervical curettage, 165–167
 Endocervical glands, 166
 Endocervical polyps, 171
 Endometrial intraepithelial neoplasia (EIN), 181
 Endometrial stromal breakdown, 180
 Endometrial stromal sarcoma, 186
 Endometrioid adenocarcinoma, 184
 Endometrioid carcinoma, 160, 184
 Endometrioid tumors
 adenoma, 160
 carcinoma, 160
 Endometriosis, 171, 172
 Endometrium, 178–181
 adenomyosis, 185
 atrophic, 177
 biopsy, 177
 bleeding
 atrophy, 181
 benign endometrial polyp, 178
 disordered proliferative endometrium, 181
 endometrial stromal breakdown, 179
 endometritis, 180
 glandular and stromal, 184
 histologic criteria, 183
 progesterin-treated, 177
 proliferative, 177
 secretory, 177
 uterus, 177
 Enteric cyst, 258
 Enterochromaffin, 282
 Eosinophilic esophagitis, 56
 Eosinophilic granuloma, 244
 Eosinophilic variant, chromophobe, 135
 Eosinophils, 54, 56, 64
 Ependymal cell, 298
 Ependymoma, 8, 10, 298, 299
 Epidermoid cyst, 317
 Epidermoid/dermoid cyst, 151
 Epididymis, 146
 Epiphysis, 348
 Epithelial neoplasms, 156
 adenoma, 156
 borderline tumor (atypical proliferative tumor), 156
 carcinoma, 156
 carcinosarcoma, 156
 Epithelial/endothelial nuclei, 13
 Epithelioid hemangioendothelioma, 341, 342
 Epithelioid sarcoma, 343, 344
 Epithelioid trophoblastic tumor, 197
 Ergonomics, 1, 2
 Erythroids, 211
 Esophageal duplication cyst, 258
 Esophagus, 37, 54
 approach to slide, 54
 columnar epithelium, 57
 dysplasia within Barrett's esophagus, 58–60
 eosinophils, 54–56
 goblet cells, 57
 neoplasms in, 55, 59, 61
 neutrophils, 56–57
 polyps, 60–61
 squamous dysplasia, 60
 ulcers, 57
 Evans tumor, 331
 Ewing sarcoma, 348, 353–355, 358
 Extranodal mucosa-associated lymphoid tissue (MALT) lymphoma, 229
 Extraskelatal myxoid chondrosarcoma, 344
 Extrinsic allergic alveolitis, 244
 Eyeglasses, 5
 Eyelids (Plastic Repair), 43
- F**
 Familial adenomatous polyposis (FAP), 79, 80
 Fat necrosis, 11, 12, 202
 Fetal rhabdomyoma, 335
 Fetal thymus, 254
 Fetal vascular malperfusion, 196
 Fibrin, subchorionic, 194
 Fibrinoid necrosis, 11, 12, 193
 Fibroadenoma, 202
 Fibroblast foci, 243
 Fibrocystic changes
 adenosis/sclerosing adenosis, 200
 apocrine metaplasia, 200
 cysts, 200
 fat necrosis, 201
 fibroadenomas, 200
 fibrosis, 200
 phyllodes tumor, 201
 usual duct hyperplasia, 200
 Fibrocystic disease, 200
 Fibroepithelial polyp, 174
 Fibrosarcoma, 8, 9, 328, 331
 Fibrothecoma, 164
 Fibrous and miscellaneous tumors in the bone, 353–356
 Fibrous and myxoid neoplasms, 328
 Fibrous dysplasia, 353, 358
 Fibrous tumors, 328–333
 FIGO (International Federation of Gynecology and Obstetrics), 185
 Fine-needle aspiration (FNA), 261
 Florid usual ductal hyperplasia, 204
 Focal nodular hyperplasia, 94
 Follicle cyst, 154
 Follicles, 153
 Follicular adenoma, 262, 263
 Follicular carcinoma, 264
 capsular or vascular invasion, 262
 minimally invasive types, 264
 widely invasive types, 264
 Follicular cells, 263
 Follicular cyst versus inclusion cyst, 155
 Follicular epithelium, 260
 Follicular lymphoma, 226–228
 Follicular neoplasm, 262
 Follicular variant of papillary thyroid carcinoma (FVPTC), 266, 267
 Follicular-type cells, 262–265
 Foveolar hyperplasia, 64
 Fungal organisms stain, 21
 Candida, 22
 Cryptococcus, 23
 Histoplasma, 23
 Mucor, 23
 Pneumocystis carinii, 24
 Pneumocystis jirovecii, 24
 Funisitis, 192
- G**
 Gallbladder, 44–45
 Ganglion cyst, 45, 46
 Gangrene, 11, 12, 39
 Gastroesophageal reflux disease (GERD), 54, 56
 Gastrointestinal stromal tumor (GIST), 69, 70, 334
 General surgical pathology fellowships, 371
 Germ cell neoplasia in situ (GCNIS), 148, 149
 Germ cell neoplasia in situ (GCNIS) vs. spermatogonia, 149
 Germ cell neoplasms, 163
 Germ cell tumors, 147, 258, 297, 361, 362, 368
 Germinal center, 223
 Germinoma, 152
 Gestational trophoblastic disease, 197
 Giant cell arteritis, 52
 Giant cell tumor, 354
 Giant cell tumor of tendon sheath, 357
 Giant cell tumor of the bone, 353, 354, 358
 Giant cell-rich tumors, 359
 Giardia, 27
 Glandular lesions
 AIS, 172, 173
 endocervical dysplasia, 171
 invasive adenocarcinoma, 173
 Gleason Grading, 111
 Glial tumors, 290
 Glioblastoma, 291
 Glioblastoma multiforme (GBM), 290
 Glomus tumor, 342
 Goblet cells, 57
 Goiter, 261
 Goodpasture's syndrome, 142
 Graft-Versus-Host Disease, 92–93
 Granular cell tumor, 337–339
 Granulation tissue, 16, 17
 Granulocyte/monocyte pathway, 210
 Granulomas in Crohn's disease, 20
 Granulomas in sarcoid, 20
 Granulomatous cystitis, 121
 Granulomatous inflammation, 20–21
 Granulosa cell tumor, 164
 Graves disease (diffuse toxic hyperplasia), 260, 261
 Grover's disease, 321
- H**
 Hairy cell leukemia, 237
 Hamartoma, 251
 Hashimoto thyroiditis, 260, 261, 268
 Hassall's corpuscles, 253
 Heart Valves, 45
Helicobacter pylori, 25, 26
Helicobacter pylori gastritis, 64
 Hemangioblastoma, 295, 296
 Hemangioendotheliomas, 341
 Hemangiomas, 317, 340, 341
 Hemangiopericytoma, 8, 10
 Hematoxylin, 12
 Hemorrhagic corpus luteum, 154
 Hepatocellular carcinoma (HCC), 94
 Hepatosplenic T cell lymphoma, 236
 Hernia sac, 46, 47
 Herpes simplex virus (HSV), 26, 57
 High-grade B cell lymphomas (HGBL), 225

- High-grade endometrial stromal sarcoma (HGESS), 186
- High-grade papillary urothelial carcinoma, 124–125
- High-grade sarcomas, 324
- High-grade serous carcinoma (HGSC), 157, 159
- High-grade squamous intraepithelial lesions (HSIL), 33, 167, 168
- High-grade tumors (HAMNs), 81
- Histiocytes, 18–21, 25
- Histoplasma, 23
- Hodgkin lymphoma, 221, 231–233
- Human chorionic gonadotropin (hCG), 150
- Hürthle cell adenoma, 262, 264
- Hürthle cell nuclei, 260
- Hyalinized granuloma, 21
- Hyalinizing trabecular tumor, 268, 269
- Hydatidiform mole, 194
- Hypercellular, 7
- Hyperkeratosis, 28, 31
- Hyperplasia, 181–182
- Hyperplastic polyps, 76
- Hypersensitivity pneumonia, 244
- Hypocellular/paucicellular, 7
- I**
- Idiopathic interstitial pneumonia (IIP), 244
- Idiopathic pulmonary fibrosis (IPF), 243
- Immature neural tissue, teratoma, 163
- Immature squamous metaplasia, 168, 169
- Immature villi versus terminal villi, 190
- Immunostains, 116, 360
- blood vessels (endothelium), 360
 - brain and meninges, 361
 - breast, 361
 - cytokeratins, 362
 - germ cell and testis, 362
 - gynecologic, 363
 - heme path, 363–364
 - kidney and bladder, 364
 - liver, pancreas, and gastrointestinal, 365
 - lungs, pleura, 365
 - melanoma, 366
 - neuroendocrine and endocrine, 366
 - prostate, 366
 - soft tissue, 367
 - thyroid, 367
- Inclusion cyst, 154
- Independent contractor, 371
- Infarct *vs.* perivillous fibrin, 195
- Infiltrating ductal carcinoma, 206
- Inflammatory bowel disease (IBD), 82, 83
- Inflammatory myofibroblastic tumor, 328, 330
- Interface dermatitis, 320
- Interstitial cystitis, 122
- Interstitial lung disease, 244
- Interval endometrium, 183
- Intervertebral Disc, 47
- Intracystic or encysted papillary carcinoma, 209
- Intradermal nevus, 302, 303, 306
- Intraductal papillary mucinous neoplasm (IPMN), 102, 103
- Intraductal papilloma, 203
- Intramucosal carcinoma, 76
- Intramuscular myxoma, 328, 333
- Intraprostatic incision (IPI), 117
- Invasive adenocarcinoma, 103–104, 173, 247
- Invasive ductal carcinoma, 205
- Invasive lobular carcinoma, 208
- Invasive papillary urothelial carcinoma, 123
- Invasive squamous cell carcinoma, 30, 170
- Inverted papilloma, 31
- Iron accumulation, 91
- Ischemia, 10, 11
- Islet cell tumors or pancreatic endocrine neoplasms, 281
- ISUP grades, 134
- ISUP nucleolar grade, 133
- J**
- Joint lesions, 357
- Joint tumors, 356–357
- Junctional nevus, 302, 303
- K**
- Kaposi's sarcoma, 317, 320, 341
- Keratinization, 28
- Keratocystic odontogenic tumor of jaw, 43
- Kikuchi's lymphadenitis, 233
- Köhler illumination, 2–4
- Koilocytes, 167
- L**
- Lamellar bone, 346–348
- Langerhans cell histiocytosis (LCH), 244, 300, 354, 355
- Large cell carcinoma, 248
- Large cell neuroendocrine carcinoma, 284
- Leiomyoma, 8, 9, 187, 188, 333, 334
- Leiomyosarcomas, 187, 188, 334
- Lentigo maligna melanoma, 306
- Lentigo simplex, 302, 310
- Leukemia classification, 217
- Leukocytoclastic vasculitis, 321
- Leydig cell tumors, 151
- Lichen planus, 321
- Lichen sclerosus, 174, 175
- Lichen simplex chronicus, 174
- Lipoblast, 48
- Lipoma, 47
- Littoral cell angioma, 237, 238
- Liver, 88–96
- anatomy, 86
 - biopsies, 86
 - inflammatory disease categories, 87–88
 - LFTs, 86
 - mass lesions, 94
 - biliary neoplasms and mimickers, 95
 - hepatocellular neoplasms and mimickers, 94–95
 - vascular neoplasms and mimickers, 95–96
 - normal histology, 86–87
 - pathologic findings, 88–93
 - autoimmune hepatitis, 93
 - biliary compartment, 91–92
 - chronic hepatitis, 92
 - Graft-Versus-Host Disease, 92–93
 - hepatocellular compartment, 88–91
 - primary biliary cirrhosis, 93
 - primary sclerosing cholangitis, 93
 - vascular compartment, 92
- Liver function tests (LFTs), 86
- Lobular carcinoma in situ (LCIS), 203, 206, 207
- Low-grade appendiceal mucinous neoplasms (LAMNs), 81
- Low-grade endometrial stromal sarcoma (LGESS), 186
- Low-grade papillary urothelial carcinoma, 123–124
- Low-grade serous carcinomas (LGSC), 156, 158
- Low-grade squamous intraepithelial lesion (LSILs), 33–35, 167
- Lungs
- alveoli, 239
 - bronchi, 239
 - bronchioles, 239
 - bronchioles and alveoli, 240
 - bronchus, 240
 - vessels, 239
- Lymph node, 222, 223
- Lymphedema, 341
- Lymphoblastic lymphoma, 230–231
- Lymphocytes, 219
- Lymphocytic thyroiditis, 260
- Lymphoepithelial cyst, 271
- Lymphoepithelial-like carcinoma, 128
- Lymphoid infiltrates, 220
- Lymphomas, 65, 66, 151–152, 222–225
- M**
- Macrophage, 19
- Malakoplakia, 122
- Malignant fibrous histiocytoma (MFH), 322, 324
- Malignant glands, 117
- Malignant mixed Mullerian tumors (MMMT), 156
- Malignant Mullerian mixed tumor, 187
- Malignant peripheral nerve sheath tumor (MPNST), 338
- Malignant tumors, 343–344
- Mallory's hyaline, 90
- Mammary analogue secretory carcinoma (MASC), 8, 9, 276
- Mantle cell lymphoma (MCL), 229, 230
- Marginal zone lymphoma (MZL), 229, 230
- Marrow cellularity, 212
- Marrow fibrosis, 213
- Mass lesions (Neoplasms), 94
- biliary neoplasms and mimickers, 95
 - hepatocellular neoplasms and mimickers, 94
 - vascular neoplasms and mimickers, 95
- Masson's tumor, 339
- Maternal vascular malperfusion, 196
- Mature B cell neoplasms, 228
- flow cytometry, 228
 - markers, 229–230
 - MCL, 229
 - MZL, 229
 - non-Hodgkin lymphomas, 228
 - SLL, 228–229
- MDS with excess blasts (MDS-EB), 216
- MDS with multilineage dysplasia, 216
- MDS with ringed sideroblasts, 216
- MDS with single lineage dysplasia (MDS-SLD), 216
- Meconioophages, 193
- Meconium staining, 193
- Medical (non-neoplastic) kidney, 141–142

- Medicare, 372
 Medullary carcinoma, 80, 139, 269, 270, 284
 Medullary cavity, 348
 Medulloblastoma, 299, 300
 Megakaryocytes, 210–212
 Melanocytic lesions, 301
 Melanoma, 14, 15, 174, 301, 306, 307
 Melanoma of soft parts, 141, 343
 Membranoproliferative glomerulonephritis, 143
 Meningioma, 293–295
 Merkel cell carcinoma, 284, 315, 316
 Mesonephric, 130
 Mesothelioma, 251, 252
 Metanephric adenoma, 130, 139, 140
 Metanephric stromal tumor, 140
 Metaphysis, 348
 Metaplasia, 184
 Metaplastic carcinoma, 209
 Metastases, 308
 Metastatic carcinoma, 43
 Michaelis-Gutmann bodies, 122
 Microcalcifications, 199
 Microcystic adnexal carcinoma, 314, 316
 Microglandular hyperplasia, 171, 172
 Micronodular thymoma, 256
 Micropapillary pattern, 157
 Micropapillary serous carcinoma, 9, 158
 Microsatellite instability (MSI) pathway, 79
 Microscope
 ergonomics, 1–2
 eyeglasses, 5
 mechanical stage guides, 5
 Motion Sickness, 5
 parts of, 2–3
 tricks, 4–5
 use, 1–5
 Microvascular proliferation, 290
 Minimal deviation adenocarcinoma, 173
 Minimally invasive adenocarcinoma, 247
 MiT family translocation RCCs, 137
 Mitotic rate, 7
 Mixed cellularity Hodgkin lymphoma, 232, 233
 Mixed epithelial and stromal tumor (MEST), 130, 132
 Mixed germ cell tumor (MGCT), 147
 Molar villi, 195
 Monocytoid, 229
 Monomorphic aspirate, 214
 Motion Sickness, 5
 Movat's stain, 239, 241
 Mucinous adenocarcinoma, 247, 248
 Mucinous carcinoma peritonei, 81
 Mucinous carcinomas, 185, 207
 Mucinous cystic neoplasm (MCN), 104
 Mucinous fibroplasia, 110
 Mucinous tubular, 136–137
 Mucinous tumors
 borderline tumor (atypical proliferative tumor), 158
 carcinoma, 159
 cystadenoma, 158
 Mucoepidermoid carcinoma, 275
 Mucor, 23
 Mucosal prolapse, 78
 Multifocal atrophic gastritis, 65
 Multilocular cystic renal neoplasm, 131
 Multinodular hyperplasia, 261
 Muscularis propria (detrusor muscle), 126
 Myasthenia gravis, 253
Mycobacterium avium-intracellulare (MAI)
 infection, 25, 72
 Mycosis fungoides/Sézary syndrome, 233
 Myelocytic precursors, 211
 Myelodysplastic syndrome (MDS), 210, 216
 Myelodysplastic/myeloproliferative disorders, 216
 Myeloma, 219
 Myeloproliferative neoplasms, 216
 Myoepithelial cell, 272, 361
 Myoepithelioma, 273
 Myometrium, 187–188
 Myxofibrosarcomas, 14, 15, 333
 Myxoid liposarcoma, 325–328
 Myxoid tumors, 328–333
 Myxopapillary ependymoma, 298, 299
- N**
- Nabothian cysts, 171
 Nasal polyp, 14, 15
 Nasopharynx, 35–36
 Necrosis, 11–12
 Necrotizing sialometaplasia, 271
 Neoplasms
 adult, 130
 differential diagnosis, 129
 factors, 129
 features, 129
 Neoplastic lung
 carcinoma, 246–249
 hamartoma, 251
 neuroendocrine tumors, 249–251
 pleuropulmonary blastoma, 251
 precursor lesions, 244–246
 pulmonary blastoma, 251
 salivary neoplasms, 251
 Nephritic presentations
 acute and proliferative glomerulonephritis, 142
 cellular crescents, 142
 immune complex mediated, 142
 rapidly progressive glomerulonephritis, 142
 Nephroblastoma, 130, 140
 Nephrogenic adenoma, 130
 Nephrotic presentations
 chronic injury, 143
 diabetes and hypertension, 143
 glomerular basement membrane/
 podocytes, 142
 membranous and membranoproliferative
 glomerulonephritis, 143
 patterns of injury, 143
 transplant rejection, 143
 tubular diseases, 143
 Nephrotic syndrome, 142
 Nerve-related neoplasms, 337
 Nested transitional cell carcinoma, 127
 Neuroendocrine (Carcinoid) Tumors, 80–81
 Neuroendocrine carcinomas (NECs), 81, 282
 Neuroendocrine lesions, 269
 Neuroendocrine markers, 280
 Neuroendocrine morphology
 features, 280
 poorly differentiated neuroendocrine
 carcinoma, 282
 well-differentiated neuroendocrine
 tumors, 281
- Neuroendocrine neoplasm (NEN) vs.
 neuroendocrine tumor (NET), 282
 Neuroendocrine neoplasms
 cell types, 280
 definition, 279
 differentiation/component, 284, 285
 grading, 283
 neurosecretory granules, 280
 parathyroid and anterior pituitary
 glands, 279
 Neuroendocrine nuclei, 281
 Neuroendocrine tumors, 13, 249, 250
 Neurofibromas, 317, 319, 323, 332, 337–339
 Neuroma, 48, 49
 Neuron-specific enolase (NSE), 280
 Neurovascular bundles (NVB), 117
 Neutrophils, 56, 64, 70
 Nodal MZL, 229
 Nodular fasciitis, 8, 10, 322, 328, 329
 Nodular melanoma, 306
 Nodular sclerosing Hodgkin lymphoma,
 231, 232
 Noncellular entities, 15
 Non-epithelial neoplasms
 germ cell neoplasms, 163
 sex cord stromal neoplasms, 163–164
 Noninvasive follicular thyroid neoplasm with
 papillary-like nuclear features
 (NIFTP), 266
 Noninvasive low-grade serous
 carcinoma, 157
 Noninvasive papillary urothelial carcinoma,
 123, 126
 Non-neoplastic entities, 233–234
 Non-neoplastic lung
 allergic disease, 244
 differential diagnoses, 240, 241
 injury, 242–244
 interstitial lung disease, 244
 smokers, 244
 Non-neoplastic skin, 320–321
 Non-small cell lung carcinoma
 (NSCLC), 246
 Nonspecific interstitial pneumonia
 (NSIP), 244
 Normal adrenal cortex, 133
 Nuclear adjectives, 14–15
 Nucleoli, 15, 30
 Nucleus, 12–13
 NUT midline carcinoma, 258, 259
- O**
- Obliterative bronchiolitis, 242
 Oligodendroglioma, 292–293
 Oncocytoma, 8, 10, 137, 138
 Orchiectomy, 144–145
 Organizing pneumonia (OP), 242
 Orthokeratosis, 31
 Osteoarthritis, 43, 44
 Osteochondroma, 348–350, 358
 Osteonecrosis, 43, 44
 Osteopenia, 43
 Osteosarcoma, 346–350, 352–355, 358
 Ovarian stroma, 154
 Ovary
 neoplasms, 156
 Oxyntic mucosa, 62, 63

- P**
- Paget's disease, 174, 176, 345, 354, 356, 358
- Pancreas, 97, 104–107
- chronic pancreatitis, 99
 - cystic lesions
 - MCN, 104
 - pseudocyst, 106
 - serous cystadenoma, 104–105
 - solid-pseudopapillary neoplasm, 105–106
 - dysplasia in, 101–102
 - IPMN, 102–104
 - solid tumors
 - acinar cell carcinoma, 106–107
 - pancreatic neuroendocrine neoplasms, 106
 - pancreatoblastoma, 107
 - whipple procedure, 97–99
- Pancreaticoduodenectomy, 97
- Pancreatoblastoma, 107
- Panniculitis, 321
- Papillary adenoma, 138
- Papillary architecture, 162
- Papillary carcinoma, 209, 266
- nuclear features, 265
 - variants, 265, 268
- Papillary endothelial hyperplasia, 339, 340
- Papillary microcarcinoma, 265
- Papillary neoplasia, 123
- Papillary nuclei, 266
- Papillary renal cell carcinoma, 11, 12, 137–138
- Papillary Urothelial Neoplasm of Low Malignant Potential, 123
- Papillomas, 8, 10, 31, 32, 123, 209
- Paraganglioma, 7, 9, 337, 338, 340
- Parakeratosis, 28, 31
- Parasites, 27
- Cryptosporidium*, 27
 - Giardia*, 27
- Parathyroid, 49, 50
- Paratrabecular aggregate, 220
- Parfocality, 4
- Parietal pleura, 251
- Parosteal osteosarcoma, 349
- Pathologists, 370–374
- Peripheral nerve/Neuroectodermal, 337–338
- Pheochromocytoma, 11, 12
- Pheochromocytoma (adrenal)/paraganglioma (extra-adrenal), 284
- Physis, 348
- Pigmented villonodular synovitis (PVNS), 356, 357
- Pilocytic astrocytomas, 292, 295
- Pineoblastomas, 297
- Pineocytoma, 297
- Pink cells
- acquired cystic kidney disease-associated RCC, 139
 - collecting duct carcinoma, 139
 - oncocyoma, 137
 - papillary adenoma, 138
 - papillary RCC, 137–138
 - tubulocystic carcinoma, 139
- Pituitary adenoma, 297
- Pituitary adenoma versus normal, 298
- Placenta
- accreta, 196
 - amnion, 189
 - chorion, 189
 - fetal surface, 193
 - fibrinoid necrosis/vasculopathy, 196
 - maternal floor infarct, 196
 - maternal surface, 196
 - membrane roll, 191
 - umbilical cord, 190
 - villi, 189, 194
- Placental membranes, 190
- Placental site nodule, cervix, 171
- Placental site trophoblastic tumor, 197
- Plasma cell dyscrasias, 218
- Plasmacytoma, 11, 12
- Pleomorphic adenoma, 271, 273, 274
- Pleomorphic liposarcoma, 328
- Pleomorphic rhabdomyosarcoma, 335, 336
- Pleomorphic sarcomas, 322, 329, 336
- Pleura
- empyema/purulent effusion, 251
 - mesothelial cells, 251
 - mesothelioma, 251
- Pleuropulmonary blastoma, 251
- Pneumocystis*, 24
- Pneumocystis carinii*, 24
- Pneumocystis jirovecii*, 24
- Polygonal pink Leydig cells, 144
- Polymorphous adenocarcinoma, 278
- Polymorphous low-grade adenocarcinoma (PLGA), 278
- Polypoid cystitis*, 122
- Polypoid prolapsing mucosal fold, 78
- Polyps, 60, 67
- Poorly differentiated carcinoma, 265
- Poorly differentiated neuroendocrine carcinoma (Small cell carcinoma), 282
- Poorly differentiated thyroid carcinoma, 265
- Poroma, 314
- Posterior fossa (infratentorial), 295–297
- Preeclampsia, 193
- Pregnancy, 183
- Primary biliary cirrhosis, 93
- Progesterin-treated endometrium, 179
- Proliferative endometrium, 178
- Proliferative fasciitis, 328
- Prostate cancer mimickers, 113–116
- adenosis, 114
 - atrophy, 114
 - basal cell hyperplasia, 114
 - Cowper's glands, 114
 - radiation changes, 115–116
 - sclerosing adenosis, 116
 - seminal vesicle, 116
- Prostate neoplasms, 118–119
- Prostate-specific acid phosphatase (PSAP), 114
- Prostate-specific antigen (PSA), 108
- Prostatic intraepithelial neoplasia (PIN), 113
- Psmomma bodies, 265, 267
- Pseudocyst, 106
- Pseudoepitheliomatous hyperplasia*, 30–32
- Pseudorosette, 298
- Psoriasis, 320
- Pulmonary blastoma, 251
- Pyogenic granuloma, 49
- R**
- Racemase, 116
- Radical prostatectomy specimen, 117
- Reactive bronchial epithelium, 245
- Reed–Sternberg cells, 231
- Respiratory bronchiolitis, 244
- Rete ovarii*, 153, 155
- Rhabdoid tumor, 140
- Rhabdomyoma, 335
- Rhabdomyosarcoma, 335
- Rosai–Dorfman disease, 300
- S**
- Salivary duct carcinoma, 278
- Salivary glands
- anatomy and histology, 271–273
 - biopsies, 271
 - ducts types, 272
 - neoplasms
 - acinic cell carcinoma, 276
 - adenoid cystic carcinoma, 275–276
 - breast, 276–278
 - categorization, 273
 - miscellaneous malignant neoplasms, 278
 - mucoepidermoid carcinoma, 275
 - pleomorphic adenoma, 273
 - polymorphous adenocarcinoma, 278
 - Warthin tumor, 274–275
 - pleomorphic adenoma, 271
 - sublingual and submandibular, 271
- Salivary neoplasms, 251
- Salmon-pink acellular matrix, 346
- Sarcomatoid carcinoma, 249
- Scar Revision, 49–50
- Schistosoma* species, 121
- Schneiderian papilloma, 36
- Schwannoma, 14, 15, 296, 322, 323, 334, 337, 338
- Scirrhus, 205
- Sclerosing adenosis, 201
- Sclerosing angiomatoid nodular transformation (SANT), 238
- Seborrheic keratoses, 312, 313
- Secretory carcinoma, 276, 277
- Secretory cell, 271
- Secretory endometrium, 179
- Secretory or lactational change, 198
- Seminiferous tubules, 145
- Seminoma, 147–148
- Serous carcinoma, 185
- Serous cystadenoma, 104, 105
- Serous endometrial intraepithelial carcinoma, 185, 186
- Serous tubal intraepithelial carcinoma (STIC), 157
- Serous tumors
- borderline tumor (atypical proliferative serous tumor), 157
 - BRCA mutations, 157
 - cystadenoma, 157
 - fallopian tube epithelium, 157
 - high-grade serous carcinoma, 158
 - implants, 158
 - LGSC, 158
 - noninvasive low-grade serous carcinoma, 157
- Sertoli cell tumors, 151, 152

- Sertoli-only syndrome, 147
 Sessile serrated adenomas (SSA), 77, 78
 Sessile serrated polyps (SSP), 77, 78
 Severe keratinizing dysplasia, 35
 Sex cord cells, 153
 Sex cord stromal neoplasms, 163–164
 Sex cord stromal tumors, 151
 Shave margin, 97, 99
 Sideroblasts, 214
 Signet-ring cell carcinoma, 11, 12, 69
 Simple cysts, 130
 Sinonasopharyngeal system, 271
 Sinus contents, 51
 Sjögren syndrome, 271
 Skeletal muscle neoplasms, 335
 Skin
 adnexal tumors, 314–315
 biopsies, 301
 cysts, 317
 dermal tumors, 317–320
 melanocytic lesions
 benign nevi, 304–305
 dysplastic nevi, 305–306
 features of malignancy, 307
 melanoma, 306–307
 re-excision of melanomas, 309
 sign-out criteria, 308
 special stains, 309
 special types of melanoma, 308
 terminology, 302–304
 merkel cell carcinoma, 315–317
 nonmelanocytic lesions, 309–320
 Seborrheic keratoses, 312–314
 sun damage, 309–312
 verruca vulgaris, 313, 314
 Small cell carcinoma, 12, 14, 250
 Small lymphocytic lymphoma (SLL), 228–229
 Smooth muscle neoplasms, 333, 334
 Soft tissue
 fibrous tumors, 328–333
 high-grade sarcomas, 324–325
 myxoid tumors, 328–333
 tumors of fat, 325–328
 Solar elastosis, 309
 Solar lentigo, 310
 Solid-pseudopapillary neoplasms, 105
 Solitary fibrous tumor (SFT), 332
 Solitary fibrous tumor/hemangiopericytoma, 295
 Spermatocytic tumor, 148
 Spindle cell carcinoma, 136–137
 Spindle cell lesions, 119
 Spindle cell or sarcomatoid carcinoma, 249
 Spindle epithelial tumor with thymus-like elements (SETTLE), 269
 Spindle-cell/pleomorphic lipoma, 325, 326
 Spitz nevus, 305
 Spleen
 accessory spleens or splenules, 234
 leukemias, 237
 lymphomas, 235–237
 non-neoplastic processes, 238
 primary neoplasms, 237
 red pulp, 234
 splenectomy, 234
 white pulp, 234
 Splenic marginal zone lymphoma (MZL), 229, 236
 Spotty necrosis, 89
 Squamous carcinoma, 247
 Squamous cell carcinoma, 11, 12, 247, 310, 311, 313
 Squamous dysplasia, 60
 Squamous lesions
 ancillary tests, 168
 characteristics, 168
 HSIL, 168
 invasive squamous cell carcinoma, 170–171
 LSIL, 167
 placental site nodule, 170
 relative changes, 169–170
 Squamous metaplasia, 166
 Squamous/glandular dysplasia, 165
 Staghorn vessels, 295
 Steatohepatitis, 90
 Steatosis, 90
 Stomach, 62–70
 amyloid, 67
 antral mucosa, 62
 approach to biopsy, 62–64
 atrophy and intestinal metaplasia, 65
 duodenum, 70
 dysplasia and carcinoma, 68–69
 foveolar hyperplasia and chemical gastritis, 64–65
 lymphoma, 65–66
 oxyntic mucosa, 62
 polyps, 67–68
 submucosa, 69–70
 ulcers, 67
 Stroma, 15, 153
 Stromal tumors of uncertain malignant potential (STUMP), 119
 Strongyloides, 71–73
 Subependymal giant cell astrocytoma (SEGA), 292
 Subependymoma, 298
 Submucosa, 69
 Superficial carcinomas, 126
 Superficial spreading melanoma, 306
 Surface epithelium, 153
 Synaptophysin (SYN), 280
 Syncytial type, 293
 Syncytiotrophoblasts, 150
 Synovial chondromatosis, 356, 357
 Synovial sarcoma, 343
 Syringoma, 314, 315
- T**
 T cell lymphomas, 233
 Tall cell variant, 268
 Temporal artery, 51–52
 Teratomas, 151, 258
 Terminal duct lobular unit (TDLU), 198, 199
 Testicular tumors, 147
 Testis
 hemorrhage/ischemic necrosis, 144
 infertility, 145–146
 pseudostratified and ciliated epithelium, 144
 Sertoli cells and spermatogonia, 144
 sperm leaves, 144
TFE3 gene, 343
 TFE3+ alveolar soft part sarcoma, 141
- Thoracic vs. gastro-entero-pancreatic neuroendocrine neoplasms, 283
 Thymic carcinomas, 253
 Thymic cyst, 258
 Thymic follicular hyperplasia, 254
 Thymic germinal center hyperplasia, 254
 Thymic lymphoid hyperplasia, 254
 Thymic T cells, 254
 Thymocytes, 253
 Thymomas, 253, 255
 Thymus
 B and T cells, 253
 cysts, 258
 lymphoepithelial organ, 253
 lymphoepithelial structure, 253
 mediastinum, 258
 neoplasms, 255–257
 opaque classification system, 253
 Thymus-like lesions, 269
 Thyroglossal duct cyst, 269
 Thyroid
 architectural and cytologic features, 262
 C cells, 260
 classification, 260
 follicular epithelium, 260
 Tonsils, 53
 Trabecular or cancellous bone, 348
 Transitional cell carcinoma, 125–128
 Trophoblasts, 196
 True rosette, 298
 Tuberculosis, 10, 11
 Tubular carcinoma, 206
 Tubulocystic carcinoma, 139
 Tumor families characteristics, 323
 Tumor progression, breakdown of categories, 79
 Tunica albuginea, 146
 Tunnel clusters, 171
 Twin placentas, 191
 Type A thymomas, 255
 Type AB thymoma, 256, 258
 Type B thymomas, 256
 Type B1 thymoma, 256
 Type B2 thymoma, 257
 Type B3 thymoma, 257
- U**
 Ulcers, 57, 67
 Umbilical cord, 191
 Umbrella cells, 120
 Uncinate (retroperitoneal) margin, 99
 Undifferentiated pleomorphic sarcoma (UPS), 322–324, 333
 Undifferentiated uterine sarcoma (UUS), 186
 Urothelium, 35
 Usual ductal hyperplasia, 203
 Usual interstitial pneumonia (UIP), 243
- V**
 VaIN-1, 167
 Vanishing testis syndrome, 144
 Vascular neoplasms, 341
 Vascular tumors, 338–342
 Venulitis (endotheliitis), 92
 Verocay bodies, 337
 Verruca vulgaris, 313

Verrucous, 31, 33
Villitis of uncertain etiology (VUE), 194
Villous adenoma, 75
VIN-1, 167
Viral squamous papillomas, 35
von Brunn's nests, 120, 121, 126
von Hippel–Lindau syndrome (VHL), 295
von Meyenburg complex, 95
Vulvar epithelium
 HPV, 173
 inflammatory skin conditions, 174–175
 papillary lesions, 174
 squamous carcinoma, 175–176
Vulvar HSIL (VIN3), 174

W

Walther rests, 153
Warthin tumor, 274
Well-differentiated liposarcoma
 (WDLS), 326–328
Well-differentiated neuroendocrine tumors
 (Lung Carcinoid), 281
Wharton's jelly, 191
WHO classification system, 148
Wilms tumors, 139–141
World Health Organization (WHO), 286
Woven bone, 348
Woven bone formation, 358
Wright–Giemsa stain, 211

X

Xp11 translocation carcinoma
 of the kidney, 141

Y

Yolk sac tumor, 8, 10, 149–150

Z

Zellballen pattern, 284
Zygomycetes, 23