

Daniel Azoulay · Chetana Lim  
Chady Salloum *Editors*

# Surgery of the Inferior Vena Cava

A Multidisciplinary  
Approach

**EXTRAS ONLINE**



Springer

---

# Surgery of the Inferior Vena Cava

---

Daniel Azoulay • Chetana Lim  
Chady Salloum  
Editors

# Surgery of the Inferior Vena Cava

A Multidisciplinary Approach

 Springer

*Editors*

Daniel Azoulay  
Service de chirurgie hépato-biliaire,  
pancréatique et transplantation hépatique  
Hôpital Henri-Mondor  
Créteil  
France

Chady Salloum  
Service de chirurgie hépato-biliaire,  
pancréatique et transplantation hépatique  
Hôpital Henri-Mondor  
Créteil  
France

Chetana Lim  
Service de chirurgie hépato-biliaire,  
pancréatique et transplantation hépatique  
Hôpital Henri-Mondor  
Créteil  
France

ISBN 978-3-319-25563-7      ISBN 978-3-319-25565-1 (eBook)  
DOI 10.1007/978-3-319-25565-1

Library of Congress Control Number: 2017932902

© Springer International Publishing Switzerland 2017

This work is subject to copyright. All rights are reserved by the Publisher, whether the whole or part of the material is concerned, specifically the rights of translation, reprinting, reuse of illustrations, recitation, broadcasting, reproduction on microfilms or in any other physical way, and transmission or information storage and retrieval, electronic adaptation, computer software, or by similar or dissimilar methodology now known or hereafter developed.

The use of general descriptive names, registered names, trademarks, service marks, etc. in this publication does not imply, even in the absence of a specific statement, that such names are exempt from the relevant protective laws and regulations and therefore free for general use.

The publisher, the authors and the editors are safe to assume that the advice and information in this book are believed to be true and accurate at the date of publication. Neither the publisher nor the authors or the editors give a warranty, express or implied, with respect to the material contained herein or for any errors or omissions that may have been made. The publisher remains neutral with regard to jurisdictional claims in published maps and institutional affiliations.

Printed on acid-free paper

This Springer imprint is published by Springer Nature  
The registered company is Springer International Publishing AG  
The registered company address is: Gewerbestrasse 11, 6330 Cham, Switzerland



---

## In Memoriam



*This book is dedicated in memory of Tom Starzl who passed away March 04 2017.  
He will remain our Hero.*

Daniel Azoulay

---

## Foreword by Thomas E. Starzl

When Professor Daniel Azoulay requested me to write a Foreword for his book on inferior vena cava (IVC) surgery, I responded that "... I have never seen a book dealing primarily (or solely) with the inferior vena cava (IVC). In my opinion, one is justified. If I read your email correctly, that is what you seem to have accomplished ...” His answer was “You are right: there is no book in English devoted exclusively to the inferior vena cava (IVC)... There is one in French, now more than 25 years old, edited by Edouard Kieffer, consisting of presentations at a special meeting of vascular surgeons.”

After seeing the list of distinguished chapter authors, I concluded that this book would have a bright future. However, the quality of such multiauthor texts is ultimately dependent on the editor, here Daniel Azoulay. I first met him in 1989 while visiting his mentor Henri Bismuth in Villejuif, France. As a trained thoracic surgeon, Azoulay’s activities were at first limited to the resection of lung metastases. Ten years later, he arrived in Pittsburgh with Professor Bismuth to present their seminal experience with split liver transplantation. Our next rendezvous was in October 2008 when we had dinner together at the 20th year liver transplant celebration of The Royal Free Hospital in London. His transition to “liver surgeon” was now complete.

By then, Azoulay’s achievements were sufficient to make him a prime candidate for the then vacant position of leader of the Pittsburgh Transplantation Institute. Instead, he stayed in France where he ultimately became the Departmental Chief of two University surgical units at the Henri-Mondor Hospital complex in the Paris suburb of Creteil. Over the years, and while taking on an increasingly heavy load of academic duties, he has personally performed more than 1500 liver resections and an equivalent number of liver transplantations while participating in the care of more than 5000 patients in each category. Observations from this experience have been recorded in more than 650 publications that have been cited nearly 13,000 times (Institute for Scientific Information [ISI], Philadelphia).

All of the experience has involved the IVC in one way or the other, uniquely qualifying him as both contributor to and editor of this book. This book addresses almost all current topics of the IVC, ranging from surgical anatomy, IVC anomalies, imaging and radiological assessment, control of hemodynamics during surgery,

invasion of every type of malignancy into IVC, use of vena cava filters, and the contributions each to the other, of liver transplantation and nontransplant hepatic surgery. This text will be of interest to surgeons (hepatobiliary, vascular, and digestive) and urologists, as well as radiologists and anesthesiologists. I recommend reading it thoroughly and referring to it if problems with IVC are encountered or anticipated.

Thomas E. Starzl, MD, PhD  
Distinguished University Professor of Surgery  
University of Pittsburgh School of Medicine  
Pittsburgh, PA, USA

---

## Foreword by Eduardo Barroso

My friendship with Daniel Azoulay goes back to his journey at Paul Brousse as one of Henri Bismuth's brightest surgeons. When he requested me to write a small Foreword for this book, I was flattered as I consider him an outstanding innovating surgeon.

The new paradigm of precision surgery summarizes the basic needs for the correct practice of the so-called subspecialties of abdominal surgery. Of these basic needs, I cannot emphasize enough the absolute importance of a multidisciplinary approach and the creation of true referral centers.

The revolutionary idea of moving towards a super-specialization in abdominal surgery becomes now brilliantly apparent in this book dedicated exclusively to the surgery of the inferior vena cava (IVC).

After carefully reading this work, the need of a true multidisciplinary approach becomes evident. This includes the diagnostic and staging phases, imaging with several stages of sophistication, the role of oncology in the definition of a global therapeutic strategy and, of course, the surgical procedure, and the fundamental role of surgeons and anesthesiologists.

As this work is dedicated to surgery of the IVC and not only the diseases of the vena cava, it is no wonder that there is a significant predominance of diseases of other organs and systems, which despite not having origin in the IVC, will demand more or less complex surgical approaches to this vein. This culminates, most of the times, with the need of extensive venous resections associated with surgical procedures in other abdominal organs.

The level of difficulty of the approach to the IVC is not the same from its origin up to the renal veins, in its course above the renal veins to the diaphragm, and especially in its retrohepatic course. Above the liver and up to the right atrium, its approach and eventual resection may be the most complex.

The primary leiomyosarcoma of the IVC is the only intrinsic disease of the vena cava addressed by the authors. The difficulty in its resection will depend on its location. This is also true for the approach of the retroperitoneal tumors, which may invade the IVC on several levels.

The tumors of the right kidney with extensive tumoral thrombosis, sometimes up to the right atrium, are easily approachable with the collaboration of urologists and hepatic surgeons, especially surgeons with expertise in transplantation. Obviously only transplant surgeons can perform surgery of the IVC in association to liver

resection or to transplantation whether in cadaveric donor (classic or piggyback) or living donor.

The authors also approach the state of the art regarding IVC filters in the prevention of pulmonary embolism.

I believe it was not the authors' intention to support the creation of a new subspecialty related to the surgery of the IVC. This work emphasizes the need of a multidisciplinary approach involving other specialties in the diagnosis and staging of diseases that might involve surgical resections of the IVC. In this setting, experienced radiologists, along with a wide variety of imaging methods, are pivotal. Oncologists will help define, along with the use of new drugs, the survival benefit of such a radical strategy.

The authors recognize another multidisciplinary concept, which is the collaboration between surgeons, with important expertise in several areas of abdominal surgery, and anesthesiologists used to the management of IVC clamping and the eventual last resort need of extra-corporeal bypass.

As the majority of IVC surgery is performed in the segments above the renal veins, hepatobiliary and transplant surgeons have a clear advantage when dealing with these cases.

Daniel Azoulay, by being editor and author of this work, and the quality of the people he chose to co-work with him, guarantee this book to be very useful for the majority of abdominal general surgeons, as they must clearly know their competences and limitations when treating their patients.



Eduardo Barroso, MD, PhD  
Professor of Surgery, NOVA University of Lisbon  
Head, Hepato-Biliary-Pancreatic and Transplantation Centre  
Curry Cabral Hospital, CHLC  
Lisbon, Portugal

---

## Foreword by Masatoshi Makuuchi

Combined resection of the liver and inferior vena cava (IVC) for hepatic malignancy has traditionally been considered a contraindication to resection for advanced tumors of the liver because the surgical risks are high and the long-term prognosis is poor.

IVC runs through the liver and is circumferentially surrounded by the liver except on its posterior aspect. I always explain to my students that when we liken IVC to women's body, the liver is a bra and the ligament is a bra hook. Its dissection from the liver requires a high degree of skill and extensive training. Even today, after 36 years of experience of hepatectomy, I still feel some tension every time I try to separate the IVC from the liver or the tumor.

The joint part of IVC and three major hepatic veins carries risk of serious hemorrhage in liver resection. Control of blood loss is the fundamental and most crucial for safe operation.

IVC control is processed by dissection and taping of the inferior and middle right hepatic veins, ligation and division of the IVC ligament, and dissection and taping of right hepatic vein and middle and left hepatic venous trunk from left side after division of the ductus Arantius. After these processing steps, the liver is divided under the intermittent occlusion, the IVC is treated by the Pringle maneuver, clamping diagonally at the cranial side of the renal vein at the lower part of the liver, then clamping the upper part of the inferior vena cava. By this way, the liver and IVC are completely blocked and bloodless area is created. All preparations are made for safe surgery.

By these ways, the tumor with the liver and the invaded IVC wall is removed. The defect of IVC is sutured directly or replaced by the autovenous wall or cryopreserved vein, which should be prepared before division of the IVC wall.

Daniel Azoulay is an outstanding surgeon and is worthy for a "right-hand man" of Henri Bismuth. After the age of 30, he spent most of his time in the Hepato-Biliary Center at the Paul Brousse Hospital in Villejuif – an innovative, dedicated liver disease center headed by Henri Bismuth. This remarkable book reflects the experience in hepatic and biliary surgery compiled at the Center over nearly a quarter of a century.

This book addresses almost all current topics in IVC surgery ranging from surgical anatomy, imaging and radiological assessment, control of hemodynamics during surgery, invasion of every type of malignancy into IVC, juxtahepatic vena cava,

liver transplantation, and vena cava filter. The authors and editors should be congratulated for gathering a wealth of knowledge in this book that updates the state-of-the-art surgery.

It will be of a great interest to surgeons (hepatobiliary, vascular, and digestive) and urologists, as well as radiologists and anesthesiologists. I would like to recommend reading it thoroughly and referring to it each time they encounter a problem of IVC.

As such, the nightmare of IVC will soon be over.

Masatoshi Makuuchi, MD, PhD, FACS (Hon)  
Japanese Red Cross Medical Center  
Tokyo, Japan

---

# Contents

<b>1</b>	<b>Imaging and Radiological Assessment of the Inferior Vena Cava . . . . .</b>	<b>1</b>
	M. Chiaradia, F. Legou, J. Arfi-Rouche, V. Tacher, H. Kobeiter, F. Pigneur, A. Rahmouni, and A. Luciani	
<b>2</b>	<b>Anesthetic and Hemodynamic Considerations of Inferior Vena Cava Surgery . . . . .</b>	<b>21</b>
	Daniel Eyraud and Victoria Lepere	
<b>3</b>	<b>Primary Leiomyosarcoma of the Inferior Vena Cava . . . . .</b>	<b>41</b>
	Andrea Mingoli, Marco La Torre, Claudia Panzano, and Bruno Cirillo	
<b>4</b>	<b>Retroperitoneal Sarcoma Involving the Inferior Vena Cava . . . . .</b>	<b>61</b>
	Marco Fiore, Stefano Radaelli, and Alessandro Gronchi	
<b>5</b>	<b>Renal Cell Carcinoma Involving the Inferior Vena Cava . . . . .</b>	<b>75</b>
	Javier González and Gaetano Ciancio	
<b>6</b>	<b>Surgery of the Inferior Vena Cava Combined to Liver Resection . . . . .</b>	<b>107</b>
	Chetana Lim, Chady Salloum, and Daniel Azoulay	
<b>7</b>	<b>Ex Situ Resection of the Inferior Vena Cava with Hepatectomy . . . . .</b>	<b>131</b>
	Shahid G. Farid and J. Peter A. Lodge	
<b>8</b>	<b>Surgical Treatment of Adrenocortical Carcinoma with Caval Invasion . . . . .</b>	<b>149</b>
	Sebastien Gaujoux, Elisabeth Hain, Marthe Weinandt, Roberto Schiavone, Roberto Cuni, and Bertrand Dousset	
<b>9</b>	<b>Malignancy with Cavoatrial Extension . . . . .</b>	<b>161</b>
	Jean-Marc Alsac, Paul Achouh, Eleonora Du Puyfontbrun, Alain Bel, Jerome Jouan, Suzanna Salvi, Julia Pouly, and Jean-Noël Fabiani	
<b>10</b>	<b>Injuries of the Juxtahepatic Vena Cava . . . . .</b>	<b>169</b>
	Christian Létoublon, Laurence Lacaze, and Mircea Chirica	



---

<b>11</b>	<b>Inferior Vena Cava Reconstruction in Liver Transplantation . . . . .</b>	<b>183</b>
	Melissa J. Watson, Nikolaos Pararas, and Andreas Tzakis	
<b>12</b>	<b>Inferior Vena Cava Reconstruction in Living Donor Liver Transplantation. . . . .</b>	<b>203</b>
	Nobuhisa Akamatsu and Norihiro Kokudo	
<b>13</b>	<b>Vena Cava Filters: State of the Art . . . . .</b>	<b>217</b>
	Salah D. Qanadli and Charalampos Sotiriadis	

---

## List of Contributors

**Paul Achouh** Department of Cardiovascular Surgery, Hôpital Européen Georges Pompidou, AP-HP, Faculté de Médecine René Descartes, Université Paris 5, Paris, France

**Nobuhisa Akamatsu** Artificial Organ and Transplantation Division, Department of Surgery, Graduate School of Medicine, The University of Tokyo, Tokyo, Japan

**Jean-Marc Alsac** Department of Cardiovascular Surgery, Hôpital Européen Georges Pompidou, AP-HP, Faculté de Médecine René Descartes, Université Paris 5, Paris, France

**Julia Arfi-Rouche** Institut Gustave Roussy, Service de radiologie, Villejuif, France

**Daniel Azoulay** Department of HPB Surgery and Liver Transplant Unit, Henri Mondor Hospital, Créteil, France

**Alain Bel** Department of Cardiovascular Surgery, Hôpital Européen Georges Pompidou, AP-HP, Faculté de Médecine René Descartes, Université Paris 5, Paris, France

**Mélanie Chiaradia** APHP, Hôpitaux Universitaires Henri Mondor, Imagerie Médicale, Créteil, France

**Mircea Chirica** Department of Digestive and emergency surgery, University Hospital of Grenoble, Grenoble Alpes University, Saint-Martin-d'Hères, France

**Bruno Cirillo** Department of Surgery P. Valdoni, Emergency Department, Policlinico Umberto I, “Sapienza” University of Rome, Rome, Italy

**Roberto Cuni** Department of Digestive, Hepato-Biliary and Endocrine Surgery, Referral Center for Rare Adrenal Diseases, Cochin Hospital, APHP, Paris, France

**Bertrand Dousset** Department of Digestive, Hepato-Biliary and Endocrine Surgery, Referral Center for Rare Adrenal Diseases, Cochin Hospital, APHP, Paris, France

Faculté de Médecine Paris Descartes, Université Paris Descartes, Sorbonne Paris Cité, Paris, France

INSERM Unité 1016, Centre National de la Recherche Scientifique Unité Mixte de Recherche 8104, Institut Cochin, Paris, France

**Daniel Eyraud** Department of Anesthesiology and Intensive Care Unit, Assistance Publique-Hôpitaux de Paris (AP-HP), Pitié-Salpêtrière University Hospital, Paris, France

Department of Digestive, HPB Surgery, and Liver Transplantation, Assistance Publique-Hôpitaux de Paris (AP-HP), Pitié-Salpêtrière University Hospital, Paris, France

**Jean-Noël Fabiani** Department of Cardiovascular Surgery, Hôpital Européen Georges Pompidou, AP-HP, Faculté de Médecine René Descartes, Université Paris 5, Paris, France

**Shahid G. Farid** HPB and Transplant Unit, St James's University Hospital, Leeds, UK

**Marco Fiore** Sarcoma Service, Fondazione IRCCS Istituto Nazionale Tumori, Milan, Italy

**Gaetano Ciancio** Division of Transplantation, Department of Urology and Department of Surgery, Leonard M. Miller School of Medicine, Miami Transplant Institute, Jackson Memorial Hospital, University of Miami, Miami, FL, USA

**Sebastien Gaujoux** Department of Digestive, Hepato-Biliary and Endocrine Surgery, Referral Center for Rare Adrenal Diseases, Cochin Hospital, APHP, Paris, France

Faculté de Medecine Paris Descartes, Université Paris Descartes, Sorbonne Paris Cité, Paris, France

INSERM Unité 1016, Centre National de la Recherche Scientifique Unité Mixte de Recherche 8104, Institut Cochin, Paris, France

**Alessandro Gronchi** Sarcoma Service, Fondazione IRCCS Istituto Nazionale Tumori, Milan, Italy

**Elisabeth Hain** Department of Digestive, Hepato-Biliary and Endocrine Surgery, Referral Center for Rare Adrenal Diseases, Cochin Hospital, APHP, Paris, France

**González, Javier** Servicio de Urología, Hospital Central de la Cruz Roja San José y Santa Adela, Universidad Alfonso X el Sabio, Madrid, Spain

**Jerome Jouan** Department of Cardiovascular Surgery, Hôpital Européen Georges Pompidou, AP-HP, Faculté de Médecine René Descartes, Université Paris 5, Paris, France

**Hicham Kobeiter** APHP, Hôpitaux Universitaires Henri Mondor, Imagerie Médicale, Créteil, France

Faculté de Médecine, Université Paris Est Créteil, Créteil, France

**Norihiko Kokudo** Artificial Organ and Transplantation Division, Department of Surgery, Graduate School of Medicine, The University of Tokyo, Tokyo, Japan

**Laurence Lacaze** Department of Digestive and emergency surgery, University Hospital of Grenoble, Grenoble Alpes University, Saint-Martin-d'Hères, France

**Francois Legou** APHP, Hôpitaux Universitaires Henri Mondor, Imagerie Médicale, Créteil, France

Faculté de Médecine, Université Paris Est Créteil, Créteil, France

**Victoria Lepere** Department of Anesthesiology and Intensive Care Unit, Assistance Publique-Hôpitaux de Paris (AP-HP), Pitié-Salpêtrière University Hospital, Paris, France

**Christian Létoublon** Department of Digestive and emergency surgery, University Hospital of Grenoble, Grenoble Alpes University, Saint-Martin-d'Hères, France

**Chetana Lim** Department of HPB Surgery and Liver Transplant Unit, Henri Mondor Hospital, Créteil, France

**J. Peter A. Lodge** HPB and Transplant Unit, St James's University Hospital, Leeds, UK

**Alain Luciani** APHP, Hôpitaux Universitaires Henri Mondor, Imagerie Médicale, Créteil, France

Faculté de Médecine, Université Paris Est Créteil, Créteil, France

**Andrea Mingoli** Department of Surgery P. Valdoni, Emergency Department, Policlinico Umberto I, "Sapienza" University of Rome, Rome, Italy

**Claudia Panzano** Department of Surgery P. Valdoni, Emergency Department, Policlinico Umberto I, "Sapienza" University of Rome, Rome, Italy

**Nikolaos Pararas** DTCA Hygeia Hospital, Athens, Greece

**Frédéric Pigneur** APHP, Hôpitaux Universitaires Henri Mondor, Imagerie Médicale, Créteil, France

Faculté de Médecine, Université Paris Est Créteil, Créteil, France

**Julia Pouly** Department of Cardiovascular Surgery, Hôpital Européen Georges Pompidou, AP-HP, Faculté de Médecine René Descartes, Université Paris 5, Paris, France

**Eleonora Du Puymontbrun** Department of Cardiovascular Surgery, Hôpital Européen Georges Pompidou, AP-HP, Faculté de Médecine René Descartes, Université Paris 5, Paris, France

**Salah D. Qanadli** Cardio-Thoracic and Vascular Unit, Department of Radiology, Lausanne University Hospital, Lausanne, Switzerland

**Stefano Radaelli** Sarcoma Service, Fondazione IRCCS Istituto Nazionale Tumori, Milan, Italy

**Alain Rahmouni** APHP, Hôpitaux Universitaires Henri Mondor, Imagerie Médicale, Créteil, France

Faculté de Médecine, Université Paris Est Créteil, Créteil, France

**Chady Salloum** Department of HPB Surgery and Liver Transplant Unit, Henri Mondor Hospital, Créteil, France

**Suzanna Salvi** Department of Cardiovascular Surgery, Hôpital Européen Georges Pompidou, AP-HP, Faculté de Médecine René Descartes, Université Paris 5, Paris, France

**Charalampos Sotiriadis** Cardio-Thoracic and Vascular Unit, Department of Radiology, Lausanne University Hospital, Lausanne, Switzerland

**Roberto Schiavone** Department of Digestive, Hepato-biliary and Endocrine Surgery, Referral Center for Rare Adrenal Diseases, Cochin Hospital, APHP, Paris, France

**Vania Tacher** APHP, Hôpitaux Universitaires Henri Mondor, Imagerie Médicale, Créteil, France

Faculté de Médecine, Université Paris Est Créteil, Créteil, France

**Marco La Torre** Department of Surgery P. Valdoni, Emergency Department, Policlinico Umberto I, “Sapienza” University of Rome, Rome, Italy

**Andreas Tzakis** Cleveland Clinic, Cleveland, OH, USA

**Melissa Watson** Cleveland Clinic, Cleveland, OH, USA

**Marthe Weinandt** Department of Digestive, Hepato-Biliary and Endocrine Surgery, Referral Center for Rare Adrenal Diseases, Cochin Hospital, APHP, Paris, France

---

## List of Videos

- Video 6.1 Right nephrectomy with inferior vena cava and left renal vein reconstruction for renal cell carcinoma
- Video 6.2 Resection of the inferior vena cava with end-to-end cavocaval anastomosis for recurrent leiomyosarcoma
- Video 7.1 Video showing hepatectomy with IVC resection for extensive colorectal metastases

---

# Imaging and Radiological Assessment of the Inferior Vena Cava

# 1

M. Chiaradia, F. Legou, J. Arfi-Rouche, V. Tacher,  
H. Kobeiter, F. Pigneur, A. Rahmouni, and A. Luciani

---

## 1.1 Introduction

The inferior vena cava (IVC) is the main vein of the human body, formed by the confluence of the left and right common iliac veins. It ascends in the retroperitoneum to the right of the aorta and exits the abdomen through the diaphragmatic hiatus to join the right atrium. It drains the left and right renal veins, the lumbar veins, the right adrenal vein, the right gonadal vein, and the hepatic veins. The azygos venous system connects to the IVC (directly or through the renal veins). The IVC has four segments: the hepatic, suprarenal, renal, and infrarenal segments [1].

Formation of the IVC is the result of anastomoses and regression of embryonic veins including the vitelline vein and paired posterior cardinal, supracardinal, and subcardinal veins. The hepatic segment is composed of the vitelline vein, the suprarenal segment is composed of a segment of the right subcardinal vein, and the renal segment is formed by the anastomosis between the right subcardinal and the right supracardinal veins; a part of the supracardinal vein constitutes the infrarenal segment [2].

---

M. Chiaradia • F. Pigneur  
Imagerie Médicale, APHP, Hôpitaux Universitaires Henri Mondor, Créteil 94000, France

F. Legou • V. Tacher • H. Kobeiter • A. Rahmouni  
Imagerie Médicale, APHP, Hôpitaux Universitaires Henri Mondor, Créteil 94000, France  
Faculté de Médecine, Université Paris Est Créteil, Créteil 94000, France

J. Arfi-Rouche  
Service de radiologie, Institut Gustave Roussy, Villejuif 94800, France

A. Luciani, MD, PhD (✉)  
Imagerie Médicale, APHP, Hôpitaux Universitaires Henri Mondor, Créteil 94000, France  
Faculté de Médecine, Université Paris Est Créteil, Créteil 94000, France

Department of Radiology, Henri Mondor Hospital, Créteil, France  
e-mail: [alain.luciani@aphp.fr](mailto:alain.luciani@aphp.fr)

Knowledge of the IVC disease is primordial before surgery to avoid serious complications. This chapter will focus on the imaging techniques, the main diagnostic features, and the interventional radiology of IVC disease.

---

## 1.2 IVC Imaging Techniques

Different imaging techniques are available for IVC assessment—ultrasound (US), multi-detector computed tomography (MDCT), and magnetic resonance imaging (MRI)—and conventional venography can also be used [3].

### 1.2.1 Conventional Venography

Conventional venography is the historical gold standard for IVC imaging. The main limitation of this modality is its invasiveness and the use of a high quantity of iodine contrast agent. It is performed using a pigtail catheter positioned just below the common iliac vein confluence. It has been replaced by noninvasive imaging techniques, MDCT and MRI. The advantages of conventional venography are multiple: good spatial resolution, the possibility to analyze the flow, and collateral pathway visualization.

### 1.2.2 Ultrasound

Evaluation of the IVC with ultrasound is widely available. The suprarenal portion of the IVC, especially the retro-hepatic portion, is most of the time perfectly analyzed. The main advantage of US exploration is the possibility to combine Doppler assessment, which provides an estimate of the direction and speed of the blood flow within the IVC. However, the infrarenal portion of the IVC is imperfectly seen because of bowel gas interposition and depth of the IVC in the abdomen especially in obese patients. Furthermore, vessel reconstructions are not possible on US. CT and MR imaging are hence usually required for staging and surgical treatment planning.

### 1.2.3 Multi-Detector Computed Tomography (MDCT)

Imaging of the IVC is most of the time performed on MDCT because of its availability. Routine abdominal CT protocol includes venous portal phase (60–70 s of delay). IVC evaluation is limited by flow artifacts arising from non-opacification from common iliac veins and admixture from renal veins. Infrarenal IVC analysis is not optimal in this case. Uniform enhancement is obtained on late venous phase (70–90 s of delay) [3, 4]. This additional sequence however increases radiation exposure for patients. Contrast injection is performed via an antecubital vein at a rate of at least 3 mL/s as much as possible.



CT scanner allows good spatial and contrast resolution. Vessel reconstructions in multiplanar reformation are available and include maximum intensity projection (MIP) and volume rendering (VR). The optimal protocol should include non-contrast injection scan in order to depict spontaneous high-attenuation abnormality (thrombus) or chronic calcifications (chronic venous occlusion) and a delayed venous phase described above.

### 1.2.4 Magnetic Resonance Imaging (MRI)

IVC exploration can be performed with MRI, with no X-ray exposure. Furthermore, the exploration can be made with or without contrast injection. MRI is particularly interesting in IVC thrombus evaluation. MRI availability and cost limit the use of this imaging technique on a routine basis. Anatomic sequences in two planes are generally acquired (axial and coronal T2), followed by flow sequences. Balanced steady-state free sequences are key sequences (True FISP, Siemens; FIESTA, GE; Balanced FFE, Philips) that improve flowing proton signal, which appear bright, allowing vessel analysis [5].

Thick-sliced two-dimensional time-of-flight (2D TOF) imaging, which is MRI flow sequence without contrast injection, provides useful diagnostic information especially for IVC thrombosis [6, 7]. Signal from protons in flowing blood is visible, whereas protons from background tissues display no signal [6].

Three-dimensional breath-hold T1-weighted MR imaging after dynamic contrast administration (fast low angle shot sequence) in coronal planes allows both arterial and venous analysis. Maximum intensity projection reformation can be used to further improve anatomical description of abnormalities.

### 1.2.5 PET-CT

PET-CT is an interesting imaging modality in oncology setting, providing anatomical and metabolic information. Fluorine-18 fluorodeoxyglucose (18 F-FDG) PET-CT is commonly used in cancer staging (disease). It can also be used to detect avid fluorodeoxyglucose thrombus, reflecting malignant thrombus. FDG uptake increases in actively dividing cells like inflammatory cells or malignant cells. FDG uptake in thrombus may reflect septic or malignant thrombus and can help final diagnosis [8–10]. In addition, PET-CT can monitor treatment response using SUV variation over time. A fully diagnostic CT can also be combined with PET-CT imaging.

---

## 1.3 Main Imaging Diagnostic Feature

Recognition of IVC abnormalities is essential. IVC abnormalities are multiple, including congenital anomalies, neoplasms, and other postsurgical features.

**Table 1.1** IVC obstruction etiologies

<i>Intrinsic</i>
Thrombosis
Stenosis (ex: congenital membranes)
Tumor: primary, invasion from adjacent organ/retroperitoneum
Iatrogenic (central catheter placement, cava filter)
<i>Extrinsic</i>
Compression by retroperitoneal mass (lymph nodes, retroperitoneal fibrosis, tumor, aortic aneurysm)
Enlarged liver
Pregnant uterus
Surgical ligation, clip

### 1.3.1 IVC Obstruction

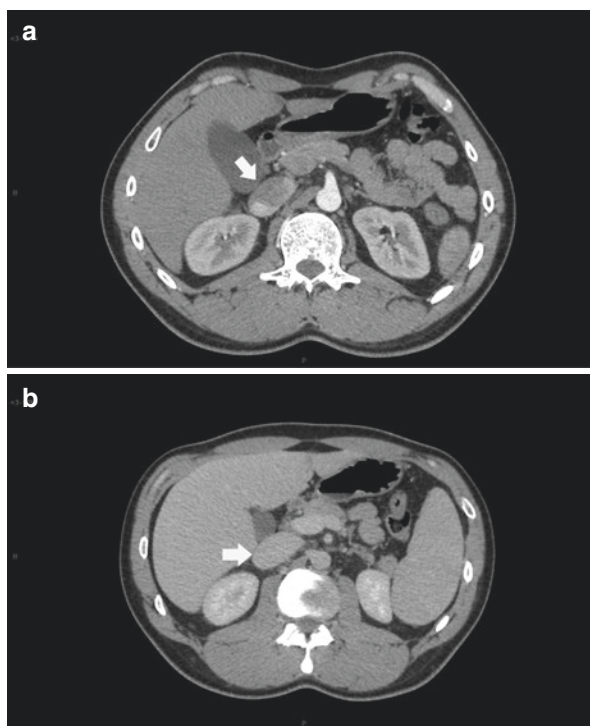
IVC obstruction concerns in 90 % of cases of the infrarenal segment. Its causes are multiple (Table 1.1). The most common etiology is thrombosis arising from common iliac vein thrombus. Predisposing conditions are frequent (coagulopathy, cancer, sepsis, immobility, dehydration, etc.). Isolated IVC thrombus can occur after liver transplantation due to stenosis of caval anastomoses or filter cava placement. Primary tumors are rare. Leiomyosarcoma is the most common malignant primary tumor. Surgical resectability depends on the location of the tumor. Extension from adjacent organs (renal cancer, adrenal carcinoma, pheochromocytoma, liver cancer) or retroperitoneum (retroperitoneal fibrosis) is more common and radiologist should be careful in these cases.

Diagnostic imaging is easy as soon as acquisition time is correct. The key imaging is based on the detection of a filling defect within the IVC. However, filling defect in IVC can result from multiple causes including flow-related artifacts, bland thrombus, benign thrombus, or malignant thrombus [11, 12]. Acute thrombus (<1 week) classically appears as intraluminal hyperdensities within the IVC on CT prior to contrast injection, with homogeneous signal intensity on MR, whereas non-acute thrombus can remain undetected on CT prior to injection, with heterogeneous signal intensity on MRI [13]. Acute and non-acute thrombi usually show filling defect on both CT and MRI after contrast injection.

#### 1.3.1.1 Artfactual Filling Defect and Bland Thrombus

Artfactual filling defects are due to incomplete filling of IVC by contrast agents. This is usually caused by flow of enhanced blood from renal veins mixed with non-opacified blood returning from lower limbs [11]. Delayed images as described above may ease the final diagnosis (Fig. 1.1).

Bland thrombus is the most common thrombus of IVC. It often extends from pelvic and lower extremity deep vein thrombosis. There is no enhancement of this thrombus after contrast injection (Fig. 1.2). Patients with IVC thrombosis are at high risk of pulmonary embolism. This thrombus can be idiopathic, the consequence of hypercoagulable state or induced by venous stasis (immobility, external compression).



**Fig. 1.1** Inferior vena cava artifactual filling defect (*arrow*) (axial CT) on early venous phase (**a**) with homogenization on late venous phase (*arrow*) (**b**)

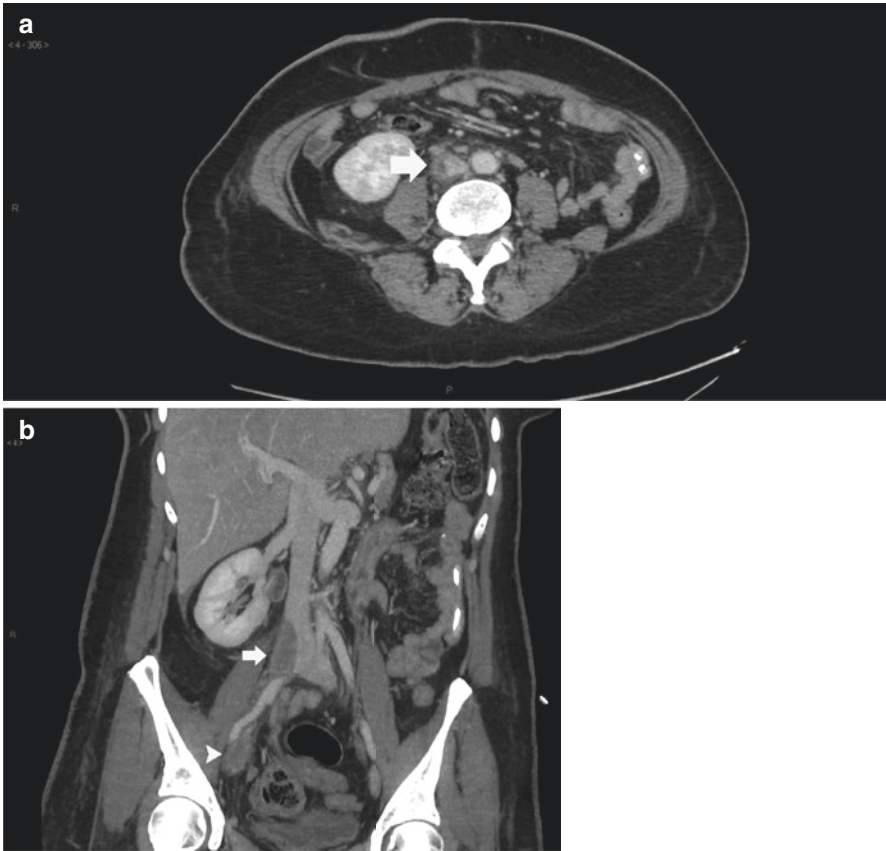
### 1.3.1.2 Benign Tumor Invasion Within the IVC

Benign tumor invasion within the IVC is rare and may be secondary to the vascular extension of renal angiomyolipoma [14], leiomyomatosis [11], or adrenal pheochromocytoma [15]. The appearance is close to that of malignant tumor invasion.

### 1.3.1.3 Malignant Tumor Invasion Within the IVC

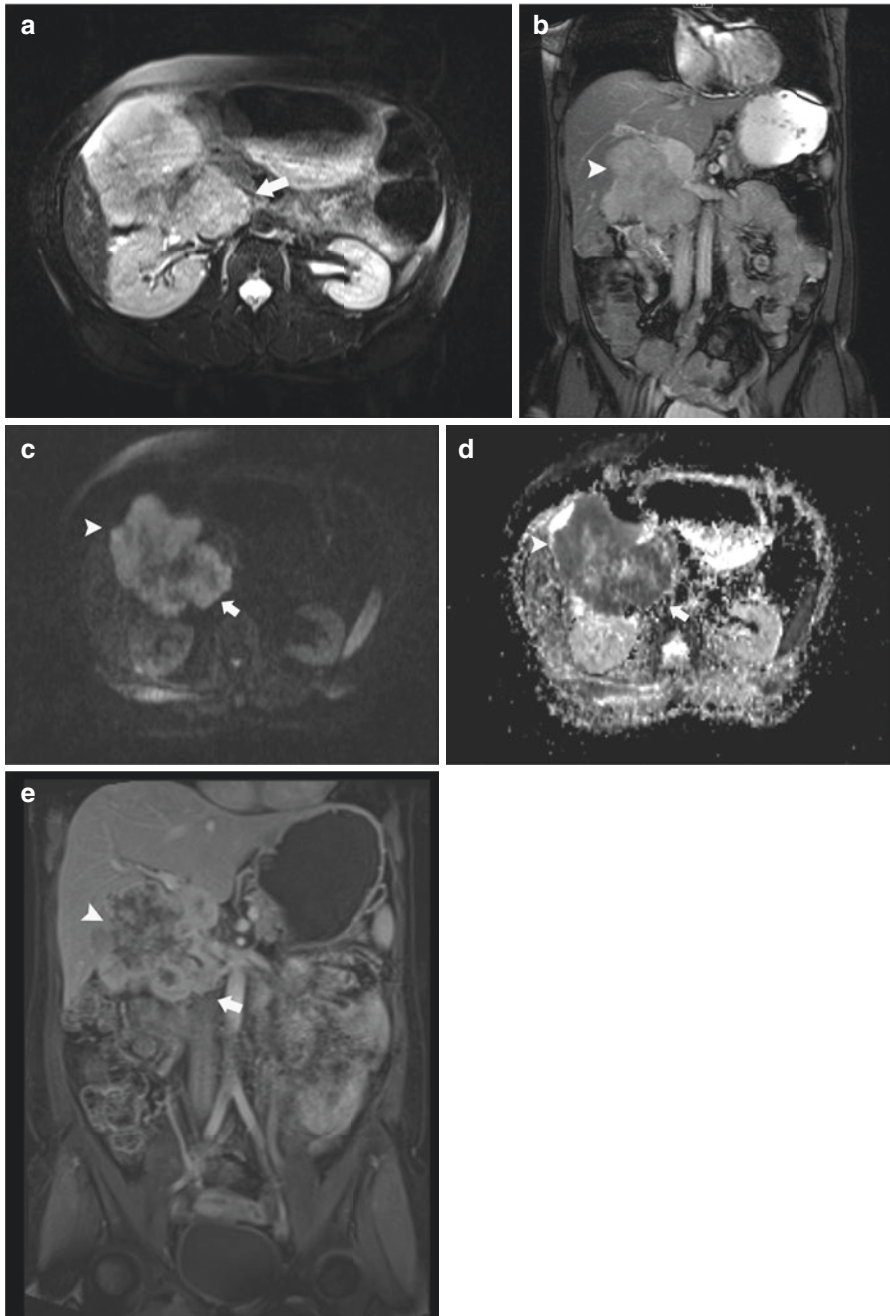
Primary and secondary tumor can extend within the IVC. Both often share similar imaging features, characterized by a contiguous adjacent mass, expansion within the lumen vessel and thrombus enhancement after contrast injection [11]. However, neoplastic IVC invasion and bland thrombus induced by neoplastic hypercoagulability state can coexist. If an adjacent mass is not found, IVC-enhancing mass may correspond to primary sarcoma. Extension of thrombus must be perfectly described by radiologist because it affects surgical procedure. Supradiaphragmatic extension must be carefully searched. In this case, IVC resection and cardiopulmonary bypass are required, increasing morbidity and mortality [11, 16].

Primary IVC tumors are rare, and leiomyosarcoma is the most common primary tumor (<1% of all malignancies) (Fig. 1.3). Differentiation of primary leiomyosarcoma arising from IVC to leiomyosarcoma arising from retroperitoneal space is

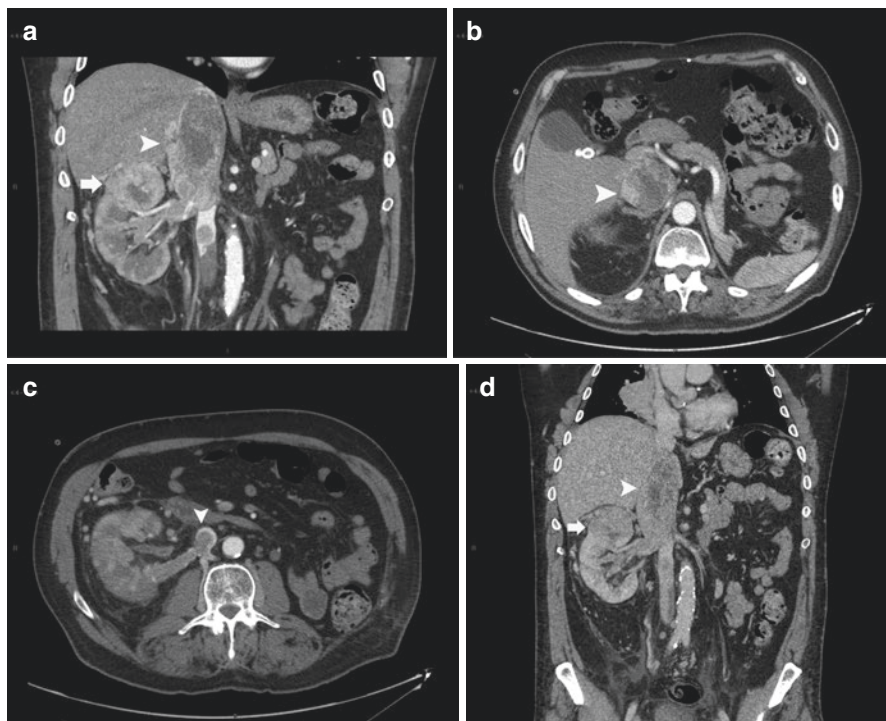


**Fig. 1.2** A 55-year-old patient with right common iliac vein thrombus (*arrowhead*) extending in the inferior vena cava (*arrow*) on axial (**a**) and coronal CT (**b**)

crucial since surgical treatment differs. Complete surgical resection is the only curative treatment. Cavoplasty or stent graft is required [17]. Distinction between these two entities on imaging is challenging because both masses are predominantly extra-luminal and are supposed to arise from smooth retroperitoneal muscle than from IVC. Some authors have suggested that tumors could be considered as primary IVC leiomyosarcoma if a segment of IVC needs to be resected during surgery. When this tumor is infrarenal and collateral vessels are well developed, IVC ligation is possible. In case of insufficient collateral vessels, edemas of lower limbs are frequent. In this case and in case of suprarenal disease, cavoplasty or stent graft is preferred. Distinction of primary IVC leiomyosarcoma on imaging allows surgery planning with vascular surgeon. The key diagnosis of IVC leiomyosarcoma is the imperceptible cava lumen (75% of cases in [18]). A positive embedded sign has also been described. Compression of IVC by retroperitoneal mass (negative embedded sign) suggests a non-cava origin.



**Fig. 1.3** A 58-year-old patient with an inferior vena cava leiomyosarcoma. Axial and coronal T2 (a, b), axial diffusion (c), apparent diffusion coefficient (d), and coronal contrast-enhanced T1-weighted MR images (e) show an inferior vena cava leiomyosarcoma (arrow) with liver invasion (arrowhead)



**Fig. 1.4** Right renal cell carcinoma (*arrow*) with malignant thrombus (*arrowhead*) in a 64-year-old patient. Axial (**a** and **c**) and coronal CT (**b** and **d**) show a right renal heterogeneous mass (*arrow*) with contrast enhancement, extending to IVC through the renal vein (*arrowhead*)

Secondary involvement of IVC by retroperitoneal sarcoma or neoplasm (renal carcinoma, hepatocellular carcinoma, or adrenocortical carcinoma for the most common neoplasms) is more common, and complete resection of this segment should be done by a surgeon.

Invasion of IVC is frequently seen in renal cell carcinoma (RCC) (4–10% of cases [19]) (Fig. 1.4). In a Mayo Clinic report, complications occurred in 15% of nephrectomy with thrombectomy of the IVC [20]. These complications included hemorrhage, pulmonary embolism (PE), acute renal failure, ileus, and wound infection. IVC extension of RCC must be screened on preoperative imaging [21, 22]. The Mayo classification [23] describes four levels of venous extension: level I when extension only concerns the renal vein and/or the IVC <2 cm, level II corresponds to extension within the IVC >2 cm below the hepatic veins, level III corresponds to retro-hepatic IVC and/or hepatic vein involvement, and level IV corresponds to extension above the diaphragm with or without atrial thrombus. Imaging should be performed no longer than 30 days and preferentially 14 days before resection for optimal surgical planning [24]. MRI is usually considered as the gold standard for thrombus evaluation, but MDCT is as accurate as MR and more available [25]. It also allows simultaneous thoracic screening. Furthermore, imaging features may predict



the need for IVC resection during nephrectomy: anteroposterior IVC diameter >24 mm, a right-sided tumor, and complete occlusion of the IVC at the ostium of the right renal vein [26].

### 1.3.1.4 IVC Obstruction Consequences and Therapeutic Implications

IVC obstruction can be asymptomatic or can lead to bilateral lower limbs edema, pulmonary embolism, the Budd-Chiari syndrome (BCS), or venous collateral formation [27–30].

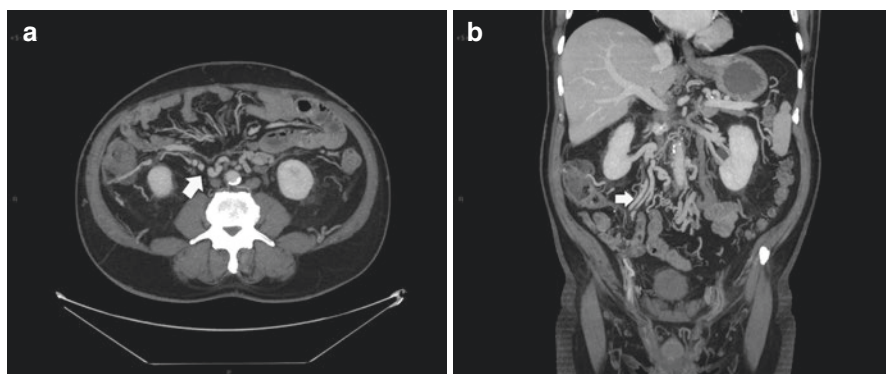
#### Budd-Chiari Syndrome

The Budd-Chiari syndrome (BCS) is a clinical and biological syndrome due to a lack of hepatic venous drainage. The etiology of BCS can be located at any portion of the hepatic venous drainage path from hepatic venules to IVC. In Europe, BCS is most of the time the consequence of hepatic vein thrombosis or of extrinsic compression. In Asia and South Africa, IVC webs (described below) are common BCS etiology [31]. The rapidity and extension of venous obstruction determine the severity of clinical and biological symptoms. BCS can be fulminant, acute, subacute, and chronic.

Imaging features of BCS include parenchyma abnormalities, ascites, signs of portal hypertension, and confirmation of venous outflow obstruction. Doppler US is the easiest imaging modality used for diagnostic confirmation with good sensitivity and specificity (approximately 85% [32]). In acute BCS, hepatic parenchyma can be heterogenous, with an enlarged caudate lobe and ascites. Splenomegaly reflecting portal hypertension is also described. On color Doppler US, hepatic vein or its confluence with the IVC is non-visualized; flow can also be diminished or reversed [33]. In chronic BCS, collateral veins can be seen. Portal vein flow can be slow and hepatofugal. On MDCT, heterogenous enhancement is present on arterial-parenchymal phase, with regenerative nodular lesions and caudate lobe hypertrophy. Ascites, splenomegaly, and venous collateral pathways are seen. Thrombosis, stenosis, or webs in hepatic veins or in the IVC can also be seen. Liver cirrhosis may be present on chronic BCS. Liver analysis must be carefully done to depict hepatocellular carcinoma. MRI displays the same imaging features than that of MDCT. Regenerative nodular lesions show hyperintensity on T1-weighted images, isointensity on T2-weighted images, and hyperenhancement on arterial phase, persisting on portal phase [34]. Specific treatment of BCS includes medical treatment with anticoagulation or interventional management in case of medical treatment failure [35].

#### Collateral Pathways

Chronic obstruction of IVC promotes collateral pathway development through deep and superficial venous collateral vessels. Four major pathways have been described [28]. The deep pathway, the most common, concerns the ascending lumbar veins, anastomosing with the azygos vein on the right side and the hemiazygos vein on the left side. Blood flow can also join vertebral, paraspinous, and extravertebral plexus. In the intermediate pathway, blood flow returns through the



**Fig. 1.5** Collateral pathway. A 56-year-old patient with IVC leiomyosarcoma, who underwent surgery. IVC occlusion leads to portal collateral pathway development (*arrow*) (axial CT (a) and coronal CT (b))

periureteric plexus bilaterally and the left gonadal vein to the left renal vein. The superficial pathway is constituted with the inferior epigastric and the abdominal wall veins, anastomosing with the superior epigastric veins and internal mammary veins to join the subclavian veins and the superior vena cava. Finally, the portal pathway concerns blood arising from lower extremities through the internal iliac veins to the hemorrhoidal plexus to join the inferior mesenteric vein and the portal system (Fig. 1.5).

Identification of these collateral pathways is essential before surgery to decrease hemorrhagic risk during procedure and to avoid pitfalls.

### 1.3.2 IVC Anatomical Variants

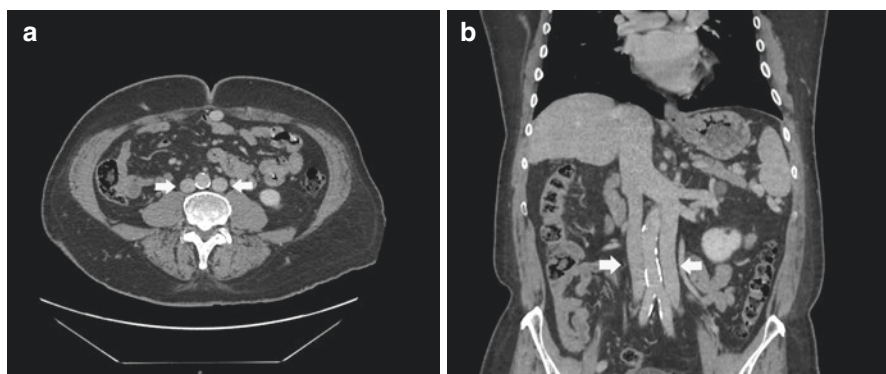
Anatomical variants of the IVC can be explained by aberrations of regression of embryologic veins described above. They are present in approximately 4% of the population and are most of the time asymptomatic [1, 3]. Correct identification of these variants is essential before vascular interventions.

The most common variants are left IVC, double IVC, retroaortic and circumaortic left renal vein, interruption of the IVC with azygos continuation, and portocaval shunt [1–5, 36].

#### 1.3.2.1 Left IVC

During embryologic development, the persistence of the left supracardinal vein combined with regression of the right supracardinal vein leads to the persistence of a left IVC. The left IVC joins the left renal vein. Then the left renal vein joins the right renal vein to form the IVC. Its prevalence is around 0.2–0.5% [2] and can also be seen in patients with situs inversus. This variant can be mistaken with left-sided para-aortic adenopathy on non-contrast injection imaging. It is of primary importance during left-sided donor nephrectomy [36].





**Fig. 1.6** A 55-year-old patient with double IVC (*arrow*) (axial, **(a)**; coronal CT **(b)**)

### 1.3.2.2 Double IVC

Both of the supracardinal veins (left and right) persist, leading to a double IVC. On imaging, the IVC presents bilaterally. The left renal vein joins the left IVC, which crosses anterior to the aorta in the normal location to join the right IVC (Fig. 1.6). This variant is asymptomatic and its prevalence is about 0.2–3% [2]. Its knowledge is important during kidney nephrectomy or vena cava filter placement to avoid pulmonary embolism recurrence. Some authors recommend contrast injection in the left and the right common iliac veins during cavography before inferior vena cava filter placement to diagnose this anomaly. Preoperative imaging is essential to correctly plan surgery and avoid vascular complications.

### 1.3.2.3 Retrocaval Ureter

The infrarenal segment develops from the right posterior cardinal vein, which lies anterior and lateral to the ureter instead of the right supracardinal vein, which is located posterior and medial to the ureter. This results in the compression of the ureter, leading to hydronephrosis or tract infections.

### 1.3.2.4 Retroaortic and Circumaortic Left Renal Vein

Retroaortic renal vein (2.1%) is classically asymptomatic but has been involved in the nutcracker syndrome with hypertension or in hematuria.

Circumaortic renal vein (5–7%) is characterized by two renal veins: one anterior to the aorta and the other posterior to the aorta. Its clinical implication is fundamental in renal transplantation and should be known before varicocele treatment by radiologist (as it is technically impossible in this case).

### 1.3.2.5 Interruption of the IVC and Azygos/Hemiazygos Continuation

It results from a failure to form the right subcardinal-hepatic anastomosis. The right subcardinal vein becomes atrophic. Blood is redirected through the retrocaval azygos vein or the hemiazygos vein and then the azygos vein. As a result, the azygos vein is enlarged and joins the superior vena cava at its normal location in the right paratracheal space. The hemiazygos can also drain directly in the coronary sinus or

in the left brachiocephalic vein [37–39]. The prevalence is 0.6%. The hepatic segment drains usually directly in the right atrium. The gonadal veins drain directly to the ipsilateral renal vein [1].

### **1.3.2.6 Absence of the IVC**

Absence of the IVC [40, 41] or only the infrarenal segment [42] is rare, and its cause is unknown. It may result from complete failure of embryonic vein development or perinatal venous thrombosis with atrophy. Collateral circulation may also be present on imaging, and patients are prone to develop deep venous thrombosis (DVT) [42] and chronic venous insufficiency (CVI) [43].

### **1.3.2.7 Portocaval Shunt**

Portocaval shunt (Abernethy malformation) is classified into two categories. The first one is characterized by absence of the portal vein with complete shunting of portal blood in IVC. It is associated with polysplenia and biliary atresia. The second one is a partial end to side anastomosis between the portal vein and IVC [44].

### **1.3.2.8 IVC Webs**

IVC webs are uncommon anomalies, either congenital or sequel of thrombosis. This entity is more frequent in Asian and South African populations [45]. Images show complete or fenestrated membrane in the lumen of the IVC [3]. It can lead to congenital Budd-Chiari syndrome and its complication (hepatocellular failure, HCC). Intra- and extrahepatic collateral circulations are present. Treatment depends on liver function and can be angioplasty, stenting, or creation of a transjugular intrahepatic portosystemic shunt (TIPS).

## **1.3.3 IVC Trauma**

In trauma, IVC can be flattened reflecting hypovolemia or hypotension and should not be misdiagnosed as IVC trauma.

IVC trauma is rare and responsible of major blood loss. Multiple injuries are common, and most of the patients arriving at the hospital with IVC injury die [46]. Most IVC bleeding is compressed by adjacent structures in case of integrity of the retroperitoneum. Surgery is advocated in patients with persistent bleeding. Diagnosis is easily made on CT: retroperitoneal hematoma around the IVC, irregular vessel contour, and extravasation of contrast on venous phase (Fig. 1.7). Retro-hepatic IVC injury must be carefully searched because of its high mortality in a patient paradoxically stable. This injury is raised in case of liver laceration extending to the IVC with irregular contour of this one [47].

## **1.3.4 Postoperative Imaging**

### **1.3.4.1 Post-Liver Transplantation**

Vascular complications involving the IVC can be seen after liver transplantation. Anastomosis of recipient and donor IVCs can be end to end or with the “piggy back”

technique. Regarding living donor transplantation, the donor hepatic vein is anastomosed to the recipient IVC. Knowledge of the type of anastomosis is important as stenosis often concerns the anastomotic site. Liver transplantation complications of the IVC are thrombosis and stenosis, which concern only 1–2% of liver transplantations. IVC stenosis is due to anastomotic narrowing or extrinsic compression by fluid, hematoma, or graft swelling. On US, flow velocity is increased by three- to fourfold when compared to normal flow, with Doppler aliasing. Hepatic veins are enlarged and their phasicity disappeared. Focal narrowing can be seen either on MDCT or MRI. Imaging features of the Budd-Chiari syndrome or portal hypertension can also be found [48]. This anomaly can be treated with angioplasty or stent placement.

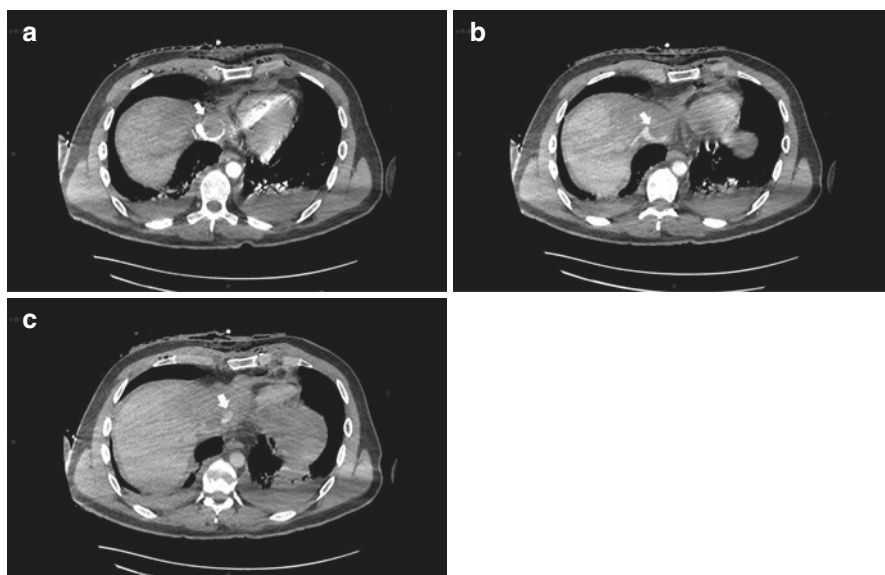
#### 1.3.4.2 Post-Portocaval Shunt

Uncontrollable variceal bleeding with failure of radiological and surgical TIPS placement can be treated by creation of a shunt between the superior mesenteric vein and the IVC. Radiologist should be aware of this atypical shunting to verify its patency.

### 1.4 Interventional Imaging of the IVC

#### 1.4.1 Inferior Vena Cava Filter

Surgical ligation of the IVC was the first technique for IVC interruption in prevention of PE. IVC thrombosis and lower limb edema were frequent complications of surgical ligation. IVC interruption by endovascular approach was possible in 1967,



**Fig. 1.7** Inferior vena cava trauma: a 25-year-old patient injured in a motor vehicle accident. Arterial and portal contrast-enhanced axial CT (**a**, **b**) show hepatic contusion involving the IVC (*arrow*) with contrast extravasation on delayed venous phase (**c**)

**Table 1.2** Society of Interventional Radiology guidelines for use of inferior vena cava filter

<i>Therapeutic: Documented thromboembolic disease</i>
Contraindication to anticoagulation
Complication or failure of anticoagulation
Recurrent PE despite anticoagulation, massive PE with residual DVT in a patient at high risk for further PE
Propagation/progression of DVT despite adequate therapy
Inability to achieve, maintain adequate anticoagulation
Free floating iliofemoral or IVC thrombus
Severe cardiopulmonary disease and DVT
<i>Prophylactic</i>
Severe trauma without documented PE or DVT
Closed head and spinal cord injury
Multiple long bone or pelvic fracture
Patients at high risk (ie in an intensive care unit, immobilized patients)

PE pulmonary embolism, DVT deep venous thrombosis

From Caplin et al. [49]

thanks to the Mobbin-Udin filter. Vena cava filter indications are listed in Table 1.2. It prevents passage of emboli from systemic to pulmonary circulation by trapping venous emboli. Vena cava filter does not treat or prevent DVT [49–51].

Vena cava filters are either permanent or retrievable. They are classically MRI compatible. The length and diameter of the infrarenal IVC, location and number of renal veins, IVC variants, IVC thrombus, or extrinsic compression must be evaluated.

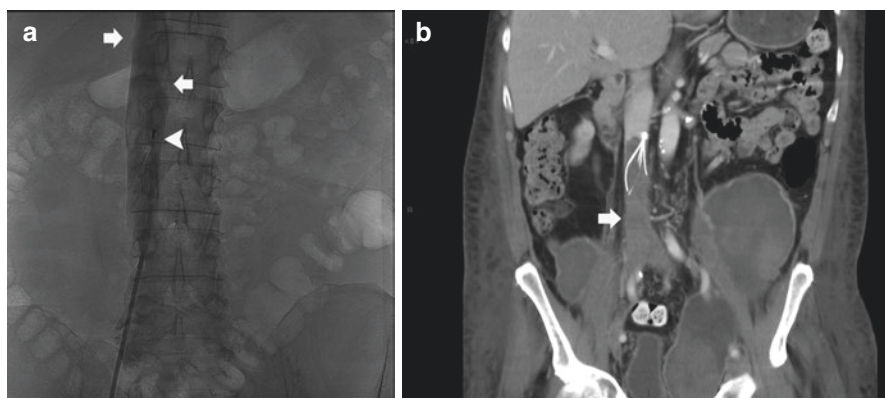
Percutaneous placement is performed through the common femoral vein, the right internal jugular vein, or the right antecubital vein. The location of IVC filters is infrarenal; the apex should be immediately inferior to the level of renal veins (Fig. 1.8). In certain cases, the location can be suprarenal: IVC thrombus in the infrarenal segment, pregnancy or women in childbearing age, intrinsic narrowing or extrinsic compression of the infrarenal IVC, gonadal vein thrombosis, extending thrombus above previously infrarenal vena cava filter, agenesis, or duplicated IVC.

Relative contraindications to vena cava filter placement are rare: uncorrectable severe coagulopathy and bacteremia or untreated infection.

Procedural complications include insertion problems resulting in an incomplete filter opening, filter tilting ( $>15^\circ$  from IVC axis), misplacement of filter outside of the infrarenal IVC (in the iliac vein), and access site complications (e.g., thrombosis, hematoma, arteriovenous fistula). Complications of vena cava filter ( $<0.5\%$  [52]) include recurrent PE, IVC thrombotic occlusion (Fig. 1.8), penetration of the vein wall by an anchor device with transmural incorporation, filter movement, and filter fracture.

### 1.4.2 IVC Obstruction and Endovascular Management

Chronic venous disease (CVD) is a common disease leading to chronic venous insufficiency (CVI). CVI concerns approximately 1–5% of the adult population.



**Fig. 1.8** Inferior vena cava filter. Cavography (a) shows IVC filter (arrowhead) placement below renal vein ostia (arrow). One month later, the patient had lower limb edema due to IVC occlusion (arrow) (coronal enhanced CT (b))

CVD has different etiologies: no thrombotic etiology (primary or idiopathic) or thrombotic etiology due to prior DVT. Iliocaval obstruction is most commonly secondary to insufficient deep vein recanalization after DVT. The May-Thurner syndrome (also called the Cockett syndrome) is a non-thrombotic cause of iliocaval obstruction involving preferentially the left common iliac vein, where it is crossed and compressed by the right common iliac artery against the 5th lumbar vertebrae. Treatment can be surgical or endovascular with balloon angioplasty and stenting. Interventional treatment indications concern patients with CEAP clinical class 3–6 (Annex 1) and chronic venous outflow obstruction [53].

Ipsilateral popliteal or femoral vein access, depending on thrombus extension, is performed using ultrasound guidance if necessary. A 5 Fr sheath is introduced, and venography is performed to locate obstruction. Hydrophilic wires are used to cross obstruction. Recanalization is controlled with contrast injection to avoid extra-anatomic way. In case of extra-anatomic recanalization, the use of a stent graft should be considered. Angioplasty with balloon is performed before stent placement. In case of persistent thrombus, thromboaspiration and catheter-directed thrombolysis could be performed [54]. The proximal and distal end of stent lies in a healthy venous segment. When multiple stents are used, overlapping is mandatory (15 mm of overlap). Large self-expanding stents are preferred in iliofemoral occlusion whereas self-expandable or balloon-expandable stents can be used in the IVC [53].

Technical success of venous stenting is high (84–88% of cases [55, 56]) but decreased to 66% in post-thrombotic lesions with complete IVC obstruction [57]. Long-term patency rate is high (86% at 6 years [58] and 93% at 10 years [59] in two large series). Symptomatology improvement (ulcer healing) is also high (ranging from 58% to 100% [57–59]). Patients should receive lifelong antiplatelet. For May-Thurner syndrome patients or those with DVT, treatment with warfarin should also be considered [53].

The most common complication of this procedure is early and late rethrombosis (1.5–3 % for early and about 5 % for late thrombosis) [58, 59]. Other complications are rare including venous tear during procedure, pseudoaneurysm of adjacent artery and arteriovenous fistula at the puncture site, stent fracture, and dislocation [53].

IVC stenosis especially after liver transplantation can also be treated with angioplasty and stenting with good results [60, 61].

---

### Conclusion

Imaging allows precise diagnostic of congenital variants, IVC obstruction, or IVC invasion by neoplasms. This screening is required to allow optimal surgical or interventional radiology planning. Cava venography has been replaced by MDCT and MRI in this evaluation. Optimal IVC evaluation is performed on venous phase (i.e., 70–90 s after contrast injection) to avoid artifactual filling defects. Knowledge of main imaging features of anatomical variants, filling defects, and neoplasm invasion of the IVC is fundamental for radiologists.

### Key Points

- Imaging the vena cava relies on optimized CT and MRI protocols.
- Obstruction of the IVC is easy to diagnose on CT and MRI and can suggest bland thrombus or tumor involvement.
- IVC disease can be amenable to interventional radiology.
- Anatomical variants are frequent and must be searched before abdominal surgery.

### Key References

- Smillie RP, Shetty M, Boyer AC, Madrazo B, Jafri SZ (2015) Imaging evaluation of the inferior vena cava. *Radiographics* 35:578–592
- Kandpal H, Sharma R, Gamangatti S, Srivastava DN, Vashisht S (2008) Imaging the inferior vena cava: a road less traveled. *Radiographics* 28:669–689
- Sonin AH, Mazer MJ, Powers TA (1992) Obstruction of the inferior vena cava: a multiple-modality demonstration of causes, manifestations, and collateral pathways. *Radiographics* 12:309–322
- Bass JE, Redwine MD, Kramer LA, Huynh PT, Harris JH, Jr (2000) Spectrum of congenital anomalies of the inferior vena cava: cross-sectional imaging findings. *Radiographics* 20:639–652
- Caplin DM, Nikolic B, Kalva SP, Ganguli S, Saad WE, Zuckerman DA, et al. (2011) Quality improvement guidelines for the performance of inferior vena cava filter placement for the prevention of pulmonary embolism. *J Vasc Interv Radiol* 22:1499–1506
- Mahnken AH, Thomson K, de Haan M, O’Sullivan GJ. (2014) CIRSE standards of practice guidelines on ilio caval stenting. *Cardiovasc Interv Radiol* 37:889–897

---

## Annex 1: CEAP Classification System

### Clinical

- C<sub>0</sub>: No clinical signs
- C<sub>1</sub>: Telangiectases or reticular veins
- C<sub>2</sub>: Varicose veins
- C<sub>3</sub>: Edema
- C<sub>4a</sub>: Pigmentation and eczema
- C<sub>4b</sub>: Lipodermatosclerosis or atrophie blanche
- C<sub>5</sub>: Healed venous ulcer
- C<sub>6</sub>: Active venous ulcer

### Etiology

- E<sub>C</sub>: Congenital
- E<sub>P</sub>: Primary
- E<sub>S</sub>: Secondary (post-thrombotic)
- E<sub>N</sub>: No venous cause identified

### Anatomy

- A<sub>S</sub>: Superficial veins
- A<sub>D</sub>: Deep veins
- A<sub>P</sub>: Perforator veins

### Pathophysiology

- P<sub>R</sub>: Reflux
- P<sub>O</sub>: Obstruction
- P<sub>R,O</sub>: Reflux and obstruction
- P<sub>N</sub>: No venous pathophysiology identifiable

---

## References

1. Bass JE, Redwine MD, Kramer LA, Huynh PT, Harris JH Jr (2000) Spectrum of congenital anomalies of the inferior vena cava: cross-sectional imaging findings. *Radiographics* 20:639–652
2. Philips E (1969) Embryology, normal anatomy, and anomalies. In: Ferris EJ, Hipona FA, Kahn PC, Philips E, Shapiro JH (eds) *Venography of the inferior vena cava and its branches*. Williams & Wilkins, Baltimore, pp 1–32
3. Smillie RP, Shetty M, Boyer AC, Madrazo B, Jafri SZ (2015) Imaging evaluation of the inferior vena cava. *Radiographics* 35:578–592
4. Sheth S, Fishman EK (2007) Imaging of the inferior vena cava with MDCT. *AJR Am J Roentgenol* 189:1243–1251



5. Kandpal H, Sharma R, Gamangatti S, Srivastava DN, Vashisht S (2008) Imaging the inferior vena cava: a road less traveled. *Radiographics* 28:669–689
6. Finn JP, Longmaid HE (1992) Abdominal magnetic resonance venography. *Cardiovasc Intervent Radiol* 15:51–59
7. Miyazaki T, Yamashita Y, Shinzato J, Kojima A, Takahashi M (1995) Two-dimensional time-of-flight magnetic resonance angiography in the coronal plane for abdominal disease: its usefulness and comparison with conventional angiography. *Br J Radiol* 68:351–357
8. Miceli M, Atoui R, Walker R, Mahfouz T, Mirza N, Diaz J et al (2004) Diagnosis of deep septic thrombophlebitis in cancer patients by fluorine-18 fluorodeoxyglucose positron emission tomography scanning: a preliminary report. *J Clin Oncol* 22:1949–1956
9. Sharma P, Kumar R, Jeph S, Karunanithi S, Naswa N, Gupta A et al (2011) 18F-FDG PET-CT in the diagnosis of tumor thrombus: can it be differentiated from benign thrombus? *Nucl Med Commun* 32:782–788
10. Sharma P, Kumar R, Singh H, Jeph S, Patnecha M, Reddy RM et al (2012) Imaging thrombus in cancer patients with FDG PET-CT. *Jpn J Radiol* 30:95–104
11. Kaufman LB, Yeh BM, Breiman RS, Joe BN, Qayyum A, Coakley FV (2005) Inferior vena cava filling defects on CT and MRI. *AJR Am J Roentgenol* 185:717–726
12. Zhang L, Yang G, Shen W, Qi J (2007) Spectrum of the inferior vena cava: MDCT findings. *Abdom Imaging* 32:495–503
13. Soler R, Rodriguez E, Lopez MF, Marini M (1995) MR imaging in inferior vena cava thrombosis. *Eur J Radiol* 19:101–107
14. Game X, Soulie M, Moussouni S, Roux D, Escourrou G, Chevreau C et al (2003) Renal angiomyolipoma associated with rapid enlargement [correction of enlargement] and inferior vena caval tumor thrombus. *J Urol* 170:918–919
15. Lau TN, Goddard P, Vaidya M, Calloway M, Bullimore J (1997) Involvement of the inferior vena cava by adrenal pheochromocytoma: MRI findings. *Br J Radiol* 70:303–305
16. Blum U, Wildanger G, Windfuhr M, Laubenberger J, Freudenberg N, Munzar T (1995) Preoperative CT and MR imaging of inferior vena cava leiomyosarcoma. *Eur J Radiol* 20:23–27
17. Hardwigsen J, Balandraud P, Ananian P, Saisse J, Le Treut YP (2005) Leiomyosarcoma of the retrohepatic portion of the inferior vena cava: clinical presentation and surgical management in five patients. *J Am Coll Surg* 200:57–63
18. Webb EM, Wang ZJ, Westphalen AC, Nakakura EK, Coakley FV, Yeh BM (2013) Can CT features differentiate between inferior vena cava leiomyosarcomas and primary retroperitoneal masses? *AJR Am J Roentgenol* 200:205–209
19. Cuevas C, Raske M, Bush WH, Takayama T, Maki JH, Kolokythas O et al (2006) Imaging primary and secondary tumor thrombus of the inferior vena cava: multi-detector computed tomography and magnetic resonance imaging. *Curr Probl Diagn Radiol* 35:90–101
20. Karnes RJ, Blute ML (2008) Surgery insight: management of renal cell carcinoma with associated inferior vena cava thrombus. *Nat Clin Pract Urol* 5:329–339
21. Calero A, Armstrong PA (2013) Renal cell carcinoma accompanied by venous invasion and inferior vena cava thrombus: classification and operative strategies for the vascular surgeon. *Semin Vasc Surg* 26:219–225
22. Lawindy SM, Kurian T, Kim T, Mangar D, Armstrong PA, Alsina AE et al (2012) Important surgical considerations in the management of renal cell carcinoma (RCC) with inferior vena cava (IVC) tumour thrombus. *BJU Int* 110:926–939
23. Neves RJ, Zincke H (1987) Surgical treatment of renal cancer with vena cava extension. *Br J Urol* 59:390–395
24. Woodruff DY, Van Veldhuizen P, Muehlebach G, Johnson P, Williamson T, Holzbeierlein JM (2013) The perioperative management of an inferior vena caval tumor thrombus in patients with renal cell carcinoma. *Urol Oncol* 31:517–521
25. Lawrentschuk N, Gani J, Riordan R, Esler S, Bolton DM (2005) Multidetector computed tomography vs magnetic resonance imaging for defining the upper limit of tumour thrombus in renal cell carcinoma: a study and review. *BJU Int* 96:291–295



26. Psutka SP, Boorjian SA, Thompson RH, Schmit GD, Schmitz JJ, Bower TC et al (2014) Clinical and radiographic predictors of the need for inferior vena cava resection during nephrectomy for patients with renal cell carcinoma and caval tumour thrombus. *BJU Int* 2015;40(6):1500–1509
27. Missal ME, Robinson JA, Tatum RW (1965) Inferior vena cava obstruction: clinical manifestations, diagnostic methods, and related problems. *Ann Intern Med* 62:133–161
28. Sonin AH, Mazer MJ, Powers TA (1992) Obstruction of the inferior vena cava: a multiple-modality demonstration of causes, manifestations, and collateral pathways. *Radiographics* 12:309–322
29. Janssen HL, Garcia-Pagan JC, Elias E, Mentha G, Hadengue A, Valla DC et al (2003) Budd-Chiari syndrome: a review by an expert panel. *J Hepatol* 38:364–371
30. Valla DC (2003) The diagnosis and management of the Budd-Chiari syndrome: consensus and controversies. *Hepatology* 38:793–803
31. Faraoun SA, Boudjella ME, Debzi N, Afredj N, Guerrache Y, Benidir N et al (2015) Budd-Chiari syndrome: a prospective analysis of hepatic vein obstruction on ultrasonography, multidetector-row computed tomography and MR imaging. *Abdom Imaging* 40(6):1500–1509
32. Bolondi L, Gaiani S, Li Bassi S, Zironi G, Bonino F, Brunetto M et al (1991) Diagnosis of Budd-Chiari syndrome by pulsed Doppler ultrasound. *Gastroenterology* 100:1324–1331
33. Copelan A, Remer EM, Sands M, Nghiem H, Kapoor B (2015) Diagnosis and management of Budd Chiari syndrome: an update. *Cardiovasc Intervent Radiol* 38:1–12
34. Brancatelli G, Federle MP, Grazioli L, Golfieri R, Lencioni R (2002) Benign regenerative nodules in Budd-Chiari syndrome and other vascular disorders of the liver: radiologic-pathologic and clinical correlation. *Radiographics* 22:847–862
35. Perello A, Garcia-Pagan JC, Gilabert R, Suarez Y, Moitinho E, Cervantes F et al (2002) TIPS is a useful long-term derivative therapy for patients with Budd-Chiari syndrome uncontrolled by medical therapy. *Hepatology* 35:132–139
36. Srivastava A, Singh KJ, Suri A, Vijjan V, Dubey D (2005) Inferior vena cava in urology: importance of developmental abnormalities in clinical practice. *ScientificWorldJournal* 5:558–563
37. Ginaldi S, Chuang VP, Wallace S (1980) Absence of hepatic segment of the inferior vena cava with azygous continuation. *J Comput Assist Tomogr* 4:112–114
38. Haswell DM, Berrigan TJ Jr (1976) Anomalous inferior vena cava with accessory hemiazygos continuation. *Radiology* 119:51–54
39. Piciucchi S, Barone D, Sanna S, Dubini A, Goodman LR, Oboldi D et al (2014) The azygos vein pathway: an overview from anatomical variations to pathological changes. *Insights Imaging* 5:619–628
40. Debing E, Tielemans Y, Jolie E, Van den Brande P (1993) Congenital absence of inferior vena cava. *Eur J Vasc Surg* 7:201–203
41. Milner LB, Marchan R (1980) Complete absence of the inferior vena cava presenting as a paraspinous mass. *Thorax* 35:798–800
42. Bass JE, Redwine MD, Kramer LA, Harris JH Jr (1999) Absence of the infrarenal inferior vena cava with preservation of the suprarenal segment as revealed by CT and MR venography. *AJR Am J Roentgenol* 172:1610–1612
43. Dougherty MJ, Calligaro KD, DeLaurentis DA (1996) Congenitally absent inferior vena cava presenting in adulthood with venous stasis and ulceration: a surgically treated case. *J Vasc Surg* 23:141–146
44. Morgan G, Superina R (1994) Congenital absence of the portal vein: two cases and a proposed classification system for portasystemic vascular anomalies. *J Pediatr Surg* 29:1239–1241
45. Kew MC, Hodkinson HJ (2006) Membranous obstruction of the inferior vena cava and its causal relation to hepatocellular carcinoma. *Liver Int* 26:1–7
46. Buckman RF, Pathak AS, Badellino MM, Bradley KM (2001) Injuries of the inferior vena cava. *Surg Clin North Am* 81:1431–1447
47. Hewett JJ, Freed KS, Sheafor DH, Vaslef SN, Kliewer MA (2001) The spectrum of abdominal venous CT findings in blunt trauma. *AJR Am J Roentgenol* 176:955–958

48. Singh AK, Nachiappan AC, Verma HA, Uppot RN, Blake MA, Saini S et al (2010) Postoperative imaging in liver transplantation: what radiologists should know. *Radiographics* 30:339–351
49. Caplin DM, Nikolic B, Kalva SP, Ganguli S, Saad WE, Zuckerman DA et al (2011) Quality improvement guidelines for the performance of inferior vena cava filter placement for the prevention of pulmonary embolism. *J Vasc Interv Radiol* 22:1499–1506
50. Harvey JJ, Hopkins J, McCafferty IJ, Jones RG (2013) Inferior vena cava filters: what radiologists need to know. *Clin Radiol* 68:721–732
51. Vena Caval Filter Consensus C (2003) Recommended reporting standards for vena caval filter placement and patient follow-up. *J Vasc Interv Radiol* 14:S427–S432
52. Kaufman JA, Kinney TB, Streiff MB, Sing RF, Proctor MC, Becker D et al (2006) Guidelines for the use of retrievable and convertible vena cava filters: report from the Society of Interventional Radiology multidisciplinary consensus conference. *J Vasc Interv Radiol* 17:449–459
53. Mahnken AH, Thomson K, de Haan M, O'Sullivan GJ (2014) CIRSE standards of practice guidelines on ilio caval stenting. *Cardiovasc Intervent Radiol* 37:889–897
54. Bozkaya H, Cinar C, Ertugay S, Korkmaz M, Guneyli S, Posacioglu H et al (2015) Endovascular Treatment of Iliac Vein Compression (May-Thurner) Syndrome: Angioplasty and Stenting with or without Manual Aspiration Thrombectomy and Catheter-Directed Thrombolysis. *Ann Vasc Dis* 8:21–28
55. Razavi MK, Hansch EC, Kee ST, Sze DY, Semba CP, Dake MD (2000) Chronically occluded inferior venae cavae: endovascular treatment. *Radiology* 214:133–138
56. Wahlgren CM, Wahlberg E, Olofsson P (2010) Endovascular treatment in postthrombotic syndrome. *Vasc Endovascular Surg* 44:356–360
57. Raju S, Hollis K, Neglen P (2006) Obstructive lesions of the inferior vena cava: clinical features and endovenous treatment. *J Vasc Surg* 44:820–827
58. Neglen P, Hollis KC, Olivier J, Raju S (2007) Stenting of the venous outflow in chronic venous disease: long-term stent-related outcome, clinical, and hemodynamic result. *J Vasc Surg* 46:979–990
59. Hartung O, Loundou AD, Barthelemy P, Arnoux D, Boufi M, Alimi YS (2009) Endovascular management of chronic disabling ilio-caval obstructive lesions: long-term results. *Eur J Vasc Endovasc Surg* 38:118–124
60. Lee JM, Ko GY, Sung KB, Gwon DI, Yoon HK, Lee SG (2010) Long-term efficacy of stent placement for treating inferior vena cava stenosis following liver transplantation. *Liver Transpl* 16:513–519
61. Huber TJ, Hammer S, Loss M, Muller-Wille R, Schreyer AG, Stroszczyński C et al (2014) Primary stent angioplasty of the inferior vena cava after liver transplantation and liver resection. *Cardiovasc Intervent Radiol* 37:949–957

---

# Anesthetic and Hemodynamic Considerations of Inferior Vena Cava Surgery

# 2

Daniel Eyraud and Victoria Lepere

---

## 2.1 Introduction

The hemodynamic changes in response to inferior vena cava clamping have been more studied during hepatic surgery than inferior vena cava (IVC) surgery. Indeed, cross clamping has been used for a long time in vascular surgery [1–3]; the strategy is relatively simple: either the disease is located below the hepatic venous confluence or the hemodynamic consequences are low and either it is located above or needs suprahepatic vena cava cross clamping. Cardiopulmonary bypass is usually indicated, with eventually a hypothermic arrest if a complex reconstruction, long or including the right atrium, is necessary or is indicated if there is a high risk of pulmonary embolism (carcinological or cruoric) [4, 5]. The situation is different in liver surgery. The use of bypass, even veno-venous bypass, is avoided other than in the context of liver transplantation, because the use of anticoagulants may entail the bleeding of the liver slice of hepatectomy or because the venous return by the IVC clamped above and below the hepatic venous confluence (combined with pedicle clamping) is low, apart from the liver transplantation where the end-stage liver cirrhotic patient presents hyperkinetic syndrome. The aim of this chapter is first to

---

D. Eyraud, MD PhD (✉)

Department of Anesthesiology and Intensive Care Unit, Assistance Publique-Hôpitaux de Paris (AP-HP), Pitié-Salpêtrière University Hospital, 43-87 Boulevard de l'Hôpital, Paris 75013, France

Department of Digestive, HPB Surgery, and Liver Transplantation, Assistance Publique-Hôpitaux de Paris (AP-HP), Pitié-Salpêtrière University Hospital, 43-87 Boulevard de l'Hôpital, Paris 75013, France  
e-mail: [daniel.eyraud@psl.ap-hop-paris.fr](mailto:daniel.eyraud@psl.ap-hop-paris.fr)

V. Lepere, MD

Department of Anesthesiology and Intensive Care Unit, Assistance Publique-Hôpitaux de Paris (AP-HP), Pitié-Salpêtrière University Hospital, 43-87 Boulevard de l'Hôpital, Paris 75013, France

expose important anatomic and physiologic points about IVC circulation and second to describe the consequences of the different IVC clamping, according to the clamping site and the eventual association with aortic or liver clamping.

---

## **2.2 Anatomic and Physiologic Considerations on the IVC Circulation**

### **2.2.1 Spontaneous Portocaval Shunts**

Although the portal and the caval systems are independent in the normal adult, many communications exist between them. These venous bypasses have no role in normal state but become crucial in pathologic situation such as portal hypertension, the Budd-Chiari syndrome, or all other situations where an obstacle to venous return exists. The typical situation is liver surgery with hepatic clamping or/and IVC clamping. To understand these situations we will detail later, we will expose the communications between the portal and the caval systems and the communications in the caval system.

These shunts could be differentiated in congenital physiologic or acquired.

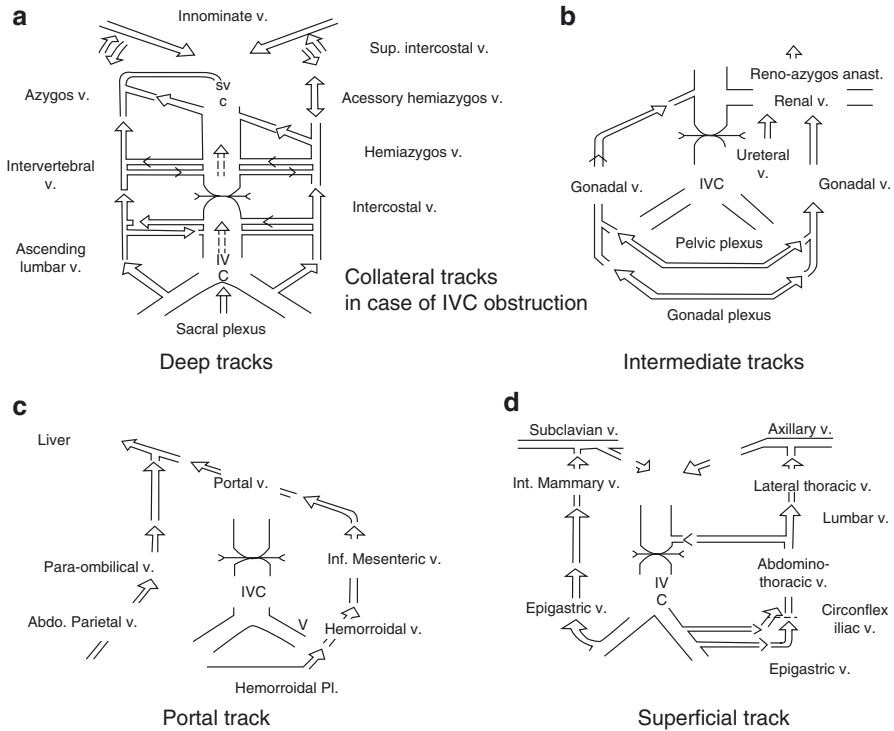
#### **2.2.1.1 Congenital Physiologic Bypasses**

They are located at four levels:

- Cardio-esophageal: They join, by the submuquous gastric venous net, the gastric veins and the coronary stomachic vein which depend on the portal circulation to venous esophageal plexus, which depends on the superior vena cava (with azygos veins, hemiazygos veins, bronchial veins, diaphragmatic veins).
- Umbilical anastomosis: The small paraumbilical veins, or sometimes the still flowing part of the umbilical vein depending on the portal circulation, communicate with the veins of the abdominal wall depending on vena caval circulation (infra and supra), by the epigastric, intercostal, lumbar, and internal mammary veins.
- Rectal anastomoses: The drainage of the rectum is organized in hemorrhoidal plexus which efferent ways are the superior hemorrhoidal vein which flows to the inferior mesenteric vein and the middle and the inferior hemorrhoidal veins which flow directly in the IVC.
- Venous retroperitoneal anastomosis between splenic, pancreatic, gonadic, left renal, and hemiazygos veins.

#### **2.2.1.2 Acquired Shunts**

The acquired shunts are neovascularization of the epiploon or the peritoneum. They occur especially in the case of chronic obstruction of the portal vein, total or partial, and are particularly frequent when history of abdominal surgery or infected ascites occurs. When favorable pressure gradient occurs, the development of collateral circulation is possible because the portal vein territory has no valves, which would prevent the blood from flowing back.



**Fig. 2.1** Collateral veins in case of obstruction of the inferior vena cava in relation with the level of obstruction

The importance of the blood flow through these shunts depends on the resistance of the vessels, which compose them, and the gradient pressure between the venous portal and caval territories. It is a major point to understand the clamping and their hemodynamic tolerance. The location and their level of development vary a lot depending on the individual [6, 7], and the importance of portal IVC shunts, portal superior VC (SVC) shunts, and IVC-SVC shunts is the most important factor for the tolerance to total hepatic vascular exclusion (THVE) of the liver (see below).

Concerning IVC-SVC shunts in the situation of total or almost, they are all the more developed as the obstruction is older. Then, the type of development depends on the level of the obstruction:

*Interrenal or infra-renal obstruction (Fig. 2.1):*

- The upstream venous circulation flows back through four directions:
- Deep veins: intrarachidian, perirachidian, ascendant lumbar, and azygos veins
- Superficial veins: abdominal and thoracic walls
- Gonadic and ureteral veins
- Portal system: inferior and middle hemorrhoidal veins and then the inferior mesenteric vein and portal vein

### *Suprahepatic IVC obstruction without portal obstruction:*

If it is acute, this situation is lethal in the mammals because of the massive blood sequestration in the portal system and the liver. If the obstacle is progressive, the shunts are the same than described before with the adjunction of back flow in the hepatic veins [8]. The liver suffers (hepatomegaly) because the perfusion is at high pressure as in right heart insufficiency or the Budd-Chiari syndrome.

## **2.2.2 Circulatory Models**

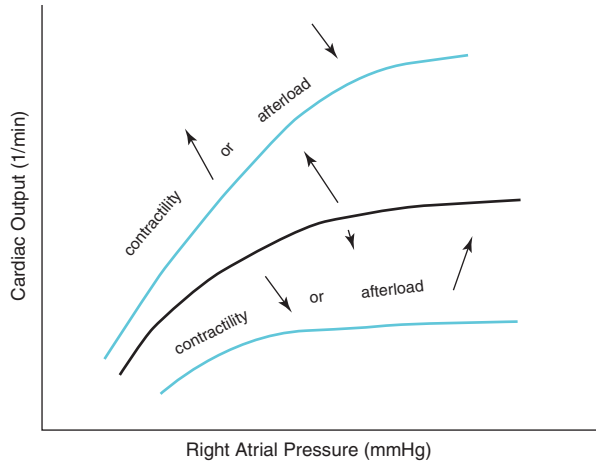
### **2.2.2.1 Generalities**

The goal of the circulatory system, meaning the heart, the vessels, the lungs, and the blood together, is to deliver to each organ oxygen and nutriment it needs. In pathologic situations, some, and more frequently many, of these factors could be affected. In healthy subject, and also in many clinical situations, the peripheral circulation (vessels and blood) is responsible alone for the decrease of oxygen delivery to the organs: the cardiac pump is normal, but it ejects only the blood returning to it – the venous return is the limiting factor of the cardiac output therefore of the circulatory system. We will expose the different steps of this “peripheral theory” of regulation of the cardiac output opened by Guyton [9] and then improved by Magder [10], Bennett [11], and Caldini [12, 13]. These circulatory models allow to explain many clinical situations and then to improve them rationally. These models reconstitute the importance of peripheral circulation, especially the splanchnic circulation in the regulation of the circulatory system. Moreover, they are indispensable for the understanding of the venous clamping we will expose after.

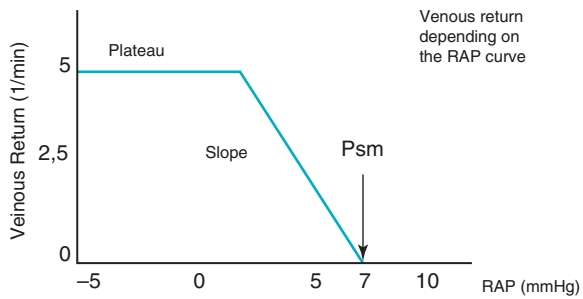
In all these models, the cardiac pump plays a tolerant role only. At some level of cardiac inotropism and afterload (impedance to the ejection, functions of the systolic arterial pressure (AP), and then of the arterial resistance, and of the dimensions of the myocardia), the cardiac output (CO) is the function of the preload (tension of myocardial fibers at the end of the diastole) assimilated in this model to right atrial pressure (RAP) which is the pressure of entry in the system. That is the relation curve of Frank-Starling. In case of changes in contractility or afterload, the function moves, depicting different curves (Fig. 2.2). For the same increase in RAP, the CO increases when the inotropism increases (stress, physic activity) or the afterload decreases (e.g., increase in external temperature with vasodilatation) and decreases when the inotropism decreases (cardiac insufficiency) or the afterload increases (arterial hypertension episode). Actually, the normal heart has a functional reserve allowing facing all the more extreme clinical situations (maximal effort, arteriovenous fistula), so the limiting factor CO is the preload.

The blood returns to the heart according to the pressure gradient. If RAP suddenly increases (tricuspid valve occlusion), the venous return (VR) stops. And if the RAP is decreased, the VR increases. This relation has been described by Guyton [9] in the dog bypassing the right heart and strictly controlling the RAP. The VR could be measured during few seconds before the reflexes modify the basic conditions of

**Fig. 2.2** Diagrammatical representation of the cardiac function in response to change in right atrial pressure



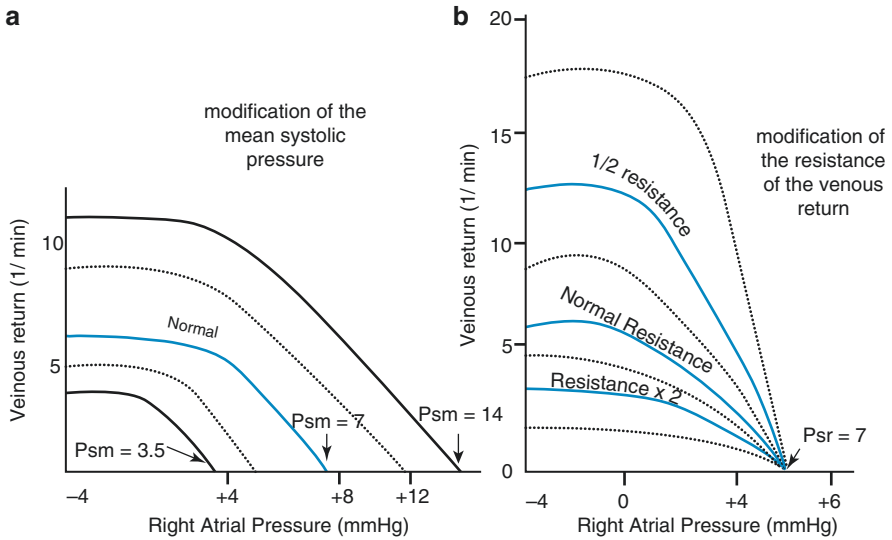
**Fig. 2.3** Curve of the venous return depending on the right atrial pressure (RAP). Psm: mean systemic pressure (see text)



inotropism and afterload (Fig. 2.3). When the RAP decreases, the VR increases to a maximum of RAP near to 0 mmHg. It is explained by the collapse of the IVC when the external pressure around the IVC becomes higher than the intravascular pressure. Immediately after the collapse, the upstream pressure increases. That opens the collapsed IVC. The IVC could be in “fluttering state,” and the transmural pressure (intravascular pressure-extravascular pressure) should remain  $\geq 0$ , if not the circuit dismantles, although the downstream pressure could be negative.

The second important result given by the curve of the VR is the slope. That is the conductance of the VR, and it inverses in the resistance to the VR (RRV). It is remarkable that the relation between the RAP and the VR is linear on a great part, regardless of the volemia or venous resistances (family of curves, Fig. 2.4). That means that, although the venous system is formed by a multitude of small vessels in parallel or in series, it behaves as a unique resultant vessel, obeying the law of Ohm.

The third important result given by this curve is the point intersection with abscises axis (RAP). It is the point where the venous return declines to 0. Indeed, if the pressure insuring a flow through the circuit decreases, it is a time when the flow stops: the time when the pressures of downstream and upstream become equal.



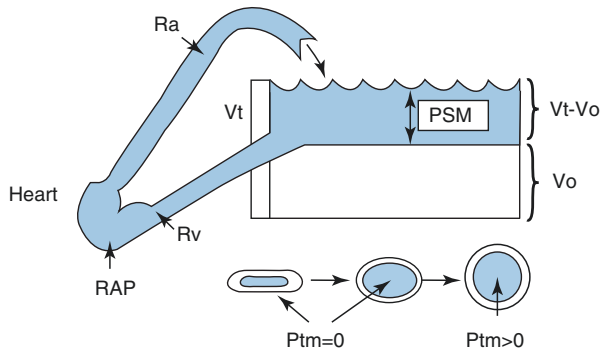
**Fig. 2.4** Venous return curves showing the effect of a modification of the mean systolic pressure (a) and of the resistance of the venous return (b)

Guyton showed that this value of RAP was 7 mmHg. He named this pressure circulatory mean pressure or mean systemic pressure (MSP): it is the pressure measured in each point of the circuit after a sudden arrest of the pump and the distribution of the blood in all the parts of the system. It is a static measure of relation content-containing, dependent on the volemia and on the total vascular capacitance (itself very dependent on the vascular tonus). This pressure could be experimentally measured by Guyton and could be also approached in clinical situation of cardiac arrest with deep hypothermia (the hypothermia modifies the vascular tonus, and then the value of MSP is a little different than the experimental value). In dynamic status, there is a point where the pressure is the MSP: because of its low value (7 mmHg), this point is necessarily on the capacitive sector. The cardiac pump transfers a blood volume from the capacitive sector (veins) to the resistive sector (arteries). That involves a slight decrease in venous pressure and an important increase in arterial pressure, but that does not change the MSP. What can change the MSP are the changes in the venous tonus or in the volemia, as the model of Guyton, adapted by Magder, illustrates it (Fig. 2.5).

### 2.2.2.2 The “One-Compartment” Circulatory Model

This model includes heart-lung pump system, constituted the right and left hearts and the pulmonary circulation; the output generated by the pump is flowing through a unique arterial tube, resistance  $R_a$ ; veins are constituted by another tube, resistance  $R_v$ ; and the capacitance of the circuit being constituted by a unique tank draining to the venous tube by a lateral orifice (Fig. 2.7). The position of the orifice separates the total volume of the tank ( $V_t$ ) into two compartments  $V_0$  and  $V_t - V_0$ . The volume  $V_0$ ,





**Fig. 2.5** Diagrammatical representation of circulation in the one compartment model from Magder [10]. Right Atrial Pressure RAP, Transmural pressure Ptm. Ra and Rv, arterial and venous resistances. Vt: total volume of the circuit. Vo=no tension volume corresponding to the volume necessary to fill the venous system without tension of the vascular wall

non-tensed volume, corresponds to the maximal blood volume necessary to fill the venous system without distending the vascular wall and then without generating positive transmural pressure (Ptm). The volume  $V_t - V_o$ , above the drainage orifice, constitutes the tensed volume (approximately 30% of the total volume in normal circumstances) and generates transmural pressure. The pressure exerted by  $V_t - V_o$  when the output becomes null is the MSP. Because the capacitance of the tank is much taller than the arterial and venous tubes, we may approximate, in dynamic regime, the driving pressure at the orifice to the MSP. The value of the MSP depends on the tensed volume (level of filling) and the capacitance of the tank (vascular tonus). The output of exit ( $Q_v$ ) of the tank represents the venous return:

$$Q_v = \frac{MSP - RAP}{R_v}$$

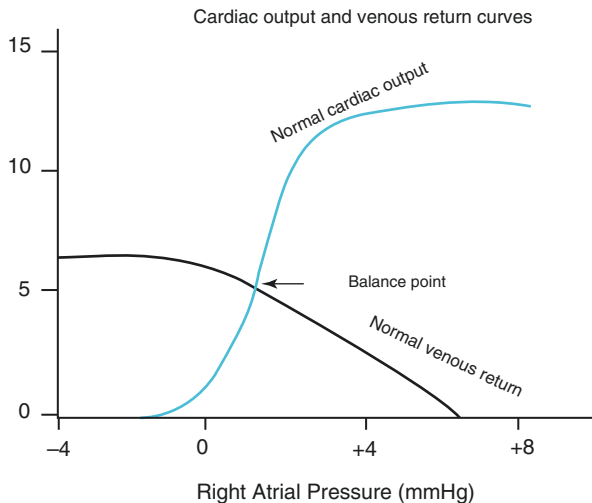
Arterial resistance does not play a role in this model, after Guyton showed that venous resistance had an importance of 20 times greater than arterials. The coupling pump-circuit in this model occurs in the right atrial, by the level of RAP. Indeed, if the decrease in RAP increases the venous return, it decreases the preload of the pump and then the output. For a level of volemia ( $V_t$ ), capacitance (surface of the tank), venous return, and power of the pump, Fig. 2.6 illustrates that, in the equilibrium, the RAP and the cardiac output (then the VR) are determined by the intersection of the curves of cardiac output and venous return. This point of equilibrium is unique.

Because some physiologic or clinical situations, intense muscular stress and vascular clamping, are not very well explained by this “one-compartment model, some authors proposed a two-compartment model [11–13].

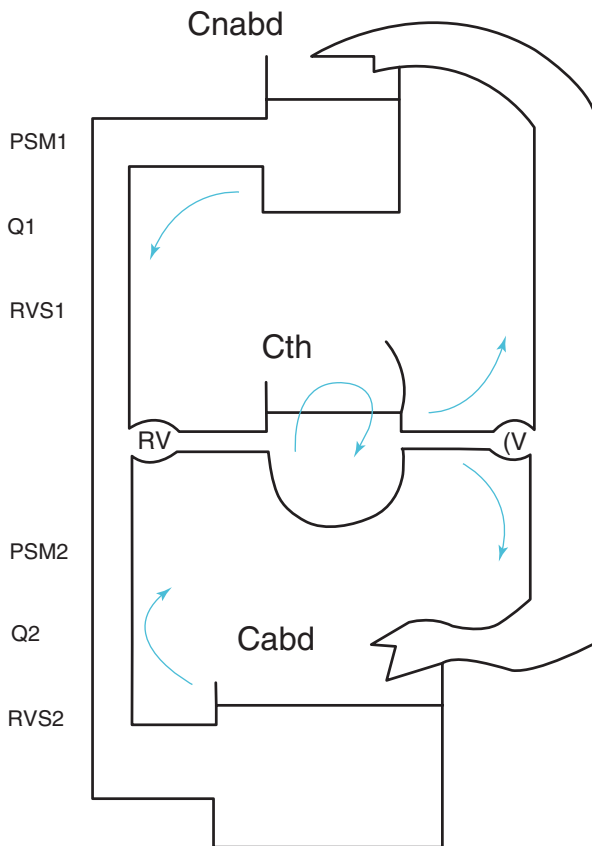
### 2.2.2.3 The “Two-Compartment” Circulatory Model

The peripheral circulation is subdivided into two compartments, splanchnic and not splanchnic (Fig. 2.7). High capacitance and venous return resistance characterize

**Fig. 2.6** Diagrammatical representation of the curves of the cardiac function and the venous return, in relation with the RAP, on the same schema



**Fig. 2.7** Diagrammatical representation of circulation in the two-compartment model. PSM1, Q1, RVS1 and PSM2, Q2, RVS2 are the mean systemic pressure, blood flow and vascular resistance in the non-abdominal compartment (Cnabd) and the abdominal compartment (Cabd) respectively. Cth: compartment thoracic with the cardiac pump represents the generator, Cabd and Cnabd two circuits in derivation



the splanchnic compartment. The MSP, in this model, is the mean of MSP of the splanchnic and not splanchnic tanks. Each MSP is determined by the fractional capacitance of the tank and the arterial and venous respective resistances conditioning the blood distribution into the circuit. The splanchnic compartment is said to be a high time constant because the transit time of a blood cell through its tank is five times longer than through the not splanchnic tank. During a muscular exercise, the transit time becomes even slower because of the vasodilatation of the not splanchnic (muscular) compartment and of the vasoconstriction of the splanchnic circuit. The main part of the volemia dividing up in the compartment of low time constant, the venous return, and then the cardiac output dramatically increases in this situation. An arteriovenous fistula has the same effect on the cardiac output. We will explore how this model allows to understand vascular clamping and in particular the total vascular exclusion.

---

### 2.3 The Different Venous Clampings

The venous clamping involves increase in the resistance of VR in the upstream territory. The decrease in VR is proportional to:

- The presence and the efficacy of collaterals
- The capacitance and the compliance of the upstream venous territory

A new equilibrium is obtained a few minutes after the clamping. This equilibrium is compatible with the vitality of clamped territory only if:

- A venous replacement return exists; if not, the increase in the venous pressure would reach to arterial pressure with irreversible congestive injuries of the clamped venous territory.
- The clamped territory has high capacitance and compliance; like the liver and the splanchnic sector, arterial vasoconstriction should occur to limit the blood pooling in the clamped territory. If not, death occurs by collapse because of the clamping, without any equilibrium. Indeed, the opening of the collateral veins is efficient enough, only if the clamped territory is not too large or too compliant. If not, the venous clamping constitutes a massive internal hemorrhage.

Depending upon the mammalian species, the inferior vena cava or splanchnic venous collaterally is more or less developed that involves a given venous clamping that could be well tolerated in a species and not in the other. It is the case of IVC clamping below the renal confluence, which provokes severe decrease of venous return and arterial pressure in the dog and which has almost no hemodynamic consequence. The example of the portal clamping is even more characteristic: it is ever well tolerated in human and provoked the death in less than 1 h in the dog, as Claude Bernard showed it in 1877 [14], preventing progress in surgery because nobody doubted that the behavior of the human was different than the dog!

In human, physiologic outputs in the IVC, below and above the renal venous confluence and above the hepatic venous confluence are, respectively, 800, 2000, and 3500 mL/min approximatively for an adult weighting 70 kg, with cardiac output of 5 L/min.

### **2.3.1 IVC Clamping Below the Renal Venous Confluence**

This clamping is always well tolerated in humans [15]. This type of clamping has specially been studied in the dog, which tolerated less: the mean arterial pressure decreases up to 15 % and CO up to 30 % of its values before the clamping [16].

### **2.3.2 IVC Clamping Above the Renal Venous Confluence (Below the Liver)**

This clamping in patient without chronic obstruction of the IVC and collaterals decrease the VR of 40 % in human [17]. Clinical studies found lower decrease in VR: 32 % in awoke patient [18] and 20 % in anesthetized patient [19]. The upstream pressure in the IVC was 20 mmHg, and the MAP decreased to 19 %. This clamping has recently been used in a randomized study of liver surgery [20] for reduction of central venous pressure (CVP) and then blood loss during hepatic resection. In this study, the decrease in CVP in response to the infrahepatic IVC clamping was approximatively 4 mmHg, without significantly change in the postoperative course of the renal function.

### **2.3.3 IVC Clamping Above the Hepatic Venous Confluence**

The acute obstruction of the IVC above the hepatic venous confluence has been studied for a long time as a model of shock in the dog [21]. The MAP suddenly decreases to 40 mmHg with contraction of the differential pressure. Pressures in the IVC and in the portal vein moderately increase to 25 mmHg, whereas the volume of the liver rapidly increases. The death occurs in less than 1 h, and the autopsy shows a very big liver, whereas the spleen, kidneys, and bowels are almost without injuries [22]. The death of the dog is then the consequence of the hemorrhage from the general circulation to the liver, “circulatory blind alley,” and territory of very high compliance and capacitance. These two properties of the liver, high capacitance and high compliance, explain why the collapse occurs without major increase in the upstream pressures. This hypothesis was confirmed by the absence of collapse in dogs with chronic obstruction of the supradiaphragmatic IVC, in which the IVC was ligated above hepatic confluence: efficient collateral veins had developed between the liver, portal system, and superior cava system, and the complete obstruction of the IVC, in the context of chronic obstruction, did not have any significant effect on the venous return or upstream pressures [23].

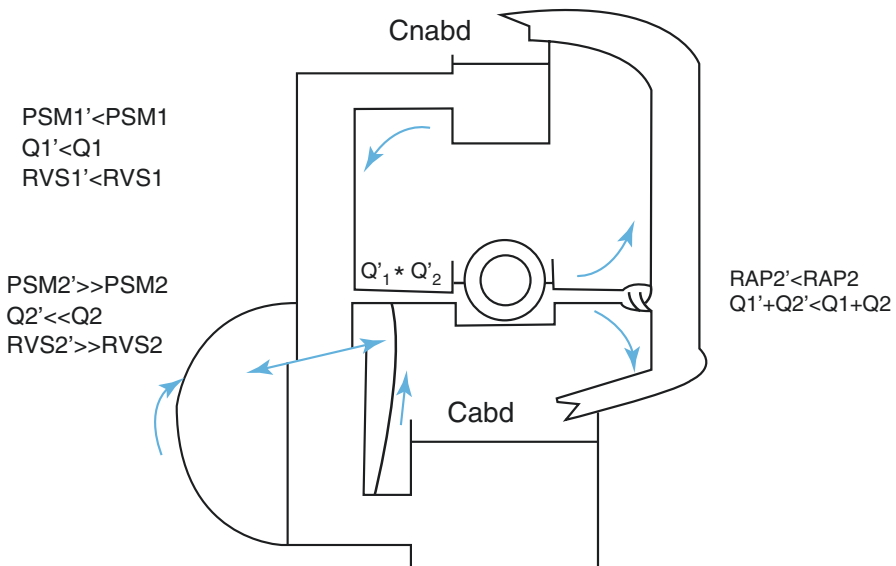
### 2.3.4 Total Hepatic Vascular Exclusion

The goal of THVE is to stop the two sources of bleeding during the hepatic resection or during the resection of the IVC above the venous confluence. The first is the inflow system consisting of the hepatic pedicle (the Pringle maneuver), and the second is the outflow system consisting of the reflux from the IVC through hepatic veins. THVE is used when a liver tumor has invaded the hepatic vein and IVC, so that it is necessary, or an at-risk eventuality, to open the vein for the resection. This technique prevents two complications: massive hemorrhage and gaseous embolism. Moreover, it allows a perfect surgery. However, it involves a continuous ischemia of the liver. Although this technique is less used, especially in liver transplant surgery where lateral clamping of the IVC is preferred, its consequences should be known.

#### 2.3.4.1 Hemodynamic Effects (Fig. 2.8)

In response to THVE, the CO decreases to 50%, accompanied by an increase of 80% of the systemic vascular resistance (SVR) and a moderate (<10%) decrease in the MAP, whereas the diastolic arterial pressure is maintained [24]. In this study, MAP did not significantly change 5 min after the THVE but slowly decreased along the maneuver, and the decrease was significant from the 30th minute.

The other hemodynamic changes were a significant decrease in parameters assessing the preload, CVP, pulmonary arterial wedge pressure (PAWP) evaluated via the Swan-Ganz catheter, or left ventricular (LV) diastolic area (LVTDA)



**Fig. 2.8** Hemodynamic effect of the total vascular exclusion of the liver in the two-compartment model. PSM, Q, RVS are the mean systemic pressure, blood flow and vascular resistance in the two compartments (1, non-abdominal and 2, abdominal) before and after the clamping (addition). RAP: right atrium pressure

evaluated via transesophageal echocardiography (TEE). The decrease in LV telesystolic area (LVTSA) did not compensate for the decrease in LVEDA and the LV function evaluated as  $(LVEDA-LVESA)$  decreased significantly.

The increase in the heart rate limits the consequences of the decrease in the LV ejection volume, on the CO. These parameters changed approximately 50% like in other studies [25]. After the unclamping, all parameters return to normal.

#### 2.3.4.2 Neurohormonal Effects

It is usually admitted that the regulation of the arterial pressure (AP) bases on three systems: the sympathetic, divided into nervous component (the baroreflex) and hormonal component (epinephrine (E), norepinephrine (NE), and dopamine (DA), produced by the suprarenal glands), the renin-angiotensin system, and the vasopressin system. Under general anesthesia, the baroreflex is inhibited, and the other components of the AP regulation compensate it. To determine the respective role of each component in response to TVHE, we measured the blood concentration of arginine vasopressin (AVP), plasmatic renin activity (PRA), E, NE, and DA, before every 15 min during the TVHE and 15 min after the unclamping. E, P, and AVP, significantly increase from the fifth minute after the clamping, remained elevated along and returned to pre-clamping values after the unclamping, whereas ARP did not significantly change. Lentschener et al. [26] demonstrated also the importance of these two hormonal systems during the sole portal triad clamping (PTC). Twenty patients undergoing liver resection were allocated randomly to have hepatic pedicle infiltration before PTC with either lidocaine 200 mg or placebo. MAP was recorded; plasma concentrations of vasopressin, epinephrine, norepinephrine, dopamine, and renin were measured. After PTC, MAP increased significantly in the placebo group but decreased significantly in the lidocaine group. Plasma concentrations of AVP, E, and NE increased significantly in the placebo group. Plasma concentrations of AVP decreased significantly in the lidocaine group, while plasma concentrations of E and NE were unchanged. The authors concluded that neurohumoral mechanism, elicited in the peritoneum, caused the pressor response associated with PTC. In our work, like in Lentschener's, we did not evaluate the baroreflex. Now, even the baroreflex is altered by the general anesthesia, it is probably not abolished, and it is why the anesthesiologist decreases the level of anesthesia before the TVHE: to improve the tolerance by the decrease of the baroreflex inhibition. However, it is interesting to consider that AVP could play a key role in response to TVHE, because this hormone exerts its action especially on the mesenteric circulation [27]. As we saw in the past paragraph, the most important factor allowing the hemodynamic tolerance in response of the THVE is the vasoconstriction of splanchnic arterial bed. This prevents the massive and continuing pooling of blood and then the dramatic decrease in LV preload and consecutive low output in cerebral and coronary arteries. The source of the neurohumoral response is located in the portal bed, where baroreceptors are disseminated [28]. The increase in pressure consecutive to PTC triggers the AVP system and the baroreflex via the vagus nerve. Indeed, the systemic response to the distension of splenic vascular bed is abolished by the section of the splenic nerve [29], branch of the vagus. In the case of TVHE, the sudden decrease in RAP could have triggered an AVP pituitary secretion, mechanism named Henry-Gauer reflex [30].

### 2.3.5 Inferior Vena Cava Clamping Combined with Supra-Celiac Aortic Clamping

Ohara et al. first showed that the clamping of the supra-celiac aorta combined with the thoracic IVC prevented the immediate lethal collapse in the dog [22]. Then Heaney et al. proposed the association of PTC and the clamping of supra-celiac aorta for major hepatic surgery [31]. The isolated clamping of the descending thoracic aorta has two main effects on the hemodynamics [32]: first, sudden increase in the afterload that decreases the cardiac function and then the CO for the same level of inotropism and preload. In the normal heart, an increase in contractility compensates for and maintains the ejection volume; second, the redistribution of the blood of the lower part of the body toward the top. The exclusion of the hepato-splanchnic compartment with low time constant (slow transit of blood) decreases the resistance to the VR. The VR increases especially as the superior territory is less compliant and especially as the MSP is raised.

Stockland et al. studied the combined descending thoracic aortic clamping with intrathoracic IVC [32]. The CO decreases to 73% and becomes equal to the baseline output of the superior vena cava (SVC). The systolic and diastolic pressures of the LV did not change. The IVC clamping then permitted to adapt the circulating blood volume to the reduced circulatory circuit consecutive to the clamping of the supra-celiac aorta, with unchanged pressures and output adapted to the distributed territory. Simultaneous occlusion with the balloon of the IVC and aorta has been used in patients treated with hypoxic abdominal perfusion for chemotherapy [33]. The procedures had severe cardiovascular effects: MAP and PAWP increased to more than 20% of baseline, and SVR increased to more than 80%, whereas CO and PAP did not significantly change. One minute after occlusion release, all patients had a 50% decrease in MAP, mPAP increase of 50%, CO increase of 100%, and left and right ventricular stroke work index increase of 75 and 147% at the baseline. These results contrasted with the experimental study of Stockland: because of general anesthesia, age of the patients, and history of myocardial toxic chemotherapy, the heart did not increase the output in response to the increase of VR and MSP.

However, Delva et al. [19] performed the quadruple clamping, combining TVHE and supra-celiac clamping, and reported also different results: the CO decreased to 70% at the baseline, whereas MAP and SVR increased to 33 and 140%, respectively. The heart pressures did not change. In comparison with the isolated TVHE, the quadruple clamping was associated with lesser decrease in CO (because of the larger VR) and well-maintained arterial pressure. The result that CO was more elevated than the output usually attributed to sole superior cava territory, in contrast with Stockland's observations, was explained with the larger redistribution of the blood in this territory: indeed, the clinical situation of the quadruple clamping allows a total exclusion of the liver. Moreover, the azygos system is not clamped in this situation contrary to the procedure of Stockland, and that allows the residual blood, coming into the inferior territory via mammary and epigastric arteries, to return to the heart. The IVC unclamping was followed by increase in CO, AP, and filling heart pressures. The aortic declamping, always progressive, was followed by a severe decrease in AP. Sometime, like in the study of Hofland et al. [33], the

cardiac tolerance was mediocre with major increase in PAWP and occurrence of arrhythmia. For these reasons, authors advised against this procedure that is moreover deleterious for the renal function and possibly dangerous for the nervous system if the Adamkiewicz artery is born below the clamping.

---

## **2.4 The Role of the Anesthesiologist**

### **2.4.1 Preoperative**

The most important role of the anesthesiologist in major surgery is to evaluate the intra- and postoperative risk and to examine how to decrease or prevent it. This discussion is usually collegial with surgeons: either the risk is important but accepted because there are no other possibilities or the risk is not acceptable, and the initial surgical procedure should be modified. In hepatic surgery including the IVC or in IVC surgery, needing TVHE or intrathoracic IVC clamping, the cardiac and pulmonary history should be known. Moreover, cardiac evaluation should be done in the case of clinical signs ( $MET < 4$ ), cardiovascular risk factors, or cardiac history. Indeed, decompensation of coronary disease or cardiac insufficiency may occur following IVC clamping or TVHE. The major bleeding of the slice of hepatectomy may occur at the decamping of THVE in patients with severe pulmonary disease and pulmonary arterial hypertension. Any chemotherapy could have coronary (5FU) or cardiac adverse effects (Adriamycin). Significant stenosis of coronary or supra-aortic artery should be considered as contraindication to TVHE or intrathoracic IVC clamping without extracorporeal circulation.

In hepatic surgery, the specific risk of postoperative liver failure could be evaluated with the surgeon and taken into account: the volume of the remnant liver (evaluated with 3D tomodensitometry); the quality of the liver (cirrhosis, steatosis, portal hypertension), evaluated by biology, indocyanine green clearance, and echography; and the need for continuous long liver clamping [34].

### **2.4.2 Intraoperative**

#### **2.4.2.1 The Risk of Hemorrhage**

Even in expert centers, sudden and massive hemorrhage may occur in this major surgery. The continuous monitoring of arterial pressure by a radial catheter and the insertion of two perfusion veins with one rapid perfusion device are required. The use of cell saver is not advised in carcinological surgery [35] but in cases of combined liver and IVC resection with complex reconstruction [36, 37], the blood aspirated by the surgeon could be directed in the container of the cell saver and treated only if the bleeding is sudden and uncontrolled.



### 2.4.2.2 The Risk of Gaseous Embolism

As frequent as the filling pressure of the heart is low, capnometry and transesophageal echocardiography allow rapid detection of gaseous embolism. Pulmonary arterial catheter could alert but has no specificity. The prevention is the TVHE during the most complex phase of the surgery.

### 2.4.2.3 The Management of the Consequences of the Clamping

The tolerance of TVEH is usually obtained after infusion of 750–1000 mL of colloidal solution and decrease of the anesthetic level, to permit arterial vasoconstriction in clamped territories. This tolerance is multifactorial and in a large part unpredictable [20]. That is why a test is performed during 7 min without any surgery. That permits to ascertain that the exclusion is well performed and that the patient will tolerate. In a < 60 years patient with a normal heart, minimal monitoring is necessary, in expert centers. In an elderly patient or patient with mild alteration of the cardiac function, mild or moderate myocardial hypertrophy Swan-Ganz catheter with mixed venous saturation (SvO<sub>2</sub>) monitoring is a good indicator of tolerance: if MAP is maintained > 70 mmHg, CO decreases < 60 % pre-clamping value, and SvO<sub>2</sub> is maintained > 65 %, the TVHE could be performed without risk [26]. TEE is also very interesting but no classification of tolerance has been reported with this “monitoring.” From our point of view, PAC permits monitoring and TEE-specific analysis of an unpredictable event. Fluid infusion during the period of TVHE should be minimal, to avoid sudden increase in pressure after declamping, especially in patient with cardiac relaxation disturbances. TVHE without bypass should not be performed in patients with coronary disease or cardiac dysfunction.

## 2.4.3 Postoperative

The postoperative course depends on:

- The remnant liver, quality and volume of the parenchyma, and time and type of the clamping if hepatectomy is the reason of the surgery.
- The quality and the type of the clamping even if the liver is not directly involved by the surgery. Indeed, if hepatopathy does exist, liver hypoxia induced by long continuous clamping could entail postoperative liver failure.

Moreover, cardiopulmonary bypass has also been involved in postoperative liver failure in cirrhotic patients submitted to cardiac surgery [38, 39].

- Intraoperative parameters: bleeding and intolerance to clamping and hemodynamic instability are important risk factors. The time of clamping of the liver (>30 min if severe hepatopathy does exist or 90 min in the normal liver) is an important point. A prolonged clamping > 90 min is probably deleterious for the pathologic kidney even if no report has specifically studied this point.

- The comorbidities of the patients: cardiac, pulmonary, renal dysfunction, denutrition.

Patients could be usually extubated in early postoperative time after controlling the normothermia, the absence of the bleeding via the drains and stable hemodynamics. Biologic parameters should be checked: arterial gaz, lactatemia, glycemia, hepatic enzymes, ionogram, urea and creatinine blood concentration, hemoglobinemia (Hb), prothrombin time (PT), platelets, and fibrinogen especially. Blood products should be infused to keep Hb > 9 g/dL, platelets count > 50 G/L, fibrinogen > 1 g/L, and PT < 18 s [40].

Several treatments should be avoided in cases of hepatopathy; large hepatic resection or long period of ischemia, especially paracetamol because of hepatic toxicity and benzodiazepines, those effects could be very prolonged. Some treatments like nonsteroid anti-inflammatory or aminosides may have increased nephrotoxicity in cases of hepatic dysfunction or hypovolemia [34].

Anticoagulation should be introduced with caution, especially if large hepatectomy has been performed or if hepatopathy exists. However, it should be introduced early, with continuous intravenous heparin, in case of the prosthetic vena cava. This dose could be increased if no bleeding appeared or thrombus is observed on abdominal echographic imaging. Heparin should be stopped in case of bleeding.

Infectious complications, especially pulmonary, are frequent after major abdominal surgery and especially hepatic surgery [41]. After bacteriologic sampling, it should be rapidly treated with large spectrum of antibiotic before adapting the antibiotherapy to the antibiogram.

---

## Conclusion

Thorough physiologic and anatomic knowledge in splanchnic and systemic hemodynamics are afforded to take in charge of the major surgery implying IVC clamping, especially if clamping the hepatic venous confluence, with or without hepatectomy. Discussions between the anesthesiologist and the surgeon are crucial before the surgery to evaluate the risk, which depends on comorbidities of the patient and the type of procedure. Adaptation of the procedure is often possible, permitting to decrease the risk in the more frail patients. The dialog should continue in the operating room because some pathology, as cirrhosis or severe liver steatosis, may be discovered only at this time; long period of ischemia should be avoided in such patients, and perfusion, hypothermic or not, of the liver should be sometimes used to preserve the liver. After surgery, the time and the dose of anticoagulant should be discussed for each patient, taking into account the thrombotic risk of the patient and the hemorrhagic risk of the surgery. Even if the modern monitoring, transesophageal echocardiography and SvO<sub>2</sub> Swan-Ganz catheterism, help to manage these patients, the most important guaranty of success is the experience and the continuous dialog between the anesthesiologist and the surgeon.

## Key Points

- The hemodynamic changes in response to inferior vena cava (IVC) clamping depend on the level of clamping.
- IVC clamping below the renal venous confluence are well tolerated, and IVC clamping above the hepatic venous confluence needs major anesthetic adaptation and sometimes the use of bypass.
- The anatomy of the collateral venous tracks and models of the cardiocirculatory system should be known to understand the adaptation of the system, especially in the case of the total vascular exclusion.
- Preoperative anesthetic evaluation should be exhaustive but has two priorities: determine with the surgeon the best operative surgery and check that the patient could support the major changes induced by this surgery.
- Intraoperative risks include first hemorrhage and embolic complication. Hemodynamic monitoring should be of great interest, for the precise adaptation of the therapy and the volemia.
- After surgery, the time and the dose of anticoagulant should be discussed for each patient, taking into account the thrombotic risk of the patient and the hemorrhagic risk of the surgery.

## Key References

1. Curet P, Bousquet JC, Grellet J (1985) Exploration de la veine cave inférieure et de ses branches. In: Kieffer E (ed) *Chirurgie de la veine cave inférieure et de ses branches*. Expansion scientifique française, Paris, pp 1–13
2. Guyton AC, Jones CE, Coleman TG (1973) *Circulatory physiology: cardiac output and its regulation*. WB Saunders Co, Philadelphia
3. Stockland O, Miller MM, Ilebekk A, Kill F (1980) Mechanism of hemodynamic responses to occlusion of hemodynamic responses to occlusion of the descending thoracic aorta. *Am J Physiol* 238:H423–H429
4. Hofland J, Tenbrinck R, van Ijken MGA, van Eijck CHJ, Eggermont AMM, Erdmann W (2002). Cardiovascular effects of simultaneous occlusion of the inferior vena cava and aorta in patients treated with hypoxic abdominal perfusion for chemotherapy. *Br J Anaesth* 88:193–198
5. Delva E, Barberousse JP, Nordlinger B, Ollivier JM, Vacher B, Guilmet C, Hugué C (1984) Hemodynamic and biochemical monitoring during major liver resection with use of hepatic vascular exclusion. *Surgery* 95:309–318
6. Savier E, Eyraud D, Taboury J, Vaillant JC, Hannoun L (2008) Technique et modalités de l'exclusion vasculaire du foie et des hépatectomies extrêmes. *Encycl Med Chir (Elsevier, Paris)*. AKOS Encyclopédie de Médecine Pratique
7. Azoulay D, Andréani P, Maggi U et al (2006) Combined liver resection and reconstruction of the supra-renal vena cava: the Paul Brousse experience. *Ann Surg* 244:80–88

## References

1. Crawford ES, De Backey ME (1956) Wide excision including involved aorta and vena cava and replacement with aortic homograft for retroperitoneal malignant tumors. *Cancer* 9:1085–1091
2. Caplan BB, Halasz NA, Bloomer WE (1964) Resection and ligation of the suprarenal inferior vena cava. *J Urol* 92:25–29
3. Cameron JL, Herlong HF, Senfey H, Boitnott J, Kaufman SL, Gott VL, Maddrey WC (1983) The Budd-Chiari syndrome: treatment by mesenteric systemic venous shunts. *Ann Surg* 198:335–346
4. Marshall FF, Reitz BA, Diamond DA (1984) A new technique for management of renal cell carcinoma involving the right atrium: hypothermia and cardiac arrest. *J Urol* 131:103–107
5. Głowiczki P, Hollier LH (1985) Remplacement prothétique de la veine cave inférieure. In: Kieffer E. (ed) *Chirurgie de la veine cave inférieure et de ses branches*. Expansion scientifique française, Paris, pp 82–95
6. Nunez D, Russel E, Yrizarry J, Pereiras R, Viamonte M (1978) Portosystemic communications studied by transhepatic portography. *Radiology* 127:75–79
7. Bigot JM, Chatel A, Chermet J (1977) La veine cave inférieure. Société française de radiologie médicale, (Cours de perfectionnement post-universitaire), Paris
8. Curet P, Bousquet JC, Grellet J (1985) Exploration de la veine cave inférieure et de ses branches. In: Kieffer E (ed) *Chirurgie de la veine cave inférieure et de ses branches*, Expansion scientifique française, Paris, pp 1–13
9. Guyton AC, Jones CE, Coleman TG (1973) *Circulatory physiology: cardiac output and its regulation*. WB Saunders Co, Philadelphia
10. Madger S (1994) Venous return and cardiac output. In: *Les interactions cardio-pulmonaire*, Arnette, Paris, pp 29–36
11. Bennett TD, Wyss CR, Scher AM (1984) Changes in vascular capacity in awake dogs in response to carotid sinus occlusion and administration of catecholamines. *Circ Res* 55:440–453
12. Caldini P, Permutt S, Waddell JA, Riley RL (1974) Effects of epinephrine on pressure flow, and volume relationships in the systemic circulation of dogs. *Circ Res* 34:606–623
13. Brunner MJ, Shoukas AA, Mac Anespie CL (1981) The effects of the carotid sinus baroreceptor reflex on blood flow and volume redistribution in the total systemic vascular bed of the dog. *Circ Res* 48:274–285
14. Bernard C (1877) *Cours de Médecine au Collège de France. Leçon sur le diabète et la glyco-génèse animale*. JB Baillière et Fils, Paris, pp 316–317
15. Kieffer E, Berrod JL, Chomette G (1985) Primary tumors of the inferior vena cava. In: Bergan JJ, Yao JST (eds) *Surgery of the veins*. Grune and Stratton, New York
16. Neeley R, Allenberg JR (1969) Acute cardiovascular effects of vena cava interruption: ligation versus clip compartmentation with cardiac output and flow measurements. *Surgery* 66:762–764
17. Braunwald E (1974) Regulation of the circulation. *N Engl J Med* 290:1420–1425
18. Sackner MA, Schnabel TG, Lewis DH (1964) Effects of venous return on the hemodynamics of normal persons and patients with congestive heart failure. *Am J Cardiol* 15:782–789
19. Delva E, Barberousse JP, Nordlinger B, Ollivier JM, Vacher B, Guilmet C, Huguet C (1984) Hemodynamic and biochemical monitoring during major liver resection with use of hepatic vascular exclusion. *Surgery* 95:309–318
20. Rahbari NN, Koch M, Zimmermann JB, Elbers H, Bruckner T, Contin P, Reissfelder C, Schmidt H, Weigang MA, Martin E, Büchler MW, Weitz J (2001) Intrahepatic inferior vena cava clamping for reduction of central venous pressure and blood loss during hepatic resection. *Annals of Surgery* 253(6):1102–1110
21. Farber SJ, Alexander JD, Earle DP (1954) Shock produced by obstruction of venous return to the heart in the dog. *Am J Physiol* 176:325–330
22. Ohara I, Sakai T (1957) Cardiovascular responses during interruption of the thoracic inferior vena cava. An experimental study. *Tohoku J Exp Med* 66:77–89

23. Seitchik MW, Poll M, Rosenthal W, Baronofsky ID (1961) Studies in the hemodynamics following supradiaphragmatic constriction of the inferior vena cava. *Ann Surg* 153:71–80
24. Eyraud D, Richard O, Borie DC, Schaub B, Carayon A, Vézinet C, Movschin M, Vaillant JC, Coriat P, Hannoun L (2002) Hemodynamic and Hormonal responses to the sudden interruption of caval flow: insight from a prospective study of hepatic vascular exclusion during major liver resections. *Anesth Analg* 95:1173–1178
25. Savier E, Eyraud D, Taboury J, Vaillant JC, Hannoun L (2008) Techniques et modalité de l'exclusion vasculaire du foie et des hépatectomies extrêmes. *Encycl Med Chir (Elsevier, Paris)*, AKOS Encyclopédie de Médecine Pratique
26. Lentschener C, Franco D, Bouaziz H, Mercier FJ, Fouqueray B, Landault C, Mazoit JX, Benhamou D (1999) Haemodynamic changes associated with portal triad clamping are suppressed by prior hepatic pedicle infiltration with lidocaine in humans. *Br J Anaesth* 82(5):691–697
27. Cohen MM, Sinar DS, Mc Neill JR, Grennway CV (1970). Vasopressin and angiotensin on resistance vessels of spleen intestine and liver. *Am J Physiol* 218(6):1704–1708.
28. Grennway CV (1983) Role of splanchnic venous system in overall cardiovascular homeostasis. *Fed Proc* 42:1678–1684
29. Calaresu FR, Tobey JC, Heidemann SR, Weaver LC (1984) Splenic and renal sympathetic responses to stimulation of splenic receptors in cats. *Am J Physiol* 247:R856–R865
30. Van de Buuse M (1998) Role of the mesolimbic dopamine system in cardiovascular homeostasis: stimulation of the ventral tegmental area modulates the effect of vasopressin on blood pressure in conscious rat. *Clin Exp Pharmacol Physiol* 25:661–668
31. Heaney JP, Stanton WK, Halbert DS, Seidel J, Vice T (1966) An improved technique for vascular isolation of the liver: an experimental study and case reports. *Ann Surg* 163:237–241
32. Stockland O, Miller MM, Ilebekk A, Kill F (1980) Mechanism of hemodynamic responses to occlusion of hemodynamic responses to occlusion of the descending thoracic aorta. *Am J Physiol* 238:H423–H429
33. Hofland J, Tenbrinck R, van Ijken MGA, van Eijck CHJ, Eggermont AMM, Erdmann W (2002) Cardiovascular effects of simultaneous occlusion of the inferior vena cava and aorta in patients treated with hypoxic abdominal perfusion for chemotherapy. *Br J Anaesth* 88:193–198
34. Eyraud D, Benmalek F (2002) In JEPU: Anesthésie et foie. Arnette (ed), Paris, pp 315–331
35. Jones CC, Stammers AH, Fristore LW, Jones KT, Beck DJ, Pierce ML (1999) Removal of hepatocarcinoma cells from blood via cell washing and filtration techniques. *J Extra Corpor Technol* 31:169–176
36. Azoulay D, Andreani P, Maggi U, Salloum C, Perdigao F, Sebahg M, Lemoine A, Adam R, Castaing D (2006) Combined liver resection and reconstruction of the supra-renal vena cava: the Paul Brousse experience. *Ann Surg* 244:80–88
37. Kim DS, Yu YD, Jung SW, Ji W, Suh SO (2013) Extracorporeal hepatic venous bypass during en bloc resection of the right trisection, caudate lobe, and inferior vena cava: a novel technique to avoid hypothermic perfusion. *J Am Coll Surg* 216(5):47–50
38. Ben Ari A, Elinav E, Elami A, Matot I (2006) Off-pump coronary artery bypass grafting in a patient with child class C liver cirrhosis awaiting liver transplantation. *Br J Anaesth* 97:468–472
39. Jacob KA, Hjørtnaes J, Kranenburg G, de Heer F, Kluin J (2015) Mortality after cardiac surgery in patients with liver cirrhosis classified by the Child-Pugh score. *Interact Cardiovasc Thorac Surg* 20(4):520–530. doi:10.1093/icvts/ivu438, Epub 2015 Jan 22
40. Enriquez LJ, Shore-Lesserson L (2009) Point-of-care coagulation testing and transfusion algorithms. *Br J Anaesth* 103(Suppl 1):i14–i22
41. Nobili C, Marzano E, Oussoultzoglou E, Pessaux P (2012) Multivariate analysis of risk factors for pulmonary complications after hepatic resection *annals of surgery*. *Ann Surg* 255(3):540–550

---

# Primary Leiomyosarcoma of the Inferior Vena Cava

# 3

Andrea Mingoli, Marco La Torre, Claudia Panzano,  
and Bruno Cirillo

---

## 3.1 Introduction

Soft tissue sarcomas (STS) are rare tumors, with 10,390 estimated new cases reported in the USA in 2008 [1]. The international incidence rates range from 1.8 to 5 per 100,000 per year and the estimated deaths from soft tissue sarcoma are 4870 [2].

Leiomyosarcoma (LMS) is one of the most frequent soft tissue sarcomas with an incidence ranging between 10 % and 20 % of all newly diagnosed STS [1, 2].

Among vascular leiomyosarcomas, the inferior vena cava (IVC) represents the most common location accounting for approximately 0.5 % of adult soft tissue sarcomas. The first case of IVC leiomyosarcoma (IVCLMS) reported in the literature was described at a postmortem examination in 1871 by Perl [3, 4]. By then, fewer than 700 cases of IVCLMS have been reported, with most studies limited to single case reports or compilations of small case series [5].

Because of the limited case numbers, evidences and conclusions about the natural history and optimal treatment of this tumor are still difficult to establish.

Traditionally, it has been held that the diagnosis of IVCLMS carries a severe prognosis, requiring a potential multidimensional treatment approach of unknown efficacy [6, 7]. The diagnosis is largely dependent on modern imaging modalities, but can often be delayed for a long time. The goals of management of these tumors include the achievement of local control, maintenance of venous return, and prevention of recurrence. The surgical complete resection is the only chance to cure for these patients, even if prognosis is traditionally considered poor and the reported 5-year survival rates after resection are usually comprised between 30 and 50 % [8, 9].

---

A. Mingoli, MD, FACS (✉) • M. La Torre, MD • C. Panzano, MD • B. Cirillo, MD  
Department of Surgery P. Valdoni, Emergency Department, Sapienza University,  
Policlinico Umberto I, Viale del Policlinico 155, 00161 Rome, Italy  
e-mail: [Andrea.Mingoli@uniroma1.it](mailto:Andrea.Mingoli@uniroma1.it)

A systematic overview and analysis of IVCLMS is here presented with the intent to produce a complete analytical study of epidemiology, histopathology, radiological diagnosis, surgical treatment, palliation, and survival outcomes of this rare tumor. To do that, a recent update of the 1996 International Registry of IVCLMS [5] has been performed and reported, presenting the clinical, surgical, and oncological findings of a new modern world series of 301 patients. A systematic PubMed review of all case series and single cases published (between 1993 and 2014) has been made, and all the patients have been inserted in our International Registry database, analyzing all the exhaustive clinical, radiological, surgical, and oncological outcomes. Non-English papers were excluded, as well as all papers including series and patients already entered in the Registry analysis published in 1996 [5].

The intent of this preliminary update of the International Registry was to evaluate, at more than 20 years from its first appearance, if the modern era and the better quality standard in surgery and anesthesiology have improved the surgical and oncological outcomes of patients who underwent surgical resection for IVCLMS.

Statistical analyses were performed using MedCalc for Windows, version 10.2.0.0 (MedCalc Software, Mariakerke, Belgium). Data are presented as means and percentages. Differences in distribution were calculated using the t-test for continuous variables and the chi-square test for categorical variables. Survival was estimated using the Kaplan-Meier method, and differences were assessed by means of the log-rank test.

---

## 3.2 Epidemiology, Etiology, and Predisposing Factors

In the USA, in 2010, the estimated new cases and deaths from soft tissue sarcoma were 11,930 and 4870, respectively [10]. In Italy, during 1998–2002 period, connective tissue cancer represented 0.4% of all newly diagnosed cancers and 0.4% (368) of all cancer deaths among males and 0.5% (334) among females [11].

Between STS, leiomyosarcoma is the more common histological type, counting for a total of 216 new diagnoses/year registered in Italy between 1998 and 2002 [11].

SEER (Surveillance, Epidemiology, and End Results) database program demonstrated that LMS comprised a significant percentage of STS and is the predominant sarcoma arising from large blood vessels [12]. As STS in general, LMS usually occurs in middle-aged or older persons, although it may develop in young adults and even in children [12].

The sex incidence depends on tumor location, with women representing a clear majority of patients with retroperitoneal and IVCLMSs but not of those with leiomyosarcomas in other soft tissue sites [13].

The cause of soft tissue leiomyosarcoma is unknown. Epstein-Barr virus (EBV) infection, in the setting of severe immunosuppression, has been associated to LMS among patients with acquired immunodeficiency syndrome (AIDS) and kidney, liver, and cardiac transplantation [13]. The predominant occurrence of retroperitoneal and IVCLMS in women raises the question of hormonal influence, but this is unclear [1]. Patients affected by hereditary retinoblastoma and affected by mutation



of RB1 gene have an increased risk to develop STS and secondary malignancies including LMS [10]. It is currently widely accepted that LMS are tumors that arise de novo, confirming the evidence that leiomyoma (the benign counterpart of LMS) does not undergo malignant transformation [1, 13].

---

### 3.3 Histopathology, Genetics, and Staging

Leiomyosarcoma is a malignant tumor composed of cells showing distinct smooth muscle features [13]. The typical histological pattern of IVCLMS consists of intersecting, sharply marginated groups of spindle cells. The tumors are usually compactly cellular, but fibrosis or myxoid change may be present; in the latter instance, a retiform or microcystic pattern may result. Hyalinized, hypocellular zones and coagulative tumor necrosis are frequent in larger leiomyosarcomas. SMA, desmin, and h-caldesmon are positive in a great majority of soft tissue leiomyosarcomas. Analysis of the genes and proteins in the Rb-cyclinD pathway (RB1, CDKN2A, CCND1, and CCND3) has revealed frequent abnormalities in leiomyosarcomas and in IVCLMS. The RB1 gene has been implicated, which is consistent with the loss of chromosome 13 material. Involvement of TP53 and MDM2 appears less frequent than in other sarcoma types, although such abnormalities have been suggested to correlate with a poorer prognosis in leiomyosarcomas [13].

TNM staging of IVCLMS is the same adopted for STS staging: TX, primary tumor cannot be assessed; T0, no evidence of primary tumor; T1, tumor  $\leq 5$  cm in greatest dimension; T2, tumor  $> 5$  cm in greatest dimension; N0, no evidence of positive lymph nodes; N1, the presence of positive lymph nodes; M0, no distant metastases; and M1, the presence of distant organ metastasis [14].

For tumor differentiation and grading, conventional G1-G2-G3 classification considers well-, moderately, and poorly differentiated tumors. Well-differentiated tumors (Grade 1) are characterized by mild nuclear pleomorphism; central location of blunt-ended, oval-shaped nuclei; and often perinuclear vacuolization. The mitotic rate is low. Longitudinal striations are identified in the cytoplasm. The tumor cells are arranged in clearly seen fascicles, often at right angles. Moderately differentiated tumors (Grade 2) are characterized by nuclear pleomorphism, nuclear hyperchromatism, and higher mitotic rate. Nuclei tend to lose their central location, and perinuclear vacuolization and identification of cytoplasmic striations are less commonly present. The fascicular arrangement is less well developed. Poorly differentiated tumors (Grade 3) display hyperchromatic, more markedly pleomorphic nuclei with a much increased mitotic rate. Fascicular arrangement is much more haphazard, and cytoplasmic boundaries are indistinct. Hemorrhage and necrosis are often present.

More recently, the conventional G1-G3 classification has been substituted by the French Fédération Nationale des Centres de Lutte Contre le Cancer (FNCLCC) system grade which is based on three factors: (1) differentiation (score 1 to 3, depending on mesenchymal tissue differentiation), (2) mitotic count (score 1 to 3, depending on the number of mitoses per 10 high power field, HPF), and (3) tumor



necrosis (score 1–3, depending on presence of tumor necrosis [13, 14]). FNCLCC histological grade is then calculated as follows: Grade 1, total score 2–3; Grade 2, total score 4–5; and Grade 3, total score 6–8 [13, 14].

### 3.4 Localization, Clinical Presentation, and Symptoms

IVCLMS is classified into three groups according to the tumor location and to the level of IVC involved [7]. The IVC is divided into three segments: lower segment (I, below the renal veins), middle segment (II, from renal vessels to retro hepatic IVC), and upper segment (III, from hepatic veins to the right atrium) [5, 7]. Most tumors arise in the lower (37%) or middle (43%) segments and only 20% arises in the upper segment [7–9]. The tumor can involve more than one IVC segment with a combination of signs and symptoms [8, 9].

IVCLMS generally presents as a mass lesion, often characterized by a slow and progressive growth, producing at the beginning only unspecific, vague, and elusive symptoms.

Also if in few cases the tumor is discovered incidentally, a large flank mass is generally present with right-sided abdominal or flank pain. Other symptoms produced by IVCLMS depend on the portion involved. When the tumor is in the upper portion, it occludes the hepatic veins and produces hepatomegaly, jaundice, and ascites, with a high risk of cardiopulmonary embolism. A Budd-Chiari syndrome has been described in few cases [15, 16]. In addition, patients can present with cardiac arrhythmias if the tumor extends into the right atrium [15, 16]. Location in the middle portion (segment II) may result in renal vein obstruction with the development of a nephrotic syndrome. Involvement of the lower portion (segment I) may cause leg edema [17, 18], which seems to be more often secondary to deep vein thrombosis as opposed to complete or partial occlusion of the IVC by the tumor or thrombus [8]. Lower extremity edema due to IVC occlusion is seen in less than 30% of patients at presentation, due to the tumor slow growth that allows for the development of a venous collateral circulation [7–9].

Sixty-two percent of IVCLMS grows extraluminally and enlarges typically displacing and not infiltrating the adjacent organs. Five percent of IVCLMS are intraluminal and thirty-three percent have both components. IVCLMS predominantly intraluminal tend to cause symptoms earlier than those completely extraluminal [19].

In case of large extraluminal tumors, symptoms of contiguous organ invasion/compression are reported. Nausea and vomiting can be frequent when the duodenum and stomach are invaded by the tumor; anorexia or dysphagia is described when cardias and esophageal junction are involved in the tumor growth.

Neoplastic cachexia is the typical presentation scenario in the presence of an advanced metastatic disease.

The update of the International Registry of IVCLMS documented a prevalence of a female gender, with a mean age of 54 years. The most prevalent symptom was the abdominal pain associated to the presence of abdominal mass and distention. The middle segment was more frequently involved (Table 3.1).

**Table 3.1** Clinical and preoperative findings

Age (mean, years)	54.5
Sex (F/M)	216/84
Dimension (mean, cm)	9.78
Symptoms (n°, %)	
Abdominal pain	163 (54)
Abdominal mass	43 (14.2)
Anorexia	18 (5.9)
Abdominal distension	17 (5.6)
Asthenia	11 (3.6)
Jaundice/Budd-Chiari syndrome	11 (3.6)
nausea/vomiting	8 (2.6)
Incidentaloma (n°, %)	26 (8.6)
IVC segment (n°, %)	
I	52 (17.2)
II	146 (48.5)
III	19 (6.3)
I+II	31 (10.2)
II+III	21 (6.9)
I–II–III	18 (5.9)
Preoperative diagnostics	
CT	197 (65.4)
Abdominal US	85 (28.2)
MRI	72 (23.9)
Cavography	36 (11.9)
PET scan	15 (4.9)
Cardio-US	11 (3.6)
Preoperative biopsy	191 (63.4)

### 3.5 Diagnostics

The role of imaging in the management of IVCLMS concerns diagnosis, preoperative planning, and detection of recurrences and metastases. IVCLMS is often an unexpected finding on imaging due to the tumor rarity and the absence of symptoms and signs of IVC compression. However, at presentation nearly half of the patients shows distant metastases to the liver and lungs.

A recent study by Ganeshalingam et al. suggests that contrast-enhanced CT scan (CECTS) is a sensitive tool in the diagnosis and follow-up of IVCLMS, delineating the intravascular component of the tumor, which is usually large, irregular, lobulate, and heterogeneous owing to hemorrhage and necrosis with peripheral enhancement [20].

Conversely, MRI accurately depicts the extent of IVCLMS and is more precise than CECTS in the determination of the tumor origin due to its superior soft tissue resolution. The signal characteristics on MRI depend on the degree of cystic necrosis within the tumor. Typically, T1-weighted images show a homogeneous low-signal-intensity mass (73%) corresponding to the regions of liquefaction, and all

T2-weighted images demonstrate areas of high-signal intensity due to the cystic components of these lesions.

The authors conclude that the optimum imaging technique for initial assessment of IVCLMS is a CECTS with images obtained during the portal venous phase of contrast medium administration, while MRI is valuable in the assessment of tumors in patients suitable for surgery [20].

Differential diagnosis includes angiosarcoma, renal cell carcinoma with extension in to the IVC, primary lymphoma, liposarcoma, and leiomyomatosis. Imaging differentiation of an IVCLMS from primary retroperitoneal sarcoma or similar-appearing mass is a difficult, diagnostic task. In a recent report, Webb et al. [21] found that the most useful sign is the identification of an imperceptible caval lumen. This was seen in 75 % of IVCLMS but not in other lesions ( $p < 0.01$ ). This sign had both high positive (100%) and negative predictive values (92%). Like previous authors, Webb found that the IVC compression by an extrinsic mass, with a crescentic configuration (negative embedded IVC sign), suggests a not caval origin of the lesion. This sign was never seen in IVCLMS cases, but was present in 79 % of other lesions ( $p = 0.01$ , PPV = 92%) [21].

Cardiac ultrasound is an important diagnostic tool for IVCLMC localized in the upper segment, to detect eventual tumor extension to the atrium with or without thrombosis.

When metastatic disease is suspected, PET scan is the elective exam to accurately identify secondary systemic extensions of the leiomyosarcoma. In this case, percutaneous preoperative biopsy is mandatory in order to get a histopathological determination, required for the choice of the chemotherapy protocol.

The update of the International Registry of IVCLMS documented that a CT scan was performed in 65 % of patients, as the main diagnostic investigation, and a preoperative biopsy was performed on 63 % of cases (Table 3.1). The comparison between the 1996 registry and the recent update demonstrated that in recent times percutaneous biopsy is often and significantly more commonly performed in order to better establish a therapeutic algorithm and eventually indicate a neoadjuvant/palliative treatment.

---

## 3.6 Treatment

Since the lack of efficient complementary treatments, complete R0 surgical resection, including IVC (with or without vascular reconstruction) and surrounding organs, is the mainstay of treatment [6–9, 17, 18].

Involvement of major blood vessels in the tumor growth had long been considered a limiting factor for curative surgery, due to high surgical risks and poor long-term prognosis. Concerns on IVC resection focused on early major morbidities such as cardiopulmonary events, hepatic and/or renal failure, lower limb edema, graft occlusion, and/or infection [5, 22]. However, technical advances have allowed wider surgical extension beyond major vascular resection, with relatively low rate of post-operative complications [23–26].

The extent of IVC resection is related to the site of the tumor and should be properly planned before surgery on the basis of preoperative imaging (CT and MRI).

There is no consensus on the optimal management of the IVC at the time of surgery. Options after resection include IVC ligation, primary or patch repair, or replacement with graft. Different materials for reconstruction are available, including autologous materials such as saphenous vein, allograft such as aortic homograft, xenograft such as bovine pericardium, and synthetic materials as Dacron and PTFE.

Three major factors influence the need and the type of vascular replacement: (1) the site of the lesion and the involvement of renal veins, (2) the extent of IVC resection (partial or circumferential), and (3) the presence of well-established collateral venous system [26, 27].

### 3.6.1 Resection

En bloc radical resection is the mandatory challenge considering the risk of local recurrence and the poor prognostic outcome after R1/R2 resection. Different techniques can be performed with this intent [5, 22].

### 3.6.2 A Resection Techniques

#### 3.6.2.1 Limited Resection

A limited resection is performed when a small portion of IVC, from which LMS is originating, is removed without resection of adjacent organs. This option, even if uncommon, is possible if the tumor (1) is small (<5 cm), (2) has a prevalent intraluminal growth pattern, (3) involves less the 50 % of the IVC lumen, and (4) does not show infiltration to adjacent organs at preoperative imaging and intraoperative exploration [15, 17].

#### 3.6.2.2 Extended Resection (Single Organ Versus Multi-organ Resection)

Extended resection is performed in case of massive IVC diffusion or in case of local extension and adhesion to adjacent organs. Frequently, the tumor is invading the right adrenal gland and/or right kidney requiring an en bloc resection with total nephrectomy. Tumor en bloc resection often requires also right hepatic trisectionectomy, pancreaticoduodenectomy, right hemicolectomy, and distal or total gastrectomy in order to achieve tumor-free margins.

The left renal vein can usually be ligated because of its substantial length and the adequate venous return maintained by collateral vessels (gonadal, lumbar, and adrenal veins). Conversely, right nephrectomy is frequently required for tumors involving IVC segment II, even if the kidney is not directly involved, due to short right renal vein stump and the lack of collateral circulation. If the tumor involves only the ostium of the right renal vein, kidney autotransplantation can be performed into the right iliac fossa [8, 23].

### 3.6.3 Reconstruction Techniques

It has been supposed that slow tumor growth or IVC thrombosis allows the development of venous collaterals and therefore permits a well-tolerated IVC ligation. Also, patients with a complete IVC obstruction above the renal veins and a stable preoperative renal function seem to tolerate suprarenal IVC ligation, thanks to an adequate renal venous outflow through venous collateral circulation [28, 29].

However, in contemporary reports a significant lower extremity edema was noted in more than 50 % of patients with ligation and no IVC reconstruction [30]. Probably the resection of large retroperitoneal tumors may disrupt venous collaterals predisposing patients to develop edema when the IVC is ligated [31].

It is important to consider the length and circumference of the IVC to be removed. If the circumference is <75 %, a cavoplasty can be performed with autologous venous or bovine pericardium grafts. If the circumference of the IVC to be resected is >75 %, complete resection and reconstruction are required [15].

Primary reconstruction with an end-to-end veno-venous direct anastomosis is possible when a short IVC segment is involved, allowing a tension-free vascular anastomosis.

Conversely, IVC reconstruction with autologous, heterologous, or prosthetic graft is always possible and has showed excellent patency rates with minimal morbidity.

Autologous graft can be easily obtained from external jugular or saphenous veins. These vein grafts can be obtained also from heterologous origin (cadaver). The use of autologous/heterologous grafts can avoid the graft infection and reduce the related morbidity/mortality rates due to concomitant enteric contamination when en bloc resection is associated to gastric, duodenal, or colic resection.

As vascular surgery technology has improved, prosthetic graft reconstruction has progressively become a better option; a recent study on 47 patients who underwent en bloc resection of the IVC for malignancy and prosthetic reconstruction demonstrated a 92 % clinical 5-year patency rate, with 0 % mortality rate and 2 % graft-related complication rate [32]. Therefore, nowadays, most authors support repair or reconstruction whenever possible, to minimize the comorbidity associated with IVC ligation [18].

Prosthetic replacement can be performed using PTFE and Dacron grafts. However, the preferred material of choice for caval replacement is reinforced PTFE [30, 31]. A study on eight patients submitted to IVC resection for malignancy and PTFE graft reconstruction reported a 75 % late patency rate, without lower limb edema in case of graft thrombosis [31]. Creation of an arteriovenous fistula is described to increase the patency graft and reduce the use of long-term anticoagulation therapy [30, 31], but in the update international series, it has been used only in four cases.

The update of the International Registry of IVCLMS documented that surgical resection was performed in 87 % of cases, while exploration or palliative resection were performed only in 2 % of cases. The remaining cases underwent medical palliative treatments. Multi-organ resection was performed in 157 case (52.1 %);

**Table 3.2** Operative findings

	(n°, %)
Complete surgical resection	263 (87.3)
Palliative resection (debulking)	4 (1.3)
Explorative laparotomy/laparoscopy	2 (0.7)
Multi-organ resection	157 (52.1)
Organ resected	
Kidney	93 (30.8)
Adrenal gland	39 (12.9)
Liver (caudate lobe/left liver)	23 (7.6)
Colon	8 (2.6)
Stomach/duodenum	8 (2.6)
Pancreas	12 (3.9)
Aorta	7 (2.5)
Type of IVC reconstruction	
Ligation	54 (17.9)
Primary reconstruction	43 (14.2)
Patch (autologous/heterologous)	11 (3.6)
Prosthetic patch	11 (3.6)
Prosthesis reconstruction	104 (34.5)
Bypass	20 (6.9)
Veno-venous	11 (3.6)
Cardiopulmonary	9 (3.3)

the right kidney and adrenal gland were the most frequent organs resected, followed by the liver (caudate lobe/left liver), colon, stomach/duodenum, pancreas, and aorta in the 7.6%, 2.6%, 2.6%, 3.9%, and 2.5% of cases, respectively (Table 3.2).

The Registry demonstrated also that a prosthetic grafting was the preferred modality for IVC reconstruction while its ligation was performed only in 18% of patients (Table 3.2).

A comparison of reconstruction techniques between 1996 International Registry and the updated version has been performed and a statistically significant higher number of patients submitted to autologous/heterologous/prosthetic IVC reconstruction was observed in the latter. In fact, the percentage of patients with IVC reconstruction was 79% (211 out of 263) compared to 58% of the old series (70 out of 120) ( $p < 0.0001$ ,  $\chi$ -square test).

### 3.6.4 Morbidity and Mortality Rates

The reported perioperative mortality rate for resection of primary IVCLMS ranges from 0% to 25% [5–9, 26, 28–34]. Postoperative outcomes calculated from the International Registry documented an overall morbidity and mortality rate of 24.2% and 3.3%, respectively (Table 3.3), with no statistically significant differences between the two period series ( $p = \text{n.s.}$ ,  $\chi$ -square test).

**Table 3.3** Postoperative and oncological outcomes

	(n°, %)
Morbidity	73 (24.2)
Abdominal complications	27 (8.9)
Systemic complications	46 (15.2)
Graft thrombosis	11 (3.6)
Leg edema	13 (4.3)
Mortality	10 (3.3)
1-, 3-, 5-, and 10-year OS rates	84 %, 67 %, 52 %, 25 %
1-, 3-, 5-, 10-year DFS rates	35 %, 9 %, 3 %, 0 %

Graft infection, though uncommon, is a life-threatening event and has been noted to occur more frequently in the setting of concomitant bowel resections [17]. However, among the nonautologous materials, PTFE graft seems to be the most resistant to infection [5–9]. Preoperative antibiotics and coverage of the graft, using retroperitoneal tissue or the omentum, as well as the use of autologous fascio-peritoneal patch from posterior fascia of rectus abdominis or banked venous homograft may decrease the risk of infection. Autologous vein graft or simple ligation would be preferred in cases of gross contamination [17].

Besides infection, the most common complication in venous reconstruction is graft occlusion, ranging between 7 and 28 % [17]. The PTFE graft is claimed to be more resistant to abdominal viscera compression and consequently less prone to thrombosis [17, 33]. Nevertheless, literature generally prefers the venous graft for its theoretical superiority against infection.

There is no consensus on the need for aspirin or anticoagulation therapy. In spite of the lower rate of graft thrombosis obtained by Fiore and colleagues with anticoagulant therapy, few studies have demonstrated a benefit of long-term postoperative anticlotting treatment, and many patients are placed on lifelong antiplatelet therapy at the surgeon's discretion [17].

### 3.6.5 Neoadjuvant/Adjuvant Treatment

Literature data emphasizes the lacking evidence for the role and efficacy of chemotherapy and radiotherapy in treatment of IVCLMS, in both neoadjuvant and adjuvant setting. Therefore, radical surgery remains the only treatment for patients affected by IVCLMS, and chemoradiotherapy is discussed and considered case by case as a supplementary choice or in case of palliative care need.

#### 3.6.5.1 Chemotherapy

The outcomes of neoadjuvant or adjuvant therapy in patients with retroperitoneal leiomyosarcomas have not been indagated in randomized controlled trials. Different chemotherapeutic agents have been utilized over the years in an attempt to increase survival. Hines and colleagues initially administered a preoperative

anthracycline-based chemotherapy, such as doxorubicin, but after demonstrating no survival benefit, the routine use of neoadjuvant chemotherapy has been discontinued [6]. Case reports and small retrospective studies of patients receiving adjuvant chemotherapy did not demonstrate an improvement in survival or in local recurrence rates. For those reasons, the National Comprehensive Cancer Network (NCCN) 2012 guidelines for retroperitoneal/intra-abdominal sarcomas recommend surgery for patients with resectable leiomyosarcomas [34]. Preoperative chemotherapy, although not common, is an acceptable alternative but is considered a category 2B recommendation [34]. If the tumor regresses after chemotherapy, NCCN guidelines recommend surgical resection [34].

### 3.6.5.2 Radiotherapy

The potential benefit of neoadjuvant radiation includes decreasing tumor size, improving resectability, and improving local control. No studies have definitely demonstrated a benefit of preoperative radiation for retroperitoneal leiomyosarcomas. In a case series reported by Mann [35] and colleagues, the 5-year disease-free survival was 37% with an overall survival of 56% in patients treated with a dose of 50.4 Gy [35]. The American College of Surgeons Oncology Group Z9031 study was started in an attempt to answer whether preoperative radiation could improve disease-free survival compared to patients undergoing surgery alone, but the study was closed early due to the low accrual. No randomized controlled trials on adjuvant radiotherapy have been published, but many clinicians advocate the use of radiotherapy in patients after a not radical resection. In a report of six patients by Kim et al. [36], four patients were given doses of radiation between 53 and 56.4 Gy after surgical resection, with different results. Similar to preoperative chemotherapy, the NCCN recommendation for preoperative radiation is a category 2B one [34]. Also for the use of postoperative radiation in selected patients, NCCN recommendation is a category 2B [34]. After an R0 resection, postoperative radiotherapy should be given to patients with high-grade or extremely large tumors and with close margins. After R1 resection, the NCCN recommends postoperative radiotherapy if neoadjuvant therapy was not given and only a boost of 10–16 Gy after preoperative treatment [34].

---

## 3.7 Oncological Outcomes and Prognostic Factors

Literature data describe prognosis and survival of IVCLMS, after resection, poor and severe mainly due to the aggressive biology of the tumor. The reported 5-year overall survival (OS) rates are commonly less than 50%, ranging between 30 and 60% [37]. Accordingly, the 5-year disease-free survival (DFS) is rarely higher than 30% with most patients (33–68%) developing recurrence within 2–3 years [37].

These data, from single small center series, are in accordance to the 1996 International Registry [5], the largest multicenter series of IVCLMS published, which reported a 5- and 10-year OS rate of 49.4% and 29.5%, respectively, associated to a recurrence rate of 53%. In this study, patients were affected by large-size



tumors (mean tumor size, 10.8 cm) and underwent to surgery as the only main oncological treatment, considering the inefficacy of chemoradiotherapy treatment protocols.

These data, objectively, describe a malignant behavior of the IVCLMS, but compared to other extremely aggressive abdominal gastrointestinal tumors (cholangiocarcinoma, pancreatic adenocarcinoma, etc.), this tumor seems to present a mild aggressive biology, characterized by not negligible long-term oncological outcomes, susceptible and commendable of potential more extensive surgical treatment.

The actuarial 5- and 10-year overall survival rates of the 301 International Registry patients are conformed to the literature data, showing 67% and 27.5%, respectively (Table 3.3, Fig. 3.1).

Several prognostic factors have been identified. Margin status and the IVC segment involved are the most validated prognostic factors affecting survival. R1/R2 resections are associated to worst oncological outcome and high recurrence rate than R0 resection. Conversely, IVCLMS located in the lower/middle segments are associated to better overall and disease-free survivals than tumors located in the upper one [5–9]. The survival analysis of the updated International Registry confirmed these outcomes; 5-year OS rates after R0/R1/R2 and for tumor located in the I/II/III IVC segments were 65, 61, and 0 months ( $p=0.0005$ ) and 56, 51, and 33 months ( $p=0.0008$ ), respectively (Fig. 3.2). In this analysis, LMS located in the IVC upper segment was associated to the worst prognosis compared to segments I and II (Fig. 3.3).

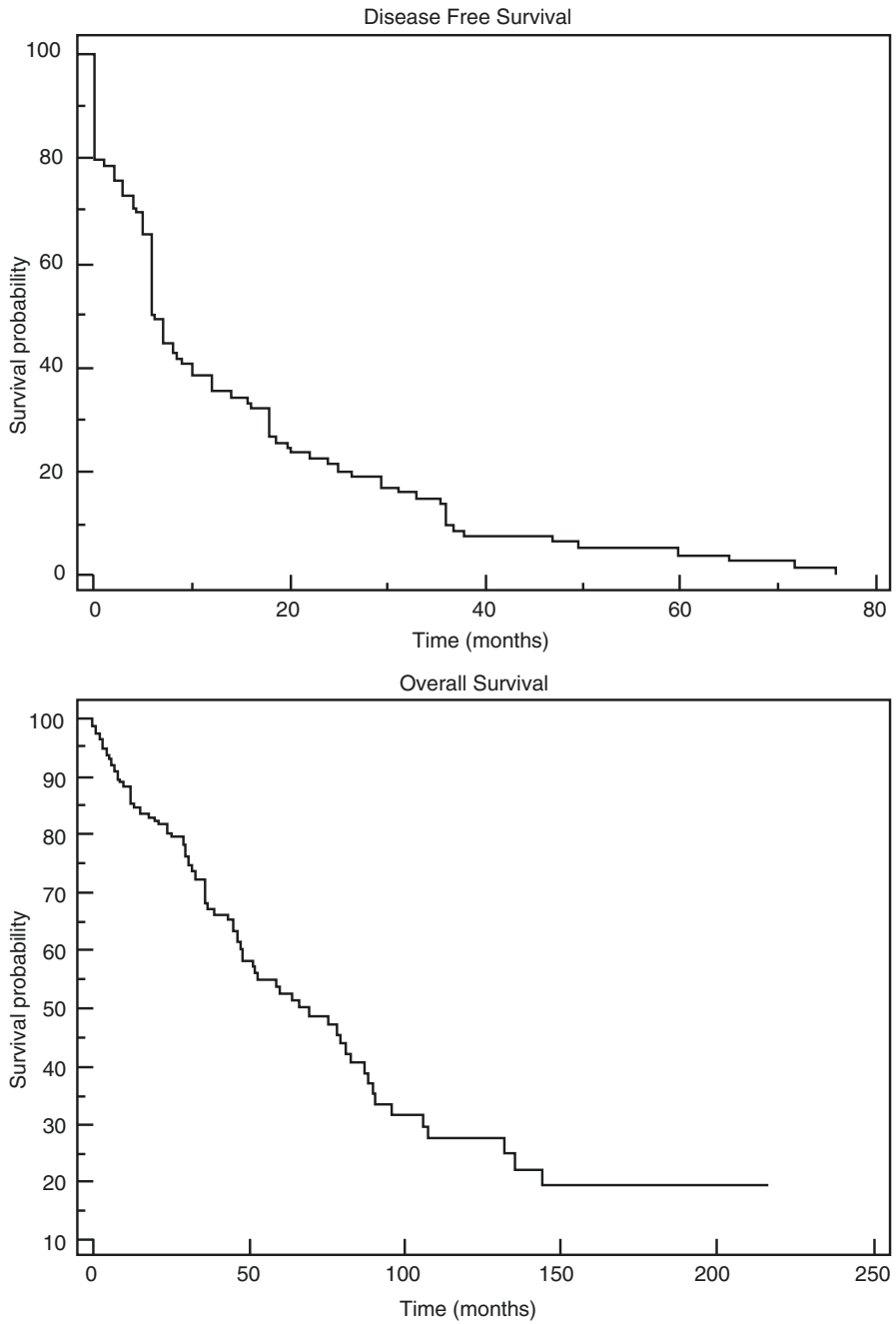
Tumor dimension affects significantly the OS and DFS, with tumor larger than 10 cm associated to 5-year OS and DFS rates of 39% and 0% compared to 62% and 8% for tumor smaller than 10 cm ( $p=0.03$  and  $p=0.001$ ) (Fig. 3.4).

Histologic grading of IVCL has not been documented in a consistent fashion in the literature. The 1996 International Registry documented a significant worse survival for patients with poorly differentiated tumors compared to patients with well- and moderately differentiated IVCLSM. The updated International Registry doesn't find any statistically significant difference when grading, or FNCLCC grade was studied as prognostic factor for both OS and DFS ( $p=n.s.$ ).

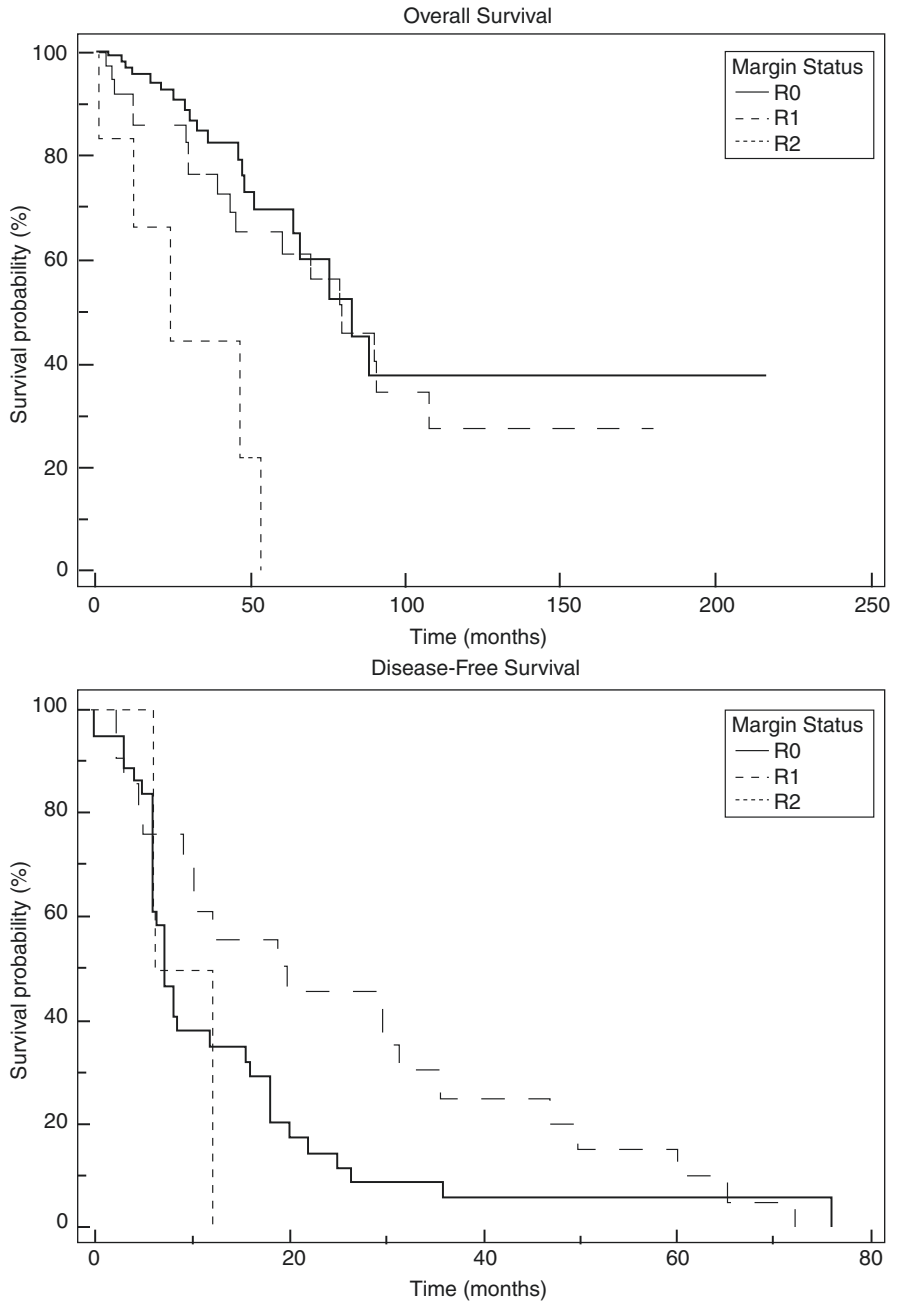
This is mainly due to the use of two different classifications (grading and FNCLCC grade) that did not allow standardization and adequate analysis.

Five-year OS/DFS rates were, respectively, 52%/10% and 59%/4% for limited and extended resections ( $p=n.s.$ ), indicating that extended IVC resection doesn't reduce the risk of local recurrence compared to limited IVC resection. The updated International Registry analyzed 32 local recurrence (10.6%) without observing any significant association to length and extension of IVC resection, margin status, tumor dimensions, etc. ( $p=n.s.$ ). These data do not agree and disprove other small series report [7, 8], reporting an oncological advantage for extended multi-organ resection even in case of limited IVC involvement [7, 8].

The preliminary analysis of this modern case series does not allow to evaluate the importance of caval resection length in terms of OS, DFS, and local recurrence rates. However, in the 1996 International Registry of IVCLMS, it has been demonstrated that caval wall radical resection could be limited to 1 cm around the



**Fig. 3.1** Actualrial OS and DFS survival analysing Margin Status



**Fig. 3.2** Actualrial OS and DFS survival analysing Margin Status

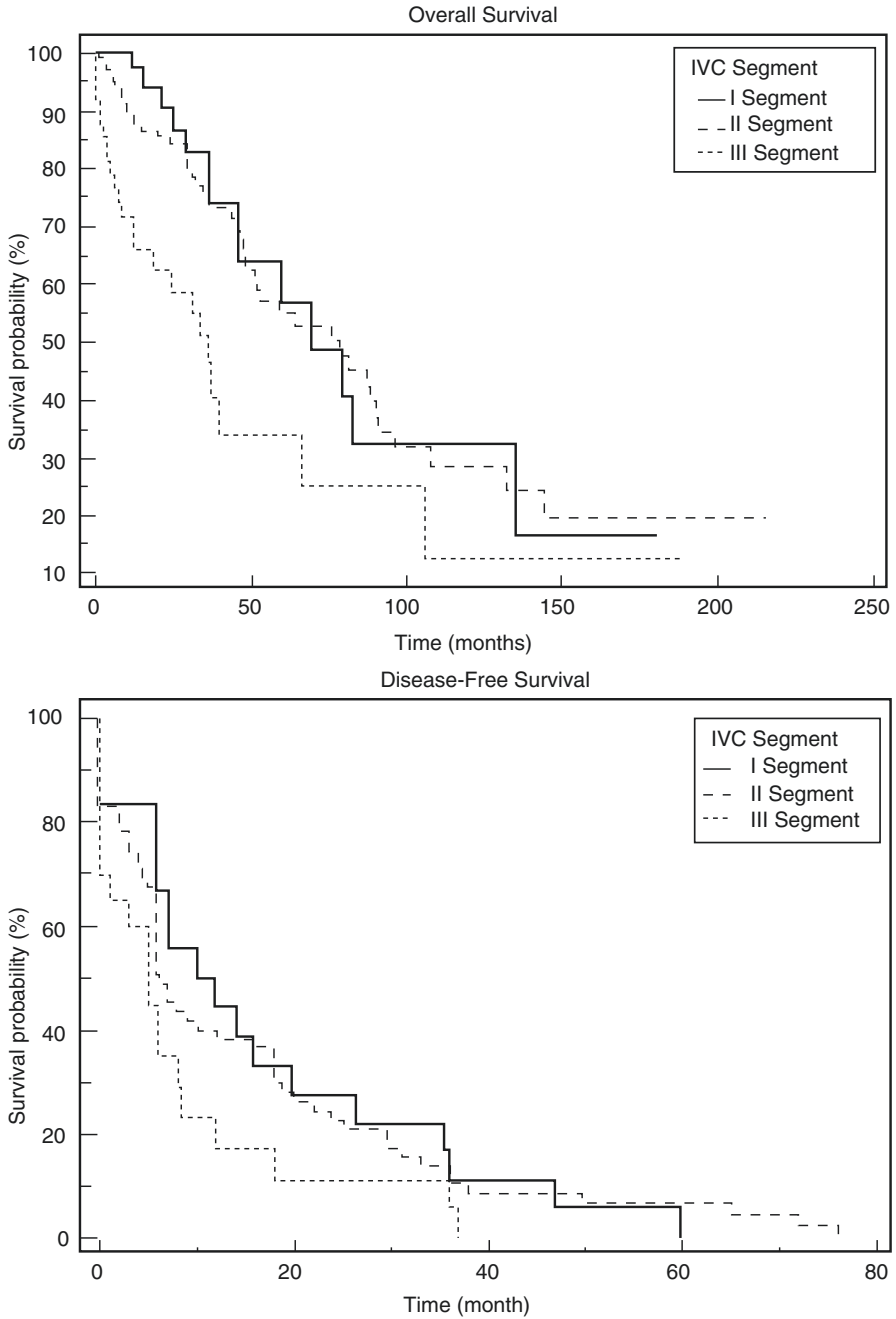
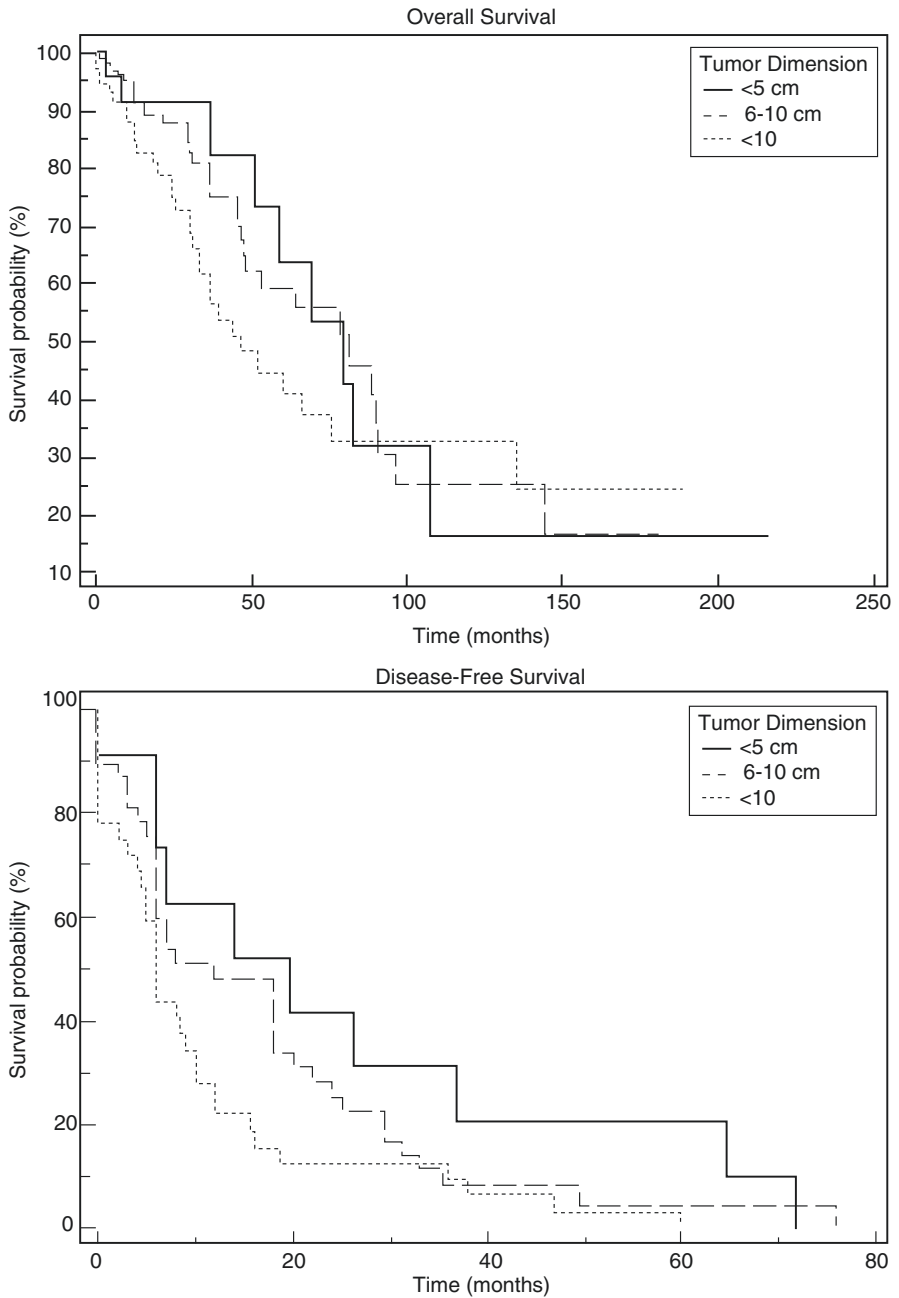


Fig. 3.3 Actualrial OS and DFS survival analysing IVC segment



**Fig. 3.4** Actualrial OS and DFS survival analysing Tumor dimension

macroscopic evidence of the tumor to reduce technical reconstruction difficulties and postoperative complications, without an increased risk for local recurrence [38]. No statistically significant differences were noted, in fact, when incidences of local and systemic recurrences were compared to the type of surgical IVC resection (caval wall resection, segmental IVC resection, or segmental IVC plus adjacent organ resection) [38].

Recurrence after curative resection of the tumor occurred in 57 % of patients, and in about a fourth of them, it was only a local recurrence [23]. The most common sites of distant metastases were the liver and the lungs. Management of recurrence poses a difficult question since there is no standard approach with proven benefit. Radiation has been used in both neoadjuvant and adjuvant settings, and some believe it may be useful in the local disease control [23]. Due to the large size of the tumor, however, a wide area needs to be incorporated in the radiation field, and this can be associated with significant damage to adjacent organs. Neoadjuvant doxorubicin-based chemotherapy has also been used in a small number of patients without proven benefit [39]. Adjuvant chemotherapy based on doxorubicin or a combination of doxorubicin and ifosfamide has been shown to prolong time to recurrence and improve overall survival in other types of sarcoma [39], but there is not enough experience in the treatment of IVCLMS. Surgical resection of IVCLMS local recurrence or metastasis is anecdotic [23].

### Key Points

1. Leiomyosarcoma of the IVC (IVCLMS) is a very rare retroperitoneal tumor, accounting for only about 0.5 % of adult soft tissue sarcomas.
2. Complete R0 surgical resection of surrounding involved organs is the mainstay of treatment, with medical oncological treatments (CT, RT, and CHRT) incompletely verified and partially ineffective.
3. IVC ligation should be abandoned considering the high risk of leg edema and local/peripheral complications.
4. IVC resection and complete reconstruction is the treatment of choice, both using homologous and prosthetic graft implants.
5. Survival is poor, but radical resection can allow long disease-free intervals and adequate cumulative survivals.

### Key References

1. Hines OJ, Nelson S, Quinones-Baldrich WJ et al (1999) Leiomyosarcoma of the inferior vena cava: prognosis and comparison with leiomyosarcoma of other anatomic sites. *Cancer* 85:1077–1083
2. Hollenbeck ST, Grobmyer SR, Kent KC et al (2003) Surgical treatment and outcomes of patients with primary inferior vena cava leiomyosarcoma. *J Am Coll Surg* 197:575–579
3. Kieffer E, Aoui M, Piette JC et al (2006) Leiomyosarcoma of the inferior vena cava: experience in 22 cases. *Ann Surg* 244:289–295

4. Dzsinič C, Gloviczki P, van Heerden JA et al (1992) Primary venous leiomyosarcoma: a rare but lethal disease. *J Vasc Surg* 15:595–603
5. Wachtel H, Gupta M, Bartlett EK et al (2015) Outcomes after resection of leiomyosarcomas of the inferior vena cava: a pooled data analysis of 377 cases. *Surg Oncol* 24(1):21–27
6. Mingoli A, Cavallaro A, Stipa S, Feldhaus RJ (1993) Inferior vena cava leiomyosarcoma. *J Vasc Surg* 17(2):451
7. Mingoli A, Cavallaro A, Sapienza P et al (1996) International registry of inferior vena cava leiomyosarcoma: analysis of a world series on 218 patients. *Anticancer Res* 16:3201–3205

---

## References

1. Serrano C, George S (2013) Leiomyosarcoma. *Hematol Oncol Clin North Am* 27(5):957–974
2. Wibmer C, Leithner A, Zielonke N et al (2010) Increasing incidence rates of soft tissue sarcomas? A population-based epidemiologic study and literature review. *Ann Oncol* 21(5):1106–1111
3. Gustafson P (1994) Soft tissue sarcoma. Epidemiology and prognosis in 508 patients. *Acta Orthop Scand Suppl* 259:1–31
4. Perl L (1871) Ein Fall von Sarkom der v cava inferior. *Virchows Arch Pathol Anat* 53:378–383
5. Mingoli A, Cavallaro A, Sapienza P, Di Marzo L, Feldhaus RJ, Cavallari N (1996) International registry of inferior vena cava leiomyosarcoma: analysis of a world series on 218 patients. *Anticancer Res* 16(5B):3201–3205
6. Hines OJ, Nelson S, Quinones-Baldrich WJ et al (1999) Leiomyosarcoma of the inferior vena cava: prognosis and comparison with leiomyosarcoma of other anatomic sites. *Cancer* 85:1077–1083
7. Hollenbeck ST, Grobmyer SR, Kent KC et al (2003) Surgical treatment and outcomes of patients with primary inferior vena cava leiomyosarcoma. *J Am Coll Surg* 197:575–579
8. Kieffer E, Aoui M, Piette JC et al (2006) Leiomyosarcoma of the inferior vena cava: experience in 22 cases. *Ann Surg* 244:289–295
9. Dzsinič C, Gloviczki P, van Heerden JA et al (1992) Primary venous leiomyosarcoma: a rare but lethal disease. *J Vasc Surg* 15:595–603
10. American Cancer Society: Cancer Facts and Figures 2015 (2015) American Cancer Society, Atlanta, GA. <http://www.cancer.org/acs/groups/content/editorial/documents/document/acspc-044552.pdf>
11. AIRTUM Working Group (2009) Cancer incidence and mortality trends of the Italian Network of Cancer Registries (AIRTUM), 1998–2005. <http://www.registri-tumori.it/cms/?q=Doc2009>. Rivista dell'Associazione Italiana di Epidemiologia
12. Howlader N, Noone AM, Yu M, Cronin KA (2012) Use of imputed population-based cancer registry data as a method of accounting for missing information: application to estrogen receptor status for breast cancer. *Am J Epidemiol* 176(4):347–356
13. Fletcher CDM, Bridge JA, Hogendoorn P et al (2013) WHO classification of tumours. IARC WHO Classification of Tumours, Volume 5 (No.5) .
14. Edge SB, Byrd DR, Compton CC et al (eds) (2010) *AJCC Cancer Staging Manual*, 7th edn. Springer, New York, pp 291–298
15. Dull BZ, Smith B, Tefera G et al (2013) Surgical management of retroperitoneal leiomyosarcoma arising from the inferior vena cava. *J Gastrointest Surg* 17(12):2166–2171

16. Laskin WB F-SJC, Burke AP et al (2010) Leiomyosarcoma of the inferior vena cava: clinico-pathologic study of 40 cases. *Am J Surg Pathol* 34(6):873–881
17. Fiore M, Colombo C, Locati P et al (2012) Surgical technique, morbidity, and outcome of primary retroperitoneal sarcoma involving inferior vena cava. *Ann Surg Oncol* 19(2):511–518
18. Wachtel H, Gupta M, Bartlett EK et al (2015) Outcomes after resection of leiomyosarcomas of the inferior vena cava: a pooled data analysis of 377 cases. *Surg Oncol* 24(1):21–27
19. Hartman DS, Hayes WS, Choyke PL et al (1992) Leiomyosarcoma of the retroperitoneum and the inferior vena cava: radiologic and pathologic correlation. *RadioGraphics* 12:1203–1220
20. Ganeshalingam S, Rajeswaran G, Jones RL et al (2011) Leiomyosarcomas of the inferior vena cava: diagnostic features on cross-sectional imaging. *Clin Radiol* 66(1):50–56
21. Webb EM, Wang ZJ, Westphalen AC, Nakakura EK, Coakley FV, Yeh BM (2013) Can CT features differentiate between inferior vena cava leiomyosarcomas and primary retroperitoneal masses? *AJR Am J Roentgenol* 200(1):205–209
22. Mingoli A, Cavallaro A, Stipa S, Feldhaus RJ (1993) Inferior vena cava leiomyosarcoma. *J Vasc Surg* 17(2):451
23. Cho SW, Marsh JW, Geller DA et al (2008) Surgical management of leiomyosarcoma of the inferior vena cava. *J Gastrointest Surg* 12(12):2141–2148
24. Bianchi C, Ballard JL, Bergan JH et al (1999) Vascular reconstruction and major resection for malignancy. *Arch Surg* 134:851–855
25. Karakousis CP, Karpaliotis C, Driscoll DL (1996) Major vessel resection during limb-preserving surgery for soft tissue sarcoma. *World J Surg* 20:345–349
26. Bower TC, Nagorney DM, Cherry KJ et al (2000) Replacement of the inferior vena cava for malignancy: an update. *J Vasc Surg* 31(2):270–281
27. Dew J, Hansen K, Hammon J et al (2005) Leiomyosarcoma of the inferior vena cava: surgical management and clinical results. *Am Surg* 71:497–501
28. Sarkar R, Eilber FR, Gelabert HA et al (1998) Prosthetic replacement of the inferior vena cava for malignancy. *J Vasc Surg* 28:75–81
29. Glocviczki P, Pairolero PC, Cherry KJ et al (1990) Reconstruction of the vena cava and of its primary tributaries: a preliminary report. *J Vasc Surg* 11:373–381
30. Daylami R, Amiri A, Goldsmith B et al (2010) Inferior vena cava leiomyosarcoma: is reconstruction necessary after resection? *J Am Coll Surg* 210:185–190
31. Hardwigsen J, Baque P, Crespy B et al (2001) Resection of the inferior vena cava for neoplasms with or without prosthetic replacement: a 14-patient series. *Ann Surg* 233:242–249
32. Quinones-Baldrich W, Alktaifi A, Eilber F et al (2012) Inferior vena cava resection and reconstruction for retroperitoneal tumor excision. *J Vasc Surg* 55:1386–1393
33. Hardwigsen J, Baqué P, Crespy B et al (2000) Resection of the inferior vena cava for neoplasms with or without prosthetic replacement: a 14-patient series. *Ann Surg* 233:242–249
34. Network NCC. Available at: [http://www.nccn.org/professionals/physician\\_gls/pdf/sarcoma](http://www.nccn.org/professionals/physician_gls/pdf/sarcoma). Accessed May 2015
35. Mann GN, Mann LV, Levine EA et al (2012) Primary leiomyosarcoma of the inferior vena cava: a 2-institution analysis of outcomes. *Surgery* 151(2):261–267
36. Kim JT, Kwon T, Cho Y et al (2012) Multidisciplinary treatment and long-term outcomes in six patients with leiomyosarcoma of the inferior vena cava. *J Korean Surg Soc* 82:101–109
37. Ito H, Hornick JL, Bertagnolli MM et al (2007) Leiomyosarcoma of the inferior vena cava: survival after aggressive management. *Ann Surg Oncol* 14(12):3534–3541
38. Mingoli A, Sapienza P, Cavallaro A et al (1997) The effect of extend of caval resection in the treatment of inferior vena cava leiomyosarcoma. *Anticancer Res* 17:3877–3881
39. Pervaiz N, Colterjohn N, Farrokhyar F, Tozer R, Figueredo A, Ghert M (2008) A systematic meta-analysis of randomized controlled trials of adjuvant chemotherapy for localized resectable soft-tissue sarcoma. *Cancer* 113(3):573–581



---

# Retroperitoneal Sarcoma Involving the Inferior Vena Cava

# 4

Marco Fiore, Stefano Radaelli, and Alessandro Gronchi

---

## 4.1 Introduction

Soft tissue sarcomas (STS) are a group of rare diseases that account for less than 1 % of all adult cancers, with an estimated incidence of 4–5/100,000/year in Europe [1]. Approximately 15 % of them arise in the retroperitoneum. The vast majority of STS originate from the connective tissue, while only a minority arises from viscera, with vessels included.

Specific treatment and prognostic issues need to be considered in retroperitoneal sarcomas (RPS), precisely because of the complex anatomy of the retroperitoneum. The disease typically presents as a large mass encasing, invading, or displacing adjacent organs with close contact to vital structures. Four well-defined histologic subtypes (well-differentiated liposarcoma, dedifferentiated liposarcoma, leiomyosarcoma, and solitary fibrous tumor) account for about 80 % of all RPS patients.

The therapeutic approach to STS has considerably changed over the last few decades, mainly in relation to surgical technique.

Complete surgical resection is the only potentially curative treatment for localized disease. Since the quality of surgery is critical to the cure of patients with localized soft tissue sarcoma, inclusion of surrounding organs in the resected specimen (mostly the colon, kidney, adrenal gland, psoas muscle) is critical to the achievement of the widest possible surgical margins. Anatomic proximity to or direct involvement of the inferior vena cava (IVC) by RPS may also prompt the indication to resect the IVC en bloc.

The latest edition of the European Society for Medical Oncology (ESMO) guidelines includes a policy of extended surgery in RPS as the standard treatment, requiring liberal en bloc resection of uninvolved organs adjacent to the tumor mass, in

---

M. Fiore, MD (✉) • S. Radaelli, MD • A. Gronchi, MD  
Sarcoma Service, Fondazione IRCCS Istituto Nazionale dei Tumori,  
Via Venezian, 1, 20133 Milan, Italy  
e-mail: [marco.fiore@istitutotumori.mi.it](mailto:marco.fiore@istitutotumori.mi.it)

order to minimize marginality [2]. A group of European and American experts [3] published a document standardizing the technical principles of the surgical approach to RPS. The general concept closely follows the principles of oncologic resection in extremity STS. This advocates proceeding beyond the safe tissues, leaving the tumor covered by the barriers where barriers exist and, where anatomic barriers do not exist, seeking to use adjacent organs as new barriers, if their sacrifice is acceptable in terms of short- and long-term morbidity.

Standard multivisceral resection for RPS usually requires en bloc nephrectomy, hemicolectomy, and psoas muscle resection. Resection of other structures, including but not limited to the aorta, IVC, iliac vessels, femoral nerve, diaphragm, duodenum, head of the pancreas, uncinat process, liver, and bone (specifically vertebral bodies, iliac wing, lower ribs), is significantly more extensive, producing greater morbidity, but is only performed in the presence of macroscopic invasion.

The IVC should therefore be resected in all cases of primary or secondary macroscopic involvement. The extent of IVC resection must be related to the tumor site, in order to obtain free margins around the vein.

The surgical, oncologic, and pathologic skills required in the management of RPS should prompt patient referral to high-volume centers, where a dedicated multidisciplinary team can offer the best possible diagnostic and therapeutic care.

In this chapter, we will discuss several aspects of surgical technique relating to secondary involvement of the IVC in the treatment of retroperitoneal sarcoma.

---

## 4.2 Retroperitoneal Sarcoma

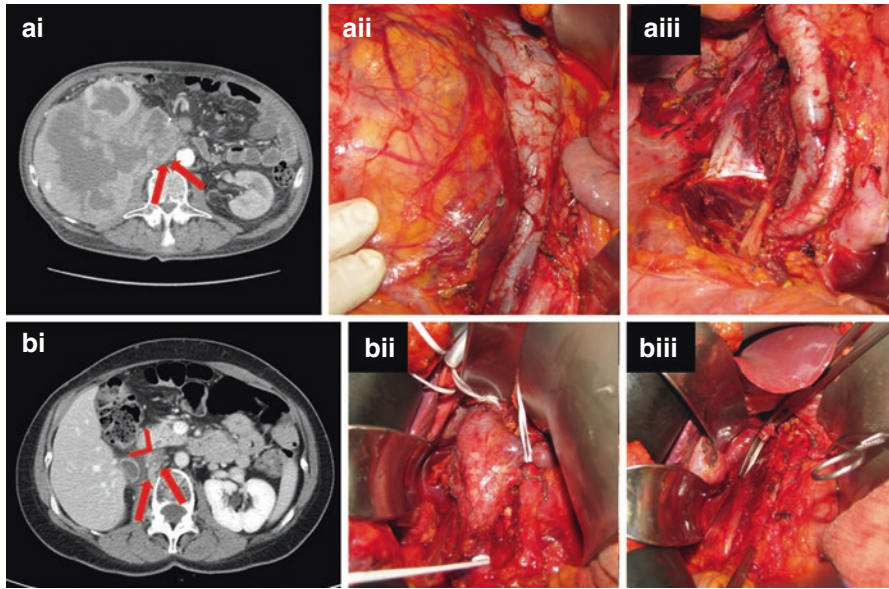
IVC management is particularly important in RPS arising in the right side of the retroperitoneum. In the case of right RPS, tumoral involvement of the IVC needs to be systematically ruled out on the preoperative CT scan, as a part of treatment planning.

In well-differentiated and dedifferentiated liposarcoma, the IVC is simply detached from the tumor mass. In the case of large masses, it can instead be difficult to recognize IVC infiltration based solely on preoperative imaging (Fig. 4.1, panel a).

One important exception is nonetheless common in the case of local recurrence: recurrences of both well-differentiated and dedifferentiated liposarcoma tend to grow with an infiltrative pattern toward the surrounding structures, with vascular adventitia included. The higher probability of vascular resection in case of recurrent RPS, partly justified by the presence of postsurgical adhesences, should therefore be kept in mind (Fig. 4.1, panel b).

When a retroperitoneal leiomyosarcoma has been diagnosed by preoperative biopsy, it should be considered that the tumor may originate from a major retroperitoneal vein. However, surgical management of leiomyosarcoma primarily arising from the IVC will not be discussed in this chapter.

Overall, resection of the IVC during RPS surgery is needed in a minority of cases (9%) and even more rarely when the RPS does not directly arise from a vein [4].

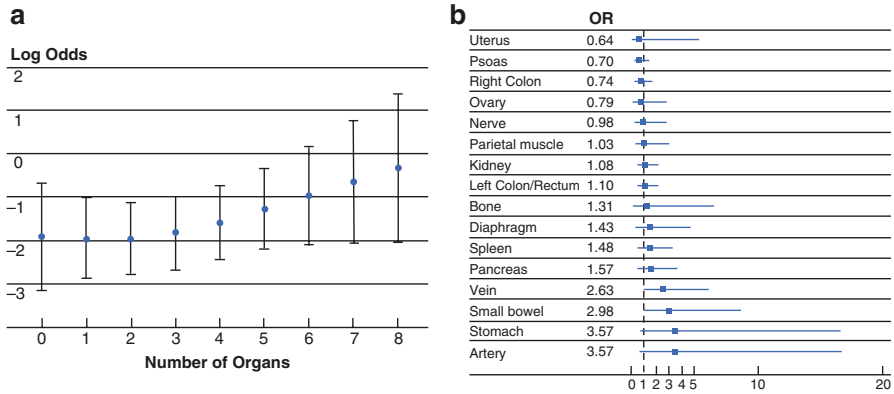


**Fig. 4.1** Radiologic assessment of IVC involvement. Panel (a) Primary retroperitoneal dedifferentiated liposarcoma, the IVC is hardly distinguishable on the preoperative CT scan (a i, arrows). Safe dissection plane found intraoperatively under IVC adventitia (a ii). Entire IVC dissection completed, right renal vein suture ligated by Endo GIA™ vascular stapler (a iii), same patient as panels (a i) and (a ii). Panel (b): Recurrent retroperitoneal leiomyosarcoma after chemotherapy treatment; the tumor remnant (b i, arrowhead) closely adheres to the suprarenal IVC (arrows). Intraoperative finding of tumor mass with no dissection plane on the IVC (b ii). Final resection of the tumor en bloc with IVC. Replacement will be achieved by PTFE grafting and left renal vein reimplantation (b iii), same patient as panels (b i) and (b ii)

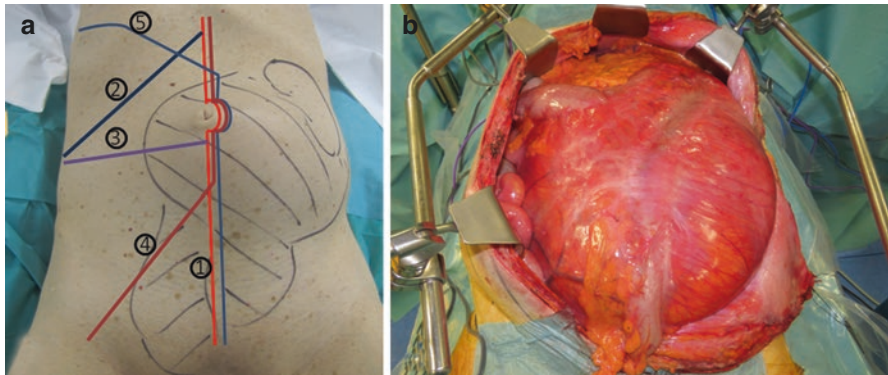
In a recent international retrospective series of more than 1000 patients surgically treated at reference institutions for primary retroperitoneal sarcoma, the rate of IVC (or iliac vein) resection en bloc with the RPS was estimated to be 10.9% [5].

In the multivisceral resection setting for primary RPS, excision of major abdominal vessels has been described to be associated with increased risk of postoperative complications, even after adjusting the risk for the total number of organs resected. This is particularly understandable for major abdominal veins (the inferior vena cava and iliac veins) since their resection may carry an increased risk of bleeding and/or fluid collection. Postoperative percutaneous drainage of any collection may be needed to avoid infection if vascular grafting has been performed. Moreover, stronger anticoagulation regimens after vascular surgery may further affect the risk of bleeding (Fig. 4.2) [6].

For the same reason, it is mandatory to achieve the safest vascular control when approaching a retroperitoneal mass. In very bulky masses, a generous midline incision may be extended either with a subcostal incision, or transversally to the flank, or sidelong to the inguinal ligament (Fig. 4.3, panel a). Right thoraco-phreno-laparotomy will enable adequate control of the retrohepatic IVC in the case of bulky



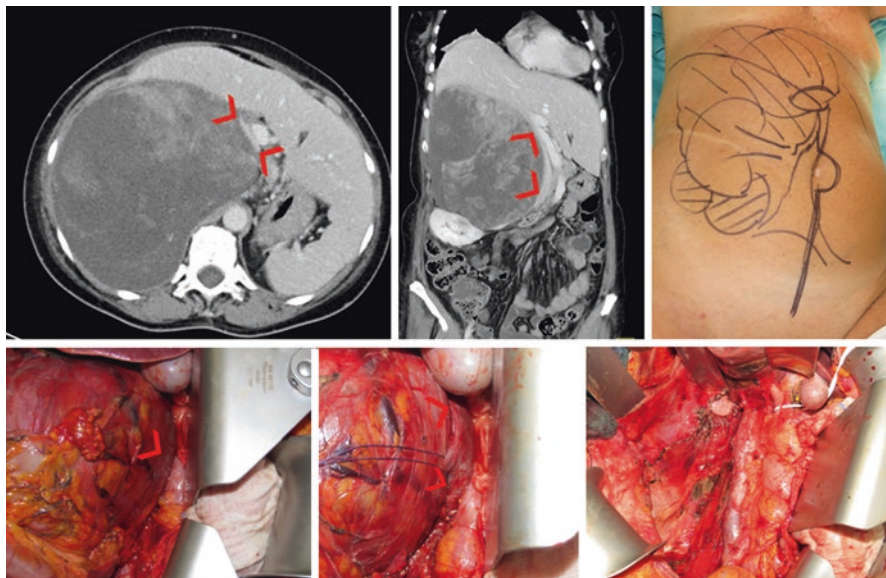
**Fig. 4.2** Risk of morbidity associated with organ resection in retroperitoneal sarcoma surgery (from Bonvalot S. et al., with permission) [6]. Panel (a): Morbidity pattern according to the number of resected organs. Morbidity increases for  $\geq 3$  resected organs. Panel (b): Forest plot showing the impact of the type of resected organs on surgical morbidity. Odds ratios (OR) of presence vs. absence of morbidity, estimated by binary logistic models; the larger the OR, the greater the association between organ involvement and morbidity. The horizontal bars represent the OR 95% confidence intervals (95% CI); when the number of patients with extension to a particular organ is low, the corresponding 95% CI is wide, denoting high imprecision in the OR estimate



**Fig. 4.3** Abdominal incisions in retroperitoneal sarcoma surgery. Panel (a): Generous midline incision (1) may be extended either with subcostal incision (2) or transversally to the flank (3). Silonguinal incision (4) is suggested if safe exposure of the iliac vessels is needed or an iliac bypass has been planned. Right thoraco-phreno-laparotomy (5) will expose retrohepatic IVC. Panel (b): Total abdomino-pelvic exposure with a Thompson™ retractor

disease in the upper right abdominal quadrant (Fig. 4.4). A good retractor will be very helpful in ensuring safe exposure and manipulation of major retroperitoneal vessels beneath a huge mass (Fig. 4.3, panel b).

An international series of 1007 primary retroperitoneal sarcoma patients with a median follow-up of 58 months produced the following outcomes: 5-, 8-, and 10-year overall survival rates of 67%, 56%, and 46%; 5-, 8-, and 10-year crude



**Fig. 4.4** Recurrent locally advanced retroperitoneal dedifferentiated liposarcoma displacing IVC (*arrowheads*). Thoraco-phreno-laparotomy enables adequate control of suprarenal and retrohepatic IVC

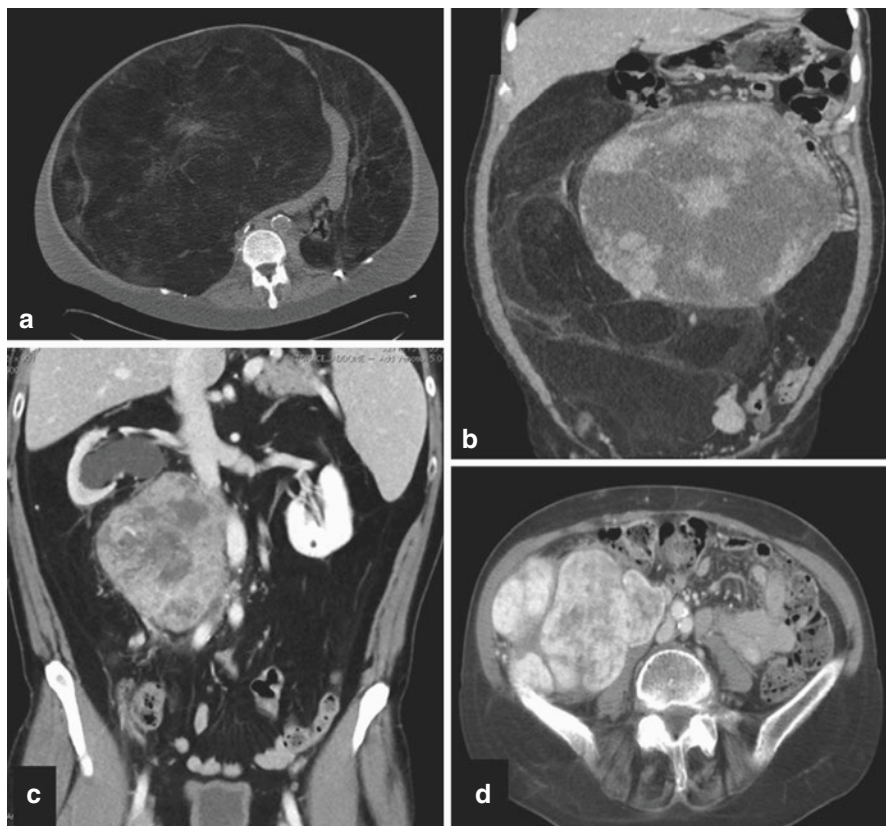
cumulative incidence of local recurrence of 25.9%, 31.3%, and 35%; and crude cumulative incidence of distant metastases of 21%, 21.6%, and 21.6%, respectively. Tumor size, histologic subtype, malignancy grade, multifocality, and completeness of resection were significant predictors of outcome.

Histologic subtype is particularly relevant in surgical decision-making due to different patterns of outcome (Fig. 4.5). Dedifferentiated liposarcoma is the most common histology in the retroperitoneum, accounting for 35% of all cases. Overall survival for dedifferentiated liposarcoma is estimated to be 43.9% at 8 years. Deaths due to dedifferentiated liposarcoma are more related to the risk of local recurrence, which is over 40% at 8 years, while the risk of distant metastases is less than 20%.

Well-differentiated liposarcoma is the low-grade counterpart and accounts for 25% of cases. Overall survival in well-differentiated liposarcoma has been estimated to be above 80% at 8 years. As the metastatic risk is virtually nil for well-differentiated liposarcoma, disease mortality is related entirely to locoregional recurrences, observed as the only mode of failure in nearly one third of patients. This emphasizes the need for optimal initial surgical management of disease, preferably at experienced reference centers.

Leiomyosarcoma is the third histotype described in retroperitoneal sarcoma and is found in 20% of cases. Leiomyosarcoma can also arise in the pelvis. The majority of purely retroperitoneal leiomyosarcomas can ultimately be found to originate from vessels, particularly from major retroperitoneal veins. Vascular leiomyosarcomas in the retroperitoneum most frequently arise from the IVC, while leiomyosarcomas

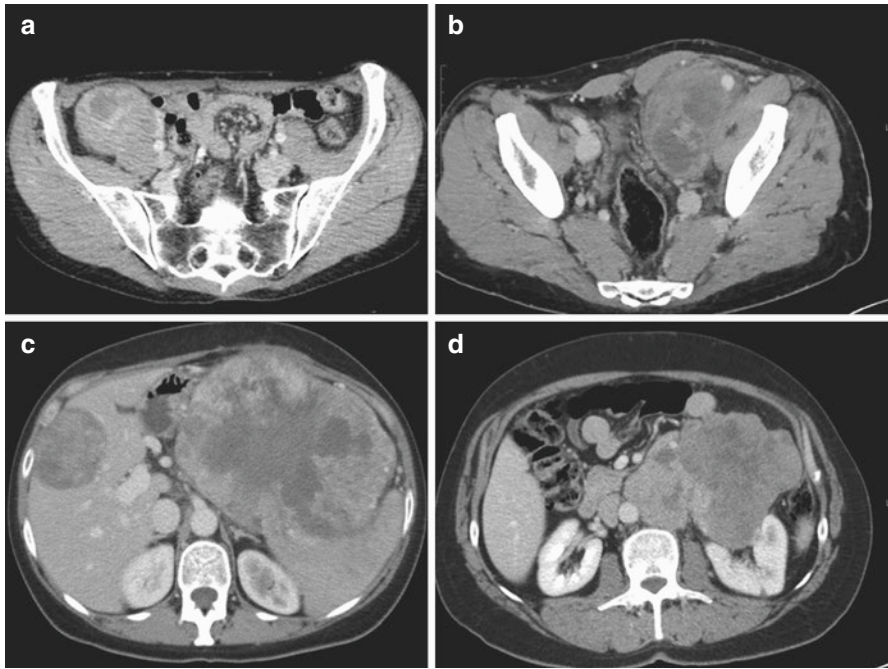




**Fig. 4.5** Principal histologic subtypes of retroperitoneal sarcoma. (a) well-differentiated liposarcoma; (b) dedifferentiated liposarcoma; (c) leiomyosarcoma; (d) solitary fibrous tumor

have been described to originate from the renal vein and from the iliac, gonadal, and splenic veins (Fig. 4.6). Secondary involvement of the abdominal aorta by an IVC leiomyosarcoma is instead very uncommon (Fig. 4.7). Overall, retroperitoneal leiomyosarcomas have shown an 8-year overall survival rate of 40%. As the risk of local recurrence in leiomyosarcoma is around 10%, disease mortality in patients with retroperitoneal leiomyosarcoma is essentially related to metastatic spread, occurring in as many as 50% of patients.

Solitary fibrous tumor (SFT) accounts for 6% of retroperitoneal sarcomas. It is usually considered to have a good prognosis with an overall survival of 80% at 8 years. The incidence of local recurrence and distant metastases is as low as 10%. For this reason, solitary fibrous tumor has often been described as a benign entity. SFTs are in fact classified as “typical” and “malignant,” based on mitotic count (< and  $\geq 4/10$  high-power microscopic fields, respectively), the presence of necrosis, and nuclear polymorphism. A strong correlation between morphology and clinical course is, however, lacking, so that to date there is no way to predict the outcome of



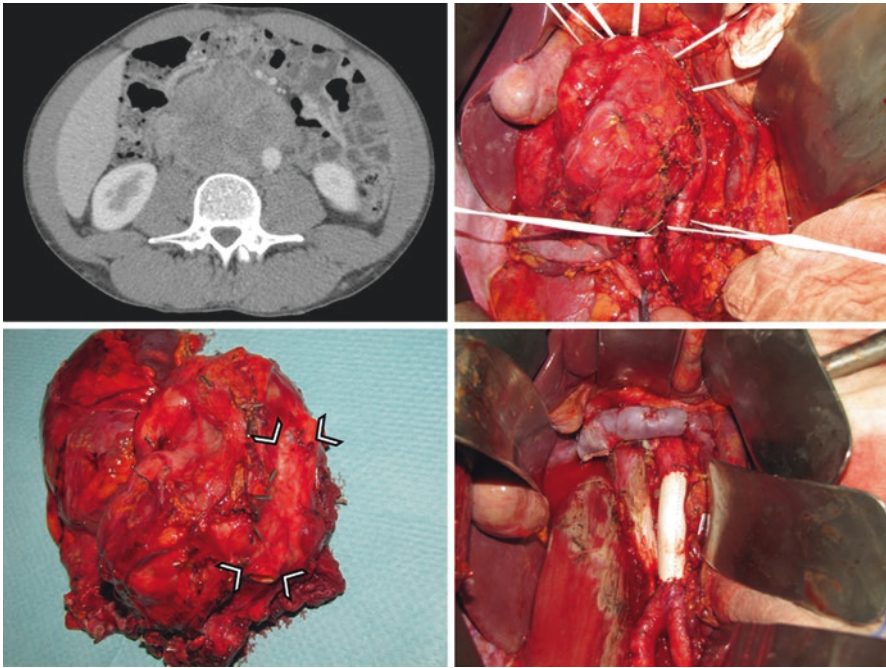
**Fig. 4.6** Retroperitoneal leiomyosarcoma of vascular origin other than IVC: leiomyosarcoma of the gonadal vein (panel **a**), leiomyosarcoma of the iliac vein (panel **b**), leiomyosarcoma of the splenic vein with synchronous liver metastasis (panel **c**), and leiomyosarcoma of the renal vein (panel **d**)

an SFT based on its pathologic features. Moreover, solitary fibrous tumors rarely show an abrupt transition from a conventional SFT to a high-grade sarcoma, also called “dedifferentiated” SFTs. These “dedifferentiated” lesions are aggressive soft tissue sarcomas. For this reason, virtually no solitary fibrous tumor should be considered purely benign, and prolonged follow-up is recommended for disease recurrence surveillance.

The role of adjuvant/neoadjuvant treatments in reducing the systemic and local risk of recurrence remains controversial for retroperitoneal sarcoma.

Radiotherapy is an option, especially in the preoperative setting, to potentially improve the chance of local control, but its role is far from being established. It is presently under investigation in a large international European Organisation for Research and Treatment of Cancer (EORTC)-led randomized trial. Conversely, postoperative/adjuvant radiation therapy is of no study-proven value and is associated with significant short- and long-term toxicities. Moreover, a therapeutic RT dose can be achieved in a minority of patients after resection.

Chemotherapy may be offered in high-grade tumors and histologies at higher risk of systemic spread, although no prospective evidence of efficacy is available to date [7].



**Fig. 4.7** IVC leiomyosarcoma invading the abdominal aorta. CT scan baseline staging; intraoperative findings after neoadjuvant chemotherapy; surgical specimen including the IVC, right kidney, and aorta (*arrowheads*); vascular reconstruction with PTFE grafting of the aorta; and cadaveric venous homograft between the left renal vein and infrahepatic IVC

### 4.3 Technical Considerations on IVC Management

Surgical treatment of retroperitoneal sarcomas, particularly when arising from the right side of the abdomen, requires special attention to be paid to IVC dissection. In the case of direct tumor involvement by RPS, IVC resection should be performed to avoid any macroscopic residual disease.

Whenever possible, vein resection must preferably be planned in advance, based on careful examination of the abdominal CT scan.

IVC dissection is important both for oncologic and technical reasons. Oncologically, the quality of surgical margins independently predicts local control. Close surgical margins (R1, i.e., <1 mm), the quality of the minimal tissue covering the tumor, the presence of tumor at the inked surface, and the histologic subtype may further predict the local outcome [5]. Vascular adventitia is considered to be a barrier to tumoral invasion, and this is particularly true in the case of non-infiltrative tumor growth, as in the majority of RPS. En bloc adventitial resection with the tumor mass may be the best option to obtain an oncologically adequate surgical margin around the IVC. This is particularly important considering the critical anatomic site, because in the event of a local relapse close to major retroperitoneal vessels, the disease may become hard to resect or not even be resectable.



Technically, subadventitial dissection may be even easier and safer than dissection along the tumoral pseudocapsule. Interruption of the tumoral pseudocapsule may result in massive bleeding from the mass itself and tumor spillage.

A peritumoral reactive zone or peritumoral edema is frequently found in primary RPS and may help to define the dissection plane. The surgeon must nonetheless be aware that no sarcomatous lesion is ever limited by a real capsule and this “pseudocapsule” plane actually corresponds to a microscopically intralesional margin. For this reason, the dissection has to be extended to include the vascular adventitia en bloc with the specimen. Ideally, this procedure aims to minimize the marginality of the resection and has been demonstrated to clearly improve local control in extremity sarcoma [8].

Suture ligation of venous collaterals is required during IVC dissection. The renal vein is usually suture ligated because of kidney involvement in the sarcomatous lesion. The gonadal vein is ligated for the same reason. Upper IVC dissection is completed by ligation of the right adrenal vein to include the adrenal gland in the specimen in order to ensure that the superior quadrant of the retroperitoneum is completely cleared. It is worth noting that during this maneuver, resection of the diaphragmatic pillar and posterior diaphragm is sometimes needed because of direct infiltration or because of a bulky lesion. In such cases, the diaphragmatic vein also has to be suture ligated. Occasionally, in the case of particularly large RPS, safe vascular control of the upper IVC may only be obtained if the retrohepatic spigelian veins are first suture ligated.

IVC collaterals on the posterior side are represented by the four right lumbar veins. They must be systematically searched for because accidental injury of a lumbar vein may result in massive bleeding. This is a challenge because both retraction of an injured lumbar vein into the vertebral foramen and the bulk of the tumor mass precluding exposure of the bleeding site until complete removal of the surgical specimen. Suture ligation of the lumbar veins is not routinely needed, but special attention is required when the psoas muscle has to be resected. During psoas resection en bloc with the RPS, lumbar veins are exposed immediately behind the muscle's origin from the lateral side of the L2-L4 vertebral bodies. Notably, when IVC resection has been planned, both right and left lumbar veins (unless they are a tributary of the left renal vein) must be ligated to allow complete mobilization of the IVC and to minimize the risk of bleeding. Should a lumbar vein be accidentally injured, hemostasis is suggested by packing and compressing the foramen. Hemostatic stitches are normally of no benefit, unless the vertebral body periosteum is included to avoid further vessel laceration: a 5/8 circle needle suture is considerably more effective in this situation.

---

#### 4.4 IVC Resection and Reconstruction

The inferior vena cava can be divided into four segments according to anatomic and surgical landmarks: segment I, between the confluence of the common iliac veins and below the inflow of the renal veins; segment II, the inflow of the renal veins; segment III, between the inflow of the renal and suprahepatic veins; and segment IV, the inflow of the suprahepatic veins.

When planning an IVC resection, the appropriateness of vascular replacement must be considered on a case-by-case basis. Three major factors influence the need for and type of vascular replacement: the site of the lesion, especially the involvement of renal veins, the extent of IVC resection (partial or circumferential), and the presence of a well-established collateral venous system.

The presence of IVC thrombosis is suspected in patients with clinical signs of flow obstruction (e.g., lower limb edema) and must be carefully evaluated on the preoperative CT scan. The existence of a well-established venous collateral system may also be adequately assessed on radiological imaging.

Preoperatively, vein resection should ideally be planned considering a 1-cm margin around the IVC at the tumor edge. We suggest routinely evaluating the adequacy of the resection margins on a frozen section.

Different options are available for IVC repair. Primary repair or autologous patch angioplasty (mainly with greater saphenous veins) may be used in partial resections. An autologous fascioperitoneal patch from the posterior rectus fascia of the abdominal wall has been proposed as a safe, alternative solution for subtotal defects of the IVC during malignancy resections. This repair technique may be preferable to prosthetic graft replacement because of the lower expected risk of infection, especially if concomitant intestinal resections are needed [9]. However, in the case of entire resection of the IVC, the fascioperitoneal patch may not be sufficient.

Simple ligation is often possible (especially when the IVC is occluded by the tumor) after complete resection of the infrarenal IVC and/or segment III, in association with resection of the right kidney. Right nephrectomy may be necessary not only for oncologic reasons but also due to the difference between collateral circulation in the right retroperitoneum, where there are no effective collaterals, and in the left side, where the collaterals (capsular, genital, reno-azygos-lumbar veins) are generally sufficient for satisfactory venous return without causing renal insufficiency. Collateral circulation usually therefore provides sufficient venous drainage for the left renal vein, and right nephrectomy can be safely performed.

In any event, IVC ligation without any vascular reconstruction is a well-tolerated option only where previous complete or slowly developing obstruction is present.

Pressure monitoring should be performed in all cases of caval ligation to rule out excessive distal venous hypertension, which would require caval reconstruction to avoid postoperative edema of the inferior limbs.

When the IVC needs to be replaced, PTFE prosthetic grafts are usually used. Due to low venous pressure, ring-reinforced PTFE grafts are often preferred, and sometimes concomitant inguinal arteriovenous fistulas are temporarily used. The limits of this well-established technique are mainly the risk of prosthetic occlusion and/or infection. The creation of an arteriovenous fistula has been suggested to ensure patency and avoid the need for long-term anticoagulation therapy.

A key point in deciding between ligation versus prosthetic replacement could be the need for concomitant resection of the digestive tract. In this case, it is preferable to avoid a prosthetic graft to reduce the risk of prosthetic infection.

Extended multivisceral resection has now been recognized as a standard approach to primary retroperitoneal sarcoma. Infectious complications might be even more likely

when extended retroperitoneal dissection is performed (i.e., seroma formation, lymphatic leak, etc.) and preoperative combined chemoradiotherapy is delivered for any reason.

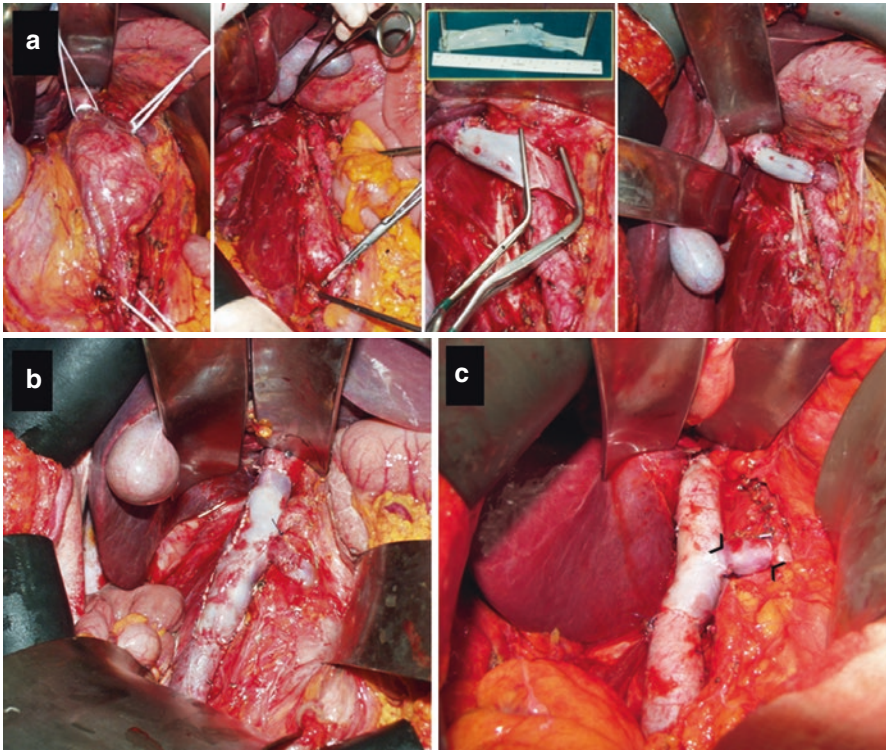
To encompass the risk of prosthesis infection and reduce the risk of postoperative limb edema, we have proposed the use of homologous venous replacement of IVC [10]. Banked venous homografts have chiefly been used as alternative grafts for femoropopliteal revascularization in critical limb ischemia. This procedure has been described as safe and effective, although long-term complications in terms of structural instability and patency rates have been reported. This has been attributed to the fact that saphenous veins harvested during stripping procedures (and thus affected by variceal disease) are the usual source of venous homografts, with cadaveric grafts being used only rarely. Moreover, most ultrastructural and immunological studies on venous homografting in humans refer to arterial bypass operations, so the suboptimal results reported in terms of graft vein survival should be attributed mainly to the high pressure regimen of the arterial district. As regards peripheral vein resection management in sarcomas of the extremities, venous homografts for vein bypasses in malignancies have only been described in limited series. These report a low rate of late patency but better control of postoperative graft infections and fewer long-term side effects due to slow progressing obstruction (for grafts which get closed), giving the collateral vein circles time to develop.

We proposed banked venous homografts, applying the same rationale used for homologous grafts in peripheral vein resection. One limiting factor for this technique is undoubtedly the availability of grafts. There is a shortage of homografts for great venous vessels, and the only ones occasionally collected by surgical donor teams are grafts of IVC or iliac veins with the lower segment of the IVC.

We demonstrated a patency rate of 60% in IVC homologous graft replacements after a median of 31 months [4]. The antithrombotic prophylaxis included in our protocol consisted of administration of low-molecular-weight heparin (LMWH) the day before surgery at a dose of 38 IU anti-Xa/Kg, intraoperative heparin infusion before vascular clamping, and postoperative LMWH for 60–90 days at the dose used the day before surgery. Patients with an IVC graft should take chronic lifelong single-agent antiplatelet therapy (ASA), unless late graft occlusion is demonstrated on CT scan.

The issue of postoperative morbidity after multivisceral resection for retroperitoneal sarcoma has been addressed by a collaborative study conducted at our facility and at the Gustave Roussy Institute (Villejuif, France) [6]. It suggested that morbidity was comparable to that of major oncologic surgery, though the resection of major abdominal vessels seemed to be associated with higher risk. Whether or not this apparent higher risk is related to the vascular resection itself or to the extent of the surgical procedure involving multiple organs is difficult to gauge. Nonetheless, data from specific analysis of patients undergoing IVC resection seem to rule out that this procedure specifically contributes to overall morbidity.

The overall clinical impact of graft occlusion in our series of patients was mild. We described early symptomatic homograft occlusion in only one patient, while late asymptomatic thrombosis was usually revealed on CT scan follow-up reevaluation. Late asymptomatic occlusion occurred mostly in patients undergoing



**Fig. 4.8** IVC reconstruction by cadaveric venous homograft: three different examples of anatomic restoration. (a) homograft restores flow between the distal left renal vein and the infrahepatic IVC (bilateral iliac thrombosis); (b) homograft replacing IVC, with reimplantation of left renal vein outflow; (c) caval homograft replacing IVC, the iliac vein of the homograft has been used to replace the resected portion of the left renal vein (*arrowheads*: renal vein/iliac vein and iliac vein/caval graft anastomoses)

bypasses between the left renal vein and the retrohepatic IVC, because pre-existing thrombosis of the IVC distally to the resection impaired complete venous reconstruction. Nevertheless, no patient developed renal failure, even in cases of late graft closure.

Cadaveric vein grafts are also a practical tool for managing various anatomic defects. When they are available, complete IVC reconstruction can be achieved and prioritized according to the following aims: restoration of left renal vein outflow, restoration of IVC continuity, and bridging a shortened left renal vein, if resected (Fig. 4.8).

### Conclusion

IVC resection should be considered feasible whenever necessary in primary retroperitoneal sarcoma. This is extremely important because complete surgical resection is the main prognosticator in retroperitoneal sarcoma.

Postoperative morbidity of multivisceral resection in RPS extended to the IVC is acceptable in experienced reference centers. Thus, major vascular resection should always be considered when needed to improve the completeness of tumor clearance.

### Key Points

- In case of right RPS, tumoral involvement of IVC need to be systematically ruled out on preoperative CT scan as a part of treatment planning.
- A higher probability of vascular resection should be kept in mind in case of recurrent RPS.
- Retroperitoneal leiomyosarcoma is very likely to originate from major retroperitoneal veins.
- IVC resection should be considered feasible and planned whenever primary or secondary involvement by retroperitoneal sarcoma is found.
- After multivisceral resection, homograft IVC replacement may be an option in order to reduce the risk of graft infection.

### Key References

- Bonvalot S, Raut CP, Pollock RE, Rutkowski P, Strauss DC, Hayes AJ et al (2012) Technical considerations in surgery for retroperitoneal sarcomas: Position paper from E-surge, a master class in sarcoma surgery, and EORTC-STBSG. *Ann Surg Oncol* 19(9):2981–2991  
*Surgical approach to retroperitoneal sarcoma is described including discussion on different anatomical presentations, histotypes. Systematic and comprehensive review of state of the art on retroperitoneal sarcoma surgery.*
- Fiore M, Colombo C, Locati P, Berselli M, Radaelli S, Morosi C et al (2012) Surgical technique, morbidity, and outcome of primary retroperitoneal sarcoma involving inferior vena cava. *Ann Surg Oncol* 19(2):511–518
- *Monoinstitutional series exploring need, extent, and outcome of IVC resection during retroperitoneal sarcoma surgery. Outcome and morbidity are described.*

---

### References

1. Stiller CA, Trama A, Serraino D, Rossi S, Navarro C, Chirilaque MD et al (2013) Descriptive epidemiology of sarcomas in Europe: report from the RARECARE project. *Eur J Cancer* 49(3):684–695
2. ESMO/European Sarcoma Network Working Group (2014) Soft tissue and visceral sarcomas: ESMO clinical practice guidelines for diagnosis, treatment and follow-up. *Ann Oncol* 25(Suppl 3):iii102–iii112
3. Bonvalot S, Raut CP, Pollock RE, Rutkowski P, Strauss DC, Hayes AJ et al (2012) Technical considerations in surgery for retroperitoneal sarcomas: position paper from E-surge, a master class in sarcoma surgery, and EORTC-STBSG. *Ann Surg Oncol* 19(9):2981–2991
4. Fiore M, Colombo C, Locati P, Berselli M, Radaelli S, Morosi C et al (2012) Surgical technique, morbidity, and outcome of primary retroperitoneal sarcoma involving inferior vena cava. *Ann Surg Oncol* 19(2):511–518

5. Gronchi A, Strauss D, Miceli R, Bonvalot S, Swallow C, Hohenberger P et al Variability in patterns of recurrence after resection of primary retroperitoneal sarcoma (RPS): a report on 1007 patients from the multi-institutional collaborative transatlantic RPS working group. *Ann Surg* (in press)
6. Bonvalot S, Miceli R, Berselli M, Causeret S, Colombo C, Mariani L et al (2010) Aggressive surgery in retroperitoneal soft tissue sarcoma carried out at high-volume centers is safe and is associated with improved local control. *Ann Surg Oncol* 17(6):1507–1514
7. Callegaro D, Fiore M, Gronchi A (2015) Personalizing surgical margins in retroperitoneal sarcomas. *Expert Rev Anticancer Ther* 15(5):553–567
8. Gronchi A, Miceli R, Colombo C, Stacchiotti S, Collini P, Mariani L et al (2012) Frontline extended surgery is associated with improved survival in retroperitoneal low- to intermediate-grade soft tissue sarcomas. *Ann Oncol* 23:1067–1073
9. Suzman MS, Smith AJ, Brennan MF (2000) Fascio-peritoneal patch repair of the IVC: a work-horse in search of work? *J Am Coll Surg* 191(2):218–220
10. Fiore M, Locati P, Mussi C, Guarino A, Piva L, Santinami M et al (2008) Banked venous homograft replacement of the inferior vena cava for primary leiomyosarcoma. *Eur J Surg Oncol* 34(6):720–724

Javier González and Gaetano Ciancio

---

## 5.1 Introduction

Renal cell carcinoma (RCC) accounts for 2–3 % of all malignant diseases in adults, representing the third most frequent and the most lethal genitourinary cancer [1, 2]. An estimated 61,560 new cases of renal cancer are expected in 2015, with an estimated 14,080 deaths from this entity in the same period [3].

This malignancy has the propensity to infiltrate the surrounding adjacent structures with unique proclivity for vascular invasion. This particular tropism for the venous system facilitates its propagation into the renal vein, inferior vena cava (IVC), and even the right cardiac chambers, generating a specific form of a locally advanced renal tumor (so-called tumor thrombus). Such an intracaval neoplastic extension is present in 4–10 %, reaching the right atrium in 1 % of patients with RCC [4–6].

There has been much debate about the prognostic significance of this entity. Currently, most authors agree that the presence of thrombus itself, in the absence of caval wall infiltration, has no specific detrimental impact on survival if it can be successfully removed, though it seems obvious that more advanced thrombi are associated with more advanced tumor stages and, thus, a negative impact on survival rates [7]. In addition to staging implications, the presence of a venous tumor thrombus increases the complexity of management due to associated parasitizing vessels, venous congestion, and the potential for embolization.

---

J. González

Servicio de Urología. Hospital Central de la Cruz Roja San José y Santa Adela, Universidad Alfonso X el Sabio, Madrid, Spain

G. Ciancio (✉)

Division of Transplantation, Department of Urology and Department of Surgery, Leonard M. Miller School of Medicine, Miami Transplant Institute, Jackson Memorial Hospital, University of Miami, 012440, Miami, FL 33101, USA

e-mail: [gciancio@med.miami.edu](mailto:gciancio@med.miami.edu)



Previous evidence had shown that aggressive surgical resection can produce long-term freedom from disease, with survival rates as high as 68% at 5 years in acceptable surgical candidates [7]. An enhanced understanding of the underlying biology of RCC has led to substantial clinical advances in the management of advanced disease, although, until the present, the only curative therapeutic strategy for this kind of tumor is the complete removal of malignant renal tissue, which appears to be not only justified but also strongly indicated and thus making nephrectomy with tumor thrombectomy the mainstay of treatment for these patients until present [7–12].

Surgical innovation has revolutionized the management of this entity in the past few years, reducing its morbidity and leading to approaches with minimized invasiveness and preserved oncologic effectiveness. Nevertheless, detailed preoperative assessment and careful attention to surgical technique are critical for the safe and efficacious management of these cases, which can be among the most challenging procedures in field of urology. This chapter provides an updated review of the current available literature concerning the diagnosis and management of this unique malignancy.

---

## 5.2 Clinical Presentation

Although the prevalent use of imaging techniques is now associated with incidental detection of many asymptomatic kidney tumors, up to 95% of patients with intracaval extension present with local or systemic symptoms, compared with 63% of those without IVC thrombus [13]. In a recent series, the primary presentation of patients with RCC extending into the IVC was hematuria (35%), flank or abdominal pain (17%), constitutional symptoms (9%), and flank or abdominal mass (2%) [11].

The presence of tumor thrombus in conjunction to renal cell carcinoma should be suspected also in patients with a renal mass and lower extremity edema, a varicocele (particularly on the right side) that does not collapse with recumbency, dilated superficial abdominal veins (*caput medusae*), or pulmonary emboli at the time of diagnosis. In addition, when the thrombus obstructs the hepatic veins, patients may have abdominal pain, hepatomegaly, and abdominal ascites (Budd–Chiari syndrome) [14, 15]. It is not infrequent that patients with this condition may present with any of the paraneoplastic syndromes associated with RCC, such as hypertension, nonmetastatic hepatic dysfunction (Stauffer’s syndrome), polycythemia, and hypercalcemia [16].

---

## 5.3 Prognostic Factors

A major advance in RCC is the realization that this disease is not one entity but rather a collection of different types, each derived from the various parts of the nephron and possessing distinct genetic characteristics, histological features, and, to some extent, clinical phenotypes [17].



**Table 5.1** Prognostic factors for RCC and tumor thrombus

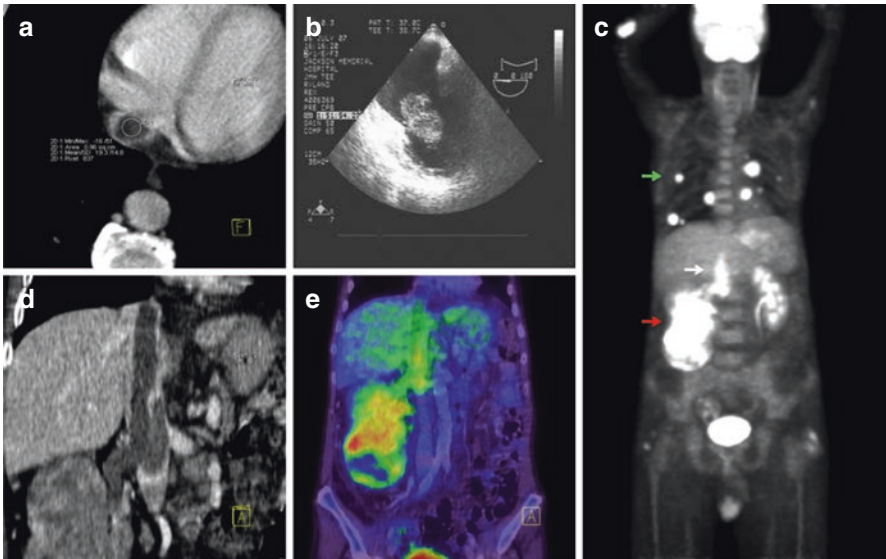
Prognostic factors for RCC and venous tumor thrombus
Nonmetastatic
TNM stage and anatomic characteristics
Tumor size >7 cm
Lymph node status
Invasion of the collecting system
Invasion of perirenal fat
Invasion of the renal vein ostium
Extension into the hepatic veins
Extension of tumor thrombus above the diaphragm
Histology
Presence of sarcomatoid features
Collecting duct carcinoma
Papillary type-II RCC
Undifferentiated RCC
Führman nuclear grade
Presence of necrosis
Tumor thrombus consistency
Metastatic
Time to metastasis
Number of metastases
Absence of immunotherapy
Cytoreductive nephrectomy

Previously identified prognostic factors for RCC include the performance status, the presence of positive lymph nodes, or distant metastasis (TNM stage), among others, and some pathological factors such as the histological type (being worse for papillary, unclassified, and collecting duct carcinoma), nuclear grade, the presence of necrosis, sarcomatoid features, and invasion of the renal sinus, perinephric fat, hepatic veins, collecting system, or renal vein ostium [10, 18]. However, no difference in prognosis was observed among other histological subtypes or different thrombus levels (Table 5.1).

The prognosis of patients with tumors invading the IVC appears to be dictated mainly by the nature of the primary lesion. The absence of prognostic value of the thrombus level highlights the importance of studying the biological factors involved instead of this feature as a determinant of survival [19]. Likewise, this fact is in agreement with several studies, leading a number of authors to propose a revised TNM staging for T3 disease [20, 21].

## 5.4 Imaging Diagnosis

Imaging studies are crucial to rule out the presence of metastatic disease and to define the level of the thrombus (Fig. 5.1). The accurate delineation of the proximal extent of the thrombus is of paramount importance because it determines the approach, the position of the patient on the operating table, and the need for bypass procedures.



**Fig. 5.1** Different imaging tests for the diagnosis of renal cell carcinoma with vena cava involvement. Intra-atrial thrombus in computed tomography (CT) cross-sectional imaging (a). Intra-atrial thrombus in transesophageal echocardiography (b). PET-CT showing a large right renal mass (red arrow) with an associated level IV tumor thrombus (white arrow) and multiple enhanced areas in the chest corresponding to metastasis (green arrow) (c). CT scan imaging showing intravascular occupation of inferior vena cava up to the right atrium (d). PET-CT imaging showing an enhanced area corresponding to a renal mass and its accompanying intracaval thrombus (e)

Ultrasonography and computed tomography (CT) have demonstrated good specificity in detecting the presence of tumor thrombus, with a reported sensitivity of 65–90%, reaching 87% when used in combination. Conversely, Doppler examination is suboptimal in visualizing the distal renal vein and the infrahepatic vena cava. Ultrasound accuracy is also strongly operator dependent and may be influenced by the patient's corporal habitus.

The improved multidetector CT would represent an option in candidates unsuitable to magnetic resonance imaging (MRI). The accuracy of multidetector CT for assessing venous tumor thrombus has been evaluated recently. These scans provide increased anatomical detail compared to conventional CT through reconstructed images [22, 23]. Guzzo et al. studied 41 patients and noted an 84% concordance rate between multidetector CT and surgical pathology, with the thrombus level accurately predicted in 96% [24]. However, no direct comparison to MRI was made in this study, and additional larger series will be needed to confirm the potential usefulness of this imaging modality.

MRI is currently considered the gold standard in the evaluation of these patients because T1-weighted images provide precise and clear anatomic depiction of the cephalad extension of the thrombus and the relationship of the thrombus to the liver, diaphragm, and right atrium. MRI also provides an accurate evaluation of the degree of

IVC occlusion and the presence of associated bland (platelet) thrombus, which is often present in the infrarenal IVC in these patients [25, 26]. In addition, Zini et al. noted that invasion of the renal vein ostium wall may be predicted on MRI, specifically by measuring the renal vein and IVC diameter [25]. They reported a 90% sensitivity for wall invasion with a renal vein or IVC diameter greater than 1.4 cm and 1.8 cm, respectively.

Transesophageal echocardiography (TEE) could be used preoperatively or intraoperatively and is especially indicated in cases with conflicting findings on MRI or in determining the presence of thrombus invading the major hepatic veins [26]. In addition, when thrombus is found in the right atrium or if pulmonary emboli are suspected, transesophageal echocardiography and CT angiography of the pulmonary vasculature should be performed.

As for all patients with suspected RCC, evaluation for potential metastatic disease necessitates chest imaging and liver function tests. When considering a possible need for cardiopulmonary bypass intraoperatively, cardiology consultation should be obtained for medical optimization and possible cardiac angiography. Moreover, cross-sectional imaging of the brain for potential metastatic disease that would be at risk for hemorrhage during anticoagulation with cardiopulmonary bypass (CPB) has also been suggested for patients with an atrial thrombus [4].

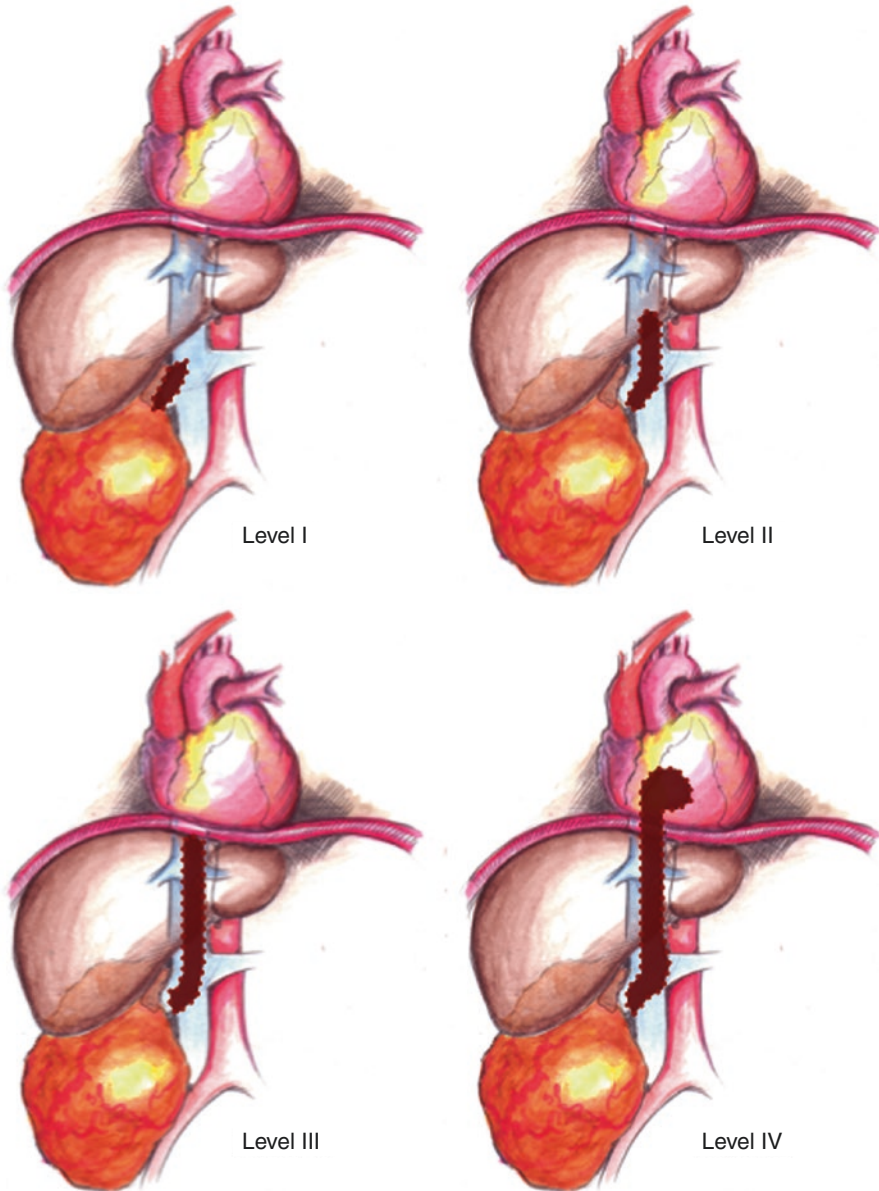
It is highly recommended for the last imaging study previous to a planned intervention to be done within 7–14 days of surgery for level II, III, and IV tumor thrombi, as propagation of thrombus may occur and accordingly that variation in cranial extension can significantly alter the surgical approach [27, 28].

---

## 5.5 Staging and Classification of Intracaval Extension

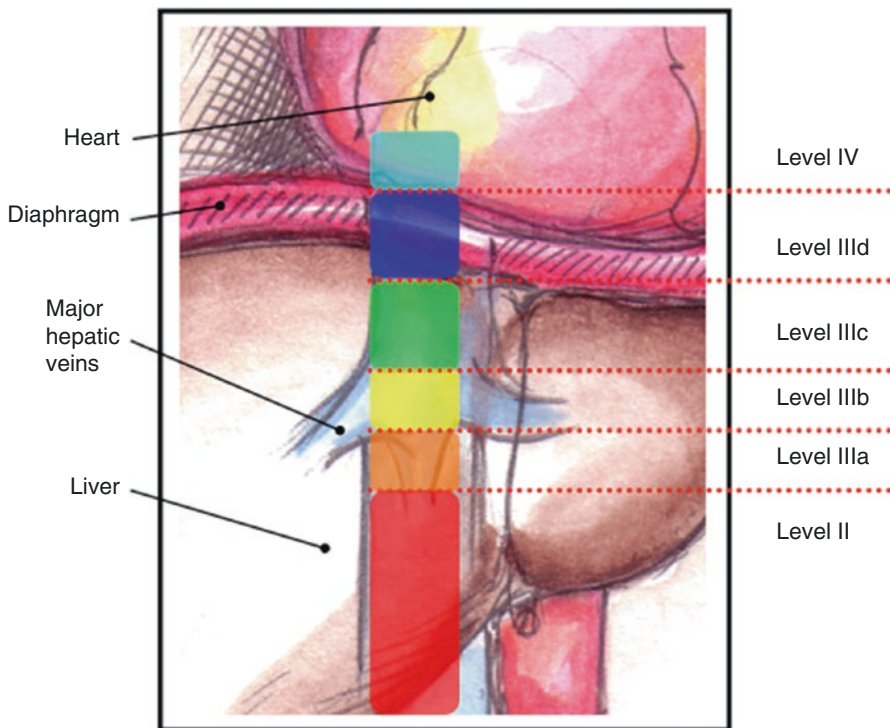
Multiple staging systems have been proposed to classify RCC with caval involvement. The recently revisited Union for International Cancer Control/American Joint Cancer Committee (UICC/AJCC) TNM staging system for renal carcinoma has supplanted Robson RCC staging classification for prognostic and, thus, therapeutic purposes. In previous TNM classifications, the pT3b group included both renal vein and IVC invasions. As the result of many studies into the independent prognostic value of vena cava compared to renal vein invasion alone [29–31], these two groups have now been separated in the latest version of the TNM classification [32]. Accordingly, this staging system stratifies RCC cases with tumor thrombus into the renal vein or segmental renal vein branches as pT3a, thrombus in the IVC below the diaphragm as pT3b, and supra-diaphragmatic thrombus and/or thrombus that invades the IVC wall as pT3c [33].

Since the anatomic level of the tumor thrombus within the IVC often impacts surgical planning, for surgical considerations, the most widely used classification remains that proposed by Neves and Zincke (i.e., Mayo Classification System) [34]. According to this system, tumor thrombus in the renal vein only is classified as level 0, thrombus extending into the IVC <2 cm from the renal vein ostium is level I, IVC extension >2 cm from the renal vein ostium and below the hepatic veins is level II, thrombus at the hepatic veins and below the diaphragm is level III, and supradiaphragmatic or atrial tumor thrombus is level IV (Fig. 5.2).



**Fig. 5.2** Mayo Classification System for RCC in conjunction with intracaval tumor thrombus. According to this system, tumor thrombus in the renal vein only is classified as level 0, thrombus extending into the IVC <2 cm from the renal vein ostium is *level I*, IVC extension >2 cm from the renal vein ostium and below the hepatic veins is *level II*, thrombus at the hepatic veins and below the diaphragm is *level III*, and supradiaphragmatic or atrial tumor thrombus is *level IV*

However, the Mayo Classification System may not provide complete information regarding some retrohepatic and suprahepatic/infradiaphragmatic (i.e., level III) tumor thrombi. Conversely, the Miami Classification System may be used to improve decision-making in this particular setting [35]. In this modified classification system, level IIIa tumors are defined as those with thrombus extending into the retrohepatic IVC but ending below the origins of the major hepatic veins, level IIIb as extending to the ostia of the major hepatic veins, level IIIc as extending above the major hepatic veins but below the diaphragm, and level IIId as extending above the diaphragm but not into the right heart (Fig. 5.3).



**Fig. 5.3** Miami Classification System for RCC in conjunction with IVC tumor thrombus. In this modified classification system, *level IIIa* tumors are defined as those with thrombus extending into the retrohepatic IVC but ending below the origins of the major hepatic veins, *level IIIb* as extending to the ostia of the major hepatic veins, *level IIIc* as extending above the major hepatic veins but below the diaphragm, and *level III d* as extending above the diaphragm but not into the right heart

## 5.6 Patient Selection

Radical nephrectomy and tumor thrombectomy were documented as early as 1913 [36]. In the past, however, patients with IVC involvement were not operated routinely due to high morbidity and poor survival rates. The widened scope of surgical alternatives with the advent of bypass procedures in the 1970s [37] along with overall improvement in perioperative care has significantly extended long-term free survival rates [38–43]. The virtually unanimous acceptance of the lack of tumor response to standard adjuvant therapy protocols, the acceptable survival rates reported in advanced stages of the disease, and the significant improvement in quality of life provided by thrombus removal in symptomatic patients also support a surgical strategy [44]. Likewise, patients with all forms of renal tumor with venous extension and nonmetastatic disease are suitable candidates for surgery. Surgery should be strongly considered after counseling in those patients with metastatic disease, given that the natural history of the disease in its free evolution ends inevitably with the death of a patient in extremely poor conditions.

## 5.7 Factors Determining the Choice of Surgical Technique

The choice of surgical technique should be individualized for each specific case based on the features of the disease process, which include (i) the comorbid status of the patient at clinical presentation, (ii) the malignancy burden, (iii) the tumor laterality, (iv) the extent of tumor thrombus inside the IVC lumen, and (v) the presence of accompanying embolic events.

In this way, each of the small technical “blocks,” or surgical steps, will be integrated to form a unique surgical technique, resulting in a procedure that is tailored to the precise requirements of the individual patient.

*Preoperative comorbid status.* Worse outcomes after surgery have been found in patients with overall poorer health and functional status preoperatively [7, 10].

*Malignancy burden.* Postoperative prognostic factors for RCC invading the IVC include a set of features associated with more aggressive tumor behavior and contributing to higher levels of local and distant invasion [10, 45]. All of these features should be considered extensively during surgical planning. However, it is possible that preoperative imaging does not provide an accurate depiction of certain important details [46], and therefore, a shift in strategy may occasionally be needed during the surgical procedure to address these contingencies.

*Tumor laterality.* The side of the abdomen where the renal mass is located determines the extent of dissection required to mobilize the neighboring visceral structures in order to gain enough exposure for thrombus excision.

*Extent of tumor thrombus.* The extent of tumor thrombus inside the IVC is the most important consideration in planning the operative strategy [47]. To adequately assess the extent of venous involvement, two parameters must be addressed: (i) the anatomic level of the tumor thrombus in the IVC and (ii) the degree of IVC occlusion generated by the thrombus intraluminal growth.



The tumor thrombus level is a critical consideration in the selection of surgical technique, given that the extent of dissection is generally predicated on the cephalad level of tumor thrombus, thus dictating the number and type of surgical maneuvers for its successful removal. There is general agreement among authors with regard to the combination of surgical steps required to remove lower thrombus cases (levels I and II) and most cases involving the right atrium (level IV). However, there is no consensus on the appropriate strategy in cases affecting the retrohepatic or suprahepatic IVC segments (level III).

The degree of IVC occlusion represents another important feature with regard to the extent of thrombus, and totally or partially occluding caval thrombus may be encountered. An extreme degree of occlusion may lead to the invasion of the venous wall containing the thrombus.

*The presence of associated embolic events.* Embolic events commonly associated with the presence of an IVC tumor thrombus are (i) the coexistence of bland thrombus with tumor thrombus inside the caval lumen and (ii) pulmonary embolism (PE), either already present at clinical presentation or suddenly generated by inadequate caval handling during the intervention.

Bland thrombus may be detected on MRI, most frequently in the infrarenal IVC. As opposed to tumor thrombus, it is characterized by a lack of contrast enhancement on MRI and may be found contiguous with tumor thrombus or as a separate distant clot, frequently within the common iliac veins.

Although these embolic events occur at a relatively low frequency (10–15 % and 1.5–3.4 % of cases for bland thrombus and PE, respectively), they cannot be overlooked during surgical planning, given that their presence may demand a radical shift in surgical strategy [48–50]. The proper management of a coexistent bland thrombus commonly requires blood flow interruption through the IVC, while evidence of a preexisting PE (or its sudden intraoperative onset) usually entails installation of extracorporeal circulation (e.g., removal of tumor thrombus from the pulmonary arteries).

---

## 5.8 Preoperative Considerations

Additional important considerations during the preoperative assessment of RCC and venous tumor thrombus are the potential roles for systemic anticoagulation, renal angioembolization, IVC filters, and tyrosine-kinase inhibitors (TKIs).

*Anticoagulation.* Indications for systemic anticoagulation for a patient with a known renal mass and tumor thrombus include (i) the presence of atrial tumor thrombus involvement, (ii) documented pulmonary emboli, and/or (iii) bland thrombus on MRI.

In cases of associated bland thrombus, systemic anticoagulation is recommended to prevent thrombus propagation. Propagation risks contralateral renal vein thrombosis and debilitating lower extremity edema and may serve as a nidus for distal or proximal embolization. Efforts should be made for expeditious surgery, and, as such, these patients are placed on low molecular weight heparin in an outpatient or

on intravenous heparin in the inpatient setting to allow for rapid discontinuation before surgery.

*Embolization of the renal artery.* This maneuver aims to reduce blood supply, mass size, and collateral blood flow around the tumor. The purported benefits of this management strategy also include a reduction in tumor thrombus extent, a decrease of intraoperative blood loss, and facilitation of renal hilar dissection [51].

Although isolated single institutional experiences support this procedure as a method to decrease the overall complexity of the intervention [52], this technique presents certain disadvantages, which may advise against its use. Subramanian et al. [53] showed that there is no significant advantage in preoperative embolization for the treatment of RCC with an IVC thrombus, and in fact, this procedure may increase the risk of complications and mortality probably by inducing a significant reaction around the kidney and surgical field. Hence, both the high frequency of postembolization syndrome and in many cases its severe clinical presentation led experts to no longer recommend this maneuver [54].

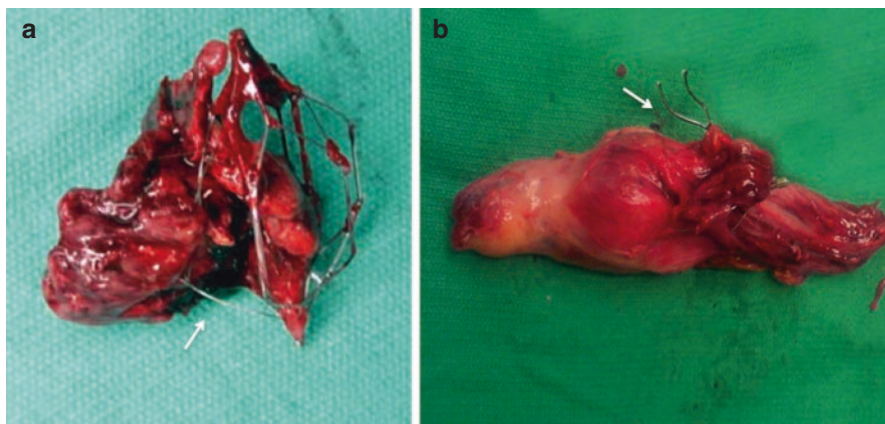
*Preoperative IVC filter deployment.* Possible migration of dislodged thrombus fragments into the pulmonary circulation favored the presurgical use of IVC filters as PE preventive strategy [55]. Currently, this recommendation remains controversial, due in part to different reports on the rupture of the caval wall during the device deployment [56], not to mention the infrequent proximal migration of the filter into the right heart chambers causing a lethal cardiac tamponade [57].

In our opinion, if the patient presents an established PE at the time of diagnosis, there is no indication for IVC filter use. In most of these cases, if not all, PE is produced by a mix of tumor and bland thrombus fragments. Tumor thrombus fragments are completely insensitive to anticoagulant therapy. Under these circumstances, CPB is advisable for a complete tumor removal from the pulmonary arteries. IVC filters are not capable of preventing tumor thrombus enlargement. Therefore, the device can be progressively entrapped within the neoplastic tissue after placement. If this occurs, the complexity of the procedure is multiplied exponentially, and what apparently would be a resectable case may become almost unresectable (Fig. 5.4).

The anatomical location of the proximal thrombus limit and the degree of IVC occlusion may also contraindicate the deployment of a filter. Filter placement may not be warranted in higher thrombus level cases (i.e., levels III–IV) due to a space conflict above the major hepatic veins (MHVs). Obviously, the filter cannot be placed in the right atrium. In addition, the use of a distal (i.e., femoral) instead of a proximal (i.e., transjugular) percutaneous approach for filter deployment may potentially induce a partial dislodgement of the thrombus with devastating consequences.

In cases of complete IVC flow interruption, filter deployment may be unnecessary since the thrombus would act as a filter itself (i.e., completely occluding the lumen of the IVC). In addition, as a result of complete IVC occlusion, venous flow redistributes through a secondary network of variable size collaterals. The diameter of these vessels is occasionally wide enough to permit the passage of thrombus fragments. Placing a filter in the IVC would not prevent an eventual PE under these circumstances. Nevertheless, if the filter is thought strongly indicated (i.e., level II,





**Fig. 5.4** Inferior vena cava filter entrapped within the tumor thrombus (a and b). IVC filters are not capable of preventing tumor thrombus enlargement. Therefore, the device can be progressively entrapped within the neoplastic tissue after placement. If this occurs, the complexity of the procedure is multiplied exponentially, and what apparently would be a resectable case may become almost unresectable

not completely obstructing, tumor thrombus cases, with or without associated bland thrombus), it should be deployed <48 h before surgery to reduce the incidence of thrombus entrapment [27].

*Tyrosine-kinase inhibitors.* Although the concept of neoadjuvant therapy to down stage locally advanced tumors and improve survival has been incorporated into the treatment approach for a variety of malignancies, to date its use in kidney cancer has been limited. Nevertheless, tyrosine-kinase inhibitors (TKIs) have an interesting ability to reduce tumor size in RCC that would have also a role in decreasing the thrombus anatomic level before nephrectomy [58]. In fact, some cases had been reported in the literature with the use of sorafenib and sunitinib [59, 60]. However, existing information on the response of primary tumors and thrombus to these agents remains limited.

## 5.9 Surgical Steps and Technical Details

*Initial Requirements.* Most authors agree that there are a number of requirements that must be met in order to carry out this type of intervention. These include (i) an adequate environment, (ii) close collaboration among the members of an experienced multidisciplinary team, and (iii) an accurate preoperative imaging assessment [61].

*Minimally invasive approaches.* The application of advanced techniques has allowed renal tumors invading the IVC to be managed in purely minimally invasive fashion, but the standard approach for tumors with intracaval extension remains open surgery because the benefits of minimally invasive techniques are temporary

or short term. Further experience will be necessary to decide if the benefits obtained justify the approach [62].

*Patient positioning, incision, and self-retaining retractor.* The positioning of the patient should be based on the choice of incision [63]. Supine position offers advantages for anesthetic and surgical control, since it allows better access to the patient's head/chest when TEE or CPB is required.

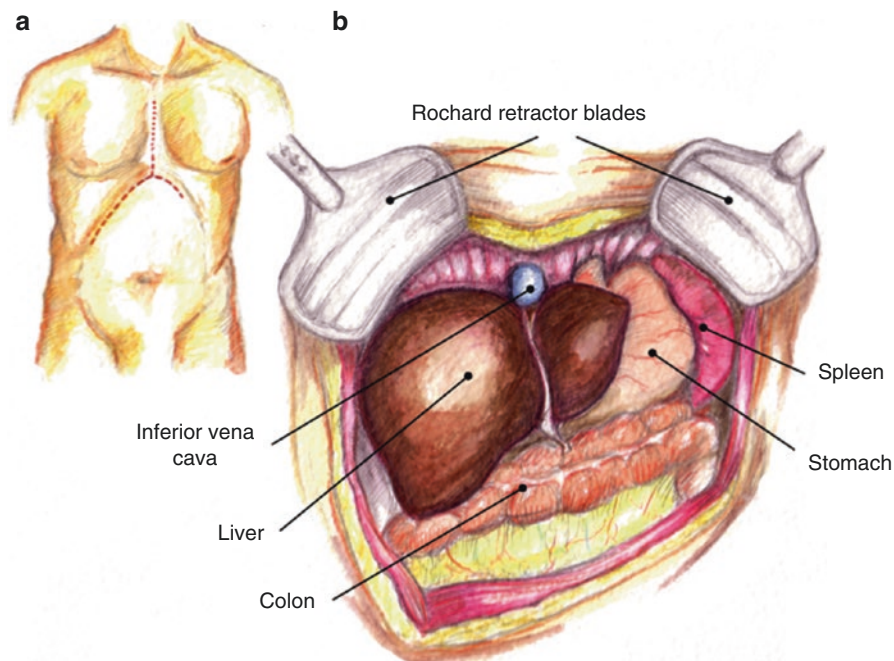
Surgical incision should be chosen under the basis of an optimal approach to the tumor and vascular control. A large number of different incisions have been used in the treatment of RCC with caval involvement. Generally, the use of a particular type of incision is in relation to the volume of the renal mass, its relationship to the surrounding structures, and the anticipated level of tumor thrombus. Thoracoabdominal and flank approaches were frequently used in the past [64] but are less common today, since thoracoabdominal access involves the use of a postsurgical chest tube and the approach through the flank does not allow proper control of the great retroperitoneal vascular structures that commonly lie hidden by the renal mass.

Midline xiphoid-pubic and transverse subcostal incisions are now preferred, as they avoid the postoperative need for a thoracic tube. In addition, both can be combined with a midline sternotomy if CPB is required. Although the approach through the midline is easier to learn and quicker to perform and can provide excellent exposure, this incision entails a typical telescopic effect, which increases with depth of surgical field, putting at risk the adequate control of "deep" areas, including vascular structures, and thus the overall safety of the procedure [65]. Conversely, transverse incisions are based on better physiological principles and should be recommended, as there are fewer complications in the early postoperative period and a lower incidence of late incisional hernia [66]. However, this does not appear to be clinically significant, as complication rates and recovery times are comparable to those obtained with midline incisions [64].

The triradiate Chevron incision combines the advantages of midline and subcostal approaches without increasing the rate of incision-related complications. This incision may represent an excellent alternative for the more complex cases [67]. Nevertheless, the optimal incision for abdominal surgery still remains the preference of the surgeon [64].

The choice of self-retaining retractor should be based on the type of incision used. While the Omni-Tract FastSystem® (Omni-Tract Surgical/Minnesota Scientific, Inc., St. Paul, MN, USA) and Bookwalter™ abdominal retractor (Codman & Shurtleff, Inc., Raynham, MA, USA) are excellent options for midline incisions, in the event that a triradiate Chevron incision is used, a retractor designed for liver surgery is preferable (e.g., Rochard and Thompson retractors). Liver retractors have the advantage of moving the costal margins toward the axillae, which flattens the diaphragmatic domes, thereby increasing exposure in areas that are difficult to access such as the upper abdominal quadrants [68] (Fig. 5.5).

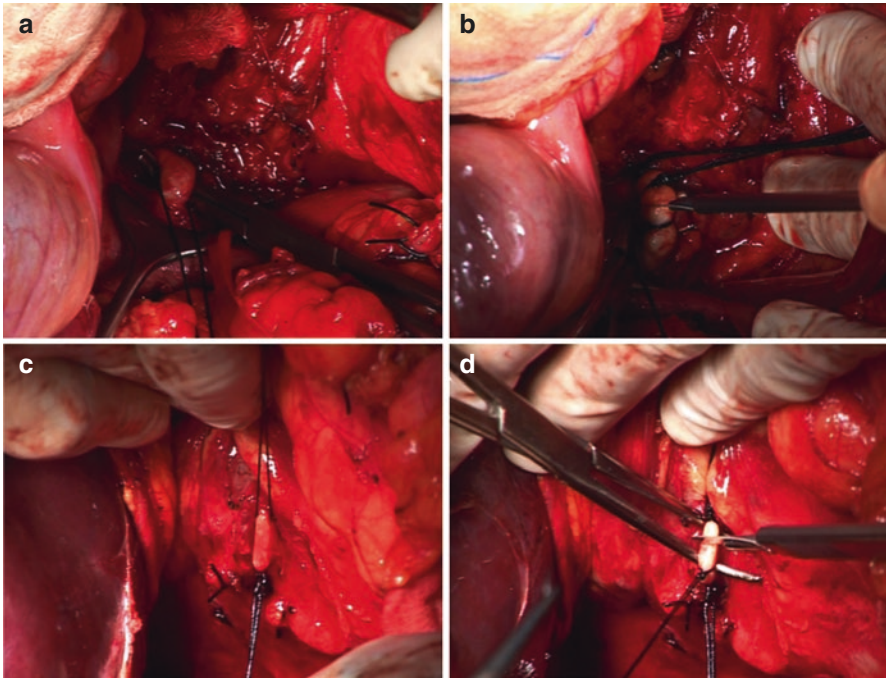
*Control of the renal artery.* Access to the main renal artery can be achieved through either an anterior or posterior approach. The anterior approach requires the full mobilization of the peritoneal structures to enter the retroperitoneum, while the posterior approach uses en bloc mobilization of the kidney with the peritoneal



**Fig. 5.5** The triradiate Chevron incision combines the advantages of midline and subcostal approaches without increasing the rate of incision-related complications. This incision may represent an excellent alternative for the more complex cases (a). The choice of self-retaining retractor should be based on the type of incision used. In the event that a triradiate Chevron incision is used, a retractor designed for liver surgery is preferable (e.g., Rochard retractor). Liver retractors have the advantage of moving the costal margins toward the axillae, which flattens the diaphragmatic domes, thereby increasing exposure in areas that are difficult to access such as the upper abdominal quadrants (b)

structures lying above it (Cattell–Braasch and Mattox maneuvers) [69], thus creating a plane of cleavage anterior to the posterior abdominal wall. Each plane of dissection has specific advantages that may facilitate arterial control in particular situations. The posterior approach requires the division of all adhesions between Gerota's fascia and the posterior abdominal wall [65]. Although it may seem more tedious to perform, this technique avoids potential engorged vessels in the anterior renal surface, providing quick and safe access to the main renal artery near its take-off in the aorta. This type of access may represent the best option in cases of marked venous collateral circulation or when access to the anterior aspect of the renal hilum is difficult (e.g., hampered by bulky lymphadenopathy) (Fig. 5.6).

Conversely, the anterior approach [70] may be the best option when the renal mass cannot be mobilized (e.g., extremely large size). This approach is perhaps faster and easier for the surgeon, providing vascular control of both renal hilar structures simultaneously. However, it requires a relatively free anterior plane and extensive dissection in the proximity of the great retroperitoneal vessels, which may more readily result in injury.



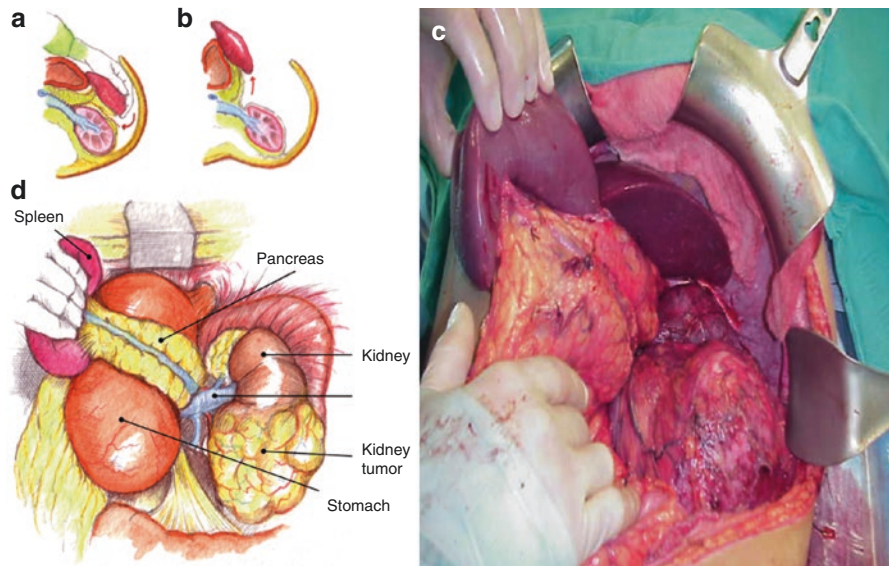
**Fig. 5.6** Control of the renal artery. Access to the main renal artery can be achieved through either an anterior or posterior approach. The anterior approach (**a** and **b**) requires the full mobilization of the peritoneal structures to enter the retroperitoneum, while the posterior approach (**c** and **d**) uses en bloc mobilization of the kidney with the peritoneal structures lying above it (Cattell–Braasch and Mattox maneuvers), thus creating a plane of cleavage anterior to the posterior abdominal wall

*Exposure.* Anterior access to the kidney is achieved through mobilization of the ipsilateral colon segment. A peritoneal incision on the avascular line of Toldt is mandatory to gain access. Medial colon rotation progressively exposes the anterior surface of Gerota's fascia. The Kocher maneuver and liver mobilization [69] complete the right renal exposure, while the dissection of the visceral complex formed by the stomach, spleen, and pancreas allows full inspection of the left anterior renal plane [71] (Fig. 5.7).

*Handling of IVC.* Management of the obstructed IVC involves surgical maneuvers to gain vascular control at three different levels: (i) infrahepatic/renal, (ii) retrohepatic/suprahepatic/infradiaphragmatic, and (iii) supradiaphragmatic [67, 72].

*Infrahepatic IVC segment and renal veins:* Every vestige of lymphatic tissue must be cleared from the anterior aspect of the infrahepatic IVC segment. Both renal veins should be encircled and clamped before opening the IVC. The posterior surface of the IVC needs to be detached from the posterior abdominal wall by ligating and dividing all of the lumbar veins found at this level, thus gaining complete circumferential control. This step should be performed with great care, given that lumbar venous vessels may be engorged in response to IVC occlusion and uncontrolled bleeding at this level can be extremely dangerous.

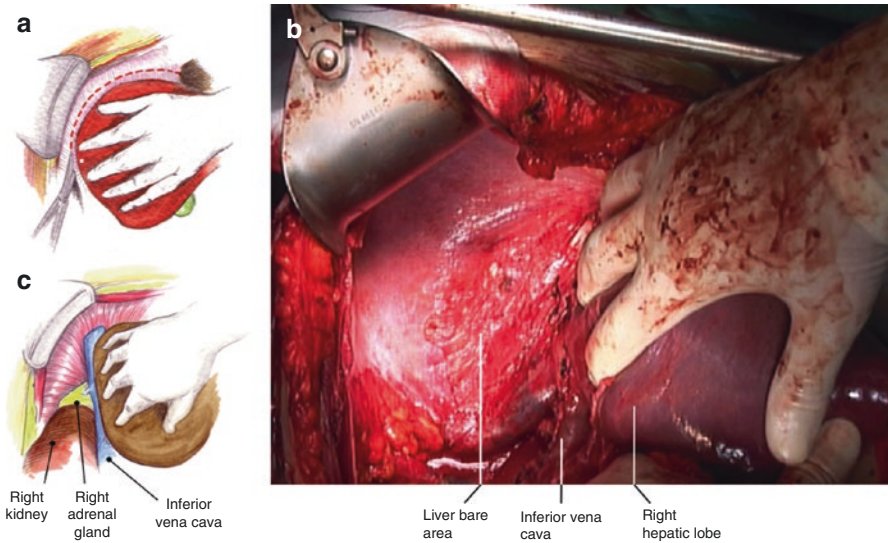




**Fig. 5.7** Mobilization of the left upper abdominal quadrant. The dissection of the visceral complex formed by the stomach, spleen, and pancreas allows full inspection of the left anterior renal plane. Exposure of the left kidney begins by mobilization of the descending colon. The spleen is dissected off the diaphragm and mobilized en bloc with the pancreas toward the midline (a–c). This exposes the entire upper retroperitoneal space from the diaphragm to the inferior border of the kidney (d)

Retrohepatic/suprahepatic infradiaphragmatic IVC segment: Exposure of this segment requires liver mobilization. The level reached by tumor thrombus inside the IVC determines the extent of liver dissection. For example, level II tumor thrombi may require only a classical mobilization of the right hepatic lobe (Langenbuch maneuver) (Fig. 5.8), whereas more proximal tumor thrombus levels (levels IIIa–IIIc) require full liver mobilization, enabling total vascular control on the abdominal segments of IVC behind and above the liver (“piggyback” liver dissection) (Fig. 5.9) [69]. Classical mobilization of the right hepatic lobe involves division of the right triangular and coronary ligaments [73]. This allows a gradual rotation of the right hepatic lobe toward the midline and allows access to the right lateral surface of the IVC, thus completely exposing the right renal upper pole and the ipsilateral adrenal gland and vein. However, this maneuver may be insufficient if there is a need for circumferential control on the IVC and CPB is not planned.

In 1989, Tzakis et al. [74] described the so-called piggyback liver transplantation technique, which is based on a tangential clamping of IVC at the level of the MHVs, avoiding complete caval occlusion during the anhepatic phase of the procedure. With this technique, the liver is fully mobilized by dividing all of its attachments (i.e., complete posterior ligament detachment and division of the short hepatic veins between the right and caudate lobes of the liver and the anterior caval aspect) until it lies fixed to the IVC only by the MHVs. It then becomes possible to freely move



**Fig. 5.8** Liver mobilization (Langenbuch maneuver). Classical mobilization of the right hepatic lobe involves division of the right triangular and coronary ligaments (a). This allows a gradual rotation of the right hepatic lobe toward the midline (b) and allows access to the right lateral surface of the IVC, thus completely exposing the right renal upper pole and the ipsilateral adrenal gland and vein (c)

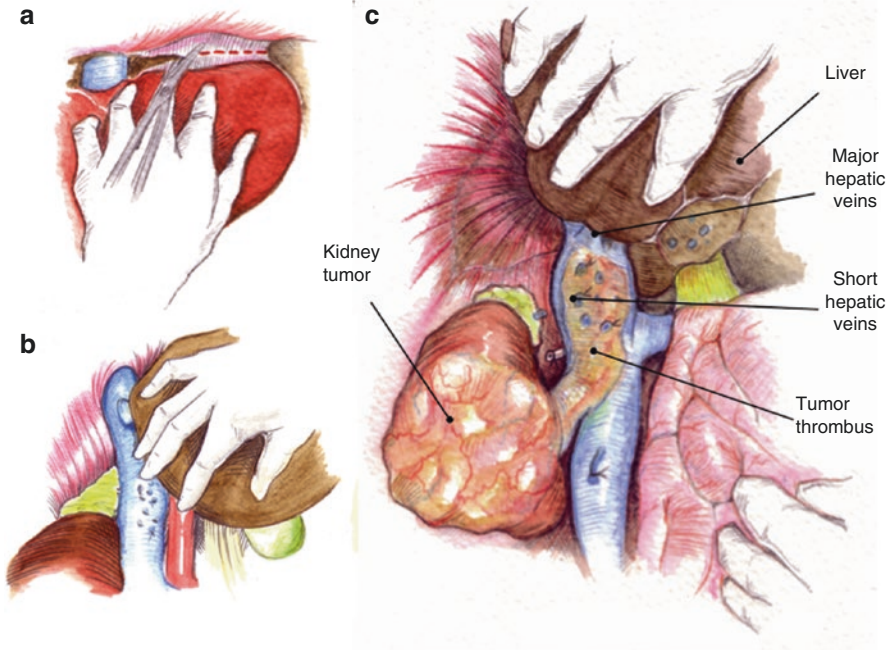
the complete liver, thus facilitating full circumferential control of the entire retrohepatic and suprahepatic IVC segments [69].

Supradiaphragmatic IVC segment and right cardiac chambers: Adequate vascular control of the right heart chambers and supradiaphragmatic segment of the IVC is perhaps more controversial, since access can be gained from the abdomen or the thorax. Although it is clear that a large mass inside the right atrium almost invariably requires a thoracic approach and extracorporeal circulation, vascular control required in levels IIIb–d may vary according to the preference of the surgical team.

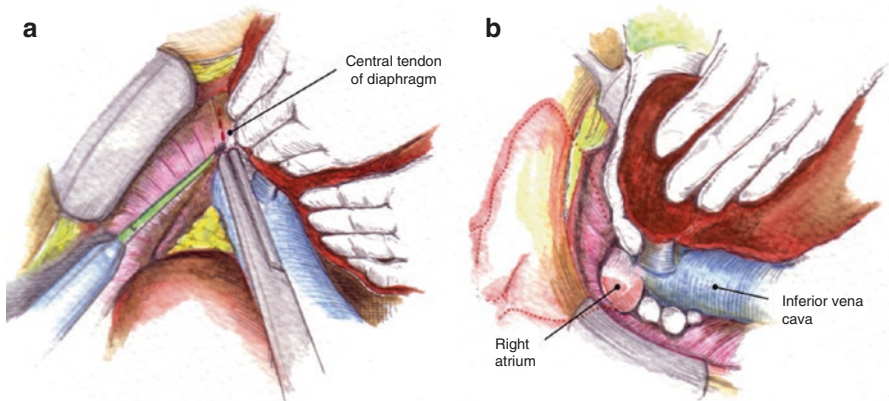
Diaphragmatic caval release, by opening the central tendon of the diaphragm and encircling the IVC, allows access to the intrathoracic IVC segment from the abdominal field [69, 72]. Thereafter, the pericardium can be opened, and the right atrium can be gently pulled through the diaphragm, to be controlled inside the abdomen. This maneuver permits the resection of level III–IV tumor thrombi without the need for extracorporeal circulation [69, 72] (Fig. 5.10).

Cardiac control can also be achieved, with good results, through minimally invasive approaches if the intent is only to place the patient on CPB [75]. However, this access may be severely limited if a clear view of the right chambers of the heart is necessary. In these cases, it may be preferable to use a wider thoracic approach by means of a midline sternotomy or thoracoabdominal access [5] (Fig. 5.11).

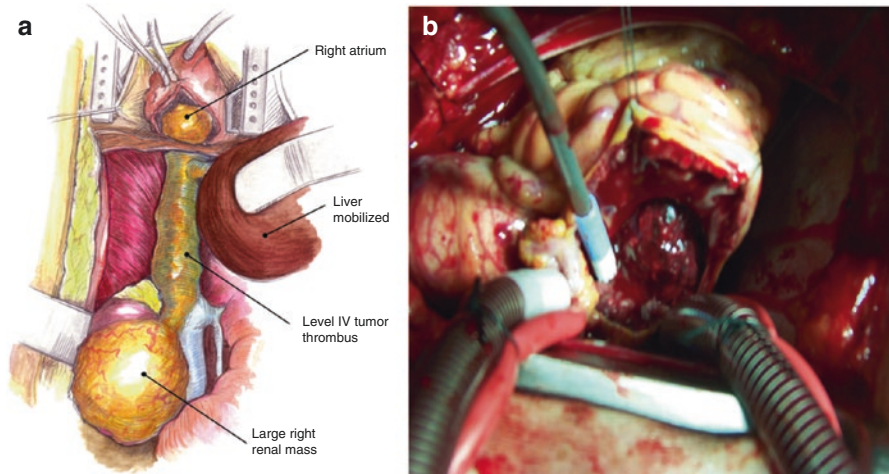
*Thrombectomy.* The extension of caval incision for tumor thrombus withdrawal should be established according to the thrombus level inside the IVC [76, 77].



**Fig. 5.9** “Piggyback” liver mobilization. With this technique, the liver is fully mobilized by dividing all of its attachments (i.e., complete posterior ligament detachment and division of the short hepatic veins between the right and caudate lobes of the liver and the anterior caval aspect) (a and b) until it lies fixed to the IVC only by the MHVs (c). It then becomes possible to freely move the complete liver, thus facilitating full circumferential control of the entire retrohepatic and suprahepatic IVC segments



**Fig. 5.10** Atrial abdominalization. Opening the central tendon of the diaphragm and encircling the IVC allow access to the intrathoracic IVC segment from the abdominal field (a). Thereafter, the pericardium can be opened, and the right atrium can be gently pulled through the diaphragm, to be controlled inside the abdomen (b). This maneuver permits the resection of level III–IV tumor thrombi without the need for extracorporeal circulation

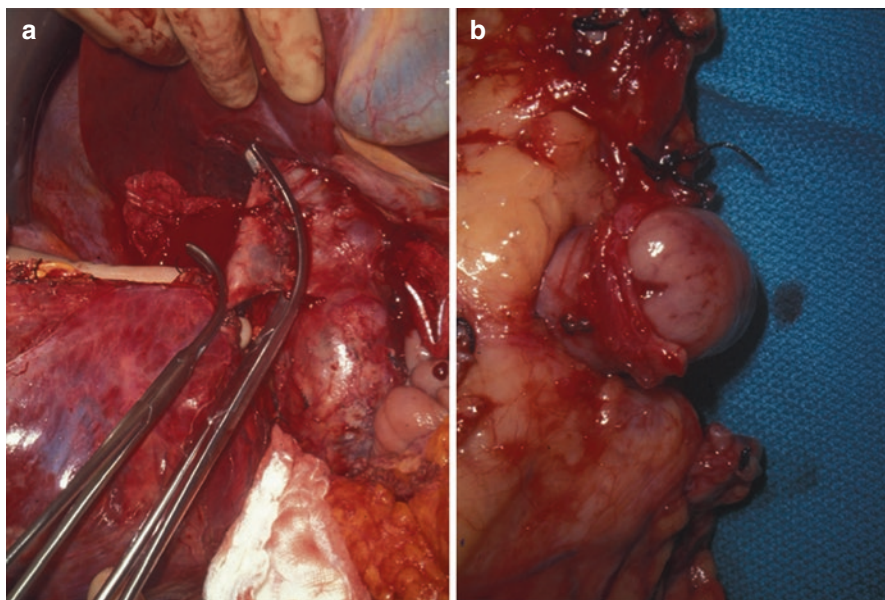


**Fig. 5.11** Cardiopulmonary bypass through midline sternotomy. Although cardiac control can be achieved with good results through minimally invasive approaches if the intent is only to place the patient on extracorporeal circulation, this access may be severely limited if a clear view of the right chambers of the heart is necessary. In these cases, it may be preferable to use a wider thoracic approach by means of a *midline* sternotomy (**a** and **b**)

Level I tumor thrombi are usually “floating” in the lumen of the IVC, which is commonly partially obstructed. They can be easily “milked” back into the renal vein. Thereafter, a side bite of the IVC with an appropriate vascular clamp permits complete thrombus control, preserving blood flow through the IVC and preventing the embolization of eventual dislodged thrombus fragments to the pulmonary circulation. The IVC is then incised, permitting the complete removal of the thrombus under direct vision. After radical nephrectomy and thrombectomy are complete, the venotomy can be sutured closed in the usual manner (commonly with a double row of continuous 4-0 polypropylene suture) (Fig. 5.12).

In level II tumor thrombi, vascular control is ensured by placing clamps or Rummel tourniquets sequentially on the infrarenal vena cava, contralateral renal vein, and suprarenal vena cava above the upper thrombus limit. Likewise, the thrombus is dissected and removed with the entire renal ostium. Once the lumen of the cava is flushed with heparin solution and the absence of residual tumor is ascertained, the cavotomy is sutured closed and the clamps are removed in a cephalad direction. To preserve renal function, it is advisable to permit venous flow return from the contralateral renal vein and lower IVC. Many times, the shape and position of the thrombus inside the IVC allow partial occlusion with a long curved vascular clamp. In some cases, the tumor configuration permits the placement of the vascular clamp in an oblique fashion so that the contralateral vein lies above the clamp and venous drainage into the proximal IVC can be maintained. However, one clamp may be insufficient to encircle the thrombus in the case of a large irregular configuration, and an additional clamp will be needed for complete IVC occlusion.





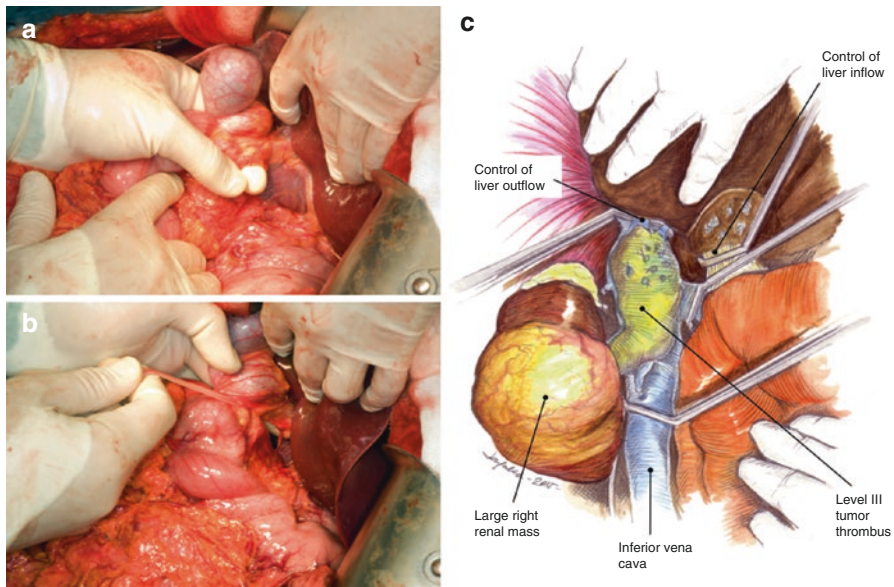
**Fig. 5.12** Level I tumor thrombi are usually “floating” in the lumen of the IVC, which is commonly partially obstructed. They can be easily “milked” back into the renal vein. Thereafter, a side bite of the IVC with an appropriate vascular clamp permits complete thrombus control, preserving blood flow though the IVC and preventing the embolization of eventual dislodged thrombus fragments to the pulmonary circulation (a). The IVC is then incised, permitting the complete removal of the thrombus under direct vision (b)

The caval approach to level III tumor thrombi requires accurate surgical planning. Sequential clamping of the IVC in these cases will be established according to the spatial relationship between the cranial thrombus limit and MHVs ostia if an exclusive transabdominal approach is planned. However, in addition to the vascular dissection necessary to approach these cases in a purely transabdominal fashion, it is essential that the patient can tolerate complete IVC occlusion at a proximal level. Caval occlusion at the suprahepatic or intrapericardial segments can compromise venous return to the heart in cases of partially occluding tumor thrombi, which results in decreased cardiac output, hemodynamic instability, and hypoperfusion. A trial of cross-clamping may be attempted to see how well the patient tolerates this maneuver, and in the case of poor tolerability, a rapid infuser may be used to increase cardiac preload. Conversely, extracorporeal circulation (by means of veno-venous or cardiopulmonary bypass) may be established.

Level IIIa tumor thrombi represent the easiest surgical scenario among level III cases. The proximal clamp should be placed below the MHV ostia, and thus, the natural venous bypass through the liver (and consequently the cardiac preload) is not altered. Level IIIb–IV thrombi may be causing occlusion of hepatic venous drainage (Budd–Chiari syndrome). In these cases, given the hepatic dysfunction and subsequent poorly functioning coagulation, it is advisable to establish

extracorporeal circulation (although bleeding can be moved to the immediate postoperative period when using CPB, given that full-dose anticoagulant therapy is needed during the procedure). Even so, levels IIIb–IV require full inspection of the MHV orifices to reestablish the natural venous bypass through the liver in the event that it was blocked. Hepatic vascular exclusion (HVE) may facilitate thrombus excision in these cases, since potential bleeding from the liver is prevented [67]. A small orifice practiced in the lesser omentum permits control of the vascular inflow to the liver (Pringle maneuver), while a vascular clamp applied at the level of the MHVs (“piggyback” liver dissection is required) controls the liver venous outflow (Fig. 5.13).

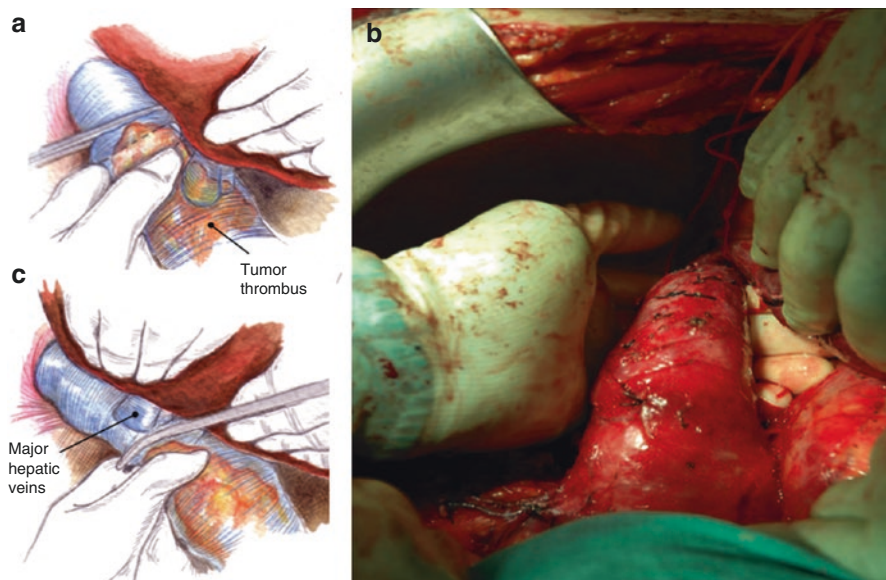
During the HVE phase, there are hemodynamic issues that affect morbidity, mortality, and the entire postoperative course. Venovenous bypass (VVB) was originally described to respond to the interruption of blood flow back to the heart, which in turn is associated with up to a 50% decrease in cardiac output and arterial pressure. However, there have been complications reported with its use, and some hemodynamic alterations cannot be completely avoided. Experience in liver surgery has demonstrated that the hemodynamic changes observed during HVE are promptly reversed after hepatic reperfusion, with renal function remaining stable, and the requirement for blood transfusion is comparable to procedures with VVB. As such, two primary conclusions can be drawn from this experience. First, the theoretical benefits of VVB on renal function during HVE are of little clinical relevance. Second,



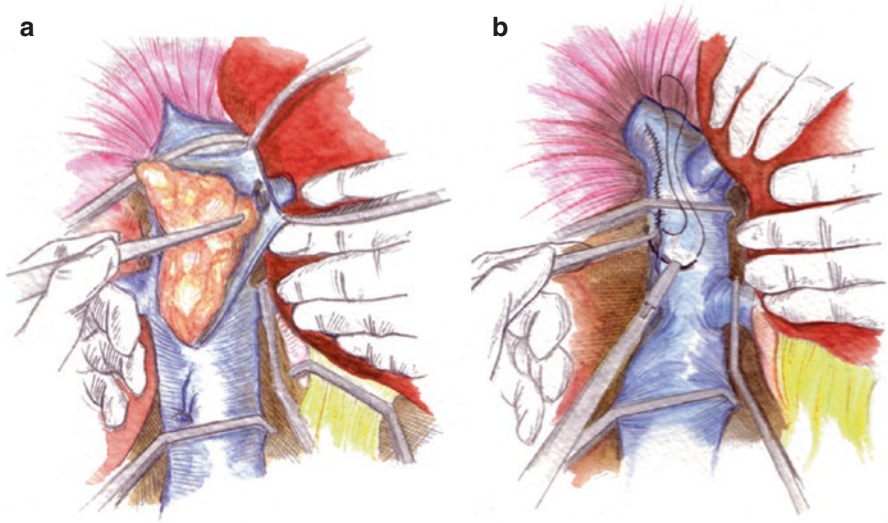
**Fig. 5.13** Hepatic vascular exclusion (HVE). A small orifice practiced in the lesser omentum permits control of the vascular inflow to the liver (Pringle maneuver) (a and b), while a vascular clamp applied at the level of the MHVs (“piggyback” liver dissection is required) controls the liver venous outflow (c)

perioperative blood loss and transfusion requirements are similar in patients with or without VVB, indicating that there is no clear advantage to its routine use [61].

In cases of level IIIb–IIIc tumor thrombi and minor intra-atrial involvement, the cranial thrombus limit may be “milked” down below the MHVs to preserve the venous liver bypass (Fig. 5.14). TEE permits optimal control over the thrombus cranial end during this maneuver. However, in many other cases, the thrombus cannot be milked down below this level, and a two-step cavotomy becomes the best option. This two-step process requires temporary HVE. When complete IVC control is achieved, the first step is commenced. The IVC wall is opened to a level below the MHVs, and the IVC lumen is flushed with heparin and completely cleared of thrombus fragments up to this level. The proximal clamp is then repositioned below the MHVs, and the IVC wall is closed with a double 4-0 running polypropylene suture. Thereafter, the Pringle maneuver is released, and natural liver bypass is restored. In a second step, the cavotomy is continued downward to the renal veins, and every vestige of neoplastic tissue is withdrawn from the IVC lumen. Commonly, the caval wall containing the renal vein ostium with tumor involvement is also excised to ensure a safe resection margin (Fig. 5.15).



**Fig. 5.14** “Milking maneuver.” In cases of level IIIb–IIIc tumor thrombi and minor intra-atrial involvement, the cranial thrombus limit may be “milked” down below the MHVs to preserve the venous liver bypass. Initially the cranial end of the tumor thrombus is placed above the MHV ostia. The vascular clamp is located above the thrombus (a). Complete circumferential control of the inferior vena cava (b) permits a gently pull down of the cranial end of the thrombus to be relocated below the MHV ostia (c). Accordingly, the clamp is repositioned below the MHVs and the natural bypass through the liver is reestablished. TEE permits optimal control over the thrombus cranial end during this maneuver



**Fig. 5.15** In cases where the tumor thrombus cannot be milked down below the level of MHV ostia, a two-step cavotomy may represent the best option. This two-step process requires temporary HVE. When complete IVC control is achieved, the first step is commenced. The IVC wall is opened to a level below the MHVs, and the IVC lumen is flushed with heparin and completely cleared of thrombus fragments up to this level (a). The proximal clamp is then repositioned below the MHVs, and the IVC wall is closed with a double 4-0 running polypropylene suture. Thereafter, the Pringle maneuver is released, and natural liver bypass is restored. In a second step, the cavotomy is continued downward to the renal veins, and every vestige of neoplastic tissue is withdrawn from the IVC lumen (b)

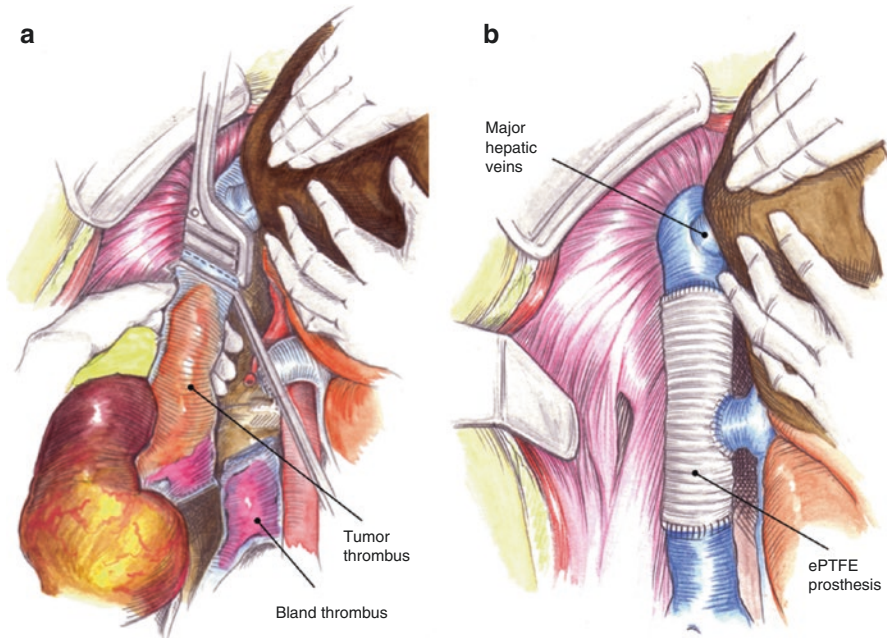
For tumors that greatly extend into the right atrium (e.g., bulky fixed intra-atrial thrombus), the use of CPB (with or without circulatory arrest) is recommended. This technique provides continuous venous return and arterial output during IVC occlusion, thus ensuring relative technical ease by providing a bloodless operative field [78–80]. However, the risks with its use are substantial [81]. Hypothermic cardioplegia, mild hypothermia with intermittent cross-clamping of the abdominal aorta, and the use of antegrade cerebral and cardiac perfusion during cardiac arrest confirm recent efforts to reduce these associated complications [82–86].

## 5.10 Adjunct Procedures: IVC Resection and Reconstruction

*Inferior vena cava resection.* Clinical conditions requiring IVC resection are rare and include (i) complete obstruction of the caval lumen, (ii) densely adherent intra-caval tumor, (iii) encasement of the great vessels by bulky disease, and (iv) direct caval wall invasion [87].

Masses involving less than half of the IVC may be managed with tangential resection.





**Fig. 5.16** IVC resection (stapling) and reconstruction with ePTFE prosthesis. IVC is stapled at a level below the MHV ostia (a). After caval resection an ePTFE prosthesis has been placed bridging the caval gap. The left renal vein has been also joined to the prosthesis (b)

Conversely, IVC interruption with circumferential resection either by ligation, stapling, or oversewing may be necessary in the following scenarios:

- (i) lesions involving more than half the circumference of the IVC,
- (ii) the presence of complete chronic obstruction in the absence of clinical symptoms suggestive of venous stasis,
- (iii) high risk of postoperative pulmonary embolism due to the presence of unresectable bland thrombus, and
- (iv) successful thrombectomy attempt complicated by vascular intima layer damage, resulting in increased risk of new clot development [87] (Fig. 5.16).

*Inferior vena cava reconstruction.* IVC interruption can be accomplished below the level of the MHVs with no major consequences if an adequate collateral venous network is fully established. Therefore, IVC resection without reconstruction is feasible in cases of complete IVC obstruction, extensive bland thrombus without a clear depicted limit, and no preoperative evidence of lower extremity edema (LEE). In contrast, acute resection without preexisting chronic obstruction is poorly tolerated in the absence of sufficient collateral circulation.

As such, IVC reconstruction should be considered in patients with preoperative LEE, inadequate collateral vessels, or intraoperative disruption of preexisting collateral circulation [87]. However, the decision to reconstruct the IVC must be

balanced with the risk of complications such as graft occlusion/thrombosis, infection, or entero-caval fistula formation.

While a small cavotomy may be closed primarily, extensive caval incisions may result in luminal narrowing. In this setting, an autologous patch can be utilized to bridge the gap, thus minimizing the risk of venous thrombosis formation. Interposition grafting is typically necessary in the absence of adequate collateral circulation when en bloc IVC resection is planned. Extended polytetrafluoroethylene (ePTFE) is the preferred synthetic material when replacement is considered, as it has low thrombogenic potential and a high reported patency rate [87] (Fig. 5.16).

---

## 5.11 Postoperative Complications

In agreement to what happen in other major interventions in the abdomen, technique-related complications, wound infections, and postoperative bleeding produce nearly one-half of all postsurgical adverse events after radical nephrectomy and tumor thrombectomy [88]. Nevertheless, this procedure is technically demanding and poses a surgical challenge due to its potential for causing life-threatening complications, including massive hemorrhage, accidental injuries, and pulmonary embolism (PE).

*Hemorrhage.* Uncontrollable hemorrhage leading to exsanguination has been reported in up to 7.5% of cases [89]. Potential for intraoperative bleeding depends mainly on the anatomic disposition of the surgical field. The intravascular burden of disease (i.e., level and the degree of occlusion), the presence and extent of collateral circulation in response to obstruction, and the involvement of surrounding structures may increase the difficulty of the surgical procedure and, thus, the possibility for massive hemorrhage. As a general rule, the extent of dissection is predicated on the cephalad level of tumor thrombus, dictating the number and type of surgical maneuvers used for its successful removal. The successive addition of surgical steps to handle increasing thrombus height also increases the risk of complications. For example, in a large series conducted by Blute et al. [28], it was noted that higher thrombus levels were associated with an increase in surgical complication rates (i.e., 8.6, 15.2, 14.1, 17.9, and 30.0%, respectively, for levels 0 to IV).

Thrombus above the diaphragm may necessitate opening the right atrium to assure complete clearance [54]. Although cardiotomy under extracorporeal circulation has been traditionally axiomatic for all instances of supradiaphragmatic venous extension [28], this maneuver has been shown correlated with significant morbidity [84]. In a recent series by Lubahn et al. [90], it was shown that tumors requiring cardiovascular procedures were associated with an increased risk of perioperative complications, including hemorrhage.

Determinants of collateral circulation are the location of the obstructed venous segment, the length and degree of obstruction, and the number of veins involved in the process [87]. These elements, taken separately or in combination, determine venous redistribution to the heart. In general, more proximal and longer occlusions condition wider distribution of collateral vessels and thus a greater risk of bleeding.

In addition, complete IVC obstruction in intimate contact or invading the venous wall may necessitate segmental caval resection for thrombus complete removal. Under these circumstances, collateral circulation is commonly present, making IVC reconstruction rarely necessary. However, in cases of insufficient collateral circulation (i.e., presence of LEE or risk of venous return impairment), a vascular prosthesis may be needed to ensure adequate venous drainage.

*Accidental injuries.* Adjacent organ resection has been also associated with non-hemorrhagic complications including injuries to adjacent structures. Vascular and visceral injuries can also be life-threatening if they go unrecognized. Involvement of surrounding structures by tumor makes excision longer and more tedious. In a recent series by Zisman et al., adjacent organ resection due to locally advanced tumor and regional lymph node involvement was highlighted as an independent predictor of vascular injury and bleeding, thus requiring transfusion. By contrast, the rate of surgical complications was not higher in the presence of locally advanced or metastatic disease, except for cases in which metastasectomy was attempted [13].

*Pulmonary embolism.* Probably, the most feared intraoperative complication in cases of RCC invading the IVC is the embolization of dislodged thrombus fragments to pulmonary circulation secondary to IVC surgical manipulation. This complication has been reported infrequently (i.e., 1.5–3.4% of cases), although when it occurs, mortality has been shown to be extremely high, reaching 60–75% of such cases [48]. Higher anatomic thrombus level and association with bland thrombus have been outlined as major factors, increasing the rate of PE [49, 50]. Meticulous attention to surgical technique, specifically avoiding excessive manipulation of the renal vein/IVC during dissection, is paramount to preventing the thrombus from dislodging.

*Long-term complications.* Late complications (i.e., complications occurred >30 days) after the intervention have consisted primarily of chronic kidney disease and proteinuria [8]. These complications have been shown more frequently in patients with higher tumor thrombi. However, this association did not reach statistical significance.

*Perioperative mortality.* The risk of perioperative mortality for patients undergoing nephrectomy with tumor thrombectomy has also been directly associated with tumor thrombus anatomic level [8]. Indeed, in-hospital and perioperative mortality for patients with level IV thrombi reached 22% in a recent multi-institutional series [48]. However, with improvements in preoperative care (diagnosis imaging, surgical technique, and postoperative critical care), the overall rate of perioperative mortality for these patients has been reported significantly decreased over time from 3.9% among patients treated in the period 1970–1990 to 1.5% for those treated from 1991–2005 [8, 91].

---

## 5.12 Oncologic Outcomes After Radical Nephrectomy and Tumor Thrombectomy

Reporting the oncologic outcomes following radical nephrectomy and tumor thrombectomy is crucial to confirm if aggressive surgical resection may afford durable cancer control in this setting. Renal tumors with isolated venous invasion in the



absence of metastases have been shown to have an acceptable 5-year disease-specific survival (DSS) after the intervention, presenting median survival rates varying between 38 and 116 months, compared with 11–20 months in those with metastatic disease. At presentation, the overall 5-year DSS reported in different studies is 40% to 65% for patients with nonmetastatic disease versus 6% to 28% for those with metastatic disease [10, 12, 17, 31, 92]. Data on inherent tumor biology or patient status at presentation are not considered in many of these studies; thus, a comparison between survival rates among the different studies is difficult, explaining its wide range. In addition, this difference in survival rate outcomes also may be related to the choice of systemic treatment or the performance of aggressive metastasectomy.

On the contrary, the prognosis for patients with metastatic disease at presentation is poor, with a mean survival of 4–6 months and a 5-year survival of 0% to 10%. This fact should be considered important because 29% to 55% of patients with IVC tumor thrombus present with concomitant distant disease [10, 92].

Taken together, the available results show that cytoreductive nephrectomy surgery should be performed unless contraindicated by poor performance status, even in the presence of metastases, and especially if multimodal strategies are considered, although no data regarding the survival in the presence of IVC tumor thrombus is available in the literature to date. Thus, it is believed that surgery would have a role in the management of metastatic RCC because these studies have strengthened the argument for resecting locally advanced RCC in carefully selected patients, even in the presence of metastases.

Hence, according to prior literature, patients with RCC and venous tumor thrombus should not be approached with “therapeutic nihilism” or the belief that the presence of a tumor thrombus inside the caval lumen confers an incurable status. As a matter of fact, surgical resection still represents the mainstay of therapy for RCC with caval involvement. Moreover, a recent population-based analysis indicated that the median survival for patients with RCC and tumor thrombus was 5 months, with a 1-year cancer-specific survival of only 29%, in the absence of specific treatment [93, 96]. While a complete review of all published data on this subject is out of the scope of this chapter, the results of a number of recent series on this topic are summarized in Table 5.2.

## Key Points

### Essential points of the chapter

- Despite a stage migration toward smaller renal masses in kidney cancer with widespread use of abdominal imaging, tumors with associated tumor thrombus are and will be encountered as the result of the inherent biological behavior of RCC.
- The mainstay of treatment for RCC with intravenous tumor thrombus remains surgical intervention with resection of the entire tumor burden.
- Durable survival outcomes can be attained in patients with nonmetastatic disease. In patients with metastasis, surgery remains the only hope for a potential cure. Adequate outcomes regarding palliation have been obtained with this approach.

**Table 5.2** Outcomes of radical nephrectomy and tumor thrombectomy for patients with RCC and venous tumor thrombus

Reference	No. of patients	% 5-year DSS	Median follow-up		
		All	Nonmetastatic	Metastatic	
Haferkamp et al. [17]	111 <sup>a</sup>	N/A	46	6.5	16
Karnes and Blute [92]	614	N/A	55	13	N/A
Klatte et al. [10]	321	36	65	19	25
Lambert et al. [11]	118	42	61	N/A	18
Wagner et al. [31]	1192	N/A	N/A	N/A	61
Sweeney et al. [12]	96	35	40	28	25
Boorjian et al. [8]	659	N/A	59	N/A	N/A
Kaag et al. [9]	78	48	58	N/A	51
Martínez-Salamanca et al. [7]	1048	N/A	50	N/A	25
Ciancio et al. [94]	87	46	55		22
Goetzl et al. [95]	33	4	N/A	N/A	6

N/A Not available

<sup>a</sup>Including 28 nonsurgical cases

- Accurate preoperative imaging with an updated high-quality MRI is crucial for preoperative planning and decision-making.
- Operative management is dictated mainly on the basis of tumor thrombus anatomic level and degree of IVC occlusion (extent of tumor thrombus) and the presence or absence of associated bland thrombus.
- Perioperative mortality rates have declined as surgical techniques and perioperative care have been refined.
- The role of preoperative systemic therapy in these cases continues to be evaluated but to date has not been largely effective in altering the extent of thrombus. Additional efforts to develop novel agents for treatment and to enhance perioperative care will facilitate continued improvements in safety and oncologic efficacy.

## Key References

### Essential references of the chapter

1. Pouliot F et al (2010) Contemporary management of renal tumors with venous tumor thrombus. *J Urol* 184: 833–841
2. Kirkali Z, van Poppel H (2007) A critical analysis of surgery for kidney cancer with vena cava invasion. *Eur Urol* 52: 658–662
3. González J, Andrés G, Martínez-Salamanca JI, Ciancio G (2013) Improving surgical outcomes in renal cell carcinoma involving the inferior vena cava. *Expert Rev Anticancer Ther* 13: 1373–1387
4. Ciancio G, Gonzalez J, Shirodkar SP, Angulo JC, Soloway MS (2011) Liver transplantation techniques for the surgical management of renal cell carcinoma

- with tumor thrombus in the inferior vena cava: step-by-step description. *Eur Urol* 59: 401–406
5. González J, Shirodkar SP, Ciancio G (2011) Multivisceral organ procurement for transplantation derived mobilization manoeuvres: very helpful auxiliary techniques in the excision of large retroperitoneal masses. *Arch Esp Urol* 64: 257–266
  6. Ciancio G, Vaidya A, Shirodkar S, Manoharan M, Hakky T, Soloway M (2009) En bloc mobilization of the pancreas and spleen to facilitate resection of large tumors, primarily renal and adrenal, in the left upper quadrant of the abdomen: techniques derived from multivisceral transplantation. *Eur Urol* 55: 1106–1111
  7. Gorin MA, González J, Garcia-Roig M, Ciancio G (2014) Transplantation techniques for the resection of renal cell carcinoma with tumor thrombus: a technical description and review. *Urol Oncol* 32: 34.e19–34.e26
  8. González J, Ciancio G (2014) Caval thrombus in conjunction with renal tumors: indication for surgery and technical details. *Curr Urol Rep* 15: 451–459
  9. González J, Gorin MA, Garcia-Roig M, Ciancio G (2014) Inferior vena cava resection and reconstruction: technical considerations in the surgical management of renal cell carcinoma with tumor thrombus. *Urol Oncol* 32: 34.e.19–34.e.26
  10. Ayyathurai R, Garcia-Roig M, Gorin MA et al (2012) Bland thrombus association with tumor thrombus: analysis of surgical significance and role of inferior vena cava interruption. *BJU Int* 110: E449–E455

---

## References

1. Gupta K, Miller JD, Li JZ et al (2008) Epidemiologic and socioeconomic burden of metastatic renal cell carcinoma (mRCC): a literature review. *Cancer Treat Rev* 34:193–205
2. Kim HL, Zisman A, Han KR et al (2004) Prognostic significance of venous thrombus in renal cell carcinoma. Are renal vein and inferior vena cava different? *J Urol* 171:588–591
3. Siegel RL, Miller KD, Jemal A (2015) Cancer statistics, 2015. *CA Cancer J Clin* 65:5–29
4. Pouliot F et al (2010) Contemporary management of renal tumors with venous tumor thrombus. *J Urol* 184:833–841
5. Boorjian SA, Blute ML (2009) Surgery for vena caval tumor extension in renal cancer. *Curr Opin Urol* 19:473–477
6. Abreu SC, Gill IS (2003) Renal cell carcinoma: modern surgical approach. *Curr Opin Urol* 13:439–444
7. Martínez-Salamanca JI, Huang WC, Millán I et al (2011) Prognostic impact of the 2009 UICC/AJCC TNM staging system for renal cell carcinoma with venous extension. *Eur Urol* 59:120–127
8. Boorjian SA, Sengupta S, Blute ML (2007) Renal cell carcinoma: vena caval involvement. *BJU Int* 99:1239–1244
9. Kaag MG, Toyen C, Russo P et al (2011) Radical nephrectomy with vena caval thrombectomy: a contemporary experience. *BJU Int* 107:1386–1393
10. Klatte T, Pantuck AJ, Riggs SB et al (2007) Prognostic factors for renal cell carcinoma with tumor thrombus extension. *J Urol* 178:1189–1195

11. Lambert EH, Pierorazio PM, Shabsiqh A et al (2007) Prognostic risk stratification and clinical outcomes in patients undergoing surgical treatment for renal cell carcinoma with vascular tumor thrombus. *Urology* 69:1054–1058
12. Sweeney P, Wood CG, Pisters LL et al (2003) Surgical management of renal cell carcinoma associated with complex inferior vena caval thrombi. *Urol Oncol* 21:327–333
13. Zisman A, Pantuck AJ, Chao DH et al (2002) Renal cell carcinoma with tumor thrombus: is cytoreductive nephrectomy for advance disease associated with an increased complication rate? *J Urol* 168:962–967
14. Ciancio G, Soloway M (2001) Renal cell carcinoma invading the hepatic veins. *Cancer* 92:1836–1842
15. Shirodkar S, Soloway MS, Ciancio G (2011) Budd-Chiari syndrome in urology: impact on nephrectomy for advanced renal cell carcinoma. *Indian J Urol* 27:351–356
16. Parekh DJ, Cookson MS, Chapman W et al (2005) Renal cell carcinoma with renal vein and inferior vena cava involvement: clinicopathological features, surgical techniques and outcomes. *J Urol* 173:1897–1902
17. Rini BI, Campbell SC, Escudier B (2009) Renal cell carcinoma. *Lancet* 373:1119–1132
18. Lam JS, Klatte T, Kim HL et al (2008) Prognostic factors and selection for clinical studies of patients with kidney cancer. *Crit Rev Oncol Hematol* 65:235–262
19. Haferkamp A, Bastian PJ, Jakobi H et al (2007) Renal cell carcinoma with tumor thrombus extension into the vena cava: prospective long-term follow up. *J Urol* 177:1703–1708
20. Ficarra V, Novara G, Iafrate M et al (2007) Proposal for reclassification of the TNM staging system in patients with locally advanced (pT3–4) renal cell carcinoma according to the cancer related outcome. *Eur Urol* 51:722–729
21. Margulis V, Tamboli P, Matin SF et al (2007) Redefining pT3 renal cell carcinoma in the modern era: a proposal for a revision of the TNM primary tumor classification system. *Cancer* 109:2439–2444
22. Hallscheidt PJ, Fink C, Haferkamp A et al (2005) Preoperative staging of renal cell carcinoma with inferior vena cava thrombus using multidetector CT and MRI: prospective study with histopathological correlation. *J Comput Assist Tomogr* 29:64–68
23. Kallman DA, King BF, Hattery RR et al (1992) Renal vein and inferior vena cava tumor thrombus in renal cell carcinoma: CT, US, MRI and venacavography. *J Comput Assist Tomogr* 16:240–247
24. Guzzo TJ, Pierorazio PM, Schaeffer EM et al (2009) The accuracy of multidetector computerized tomography for evaluating tumor thrombus in patients with renal cell carcinoma. *J Urol* 181:486–490
25. Zini L, Destrieux-Garnier L, Leroy X et al (2008) Renal vein ostium wall invasion of renal cell carcinoma with an inferior vena cava thrombus: prediction by renal and vena caval vein diameters and prognostic significance. *J Urol* 179:450–454
26. Thompson RH, Hartmann RP, Lowe VJ, Kawashima A, Leibowich BC (2004) Application of positron emission tomography imaging, intraoperative ultrasound, magnetic resonance imaging and angiography in the evaluation of renal masses. *Curr Urol Rep* 5:30–34
27. Woodruff DY, Van Veldhuizen P, Meuhlebach G et al (2013) The perioperative management of an inferior vena caval tumor thrombus in patients with renal cell carcinoma. *Urol Oncol* 31:517–521
28. Blute ML, Leibovich BC, Lohse CM et al (2004) The Mayo Clinic experience with surgical management, complications and outcome for patients with renal cell carcinoma and venous tumor thrombus. *BJU Int* 94:33–41
29. Thompson RH, Chevillie JC, Lohse CM et al (2005) Reclassification of patients with pT3 and pT4 renal cell carcinoma improves prognostic accuracy. *Cancer* 104:53–60
30. Moch H, Artibani W, Delahunt B et al (2009) Reassessing the current UICC/AJCC TNM staging for renal cell carcinoma. *Eur Urol* 56:636–643
31. Wagner B, Patard JJ, Mejean A et al (2009) Prognostic value of renal vein and inferior vena cava involvement in renal cell carcinoma. *Eur Urol* 55:452–459

32. Sobin LH, Gospodariwicz M, Wittekind C (eds) (2009) TNM classification of malignant tumors. UICC international union against cancer, 7th edn. Wiley Blackwell, pp 255–257
33. Edge SB, Byrd DR, Compton CC et al (2010) AJCC cancer staging manual, 7th edn. Springer, New York, pp 479–489
34. Neves RJ, Zincke H (1987) Surgical treatment of renal cancer with vena cava extension. *Br J Urol* 59:390–395
35. Ciancio G, Vaidya A, Savoie M et al (2002) Management of renal cell carcinoma with level III thrombus in the inferior vena cava. *J Urol* 168:1374–1377
36. Berg AA (1913) Malignant hypernephroma of the kidney, its clinical course and diagnosis, with a description of the author's method of radical operative cure. *Surg Gynecol Obstet* 17:463–471
37. Marshall VF, Middleton RG, Holswade GR et al (1970) Surgery for renal cell carcinoma in the vena cava. *J Urol* 103:414–420
38. Hatakeyama S, Yoneyama T, Hamano I et al (2013) Prognostic benefit of surgical management in renal cell carcinoma patients with thrombus extending to the renal vein and inferior vena cava: 17-year experience at a single center. *BMC Urol* 13:47
39. Skinner DG, Pritchett TR, Lieskovsky G, Boyd SD, Stiles QR (1989) Vena caval involvement by renal cell carcinoma. Surgical resection provides meaningful long-term survival. *Ann Surg* 210:387–394
40. Golimbu M, Joshi P, Sperber A, Tessier A et al (1986) Renal cell carcinoma -survival and prognostic factors. *J Urol* 27:291–301
41. Hatcher PA, Anderson EE, Paulson DF, Carson CC, Robertson JE (1991) Surgical management and prognosis of renal cell carcinoma invading the vena cava. *J Urol* 145:20–24
42. Nesbitt JC, Soltero ER, Dinney CP (1997) Surgical management of renal cell carcinoma with IVC tumor thrombus. *Ann Thorac Surg* 63:1592–1600
43. Sosa RE, Muecke EC, Vaughan ED Jr (1984) Renal carcinoma extending into the inferior vena cava: the prognostic significance of the level of vena caval involvement. *J Urol* 132:1097–1100
44. Kirkali Z, van Poppel H (2007) A critical analysis of surgery for kidney cancer with vena cava invasion. *Eur Urol* 52:658–662
45. Tilki D, Nguyen HG, Dall'era MA et al (2014) Impact of histologic subtype on cancer-specific survival in patients with renal cell carcinoma and tumor thrombus. *Eur Urol* 66:577–583
46. Krajewski KM, Giardino AA, Zukotynski K, Van den Abbeele AD, Pedrosa I (2011) Imaging in renal cell carcinoma. *Hematol Oncol Clin N Am* 25:687–715
47. Kulkarni J, Jadhav Y, Valsangkar RS (2012) IVC thrombectomy in renal cell carcinoma- analysis of outcome data of 100 patients and review of literature. *Indian J Surg Oncol* 3:103–107
48. Shuch B, Larochelle JC, Onyia T et al (2009) Intraoperative thrombus embolization during nephrectomy and tumor thrombectomy: critical analysis of the University of California-Los Angeles experience. *J Urol* 181:492–498, discussion 498-9
49. Abel EJ, Wood CG, Eickstaedt N et al (2013) Preoperative pulmonary embolism does not predict poor postoperative outcomes in patients with renal cell carcinoma and venous thrombus. *J Urol* 190:452–457
50. Ayyathurai R, Garcia-Roig M, Gorin MA et al (2012) Bland thrombus association with tumor thrombus: analysis of surgical significance and role of inferior vena cava interruption. *BJU Int* 110:E449–E455
51. Wotkowicz C, Wszolek MF, Libertino JA et al (2008) Resection of renal tumors invading the vena cava. *Urol Clin North Am* 35:657–671
52. Loffroy R, Rao P, Ota S, Geschwind JF (2010) Renal artery embolisation prior to radical nephrectomy for renal cell carcinoma: when, how and why? *Br J Radiol* 83:630, author reply 631–632
53. Subramanian VS, Stephenson AJ, Goldfarb DA, Fergany AF, Novick AC, Krishnamurthi V (2009) Utility of preoperative renal artery embolization for management of renal tumors with inferior vena caval thrombi. *Urology* 74:154–159
54. Margulis V, Master VA, Cost NG et al (2011) International consultation on urologic diseases and the European association of urology on locally advanced renal cell carcinoma. *Eur Urol* 60:673–683

55. Wellons E, Rosenthal D, Schoborg T, Shuler F, Levitt A (2004) Renal cell carcinoma invading the inferior vena cava: use of a “temporary” vena cava filter to prevent tumor emboli during nephrectomy. *Urology* 63:380–382
56. Kappa SF, Morgan TM, Keegan KA, Cookson MS (2012) Inferior vena cava filter strut perforation discovered during right robotic-assisted laparoscopic partial nephrectomy. *Urology* 79:e49–e50
57. Chandra PA, Nwokolo C, Chuprun D, Chandra AB (2008) Cardiac tamponade caused by fracture and migration of inferior vena cava filter. *South Med J* 101:1163–1164
58. Motzer RJ, Hutson TE, Tomczak P et al (2007) Sunitinib versus interferon alfa in metastatic renal-cell carcinoma. *N Engl J Med* 356:115–124
59. Motzer RJ, Rini BI, Bukowsky RM et al (2006) Sunitinib in patients with patients with metastatic renal cell carcinoma. *JAMA* 295:2516–2524
60. Escudier B, Eisen T, Stadler WM et al (2007) Sorafenib in advanced clear-cell renal cell carcinoma. *New Eng J Med* 356:125–134
61. González J, Andrés G, Martínez-Salamanca JI, Ciancio G (2013) Improving surgical outcomes in renal cell carcinoma involving the inferior vena cava. *Expert Rev Anticancer Ther* 13:1373–1387
62. Abaza R (2011) Robotic surgery and minimally invasive management of renal tumors with vena caval extension. *Curr Op Urol* 21:104–109
63. Skinner E (2012) Surgical approaches for open renal surgery. In: Smith JA, Howards SS, Preminger GM (eds) *Hinman’s atlas of urologic surgery*, 3rd edn. Elsevier-Saunders, Philadelphia, pp 799–832
64. Brown SR, Goodfellow PB (2005) Transverse versus midline incisions for abdominal surgery. *Cochrane Database Syst Rev* 4, CD005199
65. Ciancio G, Vaidya A, Soloway M (2003) Early ligation of the renal artery using the posterior approach: a basic surgical concept reinforced during resection of large hypervascular renal cell carcinoma with or without inferior vena cava thrombus. *BJU Int* 92:488–489
66. Grantcharov TP, Rosenberg J (2001) Vertical compared with transverse incisions in abdominal surgery. *Eur J Surg* 167:260–267
67. Ciancio G, Gonzalez J, Shirodkar SP, Angulo JC, Soloway MS (2011) Liver transplantation techniques for the surgical management of renal cell carcinoma with tumor thrombus in the inferior vena cava: step-by-step description. *Eur Urol* 59:401–406
68. González J, Angulo J, Ciancio G (2011) Surgical management of renal cell cancer with tumor thrombus through an exclusive transabdominal approach. *Arch Esp Urol* 64:297–309
69. González J, Shirodkar SP, Ciancio G (2011) Multivisceral organ procurement for transplantation derived mobilization manoeuvres: very helpful auxiliary techniques in the excision of large retroperitoneal masses. *Arch Esp Urol* 64:257–266
70. Gorin MA, García-Roig M, Shirodkar SP, Gonzalez J, Ciancio G (2012) Modified surgical technique for the management of renal cell carcinoma with level I or II tumor thrombus. *Urology* 79:478–481
71. Ciancio G, Vaidya A, Shirodkar S, Manoharan M, Hakky T, Soloway M (2009) En bloc mobilization of the pancreas and spleen to facilitate resection of large tumors, primarily renal and adrenal, in the left upper quadrant of the abdomen: techniques derived from multivisceral transplantation. *Eur Urol* 55:1106–1111
72. Gorin MA, González J, Garcia-Roig M, Ciancio G (2014) Transplantation techniques for the resection of renal cell carcinoma with tumor thrombus: a technical description and review. *Urol Oncol* 32:34.e19–34.e26
73. Langenbuch C (1894) *Chirurgie der leben und gallenblase*. F. Enke Verlag, Stuttgart
74. Tzakis A, Todo S, Starzl TE (1989) Orthotopic liver transplantation with preservation of the inferior vena cava. *Ann Surg* 210:649–652
75. Wotkowicz C, Libertino JA, Sorcini A, Mourtzinos A (2006) Management of renal cell carcinoma with vena cava and atrial thrombus: minimal access vs median sternotomy with circulatory arrest. *BJU Int* 98:289–297
76. González J (2012) Update in the surgical management of renal cell carcinoma with venous extension. *Curr Urol Rep* 13:8–15

77. González J, Ciancio G (2014) Caval thrombus in conjunction with renal tumors: indication for surgery and technical details. *Curr Urol Rep* 15:451–459
78. Novick AC, Kaye MC, Cosgrove DM et al (1990) Experience with cardiopulmonary bypass and deep hypothermic circulatory arrest in the management of retroperitoneal tumors with large vena caval thrombi. *Ann Surg* 212:472–476
79. Marshall FF, Reitz BA, Diamond DA (1984) A new technique for management of renal cell carcinoma involving the right atrium. Hypothermia and cardiac arrest. *J Urol* 131:103–107
80. Vaislic C, Puel P, Grondin P et al (1986) Cancer of the kidney invading the vena cava and heart. Results after 11 years of treatment. *J Thorac Cardiovasc Surg* 91:604–609
81. Murphy GJ, Angelini GD (2004) Side effects of cardiopulmonary bypass: what is the reality? *J Card Surg* 19:481–483
82. Shirodkar SP, Ciancio G (2010) Cardiopulmonary bypass and renal cell carcinoma with level IV tumour thrombus: can deep hypothermic circulatory arrest limit perioperative mortality? *BJU Int* 106:879
83. Granberg CF, Boorjian SA, Schaff HV et al (2008) Surgical management, complications and outcome of radical nephrectomy with inferior vena cava tumor thrombectomy facilitated by vascular by-pass. *Urology* 72:148–152
84. Chowdhry UK, Mishra AK, Seth A et al (2007) Novel techniques for tumor thrombectomy for renal cell carcinoma with intraatrial tumor thrombus. *Ann Thorac Surg* 83:1731–1736
85. Bertini R, Roscigno M, Lapenna E et al (2008) Radical nephrocapsulectomy and caval thrombectomy with extracorporeal circulation and deep hypothermic circulatory arrest in right anterior minithoracotomy: a minimally invasive approach. *Urology* 71:957–961
86. Mazzola A, Gregorini R, Villani C et al (2007) Cavoatrial tumor thrombectomy with systemic circulatory arrest and antegrade cerebral perfusion. *Ann Thorac Surg* 83:1564–1565
87. González J, Gorin MA, Garcia-Roig M, Ciancio G (2014) Inferior vena cava resection and reconstruction: technical considerations in the surgical management of renal cell carcinoma with renal tumor thrombus. *Urol Oncol* 32:34.e.19–34.e.26
88. Vincent C, Moorthy K, Sarker SK, Chang A, Darzi AW (2004) Systems approaches for surgical quality and safety: from concept to measurement. *Ann Surg* 239:475–482
89. Rigaud J, Hetet JF, Braud G et al (2006) Surgical care, morbidity, mortality and follow-up after nephrectomy for renal cancer with extension of tumor thrombus into the inferior vena cava: retrospective study since 1990s. *Eur Urol* 50:302–310
90. Lubahn JG, Sagalowsky AI, Rosenbaum DH et al (2006) Contemporary techniques and safety of cardiovascular procedures in the surgical management of renal cell carcinoma with tumor thrombus. *J Thorac Cardiovasc Surg* 131:1289–1295
91. Karnes RJ, Blute ML (2008) Surgery insight: management of renal cell carcinoma with associated inferior vena cava thrombus. *Nat Clin Pract Urol* 5:329–339
92. Moinzadeh A, Libertino JA (2004) Prognostic significance of tumor thrombus level in patients with renal cell carcinoma and venous tumor thrombus extension. Is all T3b the same? *J Urol* 171:598–601
93. Reese AC, Whitson JM, Meng MV (2013) Natural history of untreated renal cell carcinoma with venous tumor thrombus. *Urol Oncol* 31:1305–1309
94. Ciancio G, Manoharan M, Katkooi D et al (2010) Long-term survival in patients undergoing radical nephrectomy and inferior vena cava thrombectomy: single-center experience. *Eur Urol* 57:667–672
95. Goetzl MA, Goluboff ET, Murphy AM et al (2004) A contemporary evaluation of cytoreductive nephrectomy with tumor thrombus: morbidity and long-term survival. *Urol Oncol* 22:182–187
96. Shuch B, Crispen PL, Leibovich BC et al (2011) Cardiopulmonary bypass and renal cell carcinoma with level IV tumour thrombus: can deep hypothermic circulatory arrest limit perioperative mortality? *BJU Int* 107:724–728



---

# Surgery of the Inferior Vena Cava Combined to Liver Resection

# 6

Chetana Lim, Chady Salloum, and Daniel Azoulay

---

## 6.1 Introduction

Liver resection is the only potentially curative treatment of most malignant liver tumors. Tremendous progresses have been achieved during the last two decades in the field of liver surgery, including neoadjuvant chemotherapy to decrease tumor burden, two-step hepatectomies, repeat hepatectomies, portal vein embolization to increase the volume of the future remnant liver, low central venous pressure technique, and laparoscopic and robotic surgical approaches.

Liver resection combined to surgery of the inferior vena cava is at the forefront of this evolution. Improved surgical experience with liver transplantation has also allowed the development of this surgery. This surgery is mainly performed for primary and metastatic liver tumors invading the retrohepatic vena cava and/or the hepatic vein confluence into the vena cava but also for primitive malignant lesions of the inferior vena cava such as leiomyosarcoma and renal tumors extended to the inferior vena cava. Vascular involvement of the hepatocaval confluence and the retrohepatic vena cava have long been considered as contraindications to liver resection, due to the risks of gas embolism and massive bleeding. Surgery of the inferior vena cava has become more common in recent decades due to the development of imaging methods specific to the exploration of the inferior vena cava, improving

---

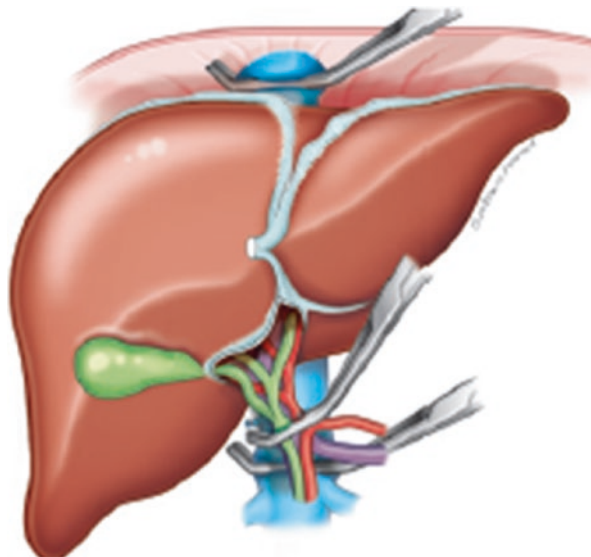
**Electronic supplementary material** The online version of this chapter (doi:[10.1007/978-3-319-25565-1\\_6](https://doi.org/10.1007/978-3-319-25565-1_6)) contains supplementary material, which is available to authorized users.

Figures 6.1; 6.2; 6.3; 6.4; 6.5; 6.10; 6.11; 6.12 published courtesy of Salloum C, Lim C, Compagnon P, Laurent A, Cochenec F, Azoulay D. *Chirurgie de la veine cave inférieure*. EMC – Techniques chirurgicales – Chirurgie vasculaire 2014:1–21 [Article 43–172].

C. Lim • C. Salloum • D. Azoulay, MD, PhD (✉)

Service de Chirurgie Hépato-biliaire, Pancréatique et Transplantation Hépatique, Henri Mondor Hospital, 51 Avenue du Marechal de Lattre de Tassigny, 94010 Créteil, France  
e-mail: [daniel.azoulay.hmn@hmn.aphp.fr](mailto:daniel.azoulay.hmn@hmn.aphp.fr)

**Fig. 6.1** Total vascular exclusion of the liver



anesthetic management which allowed to perform this surgery under stable systemic hemodynamics, and progresses in surgical resection techniques such as the development of synthetic grafts which allowed to replace the inferior vena cava when needed. When inferior vena cava surgery is combined to liver resection, this can be performed under hepatic vascular exclusion procedures, venovenous bypass, and hypothermic perfusion of the liver.

In this chapter, we present an overview of the potential indications for surgery of the inferior vena cava in the setting of liver surgery, provide some major specific technical aspects of this surgery, and review outcomes of reported series.

---

## 6.2 General Principles

### 6.2.1 Caval Cross Clamping

The goal of caval cross clamping is to avoid hepatic and kidney bleeding during surgery of the inferior vena cava. Classically, a total vascular exclusion of the liver is needed (Fig. 6.1). The hepatic hilum and the infra- and suprahepatic inferior vena cava are serially clamped. Total vascular exclusion of the liver is an essential clamping technique in liver surgery and liver transplantation [1–3]. During liver resection, it allows controlling the retrohepatic inferior vena cava or major hepatic veins, sources of significant bleeding or gas embolism. During liver transplantation, resection of the recipient's vena cava is achieved by dividing both the infra- and suprahepatic inferior vena cava, and transplantation of the donor liver then requires both supra- and infrahepatic caval anastomoses and total vascular occlusion during the anhepatic phase.

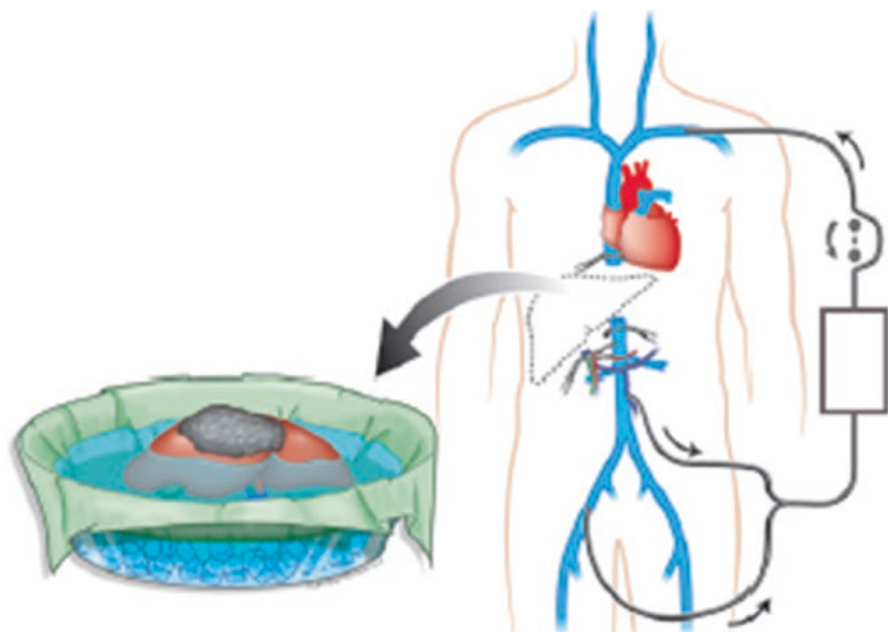
### 6.2.2 Hemodynamic Changes of the Caval Cross Clamping

Total vascular exclusion leads to a decrease of 10 % of blood pressure, 25 % of the pulmonary arterial pressure, 40 % of cardiac index, and 80 % of systemic vascular resistance [4, 5]. These hemodynamic changes are variable and depend on the volume of blood circulating and cardiac function of the patient. The inferior vena cava flow (3.5 l/min) contributes to 70 % of the total cardiac output (5 l/min). The remaining 30 % of the cardiac output comes from the superior vena cava. The inferior vena cava carries deoxygenated blood from the lower half of the body (abdomen, pelvis, and legs) into the right atrium of the heart. Inferior vena cava clamping has two consequences: (i) a significant decrease in venous return and an impaired cardiac output and (ii) clamping of the venous renal outflow and the venous drainage of the gastrointestinal tract that causes congestion of the kidney and the gastrointestinal tract. If the consequences of the infrahepatic inferior vena cava clamping are usually well tolerated, infrahepatic inferior vena cava clamping combined with suprahepatic inferior vena cava clamping induced much more marked hemodynamic consequences with a risk of cardiovascular collapse.

### 6.2.3 Hypothermic Perfusion Techniques

The liver can safely tolerate total vascular occlusion for only about 60–90 min [3, 6]. The vast majority of hepatectomies performed under standard vascular exclusion can be made in less than 60–90 min. Periods of ischemia of this order are usually well tolerated by a healthy liver, unlike the pathological liver (steatosis, cirrhosis, chemotherapy) which cannot tolerate prolonged warm ischemia [7–9].

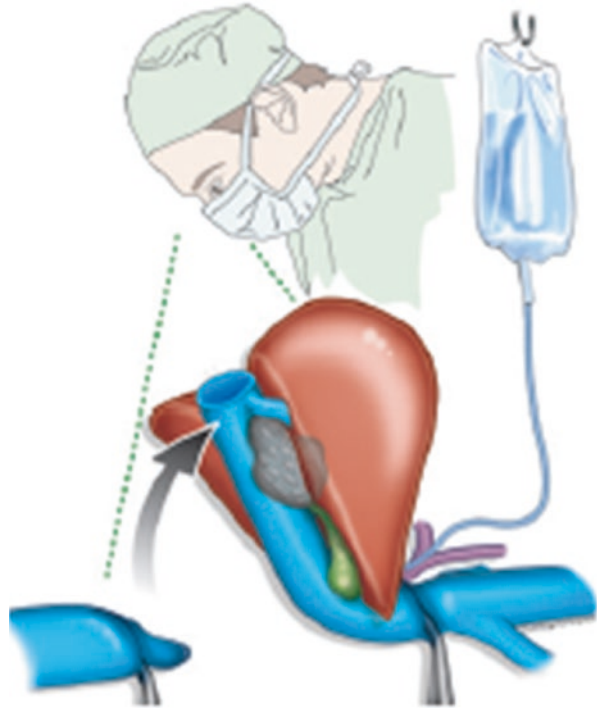
This ischemic period may be too short for complex tumors which are in the vicinity of major hepatic veins and/or the retrohepatic vena cava. Recently, we showed that preoperative factors such as portal vein embolization and/or large tumors and/or a planned vascular reconstruction were predictive for total vascular exclusion > 60 min in patients needing this vascular control [10]. A prolonged total vascular exclusion may lead to severe hepatic ischemia, hemodynamic disturbances, and potential acute kidney injury [10]. To reduce liver damage, the technique of hypothermic liver surgery has been developed [11]. The hypothermia technique has been used as an adjunct to increase the tolerance of the liver to prolonged ischemia [12]. It has been demonstrated that every 10 °C fall in temperature of liver parenchyma decreases the liver enzyme activity by 1.5–2-fold [13–17]. The principle of hypothermia approach is to perfuse the liver with conservation liquid used in organ transplantation. The temperature of the liver decreased then to about 20 °C. The most popular methods of cooling for liver surgery include hypothermia portal perfusion and topical cooling. Total body cooling technique is abandoned [18], and extracorporeal cooling (used in cardiopulmonary bypass with profound and circulatory arrest) should be considered in highly selected patients with a huge tumor associated with cardiac tumor thrombus [19].



**Fig. 6.2** Ex situ liver resection

Longmire et al. was the person to report in 1961 the use of hypothermia induced by external body cooling during a hepatectomy for liver cancer [18]. The in situ hypothermic liver resection was employed by Heaney et al. in 1956 [1] and Fortner et al. in 1974 [20]. In their technique, the liver is perfused with preservation solution at 4 °C and packed with ice during the period of total vascular exclusion. This technique has been shown to prolong safely the vascular exclusion up to several hours [10]. Pichlmayr et al. reported the technique of ex situ liver resection (Fig. 6.2) [21]. The main steps of this technique include the installation of total vascular exclusion, venovenous bypass, and the removal of the whole liver. The latter is then perfused ex situ via portal and arterial route with preservation solution. The liver is maintained in cold solution packed with ice for optimal preservation during bench hepatectomy. The remaining liver is reimplanted as an auto-transplantation. To improve the access to the dorsal part of the liver without resorting to the division of the portal triad, Hannoun et al. developed the ante situm technique in which the hepatic veins are divided, allowing mobilization of the liver anteriorly (Fig. 6.3) [22]. The future remnant liver is perfused with the Belzer's University of Wisconsin solution chilled at 4 °C (UW solution) via the portal vein or the hepatic artery [13]. The remaining hepatic veins are reimplanted into the vena cava. Then, Belghiti et al. [23] described a variation of the latter technique in which the vena cava is cut above and below the liver, enabling the resection to be done while the liver is being perfused to induce the hypothermia via the portal vein [24]. The vena cava is reconstructed after liver resection using synthetic [23, 25–30], autogenous [31–33], or pericardial grafts [34].

**Fig. 6.3** In situ ante situm liver resection

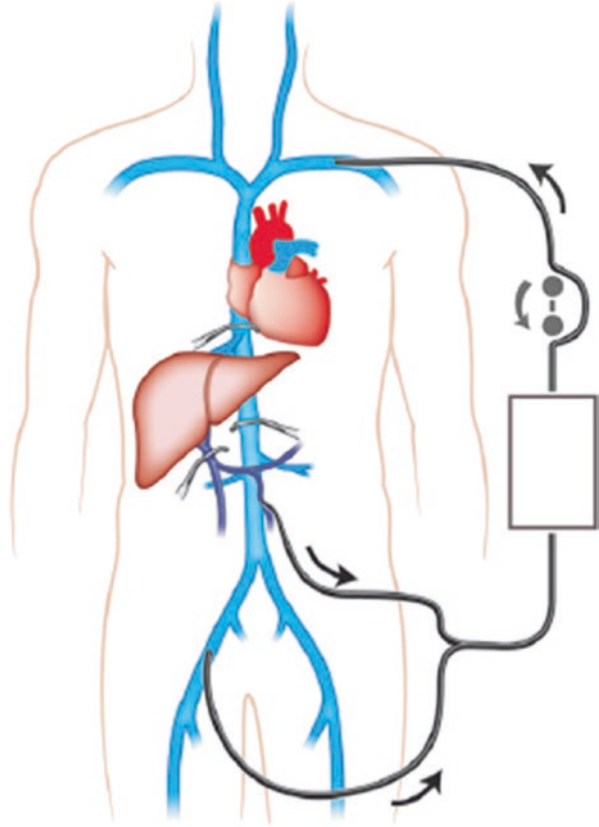


#### 6.2.4 Venovenous Bypass

Besides the need to protect the liver parenchyma, prolonged total vascular exclusion requires protection of the renal function altered by the caval clamping, decongestion of the splanchnic venous system subsequent to portal triad clamping, and maintenance of systemic hemodynamics since the caval clamping decreases the cardiac preload. The cavo-porto-jugular venovenous bypass achieves these triple goals (Fig. 6.4) [10, 25, 35–37]. The venovenous bypass circuit is used to divert blood during the vena caval interruption to the right heart from the portal venous system (i.e., inferior mesenteric vein or portal vein) and inferior caval venous system (femoral vein) through the superior caval venous system (the internal jugular or axillary veins). Venovenous bypass is indicated when resection followed by complex reconstruction of the inferior vena cava is performed or if caval cross clamping is not hemodynamically tolerated despite adequate feeling measures.

The conventional technique for establishing vascular access for bypass involves cannulation of the portal (or inferior mesenteric vein) and right femoral veins to provide pump inflow and cannulation of the left axillary vein to accept pump outflow. This procedure implies a surgical dissection of the inferior mesenteric or portal veins that can be technically demanding in case of portal cavernoma, can prolong operating time, and can be associated with significant complications such

**Fig. 6.4** Venovenous bypass



as hematoma or bleeding. The puncture and cannulation of femoral and left axillary vein is then done under ultrasonography control as described by Oken et al. in 1994 [38].

## 6.3 Perioperative Management

### 6.3.1 Anesthetic Management

This complex surgery should be performed with anesthesiologists experienced in liver transplantation and liver surgery. The anesthetic management should be specifically adapted to the risks of massive bleeding, gas emboli, general hypothermia, and coagulation disorders subsequent to ischemia-reperfusion injury [39]. They should be able to manage prolonged inferior vena cava occlusion and the rapid hemodynamic changes that occur with liver reperfusion. Patients planned to undergo total vascular exclusion with hypothermic perfusion should have a Swann-Ganz catheter and an arterial line in addition to standard noninvasive techniques. Body warmers are routinely employed to prevent hypothermia intraoperatively.

### 6.3.2 Anticoagulation Protocol

In our experience, the use of anticoagulation in patients with vascular reconstruction (caval and/or hepatic vein/s) is systematic [40]. Anticoagulation with intravenous heparin is commenced in the operating theater at 1 mg/kg body weight/24 h, and the dose is titrated to maintain the coagulation time between 1.5 and 2 times the normal level. The intravenous heparin is maintained for nearly 7 days and then replaced by daily injection of low-molecular-weight heparin for 1 month. Long-term anticoagulation is not applied. On the other hand, patients in whom only a vascular plasty is performed receive one daily injection of low-molecular-weight heparin from day 1 to discharge from hospital.

## 6.4 Specific Technical Aspects

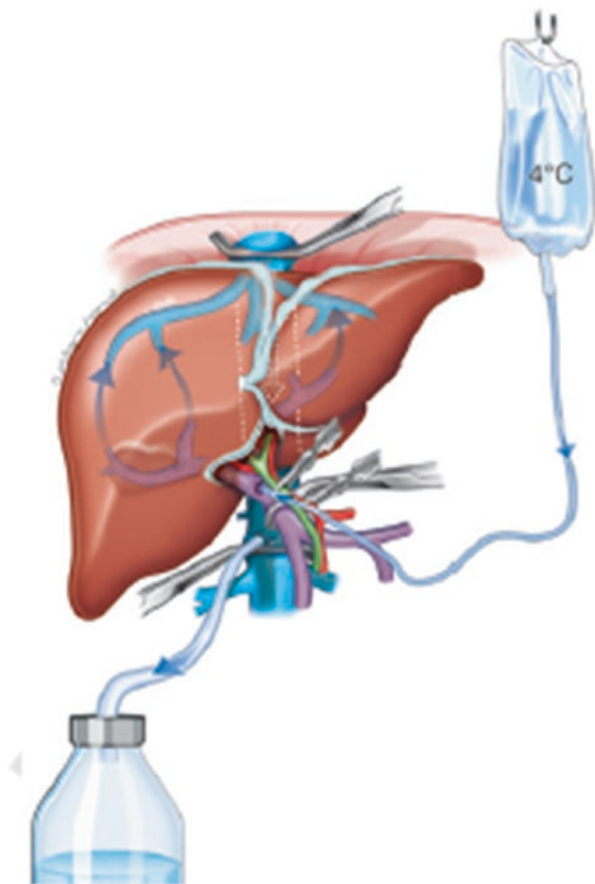
In our center, the vascular control is planned preoperatively based on the morphologic evaluation of the liver anatomy and relations of the tumor with the hepatic veins, the vena cava, and the portal triad. The common basis for *in situ* and *ante situm* liver resection is total vascular exclusion of the liver and perfusion of the liver by preservation solution under hypothermic conditions. With this technique, the use of venovenous bypass is relatively high due to hemodynamic intolerance and/or the need for complex reconstruction of the inferior vena cava. Vascular resections are performed only when the vessels cannot be separated safely from the tumor, irrespective of the preoperative procedure planned. In this paragraph, we will not describe the *ex situ* technique (for review, see Chap. 7).

### 6.4.1 Total Vascular Exclusion of the Liver [4, 6, 7]

A bilateral subcostal incision combined to midline incision is usually sufficient and provides adequate exposure for almost all types of liver resection. After surgical exploration of the abdominal cavity to eliminate extrahepatic and peritoneal metastases, a double examination of the liver by palpation and ultrasonography is performed to confirm the number and size of the lesions, to define their relationship to intrahepatic vascular structures, to assess the resectability of the tumors, and then to determine the planned resection line. The next step is to prepare the total vascular exclusion. This step can be combined with the installation of the venovenous bypass. The technique of total vascular exclusion involves complete mobilization of the right and left liver lobes and exposure and control of the supra- and infrahepatic inferior vena cava as well as the portal structures (portal vein and hepatic artery). The suprahepatic vena cava should be mobilized for cross clamping at least one or two cm above the hepatic veins. The diaphragmatic veins should be ligated and divided before. To achieve the exposure of the vena cava, a systematic ligation and division of the right adrenal vein is necessary. Once the above step is completed, the infrahepatic vena cava, portal structures, and suprahepatic vena cava are sequentially clamped (Fig. 6.1).



**Fig. 6.5** In situ hypothermic perfusion of the liver



#### 6.4.2 Hypothermic In Situ Liver Resection [10, 20, 25, 41]

Following preparation of total vascular exclusion and installation of the venovenous bypass, the preparation for hypothermic perfusion is done (Fig. 6.5). Hepatoduodenal ligament should be dissected, and the portal vein completely exposed. A small purse string 6/0 polypropylene suture is placed in the anterior wall of the portal vein. A venotomy is done at the same site, and the portal vein is cannulated above the portal clamp with a catheter, which is secured with the ends of the purse-string suture. The main portal vein, proper hepatic artery, and common bile duct are occluded individually with appropriate vascular clamps. Vascular clamps are then placed on the infra- and suprahepatic inferior vena cava, completing the total hepatic vascular exclusion. Crushed ice is placed around the liver (topical cooling), and the preservation solution cooled to 4 °C is then commenced via the inflow catheter, with the perfusate solution positioned at a height of 0.5 m.

A cavotomy is performed in the retrohepatic vena cava to drain the perfusate. The catheterization via 30-Fr catheter of the cavotomy is necessary as it prevents the spill of the cold perfusate in the peritoneal cavity, in turn decreasing the core temperature of the patient. We run the first liter wide open in order to cool the liver rapidly, and then the rate is slowed to maintain a constant low temperature of the liver (roughly 1 liter every 15–20 min). The next step involves the division of the hepatic parenchyma under total vascular exclusion, followed by the vascular reconstruction (when necessary), paying special attention to the correct orientation of the liver to ensure good outflow.

### 6.4.3 Hypothermic Ante Situm Liver Resection [21, 24, 42–51]

In this technique, the three hepatic veins or a segment of the retrohepatic inferior vena cava is divided, and the liver can be anteriorly mobilized out of the abdomen (Fig. 6.3). While the liver is perfused with cold preservation solution through the portal vein as described in the *in situ* technique, the resection plane is performed without the need for dividing the structures of the hepatic hilum. During the hypothermic phase, the inferior vena cava and venous outflow reconstruction is performed with or without the use of autogenous, pericardial, or prosthetic grafts.

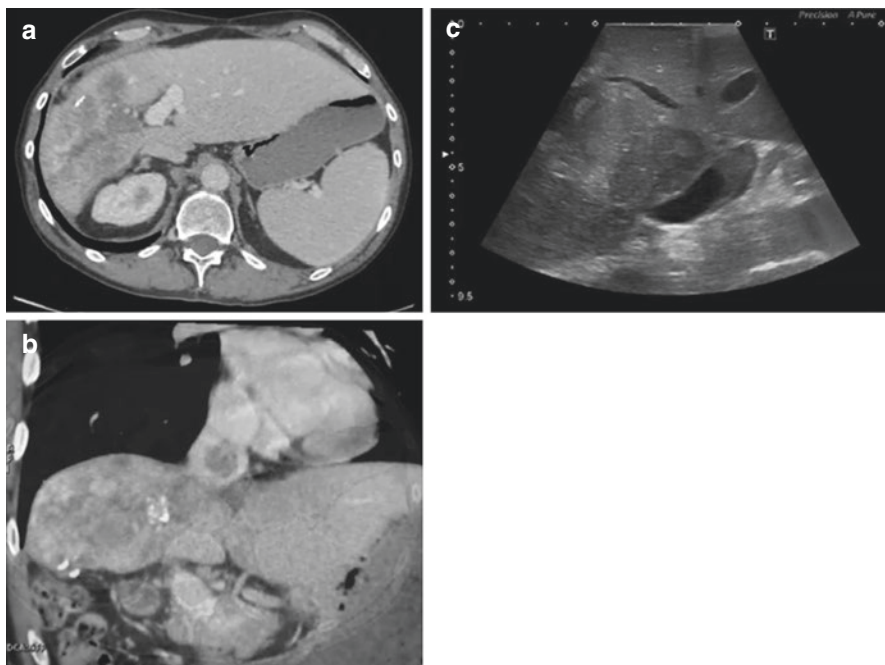
### 6.4.4 Reperfusion

After informing the anesthetist to be prepared for release of the vascular clamps, the liver is flushed with serum albumin via the portal vein. The portal cannula for perfusion is removed, and the portotomy and the cavotomy are closed. The suprahepatic clamp is the first to be released, followed by the infrahepatic clamp. The portal vein and hepatic artery are released slowly as dictated by the patient's hemodynamics. Finally, hemostasis of the remaining hepatic parenchyma is performed. Peritoneal and liver lavage with hot saline was performed until the central temperature is more than 36 °C. The venovenous bypass is removed as the last step, after hemodynamic stabilization. The inferior mesenteric vein is ligated, whereas hemostasis at the femoral and jugular puncture sites is achieved with cutaneous sutures.

---

## 6.5 Surgical Indications and Outcomes

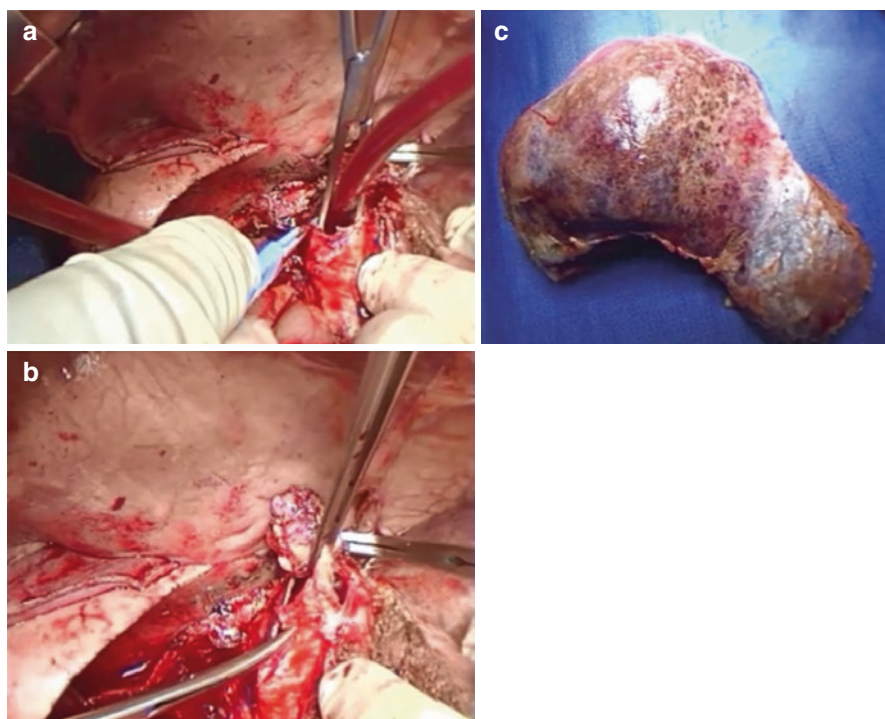
The major indication for this complex surgery are liver tumors, including primary (Figs. 6.6, 6.7, 6.8, 6.9, 6.10, 6.11 and 6.12) [31, 52] or secondary [53, 54] tumors and some huge benign tumors, that involve the retrohepatic vena cava and/or the



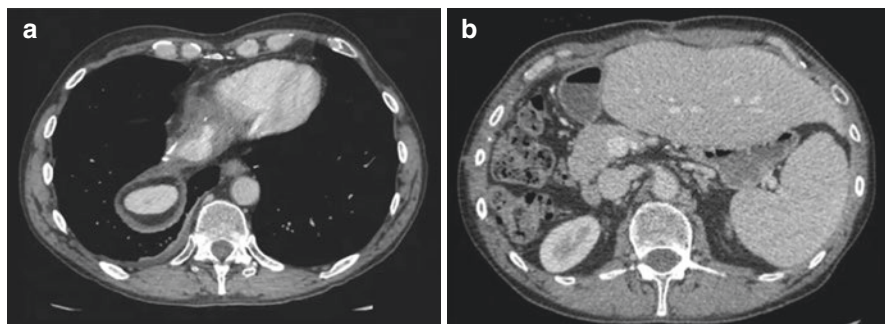
**Fig. 6.6** A 56-year-old patient with a recurrent huge hepatocellular carcinoma after partial hepatectomy in the segment 5. Preoperative computed tomodensitometry (**a**, **b**) and ultrasonography (**c**) showing a huge hepatocellular carcinoma of the right liver with inferior vena cava tumor thrombosis

confluence of the main hepatic veins or are in close proximity to them. In addition, extrahepatic tumors such as renal cancer [55–61], adrenal tumors [62–65], and leiomyosarcomas of the vena cava [66–73] involving the main hepatic veins or the retrohepatic vena cava may also be indications for this surgery. Severe liver trauma with injury of the inferior vena cava and/or hepatic veins may be another indication. Several reports have reported *in situ*, *ante situm* [19–21, 24, 41–51, 74–88], or *ex situ* [21, 44, 47, 48, 78–84, 89–104] resection techniques for these indications.

The debate over whether hypothermic perfusion of the liver should be performed *in* or *ex situ* remains unresolved. The decision which type of resection techniques is suitable depends on the location of the tumor, the vascular reconstruction required, and the experience of the centers. Compared to the *in situ* technique, the *ex situ* technique includes the division of the hepatic pedicle and then requires reconstruction of the portal triad following bench hepatectomy. In theory, *ex situ* hepatic resection is the optimal treatment option for lesions affecting the main vessels of the hepatic hilum. But *ex situ* liver resection is an invasive procedure and is associated with

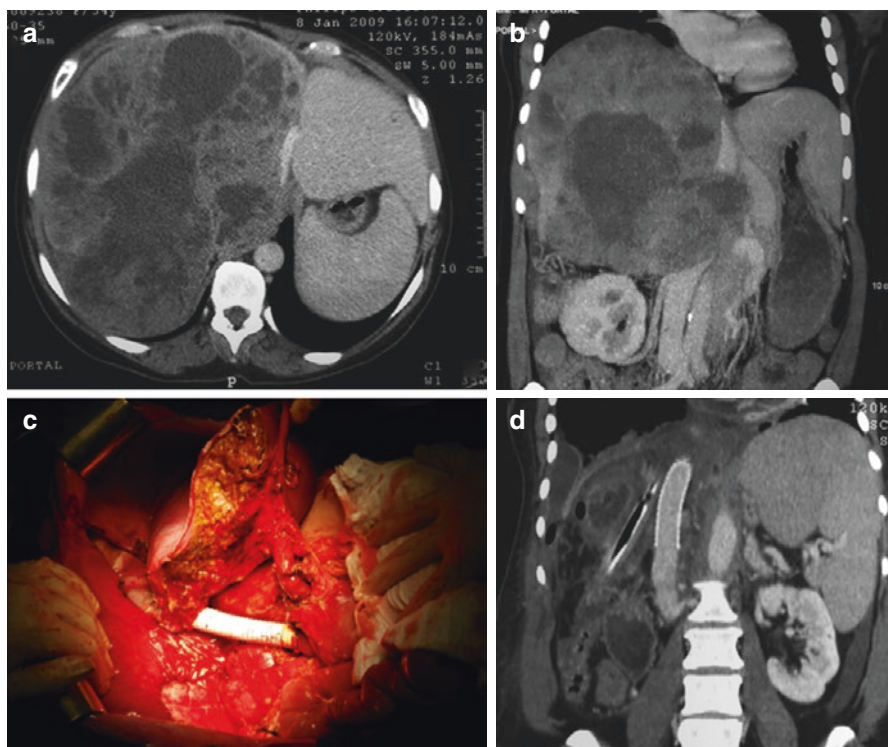


**Fig. 6.7** Intraoperative views showing the inferior vena cava thrombectomy (a, b) and the resected specimen after right hepatectomy (c)



**Fig. 6.8** Postoperative computed tomodensitometry after right hepatectomy and caval tumor thrombectomy

significant morbidity and mortality rates as high as 27.4% [41], the main cause of perioperative mortality being liver failure. These high rates of mortality limit the use of this technique (for review, see Chap. 7).

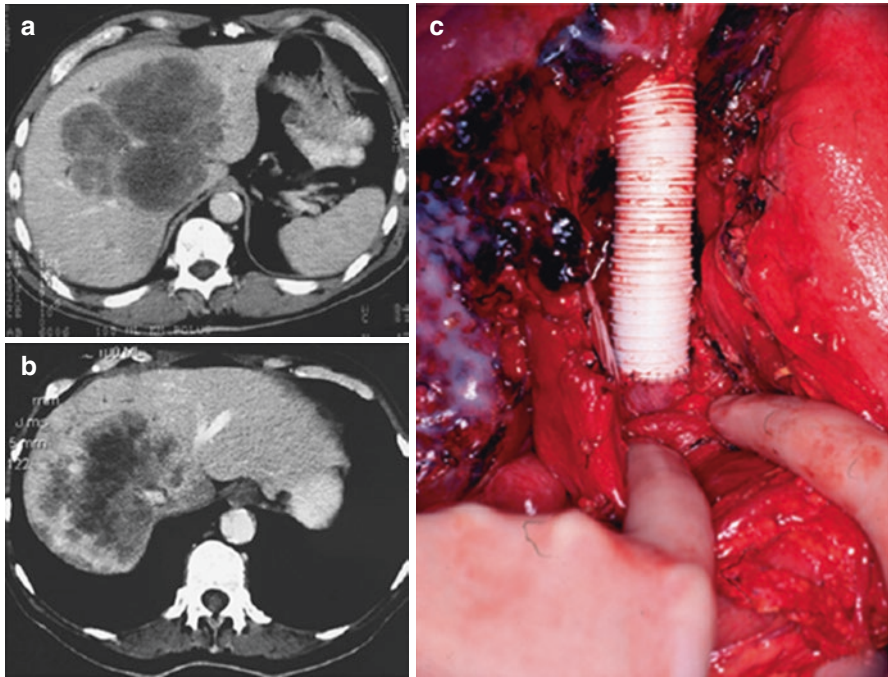


**Fig. 6.9** A 56-year-old woman with a huge hepatocellular carcinoma. (a, b) Preoperative computed tomodensitometry showing a huge hepatocellular carcinoma of the right liver with caval involvement. (c) Intraoperative view showing the caval reconstruction using a prosthetic graft. (d) Postoperative computed tomography showing the patency of the caval reconstruction

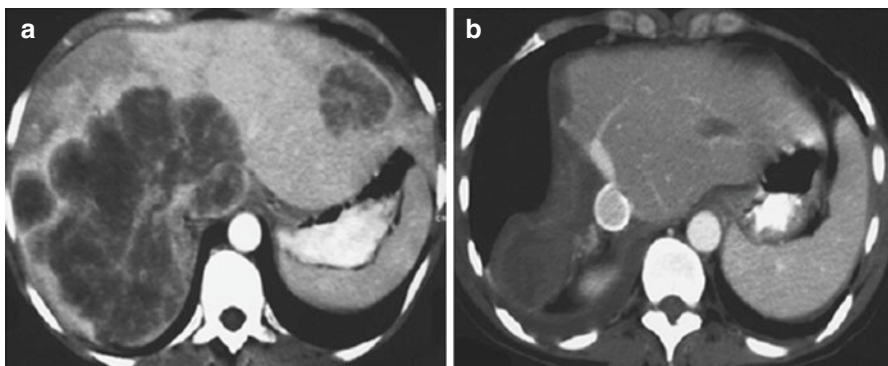
It is not mandatory to remove the liver from the body completely (*ex situ*) but to mobilize it ventrally as much as necessary (*ante situm*), since this avoids the additional morbidity of arterial and biliary reconstruction. With this approach, the *ante situm* technique would be the most appropriate technique in the majority of patients in whom the portal pedicle can be usually maintained. The *ante situm* technique for liver resection is usually employed in tumors of the liver located centrodorsally extending to the hepatic venous confluence. In this technique, the hepatic veins are excised allowing the mobilization of the liver ventrally (*ante situm*). After the resection phase, the hepatic veins are reconstructed and reimplanted to the inferior vena cava or, in case of inferior vena cava infiltration, to the interposition graft. The final decision between *in situ* or *ante situm* resection can only be made intraoperatively.

To review the current clinical application of these techniques, the English language literature was analyzed (Table 6.1). From 1974 to 2015, 205 cases of *in situ* ( $n=158$ ) or *ante situm* ( $n=47$ ) hepatectomy have been reported.



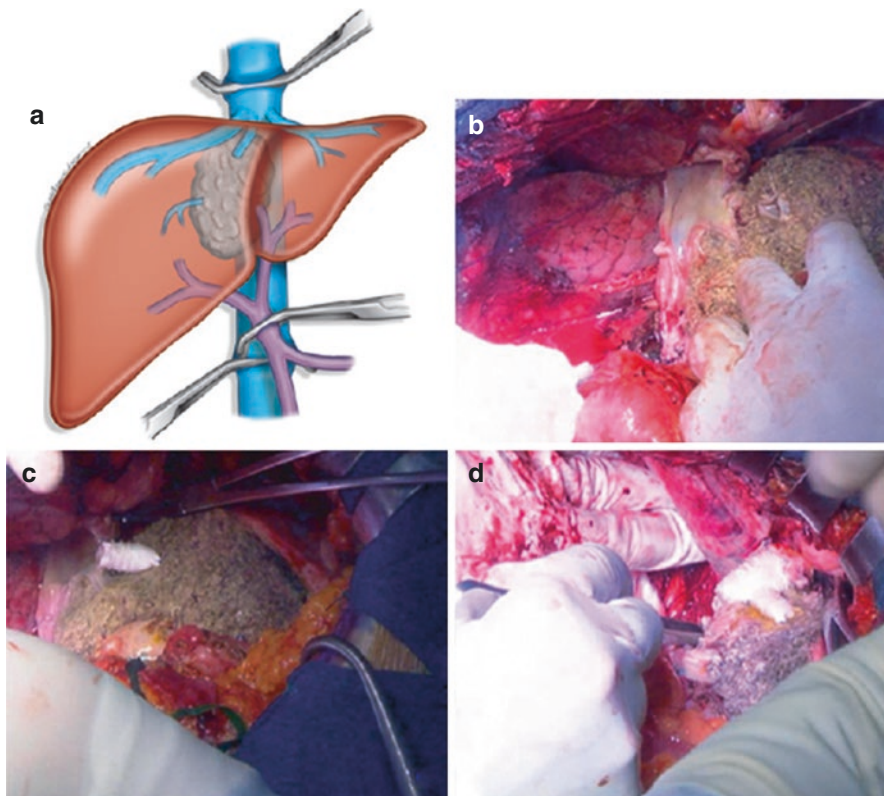


**Fig. 6.10** Retrohepatic inferior vena cava reconstruction after right extended hepatectomy. (a, b) Preoperative computed tomography. (c) Intraoperative view



**Fig. 6.11** Retrohepatic inferior vena cava and left hepatic vein reconstruction after right hepatectomy combined with contralateral partial hepatic resection. (a) Preoperative computed tomography. (b) Postoperative computed tomography

Malignant liver tumors included primary (hepatocellular carcinoma and cholangiocarcinoma) and secondary liver cancers. Benign liver tumors were mostly hemangioma. Other tumors such as leiomyosarcoma or schwannoma were most



**Fig. 6.12** Tumor involving the hepatocaval confluence. (a) Schematic view. (b) Right hepatectomy combined with hepatocaval confluence resection preserving the posterior wall of the inferior vena cava. (c) Left hepatic vein reconstruction using a prosthetic graft. (d) Inferior vena cava reconstruction using a prosthetic graft

common among the extrahepatic tumors. Postoperative mortality occurred in 23 cases (11.2%). The most frequent causes of death were liver failure, respiratory complications, bleeding, and sepsis. Recently, we have reported a case series of 77 cases of in situ hypothermic liver resection [41]. This series is the largest reported to date. Seventy-two cases were malignancies, including hepatocellular carcinoma (10 cases), cholangiocarcinoma (24 cases), and other malignant tumors (7 cases). Interestingly, complex liver resection using hypothermic perfusion was performed in five cases of benign lesions. This complex procedure achieved a 5-year survival rate of 30.4% and a high 90-day mortality of 19.5%. Yet, all 4 cirrhotic patients died after surgery. By multivariate analysis, an age-adjusted Charlson comorbidity index  $\geq 3$  (indicating at least 2 comorbid conditions), the maximum tumor diameter  $\geq 10$  cm, and the presence of 50/50 criteria



**Table 6.1** Reported series of liver resection performed with standard total vascular exclusion of the liver and in situ or ante situm hypothermic perfusion

Reference (year)	No. of cases	Indication	Ante situm	Venovenous bypass	IVC resection and reconstruction	90-day mortality
Fortner (1974) [74]	29	Primary liver cancers (16 cases) Metastatic liver cancers (10 cases) Benign diseases (3 cases)	None	None	None	3 deaths (pulmonary embolism 6 h after surgery, intraoperative hemorrhage, hepatorenal syndrome 4 weeks after surgery)
Belghiti (1991) [24]	3	Cholangiocarcinoma (2 cases) CRLM (1 case)	Yes (2 cases)	Yes (2 cases)	IVC plasty (1 case)	1 death (intraoperative hemodynamic failure after revascularization)
Yamanaka (1993) [88]	3	HCC, hemangioma	None	Yes (3 cases)	None	None
Forni (1995) [44]	1	Liver metastases	Yes	NA	NA	None
Hamazaki (1995) [19, 76, 77]	3	CRLM (1 case) HCC (2 cases)	None	Yes (3 cases)	NA	1 death (liver failure 1 month after surgery)
Vaillant (1998) [19, 42, 45]	15	HCC Cholangiocarcinoma Liver metastases	Yes (4 cases)	Yes (at least 3 cases)	NA	1 death (portal vein thrombosis on postoperative day 7)
Raab (2000) [21, 48]	30	NA	Yes (24 cases)	NA	NA	Mortality rate of 30% in the overall cohort study <sup>a</sup>
Wakabayashi (1998) [87]	1	HCC (1 case)	None	Yes	Hepatic vein reconstruction (1 case)	None
Davidson (1999) [75]	1	CRLM	None	Yes	None	NA
Barakat (2007) [74]	1	Cholangiocarcinoma (1 case)	None	Yes	None	None
Dubay (2009) [43]	7	Cholangiocarcinoma (3 cases) CRLM (1 case) Leiomyosarcoma (2 cases) Schwannoma (1 case)	Yes (7 cases)	None	IVC replacement and hepatic veins reconstruction (7 cases)	1 death (liver failure and bleeding 66 days after surgery)

(continued)

**Table 6.1** (continued)

Reference (year)	No. of cases	Indication	Ante situm	Venovenous bypass	IVC resection and reconstruction	90-day mortality
Kim (2009) [46]	1	CRLM (1 case)	Yes	Yes	NA	None
Malde (2011) [47]	7	CRLM (2 cases) HCC (3 cases) Cholangiocarcinoma (2 cases)	Yes (3 cases)	Yes	IVC replacement (4 cases) IVC plasty (3 cases) Hepatic vein reconstruction (2 cases)	None
Nuzzo (2011) [86]	4	NA	NA	NA	Hepatic vein reconstruction (4 cases)	NA
Mehrabani (2011) [85]	7	Cholangiocarcinoma (4 cases) CRLM (2 cases) HCC (1 case)	NA	NA	NA	None
Yamamoto (2001, 2013) [50, 51]	7	HCC (5 cases) Cholangiocarcinoma (2 cases)	Yes (7 cases)	Yes	IVC replacement (4 cases)	1 death (sepsis at 2 months)
Hemming (2001, 2002, 2004, 2008, 2013) [78–84]	8	Unclear	NA	NA	NA	NA
Azoulay (2014) [10, 41]	77	CRLM (31 cases) HCC (10 cases) Cholangiocarcinoma (24 cases) Other malignant (7 cases) Benign diseases (5 cases)	None	Yes	IVC replacement (13 cases) Hepatic vein reconstruction (7 cases)	15 deaths
<b>Total</b>	<b>205 cases</b>	–	–	–	–	<b>23 deaths</b>

CRLM indicates colorectal liver metastases, HCC hepatocellular carcinoma, NA not available, IVC inferior vena cava

<sup>a</sup>Mortality rate of 30% in the overall cohort study including 6 in situ, 24 ante situm, and 22 ex situ liver resections. The mortality rate was higher for ex situ resection than for the other techniques

on postoperative day 5 were independent predictors of surgical mortality measured in 90 days.

### Conclusion

Inferior vena cava resection and reconstruction combined with liver resection can be safely performed in selected patients. This aggressive surgery should be carried out at a center specialized in both liver surgery and liver transplantation. This complex surgery requires several techniques including total vascular exclusion of the liver, venovenous bypass, and hypothermic in situ, ante situm, and ex situ approach.

Due to the specific additional morbidity and mortality of the triple reconstruction (portal vein, hepatic artery, and bile duct), the ex situ technique should be considered with caution. This chapter emphasizes the interest of a multidisciplinary approach to justify this aggressive and to achieve acceptable short- and long-term outcomes.

### Key Points

- Improved anesthetic management and surgical experience with liver transplantation have allowed the development of surgery of the inferior vena cava.
- This complex surgery should be performed in a center specialized in both liver surgery and liver transplantation.
- Surgery of the vena cava combined to liver resection is mainly performed for primary and metastatic liver tumors invading the retrohepatic vena cava and/or the hepatocaval confluence.
- Leiomyosarcoma and renal tumors invading the inferior vena cava are also indications for this type of surgery.
- This surgery requires several techniques including total vascular exclusion of the liver, venovenous bypass, and hypothermic perfusion.
- Hypothermic perfusion is employed as an adjunct to increase the tolerance of the liver to prolonged ischemia and allows total vascular exclusion lasting more than 60 min.
- Resection followed by reconstruction of the inferior vena cava can be performed using hypothermic in situ, ante situm, or ex situ techniques.
- Ante situm liver resection includes the division of the retrohepatic vena cava and the mobilization of the liver ventrally before in situ hepatectomy.
- Ex situ liver resection includes the division of the retrohepatic vena cava and the portal triad before bench hepatectomy.
- Ex situ technique is associated with high morbidity and mortality rates.
- Reconstruction of the inferior vena cava can be performed using synthetic grafts.
- Reinforced PTFE graft is the material of choice to replace the inferior vena cava.

### Key References

- Longmire WP Jr, Marable SA (1961) Clinical experiences with major hepatic resections. *Ann Surg* 154:460–474

- Heaney JP, Stanton WK, Halbert DS et al (1966) An improved technic for vascular isolation of the liver: experimental study and case reports. *Ann Surg* 163(2):237–241
- Fortner JG, Shiu MH, Kinne DW et al (1974) Major hepatic resection using vascular isolation and hypothermic perfusion. *Ann Surg* 180(4):644–652
- Azoulay D, Eshkenazy R, Andreani P et al (2005) In situ hypothermic perfusion of the liver versus standard total vascular exclusion for complex liver resection. *Ann Surg* 241(2):277–285
- Yamanaka N, Dai CL, Okamoto E (1998) Historical evolution of hypothermic liver surgery. *World J Surg* 22(10):1104–1107
- Pichlmayr R, Grosse H, Hauss J et al (1990) Technique and preliminary results of extracorporeal liver surgery (bench procedure) and of surgery on the in situ perfused liver. *Br J Surg* 77(1):21–26
- Hannoun L, Panis Y, Balladur P et al (1991) Ex-situ in-vivo liver surgery. *Lancet* 337(8757):1616–1617
- Belghiti J, Dousset B, Sauvanet A et al (1991) Preliminary results with “ex situ” surgery for hepatic tumors: an alternative between palliative treatment and liver transplantation? *Gastroenterol Clin Biol* 15(5):449–453
- Azoulay D, Andreani P, Maggi U et al (2006) Combined liver resection and reconstruction of the supra-renal vena cava: the Paul Brousse experience. *Ann Surg* 244(1):80–88
- Yamamoto Y (2012) Ante-situm hepatic resection for tumors involving the confluence of hepatic veins and IVC. *J Hepatobiliary Pancreat Sci* 20(3):313–323
- Azoulay D, Lim C, Salloum C et al (2014) Complex Liver Resection Using Standard Total Vascular Exclusion, Venovenous Bypass, and In Situ Hypothermic Portal Perfusion: An Audit of 77 Consecutive Cases. *Ann Surg* 262(1):93–104

---

## References

1. Heaney JP, Stanton WK, Halbert DS et al (1966) An improved technic for vascular isolation of the liver: experimental study and case reports. *Ann Surg* 163(2):237–241
2. Huguet C, Addario-Chieco P, Gavelli A et al (1992) Technique of hepatic vascular exclusion for extensive liver resection. *Am J Surg* 163(6):602–605
3. Huguet C, Nordlinger B, Galopin JJ et al (1978) Normothermic hepatic vascular exclusion for extensive hepatectomy. *Surg Gynecol Obstet* 147(5):689–693
4. Delva E, Barberousse JP, Nordlinger B et al (1984) Hemodynamic and biochemical monitoring during major liver resection with use of hepatic vascular exclusion. *Surgery* 95(3):309–318
5. Huguet C, Gavelli A, Chieco PA et al (1992) Liver ischemia for hepatic resection: where is the limit? *Surgery* 111(3):251–259
6. Huguet C, Nordlinger B, Bloch P, Conard J (1978) Tolerance of the human liver to prolonged normothermic ischemia. A biological study of 20 patients submitted to extensive hepatectomy. *Arch Surg* 113(12):1448–1451
7. Bismuth H, Castaing D, Garden OJ (1989) Major hepatic resection under total vascular exclusion. *Ann Surg* 210(1):13–19

8. Delva E, Camus Y, Nordlinger B et al (1989) Vascular occlusions for liver resections. Operative management and tolerance to hepatic ischemia: 142 cases. *Ann Surg* 209(2): 211–218
9. Vetelainen R, van Vliet A, Gouma DJ, van Gulik TM (2007) Steatosis as a risk factor in liver surgery. *Ann Surg* 245(1):20–30
10. Azoulay D, Eshkenazy R, Andreani P et al (2005) In situ hypothermic perfusion of the liver versus standard total vascular exclusion for complex liver resection. *Ann Surg* 241(2): 277–285
11. Yamanaka N, Dai CL, Okamoto E (1998) Historical evolution of hypothermic liver surgery. *World J Surg* 22(10):1104–1107
12. Dinant S, van Veen SQ, Roseboom HJ et al (2006) Liver protection by hypothermic perfusion at different temperatures during total vascular exclusion. *Liver Int* 26(4):486–493
13. Belzer FO, Southard JH (1988) Principles of solid-organ preservation by cold storage. *Transplantation* 45(4):673–676
14. Bigelow WG, Lindsay WK et al (1950) Oxygen transport and utilization in dogs at low body temperatures. *Am J Physiol* 160(1):125–137
15. Horvath SM, Hutt BK, Spurr GB, Stevens GE (1953) Some metabolic responses of dogs having low body temperature. *Science* 118(3056):100–101
16. Heijnen BH, Straatsburg IH, Gouma DJ, van Gulik TM (2003) Decrease in core liver temperature with 10 degrees C by in situ hypothermic perfusion under total hepatic vascular exclusion reduces liver ischemia and reperfusion injury during partial hepatectomy in pigs. *Surgery* 134(5):806–817
17. Heijnen BH, Straatsburg IH, Kager LM et al (2003) Effect of in situ hypothermic perfusion on intrahepatic pO<sub>2</sub> and reactive oxygen species formation after partial hepatectomy under total hepatic vascular exclusion in pigs. *Liver Int* 23(1):19–27
18. Longmire WP Jr, Marable SA (1961) Clinical experiences with major hepatic resections. *Ann Surg* 154:460–474
19. Hamazaki K, Yagi T, Inagaki M et al (1995) Hepatectomy under extracorporeal circulation. *Surgery* 118(1):98–102
20. Fortner JG, Shiu MH, Kinne DW et al (1974) Major hepatic resection using vascular isolation and hypothermic perfusion. *Ann Surg* 180(4):644–652
21. Pichlmayr R, Grosse H, Hauss J et al (1990) Technique and preliminary results of extracorporeal liver surgery (bench procedure) and of surgery on the in situ perfused liver. *Br J Surg* 77(1):21–26
22. Hannoun L, Panis Y, Balladur P et al (1991) Ex-situ in-vivo liver surgery. *Lancet* 337(8757): 1616–1617
23. Risher WH, Arensman RM, Ochsner JL, Hollier LH (1990) Retrohepatic vena cava reconstruction with polytetrafluoroethylene graft. *J Vasc Surg* 12(3):367–370
24. Belghiti J, Dousset B, Sauvanet A et al (1991) Preliminary results with “ex situ” surgery for hepatic tumors: an alternative between palliative treatment and liver transplantation? *Gastroenterol Clin Biol* 15(5):449–453
25. Azoulay D, Andreani P, Maggi U et al (2006) Combined liver resection and reconstruction of the supra-renal vena cava: the Paul Brousse experience. *Ann Surg* 244(1):80–88
26. Sarkar R, Eilber FR, Gelabert HA, Quinones-Baldrich WJ (1998) Prosthetic replacement of the inferior vena cava for malignancy. *J Vasc Surg* 28(1):75–81, discussion 82–3
27. Huguet C, Ferri M, Gavelli A (1995) Resection of the suprarenal inferior vena cava. The role of prosthetic replacement. *Arch Surg* 130(7):793–797
28. Arii S, Teramoto K, Kawamura T et al (2003) Significance of hepatic resection combined with inferior vena cava resection and its reconstruction with expanded polytetrafluoroethylene for treatment of liver tumors. *J Am Coll Surg* 196(2):243–249
29. Maeba T, Okano K, Mori S et al (2001) Retrohepatic vena cava replacement of hepatic malignancies without using total hepatic vascular exclusion or extracorporeal bypass. *Hepatogastroenterology* 48(41):1455–1460

30. Ohwada S, Kawashima Y, Ogawa T et al (1999) Extended hepatectomy with ePTFE graft vena caval replacement and hepatic vein reconstruction: a case report. *Hepatogastroenterology* 46(26):1151–1155
31. Kurosawa H, Kimura F, Ito H et al (2004) Right hepatectomy combined with retrohepatic caval resection, using a left renal vein patch graft for advanced cholangiocarcinoma. *J Hepatobiliary Pancreat Surg* 11(5):362–365
32. Ohwada S, Takeyoshi I, Ogawa T et al (1998) Hepatic vein reconstruction at inferior vena cava confluence using left renal vein graft. *Hepatogastroenterology* 45(23):1833–1836
33. Soejima Y, Matsumoto T, Shirabe K, Maehara Y (2011) Tube cavoplasty using autologous vein grafts for resected inferior vena cava reconstruction. *Surg Today* 43(4):452–455
34. Asai K, Watanabe M, Matsukiyo H et al (2011) Combined hepatic resection with the inferior vena cava and diaphragm and reconstruction using an equine pericardial patch: report of a case. *Surg Today* 41(12):1670–1673
35. Azoulay D, Pascal G, Salloum C et al (2013) Vascular reconstruction combined with liver resection for malignant tumours. *Br J Surg* 100(13):1764–1775
36. Griffith BP, Shaw BW Jr, Hardesty RL et al (1985) Venovenous bypass without systemic anticoagulation for transplantation of the human liver. *Surg Gynecol Obstet* 160(3):270–272
37. Shaw BW Jr, Martin DJ, Marquez JM et al (1984) Venous bypass in clinical liver transplantation. *Ann Surg* 200(4):524–534
38. Oken AC, Frank SM, Merritt WT et al (1994) A new percutaneous technique for establishing venous bypass access in orthotopic liver transplantation. *J Cardiothorac Vasc Anesth* 8(1):58–60
39. Tyma A, Theodoraki K, Tsaroucha A et al (2012) Anesthetic considerations in hepatectomies under hepatic vascular control. *HPB Surg* 2012:720754
40. Hoti E, Salloum C, Azoulay D (2011) Hepatic resection with in situ hypothermic perfusion is superior to other resection techniques. *Dig Surg* 28(2):94–99
41. Azoulay D, Lim C, Salloum C et al (2014) Complex liver resection using standard total vascular exclusion, venovenous bypass, and in situ hypothermic portal perfusion: an audit of 77 consecutive cases. *Ann Surg* 262(1):93–104
42. Delriviere L, Hannoun L (1995) In situ and ex situ in vivo procedures for complex major liver resections requiring prolonged hepatic vascular exclusion in normal and diseased livers. *J Am Coll Surg* 181(3):272–276
43. Dubay D, Gallinger S, Hawryluck L et al (2009) In situ hypothermic liver preservation during radical liver resection with major vascular reconstruction. *Br J Surg* 96(12):1429–1436
44. Forni E, Meriggi F (1995) Bench surgery and liver autotransplantation. Personal experience and technical considerations. *G Chir* 16(10):407–413
45. Hannoun L, Delriviere L, Gibbs P et al (1996) Major extended hepatic resections in diseased livers using hypothermic protection: preliminary results from the first 12 patients treated with this new technique. *J Am Coll Surg* 183(6):597–605
46. Kim Z, Jeong GA, Chung JC et al (2009) Ante-situm liver resection in recurrent liver metastasis from colorectal cancer. *Hepatogastroenterology* 56(90):508–511
47. Malde DJ, Khan A, Prasad KR et al (2011) Inferior vena cava resection with hepatectomy: challenging but justified. *HPB (Oxford)* 13(11):802–810
48. Raab R, Schlitt HJ, Oldhafer KJ et al (2000) Ex-vivo resection techniques in tissue-preserving surgery for liver malignancies. *Langenbecks Arch Surg* 385(3):179–184
49. Vaillant JC, Borie DC, Hannoun L (1998) Hepatectomy with hypothermic perfusion of the liver. *Hepatogastroenterology* 45(20):381–388
50. Yamamoto Y (2012) Ante-situm hepatic resection for tumors involving the confluence of hepatic veins and IVC. *J Hepatobiliary Pancreat Sci* 20(3):313–323
51. Yamamoto Y, Terajima H, Ishikawa Y et al (2001) In situ pedicle resection in left trisegmentectomy of the liver combined with reconstruction of the right hepatic vein to an inferior vena caval segment transpositioned from the infrahepatic portion. *J Am Coll Surg* 192(1):137–141
52. Moriura S, Nimura Y, Hayakawa N et al (1990) Combined resection of the inferior vena cava for hepato-biliary and pancreatic malignancies. *Hepatogastroenterology* 37(2):253–255

53. Aoki T, Sugawara Y, Imamura H et al (2004) Hepatic resection with reconstruction of the inferior vena cava or hepatic venous confluence for metastatic liver tumor from colorectal cancer. *J Am Coll Surg* 198(3):366–372
54. Nardo B, Ercolani G, Montalti R et al (2005) Hepatic resection for primary or secondary malignancies with involvement of the inferior vena cava: is this operation safe or hazardous? *J Am Coll Surg* 201(5):671–679
55. Neves RJ, Zincke H (1987) Surgical treatment of renal cancer with vena cava extension. *Br J Urol* 59(5):390–395
56. Langenburg SE, Blackburn LH, Sperling JW et al (1994) Management of renal tumors involving the inferior vena cava. *J Vasc Surg* 20(3):385–388
57. Skinner DG, Pritchett TR, Lieskovsky G et al (1989) Vena caval involvement by renal cell carcinoma. Surgical resection provides meaningful long-term survival. *Ann Surg* 210(3):387–392, discussion 392–4
58. Staehler G, Brkovic D (2000) The role of radical surgery for renal cell carcinoma with extension into the vena cava. *J Urol* 163(6):1671–1675
59. Tsuji Y, Goto A, Hara I et al (2001) Renal cell carcinoma with extension of tumor thrombus into the vena cava: surgical strategy and prognosis. *J Vasc Surg* 33(4):789–796
60. Kaplan S, Ekici S, Dogan R et al (2002) Surgical management of renal cell carcinoma with inferior vena cava tumor thrombus. *Am J Surg* 183(3):292–299
61. Hatcher PA, Anderson EE, Paulson DF et al (1991) Surgical management and prognosis of renal cell carcinoma invading the vena cava. *J Urol* 145(1):20–23, discussion 23–4
62. Fiore M, Colombo C, Locati P et al (2011) Surgical technique, morbidity, and outcome of primary retroperitoneal sarcoma involving inferior vena cava. *Ann Surg Oncol* 19(2):511–518
63. Chiche L, Dousset B, Kieffer E, Chapuis Y (2006) Adrenocortical carcinoma extending into the inferior vena cava: presentation of a 15-patient series and review of the literature. *Surgery* 139(1):15–27
64. Mihai R, Iacobone M, Makay O et al (2012) Outcome of operation in patients with adrenocortical cancer invading the inferior vena cava—a European Society of Endocrine Surgeons (ESES) survey. *Langenbecks Arch Surg* 397(2):225–231
65. Ohwada S, Izumi M, Tanahashi Y et al (2007) Combined liver and inferior vena cava resection for adrenocortical carcinoma. *Surg Today* 37(4):291–297
66. O'Malley KJ, Stuart RC, McEntee GP (1994) Combined resection of the inferior vena cava and extended right hepatectomy for leiomyosarcoma of the retrohepatic cava. *Br J Surg* 81(6):845–846
67. Daylami R, Amiri A, Goldsmith B et al (2010) Inferior vena cava leiomyosarcoma: is reconstruction necessary after resection? *J Am Coll Surg* 210(2):185–190
68. Hollenbeck ST, Grobmyer SR, Kent KC, Brennan MF (2003) Surgical treatment and outcomes of patients with primary inferior vena cava leiomyosarcoma. *J Am Coll Surg* 197(4):575–579
69. Hines OJ, Nelson S, Quinones-Baldrich WJ, Eilber FR (1999) Leiomyosarcoma of the inferior vena cava: prognosis and comparison with leiomyosarcoma of other anatomic sites. *Cancer* 85(5):1077–1083
70. Ito H, Hornick JL, Bertagnolli MM et al (2007) Leiomyosarcoma of the inferior vena cava: survival after aggressive management. *Ann Surg Oncol* 14(12):3534–3541
71. Kieffer E, Alaoui M, Piette JC et al (2006) Leiomyosarcoma of the inferior vena cava: experience in 22 cases. *Ann Surg* 244(2):289–295
72. Mann GN, Mann LV, Levine EA, Shen P (2010) Primary leiomyosarcoma of the inferior vena cava: a 2-institution analysis of outcomes. *Surgery* 151(2):261–267
73. Mingoli A, Cavallaro A, Sapienza P et al (1996) International registry of inferior vena cava leiomyosarcoma: analysis of a world series on 218 patients. *Anticancer Res* 16(5B):3201–3205
74. Barakat O, Hoef J, Ozaki CF, Patrick WR (2007) Extended right trisegmentectomy using in situ hypothermic perfusion with modified HTK solution for a large intrahepatic cholangiocarcinoma. *J Surg Oncol* 95(7):587–592



75. Davidson BR, Rai R (1999) Prolonged lactic acidosis after extended hepatectomy under in situ hypothermic perfusion. *Liver Transpl Surg* 5(2):151–152
76. Hamazaki K, Yagi T, Inagaki M et al (1994) Hepatectomy with extracorporeal circulation for liver metastasis from colon carcinoma located at the confluence of the major hepatic vein: a case report. *Hepatogastroenterology* 41(2):150–153
77. Hamazaki K, Yagi T, Katsuta K et al (1995) Extracorporeal circulation and hypothermic perfusion for caval tumor thrombus complicating hepatocellular carcinoma: a case report. *Hepatogastroenterology* 42(3):282–285
78. Hemming AW, Cattral MS (1999) Ex vivo liver resection with replacement of the inferior vena cava and hepatic vein replacement by transposition of the portal vein. *J Am Coll Surg* 189(5):523–526
79. Hemming AW, Langham MR, Reed AI et al (2001) Resection of the inferior vena cava for hepatic malignancy. *Am Surg* 67(11):1081–1087, discussion 1087–8
80. Hemming AW, Mekeel KL, Zendejas I et al (2013) Resection of the liver and inferior vena cava for hepatic malignancy. *J Am Coll Surg* 217(1):115–124, discussion 124–5
81. Hemming AW, Reed AI, Fujita S (2006) Ex vivo extended left hepatectomy with caval preservation, temporary portacaval shunt, and reconstruction of the right hepatic vein outflow using a reversed portal vein bifurcation graft. *J Hepatobiliary Pancreat Surg* 13(6):525–529
82. Hemming AW, Reed AI, Fujita S et al (2008) Role for extending hepatic resection using an aggressive approach to liver surgery. *J Am Coll Surg* 206(5):870–875, discussion 875–8
83. Hemming AW, Reed AI, Langham MR Jr et al (2004) Combined resection of the liver and inferior vena cava for hepatic malignancy. *Ann Surg* 239(5):712–719, discussion 719–21
84. Hemming AW, Reed AI, Langham MR et al (2002) Hepatic vein reconstruction for resection of hepatic tumors. *Ann Surg* 235(6):850–858
85. Mehrabi A, Fonouni H, Golriz M et al (2011) Hypothermic ante situm resection in tumors of the hepatocaval confluence. *Dig Surg* 28(2):100–108
86. Nuzzo G, Giordano M, Giuliani F et al (2011) Complex liver resection for hepatic tumours involving the inferior vena cava. *Eur J Surg Oncol* 37(11):921–927
87. Wakabayashi H, Maeba T, Okano K et al (1998) Treatment of recurrent hepatocellular carcinoma by hepatectomy with right and middle hepatic vein reconstruction using total vascular exclusion with extracorporeal bypass and hypothermic hepatic perfusion: report of a case. *Surg Today* 28(5):547–550
88. Yamanaka N, Okamoto E, Fujiwara S et al (1993) Hepatic resection under liver surface or perfusion cooling together with hepatoprotective agents of PGE1 and urinastatin. *Nihon Geka Gakkai Zasshi* 94(3):259–268
89. Brekke IB, Line PD, Mathisen O, Osnes S (2003) Extracorporeal surgery and liver autotransplantation. *Tidsskr Nor Laegeforen* 123(22):3210–3212
90. Brekke IB, Mathisen O, Line PD, Hauss HJ (2003) Hepatic autotransplantation with ex situ neoplasm extirpation and vena cava replacement. *Hepatogastroenterology* 50(54):2169–2172
91. Chui AK, Rao AR, Wong J et al (2003) Ex situ ex vivo liver resection, partial liver autotransplantation for advanced hilar cholangiocarcinoma: a case report. *Transplant Proc* 35(1):402–403
92. Govil S (2013) Liver resection under hypothermic total vascular exclusion. *Indian J Gastroenterol* 32(4):222–226
93. Gringeri E, Polacco M, D'Amico FE et al (2012) Liver autotransplantation for the treatment of unresectable hepatic metastasis: an uncommon indication—a case report. *Transplant Proc* 44(7):1930–1933
94. Gruttadauria S, Marsh JW, Bartlett DL et al (2005) Ex situ resection techniques and liver autotransplantation: last resource for otherwise unresectable malignancy. *Dig Dis Sci* 50(10):1829–1835
95. Ikegami T, Soejima Y, Taketomi A et al (2008) Extracorporeal hepatic resection for unresectable giant hepatic hemangiomas. *Liver Transpl* 14(1):115–117
96. Lechaux D, Megevand JM, Raoul JL, Boudjema K (2002) Ex vivo right trisegmentectomy with reconstruction of inferior vena cava and “flop” reimplantation. *J Am Coll Surg* 194(6):842–845

97. Lodge JP, Ammori BJ, Prasad KR, Bellamy MC (2000) Ex vivo and in situ resection of inferior vena cava with hepatectomy for colorectal metastases. *Ann Surg* 231(4):471–479
98. Oldhafer KJ, Lang H, Schlitt HJ et al (2000) Long-term experience after ex situ liver surgery. *Surgery* 127(5):520–527
99. Shimahara Y, Yamaoka Y, Morimoto T et al (1998) Surgical treatment for hepatocellular carcinoma: liver resection using transplantation techniques. *Nihon Geka Gakkai Zasshi* 99(4):208–213
100. Sugimachi K, Shirabe K, Taketomi A et al (2010) Successful curative extracorporeal hepatic resection for far-advanced hepatocellular carcinoma in an adolescent patient. *Liver Transpl* 16(5):685–687
101. Wen H, Dong JH, Zhang JH et al (2011) Ex vivo liver resection followed by autotransplantation for end-stage hepatic alveolar echinococcosis. *Chin Med J (Engl)* 124(18):2813–2817
102. Yagyu T, Shimizu R, Nishida M et al (1994) Reconstruction of the hepatic vein to the prosthetic inferior vena cava in right extended hemihepatectomy with ex situ procedure. *Surgery* 115(6):740–744
103. Yanaga K, Kishikawa K, Shimada M et al (1993) Extracorporeal hepatic resection for previously unresectable neoplasms. *Surgery* 113(6):637–643
104. Zhang KM, Hu XW, Dong JH et al (2013) Ex-situ liver surgery without veno-venous bypass. *World J Gastroenterol* 18(48):7290–7295

---

# Ex Situ Resection of the Inferior Vena Cava with Hepatectomy

# 7

Shahid G. Farid and J. Peter A. Lodge

---

## 7.1 Introduction

The short-term survival of untreated patients with both primary and secondary liver tumours, the unpredictability of chemotherapy response on an individual patient basis and the disappointing results of transplantation for cancer provide adequate impetus for attempts to extend the boundaries of liver resection as far as possible. Most complex liver tumour cases, including those with significant hilar involvement, can be adequately dealt with by short periods of vascular isolation and warm ischemia, and this can often be done without caval or hepatic vein isolation. Inferior vena cava (IVC) involvement can most often be dealt with by simple venous side-clamping or in more extensive cases by total hepatic vascular isolation with IVC clamping and the selective use of veno-venous bypass, which is most often needed in the elderly. Tumours involving all of the major hepatic veins with or without direct IVC invasion, and particularly tumours involving the hepatocaval confluence and needing IVC replacement, continue to pose a surgical challenge, particularly if portal hilar structures are involved bilaterally. IVC resection accounts for only 1% of our centre's metastatic work, as metastases rarely invade the IVC, but when considering hepatocellular carcinoma and intrahepatic cholangiocarcinoma, there appears to be a greater need.

Ex situ resection of the IVC with hepatectomy is a potential mode of intervention performed in only a few liver surgery centres around the world. Experience remains limited, and only a few studies detail the complex procedure in terms of patient selection, radiological assessment and pre-, intra- and postoperative strategies utilised to

---

**Electronic supplementary material** The online version of this chapter (doi:[10.1007/978-3-319-25565-1\\_7](https://doi.org/10.1007/978-3-319-25565-1_7)) contains supplementary material, which is available to authorized users.

S.G. Farid, MD, FRCS • J.P.A. Lodge, MD, FRCS, FEBS (✉)  
HPB and Transplant Unit, St James's University Hospital,  
Beckett Street, LS9 7TF Leeds, UK  
e-mail: [peter.lodge@nhs.net](mailto:peter.lodge@nhs.net)

address the potential for high morbidity and mortality. Furthermore, the short- and long-term outcomes can only be derived from a small number of patients that have been reported [1–15]. In this chapter, an attempt is made to review the current experience for the reader and set it in the context of contemporary hepatobiliary practice.

---

## **7.2 Alternative Complex Techniques to Ex Situ Resection**

Surgical techniques such as resections that rely on the presence of a large inferior or middle right hepatic vein and the possibility of hepatic venous reconstruction in situ will mean that ex situ liver resection will rarely be performed. In situ hypothermic perfusion and the ‘ante situm technique’, which do not require hepatic arterial or biliary reconstruction, may be preferable in some cases where it is anticipated that the parenchymal dissection will be difficult. Careful thought must be given to these techniques both preoperatively and during the eventual surgery as these methods are widely thought to have a greater applicability than the ex situ resection technique. Furthermore, a disadvantage of the ex situ method is the number of necessary vascular anastomoses and the associated thrombotic risk. However, in the authors’ opinion, this is sometimes outweighed by the advantages of superb exposure and adequate hypothermic protection.

### **7.2.1 In Situ Hypothermic Perfusion**

The techniques involved in in situ hypothermic perfusion are very similar to those employed in total vascular isolation of the liver (also known as hepatic venous occlusion). The aim is to provide a bloodless field combined with hypothermic cellular protection, allowing a prolonged and more precise dissection. It is considered more straightforward than hepatic excision and reimplantation (ex situ method), but it should be noted that cooling may not be even and difficulties remain when considering access to the IVC and hepatic veins. It may be performed with or without portosystemic veno-venous bypass. Hepatic cooling can be achieved by portal vein or hepatic artery perfusion with a cold organ preservation solution, as used in transplantation, such as the University of Wisconsin (UW) or histidine-tryptophan-ketoglutarate (HTK) solutions. The IVC should be dissected enough to be clamped above and below the liver, and the right suprarenal (adrenal) vein is isolated as this will usually need to be clamped. The IVC is clamped above and below the liver and the infrahepatic IVC is incised above the lower clamp for venting during the period of cold perfusion and the venous effluent is aspirated from the IVC to prevent excessive body cooling.

### **7.2.2 The Ante Situm Procedure**

The ante situm procedure combines in situ hypothermic perfusion with separation of the suprahepatic IVC to allow mobilisation for dissection of the cranial and

posterior parts of the liver under direct vision by rotating the liver anteriorly onto the abdominal wall. It is usual to ligate and divide the right suprarenal vein in order to gain adequate rotation of the organ. In our experience, it has also been necessary to divide the infrahepatic IVC, and IVC replacement by a prosthetic graft is usually needed. Venovenous bypass may be an advantage for patient stability. Hepatic perfusion is as for the in situ technique, although the liver can be placed on a heat exchange plate to help keep it cool during the resection.

---

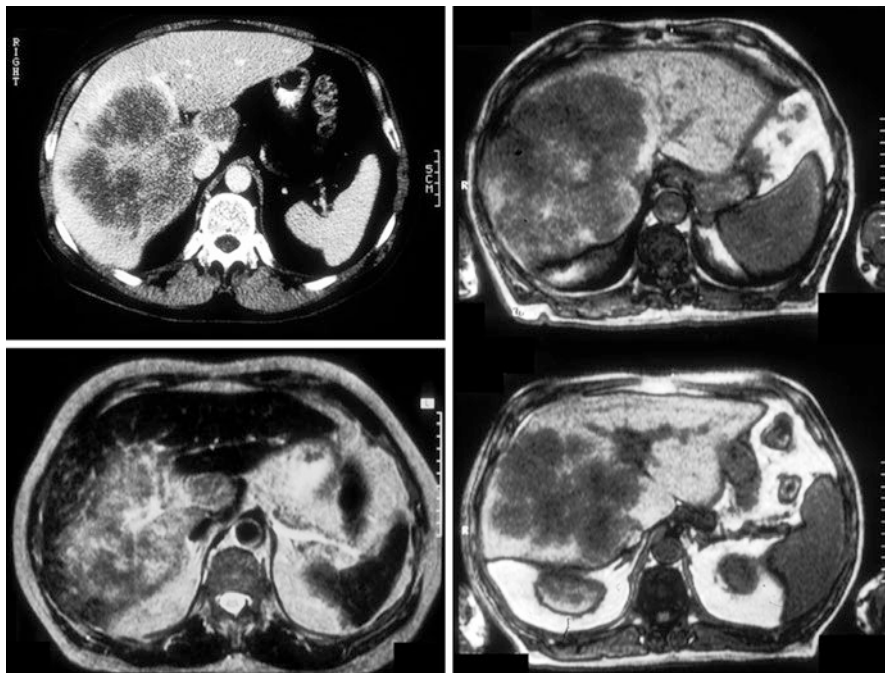
## **7.3 Patient Assessment**

### **7.3.1 Cardiorespiratory Assessment**

Before considering a surgical procedure of this scale, it is essential to be as sure as possible that the patient is fit enough to withstand the operation. It is important to take a detailed history of previous cardiovascular disease, including myocardial infarction, angina pectoris and hypertension. A history of smoking or peripheral vascular disease should raise the clinical suspicion of coronary artery disease. Cardiopulmonary exercise testing (CPX) has become the standard preoperative objective assessment test in our centre. Failure to achieve an adequate heart rate for true stress testing can be a problem in the elderly population, most often due to osteoarthritis of the hips and knees. In this situation, a great deal of useful information can be gained from echocardiography, with measurement of end diastolic and systolic volumes to calculate left ventricular ejection fraction, or by radioisotope assessment with dobutamine stress. Useful information is also gained from the chest CT which is performed primarily to look for lung metastases and diaphragm involvement by the hepatic tumour.

### **7.3.2 Hepatic Reserve Assessment**

Preoperative blood tests necessary before proceeding to major resection include full blood count, urea and electrolytes, liver function tests, clotting screen and tumour marker studies. Prothrombin time, bilirubin and albumin give a fairly accurate indication of global hepatic function, but in some cases, a liver biopsy of the residual tumour-free liver will also be necessary if there is a doubt about hepatic reserve, in particular when considering resection for hepatocellular carcinoma, or if there is a history of excess alcohol consumption and/or serological evidence of hepatitis B or C. A liver biopsy may also be useful when dealing with cholangiocarcinoma, as there may be underlying sclerosing cholangitis. If the tumour-free segments are affected by biliary obstruction, it is our current practice to attempt biliary decompression by endoscopic or percutaneous techniques a few days in advance of surgery as this may speed up the postoperative recovery and reduce risks for morbidity and mortality in major liver surgery. Consideration should also be given to the role of portal vein embolisation in line with current liver resection protocols.



**Fig. 7.1** CT and MRI images demonstrating typical cases for consideration of the ex situ IVC resection with hepatectomy technique. Note the involvement of the IVC, hepatocaval confluence and portal triad structures

### 7.3.3 Radiology Assessment

Although MRI is the imaging method of choice for the liver in our centre, other groups routinely use CT arteriography with similar results (Fig. 7.1). Three-dimensional CT and MRI imaging technologies continue to improve, and these may be of value in planning the surgical approach. It is our current practice to use CT scanning of the chest, abdomen and pelvis to exclude extrahepatic disease for all tumour types, but FDG-PET scanning is also used in selected cases, particularly biliary tract cancers. Screening for primary site recurrence (e.g. colonoscopy) is also clearly important. An isotope bone scan may also be useful as these patients have advanced disease.

## 7.4 Preoperative Preparation

Routine blood tests in our unit include full blood count, urea and electrolytes, liver function tests, coagulation screen, C-reactive protein (CRP) and tumour marker studies (primarily carcinoembryonic antigen, CA19-9 and alphafetoprotein) immediately before surgery as a baseline. A low-molecular-weight heparin may be administered on the night before surgery to reduce the risk of deep vein thrombosis

and pulmonary embolism for patients admitted preoperatively and at the end of surgery if admitted on the day of surgery. Broad-spectrum antibiotics are given at the time of anaesthetic induction.

---

## 7.5 Anaesthesia

A standard liver resection anaesthetic becomes a liver transplant anaesthetic if the ex situ dissection proceeds. It is our routine to place a central venous line, an arterial line, an oesophageal temperature probe and a urinary catheter. A warm air flow device covers the patient as well as a standard warming blanket. In our centre, we use an epidural catheter for central venous pressure manipulation as well as postoperative analgesia, although vasodilators are sometimes necessary in addition. Venovenous bypass lines are inserted percutaneously into the internal jugular and femoral veins as the morbidity associated with this technique is lower than with the classical surgical method.

It is recommended to begin the operation using low central venous pressure anaesthesia as in most cases the resection will proceed in situ as radiology assessment often overestimates the degree of major vascular involvement. Inotrope or vasoconstrictor support is often necessary for the elderly patient in particular in order to maintain an adequate blood pressure during the low venous pressure phase. If the decision to proceed to an ex situ operation is confirmed, then venovenous bypass with a high central venous pressure is necessary. The bypass lines are heparin bonded so no additional anticoagulation should be used. The use of fresh frozen plasma early in the procedure is recommended to limit clotting abnormalities during the anhepatic phase, and cryoprecipitate and platelets may be given prior to reperfusion. Tranexamic acid or aprotinin may be necessary to prevent fibrinolysis and to maintain platelet function after reperfusion of the ischemic liver. It is not our practice to use a cell saver or other blood recycling device as there is a theoretical risk of tumour cell dissemination into the blood stream.

---

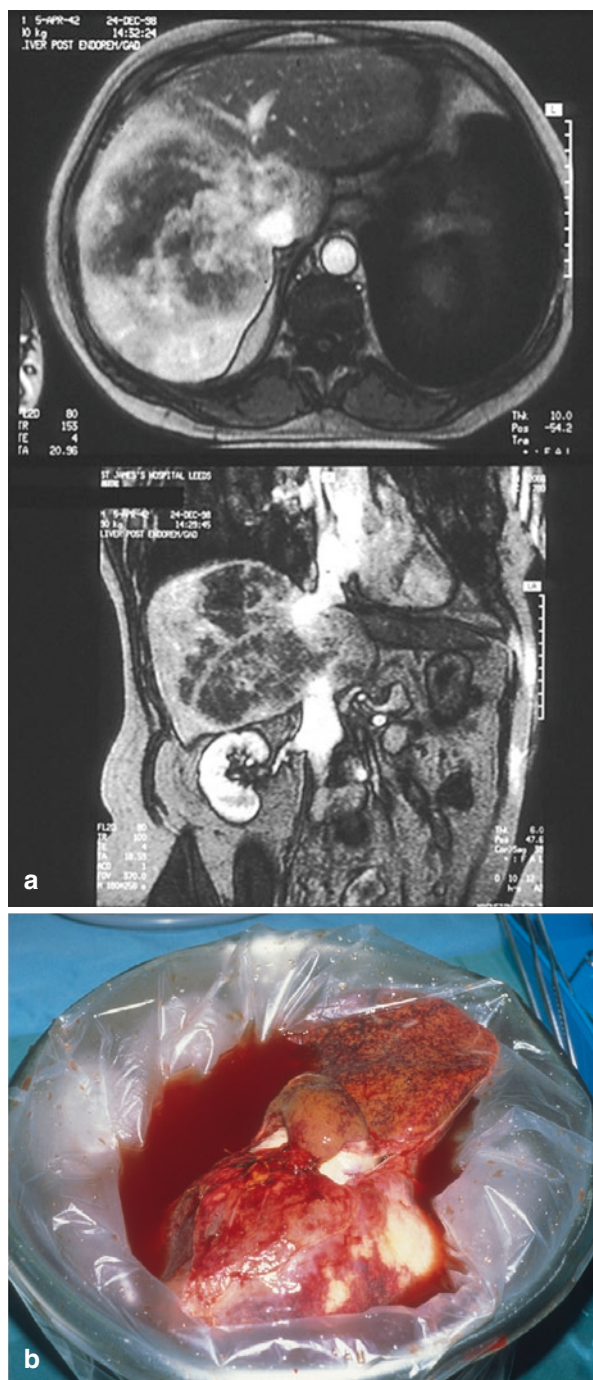
## 7.6 Operative Technique

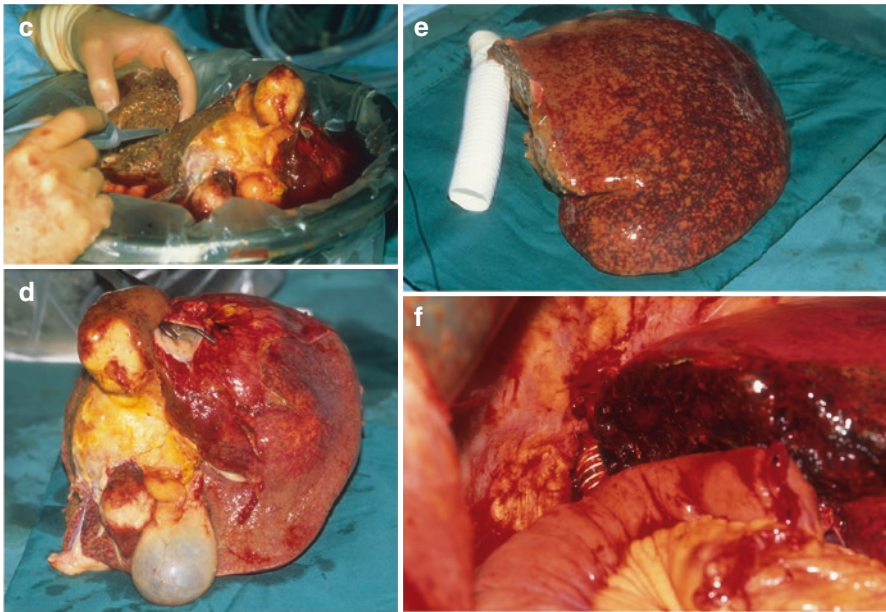
Case examples are illustrated in Figs. [7.2](#) and [7.3](#) and in the accompanying video.

### 7.6.1 Operability Assessment

The initial phase of surgery is a full laparotomy to determine operability. In the authors' opinion, the role for an initial laparoscopy is limited except to exclude peritoneal disease. Such patients tend to have had previous major and/or multiple abdominal surgeries limiting a full laparoscopic assessment. It is our practice to use an incision that will give adequate access for assessment, whilst being fairly minimalist initially in case there are clear signs of inoperability. It is often possible to make use

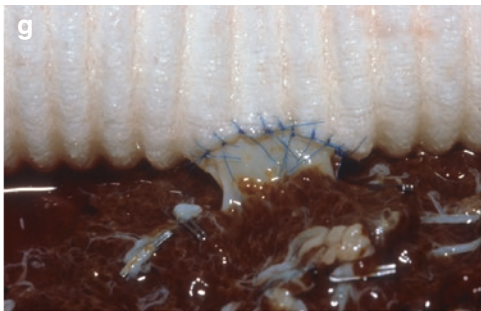
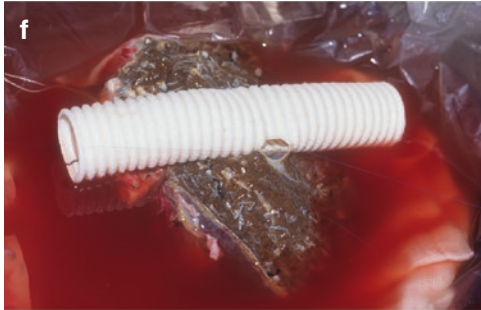
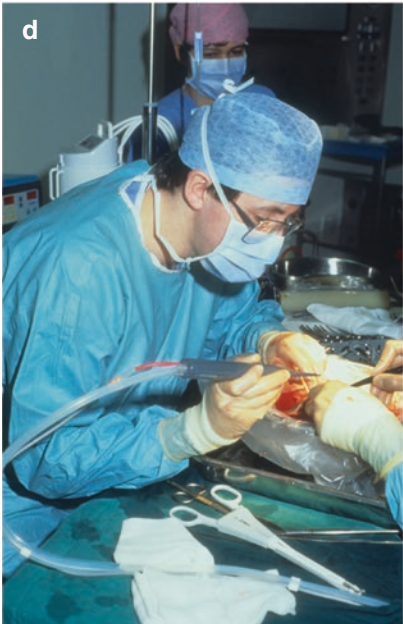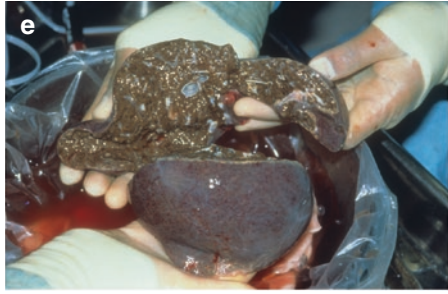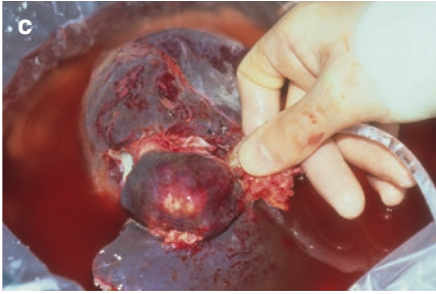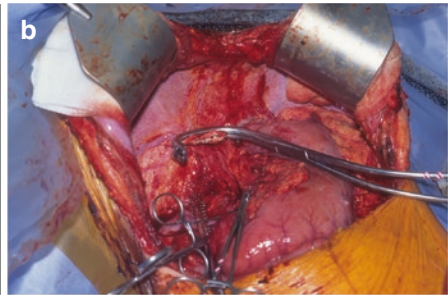
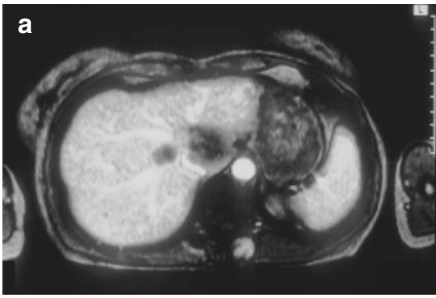




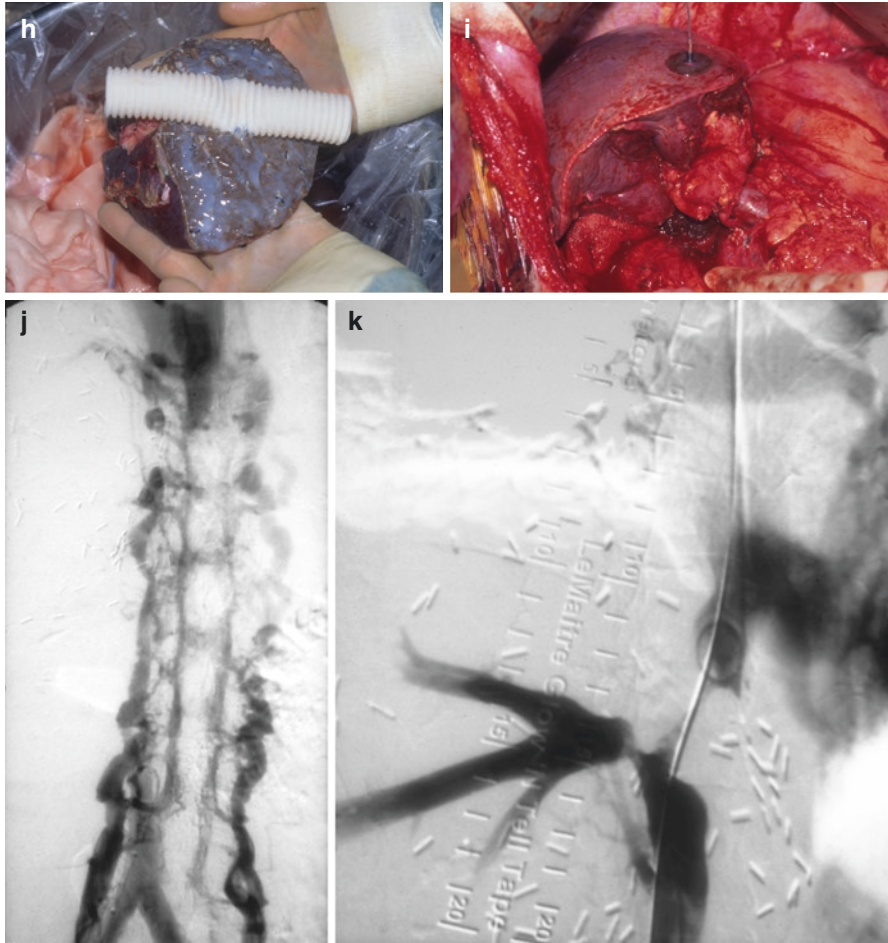


**Fig. 7.2** (continued)

**Fig. 7.2** Example case 1: A 74-year-old male, extensive colorectal liver metastases. This patient required a 4-unit blood transfusion during surgery, had 1 day on the ICU and left hospital on day 10. Histology showed the resection was R0, but there was significant vascular invasion. At 6 weeks from surgery, he walked a 26-mile marathon to raise money for a cancer charity. Recurrence occurred at 1 year with adrenal metastases. Death occurred a year later. (a) MRI shows proximity of tumour to IVC, hepatic veins and portal triad structures bilaterally. (b) Liver removed and flushed with UW organ preservation solution. (c) Resection using CUSA to preserve only the majority of liver segments 2 and 3. (d) Resected specimen, with forceps showing IVC. (e) 20-mm ringed PTFE vascular graft used to replace IVC, with the left hepatic vein anastomosed end to side to graft. The graft is trimmed at the time of reimplantation according to the length needed, but we have found that it is sensible to locate the liver remnant lower than normal in the abdomen to prevent tension on the subsequent portal vein and hepatic artery anastomoses. Note that the liver remnant is fatty and congested following extensive chemotherapy and venous obstruction, but the volume is good as it has hypertrophied in response to the major tumour involvement in the rest of the liver. (f) The liver has been reperused after reimplantation. A Roux-en-Y hepaticojejunostomy has completed the surgery







**Fig. 7.3** (continued)

**Fig. 7.3** Example case 2: A 56-year-old female with multiple colorectal metastases. In this case, a Dacron graft was used and although the initial progress was good, at 6 weeks, a Budd-Chiari-like syndrome occurred due to graft compression probably associated with liver remnant hypertrophy. Endovascular stents placed in the hepatic veins resolved the situation, with resolution of transaminitis and a massive diuresis immediately after the procedure. Histology showed the resection was R0. Recurrence occurred after 2 years with death at 30 months. (a) MRI shows proximity of tumour to IVC and hepatic veins. (b) The abdomen after hepatectomy, with vascular clamps in place just before the portal vein and systemic veno-venous bypass was established. (c) Liver removed and flushed with UW organ preservation solution. (d) Resection using CUSA to preserve only the majority of liver segments 4B, 5 and 6. (e) Resection completed, with liver segments 4B, 5 and 6 shown in the lower part of the picture. (f) Reconstruction of the intrahepatic right and middle hepatic veins directly to the Dacron graft whilst keeping the liver cold in the preservation solution. (g) Completion of the vascular anastomosis to the graft. (h) The segment 4B/5/6 graft ready for implantation. Fibrin glue has been sprayed on the liver surface to help with haemostasis. (i) The liver remnant has been reimplanted and reperused. A Doppler probe is assessing blood flow. (j) Venogram showing lack of IVC graft flow at the time of the Budd-Chiari-like syndrome which occurred. (k) Endovascular stents placement in the hepatic veins resolved the situation

of an old incision site from previous surgery, but inevitably a variety of approaches are satisfactory and depend on surgeon preference and the availability of mechanical retractors. In our practice, an upper midline incision with a right or full transverse extension is used most commonly. Adhesions should be divided to assess the primary tumour site and a careful examination of all peritoneal surfaces carried out. Doubtful areas should be sampled for frozen section histopathological analysis, and samples should also be taken from the coeliac nodes as this may suggest a more conservative approach for metastatic disease. The liver should be fully mobilised to allow adequate examination of the tumour and uninvolved liver. It is usual to sling the portal triad structures individually and the inferior vena cava above and below the liver. In addition, one must decide whether to divide the right suprarenal vein or not, and this will depend on the position of the tumour in relation to the inferior vena cava (and whether the lower IVC clamp will be above or below this vein).

The use of intraoperative ultrasound can provide additional information about the relationship of the tumour to portal triad and hepatic venous structures and may detect small metastases not seen on the preoperative CT or MRI. Although much information will have been gained by preoperative radiology, careful dissection to examine the hepatic artery and portal vein in perihilar cholangiocarcinoma or the inferior vena cava in metastatic disease, intrahepatic cholangiocarcinoma or hepatocellular carcinoma is recommended. This can all be completed without commitment to any irreversible steps, although we have frequently observed that final decisions about the degree of vessel invasion are made after liver resection and on the back table. For example, in cases where only parts of segments 2 and 3 are to be reimplanted, close application of the tumour to the portal bifurcation may necessitate resection to the level of the segmental divisions of the left portal vein. In addition, involvement of the biliary tree by metastatic tumours can necessitate a cholangiocarcinoma style approach, with resection of the biliary tree to the segmental level in order to gain a margin of surgical clearance.

Major blood vessel involvement should not prevent successful surgical resection as there are many strategies for vessel repair and conduit formation. Often an adequate repair can be created by a simple suture technique or end-to-end anastomosis. We have observed that an effective angioplasty/venoplasty patch can be created using vein remnants from the excised portion of the liver. Alternatively, the saphenous vein can be used to replace the hepatic artery, or opened out sections can be sutured together to create a wider vessel to repair the portal vein or inferior vena cava. The internal jugular vein, internal iliac vein, or external iliac vein can be used to replace a section of portal vein without compromise as collateral channels open up. If a wide area of inferior vena cava must be excised, then it is our preference to use a prosthetic graft. Some experience with vascular conduits made from vessels retrieved along with donor organs has also been reported, but there is a theoretical risk of allograft rejection and stricture formation. It has been our practice to use a jejunal Roux loop for biliary diversion to reduce the chance of ischemic stricture formation following biliary re-anastomosis.

In summary, there are many surgical options that should be considered when deciding operability.

### **7.6.2 Liver Mobilisation and Excision**

The liver needs to be completely separated from the posterior abdominal wall and any lumbar veins draining into the IVC between the diaphragm, and the right supra-renal (adrenal) vein must usually be ligated and divided so that the IVC can be encircled in slings above and below the liver. This sounds straightforward, but it can be fraught with difficulty as the liver is often congested due to chronic venous obstruction. The common bile duct is divided and ligated. The portal vein and hepatic artery should be mobilised so that they can be clamped individually, maximising lengths for subsequent re-anastomosis. The femoral (IVC) bypass is begun at this stage before vascular clamps are applied to the portal vein, the hepatic artery and the superior and inferior levels of the IVC to be excised. The liver is now ischemic, and it should be rapidly removed to the bench. The portal limb of the bypass is inserted and secured with a snigger technique and portal bypass begun. Once portal and systemic veno-venous bypass has been established, the patient should remain stable for several hours.

### **7.6.3 Hepatic Perfusion and Preservation**

Once the liver has been removed, it must be flushed (down the portal vein for cooling then down the hepatic artery and biliary tree) with a suitable organ preservation solution and cooled to 0–4 °C as in liver transplantation. UW solution is the current “gold standard” for liver preservation and is our choice for ex situ work. The accepted length of times for perfusion and preservation of a liver on the back table prior to reimplantation is not established, but our experience suggests that ex situ dissection times of between 2 and 5 h are associated with good results. The dissection bowl is kept cool by sitting it on sterile crushed ice.

### **7.6.4 Ex Situ Resection and Reconstruction**

Hepatic parenchymal fracture techniques or ultrasonic dissection (cavitron ultrasonic surgical aspirator—CUSA) may be used without the fear of blood loss during the back table dissection phase, but great care must be taken to ligate or clip all visible vessels or ducts to avoid significant haemorrhage at reperfusion. It is our practice to use a tissue sealant such as a fibrin glue at the end of dissection. The most common reason for ex situ hepatic work will be extensive involvement of the IVC or hepatic veins by tumour. Although the major hepatic veins are quite thick walled near the IVC, more peripherally they are very friable and great care needs to be taken with the choice of suture material and technique. Consideration should be given to the use of extra-venous patches to reduce tension, as is done in live donor liver transplantation. The resected IVC may be then replaced with an autologous vein graft or prosthetic graft. Whilst replacement with autologous vein has advantages in terms of infection and thrombosis, it is not always technically feasible, particularly if there is a need to

replace a long segment of IVC. In fact, we have found that the best results are obtained with IVC replacement by a ring-enforced PTFE graft. The most ideal size appears to be 20 mm in diameter and sutured with 3-0 PTFE sutures or 2-0 or 3-0 polypropylene at implantation. The hepatic vein(s) of the liver remnant needs to be anastomosed to the IVC graft, first cutting suitable-sized holes in the side of the vascular graft, and we have found that 4-0 PTFE is a good suture choice for major veins and 5-0 or 6-0 PTFE or polypropylene for smaller veins. Our preference is to carry out these anastomoses *ex situ*, but others have shown good results with IVC graft placement immediately after liver excision to reduce the need for veno-venous bypass (by creation of a temporary portocaval shunt) and then *in situ* hepatic vein anastomosis after completion of the *ex situ* resection phase. The use of a vein patch between the hepatic vein(s) and the graft may reduce tension and allow anastomosis with a lower risk of hepatic vein tears (as noted above).

Graft infection has been cited as a reason to favour the use of vein grafts whenever possible. Our experience is that the use of vein grafts is not realistic and the incidence of prosthetic graft infection is low (with only one graft infection, treated successfully with intravenous antibiotics, in a series of 35 IVC grafts performed in recent years).

Some experts have suggested that the risk of graft thrombosis may be reduced by anticoagulation, but other surgical manoeuvres have also been utilised. These include the formation of an external iliac arteriovenous fistula and the placement of a graft smaller than the surrounding native cava to increase IVC blood flow. In fact, we have tried these manoeuvres and are not impressed. The IVC flow rate is such that they are not necessary, in our opinion. Our current recommendation is to use a graft size similar to the native IVC and not to use anticoagulation or a fistula.

### **7.6.5 Hepatic Reimplantation and Reperfusion**

In our centre, the reimplantation technique is identical to that used in orthotopic liver transplantation. After the upper IVC and 75% of the lower IVC has been sutured, the liver remnant should be flushed via the portal vein with a rinse solution (such as 4.5% human albumin solution) as UW solution contains a high concentration of potassium and adenosine which can cause cardiac asystole. The lower IVC is then completed, and the portal vein bypass is stopped and the portal vein re-anastomosed. An alternative technique is a blood flush after reperfusion by closing the lower IVC anastomosis at the latter stage. It is useful to implant the liver a little lower in the abdomen than its natural position so there is no tension on the portal vein or hepatic artery (which may be shorter due to partial resection).

The IVC and portal vein clamps are removed for reperfusion. It is recommended to stay on systemic venous bypass via the femoral vein cannula until after reperfusion as this lowers the IVC pressure and may help to prevent rapid blood loss at this stage. Once haemostasis has been achieved, the bypass can be stopped (and the majority of the blood in the bypass circuit can be reinfused), and a further period of observation is needed for control of potential haemorrhage.



A direct hepatic artery to hepatic artery anastomosis will usually be possible. If a saphenous vein conduit is needed, then this is most easily anastomosed first to the liver end on the bench.

Some experts have used a duct-to-duct anastomosis but reported a high incidence of biliary stricturing, and we consider this to be related to the anastomosis being under some tension. Thus, we recommend the use of a Roux-en-Y to create a hepaticojejunostomy to the residual biliary tree without the use of t-tube or biliary stents.

---

## 7.7 Postoperative Care

The postoperative care of the ex situ liver resection patient should be similar to any major liver resection or liver transplant candidate. Nursing care should be initially on a high dependency ward or intensive care unit. We currently use an enhanced recovery (ERAS) protocol. A period of enteral supplementation may be useful in addition. Temporary gastric acid secretion suppression with a proton pump inhibitor is recommended as there is often an associated acute portal hypertension which may be additive to postoperative stress ulceration. In addition, there is usually a requirement for potassium, magnesium and phosphate supplementation intravenously following very radical resection.

We have used a low-dose intravenous infusion heparin (40 unit/kg/24 h) in our unit to help prevent hepatic arterial thrombosis in our liver transplant and ex situ resection programme, and the haematocrit is kept low at 25–35% for the first 5 days, and then we have used routine low-molecular-weight heparin for venous thromboembolism prophylaxis. As noted above, we do not routinely use anticoagulation in the long term.

---

## 7.8 Complications of Ex Situ Liver and IVC Resection

### 7.8.1 Vascular Thrombosis and Stenosis

A sudden rise in ALT postoperatively should be an indication for Doppler analysis of the portal vein and hepatic artery, and if there is any doubt, then arteriography should be performed. In our experience, if thrombosis occurs more than 7 days postoperatively after major liver resection, it can be managed conservatively. Anticoagulation with intravenous heparin and then by warfarin for 3 months should allow portal vein recanalisation or arterial collateral formation. This is at variance with experience in liver transplantation where regrafting is almost always required if early arterial thrombosis occurs.

Unfortunately, in addition, significant stenosis can occur in any of the vascular anastomoses. They are usually detected by Doppler ultrasound in response to abnormalities in liver function tests, particularly a rise in ALT (alanine aminotransferase). Radiological intervention can solve most problems by balloon angioplasty or the use of endovascular stents. In particular endovascular stent placement in our centre has been very effective in dealing with compression of a Dacron IVC graft, which caused

hepatic vein compromise after liver regeneration. In this situation, the presentation was very similar to an acute Budd-Chiari syndrome, and hepatic vein stenting resulted in an immediate diuresis and return to normal liver function tests (Fig. 7.3).

### **7.8.2 Graft-Associated Sepsis**

Ex situ IVC resection with hepatectomy is an unusual situation where a prosthetic graft is purposely implanted into a potentially infected surgical field as the gastrointestinal tract may be divided and there is a potential for bile leakage. However, graft infection is rarely reported. Prolonged intravenous antibiotic (for 6 weeks) has been necessary in one case in our centre as noted above, with a successful outcome.

### **7.8.3 Biliary Strictures**

There is a theoretical risk of biliary or biliary-enteric stricture formation. We have not experienced any difficulty in this regard, and this may be because of our preference for hepaticojejunostomy. Strictures of the external biliary tree should be dealt with in standard fashion.

---

## **7.9 Follow-Up**

Long-term follow-up after ex situ liver resection for tumour should be designed to examine the patients primarily for tumour recurrence but also for complications related to the extensive hepatic resection and vascular replacement. Tumour marker studies may indicate recurrent disease. Regular CT scans of the chest, abdomen, and pelvis form the basis of follow-up for complications and tumour recurrence at our centre at 3, 6, 12, 18 and 24 months and then annually thereafter, but there are no clear-cut guidelines. Abnormalities are followed up with MRI and PET-CT. Regular blood tests for liver enzymes and bilirubin are helpful. A progressive rise in ALT may indicate a vascular stenosis impeding hepatic inflow or outflow. Doppler ultrasound should usually be diagnostic, with rapid recourse to arteriography and venography when necessary for consideration of endovascular correction. A rise in alkaline phosphatase or bilirubin may indicate an ischemic biliary stricture or recurrent disease causing biliary obstruction.

---

## **7.10 Long-Term Results**

There exist few reports of ex situ liver resection with and without IVC resection in the world literature. Published cases and small series have detailed surgical technique but few focus on the short- and long-term outcomes. Table 7.1 reviews the main current published reports, and readers are directed to the key references. Although Table 7.1

**Table 7.1** Key studies reporting outcomes of ex situ hepatectomy and IVC resection

Author	Date	<u>n</u>	Indication	IVC replacement/ reconstruction	30 day mortality	Salvage transplant
Lodge et al.	2000	<u>4</u>	CRLM	IVC replacement	25 %	No
Malde et al.	2011	<u>6</u>	CRLM	IVC replacement/ reconstruction	16 %	–
Lechaux et al.	2002	<u>1</u>	HCC	IVC reconstruction	0	No
Oldhafer et al.	2000	<u>24</u>	HCC, CRLM, Benign	IVC replacement, IVC HV reconstruction	33 %	Yes (4)
Yagyū et al.	1994	<u>1</u>	IHCC	IVC replacement/HV reconstruction	0	No
Gringeri et al.	2002	<u>1</u>	Pancreatoblastoma	IVC replacement, HV reconstruction	0	No
Hemming et al.	1999	<u>1</u>	CRLM	IVC replacement, HV reconstruction	0	No
	2002	<u>2</u>	CRLM, HCC		0	No
	2013	<u>6</u>	CRLM, HCC		0	–

*CRLM* colorectal liver metastasis, *HCC* hepatocellular carcinoma

is compiled from the reports of combined liver and IVC resections reported to date, there is still no clear information on meaningful differences in patients operated on for varying tumour types. The perioperative mortality risk is reported as between 4 and 40% with many of these patients in the terminal phase of their illness at the time of surgery [1–15]. Disease recurrence is inevitable for some of the surviving patients as the tumours have been so extensive at the time of presentation. Five-year survival rates of 22–38% after combined liver and IVC resection have been reported [2, 3, 4, 5, 16]. Our experience does suggest, however, that a significant period of good-quality palliation can be achieved by these aggressive surgical techniques. In addition, as these techniques become more practised, the risks should reduce.

### Conclusion

Tumours involving all three major hepatic veins and IVC invasion continue to pose a surgical challenge, and the combined techniques of hepatic resection and transplantation offer a potential lifeline for this unfortunate group of patients. Ex situ resection of the inferior vena cava with hepatectomy therefore deserves consideration.

### Key Points

1. Careful patient selection according to tumour type and patient fitness and hepatic reserve is essential.

2. Anaesthesia for ex situ liver resection: a standard liver resection anaesthetic becomes a liver transplant anaesthetic if the ex situ dissection proceeds.
3. Phases of ex situ liver resection surgery: liver mobilisation and excision, venovenous bypass for patient stability, hepatic perfusion and preservation, ex situ resection and reconstruction, hepatic reimplantation and reperfusion.
4. Long-term outcomes data remains limited.

### Key References

1. Lodge JP, Ammori BJ, Prasad KR, Bellamy MC (2000) Ex vivo and in situ resection of inferior vena cava with hepatectomy for colorectal metastases. *Ann Surg* 231:471–479
2. Oldhafer KJ, Lang H, Schlitt HJ et al (2000) Long-term experience after ex situ liver surgery. *Surgery* 127:520–527
3. Hemming AW, Cattral MS (1999) Ex vivo liver resection with replacement of the inferior vena cava and hepatic vein replacement by transposition of the portal vein. *J Am Coll Surg* 189:523–526

---

### References

1. Lodge JP, Ammori BJ, Prasad KR, Bellamy MC (2000) Ex vivo and in situ resection of inferior vena cava with hepatectomy for colorectal metastases. *Ann Surg* 231:471–479
2. Madariaga JR, Fung J, Gutierrez J et al (2000) Liver resection combined with excision of vena cava. *J Am Coll Surg* 191:244–250
3. Sarmiento JM, Bower TC, Cherry KJ et al (2003) Is combined partial hepatectomy with segmental resection of inferior vena cava justified for malignancy? *Arch Surg* 138:624–630, discussion 630–621
4. Vladov NN, Mihaylov VI, Belev NV et al (2012) Resection and reconstruction of the inferior vena cava for neoplasms. *World J Gastrointest Surg* 4:96–101
5. Nuzzo G, Giordano M, Giuliante F et al (2011) Complex liver resection for hepatic tumours involving the inferior vena cava. *Eur J Surg Oncol* 37:921–927
6. Malde DJ, Khan A, Prasad KR et al (2011) Inferior vena cava resection with hepatectomy: challenging but justified. *HPB (Oxford)* 13:802–810
7. Azoulay D, Andreani P, Maggi U et al (2006) Combined liver resection and reconstruction of the supra-renal vena cava: the Paul Brousse experience. *Ann Surg* 244:80–88
8. Oldhafer KJ, Lang H, Schlitt HJ et al (2000) Long-term experience after ex situ liver surgery. *Surgery* 127:520–527
9. Hemming AW, Reed AI, Langham MR Jr et al (2004) Combined resection of the liver and inferior vena cava for hepatic malignancy. *Ann Surg* 239:712–719
10. Hemming AW, Mekeel KL, Zendejas I et al (2013) Resection of the liver and inferior vena cava for hepatic malignancy. *J Am Coll Surg* 217:115–124
11. Hemming AW, Cattral MS (1999) Ex vivo liver resection with replacement of the inferior vena cava and hepatic vein replacement by transposition of the portal vein. *J Am Coll Surg* 189: 523–526
12. Hemming AW, Reed AI, Langham MR et al (2002) Hepatic vein reconstruction for resection of hepatic tumors. *Ann Surg* 235:850–858

13. Gringeri E, Polacco M, D'Amico FE et al (2012) Liver autotransplantation for the treatment of unresectable hepatic metastasis: an uncommon indication—a case report. *Transplant Proc* 44:1930–1933
14. Yagyu T, Shimizu R, Nishida M et al (1994) Reconstruction of the hepatic vein to the prosthetic inferior vena cava in right extended hemihepatectomy with ex situ procedure. *Surgery* 115:740–744
15. Lechaux D, Megevand JM, Raoul JL et al (2002) Ex vivo right trisegmentectomy with reconstruction of inferior vena cava and “flop” reimplantation. *J Am Coll Surg* 194:842–845
16. Azoulay D, Lim C, Salloum C, Andreani P, Maggi U, Bartelmaos T, Castaing D, Pascal G, Fesuy F (2015) Complex liver resection using standard total vascular exclusion, venovenous bypass, and in situ hypothermic portal perfusion: an audit of 77 consecutive cases. *Ann Surg* 262(1):93–104

---

# Surgical Treatment of Adrenocortical Carcinoma with Caval Invasion

# 8

Sebastien Gaujoux, Elisabeth Hain, Marthe Weinandt,  
Roberto Schiavone, Roberto Cuni, and Bertrand Dousset

---

## 8.1 Introduction

Adrenocortical carcinoma (ACC) is a rare endocrine tumor with an estimated incidence ranging from one to two per million per year [1], leading to 0.1–0.2% of cancer deaths [2]. It is one of the most malignant endocrine tumors, with 20–40% of synchronous metastatic disease at the time of diagnosis [3]. The 5-year overall survival is poor ranging from 30 to 40% in most series [4–7].

Surgical resection is the only potential for cure, and complete R0 resection is one of the most powerful prognostic factors [7, 8]. Locally advanced adrenocortical

---

S. Gaujoux

Department of Digestive, Hepato-biliary and Endocrine Surgery, Referral Center for Rare Adrenal Diseases, Cochin Hospital, APHP, Paris, France

Faculté de Médecine Paris Descartes, Université Paris Descartes, Sorbonne Paris Cité, Paris, France

INSERM Unité 1016, Centre National de la Recherche Scientifique Unité Mixte de Recherche 8104, Institut Cochin, Paris, France

E. Hain • M. Weinandt • R. Schiavone • R. Cuni

Department of Digestive, Hepato-biliary and Endocrine Surgery, Referral Center for Rare Adrenal Diseases, Cochin Hospital, APHP, Paris, France

B. Dousset (✉)

Department of Digestive, Hepato-biliary and Endocrine Surgery, Referral Center for Rare Adrenal Diseases, Cochin Hospital, APHP, Paris, France

Faculté de Médecine Paris Descartes, Université Paris Descartes, Sorbonne Paris Cité, Paris, France

INSERM Unité 1016, Centre National de la Recherche Scientifique Unité Mixte de Recherche 8104, Institut Cochin, Paris, France

Service de chirurgie, Hôpital Cochin, 27 rue du Faubourg Saint-Jacques,  
75679 Paris cedex 14 Paris, France

e-mail: [bertrand.dousset@aphp.fr](mailto:bertrand.dousset@aphp.fr)

© Springer International Publishing Switzerland 2017

D. Azoulay et al. (eds.), *Surgery of the Inferior Vena Cava*,

DOI 10.1007/978-3-319-25565-1\_8

carcinomas, i.e., ENSAT stage III tumors with locoregional extension, represent a challenging surgery to achieve complete R0 resection while minimizing both surgical complications and postoperative mortality. This is especially true in the setting of vena cava extension, a rare ACC presentation, representing less than 300 reported cases [9], larger series reporting less than 40 patients [9–11].

---

## 8.2 ACC and Inferior Vena Cava Extension

Vena cava extension in patients with ACC is a rare presentation. Its real incidence is unknown but is present in less than 5% of patients with ACC. This situation is usually associated with large mass, most of the time on the right side, because (1) the renal vein is shorter on this side and (2) adrenal vein directly flows in the right side of the IVC. Most cases of IVC invasion (85%) are represented by tumor thrombus extension originating from a right-sided ACC without microscopic venous invasion.

ACC can affect the IVC either by compression, by direct invasion, or by intraluminal extension in the form of tumor thrombus, usually without attachment to the vein wall. In most cases, IVC tumor thrombus is not obstructive, therefore associated with persistence of inferior vena caval and hepatic venous outflow. Despite anatomical barriers (diaphragmatic hiatus and eustachian valve), tumor thrombus can subsequently progress to the cavo-atrial junction into the right atrium. Intravenous extension into the tricuspid valvular plan is an exceptional occurrence [12]. However, retrograde extension of thrombus into the suprahepatic veins, contralateral renal vein, or infrarenal IVC may occur once resistance has been overcome. The formation of non-tumoral fibrinocruoric thrombosis upstream to the IVC tumor thrombus may lead to complete caval obstruction of the infrarenal IVC and promote the recruitment of collateral veins. By the same mechanisms, acute Budd-Chiari syndrome has been reported as a rare complication of suprahepatic IVC tumor thrombus [9, 13].

In the natural history of adrenocortical carcinoma, large vessel extension is associated with decreased overall and recurrence-free survival [11]. Regardless of tumor size, large vessel invasion turns the stratification of the tumor into ENSAT stage III (Table 8.1). Long-term prognosis of ACC extending into the IVC remains poor.

---

## 8.3 Preoperative Workup

Adrenocortical carcinomas with IVC invasion are mainly diagnosed on clinical symptoms associated with hormonal oversecretion or secondary to mass effect (abdominal pain, palpable mass, or signs of compression). Clinical history and examination should assess (1) symptoms related to excess hormone production, including cortisol excess, Cushing's syndrome, androgen/estrogen excess (virilization in females, feminization in males), signs/symptoms suggestive of multiple hormonal oversecretion, and high blood pressure [14–16] and (2) local compressive symptoms of a large mass, usually nonsecreting, including abdominal or flank pain,



**Table 8.1** ENSAT classification

Stage	ENSAT	Definition
I	T1 ( $\leq 5$ cm), N0, M0	T1: Tumor $\leq 5$ cm, localized
II	T2 ( $> 5$ cm), N0, M0	T2: Tumor $> 5$ cm, localized
III	T1 or T2, N1, M0 T3 or T4, N0/1, M0	T3: Tumor infiltration into the surrounding adipose tissue T4: Tumor invasion into adjacent organs or a tumor thrombus in the vena cava/renal vein
IV	M1	Presence of distant metastasis

**Table 8.2** Minimal biochemical assessment for suspected adrenocortical carcinoma

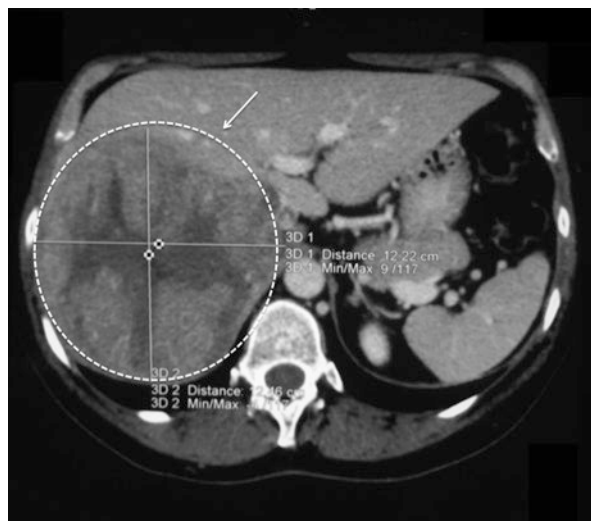
Glucocorticoid	Midnight serum cortisol Basal serum ACTH 24-h urinary-free cortisol 1-mg overnight dexamethasone suppression test
Androgens or precursor oversecretion	DHEA-S (serum) 17-OH-progesterone, compound S (serum) Androstenedione (serum) Testosterone (serum) 17 $\beta$ -estradiol (serum), in men and menopausal women Deoxycorticosterone (DOC; serum)
Mineralocorticoid oversecretion	Potassium Aldosterone and renin serum levels
Catecholamine oversecretion	24-h urinary metanephrines and normetanephrines

abdominal distension, early satiety, nausea/vomiting, weight loss, leg edema, and development of parietal collateral veins [14–17].

Biochemical and hormonal assessment (Table 8.2) should be complete to detail any abnormal oversecretion including steroid precursors, androgens, and cortisol and exclude a malignant pheochromocytoma (24-h urinary meta- and normetanephrine dosage).

The goals of imaging workup are to stage the tumor (locoregional extension, venous invasion, distant metastasis) and assess the surgical resectability. This should include thoracoabdominal CT scan, abdominal MRI (Fig. 8.1), and [18] F-fluorodeoxyglucose positron emission tomography (PET scan). The second step of imaging workup is to specify the upper level of the thrombus and direct invasion of the caval wall. This is best achieved by the combination of angio-CT scan and angio-MRI, which are currently considered the most accurate modalities for assessment of ACC with IVC extension [18–21]. Both these noninvasive techniques provide direct evidence of tumor thrombus by demonstrating enlargement of the IVC, and multiplanar reconstruction (MPR) might help to visualize intravenous extension on axial, sagittal, and coronal sections [22]. In most cases, the diagnosis of tumor invasion of caval wall is not reliably detected by preoperative imaging studies and usually made during surgical exploration. In return, the distinction between tumoral and upstream fibrinocruoric thrombus of the IVC can be assessed by the different sequences and multiplanar reconstructions of MRI. In case of thrombus extension, through the cavo-atrial junction or into the right

**Fig. 8.1** Large right adrenocortical carcinoma invading the inferior vena cava



atrium, transesophageal ultrasonography and cardiac MRI can both assess the anatomical upper limits of intracardiac extension and provide useful myocardial and hemodynamic parameters in patients presenting right atrial involvement. These complementary studies should be in our experience performed when the thrombus extends beyond the hepatic veins and when either intrapericardial hepatic vascular exclusion or cardiopulmonary bypass might be required. Conventional cavography is no more used in the preoperative workup of ACC with IVC involvement. Lower extremity deep venous thrombosis should furthermore be excluded by venous Doppler ultrasonography prior to surgical resection of ACC with IVC invasion.

## 8.4 Neoadjuvant Treatment

In patients with borderline resectable ACC, preoperative chemotherapy might represent an option, in order to select nonprogressive patients and obtain a significant shrinkage of the tumor thrombus [23]. Nevertheless, in view of the few data available, the limited response rate of current chemotherapy schedules, and risks of tumor thrombus embolism, upfront surgery remains the best therapeutic option in patients with borderline resectable ACC with IVC invasion.

## 8.5 Surgical Management

Surgical treatment should be considered a priority in patients with resectable ACC with IVC invasion. In metastatic ACC or borderline resectable ACC with IVC invasion, the decision for surgery should be made within the context of a multidisciplinary tumor board. This should take into account several factors including age and presence of comorbidities, risk of tumoral pulmonary embolism, severity of

hormonal oversecretion, clinical symptoms of an important adrenal mass, and expertise of the surgical team. The diagnostic and therapeutic pitfalls specific to ACC extending into the IVC were first described in 1972 by Castleman et al. [24]. The use of cardiopulmonary bypass (CPB) techniques to facilitate tumor resection in patients with caval involvement was reported 4 years later by Scully et al. [25]. In 1989, Shahian et al. [26] reported the first procedure using cardiopulmonary bypass (CPB) with hypothermic circulatory arrest (HCA).

Resection of a large ACC raises additional specific problems. The difficulty of achieving “en bloc” resection of a friable tumor without rupturing the peripheral capsule is enhanced by the presence of tumor neovascularization and development of venous collateral circulation due to both tumor size and caval obstruction. The fragility of tissue secondary to prolonged steroid oversecretion may furthermore increase the risks of hemorrhage or tumor disruption. Most ACC with IVC are represented by large stage III (regional involvement of adjacent organs) or stage IV (pulmonary and/or liver metastases) tumors [9]. In stage III disease, ipsilateral nephrectomy and locoregional lymphadenectomy are in our experience constantly required to ensure adequate “en bloc” and safe resection of the primary, which may be associated with right hepatectomy for right ACC or distal pancreatectomy with splenectomy for left ACC in case of locoregional invasion to adjacent organs. This furthermore allows primary vascular control of arterial inflow to the tumor and reduction of blood loss. In stage IV metastatic disease, after careful discussion of surgical indication, ipsilateral nephrectomy and locoregional lymphadenectomy are usually performed together with resection of liver metastases in the absence of concomitant lung metastases, whereas lung metastases are not considered for simultaneous resection.

The optimal approach for surgical resection of ACC with IVC extension depends on the size of the primary tumor, upper limit of intravenous extension, and need for associated procedures (nephrectomy, lymphadenectomy, hepatectomy, distal pancreatectomy, and splenectomy). Bilateral subcostal approach combined with a midline vertical incision appears in most cases the best option for a large exposure, mobilization of the liver, and exposure of the subdiaphragmatic IVC. This approach can be extended to vertical sternotomy when cardiopulmonary bypass with hypothermic cardiac arrest is requested. In favorable patients, midline incision combined with right transverse extension may be sufficient, whereas others have advocated the use of a thoracoabdominal approach extending from the xiphoid appendix to the costochondral junction and extension into the seventh intercostal space.

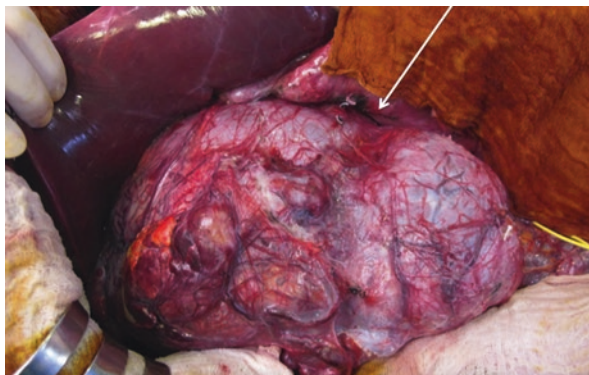The modality used for venous control depends on the location and extent of tumor involvement and the amount of collateral venous circulation.

## **8.5.1 Tumor Thrombus Located Below the Suprahepatic Veins**

### **8.5.1.1 Thrombus Extension Limited to Infrahepatic IVC**

This represents the most frequent clinical situation (Fig. 8.2). Cross-clamping of the IVC can be sufficient if the upper limit of tumor thrombus is located below the suprahepatic veins. Thrombectomy is effective for resection of tumor thrombus not

**Fig. 8.2** Intraoperative view of a right adrenocortical carcinoma invading the inferior vena cava

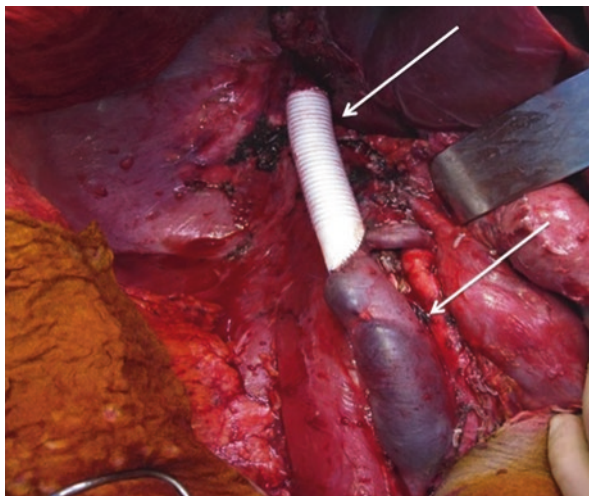


involving the venous wall. IVC should be freed up to 2 cm above the upper limits of the thrombus. Vertical cavotomy can be confined to the anterior wall of the IVC, or phlebotomy can be initiated in the renal or adrenal vein and extended to the IVC. Tumor thrombus associated with ACC has a jellylike, friable consistency similar to that of the primary tumor [27]. Resection usually begins with dissection of minor adhesences to the caval wall [28] occurring at the level of the ostia of the right adrenal vein or left renal vein. Next, retrograde thrombectomy is performed by gently pulling the endoluminal mass down through the cavotomy. Closure of cavotomy can usually be done by direct suture. The use of prosthetic (Fig. 8.3) or peritoneal patch should be considered if narrowing exceeds 50% or if there is a significant risk of postoperative thrombosis.

### **8.5.1.2 Thrombus Extension to Retrohepatic IVC**

In cases of retrohepatic IVC involvement by ACC, IVC reconstruction is typically recommended because collateral circulation is often reduced during dissection and nonadherent thrombus is not always associated with extensive collaterals [29–31]. Most of the time, the homolateral kidney to the lesion is removed en bloc. This situation always requires full right liver mobilization, 360° dissection of the retrohepatic IVC, up to the IVC below the hepatic vein confluence. IVC reconstruction can require reimplantation of contralateral renal veins whenever possible, avoiding acute renal failure. This is particularly true for the right kidney, which has a short vein without collaterals precluding renal function preservation in cases of simple ligation. Nevertheless a slanting IV section can often preserve the contralateral renal ostium avoiding renal vein clamping and kidney warm ischemia. Reconstruction of the IVC is not required, when collateral circulation is well developed because gradual occlusion of the IVC allows the development of venous collaterals [32]. End-to-end renal vein anastomosis after a retrohepatic IVC resection including the renal vein confluence should be considered as an alternative option for preserving the right kidney when IVC reconstruction is not possible or should be avoided [33]. If IVC replacement is required because of tumor extension to the venous wall, a ringed polytetrafluoroethylene (PTFE) graft should be used. Its size should be a little bit smaller than the native IVC to promote faster velocities through the graft segment and avoid thrombus formation.

**Fig. 8.3** Intraoperative view after tumor resection and inferior vena cava prosthetic replacement



### 8.5.2 Tumor Thrombus Extending Above the Suprahepatic Veins and Below the Cavo-Atrial Junction

It is important to note that most of the time the tumor thrombus is mobile at least on its upper portion. After total mobilization of the right liver, full 360° liberation of the IVC, hepatic vascular exclusion (HVE) is the technique of choice for patients with extension into the retrohepatic or interhepato-diaphragmatic IVC. As previously reported [34], control of the suprahepatic veins or IVC often requires a 5 to 7 cm-diaphragm incision 2–3 cm above the vena caval foramen. It is often necessary to ligate the termination of the left and right inferior phrenic veins at both ends. After, the dissection plan follows the space between the inferior part of the pericardium and the diaphragm. When the supradiaphragmatic IVC is identified, it is dissected on both side; a large blunt dissector is used to tape the intrapericardial portion of the vena cava. Lowering the liver during the procedure puts the IVC in tension and opens the space between the pericardium and the diaphragm. It is important during the dissection to pay a special attention to the right pleura that can be accidentally open. Once the HVE is performed, the thrombus, when free, is first extracted, allowing the replacement of the clamp below the hepatic vein, limiting HVE duration and warm hepatic ischemia. Despite the theoretical risk of engorgement of the liver, we recommend that the upper clamp be placed on the suprahepatic IVC immediately after clamping of the portal triad in order to lower the risk of massive tumor embolization. Tolerance of HVE is generally good in patients with well-developed collateral circulation, but fluid expansion can be performed if necessary [35]. Clamping of the supraceliac aorta can limit blood loss during resection of highly vascularized tumors but is rarely needed. In patients with suprahepatic IVC involvement but below the cavo-atrial junction, cross-clamping of the intrapericardial IVC or partial clamping of the right atrium during HVE can be performed. Usually, thrombectomy, at least of the proximal part of the thrombus, is possible, making unnecessary the replacement of all the IVC with hepatic vein reimplantation.

### 8.5.3 Tumor Thrombus Is Located Above the Cavo-Atrial Junction

In most cases, cross-clamping of the intrapericardial IVC or partial clamping of the right atrium during HVE can be successfully used for resection of tumors extending as far as the lower edge of the cavo-atrial junction [29]. Initially, intraoperative ultrasound can be used to localize the thrombus within the lumen. Inflow control is accomplished with a combination of clamping of the infrahepatic vena cava and a Pringle maneuver (hepatic artery and portal vein control). As in the previously reported experience [36], outflow control requires suprahepatic, supradiaphragmatic, and intrapericardial IVC control and clamping. The tumor thrombus is usually gently pulled down from the cavo-atrial junction or the atrium before clamping the intrapericardial IVC. After IVC opening, digital manipulation and balloon catheter withdrawal can be used to remove the tumor thrombus. When the tumor thrombus is pulled down, the superior clamp as previously described can be transposed below the hepatic vein confluence in order to minimize the duration of HVE.

We consider that CPB needs to be used in patients with tumors extending to the cavo-atrial junction or into the right atrium in about only a third of cases. This situation needs to be preoperatively discussed with cardiac surgeon and anesthesiologist, and, in case of doubt, the procedure needs to be performed in a bypass ready operating room with cardiothoracic surgical teams available. In our opinion, cross-clamping of the intrapericardial IVC during CPB is justified in patients presenting very high risk for embolization or excessive cavocaval collateral circulation. In addition to preventing embolization, CPB allows more precise dissection by reducing bleeding and lowers the risk of cardiac arrest during caval cross-clamping [35, 37]. An advantage of hypothermic circulatory arrest for resection of tumors extending to the upper edge cavo-atrial junction is to provide a bloodless operating field and thus allow resection under visual control. In case of involvement of the end of the IVC, vertical right atriotomy can be extended by cavotomy toward the suprahepatic veins. In cases involving extension to the supradiaphragmatic IVC, antegrade thrombectomy may be a safer method for clearing suprahepatic veins.

---

## 8.6 Results

The literature regarding IVC for ACC is scarce and consequently biased. Table 8.3 reports main series of resection for ACC, excluding clinical cases, on IVC or large vessels, i.e., renal veins. Main series reports less than 40 patients, and from these observations, we can expect that IVC involvement in ACC concerns between 5 and 10% of patients. Most of the time, the thrombus is located below the hepatic veins, and thrombectomy is most of the time sufficient to achieve a R0 resection. It is important to note that IVC involvement is considered as a negative prognostic factor in the ENSAT classification.

**Table 8.3** Summary of the main surgical series reporting IVC resection for ACC

Authors/years	Number of patients	IVC involvement	Distal location of the thrombus	Need for prosthesis	Postoperative mortality	Disease-free survival	Overall survival
Chiche/2006	105	14.3 %	Below the liver <i>n</i> =2 Behind the liver <i>n</i> =6 Above the liver <i>n</i> =7 Extension to right atrium <i>n</i> =4	<i>n</i> =2	13 %	–	8 months (median)
Mihai/2012	35	–	Prehepatic IVC <i>n</i> =21 Subdiaphragmatic IVC <i>n</i> =6 SVC/right atrium <i>n</i> =3	3 vein graft	13 %	–	24 months (median)
Ohwada/2007	6	–	–	<i>n</i> =3	0 %	20±7.7 months (median)	6.1±9.8 months (median)
Bednars/2014	53	–	–	–	–	About 20 months (median)	About 60% (5 years)
Libé/2015	444	–	–	–	–	–	24 months (median)
Turbendian/2010	57	<i>n</i> =39 (IVC and large vessels)	–	–	–	3 years (median)	6 years (median)
Heddican/1997	3	–	–	No	30 %	8 months	–



## Conclusion

Involvement of the inferior vena cava by adrenocortical carcinoma is rare and associated with impaired oncologic outcome. Neoadjuvant chemotherapy is often poorly effective, while upfront complete surgical resection is potentially curative and should be preferred.

The surgery procedure mainly depends on the upper limit of intracaval extension:

- If the tumor thrombus is located below the suprahepatic veins, this representing the most frequent clinical situation, cross-clamping of the IVC is sufficient.
- If the tumor thrombus is located between the suprahepatic veins and the cavo-atrial junction, hepatic vascular exclusion is the technique of choice, with intra- or extrapericardial suprahepatic control.
- If the tumor thrombus is located above the cavo-atrial junction, hepatic vascular exclusion with intrapericardial suprahepatic control can most of the time be done; otherwise, the use of cardiopulmonary bypass should be considered.

## Key Points

- Caval invasion in patients with adrenocortical carcinoma is rare.
- In our experience, the upper level of caval extension is best documented by the combination of transesophageal echocardiography, CT scan, or angio-MRI.
- Most cases are represented by venous invasion and intracaval progression of a tumor thrombus originating from the primary adrenal tumor.
- Direct invasion to the venous wall is often limited and can be treated by partial wedge resection with direct closure or interposition of a patch.
- Caval resection with prosthetic replacement is indicated in less than 5% of the cases.
- The upper level of caval invasion can be located below, behind, or above the hepatic vein confluence, with or without right atrial extension.
- In most instances, caval thrombectomy can be performed by cross-clamping of the IVC, conventional hepatic vascular exclusion, intrapericardial hepatic vascular exclusion, or cardiopulmonary bypass with hypothermic circulatory arrest.

## Key References

- Chiche L et al (2006) Adrenocortical carcinoma extending into the inferior vena cava: presentation of a 15-patient series and review of the literature. *Surgery* 139(1):15–27
- Mihai R et al (2012) Outcome of operation in patients with adrenocortical cancer invading the inferior vena cava—a European Society of Endocrine Surgeons (ESES) survey. *Langenbecks Arch Surg* 397(2):225–231
- Turbendian HK et al (2010) Adrenocortical carcinoma: the influence of large vessel extension. *Surgery* 148(6):1057–1064, discussion 1064

- Schteingart DE et al (2005) Management of patients with adrenal cancer: recommendations of an international consensus conference. *Endocr Relat Cancer* 12(3):667–680
- Libe R et al (2015) Prognostic factors in stage III-IV adrenocortical carcinomas (ACC): an European Network for the Study of Adrenal Tumor (ENSAT) study. *Ann Oncol* 26(10):2119–2125
- Margonis GA et al (2015) Adrenocortical carcinoma: impact of surgical margin status on long-term outcomes. *Ann Surg Oncol*, Epub

---

## References

1. Schteingart DE et al (2005) Management of patients with adrenal cancer: recommendations of an international consensus conference. *Endocr Relat Cancer* 12(3):667–680
2. Wajchenberg BL et al (2000) Adrenocortical carcinoma: clinical and laboratory observations. *Cancer* 88(4):711–736
3. Abiven G et al (2006) Clinical and biological features in the prognosis of adrenocortical cancer: poor outcome of cortisol-secreting tumors in a series of 202 consecutive patients. *J Clin Endocrinol Metab* 91(7):2650–2655
4. Icard P et al (2001) Adrenocortical carcinomas: surgical trends and results of a 253-patient series from the French Association of Endocrine Surgeons study group. *World J Surg* 25(7):891–897
5. Icard P, Louvel A, Chapuis Y (1992) Survival rates and prognostic factors in adrenocortical carcinoma. *World J Surg* 16(4):753–758
6. Libe R et al (2015) Prognostic factors in stage III-IV adrenocortical carcinomas (ACC): an European Network for the Study of Adrenal Tumor (ENSAT) study. *Ann Oncol* 26(10):2119–2125
7. Ayala-Ramirez M et al (2013) Adrenocortical carcinoma: clinical outcomes and prognosis of 330 patients at a tertiary care center. *Eur J Endocrinol* 169(6):891–899
8. Margonis GA et al (2015) Adrenocortical carcinoma: impact of surgical margin status on long-term outcomes. *Ann Surg Oncol*
9. Chiche L et al (2006) Adrenocortical carcinoma extending into the inferior vena cava: presentation of a 15-patient series and review of the literature. *Surgery* 139(1):15–27
10. Mihai R et al (2012) Outcome of operation in patients with adrenocortical cancer invading the inferior vena cava--a European Society of Endocrine Surgeons (ESES) survey. *Langenbecks Arch Surg* 397(2):225–231
11. Turbendian HK et al (2010) Adrenocortical carcinoma: the influence of large vessel extension. *Surgery* 148(6):1057–1064, discussion 1064
12. Friedrich MG et al (1994) Adrenal carcinoma with intravenous extension into the tricuspid valvular plane in a patient with patent foramen ovale. *Eur Heart J* 15(5):708–709
13. Carbonnel F et al (1988) Acute Budd-Chiari syndrome as first manifestation of adrenocortical carcinoma. *J Clin Gastroenterol* 10(4):441–444
14. Zini L, Porpiglia F, Fassnacht M (2011) Contemporary management of adrenocortical carcinoma. *Eur Urol* 60(5):1055–1065
15. Low G, Sahi K (2012) Clinical and imaging overview of functional adrenal neoplasms. *Int J Urol* 19(8):697–708
16. Libe R, Fratticci A, Bertherat J (2007) Adrenocortical cancer: pathophysiology and clinical management. *Endocr Relat Cancer* 14(1):13–28
17. Donatini G et al (2014) Long-term survival after adrenalectomy for stage I/II adrenocortical carcinoma (ACC): a retrospective comparative cohort study of laparoscopic versus open approach. *Ann Surg Oncol* 21(1):284–291
18. Schramek P et al (1985) Adrenal cortical carcinoma: preoperative demonstration of right atrial extension by sonography and computerized tomography. *J Urol* 133(2):260–262

19. Pritchett TR et al (1987) Preoperative magnetic resonance imaging of vena caval tumor thrombi: experience with 5 cases. *J Urol* 138(5):1220–1222
20. Francis IR et al (1992) Integrated imaging of adrenal disease. *Radiology* 184(1):1–13
21. Smith SM et al (1989) Magnetic resonance imaging of adrenal cortical carcinoma. *Urol Radiol* 11(1):1–6
22. Decker RA, Kuehner ME (1991) Adrenocortical carcinoma. *Am Surg* 57(8):502–513
23. Bednarski BK et al (2014) Borderline resectable adrenal cortical carcinoma: a potential role for preoperative chemotherapy. *World J Surg* 38(6):1318–1327
24. Castleman B, Scully RE, McNeely BU (1972) Case records of the Massachusetts General Hospital. Weekly clinicopathological exercises. Case 39–1972. *N Engl J Med* 287(13):656–663
25. Scully RE, Galdabini JJ, McNeely BU (1976) Case records of the Massachusetts General Hospital. Weekly clinicopathological exercises. *N Engl J Med* 294(13):712–720
26. Shahian DM, Nieh PT, Libertino JA (1989) Resection of atriocaval adrenal carcinoma using hypothermic circulatory arrest. *Ann Thorac Surg* 48(3):421–422
27. Moul JW, Hardy MR, McLeod DG (1991) Adrenal cortical carcinoma with vena cava tumor thrombus requiring cardiopulmonary bypass for resection. *Urology* 38(2):179–183
28. Cheung PS, Thompson NW (1989) Right atrial extension of adrenocortical carcinoma. Surgical management using hypothermia and cardiopulmonary bypass. *Cancer* 64(4):812–815
29. Huguet C et al (1994) Neoplastic thrombosis of the inferior vena cava involving the right atrium caused by adrenal cortical carcinoma. A new indication for vascular exclusion of the liver. *Ann Chir* 48(4):364–369
30. Bower TC et al (1993) Vena cava replacement for malignant disease: is there a role? *Ann Vasc Surg* 7(1):51–62
31. Gloviczki P et al (1990) Reconstruction of the vena cava and of its primary tributaries: a preliminary report. *J Vasc Surg* 11(3):373–381
32. Wang Q et al (2012) Leiomyosarcoma of the inferior vena cava level II involvement: curative resection and reconstruction of renal veins. *World J Surg Oncol* 10:120
33. Araujo RL et al (2014) End-to-end renal vein anastomosis to preserve renal venous drainage following inferior vena cava radical resection due to leiomyosarcoma. *Ann Vasc Surg* 28(4):1048–1051
34. Le Treut YP et al (2013) Transdiaphragmatic extrapericardial approach of the inferior vena cava. *J Am Coll Surg* 217(5):e41–e43
35. Smith BM et al (1984) Suprarenal vena caval occlusion. Principles of operative management. *Ann Surg* 199(6):656–668
36. Patil MB et al (2014) Level III-IV inferior vena caval thrombectomy without cardiopulmonary bypass: long-term experience with intrapericardial control. *J Urol* 192(3):682–688
37. Hedican SP, Marshall FF (1997) Adrenocortical carcinoma with intracaval extension. *J Urol* 158(6):2056–2061

Jean-Marc Alsac, Paul Achouh, Eleonora Du Puymontbrun,  
Alain Bel, Jerome Jouan, Suzanna Salvi, Julia Pouly,  
and Jean-Noël Fabiani

---

## 9.1 Introduction

Abdominal tumors with involvement of the inferior vena cava (IVC) are most frequently of renal origin or sarcomas [1]. Ten percent of renal tumors invade the IVC, and 1% extend up to the right atrium [2, 3]. Nevertheless, extensive caval infiltration or extension to the heart is uncommon. This latter situation is challenging as surgical difficulties and postoperative complications rise along with the level of extension of the thrombus in the IVC and the involvement of surrounding structures [4, 5]. Even in the presence of local invasion or metastasis, surgical resection is the only treatment shown to improve survival in these patients [5, 6]. The use of cardiopulmonary bypass (CPB), for tumors extending to the level of the hepatic veins or into the atrium, is highly recommended [5, 7]. Several series report the use of CPB with deep hypothermia and circulatory arrest (DHCA) [3, 7], but these procedures are associated with significant mortality. For renal cell carcinoma with cavoatrial extension, a recent multi-institutional study reported an 8.3% operative mortality with the use of DHCA [3]. Despite the fact that deep hypothermia provides organ protection, circulatory arrest is associated with a higher risk of neurologic complications and ischemia—reperfusion injury [8]. We reported our experience with the use of CPB and deep hypothermia without circulatory arrest in the surgical treatment of abdominal tumors with IVC and right atrial involvement [9].

---

J.-M. Alsac, MD, PhD • P. Achouh, MD, PhD • E. Du Puymontbrun, MD • A. Bel, MD  
J. Jouan, MD • S. Salvi, MD • J. Pouly, MD • J.-N. Fabiani, MD (✉)  
Service de Chirurgie Cardiaque et Vasculaire, Hôpital Européen Georges Pompidou, AP-HP,  
Faculté de Médecine René Descartes, Université Paris 5, Paris, France  
e-mail: [jean-noel.fabiani@egp.aphp.fr](mailto:jean-noel.fabiani@egp.aphp.fr)

## 9.2 Preoperative Staging

The staging should include thoracoabdominal computed tomography scan and magnetic resonance angiography to assess tumor extension and rule out metastasis. The upper extent of the tumor thrombus is defined in accordance with the classification of Neves and Zincke [10], which encompasses four stages. Stage 1 includes tumors with thrombus extension less than 2 cm in the IVC. Stage 2 is for thrombus extension below the hepatic veins. Intrahepatic IVC thrombus extension that remains below the diaphragm corresponds to stage 3. Thrombus extension above the diaphragm is stage 4. In case of cardiac extension of the tumoral thrombus, the tumor may cross the tricuspid valve. Acute Budd-Chiari syndrome can be seen preoperatively in case of severe hepatic vein obstruction.

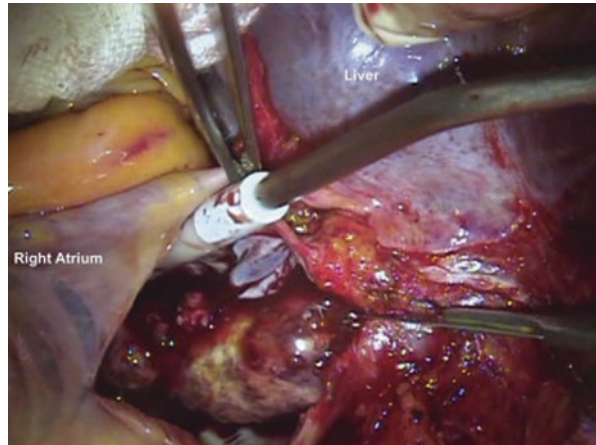
## 9.3 Surgical Technique

Under general anesthesia, the right common femoral vein is exposed through a groin incision and prepared for cannulation. A complete median sternotomy is performed. Depending on the location of the primary tumor, the sternotomy should be extended through a right subcostal incision for right renal, hepatic, and primary IVC tumors. Bilateral subcostal incision or median laparotomy should be used for left renal and left adrenal primary tumors. The pericardium is opened, and the ascending aorta is cannulated. The superior vena cava and common femoral vein are cannulated to ensure venous drainage of the upper half and lower half of the body. Mobilization of the right colon is followed by a Kocher maneuver to expose the IVC and the renal veins. The falciform ligament and the right triangular ligament are incised to allow a right hepatic lobe mobilization and exposure of the suprarenal and retrohepatic vena cava. An anteroposterior phrenotomy is achieved, widely exposing the hepatic veins and the cavoatrial junction.

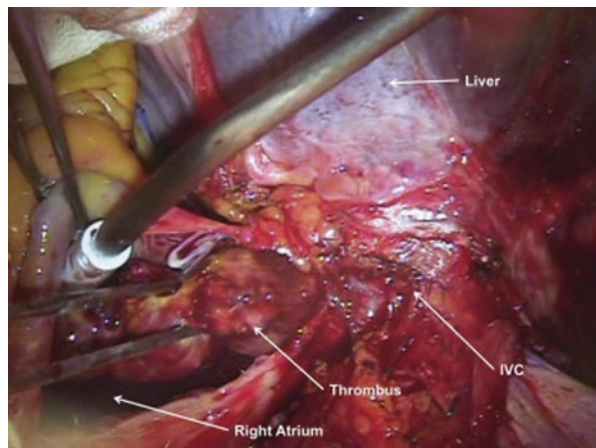
Concomitant to the beginning of tumor resection and vena cava dissection, CPB is started and systemic cooling initiated until cessation of all electrical brain activity. This would usually be achieved at an esophageal temperature of 18–20 °C. The decrease and then cessation of electrical brain activity is assessed by electroencephalography. Once the electroencephalogram is flat, CPB flow is decreased from 1 to 1.5 L/min. This would decrease the venous return through hepatic, lumbar, phrenic, and adrenal veins, facilitating dissection, tumoral resection, and atriohepatic confluent reconstruction.

In case of renal or adrenal cancer, the primary tumor would be first removed. Then, under deep hypothermia and low CPB flow, the IVC and right atrium are opened to assess thrombus extension (Figs. 9.1 and 9.2) and to consider the patency of the hepatic veins (Fig. 9.3). The right atrium is incised parallel to the right atrioventricular sulcus. When the IVC is invaded, an en bloc resection of the infiltrated part with removal of the tumoral thrombus should be carried out, respecting carcinoid margins. In the case of preoperative Budd-Chiari syndrome, the hepatic veins are thrombectomized. Small secondary veins are ligated, and the major hepatic veins

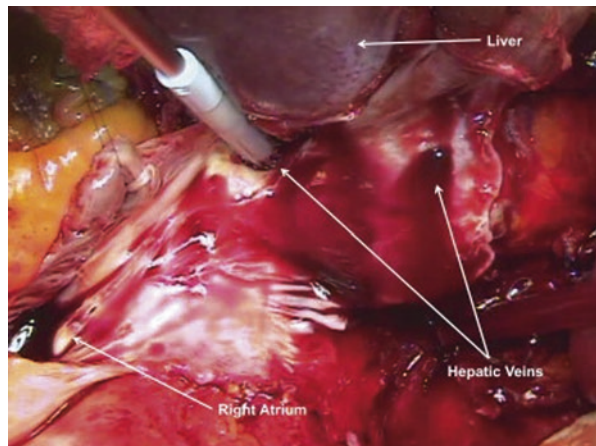
**Fig. 9.1** Longitudinal opening of right atrium and inferior vena cava allowing exposure of the thrombus and the origin of the hepatic veins



**Fig. 9.2** Extraction of the tumoral thrombus from the hepatic veins and the right heart, and resection of the infrahepatic inferior vena cava (IVC)

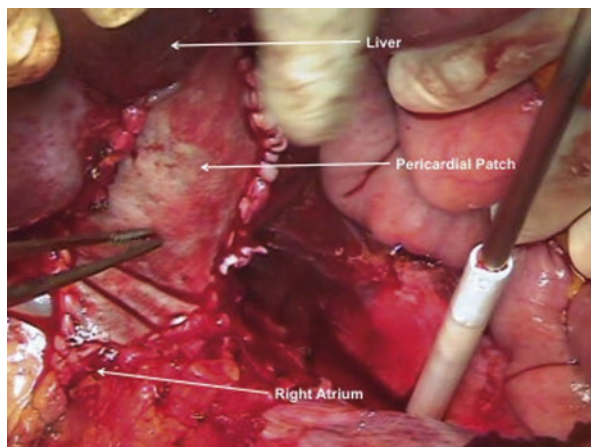


**Fig. 9.3** Surgical field after thrombus removal, with verification of the patency of the hepatic veins





**Fig. 9.4** Atriohepatic confluent reconstruction with direct anastomosis of the hepatic veins in the right atrium, using a pericardium patch



are reimplanted directly into the right atrium, using a bovine pericardial patch to offset tissue loss (Fig. 9.4), as initially described by Pasic and associates [11]. If IVC is occluded preoperatively (confirmed by preoperative imaging and by operative findings), no vena cava reconstruction (bypass) should be performed. The IVC is usually interrupted just distal to the remaining renal veins. The venous drainage of the lower part of the body and of the renal veins will be achieved through the cavoazygos collateral system.

After completion of hepatic vein reconstruction and anastomosis to the right atrium, CPB normal flow can be restored and rewarming started up to a central temperature (bladder or rectal temperature) of 36.5 °C. Then CPB is stopped, cannulas removed, heparin neutralized, and careful hemostasis performed in the thoracic and abdominal cavities.

---

## 9.4 Postoperative Management

Postoperatively, patients are placed in light Trendelenburg position to improve venous drainage of the inferior part of the body after interruption of the IVC. Compression stockings can be used to avoid lower limb edema. Patients are also started on intravenous anticoagulation as soon as bleeding is controlled and then switched to oral anticoagulation for at least a year, to prevent extensive thrombosis of the iliac and lower limb venous system. A control computed tomography angiography scan is recommended before hospital discharge, to control the patency of the atriohepatic reconstruction.

---

## 9.5 Discussion

In such complex reconstructions of the atriohepatic outflow, this technique seems safe and allows longer surgical time than circulatory arrest. While ensuring organ protection by a combination of both hypothermia and continuous perfusion, it is



associated with a lower risk of neurologic complications. Several other techniques have already been reported in the literature. All these techniques of resection of the IVC and atrial malignancy extension depend on the cephalad extension of the tumor and are independent from the nature of the tumor.

A recent literature review published by Lawindy and coworkers [5] provides guidelines on the surgical management of cavoatrial extension of renal cell carcinomas. For stages 1 (renal) and 2 (retrohepatic) thrombi, a classic abdominal approach without the use of CPB is recommended, with control of the IVC proximal and distal to the tumor. For high-level tumors (stages 3 and 4), a median sternotomy is often required to obtain vascular control distal to the thrombus. Potential complications related to these procedures, such as major bleeding and hypotension, are important concerns. This review clearly states that the use of CPB can easily circumvent such major adverse events [5]. The use of CPB is, nowadays, an essential adjunct for the management of these diseases. The surgical management of IVC leiomyosarcoma is relatively similar, but as this tumor is a rare entity, there are no consensus guidelines. To date, only 300 such cases have been reported in the literature [12].

According to multiple reports, there are two pivotal key points to guarantee a successful surgical procedure. The first key point is the quality of exposure of the operating field, which is essential to perform a complete resection of the tumoral tissues. Any significant back-bleeding from the hepatic and lumbar veins often compromises this exposure. Many authors highlighted that a reduced view of the operating field was responsible for incomplete tumor resection, higher risk of warm hepatic or renal ischemia, pulmonary embolism, and acute tubular necrosis [13–16]. The second key point is precise control of any potential major bleeding from the liver venous circulation with the use of CPB [4, 13].

In a report by Ciancio and colleagues [17], 12 patients were surgically treated without sternotomy or CPB. All 12 patients had thrombus, which did not extend deeply in the right atrium, and no tumoral invasion of the retrohepatic IVC. Thus, the tumor could be “milked” out of the right atrium in these patients. In some of these patients, blood inflow to the liver had to be interrupted to achieve a bloodless field and to allow opening of the retrohepatic IVC. Even in these last cases, no resection and subsequent reconstruction of the retrohepatic IVC had to be done, so hepatic cross-clamp time was short. Skinners and coworkers [18] described intra-atrial thrombus retrieval using CPB, in combination with hepatic vascular exclusion. This technique allows a cavotomy with a remarkable reduction of bleeding from the hepatic veins. Nevertheless, in some cases of chronic IVC obstruction, collaterals such as phrenic veins, lumbar, short hepatic, or adrenal veins become major drainage pathways, bringing unexpected back-bleeding [13]. In their series, the authors reported a high rate (41–60%) of postoperative complications, including transient hyperbilirubinemia and renal failure [18].

The technique most frequently encountered in the literature is the use of CPB with DHCA [4, 5, 7]. The bloodless field obtained allows an excellent visualization of the tumor and decreases the risk of cellular spreading, incomplete tumor excision, pulmonary embolism, or warm hepatic or renal ischemia. Nevertheless, there are several disadvantages of DHCA, such as end-organ dysfunction, ischemic injury, and ischemia–reperfusion injury. Furthermore, the duration of DHCA is

limited, with a safe duration of circulatory arrest of 30 min at 18 °C [8] according to some reports. Knowing that complete tumor excision with respect to carcinoid margins remains the principal issue qualifying the success of the operation and long-term survival of patients [6], achieving this can be technically challenging and time-consuming, especially in patients with invasion of surrounding structures.

Cardiopulmonary bypass with deep hypothermic low flow combines, in our experience, the protective effects of hypothermia associated with the positive effect of a continuous low-flow blood perfusion. This allows a longer safe surgery time with a lower risk of organ ischemia. Deep hypothermic low flow (1–1.5 L/min, which can be modulated according to the venous backflow) provides a nearly bloodless field, considerably reducing back-bleeding not only from the hepatic veins but also from the lumbar, adrenal, and short hepatic veins and thus allowing an excellent visualization of the tumor. This technique avoids hepatic vascular exclusion, which requires dissection of hepatic vessels and induces ischemic liver injury owing to cross-clamping. Continuous CPB outflow decreases the risk of cerebral ischemia and stroke. We believe that this technique can facilitate surgical management of these patients, providing a bloodless field with a high level of organ protection. In all cases, a multidisciplinary approach is mandatory for these procedures.

Cardiopulmonary bypass with deep hypothermic low flow needs to be considered as a surgical option in patients with abdominal and retroperitoneal tumors invading the IVC and extending to the right atrium, when there is a need for extensive resection of the IVC and reconstruction of the hepatic vein confluence. This technique is reliable and allows a longer safe operative time and organ protection, often necessary to obtain complete excision of the tumor, associated with an excellent view of the surgical field.

---

## References

1. Quinones-Baldrich W, Alktaifi A, Eilber F, Eilber F (2012) Inferior vena cava resection and reconstruction for retroperitoneal tumor excision. *J Vasc Surg* 55:1386–1393
2. Chiappini B, Savini C, Marinelli G et al (2002) Cavoatrial tumor thrombus: single-stage surgical approach with profound hypothermia and circulatory arrest, including a review of the literature. *J Thorac Cardiovasc Surg* 124:684–688
3. Shuch B, Crispen PL, Leibovich BC et al (2011) Cardiopulmonary bypass and renal cell carcinoma with level IV tumour thrombus: can deep hypothermic circulatory arrest limit perioperative mortality? *BJU Int* 107:724–728
4. Dedeilias P, Koletsis E, Rousakis AG et al (2009) Deep hypothermia and circulatory arrest in the surgical management of renal tumors with cavoatrial extension. *J Card Surg* 24:617–623
5. Lawindy SM, Kurian T, Kim T et al (2012) Important surgical considerations in the management of renal cell carcinoma (RCC) with inferior vena cava (IVC) tumour thrombus. *BJU Int* 110:926–939
6. Kuehnl A, Schmidt M, Hornung HM, Graser A, Jauch KW, Kopp R (2007) Resection of malignant tumors invading the vena cava: perioperative complications and long-term follow-up. *J Vasc Surg* 46:533–540

7. Novick AC, Kaye MC, Cosgrove DM et al (1990) Experience with cardiopulmonary bypass and deep hypothermic circulatory arrest in the management of retroperitoneal tumors with large vena caval thrombi. *Ann Surg* 212:472–477
8. Svyatets M, Tolani K, Zhang M, Tulman G, Charchafli J (2010) Perioperative management of deep hypothermic circulatory arrest. *J Cardiothorac Vasc Anesth* 24:644–655
9. Fabiani JN, Raux M, Alsac JM, Du Puymontbrun L, Bel A, Jouan J, Salvi S, Pouly J, Achouh P (2013) Deep hypothermia and low flow for surgery for abdominal or extraperitoneal tumors with cavoatrial extension. *Ann Thorac Surg* 95(6):2036–2041
10. Neves RJ, Zincke H (1987) Surgical treatment of renal cancer with vena cava extension. *Br J Urol* 59:390–395
11. Pasic M, Senning A, von Segesser L, Carrel T, Turina M (1993) Transcaval liver resection with hepatoatrial anastomosis for treatment of patients with the Budd-Chiari syndrome. Late results. *J Thorac Cardiovasc Surg* 106:275–282
12. Mann GN, Mann LV, Levine EA, Shen P (2012) Primary leiomyosarcoma of the inferior vena cava: a 2-institution analysis of outcomes. *Surgery* 151:261–267
13. Tsuji Y, Goto A, Hara I et al (2001) Renal cell carcinoma with extension of tumor thrombus into the vena cava: surgical strategy and prognosis. *J Vasc Surg* 33:789–796
14. Stewart JR, Carey JA, McDougal WS, Merrill WH, Koch MO, Bender HW Jr (1991) Cavoatrial tumor thrombectomy using cardiopulmonary bypass without circulatory arrest. *Ann Thorac Surg* 51:717–722
15. Nesbitt JC, Soltero ER, Dinney CP et al (1997) Surgical management of renal cell carcinoma with inferior vena cava tumor thrombus. *Ann Thorac Surg* 63:1592–1600
16. Glazer AA, Novick AC (1996) Long-term followup after surgical treatment for renal cell carcinoma extending into the right atrium. *J Urol* 155:448–450
17. Ciancio G, Shirodkar SP, Soloway MS, Livingstone AS, Barron M, Salerno TA (2010) Renal carcinoma with supradiaphragmatic tumor thrombus: avoiding sternotomy and cardiopulmonary bypass. *Ann Thorac Surg* 89:505–510
18. Skinner DG, Pritchett TR, Lieskovsky G, Boyd SD, Stiles QR (1989) Vena caval involvement by renal cell carcinoma. Surgical resection provides meaningful long-term survival. *Ann Surg* 210:387–394

Christian Létoublon, Laurence Lacaze, and Mircea Chirica

---

## 10.1 Introduction

This chapter focuses on the treatment of blunt injuries of the retrohepatic portion of the vena cava and of the extrahepatic segment of the hepatic veins which raises similar management problems. Among injuries of the intra-abdominal vena cava, the retrohepatic location raises the most difficult management challenges and is associated with the highest mortality rate [1–6]. Injuries of the retro hepatic vena cava occur in up to 15 % of blunt liver traumas.

Despite advances in surgical techniques and intensive care management, mortality is still very high ranging between 50 and 80 % in patients that reach the hospital alive. Mortality is prohibitive after attempts at open repair in critically ill patients. Survival is closely related to conditions in which these patients can be managed. Hemodynamically stable patients eligible for computed tomographic (CT) evaluation and for management protocols, similar to those of vena cava tumors, fare better than patients requiring emergency surgery for bleeding control. In emergency conditions, awareness of the lethal triad of hypothermia, acidosis, and coagulopathy should prompt decision for damage control surgery in these patients. Under these dramatic circumstances, complex reconstructive procedures are usually futile, while simple gestures aiming at bleeding arrest may be the only chance for patient survival.

---

## 10.2 Pattern of Injuries

Mortality is particularly severe when mechanisms of injuries are blunt trauma and vascular avulsion. Injuries of the vena cava segment located between the heart and the hepatico-caval junction are uniformly fatal. Hepatic vein injuries have

---

C. Létoublon (✉) • L. Lacaze • M. Chirica  
Department of Digestive and Emergency Surgery, Universitary Hospital of Grenoble,  
Grenoble Alpes University, Grenoble, France  
e-mail: [CLetoublon@chu-grenoble.fr](mailto:CLetoublon@chu-grenoble.fr)

previously been distinguished according to their location inside the liver parenchyma (type A) or outside it (type B) [5]. Nevertheless, these different types of lesions are frequently associated and such distinction doesn't have useful practical implications. In contrast, blood leak contention by adjacent retroperitoneal structures is a major prognostic factor; it may limit blood loss and allow prehospital survival. Immediate resuscitation usually fails in patients with free intracavity (peritoneal, pleural) bleeding.

---

## **10.3 Emergency Surgical Techniques in the Management of Retrohepatic Caval Injuries**

### **10.3.1 Direct Suture**

Bleeding control by direct suture necessitates surgical exposure of the vascular defect which allows direct repair. It usually requires right liver mobilization by section of its attachments if these are still intact. Direct suture should be avoided for the treatment of large vena cava or right hepatic vein defects because attempts at right liver mobilization under these circumstances may result in massive bleeding which is frequently fatal.

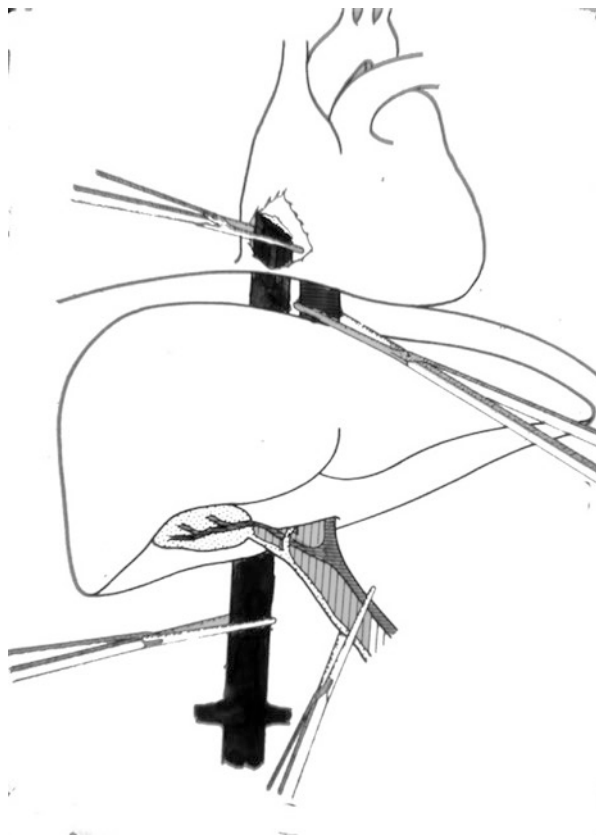
### **10.3.2 Vascular Exclusion of the Liver**

Complete vascular exclusion of the liver has been proposed in order to limit the aforementioned risks of liver mobilization. Vascular exclusion of the liver includes successive clamping of the portal triad, the suprarenal IVC, and the suprahepatic IVC in its intrapericardial portion [7]. In the context of major bleeding, this maneuver may result in sudden decrease in the cardiac preload and cardiac arrest. Concomitant clamping of the supraceliac aorta (quadruple clamping) can restore the situation by improving coronary perfusion (Fig. 10.1). Nevertheless, uncontrollable fatal collapse has been reported at the moment of aortic unclamping after repair of venous injuries, rendering eventually unfeasible the release of the aortic clamp.

### **10.3.3 Cavo-Caval Venous Bypass Procedures**

The common principle of cavo-caval bypass procedures is the maintenance of a caval venous return by securing the cardiac preload. In precarious hemodynamic situations, preservation of the caval flow aims to decrease the risks of cardiac collapse. This is in contrast to programmed liver surgery when interruption of caval flow is usually well supported and can most often be compensated by appropriate intraoperative anesthesia-reanimation management with no need for venous bypass [7].

**Fig. 10.1** Portal triad occlusion (Pringle maneuver) and clamping of supraceliac aorta (quadruple vascular clamping)



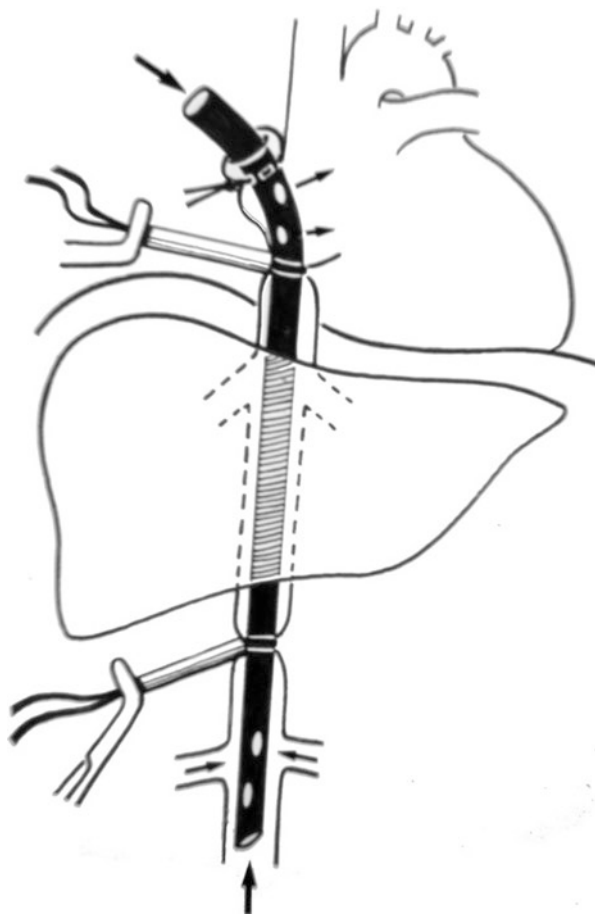
One of the first described procedures was the use of an endovenous shunt; the shunt is usually introduced through the right atrium and pushed down into the subhepatic vena cava (if it does not exit through the venous defect) (Fig. 10.2) [2, 8–11].

Successful use of endovenous shunts for the treatment of retrohepatic vena cava injuries is anecdotal in the literature. Outcomes of endovenous shunting seem less grim in the setting of open when compared to blunt traumatism. Of note, some of the pioneers of the procedure in liver trauma have eventually abandoned endovenous shunts in favor of perihepatic packing (PHP) [1, 12–15].

The veno-venous bypass is another technique which was popularized by liver transplant surgeons. Veno-venous bypass has the theoretical advantage of remote cannulation sites at the level of the femoral vein and the internal jugular far from the injury site (Fig. 10.3) [16–20].

A sophisticated maneuver which is not always adapted to extremely urgent situations is the realization of a cardiopulmonary bypass. Theoretical advantages include proper blood oxygenation, adequate coronary perfusion, control of eventual cardiac arrest, and the ability of recirculation of blood loss collected by the operative field canulas (Figs. 10.4 and 10.5) [21, 22]. Use of hypothermic cardioplegia has been

**Fig. 10.2** Atrio-caval shunt

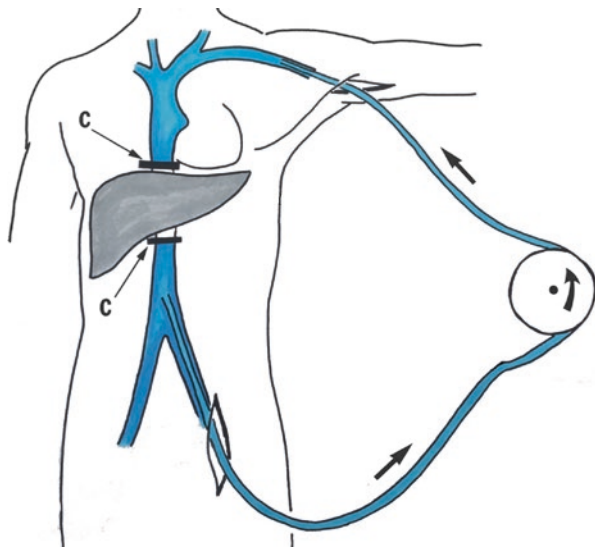


suggested to allow increasing the duration of surgery and performing more complex reparations [23]. Reconstruction of the hepatico-caval junction after complete avulsion, as well as liver autotransplantation after back-table repair, has been reported [19]. Nevertheless, such data remain anecdotal and include success-related publication bias.

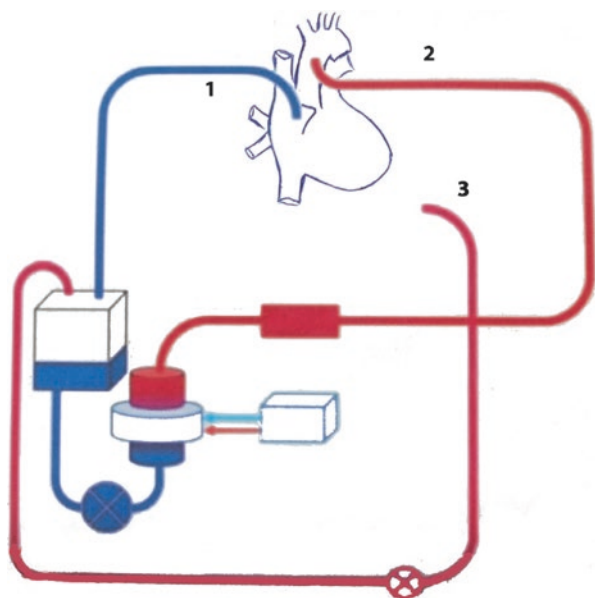
The dogma of systematic immediate repair of hepatico-caval injuries assisted or not by bypass procedures has been recently challenged [5]. Thorough analysis of successful reports suggests that most patients were actually hemodynamically stable prior to surgery. Hemodynamic stabilization was the result of either spontaneous bleeding contention by retroperitoneal structures or by surgical packing performed prior to patient transfer to level I trauma centers. Thus, it is likely that attempting to perform the complex aforementioned techniques during emergency surgery in hemodynamically collapsed patients has very small chances of success. It is probable that compression of the liver on itself and against the diaphragm supported by the establishment of perihepatic packing (PHP) offers the best chances of survival in such desperate situations.



**Fig. 10.3** Cavo-caval bypass

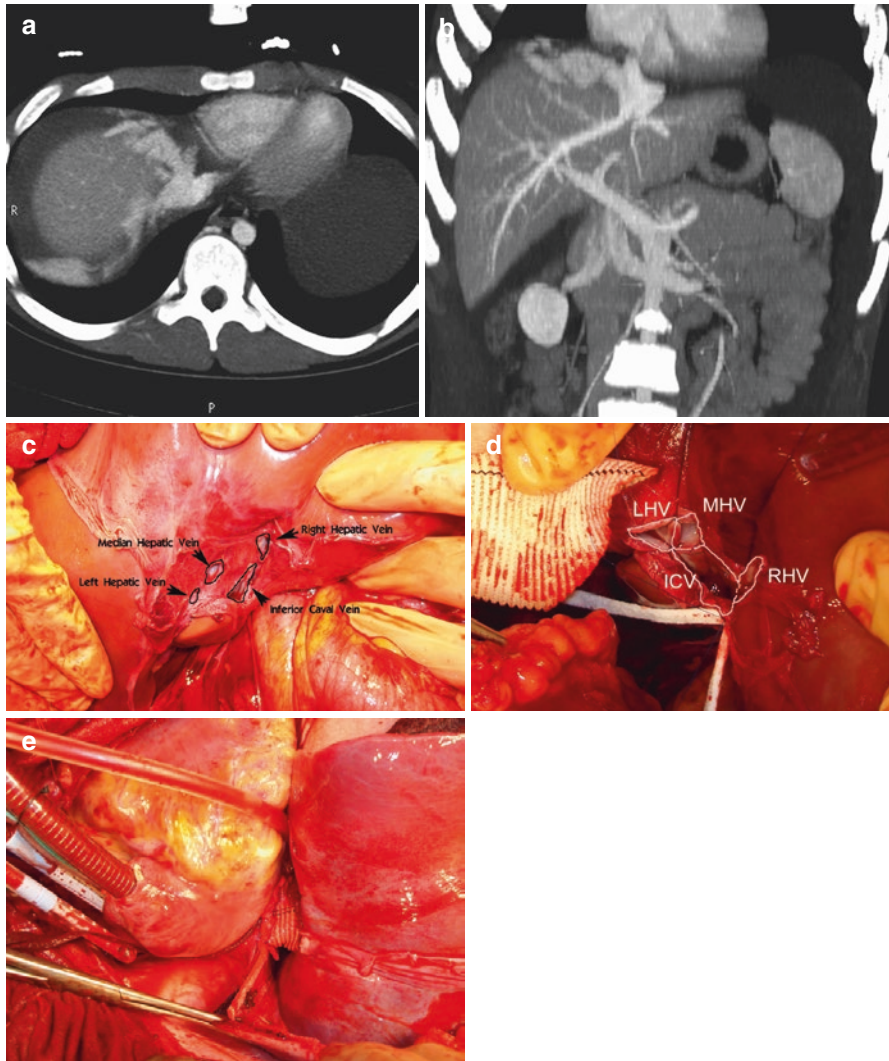


**Fig. 10.4** Cardiopulmonary bypass: 1 atrial cannula, 2 aortic reinjection, 3 suction-reinjection cannulas in the thoracic and abdominal cavity



### 10.3.4 Liver Resection to Obtain Access to the Retrohepatic Vena Cava

Theoretically, performing a right hepatectomy procedure allows exposure of the retrohepatic vena cava and direct access to the vascular defect. Some authors have proposed performing right liver resection for this indication, most often under cover



**Fig. 10.5** High-velocity ski accident in a 14-year-old man. Transport of hemodynamically stable, hypothermic (33.3 °C) patient was made to trauma center; intubation on arrival motivated by extreme agitation. CT scan showed blood extravasation at the level of the suprahepatic IVC and the absence of associated injuries (**a**, **b**). Sternotomy, CBP, and laparotomy were successively done and confirmed complete disjunction of the vena cava and of the three suprahepatic veins (**c**). After complete liver vascular exclusion, the suprahepatic veins were anastomosed together and then on a 30 mm diameter Dacron graft (Hemashield®) (**d**), the graft was then sutured to the subdiaphragmatic IVC (**e**)

of vascular exclusion of the liver [24]. Mortality of right hepatectomy performed on an emergency basis for bleeding control is prohibitive. Again, published successes correspond mostly to long management delays suggesting a contained bleeding

pattern of the initial injury [25–27]. Exposure of right hepatectomy for retrohepatic caval injuries cannot be recommended in the presence of active bleeding [13].

### 10.3.5 Perihepatic Packing (PHP)

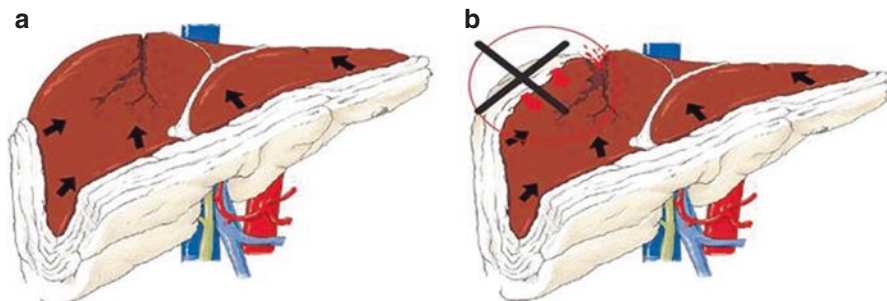
This technique has proven its effectiveness in the treatment of very severe blunt hepatic trauma. Complete liberation of the right liver is unnecessary, avoiding risks of massive intraoperative bleeding. Freeing adhesions located at the inferior part of the right lobe may be required occasionally, with no major risk. Compression of the right liver on the diaphragm is performed at the beginning by the surgeon's hand and then progressively by pads leaning on the right kidney on the right side and on the stomach on the left side. Placing pads on the superior surface of the liver should be avoided as this might open the suprahepatic region (Fig. 10.6). PHP enables control of severe injuries of the retrohepatic IVC and of the hepatico-caval junction; performed as a step of damage control surgery, PHP may save the life of these patients in the emergency setting (Fig. 10.7). Over the last two decades, the literature on this topic is particularly compelling and justifies systematic use of PHP in the emergency setting. Emergency PHP should be performed without trying to understand the type of lesions, with the hope that bleeding control without definitive repair would allow resuscitation in the operating room at first, followed by transfer in the ICU and/or CT scan [13, 23, 28–31].

### 10.3.6 Nonoperative Management

CT performed in hemodynamically stable trauma patients may show injuries of the retrohepatic vena cava or of the hepatico-caval junction which are contained to the retroperitoneum or do no longer bleed. In circumstances when secondary alteration of the hemodynamical condition requires surgical exploration (Fig. 10.7), information provided by CT is particularly useful for subsequent intraoperative decision-making. The monitoring of nonoperated patients can lead to discovery of partial or total thrombosis of hepatic veins: usually this does not justify complex desobstruction procedures but warrant secondary anticoagulation treatment [32].

### 10.3.7 Liver Transplantation

Liver transplantation is situated at the upper end of aggressive therapeutic means available for the management of hepatico-caval vein injuries. In rare cases acute liver failure has been reported after a more or less effective and more or less stricturing control of suprahepatic vein bleeding. In most reported LT cases, venous injuries were part of severe liver trauma. The majority of published cases include patients who developed liver insufficiency after failure of a previously attempted lifesaving strategy [33].



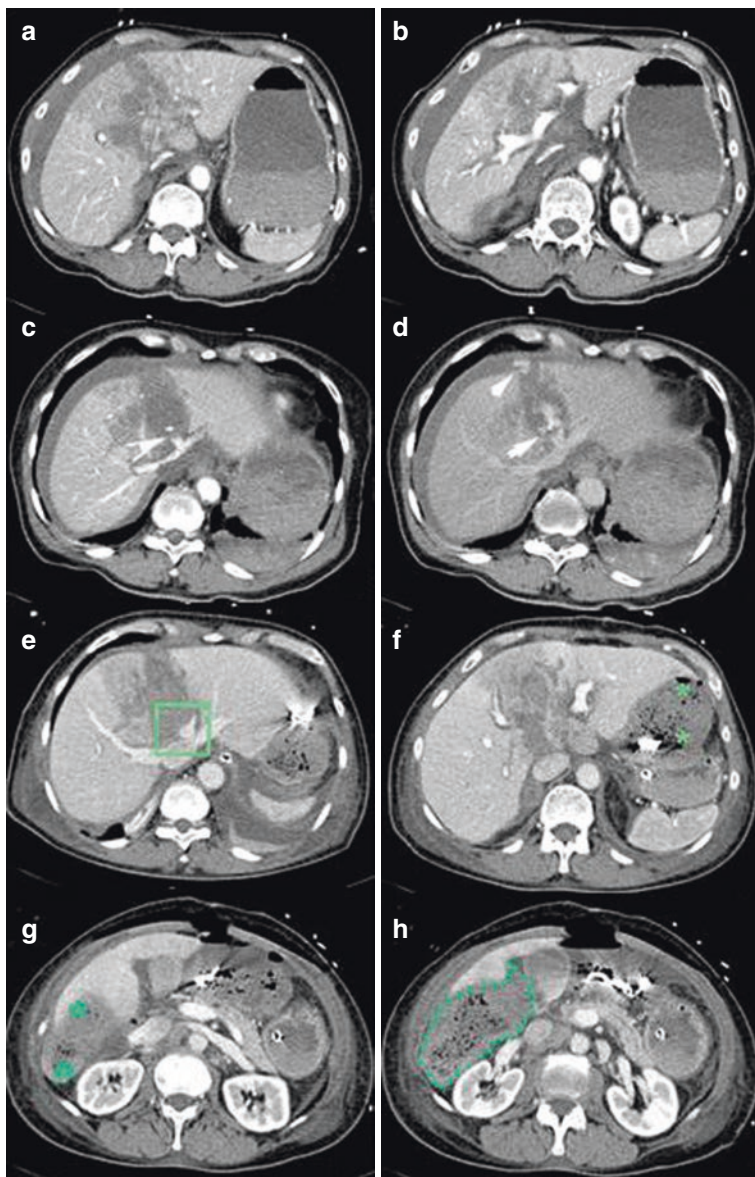
**Fig. 10.6** Perihepatic packing of hepatico-caval junction injuries. Upward hand compression that “closed” the liver fracture has been replaced by subhepatic pads (a). Pad positioning above the liver should be prohibited as it may open liver injuries and aggravate bleeding (b)

## 10.4 Management Strategies

### 10.4.1 Hemodynamically Unstable Patient: Emergency Laparotomy Mandatory

As soon as it becomes obvious that the bleeding originates from the supra-/retrohepatic area, the surgeon should realize a compression of the liver against the diaphragm. In case of hemodynamic collapse, the surgeon may be constrained to transiently associate an aortic compression against the vertebral block to allow resuscitation and recover an acceptable arterial pressure. Attempts should not be made to “look and see” the supra-/retrohepatic injuries which implies hazardous hepatic mobilization, source of uncontrollable bleeding. After rapid exploration of the abdomen, manual compression is progressively replaced by pads firmly pressed against the right kidney and the stomach. In most cases this maneuver is sufficient to stop the bleeding. At this point consultation with the anesthesiologist allows identification of the lethal triad (hypothermia, acidosis, coagulopathy) which should prompt adopting an abbreviated laparotomy strategy. In favorable situations the patient can stand exclusive skin closure and transfer to the intensive care unit (ICU) improving conditions to control the lethal triad; if the patient condition allows, angiography-CT scan (with late-passage sequences) should be performed at this point to evaluate the extent of anatomical venous damage. This is the type of situation described in the literature in which patients can be transferred in level I trauma centers and benefit of specific expertise (vascular exclusion repair, venous bypass techniques, liver resection, transplantation); in some cases PHP suffices and further injury repair may prove unnecessary [27, 29].

If PHP does not contain the bleeding, the surgeon must try to improve its effectiveness by increasing the compression of the liver alongside with intensification by the anesthesiologist of resuscitation means on table. In specific situation when hepatic pedicle clamping clearly improves the hemodynamic condition (evoking associated injuries of the hepatic artery and/or its branches), the extremity of the



**Fig. 10.7** Ski accident in a 62-year-old hemodynamically stable woman. CT shows grade IV liver injuries and absence of vascular extravasation on the arterial and portal acquisition phases (**a**, **b**). There is important blood leakage from the middle suprahepatic vein on the late acquisition phase and intraperitoneal blood leakage (**c**, **d**). Hemodynamic deterioration during the procedure prompted immediate damage control laparotomy with “blind” PHP positioning. CT performed 2 days later shows bleeding cessation (**e**); subhepatic pads press the stomach and “wrinkle” the left liver lobe (**f**); on the right side it is almost exclusively under the liver and pushing on the kidney (**g**, **h**)



turnstile can be exteriorized through the skin closure to allow attempting extreme emergency arterial embolization; if interventional radiology is unavailable, clamping or definitive ligation of the hepatic artery can be attempted.

In rare cases when PHP fails, the surgeon may attempt one of the “dangerous methods”: if expertise is available, complete vascular exclusion of the liver should be performed associating when possible venous bypass and/or cardiopulmonary bypass techniques; afterward, liver mobilization and repair of the injuries should be done as quickly as possible. If expertise with these techniques is not available, further liver compression (complementary PHP) may allow survival during transfer to a higher-level trauma center.

### 10.4.2 Hemodynamically Stable Patient

CT scan is performed following initial resuscitation. The anatomy of the hepaticocaval venous system, the type of venous injury, and the active character of venous leak can be reliably assessed during the late venous acquisition phase; CT also helps evaluate the importance of hemoperitoneum and detect associated injuries. CT examination can guide embolization of intra-abdominal arteries allowing control of associated arterial bleeding. Secondary degradation of the patient condition prompts emergency laparotomy which is usually easier and quicker to organize in the emergency setting than interventional radiology.

If the patient condition remains stable, nonoperative management should be pursued if active bleeding has been controlled; the desire to “repair” lesions is often dangerous and may be detrimental for the patient. Some patients might nevertheless benefit of a delayed operation limited to extensive lavage and drainage of the abdominal cavity [34]. In the uncommon situation when vascular reconstruction is still necessary, delayed operation after control of the lethal triad offers adequate conditions for the use of more complex surgical procedures in expert centers. Under these circumstances and if possible, cardiopulmonary bypass can be prepared to back up eventual deficiencies of veno-venous bypass. Repair of the hepaticocaval confluent may be performed by large-diameter vascular prosthesis (Fig. 10.5). In case of isolated laceration of one of the three hepatic veins, simple ligation can be performed [20].

Localized venous thrombosis can occur after both vascular reparation (direct suture, vascular reconstruction) and more conservative treatments (PHP, nonoperative management). Management does not necessarily require the use of aggressive surgical procedures as cure might be obtained by effective anticoagulant treatments [32] or interventional radiology techniques [35, 36].

### Conclusions

The injuries of the retrohepatic vena cava more can be associated with hepatic vein involvement and represent a difficult surgical challenge. Mortality of blunt trauma caval vein injuries that require immediate surgery for bleeding control is extremely high. The concept of contained venous bleeding, the liberal use of PHP, and the timely application of damage control surgery principles improve patient outcomes. Stabilization of the patient condition should be the main purpose in the

emergency setting. Anatomical vascular reconstruction should be delayed and preferentially undertaken in expert centers; more often, in surviving patients such reconstruction is eventually unnecessary. Secondary use of interventional radiology techniques may be helpful under these circumstances.

### Key Points

1. Injuries of the retrohepatic inferior vena cava are almost always lethal if not contained by surrounding tissues.
2. If an emergency operation is unavoidable, containing blood leakage by perihepatic packing may be lifesaving.
3. If patient hemodynamics allow, emergency multidetector CT angiography is helpful in establishing the diagnosis and guiding management.
4. Attempts to expose and repair the injuries should be avoided before mastering the conditions of vascular exclusion of the liver.
5. Most frequently liver vascular exclusion requires maneuvers such as venovenous bypass or cardiopulmonary bypass.
6. If bleeding could be contained either spontaneously or by perihepatic packing, emergency transfer to a level I trauma center that offers expertise for further management is advisable.
7. Major exposure liver resections are not recommended under these circumstances because mortality rates are extremely high.
8. If the patient condition remains stable and active bleeding has been contained, nonoperative management can be pursued with success.

### Key References

- Beal SL (1990) Fatal hepatic hemorrhage: an unresolved problem in the management of complex liver injuries. *J Trauma* 30:163–169
- Huerta S, Bui TD, Nguyen TH et al (2006) Predictors of mortality and management of patients with traumatic inferior vena cava injuries. *Am Surg* 72: 290–296
- Marino IR, di Francesco F, Doria C et al (2008) A new technique for successful management of a complete suprahepatic caval transection. *J Am Coll Surg* 206: 190–194
- Kaoutzannis C, Evangelakis E, Kokkinos C, Kaoutzannis G (2011) Successful repair of injured hepatic veins and inferior vena cava following blunt traumatic injury, by using cardiopulmonary bypass and hypothermic circulatory arrest. *Interact Cardiovasc Thorac Surg* 12:84–86

---

### References

1. Burch JM, Feliciano DV, Mattox KL (1988) The atriocaval shunt. Facts and fiction. *Ann Surg* 207:555–568
2. Klein SR, Baumgartner FJ, Bongard FS (1994) Contemporary management strategy for major inferior vena caval injuries. *J Trauma* 37:35–41, discussion 41–32



3. Hansen CJ, Bernadas C, West MA et al (2000) Abdominal vena caval injuries: outcomes remain dismal. *Surgery* 128:572–578
4. Huerta S, Bui TD, Nguyen TH et al (2006) Predictors of mortality and management of patients with traumatic inferior vena cava injuries. *Am Surg* 72:290–296
5. Buckman RF Jr, Miraliakbari R, Badellino MM (2000) Juxtahepatic venous injuries: a critical review of reported management strategies. *J Trauma* 48:978–984
6. Burch JM, Feliciano DV, Mattox KL, Edelman M (1988) Injuries of the inferior vena cava. *Am J Surg* 156:548–552
7. Huguet C, Nordlinger B, Galopin JJ et al (1978) Normothermic hepatic vascular exclusion for extensive hepatectomy. *Surg Gynecol Obstet* 147:689–693
8. Schrock T, Blaisdell FW, Mathewson C Jr (1968) Management of blunt trauma to the liver and hepatic veins. *Arch Surg* 96:698–704
9. Misra B, Wagner R, Boneval H (1983) Injuries of hepatic veins and retrohepatic vena cava. *Am Surg* 49:55–60
10. Chen RJ, Fang JF, Lin BC et al (1995) Surgical management of juxtahepatic venous injuries in blunt hepatic trauma. *J Trauma* 38:886–890
11. Orsoni P, Berdah S, Sebag F et al (1995) Atrio-caval shunt in injury to the suprahepatic vena cava. Apropos of a case and review of the literature. *J Chir (Paris)* 132:438–441
12. Beal SL, Ward RE (1989) Successful atrial caval shunting in the management of retrohepatic venous injuries. *Am J Surg* 158:409–413
13. Beal SL (1990) Fatal hepatic hemorrhage: an unresolved problem in the management of complex liver injuries. *J Trauma* 30:163–169
14. Cogbill TH, Moore EE, Jurkovich GJ et al (1988) Severe hepatic trauma: a multi-center experience with 1,335 liver injuries. *J Trauma* 28:1433–1438
15. Liu PP, Chen CL, Cheng YF et al (2005) Use of a refined operative strategy in combination with the multidisciplinary approach to manage blunt juxtahepatic venous injuries. *J Trauma* 59:940–945
16. Shaw BW Jr, Martin DJ, Marquez JM et al (1984) Venous bypass in clinical liver transplantation. *Ann Surg* 200:524–534
17. Rogers FB, Reese J, Shackford SR, Osler TM (1997) The use of venovenous bypass and total vascular isolation of the liver in the surgical management of juxtahepatic venous injuries in blunt hepatic trauma. *J Trauma* 43:530–533
18. Rovito PF (1987) Atrial caval shunting in blunt hepatic vascular injury. *Ann Surg* 205:318–321
19. Boggi U, Vistoli F, Del Chiaro M et al (2006) Extracorporeal repair and liver autotransplantation after total avulsion of hepatic veins and retrohepatic inferior vena cava injury secondary to blunt abdominal trauma. *J Trauma* 60:405–406
20. Marino IR, di Francesco F, Doria C et al (2008) A new technique for successful management of a complete suprahepatic caval transection. *J Am Coll Surg* 206:190–194
21. Launois B, de Chateaubriant P, Rosat P (1987) Cavo-suprahepatic lesions in severe hepatic injuries. Repair under extracorporeal circulation. *Presse Med* 16:1919–1920
22. Kaemmerer D, Daffner W, Niwa M et al (2011) Reconstruction of a total avulsion of the hepatic veins and the suprahepatic inferior vena cava secondary to blunt thoracoabdominal trauma. *Langenbecks Arch Surg* 396:261–265
23. Kaoutzanis C, Evangelakis E, Kokkinos C, Kaoutzanis G (2011) Successful repair of injured hepatic veins and inferior vena cava following blunt traumatic injury, by using cardiopulmonary bypass and hypothermic circulatory arrest. *Interact Cardiovasc Thorac Surg* 12:84–86
24. Pachter HL, Spencer FC, Hofstetter SR et al (1986) The management of juxtahepatic venous injuries without an atriocaval shunt: preliminary clinical observations. *Surgery* 99:569–575
25. Strong RW, Lynch SV, Wall DR, Liu CL (1998) Anatomic resection for severe liver trauma. *Surgery* 123:251–257
26. Tsugawa K, Koyanagi N, Hashizume M et al (2002) Anatomic resection for severe blunt liver trauma in 100 patients: significant differences between young and elderly. *World J Surg* 26:544–549, discussion 549

27. Li Petri S, Gruttadauria S, Pagano D et al (2012) Surgical management of complex liver trauma: a single liver transplant center experience. *Am Surg* 78:20–25
28. Carmona RH, Peck DZ, Lim RC Jr (1984) The role of packing and planned reoperation in severe hepatic trauma. *J Trauma* 24:779–784
29. Sharp KW, Locicero RJ (1992) Abdominal packing for surgically uncontrollable hemorrhage. *Ann Surg* 215:467–474, discussion 474–465
30. Vargo D, Sorenson J, Barton R (2002) Repair of a grade VI hepatic injury: case report and literature review. *J Trauma* 53:823–824
31. Madigan M, Forsythe RM, Peitzman AB et al (2014) Suprahepatic inferior vena cava injury II. *J Trauma Acute Care Surg* 77:516–517
32. Kassir R, Boutet C, Barabino G, Porcheron J (2015) Thrombosis of the hepatic veins secondary to abdominal trauma. *J Visc Surg* 152:201–202
33. Patrono D, Brunati A, Romagnoli R, Salizzoni M (2013) Liver transplantation after severe hepatic trauma: a sustainable practice. A single-center experience and review of the literature. *Clin Transplant* 27:E528–E537
34. Letoublon C, Chen Y, Arvieux C et al (2008) Delayed celiotomy or laparoscopy as part of the nonoperative management of blunt hepatic trauma. *World J Surg* 32:1189–1193
35. Denton JR, Moore EE, Coldwell DM (1997) Multimodality treatment for grade V hepatic injuries: perihepatic packing, arterial embolization, and venous stenting. *J Trauma* 42:964–967, discussion 967–968
36. Hommes M, Kazemier G, van Dijk LC et al (2009) Complex liver trauma with bilhemia treated with perihepatic packing and endovascular stent in the vena cava. *J Trauma* 67:E51–E53

Melissa J. Watson, Nikolaos Pararas, and Andreas Tzakis

---

## 11.1 Introduction

Liver transplantation is the only cure for end-stage liver disease, and its use has become widespread with the growth of hundreds of transplant centers worldwide. The technique originally described by Starzl in the 1960s spread throughout the globe, undergoing few modifications and adaptations [1–3]. The development and expansion of liver transplantation has advanced the field of liver surgery as a whole, evolving complex resection and reconstruction techniques. Over the past 50 years, improvements in surgical approach and patient management have allowed liver transplantation to be performed in an increasingly complicated patient population, overcoming many factors previously considered contraindications to transplant. Surgical techniques employed in reconstruction of the inferior vena cava (IVC) and associated variations in liver transplantation are discussed herein.

---

## 11.2 Conventional Vena Cava Technique

The conventional recipient hepatectomy involves removing the IVC with the liver, from the level of the hepatic veins to the infrahepatic IVC above the renal veins. The excised retrohepatic IVC is then replaced with the donor IVC of the new liver graft. The recipient liver is mobilized by dividing the right and left triangular ligaments,

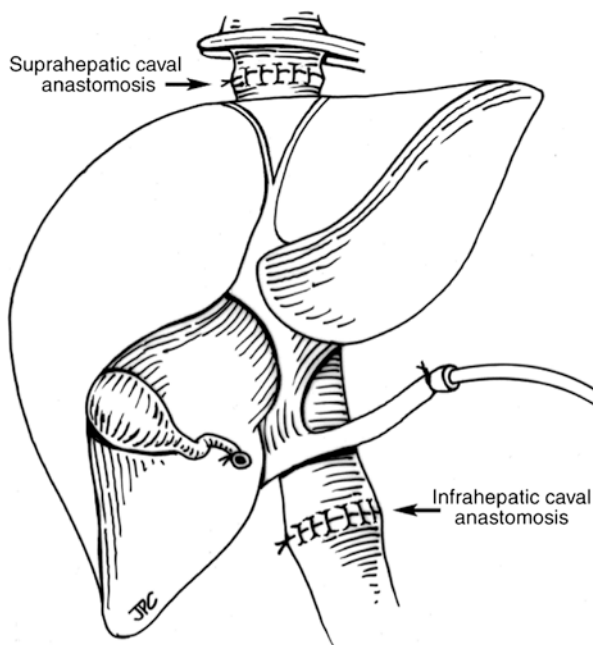
---

Illustrations: Jon Coulter

M.J. Watson, MD • A. Tzakis, MD, PhD (✉)  
Cleveland Clinic, Cleveland, OH, USA  
e-mail: [WatsonM5@ccf.org](mailto:WatsonM5@ccf.org); [TzakisA@ccf.org](mailto:TzakisA@ccf.org)

N. Pararas, MD, PhD  
DTCA Hygeia Hospital, Athens, Greece  
e-mail: [npararas@gmail.com](mailto:npararas@gmail.com)

the hilar structures are dissected and divided, and the supra- and infrahepatic cava are mobilized circumferentially. The IVC is then clamped below the liver with a large straight or angled vascular clamp and above the liver with a large, usually curved vascular clamp positioned high up to the diaphragm. The suprahepatic IVC is divided at the level of the hepatic veins and the lumens are all joined to create one large orifice. Inferiorly the IVC is divided high up into the liver to ensure plenty of length, and the recipient liver is removed. At this stage, before beginning construction of the vascular anastomoses, hemostasis of the retrohepatic area must be obtained. The liver graft is brought onto the operative field, and the upper cava anastomosis is constructed first using a running monofilament polypropylene suture. In a similar manner, the lower cava anastomosis is performed (Fig. 11.1). During this second anastomosis, the liver is flushed with a liter of room temperature saline via the portal vein to remove the preservation solution and raise the temperature of the liver before reperfusion. The portal vein anastomosis is performed with running polypropylene suture after trimming both recipient and donor portal veins to the appropriate length. Before completion of the anastomosis, the clamp on the recipient portal vein is quickly released to flush out any clot that may have accumulated while clamped. The suprahepatic clamp may be released and allow some back bleeding through the graft at this point. The suture is then tied leaving a generous growth factor to allow the vein to fully expand and prevent stenosis [4]. The liver is then reperfused by releasing the portal vein clamp. The anesthesiologist is made



**Fig. 11.1** Conventional vena cava reconstruction. The liver graft is shown in place after completion of both suprahepatic and infrahepatic IVC anastomoses

aware in advance so that they may prepare for the hemodynamic changes associated with reperfusion.

---

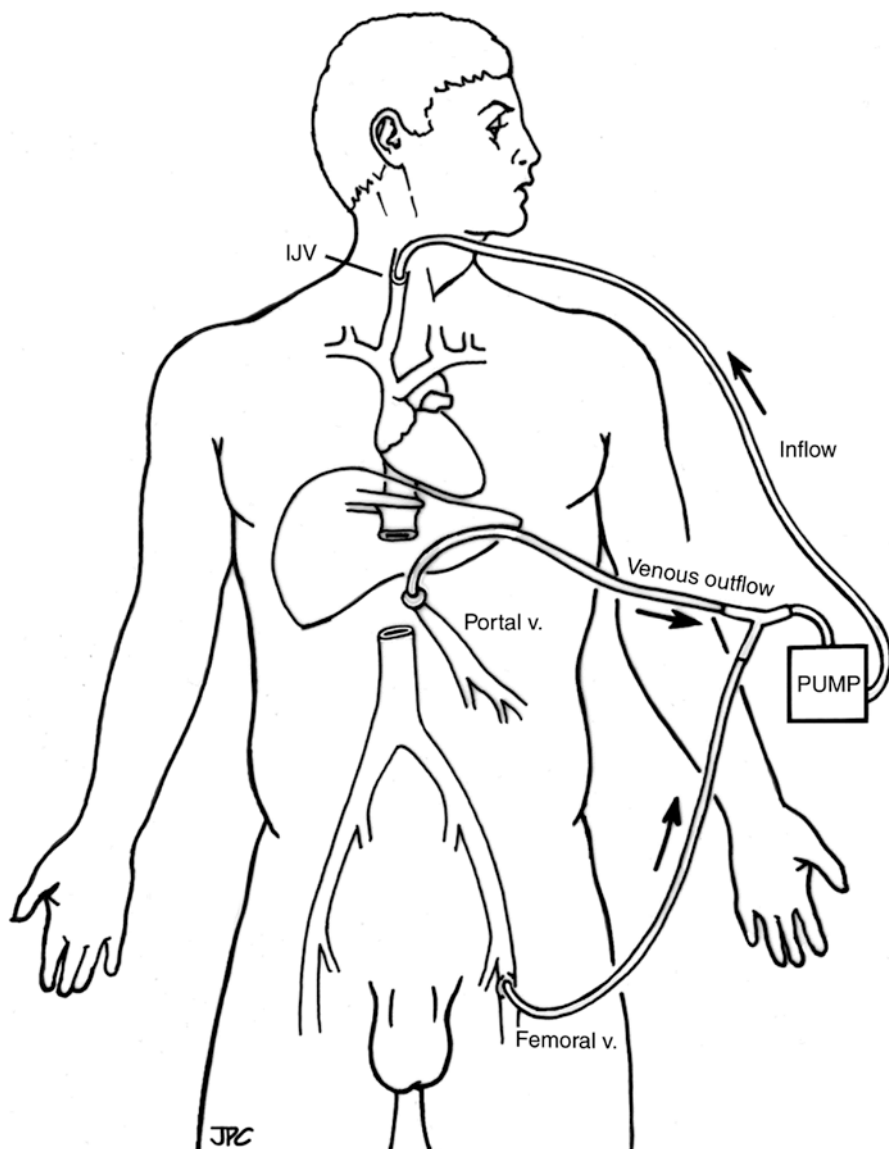
### 11.3 Venovenous Bypass

One of the consequences of the conventional cava technique is hemodynamic instability as the blood flow through the IVC is completely interrupted. In this situation the blood return to the heart is entirely from the superior vena cava. Combined with portal vein clamping during the hepatectomy, the result is massive sequestration of blood volume in the mesenteric and lower body venous circulation. In addition to systemic hypotension, this obstruction of systemic and splanchnic venous return causes renal venous hypertension, which can lead to renal dysfunction, diffuse edema of the gastrointestinal tract, and exacerbation of hemorrhage from thin-walled venous collaterals and varices. Cardiovascular instability requires volume preloading which can then result in volume overload and pulmonary edema after liver revascularization [5]. Moreover the high potassium and acidity of the stagnant blood can result in hemodynamic collapse when returned to the systemic circulation.

Venovenous bypass was developed to prevent these undesirable effects by providing an alternate route for blood flow back to the heart [6–8]. The bypass mechanism facilitates hemodynamic stability during the anhepatic phase of the operation and avoids the consequences of systemic and splanchnic venous sequestration.

Venovenous bypass can be performed as single bypass using the femoral vein with return through either the internal jugular or axillary vein or as double bypass in which the portal system is also decompressed via a cannula in circuit. A cannula is placed into the greater saphenous vein either percutaneously or via open technique and advanced through the saphenofemoral junction to near the confluence of the common iliac veins. A portal cannula is placed into the transected portal vein and these two cannulae are joined together via a Y connection. The blood flows through heparin-bonded shunt tubing to a centrifugal pump and is returned to the patient via the axillary or jugular vein (Fig. 11.2). Flow rates are generally maintained at 1–4 L/min, but can be higher [5]. Alternatively, the portal system can be cannulated through the inferior mesenteric vein. This variation is particularly useful in cases of abnormalities of the extrahepatic portal vein such as thrombosis, friability, short length, and retransplantation.

The use of venovenous bypass in liver transplantation has allowed for a safer and easier operation and has also facilitated the training of surgeons while keeping the patient stable. It is, however, not without risks such as air emboli, venous thromboemboli, vascular injury, and bleeding complications from cannula placement. It is therefore not recommended for universal use, but rather on an individual basis. It is most often used in hemodynamically labile patients, those with decreased cardiac reserve, those with poorly developed venous collaterals (fulminant liver failure, prior portocaval shunt, TIPS, etc.), and those who otherwise do not tolerate test clamping of the IVC.

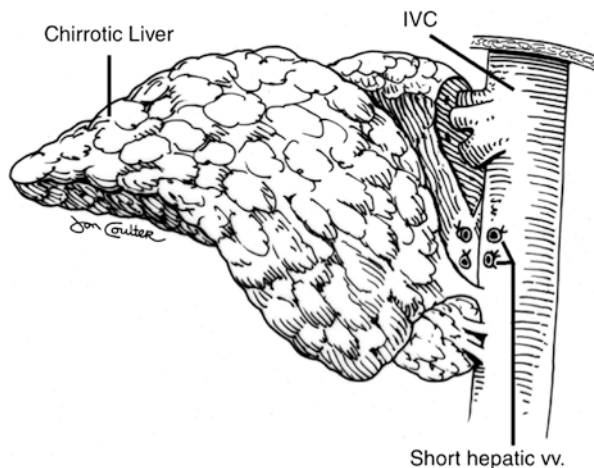


**Fig. 11.2** Venovenous bypass circuit. The pump collects blood from the systemic venous system via the femoral vein cannula and the mesenteric venous system via the portal vein cannula and returns it to the superior vena cava via the jugular vein cannula

#### 11.4 Piggyback Technique

The technique of vena cava-sparing hepatectomy in liver transplantation was first described in dogs by Fonkalsrud in 1966 [9]. The method was further developed and refined in humans over the next several decades [10–12]. The

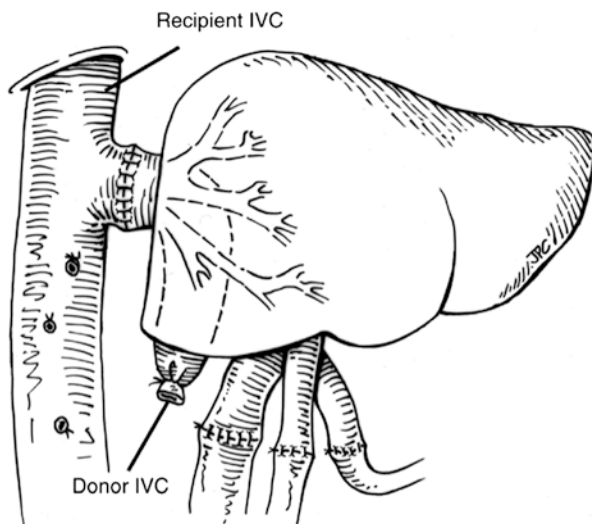
**Fig. 11.3** Piggyback dissection. The cirrhotic liver is dissected off of the IVC by ligating all short hepatic veins



feasibility of maintaining continuity of the recipient IVC remedies the hemodynamic instability encountered with the conventional method and generally obviates the need for venovenous bypass. The technique is accomplished by first freeing the falciform, left and right triangular ligaments to mobilize the liver as with conventional hepatectomy. The short hepatic veins are then individually ligated and divided, generally inferiorly to superiorly and either right to left or left to right (Fig. 11.3). The isthmus of the caudate must be divided as well to completely free the liver and to allow skeletonization and clamping of the right, middle, and left hepatic veins. Once these veins are controlled at their base with clamps, they are divided inside the liver to ensure adequate length and the hepatectomy is completed. A large vein cuff for the anastomosis is then created by placing a large curved vascular clamp behind the confluence of the hepatic veins with the IVC and joining the orifices of the three hepatic veins. As opposed to conventional technique, the upper cava is only partially clamped for a short interval, minimizing physiologic disturbance of the circulation. After the suprahepatic anastomosis is complete, another clamp can be placed on the donor side of the anastomosis and the first clamp removed to restore unimpeded blood flow through the IVC while the portal vein anastomosis is being performed. Additionally the time to revascularization of the liver is reduced as only one caval anastomosis is required. The liver can be flushed of preservation solution via the portal vein as described above and the effluent removed via the infrahepatic IVC before it is ligated. Alternatively the liver can be flushed with blood via the completed portal vein anastomosis and vented from the infrahepatic IVC before it is ligated. The subsequent portal vein, hepatic artery, and bile duct anastomoses are performed in an identical manner as with the conventional technique (Fig. 11.4).

Less retroperitoneal dissection is an additional advantage of IVC preservation as it creates less raw surface area and less bleeding. Preservation of the native IVC also allows transplantation using smaller donor grafts despite IVC size discrepancy [10].



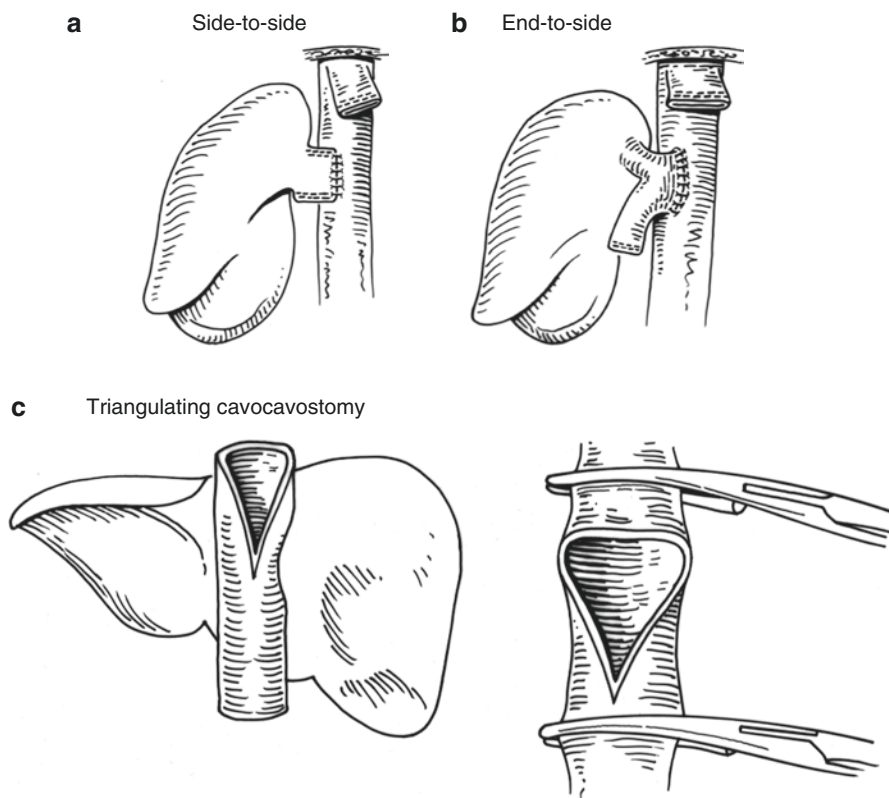


**Fig. 11.4** Piggyback vena cava reconstruction. The liver graft is shown in place after completion of the suprahepatic IVC anastomosis. The donor infrahepatic IVC is ligated

In these cases of small grafts, two rather than three suprahepatic veins are joined to provide the appropriate-sized outflow of the graft. The routine use of only two hepatic veins for outflow reconstruction is discouraged, however, because it has been associated with a higher incidence of outflow obstruction [13]. The piggyback hepatectomy is feasible in most cases [14, 15]. Technical difficulty can be encountered in the presence of a circumferential caudate lobe and in cases of notable recipient hepatomegaly such as polycystic liver disease.

### 11.5 Piggyback Variants: End-to-Side, Side-to-Side Cavocavostomy, and Reverse Piggyback

As surgeons gained more experience with the piggyback approach, other variations of IVC reconstruction evolved [14, 16–18]. These were developed not only to allow preservation of the IVC but to decrease venous outflow complications. Alternate approaches include side-to-side cavocavostomy and end-to-side cavocavostomy. The hepatectomy for these techniques is similar to that described above for piggyback technique. A temporary portocaval shunt can be created [19] depending on the operating team's preference and the patient's clinical status (discussed below). To perform the side-to-side cavocavostomy, the liver is removed and the recipient hepatic veins are oversewn. A partially occluding clamp is placed on the IVC and a longitudinal cavotomy is created in the anterior wall of the recipient IVC. The suprahepatic and infrahepatic IVC of the donor are oversewn or stapled closed. A cavotomy is made in the posterior aspect of the retrohepatic donor IVC and the anastomosis is created between the donor and recipient IVC (Fig. 11.5a). For the



**Fig. 11.5** Piggyback variations. (a) Side-to-side cavocavostomy. (b) End-to-side cavocavostomy. (c) Triangulating cavocavostomy

end-to-side cavocavostomy, the recipient hepatic veins are oversewn, and the anastomosis is created between the donor suprahepatic IVC and a longitudinal cavotomy on the anterior wall of the recipient IVC (Fig. 11.5b). These techniques create a large and unimpeded outflow and can also be advantageous in gaining better exposure for the anastomosis. The resulting positioning of the liver more inferiorly can also facilitate a spatulated or side-to-side biliary anastomosis [20].

A variation on this approach is to combine the longitudinal cavotomy incision with the confluence of the hepatic veins on both the donor and recipient [21]. This has been referred to as a suprahepatic cavoplasty [22] or a triangulating cavocavostomy [23]. It is similar to the variant of the piggyback technique described above but creates a much larger cavotomy. This method requires full clamping of the IVC, and the hemodynamic changes are similar to the standard bicaval technique, potentially requiring the use of venovenous bypass. However, unlike the bicaval technique, there is no need for retroperitoneal dissection of the IVC, nor is there a need for the usual piggyback dissection ligating all the short hepatic veins. For this method, the recipient suprahepatic and infrahepatic IVC are clamped and the short hepatic veins

are sharply divided with scissors up to the main hepatic veins. During this dissection a longitudinal patch of the recipient anterior IVC can be excised along with the short hepatic veins. Subsequently the main hepatic veins are transected creating a large “triangular” opening along the IVC including the orifices of the right, middle, and left hepatic veins. The short hepatic veins are either removed with the cavotomy, are excluded by the suture line, or are suture ligated. Extraneous tissue on the remnant hepatic veins is trimmed in preparation for the anastomosis. For the donor liver, a cavotomy is made in the posterior aspect of the IVC starting from and incorporating the suprahepatic IVC opening. This cavotomy is created to match the opening of the recipient IVC (Fig. 11.5c). Using 3–0 polypropylene suture, the three corner sutures are placed. Care must be taken to avoid compromising the hepatic vein orifices on the donor liver. Initially the right lateral wall is created, followed by the left side, and finally the superior aspect. Sometimes it may be easier to perform the entire anastomosis from the left side of the table by approaching the right suture line intraluminally. The infrahepatic donor cava is stapled closed or ligated.

Although this modification requires full IVC clamping with potential need for venovenous bypass, it does have several advantages. It allows creation of the largest possible outflow. Additionally, in cases with difficult exposure, it allows excellent exposure during both the IVC reconstruction and after reperfusion for examination of the suture line. Since minimal dissection is required and short hepatic veins will be either removed with the patch of IVC or incorporated into the anastomoses, the hepatectomy is very fast. Furthermore, bleeding during the hepatectomy is minimized since there is full control of the IVC during mobilization of the liver. The technique can be done expeditiously and it may be possible to forego systemic and/or portal bypass. Any potential size mismatch between the donor and recipient IVC is also eliminated [22].

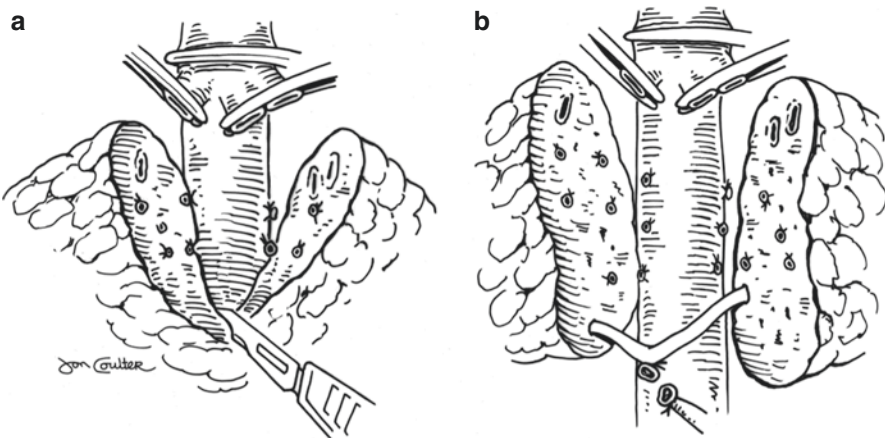
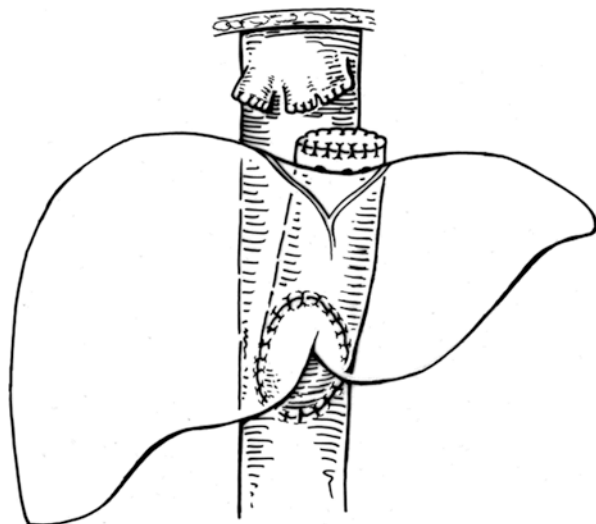
Another piggyback variant is the reverse piggyback or infrahepatic cavocavotomy [24]. In this case, the donor suprahepatic IVC is closed and the infrahepatic IVC is used for an end-to-side anastomosis (Fig. 11.6). This technique has been used as an alternative when either recipient or donor factors make using the suprahepatic cava inadvisable. Such examples include a short suprahepatic donor IVC or injury during organ recovery, Budd-Chiari syndrome, retransplantation, TIPS stent disrupting the hepatic vein, or significant size mismatch between the donor and recipient. It has also been used in domino transplantation and autotransplantation when the donor suprahepatic cuff is very short [25].

---

## 11.6 Piggyback Variant: Anterior Approach Hepatectomy

In cases where dissection of the suprahepatic IVC and development of a sufficient cuff are difficult, an anterior approach to the hepatectomy can be utilized. The native liver is devascularized and mobilized by techniques described above, including clamping of the infrahepatic IVC. The suprahepatic IVC is encircled and clamped, but the hepatic veins are not dissected. Instead an anterior vertical incision is made in the cirrhotic liver, and the anterior IVC is cleaned sharply (Fig. 11.7a, b). Working

**Fig. 11.6** Reverse piggyback vena cava reconstruction. The infrahepatic IVC is used for the anastomosis and the suprahepatic IVC is closed



**Fig. 11.7** Anterior approach hepatectomy. (a, b) After total vascular isolation of the liver, an incision is made anteriorly in the liver and the IVC is dissected sharply. From within the split parenchyma, the three hepatic veins are dissected and clamped, and the liver is removed

from within the split parenchyma, the left, middle, and right hepatic veins are dissected and clamped and the liver is removed. The IVC anastomosis can be created by any method described above. This intraparenchymal exposure is also useful in major hepatic resections. In certain patients the liver may be frozen into the hepatic fossa by previous operations to the extent that it cannot be safely and expediently removed by other methods [11, 26].

## 11.7 Temporary Portocaval Shunt

As previously discussed, the consequences of clamping the portal vein and IVC during the hepatectomy and anhepatic phase led to the development of venovenous bypass [6, 8]. Although the development of the piggyback technique allowed uninterrupted blood flow in the IVC, clamping of the portal vein must still occur. The use of a temporary portocaval shunt was described in order to minimize the effect of portal venous interruption [19, 27]. To construct the shunt, the hilar dissection proceeds as usual and the common bile duct and hepatic artery are divided. The portal vein is transected high into the liver beyond its bifurcation (Fig. 11.8a). The infrahepatic IVC is exposed and a side-biting vascular clamp is applied. A cavotomy is made, and the free end of the portal vein is sewn to the IVC in an end-to-side manner using continuous polypropylene suture (Fig. 11.8b). The remainder of the hepatectomy proceeds as usual. After the liver is brought in and the IVC anastomosis is completed, the shunt is ligated just proximal to the anastomosis, and the portal vein anastomosis is performed (Fig. 11.8c).

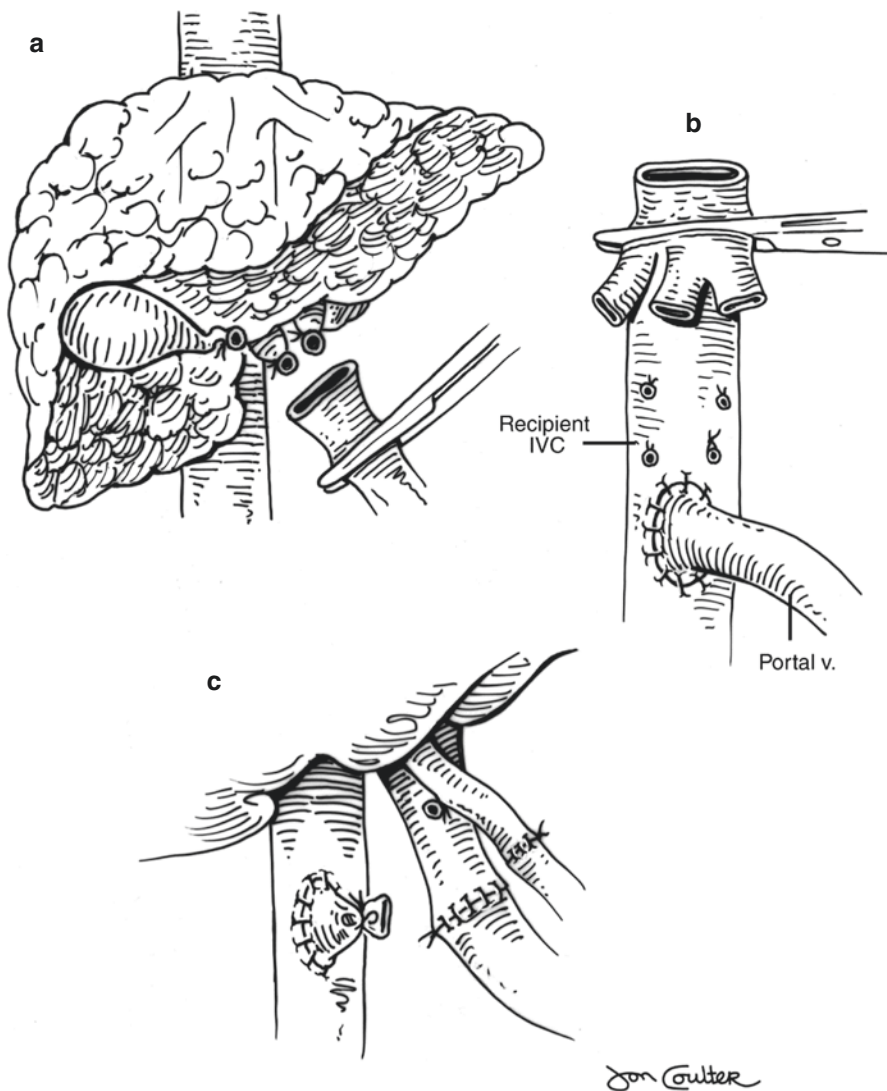
---

## 11.8 Reconstruction in Special Situations

### 11.8.1 Domino Transplantation

The ongoing organ shortage has driven the development of numerous strategies to expand the donor pool. One innovative strategy is domino liver transplantation in which a select group of liver transplant recipients can donate their explanted livers for use as liver grafts in other patients. Several hereditary metabolic diseases (such as familial amyloid polyneuropathy, maple syrup urine disease, and familial hypercholesterolemia) are caused by aberrant or deficient protein production in the liver, and these conditions can be cured with liver transplantation. Although these livers eventually cause systemic disease over time, they are otherwise structurally normal and functional and can be used in domino transplantation. Every transplant center performing domino transplantation has a unique set of guidelines for selecting potential domino graft recipients. For example, at the Karolinska University Hospital in Sweden, patients are considered for the domino transplant waiting list if they have a hepatic malignancy, are older than 40 years with hepatitis-induced cirrhosis, are older than 60 years (regardless of liver disease), or if they require retransplantation for chronic graft failure [28]. Many centers select older patients as candidates for domino liver transplantation, as these recipients are less likely to have time to develop significant systemic metabolic disease posttransplant.

Domino transplantation offers some unique technical challenges, most notably the difficulty of reconstructing the venous outflow of the domino liver graft. To circumvent problems related to a short suprahepatic cuff, a vein graft can be used to extend the suprahepatic IVC cuff of the donor liver [29]. On the back table, the three hepatic veins are joined with running polypropylene suture. Then a vein graft is



**Fig. 11.8** Temporary portocaval shunt. (a) The portal vein is transected beyond its bifurcation. (b) End-to-side anastomosis between portal vein and IVC. (c) The shunt is ligated after completion of the caval anastomosis, and the portal vein anastomosis is performed

opened longitudinally. One edge of the vein graft is joined to the free edge of the hepatic vein cuff using running polypropylene suture. As the suture line meets itself after sewing the circumference of the cuff, the lateral edges are sewn together [30, 31]. This augmented IVC greatly facilitates implantation of domino liver grafts. Another alternative technique for IVC reconstruction in domino liver transplantation is the reverse piggyback technique as discussed above [25].

### 11.8.2 Budd-Chiari Syndrome

Budd-Chiari syndrome is characterized by hepatic venous outflow obstruction and resulting hepatic dysfunction and can be caused by any mechanical impediment to adequate outflow. The spectrum can range from veno-occlusive disorders and small vessel occlusion to thrombosis of the major hepatic veins and IVC. A wide variety of underlying disorders and risk factors such as paroxysmal nocturnal hemoglobinuria, polycythemia vera, other myeloproliferative diseases, tumors, amoebic abscesses, congenital caval webs, oral contraceptives, and pregnancy have been associated with the syndrome, although many causes are unknown [32, 33]. More recently antithrombin III deficiencies, lupus anticoagulant, and occult myeloproliferative diseases have been suggested to comprise a part of this cryptogenic group [34–36].

Budd-Chiari progressing to liver failure is treated with liver transplantation. One potential difficulty encountered at time of operation is the presence of dense adhesions between the liver and diaphragm surrounding the suprahepatic IVC. The dissection can be difficult due to the usually large size of the liver and enlarged caudate lobe. Portal bypass is commonly instituted early in the operation to decompress the severe portal hypertension. In some cases the connective tissue around the suprahepatic IVC is so dense that it cannot be safely encircled to apply a clamp. In these cases the infrahepatic IVC can be clamped and the liver dissected in a retrograde fashion up to the suprahepatic IVC. The distal and proximal surgical margins for the resection are primarily determined by the extension of the thrombosis and fibrosis of the IVC. Fashioning of the suprahepatic IVC cuff sometimes requires dissecting superiorly through the diaphragm up to the right atrium. In other cases the suprahepatic IVC is resected, and reconstruction is achieved by interposing a cadaveric aortic conduit between the IVC and right atrium [37]. Control of the suprahepatic IVC can be obtained by opening the pericardium and extending through the diaphragm as needed to expose the cava. Without performing any dissection, a large vascular clamp is placed on the IVC, taking care to avoid clamping of the coronary sinus. This technique is also useful in traumatic or iatrogenic injuries of the IVC which cannot be controlled by clamping below the diaphragm.

There are several surgical procedures described to treat the venous hypertension caused by Budd-Chiari syndrome. The decompression operation of choice depends on the extent and involvement of the portal vein and IVC. When the IVC and portal vein are patent, splenorenal shunt, side-to-side portocaval shunt, and mesocaval shunt are options. Additionally the mesocaval shunt has been utilized when an enlarged caudate lobe precludes adequate exposure for portocaval shunting. With a thrombosed portal vein, a splenorenal shunt can be performed as long as the splenic and left renal veins are patent. When the IVC is thrombosed or stenosed, a mesoatrial shunt or combined portocaval shunt with cavo-atrial shunt may be performed. Success rates for these surgical procedures range from 30% to 92%, with the majority having survival rates in the 60–75% range [38, 39].

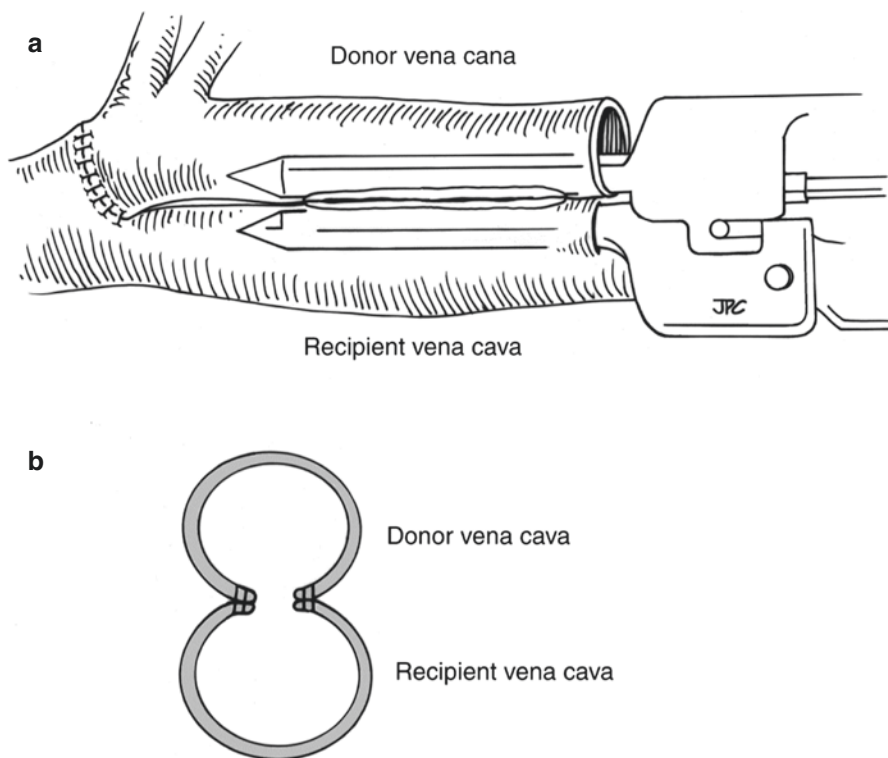


### 11.8.3 Outflow Obstruction

Venous outflow obstruction is an uncommon but potentially lethal complication after liver transplantation. When the obstruction involves the retrohepatic or infrahepatic IVC, the most common findings are lower-extremity edema, renal failure, hypotension, and decreased cardiac output. If stenosis of the suprahepatic IVC or hepatic veins affects hepatic venous outflow, ascites and liver failure can also occur [13, 40]. Therapeutic options include radiologic venoplasty with or without stent placement, surgical reconstruction of the venous anastomosis, and retransplantation [41]. Some centers have reported more frequent outflow complications with the piggyback technique [42–44]. A rare cause of suprahepatic IVC stenosis is narrowing at the diaphragmatic hiatus which can be diagnosed by venography and visually on re-exploration after liver transplantation. A very careful lysis of the diaphragmatic impingement can restore normal venous flow from the lower torso without the need for revision of the anastomosis [13].

When the suprahepatic anastomosis or hepatic veins are stenotic after piggyback liver transplantation, one solution is an end-to-side anastomosis between the donor infrahepatic IVC and the recipient IVC [24]. If there is stenosis of the IVC below the hepatic veins, a patch cavoplasty using vein graft can be an option. Prosthetic conduits to repair a strictured IVC should be reserved for extreme cases because of a high thrombosis rate. These techniques are appropriate for isolated IVC and suprahepatic anastomotic strictures but do not represent a solution for stenosis involving a long segment of the IVC or extending proximally to the hepatic venous orifices. In the rare case of a long-standing suprahepatic stricture which cannot be repaired radiologically, one can create a bypass from the infrahepatic IVC to the auricle of the right atrium [45].

To relieve a more extensive stenosis, a vascular stapler can be used to create a side-to-side cavocavostomy between the posterior wall of the donor IVC and the anterior wall of the recipient IVC [46]. The retrohepatic donor IVC is exposed and dissected up to the anastomosis and freed from the caudate lobe. After total vascular exclusion of the liver (clamping of IVC above and below the liver combined with a Pringle maneuver), a stay suture is placed to align and approximate donor and recipient IVC. A 1-cm venotomy is made in each IVC to introduce the jaws of an endovascular stapler (Fig. 11.9a). The stapler is fired in succession to join the two IVC together (Fig. 11.9b). Three stapler loads are often needed, the final one dividing the posterior portion of the piggyback anastomotic ring and resolving the outflow obstruction. The last stapler load is fired after removal of the clamp above this anastomosis to allow the stapler to pass through. Even though the stapler is fired on a running suture, the stapler allows fixation of both ends of the divided suture line and prevents disruption of the anastomosis. At this point, a vascular clamp is placed above the lower cavotomy, and the liver is reperfused. The cavotomy is then closed with running polypropylene suture.



**Fig. 11.9** Stapler cavocavostomy. A vascular stapler is used to create a side-to-side anastomosis between the donor and recipient IVC. (a) The two limbs of a stapler are introduced into each IVC via a venotomy on both donor and recipient. (b) The stapler is fired to join the two IVC together

### 11.8.4 Split-Liver Transplantation

Split-liver transplantation and living donor liver transplantation have been developed to address the worldwide organ shortage and expand the number of lifesaving liver grafts. A split is defined as obtaining two grafts from a single deceased donor. The strategies for anatomical surgery of the liver described by Couinaud [47] and Bismuth [48] have made using partial liver grafts feasible. It was first described by Pichlmayr and colleagues in 1988 [49]. Traditionally, the liver is split for an adult and a child (right trisegment graft/left lateral segment), but splitting the liver for two adults can also be done (full-right graft/full-left graft).

Dividing the liver parenchyma follows the vascular anatomy, preserving adequate vascular supply and biliary and venous drainage of both grafts. Because the vascular supply and outflow of the caudate lobe can be compromised with full-right/full-left splitting, it can be resected [47, 48, 50–52]. The IVC is kept with one graft and the contralateral graft requires reconstruction of the venous outflow. Usually the left lobe outflow is easier to reconstruct (left or left and middle hepatic veins) [53] when the IVC is kept with the right lobe. This allows preservation of all accessory

hepatic veins draining the right graft. Alternatively, and in case of complex outflow on both sides, the IVC can be split into right and left halves [54].

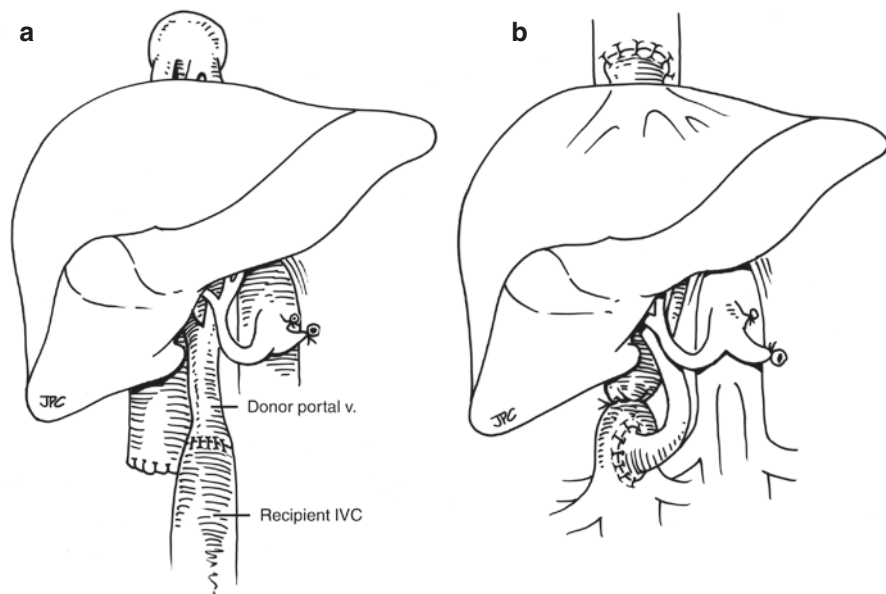
Hepatic veins are varied in their branching anatomy, and many anastomotic arcades have been described. This was not considered a potential contraindication for splitting until smaller-sized split grafts were used. The importance of optimal venous outflow was recognized as paramount to proper graft function and regeneration [48, 55–57]. Hepatic venous tributaries must be reconstructed and this can be performed using vein allografts from the same donor [55].

The right lobe graft consists of segments V, VI, VII, and VIII, and the left lobe graft consists of segments I, II, III, and IV. Either graft may be procured with or without the IVC attached. The length of portal vein, hepatic artery, and bile duct included on each graft depends on what is needed for the contralateral graft. The implantation is performed using the conventional techniques with special attention to reconstruction and augmentation of the hepatic vein outflow if the IVC is not included. This can be accomplished by creating a large triangular anastomosis [58] and reconstruction of accessory hepatic veins [55]. Torsion and outflow obstruction of the left lobe must be prevented; this can be accomplished by anchoring the graft along the falciform at the end of the operation.

### 11.8.5 IVC as Source of Portal Inflow

Portal vein thrombosis, once considered an absolute contraindication to liver transplantation, is now handled successfully in the majority of cases. Operative approaches include thrombectomy of the portal vein when possible, replacement of the clotted portal vein with a venous interposition graft [59, 60], and bypass of the clotted portion with an interposition graft from the superior mesenteric vein [61, 62]. In some cases in which both portal and superior mesenteric veins are clotted, large collaterals can be used to provide portal inflow to the graft [60, 63]. In a few patients, satisfactory hepatopetal portal flow to the graft cannot be established because the entire portal system of the recipient is clotted and venous outflow of the gut is through minute venous collaterals. Portocaval hemi-transposition can be performed when adequate inflow to the graft portal vein cannot be achieved [64, 65]. The hepatectomy is performed using either conventional or piggyback technique. When the piggyback technique is used, flow through the IVC is uninterrupted until reperfusion, at which time the IVC is ligated. The portocaval anastomosis is performed either as an end-to-end anastomosis (Fig. 11.10a) or an end-to-side anastomosis (Fig. 11.10b). The right adrenal vein should be ligated to prevent collateralization. There is usually a significant size discrepancy between the IVC and portal vein, which has to be adjusted during the performance of the end-to-end anastomosis (Fig. 11.10a). Portocaval hemi-transposition offers a surgical alternative for liver transplantation with acceptable long-term results in those select patients for whom liver transplantation was once considered impossible. Although the use of portocaval hemi-transposition is still somewhat limited, this operation can be performed safely when other options at portal revascularization have failed.

Alternatively, the renal vein can be used as the portal inflow if either a spontaneous or surgical shunt is present. After the hilar dissection, a test clamp of the portal



**Fig. 11.10** Portocaval hemi-transposition. (a) End-to-end portocaval anastomosis. (b) End-to-side portocaval anastomosis

vein can reveal the adequacy of the shunt. If the bowel becomes congested, there is insufficient communication between the portomesenteric system and the central venous system, and renoportal reconstruction should be avoided [66, 67]. If the shunt is adequate, the infrahepatic IVC is dissected and the left renal vein exposed. For the renoportal anastomosis, the left renal vein is clamped and divided near the IVC. The bowel will become congested when the left renal vein is clamped since it is the main outflow for the mesenteric venous system. A donor iliac vein graft is used as an interposition graft between the renal and portal veins. After the suprahepatic cava anastomosis is completed, the donor portal vein is anastomosed to the interposition graft.

### Conclusions

Liver transplantation has seen enormous progress over the last 50 years and is now a well-established lifesaving procedure for patients with end-stage liver disease. Surgical technique and patient management have evolved greatly since the first series, and improved outcomes are also due to advances in immunotherapy and antimicrobial treatment. There are several options for IVC reconstruction in liver transplantation, each with its own advantage. Of utmost importance for the transplant surgeon is familiarity with a variety of techniques and a readiness to tailor these techniques to each individual patient's needs. The quality of the operation is more important than the specific technique employed in achieving excellent outcomes.

## Key Points

- Liver transplantation, developed in the early 1960s by Dr. Thomas Starzl, is the only cure for end-stage liver disease and has greatly advanced the field of liver surgery with the implementation of complex resection and reconstruction techniques.
- The conventional recipient hepatectomy involves removing the IVC with the liver, while the piggyback technique maintains the IVC in continuity.
- Venovenous bypass enables hemodynamic stability during the anhepatic phase of the operation and avoids the consequences of systemic and splanchnic venous sequestration. A temporary portocaval shunt can be used to minimize the effect of portal venous interruption prior to reperfusion.
- There are several techniques for implantation of the liver onto the recipient IVC; however, the common objective is adequate venous outflow of the graft.
- Venous outflow obstruction of the liver is a life-threatening complication and must be addressed promptly. This is particularly important with partial liver grafts, and venous tributaries at the cut surface are reconstructed to the IVC with vein grafts.
- In circumstances where no adequate portal flow can be established, the IVC can be used as portal inflow to the liver.

## Key References

1. Starzl TE, Groth CG, Brettschneider L et al (1968) Orthotopic homotransplantation of the human liver. *Ann Surg* 168:92–415
2. Shaw BW Jr, Martin DJ, Marquez JM et al (1984) Venous bypass in clinical liver transplantation. *Ann Surg* 200:524–534
3. Tzakis A, Todo S, Starzl TE (1989) Orthotopic liver transplantation with preservation of the inferior vena cava. *Ann Surg* 210:649–652
4. Bismuth H, Castaing D, Shellock DJ (1992) Liver transplantation by “face-à-face” venacavaplasty. *Surgery* 111:151–155
5. Tzakis AG, Reyes J, Nour B et al (1993) Temporary end to side portacaval shunt in orthotopic hepatic transplantation in humans. *Surg Gynecol Obstet* 176:180–182
6. Nishida S, Pinna A, Verzaro R et al (2001) Domino liver transplantation with end-to-side infrahepatic vena cavocavostomy. *J Am Coll Surg* 192:237–240
7. Halff G, Todo S, Tzakis AG et al (1990) Liver transplantation for the Budd-Chiari syndrome. *Ann Surg* 211:43–49
8. Quintini C, Miller CM, Hashimoto K et al (2009) Side-to-side cavocavostomy with an endovascular stapler: Rescue technique for severe hepatic vein and/or inferior vena cava outflow obstruction after liver transplantation using the piggyback technique. *Liver Transpl* 15:49–53
9. Doyle MB, Maynard E, Lin Y et al (2013) Outcomes with split liver transplantation are equivalent to those with whole organ transplantation. *J Am Coll Surg* 217:102–112
10. Selvaggi G, Weppler D, Nishida S et al (2007) Ten-year experience in portocaval hemitransposition for liver transplantation in the presence of portal vein thrombosis. *Am J Transplant* 7:454–460

## References

1. Starzl TE, Kaupp HA, Brock DR et al (1960) Reconstructive problems in canine liver homo-transplantations with special reference to the postoperative role of hepatic venous flow. *Surg Gynecol Obstet* 111:733–743
2. Starzl TE, Groth CG, Bretschneider L et al (1968) Orthotopic homotransplantation of the human liver. *Ann Surg* 168:92–415
3. Zarrinpar A, Busuttil RW (2013) Liver transplantation: past, present and future. *Nat Rev Gastroenterol Hepatol* 10:434–440
4. Starzl TE, Iwatsuki S (1984) A growth factor in fine vascular anastomoses. *Surg Gynecol Obstet* 159:164–166
5. Chari RS, Gan TJ, Robertson KM et al (1998) Venovenous bypass in adult orthotopic liver transplantation: routine or selective use? *J Am Coll Surg* 186(6):683–690
6. Denmark SW, Shaw BW Jr, Starzl TE et al (1983) Veno-venous bypass without systemic anticoagulation in canine and human liver transplantation. *Surg Forum* 34:380–382
7. Griffith BP, Shaw BW Jr, Hardesty RL et al (1985) Veno-venous bypass without systemic anticoagulation for transplantation of the human liver. *Surg Gynecol Obstet* 160(3):270–272
8. Shaw BW Jr, Martin DJ, Marquez JM et al (1984) Venous bypass in clinical liver transplantation. *Ann Surg* 200:524–534
9. Fonkalsrud EW, Shafey OA, Ono H, Longmire WP Jr (1966) Experience with orthotopic dog liver allografts. *Surg Forum* 17:215–217
10. Calne RY, William R (1968) Liver transplantation in man. I. Observations on technique and organization in five cases. *Br Med J* 4:535–540
11. Tzakis A, Todo S, Starzl TE (1989) Orthotopic liver transplantation with preservation of the inferior vena cava. *Ann Surg* 210:649–652
12. Levi DM, Pararas N, Tzakis AG et al (2012) Liver transplantation with preservation of the inferior vena cava: lessons learned through 2,000 cases. *J Am Coll Surg* 214:691–698
13. Nishida S, Nakamura N, Vaidya A et al (2006) Piggyback technique in adult orthotopic liver transplantation: an analysis of 1067 liver transplants at a single center. *HPB* 8:182–188
14. Belghiti J, Panis Y, Sauvanet A et al (1992) A new technique of side to side caval anastomosis during orthotopic hepatic transplantation without inferior vena caval occlusion. *Surg Gynecol Obstet* 175(3):270–272
15. Fleitas MG, Casanova D, Martino E et al (1994) Could the piggy-back operation in liver transplantation be routinely used? *Arch Surg* 129:842–845
16. Bismuth H, Castaing D, Shellock DJ (1992) Liver transplantation by “face-à-face” venacavoplasty. *Surgery* 111:151–155
17. Cherqui D, Dhumeaux N, Duvoux D et al (1994) Orthotopic liver transplantation with preservation of the caval and portal flows: technique and results in 2 cases. *Transplantation* 58:793–796
18. Lerut JP, Molle G, Donatiggio M et al (1997) Cavocaval liver transplantation without venovenous bypass and without temporary portocaval shunting: The ideal technique for adult liver grafting? *Transpl Int* 10:171–179
19. Tzakis AG, Reyes J, Nour B et al (1993) Temporary end to side portacaval shunt in orthotopic hepatic transplantation in humans. *Surg Gynecol Obstet* 176:180–182
20. Sonnenday C, Englesbe M, Mathur A et al Side-to-side cavocavostomy technique (video). <http://www.med.umich.edu/trans/public/liver/cavoplasty.htm>
21. Busuttil, R, Klintmalm, G (2005) The recipient hepatectomy and grafting. In: *Transplantation of the liver*. Elsevier Saunders, Philadelphia, pp 575–588
22. Wu YM, Voigt M, Rayhill S et al (2001) Suprahepatic venacavoplasty (cavoplasty) with retrohepatic cava extension in liver transplantation: experience with first 115 cases. *Transplantation* 72:1389–1394
23. Dasgupta D, Sharpe J, Prasad KR et al (2006) Triangular and self-triangulating cavocavostomy for orthotopic liver transplantation without posterior suture lines: a modified surgical technique. *Transpl Int* 19:117–121

24. Khanmoradi K, Defaria W, Nishida S et al (2009) Infrahepatic vena cavocavostomy, a modification of the piggyback technique for liver transplantation. *Am Surg* 75:421–425
25. Nishida S, Pinna A, Verzaro R et al (2001) Domino liver transplantation with end-to-side infrahepatic vena cavocavostomy. *J Am Coll Surg* 192:237–240
26. Starzl TE, Koep LJ, Weil R 3rd, Halgrimson CG (1979) Development of a suprahepatic recipient vena cava cuff for liver transplantation. *Surg Gynecol Obstet* 149:77
27. Sánchez-Cabús S, Fondevila C, Calatayud D et al (2013) Importance of the temporary portocaval shunt during adult living donor liver transplantation. *Liver Transpl* 19:174–183
28. Ericzon B-G, Larsson M, Wilczek HE (2008) Domino liver transplantation: risks and benefits. *Transplant Proc* 40:1130–1131
29. Azoulay D, Samuel D, Castaing D et al (1999) Domino liver transplants for metabolic disorders: experience with familial amyloidotic polyneuropathy. *J Am Coll Surg* 189:584–593
30. Kitchens WH (2011) Domino liver transplantation: indications, techniques, and outcomes. *Transplant Rev* 25:167–177
31. Padín JM, Pfaffen G, Pérez Fernández I et al (2011) Neo-suprahepatic cava: a case report of a modified technique for domino liver transplantation. *Transplant Proc* 43:2090–2092
32. Mitchell MC, Boitnott JK, Kaufman S et al (1982) Budd-Chiari syndrome: etiology, diagnosis and management. *Medicine (Baltimore)* 61:199–218
33. Valla D, Le MG, Poynard T et al (1986) Risk of hepatic vein thrombosis in relation to recent use of oral contraceptives. A case-control study. *Gastroenterology* 90:807–811
34. Das M, Carroll SF (1985) Antithrombin III deficiency: an etiology of Budd-Chiari syndrome. *Surgery* 97:242–246
35. Valla D, Casadevall N, Lacombe C et al (1985) Primary myeloproliferative disorder and hepatic vein thrombosis. A prospective study of erythroid colony formation in vitro in 20 patients with Budd-Chiari syndrome. *Ann Intern Med* 103:329–334
36. Disney TF, Sullivan SN, Haddad RG et al (1984) Budd-Chiari syndrome with inferior vena cava obstruction associated with systemic lupus erythematosus. *J Clin Gastroenterol* 6:253–256
37. Halff G, Todo S, Tzakis AG et al (1990) Liver transplantation for the Budd-Chiari syndrome. *Ann Surg* 211:43–49
38. Yaylak F, Ince V, Barut B et al (2015) Living related donor liver transplantation with atrio-caval anastomosis of inferior vena cava graft stored in deep-freeze for Budd-Chiari syndrome. *Int J Organ Transplant Med* 6:41–43
39. Yamada T, Tanaka K, Ogura Y et al (2006) Surgical techniques and long-term outcomes of living donor liver transplantation for Budd-Chiari syndrome. *Am J Transplant* 6:2463–2469
40. Koneru B, Tzakis AG, Bowman J III et al (1988) Postoperative surgical complications. *Gastroenterol Clin North Am* 17:71–91
41. Orons PD, Zajko AB (1995) Angiography and interventional procedures in liver transplantation. *Radiol Clin North Am* 33:541–558
42. Settmacher U, Nussler NC, Glanemann M et al (2000) Venous complications after orthotopic liver transplantation. *Clin Transplant* 14:235–241
43. Navarro F, Le Moine MC, Fabre JM et al (1999) Specific vascular complications of orthotopic liver transplantation with preservation of the retrohepatic vena cava: review of 1361 cases. *Transplantation* 68:646–650
44. Khan S, Silva MA, Tan YM et al (2006) Conventional versus piggyback technique of caval implantation; without extra-corporeal veno-venous bypass. A comparative study. *Transpl Int* 19:795–801
45. Molmenti EP, Grover DS, Thuluvath PJ et al (2004) Cavoatrial shunt in the treatment of suprahepatic vena cava stricture after liver transplantation. *Liver Transpl* 10:1216–1217
46. Quintini C, Miller CM, Hashimoto K et al (2009) Side-to-side cavocavostomy with an endovascular stapler: rescue technique for severe hepatic vein and/or inferior vena cava outflow obstruction after liver transplantation using the piggyback technique. *Liver Transpl* 15:49–53
47. Couinaud C (1957) *Le foie: études anatomiques et chirurgicales*. Masson et Cie, Paris



48. Bismuth H (1982) Surgical anatomy and anatomical surgery of the liver. *World J Surg* 6:3–9
49. Pichlmayr R, Ringe B, Gubernatis G et al (1988) Transplantation of a donor liver to 2 recipients (splitting transplantation)--a new method in the further development of segmental liver transplantation. *Langenbecks Arch Chir* 373:127–130
50. Starzl TE, Kaupp HA, Brock DR et al (1960) Reconstructive problems in canine liver homo-transplantations with special reference to the postoperative role of hepatic venous flow. *Surg Gynecol Obstet* 111:733–743
51. Gurusamy KS, Pamecha V, Davidson BR (2011) Piggy-back graft for liver transplantation. *Cochrane Database Syst Rev*. doi:10.1002/14651858.CD008258.pub2
52. Emond JC, Whittington PF, Thistlethwaite JR et al (1990) Transplantation of two patients with one liver. Analysis of a preliminary experience with 'split-liver' grafting. *Ann Surg* 212:14–22
53. Vagefi PA, Parekh J, Ascher NL et al (2011) Outcomes with split liver transplantation in 106 recipients: the University of California, San Francisco, experience from 1993 to 2010. *Arch Surg* 146:1052–1059
54. Doyle MB, Maynard E, Lin Y et al (2013) Outcomes with split liver transplantation are equivalent to those with whole organ transplantation. *J Am Coll Surg* 217:102–112
55. Marcos A, Ham JM, Fisher RA et al (2000) Surgical management of anatomical variations of the right lobe in living donor liver transplantation. *Ann Surg* 231:824–831
56. Lee SG, Park KM, Hwang S et al (2001) Congestion of right liver graft in living donor liver transplantation. *Transplantation* 71:812–817
57. Ghobrial RM, Hsieh CB, Lerner S et al (2001) Technical challenges of hepatic venous outflow reconstruction in right lobe adult living donor liver transplantation. *Liver Transpl* 7:551–555
58. Rela M, Heaton N (1998) Split liver transplantation. *Br J Surg* 85:881–883
59. Starzl TE, Halgrimon CG, Koep KLJ et al (1979) Vascular homografts from cadaveric organ donors. *Surg Gynecol Obstet* 149:76
60. Shaw BW Jr, Iwatsuki S, Bron K, Starzl TE (1985) Portal vein grafts in hepatic transplantation. *Surg Gynecol Obstet* 161:66
61. Sheil AGR, Thompson JF, Stevens MS et al (1987) Mesoportal graft from thrombosed portal vein in liver transplantation. *Clin Transplant* 1:18
62. Tzakis A, Todo S, Stieber A, Starzl TE (1989) Venous jump grafts for liver transplantation in patients with portal vein thrombosis. *Transplantation* 48:530
63. Pinna AD, Lim JW, Sugitani AD et al (1996) "Pants" vein jump graft for portal vein and superior mesenteric vein thrombosis in transplantation of the liver. *J Am Coll Surg* 183:527
64. Tzakis AG, Kirkegaard P, Pinna AD et al (1998) Liver transplantation with cavoportal hemitransposition in the presence of diffuse portal vein thrombosis. *Transplantation* 65:619–624
65. Selvaggi G, Wepler D, Nishida S et al (2007) Ten-year experience in porto-caval hemitransposition for liver transplantation in the presence of portal vein thrombosis. *Am J Transplant* 7:454–460
66. Kato T, Levi DM, DeFaria W et al (2000) Liver transplantation with renoportal anastomosis after distal splenorenal shunt. *Arch Surg* 135:1401–1404
67. Paskonis M, Jurgaitis J, Mehrabi A et al (2006) Surgical strategies for liver transplantation in the case of portal vein thrombosis--current role of cavoportal hemitransposition and renoportal anastomosis. *Clin Transplant* 20:551–562

Nobuhisa Akamatsu and Norihiro Kokudo

---

## 12.1 Introduction

Outflow reconstruction is one of the most important techniques in living donor liver transplantation (LDLT). Hepatic veins of a partial graft are often multiple (middle hepatic vein [MHV] tributaries and inferior right hepatic veins [IRHV] of the right liver grafts or short hepatic veins [SHV] of left liver grafts), which requires the meticulous venoplasty not only on the graft at the bench procedure but also in recipients. Special attention must be paid for the anastomosis not causing outflow block in the recipient operation. In this regard, careful venous reconstruction not only in the graft but also in recipient inferior vena cava (IVC) is crucial for the satisfactory caval drainage [1].

Since the partial graft does not include the cava, piggyback reconstruction with the preservation of native IVC is almost always required in LDLT. The safety and feasibility of the cava-preserving piggyback technique has been proved in deceased donor liver transplantation (DDLT) setting when compared to the conventional caval replacement [2]. Yet the piggyback reconstruction in a partial liver graft is a far more demanding technique due to small and multiple orifice of the graft.

Here we describe a knack and pitfall of the management of recipient native IVC in the outflow reconstruction during LDLT procedure.

---

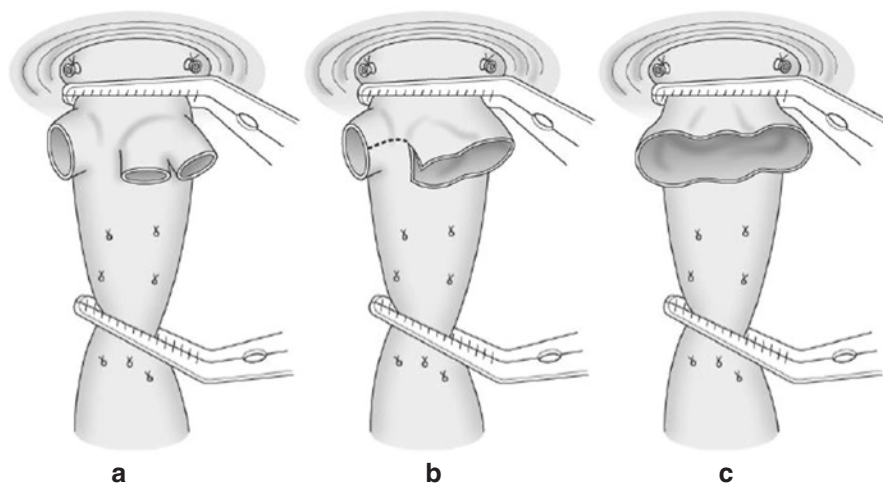
N. Akamatsu • N. Kokudo (✉)

Artificial Organ and Transplantation Division, Department of Surgery, Graduate School of Medicine, The University of Tokyo, 7-3-1 Hongo, Bunkyo-ku, Tokyo 113-8655, Japan  
e-mail: [KOKUDO-2SU@h.u-tokyo.ac.jp](mailto:KOKUDO-2SU@h.u-tokyo.ac.jp)

## 12.2 Preservation and Preparation of Native IVC in LDLT

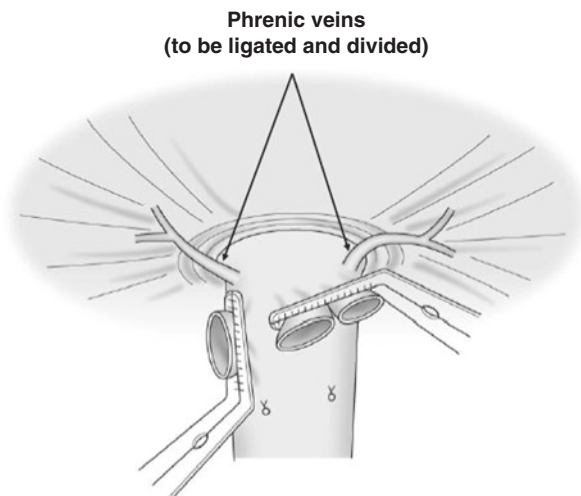
Almost all the venous reconstructions are done in the piggyback fashion, and consequently, the preservation of IVC is mandatory. Ahead of the plasty of hepatic IVC, the preservation of the native hepatic IVC is a key factor during the explant of the native liver in any type of venous reconstruction. Since a partial graft procured from a live donor has only the orifice of corresponding hepatic veins and is lacking IVC, the recipient hepatic IVC including the confluence of three hepatic veins must be preserved to the possible extent. In addition, the stumps of hepatic veins should be prepared to be widely opened for outflow reconstruction (Fig. 12.1).

There are several patterns of venous reconstruction in LDLT mainly based on the graft type, and IVC should be prepared as such in accordance with the corresponding venous orifice of the graft. Most prevalent way of reconstruction is to anastomose between corresponding veins, meaning the stump of right hepatic vein (RHV) to graft RHV and the stump of MHV+ left hepatic vein (LHV) to graft MHV + LHV; however, to secure the enough width of orifice to prevent the outflow stenosis, meticulous efforts have been reported to extend and enlarge the orifice. To enlarge the orifice to the maximum extent, three hepatic veins should be opened continuously (Fig. 12.1b, c), and meanwhile, when it is too large, the orifice can be shortened by suturing the end of the orifice (right side for left-side graft and vice versa). To secure a good and safe surgical field in making one large orifice with all three hepatic veins, the cross-clamp on the suprahepatic vena cava should be placed as far cranial as possible (Fig. 12.1a), not placing the clamp beneath the hepatic veins with a partial clamp of IVC. Ligating and dividing the phrenic veins which are draining into the root of the confluence of hepatic veins on both sides of IVC allows the IVC to be safely cross-clamped on the cranial side (Fig. 12.2).



**Fig. 12.1** For a satisfactory outflow reconstruction, the anterior wall of the vena cava and three hepatic veins are used to create a large orifice under cross-clamping of the vena cava

**Fig. 12.2** The phrenic veins draining into the inferior vena cava are ligated and divided to secure a wider space to cross-clamp the suprahepatic vena cava as cranial as possible

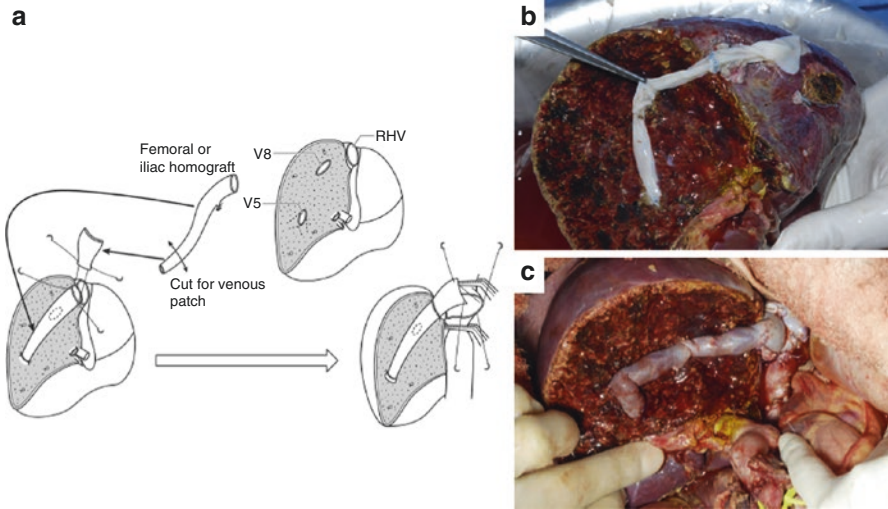


## 12.3 Outflow Reconstruction in LDLT

Besides the way to reconstruct each hepatic vein, there are several unsolved problems in the outflow reconstruction in LDLT, such as the inclusion of MHV in the right live graft [3], the reconstruction of MHV tributaries [4], and the reconstruction of short hepatic veins including inferior right hepatic vein (IRHV) [5]. However, it is widely accepted that the simple end-to-end anastomosis between corresponding hepatic veins is not sufficient to secure the adequate and long-lasting outflow drainage in LDLT recipients. Another important concern is the orthotopic position of the graft, especially in the left liver, and care should be taken for the graft position and anastomosis axis in outflow reconstruction not to hamper the outflow drainage. Accordingly, the venoplasty of both the recipient IVC and the graft veins is mandatory in the outflow reconstruction in LDLT.

### 12.3.1 Right Liver

The orifice of the recipient right hepatic vein is maximally extended caudally or to the left on IVC to provide for optimal graft outflow. There are several ways to enlarge the orifice of RHV on recipient IVC. One is to elongate RHV orifice toward caudal side, in which RHV is incised caudally with a patch plasty of the recipient RHV to remove the acute angle between RHV and IVC under the side clamp of IVC beneath the RHV, which was proposed by Asan group Korea [6]. In another way, IVC is divided horizontally for a distance corresponding to the transverse dimension of the orifice in the graft [7, 8]. The cranial and caudal flaps are excised so that a large triangular or oval opening is created and matched with that of the graft [9]. This method, which can be done with either partial clamp or cross-clamp of IVC, seems most prevalent worldwide.

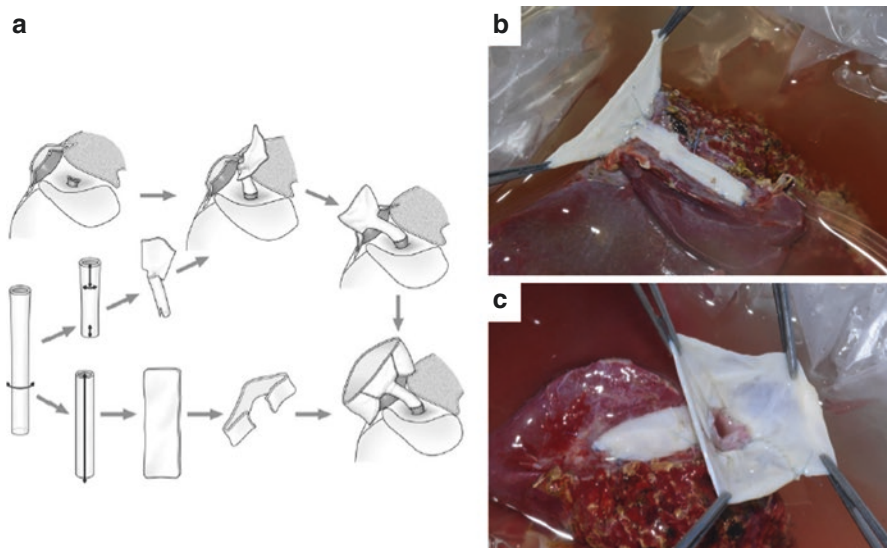


**Fig. 12.3** A modified right liver graft. Schema of the reconstruction of middle hepatic vein tributaries (V5 and V8) with a cryopreserved homologous venous graft which was finally anastomosed to the widely opened inferior vena cava with an additional venous patch (a) and photos at bench surgery (b) and after outflow reconstruction and reperfusion in the recipient (c). *RHV* right hepatic vein, *V5* drainage vein from segment V, *V8* drainage vein from segment VIII

In these methods, MHV+LHV is closed in the preparation of IVC. Our current way, which is supposed to provide the maximum orifice, is to extend the incision to connect RHV and MHV+LHV, which usually provides the orifice 5–6 cm in diameter [10]. As described above, this procedure is most facilitated by placing the cross-clamp on the suprahepatic vena cava as far cranial as possible. It is important to recognize that graft regeneration causes the right liver graft to rotate axially from right to left, which will result in a possible kinking of anastomosis or the compression of the anastomosis [11]. In this aspect, it is important to achieve an anastomosis with enough reservoir capacity to tolerate any kind of axial kink or compression by graft regeneration or surrounding tissues, for which making a large orifice on IVC to the possible extent is utmost important in recipient operation. For this purpose, we use cryopreserved homologous venous patch on the left wall of RHV to cover the widely opened anterior wall of recipient IVC as a roof-like reservoir [10, 11] (Fig. 12.3). In the presence of MHV (the extended right liver graft) or reconstructed MHV tributaries (the modified right liver graft), venoplasty between MHV and RHV is commonly undergone on bench surgery to create a common orifice with RHV permitting a single anastomosis to recipient IVC [3].

### 12.3.2 Left Liver

Unlike in right liver graft, outflow reconstruction in left liver is usually constructed between MHV+LHV on recipient IVC and the graft common orifice of MHV+LHV in end-to-end fashion [12]. However, it is also recommended as with the case in right



**Fig. 12.4** A left liver graft with a caudate (Spiegel) lobe. Schematic view of the venoplasty with a circular cuff vein patch in the liver graft (a). Both sides of the orifices of the left and middle hepatic veins were cut to make them wider, around which the venous patch was attached, to make wide orifice with as circular cuff. A conduit vein graft was sutured between the short hepatic vein and left and middle hepatic veins. Photos at bench surgery (b, c)

liver to enlarge the orifice of the confluence of MHV and LHV in both the recipient IVC and the graft. First step is to unify LHV and MHV making an incision on the septum between MHV and LHV. Second, to enlarge the orifice further, the right wall of MHV is incised, and a venous patch is attached. The same patch procedure is usually needed in the graft [13, 14] (Fig. 12.4). This plasty of IVC can be accomplished with the partial clamping of IVC beneath the confluence of MHV + LHV; however, a larger orifice can be achieved by the same technique described in Sect. 12.2. We usually open recipient's three hepatic veins continuously in left liver graft to achieve a maximal orifice on recipient IVC. When anastomosis is planned between thus widely opened anterior wall of IVC and the graft MHV+LHV which is generally short in height (2–5 mm), one certainly worries about tenting effect lifting the posterior wall of IVC upward resulting in a possible outflow block [15]. To avoid this phenomenon, a wall-like venous patch around MHV + LHV of the graft at the bench surgery to elongate the height and enlarge the orifice of MHV + LHV is mandatory [16].

## 12.4 Orthotopic Position of the Partial Graft

Caval drainage is one of the most important techniques in partial graft implantation. Not only the anastomosis but also the graft positioning can be important for the outflow. The graft should be placed in an orthotopic position, and care should be taken to consider the final position of the graft once the abdomen is closed. Especially



for left liver grafts, it is important to fix the falciform ligament to the midline of the abdominal wall to prevent graft rotation to the right side. Hepatic outflow block is one of the major complications leading to severe graft dysfunction after LDLT. Left liver grafts are prone to pivoting around the IVC if the graft is not held tightly in its position by fixing the falciform ligament in the graft to the anterior abdominal wall. Rotation of the left liver graft to the vacant right subphrenic space after operation can result in a functional Budd–Chiari-like effect due to kinking of the venous anastomosis. Moreover, the left liver graft regenerates more aggressively than right liver which may cause the rotation of the graft toward the right and posterior side around the IVC axis. This again can cause kinks and outflow issues. In contrast, the right liver graft resides comfortably in the limited right subphrenic cavity and regenerates toward the left and anteromedial sides with little positional change of the venous anastomosis.

---

## 12.5 Reconstruction of Short Hepatic Veins

Relatively large short hepatic veins in right liver graft, so-called IRHV, and middle right hepatic vein (MRHV) and a caudate vein (draining Spiegel lobe) in left liver with Spiegel lobe should be reconstructed to expect the maximal graft function and regeneration. Of course, it is possible to anastomose these veins of the graft directly to the recipient IVC in an end-to-side fashion with a side clamping of IVC [5, 17]. In such instances, recipient IVC is incised which is corresponding to these veins of the graft. Direct anastomosis between the short hepatic vein and the recipient IVC is sometimes technically demanding. Because determining the optimal anastomotic site and direction is difficult and requires time, this may increase the warm ischemic time. To overcome these problems, we have recommended the reconstruction of these veins on the bench surgery, utilizing the cryopreserved homologous veins. In right liver graft with IRHV or MRHV, if the IVC graft is available, IRHV and MRHV can be reconstructed at the bench, which is called the double IVC method [10, 11] (Fig. 12.5). If the IVC graft is not available, but a thinner vein graft such as the femoral vein is available, similar reconstruction is possible [18] (Fig. 12.6). We must note that, in this case, extensive dissection of the IVC around the hepatic vein branches, including the phrenic veins, is unnecessary.

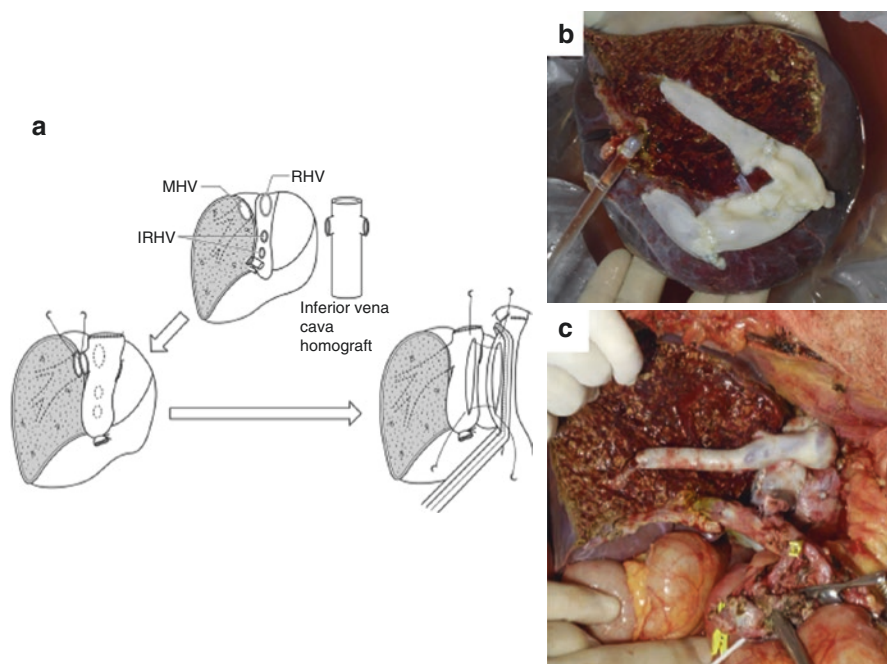
In left liver graft, when a short hepatic vein and LHV + MHV are located close to each other, simple venoplasty at the bench is possible. Another option includes venoplasty using vein grafts at the bench. On the graft side, a wide venous orifice with a long cuff is formed by gathering the left, middle, and short hepatic veins using a conduit vein graft and patch vein grafts [14] (Fig. 12.4), which is then anastomosed to wide-opened recipient IVC.

---

## 12.6 Reconstruction of Middle Hepatic Vein Tributaries

When the right liver is harvested without MHV, the reconstruction of MHV tributaries, namely, V5 draining segment V and V8 draining segment VIII, should be considered. The indication for MHV tributary reconstruction should be





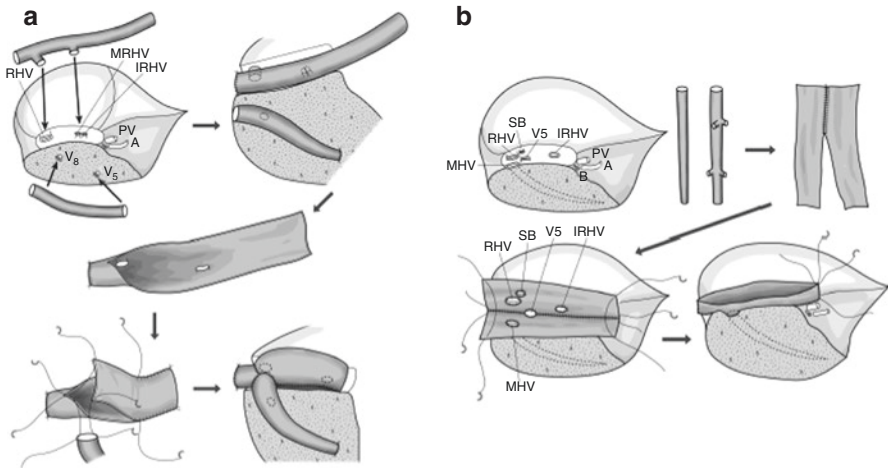
**Fig. 12.5** Double vena cava reconstruction in a right liver graft. Schema of the reconstruction of an extended right liver graft using the double vena cava technique with a cryopreserved homologous inferior vena cava (a). Photos at bench surgery (b) and after outflow reconstruction and reperfusion (c) in the recipient with the reconstruction of both middle hepatic vein tributaries and inferior right hepatic vein. *RHV* right hepatic vein, *MHV* middle hepatic vein, *IRHV* inferior right hepatic vein

determined preoperatively by measuring the drainage area volume of V5 and V8. If the uncongested area (i.e., area drained by the right hepatic vein) is sufficient for the metabolic demands of the recipient (usually 35–40% of the recipient standard liver volume), reconstruction of the MHV tributaries is not necessary and vice versa [10].

MHV tributaries are usually reconstructed at the bench surgery with interposition vein grafts, such as autografts (recipient's portal vein, hepatic vein, jugular vein, or iliac vein), cryopreserved venous or arterial grafts, and artificial grafts. The reconstructed MHV was anastomosed directly to recipient IVC in the initial report by Asan group [19]; however, nowadays venoplasty is usually performed between reconstructed MHV and RHV at bench surgery to create a common orifice with RHV which will allow a single anastomosis to recipient IVC (Fig. 12.3).

## 12.7 Grafts Used to Reconstruct IVC, Autograft, Allograft, Cryopreserved Allograft, and Artificial Graft

Numerous reports have been reported for the reconstruction of IVC and hepatic veins with various vein grafts. Internal jugular vein [20], femoral vein [21], portal vein (umbilical portion) [22, 23], and hepatic vein of the native liver [24] are



**Fig. 12.6** Two ways to create the vena cava on the graft with thinner cryopreserved homologous veins. Two venous sheets are anastomosed either in the dorsal–ventral position (a) or in the left–right position (b) to create the alternative vena cava. (Liver Transpl 2005;11:101–103.) *RHV* right hepatic vein, *MHV* middle hepatic vein, *MRHV* middle right hepatic vein, *IRHV* inferior right hepatic vein, *V5* drainage vein from segment V, *V8* drainage vein from segment VIII, *PV* portal vein, *A* hepatic artery, *B* bile duct, *SB* superficial branch

frequently utilized as autografts taken from recipient himself. Allografts from the liver donor, such as round ligament [25], and femoral vein [26] can be another option, but the latter of which is not recommended in the consideration of donor priority. As described above, cryopreserved homologous veins from cardiac death donor are an optimal option for the venous reconstruction in LDLT [27, 28]. Artificial venous graft, polytetrafluoroethylene (PTFE), for venous reconstruction in LDLT is aggressively used in Asian high-volume center with promising results [29, 30], but may include potential disadvantage when compared to allo- or auto-grafts [31]. In terms of patency, there seems no difference among these vein grafts [29]. Advantages and disadvantages are summarized in Table 12.1.

## 12.8 IVC Replacement in LDLT

As mentioned above, the preservation of recipient native IVC is utmost important in LDLT; however, there are several situations where IVC should be sacrificed and reconstructed.

Budd–Chiari syndrome (BCS) is a rare disease with a multifactorial etiology and is characterized by obstruction of the hepatic venous outflow anywhere from the intrahepatic venules to the suprahepatic portion of the inferior vena cava (IVC). In Western countries, a prothrombotic condition leading to hepatic venous thrombosis is most often the cause of BCS, while in Eastern countries, especially in Japan, BCS is most often caused by membranous obstruction of the inferior vena cava (MOVC)

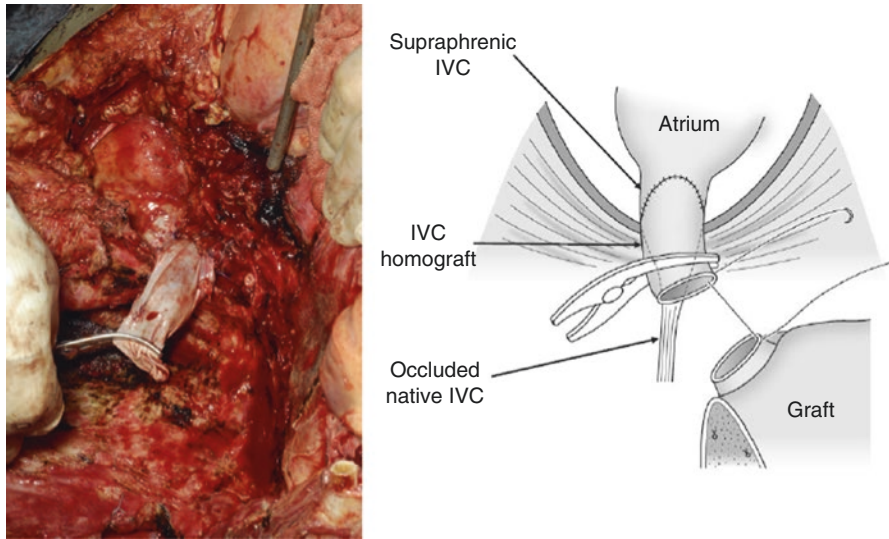
**Table 12.1** Comparison of characteristics among graft types

	Cryopreserved graft	Autograft	PTFE graft
Extensibility (volume capacity)	Fair	Good	Bad
Suturing	Good	Good	Fair
Size (diameter)	Any size available	Limited	Any size available
Length	Any length available	Limited	Any length available
Antibacterial capacity	Fair	Strong	Vulnerable
Contamination	Negligible	None	None
Patency	Fair	Fair	Fair
Cost	Expensive	None	Fair

or primary IVC thrombosis. Accordingly, LDLT for BCS in Asian countries usually requires reconstruction of recipient IVC. A point worth mentioning is outflow reconstruction during LDLT for recipients with BCS; the deceased donor graft included the hepatic IVC and hepatic veins, and the removal and replacement of the native hepatic IVC with a cavo-caval anastomosis between the recipient's native IVC and the donor IVC is easily accomplished. In contrast, the piggyback technique for LDLT involves the preservation of the recipient's IVC, and anastomosis between the recipient's IVC and graft hepatic vein is mandatory in the absence of the donor IVC. Thus, LDLT presents substantial challenges in terms of treating BCS. The key consideration for using LDLT to treat BCS is the management of a stenotic or occluded native IVC and the choice of techniques used to reconstruct the hepatic outflow. A search of the English literature yielded 32 patients with BCS who underwent LDLT, among which replacement and interpositioning of the IVC with the vascular graft was done in seven cases (22%), direct reconstruction of the outflow to the atrium (or suprarenic IVC) was done in four (13%), and patch plasty of the IVC was required in seven (22%) [32].

Cryopreserved homologous IVC which was directly anastomosed to recipient suprarenic IVC in BCS patient is shown in Fig. 12.7. In this case, hepatic IVC was completely occluded and became fibrous organization, which made it impossible to resect and replace IVC. Consequently, cryopreserved homologous IVC was interposed between recipient suprarenic IVC and the graft MHV + LHV orifice.

Another indication of IVC replacement in LDLT is for cases with hepatic malignancies. Clinically and conventionally, the piggyback technique preserving native IVC had been avoided in patients with hepatic malignancies due to the theoretical increased risk of a positive vena cava margin and the potential for metastatic spillage of tumor through the hepatic vein. However, it is now widely accepted that piggyback venous reconstruction does not result in a poor prognosis after DDLT for HCC when compared to caval replacement [33], and this may be the case also in LDLT. Nevertheless, hepatic IVC resection with the liver and IVC replacement should be considered in those with suspected invasion to IVC or with tumors adjacent to IVC. In such instances, cryopreserved homologous IVC seems optimal for IVC replacement, while PTFE graft can be used safely [34].



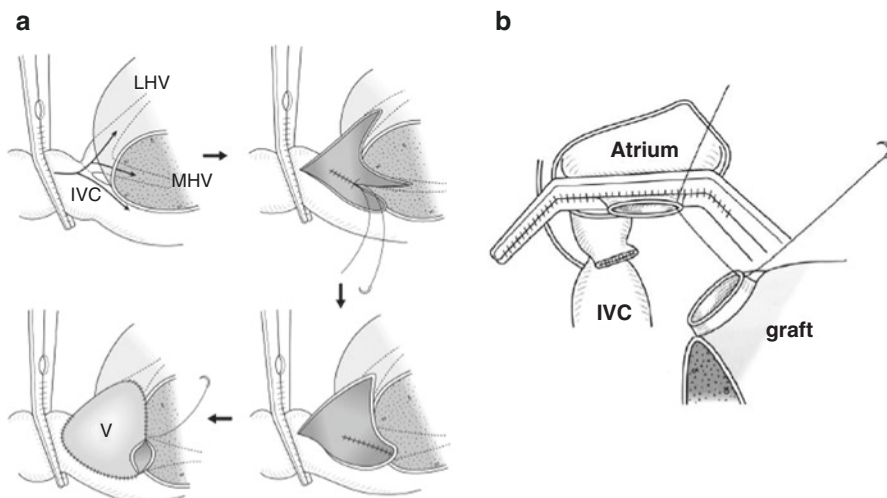
**Fig. 12.7** Interposition between supraphrenic inferior vena cava and the left liver graft with a cryopreserved homologous inferior vena cava. *IVC* inferior vena cava

## 12.9 IVC Reconstruction for Outflow Block

Outflow block is a serious complication among LDLT recipients. It can occur early after liver transplantation presenting with acute Budd–Chiari syndrome or may develop as a stenosis gradually after liver transplantation [35]. Usually, the interventional radiology (IVR) including percutaneous transluminal angioplasty via ballooning or the insertion of a metallic stent is the first choice for the treatment of venous anastomotic stricture with promising results [36]; however, surgical revision is sometimes required in cases who present with acute outflow block or are refractory to IVR treatments [37]. In such instances, the redo surgery is usually challenging due to the dense adhesion around IVC and the fibrous thickening of venous anastomosis. Venous patch plasty to enlarge the stenotic anastomosis may be one of the ways to resolve the outflow block (Fig. 12.8a), yet the direct anastomosis between graft outflow orifice and the atrium or supraphrenic IVC (Fig. 12.8b) and the graft interposition as presented in Fig. 12.7 are often required to secure the adequate outflow drainage.

### Key Points

- Recipient native IVC should be preserved to the possible extent in LDLT.
- To achieve the maximal orifice on the recipient IVC, three hepatic veins should be opened in continuous.
- The cross-clamp on the suprahepatic vena cava should be placed as far cranial as possible by ligating bilateral phrenic veins.



**Fig. 12.8** Venoplasty of the stenotic anastomosis using a venous patch (a) and the direct anastomosis between atrium and the graft orifice (b). (Transplantation 2004;77:1768–70.) LHV left hepatic vein, MHV middle hepatic vein, IVC inferior vena cava, V venous patch

- Cryopreserved homologous veins are useful in any type of venoplasty, while autologous and artificial grafts can be alternative.
- In the right liver, the venous patch should be applied to the right side of the graft vein to make a roof-like reservoir on IVC. In the presence of IRHV, double IVC method is useful.
- In the left liver, not only the size of orifice of the graft but also the height of venous cuff is crucial for caval drainage. The orthotopic graft positioning plays an important role because the outflow can be easily blocked by torsion of the liver graft.
- Budd-Chiari syndrome is most challenging in LDLT in terms of outflow reconstruction, since native IVC is usually not suitable for venoplasty nor for anastomosis.

### Key References

- Sugawara Y, Makuuchi M, Imamura H, Kaneko J, Kokudo N (2003) Outflow reconstruction in extended right liver grafts from living donors. *Liver Transpl* 9(3):306–309
- Akamatsu N, Sugawara Y, Kaneko J, Sano K, Imamura H, Kokudo N et al (2003) Effects of middle hepatic vein reconstruction on right liver graft regeneration. *Transplantation* 76(5):832–837
- Sugawara Y, Makuuchi M, Imamura H, Kaneko J, Ohkubo T, Kokudo N (2002) Outflow reconstruction in recipients of right liver graft from living donors. *Liver Transpl* 8(2):167–168
- Akamatsu N, Sugawara Y, Nagata R, Kaneko J, Aoki T, Sakamoto Y et al (2014) Adult right living-donor liver transplantation with special reference to reconstruction of the middle hepatic vein. *Am J Transplant* 14(12):2777–2787

- Sugawara Y, Makuuchi M, Akamatsu N, Kishi Y, Niiya T, Kaneko J et al (2004) Refinement of venous reconstruction using cryopreserved veins in right liver grafts. *Liver Transpl* 10(4):541–547
- Takemura N, Sugawara Y, Hashimoto T, Akamatsu N, Kishi Y, Tamura S et al (2005) New hepatic vein reconstruction in left liver graft. *Liver Transpl* 11(3):356–360.
- Kishi Y, Sugawara Y, Matsui Y, Akamatsu N, Motomura N, Takamoto S et al (2005) Alternatives to the double vena cava method in partial liver transplantation. *Liver Transpl* 11(1):101–103
- Akamatsu N, Sugawara Y, Kokudo N (2015) Budd-Chiari syndrome and liver transplantation. *Intractable Rare Dis Res* 4(1):24–32
- Akamatsu N, Sugawara Y, Kaneko J, Kishi Y, Niiya T, Kokudo N et al (2004) Surgical repair for late-onset hepatic venous outflow block after living-donor liver transplantation. *Transplantation* 77(11):1768–1770.

---

## References

1. Makuuchi M, Sugawara Y (2004) Technical progress in living donor liver transplantation for adults. *HPB (Oxford)* 6(2):95–98
2. Gurusamy KS, Pamecha V, Davidson BR (2011) Piggy-back graft for liver transplantation. *Cochrane Database Syst Rev* (1):CD008258
3. Sugawara Y, Makuuchi M, Imamura H, Kaneko J, Kokudo N (2003) Outflow reconstruction in extended right liver grafts from living donors. *Liver Transpl* 9(3):306–309
4. Akamatsu N, Sugawara Y, Kaneko J, Sano K, Imamura H, Kokudo N et al (2003) Effects of middle hepatic vein reconstruction on right liver graft regeneration. *Transplantation* 76(5):832–837
5. Hwang S, Ha TY, Ahn CS, Moon DB, Kim KH, Song GW et al (2012) Reconstruction of inferior right hepatic veins in living donor liver transplantation using right liver grafts. *Liver Transpl* 18(2):238–247
6. Hwang S, Lee SG, Ahn CS, Moon DB, Kim KH, Sung KB et al (2010) Morphometric and simulation analyses of right hepatic vein reconstruction in adult living donor liver transplantation using right lobe grafts. *Liver Transpl* 16(5):639–648
7. Kinkhabwala MM, Guarrera JV, Leno R, Brown RS, Prowda J, Kapur S et al (2003) Outflow reconstruction in right hepatic live donor liver transplantation. *Surgery* 133(3):243–250
8. Sugawara Y, Makuuchi M, Imamura H, Kaneko J, Ohkubo T, Kokudo N (2002) Outflow reconstruction in recipients of right liver graft from living donors. *Liver Transpl* 8(2):167–168
9. Liu CL, Zhao Y, Lo CM, Fan ST (2003) Hepatic venoplasty in right lobe live donor liver transplantation. *Liver Transpl* 9(12):1265–1272
10. Akamatsu N, Sugawara Y, Nagata R, Kaneko J, Aoki T, Sakamoto Y et al (2014) Adult right living-donor liver transplantation with special reference to reconstruction of the middle hepatic vein. *Am J Transplant* 14(12):2777–2787
11. Sugawara Y, Makuuchi M, Akamatsu N, Kishi Y, Niiya T, Kaneko J et al (2004) Refinement of venous reconstruction using cryopreserved veins in right liver grafts. *Liver Transpl* 10(4):541–547
12. Sudhindran S, Menon RN, Balakrishnan D (2012) Challenges and outcome of left-lobe liver transplants in adult living donor liver transplants. *J Clin Exp Hepatol* 2(2):181–187
13. Hashimoto T, Sugawara Y, Tamura S, Kaneko J, Motomura N, Takamoto S et al (2007) One orifice vein reconstruction in left liver plus caudate lobe grafts. *Transplantation* 83(2):225–227



14. Takemura N, Sugawara Y, Hashimoto T, Akamatsu N, Kishi Y, Tamura S et al (2005) New hepatic vein reconstruction in left liver graft. *Liver Transpl* 11(3):356–360
15. Takayama T, Makuuchi M, Kawarasaki H, Kawasaki S, Matsunami H, Hashikura Y et al (1994) Venacavoplasty to overcome outflow block in living related liver transplantation. *Transplantation* 58(1):116–118
16. Yamazaki S, Takayama T, Makuuchi M (2010) The technical advance and impact of caudate lobe venous reconstruction in left liver: additional safety for living-related donor liver transplantation. *Transpl Int* 23(4):345–349
17. Takayama T, Makuuchi M, Kubota K, Sano K, Harihara Y, Kawarasaki H (2000) Living-related transplantation of left liver plus caudate lobe. *J Am Coll Surg* 190(5):635–638
18. Kishi Y, Sugawara Y, Matsui Y, Akamatsu N, Motomura N, Takamoto S et al (2005) Alternatives to the double vena cava method in partial liver transplantation. *Liver Transpl* 11(1):101–103
19. Gyu Lee S, Min Park K, Hwang S, Hun Kim K, Nak Choi D, Hyung Joo S et al (2002) Modified right liver graft from a living donor to prevent congestion. *Transplantation* 74(1):54–59
20. Uchiyama H, Shirabe K, Yoshizumi T, Ikegami T, Soejima Y, Taketomi A et al (2012) Use of an internal jugular vein graft for middle hepatic vein tributary reconstruction in right-lobe living-donor liver transplantation. *Transplantation* 94(2):e17–e18
21. Sato K, Sekiguchi S, Watanabe T, Enomoto Y, Akamatsu Y, Kawagishi N et al (2009) The use of recipient superficial femoral vein as a venous graft for portal vein reconstruction in right lobe living donor liver transplantation. *Transplant Proc* 41(1):195–197
22. Ikegami T, Shirabe K, Yoshiya S, Soejima Y, Yoshizumi T, Uchiyama H et al (2013) One-step reconstruction of the right inferior hepatic veins using auto-venous grafts in living-donor liver transplantation. *Surg Today* 43(7):769–776
23. Moon D, Lee S, Hwang S, Park K, Kim K, Ahn C et al (2004) Umbilical portion of recipient's left portal vein: a useful vascular conduit in dual living donor liver transplantation for the thrombosed portal vein. *Liver Transpl* 10(6):802–806
24. Takatsuki M, Miyamoto S, Kamohara Y, Kawashita Y, Tajima Y, Kanematsu T (2006) Simplified technique for middle hepatic vein tributary reconstruction of a right hepatic graft in adult living donor liver transplantation. *Am J Surg* 192(3):393–395
25. Toshima T, Ikegami T, Matsumoto Y, Yoshiya S, Harimoto N, Yamashita Y et al (2015) One-step venous reconstruction using the donor's round ligament in right-lobe living-donor liver transplantation. *Surg Today* 45(4):522–525
26. Sato K, Sekiguchi S, Kawagishi N, Akamatsu Y, Miyagi S, Yamaya H et al (2014) Hepatic venous reconstruction using the superficial femoral vein in a right-lobe living donor liver transplant patient with interrupted inferior vena cava. *Pediatr Transplant* 18(1):E13–E17
27. Wang CC, Lopez-Valdes S, Lin TL, Yap A, Yong CC, Li WF et al (2014) Outcomes of long storage times for cryopreserved vascular grafts in outflow reconstruction in living donor liver transplantation. *Liver Transpl* 20(2):173–181
28. Hwang S, Ahn CS, Kim KH, Moon DB, Ha TY, Song GW et al (2012) Standardization of modified right lobe grafts to minimize vascular outflow complications for adult living donor liver transplantation. *Transplant Proc* 44(2):457–459
29. Hwang S, Jung DH, Ha TY, Ahn CS, Moon DB, Kim KH et al (2012) Usability of ringed polytetrafluoroethylene grafts for middle hepatic vein reconstruction during living donor liver transplantation. *Liver Transpl* 18(8):955–965
30. Yi NJ, Suh KS, Lee HW, Cho EH, Shin WY, Cho JY et al (2007) An artificial vascular graft is a useful interpositional material for drainage of the right anterior section in living donor liver transplantation. *Liver Transpl* 13(8):1159–1167
31. Ha TY, Hwang S, Jung DH, Ahn CS, Kim KH, Moon DB et al (2014) Complications analysis of polytetrafluoroethylene grafts used for middle hepatic vein reconstruction in living-donor liver transplantation. *Transplant Proc* 46(3):845–849
32. Akamatsu N, Sugawara Y, Kokudo N (2015) Budd-Chiari syndrome and liver transplantation. *Intractable Rare Dis Res* 4(1):24–32



33. Mangus RS, Fridell JA, Vianna RM, Cooper AB, Jones DT, Tector AJ (2008) Use of the piggyback hepatectomy technique in liver transplant recipients with hepatocellular carcinoma. *Transplantation* 85(10):1496–1499
34. Matsuda H, Sadamori H, Shinoura S, Umeda Y, Yoshida R, Satoh D et al (2010) Aggressive combined resection of hepatic inferior vena cava, with replacement by a ringed expanded polytetrafluoroethylene graft, in living-donor liver transplantation for hepatocellular carcinoma beyond the Milan criteria. *J Hepatobiliary Pancreat Sci* 17(5):719–724
35. Yang J, Xu MQ, Yan LN, Lu WS, Li X, Shi ZR et al (2009) Management of venous stenosis in living donor liver transplant recipients. *World J Gastroenterol* 15(39):4969–4973
36. Kubo T, Shibata T, Itoh K, Maetani Y, Isoda H, Hiraoka M et al (2006) Outcome of percutaneous transhepatic venoplasty for hepatic venous outflow obstruction after living donor liver transplantation. *Radiology* 239(1):285–290
37. Akamatsu N, Sugawara Y, Kaneko J, Kishi Y, Niiya T, Kokudo N et al (2004) Surgical repair for late-onset hepatic venous outflow block after living-donor liver transplantation. *Transplantation* 77(11):1768–1770

Salah D. Qanadli and Charalampos Sotiriadis

## Abbreviations

CT	Computed tomography
DVT	Deep venous thrombosis
IVC	Inferior vena cava
MRI	Magnetic resonance imaging
PE	Pulmonary embolism
VCF	Vena cava filter

---

## 13.1 Introduction

Acute pulmonary embolism (PE) is a major and potential fatal complication of deep venous thrombosis (DVT). Untreated proximal DVT is associated to a risk of symptomatic APE up to 40% [1]. The culprit veins as a source of embolism were found in more than 90% in the lower limb DVT [2]. Rarely the source is in the upper extremities, renal or gonadal veins. It has been advocated that treating DVT could prevent acute PE. The first-line treatment of DVT is anticoagulation. Whereas the medical treatment has been improved by using heparin with a limited risk of major bleeding complications, some patients could not be anticoagulated, and others will experience anticoagulation failure. The vena cava filtration, at least for these patients, has been described to overcome these limitations. Over the last decades, placing a filter in the inferior vena cava (IVC) has been gaining popularity to prevent acute PE in several indications [3–7].

---

S.D. Qanadli (✉) • C. Sotiriadis  
Cardio-Thoracic and Vascular Unit, Department of Radiology, Lausanne University Hospital,  
BH07, Rue du Bugnon 46, Lausanne 1011, Switzerland  
e-mail: [salah.qanadli@chuv.ch](mailto:salah.qanadli@chuv.ch)

The purpose of this chapter is to review the latest technologies and discuss the most recent recommendations for the vena cava filter (VCF) in terms of indications but also in terms of strategies for filter retrieval and device selection. Finally, an update on filter complications and their specific management will be provided.

---

## 13.2 History of the Vena Cava Filtration

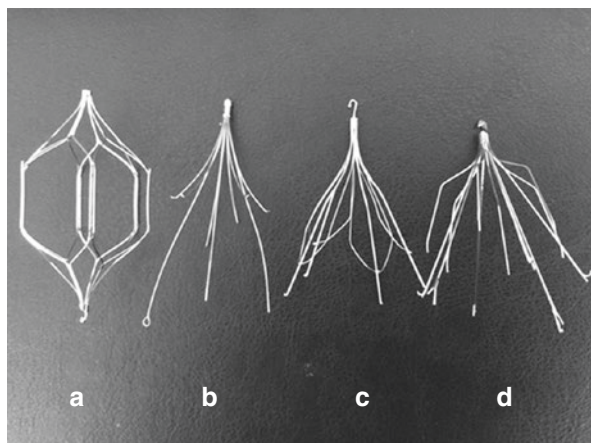
Mechanical interruption of the venous system as an approach to prevent PE started more than a century ago. First, the femoral vein ligation was described by John Hunter in 1874 [8]. Then a surgical interruption (ligation) of the IVC was proposed that had been associated to a significant perioperative mortality, induced chronic IVC syndrome, and PE recurrence [9]. Surgical improvement consisted on introducing a compartmentalization concept at the site of the IVC interruption (using staples, clips, or sutures) [10, 11]. The first generation of VCF was introduced by Mobin-Uddin in 1967 [12] and released for general use in 1973. The filter consisted of an umbrella-shaped silicone membrane with six radiation stainless steel alloy spokes. Since that time, significant technological advances have been done to develop more efficient and safe devices for endoluminal caval filtration.

---

## 13.3 Vena Cava Filter Classification

Different devices with different designs are commercially available (Fig. 13.1). These devices could be classified considering the material used in their construction (e.g., nitinol, stainless steel), their design (e.g., basket shape or umbrella shape), their profile, the vascular access used for insertion, the compatibility with magnetic resonance imaging, the maximum allowed diameter of the IVC, or even their filtration power. However, currently the most important property that better serve a comprehensive classification of devices is certainly the ability to retrieve or not the device. The permanent filters are left in place after insertion and provide a permanent filtration. The temporary filters, which are externally anchored, were designed for short-time use and must be removed. In order to take advantages from both permanent and temporary technologies, several permanent filters have been redesigned to offer the option of retrieving them after complete insertion (optional filters). The first (FDA-approved) retrievable filter was the Bard Recovery, designed to be retrieved with a dedicated cone. Several other filters were then developed with different techniques for removal. The most common one is the use of snare that allows insertion of the hook placed in the cranial part of the filter (umbrella shape) or at the caudal extremity (basket shape). This technology was introduced in 2003 and has been accompanied in few years by marked increase in filter use, particularly in the United States [13]. Due the potential adherence to venous wall, filters with basket shape are considered short-term optional filters as the temporal window of retrieval is limited to three weeks (e.g., Optease, Cordis Johnson and Johnson), while filters with umbrella shape could be retrieved several years after

**Fig. 13.1** IVC filters that are commercially available. (a) Optease (Cordis). (b) ALN filter (ALN). (c) Select (Cook). (d) Denali (Bard)



insertion [14]. Recently, a new generation of optional filters has been developed with the objective to convert the filter in situ to a shape with a limited filtration power without removing it completely [15]. As already available in other applications, resorbable materials might play a role in the VCF technology in the near future [16, 17].

Selection of the optimal device is mainly based on the clinical setting. Knowledge of the filtration power, structural integrity of the filter, rate of induced occlusion of the IVC, potential filter displacement and migration, ease of placement and retrieval, as well as the skills mandatory for the use are also crucial in the device selection.

As optional filters had similar mechanical properties, especially regarding filtration power [18] and durability, we advocate a systematic use of retrieval filter. The decision to remove or not the filter should come later. This is supported by the fact that filter insertion is frequently performed in emergency setting that couldn't allow to select permanent or retrieval filter depending on the patient condition and the underlying disease. However, at least for selected populations that include young patients, patients with transient inability to be anticoagulated, and the so controversial prophylactic indications, the optional filters are mandatory.

### 13.4 Indications for VCF Placement

Several guidelines/recommendations have been published by different professional societies regarding the appropriate indications for IVC filter insertion [4, 5, 7]. Recently, efforts were made to revise collaboratively these guidelines, particularly by the American College of Chest Physicians (ACCP) and the Society of Interventional Radiology (SIR). Despite these efforts, significant differences exist, mainly regarding prophylactic indications. For clarity, indications could be divided in three categories: absolute indications, relative indications, and prophylactic indications.

### 13.4.1 Absolute Indications

Defined as indications that reached a high level of evidence (level I or level IIa or high appropriateness) and received a consensus in the published guidelines: patients who have an acute PE or DVT and (1) who cannot receive anticoagulation therapy, (2) in whom anticoagulation therapy has failed (documented recurrent PE) [19], (3) who develop a contraindication to continue anticoagulation (induced bleeding), or (4) in whom anticoagulation could not achieve or be maintained in a therapeutic level.

### 13.4.2 Relative Indications

This group of indications is defined as acceptable indications that received an acceptable level of evidence (level IIb or mid-level appropriateness). These indications should integrate the patient condition, and it is usually recommended to adopt an institutional multidisciplinary consensus for their usage in routine practice.

Several clinical situations were reported to be relative indications for VCF placement: (1) unstable patients with PE; (2) patient with PE or DVT and considered as having a limited cardiopulmonary reserve, given the potential consequences of re-embolization [19, 20]; (3) patient with massive PE that has been treated with thrombolysis or thrombectomy [19]; (4) patient with large floating ilio-caval DVT [5]; and (5) patient at high risk of complications of anticoagulation.

### 13.4.3 Prophylactic Indications

The rationale behind this group of indications is to prevent PE in patient with no evidence of PE or DVT but considered of high risk to develop such condition as in trauma patients, patients undergoing spine surgery, patients who are candidates for elective gastric bypass surgery, and chronically immobilized patients.

There are several controversies regarding the use of VCF as a prophylactic measure. The ACCP did not recommend the prophylactic use. The largest indication is probably placement of VCF in patients with trauma despite the conflicting data in the literature and the lack of evidence to support this usage. In the meta-analysis reported by Velmohos GC et al. [21] collecting 73 studies in trauma patients, the overall incidence of PE was as low as 1.5% and was not significantly reduced by anticoagulation or by VCF. More recent systematic review published by Girard TD et al. [22] reported similar results in trauma patients receiving prophylactic VCF with incidence of PE ranging from 0% to 10%.

Furthermore, prophylactic indications are responsible for a significant increase of VCF during the last decade and represented 17–40% of the indications [23]. In the recent VCF Retrieval Registry of Cardiovascular and Interventional Radiological Society of Europe (CIRSE) [24] that collected 671 patient data from 2010 to 2012

across Europe, absolute indications represented 40 % and relative indications 31 %, while prophylactic indications represented 24 % (with 5 % missing data).

In our routine practice, we recommend to restrict the prophylactic indications to selected patients. Indications should be discussed case by case with clear information to the patient whenever possible.

The threshold for filter placement as recommended indications is 95 %. If less than 95 % are done out of these indications, the decision-making process should be reviewed according to institutional policies. Surprisingly, a decade after recommendations for using VCF, high variation between hospitals could be observed [25].

---

### 13.5 VCF Placement Procedure

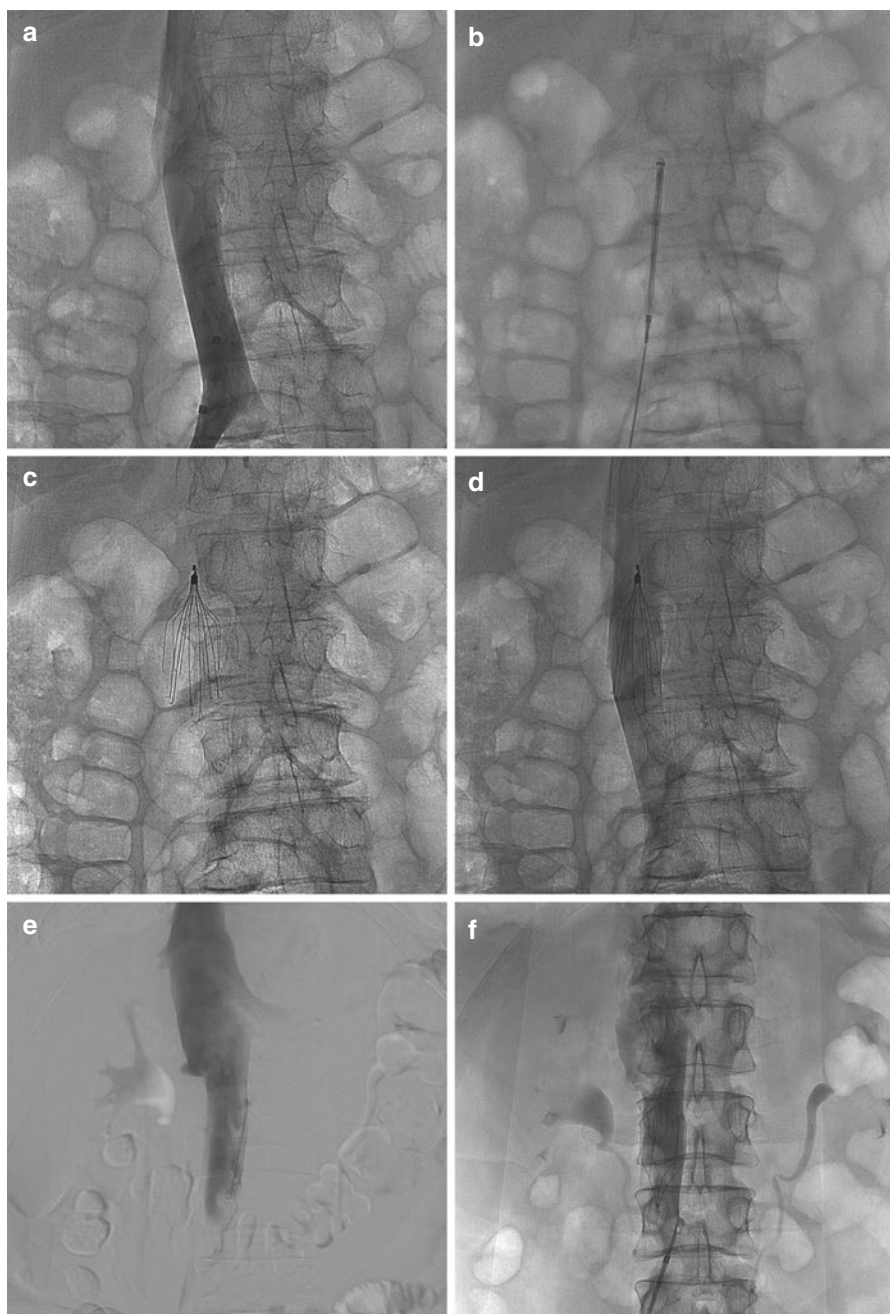
Filter insertion can be either performed as outpatient or inpatient procedure. Most filter insertion occurred, however, in inpatient population due to indications and/or the underlying disease. The local anesthesia is basically used for both insertion and retrieval procedures. Depending on the patency of the venous access, filter insertion is performed by femoral venous access (preferably right side), jugular access (usually the right side), or brachial vein.

Prior to placement, the IVC should be assessed. Transcatheter venography prior to placement assesses IVC patency and potential variants that may require specific approaches [26]. The maximum diameter of the IVC and the number and position of renal veins should also be evaluated. If available, recent noninvasive imaging (CT or MRI) may be used to obtain the required informations. With most devices, the maximum diameter that could accept a filter placement ranged from 18 to 31 mm. Only one filter could be inserted in a larger vein (Bird's Nest filter, Cook) up to 40 mm.

The standard technique of filter placement uses fluoroscopy guidance (Fig. 13.2) in dedicated facilities of interventions; however, ultrasound can alternatively be used for placement for bedside placement in unstable patients or nonmobilized patients [27, 28].

The optimal position of the filter insertion is the infrarenal segment immediately below the renal veins according to the manufacturer's information for use. However, in some circumstances other target positions may be acceptable. Indications for suprarenal placement include the presence of IVC thrombus in the infrarenal segment or extrinsic compression, gonadal vein thrombosis, and filter placement during pregnancy, prior to pelvic or abdominal surgery that potential expose to IVC mobilization.

The technical success rate of filter placement is set at 97 % in a trained hand. Procedure-related complications are rare. Death and filter embolization are reported in 0.12 % [29] and 0.1 % [30, 31], respectively. Placement outside the target region occurred from 1 % to 9 % [28]. Deployment failure and vena cava perforation have also been reported as procedure-related complications [32, 33]. More frequent and less important is the thrombosis of the access site reported from 3 % to 10 % [30, 34–36]. If the low profile latest generations (introducer size less than 6 F) should





significantly reduce the risk of site access thrombosis, a systematic use of imaging to assess the site of insertion in the postoperative course might show a relatively high rate even with modern devices [37].

### 13.6 VCF Retrieval Procedure

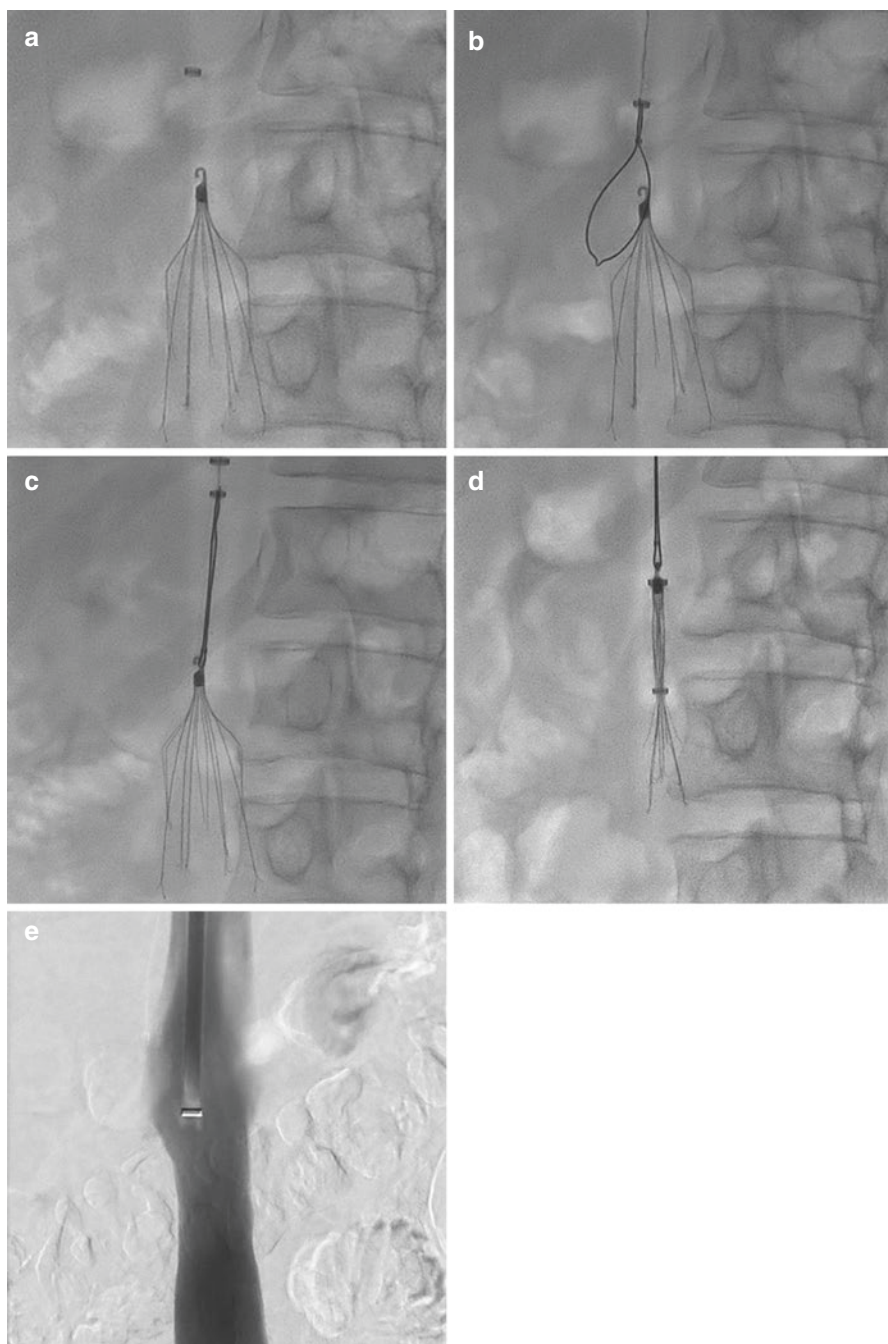
The procedure of retrieval could be done in outpatient basis under local anesthesia. Depending on the filter, venous access is femoral or jugular. Usually, a dedicated set for retrieval is commercially available for each filter. However, for the filter designed with a hook, any other materials could be used provided that the size of the catheter/introducer to be inserted over the filter is respected. While the filter placement could be done on bedside basis, the retrieval procedure requires fluoroscopy guidance. After a cavogram, the catheter/introducer (8–12 F) is positioned close to the filter. A snare or a dedicated cone (grasping device) is then advanced over the filter. After catching and securing the hook in the snare, the introducer is advanced over the filter, which will collapse during the maneuver. The filter is then pulled back through the introducer and carefully inspected. A final cavogram is obtained to assess the IVC integrity and patency. When the filter is correctly centered with a limited penetration into the wall, the procedure is simple. Figure 13.3 summarizes steps for VCF retrieval procedure.

In cases when the filter is not centered or with exaggerated tilt or deep penetration, more aggressive approaches have been reported including double venous access, curved catheters, double guidewires, balloons, forceps, or laser extraction sheaths [38–41]. The most common procedure is to use a curved catheter to insert a guidewire around the filter distal to the hook and then insert the guidewire tip into a snare to externalize the guidewire tip and form an in situ homemade guidewire-based snare, which is used to trap the filter hook.

The skills needed for retrieval procedure are higher than for placement procedure and the learning curve longer. Technical success is approximately 85 % of attempts and most successful when performed within 12 weeks after placement [19, 42, 43]. In the CIRSE VCF Retrieval Registry, technical success rate for retrieval was 92 % [24]. Major complications of VCF retrieval include IVC thrombosis (4.3 %) [44] and IVC laceration.



**Fig. 13.2** Filter placement procedure step by step (DENALI filter, Bard CR). (a) Cavogram obtained during the Valsalva maneuver, after contrast media injection through the calibrated 8.5 F introducer, inserted by the right common femoral vein. Notice the renal vein origins. (b) The filter is introduced premounted on its deployment catheter and advanced to the sheath's tip. This step could be done under fluoroscopy guidance or in a “blinded” manner using external landmarks on the deployment device. (c) The filter is deployed just below the renal vein ostia. (d) Post deployment cavogram that shows the final position of the filter. (e) Another patient where cavogram was acquired before placement of Optease filter. (f) The filter is positioned just below the right renal vein



### 13.7 Efficiency

Despite few reports that could not draw firm statements regarding efficiency of filters in preventing PE [45, 46], there are large data using recent technologies that support this objective. In the systematic review of the use of retrievable filters reported by Angel et al. in 2011 [44] and collecting 11 prospective clinical trials, the rate of recurrent PE was as low as 1.7%. In a prospective randomized controlled trial (PREPIC [47]), a significant reduction of recurrent PE was found in the group who received VCF (1.1% versus 4.8%,  $p=0.03$ ), but a significant increase in symptomatic DVT was observed in the same group (28.8% versus 11.6%,  $p=0.02$ ). No benefit on the mortality was observed in the VCF group at short term as well as after 8 years follow-up [48]. It is of interest to notice that in unstable patients who had urgent VCF, a significant benefit on the mortality was observed [49].

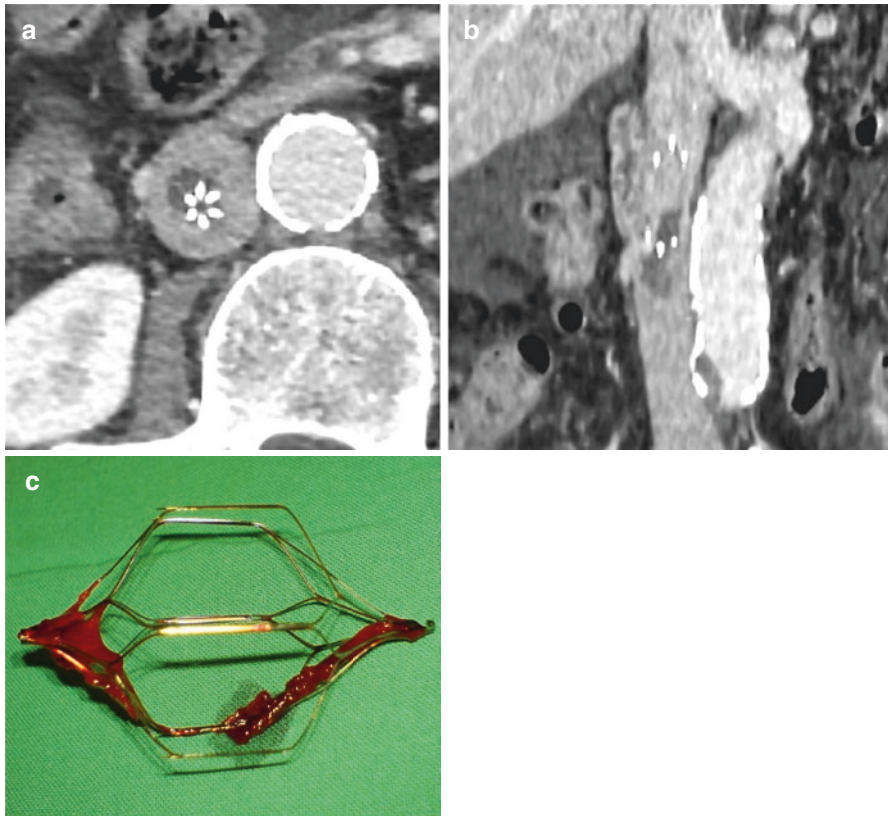
### 13.8 Long-Term Complications of VCF

Several device-related complications have been reported. These complications were the major reason for developing optimal filter and aggressive strategies for retrieval. They are appropriate to be recorded, and they might drive the quality improvement program. The Manufacturer and User Facility Device Experience (MAUDE), based on a voluntary reporting, accumulated only 842 complications from 2000 to 2010 [44]. Complications seem to vary in their rate and profile between filters. Furthermore, existing data suggest that long-term complications are correlated to the time after insertion [47, 50]. Accordingly, recent guidelines advocate filter retrieval [4, 7]. In 2010, the US Food and Drug Administration issued a statement for filter retrieval.

These complications include IVC occlusion with a rate ranging from 2% to 30% [51–54] and IVC penetration with a rate ranging from 0% to 86% [29, 51–53, 55, 56]. The IVC occlusion was probably underestimated as can sometimes be asymptomatic [57]. Also of note is that the presence of thrombus inside the filter (Fig. 13.4), which might be considered as a precursor of the IVC thrombosis, is a proof of filter effectiveness. Similarly, the IVC penetration (Fig. 13.5) is also a part of the mechanism of VCF stabilization at the target region of placement. When the penetration is



**Fig. 13.3** Denali filter retrieval procedure step by step. (a) Insertion of the double introducer retrieval sheath using right jugular vein access. The tip of the internal introducer is closed to the filter snare hook. (b) The snare is introduced with the snare catheter in the IVC, through the double introducer retrieval sheath. The snare loop engages the filter snare hook. (c) The snare, the filter snare hook, and the retrieval sheath are aligned, and tension is maintained while the retrieval sheath is advanced in the caudal direction. (d) When the sheath covers more than half of the filter, it is held stationary, and the filter is withdrawn in it by retracting the snare. (e) After filter retrieval, cavogram is realized which shows no complication

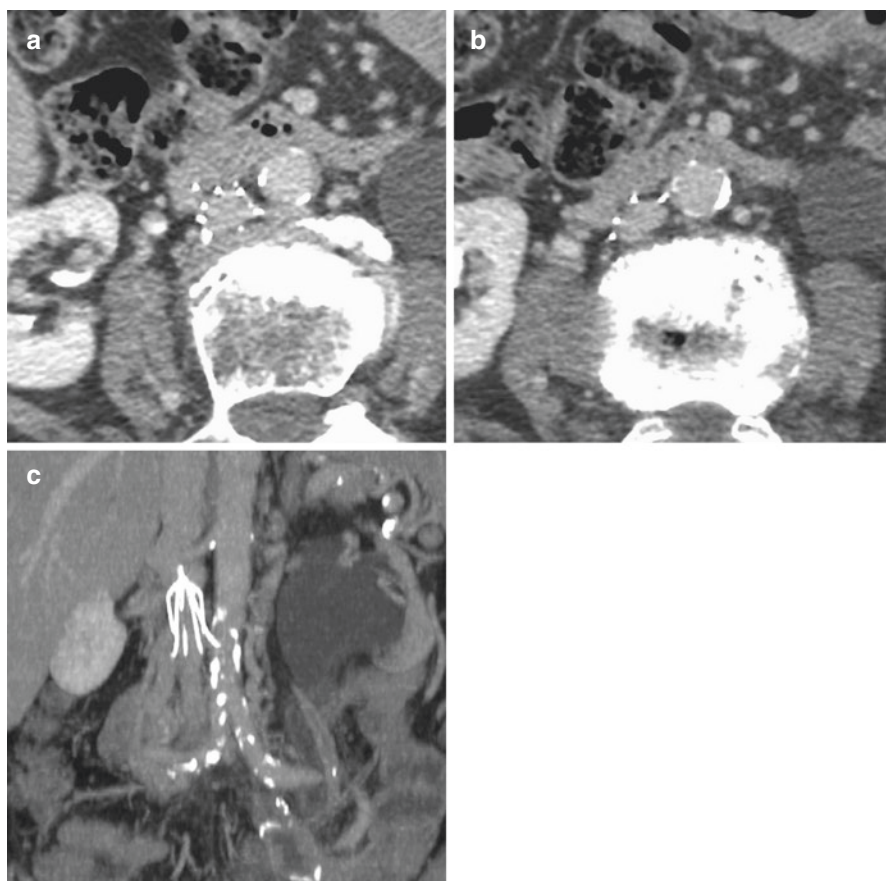


**Fig. 13.4** Thrombus in the VCF. Abdominal contrast CT scan with axial (a) and coronal (b) images showing the presence of clot at the inferior part of the filter extending in the IVC. (c) Optease filter after retrieval with the presence of small clots

too deep, it becomes a complication. The definition of threshold to becoming a complication is unclear and varied from 3 to 10 mm. Furthermore, the large majority of IVC penetrations are asymptomatic [55], and most of them did not limit retrieval procedure. Although the majority is asymptomatic, several reports pointed out induced injuries to the surrounding structures [58–60]. Recent technological advances have focused on the wall penetration control.

### 13.9 Management of Patients with VCF and Strategies for Retrieval

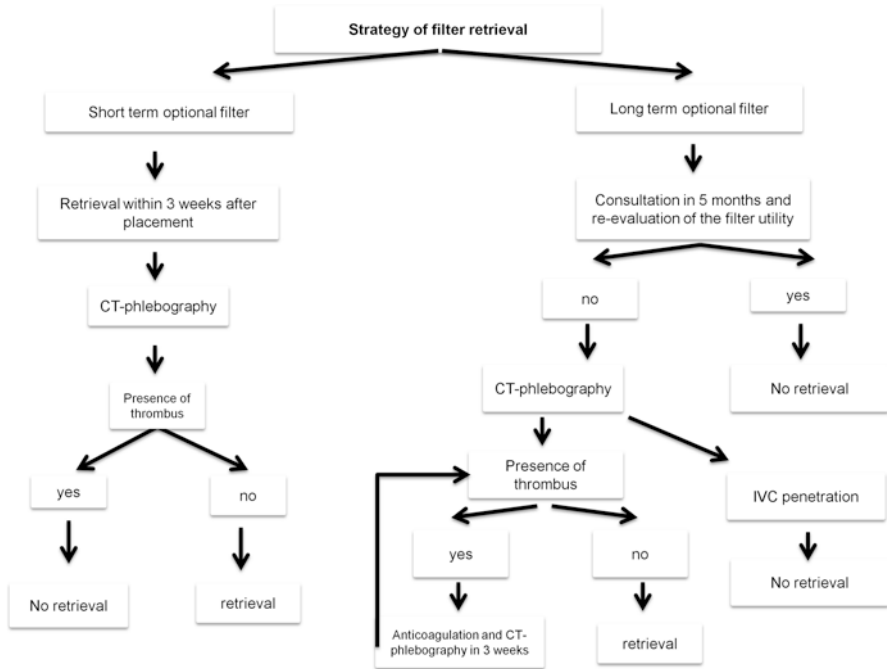
There are two major issues in managing patients with IVCF. The first one is certainly administration of anticoagulation and the second one is the time of the filter retrieval.



**Fig. 13.5** Penetration of the IVC by the filter struts. Abdominal contrast CT scan, axial images, demonstrating penetration of the IVC by the filter struts which are in contact with the duodenal (a) and aortic (b) wall. (c) MIP reconstruction in coronal plane demonstrates the relation of the filter struts with the adjacent organs

Whether filters are an indication of anticoagulation, once the preexisting contraindications subsided, is still a matter of debate. Theoretically, prolonging patients with a filter in place might prevent filter-related thrombosis and reduce recurrence of PE with, however, an increased risk of bleeding complication. Practically, there is no strong data supporting the use of anticoagulation in this population in terms of benefits but also in terms of intensity and duration of anticoagulation [61, 62]. The most common strategy regarding the filters and anticoagulation is to treat the underlying disease without considering the presence of the filter. However, since the extensive use of optional filters, the presence of thrombus inside the filter at the time of retrieval becomes a new issue. There is no clear recommendation in how to manage these patients and when to consider the presence of thrombus a matter of concern that could postpone the retrieval procedure. Usually, thrombus smaller than





**Fig. 13.6** The strategy before retrieval of the optional filters, through an algorithm

10 mm or 25% of the filter volume (Fig. 13.4) is suitable for retrieval. In case of larger thrombus, patient should receive anticoagulation for at least 3 weeks and reassessed for retrieval. This option is compromised if short-term optional filter is used. Exceptionally, thrombectomy devices are used to help filter extraction.

The second issue of filters in the era of optional filters is the filter retrieval. It is believed that early retrieval prevents filter-related complications [4, 7, 48, 50, 63]. Long-term dwell time increases the risk of adherence to the caval wall resulting in a decrease of the likelihood of successful retrieval and an increase in associated complications [42]. Filter retrieval requires, however, that there is no longer contraindication for anticoagulation and/or no longer indication for vena cava filtration, there is no significant thrombus that could compromise the procedure, and finally there is no deep wall penetration. Theoretically, it was reported that upward 85% of optional filter should be retrieved [32]. Actually, less than 35% of optional filters are effectively retrieved [23, 44]. The lack of following up patients with filters was reported as the main reason [64, 65], especially in those patients with long-term optional filters. In response to this limitation, several approaches were developed to improve patient's follow-up [66–68]. Figure 13.6 summarizes our approach based on a systematic patient visit at 5 months after filter placement planned at the time of insertion. This strategy helps increase the retrieval rate by at least 50%. Other developments to improve the retrieval rate are advanced techniques for filter retrieval and the extended use of new generations of filters that efficiently prevent deep penetration in the caval wall. Furthermore, standardized strategies through consensual

recommendations should facilitate not only harmonization in the filter use but also in the filter removal strategies [25].

### Conclusions

Over the last decades, VCF has been ingrained in our routine practice. Despite focused controversies, devices are effective in preventing fatal PE at an acceptable level of complications at the procedure placement. Facing the long-term complications, the developed concept of optional filter is an appropriate response to current clinical challenges. However, the strategy of managing patients with filters should be improved, and a structured follow-up is mandatory to retrieve the filter, when indicated, at the optimal time, particularly, in patients with long-term optional filter who are often lost to follow-up in the hand-off from inpatient to outpatient. The optional filter technology resulted in the past on a significant increase in filter placements [69]. Current knowledge did not support an extensive use beyond guidelines and recommendations. The prophylactic use should be restricted to selected patients.

Further developments are needed to develop better VCF technologies, especially regarding the penetration issue and retrieval easiness.

### Key Points

- Optional vena cava filters should be considered as the preferred technology to use.
- Indications of vena cava filters have been recently clarified. Decision making process should fulfill at least 95 % of recommended indications.
- Vena cava filter removal should be considered as soon as possible to prevent long term related complications.
- A structured program of following patients after vena cava filter placement is recommended for optimal use.

### Key References

- Caplin DM, Nikolic B, Kalva SP et al (2011) Quality improvement guidelines for the performance of inferior vena cava filter placement for the prevention of pulmonary embolism. *J Vasc Interv Radiol* 22:1499–1506
- Iliescu B, Haskal ZJ (2012) Advanced techniques for removal of retrievable inferior vena cava filters. *Cardiovasc Intervent Radiol* 35:741–750
- Jaff MR, McMurtry MS, Archer SL et al (2011) Management of massive and sub-massive pulmonary embolism, iliofemoral deep vein thrombosis, and chronic thromboembolic pulmonary hypertension: a scientific statement from the American Heart Association. *Circulation* 123:1788–1830
- Kearon C, Akl EA, Comerota AJ et al (2012) Antithrombotic therapy for VTE disease: antithrombotic therapy and prevention of thrombosis, 9th ed: American College of Chest Physicians evidence-based clinical practice guidelines. *Chest* 141:e419S–e494S
- Weinberg I, Kaufman J, Jaff MR (2013) Inferior vena cava filters. *JACC Cardiovasc Interv* 6:539–547



## References

1. Kakkar VV, Howe CT, Flanc C, Clarke MB (1969) Natural history of postoperative deep-vein thrombosis. *Lancet* 2:230–232
2. Kinney TB (2003) Update on inferior vena cava filters. *J Vasc Interv Radiol* 14:425–440
3. Weinberg I, Kaufman J, Jaff MR (2013) Inferior vena cava filters. *JACC Cardiovasc Interv* 6:539–547
4. Kearon C, Akl EA, Comerota AJ et al (2012) Antithrombotic therapy for VTE disease: anti-thrombotic therapy and prevention of thrombosis, 9th ed: American College of Chest Physicians evidence-based clinical practice guidelines. *Chest* 141:e419S–e494S
5. Kaufman JA, Kinney TB, Streiff MB et al (2006) Guidelines for the use of retrievable and convertible vena cava filters: report from the Society of Interventional Radiology multidisciplinary consensus conference. *Surg Obes Relat Dis* 2:200–212
6. Caplin DM, Nikolic B, Kalva SP et al (2011) Quality improvement guidelines for the performance of inferior vena cava filter placement for the prevention of pulmonary embolism. *J Vasc Interv Radiol* 22:1499–1506
7. Jaff MR, McMurtry MS, Archer SL et al (2011) Management of massive and submassive pulmonary embolism, iliofemoral deep vein thrombosis, and chronic thromboembolic pulmonary hypertension: a scientific statement from the American Heart Association. *Circulation* 123:1788–1830
8. Greenfield LJ (1992) Evolution of venous interruption for pulmonary thromboembolism. *Arch Surg* 127:622–626
9. Amador E, Li TK, Crane C (1968) Ligation of inferior vena cava for thromboembolism. Clinical and autopsy correlations in 119 cases. *JAMA* 206:1758–1760
10. Moretz WH, Rhode CM, Shepherd MH (1959) Prevention of pulmonary emboli by partial occlusion of the inferior vena cava. *Am Surg* 25:617–626
11. Adams JT, Deweese JA (1965) Experimental and clinical evaluation of partial vein interruption in the prevention of pulmonary emboli. *Surgery* 57:82–102
12. Mobin-Uddin K, Callard GM, Bolooki H, Rubinson R, Michie D, Jude JR (1972) Transvenous caval interruption with umbrella filter. *N Engl J Med* 286:55–58
13. Meisner RJ, Labropoulos N, Gasparis AP, Lampl J, Xu M, Tassiopoulos AK (2012) Review of indications and practices of vena caval filters at a large university hospital. *Vasc Endovascular Surg* 46:21–25
14. Pellerin O, Barral FG, Lions C, Novelli L, Beregi JP, Sapoval M (2008) Early and late retrieval of the ALN removable vena cava filter: results from a multicenter study. *Cardiovasc Intervent Radiol* 31:889–896
15. Kaufman JA, Rundback JH, Kee ST et al (2009) Development of a research agenda for inferior vena cava filters: proceedings from a multidisciplinary research consensus panel. *J Vasc Interv Radiol* 20:697–707
16. Gao X, Zhang J, Chen B et al (2011) A new self-convertible inferior vena cava filter: experimental in-vitro and in-vivo evaluation. *J Vasc Interv Radiol* 22:829–834
17. Thors A, Muck P (2011) Resorbable inferior vena cava filters: trial in an in-vivo porcine model. *J Vasc Interv Radiol* 22:330–335
18. Kim HS, Young MJ, Narayan AK, Hong K, Liddell RP, Streiff MB (2008) A comparison of clinical outcomes with retrievable and permanent inferior vena cava filters. *J Vasc Interv Radiol* 19:393–399
19. Smouse HB, Rosenthal D, Thuong VH et al (2009) Long-term retrieval success rate profile for the Gunther Tulip vena cava filter. *J Vasc Interv Radiol* 20:871–877, quiz 878
20. Carlbom DJ, Davidson BL (2007) Pulmonary embolism in the critically ill. *Chest* 132:313–324
21. Velmahos GC, Kern J, Chan LS, Oder D, Murray JA, Shekelle P (2000) Prevention of venous thromboembolism after injury: an evidence-based report--part I: analysis of risk factors and evaluation of the role of vena caval filters. *J Trauma* 49:132–138, discussion 139
22. Girard TD, Philbrick JT, Fritz Angle J, Becker DM (2003) Prophylactic vena cava filters for trauma patients: a systematic review of the literature. *Thromb Res* 112:261–267

23. Aziz F, Comerota AJ (2010) Inferior vena cava filters. *Ann Vasc Surg* 24:966–979
24. Lee MJ, Valenti D, de Gregorio MA, Minocha J, Rimon U, Pellerin O (2015) The CIRSE retrievable IVC filter registry: retrieval success rates in practice. *Cardiovasc Intervent Radiol* 38:1502–1507
25. White RH, Geraghty EM, Brunson A et al (2013) High variation between hospitals in vena cava filter use for venous thromboembolism. *JAMA Intern Med* 173:506–512
26. Siddiqui RA, Hans S (2008) Double inferior vena cava filter implantation in a patient with a duplicate inferior vena cava. *J Invasive Cardiol* 20:91–92
27. Killingsworth CD, Taylor SM, Patterson MA et al (2010) Prospective implementation of an algorithm for bedside intravascular ultrasound-guided filter placement in critically ill patients. *J Vasc Surg* 51:1215–1221
28. Savin MA, Panicker HK, Sadiq S, Albeer YA, Olson RE (2002) Placement of vena cava filters: factors affecting technical success and immediate complications. *AJR Am J Roentgenol* 179:597–602
29. Becker DM, Philbrick JT, Selby JB (1992) Inferior vena cava filters. Indications, safety, effectiveness. *Arch Intern Med* 152:1985–1994
30. Athanasoulis CA, Kaufman JA, Halpern EF, Waltman AC, Geller SC, Fan CM (2000) Inferior vena caval filters: review of a 26-year single-center clinical experience. *Radiology* 216:54–66
31. Hammond CJ, Bakshi DR, Currie RJ et al (2009) Audit of the use of IVC filters in the UK: experience from three centres over 12 years. *Clin Radiol* 64:502–510
32. Imberti D, Ageno W, Dentali F, Donadini M, Manfredini R, Gallerani M (2012) Retrievable vena cava filters: a clinical review. *J Thromb Thrombolysis* 33:258–266
33. Stein PD, Alnas M, Skaf E et al (2004) Outcome and complications of retrievable inferior vena cava filters. *Am J Cardiol* 94:1090–1093
34. Sing RF, Jacobs DG, Heniford BT (2001) Bedside insertion of inferior vena cava filters in the intensive care unit. *J Am Coll Surg* 192:570–575, discussion 575–576
35. Ray CE Jr, Kaufman JA (1996) Complications of inferior vena cava filters. *Abdom Imaging* 21:368–374
36. Vaziri K, Bhanot P, Hungness ES, Morasch MD, Prystowsky JB, Nagle AP (2009) Retrievable inferior vena cava filters in high-risk patients undergoing bariatric surgery. *Surg Endosc* 23:2203–2207
37. Ahmad I, Yeddula K, Wicky S, Kalva SP (2010) Clinical sequelae of thrombus in an inferior vena cava filter. *Cardiovasc Intervent Radiol* 33:285–289
38. Ilescu B, Haskal ZJ (2012) Advanced techniques for removal of retrievable inferior vena cava filters. *Cardiovasc Intervent Radiol* 35:741–750
39. Kuo WT, Cupp JS, Louie JD et al (2012) Complex retrieval of embedded IVC filters: alternative techniques and histologic tissue analysis. *Cardiovasc Intervent Radiol* 35:588–597
40. Stavropoulos SW, Dixon RG, Burke CT et al (2008) Embedded inferior vena cava filter removal: use of endobronchial forceps. *J Vasc Interv Radiol* 19:1297–1301
41. Van Ha TG, Vinokur O, Lorenz J et al (2009) Techniques used for difficult retrievals of the Gunther Tulip inferior vena cava filter: experience in 32 patients. *J Vasc Interv Radiol* 20:92–99
42. Marquess JS, Burke CT, Beecham AH et al (2008) Factors associated with failed retrieval of the Gunther Tulip inferior vena cava filter. *J Vasc Interv Radiol* 19:1321–1327
43. Ray CE Jr, Mitchell E, Zipser S, Kao EY, Brown CF, Moneta GL (2006) Outcomes with retrievable inferior vena cava filters: a multicenter study. *J Vasc Interv Radiol* 17:1595–1604
44. Angel LF, Tapson V, Galgon RE, Restrepo MI, Kaufman J (2011) Systematic review of the use of retrievable inferior vena cava filters. *J Vasc Interv Radiol* 22:1522–1530.e3
45. White RH, Zhou H, Kim J, Romano PS (2000) A population-based study of the effectiveness of inferior vena cava filter use among patients with venous thromboembolism. *Arch Intern Med* 160:2033–2041
46. Young T, Tang H, Hughes R (2010) Vena caval filters for the prevention of pulmonary embolism. *Cochrane Database Syst Rev* CD006212
47. Decousus H, Leizorovicz A, Parent F et al (1998) A clinical trial of vena caval filters in the prevention of pulmonary embolism in patients with proximal deep-vein thrombosis. *Prevention*

- du Risque d'Embolie Pulmonaire par Interruption Cave Study Group. *N Engl J Med* 338:409–415
48. Group PS (2005) Eight-year follow-up of patients with permanent vena cava filters in the prevention of pulmonary embolism: the PREPIC (Prevention du Risque d'Embolie Pulmonaire par Interruption Cave) randomized study. *Circulation* 112:416–422
  49. Stein PD, Matta F (2012) Case fatality rate with pulmonary embolectomy for acute pulmonary embolism. *Am J Med* 125:471–477
  50. Mismetti P, Rivron-Guillot K, Quenet S et al (2007) A prospective long-term study of 220 patients with a retrievable vena cava filter for secondary prevention of venous thromboembolism. *Chest* 131:223–229
  51. Ferris EJ, McCowan TC, Carver DK, McFarland DR (1993) Percutaneous inferior vena caval filters: follow-up of seven designs in 320 patients. *Radiology* 188:851–856
  52. Greenfield LJ, Cho KJ, Proctor M et al (1991) Results of a multicenter study of the modified hook-titanium Greenfield filter. *J Vasc Surg* 14:253–257
  53. McCowan TC, Ferris EJ, Carver DK, Molpus WM (1992) Complications of the nitinol vena caval filter. *J Vasc Interv Radiol* 3:401–408
  54. Millward SF, Peterson RA, Moher D et al (1994) LGM (Vena Tech) vena caval filter: experience at a single institution. *J Vasc Interv Radiol* 5:351–356
  55. Durack JC, Westphalen AC, Kekulawela S et al (2012) Perforation of the IVC: rule rather than exception after longer indwelling times for the Gunther Tulip and Celect retrievable filters. *Cardiovasc Intervent Radiol* 35:299–308
  56. Oda T, Fuji T, Kato Y, Fujita S, Kanemitsu N (2000) Deep venous thrombosis after posterior spinal surgery. *Spine* 25:2962–2967
  57. Paton BL, Jacobs DG, Heniford BT, Kercher KW, Zerey M, Sing RF (2006) Nine-year experience with insertion of vena cava filters in the intensive care unit. *Am J Surg* 192:795–800
  58. Arabi M, Willatt JM, Shields JJ, Cho KJ, Cwikiel WB (2010) Retrievability of optional inferior vena cava filters with caudal migration and caval penetration: report of three cases. *J Vasc Interv Radiol* 21:923–926
  59. Usuh F, Hingorani A, Ascher E et al (2009) Long-term follow-up for superior vena cava filter placement. *Ann Vasc Surg* 23:350–354
  60. Venturini M, Civilini E, Orsi M et al (2015) Successful endovascular retrieval of an ALN inferior vena cava filter causing asymptomatic aortic dissection, perforation of the cava wall and duodenum. *J Vasc Interv Radiol* 26:608–611
  61. Billett HH, Jacobs LG, Madsen EM, Giannattasio ER, Mahesh S, Cohen HW (2007) Efficacy of inferior vena cava filters in anticoagulated patients. *J Thromb Haemost* 5:1848–1853
  62. Hajduk B, Tomkowski WZ, Malek G, Davidson BL (2010) Vena cava filter occlusion and venous thromboembolism risk in persistently anticoagulated patients: a prospective, observational cohort study. *Chest* 137:877–882
  63. Baadh AS, Zikria JF, Rivoli S, Graham RE, Javit D, Ansell JE (2012) Indications for inferior vena cava filter placement: do physicians comply with guidelines? *J Vasc Interv Radiol* 23:989–995
  64. Karmy-Jones R, Jurkovich GJ, Velmahos GC et al (2007) Practice patterns and outcomes of retrievable vena cava filters in trauma patients: an AAST multicenter study. *J Trauma* 62:17–24, discussion 24–25
  65. Ko SH, Reynolds BR, Nicholas DH et al (2009) Institutional protocol improves retrievable inferior vena cava filter recovery rate. *Surgery* 146:809–814, discussion 814–816
  66. Minocha J, Idakoji I, Riaz A et al (2010) Improving inferior vena cava filter retrieval rates: impact of a dedicated inferior vena cava filter clinic. *J Vasc Interv Radiol* 21:1847–1851
  67. Irwin E, Byrnes M, Schultz S et al (2010) A systematic method for follow-up improves removal rates for retrievable inferior vena cava filters in a trauma patient population. *J Trauma* 69:866–869
  68. Dixon A, Stavropoulos SW (2013) Improving retrieval rates for retrievable inferior vena cava filters. *Expert Rev Med Devices* 10:135–141
  69. Keeling AN, Kinney TB, Lee MJ (2008) Optional inferior vena caval filters: where are we now? *Eur Radiol* 18:1556–1568