

Stefano Boriani · Livio Presutti  
Alessandro Gasbarrini  
Francesco Mattioli *Editors*

# Atlas of Craniocervical Junction and Cervical Spine Surgery



---

# Atlas of Craniocervical Junction and Cervical Spine Surgery

---

Stefano Boriani • Livio Presutti  
Alessandro Gasbarrini • Francesco Mattioli  
Editors

# Atlas of Craniocervical Junction and Cervical Spine Surgery

 Springer

*Editors*

Stefano Boriani  
Bologna  
Italy

Alessandro Gasbarrini  
Bologna  
Italy

Livio Presutti  
Modena  
Italy

Francesco Mattioli  
University Hospital of Modena  
Modena  
Italy

ISBN 978-3-319-42735-5      ISBN 978-3-319-42737-9 (eBook)  
DOI 10.1007/978-3-319-42737-9

Library of Congress Control Number: 2017939173

© Springer International Publishing Switzerland 2017

This work is subject to copyright. All rights are reserved by the Publisher, whether the whole or part of the material is concerned, specifically the rights of translation, reprinting, reuse of illustrations, recitation, broadcasting, reproduction on microfilms or in any other physical way, and transmission or information storage and retrieval, electronic adaptation, computer software, or by similar or dissimilar methodology now known or hereafter developed.

The use of general descriptive names, registered names, trademarks, service marks, etc. in this publication does not imply, even in the absence of a specific statement, that such names are exempt from the relevant protective laws and regulations and therefore free for general use.

The publisher, the authors and the editors are safe to assume that the advice and information in this book are believed to be true and accurate at the date of publication. Neither the publisher nor the authors or the editors give a warranty, express or implied, with respect to the material contained herein or for any errors or omissions that may have been made. The publisher remains neutral with regard to jurisdictional claims in published maps and institutional affiliations.

Printed on acid-free paper

This Springer imprint is published by Springer Nature  
The registered company is Springer International Publishing AG  
The registered company address is: Gewerbestrasse 11, 6330 Cham, Switzerland

---

## Acknowledgment

The Authors are indebted and thank Carlo Piovani for his strenuous activity as anatomical artist and for imaging collection and elaboration. Thanks to him we could select the most attractive and demonstrating images and clarify the details of surgical anatomy.

---

# Contents

## Part I Anatomy

- 1 Anatomy of Craniocervical Junction** . . . . . 3  
M. Alicandri-Ciufelli, M. Menichetti, M.P. Alberici, and L. Presutti
- 2 Anatomy of the Subaxial Cervical Spine** . . . . . 17  
M. Girolami, R. Ghermandi, M. Ghirelli, A. Gasbarrini, and S. Boriani
- 3 Anatomy of the Neck** . . . . . 27  
M. Bonali, D. Soloperto, E. Aggazzotti Cavazza, M. Ghirelli, and L. Presutti

## Part II Planning

- 4 Interventional Radiology: Presurgical Selective Angiographic Embolization (SAE) in Hypervascular Cervical Spine Tumours** . . . . . 49  
Luigi Simonetti, Carlotta Barbara, Salvatore Isceri, and Elena Mengozzi
- 5 Anesthesiological Management and Patient Positioning** . . . . . 63  
M.R. Bacchin, M. Di Fiore, Y.E. Akman, M. Girolami, R. Ghermandi, A. Gasbarrini, and S. Boriani
- 6 Cervical Spine Instrumentation** . . . . . 69  
M. Girolami, R. Ghermandi, A. Gasbarrini, Y.E. Akman, and S. Boriani
- 7 Tracheotomy Surgical Technique** . . . . . 87  
M. Ghirelli, F. Mattioli, G. Molinari, I. Cena, and L. Presutti
- 8 Surgical Planning in Cervical Spine Oncologic Patients** . . . . . 95  
S. Boriani, R. Ghermandi, M. Girolami, and A. Gasbarrini

## Part III Surgical Approaches

- 9 Surgical Approaches to CCJ (Endoscopic Transnasal-Transoral-Transcervical and Robotic Transoral Approach)** . . . . . 105  
F. Mattioli, G. Molteni, M. Bettini, E. Cigarini, and L. Presutti
- 10 Anterior and Lateral Approaches to Cervical Spine** . . . . . 129  
M. Ghirelli, F. Mattioli, G. Molinari, and L. Presutti
- 11 Posterior Approach to Cervical Spine** . . . . . 175  
R. Ghermandi, M. Girolami, A. Gasbarrini, and S. Boriani
- 12 Exemplificative Cases in Cervical Spine** . . . . . 185  
A. Gasbarrini, M. Girolami, R. Ghermandi, Y.E. Akman, and S. Boriani
- 13 Complications of Cervical Spine Surgery** . . . . . 217  
Gabriele Molteni, Marco Giuseppe Greco, and Pierre Guarino

---

## Contributors

**Elisa Aggazzotti Cavazza** Otorhinolaryngology, Head and Neck Surgery Department, University Hospital of Modena, Modena, Italy

**Yunus Emre Akman** Orthopaedics and Traumatology Department, Metin Sabanci Baltalimani Bone Diseases Training and Research Hospital, Istanbul, Turkey

**Maria Paola Alberici** Head and Neck Surgery Department, University Hospital of Modena, Modena, Italy

**Ciuffelli Matteo Alicandri** Head and Neck Surgery Department, University Hospital of Modena, Modena, Italy

**Maria Renata Bacchin** Rizzoli Orthopedic Institute, Bologna, Italy

**Carlotta Barbara** Emergency Interventional Unit, Ospedale Maggiore, Bologna, Italy

**Margherita Bettini** Head and Neck Surgery Department, University Hospital of Modena, Modena, Italy

**Marco Bonali** Otorhinolaryngology, Head and Neck Surgery Department, University Hospital of Modena, Modena, Italy

**Stefano Boriani** Oncologic and Degenerative Spine Surgery Department Rizzoli Orthopedic Institute, Bologna, Italy

**Isida Cena** Head and Neck Surgery Department, University Hospital of Modena, Modena, Italy

**Elisa Cigarini** Head and Neck Surgery Department, University Hospital of Modena, Modena, Italy

**Maria Di Fiore** Rizzoli Orthopedic Institute, Bologna, Italy

**Alessandro Gasbarrini** Oncologic and Degenerative Spine Surgery Department Rizzoli Orthopedic Institute, Bologna, Italy

**Riccardo Ghermandi** Oncologic and Degenerative Spine Surgery Department Rizzoli Orthopedic Institute, Bologna, Italy

**Michael Ghirelli** Otorhinolaryngology, Head and Neck Surgery Department, University Hospital of Modena, Modena, Italy

**Marco Girolami** Oncologic and Degenerative Spine Surgery Department Rizzoli Orthopedic Institute, Bologna, Italy

**Marco Giuseppe Greco** Ent Department University Hospital of Modena, Modena, Italy

**Pierre Guarino** Head and Neck Surgery Department, University Hospital of Modena, Modena, Italy

**Salvatore Isceri** Emergency Interventional Unit, Ospedale Maggiore, Bologna, Italy

**Francesco Mattioli** Head and Neck Surgery Department, University Hospital of Modena, Modena, Italy

**Elena Mengozzi** Emergency Interventional Unit, Ospedale Maggiore, Bologna, Italy

**Marcella Menichetti** Head and Neck Surgery Department, University Hospital of Modena, Modena, Italy

**Giulia Molinari** Head and Neck Surgery Department, University Hospital of Modena, Modena, Italy

**Gabriele Molteni** Department of Otolaryngology-Head and Neck Surgery, University Hospital of Modena, Modena, Italy

**Livio Presutti** Otorhinolaryngology, Head and Neck Surgery Department, Azienda Ospedaliera Universitaria Integrata, University Hospital of Verona, Verona, Italy

**Luigi Simonetti** Emergency Interventional Unit, Ospedale Maggiore, Bologna, Italy

**D. Soloperto** Otorhinolaryngology, Head and Neck Surgery Department, University Hospital of Verona, Verona, Italy

**P. Zambito, MD** ENT Department University Hospital of Verona, Verona, Italy



---

**Part I**

**Anatomy**

M. Alicandri-Ciufelli, M. Menichetti, M.P. Alberici,  
and L. Presutti

## 1.1 Osseous Anatomy

The craniocervical junction (CCJ) is an osteoligamentous complex between the occiput, atlas and axis, which provides both structural stability and movement [1].

### 1.1.1 Occipital Bone

The occipital bone extends from the clivus anteriorly to the lambdoid suture posteriorly, its embryologic origin being four primary cartilaginous centres laid down in the chondrocranium around the foramen magnum, and a fifth membranous element [2]. The superior nuchal line serves as a rough guide for the location of the transverse sinus, and the inion, found in the midline along this line, approximates the torcular herophili. The insertion of the semispinalis capitis may be the most accurate landmark for the confluence of the sinuses [3].

A fundamental anatomical part of the occipital bone is the foramen magnum, which has three parts:

1. The squamosal portion, located in the dorsal aspect of foramen magnum
2. The basal or clival portion located anterior to the foramen magnum
3. The condylar part that connects the squamosal and the clival parts [4]

The most posterior margin of the foramen magnum is called the opisthion. The most anterior midline of the foramen magnum is termed the basion. The sagittal diameter of the foramen magnum should be  $35 \pm 4$  mm. The transverse diameter at the equator of foramen magnum is slightly less.

The condylar part includes the occipital condyles, which fall just at the level and anterior to the equator of the foramen magnum. The shape of these condyles positioned on either side of the foramen magnum allows the skull to articulate with the cervical spine, whilst the angles prevent excessive axial rotation at the craniocervical junction [5].

---

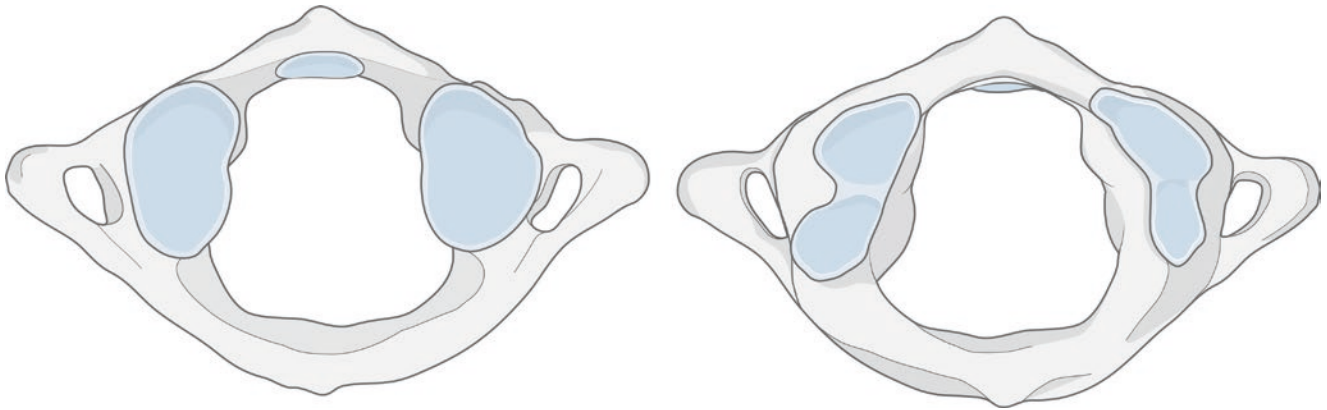
M. Alicandri-Ciufelli (✉) • M. Menichetti • M.P. Alberici  
L. Presutti  
Head and Neck Surgery Department, University Hospital of  
Modena, Modena, Italy  
e-mail: [matteo.alicandri@hotmail.it](mailto:matteo.alicandri@hotmail.it)

### 1.1.2 Atlas (Fig. 1.1)

The atlas, first cervical vertebra, has its origins in the fourth occipital and first cervical sclerotomes. It is unique among vertebrae in not having a body and is formed from three ossification sites: the anterior arch or centrum and two neural arches which fuse in later life to become a unified posterior arch, thereby completing the osseous ring which surrounds the spino-medullary junction [6]. An appreciation that this ring is incomplete in up to 5% of patients is important if one is to avoid causing a durotomy or spinal cord injury when approaching the craniocervical junction posteriorly [7, 8].

The ring of the atlas consists approximately of one-fifth anterior arch, two-fifths posterior arch, with the remaining two-fifths being contributed by the lateral masses [9]. The longus colli muscles and the anterior longitudinal ligament, which contribute to anterolateral flexion and resistance to hyperextension of the cervical spine respectively, are

attached to the anterior tubercle found in the midline on the anterior arch. Two important membranes also arise from this portion of the atlas: the anterior atlanto-occipital membrane, connecting the atlas to the occipital bone, and the anterior atlantoaxial ligament extending from the atlas to the axis immediately inferior. Atlantal lateral masses have both a superior articular facet and an inferior articular facet. These true synovial joints allow articulation with the occipital condyles and the axis, respectively. The atlanto-occipital joints' orientation at caudal angles of  $129^\circ$  from lateral to medial limits the rotation possible, compared with the atlantoaxial joint with a cranially biased angulation of between  $130^\circ$  and  $135^\circ$ , where much greater rotation is possible [10]. A posterior tubercle is found in the midline posteriorly providing attachment for the rectus capitis and the ligamentum nuchae. The posterior atlanto-occipital membrane extends from the superior border of the posterior arch of the atlas to the anterior surface of the rim of the foramen magnum [11, 12].

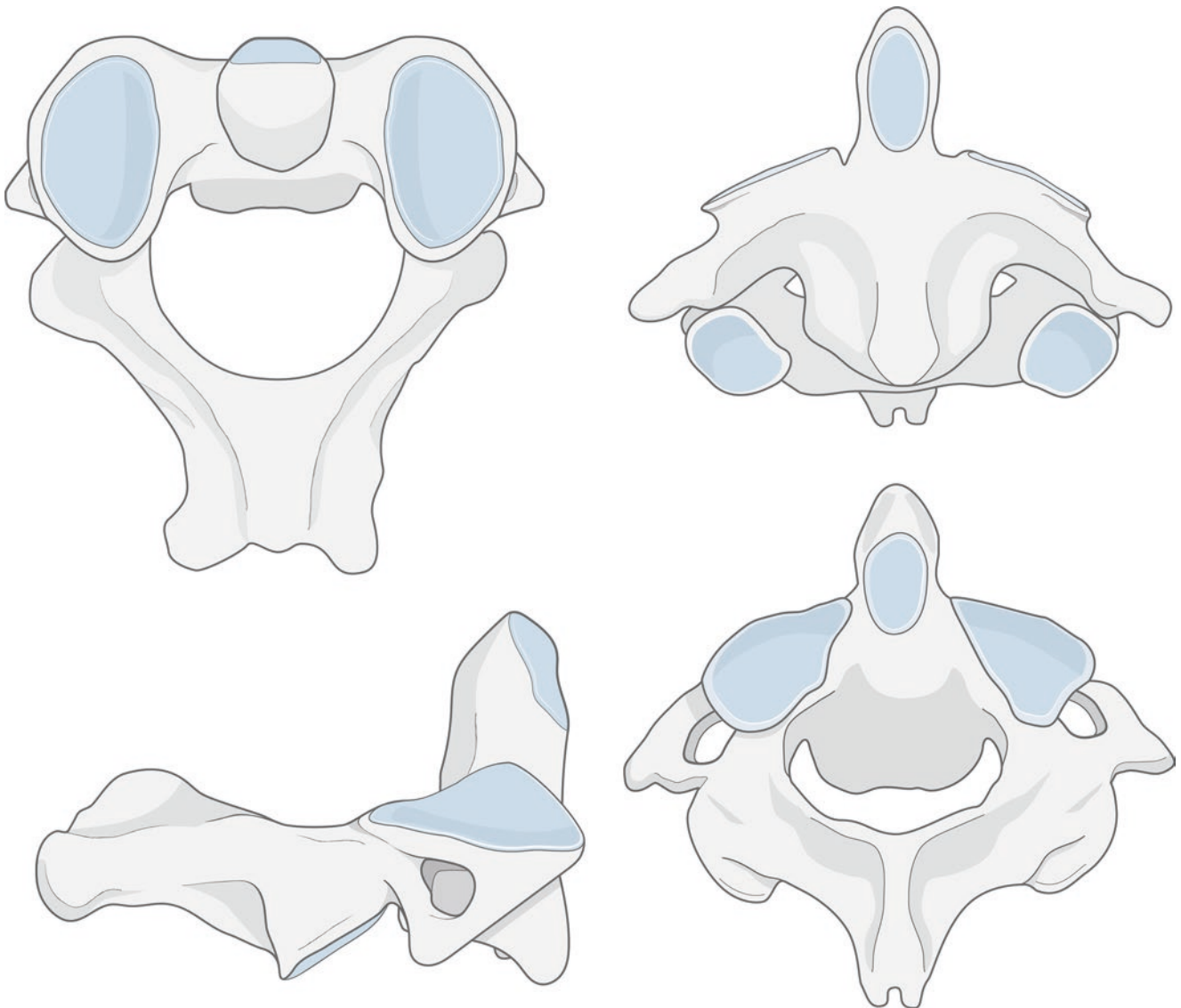


**Fig. 1.1** C1 anatomy

### 1.1.3 Axis (Fig. 1.2)

The axis is the second cervical vertebra, and it is called the epistropheus (literally “to twist”) because of its configuration that forms the pivot for the atlas and the head to rotate. The axis is formed from five ossification centres: one in the body, one in each vertebral arch and two in the odontoid process [13]. The odontoid process projects

cephalad from its articulation with the axis body. On the ventral odontoid surface is an oval facet, which articulates with the dorsal surface of the anterior arch of the atlas. In the dorsal aspect of the dens, there is a transverse groove over which passes the transverse ligament of the atlas. The axis has a spinous process, which is large and deeply concave on its caudal border, that makes the axis the first bifid vertebra in the cervical spine [4].

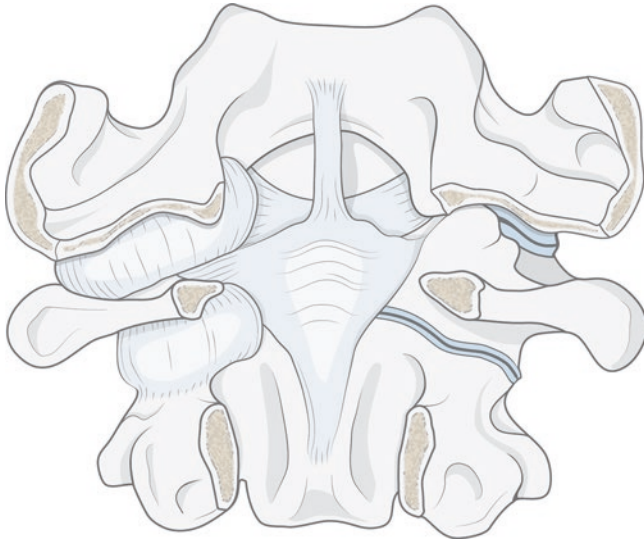


**Fig. 1.2** C2 anatomy

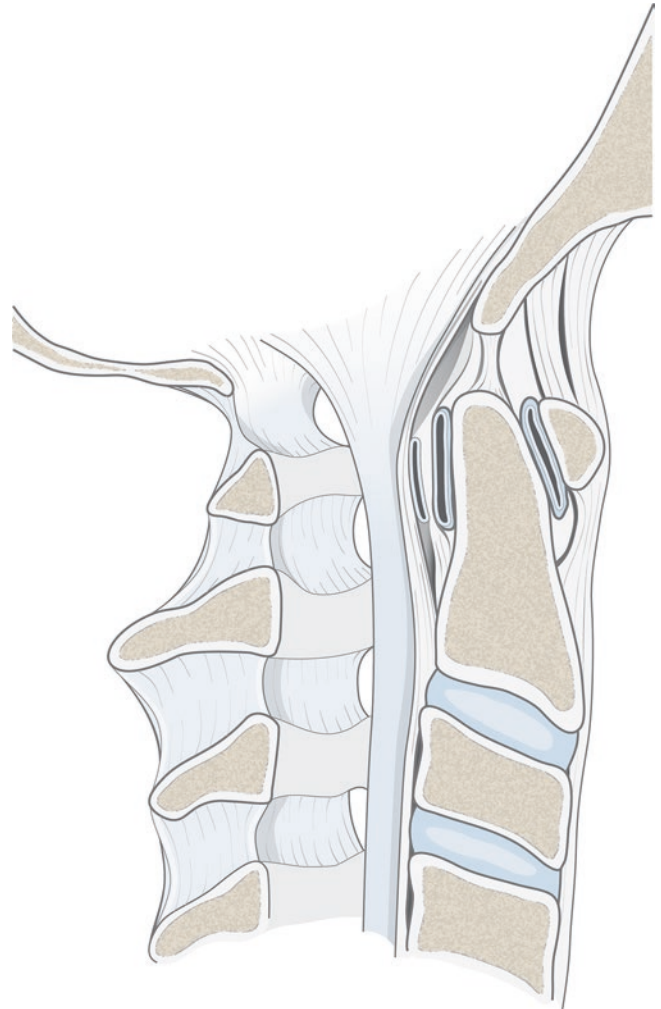
## 1.2 Articular and Ligamentous Anatomy

The CCJ is composed of two major joints: the atlanto-occipital and the atlanto-axial. These joints are responsible for the majority of the movements of the cervical spine and operate on different biomechanical principles. The mechanical properties of the atlanto-occipital joint are primarily

determined by bony structures, whereas the mechanical properties of the atlantoaxial joint are mainly determined by ligamentous structures [14, 15]. The prominent movements at the atlanto-occipital joint are flexion and extension. The primary movement at the atlantoaxial joint is axial rotation [16] (Figs. 1.3 and 1.4).



**Fig. 1.3** Ligaments of upper cervical spine, posterior view



**Fig. 1.4** Ligaments of upper cervical spine, sagittal view

### 1.2.1 Transverse Ligament

The transverse ligament of the atlas is the key component of the cruciform ligament and is one of the most important ligaments in the body. It is the largest, strongest and thickest craniocervical ligament (mean height/thickness 6–7 mm) [17]. The superior and inferior limbs of the cruciform ligament are extremely thin and offer no known craniocervical stability, whilst the transverse ligament maintains stability at the CCJ by locking the odontoid process anteriorly against the posterior aspect of the anterior arch of C-1, and it divides the ring of the atlas into two compartments: the anterior compartment houses the odontoid process, and the posterior compartment contains primarily the spinal cord and spinal accessory nerves. The transverse ligament runs posterior to the odontoid process of C-2 and attaches to the lateral tubercles of the atlas bilaterally. A synovial capsule is located between the odontoid process and the transverse ligament.

The ligament also has a smooth fibrocartilaginous surface to allow the odontoid process to glide against it [4]. The tectorial membrane, epidural fat and dura mater are located dorsal to the transverse ligament [17].

### 1.2.2 Alar Ligament

The alar ligament attaches the axis to the base of the skull, from the lateral aspects of the odontoid process to the anterolateral part of the foramen magnum and/or on the medial aspect of the occipital condyles [18–20].

### 1.2.3 Transverse Occipital Ligament

The transverse occipital ligament (TOL) is a small accessory ligament of the CCJ that is located posterosuperior to the alar ligaments and the odontoid process. It attaches to the inner aspect of the occipital condyles, posterosuperior to the alar ligament, superior to the transverse ligament, and extends horizontally across the foramen magnum [21].

Dvorak et al. [18] stated that the TOL is only present in about 10% of the population, whereas Lang [1] identified the TOL in approximately 40% of their specimens. The discrepancies in the occurrence of the TOL in specimens could be due to its proximity and similar morphology to the alar ligament that makes it difficult to distinguish the two easily.

### 1.2.4 Accessory Atlantoaxial Ligament

The accessory atlantoaxial ligament is an important but often ignored ligament that inserts medially into the dorsal surface of the axis and courses laterally and superiorly to insert on

the lateral mass of the atlas, posterior to the transverse ligament [22, 23].

Tubbs et al. [24] suggested that this ligament could be more appropriately named the accessory atlantal-axial-occipital ligament, to underline its anatomical attachments.

### 1.2.5 Lateral Atlanto-Occipital Ligament

The lateral atlanto-occipital (LAO) ligament is another ligament of the CCJ that has been neglected in the literature.

It runs just lateral to the anterior atlanto-occipital membrane, attaching to the anterolateral aspect of the transverse process of the atlas and inserting onto the jugular process of the occipital bone [25, 26]. This ligament runs immediately posterior to the rectus capitis lateralis muscle and has fibres that extend in the opposite direction to the muscle (i.e. muscle runs lateral to medial and ligament runs medial to lateral).

### 1.2.6 Barkow Ligament

Barkow ligament has been rarely described. It is a horizontal band attaching onto the anteromedial aspect of the occipital condyles anterior to the attachment of the alar ligaments. This ligament is located just anterior to the superior aspect of the dens with fibres travelling anterior to the alar ligaments, but there is no attachment to these structures.

Barkow ligament, present in 92% of studied cases [20], inserts anterior to the alar ligaments and is often adherent to the anterior atlanto-occipital membrane. Its primary function is thought to be in resisting extension of the atlanto-occipital joint, acting synergistically with the anterior atlanto-occipital membrane to achieve this.

### 1.2.7 Apical Ligament

The apical ligament, also known as the middle odontoid ligament or suspensory ligament, attaches the tip of the odontoid process to the basion. The ligament runs in the triangular area between the left and right alar ligaments known as the supraodontoid space (apical cave) [27] and travels just posterior to the alar ligaments and just anterior to the superior portion of the cruciform ligament.

### 1.2.8 Tectorial Membrane

The tectorial membrane is a thin structure at the CCJ that serves as the posterior border to the supraodontoid space [27]. It runs posterior to the cruciform ligament, and the accessory atlantoaxial ligament runs along its lateral border. The tectorial membrane is composed of 2–3 distinct layers

that run the length of the ligament and then fuse together at the posterior longitudinal ligament.

The outermost layer is the widest and attaches as far laterally as the hypoglossal canals. The second layer is thicker and runs from the clivus to the body of the axis. A small bursa is often present between the two layers over the odontoid process. The third layer is the deepest and is discontinuous as it attaches to the clivus above and then becomes frayed in the area over the odontoid apex.

Nerves and vessels often run between the different layers of the tectorial membrane [27]. Descriptions of the tectorial membrane are insufficient and inconsistent regarding the anatomy and function.

### 1.2.9 Posterior Atlanto-Occipital Membrane

The posterior atlanto-occipital (PAO) membrane is a broad, thin ligament that attaches to the posterior arch of the atlas inferiorly to the posterior rim of the foramen magnum superiorly. It is continuous with the posterior atlantoaxial membrane and then the ligamentum flavum inferiorly [28]. This structure has been noted by several authors to extend laterally over the atlanto-occipital joint capsules [29]. The PAO membrane runs adjacent to the rectus capitis posterior minor muscle posteriorly and the spinal dura mater anteriorly. Several authors have noted connection or interdigitation of the PAO membrane with both the rectus capitis posterior minor muscle and the spinal dura mater [30–32].

### 1.2.10 Anterior Atlanto-Occipital Membrane

The anterior atlanto-occipital (AAO) membrane is a thin structure that attaches the anterior aspect of the atlas to the anterior rim of the foramen magnum [19, 20, 27–32]. It is located just posterior to the prevertebral muscles of the neck and anterior to Barkow ligament. Tubbs et al. [20] observed a connection of Barkow ligament to the midline onto the AAO membrane. The AAO membrane also serves as the anterior wall of the supraodontoid space, which houses the alar, apical and Barkow ligaments, as well as fat and veins [27].

### 1.2.11 Nuchal Ligament

The nuchal ligament is the cephalic extension of the supraspinous ligament, extending from the C-7 spinous process to the inion of the occipital bone. With the shorter spinous processes of the cervical vertebrae and the lordotic curve of the cervical spine, this ligament forms a midline septation dividing the posterior neck muscles on left and right sides. Moreover, some of these muscles attach medially to this structure.

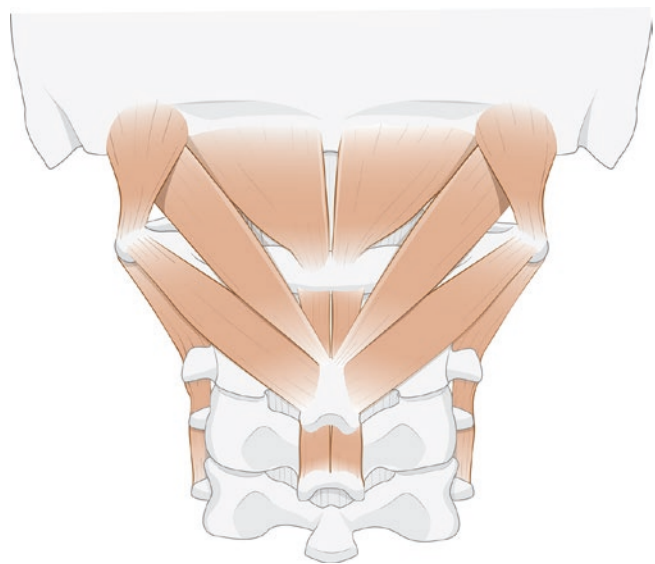
## 1.3 Muscular Anatomy

The muscles of the craniocervical junction do not limit movements of the joints. It was felt that they only had a minor role in motion of the CVJ. Their principle function is one of initiating and maintaining movement of the craniocervical region [33]. They have been grouped into those that cause extension, flexion, abduction, adduction and rotation.

The muscles involved with the C1–C2 complex on the anterior aspect are the recti capitis anterior and lateralis, both stretching from the anterior aspect of the transverse process of C1, respectively, to the inferior surface of the basilar occipital bone. The longus capitis extends from the inferior surface of the basilar occipital bone and clivus to its attachment on the transverse processes of the third to sixth cervical vertebrae. The longus colli is placed anterior to the vertebral column and covered by the longus capitis in its superior aspect. It is divided in three parts and attaches to the transverse processes of the cervical and first thoracic vertebrae, as well as to the anterior aspect of the bodies of the first thoracic vertebrae.

On the posterior aspect, the short and thick bifid spinous process of C2 gives attachment to three muscles (Fig. 1.5):

- Semispinalis cervicis, extending from the second to fifth cervical spines to the transverse processes of the upper five or six thoracic vertebrae
- Inferior oblique, extending to the transverse process of C1 and forms the inferior limit of the suboccipital triangle



**Fig. 1.5** Short neck muscles, posterior view

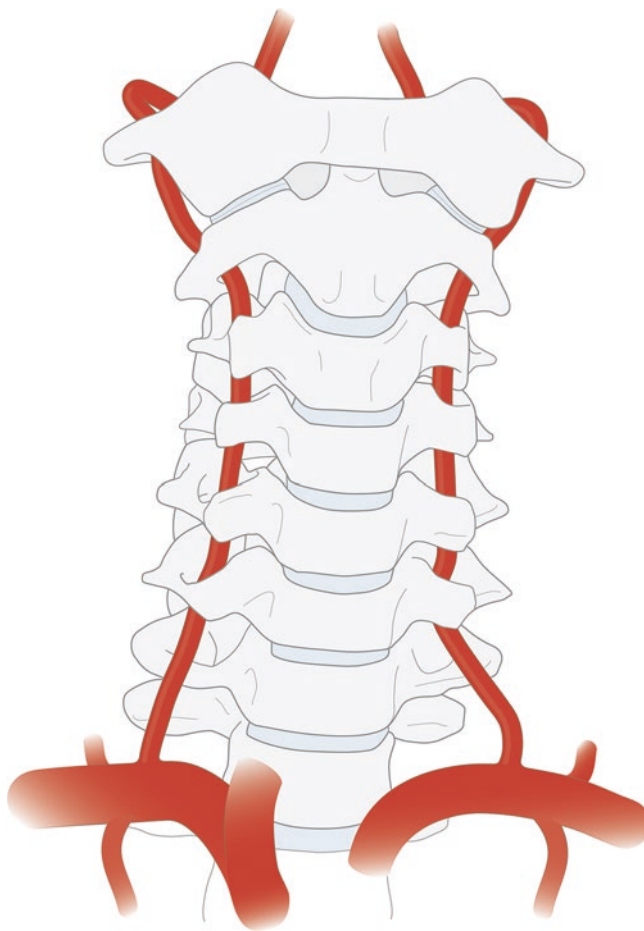
- Rectus capitis posterior major, extending to the inferior nuchal line forming the medial limit of the suboccipital triangle

The lateral limit of the triangle is formed by superior oblique, which extends from the transverse process of C1 to the inferior nuchal line. Rectus capitis posterior minor converging from the inferior nuchal line to the posterior tubercle on the arch of C1 is the only muscle that attaches to the posterior arch of the atlas. Laterally the scalenus medius attaches to the transverse process of the axis and elevator scapulae to the transverse process of the atlas [34–35].

## 1.4 The Arterial System

The *vertebral artery* is the main vessel that supplies the cervical cord. There are two vertebral arteries (one for each side), and they take their origin from the first portion of the respective subclavian artery. They go upwards and laterally until they reach the foramen transversarium of the sixth cervical vertebra on each side (first segment, V1). The arteries then ascend passing through the foramina transversarium of each cervical vertebra until the axis (second segment, V2), and they continue laterally to reach the foramen transversarium of the atlas; at this point, the vertebral arteries turn posteriorly around the lateral masses of the atlas, perforate the posterior atlanto-occipital membrane and enter the foramen magnum (third segment, V3).

Afterwards, the two vertebral arteries come together to form the basilar artery (fourth and fifth segments, V4 and V5) (Fig. 1.6).



**Fig. 1.6** Segments of vertebral artery



To sum up and assist in the description:

- The artery from its course from the C6 transverse foramina to the C2 transverse foramina is labelled as V.1
- The artery during its course from C2 transverse foramina to C1 transverse foramina is labelled as V2.
- The artery in its course from the transverse foramen of C1 to the point of its dural entry is labelled as V3 segment [36].

The left vertebral artery is dominant in 50% of the subjects, the right vertebral artery is dominant in 25% and in 25% of cases right and left arteries have equal vessel diameters that contribute to flow in the basilar artery.

For a surgical approach, it's important to consider that running from their origin (the subclavian artery) to the foramen of C6, the vertebral arteries lie between the longus colli muscle and the anterior scalene muscle, and they are in relationship with the vertebral veins and the neurovascular bundle anteriorly and with the transverse process of C7 and ventral rami of 7th and 8th cervical nerves posteriorly.

During its entire course, the vertebral artery is covered with a large plexus of veins. The venous plexuses are the largest in the region lateral to the C1–C2 joint.

The formation of the distal vertebral artery (VA) and its principal branch, the posterior-inferior cerebellar artery (PICA), involves the combination of several embryonic vascular segments. This complex developmental anatomy was well described by Congdon [37] and Padget [38, 39] in human specimens.

### 1.4.1 V1 Segment

After its exit from the transverse foramen of the C3 vertebra, the V1 segment of the artery courses posterosuperiorly and forms a loop within the vertebral artery groove on the inferior surface of the superior articular facet and then exits from C2 transverse foramina. The total length of the segment ranges from 17.2 to 46.1 mm (average 23.4 mm). The distal part of the artery is intraosseous and cannot be seen until its bony unroofing. The artery courses medially and takes a reverse loop inside the vertebral artery bony foramina on the inferior surface of the superior facet of the C2 vertebra. The angle of the loop varies and ranges from 2° to 110° (average 86°) [36].

### 1.4.2 V2 Segment

The V2 exits from the C2 transverse foramen and takes an initial lateral bend and then traverses superiorly. The artery courses anterior to the two roots of the C2 ganglion. In an anatomical study by Ciaccola et al., the length of this segment of the artery ranged from 12.6 to 32.2 mm (average 15.7 mm). The distance of the lateral edge of the ganglion from the vertebral artery ranged from 5.1 to 11.1 mm (average 7.5 mm). The distance of artery from the lateral end of the dural tube ranged from 14.7 to 17.9 mm (average 15.3 mm). Two sets of branches arise from the vertebral artery in this segment, a relatively large muscular branch and a small artery traversing along the C2 ganglion into the spinal canal [36].

### 1.4.3 V3 Segment

After exiting C1 transverse process, the vertebral artery takes an approximately 90° posterior bend and turns medially to engage in the groove on the superior surface of the posterior arch of the atlas, where turning around the superior facet of the atlas, it bends anteriorly to enter the spinal canal. In an anatomical study by Ciaccola et al., the total length of this segment of the artery was 32.3–43.5 mm (average 35.7 mm). The C1 roots course posterior-inferior in relationship to the artery. The posterior-inferior cerebellar artery did not arise from the segment in any specimen. The distance between the most medial extension of the vertebral artery and the medial edge of the vertebral artery groove on the outer cortex of the posterior arch of the atlas ranged from 2.1 to 5.2 mm (average 4.24 mm) [40].

### 1.4.4 Anatomical Variation

The incidence of vertebral artery (VA) anomalies is about 3.5%.

As regards the anomalous origins of the right vertebral artery, these conditions can be divided into three categories:

- VA originating directly from the aorta
- VA originating from the carotid arteries or from the brachiocephalic artery
- VA of duplicated origin

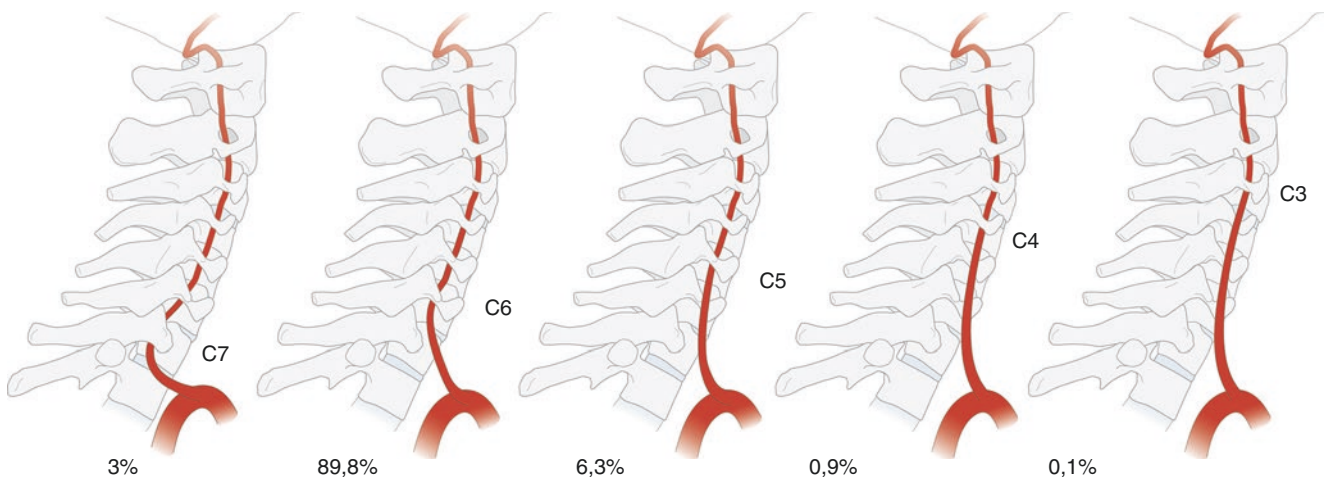
Also the anomalous origins of the left vertebral artery are divided into three categories:

- VA originating directly from the aorta
- VA originating from the left internal carotid artery
- VA of duplicated origin

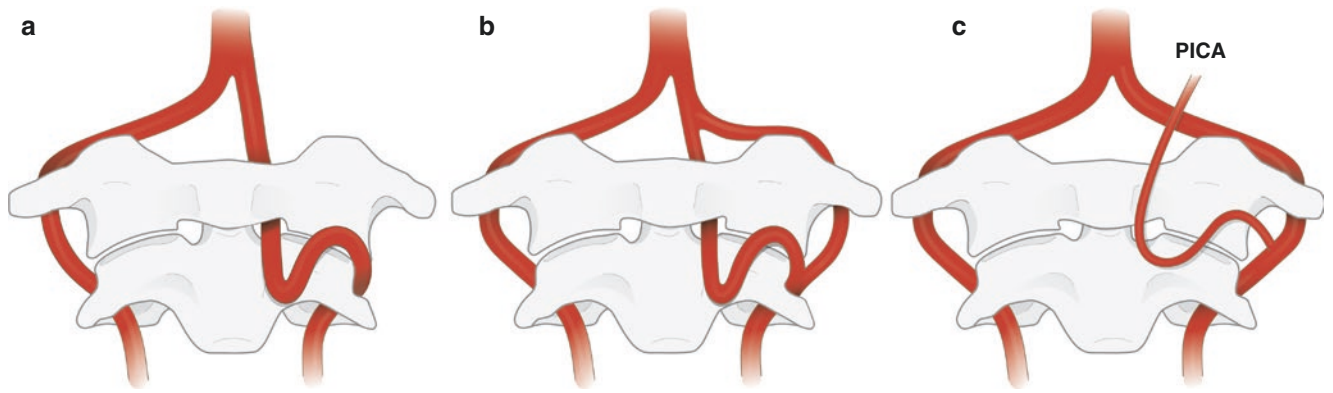
Only two of the variants described have a higher frequency: the origin of the left vertebral artery directly from the aortic arch (between the left common carotid artery and left subclavian artery) and the right vertebral artery originating from the right common carotid, usually accompanied by an aberrant right subclavian artery.

There are also other important tips for the surgeon regarding the vertebral artery anatomical variants, during the approach to the deep cervical region:

- There is a risk to damage an abnormally long prevertebral VA segment when the surgeon is performing the incision of the muscles of the transverse spinal processes. In some cases, vertebral artery enters the spinal transverse foramina at other levels from C7 to C2, and not at C6; there can also be a symmetrical entrance in 85% of cases and asymmetrical in 15% (because the right VA enters at a lower level).
- Another important tip for the surgeon is that there can be anomalous carotid-VA anastomoses (Fig. 1.7).
- The third segment of the VA can have anomalies, and in particular (A) it doesn't pierce the dura at the atlanto-occipital membrane level, but it goes into the dura at the level of atlas or between atlas and axis and courses inside the spinal canal (C2 segmental type of VA); (B) it can have a fenestration. This condition is encountered when there are two branches of VA after the artery emerges from the C2 transverse foramina. One branch has a normal course, whilst the other pierces the dura between C1 and C2 and reaches the first branch inside the skull. (C) There can be a pseudofenestration, that is, a condition where the posterior-inferior cerebellar artery originates from the second or the third segment of the VA (instead of V4), pierces the dura at the atlantoaxial level and has an ascending course laterally to the cord (Fig. 1.8) [41–42].



**Fig. 1.7** Anatomy of vertebral artery and its variations



**Fig. 1.8** Anatomy of vertebral artery and basilar artery at the level of C1–C2

## 1.5 The Venous System

Intracranial veins and venous sinuses converge to form major dural sinuses, the transverse sinus and the sigmoid sinus, which drain into extracranial veins. These major dural sinuses are connected by other venous structures to the skull base. These venous structures form a complex venous network that drains intracranial venous flow into extracranial veins at the craniocervical junction [43–44]. These venous structures are also known to have an important role as collateral pathways in cases of veno-occlusive disease.

The venous structures include the major dural sinuses and emissary veins that have a role as the main drainage route for cephalic venous blood flow. The emissary veins are also thought to have a function of redirecting blood outflow towards the vertebral venous system in the upright position [45].

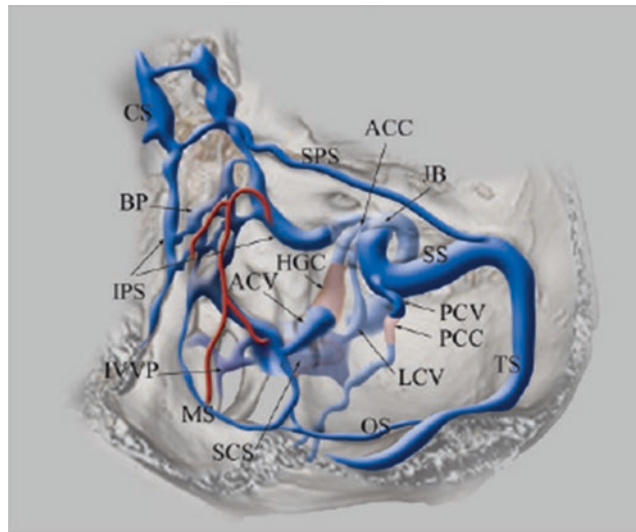
In literature there are many radiological studies of the anatomy and/or variations of craniocervical venous structures using transcatheter angiography or MRI [46–48].

Tanoue et al. [49] (Fig. 1.9) studied the IPS, SCS, MS and ACV; the anatomical architectures of the LCV and PCV

could be evaluated; the LCV was found to be absent in 27 sides (27%), and the PCV was absent in 33 sides (33%). The OS was depicted in only 18 cases, with 4 cases of prominently developed OS. There is an apparent discrepancy between these results and those of a previous anatomical study, which presented the frequency of absence of the OS as 35.5% [50].

The IPS normally connects the cavernous sinus to the jugular bulb and passes along the petroclival fissure.

Most investigators have classified the IPS in the context of the patterns of the IPS-jugular bulb junction, for example, single or multiple connections, plexiform connection, no connection or connection with cervical venous plexus. The OS could be demonstrated in prominently developed cases and all drained into the right sigmoid sinus. According to a previous anatomical description, the number of OS running towards the right side is three times larger than the number of OS going to the left [51]. Most PCVs originated from the inferolateral aspect of the sigmoid sinus, but there were cases of a PCV originating from the ACC. In some cases, the PCV originated from the jugular bulb or, rarely, originated from the sigmoid sinus [44].



**Fig. 1.9** Schematic drawing of the veins at the craniocervical junction. The inferior petrosal sinus (IPS) originates from the posterosuperior aspect of the cavernous sinus (CS), runs along the petroclival fissure and drains into the jugular bulb (JB). Basilar plexus (BP) lies on the clivus with connecting bilateral IPS. The anterior condylar vein (ACV) and lateral condylar vein (LCV) originate from the medial aspect of the JB, forming an anterior condylar confluence (ACC). ACV runs medially through the hypoglossal canal (HGC) and drains into the lateral part of the marginal sinus (MS). MS is contiguous to the medial part of the suboccipital cavernous sinus (SCS). LCV runs postero laterally and

flows into SCS. The posterior condylar vein (PCV) originates from the sigmoid sinus (SS), runs through the posterior condylar canal (PCC) and flows into SCS. SCS lies under the occipital bone surrounding the horizontal portion of the vertebral artery. The occipital sinus (OS) originates from the torcular herophili, confluence of transverse sinus (TS) and straight sinus and drains into the posterior part of MS. MS is the round-shaped sinus surrounding the foramenmagnum. MS and the medial part of SCS are connected to the internal vertebral venous plexus (IVVP) [45]

## 1.6 Neural Tissue

Neural structures related to CVJ are:

1. Caudal portion of brainstem (medulla)
2. Cerebellum
3. Fourth ventricle
4. Rostral part of spinal cord
5. Lower cranial and upper cervical nerves

In cerebellum, only the tonsils, biventral lobules and the lower part of the vermis (nodule, uvula and pyramid) are related to CVJ. Biventral lobule is located above the lateral part of foramen magno and the tonsils lie above the posterior edge.

The afferents to the spinal nerves C1–C3 must include those originating in the upper cervical synovial joints, the upper cervical muscles, the C2–C3 disc, the craniovertebral ligaments and the dura mater of the upper spinal cord and posterior cranial fossa. Collectively, the upper three cervical levels are called the sinuvertebral nerves (SVNs) which could be responsible for mediating pain from the upper cervical spine and the posterior cranial fossa [52].

The SVN had been termed the recurrent branch of the spinal nerve, meningeal rami of spinal nerves and ramus meningeus [53]. However, most authors have adopted the term SVN now for the nerve that enters the intervertebral foramen to innervate the intraspinal structures.

All three SVNs, once formed in the intervertebral foramen, give off very tenuous branches to the dura mater and run in the epidural space anterior to the DRG. Both C2 and C3 SVNs, having entered the vertebral canal, pass upwards and continue to ascend by their main ascending branches over the next vertebra above, running parallel to the membrana tectoria in the vertebral canal and continuing upwards towards the ligaments of the CVJ.

The membrana tectoria is innervated by transverse branches of C2 and C3 SVN at their level of entry into the vertebral canal. In addition, the ascending branch of the C2 and C3 SVNs provides a second source of innervation to the membrane. They run parallel to the lateral edge of the membrana tectoria, supplying its dual laminated structure periodically along the way by tiny filaments to it. They also give off

the very important tiny filaments to the overlying dura mater. The ascending and descending branches of the SVNs accompany the posterior ascending artery of the dens to the body and dens of the axis and are protected somewhat by overlying longitudinal venous sinuses and delicate neurovascular sheaths enclosing the nerves and the arteries as they ascend towards the dens where they form an apical arterial arcade between the loops of an apical venous plexus above and around the apex of the dens.

The cervical SVNs at C1–C2 and C2–C3 intervertebral levels have long ascending branches innervating structures at their level of entry and above in the vertebral canal and posterior cranial fossa. Descending branches from both SVNs could be identified and travel only one segment downwards from their level of entry into the vertebral canal.

C1 SVN, however, has a short course in the vertebral canal. The ascending branches are longer than the descending branches. The C1 SVN and its constituent roots are found between the posterior arch of the atlas below and the occipital bone above, immediately behind the atlanto-occipital joint [59].

C3 SVN innervates most of the craniovertebral structures medially, whereas the C2 SVN innervated the structures more laterally. The communication between the ascending and descending branches of C2 and C3 SVNs and between the ascending branch of C2 SVN and the hypoglossal canal is in keeping with the segmental arrangement of the innervation of the vertebral levels below. The hypoglossal canal is ranked developmentally as the next higher segmental level embryologically. Thus, the basiocciput receives at least part of its innervation from the upper SVNs. Interestingly, the communication between the ascending branch of the C2 SVN with the hypoglossal nerve confirms the long-held belief that the sensory communication does occur between cervical and cranial nerves.

Lower four cranial nerves are closely related to CVJ. Ninth and tenth cranial nerves arise from the medulla in the groove between the inferior olivary nucleus and the inferior cerebellar peduncle. They are separated by a dural sheath, which separates these nerves as they penetrate the dura to enter the jugular foramen. The accessory nerve is the only cranial nerve that passes through the FM.

## References

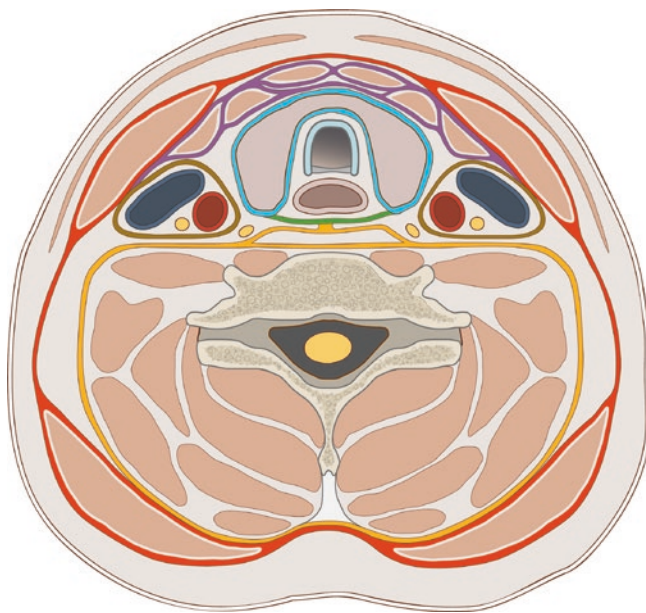
1. Lang J (1986) Cervical region, osteology and articulations. *Neuro Orthopedics* 1:67–92
2. Shapiro R, Robinson F (1976) Embryogenesis of the human occipital bone. *Am J Roentgenol* 127:281–287
3. Martin MD et al (2010) Anatomic and biomechanical considerations of the craniovertebral junction. *Neurosurgery* 66(3S):2–6
4. Menezes AH, Traynelis VC (2008) Anatomy and biomechanics of normal craniovertebral junction (a) and biomechanics of stabilization (b). *Childs Nerv Syst* 24:1091–1100
5. Noble ER, Smoker WRK (1996) The forgotten condyle: the appearance, morphology, and classification of occipital condyle fractures. *Am J Neuroradiol* 17(3):507–513
6. Kim DM et al (2007) Surgery of the paediatric spine. Thieme Medical Publications, Stuttgart. ISBN 978-3-13-141931-6
7. Torriani M, Lourenco J (2002) Agenesis of the posterior arch of the atlas. *Revista do Hospital das Clínicas* 57(2):73–76
8. Denaro L et al (ed) (2010) Pitfalls in cervical spine surgery: avoidance and management of complications. Springer Publications, Stuttgart. ISBN 978-3-540-85019-9
9. Gray H (1918) Anatomy of the human body. <http://www.bartleby.com/107/>
10. König SA et al (2005) Anatomical data on the craniocervical junction and their correlation with degenerative changes in 30 cadaveric specimens. *J Neurosurg Spine* 3(5):379–385
11. Fitzgerald RH et al (2002) Orthopaedics. Mosby Inc., Stuttgart. ISBN 0-323-01318-X
12. Murphy TM et al (2012). Rheumatoid arthritis-etiology, consequences and comorbidities. Elsevier.
13. Lustrin ES et al (2003) Paediatric cervical spine: normal anatomy, variants, and trauma. *Radiographics* 23(3):539–560
14. Steinmetz MP, Mroz TE, Benzel EC (2010) Craniovertebral junction: biomechanical considerations. *Neurosurgery* 66(3 Suppl): 7–12
15. Wolfla CE (2006) Anatomical, biomechanical, and practical considerations in posterior occipitocervical instrumentation. *Spine J* 6(6 Suppl):225S–232S
16. Tubbs RS et al (2011) Ligaments of the craniocervical junction. *J Neurosurg Spine* 14:697–709
17. Dickman CA, Mamourian A, Sonntag VK, Drayer BP (1991) Magnetic resonance imaging of the transverse atlantal ligament for the evaluation of atlantoaxial instability. *J Neurosurg* 75:221–227
18. Dvorak J, Schneider E, Saldinger P, Rahn B (1988) Biomechanics of the craniocervical region: the alar and transverse ligaments. *J Orthop Res* 6:452–461
19. Krakenes J, Kaale BR, Rorvik J, Gilhus NE (2001) MRI assessment of normal ligamentous structures in the craniovertebral junction. *Neuroradiology* 43:1089–1097
20. Tubbs RS, Dixon J, Loukas M, Shoja MM, Cohen-Gadol AA (2010) Ligament of Barkow of the craniocervical junction: its anatomy and potential clinical and functional significance. *J Neurosurg Spine* 12:619–622
21. Tubbs RS, Griessenauer CJ, McDaniel JG, Burns AM, Kumbla A, Cohen-Gadol AA (2010) The transverse occipital ligament: anatomy and potential functional significance. *Neurosurgery* 66(3 Suppl Operative):1–3
22. Schaeffer JP (ed) (1953) Morris' human anatomy a complete systematic treatise, 11th edn. The Blakiston Company, New York
23. Yuksel M, Heiserman JE, Sonntag VK (2006) Magnetic resonance imaging of the craniocervical junction at 3-T: observation of the accessory atlantoaxial ligaments. *Neurosurgery* 59:888–893
24. Tubbs RS, Salter EG, Oakes WJ (2004) The accessory atlantoaxial ligament. *Neurosurgery* 55:400–404
25. Pick TP, Howden R (eds) (1901) Gray's anatomy, descriptive and surgical. Lea Brothers, Philadelphia
26. Tubbs RS, Stetler W, Shoja MM, Loukas M, Hansasuta A, Liechty P et al (2007) The lateral atlanto-occipital ligament. *Surg Radiol Anat* 29:219–223
27. Haffajee MR, Thompson C, Govender S (2008) The supraodontoid space or "apical cave" at the craniocervical junction: a microdissection study. *Clin Anat* 21:405–415
28. Tubbs RS, Wellons JC III, Blount JP, Oakes WJ (2002) Posterior atlanto-occipital membrane for duraplasty. Technical note. *J Neurosurg* 97(2 Suppl):266–268
29. Zumpano MP, Hartwell S, Jagos CS (2006) Soft tissue connection between rectus capitus posterior minor and the posterior atlanto-occipital membrane: a cadaveric study. *Clin Anat* 19:522–527
30. Hack GD, Koritzer RT, Robinson WL, Hallgren RC, Greenman PE (1995) Anatomic relation between the rectus capitis posterior minor muscle and the dura mater. *Spine* 20:2484–2486
31. Thompson VP (1995) Anatomical research lives! *Nat Med* 1:297–298
32. Williams PL (ed) (1996) Gray's anatomy: the anatomical basis of medicine and surgery, 38th edn. Churchill Livingstone, London
33. VanGilder JC, Menezes AH, Dolan K (1987) The craniovertebral junction and its abnormalities. *Futura*, New York, pp 1–255
34. Menezes AH (2003) Developmental abnormalities of the craniocervical junction. In: Winn RH (ed) *Youmans neurological surgery*. Saunders, Orlando, p 3331–3345
35. Osenbach RK, Menezes AH (1992) Pediatric spinal cord and vertebral column injury. *Neurosurgery* 30:385–390
36. Cacciola F, Phalke U, Goel A (2004) Vertebral artery in relationship to C1–C2 vertebrae: an anatomical study. *Neurol India* 52:178–184
37. Congdon ED (1922) Transformation of the aortic-arch system during the development of the human embryo. *Contrib Embryol* 68:47–110
38. Padgett DH (1948) The development of the cranial arteries in the human embryo. *Contrib Embryol* 212:205–261
39. Padgett DH (1954) Designation of the embryonic intersegmental arteries in reference to the vertebral artery and subclavian stem. *Anat Rec* 119:349–356
40. Bruneau M, Cornelius JF, George B (2006) Antero-lateral approach to the V3 segment of the vertebral artery. *Neurosurgery* 58:29–35
41. Gaillard F (2008) Title of subordinate document. In: *Anatomy and vertebral artery*. Toshiba (Australia) Medical Division. Available via [DIALOG](http://radiopaedia.org/articles/vertebral-artery). <http://radiopaedia.org/articles/vertebral-artery>. Accessed 26 Oct 2008
42. Duan S, He H, Lv S, Chen L (2010) Three-dimensional CT study on the anatomy of vertebral artery at atlantoaxial and intracranial segment. *Surg Radiol Anat* 32(1):39–44. doi: 10.1007/s00276-009-0552-5. Epub 2009 Aug 26
43. San Milla'n Rur'tz D, Gailloud P, Rufenacht DA, Delavelle J, Henry F, Fasel JH (2002) The craniocervical venous system in relation to cerebral venous drainage. *AJNR Am J Neuroradiol* 23:1500–1508
44. Tanoue S, Kiyosue H, Sagara Y, Hori Y, Okahara M, Kashiwagi J, Mori H (2010) Venous structures at the craniocervical junction: anatomical variations evaluated by multidetector row CT. *Br J Radiol* 83(994):831–840
45. Takahashi S, Sakuma I, Omachi K, Otani T, Tomura N, Watarai J et al (2005) Craniocervical venous anatomy around the suboccipital cavernous sinus: evaluation by MR imaging. *Eur Radiol* 15:1694–1700
46. Caruso RD, Rosenbaum AE, Chang JK, Joy SE (1999) Craniocervical junction venous anatomy on enhanced MR images: the suboccipital cavernous sinus. *AJNR Am J Neuroradiol* 20:1127–1131

47. Arnautovic' KI, al-Mefty O, Pait TG, Krisht AF, Husain MM (1997) The suboccipital cavernous sinus. *J Neurosurg* 86:252–262
48. Das AC, Hasan M (1970) The occipital sinus. *J Neurosurg* 33:307–311
49. Valdueza JM, von Mu" nster T, Hoffman O, Schreiber S, Einha" upl KM (2000) Postural dependency of the cerebral venous outflow. *Lancet* 355:200–201
50. Hacker H (1974) Dural venous sinuses. In: Newton TM, Potts DG (eds) *Radiology of the skull and brain*, vol 2 Book 3 Veins. CV Mosby, Saint Louis. p. 1862–1872
51. Rennie C, Haffajee MR, Ebrahim MA (2013) The sinuvertebral nerves at the craniovertebral junction: a microdissection study. *Clin Anat* 26(3):357–366
52. Wiberg G (1949) Back pain in relation to the nerve supply of the intervertebral disc. *Acta Orthop Scand* 19:211–221
53. Kimmel DL (1961) Innervation of spinal dura mater and dura mater of the posterior cranial fossa. *Neurology* 11:800–809

M. Girolami, R. Ghermandi, M. Ghirelli, A. Gasbarrini,  
and S. Boriani

The cervical spine is a deep anatomical structure centrally located in the axial view of the neck and surrounded by a thick and powerful muscular compartment. It is contained by the deep layer of deep cervical fascia (Fig. 2.1).

This chapter describes the essential anatomy of subaxial cervical spine (C3-C7).



**Fig. 2.1** Axial view of the subaxial cervical spine

M. Girolami (✉) • R. Ghermandi • A. Gasbarrini • S. Boriani  
Oncologic and Degenerative Spine Surgery Department Rizzoli  
Orthopedic Institute, Bologna, Italy  
e-mail: [marco.girolami@yahoo.it](mailto:marco.girolami@yahoo.it)

M. Ghirelli  
Head and Neck Surgery Department University Hospital  
of Modena, Modena, Italy

## 2.1 Bony Anatomy

### 2.1.1 C3-C6

Vertebrae are composed by a vertebral body, anteriorly, and a neural arch, composed by pedicles and laminae, posteriorly (Fig. 2.2).

The typical lower cervical vertebra presents a small square vertebral body. A hook-shaped uncinate process, on each side of the superior endplate of vertebral bodies from third cervical to first thoracic, articulates with the corresponding uncus surface, on the inferior endplate of the vertebral body above, forming the uncovertebral joints (Luschka's joints).

The neural arch is formed by two pedicles and two laminae and forms the posterior border of the vertebral foramen which is triangular in shape, with apex directed posteriorly [1].

Extending posteriorly from where the two laminae meet is the spinous process which is bifid.

The transverse process extends laterally from the junction of the pedicle and the lamina on each side. Cervical transverse processes have anterior and posterior bars, which delimitate the foramen transversarium, and terminate laterally as corresponding tubercles (connected by a costal – or intertubercular – lamella).

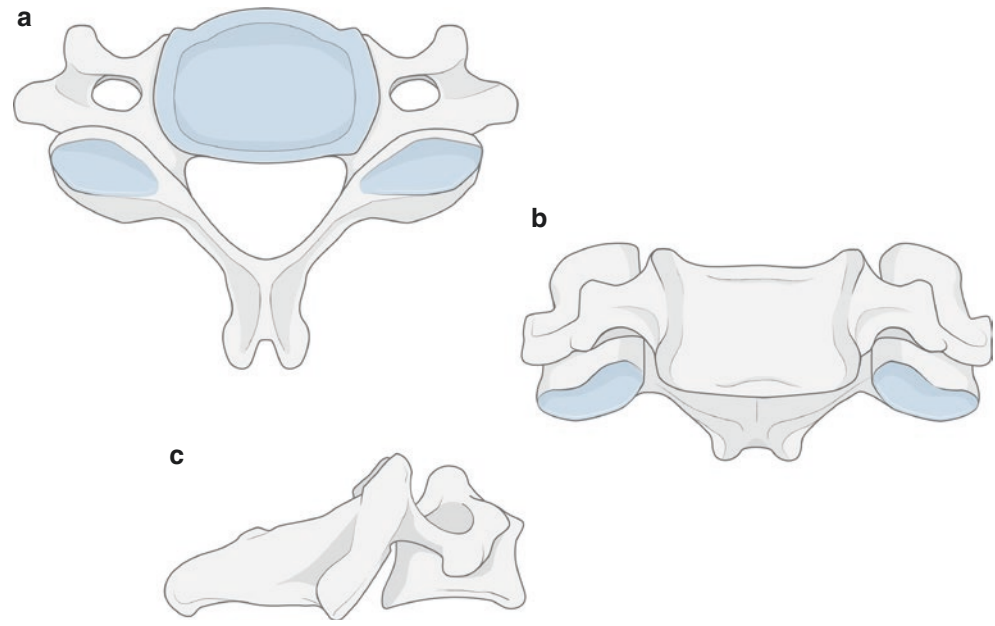
The attachment of the dorsal bar to the pediculolaminar junction represents the morphological transverse process, while the attachment of the ventral bar to the vertebral body represents remnants of ancient costal elements.

It is important to consider that the anterior tubercle of the transverse process of the 6th cervical vertebra is bulky, and it is an important surgical landmark; moreover, it has a close relationship with the common carotid artery, and so is also called the carotid tubercle (Chassaignac tubercle) [2].



The junction between lamina and pedicle bulges laterally between the superior and inferior articular processes to form lateral masses on each side.

The superior articular facets, flat and ovoid, are directed superoposteriorly, whereas the corresponding inferior facets are directed mainly anteriorly, and lie nearer the coronal plane than the superior facets [3].



**Fig. 2.2** Subaxial cervical vertebra: (a) superior, (b) anteroposterior, (c) lateral views

### 2.1.2 C7: Vertebra Prominens

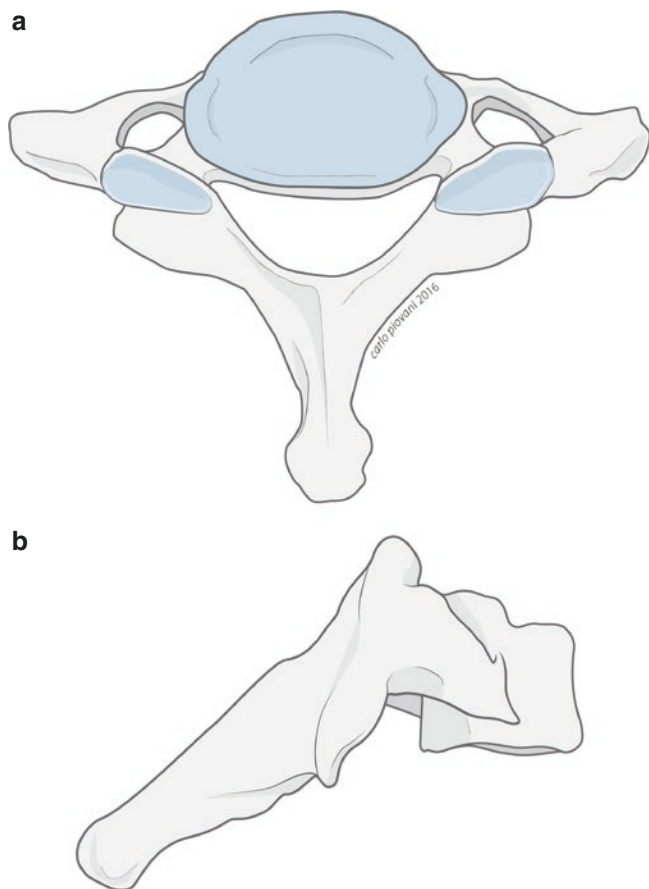
C7 has some peculiar features that make it different from the other cervical vertebrae. Some of its characteristics are that of a transitional vertebra between the cervical and thoracic spine (Fig. 2.3).

The spinous process is not bifid; it is directed dorsally and downwards ending in a prominent tubercle for the attachment of the ligamentum nuchae.

The posterior tubercle of the transverse process is thicker than that in the other cervical vertebrae, and sometimes particularly prominent (cervical rib).

Articular surfaces are more vertical but still the superior, oriented dorsally, and the inferior, ventrally.

Another important consideration concerns the content and the shape of the foramen transversarium. In fact, it only contains the vertebral vein, and not the correspondent artery, as all other lower cervical vertebrae do. Moreover, it is often divided by a bony spicule, and its ventral burden is relatively thin and may be underdeveloped or partly deficient.



**Fig. 2.3** C7 peculiar features: (a) superior and (b) lateral views

## 2.2 Joints and Ligamentous Anatomy

Joints within each motion segment are both anteriorly and posteriorly, between vertebral bodies and lateral masses, respectively.

Two adjacent vertebral bodies articulate within each other by means of three articulations: the two uncovertebral joints and a discosomatic joint. This latter is a synarthrosis since there is no joint cavity and the motion is obtained through the intervertebral disc located in between them. The intervertebral disc is a structure formed by a central nucleus pulposus enclosed by the fibers of the annulus fibrosus in the peripheral part.

The uncovertebral joints are synovial joints formed by the uncinate process of the 3rd cervical to the 1st thoracic vertebra which articulates with the correspondent surface on the inferior part of the vertebral body above. These joints allow flexion-extension limiting lateral flexion.

Dorsally, two plain synovial joints formed by the inferior articular facet of a vertebra and the superior articular facet of the vertebra below. The orientation of the facet varies within the different regions of the spine and dictates the plane of motion at each relative level. In the cervical spine, superior articular facets are directed upwards and dorsally, whereas the corresponding inferior facets, downwards and ventrally. The capsules of these joints strongly contribute to segmental stability.

There is a system of ligaments (Fig. 2.4) connecting adjacent vertebrae, thus allowing segmental motion:

1. Anterior longitudinal ligament (ALL)
2. Posterior longitudinal ligament (PLL)
3. Ligamentum flavum
4. Interspinous ligaments
5. Ligamentum nuchae

### 2.2.1 Anterior Longitudinal Ligament

This fibrous structure extends on the ventral surface of the vertebral bodies from the base of the skull to the sacrum. It resists hyperextension.

### 2.2.2 Posterior Longitudinal Ligament

This ligament lies within the spinal canal on the dorsal surface of the vertebral bodies extending from the occiput to the sacrum. Caution is advised during dissection of the anterior epidural space, since this ligament might be in close relationship with the dural sac.

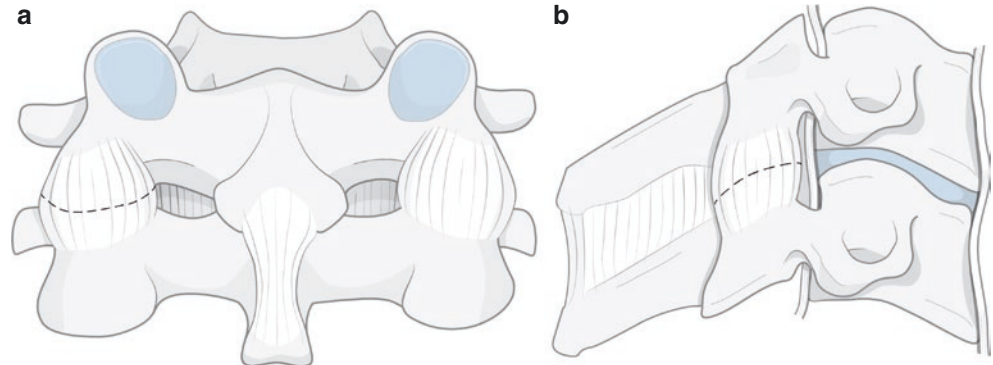
### 2.2.3 Ligamentum Flavum

This structure owes its name (lat. flavus, yellow) to the great prevalence of elastic fibers which determine its color. Ligamenta flava are coupled, one at each lamina (right and left) of the vertebra and might be separated by a central fissure. They extend from half the ventral surface of the lamina of a vertebra to the superior margin of the lamina of the vertebra

below. Caution is advised during opening of the canal, since this ligament might be in close relationship with the dural sac.

### 2.2.4 Interspinous Ligaments

These ligaments connect two contiguous spinous processes and extend anteriorly up to reach the ligamentum flavum.

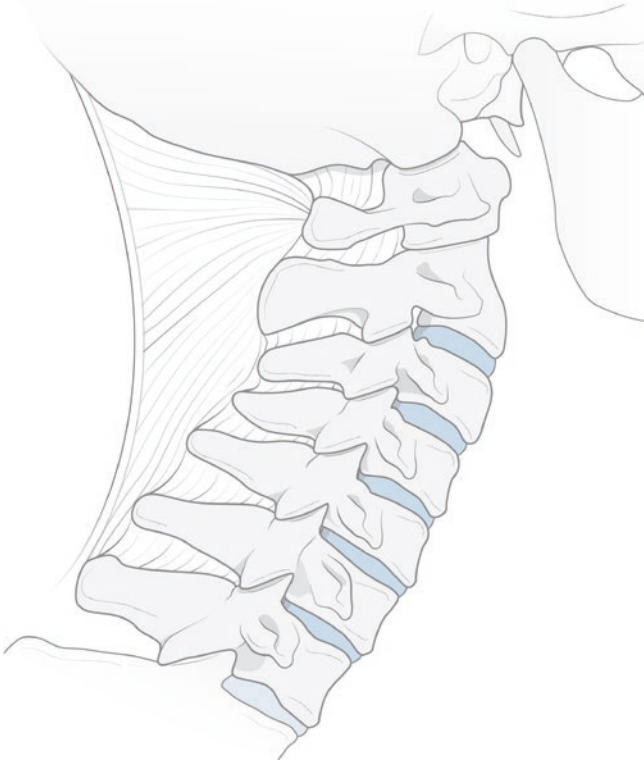


**Fig. 2.4** (a) Posterior and (b) lateral views of a functional spinal unit with its posterior capsular and ligamentous structures (posterior ligamentous complex)

### 2.2.5 Ligamentum Nuchae

This structure is stretched from the external occipital protuberance to the spinous process of C7 (Fig. 2.5). It represents the homologous of the supraspinous ligament in the thoraco-

lumbar spine. Its fibers deepen to reach the spinous processes of each cervical vertebra contributing to separate the right and left paravertebral muscle compartments [4].



**Fig. 2.5** Lateral view of the cervical spine and ligamentum nuchae

### 2.3 Muscular Anatomy

|                      | Muscle                         | Origin                             | Insertion  | Innervation                            | Action  |   |
|----------------------|--------------------------------|------------------------------------|--|--|---|---|
| Prevertebral         | Longus colli                   | <i>Superior-oblique fibers</i>     | Transverse processes from C3 to C5                           | Anterior arch of atlas                 | Flexes the cervical spine   |   |
|                      |                                | <i>Inferior-oblique fibers</i>     | Vertebral bodies from T1 to T3                               |  |   | Bends the spine to the ipsilateral side rotating it to the contralateral side |
|                      |                                | <i>Vertical fibers</i>             | Vertebral bodies from C5 to T3                               |  |   |   |
|                      | Longus capitis                 | Transverse processes from C3 to C5 | Basilar portion of the occipital bone                        | Ventral rami of C1 to C3               |   |   |
|                      | Rectus capitis anterior        | Transverse process of the atlas    | Basilar portion of the occipital bone                        | Ventral rami of C1 and C2              | Flexes the head   |   |
|                      | Rectus capitis lateralis       |                                    | Jugular portion of the occipital bone                        |  | Bends the head to the ipsilateral side  |   |
|                      | Anterior scalene               | Transverse processes from C3 to C6 | Scalene tubercle of 1st rib                                  | Ventral rami of C4 to C6               | Elevates the 1st rib  |   |
|                      | Middle scalene                 | Transverse processes from C2 to C7 | 1st rib  | Ventral rami of C5 to C8               | Flexes the spine  |   |
|                      | Posterior scalene              | Transverse processes from C5 to C7 | 2nd rib  |  | Bends the spine to the ipsilateral side rotating it to the contralateral side |   |
| Suboccipital (C0-C2) | Obliquus capitis superior      | Transverse process of atlas (C1)   | Occipital bone   | Ventral rami of C6 to C8               | Extends the spine   |   |
|                      | Obliquus capitis inferior      | Spinous process of the axis (C2)   | Transverse process of the atlas (C1)                         | Suboccipital nerve (dorsal rami of C1) | Extends head  |   |
|                      | Rectus capitis posterior major |                                    | Inferior nuchal line (lateral portion) of the occipital bone |  | Lateral flexion of head   |   |
|                      |                                |                                    | Inferior nuchal line (medial portion) of the occipital bone  |  | Rotates head to the ipsilateral side  |   |
|                      | Rectus capitis posterior minor | Posterior arch of the atlas        |  |  | Extends head  |   |

| Paravertebral                      |                         | <i>Superficial layer</i>  |  |   |  |  |  |
|------------------------------------|-------------------------|---|--|---|--|--|--|
| Trapezius                          | <i>Descending part</i>  | Superior nuchal line (medial portion), external occipital protuberance, and nuchal ligament | Lateral third of clavicle  | Spinal accessory nerve (CN XI) ventral rami of C3 and C4 nerves | Supports the weight of the arm                                   |  |  |
|                                    | <i>Transverse part</i>  | Spinous processes from C7 to T3   | Spine of scapula and acromion  |   | Adducts scapula  |  |  |
|                                    | <i>Ascending part</i>   | Spinous processes from T3 to T12  | Scapula (medial margin)  |   | Medially rotates and depresses the scapula                       |  |  |
| Sternocleidomastoid                |                         | Manubrium of the sternum and clavicle   | Superior nuchal line (anterior portion) and mastoid process of temporal bone | Spinal accessory nerve (CN XI) ventral rami of C2 and C3 nerves | Flexes the head<br>Rotates head to the contralateral side        |  |  |
| Rhomboideus minor                  |                         | Nuchal ligament and C7 spinous processes  | Scapula (medial margin)  | Dorsal scapular nerve (C4-C5-C6)                                | Adducts scapula  |  |  |
| Levator scapulae                   |                         | Transverse processes of C1 to C4  | Vertebral border of scapula between medial angle and root of spine           | C4-C5, and possibly branches from the dorsal scapular nerve     | Lifts and adducts the scapula                                    |  |  |
| <i>Intermediate layer</i>          |                         |   |  |   |  |  |  |
| Serratus posterior superior muscle |                         | Lower half of ligamentum nuchae and spinous processes from C6 to T2                         | Ribs from 2nd to 5th, beyond their angle                                     | Posterior rami from C6 to T2                                    | Elevates the ribs (aid deep inspiration)                         |  |  |
| Splenius cervicalis                |                         | Spinous processes from T3 to T5   | Transverse processes of C1 to C3   | Posterior rami from C2 to C4                                    | Extends the spine  |  |  |
| Splenius capitis                   |                         | Lower half of ligamentum nuchae and spinous processes from C7 to T2                         | Superior nuchal line (lateral portion) and mastoid process of temporal bone  | Lateral branches of posterior rami from C4 to C7                | Extends the spine<br>Bends head and neck to the ipsilateral side |  |  |
| <i>Deep layer</i>                  |                         |   |  |   |  |  |  |
| Erector spinae muscle              | Ileocostalis cervicalis | Angle from 1st to 5th rib   | Cervical transverse processes from C4 to C6                                  | Posterior rami from C4 to C7                                    | Extends the spine  |  |  |
|                                    | Longissimus cervicalis  | Transverse processes from T1 to T6  | Posterior tubercle of transverse processes from C2 to C5                     |   |  |  |  |
|                                    | Longissimus capitis     | Transverse processes from C3 to T3  | Mastoid process of temporal bone   |   |  |  |  |
|                                    | Spinalis cervicalis     | Spinous processes from C6 to T2   | Spinous processes from C2 to C4  |   |  |  |  |
|                                    | Spinalis capitis        |   | Occipital bone, merging with semispinalis capitis                            |   |  |  |  |
| Trasversospinal group              | Semispinalis cervicalis | Transverse processes from T1 to T6  | Spinous processes from C2 to C5  | Posterior rami from C4 to C7                                    | Extends the spine<br>Rotates spine to the contralateral side     |  |  |
|                                    | Semispinalis capitis    | Transverse processes from C4 to T6  | Occipital bone, merging with spinalis capitis                                |   |  |  |  |
|                                    | Multifidus              | Transverse processes  | Spinous processes of vertebrae above origin (1-4 segments)                   |   |  |  |  |
| Rotatores                          | Transverse processes    | Spinous processes of the vertebra above   | Spinous processes of the vertebra above                                      |   |  |  |  |
| Interspinales cervicalis           | Spinous processes       | Spinous processes   | Spinous processes of the vertebra above                                      | Posterior rami from segmental spinal nerve                      | Extends the spine  |  |  |
| Intertrasversarii cervicalis       | Transverse processes    | Transverse processes  | Transverse processes of the vertebra above                                   |   | Bends head and neck to the ipsilateral side                      |  |  |

## 2.4 The Arterial System

All the segments of the spinal cord receive blood supply from three spinal arteries, one anterior and two posterior. These arteries arise from the intracranial (V4) segment of the vertebral arteries before these merge into the basilar artery.

The anterior spinal artery extends downward in the anterior median fissure, on the anterior surface of the spinal cord. The two posterior spinal arteries go downward symmetrically along the posterior lateral groove of the spinal cord, just behind the dorsal roots of spinal nerves. These travel in the subarachnoid space and send branches into the spinal cord.

They form anastomoses (connections) via the anterior and posterior radicular arteries, branches of division of the medullary artery (from the spinal artery, branch of the segmental artery) that enters the dural sac along the exiting spinal nerve. These segmental connections origin at any level from the vertebral artery [5].

Two more vessels contribute to the arterial blood supply of the spinal region of the neck: the ascending cervical artery, branch of the inferior thyroid artery (thyrocervical trunk), and the deep cervical artery, branch of the costocervical trunk of the subclavian artery.

## 2.5 The Venous System

The venous system of the cervical spine can be subdivided into external and internal plexuses.

The first (Batson plexus) can be further subdivided into an anterior portion, covering the ventral surface of the vertebral bodies, and in a posterior portion, which is on the dorsal surface of the laminae, lateral masses, and spinous processes.

The internal venous plexus is located in the epidural space and is further subdivided into an anterior portion and a posterior portion connected to the contralateral by the transverse plexus. This drains the blood from the vertebral body via the basivertebral veins and the blood from the spinal cord via the medullary veins.

The subarachnoid venous system is little different from the arterial: there is an anterior spinal vein but only one posterior spinal vein. These drain into the anterior and posterior radicular veins which follow the dorsal and ventral roots of the spinal nerve, and then into the intervertebral vein which leaves the epidural space through the foramina.

Blood drains then into the vertebral vein and the deep jugular vein that, ultimately, drains into the brachiocephalic trunk which forms the superior vena cava system.

## 2.6 The Cervical Spinal Nerves

Spinal nerves are formed by anterior and posterior roots: the first (motor fibers) originates from the anterior horn of the spinal cord and leaves it from the anterolateral sulcus, while fibers of the latter (sensory fibers) originate in the dorsal ganglion from pseudo-unipolar neurons. Its central axons enter the spinal cord at the posterolateral sulcus to reach the posterior horn of the spinal cord, and peripheral axons join the ventral root to form the spinal nerve.

Spinal nerves, eight pairs in the cervical spine, right after their course in the intervertebral foramen, subdivide into ventral and dorsal roots (Fig. 2.6).

The ventral ramus of each spinal nerve goes through the groove that is bounded anteriorly by the vertebral artery and anterior tubercle, posteriorly by the transverse process and posterior tubercle, medially by the vertebral body, and laterally by the facet joint.

The anterior rami of the 1st, 2nd, 3rd, and 4th cervical spinal nerves form the cervical plexus, while the 5th, 6th, 7th, 8th cervical, and 1st thoracic form the brachial plexus.

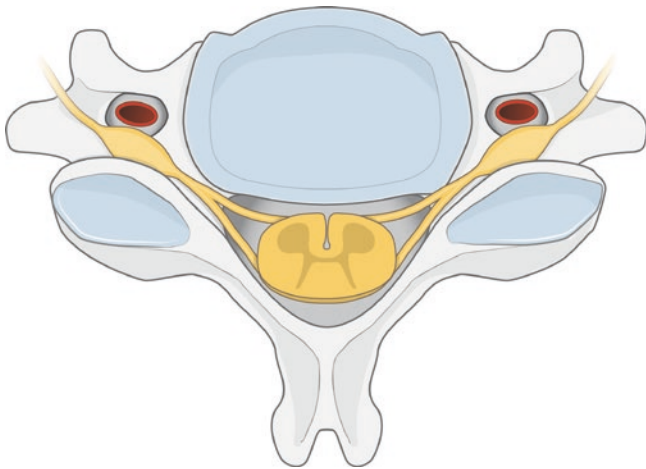
Each cervical nerve receives sympathetic fibers via gray rami communicantes.

Cervical sympathetic is composed by superior, middle, and inferior ganglia located on the ventral surface of the transverse processes and connected by a sympathetic trunk. They receive preganglionic fibers by a white rami communicantes at level of the 1st thoracic nerve and give postganglionic fibers with gray rami communicantes to the correspondent spinal nerve.

The dorsal roots are directed posteriorly to innervate posterior structures including joint capsules, muscles, and skin. The dorsal root of the 1st cervical spinal nerve (suboccipital nerve) is exceptionally composed of motor fibers for the suboccipital muscles.

The dorsal root of the 2nd cervical spinal nerve (greater occipital nerve of Arnold) is composed by a larger sensory branch, the greater occipital nerve for the skin of the scalp, and a thinner motor branch for the muscle inferior oblique, semispinalis, longissimus capitis, and trapezius.

The dorsal root of the 3rd cervical spinal nerve as well provides sensory to the scalp.



**Fig. 2.6** Superior view of subaxial cervical vertebra with the spinal cord, nerves, and vertebral artery. Spinal nerves pass dorsal to the vertebral artery and subdivide into dorsal and ventral roots



## References

1. Norton NS (2016) Netter's head and neck anatomy for dentistry. Elsevier Health Sciences
2. Anastasi G (2007) Human Anatomy [Trattato di anatomia umana]. Edi. Ermes.
3. Bogart BI (2007) Elsevier's integrated anatomy and embryology. Mosby Elsevier.
4. Hoppenfeld S (2009) Surgical exposures in orthopaedics: the anatomic approach, 4th ed. Lippincott Williams & Wilkins.
5. Paulsen W (2011) Sobotta atlas of human anatomy: head, neck and neuroanatomy. Vol.3, 15th ed. Elsevier Urban & Fisher.

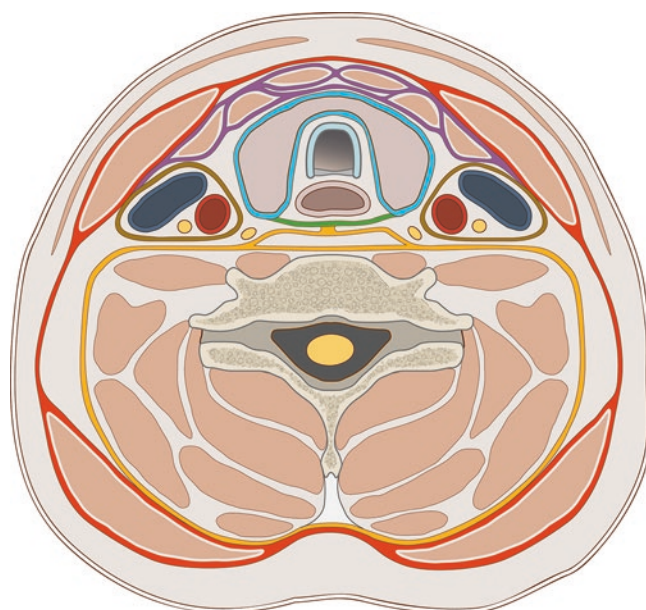
M. Bonali, D. Soloperto, E. Aggazzotti Cavazza, M. Ghirelli,  
and L. Presutti

### 3.1 Topographic Anatomy

The cervical spine is a complex and vital region, and several critically important structures are in close proximity in a small area. The neck is limited superiorly by the pericranium cervical line that goes from the inferior portion of the mental symphysis to theinion, that corresponds to the point of confluence of dural sinuses. Inferiorly, the neck continues with the thorax and the upper limbs, by clavicles and shoulders.

The first cervical vertebra is located behind the angle of the mandible, and its transverse process is palpable between the angle of the mandible and the mastoid process. The hyoid bone is just anterior to the level of C3, the thyroid cartilage is anterior to the level of C4, and cricoid cartilage is opposite to the level of C6.

On transverse section, the neck appears to be roughly divided into two sections: a posterior or nuchal region (osteomuscular) and an anterior or tracheal region (muscular-fascial). Usually the conventional dividing line extends from the transverse vertebral processes to the anterior edges of the trapezius muscle. Topographically, the anterior part of the neck is divided by the sternocleidomastoid muscle into an anterior and a posterior triangle. The description of the triangles will be the purpose of the specific section. The thoracic inlet, which is the anatomic region where the neck communicates with the mediastinum, corresponds to the superior aperture of the thorax. It is bounded by the spine posteriorly (at the level of T1), the cartilage of the first ribs laterally, and the sternal (jugular) notch anteriorly. The description of the anatomy is focused on structures and areas as they are approached during surgical procedures (Fig. 3.1).



**Fig. 3.1** Cross section of the main muscles and fascial layers of the neck

M. Bonali (✉) • E. Aggazzotti Cavazza • M. Ghirelli • L. Presutti  
Otorhinolaryngology, Head and Neck Surgery Department,  
University Hospital of Modena, Modena, Italy  
e-mail: [bonamed1984@hotmail.it](mailto:bonamed1984@hotmail.it)

D. Soloperto  
Otorhinolaryngology, Head and Neck Surgery Department,  
University Hospital of Verona, Verona, Italy

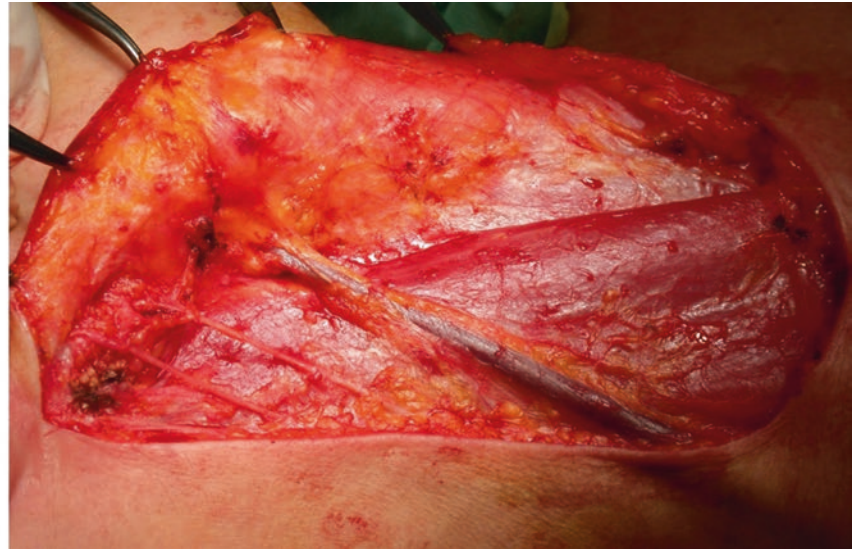
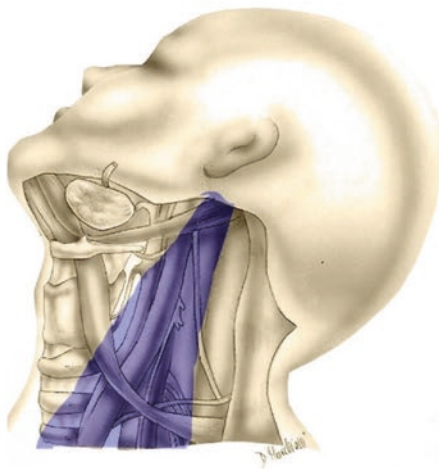
## 3.2 Muscles of the Neck

### 3.2.1 Platysma

Compared to all other muscles of the neck, which are skeletal, this is the only cutaneous. It is a wide and thin lamina in the subcutaneous tissue. It covers the frontal and lateral side of the neck and the lower face. This muscle is cut when a myocutaneous flap is created.

### 3.2.2 Sternocleidomastoid Muscle

It is a long and thick muscle, situated in the anterolateral region of the neck. It fits with one sternal, one mastoid, and one clavicular insertion. It covers the great vessels of the neck, and it is crossed superficially by the external jugular vein that goes behind the clavicle, near the frontal corner of the anterior triangle and the brachial plexus. At Erb's point, the great auricular nerve, which derives from the cervical plexus, obliquely crosses the surface of the muscle upward (Fig. 3.2).

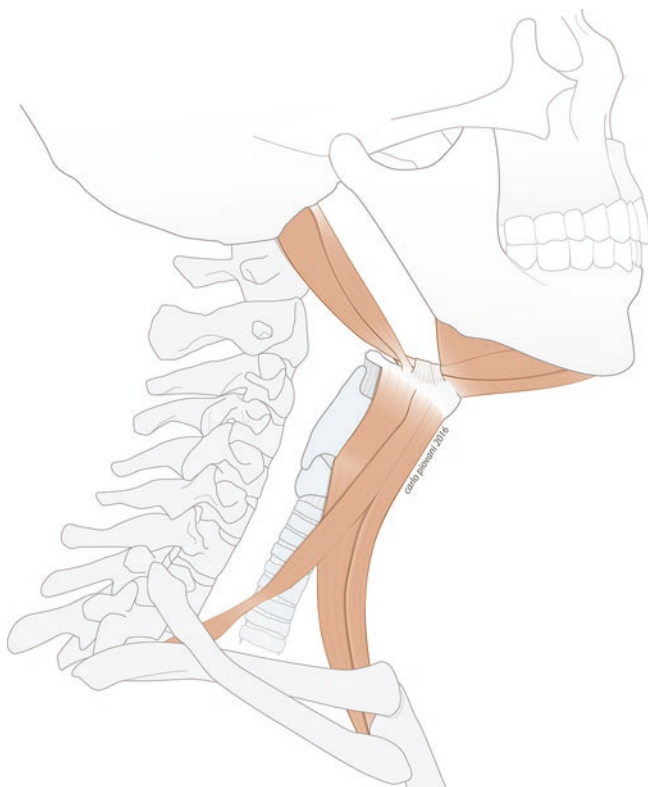


**Fig. 3.2** The SCM on the right side and its relationship with the external jugular vein and the great auricular nerve (Courtesy of Prof. Daniele Marchioni, ENT Department, Verona, Italy)

### 3.2.3 Suprahyoid Muscles (Fig. 3.3)

The suprahyoid muscles are located in the submandibular region superiorly to the hyoid bone and connect the hyoid to

the skull. They are the geniohyoid (deep layer), the mylohyoid, the stylohyoid (middle layer), and the digastric muscle (superficial layer).



**Fig. 3.3** Relationship between hyoid bone and muscles (suprahyoid and infrahyoid)

| Muscle                      | Origin   | Insertion  | Innervation  | Action  |
|-----------------------------|--|--|--|---|
| Digastric (anterior belly)  | Inner side of the lower border of the mandible | Body of the hyoid, by an intermediate tendon continuous with the posterior belly | Mylohyoid nerve, branch of the trigeminal nerve (V3) | Elevates the hyoid. Helps depression and retraction of the mandible |
| Digastric (posterior belly) | Digastric notch of the temporal bone           | Body of the hyoid, by an intermediate tendon continuous with the anterior belly  | Facial nerve (CN VII)                                | Elevates the hyoid. Helps depression and retraction of the mandible |
| Stylohyoid                  | Styloid process                                | Body of the hyoid  | Facial nerve (CN VII)                                | Helps to pull the hyoid bone up and backward during swallowing      |
| Mylohyoid                   | Mylohyoid line of the mandible                 | Body of the hyoid and median raphe   | Mylohyoid nerve, branch of the trigeminal nerve (V3) | Raises the hyoid and tongue during swallowing                       |
| Geniohyoid                  | Inferior genial tubercle                       | Body of the hyoid  | Branch of C1 through the hypoglossal nerve           | Elevates the hyoid bone and tongue                                  |

### 3.2.4 Infrahyoid Muscles (“Strap Muscles”) (Fig. 3.3)

Infrahyoid muscles vary considerably in extent of their development. They connect the hyoid with the upper part of

the thorax, shoulders, and larynx. They are the sternothyroid, thyrohyoid, sternohyoid, and omohyoid. They overlie the thyroid gland, the thyroid cartilage, the larynx, the trachea, and the esophagus.

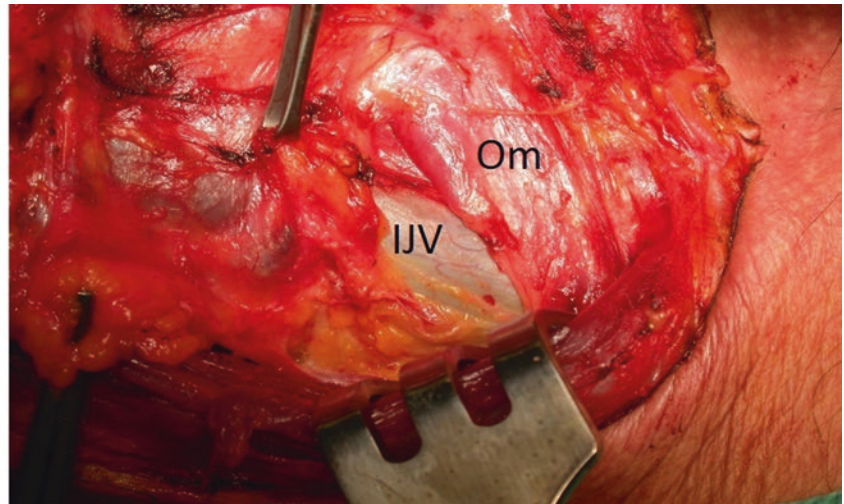
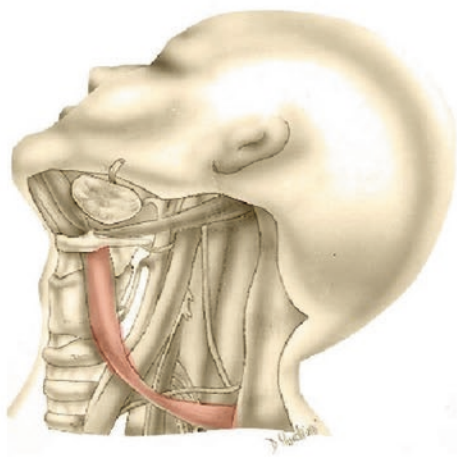
| Muscle                    | Origin   | Insertion   | Innervation   | Action  |
|---------------------------|--|---|---|---|
| Omohyoid (superior belly) | Body and greater cornu of the hyoid bone             | Deep to the SCM muscle, connected to the inferior belly by a tendon | Descendens hypoglossi (branches of C2 and C3)         | Depresses the hyoid   |
| Omohyoid (inferior belly) | Upper border of scapula                              | Deep to the SCM muscle, connected to the superior belly by a tendon | Descending cervical nerve of cervical plexus          | Depresses the hyoid   |
| Sternohyoid               | Posterior manubrium and medial third of the clavicle | Lower border of the hyoid   | Ansa hypoglossi                                       | Depresses the hyoid   |
| Sternothyroid             | Posterior manubrium and first costal cartilage       | Oblique line of the thyroid cartilage                               | Ansa hypoglossi                                       | Depresses the larynx and the thyroid cartilage                      |
| Thyrohyoid                | Oblique line of the thyroid cartilage                | Lower border of the body of the hyoid bone                          | Thyrohyoid branch of C1 through descendens hypoglossi | Depresses the larynx and hyoid bone, elevates the thyroid cartilage |

### 3.2.5 Omohyoid (Fig. 3.4)

The omohyoid muscle is an important landmark in the neck because it divides the anterior and posterior cervical triangles into smaller triangles. Also known as “resident’s friend,” the omohyoid muscle is the anatomic separation of nodal levels III and IV. It has also been used as a reliable landmark in the supraclavicular region, for endoscopic exploration of the brachial plexus.

Having a common primordium with the sternohyoid muscle, the omohyoid muscle often varies in shape and insertions. It usually has two bellies (anterior and posterior) and extends obliquely from the hyoid bone to the scapula.

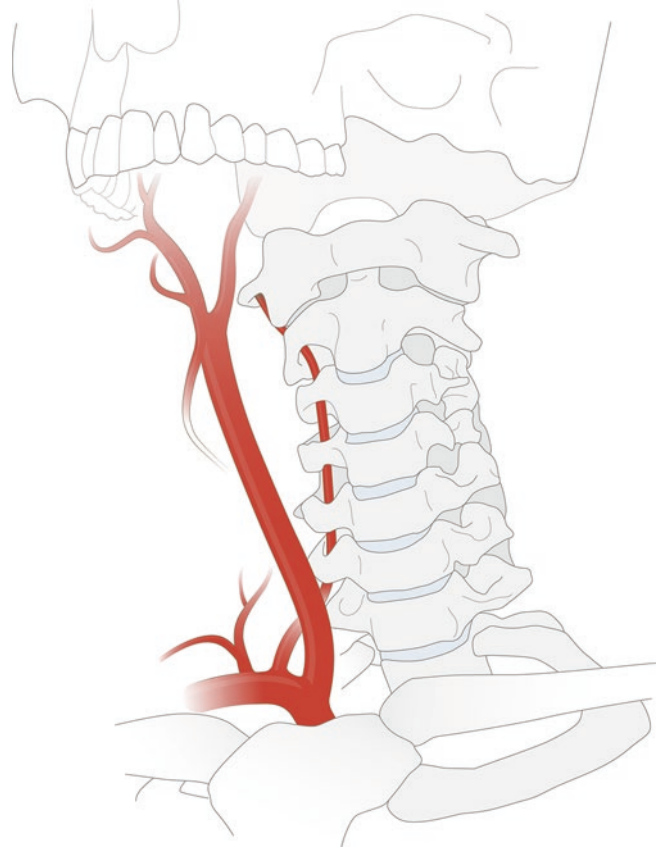
In addition to this, its intermediate tendon can have variable relationship with the internal jugular vein. It always covers the inferior part of internal jugular vein, but several abnormalities have been reported. The omohyoid is the most frequently absent muscle of the infrahyoid group. It may occur only on one side, or it may be found as a single-bellied muscle; one belly is absent more frequently than both bellies; the inferior belly may be doubled, with the second belly possibly arising from the coracoid process. When the inferior belly is absent, the superior belly arises from the clavicle, and the resulting muscle is named cleidohyoideus.



**Fig. 3.4** The omohyoid muscle (Om) and its relationship with the internal jugular vein (IJV) (Courtesy of Prof. Daniele Marchioni, ENT Department, Verona, Italy)

### 3.3 Vascular Supply: Arteries and Veins (Fig. 3.5)

**Fig. 3.5** Arterial blood supply of the neck (focus on carotid, subclavian and vertebral arteries)



### 3.3.1 Arteries

The major arteries of the neck are:

- *Subclavian – its branches involved in cervical spine approach are:*

| Artery        | Source  | Description  |
|---------------|---|--|
| Thyrocervical | A branch of 1st part of the subclavian a. along the anterior scalene muscle                         | Divides into four branches:<br>Inferior thyroid<br>Suprascapular<br>Transverse cervical<br>Ascending cervical artery |
| Costocervical | A branch of the first part of the right subclavian a. and the second part of the left subclavian a. | Divides into two branches:<br>Deep cervical<br>Supreme intercostal   |
| Vertebral     | The first part of subclavian a.   | Described in Chapter 1   |

- *Common carotid – its branches involved in cervical spine approach are:*

| Artery                  | Source   | Description   |
|-------------------------|--|---|
| Superior thyroid artery | The first branch of the external carotid artery from the bottom<br><i>Infrahyoid</i>                                 | On its path to the thyroid gland, it passes inferiorly along the inferior constrictor m.<br>The superior laryngeal a. arises from the superior thyroid a. and passes through the thyrohyoid membrane to supply the larynx   |
| Lingual                 | The second branch of external carotid a.<br><i>Suprahyoid</i>  | Passes superiorly and medially toward the greater cornu of the hyoid bone in an oblique fashion and makes a loop by passing anteriorly and inferiorly while traveling superficial to the middle constrictor m. While forming a loop, the artery is crossed superficially by the hypoglossal n.<br>The lingual a. passes deep to the posterior belly of the digastric and stylohyoid mm. as it travels anteriorly.<br>In this region, it gives rise to a hyoid branch that travels on the superior surface of the hyoid bone, supplying the muscles in the area<br>It passes deep to the hyoglossus m. and travels anteriorly between the hyoglossus and genioglossus mm. to supply the tongue |
| Facial                  | Superiorly to the lingual artery<br><i>Suprahyoid</i>  | Immediately passes superiorly deep to the posterior belly of the digastric and stylohyoid mm.<br>Passes along the submandibular gland giving rise to the submental a., which supplies the gland<br>Passes superiorly over the body of the mandible on the masseter m. with a tortuous pattern to supply the face  |
| Ascending pharyngeal    | Posterior portion of the external carotid artery, near the bifurcation of the common carotid a.<br><i>Infrahyoid</i> | The smallest branch of the external carotid artery<br>Ascends superiorly between the lateral side of the pharynx and the internal carotid a. It has a series of branches:<br>3–4 pharyngeal branches supply the superior and middle constrictor mm.<br>The upper branch passes through the gap superior to the superior constrictor m.<br>Gives rise to an inferior tympanic branch, which supplies the middle ear cavity, and to a posterior meningeal branch, which supplies the bones of the posterior cranial fossa and the dura mater.   |
| Occipital               | Lateral part of the external carotid artery<br><i>Suprahyoid</i>   | Branches along the inferior margin of the posterior belly of the digastric and stylohyoid mm.<br>The hypoglossal n. turns around the occipital a. from the posterior part of the vessel, traveling anteriorly, and then passes posteriorly along the mastoid process, making a groove on the bone<br>Pierces the fascia that connects the attachment of the trapezius with the sternocleidomastoid m.<br>Ascends in the connective tissue layer of the scalp, dividing into many branches<br>Anastomoses with the posterior auricular and superficial temporal aa.<br>The terminal part of the artery is accompanied by the greater occipital n.  |



### 3.3.2 Important Anatomical Variation of the Arteries of the Neck

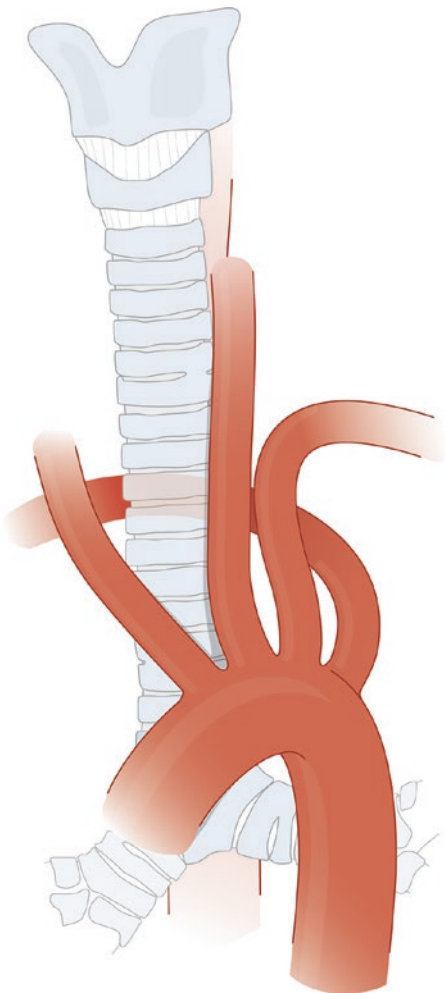
#### 3.3.2.1 Lusory Artery

It is the name of the most common embryologic anatomical anomaly of the aortic arch.

In this particular condition, there is an aberrant right subclavian artery and the brachiocephalic trunk is not present. There are, indeed, four single arteries that arise from the aortic arch: (1) right common carotid artery, (2) left common carotid artery, (3) left subclavian artery, and (4) right subclavian artery, that originates in the extreme left position, distal to the other three blood vessels.

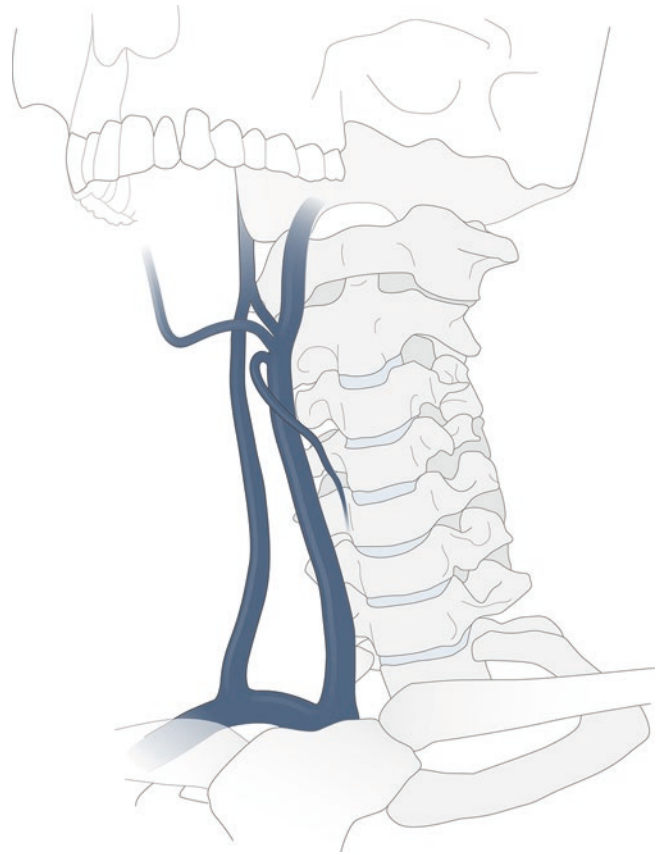
In this case the right subclavian artery goes toward the right usually passing behind the esophagus. When the artery eventually compresses the esophagus, the condition is referred to as “dysphagia lusoria” (Fig. 3.6).

An important anatomical condition related to the lusory artery is the right nonrecurrent laryngeal nerve that rises from the cervical vagus nerve but does not have the typical recurrent course.



**Fig. 3.6** Lusory artery. Right subclavian artery originates in the extreme left position and goes toward the right passing behind the esophagus

#### 3.3.2.2 Veins (Fig. 3.7)



**Fig. 3.7** Venous blood supply of the neck (focus on jugular veins)

| Vein             | Description  |
|------------------|--|
| Anterior jugular | <p>Arises by the joining of a series of superficial veins in the submental region</p> <p>Descends anteriorly to the sternocleidomastoid m. and passes deep to the muscle before draining into the external jugular or the subclavian v.</p>  |
| External jugular | <p>Formed by the confluence of the posterior branch of the retromandibular and posterior auricular vv. in the parotid gland</p> <p>Lies deep to the platysma m. but superficial to the sternocleidomastoid m. as it descends vertically</p> <p>Passes into the posterior triangle of the neck, where it drains into the subclavian v. immediately lateral to the anterior scalene m.</p>   |
| Internal jugular | <p>Continuous with the sigmoid sinus within the cranial cavity</p> <p>Begins at the base of the skull at a dilation called "superior bulb"</p> <p>Lies posterior to the internal carotid a. and the glossopharyngeal, vagus, and spinal accessory nn. as it initially descends</p> <p>Travels lateral to the internal carotid a. within the carotid sheath with the vagus n. posterior to the vessels</p> <p>Unites with the subclavian v. to form the brachiocephalic v. at the root of the neck</p> <p>Receives a series of branches</p> |
| Facial           | <p>Passes inferiorly along the side of the nose, receiving the lateral nasal v.</p> <p>Continues in a posterior and inferior path across the angle of the mouth to the cheek, receiving the superior and inferior labial vv.</p> <p>While passing toward the mandible, the deep facial v. connects the facial v. to the pterygoid plexus</p> <p>In the submandibular triangle, the facial v. joins the anterior branch of the retromandibular to form the common facial v.</p> <p>Common facial v. drains into the internal jugular v.</p> |
| Lingual          | <p>Passes with the lingual a., deep to the hyoglossus m., and ends in the internal jugular v.</p> <p>The vena comitans nervi hypoglossi (or accompanying v. of the hypoglossal n.) begins at the apex of the tongue and either joins the lingual v. or accompanies the hypoglossal n. and enters the common facial v., draining into the internal jugular v.</p>   |
| Thyroid veins    | <p>Superior: from thyro-lingual-facial trunk</p> <p>Medial: directly from the internal jugular vein</p> <p>Inferior: from brachiocephalic vein</p>   |
| Vertebral        | <p>Begins as a plexus in the suboccipital triangle and descends through the foramen transversarium of all of the cervical vertebrae before draining into the subclavian or, more commonly, the brachiocephalic v.</p>  |

### 3.4 Nerves

#### 3.4.1 Vagus

It is also known as cranial nerve X.

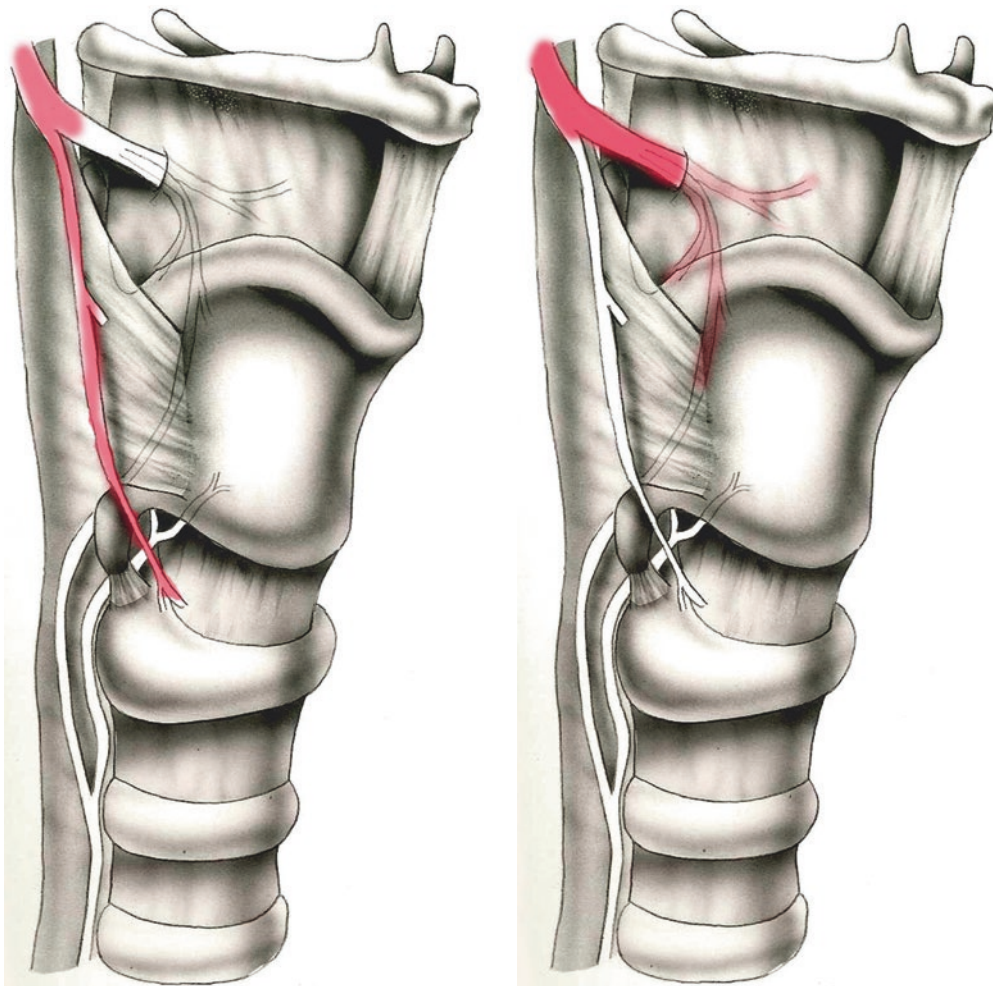
It branches from the medulla oblongata and passes through the jugular foramen together with the glossopharyngeal and spinal accessory nerves. It passes between the internal carotid artery and internal jugular vein.

A series of nerve branches from the vagus nerve as it passes from the base of the skull through the neck: auricular, pharyngeal, superior laryngeal, and recurrent laryngeal.

#### 3.4.2 Superior Laryngeal Nerve

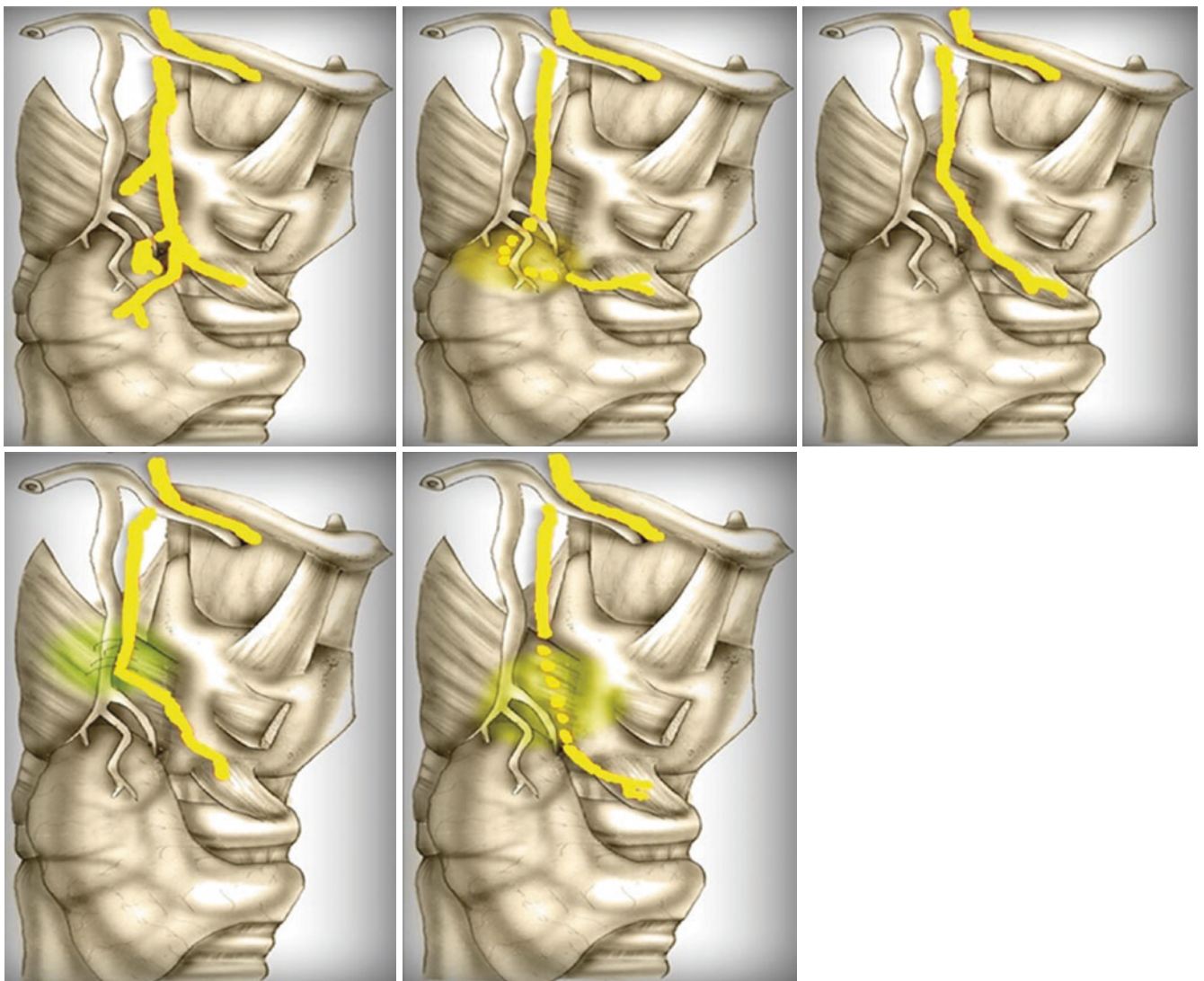
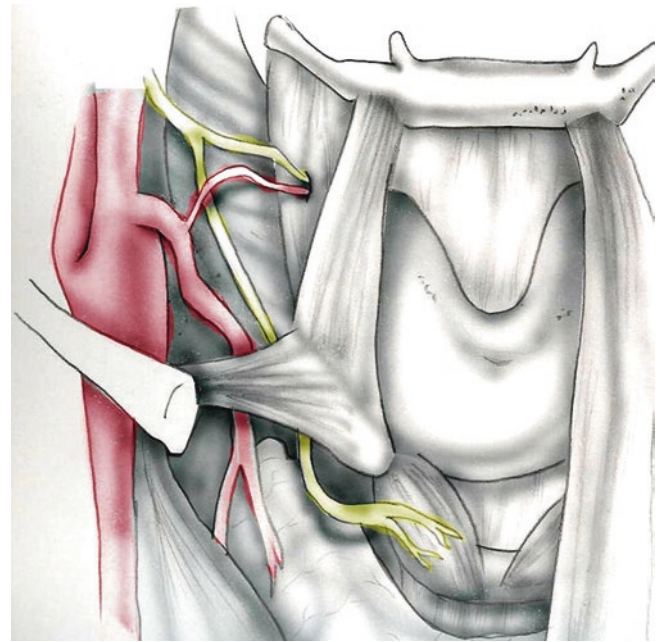
It travels inferiorly, posterior to the internal carotid and on the side of the pharynx, and divides into the:

- *Internal laryngeal nerve*
  - It passes inferiorly to the larynx through the thyrohyoid membrane along with the superior laryngeal vessels to distribute the fibers to the base of the tongue in the epiglottic region and to the mucous membranes of the larynx inferiorly as far as the false vocal folds and SVA fibers to the taste buds in the area (Figs. 3.8 and 3.9).
- *External laryngeal nerve*
  - It travels inferiorly along the inferior constrictor to supply the cricothyroid muscle and the inferior portion of the inferior constrictor (Figs. 3.10 and 3.11).



**Figs. 3.8 and 3.9** Superior laryngeal nerve: internal branch and its relationship with the laryngeal artery (Courtesy of Prof. Daniele Marchioni, ENT Department, Verona, Italy)

**Fig. 3.10** External branch of superior laryngeal nerve (Courtesy of Prof. Daniele Marchioni, ENT Department, Verona, Italy)



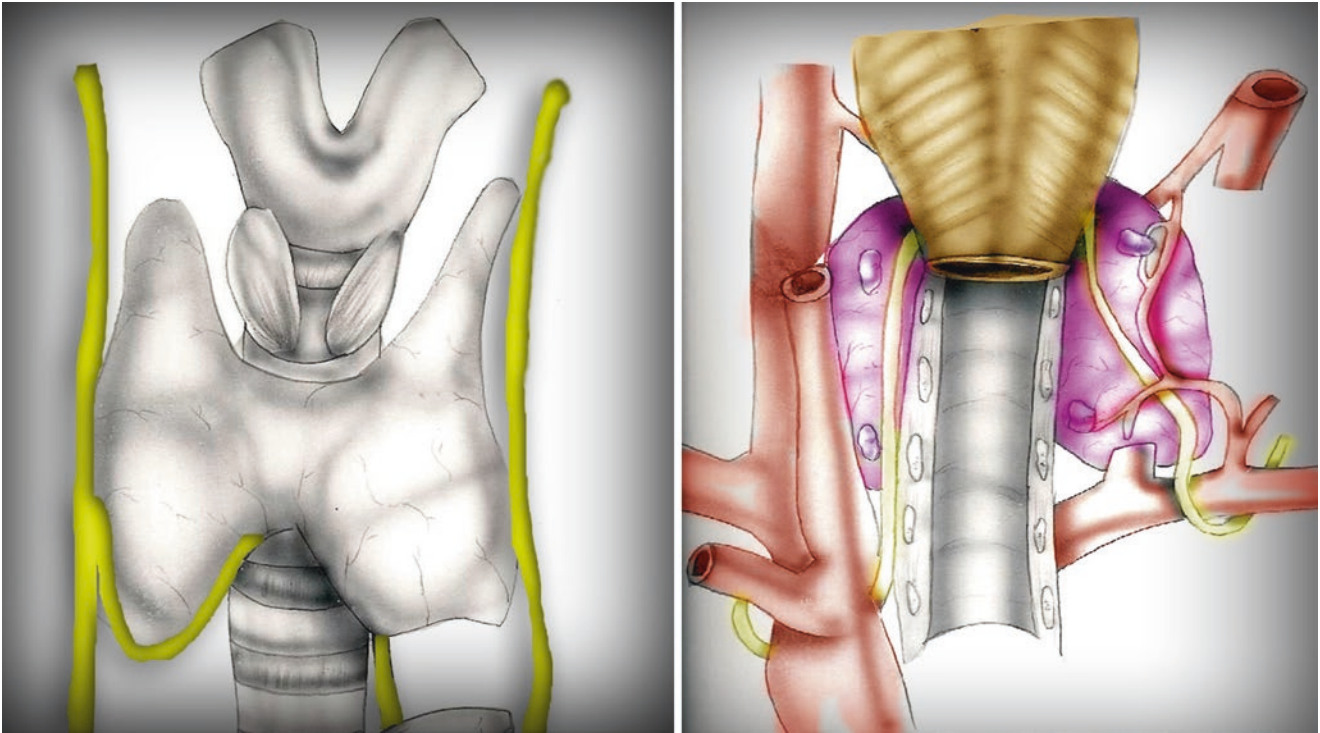
**Fig. 3.11** Anatomical variants of external branch of the superior laryngeal nerve (Courtesy of Prof. Daniele Marchioni, ENT Department, Verona, Italy)

### 3.4.3 Inferior Laryngeal Nerve or Recurrent Laryngeal Nerve

On the left side the recurrent laryngeal nerve arises from the vagus at the level of the aortic arch, and, after having surrounded it, it assumes a vertical course toward the neck.

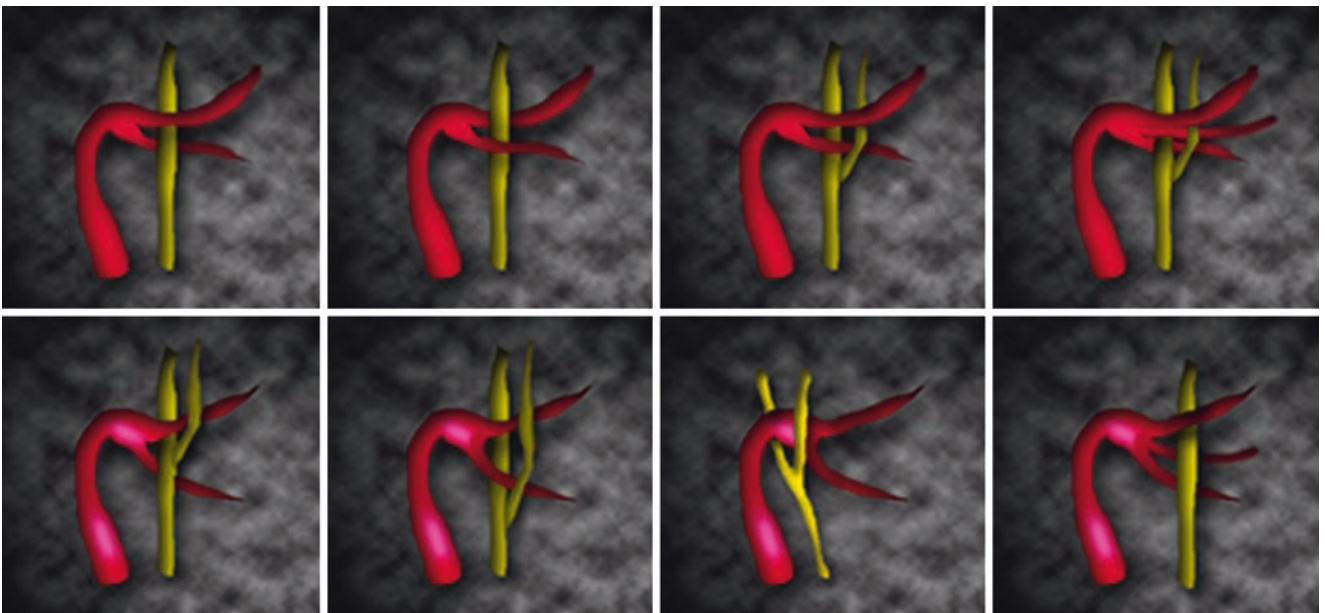
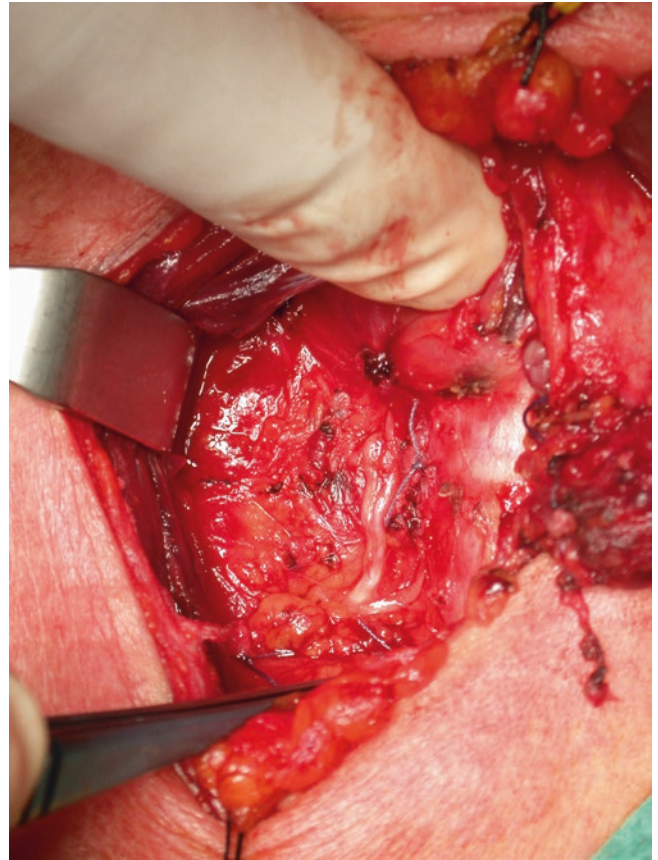
On the right side, the nerve is detached from the vagus nerve at the point where this crosses the subclavian artery,

and then it surrounds the artery and ascends with an oblique course near the esophageal margin. It ascends on the lateral side of the trachea until reaching the pharynx, where it passes deep to the inferior constrictor muscle, innervating the mucous membranes below the false vocal folds and all of the intrinsic muscles of the larynx except from the cricothyroid (Figs. 3.12, 3.13 and 3.14).



**Fig. 3.12** Course of the laryngeal recurrent nerves (Courtesy of Prof. Daniele Marchioni, ENT Department, Verona, Italy)

**Fig. 3.13** Intraoperative photos of the RLN in the right side of the neck



**Fig. 3.14** Inferior laryngeal nerve: relationship with the inferior thyroid artery (Courtesy of Prof. Daniele Marchioni, ENT Department, Verona, Italy)

### 3.4.4 Nonrecurrent Inferior Laryngeal Nerve

This anatomical variation is associated with an anomaly in the embryological development. The fourth right aortic arch and the proximal dorsal aorta are occasionally obliterated, and the subclavian artery can originate from the right side of the aortic arch, being called “lusory” artery.

This anatomical variant occurs between 0.4 and 2.4 % of people on the right side, while it is extremely rare on the left side.

Many articles describe the course patterns of non-RLN:

Abboud and Aouad [1] reported three types of courses for non-RLNs (Fig. 3.15).

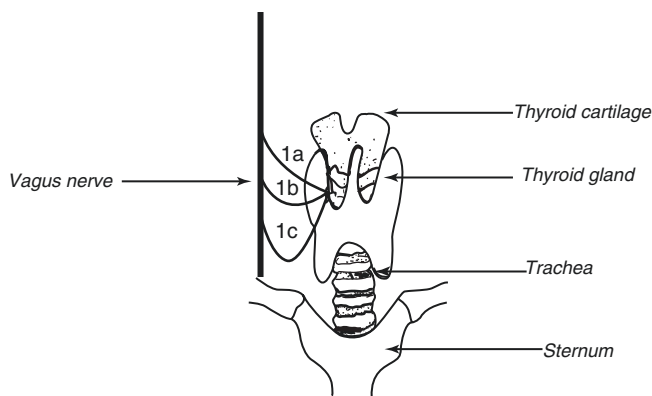
The course patterns of non-RLN are:

- *Type Ia* – the nerve has a straight course on the level with the upper thyroid pole.
- *Type Ib* – the most common, the nerve runs transversely at the level of the thyroid isthmus.

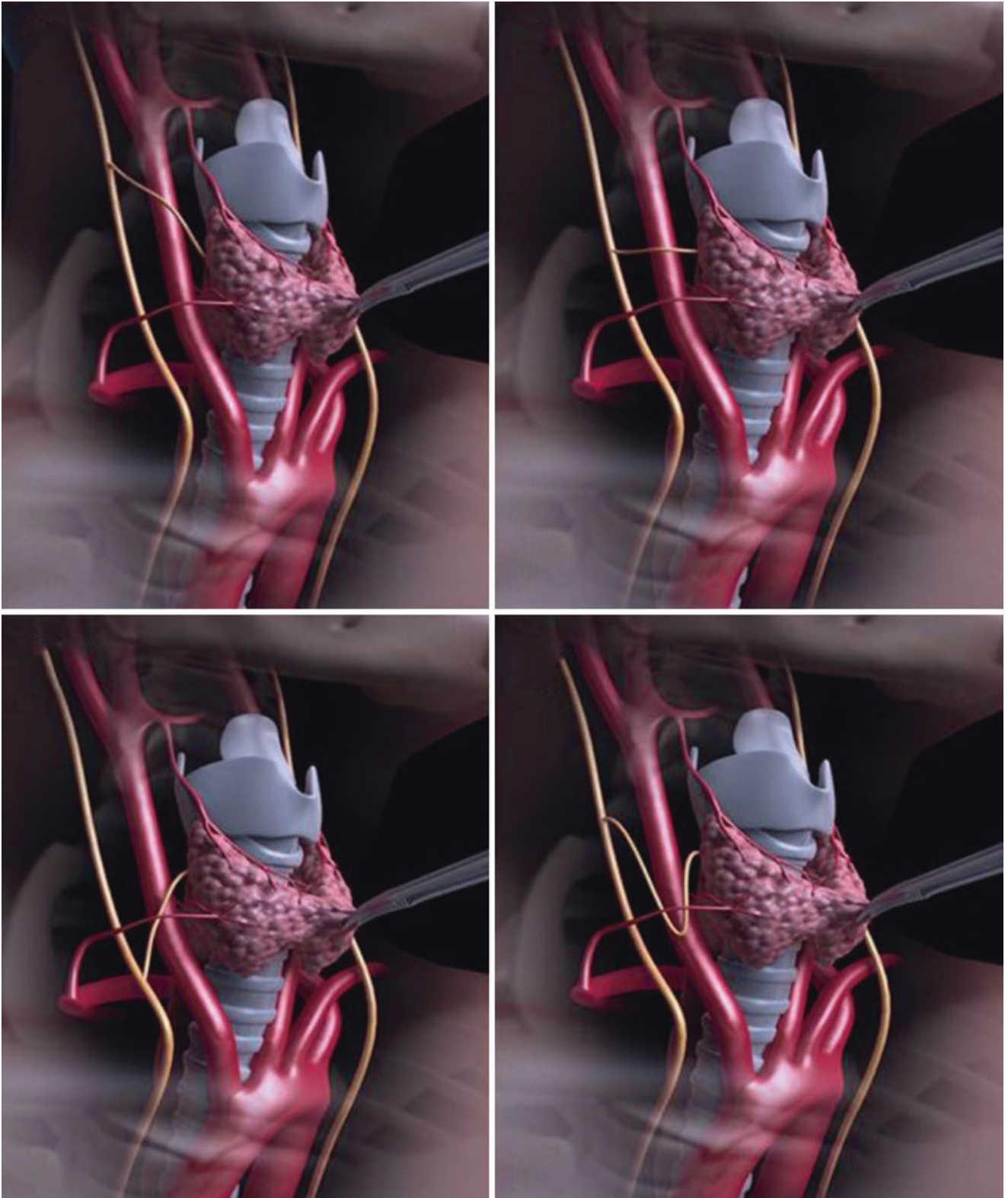
- *Type II* – the nerve curves downward, eventually reaching the lower pole of the thyroid gland.

In a case report by Yang et al. [2] the non-RLN courses are described in more detail, distinguishing four types (Fig. 3.16):

- In the descending type, the non-RLN descends after originating from the vagus nerve trunk.
- In the vertical type, the non-RLN runs vertically to the cricothyroid joint.
- In the ascending type, the non-RLN runs upward to the cricothyroid joint.
- In the V-shaped type, the non-RLN takes a downward direction and runs upward to the cricothyroid joint.



**Fig. 3.15** Course patterns of non-RLN (from Abboud and Aouad [1])



**Fig. 3.16** Course patterns of non-RLN (from Yang et al. [2])

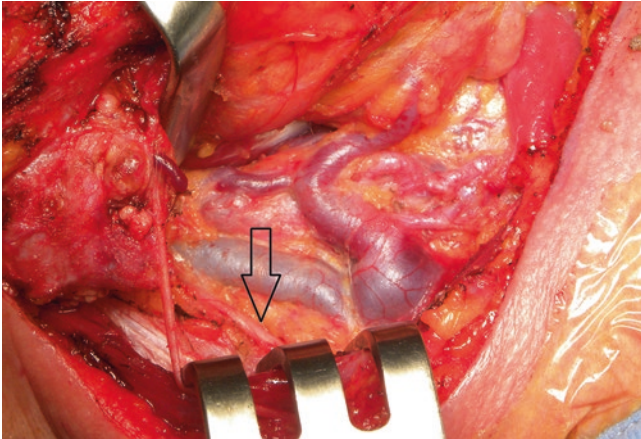


### 3.4.5 Spinal Accessory Nerve (Fig. 3.17)

It originates from the union of the vagal accessory nerve (parasympathetic fibers/visceral effector) and spinal accessory nerve (somatic motor); it exits from the posterior foramen lacerum and divides in two branches:

- *Internal or medial branch* participates in the larynx innervation.

- *The spinal portion (external or lateral branch)*: passes anteriorly to the internal jugular vein, enters the sternocleidomastoid muscle (which it innervates), and exits in proximity to the posterior margin of the muscle. Running from the bottom to the top and from front to rear, the peripheral portion of the nerve enters the trapezius, which it innervates. The common trunk of the nerve usually runs above the internal jugular vein.

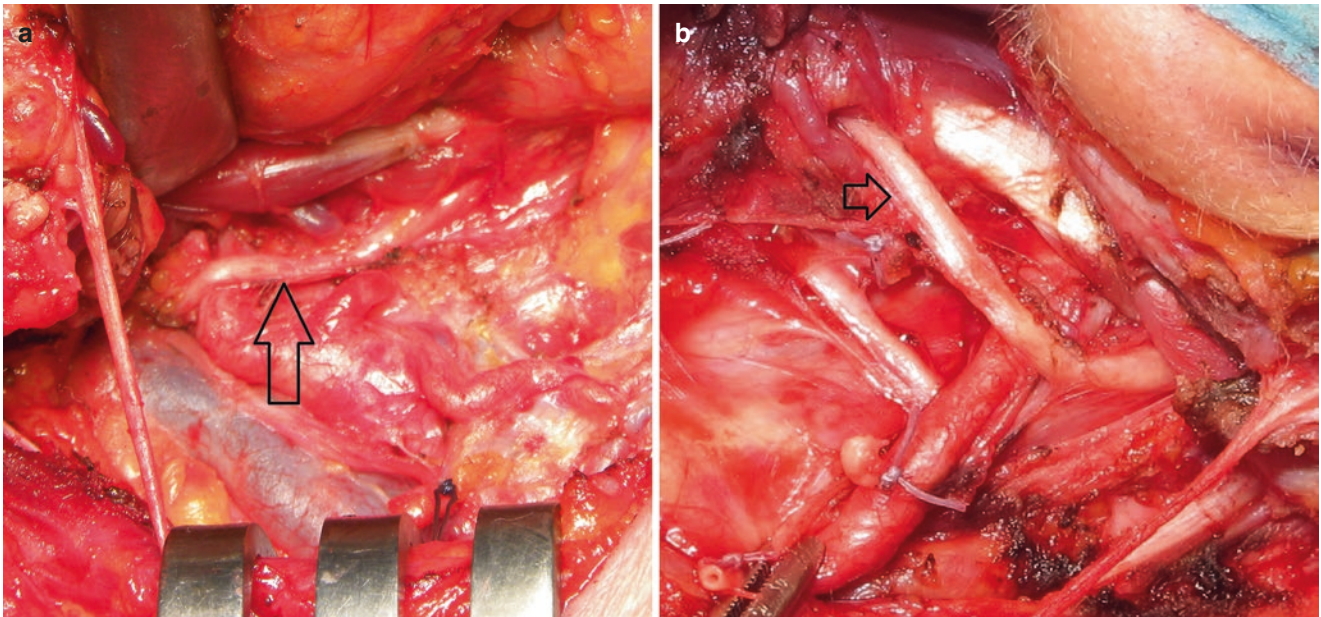


**Fig. 3.17** Spinal accessory nerve on the right side (*arrow*)

### 3.4.6 Hypoglossum (Fig. 3.18)

The hypoglossal nerve (HN), also known as cranial nerve XII, is the motor supply of the tongue. The HN can be divided into three main parts: cisternal, intracanalicular, and extracranial. When the HN emerges between the ICA and the internal jugular vein (IJV) on its course toward the tongue, inferior to the tendon of the posterior belly of the digastric muscle, it becomes more superficial. As the HN emerges from the hypoglossal canal, it is supplied by a vessel arising from the posterior neuromeningeal division of the ascending pharyngeal artery, the first branch of the posterior group of the ECA. When the HN exits through the external orifice of the hypoglossal canal, it descends medially to the IJV and posteromedially to the ICA. The descending part starts with the external exit of the hypoglossal canal, at which level the HN crosses medially to the IJV and posteromedially to the ICA. Then, the HN passes through laterally and descends beyond the posterior

aspect of the vagal nerve and crosses the external carotid and lingual arteries below the tendon of the digastricus. It passes beneath the tendon of the digastricus, the stylohyoideus, and the mylohyoideus, lying between the last-named muscle and the hyoglossus, and communicates with the lingual nerve in the anterior border of the hyoglossus; it then continues forward in the fibers of the genioglossus as far as the tip of the tongue, distributing branches to its muscular substance. The descending ramus (*ramus descendens; descendens hypoglossi*), long and slender, quits the hypoglossal where it turns around the occipital artery and descends in front of or in the sheath of the carotid vessels; it gives a branch to the superior belly of the omohyoideus and then joins the communicantes cervicales from the second and third cervical nerves, just below the middle of the neck, to form a loop, the so-called *ansa hypoglossi*. From the convexity of this loop, some branches pass to supply the sternohyoideus, the sternothyroideus, and the inferior belly of the omohyoideus.



**Fig. 3.18** HN on the *right side* (a) and on the *left side* (b)

### 3.4.7 Glossopharyngeal Nerve

The glossopharyngeal nerve exits the skull from the jugular foramen in close proximity to the vagus nerve and courses between the internal carotid artery and the internal jugular vein before passing between the stylopharyngeus and styloglossus muscles to enter the base of the tongue.

### 3.4.8 Cervical Plexus

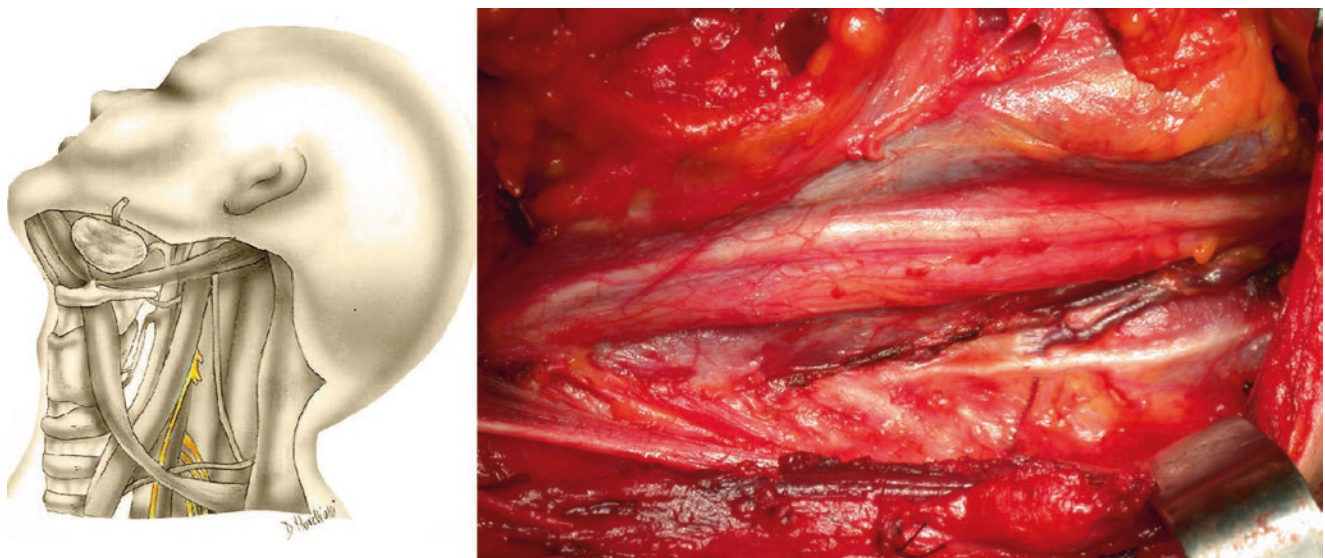
It is formed by the anterior branches of the first four cervical spinal roots. It is located in front of the middle scalene muscle and the elevator scapulae muscles. All the branches are divided in an ascending and a descending branch that are connected to each other in loops.

- The superficial plexus branches are for the skin, while the deep ones are for the muscles:
  - Superior ascending: C2 small occipital
  - C2–3 great auricular
  - C2–3 cutaneous transverse of the neck
  - Superior descending: C3–4 supra clavicular nerves
- Medial deep:
  - Anastomotic branches with con hypoglossal, vagus, and sympathetic trunk
  - Muscular branches (rectus lateral of the head, rectus anterior of the head, long of the head, long of the neck, inferior root of the cervical loop, phrenic nerve)
- Lateral deep:
  - Anastomotic branches (accessory nerve)
  - Muscular branches (SCM muscle, trapezius, elevator scapulae, middle scalene)

### 3.4.9 The Cervical Phrenic Nerve

It is the motor nerve of the diaphragm, and it also carries significant afferent fibers from the diaphragm, pericardium, pleura, and peritoneum. It originates in front of the lateral margin of the anterior scalene muscle most from C4, but also from C3 and C5. In its cervical course, it goes vertically downward in the thoracic region, covered by the prevertebral fascia, the SCM muscle, the inferior belly of the omohyoid muscle, the jugular vein, the transverse cervical artery, the suprascapular artery, and on the left, the thoracic duct. It is located anteriorly to the subclavian artery and posteriorly to the subclavian vein and enters the thorax crossing medially in front of the internal thoracic artery. The phrenic nerve ordinarily enters the thoracic cavity posteriorly to the subclavian vein, less commonly anteriorly to it, and rarely may penetrate it.

The right phrenic nerve is shorter and is separated from the subclavian artery by the anterior scalene muscle; the left phrenic nerve leaves the medial margin of the anterior scalene muscle passing over the subclavian artery and behind the thoracic duct. Prakash [4] describes a variation of the phrenic nerve that could be very close to the subclavian vein. In this dissection study, the authors describe an early communicating branch of phrenic nerve to the C5 root of the brachial plexus and just before entering the thorax, it is located in front of the subclavian vein instead of posterior or between vein and artery. Bigeleisen et al. [5] describe an accessory phrenic nerve in up to 75% cadavers examined, it follows the phrenic nerve and joins it distally (Fig. 3.19).



**Fig. 3.19** Detail of the Cervical Phrenic Nerve (Courtesy of Prof. Daniele Marchioni, ENT Department, Verona, Italy)

### 3.4.10 Cervical Sympathetic Trunk

The sympathetic trunk is sometimes damaged during the anterior and anterolateral approach to the cervical spine, resulting in Horner's syndrome (ptosis, ipsilateral miosis, anhidrosis, and enophthalmos). The cervical sympathetic chain is located posteromedial to carotid sheath and runs over the longus muscles. It extends longitudinally from the longus capitis to the longus colli over the muscles and under the prevertebral fascia. From up to down, the lateral cervical muscles diverge laterally, whereas the cervical sympathetic trunk converges medially at C6. The superior ganglion is usually located on the level with C4. The location of the intermediate (middle) ganglion of the cervical sympathetic trunk has shown some variations.

## 3.5 Fascias of the Neck

Fascias of the neck have been variously described in the literature. Description terms are different.

Guidera et al. [3] made a clear review of the terminology of fascias description.

### 3.5.1 Superficial Cervical Fascia

The SCF of the neck contains the platysma and the superficial lymph nodes and is loosely arranged to facilitate neck movement. Cranial to the mandible, the SCF continues as the fascia that "invests" the muscles of facial expression and the occipitofrontalis in the scalp; it is referred to by different names as it progresses cranially. Interest in this layer was renewed with the arising popularity of facelift surgery and the definition of the superficial musculoaponeurotic system (SMAS). Starting from the vertex, the galea aponeurotica, occipitofrontalis, and orbicularis oculi muscles are in continuity with the temporoparietal fascia and, inferior to this, the SMAS over the zygomatic arch (although not all authorities agree on the latter). This layer, which incorporates the muscles of facial expression, is then continuous with the SCF and platysma in the neck.

### 3.5.2 Deep Cervical Fascia

It is divided into:

- *Superficial layer of deep cervical fascia (SLDCF)*
- *Middle layer of deep cervical fascia (MLDCF)*
- *Deep layer of deep cervical fascia (DLDCF)*

### 3.5.3 Superficial Layer of Deep Cervical Fascia

The superficial layer of deep cervical fascia (SLDCF) is usually described as "completely encircling the neck," although it has been suggested that it is incomplete between the sternocleidomastoid and trapezius muscles. A simplified "rule of twos" describes the SLDCF as enclosing two glands (submandibular and parotid), two muscles (sternocleidomastoid and trapezius), and two "spaces" (suprasternal space and the "subvaginal" space of the posterior triangle).

### 3.5.4 Middle Layer of Deep Cervical Fascia

This is described as having muscular and visceral divisions or simply a visceral part.

#### 3.5.4.1 Muscular Layer

This term is usually used in conjunction with "visceral fascia" to describe that portion of the MLDCF that sheathes the strap muscles. Some authors subdivide it into sternohyoid/omohyoid and sternothyroid/thyrohyoid components, whereas others refer to it generally as the "strap fascia," or even part of the SLDCF. This layer runs between the bony attachments of these muscles.

#### 3.5.4.2 Visceral Layer

This term has been used to describe all components of the MLDCF or only that part surrounding the larynx, pharynx, trachea, esophagus, and thyroid. The latter is generally agreed to blend inferiorly with the fibrous pericardium. However, there is disagreement about whether it extends superiorly only to the level of the hyoid bone or if a posterior continuation reaches the skull base.

#### 3.5.4.3 Buccopharyngeal Fascia

The prefix "bucco" refers to the superior extension of this layer that is stated to continue over the buccinator muscle.

### 3.5.5 Deep Layer of Deep Cervical Fascia

This is consistently described as encompassing the vertebral column and paravertebral muscles, attaching to the transverse and spinous processes of the cervical vertebrae. As it passes laterally over the scalene muscles, it forms the floor of the posterior triangle. The term "prevertebral" is

used to describe either the complete circumferential layer of fascia or just that part covering the prevertebral muscles anteriorly between the transverse processes. Laterally, it is described as being continuous with the axillary sheath and the suprapleural membrane (Sibson's fascia). Caudally, it is stated to extend to the coccyx or "fades away" in the thorax. The alar fascia is generally stated to be a division of the deep layer of deep cervical fascia (DLDCF) spanning between the transverse processes of the cervical vertebrae anterior to the prevertebral fascia and fusing laterally with the carotid sheath.

## References

1. Abboud B, Aouad R (2004) Non-recurrent inferior laryngeal nerve in thyroid surgery: report of three cases and review of the literature. *J Laryngol Otol* 118(2):139–142
2. Hong KH, Park HT, Yang YS (2014) Characteristic travelling patterns of non-recurrent laryngeal nerves. *J Laryngol Otol* 128(6):534–539
3. Guidera AK et al (2014) Head and neck fascia and compartments: no space for spaces. *Head Neck* 36(7):1058–1068
4. Prakash, Prabhu LU et al (2007) A variation of the phrenic nerve: Case report and Review. *Singapore Med. J.* 48(12):1156–1157
5. Bigeleisen PE (2003) Anatomical variations of the phrenic nerve and its clinical implication for supraclavicular block. *Br J Anaesth* 91(6):916–917

---

**Part II**  
**Planning**

# Interventional Radiology: Presurgical Selective Angiographic Embolization (SAE) in Hypervascular Cervical Spine Tumours

Luigi Simonetti, Carlotta Barbara, Salvatore Isceri, and Elena Mengozzi

## 4.1 Introduction: Anatomy

### 4.1.1 Cervical Vascularization

The anatomical features of the vascular region of interest cannot be disregarded when performing interventional therapeutic procedures. Deep and detailed understanding of anatomy is an unavoidable necessity (Table 4.1).

The spinal cord and dura mater have a united and functionally indissociable vascularization. Characteristic of the intramedullary vessels of the spinal cord is to maintain their embryonal metameric disposition, which occasionally disappears in the arterial and venous extramedullary vessels.

The vascular structures feeding the rachis and spinal cord was first described by Adamkiewicz, Corbin, Crock and Lazorthes. There are however significant differences between vascularization at cervical level and vascularization in other portions of the rachis, where the metameric disposition is more evident. In the cervical region, the ascending branches of the right and left subclavian arteries feed the vertebro-medullary region, from where the inferior thyroid and ascending cervical, vertebral and deep cervical arteries take their origin.

Below are listed the three cervical axes:

- Anterior or prevertebral, arising from the inferior thyroid and ascending cervical arteries (vertebral body and vertebral arch)
- Median or latero-vertebral, arising from the vertebral artery (anterior and posterior spinal arteries)
- Posterior, arising from the deep cervical artery (anterior and posterior spinal arteries)

The three axes anastomose with each other through horizontal intra-rachideal or paravertebral branches that provide

blood supply to the vertebrae. At cervical level, the spinal axis receives most of the arterial vessels.

At high cervical level, up to C3, there are no anterior radiculomedullary arteries, and two anastomosing spinal arteries, arising from the vertebral ones, feed the anterior spinal axis.

At medium-low cervical level, the anterior axis is supplied blood by 2–4 anterior radiculomedullary arteries, randomly originating either on the right or on the left side from the vertebral or deep cervical arteries.

Two main radiculomedullary arteries are often present, one originating from the vertebral artery at the level of the foramen of conjugation (C5-C6 or C4-C5) and the other arising from the deep cervical artery and entering the spinal canal through the C7-T1 foramen. The anterior radiculomedullary arteries enter the spinal canal following the nervous root course.

Blood supply is provided to the posterior spinal axes by 4–6 slender posterior radiculomedullary arteries, arising from the vertebral artery, which runs between C3-C6. These small arteries penetrate into the spinal canal through the conjugation foramen, following the radicular course.

### 4.1.2 Anatomy of the Anterior Spinal Artery (ASA) at Cervical Level

The anterior spinal artery (ASA) course completely follows the median line of the spinal cord (Fig. 4.1).

It arises from two branches of the vertebral arteries in the superior cervical region, a little behind the origin of the basilar trunk. Both branches descend anteriorly to the bulb and unite forming the descending, median and anterior spinal trunks or the anterior spinal artery (ASA). The latter runs along the median anterior fissure, usually ending at the level of the fifth pair of the cervical nerves. At this level, 6–10 anterior radicular arteries, each of them feeding one descending and one ascending branch, form the anterior spinal trunk.

L. Simonetti (✉) • C. Barbara • S. Isceri • E. Mengozzi  
Emergency Interventional Unit, Ospedale Maggiore – Bologna,  
Bologna, Italy  
e-mail: lg.simonetti@gmail.com

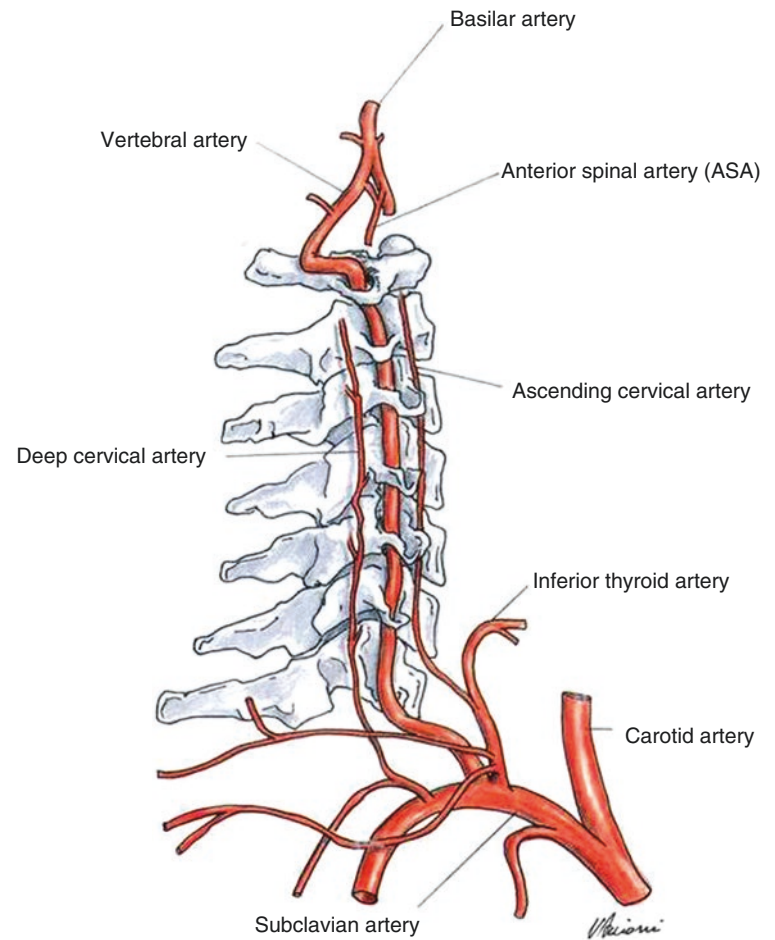
### 4.1.3 Anatomy of the Cervical Posterior Spinal Arteries

There are two cervical posterior spinal arteries, one located on the left-hand and the other on the right-hand side. They originate from the vertebral arteries and run posteriorly to the bulb and spinal cord, reaching the lateral aspect of the median posterior sulcus. Along their descending course, a variable number of posterior radicular arteries (10–23) reinforce them. Each spinal segment of the cervicodorsal region of the spinal cord averagely receives one or two tributaries.

### 4.1.4 Radicular Arteries or Lateral Spinal Arteries at Cervical Level

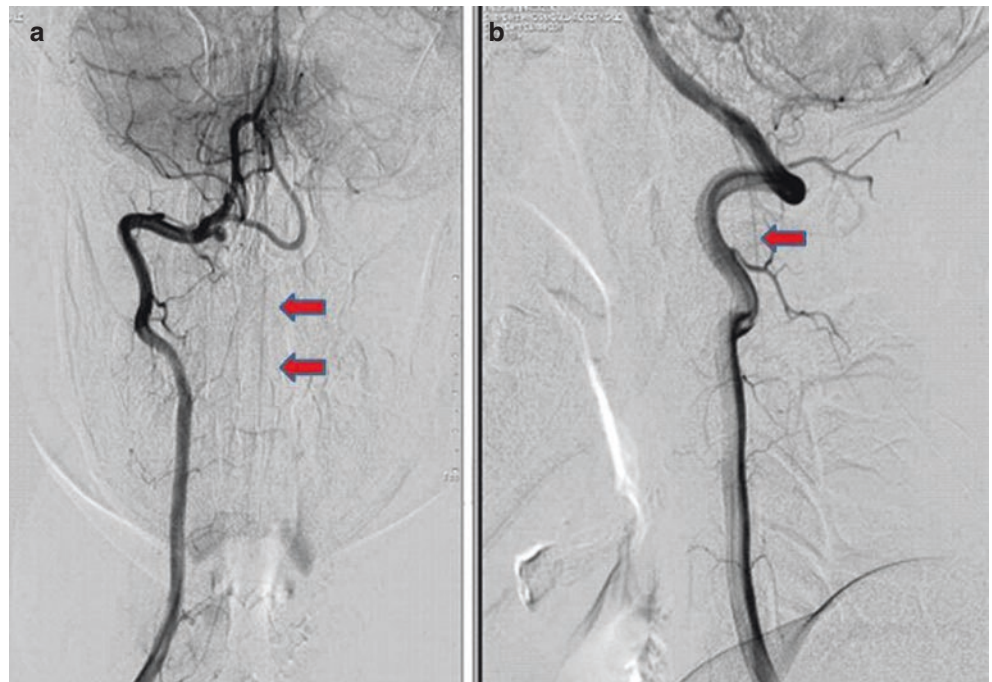
Even though of variable origin, most of the radicular arteries arise from the arteries running along the spinal roots to reach the vertebral canal. With segmental course, in the neck, they originate from the vertebral and cervical ascending arteries.

**Table 4.1** Cervical vascularization





**Fig. 4.1** Anterior spinal artery (ASA) (A) AP and (B) LL views of right vertebral artery angiography. ASA follows the median line of the spinal cord (arrows), arising from branches of the vertebral artery



## 4.2 Diagnostic Angiography of Spinal Cord: Technique

Diagnostic angiography prior to SAE is necessary for the following purposes:

- (a) To accurately evaluate the pathological circle
- (b) To identify possible presence of arteries ending in the spinal cord, which are not eligible for SAE (AKA, ASA, ASPL)
- (c) For a safe embolization, to obtain stable selective catheterization, prior to selective micro-catheterization

We routinely employ 4 F introducers, with the exception of presurgical embolization of the vertebral arteries, where 6 F catheters are necessary. All diagnostic angiographic procedures of the vertebro-medullary tracts are performed using 4 F catheters (Glidecath Terumo®, Tokyo, Japan o Tempo Aqua Codman®, J&J, MA, USA).

Catheters with “curve” distal extremities are preferably used, because they guarantee a more stable catheterization, independently of vascular site and anatomical features of the region of interest. We use a curve catheter type “vertebral” for the study of the cervical district (vertebral, thyrocervical and costocervical arteries).

In case of cervical lesions, the vertebral arteries are examined at angiography on the two orthogonal planes. To study the vertebral arteries is necessary to identify possible feeders of the lesion, as well as presence of medullary links or anastomoses with regional arteries (ascending and deep cervical arteries). The study of thyrocervical and costocervical trunks usually necessitates use of the antero-posterior projections alone. The latero-lateral projections are fundamental for lesions of the inferior cervical tract (C5-C7), to distinguish the pathologic circle of origin of the thyrocervical trunk from the normal circle of the thyroid. In case of presurgical embolization of a vertebral artery, a bilateral examination of the internal carotid arteries is necessary, to identify possible presence of carotid-vertebral compensatory vessels at the level of the vertebral artery to be treated.

To summarize, diagnostic angiography must include the study of the following districts:

- Vertebral arteries
- Thyrocervical trunks
- Costocervical trunks
- Internal carotid artery (only in case of presurgical vertebral artery embolization)
- External carotid, bilaterally (lesions affecting C1-C2)

### 4.2.1 Technical Considerations on Super-Selective Catheterization

Catheterization is optimal if performed as super-selectively as possible within the arteries feeding the lesion of interest. Super-selective catheterization is carried out with 4 F catheters and coaxial catheterization technique (micro-guide, micro-catheter, carrier catheter). In our experience, we routinely use micro-catheters (Renegade® 18 HI-FLO™) and micro-guides (Transcend EX .014; Stryker, USA). Both devices guarantee accurate navigation through vessels, albeit mobile and tortuous. Remodelling of micro-guide tip is often necessary to adapt it to the variable course of the arteries supplying blood to the lesion. The micro-catheters employed in our experience had a straight tip, and no remodelling was necessary. Road mapping provided by the carrier catheter is fundamental. Diagnostic angiography with 4 F catheters is necessary prior to injection of embolic agent and is performed through the micro-catheter. The injection is carried out at high pressure and with small syringes (3 ml). The preliminary angiography provides important morphological and haemodynamic information, since it allows:

- Visualization of the pathological circle
- Exclusion with reasonable certainty of presence of vessels ending in the spinal cord

Another advantage offered by injecting at high pressure through the micro-catheter is the visualization of possible metameric anastomoses, which in turn may help diffuse embolic agent to medullary feeders originating from the adjacent metameric levels.

### 4.2.2 Embolic Agents and Techniques

Embolic agents now available for SAE of tumours of the spine are listed below:

- Particles
- Acrylic glue (Glubran 2)
- Coils

#### 4.2.2.1 Micro-particles

Particles or micro-particles are the most widely used material for embolization. They are of two different types:

- Stable
- Absorbable

Stable particles are non-absorbable tris-acryl gelatin microspheres, with calibre ranging from 50 to 1000  $\mu$ . In our experience, we employed Embosphere® Biosphere Medical, Roissy France, and Embozene® CeloNova BioSciences, San Antonio, Texas, USA.

Due to their flexibility, stable particles can be used for vessels with calibre inferior to their diameter. Stable particles do not significantly aggregate within the proximal tract of the main vessel. The particles mainly used in our experience ranged in diameter from 250 to 700  $\mu$ .

Stable particles are chosen for the following reasons:

- Particles with calibre inferior to 250  $\mu$  (from 50 to 200  $\mu$ , i.e. inferior or comparable to the diameter of vessels ending in the spinal cord) are not easily controlled during injection and can cause incidental embolization of very small vessels, not seen at angiographic examination.
- Particles with calibre exceeding 700  $\mu$  usually aggregate precociously and cause embolization at a quite proximal level, upstream of the target circle. We used these particles in a few selected cases where also the most proximal portion of the metameric arteries had to be closed.

Absorbable particles are polyvinyl alcohol (PVA) microspheres with irregular surface, ranging in size from 45 to 1180  $\mu$ .

The estimated absorption time is about 72h. Recanalization of the occluded artery is brought about by proteolytic enzymes acting, after embolization, at variables times, depending on the size of the injected particles. The absorbable particles are preferably employed for visceral or skeletal posttraumatic embolization, where vessel recanalization is needed after haemostasis.

In our SAE experience, we employed stable and absorbable particles in the treatment of particularly highly vascularized lesions or when more proximal embolization of the pathologic artery was needed. In these cases, calibres ranging from 500 to 900  $\mu$  were preferably used.

PVA absorbable particles are similar to the stable ones as to their intralésional penetration capability. Without any doubt, their cost-effectiveness represents an advantage. There are, however, some limits, which are listed below:

- Precocious aggregation within the catheter, which makes their injection through the micro-catheter difficult. Injection is possible after dilution with contrast medium and has to be rapid and immediately followed by washout with physiological solution.
- Penetration capability of PVA particles is so high, as to increase the risk that a highly vascularized lesion become avascular, i.e. more fragile during surgery.

### Injection of Micro-particles: Technique

After advancing the micro-catheter to the right position, an injection of micro-particles is performed. The micro-particles are preliminarily diluted with the proper quantity of iodate contrast medium (see producer instructions). Very low pressure is exerted during injection, in order to avoid possible reflux. It is suggested to follow the systolic frequency. Each injection of particles is followed by an injection of physiological solution to wash the catheter from the remaining particles. A subsequent injection of contrast medium is performed for control. This sequence of injections (particles, physiological solution and contrast medium) is repeated until complete embolization of the pathologic circle is obtained.

Super-selective micro-catheterization is not always possible. In most cases, this is due to the presence of a marked ostial stenosis of the metameric artery or severe tortuosity of its proximal tract. Both conditions do not allow advancement of either the micro-guide or the micro-catheter. In these cases, in the presence of a sufficient pathologic circle feeding the metameric one, the particles are injected through the carrier catheter. With the injection of embolic particles through the carrier catheter, reflux of micro-particles into the aorta may occur. For this reason, embolization through the carrier catheter is preferably performed only in the following cases:

- The position of the carrier catheter tip is sufficiently stable.
- No doubt subsists as to the presence of arteries ending to the spinal cord and originating from the metameric artery.

Under these conditions, the injection must be performed with the flow control technique.

### Flow Control Technique

The ostium of the feeding artery to the pathologic circle is occluded pushing forward the carrier catheter tip. This allows for temporary obstruction of the anterograde flow in the artery and possible flow inversion within the distal arterial branches through the anastomoses with the adjacent metameric arteries. As a result, the embolic particles are pushed towards the lesion. At this point, through the continuous flow of physiological solution in the carrier catheter, the stable particles are injected via micro-catheter. It is sufficient that the micro-catheter tip occupies the metameric ostium. Owing to the concomitant absence of anterograde and inverted flow in the distal portion of the afferent artery, the particles will preferably spread in the main circle, i.e. the pathologic circle.

Haemodynamically speaking, the main flow of an artery feeding the pathologic circle is attracted by the lesion that “steals” most of the flow of that artery. Consequently, the

injection of micro-particles via carrier catheter can result as reasonably safe, provided that the injection be performed with low pressure and the solution properly diluted. For the same mechanism, the injection via carrier catheter is to be considered as reasonably safe also in those cases not eligible for selective micro-catheterization.

To visualize possible presence of reflux, high image quality (obtained with mA increase) and maximum magnification are mandatory.

#### 4.2.2.2 Acrylic Glue (Glubran 2®)

Glubran2® (GEM, Viareggio, Italy) is an acrylic glue introduced in Europe in 2002 as substitute of Histoacryl®. It has been initially employed in the neuroradiological settings for interventional treatments of dural arteriovenous fistulas (DAVF) and arteriovenous malformations (MAV). Previous studies report that Glubran2® penetrates into the pathological vessels causing occlusion and severe inflammatory responses of the vessel wall, with subsequent necrosis and endothelial damage, to a lesser degree with respect to Histoacryl®. The intravascular homogeneously adherent property of Glubran2® provides a good rendering of the angioarchitecture of the lesion as obtained at angiography with super-selective catheterization. Experimental studies have demonstrated that Glubran2® polymerization requires minor thermic degrees (exothermic reaction of about 45°) with respect to Histoacryl® and that its polymerization times are longer, owing to modification of Glubran2® through addition of methacryloxy-sulpholane monomer. In our experience, Glubran2® was employed in selected cases of lesions with “comb” distribution, such as vertebral bone angiomas or primitive or secondary neoplastic lesions, with similar vascular features. Care must be taken to prevent the catheter tip from being glued to the injection site. Therefore, the use of this embolic agent implies micro-catheter change after each injection. This is the reason why it is preferably employed in those cases where a low number of injections are needed.

#### Glubran2® Injection Technique

Prior to each Glubran2® injection, the micro-catheter must be accurately washed with glucose solution to remove blood and saline solution residuals. This is important, to avoid immediate glue polymerization within the catheter. Next, the glue is added with Lipiodol (Guerbet, Roissy, France), an oily, viscous mixture, composed of iodine combined with ethyl esters of fatty acids, through which the injectable solution becomes radiopaque. Different concentrations of Glubran2® and Lipiodol are used (1:1, 1:2; 1:3), depending on the desired fluidity, which, in turn, depends on the characteristics of the target region. Penetration into the lesion, in fact, depends on flow and dilution of Glubran2®. In our experience, the ratio was Glubran2/

Lipiodol 1:2 and sometimes also 1:3. These ratios proved useful to facilitate intravascular penetration and to reach more distal vessels. The glue is uninterruptedly injected, while its penetration and deposition are monitored via subtraction fluoroscopy. When glue reflux appears into the feeding vessel, the injection is suspended and the employed catheter immediately withdrawn. Obstructing the metameric artery flow with the guide catheter may prevent too rapid glue polymerization and allow monitoring of glue injection into most of the distal vessels. In the majority of cases treated with super-selective micro-catheterization, glue injection follows the main flow course within the lesion. A good penetration of the glue into the vascularization of the lesion, even in the presence of collateral vessels with “comb” morphology, provides a good rendering of the angioarchitecture of the lesion as that obtained at angiography with super-selective catheterization and avoids too distal embolization, frequent when using small particles. Differently from particles, Glubran2® injection via catheter must be performed from a more stable and distal position, which is difficult to achieve in the presence of particularly tortuous vessels. Glubran2® injection may provoke severe pain in the patient. For this reason, neuroleptoanalgesia is induced to the patient a few minutes prior to injection of the embolic agent.

#### 4.2.2.3 Coils

Coils are metallic endovascular embolic agents of variable size. Their choice depends on calibre and size of the artery to be occluded.

In our experience of SAE, coils are employed for vertebral artery occlusion in the presence of cervical tumours scheduled for surgical removal with en bloc technique. The aim is the complete occlusion of the artery along the whole tract from V2 to V3 (from the cervical intra-transversary segment to the cervico-occipital curve). When applicable (non-dominant vertebral artery, absence of macroscopic ASA feeders), coils with high filling coefficient, such as the detachable Penumbra Coil 400™ (Penumbra Inc., USA), are employed. In other cases, Target® Detachable Coils (Stryker Inc., USA) are employed.

#### Presurgical Occlusion of Vertebral Arteries:

##### Technical Notes

Being one of the most delicate SAE procedures on vertebral lesions, presurgical occlusion of a vertebral artery through detachable coils requires high skill and proficiency.

Potential risks of the procedure are mainly related to the vertebrobasilar circle and its functional peculiarities.

Cerebral pan-angiography is recommended, including the study of vertebral and internal carotid arteries, bilaterally, to visualize possible asymmetry of vertebral arteries as well as presence of posterior communicating arteries.

The procedure is declined when marked asymmetry of the vertebral arteries is present and prevails in the artery to be occluded. In such cases, the occlusion of the dominant vertebral artery would carry a high risk.

When both vertebral arteries are significantly symmetrical, the only condition under which the procedure can be carried out safely is that the patient can haemodynamically and functionally tolerate the occlusion of a vertebral artery.

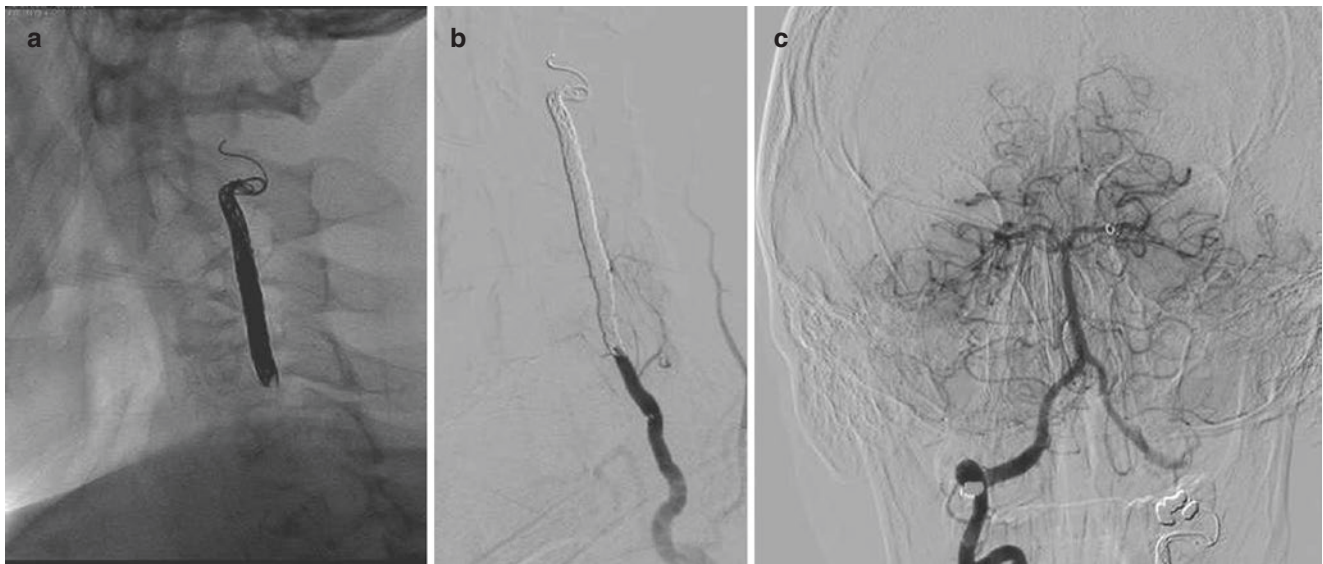To establish this necessitates a tolerability test. Whenever an accurate tolerability test of the vertebral artery occlusion is not possible, as it frequently occurs during interventional procedures involving the intracranial carotid district, catheterization of the artery through a 6 F carrier catheter is suggested.

In most cases, the external calibre of a 6 F catheter (about 2.5 mm) causes marked reduction of the vertebral artery flow, which has a mean diameter of about 4 mm. If the patient does not sufficiently compensate contralaterally, severe vertigo will occur as a sign of vertebrobasilar insufficiency. In this case, the procedure must be suspended due to very high risk. Besides, this emphasizes the importance that the patient be awake and collaborating throughout the procedure.

In the absence of vertebrobasilar signs of insufficiency after catheterization of the vertebral artery with a 6 F carrier catheter, 5000 I.U. of heparin with low molecular weight are intravenously administered. Anticoagulant agents help prevent formation of blood clots in arteries with slow flow or after positioning of the first coil.

In our experience, we preferably employed a carrier catheter (Neuron 6 F 052) with micro-catheter PX 400™ dedicated to release of Penumbra Coil 400™ (Penumbra Inc., USA). The Neuron catheters have been chosen due to their soft distal portions. However, we also employed other catheters, such as Envoy 6 F Multipurpose D (Codman J&J, MA, USA).

The coils are retrogradely released, starting from the V3 tract. Possible presence of muscular branches at V3 can be useful to “hook up” the distal extremity of the first coil and avoid an incidental as well as dangerous intracranial migration. Multiple coils are subsequently released to create a solid skein retrogradely extending almost to reach V2. At the end of the procedure, a control angiography of the contralateral vertebral artery and internal carotid arteries is performed (Fig. 4.2).



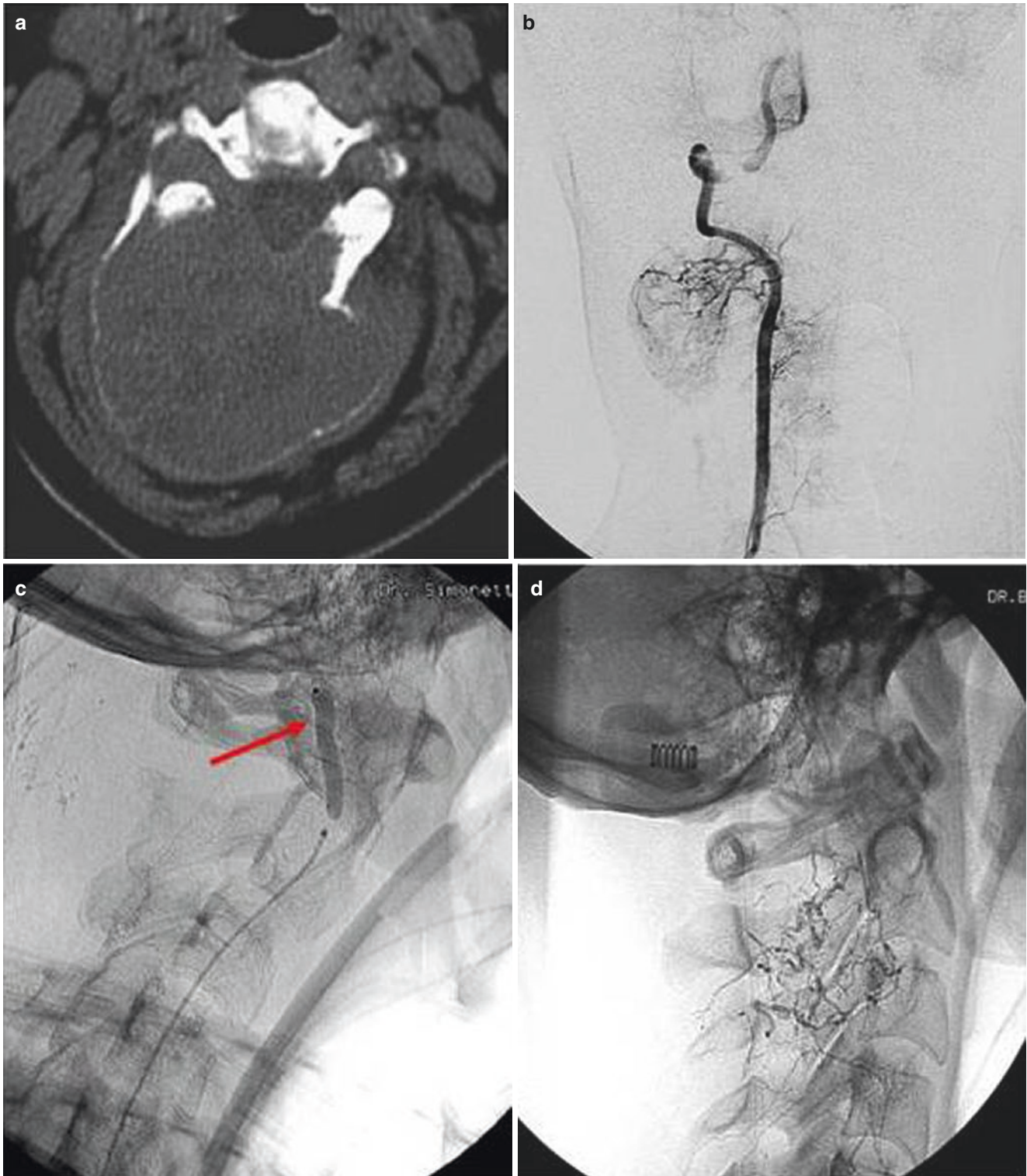
**Fig. 4.2** Presurgical occlusion of left vertebral artery The coils are retrogradely released, starting from the V3 tract. Multiple coils are subsequently released to create a solid skein retrogradely extending almost to

reach V2 (a, b). At the end of the procedure, a control angiography of the right vertebral artery (c) checks the retrograde injection of left posterior inferior cerebellar artery

### 4.3 Exemplificative Cases

#### Case 1

Cervical aneurysmal bone cyst at C3 level

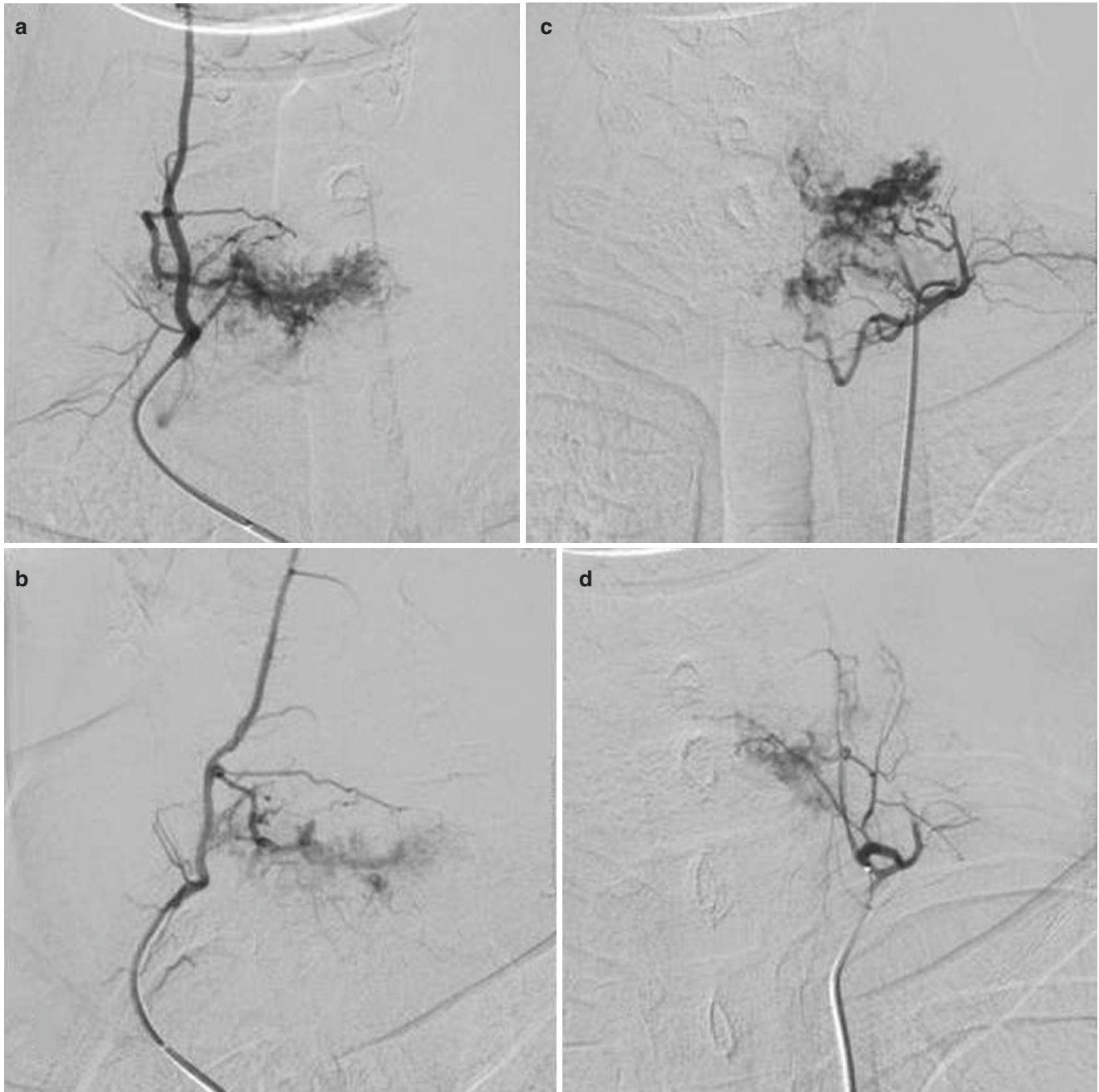


**Fig. 4.3** CT scan (a) and angiography (b). After distal protection positioning balloon in the vertebral artery (*arrow* in c), we perform treatment with super-selective micro-catheterization. Glubran2 injection

follows the main flow course within the lesion, with a good penetration of the glue into the vascularization of the lesion. Note the overlap of the final distribution of Glubran2 with pathological vascular network (d)

**Case 2**

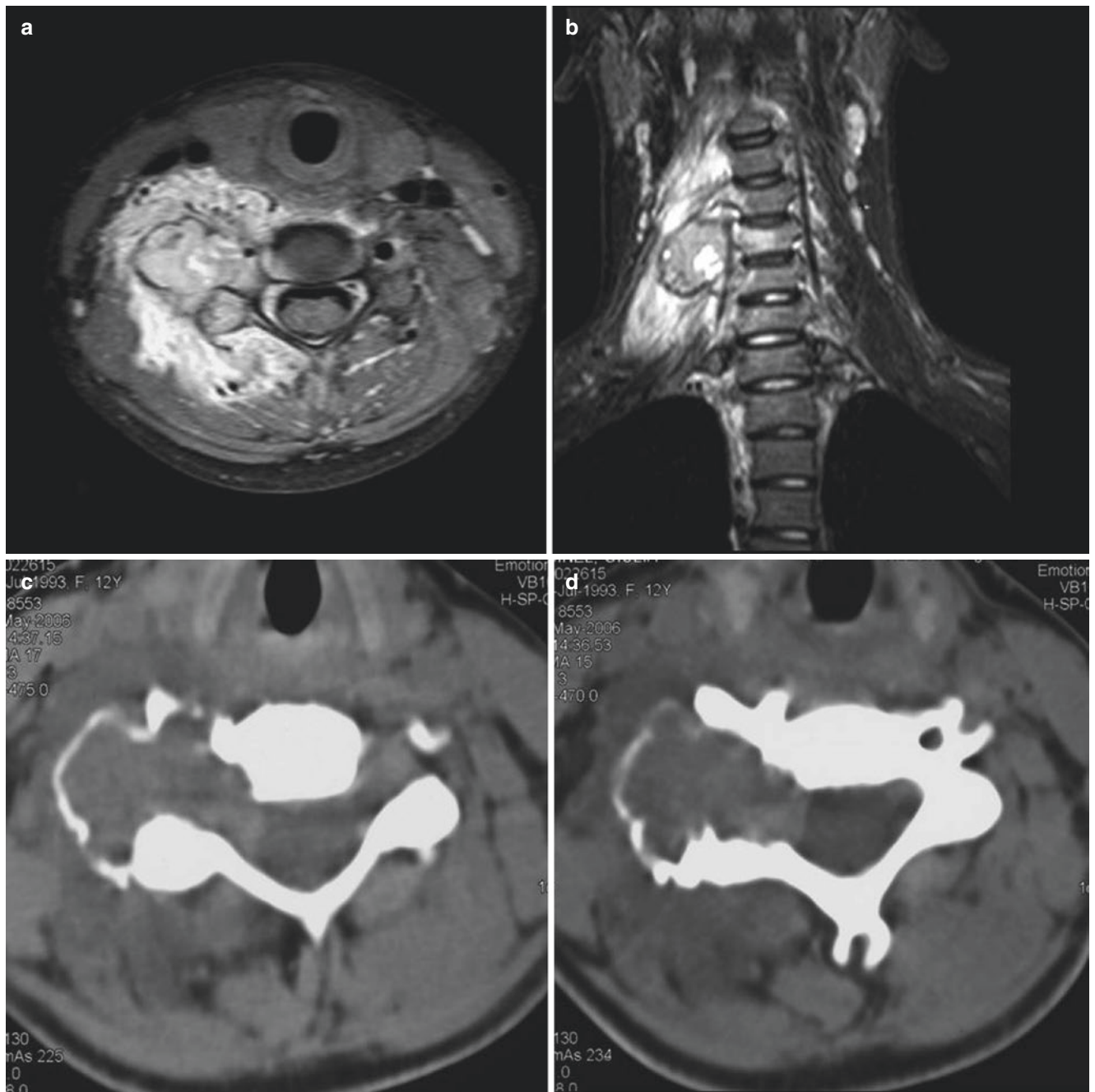
Aggressive vertebral osteoangioma at C7 level



**Fig. 4.4** Before (a–c) and after (d, f) super-selective embolization with stable microparticles

### Case 3

Cervical aneurysmal bone cyst at C5 level in a 12-year-old girl. Right, drug-resistant, cervicobrachialgia.



**Fig. 4.5** MR scans, in axial (a) and coronal (b) planes, highlight the lesion and associated extensive inflammation of the surrounding soft tissues. CT scans (c, d) outline the bone changes of the vertebra. Right vertebral angiography (e) demonstrates the narrowing of the artery due to aneurysmal bone cyst and its pathological vessels. We performed the occlusion of vertebral artery: the coils are retrogradely released, starting from stenotic segment of artery (f). The pathological vessels disap-

peared. Then we proceeded with super-selective embolization with stable microparticles of pathological vascular network arising from deep cervical artery (g, h). CT scans three months (i, j) after embolization. CT scans at six months (k, l) after embolization. Progressive recalcification of osteolytic lesion. The pain disappeared two days after the procedure



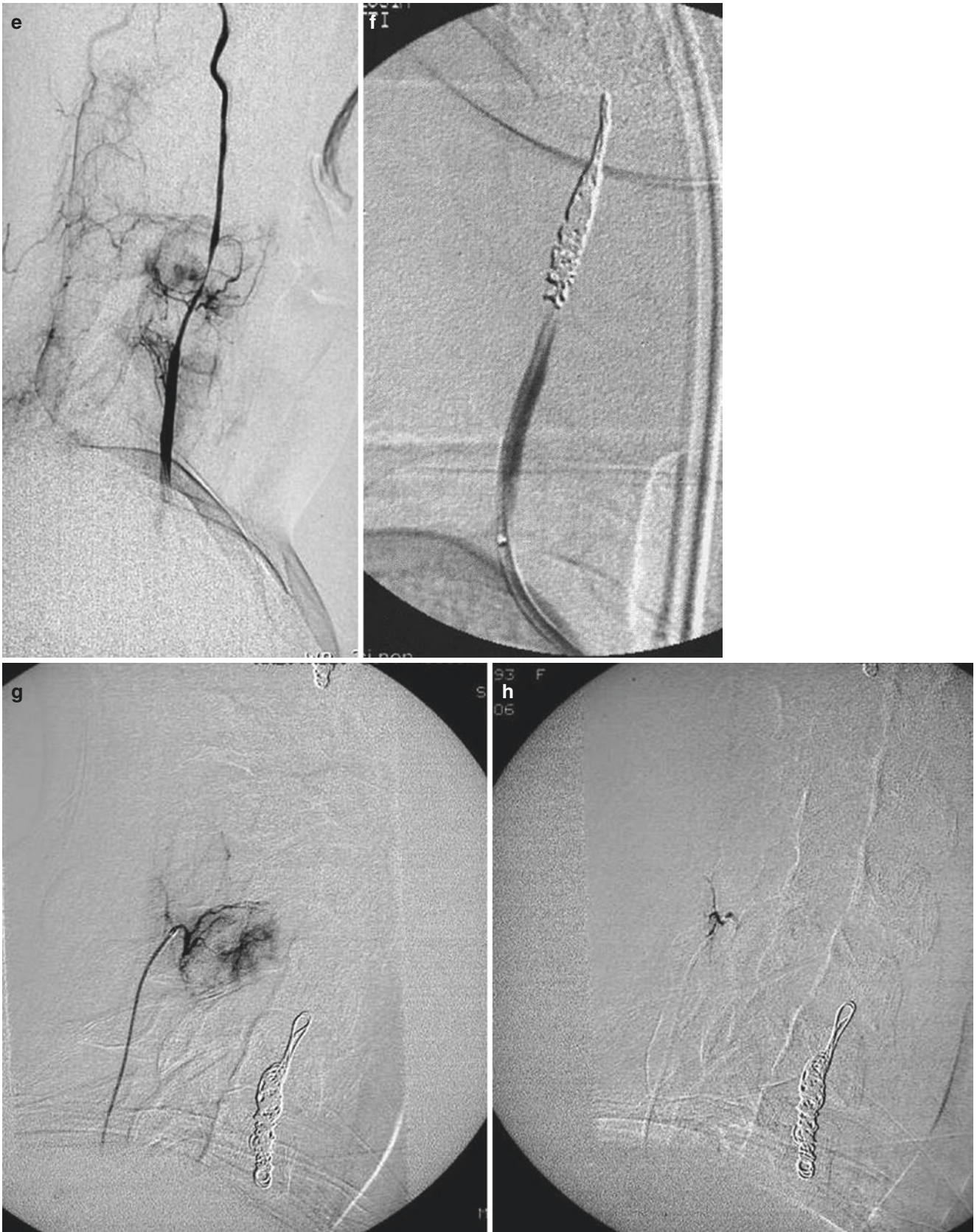


Fig.4.5 (continued)

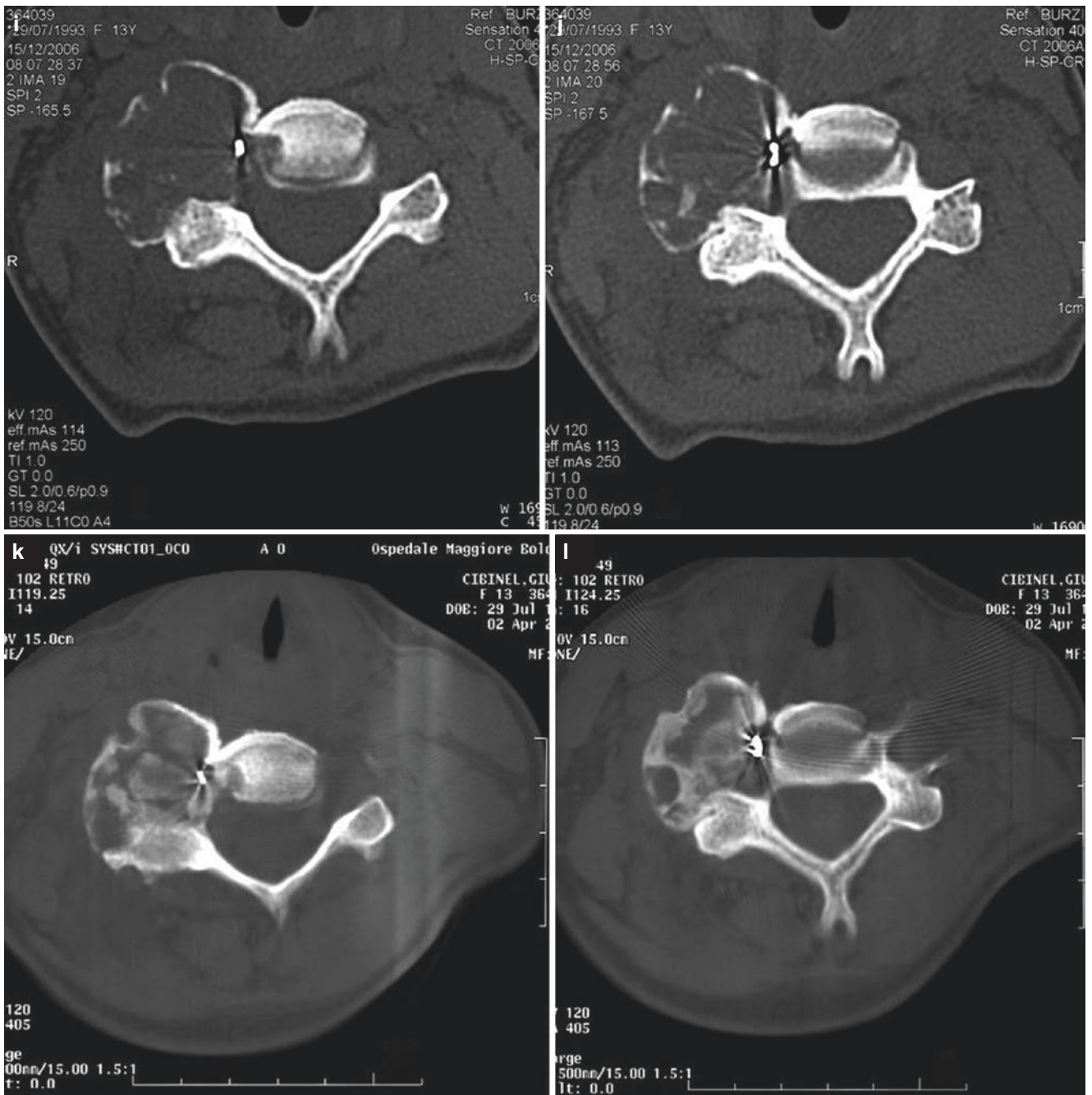


Fig. 4.5 (continued)

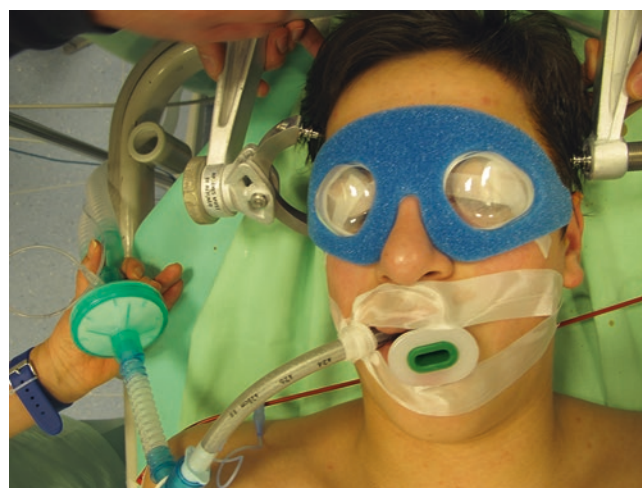## Selected References

1. Daniel H. Kim, Alexander R. Vaccaro, Curtis A. Dickman, et al (2005) Surgical anatomy and techniques to the spine. Thieme
2. Tomita K, Kawahara N, Murakami H, Demura S (2006) Total en bloc spondylectomy for spinal tumors: improvement of the technique and its associated basic background. *J Orthop Sci* 11(1):3–12
3. Broaddus WC, Grady MS, Delashaw JB, Ferguson RD, Jane JA (1990) Preoperative superselective arteriolar embolization: a new approach to enhance resectability of spinal tumors. *J Neurosurgery* 27(5):755–759
4. Guzman R, Dubach-Schwizer S, Heini P et al (2005) Preoperative transarterial embolization of vertebral metastases. *Eur Spine J* 14(3):263–268
5. M. Leonardi, L. Simonetti, R. Agati, M. Messia, F. De Santis, G. Dani(2001) Recent CT advances in spine imaging. *NRJ* Volume 14 (No. 2):207
6. Stafa A, Barbara C, Boriani\*\* S, Simonetti L, Leonardi\* M (2010) A little talk on Adamkiewicz's artery. Some practical considerations on the Pre-operative identification of this artery starting from a single team experience in Pre-surgical selective embolization of Vascularized Spinal lesions. *Neuroradiol J* 23:225–233
7. Simonetti L, Gasbarrini\* A, Boriani\* S, Leonardi M (2003) Presurgical selective arterial embolization of hypervascularized spinal tumours: embolization techniques and results in 290 patients(1998–2008). *Interv Neuroradiol* 9(4):339–349
8. Leonardi M, Barbara C, Simonetti L (2002) Glubran 2: a new acrylic glue for neuroradiological endovascular use experimental study on animal. *Interv Neuroradiol* 8:245–250
9. Leonardi M, Cenni P, Simonetti L et al (2003) Glubran 2®:a new acrylic glue for Neuroradiological Endovascular use. A complementary histological study. *Interv Neuroradiol* 9:249
10. Raffi L, Simonetti L, Cenni P, Bandiera S, Gasbarrini A, Boriani S, Leonardi M (2003) Presurgical embolization of spinal tumours using glubran 2 acrylic glue. *Interv Neuroradiol* 9(4):339–349
11. Vetter SC, Strecker EP, Ackermann LW, Harms J (1997) Preoperative embolization of cervical spine tumors. *Cardiovasc Intervent Radiol* 20(5):343–347
12. Marushima A, Matsumaru Y, Suzuki K et al (2009) Selective arterial embolization with n-butyl cyanoacrylate in the treatment of aneurysmal bone cyst of the cervical vertebra: a case report. *Spine (Phila Pa 1976)* 34(6):115

M.R. Bacchin, M. Di Fiore, Y.E. Akman, M. Girolami, R. Ghermandi, A. Gasbarrini, and S. Boriani

Prior to the surgery, reproduction of symptoms with extension of the neck should be assessed. Extension may help for better exposure and visualization. However, the severity of stenosis may limit the amount of extension that can be tolerated by the patient. In this case, a neutral neck position must be maintained till the end of the decompression procedure.

The head should be placed in slight hyperextension but not excessive traction since it causes tension on soft tissues. The combination of traction and hyperextension of the head will stretch the tissue planes, resulting to the separation and the dissection being harder and more dangerous as it is more difficult to distinguish structures in that case. All bony prominences must be appropriately padded. The extremities must be positioned in an appropriate position to avoid any peripheral neuropathy. The legs and thighs are tied to the table using straps and the feet are supported with a pillow. A roll is placed between the shoulder blades to allow the neck for extension. The shoulders are taped inferiorly as they are lowered, for better radiographic visualization of the lower cervical segments. Also, the arms can be extended with wrist bands to provide traction, but it should be kept in mind that excessive arm traction may cause stretching of the roots of the brachial plexus causing postoperative stupor of the brachial plexus. Excessive pressure by the wrist bands on wrists may cause median nerve injury. The iliac crest should be kept ready for an eventual autograft harvesting. The head is placed on a circular silicone pillow. The patient's eyes



**Fig. 5.1** The patient's eyes are protected to avoid direct pressure

should be protected with appropriate material to avoid direct pressure around (Fig. 5.1). Especially in prone position, some intraocular increased pressure-related serious ophthalmologic complications may occur. These complications are corneal abrasion (the most common), blindness as a result of posterior ischemic optic neuropathy, and central retinal artery occlusion [1].

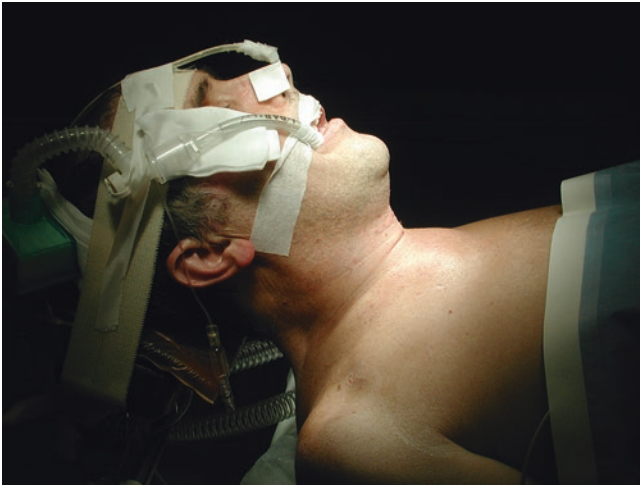The nasogastric and the endotracheal tubes must be carefully anchored to the mouth to avoid a possible displacement and must be kept away from the surgical area (Fig. 5.2). In some cases, a tracheostomy may be required (Fig. 5.3). Also the tubes must be easily accessible for the anesthesiologist for a fast replacement of the tubes during surgery. In such a case, the surgery must be immediately interrupted. The patient's position should be reassessed by the anesthesiologist as often as possible to be sure that any change has not occurred [2, 3].

For a more secure and fixed position, Mayfield traction tongs may be applied (Fig. 5.4). However, Mayfield traction should be used carefully in patients with conditions (such as tumors, osteoporosis, hemopathies, etc.) that cause fragility in the skull.

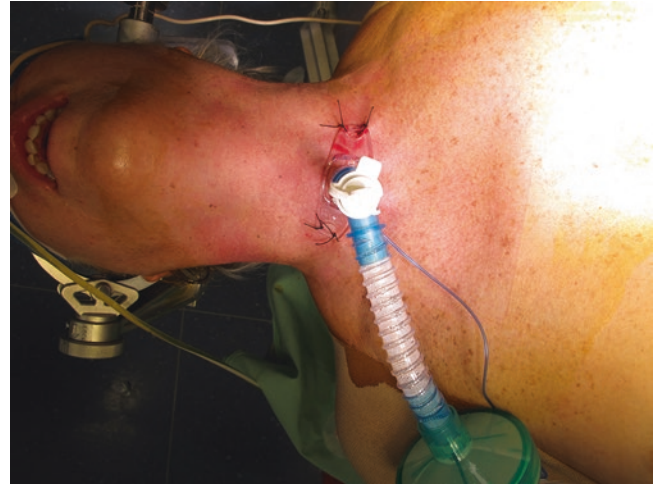M.R. Bacchin (✉) • M. Di Fiore  
Department of Anesthesiology, Perioperative and Pain Medicine,  
Rizzoli Orthopedic Institute, Bologna, Italy  
e-mail: [mariarenata.bacchin@ior.it](mailto:mariarenata.bacchin@ior.it)

Y.E. Akman  
Orthopaedics and Traumatology Department, Metin Sabanci  
Baltalimani Bone Diseases Training and Research Hospital,  
Istanbul, Turkey

M. Girolami • R. Ghermandi • A. Gasbarrini • S. Boriani  
Oncologic and Degenerative Spine Surgery Department, Rizzoli  
Orthopedic Institute, Bologna, Italy

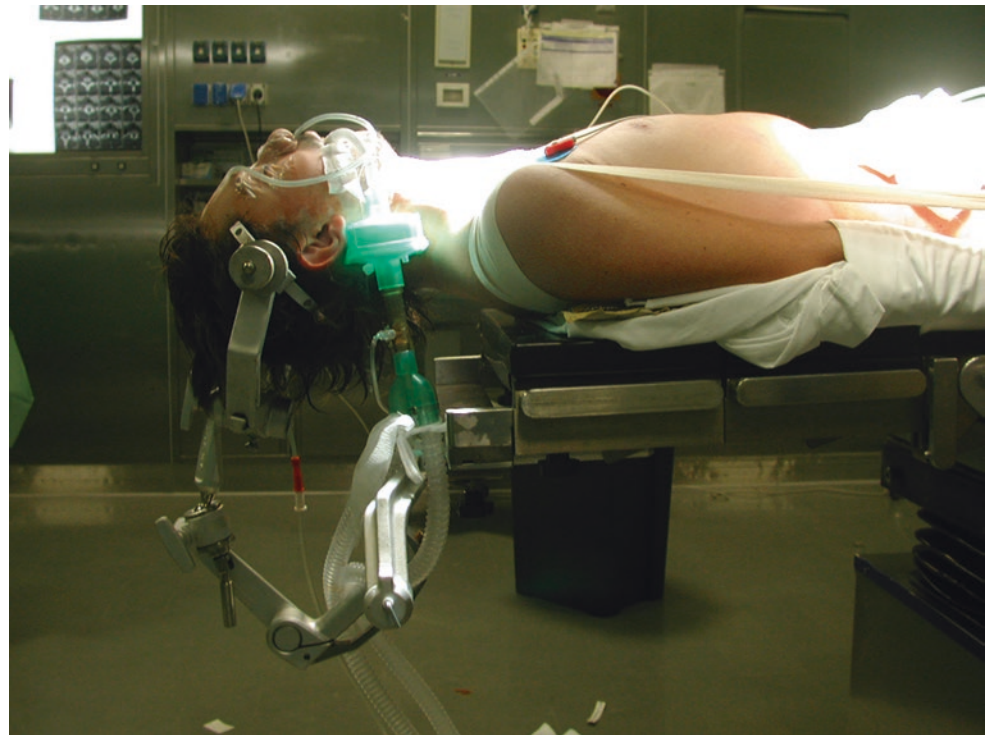

**Fig. 5.2** Positioning of nasogastric and endotracheal tubes



**Fig. 5.3** Tracheostomy opened in a patient before surgery

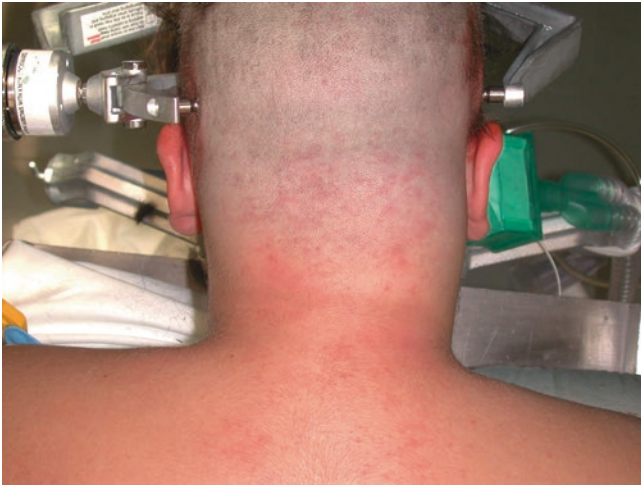**Fig. 5.4** The patient is positioned supine using Mayfield tongs with appropriate support under the cervical spine



First, the skin is cleansed by an iodine or alcohol solution. The authors do not perform shaving before the application of the Mayfield pins. However, if the surgical area extends to the upper cervical segments, hair should be shaved at least 24 h before the procedure (Fig. 5.5). One pin is placed above the ear, as a reference (Fig. 5.6), and the other two pins are placed at the same level with it on the contralateral side. When placing the pins on this side, attention must be paid as the pin that is located on the temporal bone may cause tem-

poral perforation. Mayfield tongs are squeezed together to make sure that the single contacts the skull. Then the screw is tightened until the pressure gauge shows between 60 and 80 lb (Fig. 5.7).

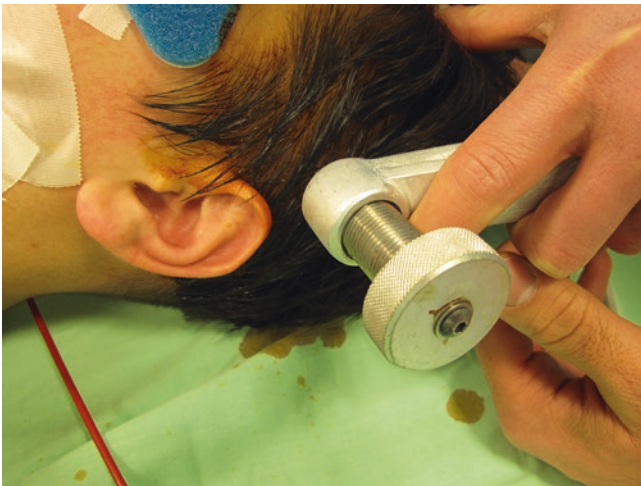Because the surgical wound is above the heart level producing a subatmospheric pressure in the open veins, the risk of venous air embolism should be kept in mind. The fixating devices on the skull must be always removed in the supine position to avoid venous air embolism. During the entire



**Fig. 5.5** For interventions in the upper cervical segments, the hair is shaved at least 24 h before surgery



**Fig. 5.7** Adequate pressure is applied in order to avoid perforations

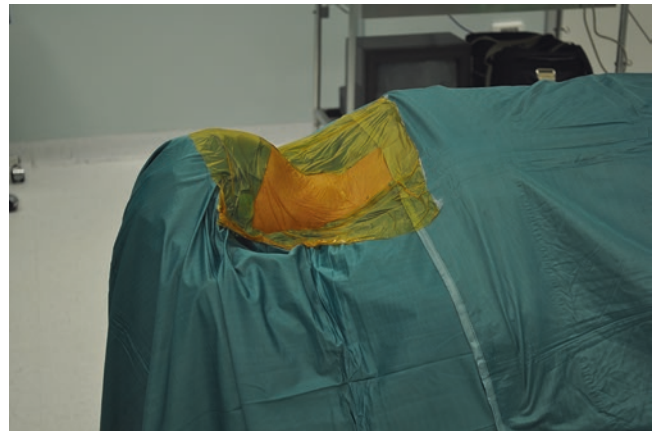


**Fig. 5.6** The application of the first Mayfield pin above the ear

operation procedure, the patient should be monitored for venous air embolism until all potential sites for air entry into the blood circulation have been closed [4]. Rigid support is essential for the neck (Fig. 5.3). The spinal processes should be well supported against pressure since considerable force may be applied on cervical spinal bodies (during graft insertion, screwing, etc.)

To determine the midline, sternal notch may be marked with a skin marker. A wide area as much as possible should be draped open, in order to let the surgeon orient for the overall position and the alignment of the patient (Fig. 5.8).

- *Anesthesia and its impact intraoperative neuromonitoring procedures*



**Fig. 5.8** Draping should be applied on the surgical area to be as wide as possible

Neuromonitoring protocols depend on the patient, surgeon, and institution and should be individualized accordingly. Both motor-evoked potentials (MEPs) and somatosensory-evoked potentials (SSEPs) may be used during surgical procedures. Communication with the anesthesia team is essential because inhaled agents and paralytic drugs must be avoided. Following the repositioning, baseline values are obtained, then the patient's head and neck are extended, and the shoulders are taped inferiorly. MEPs and SSEPs are then retested to ensure no deviation from baseline [5, 6]. For neuromonitoring, neuromuscular blockade must be minimized or avoided. As a result, each stimulation will produce movement of limb and axial muscles. The amount of movement can be minimized by using a threshold-level stimulation protocol that is based

on determining the lowest stimulus intensity that produces consistent muscle activation [7]. The variable that is used for monitoring for this technique is the change in threshold needed to elicit muscle activation. Even with this technique, however, it is necessary to warn the surgeon when a stimulus train is going to be delivered to minimize the risk of movement during a critical part of the surgery. In addition, MEP recording introduces constraints into choice of anesthetic agents (vide infra).

During the neuromonitoring, cerebral stimulation causes some other risks. The stimulation directly activates masseter muscles, and forceful contraction can produce tongue bite, tooth fracture, or even mandible fracture. These risks can be minimized or eliminated by proper use of bite blocks inside the mouth. MEP recording is considered to be contraindicated in patients with epilepsy, cortical lesions, skull defects, increased intracranial pressure, surgically implanted intracranial devices, cardiac pacemakers, or other implanted pumps. Actual experience with tceMEP monitoring has seen a very low incidence of complications [8].

The operating room is an electrical environment, and electrical interference and artifacts may deteriorate interpretation of the monitoring potentials. The depth of anesthesia, body temperature, and blood pressure may alter potentials. The monitoring personnel must be able to detect and understand the reasons of such variables in order to interpret them correctly. False interpretations may alert the surgeon in an undesirable way. It is not necessary or desirable to alert the surgeon to every change in the SSEP or tceMEP recordings, particularly if they are not physiologically meaningful. However, it is absolutely essential to warn the surgeon when a change in the potentials that may reflect neural injury is observed. Since there can be real-time changes in the potentials, any variation in the recordings must be sustained and reproducible [9].

The intraoperative neurophysiologic monitoring place requires additional demands on the anesthesiologist. In addition to conventional anesthesia for the surgical procedure, it is necessary to apply the anesthetic so that it helps maximize signal acquisition. The assessment of somatosensory (SSEPs) and motor-evoked potentials (MEPs) are the most commonly used modalities to evaluate neural risk and help decision making during the surgical procedure. These have certain impacts on the anesthetic management.

tceMEPs are particularly sensitive to interference by anesthetic agents. tceMEPs are the more difficult to evaluate during operative procedures; anesthetic conditions that are optimized for tceMEPs will usually produce acceptable

SSEPs. The anesthetic approach needs to be optimized for obtaining appropriate potentials and correct interpretations that can help in guiding the surgical procedure.

Most of the anesthetic agents depress evoked response amplitudes and increase latencies which cause intraoperative neurophysiologic monitoring to be more difficult. Notable exceptions include the intravenous anesthetic agents etomidate and ketamine which are the exceptions to increase SSEP and MEP amplitudes [9]. The infusion of etomidate causes adrenocortical suppression; thus, its use is limited to induction of anesthesia in potentially hemodynamically unstable patients [7, 10].

Significant temperature-related decreases in evoked potential amplitude may occur after the surgical exposure of the spine but before instrumentation and deformity correction. Hypothermia may lead to false-negative results [11]. As the esophageal temperature decreases, with hypothermia, a gradual increase occurs in the MEPs. An increase in stimulation threshold was also observed at lower temperatures [9]. In contrast, hyperthermia reduces the latency and increases the conduction velocity of evoked potentials. Above 42 °C, spinal SSEP amplitudes do not change, whereas cortical SSEPs and spinal MEPs deteriorate. Hypothermia increases latency and decreases conduction velocities. Below 28 °C, the spinal MEP amplitude decreases and the cortical SSEPs and spinal MEPs disappear. As hyperthermia and hypothermia cause significant changes in the latency of MEPs and SSEPs, it has been suggested that for a correct evaluation, evoked potential measurements should be performed in a range of 2–2.5 °C above or below the baseline temperature [12, 13].

Hypoxemia can lead to evoked potential deterioration before the other clinical parameters have been changed. Changes in carbon dioxide levels may cause alteration in spinal cord and cortical blood flow. The most apparent changes in cortical SEP occur when the carbon dioxide tension is extremely low, suggesting excessive vasoconstriction may produce ischemia (PaCO<sub>2</sub> 20 mmHg) [9]. This effect may be expected to produce some MEP changes. As hypocapnia may cause small SEP changes, and possibly MEP, baseline recordings should be obtained before the initiation of hyperventilation [14].

SSEP response may also change with hematocrit. An amplitude increase has been found with mild anemia, followed by an increase in latency at hematocrits of 10–15%. At hematocrits less than 10%, further latency changes and amplitude reductions are observed. No comparable studies have been performed with MEPs [9].

## References

1. Stambough JL et al (2007) Ophthalmologic complications associated with prone positioning in spine surgery. *J Am Acad Orthop Surg* 15(3):156–165
2. Manfredini M et al (2000) Unilateral blindness as a complication of intraoperative positioning for cervical spinal surgery. *J Spinal Disord* 13(3):271–272
3. Yanagidate F, Dohi S (2003) Corneal abrasion after the wake-up test in spinal surgery. *J Anesth* 17(3):211–212
4. Grinberg F, Slaughter TF, McGrath BJ (1995) Probable venous air embolism associated with removal of the Mayfield skull clamp. *Anesth Analg* 80(5):1049–1050
5. Smith PN et al (2007) Intraoperative somatosensory evoked potential monitoring during anterior cervical discectomy and fusion in nonmyelopathic patients – a review of 1,039 cases. *Spine J* 17(1):83–87
6. Khan MH et al (2006) Intraoperative somatosensory evoked potential monitoring during cervical spine corpectomy surgery: experience with 508 cases. *Spine (Phila Pa 1976)* 31(4):E105–E113
7. Cohan P et al (2005) Acute secondary adrenal insufficiency after traumatic brain injury: a prospective study. *Crit Care Med* 33(10):2358–2366
8. MacDonald DB (2002) Safety of intraoperative transcranial electrical stimulation motor evoked potential monitoring. *J Clin Neurophysiol* 19(5):416–429
9. Pajewski TN, Arlet V, Phillips LH (2007) Current approach on spinal cord monitoring: the point of view of the neurologist, the anesthesiologist and the spine surgeon. *Eur Spine J* 16(Suppl 2):S115–S129
10. Wagner RL et al (1984) Inhibition of adrenal steroidogenesis by the anesthetic etomidate. *N Engl J Med* 310(22):1415–1421
11. Seyal M, Mull B (2002) Mechanisms of signal change during intraoperative somatosensory evoked potential monitoring of the spinal cord. *J Clin Neurophysiol* 19(5):409–415
12. Oro J, Haghighi SS (1992) Effects of altering core body temperature on somatosensory and motor evoked potentials in rats. *Spine (Phila Pa 1976)* 17(5):498–503
13. Sakamoto T et al (2003) The effect of hypothermia on myogenic motor-evoked potentials to electrical stimulation with a single pulse and a train of pulses under propofol/ketamine/fentanyl anesthesia in rabbits. *Anesth Analg* 96(6):1692–1697, table of contents
14. Gravenstein MA, Sasse F, Hogan K (1992) Effects of hypocapnia on canine spinal, subcortical, and cortical somatosensory-evoked potentials during isoflurane anesthesia. *J Clin Monit* 8(2):126–130



M. Girolami, R. Ghermandi, A. Gasbarrini, Y.E. Akman,  
and S. Boriani

## 6.1 Anterior Instrumentation

### 6.1.1 Anterior Cervical Discectomy and Fusion (ACDF)

Anterior cervical discectomy and fusion (ACDF) is often used as a surgical treatment for cervical degenerative disorders (Fig. 6.1). Numerous long-term follow-up studies have shown that is effective in case of cervical myelopathy, relieving anterior compression on the spinal cord, or radiculopathy, decompressing nerve roots. This technique allows direct decompression of neural structures, restoration of disc height, and stabilization of the affected motion segments. The success of the procedure relies on achieving a solid fusion.

Anterior column (vertebral bodies and discs) is exposed through an anterior prevascular exposure (more often with transverse skin incision) and the level is identified using intraoperative fluoroscopic control.

The anterior longitudinal ligament (ALL) and the anterior portion of the annulus are incised, and discectomy is carried out in the usual manner. Vertebral bodies are prepared removing all the cartilaginous end plates with high-speed burr or curettes until bleeding bone.

By doing this, it is essential to identify the uncinete processes, which defines the lateral borders of a “safe zone” whose violation would put vertebral artery at risk.

Distraction to the disc space can be applied in order to increase the working space, thus, facilitating removal of the posterior half of the disc.

The two pins of the Caspar retractor are affixed slightly superior to the center of the vertebral bodies above and below (Fig. 6.2). Pin retractors also allow, after implant insertion, to put it under slight compression (Fig. 6.3).

Foraminotomy can be performed by removing the medial portion of the uncinete processes with a 1- or 2-mm Kerrison rongeur. By doing this, it is essential to remember the course of the exiting nerve root and to keep in mind that surgeons have the better visualization of the compression on the contralateral side to the one they are standing to.

Posterior longitudinal ligament (PLL) and posterior bony spurs can be removed allowing for complete anterior decompression of the cord.

Finally, the selected implant can be trialed and, after fluoroscopic control, implanted.

For a successful fusion, bony contact with the graft (or interbody device) must be maximized, so meticulous endplates preparation is essential.

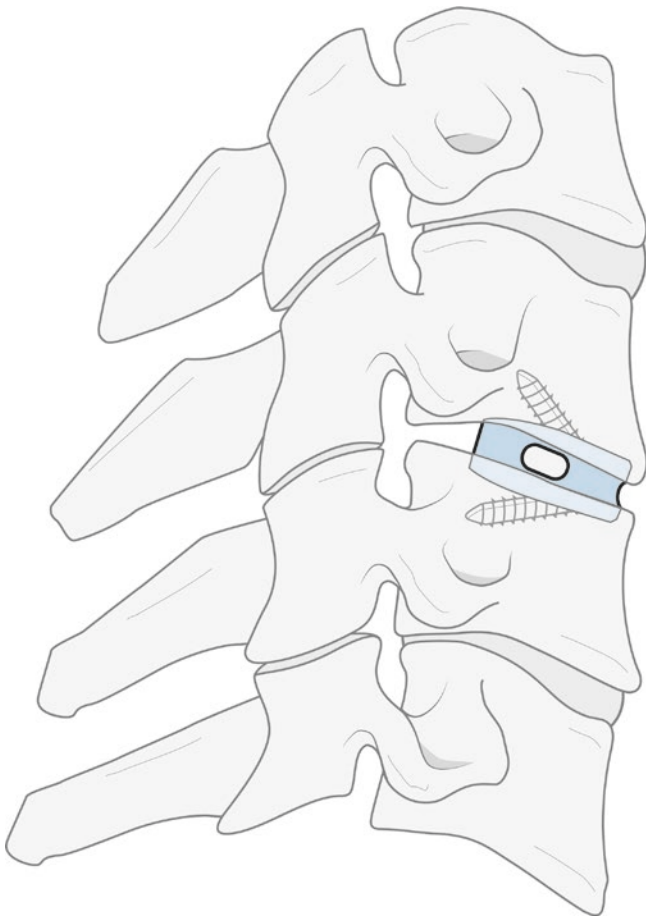
Excessive intervertebral disc space distraction, as a result of a too high graft, may cause facet impingement and post-operative neck pain. Any remaining anterior osteophytes should be removed, and the implant should be placed approximately 4 mm anterior to the posterior margin of the vertebral body in order to prevent impingement of the spinal canal.

Finally, distraction should be released and position of the cage checked using fluoroscopy.

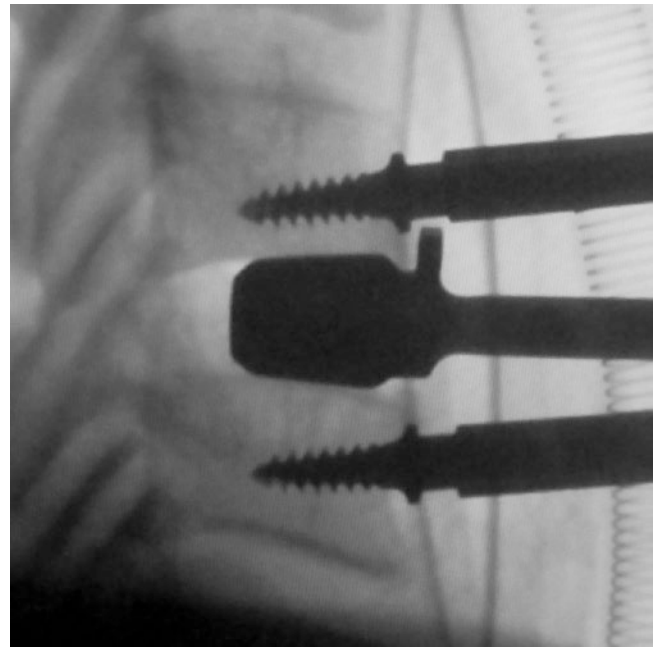
---

M. Girolami (✉) • R. Ghermandi • A. Gasbarrini • S. Boriani  
Oncologic and Degenerative Spine Surgery Department Rizzoli  
Orthopedic Institute, Bologna, Italy  
e-mail: [marco.girolami@yahoo.it](mailto:marco.girolami@yahoo.it)

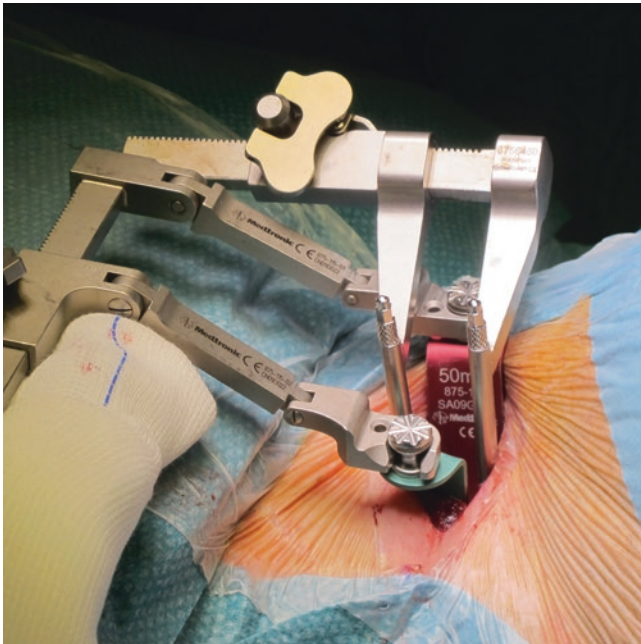
Y.E. Akman  
Orthopaedics and Traumatology Department, Metin Sabanci  
Baltalimani Bone Diseases Training and Research Hospital,  
Istanbul, Turkey



**Fig. 6.1** ACDF with stand alone anterior cage



**Fig. 6.3** Intraoperative x-ray showing Caspar pin distractors



**Fig. 6.2** Caspar pin retractors are applied in order to allow segmental distraction, easing discectomy and endplates preparation, and compression to provide stimulus for fusion

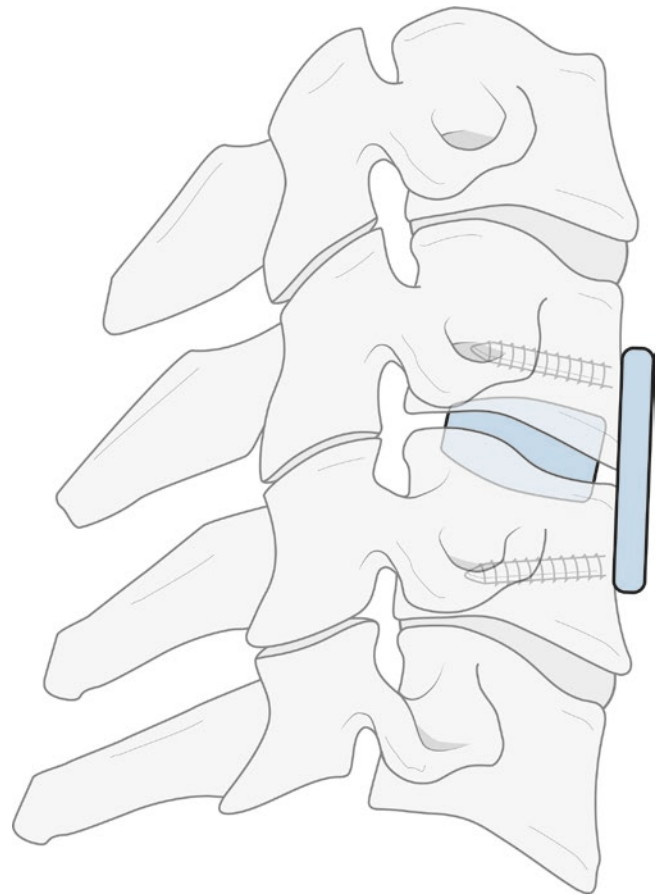
### 6.1.2 Cervical Interbody: Cages and Grafting

The anterior approach to the cervical spine for discectomy and fusion by the insertion of an autologous iliac-crest tricortical bone graft was originally introduced by Robinson and Smith in 1955. In 1958, Cloward described a wide anterior cylindrical discectomy performed with a special reamer combined with anterior fusion by the insertion of autologous iliac bone graft of the same shape.

Nowadays, several implants are available on the market to perform anterior interbody fusion. Cages of different shapes

and materials, which can be implanted with or without the need for additional anterior plating (Fig. 6.4). The cage size must be determined intraoperatively, under fluoroscopic control, using available trials. Use of allograft avoids the need for autograft harvesting, that produces significant morbidity to the donor site (i.e. iliac crest, fibula). Thus, authors prefer the use of bone bank allograft, but autograft can be easily obtained from the iliac crest too.

**Fig. 6.4** ACDF with interbody grafting and anterior plate



### 6.1.3 Anterior Cervical Corpectomy and Fusion (ACCF)

ACCF has been proven to be an effective technique in case of ventral compression posterior to the vertebral body (i.e., trauma, degenerative disease, infection, tumor; Fig. 6.5).

Moreover, cervical kyphotic deformities (especially if fixed on flexion-extension films) generally require an anterior approach, since posterior-only decompression would not allow the spinal cord to migrate posteriorly and symptoms are likely to continue postoperatively.

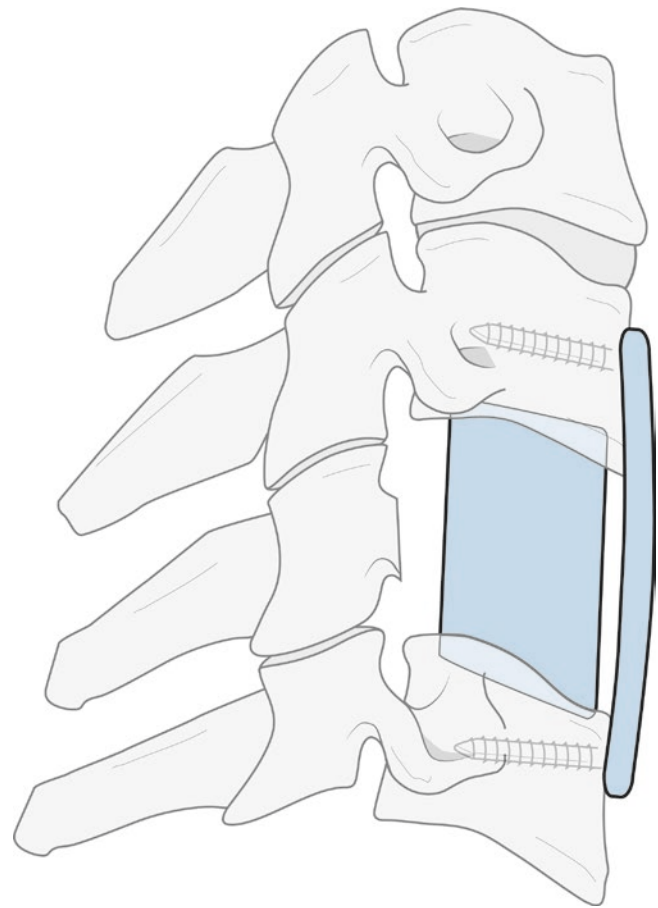
Furthermore, an anterior approach resolves compression on the anterior spinal artery that supplies up to 75–80% of the anterior spinal cord. Accurate collection of the medical history of the patient and a detailed physical examination are always mandatory and should be verified with advanced imaging modalities (MRI is the gold standard).

Anterior column (vertebral bodies and discs) is exposed through an anterior prevascular exposure, and the level is identified using intraoperative fluoroscopic control. Surgical field must be large enough to include the disc above and below the targeted vertebral body.

Then, discectomies at the levels above and below are performed as previously described.

After the discectomies have been performed, two longitudinal grooves, parallel to the uncinates processes and as deep as the anterior two thirds of the vertebral body, are made using a high-speed burr.

The central bone between the grooves is removed with a rongeur and stored for grafting. Then, the posterior wall of the vertebral body is thinned using a high-speed burr and later removed with Kerrison rongeurs along with the PLL. Finally, the decompression is accomplished removing any eventual osteophyte left.



**Fig. 6.5** Single-level ACCF, reconstructed with strut graft and anterior plating

### 6.1.4 Reconstruction of the Anterior Column

Corpectomy defect can be reconstructed with various techniques, but proper size and appropriate positioning of the implant is cornerstone as the choice of reconstruction. After implant positioning, an anterior cervical plate is applied to stabilize the construct and prevent ventral migration.

Technical options for anterior column reconstruction:

- Strut bone grafts (allograft, autograft)
- PMMA (eventually armed with Steinman pins)
- Titanium mesh cages (Harms cages)
- Polyetheretherketone (PEEK) cages
- Carbon fiber cages
- Expandable cages

Variables to take into consideration when selecting the technique:

- Number of levels to be reconstructed
- Bone quality
- Further treatment planned (i.e., radiotherapy)
- Need to minimize artifacts (early detection of local recurrences)
- Fusion (secondary stability)

#### 6.1.4.1 Graft Selection for Anterior Interbody Fusion: Autograft Versus Allograft?

- Donor site morbidity
- Single level vs. multilevel

### 6.1.5 Supplemental Posterior Fixation for Multilevel ACCF

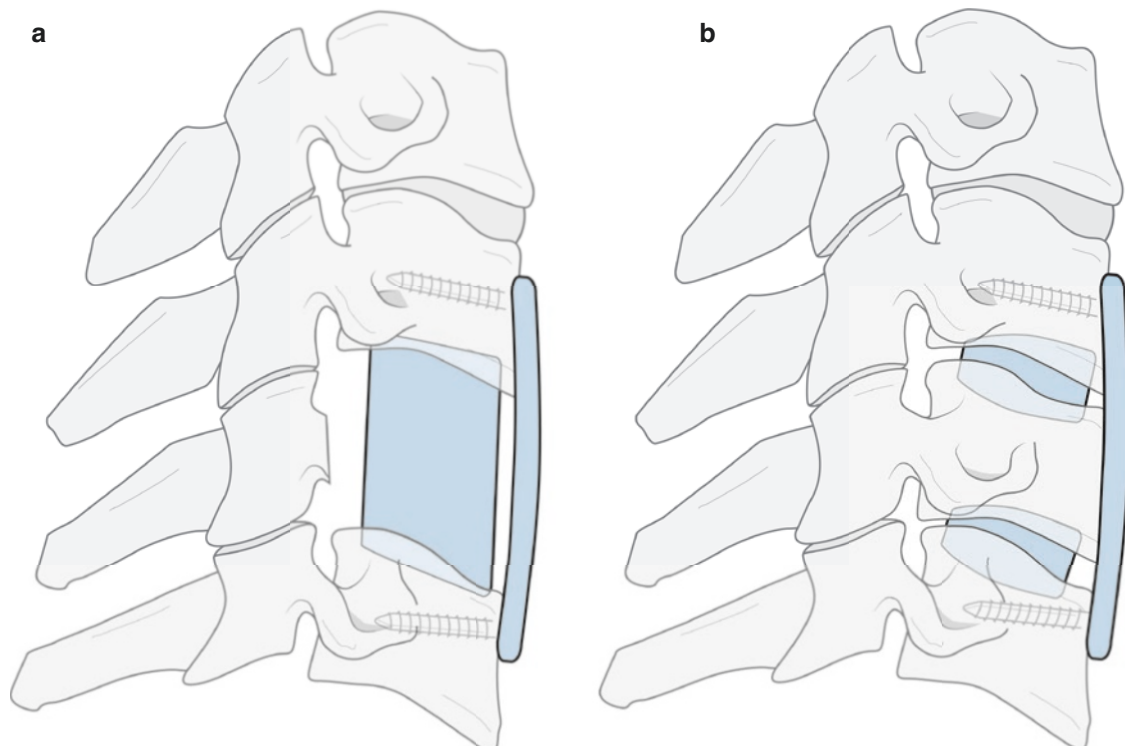
Multilevel ACCF may lead to iatrogenic instability of the cervical spine, and therefore supplemental posterior fixation must be considered (Fig. 6.7). Generally, a supplemental posterior fixation is necessary when more than three levels are involved anteriorly.

Posterior fixation with respect to the sagittal balance of the cervical spine significantly decreases the risk of complications such as pseudarthrosis, graft failure, progressive kyphotic deformity, and plate dislodgement. Regardless of the number of levels involved, poor bone quality or an unstable anterior fixation should be always supported posteriorly.

In order to achieve secondary long-lasting stability with a solid fusion, decortication and grafting are recommended.

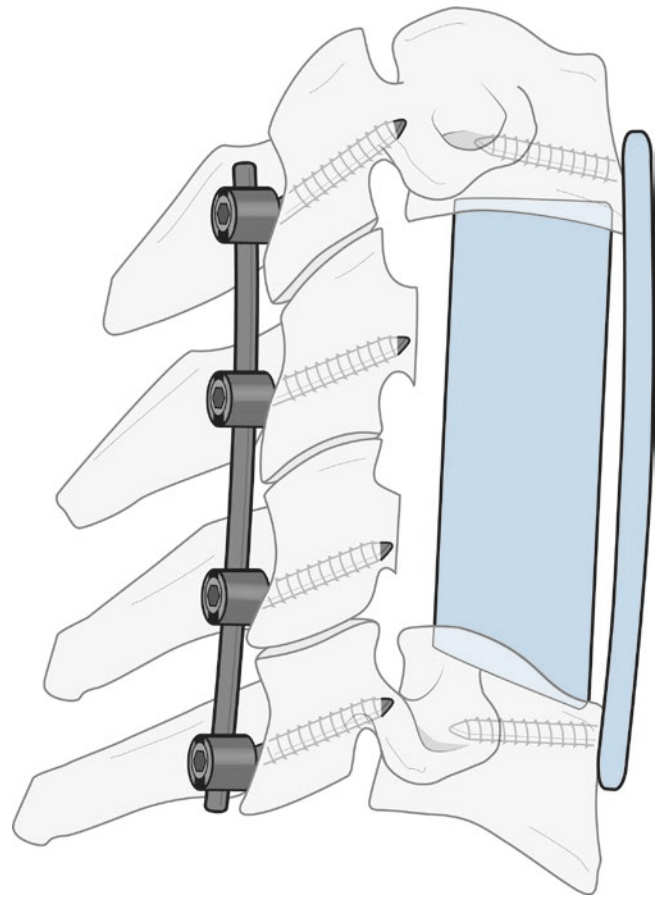
ACCF vs. double-level ACDF (Fig. 6.6)

| ACCF                                      | Double-level ACDF                     |
|---|---------------------------------------|
| <i>Pros:</i><br>Complete decompression    | <i>Pros:</i><br>More stable construct |
| <i>Cons:</i><br>Blood loss<br>Less stable | <i>Cons:</i><br>Less decompression    |



**Fig. 6.6** (a) ACCF vs. (b) double-level ACDF

**Fig. 6.7** Multi-level cervical corpectomy need to add posterior segmental instrumentation to enhance stability. Nevertheless, long-term stability is obtained only if fusion occur



### 6.1.6 Anterior Cervical Plating

Anterior cervical plate has double biomechanical behavior depending on the applied forces; in fact, it acts as a tension band in extension and as a buttress plate in flexion.

Its use was initially meant to avoid graft dislodgement and/or subsidence.

First generation implants were nonconstrained load-sharing plates which required bicortical screw purchase in order to avoid excessive motion at the screw-plate interface and decrease screw loosening. Thus, engagement of the posterior vertebral cortex was technically challenging due to the risk of neurologic injury.

Then, constrained systems (static plates) that firmly lock the screws to the plate were developed. Securing the screws to the plates allows a more direct transfer of the applied forces from the spine to the plate and improved construct stiffness without the need for bicortical screw purchase.

Rigidly locked screw-plate systems theoretically expose the anterior column to potential stress shielding. Thus, dynamic semiconstrained plates were designed allowing for

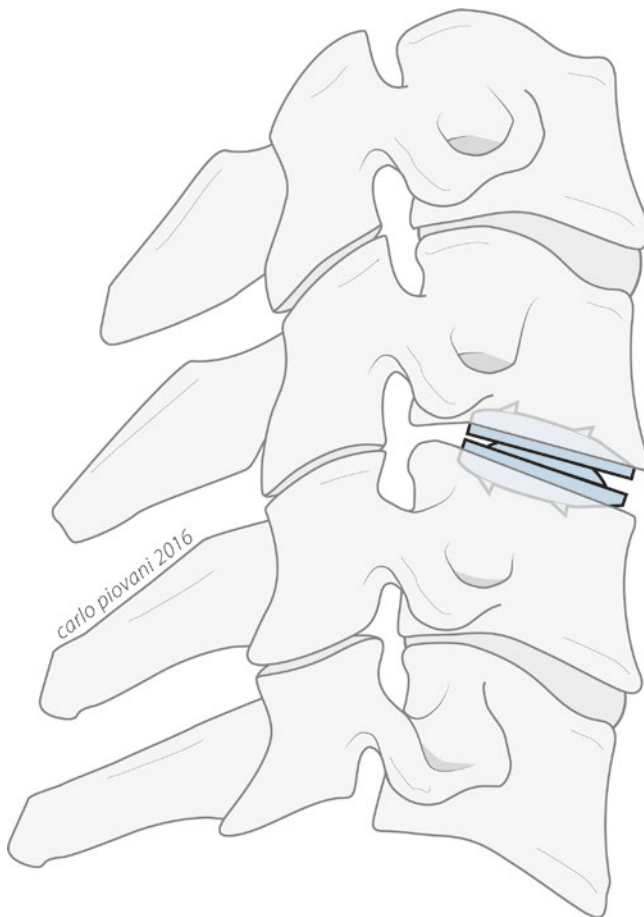
degree of load sharing between the plate and the spinal column (screw rotation, translation, or plate shortening).

Furthermore, in selected cases, specific materials need to be used (i.e. carbon-fiber plates) for oncologic patients undergoing adjuvant radiotherapy.

### 6.1.7 Motion Sparing Techniques: Cervical Disc Prosthesis

Cervical disc prosthesis gained popularity due to potential for the motion preservation and decreased rate of adjacent level degeneration (Fig. 6.8).

Despite these tempting promises, nowadays further studies still are needed to determine whether cervical disc replacement will have a lower rate of adjacent segment degenerative changes than anterior cervical discectomy and fusion. Different designs of prosthesis have been proposed, but none have been proved superior to the others, or to ACDF with regard to clinical outcomes at long-term follow-up.



**Fig. 6.8** Cervical disc prosthesis preserves motion while relieving symptoms at the operated segment

## 6.2 Posterior Instrumentation

### 6.2.1 Occipital Plate

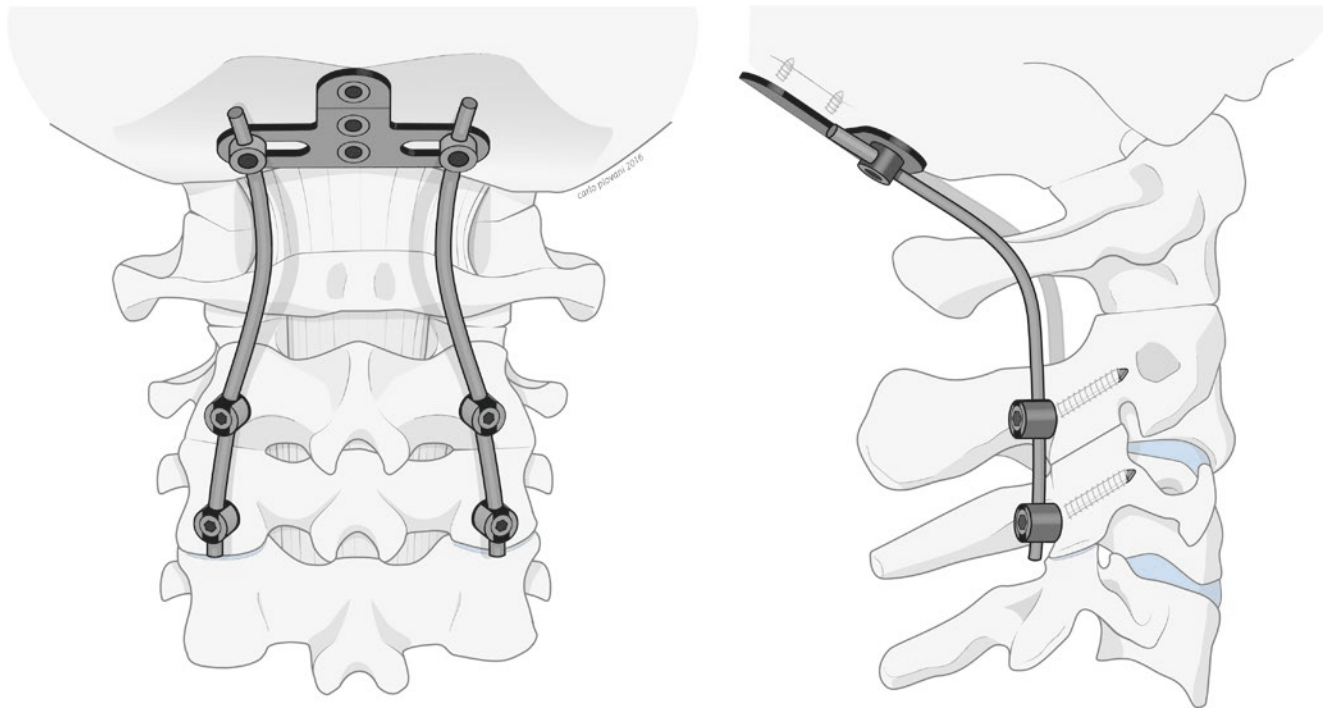
Screws can be safely placed in the occiput, below the inion (to avoid damage to the sagittal intracranial sinus), but this requires a careful understanding of the occipital anatomy. The occipital cortex is thicker along the midline ridge, allowing for a strong bone purchase. The lateral cortex is thinner, only 3–7 mm, so screws must be placed bicortically and, if possible, with a trajectory convergent toward the midline in order to maximize screw length.

After drilling the hole, depth is checked, and when penetration of the distal cortex has occurred, they can be tapped bicortically and screws inserted.

Midline occipital plate must align well with the segmental screws placed below, but, if they do not, bilateral plates are preferred (if system allows).

Care must be taken in order to avoid injury to the cerebellum. Dural laceration with cerebrospinal fluid (CSF) leak is not uncommon and is dealt just by screw insertion.

Occipitocervical fixation (i.e., C0–C2, Fig. 6.9) can be achieved by combining occipital plating to the usual C1–C2 fixation techniques: poliaxial pedicle screw inserted across the C1–C2 joint (Magerl–Seeman technique) or segmental fixation with C1 lateral mass screws and C2 screws (either with pedicle, isthmic, or translaminar trajectory). In both cases, the construct is accomplished by connecting it to the occipital plate with bilateral rods.



**Fig. 6.9** Occipito-cervical (C0–C3) fusion



## 6.2.2 Segmental Screw Fixation

Segmental fixation in the cervical spine is achieved using various techniques: lateral mass (C1 and C3-C6) or pedicle screws (C2 and C7).

Fixation can be extended cranially up to the skull using occipital plates, and caudally down to the upper-thoracic spine using connectors or double-diameter rods. In alternative to screws' segmental fixation, hooks and wires were once used for fixation in the cervical spine.

### 6.2.2.1 C1 Lateral Mass Screws (Goel, Harms, and Melcher)

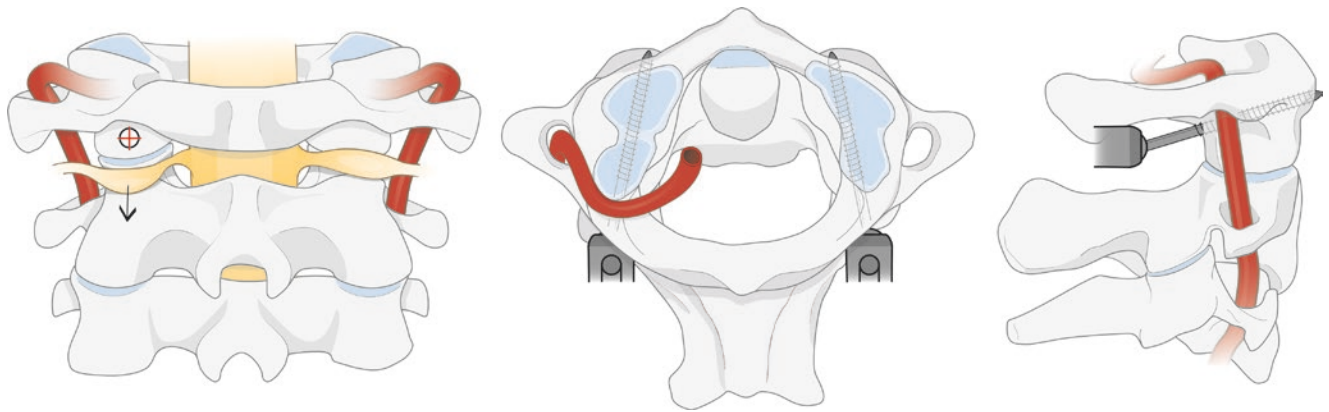
Entry point is just caudal to the posterior arch of C1, 3–4 mm lateral to the medial edge of the lateral mass (Fig. 6.10). The

C2 spinal nerve and root ganglion (greater occipital nerve), which cross posterior to the C2 isthmus, must be mobilized distally. Some authors advocate its sacrifice, but in our experience, this is unnecessary. In fact, the C1 lateral mass screw is not fully threaded, in order to avoid irritating the C2 nerve.

Significant venous bleeding from the plexus can be expected during dissection, but can be controlled with Gelfoam and Surgicel and cottonoids.

Trajectory goes slightly medial ( $10^\circ$ ) and cephalad ( $10\text{--}20^\circ$ ). The tip of the screw should stop 3 mm before the anterior tubercle of C1 (as seen in the lateral fluoroscopy). The posterior arch can be used to properly orient the drill.

Although drilling must be bicortical, if too long screws are used, internal carotid artery and hypoglossal nerve are at risk (anterior to the C1 lateral mass).



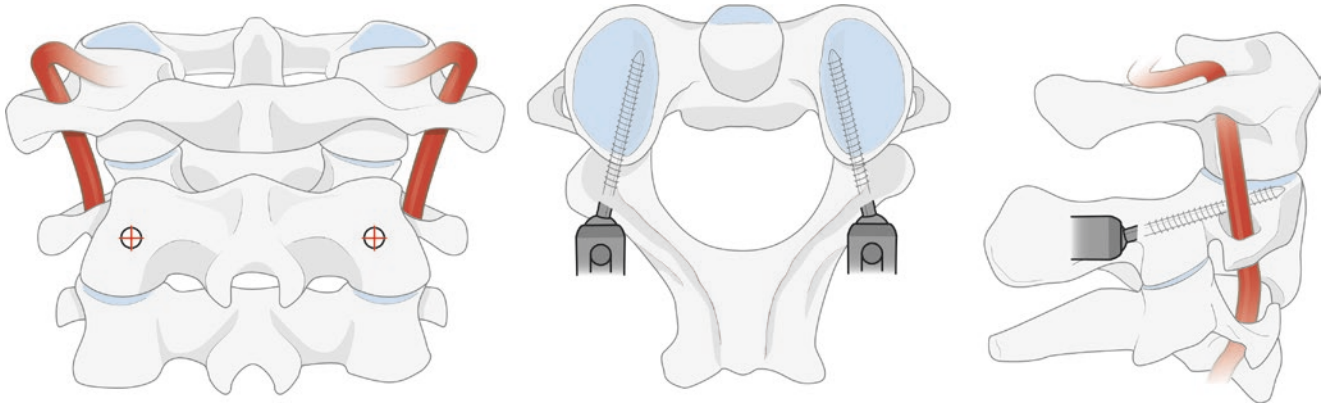
**Fig. 6.10** C1 lateral mass screws positioning

### 6.2.2.2 C2 Pedicle Screws (Judet)

Entry point is identified determining the medial cortex of the isthmus and halfway between the upper and lower articular surfaces of C2 (Fig. 6.11).

Trajectory is oriented 20–30° cephalad and 15–25° medially as checked clinically by palpation of the medial wall of the isthmus of C2.

On its trajectory to the C2 body, the course of the vertebral artery is traversed, and therefore this structure is at risk for injury. Careful preoperative planning is needed because at least 8–10% of patients do not have anatomy that allows safe pedicle screw placement.



**Fig. 6.11** C2 pedicle screws positioning

### 6.2.2.3 C2 Translaminar Screw Fixation (Wright)

This alternative technique (Fig. 6.12), described in 2004, was meant to further decrease the risk for vertebral artery injury. Generally, this method is used if anatomical constraints preclude C2 screws' placement with other trajectories.

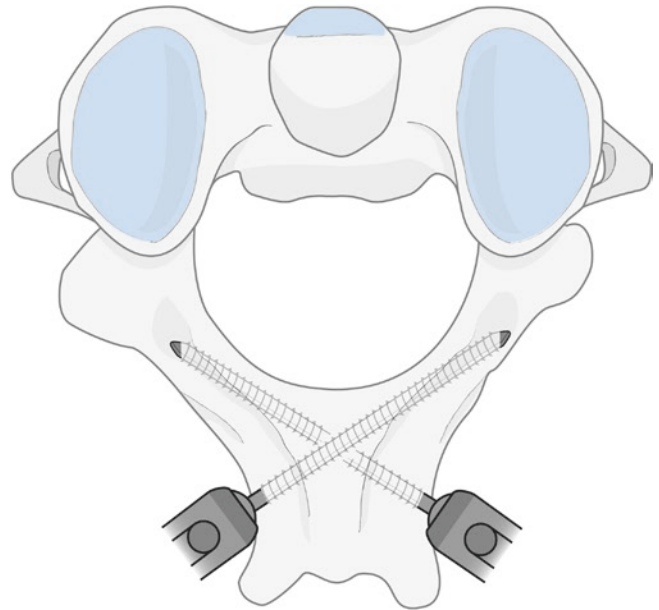
Although, there are other risks related to injuries the canal content (dura or spinal cord), when properly done, these are small. Two screws are inserted through the base of the C2

spinous process and contained within the lamina on the contralateral side.

Translaminar screws can be connected to C1 lateral mass screws providing a biomechanical equivalent construct to the Harms technique for C1-C2 fixation.

This is not true if fixation includes the occiput. If it is extended below C2, rod contouring can be problematic because the translaminar screws are not aligned with the sub-axial lateral mass screws.

**Fig. 6.12** Translaminar C2 screws

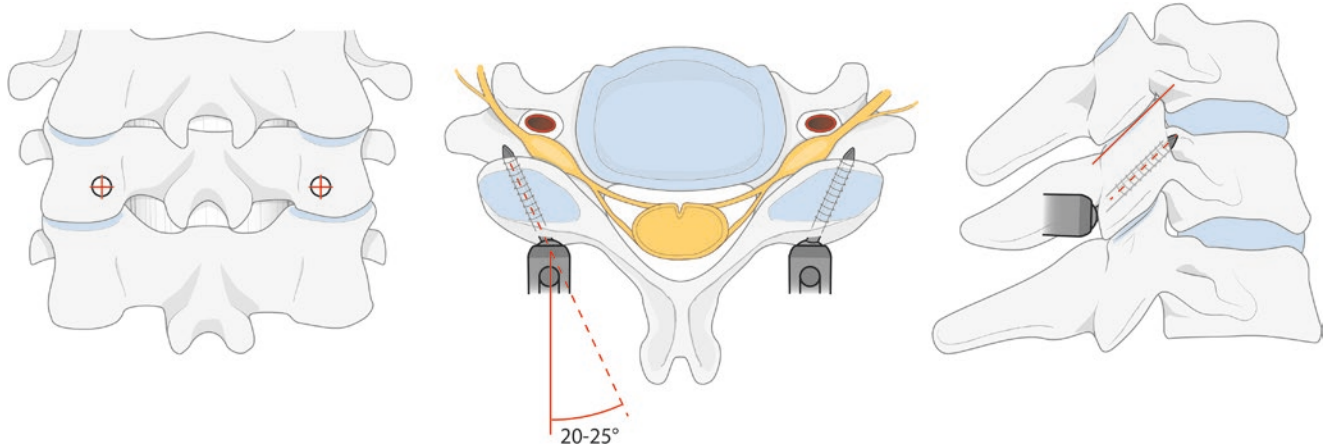


#### 6.2.2.4 Subaxial Lateral Mass Screws (Magerl)

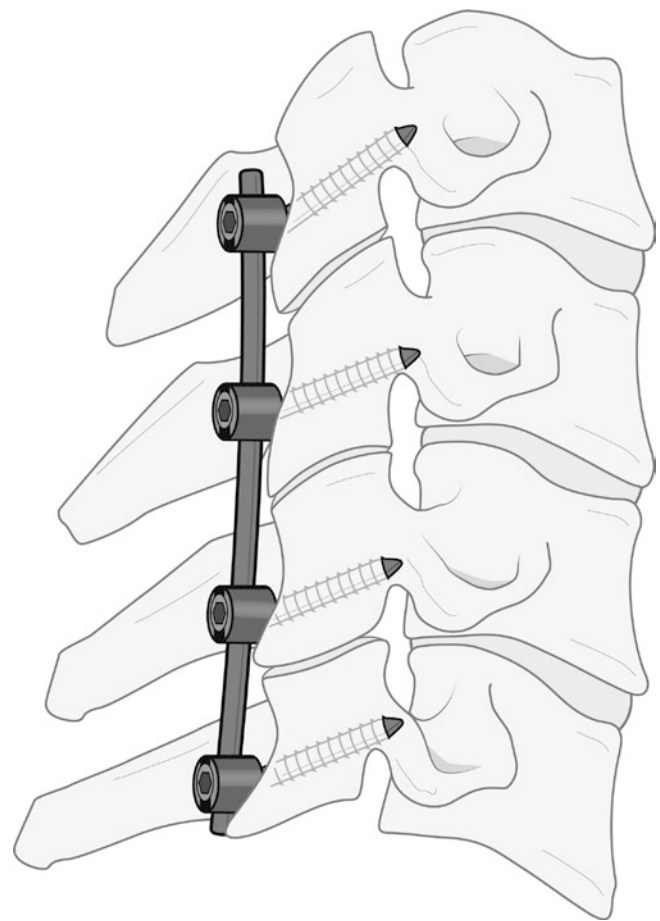
Lateral mass screws are placed by identifying the four boundaries of the lateral mass. Entry point is 1 mm medial and caudal to the geometric center of the lateral mass (Fig. 6.13). Penetrate the cortex using a high-speed burr.

Trajectory is oriented laterally and cephalad until the far cortex (ideally parallel to the joint line, Fig. 6.14).

Appropriate length is measured and screw is placed bicortically (unicortical 14-mm screws have been shown to provide satisfactory fixation, thus, can be used if needed).



**Fig. 6.13** Lateral mass screws positioning from C3 to C6 (Magerl technique)



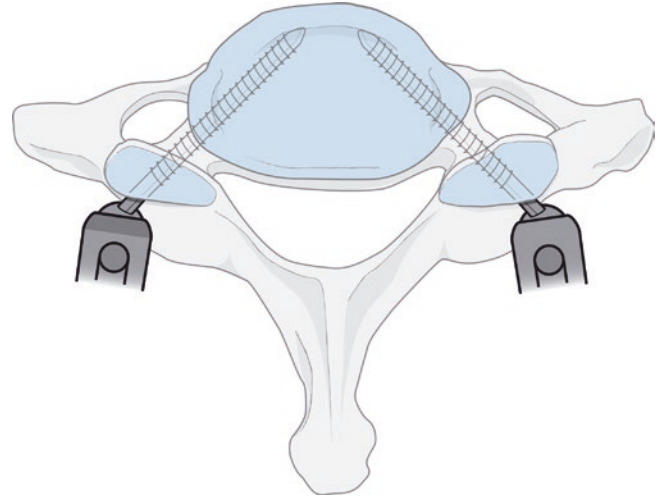
**Fig. 6.14** Posterior instrumented fusion with lateral mass screw-rod construct

### 6.2.2.5 C7 Transpedicular Screw

In case of small lateral masses, C7 can be fixed using transpedicular screws. Entry point is on the cranial part

of the middle third of the lateral aspect of the lateral masses. Trajectory is 45°convergent and slightly caudal (Fig. 6.15).

**Fig. 6.15** C7 transpedicular screws positioning



### 6.2.3 Laminoplasty

Laminoplasty is indicated to relieve multilevel compression on the spinal cord without causing iatrogenic instability (if properly performed) so supplemental fusion is not needed and cervical range of motion is preserved.

Lordotic sagittal alignment is required for posterior cervical canal expanding procedures, because the spinal cord must be free to drift posteriorly (which is not possible in patients with kyphotic alignment). Neutral sagittal alignment is a relative contraindication and should be considered on each patient individually. Flexion-extension radiographs may help to evaluate hypermobility, spondylolisthesis, or other evidence of cervical instability that may preclude the procedure.

The most popular techniques for laminoplasty are open-door laminoplasty and French-door laminoplasty. In the open-door technique, expansion of the spinal canal is achieved performing a complete opening at the level of the junction between the lateral mass and the lamina on one side, and a partial “greenstick-like” osteotomy on the contralateral side (which act as a hinge). The opening side of the lamina is chosen depending on symptoms.

In the French-door technique (Fig. 6.16), the spinous processes are splitted sagittally in the midline, and an incomplete hinge opening is made in both sides. The door is opened in the midline, and this creates a symmetric widening of the canal, which can be maintained using bone graft (resected laminae) or specifically designed plates.

#### 6.2.3.1 Kurokawa Modification

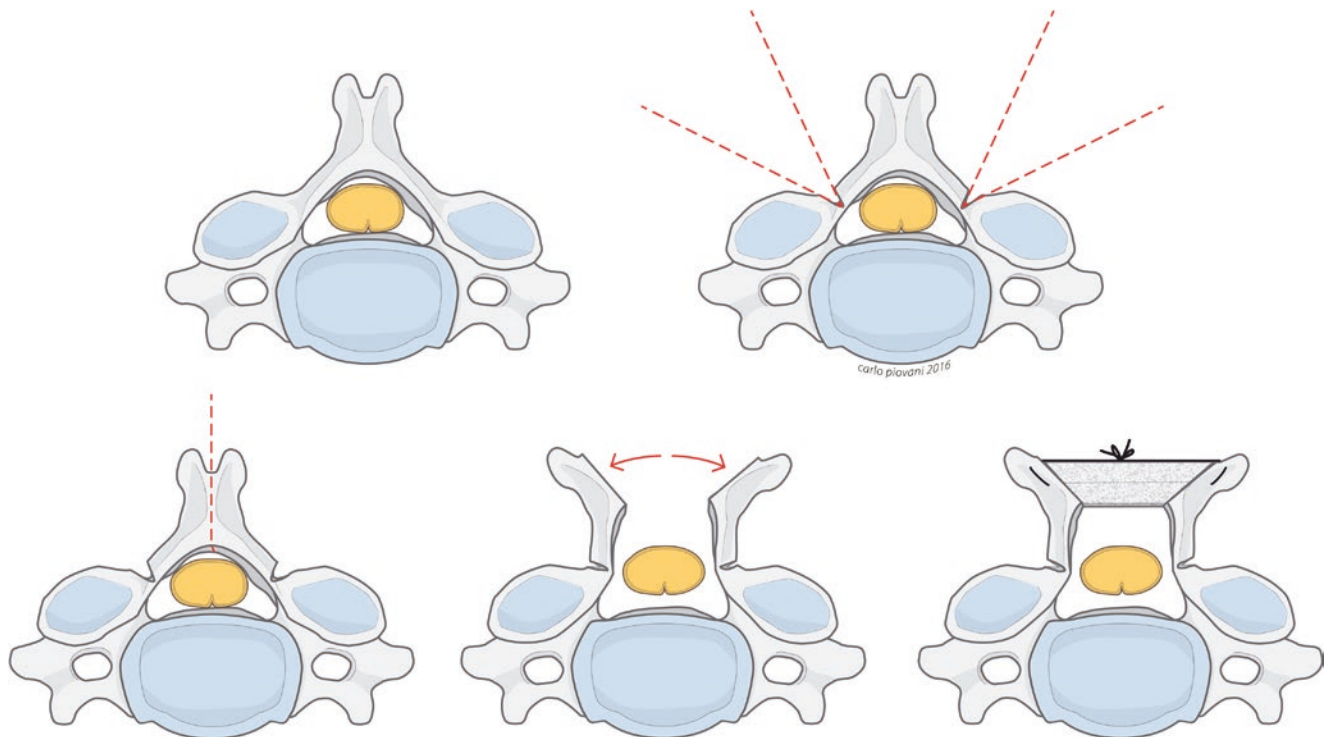
In this modification of the French-door technique, the dorsal aspect of the spinous processes is cut in the midline using a high-speed drill, removed and used as grafts to hold open the laminoplasty.

#### 6.2.3.2 Tomita Modification

In this modification, the spinous processes are split with a wire-saw. This has been termed the T-saw laminoplasty.

Foraminotomy may be indicated in addition to laminoplasty in the patients with concurrent symptomatic radiculopathy, or prophylactic, for prevention of postsurgical C5 palsy.

Performing the foraminotomy after laminoplasty on the hinge side puts the lamina at the risk of breaking. Care should be taken to preserve at least 50% of the facet joint to avoid instability.



**Fig. 6.16** Surgical steps for French-door laminoplasty

### 6.3 Focus on C1-C2 Fusion Techniques

#### 6.3.1 Posterior C1-C2 Wiring (Gallie technique; Brooks and Jenkins technique)

Wiring techniques are less rigid and have proven efficacy since they have been used for many years.

Nowadays, they are rarely used as primary method of stabilization, but they remain useful for adjunctive stabilization and to maintain corticocancellous graft in position.

These techniques are relatively easy to perform, but require integrity of posterior arch of C1.

The Gallie technique (Fig. 6.17) is less resistant against rotational forces because fixation is at the midline, while the Brooks and Jenkins technique uses bilaterally located wires which provide more rotational and tensile stability. In fact, it creates a bone block between the arch of C1 and the C2 lamina.

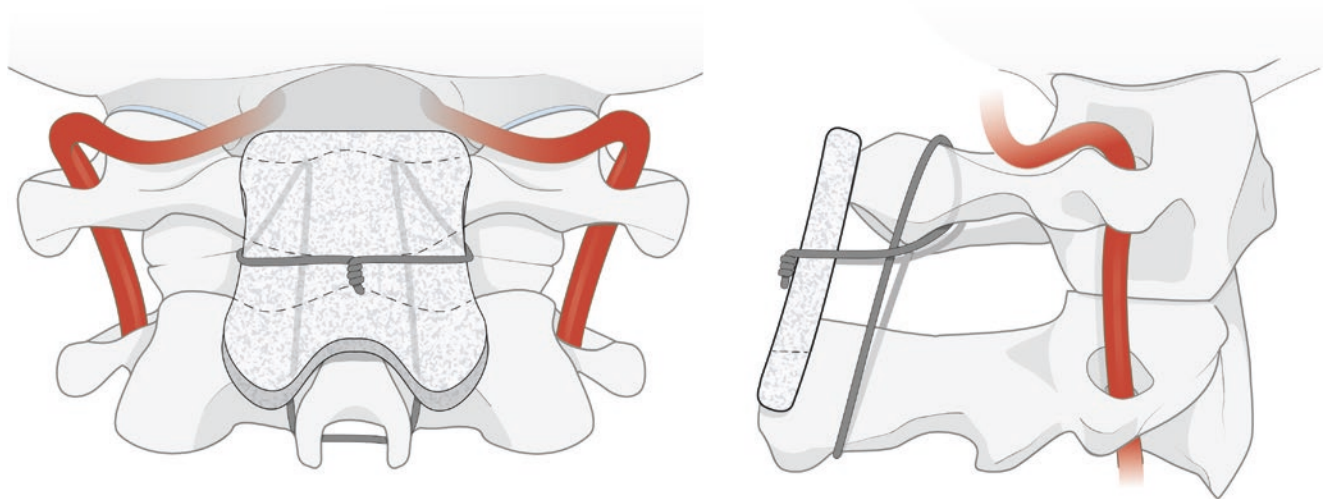
Gallie technique is particularly resistant to flexion-extension solicitations, but is less effective in limiting translation, lateral bending, and rotation forces.

The wire is passed from the inferior aspect of C1 cranially, looped over the superior aspect of C1, and then carefully pulled caudal until it is distal enough to be looped over the spinous process of C2.

The arch of C1 and the lamina of C2 are decorticated and a rectangular corticocancellous bone graft is removed from the iliac crest and fashioned into a H configuration to snugly fit around the spinous process and over the lamina of C2. The two free ends of the wire, which are laterally placed, are then brought across the midline after the graft has been applied to the posterior surfaces of C1 and C2.

Violation of the canal exposes the spinal cord at risk of damage during the procedure (Brooks and Jenkins more than Gallie technique), especially if there is any degree of subluxation between vertebrae.

When used as a primary fusion method, halo vest immobilization is continued for 10–12 weeks.



**Fig. 6.17** Posterior C1-C2 wiring (Gallie technique)

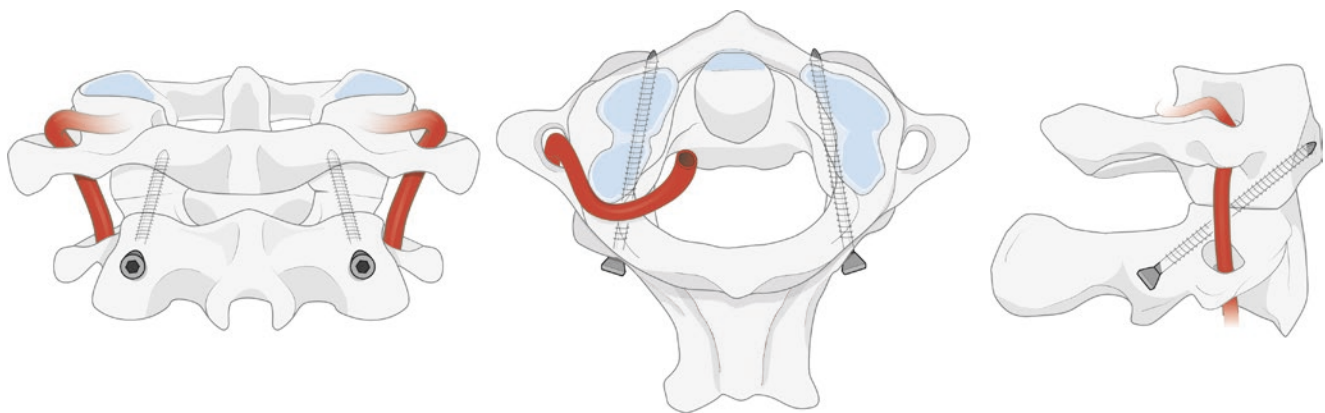
### 6.3.2 Posterior C1-C2 Transarticular Screws (Magerl and Seeman)

More stable than wiring techniques (to whom may be easily combined) and does not necessitate integrity of the posterior arch. Nonetheless, it is technically difficult and requires perfect reduction of C1-C2 before screw insertion.

The atlanto-axial joints are exposed by opening the posterior capsule, thus, making the C1-C2 joint visible. The articular cartilage of the posterior half of the facet joint is removed with either a small chisel or a sharp curette, after which the joints are packed with cancellous bone and the screws are inserted.

The entry point of the screw is at the lower edge of the caudal articular process of C2, 3 mm above the C2-C3 joint

line. The trajectory (Fig. 6.18) goes through the isthmus near to its posterior and medial surface in a strictly sagittal direction. It then enters the lateral mass of the atlas close to its posteroinferior edge. Anteriorly, the drill perforates the cortex of the lateral mass of C1. The internal carotid artery and the hypoglossal nerve, which typically lie less than 3 mm anterior to the C1 lateral mass, can be injured if the screw is too long. Drilling in horizontal direction must be avoided in order to protect the vertebral artery which runs upward anteriorly to the C1-C2 joint and could easily be damaged at the level of C2. A firm collar may be worn for 8–12 weeks, but patients are allowed to remove the collar for daily care. Aberrant trajectory of the vertebral artery may render it impossible.



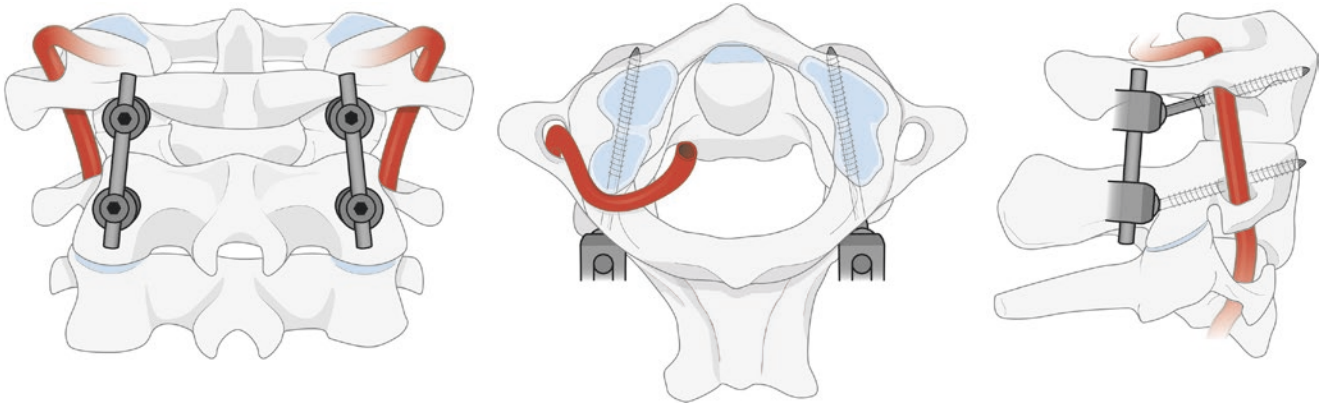
**Fig. 6.18** Posterior C1-C2 transarticular screws (Magerl and Seeman)



### 6.3.3 Posterior C1-C2 Fusion Using Rod and Polyaxial Screw Construct (Harms Technique)

Fixation using screw rods technique (Fig. 6.19) provides the more rigid fixation method.

Postoperatively, a rigid cervical orthosis must be worn for 8–12 weeks, but patients are allowed to remove the collar for daily care. If additional posterior wiring has been used, a soft collar can be worn instead of a firm collar.



**Fig. 6.19** Posterior C1-C2 stabilization using polyaxial screws (Harms technique)

## References

1. Harms J, Melcher RP (2001) Posterior C1-C2 fusion with polyaxial screw and rod fixation. *Spine (Phila Pa 1976)* 26(22):2467–2471
2. Melcher RP, Puttlitz CM, Kleinstueck FS, Lotz JC, Harms J, Bradford DS (2002) Biomechanical testing of posterior atlantoaxial fixation techniques. *Spine (Phila Pa 1976)* 27(22):2435–2440
3. Puttlitz CM, Melcher RP, Kleinstueck FS, Harms J, Bradford DS, Lotz JC (2004) Stability analysis of craniovertebral junction fixation techniques. *J Bone Joint Surg Am* 86-A(3):561–568
4. Robinson RA, Smith G (1955) A nterolateral cervical disc removal and interbody fusion for cervical disc syndrome. *Bull Johns Hopkins Hosp* 96:223–224
5. Cloward RB (1958) The anterior approach for removal of ruptured cervical disks. *J Neurosurg* 15(6):602–617
6. Lowery GL, McDonough RF (1998) The significance of hardware failure in anterior cervical plate fixation. Patients with 2- to 7-year follow-up. *Spine (Phila Pa 1976)* 23(2):181–186. discussion 186–7
7. Malloy KM, Hilibrand AS (2002) Autograft versus allograft in degenerative cervical disease. *Clin Orthop Relat Res* 394:27–38
8. Bolesta MJ, Rehtine GR 2nd, Chrin AM (2000) Three- and four-level anterior cervical discectomy and fusion with plate fixation: a prospective study. *Spine (Phila Pa 1976)* 25(16):2040–2044. discussion 2045–6
9. Chou YC et al (2008) Efficacy of anterior cervical fusion: comparison of titanium cages, polyetheretherketone (PEEK) cages and autogenous bone grafts. *J Clin Neurosci* 15(11):1240–1245
10. Fransen P (2010) A simplified technique for anterior cervical discectomy and fusion using a screw-plate implanted over the Caspar distractor pins. *Acta Orthop Belg* 76(4):546–548
11. Hauerberg J et al (2008) Anterior cervical discectomy with or without fusion with ray titanium cage: a prospective randomized clinical study. *Spine (Phila Pa 1976)* 33(5):458–464
12. Emery SE, Fisher JR, Bohlman HH (1997) Three-level anterior cervical discectomy and fusion: radiographic and clinical results. *Spine (Phila Pa 1976)* 22(22):2622–2624. discussion 2625
13. Song KJ, Lee KB (2006) A preliminary study of the use of cage and plating for single-segment fusion in degenerative cervical spine disease. *J Clin Neurosci* 13(2):181–187
14. Beutler WJ, Sweeney CA, Connolly PJ (2001) Recurrent laryngeal nerve injury with anterior cervical spine surgery risk with laterality of surgical approach. *Spine (Phila Pa 1976)* 26(12):1337–1342
15. Jung A, Schramm J (2010) How to reduce recurrent laryngeal nerve palsy in anterior cervical spine surgery: a prospective observational study. *Neurosurgery* 67(1):10–15. discussion 15
16. Palit M et al (1999) Anterior discectomy and fusion for the management of neck pain. *Spine (Phila Pa 1976)* 24(21):2224–2228

M. Ghirelli, F. Mattioli, G. Molinari, I. Cena, and L. Presutti

This procedure allows creating a reversible connection between the tracheal lumen and the skin.

Normally, tracheotomy is performed to guarantee safe ventilation after airways surgery or extensive neck surgery. Tracheotomy is mandatory in all surgical procedures at high risk of neck oedema or acute airway compromise.

In cervical spine surgery, the indications to tracheotomy are essentially correlated to avoid an upper airway

obstruction (actual or potential). This event might occur in surgery involving:

- Multilevel approach to cervical spine from C3 to C6 (the retropharyngeal space is located at this level)
- Anterior and posterior combined approach
- Transmandibular approach to upper cervical spine with median lingual split

---

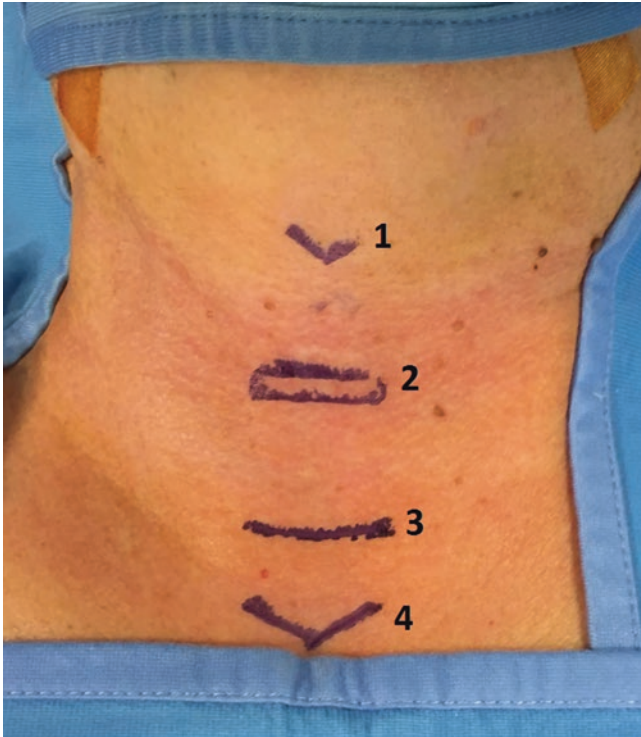
M. Ghirelli (✉) • F. Mattioli • G. Molinari • I. Cena • L. Presutti  
Head and Neck Surgery Department, University Hospital of  
Modena, Modena, Italy  
e-mail: [michael.ghirelli@gmail.com](mailto:michael.ghirelli@gmail.com)

## 7.1 Surgical Technique

The patient is placed on supine position, with the head extended using a shoulder roll.

Hyperextension of the neck is mandatory to obtain an optimal exposition of surgical landmarks.

### 7.1.1 Landmarks on the Skin

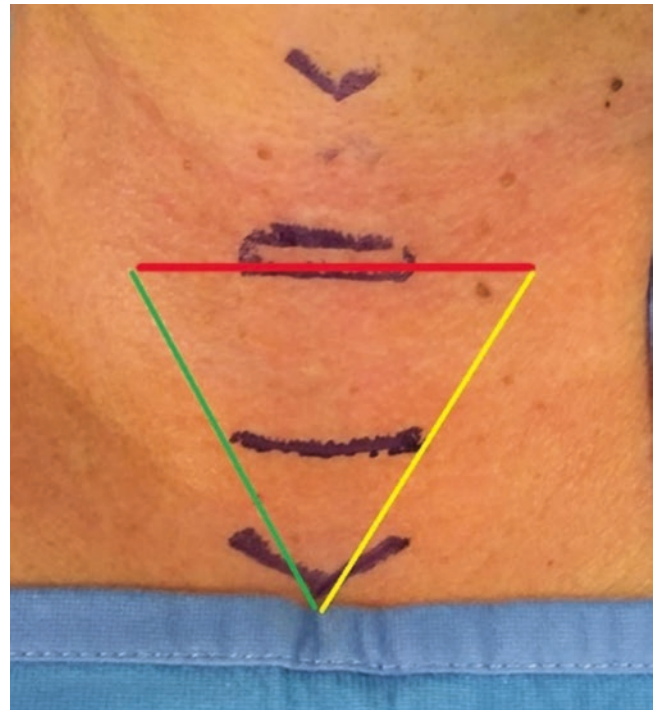


**Fig. 7.1** Identification of skin landmarks before incision

The surgeon has to identify (Fig. 7.1):

1. *Notch of thyroid cartilage*
2. *Cricoid cartilage*
3. *Skin incision line*
4. *Suprasternal notch*

### 7.1.2 1st Surgical Step: Incision of the Skin



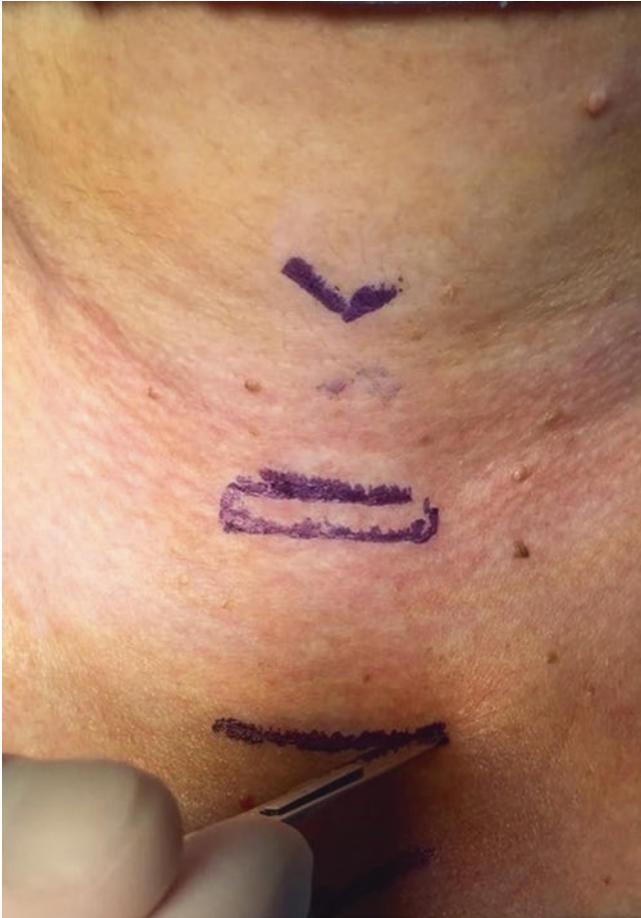**Fig. 7.2** Ideal triangle formed by cricoid cartilage, suprasternal notch and SCM

#### 7.1.2.1 Anatomical Key Points (Fig. 7.2)

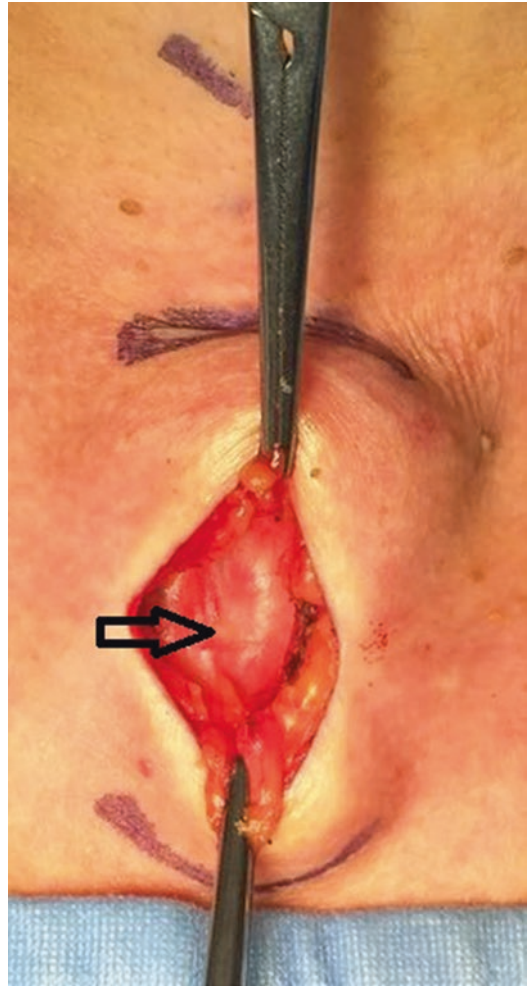
- Cricoid cartilage
- Suprasternal notch
- Sternocleidomastoid muscle (*SCM*)

### 7.1.2.2 Pearls and Potential Complications

The surgeon normally performs a 3–4 cm horizontal skin incision (Fig. 7.3). The incision is usually placed at least two fingerbreadths below the cricoid cartilage in an inverse triangular space formed by the cricoid cartilage (red line) at the base, the suprasternal notch at the apex and SCM in the lateral border (yellow and green line). The identification of the anterior jugular vein on the skin is useful to prevent its accidental section. The incision must involve the skin, subcutaneous tissue and platysma muscle until exposure of SLDCF (Fig. 7.4).



**Fig. 7.3** Skin incision with 15 or 10 blade



**Fig. 7.4** The black arrow shows SLDCF

### 7.1.3 2nd Surgical Step: Incision of SLDCF and Identification of Median Line

The incision of SLDCF is performed in order to identify the so-called strap muscles.

#### 7.1.3.1 Anatomical Key Points

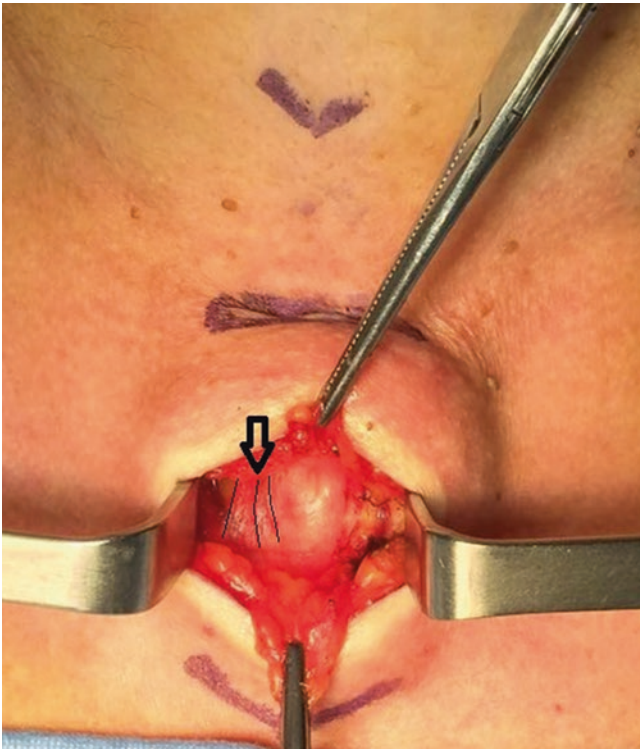
- Sternohyoid muscles
- Sternothyroid muscles

#### 7.1.3.2 Pearls and Potential Complications

The sternohyoid muscle is more superficial than the sternothyroid (Fig. 7.5).

The surgeon has to identify the midline between the strap muscles. This region is an aponeurotic space that has to be dissected. Principal complications are related to incorrect localization of the midline and consequent dissection lateral to the trachea.

In order to identify the midline more easily, the surgeon should always check the localization of the laryngeal axis and the trachea by palpation.



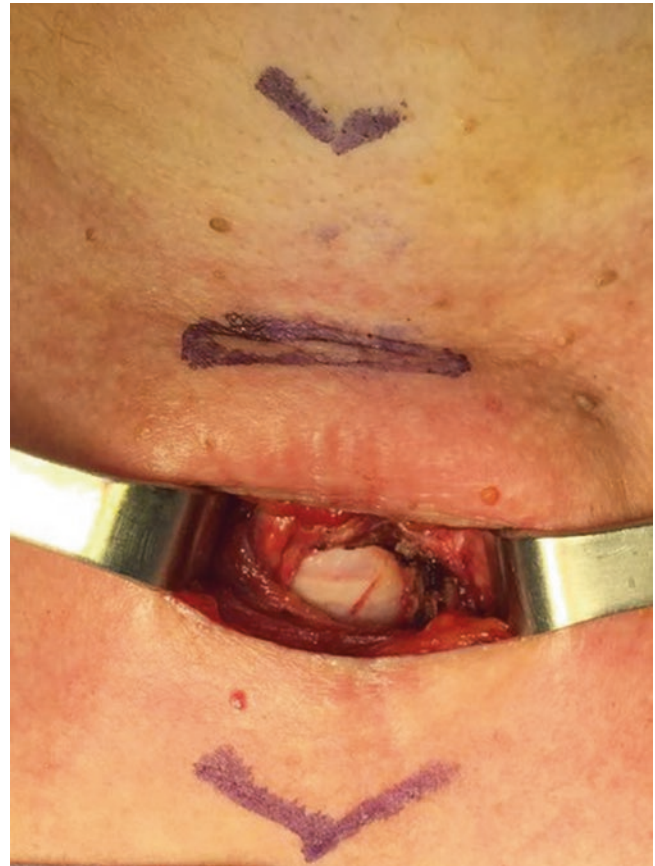
**Fig. 7.5** Identification of sternohyoid and sternothyroid muscle on the right side (black arrow)

### 7.1.4 3rd Surgical Step: Incision of MLDCF and Identification of Thyroid Gland and Trachea

Below the strap muscles, along the midline, we can find the isthmus of the thyroid gland (Fig. 7.6).

If the isthmus covers a large portion of the trachea, it is necessary to ligate the thyroid vessels and perform isthmus dissection before tracheotomy procedure (transisthmus tracheotomy).

Normally, the tracheotomy is positioned below the isthmus.



**Fig. 7.6** Thyroid isthmus is not prominent (on each side strap muscles are visible)

### 7.1.5 4th Surgical Step: Incision of the Trachea

The cricoid should be palpated to establish the correct level of the tracheal incision.

The tracheotomy could be performed in two ways:

- By a linear incision between the second and third ring of the trachea
- By an inferiorly based flap, consisting of the anterior portion of a single tracheal ring being sutured to the inferior skin margin
- The choice between the two techniques depends on several factors (Table 7.1)

**Table 7.1** How to choose tracheotomy technique

| Liner incision  | Inferiorly based flap  |
|---|--|
| Normal position of the trachea  | Deeper position of the trachea                                     |
| Management of the tracheotomy requires the presence of an ENT surgeon or an anaesthesiologist | No-ENT or anaesthesiologist management of the tracheotomy required |
| First neck surgery/no neck scars  | Previous neck surgery/neck scars                                   |
| Thin neck   | Thick and short neck   |
| Absence of thyroid goitre   |  |

#### 7.1.5.1 Pearls and Possible Complications

Caustication of the incision line with bipolar forceps is useful to prevent bleeding and to dissect the fascia surrounding the trachea (Fig. 7.7).

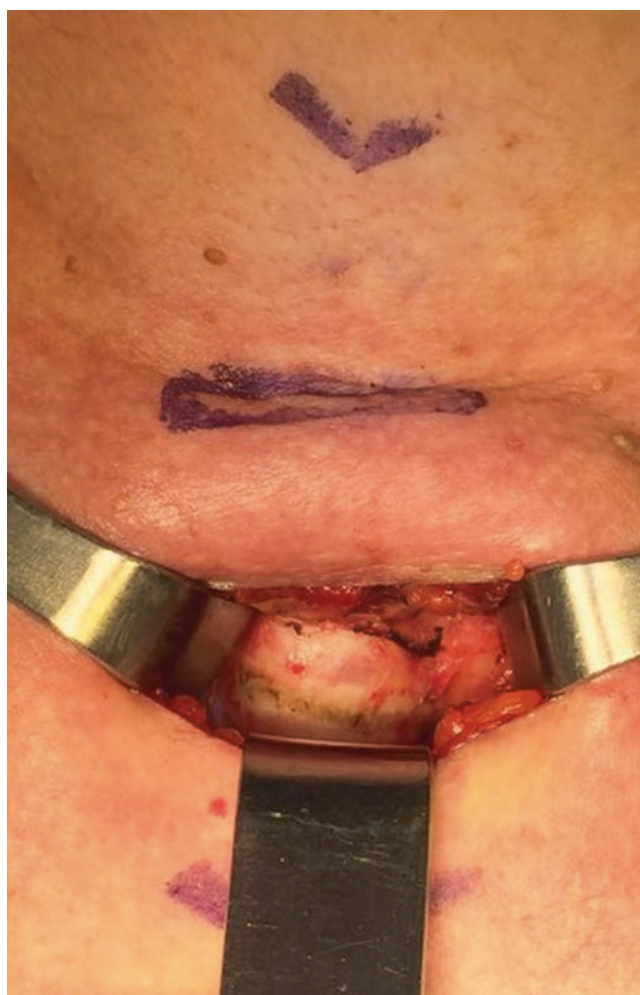
The preliminary incision on the anterior wall of the trachea has to involve only the membranous part of it, in order to prevent perforation of the cuff of the anaesthesiology tube.

The monopolar blade is useful to perform this step (Fig. 7.8 a, b). Tracheotomy should be then completed with surgical scissors (Fig. 7.9).

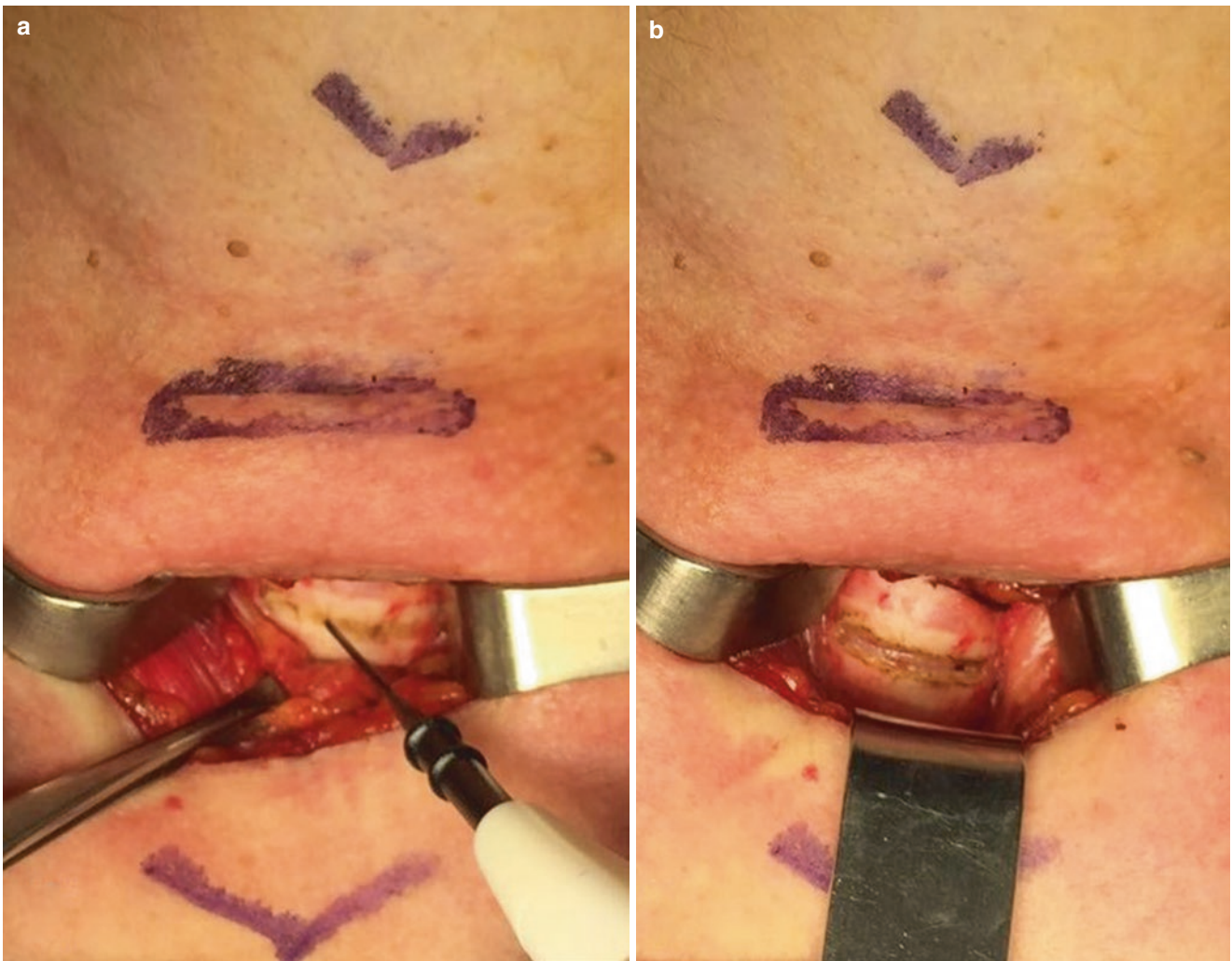After performance of complete tracheal incision, a Killian speculum is inserted to open the tracheal lumen safely (Fig. 7.10a).

A special curved endotracheal tube (Montandon endotracheal tube) is introduced in the gap to assure continuation of anaesthesia and later replaced by a tracheotomy tube at the end of the surgery (Fig. 7.10b).

The tracheotomy tube is sutured to the skin as an additional precaution to prevent accidental dislodgement of the tube. To avoid subcutaneous emphysema, pneumothorax and infection, the tracheotomy wound is never closed tightly around the tube.

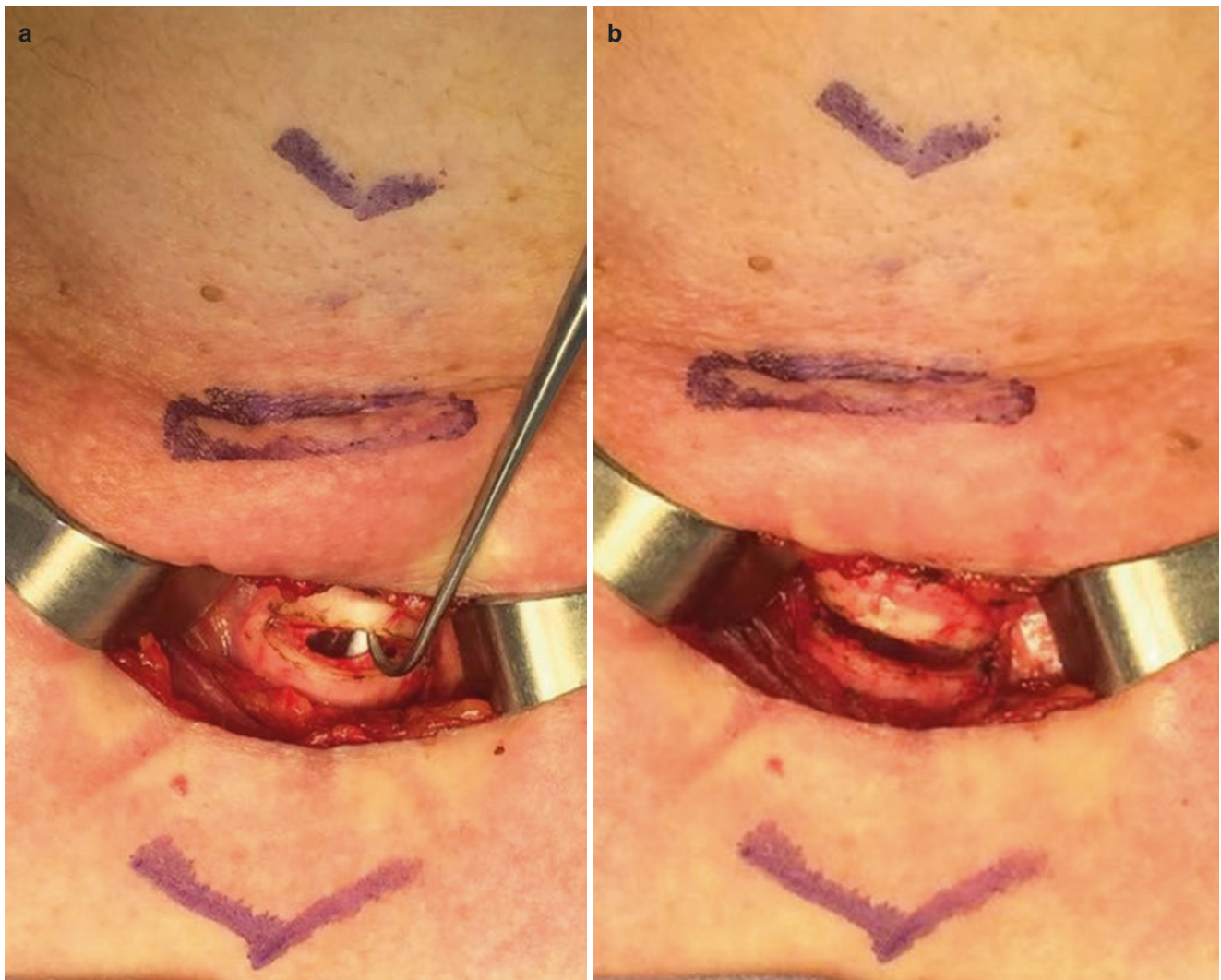


**Fig. 7.7** Cauterization of tracheal incision line before actual incision

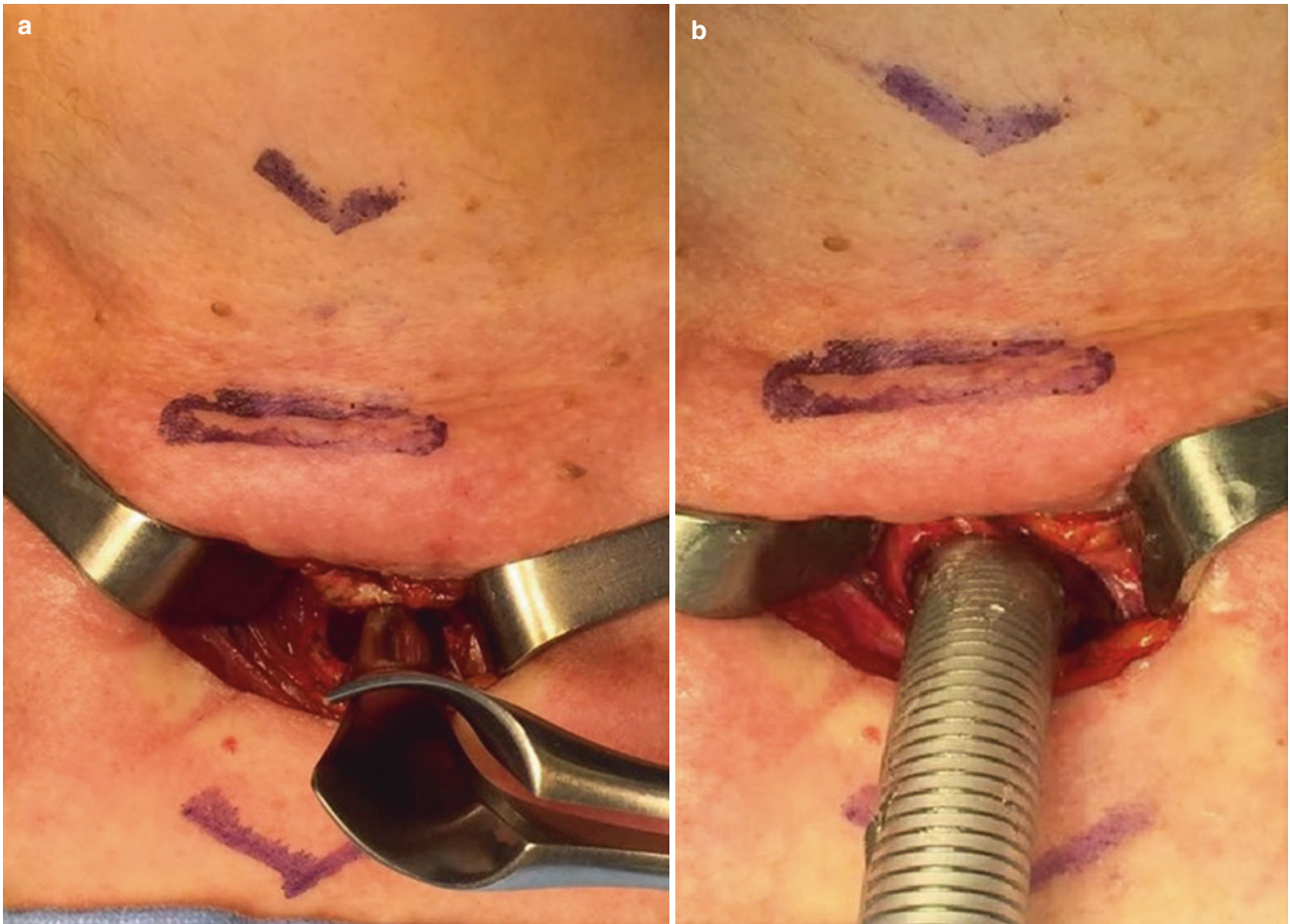


**Fig. 7.8** (a) Use of fine monopolar blade (b) Incision of the membranous part of the tracheal ring





**Fig. 7.9** (a) A hook could help separating tracheal rings; (b) Appearance of complete tracheal incision, after removal of the anesthesia tube



**Fig. 7.10** (a) Use of Killian to enlarge the tracheal window; (b) Montandon endotracheal tube positioning

S. Boriani, R. Ghermandi, M. Girolami, and A. Gasbarrini

## 8.1 Epidemiology

Primary bone tumors of the spine are very rare [1]; they comprise only 10% or less of all bone tumors. In the United States, about 7,500 new cases are estimated per year. The overall world occurrence can be expected 2.5–8.5 cases per million inhabitants per year. Compared to primary spinal tumors, metastatic tumors are much more common in the spine: the spine is the most common skeletal region for secondary tumors. Basic knowledge about diagnosis and treatment strategy must be known for early recognition of a spine tumor. Further, diagnostic elements to differentiate primary from metastatic tumor are required.

## 8.2 Clinical Findings and Imaging

In the common population, back and neck pain related to activity are very frequent symptoms, particularly in the adults, and mostly related to disk prolapse, degenerative changes, and spondylolisthesis. These symptoms should be first approached with exercise, pain killer, and postural rehabilitation.

Only rarely a primary tumor can be suspected on symptoms and clinical findings. Pain is the most frequent onset symptom, but less common compared to metastases; cord compression and pathological fracture occur as well less frequently.

Latent lesions (most of hemangiomas, fibrous dysplasia, exostosis) are asymptomatic by definition, and diagnosis is achieved incidentally on imaging performed for other reasons.

Cases of incidental detection of chordoma are also reported. This malignant tumor is characterized by very slow

growth; when arising in the sacrum, it can be diagnosed late, once already by large size.

Painful torticollis in an adolescent is strongly suggesting for osteoid osteoma or osteoblastoma located in the cervical spine, mostly not visible on standard radiograms, and technetium isotope bone scan helps to localize the lesion: CT scan – performed at the level of intense uptake – displays the pathognomonic image of osteoid osteoma, a small island of pathologic ossification surrounded by a lytic halo and frequently by a wide reactive bone formation.

Imaging studies (CT scan and MRI) can delimitate diagnostic hypothesis as some patterns are quite peculiar. Giant cell tumor and Ewing sarcoma are lytic conditions; most osteosarcomas are characterized by extensile aggressive pathologic bone formation with fuzzy borders. Multicameral balloon-like pattern with double density content is typical of aneurysmal bone cysts. Infiltrating erosions inside the cancellous bone of a vertebral body arising from the posterior wall is suggestive of chordoma. Soft tissue masses arising from the posterior elements with rounded calcifications are typical of peripheral chondrosarcoma.

Angiography shows pathologic vascularity, and selective arterial embolization has become an indispensable tool to reduce intraoperative bleeding.

Histological diagnosis should always be achieved by biopsy, but clinical, laboratory, and imaging studies are important to orientate diagnosis and select the biopsy technique.

## 8.3 Biopsy

The target of a biopsy is to obtain a specimen of the tumor which is representative of the lesion and large enough to allow histological and ultrastructural analysis as well as immunologic stains. The surgeon must be able to recognize the vital part of the tumor and to discard the necrotic or reactive part. Culture results may also confirm or rule out infection.

S. Boriani (✉) • R. Ghermandi • M. Girolami • A. Gasbarrini  
Oncologic and Degenerative Spine Surgery Department,  
Rizzoli Orthopedic Institute, Bologna, Italy  
e-mail: [stefanoboriani@gmail.com](mailto:stefanoboriani@gmail.com)

Three traditional forms of spinal biopsy are available to the surgeon: incisional, by needle or trocar, and excisional.

A number of basic principles should be observed when performing incisional and excisional biopsy in order to prevent tumor contamination of the surrounding tissue, which is the major risk of biopsy. Transverse incisions and flaps should be avoided; the tumor should be approached in the most direct manner possible, but avoiding the anatomical interspaces (so-called *extracompartmental* spaces) commonly followed in orthopedic surgery. The approach should cross muscular structures.

If the planned definitive procedure is en bloc resection, the biopsy incision from the skin to the tumor mass should be placed so that it may be excised in a single bloc with the tumor and its margins. It is evident that in the spine – particularly in the cervical spine – these principles are extremely difficult and impossible to accomplish. When the tumor is growing in the posterior elements, it can be approached crossing the muscle, but when it is located in the vertebral body, this is impossible, and any open biopsy will necessarily contaminate one or more compartments.

Pathologic tissues should be handled carefully, hemostasis should be meticulous and a suture performed on all the anatomical layers. Bleeding from exposed bone or from uncauterized vessels and injured muscle will form a postoperative hematoma that may carry tumor cells beyond the margins of the intended excision and contaminate tissues far proximal or distal to the primary lesion. The margin of the soft-tissue mass is often the most helpful to biopsy, as central portions are frequently necrotic. The surgeon should take care not to crush or distort the specimen, so as to maintain its architecture.

Frozen section biopsy can be obtained during the excisional procedure when diagnosis is highly probable and must be just confirmed. This is frequently the case in cervical tumors.

Excisional biopsy can be considered only for conditions whose radiographic pattern is pathognomonic, for example, osteoid osteoma.

Trocar biopsies allow the minimal tumor contamination but are subject to sampling errors and provide small specimens for evaluation. The authors' preferred technique is biopsy by 12-gauge trocar performed under CT scan control. Trocar allows to remove carrots useful to study tumor histological architecture and to provide material for immunohistochemical studies. CT scan allows to reach even small lesions inside the vertebral body. In the cervical spine trocar biopsy can be performed by anterior approach prevascular or by posterior approach

Diagnosis should always be decided on histological diagnosis: biopsy is mandatory. Conversely some latent, asymptomatic lesions like hemangioma, fibrous dysplasia, and

exostosis are characterized by such a pathognomonic imaging that biopsy is not immediately necessary. In this case however, it is wise to follow the evolution of the disease by sequential imaging each 3–4 months to be fully aware of the latency of the condition.

## 8.4 Oncological Staging

Enneking in 1980 [2] proposed a system to stage the biological behavior of tumors of bone and soft tissue. Later on, this system was applied also to the spine [3–6]

This system divides benign tumors into three stages (named S1, S2, and S3) and localized malignant tumors into four stages (named IA, IB, IIA, and IIB). Two further stages include metastatic high-grade intra- and extracompartmental malignant tumors (named IIIA and IIIB, respectively). This classification is based on clinical features, radiographic pattern, CT scan/MRI data, and histological findings. Each of these is related to overall prognosis and by necessity is very much linked to categories of surgical procedures based on the concept of “margin” [7].

### 8.4.1 Benign Tumors

The first stage of benign tumor (S1, latent, inactive) includes asymptomatic lesions, bordered by a true capsule, which is usually seen as a sclerotic rim on plain radiograms. These tumors do not grow or only grow very slowly. No treatment is required, unless palliative surgery is needed for decompression or stabilization. Benign tumors stage 2 (S2, active) grows slowly, causing mild symptoms. The tumor is bordered by a thin capsule and by a layer of reactive tissue, sometimes found on plain radiograms as an enlargement of the tumor outline. Bone scan is positive. An intralesional excision can be performed with a low rate of recurrence. The incidence of recurrences can be lowered further by local adjuvants (cryotherapy, embolization, radiation therapy). The third stage of benign tumors (S3, aggressive) includes rapidly growing benign tumors: the capsule is very thin, discontinued, or absent. The tumor invades neighboring compartments, and a wide reactive hypervascularized tissue (pseudocapsule) is often found, sometimes permeated by neoplastic digitations. Bone scan is highly positive, fuzzy limits are seen on plain X-rays, CT scan shows extracompartmental extension, and MRI clearly defines a pseudocapsule and its relationship to the neurological structures. Intralesional excision (curettage), even if augmented by radiation, can be associated with a significant rate of local recurrence. En bloc excision is the treatment of choice.

### 8.4.2 Malignant Tumors

Low grade malignant tumors are included in Stage I, subdivided into IA (the tumor remains inside the vertebra) and IB (tumor invades paravertebral compartments). No true capsule is associated with these lesions, but a thick pseudocapsule of reactive tissue permeated by small microscopic islands of tumor is seen. A resection performed along the pseudocapsule often leaves residual foci of active tumor; megavoltage radiation or proton-beam therapy can be added to reduce the risk of recurrence. The treatment of choice – if feasible – is a wide en bloc resection. High grade malignancies are defined as IIA and IIB. The neoplastic growth is so rapid that the host has no time to form a continuous reactive tissue. There is continuous seeding with neoplastic nodules (satellites). Moreover, these tumors can have neoplastic nodules at some distance from the main tumor mass (skip metastases). These malignancies are generally seen on plain radiograms as radiolucent and destructive and in many cases are associated with a pathologic fracture. Invasion of the epidural space is rapid in stage B, particularly in small cell tumors (Ewing sarcoma, lymphomas) characterized by semifluid tissue, being able to occupy the epidural space after infiltrating the cortical border of the vertebra.

The margin of the resection must be wide (it is not possible to achieve a “radical” margin, in the spine), and courses of radiation and chemotherapy (according to the tumor type) must be considered for the local control and for the avoidance of distant spread. Several times the anatomical constraints prevent from achieving an appropriate margin.

Stages IIIA and IIIB describe the same lesions as IIA and IIB, but are associated with distant metastasis.

### 8.5 Margins and Surgical Planning

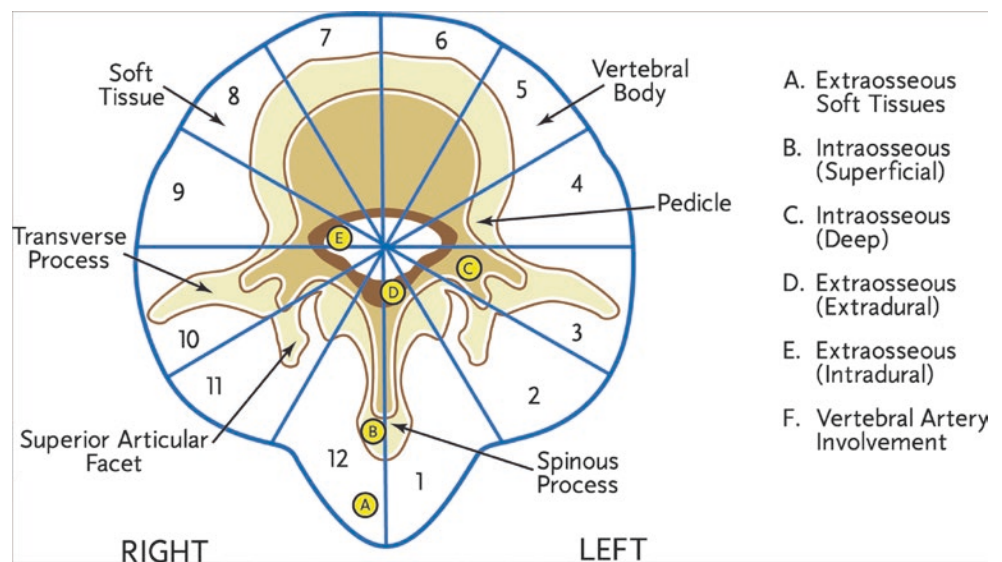
As staging must be based on the natural history, so surgical planning must be based on what the procedure achieves in relation to the margin of the lesion. Stener was the first [8] to apply to the spine these concepts; starting from the early 1970s he made exhaustive reports of “en bloc resections” in the spine. Later on, Roy-Camille [9] and Tomita [10] popularized the techniques of “en bloc resection” in the thoracic spine. The application of these principles to the cervical spine is technically demanding. Till now, the technique of performing en bloc resection in the cervical spine has not been standardized.

Since the latest 1980s, Weinstein and Boriani tried to focus on a unified classification that could start to discuss envelopes of resection as Enneking had done for the extremities by retrospectively reviewing his cases and making the most important discovery about margins of resection.

This system – called WBB (Weinstein, Boriani, Biagini) Staging System [11] (Fig. 8.1) – has been subjected to several clinical evaluations and recently submitted to a study of reliability and validity by an international multidisciplinary group of spine tumor experts [12] resulting in a moderate interobserver reliability and substantial intraobserver reliability.

WBB Staging System. On the transverse plane, the vertebra is divided into 12 radiating zones (numbered 1–12 in a clockwise order) and into 5 layers (A to E from the prevertebral to the dural involvement). The longitudinal extent of the tumor is recorded by identifying the specific vertebrae involved. This system allowed for a more rational approach to the surgical planning, provided that all efforts are made to perform surgery along the required margins.

**Fig. 8.1** WBB Surgical Staging System. (1) On the transverse plane, the vertebra is divided into 12 radiating zones (numbered 1–12 in a clockwise order) and into 5 layers (A to E from the prevertebral to the dural involvement)



## 8.6 Terminology

The application of a common terminology is mandatory to exchange informations and to compare the results among institutions. The term “vertebrectomy,” as currently used by some, describes both an intralesional eggshell excision [13], and many authors use the term “radical” [14, 15] to mean any surgical margin that does not contain tumor.

Obviously, if the same terms used to describe en bloc resection are also used to describe gross total complete excision, it is difficult and confusing to compare results.

To stress the importance of a common language, the terms proposed by Enneking are recalled.

## 8.7 Intralesional Excision

Intralesional excision means a piecemeal removal of the tumor (“curettage,” “gross total resection,” “debulking”). It is an intralesional procedure; the tumor is violated, and any chance of obtaining tumor-free margins is lost. This procedure is appropriate for stage 2 benign tumors and for metastases. Anterior and or posterior approach according to the commonly known surgical procedures can be performed at any spine level. Combination of approaches must be considered to maximize the tumor removal (so-called extracapsular excision, i.e., excision of the tumor capsule). Microscopic and possible macroscopic tumor is however always left after these procedures, and local progression can be expected according to the growing potential of the disease. Local adjuvants can be associated. These become mandatory if intralesional surgery is performed in cases where en bloc is the treatment of choice, but it is not feasible due to surgical and anatomical constraints.

The ischemic effect on the tumor mass provoked by selective arterial embolization must be considered to substantially reduce bleeding, thus strongly reducing intraoperative bleeding and associated complications and allowing the surgeon to complete the excision.

## 8.8 En Bloc Resection

It is the attempt to remove the tumor as a single intact whole, fully encased by a cuff of healthy tissue (a circumferential margin of tumor-free normal tissue). It requires that the pathologist’s confirms the resected tissue around the tumor mass (the so-called margin) is tumor free.

The effectiveness of the margin as a barrier depends on its quality and also on the aggressiveness of the tumor. The margin is defined as “wide” when the plan of dissection has been peripheral to the reactive zone through normal

tissue. Quality of the margin and thickness are relevant. A fascial barrier represents a wide margin, whereas 1 cm of muscle or cancellous bone may be inadequate to represent an appropriate barrier. The major issue in the decision-making process of planning en bloc resection concerns the possible functional sacrifices related to the quality of the structure to be resected in a whole with the tumor to achieve a wide margin. *Marginal margin* means that the plane of dissection has been performed along the reactive zone, very close to the tumor and that satellites of tumor may be left. *Intralesional margin* means that the tumor periphery is violated, and the tumor specimen is not covered by healthy tissue. *Radical*: this term should be applied to the en bloc removal of the tumor together with the whole compartment of origin. An example would be a thigh amputation for a tumor arising in the tibia. Or a scapulectomy for a tumor arising and still contained in the scapula. Consequently a radical resection in the spine defines to resect in bloc a full vertebra provided the tumor is fully confined inside the vertebra, including the spinal cord above and below. Even in this dramatic case, if the tumor has grown into the epidural space, the term radical will not be appropriate, as the epidural space is to be considered an extracompartmental area extending from the skull to the sacrum.

## 8.9 Palliative Procedure

This term describes all the surgical procedures generally directed toward a functional purpose (decompress the thecal sac, stabilize the spine) without any effective surgical removal of the tumor. Partial piecemeal removal of the tumor can be required to release the compression on the cord. An example could be the fixation of a pathologic fracture due to a mechanical collapse of a latent lesion or the decompression and fixation of a myeloma or other radio/chemo-sensitive lesion, later to be submitted for curative purpose to such oncologic treatments.

### 8.9.1 Surgical Techniques: En Bloc Resections in the Cervical Spine

The techniques of en bloc resection for tumors of the vertebral body in the thoracic and lumbar spine are well known [8–10, 16], while only single case reports of en bloc resections of cervical spine tumors have been published till now [17–20]. WBB staging system can be helpful in standardizing the surgical planning of en bloc resection according to different tumor extension and different spine regions. The great variability of these two parameters dictates that the

same surgical procedure cannot be performed in all cases and that surgical planning must be tailored on single case.

Under the guidance of WBB staging system, six different approaches or combinations of approaches have been proposed (ref), ending in a total of ten different types of surgery: only anterior; only posterior; anterior first, posterior second; posterior first, double anterior second and third; posterior first, combined anterior and posterior second; and anterior first, posterior second, combined anterior (contralateral) and posterior.

Three techniques of en bloc resection can be standardized in the cervical spine, considering three possibilities of tumor growing as criteria to achieve a tumor-free margin en bloc resection. In the author's opinion, different typology of tumor expansion will require violation of the tumor margin to save vital structures.

Single posterior approach is the obvious strategy to remove by en bloc resection a tumor arising in the posterior arch (Fig. 8.2). Criteria to achieve appropriate margins according to the WBB staging system (Fig. 8.1) include sectors 9 and 4 free from tumor. If the tumor grows in layer D, the margin will result intralésional during the release from the dura.

Three steps must be planned: the first provides the appropriate margin over the tumor posteriorly growing by resecting inside the posterior muscles which cover the tumor mass if it is expanding in layer A (I). The second step is a piecemeal excision of sectors 9 and 4 must be performed by the technique preferred: by high speed burr or ultrasound osteotome or alternatively an osteotomy can be performed by wire saw or chisel (II). Once a transverse laminotomy above and below is performed, the tumor is released from the dura, and the specimen is resected en bloc (III).

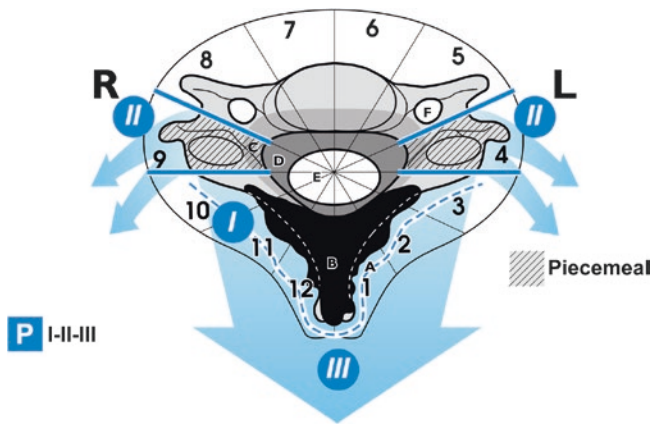
In cervical spine tumors partially occupying the vertebral body (not involving sectors 6 and 7, otherwise see Fig. 4) and the posterior arch (at least three sectors not involved) to perform en bloc resection aiming at achieving a tumor-free margin specimen, two approaches should be planned: anterior first and posterior second (Fig. 8.3).

Anterior approach is first performed to leave healthy tissue over the tumor growing in the lateral masses (I) and to perform a sagittal groove till the epidural space in the vertebral

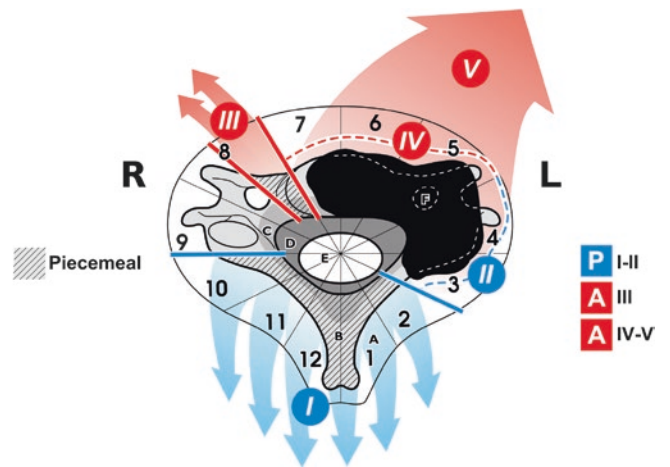
body (II). Diskectomies or transversal grooves in vertebral bodies are performed to define the upper and lower margins, including ligation of the vertebral artery.

The second stage is a posterior approach. Step III provides the appropriate margin over the tumor posteriorly growing by resecting inside the posterior muscles covering the tumor mass if it is expanding in layer A. Step IV is a piecemeal excision of the posterior arch not involved by the tumor. At least three sectors are required, starting from sector 4 or from sector 9. This allows to release of the dura from the tumor and section of the nerve root(s) involved by the tumor. Finally the specimen is removed – once the upper and lower diskectomies or osteotomies are finalized – by rotating around the dural sac (V). If the cervical tumor is particularly huge, extending over the midline, but not involving both vertebral arteries (Fig. 8.4), en bloc resection aiming to achieve a tumor-free margin can be planned, including three approaches: first posterior, second anterior contralateral to the tumor side, third anterior on the tumor side. A single wide anterior approach by transverse incision can be considered as well.

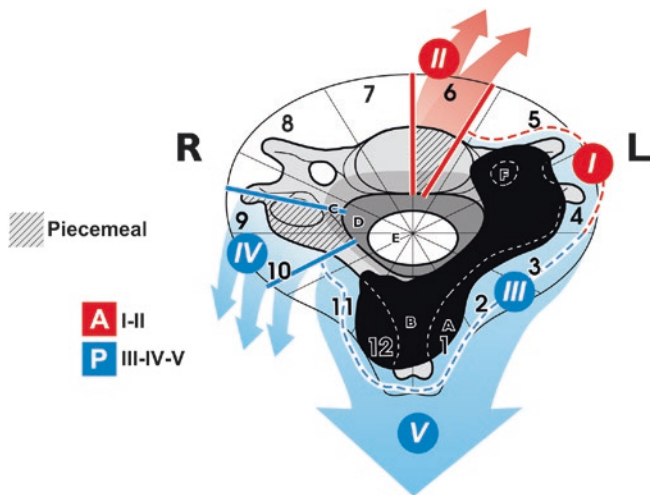
First stage is performed in prone position: the posterior arch not involved by the tumor is removed by piecemeal excision. At least three sectors are required, starting from sector 4 or from sector 9 (I) to allow the release of the dural sac and a safe manipulation. In case of tumor posteriorly growing, and invading layer A, an appropriate margin must be provided by resecting inside the posterior muscles covering the tumor mass (II). Then release the dura from the tumor (if the tumor grows in layer D, the margin will result intralésional) and section the nerve root(s) crossing the tumor. Second and third stages are performed in supine position. A sagittal groove is performed in the vertebral body not occupied by the tumor (III), till the vertebral artery, which must be saved as the other must be sacrificed as involved by the tumor. The anterior margin is provided by leaving healthy soft tissue over the tumor mass (IV). Diskectomies or transversal grooves in vertebral bodies are performed to define the upper and lower margins. The tumor is finally removed by the third approach (V), once the upper and lower diskectomies or osteotomies are finalized, including ligation of the vertebral artery.



**Fig. 8.2** Single posterior approach is the obvious strategy to remove by en bloc resection a tumor arising in the posterior arch. Criteria to achieve appropriate margins according to the WBB staging system (ref) include sectors 9 and 4 free from tumor. If the tumor grows in layer D, the margin will result intralesional during the release from the dura



**Fig. 8.4** If the cervical tumor is particularly huge, extending over the midline, but not involving both vertebral arteries, an en bloc resection aiming to achieve a tumor-free margin can be planned, including three approaches: first posterior, second anterior contralateral to the tumor side, third anterior on the tumor side. A single wide anterior approach by transverse incision can be considered as well



**Fig. 8.3** In cervical spine tumors partially occupying the vertebral body (not involving sectors 6 and 7, otherwise see Fig. 4) and the posterior arch (at least three sectors not involved) to perform en bloc resection aiming at achieving a tumor-free margin specimen, two approaches should be planned: anterior first and posterior second



## 8.9.2 Morbidity and Complications

The morbidity of en bloc resections in the cervical spine is very high. First the decision-making process has to inquire about the relationship between the functional loss consequent to the sacrifice of structures included in the tumor compared to the expected better result in terms of prognosis and expected survival of en bloc resection. The role of margins in tumor surgery has been established since many years [21, 22]. In the spine, data are available in the literature in case of chordoma [23], chondrosarcoma, and osteosarcoma. While the evidence in case of Ewing sarcoma is not so relevant [24, 25]

The possible complications include all those related to anterior spine surgery [26, 27] with those of major posterior spine surgery [28] including all the anaesthesiological problems related to a long duration procedures [29]. Specific morbidity of spine tumor surgery has been recently analyzed [30] concluding that complications are mostly connected to the manipulation of important and vital structures, as required by the need of removing the tumor en bloc with an appropriate margin of healthy tissue, sometimes contiguous to vital structures. Incomplete intraoperative control of hemodynamics and too short posterior fixation and lack of anterior support heavily affect the morbidity. Previous surgery or radiation and double combined approach increase the risk of complications, as scar dissection will expose to lesions of neighboring vascular, nervous, visceral structures. Among late complications, infection is particularly threatening, due to the wide exposure and the reduced immunocompetence of these patients.

Mortality is not negligible (2.2%). Radiation therapy did not result as a significant predictor of morbidity, but five of six patients who had a deep infection had been submitted to radiation therapy before surgery. The two cases of late dissection of the aorta occurred after RT (doses 42 and 44 Gy) was performed as an adjuvant after a vertebrectomy including anterior surgical approach and release of the aorta from the tumor<sup>41</sup>.

**Acknowledgments** The author acknowledges the outstanding contribution of Carlo Piovani for data collection and original drawings.

## References

- Chi JH, Ali B, Patrick H, Tim W, Jean-Paul W, Gokaslan ZL (2008) Epidemiology and demographics for primary vertebral tumors. *Neurosurg Clin N Am* 19:1–4
- Enneking WF, Spanier SS, Goodman MA (1980) A system for the surgical staging of musculoskeletal sarcoma. *Clin Orthop Relat Res* 153:106–120
- Boriani S, Capanna R, Donati D, Levine A, Picci P, Savini R (1992) Osteoblastoma of the spine. *Clin Orthop* 278:37–45
- Boriani S, Bandiera S, Biagini R, Bacchini P, Boriani L, Cappuccio M et al (2006) Chordoma of the mobile spine: fifty years of experience. *Spine* 31(4):493–503
- Hart RA, Boriani S, Biagini R, Currier B, Weinstein JN (1997) A system for surgical staging and management of spine tumors. A clinical outcome study of giant cell tumors of the spine. *Spine* 22:1773–1782
- Boriani S, De Iure F, Bandiera S, Campanacci L, Biagini R, Di Fiore M, Bandello L, Picci P, Bacchini P (2000) Chondrosarcoma of the mobile spine. Report on 22 cases. *Spine* 25:804–812
- Simon MA (1998) Surgical margins. In: Simon MA, Springfield D (eds) *Surgery for bone and soft tissue tumors*. Lippincott-Raven, Philadelphia, pp 77–92
- Stener B, Johnsen OE (1971) Complete removal of three vertebrae for giant-cell tumour. *J Bone Joint Surg Br* 53(2):278–287
- Roy-Camille R, Montpierre H, Mazel C, Saillant G (1990) Technique de vertebrectomie totale lombaire. In: Roy-Camille R (ed) *Rachis Dorsal et Lombaire Septieme Journees d'Orthopedie de la Pitié*. Masson, Paris, pp 49–52
- Tomita K, Kawahara N, Baba H, Tsuchiya H, Nagata S, Toribatake Y (1994) Total en bloc spondylectomy for solitary spinal metastases. *Int Orthop* 18(5):291–298
- Boriani S, Weinstein JN, Biagini R (1997) Spine update. A surgical staging system for therapeutic planning of primary bone tumors of the spine. A contribution to a common terminology. *Spine* 22:1036–1044
- Chan P, Boriani S, Fourny DR, Biagini R, Dekutoski MB, Fehlings MG et al (2009) An assessment of the reliability of the Enneking and Weinstein-Boriani-Biagini classifications for staging of primary spinal tumors by the Spine Oncology Study Group. *Spine* 34:384–391
- Magerl F, Coscia MF (1988) Total posterior vertebrectomy of the thoracic or lumbar spine. *Clin Orthop Relat Res* 232:62–69
- Fidler MW (1994) Radical resection of vertebral body tumours. A surgical technique used in ten cases. *J Bone Joint Surg Br* 76(5):765–772
- Mazel C, Grunenwald D, Laudrin P, Marmorat JL (2003) Radical excision in the management of thoracic and cervicothoracic tumors involving the spine: results in a series of 36 cases. *Spine* 28(8):782–792
- Boriani S (2000) Subtotal and total vertebrectomy for tumours. *Surgical techniques in orthopedics and traumatology*. Elsevier, Paris, Editions Scientifiques et Medicales
- Fujita T, Kawahara N, Matsumoto T, Tomita K (1999) Chordoma in the cervical spine managed with en bloc excision. *Spine* 24(17):1848–1851
- Rhines LD, Fourny DR, Siadati A, Suk I, Gokaslan ZL (2005) En bloc resection of multilevel cervical chordoma with C-2 involvement. Case report and description of operative technique. *J Neurosurg Spine* 2(2):199–205
- Currier BL, Papagelopoulos PJ, Krauss WE, Unni KK, Yaszemski MJ (2007) Total en bloc spondylectomy of C5 vertebra for chordoma. *Spine* 32(9):E294–E299
- Leitner Y, Shabat S, Boriani L, Boriani S (2007) En bloc resection of a C4 chordoma: surgical technique. *Eur Spine J* 16(12):2238–2242
- Talac R, Yaszemski MJ, Currier BL et al (2002) Relationship between surgical margins and local recurrence in sarcomas of the spine. *Clin Orthop* 397:127–132
- Bergh P, Gunterberg B, Meis-Kindblom JM, Kindblom LG (2001) Prognostic factors and outcome of pelvic, sacral, and spinal chondrosarcomas: a center-based study of 69 cases. *Cancer* 91(7):1201–1212
- Boriani S, Saravanja D, Yamada Y, Varga Peter P, Biagini R, Fisher Charles G (2009) Challenges of local recurrence and cure in Low grade malignant tumors of the spine. *Spine* 34(22S):S48–S57

24. Boriani S, Amendola L, Corghi A, Cappuccio M, Bandiera S, Ferrari S, Picci R, Di Fiore M, Gasbarrini A (2011) Ewing's sarcoma of the mobile spine. *Eur Rev Med Pharmacol Sci* 15:831–839
25. Sciubba DM, Okuno SH, Dekutoski MB, Gokaslan ZL (2009) Ewing and osteogenic sarcoma: evidence for multidisciplinary management. *Spine (Phila Pa 1976)* 34(22 Suppl):S58–S68
26. Faciszewski T, Winter RB, Lonstein JE, Denis F, Johnson L (1995) The surgical and medical perioperative complications of anterior spinal fusion surgery in the thoracic, lumbar spine in adults. A review of 1223 procedures. *Spine* 20:1592–1599
27. McDonnell MF, Glassman SD, Dimar JR, Puno HMR, Johnson JB (1996) Perioperative complications of anterior procedures of the spine. *J Bone Joint Surg Am* 78:839–847
28. Smith JS, Saulle D, Chen CJ, Lenke LG, Polly DW Jr, Kasliwal MK, Broadstone PA, Glassman SD, Vaccaro AR, Ames CP, Shaffrey CI (2012) Rates and causes of mortality associated with spine surgery based on 108,419 procedures: a review of the Scoliosis Research Society Morbidity and Mortality Database. *Spine (Phila Pa 1976)* 37(23):1975–1982
29. Di Fiore M, Lari S, Boriani S, Formaro G, Perin S, Malferrari A, Zanoni A (1998) Major vertebral surgery: intra- and postoperative anaesthesia-related problems. *Chir Org Mov* 83:65–72
30. Boriani S, Bandiera S, Donthineni R, Amendola L, Cappuccio M, De Iure F, Gasbarrini A (2010) Morbidity of en bloc resections in the spine. *Eur Spine J* 19:231–241

---

**Part III**

**Surgical Approaches**

# Surgical Approaches to CCJ (Endoscopic Transnasal-Transoral-Transcervical and Robotic Transoral Approach)

F. Mattioli, G. Molteni, M. Bettini, E. Cigarini, and L. Presutti

## 9.1 Introduction

This chapter is focused on the surgical approaches that are available for exposing lesions at the craniovertebral junction (CVJ). To reach the CVJ is necessary to cross anatomical regions that are the domains of several surgical subspecialties (neurosurgery, otolaryngology, and plastic/craniofacial surgery).

The surgeon should select an approach that allows the most extended operative field with the lowest rate of morbidity [12]. The location and extent of the lesion are the major determinants influencing selection of the appropriate cranial base approach.

When the skull base is considered in the axial plane, the CVJ can be approached from three directions:

- *Anteriorly*
- *Laterally*
- *Posteriorly*

Surgical approaches to the CVJ are classified (Fig. 9.1).

### Anterior Approach

- *Transcranial* (transfrontal, orbitozygomatic, pterional)
- *Transnasal* (transsphenoidal, transmaxillary, endoscopic)
- *Transoral* (transpalatal, buccopharyngeal, translabiomandibular, translabioglossomandibular, endoscopic)
- *Transcervical*

### Posterior Approach

- Suboccipital, retrosigmoid, extreme lateral

### Lateral Approach

- Translabyrinthine, transcochlear, presigmoid, subtemporal transpetrosal, preauricular infratemporal, preauricular transtemporal

The anterior approaches are best suited for extradural lesions. Attacking intradural pathology through one of these approaches risks contamination with pharyngeal organisms, meningitis, and cerebrospinal fluid (CSF) leaks.

Consequently, intradural lesions located laterally and lesions involving the temporal bone are better treated through a lateral approach, while intradural posterior lesions are reached through a posterior approach [7, 12].

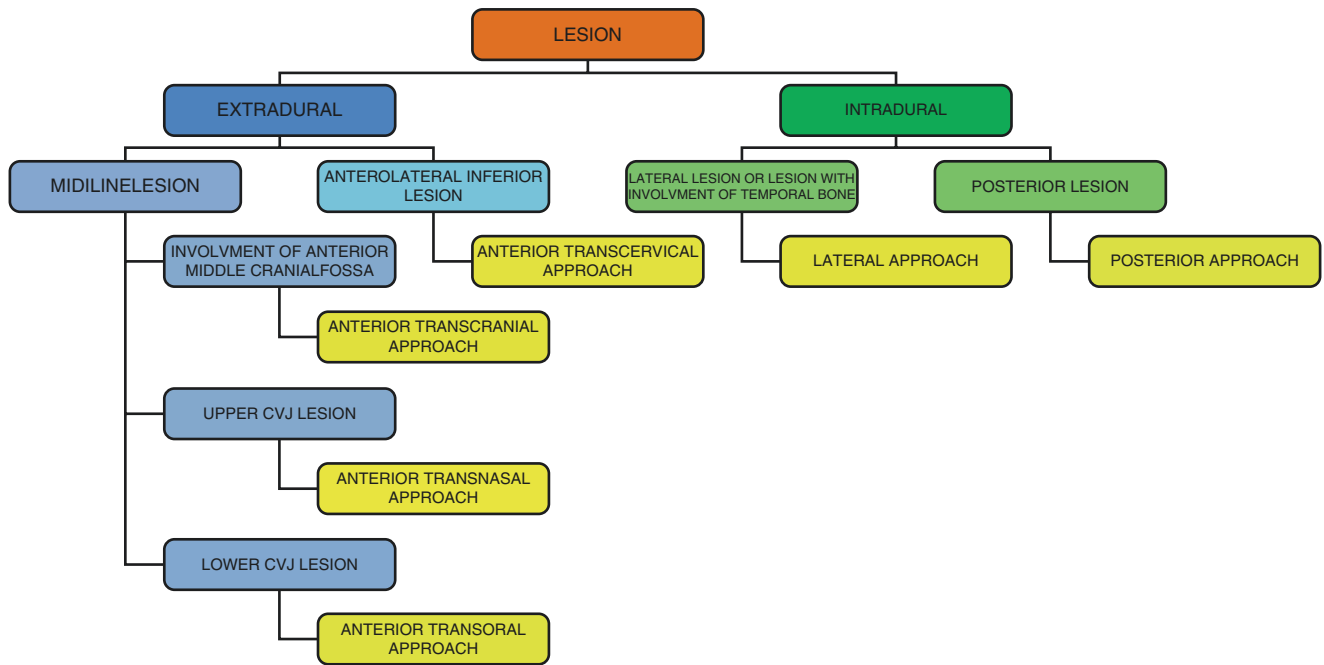
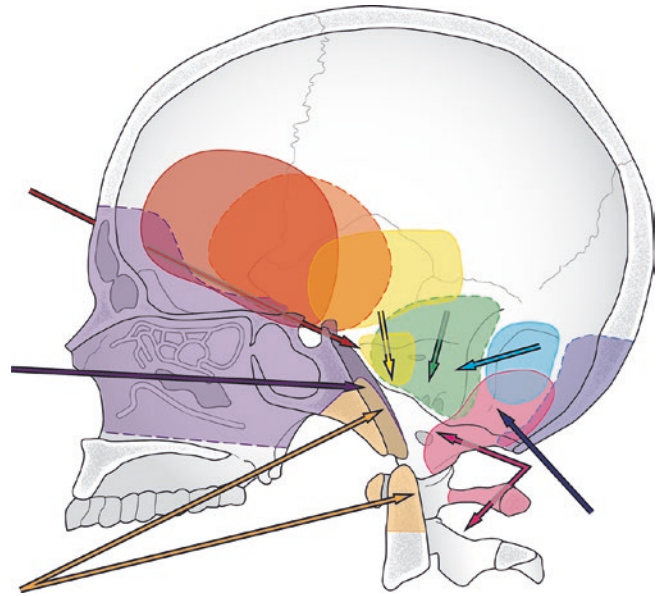
Details are shown in Fig. 9.2.

Our objective is to describe the anterior approaches performed by ENT and orthopedic surgical team, in particular, the minimally invasive endoscopic-assisted approaches.

Posterior and lateral approaches are not described in this chapter.

F. Mattioli (✉) • G. Molteni • M. Bettini • E. Cigarini • L. Presutti  
Head and Neck Surgery Department,  
University Hospital of Modena, Modena, Italy  
e-mail: [franz318@hotmail.com](mailto:franz318@hotmail.com)

**Fig. 9.1** Surgical approaches to CVJ



**Fig. 9.2** Selection of the approach according to the site of the lesion

## 9.2 Anterior Approaches

CVJ is a complex region which can harbor neoplastic, degenerative, or inflammatory lesions that can cause compression of the cervicomedullary junction and craniovertebral instability. Treatment may require surgical decompression and subsequent craniocervical stabilization.

Several surgical approaches provide anterior access to the craniocervical junction and the upper cervical spinal including transnasal, transoral, and high transcervical approaches.

In particular, anterior or anterolaterally located CVJ lesions have traditionally been most difficult to resect with high morbidity and mortality resulting from anterior traditional approaches. Recently the development of endoscopic surgery allowed to perform decompression of the craniovertebral junction with endoscopic transnasal-transoral techniques, even in patients with challenging anatomic features [14].

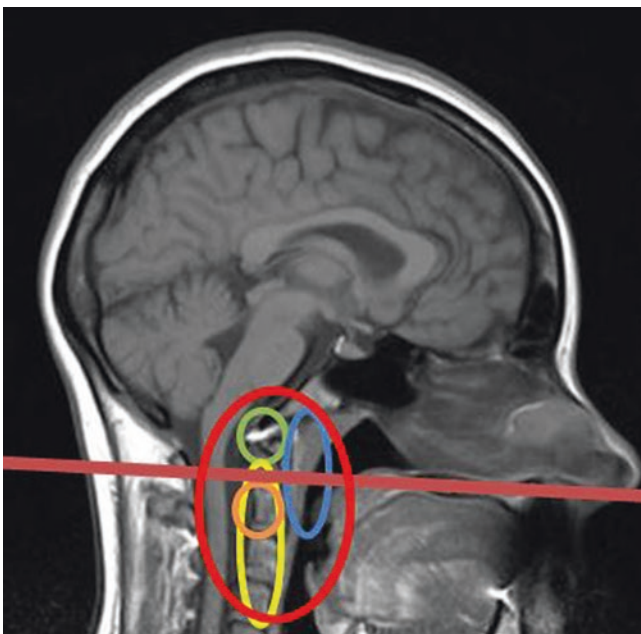
Preoperatively, estimate the superior extent of the exposure by drawing an imaginary line in the plane of the hard palate toward the craniovertebral junction on a sagittal MRI. If the lesion is midline and is situated above this line, a transnasal approach may be suitable. If, however, the lesion is situated below the plane of the hard palate, a transoral approach alone may be sufficient. Alternatively, consider a Le Fort I maxillotomy with or without a palatal split if the lesion extends above and below the plane of the hard palate. If the lesion extends inferiorly beyond the line of sight of a

standard transoral approach (roughly beyond the lower body of C2 to the C2–C3 disk space in most cases), a labiomandibular median glossotomy (transmandibular split) or cervical approach may be appropriate to gain more inferior exposure (Fig. 9.3) [11].

Transoral robotic surgery gets the opportunity to extend the approach along all upper cervical spine.

Prophylactic antibiotics are administered intraoperatively in transnasal and transoral approaches.

A high-resolution stereotactic computed tomography scan and MRI of the craniovertebral junction are necessary for preoperative planning. Moreover dynamic plain cervical radiographs in flexion and extension views to evaluate for preexisting instability at the craniovertebral junction are suggested. In some cases, the CVJ pathology has destabilized the occipitoatlantal or atlantoaxial joints, thus requiring a subsequent or prior stabilization procedure. If severe deformity or cranial settling is detected preoperatively, attempt reduction with cervical traction using Gardner-Wells tongs and mobilization in halo vest is recommended. Even if no instability is present, however, most cases will require stabilization after surgery because of postoperative iatrogenic instability [11]. Either occipitocervical or atlantoaxial stabilization can be performed postoperatively or simultaneously to the main procedure. Rarely ventral bone graft is placed intraoperatively into the bony defect because of high risk of infection, reabsorption, and dislodgement.



**Fig. 9.3** Preoperative estimate of exposure and choice of the approach: lesions suitable for transnasal approach (*green*), for transoral approach (*orange*), for maxillotomy with or without palatal split (*blue*), for labiomandibular median glossotomy or cervical approach (*yellow*), and for transoral robotic surgery (*red*)

### Take Home Messages

#### Advantages

- Low morbidity (endoscopic approaches)
- Direct extradural approach that does not require any brain retraction
- Low morbidity and mortality (traditional and extended approaches)

#### Disadvantages

- Risk of cerebrospinal fluid leak

#### Contraindications

- Intradural lesion (risk of meningitis)
- Lateral or posterior lesions

## 9.2.1 Radiological Planning of Anterior Approaches to Craniovertebral Junction [5]

It is possible to evaluate and compare the minimally invasive techniques to the anterior craniocervical junction using exclusive endoscopic approach or endoscopic-assisted approaches:

- *Endonasal (exclusive endoscopic)*
- *Transoral (endoscopic assisted)*
- *Transcervical (endoscopic assisted)*

### 9.2.1.1 Angles of Attack

The angles of attack were created with the use of a single entry point. The entry point selected allows the best “angle” to reach the surgical lesion (e.g., angled inferiorly as much as possible for the endonasal approach and anteriorly to posteriorly as much as possible for the transcervical approach).

#### 9.2.1.2 Endonasal

For the endonasal approach, the entry point was defined as a point in the midline at the inferior edge of the nasal bone. The most superior access within the surgical field was arbitrarily defined as the point on the clivus at the base of the sella (the superior aspect of the clival recess). The most inferior access within the surgical field was then approximated by fashioning a straight line starting from the inferior midline of the nasal bone and ending at the lowest point on the odontoid or C2 while remaining tangential to, but not crossing, the hard palate. This approximates the most inferior point within the surgical field, but does not take into account the use of angled instruments that allow a more inferior reach

of approximately 5 mm or an increase in the angle obtained by hard palate drilling.

#### 9.2.1.3 Transoral

For the transoral approach, the entry point was defined as a point in the midline at the inferior edge of the incisors. The most superior access within the surgical field was defined as the point in the midline at the superior aspect of the lower third of the clivus. This was chosen based on the anatomic dissections as the point of superior access without splitting the soft palate. The most inferior access within the surgical field was chosen as the inferoposterior aspect of the body of C2.

#### 9.2.1.4 Transcervical

For the transcervical approach, the entry point was defined as the midline on the skin at the C4–C5 cervical disk level. The most superior access within the surgical field was defined as the point in the midline at 1 cm above the basion. The most inferior access within the surgical field was the inferoposterior aspect of the body of C2.

The surgical goals of lower clival and odontoid (cranio-cervical) decompression were achieved using the endonasal and transoral approaches.

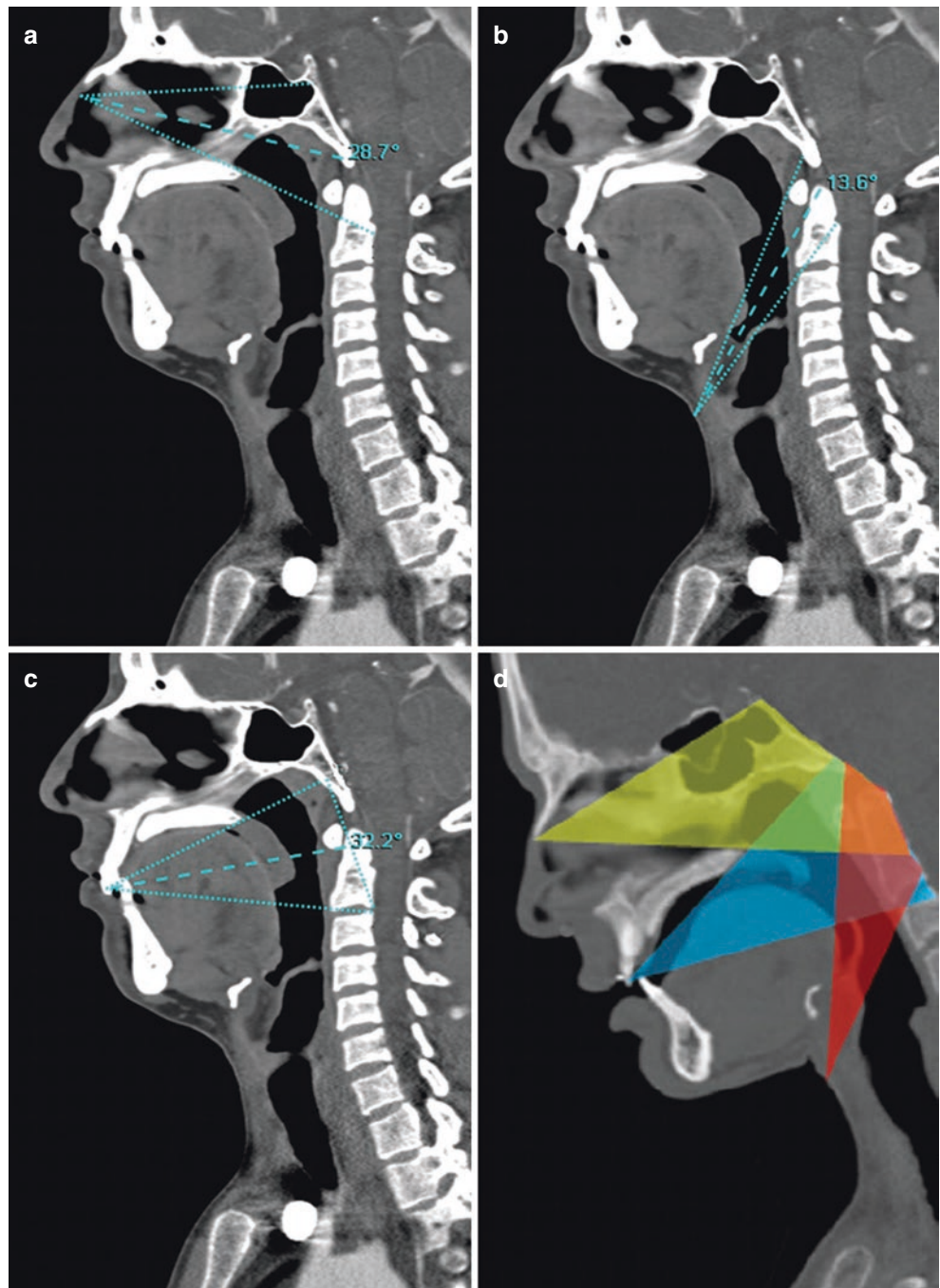
The transcervical approach was unable to achieve more than 1 cm of lower clival resection without undue retraction or was limited by the constraints of the mock chest on the angle of attack. Furthermore, it was difficult to maintain a midline dissection trajectory. This approach, like the endonasal and transoral approaches, did allow complete odontoid resection (Table 9.1).

The working angles and the overlapping working areas of each approach are illustrated in Fig. 9.4.

**Table 9.1** Summary of the angles of attack, surgical working distance, and working area in each endoscopic approach

| Approach      | Distance to surgical target (mm) | Angle of attack, sagittal (degrees) | Working area (mm <sup>2</sup> ) |
|---------------|----------------------------------|-------------------------------------|---------------------------------|
| Transnasal    | 94                               | 28                                  | 1305                            |
| Transoral     | 102                              | 30                                  | 1406                            |
| Transcervical | 100                              | 15                                  | 743                             |

**Fig. 9.4** Computed tomography scans demonstrating the surgical trajectory and angles for the endonasal approach (a), the transoral approach (b), and transcervical approach (c). (d) Common surgical area of the 3 approaches is represented by the overlapping illumination





## 9.3 Transnasal Approach

### 9.3.1 Standard Transnasal/Transsphenoidal Approach

#### 9.3.1.1 Operative Positioning

The procedure is performed under general anesthesia with the patient positioned supine and intubated orally. Sometimes neuromonitoring with somatosensory-evoked potentials is used, and spinal traction is applied as needed to get the odontoid process into a more normal position. Neuronavigation is always used for surgical guidance.

The oropharynx is packed to prevent blood and secretions from the operative site from reaching the stomach. The patient is supine with the head slightly extended on a doughnut pad or fixated with a Mayfield head holder. The operating table is adjusted to provide a semirecumbent position for the patient.

#### 9.3.1.2 Surgical Principles

In 2005 Kassam et al. [1] published the first report on endoscopic endonasal approach being used to perform odontoidectomy.

The endoscopic transnasal approach consisted of a bilateral approach to the nostril.

Kassam [1] described an expanded endonasal approach to perform resection of the odontoid process that consists in an elevation of a nasal septal flap that will be used for closure, a bilateral maxillary antrostomy, ethmoidectomy, middle turbinate resection posterior septectomy, and a wide sphenoidectomy to reach the CVJ. Actually not all patients require sphenoidectomy or middle turbinectomy. Depending on the

location of the lesion, the sphenoid floor and/or clival bone were drilled if necessary. After cauterization the posterior nasopharyngeal mucosa was incised in the midline, and the prevertebral muscles were dissected vertically and elevated laterally to expose the anterior tubercle of the atlas. Decompression can be performed using a drill, curettes, and/or Kerrison rongeur [8, 13].

Neuronavigational devices can provide more accurate information and guidance. CSF leak and venous bleeding from the epidural venous plexus are common in this procedure. A fat graft is used to pack with fibrin glue which is used to pack the cavity. If CSF leak occurs, fat should be used to pack the entire sphenoid sinus, and fascia lata may also be necessary to enhance the closure. The graft is held in place with a plate or stent of nasal bone or cartilage. A Merocel sponge is packed in the nose bilaterally (Figs. 9.5, 9.6, and 9.7).

#### 9.3.1.3 Postoperative Care

A period of postoperative lumbar drainage may be appropriate when a major CSF leak occurs.

#### Advantages

- Low morbidity

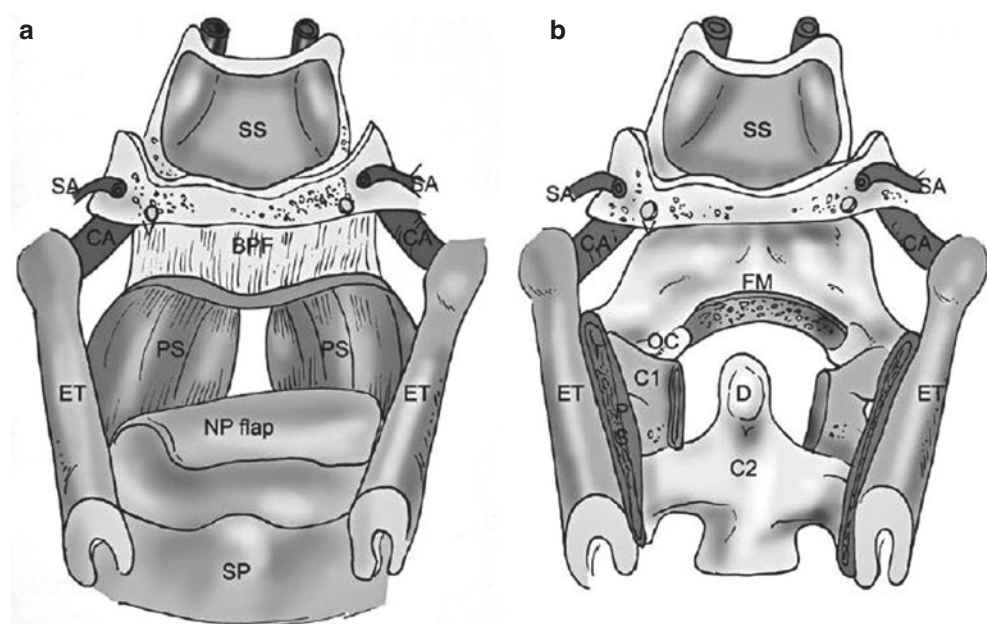
#### Disadvantages

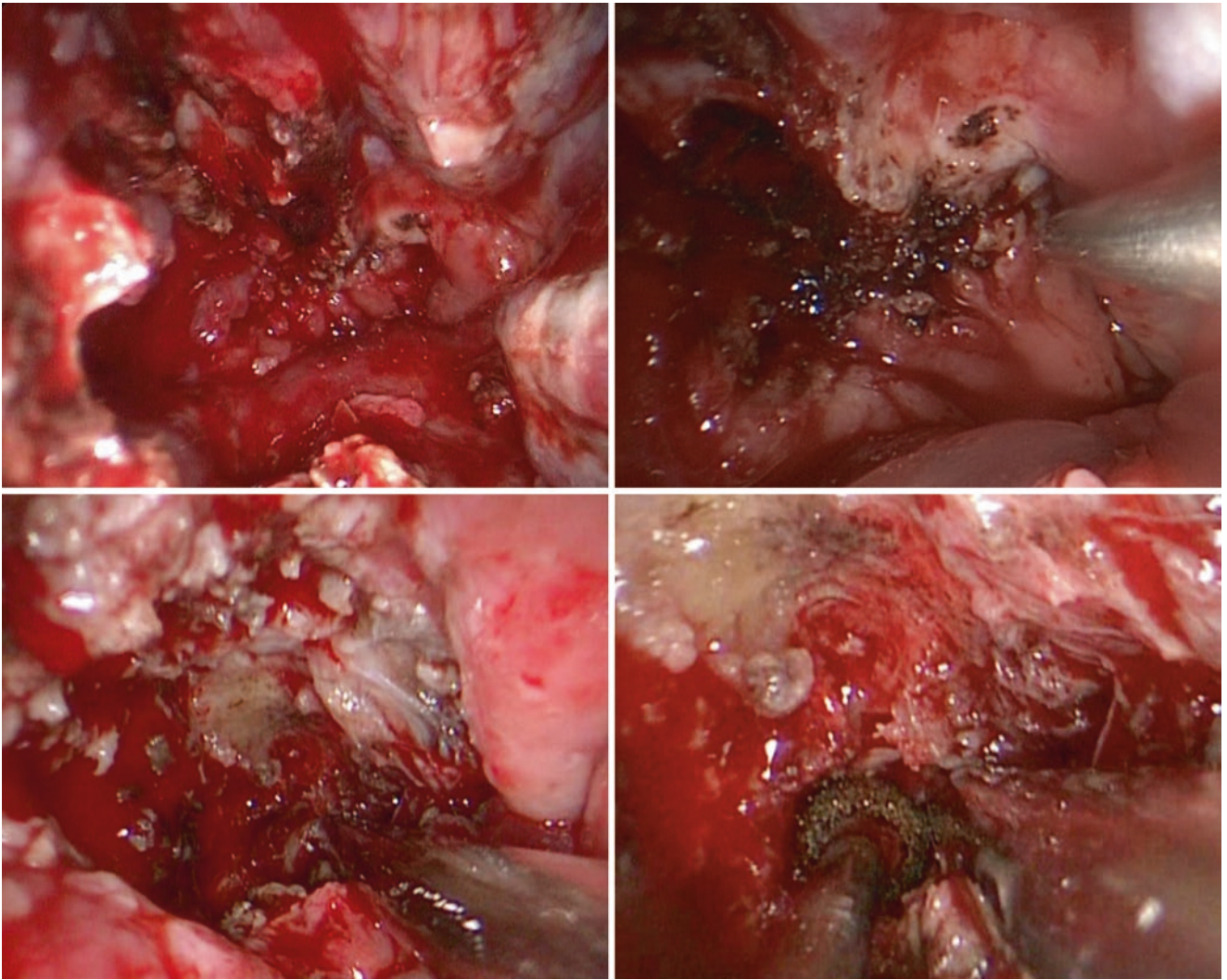
- Limited access to the upper clivus

#### Contraindications

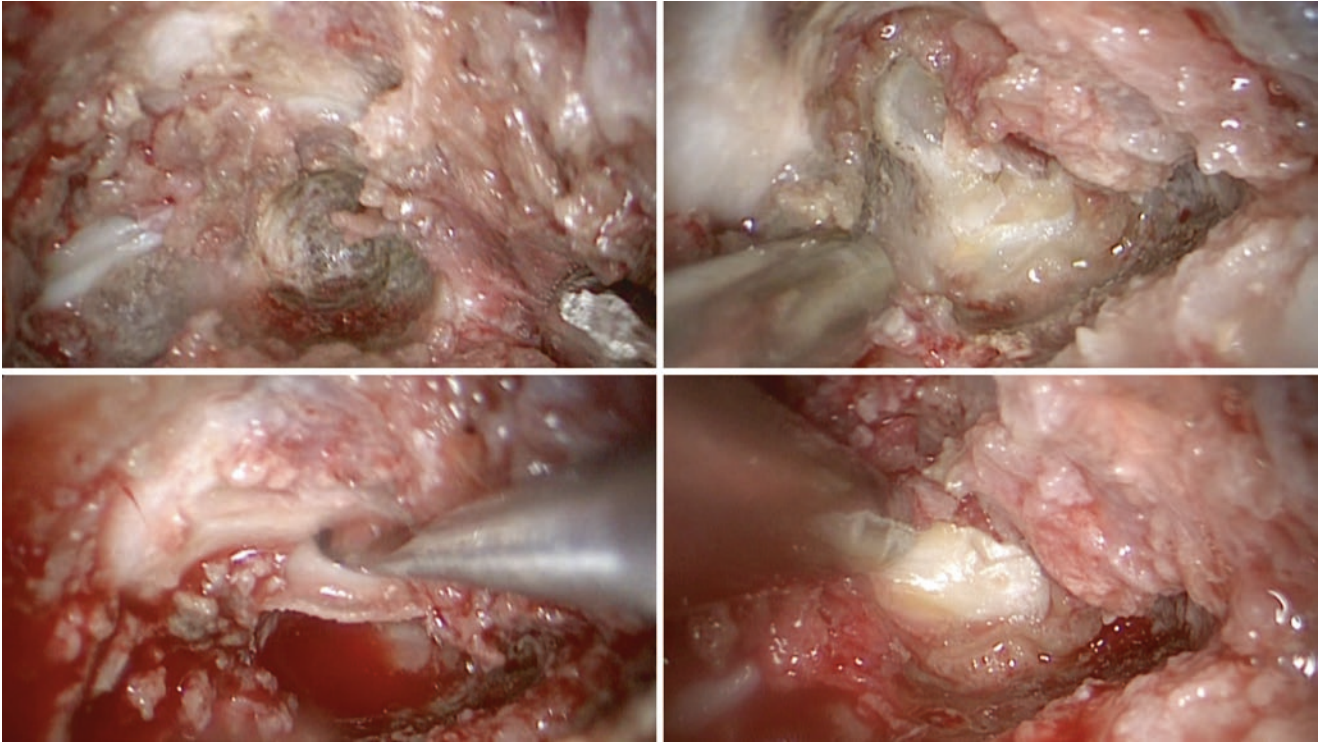
- Active nasopharyngeal infection

**Fig. 9.5** From Presutti et al. eight descriptions of transnasal/transsphenoidal approach. (a) Creation of a U shape nasopharyngeal flap to identify the prevertebral structures (b) Exposure of odontoid process and anterior tubercle of the atlas





**Fig. 9.6** Nasopharyngeal U-shaped flap to expose prevertebral plane



**Fig. 9.7** Exposure of the C1 and C2 joints; dens removal

## 9.4 Transoral Approaches

The transoral approach provides direct midline access to the craniovertebral junction and is most suitable for extradural lesions, such as chordomas, chondrosarcomas, giant cell tumors, and rheumatoid or degenerative pannus [2, 9, 10, 13].

The corridor of exposure is limited by the extent to which the patient can open his or her mouth: the location of the hard palate relative to the CVJ limits superior exposure, whereas the mandible and base of the tongue limit the inferior exposure. To obtain adequate line of sight in the superior and inferior trajectories, the opening of the mouth should be at least 2.5–3 cm between the upper and lower teeth [11].

In most of cases, exposure can be obtained from the inferior clivus to C2 so the surgical procedure can be performed by simply retracting the soft palate and tongue without incising the soft-tissue structure of the mouth.

Extended transoral approaches involve additional incisions and facial osteotomies to mobilize structures that may be obstructing the surgeon's line of sight to the lesion. These approaches include transmaxillary (Le Fort I maxillotomy), transmaxillary with midline palatal split (extended "open-door" maxillotomy), or the frequently used transpalatal and

median labiomandibular glosotomy (transmandibular split) (described in this chapter) (Fig. 9.8) [11, 13].

### Advantages

- Access from the inferior clivus to the C2 vertebra
- Low morbidity (standard oral approach)

### Disadvantages

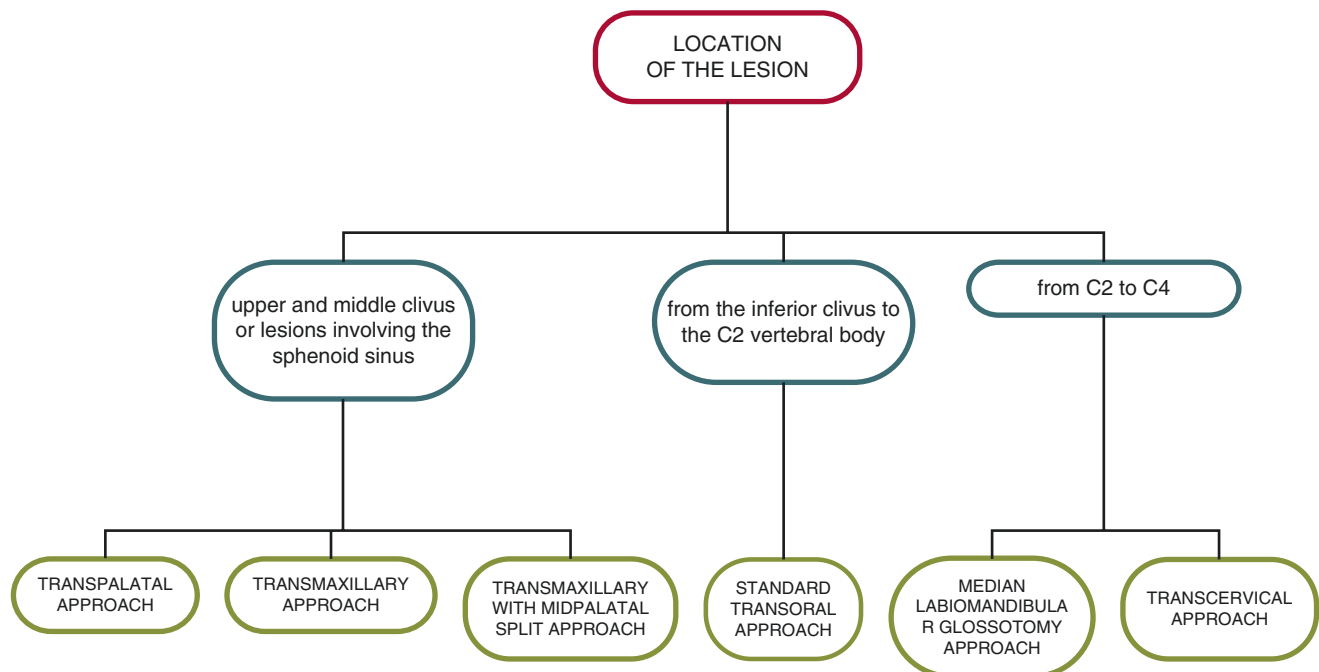
- Constrained field due to restricted jaw opening or soft-tissue hypertrophy of the pharynx
- High morbidity (extended transoral approaches)

### Contraindications

- Active nasopharyngeal infection
- Vascular structure (vertebral or basilar arteries) within or ventral to the lesion

### Possible Complications

- Dysphagia
- Hypernasal speech
- Velopharyngeal incompetence
- CSF leak



**Fig. 9.8** Relationship between location of the lesion and type of the anterior approach

### 9.4.1 Median Labiomandibular Glossotomy Approach

Trotter [15] first described this approach in 1929 for resection midline tumors located at the base of the tongue and the posterior pharynx. It is also useful for removing lesions of the lower CVJ beyond C2 and C4 levels if they are not accessible through a standard transoral approach.

#### 9.4.1.1 Operative Positioning

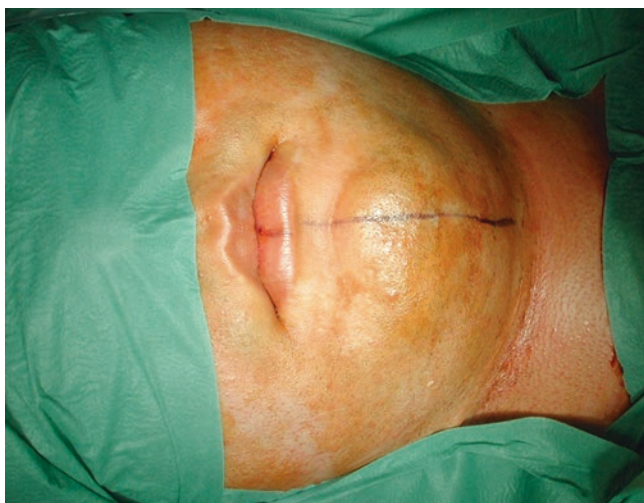The procedure is performed under general anesthesia; preoperative tracheotomy is strongly recommended in this case.

#### 9.4.1.2 Surgical Principles

A vertical curvilinear incision is made from the center of the lower lip to the prominence of the chin as showed in Fig. 9.9 and continued posteriorly in the midline to the

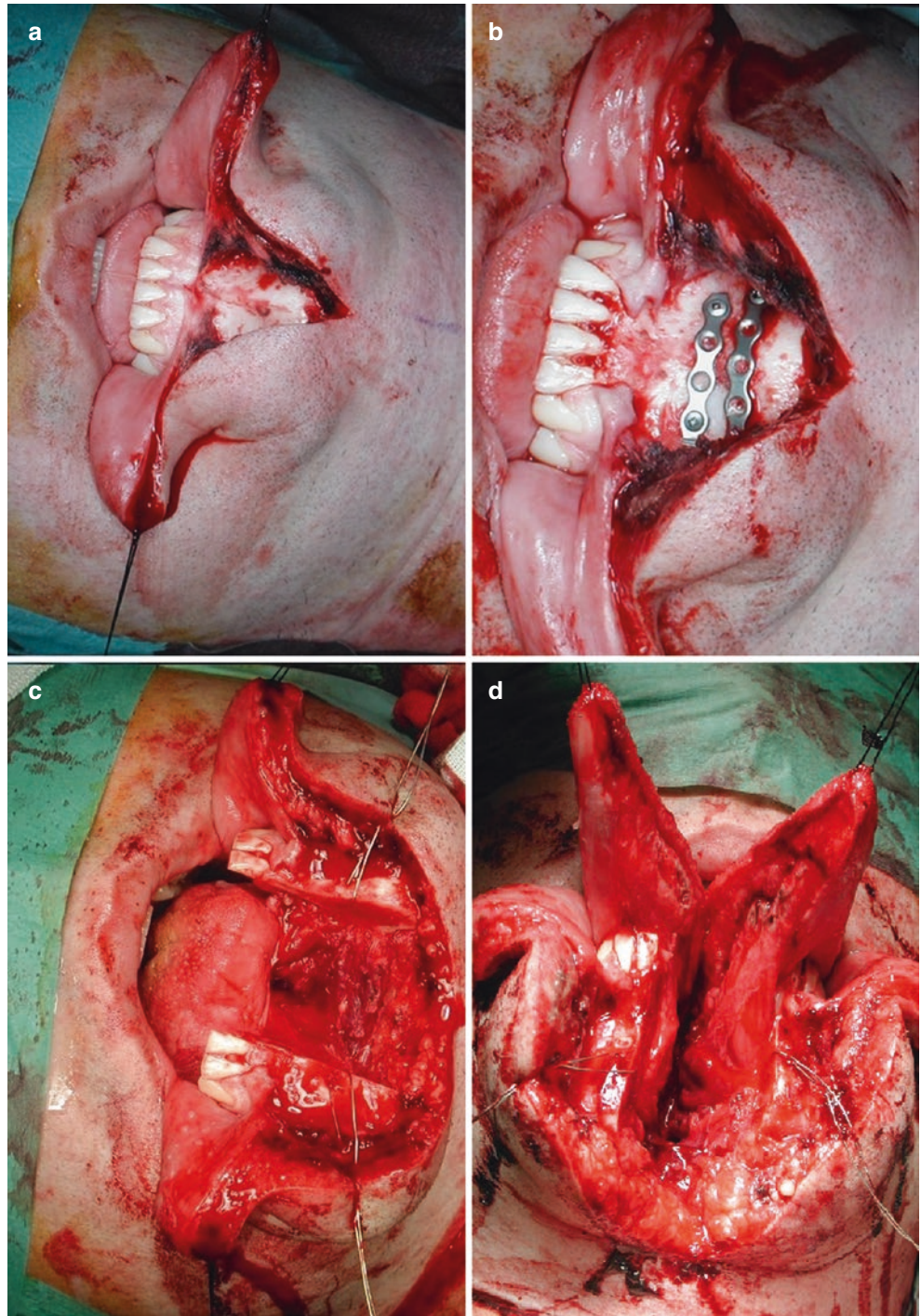
hyoid bone. The mucosa membrane is split. Titanium plates and screws are pre-plated for later replacement. The mandible is cut in a step-cut fashion to facilitate accurate reapproximation. The tongue is split longitudinally through its central raphe and posteriorly toward the median glossoepiglottic fold. In this way the vascular supply and innervations from the hypoglossal nerves are preserved (Fig. 9.10). The halves of the mandible and tongue are retracted laterally, and the floor of the mouth is split with an incision between the submaxillary ducts anteriorly extended inferiorly to the level of the hyoid bone. The posterior pharyngeal wall can be opened to expose middle and lower clivus down to C3–C4 (Fig. 9.11a).

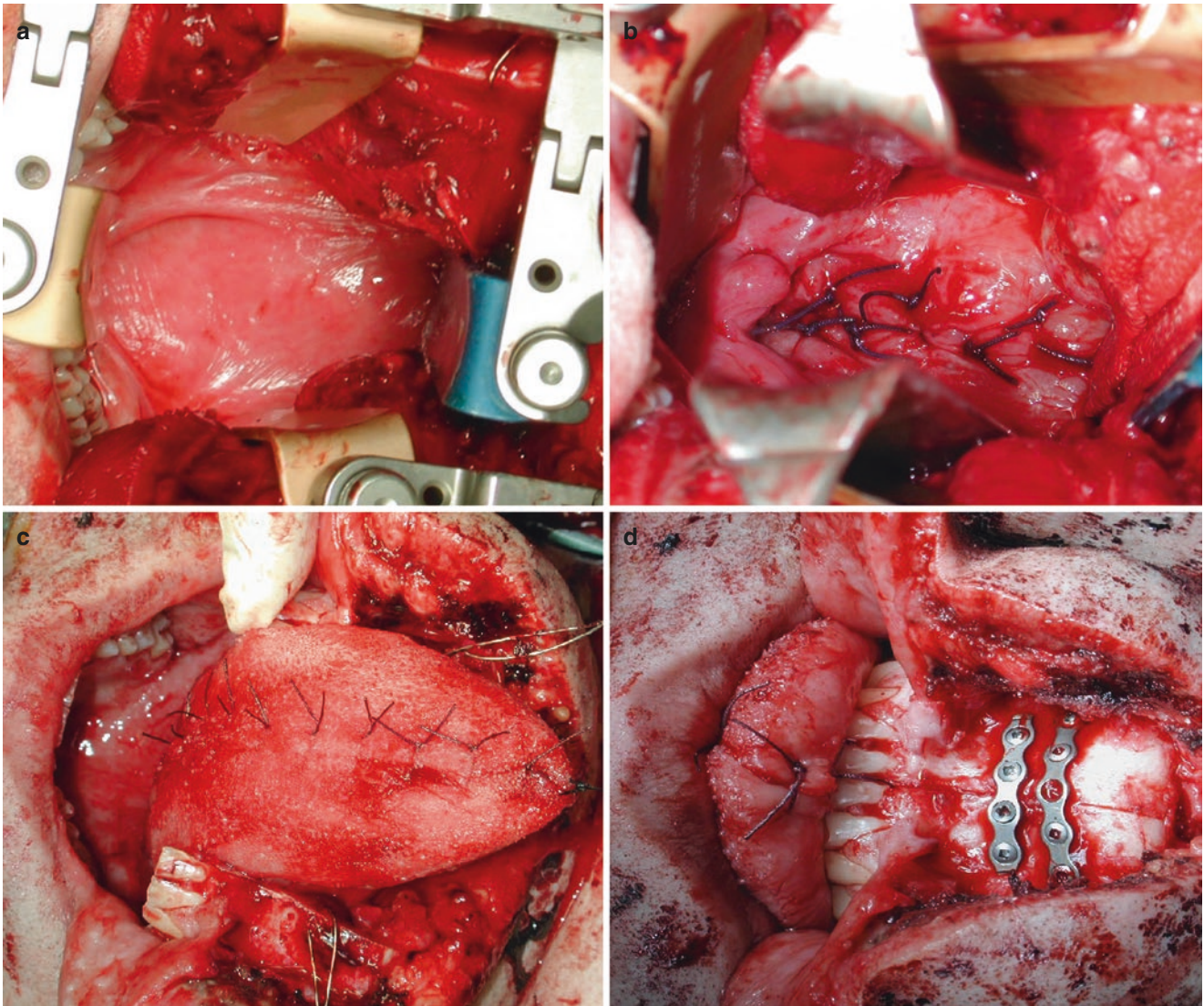
At the time of closure, tongue and mucosa are closed with absorbable sutures. The halves of mandible are reapproximated with preregistered plates and screws, and the skin is closed with nylon sutures (Fig. 9.11b, c, d).



**Fig. 9.9** Skin incision for median labiomandibular approach

**Fig. 9.10** Transmandibular approach to CVJ. (a) Labial split on the midline; (b) preplating before mandibular split. (c, d) Splitting of tongue at the midline in order to preserve main vascular and nervous structures





**Fig. 9.11** (a) Exposition of posterior pharyngeal wall; (b–d) closure time

## 9.4.2 Endoscopic Transoral Approach

In 2002, Frempong-Boaudu reported for the first time seven cases of patients which underwent endoscopically assisted transoral CVJ surgery [3].

The endoscopic transoral approach is performed with soft palate retraction using one or two rubber catheters (Fig. 9.12a) tied to the uvula and pulled cranially through the nostrils. The oral cavity and tongue are retracted with a Spetzler-Sonntag oral retractor as in standard transoral approach. The endoscope is introduced into the oral cavity to visualize the posterior wall. A pharyngeal midline incision is created to expose the C1–C2 area (Fig. 9.12b–d). Microsurgical tools are used to remove the pathology and decompress CVJ. The use of endoscope allows a better exposure above the level of the palate because it could be navigated to look around the palate.

### 9.4.2.1 Surgical Principles

The surgeon locates the midline by palpating the tubercle of C1. Using a fine-tip monopolar cautery, he incises the posterior pharyngeal wall longitudinally in the midline over the region that is to be resected. Carry the incision progressively through the mucosa, the midline raphe between the pharyngeal muscles, and the anterior longitudinal ligament down to the bone.

The anterior longitudinal ligament is dissected subperiosteally till the C1 arch and the C2 body are identified. The longus colli and longus capitis muscles are mobilized laterally and held in place with tooth-bladed retractors. Lateral dissection may be limited to no more than 1.5 cm laterally because of the proximity of the internal carotid artery.

### 9.4.2.2 Removal of C1 Arch and Odontoidectomy (Endoscopic-Assisted Procedures)

The following section describes the removal of C1 arch and odontoid process in the absence of a tumor (e.g., rheumatoid pannus, basilar invagination, etc.). However odontoidectomy could be necessary to gain deeper access in case of extradural tumors.

The boundaries of the clivus, C1 arch, and the base of the odontoid process are identified; soft-tissue structures are detached with microsurgical tools.

Drills and Kerrison rongeur are used to resect the inferior portion of C1 arch preserving the superior rim as much as

possible. Sometimes the anterior part of the C1 arch is removed completely. Apical and alar ligaments may be detached from the odontoid process before removing it to prevent upward retraction of the odontoid toward the clivus. The base of the odontoid process is transected anteriorly with drills and posteriorly with Kerrison rongeur, and the dens is pulled ventrally and caudally to remove it.

In case of pannus, transverse ligament, tectorial membrane, and any residual ligaments should be removed.

### 9.4.2.3 Extradural and Tumor Removal

After odontoidectomy dura should be identified removing transverse ligament and tectorial membrane. Soft-tissue extradural lesion can be excised in a piecemeal fashion using microsurgical tools, drills, curettes, and Kerrison rongeur. If tumors have involved the ligaments, they must be removed. If the dura mater has been violated by tumor, it must be resected without injuring the intradural structure such as the basilar artery, perforators, and brainstem [11].

If the dura mater has been violated, either by the tumor or by the surgical approach, the surgeon can reconstruct the dura mater with autologous or allograft fascia lata, fat, and fibrin glue in multiple layers. The placement of excessive fat may result in neural compression and should be avoided. A lumbar drain is inserted to reduce CSF pressure. Antibiotic cover for 1 week is necessary.

If the occipital condyle is damaged or drilled out because of tumor involved, the surgeon should be mindful of avoiding injury to the hypoglossal nerve into the hypoglossal canal located in the anterior third of the condyle.

The extent of decompression can be evaluated intraoperatively by injecting contrast into the epidural space and viewing this fluoroscopically.

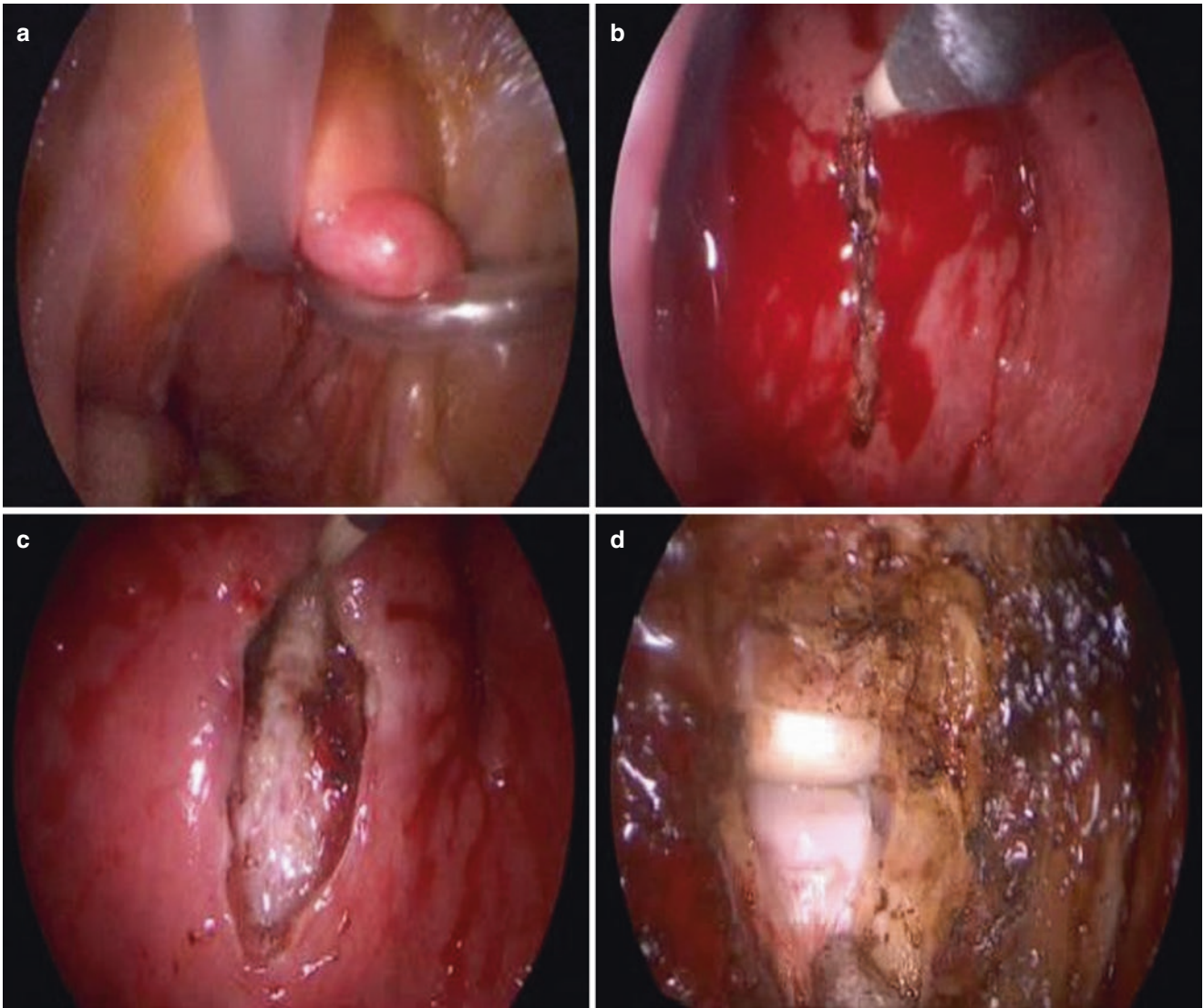
Hemostasis is achieved and absorbable hemostatic material was placed. The mucosa, pharyngeal muscles, and ligaments are closed in a single [7] or double layer [11] with interrupted or running Vicryl suture to ensure a strong tissue closure.

### 9.4.2.4 Postoperative Care

In most of cases, patient is extubated immediately after the procedure unless surgeons are concerned about a difficulty airway.

A nasogastric feed tube ensures enteral feeding for the first week, and then patients are admitted for an oral soft diet.





**Fig. 9.12** Endoscopic transoral approach. (a–c) Steps from mucosa to prevertebral fascia; (d) evidence of odontoid malformations (os odontoideum)

### 9.4.3 Endoscopic Combined Transnasal-Transoral Approach

For this approach, the exposure is a combination of the abovementioned steps in both routes. Then the endoscope and surgical instruments are brought into surgical field alternatively through the nose and mouth in order to maximize the exposure with less dissection. Decompression is easier

because visualization is gained from above and below the palate.

The most favorable feature gained via combined endoscopic approach is the possibility to reach out laterally, beyond the confines of the transnasal approach, through the oral cavity.

Limits, advantages, and disadvantages of endoscopic transnasal and transoral approaches are reported in Fig. 9.13 [4].

| Table 2. Limits, Advantages, and Disadvantages of Approaches |   |  |
|--|---|--|
|  | Transnasal  | Transoral  |
| Upper limit  | Planum sphenoidale  | Lower clivus   |
| Lower limit  | C2 body   | C3 Body  |
| Lateral limit  | Medial pterygoid plates   | Parapharyngeal carotid arteries  |
|  | Eustachian tube   |  |
|  | Tubal elevation   |  |
| Width of exposure  | Between tubal elevations  | Between parapharyngeal carotid arteries  |
| Average (range) mm   | 18.7 (15.1–22.5)  | 41.6 (36.0–47.0)   |
| Working distance to odontoid tip                             | Shorter (3)   | Longer (3)   |
| Direction of approach to reach C1 and lower clivus           | Straight ahead  | Angled upward  |
| Advantages   | Greater rostral exposure  | Wider approach unhampered by turbinates and septum   |
|  | Direct straight ahead access to clivus and C1                                 | Greater caudal limit of exposure   |
|  | Shorter working distance  | Easier maneuvering of instruments and suturing   |
|  | Avoids palatal, glossal, and mandibular split to reach mid-upper clivus       | Reduced damage to eustachian tubes, petrous carotid artery, and vidian nerve   |
|  | Avoids tongue retraction and damage to teeth and reduces need for tracheotomy |  |
|  | Possibly reduced incidence of cerebrospinal fluid leakage and meningitis      |  |
| Disadvantages  | Narrower operative corridor   | Longer working distance  |
|  | Turbinates and septum limit exposure  | Limited clival exposure  |
|  | Risks damage to eustachian tubes, petrous carotid artery, and vidian nerves   | Incision bathed in saliva, with possibly increased meningitis  |
|  |   | Tongue swelling and necrosis   |
|  |   | Splitting soft and hard palates, tongue, or mandible in past to reach mid-upper clivus with hypernasal speech, nasal regurgitation, and velopharyngeal insufficiency |
|  |   | Increased risk of need for tracheotomy   |

**Fig. 9.13** Comparison between transnasal and transoral approach (from Askin Seker et al. [4])

### 9.4.3.1 Advantages and Disadvantages of Different Approaches

|  |                                     |
|--|-------------------------------------|
| Endoscopic transoral approaches  | Traditional transoral approaches    |
| Better exposure in all directions                                      | Limited exposure                    |
| Different angles of view   | Limited angle of view               |
| Two surgeons work in tandem  | One surgeon works alone             |
| Low morbidity  | Low to high morbidity               |
| Two-dimensional visualization  | Three-dimensional visualization     |
| Allows surgical procedure in people with challenging anatomic features | Jaw opening limits the working area |
| More difficult closure [6]   | Easier closure                      |

|                                     |  |
|-------------------------------------|--|
| Extraoral approaches                | Transoral approaches                                       |
| Access limited to the clival region | Access allowed to the periclival region and subaxial areas |
| No risk of infection                | Risk of infection  |

#### 9.4.4 Transoral Robotic Approach

TORS approach allowed a minimally invasive surgical treatment with the intent to reduce morbidity and simplify the exposure if compared to the traditional transoral approach. The approach could be extended from lower clivus to C3.

The da Vinci Surgical System is used in this approach. Our experience started with cadaveric dissection to understand the main landmarks of the approach (Fig. 9.14).

##### 9.4.4.1 Surgical Principles

The da Vinci System with three arms was used (a 5 mm Maryland forceps, a 5 mm spatula-tip monopolar cautery, and one endoscopic arm with integrated 30° camera for the tridimensional view). A bedside surgeon was necessary for suction and cauterization in case of bleeding; in the same surgery room, the first operator is seated at the console (Fig. 9.15).

After cadaveric dissections in a da Vinci laboratory, this approach was then used on patients.

The head were positioned supine without fixation. The patient underwent general anesthesia via orotracheal intubation.

Transoral exposure is obtained with a Feyh-Kastenbauer or Davis Meyer mouth gag.

Two nasogastric feeding tubes are inserted inside the nostrils, and a stitch is placed on the uvula to elevate soft palate to better expose the posterior wall of the oro- and rhinopharynx (Fig. 9.16).

Robotic transoral approach provided wide surgical field from nasopharynx and eustachian tubes through the hypopharynx.

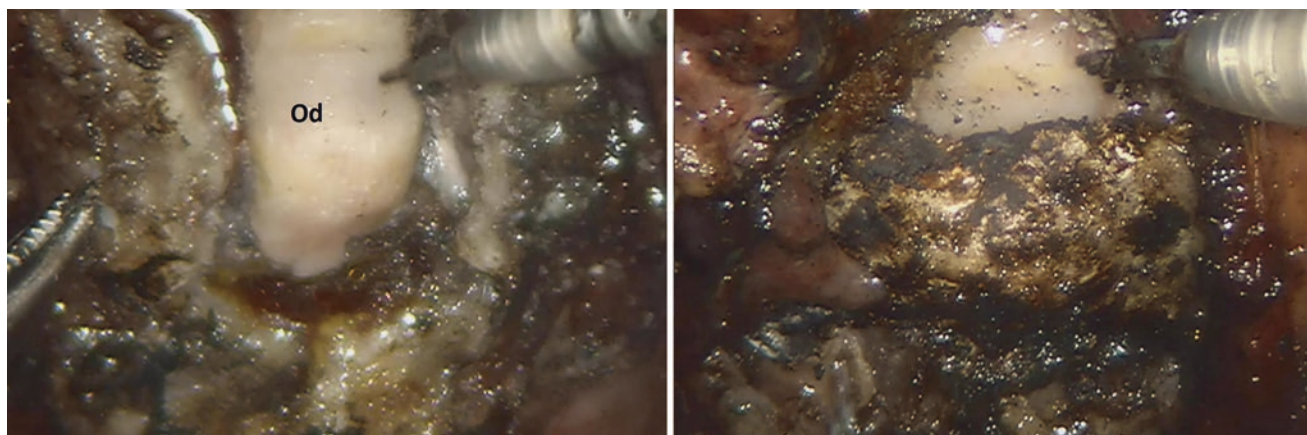
An inferior-based U-shaped flap is performed using the da Vinci's monopolar cautery, through the mucosa, submucosa, and prevertebral muscles until vertebral periosteum of C1 and C2.

The flap is pushed down in the hypopharynx and the cervical spine or pathology is exposed.

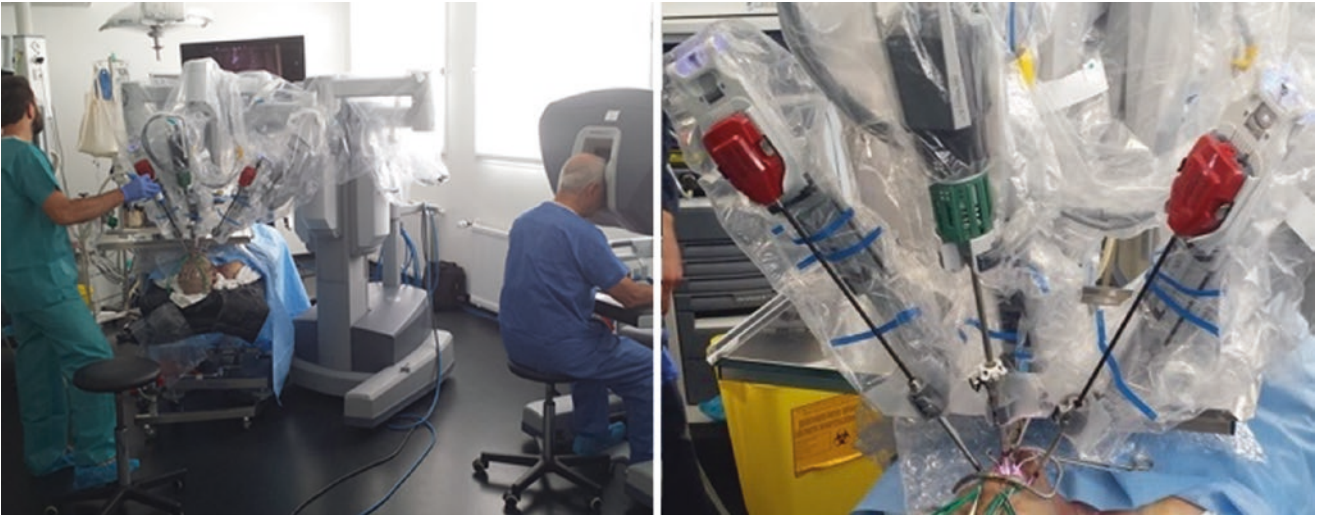The U-shaped mucosal flap based inferiorly resulted feasible and easy to perform and close compared to traditional approach. A U-shaped flap has minimal risk of dehiscence compared to midline linear incision because pharyngeal constrictor muscles movements are lower. Nonetheless the amount of saliva passing through the incision during each swallow is lower (Fig. 9.17).

At this moment surgical procedure switched to a “standard” transoral approach because no drill is actually available for the da Vinci arm. With this approach exposure is wide and goes from the clivus to C3–C4. In the picture, the below of C1 and base of C2 are shown after the soft tissue and anterior longitudinal ligament have been dissected with the robotic arms. The C1 arch was removed with the drill. Odontoid process is removed (Fig. 9.18).


At this moment great advantages from the use of the da Vinci system are shown. With TORS approach reconstruction of the mucosal flap was easily performed. A double continuous suture with V-Loc™ suture device is preferred compared to single stitches to avoid the need to tie knots, which may be difficult and time consuming up in the nasopharynx. Continuous suture of the mucosal flap is watertight and helps prevent dehiscence (Fig. 9.19).



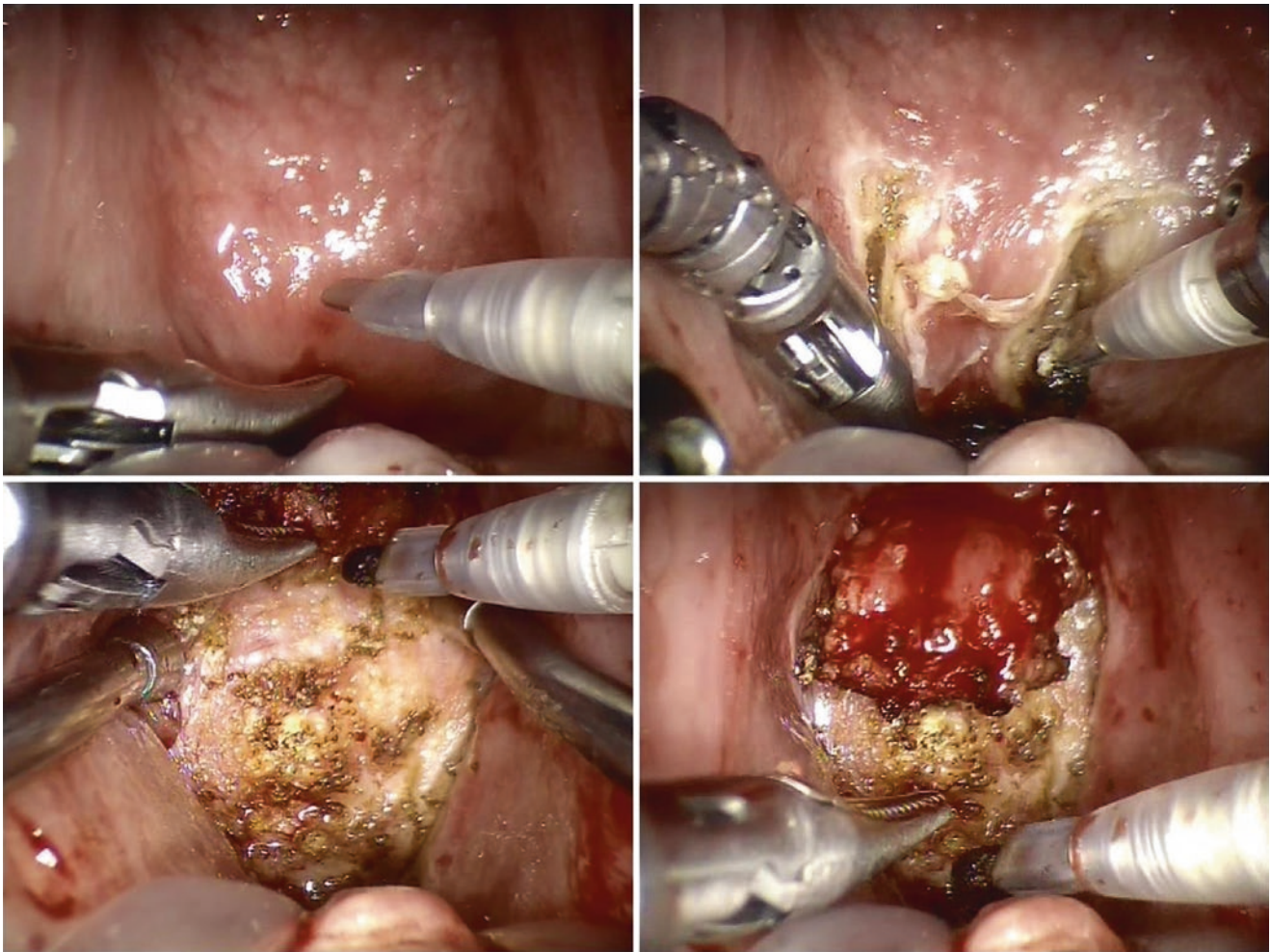
**Fig. 9.14** *Od*: odontoid process dissection and its resection



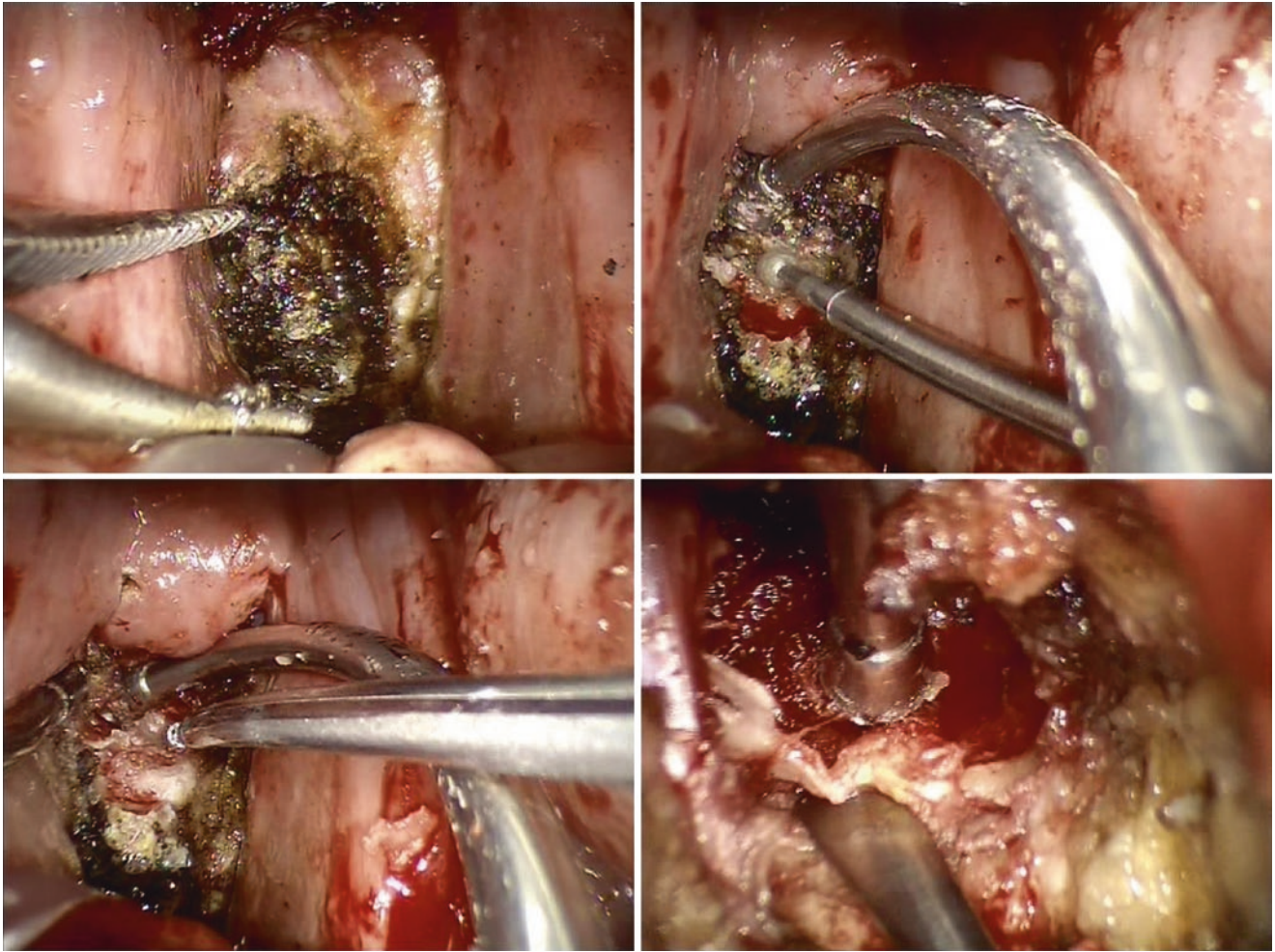
**Fig. 9.15** The da Vinci system at cadaveric dissection lab



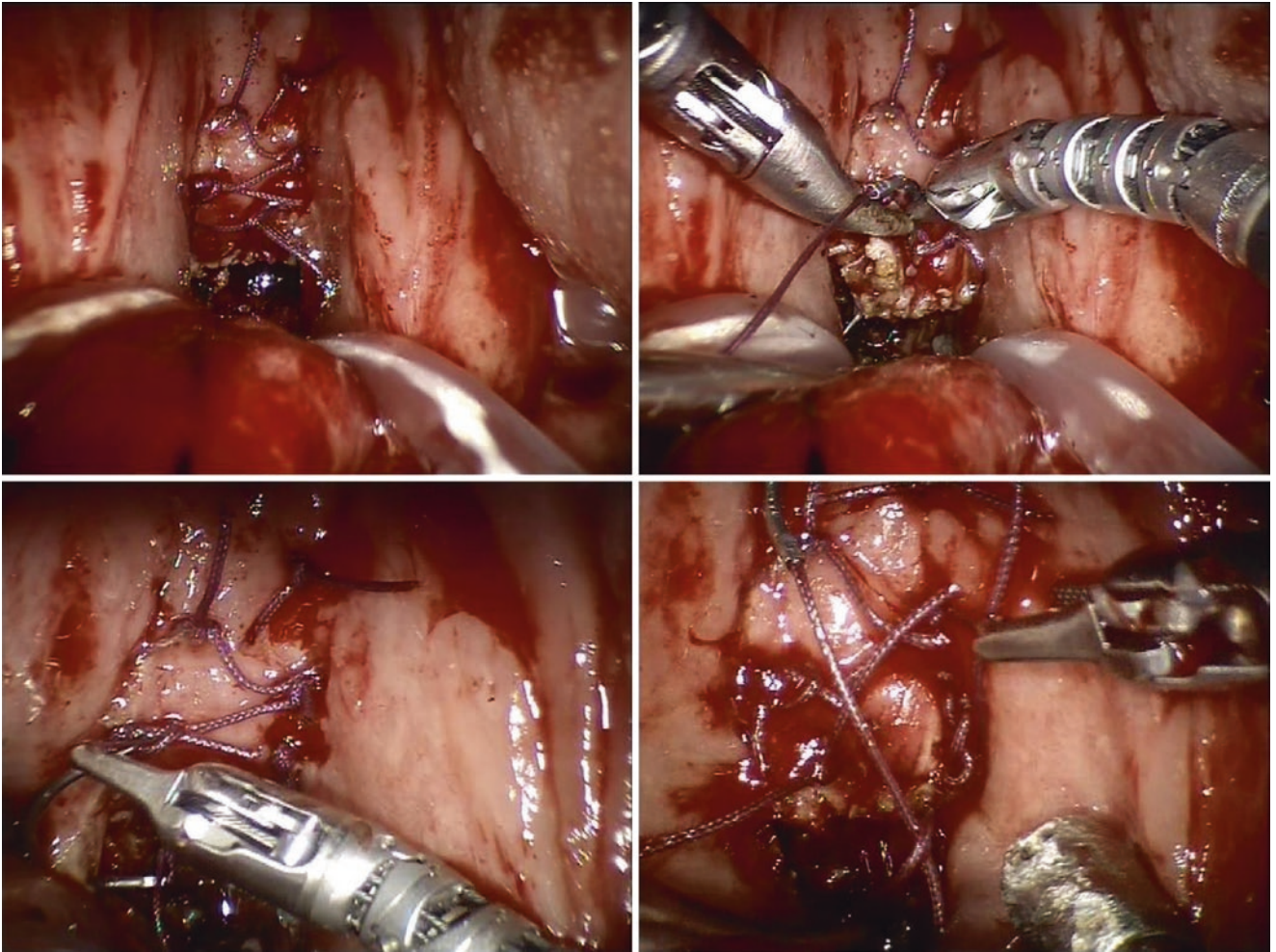
**Fig. 9.16** Positioning of mouth gag and the da Vinci instrumentation



**Fig. 9.17** U-shaped flap elevation and prevertebral fascia expose



**Fig. 9.18** CVJ dissection and dens drilling



**Fig. 9.19** Rhinopharynx suture



## 9.5 Transcervical Approaches

### 9.5.1 Standard Transcervical Approaches

This approach (Fig. 9.20) is well described in the anterior and lateral approach (Chap. 2.2.1).

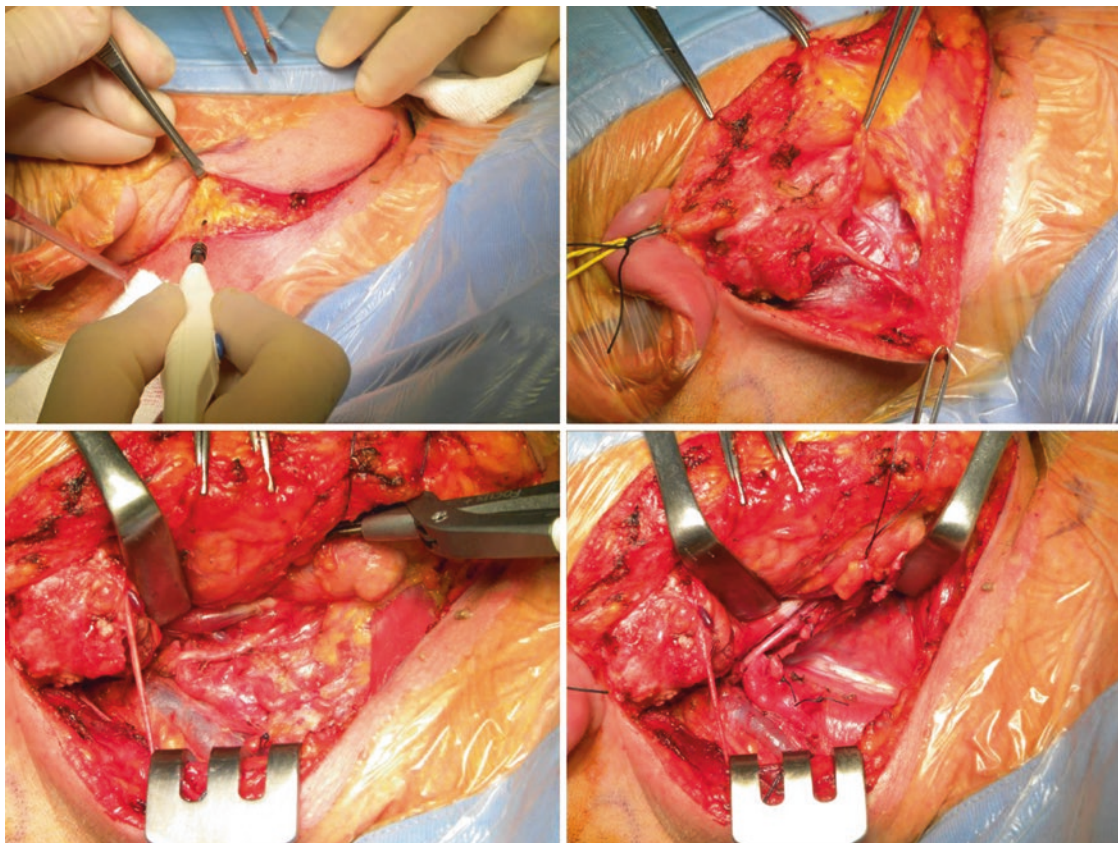
### 9.5.2 Transcervical Endoscopic Approach

Intubation is performed via the nasotracheal route. The patient is positioned supine. Somatosensory-evoked responses and motor-evoked responses are monitored through the procedure. A shoulder roll is placed behind the patient and the neck is placed into gentle extension

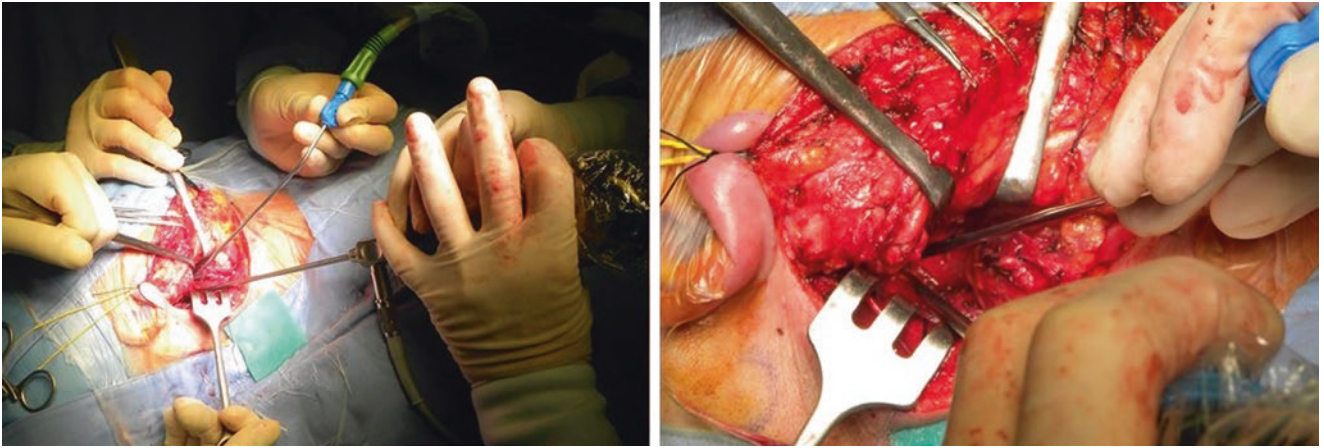
With upper cervical spine approach, the spine is exposed rostrally to the level of the C1 tubercle. The longus colli muscles are dissected off the spine laterally to expose the ventral aspect of C2. Care must be taken at this point to avoid injury to the vertebral artery as they can lie ventral to C2. Neuronavigation system is very useful to recognize principal landmarks. A 0 or 30° 4 mm endoscope is attached to the endoscope arm or is used by the first surgeon. Retractor and suction are used by the second and third operators (Fig. 9.21).

The operation then proceeds using frameless stereotactic navigation and endoscopic visualization. The resection

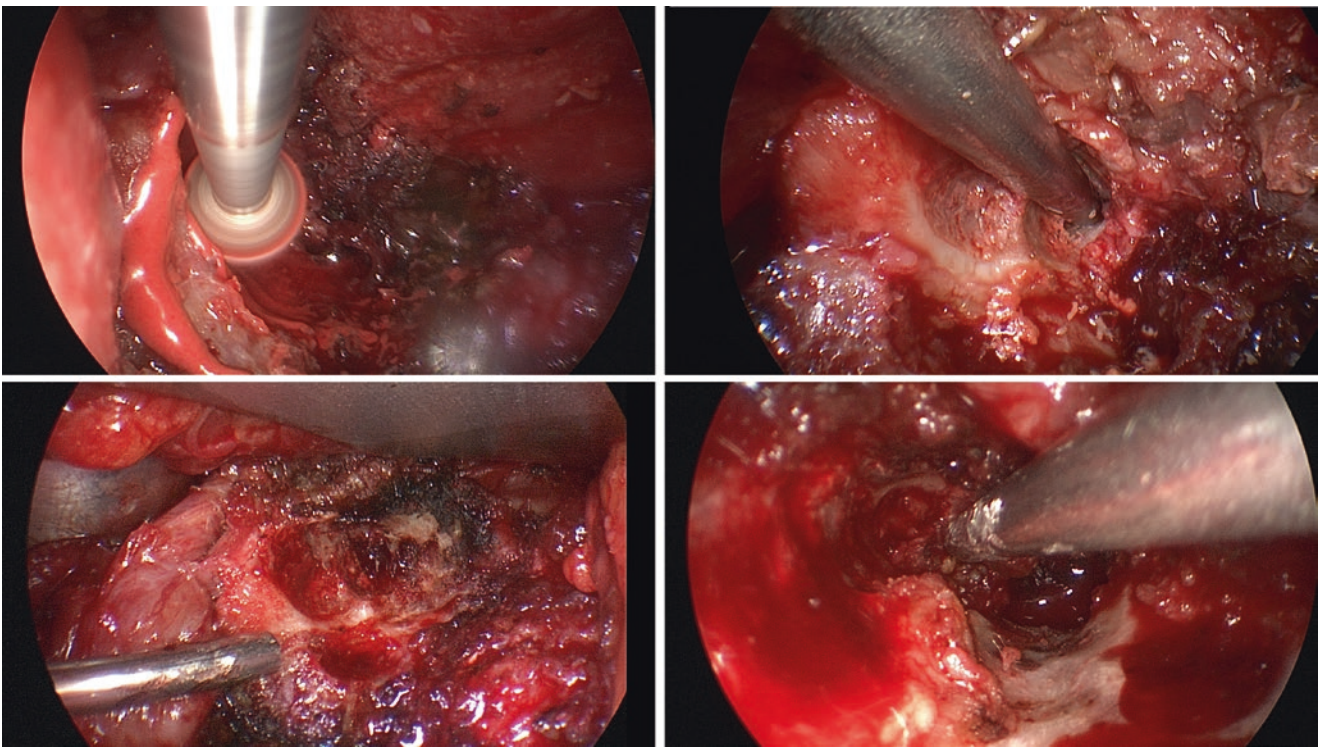
proceeds first between the posterior aspect of the anterior ring of C1 and the odontoid. Drilling proceeds rostrally until the tip of the odontoid is encountered. The resection then proceeds in a “top-down” fashion through the length of the odontoid until all bones have been removed. Resection of the odontoid in a top-down fashion avoids the problem of the odontoid tip becoming free-floating and difficult and dangerous to resect. The progress of the resection is continuously monitored by direct visualization through the endoscope and by using stereotactic neuronavigation (Fig. 9.2). The apical and transverse ligaments are not resected during resection of the odontoid, and they provide a protective barrier between the osseus resection and the dura mater. After the osseus resection has been completed, the ligaments (transverse, alar, and apical) and any pannus present are resected, exposing the underlying dura. After these resections, the cervical spine is unstable. In certain instances (especially in cases in which C1 has been assimilated into the occiput), the instability is between C1 and C2. In the majority of patients, however, there is instability from the occiput through C2. In the case of pure C1–C2 instability, an anterior arthrodesis can be achieved via the same approach through placement of bilateral anterior transarticular screw fixation and fusion across C1–C2 joints. If the anatomy is not suitable or if the instability is more extensive, then a second stage of OC fusion will be required (Fig. 9.22).



**Fig. 9.20** Upper cervical spine approach on the right side



**Fig. 9.21** Anterior approach to upper cervical spine on the *right side*. The surgeon with endoscope and two assistants with retractors



**Fig. 9.22** Endoscopic view of drilling procedure on C2

## References

1. Kassam AB (2005) The expanded endonasal approach: a fully endoscopic transnasal approach and resection of the odontoid process: technical case report. *Neurosurgery* 57(1 Suppl):E213
2. Ammirati, Bernardo (1999) Management of Skull Base Chordoma. *Crit Rev Neurosurg*: CR 9(2):63–69
3. Frempong-Boadu AK, Faunce WA, Fessler RG (2002) Endoscopically assisted transoral-transpharyngeal approach to the craniovertebral junction. *Neurosurgery* 51(5 Suppl):S60–S66
4. Seker A (2010) Comparison of endoscopic transnasal and transoral approaches to the craniovertebral junction. *World Neurosurg* 74(6):583–602. doi:[10.1016/j.wneu.2010.06.033](https://doi.org/10.1016/j.wneu.2010.06.033)
5. Baird CJ, Conway JE, Sciubba DM, Prevedello DM, Quiñones-Hinojosa A, Kassam AB (2009) Radiographic and anatomic basis of endoscopic anterior craniocervical decompression: a comparison of endonasal, transoral, and transcervical approaches. *Neurosurgery* 65(6 Suppl):158–164
6. Dlouhy BJ (2015) Evolution of transoral approaches, endoscopic endonasal approaches, and reduction strategies for treatment of craniovertebral junction pathology: a treatment algorithm update. *Neurosurg Focus* 38(4):E8. doi:[10.3171/2015.1.FOCUS14837](https://doi.org/10.3171/2015.1.FOCUS14837)
7. Dickman CA, Spetzler RF, Volker KH Sonntag (1998) *Surgery of craniovertebral junction* (1st edition) Thieme
8. Grammatica A, Bonali M, Ruscitti F, Marchioni D, Pinna G, Cunsolo EM, Presutti L (2011) Transnasal endoscopic removal of malformation of the odontoid process in a patient with type I Arnold-Chiari malformation: a case report. *Acta Otorhinolaryngol Ital : Organo Ufficiale Della Società Italiana Di Otorinolaringologia E Chirurgia Cervico-Facciale* 31(4): 248–252
9. Menezes H, VanGilder JC (1988) Transoral-transpharyngeal approach to the anterior craniocervical junction. Ten-year experience with 72 patients. *J Neurosurg* 69(6):895–903. doi:[10.3171/jns.1988.69.6.0895](https://doi.org/10.3171/jns.1988.69.6.0895)
10. Menezes H, Traynelis VC, Gantz BJ (1994) Surgical approaches to the craniovertebral junction. *Clin Neurosurg* 41:187–203
11. Liu JK, Couldwell WT, Apfelbaum RI (2008) Transoral approach and extended modifications for lesions of the ventral foramen magnum and craniovertebral junction. *Skull Base: Off J North Am Skull Base Soc* 18(3):151–166. doi:[10.1055/s-2007-994288](https://doi.org/10.1055/s-2007-994288)
12. Bambakidis NC, Dickman CA (2012) *Surgical of craniovertebral junction* (second edition) Thieme
13. Shaha R (1993) Transoral-transpharyngeal approach to the upper cervical vertebrae. *Am J Surg* 166(4):336–340
14. Komotar RJ (2010) Approaches to anterior and anterolateral foramen magnum lesions: a critical review. *J Craniovertebr Junction Spine* 1(2):86–99. doi:[10.4103/0974-8237.77672](https://doi.org/10.4103/0974-8237.77672)
15. Trotter W (1929) Operations for malignant disease of the pharynx. *Br J Surg* 16(63):485–495. doi:[10.1002/bjs.1800166310](https://doi.org/10.1002/bjs.1800166310)

M. Ghirelli, F. Mattioli, G. Molinari, and L. Presutti

## 10.1 Anterior Approach to the Cervical Spine

Literature shows high morbidity rates after cervical spine surgery with anterior approach.

In 1958 Robinson and Smith [1] were the first to employ an anterior approach to the cervical spine. In the following years, this approach has been used for several types of spinal pathology, including tumors, infections, degenerative diseases, and traumas.

Some articles described different approaches to the cervical region [1–8].

The anterior cervical approach can be extended from the craniovertebral junction (CVJ) to the cervical thoracic junction (CTJ). Obviously, the extension of the approach is based on the pathology we have to treat. However, from mini-invasive to plane-by-plane extended dissection, it is fundamental to control all risk points, in particular neurovascular structures.

---

M. Ghirelli, MD (✉) • F. Mattioli, MD • G. Molinari, MD  
L. Presutti, MD  
Otorhinolaryngology- Head and Neck surgery Department,  
University Hospital of Modena, Modena, Italy  
e-mail: [michael.ghirelli@gmail.com](mailto:michael.ghirelli@gmail.com)

Our purpose is to analyze this surgical technique from anatomy to surgery, applying a precise method:

- *Description of the target*
- *Anatomical key points*
- *Pearls and potential complications*

This method is useful for both beginners and expert surgeons to perform safe procedures.

### 10.1.1 Preliminary Steps

The positioning of the patient has already been described in the specific chapter.

The choice of the side to approach depends on which cervical vertebral level is affected by the pathology and where it is specifically located.

Right-handed surgeons prefer right-sided approach, but to expose the vertebral bodies lower than C6, the standard approach is from the left side: this is done in order to reduce the risk of injury to the recurrent laryngeal nerve which ascends vertically within the tracheoesophageal groove on the left side, while the right homonymous nerve has an oblique direction. However, an approach from the right reduces the risk of iatrogenic esophageal injury, since the physiological curvature to the left of the esophageal tube promotes a better view of the prevertebral plane.

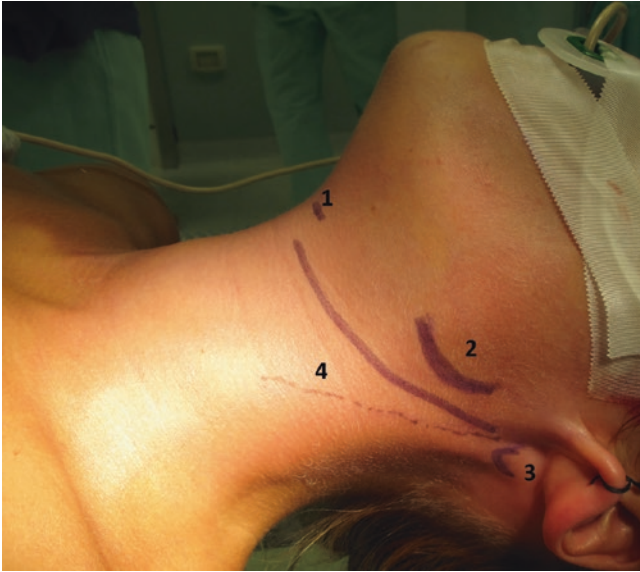Certainly, the cervical region is one of most complex of the entire human body. To fully understand and to apply this surgical technique, it is necessary to keep in mind different landmarks, from the skin to the vertebral plane.

Surgeons have to identify on the skin: (Figs. 10.1, 10.2, 10.3, and 10.4)

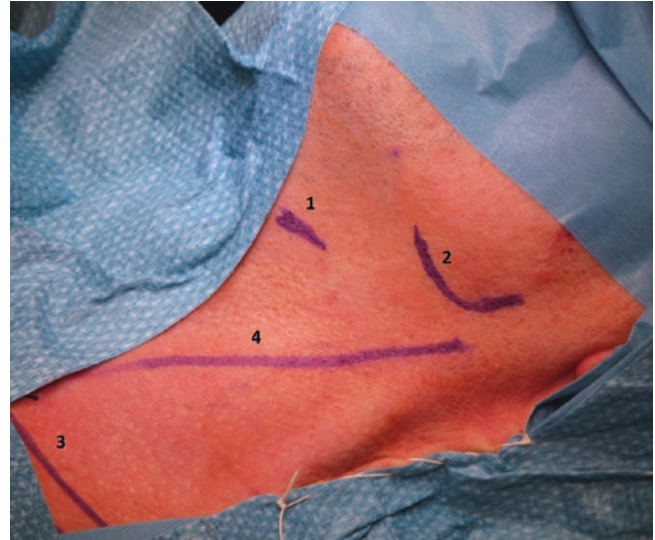
- Mastoid process
- Anterior border of the SCM
- Hyoid bone
- Cricoid cartilage
- Sternal notch

- Angle of the mandible
- Upper border of the clavicle

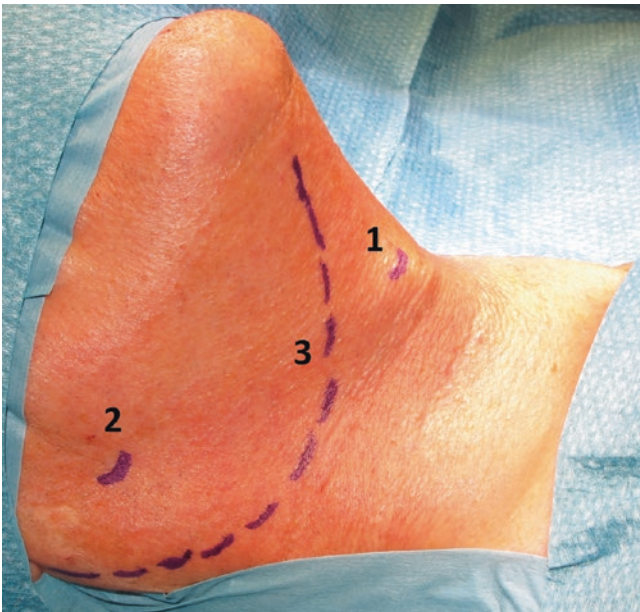Some studies have defined a direct correlation between laryngeal framework landmarks and cervical spine levels:



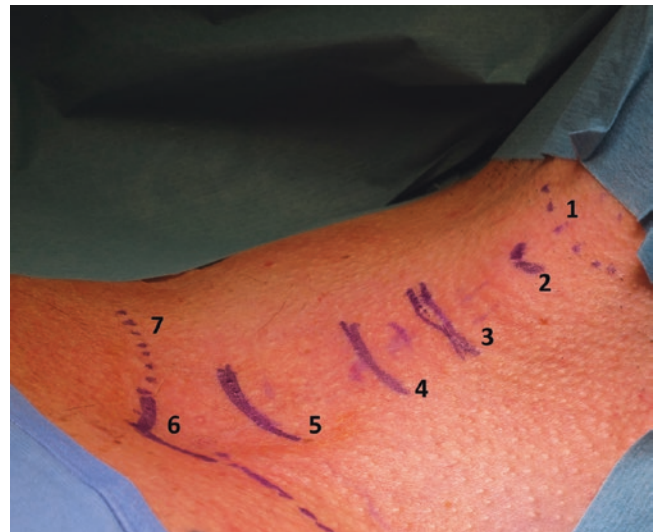**Fig. 10.1** Left side. Upper Cervical Spine (UCS) approach: (1) hyoid bone, (2) angle of the mandible, (3) mastoid tip, and (4) anterior border of sternocleidomastoid muscle



**Fig. 10.3** Left side. Midcervical Spine (MCS) approach: (1) hyoid bone, (2) angle of the mandible, (3) clavicle, and (4) anterior border of sternocleidomastoid muscle



**Fig. 10.2** Left side of UCS approach: (1) hyoid bone, (2) angle of the mandible, and (3) incision line



**Fig. 10.4** Midline of neck: (1) hyoid bone, (2) notch of thyroid cartilage, (3) inferior border of thyroid cartilage, (4) cricoid cartilage, (5) incision line for tracheotomy, (6) suprasternal notch, and (7) clavicle

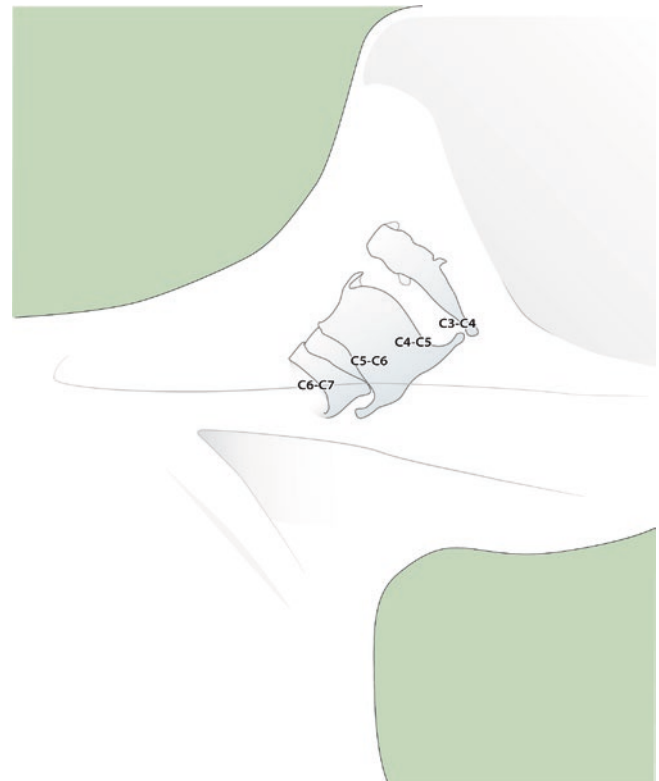
| Landmark          | Vertebral level |
|-------------------|-----------------|
| Hyoid bone        | C3-C4           |
| Thyroid cartilage | C4-C5           |
| Cricoid ring      | C6-C7           |
| Carotid tubercle  | C6              |

Four anatomical structures theoretically define three levels in which the cervical spine can be divided: (Scheme 10.1)

**Scheme 10.1** Relationship between laryngeal framework and vertebrae of cervical spine

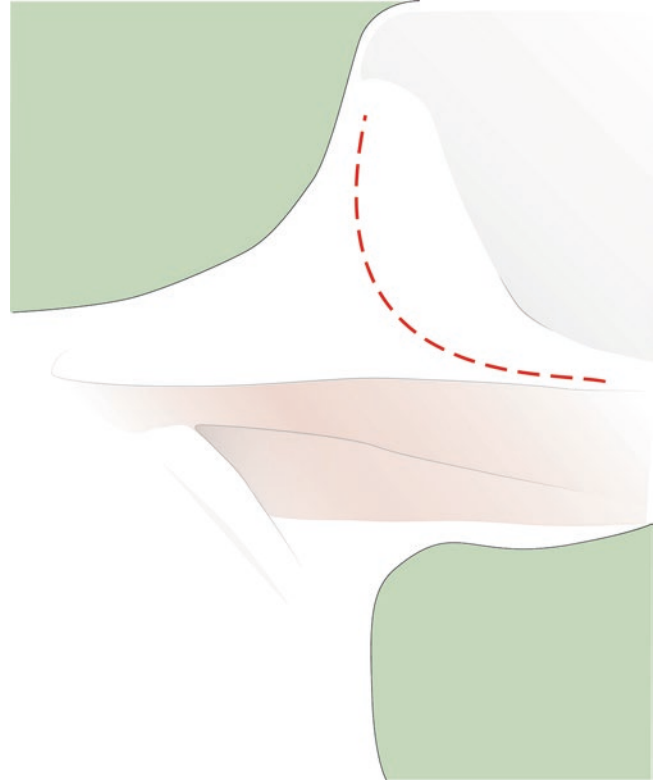
- From CVJ to C3: upper cervical spine (UCS)
- From C3 to C6: midcervical spine (MCS)
- From C6 to T2: lower cervical spine – cervical thoracic junction (CTJ)

The anterior approach to the cervical spine offers the possibility to extend the surgical field into these three levels, with a low percentage of morbidity.



### 10.1.2 Upper Cervical Spine (Scheme 10.2; Figs. 10.1, 10.2)

**Scheme 10.2** Incision (Sebileau type) for upper cervical spine approach

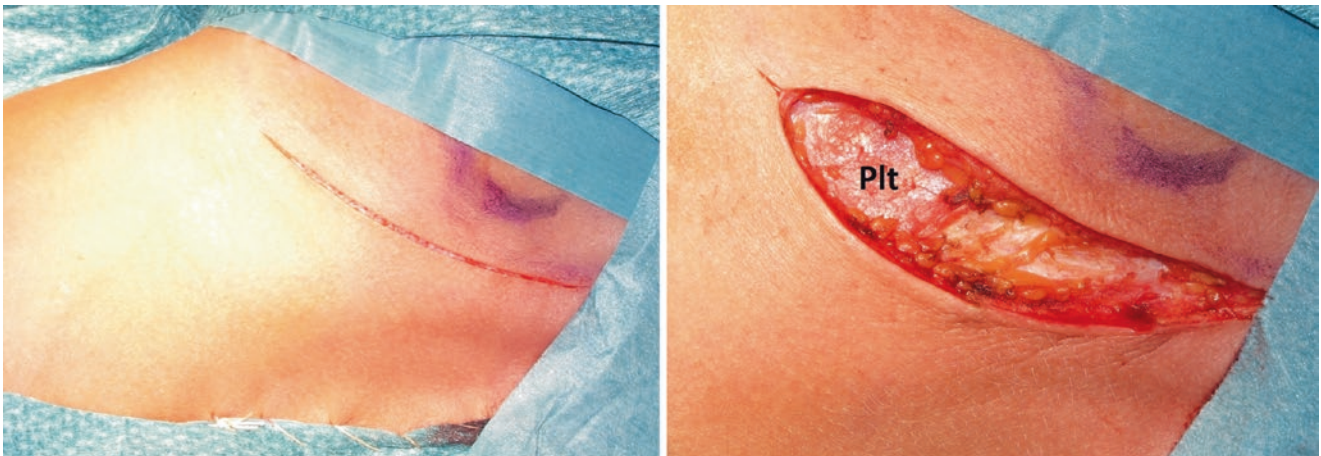


### 10.1.2.1 First Surgical Step: Incision of the Skin

As defined by Sebileau, the incision is carried out in the submandibular region. The incision is placed at least two fingerbreadths below the edge of the mandible. Its length is about 7–8 cm, and it extends from the angle of the mandible to the

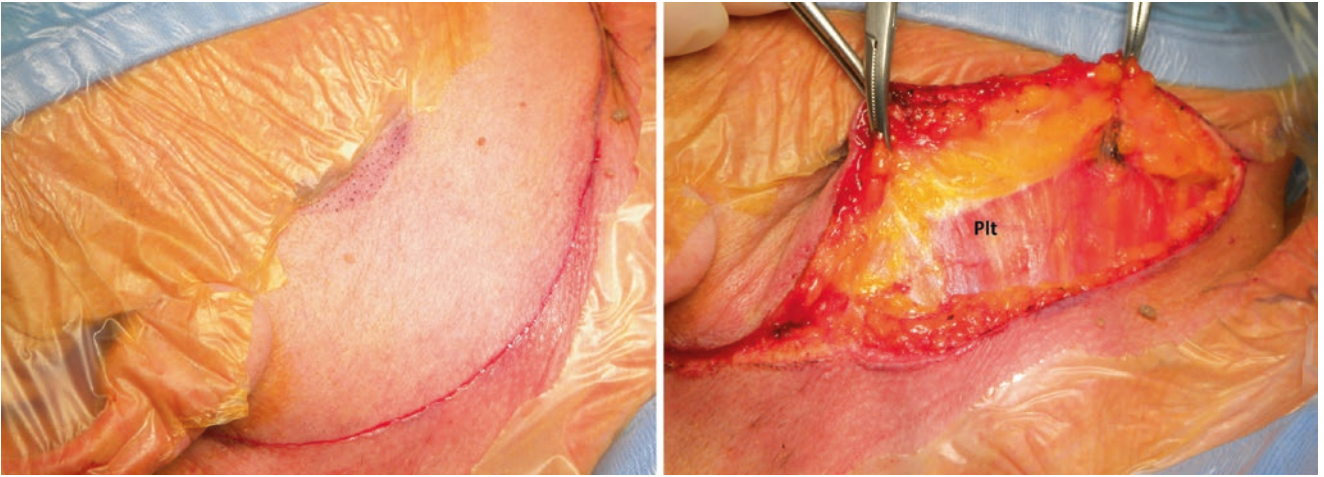
midline of the neck near the hyoid bone. The previous identification of the external jugular vein on the skin is useful to prevent its accidental section. The incision must involve only the skin and the subcutaneous tissue, possibly not the platysma muscle (Scheme 10.3; Figs. 10.5, 10.6 and 10.7).

**Scheme 10.3** Incision of subcutaneous tissue and platysma exposure



**Figs. 10.5 and 10.6** Left side: incision in the submandibular region (Sebileau type) and exposure of the platysma (*Plt*)





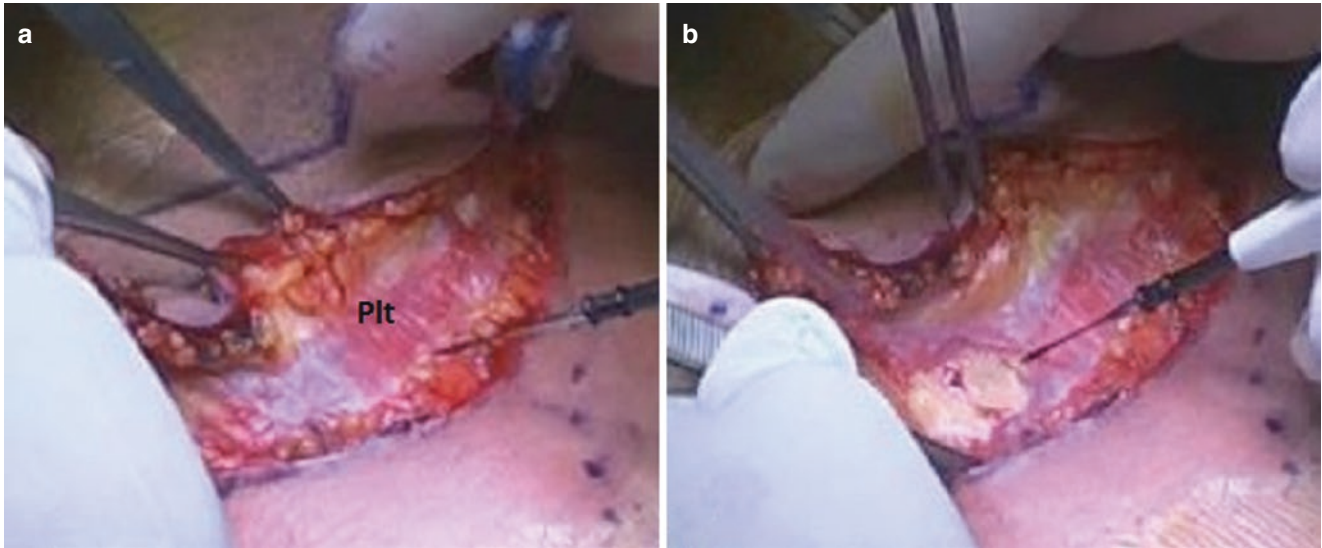
**Fig. 10.7** Right side: incision in the submandibular region (Sebileau type) and expose of platysma (*Plt*)

### 10.1.2.2 Second Surgical Step: Dissection of the Subplatysmal Flap

Following the skin incision, a dissection of the *superficial cervical fascia (SCF)* – formed by the subcutaneous tissue and the platysma muscle – is performed. The flap is then elevated above the inferior border of the mandible to

expose the *superficial layer of the deep cervical fascia (SLDCF)*.

It is important to keep in mind that the marginal mandibular branch of the facial nerve passes close to the inferior margin of the corpus mandibulae in this dissection plane (Fig. 10.8).

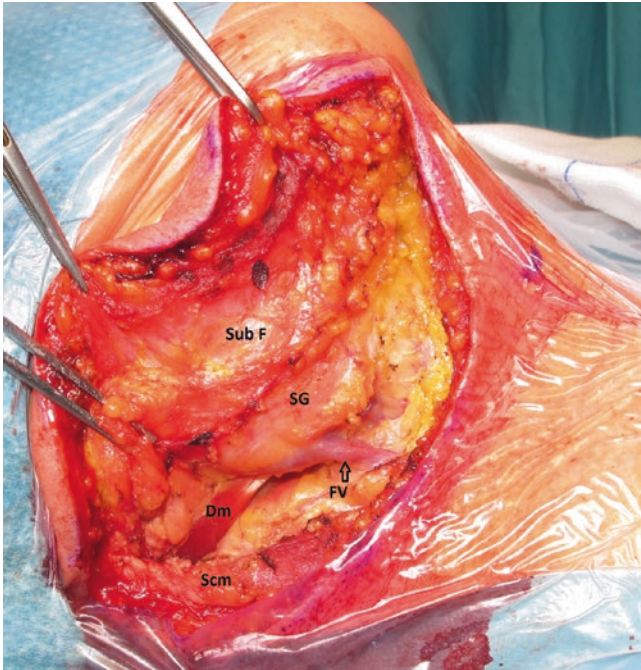


**Fig. 10.8** Left side: (a) the platysma is exposed, after dissection of the subcutaneous tissue. (b) Incision of the platysma and, elevation of the subplatysmal flap, in order to expose the SLDCF

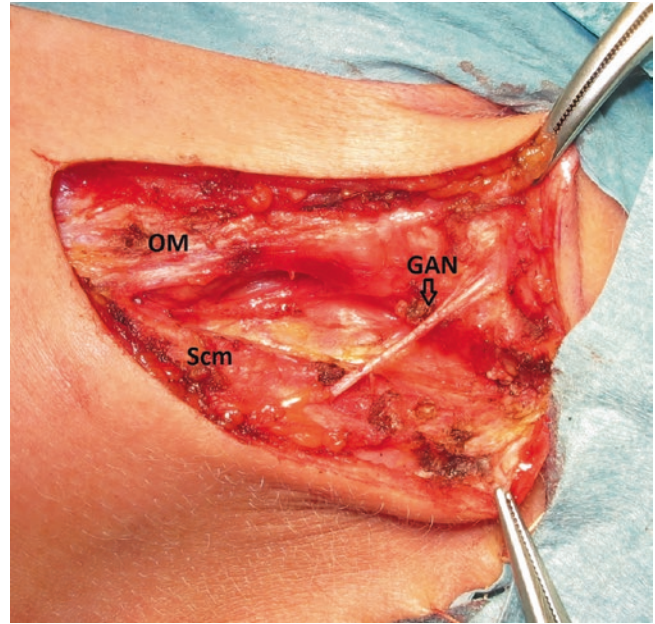
**Anatomical Key Points** (Figs. 10.9, 10.10, and 10.11; Scheme 10.4)

1. Sternocleidomastoid muscle (*SCM*)
2. External jugular vein (*EJV*)

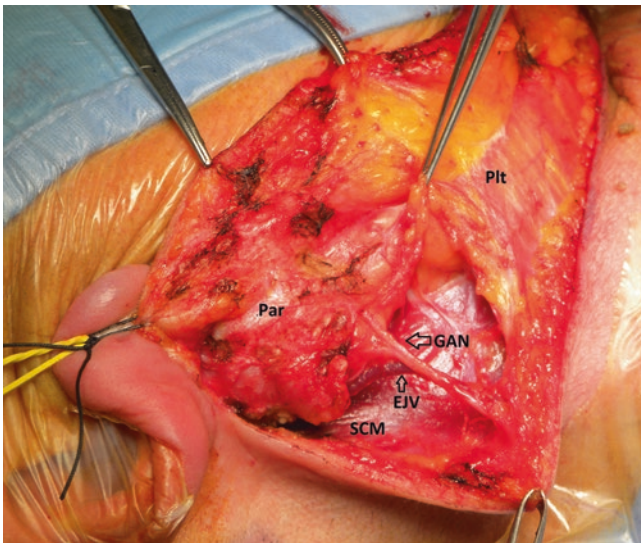
3. Great auricular nerve (*GAN*)
4. Submandibular gland (*SG*)
5. Facial vein (*FV*)
6. Marginal mandibular branch of the facial nerve (Fig. 10.12)



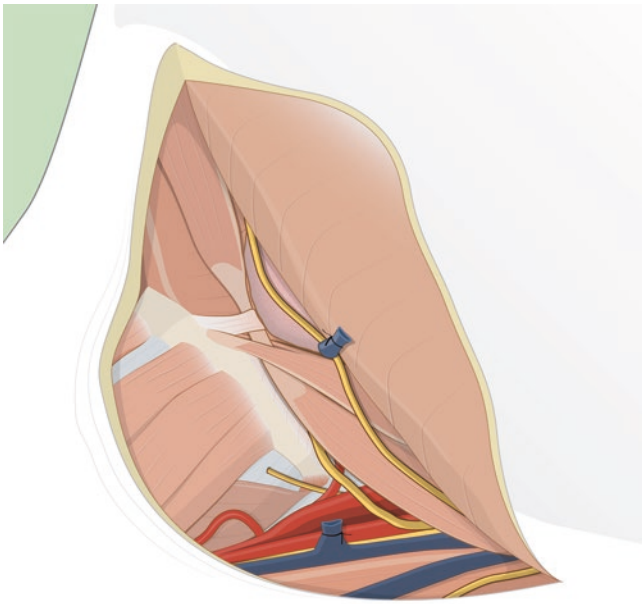
**Fig. 10.9** Right side: subplatysmal flap (*Sub F*) elevation. Exposure of anatomical landmarks: digastric muscle (*Dm*), sternocleidomastoid muscle (*SCM*), facial vein (*FV*), and submandibular gland (*SG*)



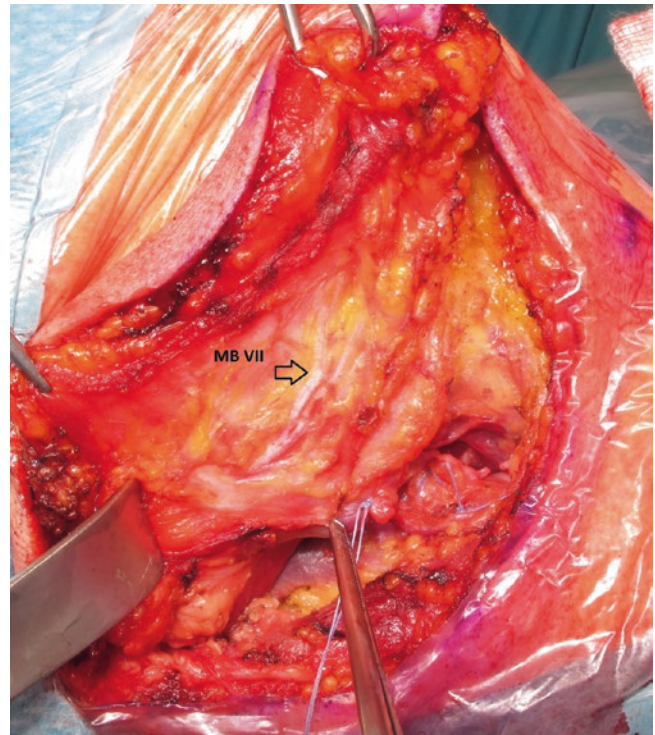
**Fig. 10.11** Left side: sternocleidomastoid muscle (*SCM*), great auricular nerve (*GAN*), and omohyoid muscle (*OM*)



**Fig. 10.10** Right side: Exposure of the anatomical landmarks. In brachytype patients, the parotid gland is lower. External jugular vein (*EJV*), great auricular nerve (*GAN*), sternocleidomastoid muscle (*SCM*), and last part of platysma (*Plt*)



**Scheme 10.4** The scheme shows the anatomical landmarks. In particular it underlines the ligation of the facial vein and its overturning in order to protect the mandibular branch of the facial nerve (Hayes-Martin maneuver)



**Fig. 10.12** Evidence of mandibular branch of the facial nerve (*MB VII*) lying into the superficial cervical fascia

### Pearls

1. Define the inferior margin of the surgical field.
2. Identification of the EJV on the skin, before skin incision, is useful for better identification and preservation of the anatomical structures. The external jugular vein emerges in the parotid loggia from the confluence of the posterior auricular vein and the posterior division of retromandibular vein and then penetrates into the SCM region on the level with the angle of the mandible and crosses the lateral face of the muscle askew. During the dissection, it may be necessary to ligate it.
3. The GAN emerges from the posterior border of the SCM, at Erb's point. It runs parallel and superior to the EJV on the superficial face of the muscle. It gives sensory branches to the skin of parotid and auricular regions. During the dissection, the surgeon usually finds the EJV first and then, about 1 cm laterally and cranially to it, the GAN.
4. The identification of the submandibular is an important step. This salivary gland is a fundamental landmark to recognize a safe plane where preserving the marginal mandibular branch of the facial nerve. The SG lies into the SLDCF division, while the nerve stays below the platysma and above this fascia.
5. The FV lies above the digastric muscle. To carry out a safe dissection, the FV has to be identified, ligated, and retracted cranially (*Hayes-Martin maneuver*). This trick allows protecting the marginal mandibular nerve since in more than 90% of cases, it passes above the FV, and, in the 10% left, it is medial to the vein (Fig. 10.13a, b and Scheme 10.3).
6. The surgeon must remain aware of the location of the marginal mandibular branches, which run in the plane of

the fascia of the submandibular gland. The nerve can be identified as it dips just below the lower margin of the mandible. In young patients, the nerve runs on the level with the inferior margin of the mandible; however, particularly in older patients, a ptotic submandibular gland can displace the nerve inferiorly. As the flap is elevated, dissection must be kept as close as possible to the platysma muscle. Once identified, it can be transposed cranially (Fig. 10.12).

### Potential Complications

Accidental section of the EJV or the FV does not lead to catastrophic bleeding but creates a nonoptimal view of the structures to dissect during the procedure.

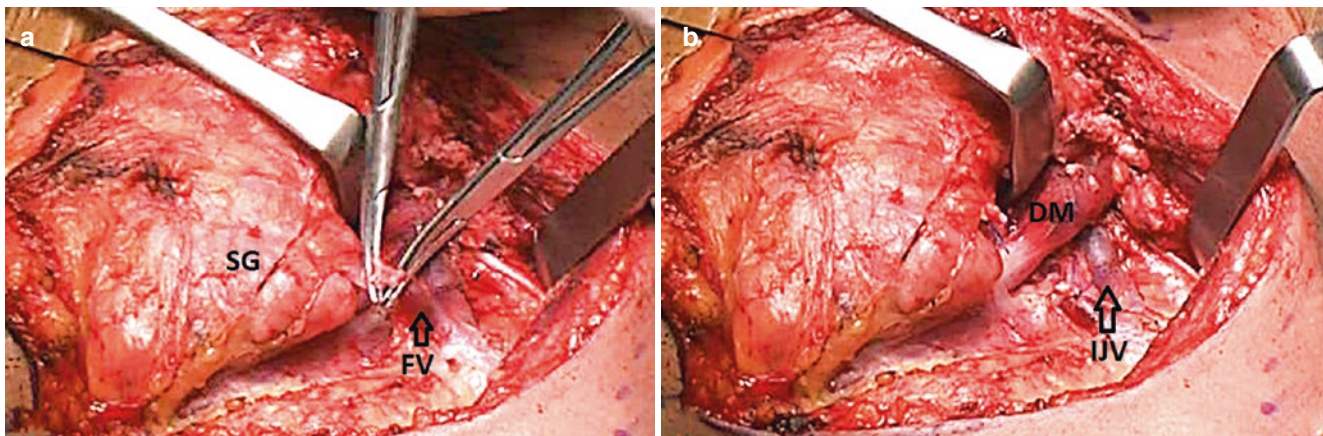
GAN section produces an ailment hypoesthesia of periauricular skin; thus, this nerve should be preserved.

The marginal mandibular branch of the facial nerve could be damaged during the elevation of subplatysmal flap. In case of nerve palsy, the patient shows an incomplete smile with very subtle flattening of omolateral nasolabial fold.

#### 10.1.2.3 Third Surgical Step: Dissection of the SLDCF Anteriorly to the SCM

Under cover of the platysma, there is "the investing layer of the deep cervical fascia" or superficial layer of the deep cervical fascia (SLDCF). It surrounds the neck like a collar but splits around the SCM and trapezius to enclose them. Posteriorly, it joins the ligamentum nuchae.

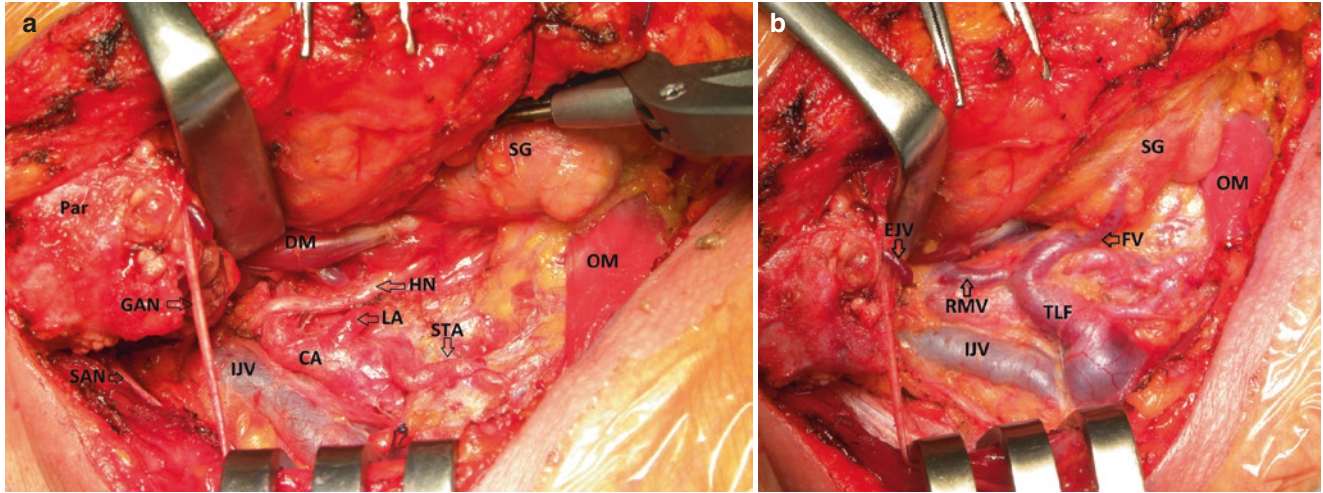
The SLDCF has to be opened along the anterior border of SCM muscle. Lateral retraction of the SCM muscle exposes some of the structures below:



**Fig 10.13** Left side: (a) ligation of the facial vein (FV), that passes over the submandibular gland (SG). (b) Hayes-Martin maneuver and exposure of digastric muscle (DM) under the SG

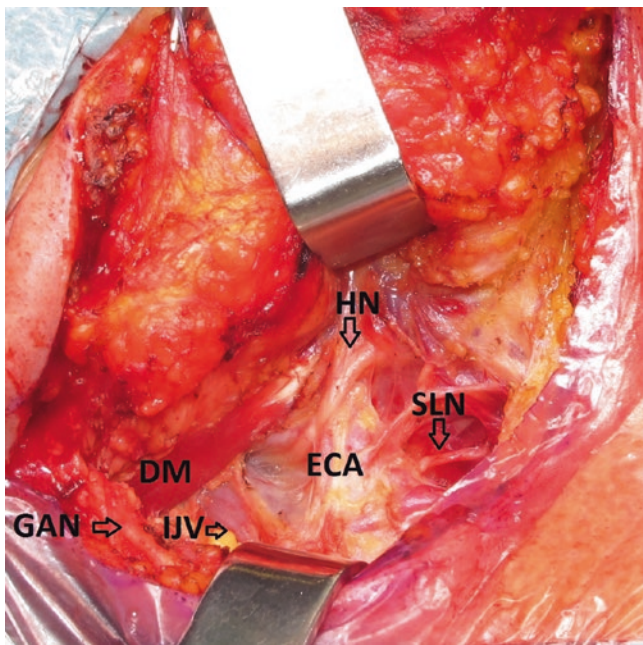
**Anatomical Key Points** (Figs. 10.14a, 10.15, and 10.16; Scheme 10.5)

1. Digastric muscle (*DM*)
2. Thyrolingual-facial venous trunk (*TLF*) (Fig. 10.14b)
3. Carotid sheath or neurovascular bundle
4. Spinal accessory nerve (*SAN*)
5. Hyoid bone (*HB*)
6. Stylohyoid muscle (*SHM*)
7. Hypoglossal nerve (*HN*)
8. Superior thyroid artery (*STA*)
9. Superior laryngeal nerve (*SLN*)
10. Lingual artery (*LA*)
11. Facial artery (*FA*)
12. External carotid artery (*ECA*)
13. Internal carotid artery (*ICA*)

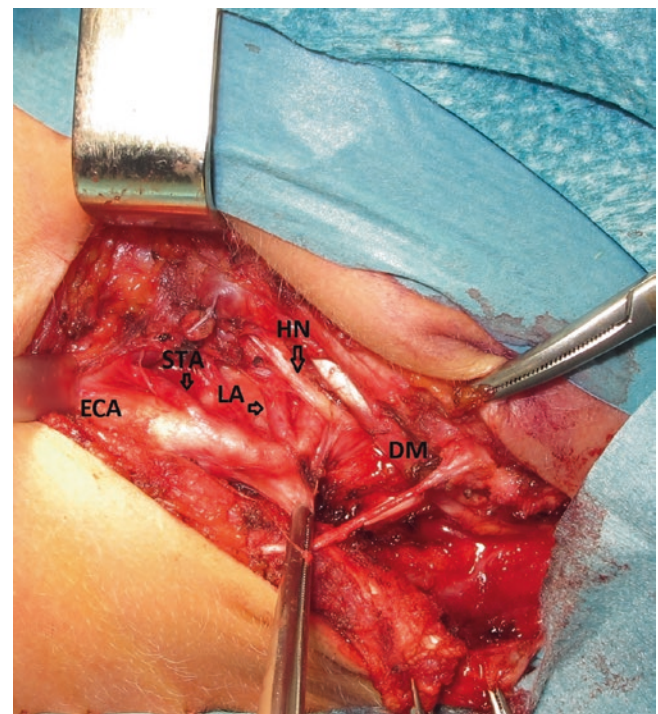


**Fig. 10.14** Right side: (a) spinal accessory nerve (*SAN*), great auricular nerve (*GAN*), posterior belly of the digastric muscle (*DM*), omohyoid muscle (*OM*), submandibular gland (*SG*), internal jugular vein (*IJV*), external carotid artery (*CA*), hypoglossal nerve (*HN*), superior

thyroid artery (*STA*), and lingual artery (*LA*). (b) Evidence of external jugular vein ligated (*EJV*), retromandibular vein (*RMV*), facial vein (*FV*), their union into thyrolingual-facial trunk (*TLF*), internal jugular vein (*IJV*), submandibular gland (*SG*), omohyoid muscle (*OM*)

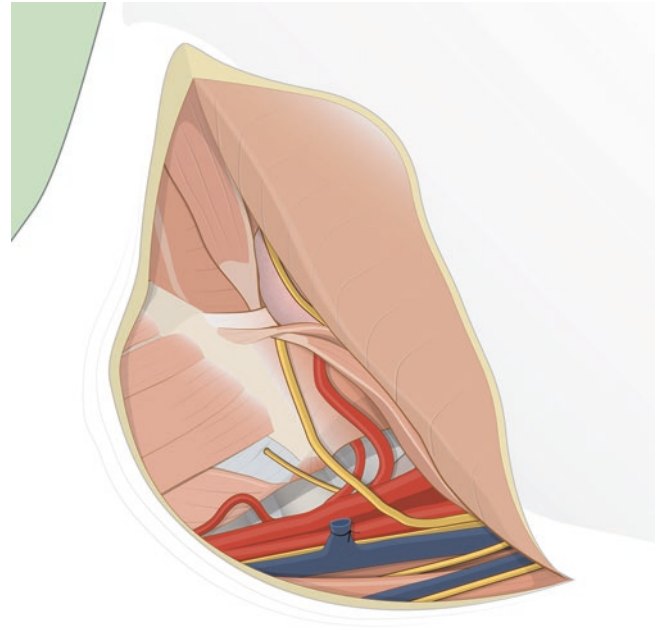


**Fig. 10.15** Right side: posterior belly of the digastric muscle (*DM*), hypoglossal nerve (*HN*), superior laryngeal nerve (*SLN*), great auricular nerve (*GAN*), internal jugular vein (*IJV*), and external carotid artery (*ECA*)



**Fig. 10.16** Left side: posterior belly of the digastric muscle (*DM*), external carotid artery (*ECA*), hypoglossal nerve (*HN*), superior thyroid artery (*STA*), and lingual artery (*LA*)

**Scheme 10.5** The scheme shows all anatomical landmarks of the surgical step in a simplified way. In the upper portion we find the SG, MG VII and DM retracted. Below the DM there are: the facial artery, the lingual artery, branches of the external carotid artery and the hypoglossal nerve that runs through the field above the external carotid artery. Below the hyoid bone there are the superior thyroid artery and the superior laryngeal nerve. The TLF has been ligated at the origin of the internal jugular vein. More laterally we see the spinal accessory nerve (SAN), EJV and GAN



### Pearls

The goal is to identify the three main structures: (Figs. 10.17 and 10.18; Scheme 10.6)

- *Digastric muscle*
- *Hypoglossal nerve*
- *Superior laryngeal nerve*

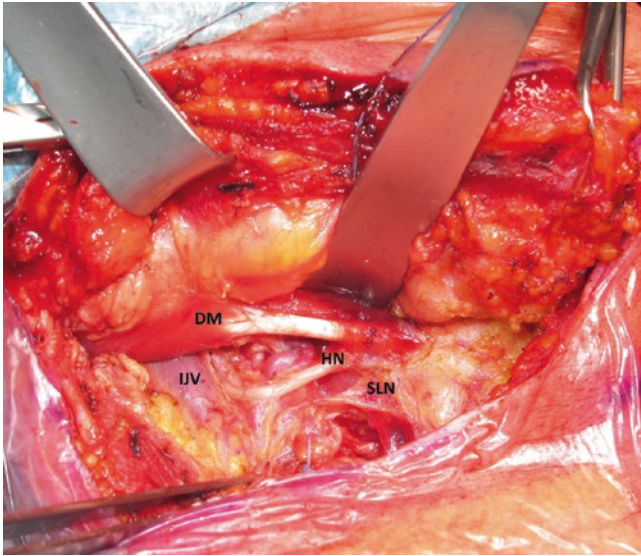
Once you have the control over these three landmarks, the approach to the vertebral plane can be carried out safely:

1. We find the posterior belly of digastric muscle, which runs obliquely forward and downward and goes to the hyoid bone, where it is fixed with its intermediate tendon to the body and the great horn; then it continues with its anterior belly. It is known as “the resident’s friend” because once it is identified, below it is possible to identify important structures like the neurovascular bundle and the TLF.
2. The TLF trunk passes deeply to the SCM and above the digastric muscle to empty into the internal jugular vein. The TLF trunk is formed by the thyroid, pharyngeal, lingual, and facial veins which merge together before opening as a unique vein into the IJV. Only occasionally these veins reach the IJV independently. Under and just before the angle of the mandible, the facial vein receives the blood from the retromandibular vein, before reaching the IJV. The ligation of the TLF trunk should be done near the confluence with the IJV; alternatively the facial vein only can be ligated (Fig. 10.14b).
3. It is formed by the internal jugular vein laterally, by the carotid artery medially, and, in the dihedral angle formed by the two vessels, by the vagus nerve posteriorly. The first vascular structure found during the dissection is the IJV, which is more lateral: it can be identified going just under the digastric muscle.
4. This nerve usually runs below, from the posterior belly of the digastric muscle before piercing the deep surface of the SCM muscle. It passes through this muscle and supplies it and finally emerges from the midpoint of the posterior border of the SCM.
5. The hyoid bone is a fundamental landmark in neck surgical anatomy. Using this approach, below the hyoid, we have to find STA and SLN. The region above shows a high complexity, with several structures that are described in the following paragraphs.
6. This muscle, which is innervated by the facial nerve, arises from the styloid process of the temporal bone and inserts onto the hyoid bone. This muscle is on the same plane of the digastric muscle. When the approach is extended from C2 to CVJ, it is necessary to dissect it.
7. The HN emerges from the hypoglossal canal just medially to the jugular foramen, passes laterally between the internal jugular vein and the internal carotid artery, and goes superficial to the internal carotid artery to reach the posterior edge of the stylopharyngeus muscle. The nerve curves below the lingual artery and disappears beneath the posterior edge of hyoglossus muscle. The triangular space designed by the digastric muscle superiorly, the internal jugular vein laterally, and the TLF inferiorly is useful to identify the HN.
8. The STA arises from the external carotid artery at the point of the hyoid bone and, after providing the upper laryngeal artery, goes down to the upper pole of the thyroid gland. The STA is the first branch of the external carotid artery. To allow the access to the prevertebral space, it is mandatory to bind and dissect this artery. The STA is always under the hyoid bone. To safely bind the artery, we should stay near its origin from the external carotid artery. This maneuver reduces the risk of superior laryngeal nerve injury. During this approach, the STA may not be properly in the surgical field, but without its ligation, it would be difficult and dangerous to obtain a good exposure of the vertebral plane. The surgeons should keep in mind, the possible anatomical variations of the origin of the STA like from thyrolingual (2 %) or thyrolinguofacial (1 %) trunk (Figs. 10.19 and 10.20).
9. The SLN runs medially to the carotid sheath, forming an oblique angle with it. The nerve moves medially toward the thyrohyoid membrane. After the ligation of the STA, it is possible to identify this nerve.
10. The lingual artery is the second branch of the external carotid artery and its first branch above the hyoid bone. Almost immediately after its origin, accompanying the middle constrictor of the pharynx, it meets the posterior margin of the hypoglossal muscle, which takes a horizontal, parallel route to the greater horn of the hyoid bone, approximately half a centimeter above it. Piragoff’s triangle is formed by the intermediate tendon of the digastric muscle, the hypoglossal nerve, and the posterior margin of the mylohyoid muscle: this triangle allows surgeons to find the artery, which is usually bound in the space between the digastric superiorly and the HN inferiorly; alternatively, it can also be bound near its origin (Figs. 10.21, 10.22, and 10.23).
11. It’s the third branch of the external carotid artery. It emerges behind the posterior belly of the digastric muscle, posteriorly skimming the submandibular gland; running backward to forward, and upward to downward, it becomes superficial to surround the inferior margin of the mandible, immediately anterior to the facial vein. Ligation of the FA should be carried out at its origin. Section of DM should be necessary to approach UCS and to correctly binding of FA (Figs. 10.24 and 10.25).
12. The internal carotid artery passes deep to the posterior suspensory muscles of the pharynx to terminate medial to the styloid process. The ICA continues posteromedially to enter the carotid canal at the base of the skull not giving out any branches.

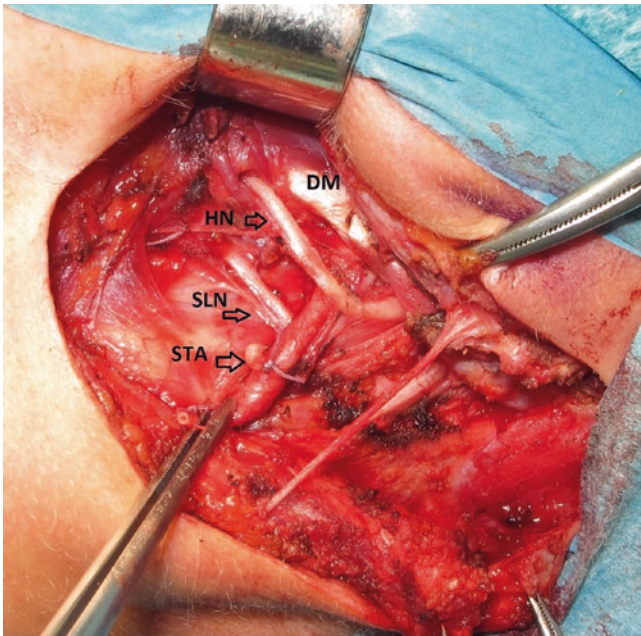


13. The ICA leaves the carotid sheath passing anterosuperiorly within the carotid triangle. It is useful to keep in mind that the external carotid artery divides the posterior suspensory complex of the larynx by passing between the digastric and stylohyoid muscles laterally and the styloglossus and stylopharyngeus muscles medially. It

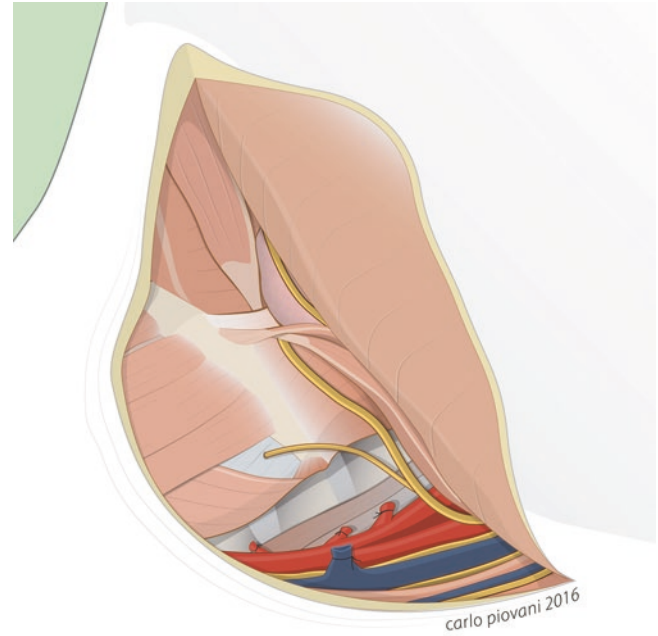
emits eight branches: five below the posterior belly of the digastric within the carotid triangle and three above it. Surgeons have to follow this artery in order to identify the right plane to approach cervical spine, which lies medially to the vascular structures and laterally to visceral ones (Fig. 10.26).



**Fig. 10.17** Right side. Evidence of three fundamental landmarks: digastric muscle (*DM*), hypoglossal nerve (*HN*), superior laryngeal nerve (*SLN*), Internal jugular vein (*IJV*)

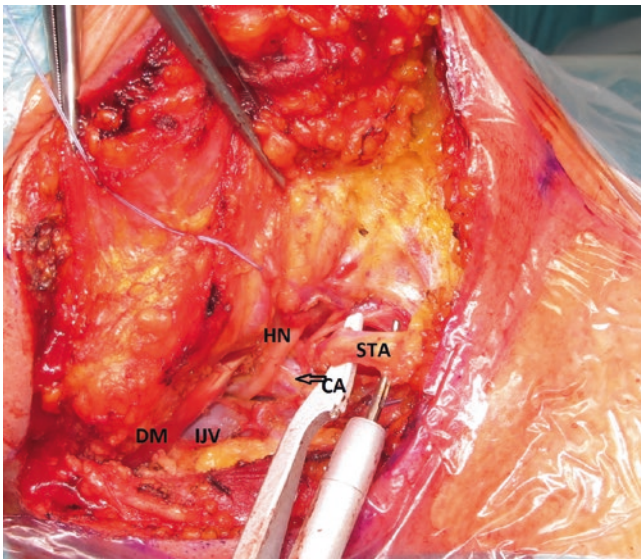
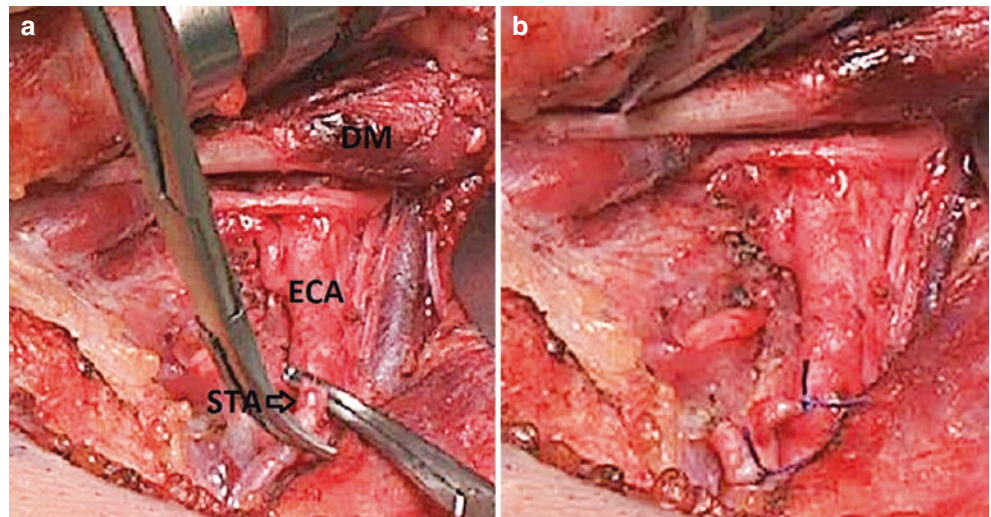


**Fig. 10.18** Left side Evidence of three fundamental landmarks. From upper to downer: digastric muscle (*DM*), hypoglossal nerve (*HN*), superior laryngeal nerve (*SLN*), superior thyroid artery (*STA*) ligated

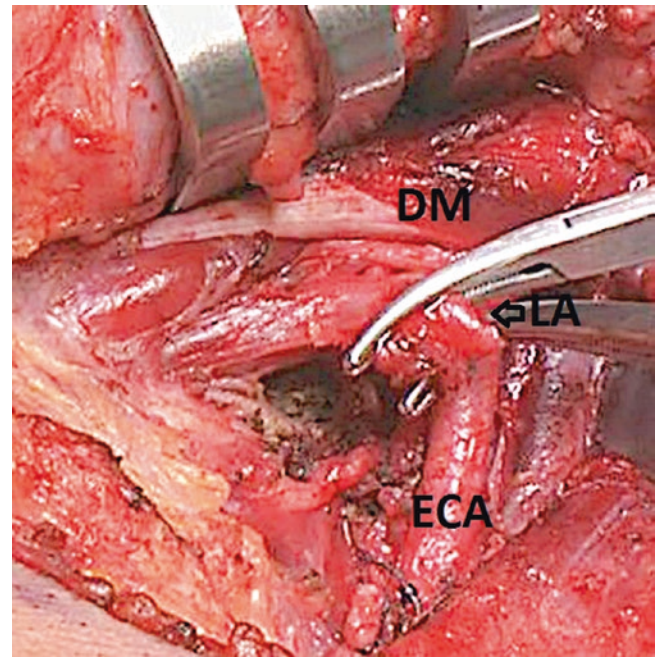


**Scheme 10.6** Once you have identified and preserved the following three structures: DM, HN and SLN, the cervical spine can be approached safely

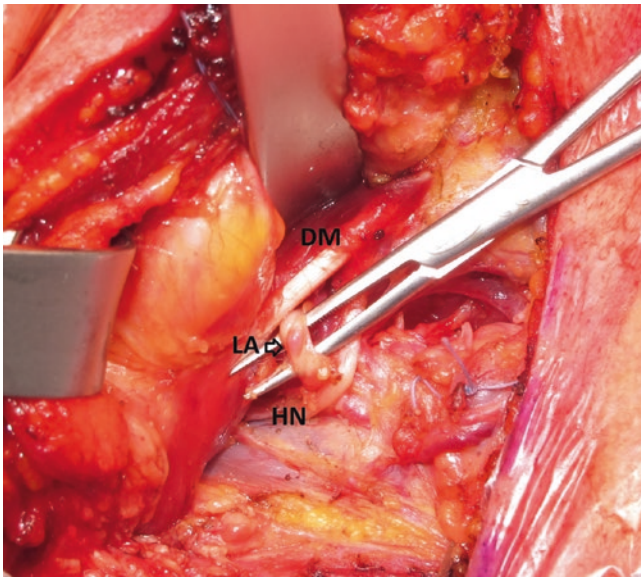
**Fig. 10.19** Left side: ligation of superior thyroid artery (*STA*). Evidence of: the posterior belly of digastric muscle (*DM*), external carotid artery (*ECA*), hypoglossal nerve (*HN*)



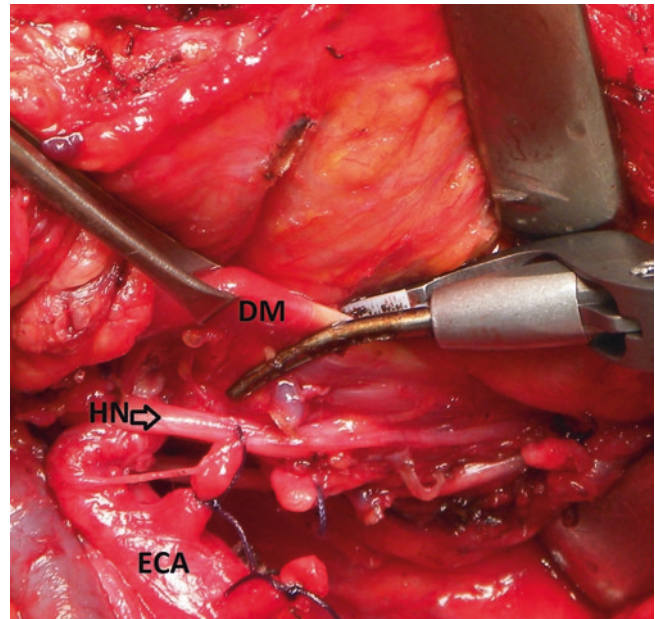
**Fig. 10.20** Right side: Ligation of superior thyroid artery (*STA*). Evidence of: the posterior belly of digastric muscle (*DM*), jugular vein (*IJV*), external carotid artery (*CA*), hypoglossal nerve (*HN*)



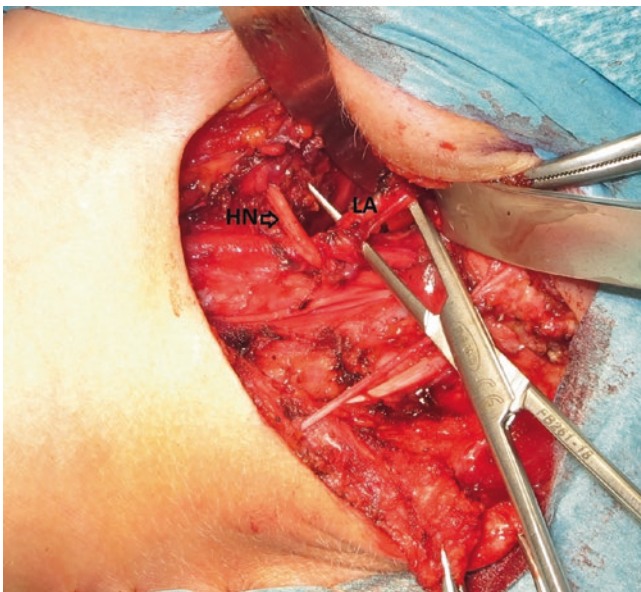
**Fig. 10.21** Left side: Ligation of lingual artery (*LA*). The posterior belly of digastric muscle (*DM*), external carotid artery (*ECA*)



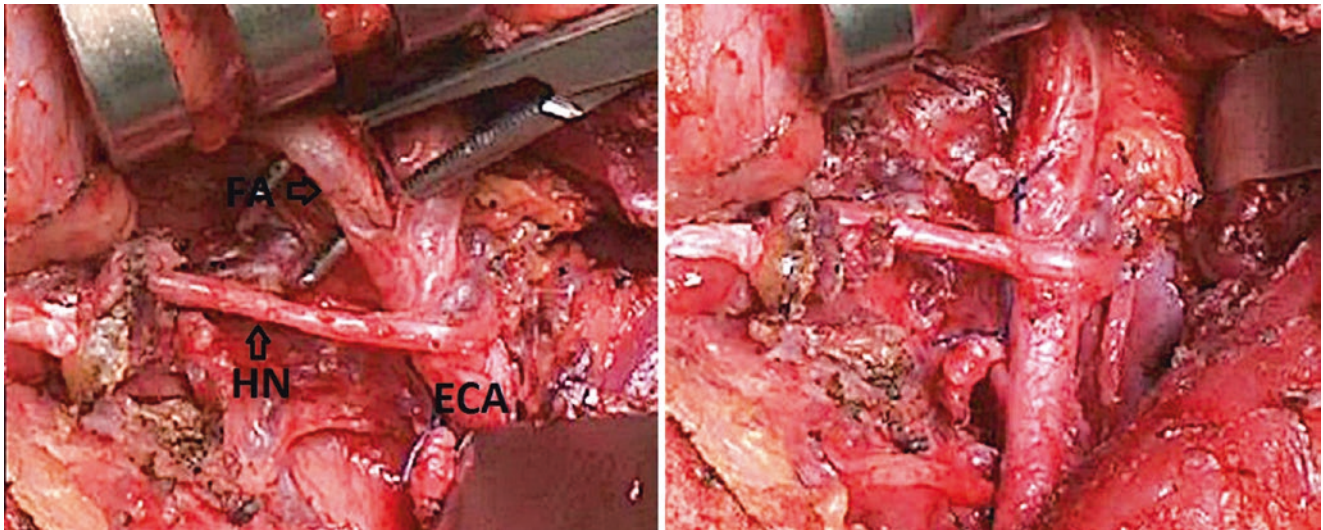
**Fig. 10.22** Right side: Ligation of lingual artery (*LA*) between hypoglossal nerve (*HN*) and digastric muscle (*DM*)



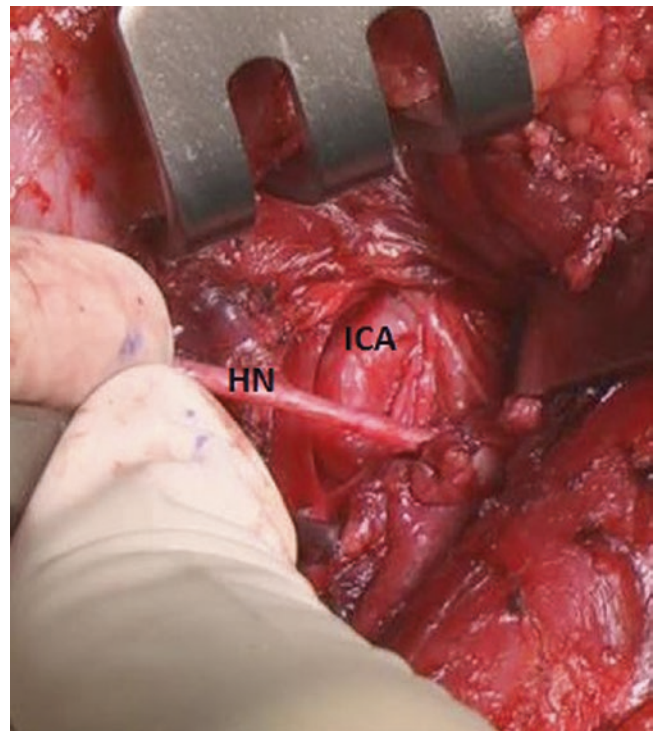
**Fig. 10.24** Section of posterior belly of digastric muscle (*DM*) in order to obtain better exposure of upper cervical spine region. External carotid artery (*ECA*) and hypoglossal nerve (*HN*)



**Fig. 10.23** Left side: Ligation of lingual artery (*LA*) between hypoglossal nerve (*HN*)



**Fig. 10.25** Left side. Ligation of the facial artery (FA) after section of digastric muscle



**Fig. 10.26** Evidence of internal carotid artery (ICA)

### Potential Complications

To avoid important bleeding during vascular structure dissection, the surgeon has to isolate veins and arteries plane by plane.

Most common complications are related to nerve injury.

Accidental section and/or palsy of the SAN could be caused by the retraction of SCM muscle. SAN lesions cause weakness of trapezius muscle on involved side and present with mild shoulder droop. The patient might report weakness in shoulder elevation and scapular winging most noticeable in arm abduction.

HN injury is a possible complication during the ligation of lingual and facial artery and in all the dissections above the hyoid bone. HN palsy causes an omolateral deviation of the tongue and difficulty in swallowing and speaking. The tongue often deviates toward the side of the lesion when it's protruded (due to imbalance of genioglossus contraction).

Ligation and dissection of STA implicate high risk of iatrogenic injury of SLN. During these maneuvers, surgeons should focus on the relationship between STA and this nerve. Palsy of SLN causes impaired cough reflex, hoarseness, voice fatigability, and impaired high-pitch phonation. Citare articolo laringeo superiore.

#### 10.1.2.4 Fourth Surgical Step: Dissection of the MLDCF between the Carotid Sheath and the Visceral Column

The middle layer of the deep cervical fascia is contiguous to the carotid sheaths and the muscular-visceral column. It

should be dissected just medial to and along the carotid sheath toward the spine. After the complete dissection of the MLDCF, the neurovascular bundle can be retracted laterally, and the midline structures (represented by pharynx and larynx) can be retracted medially. At this point, the vertebral bodies are identified by palpation and should not be confused with the anterior tubercles of the transverse processes.

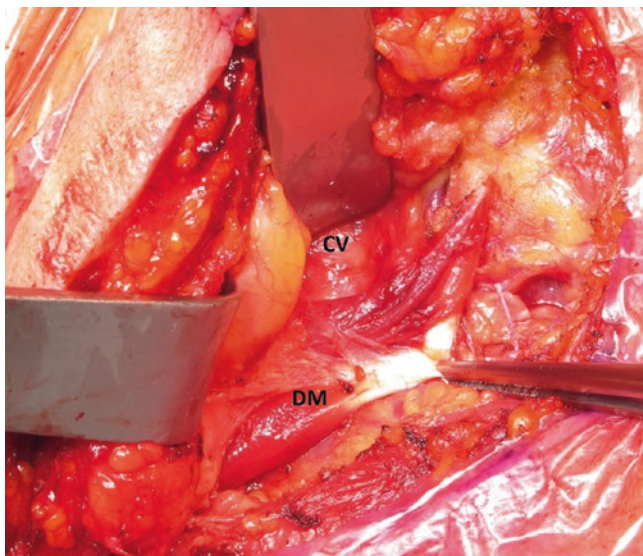
### Anatomical Key Points

#### 1. Retropharyngeal space

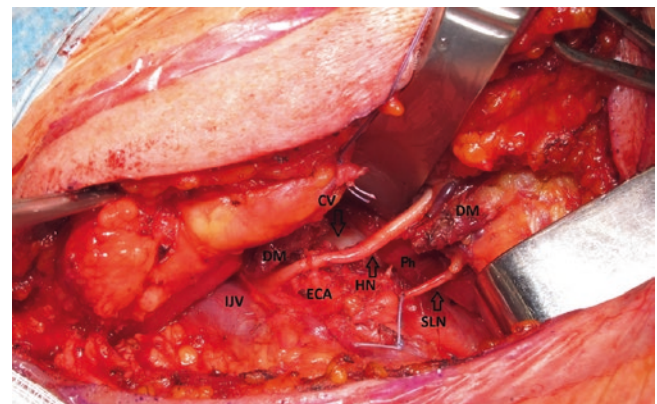
### Pearls

1. It's a virtual space that lies between the buccopharyngeal fascia anteriorly, which surrounds the pharyngeal muscles, and the alar fascia posteriorly. This space is the upper part of the retrovisceral space and continues down with the retroesophageal space. The whole retrovisceral space extends from the skull base to the mediastinum. The caudal limit is between the level of sixth cervical vertebra and the fourth thoracic vertebra. This space contains the retropharyngeal lymph nodes. Normally, the dissection of this space is carried out in an easy way.

Only if all the structures are precisely identified, it is possible to minimize the risk of complications (Figs. 10.27 and 10.28).



**Fig. 10.27** Right side: cervical vertebra C3 (CV) and digastric muscle (DM)



**Fig. 10.28** Right side: exposure of the upper cervical spine on the right side. Evidence of internal jugular vein (IJV), digastric muscle sectioned (DM), external carotid artery (ECA), hypoglossal nerve (HN), superior laryngeal nerve (SLN), pharynx (Ph), and cervical vertebra C3 (CV)

### Potential Complications

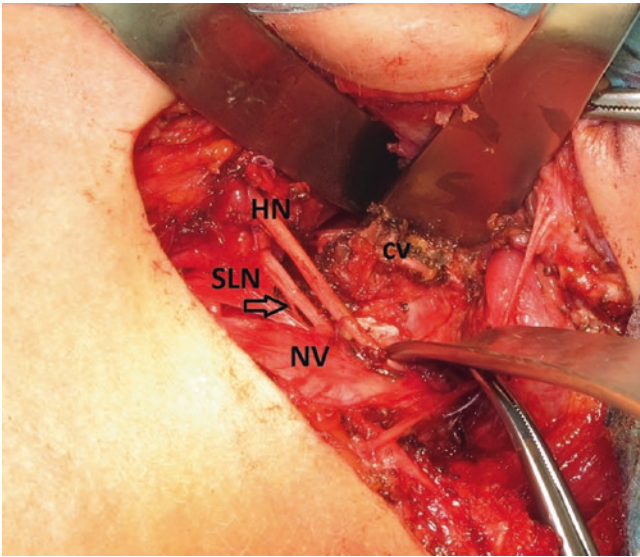
Major complications are related to massive traction of the visceral column (like pharyngeal fistula) or of the neurovascular bundle.

During this phase of the dissection, the ORL together with the orthopedic has to focus on the SLN and the HN in order to prevent any injury during traction or instruments positioning.

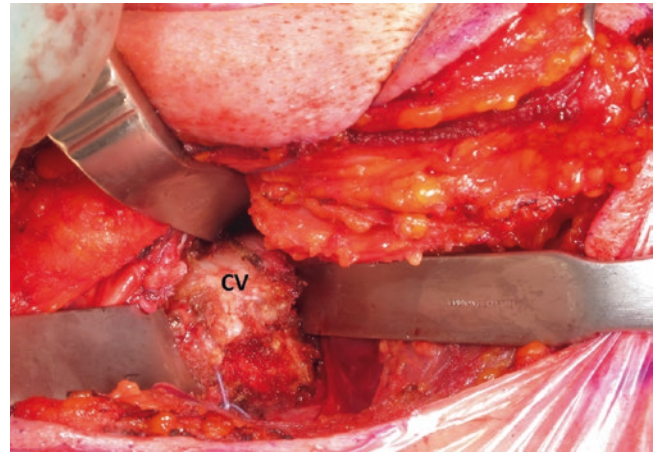
If the digastric or the stylohyoid muscles prevent an optimal exposure of the vertebral plane, it is possible to dissect them.

### 10.1.2.5 Fifth Surgical Step: Dissection of Prevertebral Structures and Exposure of the Vertebral Plane (Scheme 10.6)

The retropharyngeal area is detached from the prevertebral fascia, and the contents of the visceral fascia are retracted medially. The prevertebral fascia should be dissected on the median line, thus exposing the prevertebral muscles. The hypoglossal nerve and the superior laryngeal nerve are gently retracted to obtain a good surgical field visualization: in this way, C1, C2, and C3 are exposed. The superior laryngeal nerve crosses the field on the level with C2–C3 (Figs. 10.29 and 10.30).



**Fig. 10.29** Left side: pathological cervical vertebra (C3), hypoglossal nerve (HN), and superior laryngeal nerve (SLN)



**Fig. 10.30** Right side: evidence of a pathological cervical vertebra (CV)

**Anatomical Key Points**

1. Prevertebral muscles
2. Vertebral bodies and intervertebral disks

**Pearls**

1. The “longus capitis” is located more laterally than the longus colli and originates from the transverse process of C3-C6 and has its insertion at the basilar portion of the occipital bone. Longus colli is located on the lateral side of the vertebral bodies, from the atlas to T3. If the disease does not extend to the lateral portion of vertebral bodies, the surgeon has to identify only the longus colli. The cervical midline is defined between right and left longus colli muscles and lies lateral to vertebral bodies, which are bounded across the midline by the prevertebral layer of deep cervical fascia. Prevertebral muscles are dissected in a subperiosteal plane, the contralateral longus colli is retracted medially with the visceral column, and the ipsilateral is

retracted laterally with the carotid sheath. During dissection of the long muscles of the neck, the cervical sympathetic chain is easily recognizable compared to the vagus because it has a lower mobility and it also presents ganglion formations.

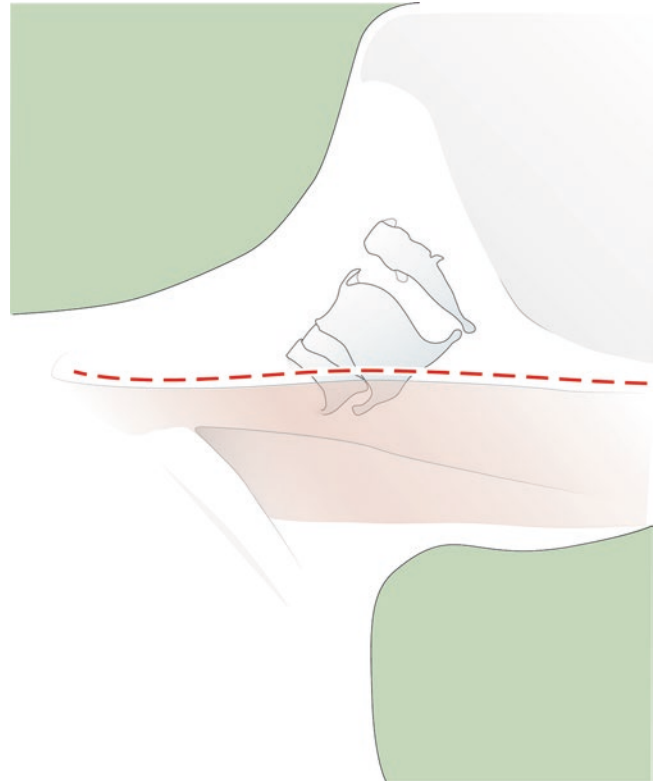
**Potential Complications**

Extended lateral retraction of prevertebral muscles might expose the vertebral artery at V2–V3 portions, where it passes through the transverse processes. In case of anatomical variation of the vertebral artery, it is possible to find the VA out of the transverse processes.

Massive traction of the neurovascular bundle could determine palsy of the cervical sympathetic chain leading to the so-called Claude-Bernard-Horner syndrome. The patient shows ptosis (droopy eyelid), miosis (constricted pupil), and facial anhidrosis (impaired facial sweating), with or without enophthalmos.

### 10.1.3 Midcervical Spine (C3–C6) (Scheme 10.7) and Fig. 10.3

**Scheme 10.7** Midcervical spine approach. SCM is a fundamental landmark for skin incision

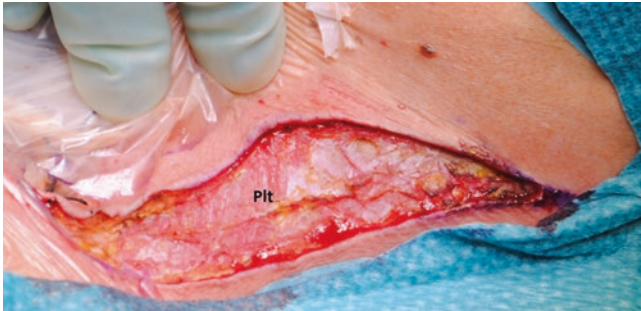





### 10.1.3.1 First Surgical Step: Incision of the Skin

The skin incision is performed along the anterior border of SCM muscle, from the tip of the mastoid process to the suprasternal notch. The extent of the incision depends on

the pathology's characteristics and the cervical level to treat. Skin and radiology landmarks are assessed during the preliminary surgical step (Fig. 10.31; Scheme 10.8).



**Fig. 10.31** Left side: incision and exposure of the platysma (*Plt*)



**Scheme 10.8** After incision of subcutaneous tissue, evidence of the platysma

### 10.1.3.2 Second Surgical Step: Dissection of the Subplatysmal Flap

Following the skin incision, a dissection of *superficial cervical fascia (SCF)* – formed by the subcutaneous tissue and the platysma muscle – is performed. Subplatysmal flap is then retracted medially to expose the SLDCF (superficial layer of deep cervical fascia) (Figs. 10.32, 10.33, 10.34, and 10.35; Scheme 10.9).

#### Anatomical Key Points

1. Sternocleidomastoid muscle (*SCM*)
2. External jugular vein (*EJV*)
3. Great auricular nerve (*GAN*)
4. Transverse cervical nerves (Scheme 10.9).

#### Pearls

1. Define the inferior margin of the surgical field.
2. Identification of the *EJV* on the skin, before skin incision, is useful for better identification and preservation of the anatomical structures. The external jugular vein emerges in the parotid loggia from the confluence of the posterior auricular vein and the posterior branch of retromandibular vein and then penetrates into the *SCM* region on the

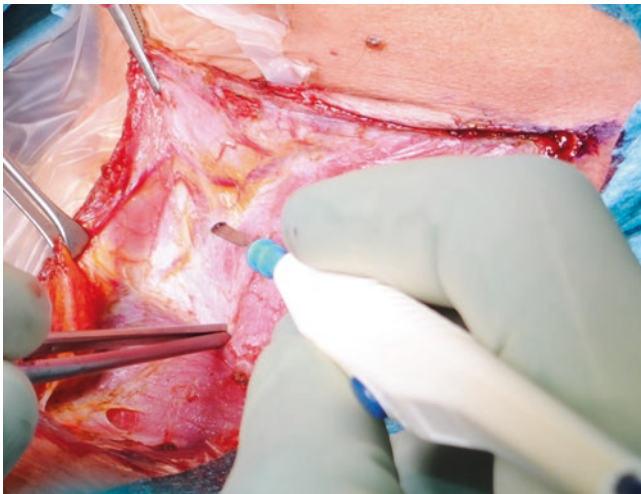
level with the angle of the mandible and crosses the lateral face of the muscle askew. During the dissection, it may be necessary to ligate it.

3. The great auricular nerve emerges from the posterior border of the *SCM* muscle, at Erb's point. It runs parallel and superior to the external jugular vein on the superficial face of the muscle. It gives sensory branches to the skin of parotid and auricular regions. During the dissection, the surgeon usually finds first the *EJV* and then, about 1 cm laterally and cranially to it, the *GAN*.
4. The transverse nerve originates from the cervical plexus, emerges at Erb's point, and crosses the sternocleidomastoid muscle transversely. It gives sensory branches to the skin. It can be preserved or sacrificed without postsurgical complications.

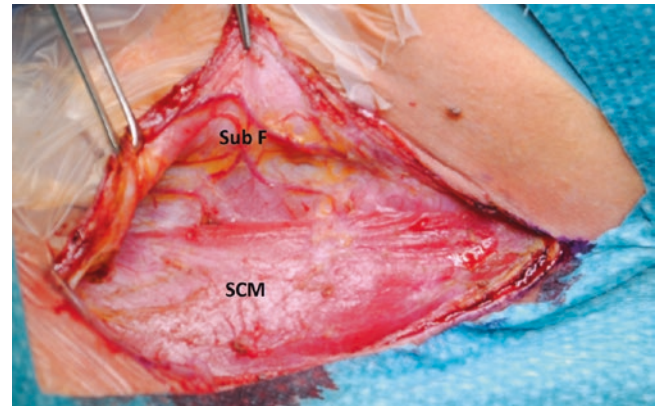
#### Potential Complications

Accidental section of the external jugular vein does not lead to a catastrophic bleeding but creates a nonoptimal visualization of the structures to dissect during the procedure.

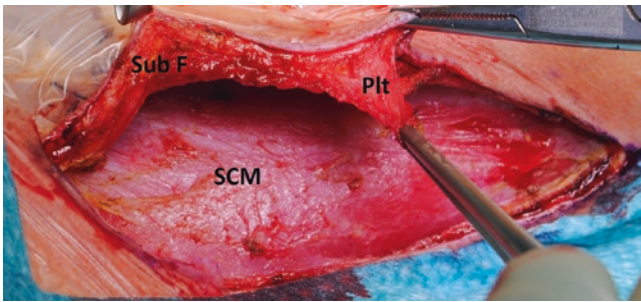
Great auricular nerve section produces an ailment hypoesthesia of periauricular skin; thus, this nerve should be preserved.



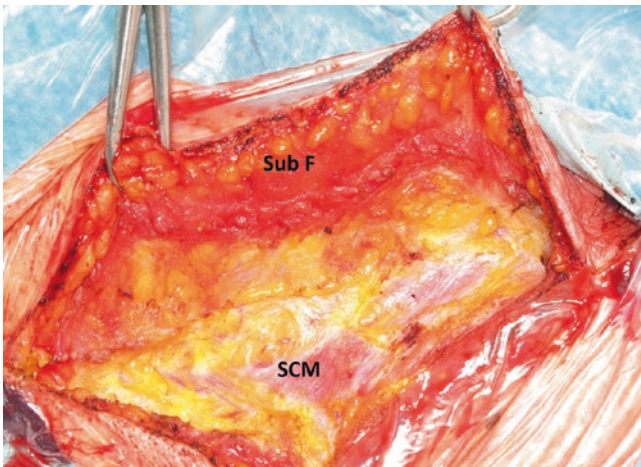
**Fig. 10.32** Dissection of the subplatysmal flap




**Fig. 10.33** Left side: dissection of subplatysmal flap (*Sub F*) and the sternocleidomastoid muscle (*SCM*)



**Fig. 10.34** Left side: evidence of platysma in the context of the subplatysmal flap and sternocleidomastoid muscle (SCM)



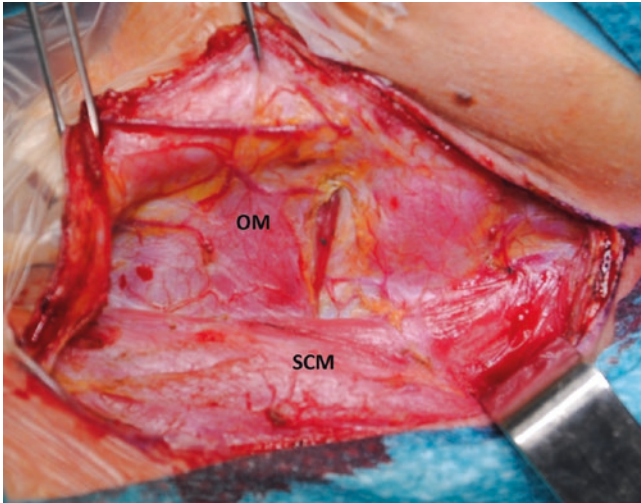
**Fig. 10.35** Right side: dissection of the subplatysmal flap (*Sub F*) and sternocleidomastoid muscle (SCM)



**Scheme 10.9** Elevated of Subplatysmal flap. Evidence of SCM, EJV and GAN. SLDCF covers the omohyoid muscle, that crosses the field

### 10.1.3.3 Third Surgical Step: Dissection of the SLDCF Anteriorly to the SCM

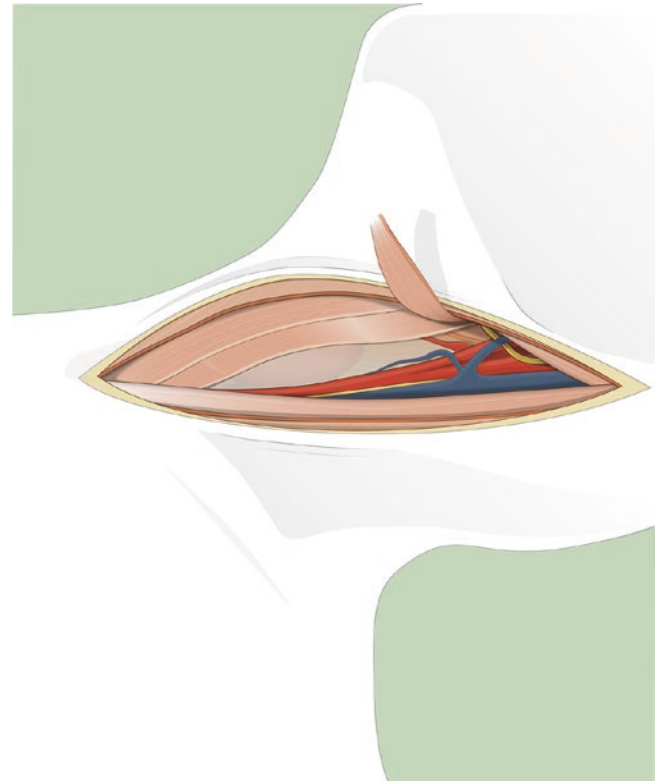
Under cover of the platysma, there is “the investing layer of the deep cervical fascia” or superficial layer of the deep cervical fascia (SLDCF). It surrounds the neck like a collar but splits around the sternocleidomastoid and trapezius muscles to enclose them. Posteriorly, it joins the ligamentum nuchae. The SLDCF is opened along the anterior border of SCM muscle. Lateral retraction of the SCM muscle exposes some of the structures below: (Fig. 10.36)



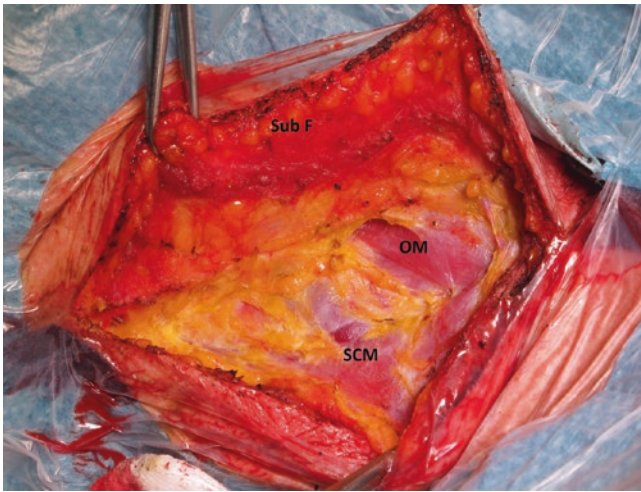
**Fig. 10.36** Left side: sternocleidomastoid muscle (*SCM*) and omohyoid muscle (*OM*)

### Anatomical Key Points (Scheme 10.10)

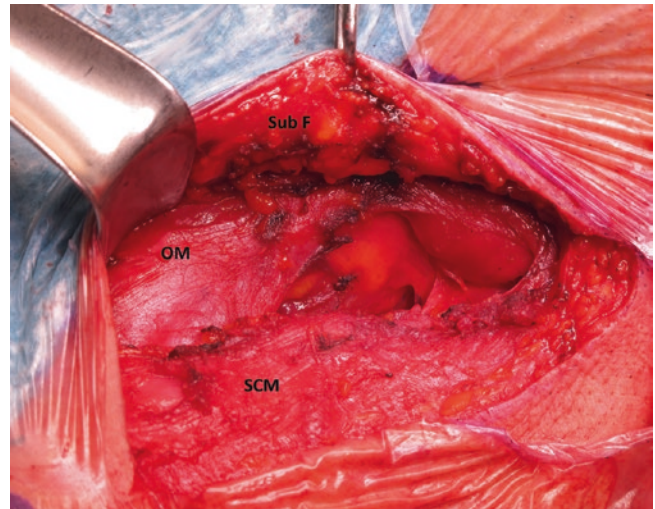
1. Omohyoid muscle (*OM*) (Figs. 10.37 and 10.38)
2. Digastric muscle (*DM*)
3. Thyrolingual-facial venous trunk (*TLF*)
4. Carotid sheath or neurovascular bundle
5. Hypoglossal nerve (*HN*)
6. Superior thyroid artery (*STA*)
7. Superior laryngeal nerve (*SLN*)
8. Recurrent laryngeal nerve (*RLN*)



**Scheme 10.10** Digastric muscle near upper part of the incision, just below TLF and HN. The image shows the first branch of the external carotid artery, the superior thyroid artery. The omohyoid muscle is dissected in order to simplify approach explanation



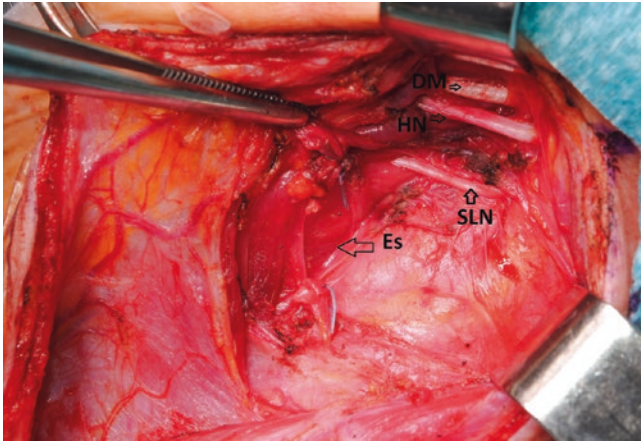
**Fig. 10.37** Right side: sternocleidomastoid muscle (*SCM*), subplatysmal flap (*Sub F*), and omohyoid muscle (*OM*)



**Fig. 10.38** Left side: sternocleidomastoid muscle (*SCM*), subplatysmal flap (*Sub F*), and omohyoid muscle (*OM*)

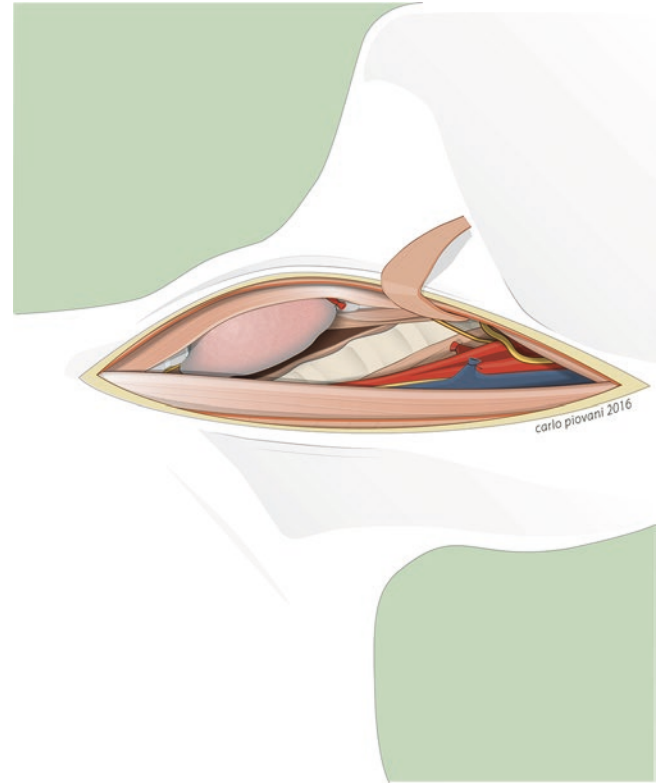
The goal is to identify the three main structures: (Fig. 10.39)

- *Digastric muscle*
- *Hypoglossal nerve*
- *Superior laryngeal nerve*



**Fig 10.39** Left side: evidence of three fundamental landmarks. From upper to lower: digastric muscle (*DM*), hypoglossal nerve (*HN*), superior laryngeal nerve (*SLN*), and esophagus (*ES*)

Once you manage to control these landmarks, the approach to the vertebral plane is carried out safely (Scheme 10.11).



**Scheme 10.11** Superior thyroid artery dissected. At this time, three fundamental landmarks, digastric muscle, HN, and SLA, are under control in order to perform safe cervical spine approach

## Pearls

1. The omohyoid muscle is a landmark: the C5–C6 vertebral disks are approximately on the level with the intersection of the omohyoid and the SCM muscle. During the dissection, it is possible to appreciate the acute angle formed by the intersection of the OM and the SCM. The OM can be pulled down or disconnected for an easier access to the plane below. The neurovascular bundle, specifically the IJV, lies under this muscle.
2. On the upper part of this dissection plane, we find the posterior belly of digastric muscle, which runs obliquely forward and downward and goes to the hyoid bone, where it is fixed with its intermediate tendon to the body and the great horn and then continues with its anterior belly. It is defined “the resident’s friend” because below it is possible to identify important structures like the neurovascular bundle and the TLF.
3. This vein passes deep to the sternocleidomastoid muscle and above the digastric muscle to empty into the internal jugular vein. It is formed by retromandibular and facial vein. Ligation of this structure should be near the confluence with the IJV.
4. It is formed by the internal jugular vein laterally, by the carotid artery medially and, in the dihedral angle formed by the two vessels, by the vagus nerve posteriorly. The first vascular structure found during the dissection is the IJV, which is just under the digastric muscle or following the TLF.
5. The HN emerges from the hypoglossal canal just medially to the jugular foramen, passes laterally between the internal jugular vein and the internal carotid artery, and goes superficial to the internal carotid artery to reach the posterior edge of the stylopharyngeus muscle. The nerve curves below the lingual artery and disappears beneath the posterior edge of hyoglossus muscle. The triangular space designed by the digastric muscle superiorly, the internal jugular vein laterally, and the TLF inferiorly is useful to identify the HN.
6. The STA arises from the external carotid artery at the point of the hyoid bone and, after providing the upper laryngeal artery, goes down to the upper pole of the thyroid gland. The STA is the first branch of the external carotid artery. To allow the access to the prevertebral space, it is mandatory to bind and dissect this artery. The STA is always under the hyoid bone. The surgeons should keep in mind, the possible anatomical variations of the origin of the STA like from thyrolingual (2 %) or thyrolinguofacial (1 %) trunk. To safely bind the artery, we should stay near its origin from the external carotid artery. This maneuver reduces the risk of superior laryngeal nerve injury. During this approach, the STA may not be properly in the surgical field, but without its ligation, it would be difficult and dangerous to obtain a good exposition of the vertebral plane (Figs. 10.40, 10.41, 10.42, and 10.43).
7. The SLN runs medially to the carotid sheath, forming an oblique angle with it. The nerve moves medially toward the thyrohyoid membrane. After the ligation of the STA, it is possible to identify this nerve.
8. On the left side, the recurrent laryngeal nerve arises from the vagus on the level with the aortic arch, and after having surrounded it, it assumes a vertical course. On the right side, the nerve emerges from the vagus where it crosses the subclavian artery; then it surrounds this artery and ascends obliquely, approaching the esophageal margin. In case of nonrecurrent laryngeal nerve, it is mandatory to convert this approach to the lateral one. In the cervical region, the ILN usually lies within the tracheoesophageal groove.

## Potential Complications

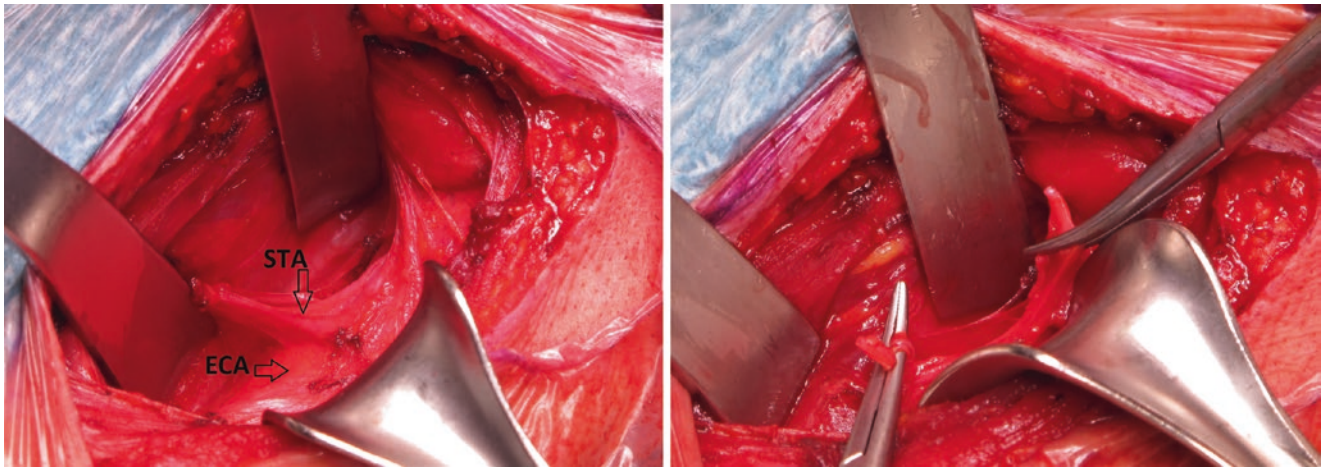
The dissection of the omohyoid muscle has to be performed gently; the surgeon has to focus on the IJV lying below.

Most common complications are related to nerve injuries.

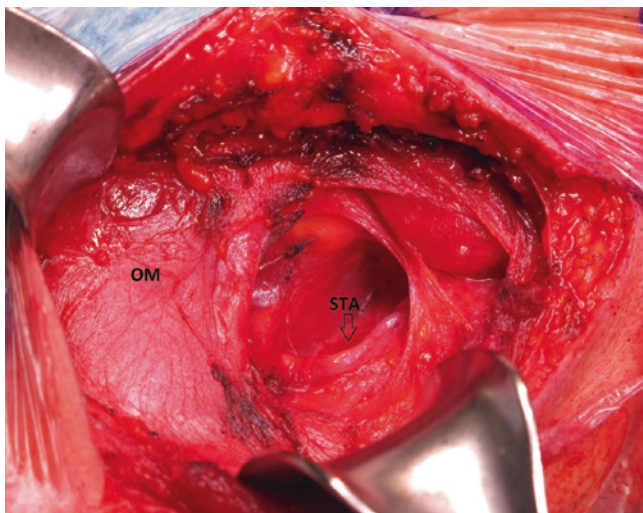
HN injury is a possible complication during the ligation of lingual and facial artery and in all the dissections above the hyoid bone. HN palsy causes an omolateral deviation of the tongue and difficulty in swallowing and speaking. The tongue often deviates toward the side of the lesion when it’s protruded (due to imbalance of genioglossus contraction).

Ligation and dissection of the STA implicate high risk of iatrogenic injury of the SLN. During these maneuvers, surgeons should focus on the relationship between STA and this nerve. Palsy of the SLN causes impaired cough reflex, hoarseness, voice fatigability, and impaired high-pitch phonation.

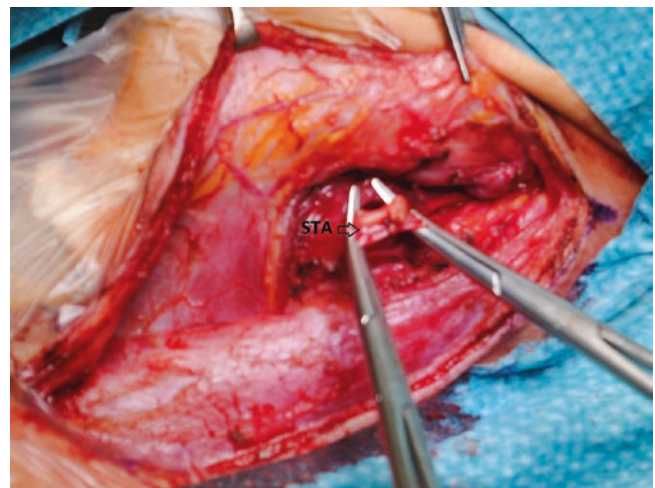
RLN palsy determines paramedian vocal chords, with poor or no movement, voice fatigability, accumulation of saliva in the piriform fossa, and inability to swallow.



**Figs. 10.40 and 10.41** Left side: identification and ligation of the superior thyroid artery (*STA*) at its origin from the external carotid artery (*ECA*)



**Fig. 10.42** Left side. Identification of superior thyroid artery (*STA*). Omohyoid muscle (*OM*)



**Fig. 10.43** Left side: identification of superior thyroid artery (*STA*)



#### 10.1.3.4 Fourth Surgical Step: Dissection of the MLDCF between the Carotid Sheath and the Visceral Column

The middle layer of deep cervical fascia is contiguous to the carotid sheath and the muscular-visceral column. It should be dissected just medial to and along the carotid sheath toward the spine. After complete dissection of the MLDCF, the neurovascular bundle can be retracted laterally, and the midline structures (represented by larynx, thyroid, trachea, and esophagus) can be retracted medially. At this point, the vertebral bodies are identified by palpation and should not be confused with the anterior tubercles of the transverse processes.

##### Anatomical Key Points (Figs. 10.44 and 10.45)

1. Larynx, thyroid gland, and trachea
2. Esophagus
3. Vagus nerve
4. Retrovisceral space

##### Pearls

Only if all the structures are precisely identified, it is possible to minimize the risk of complications.

1. All these structures are covered by the visceral fascia. A palpatory identification of cartilaginous structures like the thyroid cartilage, the cricoid ring, and the hyoid bone usually allows identifying a safe plane to continue the dissection.
2. A right-side approach reduces the risk of iatrogenic esophageal injury, because the physiological curvature to

the left of the esophageal tube promotes a better view of the prevertebral plan. Look for the nasogastric tube, preoperatively positioned by an anesthesiologist, by palpation of the posterior portion of the visceral column: this may allow the identification of the esophagus during dissection.

3. The vagus nerve lies posteriorly in the groove between the internal jugular vein and the internal and later common carotid artery. Occasionally, the vagus nerve is located in a more anterior position, related to the carotid artery at the base of the neck.
4. It is identified after the section of the MLDCF. It is an aponeurotic space formed by the buccopharyngeal, the prevertebral, and the alar fascia.

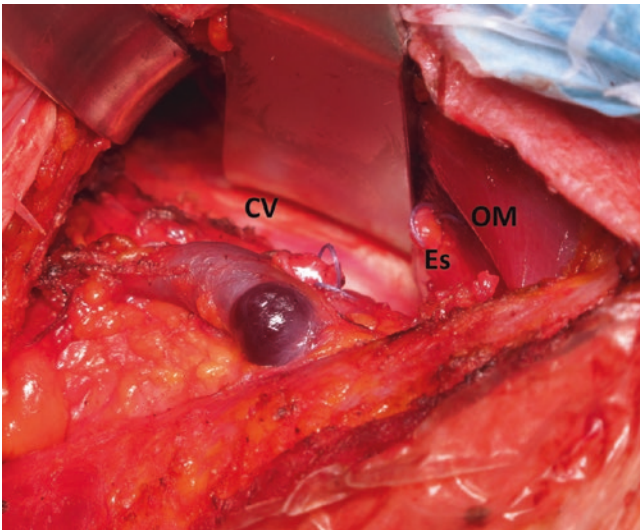
The whole retrovisceral space extends from the skull base to the mediastinum. The caudal limit is between C6 and T4. It contains the retropharyngeal lymph nodes. This space is normally easy to identify, and its dissection is made by finger or with the help of a cottonoid.

##### Potential Complications

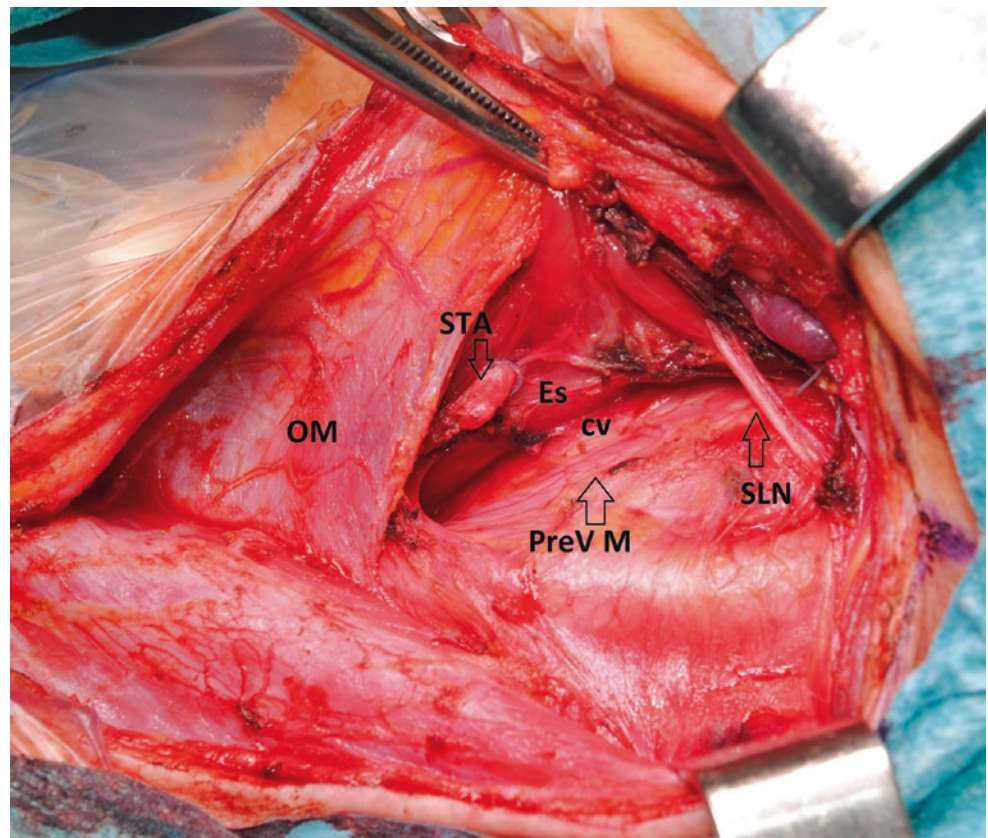
Only if all the structures are precisely identified, it is possible to minimize the risk of complications.

Major risks during this step are related to the esophageal fistula.

RLN palsy is a potential complication during the traction of the visceral column. A correct retraction of the esophagus allows the surgeon to protect the nerve. In case of NRLN, it is necessary to choose another approach.



**Fig. 10.44** Right side: evidence of cervical vertebra (*CV*). Retraction of esophagus (*Es*), omohyoid muscle (*OM*)



**Fig. 10.45** Left side: omohyoid muscle (*OM*), superior thyroid artery (*STA*) dissected, superior laryngeal nerve (*SLN*), esophagus (*ES*), prevertebral muscle (*PreV M*), and cervical vertebra (*CV*)

### 10.1.3.5 Fifth Surgical Step: Dissection of Prevertebral Structures and Exposure of the Vertebral Plane

The prevertebral layer of the deep cervical fascia originates laterally from the transverse processes and continues with the fascia of the scalene muscles. The prevertebral layer and the anterior longitudinal ligament are incised longitudinally along the midline before their cauterization.

#### Anatomical Key Points (Figs. 10.46 and 10.47)

1. Prevertebral muscles
2. Vertebral bodies and intervertebral disks (Scheme 10.11)

#### Pearls

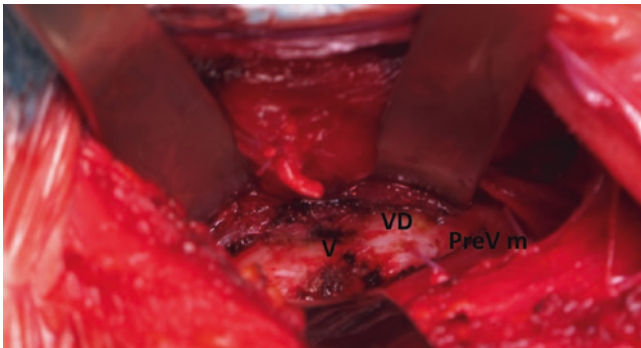
1. The “longus capitis” is located more laterally than the longus colli and originates from the transverse process of C3-C6 and has its insertion at the basilar portion of the occipital bone. Longus colli is located on the lateral side of the vertebral bodies, from the atlas to T3. If the dissection does not extend to the lateral portion of vertebral bodies, the surgeon has to identify only the longus colli. The cervical midline is defined between right and left longus colli muscles and lies lateral to vertebral bodies,

which are bounded across the midline by the prevertebral layer of the deep cervical fascia. Prevertebral muscles are dissected in a subperiosteal plane; the contralateral longus colli is retracted medially with the visceral column, and the ipsilateral is retracted laterally with the carotid sheath. During dissection of the long muscles of the neck, the cervical sympathetic chain is easily recognizable compared to the vagus nerve because it has a lower mobility and it also presents ganglion formations.

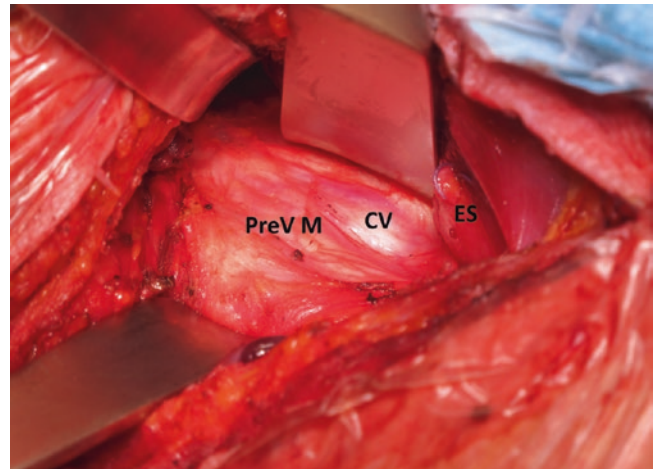
#### Potential Complications

Extended lateral retraction of prevertebral muscles might expose the vertebral artery at V2 portions, where it passes through the transverse processes. In case of anatomical variation of the vertebral artery, it is possible to find the VA out of the transverse processes.

Massive traction of the neurovascular bundle could determine palsy of the cervical sympathetic chain leading to the so-called Claude-Bernard-Horner syndrome. The patient shows ptosis (droopy eyelid), miosis (constricted pupil), and facial anhidrosis (impaired facial sweating), with or without enophthalmos.



**Fig. 10.46** Expose of vertebral plane. Cervical vertebra (V), vertebral disk (VD), and prevertebral muscles (PreV M)



**Fig. 10.47** Expose of vertebral plane. Cervical vertebra (CV) and prevertebral muscles (PreV M). Esophagus (Es) retracted laterally

### 10.1.4 Cervical Mini-invasive Approach

A correct analysis of the risk points during plane-by-plane dissection allows performing a mini-invasive approach to a specific cervical level.

A limited exposure of anatomical structures reduces the possibility of landmarks identification. Surgeons have to focus on variable courses of the structures and perform a plane-by-plane dissection.

Major anatomical details have already been described.

#### 10.1.4.1 First Surgical Step: Incision of the Skin (Figs. 10.48 and 10.49)

A horizontal incision is performed about 4–5 cm from the neck midline to the anterior border of SCM.

The surgeons have to correlate the level to treat to landmarks on the skin (hyoid bone, thyroid cartilage, and cricoid cartilage) and customize the skin incision following the same landmarks.

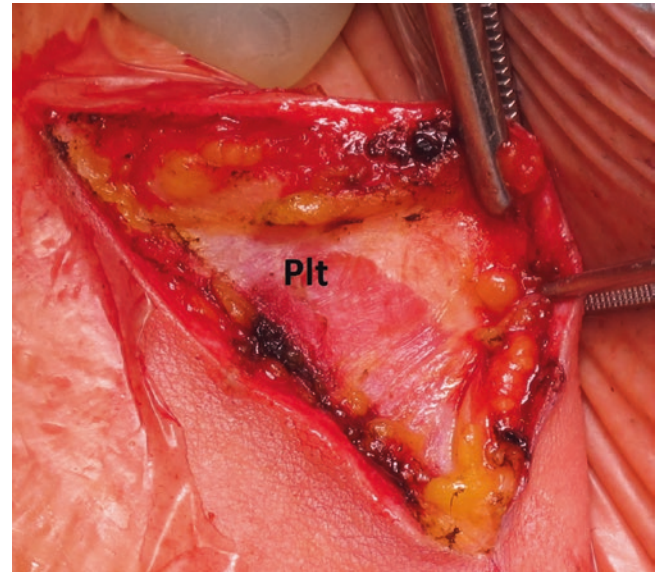
Heller et al. [9] describe the correlations between cervical spine levels and potentially at risk structures from C2–C6

| Vertebral level | Structure (s) at risk | Clinical correlate   |
|-----------------|-----------------------|--|
| C2              | HN                    | Dysphagia, dysarthria, ipsilateral tongue deviation                                  |
| C2–C3           | HN                    | Dysphagia, dysarthria, ipsilateral tongue deviation                                  |
| C3              | HN, SLN, STA          | Dysphagia, dysarthria, ipsilateral tongue deviation, impaired cough reflex           |
| C3–C4           | SLN, STA              | Impaired cough reflex  |
| C4              | SLN, STA, SLA         | Impaired cough reflex, hoarseness, voice fatigability, impaired high-pitch phonation |
| C4–C5           | SLN, STA, SLA         | Hoarseness, voice fatigability, impaired high-pitch phonation                        |
| C5              | SLN, STA, SLA         | Hoarseness, voice fatigability, impaired high-pitch phonation                        |
| C5–C6           | SLN, STA              | Hoarseness, voice fatigability, impaired high-pitch phonation                        |
| C6              | SLN, STA              | Hoarseness, voice fatigability, impaired high-pitch phonation                        |

From Heller et al. [9] article



**Fig. 10.48** Left side: incision line



**Fig. 10.49** Left side: exposure of platysma muscle (*Plt*)

### 10.1.4.2 Second Surgical Step: Dissection of the Subplatysmal Flap

Following the skin incision, a dissection of *superficial cervical fascia (SCF)* – formed by the subcutaneous tissue and the platysma muscle – is performed. The flap is then elevated above the inferior border of the mandible to expose the *superficial layer of the deep cervical fascia (SLDCF)* (Fig. 10.50).

#### Anatomical Key Points

1. Sternocleidomastoid muscle (*SCM*)
2. Anterior jugular vein (*AJV*)
3. Transverse cervical nerve (*TCN*) C4–C5 levels

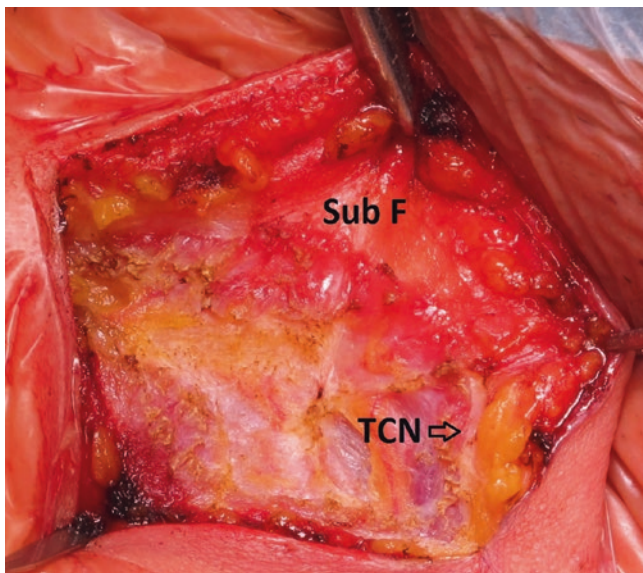
#### Pearls

This vein could be preserved or dissected without postoperative complications. The transverse nerve originates from the cervical plexus, emerges at Erb's point, and crosses the *SCM* muscle transversely. It gives sensory branches to the skin. It can be preserved or sacrificed without postsurgical complications.

#### Potential Complications

Accidental section of the *AJV* jugular vein or communicated vein between *AJV* and *EJV* vein does not lead to a catastrophic bleeding but creates a nonoptimal visualization of the structures to dissect during the procedure.

The transverse cervical nerve could be preserved or dissected without postsurgical complications.



**Fig. 10.50** Left side: subplatysmal flap (*Sub F*) and transverse cervical nerve (*TCN*)

### 10.1.4.3 Third Surgical Step: Dissection of the SLDCF Anteriorly to the SCM

In this approach, the identification of the digastric muscle, the HN, and the SLN is impossible, but it is still mandatory to know which structures could be found during plane-by-plane dissection (Figs. 10.51, 10.52, 10.53, and 10.54).

#### Anatomical Key Points

1. Omohyoid muscle (*C4–C6 levels*) (*OM*)
2. Thyrolingual-facial venous trunk (*C3–C4 levels*) (*TLF*)
3. Carotid sheath or neurovascular bundle
4. Thyroid gland (*Thy*)
5. Medial thyroid vein (*C4–C6 levels*) (*MTV*)
6. Superior thyroid artery (*STA*) *C3–C6 levels*
7. Superior laryngeal nerve (*SLN*) *C3–C6 levels*
8. Inferior thyroid artery (*ITA*) *C5–C6 levels*
9. Recurrent laryngeal nerve (*RLN*) *C5–C6 levels*

#### Pearls

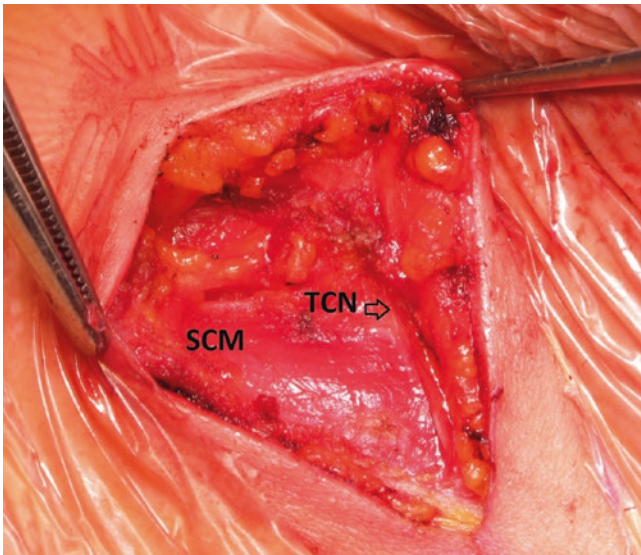
The omohyoid muscle allows recognizing the neurovascular bundle; from this point, surgeons have to find the carotid artery and the thyroid gland.

A gentle retraction of these structures simplifies STA, MTV, and ITA dissection and ligation near the neurovascular bundle.

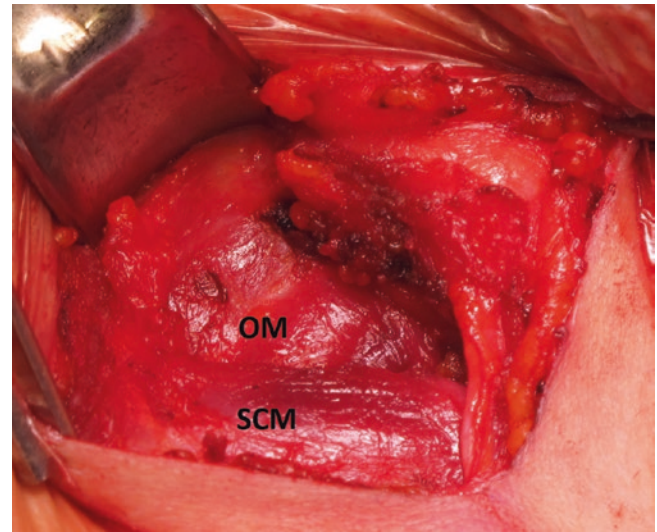
The SLN and the RLN have to be recognized and preserved. It is important to remember RLN's different courses on the left and right side, as previously described.

#### Potential Complications

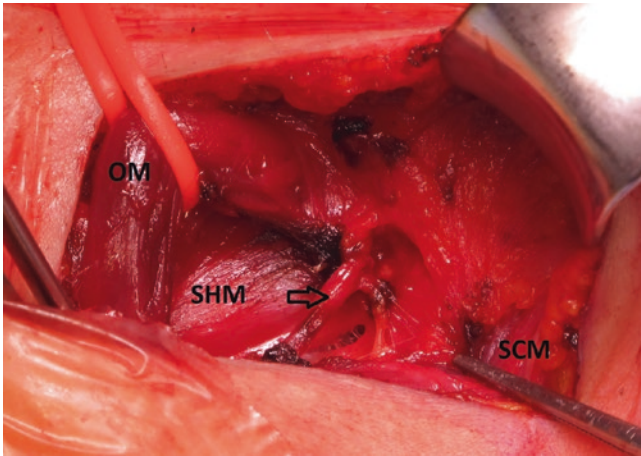
Complications are related to nerve and vascular injury. All the clinical presentations are described in the extended approach.



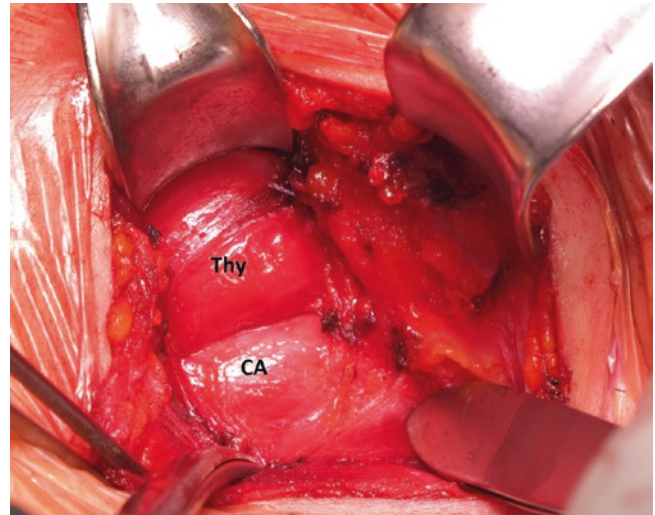
**Fig. 10.51** Left side: transverse cervical nerve (*TCN*) and sternocleidomastoid muscle (*SCM*)



**Fig. 10.52** Left side: sternocleidomastoid muscle (*SCM*) and omohyoid muscle (*OM*)



**Fig. 10.53** Left side: sternocleidomastoid muscle (*SCM*), omohyoid muscle (*OM*), sternohyoid muscle (*SHM*), and anastomosis between anterior jugular vein and external jugular vein (*arrow*)



**Fig. 10.54** Left side: thyroid gland (*Thy*) and carotid artery (*CA*)

#### 10.1.4.4 Fourth Surgical Step: Dissection of the MLDCF between the Carotid Sheath and the Visceral Column

##### Anatomical Key Points (Fig. 10.55)

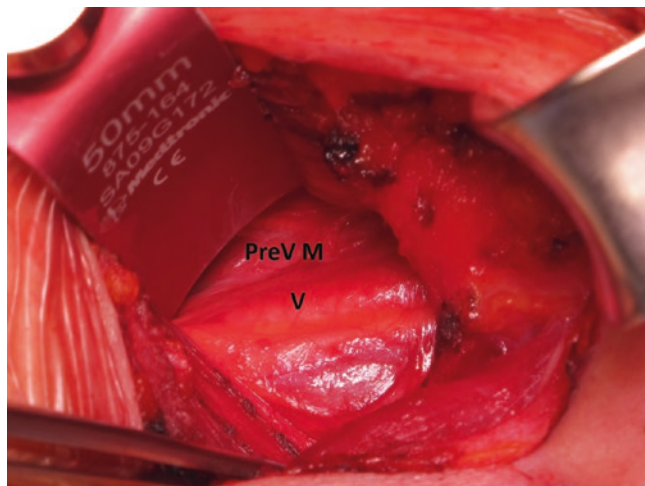
1. Larynx and trachea
2. Esophagus
3. Vagus nerve
4. Retrovisceral space

##### Pearls and Potential Complications

A right-side approach reduces the risk of iatrogenic esophageal injury, because of its physiological curvature. Major risks during this step are related to the esophagus retraction. The most important maneuver is the correct visualization of the esophagus; the surgeon could touch the gastric tube inside the lumen, preoperatively positioned by the anesthesiologist, and gently retract it medially.

RLN palsy is a potential complication during the traction of the visceral column. A correct retraction of the esophagus allows the surgeon to protect the nerve. In NRLN, it is necessary to choose another approach.

Claude-Bernard-Horner syndrome is the consequence of cervical sympathetic chain palsy due to massive traction of neurovascular bundle.



**Fig. 10.55** Left side: vertebral plane (V) and prevertebral muscle (PreV M)

#### 10.1.4.5 Fifth Surgical Step: Dissection of Prevertebral Structures and Exposure of the Vertebral Plane

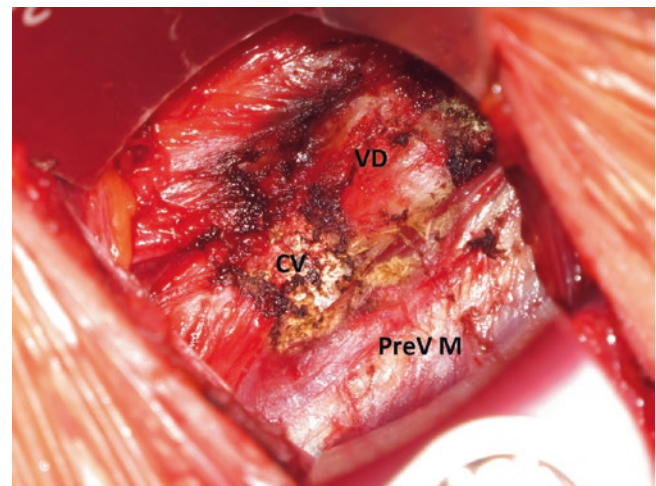
##### Anatomical Key Points (Fig. 10.56)

1. Prevertebral muscles
2. Vertebral bodies and intervertebral disks

##### Pearls and Potential Complications

Prevertebral muscles are dissected in a subperiosteal plane, contralateral longus colli is retracted medially with the visceral column, and the ipsilateral one is retracted laterally with the carotid sheath.

Extended lateral retraction of prevertebral muscles might expose the vertebral artery at V2 portions, where it passes through the transverse processes. In case of anatomical variation of the vertebral artery, it is possible to find the VA out of the transverse processes.



**Fig. 10.56** Left side: fifth cervical vertebra (CV), vertebral disk between C4 and C5 (VD), and prevertebral muscles (PreV M)



### 10.1.5 Caudal Extension: Cervical Thoracic Junction

The approach to the cervical thoracic junction can be considered a lower extension of the midcervical spine approach (Scheme 10.12).

#### 10.1.5.1 Second Surgical Step: Dissection of the Subplatysmal Flap

**Anatomical Key Points** (Scheme 10.13)

1. Sternocleidomastoid muscle (*SCM*)
2. Anterior jugular vein (*AJV*)
3. Transverse cervical nerve
4. Supraclavicular nerve

#### Pearls

1. Define the inferior margin of the surgical field.
2. The *AJV* derives by the joining of several superficial veins in the submental region. It descends anteriorly to

the *SCM* muscle and passes deep to the muscle before draining into the external jugular vein or the subclavian vein. During dissection, it may be necessary to ligate it.

3. The transverse nerve originates from the cervical plexus, emerges at Erb's point, and crosses the sternocleidomastoid muscle transversely. It gives sensory branches to the skin. It can be preserved or dissected without postsurgical complications.
4. It passes posteriorly to the *SCM* muscle at Erb's point. It travels inferiorly in an oblique direction through the posterior triangle of the neck.

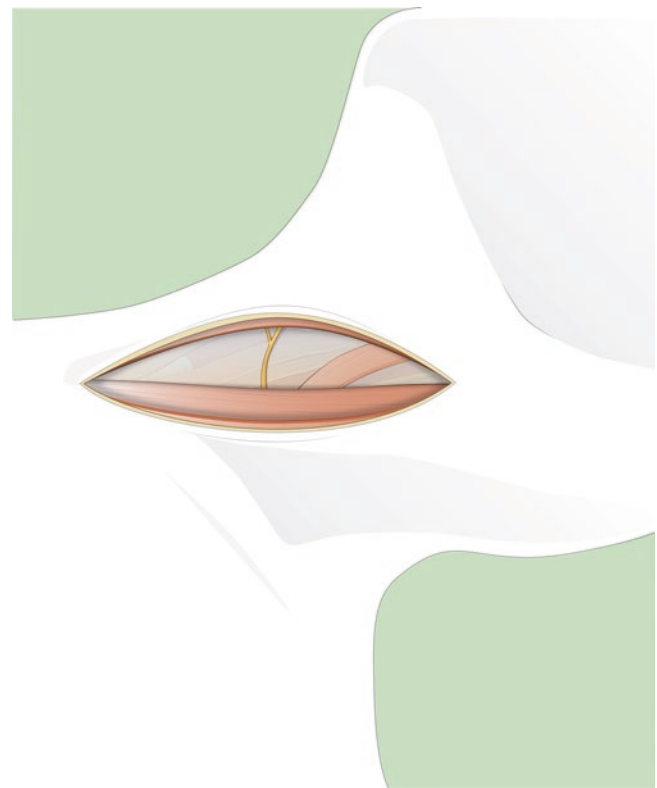
#### Potential Complications

Accidental section of the anterior jugular vein does not determine a catastrophic bleeding but creates a nonoptimal visualization of the structures to dissect during the procedure.

Dissection of the transverse or supraclavicular nerves does not lead to any functional impairment, so surgeons can decide to dissect them.



**Scheme 10.12** Incision of the subcutaneous tissue and exposure of the platysma



**Scheme 10.13** Subplatysmal flap elevation. The main structures below are: *SCM*, omohyoid muscle, and transverse cervical nerve

### 10.1.5.2 TThird Surgical Step: Dissection of the SLDCF Anteriorly to the SCM

#### Anatomical Key Points (Scheme 10.14)

1. Omohyoid muscle (*OM*)
2. Carotid sheath or neurovascular bundle
3. Thyroid gland (*Thy*)
4. Medial thyroid vein (*MTV*)
5. Inferior thyroid artery (*ITA*)
6. Recurrent laryngeal nerve (*RLN*)

#### Pearls

1. The omohyoid muscle is a landmark: the C5–C6 vertebral disks are approximately on the level with the intersection of the omohyoid and the SCM muscle. OM can be pulled down or disconnected for an easier access to the plane below. The neurovascular bundle, specifically the IJV, lies under this muscle.
2. It is formed by the internal jugular vein laterally, by the carotid artery medially and, in the dihedral angle formed by the two vessels, by the vagus nerve posteriorly. The first vascular structure found during the dissection is the IJV, which is just under the digastric muscle or following the TLF.
3. Surgeons have to recognize it, and in order to avoid bleeding, it is useful to preserve its fascia.
4. The middle thyroid vein collects the blood from the lower part of the thyroid gland, and after receiving some veins from the larynx and the trachea, it ends in the lower part of the internal jugular vein. Its ligation is normally carried out near the IJV.
5. It arises from the thyrocervical trunk and goes upward, in front of the vertebral artery and the longus colli muscle. Then it turns behind and medially to the carotid sheath and its contents and stays also behind the sympathetic trunk. When it reaches the lower border of the thyroid gland, it divides into two branches, which supply the posteroinferior parts of the gland.
6. On the left side, the recurrent laryngeal nerve arises from the vagus on the level with the aortic arch, and after having surrounded it, it assumes a vertical course. On the right side, the nerve emerges from the vagus where it crosses the subclavian artery, and then it surrounds this artery and ascends obliquely, approaching the esophageal margin. In case of nonrecurrent laryngeal nerve, it is mandatory to convert this approach to the lateral one. In the cervical region, the ILN usually lies within the tracheo-esophageal groove. Lore's triangle is useful to find the RLN. It is formed by the trachea medially, the common carotid artery laterally, and the under surface of the

retracted inferior thyroid pole superiorly, the apex of the triangle being directed toward the thoracic inlet.

#### Potential Complications


The dissection of the omohyoid muscle has to be performed gently; the surgeon has to focus on the IJV lying below.

Most common complications are related to nerve injuries.

HN injury is a possible complication during the ligation of lingual and facial artery and in all the dissections above the hyoid bone. HN palsy causes an omolateral deviation of the tongue and difficulty in swallowing and speaking. The tongue often deviates toward the side of the lesion when it's protruded (due to imbalance of genioglossus contraction).

Ligation and dissection of STA implicate high risk of iatrogenic injury of SLN. During these maneuvers, surgeons should focus on the relationship between STA and this nerve. Palsy of SLN causes impaired cough reflex, hoarseness, voice fatigability, and impaired high-pitch phonation.

RLN palsy determines paramedian vocal chords, with poor or no movement, voice fatigability, accumulation of saliva in the piriform fossa, and inability to swallow.



**Scheme 10.14** Three fundamental landmarks are not always recognizable. Main structures are the superior thyroid artery and sometimes the superior laryngeal nerve:

### 10.1.5.3 Fourth Surgical Step: Dissection of the MLDCF between the Carotid Sheath and the Visceral Column

#### Anatomical Key Points (Scheme 10.15)

1. Trachea and retrovisceral space
2. Esophagus
3. Subclavian artery and vertebral artery (VA)
4. Cervical sympathetic chain
5. Thoracic duct on the left side

#### Pearls

Only if all the structures are precisely identified, it is possible to minimize the risk of complications:

1. It is identified after the section of the MLDCF. It is an aponeurotic space formed by the buccopharyngeal, the prevertebral, and the alar fascia. The whole retrovisceral space extends from the skull base to the mediastinum. The caudal limit is between C6 and T4. It contains the retropharyngeal lymph nodes. This space is normally easy to identify, and its dissection is made by finger or with the help of a cottonoid.
2. A right-side approach reduces the risk of iatrogenic esophageal injury, because the physiological curvature to the left of the esophageal tube promotes a better view of the prevertebral plan. Look for the nasogastric tube, preoperatively positioned by the anesthesiologist, by palpation of the posterior portion of the visceral column: this may allow the identification of the esophagus during dissection.
3. The subclavian artery travels lateral to the trachea into the root of the neck, passing between the anterior and middle scalene muscles. In its first part, it gives origin to the thyrocervical trunk and the vertebral artery. During the lateral retraction of the neurovascular structures, it is important to consider its course because in its VI portion, the artery goes more superficial and is without bone protection (Fig. 10.57)

4. The stellate ganglion (or cervicothoracic ganglion) is a sympathetic ganglion formed by the fusion of the inferior cervical ganglion and the first thoracic ganglion, which exists in 80% of cases. The stellate ganglion is located at C7 level (7th cervical vertebrae), anterior to the transverse process of C7, superior to the neck of the first rib, and just below the subclavian artery.
5. The thoracic duct is located on the left side within a triangle bounded medially by the longus colli muscle and the esophagus, laterally by the anterior scalene muscle, and inferiorly by the first rib. Although it may ascend as high as C6, it is most often found between C7 and T1, before it descends to empty into a variable termination at the jugulo-subclavian junction. The rostral extension of the thoracic duct appears to vary by gender, as in patients who have a narrow thoracic inlet, as most women do; the duct may ascend as high as the level of the C6 vertebral body. Many authors have cited the increased possibility of injuring this structure in the left upper thorax.

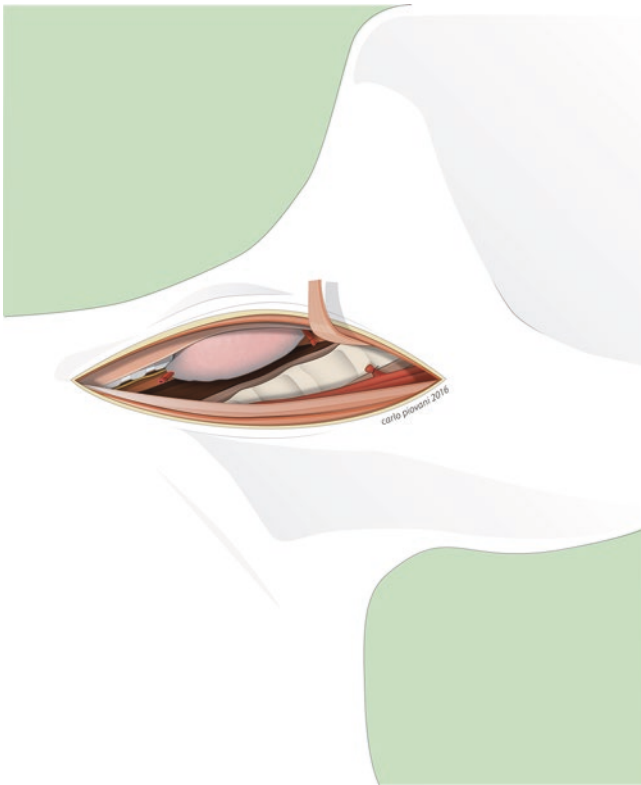#### Potential Complications

Injury of the subclavian artery or the vertebral artery produces a catastrophic bleeding and can determine neurological defects.

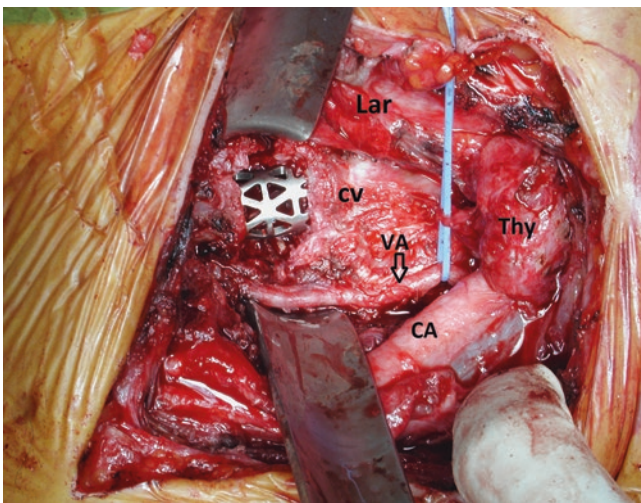
Major risks during this step are related to the esophagus retraction. The most important maneuver is the correct visualization of the esophagus that has to be gently retracted medially.

Massive traction of the neurovascular bundle could determine palsy of the cervical sympathetic chain leading to the so-called Claude-Bernard-Horner syndrome. The patient shows ptosis (droopy eyelid), miosis (constricted pupil), and facial anhidrosis (impaired facial sweating), with or without enophthalmos.

Lymphatic fistula or pneumothorax can happen as a consequence of an accidental pleuric lesion.



**Scheme 10.15** In order to show CTJ, thyroid gland dissection is mandatory. Superior and inferior thyroid arteries have to be dissected. The RLN lies into the tracheal-esophageal groove and it must be preserved



**Fig. 10.57** Right side: right lobe of thyroid gland (*Thy*), larynx (*Lar*), carotid artery (*CA*), and vertebral artery (*VA*)

#### 10.1.5.4 Fifth Surgical Step: Dissection of Prevertebral Structures and Exposure of the Vertebral Plane

The prevertebral layer of the deep cervical fascia originates laterally from the transverse processes and continues with the fascia of the scalene muscles. The prevertebral layer and the anterior longitudinal ligament are incised longitudinally along the midline before their cauterization.

##### Anatomical Key Points (Scheme 10.15)

1. Prevertebral muscles
2. Vertebral bodies and intervertebral disks

##### Pearl

1. The cervical midline is defined between right and left longus colli muscles and lies lateral to vertebral bodies, which are bounded across the midline by the prevertebral layer of the deep cervical fascia. Prevertebral muscles are dissected in a subperiosteal plane, the contralateral longus colli is retracted medially with the visceral column, and the ipsilateral is retracted laterally with the carotid sheath.

##### Potential Complications

Extended lateral retraction of prevertebral muscles might expose the vertebral artery at V1 or V2 portions. In case of anatomical variation, it is possible to find the VA in its V2 tract out of transverse processes. Gentle retraction of prevertebral muscles is mandatory.

## 10.2 Lateral Approach to the Cervical Spine

The lateral approach allows exposing the anterolateral portion of the vertebral bodies and the vertebral artery through a retrovascular way.

The indications to this type of approach are limited to those cases in which you must dominate a lateral mass having an optimum control of the vertebral artery [10].

The approach, as the front prevascular, can be performed for the UCS and MCS. In our experience you can plan an anterior approach and, if necessary, convert it into lateral approach.

This occurrence is related to anatomical abnormalities such as nonrecurrent laryngeal nerve (NRLN), or the need to better control diseases, that arise from the median line and have a lateral extension. NRLN occurs between 0.4 and 2.4 % of people on the right side, while it is extremely rare on the left side.

This anatomical variation is associated with an anomaly in the embryological development. The fourth right aortic arch and the proximal dorsal aorta are occasionally obliterated, and the subclavian artery can originate from the right side of the aortic arch, being called “lusoria” artery.

The course patterns of non-RLN are:

- *Type Ia* – the nerve has a straight course on the level with the upper thyroid pole.
- *Type Ib* – the most common. The nerve runs transversely at the level of the thyroid isthmus.
- *Type II* – the nerve curves downward, eventually reaching the lower pole of the thyroid gland.

In a case report by Yang et al., the non-RLN courses are described in more detail, distinguishing four types:

- In the descending type, the non-RLN descends after originating from the vagus nerve trunk.
- In the vertical type, the non-RLN runs vertically to the cricothyroid joint.
- In the ascending type, the non-RLN runs upward to the cricothyroid joint.
- In the V-shaped type, the non-RLN takes a downward direction and runs upward to the cricothyroid joint.

### 10.2.1 First Surgical Step: Incision of the Skin

The skin incision is performed along the anterior border of SCM muscle, from the tip of the mastoid process to the suprasternal notch. The extent of the incision depends on the pathology's characteristics and the cervical level to treat. Skin and radiology landmarks are assessed during the preliminary surgical step.

### 10.2.2 Second Surgical Step: Dissection of the Subplatysmal Flap.

Following the skin incision, a dissection of *superficial cervical fascia (SCF)* – formed by the subcutaneous tissue and the platysma muscle – is performed. Subplatysmal flap is then retracted medially to expose the SLDCF.

#### 10.2.2.1 Anatomical Key Points

1. Sternocleidomastoid muscle (*SCM*)
2. External jugular vein (*EXJ*)
3. Great auricular nerve (*GAN*)
4. Transverse cervical nerve

#### 10.2.2.2 Pearls

1. The SCM can be sectioned at its insertion to the tip of the mastoid to allow optimal exposure during extended approach. If not dissected it is displaced laterally, as in the anterior approach.
2. Identification of EJV on the skin, before skin incision, is useful for better identification and preservation of the anatomical structures. The external jugular vein emerges in the parotid loggia from the confluence of the superficial temporal vein and the internal maxillary vein, penetrates into the sternocleidomastoid region on the level with the angle of the mandible, then crosses the lateral face of the muscle obliquely. During dissection it may be necessary to ligate it.
3. The great auricular nerve emerges from the posterior border of the SCM muscle, at Erb's point. It runs parallel and superior to the external jugular vein on the superficial face of the muscle. It gives sensory branches to the skin of parotid and auricular regions. During the dissection, the surgeon usually finds first the EJV and then, about 1 cm laterally and cranially to it, the GAN.
4. The transverse nerve originates from the cervical plexus, emerges at the Erb's point, and crosses the sternocleidomastoid muscle transversely. It gives sensory branches to the skin. It can be preserved or sacrificed without postsurgical complications.

#### 10.2.2.3 Potential Complications

Accidental section of the external jugular vein does not lead to a catastrophic bleeding but creates a nonoptimal visualization of the structures to dissect during the procedure.

Great auricular nerve section produces an ailment hypoesthesia of periauricular skin; thus, this nerve should be preserved.

### 10.2.3 Third Surgical Step: Dissection of SLDCF and Identification of the Carotid Sheath

Under cover of the platysma, there is “the investing layer of the deep cervical fascia” or superficial layer of the deep cer-

vical fascia (SLDCF). It surrounds the neck like a collar but splits around the sternocleidomastoid and trapezius muscles to enclose them. Posteriorly, it joins the ligamentum nuchae. The SLDCF is opened along the anterior border of SCM muscle. Lateral retraction of the SCM muscle exposes some of the structures below:

### 10.2.3.1 Anatomical Key Points (Fig. 10.58)

1. Omohyoid muscle (*OM*)
2. Digastric muscle (*DM*)
3. Thyrolingual-facial venous trunk (*TLF*)
4. Spinal accessory nerve (*SAN*)
5. Carotid sheath or neurovascular bundle

### 10.2.3.2 Pearls

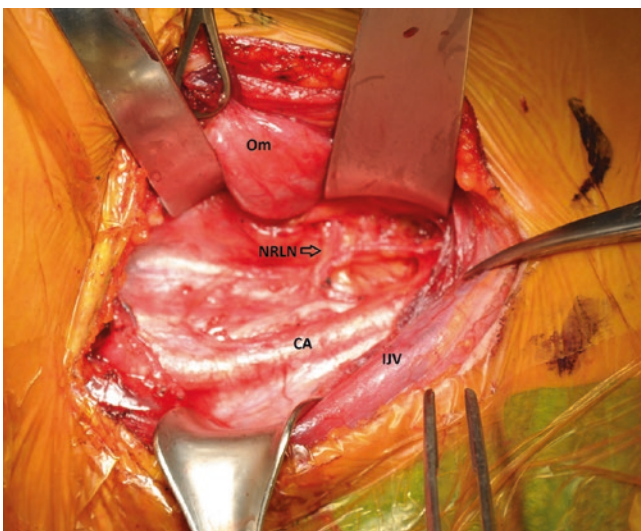
1. The omohyoid muscle is a landmark: the C5–C6 vertebral disks are approximately on the level with the intersection of the omohyoid and the SCM muscle. During the dissection, it is possible to appreciate the acute angle formed by the intersection of the OM and SCM. OM can be pulled down or disconnected for an easier access to the plane below. The neurovascular bundle, specifically the IJV, lies under this muscle.
2. On the upper part of this dissection plane, we find the posterior belly of digastric muscle, which runs obliquely forward and downward and goes to the hyoid bone, where it is fixed with its intermediate tendon to the body and the great horn and then continues with its anterior belly. It is defined “the resident’s friend” because below it is possible to identify important structures like the neurovascular bundle and the TLF.
3. This vein passes deep to the SCM muscle and above the digastric muscle to empty into the internal jugular vein. It

is formed by the retromandibular and the facial vein. Ligation of this structure should be near the confluence with the IJV.

4. This nerve usually runs below, from the posterior belly of the digastric muscle before piercing the deep surface of the SCM muscle. It passes through this muscle and supplies it and finally emerges from the midpoint of the posterior sternocleidomastoid border.
5. It is formed by the internal jugular vein laterally, by the carotid artery medially, and, in the dihedral angle formed by the two vessels, by the vagus nerve posteriorly. The first vascular structure found during the dissection is the IJV, which is just under the digastric muscle or following the TLF.

### 10.2.3.3 Potential Complications

6. HN injury is a possible complication during the ligation of lingual and facial artery and in all the dissections above the hyoid bone. HN palsy causes an omolateral deviation of the tongue and difficulty in swallowing and speaking. The tongue often deviates toward the side of the lesion when it’s protruded (due to imbalance of genioglossus contraction).
7. Accidental section and/or palsy of the SAN could be caused by the retraction of SCM muscle. SAN lesions cause weakness of trapezius muscle on involved side and present with mild shoulder droop. The patient might report weakness in shoulder elevation and scapular winging most noticeable in arm abduction.
8. Ligation and dissection of the STA implicate high risk of iatrogenic injury of the SLN. During these maneuvers surgeons should focus on the relationship between the STA and this nerve. Palsy of SLN causes impaired cough reflex, hoarseness, voice fatigability, and impaired high-pitch phonation.



**Fig. 10.58** Right side: evidence of nonrecurrent laryngeal nerve (*NRLN*), omohyoid muscle (*OM*) sectioned, carotid artery (*CA*), and internal jugular vein (*IJV*)

### 10.2.4 Fourth Surgical Step: Dissection of the MLDCF Posteriorly to the Carotid Sheath

During dissection of the IJV it could be necessary to remove the cervical lymph nodes. Once the dissection is completed, it is possible to gently retract all the neurovascular components medially

Behind carotid sheath there are some neurovascular structures: the vagus nerve, the cervical plexus and the cervical sympathetic chain, that go from skull base to C6. In the UCS approach, behind neurovascular bundle there are, also, the hypoglossal nerve (HN), glossopharyngeal nerve (GPN) and spinal accessory nerve (SAN).

From C3 to C6 it is possible to identify the phrenic nerve, that lies over the muscular plane (anterior scalene muscle).

Medial retraction of neurovascular bundle allows to exposure of the paravertebral muscles: the scalene muscles and the levator scapulae (Fig. 10.59).

#### 10.2.4.1 Anatomical Key Points

1. Phrenic nerve
2. Cervical sympathetic chain
3. Hypoglossal nerve (HN), Glossopharyngeal nerve (GPN)  
Vagus nerve and Spinal accessory nerve (SAN)
4. Vertebral artery (VA)

#### 10.2.4.2 Pearls

1. The phrenic nerve runs from ramus of C3-C4 and C5. It can be easily identified on the external surface of the anterior scalene muscle.
2. The cervical sympathetic chain is set against the prevertebral fascia and is contained in its split, medially to the anterior tubercles of the transverse processes. It descends diagonally across the anterior scalene muscles, passes lateral to the thyroid-cervical trunks, and dips between the subclavian artery and vein to enter the chest. To avoid Horner's syndrome, the sympathetic chain and the stellate ganglia should be first recognized and retracted laterally, and then the longus colli muscle and the prevertebral fascia should be longitudinally divided medially to the sympathetic chain.
3. All nerves, except from the HN that passes into the hypoglossal canal, pass through the jugular foramen. GPN, extending anteriorly and describing an anterosuperiorly concave curve, initially runs between the internal jugular vein and the internal carotid artery. Then it passes between the styloglossus and stylopharyngeus and reaches the pharynx and the base of the tongue. Other nerves are have already been described.

4. For a number of reasons, the V2 segment of the vertebral artery is more at risk during decompression of more cephalad vertebrae. First, the diameter of the artery decreases from C2–C3 to C6–C7 ( $4.88 \pm 0.63$  mm at C2–C3 to  $4.27 \pm 0.63$  mm at C6–C7), and the anteroposterior diameters of the transverse foramina decrease from C6 to C3 ( $5.4 \pm 1.1$  mm at C6 to  $4.7 \pm 0.7$  mm at C3). The amount of the inter-transverse space occupied by the artery, therefore, increases at more rostral levels. Second, the artery ascends medially from C6 to C3 at an angle of approximately  $4^\circ$  compared to the midline, making it more likely to cross the surgical field at higher cervical levels.

#### 10.2.4.3 Potential Complications

Major complications are correlated with neurovascular injuries.

Lesion of the cervical sympathetic chain, leads to Claude-Bernard-Horner syndrome characterized by ptosis (droopy eyelid), miosis (constricted pupil), and facial anhidrosis (impaired facial sweating) with or without enophthalmos.

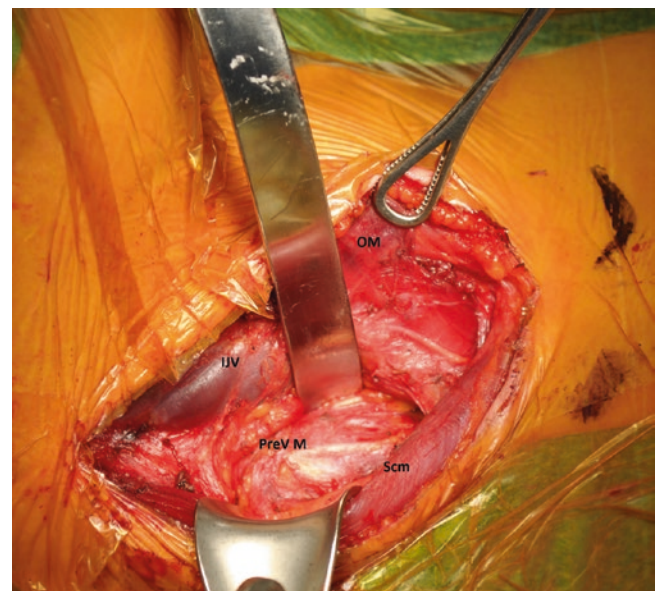Emi-diaphragm palsy is subsequent to phrenic nerve palsy.

Lesions of the glossopharyngeal nerve rarely occur in alone and usually are associated with vagus and spinal accessory nerve. Main symptoms are dysphagia, ipsilateral palatal weakness and loss of gag reflex.

Vagus nerve palsy lead to dysphonia and dysphagia, that are a consequence of the homolateral vocal cord paralysis.

A potentially catastrophic bleeding with brain injury can result from vertebral or carotid artery injury.

HN and SAN injuries have already been described.



**Fig. 10.59** Right side: prevertebral muscles (*PreV M*), internal jugular vein (*IJV*), and omohyoid muscle (*OM*) sectioned

### 10.2.5 Fifth Surgical Step: Dissection of Prevertebral Structures and Exposure of the Vertebral Plane

The prevertebral layer of the deep cervical fascia originates laterally from the transverse processes and continues with the fascia of the scalene muscles. The prevertebral layer and the anterior longitudinal ligament are incised longitudinally along the midline, before their cauterization (Figs. 10.60 and 10.61).

#### 10.2.5.1 Anatomical Key Points

1. Prevertebral Muscles
2. Vertebral bodies and intervertebral disk

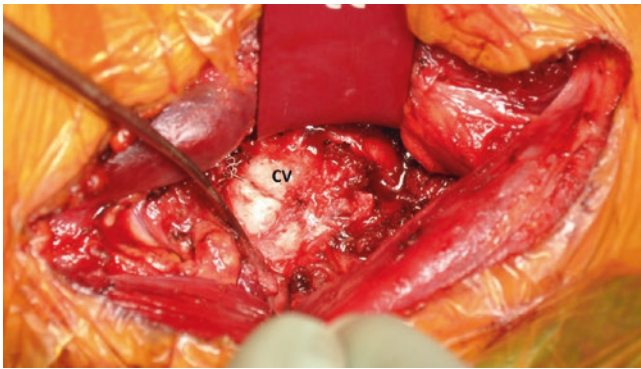
#### 10.2.5.2 Pearls

The “longus capitis” is located more laterally than the longus colli and originates from the transverse process of C3-C6 and has its insertion at the basilar portion of the occipital

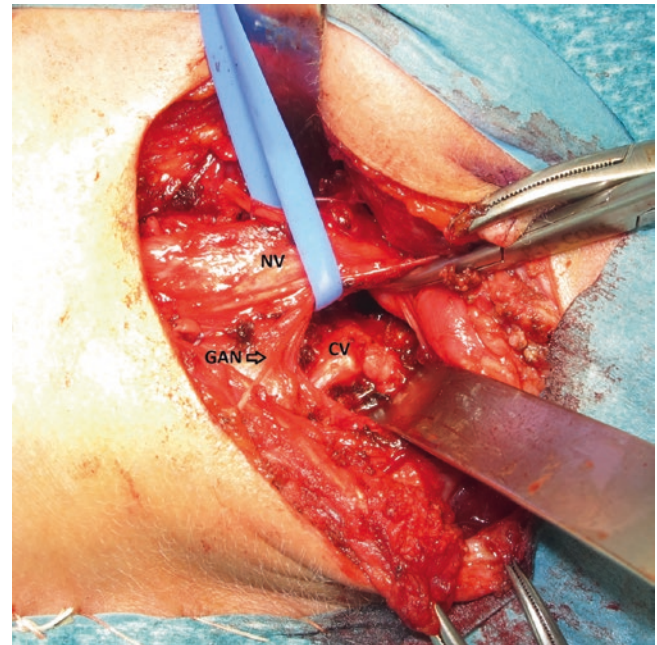
bone. Longus colli is located on the lateral side of the vertebral bodies, from the atlas to T3. In this phase of the operation, hemostasis must be accurately done using bipolar forceps and wax. The cervical midline is defined between right and left longus colli muscles and lies lateral to vertebral bodies, which are bounded across the midline by the prevertebral layer of deep cervical fascia. Prevertebral muscles are dissected in a subperiosteal plane, than are retracted medially with the carotid sheath. During dissection of the long muscles of the neck, the cervical sympathetic chain is easily recognizable compared to the vagus because it has a lower mobility and it also presents ganglion formations.

#### 10.2.5.3 Potential Complication

The complications are related to the possible vertebral artery injury, or to traction of the nerves described in the previous surgical steps.



**Fig. 10.60** Right side: lateral approach and exposure of cervical vertebra (CV)



**Fig. 10.61** Left side: neurovascular bundle (NV) retraction and cervical vertebra (CV) exposure. Great auricular nerve (GAN)



## Bibliography

1. Smith GW, Robinson RA (1958) The treatment of certain cervical-spine disorders by anterior removal of the intervertebral disc and inter-body fusion. *J Bone Joint Surg Am* 40-A:607–623
2. Southwick W, Robinson RA (1957) Surgical approaches to the vertebral bodies in the cervical and lumbar regions. *J Bone Joint Surg Am* 39:631–644
3. Cloward R (1958) The anterior approach for removal of ruptured cervical disks. *J Neurosurg* 15:602–617
4. McAfee PC, Bohlman HH, Riley LH et al (1987) The anterior retropharyngeal approach to the upper part of the cervical spine. *J Bone Joint Surg Am* 69:1371–1383
5. Fang HS, Ong GB (1962) Direct anterior approach to the upper cervical spine. *J Bone Joint Surg Am* 44:1588–1604
6. Whitesides TE, Kelly RP (1966) Lateral approach to upper cervical spine for anterior fusion. *South Med J* 59:879–883
7. Whitesides TE, McDonald AP (1978) Lateral retropharyngeal approach to the upper cervical spine. *Orthop Clin North Am* 9:1115–1127
8. Russo A, Albanese E, Quiroga M et al (2009) Submandibular approach to the C2–3 disc level: microsurgical anatomy with clinical application. *J Neurosurg Spine* 10:380–389
9. Haller JM, Iwanik M, Shen FH (2011) Clinically relevant anatomy of high anterior. *Spine* 36(25):2116–2121
10. Laus M, Alfonso C, Ferrari D et al (1995) Lateral retrovascular approach to the upper cervical spine. *Chir Organi Mov* 80(1):65–75

R. Ghermandi, M. Girolami, A. Gasbarrini, and S. Boriani

In the neck, the spine takes up the mid-part of the cross-sectional area, and its posterior aspect is surrounded by a thick layer of powerful muscles (see §2. Anatomy).

The posterior muscular coverage is subdivided in two symmetrical compartments, which extend longitudinally in continuous with the adjacent thoracolumbar extensor muscles.

The standard posterior approach to the cervical spine is carried through these two posterior muscular compartments whose innervation and vascular supply is segmental from the dorsal routes of cervical spinal nerves (Fig. 11.1).

Thus, ligamentum nuchae, the septum between the two continuous muscular compartments, is a true internervous plane, and no particular structure is at risk if dissection is carefully conducted through it. Moreover, this minimizes blood loss and maintains a stout tissue layer for closure of the wound.

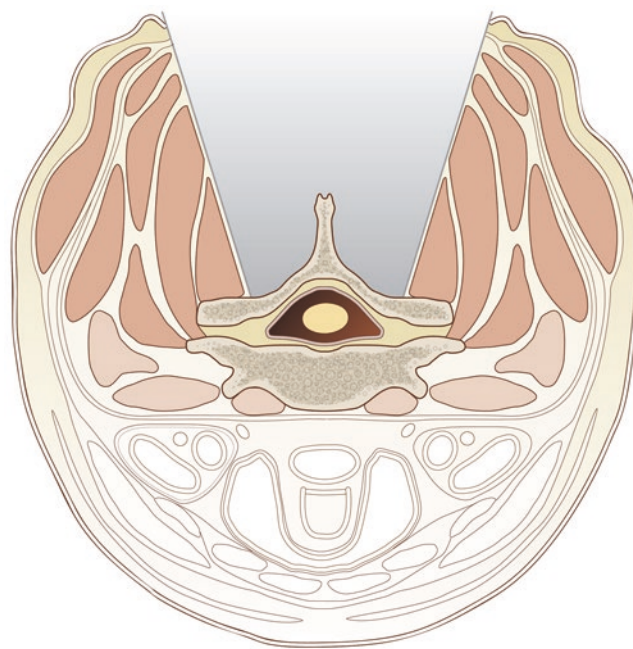
The posterior midline approach allows surgical exposure of the posterior arches of the vertebrae up to the occiput.

After positioning of the patient (Fig. 11.2), prior to any incision, an accurate trichotomy of the nuchal area might be necessary depending on the segments to be exposed.

The main superficial landmarks are as follows:

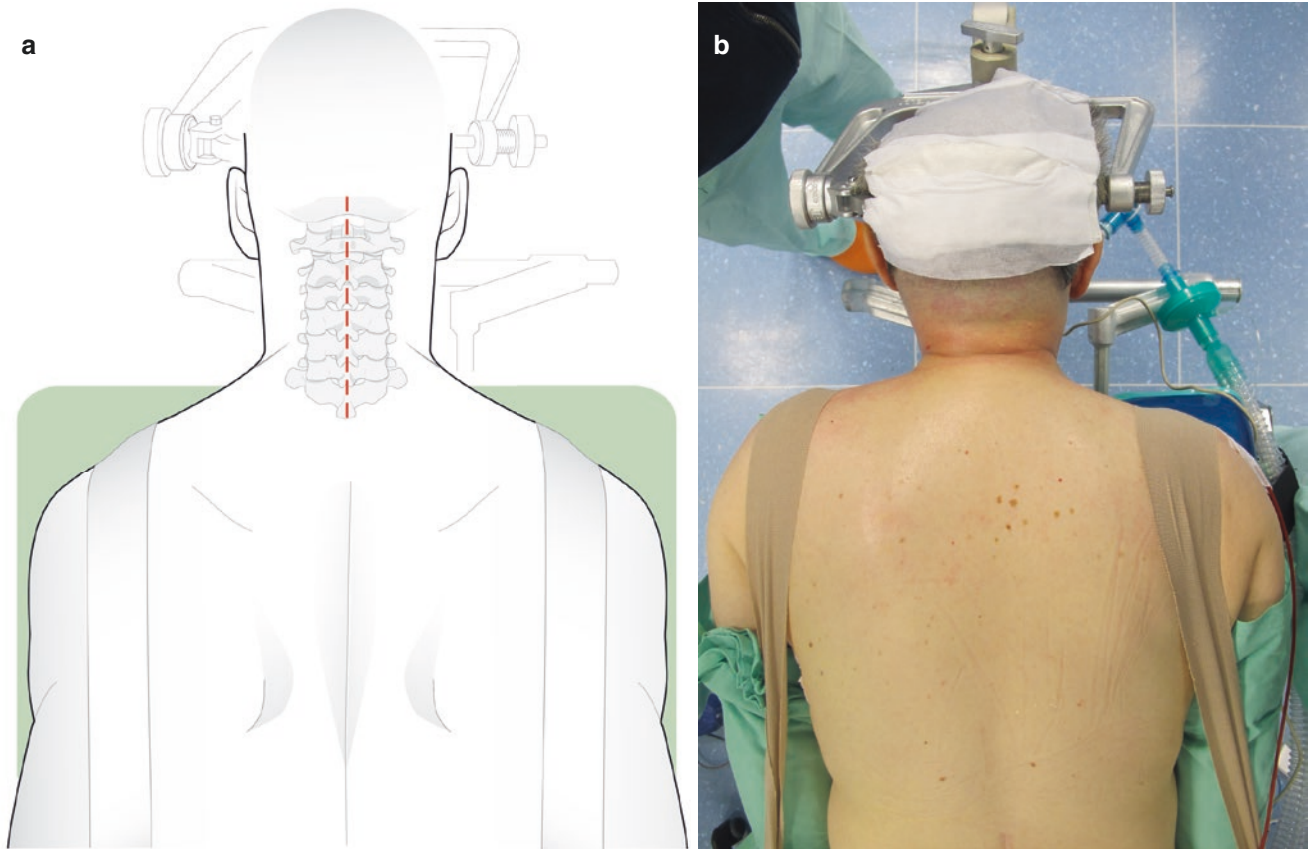
- External occipital prominence of the occiput (inion)
- First palpable spinous process → C2 (axis)

- Prominent spinous process of the cervicothoracic junction → C7 (vertebra prominens)
- Mastoid processes



**Fig. 11.1** The standard midline posterior approach to the cervical spine is carried through the two symmetrical extensor muscle compartments down to the dorsal surface of the neural arches

R. Ghermandi (✉) • M. Girolami • A. Gasbarrini • S. Boriani  
 Oncologic and Degenerative Spine Surgery Department, Rizzoli  
 Orthopedic Institute, Bologna, Italy  
 e-mail: [riccardoghermandi@gmail.com](mailto:riccardoghermandi@gmail.com)



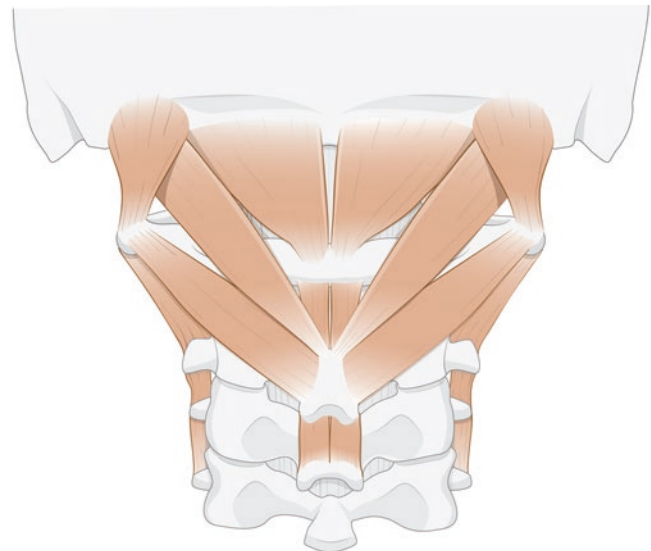
**Fig. 11.2** Prior to incision, identification of the superficial landmarks is crucial. Shoulders are retracted in order to allow intraoperative fluoroscopic control at the cervicothoracic junction

### 11.1 Upper Cervical Spine (C1-C2)

The width of the spinal canal at the craniocervical junction (CVJ) is wider than that in the lower segments of the cervical spine. Thus, instability is a more frequent indication than cord compression to assess the CVJ from posterior.

After midline skin incision, the tip of the spinous process of C2 can be palpated under the inferior aspect of the occipital bone. Immediately above, on the midline and 1–2 cm anteriorly, lies the posterior tubercle of C1 under the thick layer of suboccipital muscles (rectus capitis posterior – major and minor; oblique – superior and inferior, Fig. 11.3).

The bony topography between the lamina and the lateral mass of C2 (axis) is indistinct. Thus, dissection of these muscles must be carried gently and special care must be taken beyond the first 12–15 mm in order not to damage the following neurovascular structures:



**Fig. 11.3** Muscles of the occipitocervical region (rectus capitis posterior – major and minor; oblique – superior and inferior)

- Vertebral artery
- First cervical nerve
- Second cervical nerve (Arnold nerve)
- Suboccipital venous plexus (behind C1-C2 interspace)

### 11.1.1 Anatomical Key Points

1. Posterior tubercle of C1
2. Transverse processes of C1
3. Spinous process of C2 (bifidus)

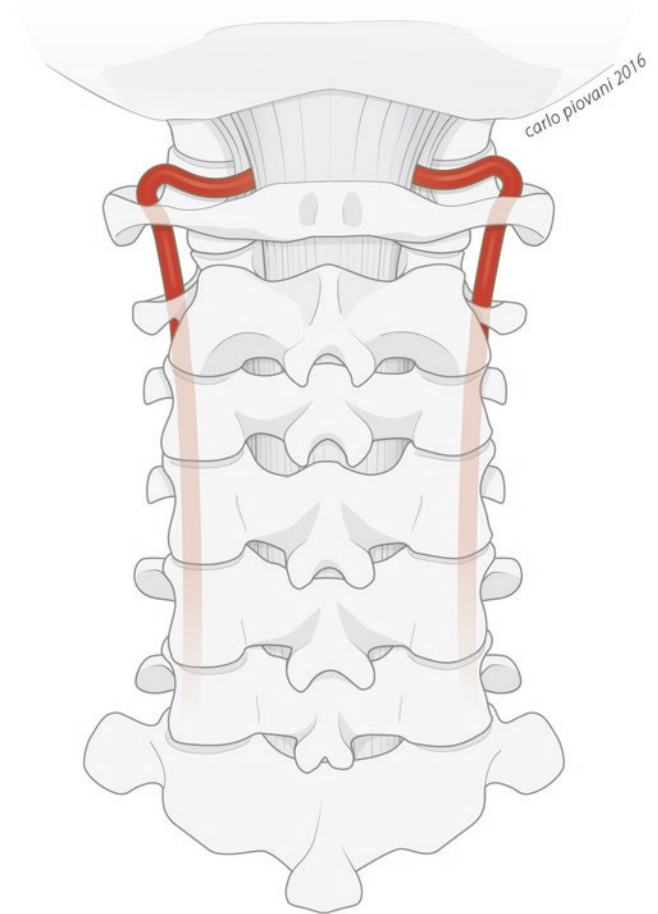
### 11.1.2 Focus On: Vertebral Artery

Surgical anatomy of the vertebral artery (VA) can be subdivided in four segments (Fig. 11.4):

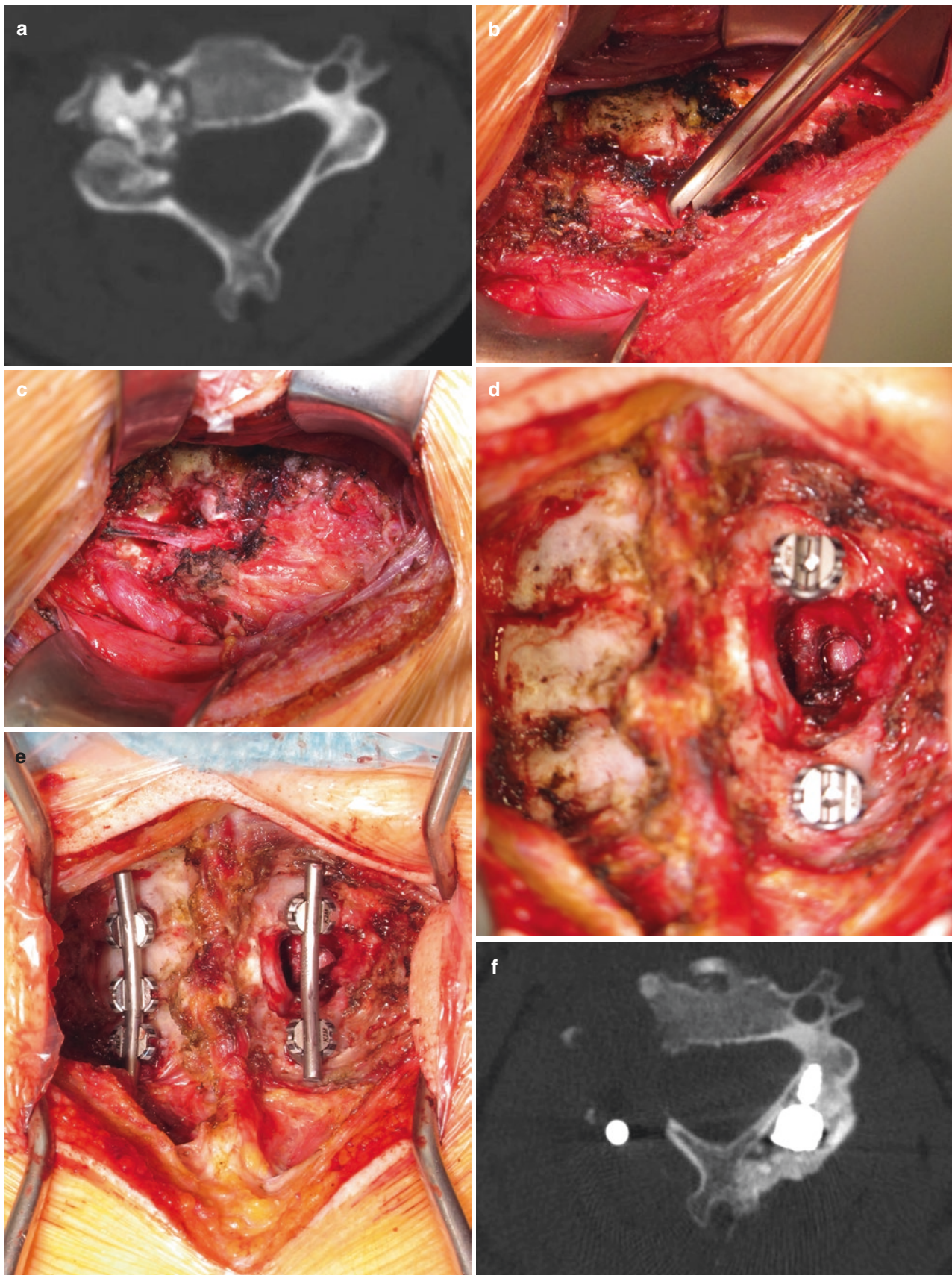
- V1, from its origin from the subclavian artery (anterior to the C7 transverse process) to the entry point of C6 foramen transversarium
- V2, within C6-C1 transverse foramina
- V3, from the superior aspect of the arch of the atlas to the foramen magnum (C0)
- V4, intradural course from the foramen magnum to unite with the contralateral VA to form the basilar artery

The highest risk for injury during posterior approaches is in the V3 tract while dissecting the occipitocervical junction (4.2–8.1%). Ebraheim et al. suggest that dissection on the posterior aspect of the posterior ring should remain within 12 mm lateral to the midline, and dissection on the superior aspect of the posterior ring should remain within 8 mm of the midline.

However, depending on the procedures to be performed, different tracts of the VA can be at risk (Fig. 11.5).



**Fig. 11.4** Course of the vertebral artery (VA)



**Fig. 11.5** Case report. A 19-year-old female, C4 right lateral mass osteoblastoma (OBL, WBB 8–10/A-D) complaining of neck pain with occasional numbness to the right arm (a). Right dominant VA symptomatic at occlusion test prior to embolization. Double-approach procedure, A: pre-SCM approach, VA release (b) and intralesional excision

(c); P: posterior approach, stabilization with lateral mass screws and complete excision (d). Unlike most posterior procedures, VA is at risk at V2 crossing the deep surgical field (e). Postoperative CT scan shows complete excision (f)

## 11.2 Subaxial Cervical Spine (C3-C7)

The most common approach is carried through a midline skin incision along the line connecting the external occipital prominence and the tip of the spinous process of C7 (Fig. 11.6).

The incision must be centered on the level of the pathology, extending it cranially and caudally depending on the levels to be exposed.

Intraoperative imaging is important for level confirmation: prior to skin incision, so as should be used, after dissection, prior to any procedure on the bone.

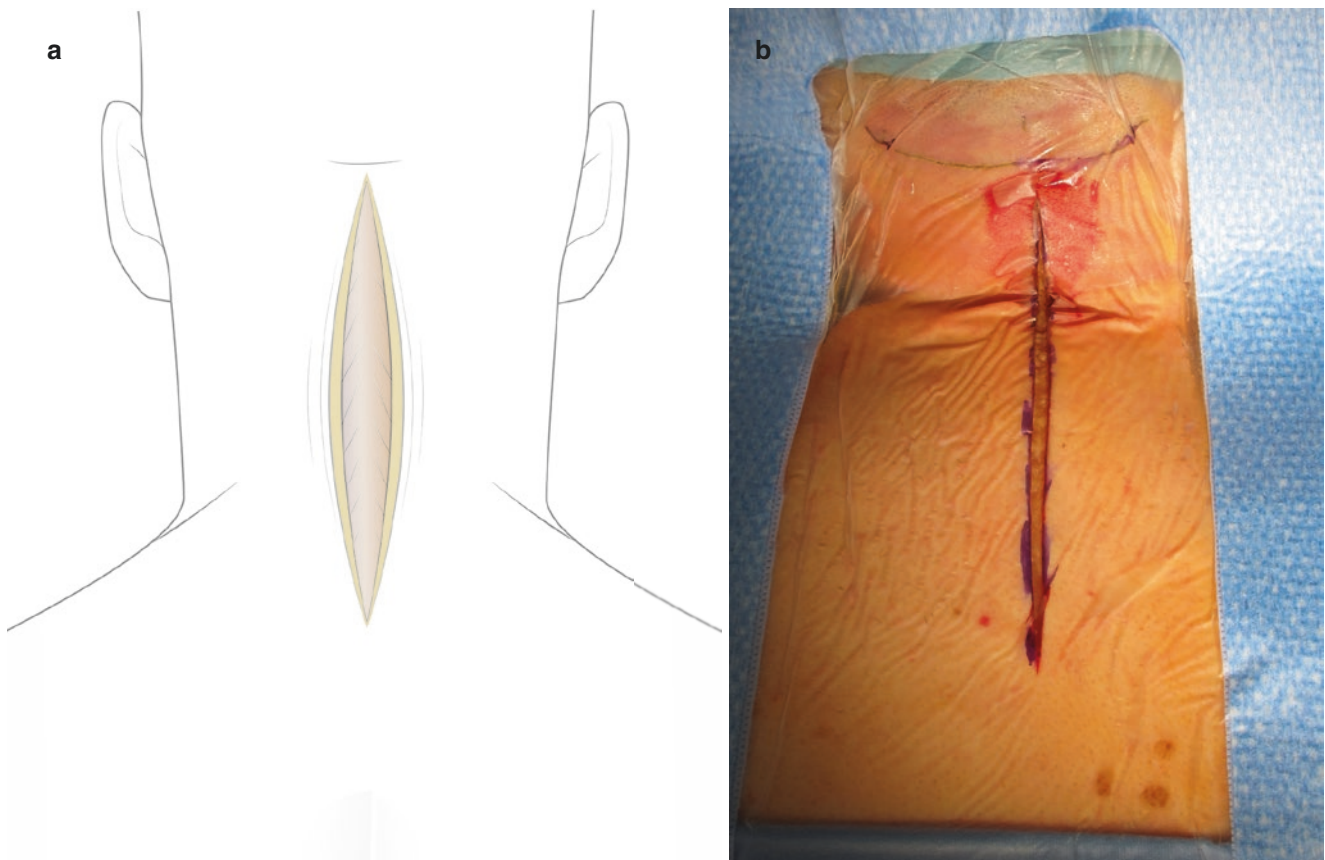
Once the tips of the spinous processes and/or the ligamentum nuchae are identified (Fig. 11.7), subperiosteal dissection of the paravertebral muscles from the posterior arches is carried out in a mediolateral direction up to the lateral margin of the lateral masses (Fig. 11.8).

### 11.2.1 Anatomical Key Points

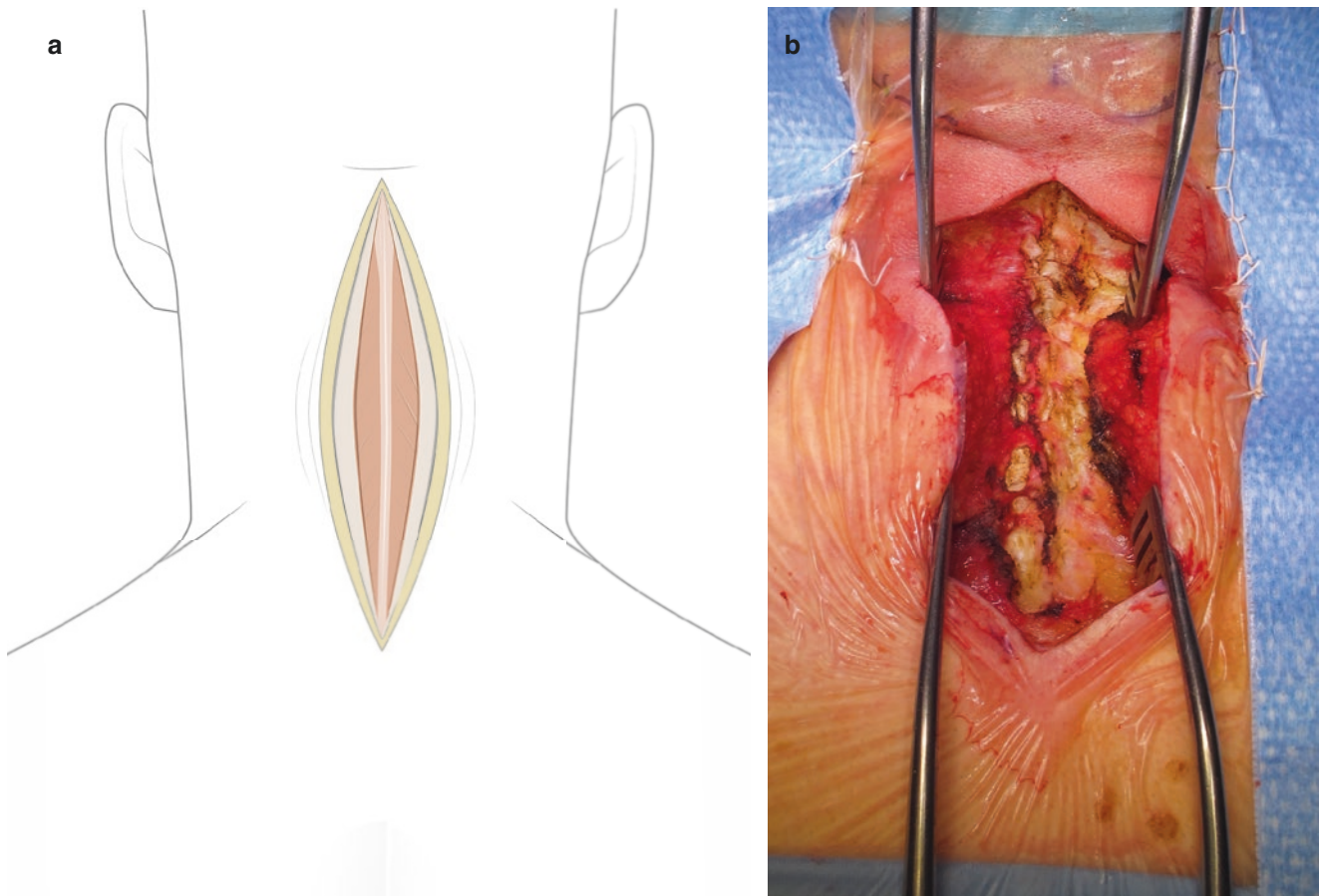
1. Ligamentum nuchae
2. Spinous processes (C2, C7-T1) and supraspinous ligament
3. Lateral masses
4. First thoracic vertebra and ribs

### 11.2.2 Pearls

1. Muscular bleeding can be particularly annoying and hard to dominate completely, impairing vision on the surgical field. Moreover, limiting the dissection without worthless exposure of levels preserves innervation and blood supply to the paravertebral muscles.
2. The superior articular surfaces of the lateral masses are directed dorsally and cranially, and the inferior surfaces ventrally and caudally. The slope increases in craniocaudal



**Fig. 11.6** Skin incision and dissection through the subcutaneous tissue



**Fig. 11.7** Incision of the fascia in correspondence to the ligamentum nuchae

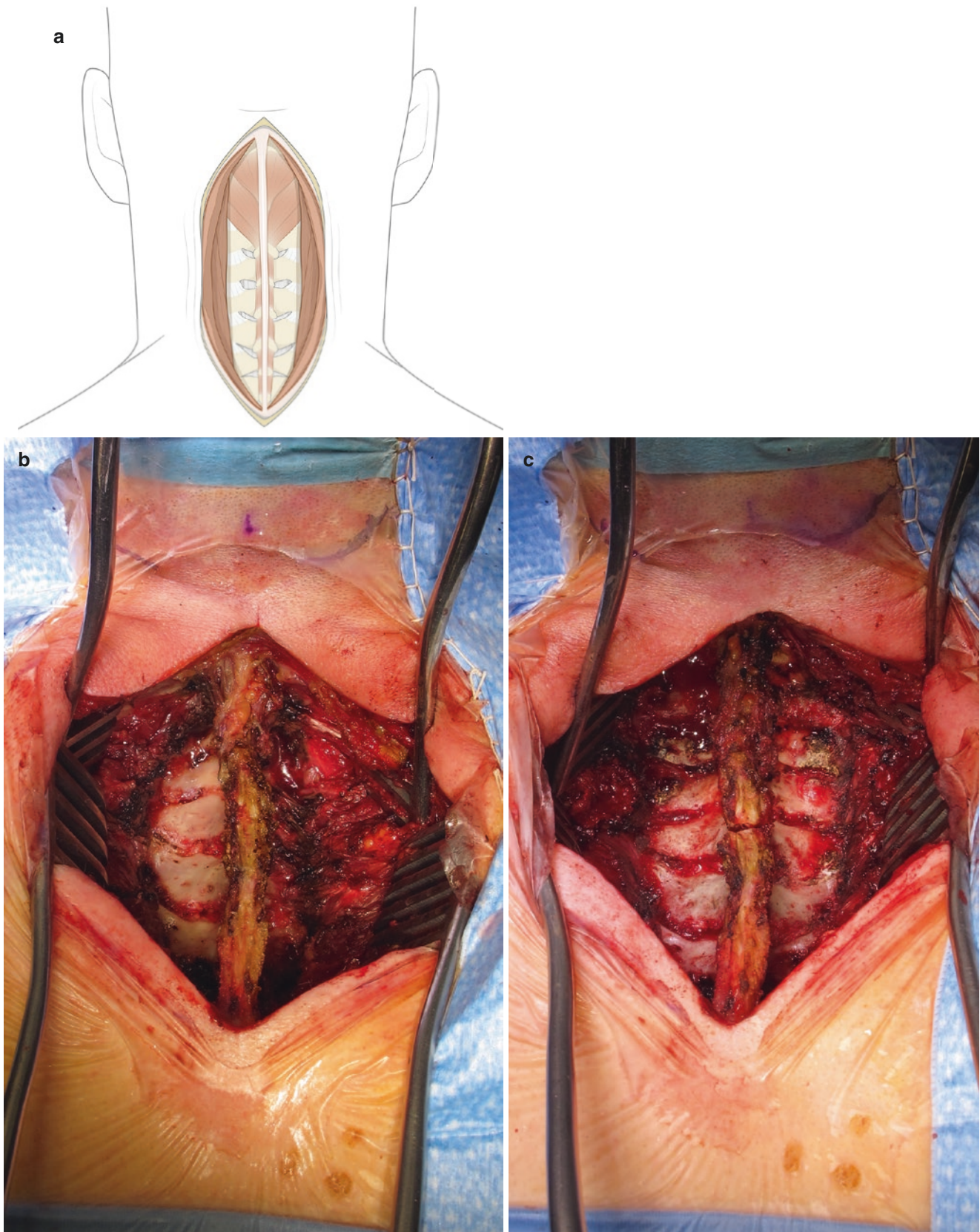
direction up to the thoracic spine where the articular surfaces are almost vertical.

3. The spinous process of the cervical vertebrae is bifid, except for C7.
4. The first thoracic vertebra has a transverse process that articulates with the first rib.

### 11.3 Caudal Extension: Cervicothoracic Junction

The posterior approach to the cervical spine can be extended downwards to the cervicothoracic junction.

The anatomical plane through which dissection is carried out is continuous until the caudal end of the spine in the lumbar spine and sacrum, so dissection could be ideally extended downwards up to the surgeon's preference.



**Fig. 11.8** Dissection is carried out along the internervous plane of the ligamentum nuchae (a). It is extended laterally until the lateral margin of the lateral masses. Identification of the correct dissection plane (b)

allows for less intraoperative bleeding – thus, avascular surgical field – and ease of identification of the anatomical key structures (i.e., entry point for screw insertion, c)



## 11.4 Dissection of Spinal Canal

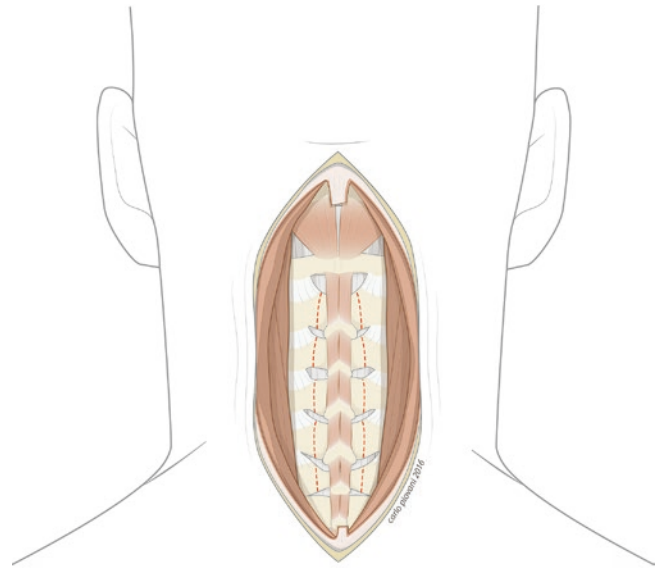
The spinal canal is an anatomical compartment circumscribed anteriorly by the discs and the vertebral bodies and posterolaterally by the neural arch, formed by the pedicles and the laminae. Preliminary to its dissection, from a standard posterior approach, subperiosteal detachment of the paraspinal muscles is required to get to the posterior surface of the laminae.

In order to enter the canal, laminae and yellow ligament must be removed mono- or bilaterally (laminectomy and flavectomy, Fig. 11.9). Flexion of the head opens the interspinous space increasing the working space available.

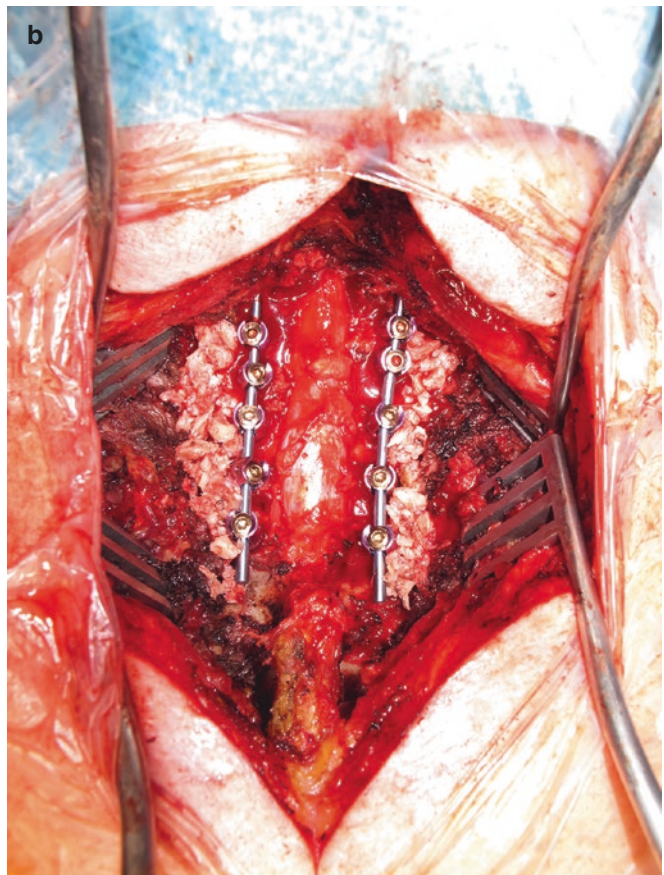
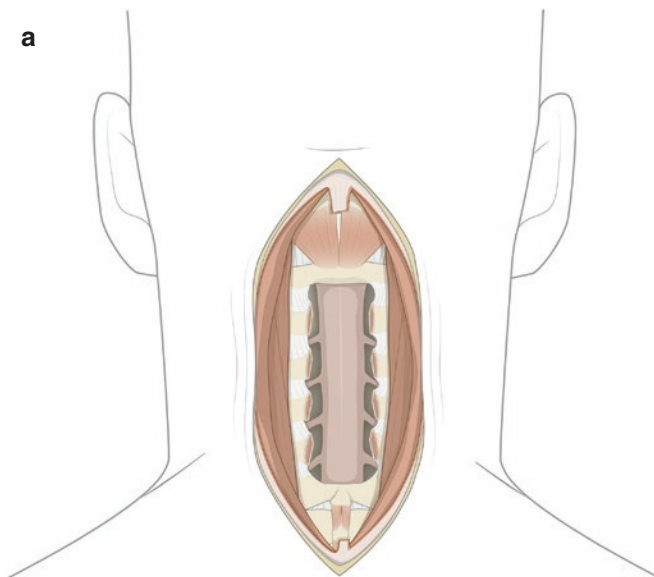
Removal of the posterior arch exposes the content of the canal: neural structures and venous epidural plexus immersed in the epidural fat (Fig. 11.10). The dorsal aspect of the vertebral body can be reached by gentle mobilization of the dural sac and displacement of the correspondent spinal nerve. Care must be taken during these maneuvers since the ventral surface of the dural sac might be linked to the dorsal surface of the anterior column by the inconstant presence of the Hoffmann ligament (uncommon in the cervical spine).

The sac itself is structured into layers: dura mater and arachnoid. Dura mater, the outer layer, is whitish, smooth,

and more thick, while the arachnoid, the inner layer, is colorless and extremely thin (spider weblike). Superficial injuries might leave the arachnoid intact; thus, it might herniate



**Fig. 11.9** In order to access the canal, laminae are removed mono- or bilaterally



**Fig. 11.10** After laminectomy is carried out, the dural sac and the emergence of the spinal nerves can be identified and explored

through the leak in the dura mater, appearing like a drop on the dural sac. Since this lesion is extremely likely to break, it must be reinforced.

## References

1. Abumi K (2015) Cervical spondylotic myelopathy: posterior decompression and pedicle screw fixation. *Eur Spine J* 24(Suppl 2):186–196
2. Bauer R, Kerschbaumer E (1987) Operative approaches in orthopedic surgery and traumatology. Thieme, New York
3. Ebraheim NA, Xu R, Ahmad M, Heck B (1998) The quantitative anatomy of the vertebral artery groove of the atlas and its relation to the posterior atlantoaxial approach. *Spine (Phila Pa 1976)* 23(3):320–323; Epstein NE (2015) Open laminoforaminotomy: a lost art? *Surg Neurol Int* 6(Suppl 24):S600–S607
4. Harel R, Stylianou P, Knoller N (2016) Cervical spine surgery: approach-related complications. *World Neurosurg* 94:1–5
5. Jalai CM, Worley N, Marascalchi BJ, Challier V, Vira S, Yang S, Boniello AJ, Bendo JA, Lafage V, Passias PG (2016) The impact of advanced age on peri-operative outcomes in the surgical treatment of cervical spondylotic myelopathy: a nationwide study between 2001 and 2010. *Spine (Phila Pa 1976)* 41(3):E139–E147
6. Phan K, Scherman DB, Xu J, Leung V, Virk S, Mobbs RJ (2017) Laminectomy and fusion vs laminoplasty for multi-level cervical myelopathy: a systematic review and meta-analysis. *Eur Spine J* 26(1):94–103
7. Schroeder GD, Hsu WK (2013) Vertebral artery injuries in cervical spine surgery. *Surg Neurol Int* 4(Suppl 5):S362–S367
8. Seng C, Tow BP, Siddiqui MA, Srivastava A, Wang L, Yew AK, Yeo W, Khoo SH, Balakrishnan NM, Bin Abd Razak HR, Chen JL, Guo CM, Tan SB, Yue WM (2013) Surgically treated cervical myelopathy: a functional outcome comparison study between multilevel anterior cervical decompression fusion with instrumentation and posterior laminoplasty. *Spine J* 13(7):723–731
9. Smith JS, Ramchandran S, Lafage V, Shaffrey CI, Ailon T, Klineberg E, Protosaltis T, Schwab FJ, O'Brien M, Hostin R, Gupta M, Mundis G, Hart R, Kim HJ, Passias PG, Scheer JK, Deviren V, Burton DC, Eastlack R, Bess S, Albert TJ, Riew KD, Ames CP; International Spine Study Group (2016) Prospective multicenter assessment of early complication rates associated with adult cervical deformity surgery in 78 patients. *Neurosurgery* 79(3):378–388

A. Gasbarrini, M. Girolami, R. Ghermandi,  
Y.E. Akman, and S. Boriani

### 12.1 Upper Cervical Spine

Fourteen-year-old female, presenting with progressive neck pain in the nuchal area radiating to the head with painful contracture of the right paraspinal musculature. Pain was unrelated to weight-bearing and was increasing during the night. Physical examination revealed mild hyperreflexia, gait disturbance, positive Hoffmann sign, and clonus.

AP and LL radiographs with transoral projection show an osteoproliferative lesion replacing the right lateral mass and extending into the vertebral body.

Subsequent CT scan provides more details on the features of the lesion, host bone reaction, and extent of bony involvement. Sagittal scan shows the lesion completely invading the lateral mass, breaching into the posterior articular space and the ipsilateral foraminal space. Axial scan shows disruption of the posterolateral cortex limiting the spinal canal revealing epidural space invasion.

Angio-MRI shows hypervascular nature of the lesion and the close relationship with the vertebral artery. Thus, angiography and embolization of the vertebral artery are mandatory prior to surgical attempt of removing the lesion.

Double-approach procedure, first anterior than posterior, was planned in order to excise, reconstruct, and restore segmental spinal stability. Through a lateral approach, which allowed full view on the right lateral mass, piecemeal removal of the tumor was performed.

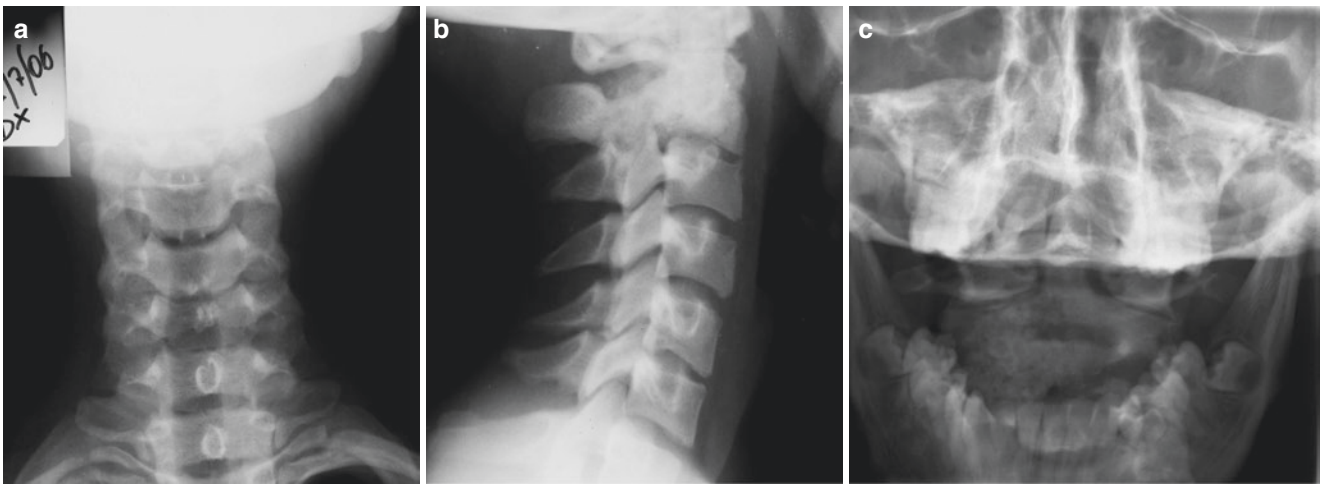
Harms cages filled with bone graft were used for reconstruction, along with posterior instrumentation.

Four-month follow-up shows signs of posterior fusion and osteointegration of the graft. No recurrence occurred and patient is NED with solid arthrodesis at 3-year follow-up (Figs. 12.1, 12.2, 12.3, 12.4, 12.5, 12.6, 12.7, and 12.8).

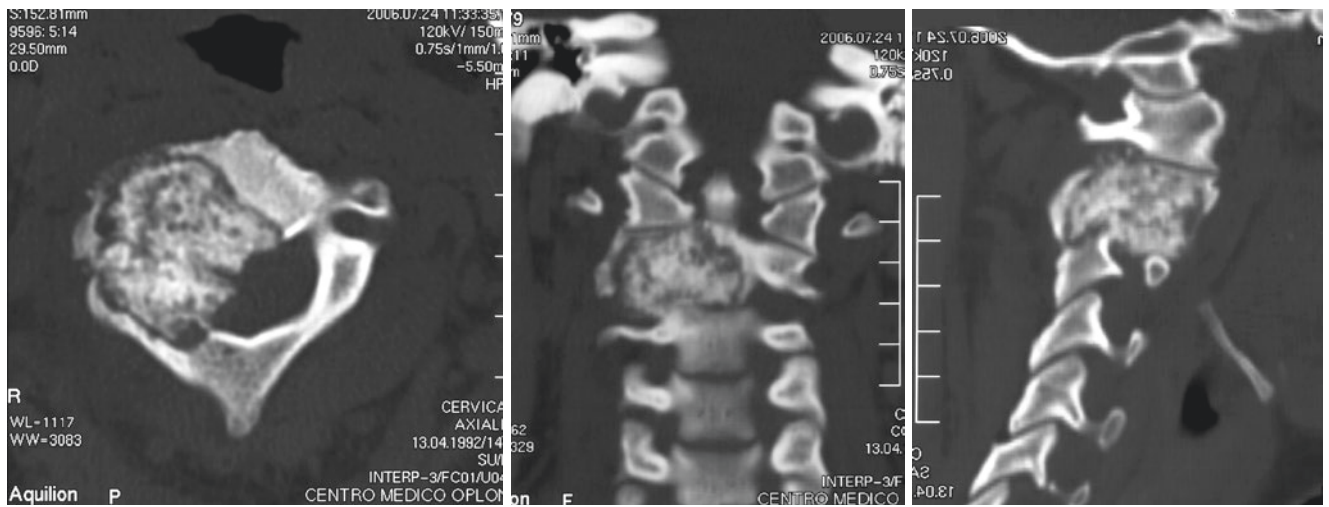
---

A. Gasbarrini (✉) • M. Girolami • R. Ghermandi • S. Boriani  
Oncologic and Degenerative Spine Surgery Department, Rizzoli  
Orthopedic Institute, Bologna, Italy  
e-mail: [gasbarrini@me.com](mailto:gasbarrini@me.com)

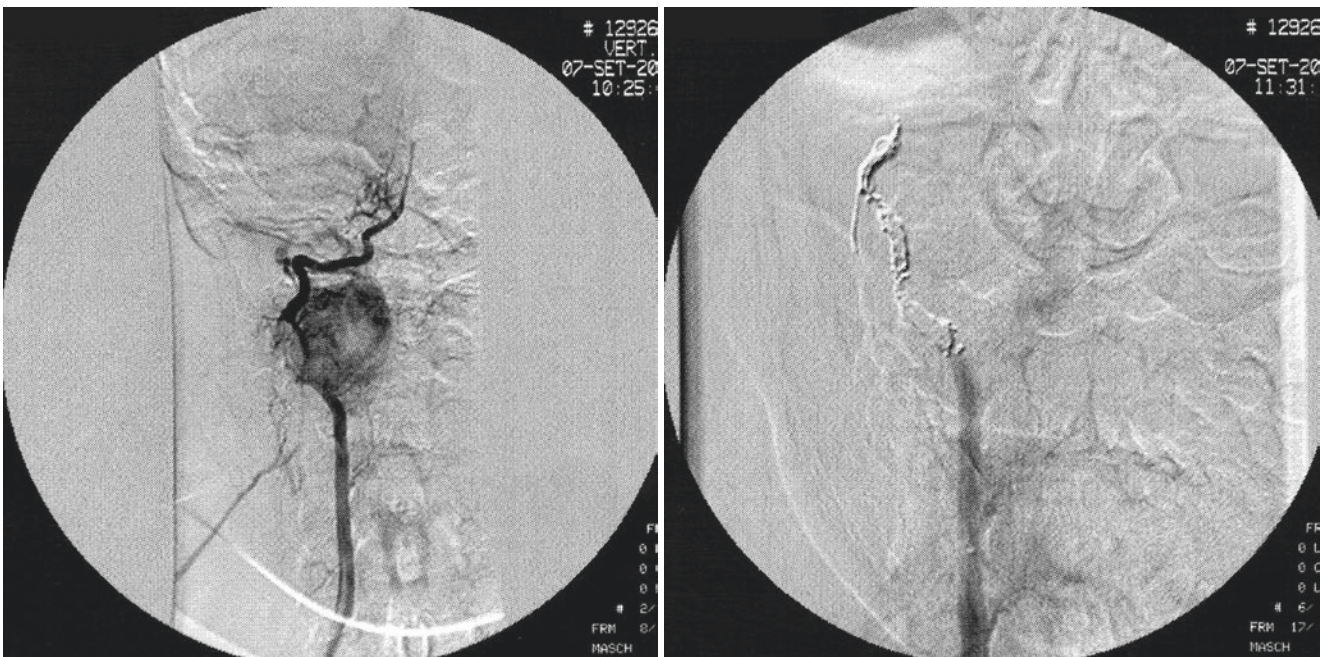
Y.E. Akman  
Orthopaedics and Traumatology Department, Metin Sabanci  
Baltalimani Bone Diseases Training and Research Hospital,  
Istanbul, Turkey



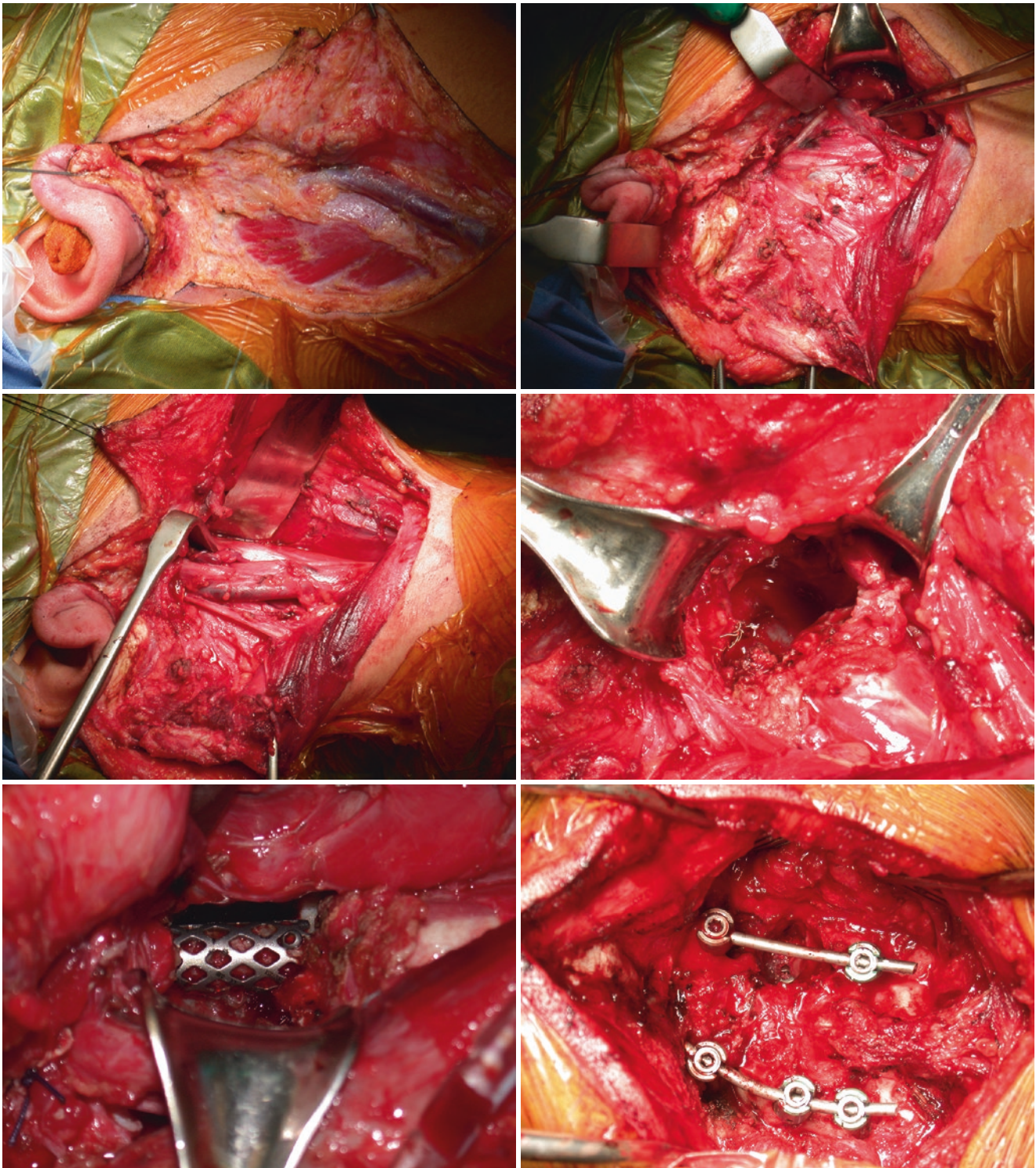
**Fig. 12.1** Pre-operative radiographs in anteroposterior (a), lateral (b) and trans-oral (c) projections



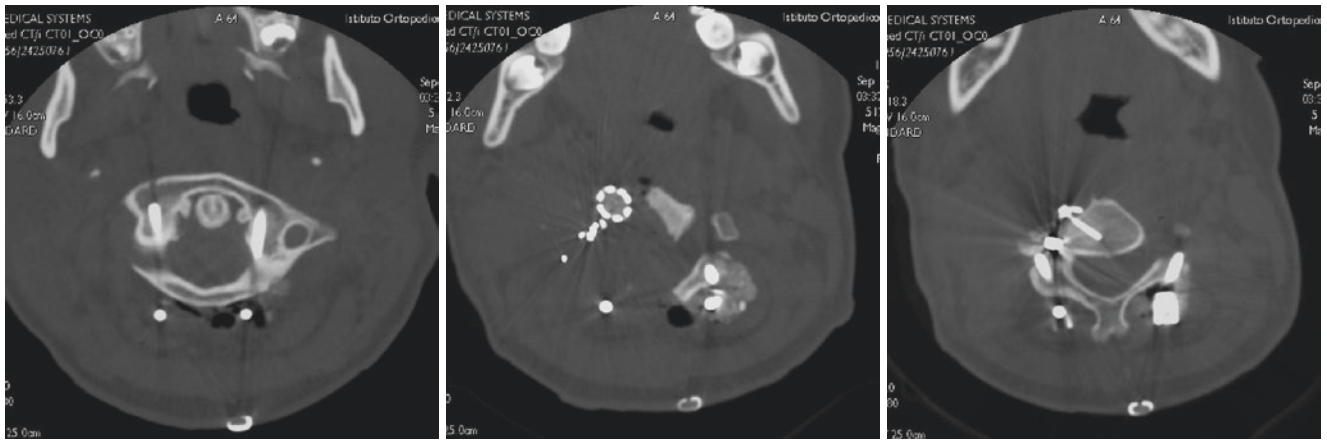
**Fig. 12.2** Pre-operative CT scans of the C2 lesion, pathognomonic for osteoblastoma



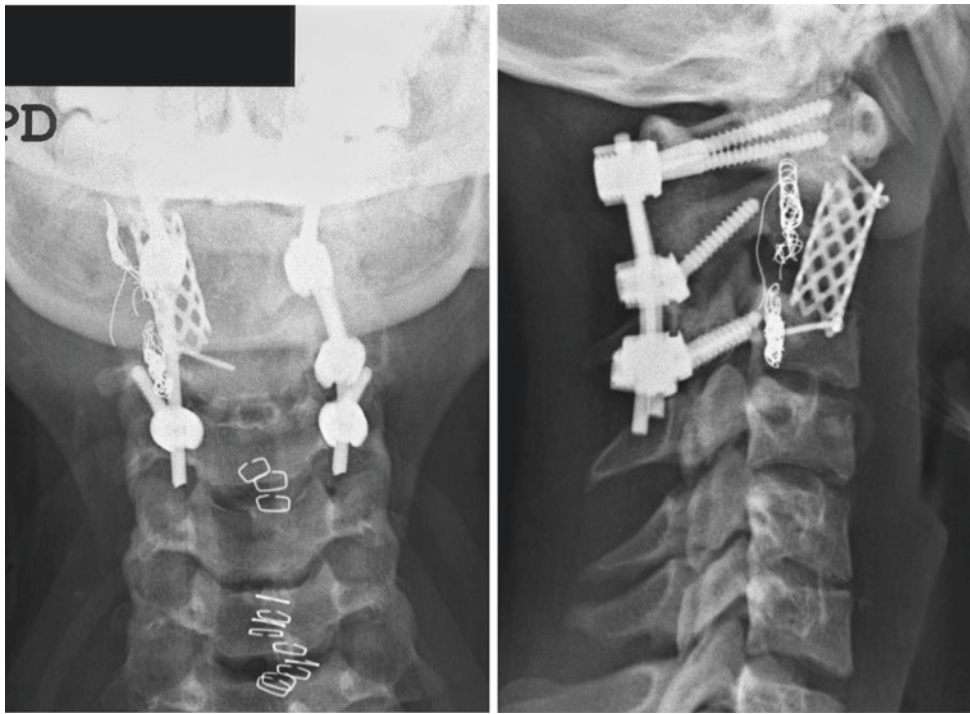
**Fig. 12.3** Pre-operative angiography and sub-sequent embolization



**Fig. 12.4** Intra-operative images, lateral and posterior approach

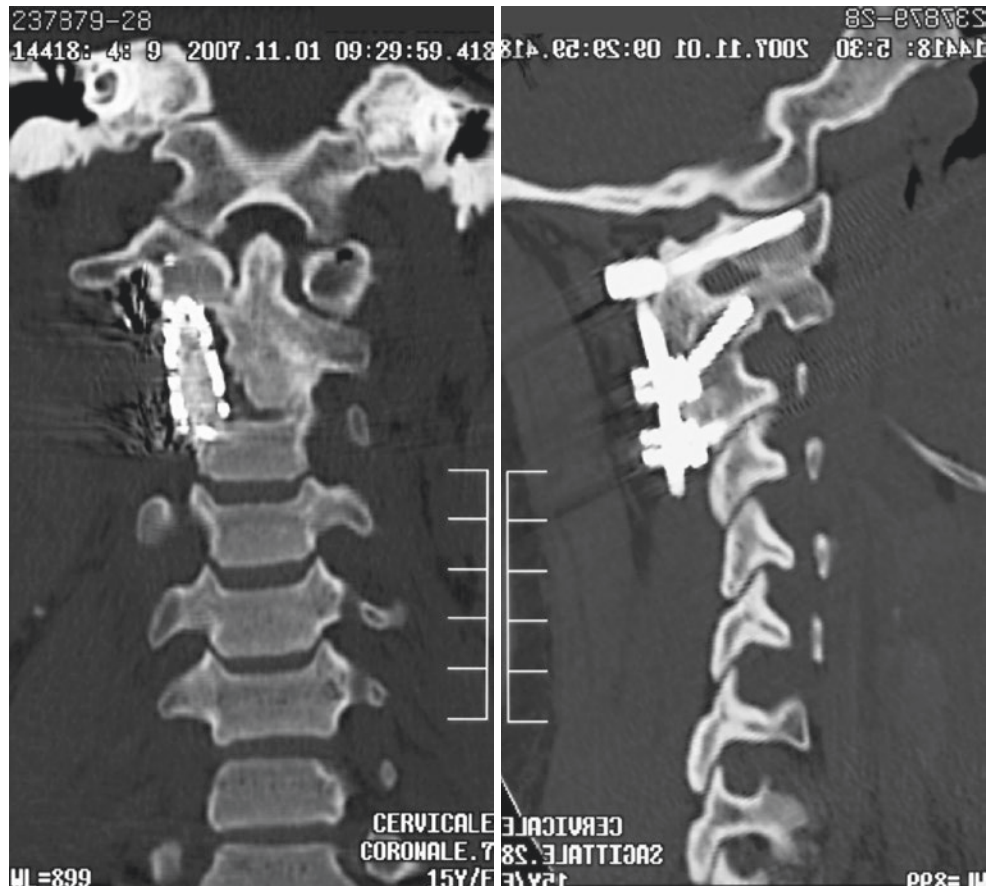

**Fig. 12.5** Post-operative CT scan

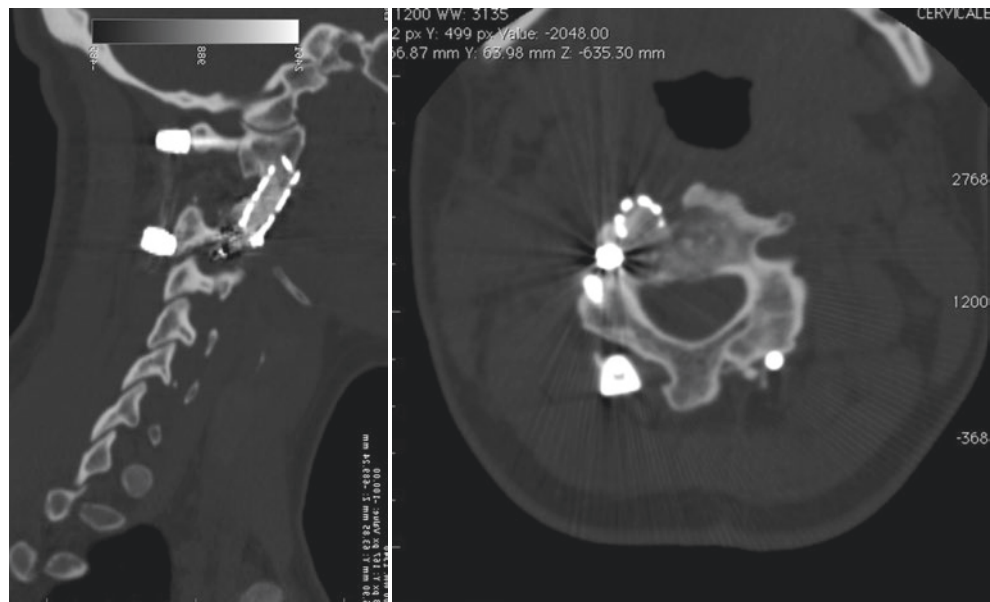


**Fig. 12.6** Post-operative standing plain radiographs

**Fig. 12.7** 4-months follow-up  
CT-scan



**Fig. 12.8** 3-years follow-up  
CT-scan



## 12.2 Subaxial Cervical Spine

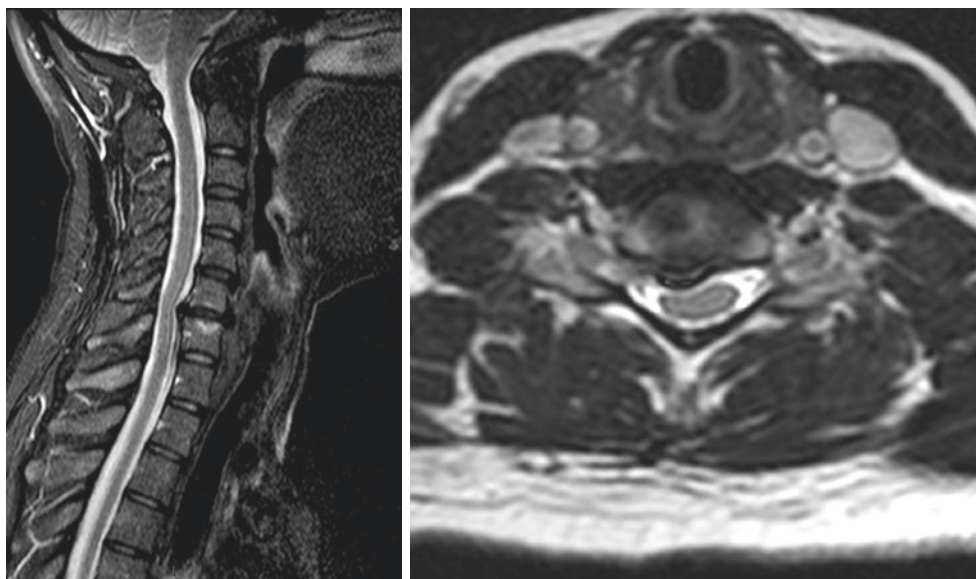
### 12.2.1 Anterior Procedures

#### 12.2.1.1 Anterior Cervical Discectomy and Fusion (ACDF)

Forty-three-year-old female, complaining of neck pain radiating to the right arm in territory of C7, resistant to a six-week course of conservative treatments. She referred paresthesias and numbness, and physical examination revealed a mild (4/5) motor deficit in wrist flexors and finger extensors and hyporeflexia in triceps reflex.

Sagittal and axial MRI shows herniated C6–C7 disk, obliteration of the anterior liquoral column, and cord compression.

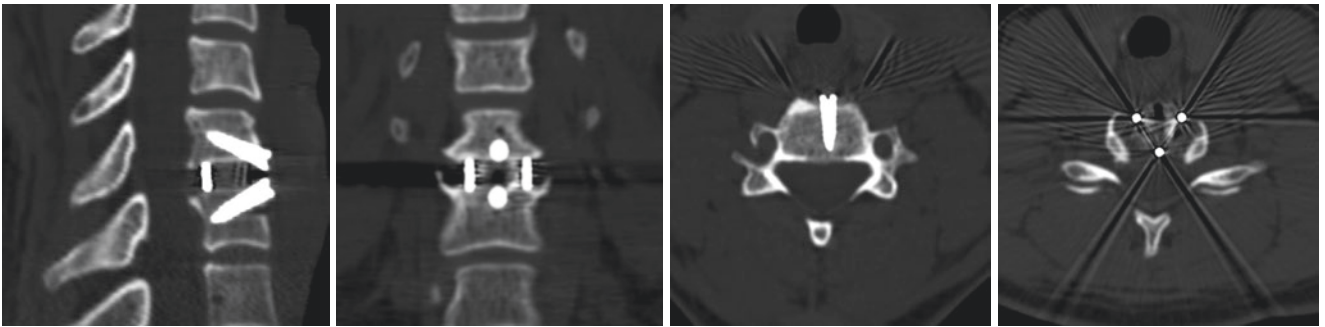
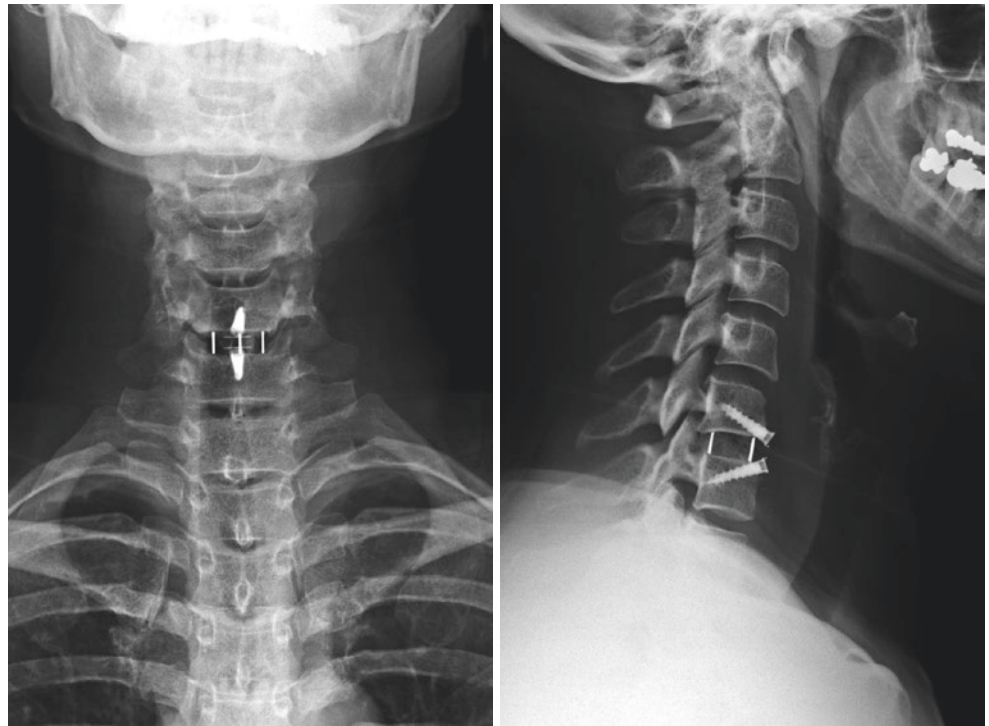
Anterior left prevascular approach was performed. After intraoperative fluoroscopic control, C6–C7 discectomy was completed in order to achieve decompression of the canal and the root. Distraction is applied to adjacent levels during end plate preparation. Wire locking PEEK and tantalum interbody cage was placed stand-alone, and mild compression is applied before final locking (3-month follow-up plain radiographs and CT scan) (Figs. 12.9, 12.10, and 12.11).



**Fig. 12.9** Pre-operative MRI



**Fig. 12.10** Post-operative standing radiographs



**Fig. 12.11** Post-operative CT-scan

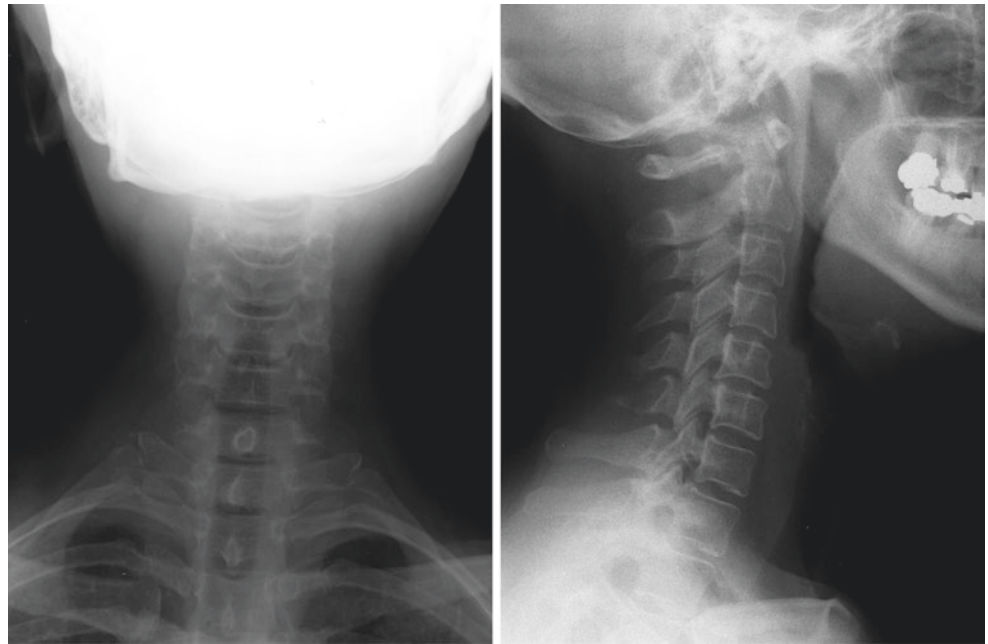
### 12.2.1.2 Cervical Disk Prosthesis

Forty-eight-year-old female, complaining of neck pain radiating to the right arm in territory of C6, resistant to six-week course of conservative treatments. She referred paresthesias and numbness, and physical examination revealed a mild (4/5) motor deficit in wrist extensors and hyporeflexia in brachioradialis reflex.

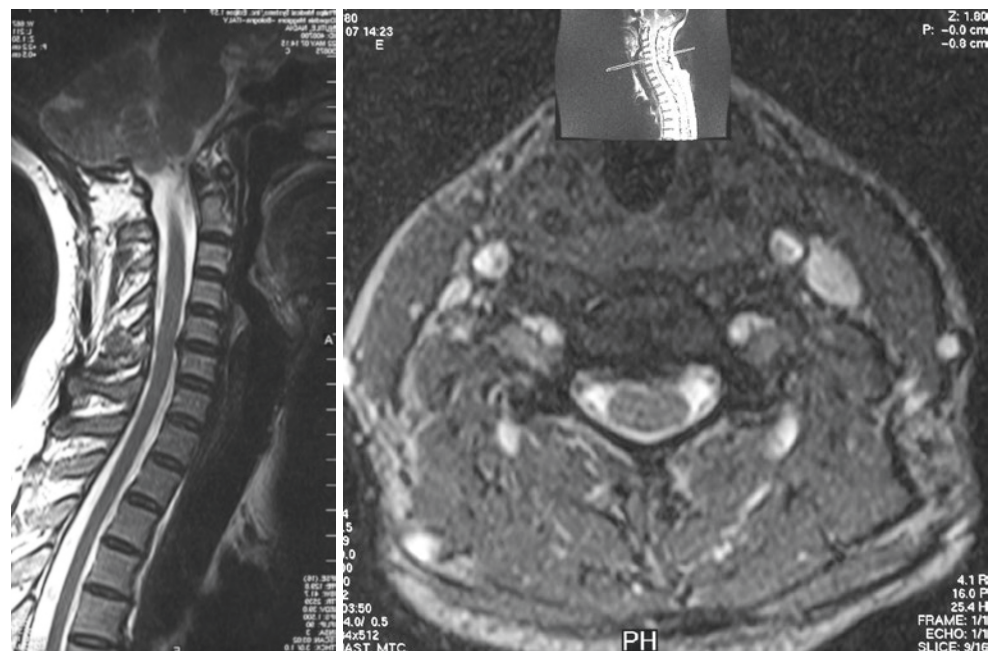
Sagittal and axial MRI shows herniated C6–C7 disk, obliteration of the anterior liquoral column, and cord compression.

Anterior left prevascular approach was performed. After intraoperative fluoroscopic control, C5–C6 discectomy was completed in order to achieve decompression of the canal and the root. Distraction is applied to adjacent levels during end plate preparation. C5–C6 Bryan Cervical Disc System was placed to restore disk height and allow motion at the treated level (Figs. 12.12, 12.13, 12.14, 12.15, and 12.16).

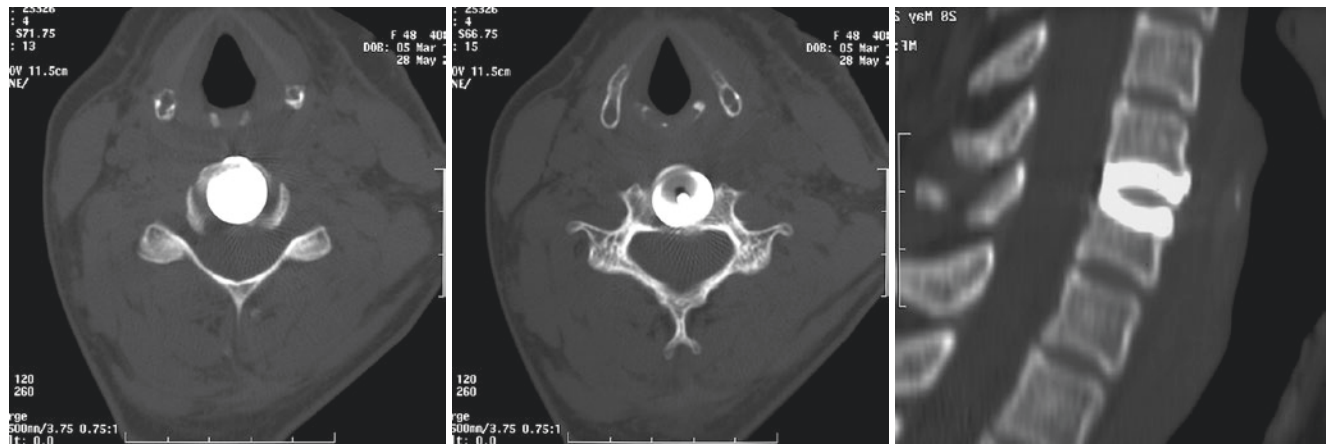
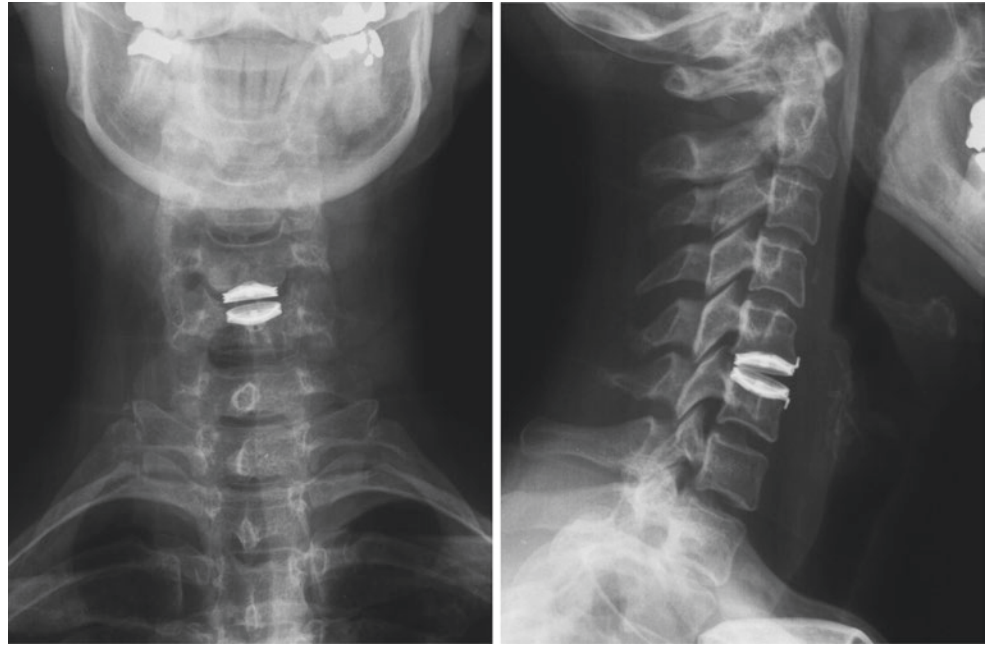
**Fig. 12.12** Pre-operative standing radiographs



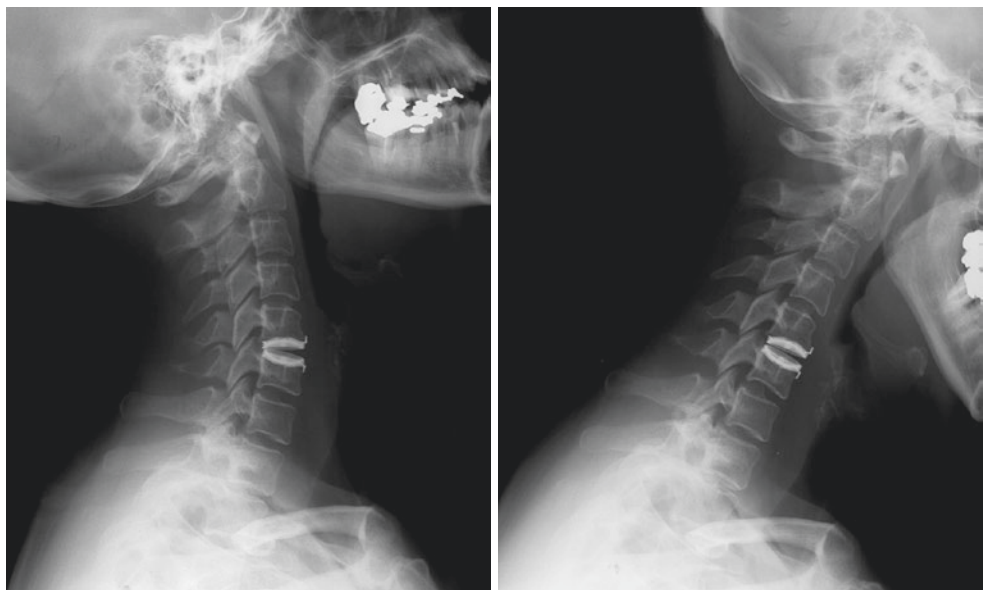**Fig. 12.13** Pre-operative MRI



**Fig. 12.14** Post-operative standing radiographs



**Fig. 12.15** Post-operative CT-scan



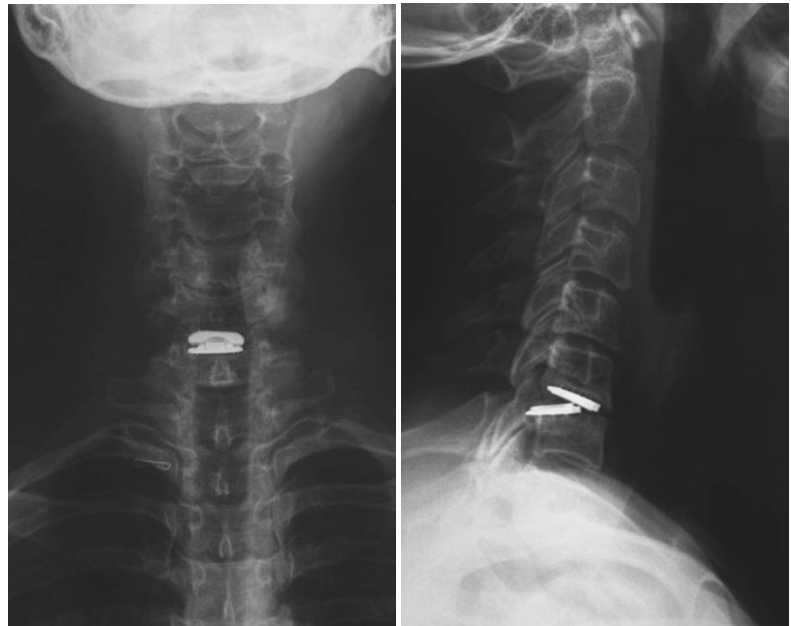
**Fig. 12.16** Post-operative flexion-extension radiographs

### 12.2.1.3 ACDF for Revision of Cervical Disk Prosthesis Failure

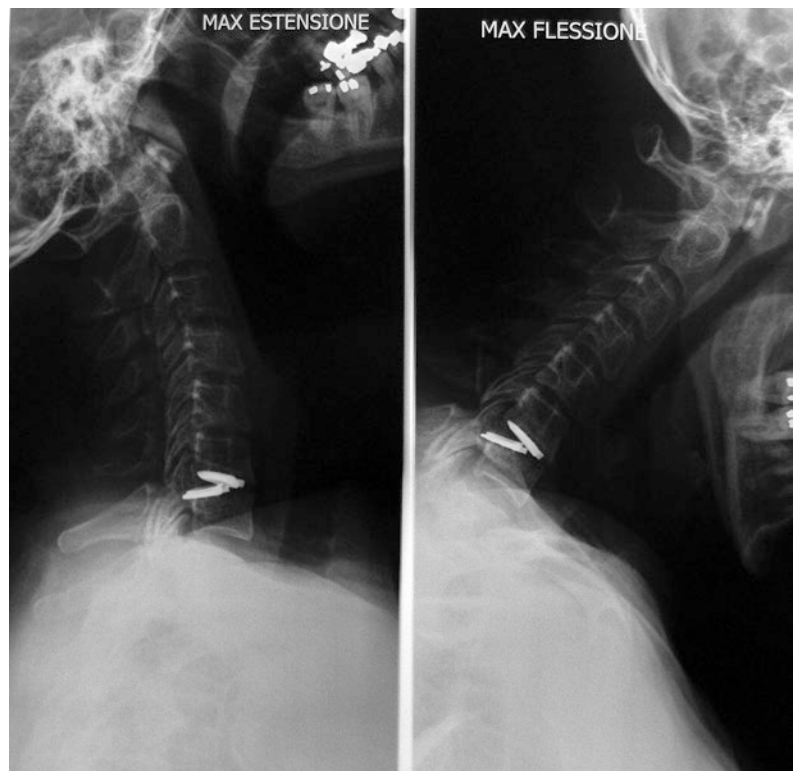
Fifty-six-year-old female, presenting with recurrency of progressive neck pain 10 months after C6–C7 disk arthroplasty. AP and LL radiographs show posterior dislocation of the implant; thus, dynamic exam did not reveal segmental instability.

Intraoperative picture shows removal of the device, and carbon fiber-reinforced polymer (CFRP) cage was placed as interbody device to restore segmental stability and provide anterior column support. Additional plate was placed to restore the anterior tension band (Figs. 12.17, 12.18, 12.19, 12.20, 12.21, 12.22, and 12.23).

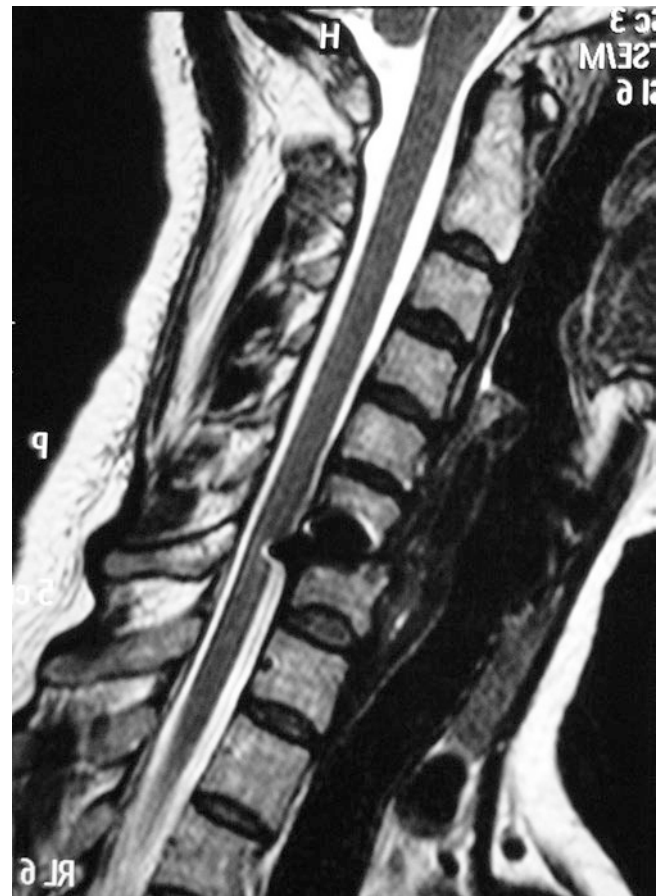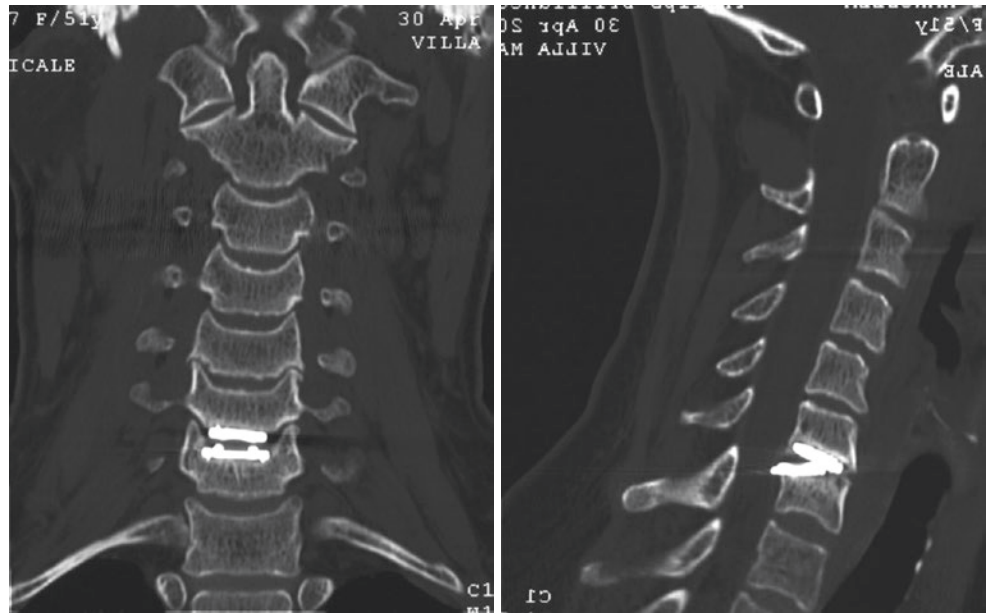
**Fig. 12.17** Pre-operative standing radiographs



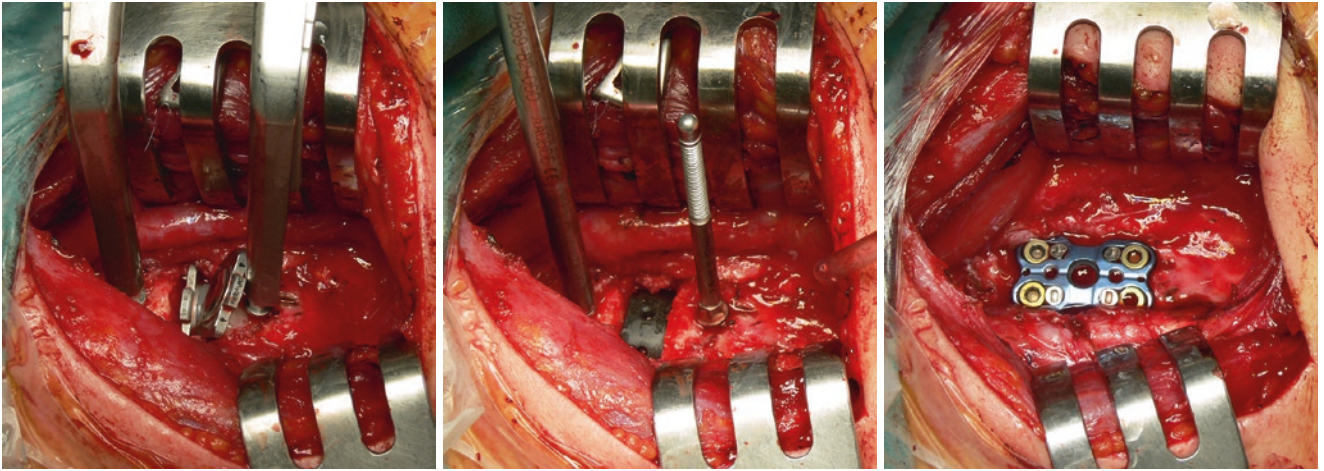
**Fig. 12.18** Pre-operative flexion-extension radiographs



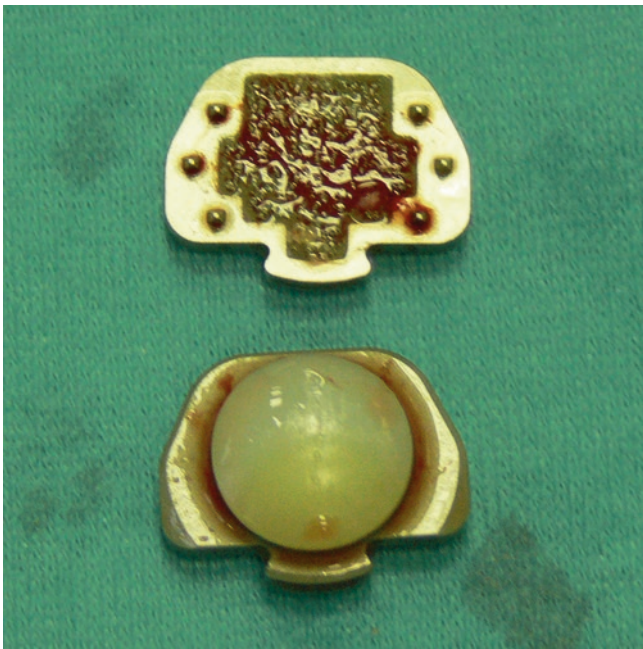
**Fig. 12.19** Pre-operative CT-scans



**Fig. 12.20** Pre-operative MRI

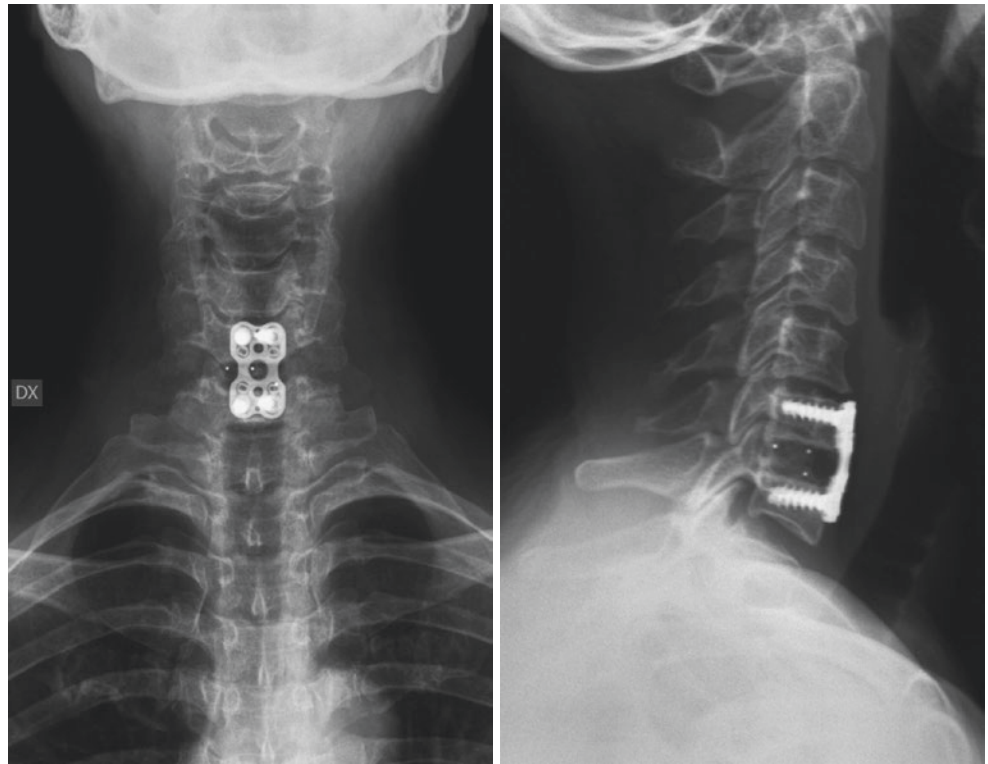


**Fig. 12.21** Intra-operative images



**Fig. 12.22** Post-operative radiologic control

**Fig. 12.23** Post-operative standing radiographs



#### 12.2.1.4 Anterior Cervical Corpectomy and Fusion (ACCF)

Fifty-three-year-old male, complaining of lower extremity numbness and gait disturbance. Patient revealed occasional neck pain with seldom irradiation to the arms with no particular dermatomal distribution. Physical examination revealed diffuse increase of muscle tone, hyperreflexia, positive Hoffmann sign, and clonus.

AP and LL radiographs show cervical spondylosis with loss of cervical lordosis.

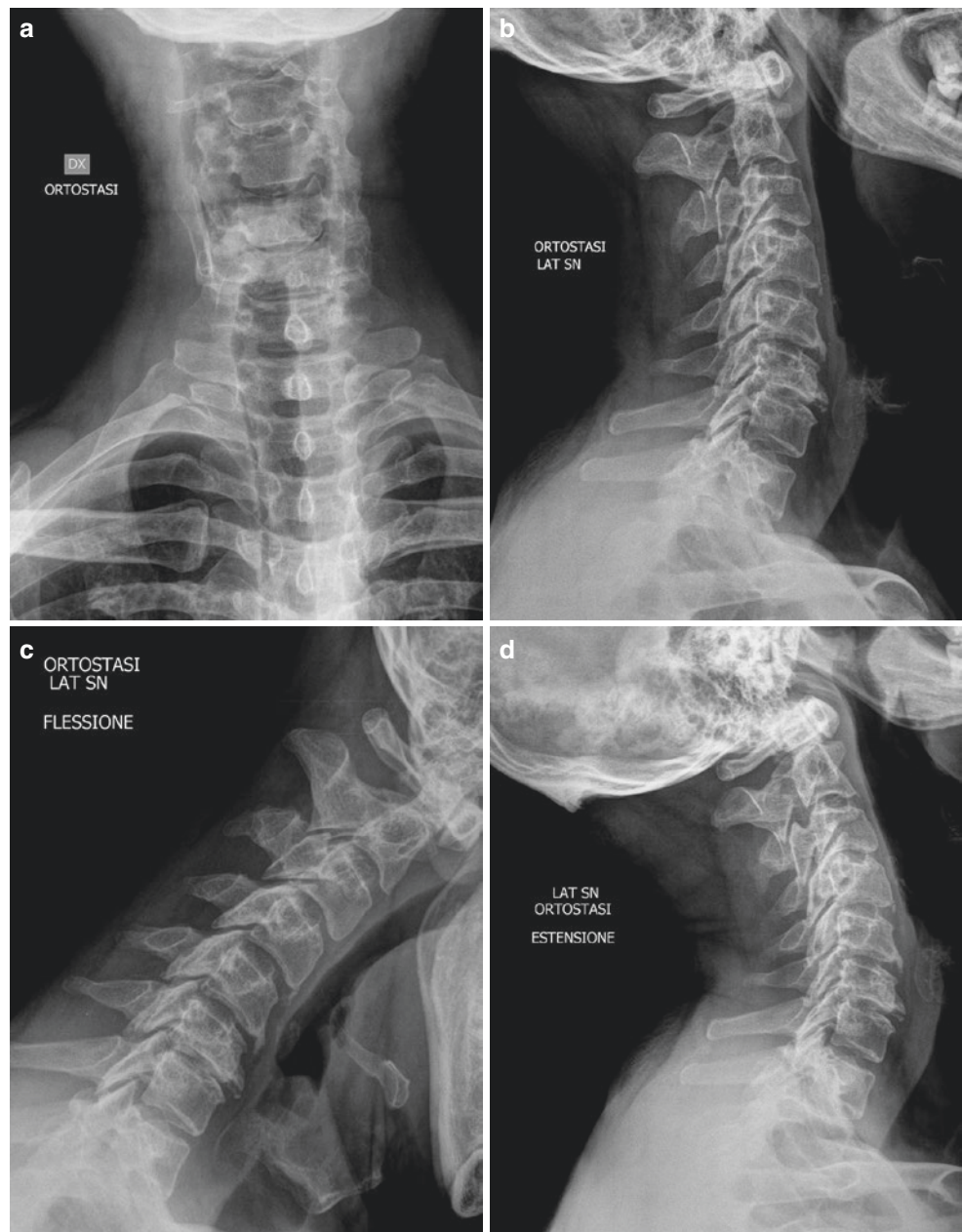
Sagittal MRI shows C5–C6 and C6–C7 disk protrusion with cord hyperintensity and sign of myelopathy. Dynamic

radiographs do not show segmental instability; thus, posterior tension band is preserved.

Intraoperative pictures show anterior approach, C6 corpectomy, and reconstruction using a titanium cage (Pyramesh, Medtronic) filled with mixture of auto- and allograft (from the registered tissue bank of the hospital).

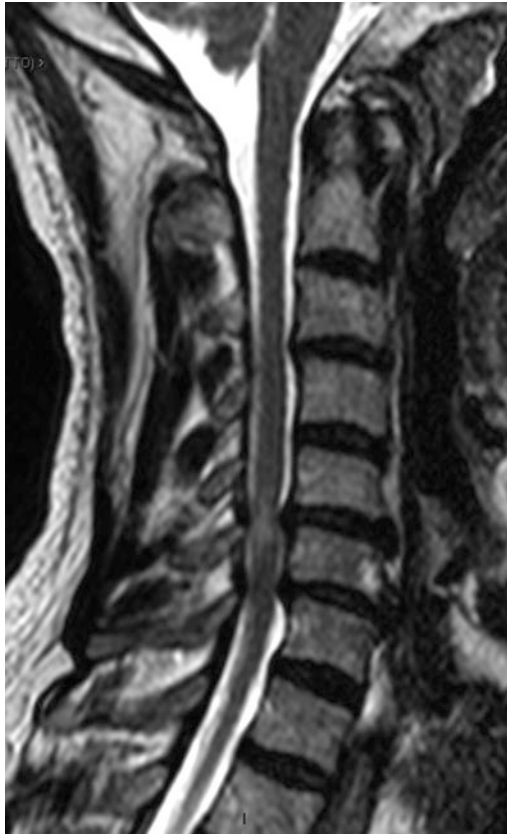
Anterior plate was used to restore the anterior tension band.

Postoperative plain radiographs and CT scan show correct placement of the hardware (Figs. 12.24, 12.25, 12.26, 12.27, and 12.28).

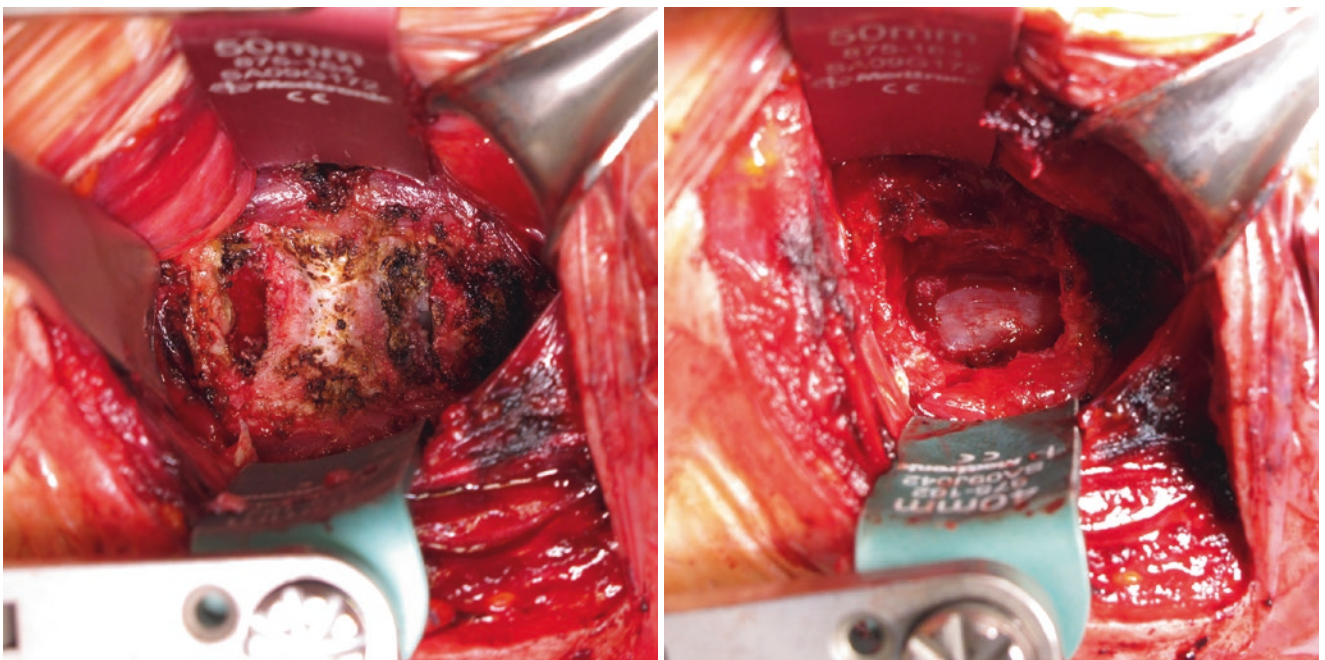


**Fig. 12.24** Pre-operative standing radiographs (a, b) and flexion-extension radiographs (c, d)





**Fig. 12.25** Pre-operative MRI



**Fig. 12.26** Intra-operative images

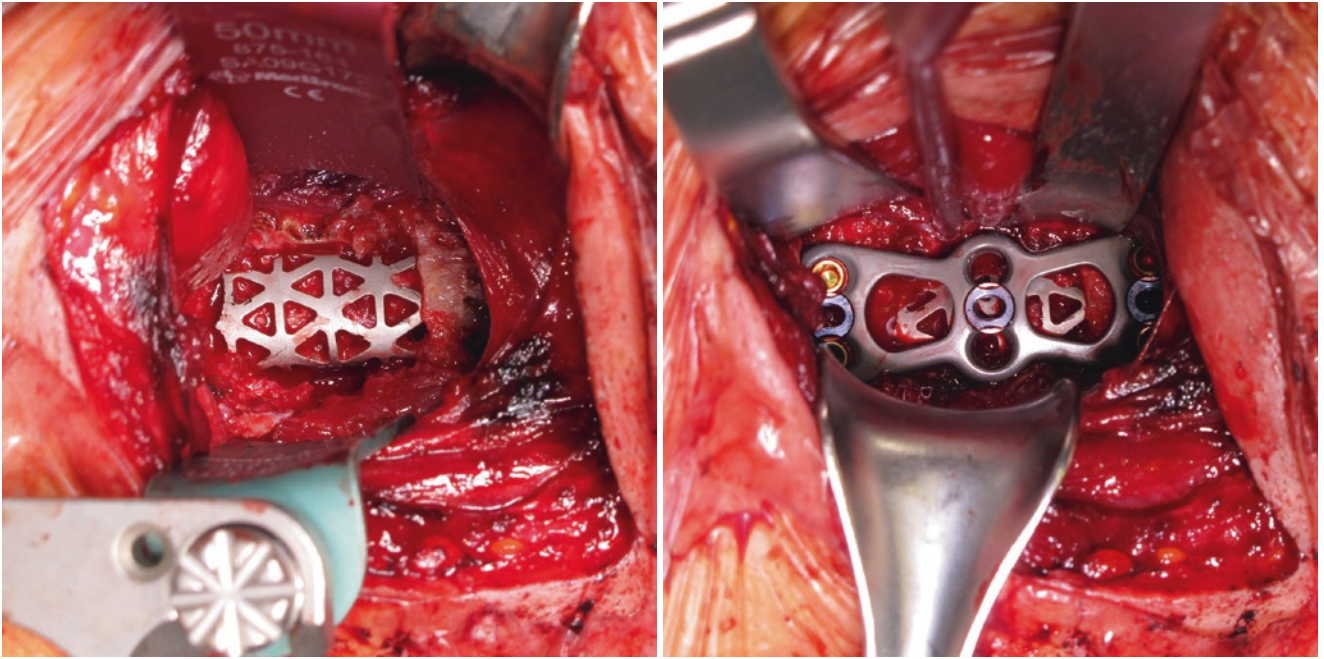


Fig. 12.26 (continued)

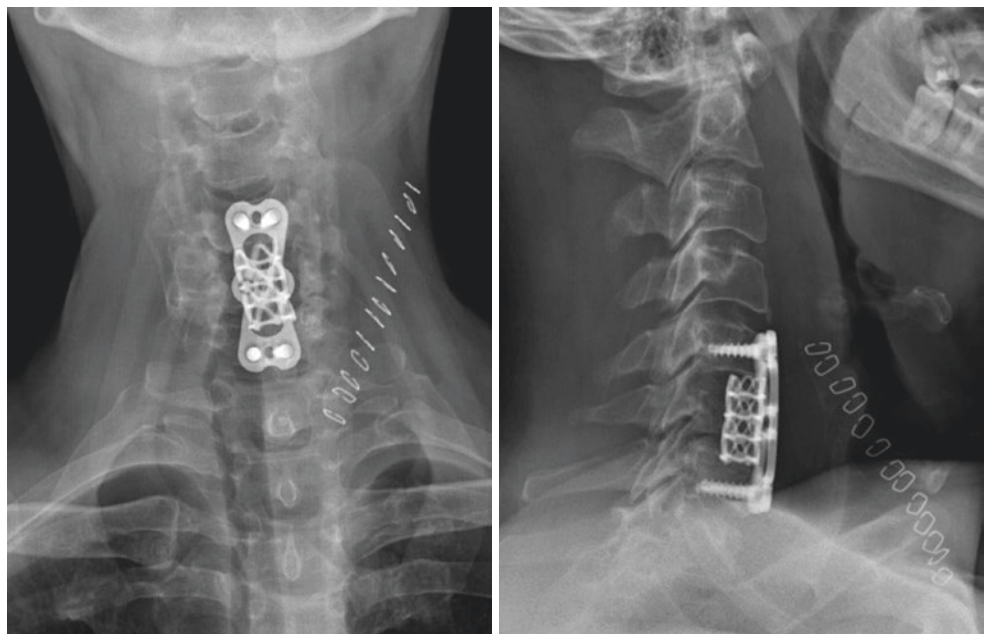
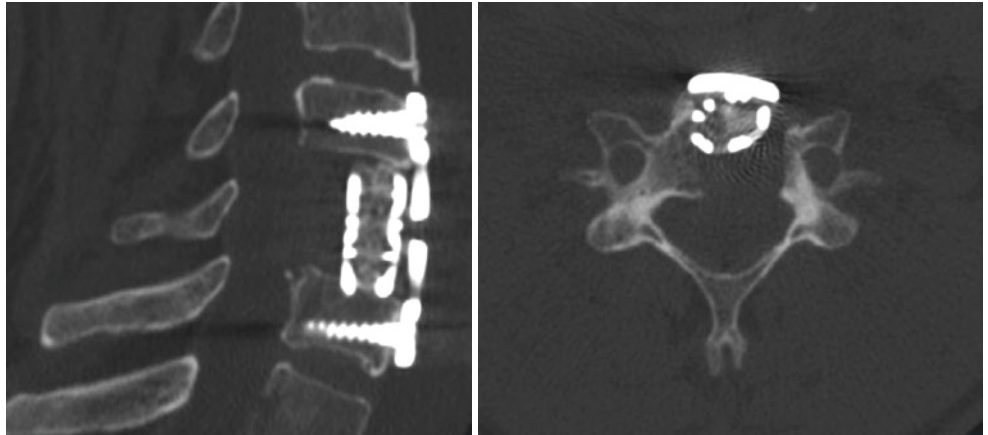


Fig. 12.27 Post-operative standing radiographs

**Fig. 12.28** Post-operative CT-scan



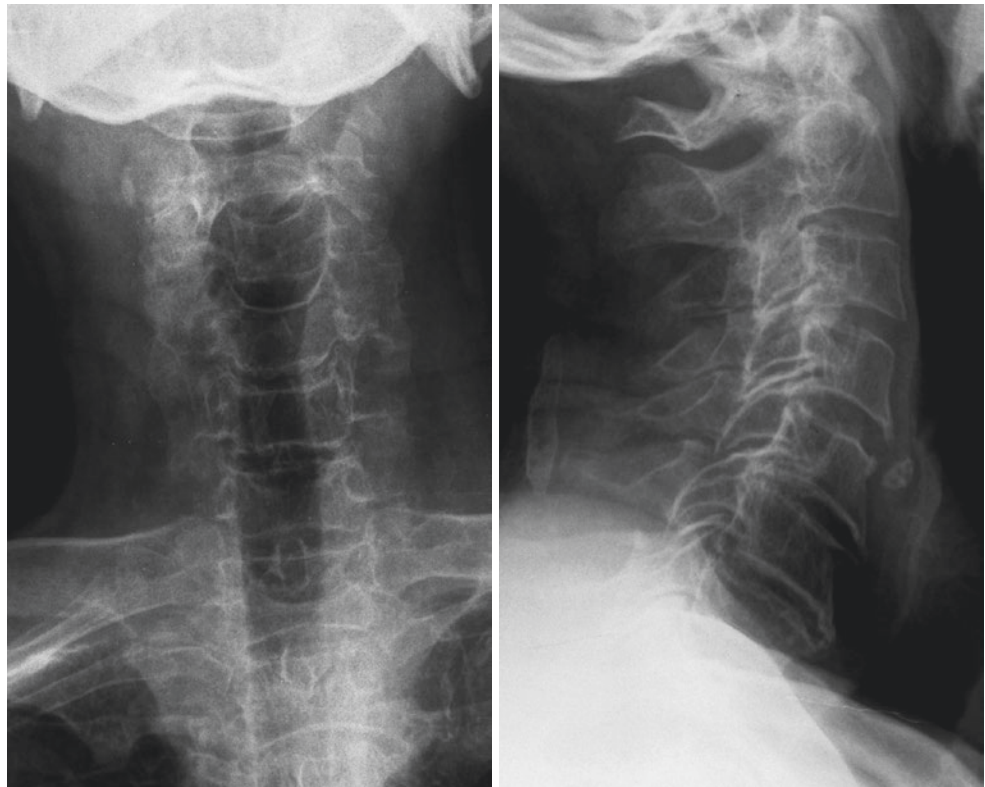
## 12.2.2 Posterior Procedures

### 12.2.2.1 Laminoplasty

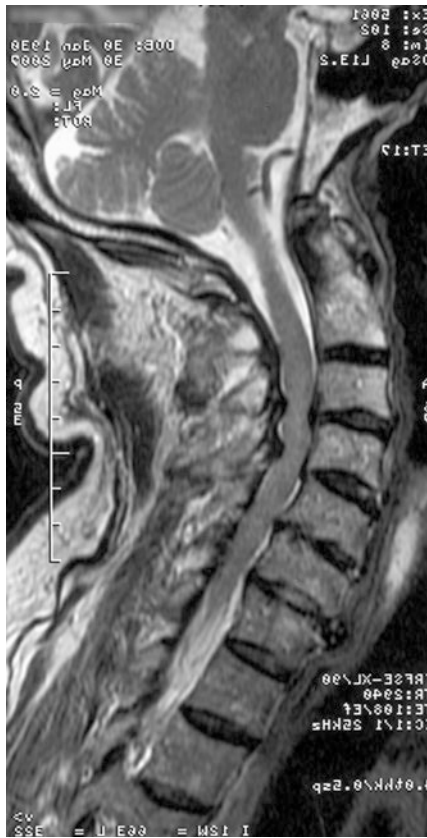Sixty-three-year-old male, complaining of lower extremity numbness and gait disturbance. Patient revealed occasional neck pain with seldom irradiation to the arms with no particular dermatomal distribution. Physical examination revealed diffuse increase of muscle tone, hyperreflexia, positive Hoffmann sign, and clonus.

AP and LL radiographs show cervical spondylosis, and sagittal MRI shows multilevel circumferential compression and narrowing of the canal.

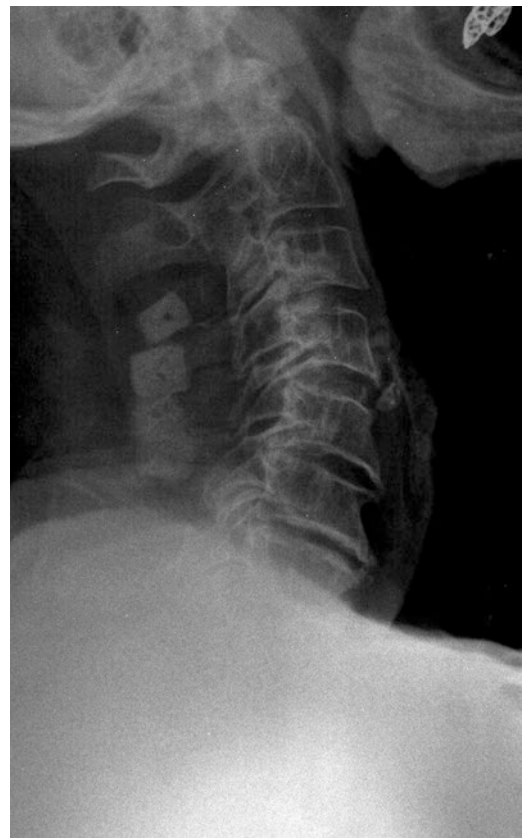Through a posterior approach, laminoplasty with Tomita technique was performed, with allograft to stabilize posterior arch widening at C3–C4–C5–C6 (Figs. 12.29, 12.30, 12.31, 12.32, 12.33, and 12.34).



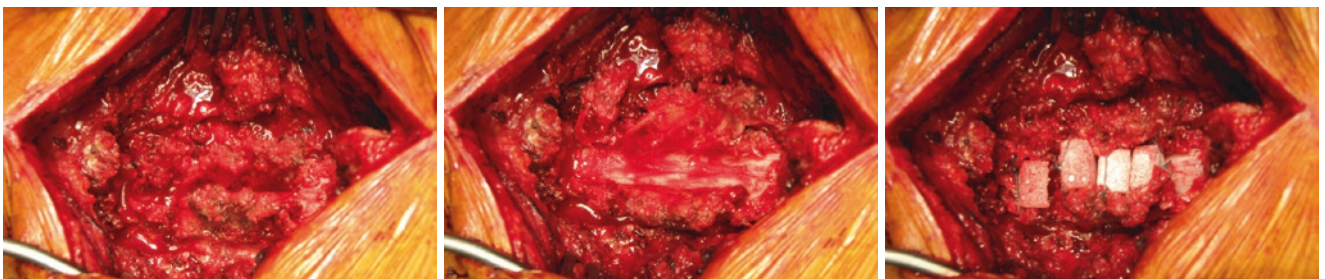**Fig. 12.29** Pre-operative standing radiographs



**Fig. 12.30** Pre-operative MRI

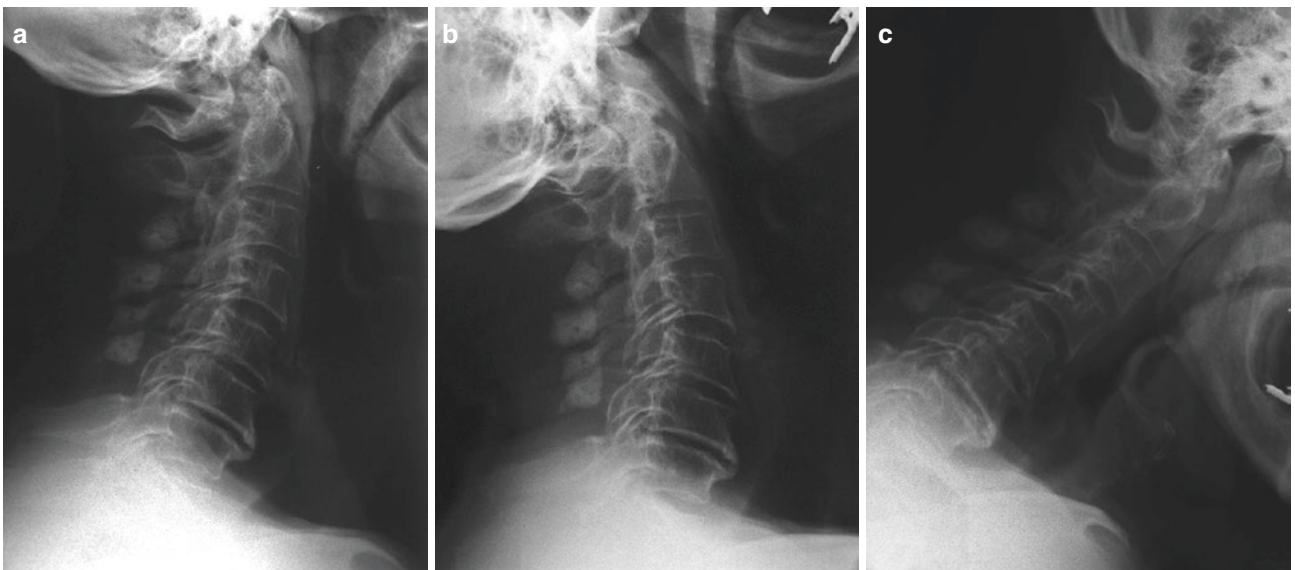
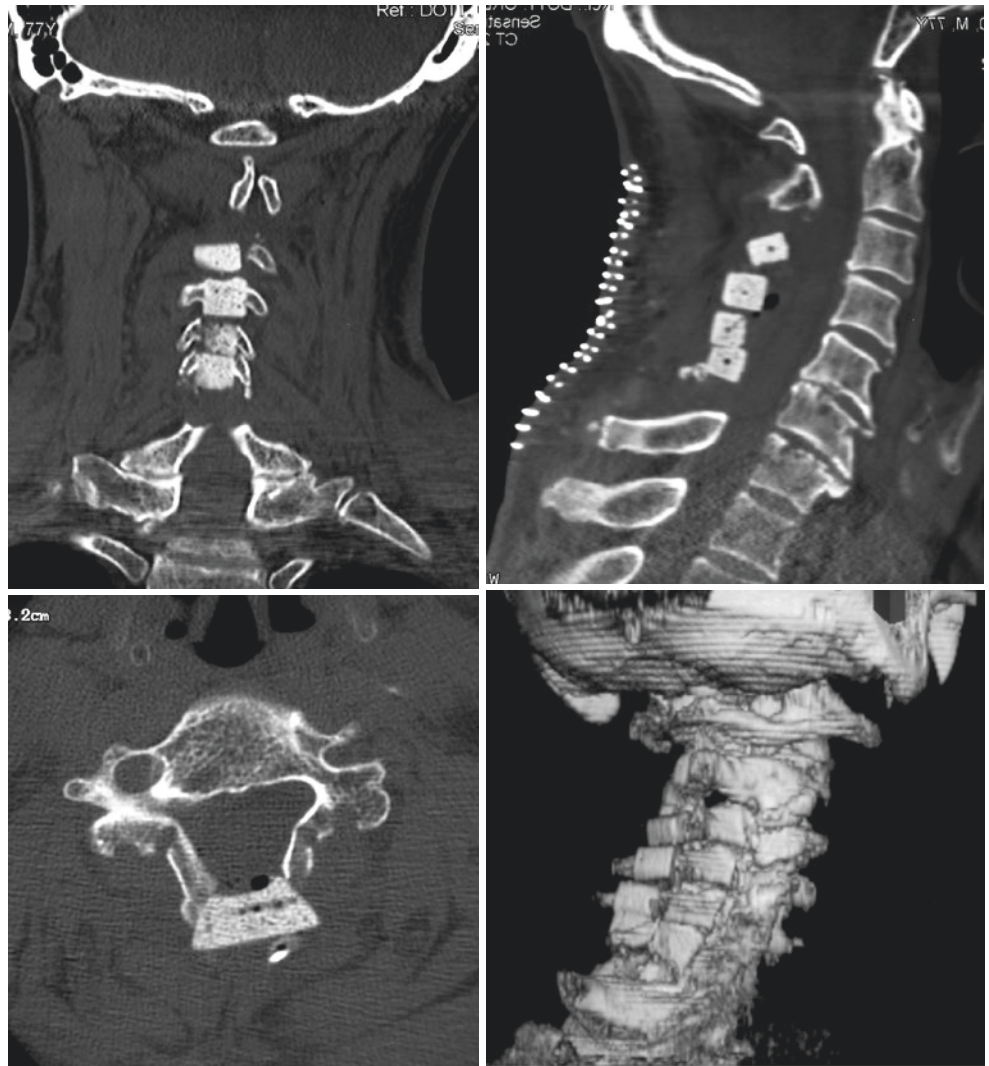


**Fig. 12.32** Post-operative standing radiographs



**Fig. 12.31** Intra-operative images

**Fig. 12.33** Post-operative CT-scans



**Fig. 12.34** Post-operative flexion-extension (A, C) and standing (B) radiographs

### 12.2.2.2 Posterior Instrumented Fusion

Thirty-two-year-old female complaining of progressive neck pain since several months and recent onset of a hard swelling in the right paravertebral muscle compartment. Neurologic examination did not reveal any pathological findings. Previous attempts to control symptoms with physical therapy resulted ineffective.

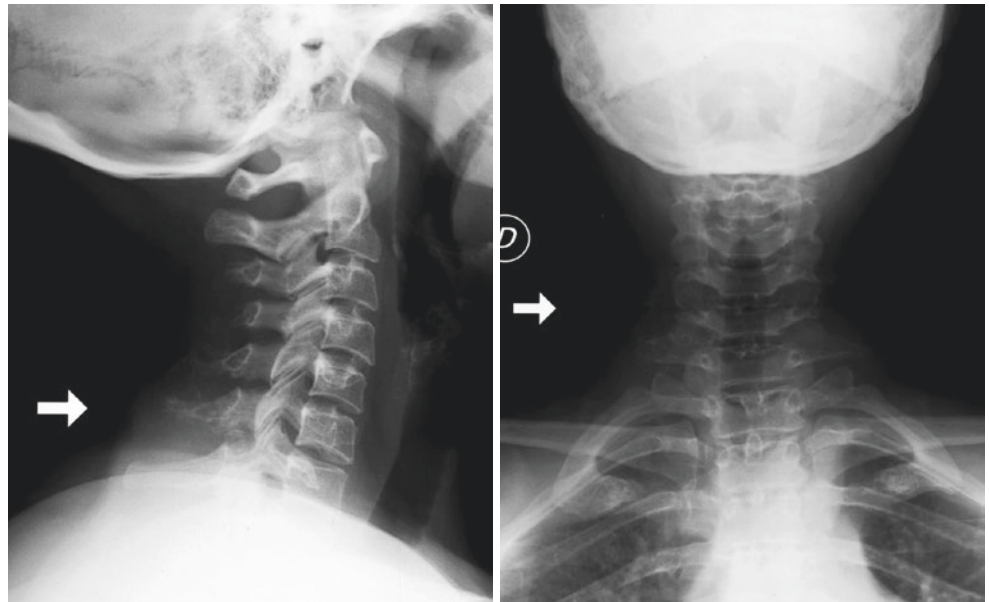
Plain radiographs show osteolytic areas in the posterior elements and a shadow in the posterior soft tissues. MRI shows lesion arising in the right lateral mass of C7 extending into the paravertebral muscle compartment. CT scan shows intralesional “popcorn” ossifications, typical of cartilage tumors.

Biopsy was performed and histopathological examination on the specimen was diagnostic for chondrosarcoma grade 1.

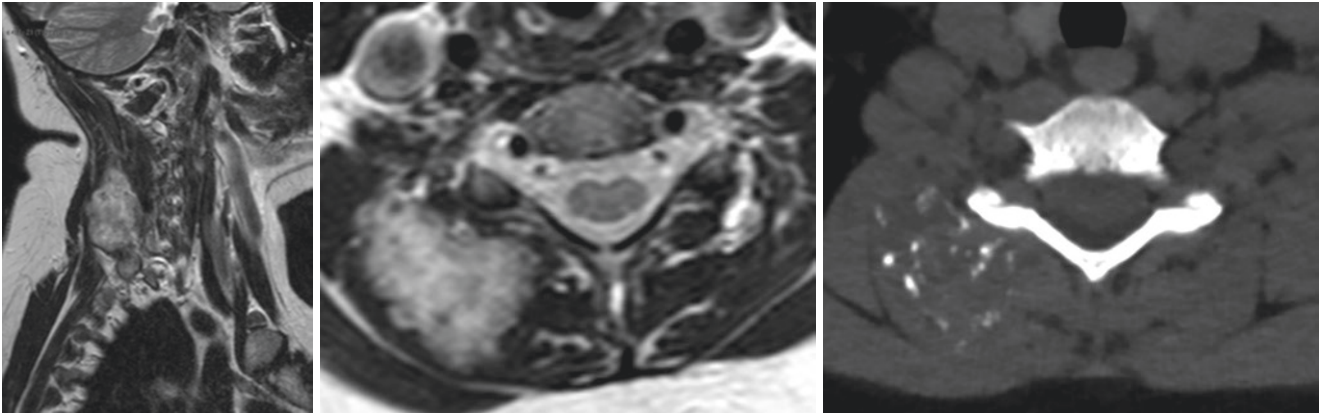
Through a posterior-only approach, en bloc resection of posterior elements from C4 to C7 was performed with wide margins.

Reconstruction of spinal stability was achieved via posterior screw-rods instrumentation and massive cortical bone allograft for spinal canal reconstruction (roof technique). Pedicle screws were placed with both transpedicular route and into the lateral masses.

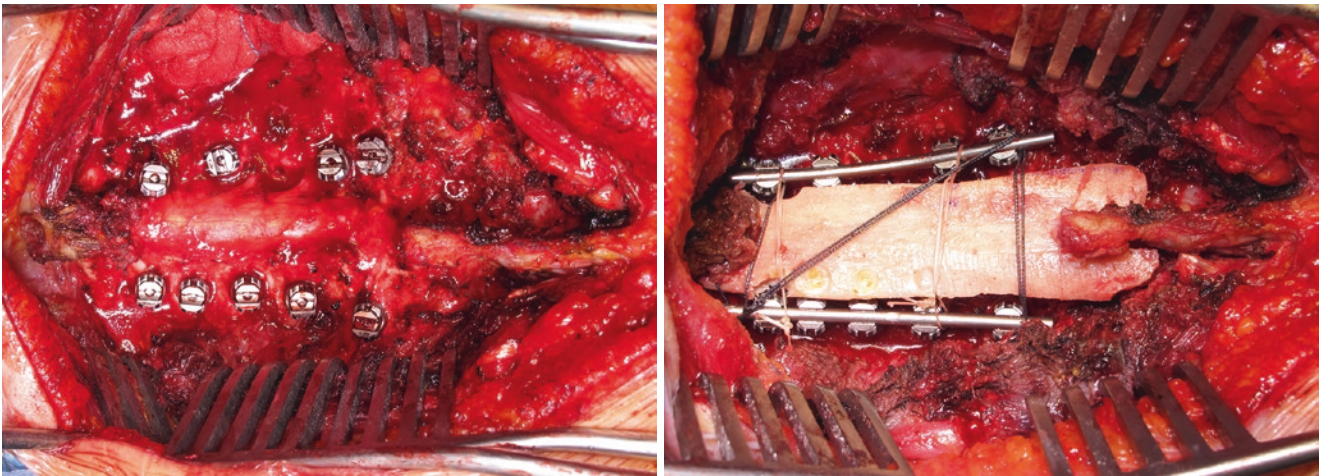
Cortical bone allograft was contoured in an H shape and placed bridging the posterior arch of C3 to that of T1 and secured to the posterior instrumentation. This technique promotes posterior arthrodesis due to the osteoconductive and osteoinductive properties of the graft. Moreover it provides a posterior covering of the spinal canal, protecting the neurostructures and providing immediate stability to the posterior column of the spine (Figs. 12.35, 12.36, 12.37, and 12.38).



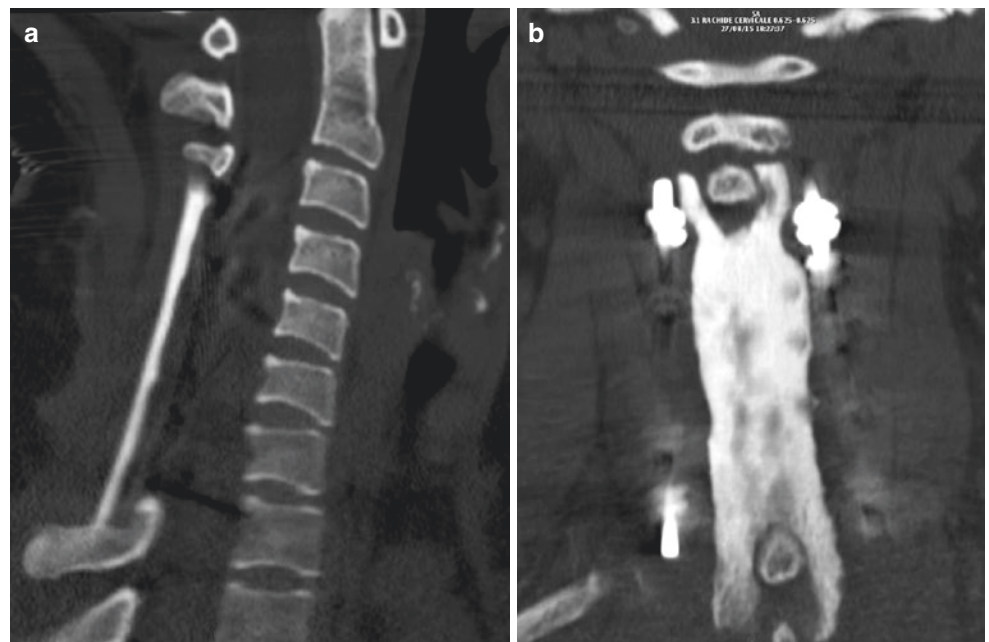**Fig. 12.35** Pre-operative standing radiographs. *Arrow* indicates the shadow of the lesion extending into the paravertebral muscular compartment



**Fig. 12.36** Pre-operative MRI and trasverse CT-scan

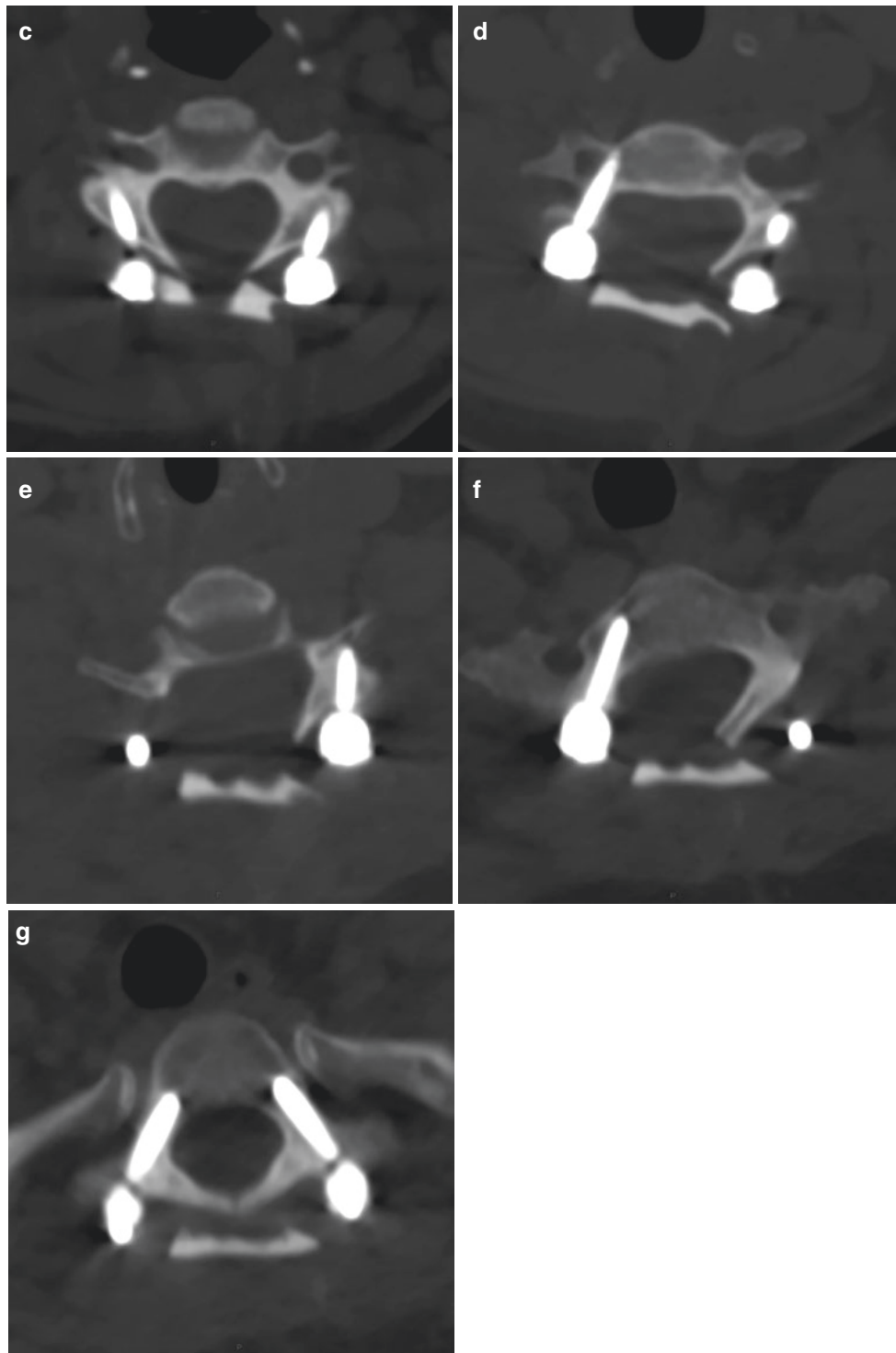


**Fig. 12.37** Intra-operative images. Posterior reconstruction with allograft (Roof technique)



**Fig. 12.38** Post-operative CT-scan





**Fig. 12.38** (continued)

## 12.2.3 A + P Procedures

### 12.2.3.1 Single-Level

Fifty-six-year-old female complaining of sudden onset of neck pain.

She had been treated for colon cancer 4 years before and was in an oncologic follow-up program ever since. Physical examination revealed incapacitating neck pain and painful contracture of the paravertebral muscles. Neurological examination did not reveal any neurological deficit.

Plain radiographs show C6 vertebral body fracture, and sagittal MRI shows signal alteration of the bone at that level but no signs of cord compression.

Further CT scan is mandatory in order to clarify the pattern of the fracture.

Biopsy was performed and histopathological examination on the specimen was diagnostic for colon cancer metastasis.

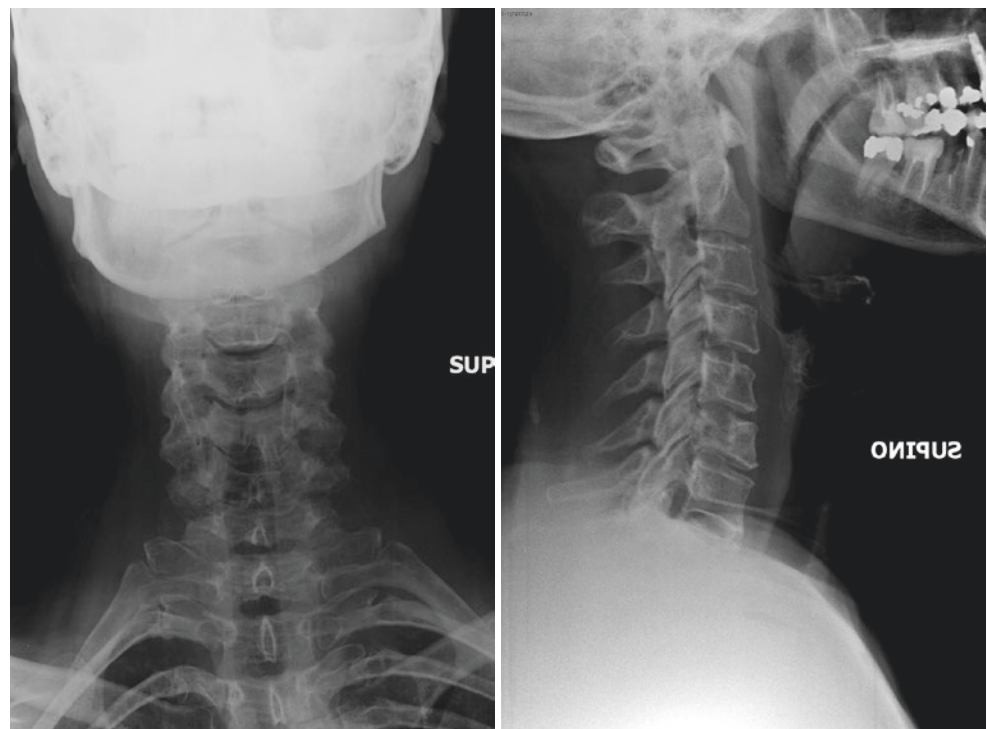
Bone scintigraphy does not show any other location of the disease. Thus, being it a solitary bone lesion, excisional surgery is indicated.

Through an anterior prevascular approach, the vertebral body is exposed, and extracapsular excision of the tumor was performed.

PMMA-armed bone allograft was used to fill the bone defect and reconstruct the anterior column. Anterior plate was used to restore the anterior tension band.

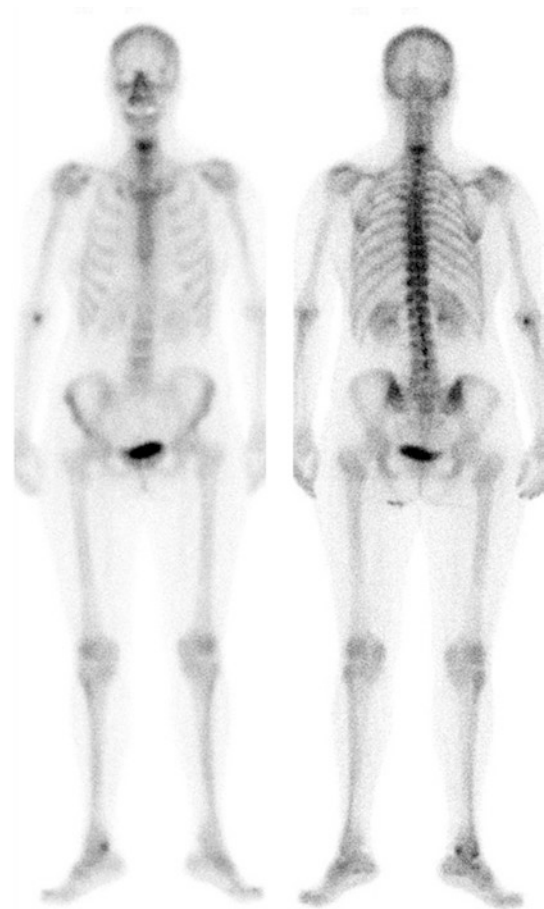
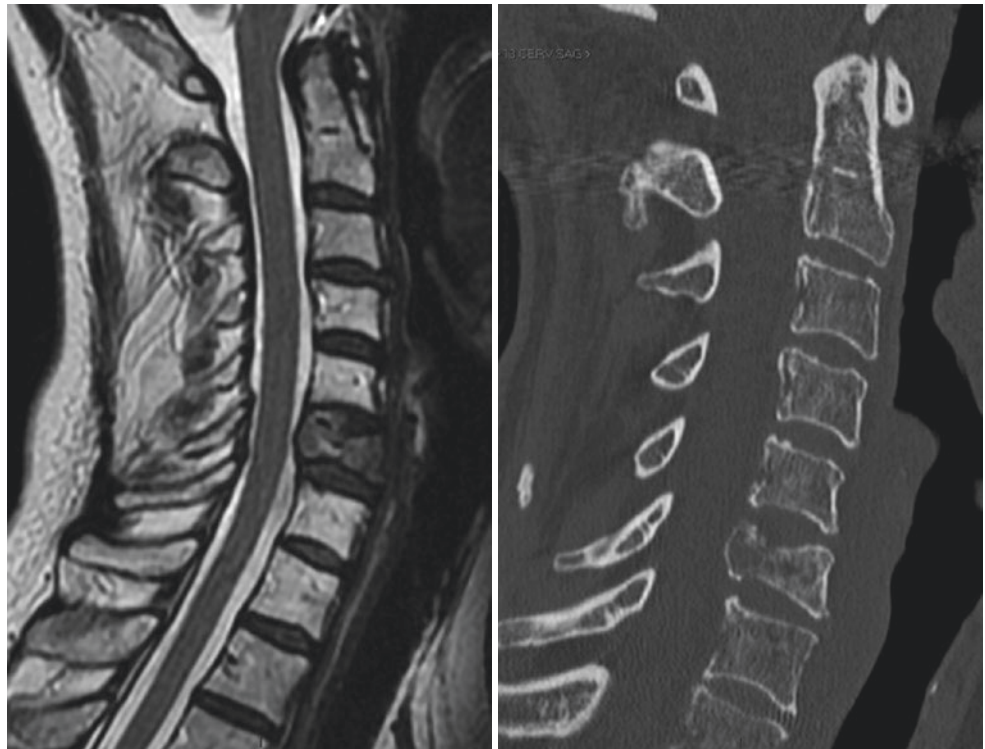Laminectomy with posterior instrumentation was used to circumferentially decompress the cord and restore spinal stability.

Postoperative CT scan shows correct placement of the hardware (Figs. 12.39, 12.40, 12.41, 12.42, 12.43, 12.44, 12.45, and 12.46).

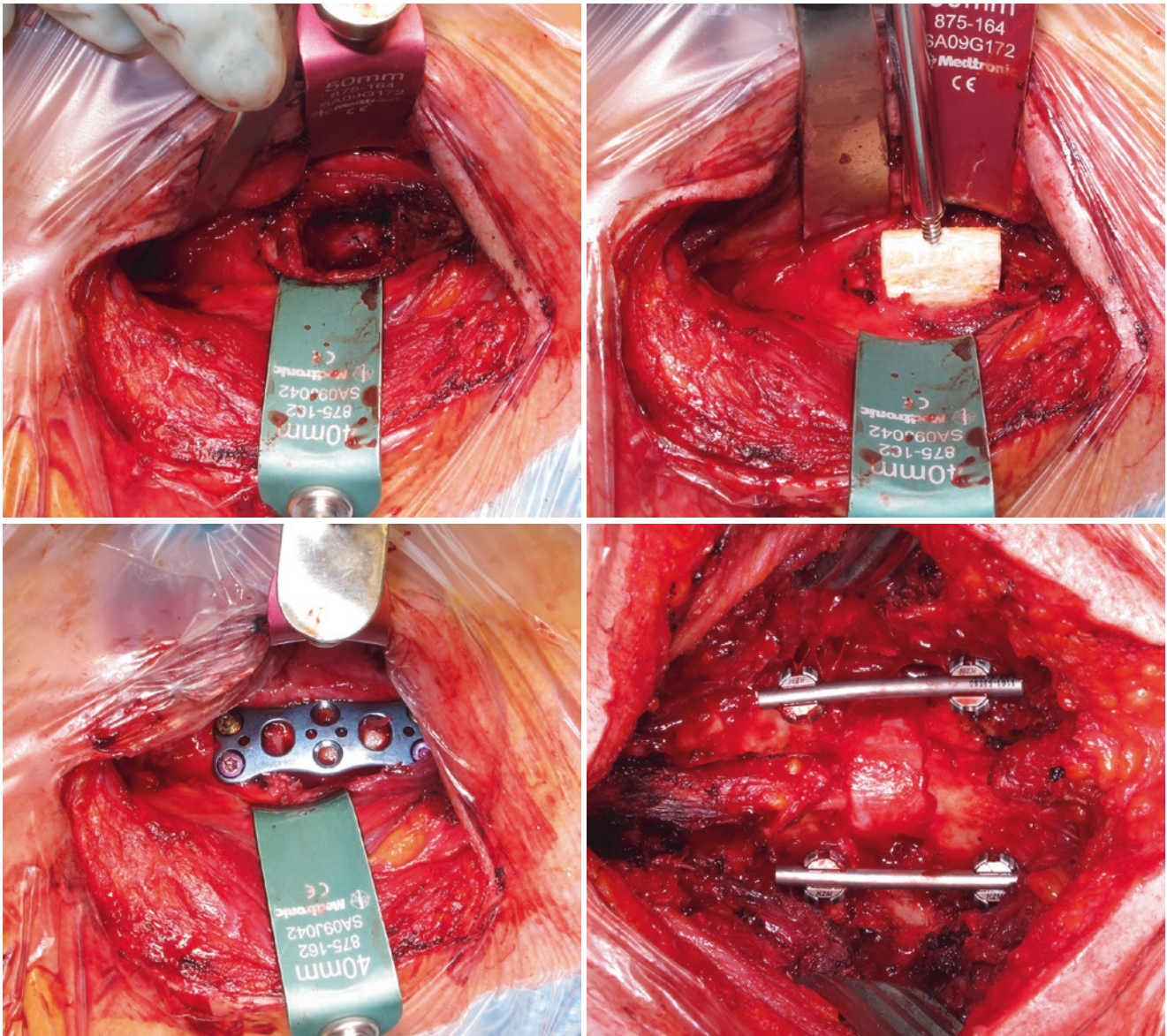


**Fig. 12.39** Pre-operative plain radiographs

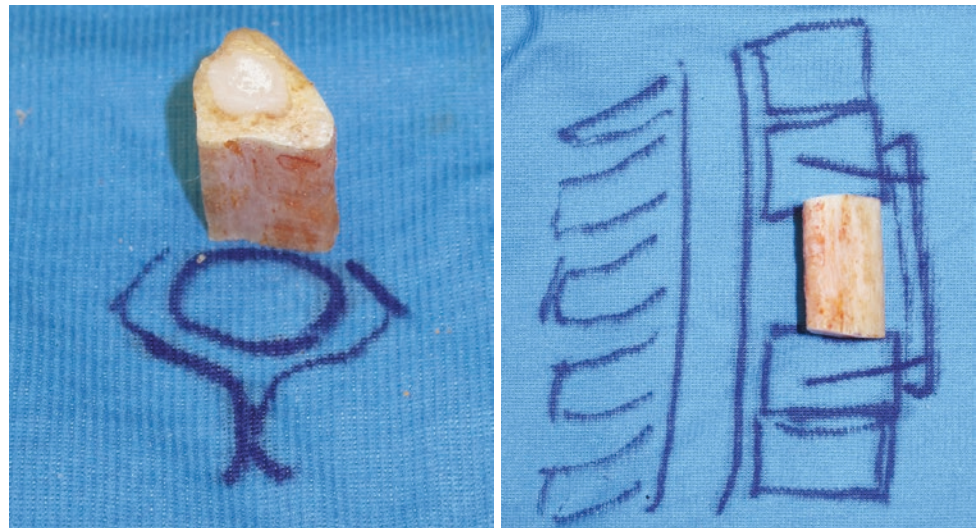
**Fig. 12.40** Pre-operative MRI and CT scan



**Fig. 12.41** Pre-operative scintigraphy

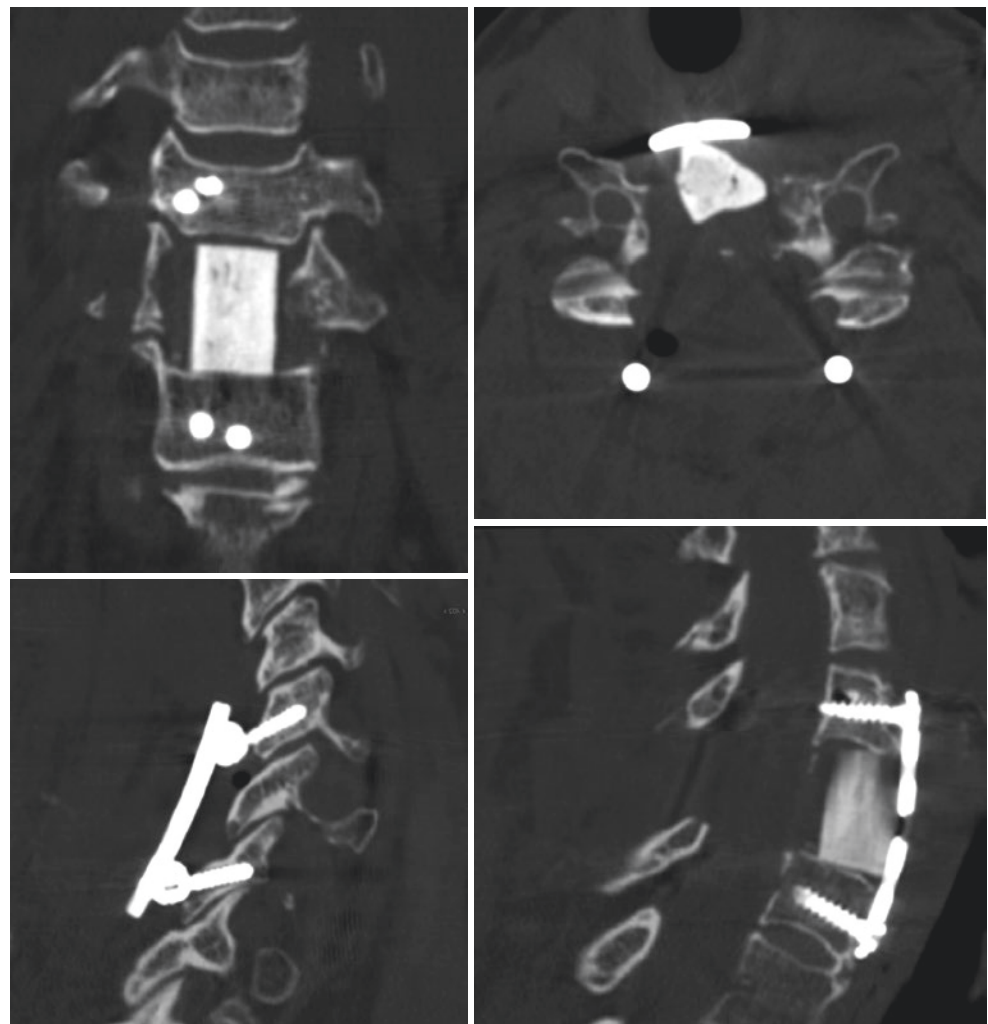
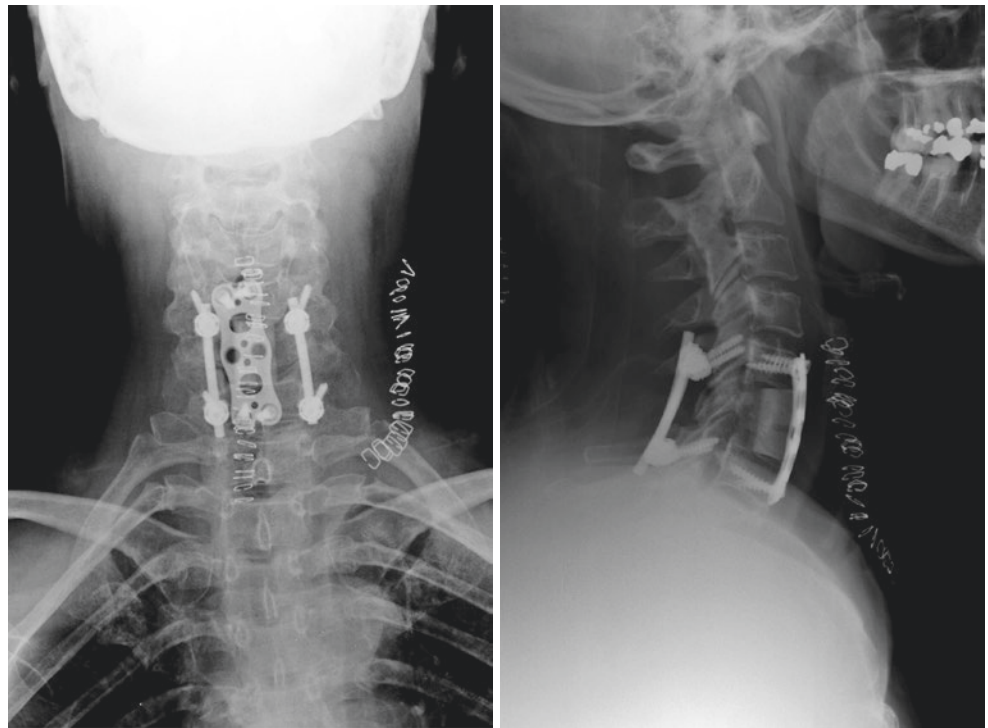


**Fig. 12.42** Intra-operative images



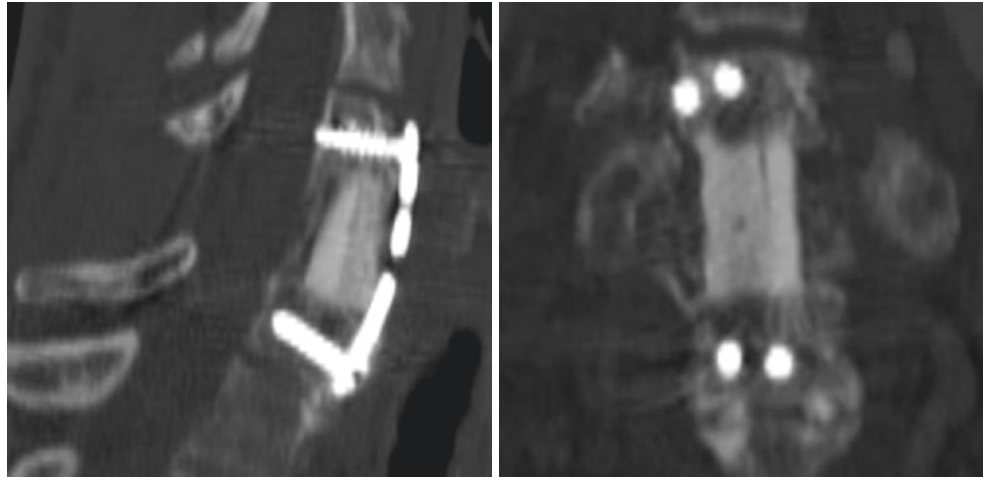
**Fig. 12.43** Reconstruction of vertebral body using PMMA-armed allograft

**Fig. 12.44** Post-operative standing radiographs



**Fig. 12.45** Post-operative CT-scan

**Fig. 12.46** 2-years follow-up  
CT-scan



### 12.2.3.2 Multiple Levels

Thirty-nine-year-old male complaining of progressive onset of incapacitating neck pain since several months. Previous attempts to control symptoms with physical therapy resulted ineffective. Past medical history was negative for oncologic disease. Physical examination revealed painful contracture of the paravertebral muscles, but neurological examination did not reveal any neurological deficit.

MRI shows a lesion replacing the left lateral mass of C4, protruding in the spinal canal and extending into the prevertebral layer. CT scan provides further information regarding the lesion and host bone reaction to it.

Biopsy was performed and histopathological examination on the specimen was diagnostic for chondrosarcoma grade 2 with dedifferentiated areas of osteogenic and chondroblastic sarcoma grade 3.

Double approach is mandatory to resect the lesion, reconstruct the spinal column, and restore segmental stability.

Through a posterior approach, screw-rods instrumentation was placed, and debulking was performed after laminectomy.

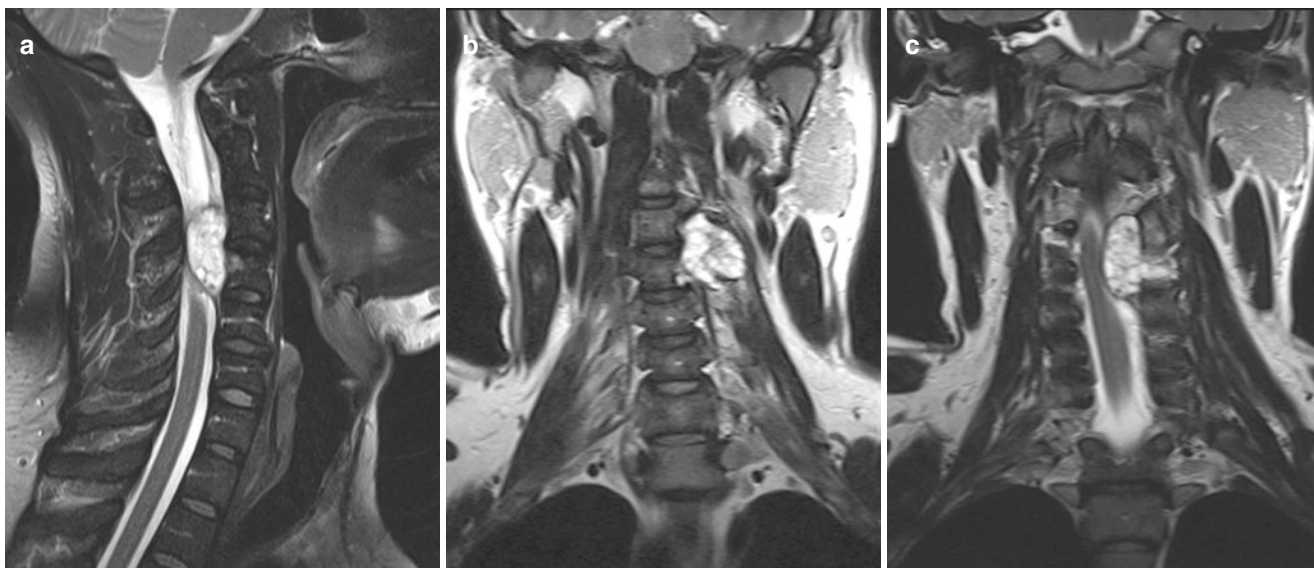
Anterior prevascular approach allowed control of the vertebral artery, mobilization, and complete excision of the tumor.

Reconstruction of the anterior column was performed using tricortical autogenous iliac bone graft.

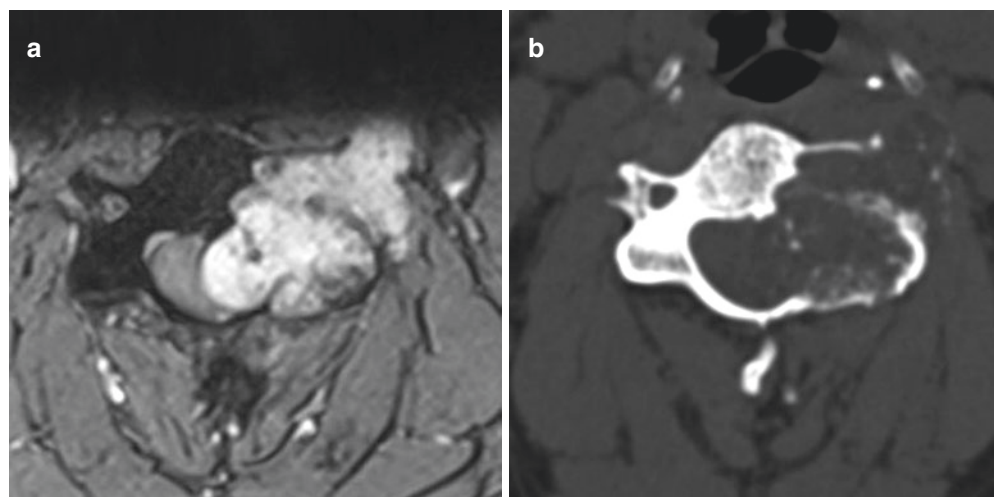
Anterior plate was used to restore the anterior tension band.

Postoperative plain radiographs and CT scan show balanced spine and correct placement of the hardware.

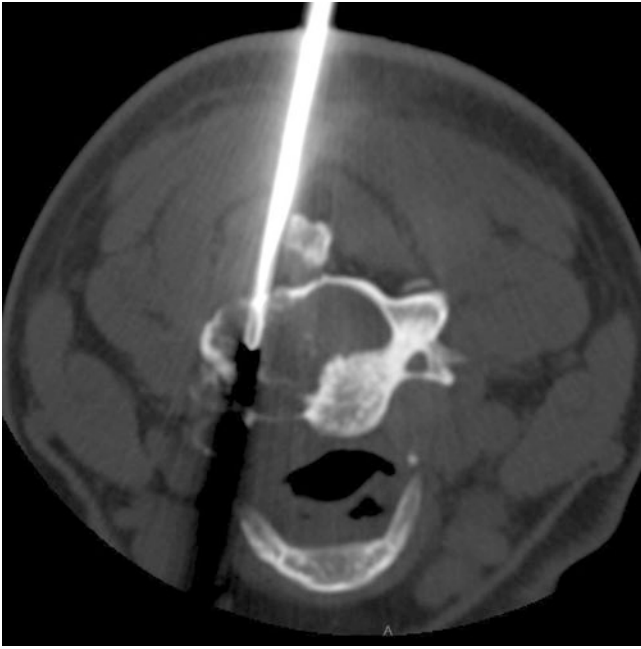
Two-year follow-up shows fusion of the allograft to the host bone (Figs. 12.47, 12.48, 12.49, 12.50, 12.51, 12.52, and 12.53).



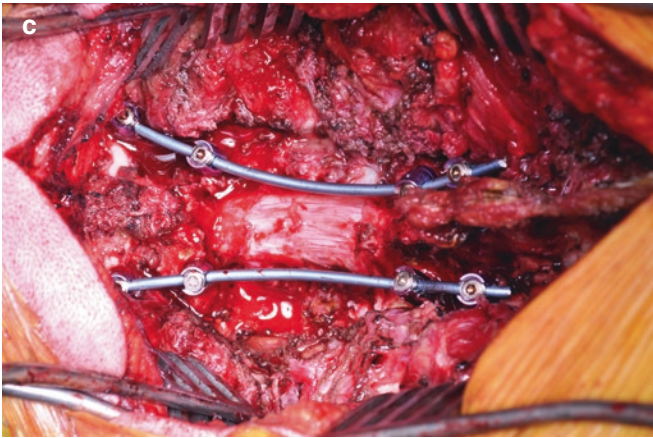
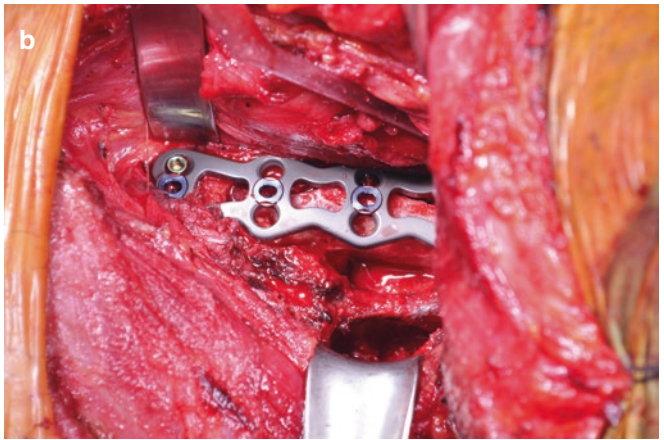
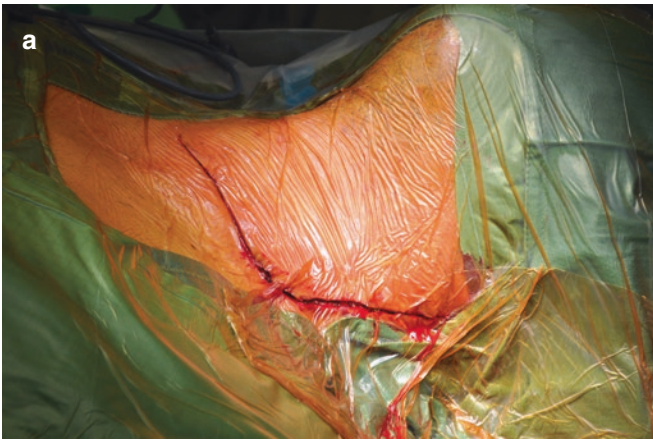
**Fig. 12.47** Pre-operative MRI



**Fig. 12.48** Pre-operative axial MRI and CT-scans



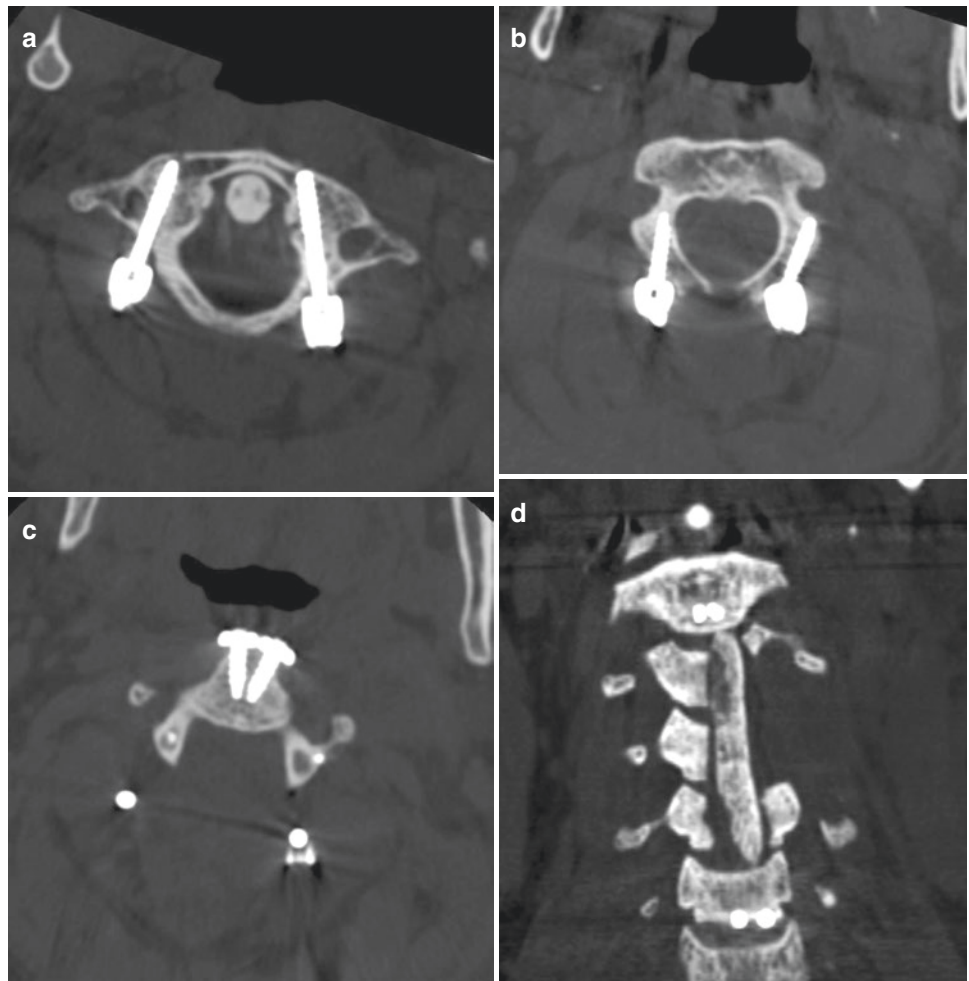
**Fig. 12.49** CT-guided trocar biopsy



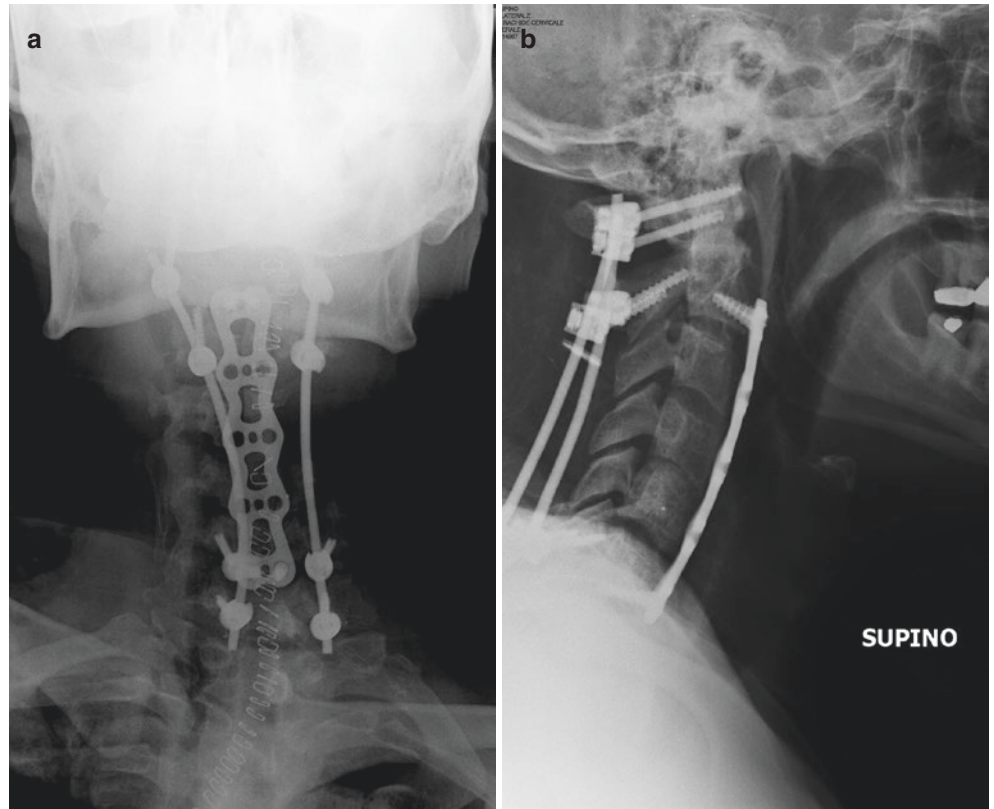
**Fig. 12.50** Intra-operative images



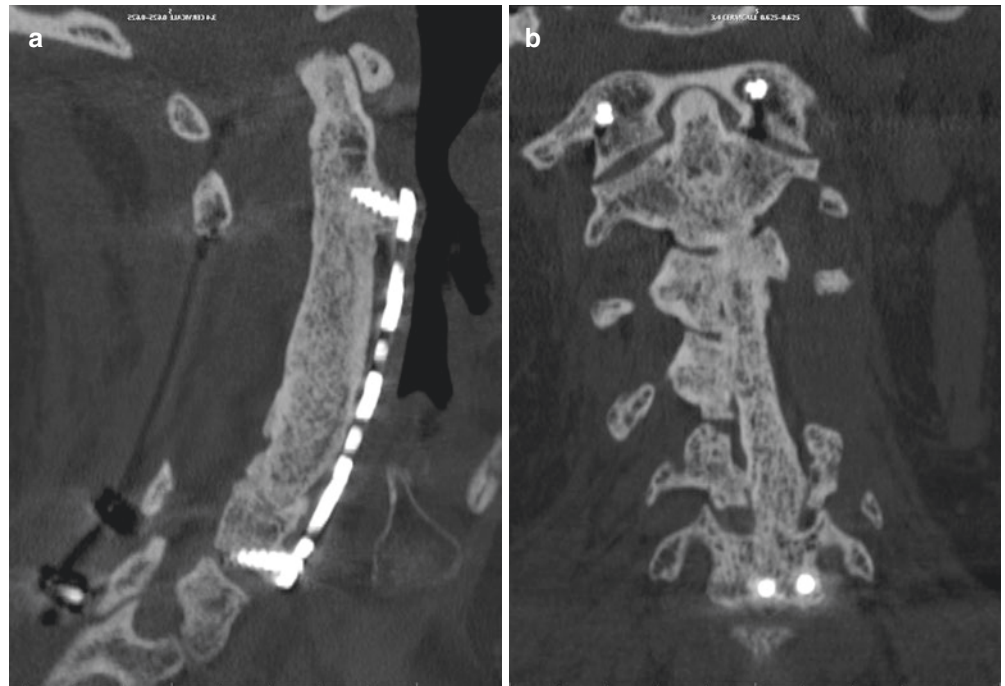**Fig. 12.51** Post-operative CT-scan



**Fig. 12.52** Post-operative plain radiographs.



**Fig. 12.53** 2-years follow-up CT-scan



Gabriele Molteni, Marco Giuseppe Greco,  
and Pierre Guarino

The surgical approach to the cervical spine requires, in addition to a good surgical experience, a thorough anatomical knowledge of the cervical region and skull base. Indeed this region is crossed by many vascular, nervous, respiratory and digestive structures. Surgical techniques have been widely described in the previous chapters. We now focus our attention on the main complications related to this kind of surgery.

In cases of cervical spine surgery for degenerative diseases in the United States, an incidence rate of complications of 3.93 % during the decade 1992–2001 was reported. More in detail, the highest incidence of complications was found in patients with a primary diagnosis of cervical spondylosis with myelopathy (6.5 %) or with a posterior fusion (10.5 %) or combined anterior and posterior fusion (9.02 %).

The number of complications is also reported to be related with a longer length of hospital stay.

In the same decade, the incidence of in-hospital mortality was 0.14 % overall and still closely related to the age of patients: from 0.03 % for patients ages 20–34 years to 1.33 % for patients ages 75 years and older. From the analysis carried out by C. Wang and colleagues, the incidence of complications appears to be significantly higher when using a posterior approach (still in surgery for degenerative diseases). This partially explains the lowest number of complications in the approach described earlier. In literature, there are therefore conflicting data regarding the number of complications encountered in relation to the type of approach [1].

The incidence of complications in cervical spine surgery over the years was not reduced significantly; this is clear in a multicenter study published in 1997 by Zeidman and colleagues conducted on 4589 patients operated on by 35 different surgeons between 1989 and 1993. The rate of complications in elective surgery, regardless of the approach used, was found to be equal to about 5 %. Comparing the number of complications arising during the 5 years, the rate remained fairly steady (65 % of patients had used an anterior approach and the remaining 35 % a posterior approach).

It was also found that the use of steroids in the perioperative period does not modify the complication rate in a negative or positive way; steroids had only partially reduced the length of hospital stay. Death occurred in 0.8 % of cases and occurred mainly in patients undergoing surgery for trauma associated with quadriplegia. Death cases were very rare in elective surgery [2].

Complications in cervical spine surgical approaches can be schematically divided in generic complications (not correlated with surgical approach) and specific complications. Specific complications, which are related to the site and to the type of surgical approach, can be distinguished in intraoperative complications and postoperative ones, which can be in turn further subdivided in short-term complications and long-term complications. As reported in literature, the risk of severe complications is significantly higher in the anterior approach than in the posterior one, and this is related to the anatomical structures encountered. Complications like tracheal-oesophageal injury, graft dislodgement and injury to large neck vessels are more frequent in the anterior approach [3].

As in all surgical operations, complications can be also related to anaesthesiologic procedures: malignant hyperpyrexia (rare occurrence), anaphylactoid reactions to anaesthetic drugs, trauma of the vocal cords with risk of tracheal or laryngeal stenosis (related with the length of the hospital stay) or respiratory failure from glottic oedema or trauma of the endotracheal tube. Among generic complications, those related to bladder catheterization (urethritis, cystitis, pyelonephritis, globe bladder) have to be kept in mind. The inci-

G. Molteni, MD, PhD, FEBORL-HNS (✉)  
Department of Otolaryngology-Head and Neck Surgery,  
Azienda Ospedaliera Universitaria Integrata, University Hospital  
of Verona, Modena, Italy  
e-mail: [gabbomolteni@gmail.com](mailto:gabbomolteni@gmail.com)

M.G. Greco, MD • P. Guarino, MD  
Head and Neck Surgery Department, University Hospital  
of Modena, Modena, Italy

dence rate of postoperative urinary retention (POUR) after cervical spine surgery with anterior approach for degenerative diseases of discs is 11.1 % as described by Jung et al. Other complications are related to venous-arterial catheterization (phlebitis, septic shock), thromboembolic risks and bedsores [4, 5].

Most important complications are certainly those specifically related to the surgical procedure. In this contest we distinguish intraoperative complications from postoperative ones.

---

### 13.1 Intraoperative Complications

Intraoperative complications in soft tissues are more frequently related to anterior surgical approach, and they may occur as lesions of carotid artery, jugular vein, vertebral artery, thoracic duct, pneumothorax, oesophageal and/or tracheal perforation, wound infection and haematoma. It is important to mention intraoperative complications affecting the nervous structures: spinal cord injury and nerve roots, dural fistula (common complications to both approaches), recurrent laryngeal nerve (RLN) palsy and Horner syndrome due to injury to the cervical sympathetic chain (typically related to the anterior approach). Among bone complications for the anterior approach, the most frequent are inadequate positioning of the graft resulting in compression of the spinal canal and improper placement of the screws in the fixation of the plate. For the posterior approach wire pull-out, a fusion of the wrong level and inadequate positioning of plate and screws are the most common.

---

### 13.2 Postoperative Complications

After an anterior approach, the most common complications that may occur are oedema; tracheal, oesophageal, or tracheal-oesophageal fistula; mediastinitis; and dysphonia.

Related to nervous structures, spinal injuries may result in monoparesis or paraparesis, Brown-Sequard syndrome, quadriparesis, central cord syndrome and anterior cord syndrome, dural fistula and meningitis.

Also bone-related complications may arise: pseudoarthrosis, aseptic necrosis and discitis, graft dislodgement into the canal, angulation deformity and fracture of bone graft (rather rare occurrence).

Rear approach can frequently cause non-union, infection, spinal cord and/or nerve root lesions and complications related to instrument failure (such as wire or screw breakage or pull-out).

Also halo-related complications may arise such as dislodgement, infection and penetration [3].

Surgical complications can be classified in many ways; we consider minor complications as those that resolve spon-

taneously within few days and major complications as those that require prolonged hospital stay and/or vigorous treatment according to Zeidman and Ducker.

Minor complications are dysphagia, hoarseness transient sore throat, haematoma and abscess. Major complications include tracheal-oesophageal injury, root injury, recurrent laryngeal nerve injury, spinal cord injury, CSF leak and graft extrusion.

One or more of these complications may be associated with each other. The most common complications are recurrent laryngeal nerve injury (range 0.07–11 %) and dysphagia (2–60). Spanu et al. reported complication rate of ten-year experience: dysphagia (5.6 %), hoarseness (5.6 %), transient sore throat (4.8 %), worsening of pre-existing myelopathy (3 %), graft extrusion in (1.7 %) and root injury, haematoma and wound infection (0.87 %). They describe one case of oesophageal injury (0.43 %) and no deaths related to surgical approach.

Death indeed is very uncommon in elective cases. Almost all cases of deaths reported occurred in trauma with severe neurologic complications and are associated with pulmonary insufficiency.

Hoarseness and temporary dysphagia resulting from oedema of the pharynx, oesophagus and trachea should not be contemplated as complication, but as a condition connected to the surgical management, similar to wound pain after any surgical procedure [2, 6].

---

### 13.3 Dysphagia

It is a common early finding after anterior spine surgery that usually recovers at 6 months after surgery. Incorrect positioning of self-retaining retractor and/or a vigorous retraction of the medial musculovisceral column are the commonest causes of this complaint. Another well-known aetiology of postoperative dysphagia may be caused by the presence of cervical plate. Causes that may not be identified immediately after surgery can be related to local haematoma and/or tissue oedema, superior laryngeal nerve lesion and denervation of pharyngeal plexus [6].

---

### 13.4 Osteophytes-Related Symptoms

Cervical osteophytes formation after multilevel ACDF (anterior cervical discectomy and fusion) or other cervical spine surgical procedures develop in approximately 20–30 % of cases, and most of them are asymptomatic. Sometimes, however, osteophytes may cause a delayed presentation of functional dysphagia and dysphonia through a mass effect on the anterior structures such as the larynx and cervical oesophagus. Persistent cough due to irritation of the vagus nerve by

osteophytes after cervical spine surgery is a very rare but described condition. Surgical untethering can alleviate symptoms [7, 8].

---

### 13.5 Recurrent Laryngeal Nerve Injury

This complication is related to the anterior cervical spine approach. It may occur contemporarily to transient sore throat and dysphagia or as the only complaint. When unilateral it is associated to voice hoarseness. Although controversial, it seems there are no differences between anterior right side and left side approach to the cervical spine in order to avoid RNL injury. The nonrecurrent laryngeal nerve, which arises directly from the main trunk of vagus nerve, is associated on the right side to an aberrant subclavian artery with an incidence of 1%. On the left side, it is very rare and associated with a right-sided aortic arch.

RLN injury is due to a sharp dissection or a direct vigorous retraction, with angled or sharp retractors, along the medial musculovisceral column [6]. It can be permanent or temporary and in the latter it recovers from few days to some month after surgical procedure.

### 13.6 Transient Sore Throat

It is a very common complaint following anterior cervical spine approach that fully disappeared in few days. It may occur alone or associated with RLN injury, dysphagia and graft extrusion [6].

---

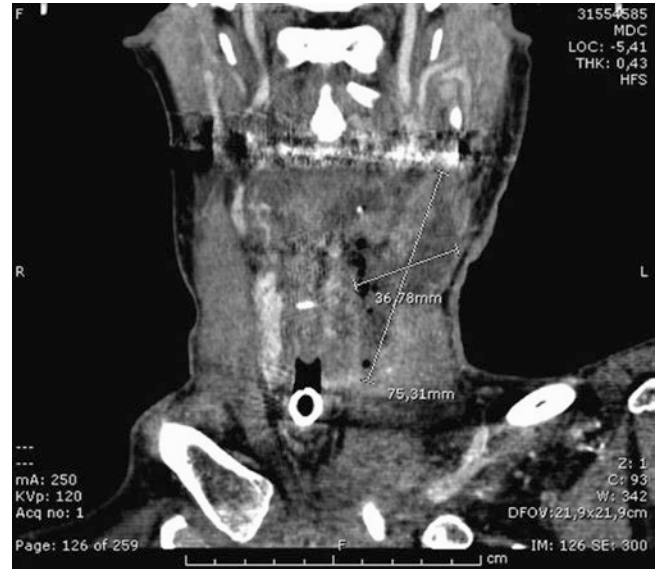### 13.7 Deep Wound Haematoma

It is usually related to a muscular bleeding of the sternocleidomastoid muscle or longus colli muscle within 12–14 h after surgery. In literature the association with dysphagia ranges between 1 and 11%. To reduce haematoma collection is mandatory to identify the medial border of the sternocleidomastoid gently opening the middle cervical fascia and approaching through the avascular plan medial to the SCM and then proceeding with blunt fingertip dissection directly to the spine. Deep wound haematoma recognition generally may be delayed by late onset (it is not palpable and not externally visible). When associated with tracheal obstruction, a rapid evacuation is required and an anterior cervicotomic approach is performed [6].

### 13.8 Wound Infections and Abscess

They are uncommon and range between 0.3 and 3%. Retropharyngeal abscess can also be a delayed complication after anterior spinal surgery. It may be associated with graft

extrusion, screw pull-out and dysphagia. CT scan could be helpful (Fig. 13.1). Immediate drainage and antibiotic coverage usually did not lead to serious consequences. These patients are going to have some degree of retropharyngeal fibrosis with persistent swallowing problems [2, 6].



**Fig. 13.1** Left lateral cervical abscess following anterior approach in cervical spine stabilization

### 13.9 Spinal Cord Damage

Spinal cord injury can be an expression of worsening of pre-existing myelopathy or associated to RLN injury, graft extrusion and hoarseness. It is described in literature as a fat graft migration causing cervical cord compression after dural tear repairs following anterior discectomy [9].

---

### 13.10 Graft Extrusion

Anterior graft extrusion occurs in 2.1 % of cases and can be associated with RLN injury, spinal cord damage retropharyngeal abscess and consequent dysphagia. It may appear if there is no appropriate distraction in the disc space to hold the graft in a correct position. Approaching the disc space to have just the proper amount of body distraction is not always easy. Anterior graft extrusion may be avoided using the correct amount of interbody distraction to place the graft and modelling it to the containing site.

Posterior graft failure occurs in 0.3 % of cases, and it is associated with wire breakage, inferior screw pull-out or fracture of the graft with a fusion failure. This is common in rheumatoid patients [2, 6].

---

### 13.11 Root Lesion (With CSF Fistula)

It may occur after ACD and it can be associated to dysphagia and dysphonia. In these cases, a quick reoperation with CSF fistula repair and a wide-spectrum antibiotic therapy is required [6].

---

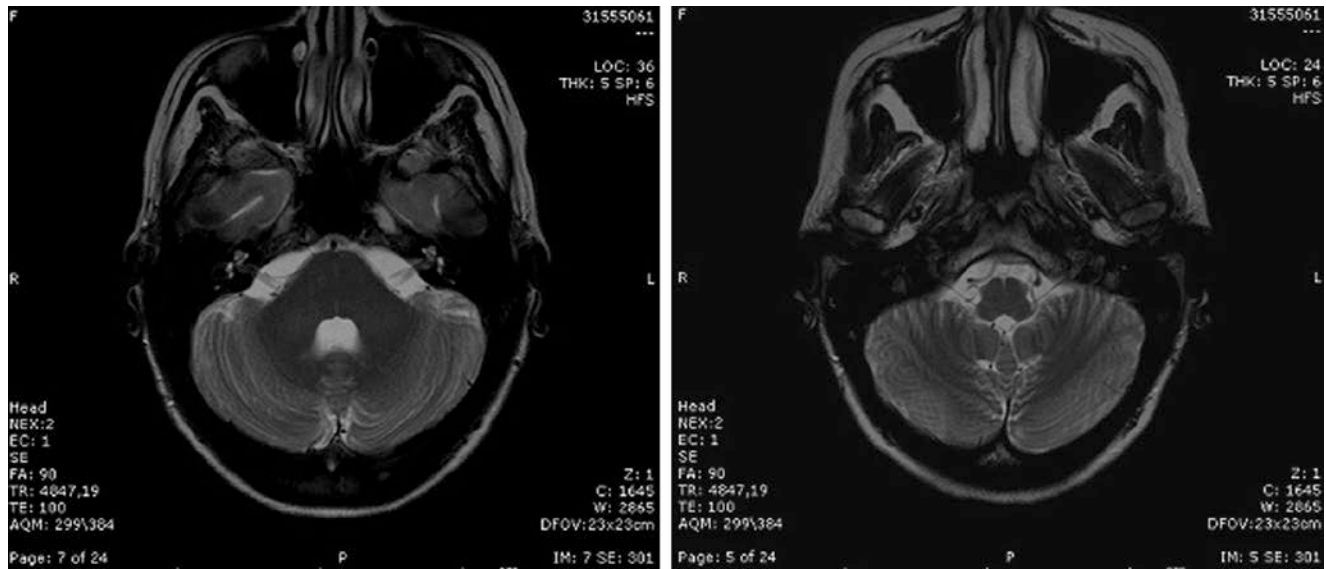
### 13.12 CSF Leaks

They occur in 0.4 % of cases and often after corpectomies associated with ossification of the posterior longitudinal ligament (OPLL) or very severe spondylosis [2]. Fistula repair is generally required.

### 13.13 Meningitis

Meningitis is a rare but potentially life-threatening complication that could happen after cervical spine surgery. A high index of suspicion for meningitis should be maintained in

patients with the clinical triad of fever, neck stiffness and consciousness disturbance after spinal surgery. Intraoperative incidental durotomy is the most important predictor. An early diagnosis, also through the imaging (Fig. 13.2) and appropriate antibiotic treatment, can lead to a good outcome [10].



**Fig. 13.2** Axial T2 MRI showing meningeal phlogosis

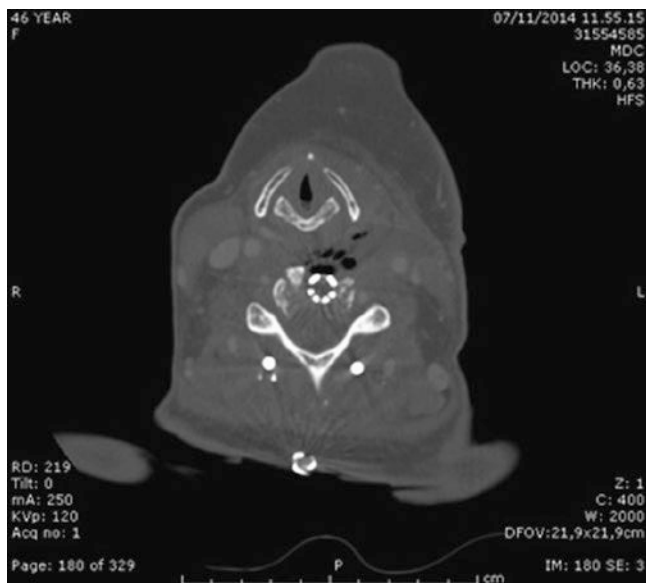

### 13.14 Oesophageal Perforation

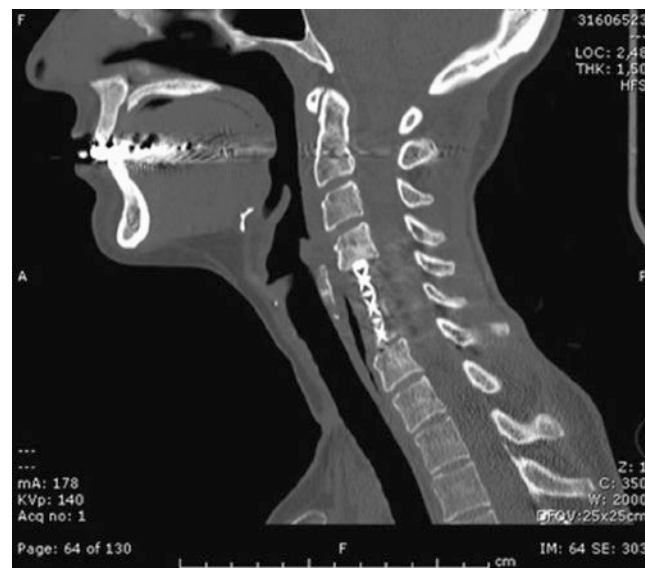
Oesophagus perforation following anterior cervical spine surgery is a rare but potentially life-threatening lesion which can lead to death in 6–34% of cases. Diagnosis is difficult and the treatment often delayed, resulting in cervical abscess, mediastinitis, septic shock and even death. The proper treatment should be surgical repair as soon as possible. Cervical oesophagus perforations are considered to be less critical than the intrathoracic and intra-

abdominal ones due to slow formation of descending mediastinitis, but they may be still fatal in up to 16% of cases.

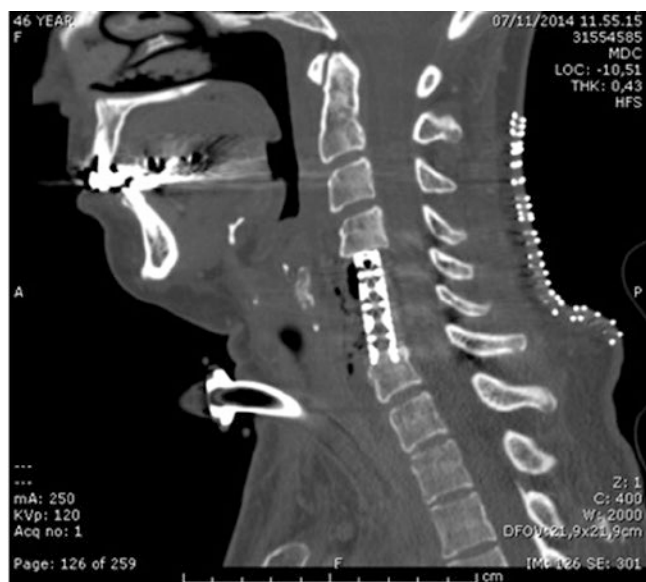It usually reveals within few hours after surgical procedure, but a case of delayed oesophageal perforation after cervical spine plating with a protruding screw is described. When a perforation is suspected (neck pain, dysphagia, odynophagia, fever, cervical emphysema), a CT scan with oral administration of a water-soluble contrast should be employed (Figs. 13.3, 13.4 and 13.5).



**Fig. 13.3** Oesophageal fistula in C5–C6 stabilization with implants (axial CT)



**Fig. 13.5** Oesophageal recanalization after tracheal-oesophageal fistula repair



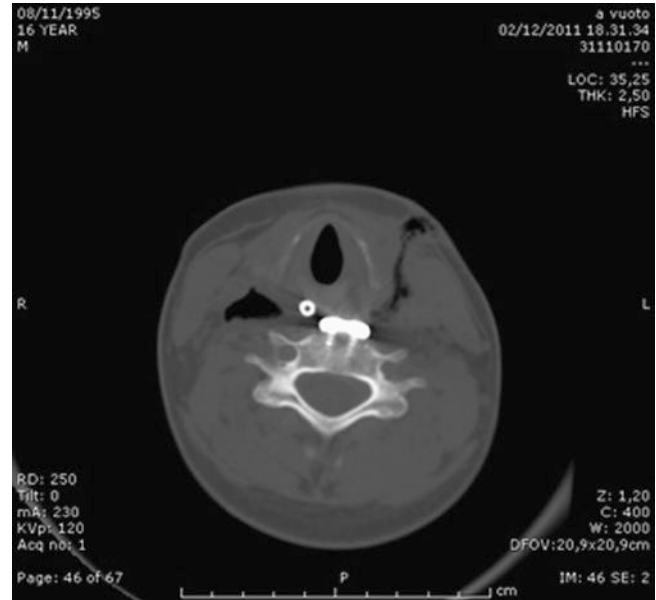
**Fig. 13.4** Anterior paravertebral abscess after cervical spine stabilization (sagittal CT)

### 13.15 Pharyngocutaneous Fistula (PEF)

It is a rare but serious complication of anterolateral approach to the cervical spine with an incidence of 0–1.62%. Proximity to the vertebral column and thin walls makes the upper diges-

tive tract vulnerable to injury in cervical trauma. Clinical presentation and management are very similar to the oesophageal perforation.

A CT scan or MRI is necessary to seek the presence of any concurrent abscesses or vertebral stabilization failures (Fig. 13.6).



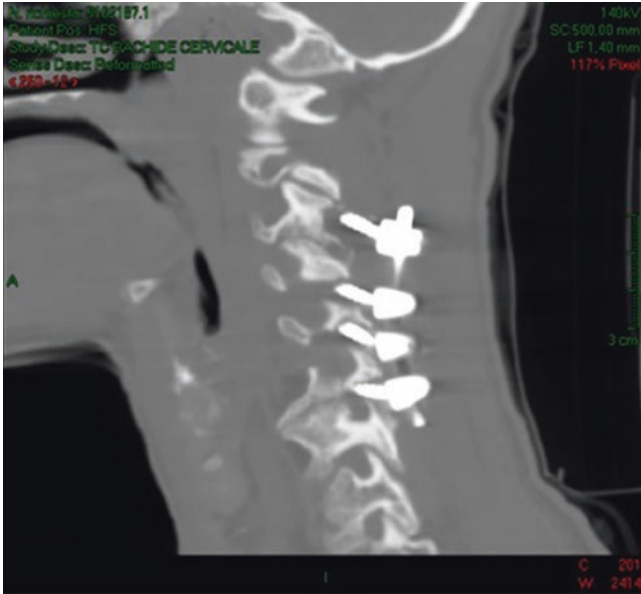
**Fig. 13.6** Axial CT scan: left oesophagocutaneous fistula; concurrent abscessal collections at C6 level; vertebral stabilization

### 13.16 Osteomyelitis

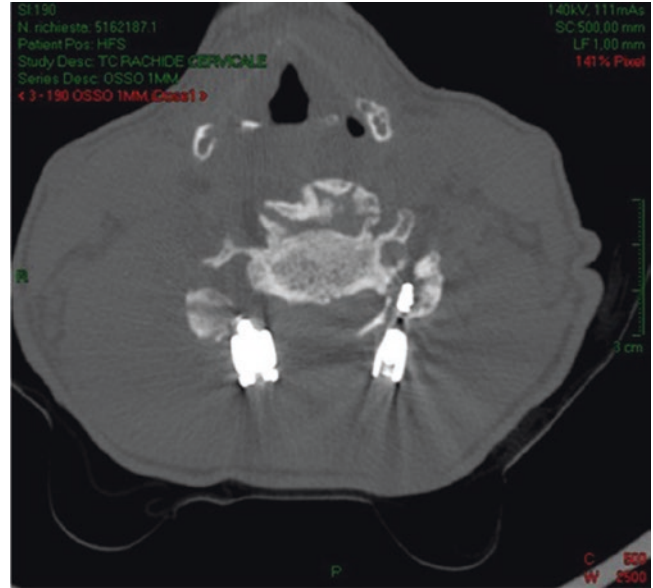Osteomyelitis following cervical spine surgery is a serious complication that can overlap other scenarios like

abscess and oesophageal and/or tracheo-oesophageal fistula [11].

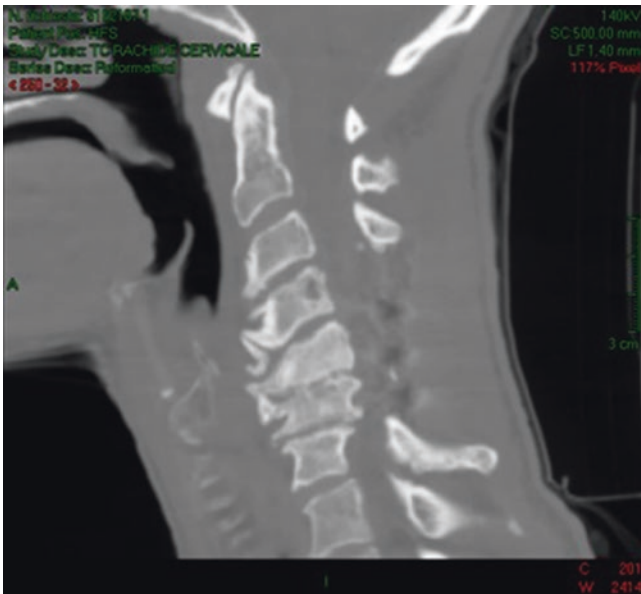CT scan is always needed for diagnosis (Figs. 13.7, 13.8 and 13.9); also bone scintigraphy may be helpful.



**Fig. 13.7** Osteomyelitis with posterior cervical plate dislodgement after post-traumatic fixation



**Fig. 13.9** Osteomyelitis after transpedicular fixation



**Fig. 13.8** Osteomyelitis with bony reabsorption of the spinous process

### 13.17 Complications Treatment

Treatment of complications after anterior cervical spine approach is often surgical, especially for major complications. Treatment options may vary and sometimes surgery is needed for more than one complication in the same patient.

Physical examination and blood test are needed, but imaging plays a key role in the evaluation and mostly in the planning of surgical approach. In case of infections, intravenous broad-spectrum antibiotic therapy is provided, and in case of serious dysphagia and oesophageal fistula, oral feeding is interrupted and nasogastric tube is used for feeding.

In the presence of a pharyngocutaneous fistula, an SCM muscle flap interposition may be performed; sometimes a cricopharyngeal myotomy can be useful in order to reduce intrapharyngeal pressure and prevent fistula recurrence, especially for defects above the upper oesophageal sphincter [12].

In case of intraoperative oesophageal perforation, primary double-layer suture (mucosal layer and muscular layer)

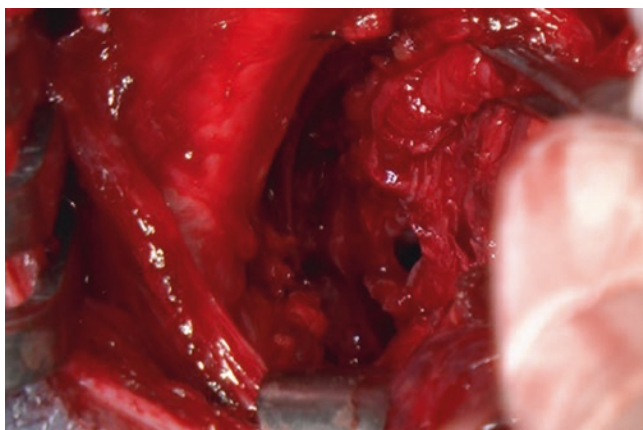
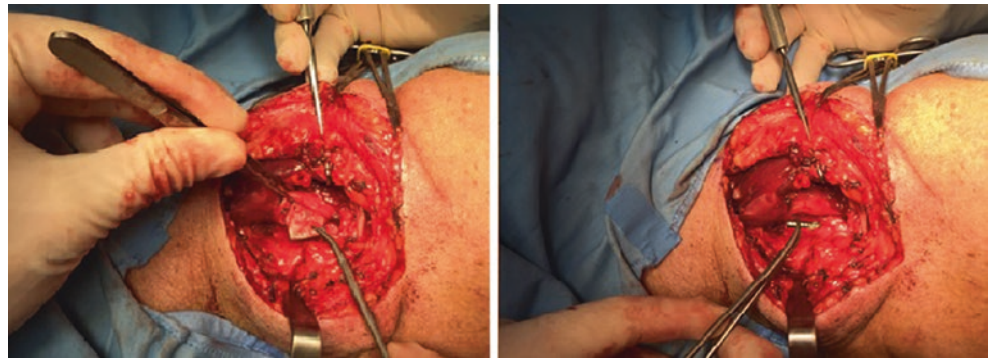
is performed with absorbable stitches in a tension-free way to avoid secondary stricture of the oesophagus.

In case of postoperative perforations, a wound debridement and direct suture of the fistula with/without interposition of a muscular flap are mandatory. When related to early failure of internal fixation, the implant should be removed, and the spine should be maintained by external or internal fixation. Furthermore, free foreign bodies like pull-out screws are removed (Fig. 13.10).

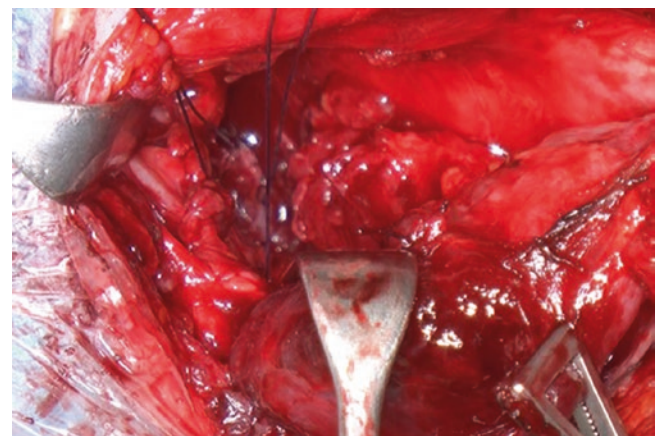
For large perforations, reinforcement of primary suture with a muscle flap repair (SCM muscle flap, pectoralis major muscle flap and longus colli muscle flap) may be helpful [6, 13, 14].

A similar management can be employed in tracheal-oesophageal fistula (Figs. 13.11, 13.12, 13.13 and 13.14) even if in these cases a muscular flap either pedicle or microvascular is required [15]. For large TEFs, especially in patients who underwent previous radiation therapy, radial forearm and anterolateral thigh free flap demonstrated their advantages [16], mostly due to the amount of vascularized tissue transferred.

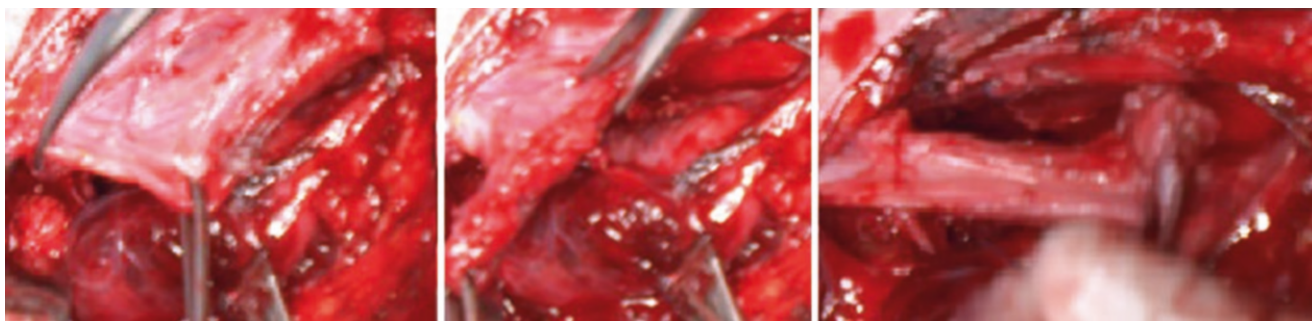**Fig. 13.10** A dislocated screw is removed from the neck



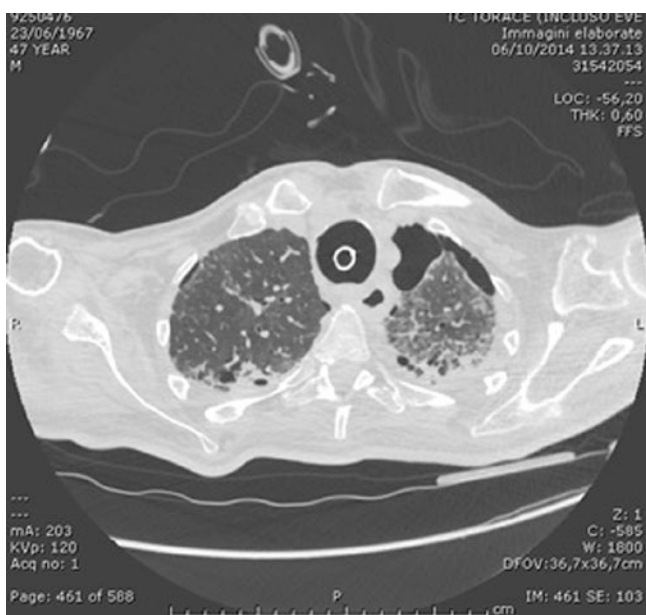
**Fig. 13.11** Tracheal-oesophageal fistula



**Fig. 13.12** Tracheo-oesophageal fistula repaired



**Fig. 13.13** Reinforcement by an SCM flap interposition between oesophagus and trachea



**Fig. 13.14** Postoperative CT scan showing the good outcome of the TEF repair

## References

1. Wang MC, Chan L, Maiman DJ, Kreuter W, Deyo RA (2007) Complications and mortality associated with cervical spine surgery for degenerative disease in the United States. *Spine (Phila Pa 1976)* 32(3):342–347
2. Zeidman SM, Ducker TB, Raycroft J (1997) Trends and complications in cervical spine surgery: 1989–1993. *J Spinal Disord* 10(6):523–526
3. Graham JJ (1989) Complications of cervical spine surgery. A five-year report on a survey of the membership of the Cervical Spine Research Society by the Morbidity and Mortality Committee. *Spine (Phila Pa 1976)* 14(10):1046–1050
4. Rampersaud YR, Moro ER, Neary MA, White K, Lewis SJ, Massicotte EM, Fehlings MG (2006) Intraoperative adverse events and related postoperative complications in spine surgery: implications for enhancing patient safety founded on evidence-based protocols. *Spine (Phila Pa 1976)* 31(13):1503–1510
5. Jung HJ, Park JB, Kong CG, Kim YY, Park J, Kim JB (2013) Postoperative urinary retention following anterior cervical spine surgery for degenerative cervical disc diseases. *Clin Orthop Surg* 5(2):134–137. doi:10.4055/cios.2013.5.2.134, Epub 2013 May 15
6. Spanu G, Marchionni M, Adinolfi D, Knerich R (2005) Complications following anterior cervical spine surgery for disc diseases: an analysis of ten years experience. *Chir Organi Mov* 90(3):229–240
7. Shih P, Simon PE, Pelzer HJ, Liu JC (2010) Osteophyte formation after multilevel anterior cervical discectomy and fusion causing a delayed presentation of functional dysphagia. *Spine J* 10(7):e1–e5. doi:10.1016/j.spinee.2010.04.014, Epub 2010 May 20
8. Orhan KS, Acar S, Ulasan M, Aydoseli A, Güldiken Y (2013) Persistent cough associated with osteophyte formation and vagus nerve impingement following cervical spinal surgery: case report. *JNeurosurgSpine* 19(2):167–169. doi:10.3171/2013.4.SPINE12428, Epub 2013 May 24
9. Kansal R, Nama S, Mahore A, Dange N, Kukreja S (2012) Fat graft migration causing recurrent cervical cord compression. *Turk Neurosurg* 22(4):502–505. doi:10.5137/1019-5149.JTN.3916-10.1
10. Lin TY, Chen WJ, Hsieh MK, Lu ML, Tsai TT, Lai PL, Fu TS, Niu CC, Chen LH (2014) Postoperative meningitis after spinal surgery: a review of 21 cases from 20,178 patients. *BMC Infect Dis* 14:220. doi:10.1186/1471-2334-14-220
11. Zairi F, Tetard MC, Thines L, Assaker R (2012) Management of delayed oesophagus perforation and osteomyelitis after cervical spine surgery: review of the literature. *Br J Neurosurg* 26(2):185–188. doi:10.3109/02688697.2011.609604, Epub 2011 Oct 4
12. Iyooob VA (2013) Postoperative pharyngocutaneous fistula: treated by sternocleidomastoid flap repair and cricopharyngeus myotomy. *Eur Spine J* 22(1):107–112. doi:10.1007/s00586-012-2451-4, Epub 2012 Sept 19
13. Lu X, Guo Q, Ni B (2012) Esophagus perforation complicating anterior cervical spine surgery. *Eur Spine J* 21(1):172–177. doi:10.1007/s00586-011-1982-4, Epub 2011 Aug 27
14. Kim SJ, Ju CI, Kim DM, Kim SW (2013) Delayed esophageal perforation after cervical spine plating. *Korean J Spine* 10(3):174–176. doi:10.14245/kjs.2013.10.3.174, Epub 2013 Sep 30
15. Jaiswal D, Yadav P, Shankhdhar VK, Gujjalanavar RS, Puranik P (2015) Tracheoesophageal puncture site closure with sternocleidomastoid musculocutaneous transposition flap. *Indian J Plast Surg* 48(3):278–282. doi:10.4103/0970-0358.173125
16. Wreesmann VB, Smeele LE, Hilgers FJ, Lohuis PJ (2009) Closure of tracheoesophageal fistula with prefabricated revascularized bilaminar radial forearm free flap. *Head Neck* 31(6):838–842. doi:10.1002/hed.20971