



Malcolm C. Bateson
Ian A.D. Bouchier

Clinical Investigations in Gastroenterology

Third Edition

 Springer

Clinical Investigations in Gastroenterology

Malcolm C. Bateson • Ian A.D. Bouchier

Clinical Investigations in Gastroenterology

Third Edition

 Springer

Malcolm C. Bateson
Bishop Auckland
United Kingdom

Ian A.D. Bouchier
Edinburgh, Midlothian
United Kingdom

ISBN 978-3-319-53785-6 ISBN 978-3-319-53786-3 (eBook)
DOI 10.1007/978-3-319-53786-3

Library of Congress Control Number: 2017939629

© Springer International Publishing AG 1988, 1997, 2017

This work is subject to copyright. All rights are reserved by the Publisher, whether the whole or part of the material is concerned, specifically the rights of translation, reprinting, reuse of illustrations, recitation, broadcasting, reproduction on microfilms or in any other physical way, and transmission or information storage and retrieval, electronic adaptation, computer software, or by similar or dissimilar methodology now known or hereafter developed.

The use of general descriptive names, registered names, trademarks, service marks, etc. in this publication does not imply, even in the absence of a specific statement, that such names are exempt from the relevant protective laws and regulations and therefore free for general use.

The publisher, the authors and the editors are safe to assume that the advice and information in this book are believed to be true and accurate at the date of publication. Neither the publisher nor the authors or the editors give a warranty, express or implied, with respect to the material contained herein or for any errors or omissions that may have been made. The publisher remains neutral with regard to jurisdictional claims in published maps and institutional affiliations.

Printed on acid-free paper

This Springer imprint is published by Springer Nature
The registered company is Springer International Publishing AG
The registered company address is: Gewerbestrasse 11, 6330 Cham, Switzerland

Preface

When Ian Bouchier had the idea of producing a practical guide to tests in the developing speciality of gastroenterology in 1969, it clearly hit on a useful topic. *Clinical Investigation of Gastrointestinal Function* went into a second edition with co-worker Malcolm Bateson in 1981. This became *Clinical Investigations in Gastroenterology* in 1988 (2nd Edition 1997), taking into account new structural, isotope and kinetic tests used in actual practice in Scotland and North East England.

Times have moved on. There is now an emphasis on low-risk non-invasive tests, though many patients will always require endoscopy, intubation and biopsy for adequate assessment.

1. The widespread use of anti-*Helicobacter pylori* therapy in dyspepsia has dramatically changed the prevalence and significance of this organism in peptic ulcers.
2. Multichannel intraluminal impedance (MII) with high resolution manometry (HRM) to locate accurately the lower oesophageal sphincter has joined pH monitoring in the assessment of gastro-oesophageal reflux.
3. Frequent self-diagnosis by patients of gluten and wheat intolerance, and consequent adoption of partial “gluten-free” diets prior to evaluation, is now common and may lead to equivocal results of tests.
4. Conversely, the increasing ethnic minority populations have an appreciable prevalence of alactasia and are often aware of milk intolerance, which is easy to verify if required.
5. Magnetic resonance cholangiopancreatography (MRCP) is now the optimal system for imaging the bile ducts and pancreatic ducts.
6. ERCP is no longer a first-line diagnostic test, but has ceded place to the much safer MRCP and endoscopic endosonography (EUS). ERCP is now generally reserved for patients where therapeutic procedures are planned.
7. Calprotectin assay screening of stool may save some irritable bowel patients unnecessary investigation for inflammatory bowel disease (IBD). Calprotectin measurement is useful to assess activity in asymptomatic Crohn’s disease and in predicting response of IBD to treatment and its risk of relapse.
8. Video colonoscopy and virtual computed tomography (CT) colonoscopy have become frequently used techniques in screening programs in apparently healthy

populations and in surveillance and management of polyps, ulcerative colitis and large bowel cancer.

9. Liver imaging now includes transient elastography, as well as MRI, CT, isotope scanning, ultrasonography (US) and laparoscopy.
10. Non-alcoholic steatohepatitis (NASH) as a cause of liver dysfunction and cirrhosis in the very obese is now well recognised and is an extra incentive to stay slim.
11. Ideas on antibiotic prophylaxis are now quite different and often the reverse of what was previously believed.

The focus is again on those tests which have been useful in modern patient care, with special emphasis on those of which the authors have personal experience. Reference is also made to newer tests used elsewhere and to traditional procedures which have historical significance and may still be needed in less well-equipped regions. Information is provided about some investigations which help understand disease patterns, without necessarily being required for individual patient management.

Special thanks are due to the continuing strong support of the staff of the Gastroenterology Unit at Bishop Auckland General Hospital and the Northern Medical Physics and Engineering Department at the University Hospital of North Durham, especially Clinical Director Alison Mackie and Adrian Davidson. Special Advisors Dr. Manohar Ahluwalia, Consultant Gastroenterologist, Airedale General Hospital, and Professor Matt Rutter, Consultant Gastroenterologist, University Hospital of North Tees, gave invaluable help on current clinical practice.

Bishop Auckland, UK

Malcolm C. Bateson

Contents

1	<i>Helicobacter pylori</i>	1
1.1	Introduction	1
1.2	Epidemiology	1
1.3	Diagnostic Tests	2
1.3.1	Presence of Active Duodenal Ulcer	2
1.3.2	Direct Urease Test	2
1.3.3	Histology	3
1.3.4	Microscopy	3
1.3.5	Culture	3
1.3.6	Serology	4
1.3.7	Urea Breath Testing	5
1.4	Practical Use	5
	Bibliography	5
2	Upper Digestive Endoscopy	7
2.1	Instruments	7
2.2	Procedures	7
2.2.1	Oesophagus	9
2.2.2	Stomach	10
2.2.3	Duodenum	11
2.3	Endosonography (EUS)	12
2.4	Endoscopic Retrograde Cholangiopancreatography (ERCP)	13
2.4.1	Instruments	13
2.4.2	Procedure	13
2.4.3	Indications	14
2.4.4	Relative Contraindications	14
2.4.5	Complications	14
2.5	Disinfection of Endoscopes	14
2.6	Prophylaxis of Infections with Antibiotics	15
2.7	Anticoagulant Therapy	16
	Bibliography	16
3	Intubation	17
3.1	Method	17
3.2	Tubes	18

3.2.1	Oesophagus	19
3.2.2	Stomach	19
3.2.3	Duodenum	19
3.2.4	Intestine	21
3.3	Complications	21
	Bibliography	21
4	Oesophagus	23
4.1	Oesophageal Acid Perfusion Test	23
4.1.1	Method	23
4.1.2	Interpretation	24
4.2	Oesophagoscopy	24
4.3	Histology	24
4.4	Radiology	25
4.5	Manometry	27
4.5.1	Method	28
4.5.2	High Resolution Manometry (HRM).	30
4.5.3	Interpretation	30
4.6	Reflux Studies	31
4.6.1	pH Monitoring	31
4.6.2	Multichannel Intraluminal Electrical Impedance (MII) and Alkaline Reflux	32
	Bibliography	32
5	Stomach	35
5.1	Gastric Emptying	35
5.1.1	Isotope Tests.	35
5.1.2	Radiology	35
5.1.3	Ultrasonography	36
5.1.4	Dye Dilution.	36
5.2	Gastric Acid Secretion (Peak Acid Output, PAO)	36
5.2.1	Interpretation	36
5.3	Basal Acid Output	38
5.3.1	Method	38
5.4	Indications for Gastric Acid Studies	38
5.5	Alternative Techniques.	39
5.5.1	Twenty-Four Hour Gastric Acidity	39
5.5.2	Radiotelemetry	39
5.5.3	Intravenous ^{99m} technetium	39
5.6	Serum Gastrin	39
5.6.1	Interpretation	40
5.6.2	Problems of Interpretation	40
5.7	Serum Pepsinogen	40
5.8	Pepsin	40
5.9	Serum Vitamin B ₁₂	40
5.10	Gastric Antibodies	41
5.10.1	Parietal Cell Antibodies	41
5.10.2	Intrinsic Factor Antibodies	41

5.11 Gastric Cytology	41
5.11.1 Fluorescence Cytology	42
5.11.2 Method	42
5.11.3 Interpretation	42
5.12 Gastric Biopsy	42
5.12.1 Interpretation	42
5.13 Radiology	43
5.13.1 Barium Meal	43
5.13.2 Iodinated Water-Soluble Opaque Media	44
5.13.3 Double-Contrast Radiology	45
Bibliography	45
6 Small Intestine	47
6.1 Intestinal Biopsy	47
6.1.1 Endoscopic Forceps Biopsy	47
6.1.2 Crosby-Kugler Capsule	48
6.1.3 Rubin Suction Biopsy Tube	49
6.1.4 Interpretation	50
6.2 Radiology	53
6.2.1 Barium Contrast	53
6.3 Radio-Isotope Studies (Little Used Nowadays)	55
6.3.1 WBC Scanning	55
6.4 Enteroscopy	55
6.5 Protein Loss	55
6.5.1 Radio-Iodinated Serum Protein	56
6.6 Intestinal Bacteria	57
6.6.1 Intubation	57
6.6.2 Urinary Indican	58
6.6.3 Breath Hydrogen	58
6.6.4 Biopsy	58
6.7 Intestinal Motility	59
6.7.1 Radiology	59
6.7.2 Markers	59
6.7.3 Radiotelemetry and Manometry	60
6.7.4 Breath Hydrogen	60
6.8 Crohn's Disease	60
6.8.1 Barium Radiology	60
6.8.2 Skin Testing with Tuberculin, Dinitrochlorbenzene (DNCB) and the Kveim Test	60
6.8.3 Ultrasonography	61
6.8.4 Capsule Endoscopy	61
6.8.5 Other Tests	61
6.9 Thiopurine Therapy	62
6.10 Metabolic Disorders	62
6.11 Carcinoid Syndrome	62
6.11.1 Screening Test	63
6.11.2 Twenty-Four Hour Urinary Excretion	63

6.11.3 Platelet Serotonin	63
6.12 Pheochromocytoma	63
6.13 Lead Intoxication	64
6.14 Immunology	64
6.14.1 Coeliac Disease	64
6.14.2 Food Allergy and Intolerance	65
6.15 Irritable Bowel Syndrome (IBS)	65
Bibliography	66
7 Absorption	69
7.1 Faecal Fat Excretion	69
7.1.1 Method	69
7.1.2 Interpretation	70
7.1.3 Indications	70
7.2 Macroscopic Appearance	71
7.3 Stool Weight	71
7.4 Prothrombin Time (PR, INR)	71
7.5 Serum Vitamin D	71
7.6 Vitamin A Absorption	71
7.7 Oxalate Loading Test	72
7.8 Breath Tests	72
7.8.1 Procedure	72
7.8.2 Results	72
7.9 Bile Acid Malabsorption	73
7.10 Monosaccharides	73
7.10.1 Xylose Excretion	73
7.10.2 Oral Glucose Tolerance Test	74
7.11 Disaccharides	75
7.11.1 Lactose Tolerance Test	75
7.11.2 Symptomatology	76
7.11.3 Intestinal Disaccharidase Activity	76
7.11.4 Indications	77
7.11.5 Other Tests	77
7.12 Haematinics	77
7.12.1 Vitamin B ₁₂	77
7.12.2 Folic Acid Absorption	77
7.12.3 Iron Absorption	77
7.13 Other Tests for Malabsorption	79
7.14 Rare Disorders of Intestinal Absorption	79
7.14.1 Dibasic Amino Acids	79
7.14.2 Tryptophan	79
7.14.3 Methionine	80
Bibliography	80
8 Colon and Rectum	81
8.1 Rectal Examination	81
8.1.1 Method	81
8.1.2 Interpretation	82

8.2	Proctoscopy (Anoscopy)	82
8.2.1	Method	82
8.2.2	Interpretation	83
8.3	Proctosigmoidoscopy	83
8.3.1	Method for Rigid Proctosigmoidoscopy	83
8.3.2	Method for Flexible Sigmoidoscopy	85
8.3.3	Interpretation	85
8.4	Rectal Biopsy	87
8.4.1	Method (Rigid Instrument)	87
8.4.2	Method (Flexible Instrument)	87
8.4.3	Interpretation	87
8.5	Radiology	89
8.5.1	Plain Abdominal Radiograph.	89
8.5.2	Barium Enema	90
8.5.3	Interpretation	91
8.5.4	CT Scanning.	94
8.5.5	MRI	94
8.5.6	Arteriography.	94
8.5.7	Ultrasonography.	94
8.6	Colonoscopy	94
8.6.1	Instruments.	95
8.6.2	Preparation	95
8.6.3	Alternative Preparation (Golytely).	95
8.6.4	Procedure	96
8.6.5	Interpretation	97
8.6.6	Indications	97
8.6.7	Complications	98
8.6.8	Cleansing of Instruments	98
8.7	Manometry.	98
8.8	Immunology.	99
8.8.1	Inflammatory Bowel Disease.	99
8.8.2	Carcinoembryonic Antigen (CEA)	99
8.8.3	Amoebiasis	100
8.8.4	Hereditary Non-polyposis Colon Cancer (HPNCC)	100
	Bibliography	101
9	Gastrointestinal Bleeding	103
9.1	Occult Blood Tests.	103
9.1.1	Chemical Tests	104
9.1.2	Test for Dietary Iron.	105
9.2	Isotope Tests.	105
9.2.1	^{99m} Tc-Technetium Colloid Test	105
9.2.2	Radio-Labelled Erythrocytes	105
9.2.3	^{99m} Tc-Pertechnetate Scanning	106
9.3	Other Tests	106
9.3.1	Radiology.	106
9.3.2	Endoscopy	106

9.3.3	Enteroscopy	107
9.4	Videocapsule Endocopy (VCE)	107
9.5	Gastrointestinal Bleeding in Liver Disease	108
	Bibliography	108
10	Stool Examination	109
10.1	Macroscopic Appearance	109
10.2	Protozoa and Helminths	110
10.2.1	Enterobiasis (Seatworm, Pinworm or Threadworm, <i>E. vermicularis</i>)	110
10.2.2	Amoebiasis	111
10.3	Bacteria	111
10.4	Viruses	112
	Bibliography	113
11	Pancreas	115
11.1	Ultrasonography	115
11.1.1	Endosonography (EUS)	116
11.1.2	Interpretation	116
11.1.3	Indications	116
11.2	Endoscopic Retrograde Cholangiopancreatography (ERCP)	117
11.2.1	Interpretation	117
11.2.2	Indications	118
11.3	Magnetic Resonance Cholangiopancreatography (MRCP)	118
11.4	Computed Tomography (CT)	118
11.5	Angiography	118
11.5.1	Interpretation	119
11.6	Other Radiology	119
11.6.1	Chest X-Ray	119
11.6.2	Straight Abdominal Radiograph	119
11.6.3	Barium Meal	119
11.7	Laparoscopy (Peritoneoscopy)	120
11.8	Histology and Cytology	120
11.9	Hormonal Tests of Pancreatic Exocrine Function	120
11.9.1	Secretin Test	121
11.9.2	Augmented Secretin Test	123
11.10	Test Meals: The LUNDH Test	123
11.10.1	Method	123
11.10.2	Interpretation	124
11.10.3	Indications	124
11.10.4	Modifications	124
11.11	Tubeless Oral Pancreatic Function Tests	125
11.11.1	Fluorescein Dilaurate Test (Pancreolauryl)	125
11.12	Oral Glucose Tolerance Test	126

11.13	Digestive Enzymes Outside the Gut	126
11.13.1	Serum Amylase	126
11.13.2	Urinary Amylase	127
11.13.3	Amylase in Other Fluids	128
11.13.4	Serum Lipase	128
11.13.5	Serum Trypsin	128
11.14	Other Blood Tests	128
11.14.1	Serum Calcium	128
11.14.2	Serum Bilirubin	129
11.14.3	Serum Alkaline Phosphatase	129
11.14.4	Blood Gases	129
11.15	Stool Examination	129
11.15.1	Macroscopic and Microscopic Examination	129
11.15.2	Steatorrhoea	129
11.15.3	Stool Trypsin and Chymotrypsin	130
11.16	Sweat Electrolytes	130
11.16.1	Pilocarpine Iontophoresis	130
11.16.2	Skin Chloride Assay	131
11.17	Gene Probes	131
11.18	Gut Endocrinology and Endocrine Tumours	132
11.18.1	Insulinoma	133
11.18.2	Gastrinoma (Zollinger-Ellison Syndrome)	134
11.18.3	Glucagonoma	135
11.18.4	Vipoma	135
11.18.5	Obscure Diarrhoea	135
11.19	Pancreatic Cancer Markers	135
	Bibliography	136
12	Liver Biochemistry	139
12.1	Serum Bilirubin	139
12.1.1	Interpretation	140
12.2	Urine Bilirubin	140
12.3	Urine Urobilinogen	141
12.3.1	Method	141
12.3.2	Interpretation	141
12.4	Serum Enzymes	141
12.4.1	Transaminases	142
12.4.2	Alkaline Phosphatase	142
12.4.3	Gamma-Glutamyl Transferase	143
12.4.4	Other Enzymes	143
12.5	Proteins	143
12.5.1	Albumin	143
12.5.2	Globulins	143
12.6	Coagulation Tests	144
12.7	Blood Ammonia	145

12.8	Bile Acids	145
12.9	Lipids	145
12.10	Others	146
12.11	Alcoholic Liver Disease (ALD)	146
12.12	Immunology	147
	12.12.1 Tumour Antigens	147
	12.12.2 Tissue Antibodies	147
12.13	Viral Liver Disease	149
	12.13.1 Liver Biopsy	149
	12.13.2 Hepatitis A	150
	12.13.3 Hepatitis B	150
	12.13.4 Hepatitis C	151
	12.13.5 Hepatitis D (Delta Viral Hepatitis)	152
	12.13.6 Hepatitis E (Epidemic Non-A Non-B Hepatitis)	152
	12.13.7 Prevalence of Viral Hepatitis	152
12.14	Kinetic Tests	152
	12.14.1 Caffeine Clearance	152
	12.14.2 Bromsulphthalein (Sulphobromophthalein, BSP) Retention Test	153
	12.14.3 Indocyanine Green Clearance (ICG)	153
	12.14.4 Ammonia Tolerance Test	154
	12.14.5 Protein Load Test	154
12.15	Electroencephalography	155
12.16	Constitutional Unconjugated Hyperbilirubinaemia (Gilbert's Syndrome)	155
	12.16.1 Reduced Calorie Intake Test	155
12.17	Haemochromatosis	156
	12.17.1 Serum Iron and Iron-Binding Capacity	156
	12.17.2 Iron Excretion	156
	12.17.3 Liver Biopsy	156
	12.17.4 Other Tests	156
12.18	Wilson's Disease	157
	12.18.1 Serum Copper and Caeruloplasmin	157
	12.18.2 Urine Copper	157
	12.18.3 Liver Biopsy	157
	12.18.4 Kayser-Fleischer Rings	157
12.19	Hydatid Disease of the Liver	158
	12.19.1 Intradermal (Casoni) Test	158
	12.19.2 Other Tests	158
12.20	Acute Intermittent Porphyria	158
	12.20.1 Screening Test for Porphobilinogen	158
	12.20.2 Confirmatory Tests	159
	Bibliography	159

13	Liver Biopsy	163
13.1	Percutaneous Liver Biopsy	163
13.1.1	Preparation	163
13.1.2	Procedure	164
13.1.3	Alternative Techniques	166
13.1.4	Aftercare	167
13.1.5	Complications	167
13.1.6	Indications	168
13.1.7	Contra-indications to Percutaneous Biopsy	168
13.2	Interpretation	168
13.2.1	Macroscopic Appearance	168
13.2.2	Histology	168
13.3	Liver Aspiration	171
	Bibliography	172
14	Liver Imaging and Manometry	175
14.1	Ultrasonography	175
14.1.1	Interpretation	175
14.1.2	Jaundice	176
14.1.3	Main Indications	176
14.2	Isotope Scanning	177
14.2.1	Interpretation	177
14.2.2	Indications	178
14.2.3	Liver Perfusion Scintigraphy	178
14.3	Radiology	178
14.3.1	Plain Abdominal Radiograph	178
14.3.2	Barium Studies	178
14.3.3	Computed Tomography	179
14.3.4	Magnetic Resonance Imaging (MRI)	179
14.3.5	Arteriography	180
14.3.6	Elastography (Fibroscan)	180
14.4	Diagnosis of Cholestasis	180
14.5	Portal Manometry and Splenoportography	181
14.6	Manometry	181
14.6.1	Splenic Puncture	181
14.6.2	Hepatic Vein Catherization	182
14.6.3	Intrahepatic Pressure	183
14.7	Portography	183
14.7.1	Splenic Venography (Splenoportography)	183
14.7.2	Transumbilical Portal Venography	184
14.7.3	Transhepatic Portography	184
14.7.4	Hepatic Venography	184
	Bibliography	185

15 Gallbladder and Bile Ducts	187
15.1 Ultrasonography	187
15.2 Magnetic Resonance Cholangiography (MRCP)	189
15.3 Endosonography (EUS)	189
15.4 Plain Radiology	190
15.5 Oral Cholecystography	191
15.5.1 Method	192
15.5.2 Interpretation	192
15.6 Operative Cholangiography	193
15.7 Percutaneous Transhepatic Cholangiography (PTC)	194
15.7.1 Method	194
15.7.2 Interpretation	196
15.7.3 Indications	196
15.8 Infusion Cholangiography	196
15.8.1 Method	197
15.8.2 Interpretation	197
15.9 Computed Tomography	197
15.10 Magnetic Resonance Imaging	197
15.11 Isotope Scanning	198
15.11.1 Gallbladder Scintigraphy	198
15.11.2 WBC Scanning	198
15.12 Biliary Physiology	198
15.12.1 Cholecystokinin	199
15.13 Bacteriology	199
Bibliography	199
16 Ascites and the Peritoneum	203
16.1 Paracentesis	203
16.1.1 Method	203
16.1.2 Complications	204
16.1.3 Interpretation	204
16.1.4 Diagnostic Paracentesis in the Acute Abdomen	205
16.1.5 Chylous Ascites	205
16.2 Peritoneal Biopsy	206
16.2.1 Method	206
16.2.2 Complications	207
16.3 Laparoscopy (Peritoneoscopy)	207
16.3.1 Rigid Laparoscopy	207
16.3.2 Procedure	208
16.3.3 Interpretation	209
16.3.4 Indications	209
16.4 Laparotomy	210
Bibliography	210
Appendix	211
Further Reading	212
Index	213

Abbreviations

AIDS	Acquired immunodeficiency syndrome
ALD	Alcoholic liver disease
ALT	Alanine aminotransferase
AMA	Antimitochondrial antibody
ANA	Antinuclear antibody
AP	Alkaline phosphatase
APC	Argon plasma coagulation (argon beamer)
AST	Aspartate aminotransferase
ATP	Adenosine triphosphate
AIDS	Acquired immunodeficiency syndrome
AZA	Azathioprine
BAO	Basal acid output
BSP	Bromsulphthalein
CA	Carbohydrate antigen
CEA	Carcinoembryonic antigen
CIIP	Chronic intestinal idiopathic pseudo-obstruction
CCK	Cholecystokinin (also pancreozymin)
CDAI	Crohn's disease activity index
CLO	Campylobacter-like organism (now <i>Helicobacter pylori</i>)
CT	Computed tomography
DIC	Diffuse intravascular coagulation
DNA	Deoxyribonucleic acid
DNCB	Dinitrochlorobenzene
DTPA	Diethylene triamine pentacetate
EDTA	Ethylenediaminetetraacetic acid
EEG	Electroencephalogram
ELISA	Enzyme-linked immunosorbent assay
EMA	Endomysial antibody
ERCP	Endoscopic retrograde cholangiopancreatography
ESR	Erythrocyte sedimentation rate
GDP	Gel diffusion precipitation
GI	Gastrointestinal
GIP	Gastric inhibitory peptide
GT	Gamma glutamyl transferase

GTT	Glucose tolerance test
H ⁺	Hydrogen ion
H&E	Haemotoxylin and eosin stain
HbA _{1c}	Glycosylated (glucose-attached) haemoglobin
HB _c Ab	Hepatitis B core antibody
HB _s Ag	Hepatitis B surface antigen
HCl	Hydrochloric acid
HDL	High density lipoprotein
5-HIAA	5-hydroxyindoleacetic acid
HIDA	Radio-labelled (hepatic) iminodiacetic acid
HIV	Human immunodeficiency virus
HLA	Human leukocyte antigen
^{99m} Tc- HMPAO	Manmade radiotechnetium-labelled hexamethyl propylene-amine monoxide
HNPCC	Hereditary non-polyposis colon cancer
HRM	High resolution manometry
HRIM	High resolution manometry and impedance
ICG	Indocyanin green
Ig	Immunoglobulin
IHA	Indirect haemagglutination
IHC	Immunohistocompatibility
IM	Intramuscular
INR	International normalised ratio for blood coagulation
IV	Intravenous
kPa	Kilopascal
LFTs	Liver function tests
LKM 1&2	Liver kidney microsomal antibody
LPX	Lipoprotein X
MALToma	Mucosa-associated lymphoid tumour
MBq	MegaBecquerel unit of radioactivity
MII	Multichannel Intraluminal Impedance
MJ	Megajoule
6-MMP	6- methylmercaptapurine
6-MP	6-mercaptapurine
MRCP	Magnetic resonance cholangiopancreatography
MRI	Magnetic resonance imaging
MSI	Microsatellite instability
NASH	Non-alcoholic steatohepatitis
NBI	Narrow Band Imaging. Use of pure blue and green light at endoscopy to enhance vascular patterns and identify suspicious areas.
NHS	National Health Service; previously British, now English, Scottish, Welsh & Northern Irish
NICE	National Institute for Health and Care Excellence
NSE	Neurone-specific enolase
PAO	Peak acid output

PBC	Primary biliary cirrhosis/Primary biliary cholangitis (two unsatisfactory established names for autoimmune cholangiolitis)
pH	Acidity measured by logarithmic hydrogen ion(H ⁺) concentration
PaO ₂	Arterial oxygen concentration
PDT	Photodynamic laser therapy
PEG	Percutaneous endoscopic gastrostomy
PEG	Polyethylene glycol
PG	Radio-labelled pyridoxylidene glutamate
PP	Pancreatic polypeptide
PPM	Parts per million
PR	Prothrombin ratio(also INR)
PSC	Primary sclerosing cholangitis
PVA	Partial villous atrophy
PVP	Polyvinyl pyrrolidone
RAST	Radioallergosorbent test
RIA	Radioimmunoassay
RIBA	Radioimmunoblot assay
SC	Subcutaneous injection
⁷⁵ SeHCAT	Radioselenium-labelled tauro-homocholeic acid
SMA	Smooth muscle antibody
STVA	Subtotal villous atrophy
TE	Transient elastography
TGN	Thiopurine nucleotide
TMTP	Thiopurine methyltransferase
TVA	Total villous atrophy
UDCA	Ursodeoxycholic acid
US	Ultrasound
VCE	Videocapsule endoscopy
VIP	Vasoactive intestinal peptide
VLDL	Very low density lipoprotein
VMA	Vanillyl mandelic acid
WBC	White blood cells
WDHA	Watery diarrhoea, hypokalaemia and alkalosis in VIPoma
ZE	Zollinger-Ellison syndrome of gastric acid hypersecretion in gastrinoma

1.1 Introduction

The discovery of the presence of this organism in many human stomachs and its association with disease revolutionized our approach to peptic ulcer. Detection of *H. pylori* infection of the gastric mucosa and proof of its absence after eradication therapy have become pivotal in patient management.

1.2 Epidemiology

H. pylori infection is strongly associated with age and cigarette smoking, and inversely with wealth. There appears to be an enhanced risk of infection in childhood and a lower rate in adult life. In British provincial patients in whom gastroscopy is normal, the overall infection rate is 16%, probably reflecting prior anti-microbial therapy in dyspepsia in *H. pylori* positive patients in the twenty first Century. Rates in the past were much higher.

Infection is much more frequent, and occurs earlier in life, in underdeveloped countries: 75% of residents of orphanages in Thailand are infected. Lower social class is associated with higher infection rates, possibly because of overcrowded conditions in childhood or the higher prevalence of cigarette smoking. There is no sex difference.

H. pylori infection is associated with endoscopic duodenal ulcer disease (32%) in patients not taking as aspirin or non-steroidal anti-inflammatory drugs. A similar but weaker association is documented for benign gastric ulcer (28%).

There is no lymphoid tissue in normal stomach, and the presence of this, particularly if it has progressed to a mucosa-associated lymphoid tumour, is strong evidence of *H. pylori* infection.

H. pylori infection is normally global in the stomach, but histological changes are mainly located in the gastric antrum where glandular destruction, polymorph

Table 1.1 Positive direct urease test at endoscopy

	Twentieth century (%)	Twenty-first century (%)
Normal	45	16
Duodenal ulcer	95	32
Gastric ulcer	75	28

and lymphocyte infiltration deeper than the epithelium; intestinal metaplasia; and gastric erosions are all common. Unfortunately the macroscopic recognition of gastritis caused by *H. pylori* infection is completely unreliable and histological proof is always required (Table 1.1).

Infections are chronic and persistent unless effective treatment is given. Important epidemiological evidence exists to link *H. pylori* with the aetiology of gastric carcinoma and ischaemic heart disease, but these observations are not of significance to individual patients.

There is debate about whether all *H. pylori* infections develop in early life and thereafter persist, or whether there is an appreciable incidence of new infections up to the age of 70. It is known that after successful eradication re-infection is uncommon, occurring at a rate of approximately 1% per year.

1.3 Diagnostic Tests

1.3.1 Presence of Active Duodenal Ulcer

In patients who can be proved to have current active duodenal ulcer disease, and who are not taking ulcerogenic drugs, it may be assumed that *H. pylori* is more likely to be present. Benign gastric ulcer, antral gastritis and gastric mucosa-associated lymphoid tumour (MALToma) are also linked with *H. pylori*, but it is necessary to seek supporting evidence of active infection.

1.3.2 Direct Urease Test

At the time of gastroscopy a biopsy can be taken and examined for urease activity. *H. pylori* is almost unique among gastric pathogens in its possession of a very potent urease: demonstration of urease activity in a gastric antral biopsy is one of the best indicators of current infection.

Commercially available slides containing urea gel and an indicator are available, (CLOtest & HpFast). The antral biopsy is embedded in the gel and the end point is indicator colour change to magenta, showing that pH has risen with the generation of ammonia. Most positive results become available within minutes, but 5–10% of true-positive results only become available in hours and it is best to read slides the next morning before discarding them. Although intrinsically very sensitive, this test may give false-negative results if patients have recently been

taking antibiotics, proton pump inhibitors or bismuth. In addition, specific anti-*H pylori* therapy may cause differential clearing of the organism from the gastric antrum, and in treated patients a biopsy should be taken from the fundus or body of the stomach as well as the gastric antrum, though they may be tested on the same slide.

A cheap alternative to this system is the use of home-made urea solution. 0.5 ml of 10% (wt/vol) aqueous urea solution is placed in an Eppendorf centrifuge tube with a drop of phenol red and no buffer. Gastric antral biopsies are immersed in the solution. The earliest colour change is a vivid pink halo around the biopsy, though this eventually colours the whole cell red. Urea solution testing was originally hoped to be more rapid than urea gel testing but this is definitely not the case and tests need to be read the following day to avoid missing some positives.

Test solutions may be stored for a couple of days in a refrigerator, but are best discarded after this and a fresh batch made.

1.3.3 Histology

Gastric antral biopsies may be fixed in the usual way and examined under the microscope for spiral Gram-negative organism with bulb-ended flagella. There are theoretical reasons why Warthin-Starry silver staining may be optimal, but this is expensive and slow, and most laboratories use a modified Giemsa technique which will probably yield comparable results. It is more controversial whether standard haematoxylin and eosin staining is as reliable, and it is best to use additional Giemsa staining. There will also be evidence of chronic gastritis when *H pylori* infection is present. The Genta triple stain (Giemsa, H&E and Alcian blue) aims to offer the most complete assessment, detecting the presence of *H pylori*, chronic gastritis and intestinal metaplasia very effectively.

1.3.4 Microscopy

A smear can be made of a gastric antral biopsy on a microscope slide and immediate Gram staining performed. While not as useful as other techniques, this can be helpful in screening for positive cases prior to attempting culture and microbiological sensitivity testing.

1.3.5 Culture

H. pylori is a fastidious organism. Demonstration of growth requires patience and even under optimal conditions up to 100% of cultures may fail altogether.

Gastric antral biopsies are taken and either immediately immersed in transport medium and sent to the laboratory, or plated at once. Culture is conducted

for up to 7 days on agar enriched with lyophilized horse blood in an atmosphere of reduced oxygen and 10% CO₂. Antimicrobials including a cephalosporin, vancomycin, amphotericin, and trimethoprim are normally added to cultures to suppress growth of other organisms, but even so fungal overgrowth is sometimes observed. Cultures should be established in parallel with a control culture of known viable *H. pylori* to ensure that technical failures are not dismissed as true negatives.

Antimicrobial sensitivity testing can only be assessed after successful microbiological culture. It is possible to use qualitative discs impregnated with antibiotics. However, a quantitative technique for assessing different minimum inhibitory concentrations may be more useful. This is the E-test.

H. pylori should always be sensitive in the laboratory to amoxicillin and tetracycline. In provincial Britain about 20% of cultures demonstrate some apparent resistance to nitro-imidazoles such as metronidazole and tinidazole. This figure is higher in cities, ethnic minority groups, and where nitro-imidazoles are freely used. Most of the detected laboratory resistance to this class of drugs is apparent rather than real, because of the different conditions required for *H. pylori* culture (micro-aerophilic) and antimicrobial testing (anaerobic), and they are widely used and effective in management. In addition 2–5% of *H. pylori* cultures show resistance to clarithromycin.

1.3.6 Serology

Patients who are infected with *H. pylori*, or who have been in the fairly recent past, regularly carry an IgG antibody as a marker. This can be conveniently detected using a double-antibody ELISA. Commercial kits are available, but comparable results can be obtained using home-made polyvalent antigen, e.g. by sonicating *H. pylori* cultures.

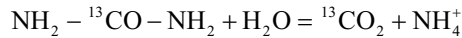
The antigen is coated on the walls of test cells in which the serum to be analysed is incubated. The serum is then removed and replaced by an antibody to human immunoglobulin chemically linked to an enzyme which can be readily detected.

This is a very useful epidemiological tool for population surveys, but there are difficulties when it is used in individual patients. IgG antibody may persist for at least 6–12 months after eradication of *H. pylori*, and the change may be one of titre, rather than positive results becoming absolutely negative.

To avoid the need for sending serum to a laboratory alternative techniques are available. Near-patient testing of whole blood samples obtained by finger pricks can be used, but results do not yield comparable sensitivity to formal laboratory serology. Antibody to *H. pylori* is also present in saliva, but the reliability of this test is even lower than that of whole blood testing, and it cannot be recommended at present. A stool antigen has also been described, but may be of more use in research than individual management

1.3.7 Urea Breath Testing

The urease activity of the total load of *H. pylori* in the stomach can be assessed by giving labelled ^{13}C urea by mouth and then measuring excretion of $^{13}\text{CO}_2$ in the breath.



Oral urea plus water with urease = breath carbon dioxide, plus ammonium

This requires a mass spectrometer. Prescribable commercial services are available via post (Pylobactell & INFAI) to overcome the difficulty of availability, and all that is required are duplicate samples of exhaled breath obtained 30 min after ingestion of the test dose. In infected cases there is significant excretion of $^{13}\text{CO}_2$ as a proportion of total CO_2 .

1.4 Practical Use

For patients attending for gastroscopy, gastric biopsy and urease testing are a convenient, cheap and rapid way of assessing the presence of *H. pylori*. Where eradication of *H. pylori* needs to be checked after treatment and gastroscopy is not required, the urea breath test comes into its own. It is very important to wait at least a month after all proton pump inhibitors, antibiotic and bismuth therapy has been completed, or else false-negative results may be obtained because of suppression rather than eradication of the organism.

Culture is important to test local antibiotic sensitivity patterns, but may not be important for individual patients.

In the management of dyspepsia, patients over 45 years, and those with alarm symptoms such as weight loss, dysphagia or anaemia should proceed to early endoscopy.

Other patients can be tested for *H. pylori* and treated with vigorous antibiotic therapy if positive, or anti-acid treatment if negative.

If symptoms persist or recur the authors have a low threshold for endoscopy.

Bibliography

- Bateson MC. Cigarette smoking and *Helicobacter pylori* infection. *Postgrad Med J*. 1993;69:41–4.
- Bateson MC. *Helicobacter pylori* infection in age. *Lancet*. 1992;339:1121.
- Bateson MC, Baborie A, Bakir A, Barnes S, Winn S. "One minute" urease testing for *Helicobacter pylori*-a case of premature evaluation? *Gut*. 1995;37:A30.
- Bateson MC, Winn G, Ahmad F. Sensitivity of *Helicobacter pylori* to metronidazole. *Eur J Cancer Prev*. 1997;6:300–2.
- Cutler AF, Havstad S, CK MA, Blaser MJ, Perez-Perez GI, Schubert IT. Accuracy of invasive and non-invasive tests to diagnose *H pylori* infection. *Gastroenterology*. 1995;109:136–41.

- Logan RPH, Dill S, Bauer FE, et al. The European I3C-urea breath test for the detection of *Helicobacter pylori*. *Eur J Gastroenterol Hepatol*. 1991;3:915–21.
- Marshall BJ, Plankey MW, Hoffman SR, et al. A 20-minute breath test for *Helicobacter pylori*. *Am J Gastroenterol*. 1991;86:438–44.
- Molyneux AJ, Harris MD. *Helicobacter pylori* in gastric biopsies – should you trust the pathology report? *J Roy Coll Phys*. 1993;27:119–20.
- Taha AS, Reid J, Boothmann P, et al. Serological diagnosis of *H pylori* – evaluation of 4 tests. *Gut*. 1993;34:461–5.
- Thillainayagam AV, Arvind AS, Cook RS, Harrison IG, Tabaqchali S, Farthing MJG. Diagnostic efficiency of an ultra-rapid endoscopy room test for *Helicobacter pylori*. *Gut*. 1991;32:467–9.

The exact diagnosis of patients with haematemesis, dyspepsia and other upper abdominal symptoms cannot be made on the history alone. Diseases may simulate each other and different disorders can affect the same patient. Video endoscopy with photography, biopsy and cytology plays a major role in evaluation and management. The technique is safe with a few contraindications, but training and experience are required to yield good results.

2.1 Instruments

A wide range of instruments is available from different manufacturers. For a panendoscopy a forward or oblique-viewing instrument is necessary. Some have a very large biopsy channel which allows particularly satisfactory histology material to be obtained. A modern standard instrument for routine use has an external diameter of about 11.5 mm and a biopsy channel of 3.5 mm. For a full view of the lesser curve of the stomach, the duodenal bulb and the ampulla of Vater, a side-viewing instrument is sometimes necessary. This is the instrument usually employed for retrograde cholangiopancreatography. Specially designed impedance catheters are in development to assist targeted assessment of mucosal disease.

Videoendoscopy systems display the image on screens so that assistants may watch. Videoendoscopy has a crucial role in training and education. The other great advantage of video equipment is improved posture for the operator compared with the earlier fiberoptic technique, though diagnostic yields are identical (Fig. 2.1).

2.2 Procedures

To achieve good results the patient must be convinced of the value of the procedure. It should be explained that they will probably be awake (but drowsy) throughout and that with sedation he may have no recollection of the procedure. It is best to provide an information sheet before the day of the procedure, and to obtain signed consent then.

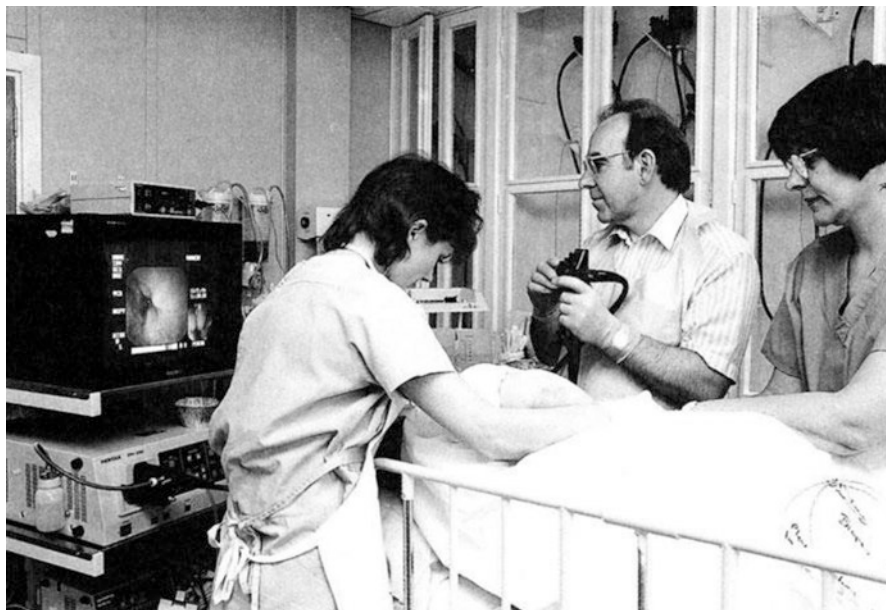

Fig. 2.1 Video gastroscopy in progress 1996 with author

It is usual to monitor the patient with pulse oximetry by finger clip, and to provide continuous oxygen by nasal catheter throughout the procedure. It is best to have two nursing assistants, one for patient care and one for instrument care. It is desirable to keep room lights on to monitor patient condition.

The stomach must be empty and this is achieved usually by fasting overnight, or for at least 4 h. If the patient has undergone gastric suction for vomiting or if it is necessary to use some form of gastric intubation when brisk haematemesis or gastric outflow obstruction is present it should be remembered that appearances of oesophageal, gastric lesser curve and antral erosions may be produced artefactually

False teeth should be removed. There is considerable variation in the techniques for preparation. If sedation is required a satisfactory one is to give midazolam 2.5–5 mg intravenously, usually by cannula, immediately before the examination, with the patient positioned on the left side. Smaller doses of midazolam (or none at all) may be required in patients with liver decompensation or respiratory failure. Repeat doses may be required in younger patients. It is rarely useful to exceed 5 mg midazolam and paradoxical hyperactivity can occur. The effect of benzodiazepine sedation can be rapidly reversed if necessary by IV administration of flumazenil 0.5 mg. Doxapram 100 mg IV is less specific but can be useful if excessive respiratory depression occurs.

In patients who prefer not to be sedated a lignocaine throat spray can be useful: it is safest not to use both sedation and throat spray.

A plastic gag with a central aperture to admit the endoscope is necessary to prevent the instrument being bitten. The endoscope is lubricated with water or clear

jelly, and the light and suction equipment is tested before passage. The patient's head is flexed and the instrument tip is passed over the tongue to the oropharynx while an assistant holds the end with the controls. The patient is then asked to give a couple of swallows to assist passage into the oesophagus. If the patient does not comply the instrument may impact in the pharynx or enter the trachea. In either case the patient may choke and splutter, develop wheezing or coughing, and become cyanosed. If this happens the instrument should be withdrawn and a further attempt at passage made. If the trachea is entered the rough feel of the cartilages is experienced, and the branching pattern of the trachea is identified under direct vision. Guidance of the tip with a finger in the patient's mouth can be helpful. In practice the oesophagus can usually be entered without difficulty.

2.2.1 Oesophagus (Fig. 2.2)

A good view of the oesophagus can be obtained on entry, but only usually over its lower two-thirds. Air insufflation assists vision but should be used sparingly. The presence of macroscopic oesophagitis, Mallory-Weiss tears, stricture or carcinoma can be detected readily. Mallory-Weiss tears are linear white ulcerated areas with surrounding erythema related to the level of the diaphragm. They are produced by the effort of retching or vomiting and usually occur at the gastro-oesophageal junction; in patients with hiatus hernia however, they are found in the cardia of the stomach. Oesophagitis is usually caused by retrograde reflux and extends proximally from the gastro-oesophageal junction. Mild oesophagitis is recognized by erythema,

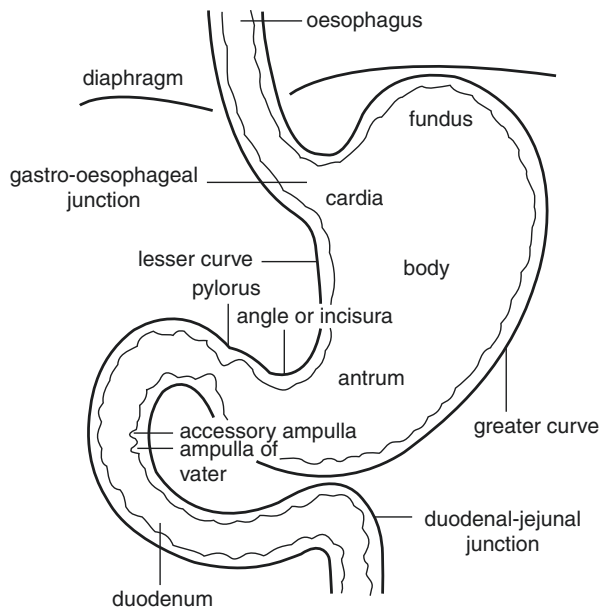


Fig. 2.2 The upper gastrointestinal tract

loss of surface glistening, vascular injection and friability. More severe changes lead to erosions, plaque formation and spontaneous bleeding. Discrete ulcers and benign strictures also occur, and in chronic oesophagitis the junction of the squamous and columnar epithelium can migrate proximally (Barrett's oesophagus).

Forceps passed down the biopsy channel of the instrument can obtain multiple 2–3 mm samples which can be studied histologically to provide proof of diagnosis. Unless there is obvious tumour or Barrett's oesophagus, it is best to take samples at least 5 cm above the gastro-oesophageal junction (usually above the level of the diaphragm and lower oesophageal sphincter), since distal changes are common in healthy individuals. Samples are immediately immersed in formol saline. Cytology brushes can also be passed in the same way using a plastic catheter to protect the sample on withdrawal before immersing in fixative. It is recommended that four biopsies and cytology brushings should be taken. If all are negative for carcinoma then this diagnosis is very unlikely in the oesophagus, though this is less certain for the stomach.

Occasionally a tight stricture cannot be passed: undue force must not be used. Gentle persuasion may pass the instrument through lesser strictures and give symptomatic relief. It may be possible to identify a hiatus hernia, though this is not always reliable.

The upper oesophagus and some of the pharynx can usually be seen with the narrow calibre instruments on withdrawal. Rigid oesophagoscopy by an ENT surgeon may be necessary if the post-cricoid region is under suspicion.

2.2.2 Stomach

On passing over the normal gastro-oesophageal junction there is a change from pale pink mucosa to the orange-red mucosa of the stomach. This does not always correlate with histological change in the epithelium. The appearance of stomach mucosa is different from that of the high pressure zone of the lower oesophageal sphincter, and normally lies below the level of the diaphragm, if this can be detected.

The greater curve and the antrum are easily viewed, with air insufflation if necessary, but the rest of the stomach is more difficult to examine adequately. The greater curve is recognized by its rippling longitudinal folds; the antrum is smooth. The cardia can be seen well only by putting a J-bend on the end of the instrument when it reaches the pylorus and looking back towards the oesophagus. A partial view of the lesser curve is obtained as the instrument slides over it, but again a reverse loop may be necessary to view it completely. A sharp angle or incisura may hide a small distal lesion. There is often a pool of gastric juice on the greater curve: this may be aspirated, though care is needed to avoid damaging the mucosa. The pool can be moved by altering the patient's position slightly, or even lying them supine temporarily, allowing a full view to be obtained.

Gastritis is often distal and is recognized by loss of surface glistening, granularity, vascular injection and friability. There may be haemorrhage or superficial erosions.

Some gastritis is usual after gastric surgery, in which pyloric reflux is increased, and its significance is doubtful. Transient erythema caused by retching is also of no significance. In atrophic gastritis the stomach appears exceptionally smooth and is often pale. The *autoimmune gastritis* which causes pernicious anaemia is associated with a characteristic undulating knobbly appearance. The correlation between macroscopic gastritis and histology is poor. Ulcers are easily recognized: biopsies should ideally be taken from the four quarters of the rim and from the base unless there has been recent bleeding.

Carcinoma of the stomach can appear either as a malignant ulcer, sometimes with rolled undermined edges; or a polypoid lesion; or endoscopic appearances may be normal. However, a small immobile stomach in which air is poorly retained should alert suspicion, and a mucosal biopsy may give a tissue diagnosis.

A negative biopsy report never completely excludes a carcinoma, and if there is a clinical suspicion of malignancy then partial or total gastrectomy with excision biopsy should be considered in patients with ulcer disease.

The pylorus opens and closes during the examination. With a forward-viewing instrument it is usually easy to advance to the pylorus and wait for it to relax and allow entry. In a stomach which is excessively mobile or an unusual shape the pylorus may be difficult to identify. It is best to withdraw the instrument further back into the body of the stomach and re-orientate before proceeding. Free reflux of bile-stained fluid may be seen through the pylorus, especially after cholecystectomy. This has no pathological significance but may foam and obscure the mucosa if air insufflation is used.

The pylorus is usually short, and of varying configuration as the peristaltic waves pass over. *Ulcers* can occur within the pyloric canal and in the immediate pre- and post-pyloric regions, so that careful inspection in all stages of constriction and relaxation is rewarding. Occasionally the pylorus is so tightly closed that the instrument cannot be passed further. If this is the case an injection of metoclopramide 10 mg intravenously relaxes muscle spasm. It also markedly increases duodenal mobility, making administration of glycopyrronium 0.2 mg, hyoscine 40 mg or glucagon 1.0 mg IV necessary to enable the duodenum to be viewed.

2.2.3 Duodenum

Duodenal ulcers typically occur in the duodenal bulb, and are often visible from the stomach before the pylorus is entered. Thus inspection before entering is useful. The duodenal folds are circumferential and the mucosa is usually paler than the stomach. While the duodenal bulb can be viewed adequately, the rest of the loop is often not seen well as the instrument is advanced, and a better view is obtained during withdrawal. The ampulla of Vater may be identifiable and can be located by the jets of bile which emerge from time to time. Duodenitis, with erythema, oedema and friability, may occur with or without ulcers. It can be patchy, making careful examination necessary. Biopsy confirms doubtful appearances.

The area immediately distal to the pylorus is difficult to view properly with a forward-viewing instrument. An oblique-viewing instrument is often satisfactory but a side-viewing one is best. Forceps biopsy of the distal duodenum is useful to evaluate the villous atrophy of coeliac disease.

2.2.3.1 Indications

1. Investigation of dyspepsia, dysphagia, abdominal pain, and of iron deficiency anaemia.
2. Diagnosis of haematemesis and melaena.
3. Obtaining tissue samples for histology and cytology, especially in gastric ulcer and to exclude eosinophilic oesophagitis in dysphagia; for microbiology in monilial oesophagitis; and in coeliac disease.
4. Assessment of healing of gastric disease following medical treatment.
5. Investigation of dyspepsia after gastric surgery.
6. Evaluation of doubtful or negative barium meal appearances.
7. Positioning of diagnostic tubes by direct vision.
8. Therapy
 - (a) Injection and ligation of oesophageal varices.
 - (b) Dilation of oesophageal strictures.
 - (c) Positioning of plastic and expanding metal stents.
 - (d) Injection and heater probe treatment of bleeding ulcers.
 - (e) Argon beam and laser therapy, especially of oesophageal carcinoma.
 - (f) Positioning of nasogastric and percutaneous feeding tubes.
 - (g) Treatment of Barrett's mucosa with radiofrequency ablation, argon beam or submucosal resection: this is a controversial area.

2.3 Endosonography (EUS)

It is possible to introduce ultrasound probes with modified upper digestive endoscopy equipment. This technique is difficult and not yet widely available. It appears to be especially valuable in three areas:

1. Staging of oesophageal carcinoma, for which it provides results superior to those obtained with computed tomography (CT) or magnetic resonance imaging (MRI), and may assist in planning management. Strictures need to be passable for this technique to be effective.
2. Investigation of suspected pancreatic carcinoma is improved by local EUS scanning with probes in the duodenal loop. It is possible to obtain tissue samples with a fine needle to improve the definite diagnosis rate. This is particularly valuable if it allows avoidance of prolonged investigation and major surgery in what is usually an incurable problem.
3. Endoscopic ultrasound is at least as effective as ERCP in identifying common bile duct stones.

2.4 Endoscopic Retrograde Cholangiopancreatography (ERCP)

2.4.1 Instruments

Side-viewing duodenoscopes are usually used, though for difficult procedures such as those in patients who have undergone partial gastrectomy, forward or oblique viewing instruments may be more effective. An image intensifier and facilities for taking radiographs are both required. Standard atraumatic catheters are suitable, though tapered tip catheters may be necessary for some procedures. Radiology is performed using 50–70% water-soluble non-ionic iodine contrast medium.

2.4.2 Procedure

Patients should have an IV cannula positioned in the right arm. If obstructive jaundice is present, a mannitol infusion should be given shortly before the procedure to prevent renal failure, and a urinary catheter should be positioned. Administration of gentamicin 80 g IV is standard prophylaxis to prevent cholangitis: this can be given an hour before or with the procedure.

Patients are positioned on the X-ray table in a semi-prone position with the left arm drawn behind the left side of the body. The position and the ERCP procedure itself are uncomfortable, and sedation with midazolam 2.5–5 mg and pethidine 25–50 mg IV assists with cooperation. It is usual to give supplemental oxygen with oximetry throughout the procedure. When the stomach is reached the duodenoscope is advanced with a slight curve on the end to identify the pylorus. The instrument is then straightened to enter the pylorus in the ‘sunset’ position: when the duodenum is entered the instrument is straightened and rotated giving a view of the ampulla. The patient is positioned fully prone and IV hyoscine 20 mg or glucagon 1 mg given to assist cannulation by suppressing peristalsis.

The catheter tip is advanced into the ampulla and contrast is injected with fluoroscopic screening to fill the ducts. Withdrawal and re-cannulation will usually be required to outline both pancreatic and bile ducts. Overfilling should be avoided as it may give confusing radiographic appearances and make pancreatitis more likely. Tilting the patient’s head down will often persuade the contrast to flow into the hepatic ducts if this does not happen in the horizontal position. An accessory ampulla may be seen, but it is not routinely cannulated unless there are special indications.

When good views have been obtained radiographs are made. It is often useful to take a further film after the duodenoscope has been removed, as this may obscure part of the duct systems. A success rate of 90% for ERCP should be achieved with experience.

Rectal indomethacin 100 mg or diclofenac 100 mg is useful after the procedure to reduce the risk of pancreatitis.

2.4.3 Indications

This is no longer a first-line procedure for diagnosis, and should generally only be used where therapeutic procedures are planned, and performed in close association with (or by) a surgeon as complications can require early operative intervention.

Initial tests should usually be MRCP, or EUS where available.

1. Confirmation of chronic pancreatitis and demonstration of pancreatic duct stones and strictures.
2. Diagnosis of carcinoma of the pancreas causing malignant strictures and distortion of the ducts.
3. Obtaining pure pancreatic juice for cytology.
4. Diagnosis of extrahepatic cholestasis.
5. Identification and retrieval of common bile duct stones by papillotomy and balloon or basket extraction.
6. Identification and dilation or stenting of biliary strictures.

2.4.4 Relative Contraindications

Recurrent acute pancreatitis and pseudocyst.

2.4.5 Complications

1. Ascending cholangitis.
2. Acute pancreatitis (uncommon, though hyperamylasaemia is frequent).
3. Haemorrhage after papillotomy.

2.5 Disinfection of Endoscopes

Endoscopes cannot be sterilised, but cleaning and disinfection between uses are important (Fig. 2.3).

Closed systems for washing and disinfection are generally used to protect both staff and patients. Peracetic acid, glutaraldehyde and orthophthalaldehyde are commonly used.

When equipment has been processed it is possible to shrink-wrap and store it if immediate reuse is not planned.

Where cannulas and other ancillary equipment are designated as single use they should not be redeployed.

Fig. 2.3 Endoscope disinfection



2.6 Prophylaxis of Infections with Antibiotics (See Table A1)

There is little convincing evidence to support this therapy, and none in prevention of sub-acute bacterial endocarditis despite previous practice.

Conversely there is now anxiety about the overuse of drugs leading to resistant organisms and *Clostridium difficile* infections.

Where such treatment is used, it is best to avoid drugs widely employed for other purposes, such as broad-spectrum penicillins.

Immunocompromise (neutrophils <1000), and transplant patients.

Cefotaxime 2 g IV; or clindamycin 900 mg IV + aztreonam 1 g IV.

Variceal therapy

Ofloxacin 1 g IV in 1 h, then 200 mg 12-hourly.

Percutaneous Endoscopic Gastroscopy

Vancomycin 1 g over 1 h.

ERCP

Gentamicin 80 mg IV.

2.7 Anticoagulant Therapy

Warfarin and nicoumalone may be continued for low risk procedures if control is good. For high risk procedures, oral anticoagulants may be discontinued for a few days and replaced by daily enoxaparin, omitted on the day of procedure.

Direct oral anticoagulants are usually omitted on the day for low risk procedures, or for 2–3 days prior to high risk ones.

Aspirin can probably safely be continued.

Other anti-platelet therapy is generally stopped 5 days before procedures, though for high risk patients such as those with coronary artery stents management should be discussed with a cardiologist.

Bibliography

Graham DY, Schwartz JT, Cain GC, Gyorkey F. Prospective evaluation of biopsy number in the diagnosis of oesophageal and gastric carcinoma. *Gastroenterology*. 1982;82:229–31.

Schembre D, Bjorkman DJ. Endoscopy-related infections. *Aliment Pharmacol Ther*. 1993;7:347–55.

Veitch AM, Vanbierliet G, Gershlick AH, et al. Endoscopy in patients on antiplatelet or anticoagulant therapy: BSG & ESGE guidelines. *Gut*. 2016;65:374–89.

The passage of various forms of nasogastric, duodenal and intestinal tubes is basic to many of the diagnostic procedures performed in the gastrointestinal system.

3.1 Method

The fasting patient's fullest cooperation should be obtained. If the patient is taking any drugs which might influence the test to be undertaken these should be discontinued.

Before the tube is introduced it is advisable to check that all connections are correct, that the syringe fits snugly on the end of the tube and whether an adaptor is required. The tube is moistened by soaking in water, or lubricated. Many patients cannot, or will not, tolerate the sensation of a tube in the pharyngeal region and a small quantity of local anaesthetic such as 2% lignocaine hydrochloride sprayed on the fauces will prevent a great deal of distress and discomfort. The hazards are minimal and there is no evidence that the agent has any influence on the results of the investigation if it is used sparingly. On the other hand some gastrointestinal functions may be profoundly influenced when the introduction of the tube is accompanied by much hawking, heaving and emotional distress. Acid secretion may be inhibited by a technically difficult intubation.

Although most of the tubes are traditionally introduced via the nose, many patients find it more comfortable to swallow by mouth. Sipping water and sucking ice have also been recommended but this may not always be advisable as the aspirate will be diluted and contaminated, and water may be inhaled if the fauces have been anaesthetized. Most patients find it easier to swallow the tube sitting up: leaning slightly forward assists passage. It is impossible to swallow when the neck is extended, and flexing the neck guides the tube into the oesophagus.

The passage of tubes through the nose may be difficult and unpleasant for the patient, and it is generally better to introduce the tube via the mouth. The nasal

passages may be deviated or narrowed and many tubes have firm metal ends. Making nasal introduction awkward, painful and traumatic at times. The firm indications for introducing a diagnostic tube via the nose include the unconscious patient; the patient who cannot voluntarily coordinate swallowing, where sipping water encourages a nasal tube to enter the oesophagus; the patient who refuses to open his mouth; and the patient who persists in biting the tube. The use of the term 'nasogastric' is retained even though the tubes are introduced via the mouth.

If a nasogastric tube enters a bronchus the patient usually coughs, wheezes, or becomes cyanosed. Methods to check the position of the tube include holding the end of the tube against the cheek to feel if air is being exhaled, injecting air via the tube and auscultating over the stomach for a bubbling sound, and testing the aspirated material for acidity. The problem of the position of a tube need never arise when it is passed for diagnostic purposes since all small intestinal tubes should be positioned under radiological control. The correct positioning of a tube is usually essential for the accuracy of a diagnostic test: failure to do this generally invalidates the result.

Ideally the position of the tube should be checked radiologically during and at the end of a procedure. The best arrangement is for the procedure room to be equipped with an X-ray image intensifier so that the patient can remain there for the duration of the test. Premenopausal women should ideally be examined within 10 days of the onset of menstruation because the radiation dose administered is considerable.

For gastric secretory studies the tube may be positioned by passing a length of 50–60 cm and then giving the patient 20 ml water to drink. This is aspirated, the tube withdrawn by 2.5 cm, and the procedure repeated. This is continued until the highest level at which water can be aspirated is found, and tube taped in position.

This method avoids the need for radiological monitoring of tube position.

The patient can be made more comfortable if the tube is taped to the side of the cheek, avoiding the hair, eyebrows and the nose. It also adds to the comfort if the external connection is pinned to the garment or pillows so that the tube does not pull on the tape attached to the skin.

It is essential to monitor the aspiration continuously during the investigation. It is unsatisfactory to attach the tube to a pump, leave the patient and return to collect the sample at the end of the test period. Material should ideally be collected by frequent manual aspiration alternating with pump suction, which allows immediate detection of any obstruction to the tube and avoids mucosa being sucked into the tube because of the development of a negative pressure. If a pump is used its pressure should not be less than 7 mmHg below atmospheric pressure.

The position of the patient will depend to some extent on the test. The usual position is semi-reclining in the supine position, but the patient may incline to left or right depending on the nature of the procedure.

3.2 Tubes

Disposable tubes should be employed and used once only. A great variety of tubes is available, and generally constructed of plastic. Only a few of the commonly used tubes are mentioned below. Before introduction it is advisable to ascertain whether

or not the tube is radio-opaque. Some are not, some are made of X-ray dense material throughout, and some radiolucent tubes have metal end pieces to indicate their position. Similar types of tube are made in either radio-opaque or non-radio-opaque material. Most tubes are available in varying diameters and it is generally advisable to use the widest diameter compatible with comfort; No. 14F is usually a convenient size. The holes for aspiration should be of a reasonable size, and may occasionally need to be enlarged with a pair of scissors. Tubes with aspiration holes extending too far proximally are valueless; aspiration only occurs if all the holes are below the fluid level: if one is not, only air will be aspirated.

When the duodenum or intestine is being aspirated it is easy for a negative pressure to be established: mucosa is then sucked in and this blocks the tube. This can be avoided by the use of an extra tube of fine bore attached to the aspirating tube (or incorporated in it) which serves to maintain atmospheric pressure in the bowel.

It is sometimes an advantage to construct a tube for a particular test. This is usually necessary if a very long tube is required for intestinal aspiration. Such tubes are readily made to the required length using either polyethylene or polyvinyl tubing, the latter being preferable because the material is soft and well tolerated by the patient. Vinyl cement or tetrahydrofuran are available for sealing and joining tubes so that double, or multiple, lumen tubes can be constructed. This makes a neat and smooth tube, although multi-lumen tubes may be assembled just as effectively by taping the tubes together with adhesive tape.

3.2.1 Oesophagus

Any nasogastric tube may be used to aspirate the oesophagus, but short oesophageal tubes are available.

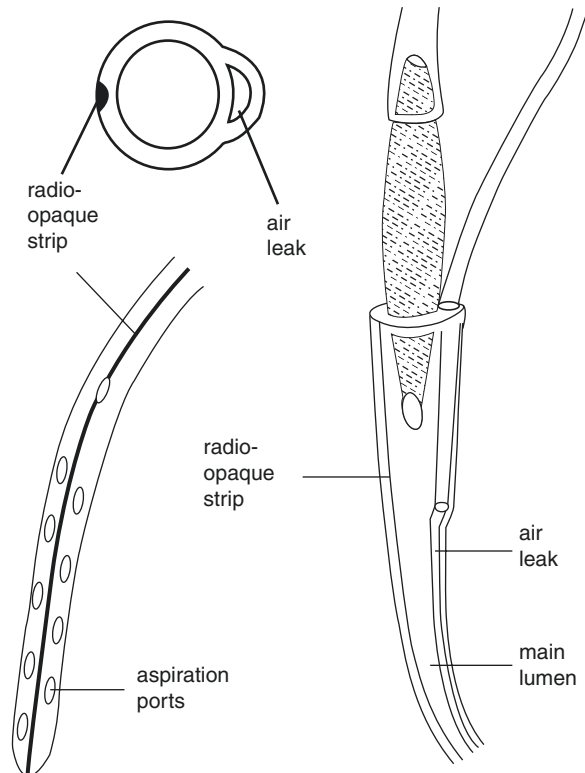
3.2.2 Stomach

The so-called stomach tube is a wide-bore tube suitable only for passage via the mouth and is only used to wash out the stomach or the oesophagus. It may be used in patients suffering from poisoning, achalasia of the cardia and gastric outflow obstruction.

Many different nasogastric tubes are available for diagnostic work. A 120 cm Salen sump tube (Fig. 3.1) with an in-built air-leak channel and a continuous radio-opaque strip is especially convenient when X-ray screening is used. The proximal end is compatible with a bladder syringe, which avoids the need for adaptors. Alternatives are the Ryle's tube, with a weighted end, and the Levin tube.

3.2.3 Duodenum

The diagnostic tubes described above are frequently used for duodenal intubation. When aspirating the duodenum it is often necessary to exclude gastric secretions.

Fig. 3.1 Salen sump tube

For this two separate nasogastric tubes may be swallowed, but bilumen duodenal tubes are also available. Widely used is the Dreiling tube, although home-made multi-lumen tubes are easily constructed. When correctly positioned, these have one set of aspirating holes situated in the stomach antrum and another in the second or third parts of the duodenum. Although it may be more comfortable for the patient to retain a single tube, it is sometimes difficult to be certain that a single multi-lumen tube is correctly positioned in both the stomach and the duodenum and for this reason many investigators prefer the separate placement of the gastric and duodenal tubes.

Steerable Burhenne-type catheters are available for rapid passage into the upper small intestine and can be used for jejunal biopsy, but they are expensive. The tip of these tubes can be manoeuvred by internal wires manipulated by proximal controls. Fluoroscopy is necessary.

Attachment of tubes to forceps in the biopsy channel of an upper digestive endoscope by thread allows rapid visual placement. Alternatively, a guide-wire can be positioned endoscopically and the diagnostic tube is then passed over it. Direct aspiration can be undertaken via a fine catheter passed down the endoscope where only small volume spot samples are required.

3.2.4 Intestine

Most operators construct their own tubes for intestinal work, but other tubes which have been used include the Miller-Abbot tube.

Scott-Harden tube This useful tube is used by the radiologist for rapid intubation of the duodenum so that barium can be introduced into the small bowel. The tube consists of a gently curved stiff outer tube, which is positioned in the stomach so that the distal end rests at the level of the pylorus. An inner tube is then slid out and inserted through the pylorus. With experience this can be undertaken with great ease and rapidity. The procedure is superior to the use of internal stiffening wires.

3.3 Complications

Gastrointestinal intubation is free from complications when used for the short periods required to perform most diagnostic procedures. Minor pharyngeal irritation is about the only significant unpleasantness, but mucosal inflammation may occur. This interferes with endoscopy, which should, if required, be performed either first or after at least a week. If the tube remains in the stomach for more than a couple of days there is always the risk of gastric contents leaking past the gastro-oesophageal junction, resulting in oesophagitis and even stricture.

Bibliography

- Hassan MA, Hobsley M. Positioning of subject and nasogastric tube during a gastric secretion study. *BMJ*. 1970;1:458–60.
- Hector RM. Improved technique of gastric aspiration. *Lancet*. 1968;1:15–6.
- Keller RT. A technique of intestinal intubation with the fiberoptic endoscope. *Gut*. 1973;14:143–4.

The major symptoms of oesophageal disease are dysphagia, heartburn, postural dyspepsia and waterbrash. There are many tests of oesophageal function, though their interpretation depends on the definition of oesophageal disease.

4.1 Oesophageal Acid Perfusion Test

This traditional investigation is useful where more sophisticated tests are not available.

Pain of oesophageal origin may be identical to that of cardiac origin. The perfusion of 0.1 mol/l hydrochloric acid into the oesophagus is an easy and reasonably consistent way of reproducing the pain that arises from the gullet.

4.1.1 Method

The patient is seated in a high backed chair and the oesophagus is intubated so that the distal end of the tube lies 30 cm from the teeth. Any convenient tube may be used, and its position can be checked radiologically. The infusions to be used are suspended on a drip stand behind the patient who is unaware of which solution is being used and when the bottles are changed. Solutions of isotonic sodium chloride and 0.1 mol/l hydrochloric acid are made up in bottles and these are connected in turn to the oesophageal tube.

Initially the isotonic sodium chloride is perfused at a rate of 10 ml/min for 10 min, followed by 20 ml/min for 5 min. Without the patient's knowledge the infusate is changed to 0.1 mol/l hydrochloric acid, initially 10 ml/min for 15 min followed by 20 ml/min for 15 min. If pain occurs the infusion is stopped and a solution of 0.05 mol/l sodium bicarbonate is infused. Perfusion of acid can be repeated to confirm that a response is genuine. A standard 12-lead electrocardiogram is obtained during any induced pain.

4.1.2 Interpretation

A positive response is pain produced by the acid but not by the saline solution: this signifies pain of oesophageal origin but not necessarily oesophagitis. The test may be positive in normal subjects who have never suffered from pain and who have no evidence of oesophagitis. However, pain generally develops earlier (during the first 10 min of acid perfusion) in patients with oesophagitis.

Patients with angina pectoris who have a positive response can usually distinguish the induced pain from that of angina pectoris.

A negative test is no pain being experienced during the perfusion, but this result does not completely eliminate oesophageal disease as the cause of chest pain. Pain of similar severity induced both by saline and acid perfusion is also regarded as a negative test. Patients with angina pectoris usually have a negative response.

The procedure may induce an attack of angina pectoris (even with the infusion of saline) and abnormalities of the electrocardiogram may then be seen. This usually occurs in patients with severe ischaemic heart disease.

Some patients with a negative test respond with pain to infusion of foodstuffs which are suspected of causing symptoms.

4.2 Oesophagoscopy

Most disorders of the oesophagus affect the lower portion, which is conveniently inspected with a flexible pan-endoscope. If a patient has severe dysphagia a barium swallow examination is sometimes useful. The frequent coexistence of upper digestive abnormalities makes oesophagogastroduodenoscopy an important investigation. The upper oesophagus is often not well seen with the flexible endoscope, and if a thorough examination of the post-cricoid region is required rigid oesophagoscopy under general anaesthetic is best. This technique also permits larger biopsy samples to be obtained.

4.3 Histology

At endoscopy it is important to take biopsies with forceps, and also to take cytology brushings if cancer is suspected. The usefulness of histology in benign oesophagitis is more contentious, but in dysphagia it may reveal eosinophilic oesophagitis. The distal 2.5 cm usually shows changes compatible with oesophagitis even in normal individuals, and it is not uncommon to find changes in health above this level. Probably the best site for biopsy is from 5 cm above the apparent gastro-oesophageal junction. In *gastric metaplasia* (Barrett's mucosa) it is recommended to take four quadrant biopsies at 2 cm intervals throughout its length, but bleeding from previous biopsy sites may make this policy difficult to practice rigorously. The findings in *oesophagitis* include cellular infiltrates, increase in length of the dermal papillae

and basal cell hyperplasia. Histology does not correlate well with symptoms, nor with macroscopic appearances at endoscopy.

4.4 Radiology (Figs. 4.1, 4.2, 4.3, 4.4 and 4.5)

A variety of techniques of barium swallow has been described and each radiologist has his favourite, particularly when it comes to the diagnosis of hiatus hernia and gastro-oesophageal reflux.

The oesophagus should be examined both during and between swallows and in the upright and lying position. The patient is frequently tilted in the

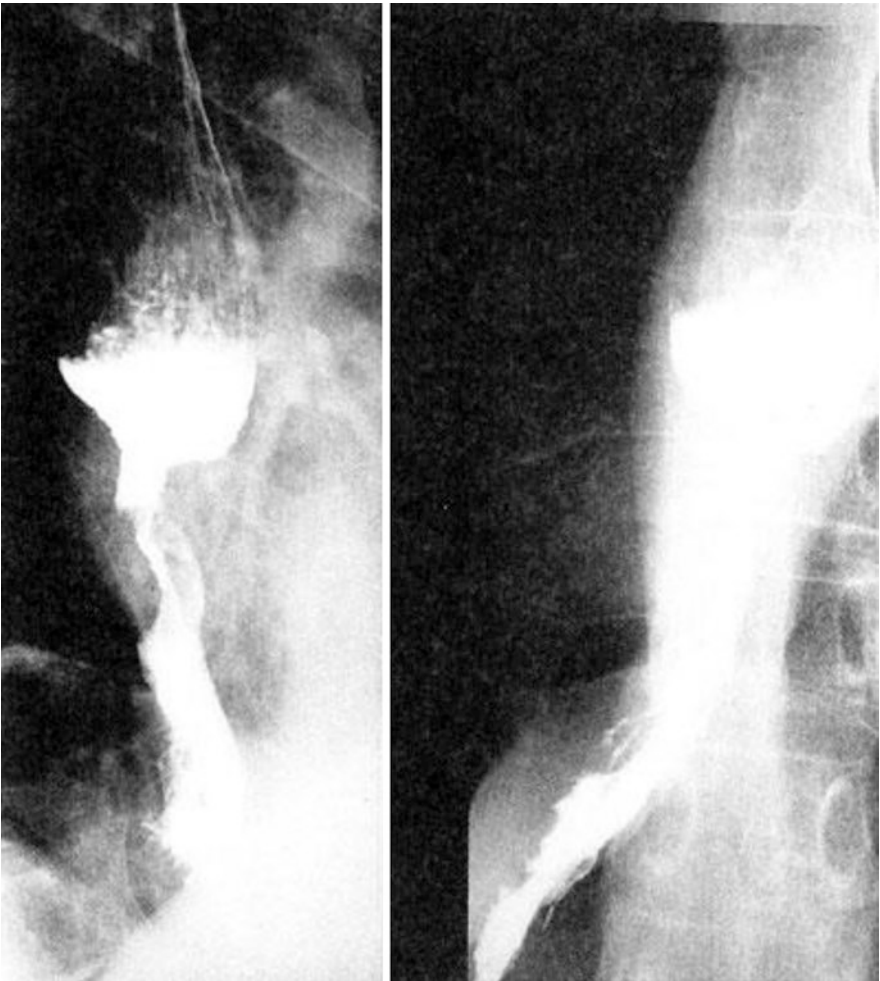
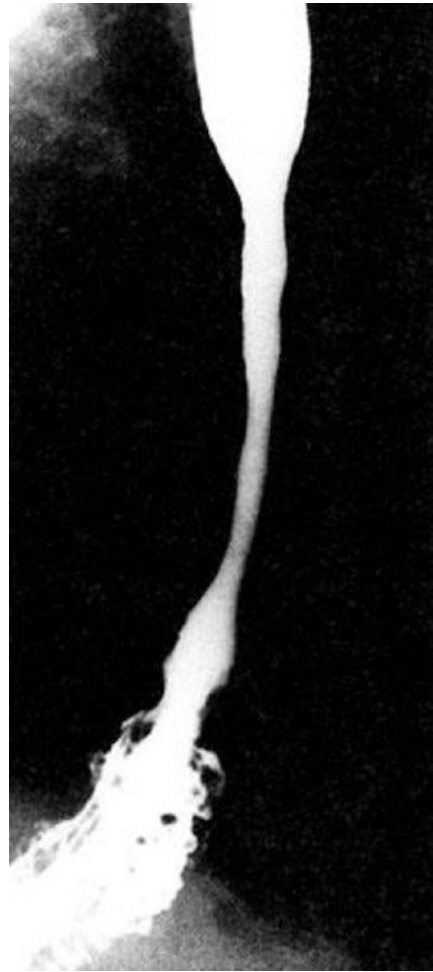

Fig. 4.1 Barium swallow. Typical 'shouldering' due to carcinoma of the lower two-thirds of the oesophagus

Fig. 4.2 Barium swallow showing long peptic stricture

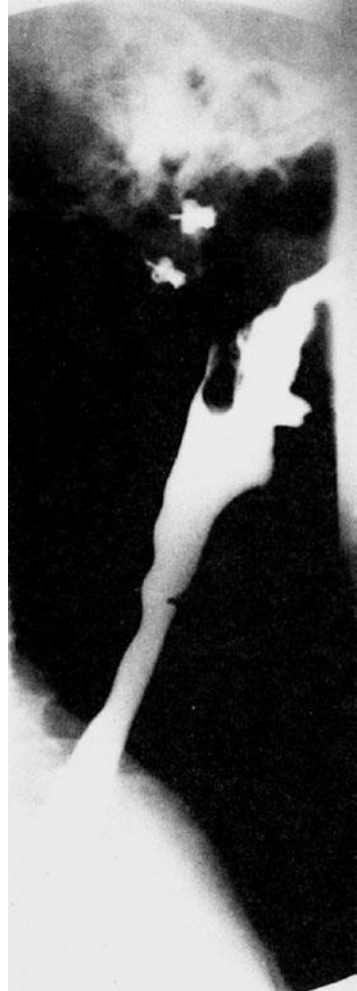

head-down position to demonstrate gastro-oesophageal reflux. When examining a patient for dysphagia the examination does not stop at failure to demonstrate an obstruction.

Careful attention to oesophageal motility is essential. Various manoeuvres can be used to bring out diffuse oesophageal spasm, oesophageal rings and other motor disturbances of the oesophagus. The use of thick barium is one; even more informative is a 'bread bolus' in which a mouthful of bread is partially chewed and then swallowed with a mouthful of barium solution. The patient must report any pain or discomfort during the act of swallowing and at such time particular attention is paid to oesophageal contractions.

Cineradiology has the advantage that both the radiologist and the clinician together can review and discuss the motility and function of the oesophagus at some time after the radiological examination.

Fig. 4.3 Barium swallow showing an oesophageal web



MRI scanning and endosonography are challenging CT scanning in the evaluation of extent of oesophageal carcinoma. Both are reported to give superior results.

4.5 Manometry

Pressure recording from the oesophagus is increasingly being used in clinical medicine. Oesophageal motility studies are particularly valuable in the early diagnosis of achalasia of the cardia and in various motor disorders. The apparatus consists of a multichannel pressure recorder and a series of tubes to conduct the oesophageal pressure. Scrupulous attention to detail is necessary to obtain interpretable results.

4.5.1 Method

Intraluminal pressures can be recorded by water-filled polyethylene tubes with lateral orifices. Tubes are sealed together and the lateral orifices are set at intervals so that simultaneous recordings can be made from eight or more multiple sites. A Dent sleeve is used to avoid missing achalasia and outflow obstruction. Pressure changes are transmitted via transducers to a multichannel direct recorder (any recorder used for cardiopulmonary studies can be used). Swallowing and respiratory movements

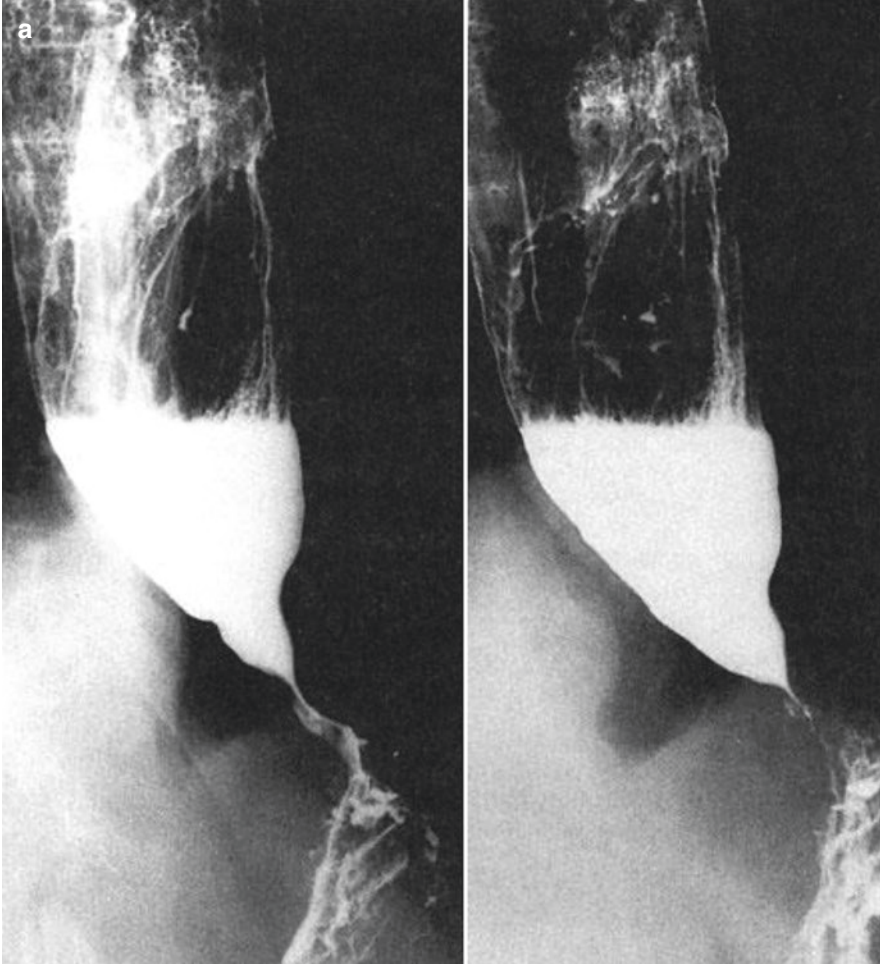


Fig.4.4 (a) Barium swallow and meal showing achalasia. (b) Chest radiograph in achalasia showing no air in the gastric fundus

Fig. 4.4 (Continued)

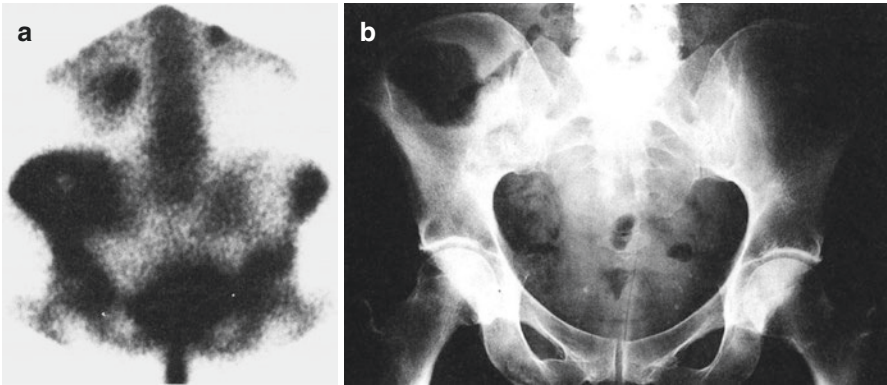
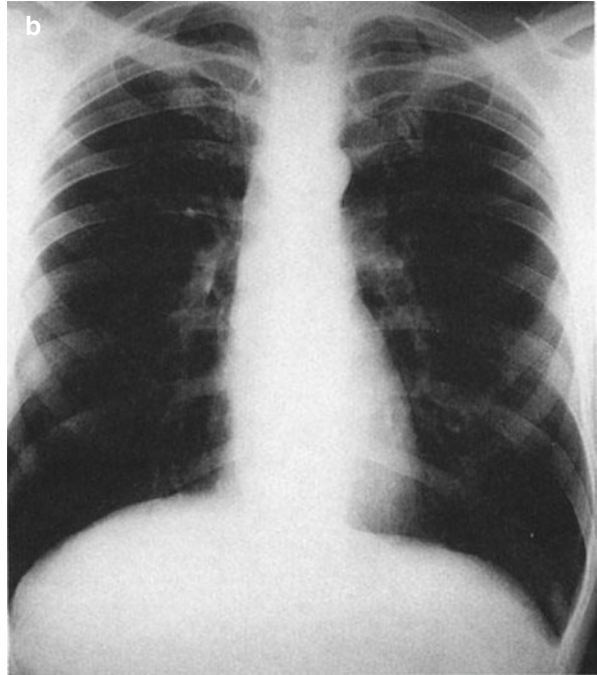


Fig. 4.5 (a) Isotope bone scan showing destruction of pelvic bone by metastasis in carcinoma of the lower two-thirds of the oesophagus. (b) Radiograph of bone metastasis in (a); note irrelevant gas in caecum and terminal ileum *top left*

are recorded. Pressure recordings are taken in the stomach, at the gastrooesophageal region and in the oesophagus both during and between swallowing.

The patient can be studied while drinking 10 ml of water or during a 'dry' swallow. Recordings are made with the tube fixed at different levels throughout the oesophagus ('station' method). There is controversy over whether a rapid pull-through technique is superior; it certainly gives different results from the standard station method. Ambulatory 24-h manometry of the oesophagus may be the most sensitive test of motility disorders, but few centres are equipped for it.

4.5.2 High Resolution Manometry (HRM)

This uses water perfusion in 20–24 channels with a 1 cm separation at the gastrooesophageal junction and 2 cm elsewhere, or solid state recorders with 36 channels at a 1 cm separation. It allows easier identification of landmarks and clearly shows movement of the lower oesophageal sphincter and diaphragm during swallowing, avoiding spurious results when the catheter drops into the stomach. This technique permits subclassification of hiatus hernias and achalasia when used with algorithms.

A manometry catheter with impedance channels has been developed, but is not yet well established and validated.

4.5.3 Interpretation

4.5.3.1 Normal Swallowing

On withdrawal of the tube from stomach to oesophagus there is a pressure reversal, the positive intra-abdominal pressure changing to a negative intrathoracic pressure. The normal resting intra-oesophageal pressure is between +2 and –20 cm water. When the patient swallows, a positive peristaltic wave of 40–80 cm water, which is coordinated and regular, sweeps down the oesophagus. A zone of increased pressure is present 2–3 cm above the gastro-oesophageal junction. This relaxes during swallowing, the relaxation preceding the arrival of the peristaltic wave.

4.5.3.2 Achalasia

There is an absence of regular peristaltic contractions in the body of the oesophagus and there is failure of the lower oesophageal sphincter to relax during swallowing. The resting tone of the lower oesophageal sphincter is normal.

HRM has identified three distinct types of achalasia. All have a 95% chance of dysphagia. Type I has a 50% prevalence of regurgitation, and no evidence of intra-oesophageal pressurisation. Type II does have increased oesophageal compression, with a 33% regurgitation risk and forms 70% of cases, with a good response to treatment. Type III is stigmatised by intermittent spastic contractions and a low (22%) rate of regurgitation.

4.5.3.3 Distal Oesophageal Spasm

Incoordinate (tertiary) contractions of the lower half to one-third of the oesophagus will be recorded and the resting pressure in the oesophagus may be raised to 200–400 cm water. The lower oesophageal sphincter functions normally although it may be included in the uncoordinated contractions.

4.5.3.4 Scleroderma

At least the lower three-quarters of the oesophagus shows feeble simultaneous contractions while the upper portion retains normal function. There is a decline in the tone of the sphincter. At a later stage the motility disorder resembles achalasia of the cardia.

4.5.3.5 Hiatus Hernia

Four characteristic changes have been described.

1. A double respiratory reversal point on withdrawing the recording device through the hernial sac: positive pressure in the stomach, negative in the hiatus, positive in the hernial sac and finally negative as the sphincter is passed.
2. Two pressure peaks representing the oesophageal hiatus and the gastrooesophageal sphincter.
3. A plateau of positive pressure in the hernia.
4. An increased length of the zone of high pressure.

Symptoms of oesophageal reflux are sometimes but not always associated with hiatus hernia.

4.6 Reflux Studies

The failure of other tests to discriminate absolutely between normal and patients thought to have oesophageal reflux symptoms has led to more elaborate procedures. The gold standard for diagnosis is now either pH studies, or best of all multichannel intraluminal impedance (MII) with pH measurement. In children with gross reflux ultrasonography may be an adequate test.

4.6.1 pH Monitoring

Intra-oesophageal pH is measured by an electrode or radio-pill. The probe is positioned in the stomach and then withdrawn up the oesophagus past the high pressure zone (as defined by manometry) with continuous pH monitoring. In a positive test pH falls below 4 above the high-pressure zone. A further modification is to position the pH electrode 5 cm above the high-pressure zone and perform manoeuvres such as head tilting, deep breathing, and Valsalva.

Long-term studies The pH electrode is positioned 5 cm proximal to the high-pressure zone and taped into position. Radiographic screening before and after the test confirms that there is no displacement. Continuous monitoring is then conducted for 24 h.

Any fall in pH of 4 units or more which lasts 10 s or more is recorded as a reflux episode. The number and duration of reflux episodes is recorded. The length of time during which oesophageal pH is below 4 is the best discriminant and should be less than 6% time supine in normal individuals. Ideally the total exposure to pH <4 should be less than 5%, in adults, but many different criteria of abnormality are used. In children the cut-off is much higher, at acid exposure pH <4 of 18% or less.

4.6.2 Multichannel Intraluminal Electrical Impedance (MII) and Alkaline Reflux

Though gastric juice is generally highly acid, some oesophageal reflux can be alkaline as a result of duodeno-gastric-oesophageal reflux of pancreatic and duodenal juice, and bile. This is illustrated by the severe oesophagitis sometimes seen in pernicious anaemia, where there is achlorhydria. Alkaline reflux can be determined by measurement of pH, bilirubin or bile acid content in oesophageal refluxate.

More convenient monitoring, especially in children, is available by using probes to estimate electrical impedance in the oesophagus, which are sensitive to any changes in conductivity, whether increase or reduction. Changes in electrical current occur when a bolus passes between a pair of metal rings mounted on a catheter. Liquid boluses with a higher number of ions have greater conductivity, and reduce impedance to a nadir. Measuring at multiple sites allows determination of direction of travel and hence reflux. This can be combined with acidity estimation (pH-MII). MII is especially useful in detecting weakly acid reflux and reflux on proton pump inhibitor therapy.

Bibliography

- Anggiansah A, Bright N, McCullagh M, Sumboon J, Anona K, Owen WJ. Alternative method of positioning the pH probe for oesophageal pH monitoring. *Gut*. 1992;33:111–4.
- Arsdorfer RC, Stef JF, Dodds WJ, Lineman JH, Hogan WJ. Improved infusion system for intraluminal oesophageal manometry. *Gastroenterology*. 1977;73:23–7.
- Bateson MC, Bouchier IAD. The association of oesophagitis with disease of the stomach and duodenum. *Postgrad Med J*. 1981;133:217–8.
- Bernstein LM, Baker LA. Clinical test for oesophagitis. *Gastroenterology*. 1958;34:760–81.
- Branicki FJ, Evans DF, Ogilvie AL, Atkinson M, Hardcastle JD. Ambulatory monitoring of oesophageal pH in reflux oesophagitis using a portable radio-telemetry capsule. *Gut*. 1982;23:992–8.

- Bredenoord AJ, Fox M, Kahrilas PJ, Pandolfino JE, Schwizer W, Smout AJP, et al. Chicago classification criteria of esophageal motility disorders defined by high resolution esophageal topography. *Neurogastroenterol Motil.* 2012;24:57–65.
- Breumelhof R, Nadorp JHS, Akkermans LMA, Shout AJP. Analysis of 24-hour esophageal pressure and pH data in unselected patients with non-cardiac chest pain. *Gastroenterology.* 1990;99:1257–64.
- Clark J, Moossa AR, Skinner DB. Pitfalls in the performance and interpretation of oesophageal function test. *Surg Clin North Am.* 1976;66:20–37.
- Emde C, Oamer A, Blum AL. Technical aspects of intraluminal pH-metry in man: current status and recommendations. *Gut.* 1987;28:1177–88.
- Gatenby P, UK Barrett's Oesophagus Registry. Short segment columnar-lined oesophagus: an under-estimated risk? *Eur J Gastroenterol Hepatol.* 2007;19:969–75.
- Goldman H, Antonioli DA. Mucosal biopsy of the oesophagus, stomach and proximal duodenum. *Hum Pathol.* 1982;13:423–48.
- Goodall RJR, Hay DJ, Temple JG. Assessment of the rapid pull-through technique in esophageal manometry. *Gut.* 1980;21:169–73.
- Hewson EG, Sinclair JW, Dalton CB, Wu WC, Castell DO, Richter JE. Acid perfusion test: does it have a role in the assessment of non-cardiac chest pain? *Gut.* 1989;30:305–10.
- Ismail-Beigi F, Pope CE. Distribution of the histological changes of gastroesophageal reflux in the distal oesophagus of man. *Gastroenterology.* 1974;66:1109–13.
- Johnsson F, Joelsson B, Isberg P. Ambulatory 24-hour intra-oesophageal monitoring in the diagnosis of gastro-oesophageal reflux disease. *Gut.* 1987;28:1145–50.
- Johnsson F, Joelsson B. Reproducibility of ambulatory oesophageal pH monitoring. *Gut.* 1988;29:886–9.
- Klauser AO, Schindlbeck NE, Muller-Lissner SA. Esophageal 24-h pH monitoring: is prior manometry necessary for correct position of the electrode? *Am J Gastroenterol.* 1990;85:1463–7.
- Massey BT, Dodds WJ, Hogan WJ, Bousseur JG, Helm JF. Abnormal esophageal motility. *Gastroenterology.* 1991;101:344–54.
- Mousa HM, Rosen R, Woodley FW, Orsi M, Armas D, Faure C, et al. Electrical impedance monitoring for gastroesophageal reflux. *J Pediatr Gastroenterol Nutr.* 2011;52:129–39.
- Nail DR, Moore OJ. Ultrasound diagnosis of gastro-oesophageal reflux. *Arch Dis Child.* 1984;59:366–7.
- Ott OJ, Gelfand DW, Wu WC. Reflux oesophagitis: radiographic and endoscopic correlation. *Radiology.* 1979;130:583–8.
- Peters L, Maas L, Petty D, et al. Spontaneous non-cardiac chest pain. Evaluation by 24-hour ambulatory esophageal motility and pH monitoring. *Gastroenterology.* 1988;94:878–86.
- Porro OB, Pace F. Comparison of three methods of intra-oesophageal pH recordings in the diagnosis of gastro-oesophageal reflux. *Scand J Gastroenterol.* 1988;23:743–50.
- Richter JE, Hewson EO, Sinclair JW, Dalton CB. Acid perfusion test and 24-hour esophageal pH monitoring with symptom index. Comparison of tests for esophageal acid sensitivity. *Dig Dis Sci.* 1991;36:565–71.
- Rokkas T, Anggiansah A, McCullagh M, Owen WJ. Acid perfusion and edrophonium provocation tests in patients with chest pain of undetermined etiology. *Dig Dis Sci.* 1992;37:1212–6.
- Roman S, Zerbib F, Queneherve L, Clermidy H, des Varranes SB, Mion F. The Chicago Classification of Achalasia in a French multicentre cohort. *Dig Liver Dis.* 2012;44:974–80.
- Schindlbeck NE, Heinrich C, Konig A, Dendorfer A, Pace F, Muller-Lissner SA. Optimal thresholds, sensitivity and specificity of long-term pH-metry for the detection of gastro-oesophageal reflux disease. *Gastroenterology.* 1987;93:85–90.
- Stanciu C, Hoare RC, Bennett IR. Correlation between manometric and pH tests for gastro-oesophageal reflux. *Gut.* 1977;18:536–40.

-
- Tio TL, Cohen P, Coene PP, Udding J, Den-Hartog Jazer FCA, Tytgat GNJ. Endosonography and computed tomography of esophageal carcinoma. *Gastroenterology*. 1989;96:1478–86.
- Varty K, Evans D, Kapila L. Paediatric gastro-oesophageal reflux: prognostic indicators from pH monitoring. *Gut*. 1993;34:1478–81.
- Winnan GR, Meyer CT, McCallum RW. Interpretation of the Bernstein test. A re-appraisal of criteria. *Ann Intern Med*. 1982;96:320–2.
- Wsu JJ, O'Connor MK, Kang YW, Kim CH. Non-specific motor disorder of the esophagus: a real disorder or a manometric curiosity? *Gastroenterology*. 1993;104:1281–4.

5.1 Gastric Emptying**5.1.1 Isotope Tests**

A standardised protocol based on experience with 123 normal controls is recommended.

After overnight fasting (clear fluids only) and nil by mouth for 2 h the patient is fed a test meal. This is 120 g egg-white omelette labelled with 12 MBq any ^{99m}Tc non-absorbable compound (half-life 6 h), a sandwich of 2 white slices and 30 g jam, and 120 ml water.

Four images of 3 min, anterior and posterior, are made immediately after the meal, and at 30, 60, 120 and 240 min. Emptying is exponential, so half-life is a useful measure.

Normal is 60–90 min. Where liquid emptying is measured at the same time, ¹¹¹In-labelled DTPA is used (half-life 2.8 days).

5.1.2 Radiology

The time required for a barium meal to clear the stomach is normally 2–3 h. Prolongation of this time may indicate disease, but is an unphysiological test. The presence of gastric barium will complicate any early surgery for obstruction. Solid radio-opaque markers can be used, e.g. 10 mm lengths of 16F nasogastric tube. Most of these should clear the stomach in 4 h and almost all will have left in 6 h.

5.1.3 Ultrasonography

Serial real-time scans parallel to the long axis of the stomach or of the antrum can be used to calculate gastric emptying of physiological meals. This is a useful and completely non-invasive test, though probably unnecessary in children with pyloric stenosis, in whom physical examination and observation confirm the diagnosis. The presence of gastric air often prevents accurate assessment.

5.1.4 Dye Dilution

This requires nasogastric intubation. A test meal of 750 ml of water is drunk, and either before or after ingestion, phenol red 30 ppm is added. After thorough mixing a 7–8 ml aliquot is withdrawn and 20 ml phenol red 500 ppm is added. After further thorough mixing a second aliquot is withdrawn, and from the concentrations gastric volume can be calculated. The procedure is repeated at intervals to determine the rate of reduction of gastric volume. In normal subjects the half-life of gastric volume is 11 min and the emptying time is 22 min.

5.2 Gastric Acid Secretion (Peak Acid Output, PAO)

The estimated output of acids has been a widely used test of gastric function. Various stimulants have been used in the past, but they have been largely superseded by the introduction of pentagastrin. This is a pentapeptide containing the key C-terminal sequence of gastrin, tryptophane-methionine-asparagine-phenylalanine-NH₂. Patients should not be receiving anti-acid medication!

5.2.1 Interpretation

There is a great deal of individual variation in tests and a large overlap between groups with different conditions. Results depend on patients' build, and height and lean body mass are both important. For adults these are usually neglected, but in children results should be expressed as mmol/kg/hour.

Men secrete more gastric acid than women, and secretion falls off with advancing age. Race is also a factor, but the data are conflicting. To assist understanding, Table 5.1 shows the results of the test outlined above during 1 year in patients who also underwent a full upper digestive endoscopy within 6 weeks.

The distribution of values is not parametric. However, for an individual the results are highly reproducible, with a coefficient of variation of 4.6%.

Normal acid secretion is usually taken to be 10–30 mmol/h for women and 15–40 mmol/h for men. Studies of endoscopy-normal dyspeptic patients and apparently healthy volunteers show that values often fall outside these ranges.

Table 5.1 Short pentagastrin test: PAO (mmol/hour)

	<i>n</i>	Men mean	Range	<i>n</i>	Women mean	Range
Normal	41	30	0.6–56.6	26	20	0–45.6
Duodenal ulcer (no duodenitis)	61	42**	21.7–72.9	38	35***	6.6–52.2
Duodenitis (no duodenal ulcer)	63	36*	0–84.8	18	28**	12.5–51.1
Oesophagitis	77	34*	1.6–84.8	50	28**	1–52.2
Gastritis and gastric erosions	63	33	2.4–84.8	36	28**	1–51.1
Pyloric and prepyloric ulcer	23	33	9.9–60.2	15	26	0–39.7
Benign gastric ulcer	10	29	1.6–41.9	12	19	10–35.7
Vagotomy and/or drainage (no gastrectomy)	47	26	0.1–47.7	22	19	0–35.7

Differences calculated versus normal endoscopy

* $p < 0.05$; ** $p < 0.01$; *** $p < 0.001$

Younger subjects have rather higher values, and over the age of 50 years the difference between the sexes becomes less marked. Any disease apart from pernicious anaemia may be found in the presence of normal acid secretion.

Benign gastric ulcer is in general associated with normal acid secretion. However, the more proximal the ulcer the lower the acid output; conversely, patients with pyloric and pre-pyloric ulcers tend to be hypersecretors.

Achlorhydria The absence of any titratable acid in a stomach whose contents have a pH of 6 or more after an adequate pentagastrin test, in a patient who has not undergone gastric resection or cholecystectomy is undoubtedly achlorhydria. If these conditions are not met the definition becomes arbitrary and the expression should not be used.

Achlorhydria may occur in apparently normal individuals and becomes more common with ageing. It is also found in the autoimmune gastritis of pernicious anaemia, in iron deficiency, in atrophic gastritis and in 18% of patients with gastric cancer. Benign peptic ulcer very rarely occurs in achlorhydria.

Reduced acid secretion A PAO of less than 10 mmol/h in women and less than 15 mmol/h in men virtually excludes active spontaneous duodenal ulcer. This may be important where radiology shows only deformity of the duodenal cap and endoscopy does not identify an active ulcer in a patient with dyspepsia. A low acid output is characteristic of gastric cancer, but is certainly not pathognomonic and is not always associated with the condition.

Increased acid secretion This is characteristically found in duodenal ulcer, though half of these patients have a normal acid output. It is occasionally caused by gastrinoma or hypercalcaemia. The hypersecretion tends to be more marked in patients with duodenal ulcer complications.

5.3 Basal Acid Output

This yields variable results and does not add to the diagnostic usefulness of the PAO in duodenal ulcer. The test should only be performed alone in special circumstances, e.g. when gastrinoma is suspected.

5.3.1 Method

The patient is intubated after an overnight fast. The overnight juice is aspirated and its volume, pH and titratable acidity are measured. The stomach is then aspirated for 1 h without any stimulation and the volume, pH and titratable acidity are measured. To ensure the most reliable results the collection should be fractionated into 4×15 min periods and the results of the analyses summated. The coefficient of variation between fractions is about 50%, but at least it provides some indication that the test is adequately performed. The basal acid output (BAO) is expressed in mmol/hour. Pentagastrin-stimulated PAO should then be measured to obtain the maximum useful information.

5.4 Indications for Gastric Acid Studies

1. *Diagnosis of pernicious anaemia.* Achlorhydria is obligatory, and PAO is nil. The test is not often used now because there are other direct means of diagnosing pernicious anaemia.
2. *Diagnosis of hypersecretion secondary to hypergastrinaemia* as in gastrinoma (Zollinger-Ellison syndrome), G-cell hyperplasia, retained antrum after gastric surgery, hypercalcaemia and short bowel syndrome. The basal hour volume is usually >200 ml, BAO >15 mmol/h, BAO/PAO $>60\%$ and PAO usually >50 mmol/h.
3. *Pre- and post-operatively in peptic ulcer.* Little elective surgery is now performed in the age of powerful anti-acid drugs and *H.pylori* eradication. A record of the change in acid output with surgery is a useful measure of the completeness of any vagotomy and risk of recurrence.
4. *Assessment of response to anti-acid treatment.* The dose of drugs in an unresponsive duodenal ulcer and in hypergastrinaemia-induced hyper-secretion can be titrated to reduce PAO to subnormal levels.
5. *Selection of operation for oesophageal reflux.* It has been claimed that hyper-secretors with oesophagitis do well after vagotomy, without the need for major plastic procedures to the cardia.
6. Occasionally in the *differentiation of benign from malignant gastric ulcer.* If a gastric ulcer exists in the presence of achlorhydria it should be regarded as malignant. In practice the PAO is of little help in management because all gastric ulcers should have a biopsy taken at the time of gastroscopy.

5.5 Alternative Techniques

Acid secretion may be stimulated by the technique of sham-feeding, where food is chewed and then spat out without swallowing. Though attractively simple and harmless, the procedure is unaesthetic and has not gained wide popularity. The concept of testing gastric pH intra-operatively during pentagastrin infusion to ensure completeness of vagotomy has appeal, but it prolongs time in theatre and increases morbidity.

5.5.1 Twenty-Four Hour Gastric Acidity

An important technique for evaluation of antisecretory drugs is the measurement of gastric pH in ambulant patients over a whole normal day.

The technique usually involves nasogastric passage of one or preferably two probes into the stomach.

The effect of meals can be identified by this method, and the potency of antisecretory drugs assessed by measuring time spent with pH 6 or more, or by calculation of areas under curves.

The test does not play much role in the evaluation of individual patients, but may help with assessment of difficult cases apparently refractory to medication.

5.5.2 Radiotelemetry

A more modern method is the use of the radiotelemetry capsule. This is 10 × 25 mm and contains a glass pH electrode, transistor oscillator and replaceable mercury battery in a polyacrylate body. The capsule is swallowed and located in the body by positioning the receiving aerial on the skin over the maximal signal. The gastric pH can be measured directly, and if desired a complete pH profile of the gut obtained before recovery from the faeces.

5.5.3 Intravenous ^{99m}technetium

Another approach is the IV injection of ^{99m}technetium pertechnetate 15 min after SC administration of pentagastrin 6 microg/kg. A scintiscan over the stomach is performed 15 min later and the activity is directly proportional to acid output ($r = 0.87$). This technique may be most useful for the identification of ectopic gastric tissue in a Meckel's diverticulum on abdominal scanning.

5.6 Serum Gastrin

There is a whole family of circulating gastrins but modern assays concentrate on GI7. This is the 'small' gastrin with 17 amino acid residues and including one sulphated tyrosine residue. Levels rise in the circulating blood in response to a meal.

5.6.1 Interpretation

The normal range in fasting serum is 5–50 pmol/l (1 pmol/l is equivalent to 2.1 pg/ml). It is not raised in duodenal ulcer disease and is of no help in diagnosis unless a gastrinoma or G-cell hyperplasia is suspected because of severe, atypical or recurrent ulceration. The diagnosis then rests on a BAO/PAO ratio >60% and a fasting serum gastrin of >100 pmol/l.

5.6.2 Problems of Interpretation

1. The serum gastrin may be elevated in the absence of gastric hypersecretion in patients with pernicious anaemia, hypochlorhydria, rheumatoid arthritis or renal failure. It rises on proton pump inhibitor therapy.
2. The serum gastrin is low when gastric surgery removes the antrum, but rises when vagotomy is performed with antral retention. Post-vagotomy values are often three to four times the upper limit of normal in the absence of hypersecretion.
3. In gastrinoma the serum gastrin may be below 100 pmol/l. If the diagnosis is suspected, fasting blood is taken for gastrin assay followed by an injection of secretin 1–2 μ /kg. Gastrin is measured in a blood sample taken 5 min later, and a rise in levels of >50% is taken as a positive result.

5.7 Serum Pepsinogen

This can be measured enzymatically or by radio-immunoassay (RIA). The Group I pepsinogens have an upper limit of normal measured enzymatically of 50 units/ml, and by RIA of 100 microgram/ml. They do not vary through the day, and correlate fairly well with PAO ($r = 0.74$). Pepsinogen is elevated in renal failure, which may not be associated with gastric hypersecretion.

5.8 Pepsin

It is possible to measure sodium, potassium, chloride, bicarbonate, calcium, pepsin, intrinsic factor, intrinsic factor antibodies, protein, lipase and amylase, mucus and viscosity in gastric juice. In practice the only technique much used is that for pepsin, the gastric protease. This is secreted in parallel with acid, which activates 80% of the gastric protease activity. The normal range is 0.15–1.0 mg pepsin/ml.

5.9 Serum Vitamin B₁₂

Normal levels are 200–800 pg/ml. Levels are very low in pernicious anaemia, low in bacterial overgrowth of the gut and intestinal hurry, and often high in parenchymal or neoplastic liver disease.

5.10 Gastric Antibodies

Antibodies directed against the parietal cells and intrinsic factor may be present in both gastric juice and serum.

5.10.1 Parietal Cell Antibodies

These can be demonstrated by conventional immunological techniques such as complement fixation and the immunofluorescent test using rabbit anti-human gamma-globulin fluorescein conjugate. About 10% of 'normal' subjects and 60–90% of patients with Addisonian pernicious anaemia have circulating parietal cell antibodies. Parietal cell antibodies are never found in the presence of a normal gastric mucosa: their presence in serum or gastric juice suggests chronic gastritis and is associated with some reduction in gastric acid output. They may be present in patients with chronic gastritis who do not have pernicious anaemia. On the other hand patients with advanced chronic gastritis may have no parietal cell antibodies.

5.10.2 Intrinsic Factor Antibodies

Antibodies to intrinsic factor are rarely found in normal sera. About 30–60% of patients with Addisonian pernicious anaemia have antibodies against intrinsic factor, but the patients differ in the type of antibody present. The antibodies correlate with an advanced degree of gastric atrophy and are associated with some degree of abnormality of B₁₂ absorption. Large doses of vitamin B₁₂ given intramuscularly within 48 h of testing the serum can cause false-positive tests for intrinsic factor antibodies.

5.11 Gastric Cytology

Exfoliative cytology is of great value in the diagnosis of gastric lesions, particularly cancer.

The use of the cytology brush at endoscopy combined with examination of the smears by experienced cytologists is claimed to yield better results than the histological examination of endoscopic biopsies. Additional material may be obtained by washing the endoscope after the examination with 200 ml physiological saline, which yields tens of thousands of cells.

Cytological interpretation is said to be easy in about 80% of gastric *cancers*. Gastric *Hodgkin's disease and lymphosarcoma* can also be diagnosed from the smears. The method is reliable and false-positive results need not exceed 0.5%. It is probably the most accurate method of establishing a pre-operative diagnosis of gastric cancer and is of particular value when deformities of the fundus or antrum are present. Failures in diagnosis are not commonly due to faulty interpretation, and are more probably the consequence of inadequate cell collection.

5.11.1 Fluorescence Cytology

The cells of gastric cancers form complexes with tetracycline, and these fluoresce under ultraviolet light. This property has been utilized in a diagnostic test for gastric malignant disease.

5.11.2 Method

Tetracycline 500 mg daily is taken orally for 2–4 days. Thirty-six hours after the last dose exfoliative cytology is performed on the fasting patient. After collection the aspirate is neutralized with 5% sodium bicarbonate solution to bring the pH to 7–9, centrifuged at 3000 r.p.m. for 10 min and the sediment spread thinly over filter paper. The paper is examined immediately on drying and again 24 h later in a dark room using ultraviolet light.

5.11.3 Interpretation

Normal cells show no fluorescence. Specks of blue represent mucosal cells and this is not abnormal. Malignant cells show bright yellow fluorescence and exfoliated lymphomatous cells also give a positive fluorescence. The test is reported to show a high degree of accuracy, with about 7% false-positive results. The presence of pyloric obstruction, even if it is partial, may give false-positive results, and it has been suggested that the tetracycline should be given intramuscularly in a dose of 250 mg twice a day for 2 days when there is gastric retention. Failure to neutralize the gastric aspirate will cause false-negative results because the tetracycline will not fluoresce in a strongly acid pH.

5.12 Gastric Biopsy

This is conveniently performed with the endoscope biopsy forceps.

5.12.1 Interpretation

The normal stomach has variable architecture, and it is necessary to take biopsies from stated and standardized positions to enable proper interpretation. One biopsy from the antrum, two from different parts of the greater curve and one from the

middle of the lesser curve provide a fair sampling procedure. It is not usually worth taking biopsies from the cardia unless there is macroscopic disease or *H. pylori* are sought. Acute gastritis is characterized by infiltration of leucocytes, mucosal haemorrhages and erosions. It may be patchy so that biopsy appearances do not always correlate with endoscopy appearances.

Chronic gastritis may result from *H. pylori* infection, pyloric reflux, gastric surgery, or may have other causes which may not be identifiable. Its relationship with symptoms remains doubtful. In the initial stage it is probably accompanied by gastric acid hypersecretion, but eventually hyposecretion supervenes. Whether this is cause or effect is contentious. There is deep infiltration with mononuclear cells and glandular destruction. In severe gastritis atrophy or metaplasia may occur, and the whole gastric mucosa may resemble the antral glandular structure or even the small intestinal architecture.

In *pernicious anaemia* a distinct pattern is seen. The stomach is involved in an autoimmune (type A) gastritis characterized by an intensely cellular atrophic mucosa containing many lymphocytes and plasma cells.

Carcinoma is usually recognized macroscopically, but *carcinoma-in-situ* is well recognized as occurring in ostensibly normal mucosa. The epithelium may also appear normal in leather-bottle stomach, when adequate histology is diagnostic. Cellular atypia is sometimes reported, but its significance is even less certain than such changes in the colon. The extent of gastric carcinoma may be assessed by spraying the stomach with congo red at endoscopy or operation (non-carcinomatous acid-secreting areas appear black) or by pretreatment of patients with toluidine blue.

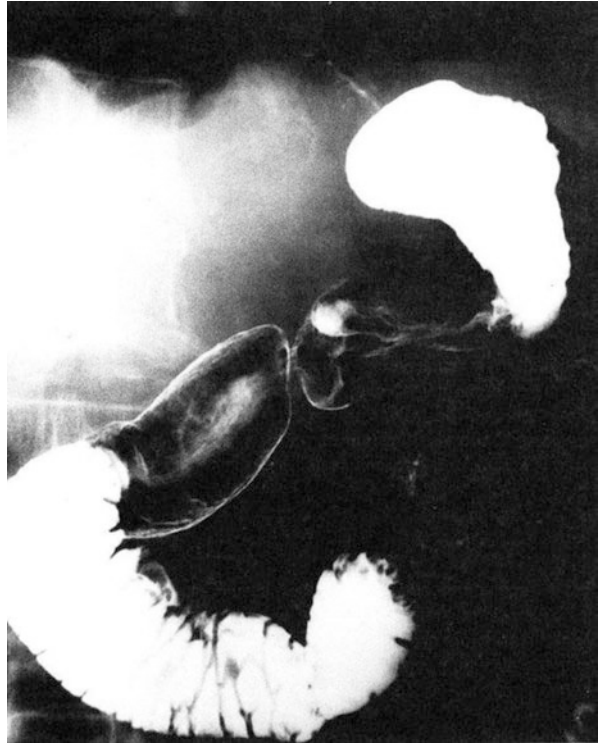5.13 Radiology

5.13.1 Barium Meal

5.13.1.1 Gastric Ulcers and Benign and Malignant Tumours

Differentiation between benign and malignant gastric ulcer may be difficult. Some of the important features of a malignant gastric ulcer are rigid angular margins to the ulcer, a long shallow ulcer having irregular edges, an ulcer lying within the line of the gastric profile, a clear zone separating the ulcer from the barium in the stomach and the barium-filled crater, irregular translucency around the base and the disappearance of the ulcer with no lessening of the surrounding rigidity. Criteria which are of little help in the differentiation of benign from malignant ulcers are the site and size of the ulcer, the appearance of the rugal folds and any shortening of the lesser curvature. Carcinomas may also appear as polyps or diffuse infiltration (leather bottle stomach) (Fig. 5.1).

Fig. 5.1 Barium meal showing leather bottle stomach in diffuse carcinoma



5.13.1.2 Gastritis

The radiological diagnosis of the various forms is difficult and controversial. Acute gastritis, gastric erosions and probably chronic gastritis are not usually associated with characteristic radiological features. Atrophic gastritis and gastric atrophy are said to have recognizable features including a long tubular stomach, the absence of rugal markings on the greater curvative and a 'bald' fundus.

5.13.1.3 Duodenal Ulcer

The barium meal is sometimes important in diagnosis, but it may be very difficult to establish the presence of active ulceration in the presence of a scarred duodenal cap.

5.13.2 Iodinated Water-Soluble Opaque Media

The older agents (e.g. 'Gastrograffin') are justifiably unpopular with many radiologists. Such materials are hypertonic and are markedly diluted in the bowel to give very poor contrast. They are dangerous in the dehydrated patient, particularly infants. Newer agents such as Gastromiro are safer but much more expensive. In an

emergency where much vomiting is present and inhalation is feared, it is still better to use a dilute barium suspension than other media. However, the water-soluble opaque agents are recommended when perforation is suspected because extravasation of these media is harmless. The new non-ionic agents are useful in dysphagia, where aspiration is a risk.

5.13.3 Double-Contrast Radiology

The introduction of the double-contrast barium meal, in which effervescent tablets or carbonated drinks are used, has improved diagnostic accuracy. Mucosal lesions can be identified much more readily, and in the hands of enthusiasts overall accuracy can equal that of endoscopy. Computed tomography, magnetic resonance imaging and endoscopic ultrasonography are useful secondary procedures for gauging the extent and operability of gastric, and more especially of gastro-oesophageal and oesophageal carcinomas. Not only can the size and position of tumours be assessed, but also the presence of metastases in nodes, liver and lung.

Bibliography

- Abell TL, Camilleri M, Donohue K, Hasler WL, Lin HC, Maurer AH, et al. Consensus recommendations for gastric emptying scintigraphy. *Am J Gastroenterol.* 2008;48:753–63.
- Ardeman S, Chanarin I. A method for the assay of human gastric intrinsic factor and for the detection and titration of antibodies against intrinsic factor. *Lancet.* 1963;ii:1350–4.
- Bateman DN, Whittingham TA. Measurement of gastric emptying by real-time ultrasound. *Gut.* 1982;23:524–7.
- Bolondi L, Bortolotti M, Santi V, Calletti T, Gaiana S, Labo G. Measurement of gastric emptying time by real-time ultrasonography. *Gastroenterology.* 1985;89:752–9.
- Butterfield DJ, Whitfield PF, Hobsley M. Changes in gastric secretion with time after vagotomy and the relationship to recurrent duodenal ulcer. *Gut.* 1982;23:1055–9.
- Chaudhuri TK. Use of ^{99m}Tc DTPA for measuring gastric emptying time. *J Nucl Med.* 1974;15:391–5.
- Collins PJ, Horowitz M, Cook M, Harding PE, Shearman DJC. Gastric emptying in normal subjects. *Gut.* 1983;24:1117–25.
- Fieldman M, Richardson CT, Fordtran JS. Experience with sham-feeding as a test for vagotomy. *Gastroenterology.* 1980;79:792–5.
- Fieldman M, Smith HJ, Simon TR. Gastric emptying of solid radiopaque markers. *Gastroenterology.* 1984;87:895–902.
- Fordtran JS, Walsh JH. Gastric acid secretion rate and buffer content of the stomach after eating. *J Clin Invest.* 1973;52:645–59.
- George JD. New clinical method for measuring gastric emptying: the double sampling test method. *Gut.* 1968;9:2237–42.
- Gillespie G, Elder JB, Smith IS, Kennedy F, Gillespie IE, Kay AW, Campbell EHG. Analysis of basal acid secretion and its relation to the insulin response in normal duodenal ulcer patients. *Gastroenterology.* 1972;62:903–11.
- Hallisey MT, Fielding JW. In vivo stain for gastric cancer. *Lancet.* 1988;1:115.
- Heading RC, Tothill P, McLoughlin GP, Shearman MC. Gastric emptying rate measurement in man. *Gastroenterology.* 1976;71:45–50.

- Hollander F. The insulin test for the presence of intact nerve fibres after vagal operations for peptic ulcer. *Gastroenterology*. 1946;7:607–14.
- Holt S, Cervantes J, Wilkinson AA, Wallace JHK. Measurement of gastric emptying rate in humans by real-time ultrasonography. *Gastroenterology*. 1986;90:918–23.
<https://www.governmentpublications/arsac-notes> for guidelines.
- Hunt IN. A modification of the method of George for studying gastric emptying. *Gut*. 1974;15:812–3.
- Hurwitz A. Measuring gastric volumes by dye dilution. *Gut*. 1981;22:85–93.
- Hveem K, Jones KL, Chatterton BE, Horowitz M. Scintigraphic measurement of gastric emptying and ultrasonographic assessment of antral area: relation to appetite. *Gut*. 1996;38:816–21.
- Johnston D, Jepson K. Use of pentagastrin in a test of gastric acid secretion. *Lancet*. 1967;ii:585–8.
- Kronborg O, Anderson D. Acid response to sham-feeding as a test for completeness of vagotomy. *Scand J Gastroenterol*. 1980;15:119–21.
- Kronborg O. The assessment of completeness of vagotomy. *Surg Clin North Am*. 1976;56:1421–34.
- Kronborg O. The discriminating ability of gastric acid secretory tests in the diagnosis of recurrence after truncal vagotomy and drainage for duodenal ulcer. *Scand J Gastroenterol*. 1973;8:483–9.
- Maybury NK, Faber RG, Hobsley M. Post-vagotomy insulin test. *Gut*. 1977;18:449–56.
- Meldrum SJ, Watson BW, Riddle HC, Brown RL, Sladen GE. pH profile of gut as measured by radiotelemetry capsule. *BMJ*. 1972;2:104–6.
- Sandlow IJ, Allen HA, Necheles H. The use of tetracycline fluorescence in the detection of gastric malignancy. *Ann Intern Med*. 1963;58:401–13.
- Taylor IL. Gastrointestinal hormones in peptic ulcer disease. *Clin Gastroenterol*. 1984;13:363–4.
- Taylor TV, Holt S, McLoughlin GR, Heading RC. A single scan technique for estimating acid output. *Gastroenterology*. 1979;77:1241–4.
- Turner MD, Tuxill JL, Miller LL, Segal HL. Measurement of pepsin I (gastricsin) in human gastric juice. *Gastroenterology*. 1967;53:903–11.
- Whitehead R, Truelove S, Gear MWL. The histological diagnosis of chronic gastritis in fiberoptic gastroscope biopsy specimens. *J Clin Pathol*. 1972;25:I–II.

The function of the small bowel can be evaluated by clinical tests of absorption (Chap. 7). Intestinal biopsy, bacteriology, radiology, radio-isotope studies, enteroscopy and serology provide additional information to enable specific diagnoses to be made.

The diagnosis of coeliac disease is complicated by the need for the patient to be on a normal diet when tests are done, since gluten-free foods are widely available and not taken consistently. It may be difficult to persuade a patient to eat normally before a small bowel biopsy is performed to avoid inconclusive results. It should be easier to repeat the biopsy after 6 months on a true gluten-free diet to show normalisation of the total or subtotal villous atrophy (TVA/STVA) of genuine coeliac disease, but it generally proves impossible or impolitic to take a third biopsy on a resumed normal diet to clinch the diagnosis. By this stage patients are aware of the need for permanent rigorous diets and know of the likelihood of ill-health returning if they lapse, including increased risk of small bowel lymphoma and carcinoma.

6.1 Intestinal Biopsy

6.1.1 Endoscopic Forceps Biopsy

This is the standard procedure since it is rapid and reliable. The best results are obtained by taking multiple biopsies of the distal duodenum with the largest available size of forceps. The duodenal bulb is not ideal for non-targeted biopsy of apparently normal mucosa, but histological confirmation of visible abnormalities may occasionally be required.

The endoscope with the widest available channel should be used, with the largest compatible forceps.

6.1.2 Crosby-Kugler Capsule

The instrument consists of a small capsule (9.5 × 18.5 mm) containing a rotating, spring-activated knife. In the wall of the capsule is a small port through which mucosa is drawn by suction. Suction also serves to trigger the knife which severs the mucosa and closes the port, thereby trapping a portion of the mucosa in the capsule. The capsule is attached to a 2 mm polyethylene catheter which serves both for holding the capsule and for suction.

Various modifications of the capsule have been proposed. If the tubing is replaced by a radio-opaque red arterial catheter the whole tube may be seen on the fluoroscope and loops identified and straightened: in addition this catheter is stiffer and allows progress by pushing the capsule onwards. There are three methods for positioning the capsule.

6.1.2.1 Endoscopic Technique

This is a rapid technique and takes minutes. The tubing should be about 50 cm longer than the endoscope, and it is necessary to check catheter length and diameter before commencing the intubation. The patient is prepared for a normal upper digestive endoscopy. The valve of a forward-viewing instrument is removed, the capsule is loaded and threaded retrogradely through the biopsy channel so that the capsule lies snugly against the distal tip of the endoscope. The endoscope is then passed in the usual way, with slight tension on the biopsy capsule catheter to keep the end closely applied to the endoscope tip. The view is partially obscured, but it can be improved if necessary by advancing the capsule 2 cm from the end of the endoscope. The pylorus is located and the tip of the endoscope is held in position while 30 cm or more of the biopsy catheter is carefully advanced through the biopsy channel. The position of the biopsy capsule may be checked fluoroscopically but this is not necessary with experience. The Luer fitting is reattached. Between 5 and 10 ml of water followed by 10 ml air are flushed through the capsule tubing and the capsule is fired by applying suction: a 30 ml syringe is convenient for both purposes. The biopsy capsule is withdrawn to the tip of the endoscope and both removed together. The biopsy capsule is disassembled, the tissue sample floated in saline, examined using a 10× hand lens or under a dissecting microscope, and quickly immersed in formol saline. If enzyme studies are required the sample must be divided immediately and a portion frozen at once. Formalin inactivates disaccharides.

This method is fast, reliable and does not require fluoroscopy. It is, however, dependent on competent endoscopy. If upper gastrointestinal endoscopy is required in the same patient the instrument must be passed a second time.

6.1.2.2 Fluoroscopic Method

The patient fasts overnight. The capsule is swallowed with the patient sitting forward and about 50 cm of tube passed. The patient then lies on the fluoroscopy bed, and it is confirmed that the tubing is not curving in the fundus of the stomach. If it is the capsule must be withdrawn to the cardia and a further attempt made at passage.

The patient is then asked to lie on the right side and the position of the capsule is checked periodically. Once it is estimated to have passed the pylorus it is advanced to the duodenojejunal flexure and fired. The technique often takes 1 h or more, and various procedures have been proposed to facilitate it. A 100 cm outer polythene tube can be used to make the catheter more rigid until the capsule reaches the pylorus, and internal stiffening wires have been used for the same purpose. Another method is to give an IM injection of 10–20 mg metoclopramide 10 min after the capsule has been swallowed. This agent relaxes sphincters and hurries the passage of the capsule into the stomach and duodenum.

The fluoroscopy method requires either a prolonged intubation or heavy commitment of the investigator's time with repeated fluoroscopy.

6.1.2.3 Traditional Method

The capsule is swallowed 2 h after the last meal of the day, which should be of light fluids. Thereafter only water is permitted. About 100 cm of tube is passed. The end of the tubing is attached to the cheek of the patient who is instructed to lie on the right side for a few hours. The following morning the patient is taken to the radiology department and the position of the capsule is identified. Sometimes it will be found to have passed well beyond the ligament of Treitz. The capsule is withdrawn into the required position if necessary, biopsies usually being taken just beyond the duodenojejunal junction. If ileal biopsies are required more time and tube must be allowed for the capsule to pass down the intestine, and because the capsule is frequently not in the right position the examination may take days to complete.

6.1.2.4 Complications

The Crosby-Kugler is a safe instrument and complications from its use are very rare. The major hazard is intestinal perforation, which is particularly liable to occur in children. There is occasionally haemorrhage from the biopsy site and failure of the knife to sever a piece of mucosa completely may make it impossible to withdraw the capsule until the mucosal fragment has sloughed off. In the latter event patience is required from clinician and patient: the capsule generally frees itself within a day or two and can be recovered, although the sample is usually too damaged to allow histological interpretation.

6.1.3 Rubin Suction Biopsy Tube

In this instrument a cylindrical knife fits into a capsule which is in turn attached to a flexible tube. Different capsules are available containing one or more ports of different sizes, and special double knives are provided for use with the multi-hole capsules. The knife is attached to a pull wire which runs through the flexible tube and stationary handle, and it is attached to an activator handle. Suction is applied via a lateral arm on the stationary handle thereby drawing mucosa into the port. A vacuum gauge is attached to the handle so that the force of suction is measured: this varies according to the age of the patient, the number of ports and the site of the biopsy.

The capsule aperture is opened by pushing the activator handle (and therefore the knife) distally. The tube is passed with the knife positioned so that the port is closed. The procedure is best performed by two operators.

6.1.3.1 Method

After an overnight fast the patient is taken to the radiology department, the pharynx is anaesthetized and the suction tube is swallowed. The tube is positioned in the region of the pylorus under fluoroscopic control, when there may be marked heaving and gastric contractions. The tube is then guided into the duodenum by gentle pressure. Alternatively the patient lies on the right lateral position for about 10 min, is re-screened and the procedure repeated until the tube is seen to have passed into the duodenum.

Once in the duodenum the tube is usually readily positioned at the duodenojejunal flexure. The port is opened by pushing the knife forwards, suction is applied and a biopsy is obtained by traction on the activator handle. It is probably advisable to move the tube slightly and repeat the procedure to ensure that a biopsy is taken. The instrument is withdrawn with the knife in the closed position. The instrument is safe and significant haemorrhage or perforation is rare.

The appreciation that upper small intestinal disease may be patchy has led to the popularity of the hydraulic instrument devised by Flick, which delivers biopsies immediately after they have been cut and allows multiple biopsies to be taken from multiple sites at one intubation.

A steerable catheter with a contoured distal Rubin biopsy capsule has been devised. This requires fluoroscopy for passage, and its advantage is the rapidity with which it can be manoeuvred into position.

The choice of biopsy capsule and technique depends on personal preference. Use of the Crosby capsule allows only one biopsy can be obtained, whereas the hydraulic capsule offers the possibility of an indefinite number. Smaller Crosby capsules are available for use in children.

6.1.4 Interpretation

6.1.4.1 Dissecting Microscope

Normal appearance The jejunal villi are long and finger-like and the vascular arcades are easily recognized. The height of a villus is about three times its width. Essentially similar features are found in the ileum. A normal variant is the broad, flat or leaf-shaped villus and this is seen particularly in duodenal biopsies where the leaves may even coalesce into ridges. An identical appearance may be seen in jejunal biopsy samples from normal subjects of Middle- or Far-Eastern extraction. These features may be identified with a hand lens.

Abnormalities In *coeliac disease* the mucosal biopsy will be 'flat' or 'convoluted'. A 'flat' mucosa shows a complete loss of villi and the normal vascular arcades. There may be a mosaic or crazy pavement appearance. The 'convoluted' mucosa

has no true villi but only ridges and whorls. While examination under the dissecting microscope or hand lens is a rapid and convenient diagnostic procedure it does not replace conventional histology. It is usually easy to recognize an abnormal villous pattern; the difficulty lies in deciding when villi are minimally abnormal. In this situation light microscopy is essential.

6.1.4.2 Light Microscopy

Normal Appearance

Tall thin villi are seen lined by columnar epithelium. There are numerous goblet cells. Paneth and argentaffin cells may be seen at the base of the crypts of Lieberkuhn. Mononuclear cells, plasma cells and eosinophils are seen in the lamina propria, the thickness of which is about one-half to one-third the villous height. Similar features are found in both finger- and leaf-shaped villi. Brunner's glands are seen in the duodenum occupying the full thickness of the glandular (non-villous) mucosa. Villi may be blunted or absent. In the ileum more goblet cells are found, and the villi are slightly broader and shorter. There are collections of lymphoid cells, and villi overlying such areas are either stubby or absent. Specimens from apparently normal subjects from the Middle- and Far-East show a greater proportion of blunt and branched villi, more abnormal surface cells and slightly more prominent mononuclear cellular infiltration.

It is important to appreciate the variations in the appearance of the normal small bowel biopsy. The suggestion has been made that the 'finding of four adjacent villi in any section justifies an interpretation of normal villous architecture'.

Abnormalities

A number of diseases may be associated with minor non-specific abnormalities of the intestinal mucosa.

Coeliac disease This is defined as the presence of total or subtotal villous atrophy which reverts to normal, or at least shows improvement, after the patient adheres to a gluten-free diet. It is important that milder abnormalities (partial villous atrophy) are not diagnosed as coeliac disease, because they are common and nonspecific findings.

Children with coeliac disease characteristically have total villous atrophy. There is virtual absence of the villi, thickening of the lamina propria, increased infiltration by lymphocytes and plasma cell, elongated crypts of Lieberkuhn, increase in the mucosal glands and obvious surface epithelial abnormalities with much increased intraepithelial lymphocytes. In less severe villous atrophy the villi are short, thickened and disorganized, the goblet cells are increased in number and there are lesser changes in the lamina propria. The mucosal changes in coeliac disease are seen maximally in the upper jejunum, but in severe involvement the changes will extend to the ileum. There is no correlation between the histological abnormalities and the absorptive function. A flat biopsy is found in some patients who do not respond to gluten withdrawal, and it is not possible to predict the response from the appearance

of the intestinal biopsy. The typical appearance of coeliac disease may be found in the biopsies of patients who have, or will subsequently develop, intra-abdominal lymphomas or cancers of the gastrointestinal tract.

Similar appearances can occur in *dermatitis herpetiformis*, and these sometimes respond to gluten exclusion. Psoriasis may occasionally be associated with villous atrophy.

Tropical sprue The distinction between coeliac disease and tropical sprue is difficult morphologically because both demonstrate moderate to severe villous abnormalities. In tropical sprue the extent of the villous loss is marked and there are uniform small lipid droplets in the basement membrane adjacent to the surface epithelium.

Abetalipoproteinaemia (acanthocytosis) There is normal villous architecture, but the intestinal cells are filled with fat-containing vacuoles.

Whipple's disease The lamina propria is virtually replaced by macrophages filled with periodic acid-Schiff-positive glycoprotein granules. The normal villous architecture is distorted, and the lymphatics are dilated and filled with fat. Tiny bacilli can be seen on high-resolution light microscopy or with electron microscopy.

Agammaglobulinaemia There is a complete absence of plasma cells. The villi may be near normal or totally atrophic, but the condition is readily differentiated from coeliac disease by this absence of plasma cells.

Other diseases In the five conditions described above jejunal biopsy is invariably helpful. In some others, such as lymphangectasia, lymphoma, giardiasis, amyloidosis and Crohn's disease, biopsy may be helpful but is not necessarily so. Non-specific changes include mild flattening and broad thickening of the villi, an increase in chronic cellular infiltration and minimal thickening of the glandular epithelium. Such an alteration is to be found in association with hepatitis, Crohn's disease, jejunal diverticulosis, ulcerative colitis, kwashiorkor, pernicious anaemia, after partial gastrectomy and after neomycin therapy. Similar changes may be found in coeliac disease and cannot be used to substantiate the diagnosis. The mucosal biopsies are normal in disaccharide deficiency, iron-deficiency anaemia, peptic ulcer disease and pancreatic disease. Villous abnormalities have been described in association with certain skin diseases such as eczema and psoriasis. These are usually non-specific changes, but occasionally severe atrophy is indistinguishable from coeliac disease is present.

The biopsy specimen can be stained with special histochemical stains to show various intracellular enzymes such as alkaline phosphatase. The biopsy sample can be frozen to -20°C and used for enzyme estimation. This technique has been used in the diagnosis of disaccharide deficiency states.

Electron microscopy has been used to identify subtle changes in the mucosa and to search for bacteria in Whipple's disease.

6.2 Radiology (Figs. 6.1, 6.2 and 6.3)

6.2.1 Barium Contrast

Though the small intestine can be studied after radiological examination of the stomach has been completed, during the course of a barium follow-through series there is unpredictable emptying of the stomach. There may be irregular and excessive filling of the intestine and the barium-filled stomach may obscure parts of the intestine. These difficulties are obviated by the use of the Scott-Harden tube which enables the duodenum to be filled rapidly by a known volume of barium. In this manner a small bowel enema is performed using large volumes of relatively dilute barium.

The *normal* small intestinal mucosa demonstrates a feathery pattern. On a follow-through in *coeliac disease* there is slowing of the transit time, the bowel lumen is dilated, intestinal folds appear thickened, and there is 'stacking' and clumping of the barium. Barium sulphate tends to flocculate in the presence of *steatorrhoea*, whether this is the consequence of intestinal or hepatic or pancreatic disease. The use of non-flocculating barium suspensions enables the radiologist to study the intestinal mucosa in the presence of steatorrhoea and it is of help in the

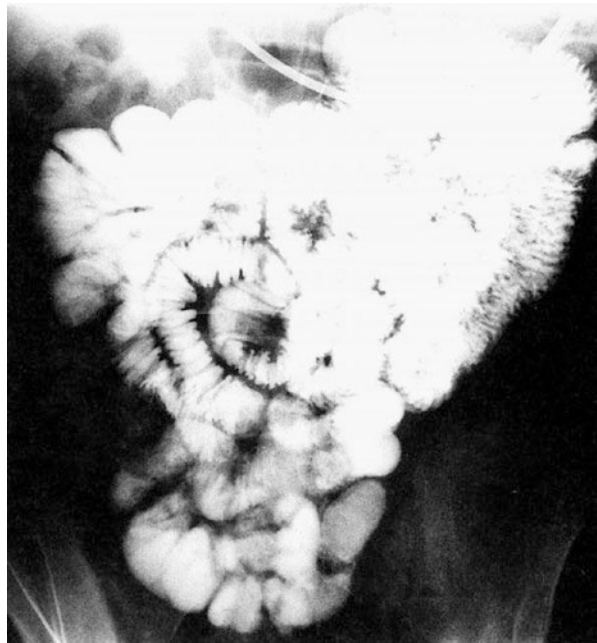

Fig. 6.1 Normal small bowel enema

Fig. 6.2 Small bowel enema showing terminal ileal Crohn's disease

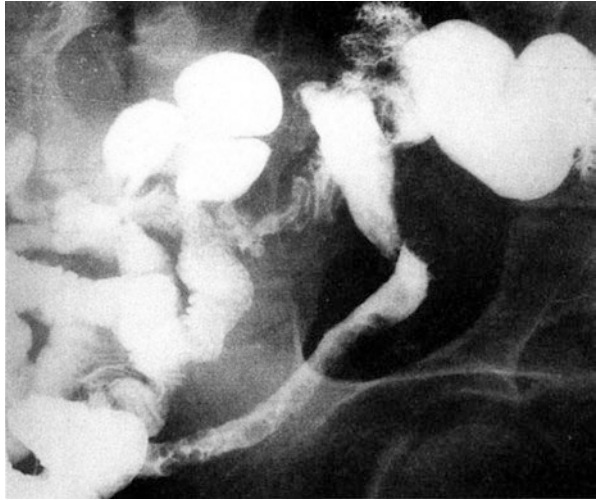
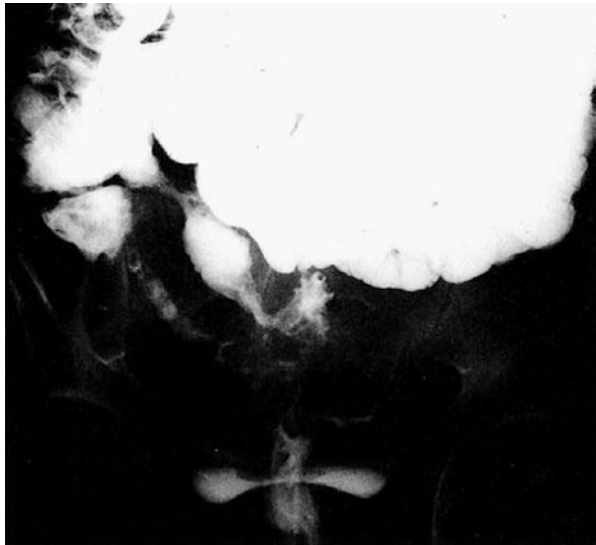


Fig. 6.3 Ileo-colo-vesical fistula in Crohn's disease



diagnosis of *Crohn's disease*, strictures, diverticula and blind loops. The terminal ileum may be better outlined by a retrograde barium enema than by small bowel series.

Angiographic techniques are available and there is a selective technique in which the catheter is introduced into either the coeliac, or superior or inferior mesenteric artery. It is possible to demonstrate vascular lesions involving the major vessels supplying the gastrointestinal tract. In this way it is possible to demonstrate neoplastic disease of the bowel as well as the site of gastrointestinal bleeding.

Lymphangiography has proved of value in the diagnosis of retroperitoneal lesions and in the demonstration of abnormal intestinal lymphatics such as are found in intestinal lymphangiectasia.

Retrograde ileography via a colonoscopically placed catheter has been described.

6.3 Radio-Isotope Studies (Little Used Nowadays)

6.3.1 WBC Scanning

The patient's own white blood cells are labelled with ^{99m}Tc -HMPAO (hexamethyl propylene-amine oxime) and re-injected. Abdominal scanning will localize areas of inflammation by increased uptake. This is particularly useful in identifying sites of Crohn's disease involvement in the small and large bowel. Appearances are not specific and corroborative evidence is necessary before a complete diagnosis is made. An alternative is the use of $^{111}\text{indium}$ -labelled pooled human immunoglobulin. This avoids the need for handling of blood, but involves use of heterologous blood products.

$^{67}\text{Gallium}$ citrate localizes in tumours and inflammatory areas. It can be used to delineate ulcerative colitis and also abdominal abscesses in Crohn's disease and other conditions, though uncomplicated Crohn's disease usually yields negative scans. The technique is simple, but ultrasonography, radiology and digestive endoscopy probably yield the same information.

6.4 Enteroscopy (See Chap. 9)

This technique will provide visual information and also the possibility of biopsy in the small bowel. Conditions which can be identified are diaphragm disease and ulceration in patients being treated with NSAIDs, angiodysplasia, tumours and Crohn's disease.

6.5 Protein Loss

Excessive protein loss into the gastrointestinal tract is a non-specific feature in a number of diseases directly or indirectly affecting the gastrointestinal tract. The loss of protein may present as oedema and hypoalbuminaemia, the clinical syndrome being known as protein-losing gastroenteropathy. Thus tests for the loss of protein into the bowel are important in the clinical investigation of a patient with unexplained hypoalbuminaemia and oedema, particularly when associated with gastrointestinal symptoms.

The quantitative evaluation of enteric protein loss has been attempted either using macromolecular substances with radioactive labels such as $^{131}\text{iodine}$ or the inert polyvinylpyrrolidone (PVP). However, the development of techniques for quantitating actual protein loss, and of labelling the patient's own albumin *in vivo* represent an improvement.

6.5.1 Radio-iodinated Serum Protein

^{131}I - or ^{125}I -labelled albumin can be used as the test substance. The method cannot be used for accurate quantitation of intestinal protein loss because of the rapid reabsorption of the radio-iodide label after catabolism of the protein in the gut, and also because of the secretion of the labelled iodine in salivary and gastric secretions.

6.5.1.1 Method

Preparations of radio-iodinated serum albumin which may be used to determine volume and cardiac output are not suitable for measuring intestinal protein loss: it is necessary to purchase commercial materials which are specially prepared for this purpose. Each new preparation of iodinated albumin must be tested in a control subject with normal protein metabolism.

The patient is given 0.5 ml aqueous iodine solution orally four times a day from the day before the test until the completion of the study. 2 MBq of radio-iodinated albumin are injected IV and blood samples are collected without a tourniquet 10–20 min later and then daily for 21 days. Quantitative 24-h urine samples are obtained throughout the study. All stools are collected and assayed for radioactivity. The serum albumin concentration is determined weekly.

The data may be analysed in a variety of ways. Isotope dilution measurements are made of the plasma volume and the intravascular and total albumin pools. The albumin turnover (g/day) is calculated and this equals the albumin synthetic rate if the patient is in a steady state. In protein-losing enteropathies the increased intestinal loss is reflected in an increased disappearance of plasma radioactivity, and faecal radioactivity is significantly elevated above normal values. Quantitative evaluation is not possible except where abnormal protein loss is restricted to the stomach when a quantitative study is possible using gastric suction.

This method is complex for routine use, but it provides much information which is of value for research purposes.

6.5.1.2 Other Methods

IV administration of autologous ^{111}In -labelled transferrin followed by abdominal imaging over 24 h is a useful technique to show protein loss. Tests using ^{59}Fe -labelled dextran and ^{67}Cu -labelled caeruloplasmin also give good results. Less than 1% of ^{59}Fe -labelled dextran is normally found in stools in the 4 days after an IV injection of 0.002–0.004 MBq/kg, and this isotope is attractive because it is relatively cheap and it is stable. Simultaneous administration of ^{131}I -labelled albumin and ^{125}I -labelled IgG followed by differential faecal counting has been advocated as an index of small bowel activity in Crohn's disease, where the ratio of ^{125}I to ^{131}I is >1.60 .

6.5.1.3 Alpha₁-Antitrypsin Clearance

Gastrointestinal loss of plasma proteins may also conveniently be measured by estimation of the faecal clearances of the endogenous marker alpha₁-antitrypsin, which

forms the main α_1 -globulin, with a serum level of 1.9–5.0 g/l. In protein loss the level in stools is higher, though the serum concentration is still usually within the normal range. A more sophisticated variant actually calculates α_1 -antitrypsin clearance over 10 days, but has the serious practical drawback of prolonged stool collection.

Indications

The tests are of value in any patient with oedema and low serum albumin concentrations in whom the cause of the hypoalbuminaemia is not apparent. Protein loss into the bowel has been recorded in congestive cardiac failure, giant rugal hypertrophy of the stomach, gastric cancer, intestinal lymphangiectasia, Crohn's disease, Whipple's disease, ulcerative colitis and allergic states involving the gastrointestinal tract.

6.6 Intestinal Bacteria

Under normal conditions the small bowel contains only low numbers of microorganisms. Bacterial overgrowth occurs in a number of disease states and the assessment of intestinal bacteria is of great value. Methods for determining the extent of bacterial proliferation in the bowel are:

1. Culture after intubation and aspiration of small bowel contents
2. Biopsy of intestinal mucosa
3. Urinary indican measurement
4. Breath hydrogen & methane assay

6.6.1 Intubation

The small bowel bacterial flora can be directly identified and quantitated by intubation techniques. Intestinal bacteria may be obtained at operation by needle aspiration of the bowel or by a special stainless steel capsule which has a hollow connection at the proximal end linking to radio-opaque tubing. Suction to the tubing displaces the cap with aspiration of the intestinal contents. The capsule is self-sealing once suction has been discontinued. These methods are no more accurate than the use of a simple sterilized disposable double-lumen radio-opaque tube.

6.6.1.1 Method

The intestine is intubated after an overnight fast. The patient, who must not be taking antibiotic therapy, has an alkaline gargle before swallowing the tube. The tube is screened into the desired position, aspirates being taken from the mid-jejunum or any known diseased area. The tube is withdrawn once samples have been obtained. The aspirated samples are delivered to the laboratory as rapidly as possible and plated for aerobic and anaerobic culture. A quantitative and qualitative determination is made

of the bacterial population. Strict attention to culture conditions is necessary for demonstration of obligatory anaerobes. Simultaneous culture of saliva is advisable to identify non-significant contaminants.

6.6.1.2 Interpretation

Normally the jejunum is sterile, or bacterial counts are less than 10^5 /ml, the organisms being mainly of the oropharyngeal type. Counts $>10^5$ /ml indicate bacterial overgrowth, the organisms being mainly strains of *Escherichia coli* and *Bacteroides*.

6.6.1.3 Indications

An assessment of intestinal bacterial growth is of value in two ways. The procedure can be used to decide whether steatorrhoea, vitamin B₁₂ deficiency or protein malnutrition is the result of bacterial overgrowth in the small bowel. This could be the consequence of intestinal stasis from strictures, fistulas, diverticula or abnormalities of mobility. On the other hand it is sometimes of value to know whether there is bacterial overgrowth in patients with known strictures, diverticula or abnormal motility of the small intestine.

6.6.2 Urinary Indican

In patients with excessive bacterial growth in the small intestine there is an increase in the excretion of indican (indoxyl sulphate) in the urine. These indoles are produced by bacterial activity, particularly *Escherichia coli* and *Bacteroides*, or by tryptophan in the diet.

With the patient on a normal diet, a 24-h urine collection is made into a bottle containing a few millimetres of either chloroform or thymol. The normal output of indican in the urine is 48 ± 20 mg/24 h. Values above 80 mg/24 h are abnormal. Slight elevations are present in a variety of diseases such as coeliac disease without necessarily indicating significant bacterial overgrowth. Values above 100 mg/24 h imply profuse bacterial proliferation, but the test is too erratic in performance to be very useful.

6.6.3 Breath Hydrogen

Bacterial colonization of the small intestine leads to an increase in breath hydrogen to more than 20 ppm after a 50 g glucose load by mouth. Unfortunately the values may be spuriously raised in cigarette smokers, after dietary carbohydrate intake and in intestinal hurry and irritable bowel syndrome. They may be reduced by exercise and hyperventilation. The test requires very careful standardization to be useful, despite the deceptive ease with which breath hydrogen can be monitored by automatic machines.

6.6.4 Biopsy

Endoscopic forceps biopsy and simultaneous intestinal aspiration followed by microscopy and culture can be very helpful in diagnosis of giardiasis.

6.7 Intestinal Motility

6.7.1 Radiology

The measurement and monitoring of intestinal motility are difficult in man and rarely necessary in the clinical evaluation of a patient with gastrointestinal symptoms. Small intestinal motility is measured most conveniently by radiology but the results are variable. Barium sulphate may well stimulate bowel activity and its rate of passage is not an index of the transit time for ordinary meals. Transit time is claimed to be more rapid when the patient is in the right lateral recumbent position and slower when there are faeces in the colon. It usually takes 60–90 min for barium to reach the colon. Intestinal motility is reduced in patients with steatorrhoea, but those with lactose intolerance have intestinal hurry: this may be demonstrated by the ingestion of a test meal containing 100 g micro-opaque barium sulphate suspension mixed with 25 g lactose. The radiological assessment of intestinal motility is often sufficient for clinical purposes.

6.7.2 Markers

Non-absorbable markers are incorporated into test solutions to be infused during perfusion studies. The dilution or concentration of the markers in samples of the perfusion fluid theoretically measures the flow rates and volumes of the intestinal contents at the site of study. Polyethylene glycol (PEG) and phenol red are the two markers of most value for perfusion studies. Marker perfusion techniques are used primarily during physiological studies of intestinal absorption. Radio-opaque solid markers with radiology of patient and/or stools can be used to assess transit. Markers have also been used to assess or fix the duration of a stool collection. However, this is seldom required in clinical practice and during a 3- or 5-day collection of faeces for fat excretion no markers are used. More precise timing may be required during metabolic balance studies.

6.7.2.1 Chromium Sesquioxide

A capsule containing 0.5 g chromium sesquioxide is taken three times a day with the meals and the amount of marker in grams recovered in the faeces is divided by 1.5 to give the number of days represented by the collection. A method described by Clarkson enables a measurement to be made within 1 h. The homogenized faeces are wet-digested with nitric and perchloric acids and the optical density of the dichromate is measured in a colorimeter.

6.7.2.2 Carmine No. 40

This is a red, non-absorbable dye which is readily recognized in the stool. The dye is administered in capsules (usually 3–4 g) at varying intervals to indicate different periods represented by the stool collection. This method suffers from erratic mixing of the dye and the difficulties of interpretation when the patient is constipated. Charcoal may be used in a similar way.

Markers are used clinically to detect whether an abdominal fistula is a faecal fistula. Carmine and charcoal are useful in this respect.

Small plastic shapes can be followed through the bowel to assess motility: however, they may themselves alter transit time.

6.7.3 Radiotelemetry and Manometry

Specialized units have developed ways of estimating pressures and both electrical and motor activity in the stomach and small intestine. This has improved understanding of physiology, and led to the definition of a discrete form of functional bowel disease (chronic idiopathic intestinal pseudo-obstruction). However, analysis of results is complicated by normal variability, and the effects of stress and the menstrual cycle, so the technique does not have general applicability.

6.7.4 Breath Hydrogen

The time of rise in breath hydrogen by 20 ppm above baseline after a meal containing 10 g lactulose taken in the recumbent posture will indicate oro-caecal transit time, usually 60–90 min in normal subjects. It is >100 min in delayed transit and <60 min in intestinal hurry.

6.8 Crohn's Disease

This is often difficult to diagnose and a number of helpful tests are available.

Excision biopsy of involved sites can show full thickness of inflammation, deep ulcers and granulomas are diagnostic features. Local lymph nodes may also contain granulomas.

6.8.1 Barium Radiology

Internal fistulas between loops of small bowel and skip lesions (diseased areas separated by normal bowel) are the most helpful findings, though a host of other abnormalities occur.

Rectal biopsies and upper gastrointestinal biopsies Sometimes diagnostic features are seen, but often non-specific changes can be identified which support a diagnosis of organic disease.

6.8.2 Skin Testing with Tuberculin, Dinitrochlorbenzene (DNCB) and the Kveim Test

The Mantoux test is negative in most patients with active Crohn's disease, even in those who have been immunized against tuberculosis. Anergy to DNCB

(no reaction after skin injection) occurs in 70% compared with 9% of controls. The Kveim test is a cutaneous injection of a prepared extract of spleen from diseased patients which provokes a granulomatous reaction, identified by histology at 6 weeks. It is positive in about half the patients with Crohn's disease.

6.8.3 Ultrasonography

Where Crohn's disease is suspected special views of the terminal ileum and other parts of the small bowel can demonstrate thickening and fistulas- the radiologist needs to be aware of the desired target!

6.8.4 Capsule Endoscopy

A 25 mm capsule containing a camera and transmitter is swallowed by the patient and followed down the GI tract. These images are necessarily rather random and there is no chance of biopsy of suspicious areas. This large capsule can become lodged on its travels, and should not be used where there is a risk of stricture.

6.8.5 Other Tests

Colonoscopy may allow direct visualization of the terminal ileum or involved large bowel.

A combination of cross-sectional luminal GI imaging, with CT colography and MR/CT scanning of the small bowel is an elaborate way of identifying foci of disease. The ⁷⁵SeHCAT test is abnormal in terminal ileitis.

Urinary oxalate excretion and faecal fat excretion are often increased. Radio-labelled granulocytes may locate diseased areas (both active Crohn's disease and abscesses). T- and B-lymphocyte functions are usually depressed, but this is variable. Laparoscopy or laparotomy are sometimes required in refractory ileo-caecal disease to exclude carcinoma, which may sometimes simulate Crohn's disease.

6.8.5.1 Investigations for Monitoring Progress

Because of the variability and chronicity of Crohn's disease, attempts have been made to establish investigations which might correlate with disease activity. Serial measurements of serum seromuroids and lysozyme, C-reactive protein, plasma viscosity, ESR and regular barium radiology have not proved very useful in practice.

The introduction of faecal calprotectin estimation has changed the game, and seems to correlate quite well with activity.

A simple **index of Crohn's disease activity** based on history and physical examination has been found satisfactory. This uses a scoring system based on:

- General well being (0 = very well, 4 = terrible)
- Abdominal pain (0 = rare, 3 = severe)
- Daily number of liquid stools

- Abdominal mass (0 = absent, 3 = definite + tender)
- Complications, e.g. arthralgia, aphthous ulcers (score 1 each).

A patient who is perfectly well scores 0, and a patient who is in severe relapse scores more than 10.

In addition, serial ultrasonography, serial WBC scanning and serial weighing in patients not on steroids, give some helpful objective data. Serial full blood counts including platelets (raised in active disease) is a practical simple objective yardstick.

6.9 Thiopurine Therapy

Treatment with azathioprine (AZA) and 6-mercaptopurine (6MP) is often considered in IBD. Results are variable, and it is suggested that testing for blood thiopurine methyltransferase (TMTP) is conducted in secondary care prior to therapy.

If values are absent or very low then the patient homozygous for the recessive gene controlling metabolism, and thiopurines should not be used. Moderate levels suggest heterozygosity, so half doses are best. Normal and high results show normal metabolism, and standard doses of AZA, 2 mg/kg, and 6MP, 1 mg/kg, may be started.

Response may be assessed by estimation of serum 6-methyl mercaptopurine (6-MMP). Low levels indicate poor compliance or inadequate dosage. Adequate serum 6-thioguanine nucleotide (6-TGN) values conversely confirm adequate treatment.

6.10 Metabolic Disorders

Gastrointestinal symptoms such as pain, diarrhoea and constipation may be the most prominent features of certain metabolic disorders. During the investigation of a patient with abdominal pain, it may be helpful to determine the serum calcium (elevated in hyperparathyroidism) and to note whether the serum is lactescent (in certain forms of hyperlipidaemia). Abdominal pain may be an early feature of diabetic ketosis and a manifestation of a haemolytic crisis as in sickle cell anaemia. Hypothyroidism may present with constipation, and diarrhoea can be prominent in pellagra.

6.11 Carcinoid Syndrome

Patients with metastases from a primary carcinoid tumour in the gut may present with a syndrome of intermittent diarrhoea, flushing, asthma and a pellagrinous rash. Occasionally diarrhoea dominates the clinical picture. Diagnostic tests are based on the knowledge that these tumours contain a high level of 5-hydroxy-tryptamine (5-HT, serotonin) which is converted to 5-hydroxyindoleacetic acid (5-HIAA) and excreted in excess in the urine.

6.11.1 Screening Test

A screening test for 5-HIAA is available based on the reaction of 5-HIAA with 1-nitroso-2-naphthol.

6.11.1.1 Method

A 0.2 ml sample of urine, 0.5 ml nitrosonaphthol reagent (1% nitrosonaphthol in 100% ethanol), 0.5 ml freshly prepared nitrous acid reagent (0.2 ml of 2.5% sodium nitrate and 2.5 mol/l sulphuric acid) and 0.8 ml distilled water are mixed together in a test tube and allowed to stand at room temperature for 10–15 min. Five millilitres ethylene dichloride is added and the layers allowed to separate. If turbidity occurs the tube is centrifuged.

6.11.1.2 Interpretation

A positive test is indicated by a purple colour in the top layer and indicates an excess of urinary 5-HIAA. In normal urine there is no purple colour or occasionally a light yellow appearance.

Three successive early morning samples should be tested. The patient should refrain from eating bananas which contain large amounts of 5-HT, or taking mephenesin, acetanilide or phenothiazine derivatives, all of which interfere with the colour reaction.

6.11.2 Twenty-Four Hour Urinary Excretion

The urine is collected into a bottle containing 25 ml glacial acetic acid to preserve the 5-HIAA, which is measured in the laboratory. Normally less than 9 mg 5-HIAA are excreted in 24 h. In carcinoid syndrome values are 40–873 mg/24 h. A moderate increase of urinary 5-HIAA, (9–20 mg/24 h) has been reported in patients with untreated adult coeliac disease, tropical sprue and Whipple's disease.

6.11.3 Platelet Serotonin

Fasting blood is collected in a heparin tube. The normal platelet serotonin content is <0.4 microg/mg protein. In the carcinoid syndrome values are 0.64–3.54 microg/mg protein.

6.12 Pheochromocytoma

Occasionally the possibility is raised that diarrhoea is due to the presence of a pheochromocytoma. Diagnosis of this tumour is based on measurement of the 24- h excretion of urinary catecholamines and metabolites, which are elevated in pheochromocytoma. The excretion of these substances is occasionally paroxysmal.

Any therapy with methyldopa is stopped for 3 days before the test because this drug can give false-positive tests. For 2 days before the test the patient should not receive caffeine products, red plums, tomatoes or food containing vanilla essence, such as ice cream.

The 24-h urinary output is collected in a bottle containing 12 ml concentrated hydrochloric acid. The urine may be tested for 2-methoxy-4-hydroxymandelic acid (vanilyl mandelic acid, VMA), which is a simple test, or for the output of metadrenaline or of catecholamines. Normally VMA is excreted at a rate of <6.5 mg/24 h, metadrenaline excretion is <1.3 mg/24 h, adrenaline excretion is <20 microg/24 h, and noradrenaline is excreted at <8 microg/24 h.

6.13 Lead Intoxication

Abdominal pain may be a prominent feature of lead poisoning. Nowadays measurement of serum lead is a readily available investigation, which is probably the best test. Screening tests of value include the demonstration of an excess urinary excretion of coproporphyrin III and delta-aminolaevulinic acid. A few millilitres of urine are acidified with acetic acid, mixed with an equal volume of ether and exposed to ultraviolet light. A positive test is given by a red fluorescence of the ether layer. Another useful screening test is the demonstration of basophilic stippling of the erythrocytes. Quantitative estimations of the excretion of lead in the urine may be undertaken: 0.2 mg/l is generally considered to be a significant concentration.

6.14 Immunology

This has had less impact on diagnosis than might have been expected. The Widal test remains a useful tool in typhoid, but is often difficult to interpret after immunization. Specific serum antigen assay may help.

Lymphocyte function and the absolute numbers of B- and T-lymphocytes circulating in the blood are disturbed in various bowel diseases.

Typing of human leukocyte antigens may be helpful: 80% of patients with coeliac disease are positive for HLA-A1 and HLA-B8, and there is an increased frequency of HLA-B5 in Behcet's disease.

6.14.1 Coeliac Disease

The commonest presentation is the rather banal iron deficiency, rather than steatorrhoea, weight loss, or failure to thrive in children. Many self-diagnose on the basis of malaise, but rarely seem to be right.

The immunoglobulin pattern is characteristic; with low, normal or mildly raised serum IgA levels in the presence of low IgM and IgG levels. After gluten exclusion the IgA level tends to fall and a subsequent rise may indicate poor adherence to diet or lymphoma formation.

IgA tissue transglutaminase, endomysial, IgA gliadin and IgA reticulin antibodies are general specific serum findings in patients with coeliac disease on a normal diet (and their relatives.) They tend to disappear on gluten-free diets.

Though near-patient testing for IgA, & IgG-deamidated gliadin peptide has been proposed, and is 99% specific, it is only 77% sensitive so cannot be recommended in a disease affecting 1–2% of the population.

IgG-class reticulin antibodies are found both in coeliac disease and inflammatory bowel disease.

6.14.2 Food Allergy and Intolerance

Anaphylactic responses to foods, including especially peanuts, may provide all the evidence needed for severe allergy, without any need for tests.

However, true food allergy is a contentious subject, and many alleged victims are suffering from psychiatric or other functional complaints. The presence of classic atopy, especially with rhinitis and a positive family history, is a helpful clue to true food allergy. Atopy is often associated with raised serum IgE levels, which are up to 100 u/ml in normal adults and up to 50 u/ml in normal children. Jejunal IgE levels are elevated in true food allergy confirmed by blind allergen food challenge and skin prick tests, mean values being four times normal (261 vs 68 u/ml).

Histology of the small intestine may show eosinophil or mononuclear cell infiltration, especially after allergen challenge, with degranulation of mast cells. Immunofluorescence can show deposition of IgE and immune complexes, together with infiltration of cells secreting IgA and other immunoglobulins. Double blind challenge with suspected food allergens can provide objective evidence to support or refute diagnosis, but is very laborious and requires in-patient supervision to be effective. It may be reserved for patients whose symptoms improve or disappear with an open hypo-allergenic diet for a week (e.g. the water, lamb, rice and pears regimen).

Skin prick testing has yielded many false positive results and is not generally helpful.

Radioallergosorbent testing (RAST) of the serum has also proved disappointing in establishing diagnoses.

6.15 Irritable Bowel Syndrome (IBS)

This diagnosis is generally made on the suggestive history of recurrent abdominal cramps and altered bowel habit without evidence of continuing organic disease. It is often precipitated by a resolved infective episode or stress. There is no weight loss or anaemia, nor any physical signs. Sigmoidoscopy excludes ulcerative colitis.

However, there is often anxiety over possible underlying physical problems such as Crohn's disease or ulcerative colitis. Measurement of *calprotectin* in a stool sample by ELISA or immunochromatography will differentiate IBS, where it is less

than 50 microg/g stool, from inflammatory bowel disease where it is usually much greater, reflecting inflammation and neutrophil infiltration of the gut

This could be used in primary care to select out patients who do not require specialist referral.

Bibliography

- Aas K. Studies of hypersensitivity to fish-allergological and serological differentiation between various species of fish. *Int Arch Allergy*. 1966;30:257.
- Aas K. The diagnosis of hypersensitivity to ingested foods: reliability of skin prick testing and radioallergosorbent test with different materials. *Clin Allergy*. 1978;8:39.
- Aburano T, Yokoyama K, Kinuya S, et al. Indium-111 transferrin imaging for the diagnosis of protein-losing enteropathy. *Clin Nucl Med*. 1989;14:681-5.
- Adman SH, Whorwell PJ, Wright R, Phil D. Diagnosis of Crohn's disease. *Dig Dis Sci*. 1980;25:911-5.
- Allun-Jones V, McLaughlan P, Shorthouse M, Workman E, Hunter JO. Food intolerance: a major factor in the pathogenesis of irritable bowel syndrome. *Lancet*. 1982;2:1115-7.
- Andre C, Descos L, Landais P, Fermanian J. Assessment of appropriate laboratory measurement to supplement the Crohn's disease activity index. *Gut*. 1981;22:571-4.
- Asmark E, Knutsson F, Thoren L. Phaeochromocytoma: diagnostic features. *Acta Med Scand*. 1967;182:673-80.
- Attwood SEA, Mealy K, Cafferkey MT, et al. *Yersinia* infection and acute abdominal pain. *Lancet*. 1987;1:529-33.
- Belut D, Moneret-Vautrin DA, Nicholas JP, Grilliat JP. IgE levels in intestinal disease. *J Dig Dis Sci*. 1980;25:323-32.
- Bradborg LL, Rubin CE, Quinton WE. A multipurpose instrument for suction biopsy of the oesophagus, stomach, small bowel and colon. *Gastroenterology*. 1959;37:1-16.
- Brignola C, Camperi M, Bazzochi G, Farruggia P, Tragone A, Lan Franch EA. A laboratory index for predicting relapse in asymptomatic patients with Crohn's disease. *Gastroenterology*. 1986;91:1490-4.
- Buscombe J. Radiolabelled human immunoglobulins. *Nucl Med Commun*. 1995;16:990-1001.
- Butterworth RJ, Williams GT, Hughes LE. Can Crohn's disease be diagnosed at laparotomy? *Gut*. 1992;33:140-2.
- Cacciari E, Salardi S, Volta U, et al. Can antigliadin antibody detect symptomless coeliac disease in children with short stature? *Lancet*. 1985;1:1469-71.
- Clarkson EM. A rapid method for the determination of chromium sesquioxide in faecal homogenates. *Clin Chim Acta*. 1966;16:571-2.
- Corazza GR, Menozzi MG, Strocchia A, et al. The diagnosis of small bowel bacterial overgrowth. Reliability of jejunal culture and inadequacy of breath hydrogen testing. *Gastroenterology*. 1990;98:302-9.
- Crosby WH, Kugler HW. Intraluminal biopsy of the small intestine. *Am J Dig Dis*. 1975;2:236-41.
- Crossley JR, Elliott RB. Simple method of diagnosing protein loss enteropathies. *BMJ*. 1977;1:428-9.
- Curzon G, Walsh J. A method for the determining of urinary indican. *Clin Chim Acta*. 1962;7:657-63. 1973;3: 191-5.
- Dawson OJ, Khan AN, Miller V, Ratcliffe JF, Shreeve DR. Detection of inflammatory bowel disease in adults and children: evaluation of a new isotopic technique. *BMJ*. 1985;291:1227-30.
- Evans N, Farrow LJ, Harding A, Stewart IS. New techniques for speeding small intestinal biopsy. *Gut*. 1970;11:88-9.
- NICE recommendation Faecal calprotectin diagnostic tests for IBD 2013.

- Flick AL, Quinon WE, Rubin CE. A personal hydraulic biopsy tube for multiple sampling at any level of the gastrointestinal tract. *Gastroenterology*. 1961;40:120-6.
- Florent C, L'Hirondel C, Desmazures C, Aymes C, Bernier JJ. Intestinal clearance of alpha-antitrypsin: a sensitive method for the detection of protein-losing enteropathy. *Gastroenterology*. 1981;81:777-80.
- Ghaffer MH. Labelled leucocyte scintigraphy in inflammatory bowel disease: clinical applications. *Gut*. 1996;38:1-5.
- Goka AKJ, Rolston DDK, Mathan VI, Farthing MJG. Diagnosis of giardiasis by specific IgM antibody enzyme-linked immunosorbent assay. *Lancet*. 1986;2:184-6.
- Gordts B, Hemelhof W, Retore P, Rahman M, Cadranel S, Butzler JP. Routine culture of *Giardia lamblia* trophozoites from human duodenal aspirates. *Lancet*. 1984;2:137.
- Hamilton I, Wolsey BW, Cobden I, Cooke EM, Shoemith JG, Axon ATR. Simultaneous culture of saliva and jejunal aspirate in the investigation of small bowel bacterial overgrowth. *Gut*. 1982;23:847-53.
- Hanser MF, Alderson PO. Gallium-67 imaging in abdominal disease. *Semin Nucl Med*. 1982;8:251-70.
- Harries AD, Fitzsimons E, Fifield R, Dew MJ, Rhodes J. Platelet count; a simple measure of activity in Crohn's disease. *BMJ*. 1983;286:1476.
- Harvey RF, Bradshaw IM. A simple index of Crohn's disease activity. *Lancet*. 1980;i:514.
- Holdstock G, Ligorria JE, Krawitt EL. Gallium-67 scanning in patients with Crohn's disease; an aid to the diagnosis of abdominal abscess. *Br J Surg*. 1982;69:277-8.
- Holt C, Samuel E. Grey scale ultrasound in Crohn's disease. *Gut*. 1979;20:590-5.
- Jamum S, Jensen KB. Faecal radioiodine excretion following iv injection of ¹³¹I-albumin and ¹²⁵I-immunoglobulin G in chronic inflammatory bowel disease. *Gastroenterology*. 1975;68:143-4.
- Jamum S, Westergaard H, Yssing M, Jensen H. Quantitation of gastrointestinal protein loss by means of ⁵⁹Fe-labelled iron dextran. *Gastroenterology*. 1968;55:229-41.
- Kerlin P, Phillips S. Variability of motility of the ileum and jejunum in healthy humans. *Gastroenterology*. 1982;92:694-700.
- Kerr RM, Dubois JJ, Holt PR. Use of the ¹²⁵I- and ⁵¹Cr-labelled albumin for the measurement of gastrointestinal and total albumin catabolism. *J Clin Invest*. 1967;46:2064-82.
- King CE, Toskes PP. Comparison of the Ig ¹⁴C-xylose, 10g lactulose-H₂, and 80g glucose-H₂ breath tests in patients with small intestine bacterial overgrowth. *Gastroenterology*. 1986;91:1447-51.
- King CE, Toskes PP. Small intestinal bacterial overgrowth. *Gastroenterology*. 1979;76:1035-55.
- Levitt MD, Hirsch P, Fetzer CA, Sheaman M, Levine AS. Hydrogen excretion after ingestion of complex carbohydrates. *Gastroenterology*. 1987;92:383-9.
- Linscheer WG, Abele JE. A new directable small bowel biopsy device. *Gastroenterology*. 1976;71:575-6.
- Mackowiak PA. The normal microbial flora. *N Engl J Med*. 1982;307:83-93.
- Maki M, Hallstrom O, Verronen P, et al. Reticulin antibody, arthritis and coeliac disease in children. *Lancet*. 1988;1:479-80.
- McCrae S, Younger K, Thompson DG, Wingate DL. Sustained mental stress alters human jejunal motor activity. *Gut*. 1982;23:404-9.
- Mee AS, Burke M, Vallon AG, Newman J, Cotton PB. Small bowel biopsy for malabsorption: comparison of the diagnostic adequacy of endoscopic forceps and capsule biopsy specimens. *BMJ*. 1985;291:769-7.
- Miller A, Green M, Robinson D. Simple rule for calculating normal erythrocyte sedimentation rate. *BMJ*. 1983;286:266.
- O'Farrelly C, Kelly J, Hekkens W, et al. Alpha-gliadin antibodies: a serological test for coeliac disease. *BMJ*. 1983;286:2007-10.
- Oias J, Unsworth OJ, Walker-Smith JA. Antigliadin and antireticulin antibodies in screening for coeliac disease. *Lancet*. 1987;2:157-8.
- Owen RL, Brandborg LL. Mucosal histopathology of malabsorption. *Clin Gastroenterol*. 1983;12:575-90.

- Pearson DJ, Rix KJB, Bentley SJ. Food allergy: how much in the mind? A clinical and psychiatric study of suspected food hypersensitivity. *Lancet*. 1983;1:1259–61.
- Peters AM, Osman S, Henderson BL, et al. Clinical experience with ^{99m}Tc-hexamethylpropyleneamineoxime for labelling leukocytes and imaging inflammation. *Lancet*. 1986;25:946–9.
- Prout BJ. A rapid method of obtaining a jejunal biopsy using a Crosby capsule and gastrointestinal fibroscope. *Gut*. 1974;15:571–2.
- Rachmilewitz D, Saunders DR. An improvement in the ease of passing a hydraulic biopsy tube. *Gastroenterology*. 1975;49:571–2.
- Rheingold OJ, Tedesco FJ, Block FE, Maldonado A, Miale Jr A. ⁶⁷Ga citrate scintiscanning in active inflammatory bowel disease. *Dig Dis Sci*. 1979;24:363–8.
- Rubini ME, Sheahy TW. Exudative enteropathy. A comparative study of ⁵¹CrCl₃ and ¹³¹I-PVP. *J Lab Clin Med*. 1961;58:892–901.
- Salter RH, Girdwood TG. Peroral jejunal biopsy with Watson capsule and Scott-Harden duodenal intubation tube. *Lancet*. 1983;2:1460.
- Savilahti E, Viander M, Perkkio M, Vainio E, Kalimo K, Reunala T. 19A anti-gliadin antibodies: a marker of mucosal damage in childhood coeliac disease. *Lancet*. 1983;1:320–2.
- Scaoili E, Cardamone C, Scagliarini M, Zagari RM, Bazzoli F, Belluzzi A. Can faecal calprotectin better stratify Crohn's Disease Activity Index? *Ann Gastroenterol*. 2015;28:247–52.
- Scott BB, Jenkins D. Endoscopic small intestinal biopsy. *Gastrointest Endosc*. 1981;27:162–7.
- Sivadasan K, Kurien B, John TJ. Rapid diagnosis of typhoid fever by antigen detection. *Lancet*. 1984;1:134–5.
- Stanghellini V, Camilleri M, Malagelada J-R. Chronic idiopathic intestinal pseudo-obstruction (CIIP): clinical and intestinal manometric findings. *Gut*. 1987;28:5–12.
- Staniforth DH, Rose D. Statistical analysis of the lactulose/breath hydrogen test in the measurement of oro-caecal transit: its variability and predictive value in assessing drug action. *Gut*. 1989;30:171–5.
- Taylor RH, Waterman S. Single intubation test for investigation of malabsorption and diarrhoea. *Gut*. 1983;24:680–2.
- Thompson DG, Binfield P, De Belder A, O'Brien J, Warren S, Wilson M. Extra-intestinal influences on exhaled breath hydrogen measurements during the investigation of gastrointestinal disease. *Gut*. 1985;26:1349–52.
- Thompson DG, Wingate DL, Archer L, Benston MJ, Green WJ, Hardy RJ. Normal patterns of human upper small bowel activity recorded by prolonged radiotelemetry. *Gut*. 1980;21:500–6.
- Unsworth OJ, Walker-Smith JA, Holborow EJ. Gliadin and reticulin antibodies in childhood coeliac disease. *Lancet*. 1983;1:874–5.
- Van Hees PAM, Van Elteren PH, Van Lier HJJ, Van Tongeren JHM. An index of inflammatory activity in patients with Crohn's disease. *Gut*. 1980;21:279–86.
- Wald A, Van Thiel DH, Hoehstetter L. Gastrointestinal transit the effect of the menstrual cycle. *Gastroenterology*. 1981;80:994–8.
- Walsham NA, Sherwood RA. Faecal calprotectin in inflammatory bowel disease. *Clin Exp Gastroenterol*. 2016;9:21–9.
- Whorwell PI, Maxton DG, Martin DL. Post-colonoscopy retrograde ileography. *Lancet*. 1988;1:738–9.

Major causes of persistent steatorrhoea are coeliac disease, chronic pancreatic disease including cystic fibrosis, pancreatic carcinoma and gastric surgery. There are many other causes, and acute self-limiting steatorrhoea is a common feature of infective diarrhoea.

7.1 Faecal Fat Excretion

This is not popular with routine laboratories, and not very widely available.

Fat is present in the faeces in three forms: as neutral fat (triglycerides, ‘unsplit’ fat); free fatty acids (‘split’ fat); and sodium, potassium and calcium salts of the fatty acids (soaps). The origin of the faecal fat is not fully understood. It is in part exogenous, being derived from unabsorbed dietary fat, but also partly endogenous from the bile, desquamated cells and the breakdown of bacteria.

7.1.1 Method

It is important that the patient is eating a normal diet: patients with steatorrhoea often control diarrhoea by reducing fat intake. Patients should be told that satisfactory results depend on diet, and it is worth arranging a consultation with the dietitian to ensure an adequate intake.

The faeces excreted over a period of 3 or 5 consecutive days are collected and sent to the laboratory. The samples should be in clearly labelled and dated containers. If the patient is constipated a longer period of collection may be undertaken and this must be made clear to the laboratory. Periods of collection shorter than 3 days are unsatisfactory and inaccurate, as the amount of fat contained in a single stool specimen can vary widely.

The faeces should be uncontaminated by barium and the patient must not be taking castor oil. Liquid paraffin does not affect the neutral fat level when the van de Kamer method is used.

The collection of stools should present no problems in hospital, where stools passed into bedpans can be transferred to labelled tins. The out-patient collection of stools is much more difficult and uncertain. The following technique has been suggested for out-patients. A polythene sheet is cut into the shape of a widemouthed cone 24 inches in diameter. This can be held conveniently in place between the seat and the basin of the lavatory, and after defecation the sheet and faeces are transferred to a container. One can is used for each day and at the end of the day the lid is sealed with adhesive tape. It is desirable but not essential that the cans are stored in a refrigerator until analysis.

In the laboratory the stool is mixed with water, homogenized, and the collection pooled. After thorough mixing, a 10 ml aliquot is analysed by hydrolysis, extraction and titration of the fatty acids. The result may be expressed as fatty acids but is usually expressed as amount of neutral fat excreted per day.

7.1.2 Interpretation

The normal maximum daily output of fat is 18 mmol or about 7 g in adults, but the upper limits vary in different laboratories. A patient who excretes more than the normal daily amount of fat in the stool is said to have steatorrhoea. There is very little difference in the amount of fat excreted in the stool when normal subjects take diets containing 50–250 g fat/day but in patients with malabsorption the stool fat content is more closely related to the dietary fat intake. The ordinary mixed diet in the UK contains 70–90 g fat/day.

The method gives poor recovery of short- and medium-chain fatty-acid triglycerides. This is normally not a problem as the average diet contains almost exclusively long-chain triglycerides, but some artificial diets contain fat as medium-chain triglycerides which do not require digestion prior to absorption. Markers such as cuprous thiocyanate, carmine or radio-opaque pellets have been used to ensure complete collections. In theory this is an attractive method, but it is handicapped by the fact that luminal contents are not homogeneous and that solids, oils and aqueous solutes travel at different rates.

7.1.3 Indications

The faecal fat output was a widely used index of the state of digestion and absorption in the small intestine. Steatorrhoea is a feature of a number of diseases involving the small intestine, the pancreas and the hepatobiliary system, and is also seen in many patients who have undergone partial gastrectomy or vagotomy and drainage procedure. The terms steatorrhoea and malabsorption are frequently used interchangeably. Steatorrhoea implies only an excess of fat in the stool, but the presence of steatorrhoea is usually one of cardinal features of malabsorption in which fluid, electrolytes, vitamins, carbohydrates and proteins may be poorly absorbed.

7.2 Macroscopic Appearance

The macroscopic appearance of a stool containing excess fat is sometimes characteristic: bulky, yellow or grey, soft and sticky with a rancid odour. The stool may be liquid, frothy and have floating oil droplets. On the other hand the stool may appear perfectly normal or even rather small and hard. Stools float in water because of increased gas content, which does not correlate with fat content.

7.3 Stool Weight

The stool weight in Britain ranges normally up to a limit of 250 g/day. Steatorrhoea is unlikely but not impossible if the stool weight is less than 80 g/day. A clinically useful guide to the severity of steatorrhoea is obtained by weighing the stool daily, even though the correlation between the stool fat content and the stool weight is not close. By following progress in this way it is possible to avoid overburdening the laboratory.

7.4 Prothrombin Time (PR, INR)

This reflects vitamin K absorption as well as liver synthesis. If the prothrombin time is more than 3 s longer than control and reverts to normal after treatment for 3 days with vitamin K 10 mg 1 M or IV daily, then vitamin K malabsorption is established. This may accompany any cause of steatorrhoea. An INR of 1.3 or more gives equivalent information.

7.5 Serum Vitamin D

In addition to dietary sources of vitamin D, there is an appreciable synthesis in the skin under the influence of daylight. Low values may be found in inadequate vitamin D intake and in individuals (especially with pigmented skins) who are not exposed to sufficient daylight. Values are markedly seasonal with higher values in summer.

The normal adult range of values is 25–75 nmol/l in summer and 15–60 nmol/l in winter. Laboratories can separate 25-OH-ergocalciferol (dietary origin), low in malabsorption, from 25-OH-cholecalciferol (endogenous synthesis).

7.6 Vitamin A Absorption

The fasting patient is given 7500 iu vitamin A/kg (maximum 350,000 iu) in 7 ml peanut oil and with a standard light breakfast.

Blood is taken before and 4, 5 and 6 h after the vitamin dose. Normal diet is allowed after the 4-h sample. All blood samples are protected from the light by

taking them into tubes covered with silver paper, and storing in the dark until analysis. The serum vitamin A level may be conveniently measured by fluorimetry.

The normal fasting serum vitamin A is 0.8–5.4 micromol/l, and the maximum increase after administration of vitamin A is 6–61.7 micromol/l. In malabsorption many of the fasting values fall in the normal range but the maximum increase is <6 micromol/l. This test is unreliable in pancreatic disease, though average values are reduced.

7.7 Oxalate Loading Test

Patients with steatorrhoea absorb excess dietary oxalate. Measurement of urinary oxalate after an oral oxalate load can be used as a screening test for steatorrhoea. Patients are given a standard diet containing 50 g fat, 1 g calcium and 30 mg oxalate for a week. On the last 3 days of this diet they are given sodium oxalate 300 mg twice daily with meals, and on the last day a 24-h urine collection is made. Patients with steatorrhoea excrete more than 0.44 mmol oxalate/24 h. Hyperoxaluria may also occur in patients with bile acid malabsorption. The test cannot be used in patients with substantially diseased or resected large intestine, as the colon is the main site of oxalate absorption.

7.8 Breath Tests

Anaerobic bacteria are found in great numbers in the large bowel (10^{15} /ml) and lesser numbers in the normal small bowel (10^2 – 10^5 /ml). They produce hydrogen and methane from dietary substrates, especially sugars, which can be measured in breath. These gases are absent in fasting subjects.

7.8.1 Procedure

Patients are studied after a 12 h fast (water only), and should not have taken antibiotics or had bowel preparation in the previous month. They should avoid laxatives for 3 days.

Breath hydrogen and methane are measured simultaneously in an analyser such as GastroCH4ECK.

Lactulose 10 g (3 × 5 ml teaspoons) is given by mouth. This is a non-absorbed hexose-pentose compound. Basal breath samples are taken, and then at 15 min intervals for 120 min. If a rise in H_2 plus CH_4 >20 ppm occurs the test is positive and may be terminated.

7.8.2 Results

A rise at 30 min >20 ppm indicates small bowel bacterial overgrowth.

A rise at 60–90 min shows normal oro-caecal transit: a rise <60 min shows rapid transit, and one >100 min shows delayed transit.

Glucose 50 g in 250 ml water can be used as substrate in patients without fructosaemia or hypoglycaemia to detect colonisation, when the reference is 10 ppm above baseline. Though the sensitivity of the two substrates is comparable at 62–68%, glucose is much more specific, 83 vs 44%.

A rise at 60 min shows jejunal colonisation and at 90 min ileal colonisation.

Lactose 50 g in 250 ml warm water can be used as a substrate in tests for lactase deficiency.

Breath samples are taken at baseline and 15, 30, 45, 60, 90 and 120 min (plus 150 and 180 min if necessary).

A rise >20 ppm in hydrogen or 12 ppm in methane indicates lactose intolerance.

A rise >10 ppm at 30 min can mean small bowel overgrowth or lactose intolerance.

7.9 Bile Acid Malabsorption

Some uncommon forms of diarrhoea are caused by excessive loss of bile acids into the colon from the small intestine. This can be measured by giving ⁷⁵selenium-labelled tauro-homocholeic acid, (SeHCAT) by mouth, and measuring retention in the body. Normal conservation of bile acids in the enterohepatic circulation means that 80% of activity is retained in the body at 24 h, 50% at 72 h, and 15% or more at 7 days. A convenient test is to count the patient's whole body with a gamma camera at 1 week to separate pathologically low retention from normal.

Although theoretically attractive, this test confers no definite advantage over a therapeutic trial of bile-acid binding resin such as colestyramine or colestipol.

7.10 Monosaccharides

7.10.1 Xylose Excretion

Xylose is a pentose sugar which is absorbed in the jejunum and excreted unchanged in the urine. The original xylose absorption test depended markedly on renal function and age. Results may be spuriously low in patients with ascites. A range of doses has been administered (5, 15 and 25 g) and xylose has been measured in both urine and blood. Results are often so difficult to interpret that many gastroenterologists have abandoned the test altogether.

If it is to be used in diagnosis then the method described by Haeney is the most attractive.

7.10.1.1 Method

The patient is fasted overnight, apart from fluids which are encouraged. Height and weight are measured and surface area is derived from *Geigy Scientific Tables*. After a baseline blood sample has been taken to estimate non-xylose reducing component, D-xylose 5 g in 250 ml water is drunk quickly. Venous blood is sampled 1 h later.

7.10.1.2 Interpretation

The result is corrected for surface area by the formula:

corrected blood value = measured value \times actual surface area (m^2) divided by standard mean surface area (1.73 m^2)

The normal corrected value is 0.65–1.33 mmol/l, and patients with malabsorption have values below this.

7.10.1.3 Indications

1. A screening test for steatorrhoea caused by small bowel disease.
2. To measure jejunal absorptive capacity in monitoring disease progress.
3. As a test for carbohydrate absorption.
4. To distinguish between maldigestion (where food is not broken down normally and hence cannot be absorbed though absorptive capacity is normal) and malabsorption without maldigestion.

7.10.2 Oral Glucose Tolerance Test

This has limited application, and should not be used in patients known to be diabetic. Blood glucose levels must be taken at defined intervals in relation to meals, and the patient must have been eating a normal diet during the 3 days before the test.

7.10.2.1 Method

Fasting blood is taken into an oxalate bottle for blood glucose estimation and a further sample is taken 2 h after a normal breakfast.

If the fasting plasma glucose is greater than 7 mmol/l or the postprandial plasma glucose is greater than 11 mmol/l the patient has diabetes mellitus and no further test is useful.

An HbA_{1c} of 6.7% or more is also taken as indicative of diabetes.

If there is doubt then a formal glucose tolerance test may be useful, and should be performed on a separate day:

1. A fasting blood sample is taken
2. The patient quickly drinks 75 g glucose dissolved in 250 ml water
3. Blood glucose is sampled every 30 min for 2 h
4. Urine is tested for sugar as often as conveniently possible

7.10.2.2 Interpretation

A fasting plasma glucose $>7 \text{ mmol/l}$ or a plasma glucose $>11 \text{ mmol}$ 2 h after glucose ingestion indicates diabetes mellitus. Glycosuria supports this but is often absent in the elderly. Diabetes mellitus develops in 15% of patients with acute pancreatitis, in 70% with chronic pancreatitis (almost always when there is steatorrhoea) and in 30% with pancreatic cancer.

When small bowel disease is responsible for malabsorption there is a flattened curve in non-diabetic patients, and the blood glucose does not rise more than 2 mmol/l over fasting values. However, this can also be seen in normal subjects and where gastric emptying is slow.

Where gastric emptying is rapid, as after gastric surgery, the first blood glucose level will be high (alimentary hyperglycaemia) followed by very low levels which may produce symptoms. This occurs because of an inappropriately timed release of insulin. If this is suspected it is best to measure blood glucose every 10–15 min after the glucose load.

7.11 Disaccharides

The main disaccharidases in man are lactase, sucrase and maltase. Deficiency syndromes involving one or more of these disaccharidases have been described. Two forms of deficiency syndromes are recognized; a primary variety in which an isolated enzyme deficiency exists in an otherwise normal mucosa, and a secondary variety in which the disaccharide deficiency is only one of many enzymes which is lacking in a mucous membrane damaged from recognizable causes. By far the most common syndrome is that involving isolated lactase deficiency: this is frequent in Mediterranean and tropical countries but less common in northern Europe. It is more often seen in black than white patients. Maltase and sucrase deficiencies are usually found in association with lactase deficiency, but infrequently occur in isolation and are then generally seen in children.

7.11.1 Lactose Tolerance Test

After an overnight fast the patient ingests 50 g lactose in 500 ml water. Venous blood samples are tested for glucose in the fasting state and every 30 min for 2 h. A normal result is a rise in blood glucose of at least 1 mmol/l. A rise of less than this is considered to represent a flat absorption curve and is suggestive of lactase deficiency. Patients with normal lactase absorption curves usually have normal mucosal lactase activities. Lactose may also be given in a dose of 1.5 g/kg body weight or, in children, as a dose of 50 g/m² body surface. This test may also be performed using maltose or sucrose instead of lactose.

A tolerance test using 25 g glucose and 25 g galactose (the hydrolytic products of lactose) may be undertaken to confirm a diagnosis of lactase deficiency. Patients with lactase deficiency have a normal rise of blood glucose levels, and are symptom-free after ingesting the mixture of glucose and galactose, in contrast to the effects of a lactose load.

Hydrogen/methane breath tests after 50 g lactose in lukewarm water yield similar information to the serum tolerance test.

7.11.2 Symptomatology

Patients who have significant lactase deficiency will often develop abdominal cramps, distention, flatulence and diarrhoea 1–6 h after ingestion of 50 g lactose. At such time the stools may contain both lactic and acetic acids which result in a low stool pH of below 4 (normal pH is 7). However, an acid stool is not invariably present, particularly in adults. While the development of symptoms after 50 g lactose suggests lactase deficiency, the failure to react does not exclude intestinal lactase deficiency but implies only that the clinical syndrome is absent. Fifty grams is the approximate lactose content of a litre of milk and this volume can be used as test dose, instead of the refined sugar.

7.11.3 Intestinal Disaccharidase Activity

After an overnight fast a jejunal biopsy is performed at or beyond the ligament of Treitz using either a Crosby capsule or the multipurpose suction biopsy tube. The biopsy specimen is orientated on filter paper and divided into two portions, one for histology and the other for enzyme estimation. The latter portion is immediately frozen on dry ice or liquid nitrogen.

It is best to measure the activity of all three disaccharides: this is done by incubation with the appropriate disaccharide substrate at 37 °C for 1 h and measuring the glucose liberated. The results are expressed in micromol/g wet weight of tissue/min (or in micromol/g protein/min). Normal ranges are: lactase 2.0–7.0 micromol/g/min, sucrase 2.5–9 micromol/g/min, and maltase 8.5–30 micromol/g/min. There is no alteration with age. Activities are lower in the stomach and duodenum, so accurate positioning of the capsule is essential.

Lactase activity below normal in the presence of normal maltase and sucrase activity indicates lactase deficiency. This may be primary or secondary to other bowel disorders. If all three enzyme activities are low the patient is unlikely to have primary lactase deficiency and the cause is probably secondary to other bowel disorders. In symptomatic lactase malabsorption, lactase activity is probably uniformly absent throughout the whole of the small intestine.

The syndrome of lactase intolerance was first recognized in children, but it is now apparent that symptoms may manifest for the first time in adult life. The prevalence of isolated lactase deficiency in symptom-free individuals is still uncertain. The results of population surveys have varied, some suggesting that selective lactase deficiency occurs in 30–55% of individuals while other studies suggest that only 15% of subjects have the enzyme deficiency.

Secondary depression of intestinal lactase activity is found in diseases of the small intestinal mucosa such as coeliac disease, tropical sprue, giardiasis and a number of other malabsorption states. Reduced enzyme activity has also been recorded in inflammatory bowel disease. Lactase is the first of the three important intestinal disaccharidases to be reduced in the presence of small intestine disease.

7.11.4 Indications

A test for lactase activity is indicated in patients with a history of mild intolerance, unexplained abdominal cramps and diarrhoea. When patients with coeliac disease or the irritable bowel colon syndrome fail to respond to conventional therapy or respond only poorly, removing lactose-containing foods from the diet may produce considerable symptomatic relief, hence documentation of the enzyme deficiency is advantageous.

7.11.5 Other Tests

Disaccharidase deficiency states may be demonstrated by mixing 25 g of the appropriate sugar (lactose, sucrose or maltose) with the barium suspension and X-ray screening the patient. Patients who have an enzyme deficiency show dilution of the contrast medium, rapid transit time and dilatation of the bowel lumen.

7.12 Haematinics

7.12.1 Vitamin B₁₂

Serum B₁₂ levels are low in many diseases causing malabsorption, often because of intestinal hurry: this is non-specific. However, a low serum B₁₂ level is commonly due to other causes such as pernicious anaemia.

7.12.2 Folic Acid Absorption

Folic acid is absorbed in the jejunum. In addition to dietary sources (mainly as polyglutamates) folic acid may be synthesized by intestinal bacteria, and in this way elevated serum levels can occur.

The patient is saturated with folic acid by a daily IM injection of 15 mg folic acid for 3 days. Thirty-six hours after the last injection, and an overnight fast, a blood sample is obtained and this is followed by oral administration of 40 microg folic acid/kg body weight. Blood samples are obtained 1 and 2 h later, and serum folic acid levels are measured. In normal subjects the peak serum concentration of folic acid is >40 microg/l. Values below this are abnormal and are found in coeliac disease and other diseases involving the upper small intestine. This is a pharmacological test and gives no information about the absorption of folic acid from dietary sources.

7.12.3 Iron Absorption

Iron is normally absorbed from the duodenum, or from the first normal part of the small bowel, which food enters after leaving the stomach. Iron deficiency is a

common feature of many disorders of absorption of the small intestine, but also occurs frequently as a result of deficient intake and blood loss. The blood film shows hypochromia and microcytosis; pale small red cells. The serum iron is low and iron-binding capacity is raised so that percentage saturation is below 15%. Serum ferritin levels correlate fairly well with body iron stores, and in iron deficiency are below 17 microg/l.

Current methods utilize isotopically labelled iron preparations. Iron in the diet may be presented to the intestine in the inorganic form (when the salts are first reduced to the ferrous state) or as haemoglobin iron, which is absorbed as haem or possibly as the whole molecule. Thus the carrier iron for labelled preparations may be either labelled inorganic iron or labelled haemoglobin iron. The nature of the carrier iron may well influence the result, and it is probable that the amount of unlabelled carrier iron is also important.

7.12.3.1 Whole Body Counting (Not Widely Available)

After an overnight fast 0.2–0.4 MBq ^{59}Fe -labelled iron is given orally, (usually as ^{59}Fe -ferric chloride) in a meal containing 5–7 mg elemental iron. The isotope may be mixed with the meal or taken in 100 ml water during the meal. A whole body count is made 4 h later. This value is taken to represent the 100% retention value. The final absorption count is made about 10–14 days later when all unabsorbed iron has been excreted. The results are expressed as a percentage of the initial dose absorbed. This is probably the best test available; it is quick and simple for the patient and avoids stool collections.

7.12.3.2 Faecal Recovery Method

Inorganic iron. After an overnight fast the patient is given 0.2–0.4 MBq ^{59}Fe , usually as ferric chloride as described above, and the stool activity counted.

Organic iron. ^{59}Fe -labelled rabbit haemoglobin is prepared. Ten millilitres of rabbit blood containing about 0.2 MBq radioactive iron is made palatable by the addition of a flavouring agent and taken with a standard meal containing about 5 mg iron. Stools are collected daily until <1% of the administered dose appears. Counting may take place in a ring of Geiger-Muller tubes or in a well-type scintillation counter if the stools are dried.

The results may be expressed in two ways, either as the percentage of the administered dose absorbed when the normal level is 8% (range 0–15%) or as the percentage of the administered dose appearing in the faeces when the normal is 87–100%.

7.12.3.3 Double Isotope Method

In this method ^{59}Fe iron is incubated with the patient's plasma and injected IV while ^{55}Fe iron is given orally in a meal similar to that mentioned above. A blood sample is tested after 14 days, and the activities of the two isotopes are measured in the red cells by differential counting. The ^{59}Fe counts indicate the percentage of the plasma iron which is used for haemoglobin synthesis, and the absorbed ^{55}Fe utilized for

haemoglobin synthesis is assumed to be the same. The ratio of the two isotopes in a blood sample gives a measure of absorption. This is normally between 1 and 13%. The accuracy of this test has been questioned, particularly in patients with liver disease.

7.12.3.4 Interpretation

Malabsorption of some form of iron occurs in a significant proportion of patients with partial gastrectomy and also in coeliac disease. Absorption is normal in achlorhydria and increased in states with erythroid hyperplasia. At some stage in haemochromatosis, in porphyria cutanea tarda, and in some patients with chronic pancreatic disease, there is increased iron absorption.

7.13 Other Tests for Malabsorption

There is no satisfactory method for measuring protein in absorption because amino acids are partly catabolised and partly reused in protein synthesis, and also many gastrointestinal diseases are associated with protein exudation. Radioisotope tests of absorption of various metal ions such as calcium and copper have been described but practice have little diagnostic usefulness.

7.14 Rare Disorders of Intestinal Absorption

There are a number of uncommon hereditary disorders involving the absorption of a variety of metabolites, and in many of these diarrhoea may be a prominent symptom.

7.14.1 Dibasic Amino Acids

There is a defect in the transport of lysine, ornithine, cystine and arginine in cystinuria. The intestinal defect may be demonstrated by a tolerance test to orally ingested arginine and also by peroral biopsies of the intestinal mucosa which show poor concentration of the dibasic amino acids.

7.14.2 Tryptophan

There is defective intestinal transport of this amino acid (monoaminomonocarboxylic) in Hartnup disease. The defect can be demonstrated by a tolerance test to orally administered tryptophan, but the tryptophan load has not been standardized. There is also a reduced intestinal transport of tryptophan in phenylketonuria, maple syrup disease and isolated intestinal tryptophan malabsorption.

7.14.3 Methionine

In patients with isolated methionine malabsorption (oast-house syndrome) there is profuse diarrhoea after the ingestion of methionine and an excess of (lhydroxybutyric acid in the urine.

Bibliography

- Braben B. Methods and functions: breath tests. *Best Pract Res Clin Gastroenterol.* 2009;23:337–52.
- Chanarin I, Anderson BB, Mollin DL. The absorption of folic acid. *Br J Haematol.* 1958;4:156–66.
- Craig RM, Atkinson AJ. D-xylose testing: a review. *Gastroenterology.* 1988;95:223–31.
- Drumme GO, Benson Jr JR, Jones CM. Microscopical examination of the stool for steatorrhoea. *N Engl J Med.* 1961;264:85–7.
- Editorial. When does lactose malabsorption matter in adults? *BMJ.* 1975;ii:351–2.
- Ferguson A. Diagnosis and treatment of lactose intolerance. *Br Med J.* 1981;283:1423–4.
- Gilbert J, Kelleher J, Walters M, Littlewood JM. Markers for faecal fat estimation in monitoring steatorrhoea in cystic fibrosis. *Gut.* 1988;29:1286–8.
- Haeney MR, Culank LS, Montgomery RD, Sammons HG. Evaluation of xylose as measured in blood and urine. A one-hour blood xylose screening test in malabsorption. *Gastroenterology.* 1978;75:393–400.
- Howell IN, Mellman J, Ehlers P, Flatz G. Intestinal disaccharidase activities and activity ratios in a group of 60 German subjects. *Hepatogastroenterology.* 1980;27:208–12.
- Ladas S, Papanikos J, Arapakis G. Lactose malabsorption in Greek adults. *Gut.* 1982;23:968–73.
- Lee MF, Temperley JM, Dick M. Estimation of faecal fat excretion using cuprous thiocyanate as a continuous marker. *Gut.* 1969;10:754–9.
- Lunn JA, Richmond J, Simpson JD, Leask JD, Tohill P. Comparison between 3 radioisotope methods for measuring iron absorption. *BMJ.* 1967;3:331–3.
- Mahlstedt J. ⁷⁵SeHCAT-test – Indication and value in clinical diagnosis. *Der Nuklearmediziner.* 1987;10:183–6.
- Merrick MY, Eastwood MA, Ford MJ. Is bile acid malabsorption under-diagnosed? An evaluation of accuracy of diagnosis by measurement of SeHCAT retention. *BMJ.* 1985;290:665–8.
- Moore JG, Englert E, Bigler AH, Clark RW. Simple faecal tests for absorption. A prospective survey and critique. *Am J Dig Dis.* 1971;16:97–105.
- National Diabetes Data Group. Classification and diagnosis of diabetes mellitus and other categories of glucose tolerance. *Diabetes.* 1979;28:1039–57.
- Pederson NT, Halgreen H. Faecal fat and faecal weight. *Scand J Gastroenterol.* 1984;19:350–4.
- Pryke ES, Whyte HM. A ganteel device for collecting faeces. *Gut.* 1970;11:966.
- Rampton DS, Kasidas GP, Rose GA, Samer M. Oxalate loading test: a screening test for steatorrhoea. *Gut.* 1979;20:1089–94.
- Rumessen JJ, Hamberg O, Gudmand-Hoyere E. Interval sampling of end-expiratory hydrogen (H₂) concentrations to quantify carbohydrate malabsorption by means of lactulose standards. *Gut.* 1990;31:37–42.
- Simpson FG, Hall GP, Kelleher J, Losowsky MS. Radio-opaque pellets as faecal markers for faecal fat estimation in malabsorption. *Gut.* 1979;20:581–4.
- Trinder P. Micro-determination of xylose in plasma. *Analyst.* 1975;100:12–5.
- Van de Kamer JH, Huinink H, Ten B, Weyers HA. Rapid method for the determination of fat in faeces. *J Biol Chem.* 1949;177:347–55.
- Watson WS, Hume R, Moore MR. Oral absorption of lead and iron. *Lancet.* 1980;2:236–7.

8.1 Rectal Examination

The importance of the rectal examination cannot be over-stressed: it should ideally form part of every complete bowel examination. A measure of the importance of the rectal examination is gauged by the fact that about 15% of all large bowel cancers can be felt digitally. It is usually possible to reach further with a finger than can be seen with an anoscope.

8.1.1 Method

Before the examination proper the procedure is explained to the patient who is warned that there may be a desire to defaecate. Many patients find this examination both embarrassing and uncomfortable, and they are considerably helped by a sympathetic and understanding attitude on the part of the examiner.

The patient is placed in the left lateral position with the head, trunk and hips well flexed. The buttocks are parted and the anal region inspected. The right index finger, covered by either a glove or finger cot, is well lubricated and inserted into the anus. It is advisable to use an anaesthetic jelly if a painful lesion such as a thrombosed haemorrhoid or fissure is suspected, and particular care is exercised in the introduction of the finger, which should be done very slowly. The examiner stands facing the patient's feet and introduces the finger from the posterior anal region. In the case of infants the little finger is used.

There are a number of other positions for rectal examination. In the left lateral position the left leg can be extended and the right thigh and knee flexed. The dorsal position is useful for a bimanual examination. The knee-chest position is convenient when a prostatic smear is being taken, though many patients find this posture fatiguing and embarrassing and it is not generally recommended.

The tone of the sphincter is noted, the anal muscle felt, and the finger is then introduced to the furthest extent. It is then swept round in a full circle to examine the whole circumference of the rectum. The sacral curve, the lateral pelvic walls and the pubis are all palpated and the patient is requested to bear down to enable a further inch of the rectum to be palpated.

Particular note is made of the character of the prostate or the cervix and uterus. The female adnexa may be palpated by bimanual examination. After withdrawing the finger the anus is cleaned. The material on the glove is examined and it can be used for microscopy and for testing for occult blood.

8.1.2 Interpretation

Cancer of the rectum will be felt as an indurated ulcerating lesion, a proliferating tumour or a stenosing infiltrative growth. Rectal polyps can be very soft and may be mistaken for a mass of faeces, and a similar error can be made when palpating an amoeboma. Internal haemorrhoids are not felt unless they are thrombosed, or are so large that they are felt as soft or 'wobbly' excrescences. Crohn's disease of the rectum causes a nodular and indurated rectal wall. Cancer of the prostate is identified by a 'rock-hard' prostate gland with or without fixation to the anterior rectal wall.

8.2 Proctoscopy (Anoscopy)

The instrument commonly referred to as a proctoscope is more correctly termed an anal speculum or anoscope. It is used to visualize the anal mucosa and in no way replaces the digital or sigmoidoscopic examination. A variety of instruments is available and an instrument with a good light and a reasonably small diameter should be chosen. There are convenient transparent plastic disposable instruments.

8.2.1 Method

The instrument is warmed in the examiner's hand or in warm water, and it is well lubricated using local anaesthetic jelly if necessary. The patient is reassured and warned about the sensation of defaecation. The proctoscope is gradually introduced into the anus with the patient in the left lateral position. The examiner stands facing the patient's feet, holding the handle of the proctoscope at the 12 o'clock position. The instrument is slowly inserted by a rotary clockwise movement so that a half circle has been described by the time the instrument is fully inserted. The handle now rests posteriorly between the gluteal folds. The obturator is withdrawn and an examination is made of the mucosa.

8.2.2 Interpretation

Details of mucosal changes in disease are given in the section dealing with the sigmoidoscope. Anoscopic examination is the best means of diagnosing internal haemorrhoids: the patient strains while the instrument is slowly withdrawn and the purplish vessels will be seen to bulge in the left lateral, right posterior and right anterior positions. Secondary, smaller, haemorrhoids may appear between these three primary positions. Other abnormalities to be seen include fissure, fistulas, anal and low rectal cancers, amoebic ulcers and proctitis.

8.3 Proctosigmoidoscopy

Proctosigmoidoscopy is an integral part of the examination of the colon. It should always be performed before referring a patient for a barium enema examination. A number of instruments are available. A rigid 25 cm instrument (with a fiberoptic light source) is commonly in routine use. Distal lighting systems have the disadvantage that they are more easily fouled and obscured, but they give superior illumination. Disposable instruments are now widely used.

A 60 cm flexible proctosigmoidoscope is available. This has the advantage that all the rectum and sigmoid colon can be seen: about 75% of large bowel cancers should be visible with this instrument. It is not certain at present whether the routine use of flexible proctosigmoidoscopy will reduce the need for colonoscopy, but flexible instruments are superior to rigid ones for examination of the distal large bowel. Video proctosigmoidoscopy may be more suitable for endoscopy units rather than outpatient clinic work.

8.3.1 Method for Rigid Proctosigmoidoscopy

8.3.1.1 Preparation

The patient is reassured and warned that some discomfort might be felt, which can be alleviated to some extent by deep breathing. There may also be the desire to defaecate. Normally no bowel preparation is necessary and the procedure can be undertaken readily on out-patients. Enemas and suppositories have the disadvantage that they alter the natural state of the mucous membrane, washing away secretions and causing hyperaemia, which is an important consideration when the diagnosis of ulcerative colitis is being considered: enemas not only add to the difficulties of making a diagnosis but are potentially dangerous. It is reasonable to give a saline enema if a cancer of the colon is being considered and a large amount of faecal material is present. Various disposal enemas are available for out-patient use, but they may all cause mucosal irritation.

8.3.1.2 Position

The patient may be examined on a surgical table; or an examination couch; or in the hospital bed, in which instance it is helpful to place a fracture board under the

mattress to ensure that the patient lies in the correct position. Two positions are recommended: the left lateral and knee-chest. The left lateral is preferred because it is more comfortable for the patient. For the proctosigmoidoscope to be successfully introduced, it is essential that the patient is correctly positioned: well flexed and lying transversely across the bed with the buttocks positioned at the very edge. The knees are slightly extended. A sandbag or pillow can be placed under the left hip, which is positioned at the edge of the couch. The left shoulder is tucked under the body and the right arm is brought forward. The head rests on a flat pillow. Failure to pass the proctosigmoidoscope fully is frequently the consequence of faulty positioning, particularly when the procedure is performed at the bedside. A soft mattress causes marked twisting of the spine, making it difficult to negotiate the curves in the rectum and lower colon. The position of the examiner is also important; he must be comfortable and relaxed and this is best achieved by either sitting on a low stool or kneeling at the bedside.

The knee-chest position may sometimes be helpful if there is much loose stool and blood, but is much less comfortable for the patient and is not recommended. In this position the knees are well drawn up and the back arched so that there is a distinct lumbar lordosis; the face is turned to one side, the chest and shoulders rest on the couch and the arms drop over the side of the couch. Multi-purpose tables are available which enable the patient to be tilted into the knee-chest position.

8.3.1.3 Procedure

Before introducing the instrument the light connections are checked and the proctosigmoidoscope is warmed. It is lubricated and an anaesthetic jelly is used if necessary. A digital examination of the rectum is made and the patient warned that the instrument is about to be introduced.

The obturator is inserted in the proctosigmoidoscope and the instrument held in the right hand. It is introduced into the anus using a rotary movement and the tip is directed forwards for 5 cm in the direction of the umbilicus. The obturator is removed and the eye piece attached. From this point the examination is performed under direct vision with gentle air insufflation. The instrument is now advanced in a backward direction and enters the rectum by following the curve of the sacrum.

As the instrument is advanced it may become necessary to separate the mucosal folds by inflating with air, but this is kept to a minimum as it is both uncomfortable for the patient and potentially dangerous. Small pieces of stool usually can be moved out of the way with the end of the instrument; they are sometimes of value in indicating the position of the bowel lumen. Stool which occludes the end of the proctosigmoidoscope may be removed by introducing the obturator, withdrawing the instrument slightly and then removing the obturator. Another way is to displace the stool with a swab which is attached to a swabholding forceps. Occasionally the forward passage of the instrument is prevented by spasm of the bowel, but if the proctosigmoidoscope is withdrawn slightly and held still for a short while the spasm will disappear and it is possible to proceed with the examination.

The rectal mucosa is smooth and it is easy to see the rectal valves. The rectosigmoid junction is reached 12–15 cm from the anal margin. This is at the level of the

sacral promontory and is identified by the change of the mucosa to concentric rugal folds. The rectosigmoid junction is usually sharply angled and may be difficult to traverse: the proctosigmoidoscope is directed anteriorly and to the right but the sharp angling may cause some discomfort. In many examinations it is impossible to lever the proctosigmoidoscope through the rectosigmoid junction without undue discomfort. The sigmoid colon is not reliably reached. The average penetration is 20 cm in men and 18.5 cm in women, but it is uncertain how far along the sigmoid colon the instrument passes, and it is probable that a mobile colon is simply displaced forwards. However, about 5 cm of the sigmoid may be seen. The instrument is now slowly withdrawn, the mucosa carefully rescrutinized and biopsies taken as required. After withdrawal of the instrument the patient is cleaned and any stool adhering to the sigmoidoscope is taken for examination. A full description of the procedure should include the distance to which the proctosigmoidoscope was introduced, the appearance of the mucosa, the presence of blood or mucus and the appearance of the stool, and whether a biopsy was taken and the site.

8.3.2 Method for Flexible Sigmoidoscopy

The patient is prepared by the use of two phosphate enemas given simultaneously, which should normally clear the lower bowel in 30–45 min. The patient is positioned in the left lateral position with the knees flexed, and the lubricated tip of the instrument is advanced into the rectum. It is often necessary to withdraw the instrument a little to obtain a good view of the rectum.

It is then possible to advance the instrument under direct vision, steering to keep the lumen in view at all times. With patience and gentle air insufflation it should be possible to view the entire rectum and sigmoid colon with only mild discomfort. Usually the descending colon can be seen also, and it may be possible to reach the splenic flexure or even enter the transverse colon, though unsedated patients do not always tolerate this. Suspect areas can be biopsied with endoscopy forceps: the largest compatible with the instrument are recommended.

8.3.3 Interpretation

When the mucous membrane is examined an overall impression is obtained; particular attention is paid to the vascular pattern and whether there is bleeding, granularity, ulceration and oedema as judged by thickening of the rectal valves.

8.3.3.1 Normal

The mucous membrane is pink, it is not friable and should not bleed with the gentle passage of the instrument. Undue bleeding during the examination suggests that the mucosa is abnormal. The normal vascular pattern is well visualized and comprises a network of small arterioles and to a lesser extent of venules. The rectal valves are sharp and crescentic in shape. A small amount of mucus may be seen.

8.3.3.2 Ulcerative Colitis and Ulcerative Proctitis

The appearances vary according to the stage of the disease. In the acute stage the mucosa is reddened, friable and haemorrhagic, and no vascular pattern can be seen. Thickening of the rectal valves almost to the point of obliteration indicates the presence of mucosal oedema. Ulcers are rarely distinguished and when seen appear shallow and irregular. There is nothing specific about these appearances, which are also seen in acute bacillary dysentery, occasionally in amoebic dysentery and in various toxic states. In the subacute and chronic stages of ulcerative colitis the normal vascular pattern is obscured, the mucosa is reddened and granular and bleeds readily when gently stroked by the sigmoidoscope or a swab. It is probable that some degree of mucosal abnormality such as excessive friability remains even with the most chronic and inactive colonic involvement. Proctosigmoidoscopy is of value in distinguishing ulcerative colitis from ulcerative proctitis, in which only the terminal 10–12 cm of bowel is diseased.

8.3.3.3 Dysentery

The appearance is very similar in bacillary dysentery to that seen in acute ulcerative colitis. The mucosa in amoebic dysentery contains small flask-shaped ulcers containing a small bead of pus, but is otherwise normal. However, the picture is variable and the mucous membrane may be quite reddened and inflamed, and may at times present a picture not unlike that of acute ulcerative colitis.

8.3.3.4 Large Bowel Malignant Disease

About half of all large bowel cancers may be seen with the rigid proctosigmoidoscope, and three-quarters are visible with the flexible sigmoidoscope. Malignant growths are seen as infiltrating or ulcerating lesions with a varying amount of haemorrhage and necrosis. Other new growths include lobulated pink or red adenomatous polyps and sessile, branching soft villous adenomas. A neoplasm should be suspected if altered or fresh blood is seen in the lumen of the bowel ahead of the proctosigmoidoscope. Screening populations at the age of 50–55 years using flexible sigmoidoscopy has been proposed as an effective way of detecting early cancer.

8.3.3.5 Other Diseases

Pneumatosis cystoides intestinalis shows as multiple glistening blue-purple submucous cysts. *Crohn's disease* of the colon is difficult to distinguish from the other forms of colitis, but a nodular 'cobblestone' appearance of the mucosa with discrete ulcers suggests this disease. The rectum is less frequently involved in granulomatous than in ulcerative colitis. In *diverticular disease* the mucosa may be reddened or normal, and the orifices of the diverticula will be seen with the flexible instrument. A false impression of the colonic mucosa is obtained when suppositories or enemas are given prior to examination. The mucosa may become reddened and oedematous and appear very abnormal. Difficulties are also found in patients with severe diarrhoea from any cause because marked mucosal hyperaemia may be present in the absence of specific colonic disease.

8.4 Rectal Biopsy

This is a simple and safe procedure and instruments capable of obtaining a biopsy should always be available when a proctosigmoidoscopy is performed.

8.4.1 Method (Rigid Instrument)

No anaesthetic is required if a biopsy is taken from the mucosa beyond the anal margin. A specimen is obtained from any growth that is seen, or from the mucosa itself, in which case it is easiest to biopsy one of the rectal valves, the uppermost being preferred. Many different biopsy forceps are available but unfortunately most are designed for biopsy of tumours and it is not always possible to obtain good samples of the mucosa. A useful instrument is a 40 cm Chevalier Jackson (basket-shaped) forceps. This is introduced via the rigid proctosigmoidoscope and the area selected for biopsy is grasped. It is simple to catch a free margin of a rectal valve. The instrument is rotated gently to free the specimen and withdrawn.

The sample is removed from the forceps with a needle and gently unrolled, placed on filter paper and immersed in formol-saline. The biopsy site is inspected. Bleeding is usually slight and stops rapidly but it may be necessary to apply compression with a cotton wool swab. It is doubtful whether 1:1000 adrenalin solution applied to the area is useful. The proctosigmoidoscope is withdrawn and the patient warned that the next stool is likely to be bloodstained. Significant bleeding and perforation are uncommon complications. A few days should elapse between the taking of a biopsy and a barium enema examination.

Rectal forceps with flexible jaws containing a fixing pin have been described. Other biopsy instruments that can be used include the Truelove-Salt biopsy instrument which works on the basis of suction. The instrument is advanced through a proctosigmoidoscope, and the cutting hole which is in the head of the instrument is placed on the site for biopsy. Suction is applied via a syringe and a small knuckle of mucosa is drawn into the orifice. The knife is advanced to amputate and trap the specimen.

8.4.2 Method (Flexible Instrument)

Biopsy forceps are passed through the channel to obtain samples, which are often smaller than obtained with rigid equipment.

8.4.3 Interpretation

Careful attention to handling, processing, and sectioning is necessary to ensure accurate interpretation. Serial sections are cut perpendicular to the submucosal

surface. Only the well-orientated sections are studied. Flattening the sample gently on a glass slide (or filter paper) prior to fixation assists optimal sectioning.

8.4.3.1 Normal

The glands are seen to be tubular and closely packed and the epithelium is columnar. There are numerous goblet cells. The lamina propria contains a moderate number of lymphocytes, plasma cells, reticuloendothelial cells and the occasional eosinophil. Variations within the normal range include slight dilatation or tortuosity of the glands, cuboidal surface epithelial cells and some increase in round cells in the lamina propria. The rectal glands are bulbous and shortened in specimens obtained from near the anal region. Homosexual men often have non-specific cellular infiltration in the lamina propria, without pathological significance.

8.4.3.2 Ulcerative Colitis

In severe cases there is marked loss of glandular structure, extensive mucosal ulceration with a heavy infiltration of cells particularly polymorphonuclear leukocytes, crypt abscesses, and a reduction in goblet cells and mucus. In moderate and mild inflammation there is oedema, dilatation of vessels, an occasional crypt abscess and superficial ulceration. There is an increase in lymphocytes, plasma cells and polymorphonuclear leukocytes. There is generally good correlation between the sigmoidoscopic and histological findings but this is not always so. The biopsy specimen is more likely to show inflammation when the proctosigmoidoscopic findings are normal than the reverse. Once the disease has developed, the mucosa remains permanently abnormal in the majority of patients whether or not symptoms are present. Biopsy samples obtained during a quiescent phase show a reduction in the number of rectal glands which tend to be bulbous, tortuous and branched. There is nothing specific about the mucosal biopsy in ulcerative colitis and all the features of the mucosal alterations in this disease may be found in colitis from other causes.

Rectal biopsies are valuable in the diagnosis of precancer dysplasia in patients with ulcerative colitis. There are two main types of abnormality: the polypoid variety, and precancerous change in a flat mucosa. Polypoid precancerous changes are recognized by the presence of multiple polyps which are usually sessile with a villous or papillary surface configuration. The villous growth pattern is the more significant. There is obvious inflammation in the lamina propria with loss of goblet cells. The nuclei are hyperchromatic with many mitotic figures.

Precancerous change in a flat mucosa is more common. The mucosa is thicker and has a fairly nodular surface. The epithelial tubes are irregular in shape and size with lateral budding and a villous growth pattern. There is a tendency for the epithelial tubes to proliferate into the submucosa. A moderate amount of inflammatory cell infiltration is present. The implication of these histological features in the management of chronic ulcerative colitis remains uncertain, but it is generally taken to indicate a need for close surveillance and possibly elective colectomy if severe or progressive.

8.4.3.3 Crohn's Disease of the Colon

The mucosa is usually normal or shows non-specific inflammatory changes. It is helpful but unusual to find non-caseating giant-cell systems in the biopsy specimen.

8.4.3.4 Tumours

A papillary or villous adenoma will show a broad base with characteristic long papillary projections springing almost directly from the basement membrane. An adenomatous polyp shows focal glandular hyperplasia; there may be short papillary projections but there are always numerous glands below the surface epithelium and the villi do not extend to the submucosal base. The stalk is often fibromuscular in character. Colonic cancers are usually adenocarcinomas and less frequently colloid cancers.

8.4.3.5 Schistosomiasis

It is claimed that 50% or more of patients with light infections with *S. mansoni* will be diagnosed if rectal biopsies are taken than if only the stools are examined. Rectal biopsies are useful also in *S. haematobium* infections. The ova are easily recognized when a fresh unstained biopsy of mucosa is compressed between two glass slides and examined under the microscope.

8.4.3.6 Other Diseases

Rectal biopsies have been used to advantage in the diagnosis of amoebic colitis, amyloidosis, histiocytosis, some of the neuropilidoses and metachromatic leukodystrophy. Hirschsprung's disease can be detected with the use of special stains for nerve fibres and acetylcholinesterase activity, but requires deeper biopsies than usually can be safely obtained sigmoidoscopically.

8.5 Radiology

Radiological examination is important in the diagnosis of colonic disease, despite advances in endoscopic techniques.

8.5.1 Plain Abdominal Radiograph

The plain radiograph of the abdomen is helpful in acute, toxic ulcerative colitis when varying degrees of colonic dilatation may be seen as well as other features of ulcerative colitis such as loss of haustrations and large pseudo-polyps. The site of a colonic cancer may be suspected when there is an abrupt end to the colonic gas shadow. In ischaemic colitis there may be gas in abnormal sites such as the bowel wall, and evidence of mucosal oedema ('thumb-printing'). Insufflation of 500–800 ml of air ('air enema') has been described as safe and useful in acute colitis.

8.5.2 Barium Enema (Figs. 8.1, 8.2, 8.3 and 8.4)

A barium enema is often required in the diagnosis of disease in the colon. It is important that the radiologist is given ample clinical information, particularly when ulcerative colitis or diverticulitis is suspected because the technique of preparation and examination may have to be modified. As a rule a barium enema should not be performed in acute ulcerative colitis or acute diverticulitis. The examination is not without danger, and it can exacerbate the colitis or cause a perforation of an acutely inflamed bowel. When a barium enema is performed it should routinely include air-contrast studies because these give far superior results and leave fewer uncertainties to be resolved by colonoscopy.

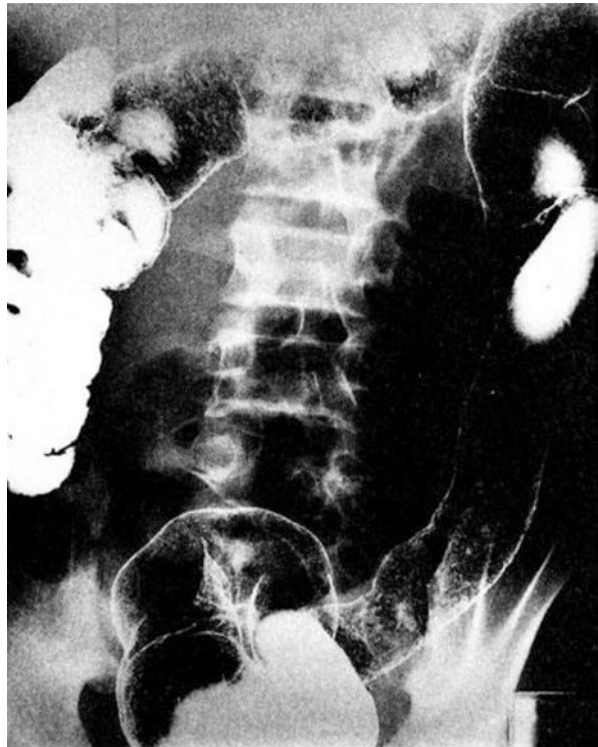
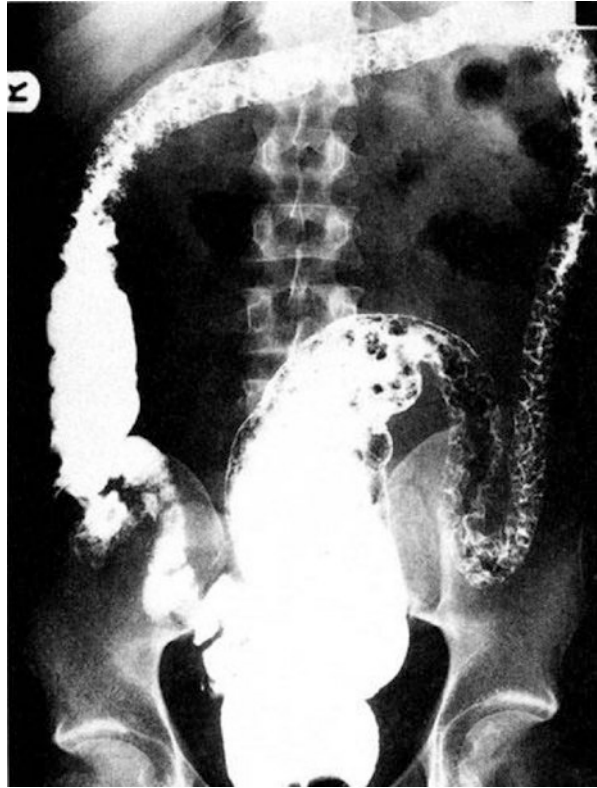
Fig. 8.1 Barium enema showing total ulcerative colitis

Fig. 8.2 Barium enema showing pan-colitis in Crohn's disease – typical 'cobblestone' appearance



8.5.3 Interpretation

8.5.3.1 Ulcerative Colitis

There are fine serrations along the bowel margin, loss of haustrations, pseudopolyps and extensive undermining of the mucosa. In long-standing disease there may be loss of haustrations, marked shortening of the bowel and rigidity producing the typical 'hose-pipe' colon; on the other hand the radiographic appearances may be virtually normal. In mild colitis flattening and blunting of the haustration give a 'corrugated' appearance. It must be remembered that a normal colon may have no haustration distal to the splenic flexure. Changes in the rectum of diagnostic value include thickening and irregularity of the mucosal folds, small ulcerations, and

Fig. 8.3 Barium enema showing a large filling defect due to carcinoma of the caecum

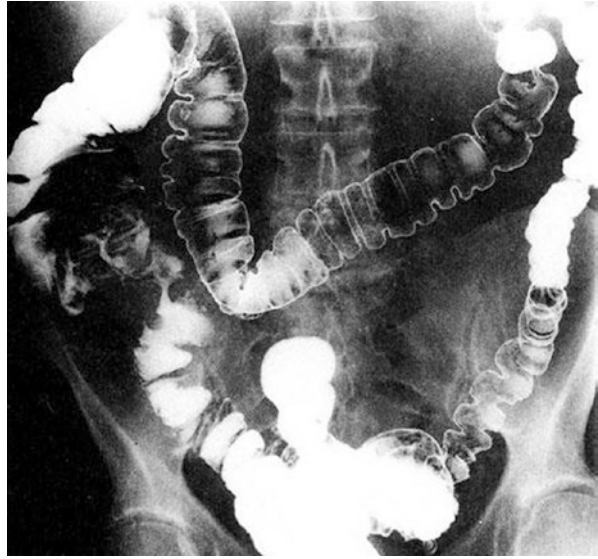
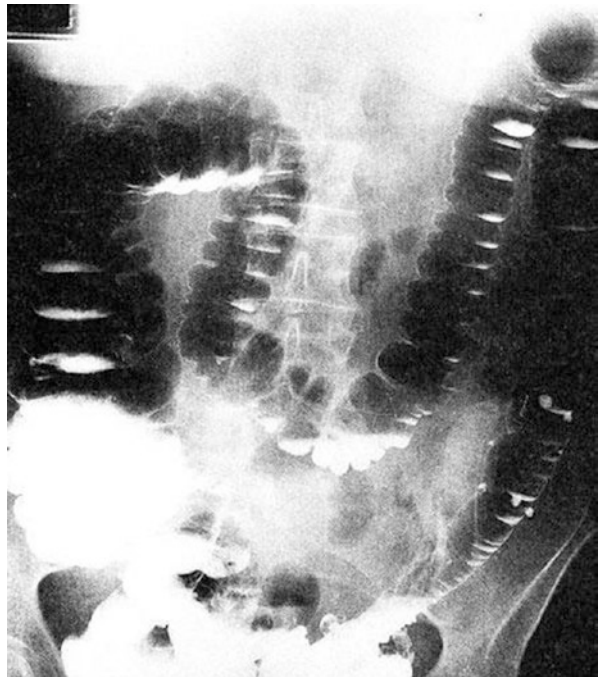


Fig. 8.4 Barium enema showing diverticular disease



contraction of the rectal wall. There is a >10 mm increase in the retrorectal soft tissue space. A barium enema is of value in determining the extent of the colonic involvement in ulcerative colitis.

While there is generally a good correlation in between colonoscopic, histological and radiological findings in this disease, this is not always so. Disease defined by colonoscopy tends to be more extensive than that seen by radiology. It is advisable to make a diagnosis of ulcerative colitis on the basis of all three investigations. Regrettably, the barium enema usually demonstrates a carcinoma superimposed upon ulcerative colitis only at a fairly advanced stage of growth.

8.5.3.2 Crohn's Colitis

At an early stage there are ileal and caecal impressions due to swollen lymph nodes at the ileocaecal junction, a decrease in the caecal lumen and a reversible narrowing of the colonic lumen associated with small ulcers. At a more advanced stage the involvement is seen to be segmental, there is thickening and blunting of the mucosal folds with asymmetrical involvement. Inflammatory polyps, linear and transverse ulcerations, pseudo-diverticula and strictures may all be seen. Characteristically, the right side of the colon is more frequently involved than the left. However, Crohn's disease may closely mimic ulcerative colitis.

8.5.3.3 Neoplasms

In the colon these appear as cicatrizing lesions or as proliferative 'polypoid' growths. The incidence of false-negative diagnosis in cancer of the colon (excluding the rectum) is about 10%. The site of the cancer determines to some extent whether or not it is detected. Growths in the rectum and at the rectosigmoid junction are particularly difficult to see, and associated diverticular disease adds to the difficulties. The Malmo technique, a modification of the double-contrast method in which special attention is given to direct preparation of the colon, has a very high detection rate for colonic polypoid tumours.

8.5.3.4 Other Diseases

In *diverticular disease* the diverticula usually fill with barium. A jagged 'sawtooth' appearances with apparently marked mucosal distortion represents failure of the colon to elongate because of muscle hypertrophy and is not evidence of inflammation. When inflammation is present there is narrowing and rigidity with intramural sinus tracts. In the chronic stages of ischaemic colitis a stricture may be seen: this characteristically involves the splenic flexure. The bowel may show a scalloped edge with mucosal irregularity, sacculation and tubular narrowing.

In *acute amoebiasis* shallow ulcers may be demonstrated and the appearances are those of ulcerative colitis. In the more chronic phase a contracted caecum may be seen or an amoeboma shows a filling defect, usually in the caecum or rectum. This condition is not usually diagnosed by radiology.

The *cathartic colon* shows an absence of normal haustral markings, a smooth bowel wall with no irregularity, no thickening of the bowel and very

characteristically, pseudostrictures which are tapering, transient contractions. The changes are found initially in the right side of the colon. Proctosigmoidoscopic demonstration of melanosis coli confirms the aetiology.

8.5.4 CT Scanning

This has been proposed as a practical alternative to barium enema, especially in the elderly.

Images can be processed and coloured to produce a “virtual colonoscopy”. While reassuring if normal, any findings are likely to require invasive endoscopy for biopsy and management.

8.5.5 MRI

This alternative to CT does not offer any unique extra advantages except it does not use ionising radiation. It has been employed in appendicitis before planning surgery.

8.5.6 Arteriography

This has enjoyed a resurgence with the appreciation of the great frequency with which angiodysplasia of the right side of the colon causes rectal bleeding in the elderly. Rapid serial radiographs are taken over 30 s, after injection of contrast medium into the superior mesenteric artery. Arterial, capillary and venous phases of filling are demonstrated. In *angiodysplasia* there are small clusters of arteries on the antimesenteric border of the caecum and the ascending colon, intense capillary filling, and early, intense and prolonged opacifications of the veins. It is of interest that aortic valve disease is frequently seen in patients with angiodysplasia.

Arteriography can diagnose and localize tumours of the colon, but it has largely been superseded by colonoscopy for this purpose.

8.5.7 Ultrasonography

External ultrasound has been used to identify acute appendicitis, and after fluid filling to examine the whole colon. Of more practical importance is the use of rectal probes to investigate rectal and prostatic cancer.

8.6 Colonoscopy

The direct inspection of the mucosa of the whole large bowel has contributed greatly to understanding of colonic disease.

The essentials for adequate examination are a clean colon and a co-operative patient. If these conditions are met it is possible to examine fully the left side of the colon in almost every patient, and in most examinations the caecum is reached. The procedure is, however, difficult and time-consuming. Success depends on experience, and it is common for the initial examinations by an investigator to be very frustrating.

8.6.1 Instruments

There is a range of lengths of instruments. Among the most useful are those of length 140 and 180 cm. These have a single biopsy and suction channel. If only the sigmoid and descending colon need to be inspected then 60 and 100 cm instruments may be used, as they are more easily manoeuvred. Biopsy forceps are available for the various colonoscopes. Other useful accessories include a diathermy snare and polyp-grasping forceps and a CO₂ insufflator for polypectomy.

8.6.2 Preparation

The procedure is discussed with the patient and an explanation given for the importance of adequate preparation. As with all invasive procedures it is best to supply written details and obtain written consent well before the test. Preparation usually begins 3 days before the examination. The following scheme is generally successful:

Day 1 Clear fluids only by mouth. Sennosides by mouth in the afternoon with a glass of water.

Day 2 Clear fluids only by mouth.

Day 3 Nil by mouth. Enema (1–2 l water) in the morning at least 3 h before the examination.

This scheme requires modification in children. It must not be used in patients with severe relapses of inflammatory bowel disease in whom colonoscopy is rarely indicated. If a patient has had appreciable bleeding, the bowel is often empty of faeces and no preparation is necessary.

8.6.3 Alternative Preparation (Golytely)

A safe technique involves the use of sodium sulphate lavage. A solution is made up with sodium sulphate, and polyethylene glycol (80 mM) to give an electrolyte concentration in mEq/l of: Na 125; K 10; SO₄ 80; Cl 35; HCO₃ 20. This may be flavoured and 2.5–4.0 l are drunk. Alternatively a nasogastric tube is passed and the patient is placed on a comfortable lavatory seat. The solution is then infused at 20–30 ml/min, and purgation is complete in 3 h. This preparation is rapid and obviates the need for any preliminaries before the day of colonoscopy.

The solution used is stated not to permit any appreciable net fluid secretion or absorption in the intestine. Physiological saline and mannitol purges proved hazardous and they should not be used.

Antibiotic prophylaxis in immunocompromise, and modification of anticoagulant or antiplatelet therapy, may be required as in upper digestive endoscopy.

8.6.4 Procedure

The patient is positioned in the left lateral position with the knees drawn up and the buttocks on the edge of the bed. Oximetry is desirable. A rectal examination is performed to ensure that there are no faeces present. Midazolam 5 mg and pethidine 50 mg IV are given slowly by IV cannula.

The dose may need reduction in the elderly or respiratory invalid, and naloxone 400 µg and flumazenil 500 µg should be available to reverse excess sedation. The lubricated instrument is introduced into the rectum and the light switched on to visualise the mucosa. If the bowel lumen is not clearly seen, gentle air insufflation and withdrawal are helpful.

The view may be partly obscured by traces of residual faeces or enema, but it is not worthwhile trying to clear the field completely. The lumen is followed as far as possible, using the directional controls, torsion and withdrawal. If the lumen cannot be brought into view, progress can nonetheless be made by 'sliding by' the mucosa, but should the mucosa blanch or fail to move past the lens the instrument should be withdrawn a little.

The sigmoid colon is tortuous and navigation is especially difficult in the presence of diverticular disease. Loops may be formed which prevent progress even when the lumen is well in view. Torsion and withdrawal usually improves the position.

Once the descending colon is reached it is usually possible to straighten out the sigmoid colon by judicious withdrawal and making the sigmoid colon concertina on the instrument. The success of this manoeuvre can be checked by rolling the patient on to the back and visualizing the position of the colonoscope using the image intensifier or magnetic locator.

In cases of difficulty in negotiating the sigmoid colon the 'alpha loop' manoeuvre may be helpful. The instrument is withdrawn to the lower sigmoid and the colonoscope twisted 180° anticlockwise before further entry. This creates a single spiral in the sigmoid and permits further passage up into the descending colon. The loop must be undone by clockwise rotation when the tip is in the descending colon. The descending colon is straight and usually traversed with ease. The splenic flexure is variable in conformation; it may be passed readily but often it is a sharp angle which necessitates much manipulation and air insufflation for passage. The dusky purplish appearance of the spleen and/or liver may be seen through the upper part of the splenic flexure and is a helpful landmark. The transverse colon is triangular in shape and freely mobile. It is possible to stretch the bowel without making progress in which event the instrument should be cautiously withdrawn, whereupon paradoxical advance of the tip is often seen. The hepatic flexure can be identified by the purplish appearance of the adjacent liver, but this part of the bowel is even more

variable than the splenic flexure and may be passed without being identified. The ascending colon is quite short and easily negotiated. If it appears that there is insufficient length of instrument to pass the whole colon, it is helpful to withdraw and suck out air. The caecum is recognized by the fact that it is a cul-de-sac, often with prominent folds. It contains the ileocaecal valve and appendix orifice, but neither of these is invariably seen, and it is useful to confirm by fluoroscopy that the whole colon has been passed. It is sometimes possible to enter the terminal ileum. A non-radiological magnetic imaging technique can also be used. If the terminal ileum can be entered gentle irrigation with saline will demonstrate the villous architecture and ensure completeness of colonoscopy.

The mucosa is inspected during withdrawal of the instrument, and in order to avoid loops rushing by the tip of the endoscope it should be removed gradually. It may be necessary to spray the mucosa with indigo carmine or iodine to better identify suspect areas worthy of biopsy.

8.6.5 Interpretation

Inflammatory bowel disease can be classified by colonoscopy according to its extent and severity. In *ulcerative colitis* there is a uniform inflammation of the mucosa which almost always affects the rectum and spreads proximally continuously. Frank bleeding may be seen, but the separate ulcers are often too small to identify. *Crohn's disease* may appear similar, but there are often discrete ulcers with relatively normal mucosa in between. Rectal spasm and discontinuous disease are common in Crohn's colitis.

Amoebiasis appears as raised ulcers overlying small amoebic abscesses. *Diverticular disease* causes problems in passing the sigmoid colon, which is tortuous and with prominent circular muscle. The mouths of the diverticula can usually be identified and sometimes may be so large as to simulate the bowel lumen. Vascular abnormalities (*angiodysplasias*) in the right side of the colon are increasingly being recognized as a cause of rectal bleeding in the elderly. They are seen as small leashes of vessels and venous lakes. Strictures and carcinomas are usually easily recognized; biopsies should always be taken.

Polyps are a very common finding. Small 2–3 mm sessile metaplastic polyps are common and of no significance. Larger and pedunculated polyps should be biopsied or removed by diathermy snare. In practice only polyps >10 mm in diameter are likely to be malignant. If the diathermy snare is used it is important to lift the polyp away from the bowel wall and to ensure that there is no persistent local bleeding.

The separated polyp is retrieved by basket snare and submitted for histology.

8.6.6 Indications

1. Evaluation and biopsy of strictures and polyps suspected of malignancy.
2. Assessment of the extent and nature of inflammatory bowel disease; and routinely at 10 years in ulcerative or Crohn's colitis, and thereafter at 1–5 yearly intervals as appropriate for individual patients.

3. Determination of the cause of rectal bleeding, either as an immediate investigation or when barium enema has been unhelpful.
4. Assessment of post-operative appearances, for example tumour recurrence, activity of inflammatory bowel disease prior to anastomosis.
5. Diagnostic and therapeutic polypectomy without laparotomy.
6. Identification of luminal lesions at open surgery.
7. Exclusion of multiple diseases, e.g. inflammatory bowel disease and coexisting diverticular disease.
8. Confirmation of ischaemic colitis.
9. Inspection of the terminal ileum in suspected Crohn's disease.

8.6.7 Complications

As with all invasive procedures of the gut there is a small risk of bleeding and perforation, which the patient must accept. In the latter case the possible requirement for surgical repair should be mentioned.

A common problem is bloating and discomfort from gas insufflation needed to obtain a good view. This can be reduced or avoided by aspiration of air at the end of the test, or using CO₂ instead, which is much more rapidly absorbed.

8.6.8 Cleansing of Instruments

Cleaning and disinfection are performed in a manner similar to that used for upper digestive endoscopes. Thorough washing is essential and a very soft toothbrush or cotton buds are helpful in cleaning the lens.

8.7 Manometry

Pressure recordings may be obtained from the colon and anorectal region by balloons, open-ended fluid-filled catheters and radiotelemetry capsules with pressure sensors. There is a wide overlap in the pressures obtained in normal and in disease states, but manometry can help in diagnosis and in monitoring progress. Results are observer-dependent, as in oesophageal manometry. Motility can be measured by following the progress of radio-opaque shapes, and by radiotelemetry capsules.

Normal colonic motor activity includes segmental contractions and mass movements. The pressure waves measured by balloons and catheters reflect uncoordinated non-propulsive segmental contractions, with an amplitude of 10–60 mmHg. They are present for 50% of the time, are apparently random and are increased by food, cholinergic stimuli and probably cholecystokinin. They are decreased by atropine, catecholamines, prostaglandin E₂ and during sleep. Segmental activity is reduced in diarrhoeal states and increased in constipation, diverticular disease and the irritable bowel syndrome.

Anorectal pressure measurement can be used in the diagnosis of *Hirschsprung's disease*. In normal controls, balloon distention of the rectum leads to reflex relaxation of the internal anal sphincter smooth muscle. In Hirschsprung's disease there is no relaxation, or even actual contraction, of the internal sphincter. This does not occur in idiopathic megacolon or other diseases. A diagnosis of Hirschsprung's disease can be confirmed by the absence of the autonomic nerve plexus on rectal biopsy samples which also contain abnormally high levels of acetylcholinesterase activity (normal up to 10.9 units/g tissue; Hirschsprung's disease 16.9–63.0 units/g tissue).

Abnormalities of anorectal pressure have also been reported in idiopathic constipation and in incontinence.

Specialised units also offer a host of other tests, including rectal sensation testing to air and water, rectal compliance with a barostat, anal electrosensitivity, balloon expulsion, 3D endoluminal ultrasonography, and the the gloriously named Functional Lumen Image Probing (EndoFLIP), which can also be used for the lower oesophageal sphincter and gastric banding.

8.8 Immunology

8.8.1 Inflammatory Bowel Disease

Despite the probable disorder of immune mechanisms present in ulcerative colitis and Crohn's disease, immunological studies have not proved useful in diagnosis. Fifteen percent of patients with ulcerative colitis have antibodies to colonic epithelial cell cytoplasm, and rather more are positive for IgG-class anti-reticulin antibodies. Patients with associated liver disease may have smooth muscle, nuclear, ANCA and mitochondrial antibodies. A high frequency of the human leukocyte antigen HLA-B27 is observed in patients with ankylosing spondylitis in association with inflammatory bowel disease. Haemagglutinating antibodies can be found, especially in children, and are not necessarily linked with auto-immune haemolytic anaemia. Levels of the acute phase reactant alpha-acid glycoprotein (orosomuroid) and haptoglobin are elevated in ulcerative colitis, and this correlates with clinical activity of the disease. By contrast pre-albumin tends to fall in active ulcerative colitis.

8.8.2 Carcinoembryonic Antigen (CEA)

This glycoprotein was first found in tumour tissue from patients with large bowel cancer, and it was later shown to be present in serum as well. It is detected in 50–90% of patients with large bowel cancer. When an upper limit of normal of 5 $\mu\text{mol/l}$ is set, only 1.1% of healthy non-smoking individuals have CEA in their serum. However, it is commonly found in apparently healthy smokers at levels in the range 5–17 $\mu\text{mol/l}$, and also in patients with carcinomas of the lung, pancreas and elsewhere in the gastrointestinal tract, in severe

alcoholic liver disease and in anaemia. It therefore has limited value as a screening test.

CEA levels usually fall to normal in patients whose large bowel carcinoma has been completely resected and who have no metastases. A subsequent rise in titre indicates recurrent tumour, and this can be detected months before clinical recurrence. Falls in CEA levels correlate with objective response to chemotherapy in 75% of patients.

The use of monoclonal antibodies for tumour localization may be helpful.

8.8.3 Amoebiasis (Table 8.1)

Entamoeba histolytica infection may be asymptomatic, or it may cause dysentery and liver abscesses. The stool should be examined for motile amoebae and cysts, and proctosigmoidoscopy can show typical appearances and yield diagnostic histology. However, there is often difficulty in confirming a diagnosis, and serology can be very helpful. A complement fixation test is available. It is not as helpful as indirect haemagglutination (IHA) and gel diffusion precipitation (GDP), and a combination of these two is used diagnostically. The use of serology for galactose-inhibitable adherence protein is said to be 99% sensitive, and may become the technique of choice.

E. histolytica may be an innocent commensal, especially in the homosexual male, and zymodeme typing by electrophoresis is useful to assess pathogenicity.

8.8.4 Hereditary Non-polyposis Colon Cancer (HPNCC)

Lynch syndrome causes 1000 deaths annually, and is strongly hereditary. It predisposes to early (<50 years) colon cancer, and various other cancers including ovarian and endometrial.

Tumours can be identified histologically by immunohistochemistry (IHC) or microsatellite instability (MSI). Genetic tests on blood of patients and their relatives can show a variety of patterns such as MLH1, MLH2, MSH6 and EPCAM.

Table 8.1 Diagnosis of amoebiasis

	Positive (%)	
	GDP	IHA
Amoebic liver abscess	85	95
Amoebic colitis	91	95
Other diarrhoea or liver abscesses	1	5
After effective treatment	Usually becomes negative at 6 months	Remains positive

Bibliography

- Aaronson I, Nixon HH. A clinical evaluation of anorectal pressure studies in the diagnosis of Hirschsprung's disease. *Gut*. 1972;13:138-46.
- Akervall S, Nordgren S, Oresland T, Hulten L. Manovolumetry: a new method for investigation of anorectal function. *Gut*. 1988;29:614-23.
- Almer S, Bodemar G, Franzen L, Lindstrom E, Nystrom P-O, Strom M. Use of air enema radiography to assess dept of ulceration during acute attacks of ulcerative colitis. *Lancet*. 1996;347:1731-5.
- Barr LC, Booth J, Filipe MI, Lawson JON. Clinical evaluation of the histochemical diagnosis of Hirschsprung disease. *Gut*. 1985;26:393-9.
- Baum S, Athanasoulis CA, Waltman AC, Galdabini J, Schapiro RH, Warshaw AL, Ottinger LW. Angiodysplasia of the right colon: a cause of gastrointestinal bleeding. *Am J Roentgenol*. 1977;129:789-94.
- Bladen JS, Anderson AP, Bell GD, Rameh B, Evans B, Heatley DJT. Non-radiological technique for three-dimensional imaging of endoscopes. *Lancet*. 1993;341:719-22.
- Cairn SR, Scholefield JH, Steele RJ, et al. Guidelines for colorectal cancer screening and surveillance in moderate and high risk groups. *Gut*. 2010;59:666-90.
- Cook MC, Goligher JC. Carcinoma and epithelial dysplasia complicating ulcerative colitis. *Gastroenterology*. 1975;68:1127-36.
- Dale G, Bonham JR, Lowdon P, Wagget J, Rangepcroft L, Scott OJ. Diagnostic value of rectal mucosal acetylcholinesterase levels in Hirschsprung's disease. *Lancet*. 1979;1:347-9.
- Davis GR, Sant Ana CA, Morawski SG, Fordtran JS. Development of a lavage solution associated with minimal water and electrolyte absorption or secretion. *Gastroenterology*. 1980;77:991-5.
- Dickinson RJ, Gilmour HM, McClelland DBL. Rectal biopsy in patients presenting to an infectious disease unit with diarrhoeal disease. *Gut*. 1979;20:141-8.
- Durdley P, Weston PMT, Williams NS. Colonoscopy or barium enema as initial investigation of colonic disease. *Lancet*. 1987;2:549-51.
- Farrand PA, Perkins AC, Pimm MY, et al. Radio-immunodetection of human colorectal cancers by an anti-tumour monoclonal antibody. *Lancet*. 1982;2:397-400.
- Findlay IG, McArdie DS. Role of CEA in detection of asymptomatic disseminated disease in colorectal carcinoma. *BMJ*. 1983;286:1242-4.
- Fork FT. Double contrast enema and colonoscopy in polyp detection. *Gut*. 1981;22:971-7.
- Goldmeier D, Sargeant PG, Price AB, et al. Is *entamoeba histolytica* in homosexual men a pathogen? *Lancet*. 1986;1:641-4.
- Hilderbrandt U, Feifer G, Ecker KW. Rectal endosonography. *Clin Gastroenterol*. 1989;3:531-41.
- Holdstock DJ, Misiewicz JJ. Factors controlling colonic motility: colonic pressures and transit after meals in patients with total gastrectomy, pernicious anaemia or duodenal ulcer. *Gut*. 1970;11:100-10.
- Holdstock G, Savage D, Harman M, Wright R. An investigation into the validity of the present classification of inflammatory bowel disease. *Q J Med*. 1985;54:183-90.
- Holdstock G, Savage D, Harman M, Wright R. An investigation into the validity of the rectal homosexual men. *Gut*. 1981;22:1035-41.
- Jass JR, Love SB, Northover JMA. A new prognosis classification of rectal cancer. *Lancet*. 1987;1:1303-6.
- Kalra L, Price WR, Jones BJM, Hamlyn AN. Open access fibresigmoidoscopy: a comparative audit of efficacy. *BMJ*. 1988;296:1095-6.
- Keighley MRB, Buchmann P, Lee JR. Assessment of anorectal function in selection of patients for ileorectal anastomosis in Crohn's colitis. *Gut*. 1982;23:102-7.
- Leigh RJ, Turnberg LA. Faecal incontinence: the unvoiced symptom. *Lancet*. 1982;1:1349-52.
- Leonard-Jones JE, Misiewicz JJ, Parrish JA, Ritchie JK, Swarbrick ET, Williams CB. Prospective study of out-patients with extensive colitis. *Lancet*. 1974;1:1065-9.

- Mach J-P, Jaeger P, Bertholet M-M, Ruegsegger C-H, Loosi RM, Rettavel J. Detection of recurrence of large bowel carcinoma by radio-immuno-assay of circulating carcinoembryonic antigen (CEA). *Lancet*. 1974;2:535-40.
- Macrae FA, Tan KG, Williams CB. Towards safer colonoscopy: a report on the complications of 5,000 diagnostic or therapeutic colonoscopies. *Gut*. 1983;24:376-83.
- Marner I-L, Friberg S, Simonsen E. Disease activity and serum proteins in ulcerative colitis. Immunochemical quantitation. *Scand J Gastroenterol*. 1975;10:537-44.
- Maule WF. Screening for colorectal cancer by nurse endoscopists. *N Engl Med J*. 1994;330:183-7.
- McMillan A, Lee FD. Sigmoidoscope and microscopic appearances of the rectal mucosa in homosexual men. *Gut*. 1981;22(12):1035-41.
- Metcalfe AM, Phillips SF, Zinsmeister AR, MacCarty RC, Beart RW, Wolff BG. Simplified assessment of segmental colonic transit. *Gastroenterology*. 1987;92:40-7.
- Morson BC, Pang LSC. Rectal biopsy as an aid to cancer control in ulcerative colitis. *Gut*. 1967;8:423-34.
- Nanda R, Baveja U, Anand BS. *Entamoeba histolytica* cyst passers: clinical features and outcome in untreated subjects. *Lancet*. 1984;2:301-3.
- Narducci F, Bassotti G, Gaburri M, Morelli A. A 24-hour manometry recording of colonic motor activity in healthy man. *Gut*. 1987;28:17-25.
- Nostrant IT, Kumar NB, Appleman HD. Histopathology differentiates acute self-limited colitis from ulcerative colitis. *Gastroenterology*. 1987;92:318-28.
- Overholt BF. Colonoscopy. A review. *Gastroenterology*. 1975;68:1308-20.
- Patterson M, Healey GR, Shabot JM. Serologic testing for amoebiasis. *Gastroenterology*. 1980;78:136-41.
- Preston OM, Butt JH, Lennard-Jones JE, Morson BC. New rectal-mucosal biopsy forceps. *Lancet*. 1983;1:157.
- Ravdin JL. Diagnosis of invasive amoebiasis - time to end the morphology era. *Gut*. 1994;35:1018-21.
- Read NW, Haynes WG, Bartolo DCC, et al. Use of anorectal manometry during rectal infusion of saline to investigate sphincter function in incontinent patients. *Gastroenterology*. 1983;85:105-13.
- Regent RHJ. The value of CEA in clinical practice. *Br J Hosp Med*. BJHM 1987; p. 335-8.
- Rex DK, Weddle RA, Leuman GA, et al. Flexible sigmoidoscopy plus air contrast barium enema versus colonoscopy for suspected lower GI bleeding. *Gastroenterology*. 1990;98:855-61.
- Reynolds JR, Armitage NC, Balfour TW, Hardcastle JD. Flexible sigmoidoscopy as out-patient procedure. *Lancet*. 1983;2:1072.
- Riddell RH, Morson BC. Value of sigmoidoscopy and biopsy in detection of carcinoma and pre-malignant change in ulcerative colitis. *Gut*. 1979;20:575-80.
- Schwerk WB, Wichtrup B, Rothmund M, Ruschoff J. Ultrasonography in the diagnosis of acute appendicitis. *Gastroenterology*. 1989;97:630-9.
- Shinya H, Wolff WI. Colonoscopic polypectomy: technique and safety. *Hosp Prac*. 1975;10:71-8.
- Weller IVA. The gay bowel. *Gut*. 1985;26:869-75.
- Wellin S. Results of the Malmo technique of colon examination. *JAMA*. 1967;199:369-71.

Bleeding from the alimentary tract is an important manifestation of gastrointestinal disease. It may present as an unexplained anaemia, as the passage of black stool, as the passage of red blood per rectum, or by vomiting of fresh or altered blood.

The investigation of gastrointestinal bleeding involves answering two major questions: (1) is the patient still bleeding? and (2) where is the bleeding site? Frank bleeding from the upper gastrointestinal tract, that is a site proximal to the duodeno-jejunal junction or ligament of Treitz, is usually obvious, presenting as a haematemesis or melaena stools. Fresh blood in the stools usually indicates rectal or colonic disease. However, it is possible for a bleeding lesion in the upper gastrointestinal tract to present with the passage of red blood per rectum; similarly a bleeding lesion in the caecum or ascending colon may cause melaena stools. The factors determining the degree of alteration of the blood in the gut include the site of the bleeding, the amount of blood lost and the motility of the bowel.

9.1 Occult Blood Tests

Between 100 and 200 ml of blood in the gut is necessary to produce a tarry stool. With smaller volumes the stools appear normal in colour, and special tests are necessary to detect the presence of blood. Tests for occult blood are used either to detect the cause of an iron-deficiency anaemia or to help in the diagnosis of those lesions of the gut which are frequently associated with bleeding such as peptic ulcer, carcinoma and polyps. An average of 0.7 ml/day of blood is normally lost in the gastrointestinal tract.

Occult bleeding can be detected by the use of chemical tests or radio-labelled erythrocytes, the microscopic examination of the stool for erythrocytes, the microscopic demonstration of crystals of haemoglobin or its derivatives, and fluorimetric and spectroscopic tests for haemoglobin or its derivative porphyrins. Of these the most widely used are the chemical tests, although the radioactive method is the most accurate and reliable.

9.1.1 Chemical Tests

Chemical tests are used universally because of their simplicity, but it is extremely difficult to devise a standard test which is neither too sensitive nor too insensitive. Faecal samples for testing may be obtained from a stool sample. This is best taken from within a lump of faeces, from the material adhering to the sigmoidoscope or proctoscope, or from the faeces on the glove after rectal examination. It is possible by vigorous digital examination to cause sufficient trauma to the rectal mucosa to give a positive test for blood in the stool, and gentle examination is essential when procuring a sample of faeces for chemical examination.

A variety of commercial tests is available. They are based on peroxidase-like activity in haemoglobin which causes the reagent used to develop a blue colour reaction. The most convenient sensitive test available is the guaiac test Hemachek, which is supplied as a kit so that the patient may send their own samples by post for examination. A specimen of stool is smeared on filter paper in a card. The reagent is added in the laboratory and development of a blue colour indicates the presence of blood in the stool. This method reliably detects amounts of bleeding of 10 ml or more daily, and usually gives positive results if there is a loss of more than 2.5 ml daily. Haemocult is a very much less sensitive guaiac test.

The Fecatwin system depends on two levels of sensitivity for guaiac testing, with additional confirmation of the presence of human haemoglobin by an immunological technique. It is rather too elaborate for routine use. Orthotolidine tests have become less popular following the development of the guaiac-haemoperoxidase tests, but laboratories can offer this test cheaply if immediate results are not essential.

9.1.1.1 False-Positive Reactions

The main objection to sensitive tests is the occurrence of false-positive reactions. These reactions are almost exclusively dietary in origin originating from the ingestion of red meat, uncooked vegetables, unboiled milk and fruit such as bananas. Opinions differ whether or not oral iron preparations can produce positive results, but it is probable that a weakly positive result may follow the ingestion of ferrous compounds.

It must be stressed that negative tests for occult blood do not exclude ulcerative or neoplastic lesions of the gastrointestinal tract. Occult blood testing in screening ostensibly healthy subjects is used to detect early large bowel cancer, to identify those requiring colonoscopy.

In patients with a history consistent with gastrointestinal bleeding, or with iron deficiency anaemia or suspected gastrointestinal disease, a different approach is used.

1. Haemorrhoids, gingivitis and epistaxis are excluded.
2. Drugs, such as aspirin, which cause gastrointestinal bleeding are stopped.
3. Three separate stool samples are tested by routine methods.
4. If not all are positive, a radio-labelled erythrocyte study will yield further information; if this is not available, repeating the test after 3 days on a meat-free diet of only cooked vegetables (and taking bulk purgatives) may be helpful to exclude false positives.

In practice barium radiology and endoscopy are necessary in the diagnosis of difficult cases.

There is usually little doubt as to whether there is fresh blood in vomit. When altered blood or coloured material is present there may be uncertainty and the tests for occult blood mentioned above may be applied to gastric aspirate or vomit. 'Coffee ground' vomit is not proven haematemesis until shown to contain blood in this way.

9.1.2 Test for Dietary Iron

Although the faecal occult blood tests should not give false-positive reactions there is sometimes difficulty in evaluating very dark stools. To exclude the presence of ingested iron as a complicating factor, a simple test may be helpful. This can also be used in testing for compliance with prescribed iron preparations and in detecting surreptitious self-medication.

9.1.2.1 Method

A small button of faecal material is emulsified in 2 mol/l hydrochloric acid and a drop of the emulsion is placed in the centre of a filter paper. After 1–2 min a thin clear halo of fluid soaks into the paper around the drop. A drop of 2.5% potassium ferricyanide in aqueous solution is placed on the paper so that the haloes around the two drops meet at their periphery.

9.1.2.2 Interpretation

A positive result is the immediate appearance of a blue crescent at the interface between the two fluids. This indicates that there is iron in the stool and suggests that the patient is taking oral iron preparations. It is claimed that the test is not invalidated by blood in the stool.

9.2 Isotope Tests

9.2.1 ^{99m}Tc Technetium Colloid Test

When bleeding is brisk, then simply injecting ^{99m}Tc colloid IV and scanning the abdomen shortly afterwards can localize sites of haemorrhage.

9.2.2 Radio-Labelled Erythrocytes

Localization of sites of GI bleeding by endoscopy and radiology is not always possible, and scanning after injection of ^{99m}Tc -labelled red cells is often helpful.

9.2.2.1 Method

Patients are given 1 mg IV stannous chloride. Twenty minutes later a heparinized syringe containing ^{99m}Tc -pertechnetate is attached to an intravenous cannula and 5 ml of blood is withdrawn into it. The whole blood is incubated in the syringe with the radiolabel at room temperature for 10 min then re-injected.

Gamma camera scanning of the abdomen is then undertaken. Rapidly bleeding sites can normally be located by scanning every 5 min for 30 min then at 1 and 2 h. If possible, lateral and oblique images as well as anterior ones are obtained to give a 3D representation.

For recurrent bleeding or when the initial images were negative then a 24 h scan is performed.

9.2.2.2 Interpretation

Focal accumulation of isotope indicates a bleeding site, but a negative investigation does not exclude it. The test is most useful for large bowel sites of bleeding, but can also be helpful in the small intestine.

9.2.3 ^{99m}Tc -Pertechnetate Scanning

Where Meckel's diverticulum is suspected, especially in children, this will locate any gastric heterotopia.

9.3 Other Tests

9.3.1 Radiology

Barium studies, including a barium meal and follow-through, small bowel enema and a barium enema, are important in the investigation of gastrointestinal bleeding. Barium enemas should be by double-contrast technique unless there is a specific contraindication. There are also advantages associated with double-contrast barium meals, though they are not so widely used. The demonstration of a lesion does not prove that it is the bleeding site. This applies particularly to sigmoid diverticula. It is extremely difficult to decide upon the site of bleeding when two lesions are demonstrated, for example oesophageal varices and peptic ulcer. Portography may be performed when oesophageal and gastric varices are suspected. Arteriography is used to demonstrate lesions such as vascular anomalies, ulcers and neoplasia, and has been particularly recommended in the diagnosis of caecal tumours. Arteriography has also been used with success in the location of acute gastrointestinal haemorrhage by observing the site at which the dye leaks into the bowel lumen; it can be used to diagnose bleeding oesophageal varices.

9.3.2 Endoscopy

Upper digestive endoscopy, sigmoidoscopy and colonoscopy may all be required to determine the site of bleeding. Endoscopy is helpful because it may demonstrate

that a lesion is actually bleeding. The performance of upper digestive endoscopy within 24 h of admission with haematemesis greatly improves the diagnosis rate.

9.3.3 Enteroscopy

9.3.3.1 Equipment

The small intestine may be examined with longer endoscopes than used for oesophago-gastric duodenoscopy. Fluoroscopic screening will identify the extent of examination. If push equipment is used then IV midazolam and pethidine make the procedure more pleasant.

Push enteroscopes Dedicated instruments about 2 m long are available. They are passed in the same way as a pan-endoscope then advanced slowly into the distal duodenum and jejunum under direct vision. Because of the tendency to loop in the stomach over-tubes have been devised to speed passage, but their use is controversial. Loops of bowel can be made to concertina in the instrument, though the ileum is not always reached. The bowel is carefully inspected on withdrawal. Both paediatric and adult colonoscopes have been used successfully in departments which do not possess a dedicated enteroscope.

Sonde enteroscopes These are about 3 m long and are of much smaller calibre. After passage into the duodenum a balloon is inflated at the distal end. The tip advances by peristalsis and by encouraging the patient to swallow the tube intermittently. Complete passage takes hours. The actual inspection of the small bowel takes only up to half an hour, because it is performed on withdrawal after deflation of the balloon. In the absence of obstructive lesions much of the ileum may be inspected, though it is not a technique of choice for investigating the terminal ileum in the intact small bowel.

9.3.3.2 Indications

1. Obscure GI bleeding where gastroscopy, colonoscopy and barium enema are negative. Typical findings are angiodysplasia, and tumours which may be biopsied.
2. Anaemia and other GI symptoms in patients on long-term NSAID therapy. Small bowel ulcers and diaphragms may be seen.
3. Evaluation of extent and severity of Crohn's disease.
4. Treatment by argon beam or laser therapy of bleeding sites and balloon dilation of strictures.

9.4 Videocapsule Endocopy (VCE)

Where other tests have been unhelpful this technique can be useful, though analysis may need to be prolonged. The patient swallows a large pill which contains a video camera, and images are taken as it passes down the gastrointestinal tract. This is most helpful for the small bowel. If the large bowel is to be examined properly then

it needs preparation to obtain a good view; capsules with cameras at either end have been described to examine both sides of the haustral folds. VCE should be avoided where there is a serious risk of marked stricturing as in Crohn's disease or NSAID ulceration of the small bowel.

9.5 Gastrointestinal Bleeding in Liver Disease

If a patient is suspected to be bleeding from oesophageal varices, the sooner the correct diagnosis is made the more promptly appropriate therapy can be given. If varices are known to be present then the early use of terlipressin and a Sengstaken tube may be the best policy. However, it is preferable to obtain an urgent endoscopy since other lesions commonly bleed even in the patient with varices. Any blind intubation procedure may produce erosions or even Mallory-Weiss tears which can be mistakenly taken as the primary bleeding site at subsequent endoscopy.

Bibliography

- Afifi AM, et al. A simple test for ingested iron in hospital and domiciliary practice. *BMJ*. 1966;1:1021-2.
- Alavi A. Detection of gastrointestinal bleeding with ^{99m}Tc-sulfur colloid. *Semin Nucl Med*. 1982;12:126-38.
- Allison JG, Tekawa IS, Ransom U, Adrain AL. A comparison of faecal occult blood tests for colorectal cancer screening. *N Engl J Med*. 1996;334:155-9.
- Ferguson A, Brydon WO, Brian H, Williams A, Mackie MJ. Use of whole gut perfusion to investigation gastrointestinal blood loss in patients with iron deficiency anaemia. *Gut*. 1996;38:120-4.
- Hakkinen I, Paasivuo R, Partanen P. Screening of colorectal tumours using an improved faecal occult blood test. Qualitative aspects. *Gut*. 1988;29:1194-7.
- Irving JD, Northfield TC. Emergency arteriography in acute gastrointestinal bleeding. *BMJ*. 1976;2:929-31.
- Macrae FA, St John DJB, Caligiore P, Taylor LS, Legge JW. Optimal dietary conditions for haemoccult testing. *Gastroenterology*. 1982;82:899-903.
- Malamitsi J, Fatsis M, Vassilarou D, Demakopoulos N, Antoniou P, Rossonis S, Koutoulidis C. The use of radionuclide angiography with autologous red blood cells in localizing (upper and lower) gastrointestinal bleeding. *Hellenic J Gastroenterol*. 1990;3:243-8.
- McIntyre AS, Long RO. Prospective survey of investigations in out-patients referred with iron deficiency anaemia. *Gut*. 1993;34:1102-7.
- Sally R, Scott BB. Iron deficiency anaemia- how far to investigate? *Gut*. 1993;34:1427-8.
- Rockey DC, Cello J. Evaluation of the gastrointestinal tract in patients with iron deficiency anaemia. *N Engl J Med*. 1993;329:1691-5.
- Winzelberg GG, Froelich JW, McKusick KA, et al. Radionuclide localization of lower gastrointestinal haemorrhage. *Radiology*. 1981;139:465-9.

It is no longer fashionable for clinicians to make a detailed inspection of the stool. Usually more is gained from a chemical analysis of faeces, for example, for haemoglobin, porphyrins and, at times, water and electrolytes. There are occasions, however, when to confirm that a patient's account of diarrhoea, blood, mucus or worms is correct, it is necessary to see the stools.

10.1 Macroscopic Appearance

Normally the stool is firm or semi-formed and is coloured varying shades of brown. It may be possible to recognize undigested food particles and their frequency reflects the nature of the diet, the amount of mastication and the degree of intestinal hurry. The shape of the stool varies greatly and is of little diagnostic significance.

Blood from anorectal diseases is seen as streaks on the surface of the stool. Blood from lesions higher up the colon will be intimately mixed with the stool, as is characteristically found in inflammatory bowel disease. The passage of pure blood with no faecal material may occur in polyps, haemorrhoids, colonic cancer, diverticular disease, infarction of the colon and intussusception. Patients with bleeding peptic ulcers occasionally pass bright red, unaltered blood per rectum. The stools may be coloured red after the ingestion of beetroot.

The stools are pale in the presence of intra- and extrahepatic cholestasis and in severe steatorrhoea. Tarry black melaena stools indicate the partial digestion of blood in the gastrointestinal tract. The appearance is usually characteristic, but if there is any doubt the stool is mixed with a small volume of water which will be coloured red. Chemical tests for blood should be performed. Iron-containing stools are grey-black, and this can usually be distinguished from melaena. Other causes of black stools include the ingestion of charcoal, bismuth compounds and large quantities of liquorice.

In cholera the stools are virtually colourless and liquid, and contain flakes of mucus, shed epithelial cells and enormous numbers of vibrios ('rice water' stool).

A very similar appearance is seen in staphylococcal enterocolitis, which may be readily diagnosed by a Gram stain of the faecal material, when numerous clumps of bacteria are seen.

10.2 Protozoa and Helminths

Various intestinal parasites may be seen by the naked eye in the stool including tapeworms (*Taenia solium* or *saginata*), roundworms (*Ascaris lumbricoides*), and threadworms (*Enterobius vermicularis*).

A microscopic examination of a stool suspension is required to diagnose pathogenic protozoa and helminthic ova. Stool can be obtained from a bedpan or other container; it is also possible to use material removed from the glove after performing a rectal examination. A wooden applicator is used to place a pea-sized portion of stool on a microscope dish previously moistened with two or three drops of isotonic saline. A coverslip is applied carefully to ensure that no air bubbles are trapped. The slide is scanned under low power, particularly at the edges. *Entamoeba histolytica* and *Entamoeba coli* can exist in vegetative and multinucleate cystic forms; the biflagellate *Giardia intestinalis* may be identified, although it is more readily found in the duodenal aspirate; and *Enterobius vermicularis* can be demonstrated. Ova which may be seen include *Ascaris lumbricoides*, *Ankylostoma duodenale*, *Necator americanus*, *Taenia saginata*, *Taenia solium*, *Enterobius vermicularis*, and *Strongyloides stercoralis*. It may be necessary to undertake repeated examinations of the stool. Stools should always be collected and examined before a barium examination. Commercial stool collection kits are available which contain preservatives for parasites and cysts.

A number of crystals are normally seen in the stool, but they are not of diagnostic significance.

10.2.1 Enterobiasis (Seatworm, Pinworm or Threadworm, *E. vermicularis*)

This condition is not usually diagnosed from an examination of the stools because the adult female parasite is seldom longer than 10 mm and the stools contain ova in only 10% of infected patients. The usual method of diagnosis is to obtain ova from the perianal skin using the transparent adhesive tape test. This test is performed preferably in the early morning and can be undertaken by parents on their children. The terminal 10 mm of a length of clear, transparent adhesive tape is pressed on one end of a microscopic slide. The rest of the tape is folded backwards with the sticky surface facing outward. The slide is directed gently into the anal verge so that the sticky surface of the tape touches the anus and immediate perianal area. The slide is then removed and the tape flipped over so that the adhesive surface attaches to the slide. The tape is smoothed over carefully using tissue paper in order to remove air bubbles and wrinkles. The slide is examined under the microscope.

10.2.2 Amoebiasis

The search for amoebae must be made before the patient undergoes a course of antimicrobial treatment, especially metronidazole. Similarly a mineral-oil enema or a barium enema renders the stool unsuitable for the diagnosis of amoebiasis. On the other hand a dose of penicillin has been used to 'chase' the amoebae into the stool, increasing the chance of finding the trophozoites in the faeces.

Only fresh, warm stool is examined. Material obtained at the time of sigmoidoscopy may also be used. A 'button' of faeces is emulsified on a slide in a drop of warm normal saline. The slide may be kept warm by heating on the microscope lamp. The preparation is examined under the low power magnification. The amoebae and their multinucleate cysts are seen as refractile objects which are examined in greater detail under the high power magnification. Trophozoites of *E. histolytica* are most likely to be found in mucus and cysts are found in the more solid parts of the stool.

10.2.2.1 Hanging Drop Preparation

If the faecal suspension is applied carefully to the lower surface of a warmed slide amoebic motility may be more readily observed. The examination is made by focusing up and down.

E. histolytica trophozoites show slow 'purposeful' movements and contain ingested erythrocytes. Once the specimen is cold the vegetative forms are no longer motile, and it becomes very difficult to distinguish trophozoites from macrophages, which may be haematophagous but are non-motile. The vegetative forms of *Entamoeba coli* demonstrate many pseudopodia but are non-motile and non-haematophagous.

Cyst forms of *E. histolytica* are >1 mm in diameter, have a finely granular cytoplasm and contain one to four nuclei. Cysts of the non-pathogenic *E. hartmanni* appear very similar to *E. histolytica* but are usually <1 mm in diameter. *Entamoeba coli* cysts have a diameter >1 mm, a coarsely granular cytoplasm and contain one to eight nuclei.

While it may be easy to identify a population of amoebae it may be very difficult to identify isolated parasites, and this applies particularly to the smaller trophozoites of *E. histolytica*. Staining for 30 min is necessary for this. Fixation in Schaudinn's fixative is recommended followed by staining with the Gomori trichrome stain.

Both amoebiasis and giardiasis are more frequent in male homosexuals, 40% of whom are infected with either or both. Cryptosporidial diarrhoea is common in HIV disease. AIDS also commonly presents as upper GI candidiasis and sometimes as hepatitis, as well as with weight loss.

10.3 Bacteria

A sample of freshly passed stool is taken with a disposable wooden spatula and placed in a screwtop container. The stool must be free of urine. Disposable containers with plastic spatulas attached to the lid are also convenient sampling devices.

The stool should be delivered to the laboratory on the day it is passed. (If amoebic dysentery is suspected a warm sample of stool should be examined immediately after the specimen has been obtained).

Alternative procedures are to take stool from the glove or proctosigmoidoscope after internal examination. Rectal swabs may be useful but it is important that they are taken from the rectum and not the perineum. This requires passage of at least a proctoscope.

Samples should be cultured in a solid selective and a liquid enrichment medium, with both aerobic and anaerobic culture. A single negative culture does not exclude infection, and normally two stool samples should be sent. However, any positive results are usually obtained with the first sample. Some individuals are asymptomatic carriers or organisms.

Bacteria which are traditionally more important in diarrhoeal illnesses are *Salmonella*, *Shigella* and *Staphylococcus*. Some strains of *Escherichia coli* (for example O157) have been shown to be pathogenic, but their detection requires serological testing.

Patients with *Salmonella* or *Shigella* in the stool usually have diarrhoea persisting for more than 24 h, fever, blood in the stool, abdominal pain and nausea. In the absence of all of these features stool culture is frequently negative, and random stool cultures in patients presenting with diarrhoea are infrequently rewarding. Serology by ELISA may be more satisfactory for *Salmonella enteritidis*. *Campylobacter* and *Clostridium difficile* are other causes of enterocolitis.

Typhoid is usually more a systemic illness, with diarrhoea a less marked feature, and blood culture is useful to identify *Salmonella typhi*.

C. difficile infection is particularly important as it may follow antibacterial therapy. It is a fastidious anaerobe which produces a cytopathic enterotoxin that can be identified in stool. Infection is one of the few diarrhoeas needing specific antibacterial therapy.

Despite the practical problems involved in processing stool, tuberculosis can sometimes be diagnosed by microscopy or culture, but the presence of TB bacilli in stool does not always imply enteric infection.

There are only two clinical situations in which a Gram stain of the faeces is of value: staphylococcal enterocolitis and the torrential diarrhoea of cholera.

Antigen to *H. pylori* is present in the stool of infected cases, but its use is subsidiary to other tests.

10.4 Viruses

Many apparently infective diarrhoeas cannot be ascribed to a specific organism. They are commonly attributed to viral infection, though this is rarely proved. Examination of paired sera taken during the first acute illness and then 2–4 weeks later may show diagnostic elevation of titres of antibodies to viruses such as those of the Coxsackie group. Norovirus is notorious for causing epidemic vomiting and diarrhoea, particularly on cruise ships and in hospitals, and isolation of cases is more important than diagnostic testing.

Rotavirus infection is common in children and clumped virions may be found after low-speed centrifugation of stool suspensions. Virus particles are concentrated with a selectively absorbent hydrophilic gel prior to diagnostic electron microscopy.

Electron microscopy may also reveal the presence of other viruses, in particular the 29 nm RNA particles of hepatitis type A virus.

Bibliography

- Barnett W. Viral gastroenteritis. *Med Clin N Am.* 1983;67:1031–58.
- Bartlett JG. Antibiotic-associated colitis. *Clin Gastroenterol.* 1979;8:783–801.
- Blaser MJ, Berkowitz ID, La Force FM, Cravens J, Reller LB, Wang WL. *Campylobacter* enteritis: clinical and epidemiological features. *Ann Intern Med.* 1979;91:179–85.
- Green EL, Miles MA, Warhurst DC. Immunodiagnostic detection of giardia antigen in faeces by rapid visual ELISA. *Lancet.* 1985;2:691–3.
- Greenfield C, Ramirez JR, Pounder RE, et al. *Clostridium difficile* and inflammatory bowel disease. *Gut.* 1983;24:713–7.
- Larson HE, Parry N, Price PR, Dolby J, Tyrrell DAJ. Undescribed toxin in pseudo-membranous colitis. *BMJ.* 1977;1:1246–8.
- Merson MH, Rowe B, Black RE, Huq I, Gross RJ, Eusof A. Use of antisera for identification of enterotoxigenic *E. coli*. *Lancet.* 1980;2:222–4.
- Quinn TC, Stamm WE, Goddell SE, et al. The polymicrobial origin of intestinal infections in homosexual men. *N Engl J Med.* 1983;309:576–82.
- Sack RH. Human diarrhoeal disease caused by enterotoxigenic *E. coli*. *Annu Rev Microbiol.* 1975;29:333–53.
- Whitby H, Rodgers FG. Detection of virus particles by electron microscopy with polyacrylamide hydrogel. *J Clin Pathol.* 1980;33:484–7.

The investigation of pancreatic disease remains problematical and unsatisfactory despite the introduction of a host of techniques. The use of MRCP, EUS, ultrasonography or CT to define the anatomy of the gland, coupled with one of the tests of exocrine secretion is probably the most satisfactory method of assessment. Estimation of steatorrhoea, glucose tolerance and serum amylase can provide valuable additional information. These tests are required to determine whether pancreatic disease is present and, if so, its nature. The differentiation of chronic pancreatitis from pancreatic cancer is an important though often unresolved question. The laboratory diagnosis of pancreatic disease can be quite simple in the presence of jaundice, glycosuria or steatorrhoea; it is when the only symptom is abdominal pain that the diagnosis frequently proves extremely difficult.

11.1 Ultrasonography

Procedures are operator dependent, but the test is non-invasive and in experienced hands the results are accurate.

Portable real-time apparatus is available for use at the bedside. High resolution real-time ultrasonography is currently the optimal method. Fasting patients are examined in three main positions: prone, lateral decubitus, and supine. This permits full visualization of the whole pancreas. Effervescent preparations are sometimes required to fill the stomach with gas and enhance contrast. A complete record with serial transverse and sagittal sections takes about 1 h to complete. The simultaneous use of ultrasonic scanning permits fine-needle aspiration of pancreatic lesions for cytological examination. The best results may be obtained by US-guided percutaneous biopsy using the automatic firing 18 gauge needle (Biopty gun).

11.1.1 Endosonography (EUS)

This is promoted as the ideal approach to US appraisal of the pancreas. It permits fine needle aspiration biopsy, but the equipment is expensive, the procedure requires much expertise, and it is not widely available at present.

11.1.2 Interpretation

Normal pancreas reflects few echoes, and interference from other structures, gaseous distention and obesity, can be a problem. The gland may be difficult to locate because of its small size and variable position. It can be identified in about 80% of individuals.

11.1.2.1 Acute Pancreatitis

The thickness of the pancreas increases to about twice normal and the parenchymal echoes lessen or disappear. More importantly the development of abscesses and pseudocysts can be readily detected in acute pancreatitis, and their progress followed by serial scans. The pancreatic scan is abnormal in 58% of patients with acute pancreatitis, and in as many as 92% whose symptoms and signs suggest a pseudocyst, when ultrasonography is the best method for diagnosis.

11.1.2.2 Chronic Pancreatitis

The gland often but not always enlarges, and irregular areas of high and low echoes are characteristic. Calcification gives scattered foci of dense echoes, and this can be detected in about one-third of patients. Positive scans are more often found during clinical relapse. Pancreatic duct abnormalities associated with chronic pancreatitis may be detectable: an increase in calibre up to 2 cm can be found. Although a diagnostic accuracy of 65–94% can be achieved in chronic pancreatitis, the method is not entirely foolproof because carcinoma of the pancreas may cause similar changes.

11.1.2.3 Pancreatic Carcinoma

This can be recognized in about 85% of patients as a well-defined tumour with few internal echoes. Growths >12 mm should be detected, but there is often associated enlargement of the gland or chronic pancreatitis which makes interpretation more difficult. It is easier to diagnose tumours in the body and tail than in the head of the pancreas. Hepatic metastases can be detected in most cases where they are present.

11.1.2.4 Obstructive Jaundice

Ultrasonography should detect dilated extrahepatic ducts in 95% of cases, and when the cause lies in the pancreas its nature can be defined in the vast majority of patients.

11.1.3 Indications

1. First investigation when chronic disease of the pancreas is suspected.
2. First investigation for cholestatic jaundice (in association with hepatobiliary scans).

3. Diagnosis of pancreatic pseudocysts and abscesses.
4. Diagnosis and monitoring acute pancreatitis.
5. Guiding percutaneous pancreatic biopsy.

Magnetic resonance and computed tomography are definitely superior to external ultrasound for non-invasive investigation of morphology, and if freely available should always be considered in case of difficulty.

11.2 Endoscopic Retrograde Cholangiopancreatography (ERCP)

The method is described in Chap. 2. Depending upon the circumstances an attempt may be made to outline only the pancreatic duct, or the biliary system as well. It is generally reserved for cases where therapeutic procedures are planned.

11.2.1 Interpretation

Provision of clinical information improves the diagnostic accuracy of pancreatogram reporting, and should always be fully supplied.

11.2.1.1 Normal

The pancreas has a duct which passed obliquely cranially from the ampulla and then is roughly transverse. The diameter decreases smoothly and maximal figures are 6.5 mm in the head to 3 mm in the tail. The side ducts are variably filled. There is a wide variation in ductal anatomy. In addition the examination is complicated by, and may be unsatisfactory in, the annular or malfused pancreas. In elderly patients the duct system may widen up to 10 mm, and ductular ectasia and narrowing can occur without definite pathological significance.

11.2.1.2 Chronic Pancreatitis

The main duct becomes dilated and tortuous. It may show strictures or contain filling defects. The earliest changes occur in the duct branches, which show variation in calibre and frank dilation, but these are difficult to detect. In advanced and calculous pancreatitis there may be complete obstruction to the proximal flow of contrast. Pancreatic fistulas can sometimes be seen. ERCP in acute pancreatitis will usually demonstrate a pseudocyst when it occurs, but needs to be done cautiously. The main reason for ERCP in this circumstance is identification and treatment of choledocholithiasis.

11.2.1.3 Carcinoma

Abnormalities of the duct system such as obstruction or stenosis occur in 65–80% of patients and the diagnostic rate is highest in the group amenable to surgical removal. The collection of pure pancreatic juice for cytology at the time of ERCP improves the diagnostic rate to 92%.

11.2.2 Indications

1. Evaluation of chronic and acute relapsing pancreatitis, especially detection of pancreatic ductal abnormalities or biliary calculi requiring surgical treatment.
2. Differential diagnosis of chronic pancreatitis and carcinoma.
3. Collection of pure pancreatic juice.
4. Extraction of bile duct stones.
5. Positioning of biliary and pancreatic stents.

11.3 Magnetic Resonance Cholangiopancreatography (MRCP)

This is the best standard method for imaging the pancreas and bile ducts, generally with gadolinium enhancement. It is preferable to ERCP as the initial procedure. Magnetic resonance uses a very strong magnetic field and pulses of radiowaves to obtain 3D pictures without ionising radiation. Atoms, especially hydrogen in water and fat, absorb and emit radiofrequency energy. Variable pulses create interpretable patterns detected by antennae.

This is particularly useful in the biliary and pancreatic systems, with T_2 weighting of images.

11.4 Computed Tomography (CT)

This technique allows a clear transverse sectional picture of the body by transmitting a series of X-rays at different angles. The beam is received by scintillation or ionization detectors instead of film, and the result displayed as an undistorted two-dimensional picture. Although no preparation is essential a low residue diet may help to eliminate gas, and administration of propantheline IM or glucagon IV reduce bowel motility artefacts. Dilute oral barium or iodine contrast media and IV iodine contrast media may help to delineate adjacent bowel and blood vessels respectively. Obesity may actually improve results by provision of greater tissue contrast.

CT scanning can diagnose some pancreatic lesions missed by US. The main indication is probably the investigation of patients in whom other tests have failed to provide a diagnosis, unless the procedure is readily available. Serial CT scanning is especially useful in acute pancreatitis.

11.5 Angiography

Super-selective angiography or phlebography can be useful ancillary investigations.

11.5.1 Interpretation

11.5.1.1 Acute Pancreatitis

Arteries are displaced with moderate dilation and irregularity of the major vessels. There is increased vascularity, but with no alteration in capillary or venous circulation. If a pseudocyst develops the vessels become sparse and are stretched.

11.5.1.2 Chronic Pancreatitis

Deformity and stenosis of the surrounding vessels with tortuosity and beading of the intrapancreatic vessels is characteristic.

11.5.1.3 Tumours

Irregular, narrowed and infiltrated vessels are seen. Carcinomas are often poorly vascularised. Angiography can be used to size tumours >1–2 cm in diameter and to assess operability. Endocrine tumours such as insulinomas are often hypervascular with a fine anastomotic pattern. They can be detected if >1 cm in diameter, but unfortunately these tumours are usually rather small.

11.6 Other Radiology

11.6.1 Chest X-Ray

This is helpful in the diagnosis of fibrocystic disease of the pancreas when there is evidence of chronic chest infection. In acute pancreatitis basal atelectasis or a pleural effusion (often left-sided) may be present.

11.6.2 Straight Abdominal Radiograph

The plain radiograph of the abdomen is helpful in acute pancreatitis. An isolated distended loop of jejunum in the upper abdomen, the 'sentinel loop', may be demonstrated, or there may be absence of gas in the transverse colon, the 'colon cut-off' sign. The pancreas may be seen to be calcified and stones may be present in the duct. There may be diffuse abdominal calcification following the fat necrosis that occurs in acute pancreatic inflammation.

11.6.3 Barium Meal

Helpful signs of pancreatic disease are pressure deformities and displacement of the stomach and duodenum. Expanding pancreatic lesions enlarge the retrogastric space and deform the posterior wall of the stomach. The indentation is smooth in the case of pseudo-cysts of the pancreas. In cancer the enlargement is usually slight and any infiltration of the stomach results in a rigid appearance. Changes in the gastric

antrum are also seen. The duodenum may be enlarged and there may be depression of the ligament of Treitz. Pressure on the medial wall of the duodenum will give the inverted-3 sign of Frostberg which is an indication of a pancreatic mass, but does not differentiate cancer from inflammation. Pressure on the lateral aspect of the duodenum with rigidity and compression may occur in pancreatic cancer.

Barium studies are seldom used to diagnose suspected pancreatic disease.

11.7 Laparoscopy (Peritoneoscopy)

With the advent of laparoscopic surgery, there is a wealth of experience in flexible laparoscopy among gastrointestinal surgeons, whose help should normally be enlisted for this investigation.

The procedure procedure for rigid laparoscopy is described in Chap. 16. An infragastric method has been devised for diagnosis and staging pancreatic cancer. Direct visualization permits biopsy or aspiration for cytology and avoids the hazards of laparotomy.

11.8 Histology and Cytology

Guided biopsy with an automatically fired needle is a technique which yields tissue samples, and histology is definitely better than cytology where it is possible. Material for cytology may be obtained by several other methods:

1. aspiration of the pancreas by direct puncture at laparotomy or laparoscopy using a standard 21-gauge needle;
2. a guided percutaneous puncture with a Chiba needle;
3. collection of pancreatic juice during ERCP or duodenal intubation for the testing of pancreatic function.
4. fine needle aspiration during EUS

At least four smears are made onto slides, which are fixed at once in 95% alcohol and stained by the Papanicolou method. Positive results are obtained in at least 75% of pancreatic cancer patients while false-positive results are rare.

11.9 Hormonal Tests of Pancreatic Exocrine Function

The pancreatic exocrine sections after pancreatic stimulation can be assessed directly by duodenal drainage. *Secretin* stimulates the output of fluid and bicarbonate by the gland and *cholecystokinin-pancreozymin* (CCK-PZ) stimulates the output of enzymes. A variety of function tests has evolved using one or both hormones in different doses. The normal values of a particular laboratory depend upon the

procedure used and the methods for determining the enzymes in the duodenal juice. Anyone of a number of variations on the basic test is satisfactory provided the laboratory consistently uses the same method, and establishes the range of normality. Completeness of collection of duodenal juice is important. This may cause problems after gastric surgery, where only a normal result is absolutely conclusive.

The many different methods which are used to stimulate pancreatic exocrine function make the comparison of pancreatic function tests difficult. It is debatable whether pancreozymin increases the diagnostic accuracy of secretin tests, and its use is associated with a significant number of reactions.

On the other hand enzyme analysis is definitely meaningful after pancreozymin and many investigators find alterations in the enzyme output of the gland to be a sensitive test of pancreatic inflammatory disease. Multiple enzyme determinations are necessary for routine clinical use. Trypsin is usually measured nowadays, but either amylase or lipase assays are also satisfactory.

Although time-consuming and relatively unpleasant for the patient, a test of pancreatic exocrine secretion is probably the most sensitive index currently available for pancreatic function.

11.9.1 Secretin Test

11.9.1.1 Method

The patient fasts overnight. A double-lumen gastroduodenal tube is passed and positioned fluoroscopically so that the tip lies in the third part of the duodenum. Alternatively, two separate nasogastric tubes can be passed, one being positioned with the tip at the third part of the duodenum and the other sited in the gastric antrum. The patient lies tilted to the left side with the head and shoulders supported by a pillow. Continuous suction is applied to both tubes at a subatmospheric pressure of 5–10 mmHg, and this is interrupted by frequent manual aspirations to ensure patency of the tubes. The patient is not required to expectorate. The gastric aspirate is discarded. The aim is to collect duodenal samples uncontaminated by gastric secretions.

A basal collection of duodenal material is made for 10–30 min during which time the pH must be >7.5 . This is followed by the IV injection over 2 min of 1.0 unit secretin/kg body weight in 10–20 ml of normal saline. Following the secretin stimulus the duodenum is aspirated continually for 60 min. The colour and pH of the gastric and duodenal aspirates are checked frequently to ensure an uncontaminated collection. The duodenal aspirate is collected into iced containers. The volume of the duodenal aspirate is recorded. An aliquot of the pooled collected provides a satisfactory measure of pancreatic function for clinical purposes. A variation of the method is to collect and assay timed samples of the duodenal aspirates. The sample for estimation is well mixed with an equal volume of glycerol to increase enzyme stability and analysed for bicarbonate and enzyme concentration. Amylase is often measured, but a variety of other pancreatic enzymes

have been studied and in general give comparable results to amylase. However, amylase is an unreliable measure of pancreatic function in infants, where trypsin provides a better index. Biliary pigment output may be recorded as + to ++++ but is of little clinical value. A search can be made for malignant cells using the cytological methods described.

11.9.1.2 Interpretation

Normal In adults the average volume is 3.2 ml/kg body weight with a lower limit of 2.0 ml/kg. The average bicarbonate concentration is 108 mEq/l with a lower limit of 90 mEq/l. The average amylase concentration is 14.2 units/kg body weight with a lower limit of 6.0 units/kg body weight, but results vary depending upon the method used for amylase estimation. Amylase values for infants are slightly lower than the adult range. In adults neither age nor sex influences the output of bicarbonate.

Acute pancreatitis The secretin test is potentially hazardous and thus of little practical value.

Chronic pancreatitis There is a reduction in the output of bicarbonate, and values as low as 30 mEq/l are recorded. The volume is usually normal but may also be reduced.

Cancer of the pancreas In cancer involving the head and body of the gland there is a reduction in the volume of pancreatic secretion with normal bicarbonate concentration. In diffuse involvement of the gland by malignant growth there is often a reduction in total bicarbonate output. In cancer of the tail, function is usually normal.

Haemochromatosis It is claimed that in haemochromatosis there is a high volume flow (10–20 ml/kg body weight) with a low bicarbonate.

Diabetes mellitus Although there is some controversy the evidence suggests that in idiopathic diabetes mellitus exocrine pancreatic function may be reduced. Some studies on patients with idiopathic diabetes have revealed a number with associated chronic pancreatitis and pancreatic cancer.

Other diseases Disturbed pancreatic function has been recorded in patients with coeliac disease, ulcerative colitis and amyotrophic lateral sclerosis. A high volume of pancreatic flow has been recorded in 50–70% of cirrhotic patients and about 40% have reduced concentrations of bicarbonate and enzymes. Alcoholic liver disease may, of course, be associated with alcoholic pancreatitis. Heavy cigarette smoking (20+ per day) will reduce pancreatic secretion. Neither the use of CCK/PZ together with secretin, nor the further estimation of enzyme output have clearly been shown to improve the diagnostic accuracy of the secretin test.

11.9.2 Augmented Secretin Test

11.9.2.1 Method

An IV infusion of 2 units secretin/kg body weight is given at a rate of 1 unit/kg/min. The duodenum is aspirated for 1 h and the volume and bicarbonate output are measured.

11.9.2.2 Interpretation

Normal subjects have a mean volume of 2.7 ml/kg body weight with a lower limit of 1.8 ml/kg body weight. The normal mean bicarbonate concentration is 78 mEq/l with a lower limit of 54 mEq/l. In chronic pancreatitis the mean volume is 1.7 ml/kg body weight and the mean bicarbonate concentration is 25 mEq/l. In cancer of the pancreas the mean volume output is 1.1 ml/kg body weight and the mean bicarbonate output is 36 mEq/l. This test is claimed to be the most reliable not only in distinguishing normals from patients with pancreatic disease but also in the differentiation of chronic pancreatitis from cancer. The accuracy of the test is increased by relating the volume output to the body weight.

11.9.2.3 Continuous High-Dose Infusion of Secretin

The maximum response of the pancreas to the intravenous infusion of secretin is reached at rates of 4–6 units/min. The continuous infusion of secretin in this dose for 2 h has been suggested as a test of pancreatic exocrine function.

11.10 Test Meals: The LUNDH Test

Attempts have been made to measure the secretion of pancreatic enzymes in response to various test meals. The test described by Lundh is the most widely used.

11.10.1 Method

After an overnight fast the patient swallows a tube which is screened into position so that the tip lies between the ampulla of Vater and the duodenojejunal flexure. Duodenal juice is drained by siphonage into a container which is kept on ice. The drainage is maintained by intermittent gentle suction. Once the tube is in the required position a resting sample of duodenal juice is obtained. This is followed by the administration of the test meal comprising 18 g corn or soya bean oil, 15 g Casilan (protein), 40 g glucose and a flavouring agent, made up to 300 ml with warm water. After ingestion of the meal the duodenum is drained over 2 h, the samples being pooled into four collections, each of 30 min. They should be collected in containers immersed in ice and may be kept for delayed analysis by addition of an equal volume of glycerol and stored in a freezer. The pH, volume and trypsin content of the samples are measured. The four samples can be analysed separately but are more conveniently pooled and the tryptic activity expressed as the mean tryptic activity of the aspirate.

Tryptic activity is measured by a variety of methods. There is a simple method in which a measurement is made of the rate at which H^+ ions are liberated by the hydrolysis of a specific substrate N-benzoyl-L-arginine ethylester hydrochloride. This is achieved by measuring the time taken to neutralize a known amount of alkali. The results are expressed in international units (mEq H^+ min/ml). A sample kit is available which is based on this method (BoehringerMannheim). Radioimmunoassay kits have also been employed for analyses of both duodenal and serum trypsin.

11.10.2 Interpretation

The normal mean 2-h tryptic activity is 15.4 iu with a range of 11–20 iu.

In pancreatic inflammatory disease associated with steatorrhoea the mean tryptic activity is usually <2 iu. In those patients in whom pancreatic inflammatory disease presents mainly as abdominal pain the values of tryptic activity are usually below the normal range. Low values are found in pancreatic cancer but equally low values may occur in biliary obstruction from other causes. The values are reduced for non-pancreatic causes of steatorrhoea, but they are not as low as in pancreatogenous steatorrhoea. Normal values are found in liver disease. Using a more complex method for estimating tryptic activity, Lundh found the normal range to be 161–612 μg trypsin/ml with a mean of 310 μg trypsin/ml. Markedly depressed values were found in chronic pancreatitis and cancer of the pancreas.

11.10.3 Indications

This test is recommended because it is simple to perform and entails little discomfort for the patient. It gives reproducible results and has proved to be a reliable method in the diagnosis of chronic pancreatitis, particularly when steatorrhoea is present. It is also helpful in the diagnosis of ampullary cancer with or without jaundice. It is of little value in the retrospective diagnosis of acute pancreatitis. However, it may be less reliable than the augmented secretin test in discriminating between the normal and abnormal pancreas.

11.10.4 Modifications

1. Zieve et al. introduced a meal containing 14 g corn oil, 15 g dextrose, 12 g skimmed milk powder, 218 ml skimmed milk and 8 g chocolate syrup. The volume of the meal is about 250 ml. It is introduced down the polyvinyl tube into the duodenum and aspiration of the duodenal contents is undertaken for 2 h.
2. Pure pancreatic juice may also be collected by cannulation of the pancreatic duct and IV injection of 1 unit/kg secretin. Unfortunately results of the analysis of the fluid collected via ERCP are no more accurate or informative than analysis of the duodenal aspirate.

The lactoferrin levels in patients with chronic pancreatitis are much higher than normal controls or patients with pancreatic cancer. In addition, trypsin concentrations are uniformly low in pancreatic cancer (up to 12 $\mu\text{g/ml}$) though variable in chronic pancreatitis. The combination of tests is a very reliable method of separating cancer from chronic pancreatitis.

3. A modification of this method is the ratio of lactoferrin: total protein in pancreatic juice. In chronic pancreatitis this ratio is $>0.5\%$, whereas in controls including normals individuals, acute pancreatitis and carcinoma of the pancreas the ratio is $<0.03\%$.

11.11 Tubeless Oral Pancreatic Function Tests (Fig. 11.1)

The goal of satisfactory tests of pancreatic secretion without the requirement for the need for intubation or handling stools has been reached. Methods are based on the pancreatic enzyme activity on bentiromide, fluorescein dilaurate and triolein. None of these tests diagnose or exclude pancreatic carcinoma.

11.11.1 Fluorescein Dilaurate Test (Pancreolauryl)

This is a 2–3 day procedure. The fasting patient is given two blue capsules of fluorescein dilaurate (0.5 mmol) with a standard breakfast including at least 500 ml fluid. A further litre of fluid should be taken 3–5 h later, then normal feeding is resumed. Urine is collected for 10 h and after hydrolysis of a 0.5 ml aliquot with 4.5 ml 0.1 mmol/l NaOH, the sample is incubated for 10 min at 65–70 $^{\circ}\text{C}$, cooled and centrifuged. The supernatant is compared with a water standard by fluorimetry at 492 nm and the percentage dye excreted calculated from the 10 h volume of urine.

On the second day after this test the procedure is repeated with one red capsule containing 0.5 mmol fluorescein sodium. The test is then conducted as before. The ratio of dye excretion after fluorescein dilaurate and after fluorescein sodium should be >0.3 . In pancreatic insufficiency the value will be 0.2 or less. Values of 0.2–0.3 are equivocal and the test should be repeated. An alternative is estimation of serum fluorescein 20 min after oral administration of fluorescein dilaurate 0.5 mmol, which should be 1.5 $\mu\text{g/ml}$ or more.

The fluorescein dilaurate test can be used in children, in whom exposure to radioactivity should be avoided, but is more tedious to perform despite the ease and reliability of chemical analysis.

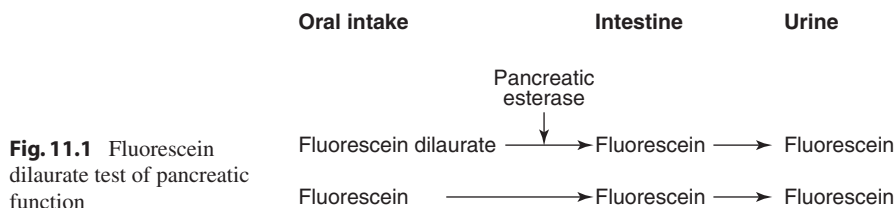


Fig. 11.1 Fluorescein dilaurate test of pancreatic function

11.12 Oral Glucose Tolerance Test

This test is described in Chap. 7.

An elevated blood sugar concentration and glycosuria occurs in 15% of patients with acute pancreatitis. In chronic pancreatitis some abnormality of glucose tolerance occurs in 70% of patients. Glucose tolerance is invariably abnormal in the presence of pancreatic steatorrhoea. The test is frequently abnormal when there is derangement of the pancreatic exocrine function tests. Occasionally an abnormal test is the only manifestation of pancreatic disease. Some abnormality of glucose metabolism has been demonstrated in 20–30% of patients with pancreatic cancer. It is thought to have an endocrine basis more complex than simple destruction of the beta-cells of the islets.

An intravenous test is used to avoid difficulties arising from defective glucose absorption. Such a test is generally unnecessary, because glucose absorption is usually normal in pancreatic disease even when steatorrhoea is present. Occasionally the test is undertaken to test for diabetes mellitus in patients with coeliac disease or after partial gastrectomy.

11.13 Digestive Enzymes Outside the Gut

At least a dozen digestive enzymes are formed by the pancreas. Not all of these are readily measured in the serum and only three, amylase, trypsin and lipase, have been studied clinically to any extent.

11.13.1 Serum Amylase

The units of amylase activity vary according to the method. The methods are potentially less accurate when there is hyperglycaemia and in the presence of jaundice. Lipaemia interferes with the assay, which should be performed only after dilution of the serum by 5–100 times until further dilution produces no more apparent increase in levels.

11.13.1.1 Interpretation

Characteristically there is elevation of serum amylase concentration in acute pancreatitis. The rise starts within 2–12 h of the inflammation, is maximally elevated by the second to fourth day and falls to normal values within 3–6 days. There is no single blood level which is diagnostic for pancreatitis, but an increase five times the upper limit of normal is regarded as diagnostic of acute pancreatitis and levels over twice normal are suggestive. It is not possible to predict the extent of the pancreatic damage from the serum levels. A fall in serum level does not necessarily indicate any improvement in the disease because it may be the consequence of severe destruction of acinar tissue.

There are a number of extra-hepatic causes of an elevated serum amylase level including perforated peptic ulcer, small bowel obstruction, peritonitis,

viral hepatitis, ectopic pregnancy, inflammation of the salivary glands, and uraemia, but they seldom cause a five-fold elevation. Drugs such as morphine and codeine which produce spasm of the sphincter of Oddi may cause a rise in the serum amylase concentration. Therefore, it is always advisable to stop these drugs for at least 24 h before estimating serum amylase. In all these situations the rise in serum amylase concentration is seldom more than three to four times the normal value.

The serum amylase concentration usually returns to normal within a week and persistent elevation generally implies the development of a pancreatic pseudocyst. Less common causes of a prolonged elevation of the serum amylase are persistent pancreatitis, partial pancreatic duct obstruction and renal failure.

Macroamylasaemia is a rare cause of raised levels in which there is binding of the amylase to an abnormal globulin with the formation of a macromolecular complex which is too large to be excreted via the kidneys. This unusual cause is suggested when an elevated serum amylase concentration is associated with normal or reduced urinary concentrations of the enzyme.

Serum amylase increases usually do not occur in chronic pancreatitis or pancreatic cancer, and if there is elevation it is of a modest degree only. Isoenzyme analysis maybe useful to determine the origin of amylase, as in pancreatic insufficiency.

11.13.2 Urinary Amylase

Amylase is normally cleared by the kidneys and there is a two- to three-fold rise in levels in acute pancreatitis. The excretion of amylase may be used as an index of pancreatic amylase released into the blood.

The test is usually performed on a 24 h sample of urine collected into a bottle containing toluene. An increased urinary excretion of enzyme occurs in acute pancreatitis. Low values are recorded when there is associated renal failure. An estimation can be performed on a single urine sample in an emergency, but this is inaccurate because enzyme values vary according to the degree of concentration of the sample. Urinary amylase has been expressed as the amount excreted per unit of time in an attempt to increase the accuracy of urinary amylase as a diagnostic test. The hourly excretion rate of the enzyme may be abnormal when the serum enzyme levels are normal. The urinary amylase concentration falls rapidly although it may take longer than the serum levels to return to normal, and may occasionally remain elevated for 1–2 weeks. The urine analysis may, therefore, be used to diagnose acute pancreatitis at a late stage. The test is of no value in the diagnosis of chronic pancreatic disease.

In an attempt to correct for the hyperamylasaemia of renal failure and for the frequent association of renal impairment with acute pancreatitis, the amylase/creatinine clearance ratio has been proposed. This is based on simultaneous estimation in the serum and urine of both amylase and creatinine. It has not proved as helpful as was originally hoped and is not recommended.

11.13.3 Amylase in Other Fluids

It is often of value to estimate the amylase activity in ascitic and pleural fluid. High levels suggest the presence of acute pancreatitis. The elevation may be as high as blood levels and may persist for 2–3 days longer than in serum. This is sometimes of diagnostic value.

11.13.4 Serum Lipase

Elevations parallel those of serum amylase though they are more prolonged and uniform. The only added information is gained in abdominal pain with mumps or alcoholic parotitis, because lipase, unlike amylase, is not produced in the salivary glands in appreciable amounts. The test is much more expensive.

11.13.5 Serum Trypsin

This is increased in acute pancreatitis, but biological assay is not practicable because of powerful serum antitrypsin activity. Radioimmunoassay has been introduced to obviate this problem. Although theoretically superior to serum amylase estimation because of its greater specificity, serum trypsin measurement has not yet been shown convincingly to confer any practical advantages in adults, despite claims that values >20 mg/l trypsin-like immunoreactivity indicate a pancreatic cause in steatorrhoea. However, in infancy dried blood spot assay can be used to screen for cystic fibrosis, where values are usually >80 mg/l.

11.14 Other Blood Tests

11.14.1 Serum Calcium

Normal levels are 2.15–2.65 mmol/l when serum albumin is 40 g/l. A correction can be made for reduced albumin levels by multiplying the number of g/l under 40 g/l by 0.2, and adding the results to the estimated value. Thus, an apparent serum calcium of 2.09 mmol/l with an albumin of 31 g/l corrects to 2.27 mmol/l. A similar correction can be made for elevated serum albumin levels by multiplying the number of g/l over 40 g/l by 0.02 mmol/l and subtracting the result from the apparent serum calcium.

The serum calcium level is commonly reduced during an attack of acute pancreatitis. It is important to correct values for serum albumin levels, which are often also markedly reduced. The maximum fall in serum calcium is seen 1–2 days after the onset of the attack of pancreatitis. A normal or elevated serum calcium level in the presence of severe pancreatic inflammation should raise the suspicion of associated hyperparathyroidism.

11.14.2 Serum Bilirubin

The serum bilirubin may be elevated during an attack of acute pancreatitis. The presence of an elevated value in a patient with recurrent or chronic pancreatitis should always raise the suspicion of pancreatic cancer, though it is not pathognomonic.

11.14.3 Serum Alkaline Phosphatase

An increased serum alkaline phosphatase level may be found when there is duct obstruction, as might occur in pancreatic cancer. Isolated raised alkaline phosphatase levels also occur in liver metastases. The association between bone disease and pancreatic dysfunction may be responsible for raised alkaline phosphatase levels and this occurs when there is chronic pancreatic insufficiency and steatorrhoea, or hyperparathyroidism and pancreatitis.

11.14.4 Blood Gases

In acute pancreatitis there are frequently various disturbances of pulmonary function, and reduction in the arterial oxygen tension (PaO_2) is one of the most constant findings in the condition.

11.15 Stool Examination

11.15.1 Macroscopic and Microscopic Examination

In pancreatic insufficiency the stool may appear normal or it may show obvious steatorrhoea by being pale, bulky and offensive.

The stool can be examined for fat droplets and meat fibres. Normally not more than one or two partially digested meat fibres are seen in a high-power field. The fibres are free from striations and have rounded ends but no nuclei. In pancreatic insufficiency there may be an increase in the number of meat fibres and they are partially digested with striations, irregular ends, and nuclei.

Gallstones can be found in the stools of patients with gallstone pancreatitis.

11.15.2 Steatorrhoea

Steatorrhoea may occur during an episode of acute pancreatitis, the stool fat output frequently returning to normal once the inflammation has subsided. Excess fat in the stool may be a prominent feature of chronic pancreatitis and is found in up to 50% of patients. Steatorrhoea is seldom the sole manifestation of pancreatic disease.

Fat maldigestion is even less common in pancreatic cancer, occurring in under 20% of patients. It is most likely to occur in cancer of the head of the pancreas.

11.15.3 Stool Trypsin and Chymotrypsin

Faecal chymotrypsin measurement in adults is a less sensitive test for pancreatic insufficiency than duodenal drainage after pancreatic stimulation. By contrast, in children the test can be very reliable as an index of pancreatic function. Analysis of a 3-day stool collection gives values of 2 mg chymotrypsin/kg body weight or less in cystic fibrosis with steatorrhoea, compared with normal values of 3 mg/kg.

11.16 Sweat Electrolytes

The measurement of the sweat electrolyte concentration is an important investigation in the child with steatorrhoea and malabsorption. Children with fibrocystic disease of the pancreas (mucoviscidosis) have a raised concentration of sodium chloride in the sweat. This fundamental abnormality is present regardless of the pancreatic function. The sweat electrolyte excretion is not abnormal in other varieties of pancreatic disease or malabsorption. Pilocarpine iontophoresis is the recommended technique for measuring the sweat electrolyte concentration, but similar results to this test are obtained using methacholine chloride stimulation.

11.16.1 Pilocarpine Iontophoresis

11.16.1.1 Method

Sweat is collected at room temperature from the flexor aspects of either forearm. A direct current source is used. The positive electrode is filled with 0.5% aqueous pilocarpine nitrate solution and the negative with 1% aqueous sodium nitrate solution. The surface of the positive electrode is covered with a circle of ashless filter paper saturated with pilocarpine nitrate solution and the negative electrode with a gauze saturated in the sodium nitrate solution. This is to prevent stinging. A rubber strap holds the positive electrode in place at the midpoint of the flexor surface, and the negative electrode on the extensor surface of the forearm. Circular electrodes 3 cm in diameter are used.

A current of 1.5 mA is passed for 5 min. The electrodes are removed and 5 min later the area covered by the positive electrode is washed with distilled water and covered with a circle of Whatman No 40 ashless filter paper of known weight. The paper is carefully handled with forceps. It is covered with Parafilm and the sweat collected for 25–35 min. The paper is removed, weighed, placed in a flask and the

electrolytes eluted in 10 ml distilled water. Sodium and chloride concentrations are measured by routine methods.

11.16.1.2 Interpretation

In normal infants the mean sweat sodium is 24 mmol/l and chloride 19 mmol/l. In cystic fibrosis the mean concentrations are 110 and 117 mmol/l, respectively, and values >70 mmol/l establish the diagnosis. Sweat chloride is the more reliable index.

After the first month of life the sweat sodium and chloride concentrations drop and are low by the end of the first year. Thereafter sweat electrolyte concentrations increase with age.

A greater range of normal values is found in adults and levels are found which overlap the fibrocystic range. No sex difference is observed in children, but adult females have lower sweat sodium concentrations than males. In adults the separation of cystic fibrosis from normal is much less satisfactory, but values of sweat electrolytes >90 mmol/l in a single test, or >70 mmol/l in each of two tests, are suggestive.

Similar results may be obtained by the use of subcutaneous injection of 2 mg methachlorine chloride instead of iontophoresis.

11.16.2 Skin Chloride Assay

This employs the principle of measuring the chloride content of sweat directly on the skin. First the skin-chloride electrode is calibrated. A pilocarpine-impregnated pad is applied to a well-washed and dried area of the forearm. Current is passed for 5 min, the pad is removed and the area is washed and dried again. The area is then covered with Parafilm and the presence of sweating is observed. Failure to detect sweating invalidates the test.

The direct-reading skin-chloride electrode is placed on the skin immediately the Parafilm is removed, taking care that good contact is made without trapping air. The chloride concentration is then read directly.

The sweat tests are not infallible and reproducibility can be poor; it is important that they are interpreted with regard to clinical features. Screening of neonatal blood for immunoreactive trypsin, detection of serum cystic fibrosis protein, estimation of salivary and nail-clipping electrolytes, and screening meconium for albumin have all been proposed for the diagnosis of cystic fibrosis.

11.17 Gene Probes

The description of the mutated gene on chromosome 7 (CFTR) has allowed the identification of affected individuals by chorionic villus sampling in the womb, and could also have a role in adults.

11.18 Gut Endocrinology and Endocrine Tumours

(Tables 11.1 and 11.2)

Many hormones and candidate hormones have been identified in the gastrointestinal tract since the original description of secretin in 1902. Peptides with a known physiological role are secretin, gastrin, cholecystokinin-pancreozymin and glucagon. There are others including vasoactive intestinal peptide (VIP), gastric inhibitory peptide (GIP), motilin, bombesin, substance P, pancreatic polypeptide (PP) and the potent secretion-inhibitor somatostatin. More recently the endorphins and

Table 11.1 Neuroendocrine tumours of the gut

Name	Peptide	Location	Clinical symptoms	Diagnostic test
Insulinoma	Insulin	Pancreas	Hypoglycaemia, mental confusion	Fasting insulin
Gastrinoma (Zollinger-Ellison syndrome)	Gastrin	Pancreas, Duodenum	Persistent peptic ulcer disease	Gastrin Secretin test
Glucagonoma	Glucagon	Pancreas	Diabetes, rash, weight loss	Glucagon
VIPoma (Verner-Morrison syndrome)	Vasoactive Intestinal Peptide	Pancreas	Secretory diarrhoea	VIP
Somatostatinoma	Somatostatin	Pancreas, gut	Diabetes, malabsorption	Somatostatin
PPoma	Pancreatin	Pancreas	Pancreatic insufficiency	PP
Carcinoid	5HT (serotonin)	Intestine liver, pancreas	Flushing, diarrhoea, wheezing	5-HT, 5-HIAA (urine)

Table 11.2 Tumour localization

<i>Standard methods</i>	
Ultrasound	
CT scanning	
Magnetic resonance	
Angiography	
Transhepatic portal venous sampling	
<i>Other techniques</i>	
<i>Pre-operative</i>	<i>Intra-operative</i>
Endoscopic ultrasonography	Operative ultrasonography
Highly selective angiography	Operative endoscopic transillumination
Digital angiogram	Longitudinal duodenotomy
Selective arterial secretion injection tests	Selective intra-arterial methylene blue injection (gastrinomas)
Somatostatin receptor scanning (Octreo-scan)	

the prostaglandins have been postulated to have important functions. Because the physiological role of most of the hormones is doubtful, measuring levels in tissue and serum does not usually assist in diagnosis, with the important exception of the endocrine tumours or hyperplasias which are frequently located in the pancreatic islets. The two most common of these are insulinomas and gastrinomas (causing the Zollinger-Ellison syndrome). Well recognized but rare are glucagonomas, and vipomas (causing watery diarrhoea/hypokalaemia/achlorhydria or Verner-Morrison syndrome due to overproduction of vasoactive intestinal peptide).

11.18.1 Insulinoma

This is a notoriously difficult tumour to diagnose. Symptoms can include periodic dizziness and blackouts, epileptic fits and psychiatric disturbances. It is necessary to demonstrate both that the symptoms are due to hypoglycaemia and that the hypoglycaemia is the consequence of an insulin-secreting tumour of the beta-cells of the pancreatic islets. The diagnosis depends on the demonstration of hypoglycaemia with appropriately high insulin levels.

11.18.1.1 Insulinoma-Prolonged Starvation

The patient is fasted for up to 72 h but allowed to drink water. This induces hypoglycaemia and produces symptoms which are relieved by rapid IV glucose administration. The test is carried out in the hospital with careful supervision of the patient. Blood sugar samples are taken at regular intervals (at least twice daily) and also if symptoms develop. Two-thirds of patients with insulinomas develop symptoms within 24 h and virtually all do so within 48 h; demonstration of a blood glucose <1.7 mmol/l when there are symptoms is especially useful. At the times of blood sugar estimation, samples of serum are taken and stored frozen. If the patient develops hypoglycaemia these are analysed for immunoreactive insulin. A positive diagnosis is made by the finding of a ratio:

$$\frac{\text{immunoreactive insulin (microunits / ml)}}{\text{blood glucose (mmol / l)}} \text{ of 0.3 or greater}$$

11.18.1.2 Glucagon Test

Glucagon 1 mg is injected IV and venous blood samples are taken at 0, 10, 20, 30, 45, 60, 90, 120, 150 and 180 min. An assay is made for glucose and insulin. In normal subjects the blood sugar rises and falls much as in an oral glucose tolerance test.

When an insulinoma is present the period of raised blood sugar levels is shorter and is followed by an abrupt and pronounced fall in blood sugar, even to hypoglycaemic levels. Plasma insulin levels are >100 microunits/ml after 10 min. This is in many respects the safest of the provocative tests.

The test can be performed by injecting 1 mg glucagon IM and testing the capillary blood.

11.18.1.3 Tolbutamide Test

The patient takes a diet containing 300 g carbohydrate for 3 days before the test. After an overnight fast 1 g tolbutamide is administered IV in 20 ml normal saline over 1–2 min. Venous blood samples are taken at 0, 10, 20, 30, 45, 60, 90, 120, 150 and 180 min and assayed for glucose and insulin. The test is positive when the blood glucose fails to return to 66% of the fasting value by 180 min. An early fall in blood glucose is of no diagnostic value.

When an insulinoma is present there is an elevated fasting insulin, the plasma insulin rises to above 120 microunits/ml within 10–30 min, and the insulin level fails to return to normal within 60 min. This test is unnecessary and dangerous if the fasting blood sugar is below 1.7 mmol/l glucose and hydrocortisone must be available during the test. The timing of samples is critical. False-positive results are rare but may occur in liver disease.

11.18.1.4 L-Leucine Test

The patient ingests 150–200 mg L-leucine/kg body weight. The leucine is prepared in a palatable form by the pharmacy without using sugar. Alternatively 200 mg L-leucine/kg body weight is administered IV over 10 min. Samples of venous blood are taken at 0, 15, 30, 45, 60 and 90 min and assayed for glucose and insulin. In normal adults there is often a slight fall of blood glucose concentration of up to 1 mmol/l. In an adult the diagnosis of insulinoma is suggested by a fall of blood glucose by >1 mmol/l in samples taken at 15, 30, 45 or 60 min. The diagnosis is also suggested by a plasma insulin rise of >20 microunits/ml.

11.18.1.5 Arteriography

This is of great help in the location of insulinomas. A well-defined round vascular shadow is often seen in the pancreatic substance. The tumours are usually too small to be demonstrated by the more routine radiological procedures or by pancreatic scanning.

Half of all cell tumours are not well differentiated. The possibilities of multiple hormone production from a single tumour and of multiple endocrine adenomatosis should be borne in mind.

11.18.2 Gastrinoma (Zollinger-Ellison Syndrome)

At present only about one-third of these tumours are diagnosed preoperatively. Clinical features include multiple unusually sited and recurrent peptic ulcers, diarrhoea and steatorrhoea, diabetes mellitus and occasional skin rashes. The best screening test is the measurement of the ratio of basal acid output to peak acid output, which is usually in excess of 60%. Fasting serum gastrin levels >50 $\mu\text{mol/l}$ confirm the diagnosis. A secretin provocation test can be helpful in doubtful cases, when IV injection of secretin 1 unit/kg provokes a rapid rise of >50% in serum gastrin levels.

Barium radiology may be helpful, showing coarse gastric folds, multiple ulcers and a dilated and oedematous duodenum. Selective arteriography may

localize a pancreatic islet tumour, though undetectable diffuse gastrin-cell hyperplasia is frequent.

11.18.3 Glucagonoma

These patients present with diabetes mellitus, diarrhoea, anaemia, vulvostomatitis and a characteristic necrotic migratory erythematous skin rash. Elevated serum glucagon levels are found. The normal range of serum glucagon is up to 120 pg/ml: levels in glucagonoma patients are usually >1000 pg/ml.

11.18.4 Vipoma

The clinical features are watery diarrhoea without steatorrhoea, and weakness. Gastric acid secretion is markedly reduced or absent. Hypokalaemia is present and can be severe. Serum vasoactive intestinal peptide levels are usually >200 pg/ml, compared with normal values of <50 pg/ml.

Gut endocrine tumours are relatively uncommon, and with the exception of insulin and gastrin levels the hormone assays are generally only available in highly specialized centres. Clinical features and the simpler investigations should be used to screen those patients in whom hormone assays may be useful. Serum pancreatic polypeptide levels >300 $\mu\text{mol/l}$ may be a reliable marker for a variety of islet cell tumours, and elevated neurone-specific enolase has also been proposed as a useful test.

11.18.5 Obscure Diarrhoea

In intractable diarrhoeas which are undiagnosable despite exhaustive investigation the estimation of a panel of serum hormones such as calcitonin, vasoactive intestinal peptide and pancreatic polypeptide may occasionally be rewarding.

Factitious diarrhoea should be borne in mind. It is more common in medical personnel, and may be diagnosed from the clinical history or from an examination of the bedside locker or medicine supply. Some proprietary laxatives contain phenolphthalein, which can be demonstrated in the stool by dropwise addition of 0.1 mol/l sodium hydroxide. In a positive reaction a purple colour develops in the stool.

11.19 Pancreatic Cancer Markers

The difficulty of diagnosing exocrine pancreatic cancer has stimulated the development of a host of tumour markers such as CEA, pancreatic oncofetal antigen and monoclonal antibody-based tests for carbohydrate antigens such as CA19-9.

None of these tests is entirely specific or satisfactory, but they may play a role in combination with other tests and in serial monitoring of progress in individuals. Normally CA19-9 should be up to 37 KU/I, CA125 up to 35 KU/I and CA195 up to 20 KU/I. Values >1000 KU/I indicate poorer prognosis. Serum testosterone is characteristically low.

Bibliography

- Acosta M, Ledesma CL. Gallstone migration as a cause of acute pancreatitis. *N Engl J Med.* 1974;290:484-7.
- Adrian TE, Bloom SR, Bryant MG, Polak JM, Heitz PH, Barnes AJ. Distribution and release of human pancreatic polypeptide. *Gut.* 1976;17:940-4.
- Adrian TE, Uttenthal LO, Williams SJ, Bloom SR. Secretion of pancreatic polypeptide in patients with pancreatic endocrine tumours. *N Engl J Med.* 1986;315:287-91.
- Arvanitakis C, Cook AR. Diagnostic tests of exocrine pancreatic function and disease. *Gastroenterology.* 1978;74:932-48.
- Axon ATR, Classen M, Cotton PB, Cremer M, Freeny PC, Lees WR. Pancreatography in chronic pancreatitis. *Gut.* 1984;2:1107-12.
- Bams RJ, Elmslie RG. Comparison of methods for estimation of trypsin in duodenal fluid. *Clin Chim Acta.* 1975;58:165-71.
- Barry RE, Barry R, Ene MD, Parker G. Fluorescein dilaurate - tubeless test for pancreatic exocrine failure. *Lancet.* 1982;2:742-4.
- Bloom SR, Polak JM. Plasma hormone concentrations in gastrointestinal disease. *Clin Gastroenterol.* 1980;9:785-98.
- Bonin A, Roy CC, Lasalle R, Weber A, Morin CL. Faecal chymotrypsin: a reliable index of exocrine pancreatic function in children. *J Paediatr.* 1973;83:594-60.
- Bray PT, Clark GCF, Moody GJ, Thomas IDR. Sweat testing for cystic fibrosis: errors associated with the in-situ sweat test using chloride ion selective electrodes. *Clin Chim Acta.* 1977;80:333-8.
- Crossley JR, Elliott RB, Smith PA. Dried blood-spot screening for cystic fibrosis in the new born. *Lancet.* 1979;1:472-4.
- Cuschieri A, Hall AW, Clark J. Value of laparoscopy in the diagnosis and management of pancreatic carcinoma. *Gut.* 1978;19:672-7.
- Denning CR, Huang NN, Cuasay LR, et al. Co-operative study comparing 3 methods of performing sweat tests in cystic fibrosis. *Paediatrics.* 1980;66:752-7.
- Deutsch V, Adar R, Jacob ET, Bank H, Moles M. Angiographic diagnosis and differential diagnosis of islet-cell tumours. *Am J Roentgenol.* 1973;119:121-32.
- Duncan JG, Imrie CW, Blumgart LH. Ultrasound in the management of acute pancreatitis. *Br J Radiol.* 1976;49:858-62.
- Durr HK, Otte M, Forell MM, Ie B. Faecal chymotrypsin: a study on its diagnostic value by comparison with the secretin-CCK test. *Digestion.* 1978;17:404-9.
- Editorial. Cystic fibrosis: prospects for screening and therapy. *Lancet.* 1990;335:79-80.
- Elias E, Redshaw M, Wood T. Diagnostic importance of changes in circulating concentration of immunoreactive trypsin. *Lancet.* 1977;2:66-8.
- Fawcett RA, Forbes WSC, Isherwood I, Braganza JM, Howat HT. Computed tomography in pancreatic disease. *Br J Radiol.* 1978;51:1-4.
- Fedai SS, Harvey RF, Salmon PR, Brown P, Read AE. Trypsin and lactoferrin levels in pure pancreatic juice in patients with pancreatic disease. *Gut.* 1979;20:983-6.
- Foster PN, Mitchell CJ, Robertson DRC, et al. Prospective comparison of three non-invasive tests for pancreatic disease. *BMJ.* 1984;289:13-6.
- Gibson LE, Cooke RE. A test for concentration of electrolytes in sweat in cystic fibrosis of the pancreas using pilocarpine by iontophoresis. *Paediatrics.* 1959;23:545-9.

- Gordon I, Levin B, Whitehead TP. Estimation of trypsin in duodenal juice. *BMJ*. 1952;1:463–5.
- Hatfield ARW, Smithies A, Wilkins R, Levi AJ. Assessment of ERCP and pure pancreatic juice cytology in patients with pancreatic disease. *Gut*. 1976;17:14–21.
- Haverback B, Dyce BJ, Gutentag PJ, Montgomeray DW. Measurement of trypsin and chymotrypsin in stool: a diagnostic test for pancreatic exocrine insufficiency. *Gastroenterology*. 1963;44:588–97.
- Heeley AF, Heeley ME, King DN, Kuzemko JA, Walsh MP. Screening for cystic fibrosis by dried blood spot trypsin assay. *Arch Dis Child*. 1982;57:18–21.
- Herlinger H, Finaly DBL. Evaluation and follow-up of pancreatic arteriograms. A new role for angiography in the diagnosis of carcinoma of the pancreas. *Clin Radiol*. 1978;29:277–84.
- Hodson M, Beldon I, Power R, Duncan FR, Bamber M, Batten JC. Sweat tests to diagnose cystic fibrosis in adults. *BMJ*. 1983;386:1381–3.
- Hovdenak N, Lees WR, Pereira J, Beilby JOW, Cotton PB. Ultrasound-guided percutaneous fine-needle aspiration cytology of the pancreas. *BMJ*. 1982;285:1183–4.
- Iwase K, Kato K, Nagasaka H, et al. Immunohistochemical study of neuro-specific enolase (NSE) and CA19-9 in pancreatic disorders. *Gastroenterology*. 1986;91:576–80.
- Jacobson DG, Curington C, Connery K, Toskes PP. Trypsin-like immunoreactivity as a test for pancreatic insufficiency. *N Engl J Med*. 1984;310:1307–9.
- Johnstone DE. Studies of cystic fibrosis of the pancreas. *Am J Dis Child*. 1952;84:191–8.
- Junglee D, Penketh A, Katrak A, Hodson ME, Batten JC, Dandona P. Serum pancreatic lipase activity in cystic fibrosis. *BMJ*. 1983;286:1693–4.
- Lake-Bakaar G, McKavanagh S, Rubio CE, Epstein O, Summerfield JO. Measurement of trypsin in duodenal juice by radio-immunoassay. *Gut*. 1980;21:402–7.
- Lankisch PG, Brauneis J, Otto J, Goke B. Pancreolauryl and NBT-PABA tests. Are serum tests more practicable alternatives to urine tests in the diagnosis of exocrine pancreatic insufficiency? *Gastroenterology*. 1986;90:350–4.
- Lankisch PO. Exocrine pancreatic function tests. *Gut*. 1988;23:777–98.
- Larvin M, Chalmers AG, McMahon M. Dynamic contrast enhanced computed tomography: a precise technique for identifying and localising pancreatic necrosis. *BMJ*. 1990;300:1425–8.
- Lees WR, Vallon AG, Denyer ME, Vahl SP, Cotton PB. Prospective study of ultrasonography in chronic pancreatic disease. *BMJ*. 1979;1:162–4.
- London NJM, Neoptolemos JP, Lavelle J, Bailey I, James D. Serial computed tomography scanning in acute pancreatitis: a prospective study. *Gut*. 1989;30:397–403.
- Lundh G. Pancreatic exocrine function in neoplastic and inflammatory disease: a simple and reliable new test. *Gastroenterology*. 1962;47:275–80.
- Mackie CR, Cooper MJ, Lewis MH, Moossa AR. Non-operative differentiation between pancreatic cancer and chronic pancreatitis. *Ann Surg*. 1979a;189:480–7.
- Mackie CR, Dhorajiwala J, Blackstone MO, Bowie J, Moossa AR. Value of new diagnostic aids in relation to the disease process in pancreatic cancer. *Lancet*. 1979b;2:385–9.
- Moeller DO, Dunn GO, Klotz AP. Comparison of the pancreozymin-secretin test and the Lundh test meal. *Am J Dig Dis*. 1972;17:799.
- Mottaleb A, Kapp F, Noguera ECA, Kellock TO, Wiggins HS, Waller SL. The Lundh test in the diagnosis of pancreatic disease: a review of 5 years experience. *Gut*. 1973;14:835–41.
- Multigner L, Figarella C, Samel J, Sarles J. Lactoferrin and albumin in human pancreatic juice. *Dig Dis Sci*. 1980;125:173–8.
- Nasrallah SM, Martin DM. Serum isoamylase as a test for pancreatic insufficiency. *Gut*. 1983;24:161–4.
- Nishida K, Sugira M, Yoshikawa T, Kond M. Enzyme immunoassay of pancreatic oncofetal antigen (POA). *Gut*. 1985;26:450–5.
- Osne M, Serck-Hanssen A, Kristensen O, Swensen T, Aune S, Myren J. Endoscopic retrograde brush cytology in patients with primary and secondary malignancies of the pancreas. *Gut*. 1979;20:279–84.
- Reuben A, Johnson AL, Cotton PB. Is the pancreatogram reliable? A study of observer variation and error. *Br J Radiol*. 1978;51:956–62.

- Russell JGB, Vallon AG, Braganza JM, Howatt HT. Ultrasonic scanning in pancreatic disease. *Gut*. 1978;19:1027–33.
- Sakamoto K, Haga Y, Yoshimura R, Egami H, Yokoyama Y, Akagi M. Comparative effectiveness of the tumour diagnostics CA19-9, CA125 and CEA in patients with diseases of the digestive system. *Gut*. 1987;28:323–9.
- Salt WB, Schenker S. Amylase – its clinical significance: a review of the literature. *Medicine*. 1967;55:269–89.
- Shorey BA. Aspiration biopsy of carcinoma of the pancreas. *Gut*. 1975;16:645–7.
- Smith EH, Bartrum RJ, Chang YC, D’Orsi CJ, Lokich J, Abbruzzese A, Dantano J. Percutaneous aspiration biopsy of the pancreas under ultrasonic guidance. *N Engl J Med*. 1975;292:825–8.
- Steinberg WM, Gelfand R, Anderson KK, et al. Comparison of the sensitivity and specificity of the CA19-9 and CEA assays in detecting cancer of the pancreas. *Gastroenterology*. 1986;90:343–9.
- Steinberg WM, Goldstein SS, Davis ND, Shama’a J, Anderson K. Diagnostic assays in acute pancreatitis. *Ann Intern Med*. 1985;102:576–80.
- Stoupis C, Dervenis C, Buchler MW. Current imaging techniques in acute pancreatitis. *Hellenic J Gastroenterol*. 1995;894:299–303.
- Tulassay Z, Sandor Z, Bodrogi L, Papp J, Feher T. An endocrine marker for pancreatic cancer. *BMJ*. 1988;297:1447–4.
- Walsh JH, Tomkins RK, Taylor IL, Lechago J, Hansky J. Gastrointestinal hormones in clinical disease: recent developments. *Ann Intern Med*. 1979;90:817–28.
- Warwick WJ, Hansen L. Measurement of chloride in sweat with the chloride selective electrode. *Clin Chem*. 1978;24:2050–3.
- Wiggins G, Schein PS, Macdonald JS, Schellinger D, Harbert D. Computerised axial tomography for diagnosis of pancreatic cancer. *Lancet*. 1976;2:233–5.
- Wong LTK, Turtle S, Davidson AGF. Secretin pancreozymin stimulation test and confirmation of the diagnosis of cystic fibrosis. *Gut*. 1982;23:744–50.
- Youngs GR, Agnew JE, Levin GE, Bouchier IAD. A comparative study of 4 tests of pancreatic function in the diagnosis of pancreatic disease. *Q J Med*. 1973;42:597–618.

Many advances in our knowledge about liver disease have followed the wider use of liver biopsy, and development of techniques such as ultrasonography, magnetic resonance and computed tomography. Nevertheless, blood tests remain the first investigations in the assessment of liver dysfunction. None of the tests is entirely specific, and interpretation usually depends on examination of a constellation of results together with the clinical presentation. There is no true 'liver function test', but merely abnormal serum biochemistry which could be explained by liver disease.

12.1 Serum Bilirubin (Table 12.1)

Although harmless in adults the visible nature of hyperbilirubinaemia makes this an obvious marker of liver disease. Jaundice may, however, result from three distinct processes:

- *Haemolysis*. There is excess production of unconjugated bilirubin due to red cell destruction. The jaundice is usually independent of hepatobiliary disease, unless there is secondary hypersplenism.
- *Hepatocellular damage*. There is a failure of conjugation of bilirubin, which accumulates in the bloodstream, but some reduction in excretory capacity for conjugated bilirubin may also contribute to the raised serum bilirubin.
- *Cholestasis*. Conjugated bilirubin is not excreted because of dysfunction of the bile secretory mechanism at the bile canaliculus (intrahepatic cholestasis) or because of an extrahepatic obstruction.

These causes can be inter-related. For example, cirrhosis with some liver cell necrosis may be accompanied by intrahepatic cholestasis and haemolysis.

Patients with carotenaemia from excess dietary carotene or associated with hypothyroidism may also develop yellow skin, but unlike hyperbilirubinaemia there is no conjunctival colouring.

Table 12.1 Changes in bile pigment metabolism associated with the various types of jaundice

Disease	Stool appearance	Urine			Blood	
		Urobilinogen	Bilirubin	Appearance	Conjugated bilirubin	Unconjugated bilirubin
Haemolytic jaundice	Normal	Increased	Absent	Normal	Normal	Increased
Cholestatic jaundice	Pale	Absent	Present	Dark	Increased	Normal or increased
Hepatocellular jaundice	Normal	Variable (high, low, normal)	Present	Normal	Increased	Increased

Jaundice is usually detectable when serum bilirubin rises above 50 $\mu\text{mol/l}$ and can often be seen at lower levels. Variable tissue levels in fluctuating jaundice may mean that skin and conjunctival appearances do not correlate. Laboratory measurements of serum bilirubin are based on a diazo colour reaction which forms the purple azobilirubin. Conjugated (direct) bilirubin reacts quickly. Unconjugated (indirect) bilirubin reacts slowly and requires the addition of alcohol for complete reaction. There are considerable technical problems associated with fractionation of bilirubin, and at very low levels of total bilirubin, as well as when there is considerable elevation, the ratio of conjugated to unconjugated bilirubin is unreliable. An alternative assay using alkaline methanolysis and high performance liquid chromatography yields lower and different results, which could be useful in assessing the significance of marginal hyperbilirubinaemia.

12.1.1 Interpretation

The normal serum bilirubin level is $<17 \mu\text{mol/l}$ in women and $<23 \mu\text{mol/l}$ in men. Half or less is conjugated. Haemolysis is associated with increased unconjugated bilirubin but, unless there is associated liver disease, the conjugated bilirubin level remains low.

In cholestasis ('obstructive' jaundice, either intra- or extrahepatic) levels of conjugated bilirubin are characteristically raised. Prolonged cholestasis may, however, lead to liver failure, and there may also be some elevation of unconjugated bilirubin.

In hepatocellular damage levels of both bilirubin fractions are raised, although unconjugated bilirubin usually predominates. Occasionally the rise is due entirely to conjugated bilirubin. For serial monitoring of the progress of liver disease total bilirubin measurement is adequate.

12.2 Urine Bilirubin

Conjugated, but not unconjugated bilirubin is excreted in the urine.

12.3 Urine Urobilinogen

Urobilinogens are formed from bilirubin by bacterial action in the intestine. Most are excreted in the faeces but some are absorbed and excreted in the urine. The excretion is maximal between 2 and 4 pm, and is enhanced by an alkaline urine. On exposure to air the urobilinogen is oxidized to urobilin, which darkens the urine.

12.3.1 Method

Ehrlich's reagent is made up by dissolving 2 g p-dimethylaminobenzaldehyde in 100 ml 20% hydrochloric acid: 1 ml is added to 10 ml freshly voided urine. If a large amount of bilirubin is present it is precipitated by adding 10% barium chloride to the urine and the filtrate is tested.

12.3.2 Interpretation

Normal urine gives either no colour reaction or only a faint red colour which is intensified by gentle heating. A distinctly red colour in the cold is indicative of increased amounts of urobilinogen. A rough quantitation can be made by serial dilutions of the coloured urine to find the greatest dilution which shows a pink colour. Normal urine shows no colour when diluted more than 1:20. A false-negative result may be obtained if urine is tested after it has been standing for some time at room temperature. Antibiotic therapy may result in urobilinogen being absent from the urine because of the destruction of the intestinal bacteria.

The test is useful for distinguishing between obstructive jaundice, and hepatocellular and haemolytic jaundice: in the former there is no urobilinogen in the urine, whereas in the latter conditions urobilirubinogenuria may be present. A positive result can be found in many febrile patients.

Porphobilinogen also forms a red compound with Ehrlich's reagent. In order to differentiate porphobilinogens from urobilinogens 1 ml saturated sodium acetate and 2 ml chloroform are added to the test tube containing the urine and Ehrlich's reagent. The tube is shaken and the mixture allowed to settle. Urobilinogen dissolves into the lower (chloroform) layer which turns pink, but no such change occurs with porphobilinogen which remains in the colourless upper aqueous phase. Testing for urine urobilinogen has been simplified by the introduction of a dipstick test which provides a semi-quantitative record.

In the presence of cholestasis the stools become pale because of absence of bile pigment in the intestine. This does not occur in haemolysis or hepatocellular jaundice.

12.4 Serum Enzymes

A number of intracellular enzymes appear in the serum when liver cells are damaged. Different patterns of elevation suggest different disorders, but none is pathognomonic. Elevated serum levels of enzymes are due to their leakage from cells linked with the increased synthesis of enzymes because of induction prior to necrosis.

12.4.1 Transaminases

Serum levels of both aspartate aminotransferase (AST, SGOT; EC2.6.1.1) and alanine aminotransferase (ALT, SGPT; EC2.6.1.2) are elevated in hepatocellular damage. ALT is slightly more specific to the liver.

The normal serum concentrations are up to 40 IU/l for AST and up to 50 IU/l for ALT. Marked elevations in concentration occur in acute hepatitis and hepatic necrosis, and levels of 150–1000 IU/l are fairly common. Lesser degrees of elevation, usually <150 IU/l, are recorded in infectious mononucleosis, drug induced cholestasis, metastatic cancer of the liver, cirrhosis and extrahepatic obstruction. Occasionally marked increases in the levels of both of ALT and AST are found in extrahepatic obstruction. On the other hand, patients may die from acute hepatitis without showing an elevation in serum enzyme concentrations.

Thus transaminase levels have their limitations in the diagnosis of liver disease and jaundice. The serum transaminase concentration may be the only biochemical abnormality present in patients with hepatitis: measurement of this enzyme has been used in epidemiological screening studies.

ALT and AST are present in many of the body cells and elevated serum levels accompany bowel necrosis, pancreatitis, myocardial infarction and other disorders. Since these conditions are usually readily distinguished from liver disease, the source of an elevated level is seldom a problem when investigating a patient. In patients with liver disease and an AST level more than twice that of ALT, alcohol is likely to be the cause.

12.4.2 Alkaline Phosphatase

Serum alkaline phosphatase (EC3.1.3.1) originates from the liver, bones, intestines and placenta. The upper limit of normal is 100 IU/l. Children and adolescents normally have increased serum alkaline phosphatase levels because of bone growth.

This enzyme is a relatively insensitive test of hepatocellular function. The concentration is raised in the presence of intra- or extrahepatic biliary obstruction. A normal value excludes mechanical obstruction of the bile ducts with 95% confidence. A more moderate increase in enzyme levels is found in acute hepatitis and cirrhosis. High levels in a patient with cirrhosis suggest the presence of either co-existent biliary tract disease or a hepatoma. Elevated concentrations in the absence of jaundice may be found in primary and secondary liver tumours, primary biliary cirrhosis, lesions of the bile duct, abscesses, granulomas and amyloidosis. While this enzyme is of help for determining whether there is obstruction to the outflow of bile, or irritation of the biliary epithelium, it is of no value in deciding the site of the lesion.

Elevated serum concentrations are found in bone disorders in which there is increased osteoblastic activity, such as Paget's disease, osteogenic secondary deposits, osteomalacia and rickets. The identification and differentiation of the serum alkaline phosphatase isoenzymes is technically difficult. The electrophoretic characteristics of the alkaline phosphatases of skeletal and hepatic origin are similar, but they can be separated on polyacrylamide gel.

12.4.3 Gamma-Glutamyl Transferase

Measurement of this enzyme (gamma-GT; EC2.3.2.2.) is the most sensitive widely available test of disordered hepatobiliary function. Unfortunately it is nonspecific, and the level can be raised in pancreatic and renal disease, as well as by drug-associated induction of liver enzymes.

Normal values are up to 50 IU/l. It is particularly useful in the diagnosis of alcoholic liver disease. Elevated levels are characteristic of biliary disease and all the disorders which raise hepatic alkaline phosphatase levels. Since gamma-GT levels are not raised in bone disease, their estimation may help to elucidate the cause of elevated alkaline phosphatase levels. Measurement of gamma-GT is more useful than of 5-nucleotidase, which has been superseded.

12.4.4 Other Enzymes

Other enzymes are somewhat more specific indicators of liver cell damage but their estimation is seldom necessary. Serum isocitric dehydrogenase and glutathione-S-transferase are examples. Serum beta-glucuronidase activity has been recommended as a biochemical index of liver disease in the anicteric subject. It is of no value when the patient is jaundiced.

12.5 Proteins

12.5.1 Albumin

This is synthesized in the liver. The normal serum values of 35–50 g/l can be affected by a number of factors: they are elevated in dehydration and low in fluid retention. Serum albumin may fall because of increased loss, especially in the nephrotic syndrome or in protein-losing enteropathy. Reduced synthesis may occur in severe malnutrition, such as kwashiorkor, as a result of insufficient dietary intake of essential amino acids. Congenitally low levels of albumin occur in alpha₁-antitrypsin deficiency, which can cause neonatal hepatitis, cirrhosis and emphysema.

The level of serum albumin is helpful in assessing the severity of liver cell failure as well as in predicting the likely cause of ascites. It should always be available to assist the interpretation of serum calcium levels.

12.5.2 Globulins

Many laboratories report globulin levels as the difference between serum total protein and serum albumin. This is only of limited use. Much more information is gained by paper immunoglobulin electrophoresis or by quantitation of serum immunoglobulins.

12.5.2.1 Immunoglobulins

The normal values for the major immunoglobulins are:

- IgG 7–18 g/l
- IgA 0.5–4.5 g/l
- IgM 0.3–2.5 g/l

The pattern of immunoglobulins is rarely diagnostic and may be affected by diseases which do not involve the gastrointestinal system. There is often considerable overlap in abnormal levels between diseases.

IgG levels are elevated in acute infections including viral hepatitis, and also in chronic autoimmune hepatitis; they are reduced in hypogammaglobulinaemia. IgM levels are elevated in primary biliary cirrhosis and macroglobulinaemia. IgA levels may be high in cirrhosis. They are usually normal in coeliac disease, and about one patient in 70 has low levels of IgA. Elevated levels in a patient with coeliac disease should raise the suspicion of a lymphoma.

Measurement of IgE levels (normal up to 100 u/l) may prove of value in appraisal of allergic symptoms.

12.5.2.2 Electrophoresis

This may provide further information. In myeloma there is a distinct monoclonal band in the gammaglobulins, which accounts for the elevated IgG levels. A diffuse increase in gammaglobulins is seen in viral hepatitis and may also occur in cirrhosis. By contrast, an increase in alpha₂- and beta-globulins is more characteristic of cholestasis. Alpha₁-globulin is markedly reduced or absent in alpha₁-antitrypsin deficiency and in neonatal hepatitis.

12.6 Coagulation Tests

Multiple coagulation defects are not uncommon in patients with acute and chronic liver disease. Combined deficiencies of factors II (prothrombin), V, VII and X contribute to an abnormally prolonged prothrombin time. The determination of the one-stage prothrombin time is a useful simple test of liver function.

Because vitamin K is a co-factor of hepatic prothrombin synthesis there may be a prolonged prothrombin time in cholestatic jaundice from any cause. The ability of parenteral vitamin K (10 mg vitamin K₁ given IV/IM for 3 days) to convert the prothrombin time to normal values has been used as a diagnostic test for the aetiology of jaundice. Patients with extrahepatic biliary obstruction respond to vitamin K₁ injections, but in severe hepatocellular disease the prothrombin time remains unchanged. This is not a reliable diagnostic test.

Other haematological defects which may be found in liver disease include deficiencies of factors IX (plasma thromboplastin component), XI (plasma thromboplastin antecedent) and platelets.

Liver disease may be accompanied by diffuse intravascular coagulation (DIC), in which fibrin degradation products appear in the serum (>40 mg/l), the platelet count falls sharply and there is evidence of haemolysis.

12.7 Blood Ammonia

Ammonia levels rise in hepatic coma. Methods for measuring the blood ammonia concentration are complex and this is not performed routinely in the management of patients with liver failure. While venous or arterial blood can be sampled the latter is favoured. The normal arterial blood ammonia concentration is <1 mg/l.

Elevated concentrations may be found in hepatocellular failure or when there is shunting of blood from the liver. Arterial blood ammonia levels do not correlate well with the clinical severity of hepatic coma and this correlation is even poorer if venous samples are measured. Elevations of blood ammonia concentration are also found in a variety of rare congenital defects of urea synthesis.

12.8 Bile Acids

It is possible to measure the concentration of serum bile acids by enzyme fluorimetry or gas liquid chromatography. Both total and the major individual bile acids can be quantitated accurately. Normal fasting levels are <4.5 $\mu\text{mol/l}$, and postprandial levels <6.5 $\mu\text{mol/l}$; these are increased in a wide variety of hepatobiliary diseases. Serum bile acids vary with fasting and feeding, during the menstrual cycle, and with vitamin C status in liver disease. Patients on ursodeoxycholic acid (UDCA) therapy regularly have fasting serum UDCA levels of 4+ $\mu\text{mol/l}$; lower values indicate non-compliance.

There can be a seven-fold fluctuation of total bile acid values through the day. Levels may also be elevated in bacterial colonization of the small bowel and associated with hyperlipidaemia. Serum bile acids are, therefore, not entirely specific to hepatobiliary disease, and although they can be used for screening and monitoring liver disease they do not add further information to the conventional screen of 'liver function' tests.

Bile acid tolerance tests and clearance studies in which serum levels are measured after oral or intravenous administration of unlabelled or radio-labelled bile acids, give results which are too variable to be helpful in individual diagnosis.

Serum levels of 7- α -hydroxycholesterol (the essential precursor in hepatic bile acid synthesis) correlate with liver cirrhosis.

12.9 Lipids

One 'normal' upper limit for serum cholesterol is 7.8 mmol/l, and for triglycerides is 2.5 mmol/l; higher values are definitely abnormal. The serum level of total cholesterol rises in both intra- and extrahepatic cholestasis. This results from the presence of an abnormal lipoprotein (LPX) in the serum which can be measured immunochemically. Very low levels of high-density lipoprotein (HDL) cholesterol are characteristic of cholestasis: the lower limit of normal is about 1 mmol/l.

The presence of altered or abnormal lipoprotein components can be associated with many liver diseases. Raised levels of cholesterol, triglycerides, low-density (LDL) and very low-density (VLDL) lipoprotein in various combinations is seen.

This may be important since markedly elevated levels of serum triglycerides (> 10 mmol/l) cause turbidity and interfere with most other biochemical measurements. Alcoholism is the most common cause of secondary hyperlipidaemia, and may itself cause cirrhosis and pancreatitis.

12.10 Others

Fluid-electrolyte disturbances including secondary aldosteronism are encountered in liver disease: hyponatraemia ($\text{Na} < 130$ mmol/l) and hypokalaemia ($\text{K} < 3.5$ mmol/l) are common. Although low serum sodium levels are often well tolerated, low serum potassium can potentiate hepatic encephalopathy. Urea is synthesized in the liver: low levels (< 3.3 mmol/l) may indicate severe hepatocellular dysfunction but can also reflect dilution with fluid retention. Blood urea levels may be apparently normal in patients with liver disease and associated renal impairment, and serum creatinine (normal range 45–150 $\mu\text{mol/l}$) is a much better index of renal failure.

Vitamin B₁₂ is normally present in liver cells and levels are elevated in metastatic liver disease, liver abscess and hepatitis. Levels also rise in patients receiving hydroxocobalamin therapy. Plasma glucose levels may be informative as both diabetes mellitus and hypoglycaemia occur in liver disease.

12.11 Alcoholic Liver Disease (ALD)

Alcohol is the most common cause of liver disease in Western societies. The main hurdle in diagnosis is to suspect the cause, and the patient's general demeanour may give clues.

The 'CAGE' questionnaire is a simple 4-point system to assess alcohol abuse. A patient who answers 'yes' to all four questions is an alcoholic, and a score of two or three out of four is suspicious.

1. Have you ever tried to Cut down alcoholic intake?
2. Have you ever been Annoyed by criticism of your drinking?
3. Have you ever felt Guilty about the amount you drink?
4. Do you ever take an Eyeopener – a drink to start the day?

Patients may be teetotal at the time when they are suffering the effects of previous heavy drinking, and an assessment of the amount drunk needs to take into account changing patterns.

Patients are not always honest about excess alcohol intake, and laboratory tests are often valuable in establishing diagnoses. They are not infallible, and all can produce normal results in people with severe alcoholic liver disease. In addition, a significant minority of alcohol abusers have non-alcohol-related liver disease.

Measurement of the alcohol level in the blood is extremely useful. If there is any alcohol at all in a morning sample then the patient is probably drinking to excess.

The assessment of long-term heavy drinking is helped by various tests. The most useful are raised gamma-GT levels (>50 IU/l) and mean corpuscular volumes (>95 fl). The alkaline phosphatase level may also be raised to a lesser extent, and the platelet count reduced. Chest radiology may reveal old or recent rib fractures in binge drinkers. Specialized tests such as measurement of glutamate dehydrogenase, mitochondrial AST, carbohydrate-deficient transferrin and apolipoprotein A₁ may prove useful but are not generally available.

12.12 Immunology

Useful in vitro migration and transformation tests may be performed by culture and challenge of lymphocytes with drugs suspected of causing toxic reactions. These should be considered if a patient has suffered a serious drug reaction: they may establish the diagnosis without the need for potentially hazardous in vivo challenge tests.

The peripheral T-cell population is reduced in alcoholic liver disease, chronic acute hepatitis and primary biliary cirrhosis. Human leukocyte antigens HLA-B40 and HLA-B8 are said to be more frequent in patients with alcoholic cirrhosis than in non-cirrhotic alcoholics and cirrhosis of other causes.

12.12.1 Tumour Antigens

12.12.1.1 Alpha-Fetoprotein

This may be detected in the serum of patients with hepatoma (primary liver cell carcinoma). In some parts of the world almost all hepatoma patients have detectable levels, though in northern Europe and North America the figure is lower. It is a reliable test if strongly positive, but expression of results semiquantitatively has shown some weakly positive results of uncertain significance. It may also be detected in ascitic fluid. This test is also positive in pregnant women carrying fetuses with spinal malformations, and in neonatal hepatitis. The normal level is up to $10 \mu\text{g/l}$, but hepatoma patients commonly have values in 4 figures or more.

12.12.1.2 Carcinoembryonic and Oncofetal Antigens

These markers of colonic and pancreatic carcinomas may have a role in monitoring the progress of proved disease, including the detection of tumour recurrence and metastasis to the liver and other sites of the body. The normal value for CEA is up to $2.5 \mu\text{g/l}$.

12.12.2 Tissue Antibodies

Circulating antibodies to various tissue components have been described in liver disease. While these antibodies are of great theoretical interest, their detection has variable diagnostic significance.

12.12.2.1 Anti-neutrophil Cytoplasmic Antibody (pANCA)

This is a very common finding in primary sclerosing cholangitis (78%) and chronic auto-immune hepatitis (88%). It is less common in primary biliary cirrhosis, but is not seen in non-auto-immune liver disease. It does, however, occur in many non-hepatic diseases.

12.12.2.2 Antimitochondrial Antibody (AMA)

These antibodies are found in the sera of 95% of patients with primary biliary cirrhosis (primary biliary cholangitis), a disease of the hepatic ductules which is not usually cirrhotic. They are rarely present in viral or drug-associated hepatitis. Of great diagnostic value is the finding that these antibodies are rarely present in extra-hepatic obstruction and then only in a very low titre. These antibodies provide the most diagnostic help of all the antibody tests.

The M₂ ATPase-associated antigen is even more specific for primary biliary cirrhosis, and should now be a routine.

12.12.2.3 Antismooth Muscle Antibody (SMA)

About one-half of patients with chronic auto-immune hepatitis are positive for antibodies reactive with smooth muscle. Positive reactions also occur in 30% of patients with primary biliary cirrhosis, 25% of patients with idiopathic cirrhosis and 15% of those with alcoholic liver disease.

Patients with chronic auto-immune hepatitis have high-titre IgG SMA, which is important because 50–80% of patients with viral hepatitis have transient low-titre IgM SMA. There is evidence that the antibody is directed against actin, and the measurement of specific anti-actin antibody is more specific than SMA, but not so readily available.

12.12.2.4 Antinuclear Antibody (ANA)

Antinuclear antibody (or factor) is present in 50% of patients with chronic autoimmune hepatitis, where it is an IgG antibody in high titre (> 1:80). It also occurs commonly in primary biliary cirrhosis and drug-associated chronic hepatitis. Low titres are of no importance.

The more specific antibody directed against double-stranded DNA is a common accompaniment of all forms of liver disease, and does not assist differential diagnosis.

12.12.2.5 Liver-Kidney Microsomal Antibody (LKM)

This is found in 'type 2' chronic auto immune hepatitis where SMA and ANA are both negative.

12.12.2.6 Other Antibodies

Liver membrane antibodies, 'liver-specific protein' and bile canalicular antibodies have all been described but are not helpful in diagnosis.

Table 12.2 Viral hepatitis markers and their significance

Finding	Usual significance
<i>Hepatitis A:</i>	
IgM anti-HAV	Acute hepatitis A
IgG anti-HAV	Immune to hepatitis A
<i>Hepatitis B:</i>	
HBsAg	Acute or chronic hepatitis B carriage
IgMHBcAb	Acute hepatitis B (high titre) Chronic hepatitis B (low titre)
IgGHBcAb	Past exposure to hepatitis B (with negative HBsAg) Chronic hepatitis B (with positive HBsAg)
HBsAb	Immune to hepatitis B
HBeAg	Acute hepatitis B. Persistence means continued infectious state
HBeAb	Convalescence or reduced infectious risk
HBVDNA	Continued infectious state
<i>Hepatitis C</i>	
Anti-HCV ELISA	Acute or chronic infection
HCV RIBA	2–4 band confirms infection
<i>Hepatitis D:</i>	
HD Ag/HDV RNA	Acute or chronic infection
IgM anti-HDV	Acute infection with delta agent
IgG anti-HDV	Past delta infection
<i>Hepatitis E:</i>	
Anti-HEV	Acute infection

12.13 Viral Liver Disease (Table 12.2)

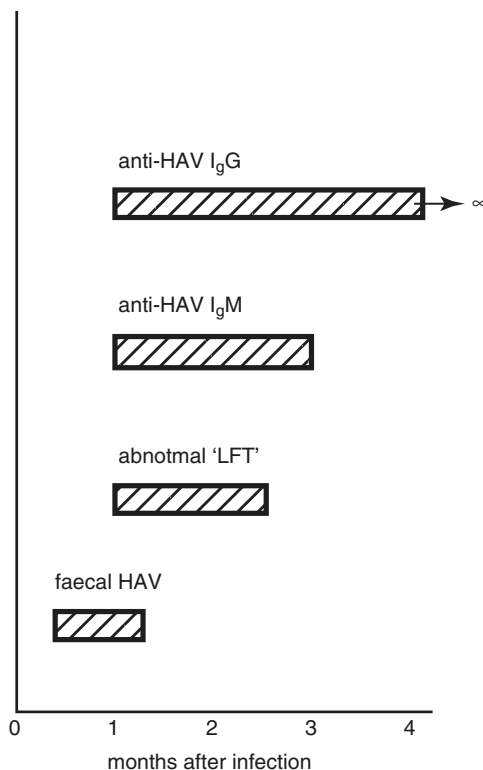
Viral hepatitis is usually diagnosed on clinical grounds supported by appropriate biochemical tests. Electron microscopy and liver biopsy can provide further evidence, but it should usually be possible to define the exact organism involved by serum immunology.

12.13.1 Liver Biopsy

This is often diagnostic, but is not usually necessary to confirm viral hepatitis. It may be misleading early in the illness. Characteristic changes include cloudy swelling of the cytoplasm ('ground-glass' appearances), with the appearance of eosinophilic cell debris (Councilman bodies) and necrotic nuclei.

Immunofluorescence demonstrates intracellular viral antigens, and viral particles can be seen on electron microscopy.

Fig. 12.1 Pattern of results in acute hepatitis A



12.13.2 Hepatitis A (Fig. 12.1)

Exposure to virus (HAV) is widespread, and infections are usually mild. It is transmitted by the faecal-oral route. Antibody to the virus (anti-HAV) in the IgG class is frequently present in serum of healthy individuals with immunity. The appearance of IgG anti-HAV in a patient known to have been previously negative is evidence of recent exposure. Better proof is the detection of anti-HAV in the IgM class, which is transient but always present at the onset of jaundice in HAV infection. It is possible to find 29 nm virus particles in stool by electron microscopy.

12.13.3 Hepatitis B (Fig. 12.2)

This is transmitted both sexually, and by blood products, especially needle-sharing by IV drug addicts.

Acute infection with this virus (HBV) is marked by the appearance in the serum of an antigen associated with the surface protein coat (HBsAg). This is usually cleared in a matter of weeks, with a rise in a specific antibody directed against it (HBsAb). In 5–10% of patients HBsAg persists indefinitely. Anti-HBs is detectable in the serum for long periods and possibly permanently: it only indicates exposure to HBV or surface antigen in vaccine at some time in the past and is a reliable marker of immunity.

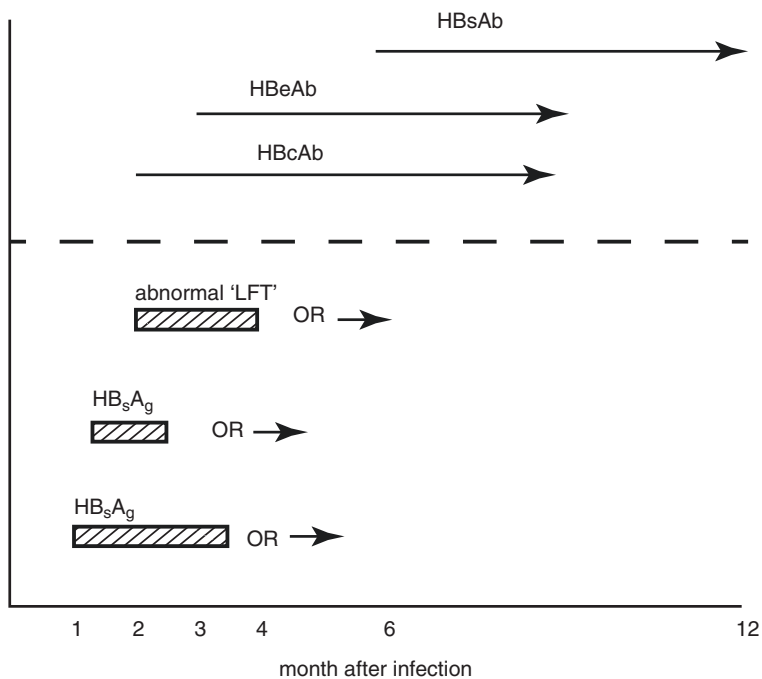


Fig. 12.2 Pattern of results in acute hepatitis B

During acute infection with HBV, antigen from the viral core (HBcAg) may sometimes be found in the serum. Antibody to HBcAg (HBcAb) is much more commonly found, and the presence of HBcAb of the IgM class in high titre reliably indicates recent infection. Another antibody directed against the intact virion may also be found in serum of currently infected patients, as may viral DNA polymerase and HBV DNA.

There are other useful markers of HBV infection. In an individual who is a chronic carrier of HBsAg, the presence of another antigen from the protein coat (HBeAg) is an indicator of infectivity. If there is antibody to HBeAg (HBeAb), or if neither HBeAg nor HBeAb are present, the serum is unlikely to be infectious.

Electron microscopy will show the 40–44 nm virus, together with the cylindrical and spherical remnants of its protein coat.

In chronic liver disease, steatosis, persistent hepatitis, or even cirrhosis are features of hepatitis B and C.

12.13.3.1 Chronic HBV Infection and Carrier State

Any of the markers of HBV infection may be present, with the exception of IgM class HBcAb.

12.13.4 Hepatitis C

This RNA virus is transmitted parenterally, and many blood transfusion recipients and haemophiliacs were chronically infected. Like hepatitis B, it may be a feature of needle sharing in IV drug abuse.

The initial illness is often mild or inapparent, but serious long-term liver damage may occur anyway. This often requires liver biopsy to document: routine serum biochemistry correlates poorly. The initial test is anti-HCV antibody estimation by ELISA. This may give false-positives so it is essential to confirm infection by back-up radioimmunoassay, which must be positive in at least 2 of the 4 bands to prove the diagnosis.

12.13.5 Hepatitis D (Delta Viral Hepatitis)

This RNA virus only infects patients with hepatitis B infection, but may be important in enhancing the pathogenicity of the DNA virus.

In patients positive for HBsAg the additional presence of IgM anti-hepatitis D antibody indicates acute or chronic infection and may be associated with more severe chronic liver disease. IgG anti-HDV antibody merely suggests past infection. It is also possible to identify hepatitis D RNA in the serum and an antigen (HD) in serum and liver, but these tests are not generally available.

12.13.6 Hepatitis E (Epidemic Non-A Non-B Hepatitis)

This is an enteric epidemic illness in developing countries, detectable by the presence of anti-HE antibody. The 27–34 nm virus particles can be seen in the stool. Sporadic cases may also occur. It carries a high fatality rate in pregnant women.

Hepatitis types F and G have also been described, and further rarities are likely to be encountered in the future.

12.13.7 Prevalence of Viral Hepatitis

In Britain hepatitis A is the most common problem. Hepatitis B and D are decidedly uncommon and affect mainly groups at high risk, such as the heterosexually hyperactive, male homosexuals and addicts using IV drugs. Hepatitis C was the most common cause of post-transfusion viral hepatitis, though now this seems to be rare because of the screened voluntary donor system. It is often found in IV drug abusers.

Transfusion and liver transplantation may also spread or reactivate cytomegalovirus, detectable by CMV antibodies.

The pattern is quite different in other countries. Hepatitis B virus-associated hepatoma is said to be the most common cause of cancer death in males worldwide.

12.14 Kinetic Tests

12.14.1 Caffeine Clearance

12.14.1.1 Method

After 17 h free of caffeine-containing drinks and food, 300 mg of caffeine citrate is given by mouth. Serum samples are taken 4 and 16 h later. Serum caffeine is measured by enzyme immunoassay and clearance calculated.

12.14.1.2 Interpretation

Normal subjects have a median clearance of 1.27 mmol/min/kg and those with liver disease 0.32 mmol/min/kg (range 0.04–2.68). Using a cut-off of 0.86 mmol/min/kg, caffeine clearance is 89% sensitive for liver disease and 100% sensitive for alcoholic liver disease. It is a simple and cheap test which may be repeated to follow disease progress.

12.14.2 Bromsulphthalein (Sulphobromophthalein, BSP) Retention Test

Most investigations for liver disease have been introduced since this test was developed in 1922. Although it has been largely replaced, it can be used in the assessment of anticteric liver disease.

12.14.2.1 Method

The patient should not be fasting, since prolonged fasting alters results. BSP is administered IV at a dose of 5 mg/kg body weight. After 5 and 45 min, 10 ml venous blood is collected from a different vein into a plain test tube and analysed for BSP. The time of collection of the samples is noted accurately.

Injection of BSP may cause allergic reactions such as fever, urticaria and other skin eruptions. Sudden death has occurred. The material is highly irritant and great care must be exercised to avoid extravascular spilling during the injection.

12.14.2.2 Interpretation

The normal liver clears 95% of the dye within 45 min and <0.5 mg/100 ml should remain in the circulation. Thus in normal adults the 45-min BSP retention should not be more than 5%.

A modification of the BSP excretion test is of help in the diagnosis of the Dubin-Johnson and Rotor syndromes. Venous blood is collected at 30, 45 and 90 min. The serum BSP concentrations fall at 30 and 45 min and then show a rise at 90 min because of the regurgitation of conjugated BSP into the blood. The BSP test has been revived somewhat by the introduction of 'compartmented' tests in which serial blood samples are used to calculate disappearance kinetics. The information obtained is usually available by other safer methods.

12.14.3 Indocyanine Green Clearance (ICG)

This dye has a number of properties which makes it an attractive alternative to BSP. It is relatively free of side-effects; it is avidly taken up and excreted by the liver without conjugation; it is easily measure spectrophotometrically; and this test can be performed at the ear lobe without skin puncture if desired.

12.14.3.1 Method

An indwelling intravenous cannula is positioned in an arm, and 4 ml blood are taken before commencing the test. Ampoules containing 2.5% ICG solution in proprandiol are prepared by dilution with four volumes of distilled water (i.e. 1 ml plus

4 ml); 0.3 mg/kg ICG are injected IV into the other arm within 30 sec. Five millilitres of blood is taken 2, 4, 6, 8 and 10 min after dye injection, washing the cannula with isotonic saline each time to avoid contamination. The clotted blood sample is centrifuged and the extinction at 814 nm is measured spectrophotometrically using control serum as a blank.

12.14.3.2 Interpretation

Normal controls have <90% retention at 4 min and <5% retention at 10 min. By contrast patients with liver disease usually retain more than 50% of the initial dose at 4 min, with a mean ICG half-life of 5–10 min. This can be used as a test of liver blood flow as well as liver cell function.

12.14.4 Ammonia Tolerance Test

Although fasting venous blood ammonia levels are usually increased in cirrhosis from the normal 10–35 $\mu\text{mol}/100\text{ ml}$, this does not correlate with disease severity nor with encephalopathy.

12.14.4.1 Method

After an overnight fast an arterial catheter is positioned in the brachial artery. Ammonium chloride 45 mg/kg body weight, up to a maximum of 3 g, is given by mouth. A sample of blood is drawn at 45 min into a heparinized syringe. Alternative procedures include using ammonium acetate 70 mg/kg or 5–10 g ammonium citrate. Since ammonia preparations cause nausea and may be vomited, ammonium acetate may be administered rectally.

12.14.4.2 Interpretation

Normal subjects have a mean blood ammonia of $117 \pm 13\ \mu\text{g}/\text{ml}$ at 45 min. The mean level in patients with venous collaterals is $243 \pm 129\ \mu\text{g}/\text{ml}$, but there is a wide overlap with normal. There is also an increase in levels of ammonia in cirrhosis without collateral circulation, and the ammonia tolerance test does not prove that portosystemic shunts are present.

12.14.5 Protein Load Test

The ability of a cirrhotic patient to tolerate protein in the diet is a guide to the degree of collateral circulation and liver cell function. A diet of increasing amounts of protein is fed while a careful watch is kept on the patient's clinical condition. The starting content of protein in the diet depends on each patient and is usually 40–60 g/day. The patient is observed for the features of impending liver coma which include hepatic foetor, a flapping tremor, slurred speech and drowsiness or restlessness. An electroencephalographic assessment may be made in addition. If no ill-effects are observed after 3 days the protein content of the diet is increased by 20 g/day until 120 g protein/day is reached.

Patients with little shunting of portal blood from the liver and/or good liver function tolerate 120 g protein/day. Patients with sensitivity to protein are unable to tolerate 40 or 60 g protein/day. The test is of value in the selection of patients with portal hypertension for shunt surgery. Those patients with a reduced protein tolerance are expected to do poorly after the operation and are rejected for shunt operations.

12.15 Electroencephalography

The EEG is a useful method for assessing hepatic precoma and coma. The essential change is a progressive slowing of the frequency until the EEG becomes 'delta dominant' and the rhythmic activity is less than 4 cycles/s. These changes are not specific for liver disease and are found in a number of metabolic confusional states. The prognosis in hepatic failure can be predicted from serial EEGs, prothrombin times and possibly also alpha-fetoprotein levels.

12.16 Constitutional Unconjugated Hyperbilirubinaemia (Gilbert's Syndrome)

Patients with this condition usually have elevated serum unconjugated and total bilirubin levels, or a history of jaundice in the absence of any other symptoms or abnormal tests. It is important to make a positive diagnosis in order to allay anxiety about more serious conditions.

12.16.1 Reduced Calorie Intake Test

Blood is withdrawn for a total and fractionated serum bilirubin estimation while the patient is taking a normal diet. A diet in which energy intake is reduced to 1.7 MJ (400 Cal) daily is then given for 2 days and further blood samples are taken at 24 and 48 h for bilirubin estimation. A positive result is a rise in serum bilirubin of 100% or more, with the proviso that the rise must be into the abnormal range and be mainly accounted for by an increase in unconjugated bilirubin. Although the test is specific it does not identify all patients; and individuals with Gilbert's syndrome may also have other hepatobiliary disorders. The test depends on appropriate dietetic advice (the permitted daily food intake is equivalent to a modest breakfast): if this is not available, putting a patient on water only for 2 days can be used.

Other tests that have been used include the administration of nicotinic acid to provoke hyperbilirubinaemia and the infusion of bilirubin followed by serial measurements of serum levels; neither confers any advantage over caloric restriction. It is possible to measure glucuronyl transferase activity in fresh liver biopsy specimens; this is markedly reduced in many, but not all, patients with Gilbert's syndrome. The test is not widely available.

12.17 Haemochromatosis

This diagnosis should only be made when there is no overt cause for iron overload. A strong family history and the presence of cardiac and endocrine disease are valuable pointers.

12.17.1 Serum Iron and Iron-Binding Capacity

The average normal serum iron level is $<170 \mu\text{g}/100 \text{ ml}$ (or $30 \mu\text{mol/l}$) and is lower in women than men. Average iron binding capacity is $330 \mu\text{g}/100 \text{ ml}$, with a saturation of 30–40%. Serum iron may fluctuate and is low in many acute and inflammatory diseases.

In haemochromatosis the serum iron is usually raised, while iron binding capacity is normal, and 80–100% saturated. Serum ferritin level is often $>1000 \mu\text{g/ml}$, and correlates well with total body stores.

12.17.2 Iron Excretion

A simple test, suitable for out-patients, is the measurement of the iron content in a 24-h urine collection after administration of 0.5 g desferrioxamine IM. An iron output $>30 \mu\text{mol}$ (2 mg) indicates iron overload, and in untreated haemochromatosis the excretion is usually $>180 \mu\text{mol}$ (10 mg) in 24 h.

12.17.3 Liver Biopsy

This is essential to prove the diagnosis. Iron deposits stain brown with haematoxylin and eosin, and blue with Perl's reagent. In haemochromatosis iron content is ++ or more on the semi-quantitative 0 to ++++ score, and is in excess of $180 \mu\text{mol/g}$ ($1 \text{ g}/100 \text{ g}$) dry weight of liver.

12.17.4 Other Tests

Excess iron in the reticuloendothelial bone marrow cells occurs and deposits also occur in the skin and gastric mucosa. Liver iron stores are shown as diffuse sonodense areas on ultrasonography and this can be used to monitor removal by treatment.

Patients are usually diabetic, though glucose tolerance is also often impaired in other forms of cirrhosis. The ECG may show dysrhythmias and flattened T-waves. Iron absorption is increased (as it is also in porphyria), though this may not be a constant abnormality. Testosterone levels are low and there may be evidence of both adrenal and pituitary failure.

Seventy-five percent of patients carry HLA A3 (compared with 30% of the general population), and affected relatives will often carry similar HLA types to patients.

12.18 Wilson's Disease

Wilson's disease (hepatolenticular degeneration) is an autosomal recessive disease in which excessive tissue copper deposits occur. It may show itself as nerve damage (Parkinsonism and mental changes) or as liver disease (cirrhosis).

Detection of asymptomatic sufferers is important to prevent progression of the disease. Abnormal hepatic copper deposits have been described in other diseases, such as primary biliary cirrhosis, sclerosing cholangitis and chronic cholestasis.

12.18.1 Serum Copper and Caeruloplasmin

Normal caeruloplasmin levels are 200–400 mg/l. This copper-binding protein with oxidase activity binds 60–120 $\mu\text{g}/100$ ml copper in the serum. There is an additional 5–10 $\mu\text{g}/100$ ml non-caeruloplasmin copper. In 95% of patients with Wilson's disease the serum caeruloplasmin levels are <200 mg/l and serum caeruloplasmin copper is <60 $\mu\text{g}/100$ ml. Non-caeruloplasmin copper may also be increased in Wilson's disease.

A screening test for copper oxidase activity, taken as equivalent to caeruloplasmin, is widely used. The normal range is 0.2–0.7 optical density units.

12.18.2 Urine Copper

The normal subject excretes about 30 $\mu\text{g}/24$ h. In symptomatic Wilson's disease >100 $\mu\text{g}/24$ h is excreted, derived from the non-caeruloplasmin serum copper.

12.18.3 Liver Biopsy

Cirrhosis is seen and copper can be stained brown-black with rubeanic acid in 70% alcohol. The copper content of the biopsy is measured. The normal level is 20–50 $\mu\text{g}/\text{g}$ dry weight of liver compared with 250–300 $\mu\text{g}/\text{g}$ dry weight in untreated Wilson's disease. The biopsy needle must be rendered copper-free by washing with 0.5% EDTA and then rinsing with 5% dextrose.

12.18.4 Kayser-Fleischer Rings

These are caused by copper deposits in the cornea. If not obvious to the naked eye they should be sought by slit-lamp examination. They may occur in other causes of copper overload.

12.19 Hydatid Disease of the Liver

12.19.1 Intradermal (Casoni) Test

An intradermal injection of 0.15 ml of hydatid fluid is given into the forearm and a similar volume of sterile normal saline is injected as a control into the other arm. There are two possible positive responses:

1. an immediate reaction in which a weal appears within 10 min. The maximum diameter which should be at least 20 mm is reached within 30 min.
2. a delayed response which appears after 6 h and lasts up to 24 h; this reaction is found less frequently.

A positive test suggests the presence of hydatid disease and is said to occur in 90% of patients with the disease. The test does not satisfactorily distinguish between living and dead cysts. The effectiveness of the antigenic response is liable to variation. False-positive reactions occur in patients who have harboured other types of tapeworm or who are infected with nematodes or trematodes.

12.19.2 Other Tests

A complement fixation test is positive in 85% of patients and this test is believed to indicate the presence of live cysts. A precipitin test is positive in 65% of patients. Fine needle biopsy (22 gauge) has been described as safe where imaging control is used.

12.20 Acute Intermittent Porphyrria

This may present as abdominal pain, neuropathy or coma, but the basic problem is over-activity of the delta-aminolaevulinic acid synthetase in the liver. Liver histology is normal.

It is convenient to perform a simple urine screening test where the diagnosis is suspected, and then proceed to a fuller biochemical evaluation.

12.20.1 Screening Test for Porphobilinogen

Equal volumes of urine and Ehrlich's reagent are mixed in a tube. If the solution turns pink either porphobilinogen or urobilinogen is present. Porphobilinogen may be confirmed by adding 2 volumes of chloroform and shaking thoroughly. On settling the pink colour should remain in the upper aqueous layer. By contrast, urobilinogen would colour the lower chloroform layer pink.

12.20.2 Confirmatory Tests

A variety of-tests can be used to prove the diagnosis:

- (a) Urine will turn port wine colour on standing.
- (b) Urine will contain increased porphobilinogen (normal 0–16 $\mu\text{mol/day}$).
- (c) Increased urine porphyrin/creatinine ratio (normal up to 42).
- (d) Increased serum protoporphyrin (normal 0–900 nmol/l).
- (e) Reduced serum porphobilinogen deaminase (normal 3–54 units).

Porphyria cutanea tarda is commonly associated with alcoholic liver disease or cirrhosis.

There is a whole family of porphyrias, hepatic and erythropoietic, and where they are suspected full evaluation will include examination of urine for increased porphyrins:

- normal delta-aminolaevulinic acid 0–40 $\mu\text{mol/day}$
- normal uroporphyrin 0–39 nmol/day
- normal coproporphyrin 0–430 nmol/day

Stool should also be examined for increased porphyrins:

- normal coproporphyrin
- normal protoporphyrin
0–76 nmol/g dry weight
0–200 nmol/g dry weight

Porphyria is familial and screening blood relatives is important to identify those at risk and to protect them from precipitating attacks.

Bibliography

- Adachi Y, Horii K, Takahashi Y, Tanahata H, Ohba Y, Yamamoto T. Serum glutathione S-transferase activity in liver diseases. *Clin Chim Acta*. 1980;106:243–55.
- Aragona M, Caredda F, Lavarini C, et al. Serological response to the hepatitis delta virus in hepatitis D. *Lancet*. 1987;1:478–80.
- Arico S, Aragona M, Rizzetto M, et al. Clinical significance of antibody to the hepatitis delta virus in symptomless HBsAg carriers. *Lancet*. 1985;2:356–8.
- Bell H, Tallaksen C, Sjaheim T, Weberg R, Raknerud N, Orjasaeter H, Try K, Haug E. Serum carbohydrate deficient transferrin as a marker of alcohol consumption in patients with chronic liver diseases. *Alcohol Clin Exp Res*. 1993;17:246–52.
- Ben Porath E, Wands JR. Monoclonal antibodies as diagnostic probes in the etiology of hepatitis. *Semin Liver Dis*. 1984;4:76–88.
- Berg PA, Klein R, Lindenborn-Fotinos J, et al. ATP-ase-associated antigen (M2); marker antigen for serological diagnosis of PBC. *Lancet*. 1982;2:1423–6.

- Blum HE, Haase AT, Vyas GN. Molecular pathogenesis of hepatitis B virus infection: simultaneous detection of viral DNA and antigens in paraffin-embedded liver sections. *Lancet*. 1984;2:881-4.
- Brugmann E, Towe J. Indocyanine green clearance in a liver function test. *Mater Med Pol*. 1974;6:123-6.
- Burrows S, Feldman W, McBride F. Serum gamma-glutamyl transpeptidase. *Am J Clin Pathol*. 1975;65:311-4.
- Chalmers OM, Rinsler MG, MacDermott S, Spicer CC, Levi AJ. Biochemical and haematological indicators of excessive alcohol consumption. *Gut*. 1981;22:992-6.
- Chen D-S, Sung J-L, et al. Serum alpha-fetoprotein in the early stage of human hepatocellular carcinoma. *Gastroenterology*. 1984;86:1404-9.
- Coken JA, Kaplan MM. The *SGOT/SGPT* ratio - an indicator of alcoholic liver disease. *Dig Dis Sci*. 1979;24:835-8.
- Colombo M, Cambieri R, Rumi MG, Ronchi G, Del Ninno E, De Franchis R. Long-term delta superinfection in HBsAg carriers and its relationship to the course of chronic hepatitis. *Gastroenterology*. 1983;85:235-9.
- Doniach D, Walker GJ. Mitochondrial antibodies (AMA). *Gut*. 1974;IS:664-8.
- Engelking LR, Dasher CA, Bl H. Within-day fluctuation in serum bile acid concentration among normal control subjects and patients with hepatic disease. *Am J Clin Pathol*. 1980;73:196-201.
- Fagan EA, Williams R. Serological responses to HBV infection. *Gut*. 1986;27:858-67.
- Felding RH, Christensen RF, Lindahl F. Ammonia tolerance test. *Scand J Gastroenterol*. 1984;19:365-8.
- Felsher BF, Carpoi NM. Calorie intake in unconjugated hyperbilirubinaemia. *Gastroenterology*. 1975;69:42-7.
- Ferraris R, Fiorentini MT, Galatola G, Rolfo P, De la Pierre M. Diagnostic value of serum immunoreactive conjugated cholic or chenodeoxycholic acids in detecting hepatobiliary diseases: comparison with levels of 3-alpha-hydroxy bile acids determined enzymatically and with routine liver tests. *Dig Dis Sci*. 1987;32:817-23.
- Finch CA, Huebers H. Perspectives in iron metabolism. *N Engl J Med*. 1982;306:1520-9.
- Gollan JL. Diagnosis of haemochromatosis. *Gastroenterology*. 1983;84:418-31.
- Grace ND, Castell DO, Wennar MH. A comparison of the oral fructose and ammonia tolerance tests in cirrhosis. *Arch Intern Med*. 1969;124:330-6.
- Halliday JW, Russo A, Collishaw J, Powell LW. Serum ferritin in the diagnosis of early haemochromatosis: a study of 43 families. *Lancet*. 1977;2:621-3.
- Holstege A, Staiger M, Haag K, Gerok W. Correlation of caffeine elimination and Child's classification in liver cirrhosis. *Klin Wochenschr*. 1989;67:6-15.
- Hoofnagle JH, Type D. Hepatitis and the hepatitis delta antigen. In: Thomas HC, Jones EA, editors. *Recent advances in hepatology*. Edinburgh: Churchill Livingstone; 1986. p. 73-92.
- Javitt NB. Clinical and experimental aspects of sulphobromophthalein and related compounds. *Prog Liver Dis*. 1970;3:110-7.
- Killenberg PF, Stevens RD, Wilderman RF, Wilderman NM. The laboratory method as a variable in the interpretation of serum bilirubin fractionation. *Gastroenterology*. 1980;78:1011-5.
- Kuroki S, Okamoto S, Naito T, et al. Serum 7-alpha OH cholesterol as a new parameter of liver function in patients with chronic liver diseases. *Hepatology*. 1995;22:1182-7.
- Lavarini C, Farci P, Chiaberge E, et al. IgM antibody against hepatitis B core antigen (IgM HBcAb): diagnostic and prognostic significance in acute HBsAg positive hepatitis. *BMJ*. 1983;287:1254-6.
- Le P, Langlois S. Fine needle biopsy of hepatic hydatids and haemangiomas: an overstated hazard. *Australas Radiol*. 1989;2:144-9.
- Lewis KO, Nicholson G, Lance P, Paton A. Aminopyrine breath test in alcoholic liver disease and in patients on enzyme inducing drugs. *J Clin Pathol*. 1977;30:1040-3.
- Lindsay KL, Nizze JA, Koretz R, Gitnick E. Diagnostic usefulness of testing for HBcAb IgM in acute hepatitis B. *Hepatology*. 1986;6:1325-8.
- Luey KL, Heaton KW. Bile acid clearance in liver disease. *Gut*. 1979;20:1083-7.

- Mannes GA, Thieme C, Stellard F, Wang T, Sauerbruck T, Paumgartner G. The prognostic significance of serum bile acids in cirrhosis. *Hepatology*. 1986;6:50–3.
- Manns MP, Nakamura RM. Auto immune liver diseases. *Clin Lab Med*. 1988;8:281–301.
- McDonagh JE, Nathan VV, Bonavia IC, Moyle GR, Tanner AR. Caffeine clearance by enzyme multiplied immunoassay technique: a simple inexpensive and useful indicator of liver function. *Gut*. 1991;32:681–4.
- Moore, MR. Porphyria. Glasgow, Porphyria Research Unit, Western Infirmary, 1994.
- Mulder AHL, Horst G, Haagsma EB, Limburg PC, Kleibeuker JH, Kallewberg CGM. Prevalence and characterisation of neutrophil cytoplasmic antibodies in AILD. *Hepatology*. 1993;17:411–7.
- Murew J, Kierulf P. The intravenous galactose test as indication of the extent of fibrosis in patients with cirrhosis of the liver. *Scand J Gastroenterol*. 1969;4:453–6.
- Nalpas B, Vassault A, Charpin S, Lacour B, Berthelot P. Serum mitochondrial (m) AST as a marker of chronic alcoholism: diagnostic value and interpretation in a liver unit. *Hepatology*. 1986;4:608–14.
- Olynyk J, Hall P, Sallie R, Reed W, Shilkin K, Mackinnon M. Computerised measurement of iron in liver biopsies: a comparison with biochemical iron measurement. *Hepatology*. 1990;12:26–30.
- Owens D, Sherlock S. The diagnosis of Gilbert's syndrome: role of the reduced calorie intake test. *BMJ*. 1973;3:559–63.
- Penn R, Worthington OJ. Is serum gamma-glutamyltransferase a misleading test? *BMJ*. 1983;286:531–5.
- Poynard J, Aubert A, Bedossa P, et al. A simple biological index for detection of ALD in drinkers. *Gastroenterology*. 1991;100:1397–402.
- Reichling JJ, Kaplan MM. Clinical use of serum enzymes in liver disease. *Dig Dis Sci*. 1988;33:1601–14.
- Saunders JB, Lewis KO, Paton A. Early diagnosis of alcoholic cirrhosis by the aminopyrine breath test. *Gastroenterology*. 1980;79:112–4.
- Scharshmidt BF, Blankaert N, Farina FA, Kabra PM, Stafford BE, Weisiger RA. Measurement of serum bilirubin and its mono- and disconjugates: applicability to patients with hepatobiliary disease. *Gut*. 1982;23:643–9.
- Skillen AW, Fifield RD, Sheraidah GS. Serum alkaline phosphatase isoenzyme patterns in disease. *Clin Chim Acta*. 1972;40:21–5.
- Skinner HA, Holt S, Sheu WJ, Israel Y. Clinical versus laboratory detection of alcohol abuse: the alcohol clinical index. *BMJ*. 1986;292:1703–8.
- Solberg HE, Skrede S, Blomhoff JP. Diagnosis of liver diseases by laboratory results and discriminant analysis. *Scand J Clin Lab Invest*. 1975;35:713–21.
- Tabor E. The three viruses of non-A, non-B hepatitis. *Lancet*. 1985;1:743–5.
- Triger DR. Auto-immune chronic active hepatitis and primary biliary cirrhosis. *Clin Gastroenterol*. 1989;3:21–38.
- Van Der Poel CL, Cuypers HTM, Reesink HW, et al. Confirmation of hepatitis C virus infection by new four-antigen recombinant immunoblot assay. *Lancet*. 1991;337:317–9.
- Van Wates L, Lieber C. Glutamate dehydrogenase: a reliable marker of liver cell necrosis in the alcoholic. *BMJ*. 1977;2:1508–10.
- Wantzin P, Nielsen JO, Tygstrup N, Soerensen H, Dybkjaer E. Screening of Danish blood donors for hepatitis B surface antigen using a third generation technique. *BMJ*. 1985;291:780–2.
- Williams ALB, Hoofnagle JH. Ratio of serum aspartate to alanine aminotransferase in chronic hepatitis. *Gastroenterology*. 1988;95:734–9.
- Yamanishi Y, Kishimoto Y, Kawasaki H, Hirayama C, Ikawa S. Oral ursodeoxycholic acid tolerance test in patients with digestive diseases. *Gastroenterol Jpn*. 1981;16:472–7.

The histology of the liver is an indispensable aid to diagnosis. It is the only way of proving the presence of cirrhosis, and it may also establish the cause of this disease, as in haemochromatosis and hepatolenticular degeneration. It has proved invaluable in the assessment of chronic hepatitis and alcoholic liver disease. The advent of other tests like elastography, and M₂ antibody in PBC may reduce some of the requirement for histology. Normal elastography will exclude cirrhosis and significant steatosis, but abnormal results do not conclusively establish the cause.

13.1 Percutaneous Liver Biopsy

Since the liver is the largest organ in the body and is relatively constant in position, blind percutaneous biopsy is satisfactory in many patients. However, the use of ultrasound or CT guidance improves results in focal lesions and may be safer in parenchymal disease.

13.1.1 Preparation

The nature of the investigation is explained to the patient: it is important to obtain written consent. Blood is taken for measurement of haemoglobin, prothrombin time and platelet count. If there is any reason to suspect that these variables may change then the tests should be repeated on the day of the biopsy. A biopsy should not normally be performed unless the haemoglobin level is >100 g/l, the platelet count > 100,000/mm³ and prothrombin time no more than 3 s longer than control values. If patients are on anti-platelet or (unusually) anticoagulant therapy this will need to be reviewed and discontinued over the procedure. Liver biopsy should also be avoided in the presence of substantial ascites or when extrahepatic cholestasis seems likely. In anxious patients premedication with oral diazepam or IV

midazolam may be helpful, but routine premedication is not necessary and may interfere with cooperation.

13.1.2 Procedure

The patient is positioned on the bed or trolley on which they will lie after the procedure. The patient lies supine close to the right edge of the bed. The right hand is placed behind the head which is supported by one pillow. The position of the liver is confirmed by percussion down the right side of the chest and abdomen. The puncture site is the point of maximal dullness between the anterior and midaxillary lines. This usually lies between the 8th and 10th intercostal spaces. The puncture site is positioned just above the appropriate rib, to avoid the vessels and nerves which run just below the ribs.

Occasionally, in case of difficulty or when a nodule can be palpated, a subcostal puncture may be made; this is a less satisfactory procedure even in the presence of marked liver enlargement.

It is not necessary to wear gowns or masks for this procedure, but the use of surgical gloves for the operator is recommended. A paper sheet placed under the patient prevents any leakage of blood onto the bedding.

The patient is instructed to practise the breath-holding procedure: after a full inspiration a full exhalation breath is held for a few seconds. During normal breathing the puncture site is thoroughly cleaned with alcohol swabs and infiltrated with 5 ml 2% lignocaine. The skin is anaesthetized with a fine needle, which is replaced by a 21 gauge needle to infiltrate down to the liver capsule with the breath held in expiration.

Two types of needle are in general use: both provide adequate biopsy samples.

The Menghini suction biopsy needle has been longer established and requires a shorter period of penetration of the liver. The Tru-Cut sheathed biopsy needle is slightly more cumbersome to use and much more expensive. An automatic needle (Biopty) did not confer any definite advantage.

13.1.2.1 Menghini Needle (Reusable) (Fig. 13.1)

The Menghini needle (Fig. 13.1) is supplied in a variety of calibres and lengths. For routine use the 1.9 × 70 mm size is recommended. The slight theoretical advantage of smaller diameter needles is offset by the larger number of liver punctures required to obtain satisfactory tissue samples. The tip of the needle has a bevelled cutting edge. The needle is supplied with a blunt nail which fits inside the proximal shaft to prevent the sample being violently aspirated into the syringe, and with an external guard for the shaft to prevent too deep penetration of the liver: neither of these is essential. A trocar reminiscent of a sardine tin key is also supplied and is non-contributory.

The needle is attached to a 20 ml syringe containing 5 ml physiological saline. A skin incision is made with a small blade scalpel and the needle is advanced through the chest wall to the pleura and diaphragm. Two millilitres of saline are

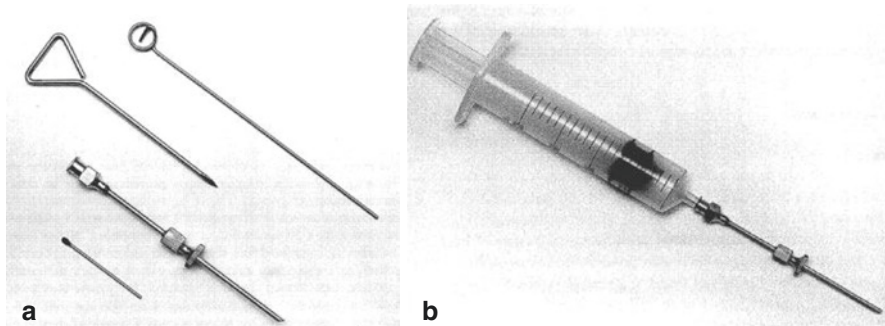


Fig. 13.1 (a) Menghini needle set displayed. (b) Menghini needle set assembled for use

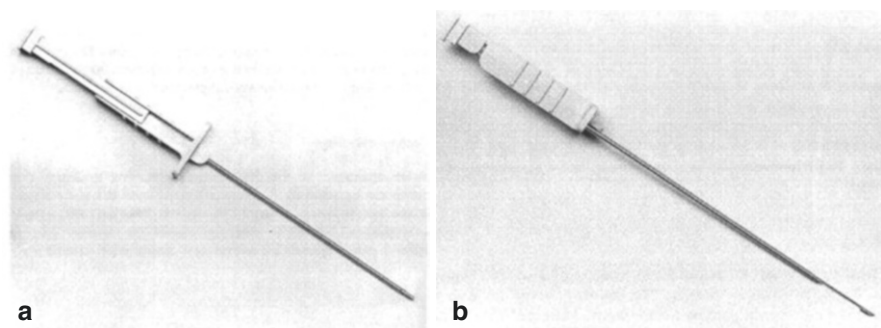


Fig. 13.2 (a) Tru-Cut needle closed (*top view*). (b) Tru-Cut biopsy needle open (*side view*)

injected to clear the needle. With the patient performing the breath-holding manoeuvre, aspiration is applied to the syringe; the needle is rapidly introduced about 4 cm into the liver and immediately withdrawn. The patient is then permitted to breathe normally. The needle is removed from the syringe, the nail removed and the core of liver tissue is gently extruded either onto filter paper or directly into formol saline, using the probe supplied. The contents of the syringe can be flushed through the needle into cytology fixative. If a satisfactory core (>5 mm) is not obtained, two more punctures are permissible at the same procedure. Various modifications of the Menghini system are available. Disposable needles are usual. The Jamshidi needle is supplied with a locking syringe which does not require the operator to maintain traction on the plunger. The Surecut needle is also supplied with a locking syringe, to the plunger of which is attached a retractable trocar which obviates the need for saline injection

13.1.2.2 Tru-Cut Sheathed Needle (Disposable) (Fig. 13.2)

This needle requires more skill in operation, but has become popular partly because of its wide application to other biopsy procedures such as sampling prostate and breast tissue.

The needle consists of an outer cutting sheath 2 mm in diameter through which is advanced a trocar with a 20 mm sampling groove positioned 10 mm from the tip. There is a choice of length of needle, the most convenient being 114 mm long. After preparation, anaesthesia and skin incision with a scalpel, the needle is advanced to the liver capsule with the trocar retracted. The patient then holds his breath in expiration while the needle is advanced 4 cm into the liver with the trocar fully sheathed. Retraction of the sheath permits a sample of liver to bulge into the trocar sampling groove. The cutting sheath is then fully advanced holding the trocar steady, and the whole needle is removed.

Operators are recommended to practise the sequence of manoeuvres several times before puncturing patients and to consult the manufacturer's instruction leaflet supplied with each needle. This procedure is an amendment of a previous one, designed to improve safety. Needles must never be reused.

13.1.3 Alternative Techniques

13.1.3.1 Bleeding Tendency

If the prothrombin time is prolonged, vitamin K 10 mg administered IV or IM daily for 3 days may cause it to return to normal. If the prothrombin time remains prolonged and the liver biopsy is mandatory an infusion of 2 units of fresh frozen plasma before and during percutaneous biopsy ensures the safety of the procedure. Similarly, if low platelet counts persist then the transfusion of 6 packs of platelets can be used to cover the procedure. Factor VIII transfusion has been described in patients with haemophilia. It is possible to occlude the needle tract by injecting gelatin sponge.

13.1.3.2 Transvenous Liver Biopsy

This ingenious method uses transjugular hepatic vein catheterization to obtain biopsy samples from patients with a bleeding diathesis. The principle is that any haemorrhage is contained in the patient's own circulation. The procedure should be reserved for centres with experience of the catheterization technique. There is an appreciable failure rate and biopsy samples tend to be very small.

13.1.3.3 Laparoscopic Liver Biopsy

This is an alternative for the patient with a bleeding tendency, since direct haemostasis can be achieved. It allows targeted biopsy in non-homogenous liver disease and can be specially helpful in macronodular cirrhosis, lymphoma and metastatic disease. Naked-eye diagnosis should be confirmed by histology, although with experience reliable macroscopic diagnosis of cirrhosis is possible

13.1.3.4 Laparotomy

Liver biopsy at laparotomy is best performed using biopsy needles to avoid spurious conclusions arising from examination of unrepresentative peripheral samples obtained with scissors or scalpel. Ideally, the biopsy should be taken at the first

procedure after opening the peritoneum. A laparotomy should never be performed for the sole purpose of obtaining a liver biopsy.

13.1.3.5 Young Children

Percutaneous liver biopsy is feasible in young children using needles 1.2 mm in diameter. One assistant is required to talk to and gently restrain the patient if necessary. Another assistant immobilizes the liver by pressing on the left chest with the right hand, while pushing up the liver with the left hand. The procedure can usually be performed under local anaesthesia, but a general anaesthetic may be required.

13.1.4 Aftercare

Gentle local pressure may be needed to stop oozing of blood. The biopsy wound is covered with an adhesive dressing. The patient is asked to lie as much as possible in the right lateral position for 3–4 h. Pulse and blood pressure are recorded every 15 min for 1 h, then hourly. The patient is warned to expect mild discomfort. If there is a severe pain at the biopsy site, in the epigastrium or right shoulder tip, then an injection of pethidine 25–100 mg IM is given.

Liver biopsy can be safely performed as an out-patient procedure provided that patients can be observed for some hours afterwards. Facilities must be available to allow admission of those who develop significant complications.

13.1.5 Complications

Serious morbidity occurs in about 5% of patients. The most important determining factor is the number of liver punctures. Pain is the most common complication and is usually transient. The major hazards are haemorrhage and bile leakage. Bleeding into the pleura or peritoneum may require transfusion and open suturing. It is diagnosed by a rising pulse and falling blood pressure, without much pain. Bleeding is said to be more common from hepatoma. An intrahepatic haematoma is common and usually of no significance, though it may interfere with subsequent liver imaging techniques.

Bile leakage may occur from an intrahepatic gallbladder. It sometimes occurs from a large duct but this is uncommon if liver biopsy is avoided in patients with extrahepatic cholestasis. Leakage of bile usually causes pain and tachycardia and hypotension may also occur. Any serious bile leak requires early laparotomy, suturing and peritoneal toilet.

The mortality rate of liver biopsy is contentious, but is probably around 1:750 overall. The mortality rate depends on the type of patient undergoing biopsy and can be expected to be higher in patients with metastatic carcinoma. In practice deaths do not seem to be much of a problem in people fit enough to be investigated as outpatients.

13.1.6 Indications

1. Evaluation and monitoring of alcoholic liver disease.
2. Diagnosis of cirrhosis, chronic auto-immune hepatitis, drug jaundice, haemochromatosis, hepatolenticular degeneration, amyloid and sarcoid.
3. Diagnosis of hepatocellular carcinoma.
4. Diagnosis of metastatic carcinoma and lymphoma.
5. Diagnosis of hepatomegaly and splenomegaly.
6. Establishment of the cause of intrahepatic cholestasis.
7. Monitoring the progress of treatment in chronic hepatitis and iron and copper storage diseases.
8. Confirmation of Dubin-Johnson syndrome (constitutional conjugated hyperbilirubinaemia).
9. Estimation of liver enzyme activity, e.g. glucuronyl transferase.
10. Occasionally in the diagnosis of tuberculosis and pyrexia of unknown origin.

13.1.7 Contra-indications to Percutaneous Biopsy

Absolute contra-indications are an uncooperative patient, gross ascites, and suspected hydatid disease, haemangioma or peliosis hepatica.

Relative contra-indications are proved extrahepatic cholestasis and a persistent bleeding tendency.

13.2 Interpretation

13.2.1 Macroscopic Appearance

It is often helpful to inspect the core of tissue which has been obtained. Normal liver is light brown or purple in colour, while biopsies from fatty liver are pale yellow. Metastatic carcinoma may contain white areas, Dubin-Johnson syndrome tissue is black, while in the conjugated hyperbilirubinaemia of the Rotor syndrome it is normal in colour. In cholestasis dark bile, pus and heavy greenish yellow pigmentation may be evident. In cirrhosis the liver appears non-homogeneous and granular, and there is a gritty feel as the biopsy needle is inserted.

After rapid inspection the liver tissue should be immersed in formol saline for light microscopy. Other procedures necessitate the tissue samples being processed separately. For electron microscopy 4% iced glutaraldehyde is satisfactory. For cytology 95% alcohol or other special fixative is used. Liver enzyme assay requires fresh tissue to be transported on ice: it should be frozen rapidly if there is to be a delay in the analysis.

13.2.2 Histology

The value of the procedure depends on the adequacy of the sample and the ability and experience of the pathologist. It is possible to diagnose acute viral hepatitis on a 5 mm core, but a sample of at least 15 mm is preferable for a reliable diagnosis of

cirrhosis and chronic auto-immune hepatitis. Percutaneous and operative needle biopsies yield comparable results. Needle biopsies obtained immediately after death are satisfactory, but the histology of tissue obtained at autopsy is often difficult to interpret because of the frequency of centrilobular ischaemic necrosis. Surgical 'knife and fork' specimens yield large quantities of tissue, but polymorphonuclear infiltrate and subcapsular fibrosis are common even in apparently healthy livers.

13.2.2.1 Normal

The liver is arranged in regular units called acini which are arranged around portal tracts, with a sinusoidal structure of mainly single cell plates between them and the central veins. In the portal tract are a portal venule, an arteriole, bile ducts, lymphatics and connective tissue. The wall of liver cells adjacent to the portal tract is known as the limiting plate. Between the parenchymal cells and the endothelial cells is the space of Disse, which contains tissue fluid and collagen and reticulin fibres. In the sinusoidal wall lie the periodic acid-Schiff-positive Kupffer reticuloendothelial cells, and also fat-storing lipocytes or Ito cells. Some of the liver cells have double nuclei and some are polyploid, but mitotic figures are rare. Some nuclei contain glycogen. A few fat vacuoles occur in the cytoplasm, and there is little stainable iron. Near bile canaliculi brown granules of lipofuscin 'wear and tear' pigment are seen. With ageing, polyploidy becomes more common, lipofuscin increases and portal tract connective tissue becomes more dense.

13.2.2.2 Acute Viral Hepatitis

There is extensive liver cell necrosis, worse around the centrilobular areas: this may be focal or confluent. Degenerate cells swell and become granular in appearance. There are rounded refractile eosinophilic bodies which reflect shrunken hepatocytes (Councilman bodies). A monocytic infiltration is observed especially round the portal tract. Marked centrilobular cholestasis may be evident. Orcein staining demonstrates the presence of the virus, which can also be shown by immunofluorescence. Liver biopsy is fairly reliable in the diagnosis of viral hepatitis but does not distinguish it from drug-associated hepatitis, and an adequate history is important. A biopsy taken very early in the course of viral hepatitis may be misleading.

13.2.2.3 Drug Reactions

The histology of drug-associated injury is variable and depends upon the nature of the drug. Some anabolic steroids cause centrilobular bile stasis, Injury due to chlorpromazine is characterized by centrilobular bile stasis with variable portal inflammation, atypical proliferation of the bile ductules and many eosinophils, while injury arising from use of monoamine oxidase inhibitors and halothane produces a histological picture identical to that of viral hepatitis. An associated peripheral blood eosinophilia may give a clue to an idiosyncratic allergic drug reaction.

13.2.2.4 Cirrhosis

It is possible to obtain an apparently normal biopsy from a patient with macronodular cirrhosis, but as a general rule liver biopsy is a reliable method of proving the diagnosis.

The essential features are liver cell necrosis and nodular regeneration, with disorganization of the normal hepatic architecture. The activity of the cirrhotic process,

regardless of the aetiology, is assessed by the presence of piecemeal necrosis, which produces an irregular border to the nodules, cellular infiltration and bile duct proliferation. In inactive cirrhosis the nodules are smooth and well demarcated by relatively acellular fibrous bands.

13.2.2.5 Non-alcoholic Steatohepatitis

This is associated with central obesity and Type 2 diabetes mellitus, and may be the commonest liver disease in the West, affecting 20% of Americans. Drugs like corticosteroids, tetracycline and aspirin in children have also been implicated. It cannot be confidently diagnosed unless alcohol intake is <25 ml daily, but liver problems may of course be multifactorial. Initially there are disturbed “liver function” blood tests and possible malaise.

Liver histology first shows mere steatosis, but then progresses to a frank hepatitis, and in up to 10% to cirrhosis.

13.2.2.6 Alcoholic Liver Disease

Abnormal liver histology is usually associated with elevated gamma-GT (and ALT) levels in the serum, but the histological lesion cannot be predicted from the clinical features. Some biopsy samples show normal architecture, though cytology of aspirated fluid usually shows necrotic liver cells, variable nuclear size and excess lymphocytes. The most common finding is increased fat in the parenchymal cells, which may be severe. Fat granulomas may occur. In alcoholic hepatitis there is extensive focal necrosis of liver cells with excess fat vacuoles (unlike viral hepatitis). Mallory’s hyaline bodies, which stain deep reddish-purple with haematoxylin and eosin, are a helpful characteristic finding in both alcoholic hepatitis and cirrhosis, but they can occur in other conditions.

Patients with alcoholic hepatitis may recover completely, die or develop cirrhosis. It is a better prognostic guide to poor outcome than the actual presence of cirrhosis, and an extra incentive for the drinker to abstain. The presence of perivenular sclerosis in alcoholic hepatitis may predict the development of cirrhosis while the presence of megamitochondria carries a good prognosis. Alcoholic cirrhosis is not always distinguishable from other forms of cirrhosis, but the presence of Mallory’s hyaline is an important clue. Some patients with alcoholic liver disease develop chronic active hepatitis and hepatoma.

13.2.2.7 Extrahepatic Biliary Obstruction

This may be difficult or impossible to differentiate by liver biopsy from causes of intrahepatic cholestasis. There are characteristically dilated and proliferating bile ducts with bile plugs.

13.2.2.8 Primary Biliary Cirrhosis/Primary Biliary Cholangitis

The histological appearance depends upon the stage of the disease. In the early stages histology is reasonably specific with proliferation of the septal or interlobular bile ducts, local portal zone lymphocyte accumulations and peripheral cholestasis. At a later stage there is ductular destruction and encircling of the portal tracts by

dense fibrous tissue. Eventually a form of cirrhosis ensues which is indistinguishable from cirrhosis of other types. Histology is graded I-IV, which predicts prognosis to some extent; early stage disease treated with UDCA therapy has a more benign outlook, and histological progression may be slowed or halted.

13.2.2.9 Chronic Auto-immune Hepatitis

Piecemeal necrosis of liver cells at the junction of connective tissue and parenchyma occurs, with extensive infiltrate of mononuclear cells (many of them plasma cells). Connective tissue increases and there is deposition of collagen to form new septa. The changes may be patchy throughout the liver.

13.2.2.10 Chronic Persistent Hepatitis

The main feature of chronic persistent hepatitis is inflammatory infiltration which is largely mononuclear and confined to the portal tract. Piecemeal necrosis and collagen deposition are absent.

13.2.2.11 Neonatal Hepatitis

This shows many parenchymal giant cells with focal necrosis and intralobular ducts. Although these features are absent in pure biliary atresia it is now considered that the conditions may represent extremes of a single disease spectrum. Reduced or absent α_1 -antitrypsin in the serum makes neonatal hepatitis more likely than atresia.

13.2.2.12 Malignant Disease

Needle biopsies can demonstrate the tumour in 75% of patients with metastatic disease, but more than one biopsy may be necessary. A similarly high diagnostic rate can be achieved in hepatocellular carcinoma. If the lesion is diffuse, blind biopsy is adequate, but if a discrete tumour is present a targeted biopsy, directed on the basis of a liver scan (ultrasonic or CT) yields better results.

Cytological analysis of the washings from the Menghini needle may show malignant cells when the biopsy histology does not.

13.3 Liver Aspiration

Diagnostic percutaneous liver aspiration is seldom undertaken without biopsy. The main indication is the strong suspicion that an intrahepatic mass is an amoebic abscess. Hydatid cysts may be aspirated by fine needle under local anaesthesia, although larger needles are required for single pyogenic abscesses. The technique is very similar to that for a liver biopsy. The procedure is relatively simple when the liver is enlarged and there is an abscess pointing into the subcostal region. The overlying skin and muscle are infiltrated with local anaesthetic and the patient is instructed to hold the breath in expiration. The needle, attached to a 20 ml syringe, is inserted into the mass or at the site of maximum liver tenderness and then slowly withdrawn while gentle aspiration is performed until necrotic fluid material is obtained. The patient breathes shallowly while the abscess is aspirated. A short

length of tubing connecting the needle to the syringe reduces the chances of damage to the liver capsule while the patient breathes.

It is also possible to perform a diagnostic aspiration through an intercostal space, but this is generally discouraged because of the danger of intrapleural soiling. The usual site for insertion of the needle is the 10th intercostal space and the liver is aspirated while the patients holds the breath.

The contents of an amoebic abscess are brown-red 'anchovy sauce' necrotic material. Vegetative forms of *E. histolytica* are rarely found in the aspirated material and the final portion of the aspirate is more likely to contain the trophozoites. As amoebic pus usually coagulates after collection the pus is liquified by the addition of one part hyaluronidase to five of pus. After incubation at 37 °C for 1 h, the samples are centrifuged at 1500 r.p.m. for 5 min and the sediment examined for amoebae.

Modern imaging techniques permit accurate localization of an abscess and the precise insertion of the aspirating needle.

Bibliography

- Adam A. Liver biopsy can be followed by embolisation of the track with steel coils to prevent bleeding. *BrJ Hosp Med*. 1989;42:102–10.
- Bateson MC, Hopwood D, Duguid H, Bouchier IAD. Comparative trial of liver biopsy needles. *J Clin Path*. 1980;33:131–3.
- Blake JC, Sprengers D, Grech P, McCormick PA, McIntyre N, Burroughs AK. Bleeding time in patients with hepatic cirrhosis. *BMJ*. 1990;301:12–5.
- Borzio M, Bruno S, Roncalli M, et al. Liver cell dysplasia and risk of hepatocellular carcinoma in cirrhosis: a preliminary report. *BMJ*. 1991;302:1312.
- Brouillette DE, Yoo Y-K, Chien M-C, Rabinovitz M, Tarter RE, Van Thiel DH. Use of midazolam for percutaneous liver biopsy. *Dig Dis Sci*. 1989;34:1553–8.
- Bru C, Maroto A, Bruix J, et al. Diagnostic accuracy of fine needle aspiration biopsy in patients with hepatocellular carcinoma. *Dig Dis Sci*. 1989;34:1765–9.
- Bruguera M, Bordas JM, Mas P, Rodes I. A comparison of the accuracy of peritoneoscopy and liver biopsy in the diagnosis of cirrhosis. *Gut*. 1974;15:799–800.
- Caturelli E, Squillante MM, Andriulli A, et al. Fine needle liver biopsy in patients with severely impaired coagulation. *Liver*. 1993;13:270–3.
- Chedid A, Mendenhall CL, Tosch T, et al. Significance of megamitochondria in alcoholic liver disease. *Gastroenterology*. 1986;90:1858–64.
- Colombo M, Ninno ED, Franchis R, et al. Ultrasound-assisted percutaneous liver biopsy: superiority of the Tru-Cut over the Menghini needle for diagnosis of cirrhosis. *Gastroenterology*. 1988;95:487–9.
- Cunningham D, Mills PR, Quigley EMM, et al. Hepatic granulomas: experience over a 10 year period in the west of Scotland. *Q J Med*. 1982;51:162–70.
- Desmet VJ, De Groote J. Histological diagnosis of viral hepatitis. *Clin Gastroenterol*. 1974;3:337–54.
- Dienes HP, Popper H, Arnold W, Lobeck H. Histologic observations in human hepatitis non-A, non-B. *Hepatology*. 1982;2:562–71.
- Fraile G, Rodriguez-Garcia JL, Moreno A. Primary sclerosing cholangitis associated with systemic sclerosis. *Postgrad Med J*. 1991;67:189–92.
- Gilmore IT, Burroughs A, Murray-Lyon M, Williams R, Jenkins D, Hopkins A. Indications, methods and outcomes of percutaneous liver biopsy in England and Wales: an audit by the BSG and RCP. *Gut*. 1995;36:437–41.

- Glenthøj A, Sehested M, Torp-Pederson S. Diagnostic reliability of histological and cytological fine needle biopsies from focal liver lesions. *Histopathology*. 1989;15:375–83.
- Greenwald R, Chiprut RO, Schiff ER. Percutaneous aspiration liver biopsy using a large calibre disposable needle. *Am J Dig Dis*. 1977;22:1109–14.
- Holund B, Poulsen H, Schlichting P. Reproducibility of liver biopsy diagnosis in relation to the size of the specimen. *Scand J Gastroenterol*. 1980;16:329–35.
- International Group. Alcoholic liver disease: morphological manifestations. *Lancet*. 1981;1:707–11.
- Ireland A, Hartley L, Ryley N, McGee JO'D, Trowell JM, Chapman RW. Raised gamma-glutamyl-transferase activity and the need for liver biopsy. *BMJ*. 1991;302:388–9.
- Janes CH, Lindor KD. Outcome of patients hospitalised for complications after out-patient liver biopsy. *Ann Intern Med*. 1993;118:96–8.
- Jennings PE, Coral A, Donald JJ, Rode J, Lees WR. Ultrasound-guided core biopsy. *Lancet*. 1989;i:1369–71.
- Jimenez W, Pares A, Caballeria J, et al. Measurement of fibrosis in needle liver biopsies: evaluation of a colorimetric method. *Hepatology*. 1985;5:815–8.
- Joseph AEA, Saverymuttu SH, Al-Sam S, Cook MG, Maxwell JD. Comparison of liver histology with ultrasonography in assessing diffuse parenchymal liver disease. *Clin Radiol*. 1991;43:26–31.
- Lebrec D, Goldfarb G, Degott C, Rueff B, Benhamou J-P. Transvenous liver biopsy. *Gastroenterology*. 1982;83:338–40.
- Lefkowitz JH, Apfelbaum TF. Non-A, non-B hepatitis; characterisation of liver biopsy pathology. *J Clin Gastroenterol*. 1989;11:225–32.
- Lindor J, Bru C, Jorgensen RA, et al. The role of ultrasonography and automatic-needle biopsy in outpatient percutaneous liver biopsy. *Hepatology*. 1996;23:1079–83.
- MacSween RNM. Pathology of viral hepatitis and its sequelae. *Clin Gastroenterol*. 1980;9:23–48.
- Maharaj B, Pillay S. 'Tru-Cut' needle biopsy of the liver: importance of the correct technique. *Postgrad Med J*. 1991;67:170–3.
- Mattsson L, Sonnerborg A, Weiland O. Outcome of acute symptomatic non-A, non-B hepatitis: a 13 year follow up study of hepatitis C virus markers. *Liver*. 1993;13:274–8.
- McVay P, Toy PTCY. Lack of increased bleeding after liver biopsy in patients with mild hemostatic abnormalities. *Am J Clin Pathology*. 1990;94:747–53.
- Menghini G, Antonini R, Bruscellini P. Open abdomen liver biopsy by a modified one-second technique. *Am J Surg*. 1977;133:383–4.
- Menghini G. One-second needle biopsy of the liver. *Gastroenterology*. 1958;35:190–9.
- Perrault J, McGill DB, Ott BJ, Taylor WF. Liver biopsy: complications in 1000 in-patients and outpatients. *Gastroenterology*. 1978;74:103–6.
- Polio J, Enriquez RE, Chow A, Wood WM, Atterbury CE. Hepatocellular carcinoma in Wilson's disease. Case report and review of the literature. *J Clin Gastroenterol*. 1989;11:220–4.
- Rasmussen SN, Holm HH, Kristensen JK, Barlebo H. Ultrasonically-guided liver biopsy. *BMJ*. 1972;2:500–2.
- Riley SA, Ellis WR, Irving HC, Lintott OJ, Axon JR, Losowsky MS. Percutaneous liver biopsy with plugging of the needle tract. *Lancet*. 1983;2:436–7.
- Rosch J, Lakin PC, Antouduic R, Dotter CT. Transjugular approach to liver biopsy and transhepatic cholangiography. *N Engl J Med*. 1973;289:227–31.
- Trujillo NP. Peritoneoscopy and guided biopsy in the diagnosis of intra-abdominal disease. *Gastroenterology*. 1976;71:1083–5.
- Van Ness MM, Diehl AM. Is liver biopsy useful in the evaluation of patients with chronically elevated liver enzymes? *Ann Intern Med*. 1989;111:473–8.
- Vlavianos P, Bird G, Portman B, Westaby D, Williams R. Transjugular liver biopsy: use in a selected high risk population. *Eur J Gastroenterol Hepatol*. 1991;3:469–72.
- Walker WA, Krivitt W, Sharp HL. Needle biopsy of the liver in infancy and childhood: a safe diagnostic aid in liver disease. *Paediatrics*. 1967;40:946–50.
- Zatlouk K, Dinges HP, Thumher M, Redl H, Schlag G. A new technique of liver biopsy with plugging of the needle track using a double channel biopsy device. *Z Gastroenterol*. 1988;26:699–703.

The anatomy of the liver and spleen and the physiology of the portal circulation can be investigated in numerous ways. Some of the techniques are too specialized for general use, but many have found a place in routine diagnosis.

14.1 Ultrasonography

Ultrasound scanning of the liver is a simple and reliable test for focal disease and for extra-hepatic obstruction. Ideally a complete upper abdominal scan should be performed when liver scanning is requested, since valuable information about the gallbladder, bile ducts and pancreas may also be gained.

14.1.1 Interpretation

14.1.1.1 Liver Metastases

Discrete echogenic areas and focal hypoechoic areas are the most common findings, but the patterns are extremely variable. Solid metastases >2 cm in diameter and cystic metastases >1 cm are reliably detected. The right lobe of the liver lateral to the porta hepatitis is easiest to scan. Tumours up to 3–4 cm may be missed occasionally in other areas. The accuracy of ultrasonography in metastatic disease is about 80–90%, and it is probably as good as or better than isotope scanning. Simple measurement of serum alkaline phosphatase has been reported to give similar results in known carcinomas, and this biochemical test may yet be the best method of screening for hepatic malignancy.

14.1.1.2 Hepatocellular Carcinoma

This may be difficult to delineate. The ultrasonic consistency of the tumour may be similar to surrounding parenchyma, and the tumour may be diffuse with multiple small abnormal areas. A diagnostic success rate of around 60% is feasible with experience.

14.1.1.3 Cysts and Abscesses

Ultrasonography is a very effective method of demonstrating hepatic cysts, and liver, subphrenic and other abdominal abscesses. Up to 100% accuracy in defining liver cysts and abscesses is possible, and guided aspiration is readily performed if desired.

14.1.2 Jaundice

Ultrasonography is an extremely useful diagnostic tool in a patient with features suggestive of cholestatic jaundice.

The intrahepatic ducts are visualized only when dilated to a calibre of 4 mm or more. Extrahepatic ducts of normal calibre are seen in 60–80% of patients, but dilated extrahepatic ducts (6–8 mm is the normal range; <10 mm if there has been a previous cholecystectomy) are regularly seen. In extrahepatic obstruction dilation of the extrahepatic ducts precedes dilation of the intrahepatic ducts. In intrahepatic cholestasis the bile ducts are usually normal, but there may be some dilation of intrahepatic (but not of extrahepatic) ducts.

There are some drawbacks to ultrasonography. Common duct stones, sclerosing cholangitis and ampullary strictures may escape detection; the distal common bile duct is obscured by bowel gas in some patients; enlargement of the pancreatic head may be due to either carcinoma or chronic pancreatitis; and gallstones may be incidental findings unrelated to the cause of jaundice. Endosonography is especially useful for detecting bile duct stones and pancreatic carcinomas.

14.1.2.1 Diffuse Disease

High-amplitude echoes are found in micronodular cirrhosis, but also occur in fatty liver, hepatitis and congestive cardiac failure. This has been termed the 'bright liver'. The appearance is non-specific and insensitive, being often absent in macronodular cirrhosis, and ultrasonography is not recommended as a diagnostic procedure if these diseases are suspected. Portal hypertension and thrombosis of the portal and hepatic veins can also be detected.

14.1.2.2 Venography

Variceal and portal venous blood flow can be assessed by ultrasound, especially if Doppler techniques are used with EUS.

14.1.3 Main Indications

1. Diagnosis of cholestatic jaundice.
2. Diagnosis of cysts and abscesses.
3. Diagnosis of liver metastases.
4. Assessment of portal blood flow and venous thrombosis.

14.2 Isotope Scanning

In many departments isotopic liver scanning has been largely replaced by the more informative US as a rapid and simple technique for screening the liver. It remains useful in the assessment of cirrhosis with portal hypertension, diagnosis of large liver tumours and definition of liver and spleen size. The isotope most commonly used is the gamma-emitting ^{99m}Tc , which can either be administered as a colloidal sulphide or as labelled macroaggregates of albumin. The isotope is taken up by the Kupffer cells and has a half-life of 6 h. ^{113m}In colloid is an equivalent alternative.

No special preparation of the patient is necessary and the patient need not be fasting. The patient is scanned in the supine position, and both anteroposterior and lateral scans are obtained. Scanning is commenced about 15 min after IV injection of the isotope, when stabilization of the count rate indicates that maximal radioactivity has been reached over the liver. The scanning procedure takes about 20 min, depending upon the size of the liver. Upon completion of the procedure the surface markings of the costal margins, xiphisternum and the liver, if enlarged, are marked on the scan to aid its interpretation.

14.2.1 Interpretation

14.2.1.1 Normal Liver

There is good, even, uptake of the isotope with the maximum activity being registered over the right lobe. The spleen is clearly outlined with ^{99m}Tc . The distribution of isotope between liver and spleen gives some assessment of liver function.

14.2.1.2 Cirrhosis

A patchy appearance may be seen and when this is marked the liver may appear to have a number of filling defects. This has given rise to diagnostic difficulties with diffuse hepatic secondaries or even hypertension. The liver may be either greatly reduced in size or enlarged.

14.2.1.3 Portal Hypertension with Collateral Circulation

A characteristic pattern is seen: the small liver has a poor uptake, the large spleen avidly concentrates ^{99m}Tc and there is clear outlining of the vertebral bodies.

14.2.1.4 Metastases

Areas of low activity are seen. Metastases >3 cm in diameter are usually seen, but the technique has a low overall sensitivity of about 60%. Isotope scans do not differentiate between metastases, abscesses and cysts.

14.2.1.5 Hepatocellular Carcinoma

This shows on the ^{99m}Tc scan as a filling defect, which may be rounded or extend as processes from the porta hepatis. A second scan with ^{75}Se selenomethionine or

⁶⁷gallium citrate shows the hepatocellular carcinoma as a 'hot' area, and subtraction of the scans gives a positive result in 90% or more cases. Hepatic abscesses and metastases may show the same pattern, but the technique is not so reliable in these diseases and the ^{99m}Tc scan may be negative.

14.2.2 Indications

1. To define liver and spleen position and size and function.
2. Diagnosis of cirrhosis with portal hypertension.
3. Diagnosis of hepatocellular carcinoma.

14.2.3 Liver Perfusion Scintigraphy

The normal liver receives 25% of its blood supply from the hepatic artery and 75% from the portal vein. In metastatic liver disease the arterial contribution increases. This can be measured by dynamic angiographic scanning after IV administration of ^{99m}Tc-labelled tin or sulphur colloid with 2-s frames for a minute and a subsequent conventional series of static frames. A hepatic perfusion index is calculated of arterial versus venous flow, which is >0.4 in metastatic disease and less than this in normal controls. There is overlap in other diseases however.

14.3 Radiology

14.3.1 Plain Abdominal Radiograph

A film of the abdomen is of help in determining the liver and spleen size. An enlarged liver frequently causes diaphragmatic elevation though an enlarged spleen does not. Calcification in the liver substance is seen in benign tumours particularly haemangiomas, and in malignant tumours, abscesses and hydatid cysts. Less than 50% of hepatic hydatid cysts show calcification which may appear as a thin rim over part or all of the cyst surface, or the cyst may be extensively calcified in a reticular pattern. Air may be seen in the biliary tract and the identification of gallstones may be useful in the icteric patient.

14.3.2 Barium Studies

A barium swallow is of help in the identification of oesophageal varices, which are best demonstrated when the lower oesophagus is coated with a thin layer of barium. The oesophagus is slightly dilated and numerous filling defects distort the vertical mucosal folds. The presence of varices indicates the opening of portasystemic anastomotic channels and is a sign of portal hypertension. Varices are present when there is either intra- or extrahepatic obstruction to the portal circulation and do not necessarily indicate hepatic cirrhosis. They may be seen in the acute fatty liver,

Fig. 14.1 CT scan of the normal liver

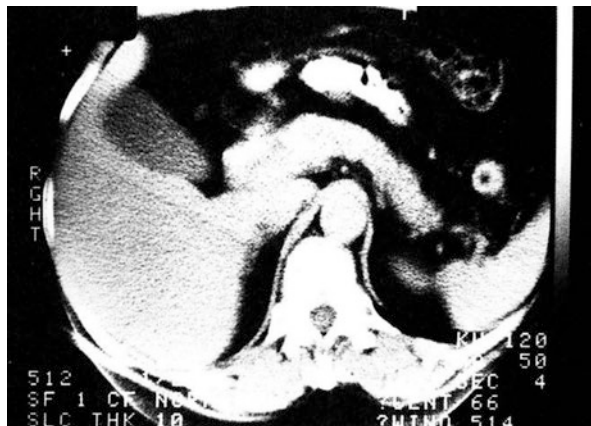
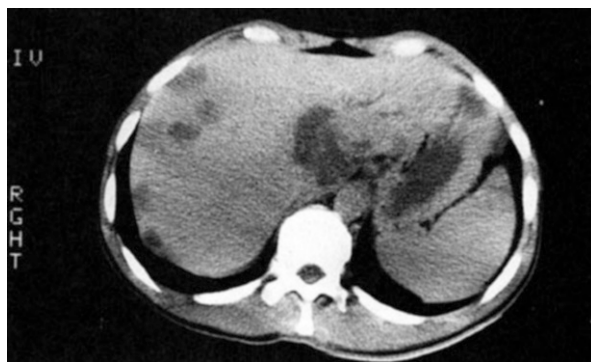


Fig. 14.2 CT of the liver showing multiple metastases from carcinoma of the stomach



infectious and alcoholic hepatitis, and presinusoidal causes of portal hypertension such as schistosomiasis.

14.3.3 Computed Tomography (Figs. 14.1 and 14.2)

This procedure provides good images of the liver and can demonstrate space-occupying lesions such as tumours, cysts and abscesses, as well as fatty liver. It is superior to isotope scanning and ultrasonic scanning. Results can be improved by use of lipiodol contrast. Spiral CT is better because it avoids misregistration problems from multiple breath holds.

14.3.4 Magnetic Resonance Imaging (MRI)

MRI is superior to ultrasonography and isotope scanning in liver disease because of its greater sensitivity. It is also superior to CT, and is likely to become more so with further technical advances and the use of contrast media, such as gadolinium-DTPA and superparamagnetic ferrite-iron oxide particles.

Though safe, it cannot be used in the presence of significant amounts of ferromagnetic materials, which excludes many patients with implants and prostheses. The technique is noisy and claustrophobic, and cannot be tolerated by some patients, when CT in a torus scanner is an alternative.

14.3.5 Arteriography

Selective coeliac arteriography is of value in the investigation of patients with liver disease. The technique can be used to distinguish between benign lesions (such as hydatid cysts) and malignant tumours, which produce a characteristic distortion of the hepatic arterioles. The vasculature is also distorted in the cirrhotic liver. The technique can be used to outline the portal vein in patients who have undergone splenectomy or when splenic venography is contra-indicated. The tip of the catheter is placed in the orifice of the superior mesenteric artery and contrast agent injected while imaging rapidly. The technique presents few problems for the radiological department versed in angiographic techniques. Selective mesenteric arteriography has been used to define the collateral circulation in portal hypertension and to enable the direct infusion of pitressin to control haemorrhage. It is also used pre-operatively to assist planning of surgery.

Magnetic resonance arteriography is an attractive alternative procedure.

14.3.6 Elastography (Fibroscan)

This highly specialised technique of vibration controlled transient ultrasonography measures stiffness of the liver, and particularly fibrosis, steatosis and cirrhosis. Increased values are also seen in congestive cardiac failure.

Normal readings are 2.5–7.5 kPa. These exclude cirrhosis and steatosis, and may make liver biopsy unnecessary, particularly in assessment of excess alcohol intake. In hepatitis C where no other problem is suspected, values >14 kPa indicate a 90% chance of cirrhosis.

In other cases the main role may be to follow the progress of known disease with serial scans.

14.4 Diagnosis of Cholestasis

There are many different causes of cholestasis, which is manifested by jaundice, itching, dark urine, conjugated hyperbilirubinaemia and raised serum alkaline phosphatase. If the cause is extrahepatic, persistent and surgically remediable, it is important to proceed to surgery promptly to avoid secondary hepatocellular failure. If the cause is intrahepatic, however, surgery is contra-indicated, both because of the possibility of causing liver and renal failure and the absence of useful relieving surgical procedures.

The most common causes of extrahepatic obstruction are common bile duct gallstones and carcinoma of the head of the pancreas. The most common causes of intrahepatic cholestasis are alcoholic liver disease, drug toxicity, viral liver disease and metastases. Rapid and safe diagnosis is essential to allow correct management. Sclerosing cholangitis and co-existing intra- and extrahepatic causes of cholestasis may give rise to diagnostic problems.

At present the major techniques for the diagnosis of cholestasis are ultrasonic scanning, HIDA scanning, EUS, MRCP, percutaneous transhepatic cholangiography, endoscopic retrograde cholangio-pancreatography, computed tomography and laparoscopy. The latter is the least useful.

The choice of technique to be used depends upon local expertise. A liver biopsy is not appropriate as an initial procedure.

14.5 Portal Manometry and Splenoportography

Several ingenious procedures for measuring portal hypertension and performing portography (often undertaken simultaneously) have been devised. They are useful in the assessment of patients being evaluated for surgery, although it should be appreciated that the level of portal hypertension does not correlate in any way with the size of the oesophageal varices or the likelihood of their bleeding.

Similarly, collateral vessels may be demonstrated at portography, but these may be peri-oesophageal rather than the submucosal veins which are prone to bleed. Endoscopy and barium swallow examinations are the simplest and best methods of demonstrating the presence of oesophageal varices. Doppler probes are available for use at endoscopy to assess flow in varices.

14.6 Manometry

14.6.1 Splenic Puncture

14.6.1.1 Method

The preparation of the patient and the precautions which are observed are similar to those for a liver biopsy. The patient lies supine with the left arm behind the head. The upper limit of splenic dullness is defined while the breath is held in deep expiration. The site for insertion of the needle is selected midway between the mid and posterior axillary line and in that intercostal space below the upper level of splenic dullness. This is usually the eighth or ninth space.

The needle is advanced 2–3 cm into the spleen, the stylet is withdrawn and the patient is permitted to breathe gently. When the needle has been positioned correctly it is connected by means of a length of polyvinyl or polyethylene tubing which has been filled with normal saline to a pressure recording transducer. The pressure is recorded while the patient breathes quietly. The zero level is taken at a

point 5 cm below the sternal angle. Once the pressure measurements have been taken a splenic venogram may be performed. The tract may be occluded by injection of an absorbable gelatin sponge.

14.6.1.2 Interpretation

The normal intrasplenic pressure is <14 mmHg. In cirrhosis this is increased 17–35 mmHg and similar values are found in patients with extrahepatic portal vein obstruction.

The intrasplenic pressure does not distinguish between intra- and extra-hepatic causes of portal hypertension. An elevated intrasplenic pressure may fall, even to within the normal range, when there is a marked portasystemic collateral circulation or after bleeding from varices. The intrasplenic pressure relates closely to the pressure in the portal vein, which it usually exceeds by 2–4 mmHg.

14.6.1.3 Indications

1. To confirm the presence of portal hypertension.
2. To assess the success of a portacaval anastomosis. When there is a patent surgical shunt the intrasplenic pressure should return to normal (Brazzini et al. 1987).

14.6.2 Hepatic Vein Catherization

This is a useful technique for the study of portal haemodynamics. It is not, however, essential to the management of a patient with liver disease and is not performed as a routine clinical investigation.

An open tip radio-opaque cardiac catheter is introduced into the right or left lobe of the liver under fluoroscopic control, via an antecubital vein. The catheter is advanced until resistance is felt and no further progress is possible. This is the wedged position and pressures obtained in this position are believed to represent the portal vein pressure. The catheter is then withdrawn so that it lies freely in the vein - the 'free' position. Hepatic vein pressures are recorded in the wedged and free positions.

The normal wedged hepatic vein pressure is between 6 and 12 mmHg and the free pressure is between 2 and 5 mmHg. The wedged hepatic vein pressure is increased when there is an intrahepatic cause for portal hypertension such as cirrhosis, but is normal when portal hypertension is due to presinusoidal or extrahepatic portal obstruction. The technique can be used to study portal pressures in the splenectomized subject and may be combined with radiological procedures to demonstrate the hepatic venous pattern.

It is possible to classify the causes of portal hypertension into pre- or postsinusoidal on the basis of information provided by the intrasplenic and wedged hepatic vein pressure measurements (Table 14.1). Chronic sinusoidal portal hypertension is important in prognosis, and is defined as a hepatic vein pressure gradient of > or >> 5 mm Hg.

Table 14.1 Interpretation of portal manometry

Site of cause of portal hypertension	Intrasplenic pressure	Wedged hepatic vein pressure	Diagnosis
Presinusoidal	Elevated	Normal	Blocked portal or splenic vein; schistosomiasis; congenital hepatic fibrosis; myeloproliferative syndrome
Postsinusoidal	Elevated	Elevated	Cirrhosis; blocked hepatic veins; veno-occlusive disease

14.6.3 Intrahepatic Pressure

The Chiba needle can be used to measure portal venous pressure. The procedure is as for PTC, but an attempt is made to penetrate a portal vein which is identified by the centripetal flow of dye. Percutaneous manometry yields results similar to the wedged hepatic vein pressure (3–9 mmHg is normal, 14–45 mmHg in portal hypertension).

14.7 Portography

This may be performed by direct puncture of spleen or liver, via the umbilical vein; or by superior mesenteric arteriography where the spleen is small or absent. Iodine contrast media and radioisotopes have both been used. Hepatic venography can be performed after wedged hepatic pressures have been taken.

14.7.1 Splenic Venography (Splenoportography)

This technique provides valuable information about the portal venous system. It is usually performed at the same time as the intrasplenic pressure is being measured. The radiological procedure should be combined with the measurement of intrasplenic pressure.

14.7.1.1 Method

The patient is prepared as for the measurement of the intrasplenic pressure. The patient is instructed to hold the breath in expiration and 40 ml of warm low osmolar iodinated contrast is injected while a series of anteroposterior films are taken. The needle is immediately removed and the patient told to breathe gently. The injection of the dye into the splenic pulp is usually painless. There is occasionally unpleasant flushing which rapidly subsides. Marked left shoulder-tip pain is felt when there is a subcapsular spilling of the dye.

14.7.1.2 Interpretation

The early films are used to assess the portal collateral circulation and the later ones to assess the intrahepatic vascular pattern. The splenic and portal veins are identified

and their calibre noted. The presence of collateral vessels is significant and gastric, oesophageal, splenic and lumbar venous channels may be seen. Filling may also occur of the inferior mesenteric, testicular or ovarian and umbilical veins. Failure to visualize the portal vein suggests that it is blocked, but when there is a large collateral circulation the flow of the dye may be sufficiently deviated to prevent opacification of what is in fact a normal portal vein. The intrahepatic venous pattern is seen as an initial 'vascular' phase when the rich branching portal vascular system is identified, and a later 'parenchymatous' phase when the liver shows as an intense homogeneous shadow. In cirrhosis there is diminution and distortion of the intrahepatic radicles, giving a sparse 'tree-in-winter' appearance. There is no filling of the intrahepatic radicles in the presence of extrahepatic obstruction to the portal vein. Tumours, cysts and abscesses cause distortion of the intrahepatic venous pattern.

14.7.1.3 Indications

1. To exclude extrahepatic causes of portal hypertension and to provide information about the portal vein in patients being considered for surgery for portal hypertension.
2. To diagnose the cause of an enlarged spleen.

14.7.2 Transumbilical Portal Venography

The place of this technique in demonstrating the portal venous system is uncertain. Under local anaesthesia the umbilical vein is exposed at the umbilicus and hemisected. The collapsed lumen is teased open – the vein is patent in the majority of patients with cirrhosis. The vein is dilated until it admits a suitable catheter which is then advanced to the hepatic hilum. Care must be exercised on entering the left branch of the portal vein which can be damaged. Injection of contrast material allows excellent visualisation of the interhepatic portal venous system, but the extrahepatic portal vein is not always seen.

14.7.3 Transhepatic Portography

The liver is punctured and the needle tip positioned in the portal vein near the hilum for manometry, after which 20 ml contrast are injected. Ten images are taken at 1 s intervals.

14.7.4 Hepatic Venography

With a hepatic catheter in the wedged position, between 10 and 20 ml of warm low-osmolar iodinated contrast are injected with rapid imaging. The normal liver demonstrates a delicate lattice network of fine venules. The larger hepatic veins are outlined as smooth regular branching vessels. In the cirrhotic liver the venule

pattern is coarse and nodular, the larger hepatic veins are tortuous and irregular and there is a portal vein filling. Abnormal venous patterns are found in tumours and the Budd-Chiari syndrome.

Bibliography

- Amouyal P, Amouyal G, Mompoin D, Gayet B, Palazzo L, Ponsot P, Vilgrain V, Flejou J-F, Paeleloggi JA. Endosonography: promising method for diagnosis of extra hepatic cholestasis. *Lancet*. 1989;ii:1195–8.
- Baron MG, Wolf BS. Splenoportography. *JAMA*. 1968;206:629–34.
- Boyer TD, Triger DR, Horisawa M, Redeker AG, Reynolds TD. Direct transhepatic measurement of portal vein pressure using a thin needle. *Gastroenterology*. 1977;72:584–9.
- Brazzini A, Hunter OW, Darcy MD, et al. Safe splenoportography. *Radiology*. 1987;162:607–9.
- Brown HS, Halliwell M, Qamar M, Read AE, Evans JM, Wells PNT. Measurement of normal portal venous blood flow by doppler ultrasound. *Gut*. 1989;30:503–9.
- Cherryman OR, Heron CW. Liver tumours: imaging techniques. *Clin Gastroenterol*. 1987;1:91–113.
- De Franchis R, et al. Expanding consensus in portal hypertension. *J Hepatol*. 2015;42:743–52.
- Debondonie JC, Pauls C, Fievez M, Wibin E. Prospective evaluation of the diagnostic accuracy of liver ultrasonography. *Gut*. 1981;22:130–5.
- Ferrucci JT. MR imaging of the liver. *Am J Roentgenol*. 1986;147:1103–16.
- Fishman EK, Jeffrey RB. *Spiral CT: principles, techniques and clinical applications*. New York: Raven Press; 1995.
- Gupta S, Barter S, Phillips GWL, Gibson RN, Hodgson HJF. Comparison of ultrasonography computed tomography and ⁹⁹Tc liver scan in diagnosis of Budd-Chiari syndrome. *Gut*. 1987;28:242–7.
- Hill MC, Dach JL, Shawker TH. Ultrasonography in portal hypertension. *Clin Gastroenterol*. 1985;14:83–104.
- Hoefs JC, Wang F, Kanel G, Braunstein P. The liver-spleen scan as a quantitative liver function test: correlation with liver severity at peritoneoscopy. *Hepatology*. 1995;22:1113–21.
- Hoevens J, Lunderquist A, Tyle NE. Percutaneous transhepatic portography. *Acta Radiol Diagn*. 1978;19:643–55.
- Irving AD, Cuschieri A. Laparoscopic assessment of the jaundiced patient. *Br J Surg*. 1978;65:678–80.
- Joseph AEA, Dewsbury KC, McGuire PG. Ultrasound in the detection of chronic liver disease (the bright liver). *Br J Radiol*. 1979;52:148–88.
- Kreel L. Computerised tomography and the liver. *Clin Radiol*. 1977;28:511–81.
- Kreel L. Radiology of the portal system. *Gut*. 1970;11:620–6.
- Levy HM, Newhouse JH. MR imaging of portal vein thrombosis. *Am J Roentgenol*. 1988;151:283–6.
- Luthra MS, Scheri NO, Golden D, Collica CJ. Scintiphography in cirrhosis. *Arch Intern Med*. 1968;122:211–4.
- MacConnack T, Martin T, Smallwood RH, Robinson P, Walton L, Johnson AG. Doppler ultrasound probe for assessment of blood-flow in oesophageal varices. *Lancet*. 1983;1:677–8.
- Medhat A, Iber FL, Dunne M. A new quantitative u/s method for diagnosis of chronic parenchymal liver disease. *Gastroenterology*. 1988;94:157–62.
- O'Connor KW, Pl S, Swonder JE, et al. A prospective study comparing four current noninvasive approaches in the differential diagnosis of medical versus surgical jaundice. *Gastroenterology*. 1983;84:1498–504.
- Okuda K, Suzuki K, Musha H, Arimizu N. Percutaneous transhepatic catheterisation of the portal vein for the study of portal haemodynamics and shunts. *Gastroenterology*. 1977;73:279–84.

- Parkin A, Robinson PI, Baxter P, Leveson SH, Wiggins PA, Giles GR. Liver perfusion scintigraphy: method, normal range, and laparotomy correlation in 100 patients. *Nucl Med Commun*. 1983;4:395-402.
- Powell-Jackson P, Karani J, Ede R, Meire H, Williams R. Diagnosis of Budd-chiari syndrome by liver ultrasound and colloid scintigraphy. *Gut*. 1985;26:A568.
- Reinig JW, Dwyer AJ, Miller DL, Frank JA, Williams-Adams G, Chang AE. Liver metastases: detection with MR imaging at 0.5 and 1.5 T1. *Cancer Res*. 1989;49:424-32.
- Ruzicka FF, Carillo FJ, D'Allessandro D, Rossi P. The hepatic wedge pressure and venogram versus the intra-parenchymal liver pressure and venogram. *Radiology*. 1972;102:253-8.
- Saverymuttu SH, Joseph AEA, Maxwell JD. Ultrasound scanning in the detection of hepatic fibrosis and steatosis. *BMJ*. 1986;292:13-5.
- Saverymuttu SH, Wright J, Maxwell JD, Joseph AEA. Ultrasound detection of oesophageal varices- comparison with endoscopy. *Clin Radiol*. 1988;39:513-5.
- Scott J, Long RG, Dick R. Percutaneous transhepatic obliteration of gastro-oesophageal varices. *Lancet*. 1976;2:53-5.
- Smith FW, Mallard JR, Reid A, Hutchinson JMS. Nuclear magnetic resonance tomography imaging in liver disease. *Lancet*. 1981;i:963-6.
- Smith FW, Mallard JR. NMR imaging in liver disease. *Br Med Bull*. 1984;40:194-6.
- Smith-Laing G, Camillo ME, Dick R, Sherlock S. Percutaneous transhepatic portography in the assessment of portal hypertension. *Gastroenterology*. 1980;78:197-205.
- Taylor KJW. Liver imaging by ultrasonography. *Semin Liver Dis*. 1982;2:1-13.
- Tudway D, Sangster G. Ultrasound diagnosis of portal vein thrombosis following splenectomy. *Postgrad Med J*. 1986;62:1153-6.
- Vallon AG, Lees WR, Cotton PB. Grey-scale ultrasonography in cholestatic jaundice. *Gut*. 1979;20:51-4.
- Viamonte M, Peraras R, Russell E, Lepage J, Maer WL. Pitfalls in transhepatic portography. *Radiology*. 1977;124:325-9.
- Vicary FR, Shirley I. Ultrasound and hepatic metastases. *Br J Radiol*. 1978;51:596-8.
- Weaver RM, Goldstein HM, Green B, Perkins C. Gray scale ultrasonographic evaluation of hepatic cystic disease. *Am J Roentgenol*. 1978;130:849-52.

Gallbladder stones form the majority of biliary disease, and are conveniently detected by ultrasonography (US).

After cholecystectomy; where the bile ducts are of especial interest; and where pancreatic evaluation is needed, contrast magnetic resonance (MRCP) is the best non-invasive test. CT has a lesser role.

Where therapeutic intervention is planned ERCP comes into its own, enabling sphincterotomy, stone extraction and stenting.

If there is direct access to the biliary tree then iodine contrast radiology and choledochoscopy have a place in finding stones and strictures.

EUS allows both imaging of the bile ducts and pancreas, with the possibility of fine needle aspiration cytology (FNA) of the pancreas.

Other techniques such as oral cholecystography and infusion cholangiography have a more restricted role nowadays.

Serum biochemistry may support a diagnosis, but is usually nonspecific. Studies of biliary physiology have not found their way into routine clinical practice. Duodenal drainage with examination of bile-rich fluid is seldom used in making a diagnosis of gallbladder disease, though in gallstone disease cholesterol crystals indicate cholesterol-rich stones, and microspheroliths indicate mineral/pigment stones.

15.1 Ultrasonography (Figs. 15.1 and 15.2)

High-definition real-time ultrasonic scanning is very rapid and simple to perform, and yields a 96% accuracy for gallbladder gallstones.

Gallstones >3 mm in size can be detected as mobile structures within the gallbladder, the wall of which is often thickened. Stones >5 mm in diameter produce prominent acoustic shadows which assist interpretation. The presence of calcium in stones increases the ultrasonic definition.

Fig. 15.1 Abdominal ultrasound showing normal gallbladder

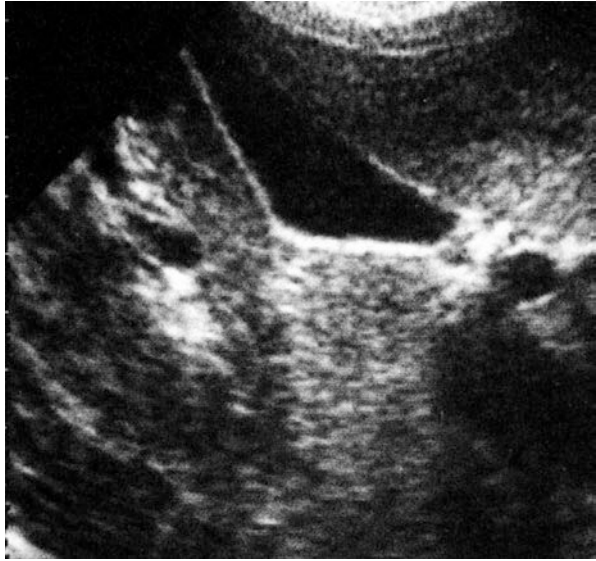
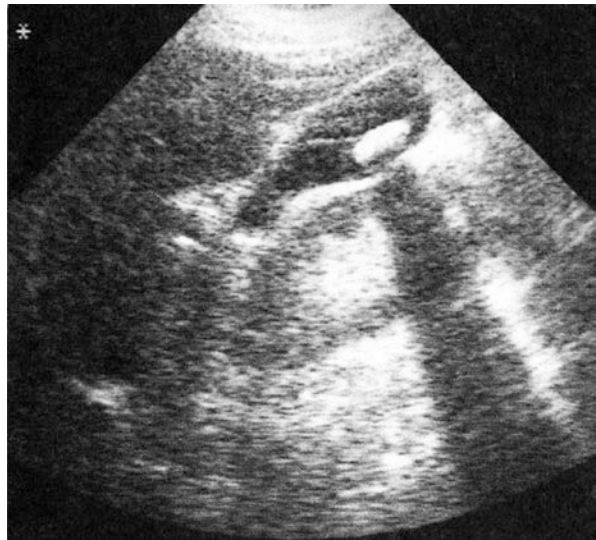

Fig. 15.2 Abdominal ultrasound showing gallstone as an echogenic focus with acoustic shadowing



The thickness of the gallbladder wall may be a clue to disease. It is no thicker than 2 mm in 97% of asymptomatic subjects without gallstones and >3 mm thick in 45% of those with gallstone disease. Large carcinomas of the gallbladder are readily seen, as are mucocoeles.

Failure to obtain an image of the gallbladder is uncommon, but may also be a sign of disease.

Ultrasonography is useful for measuring bile duct calibre but is not as accurate as MRCP for detecting duct stones. It readily defines choledochal cysts in children. Ultrasonography can be employed at laparotomy using a transducer held

adjacent to bile ducts and pancreas. This could replace the operative cholangiogram. Ultrasonic gallbladder scanning is very useful for evaluation of the nonfunctioning gallbladder or after a failed cholecystogram. High-definition real-time scanning has largely replaced the oral cholecystogram as a first-line test but the techniques are complementary.

Real-time scanning is used to study gallbladder motility and may well prove to be of value in the definition and diagnosis of ‘biliary dyskinesia’.

15.2 Magnetic Resonance Cholangiography (MRCP) (Figs. 15.3 and 15.4)

MRCP with contrast enhancement is now the standard test for bile duct and pancreatic disease. It is accurate and non-invasive. It is however claustrophobic and noisy, and not always tolerated by patients, when EUS or CT with torus scanners may be a better option.

15.3 Endosonography (EUS)

This technique is not freely available at present, but offers the chance of detecting common bile duct stones without introducing iodine contrast directly into the biliary system. Biliary tumours and strictures can also be identified. It can be used as a screen preliminary to therapeutic ERCP.

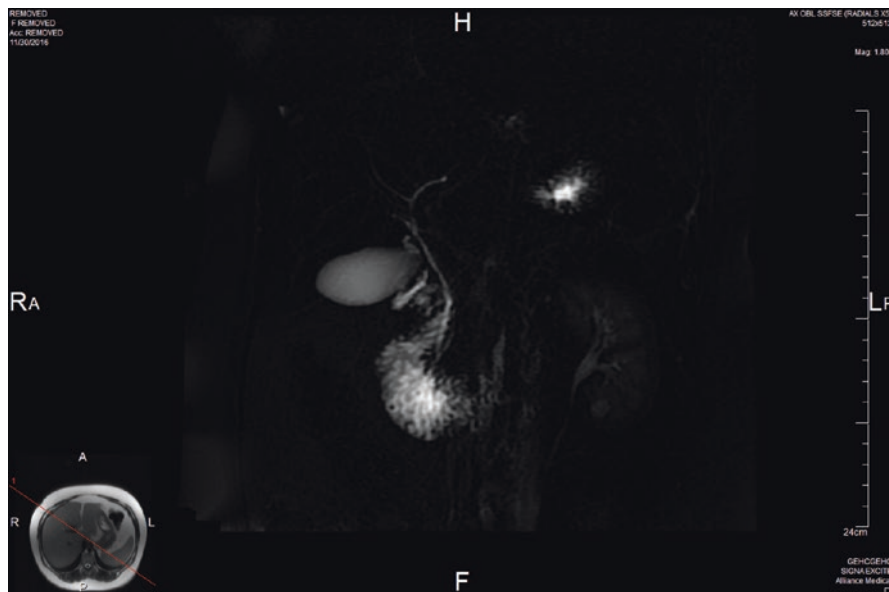


Fig. 15.3 MRCP Normal bile ducts and gallbladder. Normal proximal pancreatic duct

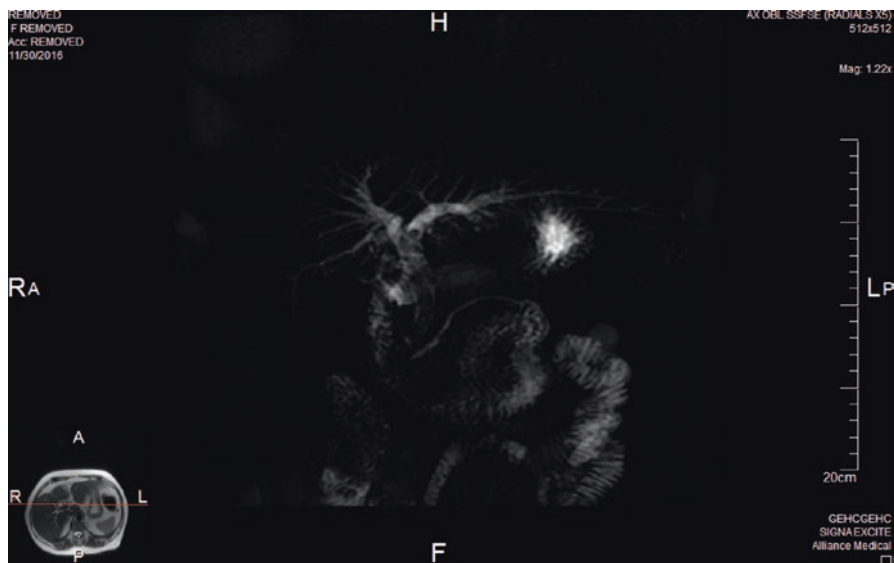

Fig. 15.4 MRCP Multiple stones in dilated bile ducts. Absent gallbladder. Normal pancreatic duct

15.4 Plain Radiology

Ten to twenty percent of gallstones are sufficiently calcified to be visible on the upper right side of the abdomen. Sometimes the calcification is homogeneous, but often it shows an internal laminar pattern which is helpful in diagnosis. Gallstones may either have rounded contours, or straight edges if they have been pressed against other stones. Multiple small irregular calcified stones are frequently composed of calcium bilirubinate. Pure cholesterol stones are radiolucent. Occasionally large gallstones show internal fractures with hyperlucent lines radiating from the centre. This is called the tri-fin or Mercedes-Benz sign and can be detected even in the absence of calcification. The position of gallstones usually requires confirmation by supplementary procedures.

Calcium deposits are occasionally seen in the gallbladder wall: the ‘porcelain gallbladder’. Even less frequently, bile contains a large amount of calcium salts in suspension: ‘limy’ or ‘milk of calcium’ bile, which outlines the biliary tree. Gas in the biliary tree occurs in infections with gas-forming organisms, called emphysematous cholecystitis. It also occurs when there is a fistula between the intestine and gallbladder or bile ducts and after some operations to the biliary tree.

Gas can also occur when there is an incompetent sphincter of Oddi, which may result from sphincteroplasty.

15.5 Oral Cholecystography (Figs. 15.5 and 15.6)

This remains a method of demonstrating gallstones in a functioning gallbladder, although it has now been superseded by ultrasonography. Oral cholecystography is less useful in acute cholecystitis when cystic duct obstruction occurs. Good results are obtained by experienced radiographers and the technique is economical of radiologists' time.

Fig. 15.5 Oral cholecystogram showing floating gallstones

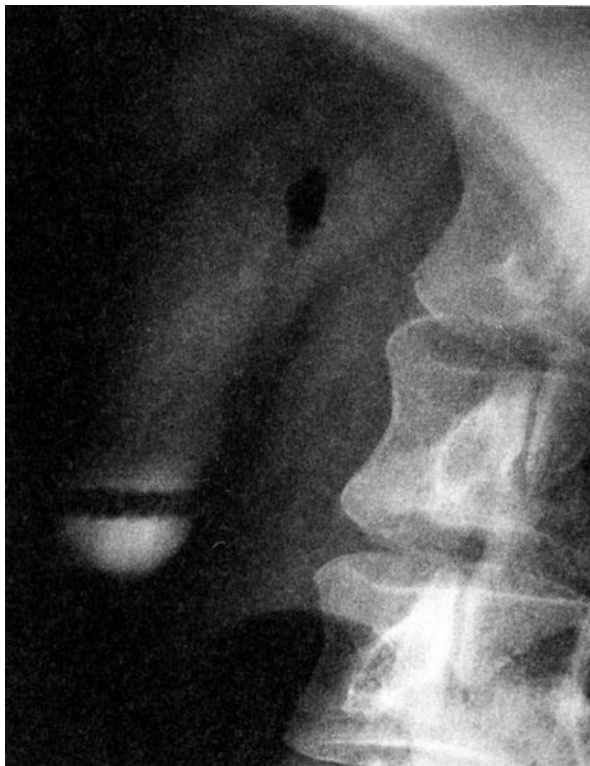
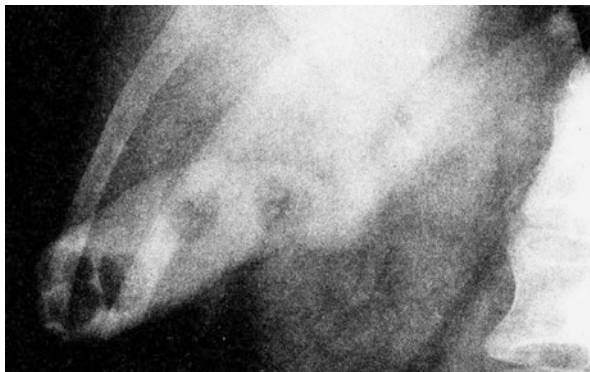
Fig. 15.6 Oral cholecystogram showing radiolucent gallstones



15.5.1 Method

A plain radiograph of the abdomen is taken prior to oral administration of an opaque contrast medium. This is absorbed from the intestinal tract, excreted by the liver, concentrated in the gallbladder and discharged via the bile ducts into the intestine. A variety of tri-iodo organic iodine compounds may be used for this purpose: a popular agent is iopanic acid, six 500 mg tablets being with a normal evening meal. The patient then fasts until the radiographic examination the following day.

An alternative technique is to administer 6 g iopanic acid over 1–2 days prior to the examination. This may yield a higher proportion of positive results at the first examination.

Some departments routinely administer a laxative with the preparation. As this may interfere with the absorption of the contrast medium, and as intestinal gas causes much more difficulty with interpretation than faeces, it cannot be recommended.

Radiographic films of the full gallbladder are obtained between 12 and 16 h after the ingestion of the opaque medium, in both erect and horizontal postures. If opacification is poor tomography is helpful. Gallbladder contraction is then stimulated by either a physiological stimulus such as eating two eggs, a cheese roll or a bar of chocolate, or by slow IV injection of cholecystokinin (CCK) 33 units. Larger doses of cholecystokinin and proprietary emulsions should not be used as they tend to cause abdominal distress and vomiting. Caerulein is an alternative pharmaceutical preparation but has no definite practical advantages. Further radiographic films are taken after gallbladder contraction, which occurs 30–60 min after an oral stimuli and 10–20 min after IV CCK.

Contraction films may show calculi which were not visible in the filled gallbladder, and at this stage it may be possible to visualize the cystic duct. The common bile duct is delineated clearly by oral cholecystography only occasionally. Failure of gallbladder function on cholecystography is not certain evidence for disease, and it is advisable to repeat the examination at least once. This may be undertaken conveniently after an initial series of films following a 3 g dose of iopanic acid by giving a further dose of 3 g iopanic acid on the day of the unsatisfactory examination and repeating the films the next day. Alternatively, some other test such as ultrasonography or infusion cholangiography should be undertaken.

15.5.2 Interpretation

Two definite appearances on oral cholecystogram provide unequivocal evidence of organic gallbladder disease. One is when there are gallbladder stones, and the other is the presence of contrast in the bile ducts but no gallbladder filling. Five percent of examinations yield evidence of some abnormality of the gallbladder wall such as cholesterolosis, adenomyomatosis, papillomas, prominent spiral valves and a Phrygian cap. These occur independently of gallstones and cholecystitis, and are not proof of symptomatic biliary disease.

Cholesterolosis of the gallbladder is suspected when there is an uneven mucosal contour with single or multiple filling defects. Adenomyomatosis of the gallbladder may show as a solitary filling defect, as a segmental stricture which must be distinguished from a 'Phrygian cap' (in which the septum is thinner and the distal segment contracts proportionately with the proximal segment) or as a diffuse condition which can be recognized by the contrast-filled Rokitansky-Aschoff sinuses. The gallbladder affected by cancer usually shows no function and generally contains stones.

A meticulous radiological technique is required for oral cholecystography: if this is achieved it is one of the most accurate of radiological investigations, detecting abnormalities with an accuracy of 95–99%. Positive evidence of gallstones is obtained in 70% of cases, and presumptive evidence is obtained in 98–99%. It probably detects 95% of significant cholecystitis.

Failure to outline the gallbladder also occurs if absorption of the contrast medium is impaired. This may result from vomiting, delayed gastric emptying and diarrhoea. In such circumstances no conclusions can be drawn regarding gallbladder function. Oral cholecystography is not undertaken when there is liver cell dysfunction, because no satisfactory excretion of the dye is obtained when the serum conjugated bilirubin concentration is $>50\mu\text{mol/l}$. Difficulty may also be encountered in anicteric patients with cholestasis. In the absence of parenchymal liver disease or hypermotility of the gut the failure to visualize the gallbladder after two attempts at cholecystography (the second being with a double dose of the contrast agent) may be accepted as evidence that the organ is diseased. The technique should be avoided in patients with renal failure, in whom it is often ineffective and also hazardous.

A problem which is sometimes encountered is the patient with classical biliary colic or acute relapsing pancreatitis in whom the oral cholecystogram is normal. In some of these cases ultrasonography (or repeat cholecystography) reveals stones. In cholecystitis without demonstration of gallstones on cholecystography, hyperlucent fat in the gallbladder wall may provide a clue to the diagnosis in about 50% of cases.

15.6 Operative Cholangiography

At the time of cholecystectomy the cystic duct is cannulated and iodine contrast such as diatrizoate is injected. Good images of the common duct and both hepatic ducts are obtained. This procedure eliminates the risk of unsuspected retained stones, which occur in up to 4% of patients after cholecystectomy. It also detects the rare hepatic and bile duct carcinomas. At present the consensus view is that operative cholangiography should be considered in all patients undergoing cholecystectomy for gallstones unless there has been careful pre-operative screening with MRCP. Digital subtraction techniques improve image quality. Both flexible and rigid choledochoscopes (cholangioscopes) are available for the same purpose; these usually require the common duct to be opened for their insertion and do not offer entirely satisfactory views of the distal common bile duct. Direct ultrasonography is another option.

Where duct stones have been removed it is usual to leave a T-tube in place and to confirm clearing of calculi by repeating the cholangiogram through the tube immediately before it is removed.

15.7 Percutaneous Transhepatic Cholangiography (PTC) (Figs. 15.7, 15.8, and 15.9)

This procedure can allow for precise localization of the cause of extrahepatic obstruction before abdominal surgery is undertaken. However, ultrasonography, EUS, MRCP and CT can often provide similar information and are less potentially hazardous.

15.7.1 Method

The patient is prepared as for a liver biopsy. It is important that a surgeon is informed when the procedure is to take place so that a laparotomy, if needed, can be performed without undue delay. Bile leakage and septicaemia may occur, even with the fine Chiba needle, and antibiotic cover starting immediately before the procedure is prudent. Gentamicin 80 mg IV is commonly used. Studies of blood haemostasis should be normal, as for liver biopsy.

The patient is placed supine on the radiology table and the procedure is carried out under fluoroscopy. The needle is 15 cm long, 0.7 mm external diameter and fitted with a stylet (Fig. 15.7). It is flexible so that the patient can breathe normally when it is in position.

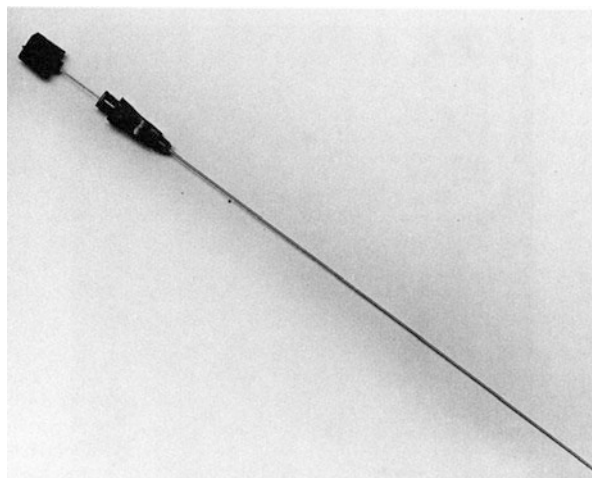


Fig. 15.7 Chiba needle

Fig. 15.8 Percutaneous transhepatic cholangiography (PTC) showing a malignant stricture of the common bile duct in carcinoma of the pancreas

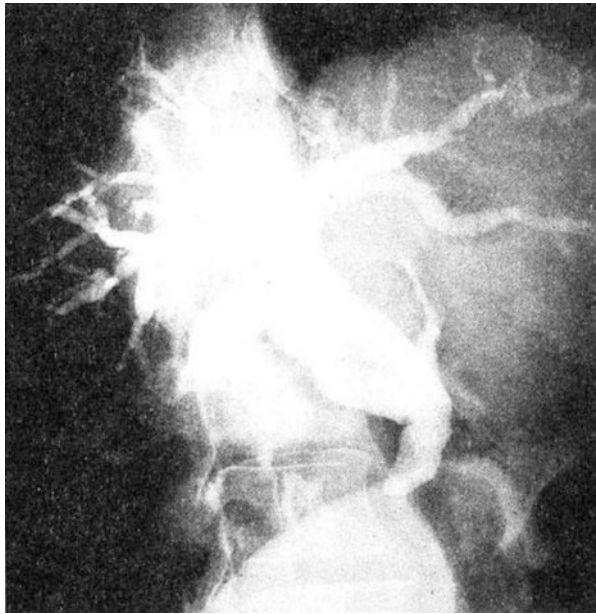
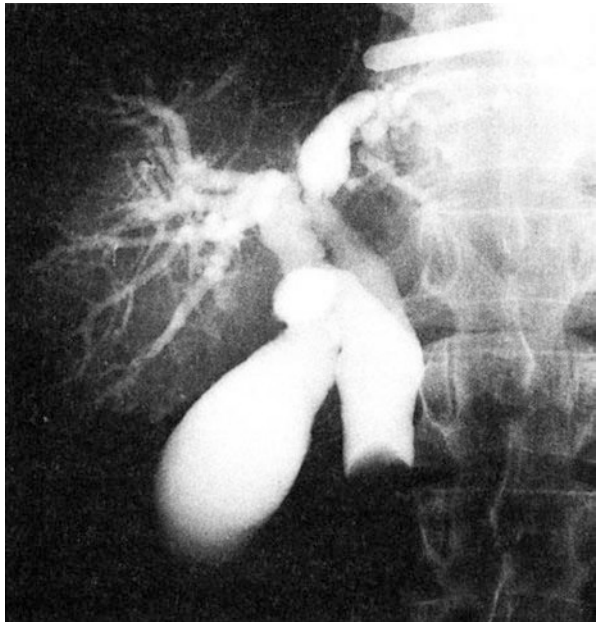


Fig. 15.9 PTC showing a large gallstone impacted in the common bile duct



The skin is punctured in the 7th–8th right intercostal space in the mid-axillary line. The needle is advanced parallel to the table and is aimed two vertebral bodies below the junction of the diaphragm with the spine. After advancing fully the stylet is withdrawn. Because it may not be possible to aspirate bile even when the needle tip is positioned correctly, it is preferable to connect a syringe containing 50 ml of a low osmolar iodinated contrast via flexible tubing and inject a little contrast continuously as the needle is slowly withdrawn. Flow is centripetal in bile ducts, as distinct from the centrifugal flow of dye injected into portal veins, and the midline drainage in the hepatic veins. While a bile duct is entered contrast is injected and films are taken. If the needle is completely withdrawn without a bile duct being identified, five more attempts are permitted, using different puncture sites separated by 3–5 cm. Post-procedure care is similar to that for a liver biopsy. If there is evidence of a bile leak immediate surgery may be required.

15.7.2 Interpretation

The procedure identifies dilated ducts in 90–100% of cases, and has the added advantage of usually identifying the precise cause of obstruction. It also succeeds in demonstrating ducts in 65% of ‘non-surgical’ disorders. The technique is so accurate that if dilated ducts cannot be demonstrated, further evidence of extrahepatic obstruction in the jaundiced patient is required before undertaking a laparotomy. The overall mortality is 0.5% and morbidity is 5%. Fever occurs in 3.5% of cases, hypotension in 2%, bile leakage in 2.5% and bleeding in 1%. In specialist centres PTC has an additional role, being used either for external biliary drainage or to insert a prosthesis in patients with malignant obstruction of the biliary tree, or to remove gallstones.

Transjugular cholangiography is feasible for the patient who has a bleeding tendency. Where PTC fails minilaparotomy or laparoscopy enables direct cholangiography before proceeding to full laparotomy.

15.7.3 Indications

1. Diagnosis of cholestasis.
2. Diagnosis of biliary strictures.
3. Diagnosis of hepatic duct carcinoma.
4. Positioning of guide-wires and biliary stents and drains.

15.8 Infusion Cholangiography

Organic iodine compounds may be administered intravenously and popular agents include sodium iodipamide, methylglucamine iodipamide and ioglycamide. These agents are excreted in the bile in much greater concentrations than the oral cholecystographic media.

15.8.1 Method

Patients with a serum bilirubin less than 50 $\mu\text{mol/l}$, who are not iodine-sensitive, and who are not in renal failure, are suitable for the test.

An infusion of 4 mg/kg ioglycamide is given over 1 h and films including tomograms are taken from 10 to 60 min after the infusion has commenced. This method avoids the flushing, nausea and vomiting which may be associated with bolus dose intravenous injection of contrast.

15.8.2 Interpretation

Bile duct calibre increases with age and after cholecystectomy. However, the normal common bile duct in adults is always less than 10 mm in diameter. Dilation of the duct above this indicates organic obstruction, where values from 12 to 25 mm are commonly seen.

The technique detects calculi and strictures. It may define anomalous bile ducts, retained cystic ducts and bile duct carcinomas. It is less accurate than operative cholangiography. Visualisation of the ducts but not the gallbladder in a patient who has not had a cholecystectomy indicates organic disease. This may be either acute cholecystitis, or a stone impacted in the cystic duct or a chronically inflamed non-functioning gallbladder.

Renal failure is a relative contraindication and alternative procedures should be considered.

Some authorities no longer consider IV cholangiography valid, but it still has a place as a reserve investigation.

15.9 Computed Tomography

This gives good results in gallstone disease, gallbladder cancer and obstructive jaundice, but other techniques do so too and should normally be the first choice.

A special use is in the evaluation of stones for non-surgical therapy. Radiolucent stones may have significant calcification precluding a successful dissolution therapy, and this is indicated by CT density >100 Hounsfield units. Since this type of treatment can be very prolonged it is helpful to use CT as a screen to exclude some of the patients in whom dissolution failure can be predicted.

15.10 Magnetic Resonance Imaging

It seems likely that MRI will eventually reach the stage where it is possible to make exact chemical analyses of stones within the patient. In other circumstances it is equivalent to CT. MRCP contrast cholangiography is of course now a procedure of first choice.

15.11 Isotope Scanning

15.11.1 Gallbladder Scintigraphy

^{99m}Tc compounds which are rapidly excreted by the liver even in the presence of cholestatic obstructive jaundice have been developed. One which has been well evaluated is ^{99m}Tc-labelled dimethyl-acetanilide iminodiacetic acid (^{99m}Tc-HIDA). There are many others. The procedure is used for the diagnosis of acute cholecystitis and is helpful in the differential diagnosis of acute abdominal pain. Scans should be performed within 48 h of admission to hospital.

15.11.1.1 Method

The patient is fasted for 4 h. 80 MBq of ^{99m}Tc-HIDA is normally injected IV; more is used if the patient is icteric. The patient is then scanned by gamma-camera with dynamic studies and serial photographs being obtained every 10 min for 1 h. If no gallbladder image is seen the scan is repeated at 3–4 h. If desired the nature of a gallbladder image may be confirmed by scanning 10–20 min after IV administration of 33 units CCK.

15.11.1.2 Interpretation

The scan is positive (no gallbladder activity) in all cases of acute cholecystitis and in about half of all patients with other gallbladder diseases. A negative scan (gallbladder activity) excludes acute cholecystitis, but does not necessarily mean that the gallbladder is normal. In infancy failure of excretion after liver uptake indicates biliary atresia. This technique has a particular role in the diagnosis of persistent cholestatic jaundice in the early months of life. Some 60% of such patients have biliary atresia which may require surgery, but 25% have neonatal hepatitis of one form or another and this is a contra-indication to operative intervention.

15.11.2 WBC Scanning

An alternative technique is labelling of leukocytes with ^{99m}Tc-HMPAO followed by their re-injection. Images are taken over the gallbladder about hourly for 4 h, and then at 24 h if required. In acute cholecystitis activity concentrates in the inflamed gallbladder wall in the first 4 h.

15.12 Biliary Physiology

Manometry of the biliary tract using catheters passed at ERCP, percutaneous transhepatic puncture, T-tubes and direct intra-operative puncture can be performed. Sphincter of Oddi manometry has been promoted. It is possible to test the response of the pressure recording to cholecystokinin, anticholinergics, spasmolytics and opiates.

The interpretation of these findings is difficult, though some authorities have taken high pressures to indicate a disease which has been termed 'biliary dyskinesia'.

This diagnosis is more certain in patients without stones who have dilated ducts on US and abnormal fluctuating 'liver function' tests.

Gallbladder emptying can conveniently be studied by planimetry of serial oral cholecystogram films, by gamma-scanning after intravenous ^{99m}Tc -HIDA, or by real-time ultrasonography. Emptying can be provoked by infusions of CCK or dietary fat. It is more rapid in men, in the elderly, and at the mid-point of the menstrual cycle. In gallstone disease many gallbladders do not function at all, but in the remainder emptying is said to be unduly rapid. There is a wide overlap with normal values.

15.12.1 Cholecystokinin

The availability of this hormone and its analogues led to the introduction of tests based on the reproduction of symptoms suspected of a biliary origin, demonstration of biliary motility patterns and analysis of bile-rich duodenal fluid. None is reliable in diagnosis.

15.13 Bacteriology

Anaerobic and aerobic cultures of bile aspirated percutaneously or directly at operation show that organisms are present in 30–56% of gallbladders in patients with biliary disease and in 20% of controls. The common duct bile is infected in 75% of patients with choledocholithiasis. There is no relationship between the profusion of bacterial isolates and biliary symptoms, though knowledge of organisms may guide antibacterial therapy (Figs. 15.3 and 15.4).

Bibliography

- Anderson A, Bergdahl L. Disease of the gallbladder in patients with normal cholecystograms. *Am J Surg.* 1976;132:322–4.
- Anderson JC, Harned RK. Grey-scale ultrasonography of the gallbladder. *Am J Roentgenol.* 1977;129:957–77.
- Bell GD, Frank J, Fayadh M, Smith PLC, Fry IK. Ioglycamide (Biligram) studies in man. *Br J Radiol.* 1978;51:191–5.
- Borsch G, Wegener M, Wedmann B, Kissler M, Glocke M. Clinical evaluation, ultrasound, cholecystography, and endoscopic retrograde cholangiography in cholestasis. A prospective comparative clinical study. *J Clin Gastroenterol.* 1988;10:185–90.
- Burhenne HJ, Obata WG. Single-visit oral cholecystography. *N Engl J Med.* 1975;292:627–8.
- Cabellon S, Brown JM, Cavanaugh DG. Accuracy of the hepatobiliary scan in acute cholecystitis. *Am J Surg.* 1984;148:607–8.
- Cooperberg PL, Burhenne HJ. Real-time ultrasonography; diagnostic technique of choice in calculous gallbladder disease. *N Engl J Med.* 1980;302:1277–9.
- Dick MC, Mowat AP. Biliary scintigraphy with DISIDA. A simpler way of showing bile duct patency in suspected biliary atresia. *Arch Dis Child.* 1986;61:191–2.
- Dye M, MacDonald A, Smith G. The bacterial flora of the biliary tract and liver in man. *Br J Surg.* 1978;65:285–7.
- Finberg HJ, Bimholz JC. Ultrasound evaluation of the gallbladder wall. *Radiology.* 1979;133:693–8.

- Gelfand DW, Wolfman NT, Ott OJ, Watson NE, Chen YM, Dale WJ. Oral cholecystography vs. gallbladder sonography: a prospective, blinded re-appraisal. *Am J Roentgenol.* 1988;151:69–72.
- Goodman MW, Ansell HJ, Vennes JA, Lasser RB, Silvis SE. Is intravenous cholangiography still useful? *Gastroenterology.* 1980;79:642–5.
- Gupta RK, Kakar AK, Jena A, Mishra PK, Khushu S. Magnetic resonance in obstructive jaundice. *Australas Radiol.* 1989;33:245–51.
- Jain S, Long RG, Scott J, Dick R, Sherlock S. Percutaneous transhepatic cholangiography using the 'Chiba' needle – 80 cases. *Br J Radiol.* 1977;50:175–80.
- Kaude JV. The width of the common bile duct in relation to age and stone disease. *Eur J Radiol.* 1983;3:115–7.
- Krishnamurthy S, Krishnamurthy GT. Technetium-99 m-iminodiacetic acid organic anions: review of biokinetics and clinical application in hepatology. *Hepatology.* 1989;9:139–53.
- Lane RJ, Galzer G. Intra-operative B-mode ultrasound scanning of the extrahepatic biliary system and pancreas. *Lancet.* 1980;2:334–7.
- Lantto E, Jarvi K, Laitinen R, Lantto T, Taavitsainen M, Talvitie I, Vorne M. Scintigraphy with ^{99m}Tc-HMPAO labeled leukocytes in acute cholecystitis. *Acta Radiol.* 1991;32:359–62.
- Laws JW. Non-invasive radiology. *Clin Gastroenterol.* 1984;13:1–286.
- Lecklitner ML, Austin AR, Benedetto AR, Growcock GW. Positive predictive value of cholescintigraphy in common bile duct obstruction. *J Nucl Med.* 1986;27:1403–6.
- Lee AW, Ram MD, Shih W-J, Murphy K. Technetium-99 m-BIDA biliary scintigraphy in the evaluation of the jaundiced patient. *J Nucl Med.* 1986;27:1407–12.
- Levesque HP. Sabulography. *Am J Roentgenol.* 1970;110:214–25.
- Lindsell DRM. Ultrasound imaging of pancreas and biliary tract. *Lancet.* 1990;335:390–3.
- Maglinte DDT, O'Connor K, Torres WE. Gallstone imaging: getting the most out of oral cholecystogram. *J Lithotr Stone Dis.* 1991;3:223–40.
- Melnick GS, Locurcio SB. The non-visualised' gallbladder on oral cholecystography. *Radiology.* 1973;108:513–5.
- Mendelson RM, Tobin MV, Gilmore IT. Bile duct measurements after ceruletide as an aid to the ultrasound diagnosis of choledocholithiasis. *Gastrointest Radiol.* 1988;13:41–4.
- Mirvis SE, Vainwright JR, Nelson AW, et al. The diagnosis of acute acalculous cholecystitis. *Am J Roentgenol.* 1986;147:1171–5.
- Motson R, Shinkwin MA, May ARL, Akhtar N. Digital subtraction cholangiography: a new technique for visualising the common bile duct during cholecystectomy. *Ann R Coll Surg Engl.* 1988;70:135–8.
- Mowat AP, Psaciaropoulos HT, Williams R. Extrahepatic biliary atresia versus neonatal hepatitis. *Arch Dis Child.* 1976;51:763–70.
- Mujahed Z, Evans JA, Whalen JP. The non-opacified gallbladder on oral cholecystography. *Radiology.* 1974;112:1–3.
- Okuda K, Tanikawa K, Emura T, et al. Non-surgical percutaneous transhepatic cholangiography -diagnostic significance in medical problems of the liver. *Am J Dig Dis.* 1974;19:21–36.
- Okuda K, Tsuchiya Y. Ultrasonic anatomy of the biliary system. *Clin Gastroenterol.* 1983;12:49–64.
- Palazzo L, Girollet P-P, Salmeron M, et al. Value of endoscopic ultrasonography in the diagnosis of common bile duct stones: comparison with surgical exploration and ERCP. *Gastrointest Endosc.* 1995;42:225–31.
- Prat F, Amouyal G, Amouyal P, et al. Prospective controlled study of endoscopic ultrasonography and endoscopic retrograde cholangiography in patients with suspected common bile duct lithiasis. *Lancet.* 1996;347:75–9.
- Reuther G, Berthold K, Tuchmann A. Cholangiography before biliary surgery: single-shot MR cholangiography versus intravenous cholangiography. *Radiology.* 1996;198:561–6.
- Rolny P, Arleback A, Funch-lensen P, Kruse A, Järnerot G. Clinical significance of manometric assessment of both pancreatic duct and bile duct sphincter in the same patient. *Scand J Gastroenterol.* 1989;24:751–4.
- Ross PE, Jacyna MR, Ramsay AE, et al. Ultrasonography and oral cholecystography in the diagnosis of gallstone disease. *Eur J Gastroenterol Hepatol.* 1990;336:209.

- Russell GB, Keddie NC, Gough AL, Galland RB. Radiology of acalculous gallbladder disease – a new sign. *Br J Radiol.* 1976;49:420–4.
- Tobin MV, Mendelson RM, Lamb GH, Gilmore IT. Ultrasound diagnosis of bile duct calculi. *BMJ.* 1986;293:16–7.
- Weissman HS, Frank M, Rosenblatt R, Goldman M, Freeman LM. Cholescintigraphy, ultrasonography and computerised tomography in the evaluation of biliary tract disorders. *Semin Nucl Med.* 1979a;9:27–35.
- Weissman HS, Frank MS, Bernstein LH, Freeman LM. Rapid and accurate diagnosis of acute cholangitis with ^{99m}Tc-HIDA cholescintigraphy. *Am J Roentgenol.* 1979b;132:523–8.
- Wermke W, Schulz H-J. Sonographic diagnosis of bile duct calculi: prospective study in 222 cases with choledocholithiasis. *Ultraschall Med.* 1987;8:116–20.
- Yeh HC. Ultrasonography and computed tomography of carcinoma of the gallbladder. *Radiology.* 1979;133:167–73.
- Zeman RK, Lee C, Jaffe MH, Burrell MI. Hepatobiliary scintigraphy and sonography in early biliary obstruction. *Radiology.* 1984;153:793–8.

The aetiology of ascites may be obvious from the history and physical examination. However, it is generally necessary to examine the fluid microscopically, chemically and bacteriologically. Even when the cause is clinically apparent, for example hepatic cirrhosis and portal hypertension, it may not be possible to exclude either superimposed infection or hepatocellular cancer.

16.1 Paracentesis

Diagnostic paracentesis is a simple technique and can easily be undertaken in all patients presenting for the first time with ascites unless there is a specific contraindication.

16.1.1 Method

The patient should be asked to empty the bladder if not catheterized. The usual site for aspiration is in the right or left lower quadrant midway between the umbilicus and the anterior superior iliac spine. A 21 gauge needle may be used to inject the local anaesthetic and a similar size needle can then be inserted through the peritoneum for the paracentesis. Other suitable needles are those used for lumbar and cisternal puncture. When there is a very tense ascites it is often possible to insert a fine needle without using local anaesthetic. After a sufficient volume of fluid has been withdrawn for examination the needle is removed and a gauze dressing is applied to the wound.

16.1.2 Complications

These are rare. Occasionally an abdominal wall vein is penetrated. The procedure may be followed by a leak of fluid from the injection site when the ascites is very tense. A skin suture inserted after aspiration may prevent this, but not infrequently the leak only stops when the ascites has been relieved.

16.1.3 Interpretation

16.1.3.1 Appearance

Ascitic fluid which is a transudate is clear and straw-coloured. An exudate may also be clear but the fluid is usually cloudy and opalescent because of a high cell content. Trauma, malignant disease or tuberculous disease of the peritoneum may cause the fluid to be bloodstained. The fluid has a high mucoid content when pseudomucinous tumours have invaded the peritoneum.

16.1.3.2 Microscopic Examination

Five millilitres of the ascitic fluid are added to a tube containing anti-coagulant, centrifuged for 10 min and a smear made of the deposit. A rough estimate is made of the number of cells and a differential count is undertaken. The presence of many polymorphonuclear leucocytes suggests non-tuberculous infection while a high lymphocyte count suggests tuberculosis or lymphoma. The unstained smear may be examined for microfilaria and trypanosomes, or it can be fixed and stained with either Leishman or Giemsa stain.

The spun deposit may be stained and examined for malignant cells by a trained cytopathologist. An accuracy of about 86% correct positive diagnosis is achieved. There is much difficulty in identifying cells when there has been ascites of long duration such as with cirrhosis of the liver. Exfoliated mesothelial cells are a particular cause of confusion and can be mistaken for malignant cells.

A counting chamber can be used for cell counts, but caution must be exercised in the interpretation of the result when there is contamination with red blood cells. In transudates, for example in alcoholic liver disease, the mean cell count is 280 mm^3 . In exudates the count is usually $>500/\text{mm}^3$. Exudates associated with carcinoma have an average cell count of $690/\text{mm}^3$ (with mixed cellularity); tuberculous exudates characteristically contain many lymphocytes (92%). Two conditions with very high counts, averaging $7000/\text{mm}^3$, are lymphomas where nearly 70% of cells are lymphocytes, and spontaneous bacterial peritonitis in which the cells are almost entirely polymorphs. If the count is $<250/\text{mm}^3$ the ascites is sterile, and peritonitis can only be confidently diagnosed when counts exceed $1000/\text{mm}^3$.

16.1.3.3 Chemical Analysis

A protein content $<25 \text{ g/l}$ suggests that the fluid is a transudate. This is usually the case in heart failure, cirrhosis of the liver, nephrosis and other conditions associated with severe hypoproteinaemia.

A protein concentration >25 g/l suggests the presence of an exudate. This is found in acute peritoneal infections, tuberculous peritonitis and metastatic malignant disease involving the peritoneum. Fluid with a high protein content is occasionally encountered in cirrhosis in the absence of infection or malignant disease. The ascitic fluid in patients with myxoedema and endomyocardial fibrosis may contain a high level of protein.

The amylase concentration of the ascitic fluid may be increased in patients with acute pancreatitis and pancreatic pseudocyst. Occasionally a perforated peptic ulcer will be associated with amylase-rich ascitic fluid.

16.1.3.4 Bacteriological Examination

At least 10–20 ml of the ascitic fluid is sent for culture. When tuberculosis is suspected a large volume of the fluid is sent to the laboratory in a bottle containing sodium citrate to prevent the fluid from clotting. TB may be sought by smear, culture or guinea-pig inoculation, but the diagnosis of tuberculous peritonitis is established by bacteriological methods in only 50% of patients.

16.1.4 Diagnostic Paracentesis in the Acute Abdomen

The technique is a modification of that used when there is ascites. A 21-gauge needle is inserted under local anaesthesia into the peritoneal cavity at four sites: the right and left upper and lower quadrants midway between the umbilicus and the anterior superior iliac spines below and the ninth costal cartilage above. Gentle suction is applied using a 2 or 5 ml syringe while the needle is moved about within the peritoneal cavity. The appearance and volume of the aspirate is noted and the material sent for biochemical and bacteriological analysis.

Normally <0.5 ml clear fluid can be aspirated. A volume exceeding 0.5 ml of fluid which is obviously abnormal suggests intra-abdominal disease. A negative paracentesis has no diagnostic significance. The technique is of value in the diagnosis of acute intraperitoneal haemorrhage, as in acute pancreatitis when pure blood is aspirated that fails to clot. Paracentesis is especially helpful in the management of patients with non-penetrating abdominal injury. Alkaline bile-stained fluid, often containing food debris, is characteristic of a perforated peptic ulcer. The technique is not useful in the diagnosis of localized inflammatory disease.

The procedure is safe although the intestine may be accidentally penetrated when there are many adhesions or if there is a malignant peritonitis. This is usually readily appreciated from the appearance and microscopy of the aspirate.

16.1.5 Chylous Ascites

The aspiration of an opalescent, cloudy fluid suggests the possibility of a chylous ascites, which follows a leak of lymph into the peritoneal cavity. Chylous fluid contains absorbed fat (>5 mmol/l) in the form of particulate chylomicrons

which float on standing. This must be distinguished from pseudo-chylous ascitic fluid which is opalescent because it contains fat and granular material derived from degenerated cells (which tend to sediment). Chronic chylous ascites is associated with malignancy in 80% of cases. A wide variety of causes may underlie subacute chylous ascites.

16.2 Peritoneal Biopsy

Peritoneal biopsy is a most helpful technique for investigating unexplained ascites. It is simple and safe and is of particular value in the diagnosis of tuberculous peritonitis.

16.2.1 Method

The biopsy is obtained from the right or left lower quadrant lateral to the rectus sheath. A small area of the abdominal wall is anaesthetized using 1% procaine hydrochloride and the needle is introduced into the peritoneal cavity. It is advisable to discontinue the procedure if ascitic fluid is not aspirated readily. A small incision is made in the skin and the biopsy needle is introduced. When there is little fluid an assistant applies contralateral abdominal pressure to ensure the largest possible volume of fluid at the biopsy site. One or several portions of the peritoneum are taken from different quadrants of the same biopsy site, the Cope needle being suitable for obtaining more than one specimen. The needle is withdrawn and a tight dressing applied. The wound may be sutured if a large quantity of ascites is present. The biopsy specimen is removed from the needle and placed in 10% formol-saline.

16.2.1.1 Types of Needle

A Tru-Cut needle can be used but is less satisfactory than the side-biting, hook type needles of the type described by Cope and Abrams.

Cope Needle This needle consists of a trocar, biopsy shaft and a snare. After penetrating the peritoneum the trocar is removed, ascitic fluid is aspirated for examination and the snare is introduced. The instrument is withdrawn until the snare engages the peritoneum. A biopsy is obtained by a forward-rotating advance of the biopsy shaft. The snare with the excised tissue is withdrawn and may be reinserted if further samples are required from a particular site.

Abrams Needle This needle comprises two concentric tubes. The outer tube has a short trocar point behind which is a deep notch which can be closed by the inner tube. The inner tube has a cutting edge. A spring clip holds a pin on the base of the inner tube in either the open or closed position. The back hexagonal grip is twisted anti-clockwise so that the notch is opened and a sample of the ascitic fluid is aspirated. When this is completed the needle is withdrawn until the notch is felt to engage the peritoneum. The outer tube is held steady and the back hexagonal grip is

twisted sharply clockwise to pinch off a portion of peritoneum. The apparatus is withdrawn and the biopsy specimen is found either in the hollow pint or inside the cutting cylinder.

Forceps Biopsy Where a trocar is placed for therapeutic paracentesis, endoscopy forceps can be introduced until resistance is reached, then opened and closed.

16.2.2 Complications

It is unusual for peritoneal biopsy to be associated with any complication if the biopsy is performed when there is ascites. Haemorrhage or a leak of ascitic fluid can be prevented by a pressure dressing or by sutures.

16.3 Laparoscopy (Peritoneoscopy)

This is a very useful technique for diagnosis of ascites because not only are the peritoneum and abdominal organs inspected, but biopsies can be obtained from the peritoneum and liver.

The procedure has been performed in humans since 1910. Despite this and its popularity in Europe and in the USA, it was not widely used for the investigation of gastrointestinal disease in the UK until the advent of laparoscopic surgery. Laparoscopy permits the visualization of the anterior surface of the liver, with the exception of the right lateral aspect, together with its leading edges and inferior surface. The anterior surface of the gallbladder and stomach can be seen, together with parts of the small bowel, colon and mesentery. The peritoneum over the diaphragm, anterior abdominal wall and falciform ligament are also seen. The pancreas can be seen by lifting the left lobe of the liver. The pelvic organs (bladder, uterus, Fallopian tubes and ovaries) can be seen with the patient in the Trendelenburg position. With patience almost all of the small bowel can be reviewed.

Many forward- and oblique-viewing instruments are available, some with an operating channel for biopsy needles and probes. Most instruments are insulated to permit diathermy. Instruments currently in general use are flexible (generally used by experienced gastrointestinal surgeons). However, rigid laparoscopy still has some place, so the procedure is described. The presence of marked ascites may mean the procedure effects a substantial paracentesis, whether or not this is planned. It is a useful precaution to have an IV cannula positioned and a ready supply of colloid infusion available to prevent circulatory collapse.

16.3.1 Rigid Laparoscopy

Rigid equipment consists of a trocar, sheath, telescope and light source. Air is insufflated through a Veress needle with retractable cannula, and this can be either via an automatic insufflator or a sterile sphygmomanometer bulb. Pre-warming in an oven

or on an electrical pad, and use of an anti-fogging liquid on the lens are convenient. Cleaning should be followed by ethylene oxide or activated glutaraldehyde sterilization between cases.

This examination is best performed on a table with full tilting facilities. The patient is premedicated with an analgesic and tranquillizer such as pethidine 50–100 mg and midazolam 5 mg IV. Doses should be reduced in patients with liver disease. General anaesthetic is an alternative, but this negates one advantage of laparoscopy over laparotomy.

16.3.2 Procedure

The operator prepares by scrubbing, and wears gown and gloves as for major surgery. A puncture site is selected, avoiding epigastric vessels and visible collateral veins, abdominal scars and the falciform ligament. The standard site is 2–4 cm inferior to the umbilicus in the midline. If better vision of the liver is needed then the puncture should be to the left of the midline above the umbilicus.

The skin and subcutaneous tissue are anaesthetized as far as the parietal peritoneum if possible. A vertical incision is made to admit the trocar through the skin and fascia. The Veress needle is inserted through the wound and advanced carefully into the peritoneal cavity. When the tip is in place the needle is laid flat on the skin, and moderate distention of the abdomen with air or CO₂ is achieved (about 2–3 l are usually required). The Veress needle is then removed and the peritoneoscope sheath (with trocar inserted) is passed into the peritoneal cavity. This requires force, and should be carried out with the table lowered and the arms of the operator extended fully to avoid sudden excessive penetration. When the peritoneal cavity has been entered the trocar is removed immediately. The sheath should be freely mobile when the telescope is passed. The room is darkened and the systematic inspection begins. It is important to remember that touching the falciform ligament and parietal peritoneum causes pain.

The liver, gallbladder, falciform ligament, parietal peritoneum and inferior surface of stomach and bowel should be inspected routinely. The spleen is seen only if enlarged. The pancreas may be seen with special manoeuvres. Pelvic organs can also be inspected if required.

When the examination is complete the telescope is removed, gas is allowed to escape and the sheath is then removed. If ascites is present the peritoneal wound should be repaired, and in all patients the skin is closed with interrupted silk sutures. Pulse and blood pressure are recorded at frequent intervals for 2–3 h, and the patient kept in hospital overnight before discharge.

Complications occur in about 1–2% of all examinations, with an overall mortality of 0.03%. These deaths probably relate to liver biopsy, and the mortality is much lower than that associated with laparotomy. Problems which can arise include haemorrhage, bowel puncture, air embolism and puncture of an ovarian cyst.

16.3.3 Interpretation

The cirrhotic liver is nodular and in hepatitis the liver is red, swollen and shiny. A green liver is seen in cholestatic jaundice and various characteristics such as the state of the gallbladder and the liver edge have been claimed to help in the distinction between intra- and extra-hepatic obstructive jaundice. Both primary and secondary malignant disease of the liver can be recognized. A hepatoma is often seen against the background of a cirrhotic liver and metastatic nodules are usually yellow-white and umbilicated. Hydatid cysts appear as characteristic pearly-white bulges. Hydrops and fibrosis of the gallbladder can be identified.

The peritoneum is dull and opaque in the presence of ascites. In *acute tuberculous peritonitis* it may be possible to see multiple millet seed-sized nodules surrounded by a halo of congestion. This appearance is very similar to that of metastatic malignant disease involving the peritoneum and the differentiation is usually made by biopsy and histological examination of a nodule. In chronic tuberculous peritonitis there are extensive adhesions, the nodules are confluent and the mesentery is contracted.

16.3.4 Indications

16.3.4.1 Liver Disease

The inspection of the liver and targeted biopsy provides useful proof of diagnosis in alcoholic liver disease, macronodular and micronodular cirrhosis, hepatoma and metastatic carcinoma. Congenital cysts are usually readily recognized. Liver biopsy, performed either by separate skin puncture or through the laparoscope, can be used in patients with coagulation defects, because undue bleeding may be seen and controlled.

16.3.4.2 Acute Abdomen

The use of laparoscopy as a preliminary evaluation, especially in patients with suspected appendicitis, may avoid some unnecessary operations. This is particularly true in women.

16.3.4.3 Ascites

Liver disease, peritoneal carcinoma or tuberculosis can usually be readily identified as causes of ascites. A forceps biopsy is practicable for the peritoneum but should be avoided for the bowel.

16.3.4.4 Portal Hypertension

Dilated veins and splenic enlargement are seen.

16.3.4.5 Identification of Masses

Enlarged upper abdominal organs can usually be seen satisfactorily. Pelvic masses may also be seen and biopsied, but other abdominal masses are often obscured by bowel or omentum.

16.3.4.6 Other Techniques

Laparoscopy can be combined with cholangiography by either hepatic or gallbladder puncture and in this way assists in the diagnosis of jaundice. It is probably inferior to laparotomy or CT scanning in the staging of lymphoma, but can be used. But can be used as a preliminary procedure in patients with serious abdominal complaints not explained by full medical investigation.

The procedure is unsatisfactory in individuals with marked obesity and after major abdominal surgery or peritonitis. It must be performed with caution when coagulation defects are present. The presence of tense ascites requires removal of fluid: hypovolaemic collapse and encephalopathy are hazards together with persistent leakage.

16.4 Laparotomy

The use of exploratory laparotomy has rightly markedly decreased. Occasionally it still has a role in undiagnosed abdominal pain and in undiagnosed fever. In addition, a full review of abdominal contents may supplement or alter diagnoses made prior to planned surgery.

Bibliography

- Jalan R, Harrison OJ, Dillon JF, Elton RA, Finlayson NDC, Hayes PC. Laparoscopy and histology in the diagnosis of chronic liver disease. *Q J Med.* 1995;88:559–64.
- Paterson-Brown S, Thompson IN, Eckersley JRT, Ponting GA, Dudley HAF. Which patients with suspected appendicitis should undergo laparoscopy? *BMJ.* 1988;296:1363–4.
- Paterson-Brown S. Strategies for reducing inappropriate laparotomy rate in the acute abdomen. *BMJ.* 1991a;303:1115–8.
- Paterson-Brown S. The acute abdomen: the role of laparoscopy. *Clin Gastroenterol.* 1991b;5:691–703.
- Qibi NM. New technique of blind peritoneal biopsy. *BMJ.* 1987;295:638.
- Runyon RA, Hoefs JC, Morgan TR. Ascitic fluid analysis in malignancy-related ascites. *Hepatology.* 1988;8:1104–9.

Appendix

Table A1 Approximate incidence of bacteraemia in immunocompetent individuals following various procedures involving the gastro-intestinal tract

Procedure incidence of bacteraemia (%) ^a	
Rectal digital examination	4
Proctoscopy	5
Barium enema	11
Tooth brushing	25
Dental extraction	30–60
Colonoscopy	2–4
Diagnostic upper gastrointestinal endoscopy	4
Sigmoidoscopy	6–9
ERCP (no duct occlusion)	6
ERCP (duct occluded)	11
Oesophageal varices band ligation	6
Sclerotherapy	10–50 ^b
Oesophageal dilatation/prosthesis	34–54
Oesophageal laser therapy	35

^aSummary of published data

^bHigher after emergency than elective management

Table A2 Causes of chronic diarrhoea

Common causes
Chronic or relapsing gastrointestinal infection ^a :
Aamoebiasis, giardiasis, <i>Clostridium difficile</i>
Inflammatory bowel disease:
Ulcerative colitis, Crohn's disease ^b collagenous colitis, microscopic (lymphocytic) colitis
Steatorrhoea.
Carbohydrate malabsorption:
Disaccharidase deficiency (lactose, sucrose), poorly absorbed substances (wheat starch, fibre, lactulose, sorbitol, fructose)
Medications and food additives:
Commonly antibiotics, anti-hypertensive drugs, anti-arrhythmic agents, anti-neoplastic agents, antacids (magnesium-containing), sweeteners (sorbitol, fructose), ethanol, caffeine
Previous surgery:
Gastrectomy, vagotomy, intestinal resection
Endocrine causes:
Adrenal insufficiency, hyper- or hypo-thyroidism, diabetes
Laxative abuse ^b
Ischaemic bowel disease
Radiation enteritis or colitis
Paradoxical diarrhoea: colon cancer
Idiopathic (functional) diarrhoea
Less frequent causes
Hormone-producing tumours:
Gastrinoma, VIPoma, villous adenoma, medullary thyroid carcinoma, ganglioneuroma, pheochromocytoma, carcinoid tumour, mastocytosis
Infiltrative disorders:
Scleroderma, amyloidosis, diffuse gut lymphoma ^b
Epidemic chronic diarrhoea (perhaps infectious agent in raw milk, untreated water)
Chronic idiopathic diarrhoea, self-limited.
Faecal incontinence ^b
Food allergy

^aCauses are listed in order of frequency. The table does not include causes of chronic diarrhoea in HIV -positive patients

^bOften missed on evaluation

Further Reading

- Haycock A, Cohen J, Saunders BP, Cotton & Williams practical gastrointestinal endoscopy. The fundamentals. Oxford: Wiley Blackwell; 2014.
- Khashab M, Robinson T, Kalloo A. Johns Hopkins manual for gastrointestinal endoscopy nurses. Thorofare: Slack International; 2014.
- Soehendra N, Binmoeller KF, Seifert M. Therapeutic endoscopy. Stuttgart: Schreiber; 2005.
- Chun HJ, Yang SK, Choi MG. Therapeutic endoscopy. A comprehensive atlas. Berlin: Springer; 2015.
- British Medical Journal/Royal Pharmaceutical Society BNF 72; 2016.

Index

A

- Abetalipoproteinaemia, 52
- Abrams needle, 206–207
- Abscesses, 176
- Absorption
 - bile acid malabsorption, 73
 - disaccharides, 75
 - intestinal disaccharidase activity, 76–77
 - lactose tolerance test, 75
 - symptomatology, 76
 - faecal fat excretion, 69
 - glucose, 72–73
 - haematinics
 - folic acid absorption, 77
 - iron absorption, 77–79
 - vitamin B₁₂, 77
 - intestinal absorption
 - dibasic amino acids, 79
 - methionine, 80
 - tryptophan, 79
 - lactose, 73
 - method, 69–70
 - monosaccharides
 - oral glucose tolerance test, 74–75
 - xylose excretion, 73–74
 - procedure, 72
- Acanthocytosis, 52
- Achalasia
 - barium swallow and meal, 28–29
 - chest radiograph, 28
 - HRM, 30
- Achlorhydria, 37
- Acid secretion, 135
- Acute abdomen, 205, 209
- Acute intermittent porphyria
 - confirmatory tests, 159
 - porphobilinogen, screening test, 158
- Acute pancreatitis
 - angiography, 119
 - pancreas, 116
 - secretin test, 122
- Acute viral hepatitis, 169
- Alanine aminotransferase, 142
- Albumin, 143
- Alcoholic cirrhosis, human leukocyte antigens, 147
- Alcoholic liver disease (ALD), 146–147, 170
- Alkaline phosphatase, 129, 142
- Alkaline reflux, 32
- Alpha₁-antitrypsin clearance, 56–57
- Alpha-fetoprotein, 147
- 7-Alpha-hydroxycholesterol, 145
- AMA. *See* Antimitochondrial antibody (AMA)
- Ammonia, 145
- Ammonia tolerance test, 154
- Amoebiasis, 111
 - acute, 93
 - colonoscopy, 97
 - immunology, 100
- Amylase
 - fluids, 128
 - serum, 126
 - urinary, 127
- Anaemia, pernicious, 43
- Anal speculum, 82
- Angina pectoris, 24
- Angiodysplasia, 94, 97
- Angiography
 - pancreas, 118–119
 - small intestine, 54
- Ankylostoma duodenale*, 110
- Anoscopy, 82–83
- Antibiotic prophylaxis, 95
- Antimitochondrial antibody (AMA), 148

- Anti-neutrophil cytoplasmic antibody, 148
 Antinuclear antibody (ANA), 148
 Antismooth muscle antibody, 148
 Arteriography
 colon and rectum, 94
 liver, 180
 pancreas, 134
Ascaris lumbricoides, 110
 Ascites, 209
 aetiology of, 203
 laparoscopy
 indications, 209–210
 instruments, 207
 interpretation, 209
 procedure, 208
 rigid laparoscopy, 207–208
 laparotomy, 210
 paracentesis, 203
 acute abdomen, diagnostic
 paracentesis, 205
 chylous ascites, 205–206
 complications, 204
 interpretation, 204–205
 method, 203
 peritoneal biopsy
 complications, 207
 method, 206
 needle, types of, 206–207
 Aspartate aminotransferase (AST), 142
 Aspirin, 1, 15, 16
 AST. *See* Aspartate aminotransferase (AST)
 ATPase-associated antigen (M₂), 148
 Augmented secretin test, 13
 Autoimmune gastritis, 11
 Azathioprine (AZA), 62
- B**
- Bacteraemia, immunocompetent individuals, 211
 Bacteria, 111–112
 Bacteriology, 198, 199
 BAO. *See* Basal acid output (BAO)
 Barium
 contrast, 53–55
 enema
 carcinoma of the caecum, 92
 diverticular disease, 92
 pan-colitis in Crohn's disease, 91
 meal
 gastric ulcers and benign and malignant
 tumours, 43
 pancreas, 119–120
 swallow, 24–27, 178, 181
 Barium sulphate, 59
 Basal acid output (BAO)
 alternative techniques, 39
 gastric acid studies, indications for, 38
 gastric antibodies, 41
 gastrin, 39–40
 intravenous ^{99m}technetium, 39
 method, 38
 pepsin, 40
 pepsinogen, 40
 radiotelemetry, 39
 vitamin B₁₂, 40
 Beta-glucuronidase, 143
 Bile acids, 145
 Bile acid malabsorption, 73
 Bile canalicular antibodies, 148
 Bile ducts, 187
 bacteriology, 198–199
 biliary physiology, 197–198
 computed tomography, 196
 EUS, 189
 infusion cholangiography, 195–196
 isotope scanning, 197
 magnetic resonance imaging, 196
 MRCP, 189, 198, 199
 operative cholangiography, 192–193
 oral cholecystography
 interpretation, 191–192
 method, 190–191
 plain radiology, 189–190
 PTC
 indications, 195
 interpretation, 195
 method, 193–195
 ultrasonography, 187–189
 Bile leakage, 167
 Bilirubin
 serum, 129, 139–140
 urine, 140
 Biopsy needle, 115, 164
 Bismuth therapy, 5
 Bleeding tendency, 166
 Blood ammonia, 145
 Bombesin, 132
 Breath hydrogen, 58, 60
 Bromsulphthalein (BSP), 153
 Brunner's glands, 51
 BSP. *See* Bromsulphthalein (BSP)
 Burhenne-type catheters, 20
- C**
- Caeruloplasmin, 157
 Caffeine clearance, 152–153
 CAGE questionnaire, 146
 Calcium, 128, 189

- Calprotectin, 65–66
 Capsule endoscopy, Crohn's disease, 61
 Carbohydrate-deficient transferrin, 147
 Carcinoembryonic antigen (CEA), 99–100, 147
 Carcinoid syndrome, 62
 Carcinoma, 43
 caecum, 92
 ERCP, 117–118
 pancreas, 116
 Cardia, achalasia, 27
 Carmine No. 40, 59–60
 Casoni test. *See* Intradermal test
 Cathartic colon, 93
 CEA. *See* Carcinoembryonic antigen (CEA)
 Chest X-ray, pancreas, 119
 Chiba needle, 183, 193
 Cholecystokinin, 198
 Cholecystokinin-pancreozymin (CCK-PZ),
 120, 132
 Cholera, 109–110
 Cholestasis, 139, 180–181
 Chromium sesquioxide, 59
 Chronic auto-immune hepatitis, 171
 Chronic diarrhoea, causes of, 212
 Chronic pancreatitis
 angiography, 119
 ERCP, 117–118
 pancreas, 116
 Chronic persistent hepatitis, 171
 Chylous ascites, 205–206
 Chymotrypsin, 130
 Cirrhosis
 alcoholic, 147
 isotope scanning, 177
 liver biopsy, 169–170
 primary biliary, 148, 170–171
Clostridium difficile, 112
 Coagulation tests, 144
 Coeliac disease
 diagnosis of, 47
 immunology, 64–65
 small intestine, 50–52
 Colon
 immunology
 amoebiasis, 100
 CEA, 99–100
 HPNCC, 100
 inflammatory bowel disease, 99
 radiology
 arteriography, 94
 barium enema, 90–92
 CT scanning, 94
 interpretation, 91–93
 MRI, 94
 plain abdominal radiograph, 89
 ultrasonography, 94
 Colonoscopy, 61, 94
 cleaning and disinfection, 97
 complications, 98
 Golytely, 95
 indications, 97–98
 instruments, 95
 interpretation, 97
 manometry, 98–99
 preparation, 95
 procedure, 96–97
 Columnar epithelium, 51
 Complement fixation test, 158
 Computed tomography (CT), 94
 colography, 61
 EUS, 12
 gallbladder and bile ducts, 196
 liver, 179
 pancreas, 118
 Constitutional unconjugated
 hyperbilirubinaemia. *See* Gilbert's
 syndrome
 Cope needle, 206
 Copper, 157
 Crohn's colitis, 93
 Crohn's disease, 52
 barium radiology, 60
 capsule endoscopy, 61
 colonoscopy, 61, 97
 CT colography, 61
 DNCCB, 60–61
 flexible sigmoidoscopy, 86
 ileo-colo-vesical fistula, 54
 Kveim test, 61
 monitoring progress, investigations, 61–62
 rectal biopsy, 89
 skin testing with tuberculin, 60–61
 small bowel enema, 52
 terminal ileal, 54
 ultrasonography, 61
 WBC scanning, 55
 Crosby-Kugler capsule, 48, 76
 complications, 49
 endoscopic technique, 48
 fluoroscopic method, 48–49
 traditional method, 49
⁶⁷Cu-labelled caeruloplasmin, 56
 Cysts, 158, 176
- D**
 Deficiency syndromes, 75
 Delta viral hepatitis. *See* Hepatitis D
 Dent sleeve, 28
 Dermatitis herpetiformis, 52

- Diabetes mellitus, 122
 Dibasic amino acids, 79
 Dietary iron test, 105
 Diffuse disease, 176
 Diffuse intravascular coagulation (DIC), 144
 Digital subtraction techniques, 192–193
 Dinitrochlorobenzene (DNCB), 60–61
 Direct oral anticoagulants, 15
 Disaccharides, 75
 intestinal disaccharidase activity, 76–77
 lactose tolerance test, 75
 symptomatology, 76
 Distal lighting systems, 83
 Distal oesophageal spasm, 31
 Diverticular disease, 86, 93
 Double isotope method, 78–79
 Dreiling tube, 20
 Drug reactions, 169
 Dubin-Johnson syndrome, 168
 Duodenal ulcers, 2, 11, 43
 Duodenitis, 11
 Duodeno­scope, 13
 Duodenum, 11–12, 19–20
 Dye dilution, 36
 Dysentery, 86, 112
- E**
 EEG. *See* Electroencephalography (EEG)
 Ehrlich's reagent, 141
 Elastography, liver, 180
 Electroencephalography (EEG), 155
 Electrophoresis, 144
 Endocrinology, and endocrine tumours,
 132–133
 gastrinoma, 134–135
 glucagonoma, 135
 insulinoma, 133–134
 obscure diarrhoea, 135
 vipoma, 135
 Endorphins, 132–133
 Endoscopic forceps biopsy, 47
 Endoscopic retrograde
 cholangiopancreatography
 (ERCP), 117–118
 complications, 14
 contraindications, 14
 indications, 14
 instruments, 13
 procedure, 13
 Endoscopy, 48
 capsule, 61
 gastrointestinal bleeding, 106–107
 upper digestive
 anticoagulant therapy, 15–16
 cleaning and sterilisation, 14, 15
 ERCP, 13–14
 EUS, 12
 infections with antibiotics,
 prophylaxis, 14–15
 instruments, 7
 procedures, 7–12
 staff, 14
 Endosonography (EUS), 12
 bile ducts and pancreas, 187
 gallbladder, 189
 oesophagus, 27
 pancreas, 116
Entamoeba coli, 110
Entamoeba histolytica, 100, 110, 111, 172
 Enterobiasis, 110
Enterobius vermicularis, 110
 Enteroscopy, 55, 107
 Enzymes, liver biochemistry, 141
 alkaline phosphatase, 142
 gamma-glutamyl transferase, 143
 transaminases, 142
 ERCP. *See* Endoscopic retrograde
 cholangiopancreatography
 (ERCP)
 E-test, 4
 EUS. *See* Endosonography (EUS)
 Excision biopsy, 60
 Extrahepatic ducts, 176
 Extrahepatic obstruction, 170, 181
- F**
 Faecal fat excretion, 69
 Faecal recovery method, 78
 Fat, unsplit, 69
 Fecatwin system, 104
⁵⁹Fe-labelled dextran, 56
 Fibroscan, 180
 Fluorescein dilaurate test, 125
 Fluoroscopic method, 48–49
 Folic acid absorption, 77
 Food allergy, 65
 Forceps biopsy, 207
- G**
 Gallbladder, 187
 bacteriology, 198–199
 computed tomography, 196
 EUS, 189
 infusion cholangiography, 195–196
 isotope scanning, 197
 magnetic resonance imaging, 196
 MRCP, 189, 198, 199

operative cholangiography, 192–193
 oral cholecystography
 interpretation, 191–192
 method, 190–191
 plain radiology, 189–190
 PTC
 indications, 195
 interpretation, 195
 method, 193–195
 scintigraphy, 187
 ultrasonography, 187–189
 Gallium citrate, 55
 Gamma camera scanning, 106
 Gamma-glutamyl transferase, 143
 Gamma-GT level, 143, 147
 Gastric acidity, twenty-four hour, 39
 Gastric acid secretion, 36–37
 Gastric antibodies, 41
 Gastric biopsy, 42–43
 Gastric cytology
 fluorescence, 42
 interpretation, 41
 Gastric emptying
 dye dilution, 36
 isotope tests, 35
 radiology, 35
 ultrasonography, 36
 Gastric inhibitory peptide (GIP), 132
 Gastric metaplasia, 24
 Gastric ulcers, 43
 Gastrin, 39–40, 132
 Gastrinoma, 134–135
 Gastritis, 11
 acute, 42
 antral, 2
 autoimmune, 11
 barium meal, 43
 chronic, 42
 Gastrograffin, 44
 Gastrointestinal bleeding
 endoscopy, 106–107
 enteroscopy, 107
 isotope tests
 ^{99m}Tc-Perchnetate scanning, 106
 ^{99m}technetium colloid test, 105
 radio-labelled erythrocytes,
 105–106
 liver disease, 108
 occult blood tests, 103
 chemical tests, 104–105
 dietary iron, 105
 radiology, 106
 VCE, 107–108
 Gastromiro, 44
 G-cell hyperplasia, 38, 40

Genta triple stain, 3
Giardia intestinalis, 110
 Gilbert's syndrome, 155
 Globulins, 143
 Glucagon, 132
 Glucagonoma, 135
 Glucagon test, 133
 Glucose, 72–73
 Glucose tolerance test, 126
 Glutaraldehyde, 14
 Glutathione-S-transferase, 143
 Glycopyrronium, 11
 Golytely, 95
 Guaiac test Hemachek, 104
 Gut
 digestive enzymes outside
 fluids, amylase in, 128
 serum amylase, 126
 serum lipase, 128
 serum trypsin, 128
 urinary amylase, 127
 endocrinology and endocrine
 tumours, 132–133
 gastrinoma, 134–135
 glucagonoma, 135
 insulinoma, 133–134
 obscure diarrhoea, 135
 vipoma, 135

H

Haemagglutinating antibodies, 99
 Haematinics
 folic acid absorption, 77
 iron absorption, 77–79
 vitamin B₁₂, 77
 Haemocult, 104
 Haemochromatosis
 liver biochemistry, 156–157
 secretin test, 122
 Haemolysis, 139
 Hanging drop test, 111
Helicobacter pylori, 112
 detection, 1
 diagnostic tests
 culture, 3–4
 direct urease test, 2–3
 duodenal ulcer, 2
 histology, 3
 microscopy, 3
 serology, 4
 urea breath testing, 5
 epidemiology, 1–2
 practical use, 5
 Helminths, 110–111

- Hepatic failure, prognosis, 155
 Hepatic vein catheterization, 182, 183
 Hepatic venography, 184–185
 Hepatitis
 acute viral, 169
 chronic auto-immune, 171
 chronic persistent, 171
 hepatitis A virus, 150
 hepatitis B virus, 150–151
 hepatitis C virus, 151–152
 hepatitis D, 152
 hepatitis E, 152
 neonatal, 171
 Hepatocellular carcinoma, 175, 177–178
 Hepatocellular damage, 139
 Hepatoma, 209
 Hereditary non-polyposis colon cancer (HPNCC), 100
 5-HIAA. *See* 5-Hydroxyindoleacetic acid (5-HIAA)
 Hiatus hernia, 31
 High resolution manometry (HRM), 30
 Hirschsprung's disease, 98–99
 HPNCC. *See* Hereditary non-polyposis colon cancer (HPNCC)
 Hydatid cysts, 158, 171, 209
 5-Hydroxyindoleacetic acid (5-HIAA), 62, 63
 Hyoscine, 11, 13
 Hyperglycaemia, alimentary, 75
 Hyperoxaluria, 72
 Hypokalaemia, 135
- I**
 IgA gliadin antibodies, 65
 IgA reticulin, 65
 Ileography, retrograde, 55
 Immunoglobulins, 144
 Immunology
 colon
 amoebiasis, 100
 CEA, 99–100
 HPNCC, 100
 inflammatory bowel disease, 99
 liver biochemistry
 tissue antibodies, 147–148
 tumour antigens, 147
 small intestine, 64
 coeliac disease, 64–65
 food allergy and intolerance, 65
¹¹¹indium-labelled transferrin, 56
 Indocyanine green clearance (ICG), 153–154
 Inflammatory bowel disease, 99
 Infusion cholangiography, 195–196
 Inorganic iron, 78
 Insulinoma, 133–134
 Insulinoma-prolonged starvation, 133
 Intestinal absorption
 dibasic amino acids, 79
 methionine, 80
 tryptophan, 79
 Intestinal bacteria, 57
 biopsy, 58
 breath hydrogen, 58
 intubation, 57–58
 urinary indican, 58
 Intestinal biopsy
 Crosby-Kugler capsule, 48–49
 dissecting microscope, 50–51
 endoscopic forceps biopsy, 47
 light microscopy, 51–52
 Rubin suction biopsy tube, 49–50
 Intestinal disaccharidase activity, 76–77
 Intestinal motility
 breath hydrogen, 60
 markers, 59–60
 radiology, 55
 radiotelemetry and manometry, 60
 Intestine
 small (*see* (Small intestine))
 tubes, 21
 Intolerance, food, 65
 Intradermal test, 158
 Intrahepatic ducts, 176
 Intrahepatic pressure, 183
 Intrinsic factor antibodies, 41
 Intubation, 58–59
 complications, 21
 method, 17–18
 tubes, 18–19
 duodenum, 19–20
 intestine, 21
 oesophagus, 19
 stomach, 19, 20
 Iodinated water-soluble opaque media, 44
 Ioglycamide, 195, 196
 Iron
 absorption, 77–78
 double isotope method, 78–79
 faecal recovery method, 78
 interpretation, 79
 whole body counting, 78
 dietary, test for, 105

- excretion, 156
- inorganic, 78
- Irritable bowel syndrome (IBS), 65–66
- Isocitric dehydrogenase, 143
- Isotope scanning
 - gallbladder and bile ducts, 197
 - liver, 177
 - cirrhosis, 177
 - hepatocellular carcinoma, 177–178
 - indications, 178
 - liver perfusion scintigraphy, 178
 - metastases, 177
 - portal hypertension with collateral circulation, 177
- Isotope tests
 - gastric emptying, 35
 - gastrointestinal bleeding
 - ^{99m}Tc-Pertechnetate scanning, 106
 - ^{99m}Tc-technetium colloid test, 105
 - radio-labelled erythrocytes, 105–106
- J**
- Jaundice, 139–140
 - cholestatic, 140
 - haemolytic, 140
 - hepatocellular, 140
 - ultrasonography, 176
- Jejunal villi, 50
- K**
- Kamer method, 69
- Kayser-Fleischer rings, 157
- Kveim test, 61
- L**
- Lactose, 72–73
- Lactose tolerance test, 75
- Lactulose, 72
- Lamina propria, 52, 88
- Laparoscopic liver biopsy, 166
- Laparoscopy
 - ascites and peritoneum
 - indications, 209–210
 - instruments, 207
 - interpretation, 209
 - procedure, 208
 - rigid laparoscopy, 207–208
 - pancreas, 120
- Laparotomy
 - ascites and peritoneum, 210
 - percutaneous liver biopsy, 166–167
- Large bowel malignant disease, 86
- ICG. *See* Indocyanine green clearance (ICG)
- Lead intoxication, 64
- Levin tube, 19
- Lipaemia, 126
- Lipase, 128
- Lipids, 145–146
- Lipoprotein, abnormal (LPX)
 - high-density (HDL), 145
 - low-density (LDL), 145
 - very low-density (VLDL), 145
- Liver
 - aspiration, 171–172
 - cholestasis, diagnosis, 180–181
 - isotope scanning, 177
 - cirrhosis, 177
 - hepatocellular carcinoma, 177–178
 - indications, 178
 - liver perfusion scintigraphy, 178
 - metastases, 177
 - portal hypertension with collateral circulation, 177
 - manometry
 - hepatic vein catheterization, 182, 183
 - intrahepatic pressure, 183
 - splenic puncture, 181–182
 - portal manometry and splenoportography, 181
 - portography
 - hepatic venography, 184–185
 - splenic venography, 183–184
 - transhepatic portography, 184
 - transumbilical portal venography, 184
 - radiology
 - arteriography, 180
 - barium studies, 178–179
 - computed tomography, 179
 - elastography, 180
 - MRI, 179–180
 - plain abdominal radiograph, 178
 - ultrasonography, 175
 - cysts and abscesses, 176
 - hepatocellular carcinoma, 175
 - indications, 176
 - jaundice, 176
 - liver metastases, 175

- Liver biochemistry
 acute intermittent porphyria, 158–159
 ALD, 146–147
 bile acids, 145
 bilirubin, 139–140
 blood ammonia, 145
 coagulation tests, 144
 electroencephalography, 155
 enzymes, 141
 alkaline phosphatase, 142
 gamma-glutamyl transferase, 143
 transaminases, 142
 Gilbert's syndrome, 155
 haemochromatosis, 156–157
 hydatid disease, 158
 immunology
 tissue antibodies, 147–148
 tumour antigens, 147
 kinetic tests
 ammonia tolerance test, 154
 bromsulphthalein, 153
 caffeine clearance, 152–153
 ICG, 153–154
 protein load test, 154–155
 lipids, 145–146
 proteins
 albumin, 143
 electrophoresis, 144
 globulins, 143
 immunoglobulins, 144
 urine bilirubin, 140
 urine urobilinogen, 141
 viral liver disease, 149
 hepatitis C, 151–152
 hepatitis D, 152
 hepatitis E, 152
 hepatitis, prevalence of, 152
 liver biopsy, 149–151
 Wilson's disease, 157
- Liver biopsy
 haemochromatosis, 156
 hepatitis A, 150
 hepatitis B, 150–151
 immunofluorescence, 149
 interpretation
 histology, 168–171
 macroscopic appearance, 168
 liver aspiration, 171–172
 percutaneous
 aftercare, 167
 bleeding tendency, 166
 complications, 167
 contra-indications, 168
 indications, 168
 laparoscopic liver biopsy, 166
 laparotomy, 166–167
 preparation, 163–164
 procedure, 164–166
 transvenous liver biopsy, 166
 young children, 167
 Wilson's disease, 157
- Liver disease, 108, 209
 Liver-kidney microsomal antibody (LKM), 148
 Liver metastases, 175
 ultrasonography, 175
 Liver perfusion scintigraphy, 178
 Liver specific protein, 148
 L-leucine test, 134
 Lundh test
 indications, 124
 interpretation, 124
 method, 123–124
 modifications, 124–125
 Lymphangiography, 55
- M**
 Macroamylasaemia, 127
 Magnetic resonance cholangiopancreatography (MRCP)
 gallbladder and bile ducts, 189, 198, 199
 pancreas, 118
 Magnetic resonance imaging (MRI), 94
 EUS, 12
 gallbladder and bile ducts, 196
 liver, 179–180
 oesophagus, 27
 Malignant disease, 171
 Mallory's hyaline bodies, 170
 Mallory-Weiss tears, 9, 108
 Maltase deficiencies, 75
 Mannitol, 13
 Manometry, 60
 liver
 hepatic vein catheterization, 182, 183
 intrahepatic pressure, 183
 splenic puncture, 181–182
 Mantoux test, 60–61
 Marker perfusion techniques, 59
 Meckel's diverticulum, 39, 106
 Menghini needle, 164–165
 Mercedes-Benz sign, 189
 Metabolic disorders, 62
 Metal ions absorption, 79
 Metastases
 isotope scanning, 177
 liver, 175
 Methionine, 80
 Miller-Abbot tube, 21
 Monosaccharides
 oral glucose tolerance test, 74–75
 xylose excretion, 73–74

Motilin, 132
 MRI. *See* Magnetic resonance imaging (MRI)
^{99m}Tc-Perchnetate scanning, 106
^{99m}Technetium, 197
^{99m}Technetium colloid test, 105
 Multichannel intraluminal electrical impedance (MII), 32

N

Nasogastric tube, 18
Necator americanus, 110
 Neonatal hepatitis, 171
 Neoplasms, 93
 Nicoumalone, 15
 Non-alcoholic steatohepatitis, 170
 Non-steroidal anti-inflammatory drugs, 1
 Norovirus, 112, 113

O

Obscure diarrhoea, 135
 Obstructive jaundice, 116
 Occult blood tests, 103
 Octreo-scan, 132
 Oesophageal acid perfusion test, 23–24
 Oesophageal carcinoma
 endosonography, 27
 metastasis, isotope bone, 29
 MRI scanning, 27
 scan showing destruction, 29
 "shouldering," barium swallow, 25
 Oesophageal varices, barium studies, 178
 Oesophageal web, barium swallow, 27
 Oesophagoscopy, 24
 Oesophagus, 9–10
 histology, 24–25
 interpretation
 achalasia, 30
 distal oesophageal spasm, 31
 hiatus hernia, 31
 scleroderma, 31
 swallowing, 30
 manometry, 27
 HRM, 30
 method, 28, 30
 oesophageal acid perfusion test, 23–24
 oesophagoscopy, 24
 radiology, 25–27
 reflux studies
 MII and alkaline reflux, 32
 pH monitoring, 31–32
 symptoms, 23
 tubes, 19
 Oncofetal antigens, 147

Operative cholangiography, 192–193
 Oral cholecystography, 190–192
 Oral glucose tolerance test, 74–75, 126
 Organic iodine compounds, 195
 Organic iron, 78
 Orosomucoid, 99
 Orthotolidine test, 104
 Oxalate loading test, 72

P

Pancreas, 115
 angiography, 118–119
 barium meal, 119–120
 bilirubin, 129
 calcium, 128
 chest X-ray, 119
 CT, 118
 ERCP, 117–118
 gene probes, 131
 gut
 digestive enzymes outside, 126–128
 endocrinology and endocrine tumours, 132–135
 histology and cytology, 120
 laparoscopy, 120
 Lundh test
 indications, 124
 interpretation, 124
 method, 123–124
 modifications, 124–125
 MRCP, 118
 pancreatic cancer markers, 135–136
 pancreatic exocrine function, hormonal tests, 120–121
 augmented secretin test, 123
 secretin test, 121–122
 serum alkaline phosphatase, 129
 stool examination
 macroscopic and microscopic examination, 129
 steatorrhoea, 129–130
 stool trypsin and chymotrypsin, 130
 straight abdominal radiograph, 119
 sweat electrolytes, 130
 pilocarpine iontophoresis, 130–131
 skin chloride assay, 131
 tubeless oral pancreatic function tests
 fluorescein dilaurate test, 125
 oral glucose tolerance test, 126
 ultrasonography, 115–116
 EUS, 116
 indications, 116–117
 interpretation, 116
 Pancreatic cancer, 115, 124, 135–136
 Pancreatic carcinoma, 116

- Pancreatic exorine function, hormonal tests, 120–121
 augmented secretin test, 123
 secretin test, 121–122
- Pancreatic polypeptide (PP), 132
- Pancreatitis
 acute
 angiography, 119
 pancreas, 116
 secretin test, 122
 chronic
 angiography, 119
 ERCP, 117–118
 pancreas, 116
- PAO. *See* Peak acid output (PAO)
- Paracentesis, 203
 acute abdomen, diagnostic paracentesis, 205
 chylous ascites, 205–206
 complications, 204
 interpretation, 204–205
 method, 203
- Parietal cell antibodies, 41
- Peak acid output (PAO), 36–37
- Pepsin, 40
- Pepsinogen, 40
- Peptic stricture, barium swallow, 26
- Peptides, 132–133
- Percutaneous liver biopsy
 aftercare, 167
 bleeding tendency, 166
 complications, 167
 contra-indications, 168
 indications, 168
 laparoscopic liver biopsy, 166
 laparotomy, 166–167
 preparation, 163–164
 procedure, 164–166
 transvenous liver biopsy, 166
 young children, 167
- Percutaneous transhepatic cholangiography (PTC), 193–195
- Peritoneal biopsy
 complications, 207
 method, 206
 needle, types of, 206–207
- Peritoneoscopy, pancreas, 120
- Peritoneum, 209
 aetiology of, 203
 laparoscopy
 indications, 209–210
 instruments, 207
 interpretation, 209
 procedure, 208
 rigid laparoscopy, 207–208
 laparotomy, 210
- paracentesis, 203
 acute abdomen, diagnostic paracentesis, 205
 chylous ascites, 205–206
 complications, 204
 interpretation, 204–205
 method, 203
- peritoneal biopsy
 complications, 207
 method, 206
 needle, types of, 206–207
- Pethidine, 96, 167, 208
- Phaeochromocytoma, 63–64
- Phenol red, 59
- Pilocarpine iontophoresis, 130–131
- Pinworm, 110
- Plasma thromboplastin antecedent, 144
- Plasma thromboplastin component, 144
- Platelet serotonin, 63
- Pneumatosis cystoides intestinalis, 86
- Polyethylene glycol (PEG), 59
- Polyps, colonoscopy, 97
- Porphobilinogen, 141, 158
- Porphyria cutanea tarda, 159
- Portal hypertension, 177, 209
- Portal manometry, 181, 183
- Portography
 hepatic venography, 184–185
 splenic venography, 183–184
 transhepatic portography, 184
 transumbilical portal venography, 184
- Potent secretion-inhibitor somatostatin, 132
- Precipitin test, 158
- Primary biliary cholangitis, 170–171
- Primary biliary cirrhosis,
 148, 170–171
- Proctoscopy, 82
 interpretation, 83
 method, 82
- Proctosigmoidoscopy, 83
 flexible sigmoidoscopy, method for, 85
 interpretation, 85–86
 rigid proctosigmoidoscopy, method for, 83
 position, 83–84
 preparation, 83
 procedure, 84–85
- Prostaglandins, 133
- Protein
 liver biochemistry
 albumin, 143
 electrophoresis, 144
 globulins, 143
 immunoglobulins, 144
 loss, 55–57
- Protein load test, 154–155

- Prothrombin, 144
Prothrombin time, 71
Proton pump inhibitors, 3, 5, 32
Protozoa, 110
 amoebiasis, 111
 enterobiasis, 110
PTC. *See* Percutaneous transhepatic
 cholangiography (PTC)
Push enteroscopes, 107
- R**
- Radioallergosorbent testing (RAST), 65
Radioimmunoassay, 128
Radio-iodinated serum protein, 56
 alpha₁-antitrypsin clearance,
 56–57
 method, 56
Radioisotope tests, 79
Radio-labelled erythrocytes, 105–106
Radio-opaque cardiac catheter, 182
Radio-opaque red arterial catheter, 48
Radio-opaque solid markers, 59
Radiotelemetry, 39, 60
Rectal biopsy
 flexible instrument, 87
 interpretation, 87–89
 rigid instrument, 87
Rectal examination, 81–82
Rectosigmoid junction, 85
Rectum
 rectal biopsy
 flexible instrument, 87
 interpretation, 87–89
 rigid instrument, 87
 rectal examination
 interpretation, 82
 method, 81–82
Reduced calorie intake test, 155
Reflux studies, oesophagus
 MII and alkaline reflux, 32
 pH monitoring, 31–32
Retention test, 153
Retrograde ileography, 55
Rotor syndrome, 168
Rubin suction biopsy tube, 49–50
Ryle's tube, 19
- S**
- Salen sump tube, 19, 20
Salmonella, 112
Schistosomiasis, 89
Scleroderma, 31
Scott-Harden tube, 21
Seatworm, 110
Secretin, 120, 132
 interpretation, 122
 method, 121–122
⁷⁵SeHCAT test, 61
Sengstaken tube, 108
SGOT, 142
SGPT, 142
Shigella, 112
Short bowel syndrome, 38
Skin chloride assay, 131
Skin prick testing, 65
Small intestine, 47
 carcinoid syndrome, 62–63
 Crohn's disease, 52
 barium radiology, 60
 capsule endoscopy, 61
 colonoscopy, 61
 CT colography, 61
 DNCB, 60–61
 Kveim test, 61
 monitoring progress,
 investigations, 61–62
 skin testing with tuberculin, 60–61
 ultrasonography, 61
 enteroscopy, 55
 IBS, 65–66
 immunology, 64
 coeliac disease, 64–65
 food allergy and intolerance, 65
 intestinal bacteria, 57
 biopsy, 58
 breath hydrogen, 58
 intubation, 57–58
 urinary indican, 58
 intestinal biopsy
 Crosby-Kugler capsule, 48–49
 dissecting microscope, 50–51
 endoscopic forceps biopsy, 47
 light microscopy, 51–52
 Rubin suction biopsy tube, 49–50
 intestinal motility
 breath hydrogen, 60
 markers, 59–60
 radiology, 55
 radiotelemetry and manometry, 60
 lead intoxication, 64
 metabolic disorders, 62
 phaeochromocytoma, 63–64
 protein loss, 55–57
 radiology, 53–55
 thiopurine therapy, 62
 WBC scanning, 55
Sonde enteroscopes, 107
Splenic puncture, 181–182

- Splenic venography, 183–184
 Splenoportography, 181, 183–184
Staphylococcus, 112
 Steatorrhoea, 53, 129–130
 Steerable Burhenne-type catheters, 20
 Stomach, 8, 10–11
 basal acid output
 alternative techniques, 39
 gastric acid studies, indications for, 38
 gastric antibodies, 41
 intravenous ^{99m}technetium, 39
 method, 38
 pepsin, 40
 radiotelemetry, 39
 serum gastrin, 39–40
 serum pepsinogen, 40
 serum vitamin B₁₂, 40
 carcinoma, 11
 gastric acid secretion, 36–37
 gastric biopsy, 42–43
 gastric cytology
 fluorescence, 42
 interpretation, 41
 gastric emptying
 dye dilution, 36
 isotope tests, 35
 radiology, 35
 ultrasonography, 36
 radiology
 barium meal, 43, 44
 double-contrast radiology, 44–45
 iodinated water-soluble opaque media, 44
 tubes, 19, 20
 Stool examination
 bacteria, 111–112
 macroscopic appearance, 109–110
 pancreas
 macroscopic and microscopic examination, 129
 steatorrhoea, 129–130
 stool trypsin and chymotrypsin, 130
 protozoa and helminths, 110
 amoebiasis, 111
 enterobiasis, 110
 viruses, 112–113
Strongyloides stercoralis, 110
 Sub-acute bacterial, 14
 Substance P, 132
 Sucrase deficiencies, 75
 Sulphobromophthalein, 153
 Surecut needle, 165
 Sweat electrolytes, 130
 pilocarpine iontophoresis, 130–131
 skin chloride assay, 131
 Symptomatology, 76
- T**
Taenia saginata, 110
Taenia solium, 110
 Terlipressin, 108
 Tetracycline, 42, 170
 Thiopurine therapy, 62
 Threadworm, 110
 Tinidazole, 4
 Tissue antibodies, 147–148
 Tolbutamide test, 134
 Transaminases, 142
 Transhepatic portography, 184
 Transjugular cholangiography, 195
 Transumbilical portal venography, 184
 Transvenous liver biopsy, 166
 Treitz, 76, 103
 Tri-fin sign, 189
 Tropical sprue, 52
 Tru-Cut sheathed needle, 165–166, 206–207
 Trypsin, 128
 serum, 128
 stool, 130
 Tryptophan, 79
 Tubeless oral pancreatic function tests
 fluorescein dilaurate test, 125
 oral glucose tolerance test, 126
 Tuberculin, 60–61
 Tuberculous peritonitis, acute, 209
 Tumours
 angiography, 119
 antigens, 147
 colon and rectum, 89
- U**
 Ulcerative colitis
 colon, 91, 93
 colonoscopy, 97
 proctosigmoidoscopy, 86
 rectal biopsy, 88
 Ulcerative proctitis, 86
 Ultrasonography
 colon and rectum, 94
 Crohn's disease, 61
 gallbladder and bile ducts, 187–189
 gastric emptying, 36
 liver, 175
 cysts and abscesses, 176
 hepatocellular carcinoma, 175
 indications, 176
 jaundice, 176
 liver metastases, 175
 pancreas, 115–116
 Urea, 146
 Urea breath testing, 5

Urinary amylase, 127
Urinary excretion, twenty-four hour, 63
Urinary indican, 58
Urine bilirubin, 140
Urine urobilinogen, 141
Urobilinogens, 141
Ursodeoxycholic acid (UDCA) therapy, 145

V

Vagotomy, 37, 38, 40
Vancomycin, 4, 15
vanilyl mandelic acid (VMA), 64
Vasoactive intestinal peptide (VIP), 132
VCE. *See* Videocapsule endocopy (VCE)
Venography, 176
Verner-Morrison syndrome, 132, 133
Videocapsule endocopy (VCE), 107–108
Videoendoscopy systems, 7, 8
Vipoma, 135
Viral liver disease, 149
 hepatitis C, 151–152
 hepatitis D, 152
 hepatitis E, 152
 hepatitis, prevalence of, 152
 liver biopsy, 149–151

Viruses, 112–113

Vitamins

 vitamin A absorption, 71–72
 vitamin B₁₂, 40, 77, 146
 vitamin D, 71
 vitamin K, 71, 144
VMA. *See* Vanilyl mandelic acid (VMA)

W

Warfarin, 15
WBC scanning
 gallbladder and bile ducts, 197
Whipple's disease, 52
Widal test, 64
Wilson's disease, 157

X

Xylose
 absorption test, 73
 excretion, 73–74

Z

Zollinger-Ellison syndrome, 134–135