

Hajo Thermann

New Techniques in Foot and Ankle Surgery

Translated by
Jeremy Somerson

 Springer

New Techniques in Foot and Ankle Surgery

Hajo Thermann

New Techniques in Foot and Ankle Surgery

Hajo Thermann
Center for Hip, Knee and Foot Surgery
ATOS Clinic
Heidelberg
Germany

Translated by Jeremy Somerson

Translation from German language edition: *Neue Techniken Fußchirurgie* by Hajo Thermann © Springer-Verlag Berlin Heidelberg 2004, 2017. All rights Reserved.

ISBN 978-3-319-59673-0 ISBN 978-3-319-59674-7 (eBook)
DOI 10.1007/978-3-319-59674-7

Library of Congress Control Number: 2017950224

© Springer International Publishing AG 2017

This work is subject to copyright. All rights are reserved by the Publisher, whether the whole or part of the material is concerned, specifically the rights of translation, reprinting, reuse of illustrations, recitation, broadcasting, reproduction on microfilms or in any other physical way, and transmission or information storage and retrieval, electronic adaptation, computer software, or by similar or dissimilar methodology now known or hereafter developed. The use of general descriptive names, registered names, trademarks, service marks, etc. in this publication does not imply, even in the absence of a specific statement, that such names are exempt from the relevant protective laws and regulations and therefore free for general use.

The publisher, the authors and the editors are safe to assume that the advice and information in this book are believed to be true and accurate at the date of publication. Neither the publisher nor the authors or the editors give a warranty, express or implied, with respect to the material contained herein or for any errors or omissions that may have been made. The publisher remains neutral with regard to jurisdictional claims in published maps and institutional affiliations.

Printed on acid-free paper

This Springer imprint is published by Springer Nature
The registered company is Springer International Publishing AG
The registered company address is: Gewerbestrasse 11, 6330 Cham, Switzerland

For Annette, Mariko and Yannick.

Preface to the Second German Edition

→If better is possible, good is not good enough!

Dettmar Cramer (National Team Football Coach)

A decade has now passed since the publication of the first edition of *New Techniques in Foot and Ankle Surgery*. The long wait until this second edition is based on the fact that the techniques are truly new and require scientific evaluation of their efficacy. The first edition proved to be very successful and was sold out after a year. Thanks to electronic media, it is no longer possible for the second edition to sell out. This book is still not intended to be a «text-book», with complete and complex descriptions of pathology and treatment of foot and ankle diseases and injuries. Rather, it continues to be a *vade mecum*: a handbook reference for the practicing surgical specialist.

The existing standard techniques serve as a thread running through this book. New techniques sometimes require special technical skills, particularly for arthroscopic/endoscopic surgeries (such as for the Achilles tendon). These new techniques do not compete with old techniques, but instead represent a special set of tools for the experienced surgeon or for the surgeons who choose to use them.

I fully describe these «new techniques», which hopefully give the reader insights into my surgical approaches to problems and my philosophy. In particular, the topic of cartilage has led to many heterogeneous viewpoints and treatments. As a result, I also try to briefly illustrate basic principles and biomechanical models in the introductions to various chapters in order to help the reader understand my approach.

As previously described in the last Foreword, this edition is also a continuum rather – as is often wrongly assumed – than a catechism. The literature refers to a gold standard, which is supported by evi-

dence to varying degrees. These treatments have certainly become accepted, but foot and ankle surgery often has unique situations due to the complexity of the pathology and biology as well as the goals for activity that are hoped to be achieved through surgery.

I am particularly thankful to Springer Publishing for the cooperation with the illustrator, Mr. Kühn. I have collaborated on many book chapters and books, but I believe that every reader will notice that the illustrations by Mr. Kühn are far better than all of the prior illustrations. They are of outstanding quality and – of particular importance to me – realistic in their artistic depictions. In my opinion, the depiction of the operative site as it is seen during surgery allows for a more rapid transfer of knowledge and makes it more enjoyable to perform these surgeries.

My first teacher of general surgery was Karlheinz Meister in Wuppertal. I consider myself lucky to have learned the fundamental techniques – which are rarely practiced today – such as «tissue touch», knot-tying, retraction, and basic handcraft from a true master; I will remain true to these principles. I would also like to mention my teachers Prof. Harald Tscherne and Prof. Hans Zwipp. Prof. Tscherne taught me that every treatment and every interaction with a patient must have a comprehensive concept and that a Plan B and a Plan C should be in place even before changes to the existing situation occur. This preparation and approach to surgery has helped me to avoid ever experiencing a truly stressful situation in my 18 years of independent practice.

Prof. Hans Zwipp has always defied the mold of a «university surgeon». His visible

emotional love for the problems of foot and ankle surgery and his attempts to find new, creative solutions entered into my DNA during our time together and have helped to develop the principles found in this book. I admire both of these teachers and owe them my deepest gratitude.

It is not easy to publish a second edition of a book in between the hectic demands of day-to-day practice and frequent participation in scientific conferences. Over the last year, I perceived the need to document my surgical development in this book. Surgical techniques, as I attempt to teach my fellows and residents, are like the Japanese art of flower arrangement, Ikebana. The principle of Ikebana, as I understand it, is that every detail is of equal importance and value. This is the same during

surgery – from incision to closure, there is no single step that is not of equal importance to the next. I hope that the next generations of surgeons can keep this vision alive.

Finally, I give my thanks to Ms. Bahle as well as Ms. Lenzen and Ms. Knüchel from Springer Publishing who gave me the greatest possible support to complete this book. Thanks also to Albrecht (Stephanskirchen) and Orthotech (Gauting--Stockdorf) for their financial support for this book.

I wish the readers fun, happiness, and success during surgery and ask for ongoing feedback from other experienced or young surgeons about topics for discussion and improvement.

Hajo Thermann

Heidelberg, Germany

Spring 2016

Preface to the First German Edition

Much like *Sleeping Beauty*, orthopaedic surgery of the foot and ankle has had a rapid awakening over the last 5 years after decades of slumber. This is primarily due to the development of new implants and the use of new techniques in combination with numerous courses and workshops among local orthopaedic surgery associations. One indication of the particular importance of foot and ankle surgery is the appearance of multiple textbooks and new editions of standard textbooks in recent years.

In my experience as a frequent co-author of large textbooks, publisher guidelines call for structured descriptions of orthopaedic foot problems. There are two problems with these types of books. First, the long times to publication limit the timeliness of certain chapters. Second, there is often inadequate space for the authors to describe certain problems in depth, particularly with regard to technical aspects.

The title of this book alone, *New Techniques in Foot and Ankle Surgery*, describes the objectives of the author and the publisher. New surgical techniques are described with particular attention to the experiences and opinions of the author with regard to technical execution. This book does not represent a systematic description of foot and ankle surgery. Rather, it highlights the preferences of the author with regard to current thinking and critical technical aspects. In addition to describing technical steps, an additional objective is to clarify the surgical concept

with regard to indications and aftercare. Operative orthopaedic surgeons should be able to use this book in daily practice.

New Techniques in Foot and Ankle Surgery is not intended to be a catechism; rather, it serves as an invitation for discussion and communication that will be reflected in future editions. When looking at individual chapters, one may note that the Achilles tendon chapter is relatively complete in itself. In my opinion, this chapter may continue to be relevant for some time to come. In contrast, other chapters such as those concerning arthroscopy of the foot and ankle or ankle arthroplasty have a great potential for new future developments and will likely be updated constantly.

The author and the publisher have the intention to give the book a format that will fulfill the word «New» and be perceived as such by the reader and end-user.

Special thanks to Steinkopff Publishers and particularly to Dr. Volkert, who has enabled this book to develop from concept to final publication with remarkable speed without compromising quality or precision. Additional thanks to Ms. Baumann, whose drawings and artistic format were successful in illustrating my thoughts. Special thanks as well to my friend and «Achilles tendon teacher» Bernhard Segesser, who was willing to collaborate on the description of his special Achilles tendon repair technique. This made it possible to illustrate this very technically demanding technique as described by the author.

Hajo Thermann

Heidelberg, Germany

Spring 2004

Contents

1	Achilles Tendon Procedures	1
1.1	Introduction	2
1.2	General Notes	2
1.3	Acute Rupture	3
1.3.1	Percutaneous Suture Repair (Simple Suture Technique).....	3
1.3.2	Percutaneous Suture Repair (Double Knot Technique)	4
1.3.3	Lace Technique (Segesser Technique).....	6
1.4	Rerupture.....	9
1.5	Shortening Tenotomy for the Elongated Achilles Tendon	11
1.6	Achilles Tendinopathy (Midportion)	15
1.6.1	Open Technique	15
1.6.2	Endoscopic Technique	18
1.7	Chronic Rupture	21
1.7.1	Double Turndown Flap Technique	23
1.7.2	Flexor Hallucis Longus Transfer	28
1.8	Semitendinosus Tendon Transfer for Tissue Defects and Infection of the Achilles Tendon (Endoscopic)	32
1.8.1	Tissue Defect	32
1.8.2	Infection.....	35
1.9	Haglund Exostosis and Insertional Tendinopathy	36
1.10	Arthroscopic Calcaneus Plasty	38
2	Lateral Ankle Ligament Procedures	41
2.1	General Notes	42
2.2	Internal Brace	42
2.3	Periosteal Flap Transfer	43
2.4	Arthroscopic Broström Technique	44
3	Arthroscopy of the Ankle Joint	47
3.1	General Notes	48
3.1.1	Microfracture, Cartilage-Stimulating Procedure.....	48
3.2	Osteochondritis Dissecans of the Talus	49
3.2.1	AMIC Procedure.....	49
3.3	Anterior Impingement.....	57
3.4	Ankle Arthrodesis.....	58
3.5	Posterior Endoscopy.....	60
4	Arthroscopy of the Subtalar Joint	65
4.1	General Notes	66
4.2	Microfracture for Osteochondral Lesions	68
4.2.1	AMIC Procedure.....	68
4.3	Subtalar Arthrodesis	68
5	Metatarsophalangeal Joint Procedures	73
5.1	General Notes	74
5.2	Hallux Rigidus	74
5.2.1	Open Technique	74
5.2.2	Cartilage Reconstruction with the AMIC Procedure.....	77
5.2.3	Arthroscopic Technique.....	79

6	Procedures for Hindfoot Axis Deviations	83
6.1	Supramalleolar Osteotomies	84
6.1.1	General Notes	84
6.1.2	Biplanar Osteotomy for the Cavovarus Foot	84
6.1.3	Gastrocnemius Slide with Opening Wedge Osteotomy	87
6.1.4	AMIC Procedure for Treatment of Cartilage Lesions.....	88
6.1.5	Oblique Varus-Producing Closing Wedge Osteotomy	89
6.2	Calcaneal Osteotomies	92
6.2.1	General Notes	92
6.2.2	Valgus-Producing and Varus-Producing Osteotomies.....	93
6.2.3	Rotational Opening Wedge Osteotomy	94
6.3	Calcaneal Lengthening Osteotomy	94
6.3.1	Valgus-Producing Dome Osteotomy of the Calcaneus	97
6.3.2	Varus-Producing Calcaneal Osteotomy with a Step-off Plate.....	98
7	Tendon Transfer for the Planovalgus Foot	105
7.1	General Notes	106
7.2	Split Tibialis Anterior Tendon Transfer	106
8	Forefoot Surgery	109
8.1	General Notes	110
8.2	Scarf Osteotomy	110
8.3	Modified Ludloff Osteotomy	113
8.4	Modified Weil Osteotomy	114
8.5	PIP Arthrodesis	115
8.6	Plantar Plate Repair	117
8.7	Hohmann Procedure	121
8.8	Chevron and Akin Osteotomy (Minimally Invasive)	122
8.8.1	Chevron Osteotomy	122
8.8.2	Akin Osteotomy.....	125
8.8.3	Modified Chevron Osteotomy	126
9	Ankle Arthroplasty	129
9.1	General Notes	130
9.2	Techniques	131
9.2.1	Approach.....	131
9.2.2	Osteophyte Resection	132
9.2.3	Soft Tissue Balancing	132
9.2.4	Soft Tissue Balancing During Prosthesis Implantation	132
9.2.5	Prosthesis Implantation	133
9.2.6	Additional Steps.....	133
9.3	Ankle Prosthesis and Transfer of the Posterior Tibialis Tendon	134
10	Aftercare Protocols	137
	Supplementary Information	
	Index	155

Achilles Tendon Procedures

- 1.1 Introduction – 2**
- 1.2 General Notes – 2**
- 1.3 Acute Rupture – 3**
 - 1.3.1 Percutaneous Suture Repair (Simple Suture Technique) – 3
 - 1.3.2 Percutaneous Suture Repair (Double Knot Technique) – 4
 - 1.3.3 Lace Technique (Segesser Technique) – 6
- 1.4 Rerupture – 9**
- 1.5 Shortening Tenotomy for the Elongated Achilles Tendon – 11**
- 1.6 Achilles Tendinopathy (Midportion) – 15**
 - 1.6.1 Open Technique – 15
 - 1.6.2 Endoscopic Technique – 18
- 1.7 Chronic Rupture – 21**
 - 1.7.1 Double Turndown Flap Technique – 23
 - 1.7.2 Flexor Hallucis Longus Transfer – 28
- 1.8 Semitendinosus Tendon Transfer for Tissue Defects and Infection of the Achilles Tendon (Endoscopic) – 32**
 - 1.8.1 Tissue Defect – 32
 - 1.8.2 Infection – 35
- 1.9 Haglund Exostosis and Insertional Tendinopathy – 36**
- 1.10 Arthroscopic Calcaneus Plasty – 38**

1.1 Introduction

Achilles tendon procedures have the primary objective of restoring the mechanism of the gastrocnemius-soleus-Achilles tendon complex as close to its physiological, uninjured state as possible. In my many years of experience, large, open approaches have shown a high rate of complications, leading to failure to achieve this objective despite one's best efforts. The high rate of complications, due to the soft tissue layer and the circulation to the Achilles tendon, has led me to a paradigm shift towards endoscopic procedures. This also makes it possible to perform large surgeries without complications in patients with a history of prior surgeries or a scarred and poor-quality soft tissue layer. In principle, Achilles tendon procedures should at least allow for functional rehabilitation. I also consider it to be very important to start light range of motion in plantar flexion in the early postoperative phase. This allows for better control of the gastrocnemius/soleus complex and prevents early anterior adhesions of the tendon, which often lead to re-rupture. In my experience, the use of biological adjuvants (platelet rich plasma) – also postoperatively – and intraoperative use of fibrin glue to increase the transfer of fibroblasts have become essential parts of the overall treatment concept.

1.2 General Notes

■ Surgical setup

Use of a tourniquet is optional. The type of anesthesia is based on the wishes of the patient; however, it should be noted that prone positioning under regional anesthesia can be very difficult for obese patients. For patients with obstructive lung disease, the surgery can be performed in a lateral position.

■ Positioning and perioperative management

A standard prone position is used with padding to the peroneal nerve of the down leg. The legs extend slightly beyond the end of the operating room table and the nonoperative leg is lowered slightly. The surgical field is shaved

if hair is present. A third-generation cephalosporin is given for preoperative antibiotic prophylaxis. Preoperative thrombosis prophylaxis is initiated by injecting low-molecular weight heparin at the time of induction. The objective is minimally-invasive repair of the Achilles tendon stumps without a traumatic approach.

■ Indications

All Achilles tendon ruptures for which the patient does not wish to undergo conservative treatment or the surgeon feels that conservative management is not advisable or possible. Indications also include incomplete tendon apposition on dynamic ultrasound testing in plantar flexion and patients with ongoing corticosteroid usage and immunosuppression (poor regenerative capacity with conservative treatment).

■ Contraindications

Chronic ruptures with no tendon apposition on ultrasound or ruptures with fixed scar tissue (in these cases, a double turndown flap technique is used). Large defects after neglected or unhealed Achilles tendon ruptures.

■ Specific patient information

Continued treatment in a Vario-Stabil therapeutic shoe. It is important for the foot to remain in plantar flexion (even while washing the feet) and to avoid any stress on the Achilles tendon to allow for tendon healing without complications. Full weight-bearing is allowed in the therapeutic shoe after pain has resolved. The rehabilitation program begins after the shoe is discontinued. Competition-level stability of the tendon and corresponding muscular performance will be at 5–6 months at the earliest. Complete recovery from muscle atrophy takes about 9–12 months.

■ Aftercare

A well-padded postoperative plaster splint is applied to the dorsal or plantar aspect of the ankle (this splint can also be used as a night splint). The Vario-Stabil shoe is fitted on postoperative day 2. A short course of physical therapy is also performed at this time with one or two

1.3 · Acute Rupture

sessions of gait training (see rehabilitation protocol in ► Chap. 10). NSAIDs such as diclofenac, ibuprofen or similar substances are used for 3–5 days. In the early phase, the leg is frequently elevated and the shoe can be loosened intermittently, as swelling can occur. Suture are removed after 7–10 days.

1.3 Acute Rupture

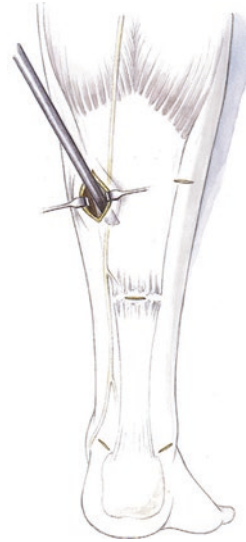1.3.1 Percutaneous Suture Repair (Simple Suture Technique)

■ Technique

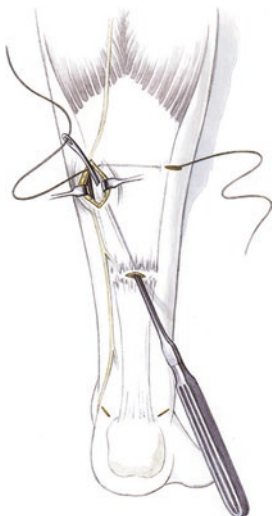■ Figures 1.1, 1.2, 1.3, 1.4, 1.5, 1.6, and 1.7.



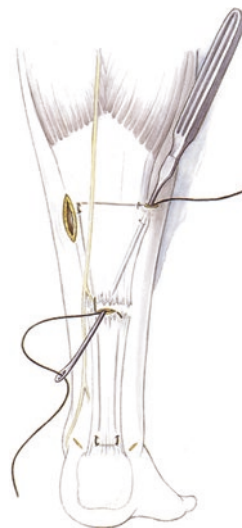■ **Fig. 1.1** Stab incisions at the medial and lateral aspects of the proximal tendon as well as a longitudinal incision for exploring the sural nerve at the location of the palpable groove and just above the calcaneal insertion of the Achilles tendon



■ **Fig. 1.2** Exploration of the stump in the epifascial plane for identification of the sural nerve. Endoscopic visualization of the sural nerve with a 2.7 or 3.5 mm arthroscope. Endoscopic-assisted repair in the proximal and lateral tendon



■ **Fig. 1.3** Pulling through a 1.3 mm PDS suture from medial to lateral while avoiding the nerve, which is protected with a small Hohmann retractor



■ **Fig. 1.4** The suture is pulled into the region of the tear from lateral and proximal. It is then pulled through into the area of the insertion and away from the tear distally and laterally. The suture is passed through the insertion into the tear area and back to the medial proximal tendon

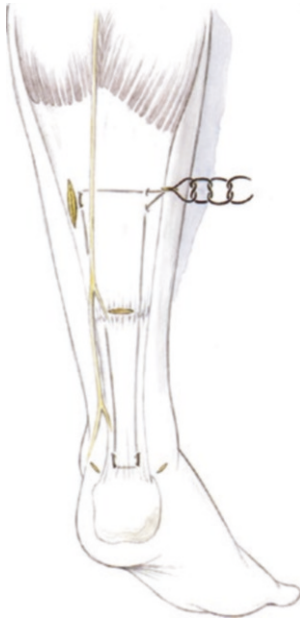

Fig. 1.5 The peripheral suture is tied with a single surgeon's knot. The ankle is moved into slight dorsiflexion to tension the suture inside the tendon. Three knots are then tied and the knot is buried in subcutaneous tissue. The stab incisions are closed with skin sutures and infiltrated with bupivacaine



Fig. 1.7 Vario-Stabil shoe with specific characteristics: a stable dorsal flap, an elevated heel pad (2 cm total) and lateral stabilization with the long boot

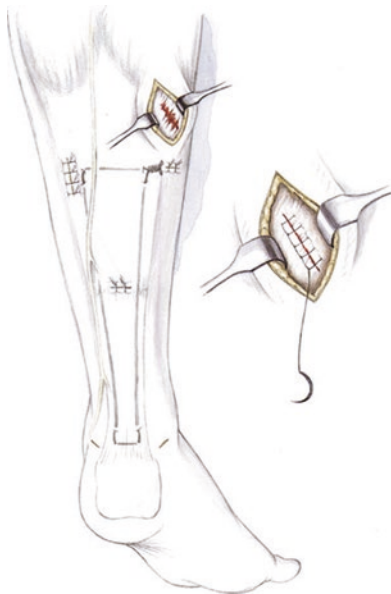


Fig. 1.6 If MRI evidence of a soleus tear is present, this is also explored through a small stab incision. A Krackow stitch with the ankle in equinus is used in addition to the peripheral suture

1.3.2 Percutaneous Suture Repair (Double Knot Technique)

■ **Indications**

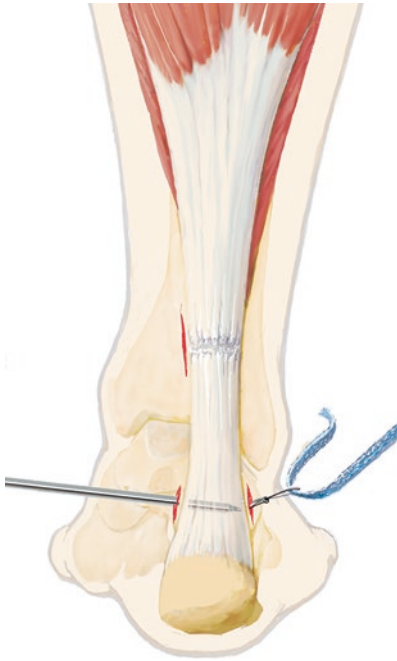
Severe degenerative changes of the Achilles tendon (old patients, MRI findings). More aggressive aftercare for young patients (athletes).

■ **Technique**

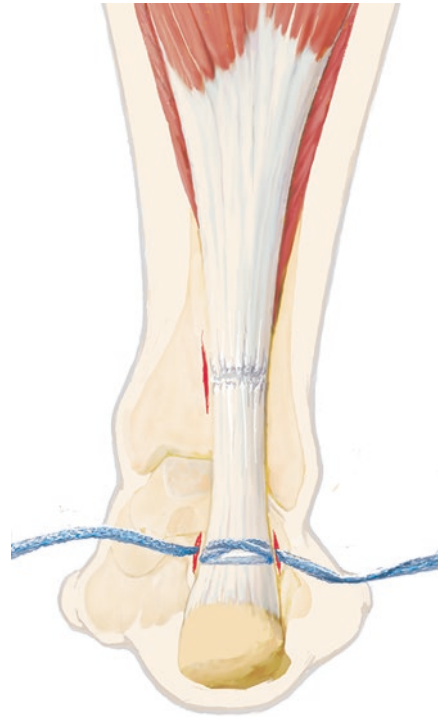
■ Figures 1.8, 1.9, 1.10, 1.11, 1.12, 1.13, and 1.14.

The double knot technique is started distally. The stab incisions are identical to those used for a simple technique except that they are 2–3 mm longer to allow the sutures to be doubly anchored distally. A lasso loop technique is used to pull a Fibertape from medial to lateral directly proximal to the calcaneal tuberosity. The Fibertape is then pulled back through proximally to create a more stable anchor point. The lateral suture is passed through the tendon medially with the suture passer through the central stab incision. This is repeated with the medial suture. The lateral suture is then pulled through the tendon through the lateral proximal stab incision and the medial suture is pulled medially. Both Fibertape sutures

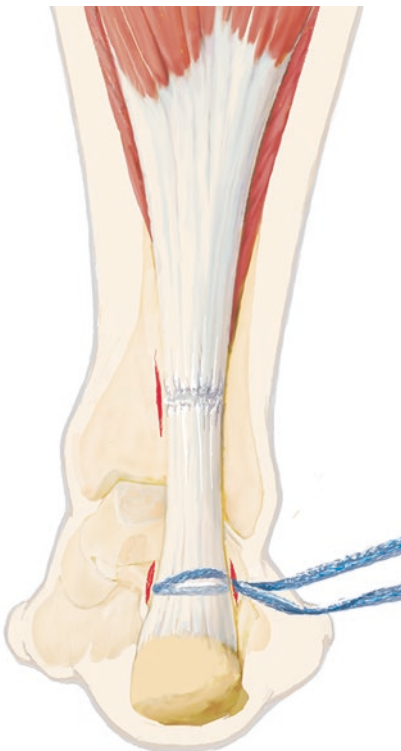
1.3 · Acute Rupture



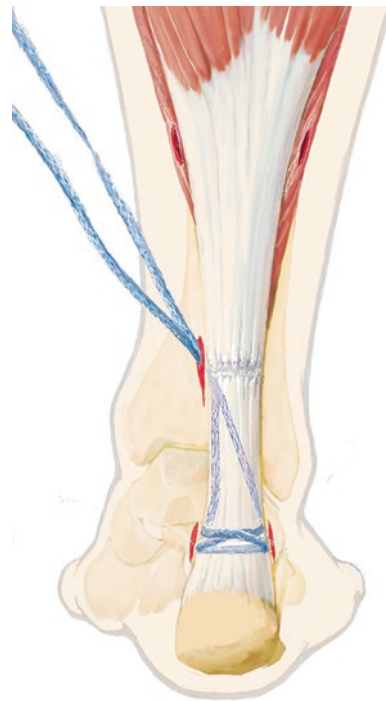
■ **Fig. 1.8** Distal medial and lateral stab incisions (1 cm length) parallel to the Achilles tendon. A Fibertape is inserted with a lasso loop technique. An additional medial incision is made at the level of the tear



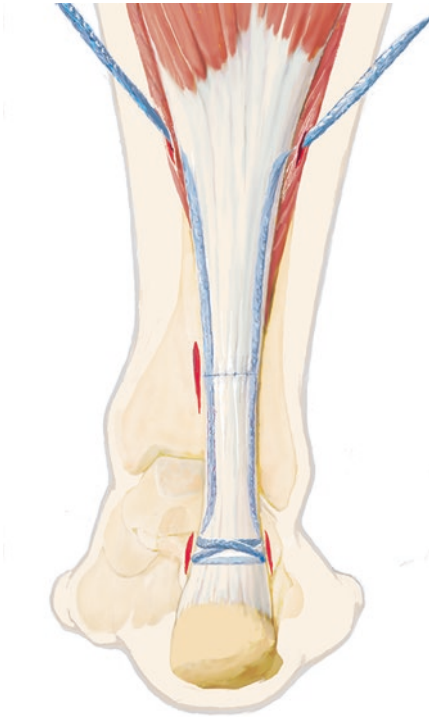
■ **Fig. 1.10** The lateral Fibertape is pulled back medially and proximally using a lasso loop technique



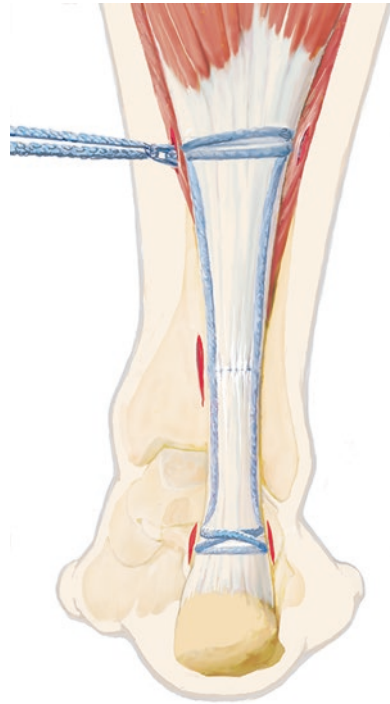
■ **Fig. 1.9** The Fibertape is pulled back from medial to lateral/proximal using a lasso loop technique



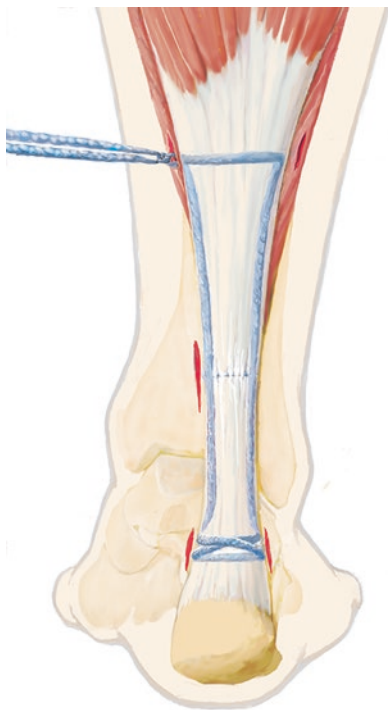
■ **Fig. 1.11** Both Fibertape sutures are pulled out the medial incision at the level of the incision using a lasso loop technique. Proximal stab incisions are made medially and laterally at the level of the aponeurosis



■ **Fig. 1.12** The medial and lateral Fibertapes are pulled out proximally using a lasso loop technique



■ **Fig. 1.14** The suture is pulled back laterally then passed medially again with a lasso loop technique proximal to the previous knot and tied three times



■ **Fig. 1.13** The lateral suture is pulled medially using a lasso loop technique and a simple knot is tied with the foot in plantar flexion, shortening the torn tendon

are pulled to tension the distal stitches. The lateral suture is pulled out medially and tied with firm tension with a double knot. One suture is then pulled proximally and laterally while protecting the sural nerve, then brought back medially and tied three times. The wound is closed in layered fashion and local anesthetic is injected at the stab incision sites.

■ **Rehabilitation**

The double knot technique allows for a more aggressive postoperative course with immediate plantar flexion from 100° to 120° out of the therapeutic shoe.

1.3.3 Lace Technique (Segesser Technique)

■ **Indications**

Soleus tear associated with an Achilles tendon rupture (common with high-level athletes). This is a very sophisticated, difficult technique that should only be performed by very experienced

1.3 · Acute Rupture

surgeons due to the extensive soft tissue procedure and the risk of soft tissue complications.

■ Contraindications

Soft tissue problems (abrasions, etc.). Achilles tendon ruptures without a soleus tear (relative).

■ Positioning

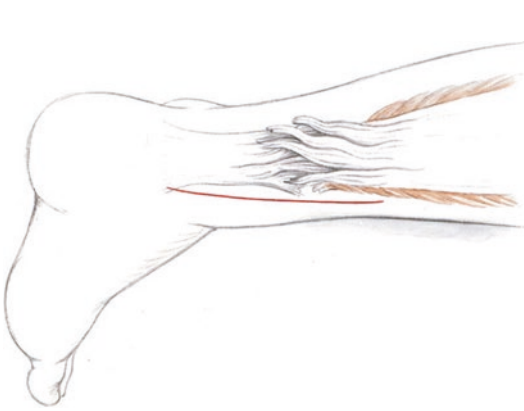
The patient is positioned as described in ► Sect. 1.2.

■ Aftercare

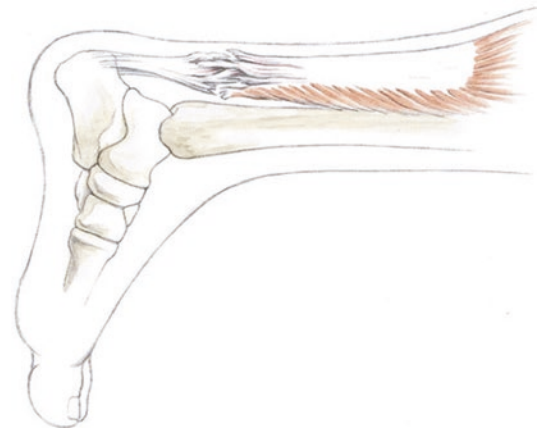
Plaster cast for 7–10 days until soft tissues are healed and stable. Subsequent placement in a Vario-Stabil shoe. Otherwise, identical to the percutaneous technique.

■ Technique

■ Figures 1.15, 1.16, 1.17, 1.18, and 1.19.



■ Fig. 1.15 Incision medial to the Achilles tendon, sometimes extending slightly laterally at the proximal aspect



■ Fig. 1.16 A tear of the Achilles tendon is noted over a long segment of the tendon with individual bundles in an athlete. The soleus muscle is also torn without continuity to the distal stump

■ Fig. 1.17 Repair of the soleus muscle at the distal Achilles stump

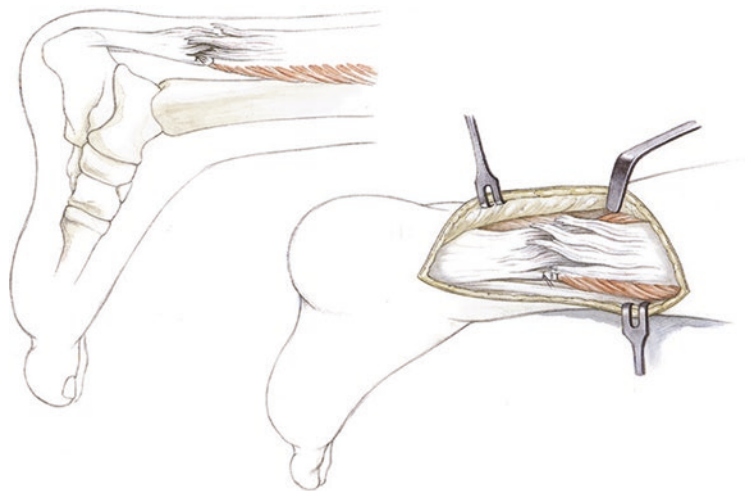

Fig. 1.18 The individual tendon bundles are held with small clamps while large bundles are fixed with suture. The bundles of varying length are woven together. It should be noted that the bundles of the distal stump are always much shorter

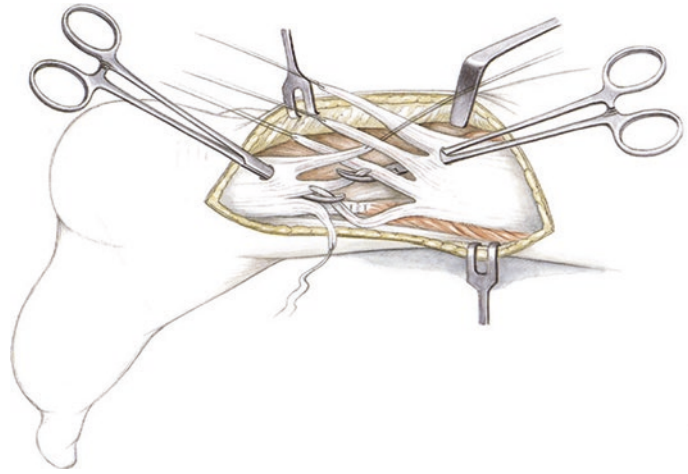
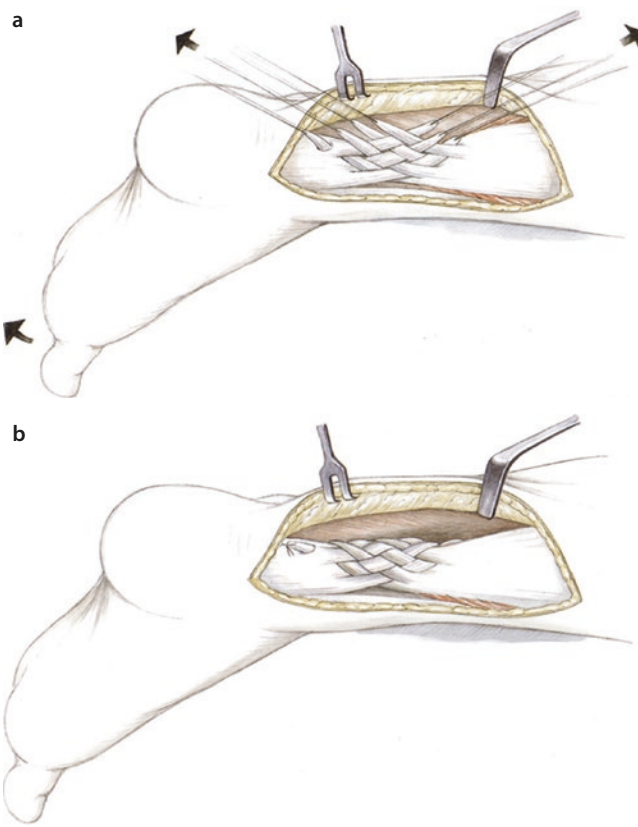


Fig. 1.19 a The bundles of varying length are woven together with the medial proximal fibers pulled distally and laterally. This restores the natural twist of the tendon. The bundles are sutured with interrupted stitches (4-0 PDS). To reinforce the repair, the plantaris tendon can be fanned out to cover the tendon repair and create a natural gliding surface. **b** Restoration of anatomic tension in the tendon using the lace technique



1.4 Rupture

■ Indications

Persistent diastasis on dynamic ultrasound examination. Old ruptures with atrophic repair tissue and minimal substance defect.

■ Contraindications

Large substance defects; chronic ruptures.

■ Positioning

The positioning is as described in ► Sect. 1.2.

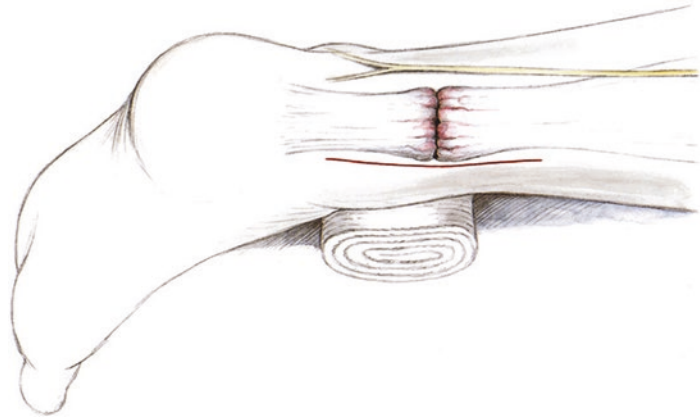
■ Technique

■ Figures 1.20, 1.21, 1.22, 1.23, 1.24, and 1.25.

■ Aftercare

Aftercare is based on the guidelines described in ► Sect. 1.2.

■ Fig. 1.20 Skin incision medial to the tendon; dissection of the fascia



■ Fig. 1.21 When dissecting the fascia and the peritenon, the sural nerve should be carefully protected due to the potential for early scar formation

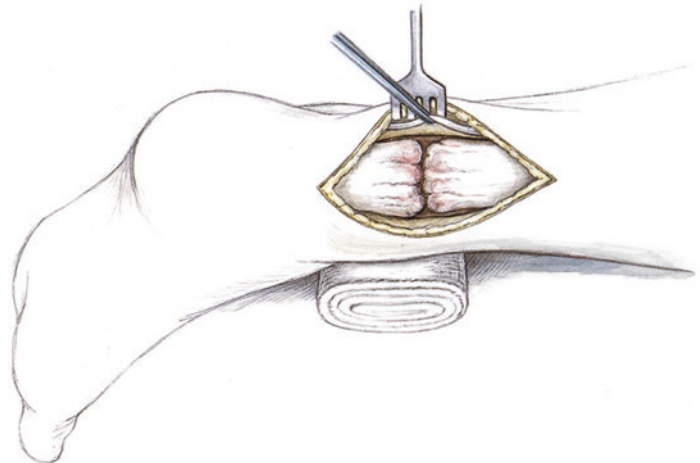


Fig. 1.22 a Digital mobilization of the proximal gastrocnemius-soleus complex medially and laterally. b An Ellis clamp is used to pull the mobilized proximal stump distally to close the diastasis

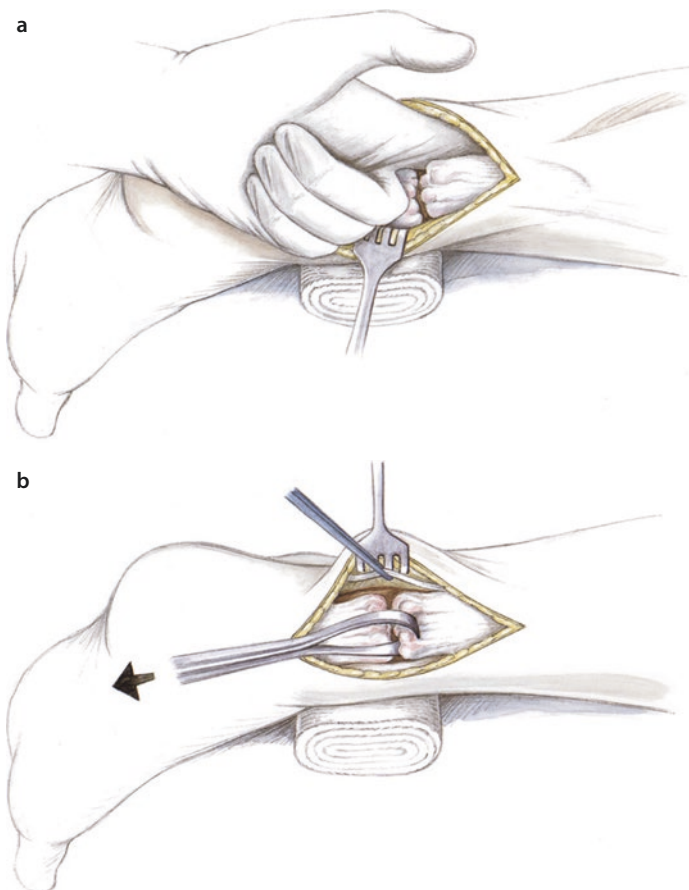
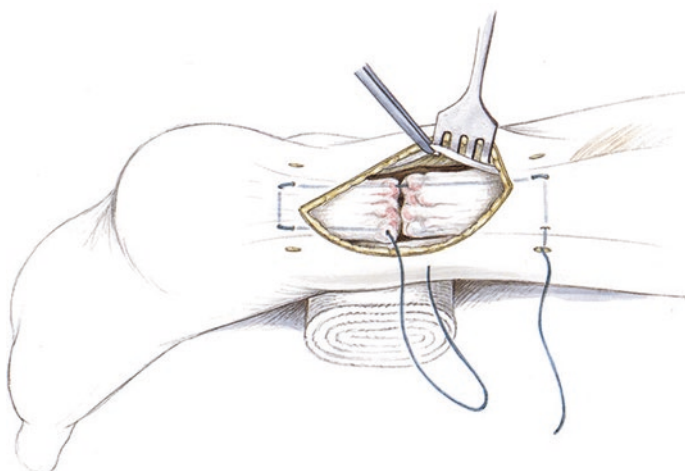
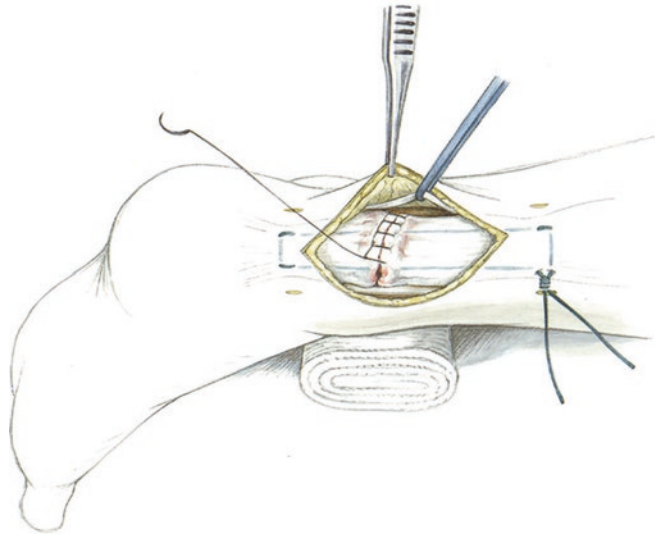


Fig. 1.23 Percutaneous placement of a peripheral stitch (Fibertape or 1.3 mm PDS suture) using the same technique as for acute repair

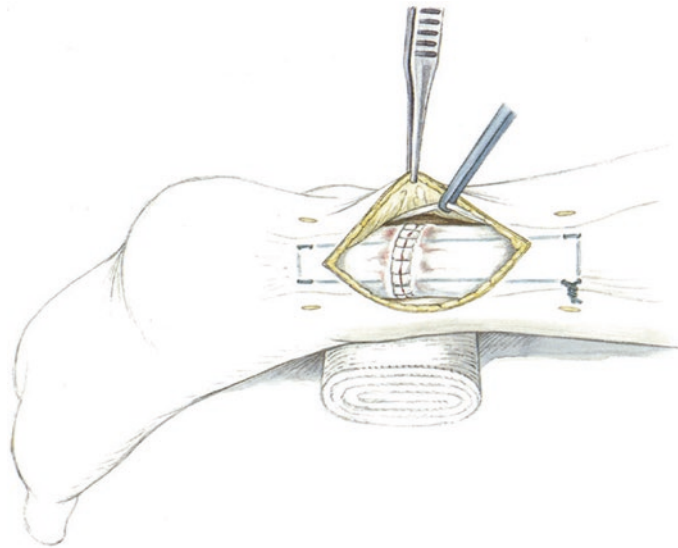


1.5 · Shortening Tenotomy for the Elongated Achilles Tendon

■ **Fig. 1.24** Tensioning, stitching and tying the suture while restoring the tension on the tendon. The tendon ends are then sutured using a circular Krackow technique (3-0 or 4-0 PDS)



■ **Fig. 1.25** When closing, the sural nerve should once again be protected. If possible, the peritenon should be closed (4-0 PDS). The fascia and subcutaneous layers are then closed. If thorough hemostasis is obtained, no drain is necessary



1.5 Shortening Tenotomy for the Elongated Achilles Tendon

■ Indications

Visible elongation of the Achilles tendon (increased dorsiflexion) compared to the healthy side with obvious clinical symptoms and decreased function. Surgery should only be considered for substantial loss of strength and accompanying loss of function. If the patient only has minimally decreased strength, a shortening tenotomy may not guarantee functional

improvement due to the pre-existing calf atrophy that often persists.

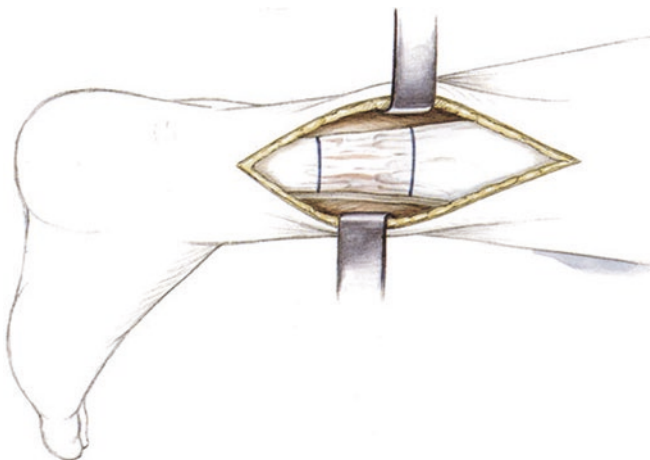
■ Contraindications

Minimal loss of functional strength. Inborn connective tissue laxity. Extensive soft tissue changes with a high risk of soft tissue complications.

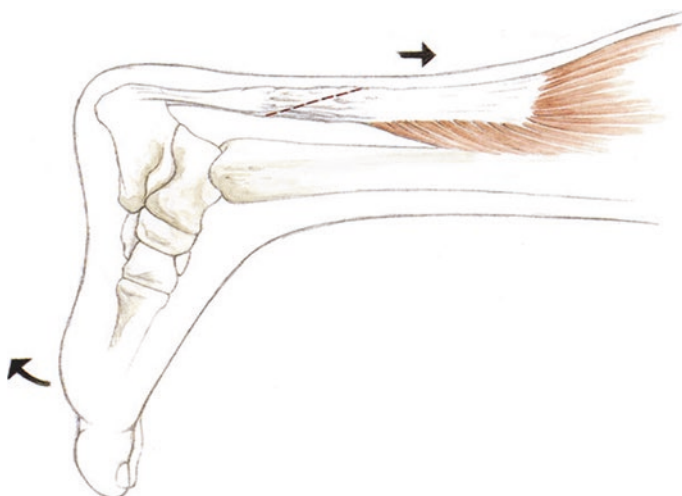
■ Technique

■ Figures 1.26, 1.27, 1.28, 1.29, 1.30, 1.31, 1.32, 1.33, and 1.34.

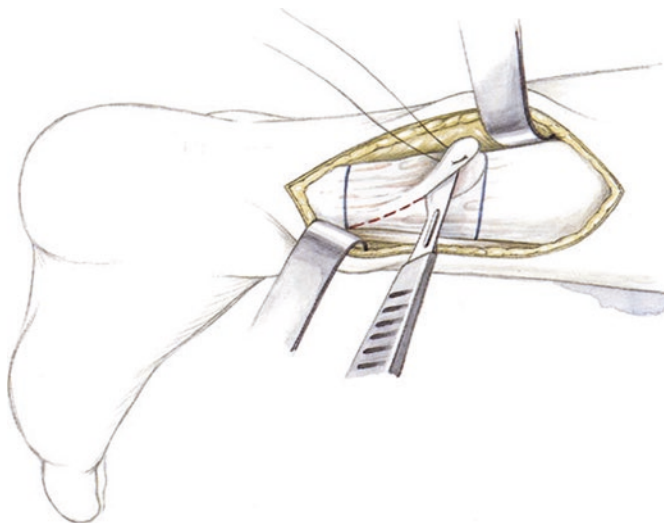
■ **Fig. 1.26** The tendon is visualized and a 5–7 cm distance in the center of the tendon is marked



■ **Fig. 1.27** The tendon is tensioned in dorsiflexion. The distal stump is then moved proximally to shorten the tendon by plantar flexing the foot

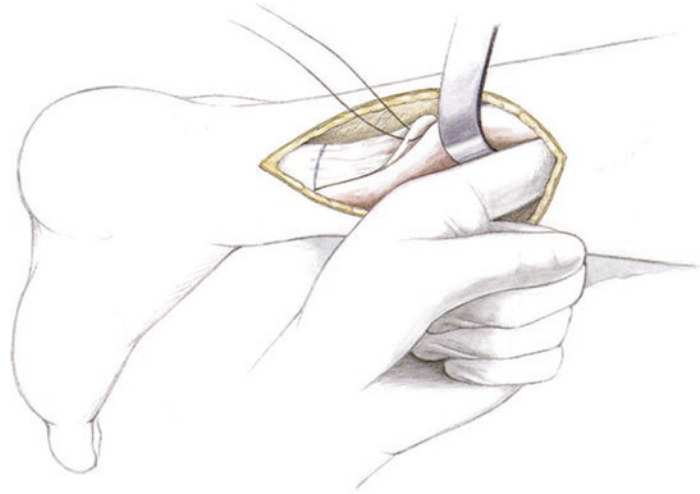


■ **Fig. 1.28** An oblique tenotomy is performed. This should be drawn out in advance with a marker with the foot in slight dorsiflexion and the tendon under tension

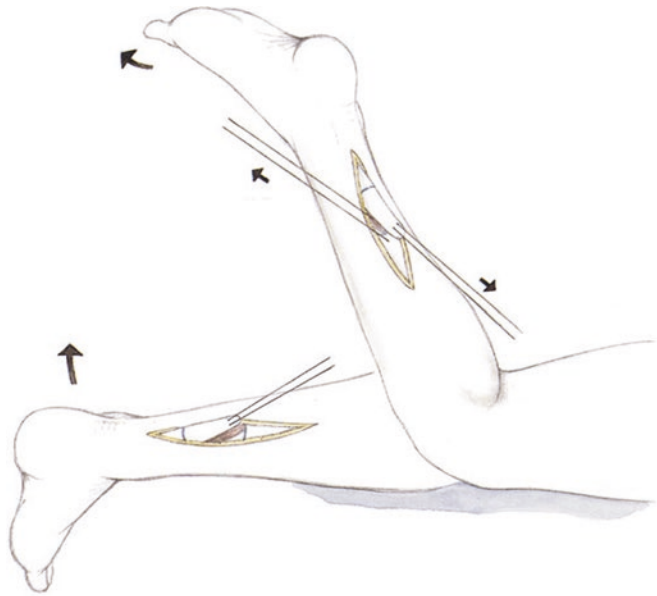


1.5 · Shortening Tenotomy for the Elongated Achilles Tendon

■ **Fig. 1.29** The gastrocnemius-soleus complex is then mobilized again, as the tendon is usually adherent after being moved proximally



■ **Fig. 1.30** The gastrocnemius-soleus complex is relaxed by flexing the knee and plantar flexing the foot to obtain adequate shortening



■ **Fig. 1.31** Anchor stitches with a Bunnell technique, 2-0 PDS or 0.7 mm PDS suture for fixation of the tendon shortening site; tied in plantar flexion

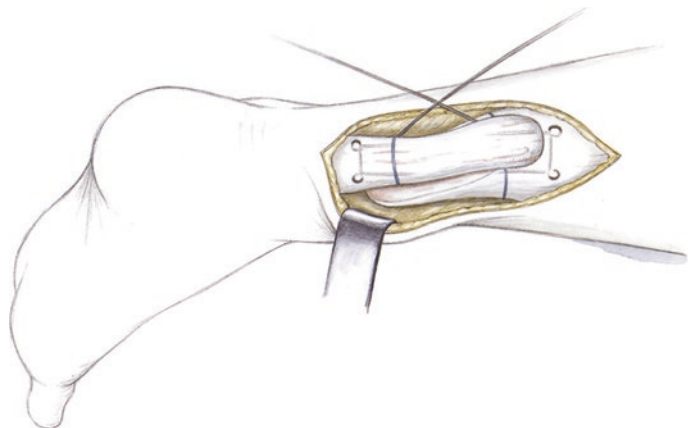


Fig. 1.32 Continuous Krackow stitches for additional stabilization and for shaping the tendon. The stitch runs from medial to lateral and completely encircles the tenotomy site

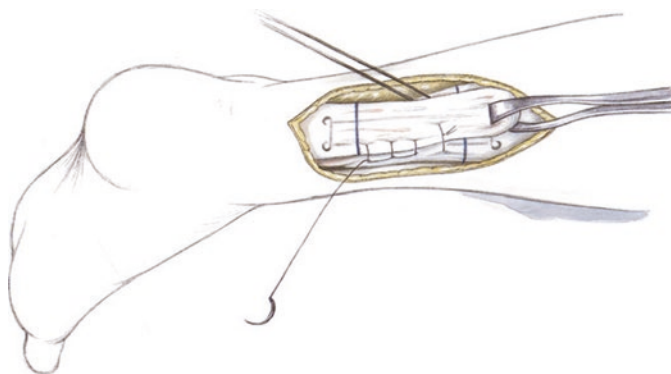


Fig. 1.33 Visualization of the completed medial/lateral and proximal suture repair of the tendon. A Redon drain is inserted. The fascia and subcutaneous tissue are closed with 2-0 PDS followed by skin staples or sutures

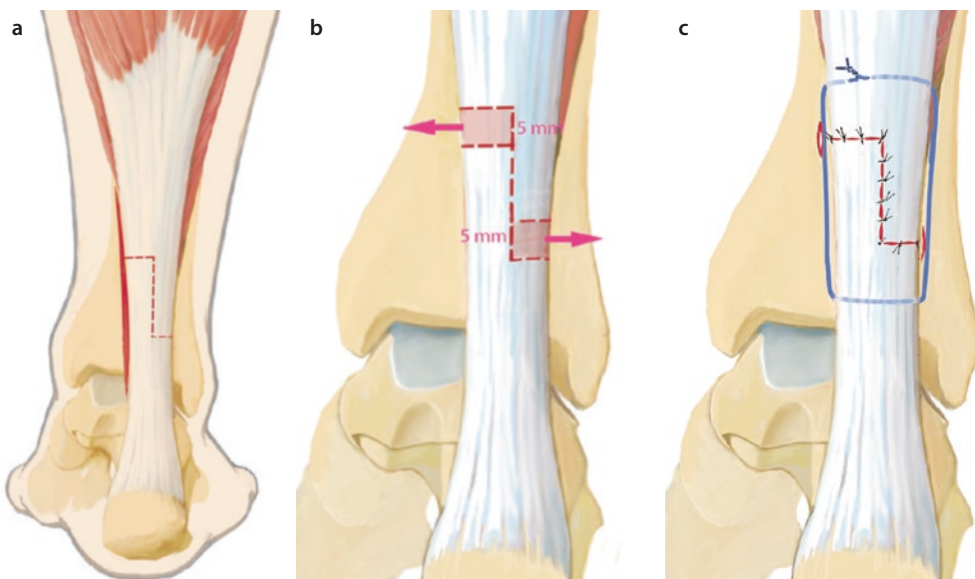
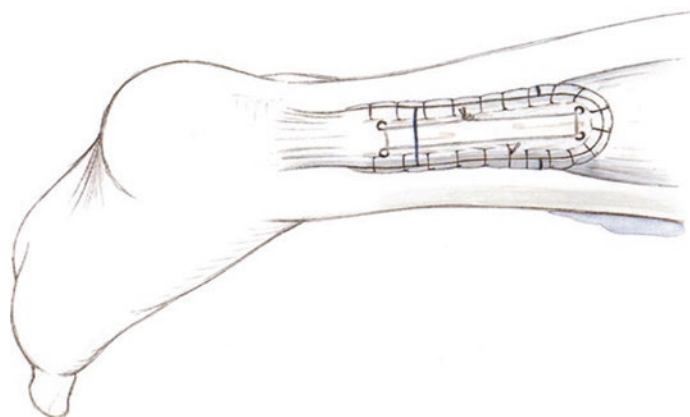


Fig. 1.34 a–c Z-plasty; minimally-invasive endoscopic-assisted procedure: Medial proximal and lateral distal 10 mm incision. Endoscopic tenolysis (avoid the sural nerve). Proximal and distal transverse tenotomy. 5 mm of the proximal and distal tendons are resected. A vertical central tenotomy is made with an #11 scalpel. A

small Langenbeck retractor is used to pull the skin proximally and distally to complete the incision. The ankle is plantar flexed and a peripheral stitch is placed while shortening the tendon. Each horizontal limb of the tenotomy is sutured with 2-0Vicryl. Growth factors are injected (ACP)

1.6 · Achilles Tendinopathy (Midportion)

■ Aftercare

Cast treatment in a high degree of plantar flexion (30°) for 1–2 weeks until the wound heals. After this, treatment in a Vario-Stabil therapeutic shoe until postoperative week 8, then a 1 cm heel lift in a normal shoe for 3 months. The exercise program includes tendon gliding exercises, gentle strengthening in plantar flexion and careful correction of the foot position from neutral to low-grade dorsiflexion. The above-mentioned criteria for aftercare after Achilles tendon rupture also apply to this procedure.

1.6 Achilles Tendinopathy (Midportion)

1.6.1 Open Technique

■ Indications

Pain in the Achilles tendon that is resistant to conservative treatment with functional limitations. If the Achilles tendon is severely thickened and pain persists for 3–6 months, complete resolution of symptoms cannot be expected with conservative treatment. Even if symptoms resolve, these patients will continue to get recurrent Achilles tendon problems. Because of this, surgical treatment is indicated in these cases.

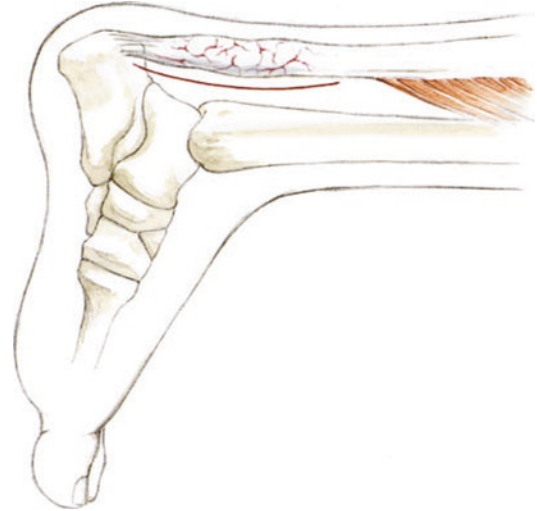
■ **Fig. 1.36** Dissection along the Achilles tendon up to the middle of the Achilles tendon, then the peritenon is split

■ Contraindications

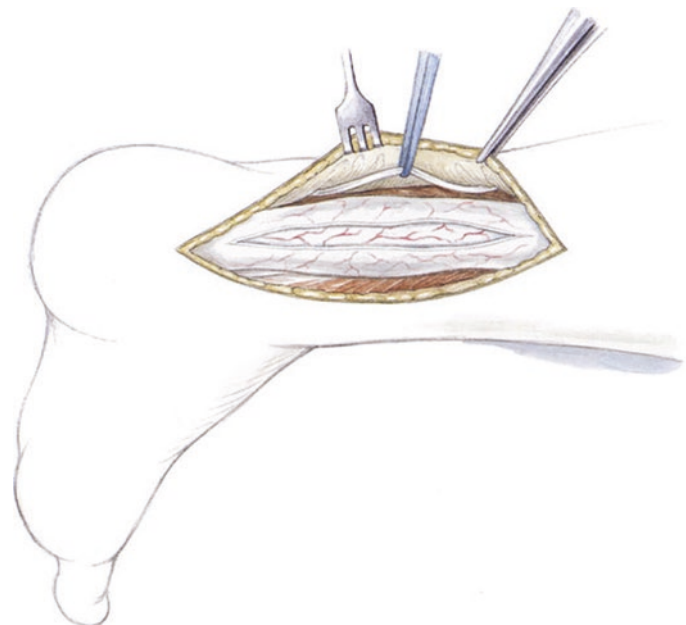
General contraindications, such as severe diabetes (with a risk of severe soft tissue complications).

■ Technique

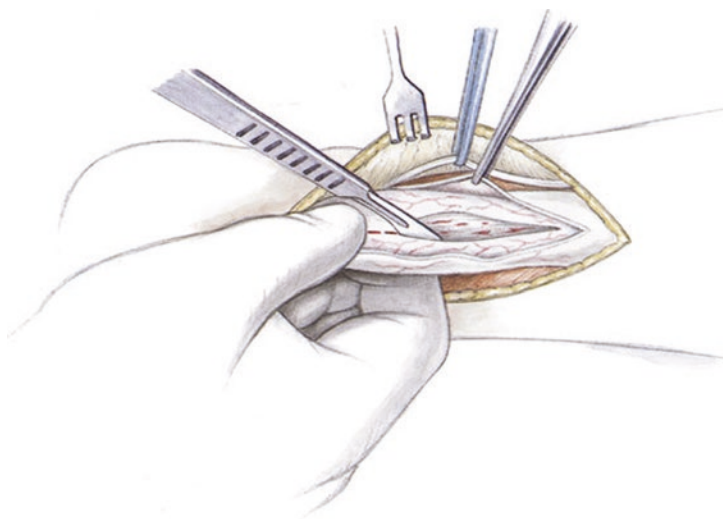
■ Figures 1.35, 1.36, 1.37, 1.38, 1.39, 1.40, and 1.41.



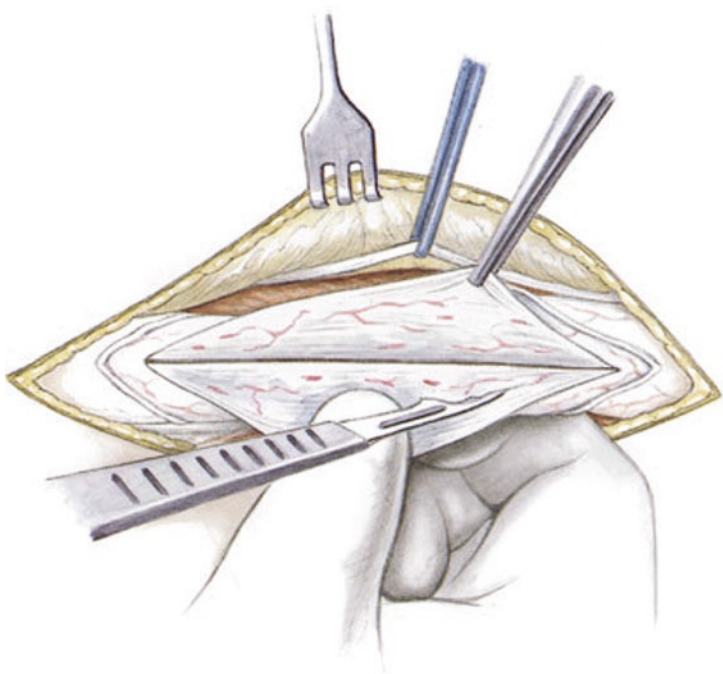
■ **Fig. 1.35** Skin incision at the inferior border of the area of palpable thickening in the Achilles tendon. The subcutaneous tissue and fascia are divided



■ **Fig. 1.37** The Achilles tendon is inspected. There is usually xanthochromic, yellowish discoloration and vascular ingrowth that is firm on palpation. The Achilles tendon is split longitudinally. Prior to surgery, an MRI should be obtained to localize the degeneration in the axial plane (medial or lateral). The longitudinal incision is placed in this location

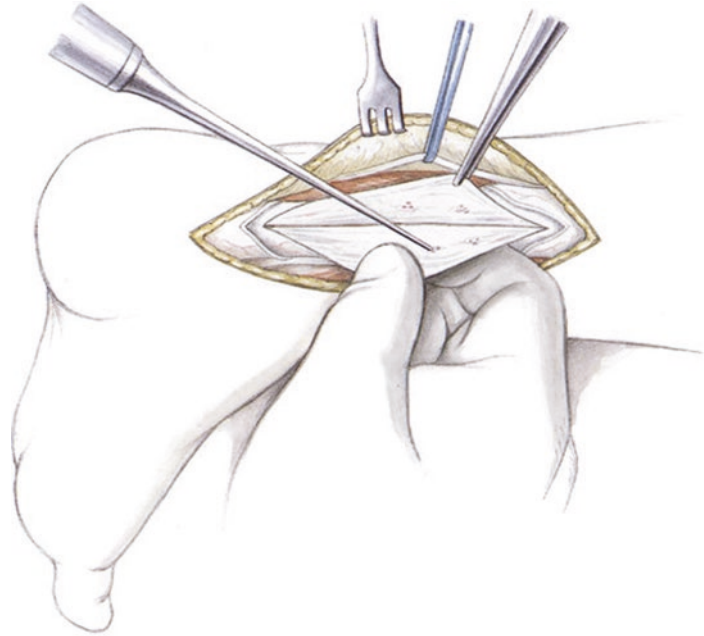


■ **Fig. 1.38** All degenerative appearing structures are dissected out. Palpation of the tendon between the thumb and index finger can be helpful to feel for firm areas of tissue that do not obviously appear pathological on macroscopic inspection



1.6 · Achilles Tendinopathy (Midportion)

■ **Fig. 1.39** Radical debridement must be performed. If the tendon is overly weakened, an augmentation procedure (such as plantaris tendon) must be performed. Any small areas of firm tissue that appear to be macroscopically normal are perforated with a ChondroPick or a microfracture awl to stimulate regeneration



■ **Fig. 1.40** The anterior aspect of the tendon is sutured followed by the posterior aspect. A running 3-0 PDS suture is used with a Krackow technique

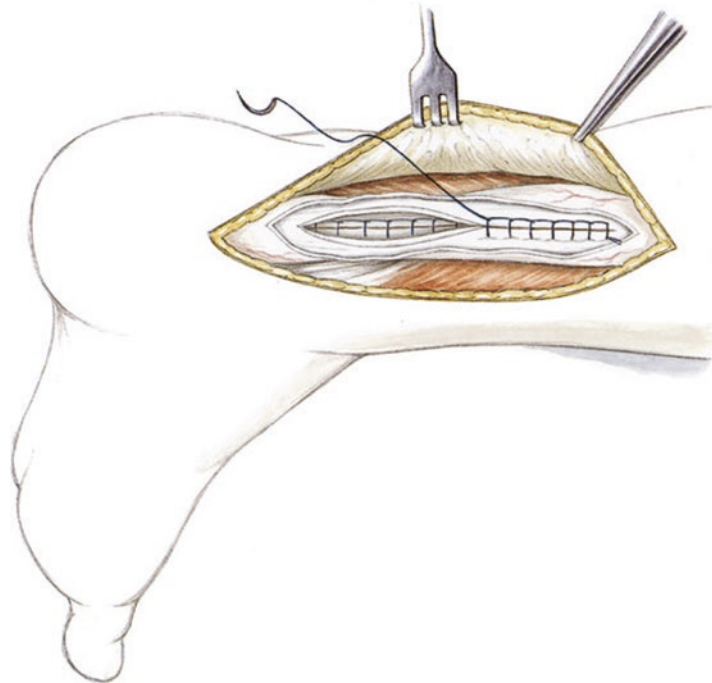
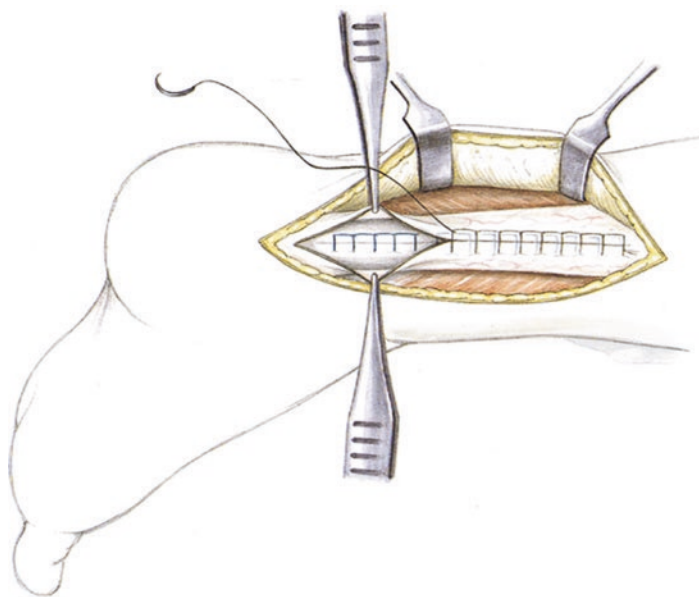


Fig. 1.41 The peritenon is closed with a running 4-0 PDS suture using a Krackow technique. The fascia and subcutaneous tissue are closed medial to this using a running 3-0 PDS suture. The skin is closed with 3-0 Prolene. After the tourniquet is let down, if bleeding persists, a Redon drain (10 Fr) can be inserted. If the tendon repair is stable, only a soft elastic compressive dressing is used



■ Aftercare

A posterior short leg splint is placed in slight plantar flexion for 7 days to allow for soft tissue rest. After this, partial weight-bearing (15 kg) for 10–14 days. The patient is then placed in a therapeutic shoe, even after augmentation (such as plantaris tendon). The Redon drain, if placed, is removed on the first postoperative day. After the first postoperative day, range of motion exercises at the ankle are initiated along with lymphatic drainage massage for improving tendon gliding. The primary objective is reduction of pain and swelling as well as restoring mobility in the ankle joint. Achilles stretching is later introduced along the entire flexor chain. Swimming and cycling are used for strengthening. No jogging prior to the 12th–14th postoperative week.

1.6.2 Endoscopic Technique

■ Indications

Painful thickening of the midportion of the Achilles tendon. Conservative treatment should be attempted for at least 3–6 months depending on the degenerative changes at the Achilles tendon. Palpable thickening at the midportion 2–8 cm proximal to the calcaneal insertion. Midportion tendinopathy can be differentiated from a chronic rupture by the ability to perform a single-leg toe stand. For endoscopic treatment of intratendinous

degeneration, an MRI with standard sequences should be obtained.

■ Contraindications

Peripheral vascular disease; otherwise, all midportion tendinopathies can be treated endoscopically if the surgeon has adequate experience. If the pathology is more severe (chronic rupture), additional techniques must be used.

■ Surgical setup

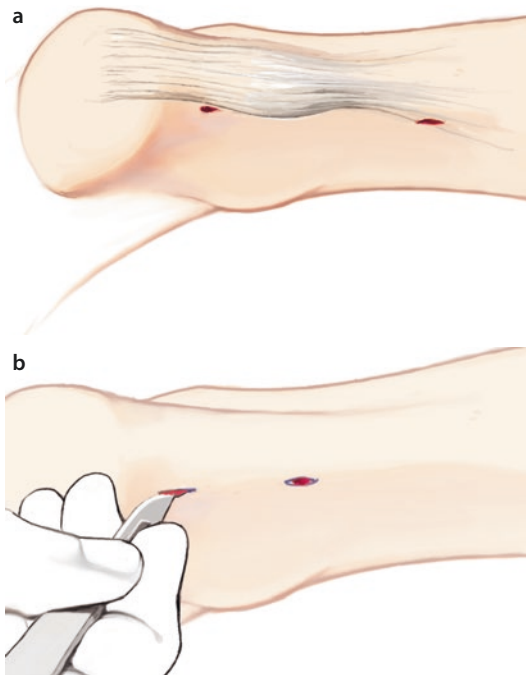
For treating midportion tendinopathy, standard arthroscopic instruments (4.0 mm) are needed. A tourniquet is inflated after exsanguinating with an Esmarch. A 3.8 mm shaver is initially used. With additional experience, a 5 mm shaver (more aggressive) can be used. A retrograde cutting scalpel (ENT instrument) is used to create a longitudinal split in addition to a hook electrocautery and fibrin glue (Tissucol 5 ml). Platelet-rich plasma is applied intraoperatively (if ACP is used, a centrifuge and double-barrel syringes are needed). A short leg plaster splint or a similar preformed splint is applied in a slight equinus position (close to neutral).

■ Positioning and perioperative management

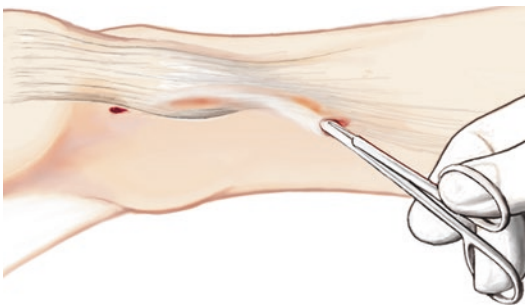
All endoscopic procedures on the Achilles tendon are performed in a prone position. The leg hangs slightly over the edge of the table. The contralateral leg is lowered slightly. To bring the hindfoot

1.6 · Achilles Tendinopathy (Midportion)

into a vertical position, a small wedge is placed under the contralateral pelvis. The leg and the foot are placed in a neutral position. The leg can also be stabilized with a special elastic cushion («camel» cushion). Pressure injury to the peroneal nerve, the sural nerve and the foot must be avoided on the lowered contralateral leg. Based on the author's experience, a tourniquet inflated to 300 mmHg at the thigh is recommended. General anesthesia is preferred, as surgeries that last for an extended period can be uncomfortable



■ **Fig. 1.42** a, b Positioning is the same as for all Achilles tendon procedures. The stab incisions are placed proximally and distally medial to the Achilles tendon. The distal incision must be proximal to the calcaneal insertion



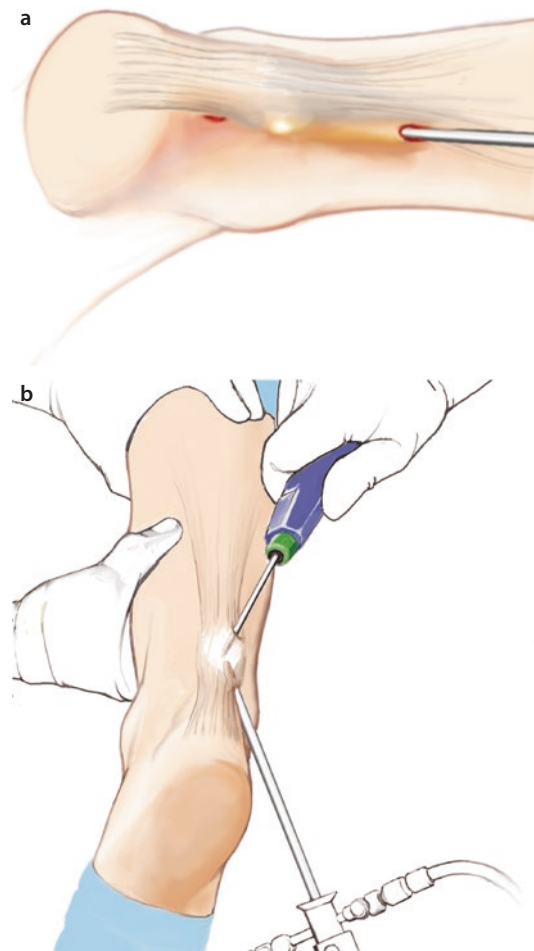
■ **Fig. 1.43** Mobilization of the subcutaneous posterior layer with the mosquito clamp. The tendon is mobilized anteriorly, staying directly on the Achilles tendon

in a prone position when a patient is conscious. A third generation cephalosporin is used for antibiotic prophylaxis. This is adjusted to the patient's individual characteristics. The extremity is draped in sterile fashion up to the thigh tourniquet and exsanguinated with an Esmarch. These are the standard principles for all endoscopic procedures on the Achilles tendon.

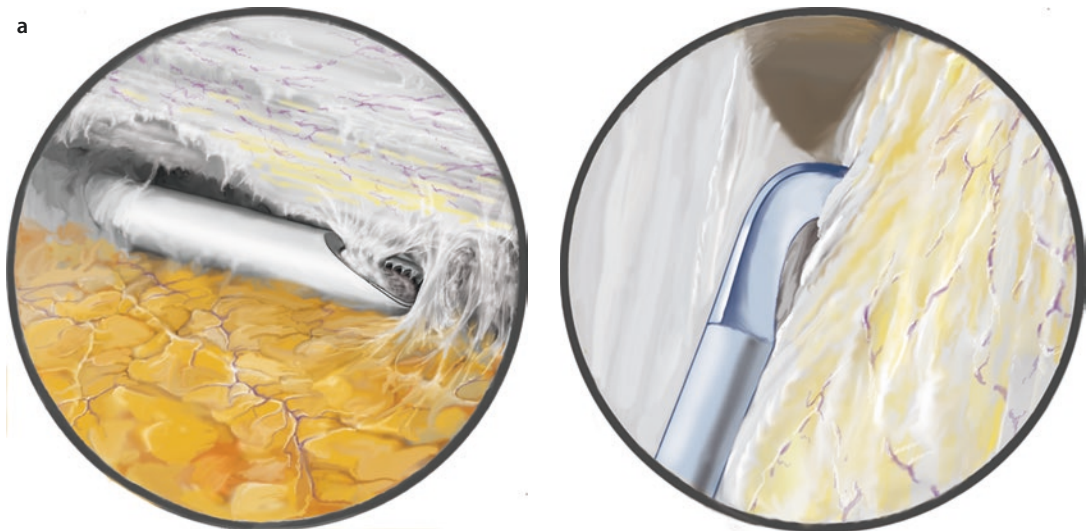
■ Technique

■ Figures 1.42, 1.43, 1.44, 1.45, 1.46, and 1.47.

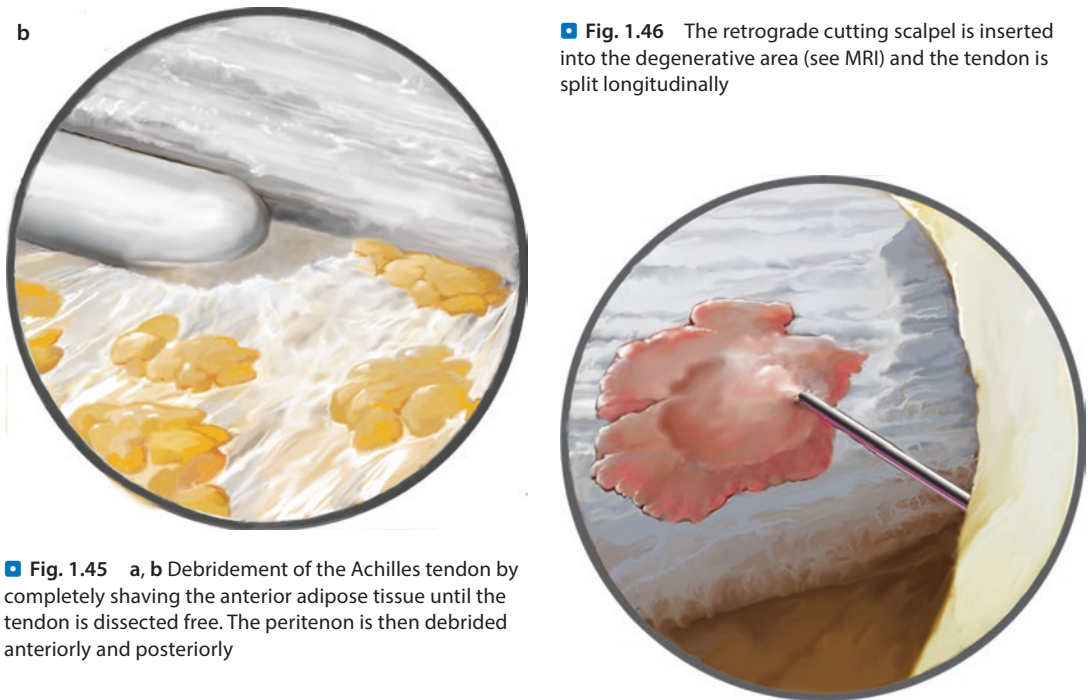
Medial incisions are made just proximal to the insertion so that an endoscope can be inserted. An additional stab incision is made at the transition from the tendon to the aponeurosis. The



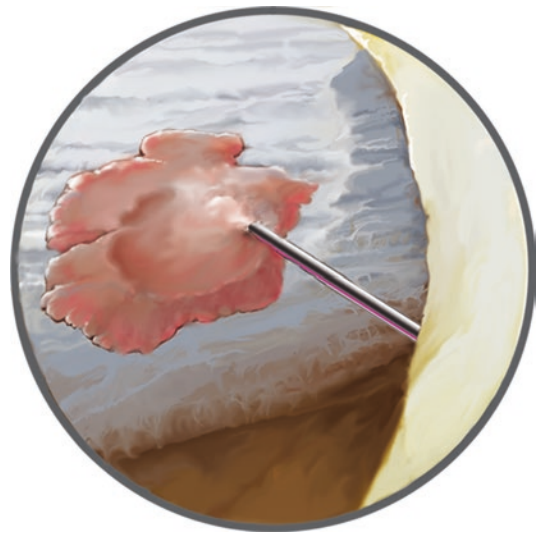
■ **Fig. 1.44** a, b The arthroscope is inserted proximally and the shaver is inserted from distal to proximal. The calcaneus is everted to make it easier to operate distally. The camera and shaver are triangulated. The Achilles tendon is then shaved and areas of vascular ingrowth in the subcutaneous tissue are completely resected



■ Fig. 1.46 The retrograde cutting scapel is inserted into the degenerative area (see MRI) and the tendon is split longitudinally



■ Fig. 1.45 a, b Debridement of the Achilles tendon by completely shaving the anterior adipose tissue until the tendon is dissected free. The peritenon is then debrided anteriorly and posteriorly



■ Fig. 1.47 Injection of platelet-rich plasma (ACP) under arthroscopic visualization

subcutaneous soft tissue is spread with a mosquito clamp at the posterior aspect of the tendon. Dissection should be strictly limited to the tendon to create space for endoscopy. It should not be carried too deep anteriorly to avoid injuries to the retinaculum and the neurovascular bundle. Posterior and anterior manipulation is performed from both proximal and distal. The arthroscopy tower is positioned at the contralateral side of the patient. A normal arthroscopy set is used with a 4.0 mm arthroscope and a 3.8 or a 5.0 mm blunt

shaver. The entry trocar is inserted into the proximal and medial aspect of the tendon without advancing anteriorly or posteriorly. The arthroscope is inserted. The shaver is then inserted distally and triangulated, bringing the shaver directly into the surgical field. The 30° camera is angled slightly anteriorly.

The Achilles tendon is visualized and the anterior vascular ingrowths, neovascular tissue and nerves are carefully resected with the shaver in gradual steps. This is started in the distal portion of the tendon and carefully advanced in small steps. The arthroscope is then inserted distally and the shaver is inserted proximally. Resection in the lateral aspect of the tendon must be performed carefully due to a peripheral branch of the peroneal artery located in the distal lateral area. The sural nerve is located posteriorly, not anteriorly, and should also be protected. Because of this, injury to the sural nerve must be avoided in the lateral dorsal aspect of the tendon. The entire tendon is gradually dissected free, switching the camera from medial to lateral. The peritenon, which is «under pressure» due to the degenerative increase in tendon volume, is then completely resected dorsally with the shaver.

Based on MRI results, a small retrograde cutting scalpel is inserted into the degenerative tissue, which is then shaved out. Any obvious degenerative tissue (xanthochromic degeneration, vascular ingrowths, etc.) is completely debrided.

However, the tendon often shows few macroscopic changes. Thorough hemostasis is obtained with the electrocautery hook. A Redon drain is inserted. After this, growth factors (ACP) are injected into the tendon in the degenerative area under visualization (■ Fig. 1.47). The portal sites are then closed. A sterile dressing and a plaster splint are applied. Local anesthetic is not used to avoid compromising the effect of the growth factors.

■ Aftercare

The patient remains in a plaster splint in a neutral position for 1 day. After this, the dressing is changed and exercises are started right away. Partial weight-bearing (15 kg) is maintained for 14 days to allow swelling to decrease. Lymphatic drainage massage is performed. Exercises for the ankle joint and stretches for the flexor muscle chain are initiated with a physical therapist and independently. After 14 days, weight-bearing as tolerated with a well-cushioned shoe. Frequent stretching on stairs and calf raises are performed to eccentrically stretch the calf muscles. Water jogging for 3–4 months (the tendon must restructure itself). After that, sport-specific training can be initiated.

1.7 Chronic Rupture

■ Indications and diagnosis

Chronic ruptures are characterized by high-grade widening and thickening of the tendon, sometimes with a diameter greater than 16–20 mm. Intratendinous dehiscence and high-grade areas of thickening and degeneration are often found in the midportion. The patient will feel a lack of strength on push-off. On physical examination, the Thompson test is often normal, but it is no longer possible to perform a one-legged calf raise into maximum plantar flexion with force. With a chronic rupture, the amount of functional limitation can vary from the ability to raise the heel slightly when attempting a calf raise to complete lack of strength with no lifting of the heel. In addition to decreased strength, the patient will feel pain that is refractory to all conservative treatment. On physical examination, increased dorsiflexion compared to the contralateral side is a key finding; this is sometimes 5° or more. MRI will show severe degenerative hyperintense signal, sometimes with fluid collections on T2 sequences.

■ Contraindications

The technique is not suitable for massive defects which must be treated with a tendon transfer as well. Low-grade infections must first be cleared and completely debrided prior to reconstruction of the tendon. In cases of severe peripheral vascular disease, indications should be highly conservative and a tourniquet is not used.

■ Surgical setup

The setup for chronic ruptures is identical to that for debridement of midportion tendinopathy (► Sect. 1.6). If high-grade adhesions are present, 3.2 mm biters as well as standard, heavy scissors can be used to more easily and safely dissect posterior adhesions to skin while protecting the sural nerve and the peripheral, lateral vascular ingrowths. Fibrin glue (Tissucol0.5 ml) and intraoperative injection of platelet-rich plasma are also needed for chronic ruptures. For ACP («autologous conditioned plasma») the appropriate centrifuge and double-barrel syringes are needed.

■ Positioning

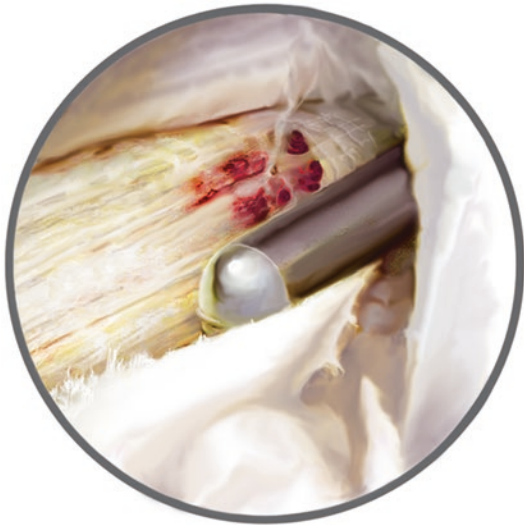The patient is positioned as described in ► Sect. 1.6.2.

■ Technique

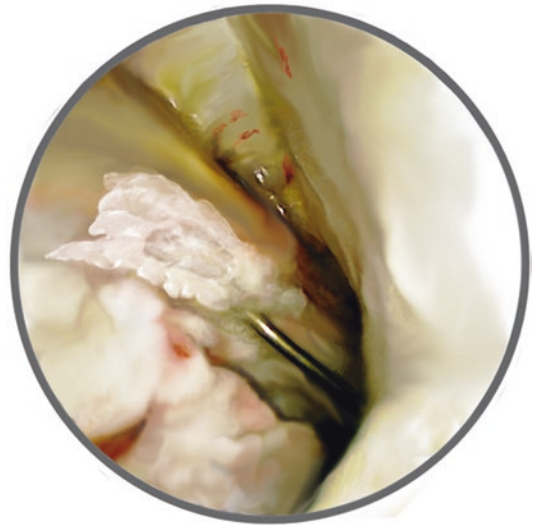
■ Figures 1.48, 1.49, 1.50, and 1.51.

Portals are made as described for midportion tendinopathy (▶ Sect. 1.6). As previously described, a space is created posteriorly and ante-

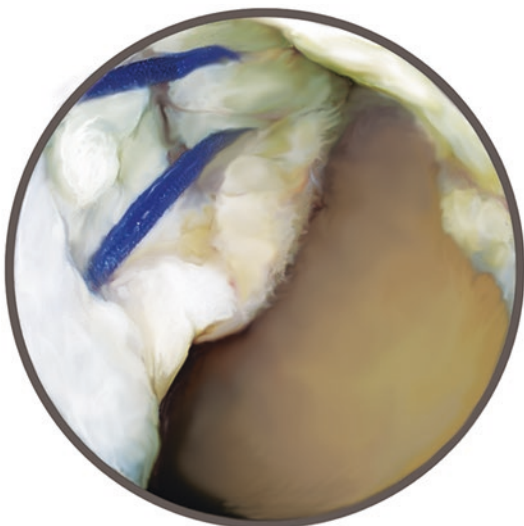
riorly using a mosquito clamp through the medial portals. The arthroscope is then inserted. The anterior neovascular tissue and nerve ingrowth tissue are resected with the shaver and the tendon is visualized. As noted on MRI imaging,



■ **Fig. 1.48** Intratendinous debridement. After resection of the peritenon (see below), degenerative partial ruptures are often noted with vascular ingrowth and xanthochromic degenerative tissue. This must be radically resected



■ **Fig. 1.50** Injection of ACP under arthroscopic visualization for biological augmentation. After removing all fluid, injection is performed into and around the entire degenerative portion of the tendon



■ **Fig. 1.49** Shortening peripheral stitch. The Achilles tendon is usually elongated, so the peripheral stitch should be placed in 20° of plantar flexion. Isolated tendon segments should not be resected



■ **Fig. 1.51** The entire debrided area is sealed with fibrin glue to «tubularize» the tendon under arthroscopic visualization. Isolated tendon segments should not be resected; instead, they should be added to the tendon structure. Any anterior adhesions are lysed with an elevator. The ankle is then plantar flexed (100–120°) to ensure that there is no central scar tissue that could lead to re-rupture

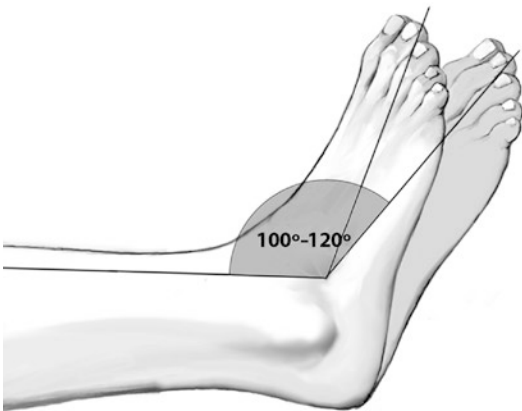
1.7 · Chronic Rupture

substantial defects with areas of severe hematoma and degenerative tearing can be seen at this point after debridement of the peritenon. These must be completely debrided without concern for weakness of the tendon. This naturally leads to significant weakness with a risk of rupture. As the tendon is additionally stretched and lengthened, it must be shortened after debridement in addition to protecting the tendon from complete rupture. This can be done using a percutaneous peripheral stitch (single or double knot technique depending on the residual stability of the tendon) using Fibertape; the same technique as for acute ruptures is used (► Sect. 1.3).

To counteract the elongation in the tendon, the suture is tied in maximum plantar flexion to shorten the tendon. Light debridement may again be necessary if any isolated areas of degenerative tendon remain. ACP (growth factors) is then injected in the degenerative area. The defect is then «sealed» using 0.5 ml of fibrin glue (Tissucol). The tissue is allowed to dry and thorough hemostasis is obtained with the hook electrocautery. An 8 mm Redon drain is inserted and the skin is closed. A posterior or anterior plaster cast is placed with the ankle in equinus.

■ Aftercare

Plaster splint for 2 days. After this, gentle range of motion exercises are started, moving from moderate to maximum plantar flexion. This will prevent adhesion of the tendon and allow for early tendon gliding (■ Fig. 1.52). The «stress bypass» procedure with Fibertape will ensure the



■ Fig. 1.52 Postoperative exercises: Mild plantar flexion to prevent anterior scar tissue, which could increase the risk of re-rupture

integrity of the portion of the tendon that underwent surgery. A Vario-Stabil shoe is used for additional protection of the Achilles tendon. Lymphatic drainage massage and independent gentle plantar flexion exercises are performed out of the shoe to preserve tendon gliding and provide an impulse for healing. In parallel, ACP (growth factors) is injected into the tendon and around the peritenon («bruising») after 14 days, 4 weeks and 6 weeks.

Weight-bearing as tolerated is allowed in a Vario Stabil therapeutic shoe. Heel lifts should be used for at least 6 weeks to allow for healing in a shortened position since the tendon has been slightly elongated. After 6 weeks, an ultrasound examination is performed. If good regenerative tissue is noted, physical therapy and strengthening (only in plantar flexion!) can be initiated in a seated position, in a standing position with both legs and against resistance. This is supplemented with proprioception and coordination training. If a patient is unsure, an additional 2 weeks can be spent in a Vario Stabil boot without a posterior support. This will allow the patient to be weaned from the boot physically and psychologically.

1.7.1 Double Turndown Flap Technique

■ Indications

Substance defects up to about 5 cm or defects that cannot be closed without tension using an open peripheral stitch and direct repair of the tendon stumps.

■ Contraindications

Primary Achilles tendon ruptures (higher complication rate due to compromised soft tissue).

■ Technique

■ Figures 1.53, 1.54, 1.55, 1.56, 1.57, 1.58, 1.59, 1.60, 1.61, 1.62, 1.63, and 1.64.

■ Aftercare

Lower leg plaster splint, partial weight-bearing (15 kg), thrombosis prophylaxis until wounds are well healed. After this, subsequent treatment in a Vario Stabil shoe. Full weight-bearing may be

Fig. 1.53 Medial incision from the calcaneal insertion to the musculotendinous junction. There is often a defect with unstable, atrophic scar tissue

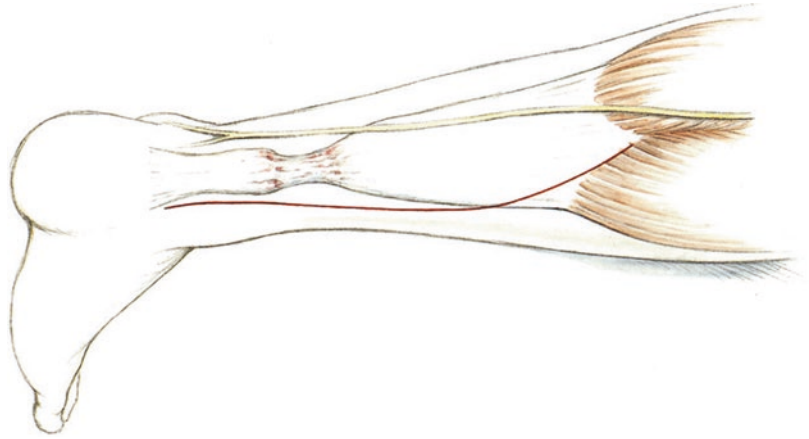


Fig. 1.54 The unstable tissue is detached at its distal aspect. Digital as well as sharp mobilization of the gastrocnemius-soleus complex is performed until the muscles are under tension at an appropriate length

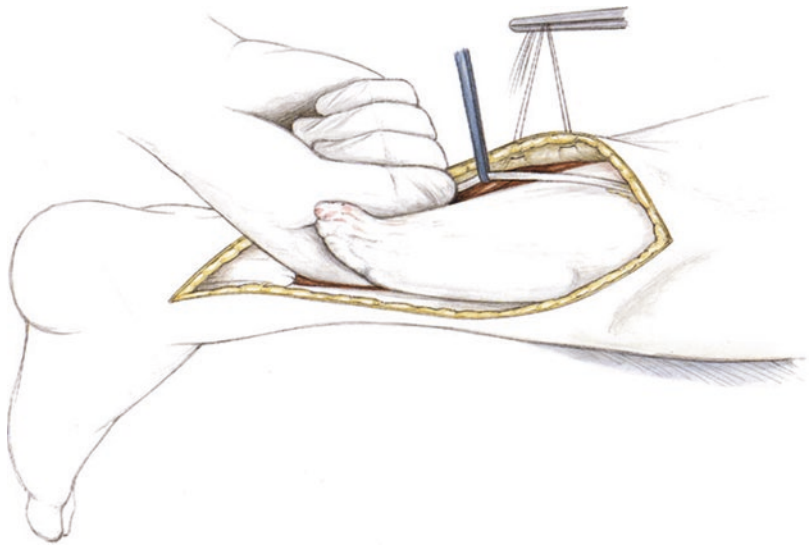
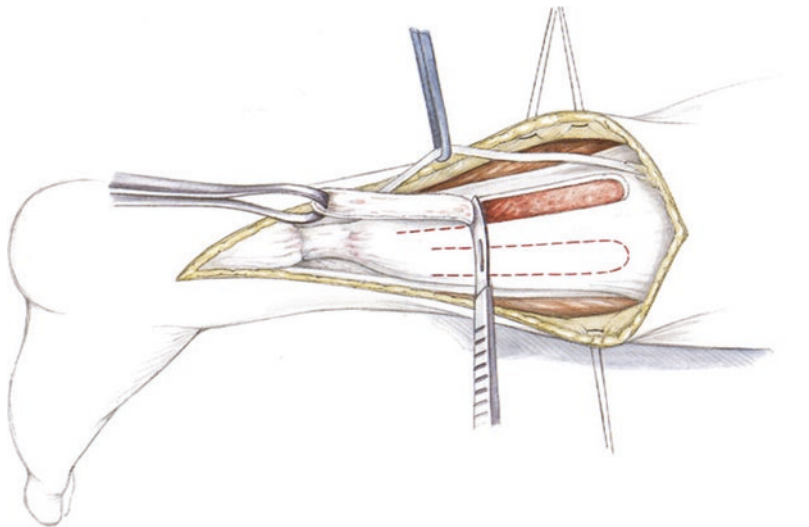
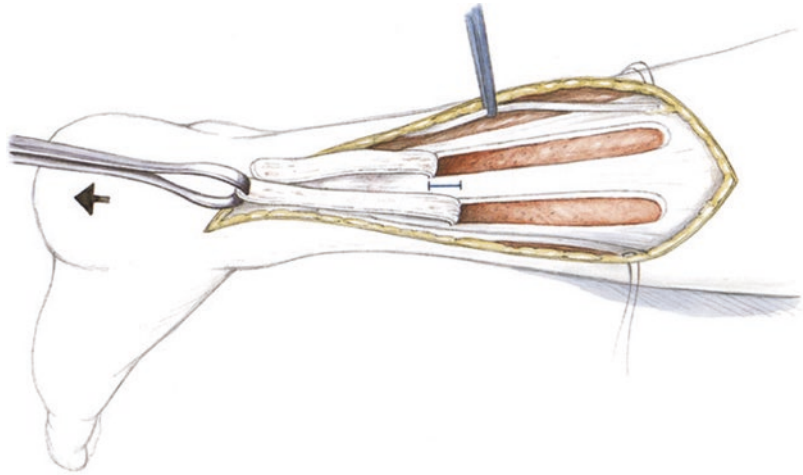


Fig. 1.55 A flap with a width of about 1 cm and the length of the aponeurosis is dissected out with a scalpel and pulled distally using an Ellis clamp

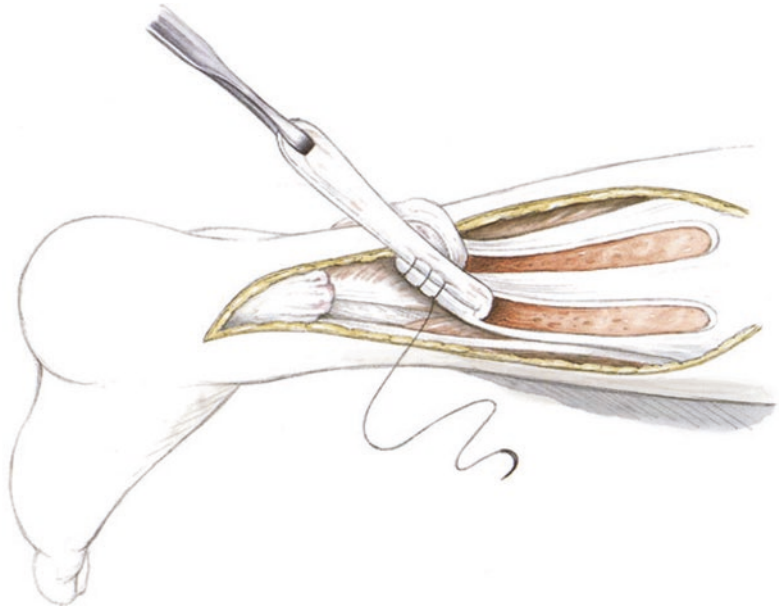

1.7 · Chronic Rupture

■ **Fig. 1.56** The flap folds should be offset by 1 cm. Otherwise, the tendon volume will be greatly increased at the site of the folds and closure can be difficult



■ **Fig. 1.57** The flap is sewed to the proximal tendon stump using a stable Krackow technique. The suture runs the entire length of the flap from distal to proximal and back distal again



■ **Fig. 1.58** The proximal and distal stumps are then held under tension in plantar flexion. The first flap is sewed to the distal stump under maximum tension using a Krackow technique

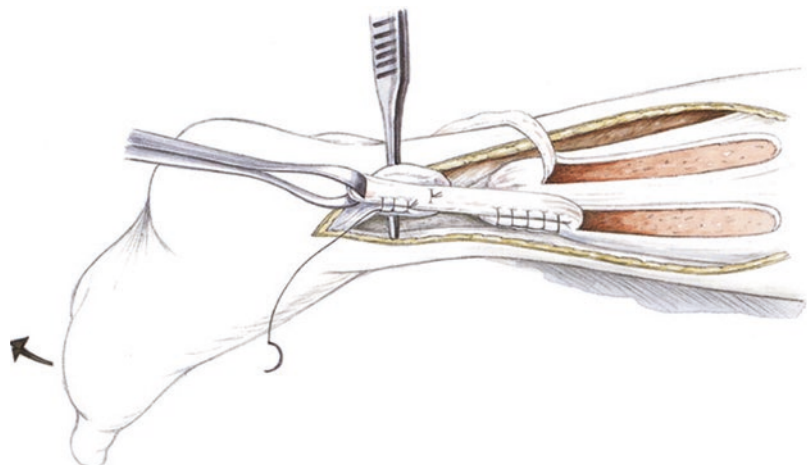


Fig. 1.59 The second flap, which was previously sewed to the distal aspect of the proximal stump, is now pulled over the distal tendon stump and secured with Krackow stitches

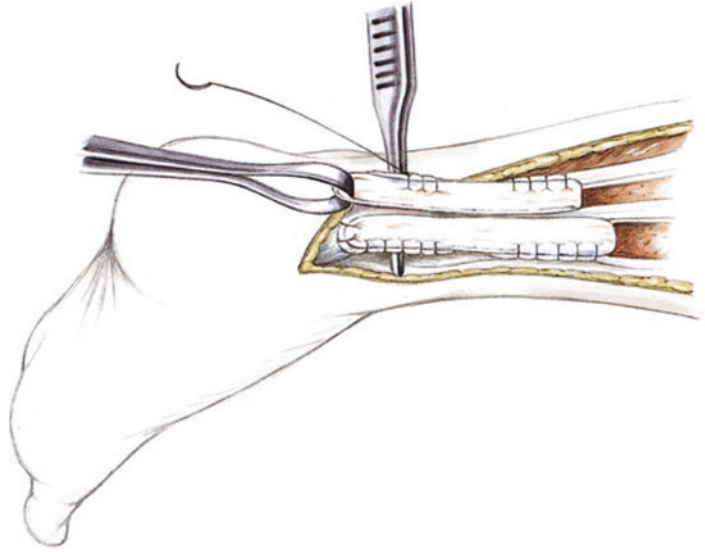


Fig. 1.60 «Tubularization» of the neotendon with running Krackow stitches at the posterior and anterior aspects of the tendon. This results in a round tendon structure

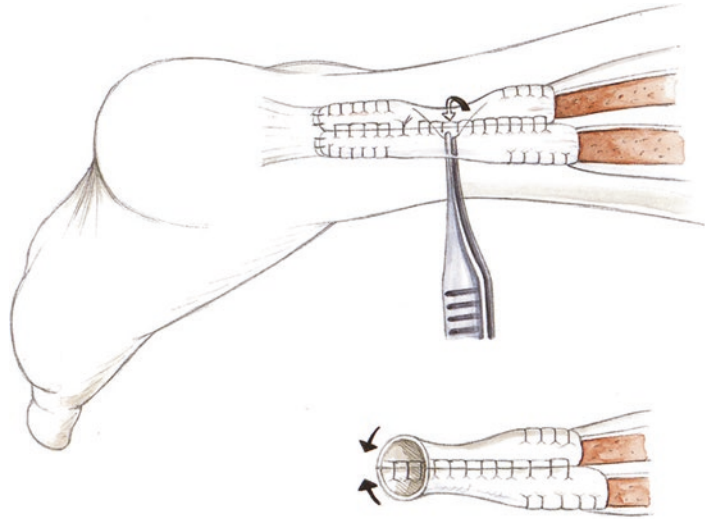
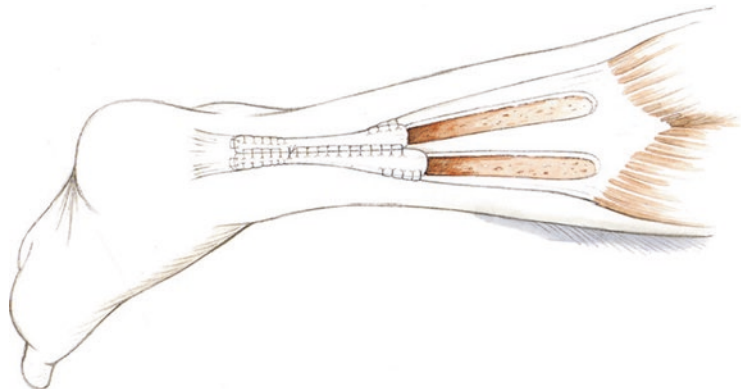
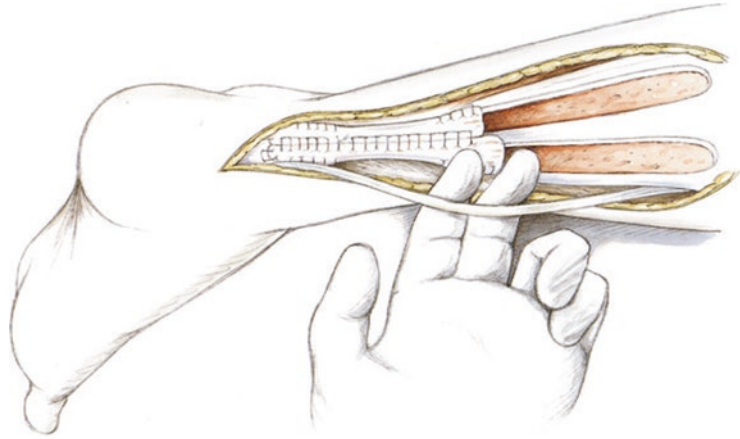


Fig. 1.61 Illustration of the Achilles tendon double turndown flap reconstruction

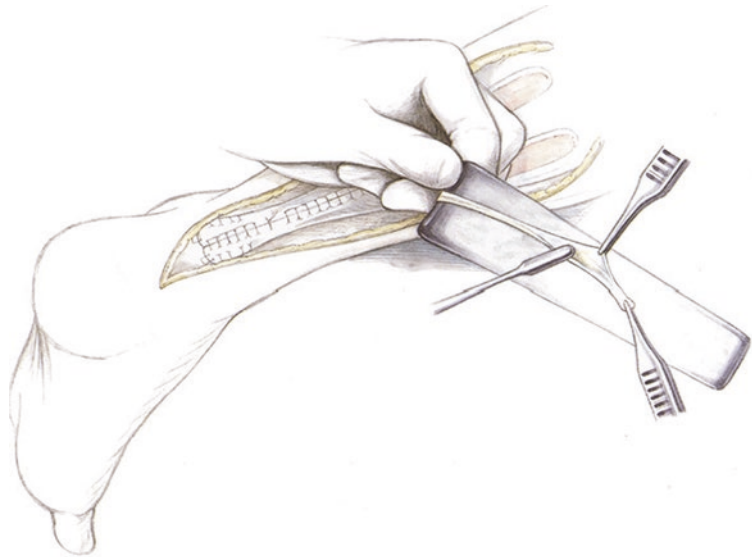


1.7 · Chronic Rupture

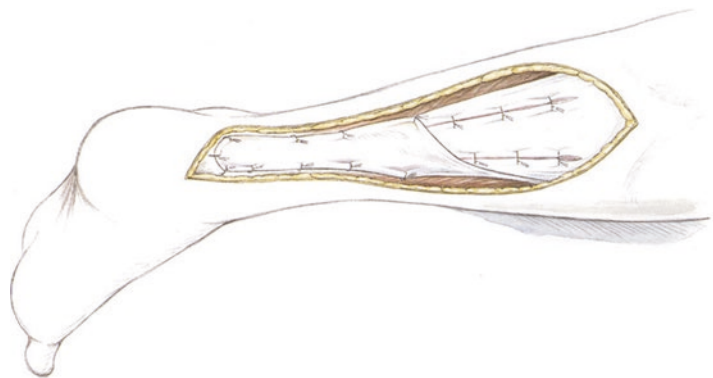
■ **Fig. 1.62** To improve tendon gliding, the plantaris tendon is detached distally



■ **Fig. 1.63** The plantaris tendon is fanned out on a Roux retractor using two small forceps and a small elevator



■ **Fig. 1.64** Plantaris tendon augmentation is performed with 4-0 sutures to cover the area that was previously sutured in order to achieve good tendon gliding. A Redon drain is inserted. The fascial and subcutaneous layers are closed with a running 2-0 PDS suture. The skin is sutured or stapled



limited by pain, but can be started immediately once the wound has healed. If a Vario Stabil shoe is used, coordination and isometric exercises can be performed (independent exercise program after a brief demonstration).

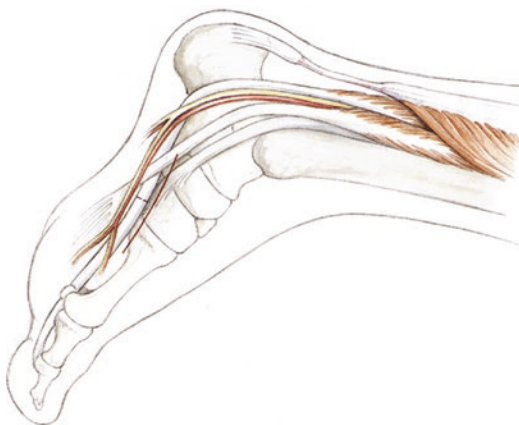After treatment with a shoe is completed (8–9 weeks depending on soft tissue healing), the ankle is gradually taken out of equinus.

The ankle should be gradually repositioned to avoid re-rupture and forceful dorsiflexion should be avoided to prevent plastic transformation of the neotendon, which could cause thinning and elongation of the tendon. Once healing is complete, the first 2 months should focus on strengthening the short foot flexors and the triceps surae muscle. If dorsiflexion is only minimally limited, complete range of motion should be achieved after 3–4 months with physical therapy.

1.7.2 Flexor Hallucis Longus Transfer

■ Indications

Large substance defects greater than 5 cm. Salvage operations after resection of the Achilles tendon due to prior infection. Surgery should only be performed after complete healing of the infection after debridement and plaster immobilization with the ankle in equinus. In extreme cases, an external fixator can be placed for 4 weeks in an equinus position. Tendon transfer will substan-



■ **Fig. 1.65** The tibialis anterior and tibialis posterior tendons are palpated. An incision is made from the navicular to the medial cuneiform

tially decrease the strength of the flexor hallucis longus and thereby the great toe («toe-off»). Because of this, the indications for this procedure should be considered carefully in active, young patients. It is technically easy and usually adequate to harvest the tendon up to the distal medial malleolus through a medial approach. For many ruptures and defects of the Achilles tendon, repair with local tissue when possible is preferred to augmentation with a flexor hallucis longus transfer.

■ Positioning

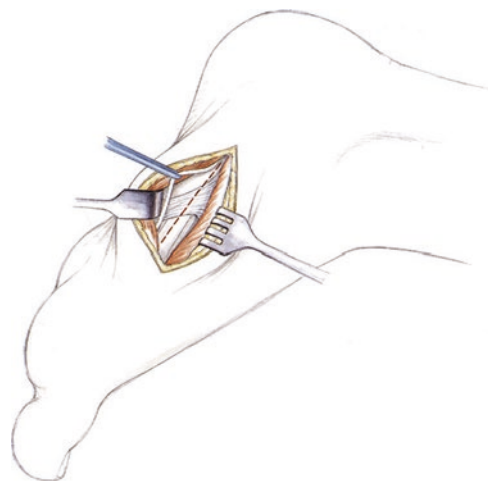
The healthy leg may be abducted slightly and lowered to facilitate access to the pulley site of the flexor hallucis muscle at the medial midfoot. The great and lesser toes are draped out separately (adhesive drape) for intraoperative testing of the flexor hallucis longus.

■ Technique

■ Figures 1.65, 1.66, 1.67, 1.68, 1.69, 1.70, 1.71, 1.72, 1.73, and 1.74.

■ Aftercare

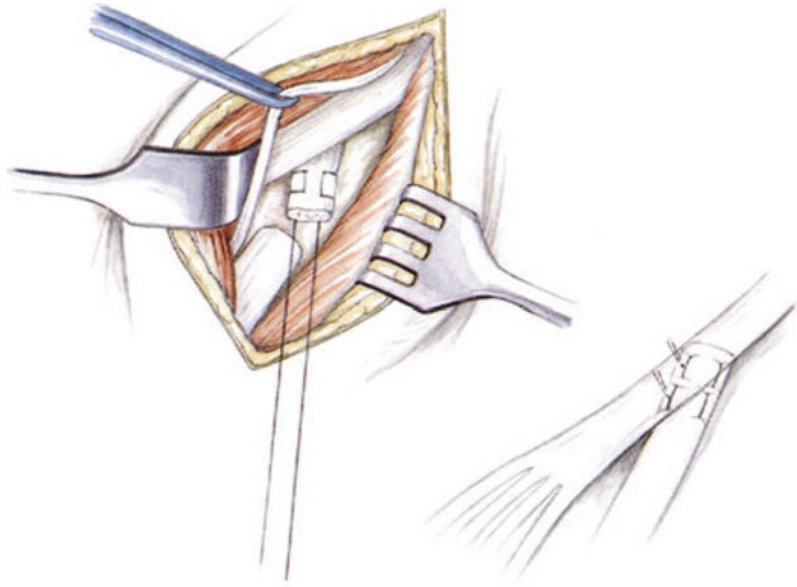
Similar to the double turndown flap technique, the ankle is immobilized in equinus with plaster for 14 days. After this, 8–10 weeks in a Vario-Stabil shoe. Gradually increasing partial weight-bearing begins after the 4th week.



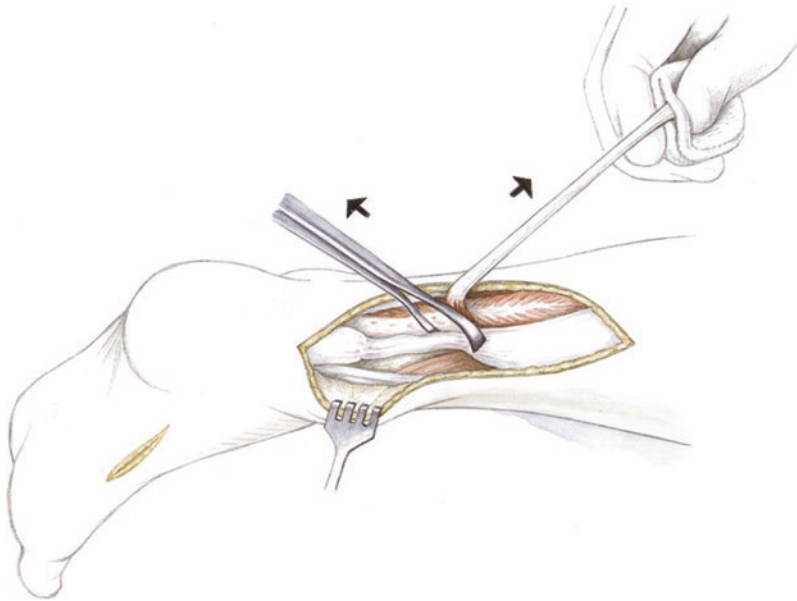
■ **Fig. 1.66** Dissection is carried to the node of Henry while retracting the abductor hallucis muscle and protecting the medial plantar nerve

1.7 · Chronic Rupture

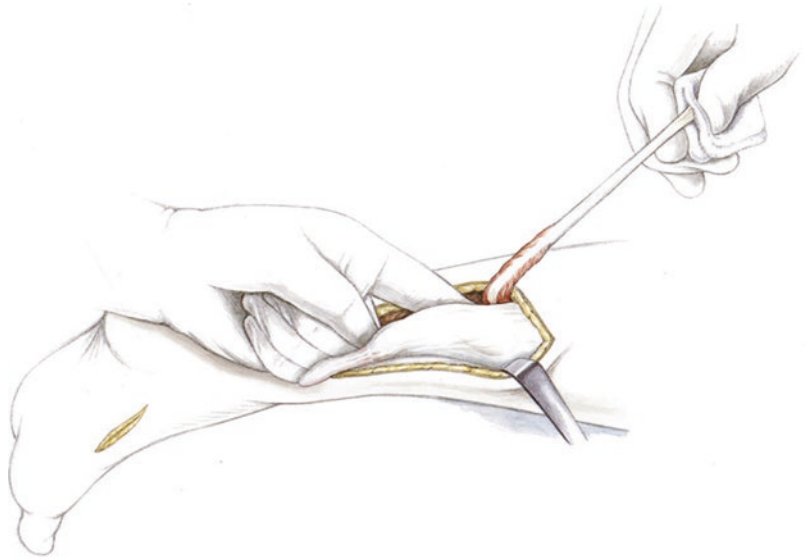
■ **Fig. 1.67** The flexor hallucis longus tendon is whipstitched. The tendon is first tested and tensioned with two sutures, then detached in the center



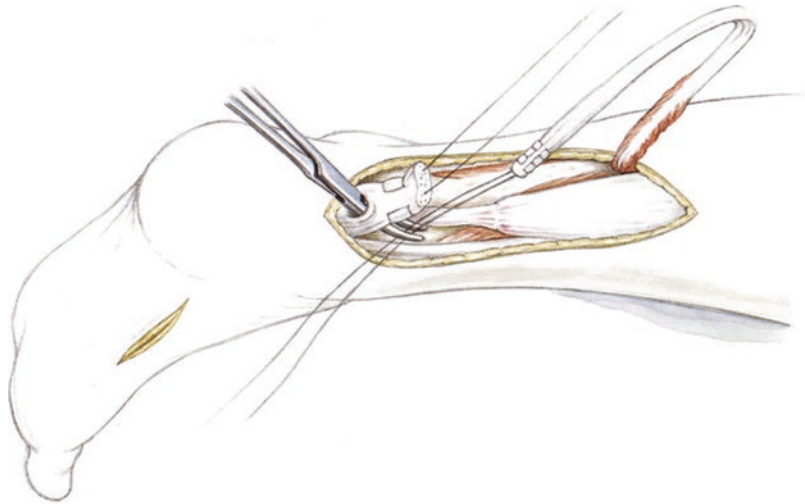
■ **Fig. 1.68** Pulling out the flexor hallucis longus tendon and placing it into a moist sponge



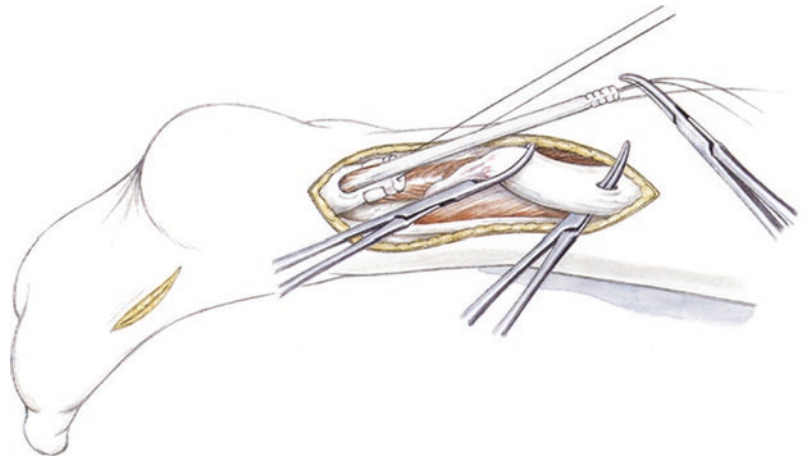
■ **Fig. 1.69** Detaching the unstable scar tissue at the junction to normal tendon while dissecting the proximal gastrocnemius-soleus complex for mobilization



■ **Fig. 1.70** Creating a tunnel in the distal stump and pulling the flexor hallucis longus tendon into the most stable portion of the distal stump with a Pulvertaft technique. The flexor hallucis longus tendon is first sutured with a Krackow technique

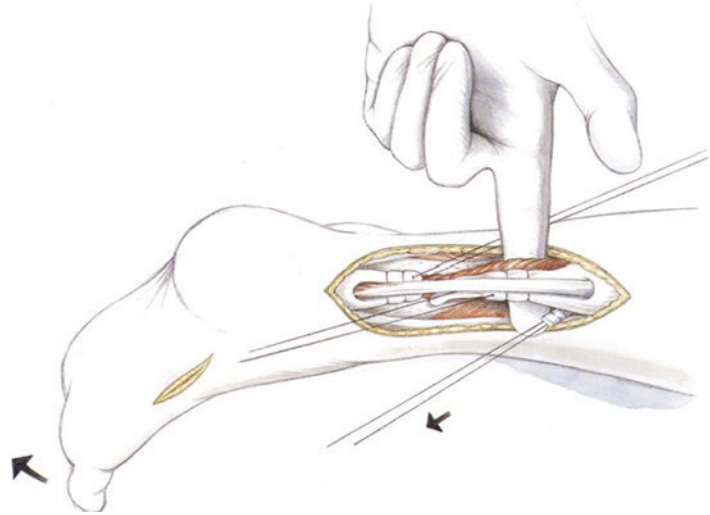


■ **Fig. 1.71** The flexor hallucis tendon is pulled through the proximal stump with an Overhold clamp. The foot is placed into equinus. The distal tendon stump is further tensioned with the flexor hallucis tendon

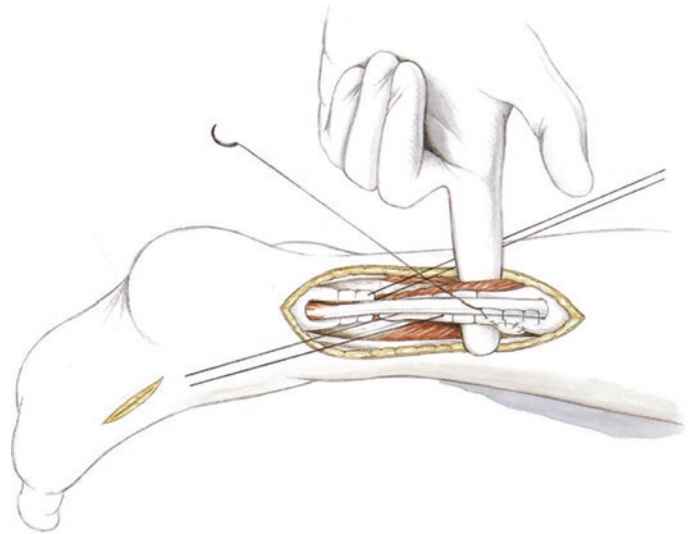


1.7 · Chronic Rupture

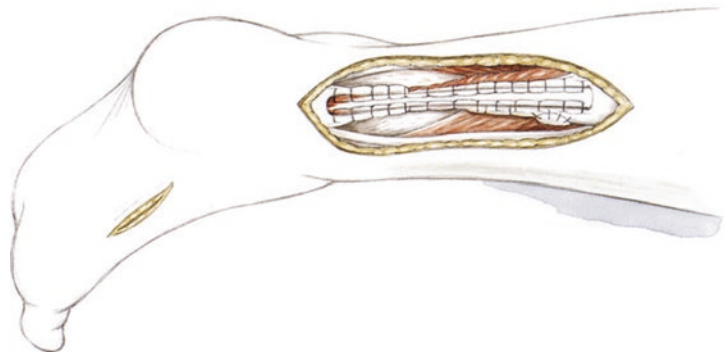
■ **Fig. 1.72** The neotendon is tensioned with maximum plantar flexion of the foot and the support of a bump



■ **Fig. 1.73** The flexor hallucis longus tendon is sutured with medial and lateral running Krackow stitches at the proximal tendon stump under maximum tension. The lead sutures in the tendon stumps are then tied



■ **Fig. 1.74** Running Krackow stitches around the flexor hallucis tendon augmentation. Any scar tissue in the defect area is included in the Krackow stitch



1.8 Semitendinosus Tendon Transfer for Tissue Defects and Infection of the Achilles Tendon (Endoscopic)

1.8.1 Tissue Defect

■ Indications

Reconstruction of the Achilles tendon with semitendinosus tendon graft may be indicated in any situation where there is a tissue defect. It is particularly useful in tissue with severe scar tissue and retracted soft tissues, as the soft tissues can be expanded with the inflow water pressure.

■ Contraindications

General contraindications include occlusive arterial disease. Severely limited mobility is a relative contraindication.

■ Surgical setup

If a tissue defect is present, the leg used for semitendinosus tendon graft harvest is prepared up to the thigh with a tourniquet in place. The tendon is harvested with a standard tendon stripper (the same that is used for anterior cruciate ligament reconstruction). The graft is then prepared on the operating room table using a Krackow technique. Muscle fibers are removed at this time.

The arthroscopic setup is the same as for all endoscopic procedures and the same instruments are used: 4.0 mm arthroscope, 5.0 mm shaver. If high-grade scar tissue is present, dissection to the lateral aspect of the tendon should be performed

carefully. This can also be dissected bluntly using a scissors under arthroscopic visualization.

■ Positioning

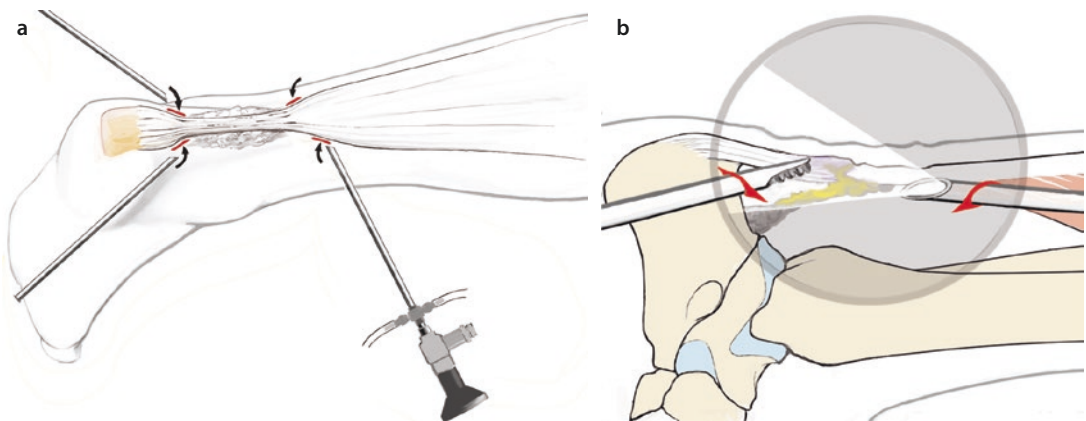
The positioning is as described in ► Sect. 1.6.2. The surgeon should ensure that the semitendinosus muscle is easily palpable in the popliteal fossa and that the tourniquet is far proximal enough to allow for easy posterior stripping of the semitendinosus tendon.

■ Technique

■ Figures 1.75 and 1.76.

After exsanguination, the portals for endoscopic surgery are made medially at the proximal aspect of the tendon. With use of the semitendinosus tendon, the portal is made somewhat closer to the aponeurosis. The incision should later be enlarged to 2–3 cm for suturing the semitendinosus tendon. A lateral-distal stab incision is made at the level of the medial portal. An accessory portal can optionally be placed medially at the level of the defect and an additional proximal portal can be made lateral to the suture near the aponeurosis for the second tendon flap. Dissection must be performed carefully to avoid injury to the sural nerve. For the PDS suture, medial and lateral stab incisions are made at the most distal aspect of the tendon, sometimes even transcalcaneally.

For chronic ruptures with a tissue defect and unstable scar tissue, the defect area is first debrided. The rupture site is dissected out and scar tissue is removed to obtain an understanding of the anatomic structures.



■ Fig. 1.75 a Debridement and tenolysis over the medial and lateral (caution: sural nerve) portals. b Distal tenolysis of the stump so that it is freely mobile

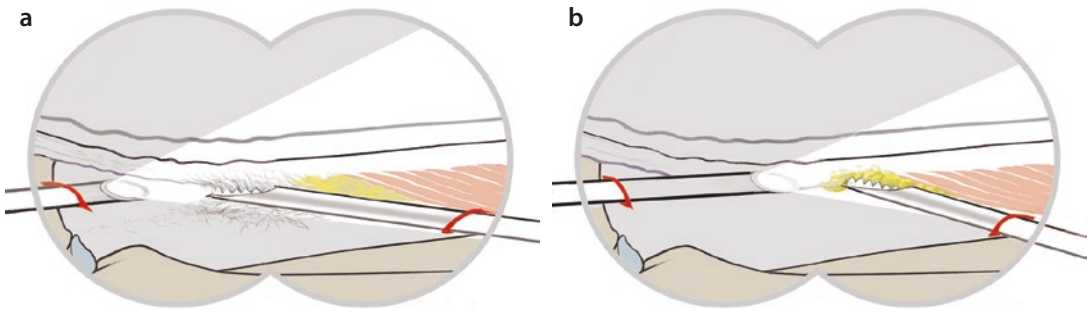


Fig. 1.76 a Proximal tenolysis. b Extremely careful lysis of the musculature. The proximal gastrocnemius-soleus-Achilles tendon complex must be mobilized again

To regain a functional gastrocnemius-soleus-Achilles tendon complex, mobilization of the distal and proximal tendon stumps is critical. At the proximal aspect, there are often anterior adhesions to the tendon if the defect has been present for a long time. It is essential to endoscopically mobilize the gastrocnemius-soleus-Achilles tendon complex distally and proximally.

Medial dissection must be performed very carefully to avoid injuries to the tibial artery or its branches.

■ Tendon harvest

■ Figures 1.77, 1.78, and 1.79.

After mobilization, the semitendinosus muscle is visualized with a skin incision just medial to the palpable semitendinosus tendon proximal to the popliteal fossa. The tendon is grasped with an Overhold clamp. Scissors are used to dissect proximally and distally. A tendon stripper (the same as that used for cruciate ligament surgery) is inserted and the tendon is stripped proximally. The tendon is re-grasped with the Overhold clamp and stripped distally. This can be somewhat more difficult at the insertion on the medial

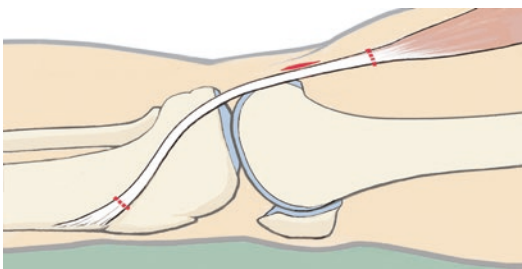


Fig. 1.77 2–3 cm long skin incision proximal to the popliteal fossa parallel to the semitendinosus tendon

tibial plateau. After this, the tendon is tensioned in the same way as for cruciate ligament surgery and sutured with FiberWire on both sides using a Krackow technique.

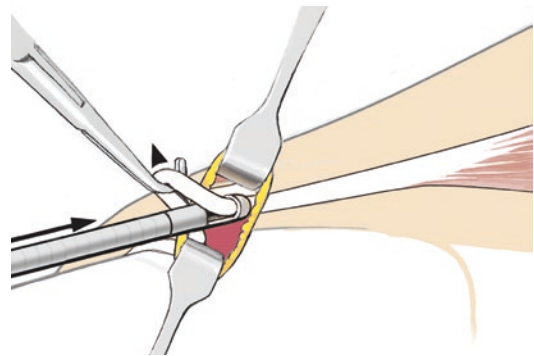


Fig. 1.78 Dissection of the tendon and insertion of a tendon stripper

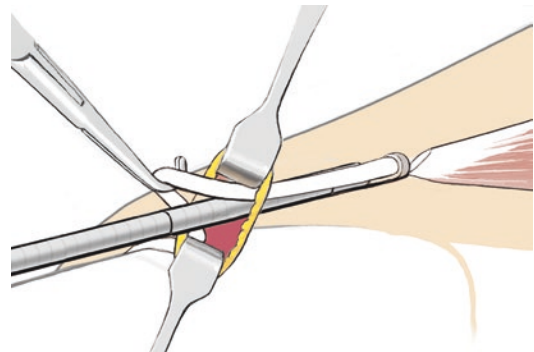


Fig. 1.79 Just as with cruciate ligament surgery, the tendon is first detached at the musculotendinous junction. The distal tendon is then detached, which is sometimes more difficult at the pes anserine. The knee is flexed at this point

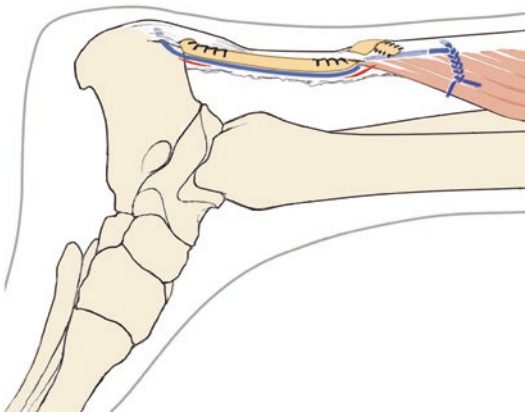
■ Peripheral augmentation stitch (Fibertape)

To ensure stable healing of the graft, a Fibertape is first placed transcalcaneally from medial to lateral. The drill tunnel should not be placed too far anteriorly to avoid changing the biomechanics of the insertion. The Fibertape is then pulled into the aponeurosis proximal to the tendon transfer site. The suture is then tied with the foot in equinus.

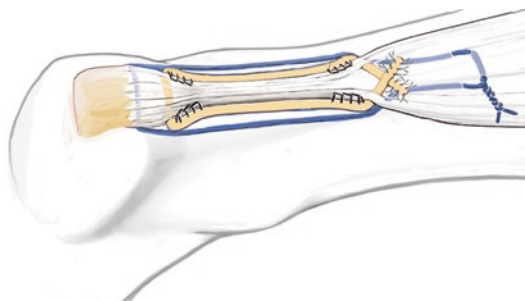
■ Semitendinosus transfer

■ Figures 1.80 and 1.81.

The distal tendon stump is held with an Ellis clamp and mobilized medially and laterally



■ **Fig. 1.80** Sagittal view: Complete reconstruction of the tendon after mobilization of the gastrocnemius-soleus complex. Augmentation may be performed transcalcaneally depending on the quality of the distal tendon stump. Fibertape augmentation is performed with the foot in maximum plantar flexion. The Achilles tendon is then reconstructed with semitendinosus tendon transfer

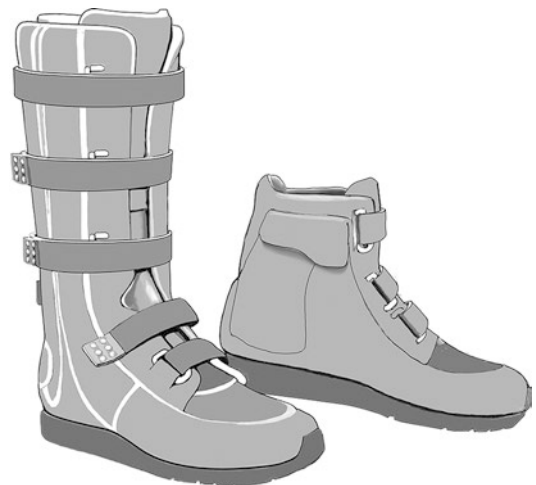

■ **Fig. 1.81** Posterior view: Reconstruction with semitendinosus transfer

close to the calcaneus, creating space for the tendon graft to be pulled through. The tendon graft is pulled through from medial to lateral with an Ellis clamp. An awl is then used to pull the graft transversely through the aponeurosis (from medial to lateral back to medial). The graft is firmly tensioned with the foot in plantar flexion and the tendons are sutured with FiberWire (2-0) at the aponeurosis. An additional stitch is placed at the distal aspect of the repair, where the semitendinosus was brought through the Achilles tendon stump, to function as a rip-stop stitch. Any protruding tendon is resected. The reconstructed tendon is visualized arthroscopically. ACP is injected primarily at the distal and proximal areas of tendon transfer. The portals are closed and a plaster splint is applied.

■ Aftercare

Plaster splint for 2 days. Then –just as for a chronic rupture (▶ Sect. 1.7) –gentle plantar flexion exercises are performed with the foot in equinus. Growth factors are injected (ACP) at 2, 4 and 6 weeks. A Vario-Stabil shoe is worn for 6 weeks, just as with treatment of chronic ruptures (■ Fig. 1.82).



■ **Fig. 1.82** Functional aftercare in a Vario Stabil shoe. Heel lift and a posterior plastic brace are used to hold the foot in plantar flexion. Weight-bearing as tolerated is permitted in the shoe after the incision has healed. ACP is injected at 2, 4 and 6 weeks

1.8.2 Infection

Infection of the Achilles tendon is the most severe complication after Achilles tendon surgery. Large portions of the tendon are often resected, as this is the only option to treat infection due to the poor circulation in this area. This often leads to multiple surgeries with large incisions and severe scar tissue formation at the skin. Skin flaps by plastic surgery are often needed. Since 2011, treatment with an endoscopic technique has allowed for a completely new approach. In the presence of infection, the tendon is gradually and completely removed endoscopically with small rotating shavers. Copious irrigation with 20 liters of fluid allows infections to be treated in a substantially improved way. The skin is not compromised due to the minimally-invasive endoscopic technique. After resection is complete, antibiotic-containing sponges are placed. The course of healing is then carefully monitored. If the infection is cleared in normal fashion with administration of antibiotics, semitendinosus tendon transfer can often be performed as described above after 2–4 weeks. Prior to tendon transfer, the entire wound is again completely lavaged and any residual tissue is removed with the small rotating blade. This technique has resulted in healing and clearance of infection in every case since 2011. Subsequent reconstruction of the Achilles tendon complex has allowed for restoration of moderate athletic abilities.

■ Indications

For infections, treatment with an endoscopic-assisted tendon transfer can only be performed if the skin is grossly intact (no fistulas, etc.) and there are no large areas of complete skin necrosis.

■ Contraindications

Large skin defects that require plastic coverage. A semitendinosus reconstruction can later be performed after skin coverage is in place. Open, putrid injuries with soft tissue defects require open debridement. A flap transplant should always be performed subsequent to this. The principles are the same as for open treatment of infection.

■ Surgical setup

This is completely identical to the setup for semitendinosus tendon transfer. However, for infections, extensive debridement must be performed

first. A portal can be placed at the distal aspect of the fistula. The surgeon should be careful not to injure the neurovascular bundle anteriorly, particularly if the retinaculum has been violated. The sural nerve and small fibular artery should be protected laterally. Instruments: 5.0 mm shaver and 4.0 mm arthroscope. Small mosquito clamps can be used to remove suture material. Genta-Coll antibiotic sponges can also be placed if the infectious organism is susceptible.

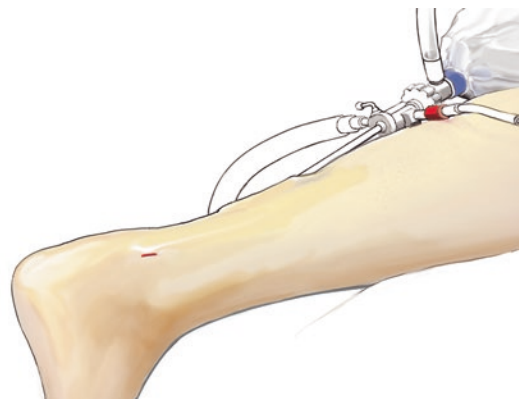
■ Positioning

The positioning and antibiotic prophylaxis are as described in ► Sect. 1.6.2.

■ Technique

The portals are the same as for reconstruction with a tissue defect. However, if a fistula is present, it should be excised as long as it is not at the site of a potential medial or lateral portal. The shaver is used to remove necrotic tendon tissue proximally and distally, with radical and complete resection up to the tendon stumps. The stumps are mobilized. For active infections, gentamicin sponges are inserted at the end of surgery if the organism is susceptible. A Redon drain is placed. The portal sites and the excised fistula, if present, are closed. At least 15–20 liters of lactated Ringer solution should be used for irrigation. If any additional necrotic tissue is seen, it should be resected until debridement is complete (■ Fig. 1.83).

After a week, a second irrigation procedure is performed. Depending on the infection, lab values, the appearance of the wound and



■ Fig. 1.83 Posterior and anterior debridement while maintaining the anterior retinaculum and protecting the sural nerve laterally. All necrotic tissue is radically resected. Copious irrigation with lactated Ringer solution

antibiotic susceptibility, tendon transfer can be performed no sooner than 1–2 weeks. At the time of the second surgery, an additional extensive debridement is performed. If it appears that the infected tissue is not adequately debrided, an additional complete debridement is performed. Semitendinosus transfer is then performed after an additional 2-week interval as described above.

1.9 Haglund Exostosis and Insertional Tendinopathy

■ Indications

Resection of the prominence at the calcaneal tuberosity with insertional tendinopathy of the Achilles tendon and often with bursitis is indicated after at least 6 months of physical therapy exercises, flexor muscle chain stretching and, possibly, ACP injections and shock wave therapy.

■ Contraindications

For severe circulatory disorders or relative contraindications such as cardiac disease or severe diabetes, the interval for conservative treatment should be lengthened and surgery should not be pursued aggressively.

■ Surgical setup

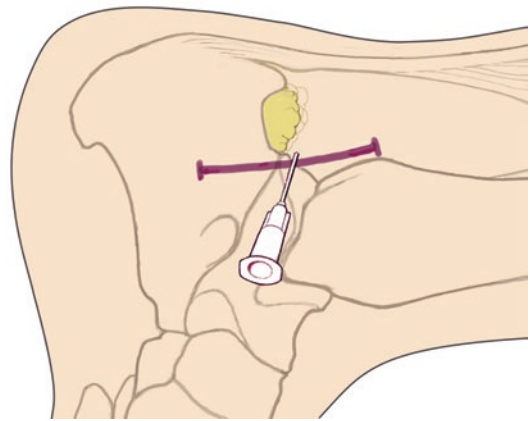
A normal arthroscopy set (4 mm) is used for arthroscopic procedures at the Achilles tendon as well as a straight osteotome, a power rasp for smoothing the distal aspect of the resected surface facing the tendon and a 5.0 shaver for debridement. The Haglund exostosis is removed through a minimally-invasive portal. Debridement is performed and the resection site is smoothed with a power rasp up to the distal insertion site. Provisional skin closure is then performed followed by additional endoscopic debridement of the Achilles tendon up to the midportion. At the anterior aspect of the tendon, debridement is carried to the inferior portion of the soleus muscle.

■ Positioning

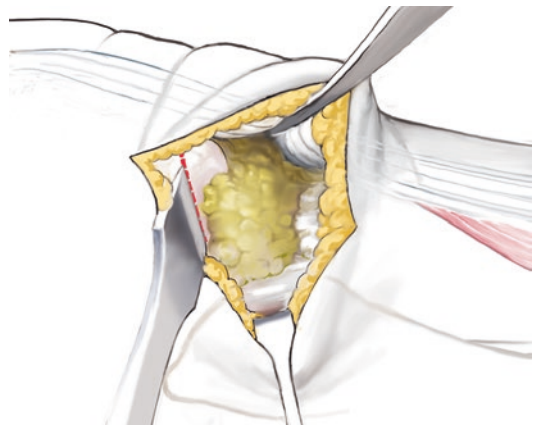
Positioning and antibiotic prophylaxis are as described in ► Sect. 1.6.2.

■ Technique

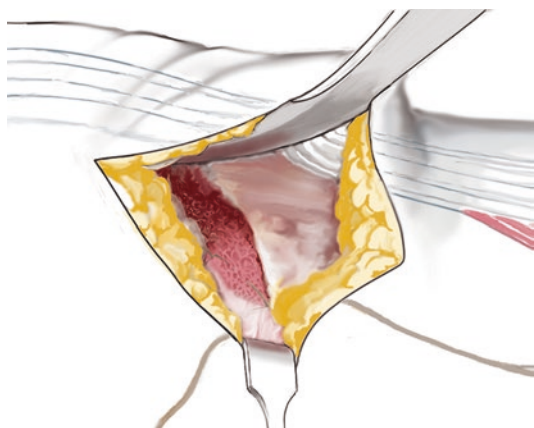
■ Figures 1.84, 1.85, 1.86, 1.87, 1.88, and 1.89.



■ Fig. 1.84 Lateral portal for access to Kager's triangle and the Achilles tendon. The Haglund exostosis is marked with a #1 needle



■ Fig. 1.85 The Haglund exostosis is visualized using a small Hohmann and a Langenbeck retractor. The exostosis is removed with a #10 osteotome up to the distal insertion of the Achilles tendon



■ Fig. 1.86 The resection site is smoothed with a rasp or a power rasp, particularly at the medial aspect

1.9 · Haglund Exostosis and Insertional Tendinopathy

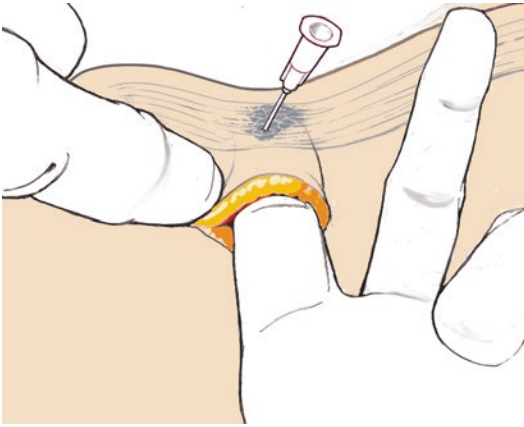


Fig. 1.87 The firm fibrotic areas of Achilles tendon degeneration are palpated and marked with a needle. These firm areas of degenerative tissue can also be removed with a #11 scalpel

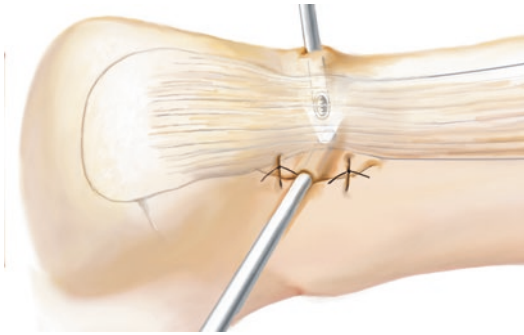


Fig. 1.88 The lateral incision is partially closed with temporary sutures for the subsequent endoscopic procedure




Fig. 1.89 Debridement of the degenerative tendon with a sharp shaver. This sometimes extends proximal to the midportion region

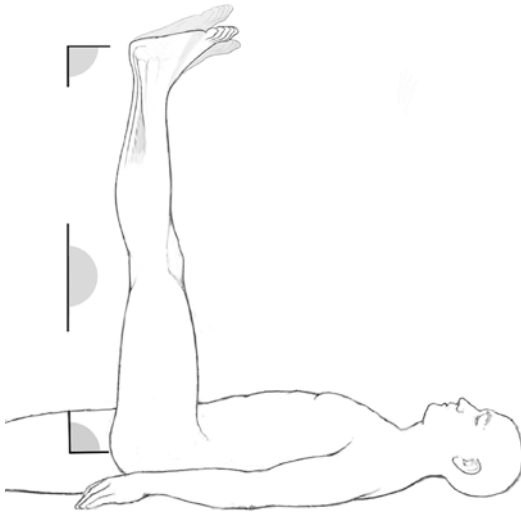
After the bone resection is complete, the medial side is carefully inspected through the lateral portal to look for residual bone. Denervation is performed with a ball electrocautery at the lateral and medial periosteum of the calcaneus. During this mini-open portion of the procedure, the Achilles tendon is palpated for firm scar tissue. If present, the tissue is removed with a #11 scalpel until soft tissue structures are encountered. To facilitate this, the tendon is held in eversion with a small three-pronged rake. The wound is then closed at the center of the 2 cm incision with external sutures. The arthroscope is then inserted up to the medial side. A second portal is created here with a #11 scalpel. The junctional areas of the Achilles tendon are extensively debrided once again arthroscopically down to the insertion site.

The camera is focused on the tendon from posterior and the entire Achilles tendon is smoothed again throughout the debrided area. As anterior adhesions are often present at the site of the midportion tendinopathy, additional debridement of the anterior vessels, ingrowth tissue and anterior periosteum is performed through the medial and lateral portals over a length of 4–5 cm or even 6 cm. The distal tendon insertion is again thoroughly debrided with various instruments.

A collagen sponge is placed at the site of the calcaneus osteotomy and resection to achieve rapid hemostasis. Any bleeding is coagulated with the electrocautery. The fascia and subcutaneous layers are sutured. A Redon drain (8 mm) is inserted laterally along the Achilles tendon to avoid injury to the sural nerve.

After layered wound closure, growth factors (ACP) are injected into the debrided area and into the osteotomy site to achieve rapid hemostasis. Early hemostasis using a collagen sponge and growth factors around the calcaneal insertion will help to avoid long-term edema formation at the resection site.

For Haglund exostosis and insertional tendinopathy, the pain radiates into the bones and mechanical obstruction is caused by the calcaneus. This prominence is removed with an osteotome through a minimally-invasive incision (2 cm) to obtain optimal resection of the bone. This can also be performed endoscopically, but this takes more time and leads to subsequent ossification. Because of this, the endoscopic-only



■ **Fig. 1.90** Stretching the flexor muscle chain against the wall while supine or on stairs. The hip is flexed to 90°, the knee is fully extended and the ankle is flexed to 90°

technique no longer seems advisable. After resection of the bone, the subsequent procedure is performed endoscopically. Areas of tendon degeneration can be removed in optimal fashion using the magnification provided by the arthroscope. Midportion tendinopathy is often present as well, in which case anterior debridement of the Achilles tendon is performed (neovascularization and nerve ingrowth tissue) as well as debridement of the peritenon.

■ Aftercare

Partial weight-bearing for 14 days, range of motion exercises and a physical therapy program (■ Fig. 1.90). After 14 days, weight-bearing is advanced to full and athletic activities can gradually be advanced with cycling and water jogging. Growth factors (ACP) are also injected into the area three times to accelerate the healing and remodeling processes of the tendon.

1.10 Arthroscopic Calcaneus Plasty

■ Indications

This is only indicated for small Haglund exostoses that present with severe bursitis and minimal degenerative changes of the Achilles tendon insertion (usually high-level runners).

■ Contraindications

For large Haglund exostoses with severe bursitis and severe degenerative insertional changes (calcifications, etc.), open resection and debridement should be performed.

■ Specific patient information

Although the minimally-invasive procedure can rapidly lead to decreased pain, weight-bearing through the joint should be progressed carefully.

■ Surgical setup

The surgery can be performed under tourniquet if desired. The type of anesthesia can be decided by the patient. However, it should be noted that prone positioning with regional anesthesia can be very difficult for obese patients. For patients with obstructive lung disease, the surgery can be performed in a lateral position. The principle of the surgery is minimally-invasive resection of the Haglund exostosis and the pre-Achilles bursa without a traumatic open incision. Due to the potential for hematoma formation after bone resection, a hemostatic sponge and a Redon drain (10 Fr) should be used.

■ Positioning and perioperative management

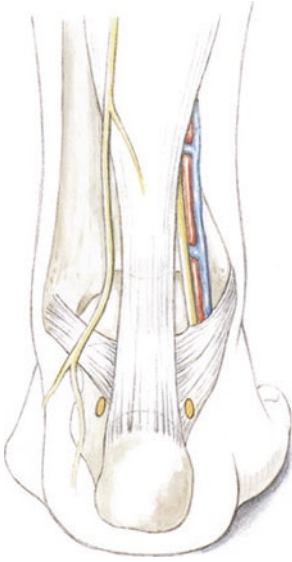
A standard prone position is used. The down leg is padded at the peroneal nerve. The feet hang just off the edge of the operating room table and the nonoperative leg is lowered slightly. If hair is present in the surgical field, the area is shaved. Preoperative antibiotic prophylaxis is provided with a third-generation cephalosporin. Perioperative thrombosis prophylaxis is provided with low-molecular-weight heparin injections at the time of induction.

■ Technique

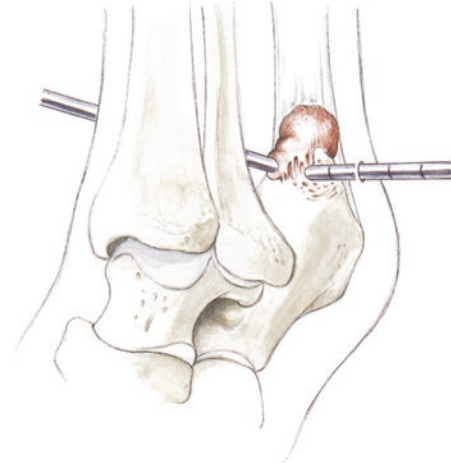
■ Figures 1.91, 1.92, 1.93, 1.94, and 1.95

■ Aftercare

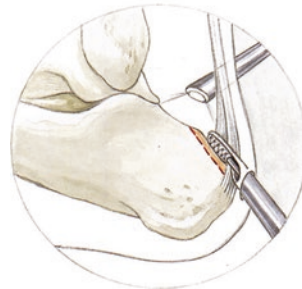
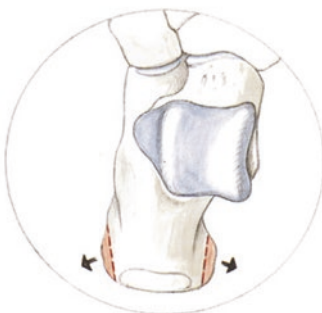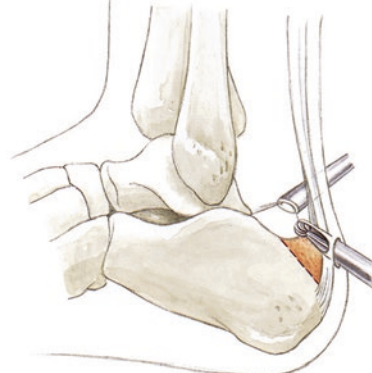
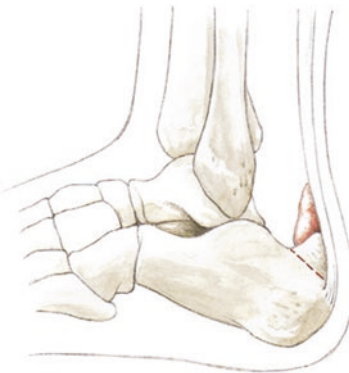The leg is elevated. On the 2nd postoperative day, ankle stretching exercises are performed with the knee flexed to relax the gastrocnemius complex. Diclofenac or other NSAIDs (such as ibuprofen) are prescribed for 2–3 weeks. Partial weight-bearing (15 kg) is continued for 7–10 days. In the early phase, the leg should be elevated frequently, as swelling can occur. The sutures are removed after 7–10 days.



■ **Fig. 1.91** Portals for resecting the Haglund exostosis. The portals are palpated 5 mm above the calcaneal insertion medial and lateral to the Achilles tendon. The calcaneal tuberosity should be palpated

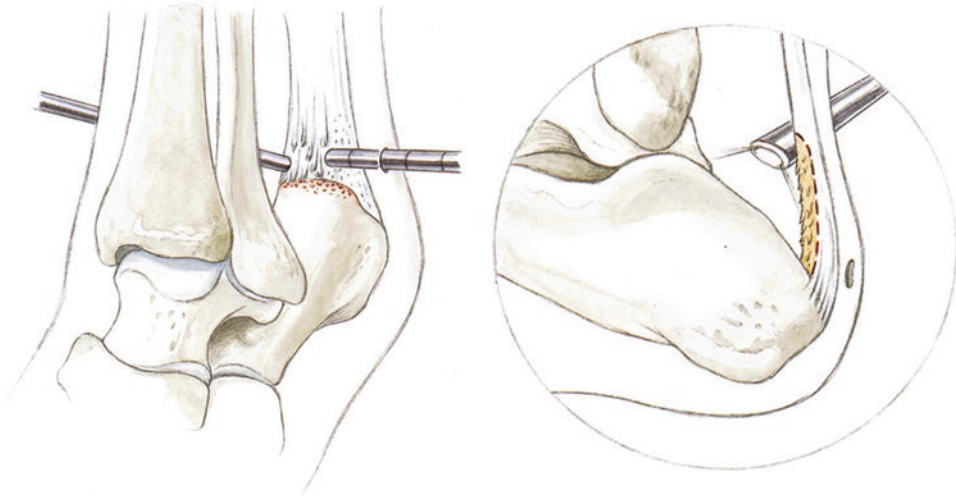


■ **Fig. 1.93** After resection of the bursa with a shaver, the calcaneus is visualized. Debridement is carried along the Haglund exostosis until the Achilles tendon insertion is reached. A needle can be inserted percutaneously at the beginning of the procedure to monitor the amount of resected tissue. After resection, fluoroscopy is checked



■ **Fig. 1.92** Resection of the bursa with a shaver. The Haglund exostosis should be resected until the tuberosity drops smoothly to the Achilles tendon insertion. It is also necessary to remove any medial or lateral osteophytes, which can be performed using a 5 mm osteotome. Release of the Achilles tendon is also necessary, sometimes with denervation of the lateral Achilles tendon fibers

■ **Fig. 1.94** Resection with a burr. The surgeon should take particular care to turn the protective hood towards the Achilles tendon. The burr is used at the site of the Haglund exostosis, resecting 4–5 mm of bone. Subsequent resection is performed with a power rasp until the resection is optimal



■ **Fig. 1.95** Debridement of the Achilles tendon. At first, any areas of macroscopic changes are resected with a shaver. The tendon is then palpated with a probe.

Needling with a Chondropick can be performed under arthroscopic visualization if necessary

Lateral Ankle Ligament Procedures

- 2.1 General Notes – 42
- 2.2 Internal Brace – 42
- 2.3 Periosteal Flap Transfer – 43
- 2.4 Arthroscopic Broström Technique – 44

2.1 General Notes

■ Indications

Chronic rotational instability of the lateral ankle ligaments with significant residual perceived instability despite stabilizing proprioceptive training and physical therapy with peroneal strengthening. Clinical instability is usually graded as 1 to 2+. This can also be performed as a revision surgery after ligament repairs and reconstructions.

■ Contraindications

If a periosteal flap transfer has already been performed, the periosteum usually cannot be used again. Instead, plantaris-gracilis tendon transfers should be recommended to reconstruct the defective structures.

■ Specific patient information

The patient is placed into a plaster cast for 7–10 days to assist with wound healing. After this, the patient is fitted into a stabilizing brace to prevent supination. The patient can weight-bear as tolerated in the brace based on pain and wound healing. To improve tendon healing, growth factors are injected. Strengthening is performed with cycling and water jogging.

■ Surgical setup

The procedure can optionally be performed under tourniquet. The type of anesthesia is based on the wishes of the patient.

■ Positioning and perioperative management

Supine with a wedge placed under the ipsilateral pelvis/thigh. The leg can be stabilized with a small bump or silicone cushion («camel») at the level of the calf. Standard antibiotics and perioperative thrombosis prophylaxis are given based on surgeon preference.

■ Technique

For patients with congenital tendon and ligament laxity, augmentation with an Internal Brace has proven to be useful. This provides primary stability by implanting a FiberWire in an anatomic position. I use the Internal Brace in addition to periosteal flap transfer and concurrent treatment of cartilage lesions with reconstruction and the AMIC technique. The use of the Internal Brace allows for sufficient stability after 14 days to allow for early dorsiflexion and plantar flexion range of motion

exercises at the ankle. This allows for regeneration and healing of the reconstructed cartilage.

■ Aftercare

Splint for 7–10 days. After the wound has healed, a brace is worn. If pain has adequately subsided, the patient can weight-bear as tolerated. Frequent pronation exercises, proprioceptive exercises and peroneal contraction exercises are performed independently and with a physical therapist. As rehabilitation progresses, mini-trampoline, balance board and soft cushion exercises can be added to improve proprioception and stability. Jogging on even ground is not permitted after reconstruction until the 8th postoperative week. If motion is limited or if a complete tendon transfer was performed, growth factors and ACP are injected after 14 days or 4 weeks.

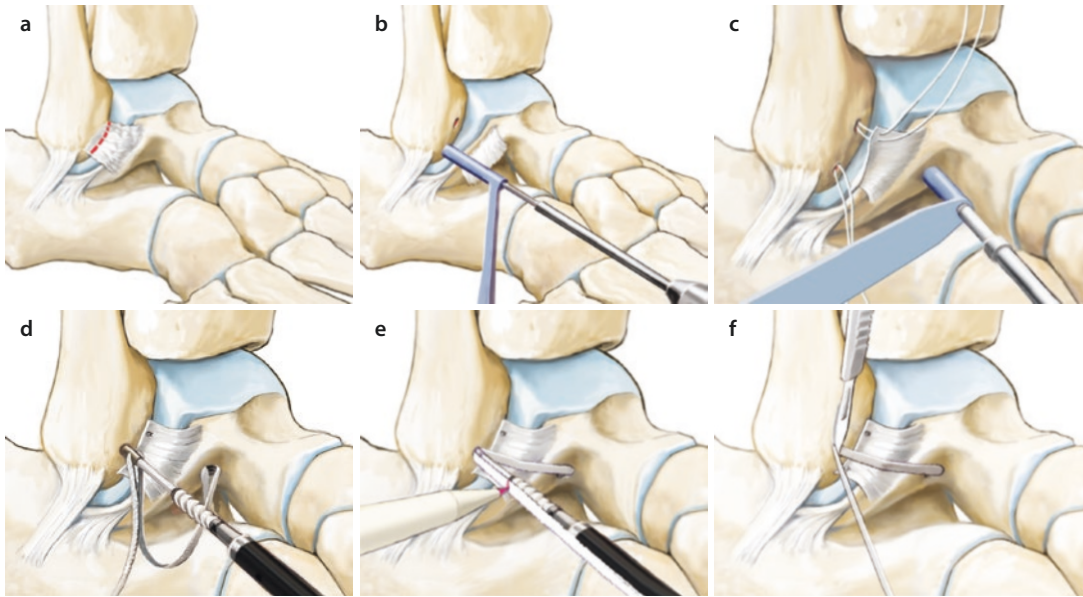
2.2 Internal Brace

The Internal Brace is an augmentation for the Broström procedure or for large defects treated with a periosteal flap technique.

An incision is made at the center of the fibula. Dissection is carried distally to the talar bone-cartilage junction to visualize the talar insertion. The tip of the fibula is also visualized. For the Broström procedure, the drill tunnels can be created with a suture tag. The distal exit points are identified with a lasso loop. A 3.5 mm drill is then used to create a tunnel in the fibula up to the laser line. The tunnel is tapped.

A SwivelLock suture anchor is inserted with a special implantation instrument. The bone-cartilage junction is completely visualized at the insertion site of the anterior talofibular ligament at the neck of the talus using two small Langenbeck retractors (■ Fig. 2.1). A tunnel is created with the 4.5 mm drill. The tunnel is directed slightly proximally and relatively parallel in the sagittal plane to avoid penetrating into the sinus tarsi. The tunnel is then tapped. The screw length is then measured and marked on a FiberTape. The FiberTape is then elongated to include the length of the screw. The screw is inserted with the ankle in pronation and neutral flexion, resulting in firm tension on the Internal Brace. The suture tags can then be secured again. If reconstruction is being performed for a large defect, the periosteal flap can be prepared for transfer.

2.3 · Periosteal Flap Transfer



■ **Fig. 2.1** a The elongated anterior talofibular ligament is detached from the fibula; b Two suture anchors are inserted at the anatomic insertion site; c The ligament is repaired and a drill tunnel (4.5 mm) is created in the talar neck; d The FiberTape is attached to the talus using

a SwivelLock anchor; e The length of the FiberTape is measured to allow for adequate tensioning; f The SwivelLock anchor is inserted in full pronation and the extra FiberTape is trimmed

2.3 Periosteal Flap Transfer

■ Indications

For defects, revision surgery, chronic instability with elongation or complete loss of the ligamentous structures.

■ Technique

A straight incision is made over the fibula extending 1 cm past the tip. The crural fascia is dissected and the incision is expanded proximally 4–5 cm to allow for adequate periosteal flap length.

The anterior border of the fibula is visualized. A #11 scalpel is used to raise a periosteal flap from the anterior and posterior borders of the proximal fibula (4–5 cm from the tip of the fibula). An elevator is used to completely separate the flap from the residual periosteum on the fibula. An elevator or rasp is then used to elevate the flap distally to 3 mm proximal to the tip of the fibula. A suture anchor is placed here to prevent the periosteal flap from tearing. A 2.7 mm suture anchor is inserted into the distal fibula at the insertion site of the ligament. The periosteal flap is then attached to the tip of the fibula with two sutures to prevent rupture.

The insertional site between the cartilage and the bone-cartilage junction of the talus is then visualized. Another 2.7 mm suture anchor is placed at the insertion site. The flap is then tunneled distally with the ankle held in pronation using firm pressure. The sutures are tied with the ankle in pronation. The posterior flap is also tunneled and securely attached at the talar insertion site. The flap is then brought back proximally and securely attached with a second suture anchor. This generally results in a very solid reconstructed ligament. The capsule and fascia are oversewn, creating a second layer of the reconstruction. ACP is injected. The subcutaneous and skin layers are sutured. A plaster cast is placed in pronation and neutral flexion.

■ Aftercare

A cast is used for 1 week to allow for wound healing. After this a splint/brace is used to keep the ankle in pronation. Full weight-bearing is permitted as pain allows. For better ligament healing, ACP should be injected into the area after 2 and 4 weeks.

2.4 Arthroscopic Broström Technique

The arthroscopic Broström technique allows for minimally invasive reconstruction compared to the classic open Broström technique.

■ Indications

Mild instability with primary lateral ligament ruptures after failure of conservative treatment. Mild instability with concurrent osteochondral lesion.

■ Contraindications

Instability greater than 2+ with tissue defects of the fibulocalcaneal and anterior talofibular ligaments. Tissue defects of the fibulocalcaneal ligament.

■ Technique

Standard medial and lateral portals are used. The camera is placed medially and synovectomy is often performed laterally with the shaver. The anterior aspect of the fibula and tip of the fibula are visualized. The fibula is then debrided. This is performed with a sharp shaver or preferably with a power rasp. A guidewire is inserted at the proximal aspect of the fibula at the insertion site of the anterior talofibular ligament. This is overdrilled with a cannulated drill until the suture anchor can be easily placed. The suture anchor is then advanced until it is buried below the cortex. This

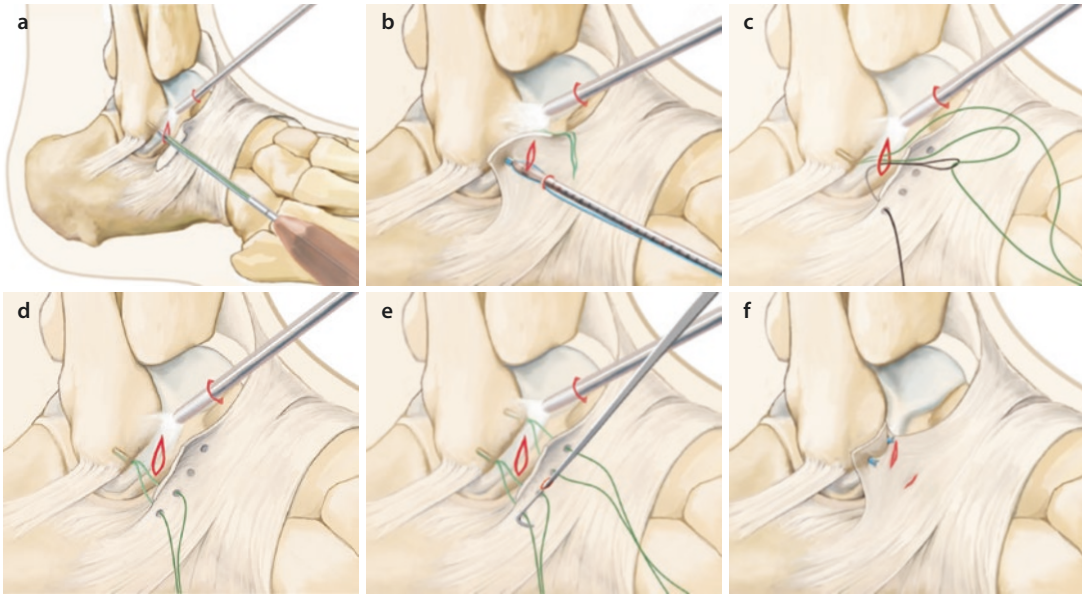
is repeated further distally. The surgeon should be careful not to move too far distally to avoid breaking off a distal fragment of bone. Both guidewires should be inserted based on the fibular anatomy, parallel to the medial joint surface.

Both sutures are then retrieved out the lateral portal. The banana loop is inserted and the first suture is pulled through at the anterolateral aspect. The banana loop is inserted laterally at the level of the peroneus tertius. The sutures are pulled in here and brought out distally. The banana loop is then inserted again posteriorly behind the retinaculum and the second suture is pulled through. At the midpoint between the two sutures, a stab incision is made with a #11 scalpel and both sutures are pulled out with a mosquito clamp. The foot is then brought into pronation and neutral position and the sutures are tied, securely attaching the retinaculum to the lateral fibula. The stab incisions are then closed. Local anesthetic or ACP can be injected near the fibula at the reconstruction site. A plaster splint is placed (■ Fig. 2.2).

■ Aftercare

A brace (Albrecht brace) is worn for 5 weeks. Full weight-bearing as pain permits. If an AMIC procedure and cartilage reconstruction are performed concurrently, partial weight-bearing for 8 weeks. After this, gradual strengthening and proprioceptive training (balance board, peroneal strengthening and stabilizing exercises).

2.4 · Arthroscopic Broström Technique



■ **Fig. 2.2** **a** Standard arthroscopic portals, debridement of the tip of the fibula with a shaver and/or power rasp. The drill guide is placed about 5 mm from the tip of the fibula. The drill tunnel is directed cranial and parallel to the medial fibular cortex in the sagittal plane to avoid fracture; **b** The suture anchor is inserted. A second drill tunnel is placed 5 mm proximal to the first suture anchor using the same technique; **c** A stab incision is made in the lateral inferior retinaculum while protecting the cutane-

ous nerve. The suture is retrieved with a banana loop from distal to proximal and brought back distally; **d** The same procedure is performed at the anterior superior retinaculum at a distance of 2 cm; **e** A stab incision is made at the midpoint between the two suture arms. The sutures are retrieved with an arthroscopic hook or a mosquito clamp; **f** The sutures are tied in neutral flexion and slight pronation of the ankle

Arthroscopy of the Ankle Joint

- 3.1 General Notes – 48**
 - 3.1.1 Microfracture, Cartilage-Stimulating Procedure – 48
- 3.2 Osteochondritis Dissecans of the Talus – 49**
 - 3.2.1 AMIC Procedure – 49
- 3.3 Anterior Impingement – 57**
- 3.4 Ankle Arthrodesis – 58**
- 3.5 Posterior Endoscopy – 60**

3.1 General Notes

■ Surgical setup

The skin in the area of the planned incision is shaved immediately prior to induction of anesthesia. A tourniquet is placed. General anesthesia is preferred due to superior muscle relaxation. Spinal, epidural or a regional block for the foot are also possible, but joint distraction can be very difficult.

■ Positioning and perioperative management

Ankle arthroscopy is performed in a standard supine position with the leg on the table. A roll is placed in the popliteal fossa. It is important to relax the gastrocnemius-soleus-Achilles tendon complex in slight flexion. The other leg is lowered slightly to provide room to move the arthroscope. The tourniquet is placed high to avoid compression of the gastrocnemius muscle at the distal thigh; this can make it more difficult to distract the joint. A third generation cephalosporin can be used for antibiotic prophylaxis. For arthroscopy, antibiotics are only continued perioperatively. Intraoperative thrombosis prophylaxis is obtained with injection of low-molecular-weight heparin at anesthesia induction.

3.1.1 Microfracture, Cartilage-Stimulating Procedure

Arthroscopic procedure. Bone perforations are created with a depth of 2–3 mm and separation of 2–3 mm. This creates a «super-clot» that covers the entire defect and remains adherent to the rough surface. It develops into fibrocartilage due to the stem cells and other inductive substances that are present in the clot. In contrast to Pridie drilling, there is no heat generation and bone necrosis of the subchondral layer is avoided. This could otherwise lead to an unstable subchondral layer. With proper technique, the entire defect can be treated, not just the tangential area. The disadvantage of this method is the regeneration of fibrocartilage with little hyaline cartilage.

■ Indications

Subchondral lesions such as osteochondritis dissecans. Degenerative osteochondral lesions with only one grade 4 cartilage defect up to a size of 1.5–2.0 cm in length and 1 cm in width.

■ Contraindications

Anteromedial and anterolateral defects with chronic anterolateral instability. Spontaneous osteonecrosis or osteochondral lesions with subchondral cysts. Lack of compliance for participating in aftercare or biologically old patients with substantially lower stem cell activity.

■ Specific patient information

Light partial weight-bearing (15 kg) through the ankle for 6–8 weeks. An electric motorized passive motion device (continuous passive motion; CPM) is used for 4–6 h daily if possible. Gradual strengthening begins later with water jogging or cycling for at least 6 months. Jogging – if ever – no earlier than 8 months.

■ Technique

The tendon and joint space are drawn out. The joint is then distended with 20 ml of lactated Ringer solution at the anteromedial portal, medial to the tibialis anterior tendon. If the injection is performed correctly into the joint, the distention of the anterior joint capsule will cause passive plantar flexion as the fluid is injected. A stab incision is made with a #11 scalpel. The portal is spread with a mosquito clamp to prevent injury to deep structures. A small joint arthroscope (2.7 or 2.5 mm) is used.

The arthroscope is inserted using transillumination to avoid vessels and the superficial peroneal nerve. An anterolateral portal is created at the level of the peroneus tertius muscle. For this, a stab incision is made through skin only and the joint is entered with a mosquito clamp. It is usually possible to enter the joint immediately using the small joint arthroscope. If the patient has had prior surgery or if high-grade synovitis is present, a partial synovectomy must be performed first with a shaver (2.8 or 3.8 mm) to allow for adequate visualization. The soft tissues are placed in distraction. This is performed using an elastic bandage that is tied under the medial and lateral malleoli and two additional loops that are pulled medially and laterally. When the loops are pulled, the bandage can slide over the malleoli to avoid interfering with the arthroscopic instruments.

The assistant pulls from a seated position and the instruments are medial to the assistant. Using the MRI findings as a guide, the stability of the cartilage is checked with a probe. If the probe can

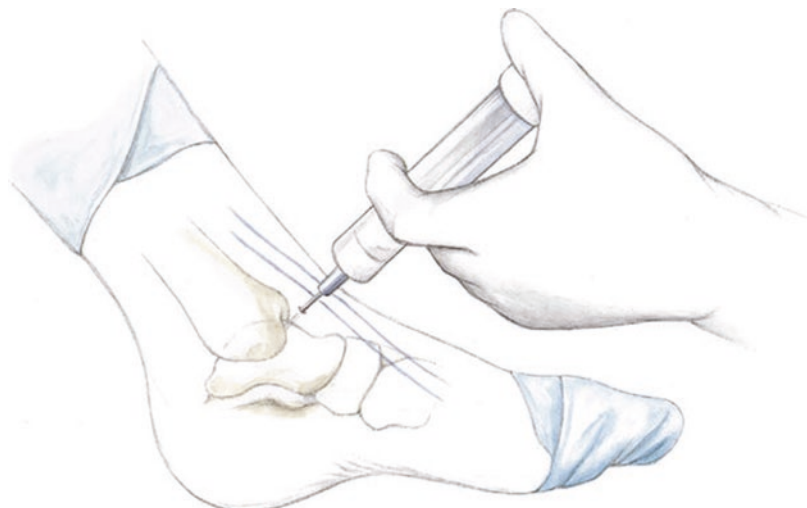
3.2 · Osteochondritis Dissecans of the Talus

be pushed against subchondral bone with very soft, sometimes even fully detached cartilage, the cartilage should be debrided. A small special curette is used to remove the necrotic osteochondral area, which is removed en bloc with a grasper. The cartilage edges are then shaped to be perpendicular until stable cartilage is reached.

The superomedial portal is created under arthroscopic visualization using a needle to localize the correct angle. An additional stab incision is made through skin with a #11 scalpel about 1 cm superior to the anteromedial portal. The capsule is spread using a mosquito clamp and the curved awl is inserted.

A 1.8 or 2.2 mm burr or power rasp is used to debride the defect or exposed subchondral bone. A superomedial portal is then created and a curved awl is inserted. This tool is absolutely necessary for posteromedial microfracture. The awl is brought to the correct entry point and placed nearly perpendicular to the surface. Light, small taps are used to sink the awl the first 1 mm, then heavier taps are used to advance the awl to a depth of 3–4 mm. It is important to start the insertion with gentle taps to avoid slipping out of position, which could damage the subchondral layer. Microfracture is performed in a chess-board pattern with about 2–3 mm between the perforations. After completing the microfracture, any small bone fragments are removed with the shaver and burr. An anatomically-curved shaver should be used to reach the joint surface without injuring other areas of cartilage.

■ **Fig. 3.1** The joint is distended with about 20 ml of lactated Ringer solution after palpating the joint line medial to the tibialis anterior tendon. The needle is inserted slightly lateral to the center of the joint to avoid iatrogenic injury to the cartilage



After surgery is complete, a bupivacaine/morphine mixture (about 10 ml) is injected around the portal sites and at the joint. The anteromedial, superomedial and anterolateral stab incisions are closed. A compressive bandage is applied and the leg is elevated. The superomedial stab incision is closed with a butterfly dressing on postoperative day one.

■ Aftercare

The leg is elevated well above the level of the chest. Lymphatic massage is performed on the first day with gentle ankle stretching exercises in the sagittal plane with gentle joint distraction. Gentle range of motion exercises are performed in dorsal and plantar flexion. After day two, a CPM machine is initiated with gradually increasing range of motion along with cryotherapy.

3.2 Osteochondritis Dissecans of the Talus

■ Technique

■ Figures 3.1, 3.2, 3.3, 3.4, 3.5, and 3.6.

3.2.1 AMIC Procedure

The AMIC procedure (autologous matrix-induced chondrogenesis) is a further development of microfracture. Our own studies have shown that microfracture is only capable of successfully

Fig. 3.2 Atraumatic joint distraction. An elastic bandage is used with loops on either side of the ankle joint to allow the assistant to pull firmly. The assistant should sit on the lateral side to avoid interfering with the arthroscopy procedure

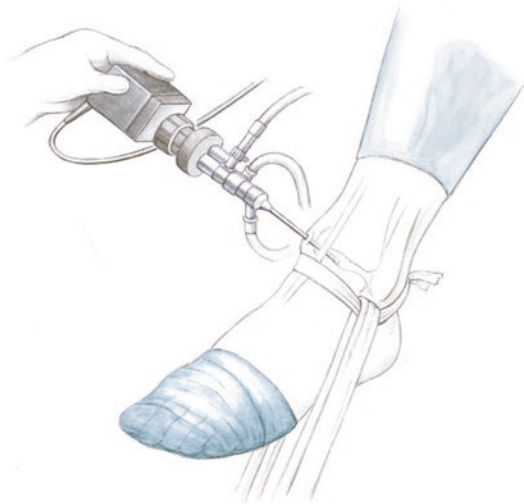
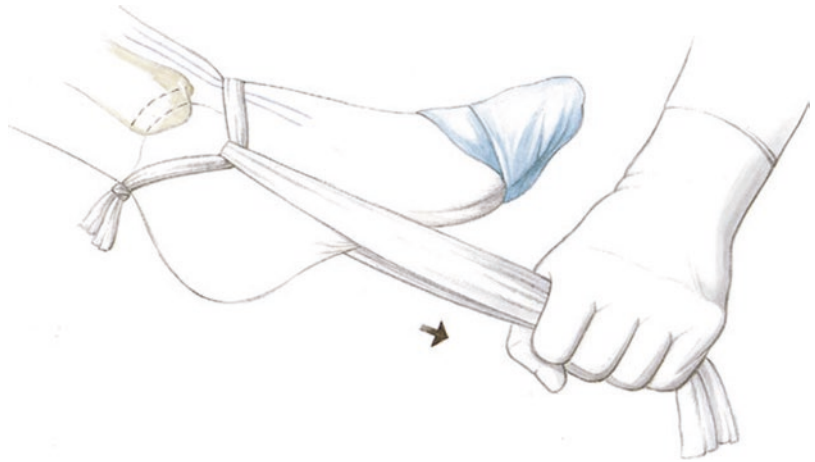


Fig. 3.3 The loops can be used to create inversion and eversion of the hindfoot to enlarge the compartment

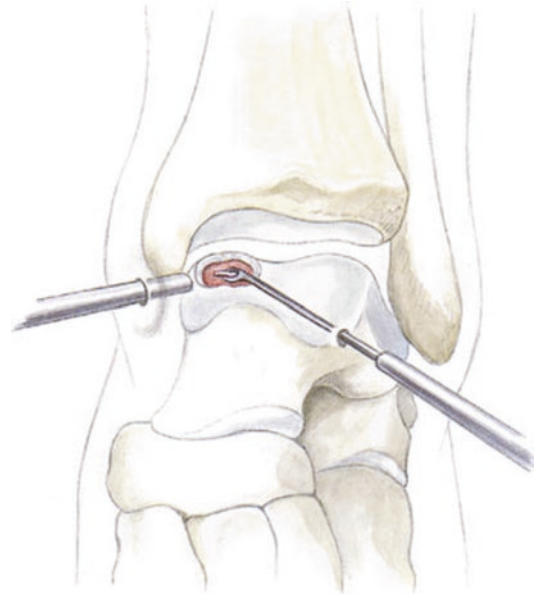


Fig. 3.4 Debridement of the osteochondritis lesion with a special curette. All of the subchondral detached fragments should be detached sharply to leave a solid, sharp border. The arthroscope and instruments can also be brought in from lateral and medial, respectively, depending on the intraoperative conditions. When instruments are used through the superomedial portal, the arthroscope is usually placed in the lateral portal

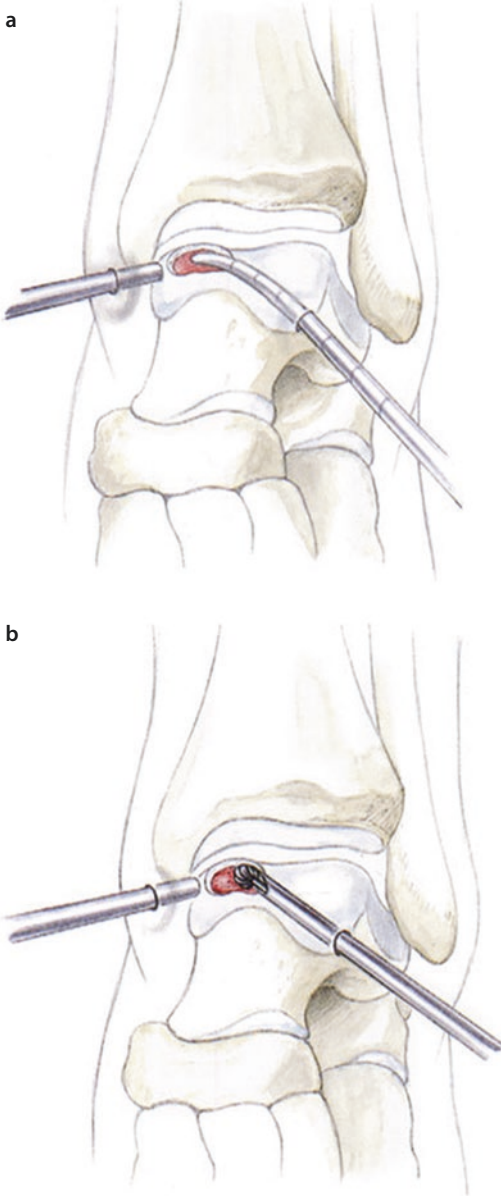
treating small defects. Recent histological studies have also shown severe changes at the plantar plate, which raises the question as to whether traditional microfracture could actually prolong the healing process. For larger defects, it is unlikely that the «super clot» will seal the entire defect area. The use of a matrix that contains the local stem cells is more likely to succeed. Our arthroscopic classification of osteochondral lesions differs from the Ferkel classification in that there are only two large groups:

- Chondral lesions: The cartilage can be detached from the subchondral plate like an eggshell (**Fig. 3.7**).

- Chondral and subchondral lesions with osteochondral fragments (**Fig. 3.8**):
 - Osteochondral fragments alone
 - Fragments with cyst formation

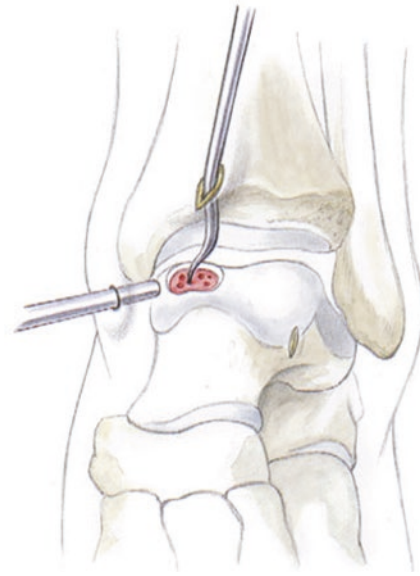
In the procedure described below, the AMIC procedure is augmented with bone marrow and stem

3.2 · Osteochondritis Dissecans of the Talus

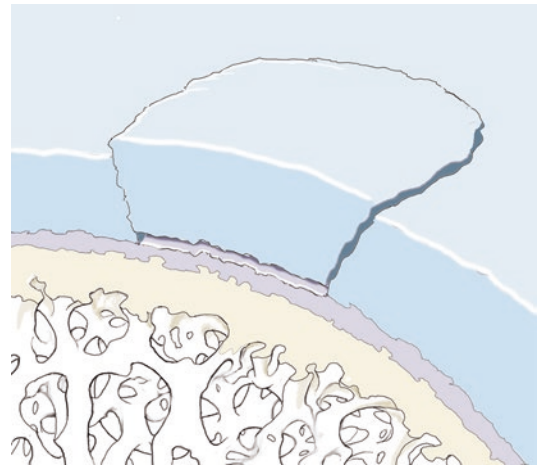


■ **Fig. 3.5** a The 3.0 mm shaver is used to debride the lesion. b Subchondral debridement with a burr or a power rasp

cells harvested from the iliac crest (Jamshidi needle). As a result, the stem cells from the talus are not needed and important elements for healing the subchondral plate are brought into the defect with the bone marrow instead. The matrix is sealed with fibrin glue. For all AMIC procedures, ACP (autologous conditioned plasma) is also injected at the end of surgery in the area of the cartilage defect.



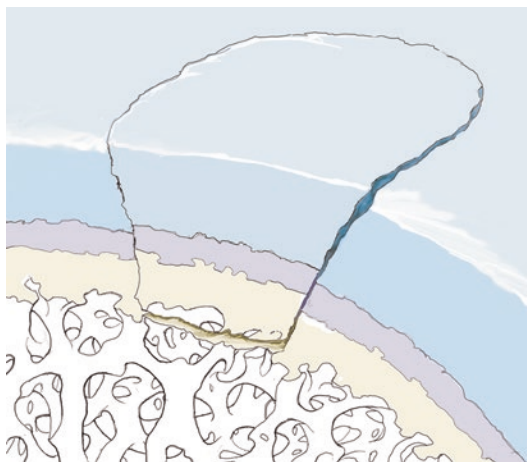
■ **Fig. 3.6** Microfracture is performed through a superomedial portal. Microfracture awls with a swan-neck shape should be used to allow for microfracture in the postero-medial area



■ **Fig. 3.7** Type 1 chondral lesion based on our own classification. The cartilage is detached from the subchondral plate («eggshell phenomenon» during debridement)

■ Indications

Medial or lateral osteochondral lesions in the anterior or middle third of the talus. Posterior arthroscopy should be performed for lesions that are far posterior below the curve of the talar dome or for lesions at the far posterior aspect of the tibial plafond.



■ **Fig. 3.8** Type 2a osteochondral lesion based on our own classification. The cartilage detaches along with bone from the subchondral plate during debridement. Type 2b also includes cystic changes in the subchondral bone

■ Contraindications

Cystic lesions are no longer a contradiction if the cysts are small and superficial. Large cysts require grafting with cancellous bone as well as bone marrow. A small bone marrow layer should be coagulated between the cancellous bone layer and the matrix to allow for different healing behavior of the cancellous bone and the bone marrow aspirate.

■ Surgical setup

For the AMIC procedure, a 2.7 or 2.5 mm arthroscope is used with a normal arthroscopy tower. Due to the low flow rate of the small arthroscope, the flow pressure should be set to 100–120 mmHg.

An 11 mm scalpel and a mosquito clamp are used to make the portals. 3.0 mm shaver, curettes (preferably special curettes with a slight curve, no larger than 1.5–2.5 mm). If these curettes are not available, the smallest sharp spoon available should be used. Power rasp (Arthrex), small 2.5 mm biters, 2.5 mm suction biter, small 2 mm elevator for spreading out the matrix, Jamshidi needle for aspirating bone marrow from the iliac crest. Tourniquet and Esmarch for exsanguination.

■ Positioning and perioperative management

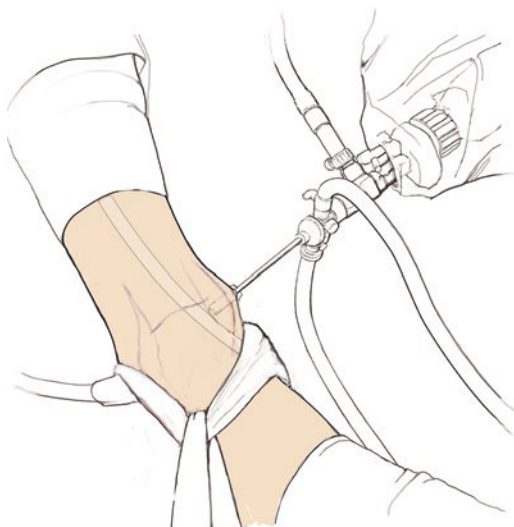
Standard supine positioning. Padding to prevent pressure injuries at the knee and the sural nerve. A small stabilization pillow is placed at the calf.

The contralateral leg is lowered to allow space for the arthroscopic instruments. A third generation cephalosporin or similar is given for antibiotic prophylaxis, which is only continued perioperatively for arthroscopy. Intraoperative thrombosis prophylaxis with low-molecular-weight heparin at the time of induction.

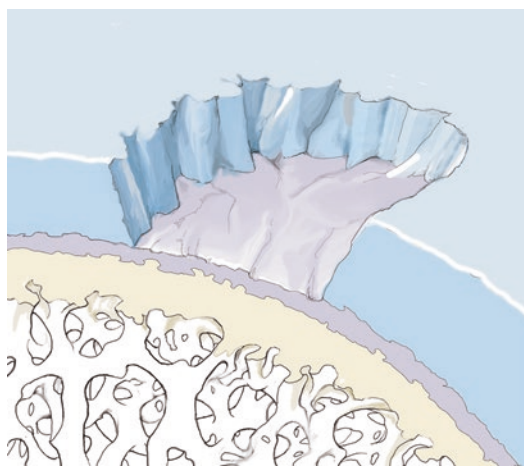
■ Technique

■ Figures 3.9, 3.10, 3.11, 3.12, 3.13, 3.14, and 3.15.

The joint line is palpated by dorsiflexing the ankle. The tibialis anterior tendon is palpated and

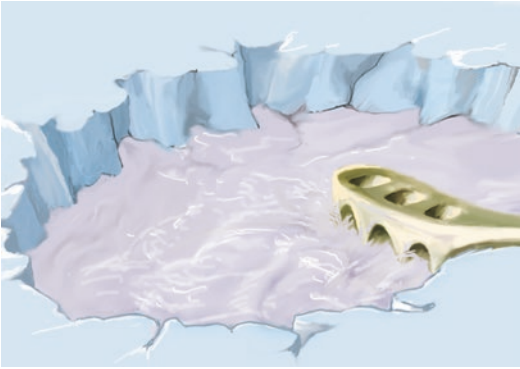

■ **Fig. 3.9** Arthroscopic technique, optional use of soft tissue traction

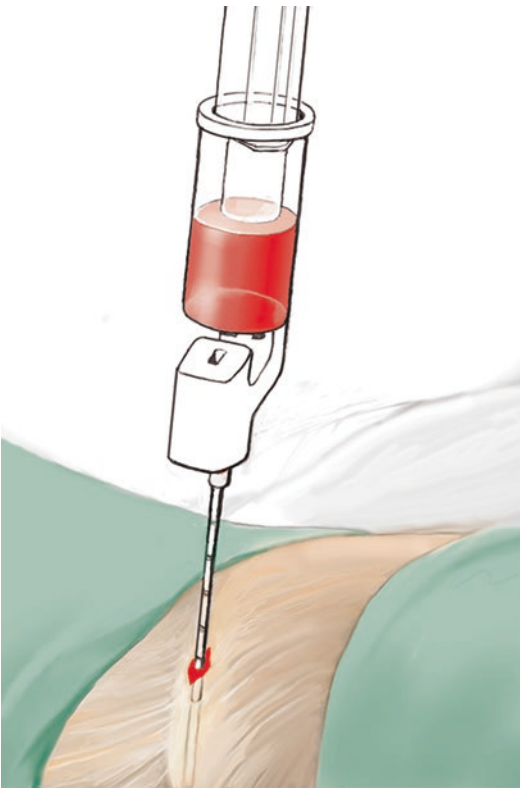


■ **Fig. 3.10** Debridement of the cartilage until stable borders are created

3.2 · Osteochondritis Dissecans of the Talus

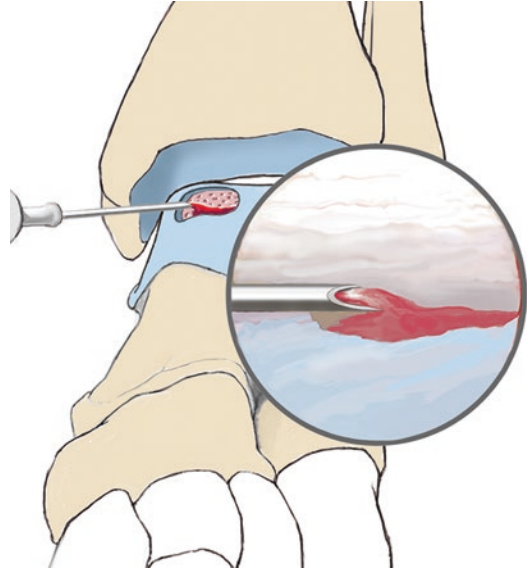


■ **Fig. 3.11** Chondroplasty with a power rasp for debriding the subchondral bone. Debridement must be continued until bleeding cancellous bone is seen



■ **Fig. 3.12** Bone marrow aspirate through a stab incision. The Jamshidi needle is malleted into the center of the iliac crest. A 20 ml needle is used to create adequate suction during aspiration. Only the first 3–5 mm are aspirated, as this portion has the highest quantity of stem cells

the joint is distended with lactated Ringer solution. The needle is inserted parallel to the joint to avoid cartilage injury. This will cause the ankle to plantar flex slightly. A stab incision is made



■ **Fig. 3.13** Injection of bone marrow (this should be allowed to coagulate for a few minutes) and growth factors into the defect area

through skin only and the portal is spread with a mosquito clamp. The arthroscope is inserted. The lateral portal is made in the same way as the medial portal. A 2.8–3.0 mm shaver is then inserted and anterior synovectomy is performed. If necessary, shaving is also performed at the medial and lateral joint line to allow for good visualization.

The entire joint is visualized arthroscopically. Low-grade cartilage lesions can usually be identified based on slight color differences as well as irregularities and cracks. The mosquito clamp is inserted to lift up the chondral or osteochondral lesion. The damaged cartilage is completely removed with a curette or a small spoon until stable borders remain. Palpation with the probe. Small posterior fragments can be removed with the 2.5 mm suction biter or the mosquito clamp. For chondral lesions, the area is gently debrided with a shaver and/or power rasp and minimal perforations are made for a «mini-microfracture» or «nanofracture». This step can even be skipped altogether, instead using the power rasp alone to debride the surface, as the stem cells are not brought in from the talus. Instead, the stem cells are included in the bone marrow that was aspirated with the Jamshidi needle. Injection of the bone marrow aspirate is also a valid treatment for the sub-

Fig. 3.14 The matrix is inserted with excess material overlapping the defect edges


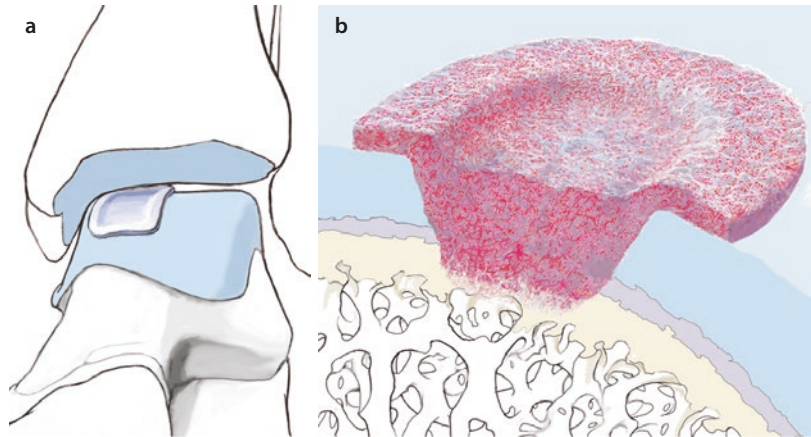


Fig. 3.15 The fibrin glue is only used on the talar side if possible. For «kissing lesions», the entire area is sealed

chondral layer, which always shows degenerative changes.

For the next step, the Jamshidi needle is inserted into the iliac crest through a stab incision with small mallet taps (about 2 cm). About 3–5 mm of bone marrow is aspirated with a syringe (20 mm, to generate adequate suction). This first portion contains the highest fraction of stem cells; subsequent aspiration is mostly just blood. In the meantime, the joint is suctioned out and small unfolded sponges are held in the mosquito clamp to completely dry the area. The bone marrow is then injected. After waiting for the marrow to start coagulating, the matrix (cut to

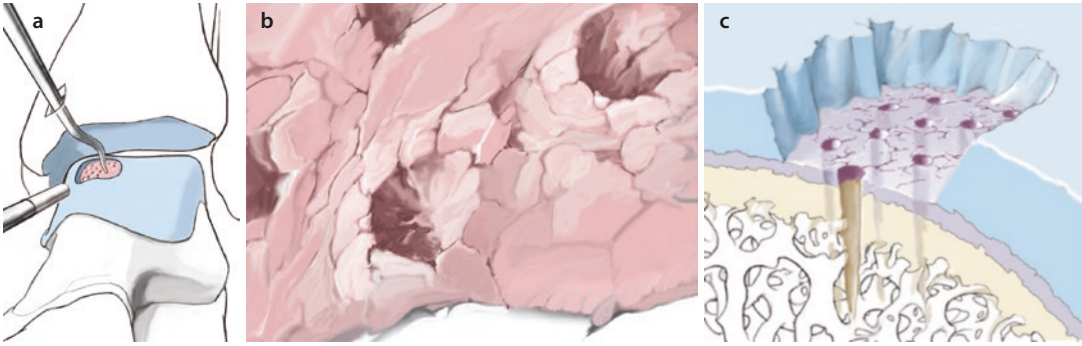
size in a previous step after measuring with the probe) is inserted. To insert the ChondroGide (collagen membrane) or Hyalofast (hyaluronic acid membrane), a small half-pipe guide is inserted to prevent the graft from getting stuck in the portal. This also directs the graft to the correct location and the correct orientation. The graft usually fills up completely with fluid. However, additional bone marrow aspirate can also be injected at this point.

The membrane is then smoothed out with a small elevator. If additional bone marrow was injected, the membrane can also be smoothed out with a mosquito clamp holding a small unfolded sponge. The membrane is then sealed with fibrin glue (Tissucol, 5 ml). Any adhesions to the tibial plafond are detached with the small elevator. The ankle is then carefully ranged. A plaster splint is then placed with the ankle in a neutral position to allow the graft to heal.

■ Technique for 3–5 mm large cysts

■ Figure 3.16.

Medium-sized cysts are debrided with a mosquito clamp or a chondropick and suctioned out with a small suction tip. The fluid is allowed to egress for this step. A deep microfracture is performed. The cyst is then lavaged with a small suction tip (hypodermic needle) to clean out any debris. The power rasp is inserted and the cavity is debrided. The cyst is filled with bone marrow to fill the defect. After waiting several minutes for the bone marrow to start coagulating, the matrix soaked in bone marrow is inserted (see above).



■ **Fig. 3.16** a–c Microfracture or «nanofracture» based on the surgeon's preference. If extensive debridement is performed with the power rasp, microfracture or nanofracture can be skipped

■ Technique for cysts larger than 5 mm

If large defects are present, a small trepanation (5 mm) is performed at the tibial plateau and cancellous bone is harvested with a spoon. This is inserted into the dry joint arthroscopically. A small amount of fibrin glue is applied to bring fibroblasts to the site early. The bone marrow is then injected to create a second 2–3 mm layer. The matrix is placed on top of this. This avoids placing the matrix directly on top of the cancellous bone graft, which could interfere with healing.

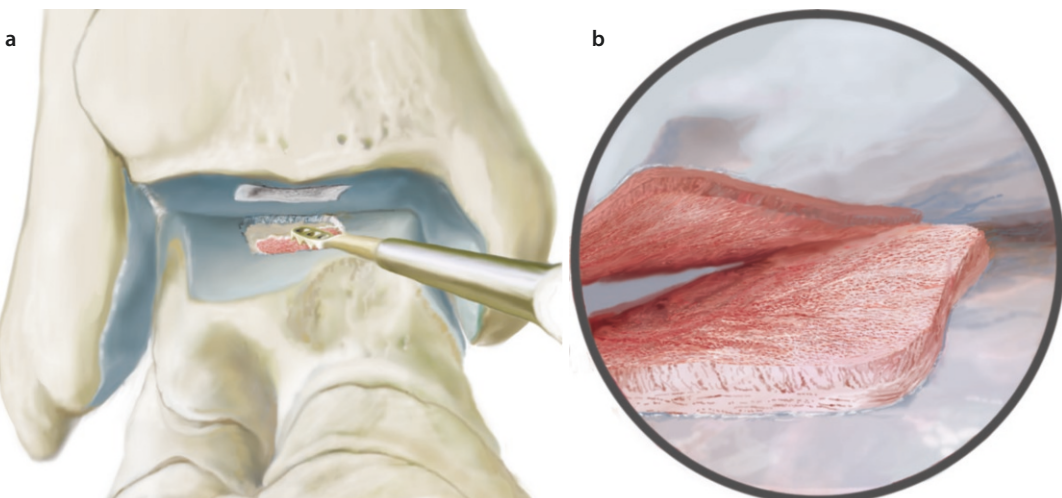
■ Technique for «kissing lesions»

■ **Figure 3.17.**

«Kissing lesions» are often found with post-traumatic ankle stiffness. Before the cartilage can be reconstructed, complete lysis of adhesions

must be performed. This must be performed posteriorly as well as anteriorly in the author's opinion. The procedure is begun posteriorly. The entire posterior capsule of the ankle and subtalar joints is resected through the posterior portals along with any adhesions up to the posterior tibia, allowing space for movement. After this, complete lysis of adhesions is performed anteriorly. If range of motion is limited due to shortening of the Achilles tendon and the ankle cannot be dorsiflexed 10°, a gastrocnemius slide should always be performed to allow for optimal range of motion.

The procedure for a «kissing lesion» without limited range of motion usually begins with a complete synovectomy and scar resection. The lesion on the tibial plafond should be treated first.



■ **Fig. 3.17** a,b Debridement of the tibia and talus to subchondral bone with the power rasp

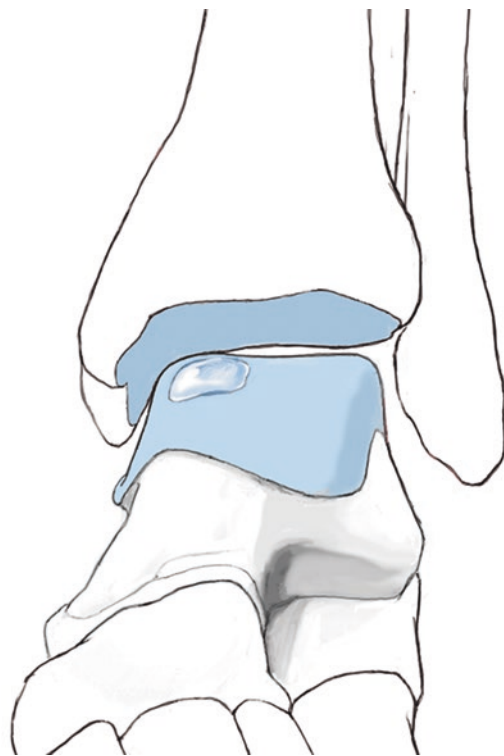
The loose cartilage is radically resected and any cystic lesions are debrided as described previously. The talar portion is then debrided. Light microfracture is performed along with chondroplasty with the power rasp to create a large surface area. This is particularly important for tibial plafond reconstruction, as this allows the stem cells and bone marrow to enter the subchondral bone. Light microfracture is also performed at the talus to increase the surface area.

The graft or matrix is cut slightly too large and placed on the tibial plafond first. It is important for the assistant to pull on the calcaneus in plantar flexion. A Hintermann distractor can also be helpful if the joint is very tight. The matrix should ideally be inserted dry so that it can soak up the injected bone marrow. After the matrix is fit to the defect, a small amount of fibrin glue is applied at the superior aspect. If any of the fibrin glue has displaced into the talus, the glue is removed with a very small elevator. This will allow the graft to be placed under normal conditions. The talar component is also implanted in slight distraction to avoid damaging the tibial defect reconstruction. At the end, the talar defect is sealed with fibrin and the joint is brought back into a neutral position at 90°. The glue is allowed to harden for 5–10 min. After this, the remaining bone marrow and ACP is injected and the portal sites are sutured. A plaster cast is applied in neutral position. The joint should not be taken through a range of motion.

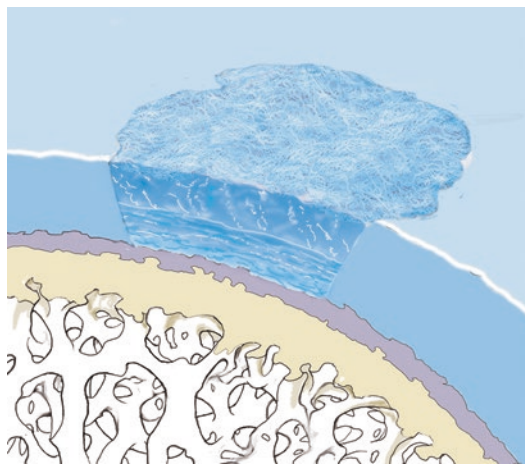
■ Aftercare

■ Figures 3.18 and 3.19.

To allow the matrix to heal, the cast is left in place for 3 days at 90° and the foot is immobilized (ingrowth phase). After removal of the cast, range of motion exercises can be started immediately. This is intended to cover the defect in «press-fit» fashion and the redundant graft tissue overlying healthy tissue is rubbed away. Physical therapy is started immediately with lymphatic drainage massage and range of motion exercises at the ankle joint. The goal is full range of motion at the ankle. Eversion and inversion are not permitted. A CPM machine is used for 4–6 h per day. Growth factors (ACP) are injected after 2, 4 and 6 weeks. Partial weight-bearing at 15 kg for 6 weeks and 30 kg for 2 weeks. For cystic lesions, partial weight-bearing is limited to 15 kg for



■ Fig. 3.18 Range of motion after the initial «ingrowth phase» results in the matrix being «cut to size» to fit the lesion, as the matrix cannot grow into healthy cartilage



■ Fig. 3.19 Range of motion in the sagittal plane (independently or with a CPM machine) with slight pressure (15 kg partial weight-bearing) leads to better stimulation of healing and incorporation of the regenerated tissue

8 weeks and 2 weeks with 30 kg. No impact sports for 1.5 years. Cycling, water jogging, free-style swimming and walking for the first year in

3.3 · Anterior Impingement

non-professional athletes. For professional athletes, AlterG training may be started after 6–10 weeks and sport-specific activities can gradually be initiated after 6 months. Pain is always a sign that the regenerated tissue is being overburdened.

■ Aftercare for «kissing lesions»

A longer ingrowth phase is required. The foot is left in a plaster cast for 4 days without changing dressings. On the 5th day, range of motion is initiated. Weight-bearing is restricted for longer periods: 8 weeks of 15 kg and 2 weeks of 30 kg partial weight-bearing. After 2, 4, 6 and 8 weeks, growth factors are injected. A CPM machine is used for 6 weeks for 4–5 h per day if possible. The main goal of physical therapy in the early phase is full range of motion, especially in dorsiflexion. Any tightness in the flexor muscle chain should also be treated simultaneously.

3.3 Anterior Impingement

Using a medial or lateral portal, a special 5 mm osteotome is used to remove medial or lateral osteophytes. A burr is then inserted and any remaining osteophytes are resected and smoothed. The arthroscope is inserted through the superomedial portal to check whether the resection is complete. It is important to perform a capsular release as well by detaching the capsule at the distal tibial plafond. This is performed using a shaver or bluntly with a rasp placed through the anterolateral or anteromedial portal. If there is severe synovitis, a water-soluble corticosteroid such as betamethasone is injected in addition to local anesthesia.

■ Indications

Painful synovial entrapment caused by osteophytes or scar tissue with dorsiflexion and during athletics, particularly with weight-bearing.

■ Contraindications

Severe arthritis with osteophytes that are so extensive that surgery would not result in pain relief. In these cases, joint replacement is indicated.

■ Specific patient information

Partial weight-bearing through the ankle joint (15 kg) for 5–10 days, depending on swelling.

Weight-bearing is gradually increased. Sports activities are initiated with cycling and water jogging.

■ Positioning

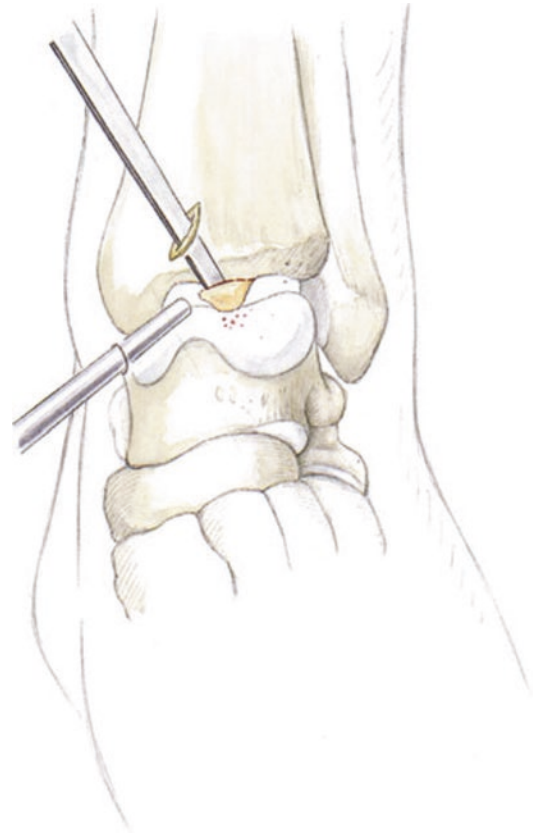
Positioning is the same as for arthroscopy of the ankle joint.

■ Technique

■ Figures 3.20 and 3.21.

■ Aftercare

Immediate range of motion exercises. Non-steroidal anti-inflammatories are given for 10–14 days. The goal of the aftercare is to achieve full range of motion, particularly in dorsiflexion. After swelling and pain have resolved, sports activities are initiated with elliptical training, cycling and water joggings once the portal sites are healed.



■ Fig. 3.20 Anteromedial or anterolateral working portal for the arthroscope

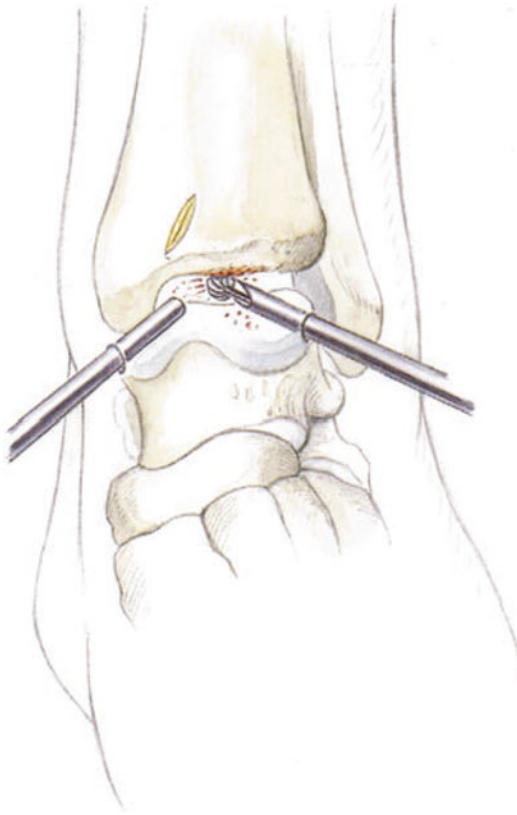


Fig. 3.21 Superomedial working portal. A 5 mm osteotome is used to remove the anterior lip. The burr is then used to smooth the area and resect any additional bone. This can be done from the anterolateral, anteromedial or superomedial portal. To determine whether the bone has been resected adequately, the arthroscope is inserted into the superomedial portal for optimal visualization of the resection

3.4 Ankle Arthrodesis

«Anatomic» resection is performed and the tibiotalar joint is debrided. This is done with osteotomes, sharp spoons, curettes and a shaver. If sclerosis is present, the power rasp is used. The subchondral cartilage and sclerotic bone are removed without flattening the joint surface or creating large defects.

To stimulate circulation, deep microfracture is performed. This is done forcefully rather than cautiously to break through the subchondral plate.

■ Indications

Arthritis of the ankle without severe anatomic axis deviation (up to 10° of varus or valgus).

■ Contraindications

Charcot foot, polyneuropathy or similar history, large defects with osteonecrosis such as post-traumatic changes after a pilon fracture.

■ Special patient information

There is a risk of pseudarthrosis after surgery with residual pain. Otherwise, the patient should be advised of the same risks and benefits as for the open procedure. The risk of injury to superficial nerves is definitely higher compared to an open approach due to arthroscopic portal creation and screw insertion.

Partial weight-bearing through the ankle (15 kg) for 4–6 weeks in a short walking boot, depending on radiographic findings. Lymphatic drainage massage and range of motion exercises in flexion and extension can be performed out of the boot.

■ Surgical setup

Normal 4 mm camera and instruments are used, the same as those used for knee arthroscopy. Curettes, 5 mm osteotome, microfracture awl, power rasp.

■ Positioning

The same as for ankle arthroscopy. Standard portals are used. The ipsilateral iliac crest should also be draped out.

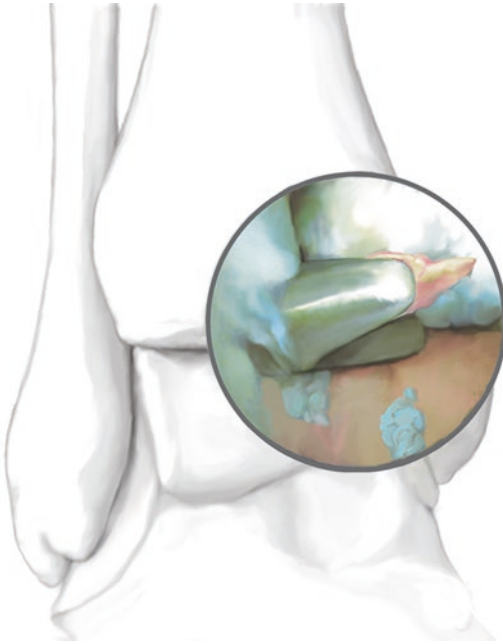
■ Technique

■ Figures 3.22, 3.23, and 3.24.

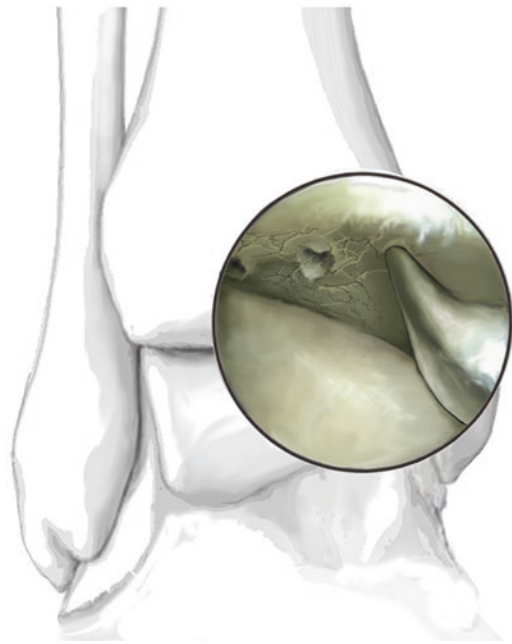The arthroscope is inserted. Complete synovectomy is performed and anterior osteophytes are removed with the burr, nucleotome (■ Fig. 3.22) and osteotome. The 3.8 mm shaver is used starting at the anterior talus.

Debridement is performed gradually and the joint will typically widen. Firm cartilage or sclerotic bone is debrided through the subchondral layer with an osteotome, a spoon or a power rasp until well-vascularized cancellous bone is visualized. Extensive microfracture is performed at the tibial plafond as well as the talar dome. This may result in small superficial fractures as the subchondral plate is broken. The perforations should be carried very deep.

The joint is placed in a neutral position and axis deviations are corrected if necessary. A guide-wire is inserted posteromedially above the medial malleolus running obliquely into the lateral aspect

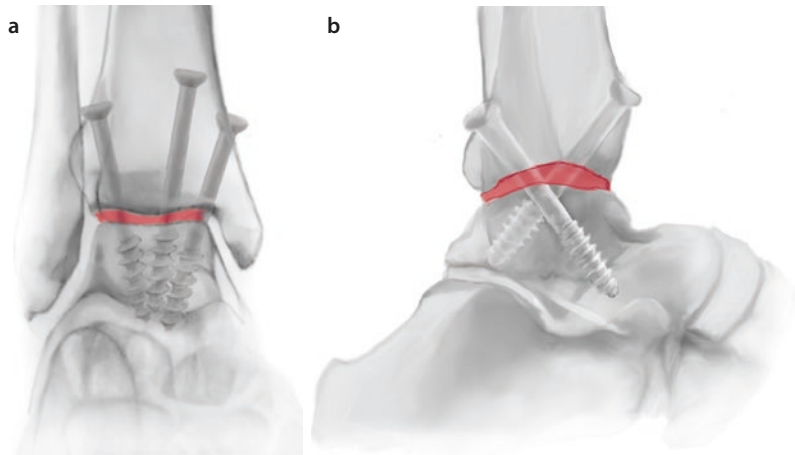


■ Fig. 3.22 After synovectomy, anterior osteophytes are removed with a nucleotome and a burr



■ Fig. 3.23 Aggressive microfracture to break through the sclerotic subchondral plate

■ Fig. 3.24 a, b Status post screw placement. a AP view b Sagittal view



of the talar neck. A stab incision is made at the lateral border of the tibia about 3–4 cm above the joint line and an osteotome is inserted to make an indentation in the cortical bone. A wire is then inserted perpendicularly. The wire driver must be touching the tibia during insertion; otherwise, the wire will not catch the talus posteriorly. The wire should stop in the posterior aspect of the talus. This will result in good biomechanical compression from posteromedial to lateral and anterolat-

eral with the second screw. The screw should have a short thread, as there is only a small area of bone. The surgeon should ensure that the lateral screw does not enter the posterior facet of the subtalar joint. If an axis deviation such as varus deformity is corrected, there will be a small area of empty space (■ Fig. 3.24).

A small incision is made at the iliac crest or the medial tibial plateau. After trepanation with a 5 mm osteotome, a spoon is used to harvest

cancellous bone and bone marrow with stem cells. The bone marrow is injected into the joint and the cancellous bone is placed into the area of empty space. Local anesthesia is injected at the portal sites and radiographs are taken. The guidewires are drilled through cortical bone and 6.5 mm screws with short threads are placed over the wires.

3.5 Posterior Endoscopy

■ Indications

Impingement at the posterior talar process or from an os trigonum, soft tissue impingement, pathology of the flexor hallucis longus tendon or the subtalar joint, cartilage lesions, arthritis.

■ Contraindications

Charcot foot, severe osteonecrosis, bone defects (e.g. after calcaneus fracture).

■ Surgical setup

A standard 4.0 mm arthroscope is used. For debridement of the posterior space, a 3.8 or 5.0 mm shaver is ideal. If cartilage reconstruction procedures are necessary, it may be necessary to advance deeper into the subtalar joint using a 2.7 or 2.8 mm arthroscope, a 3.0 mm shaver and a power rasp. A mosquito clamp is used to create the portal and to remove ossifications and small fragments. Other instruments include the nucleotome, an osteotome to remove bone structures and Chondropicks and swan-neck awls to perform subtalar microfracture.

■ Positioning and perioperative management

Prone with slight elevation of the contralateral iliac crest so that the leg and hindfoot are perpendicular to the floor. The leg is held in place with a small silicone cushion («camel»). The surgery is performed under tourniquet. Antibiotics are given for 24 h (single shot). Low-molecular-weight heparin is injected upon induction of anesthesia.

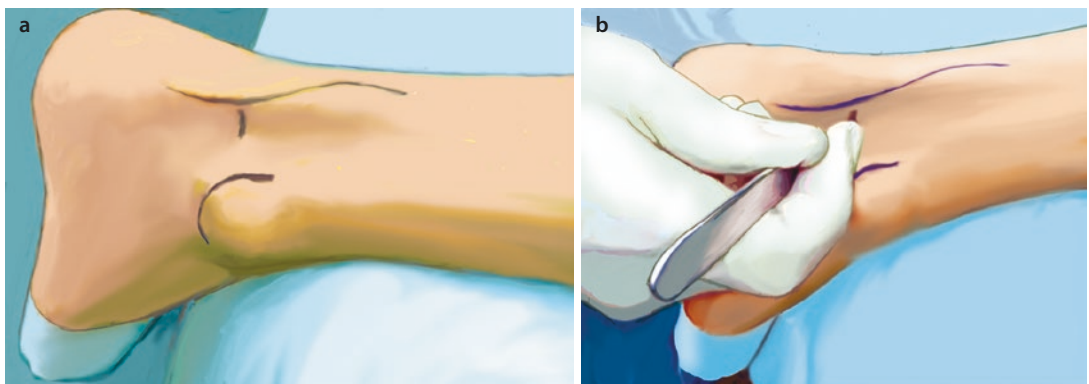
■ Technique

■ Figures 3.25, 3.26, 3.27, 3.28, 3.29, 3.30, 3.31, 3.32, and 3.33.

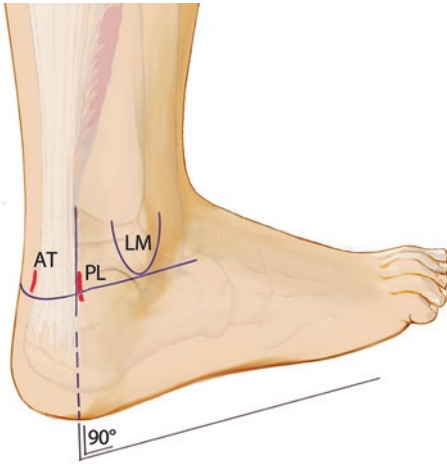
A stab incision is made laterally at the level of the tip of the fibula (subtalar joint). A corresponding incision is made at the medial side. The mosquito clamp is inserted through the soft tissues and spread until the subtalar joint is reached. This will be in the direction of the space between the first and second ray. The same procedure is performed at the medial side.

The standard arthroscope is inserted, the camera is pointed at 6 o'clock and the lens is directed at 3 o'clock so that the surgeon is looking laterally. The 3.8 mm shaver is inserted and triangulated to reach the arthroscope. The arthroscope is then pulled back so that the shaver immediately becomes visible. There is usually scar and adipose tissue at Kager's triangle. Debridement is carried laterally until the posterior facet is visible.

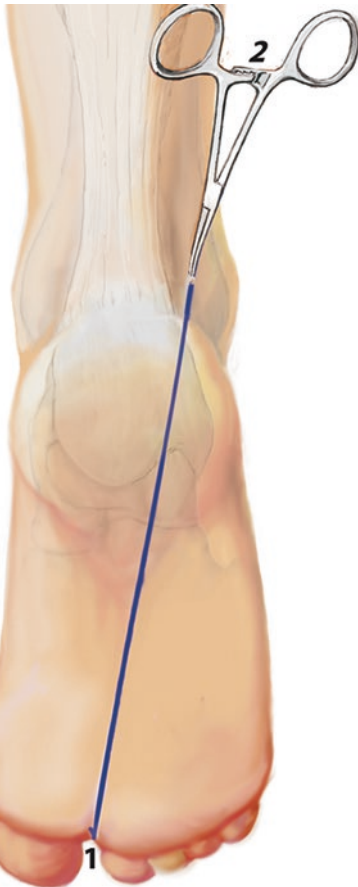
After visualizing the posterior facet laterally, debridement is carried laterally. It is important to keep the rotating shaver blade immediately adjacent to the medial wall of the calcaneus. Dissection



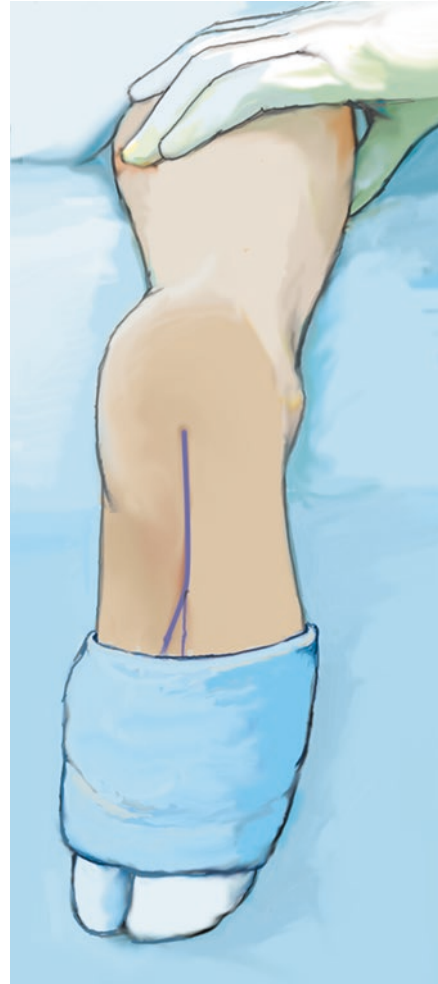
■ Fig. 3.25 a Lateral portal for posterior arthroscopy. The landmark is the distal lateral malleolus (level of the ankle joint line). b The stab incision is made lateral to the Achilles tendon



■ **Fig. 3.26** Landmarks for posterior arthroscopy. Medial portal at the level of the lateral malleolus in line with the lateral portal. *AT* Achilles tendon, *PL* posterolateral portal, *LM* lateral malleolus



■ **Fig. 3.27** Approach through the soft tissue towards the first/second interdigital space with the mosquito clamp until the subtalar joint can be palpated



■ **Fig. 3.28** The great toe and lesser toes are draped separately in sterile fashion so that the flexor hallucis longus muscle can be identified by moving the great toe during arthroscopy

is carried superiorly. Either the low muscle belly or the tendon of the flexor hallucis longus will be seen as an anatomic landmark. Because the great toe was draped out separately from the lesser toes, the great toe can now be moved to identify the flexor hallucis longus tendon.

After identification, the posterior process or os trigonum is visualized until no further impingement can be seen. The subtalar joint can now be inspected in inversion without distraction. For females and patients with joint laxity, the entire joint can usually be visualized up to the sustentaculum tali medially. In tight joints, a 2.7 mm scope can be used to advance further into the joint.

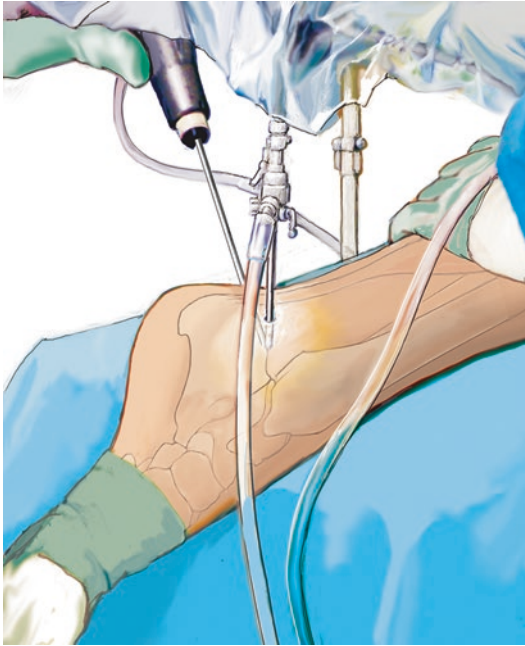


Fig. 3.29 Portal and triangulation: The arthroscope is brought up to the subtalar joint from lateral. The shaver is then brought to the tip of the arthroscope. The arthroscope is then pulled back a few millimeters to show the tip of the shaver



Fig. 3.31 Soft tissues around the talus are removed with the shaver and the 3.2 mm biter

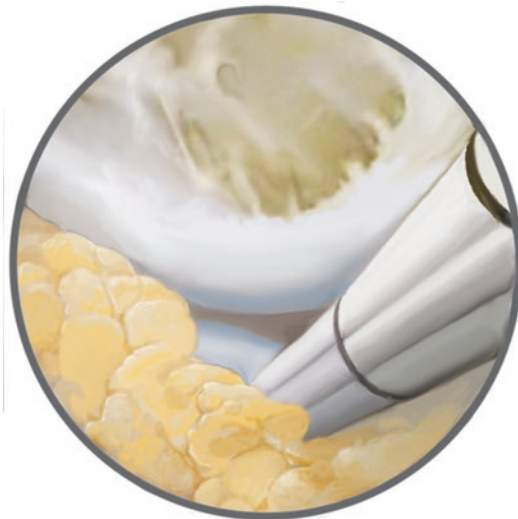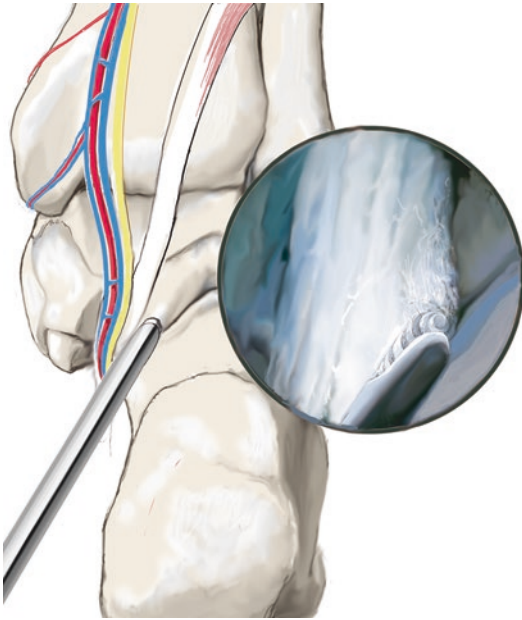


Fig. 3.30 The os trigonum is dissected away from the subtalar joint using the shaver. The shaver blade should always be kept medial, close to the calcaneus, and always be turned away from neurovascular structures



Fig. 3.32 In cases of posterior process impingement, the process is removed with a 5 mm osteotome after it is visualized. The area is then smoothed with a shaver

A curette is inserted for debridement. The surfaces are gently debrided with the burr. The AMIC procedure is performed (▶ Sect.3.2.1). Bone marrow and ACP are injected and a matrix is inserted. The bone marrow is harvested from the posterior superior iliac crest. The area is then sealed.



■ **Fig. 3.33** Debridement of the flexor hallucis longus tendon must be performed with care, as the neurovascular bundle is just 3–4 mm medial to the tendon. Debridement is always performed close to the calcaneus. The tendon must be debrided up to the retinaculum, which sometimes must be enlarged

■ Aftercare for the AMIC procedure

Aftercare for subtalar AMIC follows the same guidelines as for all AMIC procedures. For simple lesions, a plaster cast is placed for 3 days followed by range of motion exercises. The subtalar joint should be moved immediately at this point with inversion, eversion and circular motions. This can be performed by the patient independently. If possible, a CPM machine that allows for

inversion and eversion should be used. Partial weight-bearing for 6 weeks at 15 kg and for 2 weeks at 30 kg. For «kissing lesions», the ingrowth phase is longer for the matrix. The plaster cast is left for 4 days and range of motion is started on day five. Partial weight-bearing for 8 weeks at 15 kg and for 2 weeks at 30 kg. Physical therapy should have the primary goal of achieving early range of motion at the ankle joint (flexor muscle chain!). Particular attention should be paid to eversion and inversion so that the joint is immediately mobilized.

■ Aftercare for os trigonum/posterior process resection and flexor hallucis longus tenolysis

At the end of surgery, local anesthetic with corticosteroid (dexamethasone, water soluble!) is injected to avoid adhesions and to accelerate rehabilitation. With this, patients are often almost free of symptoms on the day after surgery. For pain control, a splint is placed the afternoon of surgery and at night to avoid involuntary motion. A plaster cast is then placed for 2–3 nights and removed during the day. Partial weight-bearing is continued for 10–14 days depending on pain. The joint is mobilized immediately, particularly in dorsiflexion, to avoid posterior adhesions. Due to the depth of the portals, scar tissue is more likely to form posteriorly than with anterior arthroscopy. This can cause low-grade pain, particularly in dorsiflexion, so every physical therapy session should include scar mobilization and manipulation. This can also be done by the patient independently using a lotion (such as Voltaren gel).

Arthroscopy of the Subtalar Joint

- 4.1 General Notes – 66
- 4.2 Microfracture for Osteochondral Lesions – 68
 - 4.2.1 AMIC Procedure – 68
- 4.3 Subtalar Arthrodesis – 68

4.1 General Notes

■ Indications

Osteochondrosis dissecans of the subtalar joint, both talar and calcaneal. Arthrofibrosis of the subtalar joint (such as after calcaneus fracture, lateral talar process fractures, etc.). Lack of compliance for aftercare and age greater than 60 years with reduced stem cell activity for microfracture can limit the indications. Due to the minimal trauma to soft tissues, this technique has the advantages of decreased postoperative morbidity and early mobilization of the joint.

■ Contraindications

End-stage subtalar joint arthritis. High-grade stiffness of the joint that prevents posterior access is a borderline indication. For this, an arthroscopic-assisted technique should be used to mobilize the joint.

■ Specific patient information

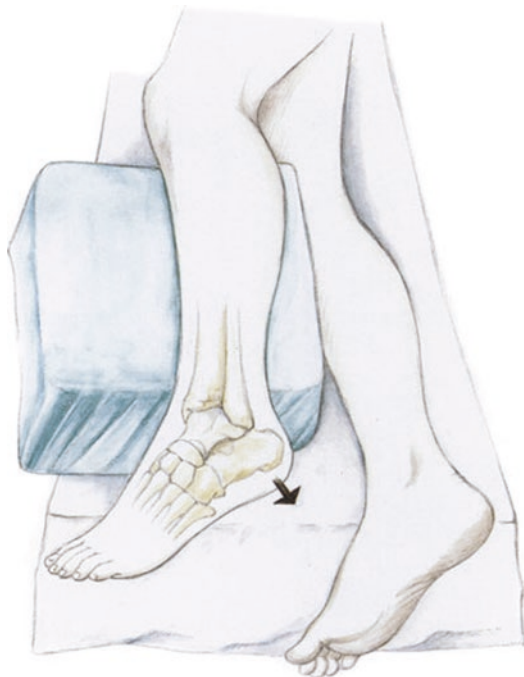Partial weight-bearing for 14–21 days to reduce swelling and allow for maximum range of motion. For marrow-stimulating procedures such as microfracture, particularly at the subtalar joint, long-term results are unknown at this time. Patients should be informed that substantial symptoms could remain after surgery.

■ Surgical setup

The procedure is performed under tourniquet in a lateral position. The contralateral leg is padded to prevent nerve palsies at the peroneal and sural nerves. The ipsilateral leg is placed on a cushion about 20 cm thick. The ankle joint hangs over the side of the cushion so that the foot can be inverted to open the subtalar joint (■ Fig. 4.1).

The joint is distended from an anterolateral portal and from a posterolateral portal with 10–15 ml of lactated Ringer solution. In post-traumatic cases, the joint often has adhesions that limit visualization. Similar to a subacromial resection, soft tissue must be debrided first. In this case, the shaver is inserted through a second anterolateral portal and triangulated so that it is visible to the arthroscope. Soft tissue resection is performed for lysis of the joint adhesions.

For stiff joints (such as after calcaneus fracture), a Hintermann spreader can be inserted percutaneously at the lateral posterior talus to open the joint (■ Fig. 4.2). The joint can be instrumented



■ Fig. 4.1 Patient is in a lateral position with padding of the contralateral leg to protect the peroneal nerve and the sural nerve at the level of the foot. The ipsilateral leg is placed over a cushion that is about 20 cm thick. This allows the hindfoot to be inverted at the ankle joint. Traditional distraction techniques usually do not substantially widen the subtalar joint; as a result, distraction with inversion is the only way that the subtalar joint can be opened

with the aid of the spreader until the joint is loose enough that it can be opened without the spreader.

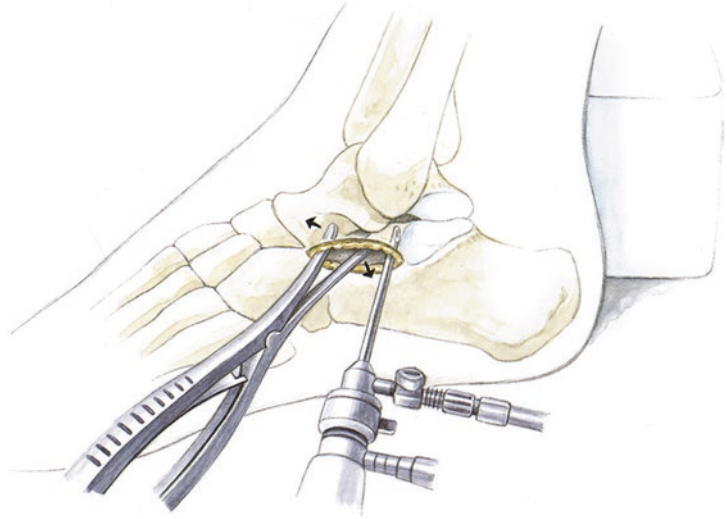
■ Surgical principles for lysis of adhesions and microfracture

Complete lysis of adhesions is performed first at the sinus tarsi. The interosseous talocalcaneal ligament is a distal landmark. The arthroscope is then directed laterally once the anterior portion of the posterior facet and the talar dome are visible. A posterolateral portal is placed under arthroscopic visualization. Scar tissue is removed using a special suction biter (2.5 mm). The joint is entered posteriorly and the scar tissue in the subtalar joint – often completely obscuring the joint – is gradually resected.

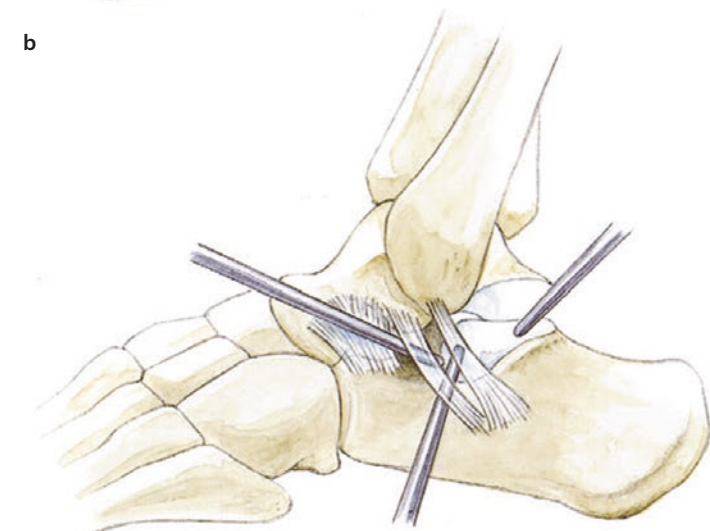
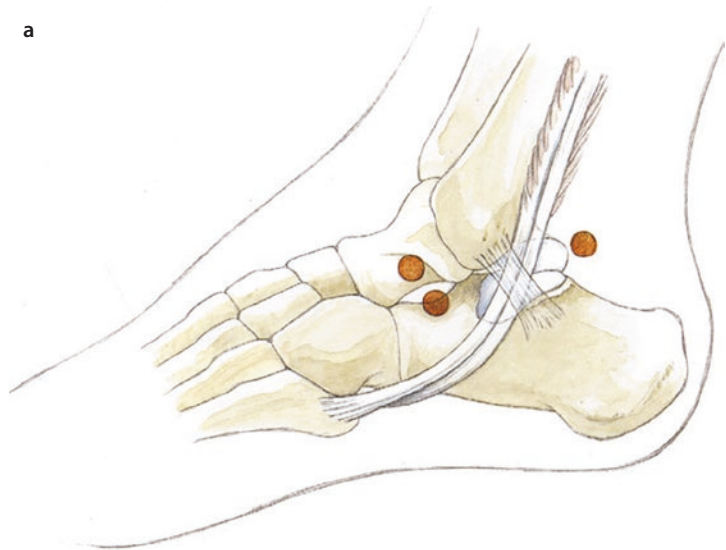
After visualization has been achieved, the arthroscope is inserted posterolaterally. The anterior aspect of the posterior facet is again debrided in the sinus tarsi. Microfracture is performed through a posterolateral portal with the arthroscope in an anterolateral portal (■ Fig. 4.3a,b).

4.1 · General Notes

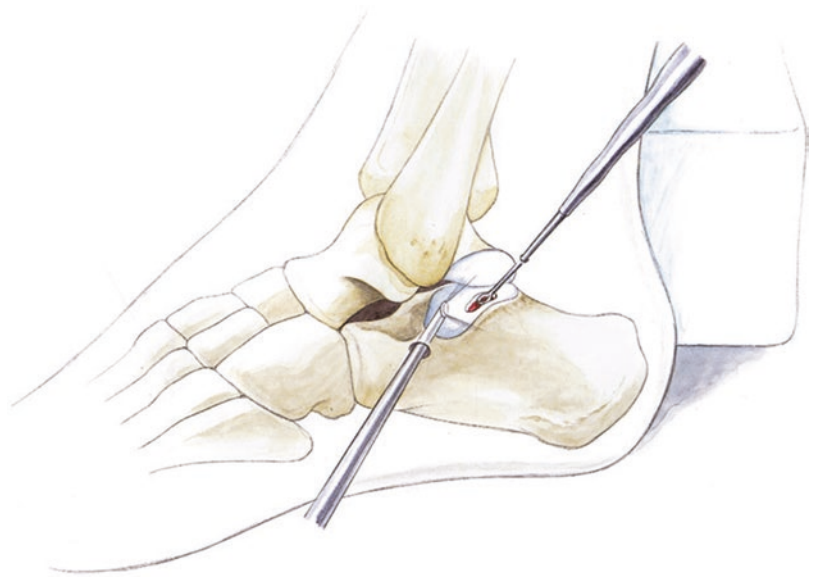
■ **Fig. 4.2** If the subtalar joint is stiff (such as following a calcaneus fracture), it can be helpful to insert an arthrodesis spreader into the sinus tarsi. The incision is lengthened into an Ollier approach. The joint can then be widened, creating space for arthroscopy. A Hintermann spreader can also be used



■ **Fig. 4.3 a,b** Illustration of portals. **a** Anterolateral portal at about the level of the sinus tarsi («soft spot»), superolateral portal about 1 cm higher, posterolateral portal behind the peroneal tendons about 1 cm distal to the tip of the fibula, **b** Traditional portals: anterolateral, superior anterolateral and posterolateral



■ **Fig. 4.4** Osteochondral lesions are often present in the middle or anterior aspect of the posterior facet (such as after calcaneus fracture or lateral talar process fracture). After extensive debridement, sharp cartilage borders are created with a small curved curette



■ Posterior lysis of adhesions through a posterior portal

The portals and setup are as described in ► Sect. 3.4. Post-traumatic scar tissue is usually present, so debridement and visualization of anatomic structures is much more difficult. The lateral compartment is visualized first as the risk of iatrogenic injury is lower. The space along the lateral wall of the calcaneus and the posterior facet of the fibula is debrided. Tenolysis of the peroneal tendons is sometimes indicated. After visualization of the subtalar joint, the arthroscope is directed medially to the medial wall of the calcaneus. The flexor hallucis longus tendon is carefully tenolysed from lateral up to the retinaculum. Lysis of adhesions is then performed for the ankle joint. This is complete when the entire ankle joint can be visualized at an inclination of 20–25°. The medial and lateral ankle joint is debrided intra-articularly if necessary.

■ Aftercare

Patients should have a pain catheter postoperatively to allow for optimal pain control in continuous fashion. Manual techniques are used. Range of motion exercises are performed with a CPM machine that can perform both dorsiflexion/plantar flexion as well as inversion/eversion. CPM exercises are continued for 4 weeks (a prescription is given for home use). Chondroitin sulfate and/or glucosamine are administered. Partial weight-bearing (15 kg) for 4 weeks,

gradual strengthening with an elliptical trainer, water jogging and cycling. Jogging and regular participation in impact sports (3–10 times body weight!) is not advisable if severe cartilage damage is present.

4.2 Microfracture for Osteochondral Lesions

■ Technique

■ Figures 4.1, 4.2, 4.4, 4.5, and 4.6.

4.2.1 AMIC Procedure

The AMIC procedure for the subtalar joint is performed in similar fashion as described in ► Sect. 3.2.1.

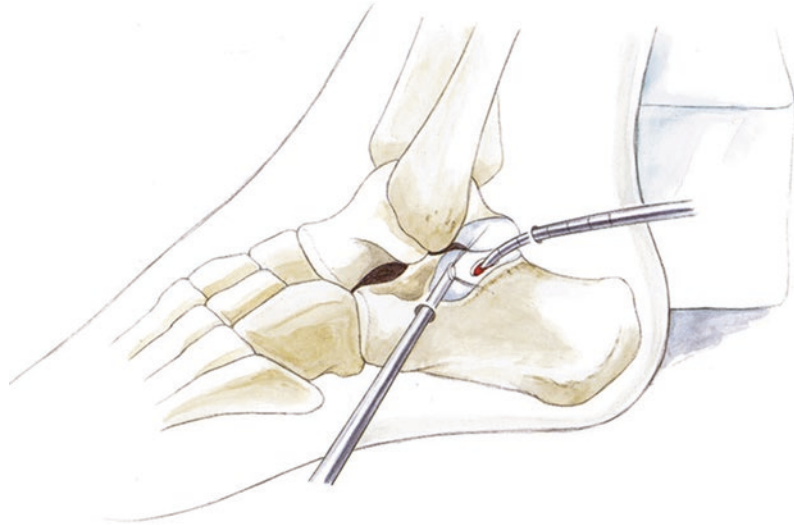
4.3 Subtalar Arthrodesis

The advantages of arthroscopic-assisted subtalar arthrodesis are as follows:

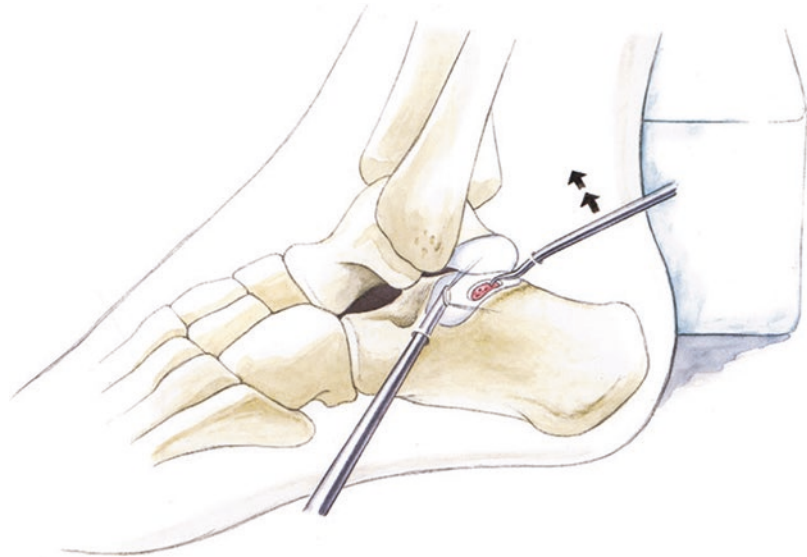
- Posterior arthroscopy results in less traumatic surgery with decreased soft tissue injury and swelling.
- The procedure is technically easier with screw insertion in the prone position.
- Minimal postoperative pain and rapid return to weight-bearing.

4.3 · Subtalar Arthrodesis

■ **Fig. 4.5** Shaving, light debridement of the subchondral layer with a 3.0 mm shaver. This allows the posterior facet to be reached in tight joints. The lateral aspect of the joint can be opened slightly by inverting the foot



■ **Fig. 4.6** Microfracture with a swan-neck Chondropick. This is levered superiorly a small amount so that the awl will create perpendicular perforations



■ Indications

Subtalar arthritis with a straight hindfoot axis and no bone loss. Moderate-grade infections of the subtalar joint. For posterior infections, the ankle joint can also be debrided simultaneously. Low-grade axis deviations with a varus or valgus hindfoot.

■ Contraindications

Large bone defects after calcaneus fractures and severe axis deviations that require osteotomies and fusion.

■ Surgical setup

Subtalar 4.0 mm arthroscope with a 3.8 mm shaver, slightly curved osteotome (5 mm), curettes or sharp spoons, mosquito clamp. A nucleotome, suction biter, power rasp and Chondropick are sometimes needed to break up the subchondral plate and allow for improved vascularity. Cannulated screws (6.5–7.4 mm). Bone marrow aspirate from the posterior superior iliac crest can be harvested if needed to increase the surface area and accelerate healing of the arthrodesis. If small defects

are present, graft can also be harvested from the proximal tibia. The knee is flexed to allow for cancellous bone harvest.

■ Positioning and perioperative management

Prone position with the contralateral iliac crest slightly elevated so that the leg and hindfoot are perpendicular to the ground. A small silicone cushion («camel») is used to hold the leg in position. Surgery is performed under tourniquet. Antibiotics are given for 24 h («single shot»). Low-molecular-weight heparin is given at the time of induction.

■ Technique

■ Figures 4.7, 4.8, 4.9, 4.10, 4.11, 4.12, and 4.13.

The arthroscope is inserted posteriorly using a standard technique. Anatomic landmarks are completely visualized (flexor hallucis longus, lateral gutter and joint facets). Posterior osteophytes are removed with a burr, osteotome and nucleotome.

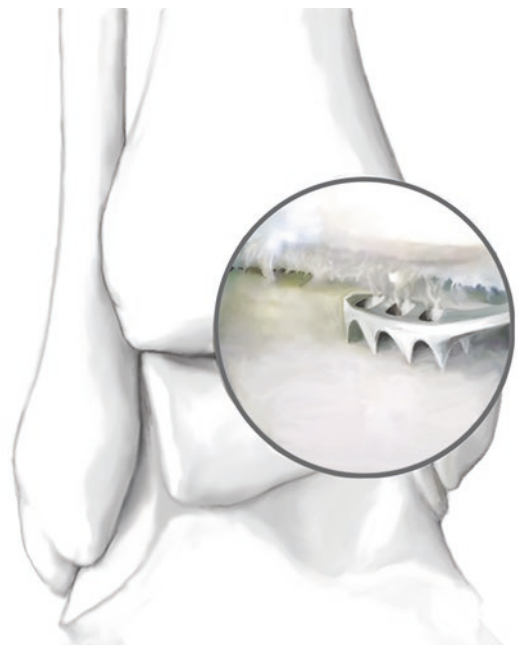Debridement is performed with the 3.8 mm shaver and the subtalar joint is entered from posterior and posterolateral. Debridement is gradually continued with the foot in inversion and the joint usually widens. Firm areas of cartilage or sclerosis are removed to the subchondral layer with a curved 5 mm osteotome, a spoon or a power rasp until vascularized cancellous bone is visible.



■ Fig. 4.7 Debridement with a sharp spoon



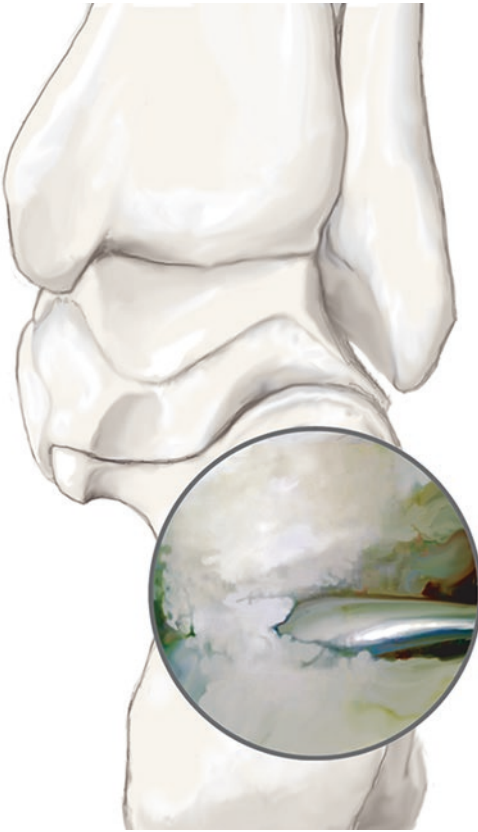■ Fig. 4.8 Sclerotic bone and cartilage are removed, working distally, with a curved 5 mm osteotome



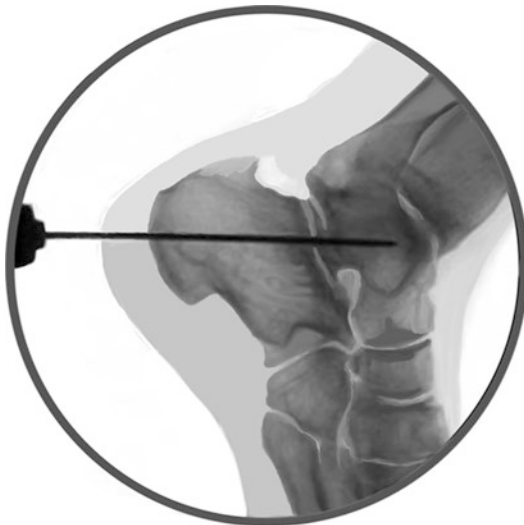■ Fig. 4.9 Power rasp (see ankle arthrodesis)

Extensive microfracture is performed at the tibial plafond and at the dome of the talus. This can cause small superficial fractures to break through the subchondral plate. Microfracture should be performed with very deep perforations.

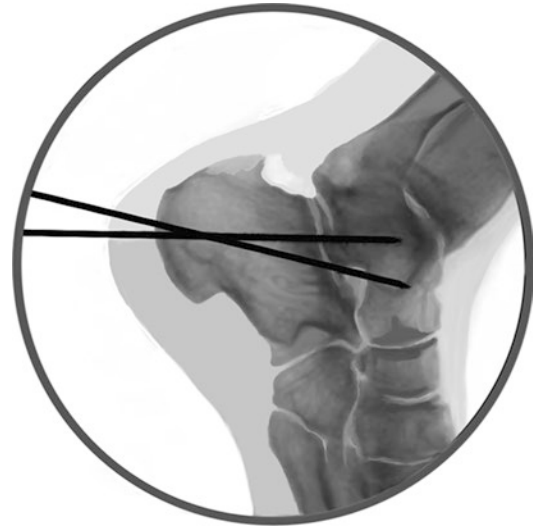The joint is placed in neutral position and varus/valgus deviations are corrected if necessary. A stab incision is made at the medial calcaneus,



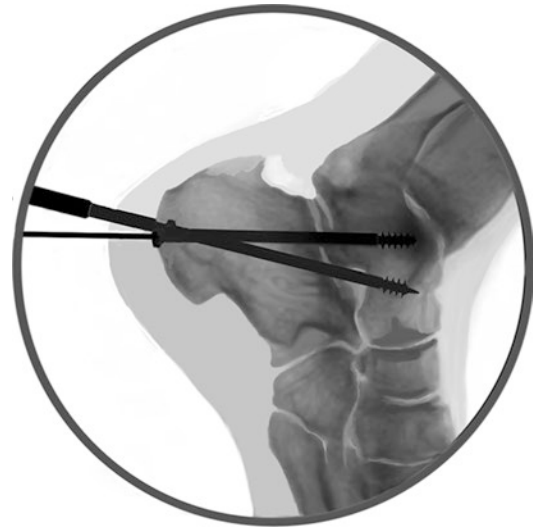■ Fig. 4.10 «Aggressive»microfracture to break through the subchondral plate



■ Fig. 4.11 The guidewires for the subtalar fusion screws are inserted. These are inserted from a slightly medial starting point and close to perpendicular to the posterior facet of the calcaneus



■ Fig. 4.12 The second screw (with a slightly lateral starting point) is advanced into the neck of the talus to create a triangular construct with the two screws



■ Fig. 4.13 After overdrilling, the 6.5 mm or 7.3 mm screws are inserted

almost vertically, to reach the posterior facet. A guide wire is inserted in this direction, aiming slightly lateral to reach the body of the talus. A second stab incision is made at the lateral border of the calcaneus. The lateral wire is advanced into the neck of the talus to create a triangular compression construct. Radiographs are taken in AP, lateral and Broden views to evaluate the subtalar joint. Bone marrow is injected and small cancellous chips taken from the tibial plateau are inserted. The wires

are then overdrilled and the 6.5 or 7.3 mm cancellous short-thread screws are inserted.

■ Aftercare

Six weeks in a short walking boot with 15 kg partial weight-bearing. Range of motion exer-

cises are performed at the ankle joint as pain allows. Stretching for the flexor muscle chain is started early if tightness is present. Standard anti-inflammatory treatment is given for 14 days. Physical therapy is performed for the ankle joint with the addition of lymphatic drainage massage.

Metatarsophalangeal Joint Procedures

- 5.1 **General Notes – 74**
- 5.2 **Hallux Rigidus – 74**
 - 5.2.1 Open Technique – 74
 - 5.2.2 Cartilage Reconstruction with the AMIC Procedure – 77
 - 5.2.3 Arthroscopic Technique – 79

5.1 General Notes

The first step is restoring mobility by resecting osteophytes. The second step is release of the shortened plantar structures – both the joint capsule and the short flexor tendons – caused by chronic decreased extension. In contrast to the conventional technique, this technique includes the phalangeal capsule at the tendon insertion (flexor hallucis brevis muscle) rather than the metatarsal region alone. Dissection must be very careful here to avoid detaching the short foot flexors. To augment the release surgery and improve the joint mechanics, areas with absent cartilage (Outerbridge type IV) are treated with traditional microfracture to induce regenerated cartilage. This uses a special awl that is somewhat smaller than that used for microfracture at the ankle and knee. The «chess board» pattern is somewhat tighter, with a distance of about 2 mm between perforations.

■ Indications

Hallux rigidus with severe osteophytes (Hatstrup and Johnson type I and II).

■ Contraindications

None. Hatstrup and Johnson type IV may be considered a contraindication; however, in my opinion, joint-preserving surgery can still be performed. If the joint space is completely obliterated, the chances of success for joint-preserving surgery are relatively low. The patient must be informed that symptoms may not resolve. In this case, surface replacement or arthrodesis is indicated.

■ Specific patient information

Weight-bearing as tolerated in a forefoot-unloading shoe for 14 days to reduce soft tissue swelling and pain. This allows the patient to perform maximum range of motion exercises in this phase. Muscle strengthening is started with water jogging if possible. Tiptoe walking in water, cycling and independent range of motion exercises in addition to physical therapy. Dorsiflexion of the MTP (metatarsophalangeal) joint is performed on the edge of the shower every day under running cold water.

Additional exercises are performed to improve range of motion and roll-off (shoes with

flexible soles and barefoot walking, optionally with socks). Range of motion exercises are continued for 6–9 months. Stretching and range of motion exercises are continued after this to retain mobility.

■ Positioning and perioperative management

Standard supine position, tourniquet, antibiotic prophylaxis (such as with a third-generation cephalosporin). In routine cases, antibiotics are only given perioperatively. Intraoperative thrombosis prophylaxis with low-molecular-weight heparin given at the time of induction.

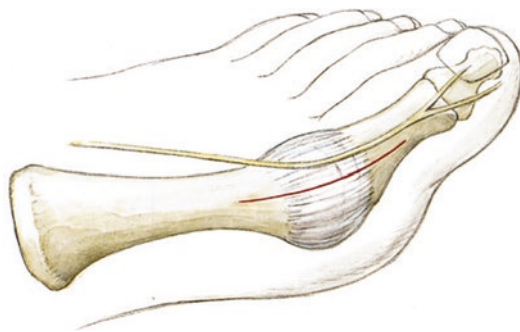■ Aftercare

Anti-inflammatories and antibiotics (Third generation cephalosporin) are given for 24 h. Gentle range of motion exercises and lymphatic drainage massages are performed on the first day. Stretching is performed with slight distraction of the joint starting on the second day after surgery. An MTP CPM machine can also be used starting on the second day while gradually increasing the range of motion. A CryoCuff shoe is worn. The foot is elevated well above the level of the body after surgery. Non-steroidal anti-inflammatories.

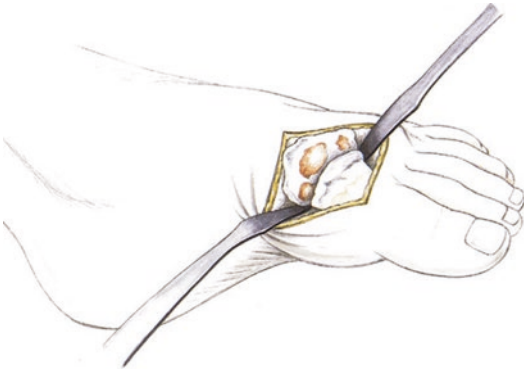
5.2 Hallux Rigidus

5.2.1 Open Technique

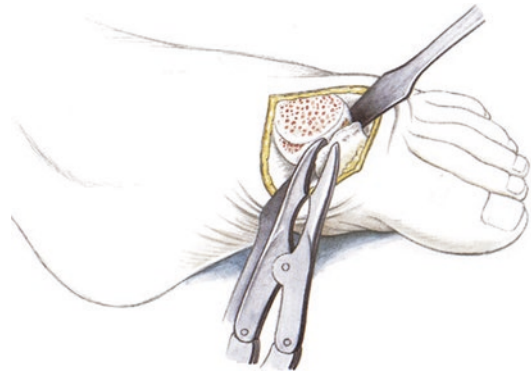
■ Figures 5.1, 5.2, 5.3, 5.4, 5.5, 5.6, 5.7, 5.8, 5.9, and 5.10.



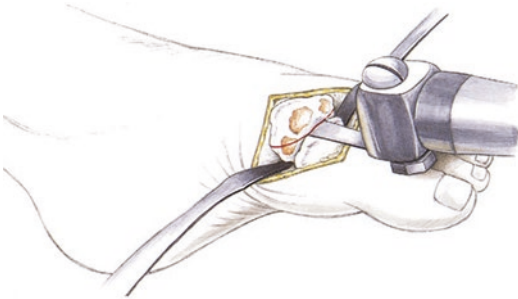
■ Fig. 5.1 Anteromedial incision protecting the dorsal nerve



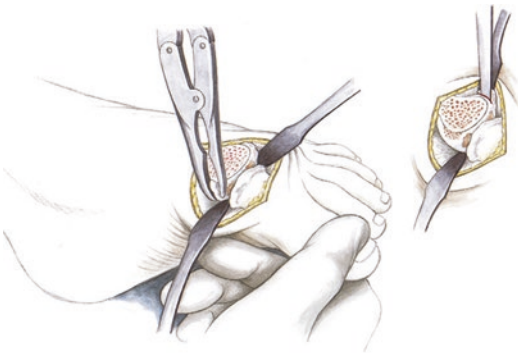
■ Fig. 5.2 Visualization of the joint after a straight capsulotomy. Osteophytes and areas of absent cartilage are seen at the 1st metatarsal head and the joint surface of the proximal phalanx



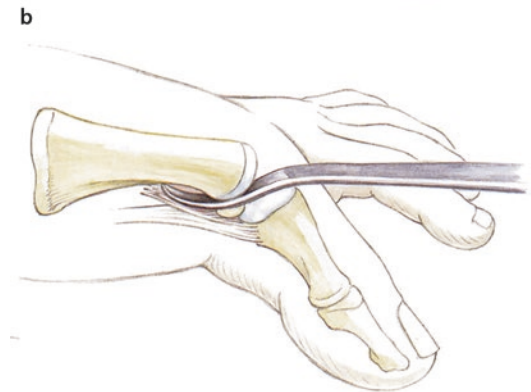
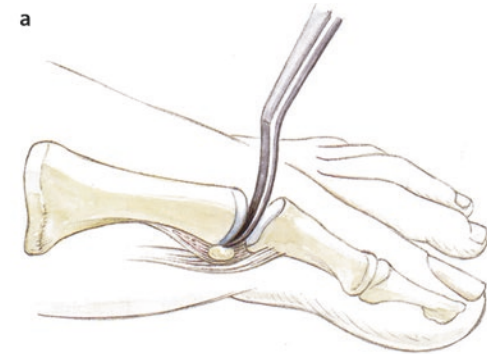
■ Fig. 5.5 Removal of osteophytes at the dorsal, medial and lateral aspect of the proximal phalanx



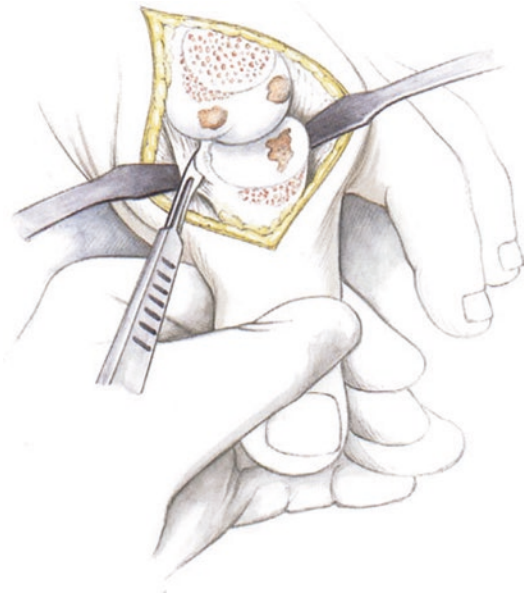
■ Fig. 5.3 Traditional cheilectomy. No more than 20–25% of the diameter of the metatarsal head should be removed



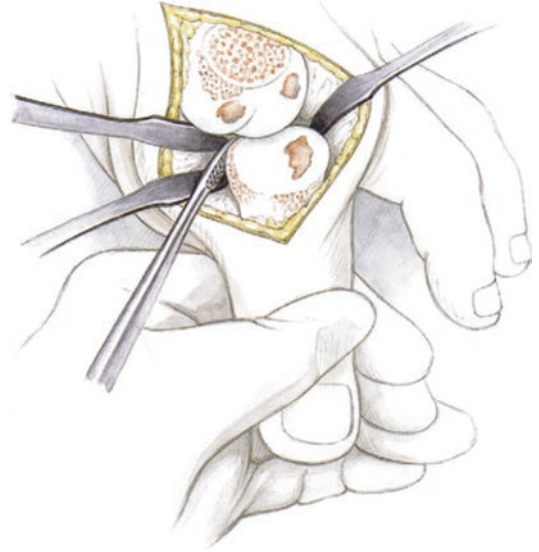
■ Fig. 5.4 Removal of medial and lateral osteophytes



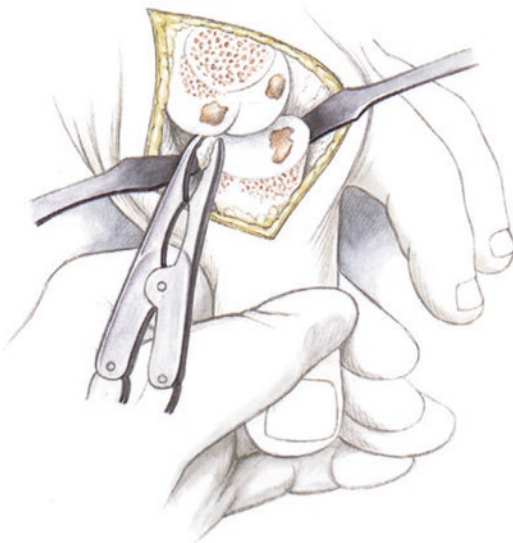
■ Fig. 5.6 a,b Capsular release and release of the flexor tendons using a McGlamry rasp at the first metatarsal. There should be an audible and palpable release



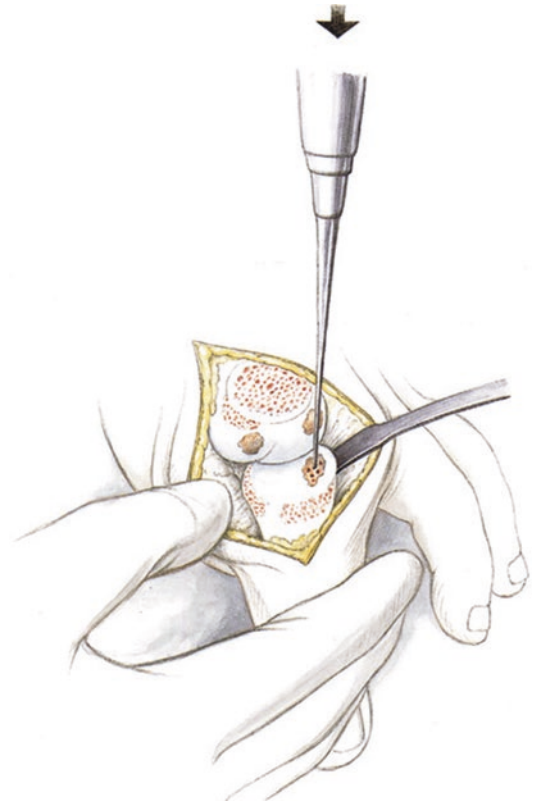
■ **Fig. 5.7** Release of the distal capsule and the insertion of the short flexor tendons is performed using subperiosteal dissection with a scalpel



■ **Fig. 5.9** The short flexors are again released subperiosteally with a rasp



■ **Fig. 5.8** Blunt release is continued at the plantar joint with a rasp and osteophytes are removed. This will lead to substantial improvement of plantar flexion



■ **Fig. 5.10** Microfracture is performed in areas of absent cartilage (Outerbridge type IV) using a special microfracture device for the toes

5.2.2 Cartilage Reconstruction with the AMIC Procedure

AMIC procedures are unlikely to be successful with end-stage arthritis of the MTP joint. In these cases, arthrodesis is the technique of choice. Patients with early arthritis at the dorsal aspect of the metatarsal head and low grade osteophytes with gradually increasing intermittent pain are optimal candidates for cartilage reconstruction. Osteochondral lesions are another source of pathology that are usually not recognized on plain radiographs. MRI almost always shows a central cartilage lesion with minimal dorsal osteophytes. Range of motion is only limited at the end-range, but the joint is constantly painful, causing problems in patients who actively participate in sports. Advanced stages of cartilage damage with high-grade deformation of the local anatomy and large areas of absent cartilage, particularly at the dorsal aspect, indicate a guarded prognosis. However, patients are often fearful of a complete fusion and see this as an option for later in life. These cases are a relative indication. The basic principles include lysis of adhesions, especially a plantar release, and dorsal resection of osteophytes (cheilectomy). In my opinion, it is critical to restore the center of rotation of the first MTP joint, as hallux rigidus always causes plantarization of the proximal phalanx. Because of this, plantar release is absolutely necessary.

It should be noted that severe shortening and tension are always present after surgery, which is primarily caused by the plantar capsule and the insertions of the short flexor muscles. Because of this, in my opinion, a radical plantar release at the distal aspect of the proximal phalanx must be performed to ensure free range of motion in dorsiflexion and reduce the compression in the joint. At the end of mobilization and reconstruction, the proximal phalanx should have free range of motion without any catching. Even the smallest «catch» can lead to substantial pain, scar formation and recurrent stiffness, which would put the results of surgery at risk.

■ Indications

Circumscribed central cartilage lesions. A salvage procedure without arthrodesis can be considered if the patient wishes. Clear information must be

given about the risk of failure. Patients who refuse arthrodesis despite advanced cartilage lesions, particularly at the dorsal aspect, of the 1st MTP head with significant osteophyte formation.

■ Contraindications

End-stage arthritis with no chance of delaying disease progression with surgery. General medical contraindications.

■ Surgical setup

Small McGlamry saw (13 mm). Elevator and #11 scalpel for subperiosteal dissection around the plantar proximal phalanx. Rongeur for removal large osteophytes, particularly around the phalanx. File for creating a completely smooth gliding surface. Chondro-Gide collagen matrix, microfracture instruments, bone marrow aspirate from the iliac crest with a Jamshidi needle. Fibrin glue (Tissucol 5 ml).

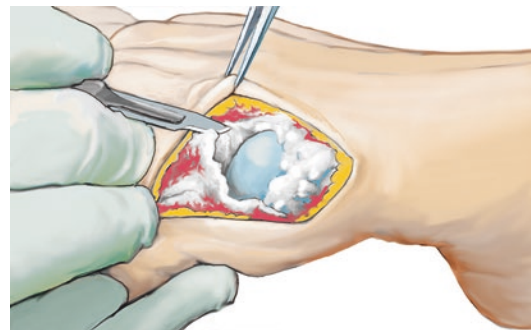
■ Positioning

Normal positioning with the contralateral foot lowered. Surgery is performed standing at the contralateral side. Exsanguination with an Esmarch. Tourniquet at 300 mmHg.

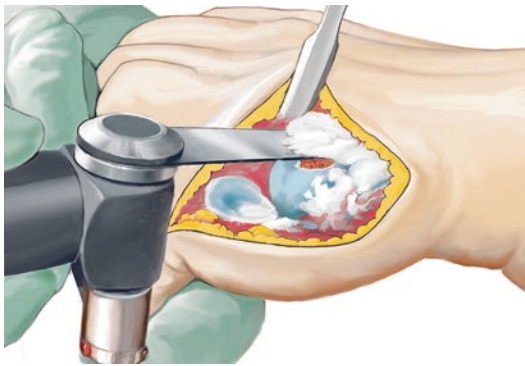
■ Technique

■ Figures 5.11, 5.12, 5.13, 5.14, 5.15, 5.16, 5.17, 5.18, and 5.19.

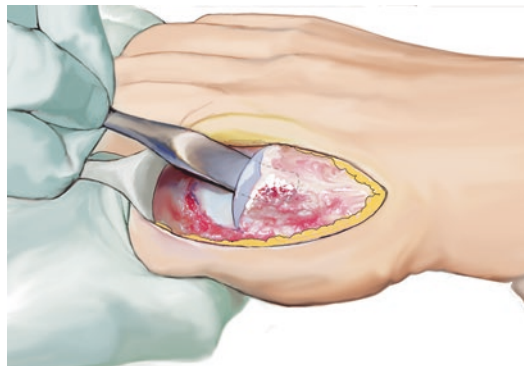
A medial incision is made, protecting the dorsal tendons. A joint arthrotomy is made. Dissection is carried laterally and plantarly from the joint and Hohmann retractors are inserted. The plantar aspect of the joint is gradually visualized until the joint can be flexed to 90°. Cheilectomy is performed. Rather than performing a simple



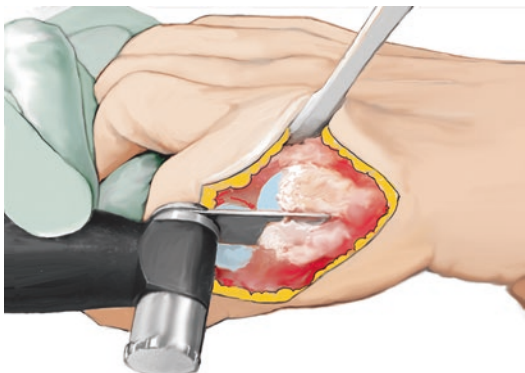
■ Fig. 5.11 Visualization of the first MTP joint with osteophyte formation



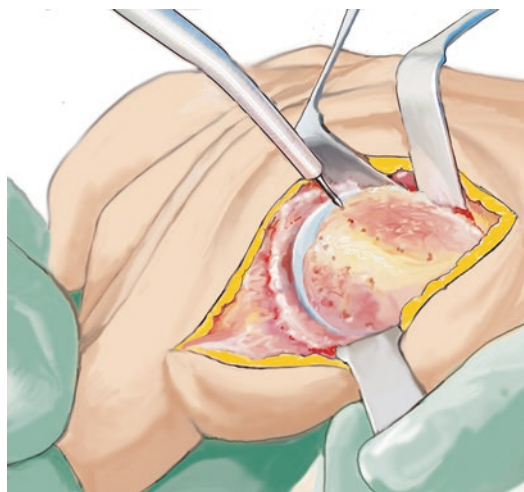
■ Fig. 5.12 Standard cheilectomy



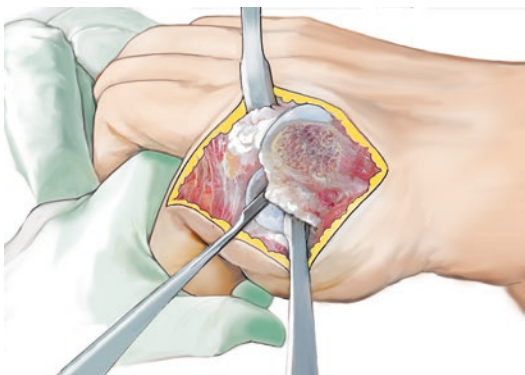
■ Fig. 5.15 Plantar release with a #13 McGlamry rasp



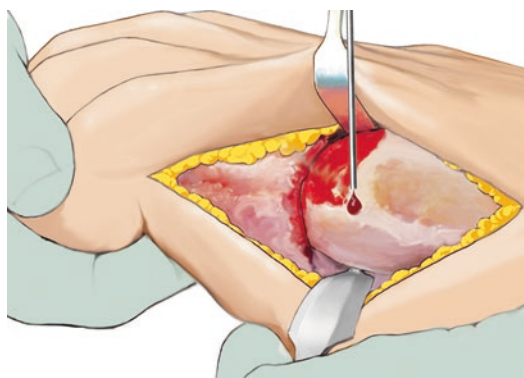
■ Fig. 5.13 Resection of medial and lateral osteophytes



■ Fig. 5.16 The sclerotic subchondral plate is punctured with a file or a power rasp, «nanofracture»

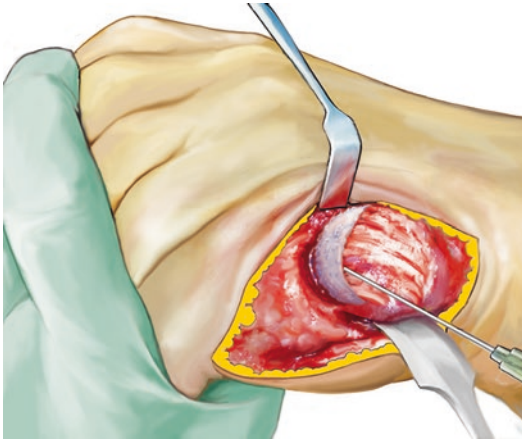


■ Fig. 5.14 Plantar release with subperiosteal release of the dorsal capsule and the short toe flexors at the proximal phalanx using the scalpel and rasp

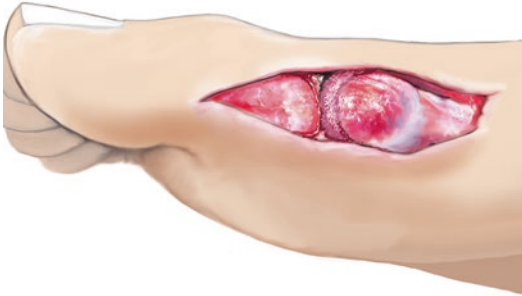

■ Fig. 5.17 Bone marrow stem cell transplantation (aspirated from the iliac crest with a Jamshidi needle), which is allowed to coagulate for a short time

resection, a natural, round head shape should be achieved with a ball-and-socket shape. This will allow for optimal range of motion. To accomplish this, lateral and medial osteophytes are removed. Dissection is performed with a #11 scalpel and a



■ **Fig. 5.18** The matrix is inserted and fixed with fibrin glue, which is allowed to harden for 5–10 min



■ **Fig. 5.19** The matrix is allowed to harden in a neutral position. The wound is closed without tension in layers. No capsular reefing is performed

rongeur. All osteophytes are removed from the proximal phalanx. Blunt subperiosteal dissection is performed using an elevator to detach the plantar capsule and the short flexor tendon. A plantar release is then performed proximally at the metatarsal head using a McGlamry saw. Range of motion should now be unobstructed.

The joint is then dorsiflexed to see if there is any catching of the joint. Any obstruction is gradually smoothed with a file. A 1.0 mm wire is then used to perform a small-bore microfracture. Bone marrow aspirate (containing bone marrow and stem cells) is injected and allowed to coagulate for several minutes. The area around the neomembrane and neocartilage is then injected with bone marrow as well. An acellular collagen matrix (Chondro-Gide) soaked in bone marrow aspirate is then placed and held in place with additional bone marrow aspirate, which coagulates quickly.

This is sealed with fibrin glue and allowed to dry. The joint is reduced without damaging the construct. The capsule is closed in tension-free fashion in a neutral position. The soft tissues are loosely closed. A plaster splint is applied to prevent unnecessary motion and reduce pain.

■ Aftercare

Plaster is left in place for 2 days to allow for matrix ingrowth. Range of motion exercises are then initiated with dorsiflexion and plantar flexion and concurrent joint distraction. These are performed both with a physical therapist and independently. A flat forefoot-unloading shoe is worn for 6 weeks, then weight-bearing is gradually progressed. Water jogging and range of motion exercises are started, particularly in plantar flexion. Due to the plantar soft tissue trauma, this can often lead to painful scars that are not correctable. Impact sports such as jogging or basketball with jumping motions are not recommended for non-elite athletes.

5.2.3 Arthroscopic Technique

■ Surgical setup

Supine position and tourniquet. Gauze is wrapped around the toe for soft tissue distraction. Medial and lateral portals are made at the MTP joint in addition to a medial plantar portal for plantar access. The joint is distended with 5–10 ml of lactated Ringer solution.

The joint is entered from the anteromedial portal with instrumentation through the anterolateral portal. A small elevator or a small curved mosquito clamp can be inserted first to puncture the capsule and spread the portal. The entire joint is then visualized from both portals to visualize the dorsal margin of the joint and the resection level.

A small burr is then inserted and advanced until the entire burr has reached the posterior osteophyte. A small osteotome or cylindrical burr can be used to smooth out the bone. The instrument and arthroscope portals can be switched as needed to obtain a complete view of both sides.

The resection should be continued up to the diaphyseal junction. Fluoroscopy can also be used to check the extent of resection. A guidewire can be inserted to mark the insertion depth if desired. Complete cheilectomy is then performed with dorsal release at the metatarsal head. A plantar

medial portal is then created. The arthroscope (2.5 or 1.9 mm) is inserted through the dorsal superior medial portal and advanced inferiorly. A needle is inserted under arthroscopic visualization to localize the portal. A stab incision is made and an elevator is inserted to release the capsule proximally. Any adhesions can be removed with a 2.5 mm shaver. Microfracture is also performed from the medial or lateral portal depending on the extent and location of the cartilage lesions. At

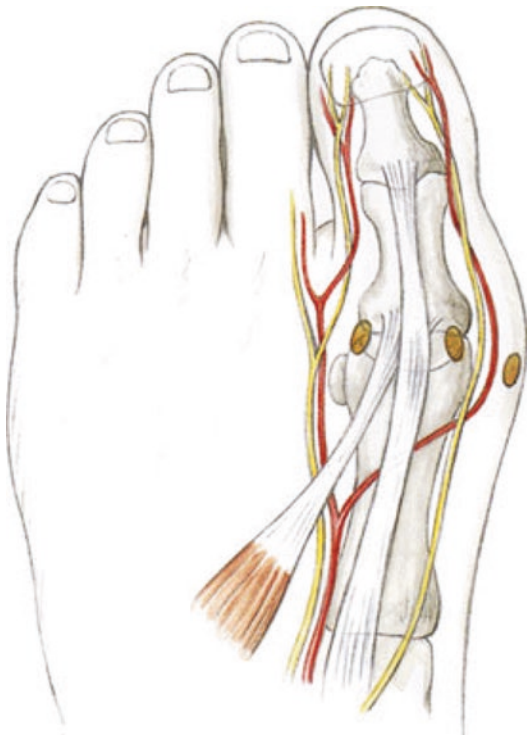
the end of surgery, local anesthetic is injected. If severe synovitis is present, a water-soluble corticosteroid is injected after synovectomy.

■ Aftercare

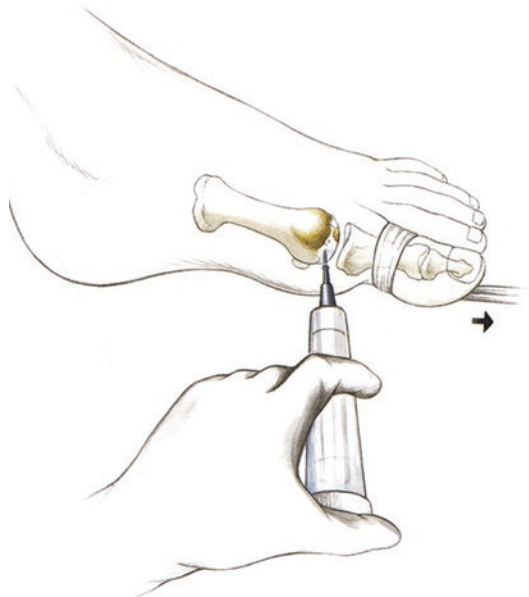Identical to the open technique. Partial weight-bearing for 14 days with a forefoot-unloading shoe. Arthroscopic cheilectomy and arthroscopic soft tissue release have substantial advantages due to the decreased postoperative morbidity and patients are able to move much earlier without pain or swelling.

■ Technique

■ Figures 5.20, 5.21, 5.22, 5.23, 5.24, 5.25, and 5.26.

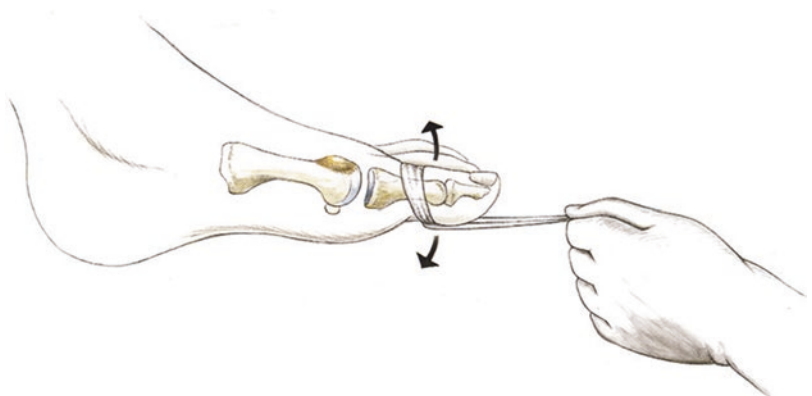


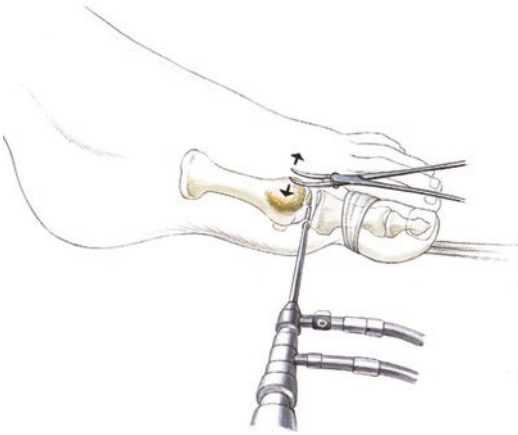
■ Fig. 5.20 Illustration of the medial and lateral portals at the 1st MTP joint as well as the plantar medial portal for plantar release



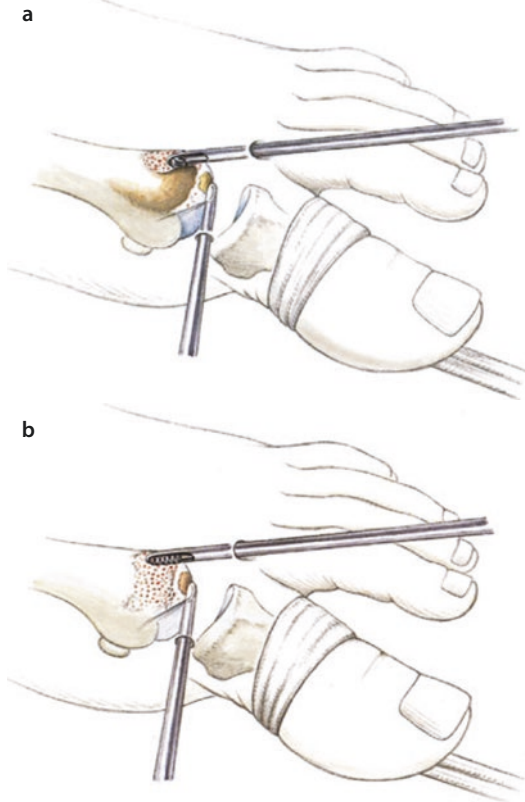
■ Fig. 5.21 Gauze is applied to the proximal phalanx to use for distraction of the joint. Distension with 5–10 ml of lactated Ringer solution

■ Fig. 5.22 The great toe should be pulled into plantar flexion while working through the dorsal portals and pulled into dorsiflexion for the plantar portals

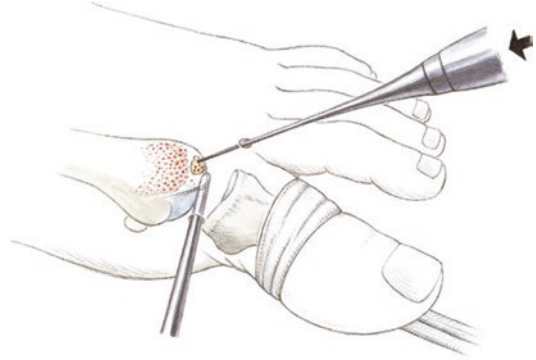




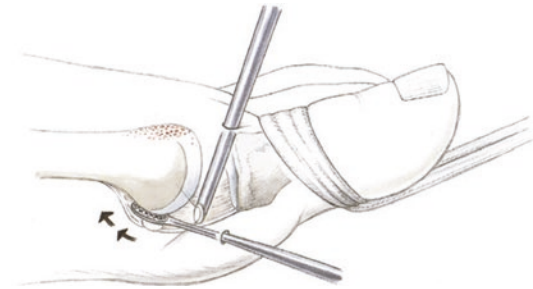
■ Fig. 5.23 If capsular adhesions are present, a mosquito clamp or elevator should be inserted prior to the arthroscope to spread the capsular space. This will improve the joint volume and visualization. The lateral portal is then established



■ Fig. 5.24 a,b Debridement of soft tissue with a shaver. The ball-shaped burr is then inserted fully up against the dorsal osteophytes to determine the depth of resection. The dorsal osteophytes are then resected and smoothed with a 2.5 mm cylindrical burr



■ Fig. 5.25 Microfracture using the Mikrofrac instrument (Wolff)



■ Fig. 5.26 Plantar capsular release through a plantar medial portal in slight dorsiflexion. The arthroscope must be inserted in the dorsal medial portal. The dorsal lateral portal can also be used, but this requires the toe to be dorsiflexed somewhat less to allow the arthroscope to be advanced plantarly

Procedures for Hindfoot Axis Deviations

6.1 Supramalleolar Osteotomies – 84

- 6.1.1 General Notes – 84
- 6.1.2 Biplanar Osteotomy for the Cavovarus Foot – 84
- 6.1.3 Gastrocnemius Slide with Opening Wedge Osteotomy – 87
- 6.1.4 AMIC Procedure for Treatment of Cartilage Lesions – 88
- 6.1.5 Oblique Varus-Producing Closing Wedge Osteotomy – 89

6.2 Calcaneal Osteotomies – 92

- 6.2.1 General Notes – 92
- 6.2.2 Valgus-Producing and Varus-Producing Osteotomies – 93
- 6.2.3 Rotational Opening Wedge Osteotomy – 94

6.3 Calcaneal Lengthening Osteotomy – 94

- 6.3.1 Valgus-Producing Dome Osteotomy of the Calcaneus – 97
- 6.3.2 Varus-Producing Calcaneal Osteotomy with a Step-off Plate – 98

6.1 Supramalleolar Osteotomies

6.1.1 General Notes

Supramalleolar osteotomies have the greatest effect for correction of varus or valgus deformity at the ankle joint. This creates optimal load transfer in cases of imminent or existing cartilage damage and compartmentalized varus or valgus arthritis patterns. A medial approach is made with the patient supine. For opening wedge osteotomies, cancellous bone grafting is always necessary. New locking plates have eliminated the need to implant corticocancellous bone wedges, which take longer to heal than cancellous grafting alone.

The problem with opening wedge osteotomies is that they create distraction in addition to angular rotation. Because of this, I developed a biplanar osteotomy technique that is carried across the tibia in the axial plane, then angled upwards towards the joint approaching the sagittal plane. The tip of this osteotomy serves as a fulcrum, with only a small bone defect at the lateral tibia. The opening wedge lever effect for axis correction is also substantially improved without distracting through the osteotomy. Bone healing is extremely rapid after conventional cancellous bone grafting and the optional addition of bone marrow and growth factors.

For surgical planning, weight-bearing radiographs should always be obtained for analysis of the hindfoot and ankle deviation. A Salzman view with the radiographic beam angled 20° in the coronal plane has proven to be useful for this.

6.1.2 Biplanar Osteotomy for the Cavovarus Foot

■ Indications

Correction of hindfoot axis deviations based on the degree of deviation and/or clinical symptoms; only with a flexible subtalar joint. Hindfoot and supramalleolar osteotomies can be combined with calcaneal osteotomies. The correction serves to place the Achilles tendon at the center of the tibia, providing a centralized lever for the gastrocnemius-soleus-Achilles tendon complex.

■ Contraindications

Planovalgus foot or cavovarus foot with symptomatic subtalar arthritic changes, stiffness of the subtalar joint.

■ Surgical setup

The following equipment is needed for biplanar osteotomy: Sharp osteotome set (5–15 mm), saw (narrow saw blade, conical-shaped, no wider than 1 cm distally), locking plate. Tibial plates from various manufacturers are currently used. A high level of stability is required in this difficult area, as pseudarthrosis often occurred in the past after fractures. Because of this, locking plates are absolutely necessary. It is also important to completely fill the defect. Autologous cancellous bone from the iliac crest or tibial plateau is the graft of choice. Locking plates do not allow for micromotion at the fracture site that encourages healing; therefore, in my opinion, corticocancellous wedges are not recommended due to the potential for necrosis. If there is not adequate cancellous bone autograft available, a homogeneous mix of autologous cancellous bone and bone marrow should be mixed. The cancellous bone should be firmly impacted.

■ Positioning and perioperative management

Supine position without additional supports. The leg is supported with a gel pad. The surgeon should ensure that a radiolucent operating table is used or that the distal leg is positioned at a radiolucent portion of the table. The contralateral leg is padded, with particular attention to protecting the peroneal and sural nerves. Perioperative antibiotic prophylaxis is given with a 3rd generation cephalosporin or other appropriate antibiotic in cases of allergy. Low-molecular-weight heparin is given at the time of anesthesia induction for thrombosis prophylaxis.

■ Technique

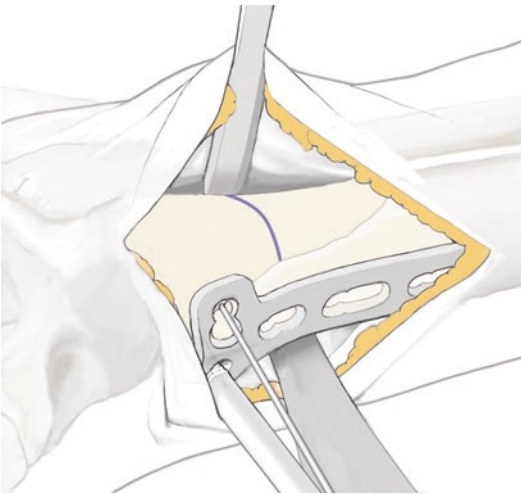
■ Figures 6.1, 6.2, 6.3, 6.4, 6.5, 6.6, and 6.7.

A medial approach is used. If an AMIC procedure is performed as well, the incision is carried to the medial malleolus for a medial arthrotomy. The saphenous vein is protected. This is dissected out superiorly and protected with an anterior

6.1 · Supramalleolar Osteotomies

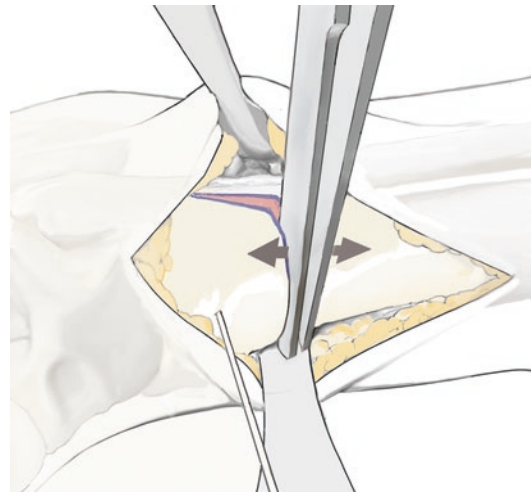
Hohmann retractor. The lateral periosteum is dissected. The incision should not be too small, as is frequently recommended, as this could lead to skin necrosis. In my opinion, it is completely irrelevant whether the incision is 3 or 4 cm long. The lateral tibia is then visualized and a Hohmann retractor is inserted while protecting the neurovascular bundle at the tibiofibular junction.

A locking plate is then placed and provisionally held with K-wires. The osteotomy and distal screw position is checked under fluoroscopy. If the position is ideal, the osteotomy site is marked and the plate is removed, leaving the wire in place.



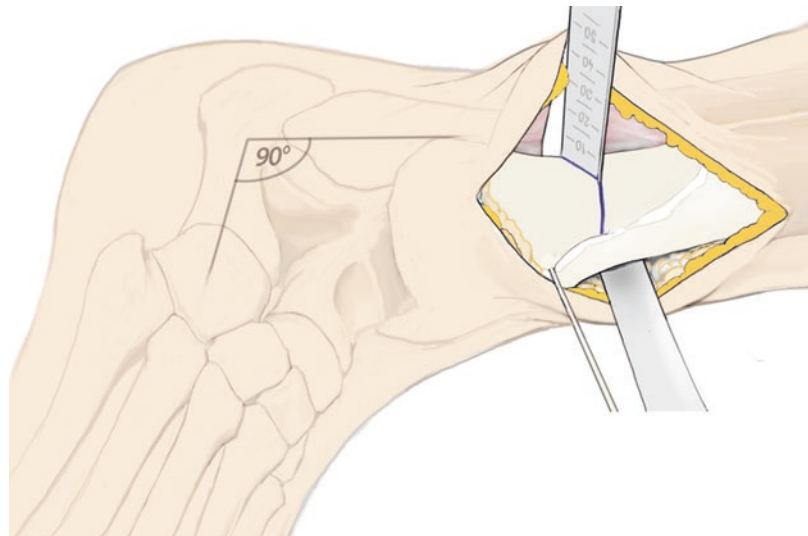
■ **Fig. 6.1** Placement of a locking plate and marking the osteotomy under fluoroscopy

Dissection is then carried posteriorly and superiorly up to the tibialis posterior tendon. Dissection is continued staying directly on bone using a rasp or elevator. A curved Hohmann retractor is then inserted to ensure protection of the posterior neurovascular bundle. The osteotomy is then performed through 50% of the tibia. The osteotomy is then angled about 45° and continued laterally. The lateral aspect closest to the tibiofibular region is not cut and the periosteum is left intact.



■ **Fig. 6.3** Spreading the osteotomy with arthrodesis or Hintermann spreaders at the medial osteotomy site. This uses the sagittal osteotomy as a fulcrum and minimizes distraction. The osteotomy is spread under fluoroscopy until the desired correction is achieved

■ **Fig. 6.2** Transverse osteotomy with a narrow saw blade to the center of the tibia, then an oblique osteotomy (sagittal) with an osteotome at a 45° angle up to the lateral cortex



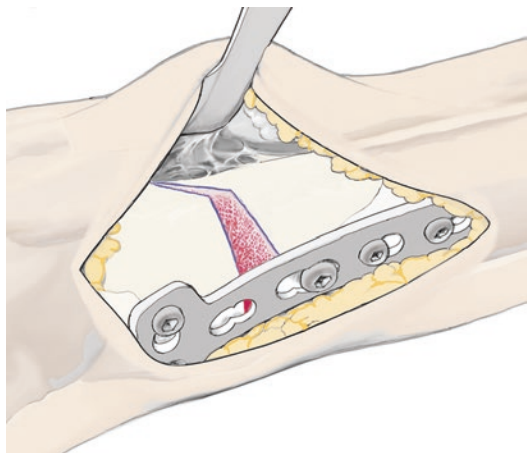


Fig. 6.4 Fixation is started with the distal locking screws, then a lag screw is used for the screw closest to the osteotomy site. This pulls the tibia against the plate. The two proximal locking screws are then inserted. Radiographs in two planes



Fig. 6.6 Locking plate fixation

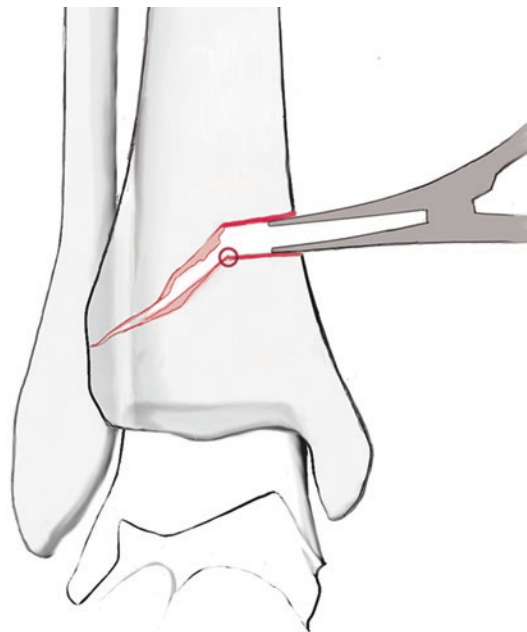


Fig. 6.5 Schematic illustration of the medial opening wedge with a lateral fulcrum

Osteotomes are then stacked to break through the lateral cortical bone at a sharp angle while leaving the periosteum intact. This results in a very stable opening wedge osteotomy as well as intact periosteal covering.

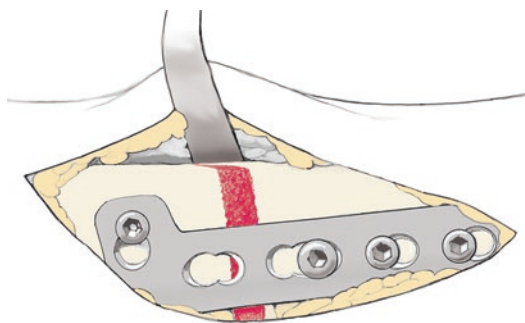


Fig. 6.7 Cancellous bone grafting. This should completely fill the defect. If there is not adequate cancellous bone at the iliac crest or tibial plateau, allograft cancellous chips from the bone bank are mixed with autologous cancellous bone and additional bone marrow

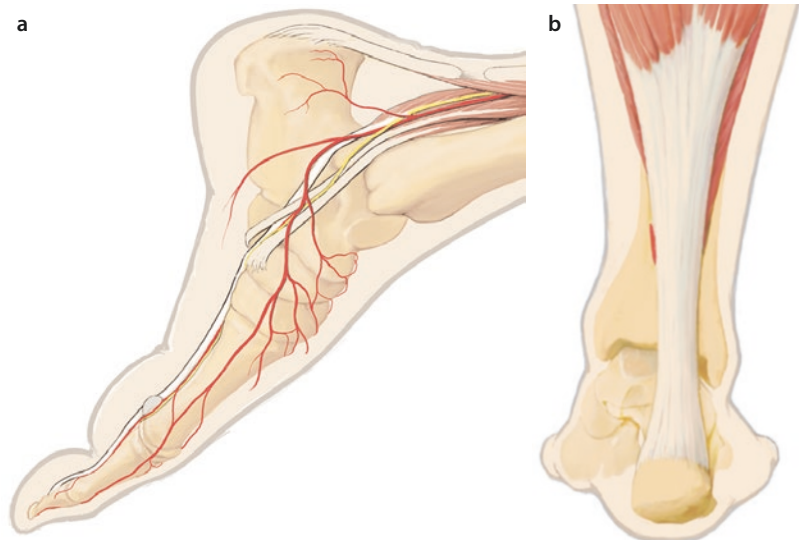
The osteotomy is then opened using a spreader based on the amount of desired correction. For high-grade cartilage lesions, the talar and tibial joint surfaces should be made at least parallel. Overcorrection into valgus can also be considered for severe problems. The distal locking screws are then placed. The screw closest to the osteotomy is

placed using a lag technique, restoring the lateral distraction of the osteotomy by pulling the proximal aspect of the tibia in line with the distal aspect. The lateral osteotomy site will be closed down at the cortex with a sharp angle. Prior to completing proximal fixation, the positioning and orientation of the plate should be checked carefully. The distal portion of the plate should be carefully checked in the sagittal plane with fluoroscopy. After fixation, locking screws are also placed at the proximal aspect of the plate to provide optimal stability.

An approach is made to the iliac crest while protecting the femoral cutaneous nerve, which runs along the tip of the crest. A skin incision is made through subcutaneous tissue then dissection is carried below the oblique abdominal musculature.

These muscles are elevated and the iliacus muscle is mobilized from the outer table with a curved osteotome. The crest and table are visualized with two Hohmann retractors and a generous window is made in the crest. Bone marrow is aspirated with multiple 20 gauge syringes to generate adequate pressure. The bone marrow and stem cells are injected into the osteotomy site. This is also mixed with the cancellous bone, particularly if allograft is used. The cancellous bone should be impacted enough to firmly fill the defect. A hemostatic sponge (Lyostypt) is placed at the iliac crest harvest site. The cap is closed and the wound is closed in layered fashion.

■ Fig. 6.8 a, b Medial approach and visualization of the aponeurosis



For complete alignment of the hindfoot, a valgus-producing osteotomy is performed to create a neutral hindfoot and centralize the Achilles tendon line of pull (► Sect.6.3.1).

6.1.3 Gastrocnemius Slide with Opening Wedge Osteotomy

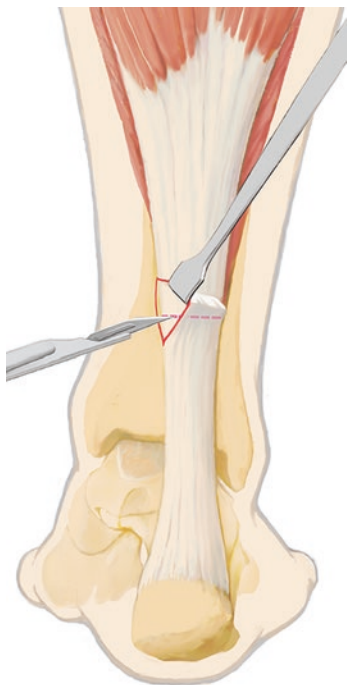
The gastrocnemius slide serves to lengthen the gastrocnemius-soleus-Achilles tendon complex. My experience has shown that this technique does not result in high-grade loss of Achilles tendon strength, while percutaneous intratendinous lengthening often results in the inability to stand on tiptoes.

Opening wedge osteotomy always leads to shortening of the gastrocnemius-soleus-Achilles tendon complex. Dorsiflexion is less than optimal in the cavovarus foot, particularly with pre-existing shortening of the complex. Because of this a gastrocnemius slide should always be performed as described.

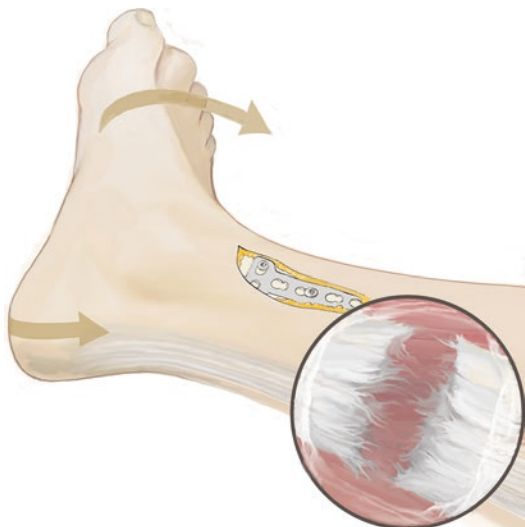
■ Technique

■ Figures 6.8, 6.9, and 6.10.

A medial approach is made at the level of the aponeurosis where the gastrocnemius-soleus complex joins the tendon. The aponeurosis is cut. This can also be performed with forced dorsiflexion with an extended knee. Dorsiflexion (10°) to distract the anterior musculature. Layered wound closure.



■ Fig. 6.9 Incision of the tendinous portion with a #11 scalpel



■ Fig. 6.10 Percutaneous tenotomy at the musculo-tendinous junction of the aponeurosis. With dorsiflexion, lengthening of about 5–10 mm is achieved

6.1.4 AMIC Procedure for Treatment of Cartilage Lesions

Arthritis changes with a varus foot are usually «kissing lesions» at the medial joint, the medial talar dome and the junction of the medial tibial plafond with the medial malleolus. There is often complete loss of cartilage and sclerotic changes with arthritic sequelae of the cartilage lesion by the time that patients become symptomatic and have surgery. These serious lesions of the cartilage and subchondral layer require a different procedure from cartilage lesions of the ankle. Due to the sclerosis, the technique and preparation of the subchondral layer are more aggressive. Experience has shown microfracture to lead to restoration of a fibrocartilage-cartilage mix at the lesion site.

■ **Surgical setup**

Setup is the same as for ankle arthroscopy with 3.0 mm shavers and standard ankle arthroscopy instruments with the addition of a power rasp. The surgery is performed in arthroscopic-assisted fashion to allow for visualization of the posterior areas as well.

■ **Technique**

■ **Figure 6.11.**

The joint is visualized through a medial approach and the arthroscope is inserted through a lateral arthroscopic portal. A mini-open technique is used to treat the sclerotic areas under arthroscopic visualization. Soft tissue distraction (Hintermann spreader) may be necessary to access the posterior joint. Lateral and medial portals are created so that the medial compartment can be easily visualized. Soft tissue and synovium are debrided with lateral instrumentation. The power rasp is used to resect the entire sclerotic area using the technique described by Lanny Johnson («salt ‘n pepper»). Bleeding subchondral bone should be visible. The same procedure is performed at the tibial plafond up to the medial malleolus. If performed correctly, there should be a small 1–1.5 mm step-off here into which bone marrow can be injected and the matrix can be completely fitted to the prepared surface. The area is then sealed with fibrin glue.

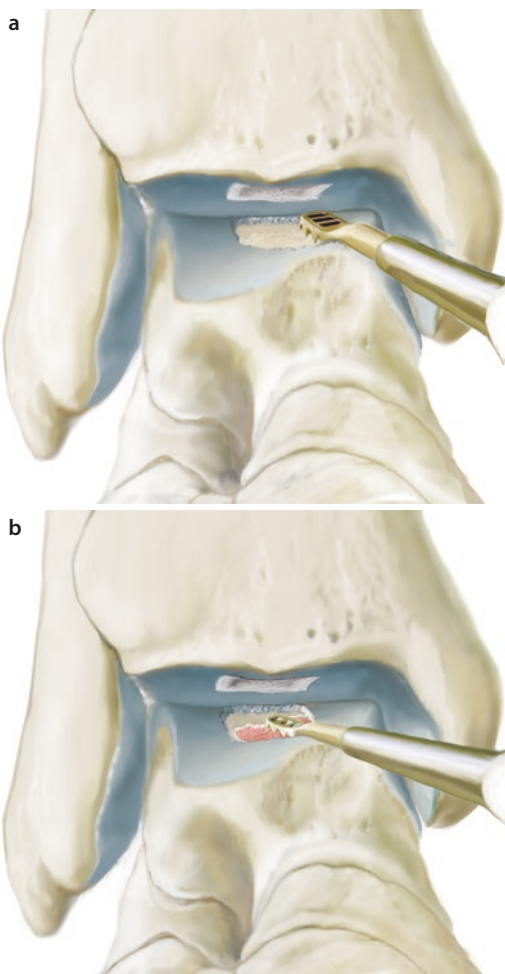


Fig. 6.11 a, b The sclerotic talar and tibial bone is resected with a power rasp until bleeding subchondral bone is seen (Chondroplasty as described by Lanny Johnson)

This bone defect that is created allows for good separation between the superior and inferior axes for ingrowth into the defect. The area is then completely sealed with fibrin glue and growth factors (ACP) are injected again with the rest of the bone marrow aspirate (bone marrow and stem cells). The tourniquet is let down and hemostasis is obtained. Layered wound closure. Sterile dressing and plaster cast with the ankle at 90°.

6.1.5 Oblique Varus-Producing Closing Wedge Osteotomy

For a varus-producing osteotomy, I prefer a closing wedge osteotomy that allows for optimum bone healing and immediate joint mobilization.

As with the valgus-producing osteotomy, the lever effect on the ankle joint is highest with a proximal osteotomy. The cause for valgus cartilage lesions and arthritis is typically post-traumatic changes after ankle fractures. The loss of bone caused by arthritis leads to some degree of hindfoot valgus. For primary planovalgus foot deformities, which can also involve the ankle joint, subtalar mobility is often severely limited due to the advanced planovalgus pathology. In these cases, a more complex treatment concept is needed.

■ Indications

Typically post-traumatic, moderate-grade valgus deformity with cartilage lesions, «kissing lesions» in the lateral compartment. No post-traumatic fibula changes such as shortening or lengthening. A flexible subtalar joint is required with no severe planovalgus foot pathology. Circumscribed cartilage defects at the lateral ankle joint. If moderate cartilage lesions are present, the procedure can be performed for preventive and unloading purposes.

■ Contraindications

High-grade planovalgus foot pathology with stiffness of the subtalar joint. Incongruity of the ankle joint due to fibular pathology or post-traumatic medial malleolus deformity and end-stage arthritis of the ankle joint with hindfoot valgus.

■ Specific patient information

Partial weight-bearing (15 kg) of the hindfoot for 6–12 weeks depending on the extent and volume of cancellous bone grafting. Risks of pseudarthrosis and need for revision internal fixation, long-term deformity and malalignment of the mechanical axis and ligamentous/muscular adhesions. It can take up to a year before the hindfoot correction leads to relief of pain at the midfoot and forefoot due to adjustments and accustomization. Because of this, stabilization exercises for the foot are performed when full weight-bearing is achieved as well as high-intensity physical therapy, possibly also manual therapy at the midfoot and forefoot. Custom insoles can be used no sooner than 6 months to allow for adjustment and adaptation of the foot to the new static and dynamic conditions. Coordination and proprioception training is also initiated; this can be started as a water exercise.

Because the opening wedge osteotomy leads to shortening of the gastrocnemius-soleus-Achilles tendon complex, a gastrocnemius slide

(Achilles tendon lengthening) should also be performed. This, of course, leads to weakened toe-off power but is necessary to allow for complete dorsiflexion.

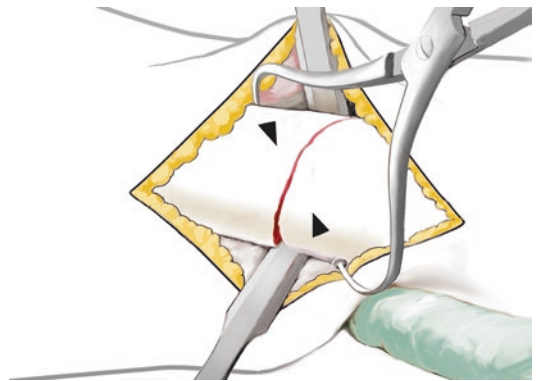
■ **Surgical setup**

Large plates are not needed for valgus-producing closing wedge osteotomies. T-shaped 3.5 mm low-profile locking plates are adequate to ensure good congruence and osseous healing at the bone edges.

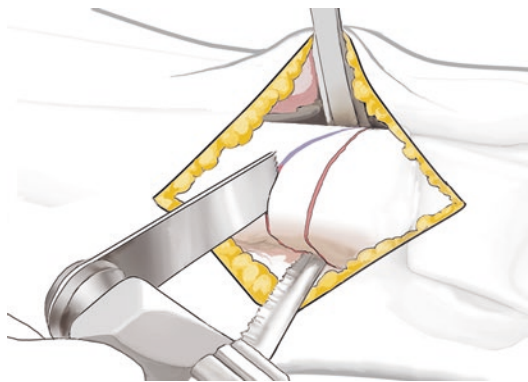
■ **Technique**

■ Figures 6.12, 6.13, 6.14, 6.15, 6.16, and 6.17.

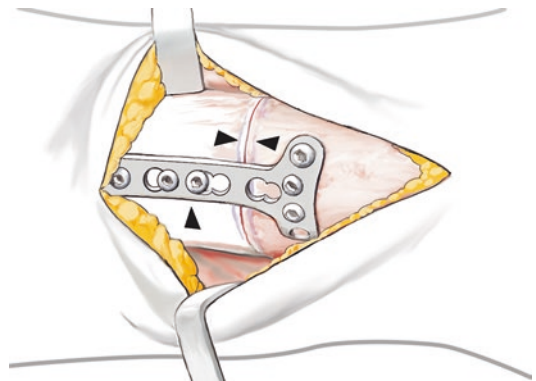
Medial approach. The saphenous vein and the neurovascular bundle are protected using a Hohmann retractor or a swan-neck Hohmann



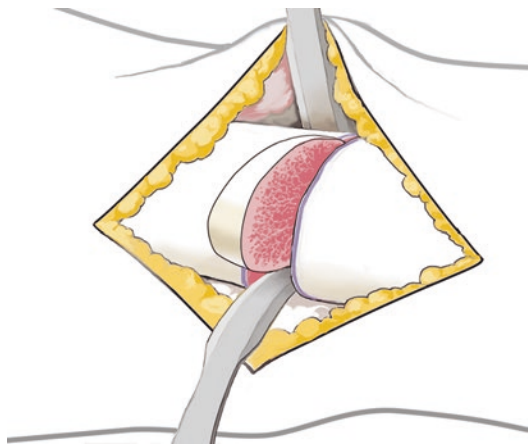
■ **Fig. 6.14** Closing the defect. Compression with a reduction forceps or a pelvic clamp



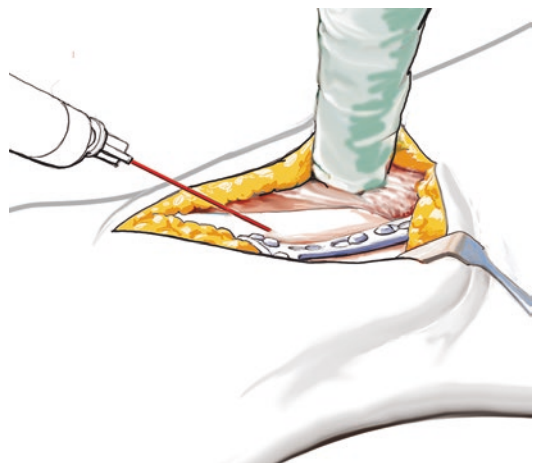
■ **Fig. 6.12** Oblique osteotomy to ensure that there is no significant shortening. A thin saw blade is used to minimize bone loss



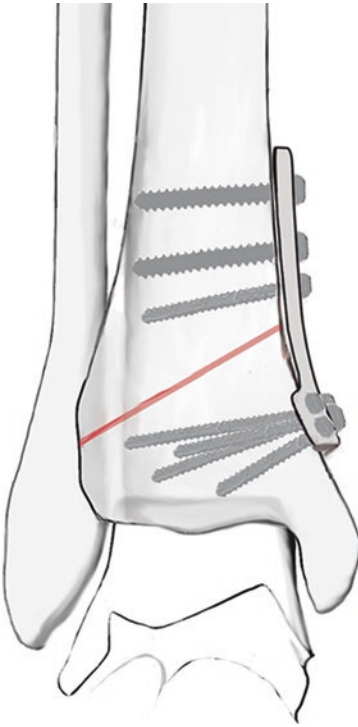
■ **Fig. 6.15** Plating with a 3.5 mm T-plate or similar. The proximal holes should be drilled eccentrically to increase compression



■ **Fig. 6.13** Resection of a wedge for appropriate correction. This is always cut starting with 5–6 mm; more can always be resected. The lateral wall is then cracked and the defect is closed. Compression with a reduction forceps



■ **Fig. 6.16** Bone marrow is injected into the osteotomy gap before and after plating

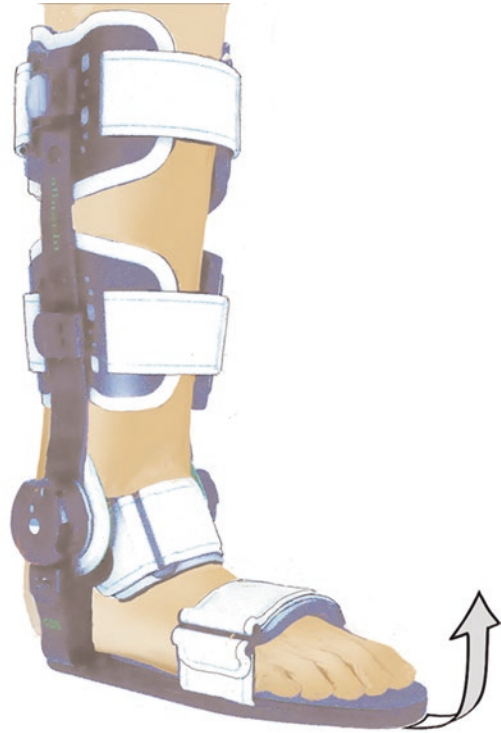

■ **Fig. 6.17** Closing wedge osteotomy, AP view. The lateral cortex is only cracked to preserve the periosteum

retractor placed against periosteum at the distal aspect of the incision. The osteotomy site is marked under fluoroscopy to ensure that the distal fragment can be stabilized with a plate and screws. Oblique osteotomies, in particular, can lead to low-grade shortening. This can be a problem, not only due to the overall shortening of the leg, but also due to changes at the muscular and ligamentous insertions.

An oblique osteotomy with a width of about 1 cm is performed at a 45° angle from medial superior to lateral inferior. The lateral cortex is not osteotomized; instead, it is cracked when the osteotomy is reduced to preserve the overlying periosteum.

The osteotomy is then clamped to provide optimum compression at the osteotomy site. This should be anatomically reduced on AP and lateral radiographs. The plate is then aligned. For non-locking plates, the proximal holes are drilled eccentrically to produce compression at the osteotomy site. Prior to this, bone marrow is aspirated with a Jamshidi needle from the iliac crest. This is injected into the osteotomy site and around the periosteum. The bone marrow is also used later for cartilage reconstruction.



■ **Fig. 6.18** CDS splint (Albrecht): Dynamic dorsiflexion splint used after gastrocnemius slide Achilles tendon lengthening and/or ankle release surgeries

■ Aftercare

Postoperative ankle range of motion exercises are performed in the sagittal plane starting on postoperative day 4 or 5 (if concurrent AMIC and cartilage reconstruction is performed). If locking plates are used, the fixation allows for immediate range of motion and casting is never necessary. A CDS (continuous dynamic stretching) device is used to improve dorsiflexion in cases of a tight (lengthened) gastrocnemius-soleus-Achilles tendon complex (■ Fig. 6.18). This improves dorsiflexion by «overpowering» the musculature with continuous tension on the calf muscles and the Achilles tendon without causing painful contractures.

For Achilles tendon lengthening, in addition to treating pain and swelling, the initial objective is to achieve maximum possible dorsiflexion. A CDS splint (Albrecht) should be used starting immediately (■ Fig. 6.18). This allows for passive subtalar joint range of motion stretching. After the supramalleolar osteotomy has achieved relative stability at about 4 weeks (closing wedge) or after 6–8 weeks (large opening wedge) with bone healing, passive ankle joint stretching can also be performed, particularly if there is substantial scar tissue formation.

The extremity is treated with elevation and cryotherapy (possibly Cryofos treatment) until wounds heal. If there is severe swelling, NSAIDs and lymphatic drainage massage are prescribed. Range of motion exercises are not performed at the subtalar joint (eversion/inversion) for the first few weeks until the hindfoot is relatively symptom-free.

Physical therapy exercises are started with a CPM (continuous passive motion) machine for 6 weeks, particularly for cartilage reconstructions. The patient should use the machine for 4–6 h daily through the maximum range of motion. The ankle is protected in alternating fashion with a CDS splint and a short leg (closing wedge osteotomy) long leg (opening wedge osteotomy) walking boot to allow for exercises. After radiographic evidence of bone healing, weight-bearing can gradually be increased in a short or long leg walking boot for a week. After this, weight-bearing is carefully advanced to full with well-padded shoes (jogging shoes).

For cartilage reconstructions, partial weight-bearing is maintained for 8 weeks, then increased by 15 kg. Mobilization is advanced over 2–3 weeks with a four-point gait. For cartilage reconstructions, autologous conditioned plasma (growth factors) is always injected at 2, 4 and 6 weeks.

If pain continues from the cartilage lesions or arthritic area, early implant removal is performed after 4–5 months to improve cartilage reconstruction with a revision AMIC procedure. Opening wedge osteotomies often result in significant worsening of complaints related to decreased dorsiflexion, which is due to the modified joint axis. Implant removal can be performed 3 months after osseous healing to prevent further stiffness.

6.2 Calcaneal Osteotomies

6.2.1 General Notes

■ Indications

Based on the axis deviation and/or clinical symptoms. Correction of hindfoot axis deviations is only performed with a flexible subtalar joint. Hindfoot osteotomies with concurrent subtalar arthrodesis are only performed for extremely high-grade hindfoot deformities, usually post-traumatic, that cannot be addressed with subtalar arthrodesis alone. Valgus-producing calcaneal osteotomy is performed as an opening wedge osteotomy on the

medial side using a dome osteotomy technique. This allows for better lateral translation.

■ Contraindications

Planovalgus or cavovarus foot deformities with symptomatic subtalar arthritic changes and stiffness of the subtalar joint.

■ Specific patient information

Partial weight-bearing (15 kg) through the hindfoot for 6–12 weeks depending on whether corticocancellous grafts were used (12 weeks). Risks include pseudarthrosis with the need for revision internal fixation and long-term deformities with mechanical axis deviations and ligamentous or muscular adhesions. It can take up to a year before adaptation and accustomization to the hindfoot correction leads to freedom from pain at the midfoot and forefoot. Stabilization exercises are needed for the foot once full weight-bearing is achieved. High-intensity physical therapy and possibly manual therapy for the midfoot and forefoot. Custom insoles are provided no sooner than 6 months after surgery to ensure adjustment and adaptation of the foot to the new static and dynamic conditions. Coordination and proprioception exercises are also performed, which can be done in water at first.

■ Surgical setup

Hindfoot osteotomies are «safest» to perform from the lateral side, as the approach is much less complicated due to the anatomic structures. A precise radiographic analysis should be performed prior to surgery. Along with surgical planning, this makes it very probable that surgical goals will be achieved. A lateral weight-bearing view of the foot should be obtained preoperatively to evaluate the pitch of the calcaneus and determine the size of the wedge needed for correction. To analyze the axes in the coronal plane, hindfoot weight-bearing views should be obtained with a 20° beam angle to determine the varus or valgus axis of the hindfoot. In cases of severe deformity, a corticocancellous wedge from the iliac crest may be used to augment the traditional translation technique. This is particularly useful in post-traumatic situations (such as calcaneus fractures) with shortening and bone defects as well as poor bone quality and severe deformity.

■ Positioning and perioperative management

Supine with padding to the buttocks to create a sloppy lateral position. A medial support is

6.2 · Calcaneal Osteotomies

attached to allow the table to be angled more medially. The patient's foot should be located on a radiolucent portion of the table. The contralateral leg is padded with particular care to protect the peroneal and sural nerves. Preoperative antibiotic prophylaxis is provided with a 3rd generation cephalosporin or an individually-selected antibiotic in cases of allergy. Thrombosis prophylaxis is provided with low-molecular weight heparin injections at the time of induction of anesthesia.

■ Aftercare

Postoperative range of motion exercises are started in the sagittal plane of the ankle starting on the second postoperative day. Generally, 7.3 mm screws result in stable internal fixation and a cast is not needed. A CDS splint is provided to improve dorsiflexion, as the gastrocnemius-soleus-Achilles tendon complex is usually shortened. Percutaneous Achilles tendon lengthening or a gastrocnemius slide should always be performed if 10° of dorsiflexion cannot be achieved intraoperatively. Postoperative use of a CDS brace for the ankle allows for continuous, pain-free improvements in dorsiflexion by «overpowering» the musculature with continuous pull and variable tension. This avoids painful contractures.

While the wound heals, the leg is elevated and treated with cryotherapy, NSAIDs, lymphatic drainage massage and range of motion exercises at the subtalar joint. Eversion/inversion exercises are not performed in the first few weeks until the ankle is relatively symptom-free. In cases with Achilles tendon lengthening, the initial objective

is achieving maximum possible dorsiflexion in addition to minimizing pain and swelling. After this, passive inversion/eversion exercises can be performed. At this point, osseous consolidation of the osteotomies should be present (no sooner than week 4–6). Physical therapy can be supported with a CPM device for dorsiflexion and plantar flexion of the ankle joint during inpatient care.

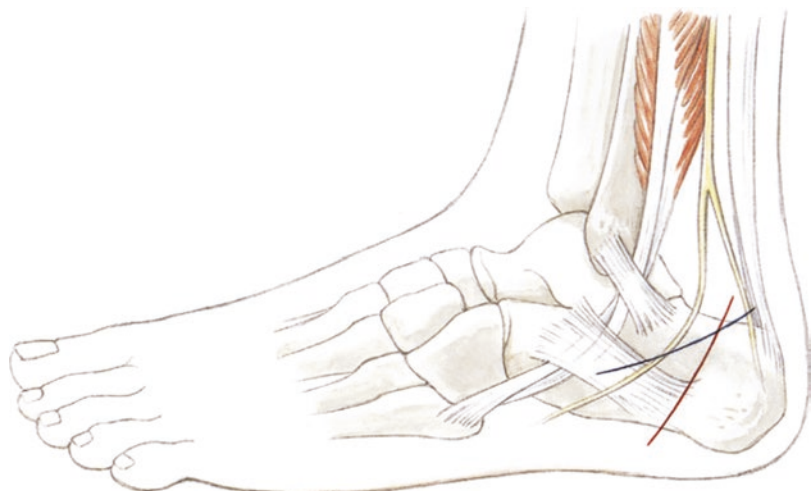
Partial weight-bearing for 6 weeks for non-augmented (corticocancellous wedge or rotational wedge) calcaneal osteotomies or 10–12 weeks for augmentation with a corticocancellous wedge or a rotational wedge depending on radiographic findings. Partial weight-bearing (15 kg) with underarm crutches. When healing is visible and there is no tenderness at the implant site, patients can be transitioned to a 4-point gait after 4–5 weeks following a simple osteotomy. At that point, water jogging and range of motion exercises in water can be started. Once full weight-bearing has been achieved, manual treatments to the subtalar joint are initiated with continued stretching in dorsiflexion. The patient should wear well-padded shoes with shock-absorbing heels. Custom insoles are provided no earlier than 6 months to allow for adaptation to the new dynamic and static conditions.

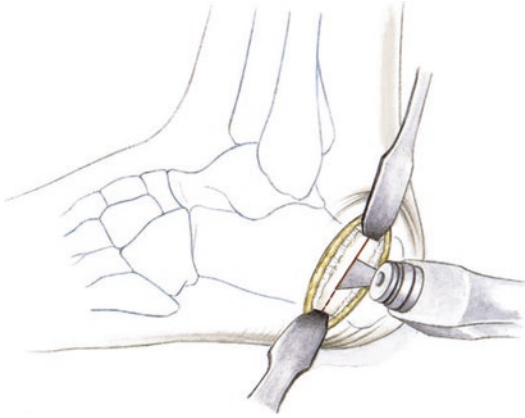
6.2.2 Valgus-Producing and Varus-Producing Osteotomies

■ Technique

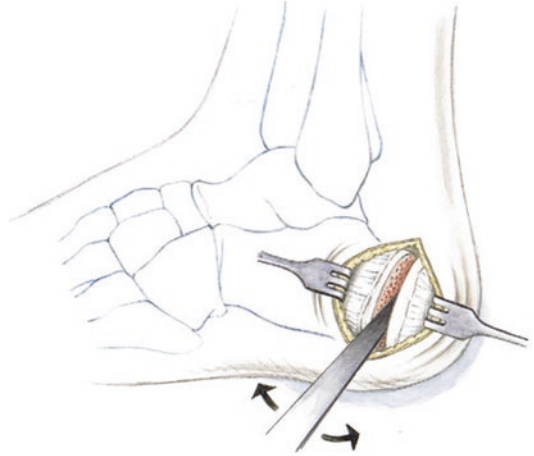
■ Figures 6.19, 6.20, 6.21, 6.22, 6.23, 6.24, and 6.25.

■ **Fig. 6.19** Approaches for calcaneal osteotomies showing the path of the sural nerve. The modified Palmer approach (blue) is better suited for complex osteotomies with three-dimensional translations and wedge harvest

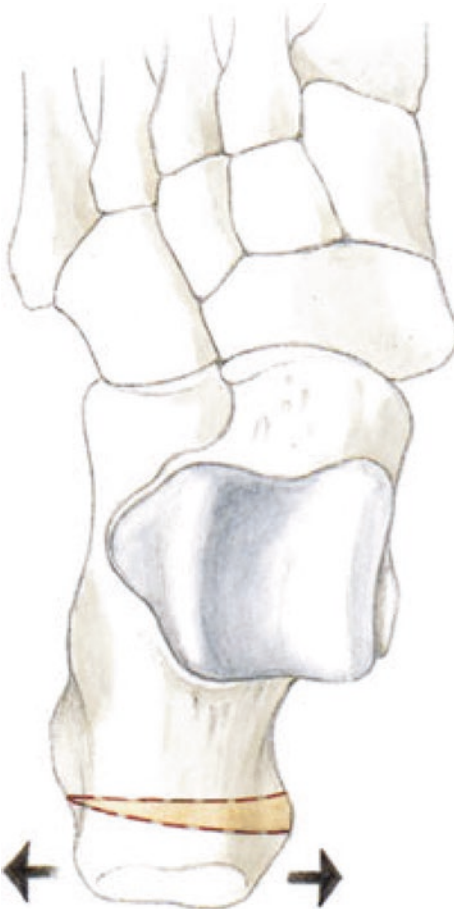



■ **Fig. 6.20** Simple osteotomy for medial or lateral translation. Direct approach and visualization of the calcaneal tubercle with two Hohmann retractors. The lateral cortex is osteotomized with an oscillating saw up to the medial cortex



■ **Fig. 6.22** The lateral cortex is split with a Lambotte osteotome. The Lambotte osteotome is manipulated to release the medial capsuloligamentous structures, mobilizing the posterior fragment



■ **Fig. 6.21** Illustration of varus/valgus correction

6.2.3 Rotational Opening Wedge Osteotomy

■ **Technique**

■ Figures 6.26, 6.27, 6.28, 6.29, 6.30, 6.31, 6.32, 6.33, 6.34, and 6.35.

6.3 Calcaneal Lengthening Osteotomy

■ **Indications**

Flexible planovalgus foot with or without posterior tibialis insufficiency, depending on the age and severity of the planovalgus foot deformity.

■ **Contraindications**

Early arthritic changes at the subtalar joint, subtalar joint symptoms, severe deformities.

■ **Surgical setup**

Special equipment includes K-wire spreaders, 4.5 mm screws or interposition plates (Arthrex, locking low-profile plate), saws (conical, low-profile, 3–4 cm, distal saw blade width 1 cm), Hohmann retractors and standard surgical instruments. AO (Arbeitsgemeinschaft Osteosynthese) tamps and various curettes.

6.3 · Calcaneal Lengthening Osteotomy

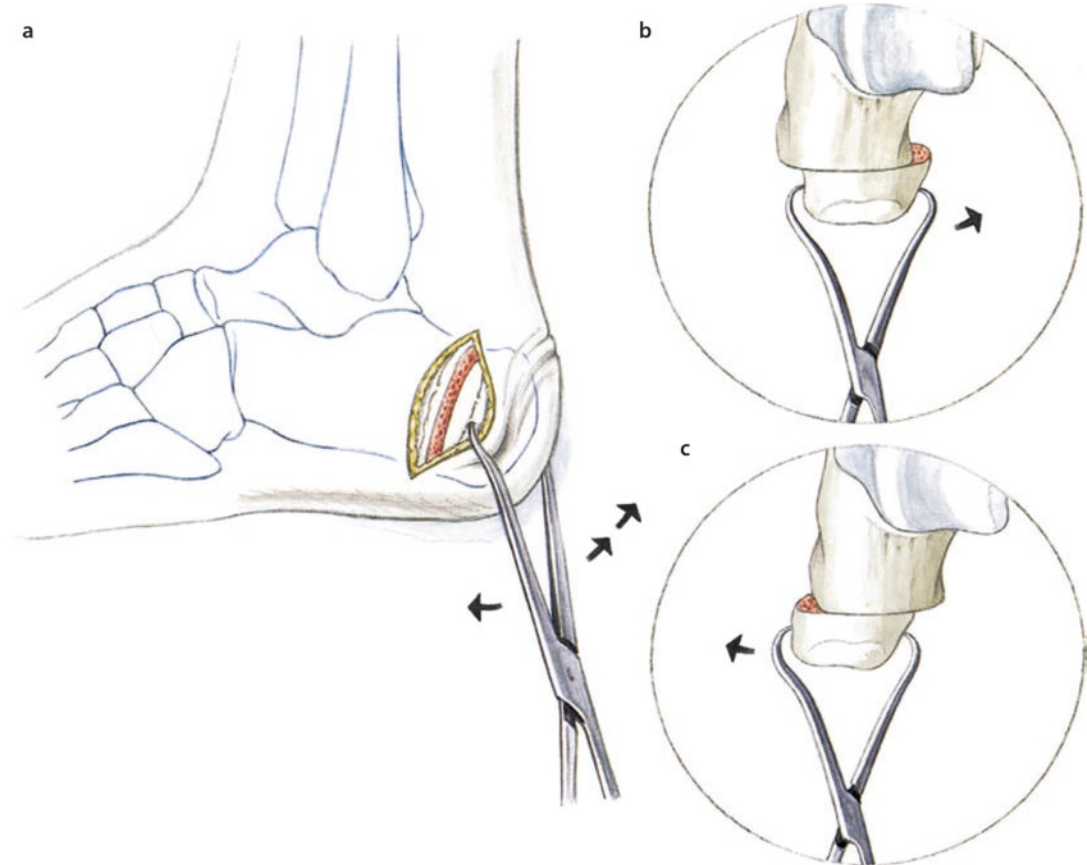


Fig. 6.23 a Manipulation with a large pointed reduction clamp. This allows for medial or lateral as well as inferior or superior translation. In some cases, the insertion

of the plantar fascia must be bluntly mobilized. b Medial translation for hindfoot valgus; c Lateral translation for hindfoot varus

■ Positioning

Lateral position with a triangular wedge under the hip to lateralize the patient. Medial support. Standard foot positioning. For flatfoot surgery, the medial soft tissues always require reconstruction. This can also be performed in the same position by externally rotating the foot from the sloppy lateral position to access the medial side.

■ Technique

■ Figures 6.36, 6.37, 6.38, 6.39, 6.40, and 6.41.

A straight incision is made at the sinus tarsi using a modified Palmer approach. The sinus tarsi is debrided. Dissection is then carried inferiorly while protecting the peroneal tendons, which are pushed inferiorly and held with a Hohmann retractor. A K-wire is inserted at the desired

osteotomy site. A lateral radiograph is taken. The osteotomy should be directed slightly anteriorly towards the medial facet. The saw is used to start the osteotomy. The medial cortex is carefully weakened. A spreader is then inserted over 2 K-wires and opened to complete the medial osteotomy.

The foot is then visualized in the dorsoplantar plane. The dorsoplantar alignment is assessed, primarily based on the relationship and covering of the talar head by the navicular. This should be optimally aligned and should eliminate forefoot abduction. To maintain the position, a 1.8 mm K-wire is used for temporary arthrodesis of the talonavicular joint.

An approach is then made to the iliac crest as previously described (see Cancellous bone grafting). A corticocancellous wedge is measured so that it is slightly wider than the defect (usually about 1 cm)

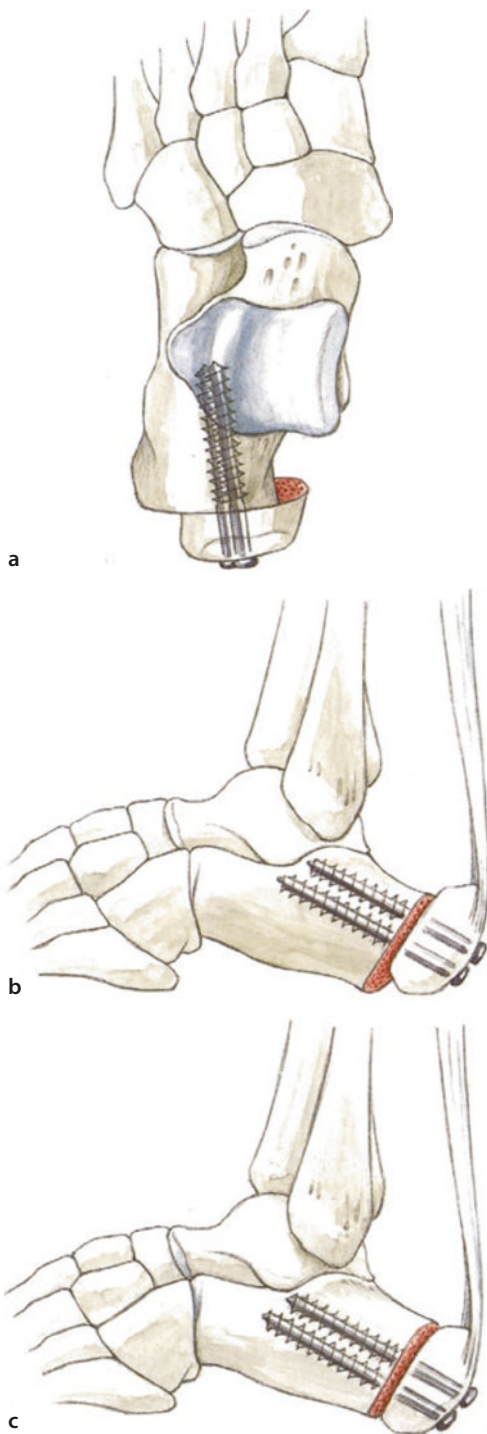


Fig. 6.24 a, b Fixation with cannulated 7.3 mm cancellous screws, which allow for full weight-bearing after 4 weeks in cases of simple translation. c In cases with Achilles tendon shortening, the tubercle fragment can be translated superiorly slightly to create relative lengthening of the Achilles tendon. This should only be performed if there is adequate calcaneal pitch

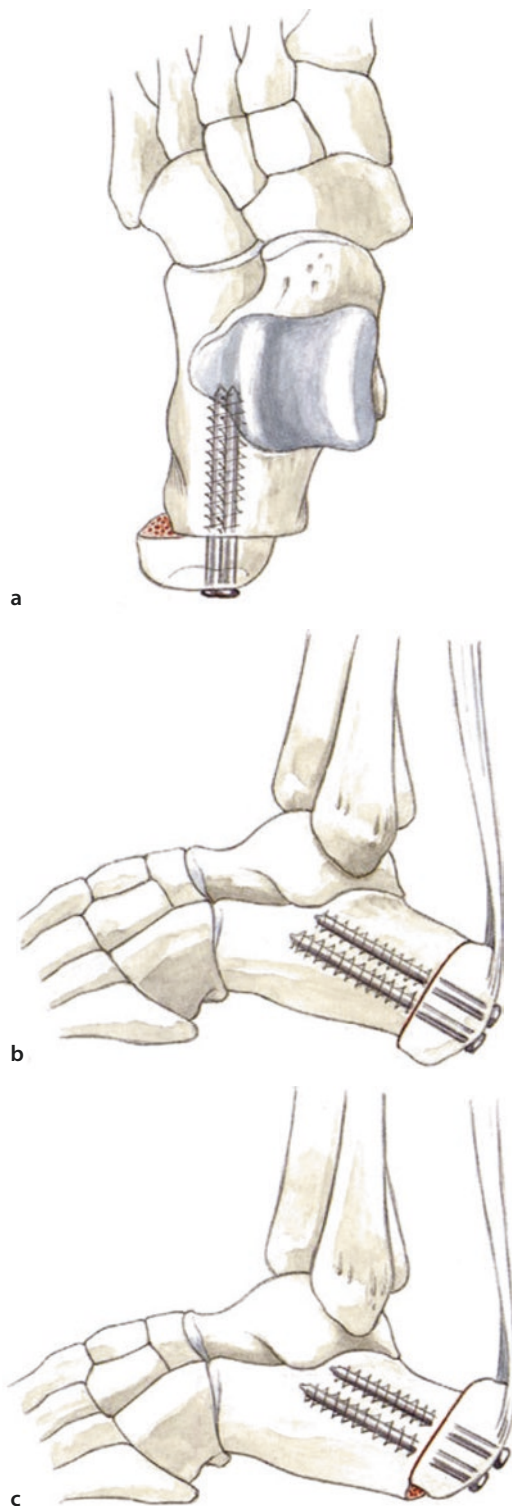
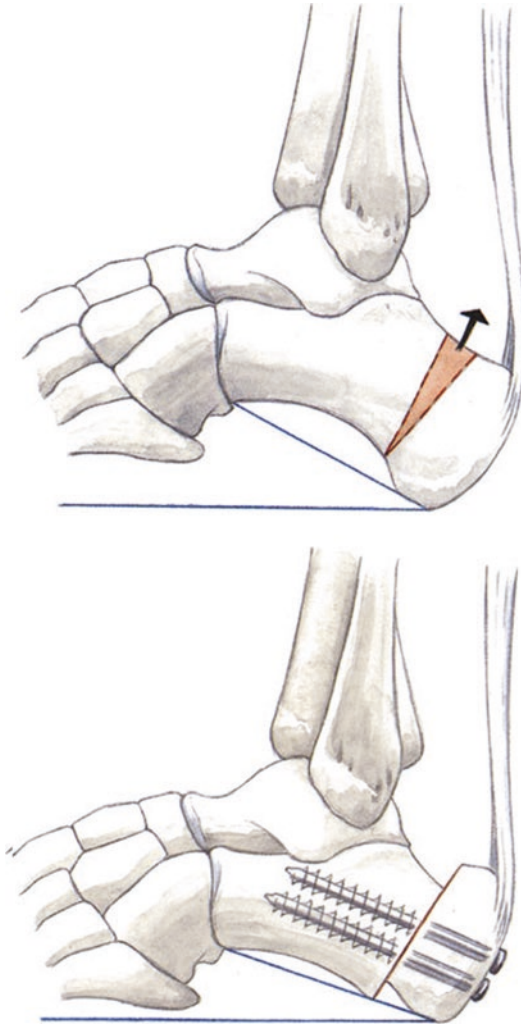


Fig. 6.25 a, b Lateralization for hindfoot varus with two cannulated 7.3 mm screws. c If the Achilles tendon is shortened, the distal fragment can be translated superiorly in this case as well to decrease the calcaneal pitch



■ **Fig. 6.26** To improve the calcaneal pitch, a superiorly-based trapezoidal wedge is removed and a closing wedge osteotomy is performed

so that it is compressed after insertion. Additional cancellous bone is harvested (about 30 cc) because the corticocancellous wedge usually does not fill the entire defect. A Lyostypt hemostatic sponge is inserted. The wound is closed in layered fashion.

Local anesthetic is injected around the iliac crest. Cancellous bone is grafted up to the medial crest. The wedge is then impacted with an AO bone tamp. The surgeon should ensure that the wedge does not migrate superiorly or inferiorly. A low-profile plate is placed. The amount of wedge distraction is confirmed and locking screws are inserted. Radiographs are taken in two planes. A Broden view with 20° tilt should be obtained in addition to anteroposterior and lateral radiographs

to adequately visualize the subtalar joint. The medial soft tissues are then addressed. ACP is injected. The wound is closed in layers and a sterile dressing is placed. A plaster cast is placed with the ankle in a neutral position. The temporary arthrodesis is left in place for 4 weeks to protect the reconstructed soft tissues and allow for adequate proximal healing of the corticocancellous wedge.

■ Aftercare

Cast for one week for initial wound healing. Depending on bone healing, a short-leg walking boot is worn for 5 or 6 weeks. Partial weight-bearing with 15 kg followed by full weight-bearing for 2 weeks in a short-leg walking boot without crutches. Depending on osseous consolidation, mobilization in a normal shoe and physical therapy can begin after 6–8 weeks.

6.3.1 Valgus-Producing Dome Osteotomy of the Calcaneus

■ Technique

■ Figures 6.42, 6.43, 6.44, 6.45, 6.46, and 6.47.

The osteotomy site is determined with fluoroscopy to ensure that it is not too distal or posterior. This ensures an adequate lever arm.

The plantar fascia can also be released at the osteotomy site in cavus foot deformities (Steindler procedure). A skin incision (about 20–25 mm) is then made at the medial aspect of the calcaneus.

After dissection, a curved osteotomy is made at the posterior facet with a #15 curved osteotome. The osteotomy is carried just anterior to the insertion of the plantar fascia at the inferior aspect up to the lateral wall. The osteotomy is then carefully completed and the lateral wall is mobilized along with the medial lateral soft tissues. The osteotomy is mobilized by moving the osteotome back and forth. The fragment is then lateralized (6–10 mm) and fixed with a guidewire for cannulated 6.5 or 7.3 mm screws. The inferior aspect is mobilized again at the plantar fascia.

Fluoroscopy is checked. The screw should be placed into the central aspect of the osteotomy and be drilled almost perpendicular to the posterior facet. If the wire is in good position, it is overdrilled and the cannulated screw is inserted. No additional screws are needed due to the large contact area. Final radiographs are checked.

Fig. 6.27 Complex corrective osteotomy for planovalgus foot with a rotational calcaneal wedge

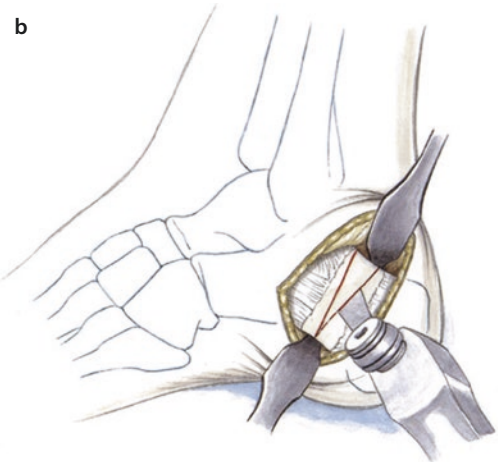
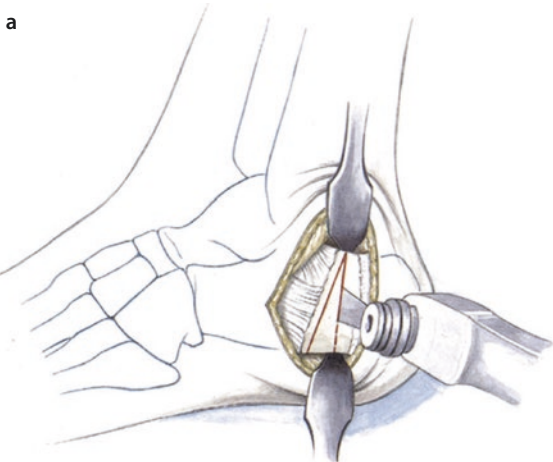
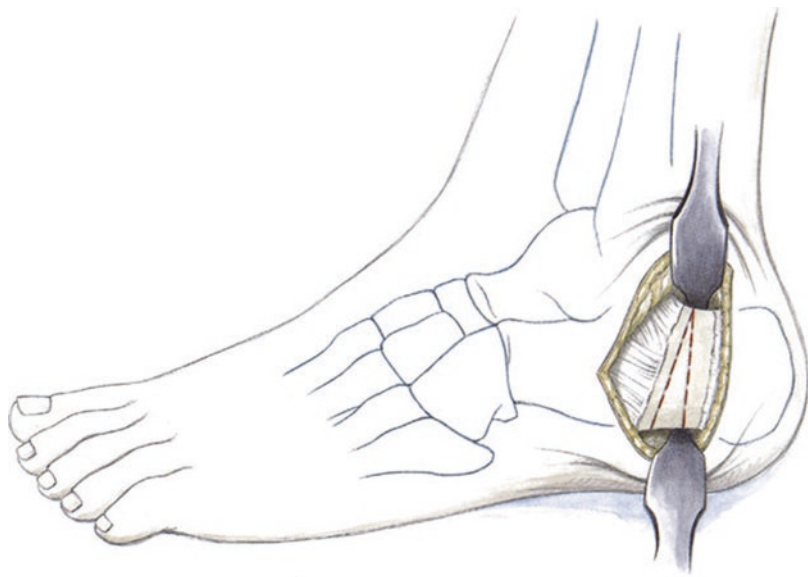


Fig. 6.28 a Modified Palmer approach and visualization of the calcaneal tubercle. A plantar-based 5–8 mm wedge is drawn out and cut with the oscillating saw. The

wedge is removed with a pointed reduction clamp. b Rotational opening wedge osteotomy with correction of a cavus foot. A superiorly-based wedge is cut with the saw

6.3.2 Varus-Producing Calcaneal Osteotomy with a Step-off Plate

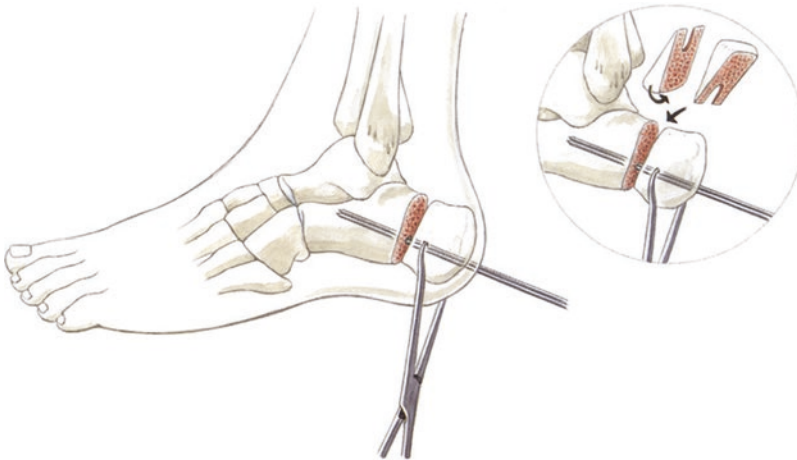
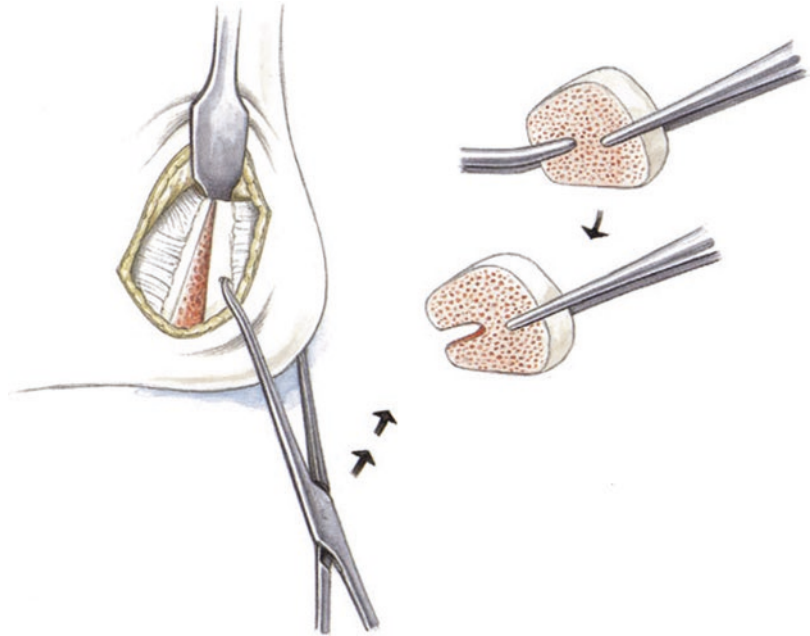
Small lateral approach to the calcaneus, slightly curved. This should not be L-shaped, as a right angle can lead to wound edge necrosis. The scalpel is taken directly down to bone. Retraction sutures are used rather than sharp rakes. The drill guide is placed at a 30–40° angle centered between the subtalar joint and the tip of the calcaneal tubercle. The osteotomy is

performed with a saw and the medial cortex is perforated with an osteotome (avoiding the neurovascular bundle!). The calcaneus step-off plate is fixed at the distal calcaneal tubercle with locking screws.

The calcaneus is medialized with the S-shaped retractor and the compression screw is inserted. The proximal locking screws are then inserted. The amount of medialization is determined by the offset of the plate. Greater degrees of medialization should be obtained with the method described above (Fig. 6.48).

6.3 · Calcaneal Lengthening Osteotomy

■ **Fig. 6.29** The removed wedge is turned and a tongue is cut into the wedge with a rongeur



■ **Fig. 6.30** Reduction with plantar flexion of the tuberosity fragment and medial translation. This reduces the pull of the Achilles tendon by plantar flexing the foot. The opening wedge position should also be observed

to improve the pitch of the calcaneal tuberosity. Two guidewires are inserted for the 7.3 mm screws. The entire wedge is then malleted into place with the base superiorly and the tongue fitting over the wires

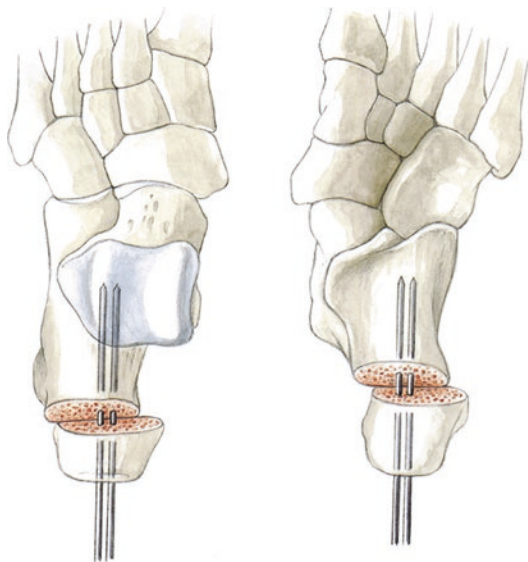


Fig. 6.31 Illustration of the wire positions and medial translation with an opening wedge technique. **a** Rotational osteotomy (opening wedge technique) for cavus deformity with a superiorly-based wedge and medial translation of the calcaneal tubercle. **b** View from plantar for a cavovarus foot. Opening wedge correction with lateralization of the tubercle

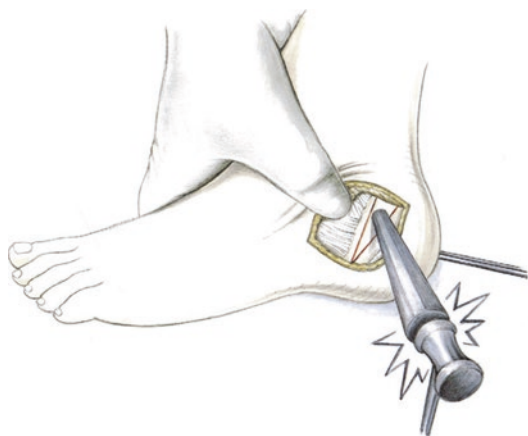


Fig. 6.32 Impaction of a corticocancellous wedge using a tamp

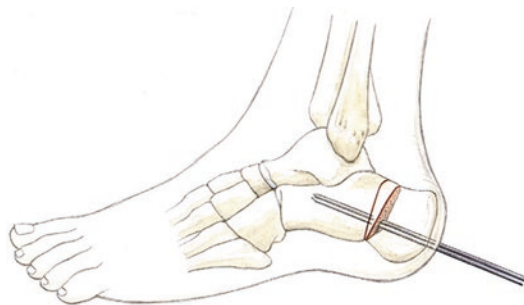


Fig. 6.33 Finished corrective osteotomy with improved calcaneal pitch

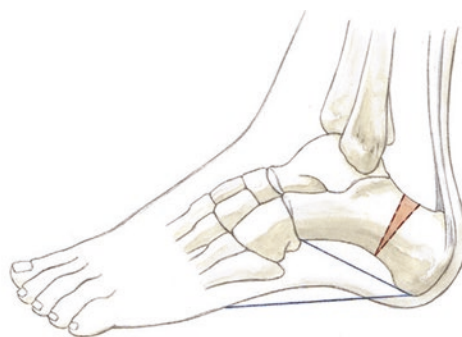
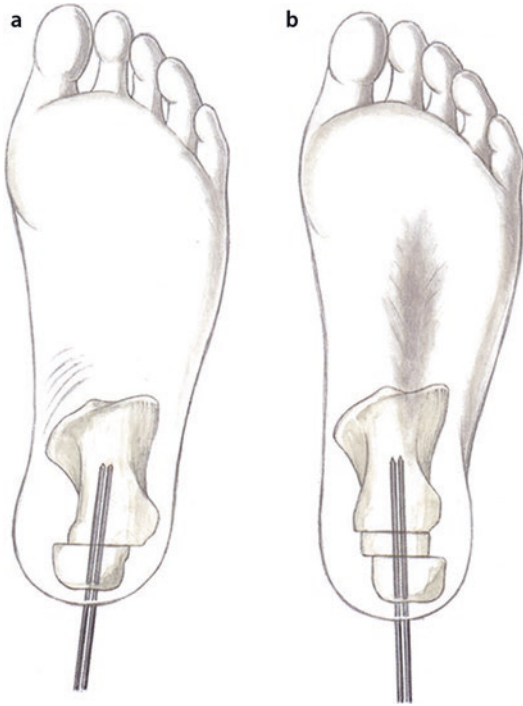
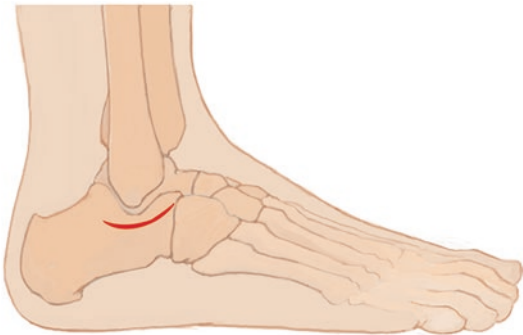

Fig. 6.34 Corrected calcaneal pitch with a rotational opening wedge osteotomy and flattening of the calcaneal inclination angle

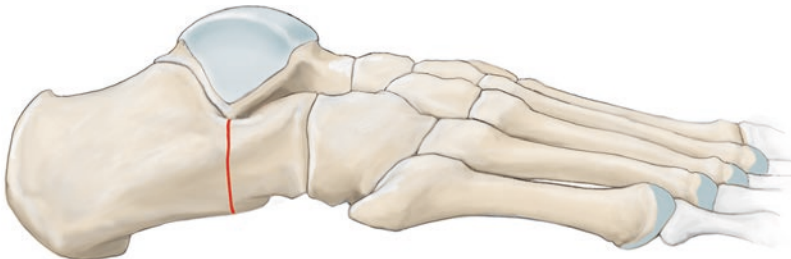6.3 · Calcaneal Lengthening Osteotomy



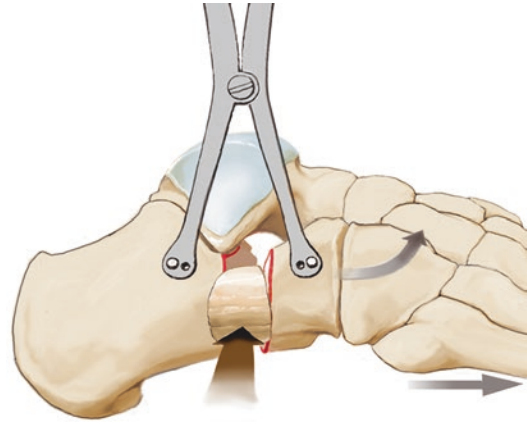
■ Fig. 6.35 a, b Illustration of the wire position for varus-producing or valgus-producing hindfoot osteotomies



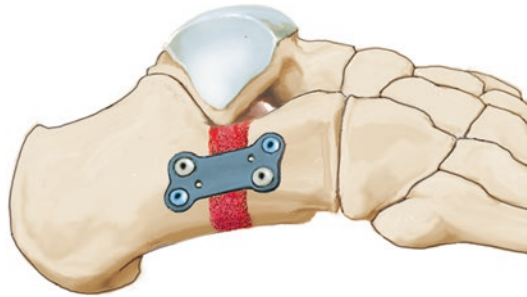
■ Fig. 6.36 Lateral approach below the sinus tarsi. The peroneal tendons should be protected during sharp dissection



■ Fig. 6.37 Osteotomy (anterior to the posterior facet angled medially toward the middle facet). Fluoroscopy can be used for precise positioning. Correction should be

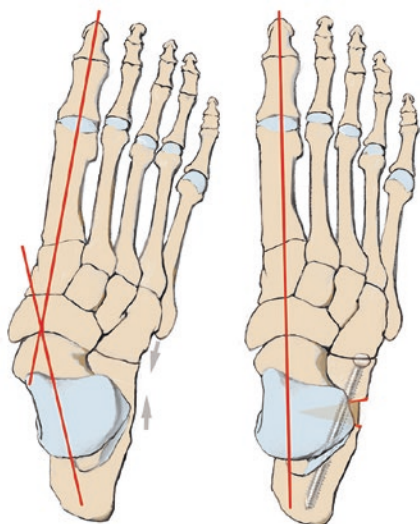


■ Fig. 6.38 A tricortical bone block is inserted after spreading with a Hintermann spreader. The surgeon should take care not to place this too superiorly

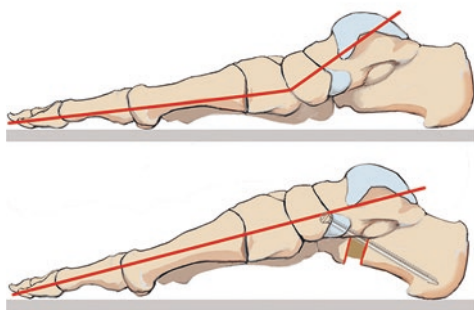


■ Fig. 6.39 Locking plate application (Arthrex CC plate). To protect the soft tissue correction, a temporary arthrodesis (4 weeks) of the talonavicular joint should be performed with a 1.8 mm K-wire

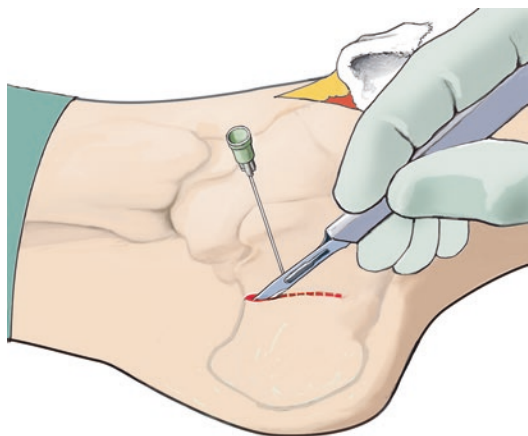
checked in an anteroposterior view. The talar head should be completely covered by the navicular after correction



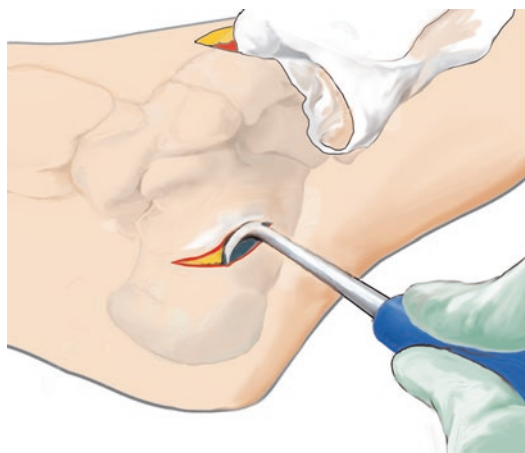
■ Fig. 6.40 Illustration of the axis correction in the anteroposterior plane



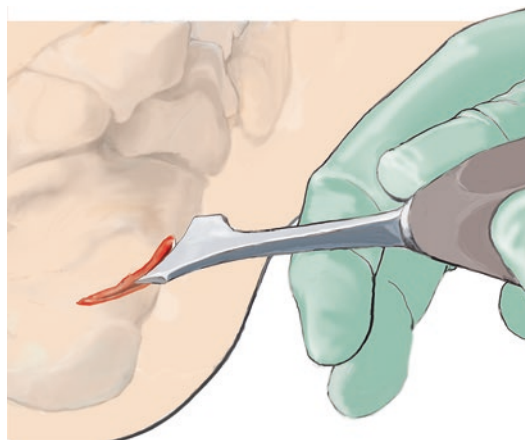
■ Fig. 6.41 Illustration of the sagittal alignment with calcaneal lengthening. Screw fixation is shown here



■ Fig. 6.42 A small slightly curved oblique incision is made inferior to the peroneal tendons. The incision is marked with a needle to visualize the center of the calcaneal tubercle with fluoroscopy

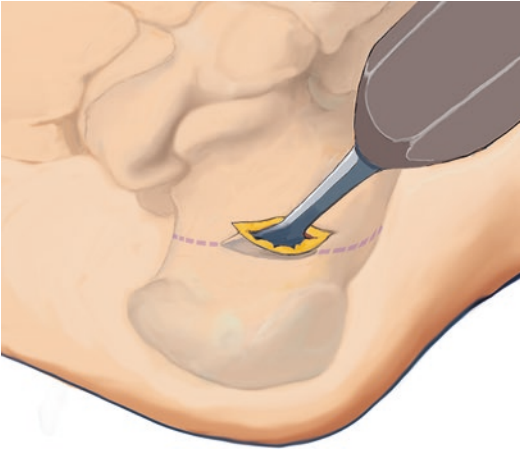


■ Fig. 6.43 Dissection and mobilization of subcutaneous tissue with the rasp

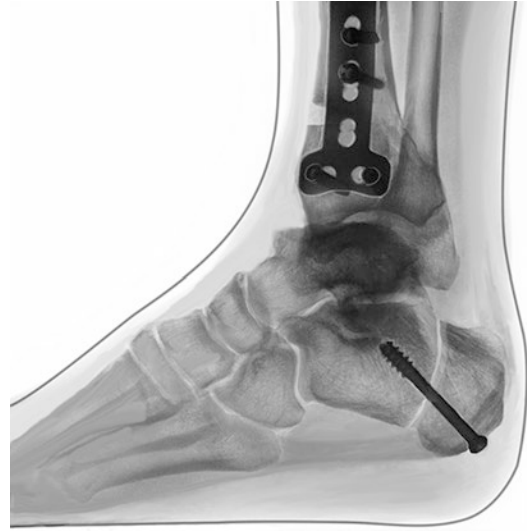

■ Fig. 6.44 Curved dome osteotomy using a 15 mm curved osteotome. This should be an adequate distance from the subtalar joint superiorly. For a cavus foot, the osteotomy should exit inferiorly so that the plantar fascia is released (Steindler procedure)

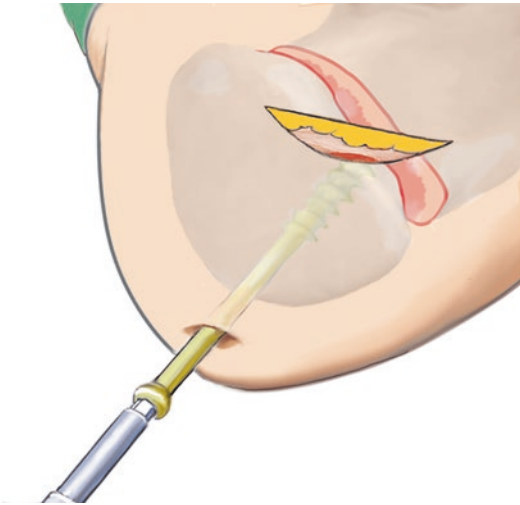
6.3 · Calcaneal Lengthening Osteotomy



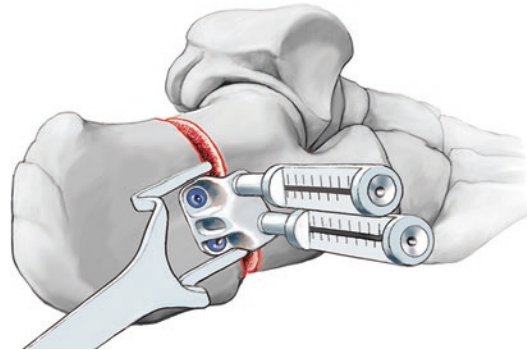
■ Fig. 6.45 Lateralization and correction with a Hohmann retractor. This should be about 10 mm



■ Fig. 6.47 Lateral radiograph after opening wedge and dome osteotomy



■ Fig. 6.46 Fixation with a 2.7 mm guidewire and fluoroscopy to check the correction. The osteotomy is fixed with a single screw, as the dome osteotomy provides excellent contact of the surface areas



■ Fig. 6.48 Step-off plate with compression screw and offset for medial translation. Locking screw fixation

Tendon Transfer for the Planovalgus Foot

- 7.1 General Notes – 106
- 7.2 Split Tibialis Anterior Tendon Transfer – 106

7.1 General Notes

For insufficiency of the tibialis posterior tendon, two points should always be noted with regard to augmentation. First, all of the degenerative tissue should not be resected from the tibialis posterior tendon. The tibialis anterior tendon should also not be augmented excessively to prevent tendon impingement after closure of the retinaculum. This could completely eliminate the desired dynamic effect due to massive scar formation. As a general principle when determining the tension in supination and equinus, the more tension at the end of surgery, the better the outcome of the correction. In my own experience and the reports of other experienced colleagues, excessive shortening with functional limitations is very rarely a problem.

Tendon transfer alone is not adequate to treat the complex pathology of flexible planovalgus foot deformity. The shortened lateral column of the foot should always be corrected to unload the medial structures by anatomically aligning the talonavicular joint.

After correcting the Chopart joint deformity, temporary arthrodesis of the talonavicular joint should be performed with a 2.0 mm K-wire in supination and equinus.

■ Indications

Significant degeneration of the tibialis posterior tendon with corresponding clinical symptoms. In most cases, this is combined with additional procedures such as CC fusion and calcaneal osteotomy. Tendon transfer alone for treating planovalgus foot deformity is not successful.

■ Contraindications

Severe arthritic changes at the subtalar joint and the talonavicular joint. In these cases, triple arthrodesis must be performed.

■ Specific patient information

Cast for 6 weeks, then range of motion exercises, primarily at the ankle joint to achieve dorsiflexion. After 8 weeks, manipulation of the subtalar joint. Mobilization is initially supported by physical therapy and range of motion exercises in water. Custom insoles after 6 months (► Sect. 6.2.1 «Aftercare»).

■ Positioning and perioperative management

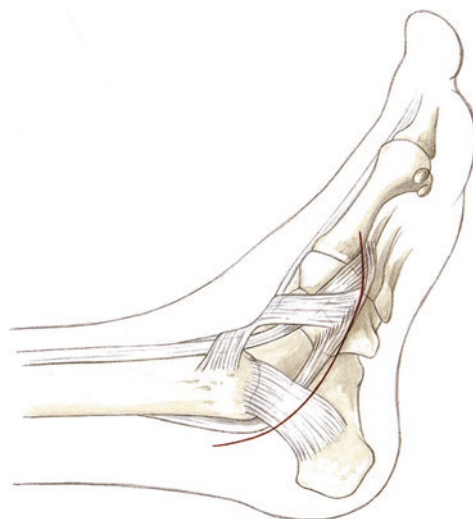
Supine position. The contralateral leg is lowered. Lateral and medial supports are placed to allow the

leg position to be adjusted for improved access. The surgical field is shaved at the distal ankle joint. Antibiotic prophylaxis with third generation cephalosporin or similar. Intraoperative thrombosis prophylaxis with low-molecular-weight heparin at the time of induction of anesthesia.

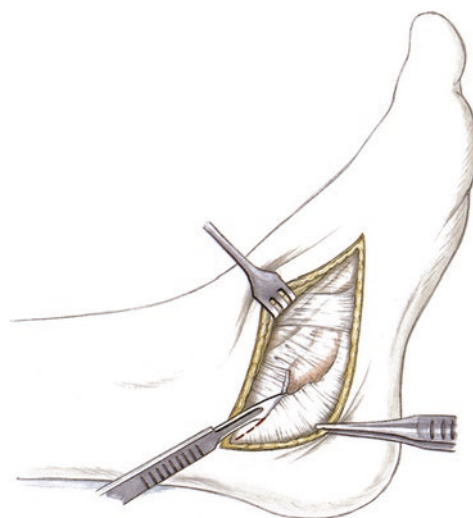
7.2 Split Tibialis Anterior Tendon Transfer

■ Technique

■ Figures 7.1, 7.2, 7.3, 7.4, 7.5, 7.6, 7.7, 7.8, 7.9, and 7.10.

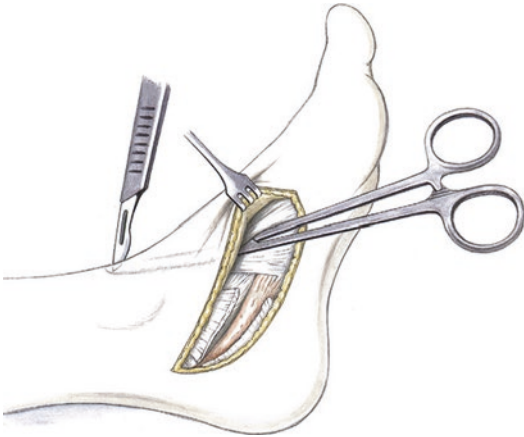


■ Fig. 7.1 Traditional incision posterior to the tibialis posterior tendon up to its insertion, slight curve towards the tibialis anterior tendon

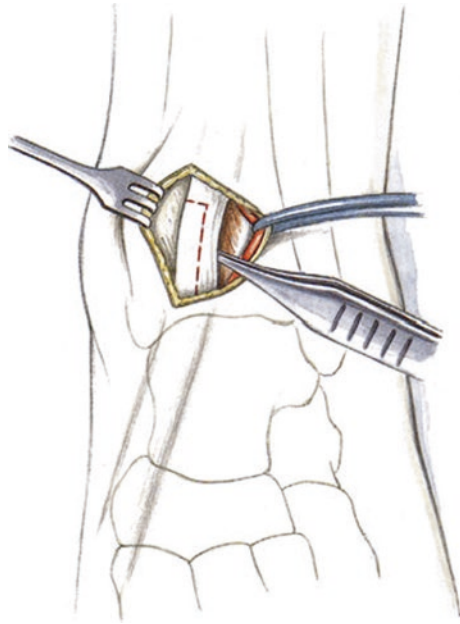


■ Fig. 7.2 Opening the retinaculum, visualization of the tibialis posterior tendon

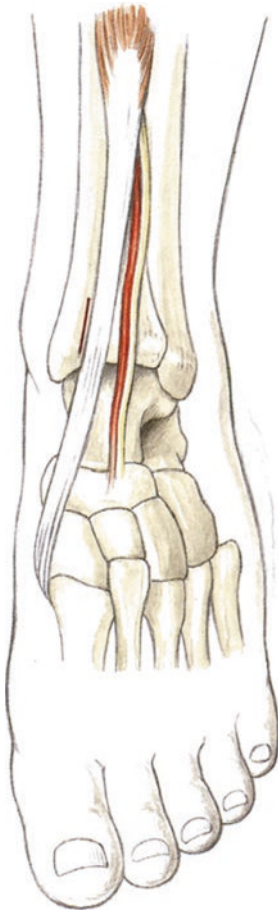
7.2 · Split Tibialis Anterior Tendon Transfer



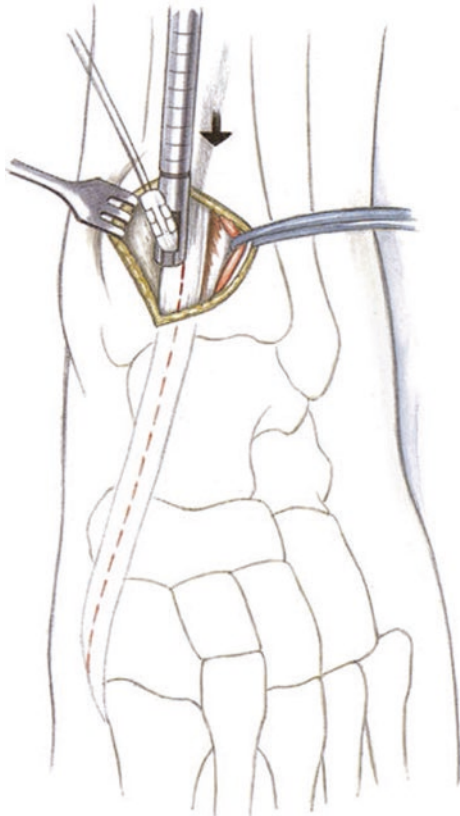
■ Fig. 7.3 After visualizing the tendon, a dressing forceps is used to tunnel through to the ankle joint. An incision is made just superior to the ankle joint



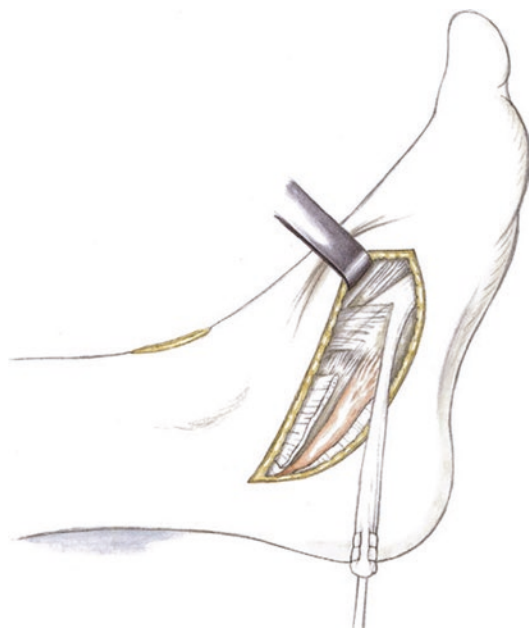
■ Fig. 7.5 Preparation of a partial tendon transfer



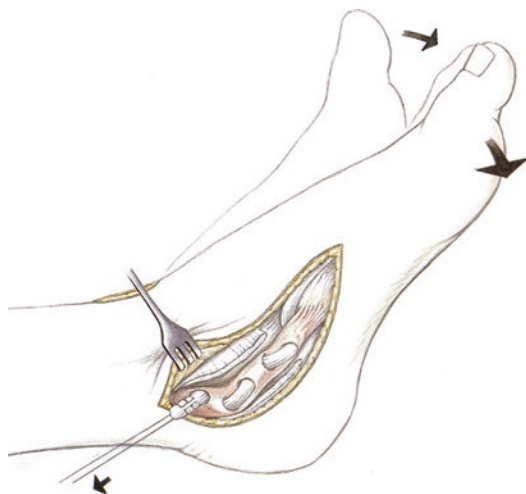
■ Fig. 7.4 Illustration of the incision at the ankle joint for preparing the tibialis anterior tendon



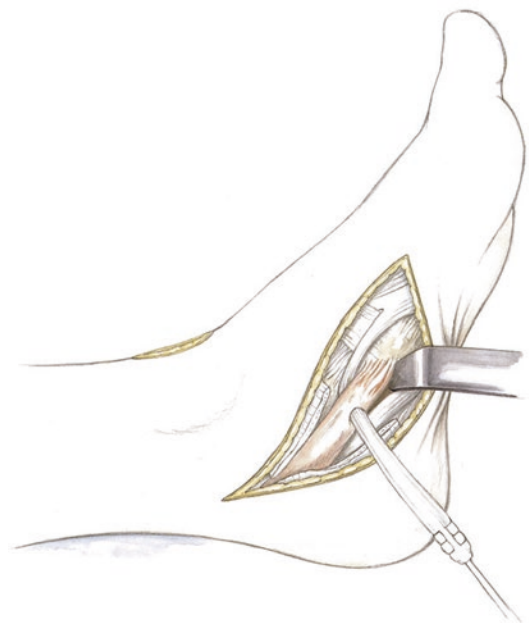
■ Fig. 7.6 Krackow stitches at the proximal aspect of the tendon. The tendon is split distally with a tendon stripper. The inferomedial aspect of the tendon should be harvested



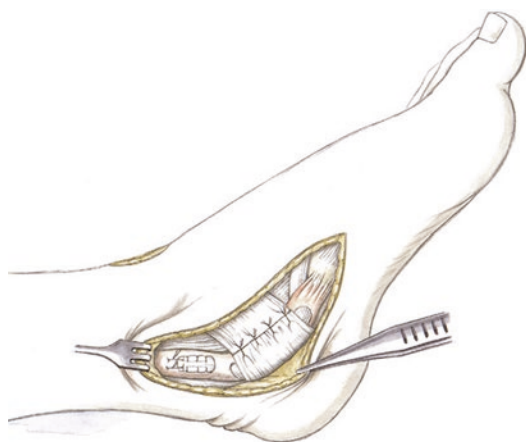
■ Fig. 7.7 The split tibialis anterior tendon is pulled out of the incision



■ Fig. 7.9 To improve the static and dynamic function of the tibialis posterior tendon, the tibialis anterior split transfer is tensioned in supination and plantar flexion (maximum shortening)



■ Fig. 7.8 The tibialis anterior tendon is pulled through the tibialis posterior tendon using a Pulvertaft technique



■ Fig. 7.10 This is sewed to the tibialis posterior tendon and the retinaculum is closed. Severely degenerative tibialis posterior tissue should be aggressively debrided. Macroscopically healthy tissue can be sewed to the tibialis anterior tendon under tension

Forefoot Surgery

- 8.1 General Notes – 110
- 8.2 Scarf Osteotomy – 110
- 8.3 Modified Ludloff Osteotomy – 113
- 8.4 Modified Weil Osteotomy – 114
- 8.5 PIP Arthrodesis – 115
- 8.6 Plantar Plate Repair – 117
- 8.7 Hohmann Procedure – 121
- 8.8 Chevron and Akin Osteotomy (Minimally Invasive) – 122
 - 8.8.1 Chevron Osteotomy – 122
 - 8.8.2 Akin Osteotomy – 125
 - 8.8.3 Modified Chevron Osteotomy – 126

8.1 General Notes

■ Specific patient information

Swelling can persist for up to 6 months with associated limitations of range of motion. Range of motion limitations are particularly common after surgeries to the small toes due to scar formation. Range of motion limitations in dorsiflexion and plantar flexion, possibly accompanied by decreased strength due to the modified lever arm.

■ Surgical setup

Anesthesia and tourniquet use are critical issues for surgical setup. Logistical conditions are an important part of this. In my opinion, forefoot surgery requires extreme precision, which is only possible with excellent visualization and relaxation of all involved parties (both the patient and the surgeon). Because of this, I prefer general anesthesia and complete exsanguination with a tourniquet if possible. For postoperative pain control, a foot block should always be performed. This will ensure that the patient does not have a traumatic experience when anesthesia wears off after this extremely painful surgery.

■ Positioning and perioperative management

Standard supine position. The contralateral leg is dropped and the surgeon stands at the contralateral side. The position is changed if additional small toe surgeries are performed; in my opinion, standing directly in front of the leg allows for the best visualization. Preoperative antibiotic prophylaxis (third generation cephalosporin) and thrombosis prophylaxis (heparin). A roll is placed under the leg to ensure adequate access during surgery. Redon drains (8 Fr) are always placed after great toe surgery and more complex small toe surgery (2 toes or more).

■ Aftercare

A forefoot unloading shoe is placed for 2–3 weeks depending on wound healing and swelling. If swelling and pain persist, the forefoot unloading shoe should be left in place for 3 weeks. Physical therapy and lymphatic drainage massage are performed to improve the range of motion. This is performed carefully with slight distraction at the MTP joint. The range of motion will be determined by the level of pain. Cryotherapy is continued long-term, particularly if achieving the maximum range of motion is painful. For physical therapy, the metatarsal and great toe should be guided to ensure that there is no force transmitted

onto the osteotomy sites. After the forefoot unloading shoe, the patient is transitioned to sandals with a large forefoot space (possibly with Velcro closure). Weight-bearing is advanced after the osteotomy starts to heal. After 3 months, jogging can start. Biomechanical studies have shown significantly greater stability with Ludloff osteotomies compared to Scarf osteotomies.

■ Specific aftercare protocol

In our experience, postoperative cortisone administration (dexamethasone 1 mg) has proven to be excellent (8 mg the evening of surgery, 4 mg on postoperative day 1, 2 mg on day 2 and 2 mg on day 3). This is accompanied by antibiotic treatment. Patients usually are nearly free of pain after 2–3 days. In particular, this reduces swelling after complex forefoot reconstruction and reduces the risks of soft tissue complications significantly.

8.2 Scarf Osteotomy

■ Indications

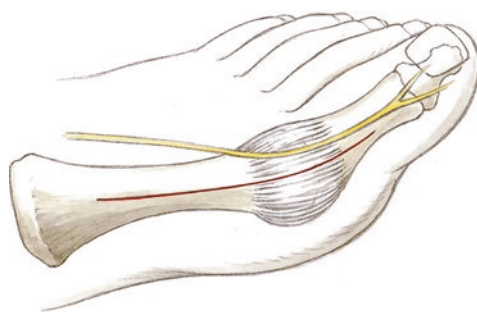
Intermetatarsal angle over 15°, corrections for hallux valgus with lengthening, shortening or rotational deformity in the sagittal plane.

■ Contraindications

Intermetatarsal angle below 15°. This procedure has been shown to be less stable compared to the Ludloff osteotomy in biomechanical studies, so the indications for a Scarf osteotomy should be carefully considered in osteopenic bone or in very old patients. The procedure is not indicated in cases with very large intermetatarsal angles ($\geq 20^\circ$).

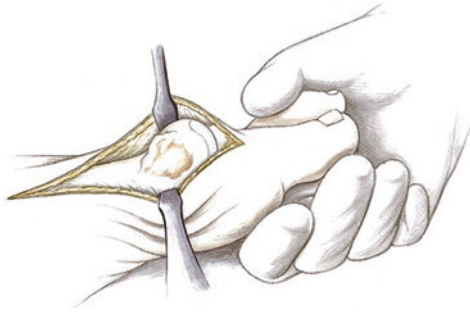
■ Technique

■ Figures 8.1, 8.2, 8.3, 8.4, 8.5, 8.6, 8.7, and 8.8.

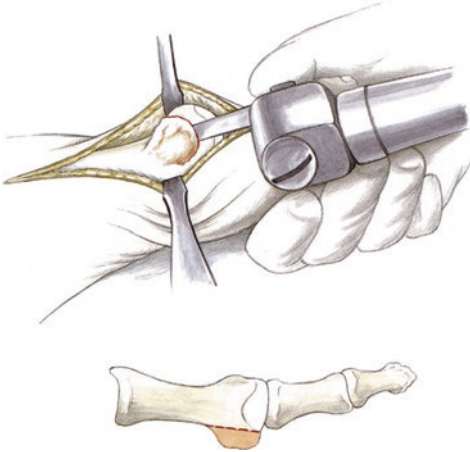
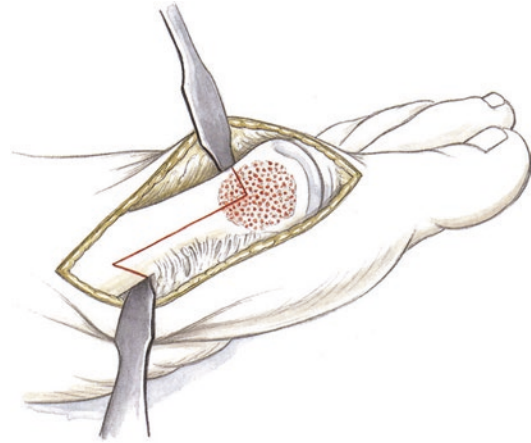


■ Fig. 8.1 Anteromedial skin incision almost to the base of the first metatarsal, while protecting the dorsal nerve

8.2 · Scarf Osteotomy



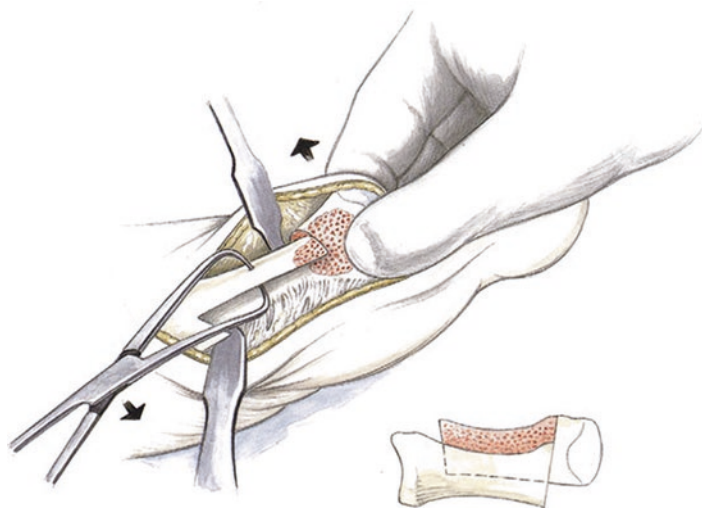
■ **Fig. 8.2** Dissection and visualization of the joint. The capsule is incised horizontally



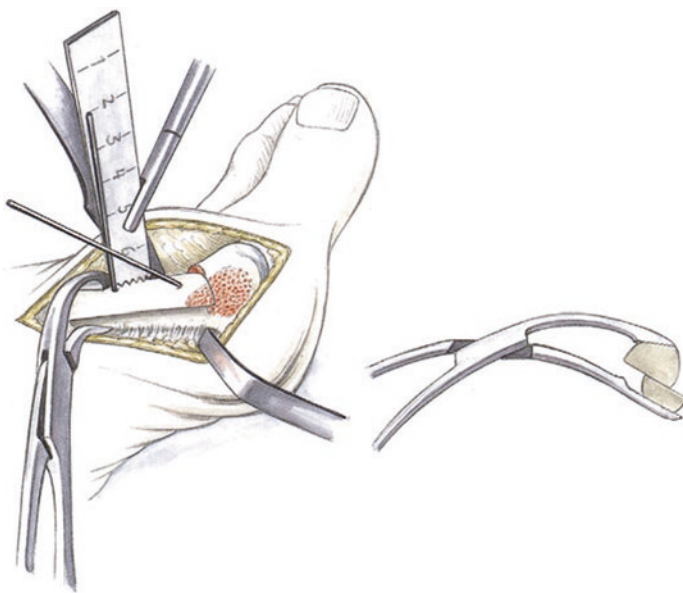
■ **Fig. 8.4** Traditional Scarf osteotomy. For simple lateral translation, it is important to perform an opening distal osteotomy that exits further distal on the lateral side. This can only be achieved if an angle of almost 90° to the horizontal osteotomy is used. The advantage is that it is much easier to slide the bone laterally. A very long osteotomy is performed to avoid plunging during translation

■ **Fig. 8.3** The pseudoexostosis is removed along the diaphysis of the metatarsal with a small oscillating saw

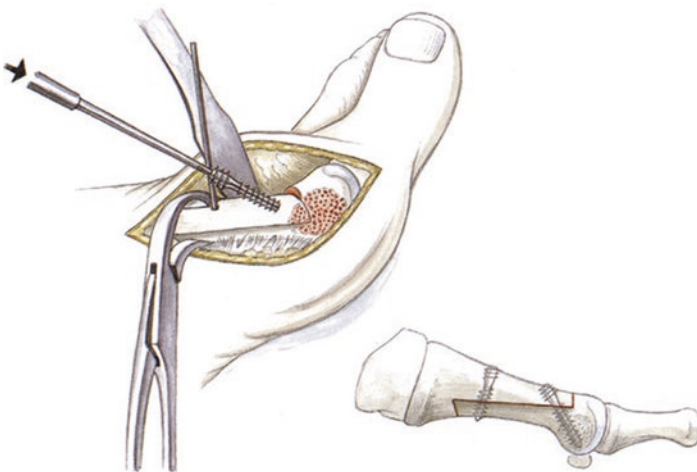
■ **Fig. 8.5** Translation of the metatarsal head. The dorsal cortex is held in place with a Backhaus clamp and the head is translated laterally. The small Hohmann retractor can sometimes interfere with lateral translation; if so, it can be replaced with a Langenbeck retractor that only holds the soft tissue. In cases of metatarsus primus varus, more distal/lateral rotation should be performed while leaving the proximal segment medially. This will better correct the varus component



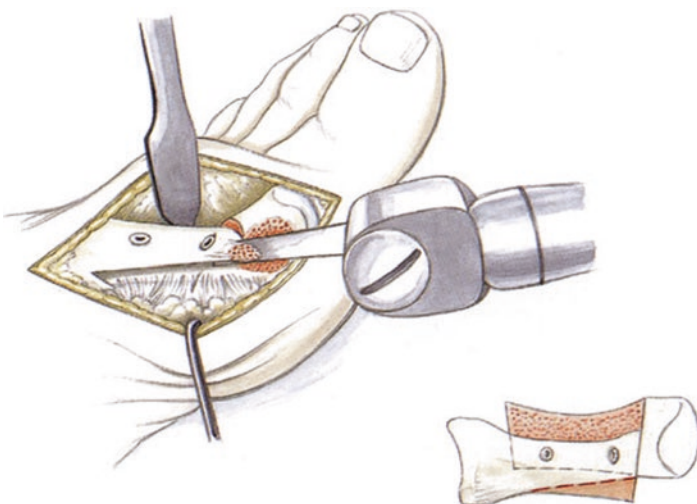
■ **Fig. 8.6** After holding the corrected position with an eccentric Barouk clamp, the guidewires are inserted for a cannulated screw system. The Barouk clamp should either be left in a distal or a central position between the two guidewires so that there are no problems overdrilling the wires or inserting the screws



■ **Fig. 8.7** It is absolutely necessary to pre-drill with the guidewires. The drill should be advanced up to the stop so that the proximal enlarged segment passes through the dorsal cortex. Otherwise, there is a risk of a longitudinal fracture when the proximal screw threads are inserted. In osteoporotic bone, 2.7 AO screws with a standard head can be used instead to reduce the risk of iatrogenic fracture



■ **Fig. 8.8** After fixation with screws, any prominent bone is removed with the oscillating saw



8.3 Modified Ludloff Osteotomy

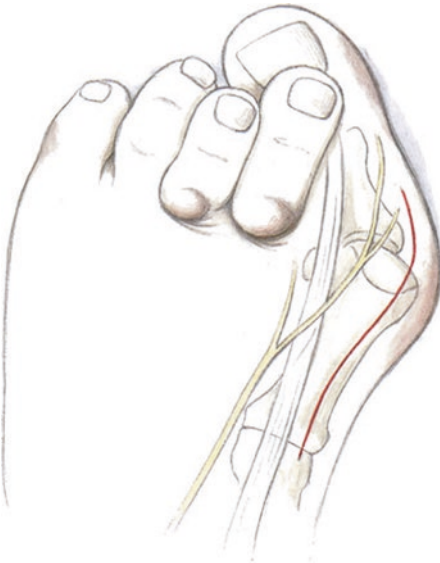■ Indications

The modified Ludloff osteotomy is particularly important in cases of metatarsus primus varus, in which proximal rotation results in optimal correction. It is almost always indicated in cases of metatarsus primus if the sesamoids are not substantially lateralized compared to the metatarsal. Compared to the Scarf osteotomy, the Ludloff osteotomy has significantly greater stability in biomechanical tests. It should be used in osteopenic bone to avoid fractures. The modified Ludloff

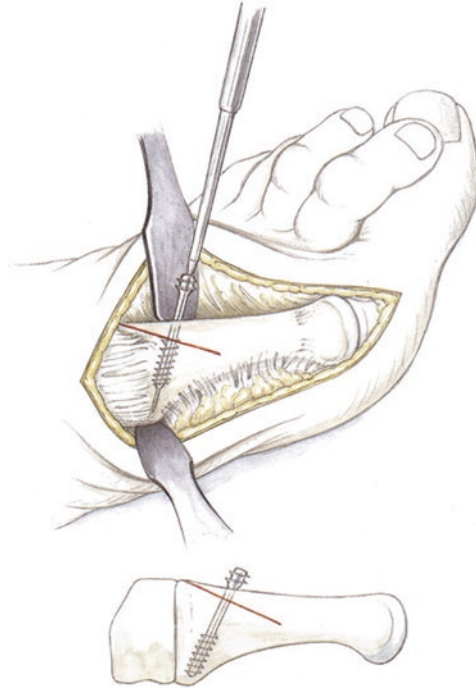
osteotomy allows for correction in the coronal plane without shortening or sagittal translation. It can also be used in cases with wide intermetatarsal angles (around 20°).

■ Technique

■ Figures 8.9, 8.10, 8.11, 8.12, and 8.13.

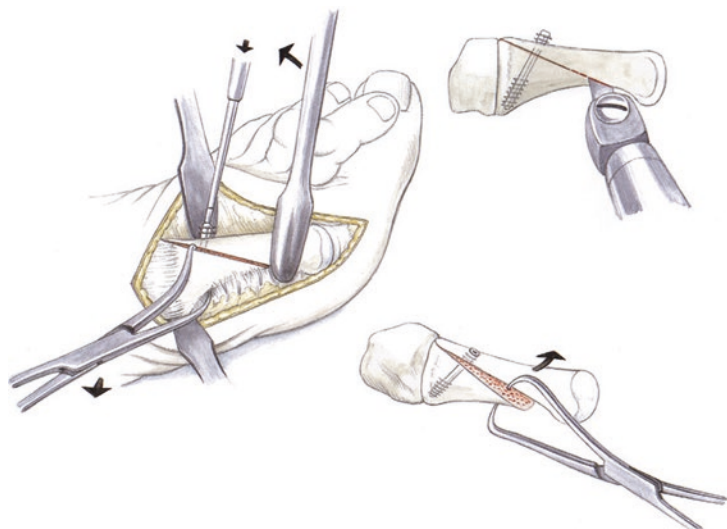


■ Fig. 8.9 Anteromedial skin incision carried to the base of the first metatarsal while protecting the nerve

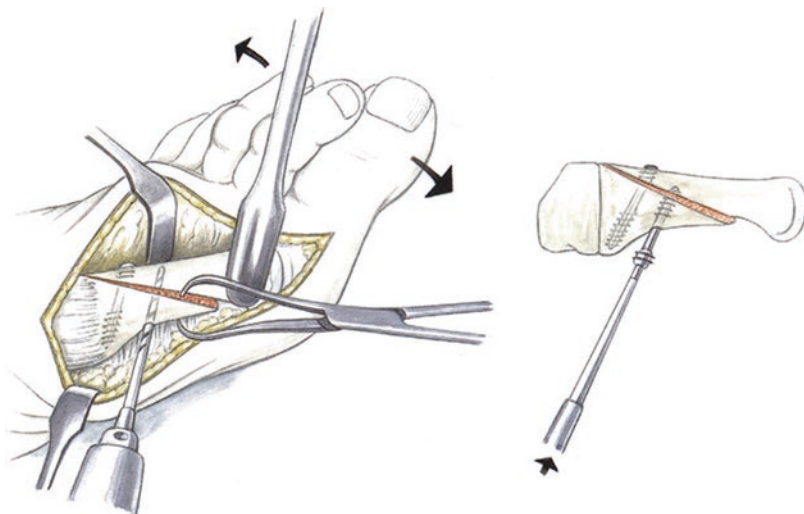


■ Fig. 8.10 Two-thirds of the Ludloff osteotomy is cut and a cannulated screw is inserted in the metadiaphyseal region over a guidewire without creating a stable fixation construct. The proximal screw should have an adequate dorsal bone bridge to avoid fracture and instability during insertion

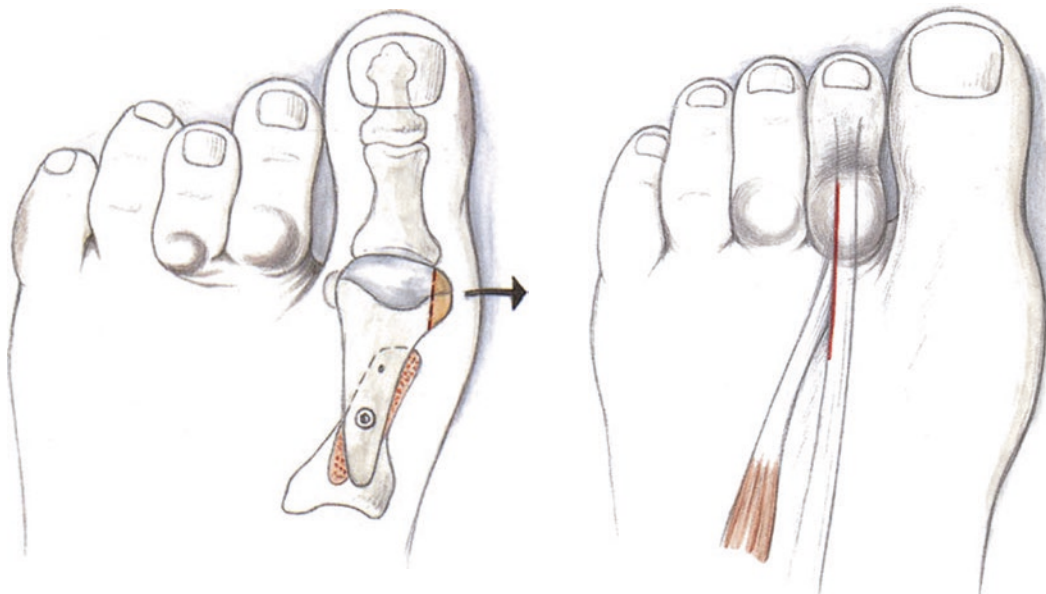
■ Fig. 8.11 The osteotomy is then completed at the plantar aspect and rotational correction is performed using a Backhaus clamp and an elevator. The final corrected position is held in place with a Backhaus clamp at the proximal aspect. The cannulated screw is then fully inserted to fix the osteotomy in place



■ **Fig. 8.12** The site for the second screw is then drilled, which runs from plantar to dorsal. This completes fixation of the Ludloff osteotomy



■ **Fig. 8.13** At the end, the pseudoexostosis is resected at the level of the diaphysis



■ **Fig. 8.14** The MTP joint is opened between the tendons of the extensor hallucis longus and brevis tendons at the level of the split phalanx. The capsule and collateral ligaments are split

8.4 Modified Weil Osteotomy

■ Indications

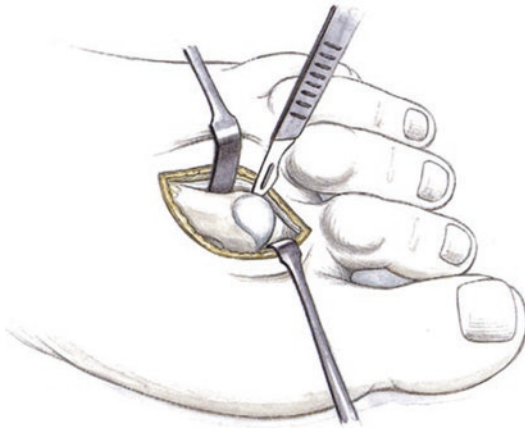
The modified Weil osteotomy has the advantage of avoiding plantarization. This improves the range of motion in the MTP joint (no «floating toe»). The indications are the same as those for the conventional Weil osteotomy: fixed hammertoe deformity, particularly with an intrinsic-plus position, Lefievre forefoot deformity.

■ Contraindications

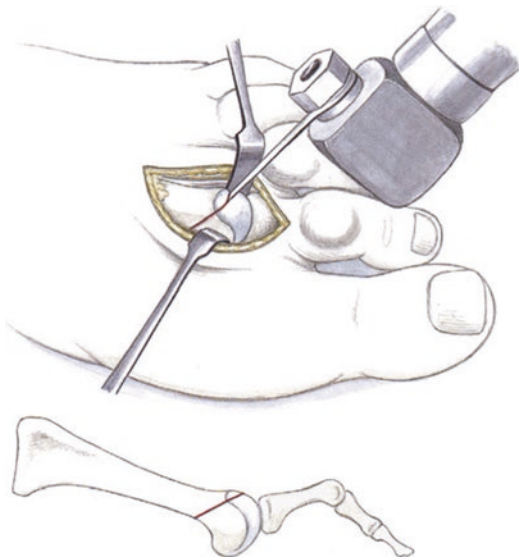
Flexible hammertoes, hammertoes without metatarsalgia complaints. A correction of only one metatarsal with a Weil osteotomy should only be performed in exceptional cases (e.g., a very long second metatarsal) to avoid a transfer lesion.

■ Technique

■ Figures 8.14, 8.15, 8.16, 8.17, and 8.18.



■ **Fig. 8.15** The toe is dorsiflexed and the MTP head is dislocated out of the joint. Hohmann retractors should not be used, as the tension on the lateral soft tissues could become so great that the toe cannot be flexed and the head will dislocate

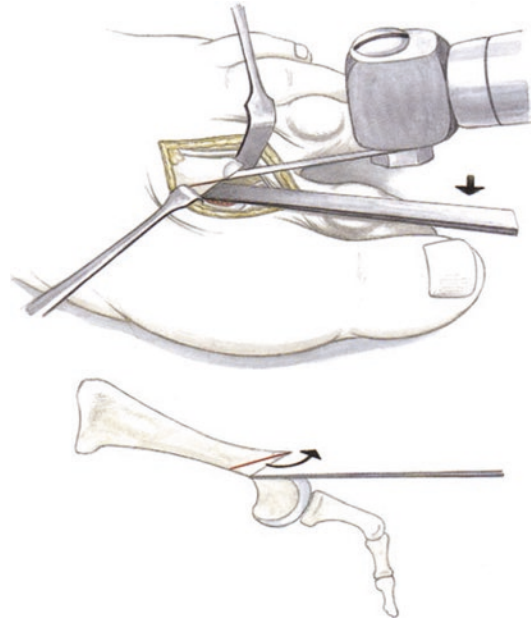


■ **Fig. 8.16** Oblique osteotomy with the oscillating saw proximal to the metatarsal head up to the plantar metaphyseal junction

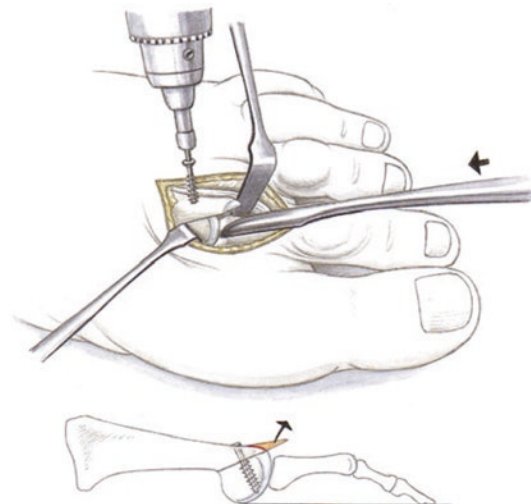
8.5 PIP Arthrodesis

■ Indications

Fixed hammertoes, particularly the second toe, with a «Greek foot» (second toe longer than great toe). In these cases, there is a risk that other techniques (such as the Hohmann procedure) will lead to recurrence due to the second toe extending further than the great toe. The PIP arthrodesis must be performed so that the joint resection makes the second toe shorter than the great toe.



■ **Fig. 8.17** A small Lambotte osteotome is used to push the head plantarly to allow for adequate visualization for the second cut. This is performed at an angle of 10–15°. The resected bone is removed with a small curved mosquito clamp



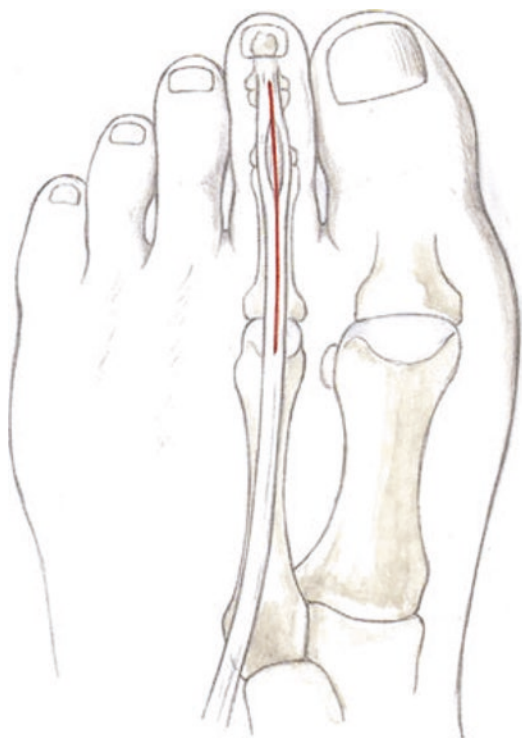
■ **Fig. 8.18** The head is then with reduced with a rasp or other instrument and fixed with a twist-off screw. If the cortical bone is very hard, the screw can be pre-drilled with a 1.0 mm K-wire dorsally. Protruding bone is resected. The closing wedge osteotomy with partial resection avoids plantarization and improves the alignment of the entire MTP joint. This avoids a «floating toe»

■ **Contraindications**

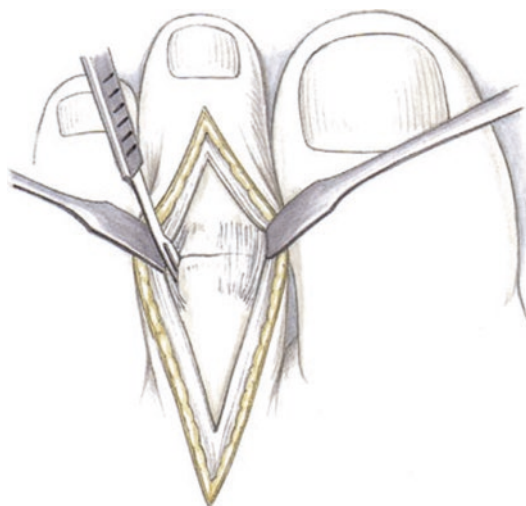
Flexible hammertoes; in these cases, flexor digitorum longus transfer is sufficient.

■ **Technique**

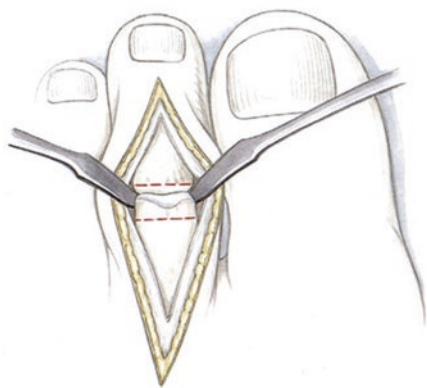
■ Figures 8.19, 8.20, 8.21, 8.22, 8.23, 8.24, 8.25, 8.26, and 8.27.



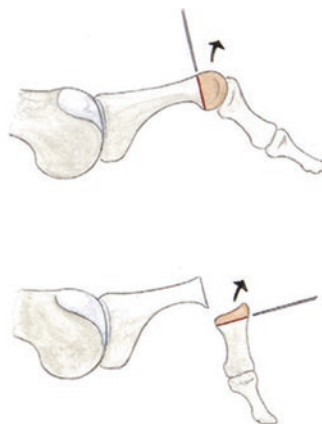
■ **Fig. 8.19** Dorsal skin incision over the second toe



■ **Fig. 8.20** Splitting the extensor tendon. The capsule of the PIP joint is visualized. The extensor tendon is detached distally and proximally along the sides of the joint to visualize the joint



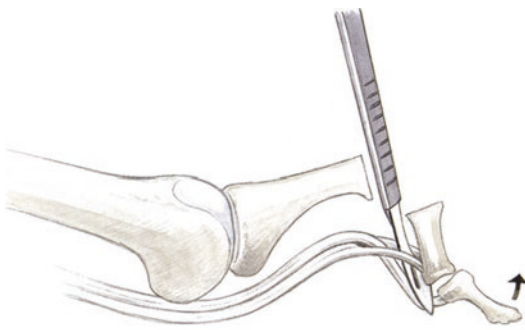
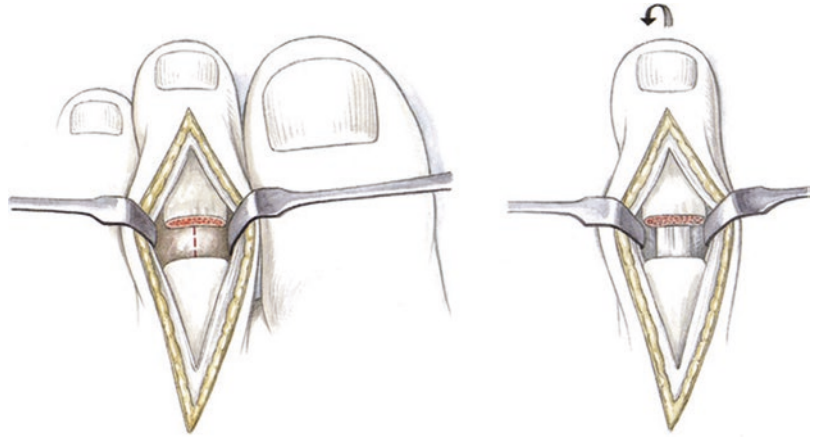
■ **Fig. 8.21** The capsule and collateral ligaments are split while retracting both portions of the tendon with a small Hohmann retractor. The PIP joint is resected with a fine oscillating saw to obtain smooth resection edges. The resection of the head should almost always include



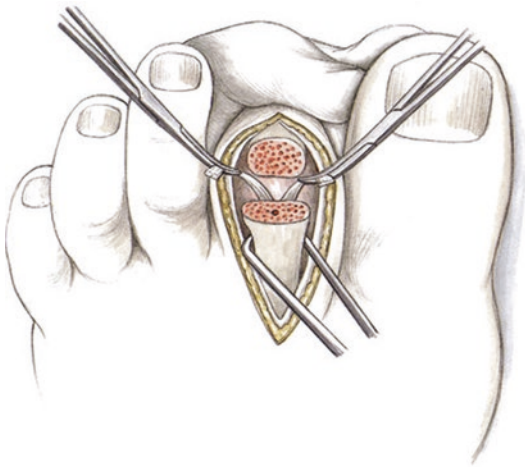
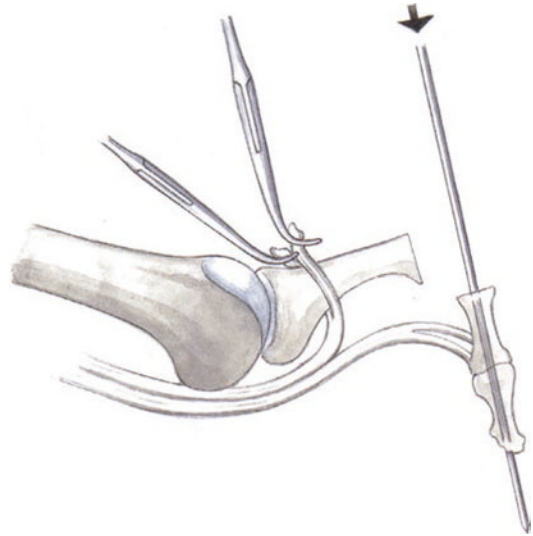
the condyles. The final extent of resection depends on the relative length of the second ray compared to the first ray. After joint resection, the second toe should be about 2 mm shorter than the first toe to avoid recurrent hammertoe

8.6 · Plantar Plate Repair

■ **Fig. 8.22** The plantar raphe is visualized and a longitudinal excision is made to visualize the tendons of the flexor digitorum longus and brevis



■ **Fig. 8.23** The insertion of the flexor digitorum longus tendon is released with a scalpel. To facilitate this, the tendon is tensioned by dorsiflexing the distal phalanx



■ **Fig. 8.24** The flexor digitorum longus tendon is cut at the level of the raphe, creating two tails. These are held with small mosquito clamps

■ **Fig. 8.25** The dissection is carried distally, staying directly on bone. The central intramedullary canal is marked for later insertion of the wire into the proximal phalanx. A 1.4 or 1.6 K-wire is then inserted into the distal segment (the sharp cut end of the K-wire is drilled distally at first) and through the DIP joint out distally. The wire should exit directly under the nail at the center of the distal phalanx to ensure that the toe is straight when fixation is completed

8.6 Plantar Plate Repair

In the past, treatment with an intrinsic procedure and tendon transfer were not successful in preventing subluxation or dislocation at the MTP joint due to the underlying instability. Treatment of the actual lesion and its accompanying pathol-

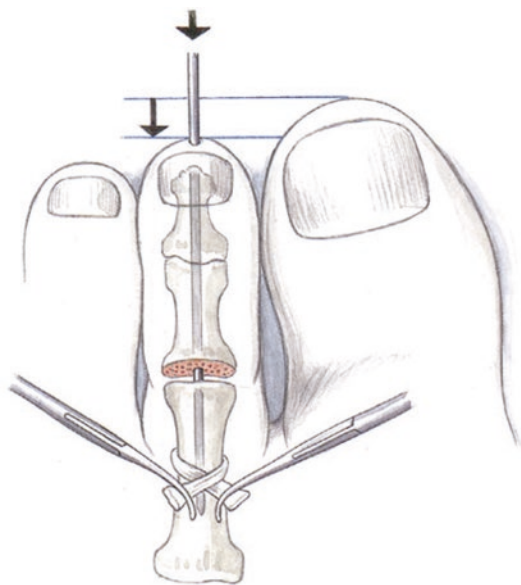


Fig. 8.26 The wire driver is moved distally and the wire is advanced into the prepared canal of the proximal phalanx

ogy is now an approach that can result in optimal results if proper technique is used. For technical reasons, plantar plate repair is always performed in conjunction with a Weil osteotomy. The surgeon should consider if a correction should be performed, particularly if there is plantarization and shortening.

The second ray should always be shortened if it is excessively long. This includes the metatarsal, the metatarsal head and the PIP joint. The need for stabilization after plantar plate repair is optional based on the literature depending on the author. I prefer soft tissue splinting to avoid unnecessary stress on the repaired tendon.

■ Indications

Unstable second ray with dorsal subluxation and dislocation of the proximal phalanx, often in conjunction with fixed hammertoe pathology. The unstable second ray is often present in isolation; however, it is often accompanied by hammertoes in the digits 3–5 that are usually not unstable. There is typically no cavovarus deformity with extensor tendon suspension. The foot axis is usually relatively normal. It is more common in women.

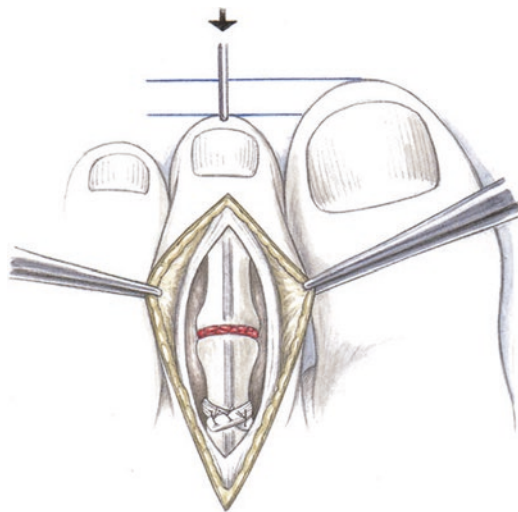


Fig. 8.27 The PIP arthrodesis is reduced. The surgeon should ensure that there is no malrotation distally. The middle and distal phalanx are pushed against the resected proximal phalanx with maximum force. To improve bone healing, small cancellous bone fragments are inserted from the resected head. The two tails of the flexor digitorum longus tendon are then crossed near the base of the bone and sewed with 4-0 PDS. The toe is positioned in 20° of plantar flexion at the ankle and slight plantar flexion at the MTP joint. To secure the sutured tendon, the K-wire is advanced into the metatarsal head. The K-wire is removed after 4 weeks. If the extensor tendons and the dorsal capsule of the MTP joint are shortened, the incision is elongated proximally and a dorsal capsulotomy and extensor tendon lengthening are performed prior to advancing the wire

■ Contraindications

There are no contraindicated pathologies. General contraindications include conditions such as cortisone treatment, chemotherapy or Charcot foot.

■ Surgical setup

Special instruments: Mini-Scorpion device, suture passer, Weil osteotomy set.

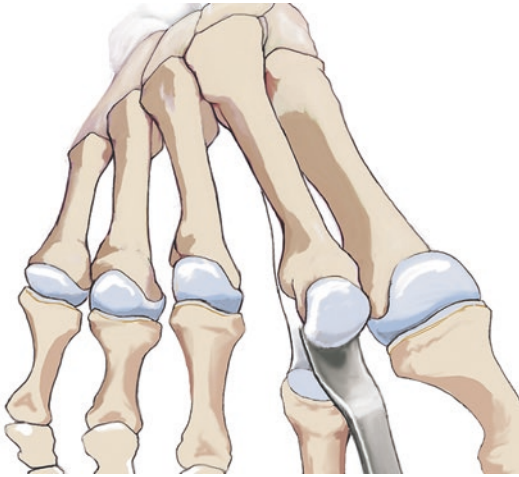
■ Positioning

Normal positioning. The contralateral leg is lowered. The surgeon stands at the contralateral side. A tourniquet set to 300 mmHg is used. Prior to inflation, the limb is exsanguinated with an Esmarch.

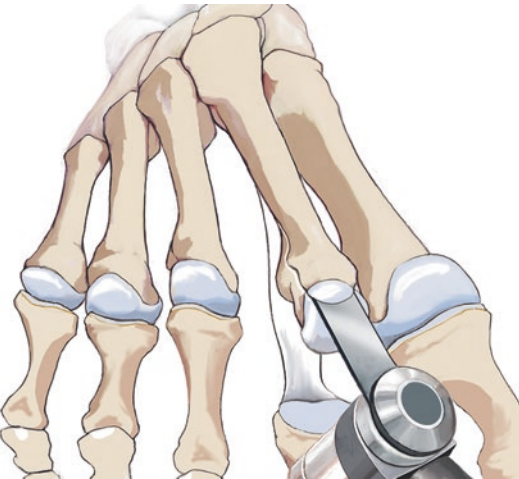
■ Technique

■ Figures 8.28, 8.29, 8.30, 8.31, 8.32, 8.33, 8.34, and 8.35.

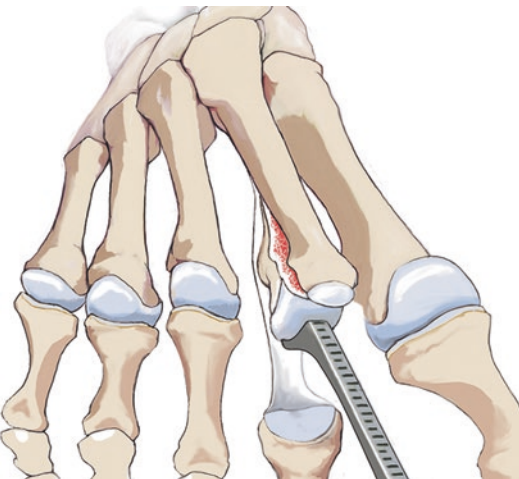
8.6 · Plantar Plate Repair



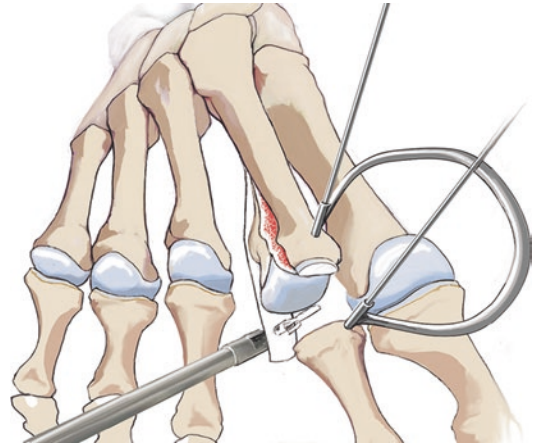
■ Fig. 8.28 Plantar release with the McGlamry rasp



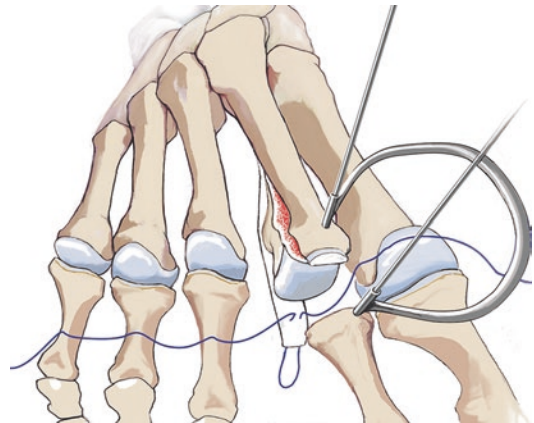
■ Fig. 8.29 Weil osteotomy



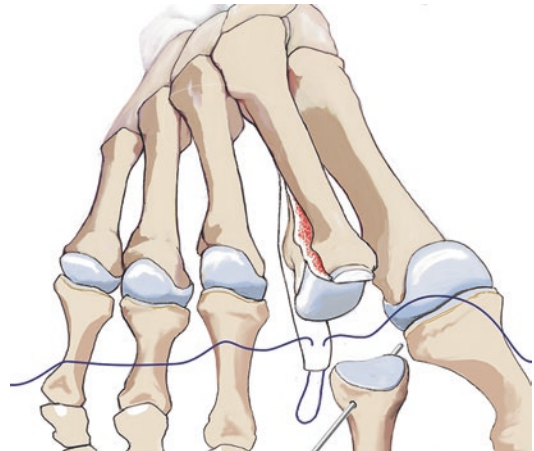
■ Fig. 8.30 Translation and fixation with a K-wire



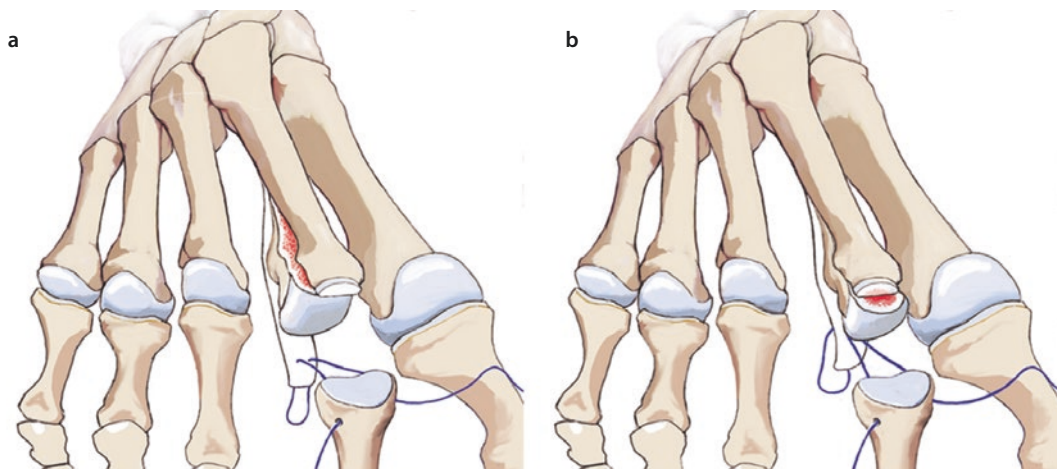
■ Fig. 8.31 The MTP joint is distracted. The plantar plate is completely detached. The proximal aspect of the plantar plate is grasped and suture is inserted with the mini-Scorpion device



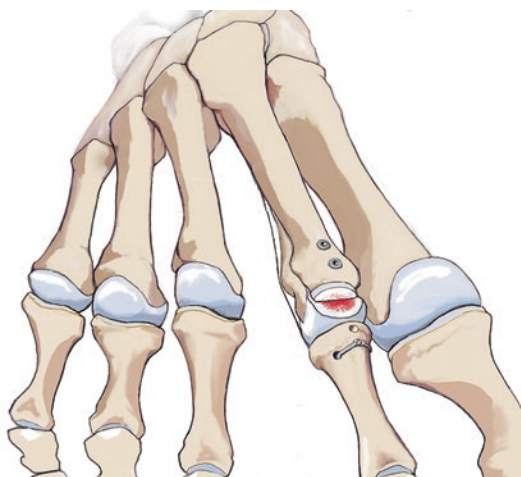
■ Fig. 8.32 Two FiberWire stiches are placed



■ Fig. 8.33 Crossing transosseous 1.2 mm tunnels are drilled in the metaphysis of the metatarsal for later repair



■ Fig. 8.34 a, b Pulling through the FiberWire



■ Fig. 8.35 The Weil osteotomy is repaired (anatomically or with shortening, depending on the pathology) with twist-off screws. The plantar plate reconstruction is firmly tied in a neutral position

A skin incision is made at the interdigital space between the second and third metatarsals. Dissection is carried through soft tissue. Light electrocautery. The short and long extensor digitorum tendons are visualized. In my technique, I perform a tendon transfer at this point. The second extensor digitorum brevis tendon is cut distally. After proximal dissection, the longus tendon is cut as well. A capsulotomy is performed and the joint is visualized. There are always adhesions at the plantar aspect, so a plantar release is performed using a McGlamry rasp. After repositioning and subluxating, the interossei and lumbricals

will act as extensors, decreasing or eliminating the pull into extension.

A Weil osteotomy is then performed and the head is retracted out of the way. The plantar plate is visualized. This often has degenerative changes. For older patients with a long history of instability, the plate is often almost completely macerated from the insertion to the base. The plate is detached and grasped with the Mini-Scorpion device. A drill tunnel is then created at the exposed proximal phalanx using a 1.2 mm K-wire. The suture is pulled through the tunnel in crossing fashion to the medial side using a suture passer. The same procedure is repeated on the lateral side so that the plantar plate can be pulled back against the base of the phalanx. The head is then reduced and held in place with a twist-off screw. The joint is reduced in plantar flexion to achieve maximum tension. The plantar plate is tied in place. If the second toe is very long, a Hohmann procedure should be performed first.

■ Aftercare

A forefoot unloading shoe is worn for 4 weeks. If transfixation was performed, the pin is removed after 4 weeks. Gentle range of motion exercises are performed. Initially, these are primarily in plantar flexion to avoid putting stress on the reconstructed plantar plate with dorsiflexion. Gentle dorsiflexion is continued until 4–5 weeks. After this, normal and more aggressive range of motion exercises are performed in both directions. Tiptoe walking in water. Dorsiflexion stretching is performed on the edge of the shower to regain full range of motion.

8.7 Hohmann Procedure

■ Indications

Fixed hammertoe deformity, always combined with plantar release at the proximal phalanx or plantar plate repair. Cases with an excessively long first ray to prevent recurrence. Shorter second toes can be treated with soft tissue procedures, extensor tendon tenotomies and capsulotomies. They do not tend to result in fixed hammertoes.

■ Contraindications

Circulatory diseases. Other general contraindications for foot surgery.

■ Surgical setup

Standard surgical instruments, very small saw blade (2 and 6 mm), small rongeur or minimally-invasive burr. Depending on personal preference, a wire, twin-pin or arthrodesis screws from various manufacturers can be used. A special small fluoroscope for foot surgery is used.

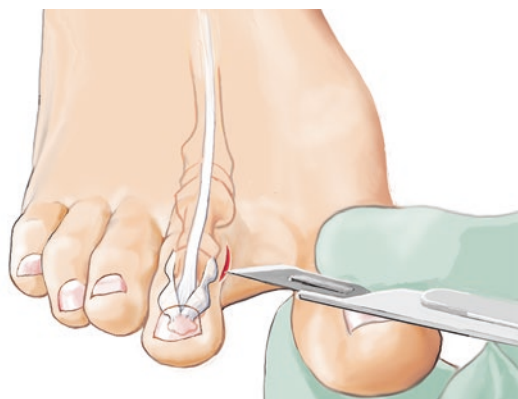
■ Positioning

Standard supine position, tourniquet, exsanguination.

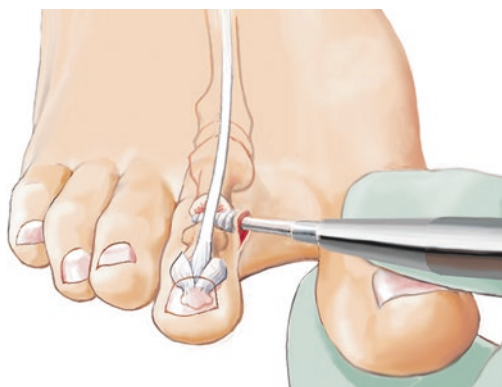
■ Technique

■ Figures 8.36, 8.37, and 8.38.

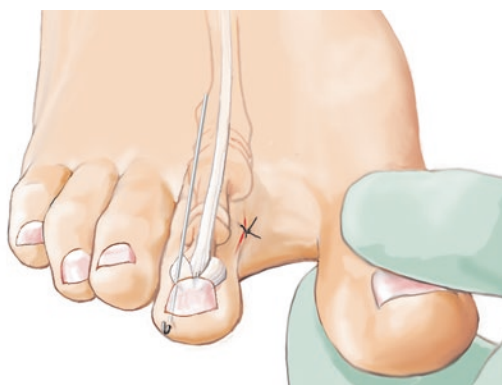
A lateral or medial approach is made to the PIP joint, which provides better cosmesis and avoids adhesive scar formation. The joint is visualized while protecting the extensor tendon.



■ **Fig. 8.36** Lateral or medial approach to the PIP joint with plantar capsulotomy and flexor tendon tenotomy



■ **Fig. 8.37** Joint resection with a burr including the condyles of the proximal phalanx and the base of the middle phalanx



■ **Fig. 8.38** Soft tissue splint (K-wire, 1.6 mm) for 3–4 weeks

Hohmann retractors are inserted and the base of the phalanx, the interphalangeal joint and the head of the proximal phalanx are resected from lateral. This is performed minimally-invasively using a burr. The amount of resection is checked with the C-arm. The second ray should be shorter than the first ray. After repair of the plantar plate, the PIP joint is aligned and a 1.6 mm K-wire is inserted as a soft tissue splint medially or laterally at the great toe and at the MTP joint. This should be straight and stable with minimal plantar flexion.

■ Aftercare

Plaster splint for 2 days postoperatively and for at least 3 nights to avoid painful movements. Dressing change after 2 days. The bandage is applied with specific alignment technique as described in ► Sect. 8.3, «Aftercare». After 4 days,

a forefoot toe plate is placed to ensure alignment of all of the toes. This plate can also be used on individual toes after surgery. A dressing or toe plate is worn for 4 weeks. Weight-bearing as tolerated with a forefoot-unloading shoe. After this, range of motion exercises are started, particularly in plantar flexion and dorsiflexion at the MTP and DIP joints.

8.8 Chevron and Akin Osteotomy (Minimally Invasive)

■ Indications

Moderate hallux valgus, depending on the expertise and philosophy of the surgeon regarding minimally-invasive techniques. At the beginning, distal osteotomies are the most suitable indications. Painful pseudoexostoses with moderate lateral deviation (at the level of the lateral sesamoid on weight-bearing radiographs) with no coverage of the metatarsal head. This can be managed well with a closed technique.

■ Contraindications

Higher-grade hallux valgus deformities and early symptomatic hallux rigidus components.

■ Surgical setup

Instruments: Minimally-invasive MAS system from various manufacturers; the rotational speed, torque and coolant can be adjusted specifically for the osteotomy. Special instruments include various small curved rasps and burrs (conical and straight) in various widths and lengths. A screw system is used for percutaneous screw fixation of the Chevron osteotomy (cannulated and double-threaded). K-wires.

The surgery is performed by some surgeons using a small low-dose fluoroscope (specially designed for foot surgery). The foot is draped similarly to old techniques for draping out knee arthroscopy with a special draping system. 1.8 mm drill, small beaver blade scalpel.

■ Positioning

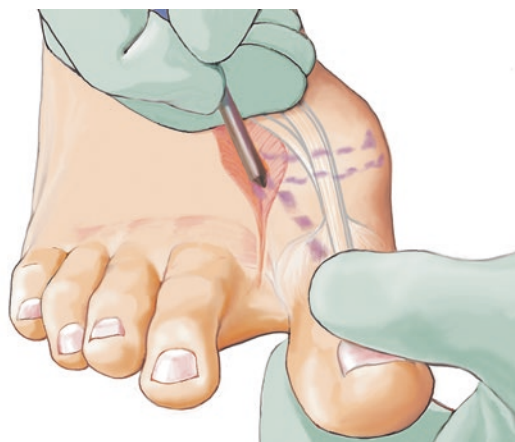Normal positioning with the contralateral leg lowered. Surgery is performed from the contralateral side. Tourniquet at 300 mmHg after exsanguination with an Esmarch.

8.8.1 Chevron Osteotomy

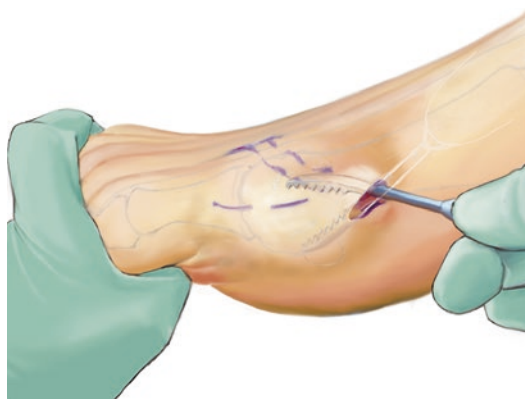
■ Technique

■ Figures 8.39, 8.40, 8.41, 8.42, 8.43, 8.44, 8.45, and 8.46.

The lateral release is started by making a stab incision with a beaver blade. The blade is passed along the lateral third of the dorsal aspect of the joint line of the first metatarsal. The scalpel is advanced parallel to the joint to avoid injuring the joint surfaces and up to the plantar, lateral aspect of the first MTP joint. The lateral insertion of the flexor hallucis longus and brevis tendons and the lateral sesamophalangeal ligament are split at the



■ Fig. 8.39 Soft tissue release with a beaver blade after a stab incision at the joint. The periosteum is then released at the MT head using a curved rasp. This facilitates lateral translation of the osteotomy



■ Fig. 8.40 3–5 mm incision down to bone at the apex of the Chevron osteotomy. The joint capsule is mobilized with a curved rasp until the joint capsule is «mobile»

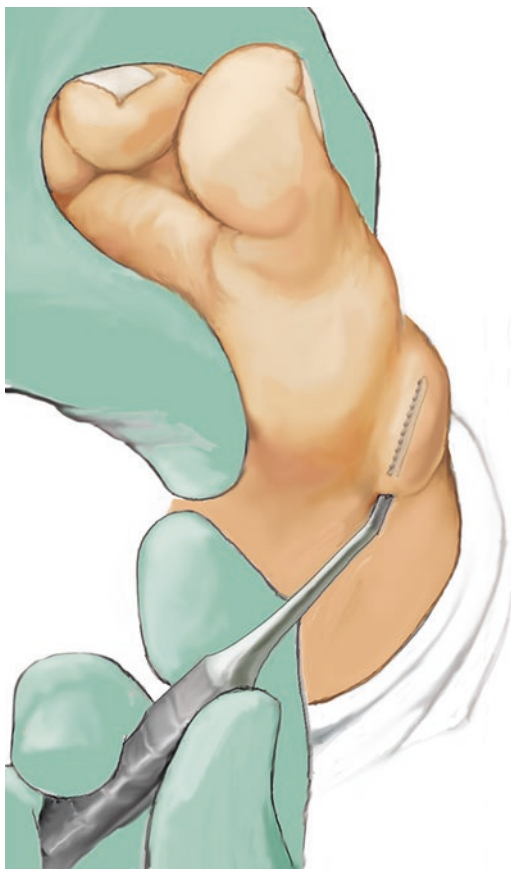

Fig. 8.41 Mobilization of the inferior aspect of the joint capsule

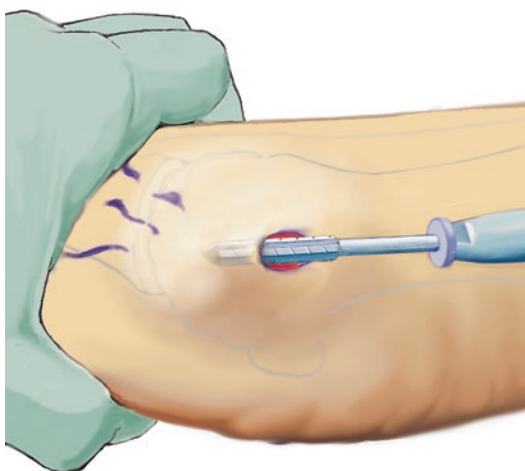


Fig. 8.42 The cylindrical rasp is used to remove the pseudoexostosis; fluoroscopy is needed for this

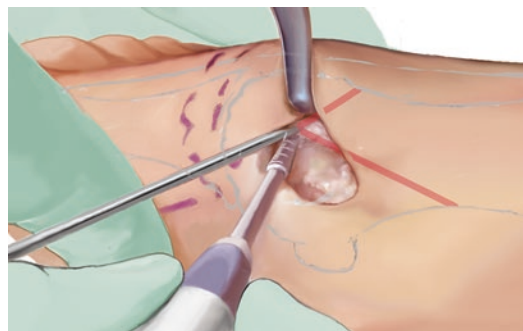


Fig. 8.43 A 1.6 mm K-wire is inserted centrally at the apex of the osteotomy and checked on fluoroscopy. A conical burr is passed through the entire metatarsal head directly above the K-wire towards the osteotomy. The superior aspects of the bone are cut at an angle of 40–45°. The surgeon must check to ensure that the bone has been completely cut, especially laterally. The same steps are then performed inferiorly

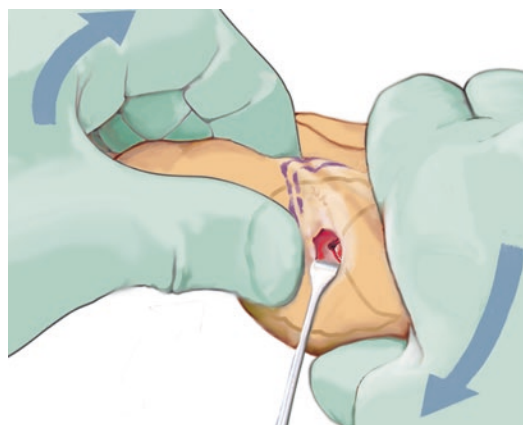


Fig. 8.44 The distal segment is distracted and lateralized, aligning the MT head in the correct position. The great toe is then compressed to hold the reduction

plantar aspect of the joint. Fluoroscopy can be used to visualize the scalpel position. Varus stress is placed on the joint. The adductor hallucis is also released, particularly in cases of lateralization, if the lateral sesamoid is not covered. The sesamoid metatarsal ligament can also be released. A file is used to dissect the soft tissues proximally off the metatarsal head. This allows the Chevron osteotomy to be moved laterally without difficulty.

A medial stab incision is made at the center of the metatarsal head. This should be performed

under fluoroscopy so that it is parallel to the plane of the joint. To shorten the ray, the cut can be made with a slight inferior angle. For lengthening osteotomies, the K-wire can be inserted with slight superior angulation.

The capsule is cut first and the rasp is used to free the pseudoexostosis of soft tissues. The non-conical burr is then inserted. The pseudoexostosis is resected, working slightly superiorly or inferi-

orly towards the wall. Switching instruments, the resection is performed once from distal to proximal and once from proximal to distal. The resection is checked with fluoroscopy regularly throughout the procedure and at the end to confirm adequate resection. A K-wire is then inserted at the center of the metatarsal head.

A small rasp is used to remove the soft tissues dorsally and plantar. In particular, the flexor and extensor tendons should be released somewhat. A small Hohmann special retractor can be inserted dorsally. A conical burr is then used starting at the K-wire, working from medial to lateral to create the superior dorsal osteotomy (normal saw technique), then the plantar osteotomy. A small osteotome can be used to check under fluoroscopy whether the osteotomy is complete. To achieve a slight varus position at the head, somewhat more bone can be removed at the medial aspect.

Translation is usually not easy with the Chevron technique. The great toe is first pulled to create distraction. A small osteotome is then used to check whether the osteotomy is complete laterally. This can leave small bony prominences that must first be removed with an osteotome or the conical burr. With the simple Chevron osteotomy, it is common that the dorsal aspect gets caught laterally, especially when the osteotomy is brought slightly proximal as well as lateral. This can require additional resection. Soft tissue impingement that impedes lateralization should be thoroughly

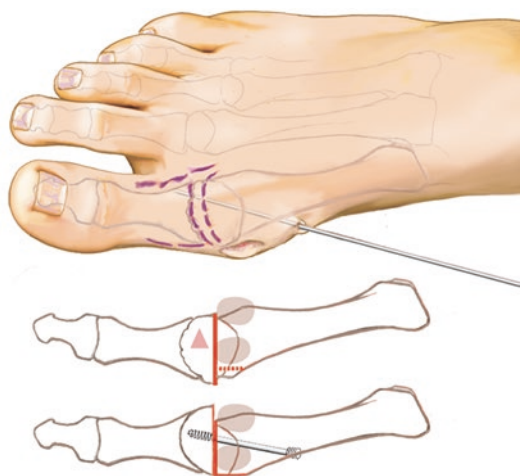


Fig. 8.45 Fixation with a 1.6 mm K-wire. Once the wire is in an optimal position in both planes (avoid dorsal translation of the head), a double-threaded screw is placed through a stab incision. The protruding proximal bone caused by translation is resected

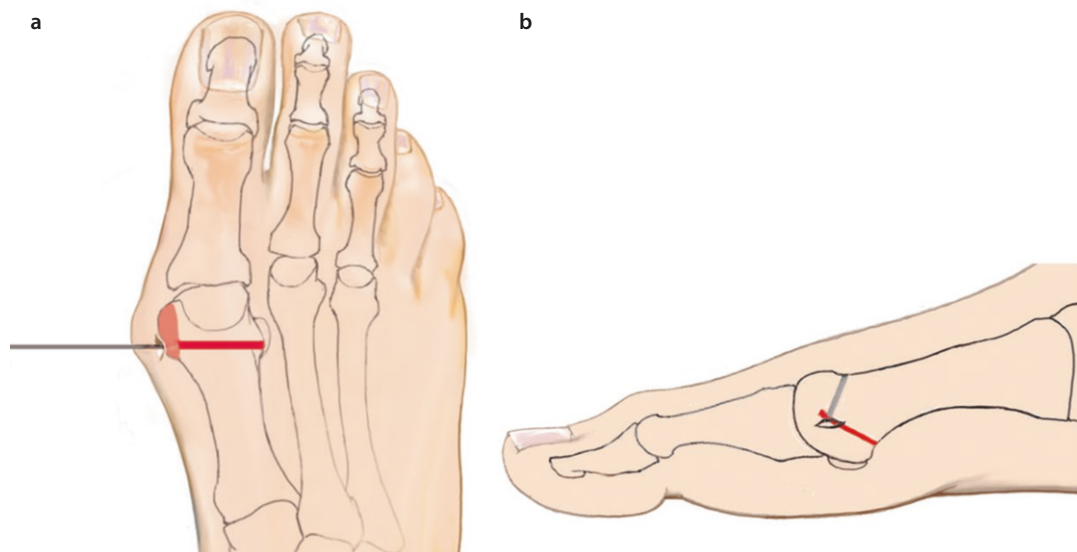


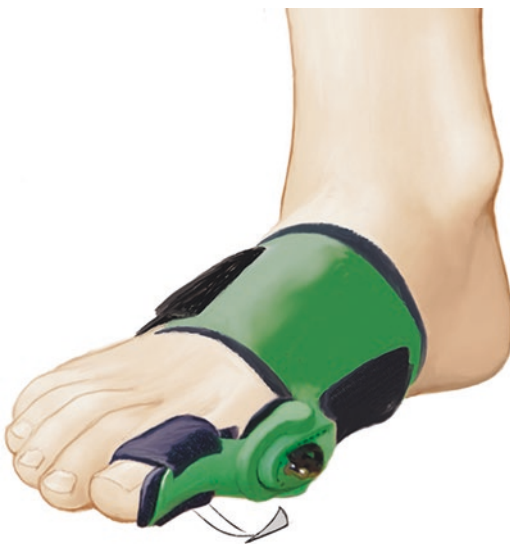Fig. 8.46 a, b Illustration of the osteotomy and exostosis removal

cleared with a rasp inserted through the intermetatarsal incision.

In my experience, pulling on the toe with a small Backhaus clamp or pushing on the metatarsal head with the thumb can lateralize the proximal aspect. Once adequate lateralization has been achieved, a 1.8 K-wire is inserted at the center of the shaft to stabilize it in the sagittal plane. The position is checked on fluoroscopy. The surgeon should ensure that there is no dorsal translation of the head. A stab incision is then made to insert a guidewire (1.0 mm) for the double-threaded screw percutaneously. After overdrilling, the screw is inserted from dorsal to plantar, avoiding any interference with the wire. The wire is then removed and the medial prominence is then removed with a burr. The principles of the translation are the same as with the open Chevron osteotomy, with the objective of covering the lateral sesamoid.

■ Aftercare

A dressing is applied as described by Mariano Di Prado (► www.minimallyinvasivefootsurgery.com). A cast or forefoot-unloading shoe is worn for one night. A toe splint is worn to stabilize the correction (■ Fig. 8.47). Patients can weight-bear as tolerated immediately. Standard pain control.



■ Fig. 8.47 Aftercare following great toe surgery with a dynamic toe splint to stabilize the correction

8.8.2 Akin Osteotomy

The indications for an Akin osteotomy should be broad. To me, it seems important to correct toe pronation in addition to the DMAA for hallux valgus deformity. If significant lateralization of the great toe remains, usually due to valgus deviation of the intermetatarsal joint, a distal Akin osteotomy is performed. For this, a stab incision is made at the middle to distal third. A wedge-shaped resection is performed with the burr and the position of the bone is corrected. The osteotomy is fixed with a K-wire from proximal to distal. A guidewire for the double-threaded screw is then placed from distal to proximal.

If the correction is adequate, it is fixed with a screw. If the surgery was not performed under a foot block, local anesthesia should be injected to ensure postoperative pain control.

■ Indication

The Akin osteotomy is an additional correction for forefoot osteotomies. The indications are not fully clear. There are two primary aspects to the surgery: «realignment» of the long flexor and extensor tendons in a central position and the correction of incongruity at the interphalangeal joint that is not a result of head deformity. The simplest clinical rule is that an optimal metatarsal osteotomy always results in residual lateral deviation and an Akin osteotomy should always be performed if the joint is congruent.

Lateral deviation can also result from lateral deviation in the interphalangeal joint. The Akin osteotomy, if performed without shortening, can result in a very good cosmetic correction, even if the medial cortex is longer than the lateral cortex. For severe deformity at the interphalangeal joint, a distal Akin osteotomy should also be considered.

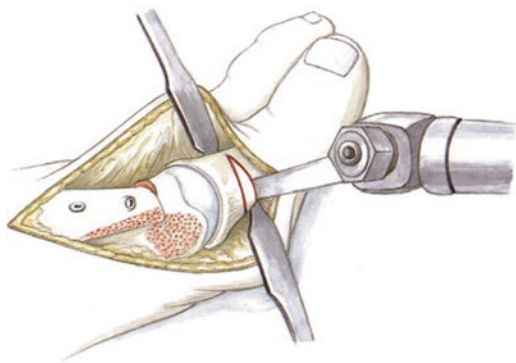
The minimally-invasive technique is performed through a 3–5 mm stab incision using a conical burr. A medial-based wedge is resected and closed medially to correct the angulation. The extent of resection is monitored with fluoroscopy. The osteotomy is fixed with a double-threaded screw or a wire.

■ Technique

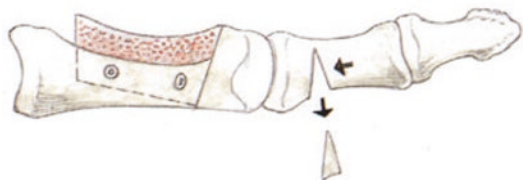■ Figures 8.48, 8.49, 8.50, and 8.51.

■ Aftercare

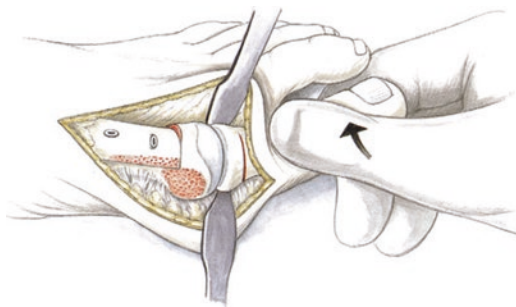
Bandages are placed as described by Di Prado with varus support and stabilization of the great and lesser toes. Dressing change after 2 days. A Halluxsan splint is then placed. This should be



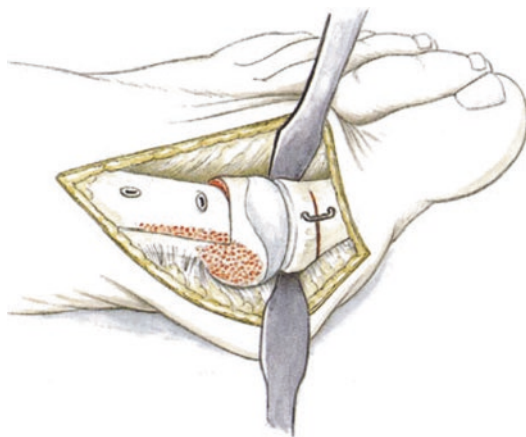
■ **Fig. 8.48** Open technique: After dissection and insertion of 2 Hohmann retractors, a 2–3 mm medial-based wedge is removed. The lateral cortex remains intact



■ **Fig. 8.49** It is psychologically important for the patient that the great toe is completely straight after surgery. This is an important clinical reason for resecting a wedge for an Akin osteotomy. After dissection and insertion of 2 Hohmann retractors, a 2–3 mm medial-based wedge is removed. The osteotomy is carried up to the cortex laterally



■ **Fig. 8.50** Correction of the rotational deformity by supinating and closing the open wedge. The lateral wall should remain stable



■ **Fig. 8.51** If the lateral wall remains stable, the osteotomy can be fixed medially using a small titanium staple (K-wire). If the osteotomy is complete, the osteotomy is either fixed with a K-wire inserted from proximal to lateral-distal or with a more stable memory staple

worn daily for several hours for the next 3 months. A forefoot-unloading shoe should also be worn for the first 4 weeks every day. The shoe can also be worn overnight, although this is not required. The patient can weight-bear as tolerated in the forefoot-unloading shoe. An appropriate physical therapy routine is then performed, with particular attention to plantar flexion, as physical therapists usually emphasize dorsiflexion. This can lead to tightness of the dorsal capsule, which can result in compression of the joint in plantar flexion.

8.8.3 Modified Chevron Osteotomy

This technique is a modification of the Scarf and Chevron osteotomies. To create translation, which is impossible with a traditional Chevron osteotomy, the plantar saw cut is made longer (about 2 cm) to allow for lateral translation as well as rotation. This is particularly important for incongruent joints to restore the joint axis. This technique is also less complication-prone than a Scarf osteotomy, which uses a «trephining» technique (telescoping of the diaphysis after the osteotomy). In addition to translation, rotational correction can allow for a large intermetatarsal angle to be anatomically reconstructed.

■ Indications

In general, any hallux valgus deformity with lateralization of the sesamoid can be treated surgically

8.8 · Chevron and Akin Osteotomy (Minimally Invasive)

with a modified Chevron technique. The rotational components are then adapted based on the individual needs of the anatomic reconstruction or correction. Due to the long plantar resection surface, there is good contact area for bone healing and pseudarthrosis is impossible with adequate fixation.

■ Contraindications

Unstable first ray (a Lapidus fusion should be performed in this case).

■ Surgical setup

Standard surgical instruments. Depending on personal preferences, cannulated Herbert screws or percutaneous K-wires. Cannulated Herbert screws are a useful addition to any foot instrument set. The set should also include standard reduction clamps.

■ Positioning

Normal positioning. The contralateral foot is lowered. Surgery is performed from the contralateral side. Tourniquet at 300 mmHg after exsanguination with an Esmarch.

■ Technique

Medial incision. Dissection and visualization of the joint. A K-wire (1.6 mm) is inserted into the center of the metatarsal head. To lengthen the metatarsal, this wire is drilled with slight superior inclination; for shortening, the wire is inserted at an inferior angle. The oblique cut is then made at the dorsal surface. This should create an angle of about 45°. Careful dissection is then performed at the plantar aspect and a slight release is performed without injuring the vessels entering medially. The diaphyseal junction is visualized. A 2 cm long cut is made with the saw. Cutting through the cortex at a flat angle can be somewhat tedious. The saw blade can be plantar flexed slightly to place more force on the cortex. It is important to obtain lateral mobilization to allow for translation. The medial aspect of the cortex must sometimes be broken through with a small osteotome. This should be performed carefully to avoid risking a fracture of the head. Translation and rotation is performed to cover the lateral sesamoid. Provisional (or definitive) fixation is achieved with a 1.6 mm K-wire.

The head is entered from dorsomedial to plantar-lateral. For the final position of the K-wire, the skin is lifted up dorsally to perform

fixation through the skin into bone. Any tension on the skin is released with a #11 scalpel. The position of the wire is checked (to rule out intra-articular perforation) and the joint is visualized. Anatomic correction is confirmed using dorso-plantar C-arm views in 2 planes. The medial prominence is then removed. A cannulated double-threaded screw is inserted over a guidewire and the wire is then removed.

A small saw is then used to round off the medial border slightly. If necessary, an Akin osteotomy is performed. Layered wound closure. Capsular reefing alone should not be relied on for correction of the sesamoids. If correction of bone is not achieved by translation, the pathology will recur despite reefing. Because of this, the medial sesamoid should be up against the medial wall of the metatarsal after correction. A capsular stitch is placed here, fixing the medial sesamoid to the medial aspect of the metatarsal head. The stitch is placed with the MTP joint in neutral position, to avoid limiting the range of motion in plantar flexion and dorsiflexion. Skin closure. A Redon drain (8 Fr) can be placed depending on hemostasis. Sterile dressing. Plaster splint (important for pain control); this can also be worn as a night splint for the first 3 days.

■ Aftercare

■ ■ Dressing/bandage technique for hallux valgus

The surgeon should take advantage of the opportunity to perform a slight soft tissue varus correction using the dressing. The individual gauze bandages are opened up and pulled medially through the first interdigital space. Interdigital bandages are also placed between the lesser toes and pulled laterally. A 5 mm gauze roll is then used to achieve slight medialization or neutralization as a compressive dressing. A 5 mm plaster splint can also be applied for stabilization. This dressing is left for 2–3 days. All subsequent dressing changes are performed in the same way. After wound healing, a Halluxsan splint is worn for several hours each day (7–10 days). This holds the medialized position with a dynamic spring. If well-tolerated, the splint can be worn at night for an additional 3–6 weeks.

■ ■ Weight-bearing and exercises

Flat forefoot-unloading shoe to allow for slight loading (in contrast to a plateau shoe). Range of motion exercises are started on the second post-

operative day after fixation of the osteotomy (Akin, modified Chevron osteotomy). Guided range of motion exercises are performed by physical therapists. Immediate weight-bearing as tolerated in a forefoot-unloading shoe for 4 weeks. Home exercise program. The K-wire is removed if a screw was placed and the patient is transitioned to normal-width shoes or sandals. More intensive exercises and water jogging are started after 4–5 weeks. Plantar flexion is particularly important after Chevron and great toe surgeries, as capsular tightness often leads to problems that can be as serious as arthrofibrosis. Patients should

also practice plantar flexion exercises on their own, as this can be more painful than dorsiflexion in the early phase due to the tension on the traumatized dorsal soft tissue.

Well-cushioned, wide shoe. Gradually increasing activity with cycling, water jogging, impact sports (jogging) after 3 months postoperatively depending on soft tissues. The patient should be informed that swelling can last over 6 months. It is often not possible to wear stylish shoes. The patient should also know that the final result after surgery («I can't tell that I have had surgery») and the capacity for endurance can take up to a year.

Ankle Arthroplasty

- 9.1 General Notes – 130**
- 9.2 Techniques – 131**
 - 9.2.1 Approach – 131
 - 9.2.2 Osteophyte Resection – 132
 - 9.2.3 Soft Tissue Balancing – 132
 - 9.2.4 Soft Tissue Balancing During Prosthesis Implantation – 132
 - 9.2.5 Prosthesis Implantation – 133
 - 9.2.6 Additional Steps – 133
- 9.3 Ankle Prosthesis and Transfer of the Posterior Tibialis Tendon – 134**

9.1 General Notes

There are numerous types of arthroplasty implants available for the ankle. In my opinion, six prostheses will be in widespread use for the mid-term future. Two-component prostheses are not used in Europe. There are two types of three-component prostheses: an onlay type and a «talar cap» type, with differences in tibial and talar fixation. The main problem today is the appearance of periprosthetic cysts. In my opinion, this is due to primary instability of the (mini-) interface, which leads to increasing bone resorption. This is less common with «cap» prostheses, so I have returned to my initial use of the STAR prosthesis. A substantial improvement in the instruments was also a deciding factor. If the guidelines are followed, successful implantation is possible for the experienced surgeon.

The goal of this chapter is not to list all of the individual surgical techniques in detail and analyze their relative strengths and weaknesses, although I have experience with all of the implants in current use. Rather, this is intended to discuss principles and technical problems as well as my own tips and tricks and those of other experienced ankle arthroplasty surgeons.

■ Positioning

The patient is positioned supine with a small cushion under the hip. Medial and lateral posts are used so that the ankle joint and the lower extremity are straight and the table can be moved into internal and external rotation. The contralateral leg is lowered. For this procedure, in my opinion, a tourniquet or exsanguination is indicated, particularly for surgeons without sufficient experience.

■ Intraoperative management

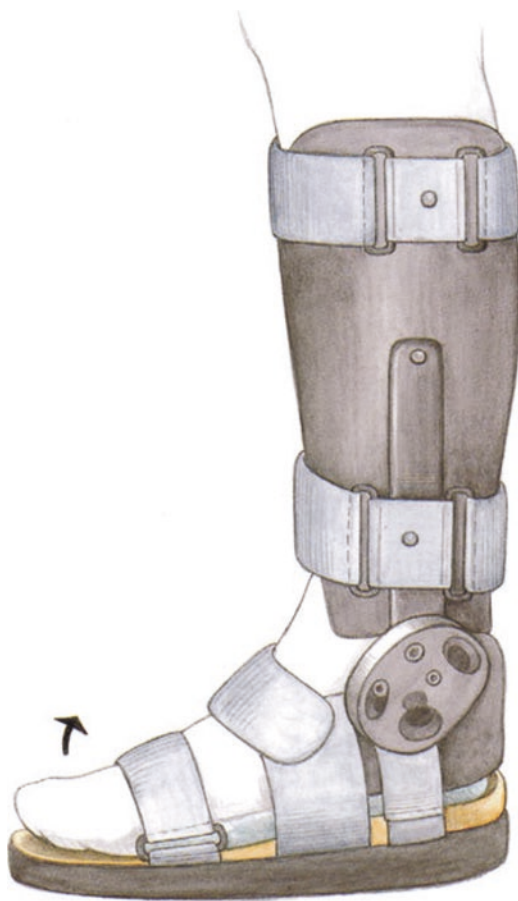
At the time of prosthesis implantation, the tourniquet should always be let down to allow for hemostasis at the posterior joint. If heavy bleeding is present, this can then be more carefully evaluated. After hemostasis is achieved, a tamponade with a hemostatic sponge is recommended to reduce the high-grade posterior bleeding. Severe hematomas can lead to serious soft tissue complications and skin necrosis. For this reason, a functioning intra-articular Redon drain is critical. For implantation, I impregnate the bone surfaces as well as the back-sides of the prosthesis with bone marrow aspirate (taken with a Jamshidi needle from the iliac crest).

Radiolucent lines, particularly at the tibial interface, are no longer seen.

Fluoroscopy is used to check the alignment of the axis and the cut surfaces with transparent radiographic templates. Even for experienced surgeons, I consider this a necessary step. Antibiotic prophylaxis should be given perioperatively and low-molecular-weight heparin is given at the time of induction. For thrombosis prophylaxis, I have had success with Arixtra. This is given 6–8 hours after surgery to reduce the risk of postoperative bleeding.

■ Aftercare

Cast at 90° to relax the skin. After this, a CDS splint (■ Fig. 9.1) is placed to improve dorsiflexion, which can be limited by pain. In cases of posterior release and Achilles tendon lengthening, this allows for



■ Fig. 9.1 CDS splint. This has 3 basic settings (0°, 15° or 30° dorsiflexion). There are also 15 levels of adjustable tension. For postoperative use, there should always be slight pressure in dorsiflexion. This both relaxes the anterior skin and stretches the gastrocnemius-soleus-Achilles tendon complex, which is usually tight

improved dorsiflexion as early as possible. Range of motion exercises are performed with the leg elevated in bed for 2 days. If the wounds are well healed, gait training can proceed with partial weight bearing at 15 kg. However, priority is placed on range of motion exercises at the ankle joint. If high-grade swelling is present, exercises should only be performed in dorsiflexion. Plantar flexion exercises that increase joint pressure should be avoided.

After the soft tissues have stabilized and swelling in the foot and ankle have gone down, range of motion is increased in both. If necrosis is noted at the suture line, growth factors (ACP) should be injected subcutaneously and the ankle joint is immobilized until the soft tissues are stable.

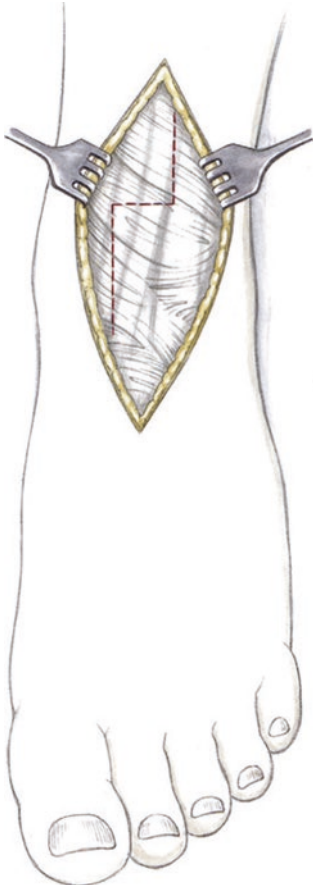
Lymphatic drainage massage, partial weight-bearing for 6 weeks, daily wear of the CDS splint. If

possible, the splint is also worn also every night, as stretching is most successful when asleep due to muscle relaxation. The spring is gradually tightened in the CDS splint so that there is always a sensation of gentle tension. Cyrotherapy is performed in the early postoperative phase. After the soft tissues have completely healed, water jogging in high water can be started in the 3rd and 4th week.

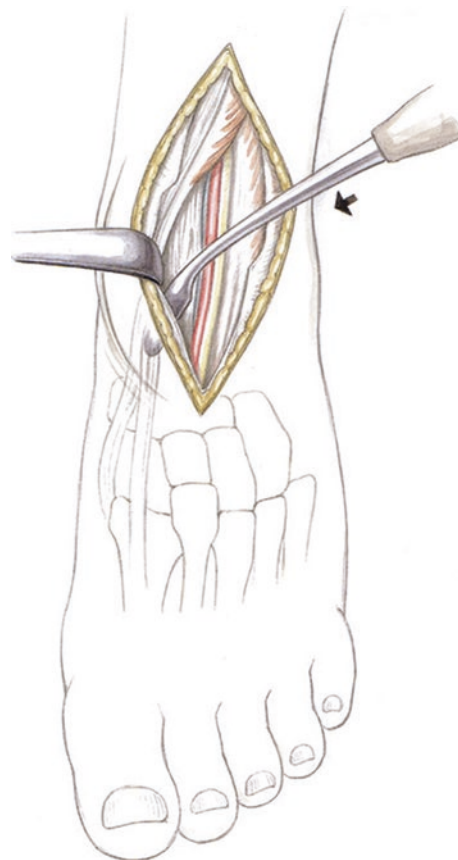
9.2 Techniques

9.2.1 Approach

Z-shaped split of the extensor retinaculum (■ Fig. 9.2) and detachment of the soft tissues to visualize the medial and lateral capsule (■ Fig. 9.3).



■ **Fig. 9.2** Z-shaped split of the extensor retinaculum, as a straight split is often impossible to close due to intraoperative swelling. To avoid wound complications while healing, however, it is critical to close the retinaculum. Otherwise, the extensor tendons will cause mechanical irritation and skin necrosis



■ **Fig. 9.3** The soft tissues are released to visualize the capsule medially and laterally. The joint capsule should always be left intact and not resected. Resections at the posterior joint will always cause bleeding. The joint capsule is closed and a Redon drain is placed to avoid severe hematoma formation. Otherwise, this could lead to severe anterior soft tissue swelling with tension blisters and skin necrosis

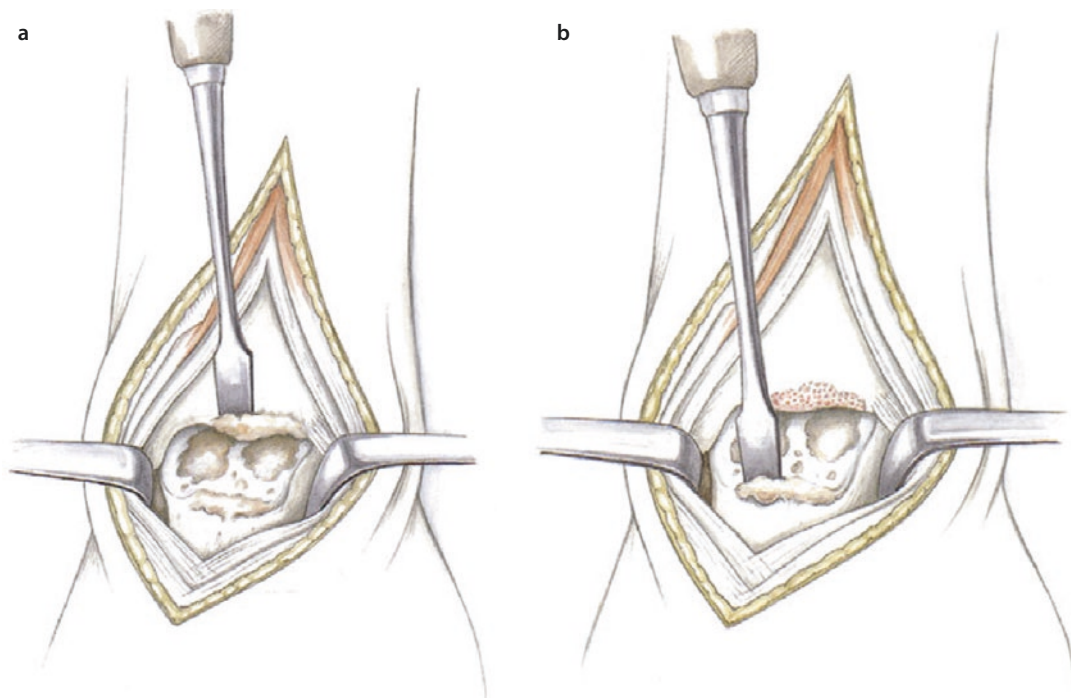


Fig. 9.4 a, b Thorough resection of osteophytes at the transition between the talar joint surface and the talar neck is essential, as the talar cut is performed at a right

ankle for most modular component prostheses. Incomplete resection will result in an insufficient cut

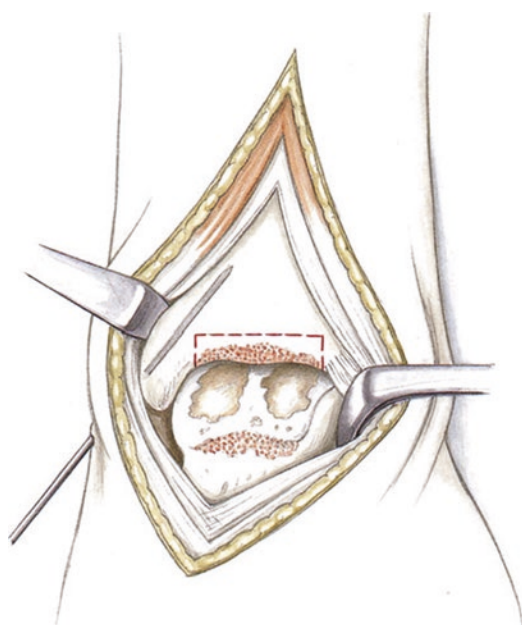


Fig. 9.5 To secure the medial malleolus, prior to making the distal tibial cut, a 1.8 mm K-wire is inserted percutaneously for temporary fixation. Resection of the posteromedial bone can result in iatrogenic fracture of the medial malleolus, even with modern resection guides

9.2.2 Osteophyte Resection

Extensive resection of the osteophytes around the talus and tibial rim to identify the appropriate resection height. This is an important initial step for all modular component systems (■ Figs. 9.4 and 9.5).

9.2.3 Soft Tissue Balancing

Soft tissue balancing is shown in ■ Fig. 9.6.

9.2.4 Soft Tissue Balancing During Prosthesis Implantation

If a decreased range of motion is noted intraoperatively or at final evaluation after implanting a three-component prosthesis, the following points should be considered:

- Decreased dorsiflexion
 - Was adequate posterior release and capsulotomy performed? Does an Achilles tendon lengthening need to be performed if the foot was in equinus prior to surgery?

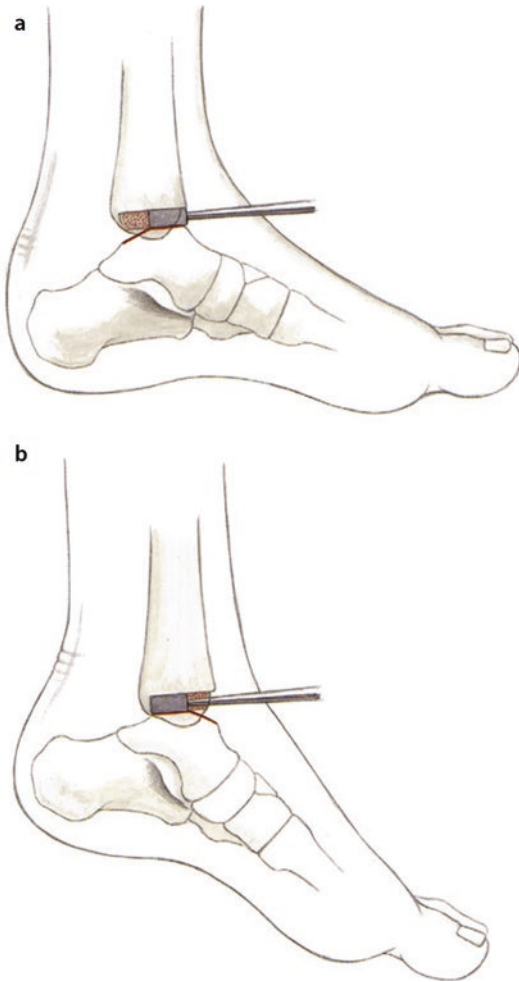


Fig. 9.6 a, b Soft tissue balancing of the dorsal extension gap. The talus is prepared with a dorsal extension resection surface and a plantar flexion resection surface in all three compartment systems. This allows the tension to be checked in each position with a spacer. **a** Measuring the dorsal extension gap with a spacer, **b** Measuring the plantar flexion gap with a spacer

- Was inadequate bone resection performed (usually at the tibial side), resulting in excessive tension on the prosthesis? Is the polyethylene insert too large, resulting in excessive tension in the ankle? Was the cut made with an anterior slope? Are the talar components too far anterior?
- Decreased plantar flexion (with adequate dorsiflexion)
 - Was the posterior talar resection inadequate? Was the prosthesis placed too far posteriorly?
 - Was an excessive posterior release of the Achilles tendon and capsule performed?

Was a larger polyethylene insert placed to stabilize this, resulting in imbalance in plantar flexion?

9.2.5 Prosthesis Implantation

Extremely sclerotic bone can cause the saw to drift, leaving incongruity at the bone-prosthesis interface. This should be carefully corrected with a rasp. In my opinion, it is a myth that the bone grows into the back of the prosthesis. Small incongruities will lead to instability and decreased shock absorption and increased impact at the bone-prosthesis interface. The bone will respond with a localized catabolic reaction, causing cyst formation. This is the result of circumscribed instability. This should be treated with component revision before so much bone is lost that arthrodesis is the only option.

In my opinion, the bone-prosthesis interface can be improved by «impregnating» the backside of the prosthesis as well as the resected bone surface with bone marrow (iliac crest, Jamshidi needle). After a «coagulation phase» of a few minutes, the coated prosthesis is inserted. Since I had done this, I have seen significantly less cyst formation in my 2 and 3 year outcomes.

9.2.6 Additional Steps

Additional steps are shown in [Fig. 9.7](#), [9.8](#), [9.9](#), [9.10](#), [9.11](#), [9.12](#), and [9.13](#).

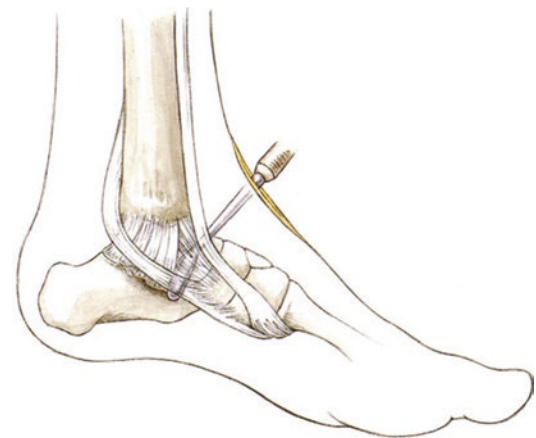


Fig. 9.7 Hindfoot varus and contracture of the medial column of the foot. This can be seen due to the increased lateral laxity and tension at the medial column of the foot. The anterior and posterior tibialis tendons are released around the deltoid ligament

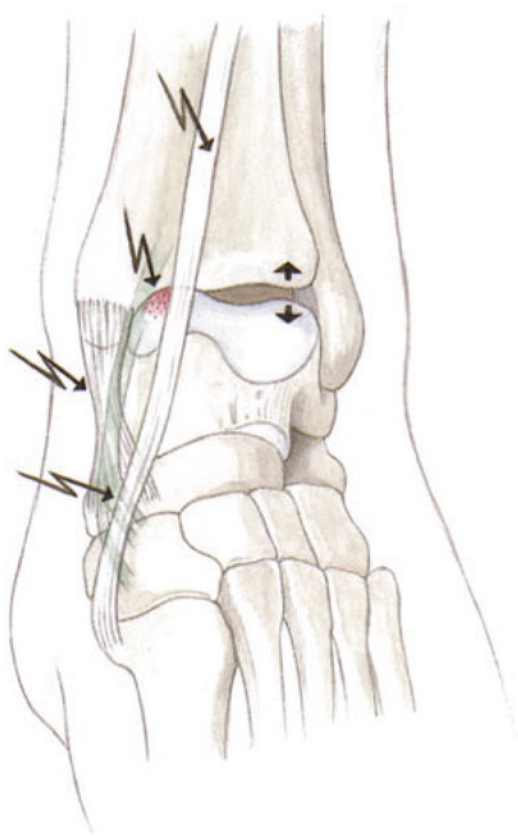


Fig. 9.8 The medial structures are detached with soft tissue release: deltoid ligament (anterior and posterior portions), tibialis anterior and posterior tendons. A small rasp or hollow osteotome are used to detach the anterior and/or posterior oblique bundles around the deltoid ligament. A longitudinal split is created and the capsule of the talonavicular joint is opened. The navicular insertions of the anterior and posterior tibial tendons are released subperiosteally, substantially decreasing the tension on the medial column of the foot. The navicular insertions of the superior naviculocalcaneal ligament (spring ligament) are released subperiosteally

9.3 Ankle Prosthesis and Transfer of the Posterior Tibialis Tendon

Cavovarus deformities with severe hindfoot deformities, talar angulation and imbalance of the midfoot and forefoot caused by weakness of the anterior tibialis and peroneal tendons cannot be balanced with arthroplasty. After several failures, my algorithm today includes a complex procedure: correction of the deformity followed by prosthesis implantation and balancing the midfoot and forefoot. In the first stage, a supramalleo-

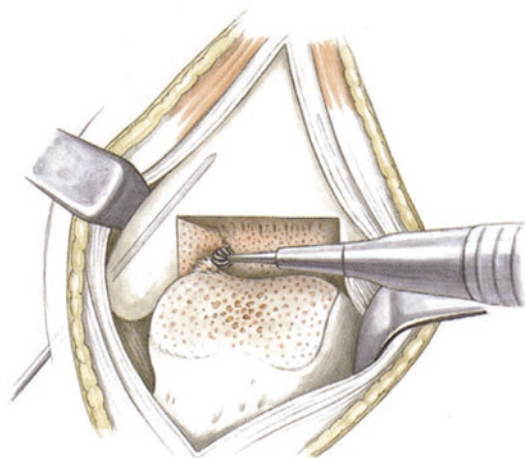


Fig. 9.9 After the horizontal osteotomy at the medial malleolus, there are often residual small posteromedial osteophytes. The prosthetic bed should be corrected with a small burr rather than an osteotome to avoid fracture to allow the tibial and, in particular, the talar trial components to be inserted without tension. If the talus is in varus or valgus, enough bone should be resected from both the medial or lateral talus and the distal tibia until an anatomic reduction is possible. If a small osteotomy is accidentally created in the medial malleolus, it should be packed with cancellous bone to avoid cyst formation

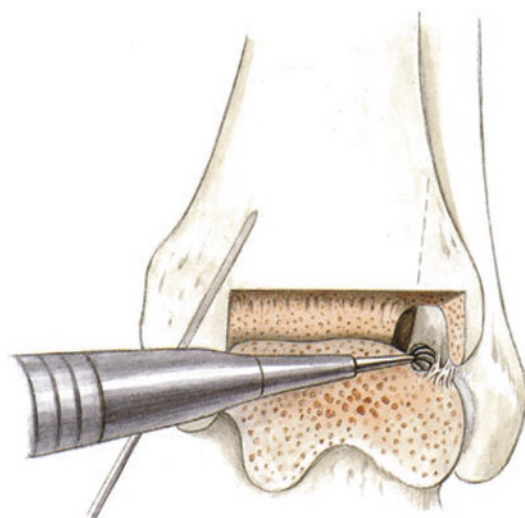
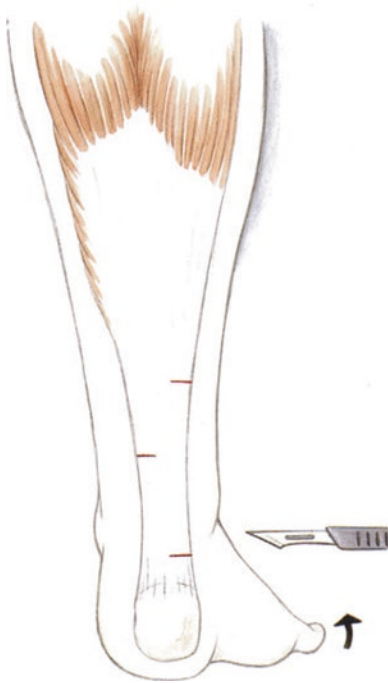
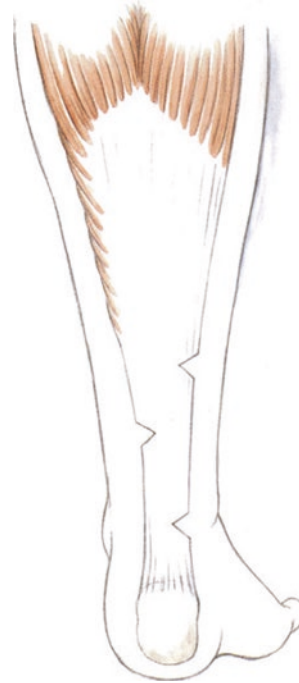
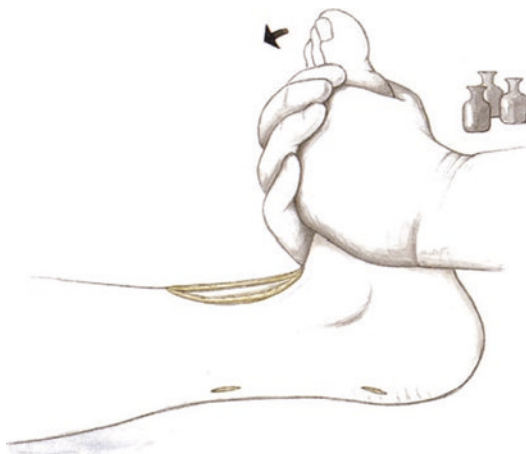Fig. 9.10 Osteophytes are most commonly found at the posterior aspect of the syndesmosis, sometimes even in contact with the fibula. The fibula is externally rotated relative to the talus, so resection of posterior bone with an osteotome is dangerous and can lead to fibula fracture. Posterior osteophytes at the talus should also be removed



■ **Fig. 9.11** Percutaneous medial Achilles tenotomy starting about 2 cm above the calcaneal incision. After a stab incision, about half of the tendon width is cut using a #11 scalpel. A second incision is made about 4–5 cm away. A lateral incision is made at the center between these two incisions. This should only be performed in selected cases, as it results in substantial loss of plantar flexion strength. The gastrocnemius slide is the gold standard



■ **Fig. 9.13** Intratendinous lengthening with V-shaped distraction at the incision sites. Dorsiflexion of 10° should always be achieved intraoperatively while the trial implants are in place



■ **Fig. 9.12** Achilles tendon lengthening at the aponeurosis with careful pressure. This can be assisted by leaning on the foot with the upper body

lar osteotomy and a lateralizing calcaneal osteotomy should always be performed.

The second stage is implantation of the prosthesis if the corrective osteotomy has not led to resolution of symptoms. The prosthesis is implanted in standard fashion as described above. Depending on the system, it may be advisable to transfer the entire posterior tibialis anteriorly, as the medial tension at the longitudinal arch is already very high with shortening or increased activity in the posterior tibial tendon. A single lateral arm may be less stable compared to combined lateral and medial arms. Because of this, split medial and lateral arms are used.

■ Indications

Unbalanced cavovarus deformity, unbalanced deformity with a supinated midfoot, imbalance and deformity of the supinated midfoot.

■ Contraindications

Uncorrectable, fixed deformity that cannot be corrected with a soft tissue procedure. Neuropathic feet, general medical contraindications.

■ Surgical setup

Standard setup for ankle arthroplasty. Tendon stripper for the posterior tibialis tendon. Stable Overhold clamps for tunneling the tendon through the syndesmosis. Suture anchor, Corkscrew (5.0) for lateral fixation at the cuneiform and cuboid and medial fixation at the anterior tibialis tendon. This can also be woven together if adequate stability is present using a Pulvertaft technique. The position is checked with fluoroscopy.

■ Positioning

Lateral wedge, medial post to allow the ankle to be ranged in two planes. Padding below both extremities to protect the nerves.

■ Technique

The tendon is pulled anteriorly through the syndesmosis using a stab incision. The tendon is then spread and dissected into two arms. A medial arm is attached to the tibialis anterior tendon and a lateral arm is attached to the lateral cuneiform or the cuboid. To augment this and to create a teno-

desis effect in pronation, the peroneus brevis tendon is transferred through the fibula onto the lateral arm of the tendon transfer. This should be done using a Corkscrew anchor for fixation at the insertion in 0° flexion and slight pronation. Final fixation of the tendon transfer is not performed until the prosthesis has been completely implanted and the retinaculum has been closed. The two arms of the transfer are then fixed. The arms of the tendon should be pulled under the fascia. The proximal skin should be closed prior to tensioning the tendon transfer or it may not be possible.

■ Aftercare

Two weeks of casting followed by a CDS splint, as a gastrocnemius slide is usually performed. Without dynamic splinting, scar tissue will form in dorsiflexion. Plantar flexion is avoided with the CDS splint. After the tendon transfer has healed at 6 weeks, sagittal range of motion is performed with full weight-bearing as limited by pain. ACP (PRP) is injected into the insertion site of the tendon transfer.

Aftercare Protocols

Aftercare protocols are described in ■ Tables 10.1, 10.2, 10.3, 10.4, 10.5, 10.6, 10.7, 10.8, 10.9, and 10.10.

Table 10.1 Ankle arthroscopy

	Weight-bearing	Physical therapy	Physical treatments	Electro-stimulation	Lymphatic drainage massage	Ice/heat	CPM	Medical training therapy
Postoperative time point			Massage					
Day 1–4	Partial weight-bearing (15 kg) and passive mobilization in dorsiflexion and plantar flexion Elevation of the leg			X	X 3–5x if swelling occurs in the foot	CryoCuff for several hours each day	Active As limited by pain	Passive As limited by pain
After day 4		Active motion in dorsiflexion and plantar flexion		X	X 3–5x if swelling occurs in the foot			Isometric strengthening
Starting week 4	Progressive weight-bearing as tolerated (if pain and swelling persists, partial weight-bearing at 30 kg for an additional 2 weeks)	Active and passive range of motion exercises in inversion and eversion						Independent isometric training of the entire muscle chain Coordination and proprioception training Isokinetic training Medical training therapy

■ **Table 10.2** Achilles tendon rupture, operative

				Physical treatments					CPM	Medical training therapy
Postoperative time point	Weight-bearing	Physical therapy	Massage	Electrostimulation	Lymphatic drainage massage	Ice/heat	Active	Passive		
Starting at day 1	Weight-bearing as limited by pain in a special shoe (heel wedge is decreased from 2 to 1 cm after day 3)	Active-assisted plantar flexion and careful dorsiflexion Proprioceptive neuromuscular training Manual therapy		X muscle stimulation in prone position. The dorsum of the foot is placed against the bench. 3–5× (ultrasound 1 MHz)	X 3–5× if swelling occurs in the foot	X CryoCuff system	X	X	Training of adjacent muscle groups Training of contralateral muscle groups (crossing effect)	
Starting at week 3	Weight-bearing as tolerated in a special shoe	Ankle exercises in extension and flexion against controlled resistance Underarm crutches are used as long as a limp is present							Freestyle swimming Water jogging	
Starting at week 8	Removal of the plastic splint for all-day wear of the special shoe A custom shoe is worn with an elevated heel (about 1.5 cm) when ultrasound shows a normal course of healing	Continued physical therapy, manual therapy							Coordination and proprioceptive training Controlled strength training Closed chain exercises Starting at about week 9: Initiate sport-specific training Starting at about week 12: Running training after ultrasound exam. Training is started on a treadmill at first and advanced prior to running on normal surfaces Starting at about month 5: Initiate jumping and cutting sports	

■ **Table 10.4** Achilles tendon, conservative

			Physical treatments	Electrostimulation	Lymphatic drainage massage	Ice/heat	CPM	Medical training therapy
Postoperative time point	Weight-bearing	Physical therapy	Massage	Electrostimulation	Lymphatic drainage massage	Ice/heat	Active	Medical training therapy
Starting on day 1	Weight-bearing as tolerated	Slight gait modification (turn heels) Discuss shoe wear with physician/therapist Shoe worn at all times up to and including week 4 Remove shoe only for exercises after week 4 Caution: Position the foot in plantar flexion for all treatments. Full function of the 1st MTP joint, the ankle and the tarsal joints Trigger point treatments in the symptomatic area	X Legs and back 0–3x	X Muscle stimulation in a prone position with the dorsum of the foot against the table, 3–5x (ultrasound 1 MHz)	X 3–5x if swelling occurs in the foot	X Ice for pain control, 3–5x	///	Training objective: All musculature of the affected side (no calf strengthening) Stationary bicycle with heel contact Leg press training after week 4–6 with heel contact Coordination and proprioception training in a Vario-Stabil shoe
Starting week 8	Weight-bearing as limited by pain	Dorsiflexion stretching at the ankle with a flexed knee		X Muscle stimulation and ultrasound at the site of scar tissue, 3–5x		X Ice/heat 3–5x		Treadmill training (without incline) High-intensity training of the affected extremity Initiate strength training of the calf when the tendon has healed on ultrasound
Starting week 12		Continue to wear 1 cm heel inserts after training is complete for about 6 months Evaluate the function of all adjacent regions: Knee, hips, SI joint, lumbar spine If possible, eliminate factors that could contribute to re-rupture						Routine and sport-specific training until return to sport is possible (usually after 14–16 weeks) Proprioception training on an unstable surface Running is gradually advanced on a treadmill prior to running on normal surfaces Isokinetic testing of the calf muscles

Table 10.5 Ankle arthroplasty

			Physical therapy	Physical treatments	Electrostimulation	Lymphatic drainage massage	Ice/heat	CPM	Medical training therapy
Postoperative time point	Weight-bearing		Physical therapy	Massage	Electrostimulation	Lymphatic drainage massage	Ice/heat	Active	Passive
Up to and including postoperative day 1	L and U splint in neutral position, non-adherent dressing, elevation of the leg with the knee slightly flexed to relax the calf muscles Partial weight-bearing (15 kg) up to and including week 6 for ankle arthroplasty Redon drain left in place								
Up to and including day 2	Redon drain is removed Continue padded dressing Place a CDS splint and allow for motion in the pain-free range								
Up to and including week 1	Progressively increase the tension on the CDS splint as limited by pain and swelling (maximum tension in 0° joint position is achieved after about a week)	Start gait training Passive range of motion only in dorsiflexion (plantar flexion can lead to skin irritation) Careful mobilization of the extensor tendons without a CDS splint							

(continued)

Table 10.5 (continued)

		Physical treatments			CPM	Medical training therapy
After week 2	Switch the CDS splint to 15° joint position If the CDS splint is tolerated with no problems, switch the joint position to 30° Splint is worn day and night	Advance mobility, flexibility, gliding and neural control Careful manual joint distraction if soft tissues are stable Passive dorsiflexion and plantar flexion	X 3–5× if swelling occurs in the foot			Start gentle and controlled strengthening with and without equipment High-intensity weight-training on the contralateral side with equipment
After week 4		Continue the above physical therapy treatments	X 3–5× if swelling occurs in the foot			Start proprioception and coordination training When soft tissues are healed, initiate water jogging and range of motion exercises in water
After week 6	Begin walking without the CDS splint if possible	Continue to advance range of motion and continue to work on mobility, flexibility, gliding and neural control Forced passive stretching in dorsiflexion and plantar flexion with manual techniques Soft tissue techniques at the scar site (particularly if extensor tendon adhesions are present)				If mobility is good and soft tissues are healed, initiate training on a step machine and an elliptical Gradually advance weight-bearing based on pain and swelling Padded shoe with shock-absorbing heels

<p>4–12 months</p>	<p>Proprioceptive neuromuscular training Manual strengthening of hip, gluteal, thigh and calf muscles Fine tuning of gait Continue to mobilize all joints of the foot and toes that could interfere with gait if stiff</p>		<p>Progressively increase activity based on pain and swelling Device-based strengthening of the hip, gluteal, thigh and calf muscles Advance aerobic and strength endurance Increase intensity of coordination training (unstable surfaces, increase dynamic exercises and strength endurance)</p>
--------------------	--	--	--

Table 10.6 Forefoot: Hallux and hammer toes

Postoperative time point	Weight-bearing	Physical therapy	Physical treatments	Electro-stimulation	Lymphatic drainage massage	Ice/heat	CPM	Medical training therapy
Day 1	15 kg partial weight-bearing Dressing change	Physical therapy	Massage				Active	Passive
Day 2	15 kg partial weight-bearing Dressing change Redon drain removed	Mobilization at the ankle and subtalar joints Dorsiflexion and plantar flexion at the MTP joint after osteotomy fixation Ensure full range of motion of the other toes			X 3–5x if swelling occurs in the foot	CryoCuff		
Day 3 to week 4	Fit patient with a forefoot-unloading shoe The shoe is worn at all times with weight-bearing as tolerated	Mobilization at the ankle and subtalar joints Dorsiflexion and plantar flexion at the MTP joint after osteotomy fixation Ensure full range of motion of the other toes Gait training Progressively advance activity			X 3–5x if swelling occurs in the foot			Independent isometric exercises of all leg muscles Upper body and contralateral extremity training

<p>After week 5</p>	<p>Soft shoes with comfortable toe box</p>	<p>Mobilization at the ankle and subtalar joints Plantar flexion at the MTP joints (2–5) with extension at the PIP and DIP joints after hammertoe surgery Dorsiflexion and plantar flexion at the MTP joint after osteotomy fixation Ensure full range of motion of the other toes Gait training Progressively advance activity</p>	<p>Moist heat to stretch scar tissue</p>	<p>Start or intensify medical training therapy based on soft tissue conditions and wound healing Sport-specific training depending on pain and swelling</p>
<p>After week 8</p>	<p>Forced manual therapy at the MTP and PIP joint and scar mobilization Plantar flexion at the MTP joints (2–5) with extension at the PIP and DIP joints after hammertoe surgery</p>	<p>Start or intensify medical training therapy based on soft tissue conditions and wound healing Resume sports when pain and swelling allows</p>		

Table 10.8 AMIC procedure at the ankle joint

Postoperative time point	Weight-bearing	Physical therapy	Physical treatments	Electrostimulation	Lymphatic drainage massage	Ice/heat	CPM	Medical training therapy
Day 1–4		Mobilization of the hip and knee	Massage	X	X	Multiple hours a day to reduce swelling	X	Passive
Day 4 to week 6	Partial weight-bearing (15 kg)	Active and passive range of motion for dorsiflexion and plantar flexion Elevation of the leg		X	3–5x if swelling occurs in the foot	Multiple hours a day to reduce swelling	As limited by pain	Week 1: 10°-0°-10°, then gradually increase range of motion as limited by pain
6–8 weeks	Partial weight-bearing (30 kg)							Range of motion exercises as limited by pain
Week 8 to month 6	Weight-bearing as tolerated, cycling, swimming Jogging, soccer and impact sports should be avoided	Calf stretching						Isometric exercises Proprioceptive training Foot extensor strengthening
Weeks 2, 4 and 6	ACP injections							

Table 10.10 Minimally-invasive Chevron osteotomy

Day 1	Plaster splint
Day 2	<p>Dressing change, radiographs</p> <p>Fit patient with a flat forefoot-unloading shoe</p> <p>Lymphatic drainage massage 3–4× per week</p> <p>Elevate the foot and apply ice several times a day</p> <p>Passive mobilization of the MTP joint while holding the first metatarsal between the thumb and index finger</p> <p>Gait training, weight-bearing as tolerated in the shoe</p>
Week 2–4	<p>Remove sutures</p> <p>Lymphatic drainage massage 3–4× per week</p> <p>Elevate the foot and apply ice several times a day</p> <p>Passive mobilization of the MTP joint while holding the first metatarsal between the thumb and index finger</p> <p>Gait training, weight-bearing as tolerated in the shoe</p> <p>Proprioceptive training in the shoe</p>
Week 4–6	<p>Remove the K-wire after radiographs</p> <p>Continue proprioceptive and stabilization training</p>
After 6 weeks	<p>Home exercise program:</p> <ul style="list-style-type: none"> – Abduct the great toe – Toe gripping exercises – Increase loads through the great toe <p>Foot muscle strengthening starting week 10</p>

Supplementary Information

Index – 155

Index

A

- Abductor hallucis muscle 28
- Achilles tendinopathy
 - endoscopic procedure 2, 18, 19, 37
 - open technique 15–18
- Achilles tendon 36, 133, 142
 - aftercare 2, 4, 7, 9, 15, 21, 23–28, 34, 38, 48, 56, 57, 91–93, 131, 136, 138
 - defect 2, 28, 32–36, 56, 87, 95
 - infection 28, 32–36
 - insertion 39
 - lengthening 130, 132, 135
 - re-rupture 2, 23, 28
- Achilles tendon lengthening 90, 91, 93
- Achilles tendon rupture 2, 140
 - acute 3–9, 23
 - aftercare 2, 7, 15, 23
 - chronic 2, 9, 18, 21–28
 - flexor hallucis longus transfer 28
- Adductor hallucis muscle 123
- Akin osteotomy 125–127
- AMIC procedure
 - for hallux rigidus 77–76
 - hindfoot deformity 92
 - for osteochondral lesions 50, 77
 - for osteochondritis dissecans 48–57
- Arthritis
 - ankle 58, 88, 89
 - MTP joint 77
 - subtalar 84, 92
- Arthrodesis
 - ankle 58–60, 70
 - subtalar 68
- Arthroplasty, aftercare 130
- Arthroscopic calcaneus plasty 38
- Arthroscopy, aftercare 48, 57, 63, 67
- Augmentation peripheral suture 4
- Autologous conditioned plasma (ACP) 14, 20–23, 34, 36–38, 42–44, 51, 56, 62, 89, 92, 97, 131, 136

B

- Bone marrow aspirate 52–54, 69, 77, 79, 89, 130
- Broström procedure 42
- Broström technique 44
- Bunnell technique 13
- Bursitis 36, 38

C

- Calcaneal lengthening osteotomy 94–100
- Calcaneal tuberosity 4, 36, 39, 99

- Calcaneoplasty, arthroscopic 52, 79, 80
- Calcaneus osteotomy 37
 - varus-producing 97, 98
- Calf atrophy 11
- Cavovarus deformity 118, 135
- Cavovarus foot 84, 87, 92, 100
- CDS brace 93
- Chevron osteotomy 122–126, 128, 151
 - modified 126–128
- Chronic ruptures 34
- Closing wedge osteotomy 89–91, 97, 115, 148
- Cortisone use, continuous 110, 118
- CPM machine 49, 56, 57, 63, 68, 74
- Cysts, periprosthetic 130

D

- Dome osteotomy 92, 97
- Double turnaround flap technique 2, 28, 36–38

E

- Extensor digitorum tendons 120
- Extensor tendons 116, 118, 121, 124, 125, 131, 143

F

- FiberTape 4, 5, 10, 23, 34, 42, 43
- FiberWire 33, 34, 42, 119, 120
- Fibrin glue 2, 18, 21–23, 51, 54–56, 77, 79, 88
- Flexor digitorum longus tendon 117, 118
- Flexor hallucis longus muscle 28–30, 60, 61, 63, 68
- Flexor muscle chain, stretching 21, 36, 38, 57, 63, 71

G

- Gastrocnemius muscle 48
- Gastrocnemius slide 55, 87, 89, 93, 135, 136
- Gastrocnemius-soleus complex 10, 13, 24, 30, 34, 87

H

- Haglund exostosis 36–39
- Hallux rigidus
 - aftercare 74, 121
 - AMIC procedure 77

- arthroscopy 79
- open technique 74–77
- Hallux valgus
 - aftercare 110, 122, 125–127
 - dressing technique 127
- Hammertoe 114, 116, 118, 121
 - aftercare 120
- Hammertoes 114–116, 121, 146, 147
- Heel elevation 4, 140
- Hemostatic sponge 38, 87, 97, 130
- Hohmann procedure 115, 120–122

I

- Immunosuppression 2
- Impingement
 - anterior 57
 - os trigonum 60–62
 - posterior process 61, 62
- Insertional tendinopathy 36, 37
- Internal Brace 42, 43
- Intrinsic-plus position 114

K

- Kissing lesions 54, 55, 57, 88, 89
- Krackow stitch 31
 - Achilles tendon 4
 - flexor hallucis longus transfer 31

L

- Lace technique, Achilles tendon rupture 4–9, 15, 23, 140, 141
- Lateral ligament 44
- Ludloff osteotomy 110, 113, 114
- Lysis of adhesions
 - for kissing lesions 54–57, 63, 88, 89
 - subtalar joint 61, 63, 66–72, 93

M

- Medial plantar nerve 28
- Metatarsus primus varus 111, 113
- Microfracture
 - ankle joint 50, 57, 66, 69
 - for hallux rigidus 74
 - for osteochondral lesions 48, 49, 69
 - subtalar joint 56, 59, 66, 68, 70
- Midportion tendinopathy 18, 21, 22, 37, 38

N

- Nanofracture 53, 55, 78

O

- Opening wedge osteotomy 84, 86, 87, 89, 94, 98, 100
 - gastrocnemius slide 87, 91, 92
- Osteochondral lesions 68
- Osteochondritis dissecans 48, 49
- Osteophyte resection 132
- Osteophytes 39, 57–59, 70, 74–78, 81, 132, 134
- Osteotomy
 - biplanar 84–87
 - supramalleolar 84–97, 134, 135
 - valgus-producing/varus-producing 87, 89, 90, 92, 93, 97

P

- Periosteal flap transfer 42–45
- Peripheral augmentation stitch 34
- Peripheral suture 4
- Peroneal nerve 2, 19, 38, 48, 66
- PIP fusion 115, 116, 118, 121
- Planovalgus foot 84, 89, 94, 98, 106
- Plantar plate repair 118, 121
- Plantaris tendon 8, 17, 18, 27
 - augmentation 27
- Plantaris-gracilis tendon transfers 42

- Plantar plate repair 117–120
- Pulvertaft technique 30, 108, 136

R

- Redon drain 14, 18, 21, 23, 27, 35, 37, 38, 110, 127, 130, 131, 143, 146
 - for arthroplasty 130, 134
- Re-rupture, Achilles tendon 2, 22, 28
- Retinaculum 20, 35, 44, 45, 63, 68, 106, 108, 131, 136
- Rotational instability 42
- Rotational osteotomy 100
- Rupture, Achilles tendon 2, 6, 7, 15, 140, 141

S

- Scarf osteotomy 110, 111, 113, 126
- Semitendinosus muscle 32, 33
- Semitendinosus tendon transfer 32–36
- Short leg L splint 18, 92, 97
- Shortening tenotomy 11–15
- Short-leg walking boot 97, 148
- Single-leg toe stand 18
- Soleus muscle 7, 36
- Soleus tear 4, 6, 7

- Split tibialis anterior tendon transfer 106
- Step-off plate 103
- Stitch, percutaneous 3–6, 10, 23
- Substance defect 9, 23, 28
- Subtalar joints 55
- Sural nerve 3, 6, 9, 11, 14, 19, 21, 32, 35, 37, 52, 66, 84, 93
- Synovial entrapment 57

T

- Tenotomy 12, 14, 88, 121, 135
- Thompson test 21
- Tibialis anterior tendon transfer 106
- Tibialis posterior insufficiency 94
- Tibialis posterior tendon transfer 28, 85, 106, 108
- Triangulation 62

V

- Valgus deformity 84, 89, 125, 126
- Vario-Stabil shoe 2, 4, 7, 23, 28, 34, 141

W

- Weil osteotomy 114, 115, 118–120