

Yizhi Liu *Editor*

Pediatric Lens Diseases

 Springer

Editor

Yizhi Liu

Pediatric Lens Diseases



Editor

Yizhi Liu

State Key Laboratory of Ophthalmology, Zhongshan Ophthalmic Center,
Guangzhou, Guangdong, China

ISBN 978-981-10-2626-3 e-ISBN 978-981-10-2627-0

DOI 10.1007/978-981-10-2627-0

Library of Congress Control Number: 2016960535

© Springer Science+Business Media Singapore 2017

This work is subject to copyright. All rights are reserved by the Publisher, whether the whole or part of the material is concerned, specifically the rights of translation, reprinting, reuse of illustrations, recitation, broadcasting, reproduction on microfilms or in any other physical way, and transmission or information storage and retrieval, electronic adaptation, computer software, or by similar or dissimilar methodology now known or hereafter developed.

The use of general descriptive names, registered names, trademarks, service marks, etc. in this publication does not imply, even in the absence of a specific statement, that such names are exempt from the relevant protective laws and regulations and therefore free for general use.

The publisher, the authors and the editors are safe to assume that the advice and information in this book are believed to be true and accurate at the date of publication. Neither the publisher nor the authors or the editors give a warranty, express or implied, with respect to the material contained herein or for any errors or omissions that may have been made.

Printed on acid-free paper

This Springer imprint is published by Springer Nature

The registered company is Springer Nature Singapore Pte Ltd.
The registered company address 152 Beach Road, #22-06/08 Gateway East,
Singapore 189721, Singapore

Foreword

Because of the prevalence of adult cataract and our focus on new surgical and IOL technologies, managing the pediatric patient remains the most neglected subject in the field of cataract surgery. As a group, these cases are the most difficult to manage – presenting the triple challenge of diagnosis, surgical removal, and postoperative treatment and rehabilitation. Unfortunately, precious little attention is devoted to this topic in residency training, in print, or on the podium.

Pediatric Lens Diseases is a much needed new and comprehensive book on this important subject. It organizes and imparts the collective expertise of the dedicated pediatric cataract team at the Zhongshan Ophthalmic Center (ZOC) of Sun Yat-Sen University in Guangzhou, China. Professor Yizhi Liu is the director of ZOC – one of the top academic ophthalmology departments in China – and also the chief editor of this book. Professor Liu is widely recognized as one of the top ophthalmic surgeons in the country and has been a global leader in the field of pediatric cataract.

As the largest eye hospital in Southeast Asia, ZOC is a tertiary referral center serving an enormous population. After establishing China's first Pediatric Cataract Center in 2011, Professor Liu and his team have now treated more than 2000 pediatric cataract patients. As a result, the ZOC team is one of, if not, *the* most experienced in the world. This unique clinical database has advanced clinical training and spawned important basic and clinical research.

This impressive book on pediatric cataract is the product of this remarkable research, experience, and proficiency. Professor Liu and his colleagues have authored 27 beautifully illustrated chapters that cover every major area of pediatric lens pathology and surgery. This includes some of the best digital images of pediatric cataract and surgery available. This book is particularly well organized because the authors largely come from a single pediatric referral center. Their clinical approach is therefore well integrated and unified.

Thanks to the enormous effort that compiling this authoritative resource entailed, ophthalmologists worldwide can now benefit from the collective expertise of one of the best and busiest international pediatric cataract programs. I congratulate Professor Liu and his coauthors on this monumental

achievement and for sharing with us the treasure that this valuable book represents.

David F. Chang
San Francisco, California, USA

Preface

Pediatric lens diseases are the leading cause of blindness in children. They are characterized by poorly understood etiologies and widely varied clinical manifestations. Worse still, current strategies for managing these diseases remain controversial. Simply applying the treatment strategies for adult cataracts and ectopia lentis to pediatric patients without a thorough consideration of anatomical and pathophysiological differences of pediatric eyes may give rise to severe reaction to surgery and frequent complications. This may interfere with visual development and rehabilitation and lay a lifelong disease burden on the children and their family.

With the latest advances in developmental biology and pathophysiology of the lens, knowledge of pediatric lens diseases has been advanced. Technical innovations in minimally invasive cataract surgery have greatly improved the treatment outcomes of pediatric lens diseases. In this book, we summarize cutting-edge studies from around the world and emphasize, in particular, the characteristics of ocular structures and visual development in children. A vast amount of valuable clinical data, images, and videos have been collected, and the pathophysiology, perioperative management, surgical techniques and prevention and treatment of complications, as well as visual rehabilitation, are all discussed in great detail. We hope that it will bring more attention and scrutiny to this field that keeps driving the perfection of diagnosis and treatment of these blinding diseases.

Medicine is an ever-changing science with new findings and experience in diagnosis and treatment occurring on a daily basis. We have spared no effort to provide information that is comprehensive and generally consistent with the best standards at the time of publication. However, this book might still contain information that is not quite accurate or complete. We encourage and welcome pertinent criticisms and suggestions from every single reader.

Yizhi Liu

Guangzhou, Guangdong, China

Acknowledgments

This book is the product of the enormous, consistent, and coordinated efforts of the excellent team of contributors at Zhongshan Ophthalmic Center, together with the editors at Springer. We are grateful to each and every one of them for their expertise and commitment in building this valuable knowledge base for present and future ophthalmologists around the world.

I would also like to thank, in particular, Xiaojian Zhong, Philip Wall, and Zhuoling Lin, for their special contributions to this book. Dr. Zhong has devoted substantial time and energies in the editing and proof-reading of the translated English manuscripts of all 27 chapters; Mr. Wall's dedication has helped improve the text of each chapter into its present form; and Ms. Lin has collected a vast and precious archive of clinical images of pediatric lens diseases, which is indispensable for a book in pediatric ophthalmology.

China

Yizhi Liu, MD, PhD

Contents

1 Embryonic Development of the Human Lens

Yongping Li and Yungang Ding

2 Human Visual Development

Yongping Li and Yungang Ding

3 Anatomy and Physiology of the Crystalline Lens

Weirong Chen, Xuhua Tan and Xiaoyun Chen

4 Etiology of Pediatric Lens Diseases

Kaili Wu, Xiaoyun Chen and Xiaojian Zhong

5 Epidemiology of Pediatric Cataracts

Mingguang He and Meng Li

6 Classification and Morphology of Pediatric Cataracts

Weirong Chen

7 Overview of Pediatric Cataract Treatments

Xialin Liu, Xinyu Zhang and Yao Ni

8 History Taking and Specialized Examination of Lens Diseases in Children

Jingjing Chen, Haotian Lin and Weirong Chen

9 Perioperative Challenges and Solutions in the Management of Children with Cataracts

Jingjing Chen, Haotian Lin and Weirong Chen

10 General Anesthesia in Pediatric Lens Surgery

Xiaoliang Gan and Hongfeng Ling

11 Care of Pediatric Lens Surgery

Huiming Xiao

12 Pediatric Cataract Extraction

Xinyu Zhang, Lixia Luo, Qianzhong Cao, Haotian Lin and Yizhi Liu

13 Calculation and Selection of Intraocular Lens Power for Children

Danying Zheng, Yi Sun and Qianzhong Cao

14 Selection of Intraocular Lenses for Children

Haotian Lin

15 Pediatric Intraocular Lens Implantation

Haotian Lin, Xinyu Zhang and Xiaojian Zhong

16 Cataract Surgery in Children with Anomalies of the Uvea

Mingxing Wu, Weirong Chen and Zhenzhen Liu

17 Ectopia Lentis in Children

Danying Zheng and Qianzhong Cao

18 Cataract Surgery in Children with Preexisting Posterior Capsular Defects

Mingxing Wu, Zhenzhen Liu and Bo Qu

19 Surgery of Congenital Cataracts Associated with Persistent Fetal Vasculature

Xiaoyan Ding

20 Pediatric Cataract Surgery in Microphthalmic Eyes

Xinyu Zhang, Xiaojian Zhong and Xiaoyun Chen

21 Lens Trauma in Children

Zhaohui Yuan and Bingsheng Lou

22 Intraoperative Complications and Management

Xialin Liu and Yao Ni

23 Postoperative Complications and Management

Xinyu Zhang and Xiaoyun Chen

24 Prevention and Management of Pediatric Secondary Cataracts

Mingxing Wu, Zhenzhen Liu and Liangping Liu

25 Reposition, Explantation, and Exchange of Intraocular Lenses

Danying Zheng

26 Postoperative Visual Rehabilitation in Children with Lens Diseases

Daming Deng, Jinrong Li and Minbin Yu

27 Quality of Life Assessment in Children with Lens Anomalies

Weirong Chen

Appendix 1

1. Embryonic Development of the Human Lens

Yongping Li¹✉ and Yungang Ding¹

- (1) State Key Laboratory of Ophthalmology, Zhongshan Ophthalmic Center, Sun Yat-sen University, 54S Xianlie Road, Guangzhou, 510060, People's Republic of China

✉ **Yongping Li**

Email: yongpingli1961@aliyun.com

Abstract

The crystalline lens, which is derived from the surface ectoderm in contact with the optic vesicles, is the most important refractive media of the eye. The embryonic lens plays a regulatory role in the process of eye development and anterior segment formation. Any abnormality in embryonic development may lead to the occurrence of lens diseases such as congenital cataracts or even affect normal eye development. Gene transcription regulation is one of the most important factors for lens development and is involved in the whole development process. This chapter focuses on the process of embryonic lens development and its regulatory factors and also discusses the regulatory effect of the embryonic lens on eye development, which will help us understand the nature of lens diseases and explore the possibility of genetic intervention at the early stage of lens development.

The crystalline lens, an important part of the ocular refractive media, develops from the surface ectoderm immediately overlying the optic vesicle. Its development is regulated by multiple transcription factors and plays an

important role in the development of the anterior segment of the eye and even the entire eyeball. Any abnormality in the embryonic development of the lens may lead to lens disorders such as congenital cataract or even affect the normal development of the entire eyeball. Therefore, knowledge of the embryonic development of the lens can facilitate our understanding of the molecular mechanism of lens abnormalities.

1.1 Histology and Embryology of Lens Development

1.1.1 The Formation of the Lens Primordium

Originating from the surface ectoderm immediately overlying the optic vesicle, the lens starts to form at the third week of gestation due to the interactive induction between the optic vesicle and the surface ectoderm (Fig. 1.1a). The optic vesicle contacts with the overlying surface ectoderm and induces the latter to thicken to form the lens placode, which is the primordium of lens formation (Fig. 1.1b). As the cellular source of the lens placode, the surface ectodermal cells beyond the contact site also divide and proliferate rapidly. They migrate and begin to differentiate when they reach the lens placode.

If the formation of the lens placode is disturbed, lens development will be hindered, which may even lead to aphakia. Isolated aphakia is rare and it is almost concurrent with other developmental disorders of the eyeball [1]. The authors once seen a case of developmental malformation diagnosed as aphakia, which manifested as a bean-sized lump of soft tissue beneath the conjunctiva. Despite its lack of complete ocular structures, consecutive pathological sections revealed partially developed uveal tissues with an irregular arrangement, lumpy and undeveloped retina-like tissue, and lumpy smooth muscle tissue (ciliary muscle). The cornea, trabecular meshwork, iris, lens, and vitreous body were not found. Besides, irregular collagen fiber bundles, adipose tissues, and cartilage lumps were visible.

1.1.2 Development of the Lens Vesicle

Induced by optic vesicle invagination that leads to the formation of the optic cup, the center of the lens placode also invaginates and forms the lens pit (Fig. 1.1c). As the lens pit expands, its bilateral front edges contract and migrate toward the center, gradually forming a thin stalk adherent to the

surface ectoderm.

In the sixth week of gestation, the lens pit completely separates from the surface ectoderm and forms a vesiculose structure, i.e., the lens vesicle (Fig. 1.1d), which will descend into the optic cup with the further invagination of the optic vesicle. After the separation, differentiation of the lens vesicle accelerates. The cells in the anterior wall of the lens vesicle, i.e., the cells originating from the peripheral lens placode, differentiate into the anterior subcapsular epithelial layer, which remains as a monolayer epithelium throughout life. The cells in the posterior wall, originating from the central lens placode, elongate to form the primary lens fibers that protrude toward the lumen of the vesicle. The apex of these cells continues to grow forward and eventually reaches the anterior wall and transforms into primary lens fibers (Fig. 1.1e). The epithelial cells at the junction of the anterior and posterior wall of the lens vesicle will differentiate into the equatorial epithelium, which will generate secondary lens fibers throughout life (Fig. 1.2). If the development of the lens vesicle is interfered, developmental disorders of the lens will occur and manifest as various lens abnormalities.

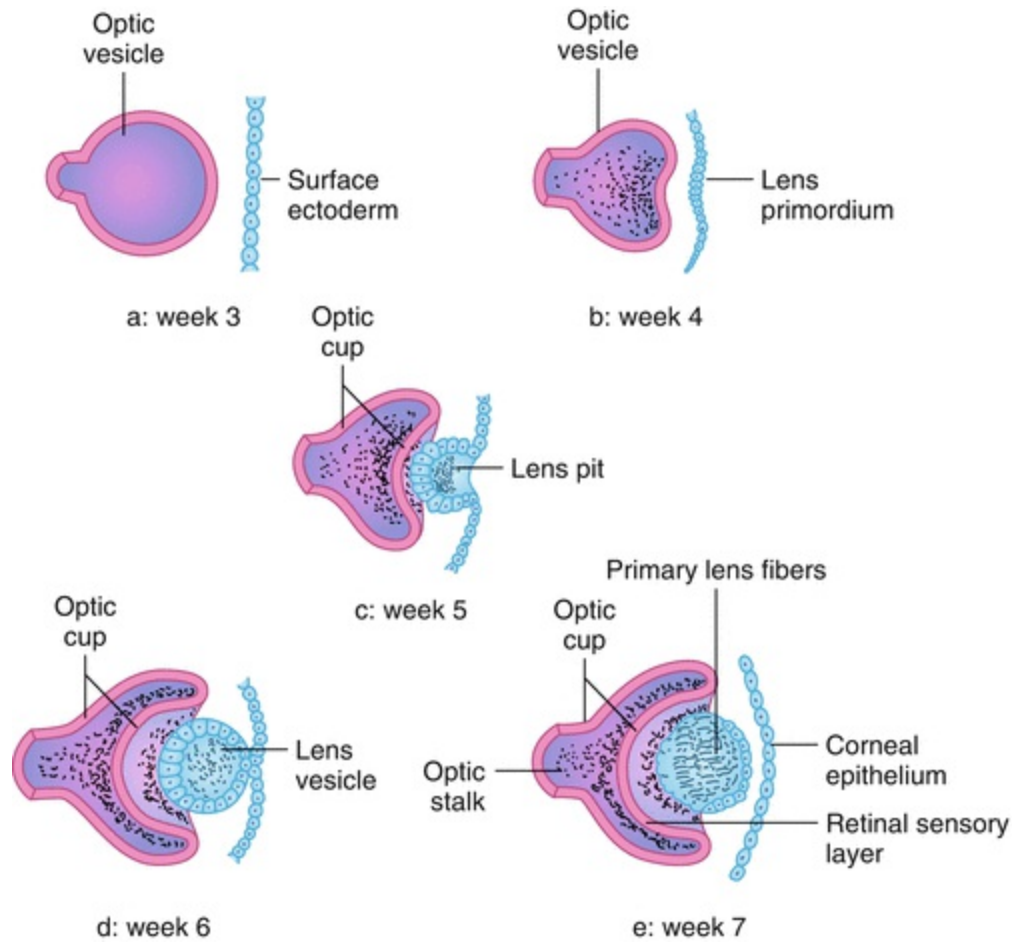


Fig. 1.1 Schematic diagrams of embryonic development of the lens. (a) The optic vesicle forms in the third week of gestation and begins to gradually make contact with the surface ectoderm. (b) The lens placode forms in the fourth week of gestation. (c) The lens placode and the optic vesicle invaginate in the fifth week of gestation. (d) The lens vesicle forms completely in the sixth week of gestation. (e) The primary lens fibers form in the seventh to eighth week of gestation

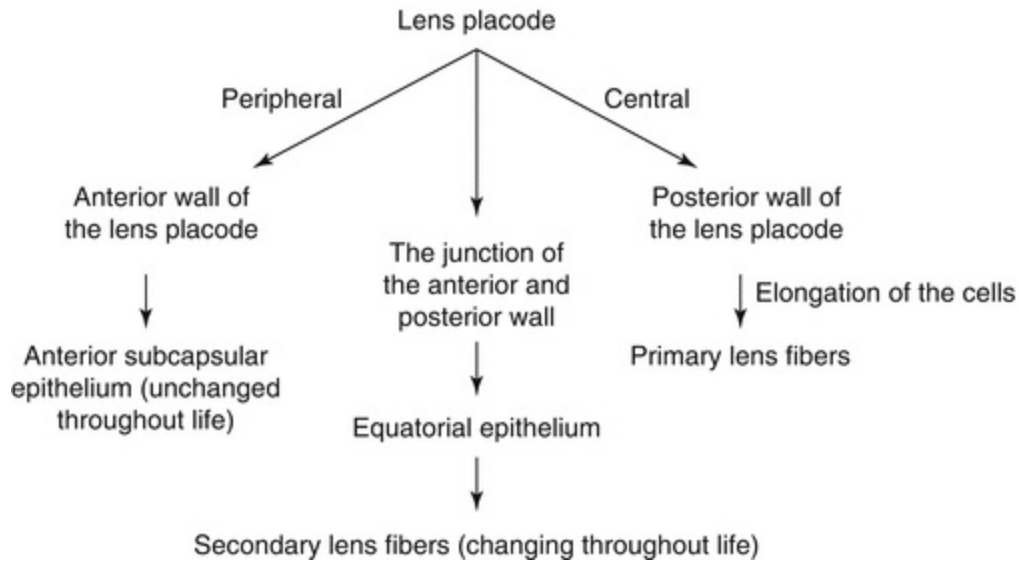


Fig. 1.2 Differentiation of the lens placode cells. The peripheral cells in the lens placode terminally differentiate into the anterior subcapsular epithelium, the central cells terminally differentiate into primary lens fibers, and the cells at the junction of the anterior and posterior wall terminally differentiate into the equatorial epithelium and form the secondary lens fibers

1.1.3 Development of Lens Epithelium

Although the mature lens develops from the same lens placode cells, the structures of its various parts are different to some extent. Beneath the anterior lens capsule is a monolayer of epithelial cells, bilateral equatorial zones are constituted by spindle-shaped cells, and there are no cells beneath the posterior lens capsule. To know the reasons for this different differentiation, we need to retrace the morphogenesis of the lens placode. The lens placode cells originate from the surface ectoderm overlying the optic vesicle, and they are the primitive stem cells of the lens. The lens placode is a monolayer of primitive cells and different parts of cells vary in morphology and size. In the lens placode, the cells approximating the center, i.e., the basement cells of the vesicle pit, show a greater level of differentiation and become columnar. The more peripheral cells, which will transform into the anterior surface cells of the lens vesicle, are round and exhibit a lower level of differentiation, as well as features of stem cells. The cells on the peripheral edges are adjacent to the corneal epithelial stem cells, and a potential association exists between the development of these two types of cells.

In the sixth to seventh week of gestation, the lens epithelial cells are visible. However, morphologically, they are not the typical monolayer cells

but pseudostratified cells with active proliferation. From the fourth month to birth, these epithelial cells remain mostly unchanged.

1.1.4 Formation of Lens Fibers

The lens fibers are divided into primary lens fibers and secondary lens fibers.

1.1.4.1 Primary Lens Fibers

After the lens vesicle separates from the surface ectoderm, the differentiation of the epithelial cells in the vesicle accelerates. The cells of the posterior wall expand and tend to be fusiform shaped. They protrude from the posterior wall toward the center of the lens vesicle, with their nuclei gradually migrating from the center to the front of the cells. Then, the cells gradually elongate and their nuclei move close to the cellular equator. During this process, the lumens in the lens vesicle are getting narrower and narrower, changing gradually from an empty sphere to an arc-filled or crescent-filled sphere. As the fusiform lens fiber cells reach the anterior subcapsular epithelium, the vesicle lumen disappears and a solid sphere comes into being. The nuclei in the elongated fiber cells gradually disappear and finally, the cells differentiate completely into fibers, which are referred to as the primary lens fibers. Thus, the primary lens fibers become the embryonic nucleus. Embryonic nuclear cataract is caused by the malformation of the front apices of the primary lens fibers in the sixth to the eighth week of gestation and manifests as small, sporadic white opacified dots in the central lens. It is less likely to affect visual acuity.

1.1.4.2 Secondary Lens Fibers

In the seventh week of gestation, the epithelial cells derived from the lens equatorial zone begin to differentiate, become spindle shaped, and migrate toward the central core of the lens vesicle. Their anterior pole grows toward the anterior subcapsular epithelium and their posterior pole toward the posterior capsule, meeting the lens fibers coming from the opposite direction at the posterior and anterior poles of the lens. These fibers lie tightly outside the primary lens fibers and encircle the latter layer by layer. The secondary lens fibers encircling the embryonic nucleus are also known as the fetal nucleus. If the lens is impaired in the third month of gestation, fetal nuclear

cataract will occur and manifest as opacity between the anterior and posterior Y sutures, which is often combined with embryonic nuclear cataract and impacts visual acuity significantly.

1.1.5 Formation of the Lens Capsule

The lens capsule is a basement membrane formed by the accumulated lamina of substances secreted by lens epithelial cells, and its components mainly include laminin, fibronectin, collagen type IV, and sulfated glycosaminoglycans [2]. In the fifth week of gestation, the homogeneous, transparent, integrated, and ultrathin capsular membrane begins to form. In the seventh week, the structure of the lens capsule is clearly visible. In the tenth week, the thickness of the anterior and posterior polar region is almost the same. In the following period, the thickness of all parts of the capsule will also increase with lens development.

1.1.6 Formation of the Lens Sutures

In the eighth week of gestation, the formation of the lens sutures begins. The lens sutures are the Y-shaped structures, derived from the equatorial secondary lens fibers ending at the specific locations of the anterior and posterior poles (Fig. 1.3). The fibers, which proceed to the fork of the Y suture at the anterior pole, extend to the apex of the Y suture at the posterior pole and vice versa. The lens fibers become tapered and flared at the ends and connect with contralateral fibers precisely. After the Y sutures are formed, the lens gradually becomes ellipsoidal. From the third trimester to after birth, the lens sutures become irregular and appear as complex branches with the growth of the lens and the elongation of lens fibers. Lens impairment in the third month of gestation may lead to sutural cataract, manifesting as opacification of the anterior and posterior sutures.

After the formation of the embryonic nucleus, the new fibers derived from lens epithelial cells at the equatorial zone encircle the previously formed lens sutures, forming a regular and layered structure. If the lens is impaired after the formation of the fetal nucleus, lamellar cataract may occur, manifesting as a white circular opacity surrounding the fetal nucleus. It is shaped like a white shell, which is concentric with the lens capsule. It is transparent within the shell, as well as the outer lens cortex. The arrangements of lens fibers at different developmental stages determine the

layered appearance of the lens. The layers of an adult lens, which can be distinguished in a slit-lamp biomicroscopic section, include embryonic nucleus, fetal nucleus, adult nucleus, and cortex (Fig. 1.3).

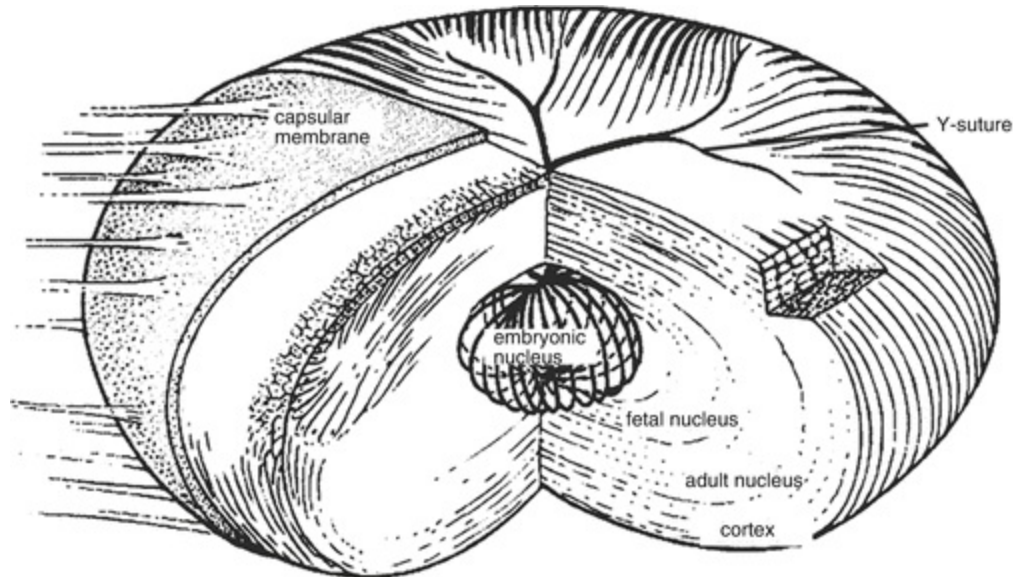


Fig. 1.3 Lens sutures and the layered lenticular structure. Y sutures are formed by lens fibers at the anterior and posterior poles of the lens. The layers of the lens from the core to the surface are embryonic nucleus, fetal nucleus, adult nucleus, cortex, and lens capsule

1.1.7 Formation of the Vascular Sheath of the Lens

Around the embryonic lens, there is a complex network of vessels, which provides nutrition for the embryonic development of the lens and is referred to as the vascular sheath of the lens. In the first month of gestation, the hyaloid artery branches into many confluent vessels, which form a vessel network that covers the entire posterior surface of the lens and is known as the posterior vascular sheath of lens. The capillaries, developing from the branches of the posterior vascular sheath, grow to the equatorial zone of the lens and anastomose with the choroidal veins, forming the capsulopupillary zone of the vascular sheath. Branches from this zone anastomose with the long posterior ciliary artery and form the anterior vascular sheath of the lens. This anastomosis of vessels is also referred to as the pupillary membrane. These vessel networks are completely developed in the ninth week of gestation and will gradually regress with fetal development and disappear by birth. If the posterior vascular sheath fails to regress completely, it will manifest as a small patch of opacity on the posterior capsule, which is known as a

Mittendorf dot. Clinically, the remnant of the anterior vascular sheath of lens can also be seen, manifesting as a remnant of linear pigmented tissue in the pupillary zone.

The lens continues to grow and develop after birth and it grows most rapidly in the first year [3–5]. Then the growth gradually slows down from 1 to 10 years old and continues after the age of 10 but in an extremely slow manner. The lens becomes approximately 0.5 mm thinner before the age of 10 and this usually happens before the age of 3. The radii of anterior and posterior surface increase by 1.0 mm and 0.2 mm, respectively. These changes may be caused by the lens being passively stretched by its equatorial growth, which flatten the lens surface curvature and eventually leads to the decrease of refractive power [6].

1.2 The Main Regulatory Factors of Lens Development

Lens development is regulated by multiple transcription factors and signaling pathways. Abnormal expression of transcription factors and the aberration of signaling pathways may lead to lens dysplasia and cataract. It is essential to study the spatiotemporal regulatory network of the lens development, which in turn will facilitate to better understand the molecular mechanism of lens disorders. Currently, several important transcription factors have been found to be involved in lens development.

1.2.1 *PAX6*

The *PAX6* gene is a highly conserved paired box gene, which acts as a “master control” regulator for ocular development. The products of *PAX6* are DNA-binding proteins and transcription factors. *PAX6* is expressed as early as in the precursor cells of the lens placode and is essential for lens placode formation [7]. *PAX6* proteins are classified within a sparse group of “master” regulatory proteins, including *BSAP/Pax5*, *Gata1*, *Gata2*, *MyoD*, *PU.1*, *Runx2*, *Sox9*, and a few others, that work at the top of genetic networks as “molecular switches” that control cell type specification and differentiation. The *PAX6* function is dosage dependent, such as haploinsufficiency. Mutation or loss of one allele in humans leads to a spectrum of eye abnormalities including lack of iris, cataract, corneal opacification, and

neovascularization, as well as optic nerve hypoplasia [8]. The first notable phenotype of *PAX6* deficiency was reduced size of the eye with progressively deteriorating eye morphology in mouse or rat. *PAX6* regulates the expressions of various transcription factors, such as *Sox2*, *Maf*, and *Prox1*, which, in turn, regulates lens fiber differentiation and lens formation [9]. During the lens fiber differentiation, *PAX6* ensures the differentiating cells exit from cell cycle, elongation, and expression of lens fiber-specific proteins, such as crystallins, and complete the lens formation. *PAX6* can also act cooperatively with transcription factors, like *Maf*, *Prox1*, *Sox2*, and *Six3*, and exert its function via other factors like *pRB* and *Mitf*. Xia and colleagues examined the expression of *PAX6* at different developmental stages of the lens in mice and found that *PAX6* was expressed on embryonic day (E12.5) and E17.5 and on days 10, 20, and 60 after birth [10]. The expression of *PAX6* was evenly expressed in lens epithelium. The results suggest that *PAX6* is not only required for lens embryonic development but also essential for the continuing lens fiber differentiation after birth. In vitro studies also confirmed that the normal expression of the *PAX6* gene was vital for the proliferation and differentiation of lens epithelial cells [11]. Furthermore, *PAX6* is essential for lens fiber regeneration after cataract surgery [12].

1.2.2 *Maf*

The *Maf* proteins are a family of transcription factors containing the basic region of bZIP (basic region-leucine zipper). Two copies of the *Maf* protein or a copy of *Maf* protein and a copy of another related protein form a dimer, which can bind to specific DNA sequences. Members of the *Maf* family include *L-Mafs*, *C-maf*, *V-maf*, *MafB*, and *NRL*. In 1998, it was discovered for the first time that *L-Maf*, a member of the *Maf* gene family, plays a key role in lens development [5]. It affects the chick α A-crystallin expression by regulating the enhancer α CE2 [13]. Later studies discovered that *C-maf* and *MafB* of the *Maf* family also participate in lens development [14–16]. In addition, studies also confirmed that the missense mutation of the *Maf* gene can cause congenital cataract [17]. Hence, the *Maf* gene family directly participates in lens development and their mutations may cause cataract. However, recent studies have also shown that for lens development, only *C-Maf* is essential, while *L-Maf* and *MafB* appear redundant [18].

1.2.3 *Sox* Family

The *Sox* family encodes a set of highly conserved transcription factors and their products share a conserved sequence of the HMG domain. At the initial stage of lens differentiation, *Sox2*, *Sox3*, and *PAX6* are expressed in the lens, regulating the expression of δ - and γ -crystallins. After δ -crystallins come into being, *Sox1* begins to be expressed at the depression of the lens placode with the expression of *Sox2/3* decreased and lost [19]. These studies indicated that *Sox2/3* are supposed to only take effect at the initial stage of lens differentiation and that it is *Sox1* that plays the key role in the whole lens development process. Furthermore, *Sox11* has also been demonstrated to be involved in ocular anterior segment development. The absence of *Sox11* results in delayed lens development in mice and consequently microphthalmia and even anterior segment dysgenesis at birth. The mechanism of its effect was via regulating BMP signaling to control early eye development [20].

1.2.4 *Six3*

Six3 is a crucial regulatory factor in vertebrate eye development, and it is a key gene that regulates lens formation in the earliest stage. During lens development in mice, *Six3* is first expressed during the formation of the neural plate, and it is also expressed in the formation of the lens vesicle and the lens. Lengler and colleagues discovered that at E14.5, expression of *Six3* in lens fibers decreased while that in the lens epithelium increased, which was similar to the expression of *PAX6*. It was hypothesized that *PAX6* might activate the expression of *Six3* [21]. However, Liu and colleagues reported that *Six3* directly activated *PAX6* expression in the early stage of mammalian lens morphogenesis, which then further activated a series of genes necessary for lens development. These results suggested *Six3* is at the top of the regulatory factor cascades initiating lens development [22].

1.2.5 *Msx2*

As a member of the muscle segment homeobox gene family, *Msx2* is expressed in both the lens placode and the mature lens. A study revealed that *Msx2* has an inhibitory effect on *Sox2* promoters [23]. In 2012, in *Msx2* knockout (KO) mice, Zhao first confirmed that the absence of *Msx2*

downregulates *FoxE3* expression, while it upregulates *Prox1* and crystallin expressions, which led to a disturbed lens cell cycle in lens vesicles and eventually caused cornea-lentoid adhesions and microphthalmia [24].

1.2.6 *BMP*

Two members of the bone morphogenetic protein (BMP) family, *BMP4* and *BMP7*, also play an important role in early lens development. Knockout of *BMP7* results in failure of formation of the lens placode and it also downregulates the expression of *PAX6* and *Sox2* [25]. *BMP4* does not affect *PAX6* expression, but it can induce the upregulated expression of *Sox2* [26].

Moreover, *Prox1*, *RAR β /RXR β* , *HSF2*, *Pitx3*, *Foxe3*, and *GATA-3* are also transcriptional regulators in lens development. They regulate lens development by balancing the effects of synergy and antagonism. Apart from transcriptional regulators, plenty of studies have demonstrated that Wnt, BMP, and FGF signaling pathways also play key regulatory effects in lens development [27–29]. Liu and colleagues also found that calmodulin participates in lens development and cataract formation through the Ca^{2+} /CaM signaling pathway [30]. The abnormality of the abovementioned factors can lead to dysplasia of the lens and cataract formation.

1.3 The Regulatory Effect of Embryonic Lens on Eyeball Development

The development of embryonic lens is regulated by various transcriptional regulators, signaling pathways, and adjacent tissues; meanwhile, the lens also sends a series of signals back to the adjacent tissues to ensure the normal development of the eyeball.

During the development of the anterior segment of the eye, neural crest-derived mesenchymal cells migrate to the space between the lens and the corneal epithelium and differentiate into the corneal endothelium and stroma, iris stroma, and trabecular meshwork. Early studies found that mechanically removing the developing lens during the early embryonic stage results in the absence of corneal endothelium, dysplasia of corneal stroma, and dysplasia or absence of iris-ciliary body and anterior chamber [31, 32]. For example, Zinn and colleagues removed the lenses in chicks at E4 and found that the corneal endothelium was not formed, while collagen fibers with irregular

arrangements and varied diameters were visible in corneal stroma and resembled those in sclera [33].

Mechanical removal of the lens may cause physical damages to the eye and interfere with eye development. To rule out that possibility, researchers investigated the role of lens on eye development by disrupting the normal lens development genetically and observed the development of other eye tissues. They discovered that ablation of lens at early stages not only affects the development of anterior segment but also the development of the posterior segment. Harrington and colleagues used lens-specific alpha A-crystallin promoter to drive the expression of diphtheria toxin to gradually ablate the lens from E12 and found that ablation of lens results in coincided retardation of development of the neuroretina, sclera, and cornea. The anterior lip of the optic cup also failed to differentiate into the normal epithelium of iris and ciliary body, the vitreous body was also not developed in the transgenic mouse [34]. Zhang and colleagues used an attenuated version of diphtheria toxin A subunit driven by a modified crystallin promoter to ablate lens during development and found multiple defects in the anterior chamber, including corneal endothelial cells did not differentiate properly and the differentiation of ciliary body and iris were terminated prematurely [35]. The Rho GTPase signal transduction pathway is essential for lens development, and C3-exoenzyme can selectively inactivate all Rho GTPase. Transgenic mice with lens-specific expression of C3-exoenzyme not only show defects in lens fiber cell differentiation and elongation, and thickened anterior capsule, but also anterior segment abnormalities, such as anterior chamber hemorrhage and iris abnormalities (iridolenticular and iridocorneal adhesions), and posterior segment abnormalities, such as vitreous hemorrhage and hypoplastic vitreous with persistent blood vessels [36]. Collectively, these results suggest that the normal lens development is essential for the development of the corneal endothelium, ciliary body, and iris as well as the development of neuroretina and vitreous.

It appears that lens is the organizer of eye development, but the mechanism remains to be elucidated. It was thought that the embryonic lens produces certain regulatory factors to facilitate the complete development of the anterior and posterior ocular segments, but the specific factors still remain to be discovered.

1.4 Summary

The development of the lens is a precisely regulated process that is controlled by concerted action of multiple factors. The proper lens development is also essential for the development of other eye tissues, such as the corneal endothelium, ciliary body, iris, and neuroretina. A better understanding of lens development process will help to advance knowledge of molecular mechanisms of lens diseases. It is promising that in the future, treatment and correction at the gene level may be achieved in the early developmental stage for prevention of development-related eye diseases.

References

1. Johnson BL, Cheng KP. Congenital aphakia: a clinicopathologic report of three cases. *J Pediatr Ophthalmol Strabismus*. 1997;34(1):35–9.
[\[PubMed\]](#)
2. Dische Z, Zelmenis G. The content and structural characteristics of the collagenous protein of rabbit lens capsules at different ages. *Invest Ophthalmol*. 1965;4:174–80.
[\[PubMed\]](#)
3. Augusteyn RC. Growth of the human eye lens. *Mol Vis*. 2007;13:252–7.
[\[PubMed\]](#)[\[PubMedCentral\]](#)
4. Augusteyn RC. On the growth and internal structure of the human lens. *Exp Eye Res*. 2010;90(6):643–54.
[\[CrossRef\]](#)[\[PubMed\]](#)[\[PubMedCentral\]](#)
5. Augusteyn RC, Nankivil D, Mohamed A, et al. Human ocular biometry. *Exp Eye Res*. 2012;102:70–5.
[\[CrossRef\]](#)[\[PubMed\]](#)
6. Mutti DO, Zadnik K, Fusaro RE, et al. Optical and structural development of the crystalline lens in childhood. *Invest Ophthalmol Vis Sci*. 1998;39(1):120–33.
[\[PubMed\]](#)
7. Cvekl A, Yang Y, Chauhan BK, et al. Regulation of gene expression by Pax6 in ocular cells: a case of tissue-preferred expression of crystallins in lens. *Int J Dev Biol*. 2004;48(8–9):829–44.
[\[CrossRef\]](#)[\[PubMed\]](#)[\[PubMedCentral\]](#)
8. Glaser T, Jepeal L, Edwards JG, et al. PAX6 gene dosage effect in a family with congenital cataracts, aniridia, anophthalmia and central nervous system defects. *Nat Genet*. 1994;7(4):463–71.
[\[CrossRef\]](#)[\[PubMed\]](#)
9. Shaham O, Smith AN, Robinson ML, et al. Pax6 is essential for lens fiber cell differentiation.

- Development. 2009;136(15):2567–78.
[CrossRef][PubMed][PubMedCentral]
10. Xia ZX, Liu YZ. Expression of Pax6 homeobox gene in lens epithelial cells in mice. *J Sun Yat-Sen Univ (Med Sci)*. 2005;26(z1):54–6.
 11. Liu YZ, Xia ZX, Liu XL, et al. Expression of Pax-6 homeobox gene in lens epithelial cells in vitro. *Zhonghua Yan Ke Za Zhi*. 2003;39(7):395–9.
[PubMed]
 12. Lin H, Ouyang H, Zhu J, et al. Lens regeneration using endogenous stem cells with gain of visual function. *Nature*. 2016;531(7594):323–8.
[CrossRef][PubMed]
 13. Ogino H, Yasuda K. Induction of lens differentiation by activation of a bZIP transcription factor, L-Maf. *Science*. 1998;280(5360):115–8.
[CrossRef][PubMed]
 14. Sakai M, Serria MS, Ikeda H, et al. Regulation of c-maf gene expression by Pax6 in cultured cells. *Nucleic Acids Res*. 2001;29(5):1228–37.
[CrossRef][PubMed][PubMedCentral]
 15. Kawauchi S, Takahashi S, Nakajima O, et al. Regulation of lens fiber cell differentiation by transcription factor c-Maf. *J Biol Chem*. 1999;274(27):19254–60.
[CrossRef][PubMed]
 16. Reza HM, Urano A, Shimada N, et al. Sequential and combinatorial roles of maf family genes define proper lens development. *Mol Vis*. 2007;13:18–30.
[PubMed][PubMedCentral]
 17. Narumi Y, Nishina S, Tokimitsu M, et al. Identification of a novel missense mutation of MAF in a Japanese family with congenital cataract by whole exome sequencing: a clinical report and review of literature. *Am J Med Genet A*. 2014;164A(5):1272–6.
[CrossRef][PubMed]
 18. Takeuchi T, Kudo T, Ogata K, et al. Neither MafA/L-Maf nor MafB is essential for lens development in mice. *Genes Cells*. 2009;14(8):941–7.
[CrossRef][PubMed]
 19. Kamachi Y, Uchikawa M, Collignon J, et al. Involvement of Sox1, 2 and 3 in the early and subsequent molecular events of lens induction. *Development*. 1998;125(13):2521–32.
[PubMed]
 20. Wurm A, Sock E, Fuchshofer R, et al. Anterior segment dysgenesis in the eyes of mice deficient for the high-mobility-group transcription factor Sox11. *Exp Eye Res*. 2008;86(6):895–907.
[CrossRef][PubMed]
 21. Lengler J, Graw J. Regulation of the human SIX3 gene promoter. *Biochem Biophys Res Commun*. 2001;287(2):372–6.
[CrossRef][PubMed]
 - 22.

- Liu W, Lagutin OV, Mende M, et al. Six3 activation of Pax6 expression is essential for mammalian lens induction and specification. *EMBO J.* 2006;25(22):5383–95.
[CrossRef][PubMed][PubMedCentral]
23. Lengler J, Bittner T, Munster D, et al. Agonistic and antagonistic action of AP2, Msx2, Pax6, Prox1 AND Six3 in the regulation of Sox2 expression. *Ophthalmic Res.* 2005;37(6):301–9.
[CrossRef][PubMed]
 24. Zhao J, Kawai K, Wang H, et al. Loss of Msx2 function down-regulates the FoxE3 expression and results in anterior segment dysgenesis resembling Peters anomaly. *Am J Pathol.* 2012;180(6):2230–9.
[CrossRef][PubMed][PubMedCentral]
 25. Faber SC, Dimanlig P, Makarenkova HP, et al. Fgf receptor signaling plays a role in lens induction. *Development.* 2001;128(22):4425–38.
[PubMed]
 26. Furuta Y, Hogan BL. BMP4 is essential for lens induction in the mouse embryo. *Genes Dev.* 1998;12(23):3764–75.
[CrossRef][PubMed][PubMedCentral]
 27. Nakayama Y, Miyake A, Nakagawa Y, et al. Fgf19 is required for zebrafish lens and retina development. *Dev Biol.* 2008;313(2):752–66.
[CrossRef][PubMed]
 28. Patthey C, Gunhaga L, Edlund T. Early development of the central and peripheral nervous systems is coordinated by Wnt and BMP signals. *PLoS One.* 2008;3(2):e1625.
[CrossRef][PubMed][PubMedCentral]
 29. Song N, Schwab KR, Patterson LT, et al. *pygopus 2* has a crucial, Wnt pathway-independent function in lens induction. *Development.* 2007;134(10):1873–85.
[CrossRef][PubMed]
 30. Wang XZ, Liu YZ, Gu XF. Effect of calmodulin on lens development and cataractogenesis in rat. *Chinese Ophthal Res.* 2004;22(3):236–9.
 31. Genis-Galvez JM. Role of the lens in the morphogenesis of the iris and cornea. *Nature.* 1966;210(5032):209–10.
[CrossRef][PubMed]
 32. Genis-Galvez JM, Maisel H. Lactic dehydrogenase isozymes: changes during lens differentiation in the chick. *Nature.* 1967;213(5073):283–5.
[CrossRef][PubMed]
 33. Zinn KM. Changes in corneal ultrastructure resulting from early lens removal in the developing chick embryo. *Invest Ophthalmol.* 1970;9(3):165–82.
[PubMed]
 34. Harrington L, Klintworth GK, Secor TE, et al. Developmental analysis of ocular morphogenesis in alpha A-crystallin/diphtheria toxin transgenic mice undergoing ablation of the lens. *Dev Biol.* 1991;148(2):508–16.

[\[CrossRef\]](#)[\[PubMed\]](#)

35. Zhang Y, Overbeek PA, Govindarajan V. Perinatal ablation of the mouse lens causes multiple anterior chamber defects. *Mol Vis.* 2007;13:2289–300.

[\[PubMed\]](#)

36. Rao V, Wawrousek E, Tamm ER, et al. Rho GTPase inactivation impairs lens growth and integrity. *Lab Invest.* 2002;82(2):231–9.

[\[CrossRef\]](#)[\[PubMed\]](#)

2. Human Visual Development

Yongping Li¹✉ and Yungang Ding¹

- (1) State Key Laboratory of Ophthalmology, Zhongshan Ophthalmic Center, Sun Yat-sen University, 54S Xianlie Road, Guangzhou, 510060, People's Republic of China

✉ **Yongping Li**

Email: yongpingli1961@aliyun.com

Abstract

Visual development, starting from the embryonic period until after birth, is a complex process in which the structures and functions of the visual system develop from an immature state to a mature one. Child's visual system still develops after birth, and pediatric lens diseases may induce visual deprivation, affect visual development, and thereby result in amblyopia. This chapter mainly addresses the development process of the visual system and visual functions as well as the influencing factors, the sensitive period of visual development and its influencing factors, and the impact of pediatric lens diseases on visual development, so as to provide a theoretical basis for decision over conservative/nonsurgical versus surgical interventions for pediatric lens diseases, determination of the timing of surgery, and postoperative rehabilitation of visual function.

As one of the important components of the nervous system, the visual system enables humans and animals to perceive the world and acquire various kinds of information by visible light. Visual development involves the complex process in which the structure and function of the visual nervous system develops progressively from embryo to birth. In broad terms, visual

development is composed of two consecutive phases, prenatal and postnatal. Based on the timeline of visual development and its associations with endogenous and exogenous stimulations, the development process may be divided into three stages: stimulus-independent stage, endogenous stimulus-dependent stage, and exogenous stimulus-dependent stage. The three stages occur in succession with partial overlaps [1].

Being an important component of the ocular refraction system, the lens is critical to the developmental and functional maturation of the visual system. The visual system in infants continues to develop after birth, during which pediatric lens disorders can cause form deprivation and interfere with visual development, resulting in the occurrence of amblyopia.

2.1 The Visual Development Process

2.1.1 The Human Visual System and Visual Formation

The human visual system is made up mainly of the retina, optic nerve, optic chiasm, optic tract, lateral geniculate body, optic radiation, and visual cortex (Fig. 2.1). The process of visual formation is extremely complicated. After refracting by the cornea and the lens, the incoming light subsequently projects itself onto the retina. After that, the retinal photoreceptors (rods and cones) start up the photoelectric switch mechanism, converting the optical information into neural signals after preliminary processing. Then neural signals go through the retinal photoreceptors, bipolar cells, ganglion cells, optic nerve, and eventually reach the visual cortex. At an intersection of optic nerve (the optic chiasma) on top of sella turcica, fibers from the nasal retina cross over to the opposite side, whereas the counterparts from the temporal side continue to run on the same side and converge into the optic tract with the decussating fibers from the contralateral eye and terminate at the lateral geniculate nucleus – the first synaptic relay site of the visual system in the brain. Neurons in the lateral geniculate body send out fibers projected in layers, of which layer I, layer IV, and layer VI receive afferent fibers of the ipsilateral eye, while layers II, III, and V receive fibers of the contralateral eye. These fibers form the optic radiation at the rear of the posterior limb of the internal capsule and terminate at the primary visual cortex, also known as the striate cortex. The human visual cortex consists of the primary visual

cortex (V1) and the extrastriate cortex (V2, V3, V4, V5). The primary visual cortex is located in Brodmann area 17, while the extrastriate cortex is in Brodmann areas 18 and 19. The visual cortex is responsible for the advanced processing of visual information that is passed successively from the primary visual cortex to the more advanced visual cortex. Eventually the visual information is sophisticatedly organized to form vision.

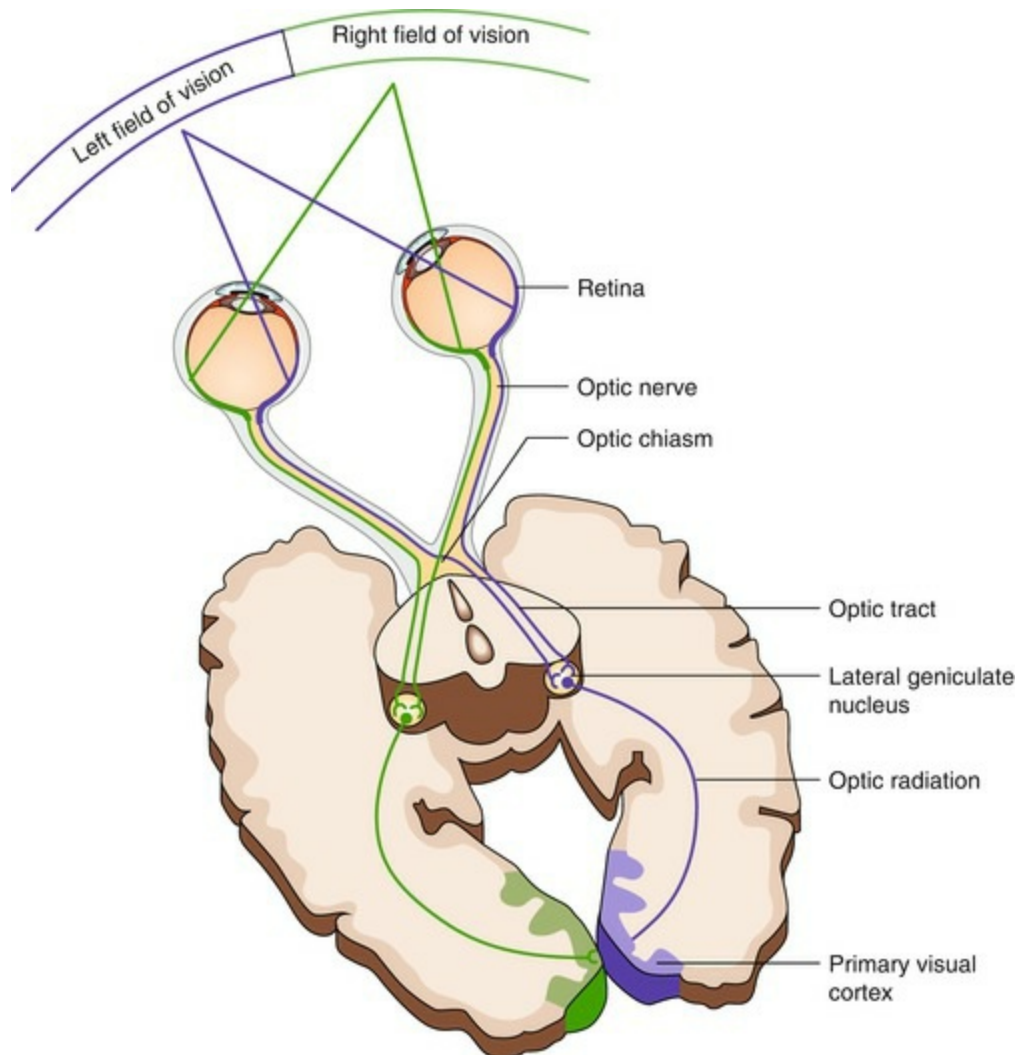


Fig. 2.1 Visual pathway. The visual pathway comprises the retina, optic nerve, optic chiasm, optic tract, lateral geniculate nucleus, optic radiation, and neurons in visual cortex

2.1.2 Prenatal Visual Development

In the prenatal (embryonic) period, the general structure of the visual system has taken shape. The generation of vision-related neurons and their functional

localization, production of neuron axons and their projection onto the targeted neurons at the next level, and decussation of nerve fibers at the optic chiasma and functional ocular columns in the visual cortex have been formed. Prenatal visual development is mainly regulated by genetic information and molecular and endogenous electrophysiological stimulation. It is the developmental stage of the topographic projections that is independent of visual experience. Based on the regulating factors and the formation of neural circuits, prenatal visual development can be divided into two stages, the stimulus-independent and the endogenous stimulus-dependent. At the stimulus-independent stage, relatively disordered connections form among neuron synapses, which depend on genetic factors. At the endogenous stimulus-dependent stage, early visual neural circuits develop after stimulus from spontaneous neuron activities, which is primarily influenced by a series of regular action potentials spontaneously generated by the ganglion cells.

2.1.2.1 Stimulus-Independent Stage of Visual Development

Mediated by inherent genetic signals instead of electrophysiological activity and visual stimulus, it is the first stage of visual development, including cell division, differentiation, migration, and early adjustment, as well as early axon growth. At this stage, early normal structures and initial synaptic connections are formed [1]. Distribution and localization of rods, cones, and bipolar cells of the retina are determined by genetic information and eye development, neither of which is dependent on electrophysiological activity and visual stimulus.

The retinal ganglion cells, neurons in the lateral geniculate nuclei and in the primary visual cortex, are far apart during early embryo development. The axons of ganglion cells and neurons in the lateral geniculate nucleus grow to their target cells under the guidance of guiding molecules to form early synaptic connections. In animal experiments, it was found that the layered structures of lateral geniculate nucleus came into being prior to the formation of photoreceptor cells. Extending out to the lateral geniculate nucleus from the retinal ganglion cells, some early axons form imprecise synaptic connections with neurons in the lateral geniculate nucleus. Then the axons of neurons in the lateral geniculate nucleus reach the visual cortex.

2.1.2.2 Endogenous Stimulus-Dependent Stage of Visual Development

Early synaptic connections based on genetic factors are imprecise. They must be refined by spontaneous endogenous stimuli. Some researchers believe that endogenous stimuli originate mainly from retinal waves [2], the spontaneous cellular action potentials in the course of retinal development found in many vertebrates. The retinal waves are formed by retinal ganglion cells spontaneously generating a series of regular action potentials at random locations, which rapidly form synchronized stimulus waves spreading to both the inner and outer retina. With stimulation by retinal waves, the neurons in the lateral geniculate nucleus migrate to their six-layered structures, respectively, and form layered and topological projection of the axons of binocular ganglion cells in the lateral geniculate nucleus. Meanwhile, similar endogenous neural activity is found in the lateral geniculate nucleus and the visual cortex, and the topological projection of the lateral geniculate nucleus onto the visual cortex has developed [3]. Stimulated by these neural activities, the early topological projection of the axons takes shape, which prepares for greater refinement induced by postnatal visual stimuli. Under the joint effects of such mechanisms as direct stimulus, stimulus competition, and neurofeedback, the development of the ocular dominance columns and orientation columns in the visual cortex becomes more refined. Furthermore, some studies put forward an argument that, in addition to retinal waves, some eye-specific molecular signals are also involved [4].

Due to inadequate research on the visual development of human embryos, most of the knowledge about human visual development is derived from studies of mammals and primates. In fact, the process of human visual development bears a striking similarity to that of such animals, particularly primates. Their differences lie mainly in functional localization, duration of visual development, and advanced functionality. Hence, although these theories of visual development are applicable to humans, these theories cannot explain accurately the development of the human visual system.

Early morphological studies investigated the spatial-temporal distribution of the development of the human embryonic visual system [5]. Soon afterward, researchers learned about the morphological features and the dynamic developmental process of the retina, lateral geniculate body, and axon projections in the visual cortex by means of applying the axon tracing

technique of DiI labeling to the human embryo [6]. In the human embryo, the nerve projection of the retina reaches the lateral geniculate nucleus at 7-week gestational age, whereas synaptic connections between the nerve fibers and the cells of the lateral geniculate nucleus form between 13 and 14 weeks of gestation. The axon tracing experiment conducted by Hevner demonstrated that the formation of the layered structures of lateral geniculate nucleus was preceded by separation of the retina, lateral geniculate nucleus, and nerve fiber terminal, and the latter is supposed to occur between 12 and 20 weeks of gestation, while the former remained hidden at 22-week gestational age. Early in fetal life, the lateral geniculate nucleus is merely a cell mass, and two big cellular layers are present at 22-week gestational age. Between 25 and 27 weeks of gestation, the six-layered structure becomes more obvious. Moreover, axons in the optic nerve reach its maximum density between 16 and 17 weeks of gestation and then gradually decrease, closing in on adult level at 29-week gestational age. The decrease of axons is probably associated with the refinement process of their projections.

2.1.3 Postnatal Visual Development

Formation of visual perception is dependent on sufficient visual stimulation, an accurate optical system, and construction of normal physiological and neural pathways. The optical and visual pathways in neonates are not well developed, and thus their visual perception is not refined. Visual development after birth involves the development of structure, physiology, and function of the visual system. Receiving visual stimuli and pattern stimuli from retinal ganglion cells, this stage is characterized with high plasticity and is equivalent to the exogenous stimulus-dependent stage after eye opening in infants. Visual environment and visual experience are of vital importance to visual development in this stage, especially during the critical period of visual development. Since the 1960s, Hubel and Wiese have made tremendous contributions to the research on visual development, with pioneering studies of the role of visual experience in visual development laid a foundation for subsequent studies [7, 8]. New techniques and equipment developed particularly in the last 20 years have provided the research on visual development in children with more conveniences.

2.1.3.1 Anatomical and Physiological Changes in

Postnatal Visual System

At birth, the structure, physiology, and function of the optic nerve have begun to take shape, but in the visual system, the retina, the lateral geniculate nucleus, and the visual cortex, in particular, are not fully developed, and the connections among them remain to be refined. Subtle alterations will occur in both the organization and neural circuits of the postnatal visual system.

Retina Development

The fastest retina development in normal term infants is in the 6 months after birth, and the retina becomes fully developed in the following 1–4 years. At birth, the structure and function of the peripheral retina is almost fully developed, and the changes after birth occur mainly at the posterior pole, especially at the macula. The retinal ganglion cell layer, inner nuclear layer, and rod cells in the macula move to the periphery to form a pit (foveola), whereas cone cells keep migrating from the periphery to the central macula, resulting in a contracting foveola. The fovea is immature at birth and becomes similar to that of adults only at 15–45 months, which is not associated with visual stimuli. Both inner and outer segments of cones keep growing slimmer and longer after birth, with the inner segments comparable to the adult shape at 15 months but the outer segments less than half the length of those in adults. At 45 months, the inner segments reach the adult size, while the outer segments achieve 50–70 % of the adult length. It is a crucial factor in the rapid enhancement of visual sensitivity after birth that the density of cones in the macula increases rapidly by central migration and the cones growing longer and thinner. Both the density and length of cones in the foveola will increase from birth to adulthood.

The Development of the Lateral Geniculate Nucleus

Projection areas of retinal neurons in each layer of the lateral geniculate nucleus continue to develop after birth. Immediately after birth, the neurons in the lateral geniculate nucleus are identifiable but not fully developed. There are numerous dendrites and dendritic spines that reach the maximum in 4-month-old infants. They are comparable to that in adults around the second year, showing that they are fully grown [9]. The anatomical and histological observations in primates revealed that the differentiation of six layers of neurons in the lateral geniculate nucleus has been completed before birth. The ventral layers, layer I and layer II, consist of magnocellular neurons, while

layers III, IV, V, and VI are composed of parvocellular neurons. After birth, parvocellular layers develop faster than magnocellular layers, reaching the adult level at the age of 1 year or so, while the development of magnocellular layers is not comparable with that of an adult until around 2 years of age. In infancy and early childhood, the spatial resolution of the lateral geniculate nucleus receiving the foveal fibers is extremely low, which can be comparable with that of an adult until 30 weeks.

The Development of the Visual Cortex

With the development of the visual function, the quantity, structure, and function of neurons in the visual cortex, as well as their synapses, may alter with circumstances, and they possess experience-dependent plasticity. There is a rapid increase of synaptic density in these neurons after birth, reaching the maximum peak at 8 months, twice as great as that at birth. With a slow decrease subsequently, the synaptic density in the visual cortex is comparable to that of an adult at 4 years. Advanced cortices develop to the adult level as late as the age of 11 [9, 10]. Increasing rapidly after birth, horizontal connections in the visual cortex form a homogeneous bundle at 7 weeks, becoming adult-type irregular projections after 8 weeks, and reach maturity by 15 months [11]. Nevertheless, a growing number of studies suggest that the function and structure in the visual cortex change through adolescence and adulthood [12–14].

Myelination

Myelination of the optic nerve progresses from the distal end to the proximal end of cells. It mainly occurs in the first 3 months after birth, and it ceases when it reaches the cribriform plate at the age of 2 years [15]. Yet the myelination of some of the visual areas of extrastriate cortex and interneurons among the cortical layers requires a longer period.

The Development of the Neural Circuit of Retina, Lateral Geniculate Nucleus, and Primary Visual Cortex Neurons

The development and maturity of the visual system involves not only the structural development of the fovea, the lateral geniculate nucleus, and the visual cortex but also the refinement of axonal connections among the retina, the lateral geniculate nucleus, and the visual cortex, as well as the changes into the primary and secondary visual areas in the visual cortex. The synaptic projection from the retina onto the lateral geniculate nucleus is complete

before birth, and it is further modified after birth under the regulation of visual stimulation. Ocular dominance columns, which pass through the visual cortex, will continue to develop, and orientation columns, in particular, are almost completely developed at this stage. Visual experience is essential to the completion of modification of the visual pathways from the retina to the visual cortex, and the different activities between binocular neurons induced by it also influence the formation of ocular dominance columns. In other words, visual neural circuits go through a more delicate modification in the presence of neuronal activities induced by visual experience stimulation, giving rise to topological synaptic connections at all levels of the visual pathways and finally becoming the fully developed visual system [2].

2.1.3.2 Development of Visual Function

Vision

Vision refers to visual acuity. Children's visual acuity changes dynamically. It is generally believed that it is almost fully developed at 5 years and relatively stable at 6 years and is similar to that of adults.

It is quite difficult to measure visual acuity in neonates and infants. Different examinations, such as subjective psychophysical examination and objective electrophysiological testing, show great discrepancy in results. Behavioral research observed that neonates develop slowly in grating acuity, reaching adult level as late as 3–5 years [16]. The study of visual evoked potential (VEP) discovered that, when amplitude is used as a grating frequency or contrast indicator, infants' vision becomes comparable to that of adults between 6 months and 1 year [17]. As for preschool children, some researchers performed assessment on the visual acuities of children aged 3–6 years with the Landolt C chart and the tumbling E game, respectively. They found that, among young children aged 3–4 years, the visual acuity measured by E chart is far better than that measured by Landolt C. But for children aged 5–6 years, there is no difference in visual acuities between the two tests, and the visual acuities are indistinguishable from those of adults [18]. Therefore, children's visual acuity test results are age specific and closely associated with testing methods as well. So particular care is required for children's visual acuity assessment.

Binocular Vision

An external object forms a single image at the binocular corresponding

retinal points and induces nerve impulses that are transmitted to the cerebral visual cortex, where two separate images can be fused into one single full image. This function is termed binocular vision or binocular single vision. Binocular visual function is divided into three levels from the basic to the advanced: simultaneous vision, sensory fusion, and stereopsis. In 1959, Hubel and Wiesel studied the interrelation of binocular vision, pointing out that the visual information converged at a very early stage [19]. In 1967, the driving cells sensitive to binocular parallax in the cat's visual cortex were first found to be at Brodmann areas 17 and 18 [20]. Banks and colleagues stated that the sensitive period of the development of binocular vision starts several months after birth, with the peak between 1 and 3 years [21]. Leguire and colleagues investigated binocular summation of visual evoked potential among normal and strabismic children aged 1–58 months and revealed that there was a rapid increase in binocular summation response between 1.5 and 3 months, with a gradual decrease subsequently at 3–58 months [22]. They believed that it was associated with the emergence of conjugate ocular movements, sensory fusion, and stereopsis [22]. Fox and colleagues measured stereoacuity by using dynamic random-dot stereogram (RDS), demonstrating that stereoacuity emerged at 3.5–6 months. The result is consistent with the rapid development of the visual system after birth [23]. In terms of the mature stage of children's development of binocular vision, there is a lack of systematic study. Romano and colleagues investigated the stereoscopic acuity of 1.5 to 13-year-old children with normal visual functions by means of the Titmus stereotest. They found that stereoacuity has been improving until the age of 9, and 40 s of arc in stereoacuity is the normal average level for children aged 9 and above [24]. Simons studied the stereo acuities of 3 to 5-year-old children and adults using the Frisby stereotest, Randot stereotest, random-dot stereogram, and TNO stereotest. He found that children's binocular visual function has not yet been fully developed by the age of 5 [25]. Walraven and colleagues tested a population of 4–18 years using TNO stereotest and random-dot stereogram. They believed that stereopsis became gradually mature under the long-term stimulation of normal visual stimuli after children's binocular vision had been established [26].

2.2 The Sensitive Period of Visual Development

2.2.1 The Sensitive Period of Visual Development

The theory of the critical period of visual development was first put forward by Hubel and Wiesel [27]. When studying monocular visual deprivation in kittens, they found that form deprivation for a certain period after birth may bring about lasting anomaly of ocular dominance columns in the visual cortex, and it may also cause lifetime amblyopia and blindness [27]. The period of time of utmost importance to the development of ocular dominance cells, in which visual stimulation could exert an extensive and long-lasting influence on the visual system, is defined as the critical period. Later studies revealed that there are no clear-cut time limits for the critical period and it is a gradually transitioning period instead. As a result, it is more often referred to as the sensitive period, and there are different sensitive periods for different visual functions [28]. It can be inferred from animal studies that the human sensitive periods of the anatomic plane at higher levels occur earlier, last longer, and end later than that at lower levels. In addition, visual experience can affect the starting and ending time of the sensitive period [29]. It is now generally believed that, starting at birth, the sensitive period of human visual development is the most plastic at 2–3 years, weakening significantly at 4–6 years, and ends at 9–12 years.

Some argue that the early stage of the sensitive period is the period of extreme sensitivity and termed it as the highly sensitive period or the critical period. Thus a distinction can be made between the two concepts of sensitive period and critical period. It is inferred from laboratory findings on studies of higher mammals and primates that the critical period of human visual development is between birth and about 3 years and the sensitive period of visual development can last from birth till 12 years. Clinical observational studies reveal that there exists a latent period at the beginning of the sensitive period. There are special cases of form deprivation since birth such as congenital cataracts. Within 6 weeks after birth, these causes remain. However, if surgery is performed within 6 weeks, no significant anomalies will show up in children's visual function. Therefore, there is a latent period prior to the beginning of the sensitive period with a length of at least 6 weeks [28].

The sensitive period of visual development also depends on different visual functions. Visual acuity in infants quickly improves from 6 months and becomes comparable to that of an adult at 4–6 years. The sensitive period of the development of the nasal visual field (NVF) falls behind that of the

temporal visual field, and it remains uncertain about when the sensitive period of visual development of the entire visual field ends. The development of eye movement is not comparable with that of an adult until the age of 6–11 years [28]. Current research suggests that there may be more than one sensitive period of visual development even for the same kind of visual function.

2.2.2 Factors Influencing Visual Development

The factors influencing visual development involve both internal and external ones. The former consists of genetic factors, neurotransmitters (e.g., dopamine, catecholamine, glutamate, tryptophan, γ -aminobutyric acid), and neurotrophic factors (e.g., neurotrophin, brain-derived neurotrophic factor (BDNF), nerve growth factor (NGF)). The external factors include perinatal factors, such as premature birth, intrauterine growth retardation (IUGR), and low birth weight. Additionally, external factors also include nutritional factors, like docosahexaenoic acid (DHA), vitamin A, calcium, zinc, copper, vitamin D, vitamin E, iron, lutein, and zeaxanthin deficiencies [30].

Visual stimuli after birth are of vital importance to visual development. It is the important factor responsible for amblyopia and the reason why early surgery is needed for cataract in children. Form deprivation may cause impaired visual development or amblyopia. Wiesel and colleagues reported that visual deprivation by suturing one eye for a week or more could lead to amblyopia or blindness of the eye during the critical period in the mammal [27]. The effects of visual deprivation are varied on different levels of vision and at different times of visual development. For instance, binocular visual deprivation exerts a far less effect than that of monocular visual deprivation [31]. Additionally, color vision experience in visual surroundings has a vital effect on the development of color vision [32, 33].

Some researchers also observed how exercises exerted influence on visual development using cats and movable robots. They all believed that active exercises can promote the development of the visual system, whereas passive body movement does not work [34, 35].

2.3 Effects of Pediatric Lens Disorders on Visual Development

Lens disorders in children are the primary cause of pediatric amblyopia and blindness. They give rise to fuzzy imaging on the retina, or, in worst cases, retinal images cannot be focused. They also retard the normal visual development in children. Monocular cataract, in particular, can cause severe amblyopia. The critical period of human visual development is roughly before age 3 years. During the sensitive period, visual stimulation is of vital importance to visual development, and lack of visual experience together with delayed treatment can lead to irreversible developmental disorders of visual function. To prevent form deprivation amblyopia from occurring, it is suggested that the diseased lens should be removed and optical correction should be made earlier.

Surgical removal of the lens as early as possible before the visual system is fully developed and timely IOL implantation will be of benefit to the regaining of transparency of refractive media, so that the retina gains access to enough visual stimulation. In addition, they allow proper refractive correction, thus blocking the development of amblyopia and promoting the development of visual function. Currently, a large number of studies have demonstrated that early removal of pediatric cataract and the implantation of IOL combined with visual training can bring about not only satisfactory visual acuity but also desired regaining of binocular visual function.

Dense congenital cataracts may cause form deprivation, and adequate corrected visual acuity (CVA) is available only by surgery. For cases with unilateral dense cataract, the best timing of surgery is within 6 weeks after birth, during which the long-term visual acuity outcomes of surgery are similar at any time point, while the surgical outcomes sharply decrease after 6 weeks [36]. Although there has been form deprivation in such children for 6 weeks since birth, postoperative treatment like occlusion therapy if performed timely, short-term visual interference does not have a significant impact on their long-term visual acuity. Therefore, it is speculated that a latent period exists prior to the critical period (sensitive period) of human visual development. For unilateral congenital cataract, this latent period is most likely within 6 weeks of birth [37]. For binocular dense congenital cataract, the latent period is within 10 weeks of birth, so cataract surgery is typically recommended before the eighth week [38]. Additionally, based on long-term follow-up for children with binocular dense congenital cataract, the dominant factor for prognosis is the age at surgery. Surgery within 3 months of birth can reduce the risk of visual loss dramatically [39].

Through clinical observation of childhood cataract, some have suggested that there are three different sensitive periods in the development of visual function, including the sensitive period for normal development of vision, the sensitive period for visual impairment, and the sensitive period for recovery [28]. The first one refers to the developmental stage of visual organs induced by visual stimuli; the second is the stage in which normal development is susceptible to damage by visual deprivation; and the third is the stage in which the visual system has the potential to recover from damage by visual deprivation. In terms of the development of visual acuity and contrast sensitivity, the first two periods can last till 5–7 years and 10 years, respectively. The third period for low spatial frequency can last on till 7 years, whereas the same period for high spatial frequency can only last till 5 years. It has also been reported that adults might partially recover from visual impairment by means of training [40, 41].

Lens surgery in children mainly aims to regain the transparency of refractive media, to restore a favorable optical system, to promote visual development, and to prevent the occurrence of deprivation amblyopia. Both related theories and clinical observations about the surgical timing of pediatric lens disorders emphasize the importance of early surgery for visual function recovery. The past decade has witnessed spectacular progress in pediatric lens surgery. However, since perplexed by postoperative complications as well as the issues of visual reconstruction, early surgery in infants remains challenging. It is believed that the outcomes of lens surgery in children, especially early surgery in infants, will become better with the improvement of surgical techniques and intraocular lens (IOL) quality, postoperative treatment for amblyopia, and further studies of pediatric eyes and visual development.

2.4 Summary

Human visual system development is a complex process which last from embryo to birth. During this process, any factors disturbing visual development, such as genetic factors, nutritional deficiency, or visual stimuli, may induce visual impairment, like amblyopia and even blindness. Pediatric lens disorder is one of the most common causes for form deprivation and amblyopia, especially in the critical period of visual development. Lens surgery can help children to regain the transparency of refractive media and

promote visual development and further to prevent deprivation amblyopia. However, pediatric lens surgery is still a challenging problem for the ophthalmologist. We will describe it in more detail in the following chapters.

References

1. Graven SN. Early visual development: implications for the neonatal intensive care unit and care. *Clin Perinatol*. 2011;38(4):671–83.
[CrossRef][PubMed]
2. Feller MB. Retinal waves are likely to instruct the formation of eye-specific retinogeniculate projections. *Neural Dev*. 2009;4:24.
[CrossRef][PubMed][PubMedCentral]
3. Ackman JB, Burbridge TJ, Crair MC. Retinal waves coordinate patterned activity throughout the developing visual system. *Nature*. 2012;490(7419):219–25.
[CrossRef][PubMed][PubMedCentral]
4. Chalupa LM. Retinal waves are unlikely to instruct the formation of eye-specific retinogeniculate projections. *Neural Dev*. 2009;4:25.
[CrossRef][PubMed][PubMedCentral]
5. Provis JM, van Driel D, Billson FA, et al. Human fetal optic nerve: overproduction and elimination of retinal axons during development. *J Comp Neurol*. 1985;238(1):92–100.
[CrossRef][PubMed]
6. Hevner RF. Development of connections in the human visual system during fetal mid-gestation: a DiI-tracing study. *J Neuropathol Exp Neurol*. 2000;59(5):385–92.
[CrossRef][PubMed]
7. Hubel DH, Wiesel TN. Receptive fields, binocular interaction and functional architecture in the cat's visual cortex. *J Physiol*. 1962;160:106–54.
[CrossRef][PubMed][PubMedCentral]
8. Hubel DH, Wiesel TN. The period of susceptibility to the physiological effects of unilateral eye closure in kittens. *J Physiol*. 1970;206(2):419–36.
[CrossRef][PubMed][PubMedCentral]
9. Garey LJ. Structural development of the visual system of man. *Hum Neurobiol*. 1984;3(2):75–80.
[PubMed]
10. Huttenlocher PR. Morphometric study of human cerebral cortex development. *Neuropsychologia*. 1990;28(6):517–27.
[CrossRef][PubMed]
11. Burkhalter A, Bernardo KL, Charles V. Development of local circuits in human visual cortex. *J Neurosci*. 1993;13(5):1916–31.
[PubMed]

12. Giedd JN, Snell JW, Lange N, et al. Quantitative magnetic resonance imaging of human brain development: ages 4–18. *Cereb Cortex*. 1996;6(4):551–60.
[CrossRef][PubMed]
13. Kovacs I, Kozma P, Feher A, et al. Late maturation of visual spatial integration in humans. *Proc Natl Acad Sci U S A*. 1999;96(21):12204–9.
[CrossRef][PubMed][PubMedCentral]
14. Sowell ER, Thompson PM, Holmes CJ, et al. In vivo evidence for post-adolescent brain maturation in frontal and striatal regions. *Nat Neurosci*. 1999;2(10):859–61.
[CrossRef][PubMed]
15. Okuda T. The development of myelin formation in the human optic nerve. *Nippon Ganka Gakkai Zasshi*. 1985;89(11):1156–65.
[PubMed]
16. Teller DY. The development of visual acuity in human and monkey infants. *Trends Neurosci*. 1981;4:21–4.
[CrossRef]
17. Sokol S. Measurement of infant visual acuity from pattern reversal evoked potentials. *Vision Res*. 1978;18(1):33–9.
[CrossRef][PubMed]
18. Lai YH, Wang HZ, Hsu HT. Development of visual acuity in preschool children as measured with Landolt C and Tumbling E charts. *J AAPOS*. 2011;15(3):251–5.
[CrossRef][PubMed]
19. Hubel DH, Wiesel TN. Receptive fields of single neurons in the cat's striate cortex. *J Physiol*. 1959;148:574–91.
[CrossRef][PubMed][PubMedCentral]
20. Barlow HB, Blakemore C, Pettigrew JD. The neural mechanism of binocular depth discrimination. *J Physiol*. 1967;193(2):327–42.
[CrossRef][PubMed][PubMedCentral]
21. Banks MS, Aslin RN, Letson RD. Sensitive period for the development of human binocular vision. *Science*. 1975;190(4215):675–7.
[CrossRef][PubMed]
22. Leguire LE, Rogers GL, Bremer DL. Visual-evoked response binocular summation in normal and strabismic infants. Defining the critical period. *Invest Ophthalmol Vis Sci*. 1991;32(1):126–33.
[PubMed]
23. Fox R, Aslin RN, Shea SL, et al. Stereopsis in human infants. *Science*. 1980;207(4428):323–4.
[CrossRef][PubMed]
24. Romano PE, Romano JA, Puklin JE. Stereoacuity development in children with normal binocular single vision. *Am J Ophthalmol*. 1975;79(6):966–71.
[CrossRef][PubMed]

25. Simons K. Stereoacuity norms in young children. *Arch Ophthalmol*. 1981;99(3):439–45.
[CrossRef][PubMed]
26. Walraven J, Janzen P. TNO stereopsis test as an aid to the prevention of amblyopia. *Ophthalmic Physiol Opt*. 1993;13(4):350–6.
[CrossRef][PubMed]
27. Wiesel TN, Hubel DH. Comparison of the effects of unilateral and bilateral eye closure on cortical unit responses in kittens. *J Neurophysiol*. 1965;28(6):1029–40.
[PubMed]
28. Lewis TL, Maurer D. Multiple sensitive periods in human visual development: evidence from visually deprived children. *Dev Psychobiol*. 2005;46(3):163–83.
[CrossRef][PubMed]
29. Daw NW. Critical periods and amblyopia. *Arch Ophthalmol*. 1998;116(4):502–5.
[CrossRef][PubMed]
30. Hammond Jr BR. Possible role for dietary lutein and zeaxanthin in visual development. *Nutr Rev*. 2008;66(12):695–702.
[CrossRef][PubMed]
31. Lewis TL, Maurer D. Effects of early pattern deprivation on visual development. *Optom Vis Sci*. 2009;86(6):640–6.
[CrossRef][PubMed]
32. Intskirveli IE, Roinishvili MO, Kezeli AR. Experience-dependent color constancy in guppies (*Poecilia reticulata*). *Neural Plast*. 2002;9(3):205–16.
[CrossRef][PubMed][PubMedCentral]
33. Sugita Y. Experience in early infancy is indispensable for color perception. *Curr Biol*. 2004;14(14):1267–71.
[CrossRef][PubMed]
34. Held R, Hein A. Movement-produced stimulation in the development of visually guided behavior. *J Comp Physiol Psychol*. 1963;56:872–6.
[CrossRef][PubMed]
35. Suzuki M, Floreano D, Di Paolo EA. The contribution of active body movement to visual development in evolutionary robots. *Neural Netw*. 2005;18(5–6):656–65.
[CrossRef][PubMed]
36. Birch EE, Stager DR. The critical period for surgical treatment of dense congenital unilateral cataract. *Invest Ophthalmol Vis Sci*. 1996;37(8):1532–8.
[PubMed]
37. Lloyd IC, Ashworth J, Biswas S, et al. Advances in the management of congenital and infantile cataract. *Eye (Lond)*. 2007;21(10):1301–9.
[CrossRef]
38. Kim DH, Kim JH, Kim SJ, et al. Long-term results of bilateral congenital cataract treated with early cataract surgery, aphakic glasses and secondary IOL implantation. *Acta Ophthalmol*.

2012;90(3):231–6.
[\[CrossRef\]](#)[\[PubMed\]](#)

39. Sjostrand J, Magnusson G, Nystrom A, et al. Stability of visual outcome from 7 years in children treated surgically for bilateral dense congenital cataracts before 37 weeks of age. *Acta Ophthalmol.* 2011;89(1):30–6.
[\[CrossRef\]](#)[\[PubMed\]](#)
40. Li RW, Ngo C, Nguyen J, et al. Video-game play induces plasticity in the visual system of adults with amblyopia. *PLoS Biol.* 2011;9(8):e1001135.
[\[CrossRef\]](#)[\[PubMed\]](#)[\[PubMedCentral\]](#)
41. Plow EB, Obretenova SN, Fregni F, et al. Comparison of visual field training for hemianopia with active versus sham transcranial direct cortical stimulation. *Neurorehabil Neural Repair.* 2012;26(6):616–26.
[\[CrossRef\]](#)[\[PubMed\]](#)

3. Anatomy and Physiology of the Crystalline Lens

Weirong Chen¹✉, Xuhua Tan¹ and Xiaoyun Chen¹

- (1) State Key Laboratory of Ophthalmology, Zhongshan Ophthalmic Center, Sun Yat-sen University, 54S Xianlie Road, Guangzhou, 510060, People's Republic of China

✉ Weirong Chen

Email: chenwrq@aliyun.com

Abstract

Understanding the anatomical structure and normal physiology of the lens is essential for understanding the pathogenesis of lens diseases. The anatomical structure of the pediatric lens is still developing after birth, including the size, weight and volume, the thickness and elasticity of the lens capsule, the density and proliferation rate of lens epithelial cells, the number of zonular fibers, the relationship between the posterior lens capsule and the anterior vitreous body, and so on. This chapter discusses how the anatomy and physiology of the lens change with age, the maintenance of lens transparency, and its associated factors, as well as the role of the lens in the refraction and accommodation of the eye, all of which will provide useful information for deciding on the appropriate therapeutic regimen for pediatric patients with lens diseases.

The crystalline lens is an important refractive media of the eye. A normal crystalline lens is flexible and transparent and has an ellipsoid, biconvex shape. The curvature of the anterior surface is less than that of the posterior

surface. The junction zone where the anterior and posterior surfaces meet is called the lens equator. The lens is suspended on the ciliary processes by the zonules at the equator and is thus fixed behind the iris and in front of the vitreous body. As the only refractive media which has an accommodative function in the eye, the lens is capable of focusing on objects at various distances, thus allowing a sharp image of the object to be formed on the retina. But the accommodative capacity decreases gradually with age, finally resulting in presbyopia.

3.1 Anatomy of the Lens

3.1.1 Morphology of the Lens

The lens grows with age in a nonlinear fashion through several specific stages. Early in its fetal development, the lens is spherical with the equatorial diameter being similar to the anterior–posterior diameter. During the late fetal period, since the equatorial diameter grows faster than the anterior–posterior diameter, so the lens takes on an ellipsoid shape. However, during infancy until puberty, the anterior–posterior diameter grows faster than the equatorial diameter, resulting in an increased anterior surface curvature and a greater refractive power, which involves in the eye emmetropization [1].

The equatorial diameter of the lens is about 6.5 mm at birth and grows fastest at 2–3 years, reaching 7.5 mm and 8.2 mm at 1 and 2 years, respectively. Thereafter, it grows slower, with an equatorial diameter of 9 mm at 15 years, and its average in adult life is about 9–10 mm. The increment change during decades of adult life is merely 1 mm [2, 3]. The anterior–posterior diameter of the lens is 4 mm at the eighth month of gestation and grows slowly after birth [4]. It changes little until the age of 20, increases at a rate of 25 μm per year after 20 years, and reaches about 5.5 mm in elderly life [1].

The weight of the lens is 65.6 ± 1.9 mg at birth and increases to 230.1 ± 3.1 mg at 60–70 years, at a rate of 1.32 mg per year (Tables 3.1 and 3.2) [6–10]. The volume of the lens is about 72 mm^3 at birth, increases to $162.9 \pm 1.8 \text{ mm}^3$ at 20–30 years of age, and grows steadily afterwards (Tables 3.1 and 3.2) [6–10].

Table 3.1 Changes in the lens weight from fetus until later years of life

--	--	--

Periods	Age	Growth rate (mg/year)
Fetus	13–39 gestational weeks	181
Newborn	0–11 months	24
Infancy to adolescence	1–10 years	2.8
Adolescence to old age	10–90 years	1.43

Reproduced with permission from Nicholas Phelps Brown et al. [5]

Table 3.2 Changes in weight and volume of the lens after birth

Age	Number of lenses	Mean weight (mg±)	Number of lenses	Mean volume (mm ³ ±)
Newborn	10	65.6 ± 1.9	–	–
1–3 months	24	92.9 ± 1.2	–	–
4–5 months	4	109.0 ± 6.1	–	–
10–11 months	2	124.5	–	–
1–10 years	1	146.8	–	–
10–20 years	6	152.8 ± 2.1	–	–
20–30 years	24	172.0 ± 2.0	21	162.9 ± 1.8
30–40 years	31	190.3 ± 1.5	22	177.3 ± 1.7
40–50 years	34	202.4 ± 1.9	23	188.1 ± 2.1
50–60 years	25	223.3 ± 2.5	22	205.4 ± 2.7
60–70 years	41	230.1 ± 3.1	32	213.0 ± 3.0
70–80 years	22	237.1 ± 3.4	21	218.3 ± 2.9
80–90 years	15	258.2 ± 2.8	15	238.7 ± 3.0

Reproduced with permission from Nicholas Phelps Brown et al. [5]

The lens has an asymmetric biconvex structure, the anterior surface curvature being less than the posterior surface curvature. The curvature radii of the anterior and posterior surfaces are about 10 mm and 6 mm, respectively, and the posterior lens surface is sometimes described as elliptic hyperboloid in shape [1]. The curvature radius of the anterior or posterior surface may vary widely across populations, but it generally decreases with age (so the curvature increases with age). As the lens grows, the anterior chamber volume decreases with age, but the posterior chamber volume changes little because the posterior pole of the lens does not tend to move backward (Figs. 3.1 and 3.2).

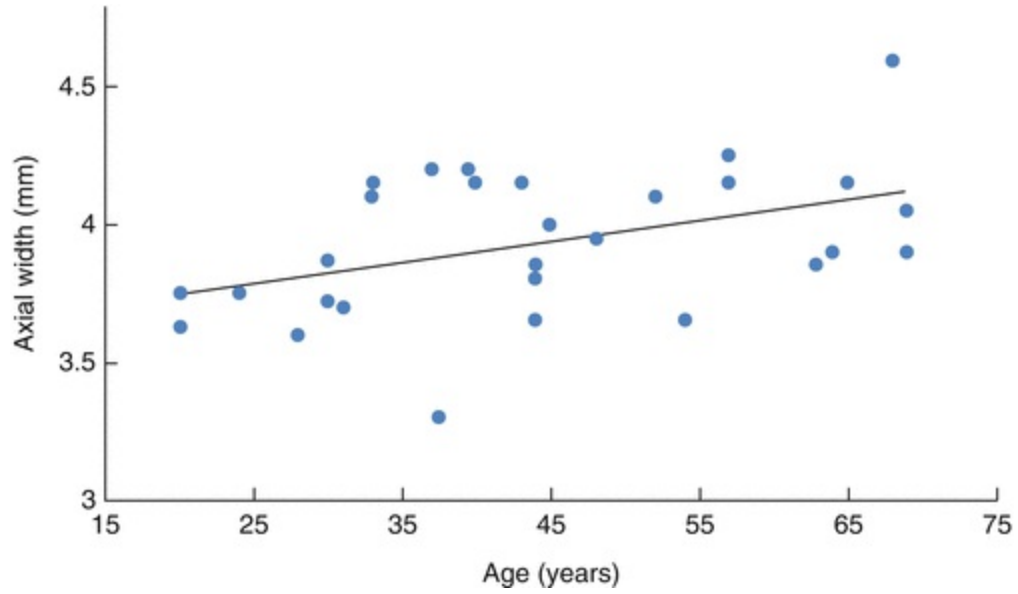


Fig. 3.1 Changes in the anterior–posterior diameter of the lens with increasing age (Reproduced with permission from Nicholas Phelps Brown et al. [5])

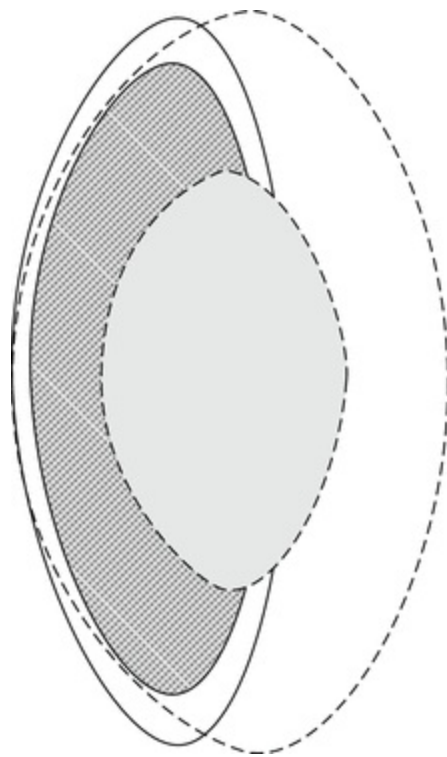


Fig. 3.2 Changes in the anterior–posterior diameter and volume of the lens with increasing age. —: at 8 years of age; -----: at 80 years of age (Reproduced with permission from Nicholas Phelps Brown et al. [5])

3.1.2 Lens Capsule

The lens capsule is in fact a transparent and elastic basement membrane that completely surrounds the lens. It is initially derived from the secretory product of the surface ectodermal cells that form the lens vesicle during embryonic development, and afterwards it is secreted by the lens epithelial cells. It is believed to be the thickest basement membrane of the body. Under light microscopy, the capsule is homogeneously positive in PAS staining; under electron microscopy, it appears to consist of up to 40 parallel layers of collagen fiber lamellae. These collagen lamellae are mainly composed of type IV collagen. Other components include type I and type III collagen, laminin, fibronectin, and sulfated glycosaminoglycan [11]. The lens capsule varies in thickness in different parts, being thickest near the equator (21–23 μm) and thinnest at the posterior pole (2–3 μm). Therefore, rupture of the lens capsule is most likely to occur at the posterior pole during cataract surgery [12]. Besides, the thickness of the anterior lens capsule increases with age, but its elasticity decreases conversely. Hence, the anterior capsule is relatively thin and elastic during childhood, posing a greater challenge to continuous curvilinear capsulorhexis (CCC) [12].

Beneath the capsule at or near the equator is the actively germinative lens epithelium. This portion of capsule is thicker than at the anterior and posterior poles, and it is also connected with the zonules. Ultrastructure studies reveal that the part of the capsule where the zonules insert has a two-layer structure. The outer layer is an extremely thin zonular layer, while the inner layer is the real lens capsule [13]. The zonular layer is where the zonules attach to the lens capsule. The collagen bundles of the zonules intertwine with the collagen fiber lamellae of the capsule, forming close attachments. The “frontier” of the zonule insertion is situated 6–7 mm from the center of the anterior capsule, and thus a capsulorhexis diameter larger than 6 mm may lead to zonule injury and lens instability, and an outward radial tear may occur at the site of capsulorhexis [13].

3.1.3 Lens Epithelium

The lens epithelium, located directly beneath the capsule at the anterior and equator of the lens, is a single-layer cuboidal epithelium. It is differentiated from cells that formed the lens vesicle during embryonic development. The cells beneath the equatorial capsule are cuboidal and rich in mitochondria,

with active proliferation and smaller volumes than cells located below the anterior capsule. This region is referred to as the germinal zone [14]. Since the embryo was 25 mm in length, the lens epithelial cells have been proliferating and differentiating into secondary lens fiber cells, which elongate and further differentiate into lens fibers. In this manner the lens maintains a lifelong growth. The total number of lens epithelial cells in a mature human lens is about 500,000, but it varies substantially among individuals. The mean cell density in male adults is 5000 cells/mm² and in female adults 5800 cells/mm², which tends to increase from the center outward to the peripheral region [15]. It is generally believed that both the average density and proliferative capacity of the lens epithelial cells decrease with age, but some insist that there is no significant correlation between age and changes in density of the lens epithelial cells [16]. After cataract surgery, migration, proliferation, and epithelial–mesenchymal transition (EMT) of the residual lens epithelial cells contribute to the pathogenesis of posterior capsular opacification (PCO) [17–19].

3.1.4 Lens Fibers

The lens fibers, derived from the lens cells, appear as long stripes and are hexagonal in cross section. The primary lens fibers of embryonic nucleus are less than 250 μm long, but their length in adults is up to 10 mm. During the formation of the lens fibers, the lens cells derived from the lens epithelium transform into long stripes with elongation of cell nuclei. The basal projections of these cells stretch along the posterior capsule toward the posterior pole, while the apical projections stretch along the anterior capsule toward the anterior pole. Subsequently, the cell nuclei migrate anteriorly with an increase in cytoskeletal structures, e.g., microtubules, microfilaments, and intermediate filaments. As the transforming lens cells extend anteriorly and posteriorly, cellular nuclei are degraded, the basal part of the cell is separated from the posterior capsule, and all organelles migrate toward the anterior or posterior ends and gradually disappear. Finally, lens cells transform into lens fibers, which keep being pushed toward the center of the lens by new cells. The rate of differentiation of lens cells into lens fibers, as well as the rate of proliferation of lens epithelial cells, decreases with age, indicating a potential interaction between them. Both processes constantly repeat, so older fibers are continuously pushed by new fibers toward the center of the lens.

The lens fibers are unable to contract. However, the entire lens has to change its curvature during accommodation. Therefore, the cortical fibers located in the mid-peripheral portion of the lens are joined tightly with one another via “ball-and-socket” junctions, which can hold the lens against the traction force from the zonules during accommodation, leading to a change in the curvature of the lens.

3.1.5 Lens Nucleus

Primary lens fibers, derived from the posterior cells of the lens vesicle during embryonic development, reach the center of the lens and form the embryonic nucleus, while secondary fibers formed during fetal life become the fetal nucleus. Junctions at the ends of lens fibers at the anterior and posterior of the lens are known as lens sutures. The suture anterior to the fetal nucleus is an upright Y and the posterior one is an inverted Y. As the lens grows and the fibers elongate, more complex lens sutures are formed, such as stellate-shaped sutures. In addition to the embryonic and fetal nuclei, the adult lens also has some other layers with different densities. These include, from inner to outer layers, the infantile nucleus consisting of lens fibers formed 1 month before birth until puberty, the adult nucleus consisting of fibers formed after puberty until adulthood, as well as the lens cortex consisting of superficial lens fibers after adulthood. As the lens epithelium continues to differentiate into lens fiber cells, the thickness of the lens cortex increases with age, while the thickness of the nucleus remains constant or even decreases. The density of the lens nucleus increases with age, adding a yellow or brown tint to the nucleus, and radial or gravel-like relief textures appear on the surface of the adult nucleus. With time, the rigidity of the nucleus progressively increases, the elasticity decreases, and its accommodative power reduces, resulting in presbyopia.

3.1.6 Zonules

The zonules, also referred to as the suspensory ligaments of the lens, arise from the pars plana of the ciliary body near ora serrata. The zonules insert at the lens capsule around the equator, cross-linking with the capsular tissue in the outer zonular layer to maintain a firm attachment. The major role of the zonules is to hold the lens in its anatomic position and enable the lens to change its shape by transmitting the tension from the ciliary body onto the

lens capsule during accommodation. In newborns, the fibers of zonules are relatively dense, but the amount of fibers decreases gradually with increasing age [20]. It is shown that the zonules are composed of a myriad of fibril bundles, with the pre- and post-equatorial bundles being thicker than the equatorial bundles [21]. Each fibril bundle, about 0.35–1.0 μm in diameter, consists of multiple microfilaments, which are 8–12 nm in diameter. Unlike the lens capsule that is made up of collagen, these microfilaments are mainly composed of fibrillin [20, 21]. Fibrillin is widely found in blood vessels and various types of connective tissue. It has been reported that fibrillin gene mutations can cause weakening of zonular fibers and subsequent subluxation or complete dislocation of the lens in Marfan's syndrome [20, 21]. Some researchers further divide the zonular fibers into major fibers and accessory fibers. Fibers running from the ciliary body to the lens are major fibers, while those short fibers running perpendicularly to the major fibers in order to support and strengthen the principal fibers are accessory fibers. Once damaged, the zonular fibers cannot be regenerated [22].

3.1.7 Relationship between the Posterior Lens Capsule and the Anterior Vitreous Body

The anterior vitreous body is in contact with the posterior lens capsule in a circular zone, approximately 9 mm in diameter, which is called Wieger's ligament. Central to this is a potential space between the lens and the anterior vitreous called Berger's space. During childhood, there is a firm attachment between the posterior capsule and the anterior surface of the vitreous, and thus the anterior hyaloid membrane is likely to be opened when the procedure of posterior capsulorhexis is performed during pediatric cataract surgery. It is suggested that after pediatric cataract surgery, the anterior vitreous body may act as a scaffold for the proliferation and migration of residual lens epithelial cells, which may contribute to the occurrence and progression of PCO [23]. Thus, for pediatric cataract surgery, posterior continuous curvilinear capsulorhexis should be combined with anterior vitrectomy, which may help to reduce the risk of PCO.

3.2 Physiological Functions of the Lens

The physiological functions of the lens are (1) refraction, the lens is an

important refractive media of the eye, acting to focus the incoming light on the retina through refraction; (2) accommodation, achieved through coordinated contraction and relaxation of zonules and ciliary muscles; and (3) ultraviolet light absorption, the lens can protect the retina from ultraviolet light damage.

3.2.1 Maintenance of Lens Transparency

Maintaining the transparency of the lens is a prerequisite for its physiological functions, and its unique anatomic and protein structures play a major role in its transparency maintenance. Ultrastructure analysis of the lens reveals that the lens capsule is composed of multiple parallel lamellae of collagen. Each lamella contains a large number of microfilaments which are composed of type IV collagen, making the capsule transparent and elastic. The lens capsule has selective permeability, which permits water, ions, and other small molecules to pass freely into the lens, while restricting the passage of large molecules such as albumins, hemoglobins, and immunoglobulins [24]. Such selective permeability also contributes to the maintenance of the transparency of the lens.

The epithelial cells beneath the lens capsule are closely attached to both the capsule and the lens fibers via tight junctions, and these cells also communicate with one another via gap junctions. These connections serve as a second barrier between the lens and the ocular environment, helping to maintain the transparency of the lens [25]. The physiological functions of the lens epithelium mainly include generation of lens fibers, secretion of bio-components of the lens capsule, and transportation of nutrients and metabolites to the lens.

The lens fibers are arranged parallel to the lens capsule in both tightly packed and highly ordered centripetal cell columns, and such arrangements make an important contribution to the lens transparency [26]. The lens fibers are rich in various crystallins and the protein content of the whole lens is up to 30–35 %. The presence of crystallins can make the lens either transparent or opacified. A tightly packed and highly ordered arrangement of a large number of protein molecules ensures the transparency of the lens, while protein denaturation or destruction of the spatial structure of proteins would result in an opacified lens [27]. During the formation of lens fibers, most organelles in the nucleus and cytoplasm disappear gradually, making the cytoplasm almost homogeneous. This unique characteristic of intracellular

ultrastructure also plays an important role in the maintenance of lens transparency [28]. As in muscle or nerve tissues, active ion exchanges are also present across the membrane of the lens fiber cells. The intracellular high-potassium and low-sodium state, as well as the extracellular low-potassium and high-sodium state, is maintained by ion pumps on the cell membrane. The electrolyte balance inside and outside the cells is crucial to maintaining the membrane potential and stability of intracellular water content. Calcium homeostasis also contributes to the transparency of the lens. Animal experiments indicate that a lowered calcium concentration outside the lens can make the cell membrane inside the lens more permeable to sodium and potassium and induce an increased inflow of sodium and outflow of potassium, as well as an increased water content of the lens, and thereby a reduction in lens transparency [29].

In addition, the absence of nerves or blood vessels in the lens tissue is another key factor in maintaining the transparency of the lens. The main source of energy for the lens is glucose in the aqueous and vitreous humors. Approximately 80 % of the glucose is metabolized via anaerobic glycolysis, producing lactic acid and ATP, while only a small fraction of the glucose is metabolized via the aerobic tricarboxylic acid cycle. Multiple enzymes and coenzymes are involved in the glucose metabolism of the lens, helping to maintain its normal growth and the transparency. Changes in the activity or content of certain key enzymes may induce metabolic disturbance of the lens and thus result in the occurrence of cataract.

3.2.2 Role of the Lens in Refraction and Accommodation

The lens, along with the cornea, constitutes the main part of the refractive system of the adult eye. The human lens is an asymmetrical biconvex structure, and the mean radii of curvature of the anterior and posterior surface are 10 mm and 6 mm, respectively. Its refractive power is correlated with the radius of surface curvature and the internal refractive index. In the reduced schematic eye, the lens is considered as a homogeneous refractive media, with a refractive power ranging from 16 to 20 D. But in fact, the human eye has a much more complex refractive state. There are well-defined layers inside the lens from the cortex to the nucleus, each with varying fiber densities and protein concentrations. Therefore, the lens is a complex

refractive media with a gradient refractive index. The refractive index in the central layers is high, while that in the peripheral layers is relatively low. Moreover, the actual refractive index of the lens is not simply the average value of all the layers. Among studies of lens refraction, the calculated refractive index of the lens differs, depending on how the refractive system of the human eye is simplified. In the reduced schematic eye of Gullstrand, the average refractive index of the lens is 1.386, whereas in the Helmholtz model, the average value is 1.473.

Among theories of accommodation of the lens, Helmholtz's theory has been widely accepted, which claims that the change in lens shape caused by the tension from the ciliary muscle is a key contributor to lens accommodation [30]. When the ciliary muscle contracts, the zonular fibers relax and the capsular tension reduces. The lens gets thicker with increased curvature and moves forward, thus increasing the refractive power of the lens. Conversely, relaxation of the ciliary muscle increases tension of the zonular fibers, flattening the lens and, thereby, decreasing the refractive its powers. As the zonules are located between the ciliary muscle and the lens, there is a misunderstanding that contraction or relaxation of the ciliary muscle would produce a direct effect on the zonules that are interlaced on the surface of the lens capsule. However, the fact is that the zonules arise from the dents between the ciliary processes rather than the surface of the ciliary processes. Thus, the effect of the tension of ciliary muscle on the zonules is probably achieved via changes in the surface tension of the whole ciliary body and the diameter of the ciliary ring. The tension transmitted from the zonules to the lens capsule finally induces changes in lens shape, contributing to the accommodative function of the eye. In conclusion, during accommodation, the transverse diameter of the lens decreases, and its thickness increases, with increased curvature of the anterior surface. At the same time, the anterior lens pole moves forward while the posterior pole moves backward, and the whole lens becomes more spherical. However, another theory, proposed by Schachar and colleagues in 1992, suggests that during accommodation, contraction of the ciliary muscle increases tension on the equatorial zonular fibers while decreasing tension on the anterior and posterior zonules. Schachar believes that the combined action would cause a flattening of the peripheral surfaces of the lens while increasing the central curvatures of both the anterior and posterior surfaces, and thus the lens equatorial diameter increases with accommodation [31]. However, the

amplitude of accommodation does not remain constant. As age advances, the lens materials become stiffer, and the capsule gets thicker and less elastic, along with a reduced zonular elasticity or even partial or complete loss of zonules. All of these factors may lead to a rapid decline of lens accommodative capacity [32]. The accommodative amplitude diminishes from about 14 D during childhood to only 11 D at age 20 years, further down to 6 D at age 40 years. At 50–60 years, there is an almost complete loss of accommodation, which finally results in presbyopia [33].

3.2.3 Ultraviolet Light Absorption

The lens absorbs most visible light in the wavelength range of 380–400 nm, and only a small amount of ultraviolet light reaches the retina. The capacity of the lens to absorb visible light increases with age, so as to protect the retina from visible light-induced damage [34].

3.3 Summary

As the only refractive media that has an accommodative function in the eye, the lens cannot only help to refract light to be focused on the retina but also alters the refractive power via contraction or relaxation of the ciliary muscles, thus allowing a clear image of objects at various distances to be formed on the retina. Therefore, lens disorders such as cataract, lens dislocation, and aphakia can lead to visual impairment. Moreover, the lens can also block some of the incoming ultraviolet light to protect the retina against long-term ultraviolet radiation. Its accommodative capacity, however, progressively decreases with age, finally resulting in presbyopia.

References

1. Iribarren R. Crystalline lens and refractive development. *Prog Retin Eye Res.* 2015;47:86–106. [\[CrossRef\]](#)[\[PubMed\]](#)
2. Augusteyn RC, Nankivil D, Mohamed A, et al. Human ocular biometry. *Exp Eye Res.* 2012;102:70–5. [\[CrossRef\]](#)[\[PubMed\]](#)
3. Augusteyn RC. On the growth and internal structure of the human lens. *Exp Eye Res.* 2010;90(6):643–54.

[\[CrossRef\]](#)[\[PubMed\]](#)[\[PubMedCentral\]](#)

4. Augusteyn RC. Growth of the human eye lens. *Mol Vis*. 2007;13:252–7.
[\[PubMed\]](#)[\[PubMedCentral\]](#)
5. Brown NP, Bron AJ. *Lens disorders: a clinical manual of cataract diagnosis*. 3rd ed. Oxford: Butterworth-Heinemann; 1996. p. 19–23.
6. Bours J, Födisch HJ, Hockwin O. Age-related changes in water and crystallin content of the fetal and adult human lens, demonstrated by a microsectioning technique. *Ophthalmic Res*. 1987;19(4):235–9.
[\[CrossRef\]](#)[\[PubMed\]](#)
7. Scammon RE, Hesdorffer MB. Growth in mass and volume of the human lens in postnatal life. *Arch Ophthalmol*. 1937;17:104–12.
[\[CrossRef\]](#)
8. Broekhuysen RM. Phospholipids in tissues of the eye. 3. Composition and metabolism of phospholipids in human lens in relation to age and cataract formation. *Biochim Biophys Acta*. 1969;187(3):354–65.
[\[CrossRef\]](#)[\[PubMed\]](#)
9. Clapp CA. A communication upon the weight of infant's lenses and their solids. *Arch Ophthalmol*. 1913;42:618–24.
10. Smith P. Diseases of crystalline lens and capsule. 1. On the growth of the crystalline lens. *Trans Ophthalmol Soc UK*. 1883;3:79–99.
11. Dische Z, Zelmenis G. The content and structural characteristics of the collagenous protein of rabbit lens capsules at different ages. *Invest Ophthalmol*. 1965;4:174–80.
[\[PubMed\]](#)
12. Parmigiani CM, McAvoy JW. A morphometric analysis of the development of the rat lens capsule. *Curr Eye Res*. 1989;8(12):1271–7.
[\[CrossRef\]](#)[\[PubMed\]](#)
13. Fox J. Anatomy of the lens. *Nurs Mirror*. 1984;158(18):31–5.
[\[PubMed\]](#)
14. Boulton M, Albon J. Stem cells in the eye. *Int J Biochem Cell Biol*. 2004;36:643–57.
[\[CrossRef\]](#)[\[PubMed\]](#)
15. Francois J, Victoria-Troncoso V. Histology of the epithelium of the normal and cataractous lens. *Ophthalmologica*. 1978;177(3):168–74.
[\[CrossRef\]](#)[\[PubMed\]](#)
16. Vrensen GF. Aging of the human eye lens—a morphological point of view. *Comp Biochem Physiol A Physiol*. 1995;111(4):519–32.
[\[CrossRef\]](#)[\[PubMed\]](#)
17. Wallentin N, Wickstrom K, Lundberg C. Effect of cataract surgery on aqueous TGF-beta and lens epithelial cell proliferation. *Invest Ophthalmol Vis Sci*. 1998;39(8):1410–8.

[PubMed]

18. Meacock WR, Spalton DJ, Stanford MR. Role of cytokines in the pathogenesis of posterior capsule opacification. *Br J Ophthalmol*. 2000;84(3):332–6.
[CrossRef][PubMed][PubMedCentral]
19. Duncan G. Lens cell growth and posterior capsule opacification: in vivo and in vitro observations. *Br J Ophthalmol*. 1998;82(10):1102–3.
[CrossRef][PubMed][PubMedCentral]
20. Streeten BW. The nature of the ocular zonule. *Trans Am Ophthalmol Soc*. 1982;80:823–54.
[PubMed][PubMedCentral]
21. Streeten BW, Swann DA, Licari PA, et al. The protein composition of the ocular zonules. *Invest Ophthalmol Vis Sci*. 1983;24(1):119–23.
[PubMed]
22. Streeten BW, Licari PA. The zonules and the elastic microfibrillar system in the ciliary body. *Invest Ophthalmol Vis Sci*. 1983;24(6):667–81.
[PubMed]
23. Mackool RJ, Chhatiawala H. Pediatric cataract surgery and intraocular lens implantation: a new technique for preventing or excising postoperative secondary membranes. *J Cataract Refract Surg*. 1991;17(1):62–6.
[CrossRef][PubMed]
24. Trokel S. The physical basis for transparency of the crystalline lens. *Invest Ophthalmol*. 1962;1:493–501.
[PubMed]
25. Lo WK, Biswas SK, Brako L, et al. Aquaporin-0 targets interlocking domains to control the integrity and transparency of the eye lens. *Invest Ophthalmol Vis Sci*. 2014;55(3):1202–12.
[CrossRef][PubMed][PubMedCentral]
26. Cvekl A, Ashery-Padan R. The cellular and molecular mechanisms of vertebrate lens development. *Development*. 2014;141(23):4432–47.
[CrossRef][PubMed][PubMedCentral]
27. Jaenicke R, Slingsby C. Lens crystallins and their microbial homologs: structure, stability, and function. *Crit Rev Biochem Mol Biol*. 2001;36(5):435–99.
[CrossRef][PubMed]
28. Bassnett S. On the mechanism of organelle degradation in the vertebrate lens. *Exp Eye Res*. 2009;88(2):133–9.
[CrossRef][PubMed]
29. Rhodes JD, Sanderson J. The mechanisms of calcium homeostasis and signalling in the lens. *Exp Eye Res*. 2009;88(2):226–34.
[CrossRef][PubMed]
30. Lee DB. Error tolerance in helmholtzian accommodation. *Ophthalmology*. 2002;109(9):1589–90.
[CrossRef][PubMed]

31. Schachar RA. Cause and treatment of presbyopia with a method for increasing the amplitude of accommodation. *Ann Ophthalmol.* 1992;24(12):445–7, 452.
[\[PubMed\]](#)
32. Schachar RA, Cudmore DP, Black TD. Experimental support for Schachar’s hypothesis of accommodation. *Ann Ophthalmol.* 1993;25(11):404–9.
[\[PubMed\]](#)
33. Kirkwood BJ, Kirkwood RA. Accommodation and presbyopia. *Insight.* 2013;38(3):5–8.
[\[PubMed\]](#)
34. Sliney DH. How light reaches the eye and its components. *Int J Toxicol.* 2002;21(6):501–9.
[\[CrossRef\]](#)[\[PubMed\]](#)

4. Etiology of Pediatric Lens Diseases

Kaili Wu¹✉, Xiaoyun Chen¹ and Xiaojian Zhong¹

- (1) State Key Laboratory of Ophthalmology, Zhongshan Ophthalmic Center, Sun Yat-sen University, 54S Xianlie Road, Guangzhou, 510060, People's Republic of China

✉ **Kaili Wu**

Email: wukaili@mail.sysu.edu.cn

Abstract

Pediatric lens disorders can be classified as cataract and crystalline lens dislocation. The etiology of pediatric cataract is extremely complex but can be divided into hereditary, non-hereditary, and idiopathic. Hereditary cataracts account for about one third of all pediatric cataracts, and they are related to genetic mutations. It has been well demonstrated that the mutations of crystallin genes, membrane protein-associated genes, cytoskeletal protein genes, and developmental regulator genes can all result in cataract. Non-hereditary cataracts may be secondary to intrauterine infections or metabolic, traumatic, or iatrogenic factors, while the causes of idiopathic cataracts remain unknown. Along with the development of molecular biology, the etiological research on hereditary cataract has evolved from pathogenic gene mapping and mutation screening to exploring mutation-related pathogenesis. Furthermore, the application of whole-genome sequencing and gene chip technologies makes it possible to achieve genetic diagnosis and treatment of hereditary cataracts.

Pediatric cataracts have a diverse etiology, which can be classified into hereditary, non-hereditary, and idiopathic cataracts. More specifically,

hereditary cataracts can occur in isolation or in association with other ocular and/or systemic abnormalities; non-hereditary cataracts may be secondary to intrauterine infections or metabolic, traumatic, or iatrogenic; and cataracts with undetermined causes are classified as idiopathic.

Traditionally, it was believed that each of these three types of cataracts accounted for about one third of all cases. But a recent Danish study on the etiology of pediatric cataracts revealed that idiopathic etiology was the most frequent cause (63 %) followed by hereditary (29 %) and non-hereditary (only 8 %) [1]. Although many cases of pediatric cataracts are now of unknown origin, there is a tendency that more and more mutant genes and developmental anomalies will be identified owing to the rapid advances in genetics and developmental biology. As a result of this, the proportion of idiopathic cataracts would be decreased.

4.1 Hereditary Pediatric Cataracts

Cataracts caused by genetic factors are called hereditary cataracts. They are related to genetic mutations or familial inheritance. Isolated lens opacification accounts for approximately 70 % of all hereditary pediatric cataracts, those with concurrent ocular abnormalities account for about 15 %, and those in association with multisystem genetic disorders make up the remaining 15 % [2].

4.1.1 Isolated Hereditary Cataracts

Isolated hereditary cataracts, as a monogenic disease, refer to the inherited cataracts not associated with any other ocular or systemic abnormalities. Based upon the chromosome where the pathogenic gene is located as well as the mode of inheritance, monogenic diseases can be divided into five categories, i.e., autosomal dominant inheritance, autosomal recessive inheritance, X-linked dominant inheritance, X-linked recessive inheritance, and Y-linked inheritance. The inheritance patterns associated with isolated hereditary cataracts mainly include autosomal dominant, autosomal recessive, and X-linked recessive, among which autosomal dominant inheritance is the most common pattern. Up till now, over 20 genes have been identified to be responsible for isolated autosomal dominant congenital cataract, about half of which are observed in crystallins, 25 % in connexins, and the others in heat

shock factor-4 (HSF-4), lens fiber major intrinsic protein (MIP), beaded-filament structural protein (BFSP), and so on [2]. Moreover, the phenotypes of congenital cataracts are complex and variable. Despite the same mutant gene at the same locus, lens opacities may have different morphologies and/or degrees among different families or even individuals from the same family. On the other hand, the same lens opacities may result from different mutations. Thus, it is assumed that other factors, besides mutant genes, may also be involved in the regulation of lens opacities.

The following types of mutant genes have been described to be associated with isolated hereditary cataracts.

4.1.1.1 Crystallin Genes

Crystallins are the major protein components of the lens and can be divided into three types, namely, α -, β -, and γ -crystallins. Mutations in these crystalline genes are responsible for about 50 % of hereditary cataracts [2]. Genes that encode crystallins include CRYAA, CRYAB, CRYBB1, CRYBB2, CRYBA1, CRYGC, CRYGD, and CRYGS.

α -Crystallins

α -crystallins (CRYAA/CRYAB) are the major structural proteins of mature lens fiber cells and consist of α A- and α B-crystallins, which account for up to 40 % of the total protein of the lens and 20 % of the soluble lens proteins in newborns. They play important roles in the maintenance of lens transparency. Moreover, α -crystallins belong to the family of small heat shock proteins (HSPs) and act as both structural proteins and molecular chaperones. Congenital cataracts due to α A-crystallin gene mutation are often inherited in an autosomal dominant or recessive fashion. Several studies have focused on the R116C mutation, a change that substitutes arginine at position 116 by cysteine. The R116C mutation may alter the tertiary structure of CRYAA proteins, leading to a loss in hydrophobic surface and an increased tendency to aggregate, and thereby the increased molecular weight and reduced solubility result in protein deposition [3]. The R116C mutation may also diminish the interactions between CRYAA and CRYBB2 or CRYGC and destroy organized connections among structural proteins of the lens [4]. Besides, this type of mutation may cause partial reduction in the chaperone activity of α -crystallins [4]. Another type of mutation, R49C in exon 1 of CRYAA, results in abnormal distribution of α A-crystallins in the cell

nucleus, which may reduce their capacity to protect lens epithelial cells (LECs) from staurosporine-induced apoptosis [5]. Mutation of the glycine 98 residue to arginine (G98R) may lead to protein misfolding and hence induce protein aggregation and inclusion body formation [6]. Previous study also reported that congenital cataracts caused by CRYAA mutation may be accompanied by microcornea (Fig. 4.1), indicating that the mutation may also play a role in the development of the anterior segment [7].

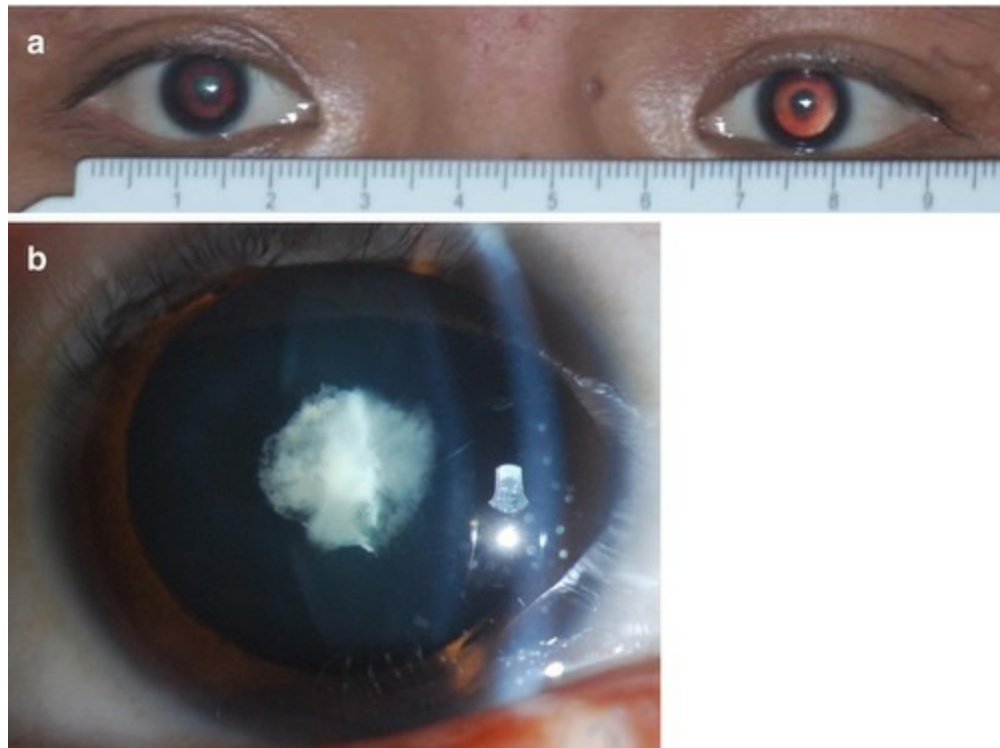


Fig. 4.1 Congenital cataracts with microcornea due to mutation in the CRYAA. (a) A 24-year-old male with congenital nuclear cataract and microcornea due to c.34C > T mutation in the CRYAA gene; (b) slit-lamp examination reveals nuclear opacities in the lens (Reproduced with permission from Sun et al. [7])

Other cataract-related mutations in α A- and α B-crystallins are listed in Table 4.1 [3–7, 12–15].

Table 4.1 Human hereditary cataract genes and associated clinical phenotypes

Gene	Chromosome	Mode of inheritance	DNA alteration	Amino acid alteration	Phenotypes
BFSP2	3q21–q25	AD	c.859C > T	R287W	Juvenile progressive lamellar cataract [8]
		AD	c.697-	E233del	Sutural cataract [9]

		AD	699delGAA c.1091G > A	R339H	Lamellar cataract [10]
BFSP1	20p11.23– p12.1	AR	C736- 1384_c.957- 66del	T246fsX7	Developmental cataract [11]
CRYAA	21q22.3	AD	c.346C > T	R116C	Lamellar, central nuclear opacities, iris coloboma, microcornea [12]
		AD	c.14C > T	R49C	Nuclear opacity [5]
		AD	c.347G > A	R116H	Anterior polar, cortical, embryonic nuclear, anterior subcapsular opacities, microcornea, corneal opacity [13]
		AR Sporadic AD AD AD	c.27G > A c.62C > G c.247G > A c.1134C > T c.130C > T	W9X R21L G98R R12C R21W	Congenital cataract [14] Nuclear opacity, inferior macular dislocation [4] Presenile progressive lamellar or total cataract [6] Posterior polar progressing nuclear or lamellar cataract [13] Anterior or posterior polar opacity [13]
CRYAB	11q23.3– q24.2	AD	c.358A > G	R120G	Lens opacity and myopathy [4]
		AD	c.450delA	K150fs	Posterior polar cataract [15]
		AD AD	c.418G > A c.58C > T	D140N P20S	Thin lamellar cataract [4] Posterior polar cataract [4]
CRYBA1/3	17q11.1–q12	AD	IVS3 + 1 G > T		Sutural cataract [16]
		AD	IVS3 + 2 T > G		Nuclear cataract [17]
		AD	IVS3 + 1 G > A		Lamellar and sutural cataract [18]
		AD	IVS3 + 1 G > A		Posterior polar cataract [19]
CRYBA4	22q11.2– q13.1	AD	c.317 T > C	F94S	Bilateral lamellar cataract and microphthalmia [20]
		AD	c.225G > T	G64W	Bilateral nuclear cataract and microcornea [21]
CRYBB1	22q11.2– q12.1	AD	c.658G > T	G220X	Bilateral pulverulent opacity, typically in the fetal nucleus, also seen in cortex, anterior and posterior Y sutures [22]
		AR AD	c.2 T > A c.737C > T	M1K Q223X	Nuclear pulverulent cataract [23]

					Nuclear cataract [24]
CRYBB2	22q11.2–q12.2	AD	c.463C > T	Q155X	Various morphologies including punctate, cerulean, Coppock-like, sutural opacities [25, 26]
		AD	c.453G > C	W151C	Nuclear cataract [27]
		AD	c.383A > T	D128V	Nuclear and circular cortical opacities [28]
		AD	c.607G > A	V187M	Nuclear cataract [29]
		AD	c.453G > C	W151C	Membranous cataract [30]
CRYGC	2q33–q35	AD	c.125A > C	T5P	Coppock-like cataract [31]
		AD	c.502C > T	R168W	Lamellar cataract [18]
		AD	c.327C > A	C109X	Nuclear cataract [31]
		AD	c.470G > A	W157X	Nuclear cataract, microcornea [31]
CRYGD	2q33–q35	AD	c.67C > A	P23T	Cerulean, coralliform cataract [32–35]
		AD	c.176G > A	R58H	Aculeiform cataract [36]
		AD	c.109C > A	R36S	Symmetrical crystal deposition and grayish opacities, bilateral [37]
		AD	c.70C > A	P24T	Cerulean or aculeiform cataract [38, 39]
		AD	c.466G > A	W156X	Nuclear cataract [40]
		AD	c.229C > A	R77S	Anterior polar cerulean cataract [36]
		AD	c.34C > T	R14C	Coralliform cataract [40]
GCNT2	6p24–p23	AR	c.1043G > A	G348E	Congenital (total) cataract, adult I phenotype [41]
		AR	c.1148G > A	R383H	I phenotype-related [41]
GJA3	13q11	AD	c.188A > G	N63S	Lamellar pulverulent cataract [42, 43]
		AD	c.1138insC	S380fs	Zonular pulverulent cataract [43]
		AD	c.560C > T	P187L	Zonular pulverulent cataract [42, 43]
		AD	c.114C > A	F32L	
		AD	c.227G > A	R76H	Nuclear pulverulent cataract [42, 43]
		AD	c.563A > C	N188T	
		AD	c.82G > A	R76G	Nuclear pulverulent cataract [42, 43]
		AD	c.176C > T	V28M	
		AD	c.7G > T	P59L	Nuclear pulverulent cataract [43]
		AD	c.32 T > C	D3Y	Total cataract [43]
		AD	c.260C > T	L11S	

					Cortical, capsular cataract [43] Nuclear punctate opacity [42, 43] Zonular pulverulent opacity [42] “Ant-egg” opacity [43]
GJA8	1q21.1	AD AD AD	c.262C > T c.143A > C c.263C > A	P88S E48K P88Q	Zonular pulverulent cataract [44] Lamellar pulverulent cataract [45] Lamellar pulverulent cataract [46]
HSF4	16q21–q22.1	AR AR	c.221G > A c.524G > C	R74H R175P	Congenital total cataract [47] Nuclear, cortical cataract [48]
LIM2	19q13.4	AR	c.313 T > G	F105V	Presenile cataract [49]
		AR	c.587G > A	G154E	Juvenile-onset cataract [50]
MAF	16q22–q23	AD	c.863G > C	R288P	Juvenile-onset lamellar opacity [51]
		AD	c.890A > G	K297R	Congenital cerulean cataract [52]
AQP0	12q13	AD AD	c.413C > G c.401A > G	T138R E134G	Nonprogressive lamellar and sutural opacities [53] Polymorphic cataracts (bilateral progressive punctate, lamellar, uneven anterior/posterior opacities, cortical opacity) [53]
NHS	Xp22.13	XL	c.2387insC	A797fsX35	Cataract, dental abnormalities, mental retardation [54]
		XL	c.3459delC	L1154fsX28	Congenital total cataract [54]
		XL	c.718insG	E240fs	Congenital total cataract [54]
		XL	c.400delC	R134fsX61	Congenital total cataract [54]
		XL XL	c.3738delTG c.2687delA	C1246AfsX15 Q896fsX10	Congenital total cataract [54] Congenital total cataract [54]
OCRL	Xq26.1			R577Q	Punctate cataract, proteinuria, mild metabolic acidosis [55]
PAX6	11p13	AD	c.669C > T	R103X	Aniridia, congenital cataract, nystagmus, ptosis, glaucoma, corneal pannus [56]

		AD	c.1080C > T	R240X	Cataract, aniridia, macular hypoplasia, glaucoma [57]
		AD	c.553G > T	G64V	Presenile cataract, macular hypoplasia [57]
		AD	c.475_491del17	R38PfsX12	Congenital cataract, aniridia [58]
		AD	c.572 T > C	L46P	
		AD	c.655A > G	S74G	Bilateral microphthalmia, congenital cataract, and congenital nystagmus [59]
		AD	c.51C > A	N17K	
		AD	c.579delG	V48fsX53	Bilateral multidirectional nystagmus, progressive cataract, inferior macular dislocation or even coloboma, and developmental abnormalities of the nervous system [59]
					Serious abnormalities of both eyes, including congenital nystagmus, leukoma, anterior synechia, and anterior polar cataract [60]
					Bilateral nystagmus, congenital cataract, congenital iris coloboma, and inferior macular dislocation [59]
VIM	10p13	AD	c.596G > A	E151K	Pulverulent cataract [10]

Notes: *AD* autosomal dominant inheritance, *AR* autosomal recessive inheritance, *XL* sex-linked inheritance

β-Crystallins

β -crystallins are the most abundant water-soluble structural proteins in the lens, making up approximately 35 % of the total protein. They are mainly expressed in lens fiber cells, with the highest level in cortical fiber cells [61]. β -crystallins have been shown to consist of seven subunits (β B1, β B2, β B3, β A1, β A2, β A3, and β A4) that are encoded by six *CRYB* genes; of these, both β A1 and β A3 are encoded by the same gene called *CRYAB1*.

A dozen mutation sites in β -crystallins have been identified to be associated with hereditary cataracts, most commonly seen in β B2-crystallins (Table 4.1) [16–30, 62, 63]. Mutations in β -crystallin result in diverse cataract phenotypes. An identical mutation may produce vastly different

phenotypes among different families, or different degrees of the same phenotype within one family. For example, we found that in a family in South China, 22 family members were diagnosed as membranous cataract due to W151C mutation in exon 6 of the *CRYBB2* gene (Fig. 4.2a). The same mutation was also reported in an Indian family, but its associated phenotype was nuclear cataract, indicating that an identical mutation might have diverse clinical phenotypes among different ethnic groups [27, 30]. In addition, even in this single Chinese family, the severity of membranous cataract also varied. The lens opacities were progressive with increasing age, accompanied by lens dislocation and membrane permeability changes, and the opacified cortex was gradually dissolved and absorbed (Fig. 4.2b) [30]. The mechanism of cataract development due to mutation in β -crystallin is that the amino acid substitution caused by the mutation leads to structural changes of proteins, resulting in an increase in hydrophobicity and a decrease in solubility and consequently protein aggregates and lens opacification [63].




Fig. 4.2 The clinical data of the family with membranous cataract induced by W151C mutation in CRYBB2. (a) Pedigree of the family. Inquiry of the family history identified 22 affected subjects across four generations. The *black symbols* represent the affected subjects and the *white symbols* indicate the healthy family members. *Squares* and *circles* indicate males and females, respectively. The proband is marked with an *arrow*. The pedigree of the family suggests an autosomal dominant pattern of inheritance. (b) Clinical features of the family. Slit-lamp photographs of affected subjects demonstrate that the phenotype of the congenital cataract is membranous cataract. Opacities of these lenses gradually became denser and displaced upward with increased age, along with absorption of the lens cortex (Reproduced with permission from Chen et al. [30])

γ -Crystallins

γ -crystallins, accounting for about 25 % of the total protein of the lens, are highly stable monomeric proteins and are encoded by seven distinct genes. The genes encoding γ A- to F-crystallins are all located on chromosome 2 with highly similar sequences, while the gene encoding γ S-crystallins is found on chromosome 3. γ -crystallins, expressed specifically in lens fiber cells, are synthesized at the terminal stage of fiber cell differentiation. The human lens mainly expresses γ C-, γ D-, and γ S-crystallins.

The mutation patterns in γ -crystallin genes may include missense, insertion, and splice mutations, typically resulting in nuclear and zonular cataracts (Table 4.1) [31–40, 64, 65]. It is thought that γ -crystallin gene mutations contribute to cataract development and progression in a similar way to that of β -crystallin mutations, involving the destruction of protein solubility and stability. For instance, both R36S and R58H mutations in the CRYGD gene have been shown to cause a reduction in protein solubility by changing their surface properties, which may lead to protein deposition and consequently cataracts [36, 37]. Another mutation R14C may increase the sensitivity of CRYGD to sulfhydryl-mediated polymerization, making proteins susceptible to aggregation and thereby resulting in lens opacities [40]. Thus, even in the absence of degeneration or other major structural changes (such as those causing misfolding), a minor change in the lens proteins may also give rise to cataracts.

4.1.1.2 Membrane Protein Genes

The membrane protein content is very low in the lens, accounting for less than 1 % of the lens wet weight. But these proteins play an essential role in intercellular signaling and maintenance of lens transparency. In membrane protein genes, cataract-related mutations are commonly seen in gap junction protein (GJP), major intrinsic protein of lens fibers, and lens intrinsic

membrane protein-2 (LIM-2).

Gap Junction Protein

GJP is also called connexin. Six connexin proteins from adjacent cells that form a dual-loop structure assemble into an intact gap junction channel. There are at least 21 human genes that encode connexins, 3 of which can be found in the lens, i.e., GJA1 (α 1 connexin, connexin43, Cx43), GJA3 (α 3 connexin, connexin46, Cx46), and GJA8 (α 8 connexin, connexin50, Cx50). The LECs mainly express GJA1 and GJA8, while the fiber cells mainly express GJA3 and GJA8. Since the lens is avascular, GJP-mediated intercellular communication and small-molecule (such as ions, metabolites, and second messengers) transport are crucial in the maintenance of cellular functions as well as cellular growth, differentiation, and development. GJA3 and GJA8 mutations are often inherited in an autosomal dominant pattern and produce similar clinical phenotypes, including pulverulent, punctate, nuclear cataracts, or perinuclear lamellar opacification (Fig. 4.3, Table 4.1) [42–46, 66–72]. The mechanism of cataract development is mainly attributed to transport dysfunction after protein synthesis. The mutant proteins are accumulated in the endoplasmic reticulum and Golgi complex and cannot be transported across the cell membrane to form gap junction channels, leading to defective intercellular transport and thus cataracts [46, 68, 72].

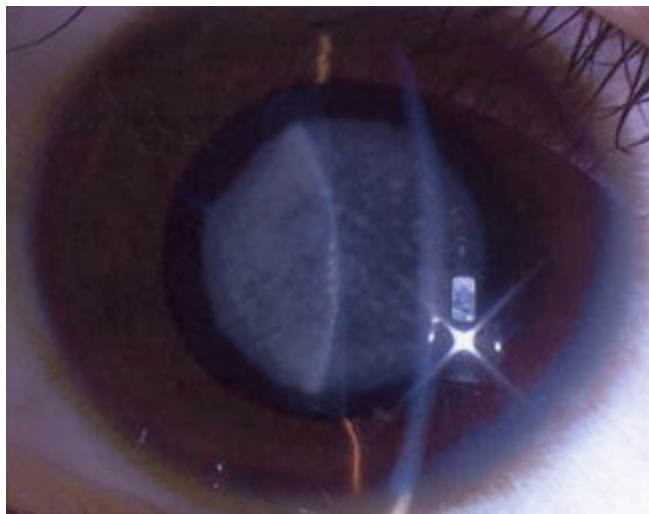


Fig. 4.3 Nuclear cataracts due to mutation in the CJA3. A 17-year-old female with punctate nuclear cataract due to c.1143–1165del23 mutation in the CJA3 gene (Reproduced with permission from Sun et al. [66])

Major Intrinsic Protein in Lens Fibers

MIP in lens fibers, also known as MIP26 or aquaporin-0 (AQP0), belongs to the family of aquaporins. AQP0, specifically expressed in the lens, is mainly distributed in terminally differentiated fiber cells and is the most abundant integral membrane protein in the lens. It not only acts as a water channel but also has an important structural function in maintaining lens transparency and accommodation. MIP/AQP0 mutations have been associated with autosomal dominant congenital cataracts, typically bilateral. For example, both T138R and E134G missense mutations in the transmembrane domain H4 of AQP0 as well as deletion mutations in domain H6 may cause retention of synthesized AQP0 in the cytoplasm, which cannot be inserted into the membrane to form water channels and finally results in cataracts [53, 73].

Lens Intrinsic Membrane Protein-2

LIM-2, also known as intrinsic membrane protein 19 (MP19), is the second most copious membrane protein in the lens fibers after MIP. LIM-2, found at junctions between lens fiber cells, appears to play a key role in maintaining the ion exchange and metabolic balance among fibers cells, among LECs, as well as between fiber cells and LECs. Only a few mutations in LIM-2 have been identified and described. The G154E point mutation may result in serious congenital total cataract and visual impairment [50], and the F105V point mutation may cause presenile lens opacity [49]. In addition, in LIM-2 knockout mice, pulverulent cataracts can be observed with an impaired gradient refractive index of the lens, indicating that LIM-2 also plays a role in maintaining the refractive properties within the lens [74].

4.1.1.3 Cytoskeletal Protein Genes

Cytoskeleton is a network composed of filamentous proteins within a eukaryotic cell, which supports the cell shape and is involved in intracellular transportation, cell division, and motility. In the lens, cytoskeletal proteins include microfilaments, microtubules, and intermediate filaments. Interaction between cytoskeletal proteins and crystallins is important in lens cell differentiation and maintenance of lens transparency.

Beaded-Filament Structural Protein

BFSP is an important cytoplasmic protein and is a component of the cytoskeleton which consists of BFSP1 (also called CP115 or filensin) and

BFSP2 (also called CP49 or phakinin). BFSP is not expressed in the LECs but specific to differentiated lens fiber cells. In lens fiber cells, BFSP1 binds to BFSP2 to form beaded filaments, which interact with α -crystallins, support cell shape and participate in cell movement, and thereby help to maintain the architecture and functions of the lens.

Mutations in the BFSP gene usually result in nuclear and lamellar cataracts, but cortical cataracts due to BFSP1 mutation have also been described. A deletion mutation in exon 6 of the BFSP1 gene (c.736-1384_c.957-66 del) has been shown to cause an autosomal recessive form of hereditary cataracts, characterized by developmental cortical cataracts, or nuclear sclerotic cataract after age 50 years. That is caused by the damage to filament formation induced by the loss of the BFSP1 protein [11]. According to a recent study of a South Chinese family, a deletion mutation in the BFSP2 gene (E233del) can lead to Y-shaped sutural cataracts accompanied by myopia (Fig. 4.4) [9]. Additionally, a missense mutation in exon 4 of BFSP2 (R278W) is responsible for autosomal dominant juvenile progressive cataracts, and the R339H mutation in exon 5 leads to lamellar cataracts [8, 75].

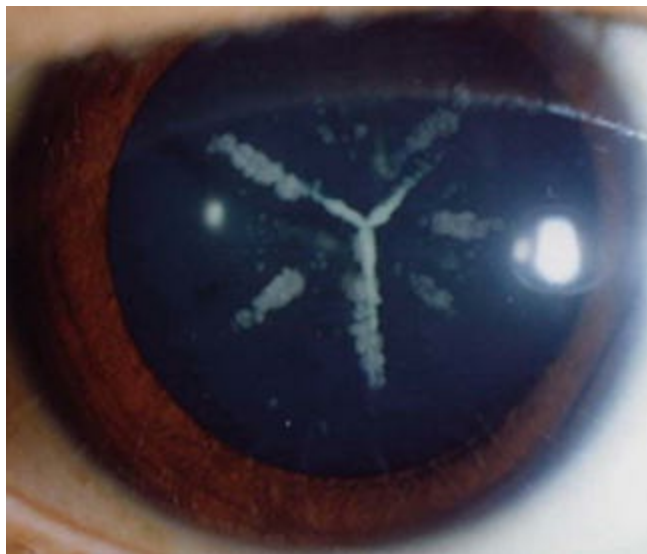

Fig. 4.4 Y-shaped sutural cataracts due to mutation in the BFSP2. A 20-year-old female with Y-shaped sutural cataract due to E233 deletion mutation in the BFSP2 (Reproduced with permission from Zhang et al. [9])

Vimentin

Vimentin is a type III intermediate filament protein, which is mainly

expressed in the LECs, but also in lens fiber cells. Vimentin, along with BSFP2 and BSFP1, comprises the cytoskeleton that is linked to the cell membrane. As the LECs elongate and differentiate into fiber cells, the level of vimentin expression tends to decrease and finally disappears. Mutations of vimentin have been shown to cause hereditary cataracts. For example, E151K missense mutation in vimentin exon 1 may result in pulverulent cataract, which is because E151K induces defects in vimentin assembly and folding, leading to its abnormal accumulation in the cytoplasm and consequently the development of cataract [10].

4.1.1.4 Developmental Regulators

The development of the lens is under precise spatiotemporal regulation by a series of regulators that mainly include transcription factors and growth factors. In particular, transcription factors regulate the interactions between the ectoderm and the optic vesicles, as well as the induction of lens development, growth, and differentiation, playing crucial roles in the embryonic development of the lens. Genetic mutations in these transcription factors have been linked to both lens opacities and anterior segment developmental anomalies. Mutations in the PITX3, PAX6, FOXE3, EYA1, MAF, and HSF4 genes have been reported to cause hereditary cataracts. Except for HSF4, mutation gives rise to isolated cataracts, while the other mutations often result in cataracts accompanied by other ocular abnormalities that will be discussed in the next section.

The HSF family has six members, i.e., HSF1, HSF2, HSF4, HSF5, HSFY, and HSFX. They are widely expressed in the embryonic and adult lens, reflecting their important roles in the lens development; however, the underlying regulatory mechanism remains unknown [76]. As molecular chaperones, HSFs participate in protein synthesis, assembly, folding, and denaturation. Any abnormality in the structure or expression of HSFs may contribute to the development of cataracts [77].

Mutations in HSF4 are associated with hereditary cataracts with autosomal dominant or recessive inheritance. The former is characterized by childhood onset, typically as lamellar opacity [78], whereas the latter is usually present at birth, manifesting as significant nuclear opacities with partial cortical opacities, or severe total cataract, often complicated with nystagmus [47, 48]. Recently, it has been postulated that HSF4 mutations contribute to cataractogenesis via three pathways: downregulation of γ -

crystallins (particularly γ S-crystallins) and BFSP expressions, as well as mediation of the loss of posttranscriptional modification of α A-crystallin [79].

4.1.1.5 Other Genes

β -1,6-N-Acetylglucosaminyl Transferase 2 (GCNT2)

GCNT2, also known as I-branching enzyme, is expressed in LECs. It functions to convert the fetal linear chain I antigen on the surface of erythrocytes to the adult I antigen of a branched poly-N-acetyllactosamine structure. G348E and R383H mutations in GCNT2 have been reported to cause congenital cataracts [41].

4.1.2 Hereditary Cataracts Associated with Other Ocular and/or Systemic Abnormalities

This subtype accounts for approximately 30 % of all hereditary cataracts, which can be classified as monogenic or chromosomal disease based on etiology. The monogenic diseases associated with hereditary cataracts may only have ocular conditions, or sometimes be accompanied by systemic abnormalities (Table 4.1 and Table 4.2); while all cases of chromosomal diseases have systemic abnormalities along with cataracts (Table 4.2).

Table 4.2 Systemic syndromes associated with hereditary cataracts

Syndrome	Systemic abnormalities	Ocular abnormalities	Mode of inheritance
With kidney anomalies			
Lowey syndrome (oculocerebrorenal syndrome)	Frontal bossing, deep-set eyes, and other typical facial features; motor and intellectual disabilities after 1 year of age; some patients have rickets and osteomalacia, proteinuria, and finally metabolic acidosis	Bilateral cataracts, posterior lenticonus, corneal opacification and edema, anterior capsular excrescence, congenital macrocornea or microcornea, etc.	XR [55]
Alport syndrome (familial hereditary nephritis)	Familial hereditary kidney disease with bilateral symmetrical deafness	Different types of cataracts, mainly anterior and posterior subcapsular opacities; spherophakia or lenticonus; optic disk drusen and punctate keratopathy seen in a minority of	AD [80]

		patients	
With central nervous system disorders			
Marinesco–Sjögren syndrome (ataxia–cataract syndrome)	Nervous system abnormalities, presenting as cerebellar ataxia and pyramidal signs, mental retardation, delays in language development, cretinism, and agenesis of reproductive organs	Typically congenital lamellar cataracts, epicanthus, nystagmus, strabismus, microphthalmia, aniridia, retinitis pigmentosa, and progressive ophthalmoplegia	AR [81]
Smith–Lemli–Opitz syndrome (microcephaly–micrognathia–syndactyly syndrome)	Multisystem defects: microcephaly, micrognathia, low-set ears, upturned nose, extra fingers or toes, and polycystic kidney	Cataracts, epicanthus, strabismus, and nystagmus	AR [82]
Laurence–Moon–Bardet–Biedl syndrome	Obesity, polydactyly, hypogonadism, and mental retardation	Cataracts (late onset), posterior subcapsular opacities, ametropia, nystagmus, and retinitis pigmentosa	AR [83, 84]
Cockayne syndrome (dwarfism–retinal dystrophy–deafness syndrome)	Loss of subcutaneous fat, enophthalmos, large ears, a prematurely aged facial appearance, and mental retardation	Nystagmus, pigmentary retinal degeneration, small pupils, and cataracts	AR [85]
With skeletal anomalies			
Marfan syndrome	Long, thin, spider-like fingers and toes; long, thin arms and legs with a high risk of fracture; pigeon chest or barrel chest; cardiovascular abnormalities, mainly aortic dissecting aneurysm and dysplasia	Congenital cataracts, ectopia lentis, mostly superonasal lens subluxation or dislocation into the anterior chamber or vitreous body; some patients have spherophakia with glaucoma; hypoplasia of the pupil dilator muscle resulting in poor pupil dilation, myopia, congenital macrocornea or microcornea, and aniridia	AD [86]
Weill–Marchesani syndrome (spherophakia–brachymorphia syndrome)	Short stature, obesity, brachydactyly, short neck and limbs	Cataracts, microspherophakia, myopia, inferonasal subluxation or dislocation of the lens; some patients may have glaucoma and microcornea	AD/AR [87]
Stickler syndrome	Dysplasia of limbs and joints, micrognathia, high palate arch, cleft palate, and neural hearing loss	Punctate, nuclear, or total cataracts; over 80 % of patients have high myopia; choroidoretinal degeneration, possibly retinal detachment	AD [88]
With head and face anomalies			
Hallermann–Streiff syndrome	Cranial maldevelopment, micrognathia, hypoplasia	Cataracts, in a few patients the capsule remains after spontaneous absorption	AR [89]

(oculomandibulofacial syndrome)	of facial muscles, beaked nose and “bird-like” face	of cataract with capsule pigmentation; phacotoxic uveitis and phacolytic glaucoma may occur during phacolysis; glaucoma due to dysplasia of the anterior chamber angle	
Pierre Robin syndrome	Micrognathia, cleft palate, glossoptosis, depressed nasal bridge, anomalies of fingers and toes, heart disease, deafness, and hydrocephalus	Congenital cataracts, posterior subcapsular opacities; dysplasia of the anterior chamber angle, glaucoma; high myopia, retinal detachment, strabismus, and microphthalmia	AD [90]
Crouzon syndrome (craniofacial dysostosis)	Craniosynostosis, elevated intracranial pressure; protruding frontal bone, hypoplastic maxilla, mandibular prognathism, beak-like nose; hearing loss; and mental retardation	Cataracts, glaucoma; proptosis and midfacial hypoplasia secondary to shallow orbits; orbit hypertelorism and exotropia; optic disk edema or optic atrophy	AD/AR [91]
With skin anomalies			
Bloch–Sulzberger syndrome (incontinentia pigmenti)	Blisters and papula on the skin of the trunk, leaving dark pigmentation	Cataracts are commonly seen; some also have conjunctival pigmentation, corneal opacities, blue sclera, pigmentary retinal lesions, and optic atrophy	XD [92]
Rothmund–Thomson syndrome (poikiloderma congenitale)	Skin atrophy with pigmentary changes and telangiectasis	Lamellar or punctate cataracts, occasionally band keratopathy, keratoconus, and retinal telangiectasis	AR [93]
Werner syndrome (cataract–scleroderma–progeria syndrome)	Premature aging, skin atrophy, calcinosis, short stature, and endocrine dysfunction	Early cataracts, eyelash alopecia, and incomplete eyelid closure	AR [94]
Chromosomal diseases			
Trisomy 21 (Down syndrome)	Developmental delay, small head, flattened facial profile, small nose with a low nasal bridge, small ears, enlarged and protruding tongue, short in stature with short limbs, short fifth finger and curved inward	Bilateral cataracts, typically white punctate opacities, but Y-shaped sutural, plume or equatorial arch-like opacities may also be seen; these opacities may progress to total cataracts over time; upslanting palpebral fissures and epicanthus [95]	
Trisomy 13 (Patau syndrome)	Low-set ears, polydactyly, nose and mouth defects; intellectual	Cataracts, microphthalmia, uveal coloboma, persistent fetal vasculature, retinal detachment, optic nerve	

	disability, often with epilepsy, diminished or increased muscle tone, sometimes with ataxia	hypoplasia, monophthalmia [96]	
Turner syndrome	Only occurs in females; short stature, skeletal abnormalities, cubitus valgus, webbed neck, primary amenorrhea, etc	Cataracts, typically Y-shaped sutural or posterior subcapsular punctate and flake-like opacities; also accompanied by epicanthus, orbital hypertelorism, peripheral corneal opacities, pigment accumulation on the surface of the iris, strabismus, and red-green color blindness [97]	
Klinefelter syndrome	Only occurs in males; lack of secondary sexual characteristics	Cataracts seen in one third of patients [98]	

4.1.2.1 Monogenic Diseases

A monogenic disease refers to a disorder or a pathological condition that is controlled by a single gene. Based upon the mode of inheritance, monogenic disease can be divided into five types, i.e., autosomal dominant inheritance, autosomal recessive inheritance, X-linked dominant inheritance, X-linked recessive inheritance, and Y-linked inheritance.

Hereditary Cataracts with Only Concurrent Ocular Abnormalities

Transcription factor Maf (MAF) acts as a transcriptional activator or repressor by binding to the MAF-responsive elements (MAREs). MAREs can be found in the crystallin coding genes and PITX3 promoter, and thus it is believed that MAF participates in the regulation of crystallin expression and differentiation of embryonic lens fiber cells. Three mutation sites in MAF have been identified to cause congenital cataracts with microcornea, all of which are located at the basic DNA-binding region of MAF, indicating that this region is particularly susceptible to mutations associated with congenital cataracts and microcornea. Specifically, R288P mutation may lead to nuclear and cortical lens opacities, accompanied by microcornea and bilateral iris coloboma [51]; K297R mutation may result in bilateral cerulean cataracts with microcornea [52]; and R299S mutation may give rise to posterior polar cataracts with microcornea [99]. Therefore, it is speculated that MAF plays important roles in the development of both the lens and the anterior segment.

PITX3, a member of the paired-like homeodomain transcription factor (PITX/RIEG) family, regulates the early development of ocular tissues

including the cornea, iris, lens, trabecular meshwork, and retina. Typically, mutations in the PITX3 gene result in posterior polar cataracts or, less frequently, total cataracts. They are often accompanied by anterior segment mesenchymal dysgenesis (ASMD), including leukoma, microcornea, synechia, iris atrophy, and optic nerve hypoplasia [100–102].

Hereditary Cataracts with Systemic Abnormalities

1. Multisystem abnormalities due to PAX6 mutations.

The paired-like homeobox-containing gene 6 (PAX6), located on chromosome 11p13, consists of two DNA-binding domains: the paired domain of 128 amino acids and the homeodomain of 61 amino acids, which are separated by a linker region of 79 amino acids. PAX6 exerts regulatory effects on the expression of a myriad of factors and structural proteins and is required for the development of the nervous system, eyes, nose, pancreas, and pituitary gland [103–106]. In eyes, PAX6 is expressed in the developing iris, lens, ciliary body, corneal epithelium, and retina, playing an important regulatory role in the development of various ocular tissues, including the CRYAA/CRYAB expression during early and middle development of the lens [106]. A heterozygous mutation of PAX6 may lead to congenital cataracts, aniridia, corneal deformity, and microphthalmia, while a homozygous mutation may result in congenital eye diseases as well as multisystem disorders such as brain defects, absence of nasal cavities, and pancreas abnormalities [103–106]. More than 60 mutation sites in PAX6, almost covering the whole gene, have been identified and reported, and eight of these have been linked to ocular abnormalities (Table 4.1) [56–60, 106]. For instance, N17K missense mutation may result in serious ocular abnormalities of both eyes, including nystagmus, leukoma, anterior synechia, and anterior polar cataracts [60].

2. Hyperferritinemia-cataract syndrome.

Ferritin L-related gene mutations have been shown to cause hereditary hyperferritinemia-cataract syndrome (HHCS), commonly seen in the ferritin L iron-responsive elements, such as A146G, T22G, G32C, G51C, C39T, and G32T [107–109]. HHCS is an autosomal dominant

disorder characterized by pulverulent, cerulean lens opacities and hyperferritinemia.

3. Xp cataract syndromes.

Lens opacities due to Xp chromosome abnormalities are relatively rare, and the underlying pathogenesis remains unclear. Total lens opacities are observed at birth in male infants with X-linked hereditary cataracts.

Nance–Horan syndrome (NHS) results from mutations in the NHS gene which is located on the Xp22.13 locus. This is an X-linked syndrome characterized by nuclear cataract, microcornea, dental anomalies, abnormal stature, and mental disorders [54, 110]. The exon of the NHS gene has two isoforms, NHS-1 and NHS-1A. The latter encodes a cytoplasmic protein, while the former encodes proteins on the cell membrane with tight junction protein. It is believed that disturbances to the function of tight junctions underlie cataractogenesis in Nance–Horan syndrome [56, 59].

Lowe syndrome, also called oculocerebrorenal syndrome of Lowe (OCRL), is an X-linked hereditary disorder characterized by bilateral congenital cataracts, proteinuria, and mental retardation [58]. As for its pathogenesis, a mutation in the OCRL-1 gene causes functional deficiency of the phosphatidylinositol 4,5-bisphosphate 5-phosphatase (encoded by the OCRL-1 gene), which fails to act on its substrate phosphatidylinositol 4,5-bisphosphate, leading to an increased level of the latter as well as abnormalities in cytoskeleton proteins such as gelsolin and α -actinin [55].

4. Other syndromes with hereditary cataracts and systemic abnormalities are summarized and listed in Table 4.2 [80–94].

4.1.2.2 Chromosomal Diseases

A chromosomal disease refers to a disorder caused by changes in the number or structure of chromosome (s), which are the carriers of genetic materials. Based upon the type of chromosome that is affected, chromosomal diseases

can be classified as autosomal disorder or sex chromosome disorder. Autosomal disorder is characterized mainly by congenital mental retardation and developmental delay, while sex chromosome disorder presents as sexual aplasia and mental retardation. Both autosomal and sex chromosome disorders might be associated with pediatric hereditary cataracts.

Autosomal Disorder

An autosomal disorder is a genetic condition caused by an error on chromosomes 1–22. Based upon the number and extent of the affected chromosomes, it can be subdivided into monosomy syndrome, trisomy syndrome, partial monosomy syndrome (mosaic), and partial trisomy syndrome (mosaic). The term monosomy is used to describe the absence of one member of a pair of homologous chromosomes; therefore, there are a total of 45 chromosomes in each cell of the body, rather than the usual 46. Trisomy refers to the presence of three homologous chromosomes, instead of the normal two chromosomes; thus, the trisomic cell contains 47 chromosomes. Partial trisomy means that there is an extra copy of a segment of the chromosome, and partial monosomy occurs when a segment of one of the homologous chromosomes is missing. Most autosomal diseases associated with congenital cataracts are trisomy syndromes, which are discussed in detail as follows:

1. *Trisomy 21 (Down syndrome)*

Trisomy 21, also known as Down syndrome or the older term mongolism, is one of the most common autosomal disorders. It is caused by an error in oocyte meiosis that results in the presence of an extra copy of chromosome 21. Patients with Down syndrome mainly present with intellectual and developmental disabilities (Table 4.2). Ophthalmic manifestations may include (1) strabismus (nearly half of patients have strabismus), (2) ametropia, (3) keratoconus, (4) glaucoma, (5) small palpebral fissures with a laterosuperior orientation and epicanthus, and (6) congenital cataracts (bilateral, typically white punctate opacities, but Y-shaped sutural, plume, or equatorial arch-like opacities may also be seen) [89]. These lens opacities may progress to total cataracts over time [95].

2. *Trisomy 13 (Patau syndrome)*

Trisomy 13 syndrome, also called Patau syndrome, can be complete or partial. Complete trisomy 13, accounting for 80 % of cases, refers to having three copies of chromosome 13 in every cell of the patient rather than the natural two copies. Partial trisomy 13 is less severe than the complete form and is usually due to a Robertsonian translocation (13; 14), which means that each cell carries an extra long arm of chromosome 13. Similar to trisomy 21 syndrome, advanced maternal age is a risk factor for Patau syndrome. Its clinical manifestations may be more serious than those of trisomy 21 syndrome, mainly including multi-organ defects and severe mental retardation (Table 4.2) [96]. Ocular abnormalities may include congenital cataracts, microphthalmia, uveal coloboma, persistent hyperplastic primary vitreous, retinal detachment, and optic nerve hypoplasia [96].

Sex Chromosome Disorder

A sex chromosome disorder is a genetic condition caused by an abnormal number or constitution of the 23rd chromosome (sex chromosome). Sex chromosome diseases associated with cataracts include Turner syndrome and Klinefelter syndrome.

1. *Turner syndrome*

Turner syndrome, also known as congenital ovarian dysgenesis syndrome, is named after Dr. Henry Turner who first described it in 1938. About 55 % of patients have the 45, XO karyotype; various mosaic karyotypes and structural aberrations have also been described. In mosaic cases, the symptoms are generally mild and most patients survive except for those who died from severe malformations in the neonatal period. The major clinical features of Turner syndrome are short stature and aberrant development of gonads, secondary sexual characteristics, and the skeleton, normal intelligence or mild intellectual disability [90]. Ophthalmic abnormalities may include (1) cataracts, typically Y-shaped sutural, posterior subcapsular punctate or flake-like opacities, (2) epicanthus and orbital hypertelorism, (3) peripheral corneal opacities, (4) hyperpigmentation on the surface of the iris, (5) strabismus, and (6) red-green color blindness [97].

2. *Klinefelter syndrome*

Klinefelter syndrome, also called congenital testicular dysgenesis, is named after Dr. Harry Klinefelter who first described it in 1942. Over 80 % of patients have a karyotype of 47, XXY, mosaic forms have also been described, and sometimes four or even five sex chromosomes may be present. Its clinical features include structural and functional abnormalities of the reproductive system, normal intelligence or mild intellectual disability, and susceptibility to diabetes, thyroid diseases, asthma, and breast cancer [111]. Ocular manifestations mainly include bilateral congenital cataracts, glaucoma, microphthalmia, and pupillary deformity [98].

4.2 Non-hereditary Pediatric Cataracts

Non-hereditary cataracts account for the smallest proportion (<10 %) of all pediatric cataract cases, but with diverse etiologies. They may be secondary to intrauterine infections, metabolic, traumatic, or iatrogenic factors.

4.2.1 Cataracts Secondary to Intrauterine Infections

4.2.1.1 *Congenital Rubella Syndrome*

Congenital rubella syndrome is caused by maternal infection with the rubella virus during pregnancy, with widely different clinical phenotypes. About 10–12 days after maternal infection, rubella virus crosses the placenta to infect the fetus. When infection occurs during the first trimester, fetal cells undergo mitotic arrest, leading to fetal death or abortion. Systemic manifestations of congenital rubella syndrome include cardiac defects, microcephalus, neonatal thrombocytopenic purpura, hepatosplenomegaly, interstitial pneumonia, meningitis, deafness, and mental retardation [112]. As patients enter adulthood, they are more prone to diabetes, thyroid diseases, or other autoimmune disorders [112]. Ocular abnormalities include congenital nuclear, lamellar, or total cataracts, often bilateral (about 80 % of patients) and progressive. Spontaneous absorption of cataracts might occur in a minority of cases. The mechanism for cataract formation is metabolic disturbance of the lens by the virus [113, 114]. Hypoplasia of the iris dilator muscle gives rise to poor pupil dilation. Other manifestations include

microphthalmia, corneal opacity, strabismus, and “salt-and-pepper” pigmentation of the retina [113, 114].

4.2.1.2 Other Intrauterine Infections

Other intrauterine infections mainly involve viral and parasitic infections. Common viral infections include measles, varicella, smallpox, herpes zoster, polio virus infection, cytomegalovirus infection, and infectious mononucleosis [115]. Parasitic infection is usually caused by toxoplasma or helminths [116].

4.2.2 Complicated Cataracts

Complicated cataracts refer to those caused by other non-hereditary eye diseases, mainly including uveitis, retinopathy of prematurity (ROP), and persistent fetal vasculature (PFV).

4.2.2.1 Uveitis

Anterior uveitis is the most common cause of pediatric complicated cataracts [117]. Once inflammation occurs, a large quantity of fibrinous exudates and inflammatory cells enter into the aqueous humor, affecting the aqueous metabolism and thus leading to cataracts. Besides, localized synechiae between the iris and the anterior surface of the lens may also result in cataract formation (Fig. 4.5) which begins in the anterior cortex. In children with intermediate uveitis, massive exudates at the pars plana may encompass the posterior surface of the lens, inducing posterior capsule degeneration and thereby the development of cataracts. Before the occurrence of lens opacities, there is a golden-brown “rice crust”-like reticular membrane in the Berger’s space behind the lens (Fig. 4.6).

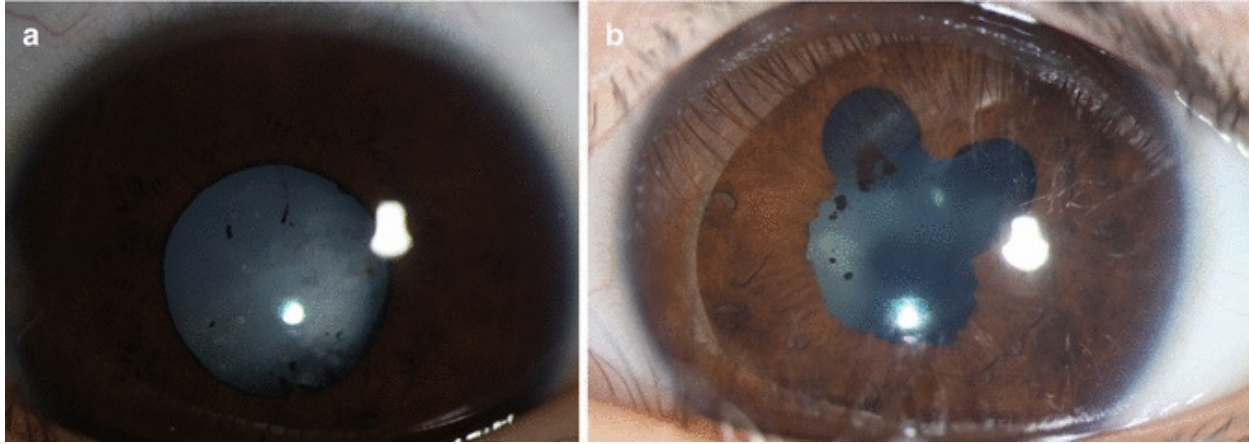


Fig. 4.5 Cataracts secondary to uveitis. (a) Sporadic iris pigments seen on the surface of the anterior lens capsule; (b) localized synechiae between the iris and the anterior surface of the lens results in pupil deformation

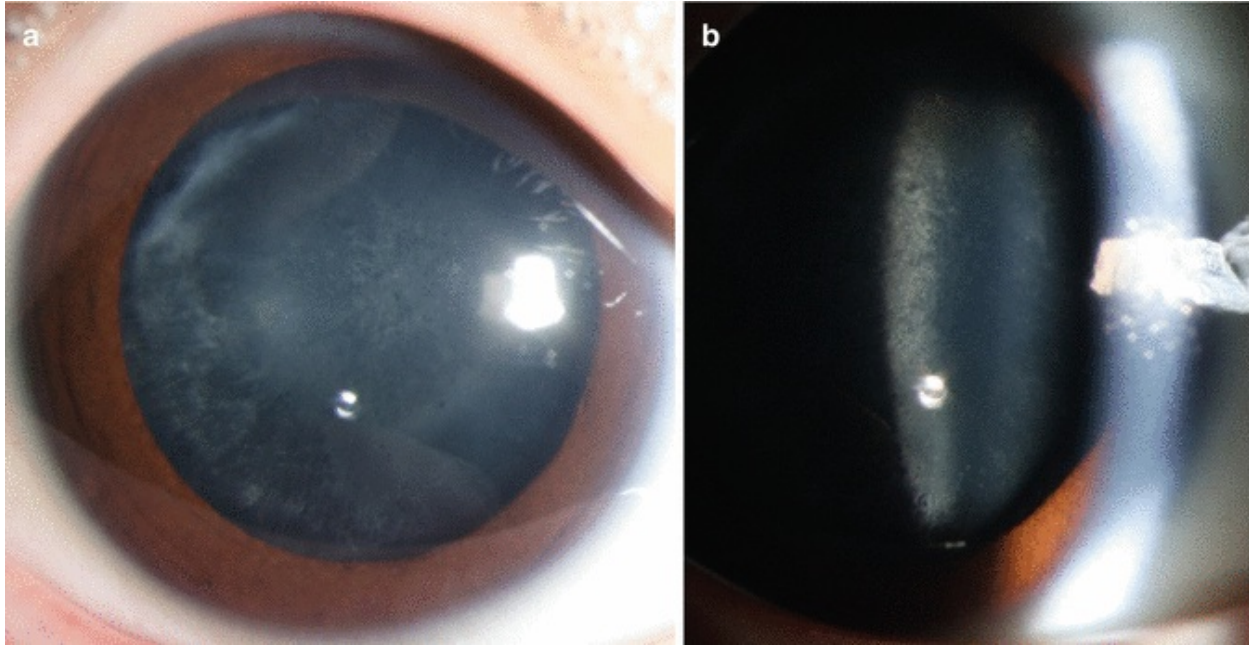


Fig. 4.6 Posterior subcapsular opacities secondary to intermediate uveitis. (a) Slit-lamp image under diffuse illumination; (b) slit illumination

4.2.2.2 *Retinopathy of Prematurity*

Patients with ROP are often complicated with cataracts, which are probably due to lens cell damage by oxygen free radicals. Premature infants usually suffer hypoxia after birth and require oxygen therapy, but inhalation of excessive oxygen may produce a large number of oxygen free radicals,

especially in the hypoxia-reoxygenation state. Moreover, a sudden withdrawal of oxygen delivery after high-concentration inhalation may induce tissue “relative hypoxia,” which induces generation of oxygen free radicals. Oxygen free radicals and their metabolites can cause injuries to the LECs and the lens proteins. Most of these injuries occur in the cicatricial phase of ROP, leading to retrolental fibrosis, organization, and consequently opacification.

4.2.2.3 *Persistent Fetal Vasculature (Persistent Hyperplastic Primary Vitreous)*

Persistent hyperplastic primary vitreous (PHPV) refers to a condition in which primary vitreous fibers and vascular remnants exist between the retinal surface and the lens (Fig. 4.7). PHPV is often accompanied by small ruptures in the posterior capsule, which may result in the development of cataracts. In 1997, Goldberg suggested renaming PHPV as persistent fetal vasculature (PFV), which accurately describes the anatomic and pathological features of this disorder. Therefore, PFV has now replaced the term PHPV [118]. Its pathogenesis, clinical manifestations, and treatment are discussed in detail in Chap. 19.

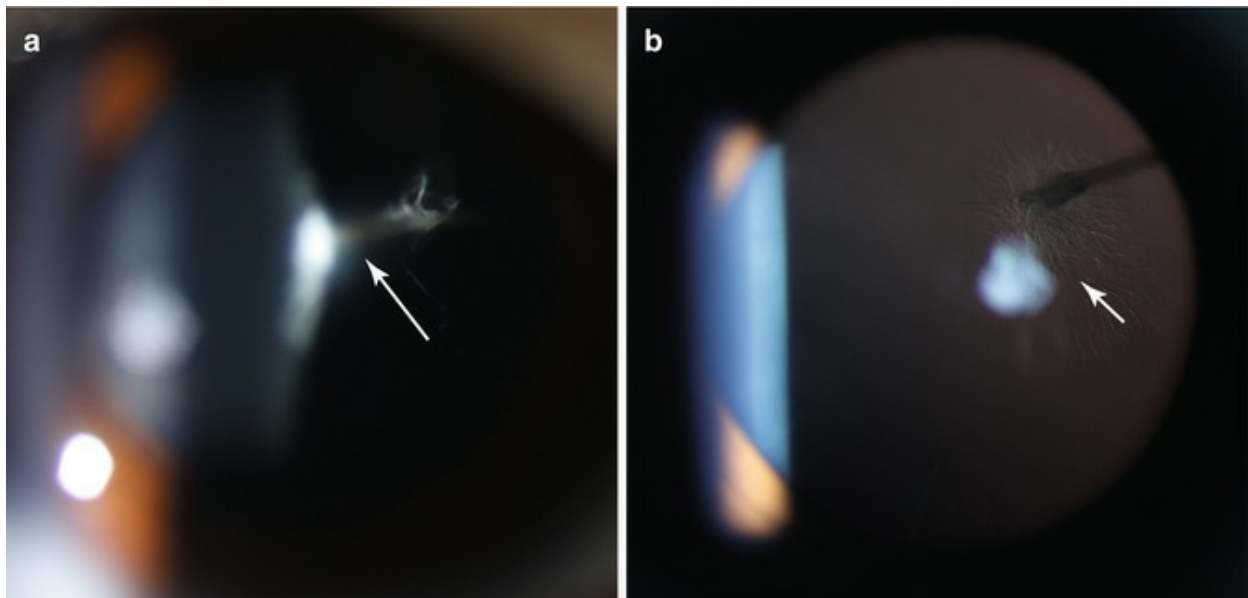


Fig. 4.7 Persistent fetal vasculature. (a) Retrolental hyperplastic strands of the primary vitreous (*arrow*); (b) posterior capsular opacities (*arrow*)

4.2.3 Metabolic Cataracts

Cataracts caused by a disturbance in the lens metabolism (e.g., hypocalcemia and diabetes) are called metabolic cataracts.

4.2.3.1 *Hypocalcemia*

Cataracts resulted from a low blood calcium level are named hypocalcemic cataracts. Due to their characteristic symptom of tetany, they are also known as tetany cataracts. Affected children are typically characterized by tetany, osteomalacia, and cataracts. As Ca^{2+} is essential for normal lens metabolism, so reduced serum calcium may interfere with lens metabolism, resulting in an increase in the capsular permeability, electrolyte imbalance, and consequently cataracts. This type of cataract is commonly seen in patients with myotonia, hypoparathyroidism, infantile acute renal failure, as well as other hypocalcemia-related disorders [119, 120]. In patients with congenital hypoparathyroidism, cataract generally progresses slowly, while in patients with autoimmune hypoparathyroidism accompanied by hepatic and renal failure, cataract may progress aggressively [121].

4.2.3.2 *Diabetes*

Pediatric diabetic cataract, a rare condition, mainly occurs in children with Type I diabetes mellitus. That is probably due to disturbance of the glucose metabolism in the lens. Glucose is mainly metabolized via glycolysis, pentose pathway, and tricarboxylic acid (TCA) cycle in the lens, while aldose reductase only takes an alternative role in the presence of abnormalities. In diabetic children, there is an increased glucose level in the lens which cannot be adequately metabolized via glycolysis, pentose pathway, and TCA cycle. The aldose reductase pathway is then activated by the redundant glucose to convert glucose into sorbitol and fructose, which tend to accumulate in the lens because of their poor permeability. Thus, the osmotic pressure in the lens is elevated, resulting in the influx of excessive water into the lens with subsequent lens swelling, degeneration, and finally opacification.

4.2.4 Traumatic Cataracts

4.2.4.1 *Cataracts Caused by Blunt Injuries*

With Intact Capsule (Fig. 4.8)

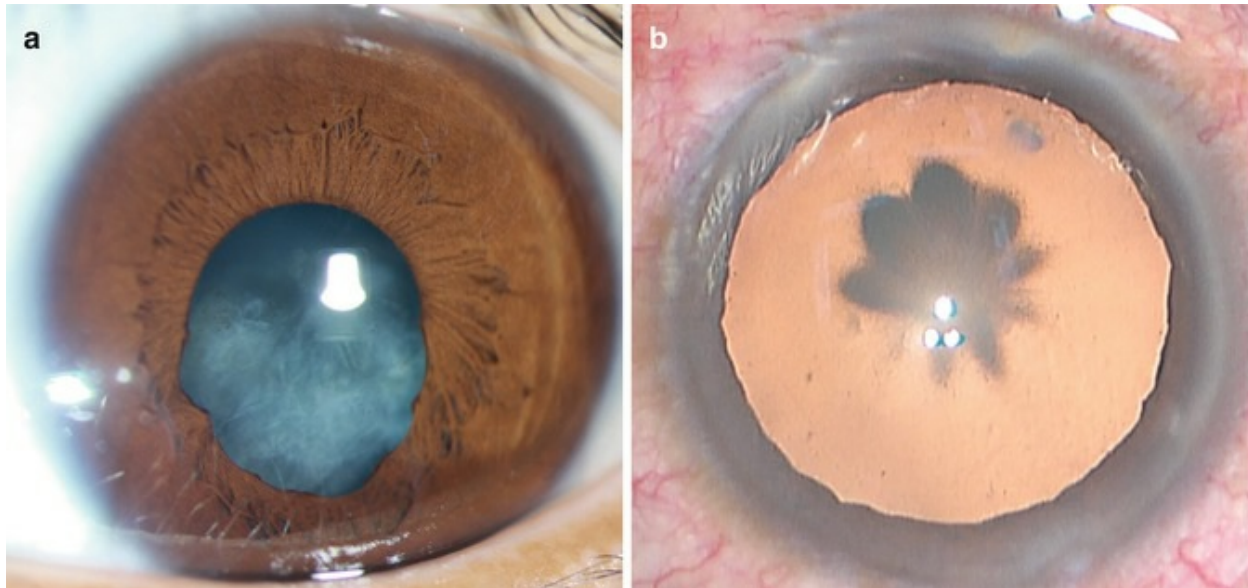


Fig. 4.8 Cataracts caused by blunt injury with an intact capsule. (a) Localized cortical opacities; (b) posterior subcapsular rosette-shaped opacities

Mild blunt trauma to the lens can lead to opacities of special morphologies when the lens capsule remains intact, mainly including Vossius ring and rosette-shaped opacities:

1. Vossius ring: It is due to the impression of the iris on the lens produced by the force of contusion. The iris pigment epithelial cells at the pupillary margin are imprinted on the surface of the lens anterior capsule, leaving a circular ring of stippled opacities. It has the same diameter as the contracted pupil and is often accompanied by anterior subcapsular punctate opacities. Generally speaking, it is visually insignificant.
2. Rosette-shaped opacities: Under the impact of both aqueous and vitreous humor, contrecoup injury to the lens may lead to the formation of rosette-shaped opacities between the LECs or capsule and lens fibers. They can be seen on the anterior capsule, the posterior capsule, or in the subcapsular region, most commonly as posterior subcapsular opacities (Fig. 4.8b).

With Ruptured Capsule

Capsular rupture often occurs following severe blunt trauma, and the aqueous humor can flow into the lens via the rupture, causing lens fiber edema, degeneration, and opacification. If the rupture is small or there is a synechia of the iris to the capsule, the ruptured capsule may close up rapidly, and localized lens opacities may be formed. If the rupture is large, the aqueous humor may continuously flow into the lens, resulting in rapid opacification and progression into total cataracts (Fig. 4.9).

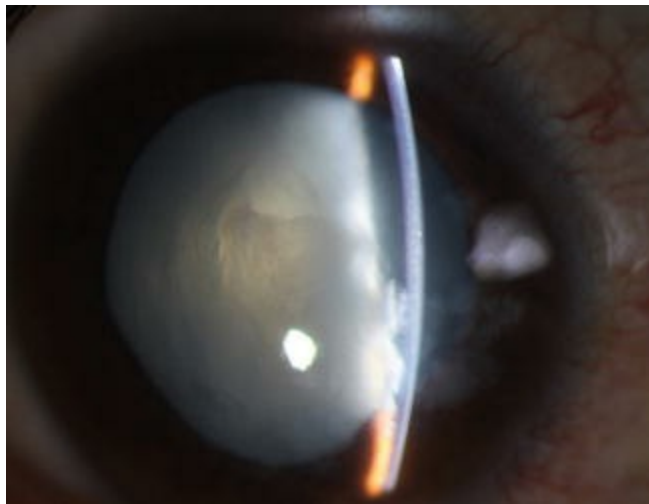


Fig. 4.9 Cataracts caused by blunt injury with ruptured capsule. The lens cortex dislocates into the anterior chamber via the rupture

4.2.4.2 Cataracts Caused by Penetrating Injuries

When a sharp object like a knife, scissors, or bodkin accidentally penetrates the lens, the injury can cause cataract. Such penetrating injuries are especially common in younger children. In most cases, the rupture is small or there is a synechia of the iris to the capsule; the ruptured capsule may close up rapidly and only result in localized cataracts. But if the rupture is large, the aqueous humor may continuously flow into the lens, resulting in rapid progression into total cataracts (Fig. 4.10).

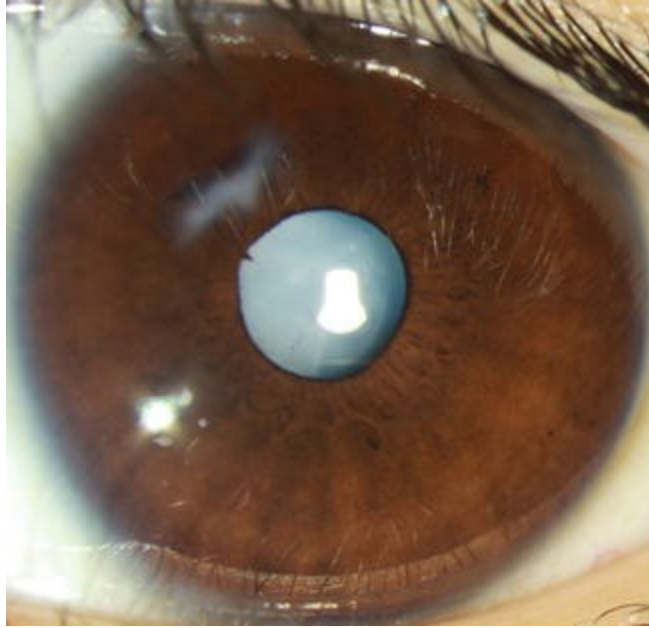


Fig. 4.10 Cataracts caused by penetrating injury. Total cataract is developed after penetrating injury, with a scar left on the cornea

4.2.4.3 Electric Cataracts

Electric cataracts may occur as a result of electric shock or lightning strike. The voltage which causes cataract ranges from 220 to 5000 V. The incidence is reported to be 0.2–8 %, depending on causative factors such as the electrical source, tissue sensitivity, site of contact, as well as the pathway the electrical current travels through the body [122]. Its pathogenesis has not been fully understood, possibly due to impairment of the LECs, iritis, circulatory disturbance, or mechanical effect (e.g., capsular rupture, local heat effect). Electrical burn can cause formation of anterior subcapsular scarring (Fig. 4.11), and histopathological findings indicate anterior subcapsular fibroblast proliferation and hyaline deposits.

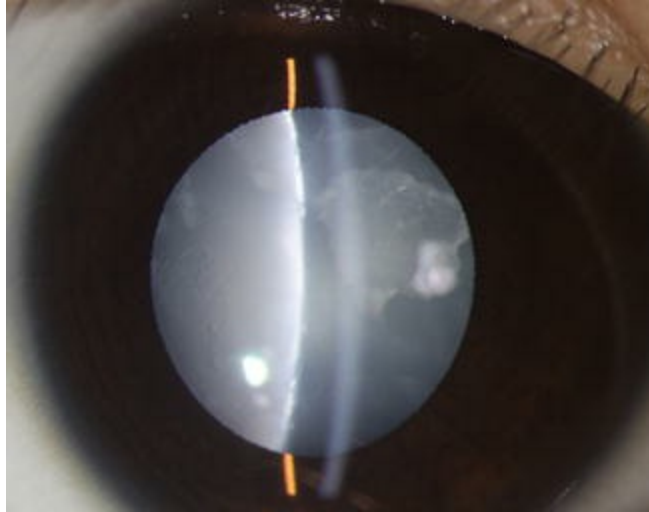


Fig. 4.11 Electric cataracts. Slit-lamp biomicroscopy reveals well-defined white opacities beneath the anterior capsule

4.2.5 Iatrogenic Cataracts

4.2.5.1 Radiation

Exposure to infrared rays, ultraviolet rays, X-rays, γ -rays, charged particles, fast neutrons, or white light may result in radiation cataracts [123]. Such radiation may induce oxidative damage to the LECs and thereby the development of cataracts. The LECs are very sensitive to radiation exposure, and the level of sensitivity is inversely correlated with age, which means that younger children are more susceptible to LECs injuries. The oxidative damage to cellular DNA can be transmitted in DNA replication and gradually accumulates. Moreover, abnormal migration of the impaired LECs leaves the lens surface acellular. Oxygen in the external environment may enter into the lens and produce oxygen free radicals, resulting in further oxidative damage to lens proteins and their coagulation and thereby cataract formation [123]. The injury is dose- and time-dependent, when the radiation exposure is over 15 Gy, the incidence of cataracts can be as high as 50 %.

Radiation cataracts are commonly seen in leukemic children receiving radiotherapy, which may occur after 1–2 years of treatment. Once a cataract begins, it can progress rapidly. Additionally, in children with ROP, laser retinal photocoagulation may also lead to lens injuries and thus cataracts [124].

4.2.5.2 Medications

Cataracts induced by topical or systemic medications have gained an increasing attention among clinicians. Long-term use of drugs such as glucocorticoids, miotics, and chlorpromazine has been shown to contribute to the development of cataracts.

Glucocorticoids

In children diagnosed with autoimmune diseases or any other disorder requiring long-term use of high-dose glucocorticoids, there is an increase in both plasma and aqueous glucose levels, leading to an increased ion permeability, decreased Na^+ - K^+ -ATPase activity, activation of alternative metabolic pathways of glucose, and thus formation of posterior subcapsular fine punctate or stripe-shaped opacities. Long-term use of topical glucocorticoids for treating juvenile congenital arthritis with uveitis has been associated with an increased risk of cataracts, but when the frequency of dosing is no more than three times per day, the risk is much lower [125].

Miotics

By inhibiting oxidative phosphorylation, anticholinesterase miotics have been shown to decrease the glucose and ATP levels while increase the lactate and phosphate levels, resulting in lens swelling and opacification as well as anterior subcapsular small vesicles.

Phenothiazines

Chlorpromazine may cause cataracts by absorbing ultraviolet radiation to generate oxygen free radicals and induce oxidative damage to the lens, or by binding to melanin to form pigmentations. Such cataracts are typically characterized by stellate opacities at the pupillary area.

Others

Long-term exposure to certain chemicals (e.g., trinitrotoluene), fluorine, sodium cyanate for treating sickle cell anemia, mitotic inhibitors (e.g. busulfan), the anesthetic agent tetracaine, and antiepileptic agent carbamazepine has been shown to contribute to the development of cataracts.

4.3 Idiopathic Pediatric Cataracts

Despite comprehensive history taking clinical and laboratory examination, the etiology of more than half of cataracts cannot be determined, and these cataracts fall into the category of idiopathic cataracts. In the absence of any other ocular abnormalities, systemic disorders, or significant genetic or environmental factors, it is speculated that multiple factors may contribute to the development of lens opacities. Some cataracts may be caused by a spontaneous genetic mutation, while others may be associated with a systemic condition which is ignored or difficult to identify due to its latent or mild symptoms. Along with the advances in genetic testing, it would be possible in the near future to detect spontaneous genetic mutations or abnormalities in the regulation of gene expression by using novel techniques such as whole-genome sequencing, which should help to determine the underlying etiology of these cataracts. Thus, it is believed that the proportion of idiopathic cataracts will decrease gradually over time.

4.4 Pediatric Ectopia Lentis

The etiology, clinical presentations, and management of pediatric ectopia lentis are discussed in detail in Chap. 17.

4.5 Genetic Diagnosis of Pediatric Cataracts

Hereditary cataracts account for a large portion of all pediatric cases, often as a monogenic disease. They are usually inherited in an autosomal dominant fashion, autosomal recessive and X-linked inheritances have also been described. Based on the available literature, it has been well demonstrated that the following genes are cataract related: crystallin genes, membrane protein-associated genes, regulatory genes of transcription factors, cytoskeletal protein genes, GCNT2 gene, growth factor genes, ferritin light-chain gene, and chromatin-modifying protein genes. In recent years, owing to the development of molecular biology, studies on hereditary cataract-related genes have extended from pathogenic gene mapping and mutation screening to the underlying mechanisms of mutation.

4.5.1 Recent Advances in Genetic Diagnosis

Expansion of the mutation spectrum in hereditary cataracts is inseparable

from the development and application of linkage analysis, direct sequencing of candidate genes, as well as whole-exome and whole-genome sequencing based on high-throughput sequencing technologies. In particular, the emergence of the second-generation sequencing and gene chip technologies, characterized by high-throughput and automation, has made an enormous contribution to the development of genetic diagnosis. Gene chip is a novel high-throughput technology in the field of molecular biology that has undergone rapid development in recent years. The basic principle is hybridization of a nucleic acid sample to a very large set of oligonucleotide or gene fragment probes, which are orderly attached to a solid support. A microarray chip may contain tens of thousands of matrix spots, each representing a single gene. Through PCR amplification or in vitro transcription, a fluorescence marker is added into the sample DNA/RNA followed by base-pairing hybridization. The chip is then scanned using a fluorescence detection system, and the fluorescence signals for each probe are analyzed and compared to obtain useful information. Gene chip technology has several advantages:(1) high sensitivity and accuracy, (2) fast and convenient, and (3) simultaneous detection of multiple pathogenic loci. With the improvement of diagnostic methods as well as reduction in sequencing cost, we believe that gene sequencing may be included as a part of the routine “health check-up” in the near future, which will make the genetic diagnosis and treatment of hereditary cataracts possible.

4.5.2 Prenatal Genetic Diagnosis of Hereditary Cataracts

Prenatal genetic diagnosis of hereditary cataracts is very important in timely identification of affected fetuses and prevention of infants born with serious visual impairment. Traditionally, an invasive technique was the only option to collect samples for the detection of pathogenic genes, such as transabdominal chorionic villus sampling, amniocentesis, and percutaneous umbilical vein puncture. The latest discovery of free fetal DNA in maternal plasma makes noninvasive prenatal diagnosis possible. By detecting and analyzing the fetal DNA from maternal plasma, prenatal diagnosis can be accurate, efficient, and noninvasive.

China has a rich resource of clinical data for pediatric cataracts. Rational application of genetic diagnostic techniques may not only help to fully

understand the pathogenesis of hereditary cataracts but also lay a foundation for future gene therapy so as to tackle the root cause and to eventually “cure” hereditary cataracts.

4.6 Summary

The etiology of pediatric lens disorder is extremely complicated, and the pathogenesis of a large number of them is currently unclear. It is essential to better understand the disease-causing genes or other molecular mechanisms of lens disorder, which in turn will facilitate the development of appropriate preventive and therapeutic strategies. With the emergence of the high-throughput sequencing and gene chip technologies, more and more genetic mutations or abnormalities will be identified, and gene therapy may be used to treat hereditary lens disorders in the future.

References

1. Haargaard B, Wohlfahrt J, Fledelius HC, et al. A nationwide Danish study of 1027 cases of congenital/infantile cataracts: etiological and clinical classifications. *Ophthalmology*. 2004;111(12):2292–8.
[\[PubMed\]](#)
2. Hejtmancik JF. Congenital cataracts and their molecular genetics. *Semin Cell Dev Biol*. 2008;19(2):134–49.
[\[PubMed\]](#)
3. Bera S, Abraham EC. The alphaA-crystallin R116C mutant has a higher affinity for forming heteroaggregates with alphaB-crystallin. *Biochemistry*. 2002;41:297–305.
[\[PubMed\]](#)
4. Kumar LV, Ramakrishna T, Rao CM. Structural and functional consequences of the mutation of a conserved arginine residue in alphaA and alphaB crystallins. *J Biol Chem*. 1999;274:24137–41.
[\[PubMed\]](#)
5. Mackay DS, Andley UP, Shiels A. Cell death triggered by a novel mutation in the alphaA-crystallin gene underlies autosomal dominant cataract linked to chromosome 21q. *Eur J Hum Genet*. 2003;11:784–93.
[\[PubMed\]](#)
6. Singh D, Raman B, Ramakrishna T, et al. Mixed oligomer formation between human alphaA-crystallin and its cataract-causing G98R mutant: structural, stability and functional differences. *J Mol Biol*. 2007;373:1293–304.
[\[PubMed\]](#)

7. Sun W, Xiao X, Li S, et al. Mutational screening of six genes in Chinese patients with congenital cataract and microcornea. *Mol Vis.* 2011;17:1508–13.
[\[PubMed\]](#)[\[PubMedCentral\]](#)
8. Conley YP, Erturk D, Keeverline A, et al. A juvenile-onset, progressive cataract locus on chromosome 3q21-q22 is associated with a missense mutation in the beaded filament structural protein-2. *Am J Hum Genet.* 2000;66:1426–31.
[\[PubMed\]](#)[\[PubMedCentral\]](#)
9. Zhang Q, Guo X, Xiao X, et al. Clinical description and genome wide linkage study of Y-sutural cataract and myopia in a Chinese family. *Mol Vis.* 2004;10:890–900.
[\[PubMed\]](#)
10. Muller M, Bhattacharya SS, Moore T, et al. Dominant cataract formation in association with a vimentin assembly disrupting mutation. *Hum Mol Genet.* 2009;18:1052–7.
[\[PubMed\]](#)
11. Ramachandran RD, Perumalsamy V, Hejtmancik JF. Autosomal recessive juvenile onset cataract associated with mutation in BFSP1. *Hum Genet.* 2007;121:475–82.
[\[PubMed\]](#)
12. Vanita V, Singh JR, Hejtmancik JF, et al. A novel fan-shaped cataract-microcornea syndrome caused by a mutation of CRYAA in an Indian family. *Mol Vis.* 2006;12:518–22.
[\[PubMed\]](#)
13. Hansen L, Yao W, Eiberg H, et al. Genetic heterogeneity in microcornea-cataract: five novel mutations in CRYAA, CRYGD, and GJA8. *Invest Ophthalmol Vis Sci.* 2007;48:3937–44.
[\[PubMed\]](#)
14. Pras E, Frydman M, Levy-Nissenbaum E, et al. A nonsense mutation (W9X) in CRYAA causes autosomal recessive cataract in an inbred Jewish Persian family. *Invest Ophthalmol Vis Sci.* 2004;41:3511–5.
15. Berry V, Francis P, Reddy MA, et al. Alpha-B crystallin gene (CRYAB) mutation causes dominant congenital posterior polar cataract in humans. *Am J Hum Genet.* 2001;69:1141–5.
[\[PubMed\]](#)[\[PubMedCentral\]](#)
16. Yang Z, Li Q, Ma Z, et al. A G → T splice site mutation of CRYBA1/A3 associated with autosomal dominant suture cataracts in a Chinese family. *Mol Vis.* 2011;17:2065–71.
[\[PubMed\]](#)[\[PubMedCentral\]](#)
17. Yang Z, Su D, Li Q, et al. A novel T → G splice site mutation of CRYBA1/A3 associated with autosomal dominant nuclear cataracts in a Chinese family. *Mol Vis.* 2012;18:1283–8.
[\[PubMed\]](#)[\[PubMedCentral\]](#)
18. Devi RR, Yao W, Vijayalakshmi P, et al. Crystallin gene mutations in Indian families with inherited pediatric cataract. *Mol Vis.* 2008;14:1157–70.
[\[PubMed\]](#)[\[PubMedCentral\]](#)
19. Gu Z, Ji B, Wan C, et al. A splice site mutation in CRYBA1/A3 causing autosomal dominant posterior polar cataract in a Chinese pedigree. *Mol Vis.* 2010;16:154–60.

[\[PubMed\]](#)[\[PubMedCentral\]](#)

20. Billingsley G, Santhiya ST, Paterson AD, et al. CRYBA4, a novel human cataract gene, is also involved in microphthalmia. *Am J Hum Genet.* 2006;79(4):702–9.
[\[PubMed\]](#)[\[PubMedCentral\]](#)
21. Zhou G, Zhou N, Hu S, et al. A missense mutation in CRYBA4 associated with congenital cataract and microcornea. *Mol Vis.* 2010;16:1019–24.
[\[PubMed\]](#)[\[PubMedCentral\]](#)
22. Mackay DS, Boskovska OB, Knopf HL, et al. A nonsense mutation in CRYBB1 associated with autosomal dominant cataract linked to human chromosome 22q. *Am J Hum Genet.* 2002;71(5):1216–21.
[\[PubMed\]](#)[\[PubMedCentral\]](#)
23. Meyer E, Rahman F, Owens J, et al. Initiation codon mutation in betaB1-crystallin (CRYBB1) associated with autosomal recessive nuclear pulverulent cataract. *Mol Vis.* 2009;2009(15):1014–9.
24. Yang J, Zhu Y, Gu F, et al. A novel nonsense mutation in CRYBB1 associated with autosomal dominant congenital cataract. *Mol Vis.* 2008;14:727–31.
[\[PubMed\]](#)[\[PubMedCentral\]](#)
25. Wang L, Lin H, Gu J, et al. Autosomal-dominant cerulean cataract in a chinese family associated with gene conversion mutation in beta-B2-crystallin. *Ophthalmic Res.* 2009;41:148–53.
[\[PubMed\]](#)
26. Yao K, Tang X, Shentu X, et al. Progressive polymorphic congenital cataract caused by a CRYBB2 mutation in a Chinese family. *Mol Vis.* 2005;11:758–63.
[\[PubMed\]](#)
27. Santhiya ST, Manisastry SM, Rawlley D, et al. Mutation analysis of congenital cataracts in Indian families: identification of SNPS and a new causative allele in CRYBB2 gene. *Invest Ophthalmol Vis Sci.* 2004;45:3599–607.
[\[PubMed\]](#)
28. Pauli S, Soker T, Klopp N, et al. Mutation analysis in a German family identified a new cataract-causing allele in the CRYBB2 gene. *Mol Vis.* 2007;13:962–7.
[\[PubMed\]](#)[\[PubMedCentral\]](#)
29. Weisschuh N, Aisenbrey S, Wissinger B, et al. Identification of a novel CRYBB2 missense mutation causing congenital autosomal dominant cataract. *Mol Vis.* 2012;18:174–80.
[\[PubMed\]](#)[\[PubMedCentral\]](#)
30. Chen W, Chen X, Hu Z, et al. A missense mutation in CRYBB2 leads to progressive congenital membranous cataract by impacting the solubility and function of β B2-crystallin. *PLoS One.* 2013;8(11):e81290.
[\[PubMed\]](#)[\[PubMedCentral\]](#)
31. Guo Y, Su D, Li Q, et al. A nonsense mutation of CRYGC associated with autosomal dominant congenital nuclear cataracts and microcornea in a Chinese pedigree. *Mol Vis.* 2012;18:1874–80.
[\[PubMed\]](#)[\[PubMedCentral\]](#)

32. Khan AO, Aldahmesh MA, Ghadhfan FE, et al. Founder heterozygous P23T CRYGD mutation associated with cerulean (and coralliform) cataract in 2 Saudi families. *Mol Vis.* 2007;15:1407–11.
33. Burdon KP, Wirth MG, Mackey DA, et al. Investigation of crystallin genes in familial cataract, and report of two disease associated mutations. *Br J Ophthalmol.* 2004;88:79–83.
[\[PubMed\]](#)[\[PubMedCentral\]](#)
34. Mackay DS, Andley UP, Shiels A. A missense mutation in the gammaD crystallin gene (CRYGD) associated with autosomal dominant “coral-like” cataract linked to chromosome 2q. *Mol Vis.* 2004;10:155–62.
[\[PubMed\]](#)
35. Nandrot E, Slingsby C, Basak A, et al. Gamma-D crystallin gene (CRYGD) mutation causes autosomal dominant congenital cerulean cataracts. *J Med Genet.* 2003;40:262–7.
[\[PubMed\]](#)[\[PubMedCentral\]](#)
36. Santhiya ST, Shyam Manohar M, Rawlley D, et al. Novel mutations in the gamma-crystallin genes cause autosomal dominant congenital cataracts. *J Med Genet.* 2002;39:352–8.
[\[PubMed\]](#)[\[PubMedCentral\]](#)
37. Kmoch S, Brynda J, Asfaw B, et al. Link between a novel human gammaD-crystallin allele and a unique cataract phenotype explained by protein crystallography. *Hum Mol Genet.* 2000;9:1779–86.
[\[PubMed\]](#)
38. Zhang LY, Gong B, Tong JP, et al. A novel gammaD-crystallin mutation causes mild changes in protein properties but leads to congenital coralliform cataract. *Mol Vis.* 2009;15:1521–9.
[\[PubMed\]](#)[\[PubMedCentral\]](#)
39. Shentu X, Yao K, Xu W, et al. Special fasciculiform cataract caused by a mutation in the gammaD-crystallin gene. *Mol Vis.* 2004;10:233–9.
[\[PubMed\]](#)
40. Gu F, Li R, Ma XX, et al. A missense mutation in the gammaD-crystallin gene CRYGD associated with autosomal dominant congenital cataract in a Chinese family. *Mol Vis.* 2006;12:26–31.
[\[PubMed\]](#)
41. Yu LC, Twu YC, Chou ML, et al. The molecular genetics of the human I locus and molecular background explain the partial association of the adult i phenotype with congenital cataracts. *Blood.* 2003;101:2081–8.
[\[PubMed\]](#)
42. Addison PK, Berry V, Holden KR, et al. A novel mutation in the connexin 46 gene (GJA3) causes autosomal dominant zonular pulverulent cataract in a Hispanic family. *Mol Vis.* 2006;12:791–5.
[\[PubMed\]](#)
43. Hansen L, Yao W, Eiberg H, et al. The congenital “ant-egg” cataract phenotype is caused by a missense mutation in connexin46. *Mol Vis.* 2006;12:1033–9.

[\[PubMed\]](#)

44. Shiels A, Mackay D, Ionides A, et al. A missense mutation in the human connexin50 gene (GJA8) underlies autosomal dominant “zonular pulverulent” cataract, on chromosome 1q. *Am J Hum Genet.* 1998;62:526–32.
[\[PubMed\]](#)[\[PubMedCentral\]](#)
45. Banks EA, Toloue MM, Shi Q, et al. Connexin mutation that causes dominant congenital cataracts inhibits gap junctions, but not hemichannels, in a dominant negative manner. *J Cell Sci.* 2009;122:378–88.
[\[PubMed\]](#)[\[PubMedCentral\]](#)
46. Arora A, Minogue PJ, Liu X, et al. A novel GJA8 mutation is associated with autosomal dominant lamellar pulverulent cataract: further evidence for gap junction dysfunction in human cataract. *J Med Genet.* 2006;43:e249.51.
47. Ke T, Wang QK, Ji B, et al. Novel HSF4 mutation causes congenital total white cataract in a Chinese family. *Am J Ophthalmol.* 2006;142(2):298–303.
[\[PubMed\]](#)
48. Forshew T, Johnson CA, Khaliq S, et al. Locus heterogeneity in autosomal recessive congenital cataracts: linkage to 9q and germline HSF4 mutations. *Hum Genet.* 2005;117:452–9.
[\[PubMed\]](#)
49. Pras E, Levy-Nissenbaum E, Bakhan T, et al. A missense mutation in the LIM2 gene is associated with autosomal recessive presenile cataract in an inbred Iraqi Jewish family. *Am J Hum Genet.* 2002;70:1363–7.
[\[PubMed\]](#)[\[PubMedCentral\]](#)
50. Ponnamp SP, Ramesha K, Tejwani S, et al. A missense mutation in LIM2 causes autosomal recessive congenital cataract. *Mol Vis.* 2008;14:1204–8.
[\[PubMed\]](#)[\[PubMedCentral\]](#)
51. Jamieson RV, Munier F, Balmer A, et al. Pulverulent cataract with variably associated microcornea and iris coloboma in a MAF mutation family. *Br J Ophthalmol.* 2003;87:411–2.
[\[PubMed\]](#)[\[PubMedCentral\]](#)
52. Jamieson RV, Perveen R, Kerr B, et al. Domain disruption and mutation of the bZIP transcription factor, MAF, associated with cataract, ocular anterior segment dysgenesis and coloboma. *Hum Mol Genet.* 2002;11:33–42.
[\[PubMed\]](#)
53. Berry V, Francis P, Kaushal S, et al. Missense mutations in MIP underlie autosomal dominant ‘polymorphic’ and lamellar cataracts linked to 12q. *Nat Genet.* 2000;25:15–7.
[\[PubMed\]](#)
54. Brooks SP, Ebenezer ND, Poopalasundaram S, et al. Identification of the gene for Nance-Horan syndrome (NHS). *J Med Genet.* 2004;41:768–71.
[\[PubMed\]](#)[\[PubMedCentral\]](#)
55. Kawano T, Indo Y, Nakazato H, et al. Oculocerebrorenal syndrome of Lowe: three mutations in the OCRL1 gene derived from three patients with different phenotypes. *Am J Med Genet.*

1998;77:348–55.

[\[PubMed\]](#)

56. Jin C, Wang Q, Li J, et al. A recurrent PAX6 mutation is associated with aniridia and congenital progressive cataract in a Chinese family. *Mol Vis.* 2012;18:465–70.
[\[PubMed\]](#)[\[PubMedCentral\]](#)
57. Brown A, McKie M, van Heyningen V, et al. The Human PAX6 Mutation Database. *Nucleic Acids Res.* 1998;26:259–64.
[\[PubMed\]](#)[\[PubMedCentral\]](#)
58. Cai F, Zhu J, Chen W, et al. A novel PAX6 mutation in a large Chinese family with aniridia and congenital cataract. *Mol Vis.* 2010;16:1141–5.
[\[PubMed\]](#)[\[PubMedCentral\]](#)
59. Dansault A, David G, Schwartz C, et al. Three new PAX6 mutations including one causing an unusual ophthalmic phenotype associated with neurodevelopmental abnormalities. *Mol Vis.* 2007;13:511–23.
[\[PubMed\]](#)[\[PubMedCentral\]](#)
60. Jia X, Guo X, Xiao X, et al. A novel mutation of PAX6 in Chinese patients with new clinical features of Peters' anomaly. *Mol Vis.* 2010;16:676–81.
[\[PubMed\]](#)[\[PubMedCentral\]](#)
61. Feng J, Smith DL, Smith JB. Human lens beta-crystallin solubility. *J Biol Chem.* 2000;275:11585–90.
[\[PubMed\]](#)
62. Reddy MA, Francis PJ, Berry V, et al. Molecular genetic basis of inherited cataract and associated phenotypes. *Surv Ophthalmol.* 2004;49:300–15.
[\[PubMed\]](#)
63. Liu BF, Liang JJ. Interaction and biophysical properties of human lens Q155* betaB2-crystallin mutant. *Mol Vis.* 2005;11:321–7.
[\[PubMed\]](#)
64. Vanita V, Singh D. A missense mutation in CRYGD linked with autosomal dominant congenital cataract of aculeiform type. *Mol Cell Biochem.* 2012;368:167–72.
[\[PubMed\]](#)
65. Pande A, Pande J, Asherie N, et al. Crystal cataracts: human genetic cataract caused by protein crystallization. *Proc Natl Acad Sci U S A.* 2001;98:6116–20.
[\[PubMed\]](#)[\[PubMedCentral\]](#)
66. Sun W, Xiao X, Li S, et al. Mutation analysis of 12 genes in Chinese families with congenital cataracts. *Mol Vis.* 2011;17:2197–206.
[\[PubMed\]](#)[\[PubMedCentral\]](#)
67. Mackay D, Ionides A, Kibar Z, et al. Connexin46 mutations in autosomal dominant congenital cataract. *Am J Hum Genet.* 1999;64:1357–64.
[\[PubMed\]](#)[\[PubMedCentral\]](#)

68. Minogue PJ, Liu X, Ebihara L, et al. An aberrant sequence in a connexin46 mutant underlies congenital cataracts. *J Biol Chem.* 2005;280:40788–95.
[\[PubMed\]](#)[\[PubMedCentral\]](#)
69. Thomas BC, Minogue PJ, Valiunas V, et al. Cataracts are caused by alterations of a critical N-terminal positive charge in connexin50. *Invest Ophthalmol Vis Sci.* 2008;49:2549–56.
[\[PubMed\]](#)[\[PubMedCentral\]](#)
70. Minogue PJ, Tong JJ, Arora A, et al. A mutant connexin50 with enhanced hemichannel function leads to cell death. *Invest Ophthalmol Vis Sci.* 2009;50:5837–45.
[\[PubMed\]](#)[\[PubMedCentral\]](#)
71. DeRosa AM, Mese G, Li L, et al. The cataract causing Cx50-S50P mutant inhibits Cx43 and intercellular communication in the lens epithelium. *Exp Cell Res.* 2009;315:1063–75.
[\[PubMed\]](#)[\[PubMedCentral\]](#)
72. Berthoud VM, Minogue PJ, Guo J, et al. Loss of function and impaired degradation of a cataract-associated mutant connexin50. *Eur J Cell Biol.* 2003;82:209–21.
[\[PubMed\]](#)[\[PubMedCentral\]](#)
73. Varadaraj K, Kumari SS, Patil R, et al. Functional characterization of a human aquaporin 0 mutation that leads to a congenital dominant lens cataract. *Exp Eye Res.* 2008;87:9–21.
[\[PubMed\]](#)[\[PubMedCentral\]](#)
74. Shiels A, King JM, Mackay DS, et al. Refractive defects and cataracts in mice lacking lens intrinsic membrane protein-2. *Invest Ophthalmol Vis Sci.* 2007;48:500–8.
[\[PubMed\]](#)
75. Ma X, Li FF, Wang SZ, et al. A new mutation in BFSP2 (G1091A) causes autosomal dominant congenital lamellar cataracts. *Mol Vis.* 2008;14:1906–11.
[\[PubMed\]](#)[\[PubMedCentral\]](#)
76. Bagchi M, Katar M, Maisel H. Heat shock proteins of adult and embryonic human ocular lenses. *J Cell Biochem.* 2002;84:278–84.
[\[PubMed\]](#)
77. Hartl FU. Molecular chaperones in cellular protein folding. *Nature.* 1996;381:571–9.
[\[PubMed\]](#)
78. Bu L, Jin Y, Shi Y, et al. Mutant DNA-binding domain of HSF4 is associated with autosomal dominant lamellar and Marner cataract. *Nat Genet.* 2002;31:276–8.
[\[PubMed\]](#)
79. Shi X, Cui B, Wang Z, et al. Removal of Hsf4 leads to cataract development in mice through down-regulation of gamma S-crystallin and Bfsp expression. *BMC Mol Biol.* 2009;10:10.
[\[PubMed\]](#)[\[PubMedCentral\]](#)
80. Colville DJ, Savige J. Alport syndrome. A review of the ocular manifestations. *Ophthalmic Genet.* 1997;18(4):161–73.
[\[PubMed\]](#)
- 81.

- Hakamada S, Sobue G, Watanabe K, et al. Peripheral neuropathy in Marinesco-Sjögren syndrome. *Brain Dev.* 1981;3(4):403–6.
[\[PubMed\]](#)
82. Kretzer FL, Hittner HM, Mehta RS. Ocular manifestations of the Smith-Lemli-Opitz syndrome. *Arch Ophthalmol.* 1981;99(11):2000–6.
[\[PubMed\]](#)
83. Riise R. Visual function in Laurence-Moon-Bardet-Biedl syndrome. A survey of 26 cases. *Acta Ophthalmol Suppl.* 1987;182:128–31.
[\[PubMed\]](#)
84. Schachat AP, Maumenee IH. Bardet-Biedl syndrome and related disorders. *Arch Ophthalmol.* 1982;100(2):285–8.
[\[PubMed\]](#)
85. McElvanney AM, Wooldridge WJ, Khan AA, et al. Ophthalmic management of Cockayne’s syndrome. *Eye.* 1996;10(Pt 1):61–4.
[\[PubMed\]](#)
86. Konradsen TR, Zetterström C. A descriptive study of ocular characteristics in Marfan syndrome. *Acta Ophthalmol.* 2013;91(8):751–5.
[\[PubMed\]](#)
87. Faivre L, Dollfus H, Lyonnet S, et al. Clinical homogeneity and genetic heterogeneity in Weill-Marchesani syndrome. *Am J Med Genet A.* 2003;123A(2):204–7.
[\[PubMed\]](#)
88. Snead MP, McNinch AM, Poulson AV, et al. Stickler syndrome, ocular-only variants and a key diagnostic role for the ophthalmologist. *Eye (Lond).* 2011;25(11):1389–400.
89. Bardelli AM, Lasorella G, Barberi L, et al. Ocular manifestations in Kniest syndrome, Smith-Lemli-Opitz syndrome, Hallermann-Streiff-François syndrome, Rubinstein-Taybi syndrome and median cleft face syndrome. *Ophthalmic Paediatr Genet.* 1985;6(1–2):343–7.
[\[PubMed\]](#)
90. Witmer MT, Vasan R, Levy R, et al. Bilateral maculopathy associated with Pierre Robin sequence. *J AAPOS.* 2012;16(4):409–10.
[\[PubMed\]](#)
91. Altintas AG, Gül Aksoy FG, Altintas CS, et al. Evaluation of findings in Crouzon’s syndrome. *Orbit.* 1999;18(4):247–59.
[\[PubMed\]](#)
92. Scott JG, Friedmann AI, Chitters M, et al. Ocular changes in the Bloch-Sulzberger syndrome (Incontinentia pigmenti). *Br J Ophthalmol.* 1955;39(5):276–82.
[\[PubMed\]](#)[\[PubMedCentral\]](#)
93. Vennos EM, James WD. Rothmund-Thomson syndrome. *Dermatol Clin.* 1995;13(1):143–50.
[\[PubMed\]](#)
- 94.

- Rosenthal G, Assa V, Monos T, et al. Werner's syndrome. *Br J Ophthalmol*. 1996;80(6):576–7.
[PubMed][PubMedCentral]
95. Creavin AL, Brown RD. Ophthalmic abnormalities in children with Down syndrome. *J Pediatr Ophthalmol Strabismus*. 2009;46(2):76–82.
[PubMed]
96. Koole FD, Velzeboer CM, van der Harten JJ. Ocular abnormalities in Patau syndrome (chromosome 13 trisomy syndrome). *Ophthalmic Paediatr Genet*. 1990;11(1):15–21.
[PubMed]
97. Lessell S, Forbes AP. Eye signs in Turner's syndrome. *Arch Ophthalmol*. 1966;76(2):211–3.
[PubMed]
98. Juhn AT, Nabi NU, Levin AV. Ocular anomalies in an infant with Klinefelter Syndrome. *Ophthalmic Genet*. 2012;33(4):232–44.
[PubMed]
99. Hansen L, Eiberg H, Rosenberg T. Novel MAF mutation in a family with congenital cataract-microcornea syndrome. *Mol Vis*. 2007;13:2019–22.
[PubMed]
100. Semina EV, Ferrell RE, Mintz-Hittner HA, et al. A novel homeobox gene PITX3 is mutated in families with autosomal-dominant cataracts and ASMD. *Nat Genet*. 1998;19:167–70.
[PubMed]
101. Addison PK, Berry V, Ionides AC, et al. Posterior polar cataract is the predominant consequence of a recurrent mutation in the PITX3 gene. *Br J Ophthalmol*. 2005;89:138–41.
[PubMed][PubMedCentral]
102. Berry V, Yang Z, Addison PK, et al. Recurrent 17 bp duplication in PITX3 is primarily associated with posterior polar cataract (CPP4). *J Med Genet*. 2004;41:e109.
[PubMed][PubMedCentral]
103. Georgala PA, Carr CB, Price DJ. The role of Pax6 in forebrain development. *Dev Neurobiol*. 2011;71:690–709.
[PubMed]
104. Kioussi C, O'Connell S, St-Onge L, et al. Pax6 is essential for establishing ventral-dorsal cell boundaries in pituitary gland development. *Proc Natl Acad Sci U S A*. 1999;96:14378–82.
[PubMed][PubMedCentral]
105. Dohrmann C, Gruss P, Lemaire L. Pax genes and the differentiation of hormone-producing endocrine cells in the pancreas. *Mech Dev*. 2000;92:47–54.
[PubMed]
106. Glaser T, Jepeal L, Edwards JG, et al. PAX6 gene dosage effect in a family with congenital cataracts, aniridia, anophthalmia and central nervous system defects. *Nat Genet*. 1994;7:463–71.
[PubMed]
107. Girelli D, Bozzini C, Zecchina G, et al. Clinical, biochemical and molecular findings in a series of

- families with hereditary hyperferritinaemia-cataract syndrome. *Br J Haematol.* 2001;115:334–40.
[PubMed]
108. Cazzola M, Foglieni B, Bergamaschi G, et al. A novel deletion of the L-ferritin iron-responsive element responsible for severe hereditary hyperferritinaemia-cataract syndrome. *Br J Haematol.* 2002;116:667–70.
[PubMed]
109. Camaschella C, Zecchina G, Lockitch G, et al. A new mutation (G51C) in the iron-responsive element (IRE) of L-ferritin associated with hyperferritinaemia-cataract syndrome decreases the binding affinity of the mutated IRE for iron-regulatory proteins. *Br J Haematol.* 2000;108:480–2.
[PubMed]
110. Coccia M, Brooks SP, Webb TR, et al. X-linked cataract and Nance-Horan syndrome are allelic disorders. *Hum Mol Genet.* 2009;18:2643–55.
[PubMed][PubMedCentral]
111. Pamuk BO, Torun AN, Kulaksizoglu M, et al. 49, XXXXY syndrome with autoimmune diabetes and ocular manifestations. *Med Princ Pract.* 2009;18(6):482–5.
[PubMed]
112. Saraswathy TS, Rozainanee MZ, Asshikin RN, et al. Congenital rubella syndrome: a review of laboratory data from 2002 to 2011. *Southeast Asian J Trop Med Public Health.* 2013;44(3):429–35.
[PubMed]
113. Vijayalakshmi P, Kakkar G, Samprathi A, et al. Ocular manifestations of congenital rubella syndrome in a developing country. *Indian J Ophthalmol.* 2002;50(4):307–11.
[PubMed]
114. Weisinger HS, Pesudovs K. Optical complications in congenital rubella syndrome. *Optometry.* 2002;73(7):418–24.
[PubMed]
115. Newman H, Gooding C. Viral ocular manifestations: a broad overview. *Rev Med Virol.* 2013;23(5):281–94.
[PubMed]
116. Suhardjo, Utomo PT, Agni AN. Clinical manifestations of ocular toxoplasmosis in Yogyakarta, Indonesia: a clinical review of 173 cases. *Southeast Asian J Trop Med Public Health.* 2003;34(2):291–7.
[PubMed]
117. Jancevski M, Foster CS. Cataracts and uveitis. *Curr Opin Ophthalmol.* 2010;21(1):10–4.
[PubMed]
118. Goldberg MF. Persistent fetal vasculature (PFV): an integrated interpretation of signs and symptoms associated with persistent hyperplastic primary vitreous (PHPV). *Am J Ophthalmol.* 1997;124(5):587–626.
[PubMed]
119. Arora R, Menon PS, Angra SK, et al. Hypocalcemic cataract secondary to idiopathic

hypoparathyroidism. *Indian Pediatr.* 1989;26(11):1157–9.
[\[PubMed\]](#)

120. Chugh SK, Goel A. Bilateral cataracts as the presenting manifestation of chronic renal failure. *J Assoc Physicians India.* 1992;40(4):273–4.
[\[PubMed\]](#)
121. Haviv YS, Safadi R, Zamir E. A rapidly progressive cataract in a patient with autoimmune hypoparathyroidism and acute liver and renal failure. *Am J Nephrol.* 1999;19(4):523–6.
[\[PubMed\]](#)
122. Boozalis GT, Purdue GF, Hunt JL, et al. Ocular changes from electrical burn injuries. A literature review and report of cases. *J Burn Care Rehabil.* 1991;12(5):458–62.
[\[PubMed\]](#)
123. Wolf N, Pendergrass W, Singh N, et al. Radiation cataracts: mechanisms involved in their long delayed occurrence but then rapid progression. *Mol Vis.* 2008;14:274–85.
[\[PubMed\]](#)[\[PubMedCentral\]](#)
124. Lambert SR, Capone Jr A, Cingle KA, et al. Cataract and phthisis bulbi after laser photoablation for threshold retinopathy of prematurity. *Am J Ophthalmol.* 2000;129(5):585–91.
[\[PubMed\]](#)
125. Thorne JE, Woreta FA, Dunn JP, et al. Risk of cataract development among children with juvenile idiopathic arthritis-related uveitis treated with topical corticosteroids. *Ophthalmology.* 2010;117(7):1436–41.
[\[PubMed\]](#)[\[PubMedCentral\]](#)

5. Epidemiology of Pediatric Cataracts

Mingguang He¹✉ and Meng Li¹

- (1) State Key Laboratory of Ophthalmology, Zhongshan Ophthalmic Center, Sun Yat-sen University, 54S Xianlie Road, Guangzhou, 510060, People's Republic of China

✉ **Mingguang He**
Email: mingguang_he@yahoo.com

Abstract

The epidemiology of pediatric cataracts provides crucial evidence for improving or preserving visual acuity and preventing blindness in pediatric patients with cataracts. This chapter describes the distributions of blindness or moderate and severe vision impairment (MSVI) caused by pediatric cataracts across different populations, regions, and time periods, so as to characterize the epidemiological pattern of pediatric cataracts and provide scientific evidence for developing preventative and management strategies. Early detection and early intervention are key to treating pediatric cataracts. Establishing a referral system incorporating tertiary general hospitals with ophthalmic departments and specialist ophthalmic centers will help improve the prevention, diagnosis, and treatment of pediatric cataracts and streamline medical resource allocation.

Epidemiology is the scientific study of the patterns and causes of health and disease conditions in defined populations as well as the strategy and measures for disease prevention, treatment, and health promotion. There is currently a paucity of data on the prevalence of pediatric cataracts and considerable variation between research reports in the literature. The available data

describes the prevalence of pediatric cataracts as ranging from 0.01 to 0.15 %. The etiological epidemiology of pediatric cataracts shows that in most cases the cause is unclear, though hereditary conditions (e.g., isolated hereditary cataracts, Down syndrome, Alport syndrome) and intrauterine infection are the major known etiological factors. Bilateral cataract cases are more frequently observed than unilateral cases, and trauma is a common cause of cataracts among older children. Furthermore, the prevalence of visual impairment and blindness caused by pediatric cataracts in developing countries is ten times that of developed countries. The key to successful management of pediatric cataracts is early diagnosis and treatment. Establishing a three-tiered referral network of primary clinics, secondary facilities, and tertiary hospitals can effectively improve diagnosis and treatment of pediatric cataracts, especially in low-resource and low-access settings.

5.1 Epidemiology of Pediatric Cataracts

The primary objective of studying the epidemiology of pediatric cataracts is to determine the distribution of blindness and of moderate and severe vision impairment (MSVI) caused by pediatric cataracts in different populations, regions, and time periods. This may reveal the epidemiological patterns of pediatric cataracts and offer a scientific rationale for developing public health prevention strategies and measures. Toward this end, epidemiological research designs often feature, among other methodologies, cross-sectional studies, population-based studies, and cohort studies. In recognizing this, it is difficult to draw comparisons between earlier studies owing to the variations in methodologies, inclusion criteria, and definitions. In assessing the impact of pediatric cataracts on vision in the population, it is necessary to use a system for quantifying the degree of impairment. In 1973, the World Health Organization (WHO) developed a universal definition for visual impairment, which was revised and integrated in ICD-10 in 2010. In the 1973 edition, best-corrected visual acuity (BCVA) of 0.3 was defined as the upper limit for low vision including MSVI, 0.1 for severe visual impairment, and 0.05 for blindness (Table 5.1). In the latest edition, BCVA has been substituted with presenting visual acuity (PVA), indicating that uncorrected refractive error is a cause for blindness and MSVI. Furthermore, categories “1” and “2” are used to replace the term “low vision” in the previous version so as to avoid

confusion with patients requiring low vision care.

Table 5.1 2010 WHO definition of visual impairment

Category	Presenting distance visual acuity	
	Worse than	Equal to or better than
0. Mild or no visual impairment		6/18 3/10 (0.3) 20/70
1. Moderate visual impairment	6/18 3/10 (0.3) 20/70	6/60 1/10 (0.1) 20/200
2. Severe visual impairment	6/60 1/10 (0.1) 20/200	3/60 1/20 (0.05) 20/400
3. Blindness	3/60 1/20 (0.05) 20/400	1/60 ^a 1/50 (0.02) 5/300 (20/1200)
4. Blindness	1/60 ^a 1/50 (0.02) 5/300 (20/1200)	Light perception
5. Blindness	No light perception	
	Undetermined or unspecified	

Reproduced with permission from the World Health Organization [1]

Note: To assess binocular visual impairment, visual acuity should be measured with both eyes open with habitual correction. To assess monocular visual impairment, visual acuity should be measured with only one eye open with habitual correction

If visual field is taken into account, patients with a visual field in the better eye no more than 10° in radius around central fixation should be classified as category 3. For monocular blindness, the field loss criterion is applied to the affected eye

^aOr counting fingers (CF) at 1 m.

5.1.1 Distribution of Pediatric Cataracts

The distribution of a disease across different regions, periods, and populations is an external representation of how the etiological factors impact on the target population. It reveals epidemiological patterns, providing

etiological clues that form the basis for further scientific enquiry and the formulation of research studies. These provide evidence for developing effective prevention and treatment policies, health resource allocation, and disease diagnosis. The main metrics of disease distribution include disease prevalence and incidence.

Prevalence, also known as prevalence rate, is the proportion of a population found to have a certain disease (including old and new cases) at a given time. Period prevalence and point prevalence refer to different time scales. In practice, point prevalence applies to a time period no longer than a month according to the following formula:

$$\text{Point prevalence} = \frac{\text{Number of old and new cases of a disease in a particular population at a certain time point}}{\text{Population of the time point}} \times k$$

$$\text{Period prevalence} = \frac{\text{Number of old and new cases of a disease in a particular population in a certain time period}}{\text{Population of the time period}} \times k$$

Incidence is defined as the frequency of which new cases of a given disease occur in a population, within a specified period of time. It describes the severity of risk factors in a given population and indicates the population's susceptibility. It is calculated as:

$$\text{Incidence} = \frac{\text{Number of new cases of a disease in a particular population in a certain time period}}{\text{Exposed population of the time period}} \times k$$

Cumulative incidence is the number of new cases of a certain disease in a particular population over a certain period divided by the size of total population at the beginning of the period. Cumulative incidence reflects the cumulative impact of incidence. It is calculated with the following formula:

$$\text{Cumulative Incidence of a disease over } n \text{ years} = \frac{\text{Number of new cases of a disease in a particular population in } n \text{ years}}{\text{Average exposed population in } n \text{ years}} \times k$$

Cumulative incidence can be expressed in %, ‰, or ‰‰ as needed.

5.1.2 Update on Epidemiological Study of Pediatric

Cataracts

There is a paucity of data on the epidemiology of pediatric cataracts with considerable variations due to different study designs, definitions of pediatric cataracts, and age groups used in different reports (Table 5.2). Most existing data on pediatric cataracts is derived from population-based studies of childhood blindness, and relatively few studies have investigated pediatric cataracts primarily as a disease. Failure to adjust for refractive errors in a number of studies also compromises data validity. Currently, data on epidemiology of pediatric cataracts in China is still absent.

Table 5.2 Estimates of incidence of congenital cataracts in epidemiological studies of pediatric cataracts

Author	Time of research	Study designs	Number of samples	Location	Indicator	Estimate (/10,000)
Kohler [2]	1967–1969	Cross-sectional study (age 4)	2573	Sweden	Prevalence	7.7
Myriantopoulos [3]	1985	Cohort study (age 0–7)	56,000	USA	Cumulative incidence	18.2
Stewart-Brown [4]	1970	Cohort study (age 0–10)	14,907	UK	Cumulative incidence	4.7
Stoll [5]	1979–1988	Cohort study	131,760	France	Cumulative incidence	2.3
James [6]	1988–1991	Birth defect monitoring	1,808,225	USA	Prevalence	1.2
Stayte [7]	1984	Cohort study (age 2–5)	6687	UK	Cumulative incidence	6.0
Bermejo [8]	1980–1995	Birth defect monitoring	1,124,654	Spain	Prevalence	0.6
Abrahamsson [9]	1980–1997	Cohort study	337,334	Sweden	Cumulative incidence	3.6
Rahi [10]	1995–1996	Cohort study (Below age 15)	Nationwide	UK	Cumulative incidence	2.5–3.5
Holmes [11]	1978–1997	Cohort study (age 0–17)	Entire	USA	Cumulative incidence	3.0–4.5

5.1.3 Prevalence of Pediatric Cataracts

The prevalence of pediatric cataracts measures the proportion of children with cataracts in the target population within a particular time frame. Given the difficulty of eye examinations in children, previous epidemiological

studies have mainly focused on congenital/newborn cataracts and produced wide-ranging results. Based on the WHO definition of visual impairment, Parikshit and colleagues made projections of different childhood blindness etiologies in countries of varying income levels, using the World Bank income-based country classifications [12]. Their findings show that lens abnormalities (cataracts, aphakia, etc.) are as important as retina and whole-globe lesions in being etiological causes of childhood blindness in China (Table 5.3).

Table 5.3 Estimates and classification of childhood blindness in various regions

	Established market economies	Former socialist economies	Latin America and the Caribbean	Middle East Crescent	China	India	Other Asian countries and islands	Sub-Saharan Africa
Number of countries	3	4	8	4	1	1	6	11
Number of people examined	1623	504	1007	1758	1131	4712	2950	1748
Estimated number of blind children	50,000	40,000	100,000	190,000	210,000	270,000	220,000	320,000
Globe (%)	10	12.1	11	16	25.5	33.3	16.5	8.8
Cornea (%)	1	2.2	8.4	5.8	4.3	24.6	24.3	36.2
Lens (%)	8	10.7	7.4	16.7	18.8	9.7	27.4	10
Uvea (%)	2	5.4	2.3	2.7	1.5	4.3	2.3	4.5
Retina (%)	25	44.2	46.5	42.4	24.9	16.6	15.8	20
Optic nerve (%)	25	14.7	11.6	7.4	13.6	6	7.5	9.5
Glaucoma (%)	1	2.8	8.3	6.4	9	2.5	4.6	6.2
Other (%)	28	7.9	4.5	2.6	2.4	3	1.6	4.8
Total (%)	100	100	100	100	100	100	100	100

Reproduced with permission from Parikshit et al. [12]

Foster and colleagues reported that the prevalence of pediatric cataracts ranges from 0.01 to 0.15 % [13]. Furthermore, they extrapolated that there were ten new cases of bilateral congenital cataracts/million population/year in

developing countries compared to four new cases/million population/year in developed countries, attributing this difference to higher birth rate and increased exposure to rubella and other etiological factors in developing countries. The report also estimated there were 200,000 blind children living globally due to bilateral congenital cataracts.

The Birth Defects Monitoring Program (BDMP) of the United States of America (USA) is a population-based epidemiological study, and from 1970 to 1987, 15,487,449 newborns in 48 states were surveyed. The prevalence of congenital cataracts was reported as 0.008 % [6], with Michigan posting the highest rate and Eastern New York the second highest rate. The Metropolitan Atlanta Congenital Defects Program (MACDP) monitored 696,057 newborns in the five districts of Atlanta from 1968 to 1991 and reported the prevalence of congenital cataracts to be 0.021 % [14]. In this study, the prevalence was 0.018 % for the white population and 0.026 % for other ethnicities. A collaboration study by 12 US universities found that the prevalence of cataracts in newborns was 0.136 %, with 6.5/10,000 for bilateral cataracts, 7.1/10,000 for unilateral cataracts, and 7.6/10,000 with associated congenital anomalies [15].

Cataract is a major cause of childhood blindness in middle-income countries in Europe. A cohort study with 10-year follow-up by Stewart-Brown and colleagues in the UK in 1970 studied 1500 10-year-olds from schools for the blind and other special schools. The prevalence of pediatric cataracts was reported to be 0.047 % [4]. Stayte and colleagues similarly found the prevalence of cataracts in children aged 2–5 years to be 0.044 % [7].

To date, China has yet to produce a systematic and complete dataset for the epidemiology of pediatric cataracts. In a nationwide sampled survey of low vision and blindness in 2001, the prevalence of visual disability in 6024 children aged 0–6 years from six provinces and municipalities was found to be 0.11 %. This is similar to the reported prevalence of many developed countries. The study revealed nine cases of congenital cataracts, which accounted for 14.1 % of the visual disability [16]. The Beijing Childhood Visual Impairment Program conducted in 2004 is a population-based study. Eye examinations were performed in children aged 3–6 years old with visual acuity below 6/18, from eight urban and ten rural communities. Among the 17,699 children examined, there were three cases of congenital cataracts, resulting in a prevalence of 0.0169 % [17].

A population-based epidemiological study in rural southern India by Cyril K. Dorairaj and colleagues examined 14,423 children under the age of 16 years and reported the prevalence of lens-related visual impairment including cataracts, aphakia following cataract surgery, and pseudophakia to be 4.5/10,000 [18].

Epidemiological data on pediatric cataracts alone is largely absent in Africa. Lawan and colleagues studied children with congenital eye and adnexal anomalies under the age of 10 years at an ophthalmic clinic of a teaching hospital in Nigeria between 2001 and 2005. It is found that cataracts accounted for 35 % of congenital ocular anomalies [19].

5.1.4 Incidence of Pediatric Cataracts

The incidence of pediatric cataracts measures the proportion of new cases of cataracts in the target population over a certain time period. As studies assessing incidence are often time-consuming and resource-intensive, there are currently no specific reports of the incidence of pediatric cataracts. A 25-year (1975–2000) longitudinal cohort study conducted by Wirth MG in Australia found 421 new cases of pediatric cataracts in total and estimated the incidence to be 2.2/10,000 in Australia [20]. A cohort study in Denmark documented the nationwide cumulative incidence of cataracts, providing classifications for 2.6 million children under 17 from 1980 to 2000 [21]. Only inpatients of childhood cataracts were registered from 1980 to 1994. The cumulative incidence of cataracts in the 20-year follow-up was 92.4/100,000; and gender-specific cumulative incidence was 107.9/100,000 in boys and 76.2/100,000 in girls [21]. The overall cumulative incidence of pediatric cataracts from 1995 to 2000 was 108.4/100,000 [21]. The gender-specific incidence was 119.2/100,000 in boys and 97.0/100,000 in girls. The incidence of congenital/newborn cataracts declined with age, whereas the incidence of traumatic cataracts increased with age.

5.2 Etiological Epidemiology of Pediatric Cataracts

Investigating the etiology of pediatric cataracts is important for targeted prevention and the development of treatment strategies. Due to the low incident rate and the relatively small number of patients, reliable epidemiological studies of pediatric cataracts etiology are rare. In the UK,

among the 243 children diagnosed with congenital or infantile cataracts from 1995 to 1996, bilateral cases accounted for 66 % of all cases [22]. In bilateral cases, 61 % were isolated cataracts and 25 % were associated with systemic anomalies. In unilateral cases, 47 % were isolated cataracts and 6 % were associated with systemic anomalies, while the rest had concurrent eye anomalies [22]. Unilateral cataracts were more likely to be associated with other eye anomalies than bilateral cataracts (47 % vs. 14 %). Etiological factors were not identifiable in 92 % of the unilateral cases and 38 % of the bilateral cases. In bilateral cases, 56 % of these children had concurrent hereditary conditions associated with cataracts, while only 6 % of unilateral cases were associated with hereditary conditions.

Haargaard and colleagues classified the etiology of congenital/newborn cataracts in a cohort study registering 1027 cases in children aged under 17 years (Table 5.4) [23]. Persistent fetal vasculature (PFV) was the most common eye anomaly associated with pediatric cataracts, whereas Down syndrome was the most common genetic disorder associated with congenital cataracts. Rubella infection accounted primarily for intrauterine infection-related congenital/infantile cataracts. Low birth weight (LBW) was also a significant risk factor for infantile cataracts. The Collaborative Perinatal Project, a joint study by 12 US university medical centers, found that the incidence of cataracts in newborns of LBW (≤ 2500 g) was 3.8 times higher than that of newborns with normal weight (>2500 g) [15]. Older maternal age is also a significant risk factor for pediatric cataracts, as it is closely related to adverse pregnancy outcomes, such as premature birth, fetal distress, gestational diabetes mellitus (GDM), increased likelihood of cesarean section, and LBW.

Table 5.4 Etiological and clinical classification of 1027 cases of congenital/infantile cataracts registered in Denmark from 1977 to 2001 among children (0–17 years old) by laterality

Etiological and clinical classification	No. of cases		
	Unilateral	Bilateral	Total
<i>Unknown/idiopathic (63 %)</i>			
Isolated cataract	231	244	475
Additional ocular dysmorphology, nonsystemic	91	31	122
Systemic anomalies	4	44	48
<i>Genetic (29 %)</i>			
<i>Hereditary cataract (23 %)</i>			
Isolated cataract	4	211	215

Additional ocular dysmorphism, nonsystemic	2	14	16
Systemic anomalies	0	9	9
<i>Other hereditary ocular dysmorphism (<1 %)</i>			
Additional ocular dysmorphism, nonsystemic	0	4	4
<i>Syndromes/chromosomal anomalies (6 %)</i>			
Systemic anomalies	6	54	60
<i>Intrauterine infection (3 %)</i>			
Isolated cataract	2	1	3
Additional ocular dysmorphism, nonsystemic	1	0	1
Systemic anomalies	6	24	30
<i>Chemical substances during embryogenesis (<1 %)</i>			
Thalidomide, ocular dysmorphism, nonsystemic	0	1	1
<i>Classification not possible (4 %)</i>			
Isolated cataracts	21	15	36
Additional ocular dysmorphism, nonsystemic	5	0	5
Systemic anomalies	1	1	2
<i>Total</i>	374	653	

Reproduced with permission from Haargaard et al. [23]

Trauma is a common cause for cataracts in older children, with the age group of 1 to 10 years old being the most susceptible [21, 24]. A cohort study in Denmark examined the cumulative incidence of cataracts in children under the age of 18 from 1980 to 2000. The cumulative incidence of traumatic cataracts in girls remained relatively stable at 5.6–11.7/100,000, compared to the cumulative incidence in boys, which declined by 23 % every 5 years (53 to 22/100,000) [21]. Traumatic cataracts accounted for 11.6 % of pediatric cataract cases below 15 years of age in western India, and 80 % of those were boys and 75 % were from cities [24].

5.3 Visual Impairment and Blindness Caused by Pediatric Cataracts

The prevalence of cataract-related visual impairment and blindness in children stands at between 0.01 and 0.04 % in developing countries, approximately ten times that of developed countries [13]. The following table outlines the regional distribution of cataract-caused severe visual impairment

and blindness (Table 5.5).

Table 5.5 Global regional distributions of childhood blindness and MSVI caused by pediatric cataracts

Region	No. of patients examined	Proportion of visual impairment due to lens anomalies (%)	Cause of visual impairment	Studied population	Author
Canada	1046	13	Cataracts	School for the blind	Pearce [25]
Jamaica	108	39	Cataracts	School for the blind	Moriarty [26]
Bolivia	78	21	Cataracts	School for the blind	Foster [27]
Thailand	65	16.9	Cataracts	School for the blind	Gilbert [28]
The Philippines	113	16.8	Cataracts	School for the blind	Gilbert [28]
West Africa	284	15.5	Cataracts	School for the blind	Gilbert [29]
East Africa	244	13.5	Cataracts	School for the blind	Gilbert [30]
East Africa	1062	18	Cataracts	School for the blind	Msukwa, G. [31]
Chile	217	9.2	Cataracts	School for the blind	Gilbert [29]
Argentina	573	8	Cataracts	School for the blind	Gilbert [32]
Sri Lanka	226	17	Cataracts	School for the blind	Eckstein [33]
USA	123	13	Cataracts	School for the blind	Decarlo [34]
China	1245	18.8	Lens anomaly	School for the blind	Hornby [35]
India	1318	12.3	Cataracts and aphakia, low vision	School for the blind	Rahi [36]
India	291	7.9	Lens anomaly	School for the blind	Hornby [37]
Brazil	395	10.4	Cataracts	Community	De Carvalho [38]
Brazil	3210	6.1	Cataracts	Low vision service	Haddad [39]
Uganda	443,692	21.7,36.4	Cataracts and	School for the	Waddell

			aphakia	blind, community	[40]
Poland	3000	14.1	Cataracts	School for the blind	Seroczynska [41]
Malaysia	358	22.3	Lens anomaly	School for the blind	Reddy [42]
Mongolia	64	34	Lens anomaly	School for the blind	Bulgan [43]
Malawi	151	8.8	Cataracts	Community	Kalua [44]
DR Congo	81	6.9	Cataracts	School for the blind	S. Knappe [45]
Brazil	3210	7.1	Congenital Cataracts	Low vision service	Haddad [39]
Azerbaijan	124	14.5	Cataracts and aphakia	School for the blind	D. Gharabaghi [46]

5.4 Prevention and Treatment of Pediatric Cataracts

As aforementioned, the key to successful management of pediatric cataracts is early detection and treatment. The WHO suggests performing surgery at tertiary eye care centers for pediatric cataract cases, as cataract surgeons in general medical centers may be inexperienced and inadequately trained in pediatric cataract surgery. The procedure itself requires specialized surgical equipment including a vitrectomy system and A-scan ultrasound, in addition to intraocular lenses (IOLs) and ophthalmic viscoelastic devices (OVDs) of excellent quality. It also requires interdisciplinary collaboration with pediatric anesthesiologists, nurses, optometrists, and trained visual acuity (VA) examiners. The Vision 2020 initiative aim is to establish one tertiary eye care center for every 20 million people by 2010 and one for every ten million people by 2020. At present, each province in China has established a blindness prevention and treatment system, offering new hope for treating pediatric cataracts in under-resourced areas. The National Blindness Prevention and Treatment Plan for 2006–2010, introduced by the Department of Medical Administration of the Ministry of Health of China, set forth to ensure the development of organizations for blindness prevention and treatment, to integrate the available resources, strengthen human resource development, and enhance professional skills. The plan aims to improve community-level blindness prevention and treatment, acknowledging the need for

comprehensive prevention and treatment systems, as well as national, evidence-based clinical guidelines for pediatric cataracts, in China.

5.4.1 Surgical Epidemiology of Pediatric Cataracts

Surgery is an effective treatment for pediatric cataracts. In developed countries, early surgical treatment for pediatric cataracts has become the established standard practice. Studies from Denmark reported that IOL implantation was performed in 55 % of congenital cataract patients aged 0–17 years within 1 year of diagnosis. IOL implantation covered 79.2 % of traumatic cataract cases, 61.4 % of secondary cataract cases, and 69.3 % of other types of cataract cases. In children under 2 years, IOL implantation was performed in 65.7 % of all cases within 1 year of diagnosis. It can hence be inferred that there are still many pediatric cataract patients with severe visual impairment that do not receive surgery as required.

In the UK, the research of Melanie Chak showed that 6 years after IOL implantation, the average BCVA was 6/18 for bilateral pediatric cataracts and 6/60 for unilateral cases [47]. Hussin's study reported the average corrected VA 5 years after IOL implantation was 0.57logMAR for bilateral pediatric cataracts and 0.91logMAR in unilateral cases. A total of 56 % bilateral cases and 25 % unilateral cases reported nystagmus after the surgery; 78 % bilateral cases and 86 % unilateral cases developed strabismus after the surgery [48]. In Kenya, after pediatric cataract surgery (at an average age of 3.5 years), 44 % of the operated eyes had a corrected VA better than 6/18, and 91.2 % had a corrected VA of 6/60 or better. In Uganda, only 8 % of the pediatric patients presented with VA better than 6/18, which may be associated with delayed IOL implantation [40, 49].

Postoperative follow-up and amblyopia rehabilitation are crucial in treating pediatric cataract patients, given their young age, susceptibility to infection and significant postoperative inflammation, as well as other frequently encountered complications such as posterior capsular opacification, glaucoma, and anisometropia. In particular, delayed follow-up and ineffective amblyopia treatment can often lead to poor postoperative vision. The average VA of patients with good follow-up compliance is a staggering 7.92 times better than that of patients with poor compliance, with compliance being significantly related to the distance between the patient's residence and the follow-up clinic [50].

5.4.2 Three-Tier Prevention System for Pediatric Cataracts

In Africa and Asia, many developing countries have established a comprehensive three-tier system for preventing and treating pediatric eye conditions [51]. Some preventable eye diseases, such as German measles and vitamin A deficiency, can be adequately addressed and managed at primary care centers. Other treatable pediatric eye diseases such as cataracts can be promptly detected and referred to certified eye care centers and tertiary general hospitals for early surgical treatment and timely low-vision rehabilitation training to avoid childhood visual impairment. The three-tier prevention and treatment system is supported by tertiary general hospitals and eye care centers with sufficient resources to provide the training and specialist support for the community and local hospitals and serve as a facility for pediatric cataract surgeries and postoperative visual rehabilitation.

5.4.2.1 Primary Prevention and Treatment

The primary prevention and treatment system for pediatric cataracts relies on specially trained primary care providers who screen local children for early identification of risk factors for pediatric cataracts in the general population. Efforts are focused on eye examinations in newborns for early detection and evaluation of disease. Mild cases of cataracts can be treated by primary care providers, while severe cases are referred to secondary or tertiary centers. The primary system is also tasked with providing vaccinations, long-term follow-up for patients, health education for higher-risk population to avoid traumatic pediatric cataracts, and counseling for a population with a hereditary predisposition.

5.4.2.2 Secondary Prevention and Treatment

The secondary prevention and treatment system of pediatric cataracts should be staffed by full-time ophthalmologists who are skilled at performing specialist examinations for pediatric patients and capable of actively treating conditions to preserve or improve visual function. Ophthalmologists in the secondary-level centers should also be able to plan surgeries for cataract patients, refer them to tertiary-level centers, and follow up postoperative children to identify complications as early as possible. They should also

communicate effectively with pediatric patients and their guardians to ensure their active participation. The secondary level of the system serves as a bridge between community hospitals at the primary level and eye care centers/general hospitals at the tertiary level.

5.4.2.3 Tertiary Prevention and Treatment

The tertiary prevention and treatment system for pediatric cataracts should be staffed by fully trained ophthalmologists, optometrists, anesthetists, pediatricians, and neonatologists. Physicians within the tertiary level of the system should be competent at diagnosing and treating pediatric cataracts caused by a variety of factors. In every region (province), there should be at least one well-equipped eye center or tertiary general hospital at the core of the three-tier prevention and treatment system, capable of providing specialist consultation and support for complicated cases. These tertiary centers should be equipped with a complete range of surgical equipment, including phacoemulsification and vitrectomy systems, and provide quality surgery and low vision services. They are also responsible for training, supervising, and mentoring primary- and secondary-level physicians and ophthalmologists, for providing regular postoperative follow-up to recognize and treat complications such as posterior capsular opacification, glaucoma, and amblyopia and also for conducting research on pediatric cataracts, to improve existing diagnostic and treatment methods and provide more efficient, cost-effective care.

5.5 Summary

It is estimated that there are 32,000 blind children due to bilateral congenital cataracts in China, with a larger number of children suffering from cataract-induced unilateral blindness or visual impairment. Management of pediatric cataracts is of great significance for these children and their families and for reducing the burden of cost for society as a whole. Unfortunately, the validity of past studies is limited owing to small sample sizes and differences in the inclusion criteria of the target population, and it is difficult to compare studies due to lack of standardized methodology. The systematic collection of data and use of universal definitions and inclusion criteria would benefit the epidemiological study of pediatric cataracts. The management of pediatric

cataracts is a complex process that requires collaboration between many organizations and health-care professionals.

References

1. World Health Organization. Change the definition of blindness. In: Table 1 proposed revision of categories of visual impairment. 2010. <http://www.who.int/blindness/en/>. Accessed 24 Feb 2012.
2. Kohler L, Stigmar G. Vision screening of four-year-old children. *Acta Paediatr Scand*. 1973;62(1):17–27.
[CrossRef][PubMed]
3. Myrianthopoulos N. Malformations in children from one to seven years: a report from the Collaborative Perinatal Project. New York: Alan R. Liss; 1985.
4. Stewart-Brown SL, Haslum MN. Partial sight and blindness in children of the 1970 birth cohort at 10 years of age. *J Epidemiol Community Health*. 1988;42(1):17–23.
[CrossRef][PubMed][PubMedCentral]
5. Stoll C, Alembik Y, Dott B, et al. Epidemiology of congenital eye malformations in 131,760 consecutive births. *Ophthalmic Paediatr Genet*. 1992;13(3):179–86.
[CrossRef][PubMed]
6. James LM. Maps of birth defects occurrence in the U.S., Birth Defects Monitoring Program (BDMP)/CPHA, 1970-1987. *Teratology*. 1993;48(6):551–646.
[CrossRef][PubMed]
7. Stayte M, Reeves B, Wortham C. Ocular and vision defects in preschool children. *Br J Ophthalmol*. 1993;77(4):228–32.
[CrossRef][PubMed][PubMedCentral]
8. Bermejo E, Martinez-Frias ML. Congenital eye malformations: clinical-epidemiological analysis of 1,124,654 consecutive births in Spain. *Am J Med Genet*. 1998;75(5):497–504.
[CrossRef][PubMed]
9. Abrahamsson M, Magnusson G, Sjostrom A, et al. The occurrence of congenital cataract in western Sweden. *Acta Ophthalmol Scand*. 1999;77(5):578–80.
[CrossRef][PubMed]
10. Rahi JS, Dezateux C. Measuring and interpreting the incidence of congenital ocular anomalies: lessons from a national study of congenital cataract in the UK. *Invest Ophthalmol Vis Sci*. 2001;42(7):1444–8.
[PubMed]
11. Holmes JM, Leske DA, Burke JP, et al. Birth prevalence of visually significant infantile cataract in a defined U.S. population. *Ophthalmic Epidemiol*. 2003;10(2):67–74.
[CrossRef][PubMed]

12. Parikshit G, Clare G. Blindness in children: a worldwide perspective. *Community Eye Health*. 2007;20(62):32–3.
[\[PubMed\]](#)[\[PubMedCentral\]](#)
13. Foster A, Gilbert C, Rahi J. Epidemiology of cataract in childhood: a global perspective. *J Cataract Refract Surg*. 1997;23 Suppl 1:601–4.
[\[CrossRef\]](#)[\[PubMed\]](#)
14. Metropolitan Atlanta congenital defects program surveillance data, 1988–1991. *Teratology*. 1993;48(6):695–709.
15. SanGiovanni JP, Chew EY, Reed GF, et al. Infantile cataract in the collaborative perinatal project: prevalence and risk factors. *Arch Ophthalmol*. 2002;120(11):1559–65.
[\[CrossRef\]](#)[\[PubMed\]](#)
16. Fu P, Yang L, Bo SY. A national survey on low vision and blindness of 0–6 years old children in China. *Nat Med J China*. 2004;84:1545–8.
17. Lu Q, Zheng Y, Sun B, et al. A population-based study of visual impairment among pre-school children in Beijing: the Beijing study of visual impairment in children. *Am J Ophthalmol*. 2009;147(6):1075–81.
[\[CrossRef\]](#)[\[PubMed\]](#)
18. Dorairaj SK, Bandrakalli P, Shetty C, et al. Childhood blindness in a rural population of southern India: prevalence and etiology. *Ophthalmic Epidemiol*. 2008;15(3):176–82.
[\[CrossRef\]](#)[\[PubMed\]](#)
19. Lawan A. Congenital eye and adnexial anomalies in Kano, a five year review. *Niger J Med*. 2008;17(1):37–9.
[\[CrossRef\]](#)[\[PubMed\]](#)
20. Wirth MG, Russell-Eggitt IM, Craig JE, et al. Aetiology of congenital and paediatric cataract in an Australian population. *Br J Ophthalmol*. 2002;86(7):782–6.
[\[CrossRef\]](#)[\[PubMed\]](#)[\[PubMedCentral\]](#)
21. Haargaard B, Wohlfahrt J, Fledelius HC, et al. Incidence and cumulative risk of childhood cataract in a cohort of 2.6 million Danish children. *Invest Ophthalmol Vis Sci*. 2004;45(5):1316–20.
[\[CrossRef\]](#)[\[PubMed\]](#)
22. Rahi JS, Dezateux C. Congenital and infantile cataract in the United Kingdom: underlying or associated factors. British Congenital Cataract Interest Group. *Invest Ophthalmol Vis Sci*. 2000;41(8):2108–14.
[\[PubMed\]](#)
23. Haargaard B, Wohlfahrt J, Fledelius HC, et al. A nationwide Danish study of 1027 cases of congenital/infantile cataracts: etiological and clinical classifications. *Ophthalmology*. 2004;111(12):2292–8.
[\[CrossRef\]](#)[\[PubMed\]](#)
24. Johar SR, Savalia NK, Vasavada AR, et al. Epidemiology based etiological study of pediatric cataract in western India. *Indian J Med Sci*. 2004;58(3):115–21.

[\[PubMed\]](#)

25. Pearce WG. Causes of blindness in children. 1046 cases registered with the Canadian National Institute for the Blind 1970–1973. *Can J Ophthalmol*. 1975;10(4):469–72.
[\[PubMed\]](#)
26. Moriarty BJ. Childhood blindness in Jamaica. *Br J Ophthalmol*. 1988;72(1):65–7.
[\[CrossRef\]](#)[\[PubMed\]](#)[\[PubMedCentral\]](#)
27. Foster A. Childhood blindness. *Eye (Lond)*. 1988;2(Suppl):S27–36.
[\[CrossRef\]](#)
28. Gilbert C, Foster A. Causes of blindness in children attending four schools for the blind in Thailand and the Philippines. A comparison between urban and rural blind school populations. *Int Ophthalmol*. 1993;17(4):229–34.
[\[CrossRef\]](#)[\[PubMed\]](#)
29. Gilbert CE, Canovas R, Hagan M, et al. Causes of childhood blindness: results from west Africa, south India and Chile. *Eye (Lond)*. 1993;7(Pt 1):184–8.
[\[CrossRef\]](#)
30. Gilbert CE, Wood M, Waddel K, et al. Causes of childhood blindness in east Africa: results in 491 pupils attending 17 schools for the blind in Malawi, Kenya and Uganda. *Ophthalmic Epidemiol*. 1995;2(2):77–84.
[\[CrossRef\]](#)[\[PubMed\]](#)
31. Msukwa G, Njuguna M, Tumwesigye C, et al. Cataract in children attending schools for the blind and resource centers in eastern Africa. *Ophthalmology*. 2009;116(5):1009–12.
[\[CrossRef\]](#)[\[PubMed\]](#)
32. Gilbert CE, Canovas R, Kocksch DCR, et al. Causes of blindness and severe visual impairment in children in Chile. *Dev Med Child Neural*. 1994;36(4):326–33.
[\[CrossRef\]](#)
33. Eckstein MB, Foster A, Gilbert CE. Causes of childhood blindness in Sri Lanka: results from children attending six schools for the blind. *Br J Ophthalmol*. 1995;79(7):633–6.
[\[CrossRef\]](#)[\[PubMed\]](#)[\[PubMedCentral\]](#)
34. DeCarlo DK, Nowakowski R. Causes of visual impairment among students at the Alabama School for the Blind. *J Am Optom Assoc*. 1999;70(10):647–52.
[\[PubMed\]](#)
35. Hornby SJ, Xiao Y, Gilbert CE, et al. Causes of childhood blindness in the People’s Republic of China: results from 1131 blind school students in 18 provinces. *Br J Ophthalmol*. 1999;83(8):929–32.
[\[CrossRef\]](#)[\[PubMed\]](#)[\[PubMedCentral\]](#)
36. Rahi JS, Sripathi S, Gilbert CE, et al. Childhood blindness in India: causes in 1318 blind school students in nine states. *Eye (Lond)*. 1995;9(Pt 5):545–50.
[\[CrossRef\]](#)
37. Hornby SJ, Adolph S, Gothwal VK, et al. Evaluation of children in six blind schools of Andhra

- Pradesh. *Indian J Ophthalmol*. 2000;48(3):195–200.
[PubMed]
38. de Carvalho KM, Minguini N, Moreira FD, et al. Characteristics of a pediatric low-vision population. *J Pediatr Ophthalmol Strabismus*. 1998;35(3):162–5.
[PubMed]
39. Haddad MA, Sei M, Sampaio MW, et al. Causes of visual impairment in children: a study of 3,210 cases. *J Pediatr Ophthalmol Strabismus*. 2007;44(4):232–40.
[PubMed]
40. Waddell KM. Childhood blindness and low vision in Uganda. *Eye (Lond)*. 1998;12(Pt 2):184–92.
[CrossRef]
41. Seroczynska M, Prost ME, Medrun J, et al. The causes of childhood blindness and visual impairment in Poland. *Klin Oczna*. 2001;103(2–3):117–20.
[PubMed]
42. Reddy SC, Tan BC. Causes of childhood blindness in Malaysia: results from a national study of blind school students. *Int Ophthalmol*. 2001;24(1):53–9.
[CrossRef][PubMed]
43. Bulgan T, Gilbert CE. Prevalence and causes of severe visual impairment and blindness in children in Mongolia. *Ophthalmic Epidemiol*. 2002;9(4):271–81.
[CrossRef][PubMed]
44. Kalua K, Patel D, Muhit M, et al. Causes of blindness among children identified through village key informants in Malawi. *Can J Ophthalmol*. 2008;43(4):425–7.
[CrossRef][PubMed]
45. Knappe S, Schittkowski M, Schroder W, et al. The currently most common causes of childhood blindness in Kinshasa (d. R. Congo). *Klin Monbl Augenheilkd*. 2007;224(7):597–602.
[CrossRef][PubMed]
46. Gharabaghi D. Causes of blindness and severe visual impairment in children in schools for the blind in East Azerbaijan State. *Iran J Ophthalmol*. 2008;20(4):24–9.
47. Chak M, Wade A, Rahi JS. Long-term visual acuity and its predictors after surgery for congenital cataract: findings of the British congenital cataract study. *Invest Ophthalmol Vis Sci*. 2006;47(10):4262–9.
[CrossRef][PubMed]
48. Hussin HM, Markham R. Long-term visual function outcomes of congenital cataract surgery with intraocular lens implantation in children under 5 years of age. *Eur J Ophthalmol*. 2009;19(5):754–61.
[PubMed]
49. Yorston D, Wood M, Foster A. Results of cataract surgery in young children in east Africa. *Br J Ophthalmol*. 2001;85(3):267–71.
[CrossRef][PubMed][PubMedCentral]
50. Congdon NG, Ruiz S, Suzuki M, et al. Determinants of pediatric cataract program outcomes and

follow-up in a large series in Mexico. *J Cataract Refract Surg.* 2007;33(10):1775–80.
[CrossRef][PubMed]

51. Wilson ME, Trivedi RH. Pediatric cataract surgery: techniques, complications, and management. In: Trivedi RH, Wilson ME, editors. *Epidemiology of pediatric cataract and associated blindness*, 2nd edn. Wolters Kluwer Health, Philadelphia; 2014. p. 24.

6. Classification and Morphology of Pediatric Cataracts

Weirong Chen¹ 

- (1) State Key Laboratory of Ophthalmology, Zhongshan Ophthalmic Center, Sun Yat-sen University, 54S Xianlie Road, Guangzhou, 510060, People's Republic of China

 **Weirong Chen**

Email: chenwrq@aliyun.com

Abstract

There is no widely accepted classification system for pediatric cataracts. Generally speaking, cataracts are classified according to the etiology, age of onset, morphology, location, or degree of lens opacity. Since opacity may occur in any part of the lens, the morphological manifestation of pediatric cataract is diverse and complex. Based on the abundant patient resources and first-hand clinical data from the “Cataract Children’s Home” of Zhongshan Ophthalmic Center, this chapter discusses the classification and morphological manifestation of pediatric cataracts using a large number of precious slit-lamp microscopic images.

Pediatric cataracts, defined as any opacity of the lens in the pediatric eyes, are the most common lens abnormality among children. Without a unified system to classify pediatric cataracts, classification is generally based on the etiology, age of onset, morphology, location, and degree of lens opacification [1, 2]. Opacities can occur in any part of the lens, which makes the morphology of pediatric cataracts variable and complex. This chapter will

discuss the classification and morphological characteristics of pediatric cataracts.

6.1 Classification of Pediatric Cataracts

Due to the absence of a unified classification of pediatric cataracts, clinicians generally classify the lens abnormality based on anatomical (cortical, nuclear, total and membranous cataracts, etc.) or etiological (hereditary, traumatic, and secondary cataracts, etc.) characteristics [3]. However, in clinical practice, the degree and location of lens opacities has a major impact on the timing of pediatric cataract surgery and postoperative vision function, whereas the methods mentioned above cannot fully estimate the severity of cataracts, which limits their application in clinical practice. The grading systems of lens opacities mainly apply to the age-related cataracts, including the LOCS I–III, Oxford system [4, 5], Wilmer system, and Wisconsin system [6, 7]. Recently, many domestic and international scholars have proposed the classification of pediatric cataracts into dense and non-dense cataracts according to retina visibility through the opaque lens. The authors proposed a new classification system that divides congenital cataracts into anterior, interior, and posterior cataracts based on the specific location of the lens opacities, which might reflect the characteristics of each subtype (Lin HT, 2016, unpublished data). The main classifications are introduced as follows:

6.1.1 Classification Based on Etiology

See Chap. 4.

6.1.2 Classification Based on Age of Onset

(1) Congenital cataracts (at birth or shortly after birth) and (2) acquired cataracts (secondary, traumatic, etc.). Some scholars classify pediatric cataracts into congenital cataracts (at birth), infantile cataracts (birth–2 years old), and juvenile cataracts (2–10 years old) [8].

6.1.3 Classification Based on Morphology

(1) Total cataracts, (2) polar cataracts (anterior or posterior), (3) lamellar cataracts, (4) nuclear cataracts, (5) lentiglobus cataracts (anterior lentiglobus

or posterior lentiglobus), (6) sutural cataracts, (7) membranous cataracts, (8) cerulean cataracts, (9) pulverulent cataracts, (10) subcapsular cataracts (anterior or posterior subcapsular), and so on

6.1.4 Classification Based on Location

(1) Nuclear cataracts, (2) cortical cataracts, (3) capsular cataracts, and (4) total cataracts

6.1.5 Classification Based on Degree of Opacities

(1) Dense cataracts and (2) non-dense cataracts

6.2 Morphology of Pediatric Cataracts

Due to poor compliance of child patients, sometimes it can be difficult to determine the etiology of pediatric cataracts. Under such circumstances, the age of onset and nature of the condition can be inferred from the location of opacities, as different parts of the lens correspond to different stages of lens development. Clinically, congenital cataracts are generally classified on morphology via slit-lamp biomicroscopy.

Based on the location and morphology of lens opacities, this section will describe the morphological characteristics of five types of pediatric cataracts, including nuclear cataracts, cortical cataracts, capsular opacities, total cataracts, and membranous cataracts.

6.2.1 Nuclear Cataracts

6.2.1.1 *Embryonic Nuclear Cataracts*

Anterior Axial Embryonic Nuclear Cataracts

Anterior axial embryonic nuclear cataracts are characterized by fine and sporadic white dots near the anterior Y-suture (Fig. 6.1). They are unilateral or bilateral, are static, and usually do not impair vision. The abnormality is caused by the deformity of the primordial terminal of the lens at 6–8 weeks of gestation.

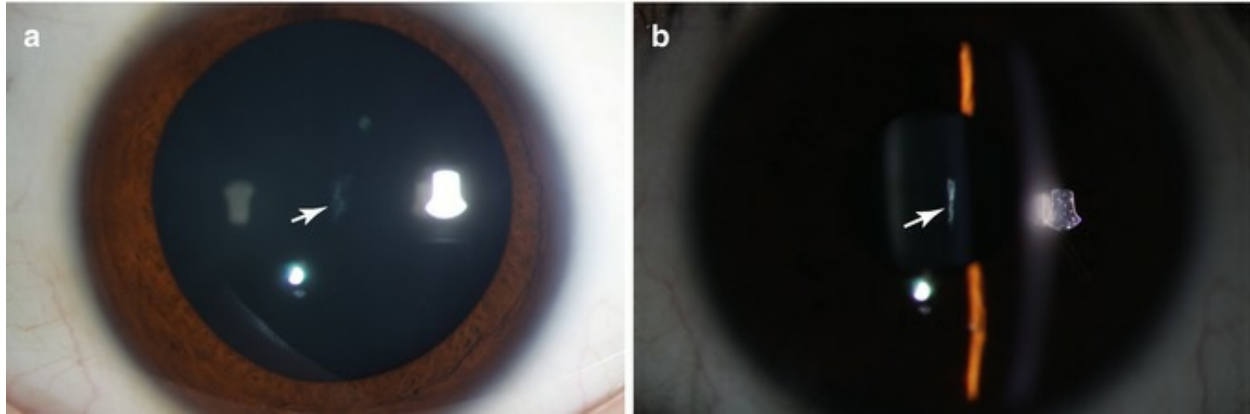


Fig. 6.1 Anterior axial embryonic nuclear cataract. (a) Slit-lamp biomicroscopy shows fine and sporadic white dots near the anterior Y-suture (see *arrows*); (b) optical section under slit-lamp biomicroscopy

Sutural Cataracts

The opacities are located at the anterior and posterior Y-sutures of the embryonic nucleus. Occurring during the lens formative stage, sutural cataracts are static and present as white or blue band-shaped opacities. They are usually confined to the Y-suture and may be combined with cerulean cataract, coronary cataract, or other forms of cataracts (Fig. 6.2). It has been reported that the mutation of beaded filament structural protein 2 (BFSP2), which codes an important cytoskeleton protein BFSP, can result in sutural cataract [9]. Sutural cataract is inherited in an autosomal dominant pattern. Obvious lens opacities are presented in male patients with X-linked inheritance, while mild presentation is noted in female patients. It is visually insignificant.

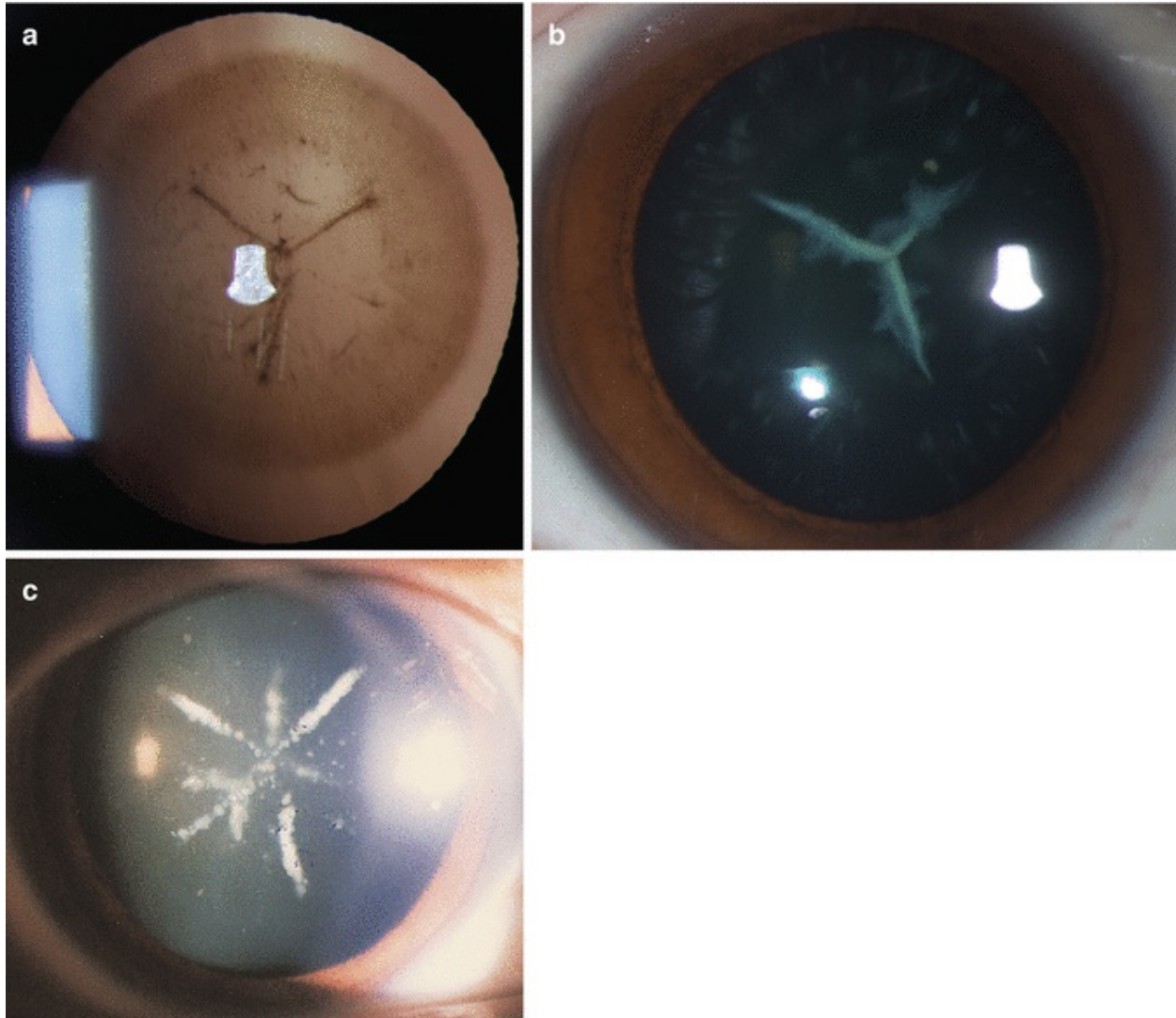


Fig. 6.2 Sutural cataracts. (a) Y-suture with perinuclear opacities; (b) anterior Y-suture with cortical cerulean opacities; (c) anterior and posterior Y-sutures with cortical punctate opacities

Lamellar Cataracts

One of the most common types of congenital cataracts, the lamellar cataract, is usually bilateral, disk-like and static, which affects certain layers of the lens. The size of the opaque disk corresponds to the diameter of the lens at the age of onset. If the cataract occurs at birth, the disk measures around 6.5 mm in diameter. A circle of shell-like white opacities composed of fine white dots around the fetal nucleus can be seen via slit-lamp biomicroscopy. Sometimes the lamellar opacities are not complete; thus, the wedges formed by transparent fibers can be observed within the shell-like opacities. It can be combined with V-shaped opacities that wrap around the edge of the lamellar

opacities called cortical riders (Fig. 6.3). The cortical rider is separated from the disk-shaped opacities by a transparent layer. Because the center of the lens nucleus remains transparent, visual prognosis is good with lamellar cataracts. In clinical practice, the age of onset can be inferred from the association between the opacity layer and fetal nucleus. If the opacities encircle the fetal nucleus, congenital cataract may be considered, and if the opacities encircle the adult nucleus, then acquired cataract may be considered. Most lamellar opacities are congenital and generally inherited as an autosomal dominant trait, with only a minority of cases being inherited in a recessive fashion or as a result of rubella infection during pregnancy. Congenital lamellar cataract can be caused by the mutations of CRYAA and CRYGC, which code the major structural proteins of the lens, α A- and γ C-crystallins [10, 11]. Moreover, BFSP2 mutation can also lead to lamellar cataract [12].

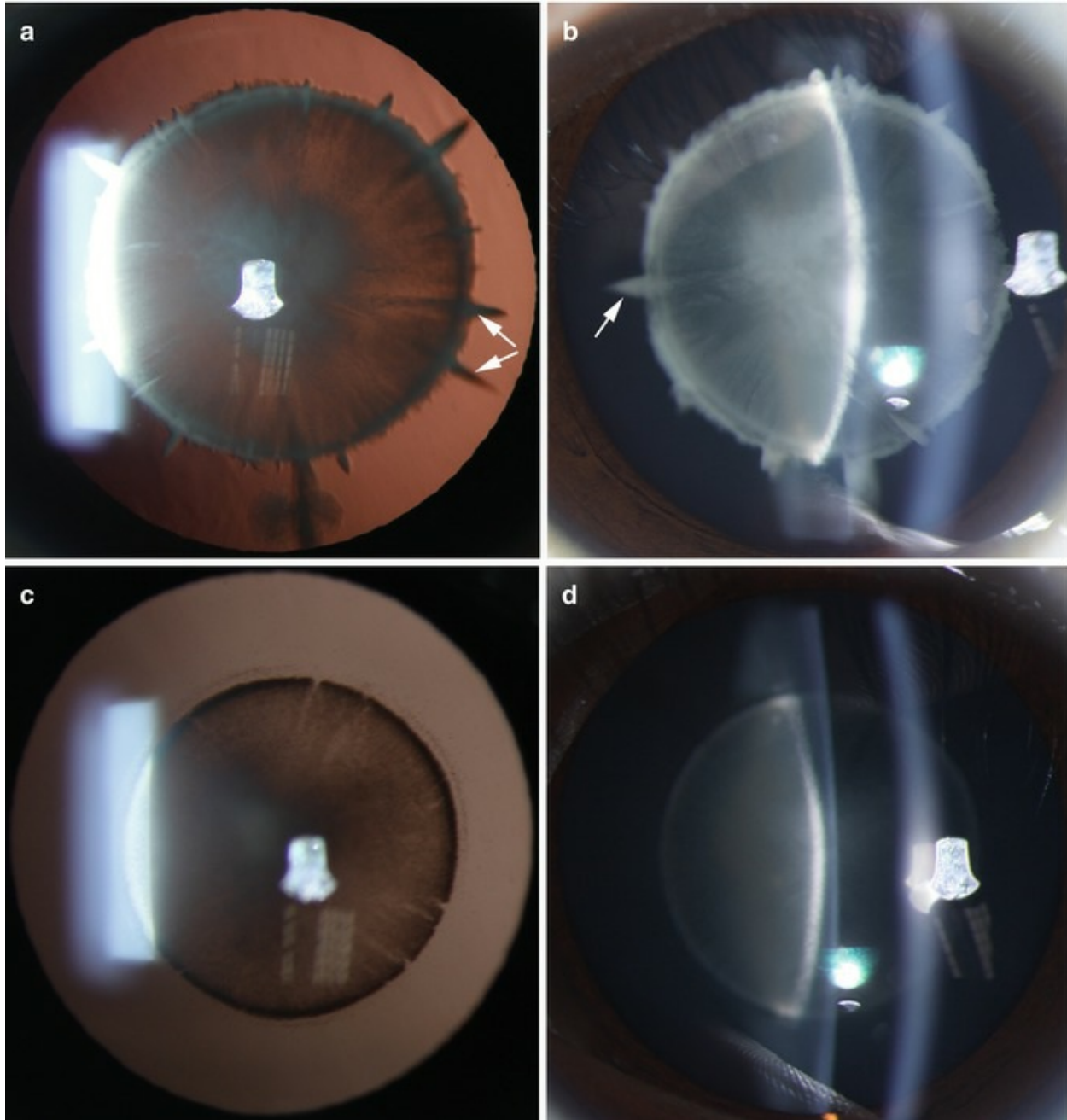


Fig. 6.3 Lamellar cataracts. (a) Lamellar opacities around the fetal nucleus with cortical riders (see *arrows*); (b) optical section under slit-lamp biomicroscopy; (c) lamellar opacities around the fetal nucleus without cortical riders on the periphery; (d) optical section under slit-lamp biomicroscopy

Metabolic factors after birth can also cause lamellar cataracts, which present as fine white dots surrounding the adult nucleus and are characteristically without cortical riders. It is common in Type 1 diabetes or galactosemia. If these causative factors can be addressed promptly, the

cataract will not develop further.

Nuclear Cataracts

Pediatric nuclear cataracts are observed in congenital and secondary cases. The morphology is characterized by opacities of gray dots in the embryonic and fetal nuclei. The congenital nuclear cataract can be caused by the mutations of CRYAA, CRYBB2, and CRYGC, which code α A-, β B-, and γ C-crystallins, respectively, largely inherited in an autosomal dominant pattern [13–15] (Fig. 6.4).

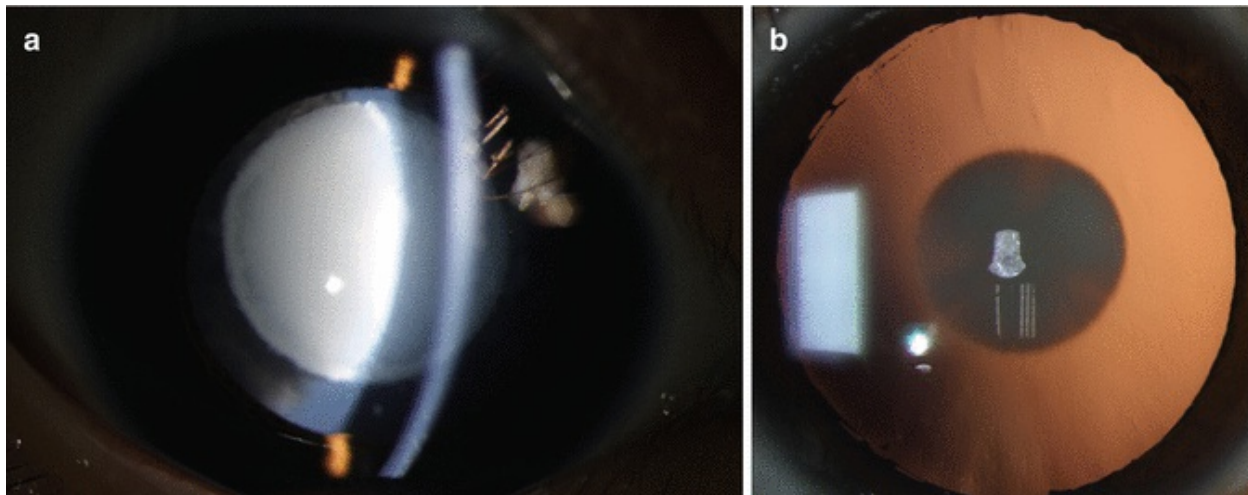


Fig. 6.4 Congenital nuclear cataracts. (a) Optical section under slit-lamp biomicroscopy; (b) retroillumination view

Coralliform Cataracts

The coralliform cataract features disk-, tube-, or oval-shaped white or gray opacities in the embryonic nucleus. They form a radiating pattern or an irregular stack toward the anterior capsule like a forward-growing coral, hence the name coralliform cataract (Fig. 6.5). This type of cataract can affect vision and is generally static. Most pediatric cases have a family history of cataracts, inherited as autosomal dominant or recessive pattern. Previous study has demonstrated that CRYGD mutation can induce coralliform cataract, which code γ D-crystallin [16].

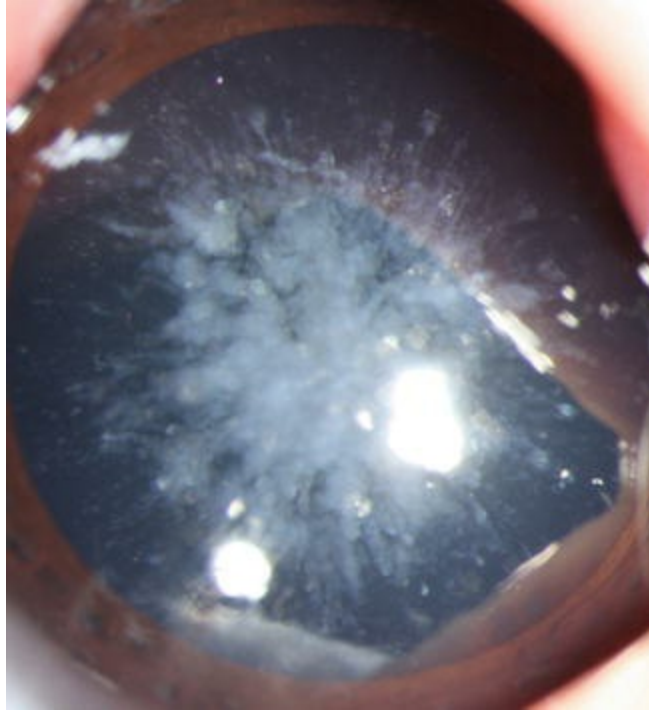


Fig. 6.5 Coralliform cataract. Disk-, tube-, and oval-shaped white opacities in a radiating pattern with speckled crystallization in the fetal nucleus

Central Pulverulent Cataracts

The central pulverulent cataract is caused by affection to the embryonic nucleus during the first three months of gestation, without involvement of the fetal nucleus. It is characterized by fine white dots or pulverulent opacities confined between the Y-sutures. The opacities only occur in part of the embryonic nucleus in the form of scattered fine pulverulent granules (Fig. 6.6), unlike the homogeneous and dense opacities seen in the nuclear cataract. The central pulverulent cataract is generally bilateral and static and does not impair vision significantly.

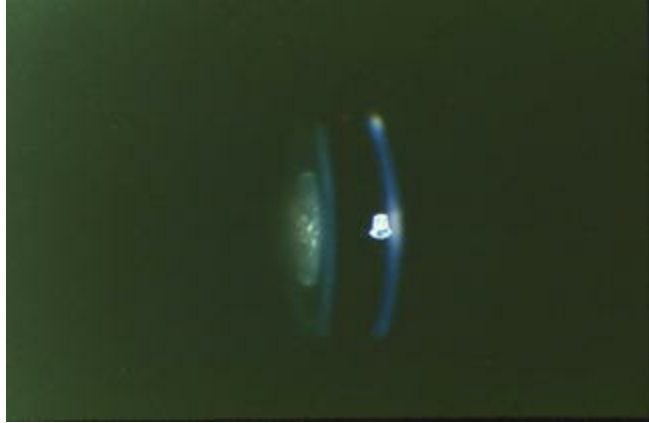

Fig. 6.6 Central pulverulent cataract. Granular opacities in the center of the fetal nucleus covers the Y-suture

Cerulean Cataracts

Cerulean cataracts feature opacities of irregular and sporadic blue dots in the fetal nucleus or adult nucleus (Fig. 6.7). The blue dots are generally 0.1–0.2 mm in diameter. They are static and bilateral [17], with normal or slightly affected vision. They are noted in congenital or acquired cataracts. The congenital cerulean cataract can also be caused by CRYGD mutation [18].

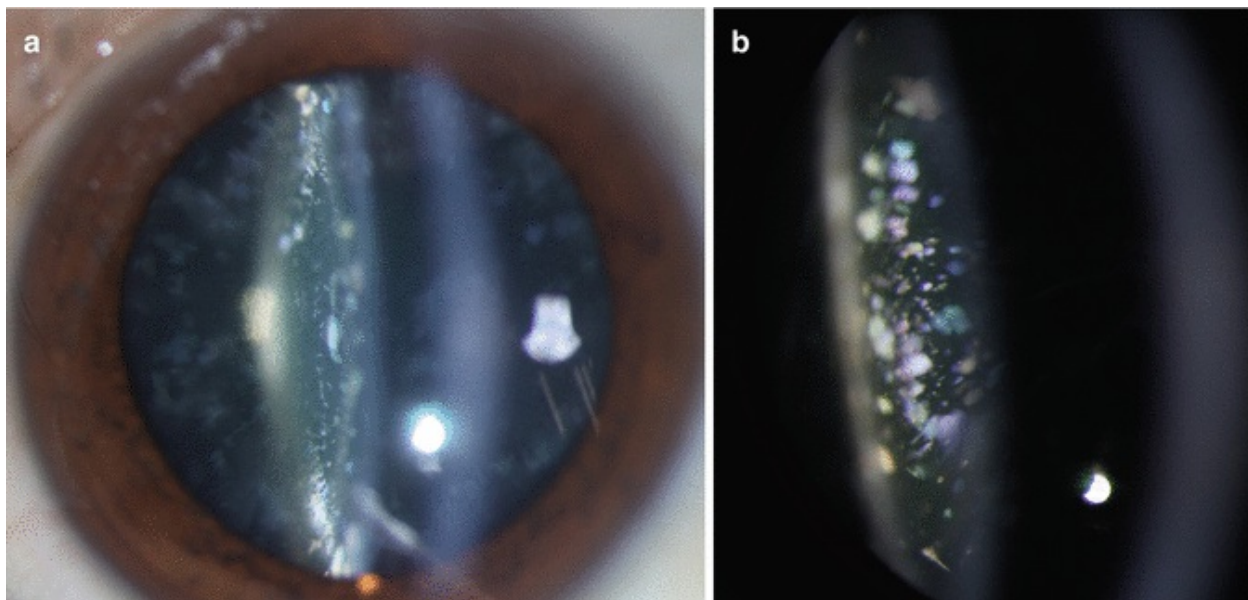


Fig. 6.7 Cerulean cataracts. (a) Irregular blue dot opacities can be seen in the fetal or the adult nucleus. (b) The lateral view under slit-lamp biomicroscopy

6.2.1.2 Adult Nuclear Opacities

Nuclear Cataracts

See section “**Nuclear Cataracts**” under “Embryonic Nuclear Cataracts”.

Coronary Cataracts

The opacities distribute radially at the equator of the adult nucleus and/or around the peripheral deep cortex. The club-shaped opacities point toward the center of the lens like a crown, which gives the condition its name (Fig. 6.8). The coronary cataract occurs during puberty and is a developmental cataract. Usually it remains static and does not affect vision dramatically. It is reported that the mutation of CRYBB2 may result in congenital coronary cataract [19, 20].

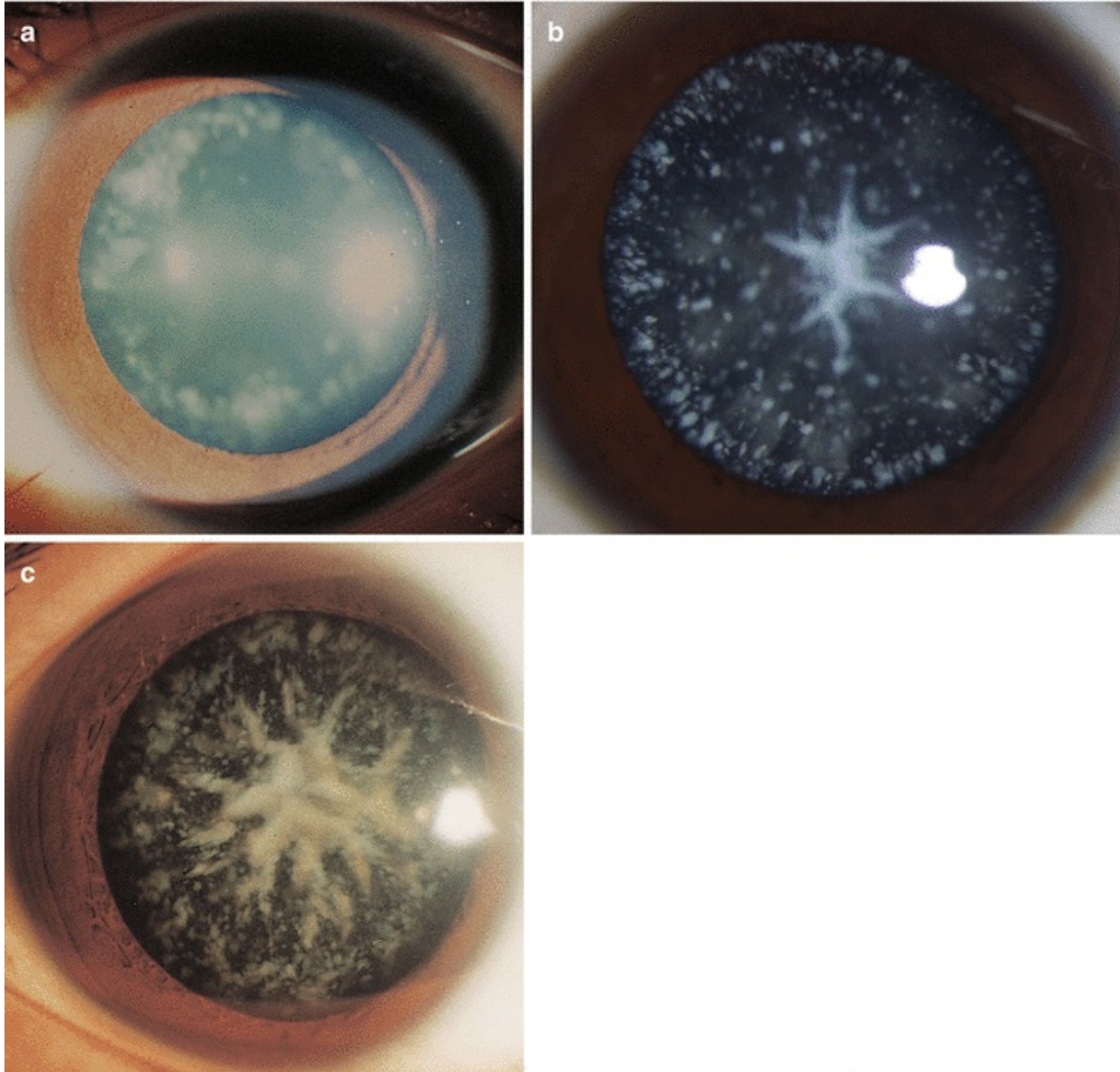


Fig. 6.8 Coronary cataract. (a) Opacities around the peripheral deep cortex in a radial pattern; (b) the opacities distribute radially around the peripheral cortex with stellate opacities in the fetal nucleus; (c) coronary cataract with chrysanthemum-shaped opacities

Cerulean Cataracts

See section “**Cerulean Cataracts**” under “Embryonic Nuclear Cataracts”.

Axial Fusiform Cataracts

The axial fusiform cataract is a special type of nuclear cataracts. The opacities extend axially through the lens, from the anterior pole to the posterior pole. It is seen in patients with congenital cataracts (Fig. 6.9).

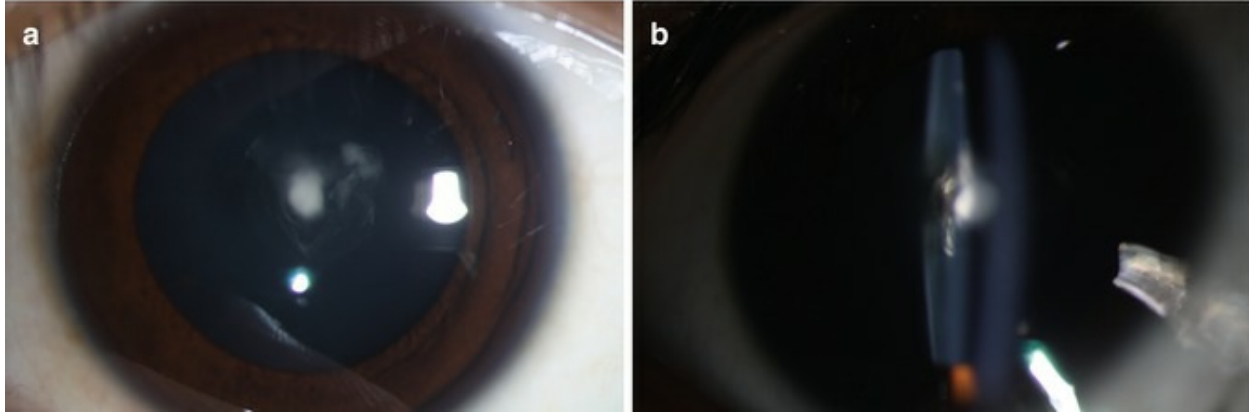


Fig. 6.9 Axial fusiform cataracts. (a) Opacities extend axially from the anterior pole to the posterior pole of the lens; (b) optical section under slit-lamp biomicroscopy

Diffuse Punctate Cataracts

These opacities appear as light gray, extremely fine dots in the adult nucleus or cortex. Diffuse punctate cataracts occur shortly after birth or in puberty. They are static and generally cause minor or no visual impairment. Sometimes, they are associated with other forms of lens opacities (Fig. 6.10).

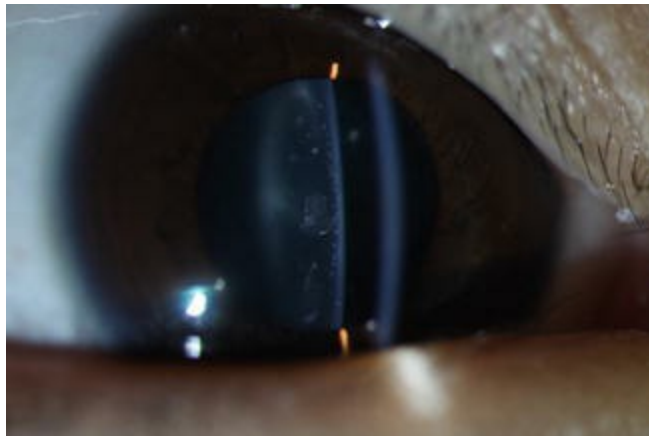


Fig. 6.10 Diffuse punctate cataract

6.2.2 Cortical Cataracts

6.2.2.1 Subcapsular Cataracts

Posterior subcapsular opacities are common, while anterior subcapsular opacities are relatively rare. Pediatric subcapsular cataracts often occur in patients with secondary, metabolic, and corticosteroid-induced cataracts (Fig.

6.11).

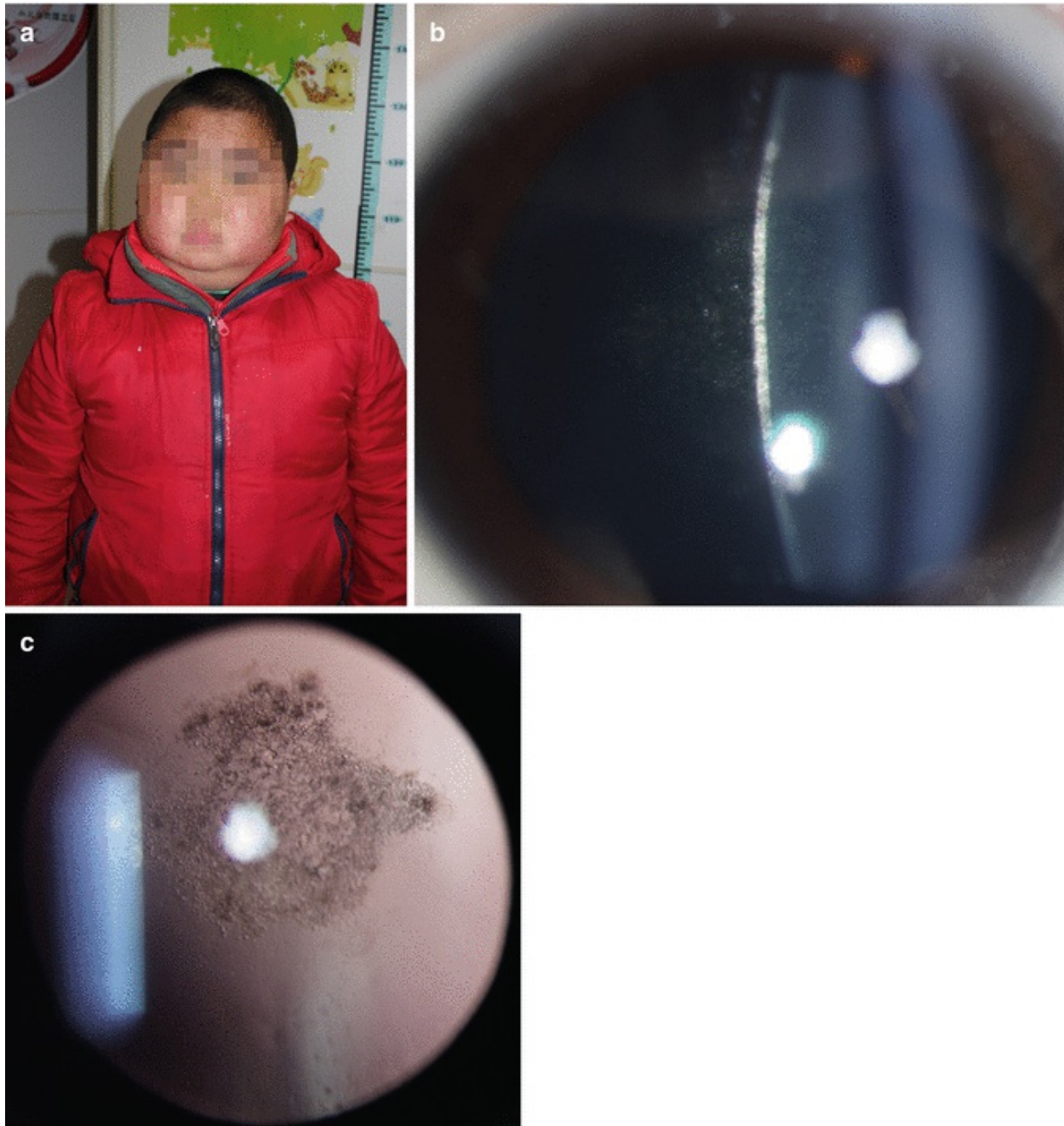

Fig. 6.11 Posterior subcapsular cataract.(a) Central obesity and moon face in a child caused by corticosteroid therapy; (b) a slit-lamp image of steroid-induced posterior subcapsular opacities; (c) a retro-illuminated image of thick granular posterior subcapsular opacities

6.2.2.2 *Punctate and Cerulean Opacities*

The opacities are generally located in the peripheral cortex (Fig. 6.12).

Typical blue or colorful punctate opacities in the peripheral cortex can be seen in female carriers of Lowe's syndrome [21]. Patients with siderosis lentis present with brown iron deposits in the anterior subcapsular cortex (Fig. 6.13). Punctate opacities do not usually affect vision. However, if the opacities progress or involve the visual axis, vision may be impaired.

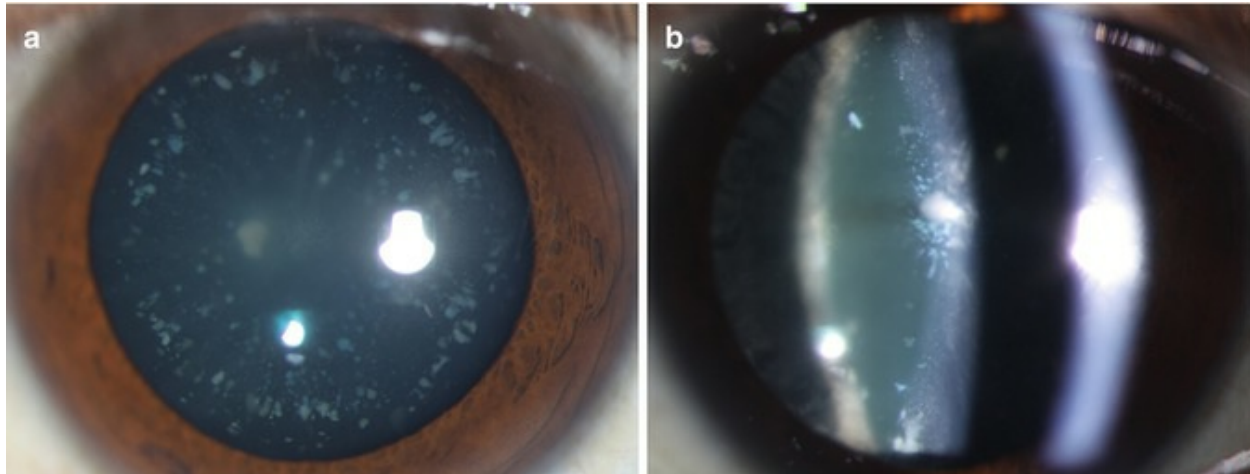


Fig. 6.12 Cortical cerulean cataracts. (a) Cerulean opacities located in the peripheral cortex; (b) optical section under slit-lamp biomicroscopy

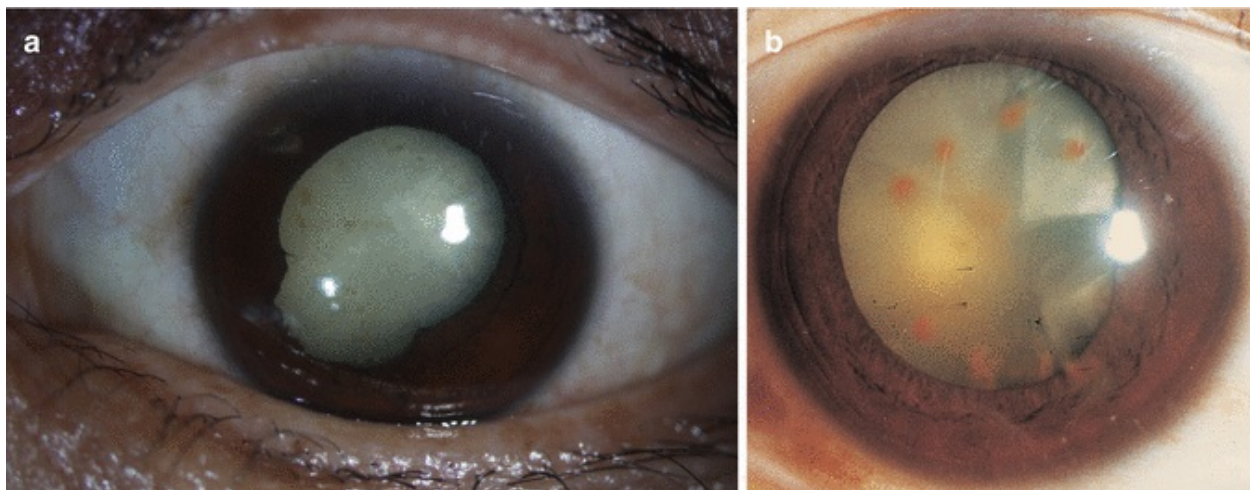


Fig. 6.13 Siderosis lentis causes brown punctate opacities in the anterior subcapsular cortex. (a) Brown punctate opacities in the anterior subcapsular cortex with posterior synechia of the iris from 6-8 O'clock and pupillary deformation; (b) More and severer brown punctate opacities in the anterior subcapsular cortex after mydriasis.

6.2.2.3 Lamellar Opacities

See section “**Lamellar Cataracts**” under “Embryonic Nuclear Cataracts”.

6.2.3 Capsular Opacities

6.2.3.1 *Capsular Opacities*

Capsular opacities are divided into congenital and acquired.

Congenital Capsular Opacities

The common inheritance pattern of congenital capsular opacities is autosomal dominant. The opacities often occur in the anterior pole of the lens and appear as patches (Fig. 6.14a, b). When the lens opacity protrudes anteriorly in a conical shape, it is called anterior polar pyramidal cataract (Fig. 6.14c, d) [22]. Posterior polar opacities are relatively rare (Fig. 6.15a) and may be associated with localized defects of the posterior capsule [23], presenting as posterior lentiglobus (Fig. 6.15b). The opacities may expand to the deeper layer of lens fibers. When superficial opacified layers overlap with deep layers and are separated by a transparent layer of lens fibers in between, it is called reduplicated cataract. Congenital capsular opacities can be associated with persistent pupillary membrane, persistent fetal vasculature (previously known as persistent hyperplastic primary vitreous) (Fig. 6.16), or other ocular anomalies. Vision is not significantly affected when the opacities of anterior and posterior capsules are small. However, larger opacities that involve the visual axis may severely affect vision.

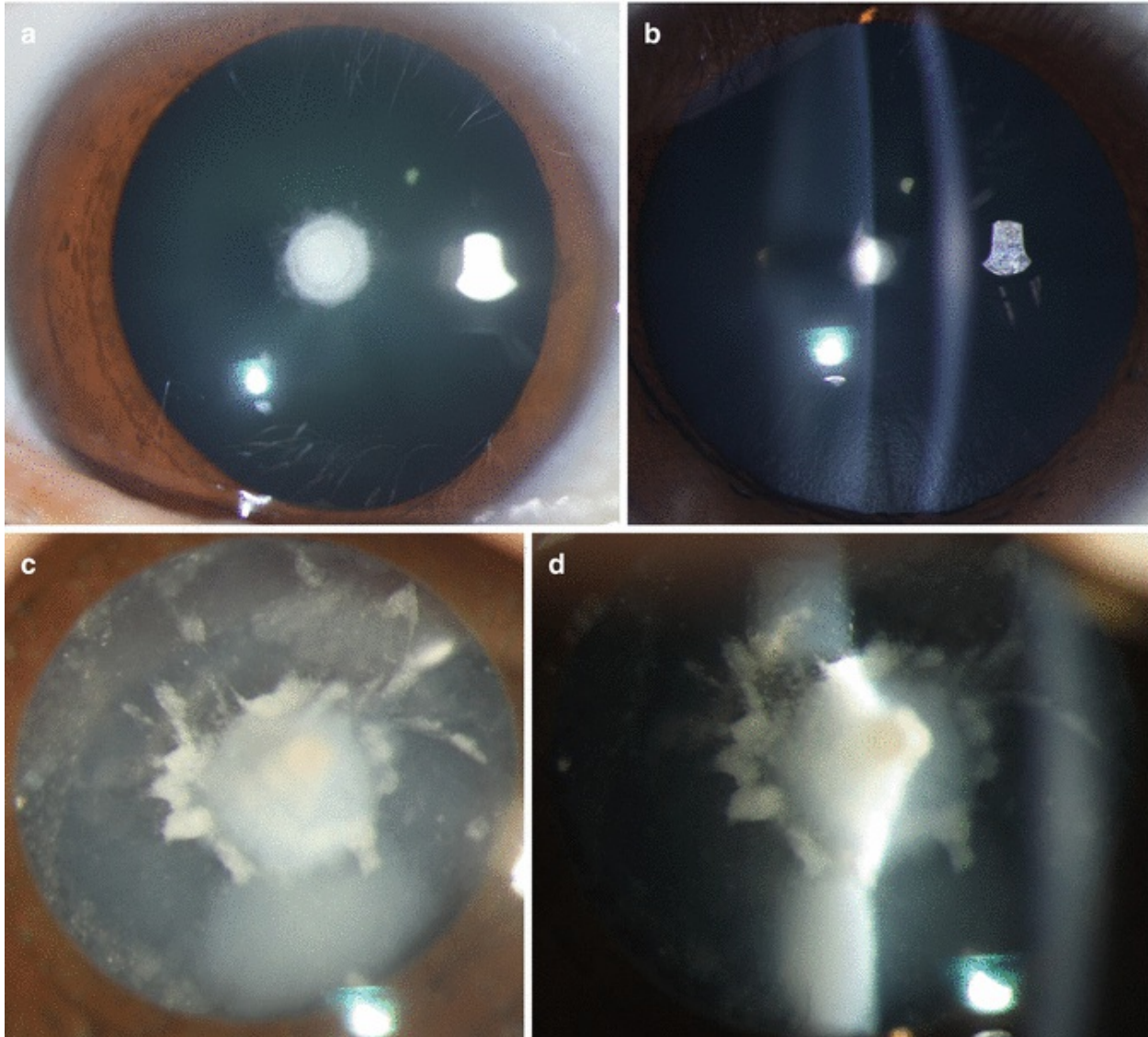


Fig. 6.14 Anterior polar cataracts. (a) Front view of anterior polar opacities; (b) optical section of anterior polar opacities under slit-lamp biomicroscopy; (c) front view of anterior polar pyramidal cataract; (d) optical section of anterior polar pyramidal cataract under slit-lamp biomicroscopy

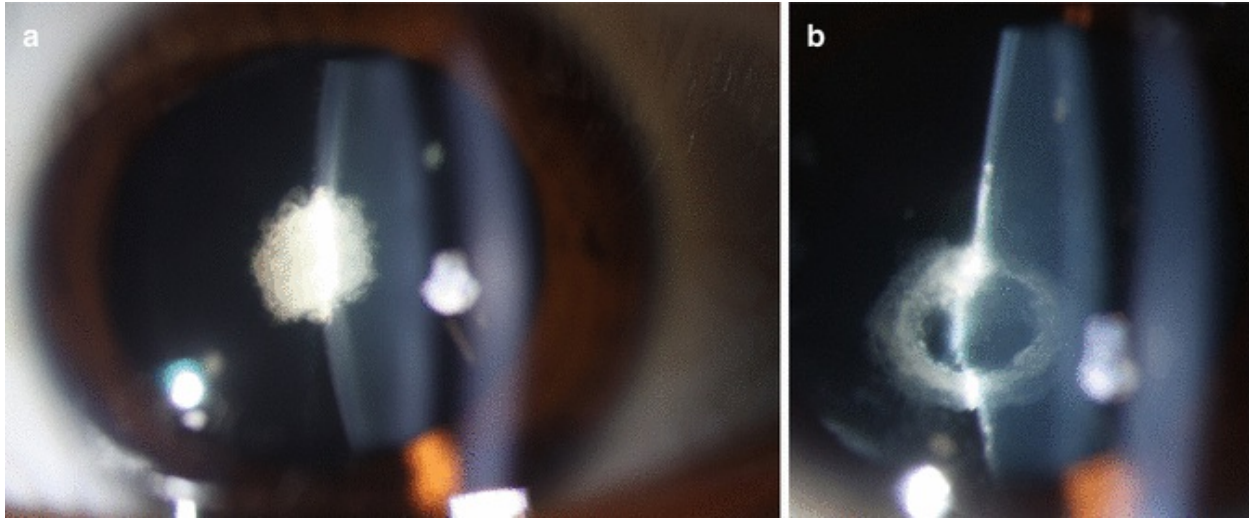


Fig. 6.15 (a) Posterior polar cataract; (b) posterior lentiglobus

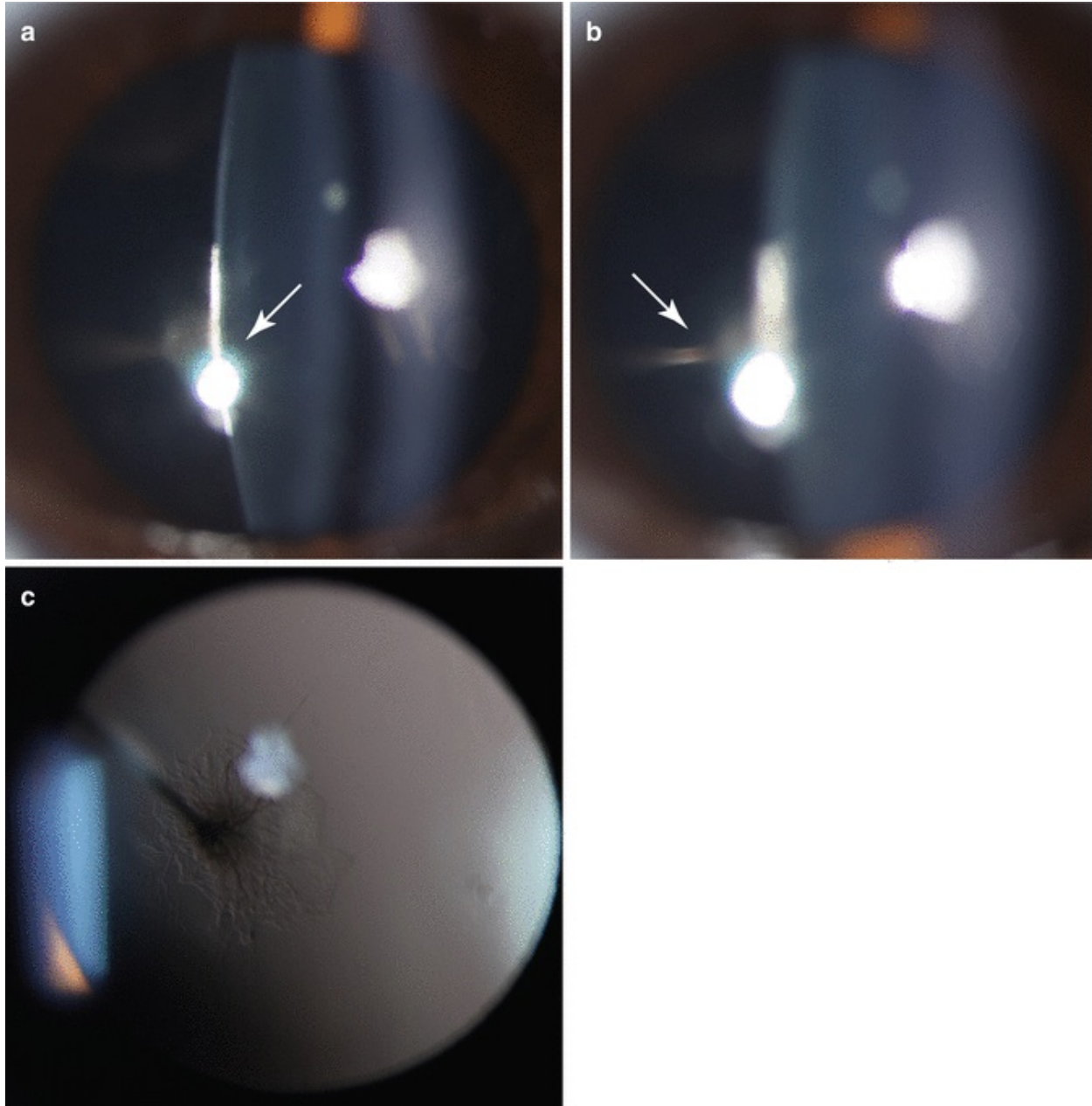


Fig. 6.16 Congenital posterior capsular opacities associated with persistent fetal vasculature. (a) Posterior capsular opacities with a visible blood vessel (see *arrow*); (b) persistent fetal vasculature with visible vascular remnants (see *arrow*); (c) retro-illuminated view

Acquired Capsular Opacities

Acquired capsular opacities are usually caused by inflammation or trauma. Keratitis and iridocyclitis (especially with posterior synechiae) usually contribute to anterior capsular opacities (Fig. 6.17a). In the case of anterior capsule rupture caused by penetrating eye injuries, small ruptures can be

repaired by proliferation and fibroblast metaplasia of lens epithelial cells. Thus, with only localized anterior capsular opacities, the lens can largely remain transparent (Fig. 6.17b). Electrical injuries also lead to anterior capsular opacities, characterized by well-defined white flaky opacities (Fig. 6.18).

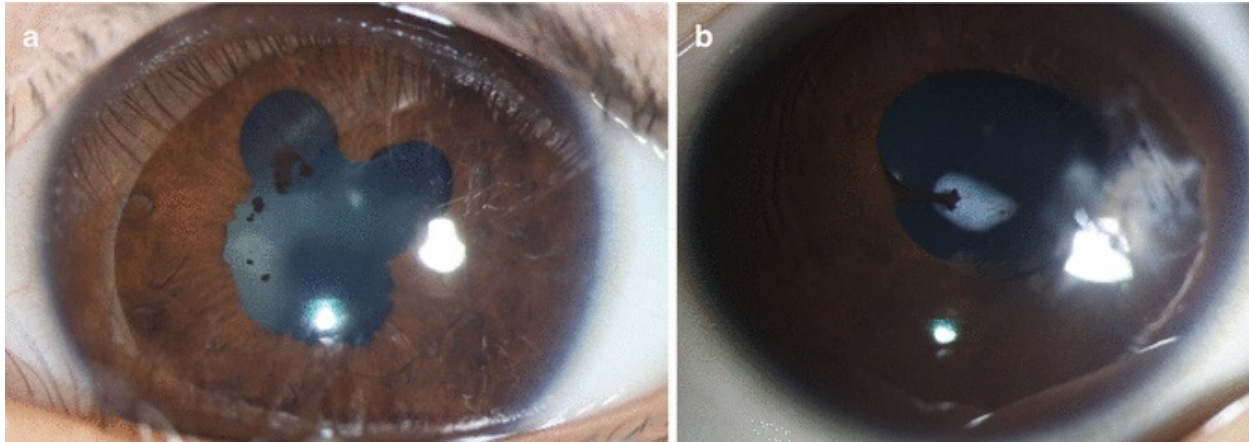


Fig. 6.17 Acquired capsular opacities. (a) Chronic uveitis results in localized posterior synechia, pupil deformity, and localized anterior capsular opacities. (b) Penetrating eye injury induces localized lens anterior capsule to undergo organization and opacification, while the lens largely remains transparent

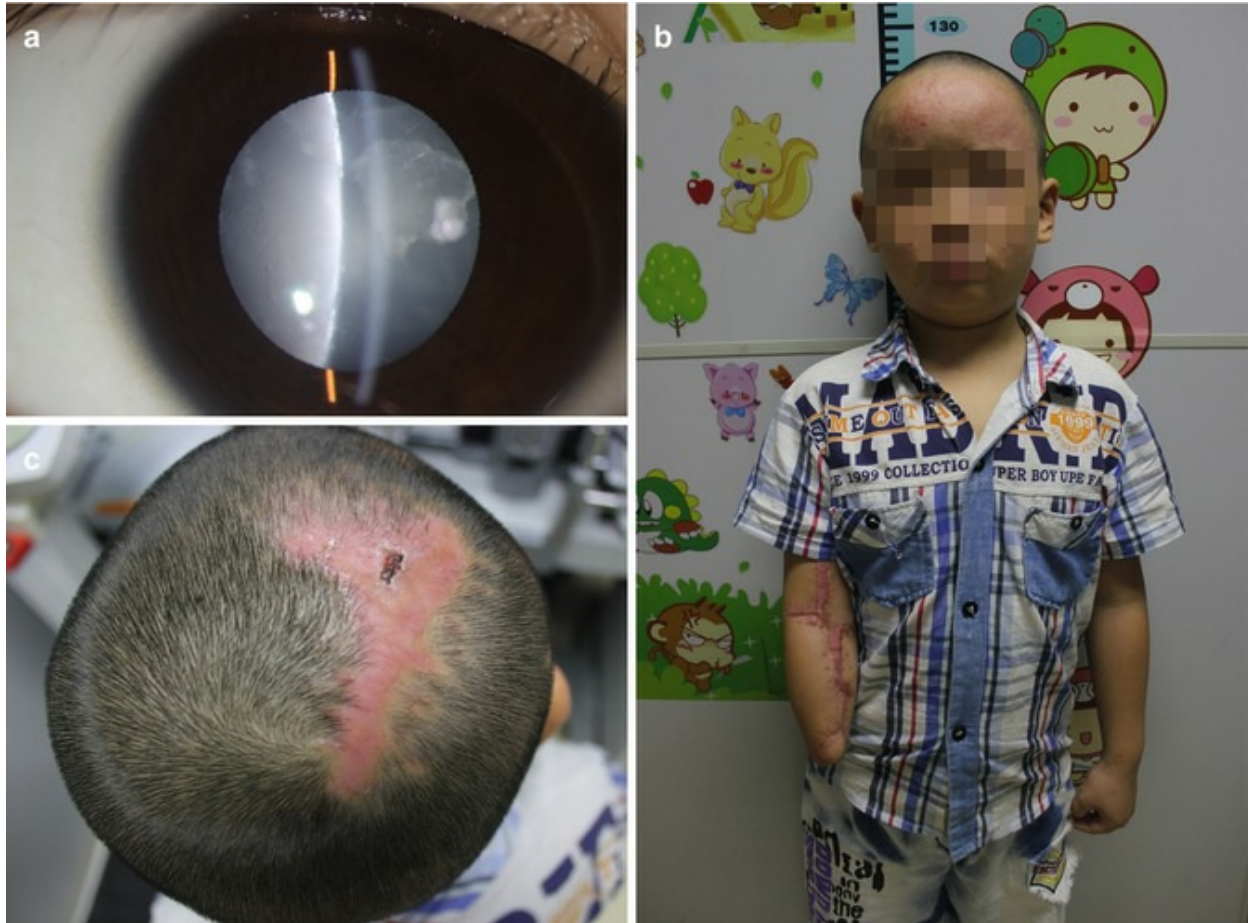

Fig. 6.18 Electric cataract. (a) Well-defined white opacities in the lens anterior capsule caused by electric shock; (b) the electric current traveled through the right hand (amputated), and scars remained on the right forearm and upper arm; (c) the electric current exited from the head, leaving scars on the scalp

6.2.3.2 Capsular Pigmentation

Ocular inflammation, trauma, and pigment dispersion syndrome can cause anterior capsular pigmentation (Fig. 6.19). Spots of pigment on the anterior capsule secondary to iridocyclitis usually occur at the site of posterior synechiae. Ocular blunt trauma can result in the formation of a pigment ring on the anterior capsule, known as the Vossius ring. This is caused by the deposition of iris epithelium pigmentation from the pupillary ruff against the lens capsule. Pigment dispersion syndrome features typical deposition of pigmentation on the lens capsule and trabecular meshwork. Posterior capsular pigmentation can sometimes be observed in patients with retinal detachment.

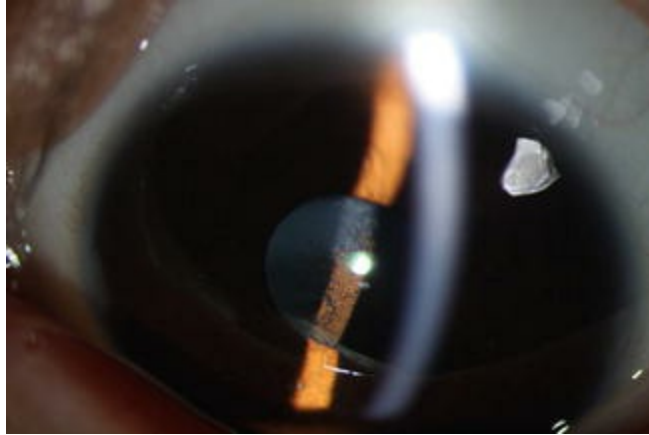


Fig. 6.19 Anterior capsular pigmentation secondary to iridocyclitis

6.2.3.3 Other Types of Capsular Deposition

In patients with Fabry disease, abnormal metabolites may deposit on the lens capsule and form white granules [24]. The deposition of drugs or metals on the lens capsule usually appears as typical dust-like opacities.

Chlorpromazine-induced cataract is characterized by white stellate opacities on the anterior capsule (Fig. 6.20). In patients with chalcosis, fine granules with copper glows are deposited radially on the lens capsule, which forms a sunflower cataract [25]. Cataracts associated with mercury poisoning feature gray reflection of the lens capsule.

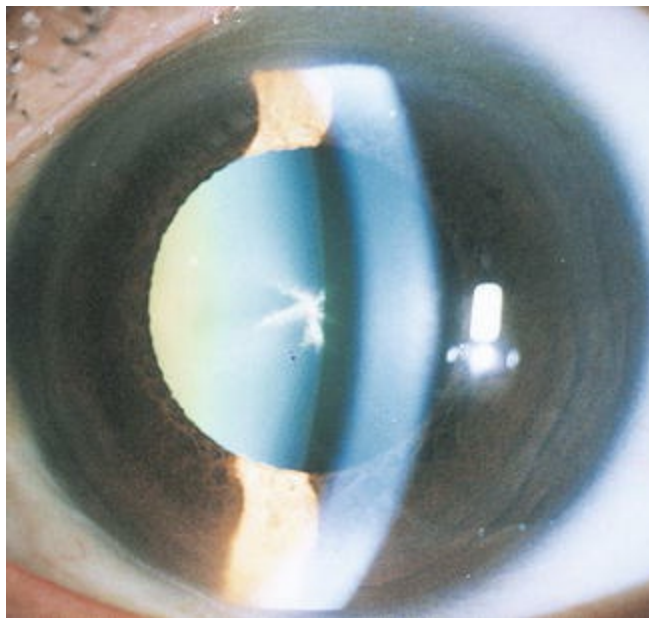


Fig. 6.20 Chlorpromazine induces white stellate opacities on the anterior capsule

6.2.3.4 Capsular Pits

Capsular pits are herpes-like defects near the center of the anterior capsule. They are rare and of unclear clinical relevance.

6.2.4 Diffuse/Total Cataracts

The morphological manifestation of total cataracts is the complete opacification of the lens fibers with a milky-white pupil. Although it is commonly seen in congenital cataracts and blunt trauma-induced cataract, a minority of secondary pediatric cataracts can also present as total cataracts. Congenital total cataracts are most commonly inherited as an autosomal dominant trait, accounting for about 20 % of all congenital cataracts. They are mostly bilateral, present after birth, and visually significant (Fig. 6.21). This abnormality can be seen in patients with chromosome abnormality-induced Down's syndrome and NHS mutation-induced Nance-Horan syndrome [26, 27]. It can be also induced by rubella virus infection during the pregnancy period. Total lens opacification occurring at birth in male children is usually inherited in an X-linked fashion, while heterozygous female children often present with mild opacities along the lens sutures.




Fig. 6.21 Total cataract

6.2.5 Membranous Cataract

When the lens fibers are damaged in the middle or late developmental stages and new lens fibers are poorly developed after birth, the lens nucleus may be

absorbed over time; subsequently, the anterior and posterior lens capsules adhere to each other and form a membranous cataract (Fig. 6.22). It severely affects vision and thus needs surgical intervention as early as possible. We have reported previously that CRYBB2 gene mutation induces progressive membranous cataract in 21 family members in a big family [28].

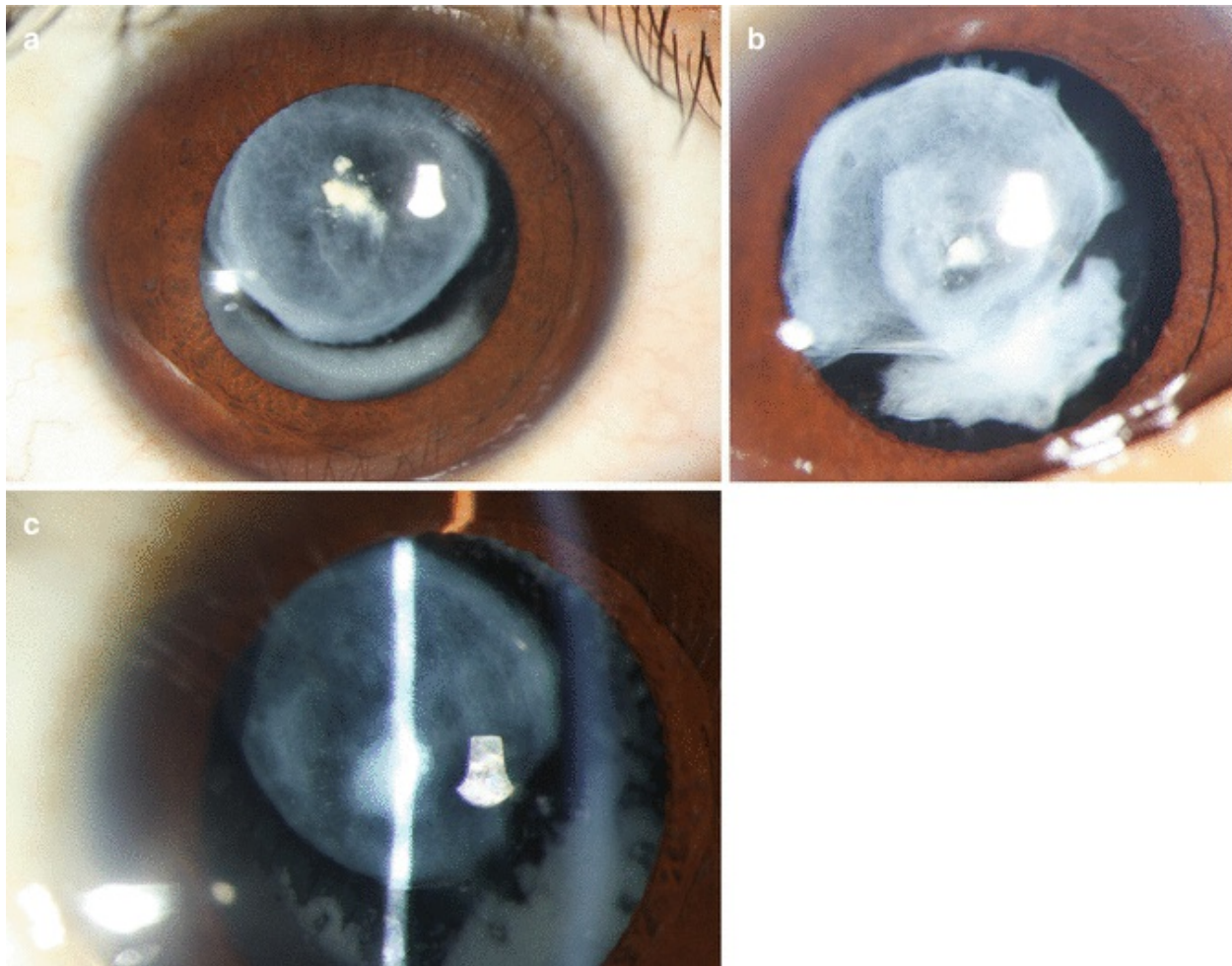


Fig. 6.22 Membranous cataracts caused by CRYBB2 mutation. (a) Membranous cataract of intermediate severity: normal anatomy of the crystalline lens is missing. (b) Severe membranous cataract: dense, irregularly shaped opacity obscuring the visual axis. (c) Optical section of a less severe membranous cataract

6.3 Summary

Currently, there is no consensus on the classification of pediatric cataracts. The common practice is to classify the lenticular opacities based on morphological (cortical, nuclear, total and membranous cataracts, etc.)

characteristics. As each part of the crystalline lens represents a specific phase of embryonic development of the lens, location of the opacity provides clues regarding time of occurrence, and nature of the disease. Additionally, location and severity of the opacity are the critical factors in determination of surgical timing and visual outcomes of pediatric cataracts. Therefore, morphological classification of pediatric cataracts is of great clinical significance.

References

1. Hiles DA, Carter BT. Classification of cataracts in children. *Int Ophthalmol Clin.* 1977;17:15–29. [\[PubMed\]](#)
2. Maumenee IH. Classification of hereditary cataracts in children by linkage analysis. *Ophthalmology.* 1979;86:1554–8. [\[CrossRef\]](#)[\[PubMed\]](#)
3. Merin S, Crawford JS. The etiology of congenital cataracts. A survey of 386 cases. *Can J Ophthalmol.* 1971;6:178–82. [\[PubMed\]](#)
4. Chylack Jr LT, Wolfe JK, Singer DM, et al. The lens opacities classification system III. The Longitudinal Study of Cataract Study Group. *Arch Ophthalmol.* 1993;111:831–6. [\[CrossRef\]](#)[\[PubMed\]](#)
5. Thompson JR, Deane JS, Hall AB, et al. Associations between lens features assessed in the Oxford Clinical Cataract Classification and Grading System. *Ophthalmic Epidemiol.* 1997;4:207–12. [\[CrossRef\]](#)[\[PubMed\]](#)
6. Adamsons I, Taylor KI, Enger C, et al. A new method for documenting lens opacities. *Am J Ophthalmol.* 1991;111:65–70. [\[CrossRef\]](#)[\[PubMed\]](#)
7. Panchapakesan J, Cumming RG, Mitchell P. Reproducibility of the Wisconsin cataract grading system in the Blue Mountains Eye Study. *Ophthalmic Epidemiol.* 1997;4:119–26. [\[CrossRef\]](#)[\[PubMed\]](#)
8. Sudarshan AP. Infantile cataracts. *Surv Ophthalmol.* 1997;41:357. [\[CrossRef\]](#)[\[PubMed\]](#)
9. Zhang Q, Guo X, Xiao X, et al. Clinical description and genome wide linkage study of Y-sutural cataract and myopia in a Chinese family. *Mol Vis.* 2004;10:890–900. [\[PubMed\]](#)
10. Vanita V, Singh JR, Hejtmancik JF, et al. A novel fan-shaped cataract-microcornea syndrome caused by a mutation of CRYAA in an Indian family. *Mol Vis.* 2006;12:518–22.

[\[PubMed\]](#)

11. Devi RR, Yao W, Vijayalakshmi P, et al. Crystallin gene mutations in Indian families with inherited pediatric cataract. *Mol Vis*. 2008;14:1157–70.
[\[PubMed\]](#)[\[PubMedCentral\]](#)
12. Conley YP, Erturk D, Keverline A, et al. A juvenile-onset, progressive cataract locus on chromosome 3q21-q22 is associated with a missense mutation in the beaded filament structural protein-2. *Am J Hum Genet*. 2000;66:1426–31.
[\[CrossRef\]](#)[\[PubMed\]](#)[\[PubMedCentral\]](#)
13. Sun W, Xiao X, Li S, et al. Mutational screening of six genes in Chinese patients with congenital cataract and microcornea. *Mol Vis*. 2011;17:1508–13.
[\[PubMed\]](#)[\[PubMedCentral\]](#)
14. Santhiya ST, Manisastry SM, Rawlley D, et al. Mutation analysis of congenital cataracts in Indian families: identification of SNPS and a new causative allele in CRYBB2 gene. *Invest Ophthalmol Vis Sci*. 2004;45:3599–607.
[\[CrossRef\]](#)[\[PubMed\]](#)
15. Guo Y, Su D, Li Q, et al. A nonsense mutation of CRYGC associated with autosomal dominant congenital nuclear cataracts and microcornea in a Chinese pedigree. *Mol Vis*. 2012;18:1874–80.
[\[PubMed\]](#)[\[PubMedCentral\]](#)
16. Gu F, Li R, Ma XX, et al. A missense mutation in the gammaD-crystallin gene CRYGD associated with autosomal dominant congenital cataract in a Chinese family. *Mol Vis*. 2006;12:26–31.
[\[PubMed\]](#)
17. Ghadfan FE, Al-Mesfer S, Khan AO. Cerulean (“blue-dot”) cataract. *J Pediatr Ophthalmol Strabismus*. 2009;46:190.
[\[CrossRef\]](#)[\[PubMed\]](#)
18. Nandrot E, Slingsby C, Basak A, et al. Gamma-D crystallin gene (CRYGD) mutation causes autosomal dominant congenital cerulean cataracts. *J Med Genet*. 2003;40:262–7.
[\[CrossRef\]](#)[\[PubMed\]](#)[\[PubMedCentral\]](#)
19. Lou D, Tong JP, Zhang LY, et al. A novel mutation in CRYBB2 responsible for inherited coronary cataract. *Eye (Lond)*. 2009;23(5):1213–20.
[\[CrossRef\]](#)
20. Li FF, Zhu SQ, Wang SZ, et al. Nonsense mutation in the CRYBB2 gene causing autosomal dominant progressive polymorphic congenital coronary cataracts. *Mol Vis*. 2008;14:750–5.
[\[PubMed\]](#)[\[PubMedCentral\]](#)
21. Gardner RJ, Brown N. Lowe’s syndrome: identification of carriers by lens examination. *J Med Genet*. 1976;13:449–54.
[\[CrossRef\]](#)[\[PubMed\]](#)[\[PubMedCentral\]](#)
22. Bitton E. Unique advantage of gonioscopy for viewing an anterior pyramidal cataract. *Clin Exp Optom*. 2001;84:361–5.
[\[CrossRef\]](#)[\[PubMed\]](#)

23. Grewal DS, Jain R, Brar GS, et al. Scheimpflug imaging of pediatric posterior capsule rupture. *Indian J Ophthalmol*. 2009;57:236–8.
[CrossRef][PubMed][PubMedCentral]
24. Zarate YA, Hopkin RJ. Fabry's disease. *Lancet*. 2008;372:1427–35.
[CrossRef][PubMed]
25. Deguti MM, Tietge UJ, Barbosa ER, et al. The eye in Wilson's disease: sunflower cataract associated with Kayser-Fleischer ring. *J Hepatol*. 2002;37:700.
[CrossRef][PubMed]
26. Creavin AL, Brown RD. Ophthalmic abnormalities in children with Down syndrome. *J Pediatr Ophthalmol Strabismus*. 2009;46(2):76–82.
[CrossRef][PubMed]
27. Brooks SP, Ebenezer ND, Poopalasundaram S, et al. Identification of the gene for Nance-Horan syndrome (NHS). *J Med Genet*. 2004;41:768–71.
[CrossRef][PubMed][PubMedCentral]
28. Chen W, Chen X, Hu Z, et al. A missense mutation in CRYBB2 leads to progressive congenital membranous cataract by impacting the solubility and function of β B2-crystallin. *PLoS One*. 2013;8(11):e81290.
[CrossRef][PubMed][PubMedCentral]

7. Overview of Pediatric Cataract Treatments

Xialin Liu¹, Xinyu Zhang¹✉ and Yao Ni¹

- (1) State Key Laboratory of Ophthalmology, Zhongshan Ophthalmic Center, Sun Yat-sen University, 54S Xianlie Road, Guangzhou, 510060, People's Republic of China

✉ **Xinyu Zhang**

Email: zhangxinyu0294@163.com

Abstract

The treatment of pediatric cataracts includes surgical and conservative interventions. The ultimate goal of both treatment strategies is to improve visual functions of pediatric patients to the maximum extent and thereby enhance their quality of life. This chapter briefly reviews the history of pediatric cataract surgeries, indicating that the operative methods are constantly evolving with the development of surgical techniques and devices. However, surgery is not the only treatment option for pediatric cataracts. Conservative treatment may be considered for pediatric patients when the lens opacity is mild or the visual axis is not affected. For premature infants or children complicated with developmental disorders or systemic diseases, conservative treatment should also be considered. This chapter also introduces lens regeneration as a treatment of infantile cataracts—a new approach in pediatric cataract management.

7.1 Evolution of Pediatric Cataract Surgical

Techniques

The therapeutic strategies for pediatric cataract include surgery and conservative treatment. The ultimate goal of both treatments is to improve the visual function of children with cataract as much as possible and further enhance their quality of life.

In the early days, due to the limitations of surgical equipment and techniques, pediatric cataract surgery often resulted in a high incidence of complications, poor restoration of visual function, and in the worst cases, blindness. Therefore, the majority of earlier ophthalmologists were inclined to a conservative approach when it came to the treatment of pediatric cataract. In the last 20 years, with the rapid development of microsurgical techniques in cataract surgery, major progress has also been made in pediatric cataract surgery, which has led to better surgical outcomes, much fewer complications, and improved quality of life for pediatric patients. However, surgery is not the only option for children with cataract. If the opacity in the lens is not large, dense, or situated in a vital optical area, a conservative strategy including optical correction, regular follow-ups, and amblyopia management may be sufficient to improve visual function and prevent amblyopia. On the other hand, when surgery is needed, the selection of proper surgical timing and approach is very important. In this chapter, an overview will be given on the evolution of pediatric cataract treatments, the surgical timing, as well as indications of pediatric cataract extraction and intraocular lens implantation.

Since the first recorded pediatric cataract surgery in the early nineteenth century, the surgical techniques have undergone the following changes.

7.1.1 Cataract Discission/Needling

Cataract discission was the first recorded technique of pediatric cataract extraction. Since the procedure was simple and easy to follow, it prevailed in the early twentieth century. There are three surgical approaches in discission/needling, i.e., anterior discission, posterior discission, and through-and-through discission [1, 2]. The rationale of such a surgery is that the nucleus within pediatric cataracts is soft and the lens tissue is mainly composed of soluble proteins. Therefore, it was believed that after discission of the capsule, the effused lens material would be gradually absorbed within the eye over the following weeks and months. However, the large amount of

lens proteins that enters into the aqueous humor or the vitreous body might be erroneously recognized as foreign proteins by the immune system, invoking a violent immune response that would lead to a series of serious complications like refractory uveitis and secondary glaucoma. As a result, most patients ended up blind. Hence, this type of surgery was abandoned.

1. Anterior discission

An incision was made on the anterior capsule using various techniques so as to disperse the lens material into the aqueous humor to be gradually absorbed.

2. Posterior discission

The posterior capsule was incised from the rear of the lens to disperse the lens tissue into the vitreous body to be better absorbed.

3. Through-and-through discission

Both the anterior and the posterior capsules were incised so as to disperse the lens proteins into both the aqueous humor and the vitreous body in the hope of promoting complete absorption.

7.1.2 Optical Iridectomy

The serious complications of pediatric cataract discission prompted ophthalmologists to consider a “safer” surgical method, and thus, optical iridectomy came into being. Optical iridectomy was used for the treatment of lamellar cataract, nuclear cataract, and anterior or posterior polar cataract when the opacity was small and located at the visual axis with peripheral transparent areas and visual improvement after pupil dilation. Optical iridectomy aimed to improve vision by allowing light to pass through the peripheral transparent areas while keeping the lens intact [3]. According to the extent of resection, optical iridectomy could be divided into the following three types:

1. Local iris sphincterectomy

The purpose of local iris sphincterectomy was to dilate the pupil, and thus, the amount of light that enters the pupil could be increased. The

surgery was suited to small cataracts that were centrally located. During a local sphincterectomy, the pupillary margin of the iris was grasped and pulled out with forceps through an incision at the corneal limbus, and a 1-mm-long piece of iris was resected with scissors. Then, the remaining iris was repositioned in the eye, giving formation of a semilunar notch in the iris (Fig. 7.1a).

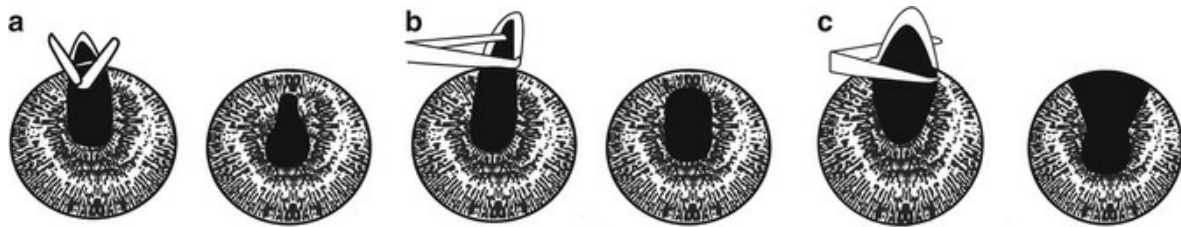


Fig. 7.1 Schematic diagram of optical iridectomy. (a) Local iris sphincterectomy. (b) Medium-width iridectomy. (c) Segmental iridectomy

2. Medium-width iridectomy

The indication of a medium-width iridectomy was the same as that of sphincterectomy, but the resected area was larger (Fig. 7.1b).

3. Segmental iridectomy

Segmental iridectomy, also known as sector iridectomy, involved an even larger area of resection compared with the former two approaches. It would remove a complete sector of the iris tissue, including both dilator and sphincter (Figs. 7.1c and 7.2).

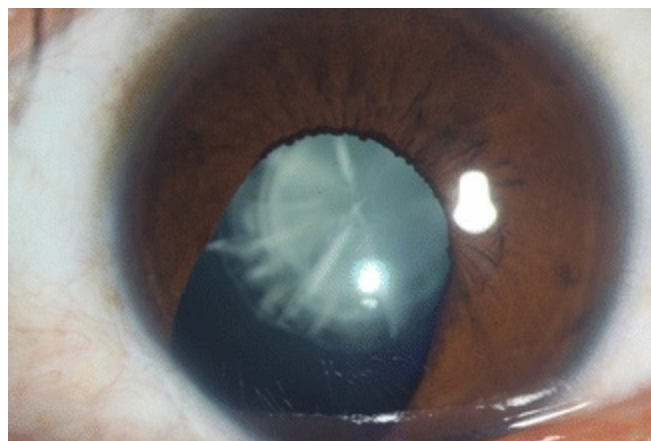


Fig. 7.2 Slit-lamp microscopic image of segmental iridectomy in a 16-year-old boy

Optical iridectomy was previously considered to have the following advantages: (1) The surgical techniques were relatively simple and safe. (2) As the lens was left intact, the postoperative inflammatory response was mild, which might be associated with a much lower incidence of secondary membranes and glaucoma. (3) Accommodation was preserved after the surgery. However, the surgery also had several important limitations, which included: (1) The light came from the off-axis area, resulting in poor imaging quality; thus, the postoperative visual results in most pediatric patients were not satisfactory. (2) The barrier function of the iris was damaged during the surgery, and it would be difficult to perform subsequent operations and optic corrections in the future. (3) It was of poor efficacy in treating unilateral cataracts. (4) It was futile in cases of total cataracts. For these reasons, optical iridectomy was abandoned as well.

7.1.3 Linear Cataract Extraction

In the first half of the twentieth century, the procedure of linear cataract extraction was proposed based on surgical principles of discission. During the surgery, pressure was exerted on the surface of the cornea with a surgical device after cataract discission. In the meantime, irrigation was performed to flush out lens materials from the anterior chamber through the corneal or scleral incision [4]. This surgical technique had undergone many modifications. The removal of lens substance with irrigation was sometimes performed at the same time as the discission/needling procedure (one-stage procedure) or after about a week later (two-stage procedure). Compared with discission/needling alone, linear cataract extraction was associated with lower incidences of postoperative inflammatory reaction, secondary membranes, and secondary glaucoma. However, most pediatric patients still ended up blind, and this technique was also abandoned.

7.1.4 Cataract Aspiration

In the early 1960s, cataract aspiration, a more effective approach to removing the lens material than anterior chamber irrigation, was adopted and continually modified by pediatric ophthalmologists [5]. This technique involved an anterior capsulotomy approximately 2 mm in diameter and aspiration of the lens material with a syringe through the capsulotomy,

leaving most of the lens capsule intact. Limitations of cataract aspiration were as follows: (1) The cortex removal was usually incomplete; (2) the collapsed capsular bag and fibrous adhesion of anterior and posterior capsule provided a scaffold for lens fiber regeneration, often resulting in a thick secondary membrane. Although the procedure of cataract aspiration alone is no longer employed, it did lay the foundation for cataract irrigation and aspiration.

7.1.5 Intracapsular Cataract Extraction

As the surgical approaches that preserve the lens capsule would inevitably lead to secondary opacification of the posterior capsule, intracapsular cataract extraction, previously performed only in adults, was also conducted in pediatric patients. However, because the zonule of pediatric patients was resilient and the surgery gave rise to multiple complications, this surgical approach did not find acceptance among pediatric ophthalmologists [5].

7.1.6 Cataract Irrigation and Aspiration

Restoring transparency of the visual axis was the principal purpose of pediatric cataract surgery. In the mid-1960s, a double-barreled cannula was introduced, which was a critical breakthrough in the development of cataract extraction. The dual irrigation and aspiration technique, especially after the introduction of phacoemulsification, enabled the ophthalmologists to maintain the anterior chamber depth during cataract aspiration, which made the removal of the lens material safer, more complete, and more effective. At present, cataract irrigation and aspiration are among the most favored surgical techniques for pediatric cataract extraction.

1. Manual irrigation and aspiration

The irrigation and aspiration of the lens material were conducted manually with a double-barreled cannula (Fig. 7.3). The cannula needle was mounted on a 5 ml syringe, which was filled with 1–2 ml of balanced salt solution (BSS). Then, the lens cortex, after being sucked onto the needle and gently pulled to the middle of the anterior chamber, was aspirated with the cannula.

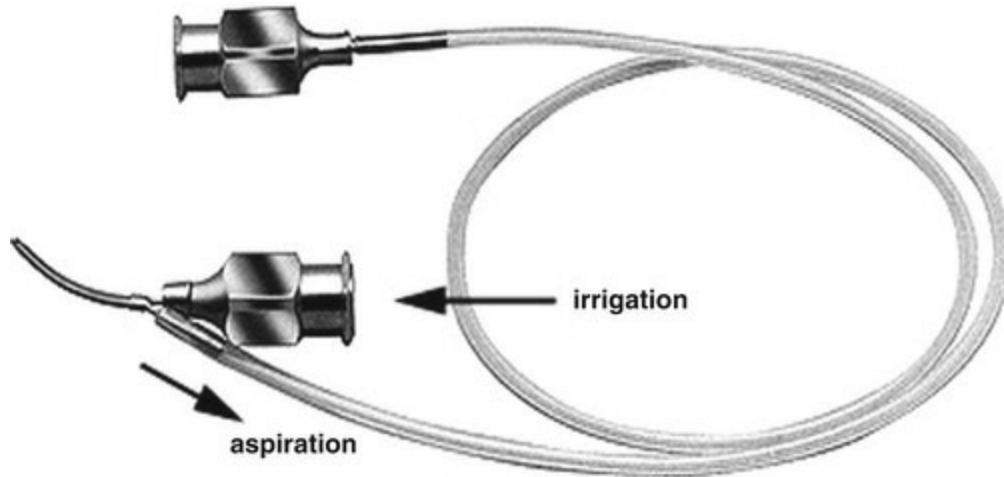


Fig. 7.3 A double-barreled cannula

2. Automated irrigation/aspiration handpiece

The invention of phacoemulsification and the application of the automated noncutting irrigation/aspiration handpiece (Fig. 7.4a) made it possible to maintain the anterior chamber depth, increase the efficiency in removing the lens material with greater suction, and reduce frequency of surgical instruments entering into the anterior chamber. When these two techniques were incorporated with tunnel incision and continuous curvilinear capsulorhexis, most of the surgical maneuvers could be completed within the capsular bag, this leading to less disturbance of intraocular tissues, much lower incidences of postoperative inflammation and complications, and subsequently improved surgical outcomes greatly (Fig. 7.4b).

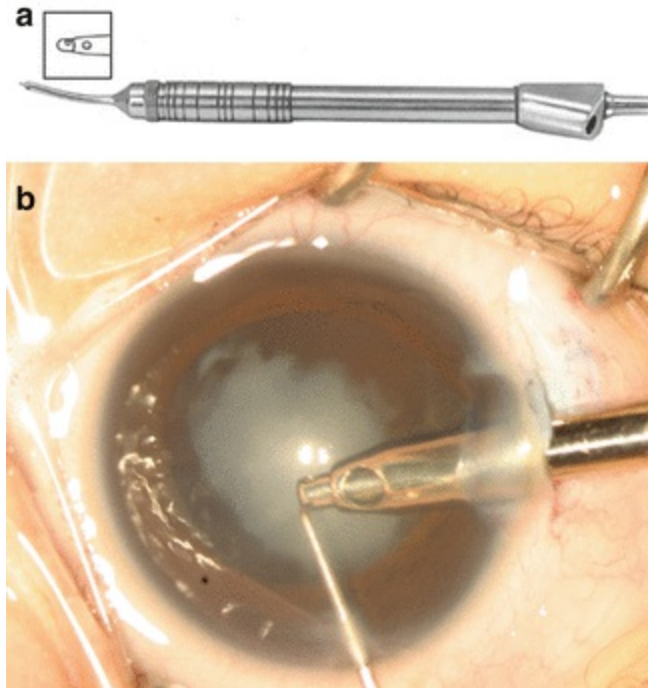


Fig. 7.4 (a) An automated irrigation/aspiration handpiece. (b) Irrigation/aspiration of the lens cortex with an automated irrigation/aspiration handpiece

7.1.7 Lensectomy with Anterior Vitrectomy (LAV)

In the 1970s, the automated vitrector (Fig. 7.5a) was introduced into pediatric cataract surgery. The thick and gummy lens material found in children is more easily and efficiently aspirated using this instrument as opposed to using a double-barreled cannula. Moreover, posterior capsulotomy and anterior vitrectomy (Fig. 7.5b) could also be performed at the same time, which lower the incidence of reopacification of the visual axis to some extent [6]. There are two approaches for LAV. One is through the pars plana, and it is a more efficient approach in removing the lens material. Since the operation is performed in the posterior chamber and the vitreous, it is associated with lower risks for endothelial loss of the iris and cornea. The other approach is through the limbus, and it is a more familiar surgical technique for anterior segment surgeons despite its lack of advantages compared to the pars plana approach. Apart from cataract irrigation and aspiration, LAV is another surgical technique that is still in use for pediatric cataract extraction.

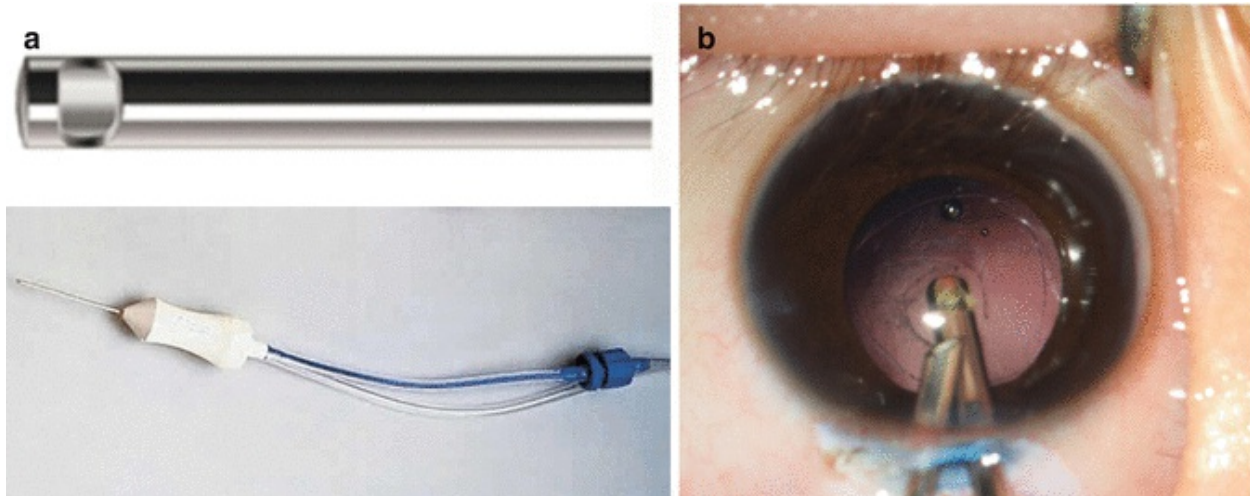


Fig. 7.5 (a) An automated vitrectomy handpiece. (b) Anterior vitrectomy with an automated vitrectomy handpiece

7.1.8 Phacoemulsification

In the 1970s, phacoemulsification was used in pediatric surgery for the first time [7]. Since a hard nucleus is seldom found in pediatric patients, the lens material can be eliminated merely by aspiration in most cases. If any hard material is encountered, ultrasound is available to help remove it. Moreover, the larger aspiration port of the phacoemulsification handpiece is more efficient than that of the irrigation/aspiration handpiece in aspirating the lens material. Phacoemulsification has become one of the routine options for pediatric cataract surgery due to its high efficiency and safety (Fig. 7.6).

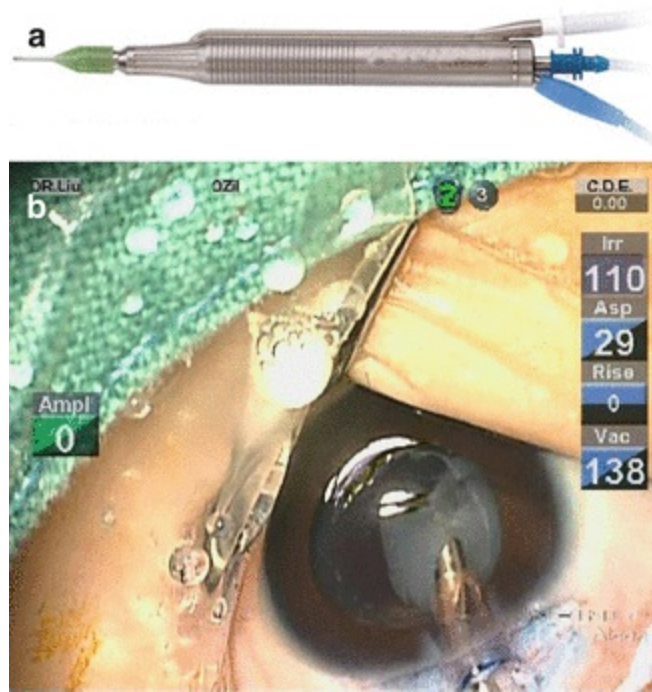


Fig. 7.6 (a) A phacoemulsification handpiece. (b) Phacoemulsification cataract extraction surgery

7.1.9 Pediatric Intraocular Lens Implantation

For pediatric patients with cataract, clearing the visual axis is just the beginning for restoring visual function, and the postoperative correction of refractive errors of the aphakic eyes is equally important. Intraocular lens (IOL) implantation is an ideal approach for aphakic correction in pediatric patients, and the details of the implantation will be elaborated in Chap. 15 (Fig. 7.7).

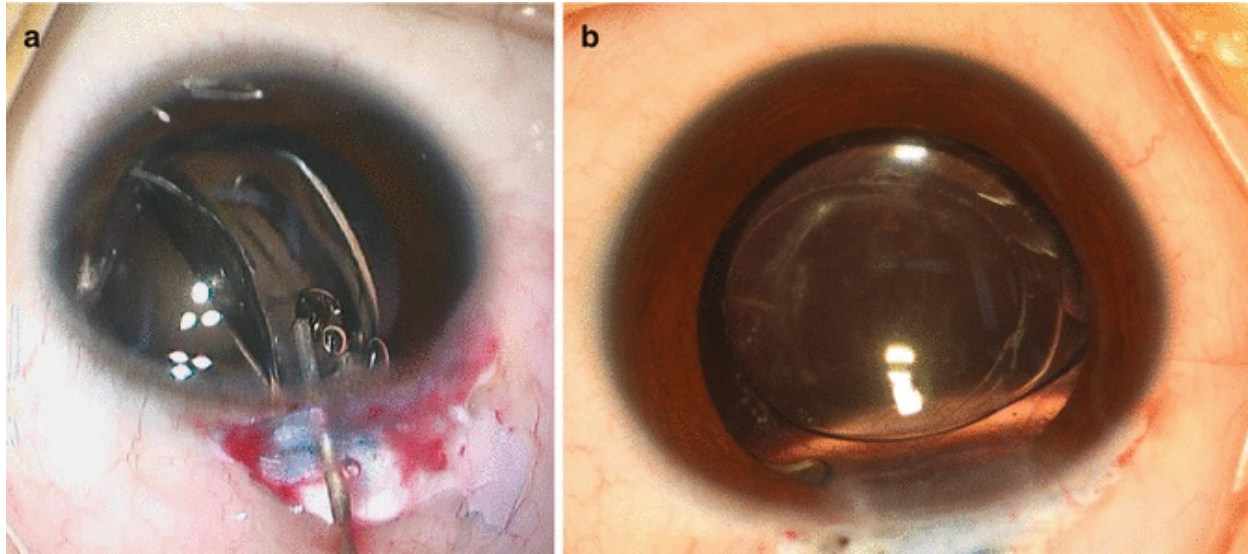


Fig. 7.7 Intraocular lens implantation. (a) A foldable IOL is inserted into the eye. (b) The IOL unfolded in the capsular bag

To sum up, throughout the evolutionary history of pediatric cataract surgery, we have come to know more about the anatomy and physiological characteristics of pediatric eyes, the development of the eye and vision, and the mechanisms for the occurrence of surgical complications. Meanwhile, the surgical instruments and techniques have also improved. Now, pediatric cataract surgery is safer, less invasive, and associated with fewer complications than before.

7.2 Conservative Treatment for Pediatric Cataract

In the 1960s, Chandler and some researchers found that the surgery for many pediatric patients with congenital cataract usually resulted in poorer visual acuity or even vision loss. Therefore, they proposed that cataract surgery should not be recommended unless preoperative vision was extremely poor [8, 9]. With the development of medical technology, a consensus has been reached among ophthalmologists that the surgical treatment for pediatric cataracts that greatly hinder the development of visual function should be conducted as soon as possible to clear the visual axis and restore visual function [10–12]. In children with cataracts that are not dense (e.g., lamellar cataract) or not on the visual axis, follow-up observations are advisable since it preserves accommodation and a series of problems like secondary opacification can be avoided. In children with unilateral cataract,

anisometropia should also be taken into consideration apart from accommodation; therefore, the treatment should tend to be more conservative. Moreover, for premature infants and children with systemic dysplasia or disorders, general anesthesia poses a high risk. In these patients, systemic abnormalities should be treated before the elective cataract surgery.

7.2.1 Indications of Conservative Treatment for Pediatric Cataract

Even though there is still no solid evidence for indications of conservative treatment of pediatric cataract, some consensus has been reached in clinical practice. They agree that the choice of treatment should be mainly based on the location, degree, and range of the lens opacity. Now, there are certain examination devices that can perform quantitative analysis of the range and degree of lens opacity to provide more scientific guidance for clinical practice (Fig. 7.8).

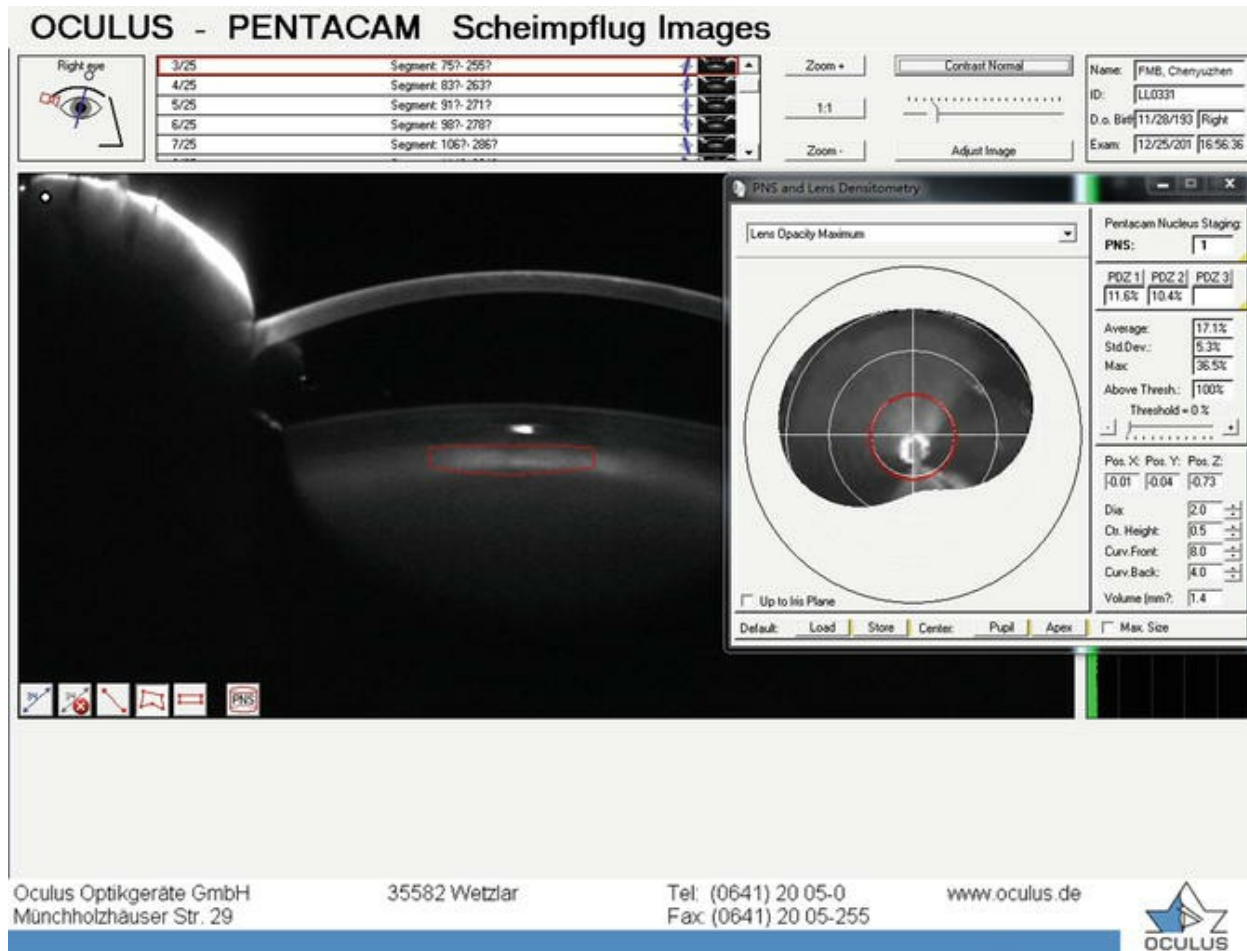


Fig. 7.8 Quantitative evaluation of the degree of lens opacity by Pentacam

7.2.1.1 Nondense Lens Opacities on the Visual Axis

When nondense lens opacity (Fig. 7.9) is not dense enough to obscure the light passing through the visual axis and fundus observation, conservative treatment can be adopted. With optical correction and visual training, the visual function can be improved in children with localized nondense lens opacity. Meanwhile, the surgery-induced problems like loss of accommodation and anisometropia can be avoided.

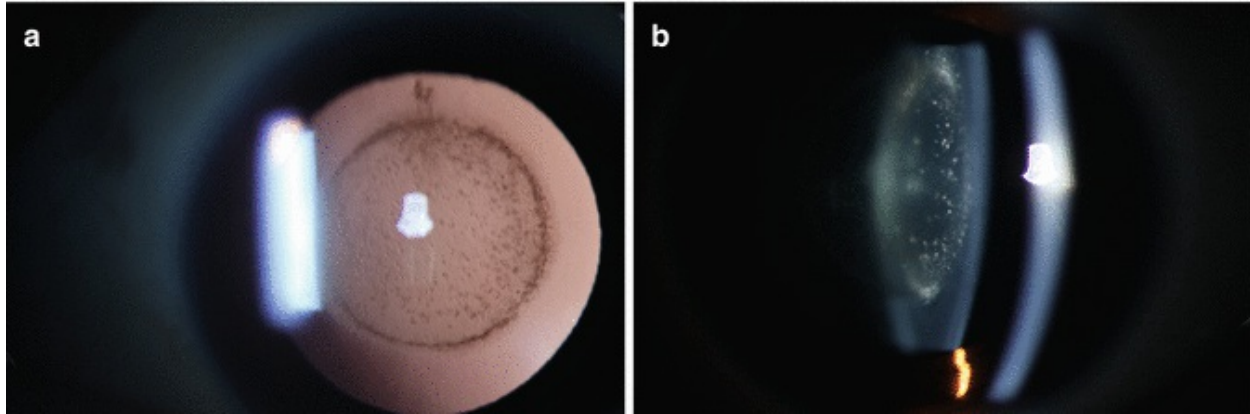


Fig. 7.9 Nondense lens opacity. (a) A representative image of nondense lens opacity from slit-lamp retroillumination. (b) An image of localized nondense lens opacity from slit-lamp oblique illumination

7.2.1.2 *Off-Axis Lens Opacities*

For opacities that do not involve the visual axis (Fig. 7.10), conservative treatment should be the first consideration. Even though the off-axis lens opacity is obviously dense, light can still pass through the visual axis and reach the retina, thus leading to no significant influence on the development of visual function. However, for opacity which makes lens shape abnormality, such as pyramidal cataract, surgical treatment will be required in case of irregular astigmatism that cannot be corrected.

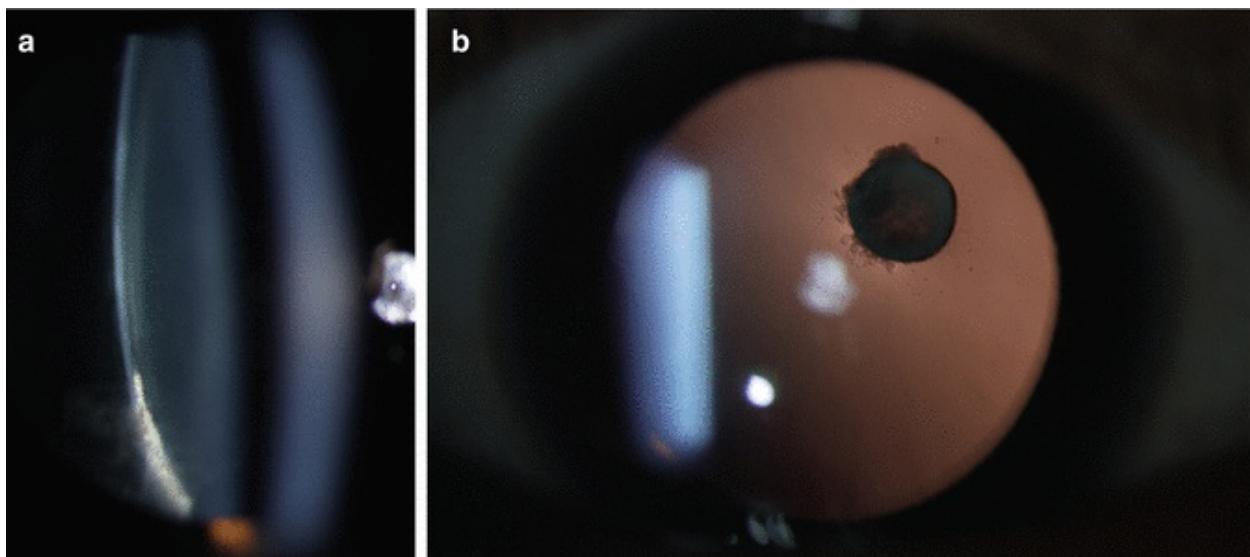


Fig. 7.10 Off-axis lens opacity. (a) Off-axis posterior subcapsular opacity. (b) Retro-illumination view of off-axis lens opacity

7.2.1.3 Dense Lens Opacities on the Visual Axis with a Diameter Smaller than 3 mm

For dense opacity on the visual axis with a diameter smaller than 3 mm, a cautious assessment should be performed before making a decision on the treatment strategy. When the opacity has no significant effect on the visual function and the child has good fixation ability, but without strabismus and nystagmus, conservative treatment, like dilation of the pupil and refractive errors correction, can be conducted, and the patients should also be put under long-term observation (Fig. 7.11). Conversely, for children with poor vision, inability of fixation, and presentation of strabismus and nystagmus, after careful refraction and fundus examinations to rule out poor unaided vision caused by refractive errors or fundus diseases, surgery should be performed as soon as possible.




Fig. 7.11 Dense lens opacity on the visual axis with a diameter less than 3 mm. (a) Dense anterior capsular opacity. (b) Retro-illumination view of a dense opacity on the visual axis

7.2.1.4 Intolerance of General Anesthesia Due to Systemic Status

Pediatric cataract can be one of the clinical manifestations of a certain syndrome and is often associated with genetic or systemic disorders [13]. For infants with systemic abnormalities, there are many complex and uncertain factors in their surgery and prognosis. As operations on young children all need to be performed under general anesthesia, the poor tolerance of the

newborn, premature babies, and infants with immature vital organ system renders them vulnerable to anesthesia accidents that might be life-threatening [14, 15]. For these patients, life is the foremost priority over elective cataract surgery. Therefore, the systemic status of pediatric patients should be cautiously evaluated before surgery to rule out surgical contraindications. If a surgery is not performed in the short term, conservative treatments should be conducted first.

7.2.2 Conservative Treatment for Pediatric Cataract

7.2.2.1 *Dilation of the Pupil*

If an opacity in the visual axis is small (less than 3 mm in diameter) and not dense, like a nuclear cataract or an anterior polar cataract, dilation of the pupil can be carried out to let more light pass through the transparent area of the lens to facilitate visual development in pediatric patients [16, 17]. Commonly used mydriatics include compound tropicamide 0.5–1 %, cyclopentolate 1 %, and atropine ointment. Glare and reduced accommodation may occur after dilation. Glare can be managed by wearing polarized or photo-gray spectacles to avoid strong light stimulation, and reduced accommodation can be controlled by wearing double-focus spectacles to aid near vision for reading. Moreover, mydriatics can also be prescribed to pediatric patients with cataracts that progress slowly or those who have postponed surgery due to various considerations like intolerance of general anesthesia, systemic risk factors, and social and economic issues.

7.2.2.2 *Correction of Refractive Errors*

Since the refractive status of pediatric patients is constantly changing along with eye development, pediatric cataracts are often associated with ametropia. Therefore, when conservative treatment is being conducted, refraction examination is carried out every 3–6 months to adjust the spectacle/contact lens prescription so as to avoid ametropic amblyopia. Due to poor compliance by pediatric patients during a vision examination, a retinoscopy can be performed under sedation or general anesthesia to determine refractive changes so as to timely adjust the prescription for either spectacles or contact lenses. As anisometropia often occurs in young children with unilateral cataract, contact lenses can be adopted under this

circumstance to avoid the size difference between binocular retinal images induced by spectacles.

7.2.2.3 Treatment of Amblyopia

Ametropia and anisometropia as well as form deprivation are important causes for amblyopia in children with congenital cataracts [18, 19]. The therapeutic regimens should be tailored to the needs of these patients. For those with unilateral cataract, the affected eye is more susceptible to amblyopia due to competitive inhibition. Therefore, a well-designed occlusion therapy based on effective refractive correction is an important method of managing amblyopia in these children. Moreover, physiotherapies like He-Ne laser, pulse red light stimulation, afterimage stimulation, Haidinger's brush (light brush) stimulation, and grating stimulation can also be part of the personalized treatment of amblyopia.

7.2.2.4 Regular Follow-Up

The key to successful treatment of pediatric cataract is early diagnosis and decision of surgical timing, since advancing lens opacity is likely to develop progressive vision impairment and other complications like amblyopia, strabismus, and nystagmus. As the cataractous eyes are still developing and especially their refractive status is constantly changing with the increase of the axial length [20], their refractive status should be regularly assessed in order to adjust the eyeglass prescription along with amblyopia management. Therefore, regular follow-up is of great significance during conservative treatment. However, children with congenital cataracts used to have a poor follow-up adherence in clinical practice. The statistics of Zhongshan Ophthalmic Center of Sun Yat-sen University shows that adherence to follow-up drops sharply as follow-up visits increase. It is estimated that attendance to visits drops from 87.8 to 33.3 % from the first visit to the fourth. In 2010, in order to improve the poor follow-up adherence, Zhongshan Ophthalmic Center of Sun Yat-sen University first provided the short message service based on the patient database to remind the parents of the pediatric patients of the follow-up visits in addition to patient education and explaining to parents the importance of scheduled visits. With a large-scale, randomized controlled trial, it has been found that, compared with the standard clinical practice of reminding parents of the scheduled visits, the

short message reminder can effectively improve adherence by the parents and attendance, which has led to better visual prognosis [21]. In light of the introduction and popularization of smartphones, the center independently developed and established the follow-up system for pediatric patients with congenital cataract in 2014 (Fig. 7.12), which has, for the first time, made it possible to make accurate visit arrangements on the basis of the follow-up database of the pediatric patients. With this system, doctors can be reminded via the doctor app on cell phones of their daily scheduled visits. Meanwhile, notifications of upcoming visits can be sent via the patient app to parents in advance, and parents can also obtain the results of each visit promptly. This has led to better compliance by parents for follow-up treatment.

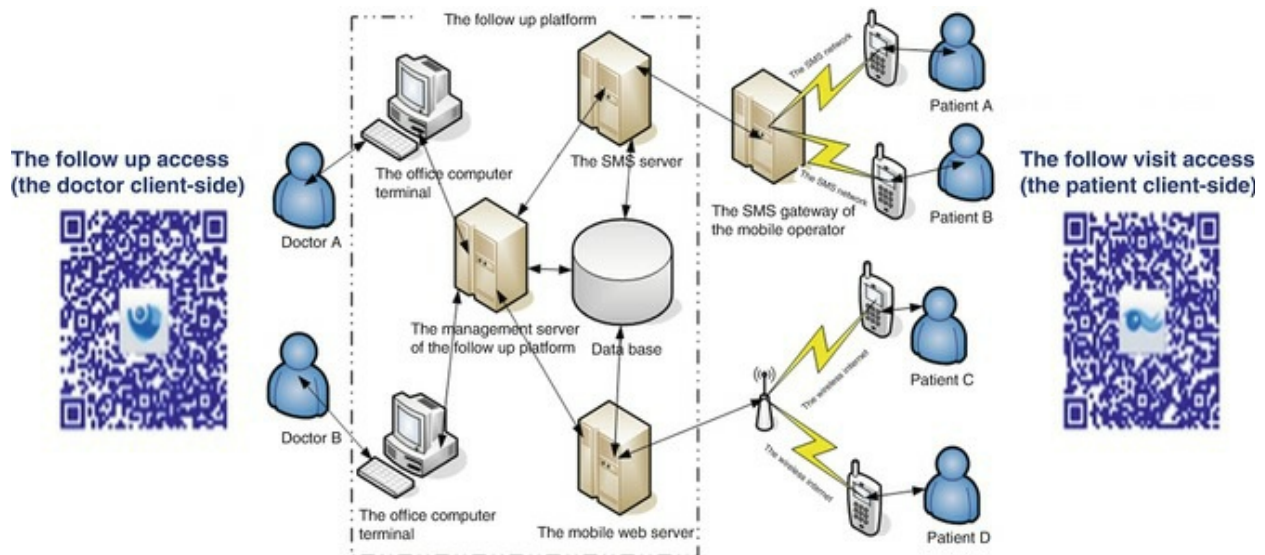


Fig. 7.12 The follow-up system for pediatric cataract patients at Zhongshan Ophthalmic Center of Sun Yat-sen University. This system consists of a computerized follow-up platform and two mobile apps. Both the doctor app and the patient app can be downloaded from the Apple App Store or various Android stores

7.2.3 Observation Indexes and Adjustment of Treatment Regimens in Conservative Treatment

Choosing conservative methods to treat pediatric cataract is a prudent decision after weighing the pros and cons. As a congenital cataract may be stationary or progressive, and the visual function of the pediatric patient is in close relation with the degree of lens opacity, regular follow-ups and timely adjustment of the treatment regimens are an indispensable link in

conservative treatment. The follow-up system for pediatric cataract patients at Zhongshan Ophthalmic Center of Sun Yat-sen University collects and documents personal information and all follow-up data of each pediatric cataract patient (Fig. 7.13). For cataractous children under conservative treatment, we need to note the following observation indexes so as to evaluate the efficacy of the treatment and adjust the treatment strategies in a timely manner.

Zhongshan Ophthalmic Center of Sun Yat-sen University Family of children with cataract Chinese 101

a

Input of basic information

Inquiry of general information

Input of examination information

Inquiry of reexamination information

Display of reexamination information

Basic information

Reset Edit Upload Photos

Patient ID Inquiry Name Sex Male Date of birth(BOD) 2000-01-01

Height(hs.) CM Wweight(Wt.) KG Eye OD Age of onset Months

Family history(FHx) Family history(FHx) Remarks on basic information

Reproductive history

Delivery mode Natural Timing of birth Term Weeks premature Disease during pregnancy

Medications during pregnancy Medications of the pediatric patient Reproductive history Parity Associated disease of the pediatric patient

Usage of incubator History of oxygen inhalation Remarks on reproductive history

Parental information

b

Return visit information Patient Patient Date of examination Inquiry of results of last examination Reset

Vision/ position of eye / anesthesia(ANA)/IOP Slit-lamp examination/ fundus examination Optometry and prescription glasses/IOLMASTER/FM/Corneal endothelial cell count/ Items examined/Examination results/Medications

Eye	Distant vision	Near vision	Corrected visual acuity (CVA)	CSM	Teller	Teller corrected visual acuity (CVA)
OD	0.1	0.1	0.1	CSM	0.01	0.01
OS	0.1	0.1	0.1	CSM	0.01	0.01
OU	0.1	0.1	0.1	CSM	0.01	0.01

3-dimensional visual function Color vision Video of visual function examination External ocular abnormalities Height(CM) Weight(KG)

Positive Normal

Eye	Position of eye	Internal medicine	Surgery	IOP/Tonopen	NCT	Goldman
OD				5-50mmHg	5-50mmHg	5-50mmHg
OS				5-50mmHg	5-50mmHg	5-50mmHg

Examination under anesthesia

Anesthetics	Dosage	Actual dosage	Duration of anesthesia (mins.)	Administrative route	Results	Abnormal reaction
水合氯醛		ml/kg	5-60			

Fig. 7.13 (a) Basic information of pediatric patients in the follow-up system at Zhongshan Ophthalmic Center. (b) Visual acuity, ocular alignment, anesthesia, and intraocular pressure of each patient are collected and documented using the follow-up system

7.2.3.1 *Changes of Lens Opacity*

Although most congenital cataracts are relatively stationary, it is also likely that the lens opacities will progress in a few cases. Therefore, observation of the lens opacities during follow-up visits should be prioritized. If possible, slit-lamp photographs of the anterior segment should be taken with the pupil dilated on each visit so as to sequential image data of the lens, which will in turn facilitate the comparative analysis of the progression of lens opacity (Fig. 7.14). When a cataract is found to be progressive through several visits, especially when its diameter increases to 3 mm or above and the opacity is close to the posterior pole and/or on the visual axis, surgery should be scheduled without delay [22–24].

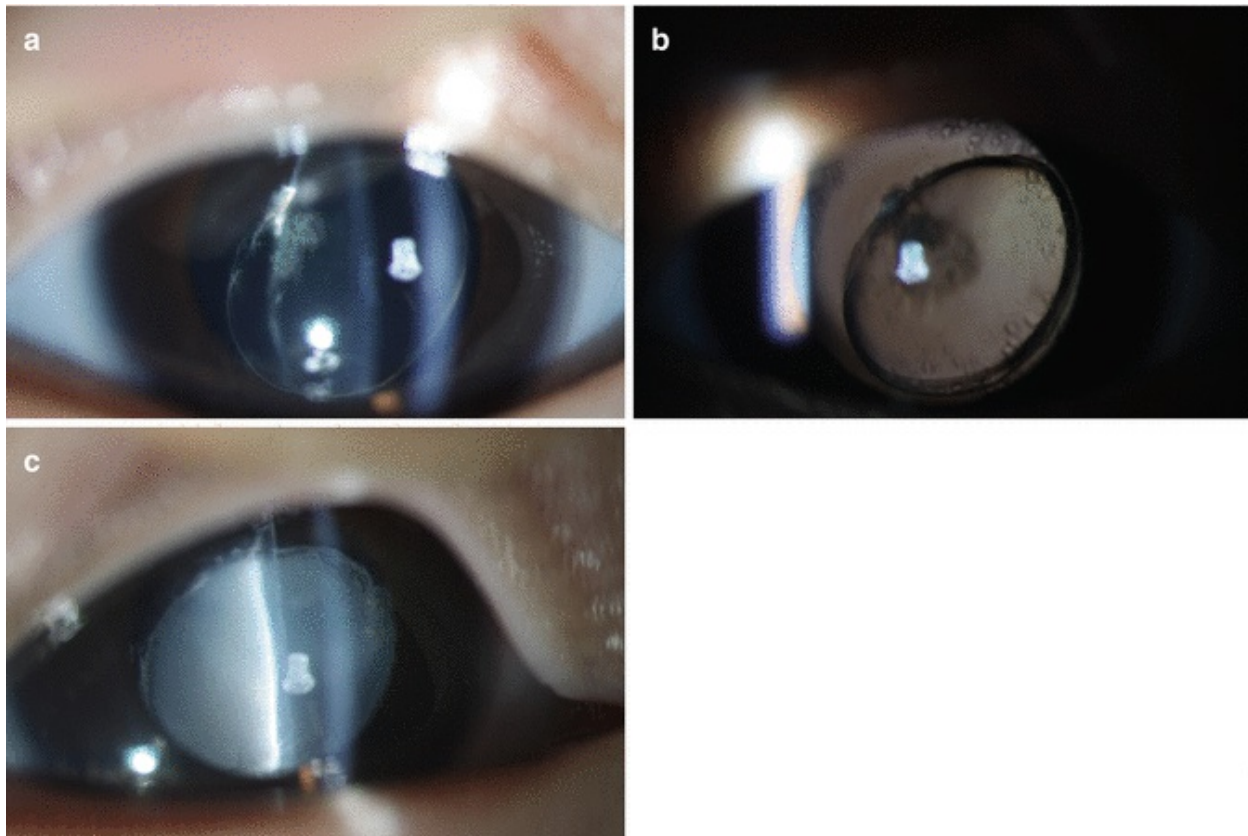


Fig. 7.14 Changes in degree of lens opacity. (a) and (b) Peripheral vacuolar lens opacity observed in a boy when he was 2 months old. (c) Total cataract developed when the same patient was 5 months old

7.2.3.2 Visual Function

During conservative treatment, examination of the visual function is of great significance in assessing the progression of cataract, for it can clearly demonstrate whether the visual function is altered due to the lens opacity. However, poor compliance in pediatric patients, especially infants, makes it challenging to assess their visual function, particularly their visual acuity. In children with bilateral cataracts, the effect of the cataracts on visual function can be judged from their daily activities. But in children with unilateral cataracts, there are few relevant visual symptoms. The assessment should be carried out with occlusion of the unaffected eye. In addition to the subjective visual acuity test, assessment of visual function can also include objective procedures like fixation test, visual electrophysiological examination, and preferential looking acuity cards. Currently, the most commonly used preferential looking acuity card in clinical settings is the Teller acuity card, which is used to measure the grating acuity of infants based on the preferential looking theory. This procedure has gained wider and wider acceptance among pediatric ophthalmologists and is often used in multicenter clinical trials of congenital cataract to evaluate the visual status of nonverbal infants [25].

7.2.3.3 Ocular Alignment, Fixation, and Fix and Follow

Whether the lens opacity has affected the visual acuity can be inferred by examining ocular “fix and follow” behavior of the pediatric patients of the pediatric patients. Bilateral examination should be performed before unilateral assessments in fix and follow. Fix and follow behavior is usually well developed in a normal infant that is 4 months old. However, if nystagmus and inability of fixation are present in a 4-month-old, significant form deprivation might have occurred. Once strabismus and nystagmus progress, amblyopia will become irreversible, and conservative treatment should be replaced by surgery as soon as possible. On the other hand, for children without strabismus and nystagmus, frequent follow-up observations should be kept, and ocular alignment, as well as fixation ability, should be documented during every follow-up visit.

7.2.3.4 *Refractive Status*

Effective correction of refractive errors is essential for the conservative treatment of pediatric cataract, and accurate refractive examination is fundamental to refractive correction. Therefore, it is advised that objective refraction be conducted every 3–6 months to monitor the changes of the refractive status. If the change in spherical is over 2.0 D or the change in cylinder is over 1.0 D, the refractive prescription of the pediatric patients should be adjusted.

It is still controversial whether the conservative treatment of pediatric cataract should be chosen. The current few consensus are mainly based on clinical experience, and there is a lack of guidelines based on rigorous studies. In general, when deciding whether surgery should be adopted, we must follow the principle of giving priority to life and also take into consideration the location, range, and severity of the lens opacity. Meanwhile, in developing countries, medical equipment, health-care quality, and skills of the surgeons in the resident regions of the pediatric patients should also be considered. Therefore, when choosing the treatment regimen for pediatric cataract, ophthalmologists should carry out a comprehensive evaluation and use integrated thinking to find a balance between timely surgery that removes form deprivation and conservative treatment that avoids serious complications caused by surgery.

7.3 Prospect: Lens Regeneration for Treatment of Infantile Cataracts

In the current clinical practice of infantile cataract treatment, the key techniques of the most common surgical procedure include removal of the cataract through a large anterior continuous circular capsulorhexis (ACCC), additional posterior capsulotomy, and anterior vitrectomy (Fig. 7.15a), which is followed by optic correction through IOL implantation, aphakic spectacles, or contact lenses. However, surgical complications, e.g., visual axis opacification, frequently occur among infant patients. Furthermore, other challenging issues including refractive correction of developing eyes and secondary glaucoma may give rise to a worse outcome. The current technique of capsulorhexis for infantile cataract surgery involves creating a large opening of a 6-mm diameter at the center of the anterior capsule, which

leaves a broad wound area and destroys a significant amount of lens epithelial cells (LECs) (Fig. 7.15a). To address these issues and to facilitate lens regeneration, our team of investigators at Zhongshan Ophthalmic Center (Yizhi Liu's team) created a new technique of capsulorhexis [26]. We first reduced the diameter of the capsulorhexis opening to 1.0–1.5 mm, which leaves a minimal wound of 1.2 mm² on the capsule, only 4.3 % of the size of the wound created by the current technique. Furthermore, we moved the location of the capsulorhexis to the peripheral capsule instead of the central zone (Fig. 7.15b). A 0.9-mm phacoemulsification cannula was applied to eliminate the lens materials and/or cortical opacities. These changes introduce substantial advantages. First of all, the technique greatly decreases the size of surgical injury, which is associated with a lower incidence of postoperative inflammation and much earlier healing. In addition, the scarring tissue formed after wound healing will be away from the visual axis, which provides increased visual axis transparency. Most importantly, a nearly intact transparent lens capsule and LECs are preserved. They possess regenerative potentials and are the critical prerequisites for the regeneration of a natural crystalline lens. We finished a clinical trial in children with cataracts who were ≤ 2 years to examine whether we could regenerate lenses in human eyes via minimally invasive surgery. Our approach is conceptually different from current practice of surgery in that endogenous LECs are preserved to a maximum as well as their natural environment and the regenerated lenses are able to improve visual functions [26].

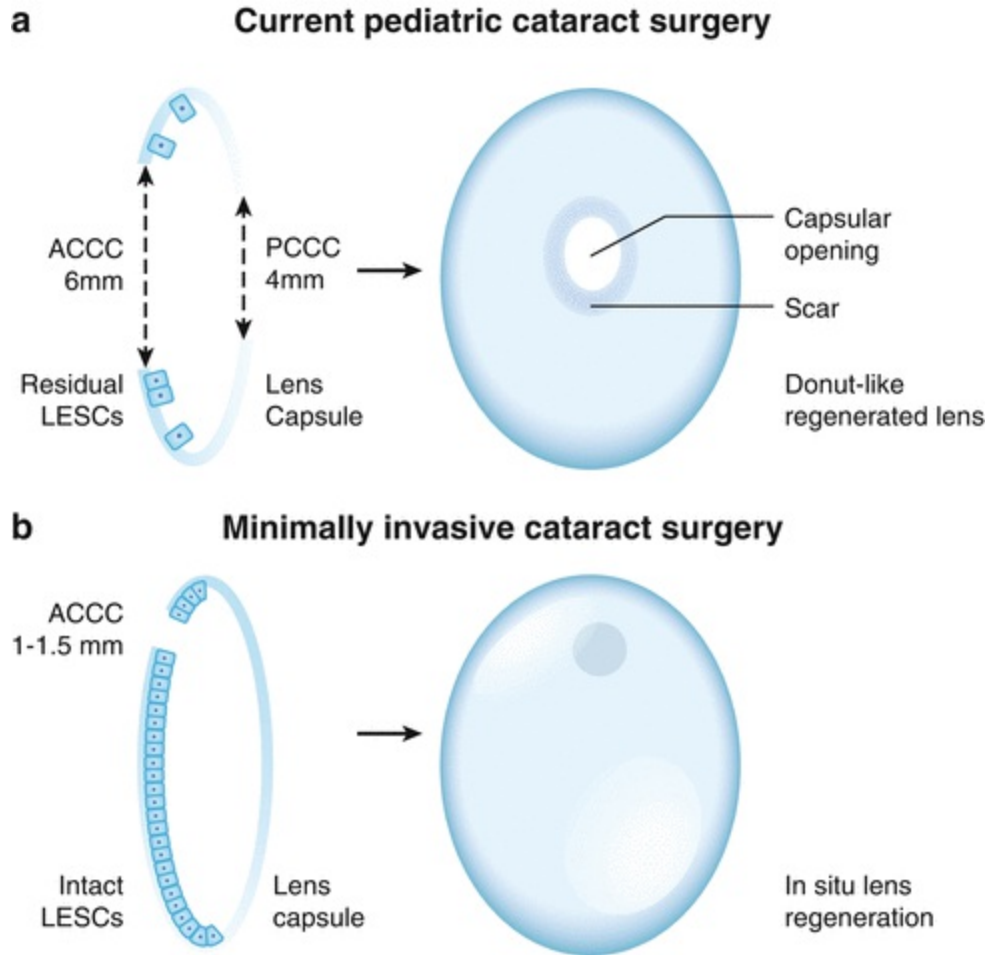


Fig. 7.15 (a) Diagrams of the traditional technique for pediatric cataract surgery. The routine anterior continuous curvilinear capsulorhexis (ACCC) for children creates an opening of a 6-mm diameter at the center of the anterior capsule, eliminates the lens epithelial cells (LECs) beneath it, and results in a large wound area of 28 mm^2 . The scars formed afterward frequently lead to postoperative visual axis opacification (VAO). In these cases, PCCC and anterior vitrectomy are usually performed during follow-up visits. (b) The new minimally invasive technique. The diameter of capsulorhexis is reduced to 1.0–1.5 mm, resulting in a small wound area of 1.2 mm^2 . The location of capsulorhexis is at the periphery of the lens capsule

7.4 Summary

Treatment of pediatric cataracts falls into two categories, i.e., surgical and conservative. Pediatric cataract surgery has been evolving for nearly two centuries. With growing knowledge of anatomical and physiological characteristics of pediatric eyes, mechanisms of visual development and surgical complications, as well as constant improvement of surgical techniques and devices, pediatric cataract surgery is becoming safer, less

invasive, and associated with fewer complications. Indications and planning of conservative treatment are based on location, severity and size of the lens opacity, as well as the visual function and systemic condition of the affected child.

References

1. Taylor D. The Doyne lecture. Congenital cataract: the history, the nature and the practice. *Eye*. 1998;12:9–36.
[\[CrossRef\]](#)[\[PubMed\]](#)
2. Ziegler SL. Complete discission of the lens by the V-shaped method. *JAMA*. 1921;77:1100–2.
[\[CrossRef\]](#)
3. Foster J. Optical iridectomy, indications, method and value. *Br J Ophthalmol*. 1932;16(8):476–84.
[\[CrossRef\]](#)[\[PubMed\]](#)[\[PubMedCentral\]](#)
4. Cordes FC. Linear extraction in congenital cataract surgery. *Trans Am Ophthalmol Soc*. 1960;58:203–18.
[\[PubMed\]](#)[\[PubMedCentral\]](#)
5. Ryan SJ, Blanton FM, von Noorden GK. Surgery of congenital cataract. *Am J Ophthalmol*. 1965;60:583–7.
[\[CrossRef\]](#)[\[PubMed\]](#)
6. Parks MM. Posterior lens capsulectomy during primary cataract surgery in children. *Ophthalmology*. 1983;90:344–5.
[\[CrossRef\]](#)[\[PubMed\]](#)
7. Hiles DA, Hurite FG. Results of the first year's experience with phacoemulsification. *Am J Ophthalmol*. 1973;75:473–7.
[\[CrossRef\]](#)[\[PubMed\]](#)
8. Chandler PA. Surgery of congenital cataract. *Trans Am Acad Ophthalmol Otolaryngol*. 1968;72(3):341–54.
[\[PubMed\]](#)
9. Chandler PA. Surgery of congenital cataract. *Am J Ophthalmol*. 1968;65(5):663–74.
[\[CrossRef\]](#)[\[PubMed\]](#)
10. Birch EE, Stager DR. The critical period for surgical treatment of dense congenital unilateral cataract. *Invest Ophthalmol Vis Sci*. 1996;37(8):1532–8.
[\[PubMed\]](#)
11. Taylor D, Wright KW, Amaya L, et al. Should we aggressively treat unilateral congenital cataracts? *Br J Ophthalmol*. 2001;85(9):1120–6.
[\[CrossRef\]](#)[\[PubMed\]](#)[\[PubMedCentral\]](#)

12. Zetterstrom C, Lundvall A, Kugelberg M. Cataracts in children. *J Cataract Refract Surg*. 2005;31(4):824–40.
[CrossRef][PubMed]
13. Merin S, Crawford JS. The etiology of congenital cataracts. A survey of 386 cases. *Can J Ophthalmol*. 1971;6(3):178–82.
[PubMed]
14. Williams AR, Conroy JM. The anesthetic management of the pediatric strabismus patient. *J AAPOS*. 1998;2(2):113–5.
[CrossRef][PubMed]
15. Pun MS, Thakur J, Poudyal G, et al. Ketamine anaesthesia for paediatric ophthalmology surgery. *Br J Ophthalmol*. 2003;87(5):535–7.
[CrossRef][PubMed][PubMedCentral]
16. Drummond GT, Hinz BJ. Management of monocular cataract with long-term dilation in children. *Can J Ophthalmol*. 1994;29(5):227–30.
[PubMed]
17. Choi J, Kim JH, Kim SJ, et al. Clinical characteristics, course, and visual prognosis of partial cataracts that seem to be visually insignificant in children. *J AAPOS*. 2012;16(2):161–7.
[CrossRef][PubMed]
18. Ceyhan D, Schnall BM, Breckenridge A, et al. Risk factors for amblyopia in congenital anterior lens opacities. *J AAPOS*. 2005;9(6):537–41.
[CrossRef][PubMed]
19. Denion E, Dedes V, Bonne M, et al. Importance of occlusion therapy for amblyopia in partial unilateral congenital cataracts that are discovered late. *J Fr Ophtalmol*. 2004;27(9 Pt 1):1017–24.
[CrossRef][PubMed]
20. Gordon RA, Donzis PB. Refractive development of the human eye. *Arch Ophthalmol*. 1985;103(6):785–9.
[CrossRef][PubMed]
21. Lin H, Chen W, Luo L, et al. Effectiveness of a short message reminder in increasing compliance with pediatric cataract treatment: a randomized trial. *Ophthalmology*. 2012;119(12):2463–70.
[CrossRef][PubMed]
22. Hamill MB, Koch DD. Pediatric cataracts. *Curr Opin Ophthalmol*. 1999;10(1):4–9.
[CrossRef][PubMed]
23. Nelson LB, Wagner RS. Pediatric cataract surgery. *Int Ophthalmol Clin*. 1994;34(2):165–89.
[CrossRef][PubMed]
24. You C, Wu X, Zhang Y, et al. Visual impairment and delay in presentation for surgery in chinese pediatric patients with cataract. *Ophthalmology*. 2011;118(1):17–23.
[CrossRef][PubMed]
25. Lambert SR, Buckley EG, Drews-Botsch C, et al. A randomized clinical trial comparing contact lens with intraocular lens correction of monocular aphakia during infancy: grating acuity and

adverse events at age 1 year. Arch Ophthalmol. 2010;128(7):810–8.
[\[CrossRef\]](#)[\[PubMed\]](#)

26. Lin H, Ouyang H, Zhu J, et al. Lens regeneration using endogenous stem cells with gain of visual function. Nature. 2016;531(7594):323–8.
[\[CrossRef\]](#)[\[PubMed\]](#)

8. History Taking and Specialized Examination of Lens Diseases in Children

Jingjing Chen¹, Haotian Lin¹✉ and Weirong Chen¹

(1) State Key Laboratory of Ophthalmology, Zhongshan Ophthalmic Center, Sun Yat-sen University, 54S Xianlie Road, Guangzhou, 510060, People's Republic of China

✉ **Haotian Lin**
Email: gddlht@aliyun.com

Abstract

The history taking and ophthalmic examination of pediatric patients with lens diseases have special requirements and methods. Doctors and nurses of pediatric ophthalmology should not only be equipped with adequate ophthalmic knowledge but also understand the physiological and psychological characteristics of pediatric patients of different ages or in different conditions. This may facilitate the design, development, or selection of the most appropriate devices or methods to perform detailed and accurate ophthalmic examinations for pediatric patients. In clinical practice, how to communicate with pediatric patients is an art. A child-friendly environment may result in better patient cooperation, and appropriate methods and devices are the key to a successful examination. This chapter discusses the psychological characteristics of pediatric patients, communication skills, as well as some practical methods and patent devices for pediatric ophthalmic examination.

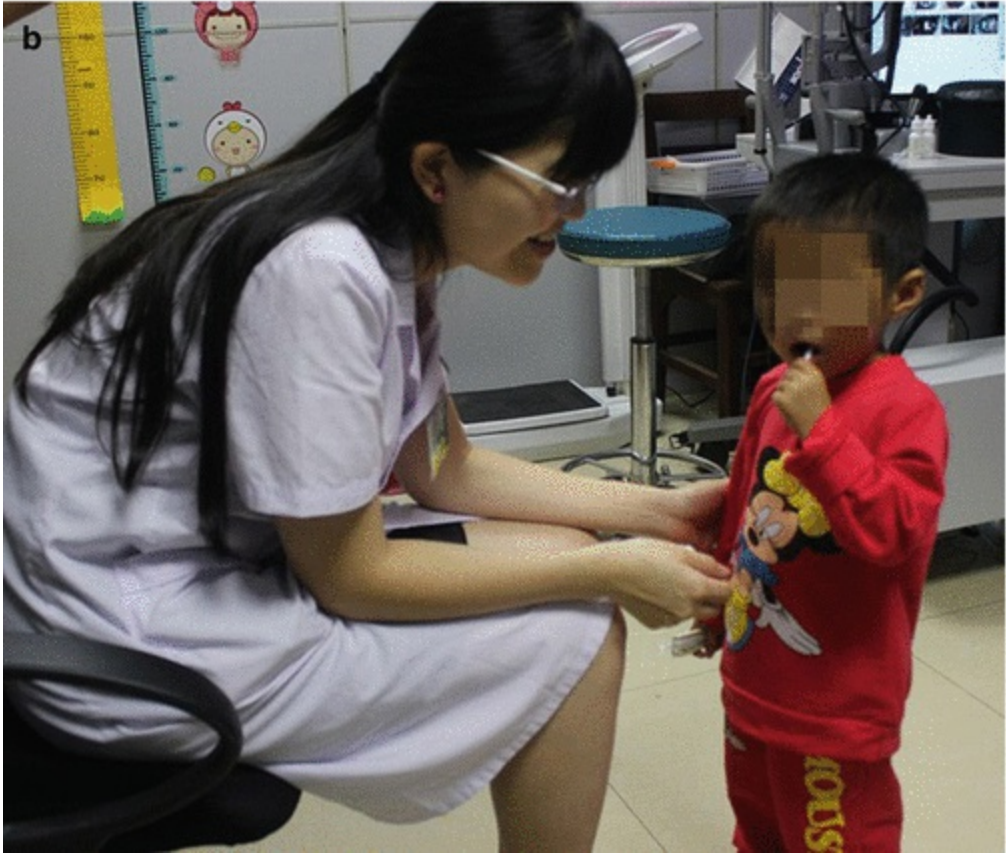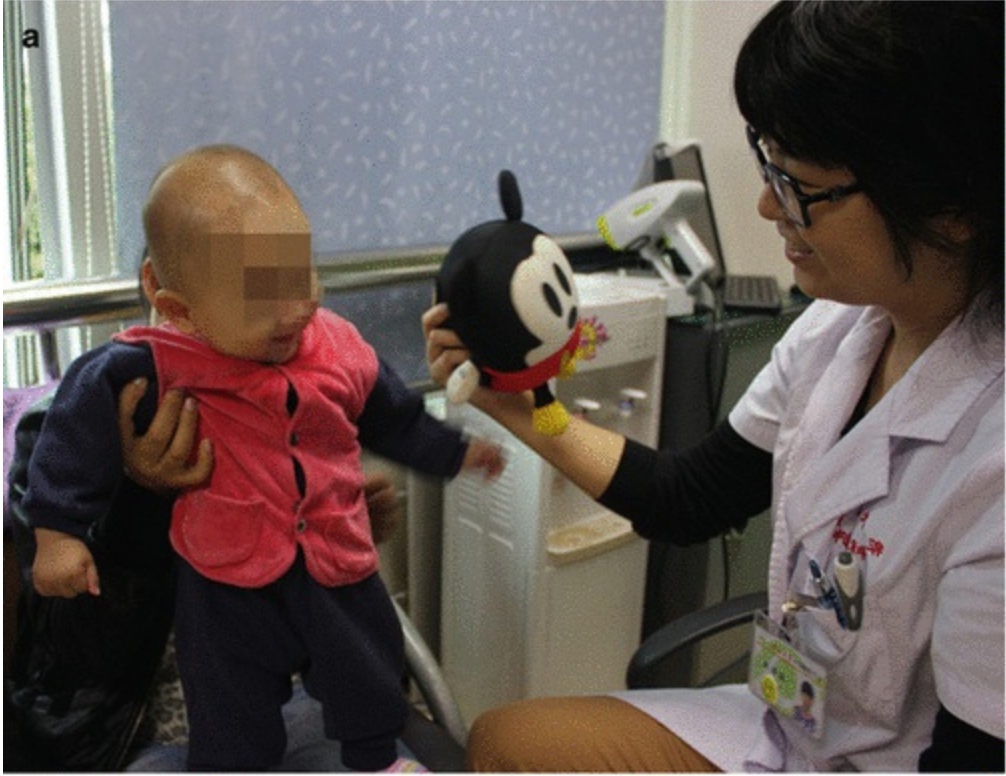There are specific requirements and techniques for history taking and specialized examinations for lens diseases in children. Therefore, a pediatric ophthalmologist should have a command of the right methods to quickly complete detailed and accurate history taking and eye examinations and then map out a proper therapeutic plan. Due to different ages, different disease conditions, and greater differences in psychological features of child patients, pediatric ophthalmologists should not only possess expertise in ophthalmology but also have a grasp of the psychological characteristics of children at all ages. Only by doing so can they select the most appropriate examination method and instrument. Likewise, communication with children is actually an art during clinical examination. A friendly manner, patience, and praise are of utmost significance to alleviate a child patient's fear and get close to him/her. Furthermore, creating a warm, child-friendly hospital environment with playfulness is also a key factor to enhance cooperation for examination from children. Candies, lovely stickers, and a variety of toys are important means for pediatric ophthalmologists to earn children's trust. This chapter will expound on children's psychological features, communication skills, and methods of history taking and specialized examinations.

8.1 Features of Psychological Development of Children and Communication Skills

Since there are different attention spans and levels of understanding for children of different ages, routine ophthalmic examination techniques for adults will typically not work. Forced cooperation of children not only affects the accuracy of the results but also causes possible iatrogenic injuries, which brings about fear and adverse memory to child patients, thus ending up in a vicious circle. For this reason, pediatric ophthalmologists need to be aware of the features of psychological development of children at different ages so as to choose the correct ways of communication and examination. Since the founding of the Home for Cataract Children of Zhongshan Ophthalmic Center (ZOC) of Sun Yat-sen University, we have set up a series of relatively well-developed and effective methods for examinations based on cognitive competence and psychological features of children at different ages.

8.1.1 Infancy and Early Childhood (0–3 Years)

At this stage, young children undergo rapid physical growth but relatively slow mental development. As a result, they are afraid of being in unfamiliar surroundings and with strangers. During this period, with the gradual development of their consciousness and self-awareness, they start language learning and emotional communication and engage in advanced neural activities like imagination, thinking, etc. In addition, they usually present themselves as capricious with the advent of the first period of resistance [1]. Based on previous clinical statistics, approximately 90 % of child patients in this period have developed a sense of strangeness and a fear of the doctor [2]. Therefore, examination on these children must be performed with the help of sedatives. However, examiners can relieve the skin hunger of child patients (i.e., the skin of infants can generate a “sense of hunger” due to disease or fear) by means of desensitization, such as hugging and stroking, so that their emotional needs can be satisfied. Examiners may also earn child patients’ trust by playing with colorful toys that can make melodious sounds (Fig. 8.1a). Lastly, pediatric ophthalmologists need to strengthen psychological support to child patients by working with their parents. The abovementioned solutions can minimize the use of auxiliary sedatives so that some child patients can be cooperative and complete an eye examination under the guidance of doctors.



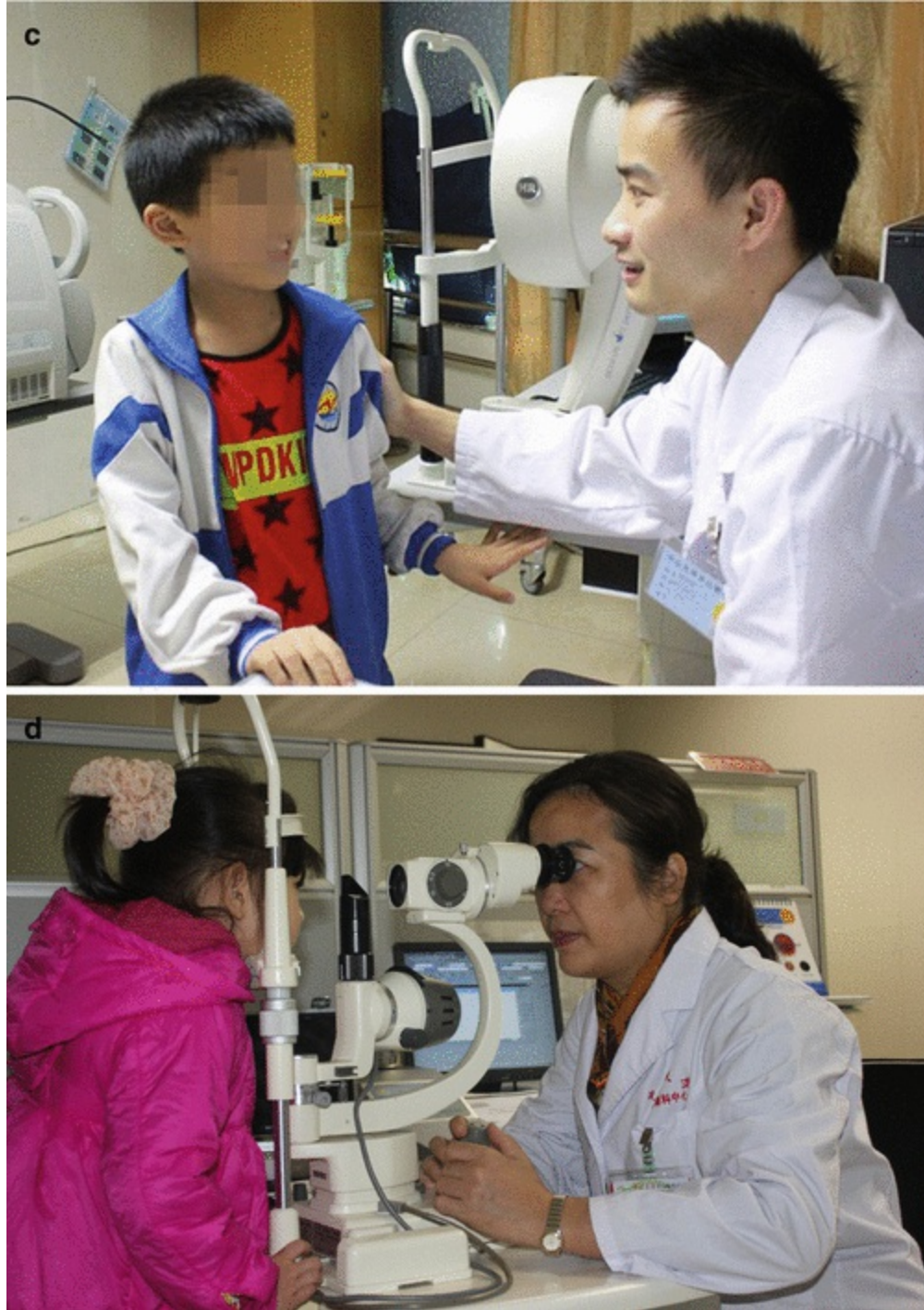

Fig. 8.1 The communication skills with children at different ages. (a) Examination of infants: play with toys together to increase trust. (b) Examination of a young child aged 1–3: reward the child with candies to enhance his/her cooperation. (c) Examination of a young child aged 3–6: by means of verbal praise, lead the child through the examination in a light-hearted, happy manner. (d) Examination of a child aged 6–12: given a gentle verbal praise, most child patients can be actively cooperative for examination

8.1.2 Preschool Age (3–6 Years)

At this stage, the development of children’s brain function is reaching a plateau. Children exhibit an increase in vocabulary, a rapid progress in body movements, an expansion of living space, and a keen interest in all surroundings. Features in this period include (1) emotional instability and vulnerability to environmental influence; (2) showing talents for imitation and fondness of imitating their parents or actions of other child patients when being examined; (3) being playful, animated, and active; and (4) individuality beginning to take shape with a certain aptitude of self-control. Hence, pediatric ophthalmologists can well create a relaxing environment full of childishness and playfulness in the examination room. Moreover, they might as well ask parents and their children to do “role-playing” of seeing a doctor, give praise and award to the child patient who is cooperative for examination, and try to minimize the use of body immobilization and auxiliary sedatives (Fig. 8.1b, c).

8.1.3 School Age (6–12 Years)

At this stage, children’s capacities in comprehension, synthesis, analysis, and induction develop rapidly due to their intellectual maturity. A certain amount of self-discipline and tolerance has also developed. According to previous clinical statistics, roughly 95 % of child patients of school age are cooperative enough to be examined [3]. Examiners need to communicate patiently with them in a gentle voice, adopting the method of demonstration to get them actively involved in the examination. It is necessary for the examiner to be gentle in manipulation and try to shorten the duration of examination (Fig. 8.1d). Besides, the examiner can give proper praise to the child patient in order to stimulate his/her performance desire so as to facilitate examination.

8.2 History Taking

A detailed medical history must include a child patient’s basic information, chief complaint (CC), history of present illness (HPI), maternal pregnancy-labor history, the child’s birth, and family history.

Basic information: name, gender, age, date of birth, height, and weight.

Common chief complaint (CC): the child patient was found to have

“white spots” in his/her eyes, predisposed to falling and getting hurt, with nystagmus, strabismus, squinting, short visual distance to an object, rubbing eyes with hands, photophobia, and binocular asymmetry. They could also be referred to the clinic after physical examination in the kindergarten and eye injury or when lens opacity is detected by other physicians. An ophthalmologist’s inquiries may begin with some simple questions (like patient’s visual acuity, whether he/she can follow light, whether he/she is cross-eyed when looking at objects, whether he/she often falls and gets hurt, whether he/she sits very close when watching television, and when he/she noticed the vision change) to know more about the child’s visual acuity. Due to the child’s short attention span and unwillingness to stay in unfamiliar surroundings, ophthalmologists should finish all the examinations rapidly after the child’s chief complaint is certain and then complete the history taking.

History of present illness (HPI): a detailed record of ocular abnormalities of the child patient, when they occurred, whether they had any causes or inducing factors, the progressions of the symptoms or any associated symptoms exist, and the examinations and the treatments given previously, including medication therapy or surgery.

Past medical history (PMH): a record of previous eye examination, drug allergies, glucocorticoid therapy (especially in the case of posterior subcapsular cataract), injuries, and surgeries.

Maternal pregnancy-labor history: maternal age at pregnancy, presence of any pregnancy-related diseases or infections during pregnancy (particularly TORCH infections, viz., toxoplasmosis, rubella virus, cytomegalovirus, herpes simplex virus 1 and 2, measles virus, and *Treponema pallidum* infection), presence of rash or fever during pregnancy (possibly suggesting recessive intrauterine infection), and presence of antenatal or perinatal factors (such as alcoholism, smoking, medications, and exposure to ionizing radiation during pregnancy).

Child’s birth: timing of birth (full term or premature), way of labor (eutocia, cesarean section, or other means of midwifery), and whether there was asphyxia, oxygen therapy, or incubation.

Family history of genetic diseases: About one third of children with congenital cataracts have family histories. Ophthalmologists should ask about the treatments and prognoses of the other patients within the families during history taking, which can serve as a reference for children’s postoperative

visual function assessment [4].

8.3 Specialized Examinations of Pediatric Cataracts

Specialized examinations of pediatric cataract consist of evaluations of visual function and anatomical structures of the eye. However, child patients fail to cooperate with the examination, so anesthesia is usually needed.

8.3.1 Examination Under Anesthesia (EUA)

For a long time, specialized examination of pediatric eye diseases has been a tough issue for ophthalmologists across the globe. First of all, child patients are not cooperative enough to be examined. In addition, most of the ophthalmic examination equipments in practice are desktop machines that require examinees to remain seated. Although some handheld, noncontact devices have been recently developed, such as handheld slit lamp and handheld fundus camera, devices for adults are still used in the majority of pediatric eye examinations. All of these have caused inconvenience to the examinations, data analyses, and diagnoses of childhood eye diseases.

To resolve this tough issue, we have set up a series of effective methods of pediatric examination under anesthesia (EUA) aimed at various ages through years of clinical practice and experience.

8.3.1.1 *Under Age 1 (Flying Baby)*

During the examination, parents should work closely with the examiner. One parent or examiner lifts up the baby under the armpits with both hands and thumbs on the baby's neck for support (Fig. 8.2a). The baby is held in a flying position with their head tilted forward to the forehead strap of the slit lamp (Fig. 8.2b). Another examiner or parent can put their left hand on the child's occipital and help them get closer to the forehead strap. The right hand can also be put between the chin rest of slit lamp and the baby's chin to stabilize the child's head and protect it from collision. Then another examiner gently holds the child's eyelids open, and the examination of the baby begins. The flying baby position facilitates smooth examination and manipulation.

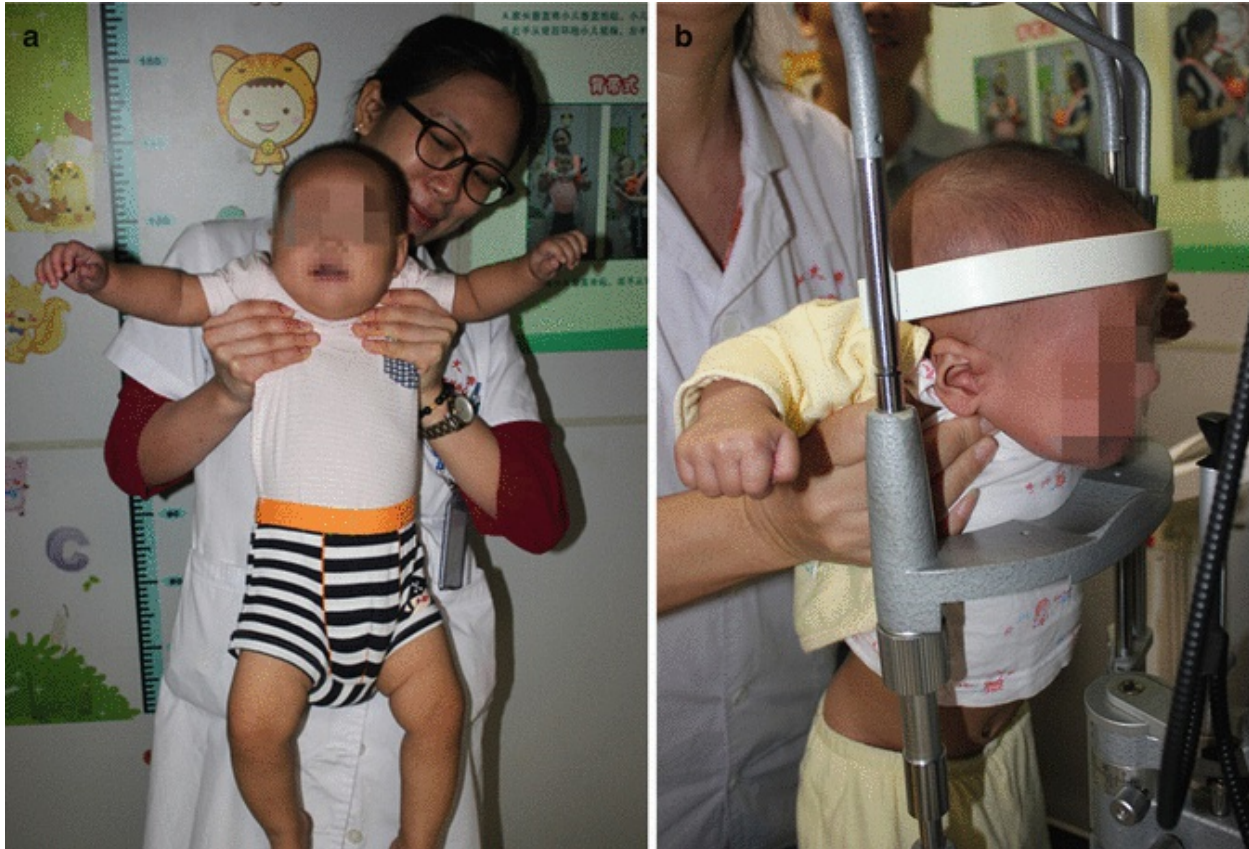

Fig. 8.2 Slit-lamp examination for a baby under age 1 year. (a) The infant is lifted up by the examiner in a flying position. (b) The examiner holds the infant in a flying position for slit-lamp examination

8.3.1.2 Age 1–3 Years (Baby Carrier)

As the baby has been gaining weight steadily, it is difficult for the parents to keep the baby “flying” for long. In this scenario, the examination can be performed with the help of a baby carrier. One parent holds the baby on the chest with the baby carrier and places the baby’s head close to the forehead strap with both hands (Fig. 8.3). The other parent lays his/her right hand over the chin rest to fix and protect the baby’s head, with the left hand in the baby’s occipital region, and gently tilts the baby’s head closer to the forehead strap. Lastly, the examiner gently holds open the baby’s eyelids and completes the examination and manipulation.

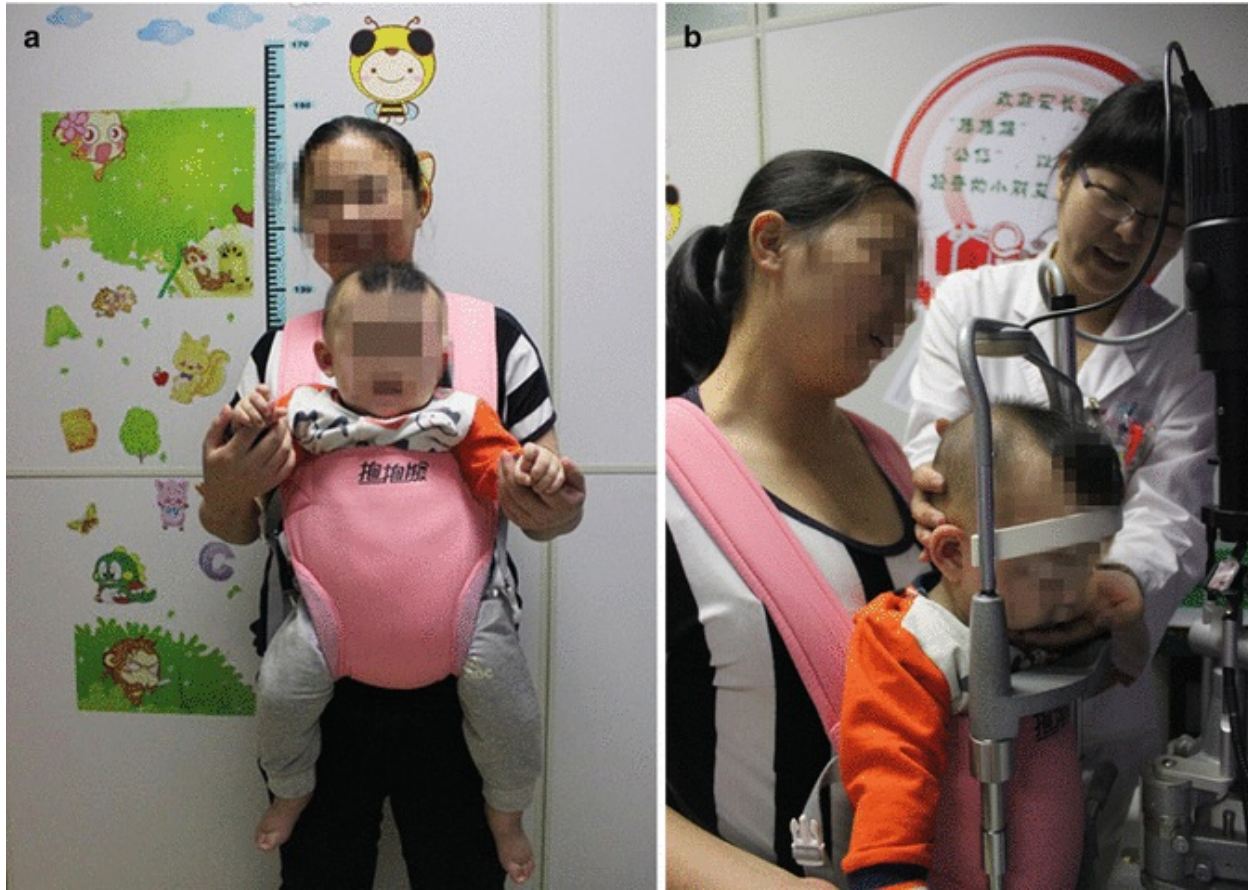
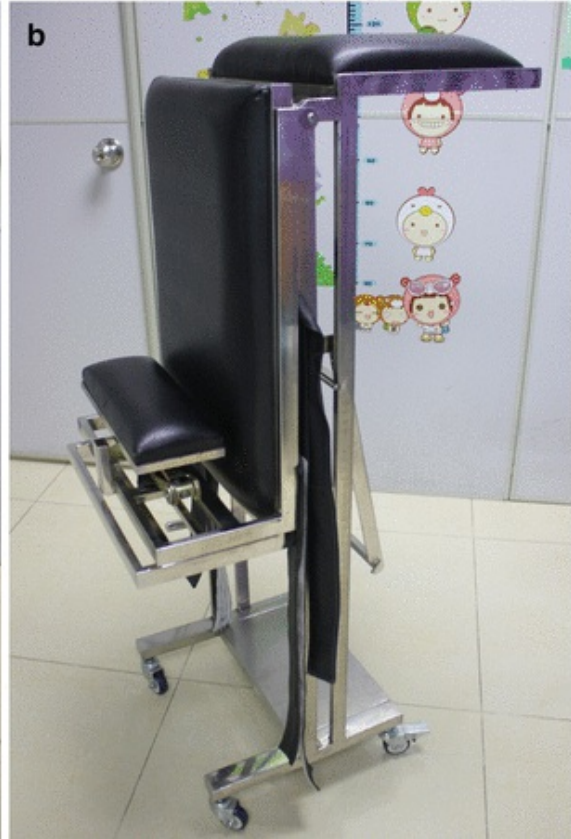
Fig. 8.3 Slit-lamp examination for a baby aged 1–3 years. (a) Mother holding her baby with a baby carrier. (b) Examiner helping the baby's parent with slit-lamp examination using a baby carrier

8.3.1.3 Age 3 Years or Older (*Flexible Bed*)

Due to the baby's weight and height, holding them or using a baby carrier alone does not ensure complete examination. In this case, a flexible bed for ophthalmic examination of children may be used (Fig. 8.4). Developed independently by the Home for Cataract Children, Zhongshan Ophthalmic Center (ZOC) of Sun Yat-sen University, the flexible bed for ophthalmic examination of infants and children possesses the functions of anesthesia bed and trolley. It has been patented in both China and the USA (China Patent No. ZL 201120251679.3; US Patent No. US9,015,882 B2). As a trolley, it can be used for the examination of child patients under anesthesia or in a conscious state. The height of the baby's seat may be adjusted swiftly and freely as required by various table-mounted ophthalmic devices. During the examination, the parent may only need to push the flexible bed up to the slit lamp, with the right hand over the chin rest to stabilize and protect the baby's

head and the left hand in the baby's occipital region to gently tilt their head closer to the forehead band. In doing so, the examiner can complete the examination smoothly and quickly.



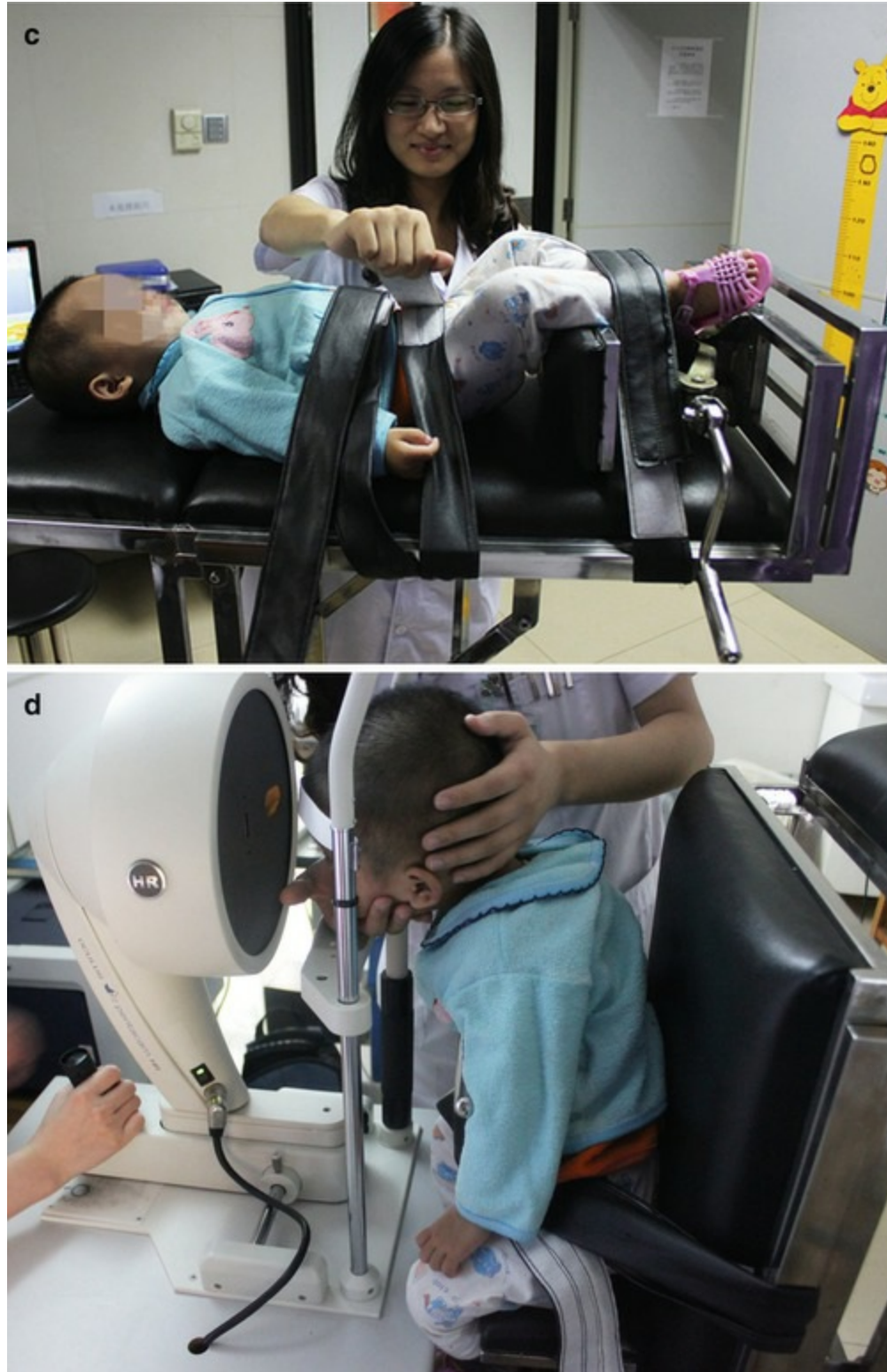


Fig. 8.4 A flexible bed for ophthalmic examination of infants and children. (a) A flexible bed in the form of “rollaway bed.” (b) A flexible bed in the form of “rollaway chair.” (c) A baby lies flat on the flexible bed and is fastened with a magic strap. (d) An ophthalmologist holds the chin and fixes the

head of the baby in a sitting position and then gently opens both the upper and lower eyelids with fingers or a speculum

8.3.2 Assessment of Visual Function

Since children's intelligence and visual function are developing rapidly, ophthalmologists should choose appropriate tests in accordance with their ages, state of visual function, and the levels of their understanding and willingness to cooperate. Meanwhile, they should keep a record of whether the child patient is cooperative for the assessment. If any child patient is poorly cooperative, he/she needs to be reevaluated.

8.3.2.1 *Infants and Toddlers Aged 0 to 3 Years*

Fixation Behavior

The existence of fixation and following is an important manifestation of poor vision and an essential item in evaluation of a child's visual function. However, an inattentive or uncooperative child might give a false-positive result. To avoid this consequence, the child must stay conscious during examination. The child is asked to stare at a target at a distance of 20–30 cm. Watch and see if their eyes can fix on it, and follow it moving in all directions. The target can be either a penlight or a colorful toy. The examination is performed binocularly and then monocularly. The results can be recorded as whether there is presence of "fixation" and "following." Three indicators of "central, steady, and maintained" are further used to describe the visual function of children with fixation and following. The performance of every indicator should be recorded (presence or absence).

Red Reflex and Cover Test

The principle of red reflex may be used to roughly rule out lens opacity. The test uses a flashlight to illuminate the pupils at a distance of 30–40 mm from the child's eyes. If the color, intensity, and clarity of reflexes from both eyes are balanced, absence of lens opacity is suggested, and the result is recorded as negative or normal. Otherwise the result is recorded as positive or abnormal. Furthermore, cover tests can be used to make a general judgment on visual acuity. When examined, the baby is supposed to stay conscious with both eyes covered alternately. When the affected eye is covered, the child can play as usual, whereas the child shows defiance when the normal eye is covered.

Teller Acuity Cards

After the above qualitative assessments of visual function, the Teller acuity cards can be used for semiquantitative assessment of visual function (Fig. 8.5). The Teller acuity represents the spatial contrast sensitivity of the human eye. The test utilizes the contrast of light-dark stripes with a certain contrast ratio and blank background. A pair of light-dark stripes is termed a cycle, and the number of cycles per degree of visual angle (cpd) represents spatial frequency. According to the “preferential looking” principle, the child’s head and eye positions and reactions are observed to determine the frequency of the smallest stripe that the baby’s affected eye can distinguish, which reveals their visual acuity. During the Teller acuity test, the acuity cards are sequentially presented from the thickest stripes to the thinnest, and binocular examination is performed before monocular examination. With accuracy and repeatability, this test is of reference value in clinical practice.



Fig. 8.5 Teller acuity cards designed by Zhongshan Ophthalmic Center (ZOC) can be used to semiquantitatively evaluate the baby’s visual function

Vision Cabinet with Remote Control Lamps

Teller acuity cards are expensive and hardly accessible in developing countries; thus this technique has yet to be widely applied. To solve this problem, Zhongshan Ophthalmic Center (ZOC) of Sun Yat-sen University

where the authors work has developed a test to estimate vision using the vision cabinet with remote control lamps. The cabinet is made up of 24 lattices of the same size, with remote control lamps and a variety of toys in it (Fig. 8.6). During the evaluation, the cabinet is in dark illumination. The examiner turns on/off the lamps of one or several lattices by remote control. When a certain lamp is lit up, observe and record the changes of baby's gaze and head position, and/or let them point out where the toy is as well as its name. However, the credibility and repeatability of this test need further investigation.



Fig. 8.6 A 24-lattice vision cabinet with dolls and remote control lamps. (a) A 24-lattice vision cabinet with dolls. (b) When evaluating a baby's vision, the examiner selectively turns on the lamps of different dolls with a remote switch in the darkroom

8.3.2.2 Young Children Aged 3 Years or Older

Visual Acuity Chart for Children

Since young children aged 3 years or older are able to understand and cooperate in simple tasks, the visual acuity chart for children can be used for assessment of visual function [5]. This acuity chart (Fig. 8.7) uses figure optotypes that are graded according to the principle of visual angle and designed to attract children. Prior to examination, the child is patiently guided to familiarize themselves with various figure optotypes. The room for examination is kept quiet with sufficient ambient lighting. Try to alleviate the child's emotional tension. Initial testing distance is supposed to be 3 m, and testing should be performed binocularly and then monocularly. There are different standards of normal vision for different age groups, as listed in Table 8.1.




Fig. 8.7 Visual acuity charts in figures. (a) Figure visual acuity chart for children. (b) Internationally used lamp box of LEA visual acuity chart for children only. (c) Optotypes used in figure charts

Table 8.1 Interrelation between age and vision

Age	Normal standard
0–2 months	Occasional fixation and tracking of visual targets with rapid ocular motility
2–6 months	Fixation, tracking of visual targets with rapid ocular motility
6 months–2 years	Grabbing toys, central fixation, and rapid or smooth ocular motility
2 years	0.4–0.5, binocular variation <2 lines
3 years	0.6–0.8, binocular variation <2 lines
4 years	0.8–1.0, binocular variation <2 lines

Testing Color Vision

Children with family histories of achromatopsia or with suspected color vision abnormalities should receive color vision tests. Currently there is no accurate, reliable color vision test for preverbal children. The method of colored object identification (Fig. 8.8) may be adopted. A child is asked to pick out the thread of the same color to as that in the examiner’s hand from threads of different colors and hues. Crayons are also useful in testing color vision. Just let the child select a crayon and draw a design of the same color as one of the previously drawn patterns. The above methods can be used as a preliminary test of a child’s color vision.



Fig. 8.8 Testing color vision with colored beads. The child is asked to put beads of different colors into different lattices during the testing

Visual Electrophysiology Testing

Being noninvasive and objective, visual electrophysiology testing involves electroretinography (ERG), electrooculography (EOG), and visual evoked potential (VEP) [6–8]. They can rule out the influence of opacity of refractive media on the visual functions of infants and young children. They can also evaluate the functions of the retina and optic nerve and help to predict postoperative visual acuity rehabilitation [7]. At present, some devices of visual electrophysiology testing specifically for children have been used in clinical practice (Fig. 8.9).

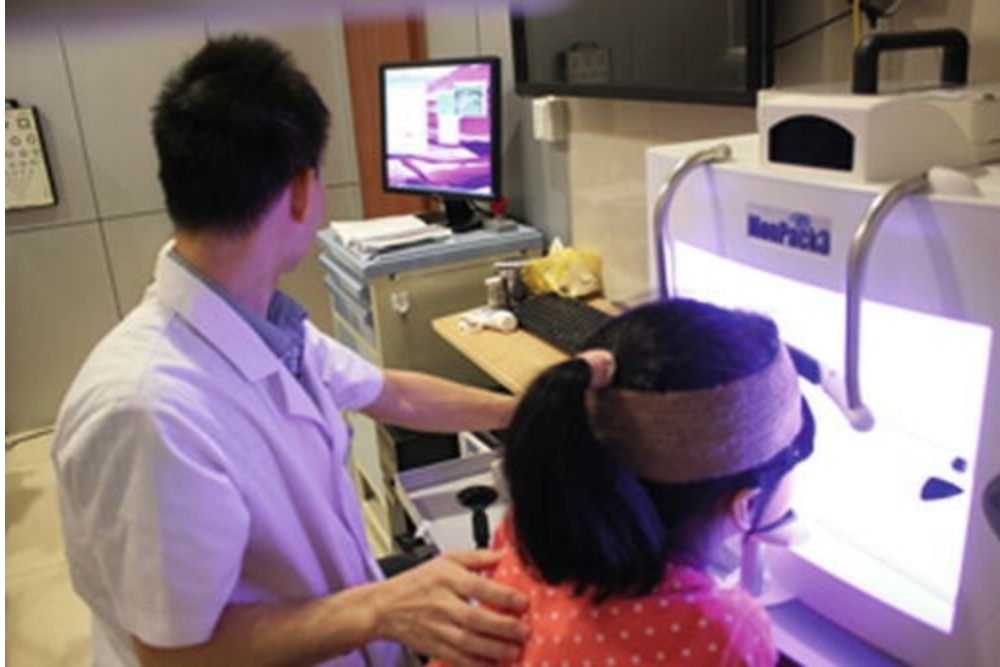


Fig. 8.9 Visual electrophysiology testing. Children's special chart is used to improve their cooperation during the testing

8.3.2.3 Structure Examination

Slit-Lamp Examination and Photography

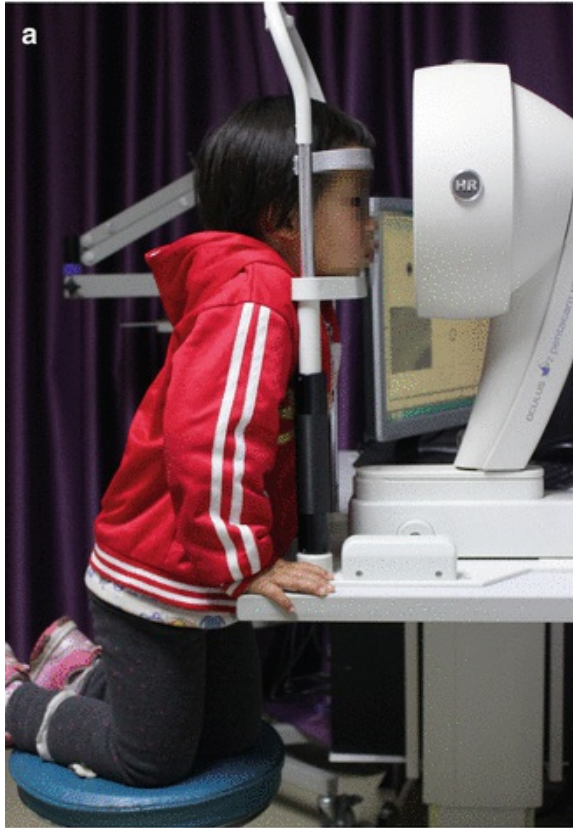The system of slit-lamp photography carries two advantages in evaluating lens diseases in children. Firstly, slit-lamp photography can keep a real-time record of a child's lens condition and observe dynamic changes of diseases (Fig. 8.10a). In the era of big data, slit-lamp images can be integrated into a database. Secondly, the area and severity of lens opacity are recorded through slit-lamp images and graded by dedicated software, so as to guide the judgment and study of timing of surgery, as well as indications for surgery. Thirdly, postoperative changes can be recorded through slit-lamp images. Lastly, the image of the child's eye may be displayed on a computer screen in real time, which helps in the counseling with the child's parents and facilitates doctor-patient communication (Fig. 8.10b).



Fig. 8.10 Examination with the system of slit-lamp photography and counseling with parents. (a) A slit-lamp photography system is used to examine and photograph a child. (b) The ophthalmologist is able to explain the disease condition to the parent with direct display of the child's eye

Anterior Segment Analysis in Children

Pentacam (OCULUS, Germany) is a three-dimensional analytic and diagnostic system for the anterior segment of the eye, which can capture 25/50 rotating Scheimpflug images of the anterior segment of the eye (from anterior corneal surface to posterior capsule of lens) with 360° coverage within 5 s. It is not only appropriate for the examination of a child who is under anesthesia or cooperative for only a short time but also performs morphological classification and opacity grading of cataracts through the images. What's more, Pentacam provides important anterior segment data including total corneal thickness, refractive power, and curvature of the anterior/posterior cornea, anterior chamber depth, anterior chamber angle, anterior chamber volume, and lens density [9]. Like other benchtop devices, Pentacam examination is more demanding for a child's body and eye position (Fig. 8.11). A child under anesthesia requires help of a flexible bed for pediatric ophthalmic examination and cooperation with their parents to complete the Pentacam examination.



OCULUS - PENTACAM Overview

	15/25 Segment: 1937-137 16/25 Segment: 1857-57 17/25 Segment: 1777-357 18/25 Segment: 1707-3507 19/25 Segment: 1627-3427 20/25 Segment: 1547-3347	<input type="checkbox"/> Contrast Normal <input type="text"/> <input type="button" value="Adjust Image"/>																																	
	<table border="1"> <tr> <td>Last Name:</td> <td colspan="2">Litt</td> </tr> <tr> <td>First Name:</td> <td colspan="2">Baigan</td> </tr> <tr> <td>ID:</td> <td colspan="2">oc0206</td> </tr> <tr> <td>Date of Birth:</td> <td>11/15/1973</td> <td>Eye: Left</td> </tr> <tr> <td>Exam Date:</td> <td>06/31/2011</td> <td>Time: 12:04:16</td> </tr> </table>			Last Name:	Litt		First Name:	Baigan		ID:	oc0206		Date of Birth:	11/15/1973	Eye: Left	Exam Date:	06/31/2011	Time: 12:04:16																	
Last Name:	Litt																																		
First Name:	Baigan																																		
ID:	oc0206																																		
Date of Birth:	11/15/1973	Eye: Left																																	
Exam Date:	06/31/2011	Time: 12:04:16																																	
		<table border="1"> <tr> <td>K1:</td> <td>42.9 D</td> <td>Axis:</td> <td>1.8 D</td> </tr> <tr> <td>K2:</td> <td>44.7 D</td> <td>Q-val:</td> <td>0.03</td> </tr> <tr> <td>Axis (Rad):</td> <td>141.4 ?</td> <td>QS:</td> <td>OK</td> </tr> </table>	K1:	42.9 D	Axis:	1.8 D	K2:	44.7 D	Q-val:	0.03	Axis (Rad):	141.4 ?	QS:	OK																					
K1:	42.9 D	Axis:	1.8 D																																
K2:	44.7 D	Q-val:	0.03																																
Axis (Rad):	141.4 ?	QS:	OK																																
<table border="1"> <tr> <td>Pupil Center:</td> <td>+ [571] μ</td> <td>x(mm)</td> <td>-0.06</td> <td>y(mm)</td> <td>0.50</td> </tr> <tr> <td>Thinnest Local:</td> <td>○ [569] μ</td> <td>+0.24</td> <td>0.67</td> <td colspan="2"></td> </tr> </table>		Pupil Center:	+ [571] μ	x(mm)	-0.06	y(mm)	0.50	Thinnest Local:	○ [569] μ	+0.24	0.67			<table border="1"> <tr> <td>Chamber Volume:</td> <td>[122 mm³]</td> <td>Angle:</td> <td>[14.9 ?]</td> </tr> <tr> <td>A. C. Depth (Int.):</td> <td>[2.58 mm]</td> <td>Pupil Dia:</td> <td>[5.47 mm]</td> </tr> <tr> <td>Enter IOP: IOP(Sum):</td> <td>[1.0 mmHg]</td> <td>Lens Th:</td> <td>[3.78 mm]</td> </tr> </table>		Chamber Volume:	[122 mm ³]	Angle:	[14.9 ?]	A. C. Depth (Int.):	[2.58 mm]	Pupil Dia:	[5.47 mm]	Enter IOP: IOP(Sum):	[1.0 mmHg]	Lens Th:	[3.78 mm]								
Pupil Center:	+ [571] μ	x(mm)	-0.06	y(mm)	0.50																														
Thinnest Local:	○ [569] μ	+0.24	0.67																																
Chamber Volume:	[122 mm ³]	Angle:	[14.9 ?]																																
A. C. Depth (Int.):	[2.58 mm]	Pupil Dia:	[5.47 mm]																																
Enter IOP: IOP(Sum):	[1.0 mmHg]	Lens Th:	[3.78 mm]																																
<table border="1"> <tr> <td>Cornea Front</td> <td><input checked="" type="checkbox"/> Show</td> <td><input checked="" type="checkbox"/> Fill</td> </tr> <tr> <td>Cornea Back</td> <td><input checked="" type="checkbox"/></td> <td><input checked="" type="checkbox"/></td> </tr> <tr> <td>Iris</td> <td><input checked="" type="checkbox"/></td> <td><input checked="" type="checkbox"/></td> </tr> <tr> <td>Lens Front</td> <td><input checked="" type="checkbox"/></td> <td><input checked="" type="checkbox"/></td> </tr> <tr> <td>Lens Back</td> <td><input checked="" type="checkbox"/></td> <td><input checked="" type="checkbox"/></td> </tr> <tr> <td>Scale</td> <td><input checked="" type="checkbox"/></td> <td><input checked="" type="checkbox"/></td> </tr> <tr> <td>Outout Width</td> <td><input type="text"/></td> <td><input type="text"/></td> </tr> <tr> <td>Outout Pos</td> <td><input type="text"/></td> <td><input type="text"/></td> </tr> </table>	Cornea Front	<input checked="" type="checkbox"/> Show	<input checked="" type="checkbox"/> Fill	Cornea Back	<input checked="" type="checkbox"/>	<input checked="" type="checkbox"/>	Iris	<input checked="" type="checkbox"/>	<input checked="" type="checkbox"/>	Lens Front	<input checked="" type="checkbox"/>	<input checked="" type="checkbox"/>	Lens Back	<input checked="" type="checkbox"/>	<input checked="" type="checkbox"/>	Scale	<input checked="" type="checkbox"/>	<input checked="" type="checkbox"/>	Outout Width	<input type="text"/>	<input type="text"/>	Outout Pos	<input type="text"/>	<input type="text"/>			<table border="1"> <tr> <td colspan="2">Corneal Thickness</td> </tr> <tr> <td colspan="2">OS</td> </tr> <tr> <td colspan="2"> </td> </tr> <tr> <td colspan="2"> 10 μ Pachy. Abs </td> </tr> </table>	Corneal Thickness		OS				10 μ Pachy. Abs	
Cornea Front	<input checked="" type="checkbox"/> Show	<input checked="" type="checkbox"/> Fill																																	
Cornea Back	<input checked="" type="checkbox"/>	<input checked="" type="checkbox"/>																																	
Iris	<input checked="" type="checkbox"/>	<input checked="" type="checkbox"/>																																	
Lens Front	<input checked="" type="checkbox"/>	<input checked="" type="checkbox"/>																																	
Lens Back	<input checked="" type="checkbox"/>	<input checked="" type="checkbox"/>																																	
Scale	<input checked="" type="checkbox"/>	<input checked="" type="checkbox"/>																																	
Outout Width	<input type="text"/>	<input type="text"/>																																	
Outout Pos	<input type="text"/>	<input type="text"/>																																	
Corneal Thickness																																			
OS																																			
10 μ Pachy. Abs																																			



Fig. 8.11 The examination with Pentacam is performed on a young child. (a) Pentacam is used to examine the anterior segment of the eye of a child. (b) The outcomes of Pentacam examination are shown

Biometry

Compared with conventional A-scan ultrasound biometry (A-scan), IOLMaster (Fig. 8.12) has a higher resolution and accuracy and is noncontact, easy to operate, and time-saving. It is useful for child patients who can be cooperative for the examination. Nevertheless, a small number of children, who fail to cooperate or have obvious opacification of refractive media, nystagmus, and fixation loss, are unfit for IOLMaster. In this case, A-scan biometry is chosen.

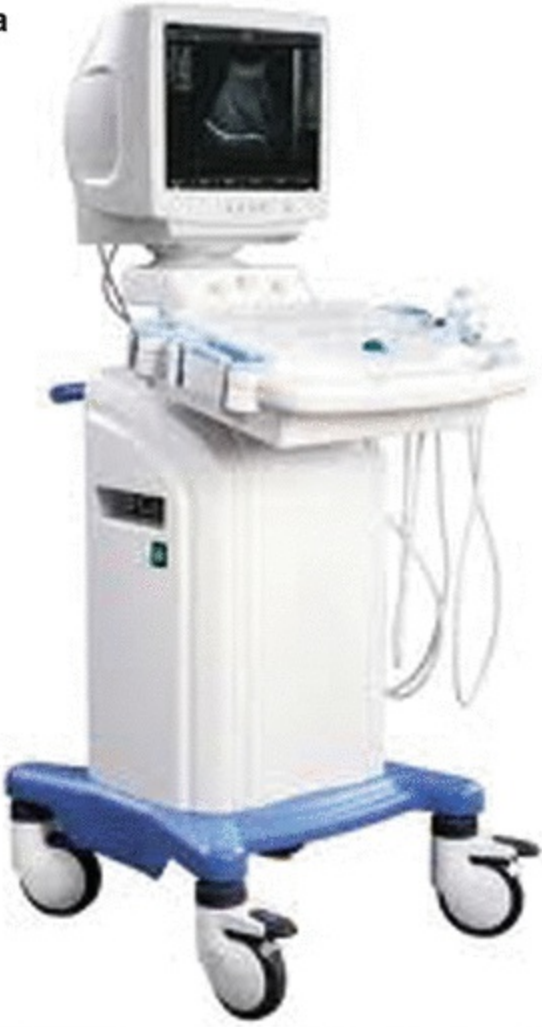


Fig. 8.12 Biometry. (a) IOLMaster optical biometer (IOLMaster) is used to test the anterior segment of the eye of a child. (b) The outcomes of IOLMaster examination are shown

B-scan Ultrasonic Examination

When the lens opacity is too severe to perform fundus examination, B-scan ultrasonic examination of the eye should be carried out (Fig. 8.13). This technique can determine if there is undetected vitreoretinopathy and help judge the timing of surgery and surgical options.

a



b

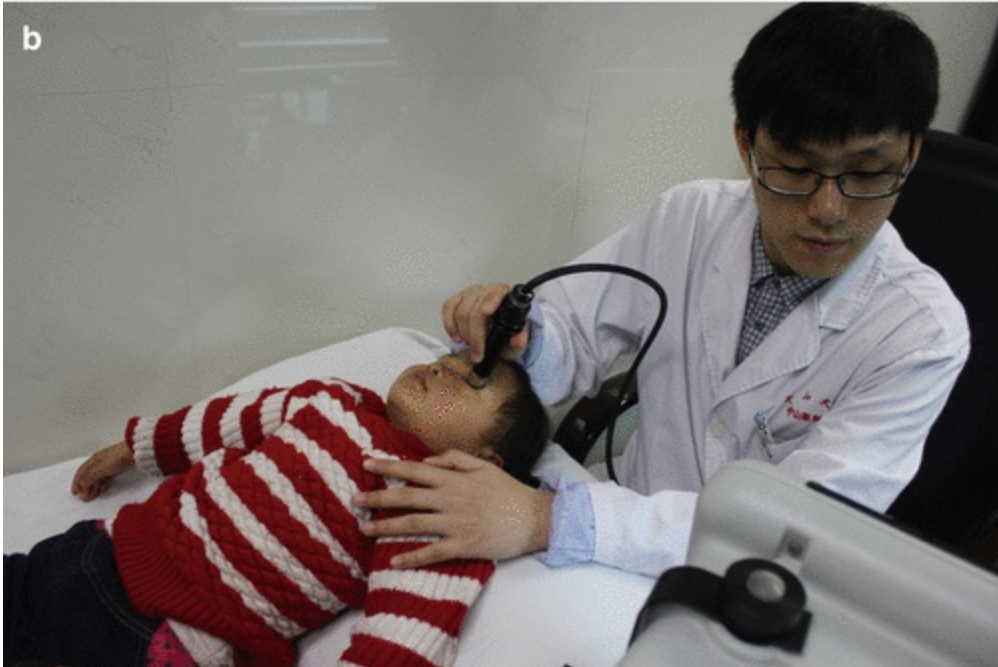

Fig. 8.13 B-scan ultrasonic examination. (a) A B-scan ultrasound device. (b) A child undergoing B-ultrasonic examination under anesthesia

8.3.2.4 *Pediatric Intraocular Pressure (IOP)*

Measurement

Tono-Pen can be used to perform tonometry for a child under anesthesia. It is a pen-like, contact electronic tonometer and easy to operate and provides accurate readings. The child can lie on their back in the parent's arms, on the doctor's lap, or on the examination bed (Fig. 8.14). With the examiner's left hand lightly pulling open the child's eyelids, the right hand holds a Tono-Pen perpendicular to the cornea and gently touches the central cornea 7–9 times to obtain the mean value of IOP. When monocular IOP becomes excessively high or the difference between binocular readings exceeds 5 mmHg, another examiner should repeat the measurement, and when necessary, the Goldmann tonometer may be used to take a third measurement.

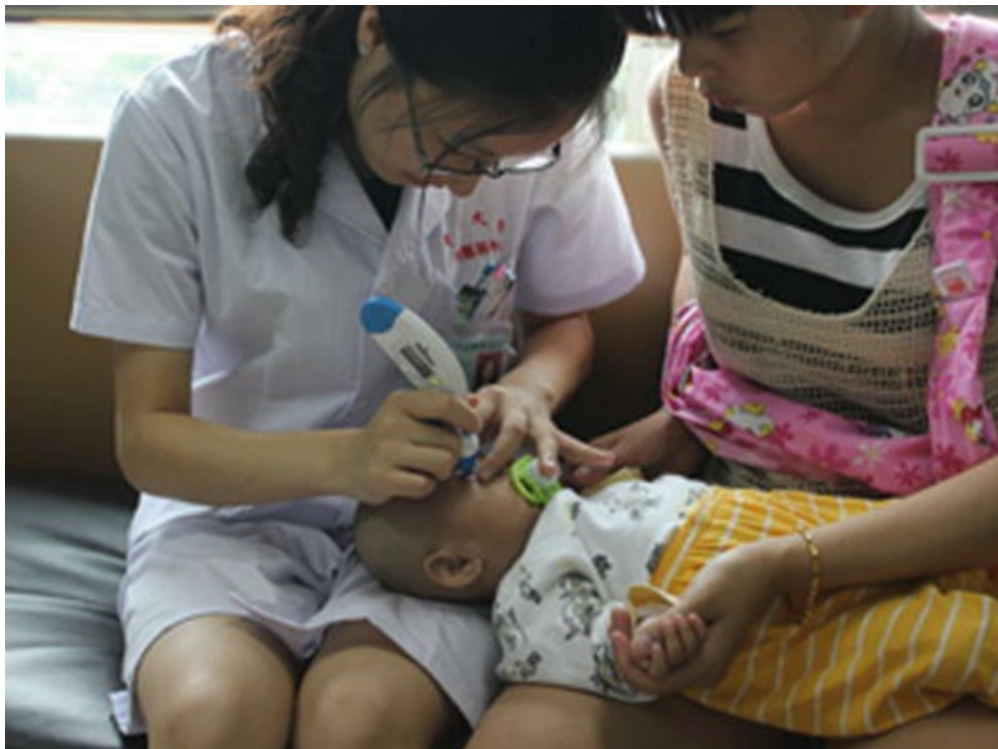

Fig. 8.14 Tono-Pen is applied to measure the child's IOP

8.4 Summary

In short, ophthalmic examination of pediatric cataract patients requires not only advanced instruments but also pediatric ophthalmologists who fully grasp the characteristics of both psychological and behavioral development of children. Appropriate and standard procedures, child-friendly environment, and active cooperation of both parents and doctors, along with patience and love, can turn the methods and techniques of pediatric ophthalmic examination into an art, which can bring a bright future to our children.

References

1. Zhu Z. Child psychology. China: People Education Press; 1993.
2. Marsh E. Anxiety disorder. In: Marsh E, editor. Abnormal child psychology. 2nd ed. Guangzhou: Jinan University Press; 2005. p. P246–7.
3. Shen Y. Self control. In: Shen Y, editor. Encyclopedia of child psychology. 3rd ed. Beijing: World Books Publishing House; 2009. p. P247–50.
4. Zhang Z. Lens disorders and surgical management. China: Guangdong science and Technology Press; 2005.
5. Buchner TF, Schnorbus U, Grenzebach UH, et al. Examination of preschool children for refractive errors. First experience using a handheld autorefractor. *Ophthalmologe*. 2003;100(11):971–8.
[CrossRef][PubMed]
6. Oner A, Coskun M, Evereklioglu C, et al. Pattern VEP is a useful technique in monitoring the effectiveness of occlusion therapy in amblyopic eye under occlusion therapy. *Doc Ophthalmol*. 2004;109(3):223–7.
[CrossRef][PubMed]
7. Westall CA, Panton CM, Levin AV. Time courses for maturation of electroretinogram responses from infancy to adulthood. *Doc Ophthalmol*. 1999;96:355–79.
[CrossRef]
8. Vrijland HR. The value of preoperative electro-ophthalmological examination before cataract extraction. *Doc Ophthalmol*. 1983;55(1–2):153–8.
[CrossRef][PubMed]
9. Konstantopoulos A, Hossain P, Anderson DF. Recent advances in ophthalmic anterior segment imaging: a new era for ophthalmic diagnosis? *Br J Ophthalmol*. 2007;91(4):551–7.
[CrossRef][PubMed][PubMedCentral]

9. Perioperative Challenges and Solutions in the Management of Children with Cataracts

Jingjing Chen¹, Haotian Lin¹✉ and Weirong Chen¹

(1) State Key Laboratory of Ophthalmology, Zhongshan Ophthalmic Center, Sun Yat-sen University, 54S Xianlie Road, Guangzhou, 510060, People's Republic of China

✉ **Haotian Lin**

Email: gddlht@aliyun.com

Abstract

The perioperative period refers to the time from the determination of surgical plan until the end of surgery-related basic treatments. In contrast to adult cataract surgery, pediatric cataract surgery may produce suboptimal outcomes due to the ever-changing condition of pediatric patients, countless operative difficulties, as well as potential complications. The perioperative period of pediatric cataract surgery often lasts up to 1 month, including preoperative, intraoperative, and postoperative phases. Considering the uniqueness in terms of patient communication, anesthetic risk, eye condition, surgery-related inflammation, and postoperative prognosis, pediatric ophthalmologists should be fully aware of these perioperative characteristics and develop coping strategies accordingly, which will contribute to the success of the surgery as well as better postoperative outcomes.

Perioperative period is from the moment the decision is made for the patient

to receive surgery to the time when the surgery-related treatment is completed. Due to the complexity and variability of the disease, the challenging surgery, as well as a higher risk of complications, particularly hidden complications, the perioperative period of pediatric cataract surgery is much longer than that of adult cataract surgery, usually 1 month. Perioperative period generally includes three phases: preoperative, intraoperative, and postoperative. For children with cataracts, the perioperative challenges and solutions include:

1. Before surgery, the physician needs to explain to the patient the details of the surgery, why long-term treatment is needed, as well as the importance of postoperative follow-ups.
2. As general anesthesia that is associated with an increased risk is required for pediatric surgeries, careful evaluation of his/her cardiopulmonary functions are required.
3. In light of the complexity and variability of pediatric lens disorders, careful surgical planning should be made before surgery.
4. As complications frequently occur within the first week following the surgery, it is crucial for both physicians and parents to monitor closely and take proper measures whenever necessary, so as to ensure favorable postoperative outcomes [1].

9.1 Preoperative Counseling

Preoperative counseling includes disease-based counseling, emotion-based counseling, and informed consent. A good preoperative counseling may help the patient's parents understand the necessity and risks of surgery, possible outcomes, as well as the need for long-term treatment, and thus the parents are more likely to agree on the treatment regimen and comply with long-term follow-ups, which may contribute to optimal therapeutic outcomes.

9.1.1 Disease-Based Counseling

Disease-based counseling is a process that the physician explains to the parents the ocular conditions of their child and the proposed treatment regimen and then answer questions from the parents (Table 9.1), which is usually done after all ophthalmological and systemic examinations have been completed (Fig. 9.1a). For children who are scheduled for surgical treatment, the following information should be provided:

Table 9.1 Frequently asked questions by parents of children with cataract

What causes the cataract of my child?
What is its incidence?
Is surgery really needed?
How about the postoperative visual outcome?
When shall we come back for follow-ups?
When to implant an intraocular lens?



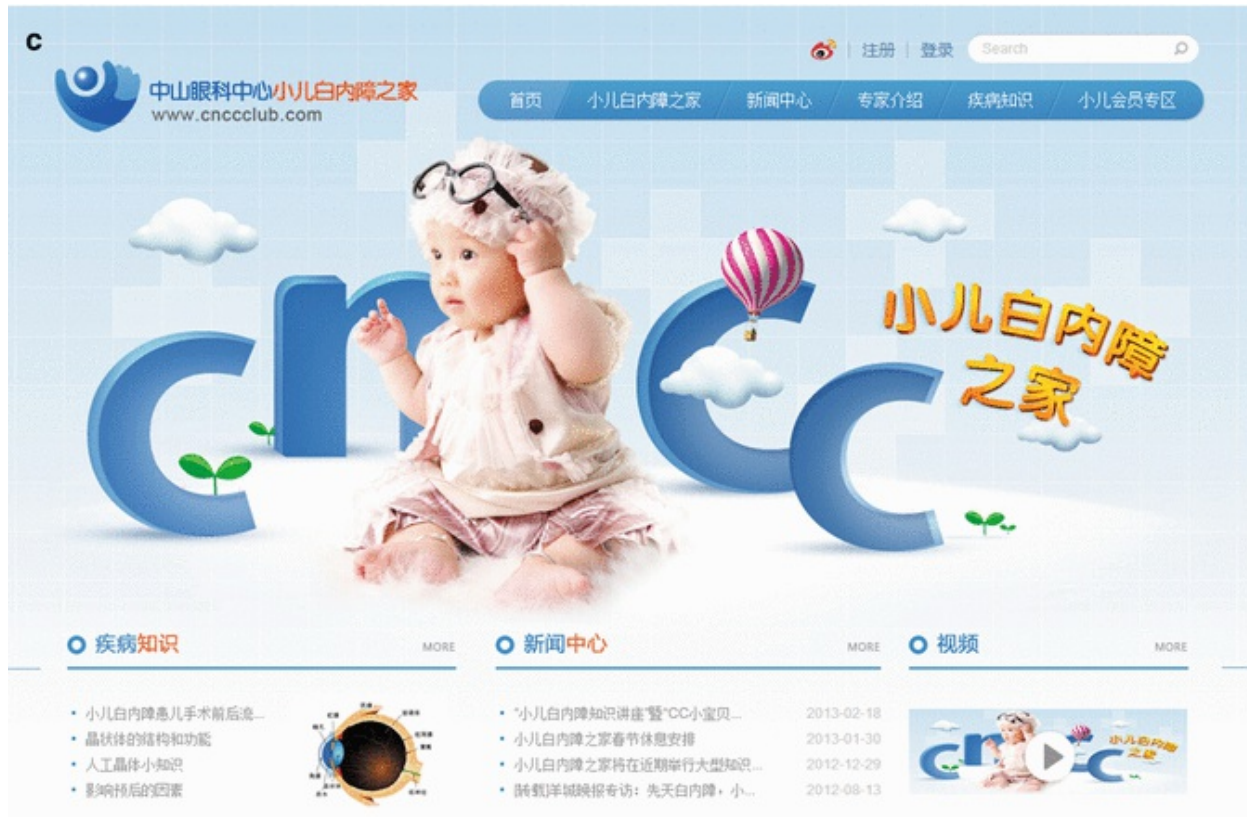

Fig. 9.1 Preoperative counseling. (a) Disease-based counseling: The physician is explaining the child's ocular conditions and the proposed treatment plan to his parent; (b) Emotional-based counseling: The physician is communicating with the child via hug or touching; (c) An online platform for physician-patient communication developed by the Cataract Children's Home in Zhongshan Ophthalmic Center

1. The pros and cons of different surgical timings and strategies.
2. Preoperative preparations, including preoperative medication, preoperative systemic and ophthalmological examinations, pre-anesthesia evaluation, preoperative nursing care, as well as cost and duration of the surgery.
3. Warning signs of postoperative complications, such as eye redness, eye pain, agitation and crying, or other ocular abnormalities.
4. Postoperative visual outcome and its influencing factors (Table 9.2). A well-conducted disease-based counseling can not only demonstrate that

the physician is responsible, but also enhance the parents' trust and cooperation, which is the basis of optimal treatment outcomes.

Table 9.2 Factors associated with a suboptimal visual outcome following pediatric cataract surgery

Long interval from onset of symptoms to surgery
Unilateral cataract
Asymmetric bilateral cataracts
Significant strabismus
Nystagmus
Signs of severe visual impairment (e.g., poor fixation and pursuits)
Juvenile idiopathic arthritis-related cataract or cataract complicated with intermediate uveitis
Developmental abnormalities of the eye
Postoperative complications without timely management

9.1.2 Emotion-Based Counseling

As postoperative recovery may be very slow and the postoperative conditions may become complex and variable, most parents undergo a tough episode of stress. Therefore, in addition to explaining the disease itself, physicians should also show understanding and sympathy for these parents and take time to establish a good rapport or communication with them.

In our clinical practice, the pediatric ophthalmologists interact with the patients and their parents via both direct face-to-face communication and indirect communication on social media. Direct communication includes hugging or touching the child (Fig. 9.1b), gentle verbal communication, giving the child candies or toys as awards, listening to the parents with patience, etc. A good direct communication is the most effective and efficient approach of communication, helping to earn the acceptance and trust of the child and his/her parents, which is associated with enhanced cooperation.

Physicians may also interact with the parents via several indirect ways (e.g., QQ groups, Wechat groups, and websites), disseminating knowledge about pediatric cataract and answering questions from the parents in a timely fashion (Fig. 9.1c). The physicians can also track the patient's condition and guide the parents to cooperate and comply with the treatment. Meanwhile, owing to the long-term communication, a harmonious, healthy, sincere, and

trustful relationship can be established between the physicians and the patients and/or their parents.

9.1.3 Informed Consent

Surgical consent form is an essential legal instrument in the framework of modern healthcare system, which protects both the patients' right to be informed and the physician's practice. Before obtaining the informed consent, the physician has to fully explain to the patient's parents the purpose and methods of the proposed surgery, precautions before and after the surgery, adverse events that may occur during the surgery, etc. According to the applicable laws, children under the age of 18 are considered not competent to make informed consent decisions. As a result, it is their parent(s) or guardian(s) who sign the surgical consent form in person. If this is not possible, there has to be a surrogate with written authorization from the patient, parent(s), or guardian(s) to sign the surgical consent form.

9.2 Preoperative Preparations

9.2.1 Preoperative Medication

The main purpose of preoperative medication is to prevent surgical infection and reduce postoperative inflammatory response. Generally speaking, 3-day preoperative application of antibiotic and/or nonsteroidal anti-inflammatory drug (NSAID) eye drops is recommended (Fig. 9.2). Antibiotics with broad spectrum activity, superior ocular penetration, and favorable safety and tolerability profiles in children should be selected [2]. For complicated cases, such as children with concomitant uveitis or ocular trauma, NSAID eye drops can be added preoperatively to further mitigate postoperative inflammatory response. In order to facilitate safe surgery, drugs such as compound tropicamide drops should be applied to quickly dilate the pupil, starting from 1 h before surgery, once every 15 min, totally three times. Rational and strict preoperative medication will ensure the safety of the surgery, effectively prevent postoperative infection, and alleviate postoperative inflammatory response [3].

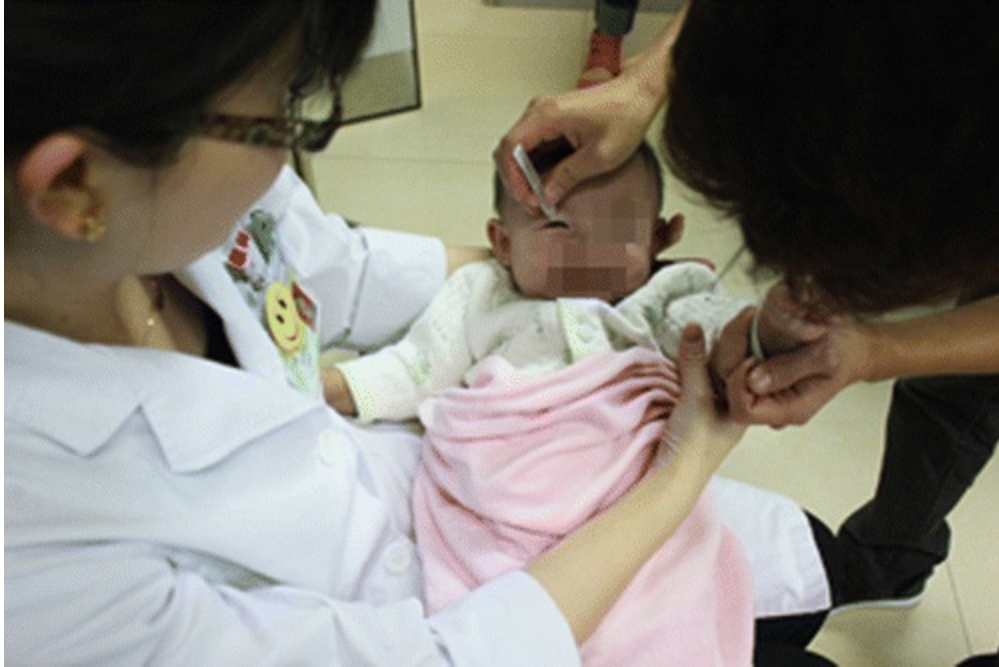

Fig. 9.2 Preoperative medication. A parent and a physician are cooperating to apply the eye drop for a pediatric patient

9.2.2 Preoperative Examination and Nursing Care

Preoperative examination for pediatric cataract surgery can be broadly divided into ophthalmological and systemic examinations. Ophthalmological examination includes visual acuity, ocular motility, ocular alignment, the anterior segment of the eye (particularly density and morphology of the lens opacities), vitreous, fundus, the presence of nystagmus and strabismus, etc. In order to reduce the risk of surgical infection, saline irrigation of bilateral lacrimal passages should be performed 1 day before surgery. If purulent discharge is observed, lacrimal passage inflammation should be treated first, and the surgery may need to be rescheduled. On the other hand, the systemic examination usually includes electrocardiograph, chest X-ray, blood routine, urine routine, blood biochemistry, blood clotting function, etc. The main purpose of the systemic examination is to evaluate whether the pediatric patient can tolerate general anesthesia and the surgery itself. As cataract surgery is always elective, any abnormalities identified by the systemic examination should be consulted and treated before the surgery. Considering the poor immunity of pediatric patients due to their young age and immaturity, they should receive cautious preoperative care once the surgery

is scheduled. Cough, fever, or other undesirable events may lead to postponement of the surgery.

9.3 Postoperative Management and Follow-up

9.3.1 Postoperative Medication and Nursing Care

For children undergoing cataract surgery, postoperative medication and nursing care are crucial in controlling inflammation and preventing infection after surgery. Selection of drugs and timing of administration are also very important. Once endophthalmitis occurs after pediatric cataract surgery, it may exert a devastating effect on the patient's visual functions. Thus, postoperative medication should focus on preventing infection. But due to the unique characteristics of drug metabolism in children, systemic use of antibiotics may cause intestinal flora imbalance and microecological disturbance, making the body prone to fungal or drug-resistant bacterial infection. For this reason, routine use of systemic antibiotics after pediatric cataract surgery is not recommended by most surgeons. Topical antibiotic prophylaxis appears to be rational for most pediatric patients. Systemic use of antibiotics is only indicated when the surgical procedure is complex and lengthy, any intraoperative complication occurs, or postoperative inflammatory response is significant, particularly when endophthalmitis is highly suspected.

Reducing inflammation is key to the postoperative medication after pediatric cataract surgery. As the pediatric eye is still developing, especially the immature blood-ocular barrier, its response to the surgical stimulation is always intense; thus fibrinous inflammatory response is commonly seen after the surgery. Excessive inflammatory response may result in several postoperative complications such as pupillary fibrinous membrane, pupillary block, posterior synechiae, pigmentary deposits on the intraocular lens (IOL), IOL capture, posterior capsular opacification, and cystoid macular edema (CME). Rational use of anti-inflammatory drugs can effectively prevent these complications. At present, the most commonly used anti-inflammatory drugs in ophthalmology include topical or systemic steroids and NSAIDs. Besides, depending on the intensity of the inflammatory response, appropriate mydriatics may also be used to reduce the risk of posterior synechiae.

Immediately after surgery, antibiotic ointments are applied, and an eye

patch is placed over the operated eye. A plastic or metal shield is used to cover the eye patch for protection. Antibiotic plus steroid eye drops (e.g., tobramycin/dexamethasone drops) are usually administered every 2 h in the first week following cataract surgery and, thereafter, 4–6 times a day for 1 month if the patient does not show any abnormalities. Antibiotic plus steroid eye ointments (e.g., tobramycin/dexamethasone ointments) are often applied once daily at bedtime for 4 weeks. For those patients with intense postoperative inflammatory response, concomitant use of NSAIDs (e.g., pranoprofen or diclofenac sodium eye drops) is recommended. Mydriatics (e.g., compound tropicamide) may also be used if necessary. The intraocular pressure (IOP) should be monitored regularly after surgery, and IOP-lowering drugs should be administered when an elevated IOP is observed. Moreover, the specialized nurse should educate the patient's parents on the correct usage of eyedrops and ointment so as to avoid inadvertent injury.

9.3.2 Postoperative Follow-up

Postoperative follow-up aims to monitor postoperative inflammatory response, find out, and treat potential postoperative complications timely [4]. A follow-up plan includes visit scheduling and parameters that need to be monitored at each visit. Before discharging the patient, the operated eye should be carefully examined. Follow-up visits on 1 week and 1 month after surgery are scheduled for uncomplicated patients, while more visits will be needed for complicated patients. Routine postoperative examination includes visual acuity (graphic visual acuity chart for children or Teller acuity cards), IOP (NCT or Tono-Pen), and slit-lamp examination. Pentacam and optical coherence tomography (OCT) may also be performed if feasible, which may help to fully assess the postoperative condition of the operated eye.

Posterior capsule opacification (PCO) and ocular hypertension are the most commonly seen complications following pediatric cataract surgery. In younger patients, PCO may occur as early as the first week following surgery if the posterior capsule remains intact. Even if posterior capsulotomy combined with anterior vitrectomy has been performed during surgery, PCO may also occur. When the visual axial region is obscured by PCO, Nd:YAG laser posterior capsulotomy should be performed immediately after the parental informed consent is obtained, so as to ensure the transparency along the visual axis. Postoperative ocular hypertension is another common but potentially dangerous complication. Etiological factors may include residual

viscoelastic agents and/or lens cortex, postoperative inflammatory response, posterior synechia or pupillary membrane occlusion, drug-related events (e.g., steroid-induced ocular hypertension), etc. Both physicians and parents should pay serious attention to ocular hypertension and decide on an appropriate treatment regimen according to its underlying cause [5]. Early detection and treatment are crucial to managing ocular hypertension, or else irreversible visual impairment may occur. When ocular hypertension is observed for the first time after surgery, timely medication is required, and the IOP should be monitored closely. Based on our research findings, if steroid-induced ocular hypertension is highly suspected after excluding all surgical and ocular factors, the following diagnostic therapy of drug switching and addition of stepwise IOP-lowering medication is recommended. For an IOP of 21–25 mmHg, NSAIDs may be used to replace corticosteroids; for an IOP of 25–30 mmHg, a single IOP-lowering drug should also be applied; for an IOP of 30–40 mmHg, combination of two IOP-lowering drugs is advisable; and for an IOP higher than 40 mmHg, combination of three IOP-lowering drugs is recommended. If the IOP can be controlled within the normal range after 2 weeks of medication, then dose tapering may be started which typically takes about 2 weeks. However, if the IOP continues to elevate or rebounds after the withdrawal of IOP-lowering drugs, glaucoma-related surgical treatment should be considered. As for complications like posterior synechia, pupillary membrane occlusion, or IOL pupillary capture, surgical treatment may be considered on an individualized basis.

9.4 Summary

In conclusion, pediatric ophthalmologists should pay great attention to the perioperative challenges and solutions in the management of children with cataracts and take into full consideration the possible outcomes of the patient as well as the benefits and risks of the surgery. Strategies that run across the preoperative, intraoperative, and postoperative phases, including a good preoperative counseling, careful preoperative preparation, rigorous postoperative medication, standardized postoperative follow-up plan, and proper treatment and prevention of postoperative complications, may help to ensure a successful surgery as well as a favorable outcome.

References

1. Zhang Z. Lens disorders and surgical management. Guangdong Science and Technology Press: Guangzhou; 2005.
2. Zhang Z. Intraocular lenses in the refractive surgery era. People's Medical Publishing House: Beijing; 2009.
3. Edward W, Richard A, Rupal H. Pediatric ophthalmology. Berlin/Heidelberg: Springer; 2009.
4. Lin H, Chen W, Luo L, et al. Effectiveness of a short message reminder in increasing compliance with pediatric cataract treatment: a randomized trial. *Ophthalmology*. 2012;119(12):2463–70. [[CrossRef](#)][[PubMed](#)]
5. Lin H, Chen W, Luo L, et al. Ocular hypertension after pediatric cataract surgery: baseline characteristics and first-year report. *PLoS One*. 2013;8(7):e69867. [[CrossRef](#)][[PubMed](#)][[PubMedCentral](#)]

10. General Anesthesia in Pediatric Lens Surgery

Xiaoliang Gan¹✉ and Hongfeng Ling¹

- (1) State Key Laboratory of Ophthalmology, Zhongshan Ophthalmic Center, Sun Yat-sen University, 54S Xianlie Road, Guangzhou, 510060, People's Republic of China

✉ Xiaoliang Gan

Email: ganxiaoliang@yeah.net

Abstract

Children are quite different from adults in terms of anatomy, physiology, pharmacology, etc. Thus, anesthesia in children should take into full consideration the unique characteristics of pediatric patients. Pediatric surgical patients cannot be viewed as merely miniature of adults; the anesthesia methods, doses, and devices used for adults may not be appropriate for children. Several factors must be taken into account when choosing the anesthetic agents and techniques for pediatric patients, including the anatomical, physiological, and psychological characteristics, the pharmacokinetic and pharmacodynamic profiles, the approach of lens surgery, and the estimated duration of surgery. For pediatric patients, extra caution must be exercised to maintain a stable internal environment during anesthesia, ensure safe and effective anesthesia and surgery, and facilitate recovery after surgery.

Pediatric lens diseases fall into two major categories: cataracts and ectopia lentis. The complexity of surgery varies with the different types of diseases,

as well as the surgery-induced irritation to the eyes and duration of surgery. Compared with other intraocular surgeries, lens surgery requires complete fixation of the eye at the primary position to facilitate surgical maneuvering.

Because of the unique anatomical and physiological characteristics, children differ greatly in pharmacokinetics from adults, and thus they should never be arbitrarily regarded as small adults. Therefore, children should be scheduled for a comprehensive preoperative evaluation of their systemic developmental status. Then an appropriate anesthetic regimen is selected, considering systemic conditions and the characteristics of lens surgery, to ensure complete fixation of the eye and to reduce duration of surgery to avoid anesthesia-related complications.

Moreover, anesthesia/sedation outside the operating room is another challenging job for anesthesiologists, and cautiousness is required to ensure safety. This chapter will elaborate on the following aspects: preoperative anesthetic evaluation and preparation, selection of anesthetic methods, postanesthesia recovery, management of anesthetic complications, anesthesia outside the operating room, and perioperative cardiopulmonary resuscitation (CPR).

10.1 Preoperative Evaluation and Preparation

Pediatric lens surgery is associated with less surgical trauma and very few life-threatening complications due to surgical maneuvers. However, inappropriate management of anesthesia might bring about severe complications. Thus, a comprehensive history taking and evaluation of the systemic conditions of the pediatric patients are crucial for the formulation of an appropriate anesthesia plan and prevention of complications. Additionally, basic education of parents before preoperative preparation is recommended because of the poor compliance of children. Parents' full cooperation contributes to the acquisition of the child's accurate medical history, physical examination, and thorough preoperative evaluation.

10.1.1 Preoperative Evaluation

Adequate preoperative evaluation and preparation can improve the safety of anesthesia, prevent perioperative complications, and expand indications of anesthesia for surgery and promote postoperative recovery.

1. *History taking*

It is important to obtain a full medical history including personal history, history of anesthetic surgery and allergies, as well as the existence of comorbidities for vital organs, such as the heart, lungs, etc. [1]. It should be borne in mind that congenital cataract may also be associated with a variety of systemic hereditary diseases such as homocystinuria, Marfan syndrome, and Down syndrome.

2. *Physical examination*

Pediatric physical examination is conducted in two parts: ① general condition and systemic examinations and ② examinations related to anesthesia performance.

1. General status and systemic development

The status of physical development in children may be roughly judged by general observation and measurement of his/her height and weight. In the presence of obvious dysplasia, whether this is associated with severe comorbidities should be ruled out.

2. Anesthesia-associated examination

Particular attention must be paid to airway evaluation because it is the dominant factor that affects pediatric lens surgery safety. An evaluation of the respiratory tract can be gained by the observation of the patient's phonation, respiratory amplitude, and rate [2]; presence of a cough or rhinorrhea can assist the diagnosis of upper respiratory infection (URI); it is necessary to check if there are any airway anomalies, such as cleft lip/palate, hypertrophy of the tonsils, etc; dental status such as gomphosis and anodontia should be checked during dental transitional periods; there is also a need to check if there is mandibular deformity or some other anomalies indicating difficult tracheal intubation.

Cardiac auscultation is helpful in detecting congenital heart disease. If the pediatric patient has a rectal temperature of >38.5 °C, Hb < 80 g/L, URI, or severe cardiopulmonary insufficiency, further examination and treatment should be conducted before lens surgery.

Evidence shows that airway hyperresponsiveness persists for 6–8 weeks following URI. Previous studies have demonstrated that URI is associated with laryngospasm and bronchospasm, dyspnea, and airway obstruction. The anesthesia risk does not increase for those children with frequent clear nasal discharge on the basis of anaphylactic rhinitis. However, pneumonia, pseudomembranous laryngitis, and acute asthma are the indications for surgery cancelation as these acute pulmonary diseases can pose serious threats to patient; hence, both surgery and anesthesia should be delayed for at least 2 weeks.

3. *Laboratory workup and special examination*

Examinations should be conducted preoperatively in pediatric patients, including hematological profile, routine urine test, serum biochemical profile, coagulation function, and hepatorenal function, to gain a full understanding of his/her general status and exclude severe diseases of vital organs. Electrocardiography (ECG) and chest X-ray examination are also included since they provide clues on the patient's cardiopulmonary status. Preoperative echocardiography should be carried out in children with congenital heart disease complicated by suspected cardiac dysfunction.

10.1.2 Preoperative Preparation

It mainly involves preoperative psychological guidance and reasonable selection of preoperative agents to reduce the occurrence of both intraoperative and postoperative complications.

1. *Preoperative preparation for children*

1. Preoperative psychological preparation: Both the child and the parents should be counseled to get mentally prepared for the surgery and anesthesia. To help the child fully understand the characteristics and importance of the surgery, the child and the parents should be informed of preoperative and postoperative considerations, such as the pain induced by venipuncture and the postoperative discomfort

caused by the eye patch.

2. Preoperative fasting: Vomiting and aspiration can be fatal in children. The parents should understand the importance of fasting and ensure that their children are prevented from having food (and drinks). If fasting is of sufficient duration, it can significantly reduce the risk of vomiting and aspiration in children (Table 10.1).

Table 10.1 Preoperative fasting time for pediatric lens surgery

Fasting Age	Solid food, milk (hour)	Liquids (hour)
Under 6 months	4	3
6–36 months	6	4
>36 months	8	4

2. Premedication

The main purpose of premedication for pediatric lens surgery involves the following aspects: to ease the tension and preoperative anxiety in the pediatric patient, to reduce respiratory secretions, and to adjust the autonomic nerve activity and eliminate or weaken adverse vagal reactions.

The selection of premedication should be based on the pediatric patient's condition and duration of lens surgery [3]. ① Diazepam: For children with preoperative fear and separation anxiety, midazolam syrup (0.25 mg/kg) for oral administration or intravenous/intramuscular injections (0.05 ~ 0.1 mg/kg) can be chosen 30 min preoperatively to calm the child. ② Anticholinergic agents: Atropine and scopolamine are the commonly used anticholinergic agents. With regard to pupil dilatation, inhibition of glandular secretion, and central sedation, scopolamine exceeds atropine, whereas, for inhibiting vagal activity, the latter is much more effective. The doses of atropine and scopolamine are 0.01 ~ 0.015 mg/kg and 0.01 mg/kg, respectively, and are injected subcutaneously 30 min before surgery to reduce respiratory secretion.

10.2 Selection of General Anesthesia Methods

General anesthesia may be divided into general anesthesia with laryngeal mask airway (LMA) and endotracheal tube. Indications vary for different anesthetic methods based on the advantages and shortcomings. The goal of anesthesia management of pediatric lens surgery is to provide smooth induction and tracheal intubation, stable intraocular pressure (IOP), well-controlled eye fixation at the primary position, and steady recovery.

10.2.1 Commonly Used General Anesthetics

1. *Midazolam*

Midazolam is a new class of benzodiazepine containing an imidazole ring. The characteristics of midazolam solution include chemical stability, lipophilicity, rapid onset, short duration of action, low toxicity, and little effect on respiratory and circulatory systems. Additionally, midazolam can exert excellent anterograde amnesia to prevent postoperative agitation after pediatric lens surgery.

2. *Propofol*

Propofol is an alkylphenol soluble in 10 % soybean oil, 2.25 % glycerinum, or 12 % purified lecithin. It is a new class of intravenous anesthetic with rapid onset and short duration of action. The clinical features include strong sedative effect, rapid onset, and short duration, and it allows for repetitive intravenous administration or continuous infusion. Propofol also possesses the properties of inhibiting airway reflexes to reduce the incidence of laryngospasm.

3. *Ketamine*

Ketamine is a derivative of racemized nonbarbiturate cycloheximide. Ketamine may be used in pediatric lens surgery without mechanical ventilation and be intravenously administered for general anesthesia induction or used together with other anesthetics for maintenance. Although ketamine has little influence on cardiovascular or respiratory systems, it has obvious shortcomings, including IOP elevation and

intraoperative nystagmus. Additionally, ketamine can induce increased respiratory secretions, and this is likely to trigger laryngospasm in children with URI [4].

4. *Fentanyl*

Fentanyl is a commonly used potent analgesic; it is a type of synthetic μ -opiate receptor agonist that acts on opioid receptors located in the brain stem and spinal cord to produce an analgesic effect. A single intravenous injection of low-dose fentanyl (1 ~ 4 $\mu\text{g}/\text{kg}$) in children is used for anesthesia induction. Fentanyl is also used in conjunction with muscle relaxant for the completion of endotracheal intubation.

5. *Non-depolarizing muscle relaxants*

Non-depolarizing muscle relaxants include atracurium, cisatracurium, vecuronium bromide, etc. They are mainly used for endotracheal intubation during anesthesia induction and postoperative emergency management for severe laryngospasm.

6. *Sevoflurane*

Sevoflurane is a type of inhaled anesthetic that is recognized as the most promising candidate for the title of “ideal anesthetic.” It is widely used in pediatric anesthesia, particularly in anesthesia for minor surgery and ambulatory surgery. Sevoflurane has obvious advantages in pediatric lens surgery, such as rapid onset of anesthesia, short induction period, short recovery time, and no irritation to the airway. Nevertheless, it has an obvious shortcoming that manifests postoperatively; the occurrence rate of restlessness in children is higher than that with isoflurane.

7. *Dexmedetomidine*

Dexmedetomidine is a highly selective α_2 -adrenoceptor agonist whose primary site of action is locus ceruleus. It can inhibit neuronal firing activity and block sympathetic ganglia, thus producing sedative and analgesic effects without respiratory inhibition. A clinical study from

Zhongshan Ophthalmic Center (ZOC) indicated that administration of 1–2 µg/kg of dexmedetomidine can significantly mitigate preoperative agitation/crying and reduce postoperative agitation in children receiving cataract surgery.

10.2.2 Methods of Delivering General Anesthesia

Selection of the method of delivering anesthesia for pediatric lens surgery should be evaluated comprehensively based on the physical status of the pediatric patient and the type of lens surgery. Patients may suffer from respiratory inhibition, laryngospasm, and even life-threatening complications due to hypoxia when receiving conventional intravenous anesthesia with ketamine or ketamine and propofol without intubation. Although surgery can be completed smoothly with general anesthesia combined with endotracheal intubation, the endotracheal intubation and extubation can increase IOP. In particular, extubation may lead to an increased risk of complications.

Laryngeal mask airway (LMA) is an artificial supraglottis airway device invented in 1981 by a British anesthesiologist Brain based on the anatomy of the larynx. Compared with endotracheal intubation, LMA has a number of advantages: less injury to the airway, less cardiovascular reactions, and no need to use muscle relaxant. Therefore, the use of LMA in pediatric lens surgery can significantly improve the quality of airway management with less complications (Fig.10.1).

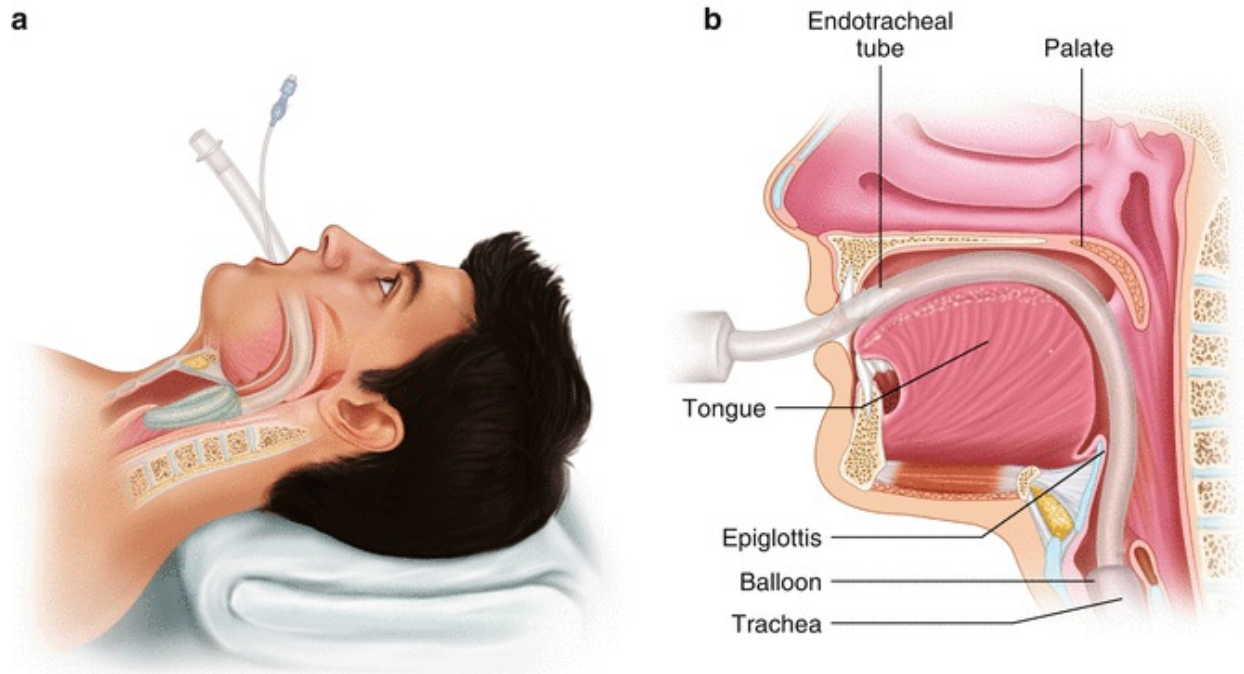


Fig. 10.1 Laryngeal mask airway (LMA) compared with endotracheal intubation: far less injury and irritation to the respiratory tract. (a) Laryngeal mask airway insertion, (b) endotracheal intubation

10.2.2.1 General Anesthesia using LMA

1. Inhaled anesthesia induction

It is an important task for every pediatric anesthesiologist to conduct a smooth anesthesia induction when a pediatric patient needs to undergo lens surgery. And it is most important to interact with the child in a calm reassuring voice when he or she is unable to cooperate, crying, or difficult to communicate with. Pediatric anesthesiologists can also engage the child's attention by telling stories or performing magic tricks. In addition, the presence of parents at the time of anesthesia induction may strengthen or replace premedication. If the above management does not work, intranasal dexmedetomidine or intravenous midazolam can be ultimately administered. Inhaled induction of anesthesia with sevoflurane can be performed after the child is sedated.

For a pediatric patient who is cooperative, mask inhalation of 8 % sevoflurane in oxygen at the rate of 6–8 L/min is used for anesthesia induction. The moment the child loses consciousness, the parents (if present) should be asked to leave and the focus should be on the

respiratory tract (Fig.10.2).

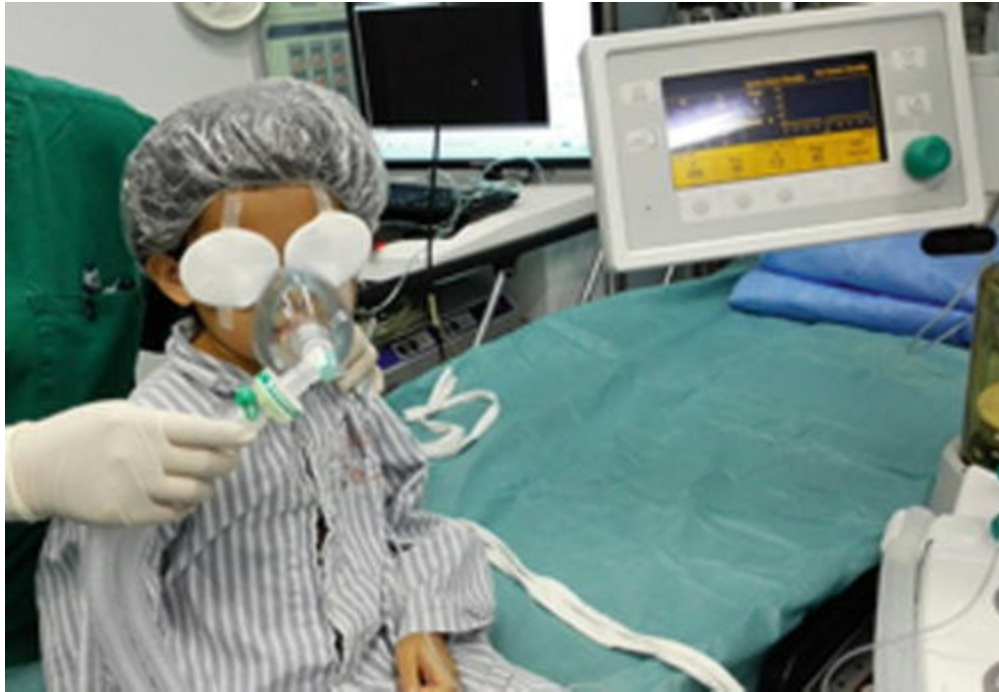

Fig. 10.2 This 4-year-old child is actively cooperative in inhalation-induced anesthesia after being psychologically encouraged

During the course of inhaled induction with sevoflurane, most children experience “excitation,” including airway obstruction, autonomic movement of the limbs, rigidity, tachypnea, and tachycardia. As the anesthesia deepens, these symptoms usually go away within a few minutes. After the “excitation period,” intravenous access can be established. Previous study has reported that there is no response to intravenous cannulation in 3–4 min following mask inhalation of sevoflurane.

2. *Maintenance of anesthesia*

As there is slight surgical trauma and no muscle relaxant is needed, an appropriate depth of anesthesia can be maintained via the inhalation of roughly 3 % sevoflurane during anesthesia. Additional intravenous injection of 10–20 mg propofol is administered intermittently to reduce any emerging agitation in the child, and the ventilation can be maintained by spontaneous respiration or synchronized intermittent mandatory ventilation (SIMV) when the child shows respiratory depression. The perioperative liquid supplement is administered on physiological demand given the short duration, slight surgical trauma, and minimal blood loss of lens surgery.

In lens surgery, stabilization of the eye at primary position may facilitate surgical procedures. But in clinical practice, an upward movement of the eye, also known as Bell's phenomenon, often occurs. This phenomenon is mainly associated with insufficient depth of anesthesia; therefore, the treatment lies in increasing the depth of anesthesia by additional intravenous administration of anesthetic agents or increasing concentration of inhaled anesthetics. It is worth mentioning that special attention should be paid to changes in respiratory rhythms and amplitude in children with spontaneous ventilation, and assisted mechanical ventilation should be used if necessary. However, in a child inhaling sevoflurane with an LMA with spontaneous ventilation, the increased concentration of sevoflurane can inhibit the respiratory system. As a result, patients display a lower tidal volume and an accumulation of carbon dioxide, which may lead to a downward movement of the eye that interferes with surgical procedures. Little is known of the underlying mechanism at present, but the treatment is not difficult since the eye will return to the primary position via assisted ventilation with end-expiratory carbon dioxide concentration decreased to the normal range.

3. *Attention to LMA applications*

Different from endotracheal intubation, which can completely isolate the respiratory tract, the LMA forms an unpressurized sealing loop in the throat by separating from the surrounding tissue. Hence, the pressure should not exceed 20cmH₂O through mechanical ventilation, and if the pressure is too high, air leakage will occur, and the air may leak into the stomach.

The selection of LMA size depends on the child's body weight. Based on the experience of ZOC's anesthetic team, the 1.5-size LMA should be applied for infants less than 6 months of age (even though their weight is less than 5 kg). Moreover, due to the soft tissue and structure of the infant, the median method can be adopted when the LMA is inserted, with the success rate over 95 %. Before the insertion of LMA, it is not necessary to have released all the air from the cuff because it can be inserted more easily with the cuff inflated. After the location is confirmed, there is no need to inject air into the cuff of LMA. If resistance occurs while the median method is being used for LMA insertion, a rotation method should be adopted to insert the LMA. Due to the narrow pharyngeal cavity of the infant in addition to the loose connective tissue, avoid any violent insertion that may induce hemorrhage in the oropharynx mucosa.

When an LMA is used, special attention should be paid to the following issues: (1) It is contraindicated for patients with full stomach and residual gastric contents. (2) Due to the higher airway pressure (>20cmH₂O), this can easily lead to air leakage into the stomach, which may induce vomiting. Patients with severe obesity or low lung compliance are recommended to undergo assisted or controlled breathing with LMA. (3) It is contraindicated in patients with potential airway obstruction, such as tracheal compression, tracheomalacia, pharyngolaryngeal neoplasm, abscess, and hematoma. (4) Laryngospasm can easily occur when LMA is inserted under insufficient anesthesia, and this should be avoided. (5) Jaw lift is not allowed after the LMA is inserted; otherwise, laryngospasm or location shift will occur. (6) In the case of patients with abundant respiratory secretions, it is not easy to clear them using LMA.

10.2.2.2 General Anesthesia with Endotracheal Intubation

The clinical experience at ZOC has shown that the majority of pediatric patients take anesthesia using LMA for lens surgery. But in some children, the LMA is found to be still not in alignment after being adjusted repeatedly. Therefore, it is necessary to switch to general anesthesia with endotracheal intubation in order to ensure the airway safety of the child.

1. Rapid intravenous induction

This is commonly used in pediatric lens surgery, with drug use mode of anesthesia induction as follows: intravenous general anesthetics + narcotic analgesics + muscle relaxants (see Table 10.2). Intravenous general anesthetics consist of etomidate, imidazole, diazepam, and propofol. Narcotic analgesics include ketamine and fentanyl. Muscle relaxants are made up of atracurium, vecuronium, and cisatracurium.

Table 10.2 Commonly used drugs and dosage for intravenous induction

Drug names	Usual dose (mg/kg)
Etomidate	0.3–0.4
Imidazole, diazepam	0.1–0.4
Propofol	2–3
Fentanyl	0.002–0.04
Atracurium	0.4–0.6
Vecuronium	0.09–0.1
Cisatracurium	0.15–0.2

2. Endotracheal intubation

Due to age-associated anatomical differences, there are some technical differences between laryngoscopy in infants and young children and that in adults. Since an infant's glottis is higher, it is "more forward" under laryngoscope observation; besides, it is difficult to control the epiglottis with a laryngoscopic blade since the infant's epiglottis is longer than that of an adult and it is hard and slippery in a U

shaped. Thus, in the case of children under 2 years old, a straight laryngoscope blade is more commonly used. Since the narrowest portion of the pediatric airway is beneath the glottis, be sure not to insert the catheter too violently if resistance is felt, even if it has been passed through the glottis without difficulty.

3. *Maintenance of anesthesia*

It is necessary to maintain sufficient depth of anesthesia during the course of surgery to avoid the cough reflex induced by tracheal tube stimulation. Apart from the use of muscle relaxants at the time of tracheal intubation, there is no need for additional muscle relaxant during the process of surgery. The pattern of controlled respiration is adopted during anesthesia, with an intermittent assisted intravenous injection of 10–20 mg propofol to reduce emergence agitation in the child.

10.3 Anesthesia Recovery After Lens Surgery

Pediatric anesthesia recovery is a process in which the child regains consciousness little by little from narcosis. During this process, there remains a higher incidence for potential complications due to the residual action of the anesthetics, the discomfort from the operated eye and coupled with pediatric physiological characteristics. Thus, postoperative recovery management is particularly important, if there is no proper management alternative, it will influence the surgical result in severe cases.

In the case of anesthesia with endotracheal intubation, the tube can be removed either in the status of conscious or in deep anesthesia; the optimal time for extubation depends on the anesthesiologist's preference and experience. Extubation under deep anesthesia allows for steady extubation with less cough reflex, while it may increase the risks of respiratory depression and airway obstruction. The abovementioned complications are particularly liable to arise when the child is rapidly moved to a different environment. For an inexperienced anesthesiologist and if the postanesthetic care unit (PACU) has no ability to support pediatric patients under anesthesia or ensure the maintenance of an open airway, it is not recommended to perform extubation under deep anesthesia. If extubation under deep anesthesia is chosen, make sure that the child has regular spontaneous

respiration. The child should be moved away from the operating bed and immobilized prior to the discontinuation of anesthesia to cope with oropharyngeal aspiration. If the pediatric patient meets all these criteria, no response to lightly moving endotracheal tube in and out or jaw thrust, the endotracheal tube can be carefully removed, but close attention should be paid to how gas is exchanged following extubation.

When the child is using inhalation anesthesia via LMA, it is recommended that the LMA should be removed under deep anesthesia when his/her tidal volume of respiration reaches over 4 ml/kg. This is because that the irritation of LMA at the pharynx leads to increased secretions when the child is regaining consciousness and would thus cause the cough reflex and even laryngospasm.

After lens surgery, the recovering pediatric patient should leave PACU to gain monitoring and management. When the child achieves over 9 points in the modified Aldrete score for children, they can leave PACU for the ward for further treatment. The specific criteria are as follows: (1) Respiratory tract: 2 points for crying or coughing as instructed, 1 point for unobstructed airway, and 0 point for warranting airway management and maintenance of open airway. (2) Vital signs: 2 points for stable vital signs and characteristics conforming to age, 1 point for stable vital signs and characteristics do not conform to age, and 0 point for instability. (3) Movement level of four limbs: 2 points for purposeful movement, 1 point for movement without purpose, and 0 point for no movement. (4) Consciousness: 2 points for being conscious, 1 point for response to stimuli, and 0 point for no response. (5) 2 points for SpO₂ > 95 % in air respiration, 1 point for 90–94 %, and 0 point for <90 %. If the child achieves over 9 points in the Aldrete score, they can leave the PACU.

10.4 Perioperative Complications and Managements

Complications associated with both surgical procedures and anesthesia can occur during pediatric lens surgery. When complications occur, timely diagnosis and treatment contribute to the perioperative safety of the child patient.

10.4.1 Oculocardiac Reflex

Oculocardiac reflex is rarely seen in pediatric lens surgery, but it should be carefully monitored and given timely management if it occurs. The cause of oculocardiac reflex is mainly associated with the surgeon's manipulations of the eye or pulling from extraocular muscles (especially rectus) that induce the vagal reflex. Patients may develop bradycardia or cardiac arrhythmia, severe bradycardia with heart rate reduction by over 50 %, and even cardiac arrest. Management measures include termination of surgical stimulation and deepen anesthesia. If the patient still displays bradycardia after above treatments, an intravenous injection of atropine (0.1–0.2 mg) can be administered.

10.4.2 Respiratory Complications

1. *Respiratory obstruction*

This is one of the common complications seen in pediatric lens surgery.

1. Causes: glossoptosis, excess secretions, aspiration, distortion of tracheal catheter, laryngeal edema, subglottic edema, laryngospasm, or bronchospasm.
2. Management: The management involves several aspects. (1) Respiratory movement should be closely observed in those patients without endotracheal intubation, and cuffed oropharyngeal airway (COPA) is inserted when necessary. (2) The secretions in the endotracheal tube and mouth should be cleared promptly. (3) The endotracheal tube should be fixed in correct position by monitoring the airway pressure. (4) Oxygen inhalation and adequate suction should be administered prior to extubation. Perform extubation while lung inflates thus avoiding hypoxia induced by suction. (5) Hormone therapy should be used immediately when laryngeal edema or laryngismus is observed. Adrenaline liquid can be sprayed if needed. If there appears severe laryngeal edema, tracheotomy should be performed.

2. *Respiratory depression*

Respiratory depression is also a complication which is commonly seen in the perioperative period of pediatric lens surgery.

1. **Causes:** Narcotic analgesics, intravenous anesthetics, and anesthetic inhalation can easily cause central respiratory depression. The characteristics of anesthetic inhalation for children are: (1) Minimum alveolar concentration (MAC) for inhaled anesthetics is related to age. (2) Rapid intake and distribution of inhaled anesthetics make for fast onset and recovery time in neonates, and the depth of anesthesia with inhaled anesthetics is easily adjusted in neonates. (3) Inhaled anesthetics can induce dose-dependent respiratory depression.
2. **Management:** (1) For transient respiratory depression, assist ventilation via mask can be employed. In the case of the child under anesthesia via LMA with spontaneous ventilation, assisted or controlled ventilation can be taken. (2) Endotracheal intubation and mechanically controlled ventilation should be performed in those with severe respiratory depression.

3. *Laryngospasm*

After pediatric lens surgery, the procedures for extubation during the period of recovery after general anesthesia can cause laryngeal muscle spasm, resulting in laryngeal stenosis and closure. Secretions, blood, or manipulation on the upper respiratory tract are the main causes of laryngospasm, which may directly cause partial obstruction and even complete obstruction of the pediatric respiratory tract, thereby triggering life-threatening complication.

Treatments: (1) Observe the child's complexion, respiratory rate, respiratory amplitude, heart rate and SPO₂. (2) Procedures for suction and removing the endotracheal tube or LMA should be gentle. Once laryngospasm occurs, such as inspiratory dyspnea accompanied with a wheezing sound and cyanosis, any manipulation should be stopped and the

child's lower jaw should be immediately held up for mask oxygen inhalation through pressurization or through an endotracheal tube with assisted ventilation. Use a muscle relaxant for mechanical ventilation if necessary.

10.4.3 Complications in Circulation System

Severe complications in the circulation system seldom arise during anesthesia as there is little trauma in pediatric lens surgery. But severe circulatory complications, such as bradycardia and cardiac arrest induced by severe hypoxemia, in turn due to respiratory obstruction or depression, can occur during surgery. Severe bradycardia in pediatric patients is a warning sign for life-threatening complication, because it is commonly associated with anoxia, vagal reflex, hypotension, direct inhibition to myocardium by anesthetics, and so on. Apart from knowing its etiology and giving related treatment in these circumstances, atropine therapy can be used if necessary. If bradycardia is not dealt with in time, cardiac arrest may eventually occur due to the poor compensative capacity of anoxia in children. For details of the treatment of cardiac arrest, please see Sec. 6 of this chapter.

10.4.4 Abnormal Body Temperature

Infants are particularly vulnerable to hypothermia due to the great ratio of body surface area to body weight and limited ability. Cold stimulation causes increased oxygen consumption and metabolic acidosis. Infants may compensate for heat loss via thermogenesis of muscle fasciculation and non-muscle fasciculation (intracellular). Infants under 3 months have a low capacity for muscle fasciculation, and thus intracellular thermogenesis has become the main way of heat generation. Anesthetics can alter the mechanism of thermoregulation and can especially affect the process of thermogenesis of infantile non-muscle fasciculation. Therefore, variations in operating room temperature and faultiness of nursing measures can easily cause hypothermia and hyperthermia in infants. It is worth mentioning that malignant hyperthermia should be highly suspected and reasonable treatment should be given without delay if there is a dramatic rise in the child's body temperature.

10.4.5 Postoperative Agitation

After elder infants and young children undergo lens surgery, there is often postanesthesia emergence agitation because of the vision disturbance. There are a lot of studies concerning this issue, and they have found that pediatric patients are more prone to show agitation after sevoflurane anesthesia, whereas the incidences of agitation decrease after anesthesia with propofol.

In addition to acute postoperative agitation, children are likely to have maladaptive behavioral changes, such as the changes in sleep or dietary pattern, and show anxiety, loneliness, and aggressive behavior in the period of being separated from their parents. A previous prospective study indicated that post-discharge maladaptive behavior correlates closely with preoperative anxieties in children and parents and emergence delirium.

Attention should be paid to the postoperative agitation and alterations in children's behavior. In a prospective study, the authors have found that the rate of dysphoria occurrence in children after cataract surgery is closely associated with preoperative anxiety, whether the performed surgery is on both eyes or not, and the duration of anesthesia. The rate of dysphoria occurrence in preschool children (aged from 3 to 5 years) is higher. If there is improper nursing care or management, the restlessness and crying of the children can affect surgical outcomes.

Precautionary measures: (1) Preoperative sedation by intranasal dexmedetomidine can be used. During dysphoria, adequate ventilation should be guaranteed to prevent hypoxemia. (2) The operating room and holding area should be quiet to minimize any harmful stress on the children. (3) Accidental injury should be avoided. The cause of restlessness in the child should be identified, and an intravenous injection of 10–20 mg propofol or 0.5–1 mg midazolam should be administered to treat the symptoms of agitation.

10.4.6 Vomiting and Aspiration

Gastric insufflation may occur due to pressurized oxygen inhalation during anesthesia induction during lens surgery, and vomiting can be caused by narcotic drugs (e.g., fentanyl). In addition, pediatric postoperative dysphoria, struggling, coughing, and suction in the pharynx and larynx can all lead to vomiting and aspiration. Aspiration caused by vomiting can block the airways and cause asphyxia in severe cases.

Precautionary measures: (1) Appropriate time of preoperative fasting and premedication. The purpose of preoperative fasting is to keep the stomach

empty and reduce the occurrence of aspiration. Premedication is taken to alleviate the anxiety in children, reduce respiratory glandular secretion, and improve the quality of recovery. The time for preoperative fasting is listed in Table 10.1. (2) Posture: In anesthesia induction, the amplitude of the breathing bag should be controlled to reduce gas leaking into the gastrointestinal tract. In the postoperative anesthetic period, the child is kept in a supine position without a pillow, with the head turned to one side and a soft pillow put under the child's shoulders when necessary. The respiratory tract should be kept unobstructed and vomit-free, thereby preventing induced asphyxia. (3) Keep the respiratory tract unobstructed; if the child vomits, secretions in the oral and nasal cavities should be removed without delay. Movement at the time of aspiration should be gentle to avoid excessive stimulation of the pharynx and larynx, which can help reduce the occurrence of vomiting. Suction should be taken gently for no more than 15 s each time with an appropriate tube with a negative pressure not exceeding 0.05 MPa.

10.4.7 Postoperative Pain

In general, postoperative pain in pediatric patients after lens surgery is slight. Therefore, there is no need to use specific analgesics or to orally administer nonsteroidal anti-inflammatory drugs and painkillers [5]. If there is severe pain in the child, the cause can usually be attributed to corneal abrasion or an acutely elevated IOP.

Precautionary measures: To avoid eye injury, oculentum based on nonionic paraffin oil should be administered preoperatively. Ophthalmodynia caused by acute ocular hypertension is often accompanied with vomiting, and it needs special treatment.

10.5 Anesthesia/Sedation in Nonoperating Room

Some children need to be under sedation or general anesthesia to perform many procedures including preoperative ophthalmic examinations and other relevant examinations, postoperative follow-up examinations, and postoperative laser therapy for posterior capsule opacification (PCO) in a nonoperating room. Although the duration for these procedures is short, sedation/anesthesia should be conducted cautiously in a nonoperating room such as the examining room and laser room. Any carelessness during the

procedures will result in severe complications since there is an insufficiency of staff in these places. Thus, it is necessary to set standard demands for anesthetics, equipment, and other objective conditions to reduce potential complications in the nonoperating room, and it is essential to standardize the anesthesia procedures and first aid equipment.

10.5.1 Choice of Anesthesia/Sedation Methods

1. *Sedation with intranasal dexmedetomidine*

To help uncooperative children with lens disorders undergo preoperative examinations and postoperative follow-up examinations, oral 50 mg/kg of chloral hydrate is recommended for sedation [6, 7]. However, the success rate of oral chloral hydrate is between 85 and 95 % due to the irritation of chloral hydrate to the gastrointestinal tract inducing nausea and diarrhea (if administered by rectum) [8, 9]. There still remain many children who fail to complete related examinations under chloral hydrate sedation. In a small-size study, ZOC adjusted an additional dose of intranasal dexmedetomidine (2 µg/kg) for rescue sedation in these children with chloral hydrate failure, so as to complete the examinations. Moreover, ZOC found that none of these children subsequently developed hypoxia, cough, nausea, vomiting, or other complications [10, 11]. Intravenous administration of anesthetics, ketamine, midazolam, propofol, and fentanyl is recommended for uncooperative children aged between 4 and 5 years (Fig. 10.3).

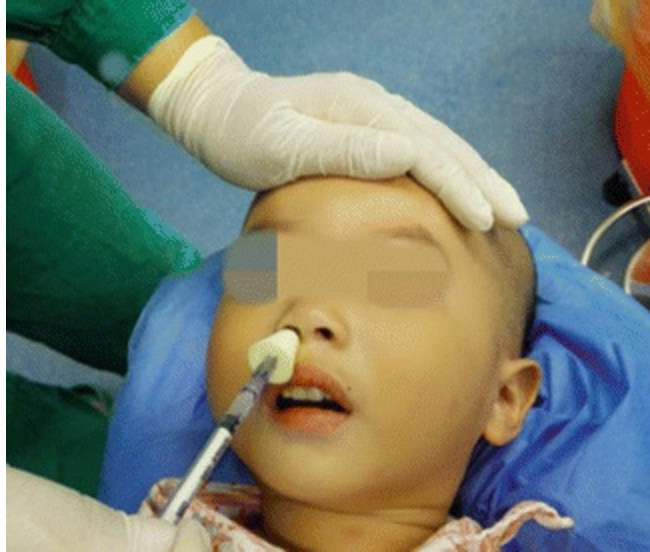

Fig. 10.3 Intranasal dexmedetomidine for sedation is adopted in the outpatient examination of a young child

2. Intravenous anesthesia

For a child who needs postoperative laser therapy after cataract surgery, an intramuscular injection of 5 mg/kg ketamine or an intravenous injection of 2 mg/kg ketamine for induction can be chosen since there may be pain stimulus in the course of laser diagnosis and management. An additional 1 mg/kg dose of ketamine can be administered if necessary and a small dose of propofol or midazolam are also recommended for anesthesia/sedation.

It was found that the combination of propofol and ketamine can provide a stable hemodynamic state with no occurrence of nightmare and abnormal behavior, and propofol can effectively reduce the adverse effects of ketamine. Most importantly, attention should be paid to the respiratory states in the pediatric patient during the surgery to ensure the respiratory tract is unobstructed. When glossoptosis appears in a child, COPA should be inserted for intraoperative administration of oxygen inhalation through a mask.

10.5.2 Anesthesia Monitoring

No matter what type of anesthesia/sedation is chosen, ECG and pulse oxygen saturation monitoring are essential. For pediatric patients with heart disease,

noninvasive blood pressure (NBP) should also be monitored, and end-tidal CO₂ monitoring via nasal cannula can be conducted while it is feasible.

10.5.3 Management of Patient Posture in Diagnosis and Treatment

Infants and young children's respiratory tracts are apt to be obstructed during anesthesia/sedation, and they present the great possibility of hypoxia and carbon dioxide retention due to the anatomical and physiological characteristics of the respiratory system. The risk of anesthesia will be higher if the child is younger. A child should be in horizontal position with a thin soft pad put at his/her shoulders to prevent tongue swallowing during examination or surgery. If it does not work, the lower jaw can be pulled down lightly. In addition, an oropharyngeal airway or a nasopharyngeal airway may also be inserted to improve ventilation. In laser therapy for infants and young children, they are usually posed lying on the side with a suitable soft pad placed in the head and neck region to avoid respiratory obstruction caused by head or neck twisting. For the child undergoing slit-lamp examination, his/her head and neck should be kept in an upright position so as to keep the airway open.

10.5.4 Instrument Configuration for Anesthesia Outside of the Operating Room

Respiratory depression and respiratory obstruction are common risk factors during anesthesia/sedation in the nonoperating room. To reduce the occurrence of anesthesia accidents in nonoperating room, the following preventive measures should be taken: (1) Be familiar with anesthesia location and prepare all the instruments and anesthetics. (2) Anesthesiologists must possess qualifications to perform anesthesia independently in the nonoperating room. (3) Pediatric patients must be fully evaluated prior to anesthesia to exclude any contraindication. (4) Select an appropriate anesthesia method. (5) Maintain appropriate sedation and depth of anesthesia to avoid airway obstruction and treat other complications promptly.

The *Guidelines for Anesthesia Outside the Operating Room* revised in 2003 by the American Society of Anesthesiologists (ASA) can be taken for reference (Table 10.3). Such locations as the laser room, which can provide

cataract diagnosis and treatment, should be fitted with necessary monitoring, first aid equipment, and guidelines for emergency events management.

Table 10.3 Guidelines for anesthesia outside the operating room (ASA criteria)

1. Reliable central oxygen supply system with spare oxygen supply
2. Reliable aspiration device
3. Reliable exhaust emission device (such as the use of inhaled anesthetics)
4. The following equipment is required: (1) An easy-to-use, handheld breathing bag that can provide at least 90 % concentration of inhaled oxygen when positive pressure ventilation is provided by the mask; (2) appropriate anesthetic agents, materials, and equipment; (3) proper monitoring devices (which should conform to <i>Basic Standards for Anesthetic Monitoring</i>), such as the use of inhalation anesthesia and required anesthesia machine
5. Plenty of power sockets and backup power to meet the needs of anesthesia machine and monitor
6. Adequate lighting equipment
7. Enough space to place essential items and facilitate personnel operation.
8. An ambulance equipped with a defibrillator, first aid medications, and other needed CPR equipment
9. Professionally trained paramedical staff should assist anesthesiologists with their work, and meanwhile reliable communication equipment should be available for seeking help
10. All safety regulations and equipment operation instructions should be posted for reading in the area
11. Safe and reasonable postanesthetic management. Apart from anesthesiologists, there should be enough professionally trained staff and essential equipment to guarantee the safe recovery of pediatric patients
12. The room temperature should be regulated and controlled

Appendix: Process of Anesthesia/Sedation for Children Outside of the Operating Room at Zhongshan Ophthalmic Center (ZOC)

1. After receiving initial diagnosis from the outpatient ophthalmology clinic, the nonhospitalized children’s physical status will be assessed by an ophthalmologist, and most of the basic laboratory tests are conducted before anesthesia evaluation by an anesthesiologist.
2. Anesthesia evaluation: (1) The anesthesiologist performs a physical examination to learn more about the child’s physical condition, past medical history (PMH), and the recent presence or absence of URI. (2) Obtain the laboratory results. Preanesthetic examinations involve chest X-ray, hematological profile, bleeding and clotting time, and the

hepatorenal function test. Workup items may be varied based on different types of procedures or surgeries. (3) On the basis of a fully evaluation, the anesthesiologist decides whether or not to perform examination or treatment under general anesthesia outside the operating room. (4) After the anesthesia plan is achieved, the patient is informed of the preoperative considerations and then asked to sign the informed consent form. How to select appropriate pediatric patients is the most crucial step in the process of diagnosis and treatment in the nonoperating room. (1) Age range: Yet there are not any authoritative guidelines that set the minimum age for anesthesia outside the operating room. Prematures with a gestational age of less than 60 weeks are not suitable for anesthesia outside the operating room, since they are often liable to show respiratory depression during general anesthesia. (2) In ASA grades 1–2, the child is usually in good physiological status without other special medical history. Those who have normal basic laboratory results are suitable for diagnosis and management outside the operating room. (3) For those children with URI, replacement of anesthesia location or anesthesia types should be considered according to the gradient of infection. The examination/treatment can be delayed when necessary.

3. After the preanesthesia evaluation, the child returns to the ophthalmologist in the ophthalmology department for an appointment examination or management.
4. Be well prepared for preanesthesia preparations on the appointment day; the child undergoes examination or management under anesthesia outside the operating room.
5. Anesthesia recovery comes after the examination or treatment.
6. When the child is wide awake with over 9 points in the modified Aldrete score, he/she can be discharged from the hospital.
7. An effective system of telephone follow-up should be established.

10.6 Perioperative Cardiac Pulmonary Resuscitation

Although there is a rare chance for cardiac arrest (CA) to happen during pediatric lens surgery, the extremely young children with various comorbidities are still vulnerable to cardiac arrest. Therefore, a better understanding of the basic knowledge on perioperative CPR in children can contribute to improved emergency management.

10.6.1 Causes of Cardiac Arrest

Many factors may contribute to cardiac arrest during the period of pediatric lens surgery. Inappropriate respiratory management is one of the main causes of cardiac arrest. For example, while the head and neck are improperly set, stimulation in laryngopharyngeal cavity can cause laryngospasm and even severe hypoxia and carbon dioxide retention. Additionally, overdose of anesthetics can also lead to cardiac arrest.

Signs of cardiac arrest include faint breathing with a slow or intermittent rhythm, cold body and limb extremities with a grayish to white color, lips and nail beds showing cyanosis, less bleeding in the surgery field with a purple color, and pale wound; heartbeats gradually become inaudible; bad reflexes, mydriasis, and blunt reflex may appear. In addition, heartbeat can be evaluated by touching the infant's brachial artery and the child's carotid artery.

10.6.2 Management

1. Once the above signs appear, manipulation and anesthesia should be terminated immediately. Find out the reasons and rule out the cause of respiratory tract obstruction first. Emergency measures should be taken according to the etiology. If the condition of patient keeps aggravating, grayish face or spontaneous cessation of wound bleeding may be observed.
2. Basic management steps: The previous management approach begins from airway (A) → breathing (B) → circulation (C). However, the new version of guidelines for CPR points out that the process of CPR for all

patients, except for neonates, has been transformed to C → A → B, to keep blood circulation as an essential step with chest compression.

For the manipulation of chest compression, see Table 10.4.

Table 10.4 Guidelines for operations of basic life support

	Neonates (<12 h)	Infants (<1 year)	Young children (1–8 years)	Children (>8 years)
Ventilation frequency (time/min)	30	20	20	12
Examination of arteriopalmus	Umbilical cord/heart rate	Brachial artery/femoral artery	Carotid artery	Carotid artery
Compression range	Beneath bilateral nipples	Lower half of the sternum	Lower half of the sternum	Lower half of the sternum
Compression techniques	Encirclement/double finger	Double finger/encirclement	Single hand	Double hand
Compression depth	1/3 anteroposterior diameter of thorax	1/3 ~ 1/2 anteroposterior diameter of thorax	1/3 ~ 1/2 anteroposterior diameter of thorax	1/3 ~ 1/2 anteroposterior diameter of thorax
Compression frequency (time/min)	90	>100	100	100
Ratio of compression to ventilation	3:1	5:1	5:1	15:2 5:1 (with tracheal intubation)

3. Tracheal intubation and assisted ventilation should be carried out simultaneously with chest compression, and the frequency should follow the data as is shown in Table 10.4. When an effective venous access is established, an electrical defibrillator should be prepared for defibrillation.
4. If there are signs of cardiac resuscitation, namely, the restoration of arterial pulsation, then heartbeat in the precordium is audible, lips and facial complexion turn ruddy, and subsequent advanced management of cardiopulmonary-cerebral resuscitation can be continued: (1) Cool and dehydrate the head for cerebral protection. (2) Make rectification to

acidosis and electrolyte disturbance to maintain homeostasis. (3) Use vasoactive agents to maintain the systolic blood pressure above 80 mmHg. (4) Maintain sufficient urine volume. (5) Use antibiotics to prevent pulmonary infection. (6) Apply energy mixture (cytochrome c, adenosine triphosphate (ATP), and coenzyme A). (7) Use adrenocortical hormone. (8) Enhance nursery care to prevent bedsores.

References

1. Lin Y, Xiaoliang G, Hongbin C, et al. Clinical observation of sevoflurane in infantile congenital cataract surgery under laryngeal mask airway. *Mod Hosp*. 2014;2:24–6.
2. Lee BJ, August DA. COLDS: a heuristic preanesthetic risk score for children with upper respiratory tract infection. *Paediatr Anaesth*. 2014;24(3):349–50.
[CrossRef][PubMed]
3. Oberacher-Velten I, Prasser C, Rochon J, et al. The effects of midazolam on intraocular pressure in children during examination under sedation. *Br J Ophthalmol*. 2011;95(8):1102–5.
[CrossRef][PubMed]
4. Marcus I, Tung IT, Dosunmu EO, et al. Anterior segment photography in pediatric eyes using the Lytro light field handheld noncontact camera. *J AAPOS*. 2013;17(6):572–7.
[CrossRef][PubMed]
5. Mahajan C, Dash HH. Procedural sedation and analgesia in pediatric patients. *J Pediatr Neurosci*. 2014;9(1):1–6.
[CrossRef][PubMed][PubMedCentral]
6. Noske W, Papadopoulos G. Chloral hydrate for pediatric ophthalmologic examinations. *Ger J Ophthalmol*. 1993;2(3):189–93.
[PubMed]
7. Wilson ME, Karaoui M, Al Djasim L, et al. The safety and efficacy of chloral hydrate sedation for pediatric ophthalmic procedures: a retrospective review. *J Pediatr Ophthalmol Strabismus*. 2014;51(3):154–9.
[CrossRef][PubMed]
8. West SK, Griffiths B, Shariff Y, et al. Utilisation of an outpatient sedation unit in paediatric ophthalmology: safety and effectiveness of chloral hydrate in 1509 sedation episodes. *Br J Ophthalmol*. 2013;97(11):1437–42.
[CrossRef][PubMed]
9. Avlonitou E, Balatsouras DG, Margaritis E, et al. Use of chloral hydrate as a sedative for auditory brainstem response testing in a pediatric population. *Int J Pediatr Otorhinolaryngo*. 2011;175(6):760–3.

[\[CrossRef\]](#)

10. Mahmoud M, Gunter J, Donnelly LF, et al. A comparison of dexmedetomidine with propofol for magnetic resonance imaging sleep studies in children. *Anesth Analg*. 2009;109(3):745–53.
[\[CrossRef\]](#)[\[PubMed\]](#)
11. Li BL, Yuen VM, Song XR, et al. Intranasal dexmedetomidine following failed chloral hydrate sedation in children. *Anaesthesia*. 2014;69(3):240–4.
[\[CrossRef\]](#)[\[PubMed\]](#)

11. Care of Pediatric Lens Surgery

Huiming Xiao¹✉

- (1) State Key Laboratory of Ophthalmology, Zhongshan Ophthalmic Center, Sun Yat-sen University, 54S Xianlie Road, Guangzhou, 510060, People's Republic of China

✉ **Huiming Xiao**

Email: 1250559136@qq.com

Abstract

This chapter focuses on the perioperative care of pediatric patients undergoing lens surgery. Since the circulatory and respiratory systems are still developing during childhood, pediatric patients may have a poor tolerance to systemic anesthesia. Therefore, a higher level of anesthesia care is required. Along with the advances in anesthetic techniques, the updated devices and equipment for lens surgery, as well as the improved skills of surgeons, the efficacy and safety of pediatric lens surgery has greatly improved, and the perioperative care has also evolved accordingly. Despite the short duration of anesthesia in eye surgeries, high-quality perioperative care including anesthesia care is a key to a successful surgery and is also very important for the safety of pediatric patients.

Pediatric lens surgery requires general anesthesia. Adequate preoperative assessment and preparation, as well as intraoperative and postoperative care, are important safeguards of a safe and successful surgery.

11.1 Preoperative Care of Pediatric Lens Surgery

This section mainly discusses preoperative nursing assessment and nursing measures.

11.1.1 Nursing Assessment

Before pediatric lens surgery, a detailed understanding of the causes for the lens disorders and elaborate nursing evaluations of children's ocular and systemic conditions are vital for the development of nursing measures.

1. Ask the parents of the pediatric patient about the medications during pregnancy and whether there were viral infections or exposures to radiation. The child's health condition at birth should also be documented, such as the presence of preterm delivery, congenital diseases or positive family history, as well as the use of medications and oxygen therapy.
2. Learn about when the visual impairment started and to what extent it affects the child. Ask whether there was a history of ocular trauma. Examine the child for ocular comorbidities, such as strabismus, nystagmus, congenital microphthalmia, etc. Irrigation of the lacrimal drainage system is performed to identify anomalies of the drainage system (Fig. 11.1).

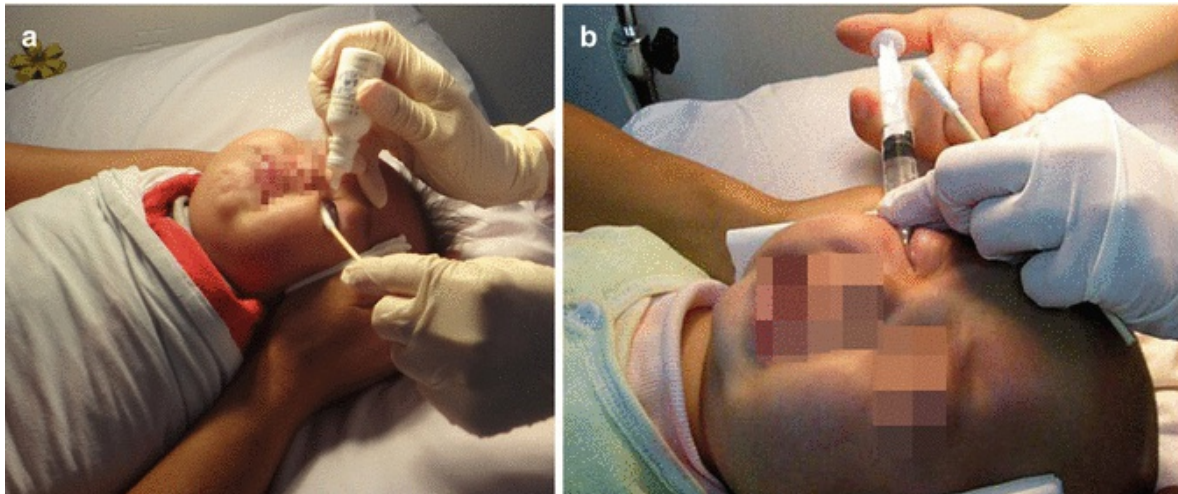


Fig. 11.1 (a) The child is anesthetized topically with eye drops before irrigation of the lacrimal passage; (b) the child is undergoing irrigation of the lacrimal drainage system

3. The evaluations of systemic conditions.

1. Observe the pediatric patient's consciousness, expression, competence of emotional and verbal exchanges, nutritional status, and intelligence development.
2. Learn about the child's systemic condition based on the results of routine blood and urine tests, serum biochemistry, four blood coagulation indexes (PT, APTT, TT, FIB), hepatorenal function, electrocardiogram (ECG), and chest X-ray.
3. Note the presence of any systemic syndrome. As in the case of Marfan syndrome, it is frequently accompanied by severe systemic anomalies, including cardiac insufficiency and systemic connective tissue diseases.
4. Rule out severe anomalies of the cardiovascular system, respiratory system, and nervous system.

4. The evaluations of psychosocial conditions.

The child's psychological status and level of cooperation in treatment and examination are evaluated. The parents' moods, educational levels, and financial situation are noted, as well as the main caretaker's understanding of disease-related knowledge [1].

11.1.2 Nursing Measures

11.1.2.1 Mental Care

Most of pediatric patients show resistance and fear for surgery. The nursing staff should proactively communicate with pediatric patients and provide appropriate counseling on the mental status of pediatric patients at different ages. A friendly atmosphere in the hospital and a good rapport between nurses and pediatric patients should be established based on the age and personality features of these children. Explain surgical considerations to the

parents of pediatric patients and the older children directly to eliminate their fears. Children's parents are prone to such undesirable emotions as anxieties toward their children's disease conditions, surgeries, and prognoses. Therefore, the nursing staff should provide psychological counseling for parents and try to win their trust and cooperation [2].

11.1.2.2 Safety Care

1. Children usually lack cognitive faculties and thus have poor hazard recognition; worse still, they do not have the capability for self-defense. Lively and active, children with a curious mind are very liable to tumbling, aspiration and ingestion of foreign objects, falling out of bed, getting lost, and trauma. Therefore, nurses must possess high safety awareness, provide better safety education, and give guidance to the family members about how to take safety precautions.
2. Children tend to be uncooperative in examination and treatment, and, worse still, ophthalmic nursing procedures are more delicate and difficult. Hence, in order to avoid damage to ocular tissue due to the child's resistance to examination and treatment, the manipulation should be light, precise, steady, skillful, and fast. The following immobilization and sedation methods can be adopted. Immobilization of a pediatric patient is done as follows: The child lies supine on the treatment table with the upper and lower limbs and the body wrapped in a sheet; meanwhile, a nurse or another healthcare provider helps fix his/her head (Fig. 11.2). For sedation, 10 % chloral hydrate can be given orally or by retention enema before the examination for a pediatric patient who is not cooperative. At present, we also use dexmedetomidine in nasal drops for anesthesia in pediatric patients.

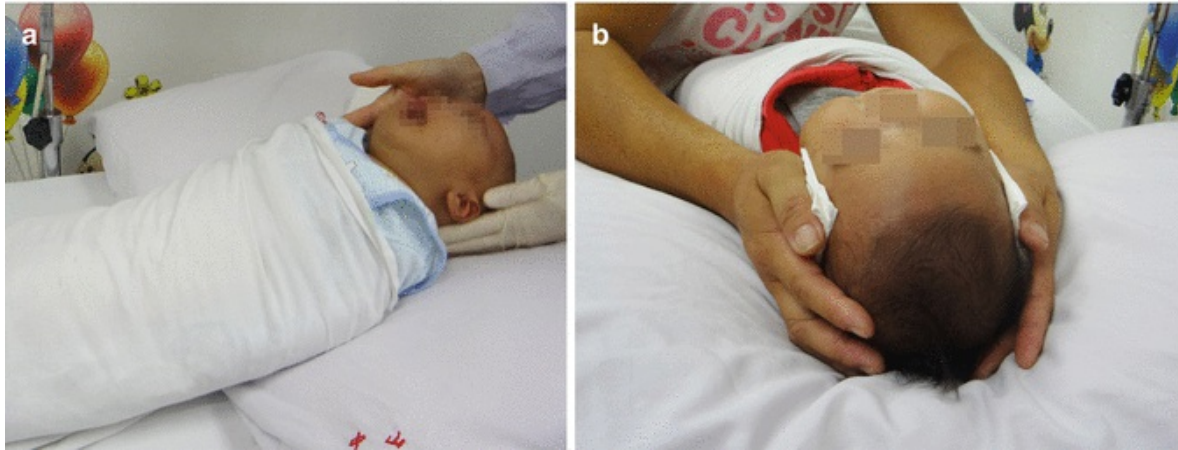


Fig. 11.2 (a) The immobilization of the pediatric patient for examination and treatment; (b) the immobilization of the pediatric patient's head

11.1.2.3 Hygiene Care

Parents are given guidance on how to give their children a full-body cleaning, including hair, body, and face washing, as well as nail trimming. Maintain periocular hygienes on the day of surgery and change in clean surgical gowns.

11.1.2.4 Preoperative Ocular Preparation

Antibiotic and mydriasis eye drops are instilled in the operated eye as directed. Press the lacrimal sac for 3–5 min to reduce the absorption of drugs via the nasal mucosa. After the pediatric patient is anesthetized, flush the eye with normal saline.

11.1.2.5 Preoperative Anesthetic Preparation

Preoperative measurement of body temperature, pulse, and respiration is carried out to confirm the absence of respiratory infections and pyrexia and to establish intravenous access.

11.2 Anesthesia Care of Pediatric Lens Surgery

The organ systems of children (particularly those under the age of 1 year) are immature, and their circulatory and respiratory systems have poor tolerance

to general anesthesia. As a consequence, more rigorous requirements are set on the anesthetic care of children compared with that in adults.

11.2.1 Preanesthetic Preparation

11.2.1.1 Preoperative Visit

Preoperative visit helps the pediatric patient and his/her parents with mental preparation for surgery and anesthesia and relieves anxiety. The pediatric patient is observed for the presence of upper respiratory infection (URI), loose teeth, and excessive nasal discharge. Moreover, cardiopulmonary function is evaluated to rule out severe congenital malformation.

11.2.1.2 Preoperative Fasting

The pediatric patient and his/her parents are informed of the importance of preoperative fasting from solid food and clear fluids. Before anesthesia, be sure to confirm that the child's fasting time is as directed by the anesthetist. For the time of fasting from solid food and fluids, see Chap. 10 "General Anesthesia for Pediatric Lens Surgery" for reference.

11.2.1.3 Environmental Support

Due to the imperfect thermoregulation function in children, labial and respiratory mucosae may become drier with increased thirst, if the room temperature is excessively high with low humidity. But if the room temperature is excessively low, the pediatric patient will be susceptible to URI. Therefore, it is more reasonable that the temperature in the operating room is kept within 22–25 °C and the relative humidity is between 40 and 60 %.

11.2.2 Electrocardiogram (ECG) Monitoring

The pediatric patient's respiration, heart rate, heart rhythm, and oxygen saturation are closely observed via the monitor during the surgery. Abnormality of any parameter should be immediately reported and collaborated resuscitation with doctors initiated instantly.

11.2.3 Management During Anesthesia Recovery

Monitored anesthesia care is a continuous process, and the management of recovery phase is mainly to test and assess the residual effects of the drugs administered intraoperatively to determine when the pediatric patient can be discharged from the recovery room. The early stage of resuscitation is a dangerous period in which airway obstruction and other severe complications usually occur. Thus vital signs and oxygen saturation should be closely observed with the respiratory tract kept patent. Continuous administration of low-flow oxygen can last till the pediatric patient is wide awake. When the child is found to have lip cyanosis and masticatory muscle spasm causing difficulty in opening the mouth, remove nasopharyngeal secretions and vomitus promptly, that is, to hold up the lower jaw of the child for such emergency measures as sputum aspiration and oxygen inhalation. During the course of recovery, a few of the pediatric patients develop restlessness, unconsciousness, hallucination, and other manifestations, who may remove the oxygen catheters and infusion tubes. Therefore, protective constraints should be strengthened with both hands fixed in a functional position. After the pediatric patient becomes fully conscious, a small amount of water is given. Observe whether the swallowing function is fully regained before eating is allowed [3, 4].

11.3 Intraoperative Care of Pediatric Lens Surgeries

The nurses should prepare surgical items in accordance with different surgical procedures. Their harmonious cooperation with the ophthalmologist during surgery can reduce the duration of procedure and ensure the surgical safety of the pediatric patient.

11.3.1 Setting of Devices

1. Surgical microscope: The surgical microscope is needed to be examined for light source, brightness, mobility, pedal control, etc. And X-Y axis is reset to the standby state.
2. Phacoemulsification machine: The performance of the machine is examined, and the parameter is adjusted prior to surgery.

3. Vitrectomy machine: As vitrectomy is likely to be performed in the course of pediatric lens surgery, the vitrectomy probe and pipe are prepared (Fig. 11.3).

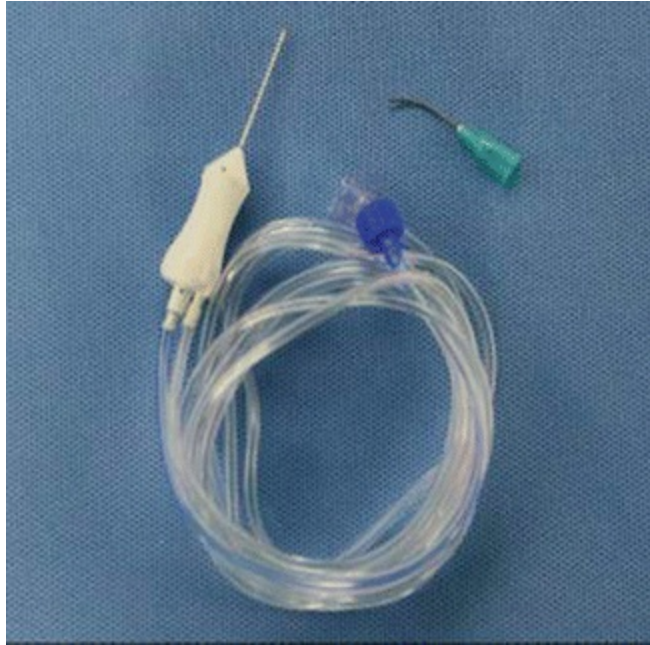

Fig. 11.3 The vitrectomy probe and pipe for anterior vitrectomy

4. Radiofrequency diathermy device for capsulotomy: Check its performance, and set its energy prior to surgery (Fig. 11.4).

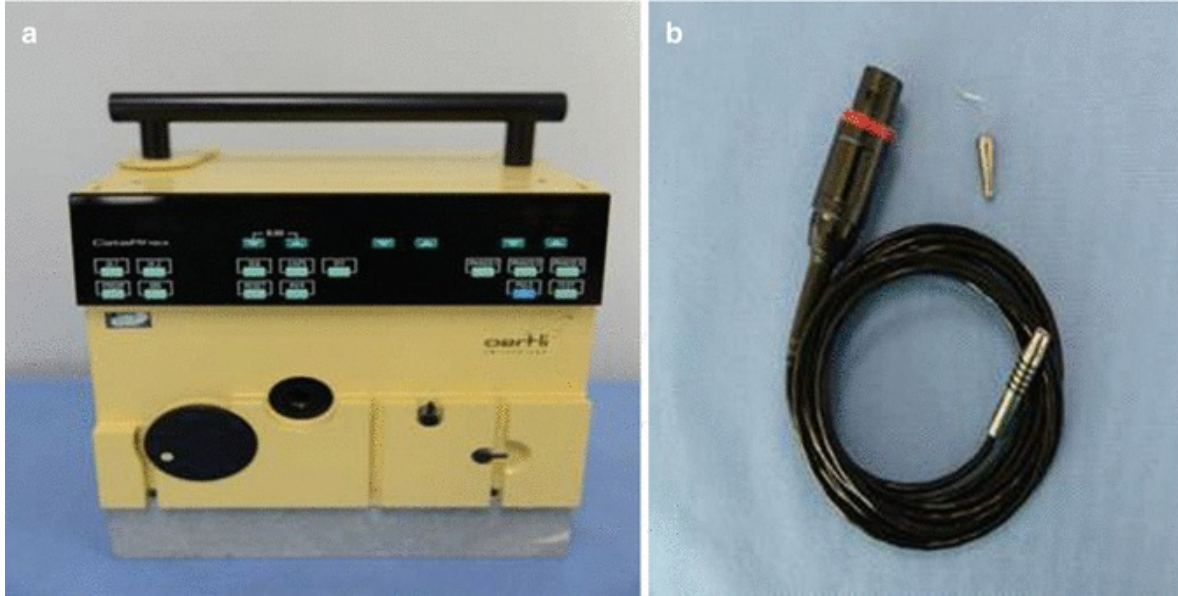


Fig. 11.4 (a) Radiofrequency diathermy device for capsulorhexis; (b) needle and wire for capsulorhexis with radiofrequency diathermy

11.3.2 Item Preparation

Items for pediatric lens surgery include intraocular irrigation solution, ophthalmic viscosurgical devices (OVDs), dyes, disposable surgical drape, diamond/steel knives, Vannas capsulotomy scissors, capsulorhexis forceps, handpiece for capsulorhexis with radiofrequency diathermy, 10-0 nylon sutures, 4-0 silk sutures, 10-0 polypropylene sutures, phacoemulsification handpiece, irrigation/aspiration handpiece, and ophthalmic hemostat. A 22 G irrigation/aspiration syringe and a vitrectomy probe are prepared if necessary, and an intraocular lens (IOL) injector should be available in the case of IOL implantation.

1. Basic package of surgical instruments for pediatric cataract surgery (Fig. 11.5)

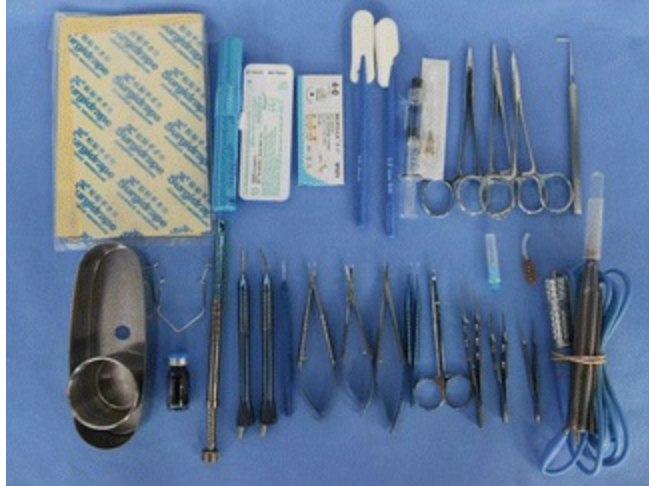

Fig. 11.5 Surgical instruments for pediatric lens surgery

Straight needle holder (small)	One pair
Curved clamps	One pair
Straight clamps	One pair
Strabismus hook	One
Suture tying forceps (toothed)	One pair
Pediatric	One
Utility scissors (curved)	One pair
Corneal scissors	One pair
Barraquer or Castroviejo needle holder	One
Microtissue forceps (toothed)	One pair
Microtissue forceps (smooth)	Two pairs
Sinsky hook	One
Irrigation cannulas	Two
26G needle	One
Iodine cup	One

2. 10-0 polypropylene suture is needed for IOL suture fixation.
3. Resuscitation devices: Aspirator, pediatric suction catheter, oxygen delivery device, etc. are prepared. Performance is maintained and devices should be immediately available in emergencies.

11.3.3 Intraoperative Nursing Cooperation

1. Operative posture: The height of the operating table is adjusted to meet the operational requirements of the pediatric ophthalmologist. The pediatric patient lies supine with his/her both hands and head fixed properly. The forehead and chin are on the same plane. A 6–8 cm cushion is placed under the shoulders to set the respiratory tract in a horizontal position. Try to be gentle when moving the child's head.
2. Protection of the cornea of the nonoperated eye: Incomplete closure of the eyelids (lagophthalmos) occurs in some of the pediatric patients under general anesthesia; what is more, anesthetic agents that inhibit glandular secretion cause conjunctival drying. Thus, the nonoperated eye needs to be applied with ointment to protect the cornea.
3. Disinfection of the operated eye: Assist the ophthalmologist to sterilize the skin around the eye and lid margins with 5 % Betadine. The conjunctival sac is flushed with normal saline or intraocular irrigating solution 3 min after Betadine is instilled.
4. Paying close attention to the process of surgery through surgical video systems (SVSs), the nurses adjust both the parameters of phacoemulsification machine and the height of the infusion bottle based on the ophthalmologist's requirements. If IOL implantation is performed, they should carefully verify the model and power of IOL with the ophthalmologist prior to implantation.
5. At the end of surgery, the operated eye is bandaged after being applied with antibiotic ointment and protected with an eye shield (Fig. 11.6).

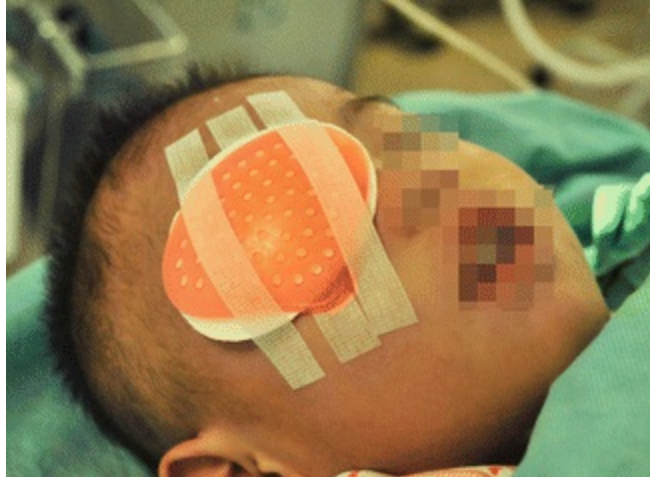

Fig. 11.6 The operated eye bandaged with a protective eye shield

11.4 Postoperative Care of Pediatric Lens Surgery

As young children are unable to accurately express their complaints, the nursing staff should evaluate the child's ocular and systemic conditions based on his/her facial expressions, crying, and actions and react in time. Regular postoperative follow-up is a guarantee of consolidating and enhancing the surgical outcomes. Nurses should provide health guidance to the parents, make arrangements for discharge, and ensure post-discharge continuing care [5, 6].

11.4.1 Postoperative Eye Care

1. Protection of the operated eye

The surgical dressing of the operated eye should be kept clean and from getting loose to prevent the pediatric patient from scratching and bruising the operated eye.

2. Routine surgical care

Since the child's skin is thin and tender, gentle manipulation is necessary when the adhesive plaster on the eye pad is torn off. After the dressing is slowly removed, cotton swab wet with normal saline is used

to clean the skin around the eye. Avoid forcing open the eyelids with fingers by all means.

3. Observation

1. General observation: Pay attention to the pediatric patient's reaction to ambient light, toys, and food. If the child is more expressive than he/she was preoperatively, has an obvious following reaction to light, shows interest in colorful toys, has a good appetite, and sleeps well, all of these indicate that he/she is in good condition postoperatively. And if the child cries and has trouble getting to sleep, observe whether he/she is hungry, and ask about urination and bowel movement. However, if the child keeps crying, refuses to eat, and even has nausea and vomiting, elevation of intraocular pressure (IOP) is suspected and should be examined for.
2. Ocular observation: Pay attention to the degree of eyelid swelling and the severity of eye irritation, conjunctival injection, secretion in the conjunctival sac, and corneal transparency to judge whether related complications have arisen in the operated eye. When IOP elevation is suspected, a rough judgment can be made via digital measurement of IOP. A sedative can be used when necessary and IOP should be measured after the child falls asleep.

11.4.2 Health Guidances

Inform the parents to trim their child's nails in time to prevent him/her from scratching the eye and to avoid such accidents as bruising the operated eye. Keep dirty water from getting in the eye and use a clean wet towel to lightly wipe the area around the operated eye.

1. Give guidances to the parents on the following aspects. Enhance their child's immunity and keep a balanced diet to ensure normal growth and development. Avoid URI and maintain a normal bowel movement. Strenuous activities like jumping and running are inadvisable within 2 months following surgery. Avoid fighting with other children to prevent

eye injuries.

2. Guidances on correct application of eye drops. Wash hands well before instilling eye drops and do not apply pressure to the eye. With a distance of 1–2 cm to the cornea, the mouth of the bottle is not allowed to touch the eyelashes or cornea. Then the drops are instilled in the lower fornix or the medial canthus. If the child is crying and remains uncooperative, do not put in eye drops by force lest the medication be washed away by tears. Instill medications after the child falls asleep to ensure their effectiveness.
3. Inform the parents of regular follow-ups. Make sure they understand that postoperative follow-up on a regular basis is an important measure of vision rehabilitation. Cooperation of the child and parents is needed for optometry examinations so that refractive changes can be monitored. Timely replacement of spectacles or contact lenses, as well as standard, appropriate training for amblyopia, can both consolidate and improve the visual outcomes.

11.4.3 Continuing Care

Healthcare providers may establish contact with the parents of the pediatric patient by telephone and a communication platform. And parents can either communicate with each other through the platform or ask healthcare providers about the issues related to home care for their children. On the other hand, healthcare providers may learn about the post-discharge care via the platform and supervise the implementation of safety measures. In addition, they can remind parents of return visits and medications and meanwhile urge them to keep long-term standard amblyopia training of the child, so that the compliance of postoperative care can be guaranteed.

11.5 Summary

General anesthesia is required in pediatric lens surgery. Good preoperative nursing care is necessary for the surgical treatment. Meticulous preparation of surgical instruments, close monitor of the surgical process and patient status,

as well as cooperation with the anesthesiologist and surgeon are key to improved safety and outcomes of surgery. Observation of ocular and systemic conditions, timely adjusting to these changes, and counseling with parents on continuous care are guarantees of long-term surgical outcomes.

References

1. Xi S. Eye, ear, nose, throat and mouth nursing. Beijing: People's Medical Publishing House; 2012.
2. Yan C. Pediatric nursing. Beijing: People's Medical Publishing House; 2012.
3. Jing L. Modern anesthesia nursing. Tianjin: Tianjin Science and Technology Press; 2008.
4. Cavuoto KM, Rodriguez LI, Tutiven J, et al. General anesthesia in the pediatric population. *Curr Opin Ophthalmol.* 2014;25:411–6.
[\[CrossRef\]](#)[\[PubMed\]](#)
5. Adams HA. A perioperative education program for pediatric patients and their parents. *AORN J.* 2011;93:472–81.
[\[CrossRef\]](#)[\[PubMed\]](#)
6. Shields L. Family-centered care in the perioperative area: an international perspective. *AORN J.* 2007;85(5):893–4, 896–902.
[\[CrossRef\]](#)[\[PubMed\]](#)

12. Pediatric Cataract Extraction

Xinyu Zhang¹, Lixia Luo¹, Qianzhong Cao¹,
Haotian Lin¹ and Yizhi Liu¹✉

- (1) State Key Laboratory of Ophthalmology, Zhongshan Ophthalmic Center, Sun Yat-sen University, 54S Xianlie Road, Guangzhou, 510060, China

✉ **Yizhi Liu**

Email: yzliu62@yahoo.com

Abstract

Pediatric cataract surgery is much more challenging than that of adult. Challenges include the narrow time window of surgical treatment, great operative difficulties, potential complications, and many different surgical approaches, all of which are closely associated with the unique anatomical and physiological characteristics of pediatric patients. Specifically, features like short axial length, small corneal diameter, and shallow anterior chamber may limit the operating space; the presence of soft eyeball, thick cornea, thin and soft sclera, immature pars plana, elastic lens capsule, and sticky lens cortex is associated with a loss of controllability of the operation and an increased risk for intraoperative complications; moreover, due to the outdated and conflicting concepts for the treatment of pediatric cataract, the selection of surgical approaches and basic techniques has not been standardized, which falls behind the rapid development of surgical devices and materials. Thus, this chapter will discuss the techniques and principles that may be used to address these challenges.

Cataract extraction is one of the major treatments for pediatric cataracts. With consideration to the distinguishing ocular features of children, including

thick cornea, thin and elastic sclera, extremely elastic capsule, narrow intraocular maneuvering space, and high intraoperative vitreous pressure, the surgical techniques adopted are different from those in adults. This chapter discusses the surgical indications, timing, techniques, and their specifics for pediatric cataract.

12.1 Indications and Timing of Pediatric Cataract Surgery

As children's eyes are still under development, controversies remain about the indications and timing of pediatric cataract surgery. Visual deprivation is the most common cause of amblyopia in children, and early management will be beneficial for visual rehabilitation. However, since children's eyes are less tolerant to surgical invasion, earlier surgeries result in more operative complications, accompanied by an increased risk of general anesthesia application due to the systemic immaturity of pediatric patients. Therefore, ophthalmologists should carefully consider the pros and cons to make the best decision for each individual patient.

12.1.1 Indications for Surgery

The question of whether surgery is necessary is decided according to the density, location, and size of lens opacities as well as their impact on visual functions. The widely accepted indications for pediatric cataract surgery are listed as below [1, 2]:

1. Complete lens opacification, unilateral or bilateral (Fig. 12.1).

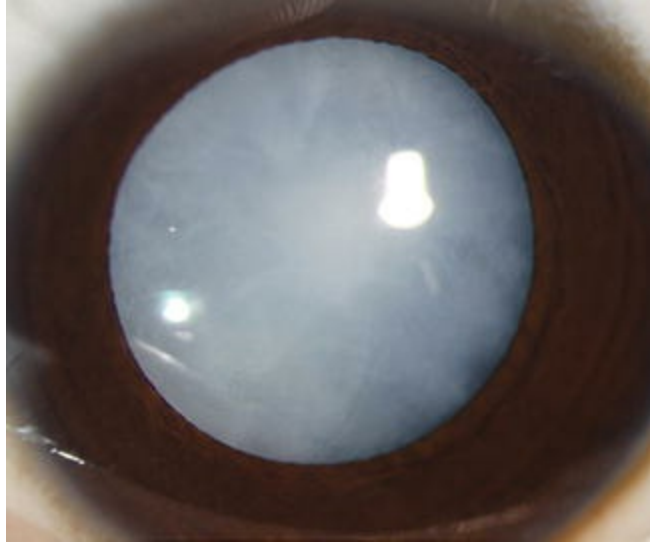


Fig. 12.1 Total cataract

2. Dense opacity located at the center of the lens with a diameter ≥ 3 mm (Fig. 12.2), including dense nuclear opacity and posterior subcapsular opacity.

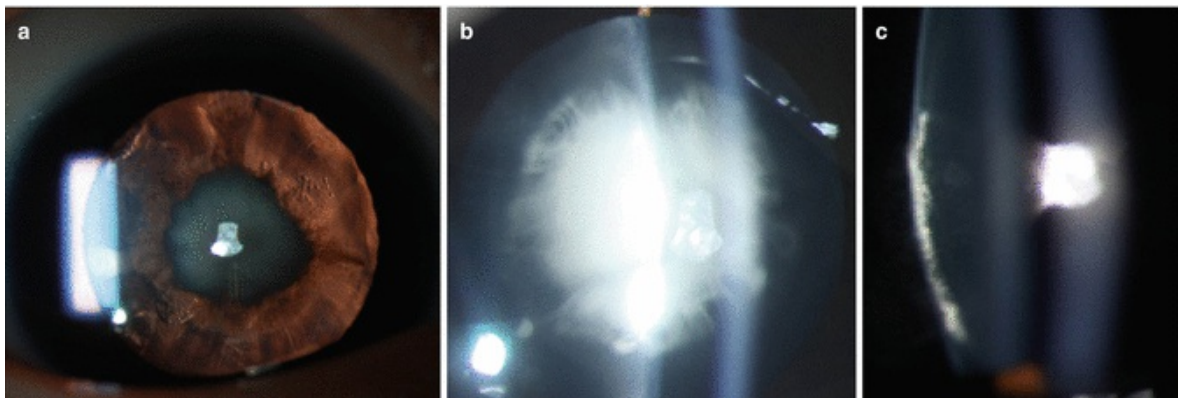


Fig. 12.2 Dense central cataracts. (a) Red reflex is blocked by the central opacity in retroillumination; (b) dense nuclear opacity; (c) dense posterior subcapsular opacity in the center

3. The opacity located near the posterior pole of the refractive system (Fig. 12.3): surgeries are required even if its diameter is less than 3 mm.

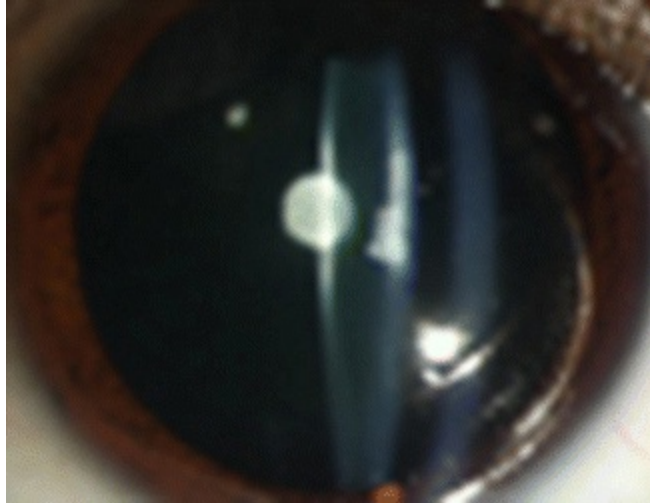


Fig. 12.3 Posterior polar opacity

4. Strabismus, loss of central fixation, or nystagmus in the affected eye, indicating the presence of significant visual deprivation: immediate surgeries are necessary.
5. Any systemic conditions that may affect anesthesia are contraindicative.

12.1.2 Timing of Surgery

The visual system is still developing in the infant period, but there is a latent period after birth, which means visual deprivation has minimal effect on visual development; thereafter, a sensitive period begins and lasts until 7–8 years old, during which time even mild visual impairment will influence visual development [3–7]. Therefore, if cataract surgery is indicated, the operation should be performed before the onset of the sensitive period, so as to minimize the detrimental effect on visual outcome. It has been shown that unilateral and bilateral visual deprivation has different effects on visual development. In full-term infants with unilateral cataract, the latent period of visual development typically lasts until 6 weeks after birth [8]. Therefore, for these patients with unilateral dense cataract, performing the operation at 4–6 weeks of age may not only avoid the highest surgical risk at 1 month postnatal but also effectively solve the visual impairment problem before the onset of the sensitive period. It is more difficult to define the latent period for

infants with bilateral dense cataract. Lambert and colleagues reported that in these patients, the visual outcomes are generally poor when surgery was postponed after 10 weeks postnatal [9]. Thus, it is recommended that the surgery be performed before 10 weeks in children with bilateral dense cataracts.

However, it remains controversial, regarding the indications and timing of pediatric cataract surgery, and further study is warranted. Thus, multicenter, large-scale, randomized controlled clinical trials may be worthy of consideration in the future.

12.2 Incision Construction

Principles of incision construction in pediatric cataract surgery include minimizing injury to ocular tissues, reducing surgically induced astigmatism, and facilitating intraoperative maneuvering. The location and type of incision depend upon multiple factors, such as age, ocular conditions, refractive status, and compliance. For pediatric patients, scleral tunnel, clear corneal tunnel, or limbal tunnel incisions can be made from a superior or temporal approach. This section will focus on the selection and construction of the incision in pediatric cataract surgeries.

12.2.1 Selection of Incision Type and Location

12.2.1.1 Incision Type

Based on the anatomical characteristics of a child's eye, there are three types of incision commonly used in pediatric cataract surgery, and these are modified scleral tunnel, clear corneal, and limbal incisions. According to the incision architecture, cataract incisions can be classified into uniplanar, biplanar, and triplanar incisions. For young children, a modified biplanar scleral tunnel incision is recommended. This may promote self-sealing of the incision by taking advantage of the scleral tension, the posterior incision flap, and the intraocular pressure (IOP). Taken all together, this improves surgical safety and lowers the incidence of surgical injuries and the possibility of surgically induced astigmatism.

12.2.1.2 Incision Location

Location of the incision may be described according to its relative position to the cornea center or its anatomic position. The most common sites of incision are superior, temporal, and on the steep meridian. If the bimanual approach is chosen for irrigation/aspiration (I/A), two paracentesis incisions are made at the 10 o'clock and 2 o'clock positions.

Infants and young children with congenital cataracts have low scleral rigidity; incisions in this population are hardly self-sealing; their compliance to postoperative treatments and care is poor, and they frequently rub their eyes. Therefore, a superior, modified scleral tunnel incision is recommended in these children, so that the wound is protected by both the upper eyelid and conjunctiva, reducing the risk of wound leakage or dehiscence due to external factors such as trauma [10]. Children receiving cataract surgery under 1 year of age, with a horizontal corneal diameter of less than 10 mm or an extremely short axial length, or accompanied by persistent fetal vasculature (PFV) are at a higher risk of developing secondary glaucoma [11–13]. Creation of a conjunctival flap during cataract surgery may be associated with local adhesion to the bulbar conjunctiva and scar formation, increasing the risk of subsequent antiglaucoma surgery failure. In such cases, the surgical incision should be made at the nasal superior or temporal superior quadrant in order to preserve healthy bulbar conjunctiva for possible antiglaucoma surgery in the future. In addition, when complicated with corneal trauma, ectopia lentis, synechia, iris coloboma, iridodialysis, or intraocular foreign bodies, the location of the incision should aim to minimize further injuries to the eye (e.g., avoid making an incision at the site of lens dislocation) and ease intraoperative maneuvering.

For children over 10 years old, the eyes are relatively mature, and the incisions have a better self-sealing capability so the incision may be made at the temporal clear corneal or limbus. Since the temporal incision is located near the palpebral fissure area, it proves to be beneficial for intraoperative maneuvering, with better visibility, and avoids destruction of the bulbar conjunctiva that would be caused by a superior corneoscleral tunnel incision. For patients with vitreous or retinal disorders, or when the surgeon prefers to use a vitrector handpiece for lensectomy, the pars plana scleral incision may be another option.

12.2.2 Techniques and Features of Incisions

12.2.2.1 Modified Scleral Tunnel Incision

The modified scleral tunnel incision has a wide range of applications, particularly for children under 10 years. The principles of a modified scleral tunnel incision construction in pediatric cataract surgery are similar to the techniques in adults, with the following steps (Fig. 12.4a–e):

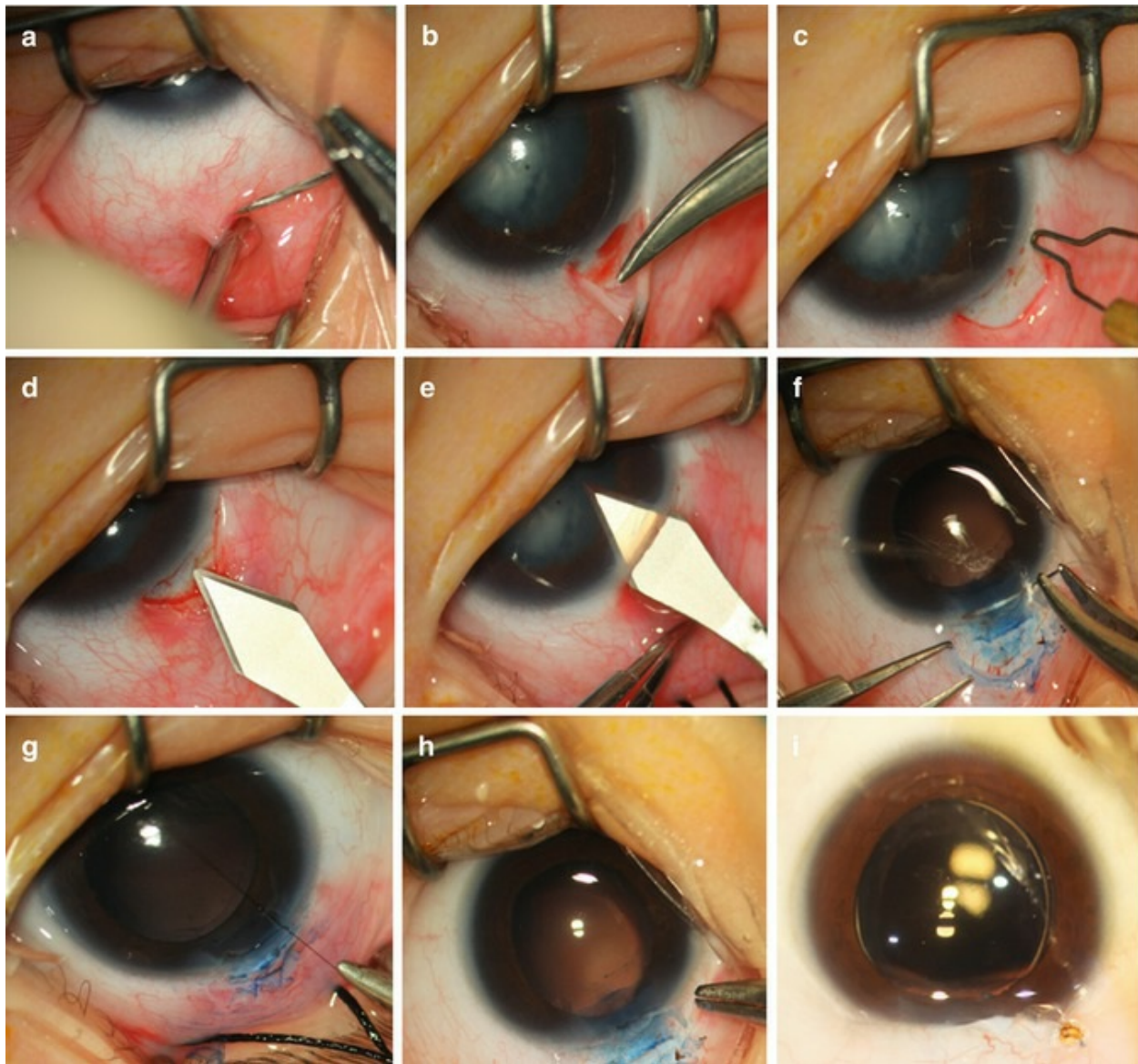


Fig. 12.4 Construction and suturing of a corneoscleral tunnel incision/limbal tunnel incision. (a) Superior rectus suspension; (b) conjunctival opening; (c) scleral cauterization; (d) starting position of the tunnel incision; (e) anterior chamber entry made at an angle of 45°; (f) suture closure parallel to the limbus; (g) knotting; (h) the knot is buried; (i) the conjunctival incision is closed using cauterization

1. The superior rectus muscle is suspended, and the globe is rotated downward to expose the upper surgical field.

2. Peritomy: a fornix-based conjunctival flap is made, and the bulbar conjunctiva is dissected along the limbus about 5 mm in width before cauterization. The superior portion of sclera is thereby exposed. The conjunctival incision may be enlarged, or a radial peritomy may be adopted to prevent conjunctival ballooning due to escaping irrigating solution into the subtenon space that interferes with surgical maneuvers.

3. Creation of a scleral tunnel:
 1. At 1.5 mm posterior to the anterior margin of the limbus, a frown-shaped incision or a straight scleral incision is made with a diamond scalpel or a 15° disposable paracentesis scalpel to a depth of almost half the thickness of the sclera.

 2. With a crescent scalpel or a tunnel scalpel, the scleral tunnel is dissected, and the tunnel is extended into the clear cornea about 2–2.5 mm in length. For children under 3 years with soft eyes, the tunnel should not be too short. In the case of iris prolapse, it not only interferes with operative maneuvers but also leads to severer postoperative inflammatory response.

 3. Following the accomplishment of the corneoscleral tunnel, the anterior chamber entry is made at an angle of 45° with a “dimple-down” maneuver, to facilitate self-sealing of the incision. After entering the anterior chamber, the direction of the blade should be changed and moved to the iris plane to avoid injuring the iris or the capsule.

A modified scleral tunnel incision has several advantages compared to a clear corneal incision [10]. With the same tunnel length, a corneoscleral

incision minimizes the incidence of corneal distortion and corneal folds affecting the surgical field. As it is far from the visual axis, a modified scleral tunnel incision can reduce the risk of surgically induced astigmatism. Besides, the blood supply to the scleral tissues is abundant, resulting in rapid and tight incision healing. Pros and cons of a modified scleral tunnel incision and its indications are listed in Table 12.1.

Table 12.1 Corneoscleral tunnel incision

Pros	Convenient for enlargement if needed
	Minimal corneal distortion during surgery
	Low risk of iris prolapse
	Self-sealing with favorable stability
Cons	Complicated maneuvers, cauterization required
	Severe conjunctival edema may occur during surgery, affecting the surgical field
	The disrupted superior conjunctiva may impact the functions of filtering blebs if subsequent filtration surgery is needed to treat secondary glaucoma
Indications	Infants and young children
	A rigid intraocular lens (IOL) has to be used, or when the type of IOL for implantation is not decided (foldable or rigid)

12.2.2.2 Limbal Tunnel Incision

The construction technique of a limbal tunnel incision is similar to that of a corneoscleral tunnel incision, except that the incision starts from the limbal vessels' ends. This type of incision not only retains some of the advantages of a corneoscleral tunnel incision, such as a lower rate of surgically induced astigmatism and a reduced risk of endophthalmitis, but also simplifies the construction procedure, by protecting the integrity of the conjunctiva, shortening the length of the incision, and enabling easier intraocular maneuvering.

12.2.2.3 Clear Corneal Tunnel Incision

The construction of a clear corneal incision in pediatric cataract surgery is similar to that of an adult eye. A uniplanar, biplanar, or triplanar clear corneal tunnel incision can be made with a paracentesis scalpel. At the end of the surgery, suture closure is not required since the incision is watertight. Besides, conjunctiva-related complications are avoided because the incision

starts before the conjunctiva, which remains unaffected.

For babies under 1 year, suturing is often required due to their soft eyes and poor compliance, and such incisions are not self-sealing. Thus, this type of incision is more appropriate for children above 10 years old whose eyes are much more mature. Pros and cons of a clear corneal incision are listed in Table 12.2.

Table 12.2 Corneal tunnel incision [14–18]

Pros	Simpler procedures without cauterization
	Untouched conjunctiva for better outcome in future filtration surgery
	Ease of intraoperative maneuvering with shorter incision
Cons	Poor self-sealing ability, prone to dehiscence if left unsutured
	Due to an avascular structure, healing possibly delayed
	Higher risk of endophthalmitis if left unsutured
	Higher incidence of surgically induced astigmatism
Indications	Children over 10 years of age with a planned foldable lens implantation

12.2.2.4 Limbal/Clear Corneal Microincision

Bimanual microincision cataract surgery is applicable to pediatric patients. Due to their soft lens nucleus, irrigation/aspiration can be used to remove the opacified lens, and therefore, the same clear corneal incision can be made, as in the bimanual microincision cataract extraction for adults, with a 1.0–1.5 mm paracentesis scalpel [19, 20].

For patients without primary intraocular lens (IOL) implantation, a vitrector tip may be used to aspirate the capsule and cortex plaque. A 20-gauge paracentesis scalpel is ideal to make the incision, starting just at or anterior to the margin of the limbal vascular arcade. The blade enters vertically to the corneal plane and then runs parallel to the iris plane into the anterior chamber. This type of incision is generally small and may ease operative maneuvering; the application of a vitrector handpiece for both anterior and posterior capsulotomy and cortex aspiration avoids frequent entering and exiting from the anterior chamber with surgical instruments and consequently decreases postoperative inflammatory responses. But on the downside, if the incision is too wide to maintain the anterior chamber, leakage occurs and the chamber may even disappear, which results in an increased risk of injuries to the iris and corneal endothelium.

12.2.2.5 Pars Plana Incision

A pars plana incision is indicated for pediatric cataract patients with concurrent vitreous and retinal disorders. As the pars plana is still immature in children and the peripheral retina is closer to the cornea compared with adult eyes, the location for incision is quite different [12]. After peritomies at the 2 o'clock and 10 o'clock positions and infra-temporally, the pars plana entry is created approximately 1.5–3.5 mm posterior to the limbus with a 20-gauge scleral paracentesis scalpel (Table 12.3).

Table 12.3 Location of a pars plana incision at different ages [21, 22]

Patient age (months)	Incision location (posterior to the limbus, mm)
≤3	1.5
4–6	2.0
7–12	2.5
12–36	3.0
>36	3.5

Frequent entries and exits of surgical instruments into the anterior chamber should be avoided. During irrigation, instruments are not allowed to slip out of the tunnel, in case of vitreous incarceration into the incision and further hyperplasia of the anterior vitreous. This kind of incision not only minimizes injuries to the anterior chamber but, in the meantime, enables the management of vitreous and retinal conditions. But the residual capsule may be insufficient to support secondary sulcus IOL implantation. In addition, the learning curve may be long for an ophthalmologist who is focused on the anterior segment to get used to this type of incision.

12.2.3 Suturing

In pediatric cataract surgery, a watertight closure of the incision should always be ensured, no matter what kind of incision is chosen. For younger children, especially those combined with posterior capsulotomy or vitrectomy, suturing the incision should always be stressed, so as to prevent spontaneous or trauma-induced wound dehiscence or leakage, or other catastrophic complications such as anterior chamber disappearance, pupillary occlusion, IOP elevation, or endophthalmitis [23–25].

Methods may vary in suturing a corneal or corneoscleral incision, e.g.,

radial suturing vertical to the limbus or mattress suturing parallel to the incision (Fig. 12.4f–h). Regardless of which method is chosen, the internal lip of the wound should always be fixed and sutured. Meanwhile, the suture tension should be adjusted to maintain corneal curvature. The conjunctival incision can be closed by either suturing or cauterization (Fig. 12.4i).

In summary, a careful and comprehensive preoperative assessment should be performed, so as to select an appropriate and safe incision based on the patient's age together with ocular conditions and plan the best surgical approach. For infants or those accompanied with glaucoma or at a high risk of developing into secondary glaucoma, the bulbar conjunctiva should be preserved as much as possible so as to support any future antiglaucoma surgery. To prevent incision leakage during surgery, the size of the incision should be compatible with the surgical instruments. Moreover, it is important to close the incision by suturing in order to avoid potential complications.

12.3 Use of Ophthalmic Viscosurgical Devices

Since their introduction in the 1970s, ophthalmic viscosurgical devices (OVDs), also called viscoelastic materials or viscoelastics, have become an integral part of ophthalmic surgeries [26–28]. Specific features of the pediatric eye, for instance, a shallower anterior chamber, a pupil that is more resistant to dilation, and a higher vitreous pressure, make it important to maintain an adequate intraoperative maneuvering space. Besides, a soft eye wall and elastic lens capsule add to the difficulties in anterior or posterior capsulotomy. Thus, better understanding of the characteristics of different OVDs and rational selection of appropriate OVDs would enable the surgery to be easier and safer.

12.3.1 OVD Rheology and Physical Properties

1. **Viscosity:** Viscosity is defined as the measurement of internal friction caused by the solution's resistance to flow such as shear stress or tensile stress. Viscosity mainly depends on the length of the molecular chain, as well as molecular weight, concentration, solvent, and temperature [29].

The viscosity of OVDs varies with shear rate. Shear rate is defined as the relative movement speed of two adjacent layers in a moving liquid.

High viscosity at zero shear rate maintains the space for surgical maneuvering; moderate viscosity at medium shear rates facilitates movement of surgical instruments or IOLs within the eye; and low viscosity at high shear rates enables easy OVD injection through a needle cannula [30].

2. Pseudoplasticity: Pseudoplasticity is defined as the OVD's ability to transform when under pressure from a gel-like state to a more liquid state [31]. All OVDs are pseudoplastic, demonstrating decreased viscosity as the shear force (external stress) is increased. Pseudoplasticity correlates with the OVD's ability to maintain surgical space and the level of difficulty of OVD injection [30]. When an OVD is injected or a surgical instrument moves across the OVD, the increased shear rate decreases the viscosity of the OVD, allowing a more liquid state and so facilitating intraoperative maneuvers.
3. Elasticity: Elasticity refers to the tendency of a material to return to its initial size and shape after it has been deformed, which often increases with viscosity. The elasticity of OVDs can reduce the ultrasonic vibration during phacoemulsification and irrigation/aspiration and minimize the intraocular injuries caused by fluctuation [29].
4. Cohesiveness: Cohesiveness describes the degree of self-adhesion; it is a function of molecular weight and elasticity [29]. Long-stranded OVDs with a high molecular weight (HMW) tend to be more cohesive and thus allow for easy removal, whereas short-stranded OVDs with a low molecular weight are less cohesive and behave in a dispersive fashion and are thus more difficult to remove completely.
5. Dispersiveness: Contrary to cohesiveness, dispersiveness is the inclination of a material to disperse when it is injected into the anterior chamber. Typically dispersive agents have lower molecular weights and shorter molecular chains [29].
6. Coatability: Coatability describes the ability of a certain material to adhere to the surface of tissues, instruments, and implants. A lower

contact angle and a lower surface tension indicate better coatability. In addition, negatively charged OVDs better coat the positively charged surface of instruments [30].

According to their viscosity, cohesiveness, and dispersiveness at rest, OVDs are classified into higher-viscosity cohesive agents and lower-viscosity dispersive agents [32, 33]. The cohesiveness and dispersiveness of an OVD may alter under different shear rates. For example, Healon5 has a high viscosity at a quiescent state and becomes dispersive by fracturing into particles under medium shear rate. This property of Healon5 is called viscoadaptivity [26, 31]. The advent of DisCoVisc, which possesses a high viscosity at rest and becomes a dispersive agent during phacoemulsification, promotes a modified classification of OVDs based on their molecular weight and cohesion-dispersion index (CDI) [31]. The new classification system as proposed in 2005 and some of the commercially available OVDs are listed in Table 12.4.

Table 12.4 New classification of OVDs and commercially available OVDs

Zero shear viscosity range (mPa · s)	Cohesive OVDs (components) CDI ≥ 30 (% asp/mmHg)	Dispersive OVDs (components) CDI ≤ 30 (% asp/mmHg)
7–18 × 10 ⁶	I. Superviscous adaptatives ^a Healon5 (2.3 % HA) iVisc Phaco (2.3 % HA)	I. Ultraviscous dispersives None
1–5 × 10 ⁶	II. Higher-viscosity cohesives A. Superviscous cohesives Healon GV (1.4 % HA) iVisc Phaco plus (1.4 % HA)	II. Higher-viscosity dispersives A. Superviscous dispersives None
10 ⁵ –10 ⁶	B. Viscous cohesives Amvisc Plus (1.6 % HA) Amvisc (1.2 % HA) Biolon (1.0 % HA) Healon (1.0 % HA) Provisc (1.0 % HA) Viscorneal Plus (1.4 % HA)	B. Viscous dispersives DisCoVisc (4.0 % HA + 1.7 % CDS)
10 ⁴ –10 ⁵	III. Lower-viscosity cohesives A. Medium-viscosity cohesives	III. Lower-viscosity dispersives A. Medium-viscosity dispersives Viscoat (3.0 % HA + 4 %

	None	CDS) Biovisc (3.0 % HA + 4 % CDS) ViTrax (3.0 % HA) Cellugel (3.0 % HPMC)
10^3-10^4	B. Very low-viscosity cohesives None	B. Very low-viscosity dispersives Adatocel (2.0 % HPMC) Hymecel (2.0 % HPMC) iCell (2.0 % HPMC) OcuCoat (2.0 % HPMC) Visilon (2.0 % HPMC)

Reproduced with permission from Arshinoff SA et al. [31]

Notes: *mPa·s* millipascal seconds, a measure of viscosity; *CDI* cohesion-dispersion index; 30 (% aspirated/mmHg) = 30 % of OVDs are aspirated when the vacuum is 100 mmHg; *HA* hyaluronic acid sodium, *HPMC* hydroxypropyl methylcellulose, *CDS* chondroitin sulfate

^aViscoadaptives

12.3.2 Types and Features of OVDs

The currently used OVDs are mainly based on sodium hyaluronate, hydroxypropyl methylcellulose (HPMC), or chondroitin sulfate (CDS).

12.3.2.1 Hyaluronic Acid (HA) Sodium

HA is a natural lubricant found in the extracellular matrices of almost all vertebrates. In ocular tissues, high levels of HA are found in the vitreous and trabecular angle, while low levels of HA are present in the aqueous humor and over the corneal endothelium, protecting the corneal endothelial cells during surgery [29, 34, 35]. As HA is very viscous and elastic [29], it can effectively maintain the depth of the intraoperative anterior chamber and stress the lens and vitreous to the back, facilitating capsulorhexis and preventing vitreous prolapse. Moreover, HA can eliminate free radicals formed during surgery, thus protecting intraocular tissues from being damaged [36]. Also, its high pseudoplasticity allows for easy injection through a needle cannula. However, since HA cannot be metabolized in the eye and is mainly eliminated through trabecular meshwork filtration, its retention may lead to transient IOP elevation. Additionally, all OVDs

containing HA require low temperature preservation and acclimation to the operating room temperature before use, which may limit its widespread use in less developed areas.

The commercially available HA products include Healon, Healon5, Healon GV, Provisc, Amvisc, Amvisc Plus, Biolon, iViz, Singclean, Yishukang, and Qisheng.

12.3.2.2 Hydroxypropyl Methylcellulose (HPMC)

HPMC does not occur naturally in the eye and is synthesized from methylcellulose. Because of its lower surface tension and smaller contacting angle, HPMC has a better ability to coat the surface of intraocular tissues and surgical instruments, helping to protect the corneal endothelial cells. Due to its small molecular weight, 97 % of HPMC can be eliminated via the trabecular meshwork about 24 h after its injection into the anterior chamber. But the poor elasticity and pseudoplasticity of HPMC means that it requires a large-bore cannula for injection. Moreover, HPMC injection into the anterior chamber is likely to bring air bubbles affecting transparency, thus reducing the visibility of intraocular structures. Since the viscosity is quite low, HPMC tends to leak out of the incision when the anterior chamber pressure is elevated. But HPMC has the advantages of lower cost and being able to be stored at room temperature [29].

OcuCoat, Hymecel, Cellugel, and Adatocel are some of the commonly used HPMC OVDs.

12.3.2.3 Chondroitin Sulfate (CDS)

CDS is found in the cornea and vitreous [37, 38], and because it is negatively charged, it has the ability to coat the positively charged intraocular tissues and instruments. Its viscosity is poor at low concentrations but can be increased when the CDS concentration exceeds 50 %. Intraocular injection at such a high concentration, however, may result in corneal endothelial dehydration and damage. Since the viscosity of CDS depends largely upon its concentration, all available CDS OVDs at present are a combined regimen. The combination of CDS and HA gives rise to a distinctive chemical configuration with favorable coating ability and viscosity, which is considered as an ideal OVD. The commercially available combination products include Viscoat (4 % CDS + 3 % HA), DisCoVisc (4 % HA + 1.7 %

CDS), and OcuGel (0.5 % CDS + 2.75 % HPMC).

12.3.3 Use of OVDs in Pediatric Lens Surgery

Considering the soft eyes and limited space for maneuvering, together with the high vitreous pressure encountered during pediatric surgery, selecting an appropriate OVD is particularly important. OVDs have the following applications during pediatric cataract surgery:

1. **Protection of corneal endothelium:** Since human corneal endothelium cannot regenerate, the use of an OVD is required in both adult and pediatric cataract surgeries, to protect the endothelial cells via physical contact and chemical reactions and minimize the thermal injuries during phacoemulsification, as well as mechanical injuries caused by irrigation and surgical instruments [39]. OVDs play an essential role in protecting corneal endothelial cells from intraoperative loss [40–43]. They are particularly essential in children who are in need of at least two intraocular surgeries. Thus, the use of OVDs with good elasticity and coating ability is recommended for protection of the corneal endothelial cells.
2. **Maintenance of anterior chamber depth:** The depth of the anterior chamber is at its minimum in the newborn eye, reaching its final adult depth at between 8 and 12 years. However, the depth will decrease in the presence of advanced intumescent infantile or childhood cataracts. Besides, as the sclera is relatively thin in pediatric eyes, repeated entries and exits of instruments into and out of the incision may lead to anterior chamber instability. For capsulorhexis or other intraocular procedures, it is necessary to inject an adequate amount of high-viscosity cohesive OVD into the anterior chamber, which can deepen it and create more space for safer surgical maneuvering.
3. **Assisting anterior capsulorhexis:** The pediatric anterior lens capsule is thinner and more elastic than that in adults, which also adds to the difficulty encountered during continuous curvilinear capsulorhexis (CCC). Moreover, vitreous upthrust from lower scleral rigidity promotes

OVDs to leak out of the incision, resulting in an anterior-posterior pressure imbalance and hence anterior capsule radial tearing during surgery. It is recommended that prior to capsulorhexis, a high-viscosity OVD be injected to fill the anterior chamber (Fig. 12.5), thus flattening the anterior lens capsule surface, diminishing the risk of anterior capsule radial tearing and reducing the chances of potential complications [44, 45].

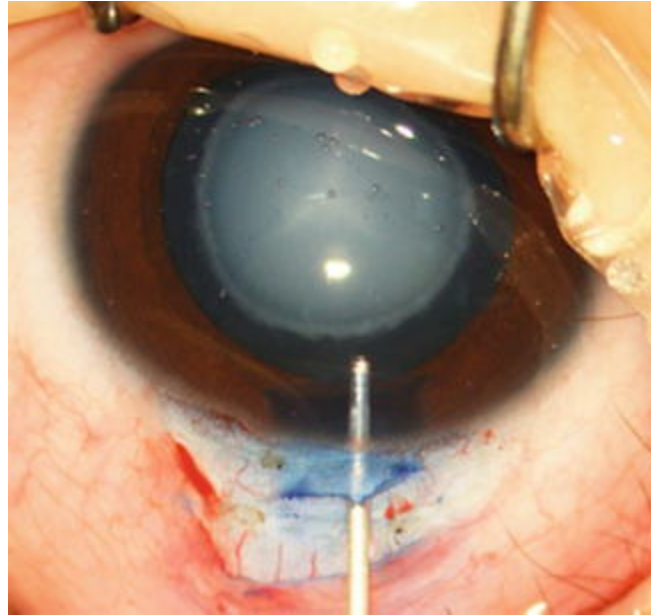


Fig. 12.5 OVD injection into the anterior chamber. Injecting an OVD into the anterior chamber to flatten the anterior lens capsule and aid anterior continuous curvilinear capsulorhexis

4. Assisting posterior capsulorhexis: Due to the increased risk of/for secondary cataract in children and the anatomic characteristics of the posterior capsule in patients with posterior polar cataract, posterior continuous curvilinear capsulorhexis (PCCC) may be required. In this case, injecting a moderate amount of highly cohesive OVD into the capsular bag can stretch and stabilize the posterior capsule and also neutralize the posterior vitreous pressure, easing posterior capsulorhexis.
5. Assisting IOL implantation: Use of OVD to fill the anterior chamber and maintain the capsular bag enables slow unfolding of a foldable IOL and increases the adjustability of the IOL in the capsule bag.

As for secondary IOL implantation, if posterior capsulorhexis and anterior vitrectomy have already been performed, using OVD to neutralize the vitreous pressure can prevent vitreous prolapse when an IOL is being implanted. If the peripheral capsular bag remains intact, an OVD should be injected after the proliferated cortex has been removed, so as to reopen the peripheral capsular bag for “in-the-bag” IOL implantation (Fig. 12.6). In addition, the OVD can adhere to the surface of the IOL, reducing its surface charge and preventing injury to corneal endothelial cells caused by direct contact with the IOL [42].

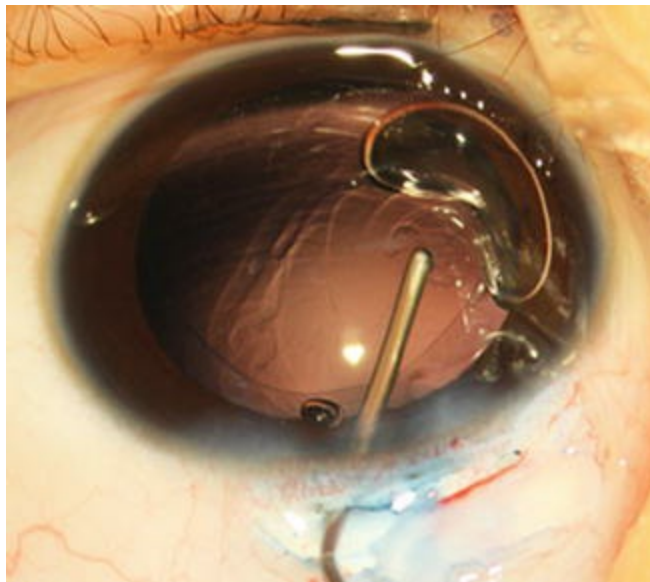


Fig. 12.6 OVD injection into the anterior chamber and capsular bag. OVD injection to maintain the anterior chamber depth and expand the capsular bag, easing IOL implantation

6. Challenging situations: OVDs play a significant role when managing complicated pediatric cases.

Small pupil: In infants, particularly those younger than 6 months, the dilator muscle is poorly developed, which explains the difficulty in obtaining adequate mydriasis. OVDs can help to dilate the small pupil.

Traumatic cataracts: Traumatic patients often have concurrent anterior capsule rupture, posterior synechia, or lens subluxation. OVDs can be used to stabilize the capsular bag, maintain the anterior chamber depth, separate the adhesion, and tamponade the vitreous.

Cataracts accompanied with uveitis or glaucoma: Abnormalities like

posterior synechia, atretopsia, or pupillary fixation are commonly found in these patients. OVDs can facilitate synechiolysis and dilate the pupil. When hemorrhage inflows into the anterior chamber, OVDs can be used to elevate the pressure in the anterior chamber and hence control bleeding.

It is crucial to maintain the anterior chamber space and protect the corneal endothelium with the use of OVDs in cataract surgery. The “soft-shell” technique [46] refers to the combined use of two OVDs: a dispersive OVD and a cohesive OVD. A dispersive OVD with lower viscosity is first injected into the anterior chamber, followed by a higher-viscosity cohesive OVD underneath. This sequence of injections allows the dispersive agent to be pushed to the corneal endothelium, thus making full use of its excellent coatibility to protect the endothelial cells during surgery. Meanwhile, the cohesive agent is able to maintain the operative space and ease capsulorhexis. These two OVDs can also be used in IOL implantation, but in a reversed manner. The capsular bag and the anterior chamber are first filled with a cohesive OVD with higher viscosity before the lower-viscosity dispersive OVD is injected into the center of the first agent. This enables free unfolding and smooth movement of the implant in the anterior chamber, with better capsular bag support, pupillary enlargement, and maintenance by the cohesive agent. At the conclusion of surgery, the dispersive agent, which is more difficult to eliminate, can be removed from the central anterior segment first before removal of the easier-to-remove cohesive agent, thus allowing for rapid eradication of OVDs. Some single-component OVDs, such as Healon5 and DisCoVisc, have high viscosity at rest as well as good dispersiveness and coatibility during phacoemulsification and are thus capable of maintaining surgical space and protecting the corneal endothelium, which are appropriate for pediatric cataract surgery [26, 47].

12.3.4 Removal of OVDs

The methods to remove OVDs vary with their different properties. Cohesive OVDs are not metabolized in the eye and are eliminated through the trabecular meshwork, while dispersive OVDs are partially metabolized prior to their exit from the eye. Incomplete removal of OVDs at the end of surgery may lead to transient postoperative IOP elevation, and its severity depends on the type of OVD and the residual amount and metabolic rate of each individual patient. As most children are unable to cooperate with postoperative examinations, meticulous removal of OVD is warranted at the

end of surgery, so as to prevent intraocular hypertension that may be caused by the retained OVD [48].

When aspirating OVD, the surgeon should use an irrigation/aspiration tip to gently press and rotate the IOL optic, or insert the tip behind the IOL to ensure the complete removal of the OVD (Fig. 12.7). Although posterior capsular striae have been reported as a sign of complete removal of OVD in adult eyes, striae may not appear in pediatric eyes due to the small capsular bag. But by careful microscopic inspection, a disappearing interface between the OVD and the irrigation solution may indicate complete removal.

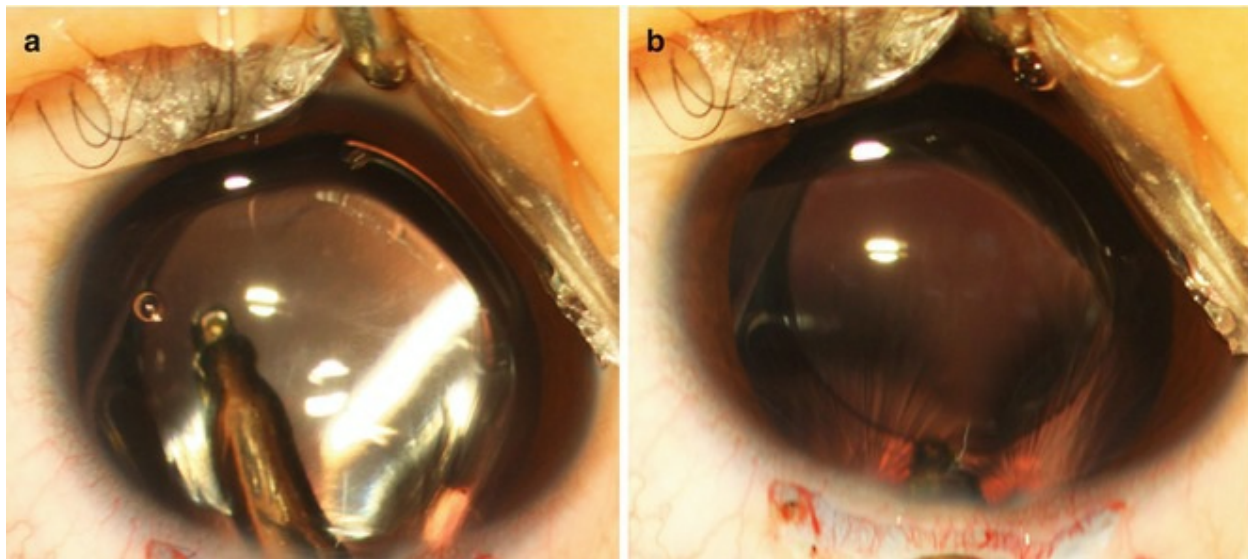


Fig. 12.7 Removal of OVDs. (a) Using an irrigation/aspiration tip to remove the OVDs in front of the IOL optic; (b) inserting the irrigation/aspiration tip beneath the IOL optic to remove the OVDs from behind the IOL

In summary, an ideal OVD is capable of maintaining space, protecting tissue, and allowing easy removal. Based on a full understanding of the characteristics of each type of OVD, the surgeon should select the appropriate OVD for each individual patient to facilitate intraoperative maneuvering and prevent complications.

12.4 Anterior Capsule Management

The management of the anterior capsule is one of the key steps in cataract surgery and is even regarded as the “soul” of modern cataract surgery. The invention of continuous curvilinear capsulorhexis (CCC) has brought a major

revolution to cataract surgical techniques [49]. Because of the extreme elasticity of the anterior capsule, positive vitreous pressure, and at times, poor dilation of the pupil in pediatric eyes, the surgeon should use an appropriate approach or technique for anterior capsulotomy to minimize complications and improve postoperative outcomes.

12.4.1 Characteristics of the Pediatric Anterior Capsule

The development of the pediatric eye is characterized by its dynamic changes, with ever-changing crystalline lens and capsular bag. The diameter of the human lens is about 6.0 mm at birth, increases to 8.0 mm at 1 year and 8.4 mm at 2 years, and reaches adult size of 9.3 mm at around 16 years. The capsular bag is slightly larger than the lens diameter, approximately 7.0 mm at birth, 9.0 mm at 1 year, 9.3 mm at 2 years, 9.5 mm at 5 years, close to adult size at 10 years, and then gradually increases to adult size at 17 years [50]. The lens capsule completely envelops the crystalline lens and is the thickest basement membrane in the human body. The capsule thickness varies at different locations, with the thickest at the anterior pole (thickness, 17–28 μm) and thinnest at the posterior pole (thickness, 2–3 μm). As the basement membrane is rich in glycoproteins with a high extensibility, the capsule is very elastic in/during infancy. Therefore, the lens tends to assume a more globular shape due to the elasticity of capsule and cortex during zonular relaxation. The capsule thickness increases and the glycoprotein level decreases with age, resulting in decreased tenacity and elasticity, but increased fragility.

12.4.2 Evolution of Anterior Capsulotomy and Surgical Techniques

Since the introduction of extracapsular cataract extraction (ECCE), anterior capsulotomy has been through multiple evaluations in the past decades (Table 12.5) [51, 52]. Given its significant advantages, CCC, first introduced by Gimbel, Thomas, and Neuhann in 1984, has received widespread acceptance among cataract surgeons. The most commonly used anterior capsulotomy techniques in pediatric surgeries are described as follows.

Table 12.5 Evolution of anterior capsulotomy [51, 52]

Surgical techniques	Year	Author/surgeon
Anterior capsulotomy	1949	Harold Ridley
Can-opener capsulotomy	1974	Font, Little, and Pearce
Envelope capsulotomy	1979	Galand/Baikoff
Continuous curvilinear capsulorhexis (CCC)	1984	Gimbel, Thomas, and Neuhann
Vitrectorhexis	1994	Wilson et al.
Bipolar radiofrequency diathermy capsulotomy	1994	Kloti

12.4.2.1 Can-Opener Capsulotomy

The key points in this technique are as follows: using the pupillary margin as the reference point, the surgeon creates dozens of superficial independent small punctures around the peripheral anterior capsule in a postage stamp or can-opener fashion and then by connecting these punctures forms a jagged but circular opening approximately 5 mm in diameter, in either a clockwise or counterclockwise direction. Then, a capsulotomy is achieved by dragging a cystotome along the circular opening from the 6 o'clock to the 12 o'clock position in a counter/counterclockwise direction and then another from 6 to 12 in a clockwise direction (Fig. 12.8) [53].

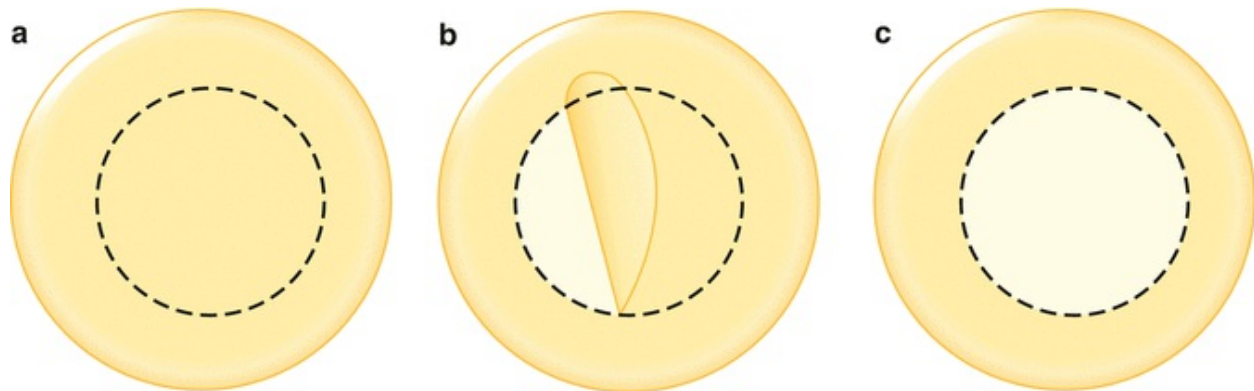


Fig. 12.8 Can-opener capsulotomy. (a) About 40 superficial independent small punctures are created in the anterior capsule at the limbus; (b) a capsulotomy is made in one half of the circumference of the anterior capsular rim by dragging the cystotome tip from the 6 o'clock to the 12 o'clock position in counterclockwise direction; (c) similar capsulotomy is made in the other half from the 6 o'clock to the 12 o'clock position in clockwise direction

The key to a successful can-opener capsulotomy is the proper control over the depth of and the interval between punctures with the cystotome. A deep puncture may induce disturbance to the cortex, resulting in poor visibility, and a wide interval may lead to radial extensions of the

capsulotomy opening. As the edge of anterior capsulotomy obtained from the can-opener technique is not smooth, peripheral extension is likely to occur, affecting the stability of the “in-the-bag” IOL [54]. Thus, this technique has almost been abandoned.

12.4.2.2 Continuous Curvilinear Capsulorhexis

The advent of CCC created a milestone in the development of phacoemulsification. Gimbel HV, a Canadian surgeon, first developed this novel capsulotomy technique in North America in 1984. Almost simultaneously, a German ophthalmologist Neuhann introduced the so-called circular capsulorhexis in Europe, and thereafter in 1986, a Japanese doctor Shimizu named it as “circular capsulotomy” [55]. CCC is based on the can-opener and envelope capsulotomy techniques. Although the can-opener and envelope techniques used to be the mainstay for anterior capsulotomy in modern extracapsular cataract extraction surgery, the role of CCC is irreplaceable in phacoemulsification. The technical principle of CCC is to create an opening with a continuous, symmetrical, and linear cutting edge in the anterior capsule, and this can be achieved by a number of different approaches/methods (Fig. 12.9). CCC is much more difficult to perform in pediatric eyes than adults because of the limited space in the anterior chamber and the extreme elasticity of the lens capsule.

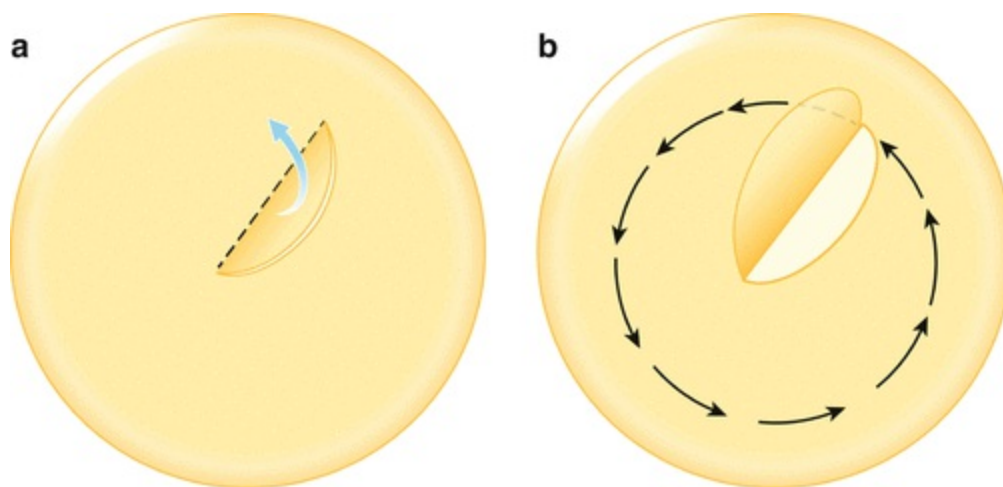


Fig. 12.9 Continuous curvilinear capsulorhexis. (a) Creating a capsulotomy opening; (b) continuous curvilinear capsulorhexis of the anterior capsule

When performing CCC in children, the following caveats should be

noted:

1. **Adequate pupil dilation:** In addition to preoperative administration of adequate mydriatic agents, epinephrine (at a concentration level of 1:1000) can also be added into the irrigation solution for intraoperative use, in order to maintain mydriasis throughout the surgery.
2. **Maintaining the anterior chamber:** High molecular weight (HMW) OVDs (such as Healon GV, Healon5, or Viscoat) can be used to maintain the anterior chamber space, flatten the anterior capsule, and minimize the risk of peripheral extensions/tears of the CCC.
3. **Controlling the size of capsulotomy:** Due to the greater elasticity of the pediatric capsule and anteriorly attached zonule having a higher tension, it is more likely to extend peripherally during capsulorhexis. So the opening should not be too large. The capsular flap is turned over, and then both shearing and traction are applied to form centripetal forces and achieve an optimal rhexis of 4–5 mm in size, smaller than that for adult eyes. Our previous study has demonstrated that openings of/between 4 and 5 mm can reduce the incidence of postoperative posterior capsular opacification than openings of 3–3.9 mm in diameter, while 5.1–6.0 mm would induce the enlargement of posterior capsular openings [56]. The opening is usually larger when the capsular flap is released, and thus the tearing should be performed using forceps and under a high-power microscope aiming for a slightly smaller-than-desired capsulotomy (Fig. 12.10).

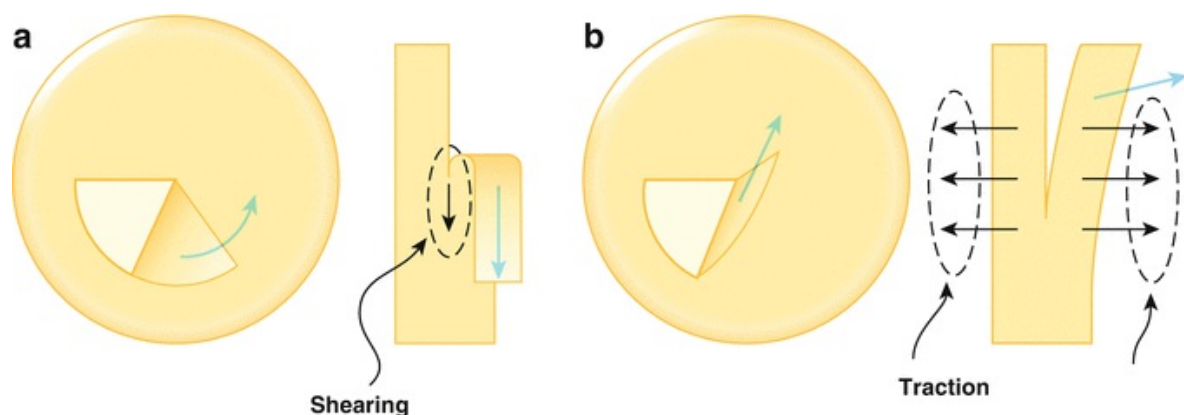


Fig. 12.10 Two different forces used during capsulorhexis. (a) Shearing; (b) traction

4. The root of the capsular flap should always be grasped, which helps to control the direction of the tearing. Meanwhile, the surgeon should frequently release the capsular flap and examine the size, shape, and direction of capsulorhexis; then regrasp the flap and readjust the direction as needed to keep the capsulorhexis on the intended path.
5. If anterior capsular fibrosis is observed in pediatric cataract patients, the fibroproliferative membrane should be cut using capsulotomy scissors to achieve an intact capsulorhexis.
6. If some of the lens cortex spills over into the anterior chamber during capsulorhexis, affecting the visibility of the tearing edge, lens aspiration to remove the cortex should be addressed first, then by injecting an adequate amount of OVD, continue the capsulotomy and subsequent maneuvers.
7. If the tear-edge of CCC begins to extend peripherally covered by the iris, the capsulorhexis should be reinitiated near the site of or on the opposite side of the tear by creating another flap, or adopting the vitrector or the bipolar radiofrequency diathermy device to rescue the errant tear out from the capsulorhexis.

12.4.2.3 Vitrectorhexis

After the invention of the vitrector, a new method named vitrectorhexis was used to manage the anterior lens capsule [57]. Supported by a Venturi pump irrigation/aspiration system, a vitrector is introduced into the anterior chamber through a limbal or scleral incision tunnel. This can be done with a coaxial or non-coaxial irrigation/vitrectomy system. The advantage of this technique is that anterior capsulotomy, lens aspiration, posterior capsulotomy, and anterior vitrectomy can be done sequentially with the same instruments, avoiding repeated entries and exits of instrument into and out of the anterior chamber and thus minimizing the occurrence of mechanical injuries to the eye.

12.4.2.4 Radiofrequency Diathermy Capsulotomy (Fig. 12.11)

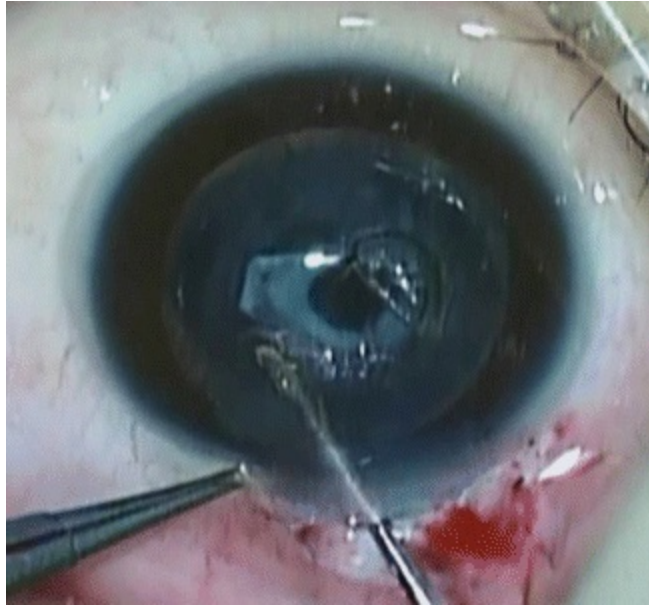


Fig. 12.11 Radiofrequency diathermy capsulotomy

Considering the thick and elastic anterior capsule of pediatric eyes, radiofrequency diathermy capsulotomy, developed by Kloti can be applied to cataract surgery in children as an alternative to CCC. The specific equipment – the Kloti device – is required for this technique [58].

The Kloti device cuts the anterior capsule with a platinum-alloy-tipped probe that is connected to high-frequency electrical current (500 kHz). The tip of the probe is heated to approximately 160 °C and produces a thermal capsulotomy as it is manipulated along a circular path on the anterior capsule. Small gas bubbles are formed when the diathermy mode is on, but they will not impair operative visibility. Gentle but consistent contact with the capsule must be maintained as the tip moves either clockwise or counterclockwise. If the contact is fixed or movement of the tip is too slow, it will burn through the capsule and reach the cortex. In this case, the subsequent tip movement would exert traction on the capsulotomy edge instead of cutting it, which may cause radial tearing. Thus, it is essential to precisely manipulate the cutting rate as well as the contact between the probe tip and the capsule. In laboratory studies, the edge of a diathermy-cut has been proven to be less elastic than a comparable CCC edge, which is associated with a higher risk of

tearing during surgery. In addition, this edge will undergo thermocoagulation, and hence any thermal injury to the corneal tissues should be avoided [59]. In our clinical practice, radiofrequency diathermy has now been widely applied to pediatric anterior or posterior capsulotomy. Besides, this technique has been shown to be specifically beneficial to secondary anterior capsulotomy in aphakic eyes, which significantly improves the success rate of secondary “in-the-bag” IOL implantation [60].

12.4.3 Complicated Situations

12.4.3.1 White Cataract

The retroillumination of the operating microscope is vital in helping visualize the anterior capsule while performing CCC. Owing to the absence of the red reflex, it is difficult to distinguish the anterior capsule from the underlying cortex in patients with white cataract. In these circumstances, the following methods can/may be beneficial [61]:

1. Anterior capsular staining (Fig. 12.12): Several dyes can be used for capsular staining, including indocyanine green 0.5 % and trypan blue 0.1 %.

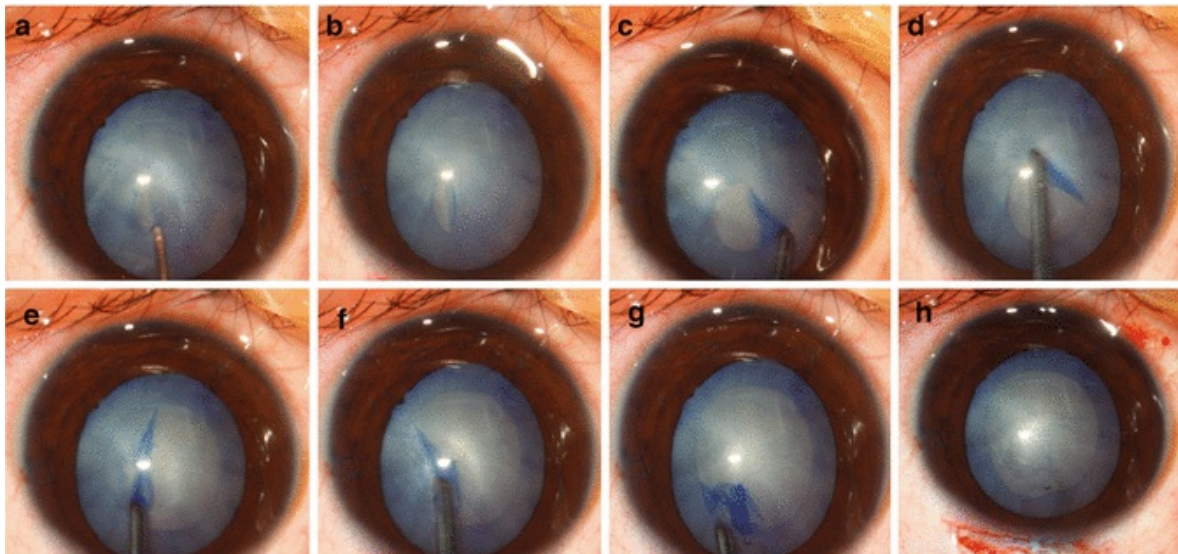


Fig. 12.12 Application of staining reagent. In patients with total white cataracts, capsular staining (trypan blue 0.1 %) is used before the initiation of capsulorhexis. (a) and (b) After trypan blue staining, a small opening was made near the center of the anterior capsule with a bend needle. (c–g) The contrast between the stained blue capsule and the underlying white cortex made

capsulorhexis easily performed with enhanced visibility. **(h)** A well centered CCC completed

2. Amplifying the illumination and increasing the optical magnification of the operating microscope, so as to enhance capsule visualization.
3. Use of HMW OVD.
4. Two-step CCC, which involves performing a small CCC followed by a second larger CCC to enlarge the initial capsulotomy.

12.4.3.2 Traumatic Cataract

In pediatric traumatic cataract with a ruptured lens capsule, staining of the capsule is helpful to enhance visibility of the location and the extent of the tearing. The surgeon should try to include the rupture when performing capsulorhexis, so that the edge is as smooth as possible and prevents further capsular rupture [62]. For organized anterior capsule, if any, the surgeon should attempt to encompass it; if this is not possible, capsulotomy scissors or radiofrequency diathermy capsulorhexis is another option. The capsular opening obtained from the latter method is prone to tear. Therefore, the surgeon should be cautious to avoid further damage to the anterior capsule.

12.5 Removal of Lens Cortex and Nucleus

Although it is relatively easy to remove cortex and nucleus in pediatric eyes, there is an increased risk for developing secondary cataracts, which may significantly affect the visual rehabilitation of these children. Thorough removal of the lens substance can help to reduce the risk of secondary cataracts.

12.5.1 Hydrodissection

Hydrodissection is an important surgical step to enhance separation of the cortex from the capsule via fluid injection. As the pediatric lens is soft without an apparent nucleus, hydrodissection may cause most of the lens cortex to prolapse into the anterior chamber through the capsulotomy

opening, and the dispersed lens material may even evacuate from the eye with the irrigation pressure when a gentle compression is applied on the external lip of the incision (Fig. 12.13). It has been demonstrated in a randomized controlled clinical trial that hydrodissection might shorten the duration of lens substance removal in pediatric cataract surgery [63].

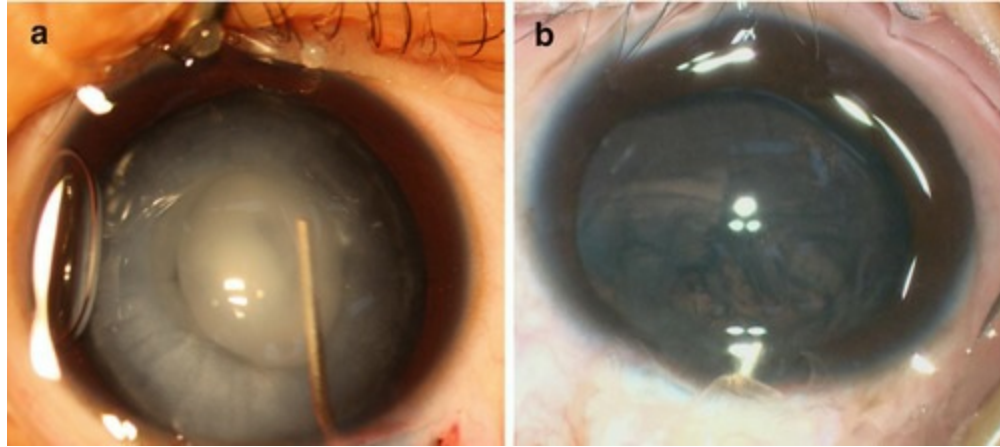


Fig. 12.13 Hydrodissection.(a) The cannula tip is inserted beneath the capsulorhexis edge for hydrodissection; (b) the lens cortex is evacuated by gently pressing the posterior lip of the incision

A 20-gauge cannula is attached to a 5 ml syringe filled with about 3 ml of balanced salt solution (BSS). The tip of the cannula is inserted into the anterior chamber via the main incision and placed under the anterior capsule through the capsulorhexis edge. A small amount of BSS is gently injected to separate the cortex from the capsule. Multiple quadrant hydrodissection of at least three quadrants is recommended, which helps to remove the equatorial lens epithelial cells, reduce postoperative inflammatory response, and minimize the risk of secondary cataracts [64, 65].

12.5.2 Lens Substances Removal

At present, three methods are applied clinically for the removal of lens substance, and they are irrigation/aspiration (I/A), phacoemulsification, and vitrectomy.

12.5.2.1 Automated Irrigation/Aspiration (I/A)

This is the most widely applied technique for pediatric lens aspiration. Before the introduction of the phacoemulsification device, the lens substance was

often aspirated by a bimanual approach. This technique is inefficient, and it is difficult to remove the lens cortex completely; the repeated entry and exit from the anterior chamber may lead to a higher risk of complications such as uveitis and corneal endothelial cell loss. The advent of the automated I/A system (Fig. 12.14) significantly improved efficiency and avoids multiple complications caused by extra manipulation.

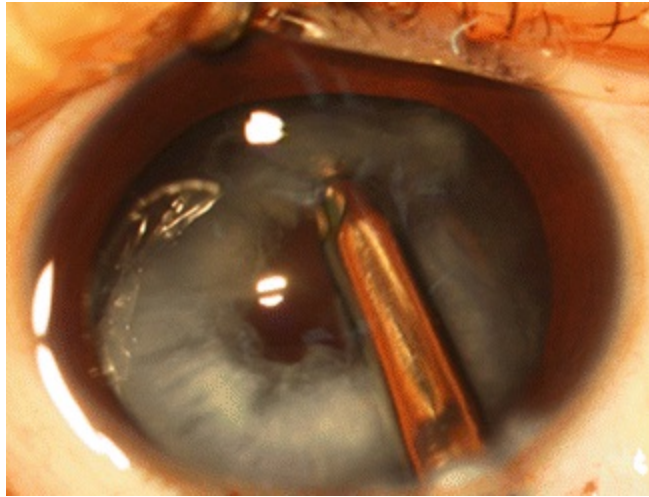


Fig. 12.14 Lens substance removal using automated I/A

It is advisable to check the patency of the cannula and ensure sufficient irrigation before inserting the I/A probe in the anterior chamber. The tip of the cannula is inserted into the anterior chamber, and irrigation is initiated when the pedal is on position 1. Then, when the tip is in contact with the cortical material, the pedal is moved to position 2 to initiate aspiration. Once the tip grabs on the cortex, it is slowly dragged toward the pupillary center to detach the lens substance from the capsule, while the aspiration vacuum level is increased. The anterior chamber stability should be maintained during I/A. The aspirating orifice must always be under direct visualization, and this prevents snagging of unwanted tissues and associated intraoperative complications such as posterior capsule rupture.

12.5.2.2 Phacoemulsification

Though rarely seen in pediatric eyes, a hard lens nucleus can be removed by aspiration forces in most cases. But, when encountering an even harder nucleus, ultrasonic energy plays an important role. In addition, as the

aspirating orifice of a phacoemulsification tip is larger than that of an I/A tip, the removal efficiency tends to be much higher (Fig. 12.15) [66].

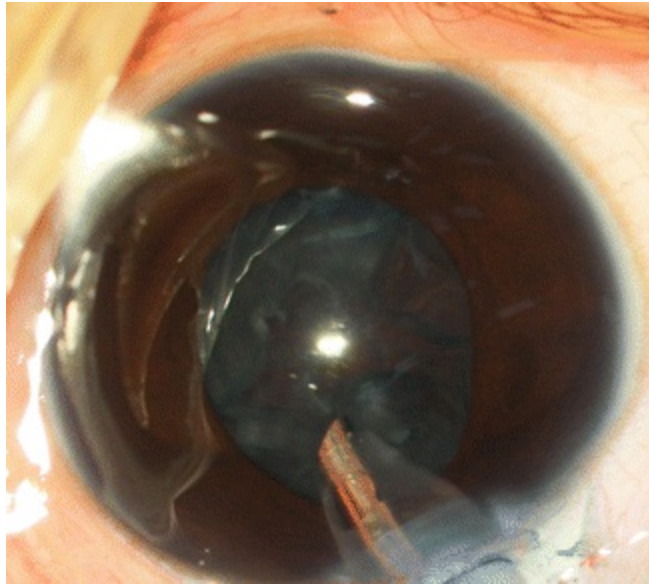


Fig. 12.15 Phacoemulsification

12.5.2.3 Vitrectomy

The development of the vitrectomy technique offers a novel approach for pediatric lens removal [67]. Via a scleral, corneal, or pars plana incision tunnel, lensectomy can be achieved (or combined with posterior capsulotomy and anterior vitrectomy) (Fig. 12.16). The advantage of this technique is that it is possible to perform capsulorhexis, lens substance removal, posterior capsulotomy, and anterior vitrectomy without changing instruments. This avoids extra manipulation and repeated changes of instruments. A pars plana approach causes minimal disturbance to the anterior segment, particularly the iris, which in turn helps to minimize postoperative inflammatory response. But the biggest disadvantage is that it is hard to maintain capsule integrity and makes it hard to accomplish secondary IOL implantation.

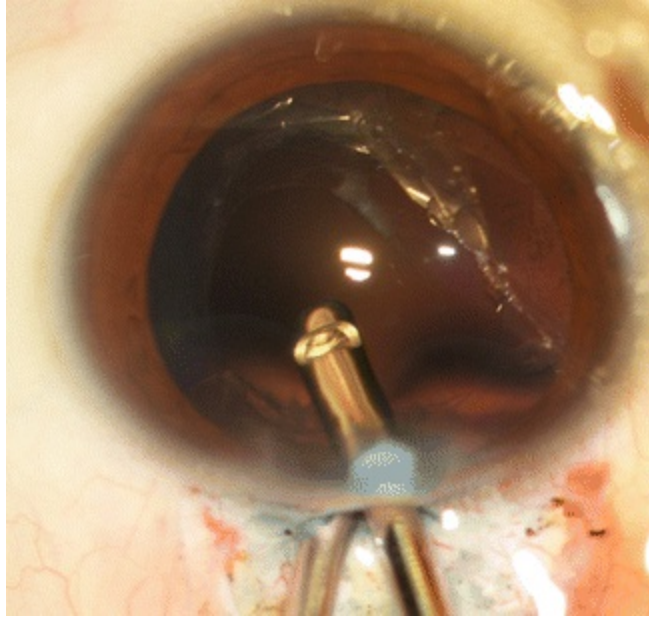


Fig. 12.16 Lens substance removal by vitrectomy

12.6 Posterior Capsule and Anterior Vitreous Management

Posterior capsule opacification (PCO) is the most common postoperative complication associated with pediatric cataract surgery where the incidence up to 100%. The development of PCO is closely related to patient age as well as the management of the posterior capsule and anterior vitreous. Due to the active proliferation of cells in pediatric patients, even if the central posterior capsule has been removed, the lens epithelial cells and inflammatory cells may still migrate and proliferate to form visual axis opacification with the anterior hyaloid membrane serving as a scaffold. Therefore, management of the posterior capsule and anterior vitreous is a crucial step of pediatric cataract surgery, which significantly affects postoperative visual recovery [68, 69].

12.6.1 Anatomic and Physiological Characteristics of the Pediatric Posterior Capsule and Anterior Vitreous

The posterior capsule of pediatric eyes is thinner than that in adults, with an average thickness of 4 μm . The thickest part is located 1 mm from the

equator (about 20 μm) and the thinnest at the posterior pole (only 2–4 μm). In infants and young children, the posterior capsule is highly elastic, and the elasticity decreases with age. Since the equatorial lens epithelial cells closely adhere to the lens capsule and also undergo active proliferation, complete removal is difficult, and hence postoperative PCO is more likely to occur in pediatric patients [70].

The pediatric vitreous is viscoelastic and difficult to compress. There is a circular zone of adhesion of the anterior hyaloid membrane to the posterior capsule that is 8–9 mm in diameter, and it is called the Weiger ligament [71]. As the Weiger ligament tightly attaches the anterior vitreous to the posterior capsule, posterior capsule rupture may cause direct or indirect damage to the anterior hyaloid membrane, allowing the vitreous to prolapse through the rupture, leading to vitreous hernia. It has been shown that an intact anterior hyaloid membrane can act as a scaffold on which the lens epithelial cells and inflammatory cells may proliferate. In patients who had received PCCC, the residual lens epithelial cells could proliferate to form a single layer of lens epithelium on the anterior hyaloid membrane and induce fibrosis and opacification on the visual axis. This finally leads to partial or complete occlusion of the posterior capsular opening in about 33 %/one third of patients [72].

12.6.2 Management of the Posterior Capsule and Anterior Vitreous

Proper management of the posterior capsule and anterior vitreous in primary pediatric cataract surgery can effectively prevent the development of PCO [73]. It is suggested that a decision on whether to perform posterior capsulotomy and anterior vitrectomy be based on the patient's age. For children younger than 2 years, PCCC should be performed in combination with anterior vitrectomy; for children between 2 and 6 years, PCCC alone is recommended; and for those older than 6 years, PCCC or anterior vitrectomy is not required and the posterior capsule can be left intact [74].

12.6.2.1 Posterior Capsule Management

Posterior Continuous Curvilinear Capsulorhexis (PCCC)

In 1990, Gimbel HV and colleagues first described posterior CCC (PCCC). It

is performed after cataract aspiration, either before or after IOL implantation. OVD is injected into the capsular bag behind the IOL to increase the tension on the posterior capsule. A 26-gauge cystotome needle is used to incise the central posterior capsule, and then OVD is injected through the incision to push the vitreous face backward. The capsular flap is grasped and turned over with capsulorhexis forceps, and then circular capsulorhexis is made in either a clockwise or counterclockwise direction, approximately 3.5–4 mm in diameter (Fig. 12.17). Performing PCCC can be technically challenging for surgeons, and inexperienced surgeons are more likely to encounter complications, including IOL dislocation and vitreous prolapse [75]. About 3–20 % of pediatric patients experienced IOL dislocation after primary PCCC. If the posterior capsular opening is too large or radial tearing occurs during capsulorhexis, it may be impossible to place the IOL in the bag, and sulcus implantation or even suture fixation of the haptics has to be performed; these extra manipulations will significantly increase the risk of postoperative uveitis, pigment dispersion, secondary glaucoma, or IOL decentration [76].

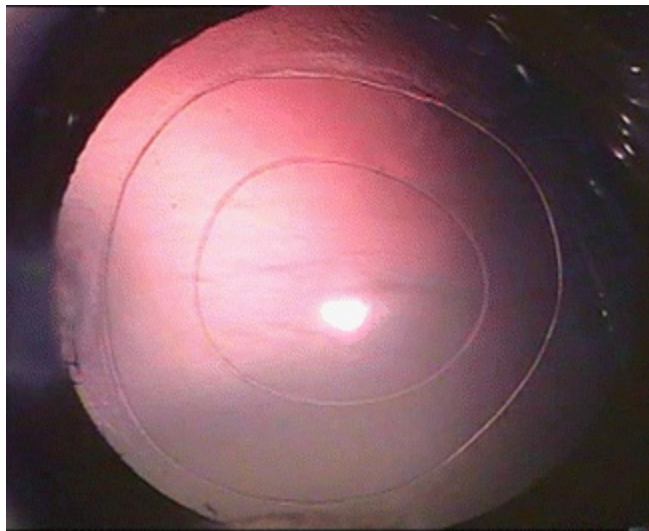


Fig. 12.17 Primary anterior (ACCC) and posterior continuous curvilinear capsulorhexis (PCCC). The posterior capsular opening is small with a continuous and smooth edge

Radiofrequency Diathermy Posterior Capsulotomy

As mentioned above, the radiofrequency diathermy technique could be applied to both anterior and posterior capsulotomy, or after IOL implantation.

Posterior Vitrectorhexis

Usage of a vitrector to create a posterior capsular opening is termed posterior vitrectorhexis [57]. This technique is easier to manipulate, though the rhexis edge is not as smooth as that obtained from PCCC.

12.6.2.2 Anterior Vitreous Management

It has been shown in clinical studies that PCCC alone only delays and does not stop/prevent the development of PCO. From our clinical practice in infants younger than 2 years, the lens epithelial cells with strong proliferation and migration capacities often form fibrous membranes on an intact anterior vitreous face. For this reason, primary anterior vitrectomy is warranted for these infants. It has been well recognized internationally that anterior vitrectomy can hinder the scaffolding effect of an intact anterior vitreous and thereby delay the development of central visual axis opacification. More importantly, during the critical period for visual development, it minimizes the risk of amblyopia resulting from opacification on central visual axis. At present, in many countries and regions, primary PCCC with anterior vitrectomy has been considered as routine surgical steps in cataract surgery for children younger than 5 years.

Anterior vitrectomy can be performed using either a pars plana or a limbal approach. In pediatric cataract surgery, the combination of anterior vitrectomy aims to remove the central anterior vitreous instead of removing the entire vitreous. The surgeon should focus on the close link between the visual axis and the posterior capsule, in order to prevent the lens epithelial cells migrating and proliferating on the anterior hyaloid membrane. For this limited vitrectomy, a limbal approach is usually adopted (Fig. 12.18). The pars plana approach, i.e., pars plana capsulotomy plus vitrectomy after “in-the-bag” IOL implantation, has also been selected by pediatric ophthalmologists for over a decade, and it is associated with a PCO incidence of only 4 % in children under 7 years. It is often anatomically difficult to locate the pars plana in pediatric eyes, which may increase the risk of retinal detachment and IOL decentration or dislocation in the operated eye. Thus, the surgeon needs to be cautious when deciding to choose a pars plana route.

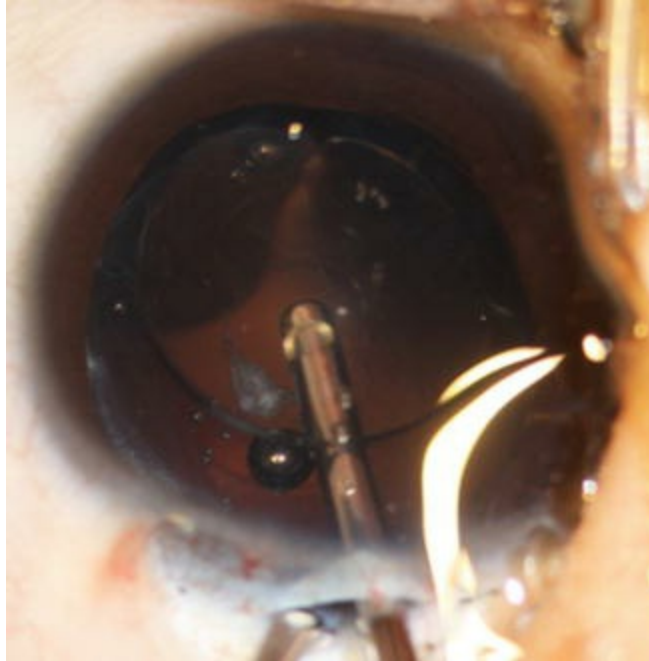


Fig. 12.18 Primary non-coaxial limbal anterior vitrectomy

The surgical steps and caveats are listed as follows:

1. After “in-the-bag” IOL implantation, PCCC (or any other capsulotomy technique) is performed with a high-viscosity OVD injected into the anterior chamber and over the anterior and posterior surfaces of the IOL.
2. Dry anterior vitrectomy (without irrigation): A high cutting rate and low vacuum help to maintain the anterior chamber stability. The vitrector tip is inserted through the anterior capsular opening, across the IOL edge, and then passes through the posterior capsular opening. In the absence of an irrigation flow, the residual vitreous in the anterior chamber, capsular bag, and around the posterior capsular opening is sequentially cut and removed completely. Next, anterior vitrectomy is initiated to remove at least 1/4–1/3 of the anterior vitreous. A round capsulorhexis edge should always be maintained, and a distorted edge may indicate removal of excessive vitreous. Besides, the aim of anterior vitrectomy is to eliminate the central anterior vitreous, rather than all of the peripheral vitreous, so the removal should be limited to the space behind the posterior capsular opening.

3. If persistent fetal vasculature is observed behind the posterior capsule, it should also be removed.
4. A miotic agent is administered. The shape of the pupil is inspected, and no vitreous remnants in the anterior chamber must be ensured. The surgeon may also insert an auxiliary instrument (e.g., spatula) via the side port to gently sweep the anterior surface of the iris, which is helpful in removing any residual vitreous strands that have prolapsed out through the incision.

Although posterior capsulotomy combined with anterior vitrectomy can help to prevent the development of PCO, its performance is limited by the surgical experience of the surgeon, availability of surgical instruments and devices, and increased risk of retinal detachment and cystoid macular edema, which may bring notable disturbance to intraocular structures. As controversy still remains regarding its routine application in pediatric cataract surgery, we do not recommend anterior vitrectomy for general use in older children.

12.7 Summary

The developing pediatric eye requires that indications and timing of pediatric cataract extraction be determined based on density, location and size of the lens opacity, as well as its effect on visual function. Due to the unique anatomy and physiology of the pediatric eye, methods and techniques of pediatric cataract extraction are different from those in adults. A water-tight construction of the incision is more emphasized in children; the lens capsule in children is highly elastic; therefore, more attention should be paid on avoiding peripheral extension of the capsulorhexis and controlling the size of the anterior capsulotomy; posterior capsulotomy and anterior vitrectomy are performed in infants and very young children to reduce the incidence of posterior capsular opacification.

References

1. Basti S, Greenwald MJ. Principles and paradigms of pediatric cataract management. *Indian J Ophthalmol.* 1995;43(4):159.

[PubMed]

2. Lambert SR, Drack AV. Infantile cataracts. *Surv Ophthalmol*. 1996;40(6):427–58.
[CrossRef][PubMed]
3. Atkinson J. Human visual development over the first 6 months of life. A review and a hypothesis. *Hum Neurobiol*. 1983;3(2):61–74.
4. Dubowitz L, De Vries L, Mushin J, et al. Visual function in the newborn infant: is it cortically mediated? *Lancet*. 1986;327(8490):1139–41.
[CrossRef]
5. Elston J, Timms C. Clinical evidence for the onset of the sensitive period in infancy. *Br J Ophthalmol*. 1992;76(6):327–8.
[CrossRef][PubMed][PubMedCentral]
6. von Noorden GK, Dowling JE, Ferguson DC. Experimental amblyopia in monkeys: I. Behavioral studies of stimulus deprivation amblyopia. *Arch Ophthalmol*. 1970;84(2):206–14.
[CrossRef]
7. Von Noorden G, Crawford M. The sensitive period. *Trans Ophthalmol Soc UK*. 1978;99(3):442–6.
8. Birch EE, Stager DR. The critical period for surgical treatment of dense congenital unilateral cataract. *Invest Ophthalmol Vis Sci*. 1996;37(8):1532–8.
[PubMed]
9. Lambert SR, Lynn MJ, Reeves R, et al. Is there a latent period for the surgical treatment of children with dense bilateral congenital cataracts? *J AAPOS*. 2006;10(1):30–6.
[CrossRef][PubMed]
10. Bayramlar H, Colak A. Advantages of the scleral incision in pediatric cataract surgery. *J Cataract Refract Surg*. 2005;11(31):2039.
[CrossRef]
11. Praveen MR, Vasavada AR, Shah SK, et al. Long-term postoperative outcomes after bilateral congenital cataract surgery in eyes with microphthalmos. *J Cataract Refract Surg*. 2015;41(9):1910–8.
[CrossRef][PubMed]
12. While B, Mudhar HS, Chan J. Lens particle glaucoma secondary to untreated congenital cataract and persistent fetal vasculature. *Eur J Ophthalmol*. 2012;25:0.
13. Saltzmann RM, Weakley DR, Aggarwal NK, et al. Glaucoma following infantile cataract surgery. *J Pediatr Ophthalmol Strabismus*. 2011;48(3):142–9.
[CrossRef][PubMed]
14. Bradfield YS, Plager DA, Neely DE, et al. Astigmatism after small-incision clear corneal cataract extraction and intraocular lens implantation in children. *J Cataract Refract Surg*. 2004;30(9):1948–52.
[CrossRef][PubMed]
- 15.

- Dick HB, Schwenn O, Krummenauer F, et al. Inflammation after sclerocorneal versus clear corneal tunnel phacoemulsification. *Ophthalmology*. 2000;107(2):241–7.
[\[CrossRef\]](#)[\[PubMed\]](#)
16. Kruger A, Schauersberger J, Findl O, et al. Postoperative inflammation after clear corneal and sclerocorneal incisions. *J Cataract Refract Surg*. 1998;24(4):524–8.
[\[CrossRef\]](#)[\[PubMed\]](#)
 17. Cooper BA, Holekamp NM, Bohigian G, et al. Case–control study of endophthalmitis after cataract surgery comparing scleral tunnel and clear corneal wounds. *Am J Ophthalmol*. 2003;136(2):300–5.
[\[CrossRef\]](#)[\[PubMed\]](#)
 18. Basti S, Krishnamachary M, Gupta S. Results of sutureless wound construction in children undergoing cataract extraction. *J Pediatr Ophthalmol Strabismus*. 1996;33(1):52–4.
[\[PubMed\]](#)
 19. Dewey S, Beiko G, Braga-Mele R, et al. Microincisions in cataract surgery. *J Cataract Refract Surg*. 2014;40(9):1549–57.
[\[CrossRef\]](#)[\[PubMed\]](#)
 20. Prakash P, Kasaby H, Aggarwal R, et al. Microincision bimanual phacoemulsification and Thinoptx® implantation through a 1.70 mm incision. *Eye*. 2007;21(2):177–82.
[\[CrossRef\]](#)[\[PubMed\]](#)
 21. Hairston RJ, Maguire AM, Vitale S, et al. Morphometric analysis of pars plana development in humans. *Retina*. 1996;17(2):135–8.
[\[CrossRef\]](#)
 22. Peyman GA, Raichand M, Goldberg MF. Surgery of congenital and juvenile cataracts: a pars plicata approach with the vitrophage. *Br J Ophthalmol*. 1978;62(11):780–3.
[\[CrossRef\]](#)[\[PubMed\]](#)[\[PubMedCentral\]](#)
 23. Keech RV, Tongue AC, Scott WE. Complications after surgery for congenital and infantile cataracts. *Am J Ophthalmol*. 1989;108(2):136–41.
[\[CrossRef\]](#)[\[PubMed\]](#)
 24. Mataftsi A, Prousalis E, Kokkali S, et al. Complications and visual outcomes after secondary intraocular lens implantation in children. *Am J Ophthalmol*. 2015;160(5):1087.
[\[CrossRef\]](#)[\[PubMed\]](#)
 25. Ma F, Wang Q, Wang L. Advances in the management of the surgical complications for congenital cataract. *Front Med*. 2012;6(4):360–5.
[\[CrossRef\]](#)[\[PubMed\]](#)
 26. Mamalis N. OVDs: viscosurgical, viscoelastic, and viscoadaptive. What does this mean? *J Cataract Refract Surg*. 2002;28(9):1497–8.
[\[CrossRef\]](#)[\[PubMed\]](#)
 27. Miller D, Stegmann R. Use of sodium hyaluronate in human IOL implantation. *Ann Ophthalmol*. 1981;13(7):811–5.
[\[PubMed\]](#)

28. Larson RS, Lindstrom RL, Skelnik DL. Viscoelastic agents. *Eye Contact Lens*. 1989;15(2):151–60.
29. Liesegang TJ. Viscoelastic substances in ophthalmology. *Surv Ophthalmol*. 1990;34(4):268–93.
[CrossRef][PubMed]
30. Wilkie DA, Willis AM. Viscoelastic materials in veterinary ophthalmology. *Vet Ophthalmol*. 1999;2(3):147–53.
[CrossRef][PubMed]
31. Arshinoff SA, Jafari M. New classification of ophthalmic viscosurgical devices-2005. *J Cataract Refract Surg*. 2005;31(11):2167–71.
[CrossRef][PubMed]
32. Arshinoff SA. Dispersive and cohesive viscoelastic materials in phacoemulsification. *Ophthalmic Pract*. 1995;13(3):98–104.
33. Arshinoff S. The safety and performance of ophthalmic viscoelastics in cataract surgery and its complications. *Proc Natl Ophthalmic Speakers Program*. 1993;21–8.
34. Theocharis DA, Skandalis SS, Noulas AV, et al. Hyaluronan and chondroitin sulfate proteoglycans in the supramolecular organization of the mammalian vitreous body. *Connect Tissue Res*. 2008;49(3):124–8.
[CrossRef][PubMed]
35. Madsen K, Steveni U, Apple D, et al. Histochemical and receptor binding studies of hyaluronic acid binding sites on the corneal endothelium. *Ophthalmic Pract*. 1989;7(92):94–7.
36. Artola A, Alio JL, Bellot JL, et al. Protective properties of viscoelastic substances (sodium hyaluronate and 2% hydroxymethylcellulose) against experimental free radical damage to the corneal endothelium. *Cornea*. 1993;12(2):109–14.
[CrossRef][PubMed]
37. Bishop PN. Structural macromolecules and supramolecular organisation of the vitreous gel. *Prog Retin Eye Res*. 2000;19(3):323–44.
[CrossRef][PubMed]
38. Lamari FN. The potential of chondroitin sulfate as a therapeutic agent. *Connect Tissue Res*. 2008;49(3–4):289–92.
[CrossRef][PubMed]
39. Holmberg ÅS, Philipson BT. Sodium Hyaluronate in Cataract Surgery: II. Report on the Use of Healon® in Extracapsular Cataract Surgery Using Phacoemulsification. *Ophthalmology*. 1984;91(1):53–9.
[CrossRef][PubMed]
40. Glasser DB, Matsuda M, Edelhauser HF. A comparison of the efficacy and toxicity of and intraocular pressure response to viscous solutions in the anterior chamber. *Arch Ophthalmol*. 1986;104(12):1819–24.
[CrossRef][PubMed]
41. Mac Rae SM, Edelhauser HF, Hyndiuk RA, et al. The effects of sodium hyaluronate, chondroitin

- sulfate, and methylcellulose on the corneal endothelium and intraocular pressure. *Am J Ophthalmol.* 1983;95(3):332–41.
[\[CrossRef\]](#)[\[PubMed\]](#)
42. Harrison SE, Soll DB, Shayegan M, et al. Chondroitin sulfate: a new and effective protective agent for intraocular lens insertion. *Ophthalmology.* 1982;89(11):1254–60.
[\[CrossRef\]](#)[\[PubMed\]](#)
 43. Soll DB, Harrison SE, Arturi FC, et al. Evaluation and protection of corneal endothelium. *J Am Intraocul Implant Soc.* 1980;6(3):239–42.
[\[CrossRef\]](#)[\[PubMed\]](#)
 44. Gibbon CE, Quinn AG. Use of capsulorhexis and Healon 5 in children younger than 5 years of age. *J AAPOS.* 2006;10(2):180–1.
[\[CrossRef\]](#)[\[PubMed\]](#)
 45. Jeng BH, Hoyt CS, McLeod SD. Completion rate of continuous curvilinear capsulorhexis in pediatric cataract surgery using different viscoelastic materials. *J Cataract Refract Surg.* 2004;30(1):85–8.
[\[CrossRef\]](#)[\[PubMed\]](#)
 46. Arshinoff SA. Dispersive-cohesive viscoelastic soft shell technique. *J Cataract Refract Surg.* 1999;25(2):167–73.
[\[CrossRef\]](#)[\[PubMed\]](#)
 47. Higashide T, Sugiyama K. Use of viscoelastic substance in ophthalmic surgery—focus on sodium hyaluronate. *Clin Ophthalmol.* 2008;2(1):21–30.
[\[CrossRef\]](#)[\[PubMed\]](#)[\[PubMedCentral\]](#)
 48. Assia EI, Apple DJ, Lim ES, et al. Removal of viscoelastic materials after experimental cataract surgery in vitro. *J Cataract Refract Surg.* 1992;18(1):3–6.
[\[CrossRef\]](#)[\[PubMed\]](#)
 49. Vasavada AR, Nihalani BR. Pediatric cataract surgery. *Curr Opin Ophthalmol.* 2006;17(1):54–61.
[\[PubMed\]](#)
 50. Krag S, Olsen T, Andreassen TT. Biomechanical characteristics of the human anterior lens capsule in relation to age. *Invest Ophthalmol Vis Sci.* 1997;38(2):357–63.
[\[PubMed\]](#)
 51. Wilson Jr ME. Anterior lens capsule management in pediatric cataract surgery. *Trans Am Ophthalmol Soc.* 2004;102:391.
[\[PubMed\]](#)[\[PubMedCentral\]](#)
 52. Trivedi RH, Wilson ME, Bartholomew LR. Extensibility and scanning electron microscopy evaluation of 5 pediatric anterior capsulotomy techniques in a porcine model. *J Cataract Refract Surg.* 2006;32(7):1206–13.
[\[CrossRef\]](#)[\[PubMed\]](#)
 53. Wood MG, Schelonka LP. A porcine model predicts that a can-opener capsulotomy can be done safely in pediatric patients. *J AAPOS.* 1999;3(6):356–62.
[\[CrossRef\]](#)[\[PubMed\]](#)

54. Coelho RP, Zanatto MC, Paula JSD. Spontaneous late in-the-bag intraocular lens dislocation after can-opener capsulotomy: case report. *Arq Bras Oftalmol.* 2005;68(6):864–6.
[CrossRef][PubMed]
55. Gimbel HV, Neuhann T. Development, advantages, and methods of the continuous circular capsulorhexis technique. *J Cataract Refract Surg.* 1990;16(1):31–7.
[CrossRef][PubMed]
56. Lin H, Tan X, Lin Z, Chen J, Luo L, Wu M, Long E, Chen W, Liu Y. Capsular outcomes differ with capsulorhexis sizes after pediatric cataract surgery: a randomized controlled trial. *Sci Rep.* 2015;5:16227.
[CrossRef][PubMed][PubMedCentral]
57. Vasavada AR, Shah SK, Praveen MR, Vasavada VA, Trivedi RH, Karve SJ. Pars plicata posterior continuous curvilinear capsulorhexis. *J Cataract Refract Surg.* 2011;37(2):221–3.
[CrossRef][PubMed]
58. Delcoigne C, Hennekes R. Circular continuous anterior capsulotomy with high frequency diathermy. *Bull Soc Belge Ophtalmol.* 1992;249:67–72.
59. Radner G, Amon M, Stifter E, et al. Tissue damage at anterior capsule edges after continuous curvilinear capsulorhexis, high-frequency capsulotomy, and erbium: YAG laser capsulotomy. *J Cataract Refract Surg.* 2004;30(1):67–73.
[CrossRef][PubMed]
60. Luo L, Lin H, Chen W, Wang C, Zhang X, Tang X, Liu J, Congdon N, Chen J, Lin Z, Liu Y. In-the-bag intraocular lens placement via secondary capsulorhexis with radiofrequency diathermy in pediatric aphakic eyes. *PLoS One.* 2013;8(4):e62381.
[CrossRef][PubMed][PubMedCentral]
61. Guo S, Caputo A, Wagner R, et al. Enhanced visualization of capsulorhexis with indocyanine green staining in pediatric white cataracts. *J Pediatr Ophthalmol Strabismus.* 2003;40(5):268–71.
[PubMed]
62. Cheema RA, Lukaris AD. Visual recovery in unilateral traumatic pediatric cataracts treated with posterior chamber intraocular lens and anterior vitrectomy in Pakistan. *Int Ophthalmol.* 1999;23(2):85–9.
[CrossRef][PubMed]
63. Vasavada AR, Trivedi RH, Apple DJ, et al. Randomized, clinical trial of multiquadrant hydrodissection in pediatric cataract surgery. *Am J Ophthalmol.* 2003;135(1):84–8.
[CrossRef][PubMed]
64. Apple DJ, Peng Q, Visessook N, et al. Surgical prevention of posterior capsule opacification: part 1: progress in eliminating this complication of cataract surgery. *J Cataract Refract Surg.* 2000;26(2):180–7.
[CrossRef][PubMed]
65. Peng Q, Apple DJ, Visessook N, et al. Surgical prevention of posterior capsule opacification: part 2: enhancement of cortical cleanup by focusing on hydrodissection. *J Cataract Refract Surg.*

2000;26(2):188–97.

[\[CrossRef\]](#)[\[PubMed\]](#)

66. Amaya L, Taylor D, Russell I, et al. Phacoaspiration in children. *J Cataract Refract Surg.* 2001;27(10):1534–5.
[\[CrossRef\]](#)[\[PubMed\]](#)
67. Ahmadieh H, Javadi MA, Ahmady M, et al. Primary capsulectomy, anterior vitrectomy, lensectomy, and posterior chamber lens implantation in children: limbal versus pars plana. *J Cataract Refract Surg.* 1999;25(6):768–75.
[\[CrossRef\]](#)[\[PubMed\]](#)
68. Vasavada AR, Praveen MR, Tassignon M-J, et al. Posterior capsule management in congenital cataract surgery. *J Cataract Refract Surg.* 2011;37(1):173–93.
[\[CrossRef\]](#)[\[PubMed\]](#)
69. Guo S, Wagner RS, Caputo A. Management of the anterior and posterior lens capsules and vitreous in pediatric cataract surgery. *J Pediatr Ophthalmol Strabismus.* 2004;41(6):330–7.
[\[PubMed\]](#)
70. Glasser A, Campbell MC. Biometric, optical and physical changes in the isolated human crystalline lens with age in relation to presbyopia. *Vision Res.* 1999;39(11):1991–2015.
[\[CrossRef\]](#)[\[PubMed\]](#)
71. Meier P. Combined anterior and posterior segment injuries in children: a review. *Graefes Arch Clin Exp Ophthalmol.* 2010;248(9):1207–19.
[\[CrossRef\]](#)[\[PubMed\]](#)
72. Luo Y, Lu Y, Lu G, et al. Primary posterior capsulorhexis with anterior vitrectomy in preventing posterior capsule opacification in pediatric cataract microsurgery. *Microsurgery.* 2008;28(2):113–6.
[\[CrossRef\]](#)[\[PubMed\]](#)
73. Ram J, Brar GS, Kaushik S, et al. Role of posterior capsulotomy with vitrectomy and intraocular lens design and material in reducing posterior capsule opacification after pediatric cataract surgery. *J Cataract Refract Surg.* 2003;29(8):1579–84.
[\[CrossRef\]](#)[\[PubMed\]](#)
74. Jensen AA, Basti S, Greenwald MJ, et al. When may the posterior capsule be preserved in pediatric intraocular lens surgery? *Ophthalmology.* 2002;109(2):324–7.
[\[CrossRef\]](#)[\[PubMed\]](#)
75. Kim KH, Kim WS. Intraocular lens stability and refractive outcomes after cataract surgery using primary posterior continuous curvilinear capsulorhexis. *Ophthalmology.* 2010;117(12):2278–86.
[\[CrossRef\]](#)[\[PubMed\]](#)
76. Shingleton BJ, Crandall AS, Ahmed IIK. Pseudoexfoliation and the cataract surgeon: preoperative, intraoperative, and postoperative issues related to intraocular pressure, cataract, and intraocular lenses. *J Cataract Refract Surg.* 2009;35(6):1101–20.
[\[CrossRef\]](#)[\[PubMed\]](#)

13. Calculation and Selection of Intraocular Lens Power for Children

Danying Zheng¹✉, Yi Sun¹ and Qianzhong Cao¹

- (1) State Key Laboratory of Ophthalmology, Zhongshan Ophthalmic Center, Sun Yat-sen University, 54S Xianlie Road, Guangzhou, 510060, People's Republic of China

✉ **Danying Zheng**
Email: zhengdy@163.com

Abstract

Intraocular lens (IOL) implantation is a common procedure for pediatric aphakia correction. The calculation and selection of IOL power are a key factor affecting postoperative visual acuity. As several biological parameters keep changing during childhood, including corneal diameter, corneal curvature, and axial length and size of the capsular bag, it is extremely difficult to select the appropriate power for the IOL. For pediatric IOL implantation, the calculation and selection of IOL power are different from that in adults and should be based on the developing patterns of the eyes during childhood. It is suggested that factors like myopic shift, severity of amblyopia, and condition of the fellow eye be taken into consideration when choosing the IOL power for pediatric patients.

The calculation and selection of intraocular lens (IOL) power are one of the key factors in the postoperative visual rehabilitation for children. However, it seems to be rather difficult due to the poor compliance to examination, the changing anatomy of the developing eyes, and the significant individual

variations in children. Up till now, IOL power formulas for adults are still applied in children patients for the lack of a formula specifically designed for children, which leads to a high possibility of errors. Clinically, the selection of appropriate IOL power for children should be based on the developmental characteristics of pediatric eye.

13.1 Biometric Parameters of Pediatric Eyes Related to IOL Power

The growth of pediatric eyes with age is nonlinear. The greatest changes occur in the early stage after birth, and the development mostly ends by the age of 2–3 years and reaches the adult value by the age of 8–9 years [1, 2]. It has been reported that the aphakic state after cataract surgery may affect the eye development and the refractive course, especially in patients who undergone lens extraction within 6 months after birth. Therefore, IOL implantation is an important technique for aphakic correction in children [3, 4]. The age-related changes in the biometric data of pediatric eyes conform to the following patterns:

1. The mean axial length of a newborn is 16.5 mm and reaches 21.4 ± 0.1 mm after the rapid growth period at the age of 2–3 years. It reaches 21.8 ± 0.4 mm and 22.7 ± 0.9 mm at the age of 3–4 years and 5–6 years, respectively. At the age of 10–15 years, the axial length reaches the adult value, approximately 23.8 ± 0.7 mm [1, 2].
2. The corneal curvature is 47.0 ~ 51.0D in a newborn and decreases rapidly within the first 6 months after birth. It declines to 44.9 ± 0.9 D at the age of 1–2 years and 44.1 ± 0.3 D at the age of 2–3 years, which is close to the adult value [1, 5].
3. In a newborn, the average anterior chamber depth is 2.05 mm and increases gradually after birth. It reaches 3.25 mm in adolescence and then decreases with aging [6, 7].
4. The diameter of the capsular bag is around 6 mm in a newborn, and it

increases rapidly within the first 2 years after birth and reaches 8.5 mm at the age of 2 years. Then the growth slows down and the diameter reaches 9.3 mm by the age of 16 years [8].

Because the axis of the eye in a child does not reach the adult level before the age of 6 years, physiologic hyperopia manifests in the majority of the eyes. As the eye grows, hyperopia gradually diminishes, and the eye reaches emmetropia. The process is termed emmetropization, which also exists in aphakic eyes after cataract surgery. Therefore, the developmental features of the eye should be considered when calculating and selecting IOL power in pediatric patients.

13.2 Calculation of IOL Power for Children

The following factors should be mainly considered in the determination of the IOL power for children [9, 10]: (1) Biometry: The precise measurements of axial length and corneal curvature are the key factors in determining IOL power. Some IOL formulas also need parameters like anterior chamber depth, corneal diameter and lens thickness, and so on. (2) Selection of formulas for IOL power calculation.

13.2.1 Biometry

13.2.1.1 Measurement of Eye Axial Length

Measurement of eye axial length is the most important factor that affects the accuracy of IOL power, for a 1-mm error of measurement can lead to approximately 2.5D refractive error. The refractive error is more prominent in the eyes with short axis and may be as high as 4–14D [11]. At present, the method of the axial length measurement includes ultrasonic and optical approaches.

Ultrasonic Measurement

Ultrasonic measurement mainly includes the contact (Fig. 13.1a) and the immersion A-mode ultrasound. Some studies have demonstrated that the results of eye axial length measurement obtained with these two techniques are similar [12, 13]. The mean axial length detected with the immersion ultrasound was 0.1 mm longer than that with the contact ultrasound [11, 14, 15]. In addition, the results from these two measurement techniques were

highly consistent with a mean error of $\pm 0.1 \text{ mm} \sim \pm 0.2 \text{ mm}$. Nevertheless, other studies suggested that the measurement with immersion ultrasound was more accurate and the resulted refractive error after IOL implantation was lower than that with contact ultrasound. Therefore, priority should be given to immersion ultrasound, if available, when measuring axial length in children [16].

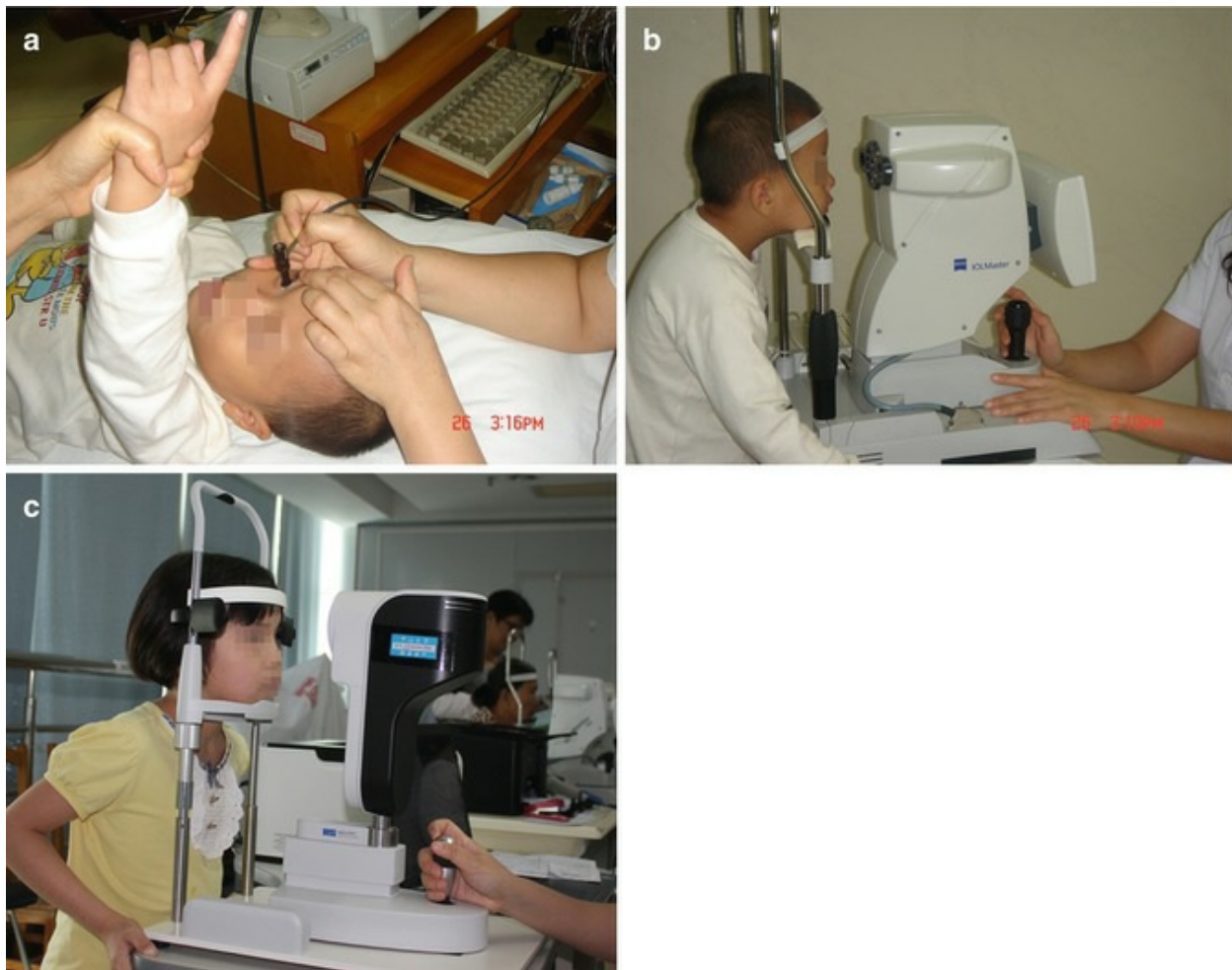

Fig. 13.1 Measurement of eye axial length. (a) Measurement of axial length with contact A-mode ultrasound; (b) measurement of axial length with IOL Master; (c) measurement of axial length with Lenstar LS 900

As there is direct or indirect contact with the cornea during both the contact and the immersion measurements, it is hard for young children (especially those under the age of 3 years) to cooperate. Therefore, these measurements need to be performed under anesthesia. Because the measurement accuracy will be affected by the possible occurrence of Bell's

phenomenon among children under light anesthesia, the measurement should be performed when the child's anesthesia score reaches 1 (being unresponsive to patting or shaking) and the Bell's phenomenon disappears to improve the accuracy. Besides, as the pediatric eye is soft and easily compressed, the measurement error of the axial length may be even higher especially in cases of poor cooperation. Therefore, an average value should be obtained with multiple repeated measurements so as to reduce the error [1, 17].

Optical Measurement

Nowadays, IOL Master and Lenstar LS 900 are the most frequently used equipments for optical measurement of eye axial length.

IOL Master

This device utilizes the principle of partial coherence interferometry. It divides the laser emitted from the laser diode into two independent rays of axial light, which reach the cornea and the retinal pigment epithelium along the axis. The reflected light passes through the light splitter and is captured by the image detector. Then the axial length is calculated [18, 19]. IOL Master is a technique of noncontact biometry. Besides axial length, it can also simultaneously measure corneal curvature, anterior chamber depth, and horizontal corneal diameter and provide formulas for IOL power calculation. IOL Master has the advantages of being multifunctional, noncontact, accurate, efficient, safe, and simple to operate [19, 20].

The traditional ultrasound method only measures the distance between the anterior corneal surface and the internal limiting membrane of the retina, whereas IOL Master measures the distance between the anterior corneal surface and the retinal pigment epithelium, which is the axial length in real sense and is about 0.2 mm longer than that measured with ultrasound [21]. Meanwhile, IOL Master is optimized for special conditions like silicone oil-filled eyes and pseudophakic eyes with corresponding measurement pattern, which guarantees a convenient and accurate axial length measurement [22–24].

Measurement procedures and techniques: The child is placed in a sitting position, with the chin on the chin rest and the eyes fixating on the marker in the machine (Fig. 13.1b). After the examiner enters the information of the child and clicks to log into the axial length measurement procedure, white spot and green cross-shaped markers appear on the screen. When examining

cataractous eyes, larger spots are suggested (with a size close to the green circle regardless of the measurement distance). When examining pediatric eyes with nuclear cataracts, smaller spot and slight vertical deviation from the optical axis are suggested. If the examined eye has a refractive error over 5D, it should be measured with spectacles to enhance fixation and improve the accuracy of the results. If the child wears contact lenses, measurement error may occur.

IOL Master examination needs to be carried out in cooperative children with stable fixation. It is rather challenging to get measurements in young children with poor compliance, in the eyes with inadequate fixation and in the eyes where the light fails to be effectively transmitted due to dense cataracts [24, 25].

Lenstar LS 900

Lenstar LS 900 (Fig. 13.1c) is based on the principle of optical low-coherence reflectometry (OLCR). The single beam of 820-nm laser emitted from the laser diode reaches the surface of each ocular structure and is reflected backward and received by the detector. The target data is obtained after analysis by the embedded software. Like IOL Master, Lenstar LS 900 is also a noncontact measurement device, and in addition to axial length, it delivers nine parameters, including corneal curvature, central corneal thickness, corneal diameter, anterior chamber depth, lens thickness, pupil diameter, angle kappa, and retinal thickness. IOL Master measures eye axial length using the partial coherence interferometry principle, while Lenstar LS 900 measures all the nine parameters based on the principle of OLCR. Though the axial length values obtained by Lenstar LS 900 are greater than those obtained by IOL Master (about 0.01–0.026 mm) [26], the two devices show a high consistency and correlation in various situations including the normal eyes, eyes with various types of cataracts, pseudophakic eyes, aphakic eyes, and silicone oil-filled eyes [22, 26, 27].

Similar to IOL Master, Lenstar LS 900 is suited to cataractous children who are cooperative, have stable fixation without dense cataracts.

13.2.1.2 Measurement of Corneal Curvature

The precision of corneal curvature measurement is another important factor that affects the accuracy of IOL power. An error of 1D in corneal curvature measurement may lead to an error of 0.8–1.3D in IOL power [7, 28]. Corneal

curvature can be measured with a manual keratometer, an autorefractor, corneal topography, an aberrometer, and IOL biometry devices based on polarization optics [4]. Common measurement techniques for children include the following types.

Manual Keratometer

Manual keratometer includes the JS (Javal–Schiotz) model and BL (Bausch–Lomb) model manual keratometers (Fig. 13.2a). The keratometer obtains the results by utilizing the principle of Purkinje imaging and measures corneal curvature at the central 3-mm diameter zone. It is suited to cooperative older children and has advantages of being simple, quick, and accurate. But it is not applicable for the eyes with flat (<40D) or steep (>50D) corneal curvature or the eyes with irregular corneal astigmatism.

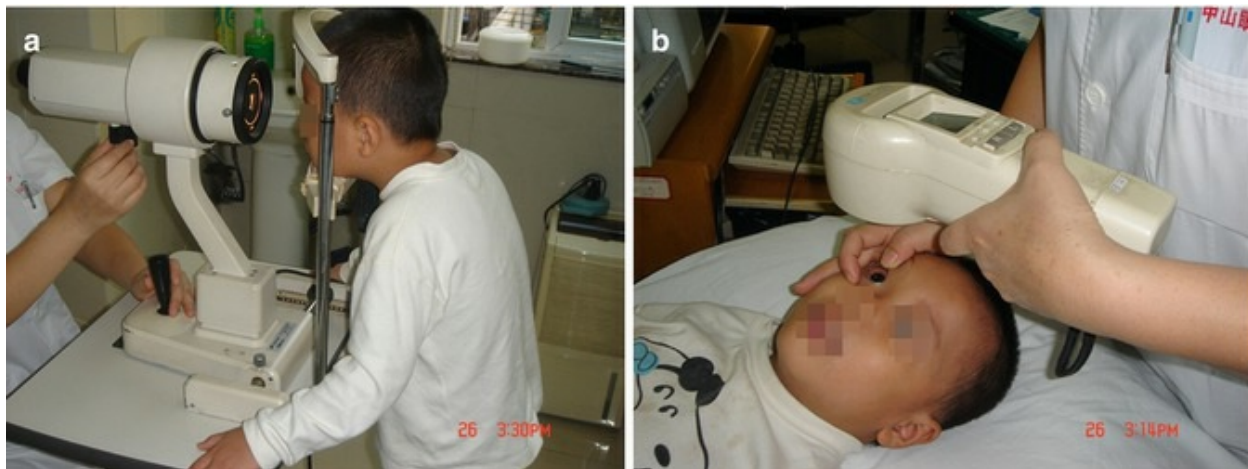

Fig. 13.2 Measurement of corneal curvature. (a) Measurement of corneal curvature with a manual keratometer; (b) measurement of corneal curvature with a handheld automated keratometer

Automated Keratometer

Automated keratometer includes a desktop model (usually attached to an automated optometer) and a handheld model (Fig. 13.2b). The desktop automated keratometer is suitable for cooperative children with stable fixation, while the handheld keratometer is suitable for supine-positioned anesthetized children. With a mean measurement error of approximately $\pm 0.25\text{D}$ [29], the desktop automated keratometer is more accurate and reproducible compared to the handheld model [9, 13, 30]. The handheld keratometer can be used in children under sedation and anesthesia, but the measurement error may be as high as 6.0D due to the lack of fixation [31].

Some studies have demonstrated that when the eyelid is opened with a speculum, the lacrimal film maintained with lubricating eye drop and fixation is kept with scleral depressor; the corneal curvature measurement has no significant difference compared with that obtained under the state of natural fixation [13].

IOL Master

IOL Master can measure both axial length and corneal curvature simultaneously. The camera with the charge-coupled device (CCD) in this machine captures and measures the distances among the six reflected light spots to calculate corneal curvature. When all six spots in the green circle are clear, the results can be obtained after pressing the button. There is strong homogeneity between the results obtained with IOL Master and that obtained with manual or automated keratometer [30].

Lenstar LS 900

Lenstar LS 900 can also measure eye axial length and corneal curvature on the same machine. When measuring corneal curvature, the stability and reliability of measurement are guaranteed by its multiple measuring spots. Meanwhile, it monitors the patient's blink and fixation loss, and only the measurements that strictly conform to the standard can be analyzed. Different from IOL Master, the corneal curvature readings of Lenstar LS 900 are the data from multiple measuring spots, which can better demonstrate the information of corneal curvature and morphology, and reduce the measurement error resulting from misalignment of the measuring direction and the axis of reference points [21]. A strong agreement is found between the measurement results of Lenstar LS 900 and that of IOL Master [25, 27].

All these four measurement techniques for corneal curvature are accurate, objective, and reproducible. However, it is still possible for measurement error to occur with any technique. The measurement errors of axial length and corneal curvature are important causes for refractive surprises [28, 32]. To enhance the accuracy of IOL power calculation, remeasurement should be conducted if the readings of axial length and corneal curvature are not within the average range, the IOL power calculated exceeds the predicted limits, or the binocular results are apparently asymmetric.

13.2.2 Formulas for IOL Power Calculation

At present, there is still no formula specially designed for the calculation of pediatric IOL power [33], and calculation is presently conducted with the adult formulas. Both the regression and the theoretical formulas are established on the basis of adult data. But for children with developing eyes, their short axial length and large corneal curvature will give rise to errors with the usage of adult formulas [34–36]. Moreover, the shorter the axial length and the larger the corneal curvature are, the higher the resulting error will be [10]. Besides, effective lens position (ELP) is considered in some IOL power calculation formulas, but the postoperative ELP in children is different from that in adults, which can also lead to certain errors when these adult formulas are used in IOL power calculation for children [37].

Nihalani [10], in a retrospective study, reported that the mean prediction error of IOL power was over 0.5D in 57 % of the pediatric eyes after surgery for 4–8 weeks, and the error was more significant in children under the age of 2 years with axial length shorter than 22 mm and corneal curvature larger than 43.5D. Up till now, lots of ophthalmologists have compared the predictive accuracy of different formulas for IOL power calculation. Andreo LK and colleagues [38] compared the predictive accuracy of four formulas: the SRK-II, SRK-T, Holladay, and Hoffer Q for pediatric IOL power calculation. They found that no significant difference existed among the four formulas at 2 months after surgery. But when the axial length was shorter than 22 mm, the Hoffer Q formula was more accurate, while the SRK-II formula was slightly less accurate. However, the difference between them was not statistically significant. Trivedi [39], in a study of 16 eyes with axial length shorter than 20 mm, also confirmed that the prediction errors of the Holladay II formula and the Hoffer Q formula were similar, ranging from -2.56D to 2.54D and -2.63D to 2.92D , respectively. However, the prediction errors of the Holladay I formula and the SRK/T formula were relatively higher, ranging from -2.94D to 1.86D and -3.24D to 1.63D , respectively. Nihalani [10] proposed that Hoffer Q formula could give a better prediction compared with the SRK-II, SRK/T, and Holladay I formulas for younger children with shorter axial length. In addition, some ophthalmologists demonstrated that in the eyes with extremely short axial length ($<19\text{ mm}$), the Haigis formula had the least refractive error ($+0.51 \pm 0.12\text{D}$), followed by the Hoffer Q formula ($-0.70 \pm 0.14\text{ D}$) and the Holladay I formula ($-1.11 \pm 0.13\text{D}$), and the SRK/T formula had the greatest refractive error ($-1.45 \pm 0.14\text{D}$) [40]. Therefore, for pediatric eyes with short or extremely short

axial length, the Haigis and Hoffer formulas are recommended. In view of the unique anatomic features of pediatric eyes, further large-scale randomized controlled clinical trials are needed to determine which formula is more appropriate for younger children (especially for those under the age of 2 years).

13.3 Selection of IOL Power for Children

With the development of ophthalmic microsurgery, IOL implantation is more and more common in pediatric cataract cases. However, there is still no consensus for the selection of pediatric IOL power. Currently, it is commonly believed that when selecting IOL power for children, ophthalmologists should take into account the pediatric patient's age at IOL implantation, the target refraction, as well as the refractive status of the contralateral eye.

13.3.1 The Age at Surgery of IOL Implantation

As pediatric eyes are still developing, myopic shift can occur after IOL implantation, and the extent varies with age [41–43]. Therefore, it is hard to predict myopic shift precisely, especially in young children [41, 42]. A clinical study demonstrated that the children receiving IOL implantation at the age of 2–3 years had a mean myopic shift of 4.6D, ranging from 0.5 to 10.75D; those at the age of 6–7 years had a mean myopic shift of 2.68D, ranging from 0.5 to 6.60D; those at the age of 8–9 years had a mean myopic shift of 1.25D, ranging from 0.75 to 2.60D; and those at the age of 10–15 years had a mean myopic shift of only 0.61D, ranging from 0 to 1.9D [41]. Another study showed comparable results which also confirmed that the younger at IOL implantation, the greater the myopic shift would be [43]. The mean myopic shift was 5.96D for children who were 1–3 years old at IOL implantation, 3.66D for children at 3–4 years old and 3.40D for children at 5–6 years old. The myopic shift decreased linearly after the age of 3 years [43]. Due to myopic shift and individual differences, the selection of IOL power for children is further complicated.

13.3.2 Target Refraction

When choosing the target refraction for children having bilateral cataract surgery, ophthalmologists should take into account not only the initial

refraction but also the refraction in adulthood. However, consensus over this issue has not been reached [33]. On one hand, some surgeons prefer initial emmetropia, especially for children with poor compliance to spectacles or contact lens wearing after surgery. The selection of IOL power targeting emmetropia in these children will facilitate the treatment and prevention of amblyopia. On the other hand, some surgeons prefer a refractive status closer to mild myopia in adulthood, and they preserve a certain degree of hyperopia according to age at surgery to ensure the mild myopia in adulthood after myopic shift [33].

13.3.3 The Refractive Status of the Contralateral Eye

For children having unilateral cataract surgery, the refractive status of the contralateral eye should be considered. Eibschitz and colleagues [33] proposed that for children at age 2–4 years, the target refraction of the operated eye could be set as the spherical equivalent of the contralateral eye minus 1.25D, while for children over 4 years old, the target refraction could be set as the same power as the spherical equivalent of the contralateral eye. When adjusting IOL power, a bilateral difference over 3D should be avoided to prevent amblyopia [33].

Given that the younger at IOL implantation, the greater the myopic shift will be. Many ophthalmologists have conducted studies on the selection of pediatric IOL power and formulated the postoperative refractive targets for children at given ages (Table 13.1). In a multicenter clinical study, VanderVeen and colleagues [36] recommended that the age-specific postoperative refractive targets should be +8D for 4–7 weeks old and +6D for 8–28 weeks old, respectively. In a survey, Wilson found that most ophthalmologists chose moderate hyperopia ($\geq 3D$ and $< 7D$) as the refractive target for children aged 6 months, low to moderate hyperopia ($> 0D$ and $< 3D$) for children aged 1 year and low hyperopia for children aged 2 years [44].

Table 13.1 Postoperative refractive targets for children at given ages

Age (year)	Enyedi et al. [42]	Plager et al. [41]	Crouch et al. [43]	Wilson et al. [44]
1	+6.0	–	+4.0	+6.0
2	+5.0	–	+4.0	+5.0
3	+4.0	+5.0	+3.0	+4.0
4	+3.0	+4.0	+3.0	+3.0
5	+2.0	+3.0	+2.0	+2.0

6	+1.0	+2.25	+2.0	+1.0
7	0.0	+1.5	+1.0	0
8	-1 to -2	+1.0	+1.0	-1.0 to -2.0
9	-	-	0	-

13.4 Summary

Accurate biometry, age-specific formulas for IOL power calculation, and the appropriate selection of postoperative refractive targets are of most importance to improve the accuracy of IOL power for children. When selecting IOL power, surgeons are supposed to give a comprehensive consideration to the following issues: the developmental characteristics of pediatric eyes, the myopic drift, the presence and severity of amblyopia, the compliance of both children and their parents, as well as the clinical experience of the surgeons. Meanwhile, timely postoperative amblyopia treatment is also indispensable for obtaining good visual function.

References

1. Hussain RN, Shahid F, Woodruff G. Axial length in apparently normal pediatric eyes. *Eur J Ophthalmol*. 2014;24(1):120–3.
[CrossRef][PubMed]
2. McClatchey SK, Parks MM. Myopic shift after cataract removal in childhood. *J Pediatr Ophthalmol Strabismus*. 1997;34(2):88–95.
[PubMed]
3. Wilson Jr ME, Trivedi RH. Eye growth after pediatric cataract surgery. *Am J Ophthalmol*. 2004;138(6):915–24.
[CrossRef]
4. McClatchey SK, Dahan E, Maselli E, et al. A comparison of the rate of refractive growth in pediatric aphakic and pseudophakic eyes. *Ophthalmology*. 2000;107(1):118–22.
[CrossRef][PubMed]
5. Inagaki Y. The rapid change of corneal curvature in the neonatal period and infancy[J]. *Arch Ophthalmol*. 1986;104(7):1026–7.
[CrossRef][PubMed]
6. Larsen JS. The sagittal growth of the eye. IV. Ultrasonic measurement of the axial length of the eye from birth to puberty. *Acta Ophthalmol (Copenh)*. 1971;49(6):873–86.
[CrossRef]

7. Jeanty P, Dramaix-Wilmet M, Van Gansbeke D, et al. Fetal ocular biometry by ultrasound. *Radiology*. 1982;143(2):513–6.
[\[CrossRef\]](#)[\[PubMed\]](#)
8. Bluestein EC, Wilson ME, Wang XH, et al. Dimensions of the pediatric crystalline lens: implications for intraocular lenses in children. *J Pediatr Ophthalmol Strabismus*. 1996;33(1):18–20.
[\[PubMed\]](#)
9. Al-Haddad C, Jurdy L, Farhat A, et al. Effect of general anesthesia and muscle relaxants on keratometry measurements using a handheld keratometer. *J Pediatr Ophthalmol Strabismus*. 2014;51(5):308–12.
[\[CrossRef\]](#)[\[PubMed\]](#)
10. Nihalani BR, VanderVeen DK. Comparison of intraocular lens power calculation formulae in pediatric eyes. *Ophthalmology*. 2010;117(8):1493–9.
[\[CrossRef\]](#)[\[PubMed\]](#)
11. Hrebцова J, Vasku A. Comparison of contact and immersion techniques of ultrasound biometry. *Cesk Slov Oftalmol*. 2008;64(1):16–8.
[\[PubMed\]](#)
12. Ben-Zion I, Neely DE, Plager DA, et al. Accuracy of IOL calculations in children: a comparison of immersion versus contact A-scan biometry. *J AAPOS*. 2008;12(5):440–4.
[\[CrossRef\]](#)[\[PubMed\]](#)
13. Rogers DL, Whitehead GR, Stephens JA, et al. Corneal power measurements in fixating versus anesthetized nonfixating children using a handheld keratometer. *J AAPOS*. 2010;14(1):11–4.
[\[CrossRef\]](#)[\[PubMed\]](#)
14. Hrebцова J, Skorkovska S, Vasku A. Comparison of contact and immersion techniques of ultrasound biometry in terms of target postoperative refraction. *Cesk Slov Oftalmol*. 2009;65(4):143–6.
[\[PubMed\]](#)
15. Giers U, Epple C. Comparison of A-scan device accuracy. *J Cataract Refract Surg*. 1990;16(2):235–42.
[\[CrossRef\]](#)[\[PubMed\]](#)
16. Trivedi RH, Wilson ME. Prediction error after pediatric cataract surgery with intraocular lens implantation: contact versus immersion A-scan biometry. *J Cataract Refract Surg*. 2011;37(3):501–5.
[\[CrossRef\]](#)[\[PubMed\]](#)
17. Mehdizadeh M. Effect of axial length and keratometry measurement error on intraocular lens implant power prediction formulas in pediatric patients. *J AAPOS*. 2008;12(4):425.
[\[CrossRef\]](#)[\[PubMed\]](#)
18. Goyal R, North RV, Morgan JE. Comparison of laser interferometry and ultrasound A-scan in the measurement of axial length. *Acta Ophthalmol Scand*. 2003;81(4):331–5.
[\[CrossRef\]](#)[\[PubMed\]](#)

19. Hitzenberger CK. Optical measurement of the axial eye length by laser Doppler interferometry. *Invest Ophthalmol Vis Sci.* 1991;32(3):616–24.
[PubMed]
20. Drexler W, Findl O, Menapace R, et al. Partial coherence interferometry: a novel approach to biometry in cataract surgery. *Am J Ophthalmol.* 1998;126(4):524–34.
[CrossRef][PubMed]
21. Tehrani M, Krummenauer F, Kumar R, et al. Comparison of biometric measurements using partial coherence interferometry and applanation ultrasound. *J Cataract Refract Surg.* 2003;29(4):747–52.
[CrossRef][PubMed]
22. Shen P, Zheng Y, Ding X, et al. Biometric measurements in highly myopic eyes. *J Cataract Refract Surg.* 2013;39(2):180–7.
[CrossRef][PubMed]
23. Kunavisarut P, Poopattanakul P, Intarated C, et al. Accuracy and reliability of IOL master and A-scan immersion biometry in silicone oil-filled eyes. *Eye (Lond).* 2012;26(10):1344–8.
[CrossRef]
24. Lege BA, Haigis W. Laser interference biometry versus ultrasound biometry in certain clinical conditions. *Graefes Arch Clin Exp Ophthalmol.* 2004;242(1):8–12.
[CrossRef][PubMed]
25. Buckhurst PJ, Wolffsohn JS, Shah S, et al. A new optical low coherence reflectometry device for ocular biometry in cataract patients. *Br J Ophthalmol.* 2009;93(7):949–53.
[CrossRef][PubMed]
26. Salouti R, Nowroozzadeh MH, Zamani M, et al. Comparison of the ultrasonographic method with 2 partial coherence interferometry methods for intraocular lens power calculation. *Optometry.* 2011;82(3):140–7.
[CrossRef][PubMed]
27. Holzer MP, Mamusa M, Auffarth GU. Accuracy of a new partial coherence interferometry analyser for biometric measurements. *Br J Ophthalmol.* 2009;93(6):807–10.
[CrossRef][PubMed]
28. Eibschitz-Tsimhoni M, Tsimhoni O, Archer SM, et al. Effect of axial length and keratometry measurement error on intraocular lens implant power prediction formulas in pediatric patients. *J AAPOS.* 2008;12(2):173–6.
[CrossRef][PubMed]
29. Edwards MH, Cho P. A new, hand-held keratometer: comparison of the Nidek KM-500 auto keratometer with the B&L keratometer and the topcon RK-3000A keratometer. *J Br Contact Lens Assoc.* 1996;19(2):45–8.
[CrossRef]
30. Mehravaran S, Asgari S, Bigdeli S, et al. Keratometry with five different techniques: a study of device repeatability and inter-device agreement. *Int Ophthalmol.* 2014;34(4):869–75.
[CrossRef][PubMed]
31. Mittelviefhaus H, Gentner C. Errors in keratometry for intraocular lens implantation in infants.

- Ophthalmologe. 2000;97(3):186–8.
[\[CrossRef\]](#)[\[PubMed\]](#)
32. Holladay JT, Prager TC, Chandler TY, et al. A three-part system for refining intraocular lens power calculations. *J Cataract Refract Surg.* 1988;14(1):17–24.
[\[CrossRef\]](#)[\[PubMed\]](#)
 33. Eibschitz-Tsimhoni M, Archer SM, Del Monte MA. Intraocular lens power calculation in children. *Surv Ophthalmol.* 2007;52(5):474–82.
[\[CrossRef\]](#)[\[PubMed\]](#)
 34. Kekunnaya R, Gupta A, Sachdeva V, et al. Accuracy of intraocular lens power calculation formulae in children less than two years. *Am J Ophthalmol.* 2012;154(1):13–9. e12.
[\[CrossRef\]](#)[\[PubMed\]](#)
 35. Mezer E, Rootman DS, Abdoell M, et al. Early postoperative refractive outcomes of pediatric intraocular lens implantation. *J Cataract Refract Surg.* 2004;30(3):603–10.
[\[CrossRef\]](#)[\[PubMed\]](#)
 36. VanderVeen DK, Nizam A, Lynn MJ, et al. Predictability of intraocular lens calculation and early refractive status: the Infant Aphakia Treatment Study. *Arch Ophthalmol.* 2012;130(3):293–9.
[\[CrossRef\]](#)[\[PubMed\]](#)[\[PubMedCentral\]](#)
 37. Hoffer KJ, Aramberri J, Haigis W, et al. The final frontier: pediatric intraocular lens power. *Am J Ophthalmol.* 2012;154(1):1–2.e1.
[\[CrossRef\]](#)[\[PubMed\]](#)
 38. Andreo LK, Wilson ME, Saunders RA. Predictive value of regression and theoretical IOL formulas in pediatric intraocular lens implantation. *J Pediatr Ophthalmol Strabismus.* 1997;34:240–3.
[\[PubMed\]](#)
 39. Trivedi RH, Wilson ME, Reardon W. Accuracy of the Holladay 2 intraocular lens formula for pediatric eyes in the absence of preoperative refraction. *J Cataract Refract Surg.* 2011;37(7):1239–43.
[\[CrossRef\]](#)[\[PubMed\]](#)
 40. MacLaren RE, Natkunarajah M, Riaz Y, et al. Biometry and formula accuracy with intraocular lenses used for cataract surgery in extreme hyperopia. *Am J Ophthalmol.* 2007;143:920–31.
[\[CrossRef\]](#)[\[PubMed\]](#)
 41. Plager DA, Kipfer H, Sprunger DT, et al. Refractive change in pediatric pseudophakia: 6-year follow-up[J]. *J Cataract Refract Surg.* 2002;28(5):810–5.
[\[CrossRef\]](#)[\[PubMed\]](#)
 42. Enyedi LB, Peterseim MW, Freedman SF, et al. Refractive changes after pediatric intraocular lens implantation. *Am J Ophthalmol.* 1998;126(6):772–81.
[\[CrossRef\]](#)[\[PubMed\]](#)
 43. Crouch ER, Crouch ER, Pressman SH. Prospective analysis of pediatric pseudophakia: myopic shift and postoperative outcomes. *J AAPOS.* 2002;6(5):277–82.
[\[CrossRef\]](#)[\[PubMed\]](#)

44. Wilson ME, Bartholomew LR, Trivedi RH. Pediatric cataract surgery and intraocular lens implantation: practice styles and preferences of the 2001 ASCRS and AAPOS memberships. *J Cataract Refract Surg.* 2003;29(9):1811–20.
[\[CrossRef\]](#)[\[PubMed\]](#)

14. Selection of Intraocular Lenses for Children

Haotian Lin¹ 

- (1) State Key Laboratory of Ophthalmology, Zhongshan Ophthalmic Center, Sun Yat-sen University, 54S Xianlie Road, Guangzhou, 510060, People's Republic of China

 **Haotian Lin**

Email: gddlht@aliyun.com

Abstract

The intraocular lens (IOL) used for pediatric patients has special requirements due to the small eyeball, small lens capsule, possibly high risk for postoperative inflammation, as well as the rapidly developing anatomical structures and visual functions. An ideal pediatric IOL should have the following characteristics: appropriate size that matches with the size of the lens capsule, stable location despite the development of the eye, good biocompatibility, mild postoperative inflammation, and the ability to inhibit the proliferation and migration of lens epithelial cells. However, an IOL specifically designed for pediatric patients is not yet available, and ophthalmologists have to choose from adult IOLs. Based on a thorough knowledge of the anatomical and physiological characteristics of pediatric eyes, ophthalmologists should choose an appropriate type of IOL for individual patients, which may greatly promote the reconstruction of visual functions after surgery. This chapter will specify the features and indications of each type of IOL used in pediatric IOL implantation and also introduce some innovative IOLs that are specifically designed for pediatric patients.

An ideal intraocular lens (IOL) for children should meet the following requirements: appropriate size matched with the child's lens capsule, accommodative function, stable position as the eye grows, good biocompatibility, minimal postoperative inflammation, and an inhibitive effect on the proliferation and migration of lens epithelial cells [1–4]. However, due to the unavailability of IOLs specifically designed for children, ophthalmologists have to choose from adult IOLs. It's worth noting that not all types of adult IOLs are applicable for children. Therefore, the selection of IOLs should be individualized based on the anatomic, physiological, and developmental properties of the child's eye, so as to provide the most favorable conditions for postoperative visual rehabilitation [5].

14.1 Classification and Selection of IOLs

There are many systems for IOL classification. Clinically, they are commonly classified according to their optic material, haptic design, and site of implantation.

14.1.1 Optic Material

According to their material and rigidity, IOLs can be divided into two categories: rigid and foldable IOLs. Rigid IOLs are mainly made of polymethyl methacrylate (PMMA), while foldable IOLs' materials include hydrophobic acrylic, hydrophilic acrylic, and silicone.

14.1.1.1 Rigid IOLs

PMMA, also known as acrylic glass, is the most widely used material for manufacturing rigid IOLs, with the longest history in clinical application. Owing to its superior transparency, good biocompatibility, and resistance to degradation, PMMA IOLs were introduced into pediatric cataract surgeries in the 1980s and early 1990s [6]. However, PMMA IOLs are unfoldable and have to be implanted through an incision larger than 5 mm, which increases surgical trauma and surgically induced astigmatism. As a result, PMMA IOLs are rarely used in pediatric surgeries nowadays.

14.1.1.2 Foldable IOLs

Foldable IOLs are manufactured from soft materials such as acrylics and silicone and represent a breakthrough in IOL implantation. With good elasticity, such kind of IOLs can be implanted through an incision smaller than 3 mm, which reduces surgical trauma, surgically induced astigmatism, and wound healing time.

Hydrophobic Acrylic

IOLs made of hydrophobic acrylic are thin and easy to manipulate during folding. They unfold slowly and have good mechanical stability. Because of their favorable biocompatibility, this type of IOL can be safely implanted in pediatric eyes with uveitis or glaucoma [7]. Since their sticky surface adheres firmly to the lens capsule, they can effectively reduce the incidence of posterior capsule opacification (PCO). However, hydrophobic acrylic IOLs are susceptible to be scratched and damaged by the surgical instruments. Applying ophthalmic viscoelastic devices (OVDs) to the IOL's surface before loading can effectively protect them from damage. In 2007, a survey among the members of the American Association of Pediatric Ophthalmology and Strabismus (AAPOS) showed that hydrophobic acrylic IOLs were the most commonly used type of IOLs in pediatric cataract surgery [8]. The AcrySof® Family (Alcon, Lab., Fort Worth, TX), the Tecnis® Family, and AR40e (Abbott Medical Optics, Santa Ana, CA) are the most widely used hydrophobic acrylic IOLs. Clinical studies with long-term follow-up have demonstrated that such IOLs have a good safety profile and a low complication rate even years after implantation.

Hydrophilic Acrylics

Hydrophilic acrylic IOLs provide the following advantages in pediatric eyes: (1) good biocompatibility; (2) a low index of refraction, which is associated with fewer postoperative glares; (3) moderate elasticity, which makes the IOL easy to fold but with slow unfolding property and therefore improves the safety when placing the IOL; and (4) good laser tolerance. Typical hydrophilic acrylic IOLs applied in clinical practice include the C-flex® IOLs (Rayner, Hove, East Sussex, UK) and AO IOLs (Bausch & Lomb Inc., Rochester, NY). Owing to their position stability, good biocompatibility, and slight postoperative inflammation, they are still being widely used in pediatric IOL implantations.

Silicone

Silicone was the first foldable IOL material available for clinical use, featuring a stable molecular structure and favorable biocompatibility, flexibility, and elasticity. In terms of optical properties, silicone IOLs have good transparency and excellent imaging performance, with few reports of visual discomfort such as halos and glares [9]. However, a major drawback of silicone IOLs is that as compared with hydrophobic acrylic IOLs, capsular contraction induced by capsular fibrosis is more common and more severe, along with a higher incidence of complications such as forward protrusion, dislocation, and pupillary capture of the IOLs. As children's eyes are more prone to capsular fibrosis than adults', silicone IOLs are not recommended for use in children.

14.1.2 Haptic Design: Single-Piece and Three-Piece IOLs

Depending on whether the haptic material is the same as the optic material, IOLs are traditionally classified into single-piece (whose haptics and optic are both made of the same material) and three-piece IOLs (whose haptics are made of rigid PMMA and optic is made of soft material) (Fig. 14.1a, b). In recent years, a new generation of single-piece IOLs, such as the iSert®251 (Hoya Surgical Optics, Inc., Chino Hills, CA), combines two materials together using a novel polymerization technology, with the optic and main supporting portion made of hydrophobic acrylic and the tip of the supporting portion made of PMMA. Such a design not only ensures identifiability but also prevents the adhesion of the supporting portion to the optic (Fig. 14.1c). With broad and soft haptics, single-piece IOLs feature good mechanical performance and resistance against the contraction from intraocular tissues; thus, they are suited for in-the-bag implantation [10, 11]. With thin and long haptics as well as a degree of haptic-optic angulation, three-piece IOLs are suited for both in-the-bag and ciliary sulcus fixation. Therefore, IOL selection in pediatric surgery should be based on the desired implantation site.




Fig. 14.1 IOLs are classified by haptic design. (a) Single-piece IOL; (b) three-piece IOL; (c) novel single-piece IOL made of two materials using a novel polymerization technology

14.1.3 IOL Implantation Site: Anterior Chamber IOLs and Posterior Chamber IOLs

Depending on the intended implantation position in the eye, IOLs can also be divided into anterior chamber (AC-) and posterior chamber (PC-) IOLs:

1. AC-IOLs: Nowadays, it is widely believed that AC-IOLs (especially chamber angle-supported IOLs) are associated with multiple complications, such as corneal endothelial decompensation, hyphema, anterior uveitis, and secondary glaucoma. Thus, AC-IOLs are not recommended for children.
2. PC-IOLs: The commonly used PC-IOLs can be divided into several types according to their haptic material, design, and shape (Fig. 14.2). Generally speaking, in-the-bag fixation and ciliary sulcus fixation are the preferred positions for implantation of PC-IOLs. The latter is often used when there is posterior capsule defect. In-the-bag IOL implantation has

the following advantages: (1) the IOL is fixed at the physiological location of the crystalline lens, which enables to obtain good imaging quality, (2) the position of IOL is relatively stable for a long time, and (3) the IOL has no contact with surrounding tissues, which may reduce complications such as chronic inflammation of the ciliary body and the resulting IOL capture and dislocation.




Fig. 14.2 PC-IOLs. (a) Single-piece IOL with anti-vaulting haptics (AVHTM); (b) single-piece IOL with J-shaped haptics; (c) and (d) three-piece IOL with C-shaped haptics

14.1.4 IOLs for Pediatric Eyes

In 2007, the AAPOS conducted a questionnaire-based survey among US pediatric ophthalmologists to find out which kind of IOL was suitable for children's eyes. Results showed that in-the-bag IOL implantation is routinely performed for children, with the use of single-piece PC-IOLs manufactured from soft materials, such as hydrophobic or hydrophilic acrylic. But silicone IOLs are not appropriate for children. When ciliary sulcus fixation or scleral-sutured fixation is planned, the use of three-piece PC-IOLs made of soft materials is recommended. Besides, AC-IOLs are usually not suitable for use in the pediatric population. The survey also indicated that as the axial length is likely to change under the age of 18 years, the refractive changes after surgery might significantly impair the effect of multifocal IOLs and increase the risk of amblyopia. Therefore, multifocal IOLs are not recommended for children.

14.2 Progress and Prospects

The basic theory, manufacturing technology, and clinical practice regarding IOLs have been rapidly evolving. Novel IOLs tailored to the anatomical and functional characteristics of children's eyes have gained significant attention. Although so far, no IOLs specifically designed for children have been approved for clinical use, some innovative products seem to be quite promising.

Since eye development is rapid during childhood, the refractive change is much greater in children than it is in adults [12]. An ideal IOL for children should be able to adjust its diopter to the growing eye and the changing refraction, so as to keep both eyes as close to emmetropia as possible in the course of their development and thereby improve vision. All of the current clinically available IOLs, however, are designed with a fixed diopter and cannot adapt to the refractive changes of pediatric eyes. In view of this, Liu Yizhi and his colleagues have designed a new type of IOL, which is detachable in the capsular bag to adjust its diopter after surgery (China Patent No. 2006200564414) (Fig. 14.3). It comprises at least two IOL pieces that are adhered together with a potential space in between, which is connected to a sealed tube. When the child's eye becomes fully developed with a stabilized refractive power, the following procedures can be performed to adjust the diopter of the IOL: cut open the sealed tube so that gas or liquid can pass through the tube to form a cavity and then grab the tube and peel off the IOL piece(s) above along a predefined peel-off line. These secondary procedures can bring the affected eye to or close to emmetropia by lowering the overall diopter of the IOL.

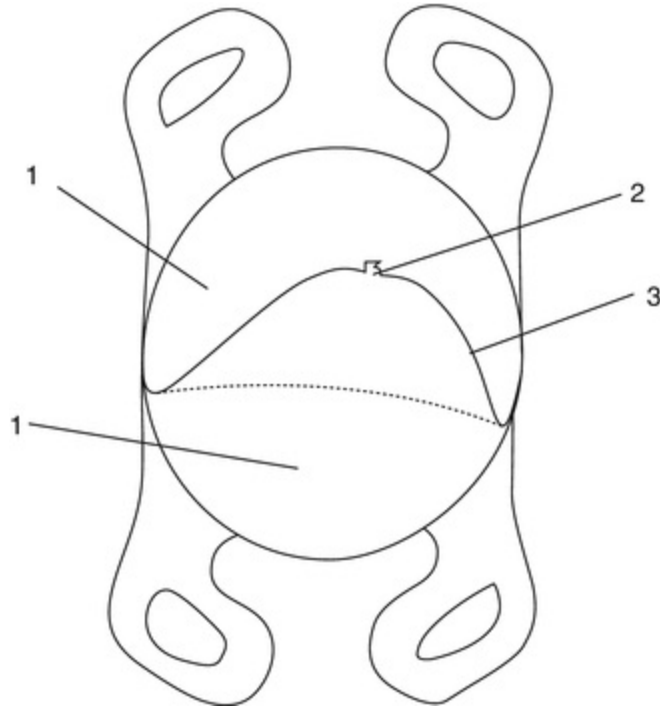


Fig. 14.3 Detachable IOL: (1) IOL pieces, (2) sealed tube, (3) peel-off line

14.3 Summary

Given the unique anatomical structures and physiological development of a child's eye, ophthalmologists should continue to review experiences and lessons about IOL selection for children; meanwhile, further studies are still required. Child-specific IOLs may be a milestone and a great significance for the treatment of pediatric lens disorders.

References

1. Lambert SR, Drack AV. Infantile cataracts. *Surv Ophthalmol.* 1996;40(6):427–58.
[CrossRef][PubMed]
2. Zetterstrom C, Lundvall A, Kugelberg M. Cataracts in children. *J Cataract Refract Surg.* 2005;31(4):824–40.
[CrossRef][PubMed]
3. Ahmadi H, Javadi MA. Intra-ocular lens implantation in children. *Curr Opin Ophthalmol.* 2001;12(1):30–4.
[CrossRef][PubMed]
- 4.

- Dahan E. Intraocular lens implantation in children. *Curr Opin Ophthalmol*. 2000;11(1):51–5.
[\[CrossRef\]](#)[\[PubMed\]](#)
5. Birch EE, Stager DR. The critical period for surgical treatment of dense congenital unilateral cataract. *Invest Ophthalmol Vis Sci*. 1996;37(8):1532–8.
[\[PubMed\]](#)
 6. Wilson Jr ME, Trivedi RH, Buckley EG, et al. ASCRS white paper. Hydrophobic acrylic intraocular lenses in children. *J Cataract Refract Surg*. 2007;33(11):1966–73.
[\[CrossRef\]](#)[\[PubMed\]](#)
 7. Wilson ME, Elliott L, Johnson B, et al. AcrySof acrylic intraocular lens implantation in children: clinical indications of biocompatibility. *J AAPOS*. 2001;5(6):377–80.
[\[CrossRef\]](#)[\[PubMed\]](#)
 8. Wilson ME, Trivedi RH. Choice of intraocular lens for pediatric cataract surgery: survey of AAPOS members. *J Cataract Refract Surg*. 2007;33(9):1666–8.
[\[CrossRef\]](#)[\[PubMed\]](#)
 9. Pavlovic S, Jacobi FK, Graef M, et al. Silicone intraocular lens implantation in children: preliminary results. *J Cataract Refract Surg*. 2000;26(1):88–95.
[\[CrossRef\]](#)[\[PubMed\]](#)
 10. Trivedi RH, Wilson Jr ME. Single-piece acrylic intraocular lens implantation in children. *J Cataract Refract Surg*. 2003;29(9):1738–43.
[\[CrossRef\]](#)[\[PubMed\]](#)
 11. Prinz A, Vecsei-Marlovits PV, Sonderhof D, et al. Comparison of posterior capsule opacification between a 1-piece and a 3-piece microincision intraocular lens. *Br J Ophthalmol*. 2013;97(1):18–22.
[\[CrossRef\]](#)[\[PubMed\]](#)
 12. Peterseim MW, Wilson ME. Bilateral intraocular lens implantation in the pediatric population. *Ophthalmology*. 2000;107(7):1261–6.
[\[CrossRef\]](#)[\[PubMed\]](#)

15. Pediatric Intraocular Lens Implantation

Haotian Lin¹✉, Xinyu Zhang¹ and Xiaojian Zhong¹

- (1) State Key Laboratory of Ophthalmology, Zhongshan Ophthalmic Center, Sun Yat-sen University, 54S Xianlie Road, Guangzhou, 510060, People's Republic of China

✉ **Haotian Lin**

Email: gddlht@aliyun.com

Abstract

Owing to the improvement in intraocular lens (IOL) design, manufacturing techniques and materials, as well as the development of microsurgery, IOL implantation has been widely accepted as a therapeutic option for pediatric patients. Generally speaking, in-the-bag IOL implantation is preferred for pediatric patients; primary in-the-bag implantation is relatively easy to perform, while secondary implantation is more challenging due to the contact between the anterior and posterior capsules and subsequent organization. We have developed an innovative secondary in-the-bag IOL implantation technique using a radiofrequency diathermy capsulorhexis device. Capsulorhexis is performed around the proliferation ring, the hyperplastic lens cortex is then removed and the capsular bag is reopened, and this dramatically enhances the success rate of secondary in-the-bag IOL implantation in pediatric patients. This chapter reviews and discusses the surgical techniques and potential complications of each type of pediatric IOL implantation, including primary, secondary, in-the-bag, sulcus, and anterior chamber IOL implantation.

With over 60 years' exploration and development, intraocular lens (IOL) implantation in children has been widely accepted among ophthalmologists and becomes the most commonly used approach to correct postoperative aphakia in children [1–4]. However, up till now, there are still no IOLs approved officially by FDA for children. The challenges lie in the rapid growth of the capsular bag, the complexity and heterogeneity of eyeball development, as well as the relatively severe postoperative inflammatory response compared to adults. Therefore, detailed preoperative evaluations should be performed by surgeons to make appropriate decisions for surgical approaches for children individually [5]. According to different surgical timing, there are primary and secondary IOL implantations for pediatric patients, and according to the site of fixation, there are in-the-bag IOL implantation, sulcus-fixed IOL implantation, suture-fixed IOL implantation, iris-fixed IOL implantation, and angle-supported IOL implantation. For certain groups of children, specific techniques of IOL implantation are needed. For example, “piggy-back” IOL implantation is adopted for children with high hyperopia. The surgical indications, techniques, and the related IOL selection principle for different IOL implantation procedures in children are varied.

15.1 Development of IOL Implantation in Children

After the first successful IOL implantation was performed in an adult by Sir Harold Ridley in 1949, pediatric ophthalmologists began attempting IOL implantation in children as well. However, the record of the first pediatric IOL implantation varied in different literature. The earliest pediatric IOL implantation ever recorded dates back to that conducted by Epstein in 1951, but it was only an account without direct evidence [6]. D. Peter Choyce claimed that he had successfully implanted the first IOL in a 10-year-old child in 1955 and completed further four cases of IOL implantation in children aged 5–12 years in the subsequent year [7]. Binkhorst and colleagues reported cases of irido-capsular supported intraocular lenses in 1959 [8]. Later, Hiles also advocated IOL implantation in children and published a series of related articles based on his personal experience [9, 10]. However, due to poor lens design and the limited surgical techniques, the early attempts at IOL implantation in children often resulted in various

postoperative complications like IOL dislocation and pupillary capture, synechia and pupillary membrane, secondary glaucoma, and corneal endothelial decompensation. A report by Binkhorst in 1970 discussed in great detail the postoperative visual rehabilitation and complications in congenital cataract surgery combined with IOL implantation [11]. As a result of the complications, IOL implantation in children didn't become a common practice among clinical ophthalmologists at that time. In the 1990s, progress in modern microsurgical techniques and application of automated irrigation/aspiration, capsulectomy, and vitrectomy in pediatric cataract surgery led to greatly improved surgical outcomes and dramatically reduced postoperative complications. It was not until then that the IOL implantation in children began to be more and more widely accepted.

15.2 Primary IOL Implantation

In primary IOL implantation, the IOL is implanted at the time of cataract extraction. According to the different fixation sites, primary IOL implantation can be divided into in-the-bag IOL implantation and ciliary sulcus-fixated IOL implantation. In-the-bag IOL implantation fits the human ocular anatomy better and the IOL is in a more natural position resembling the crystalline lens. It effectively ensures the long-term stability and centration of the IOL and prevents pigment dispersion caused by the friction between the IOL optic and the uveal tissues. Therefore, primary in-the-bag IOL implantation is generally preferred by ophthalmologists. However, when the presence of a preexisting posterior capsular defect or an extensive intraoperative posterior capsular rupture occurs leading to difficulty for in-the-bag implantation or inadequate posterior capsular support, then ciliary sulcus-fixation becomes the only alternative.

15.2.1 Surgical Indications and Contraindications

15.2.1.1 Surgical Indications

At present, it is agreed that primary IOL implantation to correct aphakia after cataract extraction is recommended for pediatric patients at a proper age and without surgical contraindications. However, it is still controversial over the appropriate age for IOL implantation in children among ophthalmologists worldwide, and no identical conclusion has been achieved up to now. It was

reported that children undergoing primary IOL implantation within their first year would bear higher risks of complications and secondary operation than the children with secondary IOL implantation after the age of 3 years [12]. Likewise, primary IOL implantation would bring a higher risk of secondary operation for the children before the age of 2 years, especially for unilateral cataract patients [13]. Since no evidence-based studies were presented to claim the advantages of primary IOL implantation with regard to postoperative visual outcomes before the age of 2 years [14], it is recommended to perform primary IOL implantation after 2 years old.

15.2.1.2 Surgical Contraindications

The contraindications for pediatric IOL implantation are as follows:

1. Congenital cataracts associated with ocular comorbidities: IOL implantation in congenital cases accompanied by glaucoma may lead to uncontrollable intraocular pressure (IOP) and aggravation of glaucoma. IOL implantation is also contraindicated for cases associated with proliferative vitreoretinopathy and optic nerve atrophy [15].
2. Pediatric cataract with concurrent severe inflammation: the eyes with a significant inflammatory response or a high risk of developing it are contraindicated for IOL implantation after the extraction of traumatic cataract immediately. Chronic intraocular inflammations, such as uveitis, toxoplasmosis, and rubella syndrome, are also contraindications for primary IOL implantation.
3. Congenital cataracts associated with developmental anomalies of the eye: in cases with concurrent microphthalmia and/or microcornea, a crowded anterior segment will lead to contact of IOL with the corneal endothelium and compression on the ciliary body and other intraocular tissues. Postoperative complications, such as glaucoma and corneal endothelial decompensation, may easily occur.

15.2.2 Primary In-the-Bag IOL Implantation

In-the-bag IOL implantation is the most stable and safest approach, and the

operation is relatively simple when the anterior capsular capsulorhexis opening and the capsular bag are intact. More and more pediatric ophthalmologists are now advocating primary continuous curvilinear capsulorhexis (CCC) and aspiration of the lens cortex followed by posterior continuous curvilinear capsulorhexis (PCCC) and anterior vitrectomy, in combination with in-the-bag IOL implantation in young children. Even when small ruptures in the posterior capsule occur accidentally, experienced surgeons can tear the ruptures into a continuous circle with capsulorhexis forceps to minimize the tendency of further rupture into the periphery and allow for IOL implantation in the capsular bag.

15.2.2.1 Selection of IOLs and Surgical Techniques

The surgical techniques in primary IOL implantation are decided according to the selection of IOLs and this will be elaborated as follows:

1. When implanting unfoldable IOLs, the surgical incisions are enlarged accordingly. Surgeons will hold the rim of the IOL optic with toothless microsurgical forceps, deliver the leading haptic into the bag, and dial the posterior haptic into the bag with forceps or a Sinsky hook. The large incisions for unfoldable IOL implantations can lead to serious tissue damage. Therefore, only a small amount of unfoldable IOLs are used in economically underdeveloped countries or regions.
2. In foldable IOL implantation, larger incisions are unnecessary and the implantation can be performed with IOL holding forceps or an IOL injector. At present, IOL injectors are the primary adjunctive instrument for IOL implantation and are much simpler in operation and safer than forceps. With the injectors, not only can the damages or scratches on the IOL optic surface be reduced, but the possibility of the IOL being catapulted can also be eliminated. The injectors for foldable IOL implantation can be divided into two types: the preloaded and the standard type.
 - ① In the preloaded IOL injection system, IOLs of different powers are already loaded in the injectors. A simple step of injecting adequate ophthalmic viscosurgical device (OVD) into the tip makes it ready to use, omitting the process of IOL loading during surgery.

This not only saves time but also minimizes the possibility of contamination and infection with the usage of disposable injectors.

② In the case of the standard injecting system, the IOL is loaded into the injector during surgery. OVD is injected into the cartridge before IOL loading with toothless microsurgical forceps. The cartridge is then fitted onto the injector, which can be used to implant the IOL into the operated eye.

3. No matter what type of injection system is used during the implantation, the injector should be at a 45° angle to the iris plane with the tip aiming at the capsular bag. After the leading haptic is delivered under the anterior capsulorhexis opening opposite to the incision, the entire IOL is pushed out of the injector. Then the haptic-optic junction is gently pushed with a Sinsky hook, irrigation needle, or OVD needle, and the trailing haptic is slightly dialed downward into the capsular bag (Figs. 15.1 and 15.2). Because of the angulation and counterclockwise orientation of haptics, reversed implantation of an IOL will lead to altered postoperative refraction; therefore, the attention should be given to the side of IOL during implantation. If the IOL is implanted the wrong way round, sufficient OVD is injected into the capsule to allow the IOL to be flipped over to the normal position with a Sinsky hook or OVD needle. Another important surgical technique is to determine whether the IOL is fixated in the bag. First of all, the surgeon observes whether the edge of the IOL optic is fully covered by the rim of anterior capsulorhexis. Then the edge of the IOL is gently pushed to determine whether the IOL can rotate freely in the bag. After the implantation, the OVD in the anterior chamber and the capsular bag, especially the OVD behind the IOL, should be thoroughly eliminated to prevent postoperative IOP elevation. The posterior segment pressure of pediatric eyes is higher than that of adults', which makes the anterior chamber prone to collapse during the operation; therefore, sufficient OVD should be injected to facilitate surgical manipulation. If the bag is found to be too small for in-the-bag implantation or the IOL haptics and optic are unable to unfold, sulcus-fixated implantation is acceptable. If the sulcus diameter is still too short for the IOL haptics and optic to unfold completely, the IOL should be taken out without hesitation. This

condition is rarely encountered and it should be avoided by rigorous control of surgical indications and thorough preoperative examination.

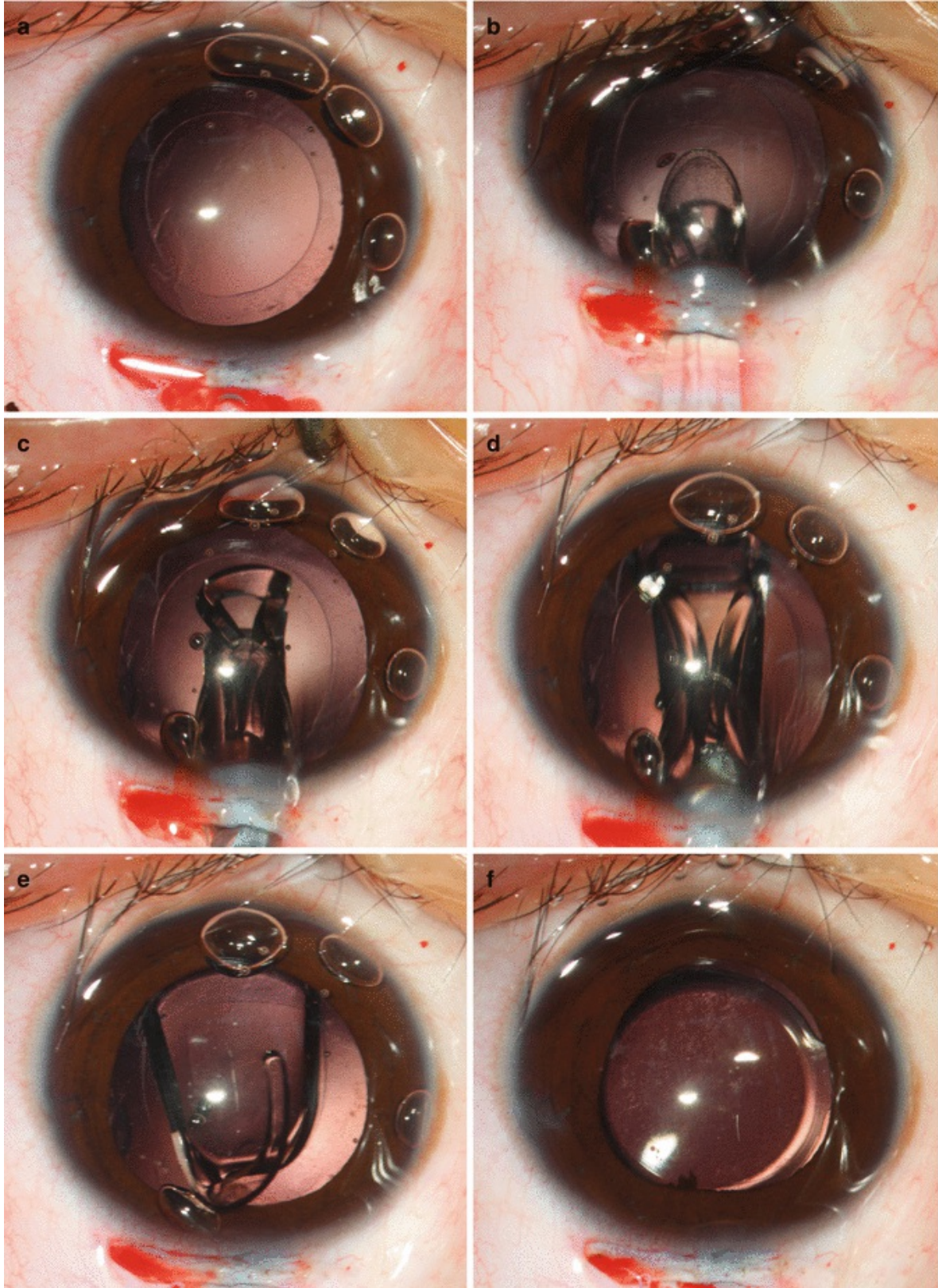


Fig. 15.1 Primary in-the-bag implantation of a one-piece AcrySof IOL. (a) OVD is injected to

inflate the capsular bag; **(b–e)** A one-piece IOL is implanted in the bag; **(f)** The anterior chamber is inflated and the incision is sealed

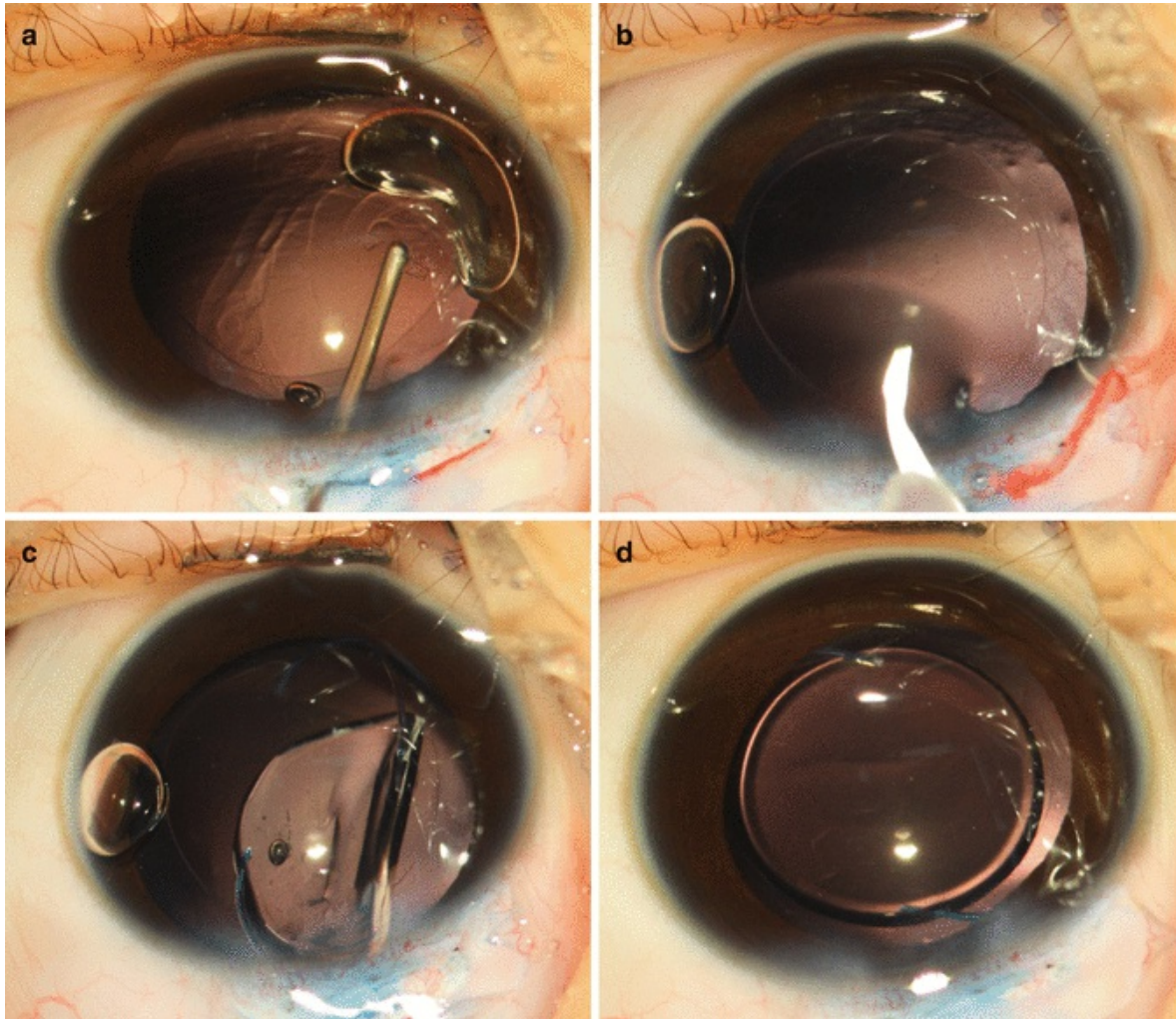


Fig. 15.2 Primary in-the-bag implantation of a three-piece IOL. **(a, b)** OVD is injected to inflate the capsular bag; **(c)** A three-piece IOL is implanted in the bag; **(d)** The anterior chamber is inflated and the incision is sealed

15.2.2.2 Management of the Posterior Capsule and the Vitreous Body

After primary in-the-bag IOL implantation, there are two conditions in need of further management: the posterior capsule and the vitreous body. Firstly, preexisting small ruptures on the posterior capsule with irregular edges should be treated with PCCC that completely envelopes the rupture to

prevent radial tearing of the posterior capsule. Anterior vitrectomy following PCCC should also be performed. Secondly, though the posterior capsule is intact, the pediatric patient is too young to conserve the entire posterior capsule without occurrence of secondary opacification. In order to avoid posterior capsular opacification on the visual axis caused by the rapid proliferation of lens epithelial cells along the posterior capsule and the anterior hyaloid membrane, PCCC combined with anterior vitrectomy is also needed to destroy the biologic scaffold for postoperative lens epithelial proliferation [16–18]. PCCC can be performed manually with capsulorhexis forceps or with a radiofrequency diathermy device for capsulotomy. The vitreous body in the central axis is removed with anterior vitrectomy via the posterior capsulorhexis opening. The surgical goal can be accomplished either way, with the selection mainly depending on the surgeon's experience and the availability of surgical equipment.

15.2.3 Primary Sulcus-Fixated IOL Implantation

In recent years, cataract extraction combined with primary IOL implantation has been widely accepted in clinical practice. However, whether primary IOL implantation is feasible depends on the integrity of the posterior capsule, which has a 0.45–5.2 % rate of rupture [19]. Preexisting posterior capsular defects or large posterior defects due to surgical complications can make it impossible for in-the-bag IOL implantation. In either case, the IOL haptics can be fixated in the ciliary sulcus after regular treatment of the vitreous body, but only on the condition that the rim of anterior capsulorhexis is continuous or there is adequate residual capsule on the periphery. However, IOL implantation is forbidden in cases with severe capsular defects to prevent IOL decentration, tilt, or even dislocation into the vitreous cavity.

15.2.3.1 Surgical Techniques

When the IOL cannot be fixated in the bag and sulcus fixation is adopted, OVD is injected between the peripheral capsule and the iris before implanting the IOL. Firstly, the leading haptic is delivered into the anterior chamber via the incision and guided through the pupil into the ciliary sulcus opposite the incision. Then the IOL optic is gently pushed down into the pupillary zone with lens implantation forceps. The trailing haptic, held in the implantation forceps, is dialed and pressed downward. Then the forceps are released to

deliver the trailing haptic into the sulcus after completing the three maneuvers – “push, dial, and press” – which can also be conducted with a Sinsky hook. To ensure the success of the primary sulcus-fixated IOL implantation, two surgical techniques are emphasized: (1) The anterior and posterior capsule should be preserved as much as possible to provide adequate support for posterior chamber IOLs. (2) Sufficient OVD should be timely injected into the anterior chamber, which is important in maintaining normal IOP and preventing vitreous prolapse. Finally, the postoperative inflammatory response in sulcus fixation is stronger in children than in adults. Therefore, some surgeons suggest the IOL optic be captured through the anterior capsulorhexis, with the haptics placed in the sulcus and optic in the bag, which is referred to as optic capture. This technique can ensure the long-term stability and centration of the IOL and avoid the inflammatory response and pigment dispersion caused by the friction between the IOL optic and the uveal tissue.

15.2.3.2 Anterior Vitreous Management

Appropriate management of prolapsed vitreous is the key to reducing the postoperative complications. When removing the prolapsed vitreous, surgeons should first deal with the vitreous incarcerated in the incision, then proceed toward the posterior capsular rupture, and meanwhile try to thoroughly eliminate the vitreous in the anterior chamber. In addition, it is better to use a vitrectomy device with separated vitrector and irrigating cannula, with the vitrector placed beneath the irrigation cannula. It avoids disturbing the vitreous in the vitreous cavity caused by hydration. The vitreous in the anterior chamber and at the margin of the posterior capsular rupture should be thoroughly eliminated so that the shape of pupil remains normal and the healing of the corneal endothelium and the incision will not be affected after surgery. Finally, retained vitreous strands in the corneal incision are identified either by dipping dry cotton swabs on the incision to reveal transparent filaments or by observing whether the pupil is round in shape. In brief, the aim of surgical management of vitreous prolapse is to prevent postoperative complications due to vitreous traction, and intraoperative vitreous disturbance should be minimized.

15.2.3.3 Selection of IOL

Currently, three-piece foldable IOL is the main option for primary sulcus-fixated IOL implantation. The haptics of a three-piece IOL are made from polymethyl methacrylate (PMMA), a material with a certain degree of rigidity and toughness, which can help the IOL remain stable and centered after IOL implantation.

15.3 Secondary IOL Implantation

When planning secondary IOL implantation for pediatric aphakic eyes, three key issues should be considered by surgeons: the space for IOL implantation, the choice of IOL fixation, and the transparency of the visual axis. In addition, the selection of IOL type and fixation are determined by the size of the eye, condition of residual capsule and capsular bag, as well as the severity of posterior synechia.

15.3.1 Secondary In-the-Bag IOL Implantation

Secondary implantation is often conducted years after primary surgery. A randomized controlled trial on different capsulorhexis openings conducted by the authors demonstrated that during primary cataract extraction, the anterior capsulorhexis diameter should be controlled between 4.5 and 5.0 mm, the cortex eliminated thoroughly, and the posterior capsule left intact or with only a small capsulotomy, to lay a solid foundation for future secondary in-the-bag IOL implantation [20]. As tissue and cell proliferation is active in children, the residual lens epithelial cells multiply and the proliferative cortex gradually fills the space between the anterior and posterior capsules. Around the anterior capsulorhexis opening, contact and fibrosis of the capsules give rise to a regenerated ring, that is, the Soemmering ring. If the capsular bag is not reopened and the regenerated cortex in the Soemmering ring is not eliminated, the uneven thickness of the regenerated cortex between the anterior and posterior capsules will lead to uneven thickening of the Soemmering ring, which will not only impose pressure on the IOL but also cause IOL decentration or tilt. In addition, if the capsular bag is reopened but the cortex is not thoroughly removed, prolapsed cortex in the pupillary zone or the anterior chamber might induce an inflammatory response and elevate IOP. In conclusion, there are two key points in secondary in-the-bag IOL implantation. First, in the primary cataract surgery, the capsulorhexis

diameter is controlled between 4.5 and 5.0 mm to ensure that enough space is preserved between the anterior and posterior capsules. Second, the potential space is reopened to allow for IOL implantation.

15.3.1.1 Surgical Indications [21]

1. Enough regenerated cortex between the anterior and posterior capsules to separate them.
2. The presence of an intact and centered Soemmering ring (Fig. 15.3).

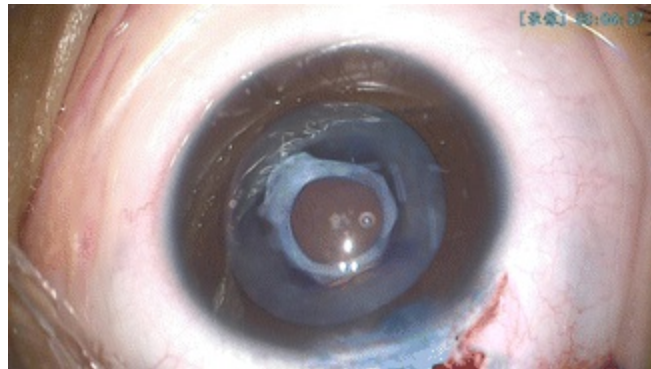


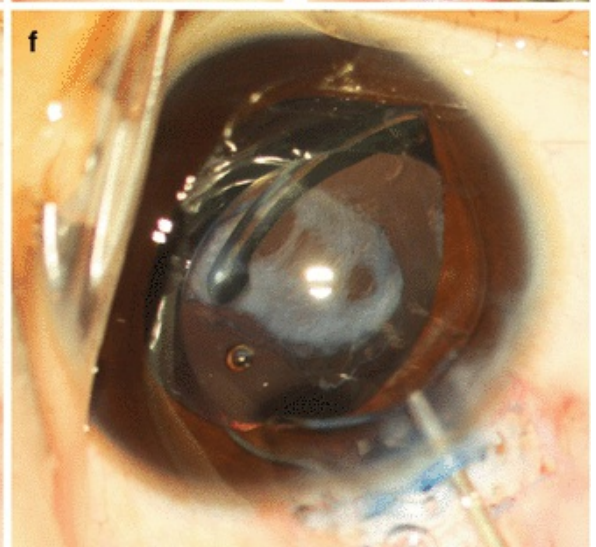
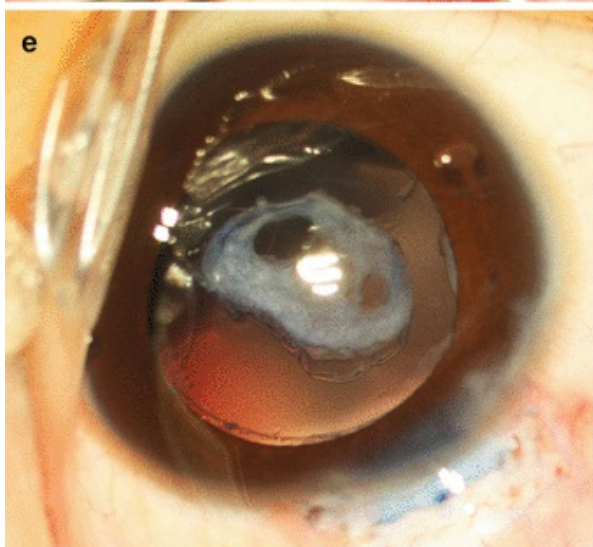
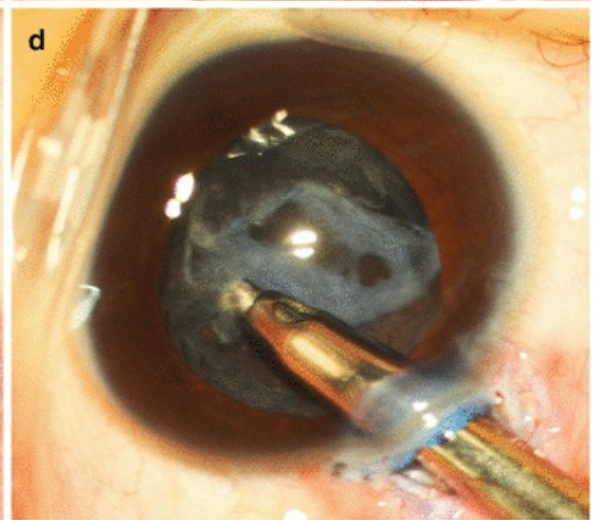
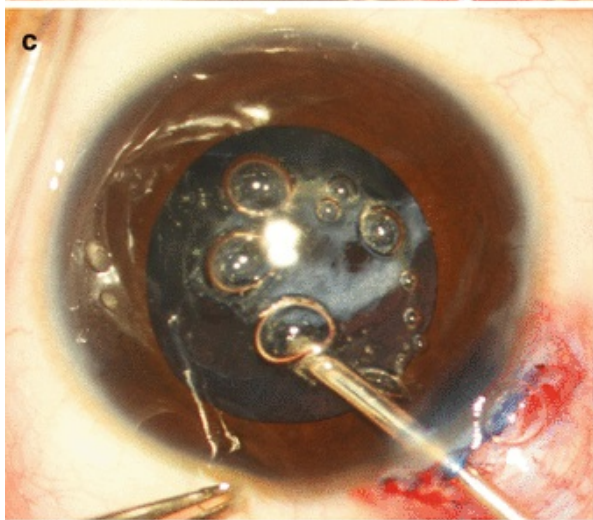
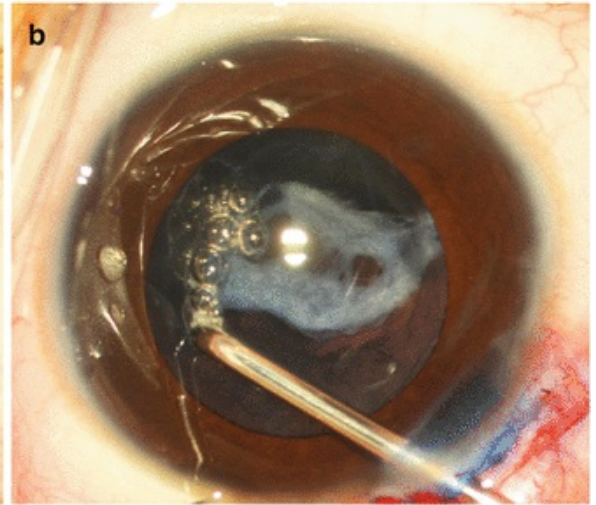
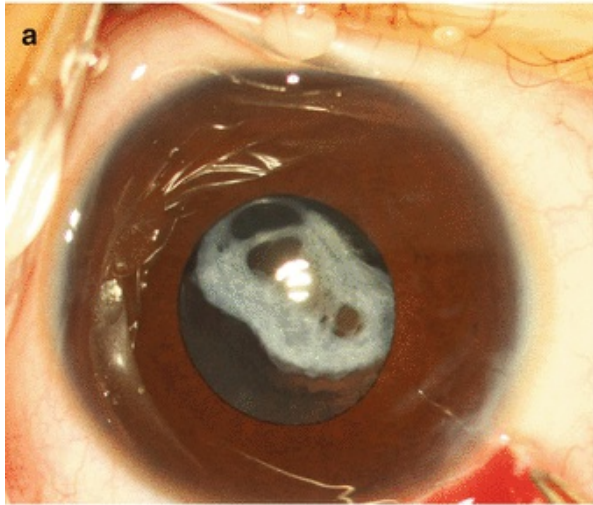
Fig. 15.3 The formation of Soemmering ring after primary surgery

3. The posterior capsule is intact or with a central defect less than 5 mm in diameter.
4. The pupil is sufficiently dilated without obvious posterior synechia.
5. The zonules are intact with normal elasticity and the capsular bag is stable.

15.3.1.2 Surgical Procedures and Techniques

1. For incision, surgeons might choose from superior corneal incision, limbal incision, or scleral tunnel incision.

2. Adequate OVD is injected into the anterior chamber to fully expose the capsular bag and synechiolysis is performed if necessary. When extensive posterior synechia is encountered, the synechia is excised with Vannas capsulotomy scissors closely along the capsular surface.
3. Conventional in-the-bag IOL implantation: After the capsule is fully exposed, use capsulorhexis forceps, cystotome needle, or OVD to separate the fused anterior and posterior capsules, remove the proliferated tissue on the capsular surface, and reopen the capsular bag. The proliferated cortex is eliminated before injection of OVD to inflate the capsular bag and aid in the subsequent implantation of IOL.
4. Innovative in-the-bag IOL placement with radiofrequency diathermy capsulorhexis device (Fig. 15.4): The capsular membrane is fully exposed with OVD. The radiofrequency diathermy capsulorhexis device is used to perform CCC in the periphery of the Soemmering ring formed by adhesion of the anterior and posterior capsules. The capsular bag is reopened, and the proliferated cortex is removed with irrigation/aspiration after hydrodissection. OVD is injected into the capsular bag, where the IOL is fixated. If posterior capsular opacification is present, the device is used again to perform PCCC. However, the diameter of PCCC should be smaller than that of the IOL optic [21].



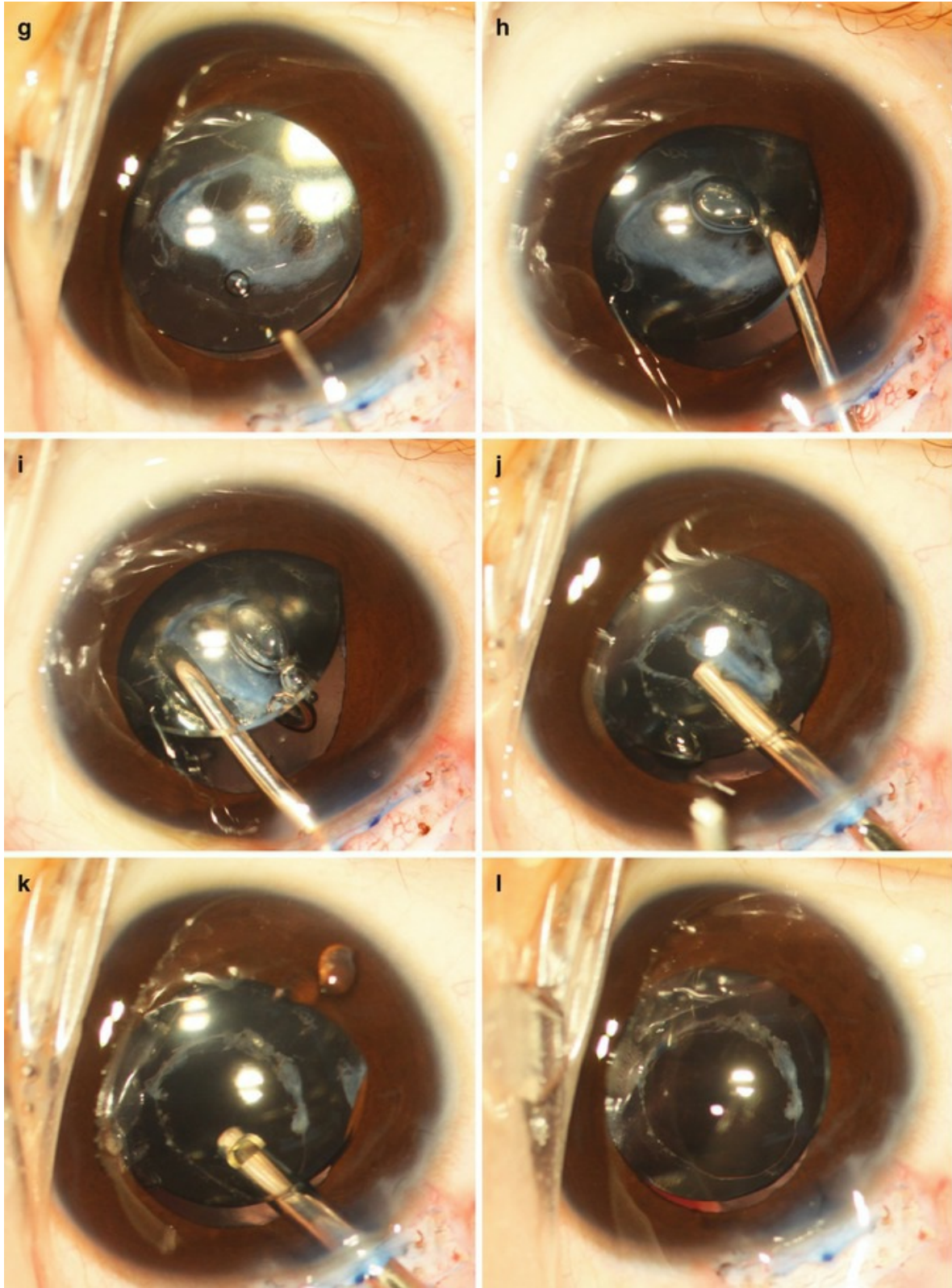


Fig. 15.4 Secondary in-the-bag IOL implantation with radiofrequency diathermy capsulotomy of the anterior and posterior capsules. (a) OVD is injected to inflate the anterior chamber and

eliminate synechia; **(b, c)** Anterior CCC is performed with radiofrequency diathermy capsulorhexis device; **(d)** The proliferated cortex is removed with irrigation/aspiration; **(e)** The capsular bag is inflated with OVD; **(f, g)** IOL is implanted in the bag; **(h–j)** Posterior capsulorhexis is performed with radiofrequency diathermy capsulorhexis device again and fibrosis is removed; **(k)** Anterior vitrectomy is performed; **(l)** The anterior chamber is inflated and the incision is sealed

5. If the posterior capsule is not intact and vitreous prolapse occurs intraoperatively, the prolapsed vitreous should be completely removed. The anterior vitreous can be eliminated with an anterior vitrectomy machine. If the machine is unavailable or only a small amount of vitreous has prolapsed, scissors can be used for excision of the vitreous strands. When resecting the vitreous with scissors, the vitreous outside the incision should be removed first. The incision is then checked with cotton swabs to ensure the absence of residual vitreous. Miotic agent is subsequently injected into the anterior chamber and the location of the vitreous strand is determined by the shape of the pupil. A Sinsky hook is inserted through the paracentesis to move the vitreous strand in the anterior chamber toward the pupillary margin until its end can be seen in the anterior chamber. Vannas capsulotomy scissors are inserted to resect the strand at the pupillary margin close to the iris surface until the pupil is round in shape.
6. Miosis, suture closure of the incision, and patching of the eye are performed at the end of surgery.

15.3.2 Secondary Sulcus-Fixated IOL Implantation

During secondary IOL implantation, if the anterior and posterior capsules are fused completely and it is impossible to reopen the capsular bag or the capsular bag can only be partially opened without adequate posterior capsule, sulcus-fixated IOL implantation can be an alternative after elimination of the regenerated cortex.

15.3.2.1 Surgical Indications

1. Fibrosis and obvious decentration of the primary capsulorhexis opening.

2. The primary capsulorhexis opening is too large, leaving inadequate anterior and posterior capsule leaflet on the periphery.
3. Complete adhesion of the anterior and posterior capsule, making it impossible to reopen the capsular bag.

15.3.2.2 Surgical Techniques

The surgical techniques and the principle of IOL selection are similar to that of primary sulcus-fixated IOL implantation. The synechia between the iris and the capsule is separated and the regenerated lens cortex is eliminated. Then the residual peripheral capsule will be assessed for adequacy of support, and the IOL haptics are fixated at the positions with more peripheral capsule (Fig. 15.5).

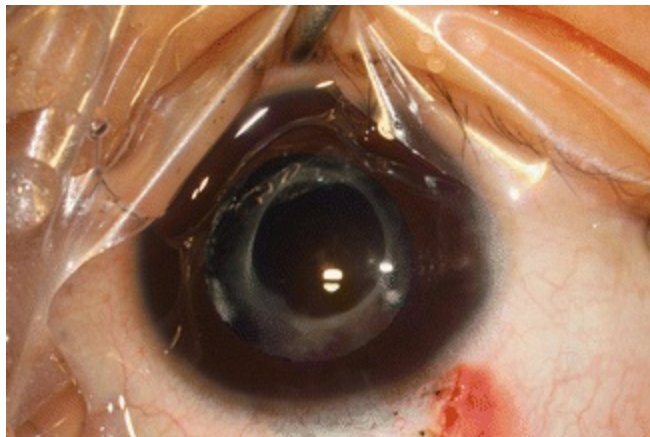


Fig. 15.5 Secondary ciliary sulcus-fixated IOL implantation. The IOL haptics should be fixed at the positions with more peripheral capsule

15.3.3 Secondary IOL Suture Fixation

15.3.3.1 Surgical Indications

Aphakic eyes with good corrected visual acuity or predicted visual acuity over 0.1, meeting one of the following criteria:

1. The eye with congenital cataract that has undergone primary cataract extraction without adequate residual capsular support for IOL

2. The eye with traumatic cataract that has undergone primary cataract extraction, with major capsular defect and resolved inflammation

15.3.3.2 Surgical Procedures and Techniques

Secondary IOL suture fixation in children is similar to that in adults, and the specific surgical procedures and techniques are detailed in Chap. 17 on pediatric ectopia lentis. We take the 7 o'clock–1 o'clock externo approach as an example and discuss the surgical procedures and techniques as follows:

1. Scleral flap: Conjunctival peritomy is performed at 7 o'clock and 1 o'clock. Cautery on the scleral surface is conducted for hemostasis. A triangular scleral flap with its base at the limbus is made.
2. A superior scleral tunnel is constructed as the incision.
3. OVD is injected into the anterior chamber.
4. Placing the polypropylene suture: With conventional technique, it requires assessment from the surgeon's experience and visual inspection. 10–0 polypropylene suture with a long and a short needle is used. The long needle is inserted into the ciliary sulcus beneath the 7 o'clock scleral flap 1 mm posterior to the limbus and pulled out of the sclera through the sulcus at 1 o'clock. If an ophthalmic endoscope is available, the ciliary sulcus can be directly viewed during surgery. Thus the suture can be precisely fixated to the sulcus, which is helpful for the subsequent accurate suture of the IOL haptics.
5. Fixating the IOL: The suture is pulled out from the incision and cut off in the middle, with each end tied to one of the IOL haptics.
6. Implanting the IOL: If a rigid IOL is implanted, the incision is enlarged and the IOL is implanted into the ciliary sulcus with forceps. If a foldable IOL is implanted, the IOL injection system is used. The leading haptic is

first pushed out of the cartridge and the suture at 7 o'clock is tied to it. Then the IOL is injected into the sulcus with the trailing haptic outside the incision. The suture at 1 o'clock is tied to the trailing haptic, which is delivered into the sulcus with forceps. Both ends of the polypropylene suture are tightened to fixate the IOL in a horizontal, centered position and tied. The knot on each end is buried under the sclera flap.

7. Anterior vitrectomy is performed.
8. The sclera flaps and the incision are closed with 10–0 nylon suture.

15.3.3.3 Characteristics of the Surgical Techniques

Currently, the wide usage of foldable IOLs in IOL suture fixation leads to much smaller incisions, improved surgical safety, reduced postoperative astigmatism, and faster visual rehabilitation. However, surgeons must pay attention to the “three consistencies” in the suture fixation of foldable IOLs. The center of the line connecting the entry and exit of the suture is consistent with the pupillary center; the fixation points of the sutures on the two IOL haptics are of equal distance to the optic; and the suture points on the sclera are of equal distance to the limbus (Fig. 15.6). The following points are the basis for the “three consistencies”:

1. The polypropylene suture should be placed before entry into the anterior chamber to avoid asymmetry of the suture positions or hemorrhage induced by inaccurate suture position points in a collapsed eyeball.

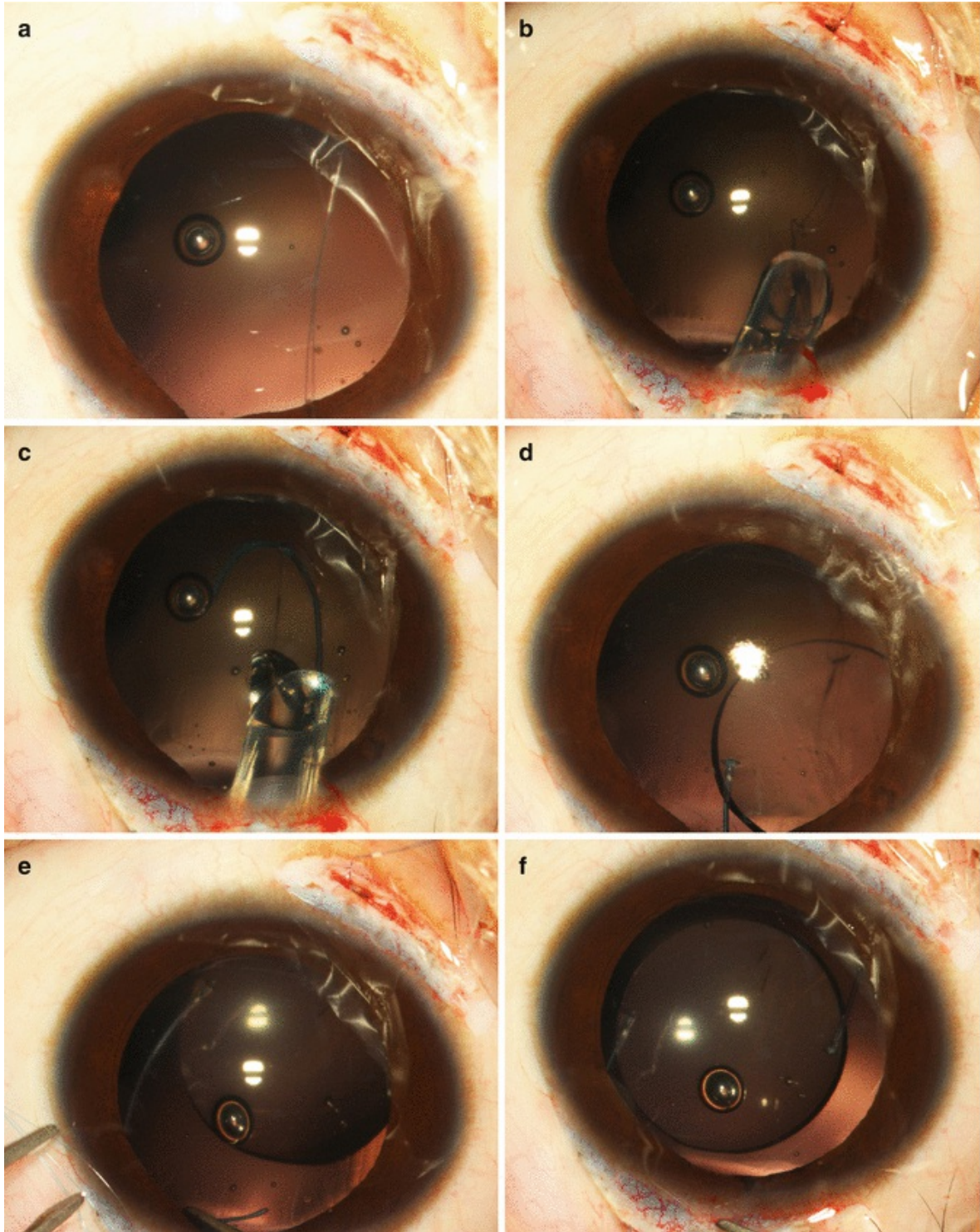


Fig. 15.6 Two-point suture fixation of a foldable IOL. (a) A 10–0 polypropylene suture is inserted through the 7 o'clock scleral flap; (b, c) The leading haptic is fixated with 10–0 polypropylene suture and implanted; (d) The trailing haptic is fixated with 10–0 polypropylene suture and implanted; (e) The ends of the polypropylene sutures are tied under the scleral flaps at 1 o'clock and 7 o'clock, respectively; (f) The scleral flaps and the incision are sutured

2. The entry and exit sites of the suture needles are either 1.0–1.2 mm posterior to the limbus with the entry perpendicular to the sclera or 1.6–2.0 mm posterior to the limbus with the entry parallel to the iris surface. This will avoid puncture of the iris root or the ciliary sulcus, which can lead to hemorrhage.
3. The sites of haptic fixation can be freely chosen as long as it is convenient for the surgeon, but they should be apart by 6 clock hours and aligned with the pupillary center to avoid IOL decentration after fixation. If the pupil is decentered and cannot be corrected, the fixation sutures might be placed to divide the pupil in equal halves to avoid diplopia due to the deviation of IOL from the pupil.
4. The polypropylene suture should be tied to corresponding positions on both haptics to avoid IOL decentration. The recommended sites are the farthest points from the optic center, which prevents tilting of the optic due to tightening of the suture.
5. Decentration and dislocation of IOLs are mainly caused by incomplete excision of the prolapsed vitreous in the anterior chamber, asymmetry of the two fixation sites on the haptics or imbalanced tension after suture tying, which distorts the IOL and leads to decentration, dislocation or even swinging of the IOL.

15.3.3.4 Complications and Potential Risks

The complications of pediatric IOL suture fixation include suprachoroidal hemorrhage, vitreous hemorrhage, retinal tear, retinal detachment, IOL decentration, tilt, and dislocation, due to erosion of the polypropylene suture. As the IOLs are implanted during infancy, they will remain in the patients' eyes for up to several decades. Therefore, IOL dislocation in these eyes draws more attention from surgeons, and some of them suggest multipoint fixation to lower the risk of this complication. In addition, new alternative suture materials to polypropylene are being developed [22].

15.4 Implantation of “Piggy-Back” IOLs

15.4.1 Concept

Implantation of “piggy-back” IOLs is a kind of refractive correction of aphakia in which two IOLs are implanted. As the second IOL is positioned on the back of the first IOL, this implantation of two IOLs is referred to as “piggy-back” implantation. It was first attempted by Gayton in 1993 for bilateral extreme hyperopia with concurrent nuclear cataracts [23] and was gradually popularized and applied in high hyperopia associated with cataract, high myopia associated with cataract and overcorrected or undercorrected pseudophakia. It can be divided into the primary and secondary “piggy-back” implantation.

15.4.2 Surgical Indications

1. Children with extreme hyperopia or myopia [24].
2. Pseudophakic eyes with refractive errors: For overcorrected or undercorrected eyes after primary IOL implantation, especially those who underwent surgery long ago with adhesion between the IOL and the peripheral capsule, IOL exchange in situ will undoubtedly increase the risk of zonule loss and rupture of the anterior or posterior capsule, cystoid macular edema, and retinal detachment. Implantation of a second IOL in the overcorrected or undercorrected pseudophakic eye can eliminate the need to replace the IOL already fixated in the bag and now is an alternative for correction of pseudophakic refractive error [25].

15.4.3 Surgical Procedures

15.4.3.1 Primary Implantation

The incision can be made at the cornea, limbus, or sclera. After routine CCC and phacoemulsification, the first IOL is implanted into the capsular bag. OVD is reinjected into the capsular fornix and superior to the IOL to inflate the upper capsular bag. Then the leading haptic of the second IOL is inserted and the trailing haptic is gently pushed and pressed into the bag. If the second

IOL is fixated in the sulcus, OVD is injected between the first IOL and the iris, and then the haptics of the second IOL are fixated into the sulcus. The haptics of the two IOLs can be adjusted to be parallel or perpendicular to each other. The OVD between the two IOLs is removed completely.

15.4.3.2 Secondary Implantation

The incision is the same as in primary implantation. When the second IOL is implanted into the capsular bag, OVD is injected beneath the capsular bag and above the first IOL to inflate the residual capsular space. If the second IOL is fixated into the sulcus, OVD is used to enlarge the space between the iris and the capsular bag. If there is a long interval after the primary IOL implantation and the capsular bag is fixated, forced implantation of a second IOL in the capsular bag will not only be difficult technically but also may cause backward displacement of the first IOL and the subsequent hyperopia. The appropriate method will be fixation of the second IOL into the sulcus. OVD is removed after the implantation.

15.4.4 Selection of IOLs and Implantation Sites

Though ophthalmologists have not reached a consensus over what type of IOL to be selected for pediatric “piggy-back” IOL implantation, it is universally accepted that AcrySof hydrophobic acrylate IOL is a relatively safe option. One-piece IOL is chosen for in-the-bag fixation and three-piece IOL for sulcus-fixation. Considering the sites of fixation for the two IOLs, in theory, the bag-bag approach (with the minimum interlenticular space) leads to a high incidence of interlenticular opacification (ILO). The bag-sulcus approach (with the maximum interlenticular space) has the lowest possibility of postoperative ILO and is an ideal option for “piggy-back” IOL implantation. When adopting the bag-sulcus approach, the haptics of the two IOLs are positioned perpendicular to each other and the interlenticular space should be maximized. However, complications like iris damage and glaucoma may occur due to friction of the IOL haptics in the sulcus. Therefore, caution should be taken when choosing this approach.

15.5 Summary

In order to minimize the complications due to IOL implantation and help

children achieve the best visual prognosis, pediatric ophthalmologists need to be aware of the development of pediatric IOL implantation, understand the physiological and pathological characteristics of the pediatric capsular bag, weigh the risks and benefits of IOL implantation, and master the surgical indications and techniques of all the associated surgical procedures.

References

1. Lambert SR, Drack AV. Infantile cataracts. *Surv Ophthalmol*. 1996;40(6):427–58.
[CrossRef][PubMed]
2. Ahmadieh H, Javadi MA. Intra-ocular lens implantation in children. *Curr Opin Ophthalmol*. 2001;12(1):30–4.
[CrossRef][PubMed]
3. Dahan E. Intraocular lens implantation in children. *Curr Opin Ophthalmol*. 2000;11(1):51–5.
[CrossRef][PubMed]
4. Choyce DP. IOLs in children. *J Am Intraocul Implant Soc*. 1979;5(2):146–7.
[CrossRef][PubMed]
5. Lambert SR, Lynn M, Drews-Botsch C, et al. A comparison of grating visual acuity, strabismus, and reoperation outcomes among children with aphakia and pseudophakia after unilateral cataract surgery during the first six months of life. *J AAPOS*. 2001;5(2):70–5.
[CrossRef][PubMed]
6. Letocha CE, Pavlin CJ. Follow-up of 3 patients with Ridley intraocular lens implantation. *J Cataract Refract Surg*. 1999;25(4):587–91.
[CrossRef][PubMed]
7. Choyce DP. Intraocular lenses and implants. London: HK Lewis & Co; 1964.
8. Binkhorst CD, Gobin MH. Injuries to the eye with lens opacity in young children. *Ophthalmologica*. 1964;148:169–83.
[CrossRef][PubMed]
9. Binkhorst CD, Greaves B, Kats A, et al. Lens injury in children treated with irido-capsular supported intra-ocular lenses. *J Am Intraocul Implant Soc*. 1978;4(2):34–49.
[CrossRef][PubMed]
10. Hiles DA, Hered RW. Modern intraocular lens implants in children with new age limitations. *J Cataract Refract Surg*. 1987;13(5):493–7.
[CrossRef][PubMed]
11. Binkhorst CD, Gobin MH. Treatment of congenital and juvenile cataract with intraocular lens implants (pseudophakoi). *Br J Ophthalmol*. 1970;54(11):759–65.
[CrossRef][PubMed][PubMedCentral]

12. Tadros D, Trivedi RH, Wilson ME. Primary versus secondary IOL implantation following removal of infantile unilateral congenital cataract: outcomes after at least 5 years. *J AAPOS*. 2016;20(1):25–9.
[CrossRef][PubMed]
13. Solebo AL, Russell-Eggitt I, Cumberland PM, et al. Risks and outcomes associated with primary intraocular lens implantation in children under 2 years of age: the IoLunder2 cohort study. *Br J Ophthalmol*. 2015;99(11):1471–6.
[CrossRef][PubMed]
14. Kumar P, Lambert SR. Evaluating the evidence for and against the use of IOLs in infants and young children. *Expert Rev Med Devices*. 2016;13(4):381–9.
[CrossRef][PubMed][PubMedCentral]
15. Struck MC. Long-term Results of Pediatric Cataract Surgery and Primary Intraocular Lens Implantation From 7 to 22 Months of Life. *JAMA Ophthalmol*. 2015;133(10):1180–3.
[CrossRef][PubMed]
16. Vasavada A, Desai J. Primary posterior capsulorhexis with and without anterior vitrectomy in congenital cataracts. *J Cataract Refract Surg*. 1997;23 Suppl 1:645–51.
[CrossRef][PubMed]
17. Vasavada A, Chauhan H. Intraocular lens implantation in infants with congenital cataracts. *J Cataract Refract Surg*. 1994;20(6):592–8.
[CrossRef][PubMed]
18. Apple DJ, Solomon KD, Tetz MR, et al. Posterior capsule opacification. *Surv Ophthalmol*. 1992;37(2):73–116.
[CrossRef][PubMed]
19. Hong AR, Sheybani A, Huang AJ. Intraoperative management of posterior capsular rupture. *Curr Opin Ophthalmol*. 2015;26(1):16–21.
[CrossRef][PubMed]
20. Lin H, Tan X, Lin Z, et al. Capsular outcomes differ with capsulorhexis sizes after pediatric cataract surgery: a randomized controlled trial. *Sci Rep*. 2015;5:16227.
[CrossRef][PubMed][PubMedCentral]
21. Luo L, Lin H, Chen W, et al. In-the-bag intraocular lens placement via secondary capsulorhexis with radiofrequency diathermy in pediatric aphakic eyes. *PLoS One*. 2013;8(4), e62381.
[CrossRef][PubMed][PubMedCentral]
22. Teichman JC, Compan J, Conlon R, et al. Use of a security suture during retropupillary implantation of an iris-claw IOL. *J Cataract Refract Surg*. 2015;41(9):2019.
[CrossRef][PubMed]
23. Gayton JL, Sanders VN. Implanting two posterior chamber intraocular lenses in a case of microphthalmos. *J Cataract Refract Surg*. 1993;19(6):776–7.
[CrossRef][PubMed]
24. Lin JT. Comparing anterior and posterior piggyback IOL power calculations in 2-optics and 3-

optics systems. *J Refract Surg.* 2008;24(7):665–6.
[\[PubMed\]](#)

25. Alio JL, Abdelghany AA, Fernandez-Buenaga R. Management of residual refractive error after cataract surgery. *Curr Opin Ophthalmol.* 2014;25(4):291–7.
[\[CrossRef\]](#)[\[PubMed\]](#)

16. Cataract Surgery in Children with Anomalies of the Uvea

Mingxing Wu¹✉, Weirong Chen¹ and Zhenzhen Liu¹

- (1) State Key Laboratory of Ophthalmology, Zhongshan Ophthalmic Center, Sun Yat-sen University, 54S Xianlie Road, Guangzhou, 510060, People's Republic of China

✉ **Mingxing Wu**

Email: wumingx@mail.sysu.edu.cn

Abstract

Congenital uveal abnormalities in the presence of pediatric cataracts include aniridia, iris coloboma, persistent pupillary membrane, and pupil deformation. Congenital uveal abnormalities are associated with gene mutations and are often accompanied by other ocular or systemic abnormalities. Pediatric uveitis complicated with cataract is a common acquired uveal abnormality. With concurrent uveal abnormalities, cataract surgery may be more difficult to perform, and postoperative outcomes may also be affected. This chapter will explain how to manage various uveal abnormalities during pediatric cataract surgery and also discusses the application of prosthetic iris devices in pediatric eyes, including iris diaphragm intraocular lens, artificial iris, and capsular tension ring with iris diaphragm.

Pediatric cataract with uveal anomalies discussed in this chapter concentrates on cataract with congenital anomalies of the uvea and uveitis-associated cataract. Congenital anomalies of the uvea consist mainly of aniridia,

coloboma of the iris, and persistent pupillary membrane. Compared with routine pediatric cataract surgery, it is quite difficult to perform cataract surgery in children with anomalies of the uvea that requires specific surgical techniques and proper auxiliary devices to achieve desirable surgical outcomes.

16.1 Pediatric Cataract with Congenital Anomalies of the Uvea

16.1.1 Pediatric Cataract with Congenital Aniridia

Congenital aniridia is caused by developmental defects of the neuroectoderm or mesoderm and cessation of iris development at a primitive stage. The incidence of the disease is approximately 1:64,000 ~ 100,000, with two-thirds of pediatric patients having family histories and one-third being sporadic cases [1]. Eighty-five percent of the cases follow the autosomal dominant inheritance pattern, whereas a small number of them belong to autosomal recessive inheritance [1].

16.1.1.1 Classification and Clinical Manifestations of Congenital Aniridia

On the basis of concurrent ocular and systemic anomalies, congenital aniridia falls into four categories: type I, dominated by ocular anomalies, aniridia with poor visual function, and accompanied by cataract, nystagmus, glaucoma, and macular (foveal) hypoplasia [2]; type II, aniridia, but with good visual acuity; type III, aniridia accompanied with intellectual disability; and type IV, aniridia with Wilms' tumor [3, 4].

Photophobia is the main symptom of pediatric patients with congenital aniridia. Slit-lamp microscopy may reveal absence of the iris as well as other ocular anomalies, and there are systemic anomalies in some pediatric patients. Specific manifestations are described as follows:

Ocular Anomalies

1. Keratopathy: Almost all pediatric patients have corneal epithelial changes with earlier emergence. In 20 % of the cases, there is a typical

aniridia-associated keratopathy (AAK), whose occurrence is related to limbal stem cell deficiency (LSCD), primarily presented as peripheral corneal thickening and neovascularization (Fig. 16.1a) [5]. Keratopathy extends progressively to the center and involves the entire cornea, resulting in corneal ulcer, sub-epithelial fibrous hyperplasia, and corneal decompensation. Additionally, there are cases presenting as microcornea and keratoconus [1, 5].

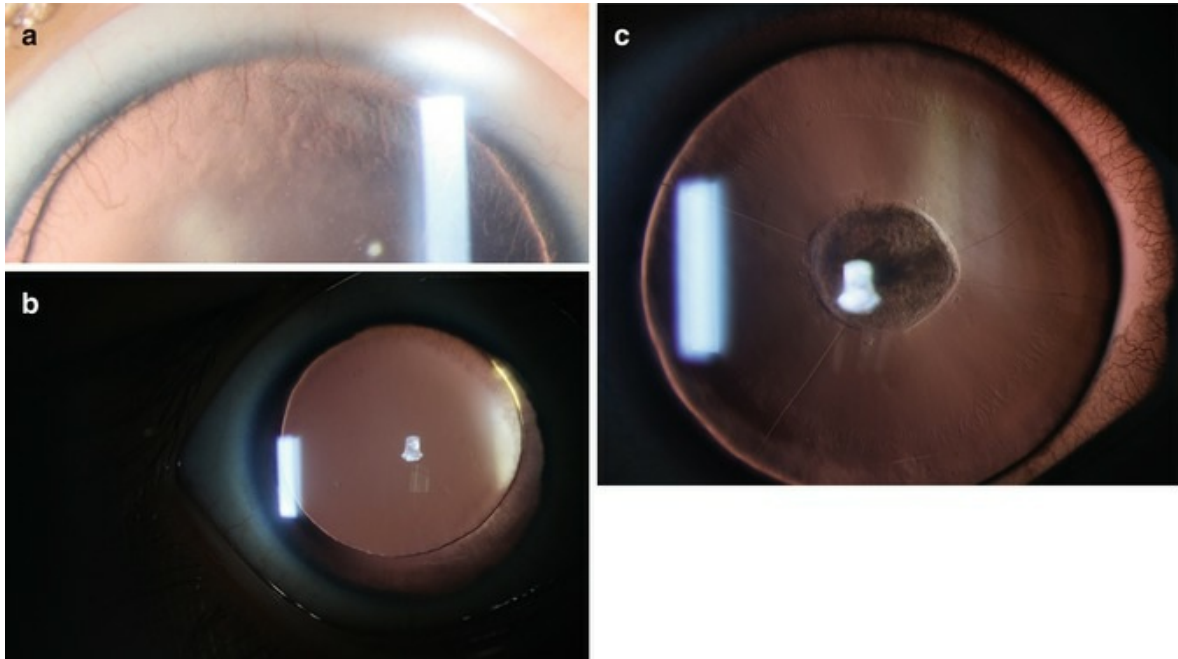


Fig. 16.1 Congenital aniridia. (a) Congenital aniridia complicated by keratopathy. Corneal neovascularization at the limbus in a 5-year-old boy. (b) Congenital aniridia complicated by cataract in a 6-year-old girl. (c) Congenital aniridia complicated by lens dislocation in an 8-year-old girl

2. Iris anomalies: They are mainly bilateral. The iris is largely absent with iris stump seen under gonioscope.
3. Glaucoma: It is one of the most frequent complications. In the early phase, the trabecular meshwork is normal, but with physical growth and development, residue of the iris may adhere to the wall of the anterior chamber angle or trabecular meshwork, which gives rise to angle closure. Moreover, glaucoma can also occasionally arise from lens dislocation.

4. Lens anomalies

1. Cataract (Fig. 16.1b): It is the most frequent complication. It has been reported that 50–80 % of cases were complicated by cataract [6]. Lens opacification often arises at birth, presented as small anterior or posterior polar cataracts. Opacification can grow worse as pediatric patients get older.
 2. Lens dislocation (Fig. 16.1c): Zamzam and colleagues reported that up to 56 % of cases were complicated by lens dislocation [7].
5. Fundus lesions: Optic nerve and macular (foveal) hypoplasia are frequent fundus changes. They might be both present as comorbidities. Children with macular (foveal) hypoplasia often have concurrent horizontal nystagmus. In addition, children with aniridia are predisposed to retinal tear and detachment.

Systemic Anomalies

1. Wilms' tumor: There are 25–33 % of pediatric patients with congenital sporadic aniridia that are complicated by this kind of renal neoplasm. The reason may be that an interstitial deletion of the short arm of chromosome 11p involves congenital aniridia and the Wilms' tumor suppressor gene simultaneously. Wilms' tumor, congenital aniridia, genitourinary anomalies, and mental retardation (Wilms' tumor-aniridia-genital anomalies-retardation) are collectively termed WAGR syndrome [3, 4].
2. Gillespie's syndrome: Being relatively rare and resulting from autosomal recessive inheritance, the syndrome is presented primarily as cerebellar ataxia, ptosis, and mental retardation [8, 9].

16.1.1.2 Surgery

Preoperative Assessment

Since pediatric patients with congenital aniridia are often complicated with various ocular anomalies, it is necessary to carry out a detailed preoperative assessment.

1. Identify the leading cause of children visual impairment. Since decreased visual acuity can be triggered by various factors such as lens opacification, corneal opacification, glaucoma, etc., doctors are supposed to identify the main contributing factor.
2. The anatomical characteristics of pediatric eyeball, such as the condition of capsular bag and zonules, should be fully assessed when adopting surgical strategies to deal with congenital aniridia. The relatively narrow intraocular space and immature capsular bag of pediatric patients are prone to exert negative effect on the implantation of iris prosthesis and capsular tension ring.
3. Assessing other coexisting factors which are related to visual acuity. As for the cases in which visual impairment is mainly triggered by cataract, other coexisting abnormalities are supposed to be fully considered when adopting appropriate treatment strategies. For example, when mild to medium corneal opacification has little effect on cataract surgery, preference should be given to cataract surgery before further treatment is considered according to corneal conditions. On the contrary, if there is severe corneal opacification which interferes with cataract surgery, corneal surgery or combined surgery is the prime option. Additionally, gonioscopy must be conducted in detail to identify whether there are anterior chamber angle anomalies. If necessary, three-mirror contact lens or an indirect ophthalmoscope may be used for fundus examination to rule out or perform prophylactic treatment to occult peripheral retinal lesions.

Selection and Techniques of Operation

1. Cataract extraction and IOL implantation: Most pediatric patients with congenital aniridia combined with cataract do not show significant lens

opacity at birth, and the lens opacity gradually increases with age; therefore, cataract extraction is normally conducted after 3 years old. Cataract extraction and IOL implantation are the most common surgical methods. In author's opinion, simple cataract extraction and IOL implantation are feasible, especially when the anterior segment narrow space and lens capsular defects are found in preoperative assessment, and no iris prosthesis implantation can be used.

1. Incision: The incision location, type, and size are of utmost importance to ensure smooth surgical procedure as well as desirable postoperation visual acuity. Children with congenital aniridia are often combined with corneal abnormalities. In order to avoid further damage to the cornea, reduce surgically induced astigmatism (SIA), provide operating convenience, and offer postoperative incision nursing care, the superior scleral tunnel incision is usually used, but some argue that a clear corneal incision can reduce intraoperative and postoperative bleeding [10].
2. Capsulorhexis: Due to the thin and brittle nature of the anterior capsule as well as the absence of iris in congenital aniridia patients, an oversized capsulorhexis easily leads to capsular rupture. Capsulorhexis is not supposed to be larger than the optical surface of IOL in diameter [11]. Oversize capsulorhexis opening may result in significant IOL edge effect. Therefore, capsulorhexis diameter should be restrained within 4.5–5 mm [11]. Furthermore, residual anterior capsule on the periphery can alleviate photophobia in these children to some extent. Capsule staining technique can be applied intraoperatively to increase visibility.
3. Hydrodissection and hydrodelineation: The anterior capsule is thin and brittle in these children, and the absence of iris eliminates the barrier between the cornea and the lens. Slow injection at multiple sites within the capsular bag is recommended. This avoids sudden elevation of pressure inside the capsule that results in capsule damage, as well as forward dislocation of the nucleus that causes mechanical damage to the cornea.

4. Lens extraction: Either cataract aspiration or phacoemulsification is chosen based on the hardness of lens opacification.
 5. IOL implantation: By measuring the limbus white-to-white distance, the diameter of the capsular bag can be estimated; thus appropriate IOL can be selected. Under the premise of intracapsular IOL implantation, IOLs with larger optics are suggested, so that the rim of the optics can be covered by the anterior capsular, which is able to reduce IOL edge effect.
2. Iris prosthesis implantation combined with IOL implantation.
- In pediatric cataract patients complicated by congenital aniridia, if simple IOL implantation is performed following cataract surgery, higher-order aberrations in the eyes with large pupils and the edge effect of IOL will be significant [12], which affects pediatric patients' visual function. At present, a variety of pigmented materials are used as artificial iris for long-term intraocular implantation in adults, such as single piece iris diaphragm IOL, emulated artificial iris, and capsular tension ring with iris diaphragm. However, those aforementioned iris prostheses are rarely used in pediatric patients with cataract complicated by congenital aniridia. Only a few argue that those prostheses can be implanted in children with traumatic aniridia. The long-term effect remains to be observed. Problems with these devices include brittleness, low plasticity, and being liable to fracture intraoperatively and postoperatively [11, 13–15]. In addition, the implanted artificial iris and tension ring tend to give rise to a crowded capsular bag, placing a heavier load on the capsular bag, which is already weak in this case. What's more, they may trigger complications including inflammatory response, corneal endothelial damage, glaucoma, and increase the incidence of posterior capsular opacification (PCO). Therefore, the authors think that this type of implant needs to be prudently chosen.

16.1.2 Pediatric Cataract with Iris Coloboma

16.1.2.1 Classification of Congenital Iris Coloboma

1. Typical iris coloboma: It is presented as total iris coloboma inferior to the pupil. It is caused by incomplete fusion of ocular fissures and might be accompanied by colobomas of the ciliary body, the choroid, and the lens.
2. Simple iris coloboma: It occurs after normal fusion of ocular fissures and is not complicated by other colobomas of the uvea. From the 1930s to the 1980s, patients with congenital cataract, particularly lamellar cataract, were often treated with optical iridectomy [16, 17]. Sector coloboma of the iris occurs mostly in the inferonasal quadrant after optical iridectomy and is easily confused with congenital iris coloboma. The main distinction between eyes with congenital iridocoloboma and those after optical iridectomy lies in the fact that the pigment collar and sphincter pupillae at the pupil edge of the former always extend from the defect zone to the limbus, whereas there is no pigment collar at the edge of the defect in the latter (Fig. 16.2).

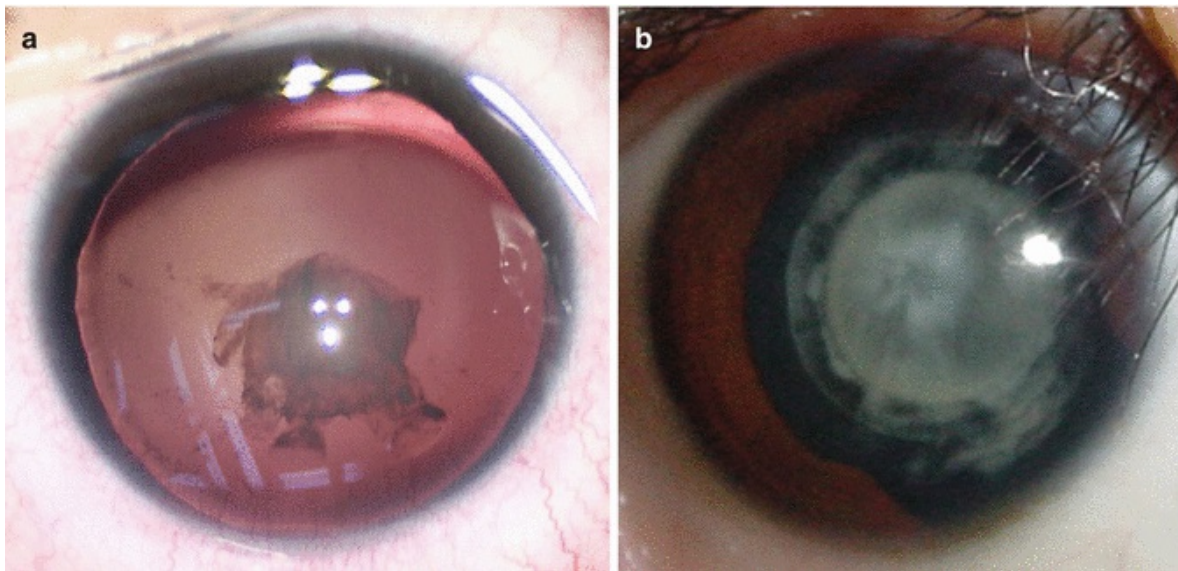


Fig. 16.2 (a) Congenital iris coloboma. (b) Acquired iris coloboma caused by segmental iridectomy

16.1.2.2 Surgical Treatment of Congenital Iris Coloboma

Selection of Surgical Intervention

For children with congenital iris coloboma complicated by cataract, surgical techniques should be determined based on the size and location of coloboma. It is generally believed that coreoplasty can be chosen when the proportion of coloboma is less than 1/4 of the iris. When the size of coloboma is more than 1/4, tension of iris sutures becomes greater and iris tear often ensues.

For children following optical iridectomy, most of the remaining sphincter pupillae functions normally. Cataract extraction combined with IOL implantation and coreoplasty are often adopted.

Surgical Techniques

1. Cataract extraction combined with IOL implantation: The surgical techniques are the same as the routine pediatric cataract extraction combined with IOL implantation (Fig. 16.3).

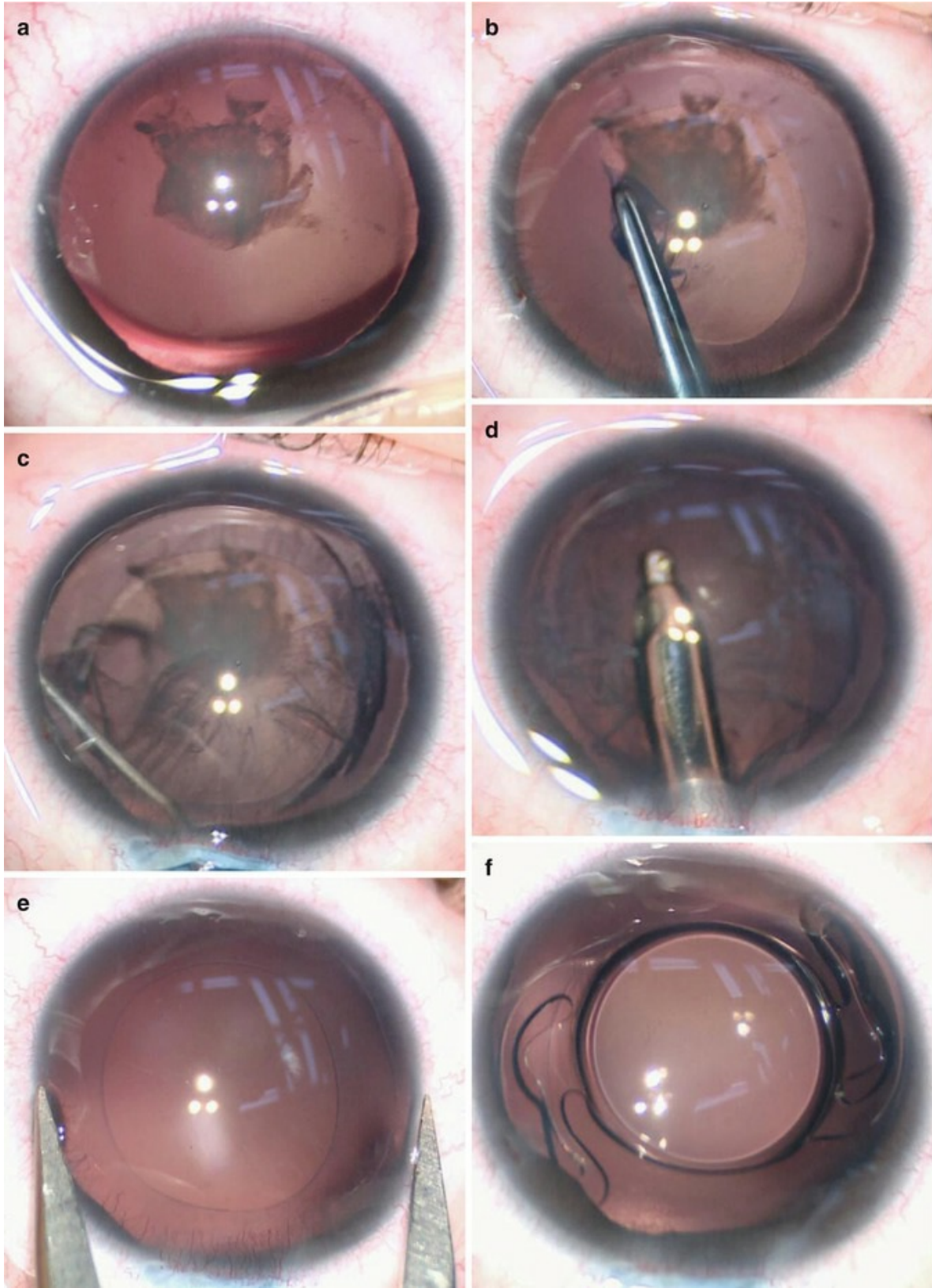


Fig. 16.3 Surgical procedure of congenital cataract combined iris coloboma. (a) Preoperative

image shows iris coloboma from 3 to 9 o'clock (the image is upside down); **(b)** capsulorhexis with the assistance of trypan blue; **(c)** hydrodissection; **(d)** cortical aspiration of the remanescant lens; **(e)** estimation of the capsular bag size by measuring the limbus white-to-white distance; **(f)** IOL implantation with appropriate diameter according to previous step results

2. Coreoplasty: One percent of carbachol is used for miosis in order to control suture tension. Sufficient OVD is instilled into the anterior chamber (preferably cohesive OVD) to provide space for manipulation and prevent hyphema. A 10–0 nylon suture or polypropylene suture is used. The needle is inserted through the cornea at the site of iris coloboma, and passes through the opposing iris at about 0.5 mm outside the pupillary margin, and is withdrawn from the opposing cornea. Make sure to keep off the pupillary zone. The forceps enter through the incision into the anterior chamber to knot, and the ligation is not supposed to be too tight in order to prevent iris tear. Finally, with the residual OVD in the anterior chamber cleared, one suture is placed in the incision for closure (Fig. 16.4). The postoperative management is similar to common intraocular surgery. If there is severe inflammatory response in the anterior chamber, mydriatics may be applied.

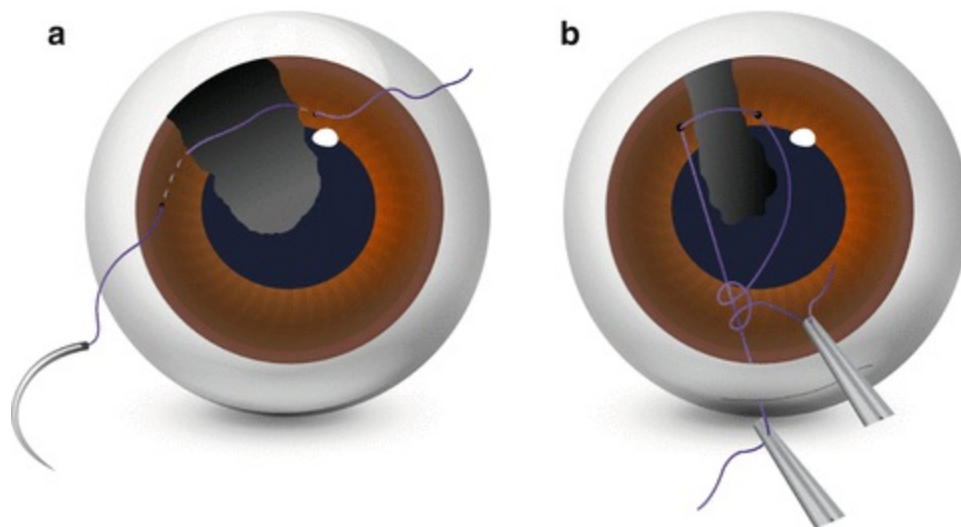


Fig. 16.4 Coreoplasty. **(a)** Entry and exit of suture. **(b)** Knot-tying in the anterior chamber

The detailed procedure of the slipknot technique for iris suture is as follows (Fig. 16.5): After the corneal paracentesis is made with a 15° blade, a

long straight needle with 10–0 polypropylene thread enters from the paracentesis into the anterior chamber. It passes through opposing edges of the iris to be sutured and leaves through the opposite limbus. Since the iris itself is soft, it might be difficult for the suture needle to go through the iris. In this case, a 1 ml syringe needle can be used to fix the long straight needle to go through the iris. A forcep enters through the paracentesis and grabs onto the suture at the other end. The tail near needle insertion and the opposite suture are wound into a double knot. Both ends of the suture are tightened and the suture is knotted by itself. The second and third knots are tied and tightened in the same way, thus forming firm knots. Vannas capsulotomy scissors are inserted through the tunnel incision to snip away the end of the knot.

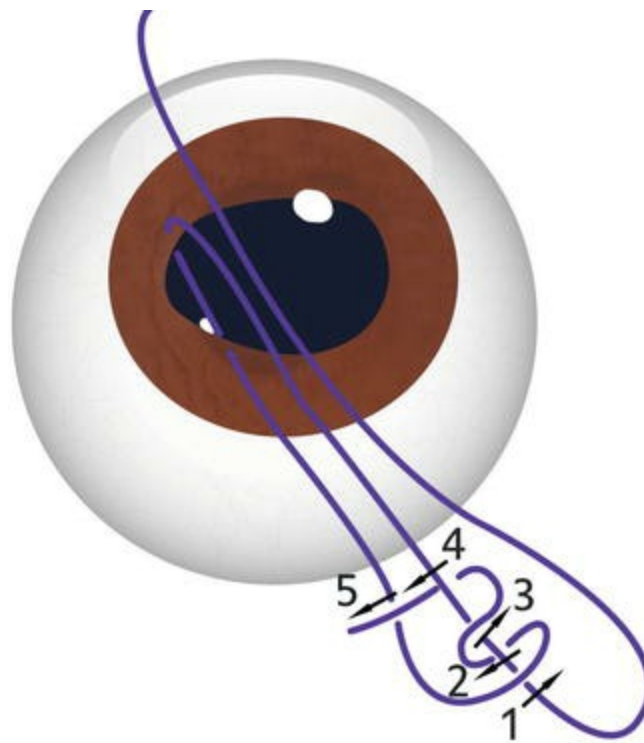


Fig. 16.5 Coreoplasty: suture closure of the iris performed with the slipknot technique

16.1.3 Pediatric Cataract with Persistent Pupillary Membranes

Incomplete regression of tunica vasculosa lentis during the embryonic period may result in residual iris tissue in front of the lens anterior capsule (i.e.,

persistent pupillary membranes). With an approximately 30–95 % prevalence in neonates, most of persistent pupillary membranes achieve complete regression within 1 year after birth, and only a few of them last for a long time.

16.1.3.1 Classification and Clinical Manifestations of Persistent Pupillary Membranes

Based on the site of occurrence, persistent pupillary membranes can be classified as those at the iris or those attached to the lens. The former originate from the iris surface, with the other end shaped like fibers, strips, or sheets and attached to the surface of the lens anterior capsule (Fig. 16.6). Localized white opacities can be seen at the site of lens attachment. The latter bear no connection to the iris and are presented as dispersed, tiny residual pigmented membranes that appear as spots or stars and are attached to the anterior capsule.

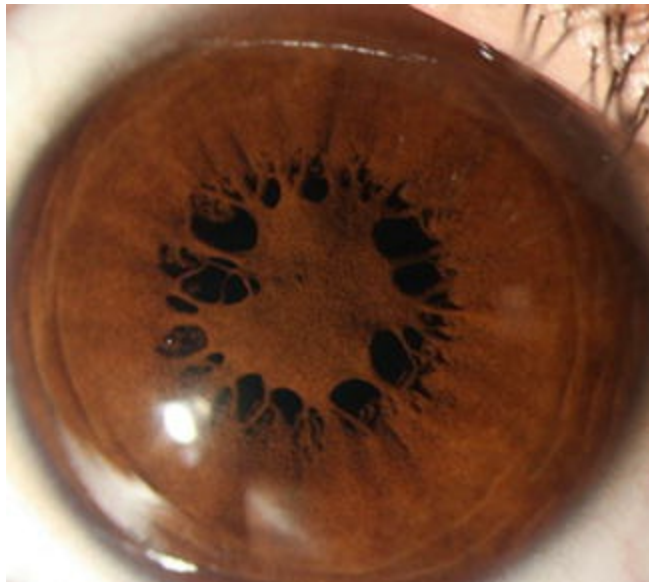

Fig. 16.6 Congenital persistent pupillary membranes

The majority of persistent pupillary membranes are isolated findings. Severe cases may be accompanied by other ocular anomalies, such as microcornea, microphthalmia, cataract, glaucoma, macular hypoplasia, and aniridia. A small proportion of pediatric patients may have systemic anomalies.

16.1.3.2 Surgical Treatments

Currently, the surgical treatments for persistent pupillary membranes are membrane removal with laser and membrane resection.

Selection of Surgical Intervention and Preoperative Assessment

Persistent pupillary membranes not affecting pupil movement and those not in the pupillary zone or occupying only a small pupil area are visually insignificant. Conservative treatments including mydriasis can be applied in this case. Nevertheless, when larger membranes in the pupillary zone obscure the visual axis and cause visual impairment or even deprivation amblyopia in pediatric patients, surgical intervention must be performed in time. Small persistent pupillary membranes without obvious organization can be treated with membrane removal by laser, whereas larger pupillary membranes with severe organization require membrane resection. Additionally, those with significant lens opacification on the visual axis require the combination of routine cataract extraction and IOL implantation.

Electroretinogram (ERG), pattern visual evoked potential (P-VEP), and fixation status can be examined preoperatively to evaluate likely visual outcomes. As persistent pupillary membranes are frequently complicated by congenital anomalies, such as angle dysplasia, which leads to a high incidence of postoperative glaucoma, so the anterior chamber angle needs to be examined carefully.

Surgical Methods

1. Residual membrane removal with laser

Nd:YAG laser is typically used. However, laser often fails to achieve effective removal in the case of thick membranes with severe organization. Moreover, laser treatment is liable to cause hyphema, secondary glaucoma, uveitis, and other complications.

2. Resection of persistent pupillary membranes

Briefly, a fornix-based conjunctival flap is made after anesthesia, and the limbus is exposed for the construction of a limbal incision. OVD is injected into the space between the lens anterior capsule and persistent

pupillary membranes. Vannas capsulotomy scissors is used to cut off the membranes along their edges and close to the iris surface before they are removed (Fig. 16.7). If necessary, routine cataract extraction with IOL implantation should be performed.

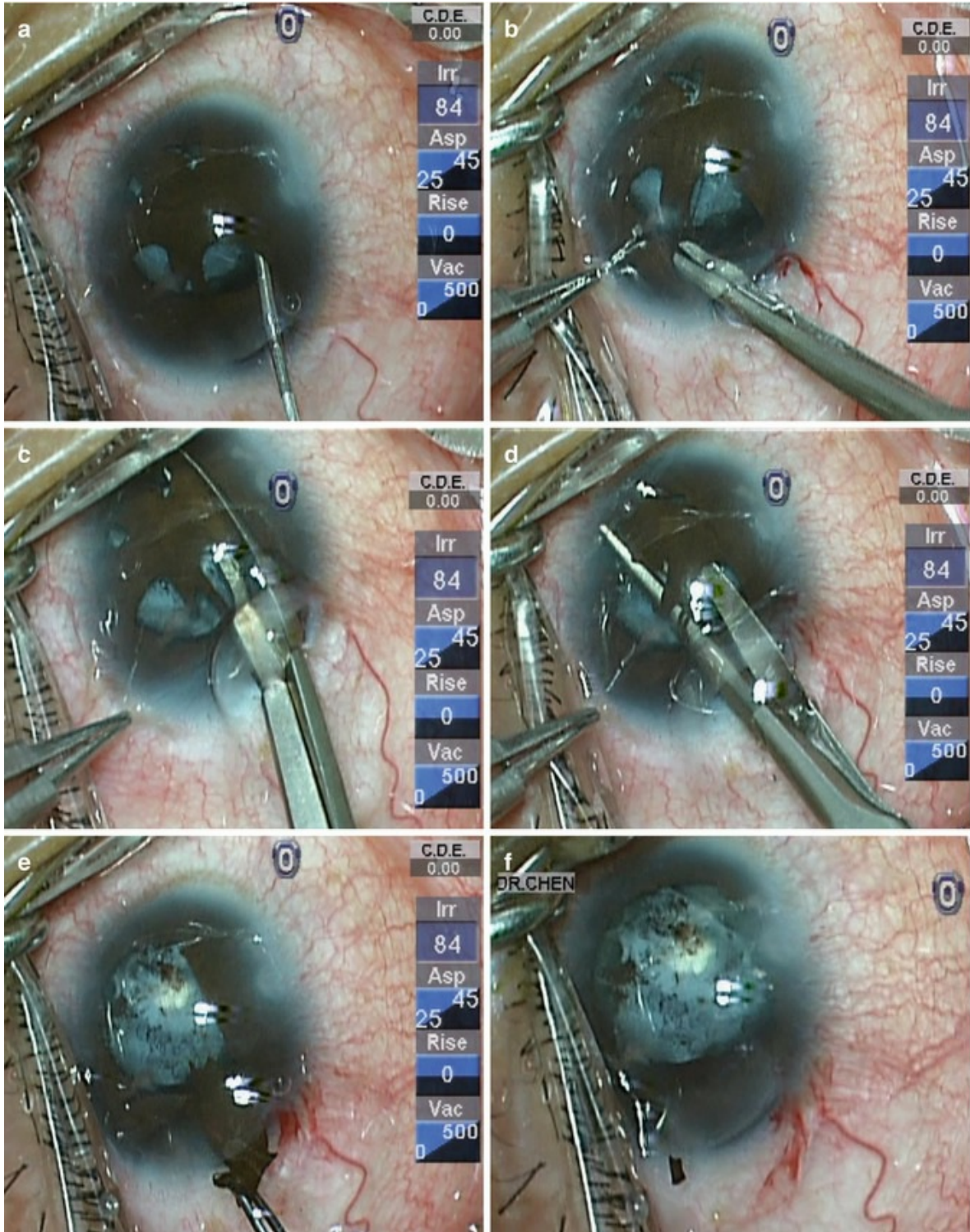


Fig. 16.7 Resection of persistent pupillary membranes. (a) OVD is injected into the space between the lens anterior capsule and persistent pupillary membranes. (b–d) Vannas capsulotomy scissor is used to cut off the membranes along the pupil edge. (e) Capsulorhexis forceps is used to remove the free persistent pupillary membranes. (f) After persistent pupillary membrane resection

16.2 Cataract in Children with Uveitis

Pediatric uveitis possesses the characteristics of insidious onset, mild symptoms, being prone to chronicity, more complications, and a high probability of causing blindness. Due to the insidious onset and the minor inflammatory response and irritation, pediatric uveitis tends to be ignored by parents, which results in delayed diagnosis and treatment. They seek medical advice only when diminished visual acuity occurs in their children.

Complicated cataract, band keratopathy, and secondary glaucoma are important causes for visual impairment in children with uveitis.

16.2.1 Classification and Clinical Manifestations of Pediatric Uveitis

16.2.1.1 Classification

According to the affected tissues, pediatric uveitis is commonly divided as anterior uveitis, intermediate uveitis, posterior uveitis, and panuveitis. But common causes of uveitis in pediatric patients are different from adults.

1. **Anterior uveitis:** It is the most common type of pediatric uveitis (30–50 %) and involves only the iris and anterior ciliary body, leaving the pars plana intact. Noninfectious inflammation is common in juvenile idiopathic arthritis (JIA), while infectious inflammation is common in herpes virus infection. Pediatric patients may have ocular pain, photophobia, tearing and reduced visual acuity. The following signs can be seen using slit-lamp microscopy: circumcorneal injection or mixed congestion, flare in the anterior chamber, keratic precipitates (KP), fibrous exudation in the anterior chamber, anterior or posterior synechia, and pupil deformation.
2. **Intermediate uveitis:** It refers to choroid retinal inflammation involving pars plana and ora serrata. Generally, it is idiopathic and accounts for 10–20 % of pediatric uveitis. Apart from decreased visual acuity and anterior segment inflammation, “snowbank” deposition over the pars plana is the typical sign. Retina involvement is sometimes present.

3. Posterior uveitis: It refers to choroid retinal inflammation involving the equatorial and posterior parts of retina. The proportion of posterior uveitis in pediatric uveitis is about 10–20 %, of which infectious inflammation is common in *Toxoplasma gondii* or tuberculosis (TB), whereas noninfectious inflammation mainly includes idiopathic inflammation or sarcoidosis. The level of visual impairment in pediatric patients depends on diseased sites and severity of vitreous opacification. Fundus examination shows focal lesions of retinal exudation, edema, and hemorrhage. In the advanced stage, retina pigmentation, “sunset glow” fundus, scarring, and proliferative lesions can be seen.
4. Panuveitis: It is the inflammation of all layers of the uvea. The proportion of panuveitis in pediatric uveitis is about 5–10 %, which is primarily related to TB or sarcoidosis. All the aforementioned ocular manifestations can be observed in panuveitis.

16.2.1.2 Ocular and Systemic Comorbidities of Pediatric Uveitis

In addition to inflammation, ophthalmic manifestations of pediatric uveitis may include complicated cataract, band keratopathy, secondary glaucoma, and retinopathy, among which band keratopathy is the common manifestation of pediatric uveitis.

Systemic diseases related to pediatric uveitis include JIA, inflammatory bowel disease (IBD), Reiter’s disease, ankylosing spondylitis, and infectious diseases, among which JIA is the most common.

16.2.1.3 Causes of Cataract in Children with Uveitis

Approximately 40–60 % of children with uveitis may develop complicated cataract, much higher than in adults. The high incidence of pediatric cataract is associated with the uveitis itself and the treatment for uveitis.

It has been reported that 18 ~ 46 % of JIA patients and 46.9 % of children with Behcet disease develop complicated cataract. Both JIA and Behcet disease may give rise to severe, repeated anterior chamber inflammation and posterior synechia. Therefore, during the early stage of cataract formation in

these two diseases, affected children typically present with anterior subcapsular opacification [18–20]. In children with intermediate or posterior uveitis, however, lens opacification often begins in the posterior subcapsular portion, which is adjacent to the location of active inflammation.

Additionally, steroid and vitrectomy treatments for uveitis patients may bring about complicated cataract, especially posterior subcapsular opacities.

16.2.2 Treatment for Cataract in Children with Uveitis

16.2.2.1 Therapeutic Strategy

Due to concurrent autoimmune diseases, or unknown pathogenic factors, inflammation in pediatric uveitis is difficult to control. What's more, the anatomical characteristics and the immature blood-aqueous of children result in severe and persistent inflammation after cataract surgery, which would definitely impact the prognosis. Therefore, effective perioperative anti-inflammation therapy is of utmost importance to ensure satisfied prognosis in pediatric uveitis of which cataract needs to be removed. Generally, only after inflammation remains stationary for at least 3 months can cataract surgery be performed for pediatric uveitis [21].

16.2.2.2 Perioperative Preparation

1. Prophylactic anti-inflammation therapy

Decisions on whether local and/or systemic use of prophylactic anti-inflammatory therapy is needed and whether a combined therapy is needed are made based on causes of disease and severity during active inflammation. For local anti-inflammation, 1 % prednisolone acetate or 0.1 % dexamethasone eye drops can be used five times per day for a week before surgery. Steroids or nonsteroidal anti-inflammatory drugs (NSAIDs) can be used for prophylactic systematic administration, for instance, oral prednisolone $0.8 \sim 1.0 \text{ mg} \cdot \text{kg}^{-1} \cdot \text{d}^{-1}$ for 3 days before surgery [22].

2. Preoperative mydriasis

Sufficient preoperative mydriasis is crucial for the operative procedure. For those children with iris synechia, mydriatic agents can be

administered 3 days prior to the surgery, and tropicamide is supposed to be applied three times topically within 30 min before operation.

16.2.2.3 Surgical Notifications

1. Incision: The location, type, and size of the incision are of significance in maintaining the stability of the operation. Modified scleral tunnel incision at the 12 o'clock is commonly constructed in order to avoid prolapse of iris during operation, which would aggravate postoperative inflammation. Additionally, pediatric uveitis is frequently accompanied by corneal degeneration. Thus, incision should not be constructed in corneal degeneration regions in order to avoid further damage to the cornea.
2. Separation of iris synechia: This is the most important and challenging step during pediatric cataract surgery combined uveitis. The intraoperative manipulation on the iris should be minimized so as to alleviate the postoperative inflammatory response. Ophthalmic viscosurgical devices (OVD) can be injected to release iris synechia and provide enough operating space. With the assistance of OVD, capsulotomy scissors can be applied to separate partial synechia of the iris. Meanwhile, surgical instruments are not allowed to stretch the iris directly and repeatedly.
3. Small pupil: Pupillary membrane should be removed during surgery. If the pupil cannot be dilated, partial radial sphincterotomy may be performed, and iris retractors or other devices to enlarge the pupillary aperture can also be used.
4. Clearance of OVD and lens materials: OVD and lens materials are ought to be removed completely to alleviate postoperative inflammation.
5. IOL implantation: IOL should be implanted in the capsular bag as far as possible in order to avoid the mechanical contact of IOL with the iris,

anterior chamber angle, and ciliary body, which may cause postoperative inflammation.

16.2.2.4 IOL Implantation and Selection

Whether an IOL should be implanted in cataract surgery for children with uveitis remains controversial. According to the author's experience, in pediatric uveitis complicated by cataract, especially in cases combined with JIA, it is not suggested to implant IOL, because of active postoperative systemic or topical inflammation, which leads to undesirable prognosis. On the contrary, some studies argued that IOL implantation on the basis of rigorous control of surgical indications is more favorable to visual rehabilitation [23–25].

There is still lack of research about IOL materials for children with uveitis. Heparin surface-modified (HSM) IOLs have been demonstrated that they have mild postoperative inflammatory response, so they might be more suitable for children with uveitis complicated by cataract than other materials [26]. However, other study reported that no distinction was found between implantation of HSM and non-heparin surface-modified IOLs in patients with inactive uveitis [27].

16.2.2.5 Postoperative Management

As mentioned before, the control of postoperative inflammation in children with uveitis is the most crucial factor that deciding visual prognosis. The postoperative ocular inflammation can induce iris synechia, pupil occlusion, and even anterior chamber angle malfunction, resulting in elevated IOP and secondary glaucoma. In addition, the formation of inflammatory exudative membrane can contract and stretch surrounding tissues, which may lead to IOL dislocation. Therefore, a close postoperative follow-up is needed in children with uveitis. Meanwhile, comprehensive measures are ought to be conducted to effectively control inflammation, which may reduce postoperative complications.

Postoperative Anti-inflammatory Treatment

1. Steroid medications

For pediatric patients with systemic autoimmune diseases, such as

JIA, subconjunctival or retrobulbar injection of betamethasone or dexamethasone 2 ~ 4 mg can be conducted at the end of operation, in order to alleviate the postoperative inflammatory [28, 29]. Postoperative administration of corticosteroid eye drops, such as prednisolone, dexamethasone, and fluorometholone, is routinely given. Frequency of administration should depend on children's individual conditions, usually once every 2 h in the first week postoperatively, and is tapered subsequently. The duration of postoperative corticosteroid therapy may be appropriately extended for children with uveitis complicated by congenital cataract. The maximum duration is about 8 weeks, but IOP should be closely monitored. If IOP is found to be elevated, there should be timely drug withdrawal as well as complication management.

At present, it is generally not recommended that systemic corticosteroids are routinely administered after pediatric cataract surgery to avoid adverse drug effects. But for children with complicated conditions, excessive intraoperative manipulations, or severe postoperative inflammatory response, systemic administration of corticosteroids can be considered [30].

2. NSAIDs

NSAIDs exert their anti-inflammatory effects by inhibiting cyclooxygenase (COX) activity and blocking prostaglandin synthesis. Long-term topical administration does not cause such adverse effects as elevated IOP, infection, and delayed wound healing. Therefore, they are regarded as ancillary or alternative drugs for the control of inflammation following childhood cataract surgery. Commonly used eye drops in clinical practice are 0.1 % bromfenac sodium, 1.0 % indomethacin, 0.1 % diclofenac sodium, 0.5 % ketorolac, and 1.0 % pranoprofen. Note that NSAID eye drops are irritating to a certain extent, and therefore some young children are not cooperative when taking them.

Monitor and Control of IOP

IOP should be monitored closely in pediatric patients postoperatively. If there is only a mild increase in IOP in early postoperative stage, IOP can return to normal after administering effective anti-inflammatory agents. If the high IOP remains after anti-inflammation therapy, IOP-lowering medication is

recommended to control IOP. In addition, surgical intervention is needed if necessary.

Cycloplegics and Mydriatics

Cycloplegics are not routine postoperative medications for pediatric cataract surgery. The use of cycloplegics should depend on the postoperative ocular conditions of children. The application of cycloplegics may eliminate ciliary muscle spasm, stabilize the blood-aqueous barrier, relieve postoperative pain, and alleviate inflammation. Long-acting cycloplegics do not possess strong pupil-dilating effect and is not conducive to prevent pupil synechia.

Meanwhile, it may bring the risk of pupillary capture of IOL. Therefore, if there is reduced pupil response or fibrinous inflammation in the pupillary zone, it is suggested that such short-acting mydriatics such as tropicamide.

16.3 Summary

For cataract surgery in children with congenital anomalies of the uvea, a comprehensive examination must be performed preoperatively to detect whether there are other ocular or systemic anomalies. Sound therapeutic plans based on the children's conditions need to be developed. And this type of surgery features the management of iris anomalies and efforts to minimize injury to the iris. For cataract surgery in children with uveitis, it should only be performed when the inflammation is well controlled. In addition, children's ocular conditions and age determine whether simultaneous implantation of IOL should be performed. At last, active postoperative anti-inflammatory therapy is required to reduce postoperative complications.

References

1. Lee H, Khan R, O'Keefe M. Aniridia: current pathology and management. *Acta Ophthalmol.* 2008;86(7):708–15.
[\[CrossRef\]](#)[\[PubMed\]](#)
2. Lee HJ, Colby KA. A review of the clinical and genetic aspects of aniridia. *Semin Ophthalmol.* 2013;28(5–6):306–12.
[\[CrossRef\]](#)[\[PubMed\]](#)
3. Fischbach BV, Trout KL, Lewis J, et al. WAGR syndrome: a clinical review of 54 cases. *Pediatrics.* 2005;116(4):984–8.

[\[CrossRef\]](#)[\[PubMed\]](#)

4. Van Heyningen V, Boyd PA, Seawright A, et al. Molecular analysis of chromosome 11 deletions in aniridia-Wilms tumor syndrome. *Proc Natl Acad Sci U S A*. 1985;82(24):8592–6.
[\[CrossRef\]](#)[\[PubMed\]](#)[\[PubMedCentral\]](#)
5. Lopez-Garcia JS, Garcia-Lozano I, Rivas L, et al. [Congenital aniridia keratopathy treatment]. *Arch Soc Esp Oftalmol*. 2006;81(8):435–44.
[\[CrossRef\]](#)[\[PubMed\]](#)
6. Nelson LB, Spaeth GL, Nowinski TS, et al. Aniridia. A review. *Surv Ophthalmol*. 1984;28(6):621–42.
[\[CrossRef\]](#)[\[PubMed\]](#)
7. Zamzam AM, Sherif SM, Phillips CI. Aniridia, ectopia lentis, abnormal upper incisors and mental retardation – an autosomal recessive syndrome. *Jpn J Ophthalmol*. 1988;32(4):375–8.
[\[PubMed\]](#)
8. Boughamoura L, Yacoub M, Abroug M, et al. [Gillespie syndrome: 2 familial cases]. *Arch Pediatr*. 2006;13(10):1323–5.
[\[CrossRef\]](#)[\[PubMed\]](#)
9. Nevin NC, Lim JH. Syndrome of partial aniridia, cerebellar ataxia, and mental retardation – Gillespie syndrome. *Am J Med Genet*. 1990;35(4):468–9.
[\[CrossRef\]](#)[\[PubMed\]](#)
10. Wilczynski M. Phacoemulsification with implantation of Morcher aniridia capsular rings for postoperative atonic pupil after iridencleisis – case report. *Klin Oczna*. 2015;117(1):20–3.
[\[PubMed\]](#)
11. Neuhann IM, Neuhann TF. Cataract surgery and aniridia. *Curr Opin Ophthalmol*. 2010;21(1):60–4.
[\[CrossRef\]](#)[\[PubMed\]](#)
12. Aslam SA, Wong SC, Ficker LA, et al. Implantation of the black diaphragm intraocular lens in congenital and traumatic aniridia. *Ophthalmology*. 2008;115(10):1705–12.
[\[CrossRef\]](#)[\[PubMed\]](#)
13. Osher RH, Burk SE. Cataract surgery combined with implantation of an artificial iris. *J Cataract Refract Surg*. 1999;25(11):1540–7.
[\[CrossRef\]](#)[\[PubMed\]](#)
14. Taneri S, Gerding H. Retinal detachment and phthisis bulbi after implantation of an iris prosthetic system. *J Cataract Refract Surg*. 2003;29(5):1034–8.
[\[CrossRef\]](#)[\[PubMed\]](#)
15. Srinivasan S, Ting DS, Snyder ME, et al. Prosthetic iris devices. *Can J Ophthalmol*. 2014;49(1):6–17.
[\[CrossRef\]](#)[\[PubMed\]](#)
16. Davis PL. Optical iridectomy in phakic and pseudophakic patients. *Can J Ophthalmol*. 1985;20(4):159–61.

[PubMed]

17. Foster J. OPTICAL IRIDECTOMY, INDICATIONS, METHOD AND VALUE. *Br J Ophthalmol.* 1932;16(8):476–84.
[CrossRef][PubMed][PubMedCentral]
18. Wolf MD, Lichter PR, Ragsdale CG. Prognostic factors in the uveitis of juvenile rheumatoid arthritis. *Ophthalmology.* 1987;94(10):1242–8.
[CrossRef][PubMed]
19. Foster CS, Barrett F. Cataract development and cataract surgery in patients with juvenile rheumatoid arthritis-associated iridocyclitis. *Ophthalmology.* 1993;100(6):809–17.
[CrossRef][PubMed]
20. Tugal-Tutkun I, Urgancioglu M. Childhood-onset uveitis in Behcet disease:a descriptive study of 36 cases. *Am J Ophthalmol.* 2003;136(6):1114–9.
[CrossRef][PubMed]
21. Rojas B, Foster CS. Cataract surgery in patients with uveitis. *Curr Opin Ophthalmol.* 1996;7(1):11–6.
[CrossRef][PubMed]
22. Zhang Y, Zhang M. [Clinical analysis on children uveitis complicated cataract surgery]. *Zhonghua Yan Ke Za Zhi.* 2014;50(10):772–6.
[PubMed]
23. Magli A, Forte R, Rombetto L, et al. Cataract management in juvenile idiopathic arthritis: simultaneous versus secondary intraocular lens implantation. *Ocul Immunol Inflamm.* 2014;22(2):133–7.
[CrossRef][PubMed]
24. Phatak S, Lowder C, Pavesio C. Controversies in intraocular lens implantation in pediatric uveitis. *J Ophthalmic Inflamm Infect.* 2016;6(1):12.
[CrossRef][PubMed][PubMedCentral]
25. BenEzra D, Cohen E. Cataract surgery in children with chronic uveitis. *Ophthalmology.* 2000;107(7):1255–60.
[CrossRef][PubMed]
26. Lundvall A, Zetterstrom C. Cataract extraction and intraocular lens implantation in children with uveitis. *Br J Ophthalmol.* 2000;84(7):791–3.
[CrossRef][PubMed][PubMedCentral]
27. Tabbara KF, Al-Kaff AS, Al-Rajhi AA, et al. Heparin surface-modified intraocular lenses in patients with inactive uveitis or diabetes. *Ophthalmology.* 1998;105(5):843–5.
[CrossRef][PubMed]
28. Li J, Heinz C, Zurek-Imhoff B, et al. Intraoperative intraocular triamcinolone injection prophylaxis for post-cataract surgery fibrin formation in uveitis associated with juvenile idiopathic arthritis. *J Cataract Refract Surg.* 2006;32(9):1535–9.

[\[CrossRef\]](#)[\[PubMed\]](#)

29. Rabinovich CE. Treatment of juvenile idiopathic arthritis-associated uveitis: challenges and update. *Curr Opin Rheumatol*. 2011;23(5):432–6.

[\[CrossRef\]](#)[\[PubMed\]](#)

30. Zaborowski AG, Quinn AG, Dick AD. Cataract surgery in pediatric uveitis. *J Pediatr Ophthalmol Strabismus*. 2008;45(5):270–8.

[\[CrossRef\]](#)[\[PubMed\]](#)

17. Ectopia Lentis in Children

Danying Zheng¹✉ and Qianzhong Cao¹

- (1) State Key Laboratory of Ophthalmology, Zhongshan Ophthalmic Center, Sun Yat-sen University, 54S Xianlie Road, Guangzhou, 510060, People's Republic of China

✉ **Danying Zheng**
Email: zhengdy@163.com

Abstract

Pediatric lens dislocation results from congenital or traumatic factors. At the critical stage of visual development, pediatric lens dislocation often leads to various degrees of ametropia and amblyopia, and meanwhile other complications associated with lens dislocation also affect children's visual development. Therefore, early surgical intervention is sometimes necessary to manage pediatric lens dislocation. Due to the abnormal location of the lens, however, such an operation is quite difficult to perform. Fortunately, along with the development of surgical devices and intraocular lens (IOL), management of zonule abnormalities is no longer limited to the traditional procedure of IOL transscleral sulcus fixation. Moreover, the invention of adjunctive devices like iris or capsular retractor and capsular tension ring makes it possible to perform surgery in situ; and the application of novel micro-endoscope gives rise to more accurate transscleral fixation of IOL, which may reduce the risk of operative complications. Based on different etiologies of the disease, this chapter discusses the surgical indications and specific techniques for pediatric patients with lens dislocation and also briefly introduces how to use novel adjunctive devices in these surgeries.

Ectopia lentis (EL) in children refers to zonular laxity, stretching, or rupture due to developmental disorder or trauma that weakens or eliminates the normal tension on the crystalline lens and causes it to be displaced from its normal physiological position. The reported prevalence of pediatric EL is 6.4/100,000 [1]. EL may induce refractive errors and impaired visual development of varying severities in children; congenital EL may also be associated with systemic diseases. Therefore, when deciding on a management strategy, the extent and severity of EL, its influence on visual function and systemic factors should be taken into consideration. Furthermore, surgical indications must be rigorously followed to ensure a rational management plan. This chapter will expound on the classification, clinical manifestations, ocular examination, and management of pediatric EL.

17.1 Classification of Ectopia Lentis in Children

Pediatric EL can be congenital or acquired. The former is a developmental disorder, whereas the latter mainly occurs secondary to ocular trauma. A minority of EL cases are induced by other intraocular pathologies.

17.1.1 Congenital Ectopia Lentis

Congenital EL refers to displacement of the lens, which might be present at birth or occurs spontaneously after birth, and is typically binocular and symmetric. It may be an isolated finding, complicated with concurrent ocular maldevelopment, or an ocular presentation of systemic developmental disorders (especially related to mesodermal dysplasia) [1]. Zonular dysplasia is the main cause of congenital EL [2]. Different gene mutations give rise to different types of congenital EL.

17.1.1.1 Simple Ectopia Lentis

Simple EL has evident genetic predisposition and occurs as an autosomal dominant condition in the majority of cases; autosomal recessive inheritance is less common [3, 4]. This disorder is presented as a binocular symmetric disease with an upward and temporal displacement of the crystalline lens [3, 5]. The cause and exact mechanism are still unknown.

17.1.1.2 Ectopia Lentis Associated with Concurrent Ocular Maldevelopment

The other EL-associated ocular abnormalities usually include spherophakia, coloboma of the lens (Fig. 17.1), iris coloboma, and pupillary displacement.

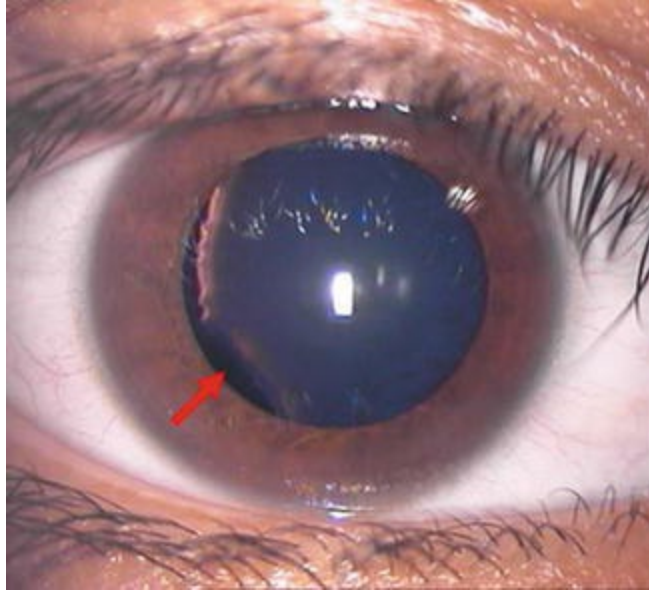


Fig. 17.1 Ectopia and coloboma of the lens (*arrow*) in the right eye of a 13-year-old girl

17.1.1.3 Ectopia Lentis Associated with Concurrent Systemic Maldevelopment

Marfan Syndrome

Marfan syndrome is the most common type of congenital EL (Fig. 17.2a). Its incidence rate is between 3 and 10/10,000, and there are no significant differences between genders, regions, or races [6–9]. This disease shows an autosomal dominant inheritance pattern and generally presents as multiple connective tissue abnormalities. It is caused by the mutation in the fibrillin-1 encoding gene *FBN1*, which is involved in mesodermal development. At present, more than 1200 *FBN1* mutation sites have been found [10].

Multisystem involvements are common in Marfan syndrome, including the musculoskeletal system, the heart and blood vessels, and the eyes [11, 12]. Most affected children have an unusually long-limbed body habitus (Fig. 17.2b), arachnodactyly, scoliosis, pectus carinatum, and ligamentous laxity; the cardiovascular abnormalities include atrial septal defect, heart valve

abnormalities, aortic dilatation, and aortic aneurysm, which are the main causes of death in these children [13]. The current international diagnostic criteria, proposed by Loeys et al. in 2010 [14], further emphasizes the importance of ocular and cardiovascular lesions in making a definite diagnosis of Marfan syndrome compared with previous diagnostic criteria.

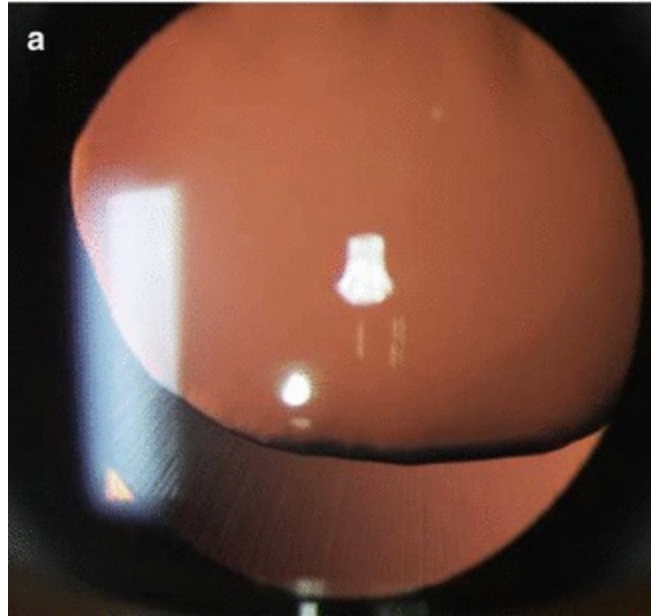

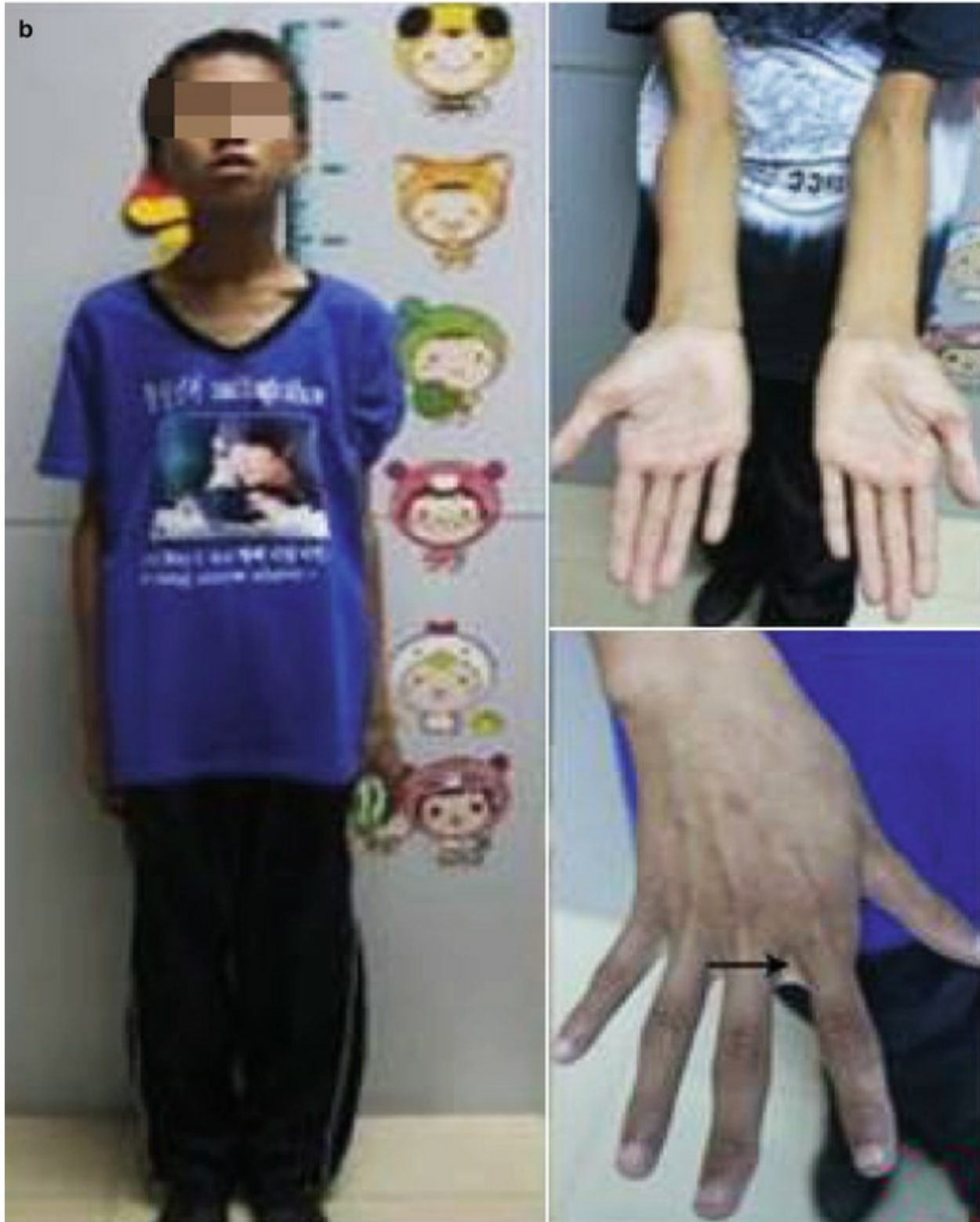


Fig. 17.2 Clinical manifestations of Marfan syndrome. (a) An 8-year-old boy with Marfan syndrome presented with EL in the right eye. The lens displacement was in the superior and nasal direction, and the excessively stretched zonules were visible with pupil dilation. (b) The boy had concomitant

musculoskeletal abnormalities of arachnodactyly and syndactyly (*black arrow*) and a tall, slim figure

The typical ocular manifestation of Marfan syndrome is progressive development of EL, which occurs in about 30–50 % of patients. The lens displacement is usually bilateral, symmetrical, and with a superior and nasal direction. When the pupil is dilated, the lens equator and the excessively stretched zonules are visible (Fig. 17.2a) [15, 16]. The ectopic crystalline lenses can cause refractive errors that are difficult to correct (mostly high myopia), as well as an increased risk of strabismus and amblyopia [17]. Other ocular abnormalities include macrocornea, poor elasticity of the iris, disappearance of the iris crypts, primary open-angle glaucoma, peripheral retinal degeneration, and retinal detachment [18, 19]. Initial subluxation of the lens may progress to complete dislocation, which gives rise to complications such as secondary glaucoma and phacogenic uveitis [18].

Homocystinuria

Homocystinuria is another common syndrome associated with congenital EL and occurs as an autosomal recessive condition. Mutation in the coding gene of cystathionine beta-synthase (CBS) [20, 21] leads to CBS defect, which causes increased cystine levels in the blood of the affected child, which in turn causes metabolic disorders. The typical ocular manifestation is bilateral and symmetrical EL, where the lens is often displaced toward in an inferior and nasal direction. EL can be accompanied by corneal opacity, congenital cataract, iris atrophy, optic nerve atrophy, and retinal detachment [22]. Systemic pathologies of homocystinuria include osteoporosis, mental retardation, epilepsy, thrombophilia, and, in severe cases, pulmonary embolism.

Weill–Marchesani Syndrome

Weill–Marchesani syndrome is an autosomal recessive genetic disease, and it is primarily associated with mutation in the ADAMTS gene, which is related to fibrillin-1 [20, 23]. Its clinical manifestations are contrary to those of Marfan syndrome, and the affected child has a short, fat figure and brachydactyly (Fig. 17.3). The typical ocular manifestations include spherophakia and the resulting high myopia, as well as EL toward the nasoinferior quadrant. In severe cases the crystalline lens can be dislocated into the anterior chamber. Therefore, there is a high incidence of secondary glaucoma in patients with Weill-Marchesani syndrome [24].

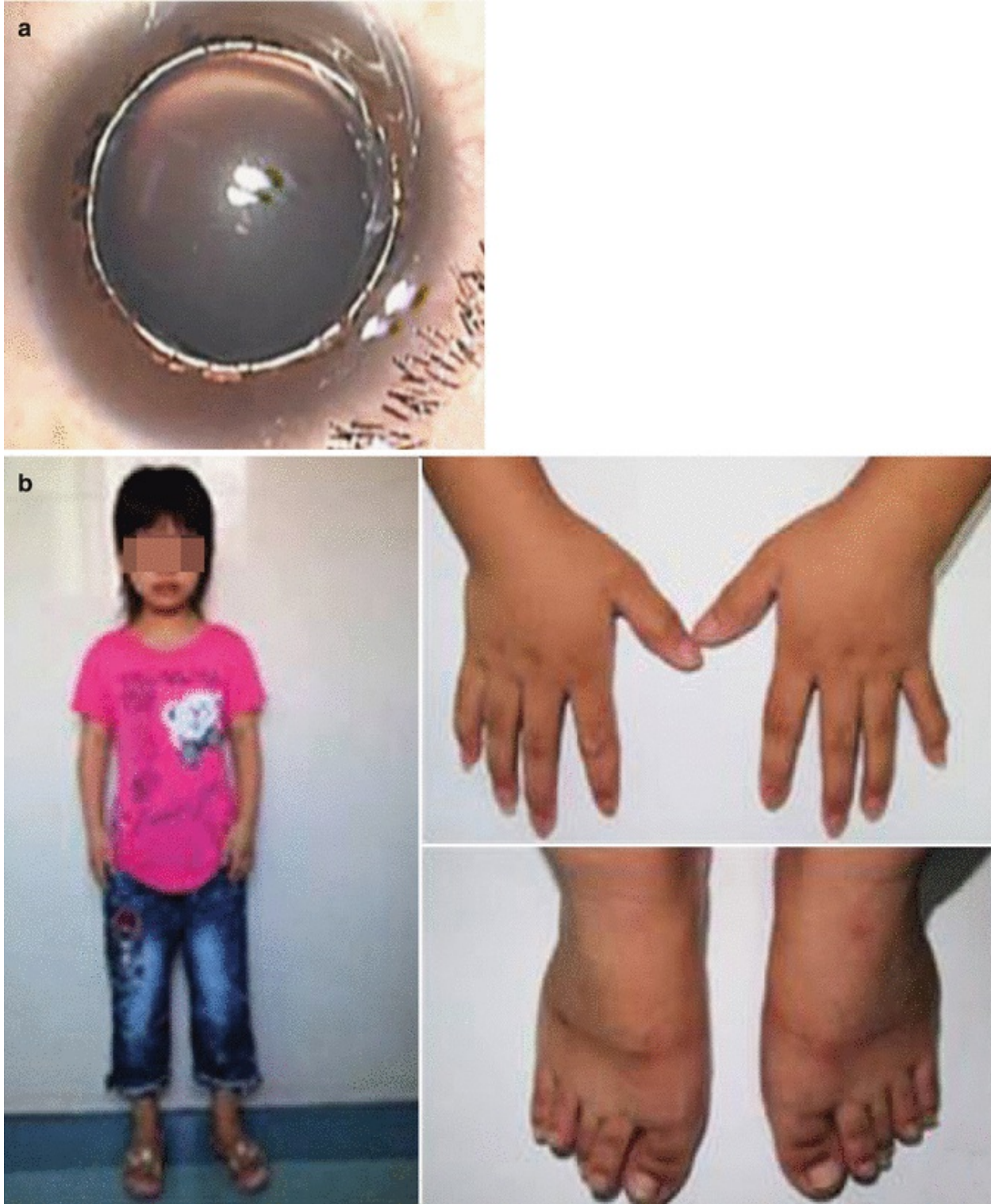

Fig. 17.3 Weill-Marchesani syndrome. (a) An 8-year-old girl with Weill-Marchesani syndrome had ectopic spherophakia; (b) the affected child had a short, fat figure and brachydactyly

Hyperlysinemia

Hyperlysinemia is a rare autosomal recessive genetic disease characterized by lysine dehydrogenase deficiency, which is caused by mutations in the AASS gene that encodes lysine-ketoglutarate reductase and saccharopine dehydrogenase (SDH) [25]. Increased plasma lysine concentration is the main criterion in making an unequivocal diagnosis. The disease mainly presents as mental retardation, spherophakia, and EL. Spherophakia is the pathognomonic manifestation of this syndrome.

17.1.2 Traumatic Ectopia Lentis

Traumatic EL is typically caused by blunt trauma. Affected children have a history of trauma that may be left unnoticed until visual symptoms emerge and ophthalmic examination reveals traumatic EL. It is unilateral in most cases and may be associated with concurrent traumatic cataract, angle recession, secondary glaucoma, and commotio retinae (contrecoup injury to the retina due to blunt ocular trauma).

17.1.3 Spontaneous Ectopia Lentis

Mechanical stretching of zonular fibers due to intraocular lesions or weakening of the zonules due to inflammation and degeneration can lead to spontaneous EL. The former is seen when enlargement of the eye occurs due to congenital glaucoma (buphthalmos) or posterior staphyloma. It can also be found in traction or occupying intraocular lesions, such as inflammatory adhesion of the ciliary body, vitreous strands, and intraocular tumors [26].

17.2 Clinical Manifestations of Ectopia Lentis in Children

Ectopia lentis is clinically divided into lens subluxation and lens dislocation according to the range of zonular dehiscence and the severity of lens displacement.

17.2.1 Lens Subluxation

When an area of the zonular fibers are weakened or ruptured and the crystalline lens deviates from its normal anatomical position, the condition is referred to as lens subluxation. There are two major manifestations. First, the

partially weakened or ruptured zonules cause an increase in lens curvature and subsequent lens-induced myopia; second, the lens displacement or tilting can cause lens-induced irregular astigmatism, which is often difficult to correct using spectacles or contact lenses. If the ametropia cannot be corrected, amblyopia and strabismus will eventually occur. Monocular diplopia and glare can occur in children with severe subluxation, as well as secondary glaucoma.

Slit-lamp examination may reveal iridodonesis, phacodonesis, and/or vitreous hernia [27]. In some affected children, the equator of the lens and the stretched or ruptured zonular fibers may be observed in the pupillary zone when the pupil is dilated. Double moon-shaped reflections and double fundus images are observed in direct ophthalmoscopy.

17.2.2 Lens Dislocation

When there is complete rupture of all zonular fibers, the crystalline lens leaves its normal anatomical position to enter the anterior chamber or vitreous cavity; this is known as lens dislocation. The dislocated lens may occlude the pupil and displace anteriorly into the anterior chamber (Fig. 17.4a) or displace posteriorly into the vitreous cavity (Fig. 17.4b). Lens dislocation can cause serious complications such as secondary glaucoma, phacogenic uveitis, and retinal detachment [28, 29]. A dislocated lens may even prolapse outside the eye through a cornea perforation or enter the subconjunctival or subtenon space through a scleral rupture. The pediatric patient may present with the following clinical findings depending on the position of the dislocated lens:

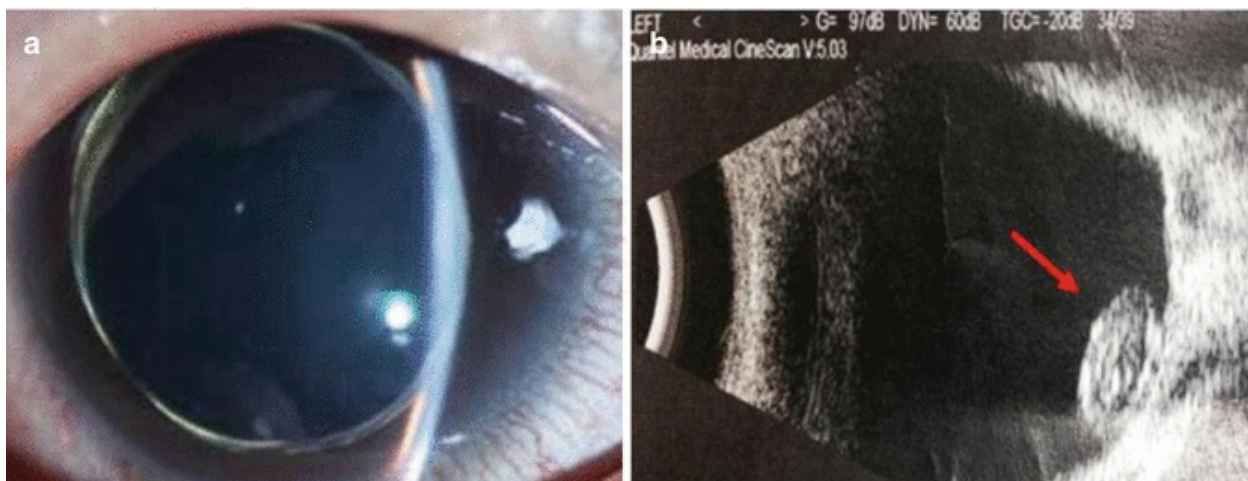


Fig. 17.4 Lens dislocation. (a) The crystalline lens was dislocated into the anterior chamber, and its edges showed a golden reflection. (b) B-scan ultrasonography of another case of lens dislocation revealed the dislocated lens (*arrow*) in the vitreous cavity

1. Captured in the pupil: Blurred vision and acute ocular hypertension together with pupillary block.
2. Dislocated into the anterior chamber: On slit-lamp examination, the dislocated lens appears as an oil droplet with a golden reflection at its edges. Lens opacity may be present. It can cause acute elevation of intraocular pressure. Corneal endothelial loss or decompensation and anterior uveitis may also occur [30].
3. Dislocated into the vitreous cavity: Slit-lamp examination shows a deepened anterior chamber, iridodonesis, absence of the crystalline lens in the pupillary zone, and sometimes vitreous hernia in the anterior chamber. A small mass with the shape of an oil droplet with dark edges is seen using direct ophthalmoscopy. If the lens capsule is intact and no complications occur, the affected eye remains aphakic without other symptoms; if the capsule has been ruptured, the escaped cortex may give rise to lens-induced uveitis and phacolytic glaucoma [31].

17.3 Ophthalmic Examination of Ectopia Lentis in Children

A complete examination of the patient is important for the development of a therapeutic regimen. If necessary, uncooperative children may undergo examinations under sedation or general anesthesia.

1. Visual acuity

The dislocated lens may lead to myopia, hyperopia, and astigmatism. If not promptly corrected, the risk of amblyopia and strabismus is increased. Therefore, distance and near visual acuities (VA) should be examined, and best corrected visual acuity (BCVA) should be obtained through accurate refraction. This will provide a basis for determining

treatment options.

2. Intraocular pressure

Both EL and disorders of ocular development can cause secondary glaucoma. Therefore, measurement of intraocular pressure is important for timely detection of glaucoma.

3. Ocular alignment

Children with congenital EL may have concurrent strabismus. A simple test of alignment may be applied, using penlight reflection on the cornea combined with a cover test.

4. Anterior segment examination

The grading of the extent of zonular weakness/dehiscence and the severity of EL is an important guide for clinical treatment. Hoffman et al. [32] divided lens subluxation into minimal to mild, moderate, and severe based on the findings from slit-lamp examination after pupil dilation: (1) minimal to mild subluxation in which the lens edge uncovers 0% to 25% of the dilated pupil; (2) moderate subluxation in which the lens edge uncovers 25% to 50% of the dilated pupil; (3) and severe subluxation in which the lens edge uncovers greater than 50% of the pupil.

The pupils of children with EL should be fully dilated for slit-lamp examination of the anterior segment. This enables the extent and direction of EL, as well as the severity and range of zonular abnormality, to be carefully examined. Alteration of lens location between erect and recumbent positions is noted to help determine the status of the zonular fibers [33]. Sometimes gonioscopy is also necessary.

5. Posterior segment examination

EL is often associated with retinopathy; thus, a retinal examination should also be performed.

6. Biological measurement of the eyeballs

Axial length measurements using A-scan ultrasonography or IOLMaster, keratometry using a keratometer or IOLMaster, and corneal

diameter and anterior chamber depth measured by IOLMaster are all obtained to evaluate the pediatric patient's status of eye development.

7. Ultrasound biomicroscopy (UBM)

UBM enables a more detailed examination of the anterior segment, including the zonule, the lens, the anterior chamber angle, and the ciliary body, providing extra details compared to slit-lamp examination alone. This information is essential for the diagnosis and treatment of EL.

8. Systemic examination

Congenital EL may be associated with concurrent abnormalities in other organ systems such as the cardiovascular, musculoskeletal, and nervous systems. Cardiovascular diseases are often insidious and therefore have a high mortality rate. 60–80 % of patients with Marfan syndrome have aortic dilation, and 82 % of them have mitral valve prolapse [34–36]. Children with binocular EL should undergo systemic examination and echocardiography, lumbosacral magnetic resonance imaging (MRI), and chest X-ray or chest CT that sometimes can lead to the timely detection of comorbidities and ensures the safety of ophthalmic surgery. Early systemic intervention and monitoring are beneficial to enhancing patients' survival and improving their quality of life.

17.4 Treatment of Ectopia Lentis in Children

The treatment of pediatric EL includes nonsurgical and surgical approaches. With current advances in techniques and equipment for cataract surgery, the surgical treatment of pediatric EL has improved significantly, but it still carries a greater risk when compared with routine cataract surgery. Radical surgery may result in adverse consequences, including blindness.

Determination of treatment options for children should be comprehensively considered based on the severity of lens opacity and the range of zonular abnormalities, visual functions of both the affected and the fellow eye, other ocular conditions, as well as the patient's age, the availability of surgical instruments, and the surgeon's experience.

17.4.1 Nonsurgical Treatment

At present, most surgeons recommend observation with regular follow-up for patients with transparent crystalline lenses and mild EL without complications. Because the affected children are at a critical stage of visual development, if the myopia and astigmatism caused by EL are not corrected in time, visual development will be disrupted [37–39]. The mild ametropia caused by EL can be corrected with spectacles; when there is anisometropia, contact lenses can avoid interocular disparity of the image size. For some children who see through the aphakic pupillary zone, spectacles may achieve an unexpectedly favorable visual outcome [40]. The amblyopia caused by EL requires refractive correction combined with occlusion and visual training, and these should be managed in a timely manner [41]. Children with EL who undergo nonsurgical treatment should adhere to a long-term follow-up schedule and receive regular examinations with pupil dilation, so as to determine whether the EL is progressing. Refraction should also be performed at the same time, and new spectacles are prescribed if there are changes in the refractive status. This prevents the risks of alternate fixation, strabismus, and amblyopia, preserves binocular vision and stereopsis, and improves overall visual quality. When the outcome of conservative treatment is poor or complications occur, reassessment should be conducted, and new treatment options should be formulated.

17.4.2 Surgical Treatment

17.4.2.1 Surgical Indications

There is no unified standard regarding the timing of surgery for pediatric EL. It is generally considered that when EL seriously impairs vision and quality of life of the pediatric patient and conservative treatment has been ineffective, surgical intervention should be adopted.

Detailed indications are as follows:

1. Significant double vision is present due to EL, which cannot be corrected by spectacles [42].
2. EL causes ametropia with BCVA ≤ 0.3 [31, 33].

3. The lens equator is at the pupil center and results in ametropia that is difficult to correct [36].
4. Significant opacification develops in the dislocated lens, which impairs visual function.
5. Serious complications occur such as secondary glaucoma, corneal endothelial decompensation, and retinal detachment.

17.4.2.2 Surgical Techniques for Lens Extraction

Most displaced lenses in children have a soft nucleus. Lens extraction for pediatric EL is performed by either an anterior or a posterior approach. The anterior approach employs a corneal, limbal, or scleral incision. The operation is relatively simple and posterior irrigation is not required. This avoids entry through the pars plana, which is not fully developed in children. It also reduces disturbance to the vitreous and retina and therefore is more popular in the surgery for pediatric EL. Phacoaspiration is the mainstay surgical technique for pediatric EL, but in the case of severe EL, or in an under-equipped clinical setting, intracapsular lens extraction or manual irrigation/aspiration of the lens is still performed [37]. The posterior approach works through pars plana incisions, and the surgeon can manage the vitreous and retinal lesions after lens removal. The major technique is the pars plana lensectomy (PPL) and requires that the surgeon is familiar with vitreoretinal surgery [37]. It is recommended that an appropriate surgical technique is selected based on EL severity, availability of surgical equipment, and the surgeon's experience.

Intracapsular Lens Extraction

Intracapsular lens extraction is indicated for almost complete dislocation with the lens visible in the pupillary area or lens dislocation into the anterior chamber. Typically, a modified superior scleral tunnel incision is made, and its size is selected based on the diameter of the lens and rigidity of the nucleus. Ophthalmic viscosurgical device (OVD) is injected both anteriorly and posteriorly to the lens to protect the corneal endothelium and the vitreous. The entire lens is delivered directly out of the capsule using an

irrigating lens loop. Vitreous strands in the anterior segment are removed completely. This technique requires a large incision and is associated with a high risk of complications. Therefore, for pediatric EL with a soft nucleus, intracapsular lens extraction is gradually being replaced by the following techniques that use smaller incisions.

Manual Irrigation/Aspiration of the Lens

Manual irrigation/aspiration of the lens is indicated for patients with mild to moderate subluxation in the presence of a soft nucleus. A 2–3 mm limbal incision is made, followed by can-opener capsulotomy or continuous curvilinear capsulorhexis (CCC) and the subsequent hydrodissection. A Simcoe cannula is used for cortex aspiration. Caution should be exercised to maintain the balance between irrigation and aspiration and the anterior chamber depth (ACD) during surgery. OVD tamponade on the capsular bag may be used to avoid its aspiration. If vitreous prolapse occurs, the prolapsed vitreous should be eliminated first, before continuing with lens cortex aspiration. This technique preserves the capsule and enables in-the-bag implantation of the IOL. It does not require a phaco machine and therefore is still used in developing countries.

Lenectomy via Anterior Approach

Lenectomy via anterior approach is indicated for soft-nucleus lenses that are subluxated or dislocated into the anterior chamber. An anterior vitreous cutter is introduced through a corneal, limbal, or scleral incision of ≤ 3.0 mm for lenectomy.

Phacoaspiration

Phacoaspiration utilizes the quick and stable irrigation and aspiration modules of a phaco machine. Lens material is removed through a corneal or limbal tunnel incision of less than or equal to 3.0 mm. The incision for this technique is small and the complication rate is low. The use of CCC, together with iris retractors, capsular hooks or capsular tension ring (CTR), greatly improves surgical safety. The surgical procedure is described below.

Pars Plana Lenectomy

Pars plana lenectomy is used for severe EL or when the lens has dislocated into the vitreous cavity. At present, a 23-gauge vitrectomy system is commonly used to perform 3-port pars plana lenectomy and vitrectomy. If a

retinal tear or degenerative lesion exists, photocoagulation or other vitreoretinal surgical techniques may be conducted in the same surgery [43].

17.4.3 Phacoaspiration

Phacoaspiration is currently the preferred technique for lens subluxation. It is a closed-chamber procedure and thus reduces the risk of vitreous prolapse [44]. The zonular fibers in congenital EL are sparse and overstretched, but none or only a small proportion of the fibers are ruptured. The intact zonules and the capsule can be used as a barrier protecting the anterior vitreous. The nucleus and cortex of the lens are removed before management of the capsule. The zonules in traumatic EL are often broken and may be associated with prolapsed vitreous in the anterior chamber. In such cases the vitreous strands in the anterior chamber should be dealt with first, before removal of the crystalline lens.

17.4.3.1 Surgical Technique

Incision Construction

Because the posterior chamber pressure in children is high and iris prolapse occurs more often, a tunnel incision is typically/usually used. At present, it remains controversial over the selection of incision locations for pediatric EL. Vasavada et al. [45] recommend a temporal clear corneal incision, while Cionni et al. [44] recommend the incision should be away from the zone of zonular weakness. In our experience, for children with congenital EL where the zonules are stretched but not broken, the area of zonular weakness is selected for a clear corneal tunnel incision of ≤ 3.0 mm to facilitate management of the part of the lens behind the iris; for children with traumatic EL with ruptured zonules and perhaps vitreous strands in the anterior chamber, an incision is made in the area of intact zonules to prevent vitreous prolapse out of the incision interfering with lens aspiration. For children less than 9 years of age, a superior scleral tunnel incision is recommended.

Capsulorhexis

The pediatric capsule is highly elastic, and the loose or ruptured zonules give rise to reduced tension on the capsular bag, which makes capsulorhexis more difficult. To tackle this problem, it is suggested that the surgeon use OVD to dilate the pupil and then slowly inject OVD to the part of lens equator with

zonular weakness/rupture. These maneuvers fully expose the lens and restore lens centration for capsulorhexis, thus protecting the residual zonules and anterior hyaloid membrane. If there are numerous vitreous strands in the anterior chamber, anterior vitrectomy is performed first. A cystotome is used to create a flap on the anterior capsule in the area with intact zonules. A cystotome or capsulorhexis forceps are used to complete a CCC of 4.5–5 mm. A capsulotomy device using radiofrequency diathermy can also be applied to complete capsulorhexis [46]. Gentle maneuvers are preferred to prevent further disturbance or damage to the zonules and vitreous. For significant lens subluxation, capsulorhexis can be completed with the assistance of iris retractors and capsular retractors. Depending on the area of zonular weakness and rigidity of the nucleus, one to four iris retractors are used to hold the capsular bag at the pupillary center. Capsulorhexis is performed with timely adjustment of the traction by retractors. Overstretching of the capsular bag may lead to rupture of the capsule (Fig. 17.5). Capsule staining can be applied to increase visibility of the capsular membrane.

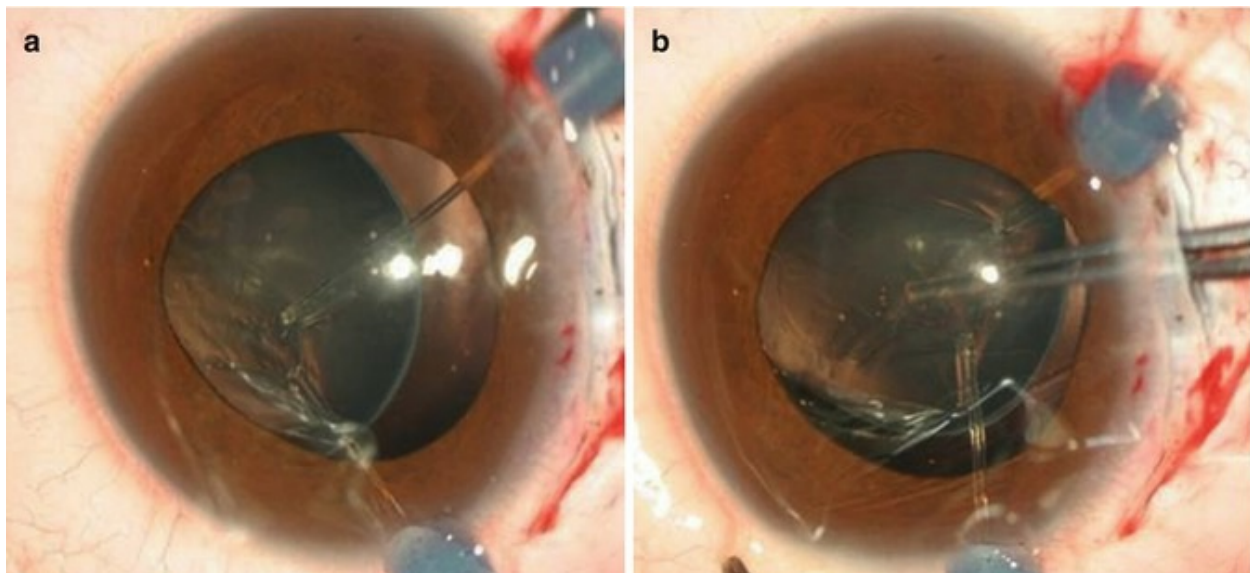


Fig. 17.5 Capsulorhexis. (a) Two iris retractors are implanted. The anterior capsule opening of the lens is engaged, and the capsular bag is fixed. (b) Capsulorhexis is completed with the assistance of iris retractors

Hydrodissection and Hydrodelineation

The displaced crystalline lens in children lacks normal zonular tension; therefore, surgical maneuvers should be as gentle as possible to avoid pressure on the lens during hydrodissection and hydrodelineation. Multiple

injections of small volumes of fluid may be applied and OVD may be used if necessary. The cortex and capsular membrane should be separated to reduce traction on the capsular membrane during subsequent removal of the cortex. In addition, when the lens has a hard nucleus, it should be completely separated. However, excessive rotation of the nucleus should be avoided because it may aggravate the damage to the zonules.

Aspiration of Lens Materials

The subluxated/dislocated capsular bag is insecure and may be easily aspirated during phacoaspiration. Therefore, the phaco machine should be adjusted to maintain the stability of the anterior chamber and capsular bag. To ensure the efficiency and safety of the surgery, the authors recommend lower bottle height, flow rate, and vacuum throughout the surgery, and these parameters should be adjusted in a timely manner based on the anterior chamber conditions. Removal of the lens materials begins at the region with normal zonules and then moves toward the area of zonular weakness or rupture. Cortex aspiration should be slow, and the surgeon should avoid applying pressure or traction on the capsular bag. OVD can be injected repeatedly between the capsule and cortex/nucleus fragments to protect the capsular bag. Additional surgical instruments may also be employed, such as Sinsky hook, CTR, and iris/capsule retractors (Fig. 17.6). In the case where the lens is almost or completely dislocated into the anterior chamber, a 25-gauge needle is used to penetrate the lens from a limbal entry and exits from the opposite limbus to secure the dislocated lens in the anterior chamber to facilitate capsulorhexis and lens extraction (Fig. 17.7). Sufficient OVD is necessary to maintain space in the anterior chamber so as to protect the corneal endothelium and tamponade the vitreous.

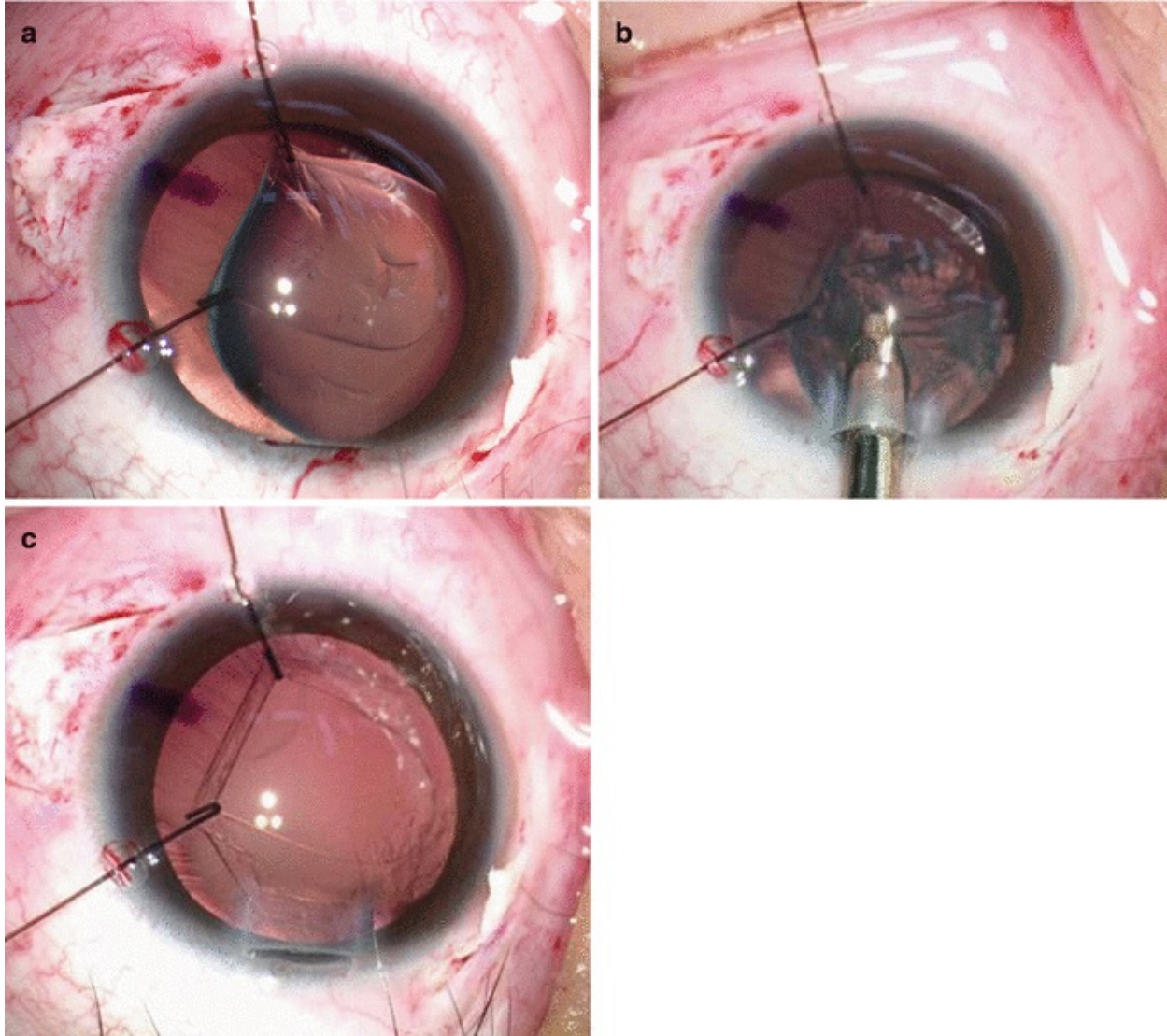


Fig. 17.6 Cortex aspiration with the assistance of iris retractors. (a) Two iris retractors are used to hold the capsular bag. (b) Iris retractors are used to facilitate cortex aspiration. (c) Cortex aspiration completed

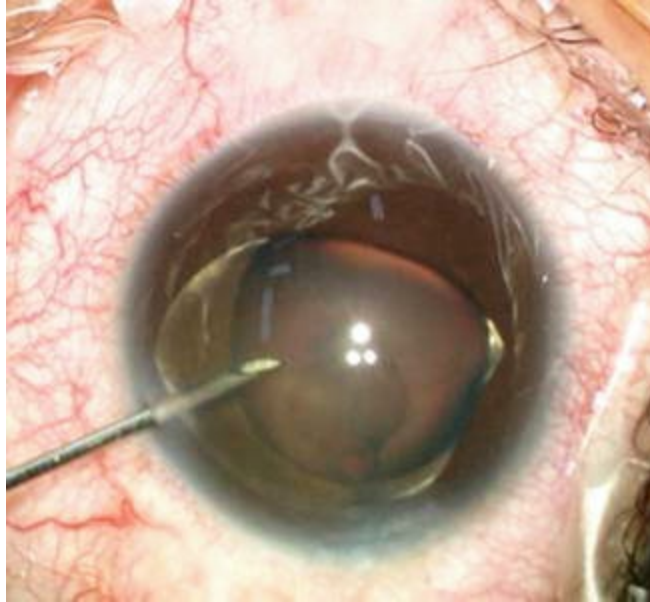

Fig. 17.7 A 25-gauge needle is used to fix the dislocated lens in the anterior chamber

Management of the Capsular Bag

In traumatic EL, the zonules that have not been ruptured usually retain their normal tension. Every effort should be made to keep the capsular bag intact to facilitate in-the-bag implantation of an IOL. In congenital EL, such as Marfan syndrome, the progressive weakness of the zonules creates the dilemma of whether to keep the capsular bag or not. Some surgeons prefer to remove it, while others prefer to keep it with a CTR placement [47]. To remove the capsular bag, the lens material is first aspirated with the capsule as a barrier to prevent vitreous prolapse. OVD is then injected between the capsule and the vitreous. Residual zonular fibers are resected and the capsular bag is taken out (Fig. 17.8). Vitrectomy may also be used to eliminate the capsular remnants.

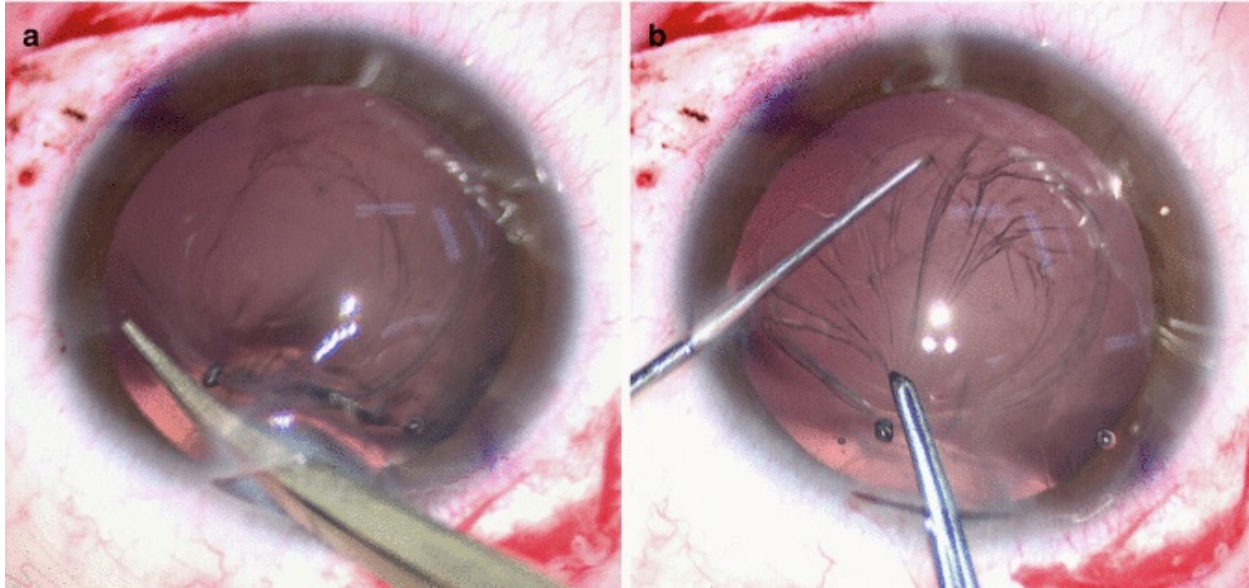


Fig. 17.8 Removal of the capsular bag. (a) The zonules are resected with capsulotomy scissors. (b) Capsule forceps are used to remove the capsular bag

Anterior Vitrectomy

The pressure of the posterior chamber in children is high, and vitreous prolapse is more likely to occur during surgery for pediatric EL. Therefore, thorough removal of the vitreous strands in the anterior chamber and extraocular vitreous is necessary to reduce the risk of pupillary block, cystoid macular edema, and retinal detachment [48].

17.4.3.2 Additional Instruments in Phacoaspiration

In pediatric EL, the diseased zonules exert a reduced tension on the capsular bag and the capsule, making them vulnerable to further damage from the flows of irrigation and aspiration. In this case the capsule is prone to aspiration, which can lead to loss of capsular integrity or exacerbation of the EL. Utilization of additional instruments may help stabilize the capsular bag or maintain centration of the lens to facilitate surgical maneuvers and reduce complications.

Capsular Tension Ring (CTR)

In 1991, Hara et al. introduced the concept of implanting a ring at the equator of the subluxated capsular bag; this initiated a new era of using implantable devices to assist in the surgical treatment of EL. The CTR that is currently

used is an open-loop PMMA ring with two foldable ends that have a hole in the tip. They are categorized as CTR and modified CTR (MCTR) (Fig. 17.9a, b.) and come in different sizes depending on the size of the capsular bag. CTRs help to maintain the original shape of the capsular bag and avoid vitreous prolapse, so that the IOL is held at a central position, thus, improving the safety and effectiveness of phacoaspiration and IOL implantation [49]. In addition, implantation of a CTR can inhibit the proliferation and migration of lens epithelial cells, thereby reducing the occurrence of posterior capsule opacification (PCO) and capsular fibrosis. In 1998, Cionni [50] developed the MCTR in the hope of using the CTR in more severe cases of lens subluxation. One or two handles with an eyelet on the end were added to the middle of the CTR (Fig. 17.9b). Through this design, the MCTR can be fixated with transscleral suturing so that the severely displaced capsular bag regains centration, allowing for implantation of a posterior chamber IOL. The authors have implanted MCTRs in children with Marfan syndrome, and long-term follow-up has shown that the IOL has been well centered [51]. It should be noted that the advent of MCTR has increased the use of CTRs, but implantation of a CTR or MCTR requires an intact capsular bag. Selection of a CTR of an appropriate size and of proper implant orientation (clockwise or counterclockwise) is recommended to avoid rupture of the capsular bag due to overexpansion. If the capsular bag is too small, it is inadvisable to implant a CTR or MCTR (Fig. 17.10).

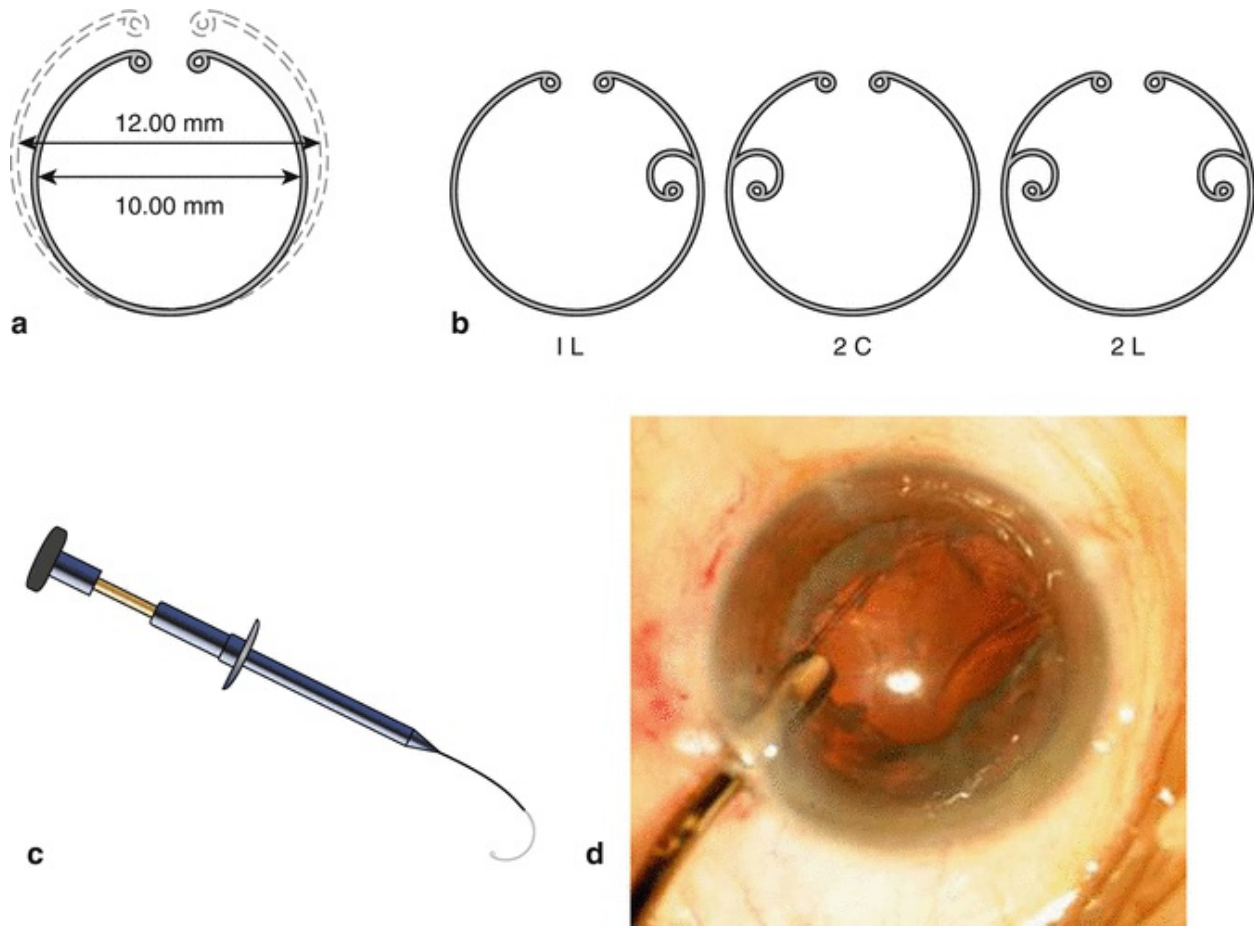


Fig. 17.9 Capsular tension ring (CTR). (a) Morcher CTR type 14. (b) Morcher MCTR. (c) An injector for the CTR. (d) The injector is used to implant an CTR into the capsular bag

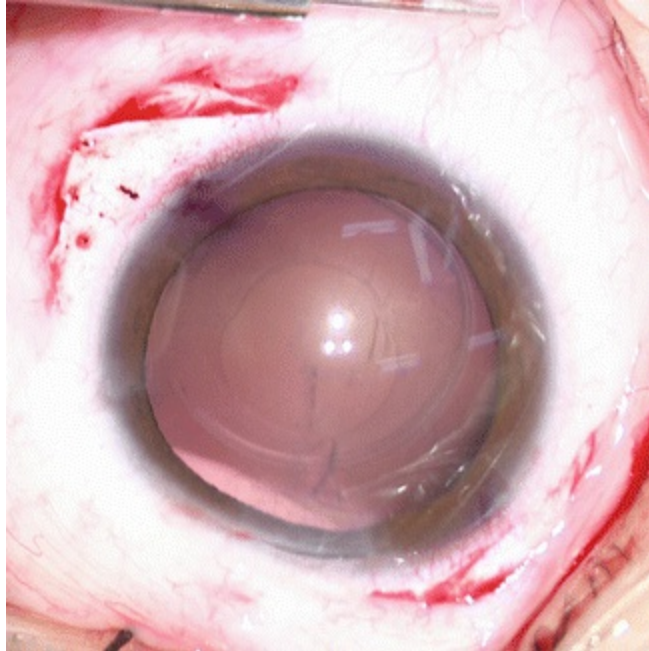


Fig. 17.10 A 6-year-old child with congenital EL, whose capsular bag was 8 mm in diameter. It was not recommended to implant a regular-sized CTR

Timing of implantation during surgery: A CTR may be implanted at different stages of surgery. If it is implanted after capsulorhexis and hydrodissection, the CTR expands at the equator. The contour of the capsular bag is thereby reestablished, protecting the capsulorhexis opening and avoiding zonular dehiscence or expanded zonular weakness. However, it is likely to cause difficulty in cortex aspiration, which may give rise to traction on the capsular bag causing extended zonular damage in severe cases. A CTR can also be implanted after cortex aspiration, but this could lead to further traction on the capsular bag. The authors suggest that CTR implantation may be performed with the assistance of capsular retractors to reduce the risk of zonular injury.

Implantation techniques for capsular tension rings: CTRs can be implanted manually or by using an injector. In manual implantation, OVD is first injected to inflate the capsular bag, and then toothless forceps are used to implant the CTR in a clockwise direction into the capsular bag from the left side of the capsular opening through the main incision. A Sinsky hook may be inserted through a limbal paracentesis on the left to gently press the CTR, which facilitates its entrance into the capsular bag. If the CTR is implanted in a counterclockwise direction, the above procedures are performed in the opposite direction from the right side of the main incision. Implantation using

an injector is relatively simple. The CTR is loaded into the injector and unloaded in a clockwise or counterclockwise direction beneath the anterior capsule opening (Fig. 17.9c, d). In traumatic EL there may be scarring in the periphery of the capsular bag in traumatic EL, and thus significant resistance may be encountered when the CTR is implanted. Therefore, implantation should be conducted gently to avoid damage to the capsular bag. Additional OVD can be injected to fill the capsular bag or assist in changing the implantation direction.

Implantation technique for MCTRs: For children with extensive zonular weakness or progressive EL, providing the tension in the residual zonules is adequate; MCTR implantation may be considered (Fig. 17.11). In MCTR implantation, the midpoint of the region with zonular abnormalities is selected, and a triangular lamellar scleral flap is made posteriorly to the corneal limbus. A 10–0 polypropylene suture enters under the scleral flap at 1.5 mm posteriorly to the corneal limbus, passes behind the iris, and exits through the main incision. The suture is then tied to the hole in the fixation hook of the MCTR, and toothless forceps are used to rotate the MCTR until the fixation hook is aligned with the scleral flap. The suture is tightened and tied to ensure centration of the capsular bag, and the scleral flap is closed with a 10–0 nylon suture.

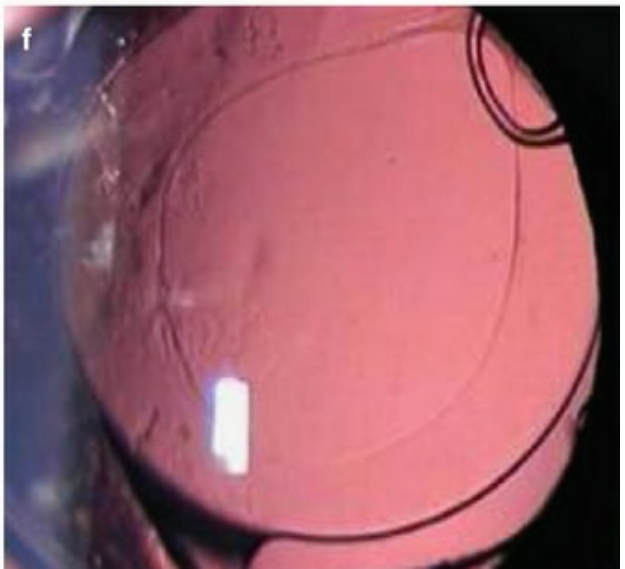
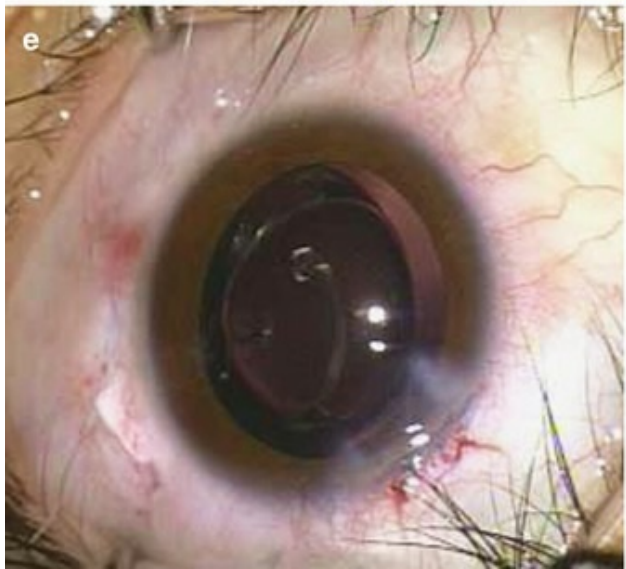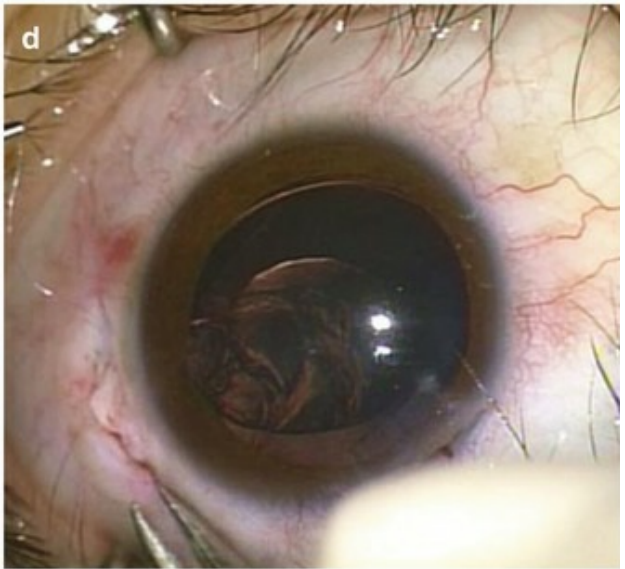
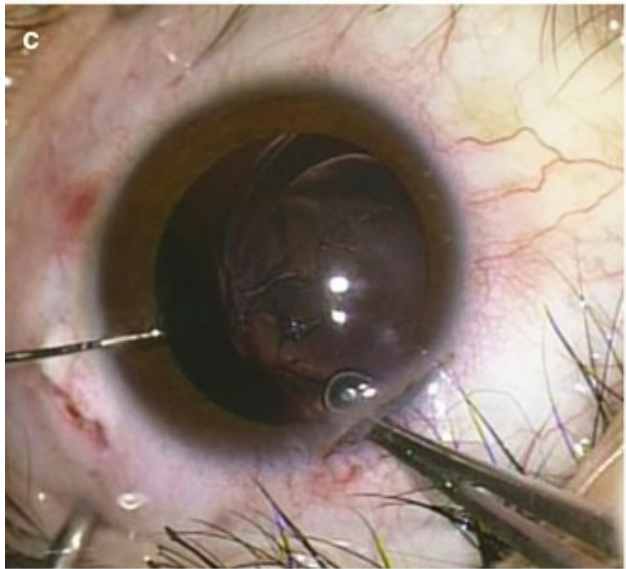
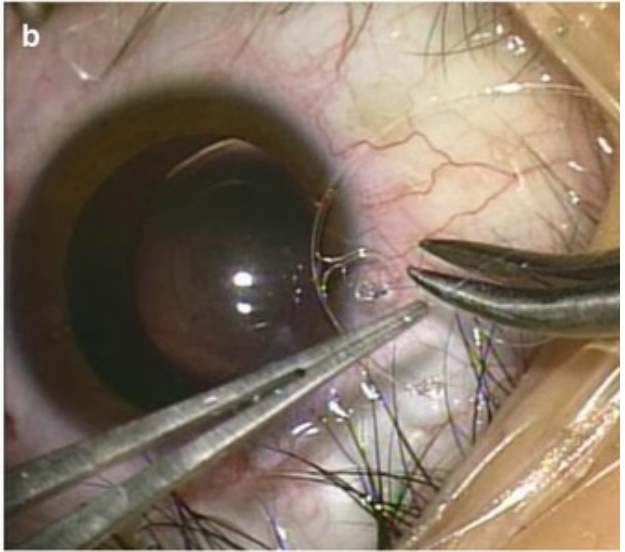
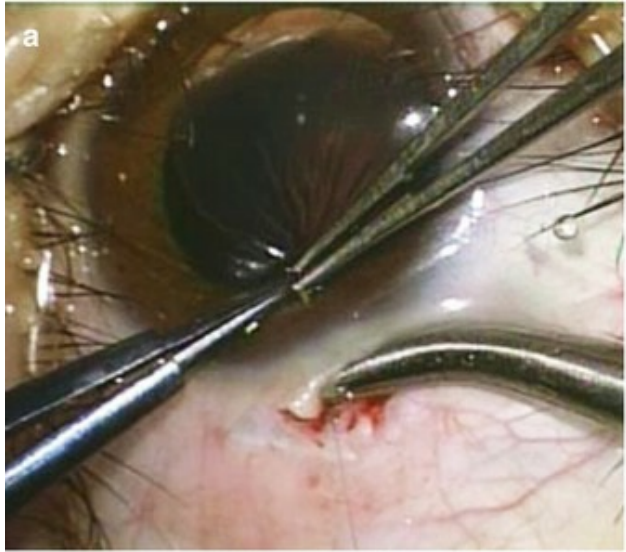


Fig. 17.11 Procedure and anatomical outcome of MCTR implantation. (a) A 10–0 polypropylene suture is preplaced. (b) The suture is tied to the fixation holes of the MCTR. (c) The MCTR is implanted. (d) The suture is tied to the sclera to fix the MCTR. (e) An IOL is implanted in the capsular bag. (f) A slit-lamp image shows that the MCTR and IOL are stable and centered

Iris/Capsule Retractors

Iris retractors (Fig. 17.12a) can be used to maintain centration of the capsular bag and facilitate easier and safer surgery. They can also reduce vitreous disturbance, avoid severe vitreous prolapse, and thereby reduce surgical complications. Novak et al. [52] recommended placing iris retractors on the opposite side of the incision in patients with zonular weakness or ruptures, thus stabilizing and expanding the capsule and therefore maintaining the stability of intraocular structures. It may also offset intraoperative miosis, provide an adequate visual surgical field and maneuvering space, and prevent further damage to the zonules and capsule. In a previous study, the authors used iris retractors to assist phacoaspiration in 27 children (31 eyes) with EL and serious complications such as capsular tear; dropped nucleus and intraocular hemorrhage did not occur during surgery [51].

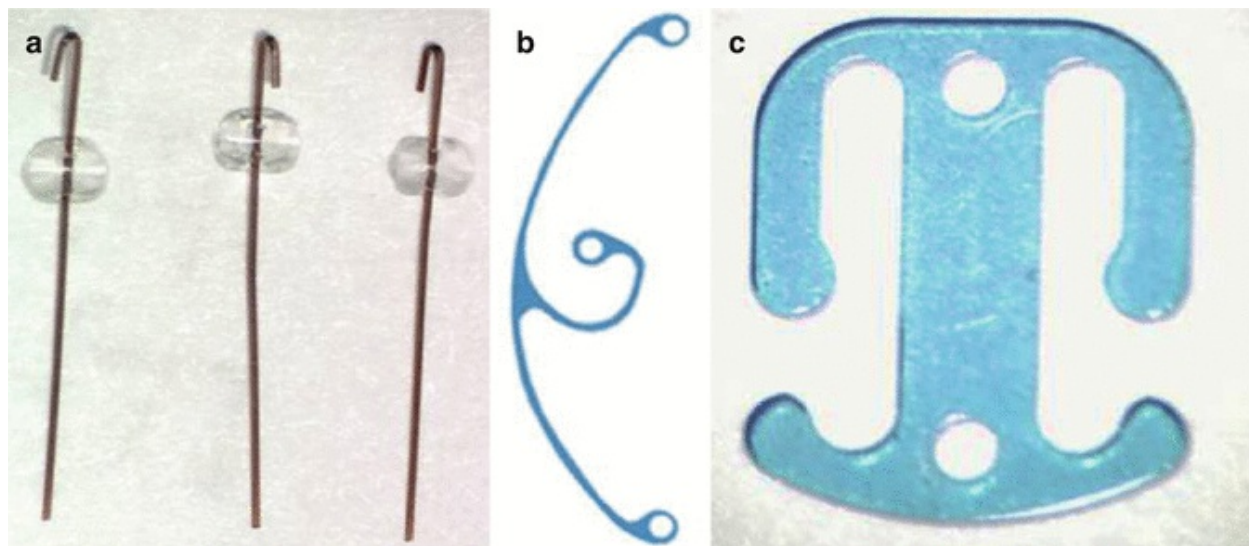


Fig. 17.12 New adjunctive instruments. (a) Iris retractors. (b) Capsular tension segments. (c) Capsular anchor

Intraoperative use of iris retractors is as follows. A paracentesis is made with a 15° slit knife at the clear cornea near the limbus on the side of zonular abnormalities. A moderate volume of OVD is placed in the anterior chamber, and a small amount of OVD is injected through the anterior capsulotomy into

the space beneath the anterior capsule which is the holding spot for the retractors. Use forceps to implant the retractors, and adjust them so that they exert moderate traction on the capsule. One to four retractors may be placed depending on the range of zonular weakness/rupture and rigidity of the nucleus. It should be noted that if there is an anterior capsule tear, retractors should not be used to prevent enlargement of the tear.

New Adjunctive Instruments

In recent years, a variety of IOL fixation tools have been reported, including capsular tension segments and capsular anchors. Selection from among these tools should be made by taking into consideration the condition of the lens capsule. For children with potentially progressive zonular lesions, appropriate tools should be chosen to reduce intraoperative and postoperative complications:

1. Capsular tension segment (Fig. 17.12b): This is a 120° open-loop segment made of PMMA, with fixation hooks and holes or eyes at the tips. It works via transscleral fixation using the holes or eyes. During surgery, an iris retractor is used to hold onto the hole or eye of the fixation hook, and the segment is placed where there is zonular weakness/rupture so that the capsular bag is stabilized. It may also be implanted in combination with a MCTR that is fixated onto the sclera [53].
2. Closed foldable capsular ring (CFCR): This is a circular foldable device consisting of 16 components with sufficient rigidity and recoil capability that can prevent the contraction of the capsular bag. The CFCR acts as a circle of “fences” along the equator of the capsular bag, which prevents contact between the anterior and posterior capsule and keeps the capsular bag inflated. This lowers the incidence of posterior capsule opacification (PCO). Traction on the zonules during implantation is also reduced for CFCR [54].
3. Capsular anchor (Fig. 17.12c): This consists of a main segment and four limbs (two limbs are perpendicular to the main segment and the other

two limbs are parallel to it). It has the shape of an anchor and it is made of PMMA.

It can stabilize the capsular bag at the site of zonular weakness or rupture [55].

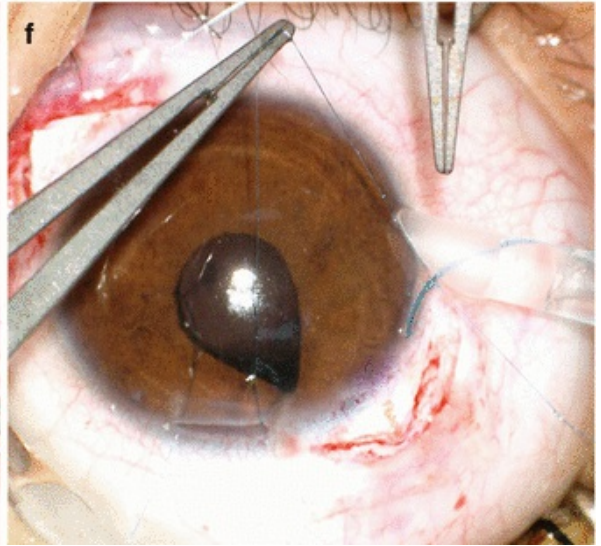
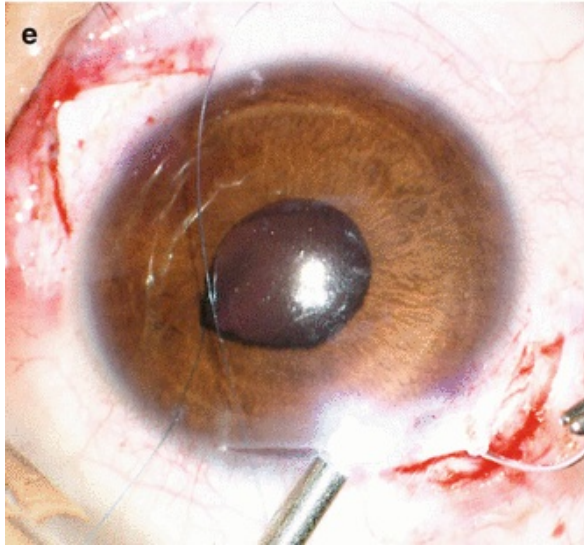
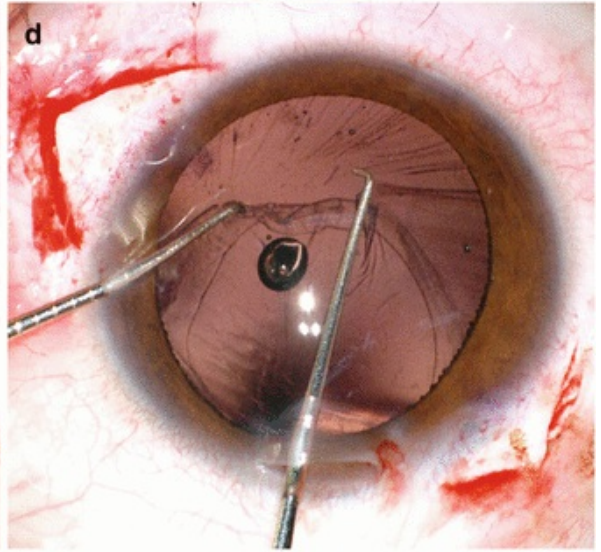
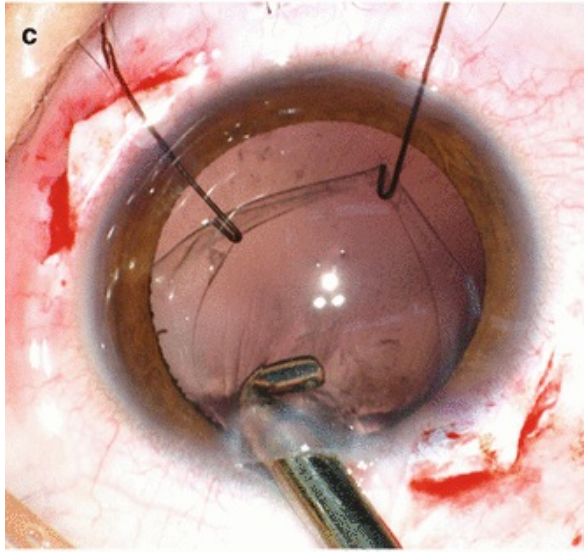
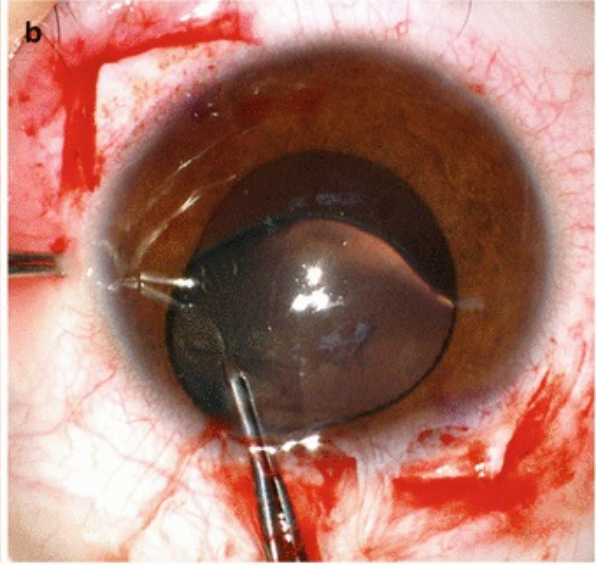
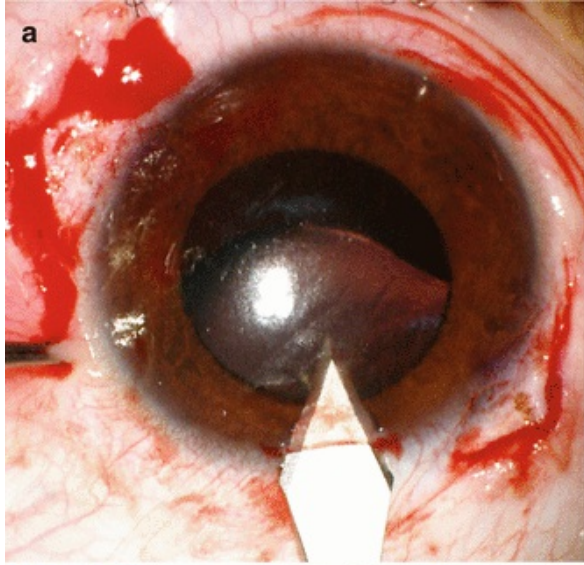
17.4.4 Intraocular Lens Implantation in EL

For nonprogressive EL, such as traumatic EL, the intact zonules still exert normal traction on the capsular bag. The IOL implantation method may be determined according to the range of zonular rupture. Viable options include in-the-bag implantation, single-haptic suture fixation, and double-haptic suture fixation. Assia et al. [47] recommended the following strategy if progressive EL is excluded:

1. For the zonular rupture of less than 90°, an IOL may be implanted directly into the capsular bag.
2. For zonular rupture of 90–150°, a CTR and an IOL may be implanted into the capsular bag.
3. For zonular rupture of 150–270°, an MCTR together with an IOL may be implanted into the capsular bag with the MCTR fixated to the sclera with polypropylene sutures.
4. For zonular rupture of more than 270°, usually the capsule is removed. Double-haptic IOL fixation to the sclera or iris is preferred. Anterior chamber IOL may also be considered.

For progressive EL in children, e.g., Marfan syndrome, the intact zonules are at risk of further elongation, weakening, and, ultimately, rupture. Therefore, selection of the IOL fixation technique should be considered from the perspective of long-term safety and effectiveness. The main techniques include combined implantation of MCTR and IOL, double-haptic sulcus fixation, and anterior chamber IOL implantation. Detailed surgical procedures are as follows:

1. In-the-bag implantation: This technique is divided into IOL implantation and a combined implantation of an IOL and a CTR or MCTR. In-the-bag IOL implantation can be achieved with a lens hook stabilizing the capsule. [See Chap. 15 for a detailed description of this technique.] A rigid or three-piece foldable IOL is recommended with the haptics placed at the location of zonular abnormalities to provide adequate capsular support. After implantation of a CTR or MCTR, OVD is injected to inflate the capsule and the IOL is implanted. IOL should be placed behind the fixation hook of the MCTR (Fig. 17.11).
2. Sulcus fixation: This involves the transscleral fixation of both haptics of a posterior chamber intraocular lens and is described in detail as follows (Fig. 17.13):



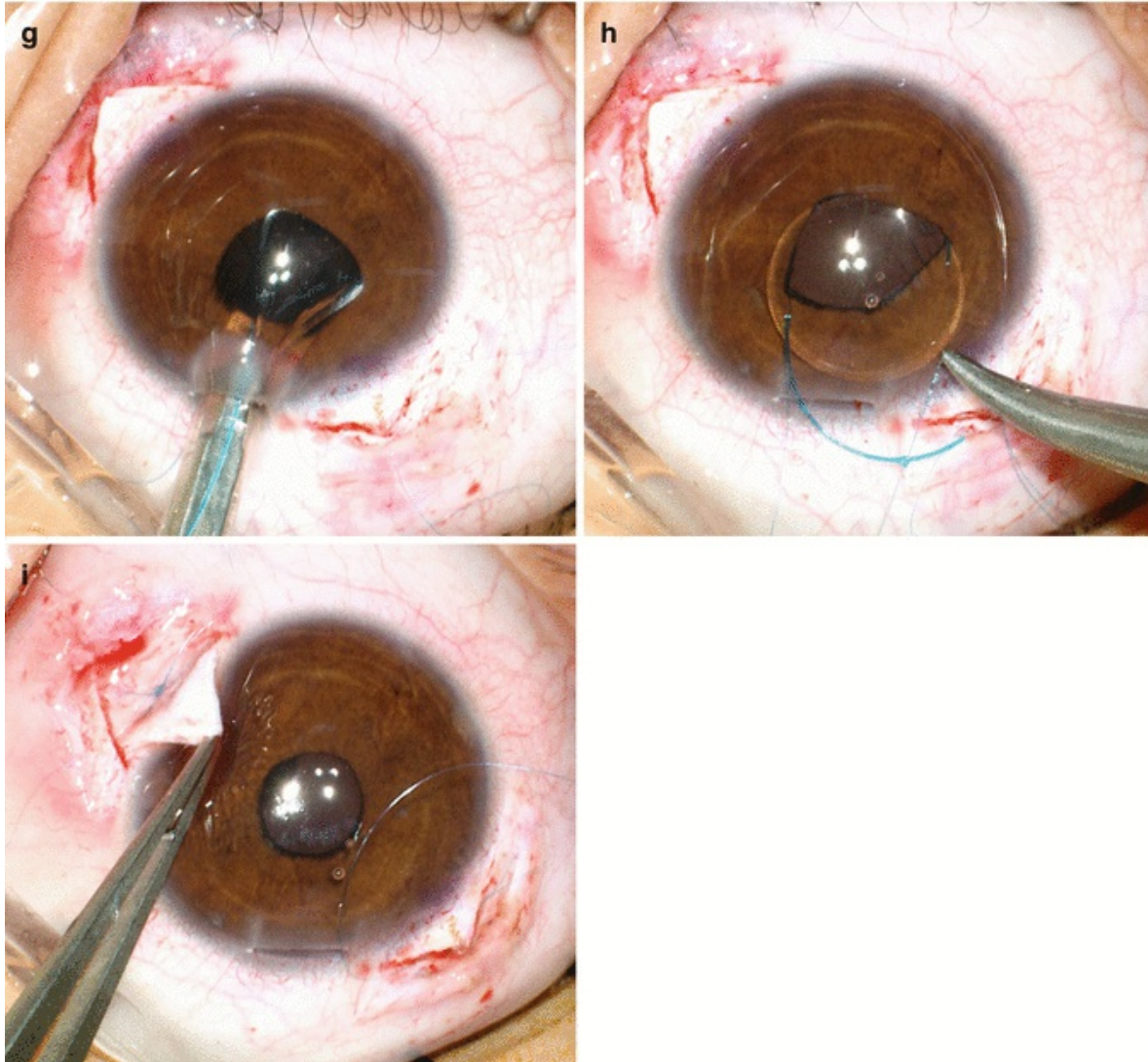


Fig. 17.13 Procedure for transscleral double-haptic fixation of a posterior chamber IOL. **(a)** Two symmetrical scleral flaps and a 3 mm limbal tunnel incision are constructed. **(b)** Capsulorhexis is conducted. **(c)** Iris retractors are used to hold the capsular bag during cortex aspiration. **(d)** The capsule is removed. **(e)** Two 10–0 polypropylene transscleral sutures are preplaced. **(f)** A suture is tied to the first haptic. **(g)** The foldable IOL is implanted using an injector. **(h)** The second suture is tied to the other haptic. **(i)** The sutures are tied off and the IOL is fixated

1. Two conjunctival peritomies are made at symmetrical clock hours (e.g., 1 and 7 o'clock). Two scleral pockets, each with a triangular lamellar flap, are constructed 3 mm posterior to the limbus before cautery hemostasis.
2. The authors prefer the ab externo approach. A double-armed 10–0

polypropylene suture enters 1.5 mm posterior to the limbus beneath the lamellar scleral flap, passes behind the iris through the pupil aperture into the anterior chamber, and exits through the clear cornea near the limbus. The suture is drawn out from the superior main incision in the clear cornea. Another polypropylene suture is then passed through the other scleral flap and pulled out from the main incision in the same manner. Single suture fixation with long and short needles may also be used. The long needle enters beneath the scleral flap, and a short, hollow needle is passed at a symmetrical position under the opposite flap. Under direct observation of the pupillary zone, the long needle is inserted into the short needle, which is then withdrawn with the long needle inside. Finally, the suture is taken out from the main incision and is cut in the middle.

3. A 3-piece foldable IOL, which has been loaded into the injector, is slightly exposed so that the leading haptic is evident. The suture at 7 o'clock is tied to the lateral 1/3 of the leading haptic. The IOL is then injected into the anterior chamber with the trailing haptic outside the principal incision. The suture at 1 o'clock is tied to the lateral 1/3 of the trailing haptic, which is dialed into the ciliary sulcus. The suture is tightened and adjusted so that the IOL optic is centered, then the suture is tied with the knots buried under the sclera.
4. For children with congenital EL, removal of the capsule may be considered. If the capsule is preserved, contact between the optic and the posterior capsule should be avoided to prevent IOL decentration due to capsular fibrosis. Prolapsed vitreous in the anterior chamber or in the incision should be completely removed.
5. A 10-0 nylon suture is used to close the scleral flap to avoid suture exposure, and the main corneal incision is sutured with the suture line.

Double-haptic fixation is an accepted technique for pediatric EL, but it involves maneuvers behind the iris, which are not under direct

vision and this may be thought of as a “blind” operation. Therefore, intraocular hemorrhage and tissue damage are possible. It may also lead to problems including postoperative IOL decentration due to inaccurate fixation. Ashraf et al. [56] found that in double-haptic fixation, only 55 % of the IOL haptics are actually located in the ciliary sulcus. Olsen [57] reported that endoscope-guided double-haptic fixation of a rigid posterior chamber IOL achieved good clinical outcomes. We performed an accurate endoscope-guided, double-haptic fixation of a foldable IOL through a small incision, in children with congenital EL. With this technique, the child’s ciliary body is directly seen, and the IOL can be accurately fixated in the ciliary sulcus. Under direct visualization, hemostasis with OVD tamponade is implemented in a timely manner to manage hemorrhage caused by needle entry, and this reduces surgical complications.

The detailed procedure is as follows. After removal of the lens material, both the anterior and posterior chambers are injected with OVD to create space in the ciliary sulcus.

An endoscopic probe together with an armed polypropylene suture is simultaneously inserted through the 3 mm main incision, and ab interno suturing is performed under direct endoscopic view without touching any ciliary process. The needle enters at the ciliary sulcus beneath the scleral flap that has been made and exits through the scleral surface. The distance between the needle exit and the limbus is measured before the suture is tied and buried under the scleral flap. The other suture may enter from the scleral surface at a point of equal distance to that measured for the first suture exit. Its entry into the ciliary sulcus is monitored under direct endoscopic view. We recommend that an angled endoscopic probe is used to monitor suturing to ensure that fixation of both haptics can be completed through only one principal incision (Fig. 17.14). If bleeding is observed during the operation, OVD should be immediately injected, aimed at the bleeding point, and subsequent operations are resumed only after the bleeding has stopped.

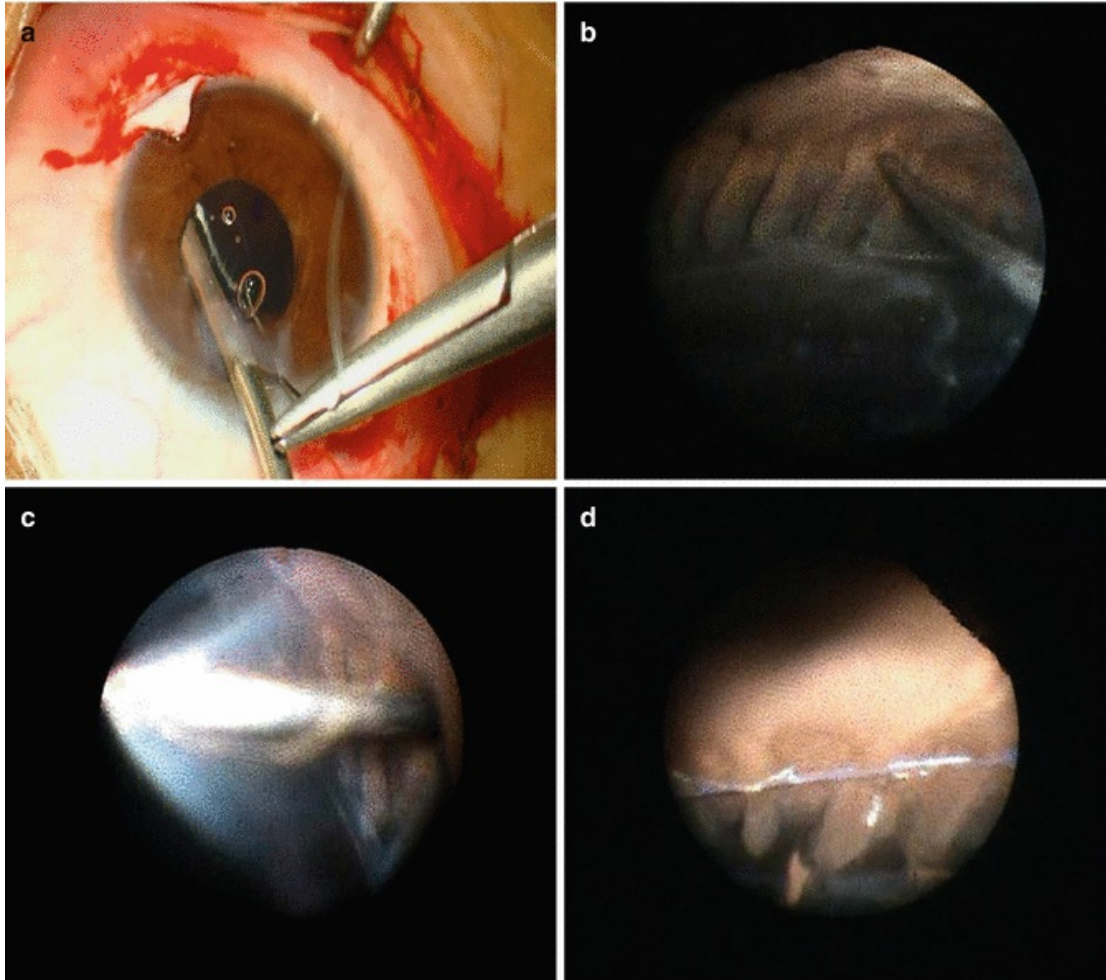


Fig. 17.14 IOL double-haptic fixation under direct endoscopic view. (a) The endoscope is introduced via the limbal incision. (b) A long needle is passed through the ciliary sulcus to the scleral surface. (c) Another long needle enters ab externo through the ciliary sulcus (endoscopic view). (d) IOL haptic is located in the ciliary sulcus (endoscopic view)

3. Anterior chamber IOL: The use of anterior chamber IOLs (AC-IOLs) in pediatric eyes is still controversial, and clinical studies of long-term outcomes are necessary. However, for children with severe EL ($>270^\circ$), an anterior chamber IOL may be considered. Preoperative evaluations, including a corneal endothelial cell count and an anterior chamber depth (ACD) measurement, should be performed. At present, iris claw IOLs are the common type of AC-IOL in clinical practice (Fig. 17.15a). Claery et al. [58] applied the iris claw AC-IOL in children with EL and achieved a better outcome compared with transscleral fixated posterior chamber

IOLs (Fig. 17.15b). However, due to the uncertain long-term outcome of AC-IOLs, e.g., risks of chronic uveitis, corneal endothelial decompensation, and secondary glaucoma, it is necessary to strictly follow the guidelines of AC-IOL implantation and ensure close follow-up.

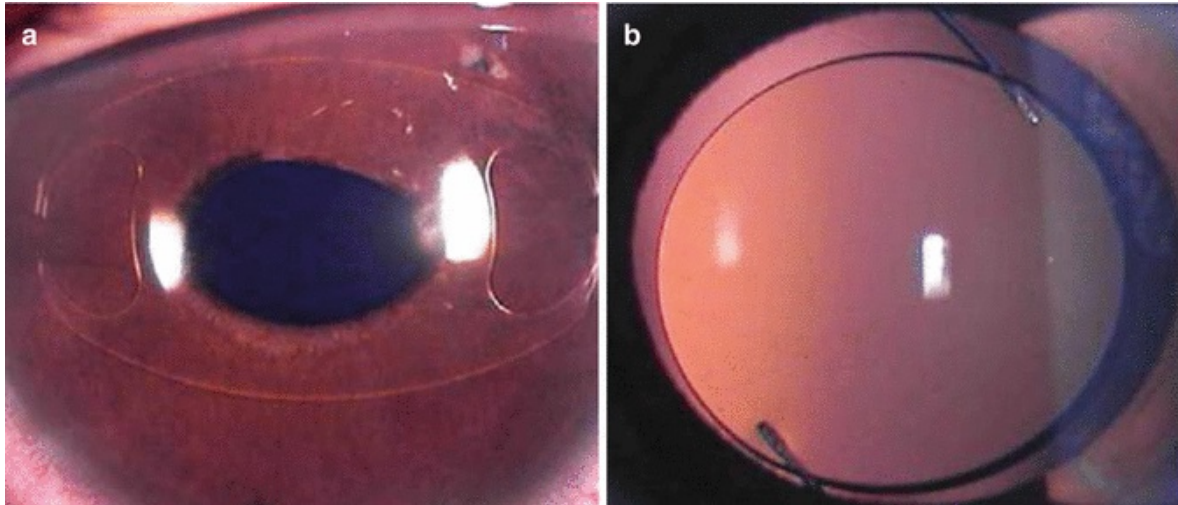


Fig. 17.15 Outcomes of different types of IOL after implantation. (a) Slit-lamp image at 3 years after anterior chamber IOL (AC-IOL) implantation. (b) Slit-lamp image at 2 years after double-haptic fixation of a 3-piece foldable IOL

4. Iris-fixated posterior chamber IOL (iris-fixated PC-IOL): Similar to an anterior chamber IOL, the use of this technique in pediatric eyes is controversial. For IOL implantation in eyes without adequate posterior capsular support, an iris-fixated PC-IOL is an alternative. Compared with an anterior chamber IOL, the posterior chamber IOL resembles more the physiological position of the natural lens and may avoid a variety of the complications associated with the anterior chamber IOL. However, there is inadequate evidence that compares the safety and efficacy among open-loop AC-IOLs, scleral-fixated PC-IOLs, and iris-fixated PC-IOLs [59]. There are various techniques for iris fixation of a PC-IOL, including Siepser slipknot fixation, simple small-incision fixation, and ab externo fixation via a small incision.

17.5 Summary

Pediatric EL is mainly caused by congenital or traumatic factors, and it may disrupt the development of visual function in children. Early correction of refractive errors associated with EL can help prevent or reduce amblyopia in these children. EL that cannot be managed with spectacles or EL with complications requires surgical intervention. Modern small-incision phacoaspiration combined with IOL implantation is associated with fewer complications. New adjunctive instruments, such as CTRs and iris retractors, may simplify surgical maneuvers and improve safety. Preoperative systemic evaluation, an individualized treatment regimen, and selection of an appropriate surgical technique based on the disease condition are the key to successful surgical treatment of pediatric EL.

References

1. Fuchs J, Rosenberg T. Congenital ectopia lentis. A Danish national survey. *Acta Ophthalmol Scand.* 1998;76:20–6.
[\[CrossRef\]](#)[\[PubMed\]](#)
2. Burian HM, Allen L. Histologic study of the chamber angle in patients with Marfans syndrome. *Arch Ophthalmol.* 1961;65:323–33.
[\[CrossRef\]](#)[\[PubMed\]](#)
3. Casper DS, Simon JW, Nelson LB, et al. Familial simple ectopia lentis: a case study. *J Pediatr Ophthalmol Strabismus.* 1985;22(6):227–30.
[\[PubMed\]](#)
4. Meire FM. Hereditary ectopia lentis. A series of 10 cases of ectopia lentis et pupillae. *Bull Soc Belge Ophthalmol.* 1991;241:25–36.
[\[PubMed\]](#)
5. Ruiz C, Rivas F, Villar-Calvo VM, et al. Familial simple ectopia lentis. A probable autosomal recessive form. *Ophthalmic Paediatr Genet.* 1986;7(2):81–4.
[\[CrossRef\]](#)[\[PubMed\]](#)
6. Chiu HH, Wu MH, Chen HC, et al. Epidemiological profile of Marfan syndrome in a general population: a national database study. *Mayo Clin Proc.* 2014;89(1):34–42.
[\[CrossRef\]](#)[\[PubMed\]](#)
7. Gray JR, Bridges AB, Faed MJ, et al. Ascertainment and severity of Marfan syndrome in a Scottish population. *J Med Genet.* 1994;31:51–4.
[\[CrossRef\]](#)[\[PubMed\]](#)[\[PubMedCentral\]](#)

8. Pyeritz RE. The Marfan syndrome. *Annu Rev Med.* 2000;51:481–510.
[\[CrossRef\]](#)[\[PubMed\]](#)
9. Pessier AP, Potter KA. Ocular pathology in bovine Marfans syndrome with demonstration of altered fibrillin immunoreactivity in explanted ciliary body cells. *Lab Invest.* 1996;75:87–95.
[\[PubMed\]](#)
10. Dagoneau N, Benoist-Lasselin C, Huber C, et al. ADAMTS10 mutations in autosomal recessive Weill-Marchesani syndrome. *Am J Hum Genet.* 2004;75(5):801–6.
[\[CrossRef\]](#)[\[PubMed\]](#)[\[PubMedCentral\]](#)
11. Meire FM, Delleman WJ, Bleeker-Wagemakers EM. Ocular manifestations of congenital Marfan syndrome with contractures (CMC syndrome). *Ophthalmic Paediatr Genet.* 1991;12:1–9.
[\[CrossRef\]](#)[\[PubMed\]](#)
12. Kumar A, Agarwal S. Marfan syndrome: an eyesight of syndrome. *Meta Gene.* 2014;2:96–105.
[\[CrossRef\]](#)[\[PubMed\]](#)[\[PubMedCentral\]](#)
13. Pyeritz R. Emery and Rimoin's principles and practice of medical genetics. In: Rimoin D, Pyeritz R, Korf B, editors. *Marfan syndrome and related disorders.* 6th ed. Oxford: Academic; 2013. p. 1–52.
14. Loeys BL, Dietz HC, Braverman AC, et al. The revised Ghent nosology for the Marfan syndrome. *J Med Genet.* 2010;47(7):476–85.
[\[CrossRef\]](#)[\[PubMed\]](#)
15. Chandra A, Ekwalla V, Child A, et al. Prevalence of ectopia lentis and retinal detachment in Marfan syndrome. *Acta Ophthalmol.* 2014;126:1311–3.
16. Cross HE, Jensen AD. Ocular manifestations in the Marfansyndrome and homocystinuria. *Am J Ophthalmol.* 1973;75:405–20.
[\[CrossRef\]](#)[\[PubMed\]](#)
17. Spanou N, Alexopoulos L, Manta G, et al. Strabismus in pediatric lens disorders. *J Pediatr Ophthalmol Strabismus.* 2011;48(3):163–6.
[\[CrossRef\]](#)[\[PubMed\]](#)
18. Remulla JF, Tolentino FI. Retinal detachment in Marfan's syndrome. *Int Ophthalmol Clin.* 2001;41:235–40.
[\[CrossRef\]](#)[\[PubMed\]](#)
19. Izquierdo NJ, Traboulsi EI, Enger C, et al. Glaucoma in the Marfan syndrome. *Trans Am Ophthalmol Soc.* 1992;90:111–7.
[\[PubMed\]](#)[\[PubMedCentral\]](#)
20. Melenovská P, Kopecká J, Krijt J, et al. Chaperone therapy for homocystinuria: the rescue of CBS mutations by heme arginate. *J Inherit Metab Dis.* 2015;38(2):287–94.
[\[CrossRef\]](#)[\[PubMed\]](#)
21. Silao CL, Fabella TD, Rama KI, et al. Novel CBS gene mutations in a Filipino patient with Classical Homocystinuria. *Pediatr Int.* 2015;57(5):884–7.

[\[CrossRef\]](#)[\[PubMed\]](#)

22. Ritelli M, Dordoni C, Venturini M, et al. Clinical and molecular characterization of 40 patients with classic Ehlers-Danlos syndrome: identification of 18 COL5A1 and 2 COL5A2 novel mutations. *Orphanet J Rare Dis.* 2013;8:58.
[\[CrossRef\]](#)[\[PubMed\]](#)[\[PubMedCentral\]](#)
23. Shah MH, Bhat V, Shetty JS, et al. Whole exome sequencing identifies a novel splice-site mutation in ADAMTS17 in an Indian family with Weill-Marchesani syndrome. *Mol Vis.* 2014;20:790–6.
[\[PubMed\]](#)[\[PubMedCentral\]](#)
24. Saricaoglu MS, Sengun A, Karakurt A, et al. Autosomal dominant Weill-Marchesani syndrome and glaucoma management. *Saudi Med J.* 2005;26(9):1468–9.
[\[PubMed\]](#)
25. Houten SM, Te Brinke H, Denis S, et al. Genetic basis of hyperlysinemia. *Orphanet J Rare Dis.* 2013;8:57.
[\[CrossRef\]](#)[\[PubMed\]](#)[\[PubMedCentral\]](#)
26. Kaliki S, Shields CL, Eagle Jr RC, et al. Ciliary body medulloepithelioma: analysis of 41 cases. *Ophthalmology.* 2013;120(12):2552–9.
[\[CrossRef\]](#)[\[PubMed\]](#)
27. Marcus DM, Topping TM, Frederick Jr AR. Vitreoretinal management of traumatic dislocation of the crystalline lens. *Int Ophthalmol Clin.* 1995;35:139–50.
[\[CrossRef\]](#)[\[PubMed\]](#)
28. Ahram D, Sato TS, Kohilan A, et al. A homozygous mutation in ADAMTSL4 causes autosomal-recessive isolated ectopia lentis. *Am J Hum Genet.* 2009;84(2):274–8.
[\[CrossRef\]](#)[\[PubMed\]](#)[\[PubMedCentral\]](#)
29. Maumenee IH. The eye in the Marfan syndrome. *Trans Am Ophthalmol Soc.* 1981;79:684–733.
[\[PubMed\]](#)[\[PubMedCentral\]](#)
30. Dagi LR, Walton DS. Anterior axial lens subluxation, progressive myopia, and angle-closure glaucoma: recognition and treatment of atypical presentation of ectopia lentis. *J AAPOS.* 2006;10:345–50.
[\[CrossRef\]](#)[\[PubMed\]](#)
31. Mennel S, Meyer CH, Kroll P. Dislocation of the lenses. *N Engl J Med.* 2004;351(18):1913–4.
[\[CrossRef\]](#)[\[PubMed\]](#)
32. Hoffman RS, Snyder ME, Devgan U, et al. Management of the subluxated crystalline lens. *J Cataract Refract Surg.* 2013;39(12):1904–15.
[\[CrossRef\]](#)[\[PubMed\]](#)
33. Loo AV, Lai JS, Tham CC, et al. Traumatic subluxation causing variable position of the crystalline lens. *J Cataract Refract Surg.* 2002;28:1077–9.
[\[CrossRef\]](#)[\[PubMed\]](#)
34. Ng CM, Cheng A, Myers LA, et al. TGF-beta-dependent pathogenesis of mitral valve prolapse in a

- mouse model of Marfan syndrome. *J Clin Invest*. 2004;114:1586–92.
[\[CrossRef\]](#)[\[PubMed\]](#)[\[PubMedCentral\]](#)
35. Pyeritz RE. Marfan syndrome: current and future clinical and genetic management of cardiovascular manifestations. *Semin Thorac Cardiovasc Surg*. 1993;5:11–6.
[\[PubMed\]](#)
 36. Van Karnebeek CD, Naeff MS, Mulder BJ, et al. Natural history of cardiovascular manifestations in Marfan syndrome. *Arch Dis Child*. 2001;84:129–37.
[\[CrossRef\]](#)[\[PubMed\]](#)[\[PubMedCentral\]](#)
 37. Hakin KN, Jacobs M, Rosen P, et al. Management of the subluxated crystalline lens. *Ophthalmology*. 1992;99:542–5.
[\[CrossRef\]](#)[\[PubMed\]](#)
 38. Wright KW. Visual development and amblyopia. In: Wright KW, Spiegel PH, editors. *Pediatric ophthalmology and strabismus*. 2nd ed. New York: Springer; 2003. p. 584–95.
[\[CrossRef\]](#)
 39. Simon JW. Basic and clinical science course. In: Section 6: pediatric ophthalmology and strabismus. San Francisco: American Academy of Ophthalmology; 2004. p. 68–374.
 40. Nelson LB, Maumenee IM. Ectopia lentis. *Surv Ophthalmol*. 1982;27:143–60.
[\[CrossRef\]](#)[\[PubMed\]](#)
 41. Kim SY, Choung HK, Kim SJ, et al. Long-term results of lensectomy in children with ectopia lentis. *J Pediatr Ophthalmol Strabismus*. 2008;45:13–9.
[\[CrossRef\]](#)[\[PubMed\]](#)
 42. Tolentino FI, Schepens CL, Freeman HM. Systemic conditions with vitreoretinal degeneration. In: Tolentino FI, Schepens CL, Freeman HM, editors. *Vitreoretinal disorders: diagnosis and management*. Philadelphia: Saunders; 1976. p. 269–89.
 43. Parolini B, Prigione G, Romanelli F, et al. Postoperative complications and intraocular pressure in 943 consecutive cases of 23-gauge transconjunctival pars plana vitrectomy with 1-year follow-up. *Retina*. 2010;30:107–11.
[\[CrossRef\]](#)[\[PubMed\]](#)
 44. Cionni RJ. Capsule tension rings and segments. In: Steinert RF, editor. *Cataract surgery*. 3rd ed. Philadelphia: Saunders; 2010.
 45. Vasavada AR, Praveen MR, Vasavada VA, et al. Cionni ring and in-the-bag intraocular lens implantation for subluxated lens: a prospective case series. *Am J Ophthalmol*. 2012;153(6):1144–53.
[\[CrossRef\]](#)[\[PubMed\]](#)
 46. Luo L, Lin H, Chen W, et al. In-the-bag intraocular lens. Placement via secondary Capsulorhexis with radiofrequency diathermy in pediatric aphakic eyes. *PLoS One*. 2013;8(4):e62381.
[\[CrossRef\]](#)[\[PubMed\]](#)[\[PubMedCentral\]](#)

47. Assia EL. Cataract surgery in eyes with loose zonules. In: Kohnen T, Koch DD, editors. Cataract and refractive surgery, essential in ophthalmology. Heidelberg: Springer Berlin; 2006. p. 13–22. [\[CrossRef\]](#)
48. Plager DA, Parks MM, Helveston EM, Ellis FD. Surgical treatment of subluxated lenses in children. *Ophthalmology*. 1992;99:1018–21. [\[CrossRef\]](#)[\[PubMed\]](#)
49. Jacob S, Agarwal A, Agarwal A, et al. Efficacy of a capsular tension ring for phacoemulsification in eyes with zonular dialysis. *J Cataract Refract Surg*. 2003;29(2):315–21. [\[CrossRef\]](#)[\[PubMed\]](#)
50. Cionni RJ, Osher RH, Marques DM, et al. Modified capsular tension ring for patients with congenital loss of zonular support. *J Cataract Refract Surg*. 2003;29:1668–73. [\[CrossRef\]](#)[\[PubMed\]](#)
51. Wu W, Zheng D, Zheng Y, et al. Iris hooks and modified capsular tension ring for subluxation lens in patients with Marfan's syndrome. *Chin J Ophthalmol*. 2007;43(2):108–11.
52. Novák J. Flexible iris hooks for phacoemulsification. *J Cataract Refract Surg*. 1997;23:828–31. [\[CrossRef\]](#)[\[PubMed\]](#)
53. Khokhar S, Gupta S, Kumar G, et al. Capsular tension segment in a case of microspherophakia. *Cont Lens Anterior Eye*. 2012;35(5):230–2. [\[CrossRef\]](#)[\[PubMed\]](#)
54. Dick HB. Closed foldable capsular rings. *J Cataract Refract Surg*. 2005;31(3):467–71. [\[CrossRef\]](#)[\[PubMed\]](#)
55. Assia EI, Ton Y, Michaeli A. Capsule anchor to manage subluxated lenses: initial clinical experience. *J Cataract Refract Surg*. 2009;35(8):1372–9. [\[CrossRef\]](#)[\[PubMed\]](#)
56. Ashraf S, Ahme M. Ultrasound biomicroscopy of haptics position after transscleral fixation of posterior chamber intraocular lenses. *J Cataract Refract Surg*. 2001;27:1418–22. [\[CrossRef\]](#)
57. Olsen TW, Pribila JT. Pars plana vitrectomy with endoscope-guided adults. *Am J Ophthalmol*. 2011;151(2):287–96. [\[CrossRef\]](#)[\[PubMed\]](#)
58. Cleary C, Lanigan B, O'Keeffe M. Artisan iris-claw lenses for the correction of aphakia in children following lensectomy for ectopia lentis. *Br J Ophthalmol*. 2012;96(3):419–21. [\[CrossRef\]](#)[\[PubMed\]](#)
59. Simon MA, Origlieri CA, Dinallo AM, et al. New management strategies for ectopia lentis. *J Pediatr Ophthalmol Strabismus*. 2015;52(5):269–81. [\[CrossRef\]](#)[\[PubMed\]](#)

18. Cataract Surgery in Children with Preexisting Posterior Capsular Defects

Mingxing Wu¹✉, Zhenzhen Liu¹ and Bo Qu¹

- (1) State Key Laboratory of Ophthalmology, Zhongshan Ophthalmic Center, Sun Yat-sen University, 54S Xianlie Road, Guangzhou, 510060, People's Republic of China

✉ **Mingxing Wu**

Email: wumingx@mail.sysu.edu.cn

Abstract

About 10 % of pediatric cataract patients have preexisting posterior capsular defects. The common types of posterior capsular defects include posterior capsular plaque, congenital membranous cataract, posterior polar cataract, posterior lenticonus, and posterior polar or posterior subcapsular cataracts with persistent fetal vasculature. Pediatric cataract surgery in the eyes with posterior capsular defects often has a significantly increased risk of intraoperative complications, and the biggest challenge lies in how to avoid or manage lens material dropping into the vitreous cavity during surgery. This chapter will describe the clinical features, diagnosis, timing of operation, and surgical techniques for each of these cataract types.

Approximately 10 % of pediatric cataracts are associated with preexisting posterior capsular defects (PPCDs) [1], which mainly include posterior capsular plaque, posterior polar cataract, posterior lenticonus, congenital membranous cataract, posterior polar or subcapsular cataract associated with persistent fetal vasculature (PFV), and cataract associated with dense

fibrovascular membrane. As cataract surgery in children with PPCD is prone to complications (e.g., dislocation of lens material into the vitreous cavity and hyphema) which lead to poor surgical outcomes, it is different from the conventional cataract surgery, and sometimes special surgical techniques need to be adopted. This chapter will elaborate on the abovementioned types of pediatric cataracts that are often associated with PPCD.

18.1 Posterior Capsular Plaque

18.1.1 Causes and Clinical Manifestations

Posterior capsular plaque is often located in the retrolental space of Berger, and its pathogenesis remains unknown. As there is occasional vascular remnant in the posterior capsular plaque, some researchers speculate that it may derive from the primary hyaloid artery [2]. Posterior capsular plaque manifests as posterior capsular opacification and can be found in total cataract or posterior subcapsular cataract.

18.1.2 Surgical Techniques

The key issue in the surgical management for posterior capsular plaque is how to remove the plaque completely. A small plaque can be removed with capsulorhexis forceps, and a large plaque can be removed by posterior capsulotomy using radiofrequency diathermy or by posterior continuous curvilinear capsulorhexis (PCCC) at the unaffected capsule area (Fig. 18.1). During the surgery, a small incision is made on the posterior capsule, and ophthalmic viscosurgical device (OVD) is injected to separate the posterior lens capsule and the anterior hyaloid membrane, in order to maintain the integrity of the anterior hyaloid membrane and prevent too much vitreous prolapse. After the removal of the plaque, anterior vitrectomy is performed.

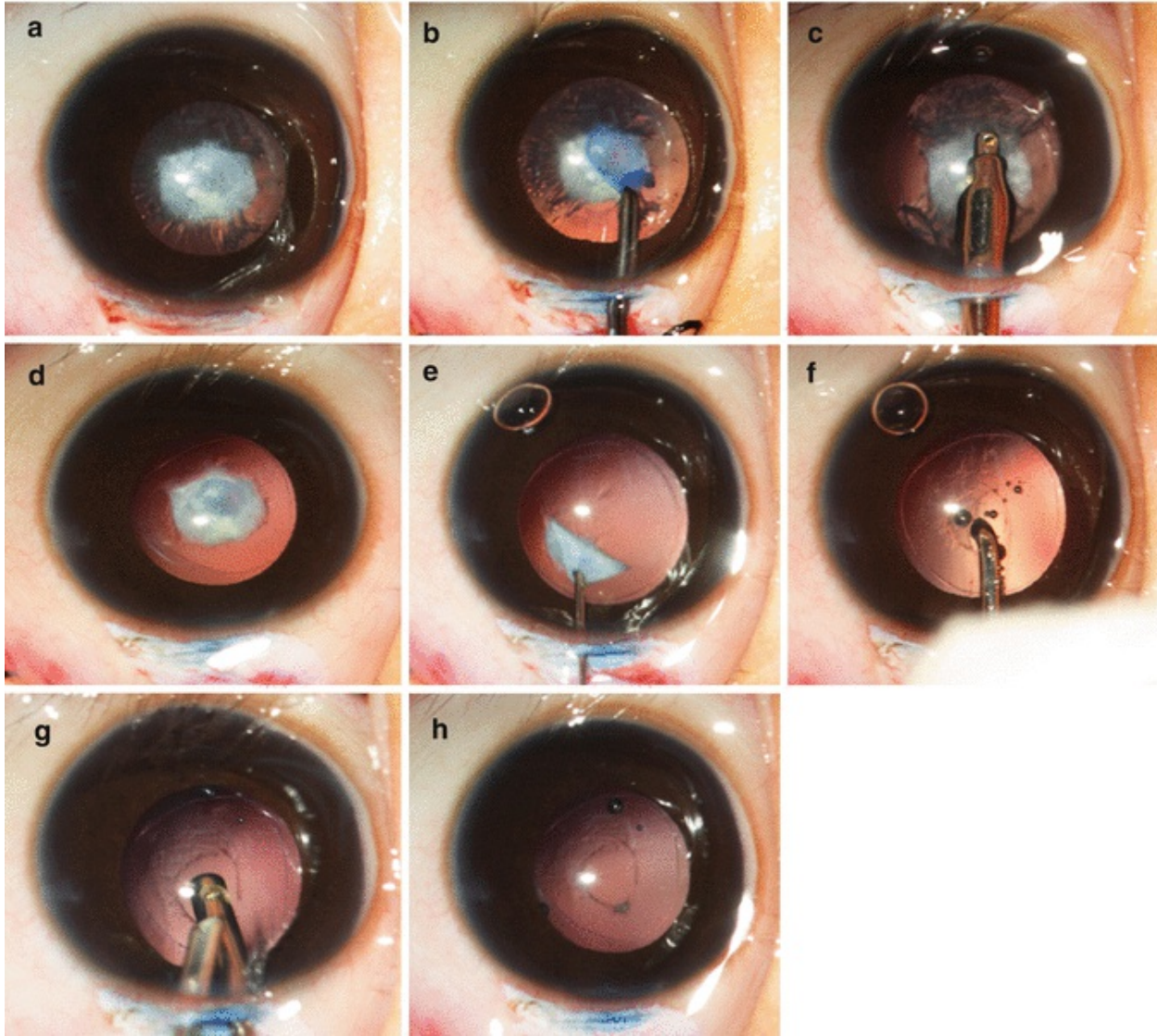


Fig. 18.1 The surgical procedures for posterior capsular plaque. (a) Posterior capsular plaque; (b) continuous curvilinear capsulorhexis (CCC) is performed after trypan blue staining; (c) irrigation and aspiration of lens cortex; (d, e) removal of the posterior capsular plaque by tearing; (f) radiofrequency diathermy capsulotomy is performed to generate a posterior capsule opening with continuous margins; (g) anterior vitrectomy is performed; (h) anterior and posterior capsulorhexis openings at the end of the surgery

18.2 Posterior Polar Cataract

18.2.1 Causes and Clinical Manifestations

Congenital posterior polar cataract can be inherited in an autosomal dominant pattern, and its possible genetic loci are 11q22–q22.3, 16q22, 14q22–23, or 20p12–q12 [3–6].

Posterior polar cataracts are often bilateral with the opacity located in the posterior lens cortex or beneath the posterior capsule. They manifest as dense white opacification with well-defined boundary (Fig. 18.2) and are likely to be accompanied by posterior capsular defect [6]. Posterior polar cataract can be divided into stationary or progressive based on whether the opacification develops over time [7]. Stationary posterior polar cataracts account for approximately 65 % of all cases and manifest as the well-defined round opacity in the central posterior capsule with concentric rings of opacification at the periphery, resembling a “bull’s eye.” Sometimes the opacities of the posterior pole are concealed by the opacified nucleus. Progressive posterior polar cataracts originate from opacities in the posterior polar cortex. They manifest as opacified radiating rings with fan-shaped margins and unclear borders, which do not involve the nucleus. In most cases of pediatric posterior polar cataract, it is difficult to determine the presence of posterior capsular defect preoperatively.

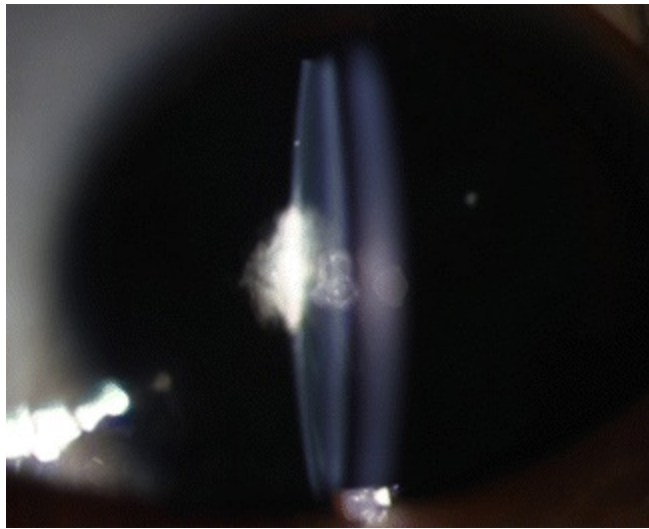


Fig. 18.2 Posterior polar cataract

18.2.2 Surgical Techniques

In posterior polar cataract extraction, attention should be given to the following issues:

1. During hydrodissection, gentle maneuvers and slow, multi-quadrant injections are warranted. The position of the lens material must be

closely observed, and if there are signs of downward movement, hydrodissection should be stopped without delay. It is recommended that hydrodissection can be performed in close proximity to the nucleus to form a thick cortex cushion beneath the nucleus, which will facilitate safe removal of the lens materials.

2. During cortex aspiration, the height of the bottle and the flow should be lower; the cortex at the periphery is first removed and finally the cortex at the center of the posterior pole.
3. The posterior polar opacity can be removed by PCCC using a cystotome, capsulorhexis forceps, or capsulotomy with radiofrequency diathermy.
4. The selection of the fixation site for intraocular lens (IOL) haptics mainly depends on the location and the size of the posterior capsular defect. In-the-bag fixation is the most ideal option. If the posterior capsular defect is too large, ciliary sulcus fixation can be an alternative.
5. An anterior vitrectomy device is recommended to remove the vitreous strands in the anterior chamber and part of the anterior vitreous in case of intraoperative vitreous prolapse (Fig. 18.3).




Fig. 18.3 The surgical procedures for congenital posterior polar cataract. (a) Posterior polar cataract; (b) anterior continuous curvilinear capsulorhexis is performed; (c) hydrodissection; (d) removal of the lens cortex; (e) the posterior polar opacity can be seen after the removal of lens cortex; (f) removal of the posterior polar opacity with a cystotome; (g) anterior vitrectomy is performed; (h) a second capsulotomy to enlarge the anterior capsulorhexis opening; (i) in-the-bag IOL implantation

18.3 Posterior Lenticonus

18.3.1 Causes and Clinical Manifestations

Posterior lenticonus refers to the congenital thinning and progressive backward bulging of the posterior capsule (Fig. 18.4). It usually occurs as a unilateral condition with most cases being sporadic and some being an X-

linked hereditary disorder [8].

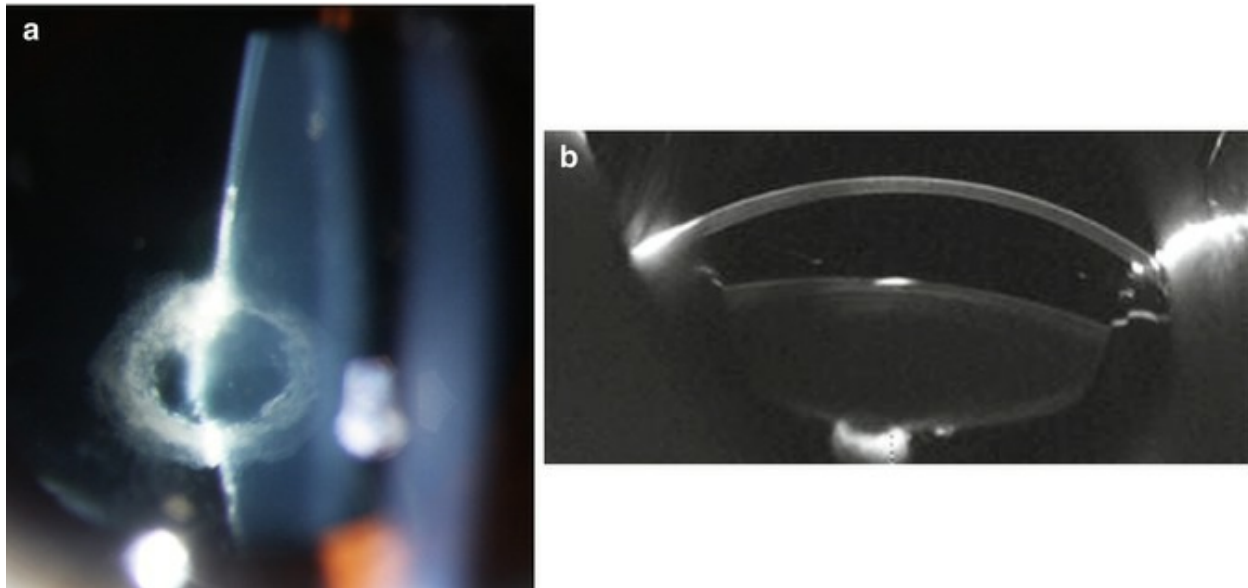


Fig. 18.4 (a) An image of posterior lenticonus obtained from slit-lamp biomicroscopy examination; (b) an image of posterior lenticonus obtained from Pentacam examination

Under slit-lamp biomicroscopy with retroillumination, posterior lenticonus appears as an oil drop-like lesion at the center of the lens against the red background illumination. Retinoscopy reveals a characteristic movement of light strip indicating that the refractive status at the center is myopic but hyperopic at the periphery. The sizes of posterior lenticonus are varied. Sometimes a localized opacity can be seen at the posterior of the lenticonus, where the posterior capsule may be absent or backward bulging and expansion of the posterior capsule may occur, giving rise to a diverticulum-like lesion. Forward progression of the opacity might occur and involve the cortex and nucleus.

During infancy, posterior lenticonus gives rise to irregular astigmatism and consequently twisting and distortion of retinal images in spite of a transparent lens, which may lead to amblyopia. Surgical intervention should be conducted as soon as visual impairment is detected in these patients. As posterior lenticonus is slowly progressive and has little effect on visual acuity in the early stage, most pediatric patients can establish a good central fixation and achieve a favorable prognosis [9].

18.3.2 Surgical Techniques

If the posterior lenticonus is transparent or the opacification is only limited to the lenticonus, surgery will be relatively easy. The surgical techniques are similar to those in posterior polar cataract (Fig. 18.5). After aspiration of the lens material, there will be forward or backward protuberance of the frail capsule at the lenticonus and in some cases, even posterior capsular rupture associated with vitreous prolapse.

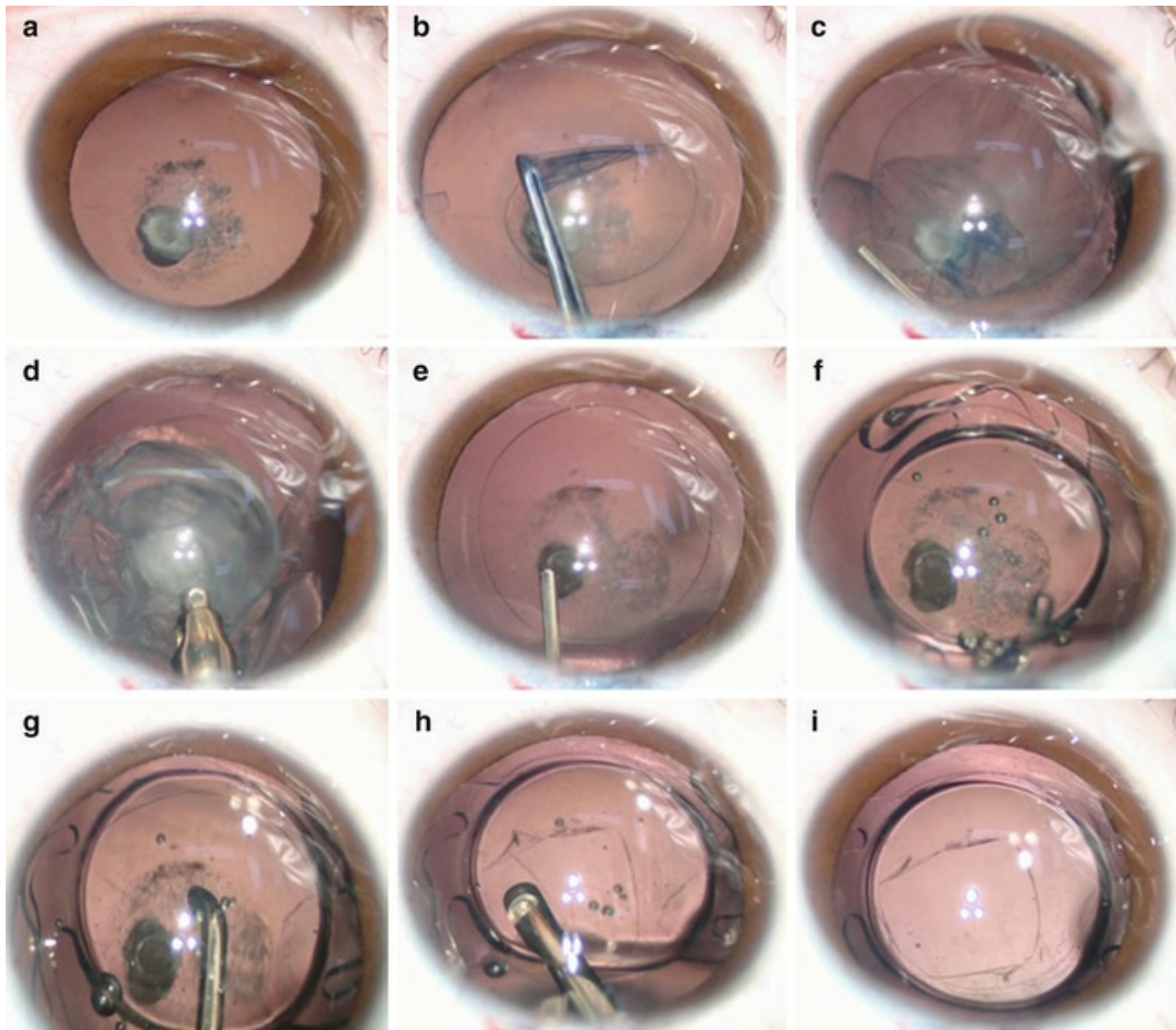


Fig. 18.5 The surgical procedures for posterior lenticonus. (a) Posterior lenticonus; (b) anterior continuous curvilinear capsulorhexis is performed after trypan blue staining; (c) hydrodissection; (d) removal of the lens cortex; (e) injection of the OVD; (f) in-the-bag IOL implantation; (g) continuous posterior capsulotomy with radiofrequency diathermy; (h) anterior vitrectomy is performed; (i) the anterior and posterior capsule opening

In the presence of dense, central opacity of the lens, it is difficult to detect

the posterior lenticonus preoperatively. Cataract surgery in these patients may be prone to posterior capsular rupture and vitreous prolapse. In this case, anterior vitrectomy should be performed, as well as the removal of the residual lens cortex.

18.4 Congenital Membranous Cataracts

18.4.1 Causes and Clinical Manifestations

Congenital membranous cataracts result from the spontaneous absorption of lens proteins, which then leads to shortened anteroposterior diameter of the lens and formation of a fibrous membrane [10, 11] (Fig. 18.6). Congenital membranous cataracts are commonly found in congenital rubella syndrome, Hallermann-Streiff-Francois syndrome, and Lowe syndrome. In some cases, fusion of the anterior and posterior capsule occurs, which gives rise to a dense, whitish fibrous membrane. The peripheral lens cortex takes the form of a Soemmering ring with possible vascular remnants. In other cases, an intact anterior capsule may be present, but it is usually thin and often adheres to the fibrous membrane. Persistent pupillary membrane may also be present. The ciliary processes may be exposed under mydriasis due to shrinking of the fibrous membrane.

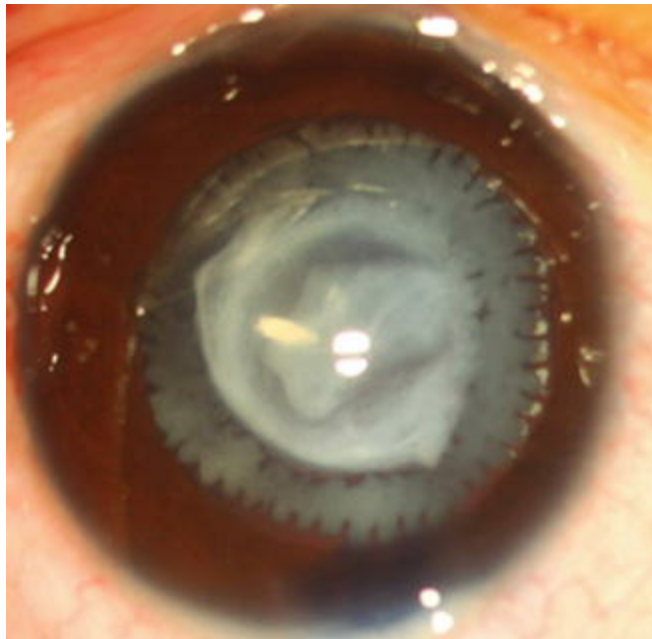


Fig. 18.6 Congenital membranous cataract

18.4.2 Surgical Techniques

Two issues should be noticed in the surgery for congenital membranous cataracts: (1) As the anterior capsule is usually thinner, more fragile, and, in most cases, adheres to the underlying fibrous membrane, it is difficult to accomplish an intact CCC. Sometimes adhesion between the anterior and posterior capsule and the fibrous membrane can form a platelike structure which is difficult to separate. (2) The fibrous membrane is usually tough, and it is difficult to remove with capsulorhexis forceps or a cystotome.

Capsulotomy with radiofrequency diathermy can be performed in this case (Fig. 18.7). During surgery, excessive traction on the fibrous membrane should be avoided to prevent damage to the ciliary body and the zonules. A 15° blade may be used to cut open the membrane at the mid-periphery. Then capsulotomy Vannas scissors are used to cut the fibrous membrane to create a capsulorhexis opening with a diameter slightly larger than that of the physiologic pupil. This ensures the stability of the intraocular lens (IOL) and prevents exposure of the margin of the fibrous membrane in the pupillary zone.

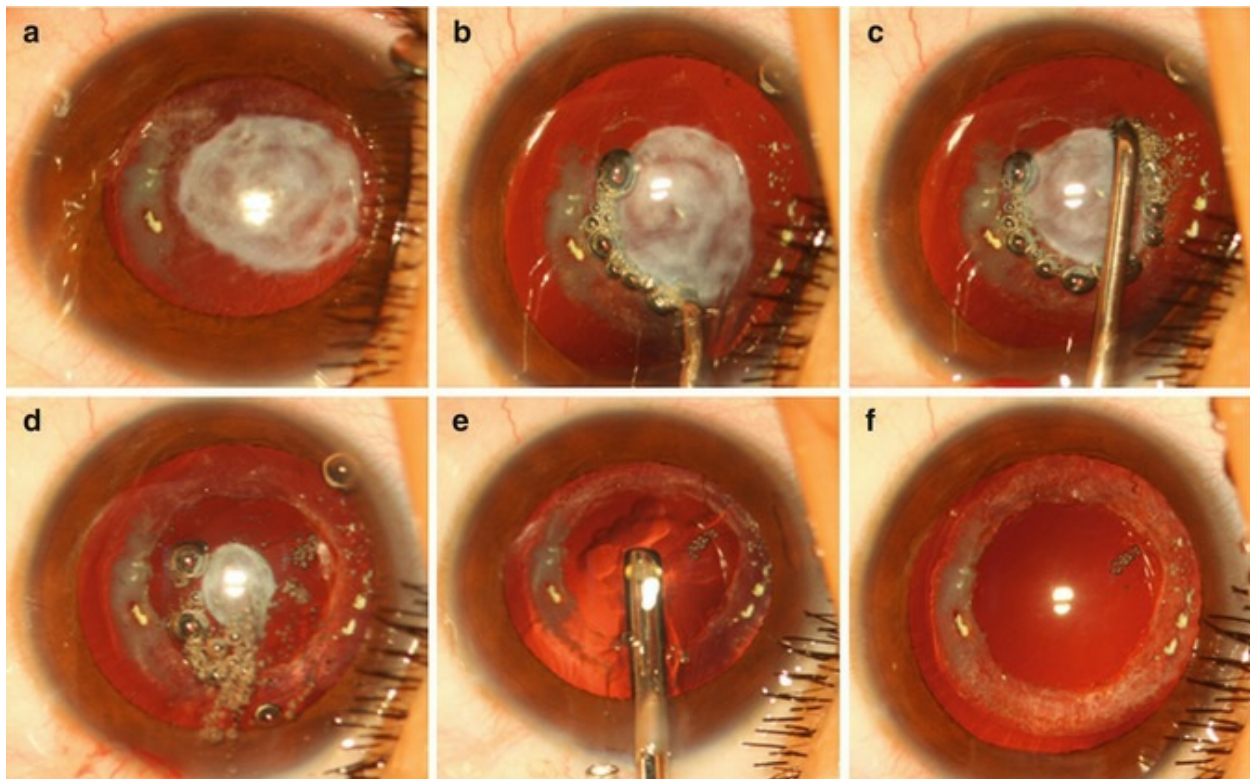


Fig. 18.7 The surgical procedures for congenital membranous cataract. (a) Membranous cataract;

(b–d) removal of the membranous opacity with a radiofrequency diathermy capsulotomy; (e) anterior vitrectomy is performed; (f) a clear visual axis and the intact peripheral capsule

18.5 Posterior Polar or Subcapsular Cataracts Associated with Persistent Fetal Vasculature

In cases of posterior polar or subcapsular cataract associated with PFV, the primary hyaloid artery connecting to the posterior capsular opacity can be found. If the artery is resected intraoperatively, hemorrhage may occur. The detailed information on this anomaly can be found in Chap. 19.

18.6 Cataracts Associated with Dense Fibrovascular Membrane

18.6.1 Causes and Clinical Manifestations

Blood vessels can grow into the lens cortex through a posterior capsular defect during the lens development, forming a dense fibrovascular membrane [12]. This type of cataract is rare. Adhesion of the fibrovascular membrane and pupillary margin may occur.

18.6.2 Surgical Techniques

For this type of cataract, routine techniques alone, e.g., usage of capsulorhexis forceps, irrigation/aspiration, and vitrector resection, may readily lead to hemorrhage. Bipolar coagulation is used for hemostasis by some ophthalmologists after routine cataract extraction. A Fugo blade is also recommended, which has both cutting and hemostatic functions.

18.7 Summary

Surgery in pediatric cataracts associated with preexisting posterior capsular defects poses a challenge to ophthalmologists. Before surgery, a comprehensive examination on the anterior and posterior segments should be carried out. During surgery, always aim for a perfect CCC. The stability of the anterior chamber should be maintained at all times. Aspiration of lens material should be carried out under low flow and low vacuum to reduce

pressure on the posterior capsule and prevent vitreous prolapse and falling of the residual nucleus into the vitreous cavity. Altogether, they ensure a more successful surgery.

References

1. Vasavada AR, Praveen MR, Nath V, et al. Diagnosis and management of congenital cataract with preexisting posterior capsule defect. *J Cataract Refract Surg.* 2004;30(2):403–8.
[CrossRef][PubMed]
2. Peng Q, Hennig A, Vasavada AR, et al. Posterior capsular plaque: a common feature of cataract surgery in the developing world. *Am J Ophthalmol.* 1998;125(5):621–6.
[CrossRef][PubMed]
3. Ionides AC, Berry V, Mackay DS, et al. A locus for autosomal dominant posterior polar cataract on chromosome 1p. *Hum Mol Genet.* 1997;6(1):47–51.
[CrossRef][PubMed]
4. Yamada K, Tomita H, Yoshiura K, et al. An autosomal dominant posterior polar cataract locus maps to human chromosome 20p12–q12. *Eur J Hum Genet.* 2000;8(7):535–9.
[CrossRef][PubMed]
5. Pras E, Mahler O, Kumar V, et al. A new locus for autosomal dominant posterior polar cataract in Moroccan Jews maps to chromosome 14q22–23. *J Med Genet.* 2006;43(10):e50.
[CrossRef][PubMed][PubMedCentral]
6. Kymionis GD, Diakonis VF, Liakopoulos DA, et al. Anterior segment optical coherence tomography for demonstrating posterior capsular rent in posterior polar cataract. *Clin Ophthalmol.* 2014;8:215–7.
[PubMed][PubMedCentral]
7. Kalantan H. Posterior polar cataract: a review. *Saudi J Ophthalmol.* 2012;26(1):41–9.
[CrossRef][PubMed]
8. Russell-Eggitt IM. Non-syndromic posterior lenticonus a cause of childhood cataract: evidence for X-linked inheritance. *Eye (Lond).* 2000;14(Pt 6):861–3.
[CrossRef]
9. Cheng KP, Hiles DA, Biglan AW, et al. Management of posterior lenticonus. *J Pediatr Ophthalmol Strabismus.* 1991;28(3):143–9, 150.
[PubMed]
10. Gatzioufas Z, Huchzermeyer CR, Hasenfus A, et al. Histological and biochemical findings in membranous cataract. *Ophthalmic Res.* 2012;47(3):146–9.
[CrossRef][PubMed]
11. Sugimoto M, Kuze M, Uji Y. Ultrasound biomicroscopy for membranous congenital cataract. *Can J Ophthalmol.* 2008;43(3):376–7.

[\[CrossRef\]](#)[\[PubMed\]](#)

12. Zhang ZD, Shen LJ, Qu J. Congenital membranous cataract associated with persistent fetal vasculature. *Int J Ophthalmol.* 2010;3(4):370–1.

[\[PubMed\]](#)[\[PubMedCentral\]](#)

19. Surgery of Congenital Cataracts Associated with Persistent Fetal Vasculature

Xiaoyan Ding¹ 

- (1) State Key Laboratory of Ophthalmology, Zhongshan Ophthalmic Center, Sun Yat-sen University, 54S Xianlie Road, Guangzhou, 510060, People's Republic of China

 **Xiaoyan Ding**
Email: dingxy75@gmail.com

Abstract

Normally, fetal ocular vasculature regresses before birth. But if the hyaloid arteries do not regress or only partially regress between the 3rd and 9th months of gestation, a fibrous proliferative membrane will be formed behind the lens, resulting in persistent fetal vasculature. As the disease may exert a serious impact on the visual functions of pediatric patients, early diagnosis and surgical intervention are considered vitally important. Thanks to the improved surgical techniques and devices for closed vitreoretinal surgery in recent years, more favorable outcomes may be obtained after surgical treatment. This chapter discusses the clinical features, imaging diagnosis, surgical indications and techniques, as well as management of intra- and postoperative complications in pediatric cataract patients complicated with persistent fetal vasculature.

The development of ocular vasculature is a complex process. During

embryogenesis, the hyaloid artery nourishes the front section of the eye. This intraocular vascular system distributes in the primary vitreous, extending from the retina to the crystalline lens. Normally, this hyaloid vessel completely regresses by birth. However, in some cases, the primary hyaloid artery partly or completely fails to regress during the period between the third and ninth months of gestation. This failure of regression gives rise to the formation of fibrous membranes behind the lens, which is termed persistent hyperplastic primary vitreous (PHPV). The reason for the partial or total persistence of the hyaloid artery is still unknown. Dass and Trese [1] once reported two cases with a history of cocaine or d-lysergic acid diethylamide (LSD) usage during pregnancy, but whether there is causality between history of medications and persistent fetal vasculature is still not conclusive.

In 1908, Collins coined the terms persistent hyperplastic tunica vasculosa lentis (PHTVL) and persistent posterior fetal fibrovascular sheath of the lens for this anomaly [2]. In 1955, Reese first came up with the name PHPV, which defined the pathological changes in both the anterior and posterior segments of the vitreous [3]. Usually found in infants and children, PHPV is one of the most common congenital abnormalities in human eyes. Ninety five percent of PHPV patients are affected unilaterally, with the other 5 % being affected bilaterally. Most PHPV cases are sporadic, but PHPV may also be inherited as an autosomal dominant or recessive trait. Inherited PHPV has also been observed in animals, e.g., dogs or cats. PHPV is characterized by the presence of white vascularized retrolental tissue, and it is occasionally associated with other ocular morbidities, such as persistent pupillary membrane, congenital cataract in the anterior pole or the posterior capsule, tractional retinal detachment, and congenital optic disk anomalies. These clinical manifestations might also be associated with the persistence or partial persistence of the fetal vasculature [4–7]. In his 1997 Jackson memorial lecture, Goldberg proposed placing all these manifestations in the same category with a general name – persistent fetal vasculature (PFV). PFV gives a better description of the abnormal clinical manifestations associated with the failure of the fetal vasculature to regress, such as a persistent retrolental fibrovascular membrane, persistent posterior fetal fibrovascular sheath of the lens, falciform retinal folds, funnel or stalk-shaped retinal detachment, and spontaneous fundus hemorrhage. The term PFV reflects a more accurate description of the anatomic and pathologic features of this disease, and it has gradually replaced the term PHPV. Therefore, we will use the term PFV in

this chapter.

19.1 Fetal Development of the Vitreous and the Hyaloid Artery

The intraocular vascular system during normal embryology of the lens was discussed in Chap. 1, and so we will not elaborate it in here. Briefly, these intraocular vessels begin development as early as the first month of gestation, reach their maximal evolution at about the second to third month, begin to involute by the fourth month, and largely disappear by birth. Their presumptive function is to provide nutrients to the developing lens at a time when aqueous production and anatomic formation of the anterior chamber have yet to begin. They also provide a morphologic foundation for the adult configuration of the eye and its vasculature.

It is necessary to understand the development and normal regression of the entire fetal intraocular vasculature to best understand the clinical manifestations of PFV. About 3 weeks after fertilization (at approximately the 5-mm embryo stage of development), a narrow space appears between the optic vesicle and the lens placode, developing from the surface ectoderm (the primary vitreous cavity). Starting 6 weeks after fertilization, a fine and soft network of cytoplasmic processes begins to fill the vitreous cavity between the back of the lens and the inner surface of the optic cup as the depth of the optic cup increases. This network, developing partially from the ectoderm cells of the lens and partially from the neuroectoderm of the retinal layer of the optic cup, constitutes the primordium of the primary vitreous.

At about the 10-mm embryo stage of development, the hyaloid artery enters the optic cup inferiorly through the fetal fissure. In a week or so, this vessel traverses the vitreous compartment, reaching toward the posterior pole of the future lens, where it eventually becomes the posterior tunica vasculosa lentis. The posterior tunica vasculosa lentis is a wide-meshed capillary network closely applied to the lens. Endothelial fenestrations appear only on the side of capillaries where they come in contact with the lens and probably serve as important routes of nutrients for developing lens cells.

At the anterior edge of the developing optic cup, the posterior tunica vasculosa lentis anastomoses with the annular vessel via a group of parallel, straight, nonbranching vessels organized in a radial palisade along the lens equator. These orderly, regular channels are variously known as lateral,

intermediary, capsulopupillary, or iridohyaloid vessels. Goldberg coined the term iridohyaloid in his lecture. Moreover, these vessels may anastomose with others in the vitreous (retrolental) space. Multiple branches of the hyaloid artery, known as the vasa hyaloidea propria, develop 1–2 weeks after the iridohyaloid vessels and contribute to the primary vitreous. The branches of the vasa hyaloidea propria are configured like the struts of an umbrella as they approach the posterior surface of the lens.

The secondary vitreous develops from the primary vitreous and the retina. It expands rapidly and fills most of the vitreous cavity, pushing the primary vitreous to the center of the eyeball and the anterior surface of the lens via the hyaloid artery. Normally, at 4 months' gestation, the primary vitreous starts to regress and the hyaloid artery begins to shrink and gradually disappears, leaving an acellular hyaloid canal called Cloquet's canal. This canal is shaped like a funnel, with a narrow end anterior to the optic nerve head and a wide end posterior to the lens.

For various reasons, the anterior/posterior tunica vasculosa lentis or the primary vitreous may fail to regress or may regress incompletely at this time and persist in front of the optic disk or behind the lens. In some cases, proliferation-induced traction and white fibrous plaques will occur and lead to diverse clinical manifestations. All of these abnormalities are referred to with the general term – PFV.

19.2 The Clinical Manifestations and Diagnosis of PFV

19.2.1 Clinical Manifestations

Any of the anatomically identifiable vascular remnants may occur alone or in combination. In this chapter, we describe the most easily recognized clinical variants or diseases caused by PFV, from anterior to posterior, according to Goldberg's categorization [8]. Each of these congenital anatomic abnormalities can be considered to represent a limited expression of the complete PFV syndrome.

19.2.1.1 Persistent Pupillary Membranes

Persistent pupillary membranes are the most common phenotype of PFV

(Fig. 19.1), and they are the remnant of the anterior tunica vasculosa lentis that fails to regress properly during embryogenesis. A more clinically descriptive term would be “persistent pupillary loops and strands.” Persistent pupillary membranes may cause pupil distortion, and they are sometimes associated with entropion uveae or ectropion uvea. Rarely, the entire pupil is occluded with persistent pigmented mesodermal tissue that may or may not disclose its vascular nature or origin. Vision may be either normal or reduced, depending on the amount of pupillary occlusion. In some cases, congenital cataracts or retrolental fibrous tissue were also noted in the same eye, which is helpful in confirming a diagnosis of PFV.

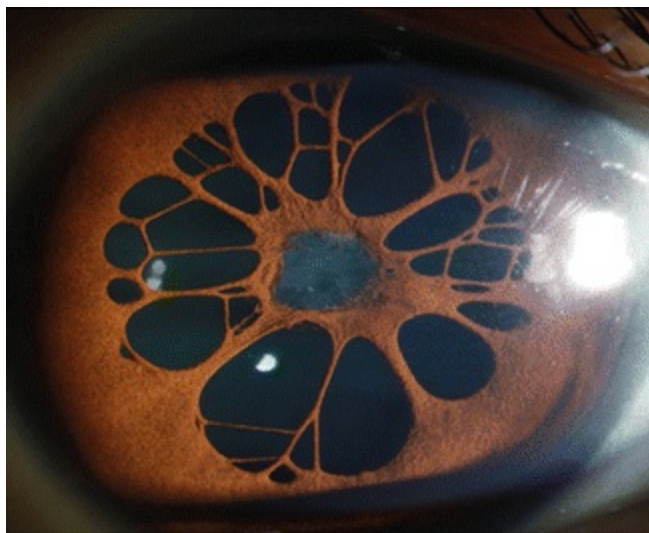

Fig. 19.1 Persistent pupillary membrane. A 5-year-old boy with a visible pupillary membrane and iris dysplasia in the right eye

19.2.1.2 Iridohyaloid Blood Vessels

Iridohyaloid blood vessels are also caused by the failure of involution in the anterior tunica vasculosa lentis. These vessels lead to the appearance of radial vessels lying superficially in the iris stroma. They appear as hairpin loops when reaching the pupil. Occasionally, limbal connective tissue malformation may be detected in the same meridian.

19.2.1.3 Mittendorf Dot

A white dot is found about 0.5 mm nasal to the posterior pole of the lens capsule, which is due to the incomplete regression of the hyaloid artery. It is

also found in 0.7–2.0 % of the normal population. Since it rarely affects the vision, no treatment is needed.

19.2.1.4 Persistence of the Posterior Fetal Fibrovascular Sheath of the Lens

Persistent posterior fibrovascular sheath of the lens is characterized by fibrous membranes located in the retrolental space and is caused by the failure of regression of the posterior tunica vasculosa lentis, which is classically called PFV syndrome (Fig. 19.2a, b). Typically, the retrolental membrane is white or pink, distinguishing it from the yellow exudation found in Coats' disease or the snow-white calcifications in retinoblastoma. The area of the retrolental membrane varies widely, and in some cases, it may be as small as a dot or, in others, the entire posterior surface of the lens is covered. The lens itself varies from completely clear to severe opacification on the posterior capsule. Sometimes, the elongated ciliary processes can be found, which is due to the proliferation and traction of the incompletely involuted posterior tunica vasculosa lentis (Fig. 19.2c).

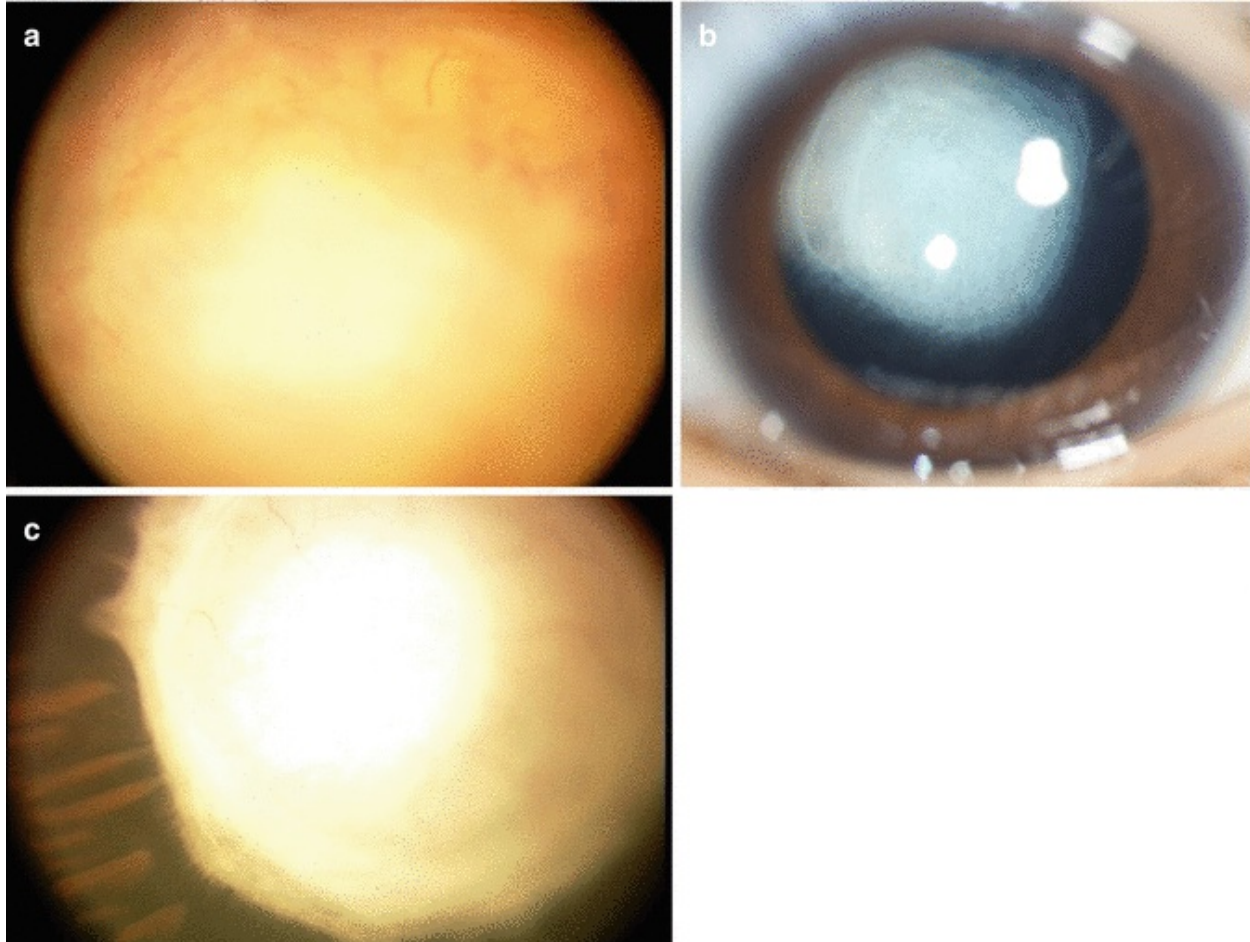


Fig. 19.2 Persistence of the posterior fetal fibrovascular sheath of the lens. **(a)** A 2-year-old boy with a yellowish-white fibrous membrane covering the entire posterior surface of the lens in the left eye. There are vessels extending on the membrane, the fundus is invisible, and the lens is clear (A photograph taken with a RetCam – a wide-field imaging system). **(b)** A 3-year-old boy with a visible fibrous membrane (5 × 5 mm) at the center and superior temporal of the posterior lens capsule in the right eye (A photograph of the anterior segment of the eye). **(c)** A 1½-year-old girl with leukokoria in her right eye. A yellowish fibrous membrane was found immediately posterior to the lens. There are vessels extending on the membrane, and the fundus is invisible. The arrows indicate the ciliary processes on the temporal side that are centrally dragged (A photograph taken using a RetCam – a wide-field imaging system)

19.2.1.5 Lens Opacity

The proliferative fibrous membrane in the vitreous chamber accounts for most cases of lens opacity. The main causes of a proliferative fibrous membrane leading to lens opacity include the following: (1) The proliferation and construction of the fibrous membrane may break through the posterior lens capsule and enter into the lens, leading to secondary cataract. (2) Due to the involution and traction of the persistent hyaloid artery, the posterior

capsular membrane of the lens may rupture, causing opacification of the lens, which then induces an immune response and the growth of granulation tissue (Fig. 19.3).

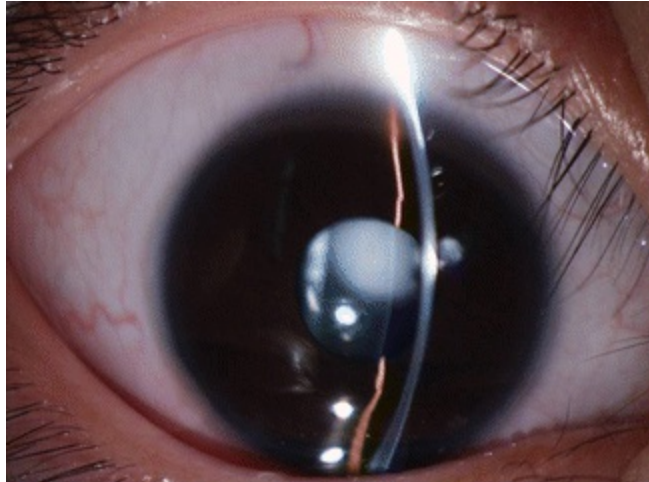


Fig. 19.3 Lens opacity. Photograph of the anterior segment of the eye shows a 4-year-old boy with lens opacity in the right eye. An attached retina is visible through the clear inferior lens

19.2.1.6 Persistent Hyaloid Artery

Fetal hyaloid vessels are usually located within Cloquet's canal and ordinarily involute by the 7th month of gestation. If this hyaloid system fails to regress completely, a remnant cord extending from the optic nerve head to the posterior lens capsule is manifested (Fig. 19.4).

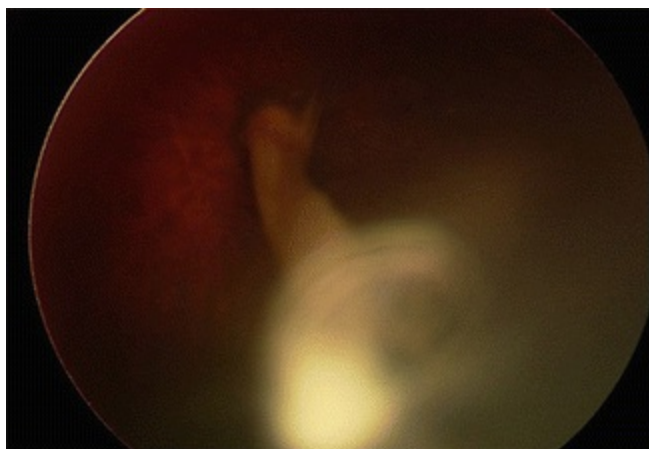


Fig. 19.4 Persistent hyaloid artery. A photograph taken using a RetCam – a wide-field imaging system – shows a 9-month-old girl with a visible remnant extending from the optic disk to the posterior lens capsule. Part of the posterior capsule is opaque and the retina is attached

19.2.1.7 Bergmeister Papilla

A Bergmeister papilla is the incomplete regression of the posterior part of the hyaloid artery, and it manifests as a membranous or short band-like lesion attached to the optic disk head (Fig. 19.5). A Bergmeister papilla itself will not affect visual function, and its impact on vision mainly depends on whether the remnant causes macula traction.

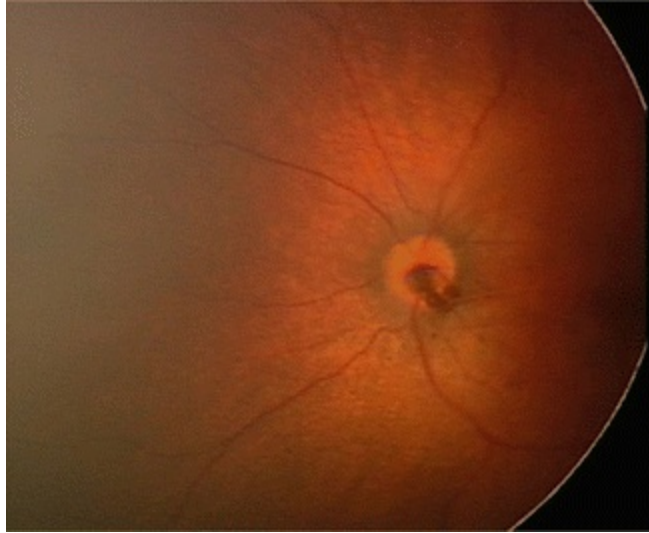


Fig. 19.5 Bergmeister papilla. A photograph taken using a RetCam – a wide-field imaging system – shows a 4-month-old boy with a short band attached to the optic papilla in the right eye. A Bergmeister papilla, a clear lens, and an attached retina are demonstrated

19.2.1.8 Retinal Folds

In some cases, PFV is also accompanied by retinal folds, which may occur in any quadrant, but is mostly an inferotemporal predilection. A normal anterior chamber and clear lens are present, with possible occurrence of microphthalmos. It is presumed that a small amount of fibroproliferative tissues backward along Cloquet's canal and attach to the retina, thus leading to the formation of retinal folds. In some serious cases, this may cause tractional retinal detachment with a poor prognosis (Fig. 19.6).

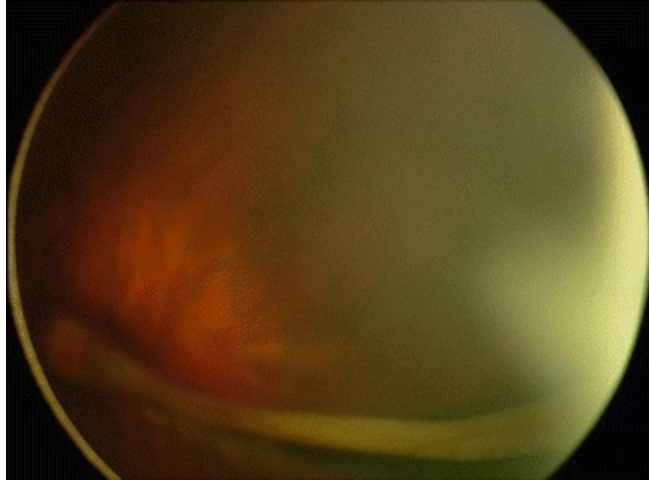


Fig. 19.6 Retinal folds. A photograph taken using a RetCam – wide-field imaging system – shows a 1-year-old boy with inferotemporal retinal folds

19.2.1.9 Congenital Tent-Shaped Retinal Detachment

The primary vitreous containing the hyaloid artery, located at the optic disk, proliferates and adheres to the retina, causing partial retinal traction and thus leading to tent-shaped retinal detachment (Fig. 19.7).

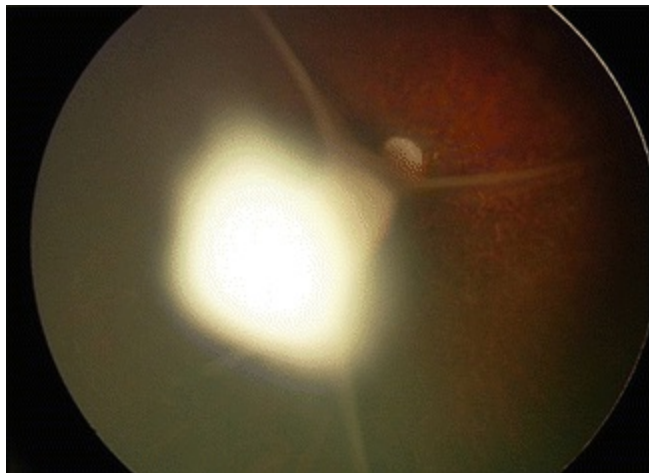


Fig. 19.7 Congenital tent-shaped retinal detachment. A photograph taken using a RetCam – wide-field imaging system – shows a 7-year-old girl with the primary vitreous located between the posterior lens capsule and the optic papilla in the left eye. The primary vitreous tracts part of the retina, forming the tent-shaped detachment

19.2.1.10 Macular Abnormalities

Macular abnormalities are secondary to tractional retinal detachment. Visual

function is extremely poor in these patients.

19.2.1.11 Microphthalmos

Microphthalmos may be found in the anterior or posterior PFV, or it may be secondary to tractional retinal detachment. Usually, PFV is accompanied by arrested development of the eyeball.

19.2.1.12 Secondary Glaucoma

Secondary glaucoma is the most common cause of eventual blindness in children with PFV. The pathogenesis of secondary glaucoma associated with PFV is as follows: (1) The traction of the retrolental fibrovascular membrane leads to the rupture of the posterior capsule and the ensuing secondary cataract, lens expansion, anterior shift of the iris diaphragm, shallow anterior chamber depth, and secondary angle-closure glaucoma. With long-term high intraocular pressure (IOP), the corneal and scleral walls expand, ultimately resulting in buphthalmos. (2) Secondary glaucoma may also result from the inflammatory reaction and depigmentation of the iris. (3) When the ciliary process is involved in the retrolental fibrovascular membrane and centrally dragged, sequential zonular laxity will exaggerate the anterior displacement of the iris diaphragm [9, 10].

According to the ocular segments involved, PFV is traditionally divided into three types: anterior, posterior, and combined PFV. Anterior PFV is relatively common, accounting for 25 % of all cases, and its main manifestations are cataracts and retrolental mass. In some pediatric patients, it can also present as a shallow anterior chamber, elongation of the ciliary processes, and thickening of the blood vessels of the iris. Secondary angle-closure glaucoma may also occur in a few cases due to the expansion of the lens. Posterior PFV, as the name suggests, mainly involves the vitreous and the retina and accounts for 12 % of the affected population. It may manifest as solid remnants in the vitreous, retinal proliferative membrane and retinal folds. Sometimes, it may also present as abnormalities of the macula or the optic disk. Combined PFV, involving the anterior and posterior segment, is commonly seen in clinical practice, accounting for approximately 60 % of all cases [4]. As this classification system provides guidance to clinical treatments, particularly the choice of surgical approach, it is now widely used clinically.

19.2.2 Imaging Diagnosis

19.2.2.1 Ultrasonography and Color Doppler Imaging

With high resolution, ultrasonography is great merit to the eyes with opaque media in PFV. A-mode ultrasonography can reveal a shortened axial length. B-mode ultrasonography demonstrates the typical umbrella-shaped lesions that occupy Cloquet's canal between the posterior capsule and anterior vitreous (Fig. 19.8). The umbrella lies behind the lens and adheres to the posterior capsule. The struts of the umbrella run through the vitreous cavity to the optic papilla. The internal reflection of the struts is irregular and without after movements.

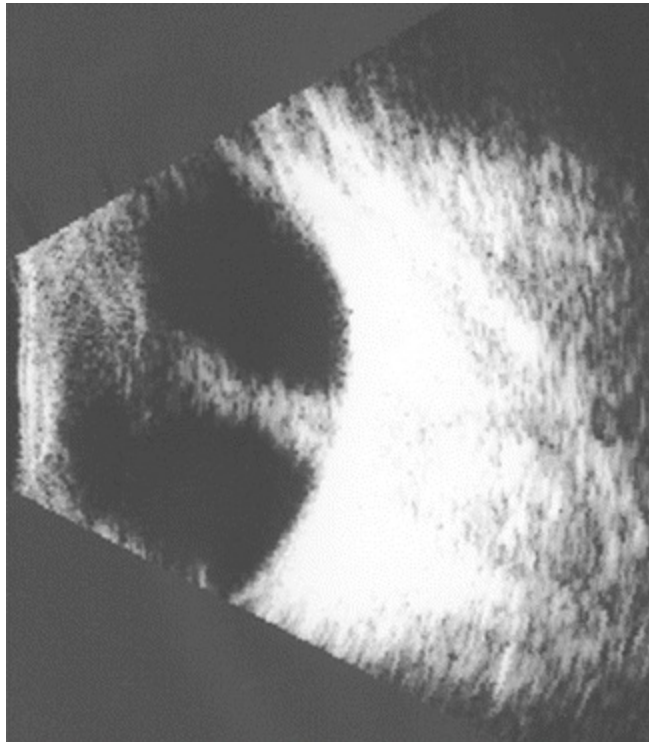


Fig. 19.8 B-mode ultrasonography examination for PFV. A B-mode ultrasound image reveals that a tubular membrane adherent to the optic disk in the vitreous cavity in the left eye of a 3-year-old boy

Color Doppler imaging (CDI) utilizes the principles of ultrasound to assess the physical characteristics, morphological structures, and functions of human tissues. With its direct revelation of the pathological location, morphology, and characteristics of the blood flow signals and spectrum in the affected location, CDI is now widely used in ocular diseases. Since it is noninvasive and reproducible, CDI is of great application value in diagnosing

PFV, especially in cases where the fundus examination cannot be conducted due to noncompliance or the opaque media.

Our research shows that according to CDI results, all PFV eyes could be grouped into four types: Type I (“I” shape), Type II (“Y” shape), Type III (inverted “Y” shape), and Type IV (“X” shape) (Fig. 19.9) [11]. Type I (“I” shape) presents as a linear narrow band extending from the optic disk to the posterior lens capsule, and blood flow can be detected in the band. Type II (“Y” shape) manifests as a membranous septum with a narrow base extending from the optic disk; however, the posterior lens capsule is widely covered. Ciliary detachment and traction or dense ciliary membranes were noted with ultrasonography. CDI showed detectable blood flow in both the membranous septum and the retrolenticular fibrovascular membrane. Type III (inverted “Y” shape) is characterized by a membranous septum with a wide base extending from the optic disk, which narrows gradually or suddenly, and is attached to the center or paracenter of the posterior lens capsule. Besides significant blood flow in the slim stalk, flow on the margin of the mass with a wide base anterior to the optic nerve was detected in all subjects. Funduscopy for these patients revealed the protrusion lesion to consist of a tractional retina detachment and fibrosis of the vitreous. The retinal artery and veins were noted to be tortuous or partially occluded with fundus fluorescein angiography (FFA). A detached and dislocated macula was found in the protrusion lesion in most of the subjects. Type IV (“X” shape) is characterized in a membranous septum extending from the optic disk with a wide base and covering the majority of the posterior lens capsule. Blood flows can be detected in the band between the optic disk and the lens and in the retrolental fibrovascular membrane.

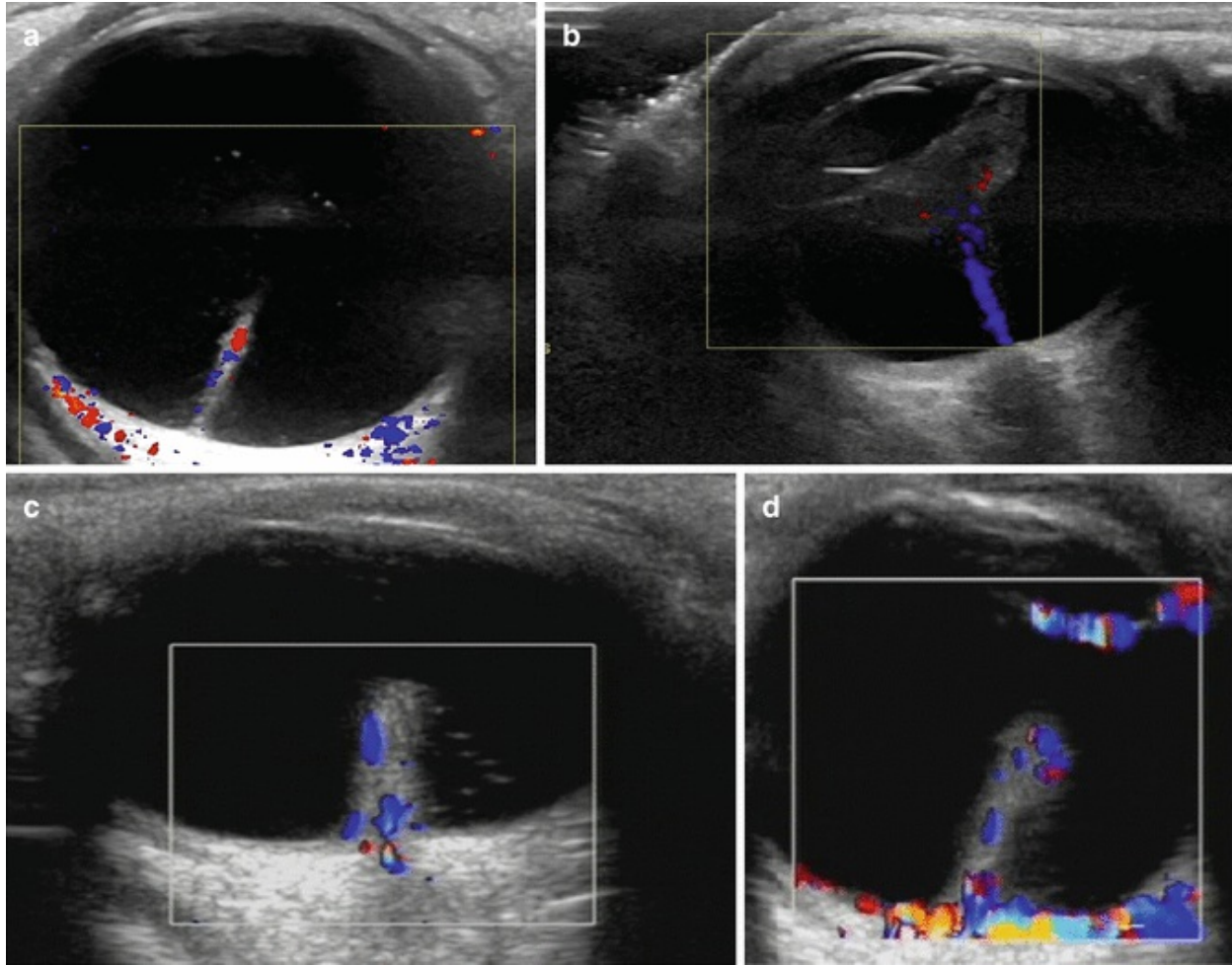


Fig. 19.9 The classification of PFV according to CDI results. **(a)** A 4-year-old boy with an “I”-shaped echo in the right eye, blood flow can be detected in the retrorenal band. **(b)** A 4-year-old girl with a “Y”-shaped echo in the left eye, blood flow can be detected in the retrorenal band and the retrorenal fibrovascular membrane. **(c)** A 4-month-old boy with an inverted “Y”-shaped echo in the right eye. The central blood flow presents as the persistent hyaloid vessel. The blood flows in the two sides present as the retina, revealing traction on the optic disk and the peripheral retina. **(d)** A 1-year-old boy with an “X”-shaped echo in the right eye. Blood flows can be detected in the band extending from the optic disk to the posterior surface of the lens and the retrorenal fibrovascular membrane. The central blood flow presents as the persistent hyaloid vessel, and the blood flow signals are also visible on either side of the prepupillary fibrous mass

Four types of combined PFV were suggested in this study, with the determination made according to the area of posterior capsule coverage and the base of the preoptic elevated echogenic tissue. Types II and IV had a wide base attached to the posterior surface of the lens, usually accompanied by ciliary detachment and traction or dense ciliary membrane. Types III and IV had preoptic stalks with a wide base, while Type I had narrow adhesion to both the lens and optic nerve. Children with different types of PFV

demonstrated different clinical characters. The axial length is normal in Type I, but decreased in the other types, especially in Type IV. However, visual function was affected more obviously in Type I, probably due to the retrolenticular stalk that was often attached to the central part of the posterior capsule. Thus, early screening is highly recommended in children, even in newborns, in order to facilitate the early detection and treatment of PFV.

Due to recent advances in surgical instrumentation and techniques, the indications for surgery in combined PFV have changed. Early surgical intervention may prevent progressive, pathologic changes and so can offer hope for a positive visual outcome [4, 6]. However, two different techniques have been advocated to remove the retrolenticular membranes associated with different forms of PFV: an anterior transpupillary approach and a posterior pars plana/plicata approach. When using ultrasound and CDI imaging, the pars plana/plicata approach should be avoided in Type II and Type IV patients according to our current classification system because of the dense coverage of the ciliary plana/plicata membranes. Surgical removal via the pars plana/plicata may increase the risk of inadvertent excision of the retina or retinal detachment. The anterior technique, which allows removal of these dense lenticular or retrolenticular membranes under continuous direct visualization, is safer and more reliable in this context. On the other hand, in patients with Types I and III PFV, if surgery is performed, it is safe to utilize a pars plana incision.

CDI, a safe, noninvasive, and real-time tool for determining intraocular morphology, provides significant evidence not only for the diagnosis of PFV but also for facilitating the design of surgical approaches and outcome prediction.

19.2.2.2 X-Ray Computed Tomography (CT)

CT is able to clearly reveal the abnormalities of the ocular structure in PFV, such as microphthalmos, buphthalmos, orbital wall incisures, and small or irregular lens (Fig. 19.10). In PFV, there is a characterized retrolental triangular or conic-shaped high attenuation area around Cloquet's canal, which is based at the lens and points to the retina. CT enhancement scanning with iodine contrast medium can help to demonstrate the important features of PFV, including the following:

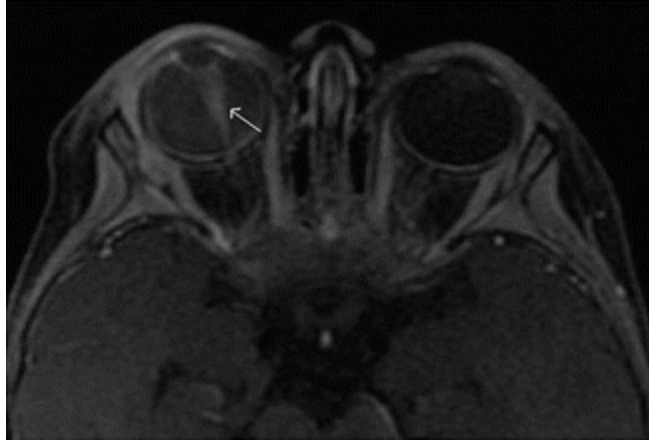


Fig. 19.10 A CT image of the right eye of a 5-year-old boy. A dense band-like shadow adherent to the optic papilla is revealed

1. Retinal detachment, which is connected to the ciliary processes or lens anteriorly and is attached to the optic nerve head posteriorly. High density fluid signals can be detected in the subretinal area.
2. Thickness of the hyaloid artery, which appears as a dense tubular signaled area in CT scanning.
3. Intraorbital or ocular calcification is absent in most cases.

19.2.3 Differential Diagnosis

Diagnosing PFV is still challenging due to its various clinical manifestations, the difficulty of comprehensive examinations in pediatric patients, and the poor understanding of the disease. The detection of persistent blood vessels is usually sufficient to exclude many other ocular diseases that occasionally cause the severe manifestations of PFV, such as isolated congenital cataracts and retinoblastoma. Direct visualization of these hallmark vessels is the best method for diagnosis, but useful adjunctive techniques including CT, MR imaging, ultrasonography, and fluorescein angiography are necessary.

When cataracts associated with PFV occur, they should be differentiated from leukokoria caused by other anomalies such as congenital cataract, retinopathy of prematurity, or retinoblastoma. Congenital cataracts usually manifest as the opacification of the lens only, without abnormalities in the

vitreous and retina, while in PFV, retrolental fibrovascular membranes are located immediately to the posterior surface of the lens. The lens itself can be transparent. However, in some cases of progressive PFV, with the traction of the fibrovascular membranes, the lens is swollen and eventually opacifies. The finding of a retrolental fibrovascular membrane via ultrasonography contributes to the diagnosis of PFV.

PFV can be differentiated from retinopathy of prematurity by comparing the patient history, e.g., a history of prematurity, low body weight, and a history of oxygen treatment. It can also be distinguished from retinoblastoma as PFV usually includes monocular involvement and the coexistence of microphthalmos. Retrolental white fibrovascular membrane and traction of ciliary processes can be seen in PFV but not retinoblastoma. In addition, the absence of calcifications in B-mode ultrasonography can also contribute to the differentiation [12–14].

19.3 Features of Congenital Cataracts Associated with PFV

PFV is the main cause of unilateral cataract in pediatric patients. A meta-analysis showed that approximately 20 % unilateral cataract cases were associated with PFV [15]. Most of them are manifested as posterior polar capsule or subcapsule cataracts, located at the posterior pole. Some patients were combined with nuclear cataracts [16]. Haargaard et al. reported that 57 % of pediatric unilateral cataract cases (0–17 years old) were due to PFV [17]. However, in light of the broad definition of PFV, Mullner-Eidenbock and colleagues found signs of PFV in 100 % of the 31 studied cases of congenital unilateral cataracts during surgical treatment [18]. These cases usually manifest as persistent vasculature immediately posterior to the lens, ghost vessels in the posterior capsular plaque, an abnormally thickened border layer of the vitreous, and defects of the posterior capsule. As the nodal point of the dioptric system is located at the posterior pole of the lens, even a small-size opacity or a non-dense opacity may cause form deprivation amblyopia and greatly hampers visual development. Therefore, in children with anterior PFV, early surgical treatment followed with postoperative amblyopia therapy is recommended.

19.4 Surgery Techniques Used for Congenital Cataracts Associated with PFV

Due to the scarcity of clinical cases and the heterogeneity of clinical manifestations of PFV, there are still no uniform treatment regimens. Early diagnosis and treatment are considered the general principle for PFV. Children with PFV-associated cataracts usually have serious amblyopia, due to visual deprivation during the critical period of visual development. Some were even born with phthisis bulbi. Though vitrectomy began to be used in PFV patients in the 1980s, the initial goals were mainly to remove the cataract and the retrolental mass so as to maintain the appearance of the eyeball and to boost the normal development of the orbital bone. This could lead to cosmetic improvement, but visual restoration was very limited. In the 1990s, the surgical outcomes for PFV were improved because of great advances in surgical techniques and instruments in vitrectomy and in amblyopia treatment.

19.4.1 Surgical Indications

The spectrum of clinical severity extends broadly in PFV. At one extreme, a Bergmeister papilla, a Mittendorf dot, or a persistent pupillary loop may only have minimal sequelae from the persistence of fetal intraocular vasculature. These anomalies rarely result in reduced visual acuity or visual-threatening complications. More extensive expressions of PFV, such as a persistent hyaloid artery and malformations of the macula or optic nerve, may be associated with visual-threatening complications, such as vitreous hemorrhage, retinal detachment, swollen lens, anterior shifting of the lens-iris diaphragm with shallowing of the anterior chamber, and glaucoma.

Surgical treatment of PFV eyes was extremely conservative in the early years, especially in unilateral cases. When the contralateral eye is normal, it is very difficult to overcome amblyopia and achieve satisfactory visual acuity in the eyes with PFV. In recent years, with deeper understanding of the disease and advances of microsurgical instruments and technology, the indications for surgical treatment in PFV are changing but still remain controversial. The advantages and disadvantages of surgery should be weighed against the chances of the eye surviving to adult life without surgery. Surgical indications may include the following: recurrent or severe

intravitreal hemorrhage; progressive retinal detachment; progressive shallowing of the anterior chamber, either because of swelling of the lens or centripetal traction on centrally dragged ciliary processes that forces the lens and iris anteriorly; or unrelenting ocular hypertension caused by closure of the anterior chamber angle. For anterior and combined PFV patients, early lensectomy and vitrectomy are beneficial to reestablish the visual pathway, release the traction, and reduce the incidence of complications. However, surgeries are not considered when the visual axis is clear, the lesion is stable, and the anterior chamber angle is not narrowed.

The surgical goals include the following:

1. Aiming to remove the opacity from the visual axis and rescue visual function. The indications include (1) early-stage uncomplicated anterior or combined PFV; (2) PFV with secondary lens opacity, but free from secondary glaucoma and corneal changes; (3) PFV with only residual fibrous membranes due to the lens' spontaneous absorption; and (4) PFV children with spontaneous hemorrhage, early lensectomy, and vitrectomy, which is significant for restoring vision, avoiding serious complications, and saving the eyeballs.
2. Aiming to halt disease development. Even when postoperative improvement in visual function is not expected, there are occasional valid anatomic reasons for surgical intervention. For cases with secondary glaucoma, timely surgical intervention can eliminate risk factors. The outcomes of PFV surgery depend on the severity of the anterior and posterior segments' involvement. In such circumstances, it is desirable to manipulate intraocular tissues as little as possible. For example, simple lens aspiration designed to open the anterior chamber angle and maintain the anterior chamber depth may be sufficient, and intravitreal surgery can therefore be delayed or eliminated. Avoidance of the posterior components of PFV will minimize the risk of uncontrolled hemorrhage and excessive traction on the retina.

The anatomical and functional outcomes of surgical treatment in anterior PFV are better. Pollard and colleagues conducted lensectomy and vitrectomy, removing the retrolenticular fibrovascular membrane, in combination with postoperative aphakic correction with soft corneal contact lens and systemic

amblyopia training in 48 cases with PFV [4]. A 0.2 or better vision was achieved in eight cases with anterior PFV [4]. Mitra and colleagues performed modern vitrectomy in combination with aphakia refractive correction and amblyopia training in 14 cases with anterior or posterior PFV. Seventy one percent of the patients obtained a 0.06 or better vision, and 57 % even obtained a 0.2 or better vision [19]. The removal of the fibrovascular membrane, which clears up the visual pathway and the ensuing amblyopia training, is key to obtaining good surgical outcomes (Fig. 19.11).

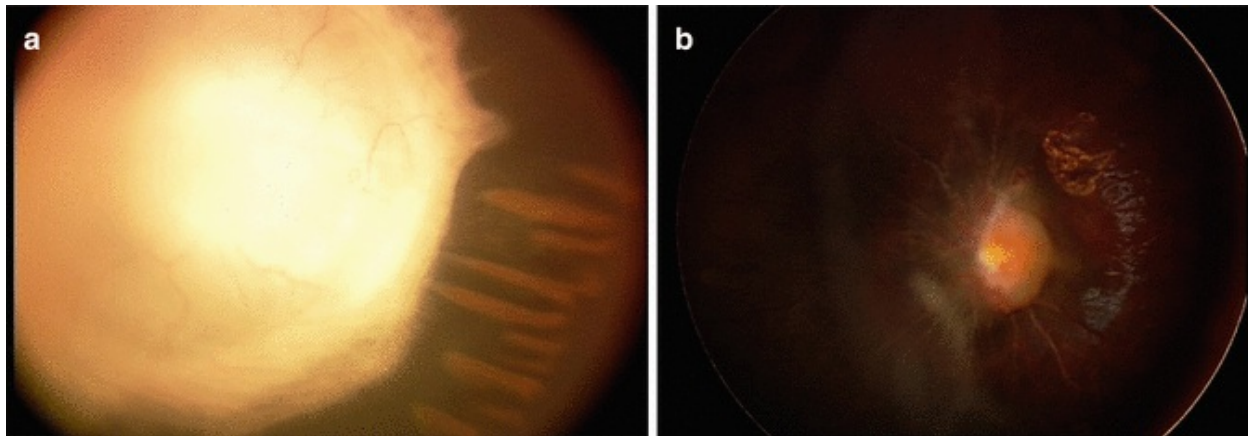


Fig. 19.11 The outcomes of surgical treatment in anterior PFV. (a) A photograph taken using a RetCam – a wide-field imaging system – shows a preoperative photograph of the right eye in a 1.5-year-old girl. A yellowish-white retrolenticular fibrovascular membrane is visible, and the ciliary processes are pulled retrolentally. (b) The *yellowish-white* retrolenticular fibrovascular membrane and tubular membranous extending from the optic disk are removed, and the retina is reattached after lensectomy combined with PPV surgery

19.4.2 Preoperative Examination

Preoperative morphological and functional examinations such as distant vision, near vision, and best corrected visual acuity should be completed as possible. Since it is difficult to perform visual examination in children under 3 years old, the preliminary visual function assessment can be accomplished using the fixation reflex test and through observation of the patient's response to the environment. Poor fixation suggests developmental disorders of the central vision and poor surgical outcomes. Before surgery, surgeons must communicate with the children's parents thoroughly. Normal pupil reflection, ERG, is predictive for better visual function after surgery.

Before the surgery, comprehensive examination of the cornea, lens, and the fundus should be conducted under general anesthesia. The location,

density of the cataract, the integrity of the lens capsule, or any presence of lens absorption, liquidation, and calcification, or any presence of iris developmental abnormalities and anterior/posterior synechia should be noted. Ultrasonic inspection should be conducted to assess axial length, the extent of the vitreous lesion, and the retinal detachment. In addition, the corneal diameter, the anterior chamber depth, and the size and appearance of the pupil should also be noted.

19.4.3 Surgical Procedures

1. Anesthesia

The anesthesia method for PFV surgery is identical with pediatric cataract surgery. It should be noted that the surgical time for cases with posterior PFV is usually longer.

2. Eyeball softening and eyelid opening

The eyeball should be massaged after anesthetics to make it sufficiently soft. Opening of the eyelid is performed with an infant eye speculum.

3. The surgery can be performed with the anterior (limbal) approach and the posterior (pars plana) approach. The anatomical differences in the eyes between infants and adults should be fully considered before surgery.

1. A translimbal/transpupillary/anterior approach

The anterior (limbal) approach is indicated for anterior PFV-associated cataracts, “Y”- or “X”-type combined PFV patients, who are usually with obvious abnormalities of the anterior segment, such as the elongating of the ciliary processes or pars plana fibrous membrane. The main purpose of the limbal approach is to avoid disturbance to the pars plana, thus to avoid iatrogenic breaks of the ora serrata or the peripheral retina. After the lens removing, the opacified posterior lens capsule is removed by electrical capsulorhexis and anterior vitrectomy is then performed. If necessary, intraocular lens implantation will also be performed in the capsular bag or the ciliary sulcus.

2. A pars plana/posterior approach

The posterior (pars plana) approach is indicated in cases of posterior PFV, “I”- or inverted“Y”-type combined PFV that are free from anterior segmental abnormalities.

Incision site: The anatomical differences in the eyes between infants and adults should be fully considered before surgery. Since the pars plana in infants has not completely developed and there is relatively more severe vitreoretinal adhesion, the sclerotomy site should be moved forward accordingly. The site at 1.5–2 mm posterior to the limbus may avoid the complications such as ora serrata dialysis and retinal breaks.

Irrigation cannula: In cases with retinal folds, the precise position of these folds should be determined before the surgery. The retinal folds may be located inferotemporally, inferiorly, or inferonasally. The irrigation cannula should be placed away from the retinal folds. After three incisions are made at the sclera with a 25- or 23-gauge cannula, the retrolental mass and persistent hyaloid vessels are carefully removed. The anterior capsule should be reserved for future IOL implantation. Hemorrhaging from the hyaloid artery may occur and can be resolved by compression or intravitreal diathermy. Sometimes, anterior vitrectomy alone is sufficient if there is no obvious posterior segment involvement. However, if posterior abnormalities exist, the peripheral membrane of the hyaloid artery should be cut to release retinal traction. Gentle manipulation is helpful to avoid iatrogenic retinal breaks.

19.4.4 Complications and Management

Fibrous exudation of the anterior chamber is very likely to occur after pediatric cataract surgery. As the blood-eye barrier in infant patients has not fully developed and due to the exudation of the iris induced by surgical stimulation, there is a higher incidence of postoperative inflammation. The exudation will eventually turn into fibrous membranes, sometimes completely covering the pupil area. Anti-inflammation treatment is critical; usually the inflammation will be resolved in 1–2 weeks. However, in some cases, fibrous membranes will form and lead to pupillary blockage. In cases

of PFV, combined surgery involving both the anterior and the posterior segments is usually necessary, and it often involves long surgical time, complicated procedures, and multiple entries of surgical instruments. The persistent pupillary membrane, which may remain after the resolution of inflammation, can be incised with a YAG laser.

19.4.5 Surgical Results

Two kinds of results must be considered: anatomic and visual. Even when postoperative improvement in visual function is unrealistic because of concomitant congenital anomalies of the macula or optic nerve head, there may well be appropriate reasons for surgical intervention, as discussed above.

The outcome of cataract surgery in cases with PFV depends on multiple factors, including the manifestations of PFV, the extent of preoperative lens or vitreous opacity involving the visual axis, the width of the persistent hyaloid stalk, the existence of blood flow, the abundance of the blood flow, the size of the retrolental fibrovascular membrane, the axial length, the onset age of lens opacity, the treatment age, and so on [5]. In a report on 89 unilateral PFV cases, Anteby and colleagues compared the visual outcomes of 60 operated eyes with 29 nonoperated eyes. In 25 % (15/60) of the operated eyes, a final visual acuity of 20/400 or better was achieved [20]. In the 14 eyes treated with surgery and amblyopia therapy observed by Mitra and colleagues, 66 % achieved a 20/100 or better vision; however, in these studies, there were no long-term follow-up results [19]. Alexandrakis and colleagues reported visual acuity of 20/400 or better in 47 % of 30 eyes with PFV treated with surgery compared to the 12 % in the control group [21]. The surgical outcomes in cases with posterior PFV are limited, especially in cases with bilateral involvement. The retrospective analysis of Walsh MK and colleagues reported that among 22 patients with combined bilateral PFV, without family history or genetic abnormalities such as Norrie's disease, 16 were treated with early bilateral vitrectomy and the other 6 were treated unilaterally. The 1-year follow-up of 13 patients showed that postoperative vision above light perception was found in only 9 patients and in 28 operated eyes phthisis bulbi ultimately occurred in 3 of them [22].

Visual rehabilitation in PFV patients requires not only early surgery (during the critical period of visual development) but also postoperative management of amblyopia. It is not known whether the use of an IOL at the time of cataract removal is safe and effective in this clinical setting. In a

report by Anteby, among 30 unilateral PFV eyes receiving IOL implantation, a final visual acuity of 20/50 or better was obtained in 20 % eyes, and 20/200 or better was found in 33.3 % of them [20]. In recent years, the advances of CDI has contributed to the early and precise diagnosis of PFV and made early treatment possible. Early surgical treatment has also become safer and effectively contributes to the advancements in microinvasive vitrectomy, which paves the way for future treatment.

19.5 Summary

PFV is a group of abnormal clinical manifestations associated with the failure of the fetal vasculature to regress, such as Mittendorf dot, persistent retrolental fibrovascular membrane, persistent posterior fetal fibrovascular sheath of the lens, falciform retinal folds, funnel or stalk-shaped retinal detachment, and spontaneous fundus hemorrhage. According to the ocular segments involved, PFV is traditionally divided into three types: anterior, posterior, and combined PFV. Combined PFV is the most commonly seen in clinical practice, accounting for approximately 60 % of all cases. In recent years, the advances of multiple imaging modalities, for example, color Doppler image, has contributed to the early and precise diagnosis of PFV and made early treatment possible. Early surgical treatment has also become safer and effectively contributes to the advancements in microinvasive cataract surgery and vitrectomy, which paves the way for better future treatment. However, postoperative management of amblyopia is even more important for visual rehabilitation.

References

1. Dass AB, Trese MT. Surgical results of persistent hyperplastic primary vitreous. *Ophthalmology*. 1999;106(2):280–4.
[CrossRef][PubMed]
2. Dawson DG, Gleiser J, Movaghar M, et al. Persistent fetal vasculature. *Arch Ophthalmol*. 2003;121(9):1340–1.
[CrossRef][PubMed]
3. Reese AB. Persistent hyperplastic primary vitreous. *Am J Ophthalmol*. 1955;40(3):317–31.
[CrossRef][PubMed]
- 4.

- Pollard ZF. Persistent hyperplastic primary vitreous: diagnosis, treatment and results. *Trans Am Ophthalmol Soc.* 1997;95:487–549.
[\[PubMed\]](#)
5. Sanghvi DA, Sanghvi CA, Purandare NC. Bilateral persistent hyperplastic primary vitreous. *Australas Radiol.* 2005;49(1):72–4.
[\[CrossRef\]](#)[\[PubMed\]](#)
 6. Shastri BS. Persistent hyperplastic primary vitreous: congenital malformation of the eye. *Clin Experiment Ophthalmol.* 2009;37(9):884–90.
[\[CrossRef\]](#)[\[PubMed\]](#)
 7. Chercota V, Munteanu M. Persistent hyperplastic primary vitreous associated with retinal folds. *Oftalmologia.* 2004;48(1):28–31.
[\[PubMed\]](#)
 8. Goldberg MF. Persistent fetal vasculature (PFV): an integrated interpretation of signs and symptoms associated with persistent hyperplastic primary vitreous (PHPV). LIV Edward Jackson Memorial Lecture. *Am J Ophthalmol.* 1997;124(5):587–626.
[\[CrossRef\]](#)[\[PubMed\]](#)
 9. Sawada H, Fukuchi T, Ohta A, et al. Persistent hyperplastic primary vitreous—a case report of adult onset acute angle-closure glaucoma. *Nippon Ganka Gakkai Zasshi.* 2001;105(10):711–5.
[\[PubMed\]](#)
 10. Alward WL, Krasnow MA, Keech RV, et al. Persistent hyperplastic primary vitreous with glaucoma presenting in infancy. *Arch Ophthalmol.* 1991;109(8):1063–4.
[\[CrossRef\]](#)[\[PubMed\]](#)
 11. Hu A, Pei X, Ding X, et al. Combined persistent fetal vasculature: a classification based on high-resolution B-mode ultrasound and color Doppler imaging. *Ophthalmology.* 2016;123(1):19–25.
[\[CrossRef\]](#)[\[PubMed\]](#)
 12. Wieckowska A, Napierala A, Pytlarz E, et al. Persistent hyperplastic primary vitreous—diagnosis and differentiation. *Klin Oczna.* 1995;97(7–8):234–8.
[\[PubMed\]](#)
 13. Milot J, Michaud J, Lemieux N, et al. Persistent hyperplastic primary vitreous with retinal tumor in tuberous sclerosis: report of a case including tumoral immunohistochemistry and cytogenetic analyses. *Ophthalmology.* 1999;106(3):630–4.
[\[CrossRef\]](#)[\[PubMed\]](#)
 14. Williams CP, Marsh CS, Hodgkins PR. Persistent fetal vasculature associated with orbital lymphangioma. *J AAPOS.* 2006;10(3):285–6.
[\[CrossRef\]](#)[\[PubMed\]](#)
 15. Forster JE, Abadi RV, Muldoon M, et al. Grading infantile cataracts. *Ophthalmic Physiol Opt.* 2006;26(4):372–9.
[\[CrossRef\]](#)[\[PubMed\]](#)
 16. Wilson ME, Trivedi RH, Morrison DG, et al. The Infant Aphakia Treatment Study: evaluation of

cataract morphology in eyes with monocular cataracts. *J AAPOS*. 2011;15(5):421–6.
[\[CrossRef\]](#)[\[PubMed\]](#)[\[PubMedCentral\]](#)

17. Haargaard B, Wohlfahrt J, Fledelius HC, et al. A nationwide Danish study of 1027 cases of congenital/infantile cataracts: etiological and clinical classifications. *Ophthalmology*. 2004;111(12):2292–8.
[\[CrossRef\]](#)[\[PubMed\]](#)
18. Mullner-Eidenbock A, Amon M, Moser E, et al. Persistent fetal vasculature and minimal fetal vascular remnants: a frequent cause of unilateral congenital cataracts. *Ophthalmology*. 2004;111(5):906–13.
[\[CrossRef\]](#)[\[PubMed\]](#)
19. Mitra RA, Huynh LT, Ruttum MS, et al. Visual outcomes following lensectomy and vitrectomy for combined anterior and posterior persistent hyperplastic primary vitreous. *Arch Ophthalmol*. 1998;116(9):1190–4.
[\[CrossRef\]](#)[\[PubMed\]](#)
20. Anteby I, Cohen E, Karshai I, et al. Unilateral persistent hyperplastic primary vitreous: course and outcome. *J AAPOS*. 2002;6(2):92–9.
[\[CrossRef\]](#)[\[PubMed\]](#)
21. Alexandrakis G, Scott IU, Flynn HW, et al. Visual acuity outcomes with and without surgery in patients with persistent fetal vasculature. *Ophthalmology*. 2000;107(6):1068–72.
[\[CrossRef\]](#)[\[PubMed\]](#)
22. Walsh MK, Drenser KA, Capone A, et al. Early vitrectomy effective for bilateral combined anterior and posterior persistent fetal vasculature syndrome. *Retina*. 2010;30(4 Suppl):S2–8.
[\[CrossRef\]](#)[\[PubMed\]](#)

20. Pediatric Cataract Surgery in Microphthalmic Eyes

Xinyu Zhang¹✉, Xiaojian Zhong¹ and Xiaoyun Chen¹

(1) State Key Laboratory of Ophthalmology, Zhongshan Ophthalmic Center, Sun Yat-sen University, 54S Xianlie Road, Guangzhou, 510060, People's Republic of China

✉ **Xinyu Zhang**

Email: zhangxinyu0294@163.com

Abstract

Congenital microphthalmos (CM) is caused by disrupted eye growth during embryonic development, which is characterized by shorter-than-normal axial length of the globe. There is a lack of consensus on the classification of microphthalmos. An anatomical classification consisting of three categories may be useful. Manifestations of CM in children differ from those in adults and they require unique management strategies. More specifically, delayed timing of IOL implantation and the avoidance of piggyback IOL implantation are recommended in these cases. Cataract extraction in children with CM requires specific techniques and is associated with an increased risk of posterior synechiae and glaucoma. This chapter elaborates on the classification and manifestations, surgical indications, preoperative evaluation, calculation of intraocular lens power, surgical techniques, and prevention and management of surgical complications.

Congenital microphthalmos (CM) is caused by disrupted embryonic development of the eye and is one of the most common ocular developmental

abnormalities. The pathognomonic manifestation of CM is smaller (shorter) anteroposterior diameter of the globe, which may be accompanied by microcornea, shallow anterior chamber, narrow anterior chamber angle, increased lens to total eye volume ratio, crowded anterior segment, high hyperopia, narrow palpebral fissure, small orbits, or deeply set eyes [1]. CM may also be complicated with other developmental abnormalities of the eye, such as anterior segment dysgenesis, congenital cataract, chorioretinal coloboma, retinal hypoplasia, or optic nerve coloboma [2].

Surgical treatments of congenital cataracts complicated by CM are challenging for ophthalmic surgeons. Main issues that need to be addressed include the following:

1. Difficulty determining the indications for and timing of cataract extraction.
2. Management of the crowded anterior segment which only allows a very limited surgical instrumentation space [3, 4].
3. A higher rate of both intraoperative and postoperative surgical complications that would typically occur in pediatric eyes with a normal axial length. During cataract surgery in pediatric eyes with CM, peripheral extension of anterior capsulorhexis/posterior capsulectomy and iris trauma may occur. Common postoperative complications include posterior synechiae, glaucoma, and posterior capsular opacification (PCO) [3–6].
4. Compared to the eyes with a normal axial length, indications and timing of intraocular lens (IOL) implantation should be more conservative than in eyes without CM [3, 4, 6]. The IOL power calculations are more challenging and thus harder to predict the final refractive error in pediatric eyes with a short axial length. Available IOL formulas have a poor predictability for short eyes, and adult-sized IOLs cannot fit into eyes with an extremely crowded anterior segment [7].
5. Furthermore, pediatric cataract surgeries in CM eyes are associated with a poor visual prognosis, especially in eyes with concurrent ocular

developmental disorders [6]. Therefore, a thorough preoperative evaluation should be performed and the benefits versus the potential risks must be weighed. Therefore, the surgeon should choose the most appropriate surgical procedure and take necessary preventive measures during surgery to minimize the risk of severe complications.

20.1 Classification and Clinical Characteristics of Microphthalmos

Microphthalmos usually results from arrested development of the eye during embryogenesis. Most cases are sporadic, while others are either autosomal dominant or recessive [1, 2, 8]. Microphthalmos has a wide spectrum of clinical manifestations, and an internationally accepted classification system is not yet available. Based on the anterior chamber depth (ACD) and the axial length, Parrish et al. classified microphthalmos into three categories (Table 20.1) [8].

Table 20.1 Classification of microphthalmos

<i>Shallow anterior chamber with short axial length</i>
Nanophthalmos/simple microphthalmos
Colobomatous microphthalmos
Complex microphthalmos
<i>Shallow anterior chamber with normal axial length</i>
Relative anterior microphthalmos
<i>Normal anterior chamber depth with short axial length</i>
Axial hyperopia

Reproduced with permission from Steinert [8]

20.1.1 Shallow Anterior Chamber with Short Axial Length

Proposed by Duke-Elder in 1964, this type of microphthalmos includes three subtypes, i.e., simple microphthalmos, colobomatous microphthalmos, and complex microphthalmos [9].

20.1.1.1 Nanophthalmos/Simple Microphthalmos

Nanophthalmos refers to the ocular condition of short axial length without other congenital ocular defects or systemic anomalies [1, 9]. Typically, the total axial length is at least two standard deviations below the mean when adjusted for age. For example, in nanophthalmic children aged 3 years or older, the mean axial length is less than 20.5 mm. Clinically, nanophthalmos is extremely rare and usually occurs bilaterally [10]. No racial difference has been observed in terms of incidence [11]. The clinical characteristics of microphthalmos in children are listed as follows:

1. Often accompanied by microcornea, with a horizontal corneal diameter of 9.5–11 mm (Fig. 20.1).

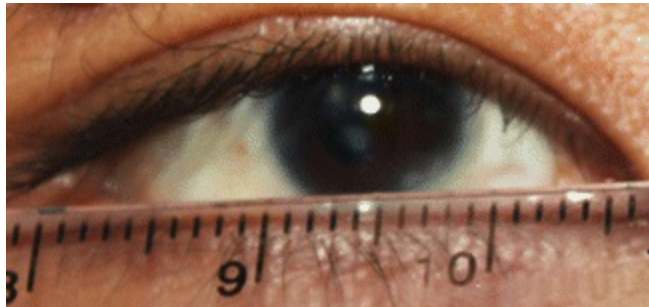


Fig. 20.1 Microcornea

The horizontal diameter of the cornea of the right eye in this patient is less than 10 mm.

2. The volume of a nanophthalmic eye is homogeneously reduced to approximately two thirds of normal ocular volume with an increased lens to total eye volume ratio and normal or slightly increased lens thickness.
3. Both the peripheral and central ACDs are shallow. The peripheral iris bulges anteriorly. The anterior chamber angle, however, remains open in nanophthalmic children. They usually have poorly dilating pupils and significant IOP fluctuations.
4. High hyperopia ranging from +7.25D to +20.00D.

5. An interesting finding in nanophthalmic children is the absence of uveal effusion, one of the cardinal pathologies in nanophthalmic adults [12]. Not a single case of uveal effusion has been reported in these children [3–6]. The underlying mechanism for this finding might be that compression on vortex veins is not so significant as to cause uveal effusion because the nanophthalmic sclera in children is softer, thinner, more permeable to fluid egress, and more flexible than in adults.

20.1.1.2 Colobomatous Microphthalmos

Colobomatous microphthalmos is associated with defective closure of the embryonic fissure during early development of the eye. Normally, complete closure of the embryonic fissure occurs by the sixth week of gestation. Incomplete closure may result in colobomatous microphthalmos, often accompanied by other ocular developmental anomalies such as coloboma of iris or choroid, or even hypoplasia of the visual pathway and visual cortex [9].

20.1.1.3 Complex Microphthalmos

Complex microphthalmos is associated with systemic diseases and concurrent anterior/posterior segment abnormalities other than incomplete closure of the embryonic fissure. In such patients, microphthalmos is merely one of the clinical manifestations of their hereditary syndromes with other ocular and systemic pathologies [2]. Syndromes associated with complex microphthalmos are listed in Table 20.2 [8].

Table 20.2 Microphthalmos-related syndromes

<i>Microphthalmos-related syndromes</i>
13 trisomy syndrome (Patau syndrome)
Chromosome 18 deletion syndrome
Congenital rubella syndrome
Hallermann-Streiff syndrome
LSD (lysergic acid diethylamide) embryopathy
Goldenhar syndrome
Oculodentodigital dysplasia (ODD) syndrome

Micrognathia-glossoptosis syndrome
Oculo-cerebro-renal syndrome (Lowe's syndrome)
Focal dermal hypoplasia (FDH)
Francois syndrome
Ullrich syndrome

Reproduced with permission from Steinert [8]

20.1.2 Shallow Anterior Chamber with Normal Axial Length

Naumann created the term relative anterior microphthalmos (RAM) for eyes with a shallow anterior chamber and a normal axial length in 1980. These eyes are characterized by a total axial length of >20 mm, a horizontal corneal diameter of 9–11 mm, and a decreased anterior segment volume. RAM is more common than nanophthalmos [13].

20.1.3 Normal Anterior Chamber Depth with Short Axial Length

The main manifestation of this subtype of microphthalmos is high axial hyperopia with a normal ACD. As there are no morphological deformities of the eye, the risk of complications associated with pediatric cataract surgery is not increased in this population.

20.2 Surgical Indications, Timing, and Preoperative Evaluation

Children with nanophthalmos, colobomatous microphthalmos, and complex microphthalmos appear to be at a higher risk when undergoing cataract surgery. Cataract surgery in RAM is also associated with certain complications. Pediatric cataract patients with normal ACDs and short axial lengths have a lower risk. Therefore, for cataract children complicated with microphthalmos, a complete assessment should be performed to determine the specific type of microphthalmos. The ophthalmologist should practice rigorous control of the surgical indications in an effort to achieve maximum visual outcomes of the affected child. When planning surgery for

microphthalmic children who meet the indications, the ophthalmologist should be well aware of all the possible intraoperative and postoperative complications, so that necessary preventive measures are taken to mitigate these risks.

20.2.1 Surgical Indications and Timing

20.2.1.1 Indications and Timing of Cataract Extraction

The surgical indications and timing of cataract extraction in microphthalmic children are similar to that in other children with cataracts. See Chap. 12, Sect. 12.1 “Indications and Timing of Pediatric Cataract Surgery” for a detailed discussion.

20.2.1.2 Indications and Timing of IOL Implantation

Microphthalmic eyes with cataract have a more crowded anterior chamber and a smaller capsular bag compared with cataractous eyes that have a normal axial length and without RAM. It is recommended that IOL implantation should be delayed in microphthalmic children to reduce risks of complications such as posterior synechia and glaucoma [3, 14]. Another concern is the availability of IOL with extreme powers ($\geq +30.0D$) for microphthalmic infants with extremely short axial lengths [15], which can also be avoided by delaying IOL implantation until the affected eye has reached an acceptable axial length with a less crowded anterior chamber. It should be noted that compared to aphakia correction by contact lenses, early implantation of an IOL produces similar visual outcomes at the cost of increased complications and adverse events in infant eyes with a normal axial length, according to the long-term results of the Infant Aphakia Treatment Study (IATS) [16, 17]. Therefore, the authors believe that it is also advisable to leave the microphthalmic children aphakic until the eyes grow longer. Of the current studies on IOL implantation in microphthalmic children, the majority of cases remained aphakic until >3 years of age [14, 15]. The general recommendation for aphakia after cataract extraction in these children is wearing spectacles or contact lenses and choosing the timing of secondary IOL implantation based on the growth of the aphakic eye [3, 4, 6]. The option of piggyback IOL implantation, one of the recommended

solutions to aphakia in microphthalmic adults with cataract [18], is not yet supported by strong clinical evidence for this use in the cataract surgery of microphthalmic children, whose ocular structures are yet to develop with an even more crowded anterior segment. The authors believe that piggyback IOL implantation is inadvisable in young children with microphthalmos.

20.2.2 Preoperative Evaluation

During preoperative evaluation for pediatric cataract patients with microphthalmos, attention must be given to the following items, apart from the routine examination before pediatric cataract surgery:

1. Measurements of corneal diameter, refractive status, and axial length: Eyes with a horizontal corneal diameter less than 11 mm, hyperopia $> +8D$, and axial length less than 20.5 mm or at least two standard deviations below the mean for age are considered as high-risk eyes.
2. Anterior segment examination: Under general anesthesia, gonioscopy is performed with a Zeiss or Sussman goniolens. The 12-mm pediatric Koeppe binocular lens can also be used to observe and compare the anterior chamber angles between the two eyes. Use ultrasound biomicroscopy (UBM) to evaluate the angle structure and peripheral choroids.
3. Posterior segment examination: B-scan ultrasonography should be performed to assess the choroid and retina when opacities of the lens obscure direct visualization of the fundus.

20.3 IOL Power Calculation

20.3.1 Measurement of Axial Length

An accurate measurement of axial length is essential for IOL power calculation and postoperative refractive outcomes, especially for children with an extremely short axial length. A minor measurement error may lead to a “refractive surprise” after surgery. Shamma et al. estimate that a 1-mm error in axial length measurement could result in a refractive error of up to

2.0–3.0D postoperatively and that this effect is amplified in eyes with a short axial length [19]. Most of the common ultrasound biometry devices are calibrated by the average sound velocity in normal-sized eyes. Some of them measure only a limited range of axial length, and eyes with an extremely short axis cannot be measured. Applanation A-scan ultrasonography, a commonly used device in primary eye centers or ophthalmology departments of general hospitals, applies an ultrasound probe on the cornea during measurement, which results in corneal compression with a 100–300 μm shortening of ACD. This measurement error is more evident in eyes with a short axial length [7]. Now, optical coherence biometry (IOL Master) and immersion A-scan ultrasonography are widely recognized as a more accurate method of axial length measurement and may help reduce measurement errors in eyes with a short axial length. If optical biometry (IOL Master) is not feasible, such as in an uncooperative child, immersion biometry should then be performed during general anesthesia.

20.3.2 Calculation of IOL Power

The calculation of IOL power for microphthalmic eyes poses a major challenge for cataract surgeons. The first-generation formulas (e.g., the SRK regression formula) and second-generation formulas (e.g., the SRK II formula) are no longer sufficiently precise in the modern era of refractive lens surgery. The third-generation formulas, including the SRK-T, Hoffer Q, and Holladay I formulas, incorporate a personalized ACD and predict the postoperative effective lens position (ELP) based on different values of axial length and corneal power. These third-generation formulas are much more accurate than the second-generation formulas. With the newest fourth-generation formulas, such as the Holladay II and Haigis, the corneal diameter and lens thickness are taken into consideration, producing a more precise prediction of ELP. The surgeon should understand the nuances and indications of these formulas and select the most appropriate for each individual patient, so that postoperative refractive errors may be avoided. Hoffer et al. reported that all third-generation formulas performed accurately with average eyes (22.0–24.5mm), while Hoffer Q formula performed more precisely with short eyes (<22.0mm), and Holladay II formula is recommended for extremely short eyes (<18.0mm) [20, 21].

20.4 Surgical Techniques for Cataract Extraction in Children with Microphthalmos

Cataract extraction in microphthalmic children is more challenging with an increased associated risk that is present due to an overcrowded anterior segment that limits maneuverability of surgical instruments and predisposes tissue damage. Thus, the surgical techniques differ from common pediatric cataract surgery in the following aspects, owing to the specific anatomic characteristics of CM eyes during childhood:

1. For eyes with a crowded anterior segment, the surgeon must protect the corneal endothelium. Due to the shallow anterior chamber, the distance between the corneal endothelium and the lens is reduced and the operating space is limited. This will increase the risk of corneal endothelial touch during surgery. Arshinoff's soft-shell technique is favorably useful for such cases. A cohesive ophthalmic viscosurgical device (OVD) is injected into the center of the anterior chamber to inflate the anterior chamber and create space. Next, a dispersive OVD is injected on top of the former to protect the corneal endothelium [22]. The corneal incision should be meticulously constructed to diminish iris prolapse and create a stable anterior chamber that is maintained with these complications avoided.
2. Management of a small pupil: Microphthalmic children tend to have poorly dilating pupils. If adequate pupil dilation is not achieved after intracameral injection of mydriatics, cohesive OVDs may be used to facilitate mydriasis [23].
3. Continuous curvilinear capsulorrhexis (CCC): Apart from the high elasticity of the anterior capsule in all infantile patients, children with CM have both a shallow anterior chamber and an elevated posterior segment pressure [6]. Adequate cohesive OVD should be injected before the capsulorrhexis to inflate the anterior chamber and enable a sufficient operating space. Meanwhile, this may act against the elevated posterior pressure and flatten the surface of the anterior capsule, minimizing the risk of peripheral extension of capsulorrhexis.

4. 10-0 nylon sutures are recommended to ensure a watertight incision during closure that may also help prevent wound leakage and minimize the risk of hypotony.
 5. For nanophthalmic eyes with an axial length <16 mm, it is controversial whether the anterior or posterior approach is more beneficial. A prospective study in 20 cataract children (37 eyes) with axial lengths ≤16 mm found that the surgical approach of phacoemulsification with posterior capsulotomy, anterior vitrectomy, and peripheral iridectomy yielded a favorable outcome [5].
-

20.5 Complications and Managements

The intraoperative and postoperative complications associated with cataract surgery in microphthalmic children are similar to those typically observed during routine pediatric cataract surgery (see Chaps. 22 and 23). However, due to the abnormal ratio of the anterior segment to the posterior segment, the risk of surgical complications, especially posterior synechiae and glaucoma, is increased. Appropriate preventive measures should be considered during surgery; close monitoring and follow-ups are also required after surgery.

20.5.1 Corneal Injury

Because of the crowded anterior segment in microphthalmic eyes of children, the distance between the phaco tip and the cornea is shortened, making the eye more susceptible to corneal endothelial injury. Application of soft-shell technique and balanced salt solution (BSS) at a low temperature may help to protect the corneal endothelium and reduce the severity of corneal injury.

20.5.2 Posterior Synechia

Posterior synechia is the most common postoperative complication of cataract extraction in microphthalmic children. Vasavada et al. reported the postoperative outcomes in 42 microphthalmic eyes of 21 infants having cataract surgery and found that 15 eyes (35.7 %) developed posterior

synechiae. The incidence and severity of the synechiae are correlated with the inflammatory response in the operated eye. Short-acting mydriatics and aggressive steroid therapy helps minimize posterior synechia [3].

20.5.3 Posterior Capsular Opacification

The incidence of PCO in microphthalmic children ranges between 5.2 and 16.7 % [3–5]. Management of PCO in these cases is similar as in common pediatric patients. See Chap. 24 for a detailed discussion on prevention and management of PCO.

20.5.4 Glaucoma

Children with nanophthalmos, colobomatous microphthalmos, complex microphthalmos, or RAM have a crowded anterior chamber and are predisposed to arrested development of the anterior segment, which is associated with a high incidence of postoperative glaucoma. Vasavada's report shows an incidence of 30.9 % (13/42) for glaucoma among these children [3]. Management includes inclusion of a peripheral iridectomy during cataract surgery, drainage of suprachoroidal fluid, and use of an anterior vitrectomy.

20.6 Summary

Microphthalmos in children is very different from that in adults. Therefore, for concomitant pediatric cataracts and microphthalmos, specific management strategies should be adopted. It is recommended to delay IOL implantation and avoid polypseudophakia (piggyback implants) in these children. With regard to prognosis, children with cataracts complicated with nanophthalmos, RAM, or high axial hyperopia are associated with a better visual outcome with timely surgical treatment and rigorous visual rehabilitation. However, in pediatric cataract patients with colobomatous or complex microphthalmos, the decision on performing cataract surgery is more guarded and the prognosis will depend on the severity of retinal impairment or the extent of the associated optic nerve and visual cortex abnormalities.

References

1. Weiss AH, Kousseff BG, Ross EA, et al. Simple microphthalmos. *Arch Ophthalmol.* 1989;107(11):1625–30.
[\[CrossRef\]](#)[\[PubMed\]](#)
2. Weiss AH, Kousseff BG, Ross EA, et al. Complex microphthalmos. *Arch Ophthalmol.* 1989;107(11):1619–24.
[\[CrossRef\]](#)[\[PubMed\]](#)
3. Vasavada VA, Dixit NV, Ravat FA, et al. Intraoperative performance and postoperative outcomes of cataract surgery in infant eyes with microphthalmos. *J Cataract Refract Surg.* 2009;35(3):519–28.
[\[CrossRef\]](#)[\[PubMed\]](#)
4. Praveen MR, Vasavada AR, Shah SK, et al. Long-term postoperative outcomes after bilateral congenital cataract surgery in eyes with microphthalmos. *J Cataract Refract Surg.* 2015;41(9):1910–8.
[\[CrossRef\]](#)[\[PubMed\]](#)
5. Prasad S, Ram J, Sukhija J, et al. Cataract surgery in infants with microphthalmos. *Graefes Arch Clin Exp Ophthalmol.* 2015;253(5):739–43.
[\[CrossRef\]](#)[\[PubMed\]](#)
6. Yu SY, Lee JH, Chang BL. Surgical management of congenital cataract associated with severe microphthalmos. *J Cataract Refract Surg.* 2000;26(8):1219–24.
[\[CrossRef\]](#)[\[PubMed\]](#)
7. Joshi P, Mehta R, Ganesh S. Accuracy of intraocular lens power calculation in pediatric cataracts with less than a 20 mm axial length of the eye. *Nepal J Ophthalmol.* 2014;6(11):56–64.
[\[PubMed\]](#)
8. Steinert RF (2009) Cataract surgery: technique, complications, & management. In: Parrish RK, Donaldson K, Mellem Kairala MB et al (ed) *Nanophthalmos, relative anterior microphthalmos, and axial hyperopia*, 3rd edn. Elsevier Saunders, Philadelphia, pp 399–410
9. Duke-Elder S. Normal and abnormal development: congenital deformities. In: Duke-Elder S, editor. *System of ophthalmology*. St. Louis: Mosby; 1964. p. 488–95.
10. Singh O. Nanophthalmos: a perspective on identification and therapy. *Ophthalmology.* 1982;89:1006.
[\[CrossRef\]](#)[\[PubMed\]](#)
11. Altıntaş AK, Acar MA, Yalvaç IS, et al. Autosomal recessive nanophthalmos. *Acta Ophthalmol Scand.* 1997;75(3):325–8.
[\[CrossRef\]](#)[\[PubMed\]](#)
12. Simmons R. Nanophthalmos: diagnosis and treatment. In: Epstein D, editor. *Chandler and Grant's glaucoma*. Philadelphia: Lea & Febiger; 1986. p. 251–9.

13. Naumann GOH. Pathologie des Auges. Berlin: Springer; 1982.
14. Yu YS, Kim SJ, Choung HK. Posterior chamber intraocular lens implantation in pediatric cataract with microcornea and/or microphthalmos. *Korean J Ophthalmol.* 2006;20(3):151–5.
[CrossRef][PubMed][PubMedCentral]
15. Sinskey RM, Amin P, Stoppel J. Intraocular lens implantation in microphthalmic patients. *J Cataract Refract Surg.* 1992;18(5):480–4.
[CrossRef][PubMed]
16. Infant Aphakia Treatment Study Group, Lambert SR, Lynn MJ, et al. Comparison of contact lens and intraocular lens correction of monocular aphakia during infancy: a randomized clinical trial of HOTV optotype acuity at age 4.5 years and clinical findings at age 5 years. *JAMA Ophthalmol.* 2014;132(6):676–82.
[CrossRef]
17. Plager DA, Lynn MJ, Buckley EG, et al. Complications in the first 5 years following cataract surgery in infants with and without intraocular lens implantation in the Infant Aphakia Treatment Study. *Am J Ophthalmol.* 2014;158(5):892–8.
[CrossRef][PubMed][PubMedCentral]
18. Holladay JT, Gills JP, Leidlein J, et al. Achieving emmetropia in extremely short eyes with two piggyback posterior chamber intraocular lenses. *Ophthalmology.* 1996;103:1118–23.
[CrossRef][PubMed]
19. John Shammas H. Intraocular lens power calculation. Thorofare: SLACK Incorporated; 2004.
20. Hoffer KJ. The Hoffer Q formula: a comparison of theoretic and regression formulas. *J Cataract Refract Surg.* 1993;19:700–12.
[CrossRef][PubMed]
21. Hoffer KJ. Clinical results using the Holladay 2 intraocular lens power formula. *J Cataract Refract Surg.* 2000;26:1233–7.
[CrossRef][PubMed]
22. Arshinoff SA. Dispersive-cohesive viscoelastic soft shell technique. *J Cataract Refract Surg.* 1999;25(2):167–73.
[CrossRef][PubMed]
23. Jhanji V, Sharma N, Vajpayee RB. Management of intraoperative miosis during pediatric cataract surgery using healon 5. *Middle East Afr J Ophthalmol.* 2011;18(1):55–7.
[CrossRef][PubMed][PubMedCentral]

21. Lens Trauma in Children

Zhaohui Yuan¹✉ and Bingsheng Lou¹

- (1) State Key Laboratory of Ophthalmology, Zhongshan Ophthalmic Center, Sun Yat-sen University, 54S Xianlie Road, Guangzhou, 510060, People's Republic of China

✉ **Zhaohui Yuan**

Email: jorphin@163.com

Abstract

Lens trauma is one of the most common types of pediatric ocular trauma, which usually results in traumatic cataract and traumatic lens dislocation. Pediatric lens trauma often has complex causes and a severe inflammatory response, which may also be complicated with other eye injuries and affect visual development. Because of inability of pediatric patients to cooperate, examination and diagnosis tend to be challenging. This chapter provides information on the classification, clinical features, examination, and precautions of pediatric lens trauma and also discusses its surgical management including the timing of surgery, surgical techniques, and benefits and risks of primary or secondary intraocular lens implantation.

Ocular trauma is one of the leading causes of unilateral blindness in developing countries. Based on whether the cornea or sclera has a full-thickness wound, the mechanical ocular injury is divided into two categories, namely, open-globe trauma and closed-globe trauma by the Ocular Trauma Classification Group. Both of them may lead to serious damage to the crystalline lens, such as traumatic cataracts, lens subluxation, or lens dislocation, which is one of the key reasons for post-traumatic blindness. The

clinical features of pediatric lens trauma include the following:

1. Unclear of injury cause: Children may not be capable of making themselves understood and sometimes conceal the truth intentionally for fear of their parents' blame; thus, the cause of injuries cannot be determined.
2. Varying degree of injury severity: Pediatric lens trauma is often complicated by cornea, sclera, iris, and other ocular tissue damage, as well as intraocular foreign bodies or fundus injuries. Additionally, since the ocular structure in children is immature, the lens trauma may stimulate a severe inflammation and proliferation.
3. Unpredictability of visual outcomes: Lens trauma can seriously disrupt the eye structure and visual functions of children, and improper management may result in amblyopia or even blindness.

In clinical practice, mechanical ocular trauma is the principal cause of lens trauma in children. This chapter discusses the diagnosis and management of pediatric lens trauma caused by mechanical ocular injuries.

21.1 Classification and Clinical Features of Lens Trauma in Children

Lens trauma is commonly found among schoolchildren (mainly boys) aged 5–15 years. It is more common in rural than urban areas [1]. Unlike adult lens trauma, pediatric lens trauma largely results from accidental injuries during play caused by scissors, iron wires, needles, sticks, peashooters, or firecrackers [2, 3]. Depending on its clinical features, pediatric lens trauma can be classified as traumatic cataracts and traumatic ectopia lentis.

21.1.1 Traumatic Cataract

Traumatic cataract is one of the leading causes of acquired cataracts in children [4]. Lens opacification may occur immediately after trauma or develop slowly depending on the causes and severity of the trauma. Depending on the integrity of the eye wall following trauma, traumatic

cataracts can be classified as cataracts caused by open-globe injury and cataracts caused by closed-globe injury, with the former more common and approximately three times the incidence of the latter according to published literatures [4]. These two types of cataracts have different clinical features.

21.1.1.1 Pediatric Cataracts Caused by Open-Globe Injury

Pediatric cataract caused by open-globe injury often results from the stab of a sharp object directly into the eyeball and the lens and may also occur after a heavy blow of blunt force. It is usually complicated by lens capsule rupture, which is associated with a more rapid onset and a more complex condition.

Traumatic Cataracts Complicated with Lens Capsule Rupture

Rupture of the lens capsule is often the result of direct trauma to the capsule. The aqueous humor flows into the lens through the ruptured capsule, causing lens edema and opacification. The size of the capsule rupture determines the progression and extent of lens opacification [5]. If the capsule rupture is small or there is an iris synechia to the capsule, the ruptured capsule may close up rapidly, often presenting as localized cortical opacification of the lens (Fig. 21.1a). If the rupture is large, it may result in rapid opacification and swelling of the whole lens, or even dislocation of the lens material into the anterior chamber (Fig. 21.1b) and/or the vitreous cavity.

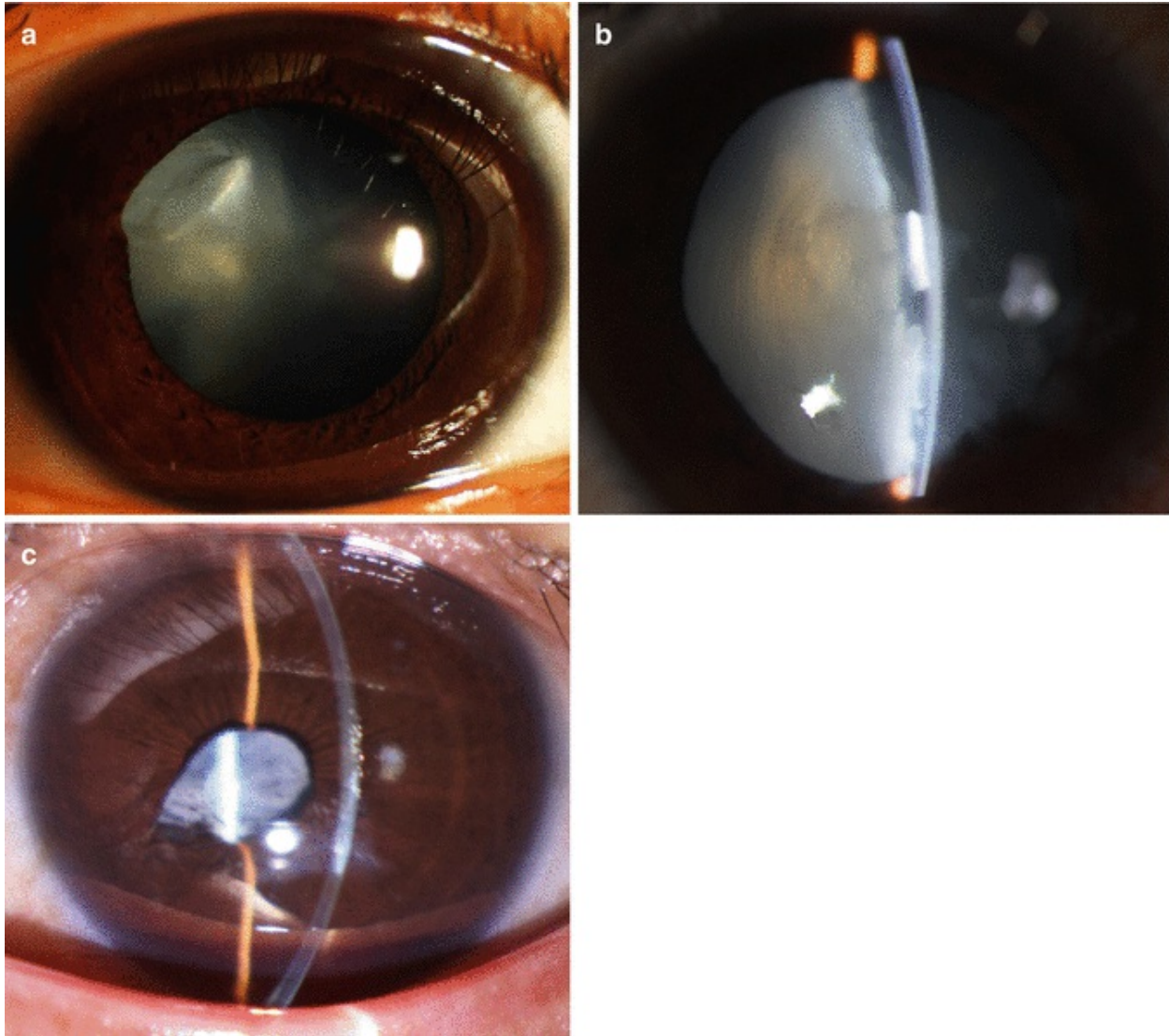


Fig. 21.1 Traumatic cataracts complicated with lens capsule rupture induced by open-globe injury. **(a)** Open-globe injury results in lens anterior capsule rupture and localized cortical opacity. A 7-year-old boy was stabbed in the right eye by a sharp blade 3 days previously. A 2 mm-long, self-sealed, full-thickness wound was observed in the mid-periphery of the temporal cornea. A long oval-shaped anterior capsule rupture was seen in the mid-peripheral region of the superior temporal lens, with exudative membrane adhering to the margin of the rupture and a localized opacity in the superior temporal lens. **(b)** Open-globe injury results in lens capsule rupture and cortex leakage. The right eye of a 6-year-old boy was injured by a metal wire 2 days before. The anterior chamber was shallow, with varying depths between the upper and lower parts of the anterior chamber. There was anterior capsule rupture, lens opacities, swelling, and loose cortex, part of which leaked into the anterior chamber. **(c)** Open-globe injury resulting in membranous cataract. A rural 12-year-old boy's left eye was injured by bamboo fragments 9 months previously. Because both his parents were migrant workers, he was left untreated after the injury. The image shows posterior iris synechia in the inferior nasal quadrant, pupillary distortion, extensive organization of the lens capsule, and partial absorption of the lens materials

Without proper and timely treatment, traumatic cataracts complicated by capsule rupture may induce secondary glaucoma, uveitis, and many other complications. The lens expansion caused by capsule rupture may lead to narrowing of the anterior chamber and pupillary block, which may induce IOP to increase rapidly. If the lens material prolapses into the anterior chamber, lens particle glaucoma could occur due to the elevated IOP induced by the obstruction of the trabecular meshwork with a large amount of lens cortex particles. It usually occurs several days after the lens capsule ruptures and may present as significant eye pain, redness, and vision loss. Slit-lamp examination may detect white cortex particles and/or capsule debris in the aqueous humor with a positive aqueous flare sign and deposition of loose lens material at the bottom of the anterior chamber as well as posterior iris synechiae. Gonioscopy findings often show an open anterior chamber angle, with large amounts of lens cortex debris adhered to the trabecular meshwork. The histologic examination demonstrates lens particles and macrophages in the aqueous humor. In addition, the exposure of lens proteins following capsule rupture may lead to the development of anterior uveitis. If the inflammation involves the trabecular meshwork, IOP elevation may be induced due to obstruction of aqueous outflow, which is called phacoanaphylactic glaucoma. Its pathognomonic sign is granulomatous inflammation of the lens, but its diagnosis is always difficult. Histology shows extensive lesions of polymorphonuclear cell, lymphocyte, macrophage, and epithelioid cell reactions around the lens cortex, which may help to establish the diagnosis.

If traumatic cataracts complicated by capsule rupture are left untreated for a long time, capsule organization may occur, and the lens material may be absorbed over time. Finally, only the organized capsule and a small amount of cortex are left, and this is defined as membranous cataract (Fig. 21.1c) [5]. It may also occur in patients with other types of traumatic cataracts. We observed that membranous cataract is more common in children with traumatic cataracts than in adults, with increased rigidity of the organized capsule, or even complicated with neovascularization.

Traumatic Cataracts Without Capsule Rupture

This condition is relatively rare in cases of open-globe injury. It may be caused directly by the trauma, but more often by indirect injuries including disruption of eye ball integrity, changes in the intraocular microenvironment,

intraocular inflammation, and disturbance to lens metabolism. It may develop slowly after the injury, presenting as varying degrees of lens opacity.

Traumatic Cataracts Complicated by Intraocular Foreign Body

The usual mechanisms of intraocular foreign body-induced traumatic cataract are:

- A. Mechanical injury by the foreign body: As the foreign body penetrates through the lens capsule, the aqueous humor enters into the cortex causing lens opacity (Fig. 21.2a).

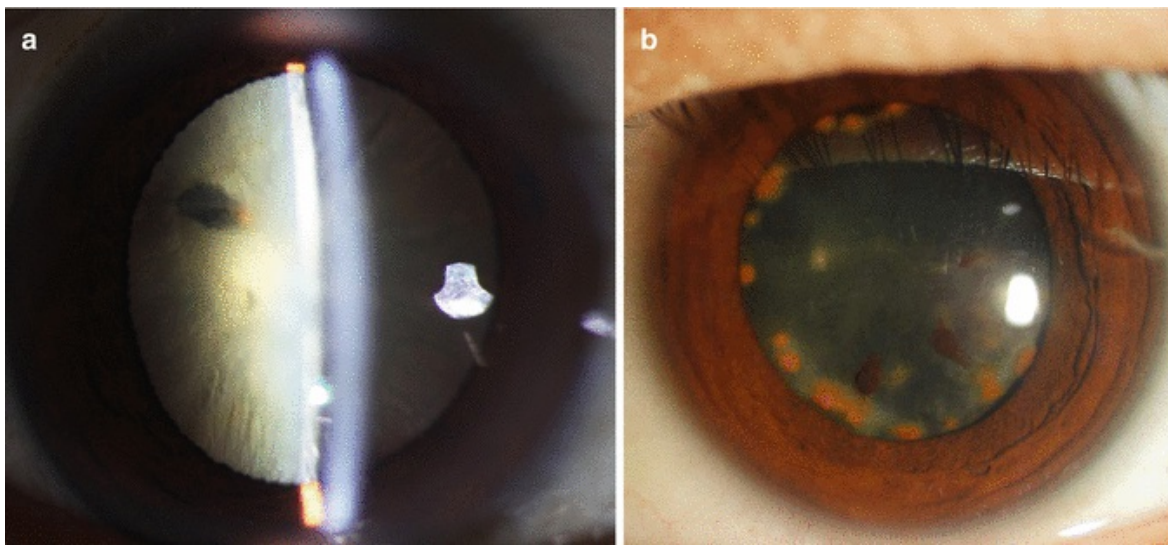


Fig. 21.2 Traumatic cataracts complicated by intraocular foreign body. **(a)** Lens foreign body. A 10-year-old boy complained of a small “stone” splashing into his left eye 2 days before. There were opacity and swelling of lens cortex and shallowing of the anterior chamber. A brownish black foreign body was seen in the mid-peripheral portion of the superior temporal lens, about 3 mm × 2 mm in size. **(b)** Siderosis. A 15-year-old boy presented with visual loss in the left eye for half a year. History taking revealed that his left eye was injured by “tiny iron sheets” when modifying a model car 1 year before, but he paid no attention to this. After pupillary dilation, multiple anterior subcapsular brown patches were seen in the mid-peripheral region of the lens, arranged in a circle, with mild lens opacities. A CT scan confirmed metal foreign bodies retained on the retinal surface of the left eye

- B. Toxic reaction to the foreign body: Even without direct lens injuries, metal foreign bodies (e.g., iron and copper) retained in the eye for a long time may produce various chemical reactions and thereby result in cataracts. Examples include lenticular siderosis (Fig. 21.2b) and

chalcosis.

21.1.1.2 Pediatric Cataracts Caused by Closed-Globe Injury

In the scenario of closed-globe injury, blunt forces per se or secondary factors may give rise to traumatic cataracts. Blunt forces on the crystalline lens may lead to capsule rupture, resulting in rapid opacification of the lens. Secondary factors after trauma, such as changes in the intraocular microenvironment, intraocular inflammatory responses, or metabolic disturbance to the lens, might cause slowly progressive lens opacity. Their clinical presentations may vary depending on the direction and intensity of the external force, but usually include a Vossius ring, rosette-shaped cataracts, punctate cataracts, and total cataracts. Besides, patients may have concurrent ocular injuries, such as iridodialysis (Fig. 21.3a), retinal breaks, and anterior chamber/vitreous hemorrhage.

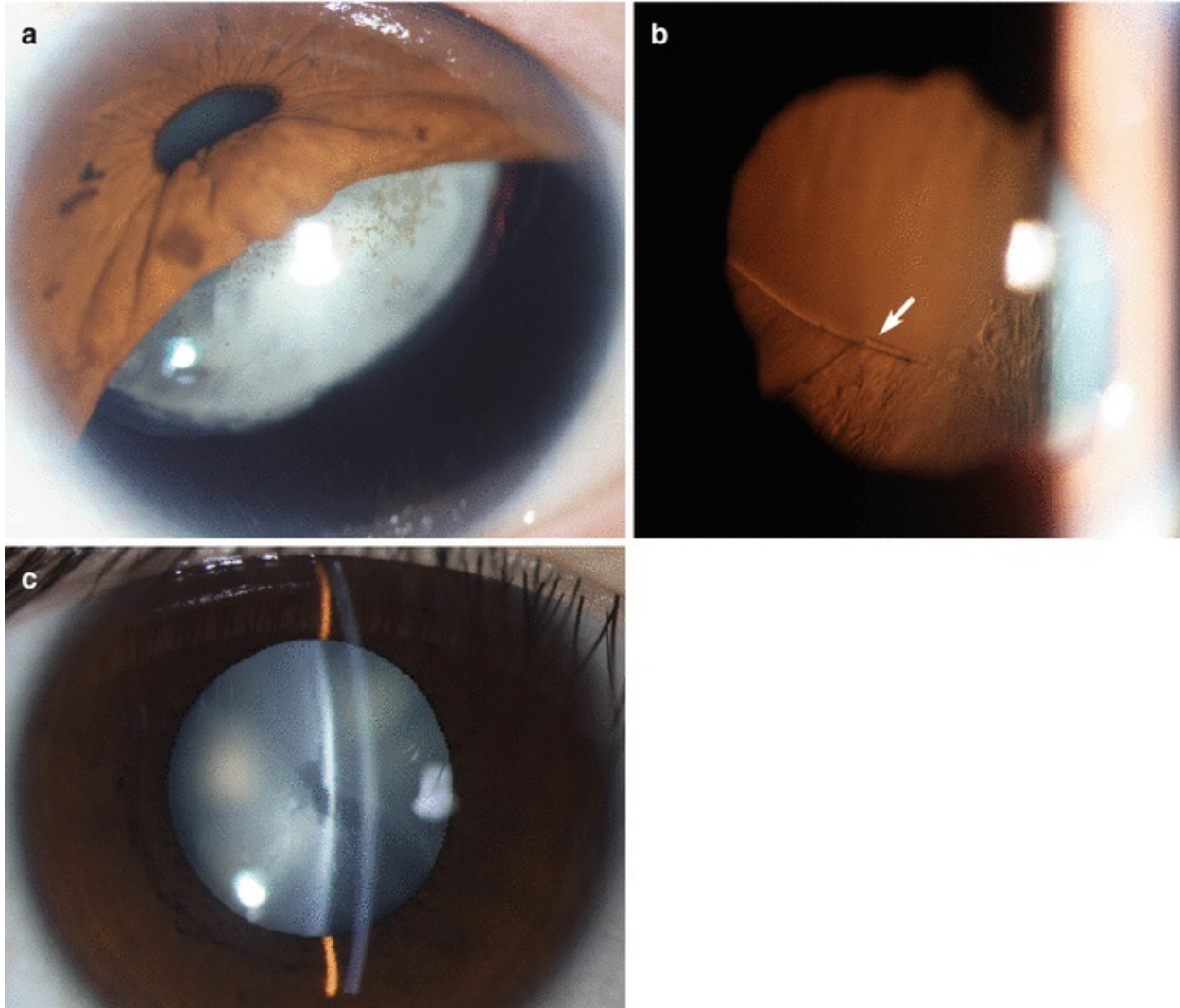


Fig. 21.3 Traumatic cataract caused by ocular contusion. **(a)** A 15-year-old boy presented 1 month after his right eye received a contusion after impacted with another player's head while playing basketball. The image shows an iridodialysis from 3 to 8 o'clock and white lens opacity, with the lens dislocated temporally and superiorly and a visible lens equator. **(b)** Posterior capsule rupture caused by ocular contusion. A 13-year-old girl presented 1 day after her left eye received a contusion after impacted with bicycle handlebars as she fell off. The image shows pupillary dilation, multiple tears at the pupillary margin, oval-shaped posterior capsule rupture, and localized cortical opacity surrounding the posterior capsule rupture. **(c)** Cataract caused by ocular contusion. A 12-year-old boy was hit with a fist 1 day before. No wound was observed on cornea or sclera. The lens rapidly opacified with cleft formation

Traumatic Cataracts Caused by Closed-Globe Injury and Complicated with Capsule Rupture

When the anterior ocular surface of the eye is hit with a blunt force, rapid anterior-posterior shortening of the eye occurs with simultaneous equatorial expansion. Severe equatorial stretching may result in capsule rupture,

typically posterior capsule rupture (Fig. 21.3b). Then, opacities occur as the aqueous humor enters into the lens through the rupture. Hydration of the lens develops soon after opacification at the site of rupture, followed by formation of vacuoles and edema. Opacification would later extend to the periphery of the lens and, eventually, involve the entire lens (Fig. 21.3c). When the capsular rupture is small, however, the opacity may remain localized. Unless examined immediately after trauma, the posterior capsule rupture caused by closed-globe injury is often dormant, which may not be detected during a slit-lamp exam. But Scheimpflug imaging with a Pentacam has been reported to have been used to reveal posterior capsule rupture [6, 7].

Cataracts Caused by Closed-Globe Injury Without Capsule Rupture

1. Vossius ring: It appears as circular opacity in the lens anterior capsule. When the eye receives blunt trauma, the iris pigment epithelial cells at the pupil edge are shed off and imprinted on the surface of the anterior capsule in a circular pattern, which is referred to as a Vossius ring. In this case, anterior subcapsular opacities might occur.
2. Ectopia lentis: Cataracts caused by closed-globe injury are often combined with various degrees of zonular fracture, leading to ectopia lentis (Fig. 21.4a).

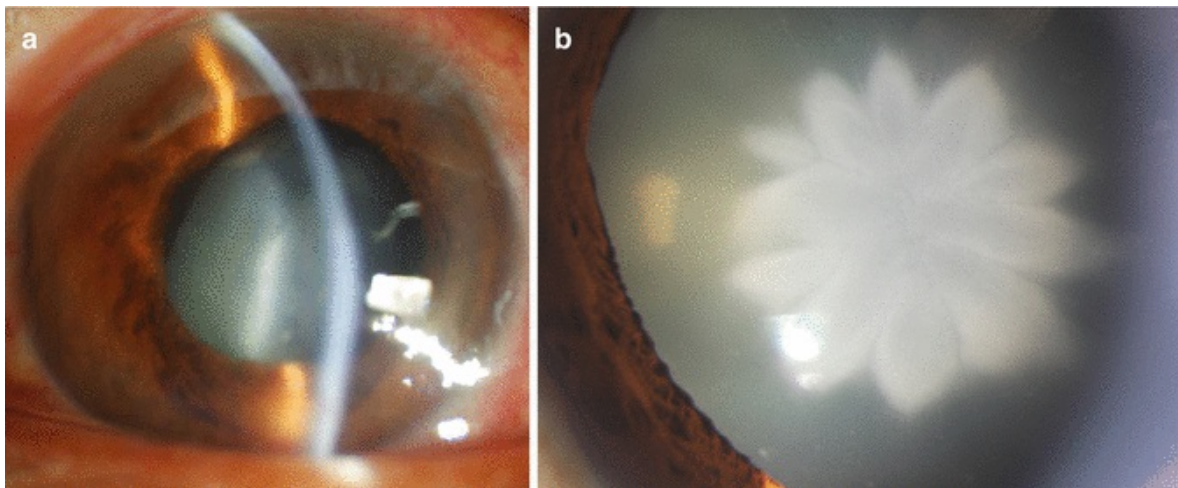


Fig. 21.4 Cataracts caused by closed-globe injury without capsule rupture. (a) Traumatic cataract caused by ocular contusion and complicated with ectopia lentis. A 16-year-old boy presented 5 days after being struck in the left eye with a badminton. A moderate degree of white

lens opacity with intact lens capsule can be seen. There was zonular fracture from 9 to 1 o'clock, with the lens dislocated temporally and inferiorly. **(b)** Rosette-shaped lens opacities. A 15-year-old boy presented 7 days after his right eye received a blow with fist while fighting. Clefts can be seen between the lens fibers, arranged in a radial pattern, like rose petals

3. Rosette-shaped cataract: When the lens is impacted by an external force, the structure of lens fibers and sutures may be disrupted, and thereby fluid may flow into the intersutural and interlamellar spaces, forming rosette-shaped radial opacity (Fig. 21.4b). Such cataracts may occur within hours or weeks of an injury, and the opacities may be resolved spontaneously in some patients. In other cases, however, cataract may develop several years after the injury, and the opacity may be permanent.
4. Punctate cataracts: Lots of tiny opaque dots are formed beneath the subepithelial of the lens. They usually develop over a period of time following the injury and remain static and impact vision slightly.

21.1.1.3 Pediatric Cataracts Caused by Other Physical or Chemical Agents

Electric shock, heat, radiation, or chemical injury may also change the structure and transparency of the crystalline lens. Although most of these cataracts are rarely seen in children, electrical injury is relatively common.

Electrical Injury

Electrical injury includes electric shock and lightning strike. Electric shock in children is often caused by inadvertent touching of household appliances or a socket. The severity of an electrical injury depends on several factors such as the duration of contact, the strength of electrical current, the size of contact area, the part of body in contact, and the pathway the electrical current passes through the body. Cataracts caused by lightning strike often present as both anterior and posterior subcapsular opacities, while those caused by electric shock mainly present as anterior subcapsular opacities. Cataracts induced by electrical injury may be static or progressive. It may take several months or even years to form complete clouding of the lens in progressive cases. For a small number of patients, the lens opacities may be completely absorbed and become transparent. If an electrical injury-induced cataract is static and

visually insignificant, observation is recommended; otherwise, surgical treatment should be considered. Favorable surgical outcomes can be achieved if not complicated with other ocular tissue injuries.

Chemical Injuries

Chemical-induced cataract is relatively rare in children, but if it occurs it is usually by alkali chemicals, such as lime. As alkali chemicals dissolve fats and proteins, they are more likely to penetrate into the eye causing lens metabolic disturbance directly or indirectly, which leads to various degrees of lens opacity. Milky white opacity of the entire lens may be detected in serious cases.

21.1.2 Traumatic Ectopia Lentis

Traumatic ectopia lentis often occurs following blunt trauma to the eye. A blunt force may cause compression and equatorial expansion of the globe and hence zonular dialysis, resulting in the lens tilting anteriorly or posteriorly. At the site of the dialysis, vitreous prolapse may occur (Fig. 21.5a), often with concurrent traumatic cataracts.

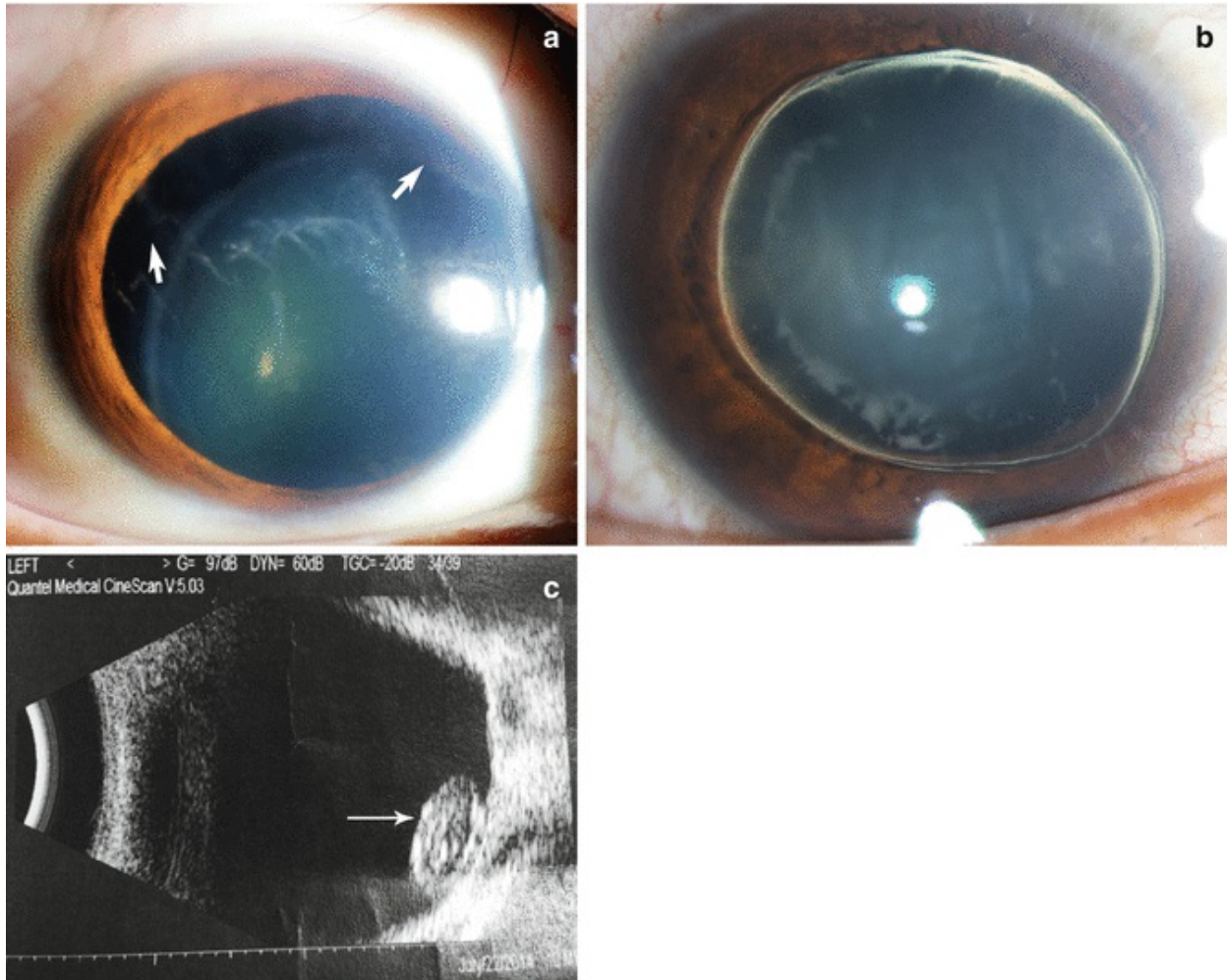


Fig. 21.5 Traumatic ectopia lentis. (a) Traumatic ectopia lentis with vitreous hernia. A 17-year-old boy presented 2 weeks after being hit in his right eye with a tennis ball. Zonular dialysis from 7 to 2 o'clock was seen in the right eye. The lens was displaced inferiorly and nasally, and the vitreous herniated into the anterior chamber through the dislocation area in the superior temporal quadrant (see *arrows*). The lens is mildly opaque. (b) Traumatic dislocation of the lens into the anterior chamber. A 10-year-old girl presented 2 days after her left eye received a blast injury from a firework during a wedding ceremony. The lens displaced into the anterior chamber, contacted with the corneal endothelium, where mild corneal edema could be seen. The dislocated lens is largely transparent, with the appearance of an oil drop. IOP in the left eye was 45 mmHg. (c) Traumatic dislocation of the lens into the vitreous cavity. A 10-year-old boy presented 3 months after a blow to the right eye with a rock. B-scan ultrasonography revealed the lens dislocated into the vitreous cavity (see *arrow*)

21.1.2.1 Lens Subluxation

The extent and presentation of lens subluxation may vary with the extent of zonular dialysis. Mild subluxation may be asymptomatic without any signs. A larger extent of lens subluxation is associated with more apparent clinical manifestations: (1) uneven anterior chamber depth (ACD) or changes in ACD

(irregular ACD along different meridians in one eye); (2) iridodonesis and/or phacodonesis, a quivering of the iris and/or the lens on eye movement, accompanied with pupil displacement; (3) lens decentration, with a partially visible equatorial region of the lens after pupillary dilation; and (4) vitreous prolapse into the anterior chamber in serious cases.

21.1.2.2 Complete Lens Dislocation

1. Dislocated into the anterior chamber: The lens is typically seen at the pupillary zone, with the transparent lens looking like an oil drop (Fig. 21.5b), and white disc-shaped opacities may also be observed. The dislocated lens may cause corneal endothelial abrasion and Descemet membrane detachment, leading to corneal edema.
2. Incarcerated at the pupil: This may induce pupillary block and affect aqueous circulation, resulting in acute elevation of IOP and secondary glaucoma.
3. Displaced into the vitreous cavity: A transparent globule in the vitreous cavity is observed (Fig. 21.5c). Adhesion to the retina may occur over time. If the lens remains in the vitreous cavity for a long time, the soluble lens proteins may leak into the anterior chamber through the lens capsule, leading to phacolytic glaucoma.
4. The lens may become dislocated to the subconjunctival space or even out of the eye following severe trauma.

21.2 Examination of Children with Ocular Trauma

Due to the mental stress and eye pain after injury, most children are not cooperative for examination, making the diagnosis and treatment even more challenging. The ophthalmologist should be very patient and careful and try to earn the patient's trust and cooperation. For older children, the ophthalmologist should encourage them with patience and help them overcome their fear. As most children cannot cooperate for a long time, it is

wise to let an experienced ophthalmologist complete the examination quickly. For children who fail to cooperate, in order to prevent further injury, 10 % chloral hydrate at a dose of 0.6–0.8 ml/kg may be administered orally or rectally for sedation. In some cases, general anesthesia may also be considered. If the ocular trauma seems to be serious, life-threatening systemic injuries must be excluded.

21.2.1 Medical History

A detailed and accurate history is exceptionally important to determine the etiology, nature, extent, and severity of the ocular trauma, which may be quite helpful for diagnosis and treatment. The physician should make a detailed inquiry of the child, their parents, and even other witnesses about the traumatic event, including time of injury, the objects that cause the trauma and its nature, how (e.g., direction and distance) the event happened, as well as any initial management. In addition to the present history, information about the visual acuity of both eyes before the injury, past history of any ocular and systemic diseases, allergy to medications, and family history should also be obtained.

21.2.2 Examination

21.2.2.1 General Examinations and Precautions

For children with ocular trauma presented to an emergency department, their systemic condition must be assessed before any ophthalmic examination, so as to identify signs of shock, brain trauma, infection, or vital organ injury. If necessary, a consultation or referral should be considered immediately after brief treatment of the injured eye.

21.2.2.2 Visual Acuity Test

A visual acuity test of the injured eye is essential at the initial visit. This includes uncorrected visual acuity (UCVA) and best-corrected visual acuity (BCVA). If there is a significant visual loss, then light perception and light projection should also be checked. For young children who are unable to cooperate, a test to check their ability to fix and follow a light is recommended. A visual acuity chart for children or other methods may be used as alternatives.

21.2.2.3 IOP Measurement

If there is no evidence of globe rupture, IOP measurement should be performed. A noncontact tonometer is the preferable option. For children who fail to cooperate, it is recommended to use a Tono-Pen tonometer under sedation or anesthesia. If a tonometer is not available, the IOP may be roughly estimated by finger palpation.

21.2.2.4 Slit-Lamp Examination

It is critical to avoid placing undue pressure on the globe during examination. Do not rush to clean the wound to avoid prolapse of intraocular contents. The slit-lamp examination helps to identify and document the location, affected area and depth of the anterior segment wound, the presence or absence of wound infection, as well as occult wounds. The transparency, position, and stability of the lens as well as the integrity of the lens capsule should also be observed. If the lens is found to be dislocated, areas of loss of zonular support and the presence of vitreous prolapse should also be carefully assessed. Besides, the ophthalmologist should be aware of the possibility of a retained intraocular foreign body.

21.2.2.5 Other Examinations

For patients with suspected orbital fracture or intraocular foreign body, orbital X-ray (sagittal and coronal views) or CT scan should be routinely performed. If the refractive media opacities prevent clear visualization of the fundus, then B-scan ultrasound is recommended. For patients with suspected lens dislocation, UBM may be used to examine the anterior eye segment (including the anterior chamber angle, ciliary body, lens, and zonules). When contact with the globe or applying pressure on the globe is necessary during examination (e.g., B-scan ultrasound or UBM), it is important to ensure the integrity of the globe before initiating the exam, so as to avoid extrusion of intraocular contents as well as causing iatrogenic intraocular infection.

21.2.2.6 Examination of the Contralateral Eye

The contralateral eye should be routinely checked to prevent the possibility of undetected injury. If primary intraocular lens (IOL) implantation is planned, parameters of the contralateral healthy eye have to be measured and

documented, including keratometry, axial length, and so on.

21.3 Management of Traumatic Cataracts in Children

As the eyes and visual functions are still developing during childhood, opacities in the refractive media may result in arrested visual development and amblyopia. Hence, the basic principles of managing pediatric traumatic cataracts include restoration of transparency on the visual axis, visual rehabilitation, and prevention of complications. Due to the complexity of ocular trauma in children, a thorough, careful, and comprehensive analysis should be done according to the clinical features of pediatric traumatic cataracts, so as to formulate a rational and individualized therapeutic regimen [8].

21.3.1 Management of Pediatric Cataracts Caused by Open-Globe Injury

21.3.1.1 Indications for Surgery

The management of traumatic cataracts may vary with the object causing the injury, intensity of the external force, and degree of the injury. Whether surgery is needed and the timing of surgery depend on the location, size, density, and progression of the opacity, as well as the presence of severe complications [9]. For localized traumatic cataract, it may be managed with observation and regular follow-up, especially when the visual axis is not affected, expected progression is slow, and the cataract is visually insignificant. Once the cataract is progressive and significantly impairs vision, surgery should be scheduled soon.

The primary indications for surgery include:

1. Total opacification of the lens
2. Localized opacification ≥ 3 mm with visual axis involvement
3. Capsule rupture combined with cortex leakage
4. Presence of lens foreign body

21.3.1.2 Timing of Surgery

Early surgery is often advisable for children with traumatic cataracts; however, due to the complexity and variability of open-globe injuries, there is no evidence-based medical proof regarding the timing of surgery. Depending on the scenario, traumatic cataract surgery can be performed at the time of primary repair of open-globe injury, or later as a secondary procedure.

Advantages and limitations of each surgical strategy are as follows [9–11]:

Cataract extraction at the time of primary repair of open-globe injury has the following advantages:

1. Visual recovery time can be shortened, which is associated with a lower risk of deprivation amblyopia.
2. Repeated surgeries and anesthesia can be avoided.
3. The lens cortex can be removed earlier, leading to lower risks of inflammatory response due to lens protein exposure as well as lens-induced glaucoma.
4. Opacities in the refractive media can be removed, which may facilitate visualization of the posterior eye segment.
5. Mixture of the lens cortex and vitreous can be avoided so as to prevent proliferative vitreous retinopathy and tractional retinal detachment.
6. For patients with financial concerns, primary cataract extraction and IOL implantation are helpful to reduce the total medical expenditure.

Nevertheless, primary cataract extraction also has its limitations: (1) the preexisting intraocular inflammation may become worse; (2) the edema and instability of the corneal wound may lead to surgical difficulties and thereby a prolonged duration of surgery, or even iatrogenic injury to the traumatized

eye, such as posterior capsule rupture and vitreous loss during surgery. By contrast, secondary cataract surgery, which is conducted after the wound is sealed and the traumatized eye is stabilized, is usually associated with lower risks of postoperative inflammation and other complications.

When complicated with retinal detachment or serious posterior segment injury, pars plana vitrectomy and lensectomy should be performed as soon as possible [9].

It is generally accepted that the risk of postoperative complication is lowered if the surgery is done when the intraocular inflammation has subsided, usually about 2–3 weeks after the trauma. A prospective, large-scale, cohort study led by Shah et al. [12] showed that patients with traumatic cataracts had a better visual outcome if the surgery was performed at 3–30 days after the trauma, of whom 44.6 % were children. As this study was prospectively designed with a large sample size, and the Ocular Trauma Classification System was used for data collection, these findings are considered more reliable than those from smaller retrospective studies.

We believe that there is no “one-size-fits-all” approach to decide whether to perform primary or secondary cataract surgery. A number of factors, such as patient age, expertise of the surgeon, availability of surgical equipment, severity of the lens injury, as well as the vitreous and retinal status, should be taken into consideration. For young emergency physicians who lack surgical experience, especially with inadequate equipment at nighttime, it is suggested that extreme caution be exercised, and only necessary management be performed.

21.3.1.3 Timing of IOL Implantation

There are still controversies regarding primary versus secondary IOL implantation following traumatic cataract extraction in children [9–11, 13]. Primary IOL implantation expedites visual rehabilitation, eliminates the need for repeated surgeries and anesthesia, prevents capsule adhesions that may be encountered in a secondary procedure, and reduces medical cost. However, primary implantation is associated with a higher risk of postoperative inflammation, and refractive error may occur because IOL power calculation may be difficult soon after injury. By contrast, due to the stabilized refraction at the time of secondary IOL implantation, calculation of IOL power and prediction of visual outcomes can be much more accurate. Moreover, the surgeon may get a better visualization of the peripheral fundus if vitreous

surgery is required for managing posterior segment lesions. But secondary IOL implantation may delay visual recovery, and exacerbated inflammation, along with a series of other complications, may be triggered by separating iris synechia.

Therefore, there is an ongoing debate on the timing of IOL implantation. Based on the morphological characteristics of traumatic cataracts and the zone classification system established by the Ocular Trauma Classification Group (Fig. 21.6), Shah and Turalba [14] proposed an algorithm to determine the appropriate timing of cataract extraction and IOL implantation (Fig.21.7).

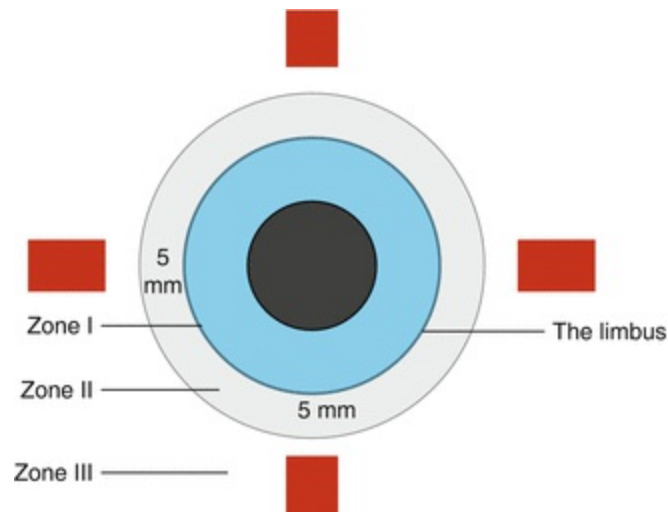


Fig. 21.6 Zone classification of open-globe injury. *Zone I* confined to the cornea and limbus, *Zone II* 5 mm or less posterior to the limbus, *Zone III* greater than 5 mm posterior to the limbus

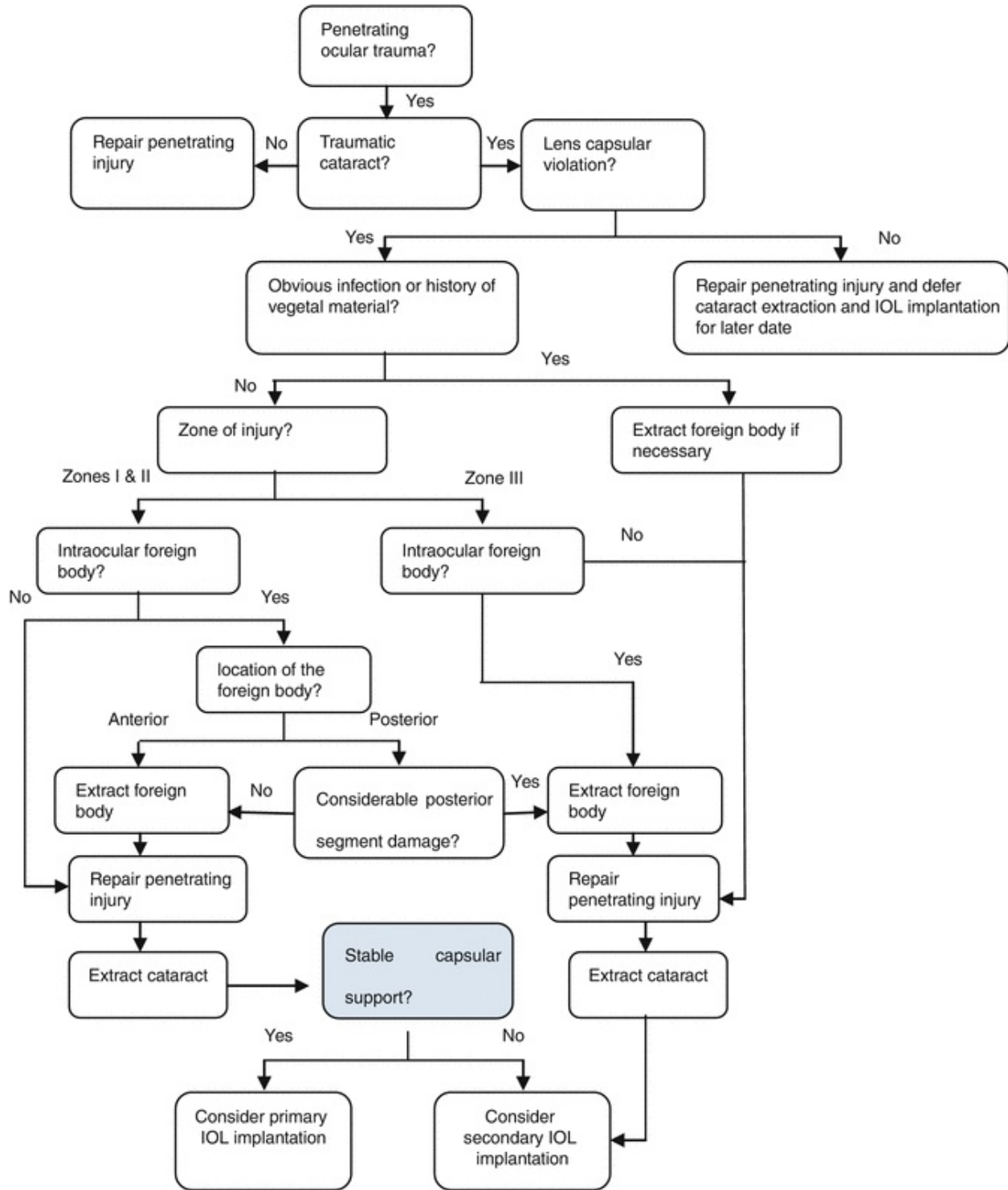


Fig. 21.7 An algorithm to determine the management of traumatic cataracts suggested by Shah and Turalba (Reproduced with permission from Shah and Turalba [14])

As shown in the algorithm, (1) if there is no capsule rupture and no obvious opacities on the visual axis, cataract surgery is not recommended

unless the cataract becomes visually significant. (2) If capsule rupture is present, the penetrating injury should first be classified by zone. For lacerations in Zone III, repair of the primary wound and removal of the lens are recommended to prevent lens related complications, and the injured eye is left aphakic until the secondary procedure. For Zone I and II injuries, primary or secondary in-the-bag or ciliary sulcus IOL fixation can be considered based on the stability of the lens capsule. (3) Significant posterior segment trauma (e.g., exit wounds and retinal detachments), evident infection, unstable capsule, ruptured zonules, severe iris damage, or botanical injury is an exclusion criterion for primary IOL implantation. Under emergency circumstances, this algorithm may be used to guide the decision-making on whether or not to perform primary cataract extraction.

But there are controversies about whether this algorithm is also applicable to children, mainly because the zone classification system is designed for adults. The anatomical structure of the eyes is under rapid development before the age of 5 years. For example, the length of the pars plana is about 1.8 mm in newborns, 3 mm at the age of 1 year, and up to 5 mm at the age of 5 years. Thus, it may not be advisable to use the adult-based zone classification system to assess ocular trauma in children. A comprehensive consideration should be given when deciding on the timing of IOL implantation. Do not rush to implant an IOL without careful planning, especially when intraocular inflammation is not controlled, the status of the posterior segment is unclear, or the IOL power is not accurately determined.

21.3.1.4 Surgical Techniques

The surgical principles for managing cataracts caused by open-globe injury mainly include avoiding further injury to ocular structures, trying to preserve the lens capsule for IOL placement and restoration of refractive status, controlling astigmatism, and preventing or reducing surgery-related complications.

1. **Incision:** Due to the complexity of traumatic cataracts and the discrepancy between preoperative evaluation and intraoperative findings, a modified scleral tunnel incision should always be attempted. The incision should be constructed away from the corneal wound and the site of zonular disruption. If posterior segment injury is presented with severe

corneal damage obscuring the surgical view, but the lens still has to be managed immediately, then the pars plana approach may be considered in this situation.

2. Lens capsule management: It has been reported that in children with traumatic cataracts, in-the-bag IOL implantation is associated with a better visual outcome than ciliary sulcus fixation [15]. Thus, the surgeon should preserve as much capsule as possible in order to support an IOL. The capsulorhexis should cover the anterior capsule rupture, allowing for a continuous and smooth opening. If the capsule has already been organized, capsulorhexis by radiofrequency diathermy may be considered. In the presence of significant anterior and posterior capsule defects, the peripheral capsule should be preserved as much as possible.

Because of the high proliferative capacity of the lens epithelial cells during childhood, preservation of an intact posterior capsule is associated with an incidence of posterior capsule opacification after surgery of almost 100 % [10, 16]. It has been shown that primary posterior capsulotomy in the visual axis area may result in a better visual outcome [16]. Hence, in order to prevent posterior capsule organization and opacification after surgery, posterior curvilinear capsulorhexis involving the axis area should be performed based on the capsule integrity, which may be combined with anterior vitrectomy if necessary.

3. Lens material management: As the lens nucleus is relatively soft in children, irrigation and aspiration (I/A) or low-energy phacoemulsification is appropriate. In the presence of vitreous prolapse before surgery, the dislocated vitreous in the anterior chamber should be removed before lens aspiration. During I/A or phacoemulsification, the noncontinuous anterior capsule should be avoided. Eliminate the lens materials completely and any foreign body in the lens must be removed.
4. Anterior vitreous management: There are two circumstances requiring anterior vitreous management in pediatric traumatic cataract surgery, i.e., planned anterior vitrectomy for prolapsed vitreous that already exists before surgery and unplanned anterior vitrectomy for prolapsed vitreous that occurs during surgery. The former is the more commonly seen. It is

preferable to perform anterior vitrectomy in a closed system and use a non-coaxial vitrector that separates irrigation from vitreous cutting, with a low bottle height (<50 cm), a high cut rate (600–800 cpm), and a moderate vacuum (150–200 mmHg). Using a high cut rate can minimize vitreoretinal traction. The surgeon can insert the vitrector tip behind the posterior capsule through the posterior capsule rupture and cut the prolapsed vitreous located at the posterior capsule rupture. Then high-speed cutting can be initiated behind the posterior capsule with the cutting port facing upward and away from the posterior capsule and always clearly visible. The prolapsed vitreous is drawn posteriorly and cut. After that, place the vitrector tip back into the capsule and remove the remaining lens cortex, with a lower cut rate at 300 cpm and a higher vacuum. Complete removal of vitreous from the anterior chamber is required. Finally, make sure no vitreous is retained in the incision.

5. IOL implantation: The fixation site of an IOL depends on the integrity of the lens capsule and the residual capsular support. In-the-bag implantation and ciliary sulcus implantation are commonly used in clinical practice. It has been demonstrated that ciliary sulcus fixation of an IOL is also safe in children. An iris clip anterior chamber IOL is not recommended for children.

21.3.2 Management of Pediatric Cataracts Caused by Closed-Globe Injury

The visual outcomes of cataracts caused by closed-globe injury are generally better than those caused by open-globe injury [10].

The indications for surgery are listed as follows:

1. For patients with a Vossius ring, the opacities rarely progress or affect vision, and thus surgery may not be needed.
2. For patients with capsule rupture, if the rupture is large and the lens rapidly opacifies, surgical treatment is usually required. Conversely, if the rupture is small and the opacity is localized without visual axis involvement, observation is recommended.

3. For patients with rosette-shaped cataracts, the opacities can be resolved spontaneously in some patients, and conservative management is generally recommended. But if significant visual impairment occurs, surgical treatment should be considered.
4. For patients with punctate cataracts, the opacities are usually static and visually insignificant. Therefore, observation is recommended.

21.3.3 Management of Pediatric Cataracts Caused by Other Factors

For cataracts caused by other physical or chemical factors, observation is recommended if there is no significant visual impairment; otherwise, surgical treatment should be considered which is similar to congenital cataract surgery.

21.4 Management of Traumatic Ectopia Lentis in Children

See Chap. 17 for the management of traumatic ectopia lentis in detail.

21.5 Summary

Open-globe or closed-globe trauma might result in injury to the crystalline lens. Children are unable to provide a detailed history and are uncooperative to examinations, which raises challenges for evaluation, diagnosis, and treatment of lens trauma. Traumatic cataracts are often accompanied by rupture of the capsule, zonular injury, and intraocular foreign bodies; and trauma-induced inflammatory response in children is severe, with rapid progression of related pathologies, which makes the management in pediatric cases more difficult. Decisions should be made on the timing of cataract extraction after trauma, surgical techniques, and timing of IOL implantation, which warrants a thorough consideration of patient age, experience and skills of the surgeon, surgical devices, severity of the lens trauma, and vitreoretinal

condition.

References

1. Johar SR, Savalia NK, Vasavada AR, et al. Epidemiology based etiological study of pediatric cataract in western India. *Indian J Med Sci.* 2004;58(3):115–21.
[\[PubMed\]](#)
2. Xu YN, Huang YS, Xie LX. Pediatric traumatic cataract and surgery outcomes in eastern China: a hospital-based study. *Int J Ophthalmol.* 2013;6(2):160–4.
[\[PubMed\]](#)[\[PubMedCentral\]](#)
3. Gogate P, Sahasrabudhe M, Shah M, et al. Causes, epidemiology, and long-term outcome of traumatic cataracts in children in rural India. *Indian J Ophthalmol.* 2012;60(5):481–6.
[\[CrossRef\]](#)[\[PubMed\]](#)[\[PubMedCentral\]](#)
4. Khokhar S, Gupta S, Yogi R, et al. Epidemiology and intermediate-term outcomes of open- and closed-globe injuries in traumatic childhood cataract. *Eur J Ophthalmol.* 2014;24(1):124–30.
[\[CrossRef\]](#)[\[PubMed\]](#)
5. Shah MA, Shah SM, Shah SB, et al. Morphology of traumatic cataract: does it play a role in final visual outcome? *BMJ Open.* 2011;1(1):e000060.
[\[CrossRef\]](#)[\[PubMed\]](#)[\[PubMedCentral\]](#)
6. Grewal DS, Jain R, Brar GS, et al. Scheimpflug imaging of pediatric posterior capsule rupture. *Indian J Ophthalmol.* 2009;57(3):236–8.
[\[CrossRef\]](#)[\[PubMed\]](#)[\[PubMedCentral\]](#)
7. Grewal DS, Jain R, Brar GS, et al. Posterior capsule rupture following closed globe injury: Scheimpflug imaging, pathogenesis, and management. *Eur J Ophthalmol.* 2008;18(3):453–5.
[\[PubMed\]](#)
8. Shah MA, Shah SM, Applewar A, et al. Ocular Trauma Score as a predictor of final visual outcomes in traumatic cataract cases in pediatric patients. *Cataract Refract Surg.* 2012;38(6):959–65.
[\[CrossRef\]](#)
9. Rumelt S, Rehany U. The influence of surgery and intraocular lens implantation timing on visual outcome in traumatic cataract. *Graefes Arch Clin Exp Ophthalmol.* 2010;248(9):1293–7.
[\[CrossRef\]](#)[\[PubMed\]](#)
10. Xie Lixin, Chief translator (2009) *Harley's pediatric ophthalmology.* People's Medical Publishing House, Beijing, pp 473–488
11. Kuhn F, Pieramici DJ; Chief translator: Zhang Maonian (2010) *Ocular trauma principles and practice.* People's Military Medical Press, Beijing, pp 193–206, 333–336
12. Shah MA, Shah SM, Shah SB, et al. Effect of interval between time of injury and timing of intervention on final visual outcome in cases of traumatic cataract. *Eur J Ophthalmol.*

2011;21(6):760–5.
[\[CrossRef\]](#)[\[PubMed\]](#)

13. Rogers GL. Pediatric cataract surgery: techniques, complications, and management. *Ophthalmic Surg Lasers Imaging*. 2005;36(6):526.
[\[PubMed\]](#)
14. Shah AS, Turalba AV. Intraocular lens implantation in penetrating ocular trauma. *Int Ophthalmol Clin*. 2010;50(1):43–59.
[\[CrossRef\]](#)[\[PubMed\]](#)
15. Kumar S, Panda A, Badhu BP. Safety of primary intraocular lens insertion in unilateral childhood traumatic cataract. *JNMA J Nepal Med Assoc*. 2008;47(172):179–85.
[\[PubMed\]](#)
16. Jensen AA, Basti S, Greenwald MJ, et al. When may the posterior capsule be preserved in pediatric intraocular lens surgery? *Ophthalmology*. 2002;109(2):324–7; discussion 328.
[\[CrossRef\]](#)[\[PubMed\]](#)

22. Intraoperative Complications and Management

Xialin Liu¹  and Yao Ni¹

- (1) State Key Laboratory of Ophthalmology, Zhongshan Ophthalmic Center, Sun Yat-sen University, 54S Xianlie Road, Guangzhou, 510060, People's Republic of China

 **Xialin Liu**

Email: liuxl28@mail.sysu.edu.cn

Abstract

The unique characteristics of pediatric eyes, such as thin and elastic sclera, shallow anterior chamber, extremely elastic lens capsule, and high posterior chamber pressure not only enhance the operative difficulty of lens surgery but also increase the risk for intraoperative complications. Prevention and proper management of intraoperative complications would help to ensure more favorable surgical outcomes. Owing to the development and application of modern phacoemulsification techniques and devices in pediatric cataract surgery, the safety of pediatric lens surgery has been greatly improved; however, even a single improper procedure at any stage of the operation may lead to the occurrence of complications. Based on the anatomical and physiological characteristics of pediatric eyes, this chapter will analyze in detail the cause, prevention, and management of potential complications at each step of cataract surgery, including incision construction, capsulorhexis, aspiration of lens materials, intraocular lens implantation, posterior capsulotomy, and vitrectomy.

Pediatric eyes have unique anatomical and physiological characteristics such as immature eye development, thin and elastic sclera, shallow anterior chamber, poorly dilating pupil, extremely elastic capsule, and high posterior chamber pressure. These features make the surgical approaches for pediatric cataracts much difficult than adults, with an increased risk of potential complications [1]. Despite the application of phacoemulsification technology in pediatric lens surgeries, which greatly improves safety and outcomes, we still need to be well-prepared to prevent and manage complications in pediatric cataract surgeries to improve surgical outcomes. This chapter discusses the causes, prevention, and management of intraoperative complications of pediatric cataract surgery.

22.1 Complications Associated with Rectus Suspension

In pediatric cataract surgery, a superior incision is preferred, which often requires superior rectus suspension in order to fully expose the surgical field and fix the eye. The potential complications associated with this procedure include extraocular muscle injury and scleral perforation.

22.1.1 Extraocular Muscle Injury

The extraocular muscles have a rich blood supply from the anterior ciliary artery, a branch of the ophthalmic artery. Inadvertent injury to the conjunctiva during superior rectus suspension may result in subconjunctival hemorrhage and even hematoma. Mild bleeding or small hematomas may be self-limited and require no specific treatment. However, excessive bleeding can lead to the formation of large hematomas, which not only interferes with surgical maneuvers but also causes undesired cosmetic appearance and limited eye movement. When necessary, conjunctival peritomy may be performed to remove hematoma and stop bleeding. As children have very thin extraocular muscles, the suture needle or thread may cause injury to the superior rectus, resulting in limited eye movement or double vision. Additionally, prolonged and excessive traction on the extraocular muscles may also lead to muscle injury. For example, traction sutures used on the superior rectus may induce widespread cicatricial adhesion of extraocular

muscles and in subtenon space, causing restricted ocular motility.

22.1.2 Scleral Perforation

Due to the low scleral rigidity in children, injury to sclera can easily occur and is often unnoticeable. During the procedure of superior rectus suspension, deep sutures may induce scleral perforation, or result in retinal detachment or other complications in severe cases. If the intraocular pressure (IOP) suddenly falls or a hematoma is spotted at the suture site, careful examination is warranted, and surgical exposure of the sclera may be performed if necessary. Scleral cryosurgery is an option in managing scleral perforation, and scleral buckling may also be employed if necessary. Active infection prophylaxis is required after surgery.

22.2 Incision-Related Complications

The incisions of lens surgery often do not self-seal in children due to the soft eye. Besides, children are physically active and rub their eyes more often. Therefore, the modified scleral tunnel incision from a superior approach is preferred in pediatric cataract surgery, which is created approximately 1–2 mm posterior to the limbus. This allows the wound to be protected by the suture closure, scleral tunnel, coverage of conjunctiva and eyelids, as well as Bell's phenomenon, making the incision more stable and safer. Nevertheless, incision-related complications may still occur, which mainly include incision tear, short incision, and long incision. Improper incision construction is associated with a series of complications, such as iris prolapse, iridodiasis, hyphema, or even posterior capsule tear. It is therefore a critical step to construct an appropriate and standardized incision in pediatric cataract surgery.

22.2.1 Incision Tear

Since young children have thin cornea and sclera with fragile structure, incision tear may occur when the incision is not properly constructed. No treatment is needed in mild cases, but if the rupture results in incomplete closure of the incision, anterior chamber instability, or iris prolapse, a single-stitch suture may be placed at the rupture site. In more severe cases, the ruptured incision has to be sutured, and another incision at a different

location is made.

22.2.2 Short Tunnel Incision

A tunnel incision that is too short may cause the same complications as those of incision tear. In mild cases, the surgery can still be accomplished with the aid of ophthalmic viscosurgical device (OVD) and careful maneuvering. But if the incision is too short, it has to be sutured and a new incision has to be constructed at another location.

22.2.3 Long Tunnel Incision

A tunnel incision that is too long often results in difficult manipulation, and the risks of Descemet membrane detachment (DMD) and corneal endothelial injury may also be increased. To prevent a long tunnel, the incision should not be made when the IOP is low. It is suggested that OVD can be injected into the anterior chamber to increase the IOP.

22.3 Descemet Membrane Detachment

The risks of DMD and corneal injury in pediatric patients undergoing cataract surgery are generally lower as compared with adults. DMD usually occurs in the presence of a narrow incision, long tunnel, preexisting corneal pathology, and shallow anterior chamber or when the internal lip of the incision is too far anteriorly. Improper maneuvers when moving the surgical instruments in and out of the anterior chamber or during intraocular lens (IOL) implantation may lead to DMD and corneal injury (Fig. 22.1). If floating transparent membranes are present in the anterior chamber, careful observation should be made to determine whether they are connected to the cornea, which may help to distinguish the anterior capsule fragments from the detached Descemet membrane. Once DMD occurs, the surgeon should stop the operative procedure so as to prevent detachments from expanding. For small localized detachments, spontaneous reposition can be achieved by injecting balanced salt solution through the opposite site to the tear. An air bubble or even inert gas may also be used for reposition in this case. And for large extensive detachments, suture fixation is recommended if injection fails.

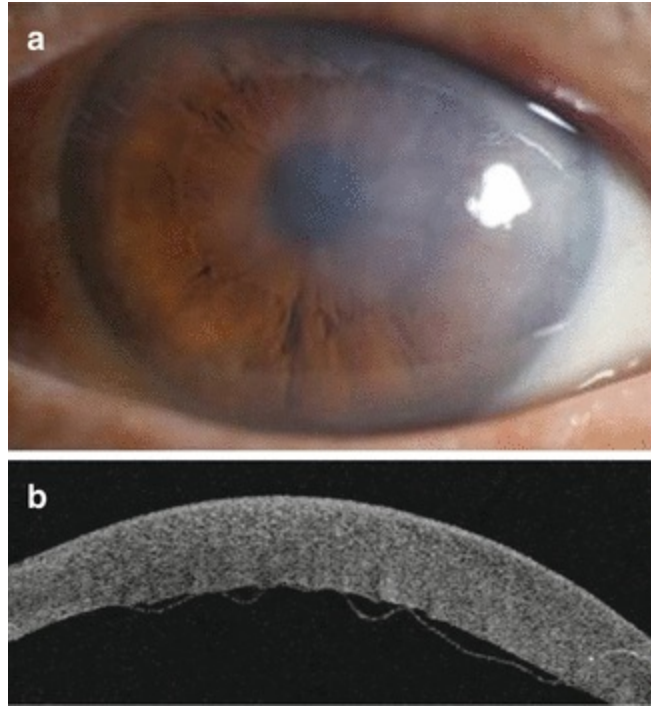


Fig. 22.1 Descemet membrane detachment (DMD) and associated corneal edema. **(a)** Anterior segment photography indicates DMD and associated corneal edema; **(b)** anterior segment optical coherence tomography (AS-OCT) indicates DMD

22.4 Capsulorhexis-Related Complications

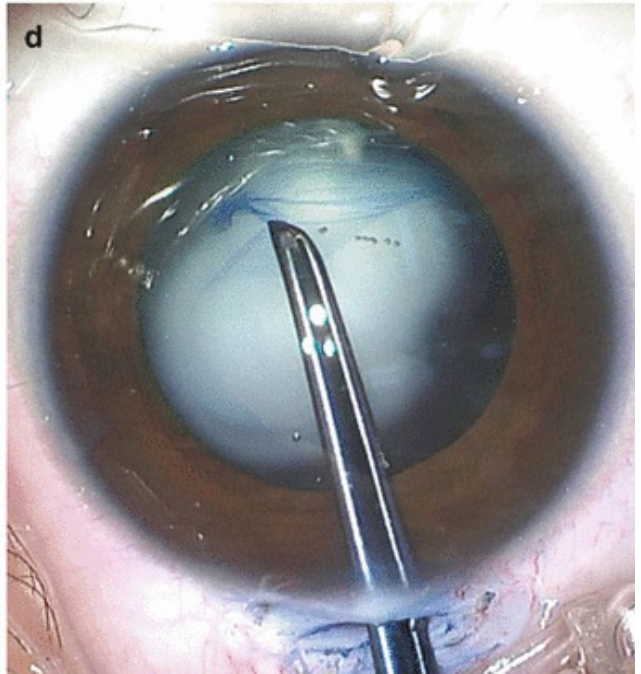
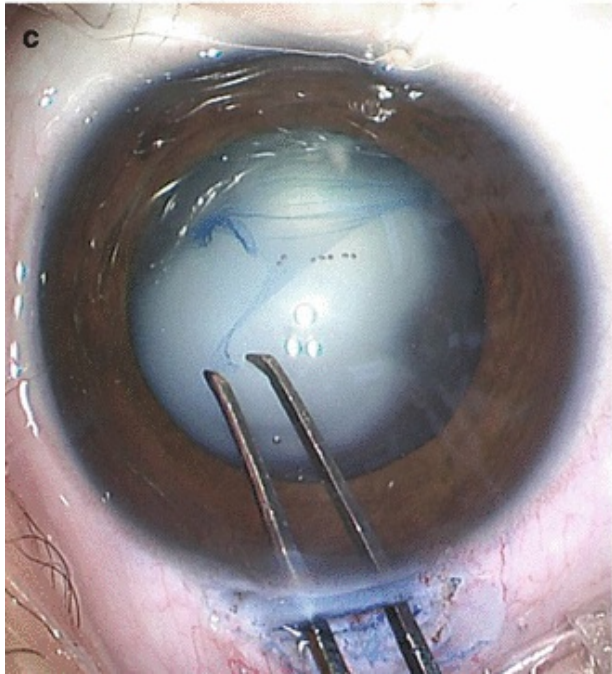
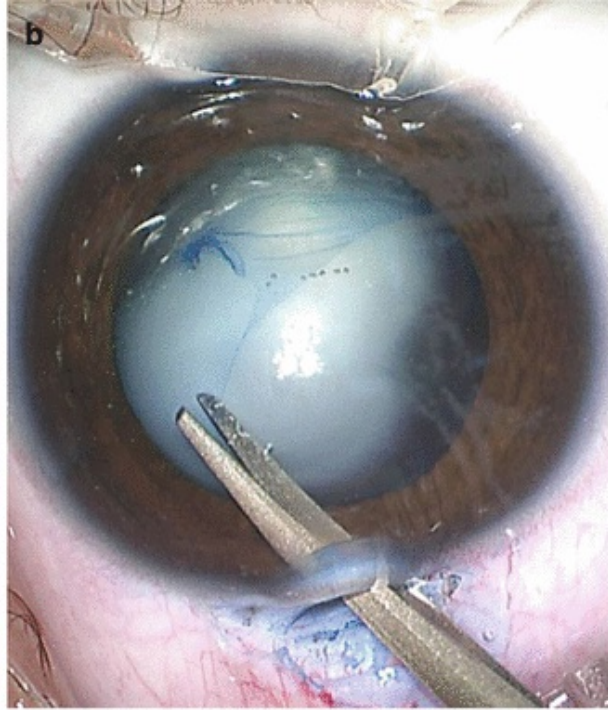
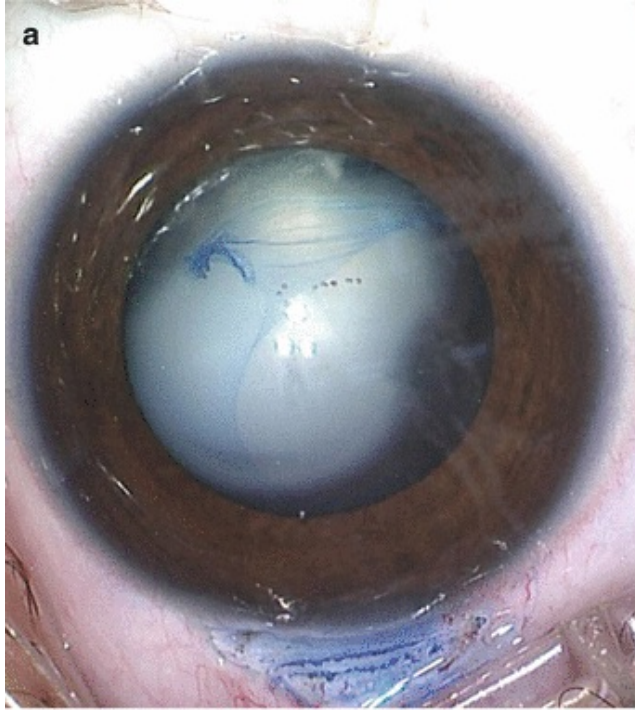
An intact capsulorhexis is essential for subsequent cataract aspiration and IOL implantation in the capsular bag. Because of the extreme elasticity of the anterior capsule, high vitreous pressure, anterior zonule insertion, and sometimes a poorly dilated pupil in infants and young children, it is much more difficult to perform continuous curvilinear capsulorhexis (CCC) in pediatric patients than in adults, with a higher incidence of capsule-related complications.

22.4.1 Capsule Radial Tear

Capsule radial tear, or “runaway rhexis,” is a major complication encountered in pediatric cataract surgery. A radial tear of the anterior capsule may severely affect all the subsequent procedures and destroy the integrity of the capsule, which may contribute to the development of posterior capsule rupture, vitreous prolapse, and IOL dislocation.

Capsule tear often occurs when the capsulorhexis opening is too large and

the surgeon fails to reverse the capsular flap in time, resulting in a “runaway rhexis” that tears out to the lens equator. Fortunately, an anterior capsule tear in pediatric patients rarely extends to the posterior capsule, and a continuous capsulorhexis can still be achieved if handled timely and properly. When an anterior capsule tear occurs, the surgeon should stop capsulorhexis immediately and check the extent of the tear. If the tear is small and has not extended to the equator, the surgeon may fill the chamber with OVD, flip the capsular flap, and pull the capsular toward the center of the pupil, which has always been successful in clinical practice. Alternatively, the surgeon may place more OVD, open the capsule opposite to the tear with capsulotomy scissors, and restart capsulorhexis in the reverse direction, after which two tears meet to form the CCC (Fig. 22.2). Besides, the technique of can-opener capsulotomy may also be used around the site of the tear to reduce tension on the anterior capsule, which may help to prevent further extension of the tear. Some researchers also recommend conversion to a radiofrequency diathermy capsulotomy when the surgeon feels uncertain about controlling the tear [2].



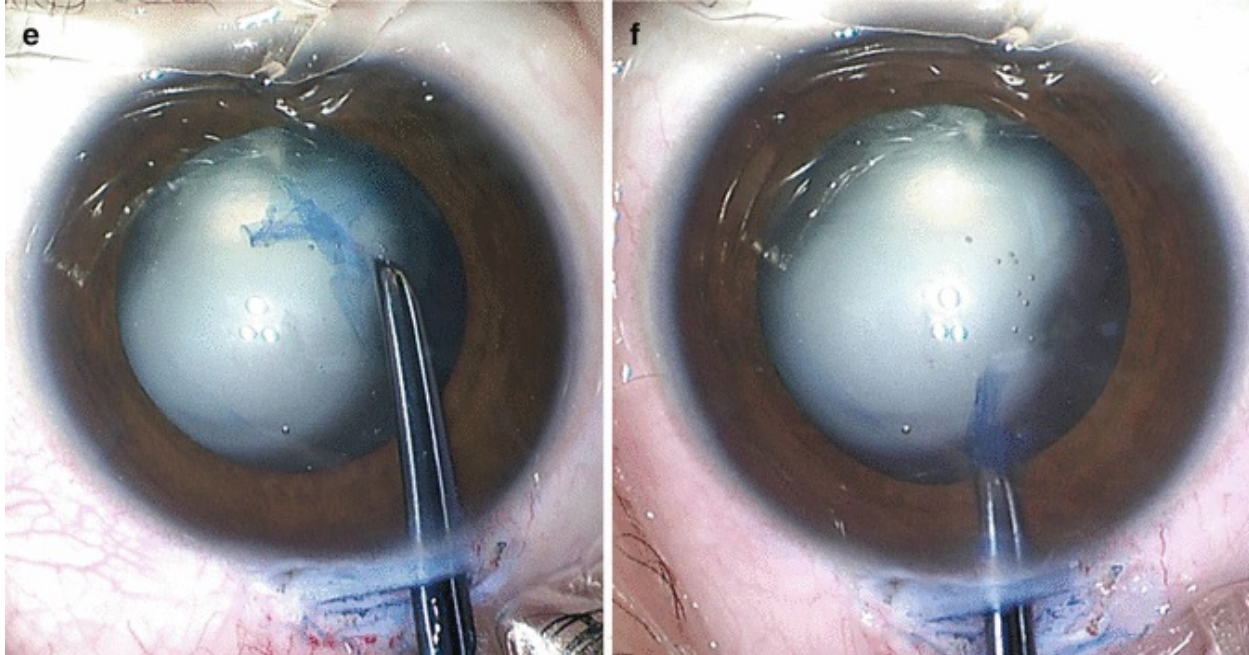


Fig. 22.2 Management of the anterior capsule radial tear. (a) Peripheral extension of capsulorhexis; (b) open the capsule opposite to the tear with capsulotomy scissors; (c) recreate a flap with capsulorhexis forceps; (d–f) restart capsulorhexis from the opposite direction

In order to prevent capsulorhexis-related complications and complete an intact CCC, the surgeon should use adequate high molecular weight OVD to maintain space, aim for a slightly smaller-than-desired capsulotomy, reverse the capsular flap and always pull the flap toward the center of the pupil, and also frequently adjust the grasp location or where the capsulorhexis needle engages the capsule. The capsulotomy edge generated by a radiofrequency diathermy device is not smooth, which may be associated with a higher incidence of secondary tear in subsequent procedures.

22.4.2 Improper Size of the Capsulorhexis Opening

A small capsulorhexis opening poses additional operative difficulties in pediatric cataract surgery, especially for cortex removal beneath the incision. It would even cause complications such as radial tear of the capsulotomy and posterior capsule rupture.

Postoperative contraction of the small opening may affect the centration and stability of the IOL and increase the risk of capsule contraction syndrome or capsular block syndrome. But as the lens cortex in pediatric eyes is soft and easy to aspirate, a relatively small opening does not affect surgical

maneuvers. When the capsulorhexis opening is found to be too small and/or poorly shaped during the surgery, a second capsulorhexis may be performed before or after removal of the lens material (Figs. 22.3, 22.4, and 22.5). If the opening is so large that the edge of capsulotomy fails to cover the edge of the IOL optic, decentration or tilting of the IOL may occur, as well as an increased risk of posterior capsule opacification (PCO). Injury to the zonular fibers and posterior capsule and radial tear of the anterior capsulotomy may also be induced.

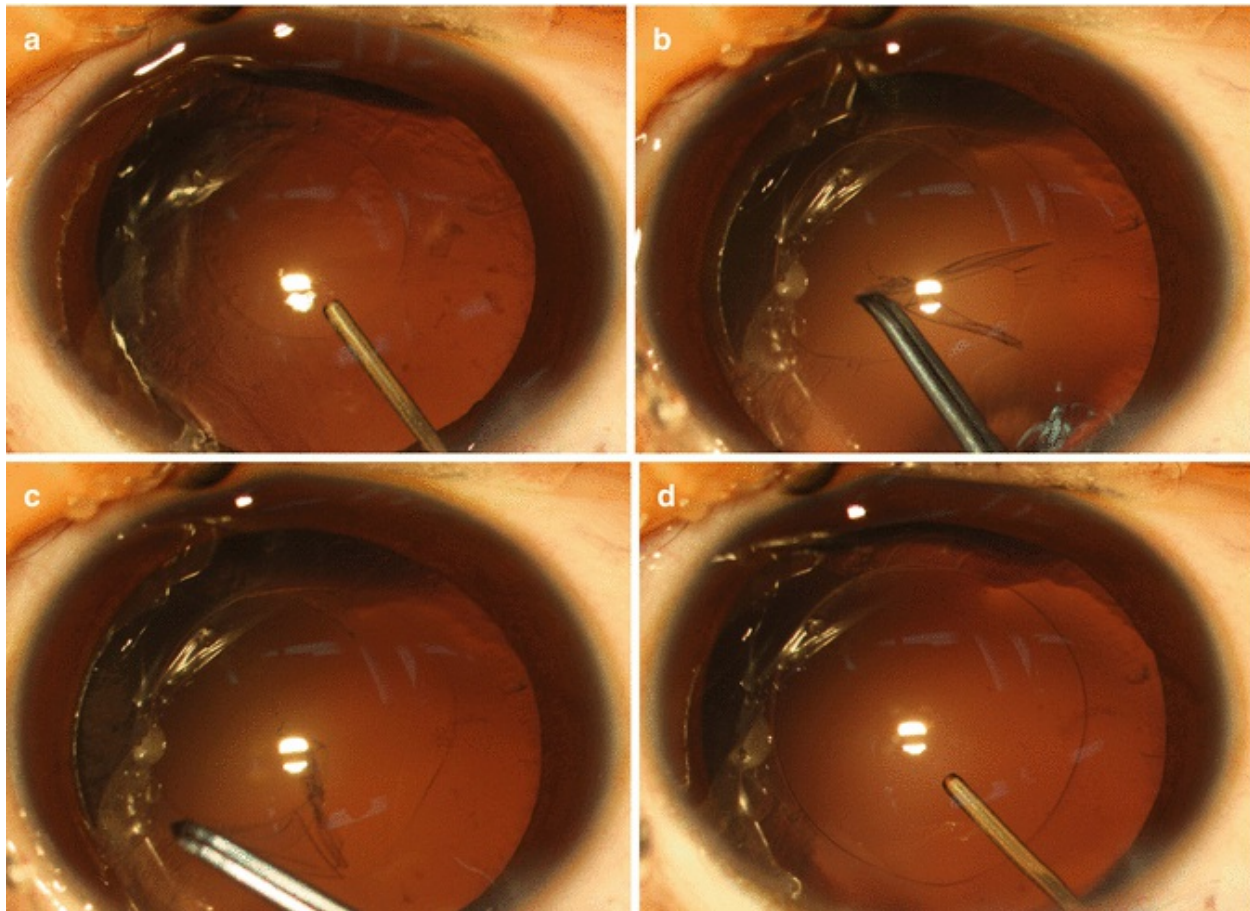


Fig. 22.3 A second anterior capsulorhexis after the removal of the lens material. (a) Inject OVD into the anterior chamber; (b) recreate a flap; (c) the second capsulorhexis opening; (d) the enlarged opening

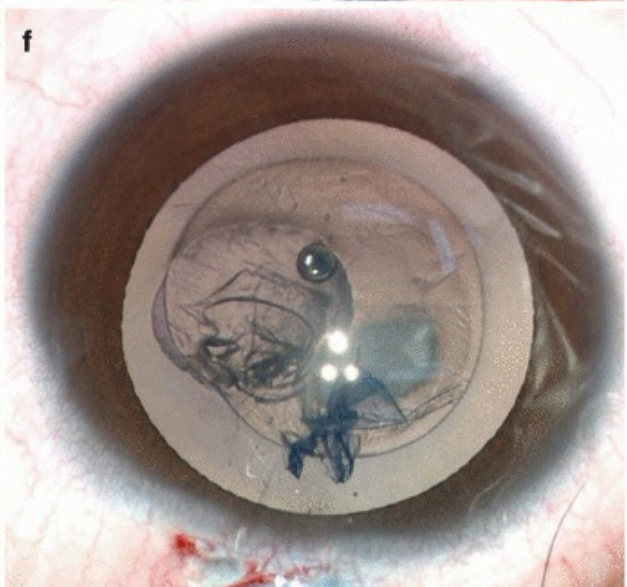
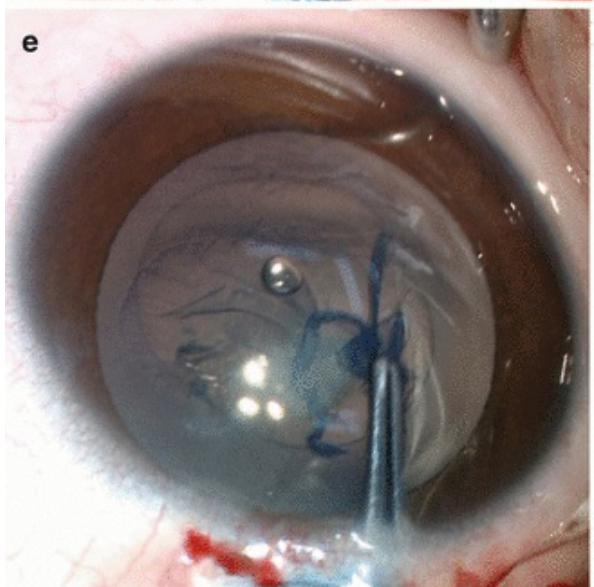
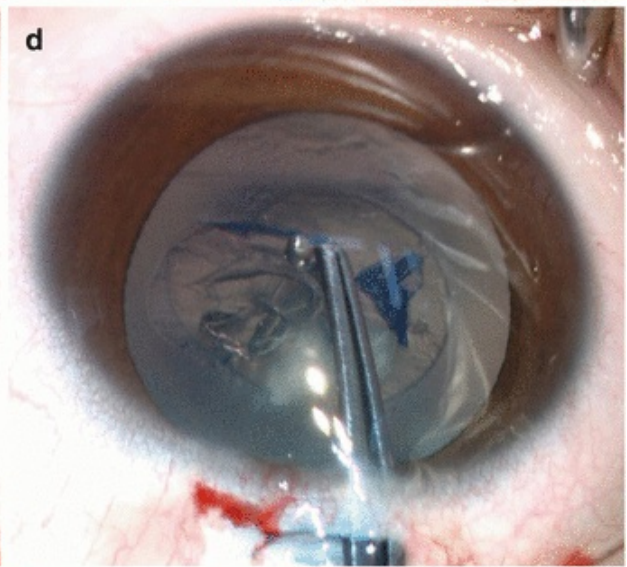
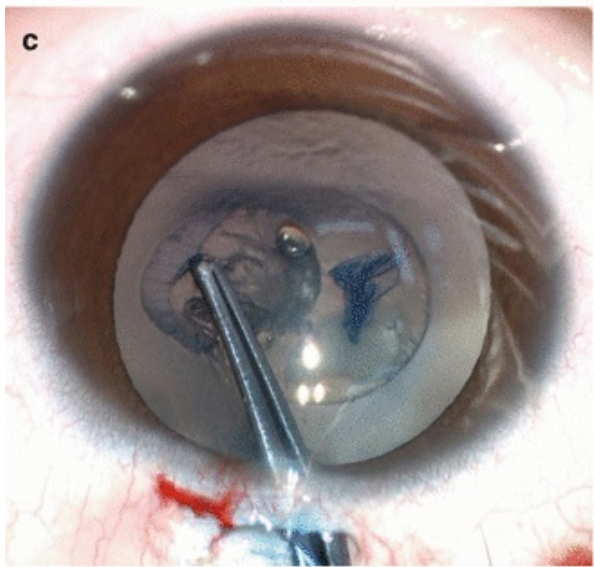
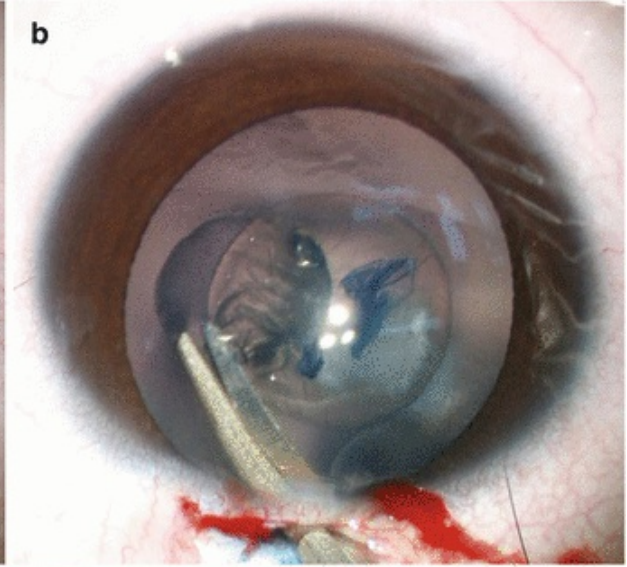
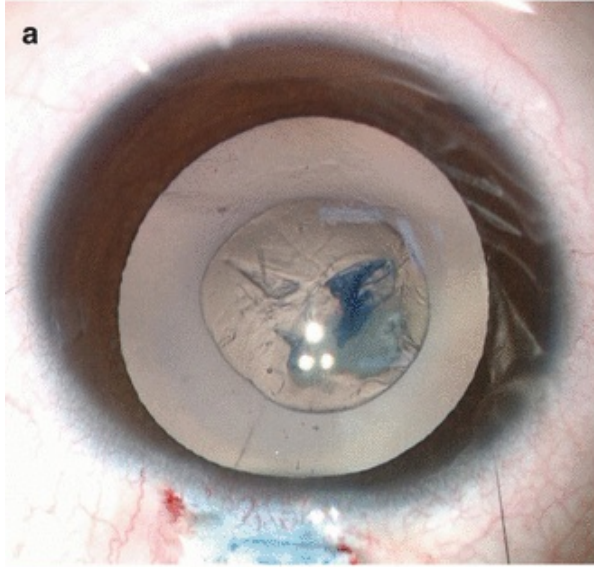


Fig. 22.4 A second anterior capsulorhexis before removal of the lens material. **(a)** A small anterior capsular opening; **(b)** recreate a flap from the edge of opening with capsulotomy scissors; **(c–e)** grasp the flap with capsulorhexis forceps and pull toward the center of the pupil for a second capsulorhexis; **(f)** complete the anterior capsulorhexis

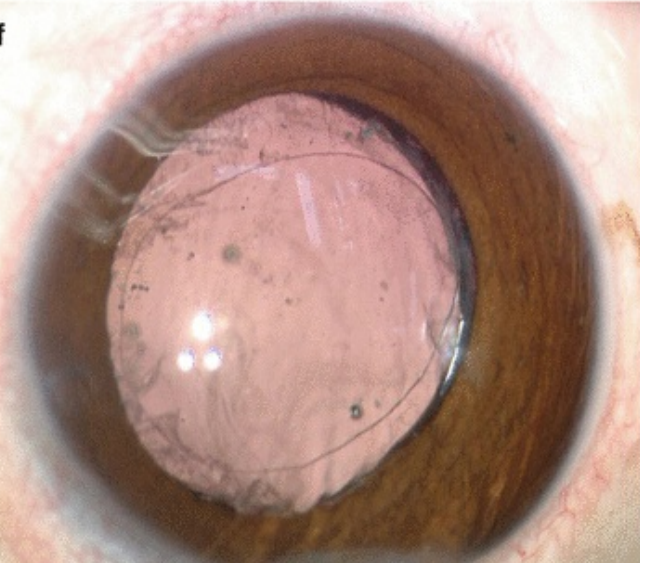
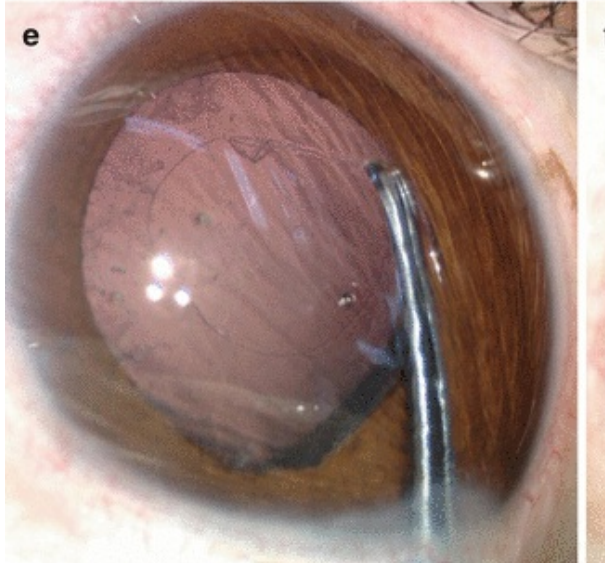
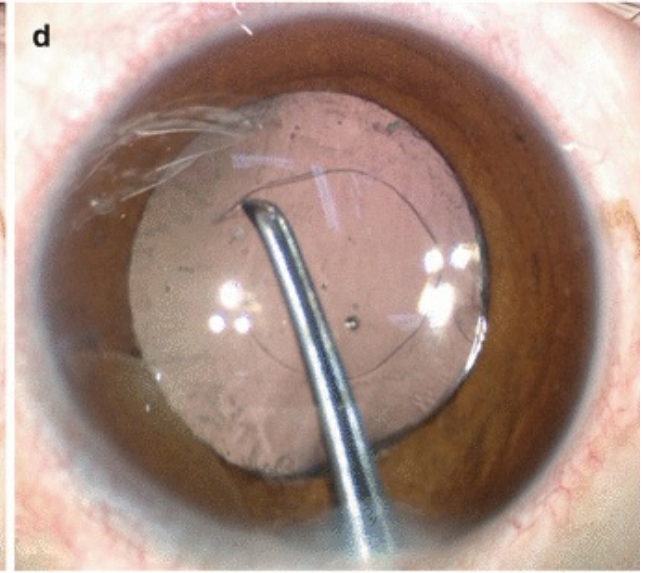
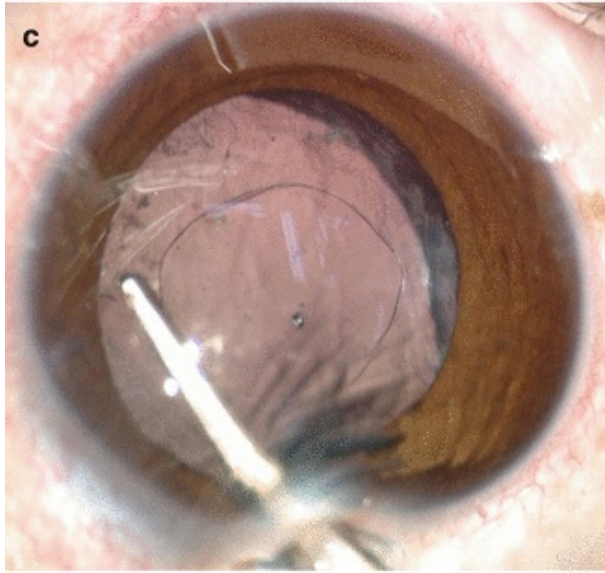
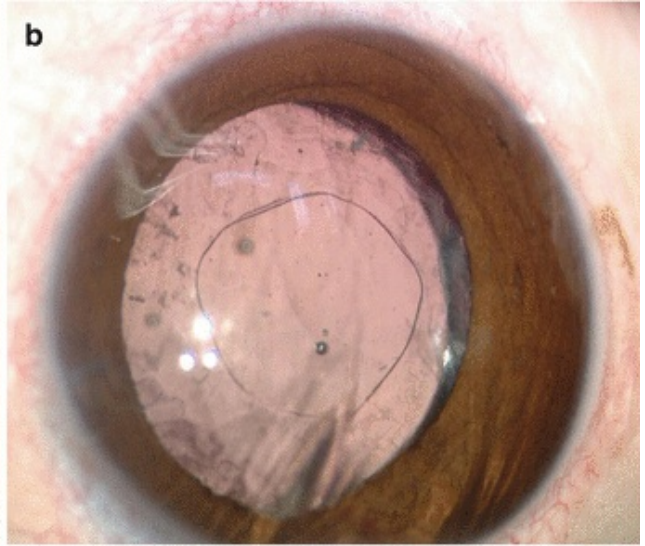
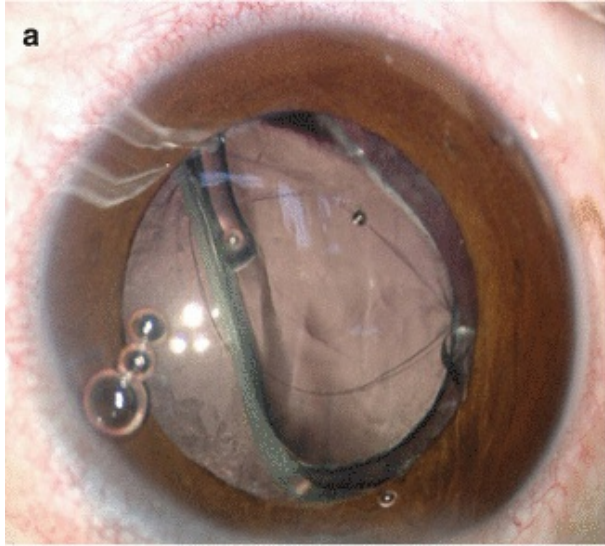


Fig. 22.5 A second anterior capsulorhexis after IOL implantation. (a, b) A small anterior capsular opening observed after in-the-bag implantation of an IOL; (c) recreate a flap from the edge of opening with capsulotomy scissors; (d, e) grasp the flap with capsulorhexis forceps and perform a second capsulorhexis; (f) complete the anterior capsulorhexis

22.5 Posterior Capsule Tear and Vitreous Prolapse

Any inappropriate maneuver during cataract surgery may lead to posterior capsule tear (Fig. 22.6), and the risk is even higher in children with congenital posterior capsule defects (Fig. 22.7).

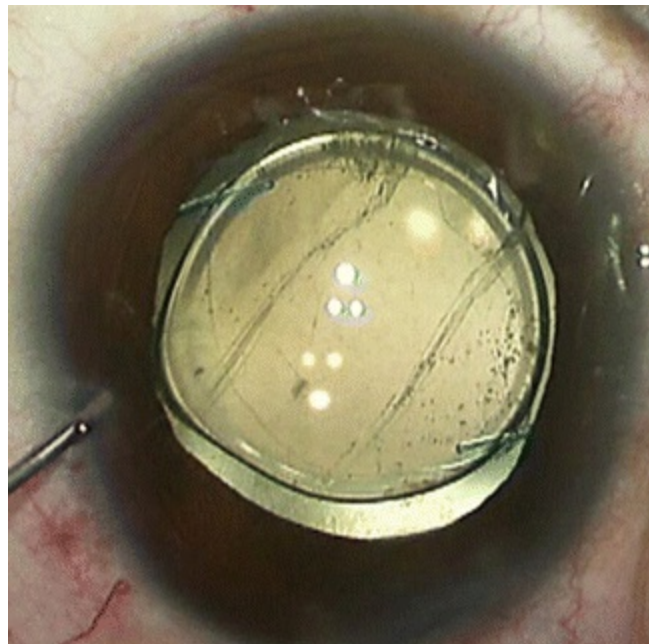


Fig. 22.6 Posterior capsule tear during surgery

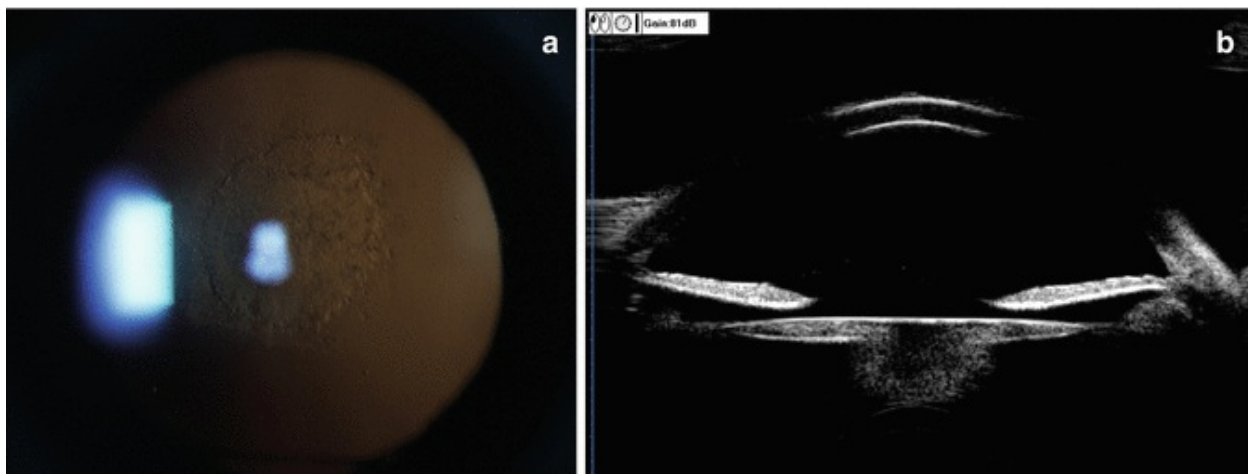


Fig. 22.7 Congenital posterior capsule defect. (a) A retro-illumination image indicates a central posterior capsule defect; (b) anterior segment optical coherence tomography (OCT) indicates prolapse of the lens cortex through the posterior capsule defect

22.5.1 Causes and Prevention of Posterior Capsule Tear

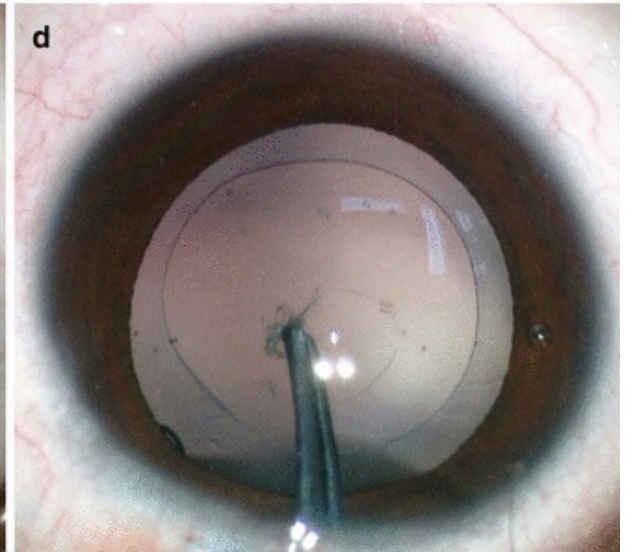
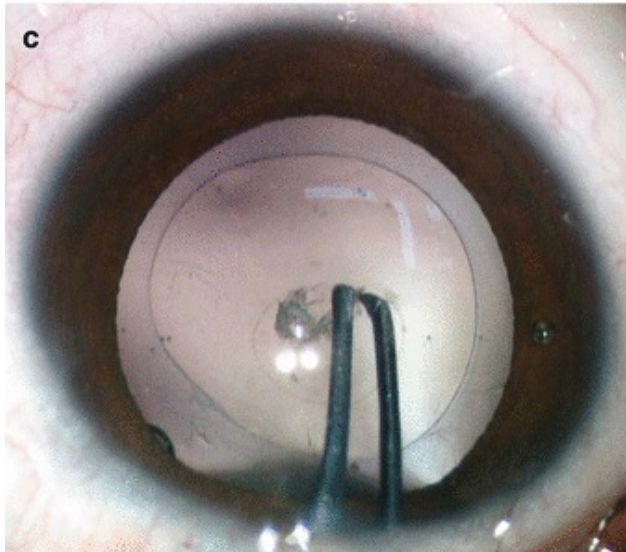
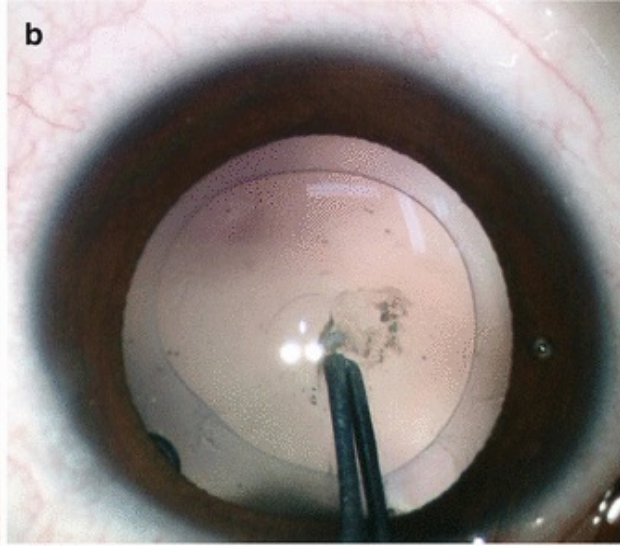
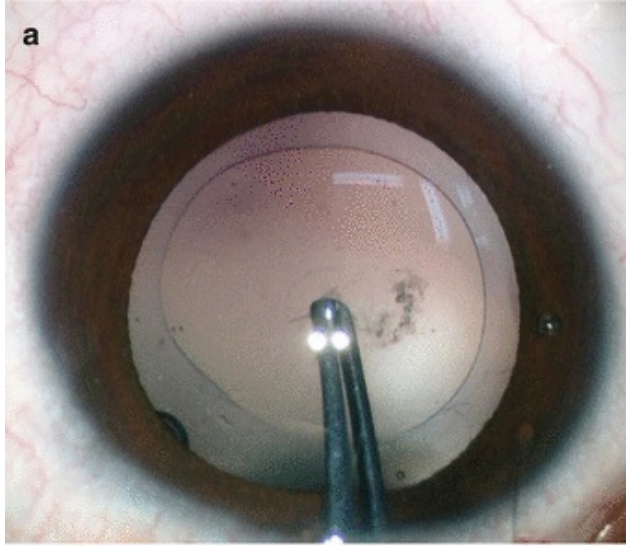
1. During capsulorhexis: If not handled properly or timely, a radial tear of the anterior capsule may extend to the posterior capsule, resulting in posterior capsule tear and even vitreous prolapse.
2. During hydrodissection: When the capsulorhexis opening is too small or in the presence of anterior capsule radial tear or preexisting posterior capsule defects, quick injection of excessive fluid in a single quadrant may lead to posterior capsule rupture, or even dislocation of the lens nucleus or cortex into the vitreous cavity. Occasionally, the tip of the hydrodissection cannula may be inadvertently inserted through the posterior capsule by a novice surgeon or under poor microscopic visualization. Therefore, hydrodissection must be slow, gentle, and multiquadrant. If the lens nucleus does not bulge forward or even tends to sink, the surgeon should stop injecting fluid immediately and check for defects on the posterior capsule if present or whether the posterior capsule has already ruptured. Moreover, hydrodissection is contraindicated in eyes with congenital posterior capsule defects, especially those with posterior polar cataracts with posterior lentiglobus.
3. During phacoemulsification or irrigation/aspiration: Shallow anterior chamber, anterior chamber instability due to development of surge, or inadvertent aspiration of the posterior capsule may lead to posterior capsule tear. If there is a sudden deepening of the anterior chamber, or poor followability of the lens nucleus or cortex which tends to drop down into the vitreous cavity, the surgeon should immediately stop and check whether there is a posterior capsule tear.
4. During IOL implantation: Inadequate OVD in the anterior chamber,

shallow anterior chamber, or improper maneuvers during IOL implantation may result in posterior capsule tear and vitreous prolapse.

22.5.2 Management of Posterior Capsule Tear and Vitreous Prolapse

It is crucial to perform a standard surgical procedure during the whole surgery to prevent posterior capsule tear and vitreous prolapse, especially during capsulorhexis, aspiration of soft nuclear material, as well as IOL implantation. Once posterior capsule tear occurs, meticulous management of the capsule is warranted in order to prevent enlargement of the tear. Remove the remaining lens materials and prolapsed vitreous and try to reduce the risk of severe complications such as lens material dropping into the vitreous cavity.

In order to stabilize the posterior capsule rupture, OVD is injected through the tear to push the vitreous face back and avoid forward bulging of the vitreous and enlargement of the tear. If the rupture is small, a posterior curvilinear capsulorhexis can be attempted (Fig. 22.8). If the rupture is large and the vitreous prolapse is severe, a thorough anterior vitrectomy is recommended.



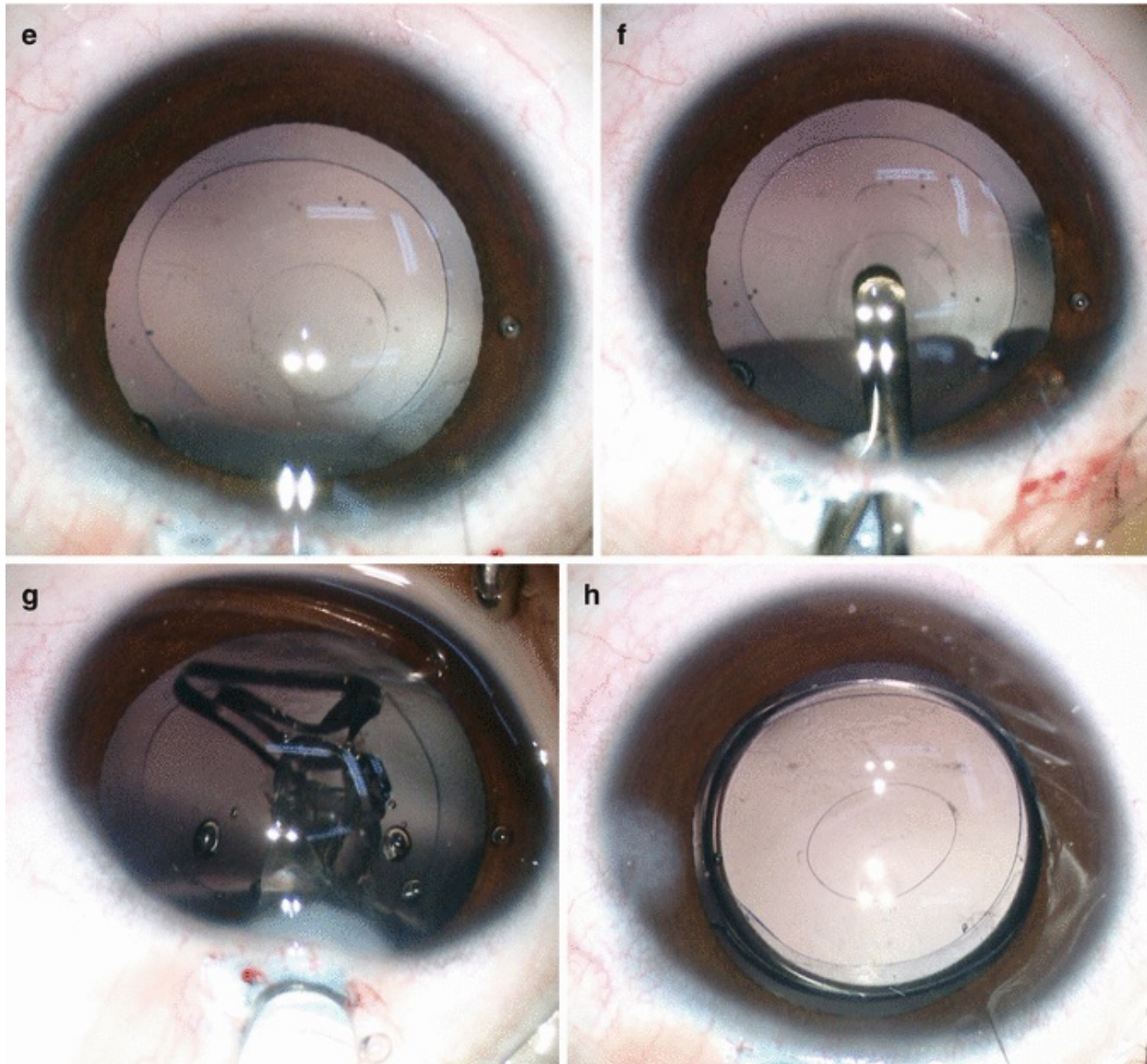


Fig. 22.8 Management of a posterior capsule rupture. (a–e) Continuous curvilinear capsulorhexis at the site of the posterior capsule rupture with capsulorhexis forceps; (f) anterior vitrectomy; (g) in-the-bag IOL implantation; (h) the IOL placed in the center of the capsular bag with visible anterior and posterior capsulorhexis openings

When removing the residual lens cortex and the prolapsed vitreous, it is recommended to eliminate the vitreous strands in the incision first under low irrigation, and then the cutter is moved gradually toward the tear. If there are large amounts of remaining cortex, the surgeon should perform “dry” vitrectomy with adequate OVD protection to remove the vitreous inside the incision and proceed to cortex removal under low vacuum and irrigation to prevent dropping of the lens material from excessive irrigation pressure.

Thorough removal of the residual lens cortex reduces the risk of postoperative inflammation. When there is no remaining cortex and the anterior vitreous is properly handled, IOL could be implanted safely. If the posterior capsule rupture is small with a continuous edge, the IOL can be implanted into the capsular bag. Due to its rigid haptics, a 3-piece IOL may exert tension on the capsular bag during implantation, which may contribute to further tearing, and thus a 1-piece IOL is recommended in this setting. But if the rupture is too large to allow for safe IOL implantation into the capsular bag, sulcus fixation of the IOL may be performed in the presence of an intact anterior capsule. In this case, a 3-piece IOL is more stable than a 1-piece IOL. In addition, some surgeons suggest that the optic of a 3-piece IOL should be captured through the anterior capsule opening with the haptics fixed in the sulcus, so as to ensure long-term centration and stability of IOL.

22.6 Zonular Dialysis

During pediatric cataract surgery, zonular dialysis may occur due to preexisting zonular abnormalities or improper operative maneuvers. Once a zonular dialysis is noted, the surgeon should immediately stop all intraocular procedures and carefully evaluate the number of clock hours of the dialysis and the integrity and stability of the capsular bag and determine whether a capsular supporting device is needed and selection of such a device.

Capsular tension ring (CTR) can effectively support the capsular bag and also provide a circumferential expansile force to the capsular equator to stabilize the bag. When removing the residual lens material, a CTR can be inserted to protect the capsular bag from the tip of the aspiration handpiece and make room for in-the-bag implantation of the IOL.

An iris or capsular retractor is another important instrument in managing zonular dialysis during pediatric cataract surgery. According to the extent of the dialysis, a single or multiple retractors may be placed in the affected area to provide reliable support to the capsule bag. For small localized zonular dialysis, a 3-piece IOL may be implanted after removal of lens material is complete, with the haptics aligned to the clock hour where the zonular fibers are weak, but for large extensive dialysis, the use of a CTR after thorough removal of the lens material is required. More details are described in Chap. 17 “Surgical Management of Pediatric Lens Subluxation and Dislocation.”

22.7 Intraocular Lens-Related Complications

22.7.1 Failure of in-the-Bag IOL Implantation Due to Small Capsular bag

Currently, most available IOLs are designed according to the size of the capsular bag in adults. Adult-sized IOLs may not be appropriate for the small capsular bag of the immature pediatric eyes. In-the-bag IOL implantation may be quite difficult for some children, which may even cause complications like capsule rupture and zonular dialysis. And thus, corneal white-to-white (WTW) distance should be measured to estimate the size of the capsular bag before surgery. In addition, if a small-sized bag is observed during surgery, the surgeon may choose sulcus fixation of the IOL haptics rather than exert excessive force to place it into the capsular bag.

22.7.2 Capsule Rupture and Zonular Dialysis During IOL Implantation

Improper maneuvers during IOL implantation may lead to capsule rupture or zonular dialysis. In these cases, management should be based on the extent of posterior capsule tear, and an appropriate IOL should be selected. If the rupture is small without vitreous prolapse, a continuous capsulorhexis should be performed, and the IOL can still be implanted into the capsular bag. If the rupture is large but there is sufficient residual peripheral anterior capsule, sulcus fixation of a 3-piece IOL haptics should be considered. If a severe capsular defect is present and the remaining anterior capsule is not able to support the IOL haptics, transscleral suture fixation of single or double haptics should be performed.

As for a zonular dialysis less than one quadrant and in the absence of vitreous prolapse, no specific treatment is needed; for a dialysis larger than one quadrant but smaller than two quadrants, a CTR should be implanted; and for a dialysis encompassing more than two quadrants, implantation of a modified CTR or single-haptic or double-haptic suture fixation of IOL should be performed. If intraocular hemorrhage, iridodiasis, or any other serious complications occur, secondary IOL implantation should be considered.

22.7.3 Iris Injury, Iridodiasis, and Hyphema

Improper incision construction or iris prolapse into the incision predisposes iris injury due to anterior chamber maneuvers, or in severe cases, iridodialysis and hyphema. As the iris is still developing during childhood, the pupil is difficult to dilate and is very likely to become miotic on surgical insults [3, 4], which may add to the operative difficulties and increase the risk of iris injury. Due to immature blood-aqueous barrier in pediatric eyes, the postoperative inflammatory response is usually intense. It is critical to construct an appropriate incision, prevent iris prolapse, and reduce touching of iris tissue during surgery for better surgical outcomes.

22.8 Summary

The distinct anatomical and physiological characteristics of children's eyes make pediatric lens surgery unique and challenging. Preoperative evaluation is essential, and standard operating procedures should be strictly followed during surgery. Modern microscopic and phacoemulsification techniques as well as ancillary methods like staining, CTR, and radiofrequency diathermy capsulorhexis are used to reduce intraoperative complications. Once a complication occurs, it should be managed properly and timely, so as to minimize injuries and maximize surgical outcomes.

References

1. Wilson Jr ME, Bartholomew LR, Trivedi RH. Pediatric cataract surgery and intraocular lens implantation: practice styles and preferences of the 2001 ASCRS and AAPOS memberships. *J Cataract Refract Surg.* 2003;29(9):1811–20.
[CrossRef][PubMed]
2. Luck J, Brahma AK, Noble BA. A comparative study of the elastic properties of continuous tear curvilinear capsulorhexis versus capsulorhexis produced by radiofrequency endodiathermy. *Br J Ophthalmol.* 1994;78(5):392–6.
[CrossRef][PubMed][PubMedCentral]
3. Wilson Jr ME, Trivedi RH, Mistr S. Pediatric intraoperative floppy-iris syndrome. *J Cataract Refract Surg.* 2007;33(7):1325–7.
[CrossRef][PubMed]
4. Vijayalakshmi P, Kakkar G, Samprathi A, et al. Ocular manifestations of congenital rubella syndrome in a developing country. *Indian J Ophthalmol.* 2002;50(4):307–11.
[PubMed]

23. Postoperative Complications and Management

Xinyu Zhang¹✉ and Xiaoyun Chen¹

- (1) State Key Laboratory of Ophthalmology, Zhongshan Ophthalmic Center, Sun Yat-Sen University, 54S Xianlie Road, Guangzhou, 510060, People's Republic of China

✉ **Xinyu Zhang**

Email: zhangxinyu0294@163.com

Abstract

The high incidence of complications after pediatric lens surgery is a bothersome issue for surgeons that may affect postoperative outcomes. Due to greater inflammatory response and immature blood-aqueous barrier, complications such as uveitis, posterior capsule opacification, secondary glaucoma, and IOL malposition are frequently seen after pediatric lens surgery. These complications may pose a serious impact on the ocular development and the visual function reconstruction of pediatric patients. This chapter will provide comprehensive and detailed information on the pathogenesis, risk factors, diagnosis, preventive strategies, and management of various postoperative complications.

Cataract extraction is the predominant method of treatment for pediatric cataracts. Due to the special anatomical structures and physiological functions of pediatric eyes, the necessary surgical techniques are demanding and different from those in adults, with a higher incidence of postoperative complications, including uveitis, posterior capsule opacification (PCO),

glaucoma, and IOL decentration or dislocation. Meanwhile, the postoperative complications in pediatric patients usually have insidious onset and are prone to misdiagnosis, which leads to delayed treatment, poor surgical outcomes, and even secondary blindness. Therefore, prevention and management of postoperative complications in pediatric cataract surgeries are crucial issues for improving surgical outcomes and reducing postoperative low vision/blindness, and this poses great challenges to practicing ophthalmologists. This chapter will illustrate in detail the causes, preventions, and managements of postoperative complications for pediatric cataracts.

23.1 Complications Associated with the Cornea

23.1.1 Corneal Edema

Corneal edema is one of the early postoperative complications for pediatric cataracts (Fig. 23.1).

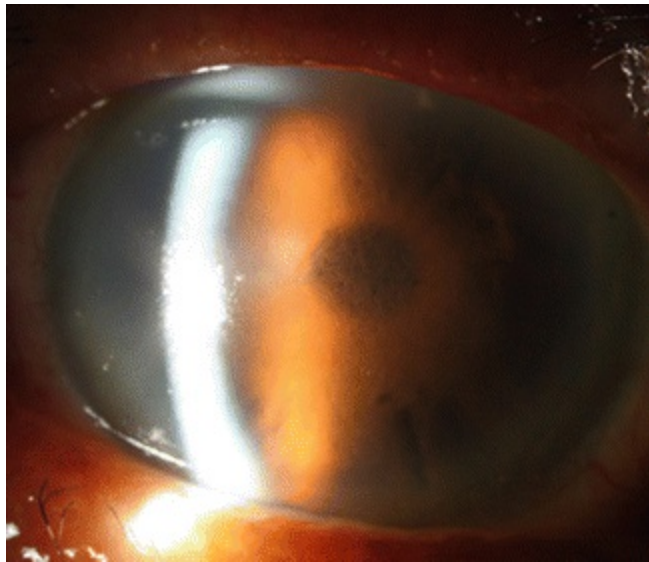


Fig. 23.1 Corneal edema after cataract surgery. A 5-year-old child develops diffuse corneal edema on postoperative day one. Slit-lamp image shows marked corneal haze

23.1.1.1 Etiology

1. Surgical trauma

Intraoperative mechanical damage is the leading cause of

postoperative corneal edema. Considering the restricted operating space due to the small eyeball and shallow anterior chamber of children, corneal endothelial injury tends to occur when surgical instruments are introduced in and out of the anterior chamber or an IOL is implanted. In addition, Descemet membrane detachment (DMD) caused by improper manipulation and excessive anterior chamber irrigation may also cause damage to the corneal endothelium. The rate of postoperative corneal endothelial cell loss is estimated to be between 5.1 and 9.2 %. Corneal edema may occur in severe cases [1, 2].

2. Postoperative inflammation

Postoperative inflammatory response can lead to corneal endothelial pump dysfunction and a certain degree of endothelial cell apoptosis.

3. Ocular hypertension

Ocular hypertension can occur in the early or late stages after cataract surgery. It can directly damage the corneal endothelial pump function and result in diffuse corneal edema, whereas sometimes in young children, the cornea remains clear even when the intraocular pressure (IOP) reaches 40 mmHg or above and therefore goes undetected.

4. Others

A dislocated IOL haptic may give rise to repeated chafing of the corneal endothelium, causing progressive corneal endothelial damage and then corneal edema. The residual lens materials or vitreous strands in the anterior chamber may adhere to the corneal endothelium and disrupt its metabolism, which results in focal corneal edema. If irritation to the corneal endothelium continues, intractable corneal edema may occur. Patients with a history of corneal endothelial dystrophy, iridocorneal endothelial syndrome, and previous intraocular surgery are prone to develop postoperative corneal edema.

23.1.1.2 Clinical Manifestations

1. Local edema

Local edema, manifesting as localized swelling and thickening of the cornea, is usually caused by surgical trauma. Residual lens matter in the anterior chamber should be considered if inferior focal corneal edema is observed.

2. Diffuse edema

Diffuse edema usually results from postoperative inflammation, toxic anterior segment syndrome (TASS), ocular hypertension, and wide range DMD, which manifests as Descemet membrane folds, diffuse thickening, and decreased transparency of the cornea.

3. Descemet membrane curled inward

Rupture of Descemet membrane may give rise to corneal edema. The curled Descemet membrane floating in the anterior chamber can be observed through the cornea or confirmed if necessary by anterior segment optical coherence tomography (OCT).

23.1.1.3 Management

1. Local edema

The vast majority of focal edema after pediatric cataract surgery is caused by temporary endothelial dysfunction and may disappear within a few days without special treatment. Xiao and colleagues retrospectively analyzed postoperative complications in 186 congenital cataract eyes (105 patients), reporting that the incidence of corneal edema in early stages after surgery is 35 % (65 eyes). The cornea edema disappeared in all cases within 3–5 days without special treatment [3]. However, anterior chamber irrigation or vitrectomy is recommended when extra amounts of lens matter or prolapsed vitreous are retained in the anterior chamber, causing persistent focal edema.

2. Diffuse edema

Diffuse or persistent cornea edema, being one of the most severe postoperative complications, should be treated promptly according to the causes. For inflammation-induced corneal edema, enhanced anti-

inflammation medication should be administered by using topical corticosteroids and nonsteroidal anti-inflammatory drugs (NSAIDs), such as prednisone acetate 1 % or dexamethasone 0.1 %. Simon JW et al. reviewed five eyes (four children) with corneal edema after cataract surgery, reporting that the edema disappeared in 5–14 days after administration of topical corticosteroids [4]. For diffuse corneal edema induced by intense anterior segment inflammation (for example, TASS), systemic corticosteroids should be added. For corneal edema resulting from DMD, urgent reattachment of the Descemet membrane is necessary for restoration of cornea clarity. Small ruptures may be cured by intracameral injection of air or inert gas, whereas wide range DMD should be reattached by suturing full-thickness cornea. If elevated IOP is detected after surgery, topical or systemic anti-glaucoma medications can be administered (for details, see Sect. 23.5). Generally, corneal clarity will be restored after IOP returns to normal.

23.1.2 Corneal Epithelial Abrasion

Corneal epithelial abrasion often occurs in the early postoperative period and may be caused by intraoperative trauma or rubbing eyes due to the discomfort caused to the patient. Additionally, for children in need of contact lens to correct aphakic refractive error without IOL implantation, caution should be consideration given to the corneal epithelium defects that may be induced by disinfectant solutions or the daily action of wearing and removing the contact lens.

Clinical manifestations of corneal epithelial abrasion include mixed hyperemia, punctuate or flake-shaped epithelial defects, positive fluorescein staining, redness of the eye, tearing, and pain.

For mild corneal epithelial abrasion, topical medications, such as recombinant bovine basic fibroblast growth factor and preservative-free artificial tears, can be used to promote corneal epithelial healing, whereas a bandage is recommended in severe cases to reduce blinking, relieve pain, and promote corneal epithelial healing.

23.2 Complications Associated with the Uvea

23.2.1 Uveitis

Uveitis is the most common complication after pediatric cataract surgery. Other complications, such as corneal edema, ocular hypertension, IOL-related complications, and even secondary blindness, may be induced or aggravated without timely treatment.

23.2.1.1 Etiology

1. Immature blood-ocular barrier

Due to the immature blood-ocular barrier in pediatric eyes, surgical trauma is likely to give rise to nonspecific inflammatory response by the release of inflammatory substances such as cytokines, prostaglandins, and arachidonic acid and the bringing about of large amounts of cellulose inflammatory exudates.

2. Improper incision construction

Since young children's eyes have thin walls, iris prolapse may occur when the incision is not properly constructed. Repeated restoration of the prolapsed iris may exacerbate postoperative inflammation.

3. Failure of in-the-bag IOL implantation

Despite the favorable biocompatibility of currently used IOLs, it is still regarded as a foreign body by nature. IOL implantation in the eye can therefore induce a series of cellular immune responses, especially when the IOL is not placed in the bag (such as in ciliary sulcus fixation and asymmetric implantation, say one haptic in the bag and the other in the sulcus). In these cases, the IOL haptics may rub the uvea and induce a significant inflammatory response.

4. Residual lens matter

Residual lens matter in the aqueous humor can give rise to the autoimmune response and lead to phacoanaphylactic uveitis.

23.2.1.2 Clinical Manifestations

In mild cases, they show signs of aqueous flare and cells in the anterior chamber (Fig. 23.2a). In severe cases, fibrinous exudates, anterior and

posterior iris synechiae, pupil deformation, and inflammatory membrane formation (Fig. 23.2b, c), as well as occlusion of the pupil, iris bombe, and secondary glaucoma, can be detected. Generally, the inflammatory response is more pronounced in pseudophakic eyes than in aphakic eyes.

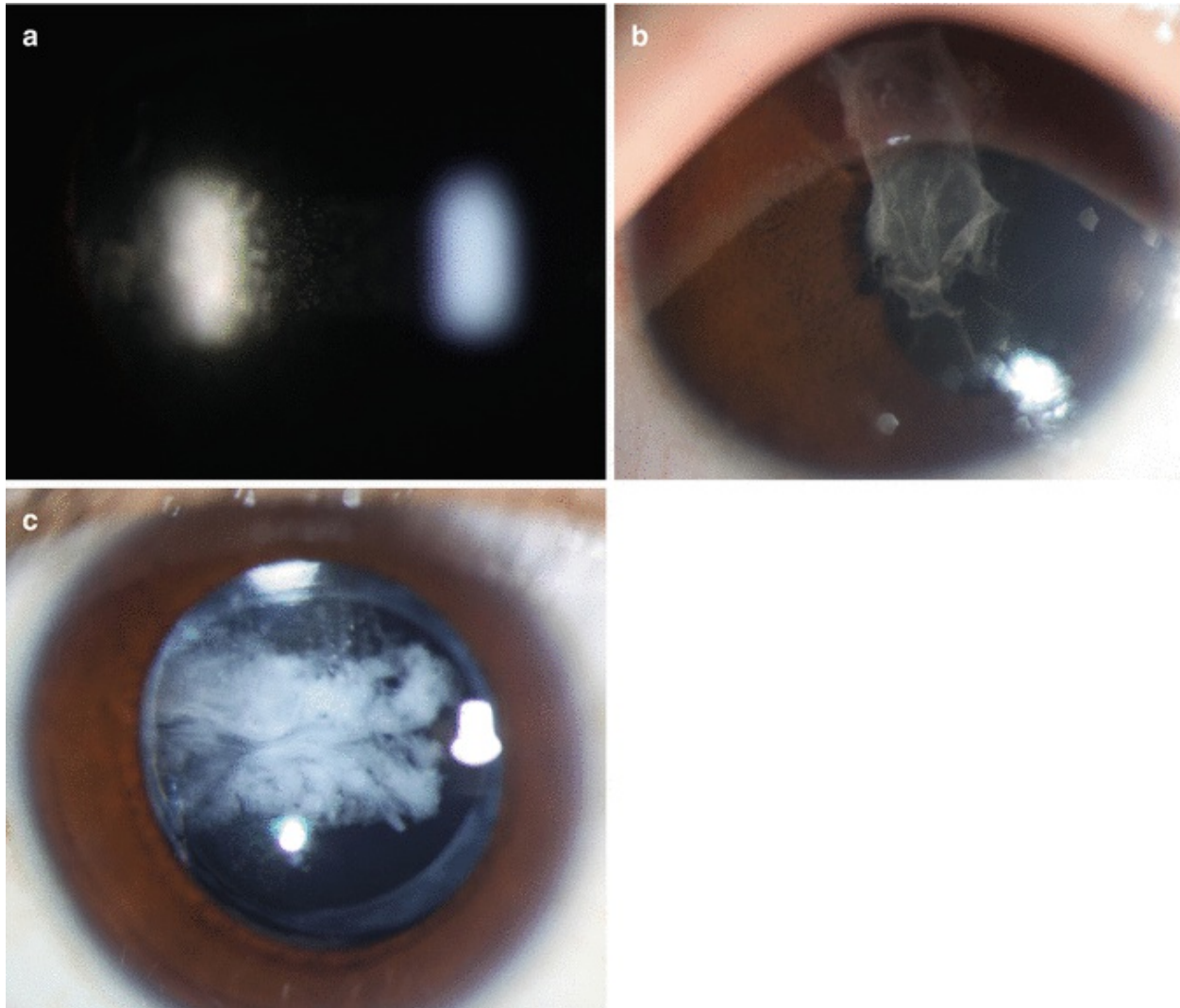


Fig. 23.2 Clinical manifestations of uveitis after pediatric cataract surgeries. (a) Cells in the anterior chamber; (b) formation of inflammatory membrane on the anterior surface of IOL; (c) formation of inflammatory membrane on the posterior surface of IOL

23.2.1.3 Prevention and Management

1. Preoperative

The pupil should be dilated adequately and NSAIDs should be

applied if necessary.

2. Intraoperative

1. Be aware of the incision construction, to prevent irritation to the iris induced by iris prolapse.
2. Reduce the frequency of the instruments moving in and out of the anterior chamber.
3. Clear lens matter as thoroughly as possible.
4. Achieve in-the-bag IOL implantation in order to reduce the contact and abrasion between IOL and the surrounding tissues. This helps to release postoperative uveal complications.
5. Irrigate the anti-inflammatory drugs into the anterior chamber. Studies have shown that the addition of heparin in irrigating solutions reduced postoperative inflammatory responses and inflammation-related complications, including posterior iris synechiae, pupil dislocation, and IOL decentration [5]. Additionally, intracameral injection of triamcinolone acetonide could relieve anterior segment inflammation and prevent visual axis obscuration (VAO) [6]. Moreover, application of intracameral recombinant tissue plasminogen activator (r-TPA) during cataract extraction, anterior vitrectomy, and IOL implantation is effective in inhibiting the inflammatory response and preventing fibrinous membrane formation [7].
6. Implant heparin-surface-modified (HSM) IOLs to control inflammation and pigment deposited on the surface of the IOL [8].

3. Postoperative

In most cases of mild postoperative inflammation, a combination of the topical short-acting mydriatics, corticosteroids, and NSAIDs can

control the inflammation, while in severe cases, systemic corticosteroids or NSAIDs should be added. However, potent mydriatics are not generally recommended because of the risk of pupillary capture of the IOL. When inflammatory membranes block the visual axis or cause pupillary occlusion, Nd:YAG laser may be performed to retract the membranes. If the inflammatory membranes are too thick for laser therapy, membranectomy may be considered.

23.2.2 Toxic Anterior Segment Syndrome

TASS is an aseptic inflammation following anterior segment surgeries [9]. It is associated with substances with incorrect pH, concentration, or osmolarity, gaining access to the anterior chamber, such as irrigating solutions, antibiotics, OVDs, and residue left behind by substances used during the cleaning and sterilization of instruments and resulting in cytotoxicity and tissue injuries.

The most common manifestations of TASS include acute diffuse corneal edema, pupil dilation and fixation, ocular hypertension, and anterior chamber inflammation with or without significant pain. Since children are often too young to describe their complaints properly, detailed examinations are essential and endophthalmitis should be considered in the differentiation.

The preventive methods of TASS include following standardized procedures for cleaning and sterilizing intraocular surgical instruments, avoiding preservatives during and after surgery, and ensuring rational use of intraocular drug dosage and concentration.

The main treatment of TASS is topical and systemic application of corticosteroids to control inflammation and reduce tissue damage. Huang et al. [9] reported that though corneal edema and inflammation were controlled after aggressive treatment, cornea opacity and pupil deformation still remained, which indicates that to deal with TASS, the emphasis should be put on prevention.

23.2.3 Implantation Cyst of Iris

Cases of implantation cyst of iris after cataract surgery are rare, most of them are traumatic cataract patients. Generally, this disease has a long course and progresses very slowly. It is caused by conjunctival or corneal epithelial cells growing along the wound and slowly migrating into the iris stroma (Fig.

23.3). The cysts are most likely found to grow at the root of the iris and are filled with a white sticky fluid. They seldom cause pain but could result in various degrees of visual axis occlusion, uveitis, and corneal edema. Large cysts may even cause severe complications, including obstruction of anterior chamber angle, IOP elevation, and secondary glaucoma.

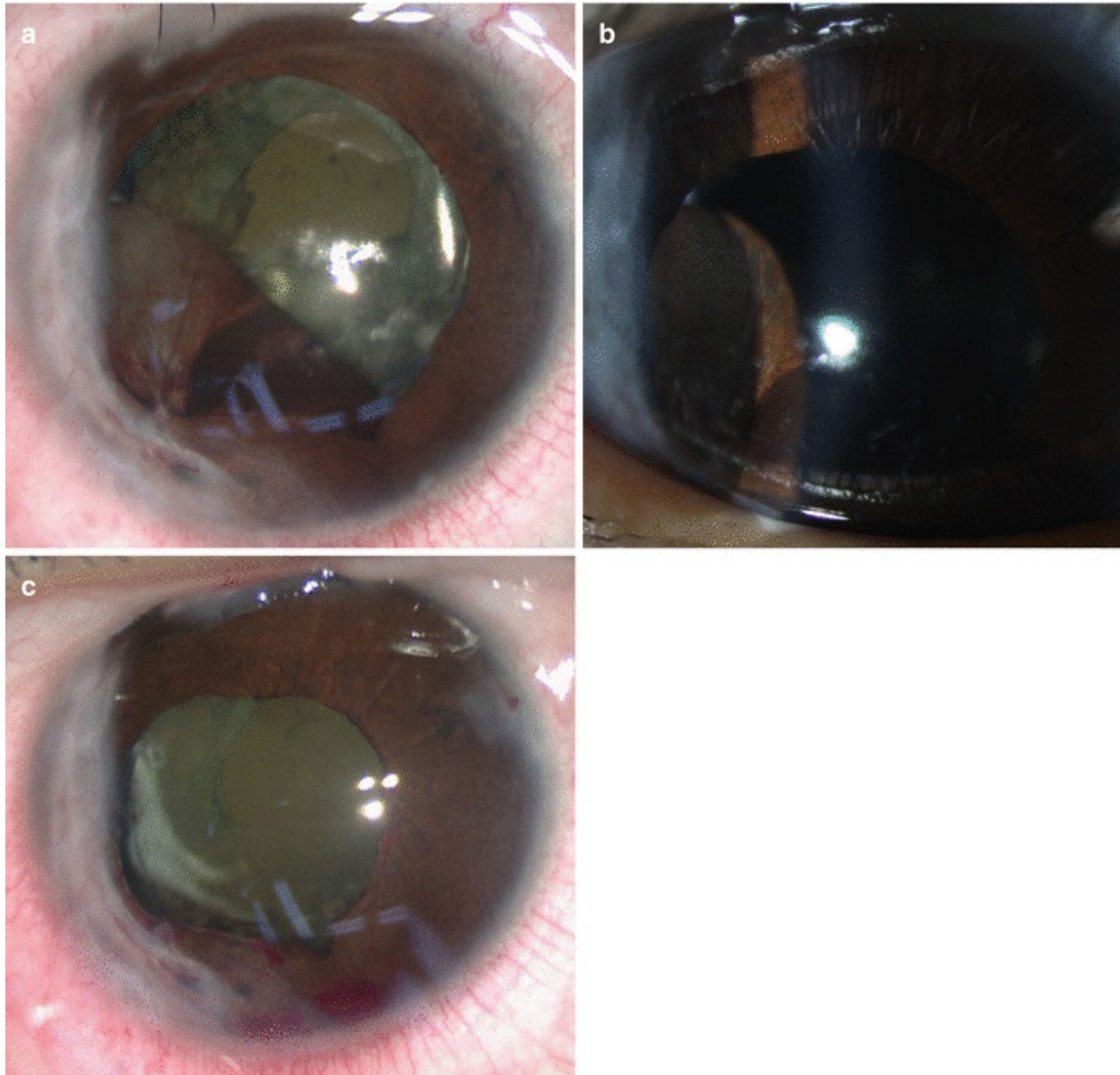


Fig. 23.3 Implantation cyst of iris. A 5-year-old boy with traumatic cataract underwent cataract extraction surgery combined with IOL implantation 1 year after surgery. (a) Iris cyst adherent to the nasal corneal wound; (b) slit-lamp examination; (c) 1 week after local iridectomy of the cyst

For small cysts, laser treatment is feasible with a certain risk of

recurrence, while for large cysts, surgical excision combined with local iridectomy is necessary. In order to prevent recurrence, the cysts should be excised integrally and completely.

23.3 Complications Associated with the Lens Capsule

23.3.1 Posterior Capsular Opacification (PCO)

PCO is one of the most common complications after pediatric extracapsular cataract extraction (ECCE) surgery and can occur as early as 1 week postoperatively. The pathogenesis and prevention of PCO are described in detail in Chap. 24.

23.3.2 Capsular Shrinkage

Capsular shrinkage usually occurs 3–30 weeks after cataract surgery, manifesting as the decreasing of capsular diameter on the equator, combined with anterior capsule cystic fibrosis and diminished capsulotomy opening [10]. Factors such as surgical injuries, irritation of IOL material, inflammatory reaction, and disruption of the blood-aqueous barrier, stimulate residual lens epithelial cells to proliferate and transform into fibroblasts. These fibroblasts highly express α -smooth muscle actin and produce large amounts of collagen and other extracellular matrix which accumulates between the retained anterior capsule and IOL optic zone, leading to anterior capsule cystic fibrosis and turbidity. Additionally, α -smooth muscle actin from the fibroblasts contracts and pulls the capsulotomy opening toward the center and results in capsular shrinkage. The shrunken capsule may contribute to IOL dislocation or IOL capture, leading to postoperative diplopia, glare, and refractive errors, severely affecting the recovery of visual acuity.

The following advice may help to prevent capsular shrinkage: gentle surgical manipulation, avoidance of iris and blood-aqueous barrier damage, and the alleviation of postoperative inflammation. Furthermore, the diameter of capsulotomy openings should be controlled to around 5 mm. Small openings are prone to capsular shrinkage [11]. Moreover, IOL materials with good biocompatibility, such as acrylic IOL, can be chosen to reduce the IOL irritation to the capsule [12]. When capsular shrinkage induces IOL dislocation and affects the visual function significantly, Nd:YAG laser may

be applied for anterior capsulotomy, while more severe cases will require surgical treatment.

23.4 Complications Associated with IOL

Compared with adults, inflammation responses are more severe, and the incidence of IOL-related complications is higher in children. The younger the patient, the higher the incidence of severe complications.

23.4.1 IOL Malposition

IOL malposition is associated with inflammation, incomplete openings during capsulotomy, organization and contraction of the capsule, asymmetric fixation of the IOL (a haptic in the bag, the other in the sulcus), IOL quality, residual lens matter, and lens epithelial proliferation following the cataract surgery.

Mild IOL malposition manifests as IOL decentration (Fig. 23.4a) and can only be detected after mydriasis. Generally, it requires no special treatment other than follow-up observation regarding changes in the IOL location and refractive error. Severe IOL malposition, shown as IOL dislocation (Fig. 23.4b) or IOL capture (Fig. 23.5), may contribute to monocular diplopia or high degree of astigmatism, significantly affecting the visual function. Pupillary capture of the IOL can also result in secondary increase of IOP. Surgery is often needed to reposition or remove the IOL. The indications and surgical techniques of repositioning and explantation are described in detail in Chap. 25.

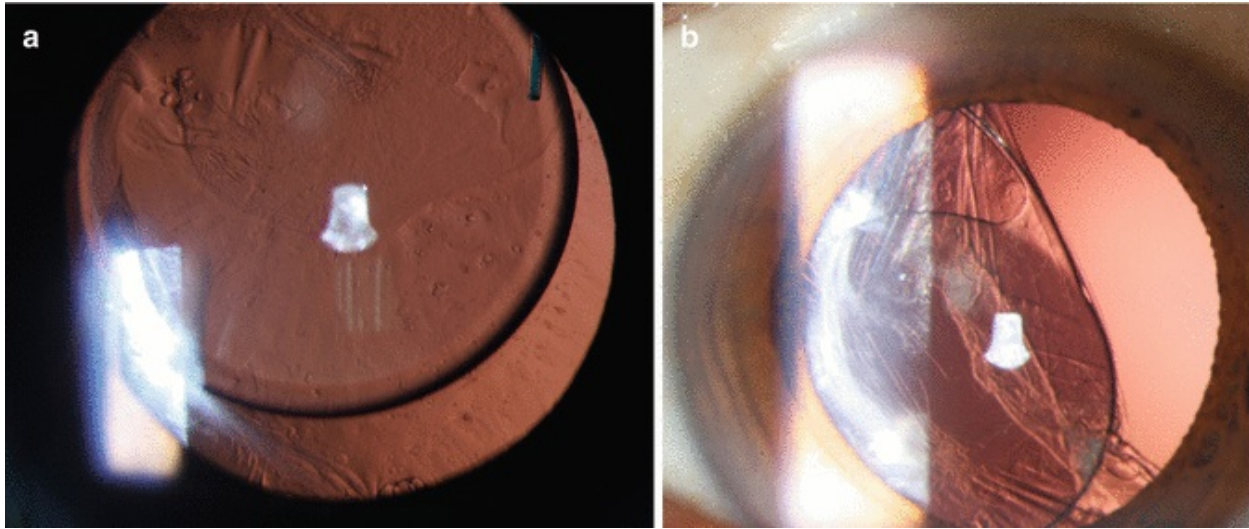


Fig. 23.4 IOL malposition. (a) IOL decentration; (b) IOL dislocation

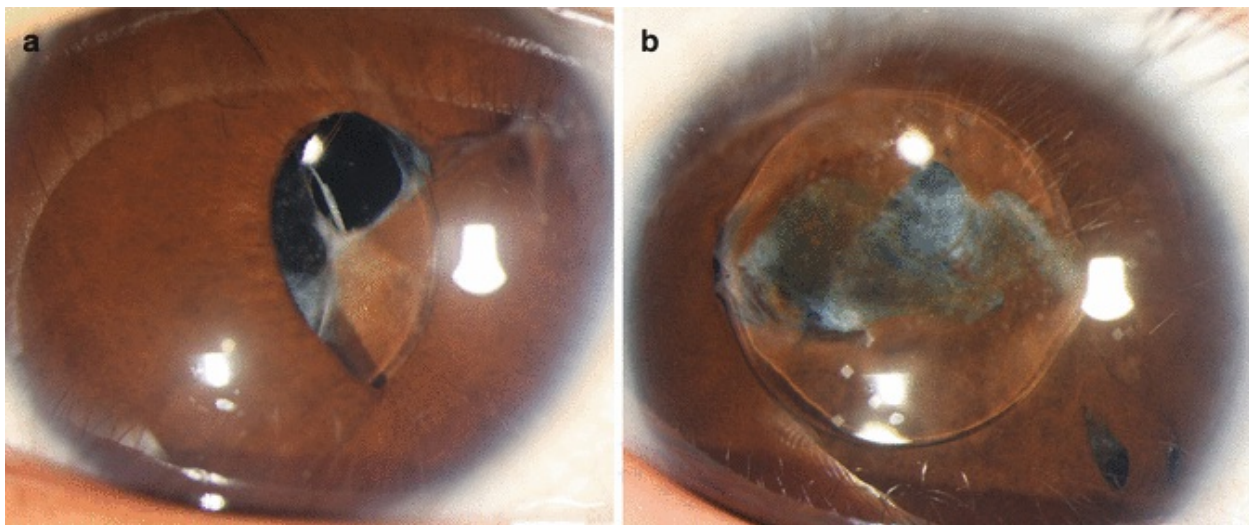


Fig. 23.5 IOL pupillary capture. (a) Partial pupillary capture of the IOL optic; (b) complete pupillary capture of the IOL optic

23.4.2 Deposits on the IOL Surface

Deposits on the IOL surface are more common in children than adults, which may be related to the immature blood-aqueous barrier and intense postoperative inflammation. It is also associated with the size, location, and quality of the IOL. If the IOL is too small, it is movable inside the eye and may rub the uvea, resulting in IOL surface deposits. Compared with sulcus-fixed IOLs, the in-the-bag fixation of IOLs has a lower occurrence of deposits, and the severity is minimal, because in-the-bag implantation

reduces the chances of abrasion between the IOL optic and the surrounding tissue. The deposits can be pigmented (Fig. 23.6) or nonpigmented. No special treatment is required if the visual acuity is not affected. However, if the visual acuity is affected, it is suggested that Nd:YAG laser be employed to eliminate the deposits.

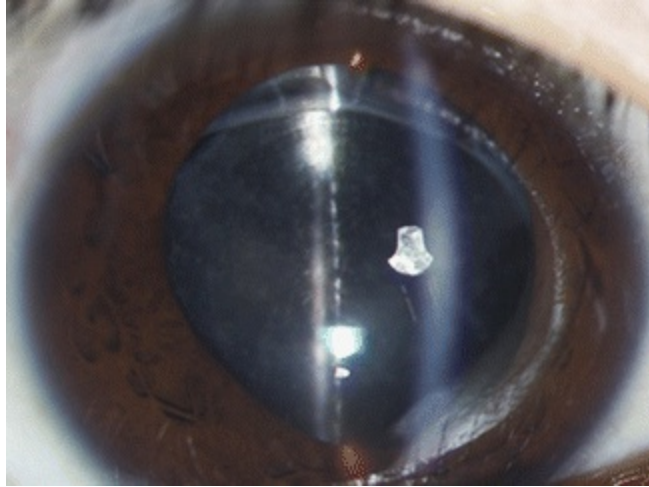


Fig. 23.6 Deposits on the surface of IOL

23.4.3 Opacification of IOL

Opacification of the IOL (Fig. 23.7) is mostly seen in silicone and hydrophilic acrylic materials [13] and is mainly associated with the biocompatibility of the IOL materials. Opaque IOL explanted from surgeries manifests calcification deposits under electron microscope examination, due to the deposition of calcium phosphate from the aqueous humor onto the surfaces or the inside of IOL. Owing to the development of IOL materials and improved production techniques over the past decades, this complication is rarely seen. Once the IOL opacification affects visual function significantly, IOL removal or exchange should be performed. Surgical techniques are detailed in Chap. 25.

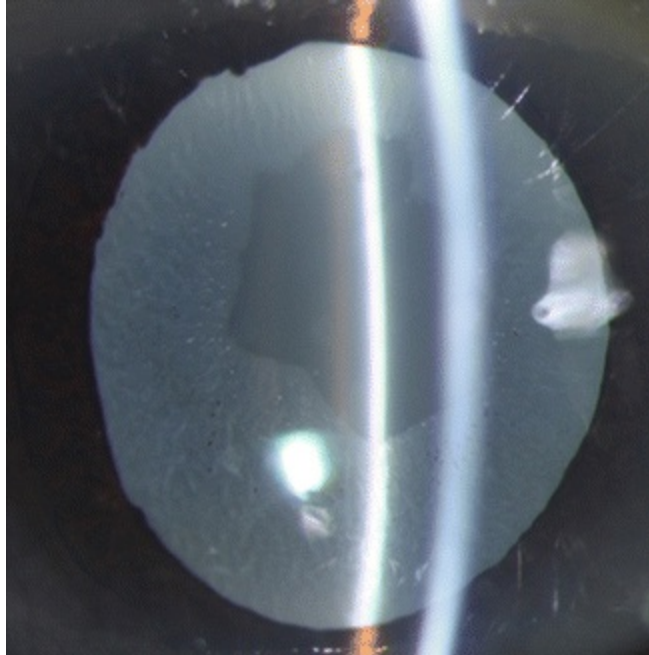


Fig. 23.7 Opacification of IOL

23.5 Postoperative Ocular Hypertension and Secondary Glaucoma

Postoperative ocular hypertension and secondary glaucoma are major complications affecting visual function rehabilitation after pediatric cataract surgery. Postoperative ocular hypertension refers to a postoperative IOP higher than 21 mmHg, which is a risk factor for secondary glaucoma. But apart from high IOP, the diagnosis of glaucoma also includes optic nerve damage and visual field defect. Since these children are too young to cooperate with examinations such as IOP, optic nerve, and visual field measurement, it's quite difficult to confirm diagnosis and evaluate the effect of treatments.

The reported incidence of ocular hypertension and glaucoma after pediatric cataract surgeries varies considerably (5–32 %) due to variance in the period of follow-up [14, 15]. From 2011, Zhongshan Ophthalmic Center (ZOC) has established a clinical database for pediatric cataract patients. Through follow-up observations of 206 pediatric cataract patients (379 eyes) under 10 years old for a period of 10–16 months, Lin reported that the incidence of postoperative ocular hypertension was 17.4 % [16]. Therefore,

long-term follow-up of IOP measurement helps to prevent the occurrence of irreversible optic nerve damage in children following cataract surgery.

The types of secondary glaucoma following pediatric cataract surgery can be divided into two types: angle-closure and open-angle glaucoma, while the late-onset open-angle glaucoma is the most common. During the early and late postoperative period, angle-closure glaucoma can sometimes also occur.

23.5.1 Secondary Angle-Closure Glaucoma

Acute angle-closure glaucoma (Fig. 23.8) is a common complication after pediatric cataract surgery due to the limitations in surgical techniques and facilities during the past decades. With the development of surgical techniques, the incidence of this kind of complication decreases remarkably. The main cause is excessive lens cortex remnants inducing peripheral iris bombe and angle closure, while other causes are vitreous hernia and posterior synechiae (Fig. 23.9) and pupillary block due to pupillary occlusion. Francois and colleagues reviewed the causes of secondary angle-closure glaucoma after cataract surgery (Table 23.1) [17].

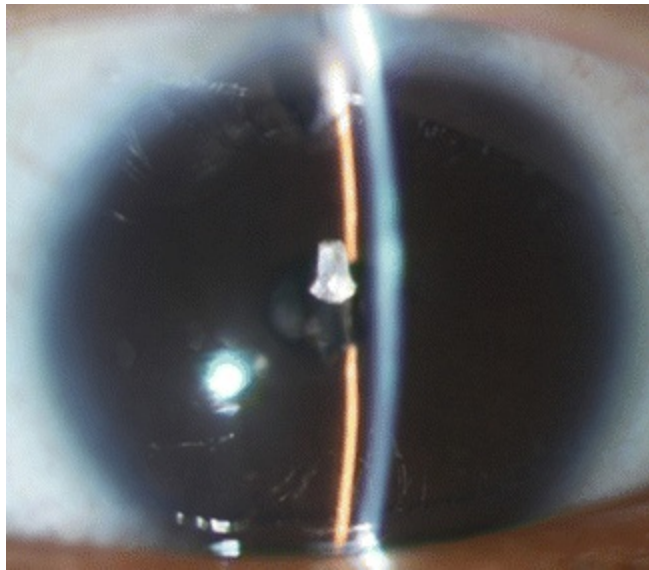


Fig. 23.8 Angle-close glaucoma after cataract surgery, showing shallow anterior chamber

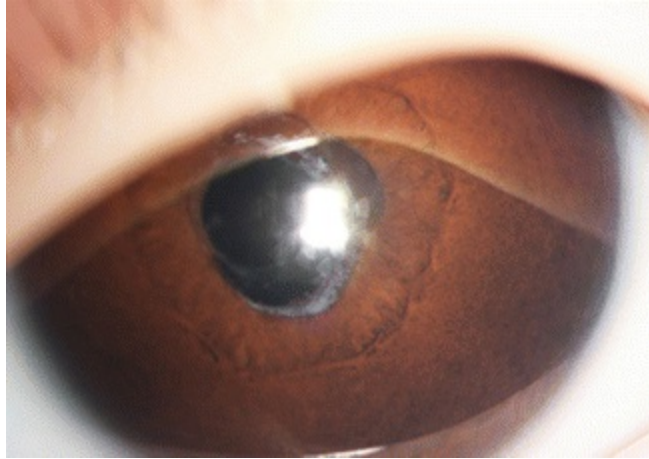


Fig. 23.9 Pseudophakic eye with pupillary posterior synechia

Table 23.1 The causes of angle-closure glaucoma after congenital cataract surgery

1. Pupillary block or peripheral anterior synechia caused by uveitis
2. Proliferative membrane and pupillary block caused by postoperative inflammation
3. Delayed formation of the anterior chamber
4. Vitreous prolapse into the anterior chamber
5. Corneal epithelium grows into the anterior chamber
6. Hyphema and intraocular hemorrhage
7. Iris prolapse
8. IOL-related glaucoma

Chronic angle-closure glaucoma is quite rare, resulting mainly from intraocular chronic inflammation caused by residual lens matter, followed by occlusion of pupil, and finally elevation of IOP.

23.5.2 Secondary Open-Angle Glaucoma

Open-angle glaucoma is usually late onset and is the most common type of glaucoma after pediatric cataract surgery. Phelps and colleagues reviewed 18 cases with secondary glaucoma following congenital cataract surgeries and reported that the IOP could elevate between 2 and 45 years following the surgeries [18]. The angle in all the above cases was open and six of them had optic nerve damage. Pathogenesis of secondary open-angle glaucoma is not yet clear. Based on present studies, it is probably associated with residual viscoelastic agents, congenital glaucoma or abnormal anterior chamber angle structure that existed preoperatively [19] and surgery-induced defects in

anterior chamber angle structure and trabecular meshwork [14], combined with ocular abnormalities including microcornea, microphthalmos, poorly dilated pupils, congenital rubella syndrome, Lowe's syndrome, persistent embryonic eye vascularization, and other ocular anomalies [15]. Open-angle glaucoma is also related to surgery-induced mechanical and biochemical injuries, long-term usage of glucocorticoids, and other factors [20].

23.5.3 Examination and Evaluation

IOP elevation or glaucoma can occur months or even years after surgery and children often lack typical signs of glaucoma, such as buphthalmos, epiphora, and blepharospasm. Therefore, the postoperative IOP and the following eye conditions should be monitored regularly, especially for children with the above risk factors. Children who cannot cooperate should be checked after sedation or general anesthesia.

1. Corneal diameter measurement

Buphthalmos or microcornea can be confirmed by measuring the corneal diameter. The IOP should be closely monitored when the corneal diameter of the affected eye is smaller than the average diameter of the same-age children. Walton et al. suggested that corneal edema, enlarged eyeball, and contact lens intolerance are early manifestations of glaucoma [21].

2. Refraction

Drastic decrease of hyperopia may be an important sign for early diagnosis of pediatric aphakic glaucoma, as was found by Egbert. This was the earliest sign in four teenagers who subsequently developed aphakic glaucoma (six eyes). The average loss of hyperopia was 17D (9.25D to 21.00D) [22].

3. Gonioscopy

The cause of the disease can be identified by gonioscopy examination. Open-angle glaucoma under gonioscopy shows that the root of iris is attached to the rear of the trabecular meshwork, sometimes partially covering the ciliary band or scleral crest. Pigment deposits in the trabecular meshwork may also be detected through gonioscopy. Lens

fragments suggest remnant lens material.

4. Central corneal thickness

IOP is the most important indicator for diagnosing glaucoma and is directly affected by corneal thickness. Using data from examinations of children 6 months postoperatively, Amir Faramarzi found that the central corneal thicknesses of the aphakic eyes are the largest, compared with pseudophakic eyes and normal children of the same age [23]. Although the mechanism is still unclear, the impact of corneal thickness on assessing IOP should be noted.

Regular follow-up is critical for the timely diagnosis of glaucoma after pediatric cataract surgery. It is generally recommended that a glaucoma test should be carried out every 3 months for the first postoperative year, every 6 months in the following 9 years and annually thereafter.

23.5.4 Treatment

Secondary glaucoma after pediatric cataract surgery should be treated according to its causes.

23.5.4.1 Medication

Since there are still certain risks in surgical treatment, medication is an important measure in dealing with postoperative secondary glaucoma. Compared to eyes with primary congenital glaucoma, aphakic and pseudophakic eyes are more sensitive to ocular hypotensive medication. Beta-blockers, carbonic anhydrase inhibitors (CAIs), and prostaglandin analogues are the main drugs used for lowering IOP. 1–2 % pilocarpine eye drops should be used with caution because it has a risk of inducing retinal detachment (RD) and aggravating inflammation. For IOP elevation due to postsurgical inflammation, a combination of corticosteroids, but not miotic or prostaglandin analogue drugs, is feasible.

1. Beta-blockers

As an effective inhibitor of aqueous humor secretion, beta-blockers are the first-line drug against ocular hypertension after pediatric cataract surgery. Although beta-blockers are well tolerated by adults, it can

induce severe systemic complications in infants, especially premature infants or infants with bronchospasm (asthma) or cardiovascular disorders. Therefore, before using beta-blockers in infants, clinicians should pay attention to the following aspects:

1. A comprehensive assessment on the physical status of the child; beta-blocker is contraindicated in patients with asthma or cardiovascular disease.
2. On the premise of effective function, use the drugs with concentrations as low as possible, for example, timolol 0.25 %.
3. Choose the selective beta-1-blocker, for example, betaxolol 0.25 %.
4. Minimize systemic absorption by pressing the lacrimal sac area when using eye drops.

2. Carbonic anhydrase inhibitors

CAIs lower the IOP by inhibiting the secretion of aqueous humor. There are two modes of administration. One is oral administration. Acetazolamide (10–20 mg/kg/day), as a representative, has a stronger effect in lowering IOP and correspondingly larger side effects compared with topical CAIs. The side effects of oral acetazolamide include metabolic acidosis, diarrhea, and decreased energy levels, appetite, and weight. Therefore, the oral CAIs are only used in recurrent cases or when the topical drugs are invalid. The other mode is topical administration. Dorzolamide (Trusopt) and brinzolamide (Azopt), as representatives, may offer less systemic side effects. They are the second-line drugs for secondary glaucoma after pediatric cataract surgery and first-line drugs when beta-blocker is contraindicated.

3. Prostaglandin analogues

Prostaglandin analogues (latanoprost and travoprost), which lower

the IOP by enhancing uveo-scleral outflow, are safe and have a low incidence of systemic side effects in pediatric patients. The side effects include thickening and elongation of eyelashes, change of iris color, and eye congestion. The long-term side effects of these drugs are still not clear. They are not the first-line drugs after pediatric cataract surgeries.

4. Epinephrine agonists

1. Alpha-2 agonist

There are two types of alpha-2 agonist commonly used in adults: lipophilic brimonidine and hydrophilic clonidine hydrochloride. The latter goes through blood-brain barrier more easily than the former, and therefore, has larger side effects on the central nervous system. Topical brimonidine has some IOP-lowering effect in older children, especially recurrent cases in whom other IOP-lowering drugs have failed. But in infants, usage of these types of drugs may cause serious or even life-threatening systemic side effects, such as bradycardia, hypotension, hypothermia, hypotonia, apnea, and somnolence. Thus, the dosage for children should be as low as possible, such as Alphagan 0.1 % and apraclonidine 0.5 %. Side effects, such as somnolence, should be monitored.

2. Other epinephrine agonists

The application of adrenaline 1 % and dipivefrin hydrochloride 0.1 % is limited in pediatric cases because of their poor IOP-lowering efficacy and potential systemic toxicity (such as tachyarrhythmia and hypertension). The ocular side effects include reactive conjunctival hyperemia, melanin pigmentation deposits on the cornea and conjunctiva, and cystoid macular edema (CME).

5. Cholinergic drugs (miotic drugs)

Cholinergic drugs lower the IOP by enhancing aqueous humor outflow in normal and high-IOP eyes; they can be used to maintain miosis before and after surgeries on anterior chamber angle or trabecular meshwork. Side effects of pilocarpine 1–2 % in aphakic or pseudophakic eyes are fewer than in phakic eyes. However, the likelihood of RD is still

worth noting.

6. Hyperosmotic agents

The glycerol 50 % solution with an oral dose of 0.75–1.5 g/kg of body weight can be added into milk, juice, and other drinks to improve adherence in children. With an intravenous dose of 0.5–1.5 g/kg of body weight and an infusion rate of 60 drops/min, mannitol 20 % solution can rapidly lower the IOP in 20–30 min, and the IOP-lowering effect can last 4–10 h. For pediatric patients, hyperosmotic agents can be used as a rapid IOP-lowering method before surgeries when conventional medications fail to control IOP.

Our present treatment protocols for ocular hypertension and glaucoma after pediatric cataract surgery are listed below.

When the IOP is lower than 25 mmHg, treatment should be performed according to the cause. For example, if the elevation of IOP is due to inflammation, NSAIDs should be applied.

When the IOP is between 25 and 30 mmHg, one of the IOP-lowering drugs, such as carteolol, should be added.

When the IOP is between 30 and 40 mmHg, two kinds of IOP-lowering drugs, such as carteolol and brinzolamide, should be used.

If the IOP is higher than 40 mmHg, three kinds of IOP-lowering drugs should be employed at the same time, for example, carteolol, brinzolamide, and brimonidine tartrate.

23.5.4.2 Laser Therapy

Nd: YAG laser peripheral iridectomy is effective in treating pupillary block glaucoma. Before laser, IOP should be controlled as low as possible. The initial laser iris hole is apt to close when intense inflammation occurs, so laser treatment may be repeated after one week to reopen it.

23.5.4.3 Surgery

1. Peripheral iridectomy

Due to the widespread application of Nd:YAG laser, surgical peripheral iridectomy has become the second choice of treatment. Surgical peripheral iridectomy is taken into consideration only if repeated laser peripheral iridectomy fails or severe inflammation occurs.

2. Filtration surgery with anti-fibrotic drugs

Currently, trabeculectomy is still a mainstream surgical method for aphakic or pseudophakic glaucoma. The previous reported success rate of trabeculectomy varies a lot. For children, the major cause of surgical failure is the relatively thick Tenon's capsule, active proliferation, after surgical trauma, and rapid healing of the wound. Therefore, the younger the child, the more likely they are to receive a failed surgery. The same as trabeculectomy in adults, the success rate may be improved by adding anti-fibrotic drugs intraoperatively. Mitomycin C (MMC) and 5-fluorouracil (5-FU) are commonly used anti-fibrosis drugs. However, due to the requirement of multiple postoperative subconjunctival injections for 5-FU and general anesthesia for injection in children, 5-FU is not suitable for anti-fibrosis therapy in pediatric glaucoma surgery. The dosage and duration of using MMC is still under debate. Although most clinicians believe that 0.2–0.4 mg/ml MMC for 2–3 min is safe and effective, large randomized controlled clinic trials with long-term follow-up are needed to further clarify the best dosage/duration and possible ocular/systemic complications. The intraoperative MMC-related complications include postoperative shallow anterior chamber, corneal epithelial defects, ocular hypotension with or without choroidal detachment, and severe late-onset infection. Therefore, clinicians should monitor the children regularly after surgery and teach the parents to be aware of and observe for the signs of complications.

3. Glaucoma drainage devices

For glaucoma children, glaucoma valve implantation may be considered when medications and traditional surgeries fail. The valve is designed to divert aqueous humor by making a track, usually behind the limbus or near the equator, between the anterior chamber and subconjunctival/sub-Tenon's space to lower the IOP. This surgical

method effectively avoids some bleb-related and medication-related complications.

4. Cyclodestructive surgery

Cyclodestructive surgery can be used for refractory glaucoma when all the other therapies fail or in eyes with poor visual acuity [24, 25]. There are two ways to destroy the ciliary body: cyclophotocoagulation (more commonly used) and cyclocryotherapy. As an adjuvant therapy to surgery, repeated cyclophotocoagulation can be applied in the cases which are not suitable for surgery. However, the long-term success rate of cyclodestructive surgery is low and it might lead to sight-threatening complications.

23.6 Posterior Segment Complications

23.6.1 Cystoid Macular Edema

CME, the pathological change with characteristic cystoid spaces, is the retinal thickening of the macula caused by the blood-retinal barrier disruption, perifoveal retinal capillary leakage, and fluid accumulation in the inner retina of the macula area (outer plexiform layer and inner nuclear layer). Possibly due to the tight vitreoretinal adherence in children, the incidence of CME after pediatric cataract surgeries is relatively low. However, CME should be taken seriously because it is harder to be monitored in children than in adults, and once it happens, the rehabilitation of the visual function will be affected considerably.

23.6.1.1 Etiology

Pathogenesis of CME after cataract surgery is not yet clear. The major influencing factors include vitreomacular traction, intraocular inflammation, and postoperative ocular hypotension. Intraoperative posterior capsule rupture and disturbance to the vitreous are both definite risk factors for postoperative CME. While preventing the PCO, a postoperative complication with very high incidence, prophylactic posterior capsulotomy and anterior vitrectomy increase the incidence of CME. In order to explore the impact of phacoemulsification combined with posterior capsulotomy and anterior

vitrectomy on macular thickness in children with congenital cataract, we tested macular thickness in 60 children during surgeries (tested under general anesthesia immediately after surgeries) and one week after surgeries by OCT examination. This study showed that 15 % (9/60) patients had remarkably increased macular thickness or even macular edema in 1 week postoperatively and indicated that the congenital cataract surgery combined with anterior vitrectomy may have a certain degree of influence on the patients' macular region.

23.6.1.2 Clinical Manifestation

Mild CME patients may show no obvious symptoms or just mild decreased visual acuity. Except for loss of the foveal reflex, no sign will be found under ophthalmoscopy examination. For severe cases, significant decrease in visual acuity, central scotoma, metamorphopsia, micropsia, and characteristic signs of retinal thickening and edema of the macula may be shown. But for infants, the symptoms and signs are hard to detect in the early period because of their vague complaints and poor adherence. The possible presence of amblyopia in children themselves may further enhance the difficulty in evaluating the visual function.

Usually, the CME occurs 4–16 weeks after cataract surgeries. There are also some late-onset cases with CME occurring in postoperative 7–16 years.

23.6.1.3 Examination

1. Direct/indirect ophthalmoscopy

Retinal thickening of the macula and the characteristic cystoid spaces caused by accumulation of fluid can be observed in typical cases.

2. Fundus fluorescence angiography (FFA)

FFA is used to assess the permeability of the blood-retinal barrier. Usually, sodium fluorescein is taken intravenously. But for infants and young children, there are two options:

1. Intravenous administration

It is the same as adults.

2. Oral administration

Oral administration may be chosen to avoid the potential risk of systemic complications caused by intravenous administration in children. For children weighing less than 25 kg, 0.5 g of fluorescein is suggested to be added into 50 ml juice (fluorescein 10 %) and taken orally. For children weighing 25–50 kg, 1 g of fluorescein in 100 ml juice (fluorescein 10 %) is prescribed. The plasma fluorescein concentration at about 30 min after oral administration is close to the level at late venous phase with intravenous administration, and it will last for about 2 h. For children with CME, macular fluorescein leakage can be observed by cobalt blue filter of direct ophthalmoscopy with the most significant leakage occurred in 45–60 min after oral administration. Many studies had already confirmed the safety and effectiveness of oral administration of fluorescein for examination in children.

3. Optical coherence tomography

OCT is a tomography imaging method with high resolution and scanning speed. With the help of OCT, retinal microstructure and changes to the macula can be observed from a two-dimensional or a three-dimensional perspective view, the retinal thickness of the macula can be quantitatively measured, and the characteristic structural changes of the retinal layers can be qualitatively described (Fig. 23.10). In essence, OCT provides a theoretical basis for diagnosis and treatment of macular disease during the early period after cataract surgery.

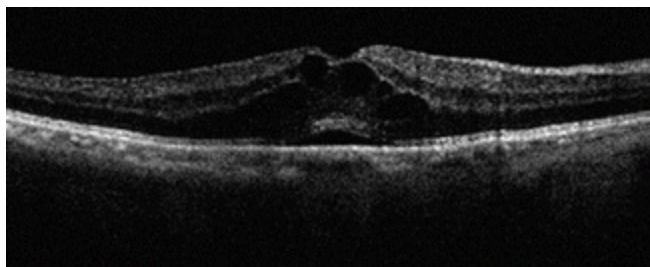


Fig. 23.10 OCT image of CME after cataract surgery. Patient, 6 months old, 1 week after phacoemulsification combined with anterior vitrectomy, OCT examination showed CME

23.6.1.4 Prevention and Management

Intraoperative vitreous disturbances and postoperative inflammation can both induce the occurrence of CME, but some perioperative managements may lower its incidence.

1. Preoperative preparation

Preoperative usage of topical NSAIDs is effective in prevention of intraoperative miosis and postoperative CME. However, there is still a lack of evidence about using it in children. For children with preexisting glaucoma, preoperative withdrawal of some antiglaucoma drugs, such as pilocarpine for 2 weeks and latanoprost for 8 weeks before surgery, is also a useful approach for prevention. For children with preexisting uveitis, cataract surgery should not be performed during the active inflammatory period.

2. Intraoperative precautions

1. Tunnel incision, closed surgery, and stable anterior chamber can minimize the incidence of intraoperative ocular hypotension, iris prolapse, and damage.
2. If anterior vitrectomy is performed in the first-stage operation, posterior capsule continuous circular capsulorhexis (PCCC), compared with other methods of posterior capsulotomy, is the best method for maintenance of the stability of the vitreous. It plays a role in restricting the movement of vitreous, preventing vitreous prolapse into the anterior chamber or even incision incarceration and, thereby, ameliorating the vitreomacular traction during vitrectomy.
3. In-the-bag implantation of IOL can form a barrier between anterior and posterior segments and, therefore, maintains the stability of the posterior segment. Additionally, the in-the-bag IOL can reduce the IOL's mechanical abrasion to its surrounding tissue which

consequently lessens postoperative uveal reaction. Therefore, it is effective in lowering the incidence of CME.

4. Ensure the incision is sealed at the end of surgery.

3. Postoperative managements

Anti-inflammatory treatment is the key in prevention and management of CME.

1. Steroids

Although there are some side effects associated with the application of steroids in children, short-term topical usage is still necessary. For cases with persistent postoperative macular edema, oral or intravenous steroids are both feasible. Intravitreal injection of long-acting corticosteroids, such as triamcinolone acetonide, has a certain effect on CME. But IOP should be monitored regularly, and once it elevates, treatment should be taken.

2. NSAIDs

Topical application of NSAIDs, such as diclofenac sodium 0.1 %, ketorolac 0.5 %, and indomethacin 1.0 %, can effectively reduce the incidence of CME. They are first-line medications for CME.

3. Cycloplegic drugs

Cycloplegic drugs can inhibit postoperative uveitis, thereby reducing the chance of CME. Especially for children with bag-fixed IOLs, topical atropine, a strong cycloplegic drug, is still safe and effective.

23.6.2 Retinal Detachment

RD is one of the most serious complications after pediatric cataract surgery.

It can occur at any time, even several decades after surgery. Owing to the development of modern cataract surgical techniques, the incidence of RD has decreased markedly. However, once it happens, it will notably affect the postoperative rehabilitation of visual function in children.

23.6.2.1 Etiology

The incidence of RD after pediatric cataract surgeries is about 1 %, without clear pathogenesis. The risk factors are high myopia, periphery retinal degeneration, intraoperative posterior capsular rupture, and vitreous prolapse.

23.6.2.2 Clinical Manifestations

The postoperative clinical manifestations of RD in children are similar to adults. However, it is harder to identify in children in the early stages because of their vague complaints and poor adherence to examination. Furthermore, the formation of PCO and secondary proliferative membrane affects the fundus examination as well. Therefore, B-scan should be performed on potential RD eyes.

23.6.2.3 Management and Prognosis

Surgical methods include scleral buckling, vitrectomy with silicone oil or gas tamponade, or combinations of these techniques. Although the retina can usually be reattached, recovery of the function is influenced by many factors. The indications for poor prognosis include preoperative poor visual acuity, RD involving the macula, and severe proliferative vitreoretinopathy (PVR).

23.6.3 Choroidal Detachment (CD)

CD is an uncommon complication after pediatric cataract surgery and may occur immediately or 1 week to several months after surgery. Ocular hypotension and decreased external pressure of the choroidal vessels cause choroidal vasodilatation, and the increased permeability of the vessels thereby leads to the occurrence of CD. In eyes with concomitant congenital glaucoma and cataract, rapid reduction of IOP after surgery gives rise to a much higher occurrence of CD than in eyes without concurrent glaucoma (Fig. 23.11). Additionally, the surgical trauma and IOL irritation can induce acute uveitis, decreased production of aqueous humor, intraocular tissue

edema, leakage of choroidal vessels, and therefore occurrence of CD. The major symptoms of CD are decreased vision and eye pain which cannot be precisely expressed by children. Fortunately, a B-scan can help confirm the diagnosis. Corticosteroids and hyperosmotic agents are two major medications for CD. The use of cycloplegic drugs, hyperosmotic agents, and systemic and topical corticosteroids can facilitate resolution of inflammation, recovery of aqueous humor secretion, and elevation of IOP. Then, the subchoroidal space will be closed gradually (Fig. 23.12).

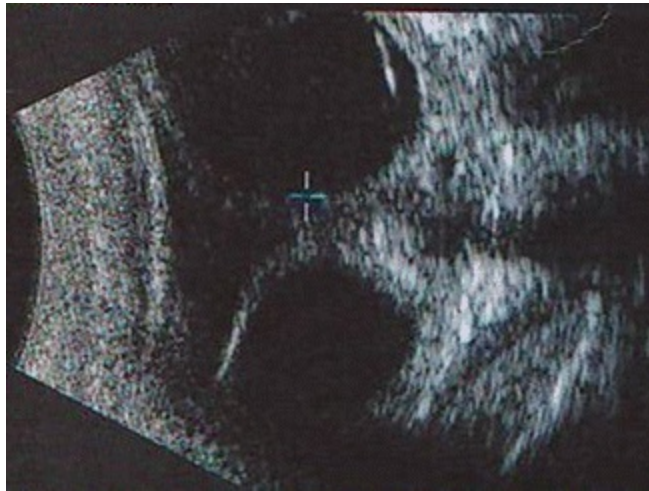


Fig. 23.11 B-scan image of choroidal detachment after cataract surgery. Patient, 8 years old, congenital glaucoma and cataract, day 1 postoperatively, B-scan image of severe choroidal spherical bulge

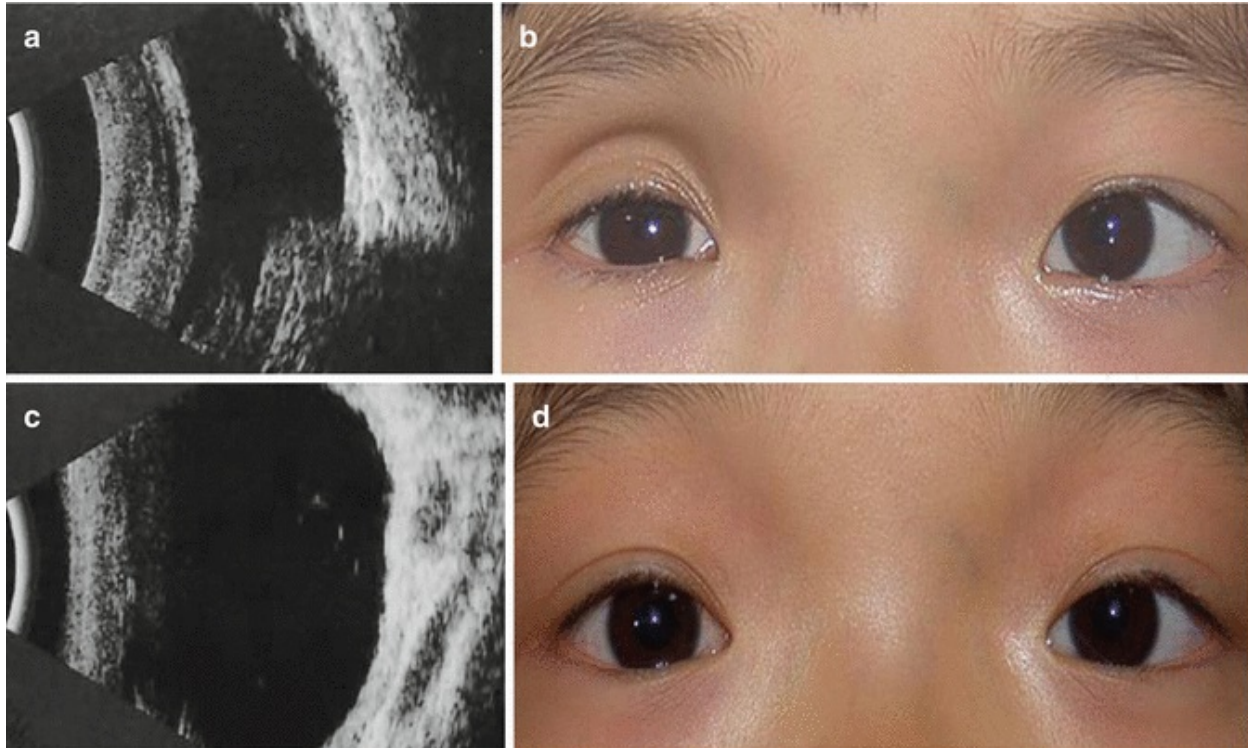


Fig. 23.12 Choroidal detachment after cataract surgery. Female patient, 8 years old, congenital cataract in the right eye, accepted phacoemulsification and IOL implantation. **(a)** Day 1 postoperatively, B-scan image of choroidal detachment; **(b)** hypotension (5 mmHg) of the right eye and enophthalmos; **(c)** day 3 postoperatively, B-scan shows ameliorative choroid detachment area and severity after being treated with corticosteroids and hyperosmotic agents; **(d)** recovery of IOP (15 mmHg) in the right eye, no apparent enophthalmos

23.6.4 Vitreous Hemorrhage (VH)

VH is a rare complication after cataract surgery and occurs mainly in children with persistent hyperplastic primary vitreous (PHPV) which is a disease caused by failure of fetal primary vitreous and hyaloid vasculature to regress and is often concurrent with cataract. The surgical treatment for PHPV requires vitrectomy which may induce the bleeding from the remaining vessels in the proliferative membrane and lead to postoperative VH.

Claudia reviewed the postoperative complications of 43 congenital cataract patients (65 eyes) with different medical histories, reporting that 12/65 eyes are complicated with PHPV [26]. Various degrees of VH were observed in seven eyes (58.3 %) postoperatively. Among them, fundus examinations can be performed in two eyes with mild VH, and a B-scan is required to assess the vitreous and retinal condition in five eyes with moderate to severe VH. The authors suggest that the presence of PHPV is

strongly associated with the occurrence of postoperative VH.

For mild VH, the blood can clear by itself without special treatment, while vitrectomy should be performed urgently in the cases with severe VH combined with retinal hemorrhage or RD.

23.7 Infectious Endophthalmitis

Infectious endophthalmitis is a rare but devastating postoperative complication with the incidence between 0.071 and 0.45 % [27–29]. 82 % of the cases had signs of endophthalmitis presented within 3 days after surgery (Fig. 23.13). 65 % of the cases finally lost light perception. The difficulty in communicating with children and in differential diagnosis from uveitis, retinal tumor and other retinal diseases makes thorough postoperative examinations extremely important for early diagnosis of infectious endophthalmitis. The most common causative organism for postoperative endophthalmitis was gram-positive bacteria which accounted for 94 % of the infections. Among them, *Staphylococcus epidermidis*, *Staphylococcus aureus*, *Streptococcus*, *Enterococcus*, and other gram-positive bacteria accounted for 70 %, 9.9 %, 9 %, 2.2 %, and 3 % infections, respectively. Only 5 % of the endophthalmitis were caused by gram-negative bacteria [30].

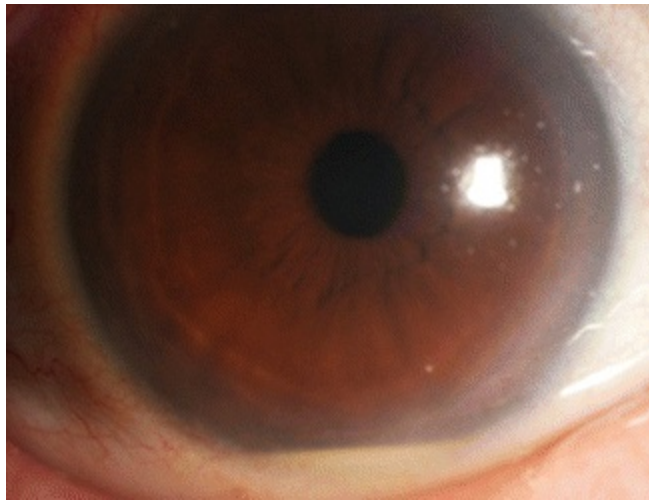


Fig. 23.13 Endophthalmitis and hypopyon after cataract surgery

23.7.1 Risk Factors

1. Ocular and systemic infectious factors

The infectious factors include nasolacrimal duct obstruction, dacryocystitis, blepharitis, upper respiratory tract infection, meningitis, urinary tract infections, and other endogenous infectious factors.

2. Incision construction

As the surgical incision provides an entry for the pathogens, it plays a key role in the occurrence of postoperative endophthalmitis. There were studies reported that transparent corneal incision increased the risk of infectious endophthalmitis. Since children are physically active and vulnerable to trauma, willing to rub their eyes, and have a poor adherence to medications, the construction of a watertight incision is particularly essential for them. The scleral tunnel incision from a superior approach with suture closure is preferred in pediatric cataract surgery because it makes the incision under multiple protections from suture, conjunctiva, upper eyelid, and Bell's phenomenon.

3. Surgical operation and intraoperative complications

Long-duration surgery, frequent movement of surgical instruments in and out of the eyes, repeated iris prolapse and posterior capsule rupture, and other intraoperative complications can increase the likelihood of postoperative inflammation.

Pediatric postoperative endophthalmitis has its own characteristics: lack of complaints, easy misdiagnosis, high blindness rate, and various infection routes. Good and colleagues reported three cases of postoperative endophthalmitis. All of them had symptoms of nasolacrimal duct obstruction and upper respiratory tract infection [28]. This indicated that systemic examination of upper respiratory tract and nasolacrimal duct before surgery is essential for children. Additionally, surgeons should be aware of that surgeries on both eyes at the same time may increase the likelihood of endophthalmitis. Therefore, two eye surgeries should be prepared and sterilized as two separate operations.

23.7.2 Prevention

Endophthalmitis is a disaster once it occurs. Therefore, prevention, with the aim of minimizing the ocular surface flora, is essential in the perioperative period

1. Preoperative usage of topical antibiotics

Although it is still under debate whether the preoperative usage of antibiotics decreases the incidence of postoperative infection, topical antibiotics are used routinely before surgery. Commonly used antibiotic eye drops include lincomycin, ofloxacin, levofloxacin, and tobramycin. According to research [31], bacterial clearance rates for conjunctival sac after using topical antibiotics were 70.59 %, 94.74 %, 100 %, and 89.47 %, respectively.

2. Povidone iodine

Preoperative povidone-iodine preparation is a recognized procedure in preventing postoperative infection. With povidone-iodine 10 % sterilization for skin around the operation area and topical povidone-iodine 5 % maintenance in conjunctival sac for several minutes before balanced salt solution (BSS) washout, ocular causative organisms can be effectively killed without severe corneal complications. Domestic and international studies showed that application of povidone-iodine reduced the incidence of postoperative endophthalmitis [31, 32].

3. Intracameral injection of antibiotics at the end of operation

Intracameral injection of antibiotics at the end of an operation is an efficient way in preventing the postoperative infectious endophthalmitis. But the toxicity and antibiotic resistance should be taken into consideration. The widely used intracameral antibiotics are cephalosporins and vancomycin. Cephalosporins mostly consist of cefazolin, cefuroxime, and ceftazidime. As the first generation of cephalosporin, cefazolin possesses strong antibacterial activity against gram-positive bacteria. But it is utilized less and less today due to its narrow antimicrobial spectrum. Cefuroxime, the second generation of cephalosporin, is the most widely used cephalosporin at present. Compared with the first generation of cephalosporins, it has stronger antibacterial activity against pneumococcus and gram-negative bacteria

but weaker ability against *Staphylococcus aureus*. Generally, the concentration for intracameral delivery is 1.0 mg/0.1 mL. To date, several studies reported that intracameral injection of cefuroxime lower the incidence of postoperative endophthalmitis from 0.42 to 0.13 % [33–36]. Ceftazidime, the third generation of cephalosporins, is largely applied in controlling gram-negative bacteria infection. Vancomycin is usable for serious penicillin- and cephalosporin-resistant gram-positive bacterial infections. *Staphylococcus epidermidis*, *Staphylococcus aureus*, and *Streptococcus* are all sensitive to it. The standard concentration for intracameral delivery is 0.4–1.0 mg. There was a study reported that intracameral injection of 0.4–0.8 mg vancomycin can reduce the incidence of endophthalmitis from 0.06 to 0.00 % [37].

23.7.3 Management

The treatment principle for endophthalmitis in children after cataract surgery is the same as in adults. Broad-spectrum antibiotics, rapid diagnosis, and prompt surgical intervention are crucial factors affecting the prognosis. Once the occurrence of infectious endophthalmitis is suspected, use topical and systemic broad-spectrum antibiotics after taking and testing the aqueous humor for the pathogen. If the diagnosis of infectious endophthalmitis is confirmed, topical and systemic sensitive antibiotics should be prescribed. Prompt vitrectomy and vitreous injection of sensitive antibiotics should be performed when the inflammation progresses rapidly.

It is difficult to achieve effective antimicrobial concentrations in the eyes through systemic administration, topical administration, or subconjunctival injection. The most effective way is intravitreal injection. Before injection, 0.2 ml vitreous is aspirated, smeared, cultured, and tested for antibiotic sensitivity. The popular medication for intravitreal injection is 1 mg vancomycin in 0.2 ml BSS, while intravitreal injection of 2 mg ceftazidime in 0.2 ml solution is also optional. After 24 h, sensitive antibiotic can be injected again according to the antibiotic sensitivity test.

As an adjuvant therapy, systemic usage of broad-spectrum antibiotic against gram-positive bacteria should be combined with the ones against gram-negative bacteria. Change the antibiotics if the used drugs are different from the result of the antibiotic sensitivity test or the treatment is invalid in 3 days. In addition to the systemic high dose combination antibiotics,

intravenous corticosteroids should be used to lessen the retinal toxicity caused by inflammation.

23.8 Summary

The distinct developmental and structural characteristics of children's eyes make the complications after pediatric cataract surgery complex and volatile, such as almost ubiquitous PCO and the remarkably high incidence of secondary glaucoma. The choice of surgical method and IOL implantation time are also associated with the occurrence of postoperative complications. Therefore, for prevention and management of complications after pediatric cataract surgery, higher surgical techniques and thorough understanding of the various complications based on postoperative examinations are required to achieve early diagnosis, early treatment, and good postoperative curative effect.

References

1. Vasavada AR, Praveen MR, Vasavada VA, et al. Corneal endothelial morphologic assessment in pediatric cataract surgery with intraocular lens implantation: a comparison of preoperative and early postoperative specular microscopy. *Am J Ophthalmol.* 2012;154(2):259–65.
[\[CrossRef\]](#)[\[PubMed\]](#)
2. Borghol Kassar R, Menezo Rozalén JL, Harto Castaño MÁ, et al. Long-term follow-up of the corneal endothelium after pediatric cataract surgery. *Cornea.* 2012;31(5):529–32.
[\[CrossRef\]](#)[\[PubMed\]](#)
3. Xiao W, Zhao D, Pu W, et al. Clinical analysis of postoperative complications of infantile congenital cataract surgery. *Int J Ophthalmol.* 2009;9(5):861–4.
4. Simon JW, Miter D, Zobel-Ratner J, et al. Corneal edema after pediatric cataract surgery. *JAAPOS.* 1997;1(2):102–4.
5. Bayramlar H, Totan Y, Borazan M. Heparin in the intraocular irrigating solution in pediatric cataract surgery. *J Cataract Refract Surg.* 2004;30:2163–9.
[\[CrossRef\]](#)[\[PubMed\]](#)
6. Dixit NV, Shah SK, Vasavada V, et al. Outcomes of cataract surgery and intraocular lens implantation with and without intracameral triamcinolone in pediatric eyes. *J Cataract Refract Surg.* 2010;36:1494–8.
[\[CrossRef\]](#)[\[PubMed\]](#)
7. Siatiri H, Beheshtnezhad AH, Asghari H, et al. Intracameral tissue plasminogen activator to

prevent severe fibrinous effusion after congenital cataract surgery. *Br J Ophthalmol*. 2005;89(11):1458–61.

[\[CrossRef\]](#)[\[PubMed\]](#)[\[PubMedCentral\]](#)

8. Basti S, Aasuri MK, Reddy MK, et al. Heparin-surface-modified intraocular lenses in pediatric cataract surgery: prospective randomized study. *J Cataract Refract Surg*. 1999;25:782–7.
[\[CrossRef\]](#)[\[PubMed\]](#)
9. Huang Y, Dai Y, Wu X, et al. Toxic anterior segment syndrome after pediatric cataract surgery. *J AAPOS*. 2010;14:444–6.
[\[CrossRef\]](#)[\[PubMed\]](#)
10. Davison JA. Capsule contraction syndrome. *J Cataract Refract Surg*. 1993;19(5):582–9.
[\[CrossRef\]](#)[\[PubMed\]](#)
11. Hollick EJ, Spalton DJ, Ursell PG, et al. Lens epithelial cell regression on the posterior capsule with different intraocular lens materials. *Br J Ophthalmol*. 1998;82:1182–8.
[\[CrossRef\]](#)[\[PubMed\]](#)[\[PubMedCentral\]](#)
12. Tognetto D, Toto L, Sanguinetti G, et al. Lens epithelial cell reaction after implantation of different intraocular lens materials: two-year results of a randomized prospective trial. *Ophthalmology*. 2003;110(10):1935–41.
[\[CrossRef\]](#)[\[PubMed\]](#)
13. Gashau AG, Anand A, Chawdhary S, et al. Hydrophilic acrylic intraocular lens exchange: Five-year experience. *J Cataract Refract Surg*. 2006;32(8):1340–4.
[\[CrossRef\]](#)[\[PubMed\]](#)
14. Simon JW, Mehta N, Simmons ST, et al. Glaucoma after pediatric lensectomy/vitrectomy. *Ophthalmology*. 1991;98:670–4.
[\[CrossRef\]](#)[\[PubMed\]](#)
15. Mills MD, Robb RM. Glaucoma following childhood cataract surgery. *J Pediatr Ophthalmol Strabismus*. 1994;31:355–60.
[\[PubMed\]](#)
16. Lin H, Chen W, Luo L, et al. Ocular hypertension after pediatric cataract surgery: baseline characteristics and first-year report. *PLoS One*. 2013;8(7):e69867.
[\[CrossRef\]](#)[\[PubMed\]](#)[\[PubMedCentral\]](#)
17. Francois J. Late results of congenital cataract surgery. *Ophthalmology*. 1979;86:1586–9.
[\[CrossRef\]](#)[\[PubMed\]](#)
18. Phelps CD, Arafat NI. Open-angle glaucoma following surgery for congenital cataracts. *Arch Ophthalmol*. 1977;95:1985–7.
[\[CrossRef\]](#)[\[PubMed\]](#)
19. Keech RV, Tongue AC, Scott WE. Complications after surgery for congenital and infantile cataracts. *Am J Ophthalmol*. 1989;108:136–41.
[\[CrossRef\]](#)[\[PubMed\]](#)
- 20.

Asrani S, Freedman S, Hasselblad V, et al. Does primary intraocular lens implantation prevent “aphakic” glaucoma in children? *J AAPOS*. 1999;3:33–9.

[\[CrossRef\]](#)

21. Walton DS. Pediatric aphakic glaucoma. A study of 65 patients. *Trans Am Ophthalmol Soc*. 1995;93:403–13.
[\[PubMed\]](#)[\[PubMedCentral\]](#)
22. Egbert JE, Kushner BJ. Excessive loss of hyperopia. A presenting sign of juvenile aphakic glaucoma. *Arch Ophthalmol*. 1990;108:1257–9.
[\[CrossRef\]](#)[\[PubMed\]](#)
23. Faramarzi A, Javadi MA, Jabbarpoor Bonyadi MH, et al. Changes in central corneal thickness after congenital cataract surgery. *J Cataract Refract Surg*. 2010;36:2041–7.
[\[CrossRef\]](#)[\[PubMed\]](#)
24. Bloom PA, Clement CI, King A, et al. A comparison between tube surgery, ND:YAG laser and diode laser cyclophotocoagulation in the management of refractory glaucoma. *Biomed Res Int*. 2013;2013:371951.
[\[CrossRef\]](#)[\[PubMed\]](#)[\[PubMedCentral\]](#)
25. Frezzotti P, Mittica V, Martone G, et al. Longterm follow-up of diode laser transscleral cyclophotocoagulation in the treatment of refractory glaucoma. *Acta Ophthalmol*. 2010;88(1):150–5.
[\[CrossRef\]](#)[\[PubMed\]](#)
26. Kuhli-Hattenbach C, Luchtenberg M, Kohnen T, et al. Risk factors for complications after congenital cataract surgery without intraocular lens implantation in the first 18 months of life. *Am J Ophthalmol*. 2008;146:1–7.
[\[CrossRef\]](#)[\[PubMed\]](#)
27. Whitman MC, Vanderveen DK. Complications of pediatric cataract surgery. *Semin Ophthalmol*. 2014;29:414–20.
[\[CrossRef\]](#)[\[PubMed\]](#)
28. Good WV, Hing S, Irvine AR, et al. Postoperative endophthalmitis in children following cataract surgery. *J Pediatr Ophthalmol Strabismus*. 1990;27:283–5.
[\[PubMed\]](#)
29. Wheeler DT, Stager DR, Weakley DR. Endophthalmitis following pediatric intraocular surgery for congenital cataracts and congenital glaucoma. *J Pediatr Ophthalmol Strabismus*. 1992;29:139–41.
[\[PubMed\]](#)
30. Endophthalmitis Vitrectomy Study Group. Results of the Endophthalmitis Vitrectomy Study. A randomized trial of immediate vitrectomy and of intravenous antibiotics for the treatment of postoperative bacterial endophthalmitis. *Arch Ophthalmol*. 1995;113:1479–96.
[\[CrossRef\]](#)
31. Speaker MG, Menikoff JA. Prophylaxis of endophthalmitis with topical povidone-iodine. *Ophthalmology*. 1991;98:1769–75.
[\[CrossRef\]](#)[\[PubMed\]](#)

32. Guan J, Wu Qiang HP. Analysis of bacterial culture after different antibiotics and pre-postoperative conjunctiva sac of cataract patients. *Chin J Pract Ophthalmol*. 2007;25:1288–91.
33. Endophthalmitis Study Group, European Society of Cataract & Refractive Surgeons. Prophylaxis of postoperative endophthalmitis following cataract surgery: results of the ESCRS multicenter study and identification of risk factors. *J Cataract Refract Surg*. 2007;33:978–88.
[CrossRef]
34. Garcia-Saenz MC, Arias-Puente A, Rodriguez-Caravaca G, et al. Effectiveness of intracameral cefuroxime in preventing endophthalmitis after cataract surgery Ten-year comparative study. *J Cataract Refract Surg*. 2010;36:203–7.
[CrossRef][PubMed]
35. Montan PG, Wejde G, Koranyi G, et al. Prophylactic intracameral cefuroxime. Efficacy in preventing endophthalmitis after cataract surgery. *J Cataract Refract Surg*. 2002;28:977–81.
[CrossRef][PubMed]
36. Sobaci G, Uysal Y, Mutlu FM, et al. Prophylactic usage of intracameral cefuroxime in the prevention of postoperative endophthalmitis. *Int J Ophthalmol*. 2009;9:1439–43.
37. Yang W, Zhou Y, Lin Z. Intracameral vancomycin in the prevention from infectious endophthalmitis on phacoemulsification with intraocular lens. *Chin J Pract Ophthalmol*. 2002;20:51–3.

24. Prevention and Management of Pediatric Secondary Cataracts

Mingxing Wu¹✉, Zhenzhen Liu¹ and Liangping Liu¹

- (1) State Key Laboratory of Ophthalmology, Zhongshan Ophthalmic Center, Sun Yat-sen University, 54S Xianlie Road, Guangzhou, 510060, People's Republic of China

✉ **Mingxing Wu**

Email: wumingx@mail.sysu.edu.cn

Abstract

Due to the active growth and high proliferative ability of lens epithelial cells, a severe uveal inflammatory response after surgery, and poor compliance with postoperative medications and follow-ups, together with uveitis-induced breakdown of the blood-aqueous barrier that may result in abnormally high levels of cytokines and proteins in the aqueous humor, all of these can be an increased risk for lens epithelial cell proliferation in pediatric patients. Therefore, secondary cataracts, or posterior capsule opacification (PCO), is the most common complication after pediatric cataract surgery. The occurrence of pediatric secondary cataracts is associated with several factors, including age at the time of operation, surgical approach, as well as the design, material, and fixation site of the intraocular lens. Management strategies may include modification of surgical techniques, laser posterior capsulotomy, medications to inhibit lens epithelial cell proliferation, a biodegradable drug-loaded capsular tension ring, gene therapy, and so on. This chapter discusses the pathogenesis, risk factors, and preventive and therapeutic strategies of pediatric secondary cataracts.

Following extracapsular cataract extraction or lens trauma, the residual lens cortex or lens epithelial cells (LECs) may proliferate to form opacities, which are called secondary cataract, or aftercataract. Clinically, this condition is often referred to as posterior capsule opacification (PCO). It is the most common complication following pediatric cataract surgery, with an incidence ranging from 39 % up to 100 % [1–4], which may affect visual rehabilitation of pediatric patients. Therefore, its prevention and management are very important in the treatment of pediatric lens disorders.

24.1 Pathogenesis of Pediatric Secondary Cataracts

Pathogenesis of PCO in pediatric eyes is similar to that in adults. After extracapsular cataract extraction or aspiration, the residual LECs undergo excessive proliferation, epithelial-mesenchymal transition (EMT), and migrate toward the posterior capsule. Meanwhile, a large amount of extracellular matrix proteins (ECM) accumulate on the posterior capsule, which eventually leads to PCO. After extracapsular cataract extraction or lens trauma, there are two types of residual LECs in the capsular bag: single-layer LECs around the anterior capsulorhexis opening, i.e., anterior LECs (A cells), and LECs located at the equator, i.e., equatorial LECs (E cells) (Fig. 24.1). It appears that cataract surgery or trauma induces a wound-healing response in the lens, in which A cells undergo proliferation, migration, and EMT; greatly upregulate expression of fibroblast markers including α -smooth muscle actin (α -SMA), N-cadherin, and vimentin; and produce abundant ECM, such as collagen type I and type IV, and fibronectin [5–7]. Finally, disordered deposition of numerous cells and excessive ECM on the posterior capsule causes capsule fibrosis and opacification. In other cases, E cell proliferation and migration to the posterior capsule, with subsequent transformation into bladder cells instead of fibroblasts with high expression of α -SMA, give rise to pearl-like opacities on the posterior capsule.

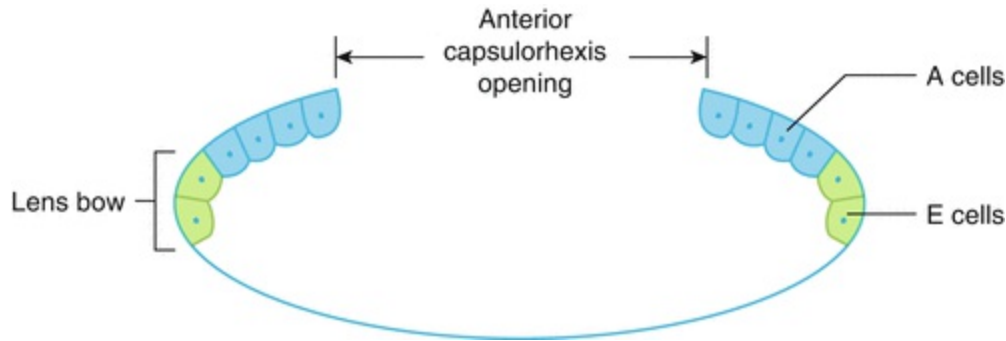


Fig. 24.1 Residual cell types after extracapsular cataract extraction. A cells: single-layer LECs around the anterior capsulorhexis opening; E cells: residual LECs located at the equator (*lens bow*)

After cataract surgery, disruption of the blood-aqueous barrier and surgical irritation stimulates an excessive increase in aqueous levels of various cytokines and growth factors, e.g., transforming growth factor- β (TGF- β), fibroblast growth factor (FGF)-2, interleukin-1(IL-1), IL-6, epidermal growth factor (EGF), and hepatocyte growth factor (HGF) [8]. Currently, TGF- β is considered the most important molecule causing the pathological fibrosis of LECs. The canonical Smad2/3 signaling activated by TGF- β is the first identified pathway of TGF- β -induced EMT, in which LECs are induced to transform into fibroblasts and produce excessive ECM [9, 10]. In addition to the canonical Smad signaling, other noncanonical signaling pathways activated by TGF- β , such as PI3K/AKT and ERK1/2 signaling, are also involved in the pathogenesis of PCO [11, 12]. Furthermore, previous studies also demonstrated that FGF-2 and HGF may stimulate massive proliferation LECs and that EGF promotes LEC migration [8]. Other studies reported that IL-1 not only stimulates LEC proliferation and ECM production but also exacerbates inflammation after cataract surgery [13]. Additionally, altered levels of growth factors are associated with disruption of blood-aqueous barrier, and therefore, in patients with preexisting conditions with disturbance to the blood-aqueous barrier, such as uveitis, the risk of developing PCO after surgery increases [14].

24.2 Clinical Manifestations and Predisposing Factors of Pediatric Secondary Cataracts

24.2.1 Clinical Manifestations of Secondary Cataracts

The main symptom of secondary cataract is visual loss once again after cataract surgery. Slit-lamp examination reveals different morphologic types of PCO of varying severity (Fig. 24.2), including the following: (1) Soemmering ring (the regenerated peripheral cortical materials adhere to and are enveloped by the anterior and posterior capsules, forming a ring that is opaque at the periphery but transparent in the center), (2) pearl-type PCO (the retained E cells proliferate as clusters, forming transparent pearl-shaped bodies, also called Elschnig pearls), (3) fibrosis-type PCO (the residual A cells migrate toward the posterior capsule and secrete fibrous collagens, inducing fibrosis and producing folds and wrinkles in the posterior capsule), and (4) mixed type.

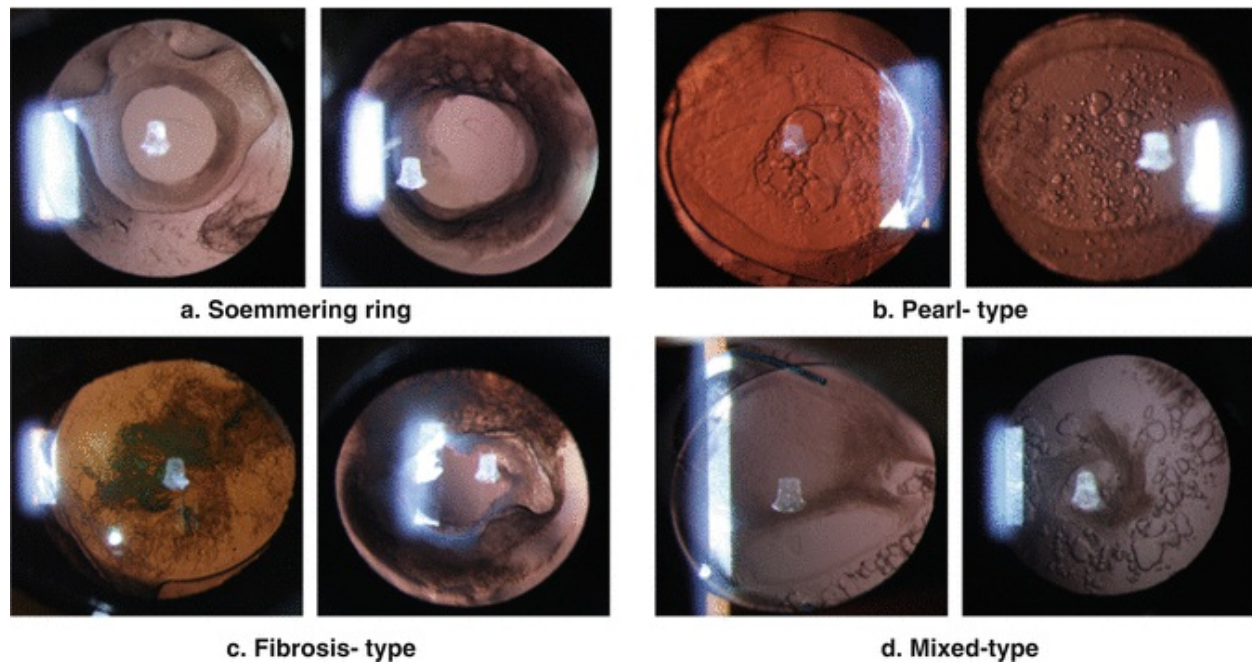


Fig. 24.2 Different morphological types of PCO. (a) Soemmering ring: the regenerated peripheral cortical materials adhere to and are enveloped by the anterior and posterior capsules (b) pearl-type PCO: the retained E cells proliferate as clusters, forming transparent pearl-shaped bodies (c) fibrosis-type PCO (the residual A cells migrate toward the posterior capsule producing folds and wrinkles in the posterior capsule (d) mixed-type PCO: posterior capsule opacification with two or more abovementioned characteristics

Among the various visual functions, secondary cataracts mainly affect visual acuity, contrast sensitivity, and glare sensitivity, depending on the type and the location of PCO. It has been shown that pearl-type PCO may exert a greater influence on central visual acuity, contrast sensitivity, and glare sensitivity across all spatial frequencies than fibrosis-type PCO [15].

24.2.2 Predisposing Factors for Secondary Cataracts

The incidence of pediatric secondary cataract is associated with multiple factors, including age at surgery, postoperative inflammatory response, surgical procedures or techniques, and the material, optic design, and implantation site of the intraocular lens (IOL) as well as the type of cataract.

24.2.2.1 *Age at Surgery*

The younger the age at surgery, the stronger the proliferative capacity of the residual LECs is. Even if posterior capsulotomy combined with anterior vitrectomy is performed during cataract surgery, there is still a high risk for developing secondary opacification. Peterseim and Wilson reported that, in cataract children undergoing posterior capsulectomy plus anterior vitrectomy, the risk of secondary cataracts was higher in children under the age of 2 months compared to older children [16]. In a study by Hosal, the relative risk for developing secondary cataracts in children younger than 1 year was 4.7 times that in older children [3].

24.2.2.2 *Postoperative Inflammatory Response*

Due to the surgical difficulties, the immaturity of blood-aqueous barrier, as well as the poor compliance with postoperative medications and follow-ups in children with cataracts, their postoperative inflammatory response is usually significant. The cytokine levels are abnormally high in the aqueous humor, creating an environment for the proliferation and EMT of LECs, which may promote the development of PCO.

24.2.2.3 *Surgical Procedures*

Today, the commonly used surgical procedure for pediatric cataracts includes phacoaspiration alone, phacoaspiration and posterior capsulotomy, and phacoaspiration and posterior capsulotomy together with anterior vitrectomy (AV). It has been shown that the first procedure has the highest incidence of PCO, while the third one has the lowest [3]. Children who did not receive posterior capsulotomy were five to ten times more likely to develop PCO than those who did [3]. Cataract extraction without posterior continuous curvilinear capsulorhexis (PCCC) or AV was associated with a PCO incidence of up to 76.9 %, surgery with PCCC but without AV was

associated with an incidence of 44.4 %, while surgery with both PCCC and AV was associated with an incidence of only 11.8 % at 1–3 years of follow-up after surgery [17, 18]. Chrousos and colleagues reported that, in children with a small posterior capsulectomy opening, 12 % developed opacification, but when the opening was large enough, PCO was rarely seen [19]. In addition, surgical techniques may also affect the incidence of PCO. Skillful maneuvers and a short duration of surgery may help to avoid surgery-related injuries and disruption of the blood-aqueous barrier and thus reduce the risk of PCO.

24.2.2.4 Material, Design, and Implantation Site of the IOL

The risk of PCO also depends on whether or not an IOL is implanted. In pseudophakic eyes, the PCO incidence is correlated with the material, design, and implantation site of the IOL. Pseudophakic eyes of children are 3.6 times more likely to develop PCO than aphakic eyes [20].

The effect of the IOL material on the risk of PCO is mainly determined by its effect on LEC degeneration. The incidence of degeneration depends on the material of the implanted IOL; acrylic, PMMA, and silicone IOL are reported to be associated with incidences of LEC degeneration of 83 %, 15 %, and 8 %, respectively. This may be due to the fact that the hydrophobic property of the IOL material affects the adhesion between the IOL and capsule. The more hydrophobic the IOL material, the stronger the adhesion is with a higher risk of degeneration. The incidence of LEC degeneration is negatively correlated with the incidence of PCO [21].

The effect of IOL design on the risk of PCO mainly depends on its haptic and optic edge design. It has been well demonstrated in both experimental and clinical studies [22–24] that anterior optic-haptic angulation and a square-edged optic could effectively prevent the E cells on the posterior capsule from proliferating and migrating into the visual axis and thereby reduce the risk of PCO.

Besides, the implantation site of the IOL may also affect the incidence of PCO. Posterior capsulotomy combined with IOL optic capture reconstructs an anatomic barrier between the anterior and posterior segments and thus further decreases the incidence of PCO [25].

24.2.2.5 Type of Cataract

Some investigators have reported the surgical outcomes for congenital, developmental, and traumatic cataracts to be different and the incidence of PCO also varies [26]. Gimbel and colleagues reported that the cumulative incidence of conditions requiring posterior capsulectomy was higher in patients with traumatic cataracts compared to those with congenital cataracts over the age of 2 years [27]. The apparently increased incidence of PCO in traumatic cataracts may be due to a more severe inflammatory response following trauma.

24.2.2.6 Systemic Comorbidities

Certain systemic diseases such as juvenile idiopathic arthritis are also associated with a high incidence of secondary cataracts. BenEzra and Cohen [28] observed retrolental membranes in 80 % of patients aged 3–17 years with juvenile idiopathic arthritis despite posterior capsulotomy and anterior vitrectomy, all of whom required a second surgical intervention.

24.3 Prevention and Management of Pediatric Secondary Cataracts

In the 1960s, the preferred method of pediatric cataract surgery was lens aspiration, leaving the posterior capsule intact as popularized by Scheie. With this method, the residual LECs proliferate and migrate on the intact posterior capsule, giving rise to PCO. In some cases, the ensuing visual axial opacity causes greater visual impairment than the original cataract itself. After the introduction of vitrectomy in the 1970s, ophthalmic surgeons began to perform lens aspiration combined with posterior capsulotomy and anterior vitrectomy, and this new technique significantly decreased the incidence of secondary cataracts. In the early 1990s, application of phacoemulsification helped to reduce postoperative inflammatory response significantly, but the occurrence of PCO still led to poor vision. Secondary capsular opacification and fibrosis and shrinking of the capsular bag may be severe enough to cause IOL decentration and even break the optic-haptic junction. Even in the era of modern cataract surgery, pediatric secondary cataracts still pose a challenge for ophthalmologists.

24.3.1 Prevention of Pediatric Secondary Cataracts

24.3.1.1 Modifications of Surgical Techniques

When cataract aspiration with posterior capsulotomy alone is performed in pediatric cataract surgery, the intact anterior hyaloid membrane may still become a scaffold for the migration, proliferation, and transition of residual LECs. In order to further reduce the risk of PCO, the common practice is to perform cataract extraction combined with posterior capsulotomy and anterior vitrectomy. We suggest that anterior vitrectomy be performed in children younger than 3 years and the posterior capsule be left intact for children at 3 years or older as most older children can cooperate with Nd:YAG laser posterior capsulotomy under topical anesthesia.

A major advantage of cataract aspiration plus posterior capsulotomy and anterior vitrectomy is that it can decrease the incidence of secondary cataracts and laser posterior capsulotomy and its associated complications can be avoided [29]. However, posterior capsulotomy plus vitrectomy may increase the risk of cystoid macular edema, retinal detachment, and vitreous incarceration in the incision [30], whereas an intact posterior capsule may facilitate in-the-bag IOL implantation and also help to maintain the long-term stability of the implanted IOL.

There are two techniques for posterior capsulotomy: (1) vitrectorhexis via limbal or pars plana approach and (2) PCCC with capsulorhexis forceps or a radio-frequency diathermy device. After posterior capsulotomy, a posterior chamber IOL can be implanted in the capsular bag or in the ciliary sulcus. To ensure better centration of the IOL and reduce the risk of secondary cataracts, optic capture through the posterior capsule opening may be performed [31].

24.3.1.2 Improvement of IOL Material and Design

As stated above, the incidence of PCO is correlated with the design and material of the implanted IOL. A square edge to the optic, the haptic-optic angulation and material that can firmly adhere to the capsule (e.g., hydrophobic acrylate) may help to prevent the development of PCO.

24.3.1.3 Pharmacologic Prophylaxis

A drug should have the following properties to be useful for preventing secondary cataracts: (1) effective in inhibiting the proliferation and migration

of LECs, (2) not harmful or toxic to other intraocular tissues, and (3) permeable into the lens capsule with adequate duration of action.

In today's clinical practice, the commonly used drugs against PCO mainly act by inhibiting the inflammatory responses during and after surgery. These include:

1. Steroids: topical or systemic steroids before and after cataract surgery may reduce the risk of secondary membrane formation. When cataract is complicated with uveitis, preoperative topical or systemic steroids may help to control the preexisting ocular inflammation.
2. NSAIDs: since cyclooxygenase-2 (COX-2) is a marker of the EMT of LECs, NSAIDs, as COX inhibitors, may play a role in preventing PCO [32, 33].
3. Heparin: low molecular weight heparin (LMWH) added to the irrigation solution during cataract surgery is likely to reduce the severity of postoperative inflammation [34]. Heparin-surface-modified (HSM) PMMA IOL may also help in reducing the formation of secondary membrane [35].

Additionally, in vitro experiments have identified some other pharmacologic agents that may inhibit the proliferation of LECs and thus prevent PCO: (1) antimetabolic agents, e.g., mitomycin-C, daunorubicin, and 5-fluorouracil; (2) proteasome pathway inhibitors, e.g., MG132; (3) drugs affecting proliferation signaling, e.g., COX-2 inhibitors, suramin, and interferon; and (4) natural herbal extracts, e.g., thapsigargin, curcumin, and elemene. But the risk of their toxic effects on surrounding intraocular tissues has restricted their clinical use.

24.3.2 Management of Pediatric Secondary Cataracts

24.3.2.1 *Nd:YAG Laser Posterior Capsulectomy*

Now, the most commonly used treatment for pediatric secondary cataracts is Nd:YAG laser posterior capsulotomy (Fig. 24.3). However, this approach cannot be used for uncooperative children. Anesthesia is always required in young children, and also there is a risk of damage to the IOL. Generally

speaking, it is indicated for use in cooperative school-aged children. In addition, the anterior hyaloid membrane remains intact after Nd:YAG laser posterior capsulotomy, which may not only act as a scaffold for the migration and transition of residual LECs but also provides a site for the deposition of inflammatory cells, capsular debris, and pigments.

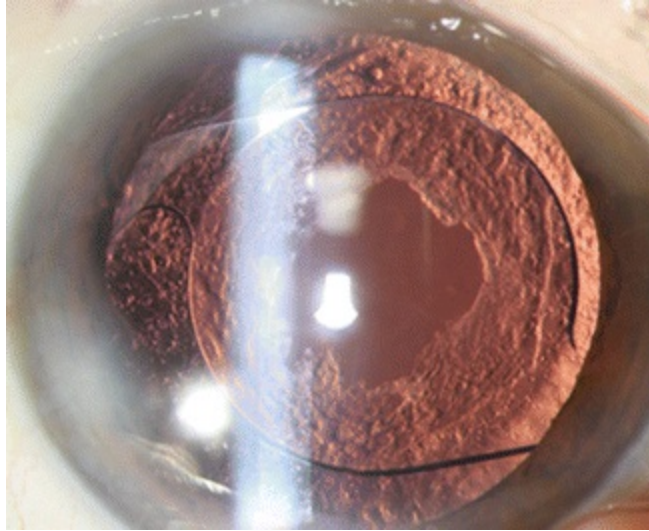


Fig. 24.3 An eye after Nd:YAG laser posterior capsulotomy

24.3.2.2 Posterior Capsulotomy Plus Anterior Vitrectomy

For PCO with severe proliferative membranes or a large amount of regenerated cortex, complete opening cannot be achieved with Nd:YAG laser. In such cases, posterior capsulotomy plus anterior vitrectomy can be chosen (Fig. 24.4). Particularly for some children who develop posterior synechia in the process of PCO formation, synechiolysis together with posterior capsulotomy and anterior vitrectomy may be conducted to prevent the relapse of PCO. This approach is also indicated when the patient is very young, general anesthesia for laser treatment outside the operation room does not seem appropriate, PCO relapses despite repeated laser treatments, or the laser device is unavailable.

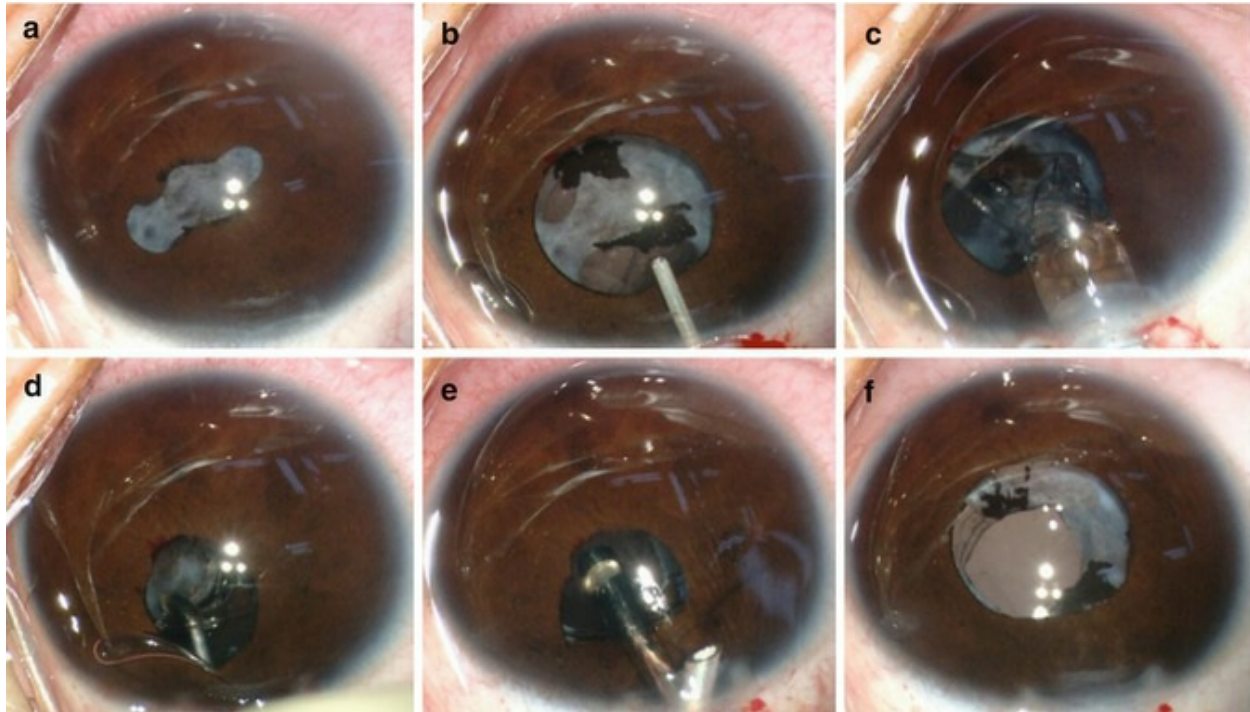


Fig. 24.4 Posterior capsulotomy plus anterior vitrectomy. (a) PCO with posterior synechia; (b) injection of the OVD to release the posterior synechia; (c) IOL implantation in the ciliary sulcus; (d) posterior capsulotomy with radio-frequency diathermy; (e) anterior vitrectomy is performed; and (f) the operation is finished

24.4 Summary

Because of the unique pathophysiological features of children, residual LECs after cataract surgery have stronger proliferative capacity than in adults, which is associated with a higher incidence and severity of secondary cataracts. Therefore, prevention and management of pediatric secondary cataract have become a challenging topic with much attention in ophthalmologic research. At present, anti-PCO strategies mainly include optimizing surgical approaches and techniques as well as refining the design and material of IOLs; pharmacologic prophylaxis is another focus among ophthalmologic researchers.

By interdisciplinary cooperation between polymer materials engineering and pharmacokinetics, a biodegradable drug-loaded capsular tension ring is being developed which combines a sustained release drug delivery system with the mechanical effect of the tension ring. It offers an innovative approach for preventing PCO. In addition, it is hypothesized that gene therapy may be used to correct cataract-related genetic defects; as the residual

LECs demonstrate strong proliferative capacity in pediatric patients, gene therapy may be able to promote in situ regeneration of the lens after extracapsular cataract extraction. In situ lens regeneration transforms pathological secondary cataracts into physiological lens regeneration, which is considered another novel paradigm to prevent and manage PCO in children.

References

1. Gimbel HV, Ferensowicz M, Raanan M, et al. Implantation in children. *J Pediatr Ophthalmol Strabismus*. 1993;30(2):69–79.
[\[PubMed\]](#)
2. Basti S, Ravishankar U, Gupta S. Results of a prospective evaluation of three methods of management of pediatric cataracts. *Ophthalmology*. 1996;103(5):713–20.
[\[CrossRef\]](#)[\[PubMed\]](#)
3. Hosal BM, Biglan AW. Risk factors for secondary membrane formation after removal of pediatric cataract. *J Cataract Refract Surg*. 2002;28(2):302–9.
[\[CrossRef\]](#)[\[PubMed\]](#)
4. Jensen AA, Basti S, Greenwald MJ, et al. When may the posterior capsule be preserved in pediatric intraocular lens surgery? *Ophthalmology*. 2002;109(2):324–7; discussion 328.
[\[CrossRef\]](#)[\[PubMed\]](#)
5. Li P, Jing J, Hu J, et al. RNA interference targeting snail inhibits the transforming growth factor beta 2-induced epithelial-mesenchymal transition in human lens epithelial cells. *J Ophthalmol*. 2013;2013:869101.
[\[PubMed\]](#)[\[PubMedCentral\]](#)
6. Lovicu FJ, McAvoy JW. FGF-induced lens cell proliferation and differentiation is dependent on MAPK (ERK1/2) signalling. *Development*. 2001;128(24):5075–84.
[\[PubMed\]](#)
7. Mansfield KJ, Cerra A, Chamberlain CG. FGF-2 counteracts loss of TGFbeta affected cells from rat lens explants: implications for PCO (after cataract). *Mol Vis*. 2004;10:521–32.
[\[PubMed\]](#)
8. Awasthi N, Guo S, Wagner BJ. Posterior capsular opacification: a problem reduced but not yet eradicated. *Arch Ophthalmol*. 2009;127(4):555–62.
[\[CrossRef\]](#)[\[PubMed\]](#)
9. Wallentin N, Wickstrom K, Lundberg C. Effect of cataract surgery on aqueous TGF-beta and lens epithelial cell proliferation. *Invest Ophthalmol Vis Sci*. 1998;39(8):1410–8.
[\[PubMed\]](#)
10. Hosler MR, Wang-Su ST, Wagner BJ. Role of the proteasome in TGF-beta signaling in lens

- epithelial cells. *Invest Ophthalmol Vis Sci.* 2006;47:2045–52.
[\[CrossRef\]](#)[\[PubMed\]](#)
11. Choi J, Park SY, Joo CK. Transforming growth factor-beta1 represses E-cadherin production via slug expression in lens epithelial cells. *Invest Ophthalmol Vis Sci.* 2007;48:2708–18.
[\[CrossRef\]](#)[\[PubMed\]](#)
 12. Yao K, Ye P, Tan J, et al. Involvement of PI3K/Akt pathway in TGF- β 2-mediated epithelial Mesenchymal transition in human lens epithelial cells. *Ophthalmic Res.* 2007;40:69–76.
[\[CrossRef\]](#)
 13. Nishi O, Nishi K, Fujiwara T, et al. Effects of the cytokines cells on the proliferation of and collagen synthesis by human cataract lens epithelial. *Br J Ophthalmol.* 1996;80(1):63–8.
[\[CrossRef\]](#)[\[PubMed\]](#)[\[PubMedCentral\]](#)
 14. Nibourg LM, Gelens E, Kuijjer R, et al. Prevention of posterior capsular opacification. *Exp Eye Res.* 2015;136:100–15.
[\[CrossRef\]](#)[\[PubMed\]](#)
 15. Cheng CY, Yen MY, Chen SJ, et al. Visual acuity and contrast sensitivity in different types of posterior capsule opacification. *J Cataract Refract Surg.* 2001;27(7):1055–60.
[\[CrossRef\]](#)[\[PubMed\]](#)
 16. Peterseim MW, Wilson ME. Bilateral intraocular lens implantation in the pediatric population. *Ophthalmology.* 2000;107(7):1261–6.
[\[CrossRef\]](#)[\[PubMed\]](#)
 17. Luo Y, Lu Y, Lu G, et al. Primary posterior capsulorhexis with anterior vitrectomy in preventing posterior capsule opacification in pediatric cataract microsurgery. *Microsurgery.* 2008;28(2):113–6.
[\[CrossRef\]](#)[\[PubMed\]](#)
 18. Raina UK, Gupta V, Arora R, et al. Posterior continuous curvilinear capsulorhexis with and without optic capture of the posterior chamber intraocular lens in the absence of vitrectomy. *J Pediatr Ophthalmol Strabismus.* 2002;39(5):278–87.
[\[PubMed\]](#)
 19. Chrousos GA, Parks MM, O'Neill JF. Incidence of chronic glaucoma, retinal detachment and secondary membrane surgery in pediatric aphakic patients. *Ophthalmology.* 1984;91(10):1238–41.
[\[CrossRef\]](#)[\[PubMed\]](#)
 20. Hosal BM, Biglan AW. Risk factors for secondary membrane formation after removal of pediatric cataract. *J Cataract Refract Surg.* 2002;28(2):302–9.
[\[CrossRef\]](#)[\[PubMed\]](#)
 21. Hollick EJ, Spalton DJ, Ursell PG, et al. Lens epithelial cell regression on the posterior capsule with different intraocular lens materials. *Br J Ophthalmol.* 1998;82(10):1182–8.
[\[CrossRef\]](#)[\[PubMed\]](#)[\[PubMedCentral\]](#)
 22. Vargas LG, Peng Q, Apple DJ, et al. Evaluation of 3 modern single-piece foldable intraocular lenses: clinicopathological study of posterior capsule opacification in a rabbit model. *J Cataract Refract Surg.* 2002;28(7):1241–50.

[\[CrossRef\]](#)[\[PubMed\]](#)

23. Nixon DR, Apple DJ. Evaluation of lens epithelial cell migration in vivo at the haptic-optic junction of a one-piece hydrophobic acrylic intraocular lens. *Am J Ophthalmol*. 2006;142(4):557–62.
[\[CrossRef\]](#)[\[PubMed\]](#)
24. Richter-Mueksch S, Kahraman G, Amon M, et al. Uveal and capsular biocompatibility after implantation of sharp-edged hydrophilic acrylic, hydrophobic acrylic, and silicone intraocular lenses in eyes with pseudoexfoliation syndrome. *J Cataract Refract Surg*. 2007;33(8):1414–8.
[\[CrossRef\]](#)[\[PubMed\]](#)
25. Gimbel HV. Posterior continuous curvilinear capsulorhexis and optic capture of the intraocular lens to prevent secondary opacification in pediatric cataract surgery. *J Cataract Refract Surg*. 1997;23 Suppl 1:652–6.
[\[CrossRef\]](#)[\[PubMed\]](#)
26. Kora Y, Inatomi M, Fukado Y, et al. Long-term study of children with implanted intraocular lenses. *J Cataract Refract Surg*. 1992;18(5):485–8.
[\[CrossRef\]](#)[\[PubMed\]](#)
27. Gimbel HV, Ferensowicz M, Raanan M, et al. Implantation in children. *J Pediatr Ophthalmol Strabismus*. 1993;30(2):69–79.
[\[PubMed\]](#)
28. BenEzra D, Cohen E. Cataract surgery in children with chronic uveitis. *Ophthalmology*. 2000;107(7):1255–60.
[\[CrossRef\]](#)[\[PubMed\]](#)
29. Rao SK, Ravishankar K, Sitalakshmi G, et al. Cystoid macular edema after pediatric intraocular lens implantation: fluorescein angiography results and literature review. *J Cataract Refract Surg*. 2001;27(3):432–6.
[\[CrossRef\]](#)[\[PubMed\]](#)
30. Hoyt CS, Nickel B. Aphakic cystoid macular edema: occurrence in infants and children after transpupillary lensectomy and anterior vitrectomy. *Arch Ophthalmol*. 1982;100(5):746–9.
[\[CrossRef\]](#)[\[PubMed\]](#)
31. Wormstone IM, Wang L, Liu CS. Posterior capsule opacification. *Exp Eye Res*. 2009;88(2):257–69.
[\[CrossRef\]](#)[\[PubMed\]](#)
32. Chandler HL, Barden CA, Lu P, et al. Prevention of posterior capsular opacification through cyclooxygenase-2 inhibition. *Mol Vis*. 2007;13:677–91.
[\[PubMed\]](#)[\[PubMedCentral\]](#)
33. Flach AJ, Dolan BJ. Incidence of postoperative posterior capsular opacification following treatment with diclofenac 0.1% and ketorolac 0.5% ophthalmic solutions: 3-year randomized, double-masked, prospective clinical investigation. *Trans Am Ophthalmol Soc*. 2000;98(101–105):105–7.
- 34.


Vasavada VA, Praveen MR, Shah SK, et al. Anti-inflammatory effect of low-molecular-weight heparin in pediatric cataract surgery: a randomized clinical trial. *Am J Ophthalmol.* 2012;154(2):252–8.

[\[CrossRef\]](#)[\[PubMed\]](#)

35. Tanaka T, Yamakawa N, Mizusawa T, et al. Interaction between inflammatory cells and heparin-surface-modified intraocular lens. *J Cataract Refract Surg.* 2000;26(9):1409–12.

[\[CrossRef\]](#)[\[PubMed\]](#)

25. Reposition, Explantation, and Exchange of Intraocular Lenses

Danying Zheng¹ 

- (1) State Key Laboratory of Ophthalmology, Zhongshan Ophthalmic Center, Sun Yat-Sen University, 54S Xianlie Road, Guangzhou, 510060, People's Republic of China

 **Danying Zheng**

Email: zhengdy@163.com

Abstract

Along with the widespread application of intraocular lens (IOL) implantation in pediatric cataract patients, IOL-related complications may occur. Surgical reposition, explantation, or exchange of IOLs may become necessary when these complications pose a serious threat to visual functions. Because of the unique characteristics of pediatric eyes, greater postoperative inflammation, as well as possible adhesion of the IOL haptics to surrounding tissues after implantation, it is more complex and risky to explant than to implant IOLs. This chapter will discuss the surgical indications, preoperative preparation, selection of surgical approach, and surgical techniques for the reposition, explantation, or exchange of IOLs.

With the increased use of intraocular lens (IOL) implantation in cataract children, IOL-related complications also increase. When decentration or dislocation of IOL leads to significant visual loss or other complications, reposition, explantation, or exchange of the IOL may be necessary. Due to the unique ocular structure and severe postoperative inflammatory response in pediatric patients, adhesion between the IOL and its surrounding tissues is likely to occur, which increases the complexity and risk of IOL reposition

and explantation. Thus, specific surgical methods or techniques may be required. This chapter elaborates on the techniques used in reposition, explantation, or exchange of an IOL.

25.1 IOL Reposition

IOL malposition is a common complication after pediatric IOL implantation [1, 2], which may result in ametropia, chronic inflammatory response, or damage to the corneal endothelium. Surgical reposition may be necessary in severe cases.

25.1.1 Causes and Clinical Presentation of IOL Malposition

In pediatric patients, common causes for IOL malposition include postoperative severe inflammatory response, asymmetric capsular shrinkage, proliferation of residual cortex, short overall diameter of the IOL, congenital or traumatic zonular loss, and/or inadequate capsular support.

Children with IOL malposition may present with:

1. Fixed pupillary capture: It means that a portion of the IOL optic or the whole optic is anterior to the iris plane, with synechia formation (Fig. 25.1). It may also be accompanied by posterior capsular opacification (PCO) or even breakage of the IOL haptic. The incidence of IOL pupillary capture is much higher in children than in adults, which is reported to be 8.5–41 %. It occurs most often in children <2 years of age, when an optic size <6 mm is used and the lens is fixated in the ciliary sulcus [3, 4]. A study of children with traumatic cataracts by Pandey and colleagues found that ciliary sulcus fixation was associated with a high risk (up to 40 %) of IOL pupillary capture, whereas no patients in the capsular bag fixation group reported such an event [5].

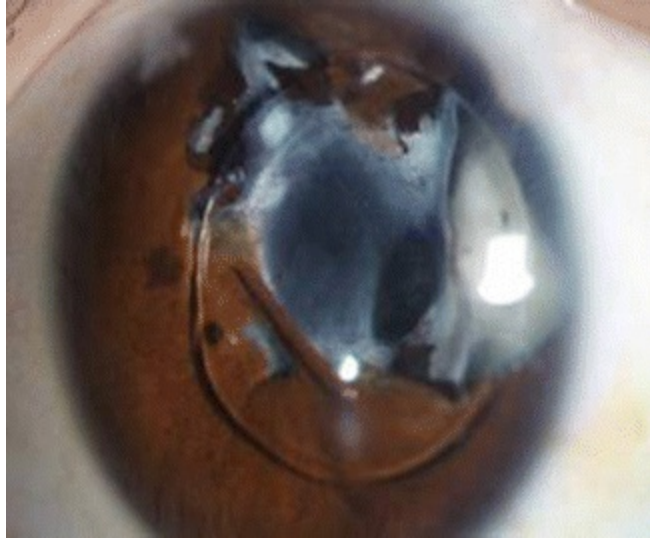

Fig. 25.1 Fixed pupillary capture. The IOL optic is present anterior to the iris accompanied by posterior capsular opacification (PCO)

2. IOL dislocation: It can be divided into two types, i.e., in-the-bag dislocation, which means that zonular abnormalities cause part of or the entire capsular bag containing the IOL to dislocate into the anterior chamber (Fig. 25.2) or the vitreous cavity [6], and out-of-the-bag dislocation (Fig. 25.3), which often occurs secondary to a defective capsular bag or asymmetric IOL fixation, leading to partial or complete dislocation of the IOL [7].

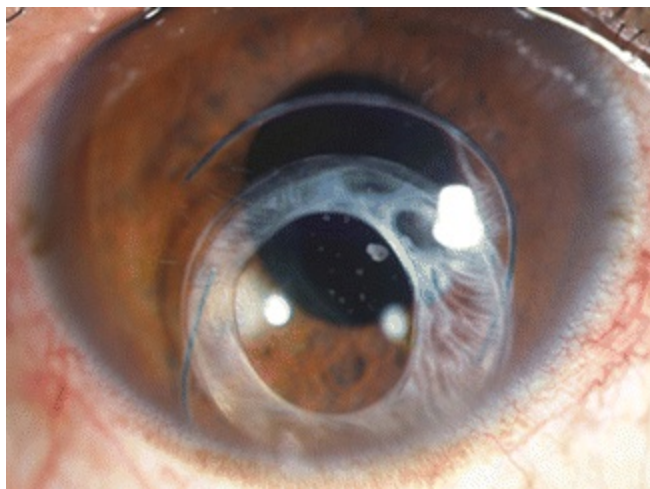


Fig. 25.2 In-the-bag IOL dislocation into the anterior chamber

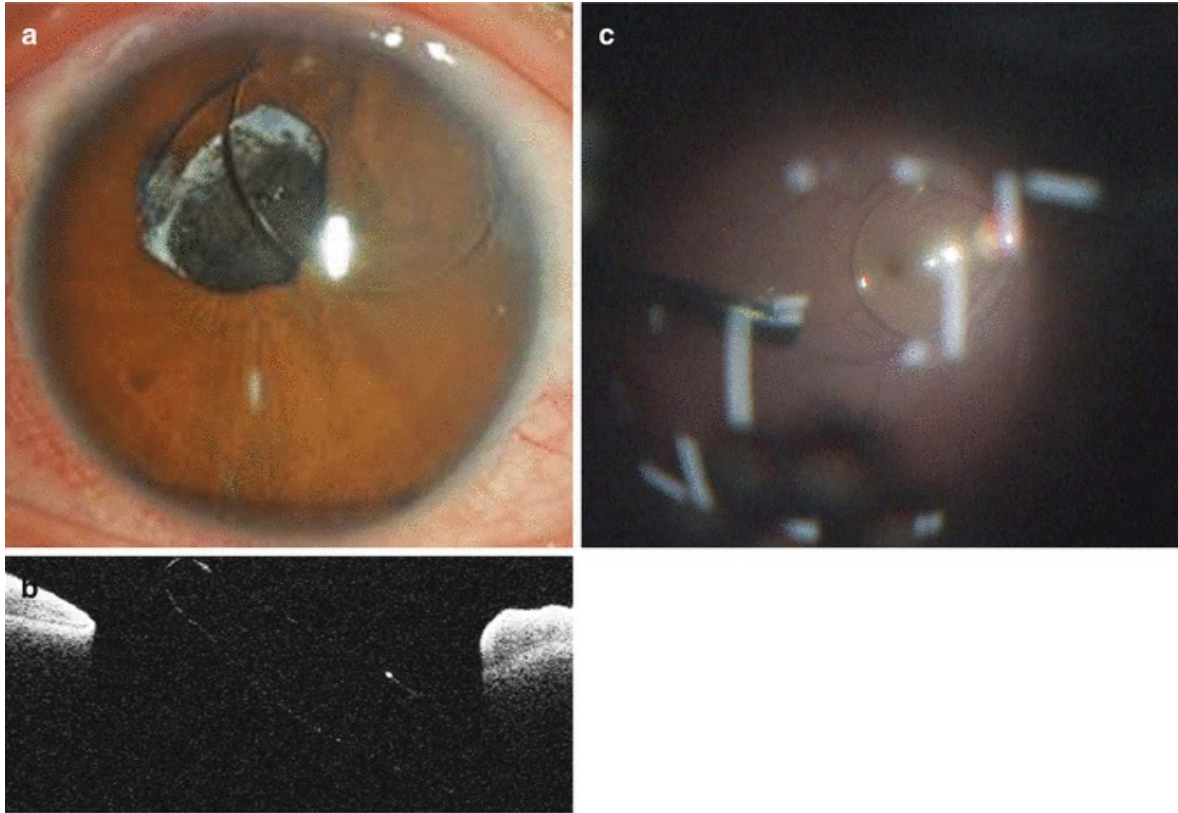


Fig. 25.3 Out-of-the-bag IOL dislocation. (a) Out-of-the-bag IOL dislocation into the anterior chamber; (b) UBM reveals out-of-the-bag IOL dislocation into the anterior chamber (*white arrow*); (c) Out-of-the-bag IOL dislocation into the vitreous cavity, with the IOL being anterior to the retina

25.1.2 Indications for IOL Reposition

As for the management of IOL malposition, if the majority of the IOL optic is still in the pupillary zone without any associated serious complications, the surgeon may elect to manage such patients by conservative observation and correction of refractive error. But if severe visual loss or other complications are caused by significant decentration of the IOL optic and the IOL remains intact with minor adhesion to surrounding tissues, then IOL reposition should be considered [1]. Preoperative evaluation of the ocular condition and the IOL is essential and may include the following items [8–10]:

1. Ocular condition: Presence of any corneal or fundus problems that are

considered contradictions of IOL implantation.

2. IOL power: Try to determine whether the power of the original IOL is suitable, as well as the severity of refractive error.
3. IOL diameter: If ciliary sulcus fixation is considered after IOL reposition, the diameter of the original IOL should be assessed, because an IOL with a short diameter placed in the ciliary sulcus may result in IOL redislocation.
4. Presence of IOL damage: Transparency of the IOL optic and the shape of the haptics.
5. IOL haptic material: The material of the original IOL haptics should meet the requirements of reposition. A PMMA haptic, non-foldable IOL or a three-piece foldable IOL is appropriate for suture fixation.

25.1.3 Surgical Techniques for IOL Reposition

Surgical techniques for reposition of posterior chamber IOL or an iris-claw anterior chamber IOL are described, respectively, as follows.

25.1.3.1 Reposition of Posterior Chamber IOLs

The surgeon should carefully inspect the capsular bag and try to identify the presence of any posterior capsular defects. Severity of synechia must be assessed, and synechiolysis is recommended if necessary. Reposition of a posterior chamber IOL can be performed via an anterior or posterior approach.

Anterior Approach

1. Incision: An incision made at the site of synechia should be avoided.
2. Separating the adhesion between the IOL and its surrounding tissues:

Synechia can be separated with the use of ophthalmic viscosurgical device (OVD), and a pair of Vannas Capsulotomy Scissors may be used for sharp dissection in difficult cases. The surgeon should try to avoid surgical disturbance to the iris tissue to reduce postoperative inflammatory response. The IOL optic and haptics should always be kept intact during the surgery.

3. Creating space for IOL reposition (Fig. 25.4a): Full separation of the adhesion between the iris and the lens capsule may be required for creating space for IOL reposition. When there is a complete synechia between the pupillary margin and the capsule, the incision should be made superiorly with peripheral iridectomy at the site of the incision. The synechia is carefully separated by injecting OVD through the iridectomy, so as to create space. Try to preserve as much of the lens capsule as possible.

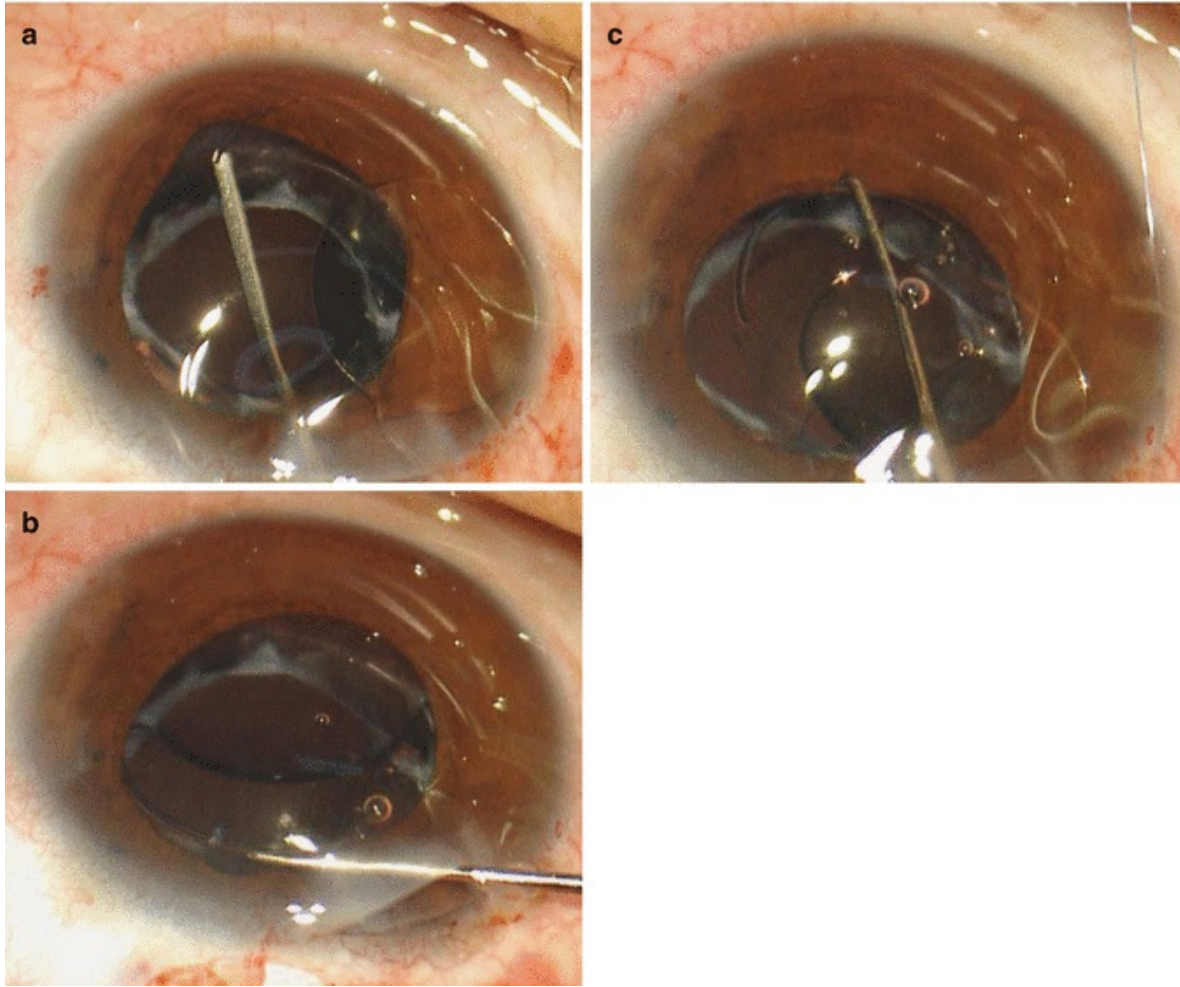
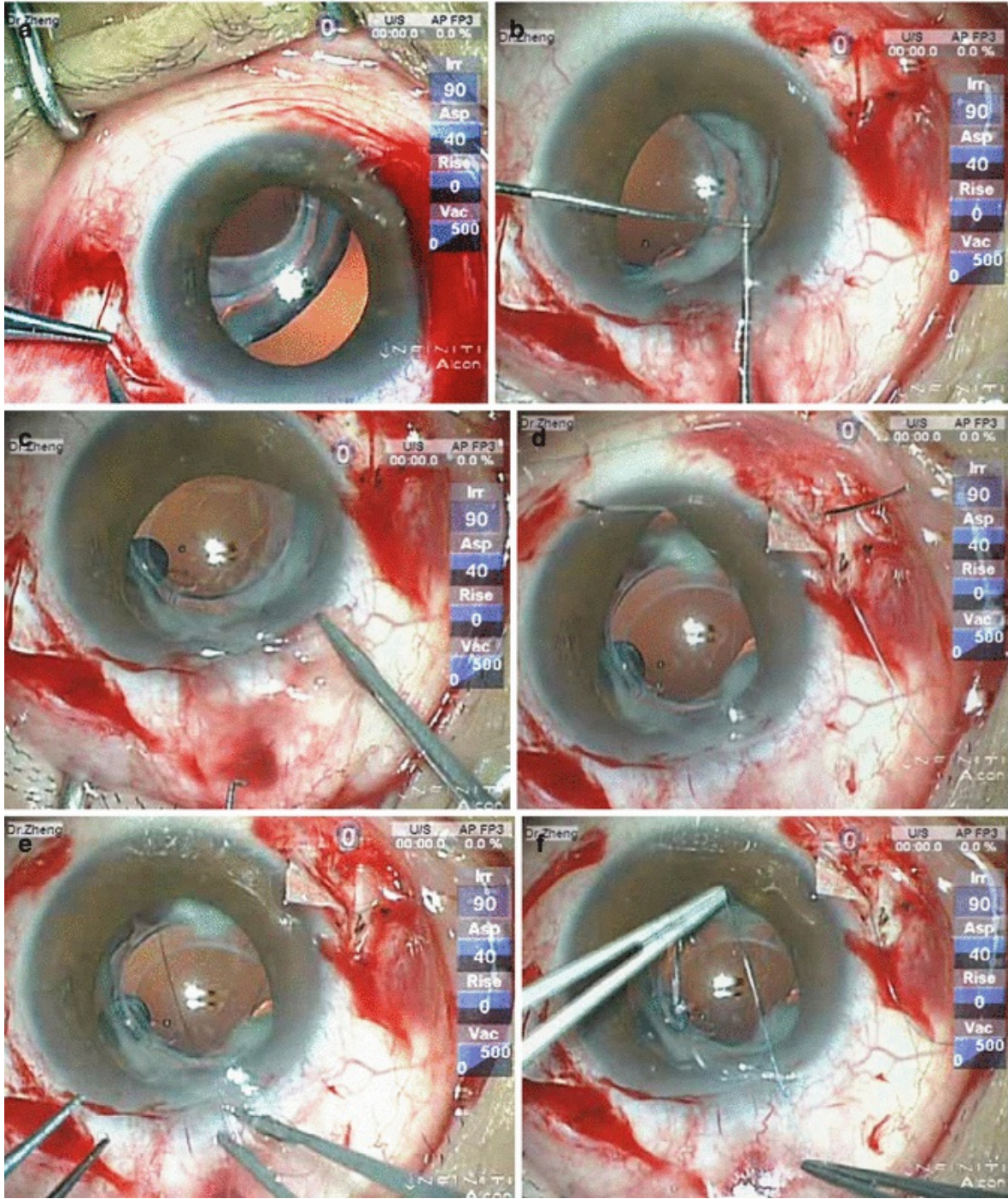
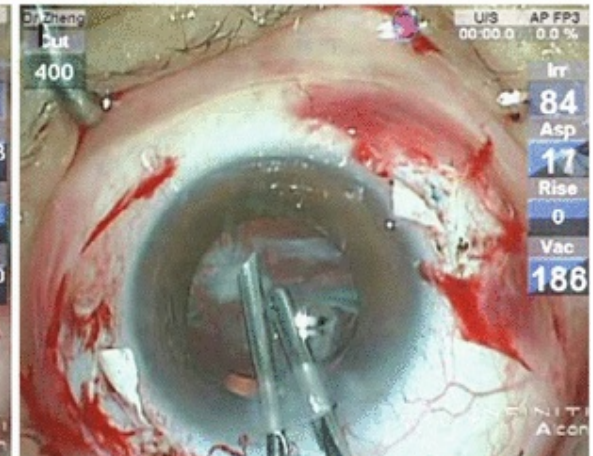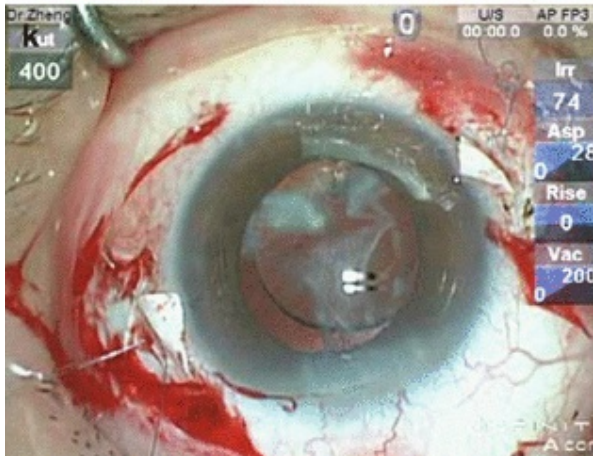
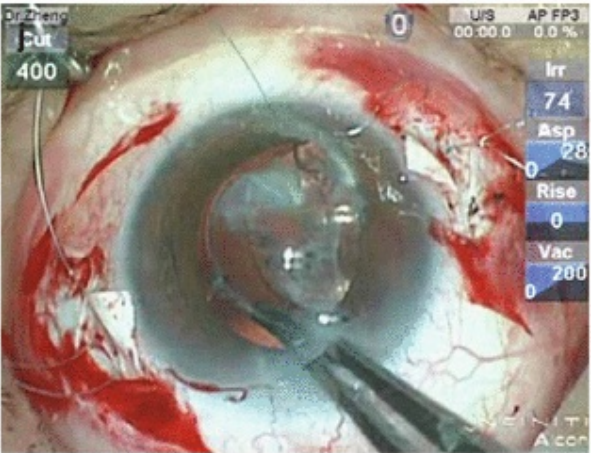
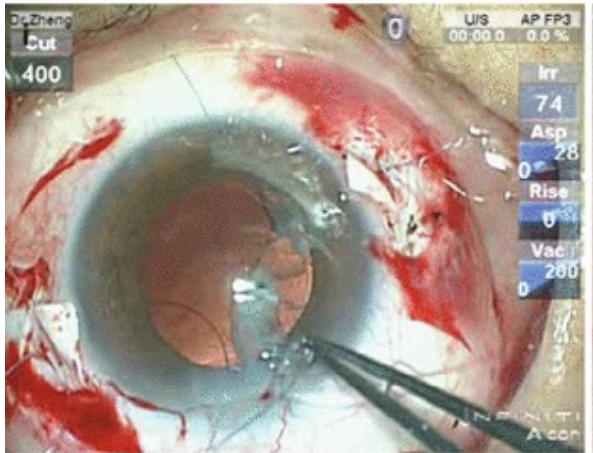
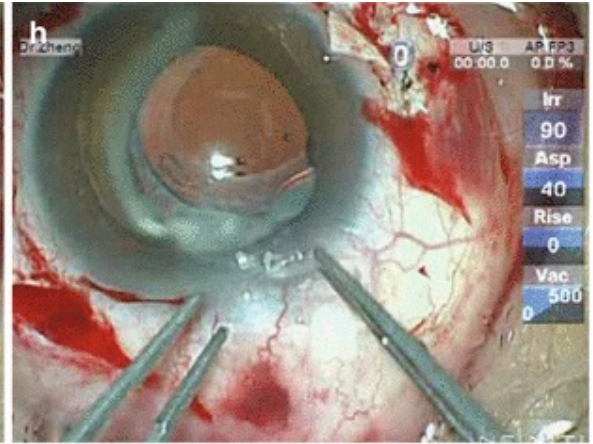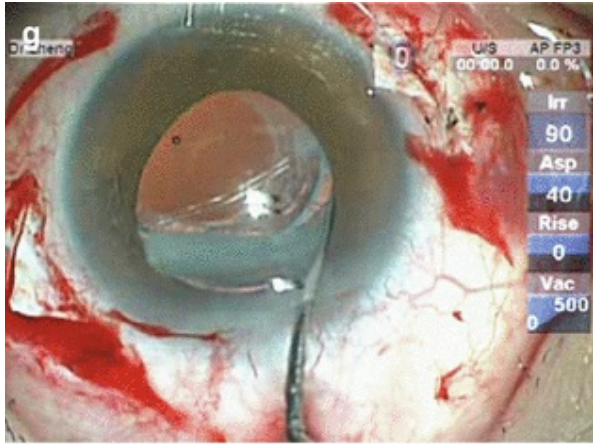


Fig. 25.4 IOL ciliary sulcus fixation. (a) Separate the adhesion between the iris and the capsule by injecting OVD, so as to create space for IOL reposition; (b) Placing the leading haptic into the ciliary sulcus; (c) Placing the trailing haptic into the ciliary sulcus

4. Reposition of the IOL: When the residual peripheral capsule is adequate, the IOL can be directly repositioned into the ciliary sulcus (Fig. 25.4b, c). But in the absence of adequate capsular support, single-loop or double-loop suture fixation of the IOL should be considered. The surgical techniques for double-loop suture fixation are described in detail as follows (Fig. 25.5):





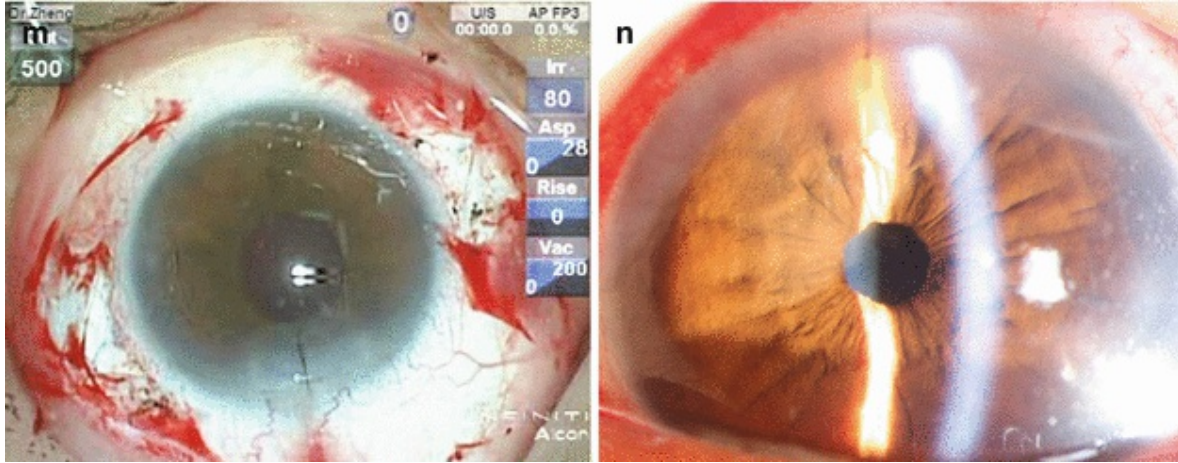


Fig. 25.5 IOL reposition (double-loop fixation). **(a)** Two half-thickness triangular limbal-based scleral flaps are made 3 mm posterior to the limbus. **(b)** After OVD injection, the IOL is carefully dissected with two Sinsky hooks and then dialed into the anterior chamber. **(c)** One haptic is dialed out of the incision with smooth forceps. **(d)** The needle of a 10-0 polypropylene suture is introduced into the eye through the sclera; passes through the posterior chamber, the pupil, and the anterior chamber; and exits through the peripheral cornea. **(e)** The suture needle is removed and the suture thread is withdrawn through the incision. **(f)** The suture on the right side of the incision is securely tied to the dialed-out haptic (at the lateral 1/4–1/3 of the haptic). **(g)** The sutured haptic is dialed back into the eye. **(h)** The second haptic is also dialed out. **(i)** The suture on the left side of the incision is tied to the second haptic (at the lateral 1/4–1/3 of the haptic). **(j)** The second haptic is also reinserted into the eye. **(k)** The sutures are gently pulled to secure centration of the IOL with two pairs of smooth forceps, and then the sutures are knotted under the scleral flaps. **(l)** The residual lens cortex and capsule are removed with an anterior vitrector. **(m)** The limbal incision is closed. **(n)** Slit-lamp image 1 day after IOL double-loop reposition

- (a) Two fornix-based conjunctival flaps are made opposite to each other, followed by scleral cautery for hemostasis.
- (b) Two half-thickness, triangular, limbal-based scleral flaps are made beneath the conjunctival flaps.
- (c) A 3.2-mm limbal tunnel incision is made temporally or superiorly (or a superior scleral tunnel incision for young children), and then a paracentesis is made at the limbus 90 degrees clockwise to the incision with a 15-degree blade.
- (d) The anterior chamber is filled with OVD and the IOL is carefully

dissected. The dislocated IOL is dialed into the anterior chamber with a Sinsky hook with one of its haptics outside the incision.

- (e) The needle of a 10-0 polypropylene suture is introduced into the eye under the scleral flap 1.5 mm posterior to the limbus, which can be achieved by either of these two techniques. In the first technique, the triangular scleral flap is lifted, and a single-armed suture passes from the superficial layer of the sclera and then enters into the eye through the sclera. After passing through the posterior chamber, the pupil, and the anterior chamber, the needle exits through the peripheral cornea. The suture needle is removed and the suture thread is withdrawn through the incision (Fig. 25.5). In the second technique, a double-armed 10-0 polypropylene suture is used. The first needle is introduced into the eye under the scleral flap, while a 25-gauge needle is introduced into the eye under the opposite scleral flap, and then the first needle is inserted into the barrel of the 25-gauge needle in the pupillary area under direct visualization. The 25-gauge needle is then removed, and the suture thread is withdrawn along with it under the scleral flap. Finally, the suture thread is exited from the eye through the incision and cut into two parts for subsequent fixation (Fig. 25.6).

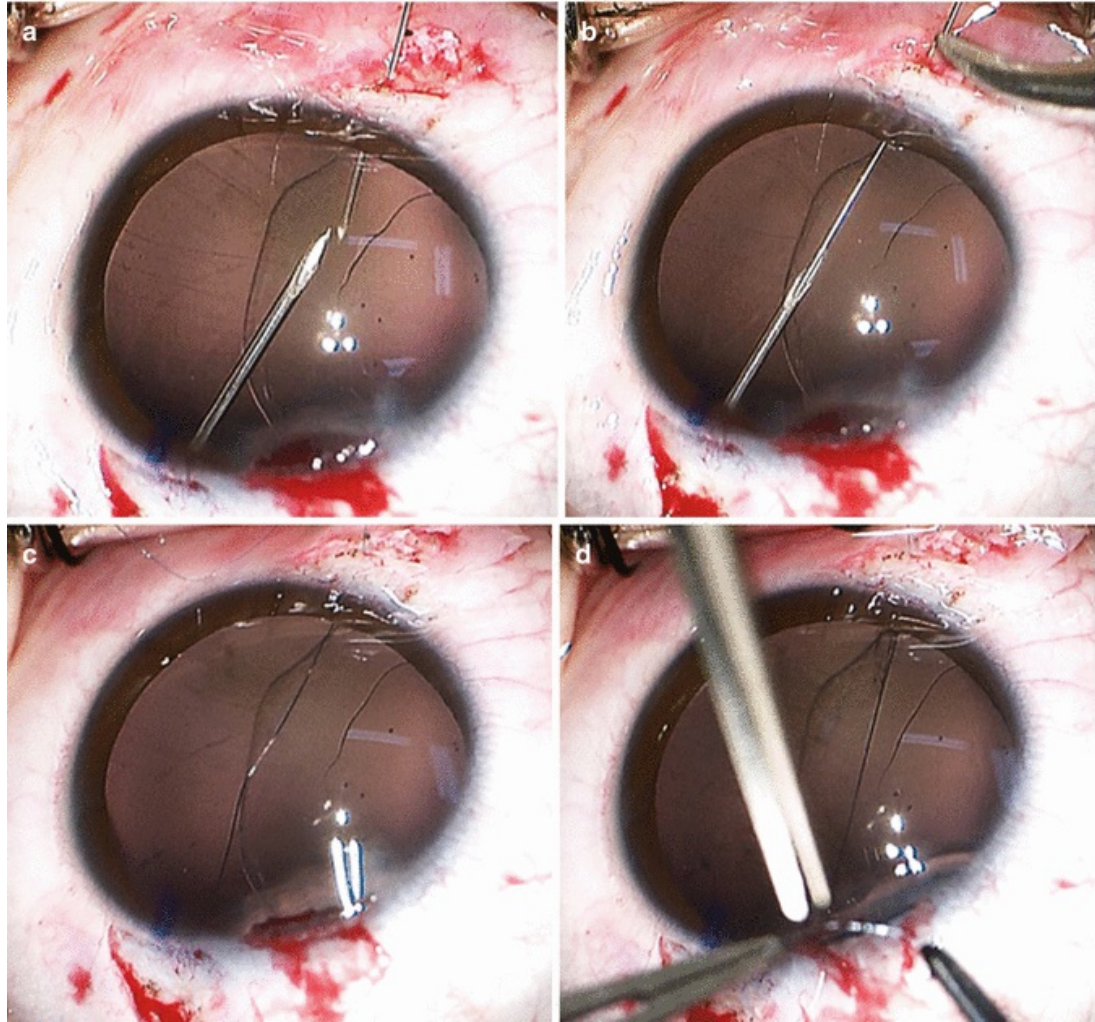


Fig. 25.6 Ciliary sulcus double-loop suture fixation (the second technique). (a) The first needle is introduced into the eye under the scleral flap. (b) A 25-gauge needle is introduced into the eye under the opposite scleral flap, and then the first needle is inserted into the barrel of the 25-gauge needle in the pupillary area under direct visualization. (c) The 25-gauge needle is removed and the suture is withdrawn through the incision. (d) The suture is cut into two parts for subsequent fixation

- (f) One haptic of the IOL is dialed out of the incision, and then the suture on the right side of the incision is securely tied to the haptic (at approximately the lateral 1/4–1/3 of the haptic). The sutured haptic is dialed back into the ciliary sulcus.
- (g) The second haptic is also dialed out, tied to the suture on the left side of the incision, and reinserted into the eye in a similar fashion.

- (h) The sutures are gently pulled to secure centration of the IOL with microsurgical smooth forceps, and then the sutures are knotted under the scleral flaps.
- (i) The OVD is removed and the anterior chamber is filled with balanced saline solution (BSS). The scleral flaps are then closed using 10-0 nylon sutures, and the conjunctival flaps are closed with cautery or suturing.

The key points during the procedure of IOL double-loop suture fixation are summarized below. The line connecting the two points of needle entry through the sclera should pass through the center of the cornea; each point of entry should be of equal distance to the limbus; besides, the distances from each point where the haptic is tied to the haptic–optic junction should be the same.

Posterior Approach

When the IOL is dislocated into the mid-posterior vitreous, the surgeon may perform posterior vitrectomy via the pars plana. With the help of the optical fiber, the vitreous cutter, or microsurgical forceps, the dislocated IOL is lifted into the anterior chamber and then repositioned. The key to this approach is to separate the adhesions between the IOL and its surrounding tissues and then remove the prolapsed vitreous body.

25.1.3.2 Reposition of Iris-Claw Anterior Chamber IOLs

There are controversies over the use of iris-claw anterior chamber IOLs in pediatric patients. We do not recommend using these IOLs in pediatric lens surgery, but cases of an IOL with a detached iris claw have been encountered occasionally in our clinical practice. In such cases, the decision on whether or not to perform IOL reposition or explantation should be based on an overall evaluation which includes the corneal endothelial cells, the anterior chamber depth, and the iris. Surgical reposition of these IOLs can be considered in older children. Reposition techniques are described as follows:

1. A 3.2-mm superior scleral tunnel incision is made and then a paracentesis is made at the 2 o'clock or 10 o'clock position using a 15-degree blade (depending on where fixing the IOL haptics). OVD is injected on both anterior and posterior surfaces of the IOL to create adequate space for manipulation. The incision is enlarged to 3.5–4 mm with a keratome.
 2. The IOL optic is fixed using a pair of anterior chamber IOL holding forceps. The mid-peripheral iris is lifted up with a 20-gauge needle with the tip bent at 90 degrees and then fixed with an iris claw. Full-thickness iris capture at an appropriate site and width is required.
 3. After OVD removal, the incision is closed with a 10-0 nylon suture (one or two stitches).
-

25.2 IOL Explantation and Exchange

25.2.1 Causes of IOL Explantation and Exchange

In the early years, explantation of IOLs was mainly undertaken due to the occurrence of uveitis–glaucoma–hyphema syndrome (UGH syndrome) induced by posterior chamber IOLs or secondary glaucoma and corneal endothelial decompensation induced by anterior chamber IOLs. Along with advances in IOL material, manufacturing, and sterilizing methods, there are new causes for IOL explantation and exchange which include the following [11]:

1. Significant refractive error

Significant refractive errors may be caused by biometrical errors, inappropriate choice of the calculation formula, or severe myopic shift after IOL implantation [12, 13]. If such a refractive error cannot be corrected satisfactorily by spectacles or contact lenses or if the child's visual development might be affected, IOL explantation or exchange

should be considered.

2. IOL opacification and damage

IOL opacification (Fig. 25.7) is mainly associated with the use of silicone or hydrophilic acrylic IOLs [14]. After surgical explantation of 22 opacified hydrophilic acrylic IOLs, we performed microscopic examination and energy-dispersive X-ray spectroscopy, and identified granular deposits of varying sizes on the surface of the optic, which contained plenty of calcium and phosphorus [15]. In addition, due to the usually significant inflammatory response after pediatric cataract surgery, the surface of the IOL may in severe cases be covered with a thick inflammatory exudative membrane, which may lead to IOL opacification. As the IOLs will stay in children's eyes for a much longer period compared with adults, we should be cautious when selecting the IOL material for pediatric patients. If the opacified IOL is exerting a serious impact on visual functions, surgical explantation or exchange should be considered.

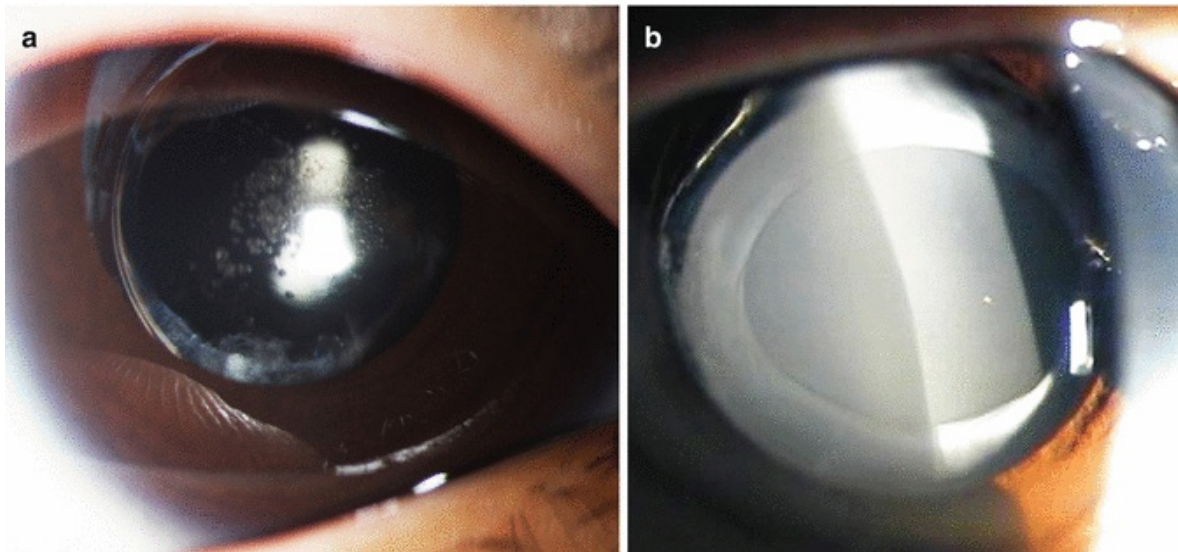


Fig. 25.7 IOL opacification. (a) Granular deposits of varying sizes on the surface of the IOL optic; (b) Plenty of calcium and phosphorus deposit and cover the whole IOL.

Due to improper manipulation or quality flaws of surgical instruments, IOL damage may occur during implantation, such as

bending or breakage of the haptic or scratching of the optic. Besides, laser injury to the IOL optic may occur when laser posterior capsulotomy is performed, possibly due to the specific material of the IOL or improper practices (Fig. 25.8). When the visual quality is impaired by these injuries, IOL explantation or exchange should be considered.

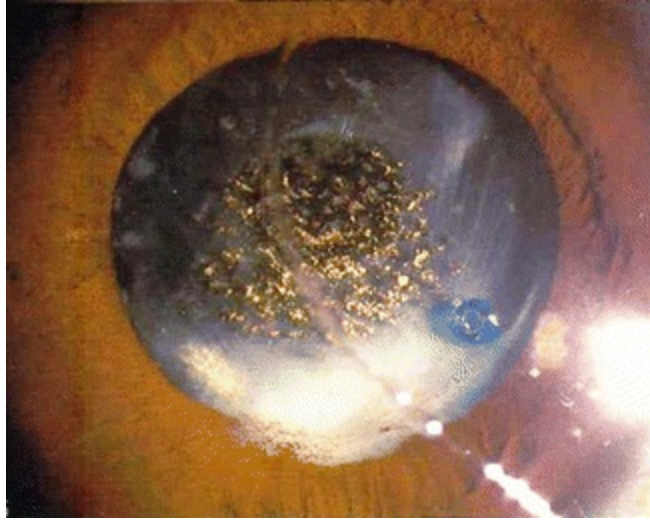


Fig. 25.8 IOL laser injury

3. Corneal endothelial damage

Corneal endothelial damage is often seen in patients receiving anterior chamber IOL implantation, such as angle-supported or iris-claw IOLs; it may also occur when a posterior chamber IOL is dislocated or subluxated into the anterior chamber (Fig. 25.9). If there is a progressive reduction in the corneal endothelial cell counts or in the presence of localized corneal edema, the IOL should be explanted immediately.

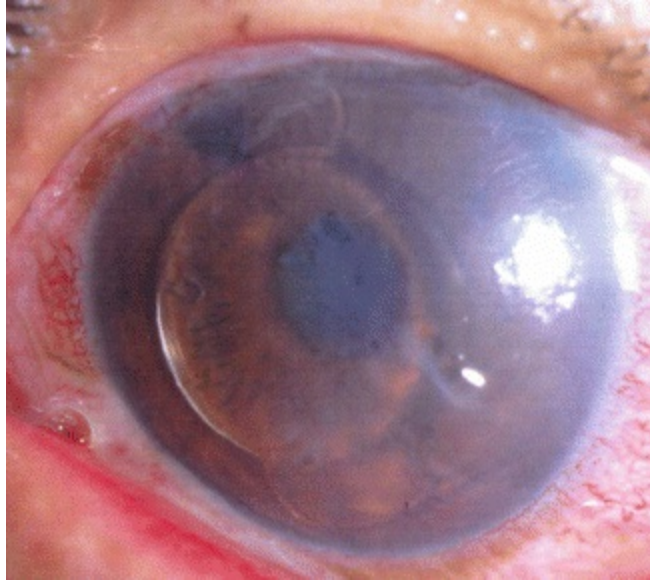


Fig. 25.9 Corneal endothelial decompensation

4. Glaucoma

Glaucoma may develop early or years after pediatric cataract surgery. Angle-supported IOLs have been associated with refractory ocular hypertension, which may be accompanied by the intermittent touch syndrome or UGH syndrome. In such instances, IOL explantation should be considered.

5. Refractory uveitis

For cataract children with concurrent uveitis, cataract extraction with IOL implantation is routinely performed after maintaining a complete absence of active inflammation for at least 3 months [16]. In some patients, however, particularly in patients with juvenile rheumatoid arthritis-associated uveitis, severe or even uncontrollable inflammatory response may occur after surgery, requiring surgical explantation of the IOL [11, 17].

6. Retinal detachment

When retinal detachment develops after surgery, there is usually no need to explant the IOL. But if the IOL interferes with fundus

observation and surgical manipulation, IOL explantation may become necessary.

25.2.2 Surgical Techniques

The surgical strategy should be decided depending upon the age of the patient as well as the specific conditions of the affected eye. The surgeon should comply with the following principles: minimizing disturbance to intraocular tissues, reducing postoperative inflammatory response, preserving as much capsule as possible, avoiding traction on the zonules, and preventing secondary injury.

25.2.2.1 IOL Explantation

The type of the IOL determines how it can be explanted.

Explantation of Anterior Chamber IOLs

1. After adequate miosis, a superior 3.2-mm limbal incision is made, and a paracentesis is made at the 2 o'clock or 10 o'clock position using a 15-degree blade.
2. OVD is injected on both anterior and posterior surfaces of the IOL to facilitate separation of the adhesion between the IOL and its surrounding tissues. For an iris-claw IOL, a pair IOL holding forceps is used to fix the optic via the incision. A Sinskey hook or a needle with the tip bent at 90 degrees is inserted through the paracentesis, and then the iris within the claw is pushed out of the claw (Fig. 25.10). For an angle-supported Z-loop IOL, the haptics are dialed out in counterclockwise fashion.

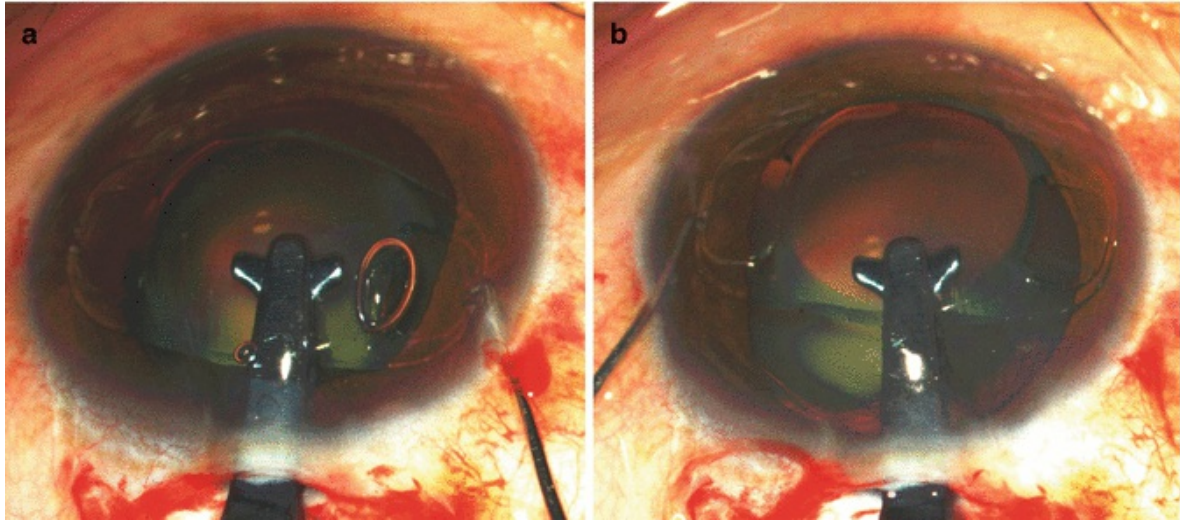


Fig. 25.10 Explantation of an iris-claw IOL. (a) A pair of IOL holding forceps is used to fix the optic via the incision. (b) A Sinskey hook is inserted through the paracentesis, and then the iris within the claw is pushed out

3. The incision is enlarged according to the IOL diameter and IOL holding forceps are used to grasp and explant the optic.
4. The incision is then closed with a 10-0 nylon suture.

Explantation of Posterior Chamber IOLs

1. Incision: It depends on the material and diameter of the IOL requiring explantation—a rigid IOL is often removed intactly without cutting (Fig. 25.11), with an incision measuring 5.5–6 mm, while an incision for explanting a soft IOL usually measures 3.0–3.5 mm; the specific techniques are described as follows (Fig. 25.12).

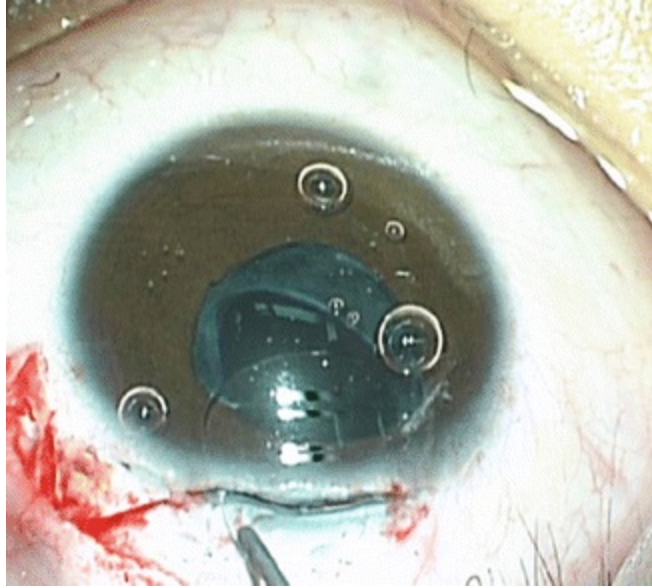


Fig. 25.11 Removal of an intact rigid IOL

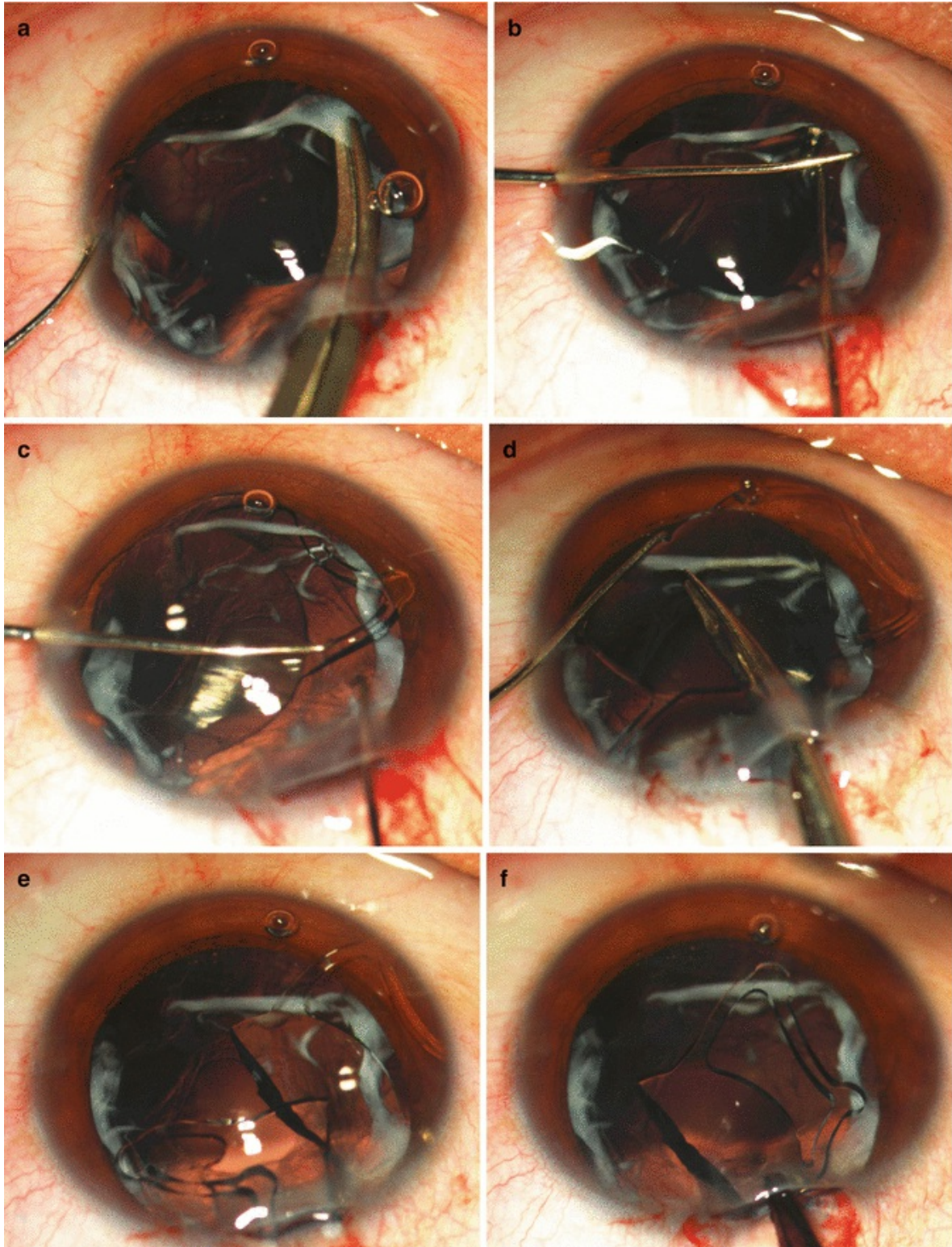


Fig. 25.12 Explantation of a posterior chamber IOL. (a) The fibrosis membrane on the anterior capsule opening is dissected with capsulotomy scissors. (b) The haptics are separated. (c) One haptic is freed into the anterior chamber. (d) The optic edge is fixed with a hook, and the IOL is

transected with an IOL cutter. (e) One half of the free IOL is explanted from the incision with IOL holding forceps. (f) The other half is also freed and removed from the anterior chamber in a similar fashion

2. Freeing the IOL (Fig. 25.12a): In the presence of an intact capsule, adequate high molecular weight OVD (e.g., sodium hyaluronate or Healon GV) is injected into the anterior chamber and the capsular bag to separate the optic and haptics from the capsule, and then the IOL is freed out of the capsular bag and released into the anterior chamber. But if significant fibrosis, shrinkage of the anterior capsule opening, or tight adhesions between the IOL and the capsule or surrounding tissues are noted, capsulotomy scissors are used in sharp dissection of these adhesions and then the IOL can be freed into the anterior chamber. For an IOL fixed in the ciliary sulcus, all adhesions between the IOL and its surrounding tissues should be removed.
3. Cutting the IOL: A rigid IOL should be removed in one piece without cutting its optic. In the presence of tight adhesions between the haptics and the fibrous membrane, making removal of the IOL difficult, the haptics should be amputated first as close to the optic as possible, and then the optic is explanted. Before the removal of a foldable IOL, more OVD is added into the anterior chamber, the optic edge of the IOL is fixed with a hook through the paracentesis, and then an IOL cutter is used to cut the optic into two removable halves (Fig. 25.12d).
4. Explanting the IOL: One half of the free IOL is explanted from the incision with IOL holding forceps, and the other half is also freed and removed from the anterior chamber in a similar fashion (Fig. 25.12e, f). For a silicone foldable IOL that cannot be transected into two halves, the incision may be enlarged to 4 mm for its removal in one piece. When the IOL is completely dislocated into the mid-posterior portion of the vitreous cavity, standard pars plana vitrectomy is performed. All vitreous adhesions should be removed, and any forceful traction on the IOL should be avoided so as to prevent traction on the retina and possible retinal tear. The IOL is lifted up by grasping the root of the upper haptic with vitreoretinal forceps, then delivered into the anterior chamber with the help of a light pipe, and finally explanted via the superior limbal

incision.

5. All the vitreous prolapsed into the anterior chamber and out of the incision should be thoroughly removed.

For an iris-supported or suture-fixated IOL, the surgeon should first grasp the optic, cut all the sutures, dial the IOL into the anterior chamber, and then proceed with subsequent manipulation.

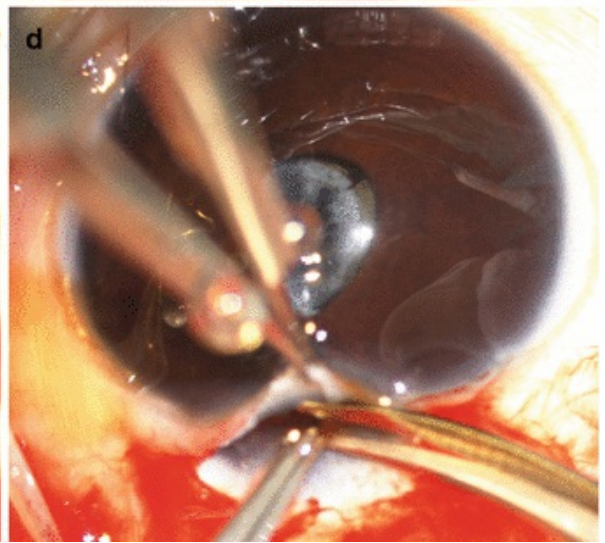
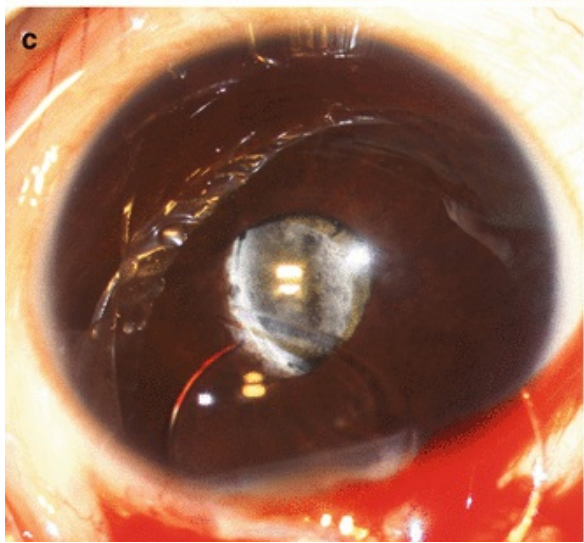
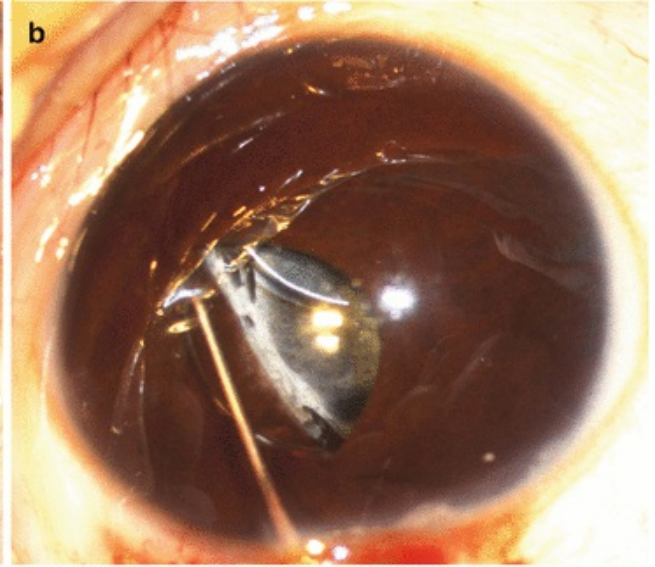
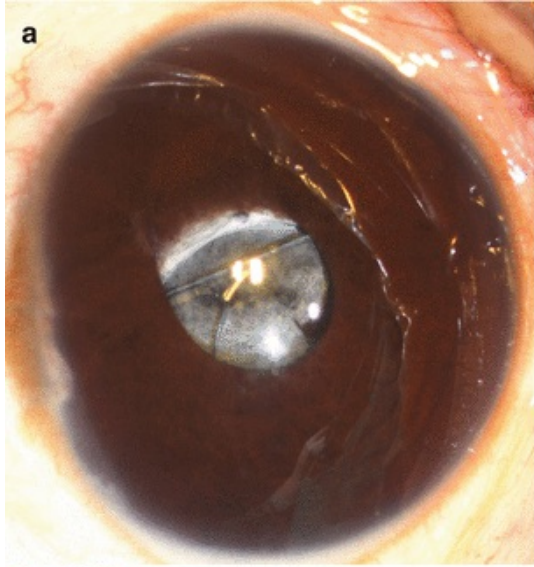
25.2.2.2 IOL Reimplantation

Before exchanging, the surgeon should choose an appropriate IOL for each individual patient based on accurate power calculation:

1. Capsular bag fixation

After IOL explantation, if there is still adequate capsular support for the new IOL, the capsular bag is filled with sufficient OVD and then the new IOL is implanted in the bag.

2. Ciliary sulcus fixation (Fig. 25.13).



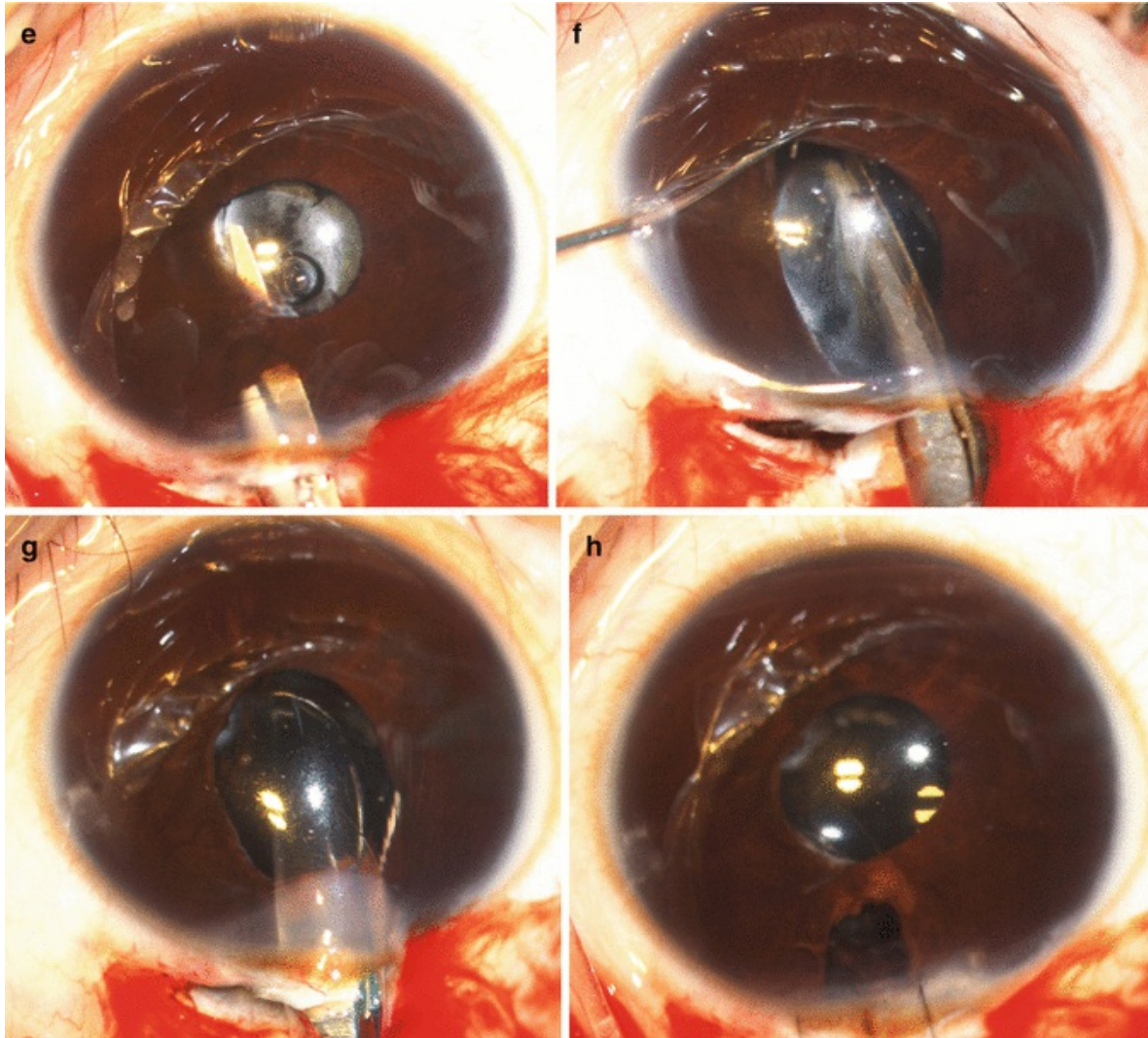


Fig. 25.13 IOL exchange and posterior capsulotomy (a) IOL decentration with posterior capsule opacification. (b) Posterior synechia is separated with an auxiliary instrument through the main incision. (c) The IOL is explanted via the incision. (d) Due to tight synechia at the main incision, a peripheral iridectomy is performed. (e) Capsulotomy scissors are entered into the posterior chamber via the iridectomy to separate the iris from the residual capsule. (f) The posterior capsule is opened with capsulotomy scissors. (g) OVD is injected to create space in the ciliary sulcus, and the IOL is implanted into the sulcus just posterior to the iris. (h) The centration of the IOL is secured

The surgeon should first confirm whether there is adequate space for implantation of the new IOL. Then the anterior chamber is filled with OVD and the IOL haptics are fixed in the ciliary sulcus.

3. Scleral suture fixation of an IOL

When the residual capsule cannot support an IOL, single-loop or double-loop scleral suture fixation of the IOL should be considered according to the condition of the remaining capsule. Details are described in Sect. 25.1.3 “Surgical techniques for IOL Reposition.”

25.3 Surgical Complications

Complications associated with IOL reposition, explantation, or exchange may include:

1. Posterior capsular tear: It is the most frequent complication in patients receiving IOL reposition, explantation, or exchange, with a reported incidence ranging from 3 to 30 % [18, 19]. It is usually caused by improper surgical maneuvers. When it is complicated with vitreous prolapse, anterior vitrectomy should be performed.
2. Zonular dialysis: When the original capsulotomy opening is too small or the adhesion between the IOL haptics and the capsule seems too tight, zonular dialysis or even vitreous prolapse may occur when freeing the IOL. Thus, gentle manipulation is required in the process of freeing the

IOL with adequate OVD injected. If the anterior capsule opening is too small, it can be enlarged with the use of scissors or a radiofrequency diathermy device for capsulotomy, and any traction on the capsule should be avoided so as to prevent zonular dialysis. Management of zonular dialysis is discussed in Chap. 17 “Pediatric Ectopia Lentis.”

3. Iris damage: Regardless of whether IOL reposition, explantation, or exchange is considered, significant posterior synechia is always present, sometimes even with extensive iris–capsule adhesion at the time of the second surgery. Therefore, there is a high risk for iris damage in synechiolysis, especially when the pupil is difficult to dilate. Proper use of OVD and adequate pupillary dilation may help to reduce such a risk.
4. Hyphema: Hyphema resulting from damaged iris vasculature may also occur in the process of synechiolysis. Hemostasis can be achieved by OVD or 2 % noradrenaline injection, wound closure, or increasing the intraocular pressure. Hyphema must be removed before the end of surgery, or else it may exacerbate the postoperative inflammatory response and result in secondary glaucoma. Hemostatic agents may also be used to prevent recurrent bleeding after surgery.
5. Corneal edema: It typically results from mechanical manipulation and can be managed with topical use of hyperosmotic or anti-inflammatory drugs.
6. Cystoid macular edema: This is rarely seen, is often self-limited, and can be treated with topical nonsteroidal anti-inflammatory drugs.

25.4 Summary

Due to a number of causes, IOL decentration, malposition, dislocation, or

significant refractive error may occur after pediatric IOL implantation, which may require surgical reposition, explantation, or exchange of the IOL. A thorough preoperative evaluation of the affected eye should be performed to decide on an appropriate surgical strategy; cautious and gentle manipulation is required during surgery to prevent any secondary injury; and anti-inflammatory therapy, as well as minimization of postoperative complications, is also essential after surgery.

References

1. Lambert SR, Drack AV. Infantile cataracts. *Surv Ophthalmol*. 1996;40(6):427–58.
[CrossRef][PubMed]
2. Hiles DA, Hered RW. Modern intraocular lens implants in children with new age limitations. *J Cataract Refract Surg*. 1987;13:493–7.
[CrossRef][PubMed]
3. Pandey SK, Wilson ME, Trivedi RH, et al. Pediatric cataract surgery and intraocular lens implantation: current techniques, complications, and management. *Int Ophthalmol Clin*. 2001;41(3):175–96.
[CrossRef][PubMed]
4. Mingxing W, Yizhi L, Yuhua L, et al. The causes and reposition of fixed intraocular lens pupillary capture in children. *Chin J Ophthalmol*. 2004;3:190–2.
5. Pandey SK, Ram J, Werner L, et al. Visual results and postoperative complications of capsular bag and ciliary sulcus fixation of posterior chamber intraocular lenses in children with traumatic cataracts. *Cataract Refract Surg*. 1999;25(12):1576–84.
[CrossRef]
6. Chan CK, Agarwal A, Agarwal S, et al. Management of dislocated intraocular implants. *Ophthalmol Clin North Am*. 2001;14(4):681–93.
[CrossRef][PubMed]
7. Zheng DY, Chen LN, Sun Y, et al. Out-of-the-bag intraocular lens dislocation: outcomes of posterior chamber intraocular lens exchange, risk factors, and prevention. *J Chin Med*. 2010;123:2562–7.
8. Mello MO, Scott IU, Smiddy WE. Surgical management and outcomes of dislocated intraocular lenses. *Ophthalmology*. 2000;107(1):62–7.
[CrossRef][PubMed]
9. Gul A, Duran M, Can E, et al. Surgical management of intraocular lens dislocations. *Arq Bras Oftalmol*. 2015;78(5):313–7.
[CrossRef][PubMed]

10. Kim SS, Smiddy WE, Feuer W, et al. Management of dislocated intraocular lenses. *Ophthalmology*. 2008;115(10):1699–704.
[\[CrossRef\]](#)[\[PubMed\]](#)
11. Carlson AN, Stewart WC, Tso PC, et al. Intraocular lens complications requiring removal or exchange. *Surv Ophthalmol*. 1998;42(5):417–40.
[\[CrossRef\]](#)[\[PubMed\]](#)
12. Jin GJ, Crandall AS, Jones JJ. Intraocular lens exchange due to incorrect lens power. *Ophthalmology*. 2007;114(3):417–24.
[\[CrossRef\]](#)[\[PubMed\]](#)
13. Eibschitz-Tsimhoni M, Archer SM, Del Monte MA. Intraocular lens power calculation in children. *Surv Ophthalmol*. 2007;52(5):474–82.
[\[CrossRef\]](#)[\[PubMed\]](#)
14. Gashau AG, Anand A, Chawdhary S, et al. Hydrophilic acrylic intraocular lens exchange: Five-year experience. *J Cataract Refract Surg*. 2006;32(8):1340–4.
[\[CrossRef\]](#)[\[PubMed\]](#)
15. Zheng DY, Lin Y, Zhang ZP, et al. Late postoperative complication of the foldable lens implantation: opacification of the intraocular lens. *Chin J Ophthalmol*. 2002;38(7):408–11.
16. Van Gelder RN, Leveque TK. Cataract surgery in the setting of uveitis. *Curr Opin Ophthalmol*. 2009;20:42–5.
[\[CrossRef\]](#)[\[PubMed\]](#)
17. Adan A, Gris O, Pelegrin L, et al. Explantation of intraocular lenses in children with juvenile idiopathic arthritis-associated uveitis. *J Cataract Refract Surg*. 2009;35(3):603–5.
[\[CrossRef\]](#)[\[PubMed\]](#)
18. Jones JJ, Jones YJ, Jin GJ. Indications and outcomes of intraocular lens exchange during a recent 5-year period. *Am J Ophthalmol*. 2014;157(1):154–62.
[\[CrossRef\]](#)[\[PubMed\]](#)
19. Fernández-Buenaga R, Alió JL, Pinilla-Cortés L, et al. Perioperative complications and clinical outcomes of intraocular lens exchange in patients with opacified lenses. *Arch Clin Exp Ophthalmol*. 2013;251(9):2141–6.
[\[CrossRef\]](#)

26. Postoperative Visual Rehabilitation in Children with Lens Diseases

Daming Deng¹, Jinrong Li¹ and Minbin Yu¹✉

- (1) State Key Laboratory of Ophthalmology, Zhongshan Ophthalmic Center, Sun Yat-sen University, 54 S Xianlie Road, Guangzhou, 510060, People's Republic of China

✉ **Minbin Yu**

Email: yuminbin@mail.sysu.edu.cn

Abstract

The treatment strategies for pediatric lens disorders mainly involve two aspects, i.e., restoration of a transparent visual axis and rehabilitation of visual functions. Postoperative rehabilitation of visual functions is very important to ensure favorable visual outcomes for pediatric patients. Functional vision rehabilitation after lens surgery mainly includes correction of ametropia, prevention and treatment of amblyopia, and recovery of fusion function and stereoscopic vision, which may substantially improve the visual prognosis of pediatric patients. The correction of ametropia is considered as the basis of visual rehabilitation after pediatric lens surgery, and the corrective methods include wearing glasses or contact lenses (CLs), refractive surgery, and intraocular lens (IOL) implantation. The treatment of amblyopia is the key to visual function recovery and should be initiated as early as possible after cataract surgery. There are several options available for the treatment of amblyopia, and clinicians should choose an appropriate regimen based on the clinical condition of individual patients. This chapter will discuss the indications and characteristics of these therapeutic options.

26.1 Overview

When refractive errors result following pediatric lens surgery, appropriate refractive correction and concurrent amblyopia treatment are key components in promoting eye development and visual rehabilitation in pediatric patients. This chapter will expand on refractive correction and amblyopia treatment following pediatric lens surgery.

26.1.1 Rigorous Refractive Correction Is the Basis for Visual Rehabilitation

During the course of normal eye development, changes in refraction are accommodated by axial growth, from hyperopia in infancy to emmetropization at school age. After lensectomy, the pediatric refractive system loses accommodation and becomes highly hyperopic due to the absence of the crystalline lens. Incident light fails to sharply focus on the retina, which results in substantial optical defocus and causes anomalous inputs from the eyes during early visual development. Consequently, abnormal emmetropization occurs and gives rise to visual development disorders. Hence, immediate refractive correction is the very basis for visual rehabilitation following pediatric lens surgery. Modalities for refractive correction include intraocular lens (IOL) implantation, spectacles, and contact lenses (CLs).

26.1.2 Amblyopia Treatment Is the Essential Means for Improving Visual Function

Aberrant visual inputs may occur as a result of pediatric lens disorders and the ensuing ocular abnormalities, including nystagmus, abnormal fixation, strabismus, etc. As infants and young children are in the sensitive period of visual development, any visual input abnormalities may result in developmental arrest resulting in amblyopia, which manifests as impairment of both monocular and binocular visual functions, especially of form perception, contrast sensitivity, and stereopsis. Pediatric IOL implantation has merely restored the transparency of the refractive media, but hindrance and impairment to pediatric visual development persists. Rigorous amblyopia treatment is required to facilitate pediatric visual rehabilitation.

With the recent advent of psychophysical analysis, the animal model, and

techniques of brain function imaging and electroencephalogram, we have gained further insights into the associated visual cortices and central mechanism of amblyopia. It is now considered not only an ocular disease but also a developmental disorder of visual perception. An increasing number of studies have employed management approaches widely used in neuroscience and cognitive science in the research of amblyopia treatment, e.g., uptake of excitatory neurotransmitter (L-dopa), neurological rehabilitation via electronic or magnetic stimulation including transcranial direct-current stimulation (tDCS) and transcranial magnetic stimulation (TMS), Visual perceptual learning in cognitive science, and acupuncture in traditional Chinese medicine (TCM). Many of these approaches have not yet been verified by rigorous randomized controlled trials (RCTs) for feasibility and validity. But with ongoing research, these approaches will probably be a potential supplement for the visual rehabilitation of amblyopia.

26.2 Refractive Correction for Pediatric Aphakia

Refractive correction is the basis and key step to amblyopia rehabilitation. Lensectomy in pediatric cataract patients results in high hyperopia, which should be corrected soon enough to create favorable refractive conditions for visual rehabilitation. The pediatric refractive system has unique characteristics in different stages of emmetropization; therefore, appropriate selection of refractive correction is of particular importance in the visual rehabilitation of these children. This section will discuss the advantages and disadvantages, as well as indications for various refractive correction modalities.

26.2.1 Spectacles

Indications: The wearing of spectacles is indicated for children with binocular aphakia, CL intolerance, or when IOL implantation is temporarily contraindicated. In children with monocular aphakia, spectacle lenses are typically not the first option if they are able to tolerate CLs or other choices of correction.

Spectacles are currently the most common form of refractive correction in infants and young children with binocular aphakia (Fig. 26.1). Their advantages are as follows: The refraction and the production of children's

eyeglasses are convenient, affordable, and safe; glasses can be readily replaced; and both monofocal and bifocal designs may be chosen based on the needs of distance or near vision. There are, however, some disadvantages presented as follow for fitting considerations:



Fig. 26.1 Pediatric aphakia is corrected using spectacles

1. Thick and heavy spectacle lenses lead to reduced compliance.

The nose bridge and ears have not yet fully developed in infants and very young children, which makes it difficult to achieve a stable fit for the spectacles. Thick and heavy aphakic lenses can make wearing uncomfortable, and most parents are unaware that decreased compliance affects spectacle correction results (Fig. 26.2). With regard to frame material, lightweight titanium, flexible metal or special memory plastic materials may be chosen to ensure proper fitting. EP plastic, a light synthetic material resistant to deformation, and nylon, which does not usually break and can be manipulated back to shape after dropping or being trampled. To reduce the lens thickness and weight, spectacle lenses with high refractive index may be chosen. But it should be noted that colour aberration can reduce the corrective effect due to increased Abbe number in the case of higher refractive index. In the past 10 years, press-on lenses have been preferred for their light weight and reduced thickness. However, press-on lenses with high powers can cause altered imaging to a certain extent. Moreover, there is space between the pressure film and the lens, which may harbor dust and cause unstable adherence and even peeling.



Fig. 26.2 Improper frame fitting in an aphakic child when he is able to see over the spectacles

2. Magnification

The magnification changes by about 1 %, for every 0.50D alteration in the power of spectacles. When differences between bilateral magnifications reach approximately 5 %—namely, a difference of 2.50D in the refractive power—the human visual system often fails to tolerate unequal visual inputs, thereby causing interocular suppression or confusion. In the case of aphakic eyes following monocular congenital cataract surgery, pediatric patients may develop severe binocular diplopia because of the great difference in magnification when wearing spectacles. Difficulty in fusion, exacerbates suppression, and refusal to wear spectacles due to discomfort will ensue and impair rehabilitation of monocular and binocular vision. In children with binocular congenital cataracts, postoperative binocular correction allows for similar or identical binocular magnifications, which can be better tolerated among infants and young children.

3. Significant spherical aberration

The spectacle lenses for aphakic children are usually convex with high diopters, through which light rays are refracted. In an emmetropic eye, imaging on the retina is presented as a curved image instead of a planar retinal image, which makes objects apparently uneven with saccadic and tracking eye movements. Additionally, most children with congenital cataracts have concurrent congenital nystagmus, in which the center of the visual axis has deviated from the optical center that can even result in a prism effect. These abnormalities cause diminished visual acuity and sharpness.

4. Obscured peripheral vision

Since the area of spectacle lenses is limited, not all peripheral light rays can enter the eyes after being refracted through the lenses, and some of them even bypass the lenses. Consequently, this part of the image cannot be clearly focused onto the retina and thus becomes a blurry field of vision. In addition, decentration of high power lenses often produces a prismatic effect, leaving a circular peripheral scotoma and narrowing of the visual field.

5. Peripheral optical defocus

Optical lenses only correct refractive error in the central field, yet refraction varies between the peripheral and central fields. Therefore, when spectacle correction is worn by children with congenital cataract, their peripheral field is often significantly uncorrected, which disrupts emmetropization and impairs visual development. Currently, new designs in soft CLs that can correct peripheral defocus are undergoing large-scale clinical trials (in myopia control). It is expected that the novel design of CLs will be used for refractive correction following congenital cataract surgery in the future.

26.2.2 Contact Lenses (Near and Distant)

Compared with spectacles, CLs have considerable advantages in the refractive correction of aphakic eyes. Advances in technological design and materials science have eliminated the following CLs drawbacks: thick and heavy lenses, uncomfortable foreign body sensation, poor oxygen permeability, and severe ocular surface disruption.

CL correction has the following advantages and disadvantages over spectacles:

Advantages of CLs: (1) There is no magnification or minification of retinal image even in the case of high refractive errors, as CLs are adjacent to the front principal point of the eye. For postoperative anisometropia, the relative consistency in the size of binocular images is unlikely to cause impaired fusion and interocular suppression. (2) CLs do not obscure the peripheral visual field, and eliminate image distortion, aberration, and chromatic aberration. (3) Wearing CLs is comfortable and does not affect

daily activities. Unlike spectacles, fogging will not form on CLs when entering a sudden change in hot or cold environment, and CLs do not cause pain or allergic reactions to the ears, nose, or skin on the temporal sides of the face. CLs are less susceptible to deformation, dropping of lenses, and even lens breakage after blowout trauma, which may lead to severe eye injuries. These features are especially beneficial to hyperactive children. (4) Children wearing CLs do not have cosmesis concern compared to thick and heavy eyeglasses, which attracts mocking or isolation in group activities. Therefore, wearing CLs is more favorable to the development of children's physical and mental health.

Disadvantages of CLs are as follows: (1) Since infants and young children (1–3 years) are not cooperative to examination, accurate measurement of corneal curvature cannot be obtained, thus making it more difficult to produce suitable CLs. What's more, decentration might occur and result in undesirable correction. (2) CLs are frequently lost, which causes reduced duration of refractive correction. (3) Frequent removal and wearing of CLs elicits psychological resistance in children. To address this challenge, investigators at Zhongshan Ophthalmic Center (ZOC) of Sun Yat-sen University have developed a device for wearing and removing CLs for children. A specially designed connecting tube links a vacuum bag to a suction disk; the CL is drawn to the sucking disk and firmly adheres to it through vacuum pressure. In this way, CLs may be worn and removed safely, rapidly, and conveniently, which is especially desirable in the case of child wearers (Fig. 26.3). (4) CLs of high diopters are expensive and the manufacturing process is complex. Therefore, the abovementioned factors lead to pediatric patients' poor compliance.

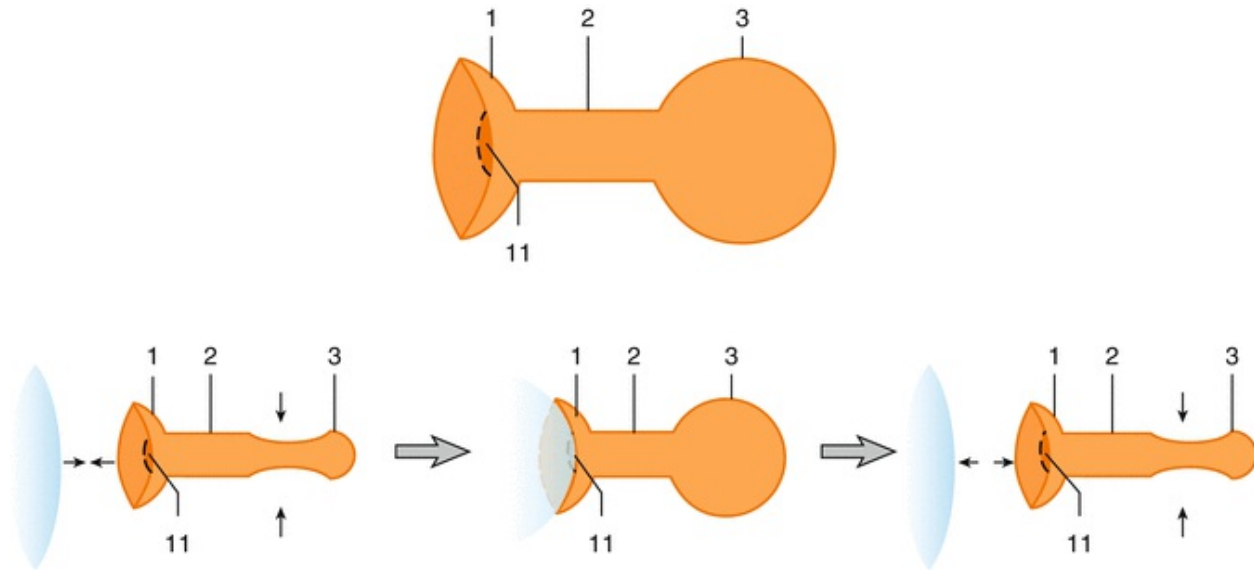


Fig. 26.3 A device for wearing and removing CLs. 1 suction disk; 2 connecting tubes; 3 vacuum bags; 11 venting holes

It works as follows: The round suction disk is attached to the exterior of the CL (dotted lines) after squeezing the vacuum bag, which is then released, and the resulting vacuum firmly grips the CL and takes it out of the lens case. Subsequently, the posterior surface of the CL is aimed at the corneal surface, and the vacuum bag is squeezed again to release vacuum so that the CL is separated from the suction disk and lodges on the corneal surface snugly.

CLs are superior to spectacles as a means of aphakic refractive correction. Nevertheless, they may cause complications including ocular surface infections and allergic hypersensitivity. The wearing and removing of CLs are demanding and require patients' cooperation. Therefore, extensive counseling for the child and the parents can never be overemphasized.

26.2.2.1 Timing and Considerations

Generally speaking, evaluations for CLs are conducted 3 months after surgery if there are no ocular contraindications. But it should be noted that refraction should be avoided when the pediatric patients appear unwell. Guidance should be patiently provided to parents on manipulation and caring of CLs, so as to help the child accept the wearing of the CLs as soon as possible.

26.2.2.2 Principles of Prescription

Choosing appropriate powers of CL is particularly important for aphakic correction in children, and CLs of improper power can cause amblyopia. Infants and young children generally require better near vision, while distance vision becomes more important as they grow. Cycloplegic refraction for each aphakic child should be performed plus over- or under-correction. The dosage of over- or under-correction is controversial. The authors prescribe under-correction of 1.50–3.50D for infants (<1 year) and under-correction of 0.50–1.50D for toddlers (1–4 years).

26.2.2.3 Indications

1. Monocular aphakia: Binocular anisometropia in children with monocular aphakia tends to exceed 10D. Since children are in the critical period of visual development, anisometropia >3D is likely to cause amblyopia. Wearing CLs reduces optical defocus and binocular disparity and is safe and effective under most circumstances.
2. Binocular aphakia: Children with binocular aphakia following cataract surgery are usually highly hyperopic. Visual rehabilitation by wearing CLs may be chosen.
3. Irregular astigmatism: Traumatic cataracts in children are often complicated by corneoscleral injury. Surgical repairs of the injury cause irregular astigmatism, which is difficult to correct using spectacles. Rigid gas permeable (RGP) lenses can correct irregular astigmatism by covering the irregular corneal surface employing the tear film.
4. Nystagmus: Children with congenital cataracts often have nystagmus. Refractive correction using CLs in eyes with nystagmus may diminish image distortion and unstable imaging caused by spectacles and facilitate the improvement of visual function.

26.2.2.4 Considerations

The following issues need to be considered prior to the decision whether or not to wear CLs:

1. **Cornea:** Although irregular astigmatism is an indication for wearing CLs, sometimes it is challenging due to excessive corneal irregular astigmatism and corneal scarring.
2. **Delayed presentation due to inability to express themselves:** Very young children are unable to clearly express their abnormal sensations. For instance, when complications such as corneal epithelial injury or inflammation occur as a result of wearing CLs, there might be delayed diagnosis and treatment which in turn leads to more serious consequences, as the child cannot fully explain what is wrong. Therefore, parents should be educated about how to identify similar abnormal findings and seek medical help in good time.
3. **Affordability and compliance:** Rapid change in pediatric refractive state requires regular visits to the hospital and frequent replacement of CLs, which may place a heavy financial burden on the child's family.
4. **Allergic Hypersensitivity:** The material or disinfectant used with CLs may cause allergic reaction in certain individuals, which can be effectively controlled by the use of anti-allergic drugs. Timely replacement, proper cleaning and disinfection, and appropriate lens care may effectively prevent hypersensitivity reactions.

26.2.2.5 The Different/Various Types of CLs

Commonly used CLs include RGP and soft CLs. With good heat conduction, a desirable moisturizing performance, and high oxygen permeability, RGP lenses are especially suitable for children with higher degrees of astigmatism and irregular corneal surface. Their disadvantages lie in weak elasticity, easy warping, lack of comfort, and a longer period of adaptation.

Soft CLs are flexible, with a desirable elasticity, and they cover the entire cornea; in addition, they have the advantages of being comfortable to wear and require only a short period of adaptation. These are compared with RGP

lenses, whose disadvantages are that they are liable to surface deposition and have a short duration of service. Currently the most widely used material in soft CLs is hydroxyethyl methacrylate (HEMA). Plastic polymeric materials (also termed hydrogel) that are soft and hydrophilic are added to this type of lens. As a result, they contain 30–80 % water, which guarantees comfortable wearing. In the last 10 years, the materials used in the manufacture of soft CLs are no longer confined to conventional hydrogel. Instead, various monomers, mostly siloxane-polydimethylsiloxane (PDMS, also called silicone hydrogel), are added to increase oxygen permeability.

For young children, CLs with high oxygen permeability and design for overnight wear should be chosen to reduce frequency of application and removal and thus reduce the opportunity for ocular surface injury. This type of lens allows for continuous use up to 30 days, which is convenient for infants and young children, as well as for parents in handling and care. They also cause less foreign body sensation due to their special hydrophilic treatment. The frequency of replacement of these lenses is typically once or twice a year. Additionally, RGP lenses with added UV filter may reduce ocular damage induced by UV irradiation. It is suggested that a backup set of lenses should be available since RGP lenses are frequently lost when crying and rubbing the eyes. In the early period of wear by older children, RGP lenses should be examined once a month, while those of infants under 1 year should be checked once a week, so as to identify any reaction of ocular tissues and to observe the appearance and condition of the CLs.

Modern design CLs with high oxygen permeability have improved safety for long-term wearing. However, CLs are more demanding on a child's ocular surface and cooperation, as well as their parents' understanding and education levels. Therefore, in offering the choice of whether or not to wear CLs, we should consider not only their indications but also practical situations of both the children and their parents.

26.2.3 Intraocular Lenses

IOLs have a lower magnification and have less effect on the peripheral visual field than spectacles. Compared with CLs, IOL implantation eliminates the cumbersome process of the wearing, removal, and care of CLs as well as reduces the risk of infection. It has become the standard practice in correction of pediatric aphakia in most scenarios. For the selection and implantation techniques of IOL, refer to Chaps. 14 and 15, respectively.

26.2.4 Corneal Refractive Surgery

Due to the limitation of corneal thickness, the maximum correction offered by corneal refractive surgery in hypermetropic refractive error (HRE) is +6D. However, the refractive state of the majority of aphakic children falls into the category of hyperopia > +12D, thus making it inadvisable to perform this surgical procedure in pediatric aphakia.

26.3 Treatment of Amblyopia

One of the main reasons for visual impairment caused by pediatric lens disorders is deprivation amblyopia. Studies have shown that disrupted development of visual function from preoperative deprivation persists even in children receiving proper IOL implantation. Therefore, amblyopia treatment is of importance in the treatment of congenital cataract. This section will elaborate on the concept, pathogenesis, and treatment of amblyopia.

26.3.1 Concept of Amblyopia

With a high prevalence worldwide (2–5 %), amblyopia is the first disorder causing monocular visual impairment in children [1, 2]. Amblyopia severely impairs both monocular and binocular visual functions. A study on monocular amblyopia has found that trauma, inflammation, and visual field damage are more likely to occur in the fellow eye [3]. The diagnostic criteria for amblyopia vary in different countries. The classical concept of amblyopia is, a developmental disorder of visual function caused by abnormal visual perception including form deprivation or binocular interaction during visual development [4]. American Academy of Ophthalmology (AAO) has proposed an accurate definition of amblyopia encompassing visual acuity criteria and diagnostic criteria (Table 26.1).

Table 26.1 Diagnostic criteria for amblyopia

Criteria	Clinical manifestations
Monocular amblyopia	
Fixation properties	Unbalanced fixation
Preferential looking	Difference of 2 octaves ^a
Best corrected visual acuity (BCVA)	Interocular differences in BCVA ≥ 2 lines
Binocular amblyopia	

BCVA	BCVA in either eye is below 20/50 (age ≤ 3 years)
	BCVA in either eye is below 20/40 (age ≥ 4 years)

Reproduced with permission from American Academy of Ophthalmology [5]

^aA difference of 2 octaves is equivalent to the difference of four cards in the Teller Acuity Card and is classified at a viewing angle of 4°

26.3.2 Pathogenesis of Amblyopia

Amblyopia is typically caused by strabismus, anisometropia, refractive errors, and form deprivation (congenital cataract and ptosis). These anomalies may lead to disrupted development of visual function if they occur during visual development [6].

Visual development may be divided into the critical period, the sensitive period, and the plastic period [7]. In the critical period, the development of visual perceptual functions reaches the same level as that in adults. In the sensitive period, visual disturbance can give rise to functional disorders of vision. While in the plastic period, visual function can be restored after developmental disorders have occurred. Actually, there are no clearly defined time limits for the three periods, and sensitivity to visual stimuli gradually decreases from the critical period toward the plastic period. There are great differences in visual functions among different species, populations, and individuals. Currently there is huge disagreement over the respective duration of these periods. It is generally acknowledged that the critical period occurs at about 5 years to 6 years, the sensitive period at 8 years, and the plastic period at 11–12 years. Previous studies have shown that normal visual perception could no longer be established once beyond the plastic period. However, studies from the authors and other investigators all reveal that there is still certain restoration capacity for impaired visual functions, even in children beyond the plastic period. Therefore, further research is required to confirm whether there is a certain time limit for the plastic period or it has a lifelong duration. But it can be deduced from the three periods of visual development that the sooner amblyopia treatment starts, the better the visual outcomes are. Additionally, treatment should start in a period of greater plasticity, so that visual function can be recovered to a greater degree.

We introduce here the pathogenesis of deprivation amblyopia caused by congenital cataracts. The main pathogenesis of amblyopia associated with

congenital cataracts is form deprivation, suppression, impaired fixation and motility, and strabismus.

1. Within the sensitive period of visual development, normal structure and function fail to be established in the visual cortices, eventually leading to abnormal visual functions. This is because photoreceptors, the lateral geniculate nuclei, and neurons in visual cortices do not receive adequate form and colour and motion input due to lens opacification. A myriad of experimental studies have demonstrated that the retinal ganglion cell function in amblyopia is relatively normal with the major impairment in visual cortices and lateral geniculate bodies [8].
2. Suppression is another major mechanism of amblyopia developed after surgical removal of monocular or binocular congenital cataracts. Numerous studies have shown that changes in lateral geniculate nuclei and visual cortices in monocular congenital cataracts are significantly different from those in binocular cases [9]. This reveals that the pathogenic mechanisms caused by the two types of cataracts are extremely different. Binocular deprivation has extended the plastic period of visual cortical neurons, while monocular deprivation may induce imbalanced binocular visual inputs. Visual cortices receiving dominant afferent stimuli may inhibit the development of those receiving stimuli from the contralateral eye. Preliminary reports from the amblyopia research team at ZOC using quantitative measurement of suppression and regional analysis (inhibition topography) in patients with interocular suppression found that suppression closely correlated monocular amblyopia and impairment of monocular and binocular visual functions (Fig. 26.4) [10–13]. At present, testing and treatment of suppression has become a new realm of interest in the research of amblyopia prevention and control.

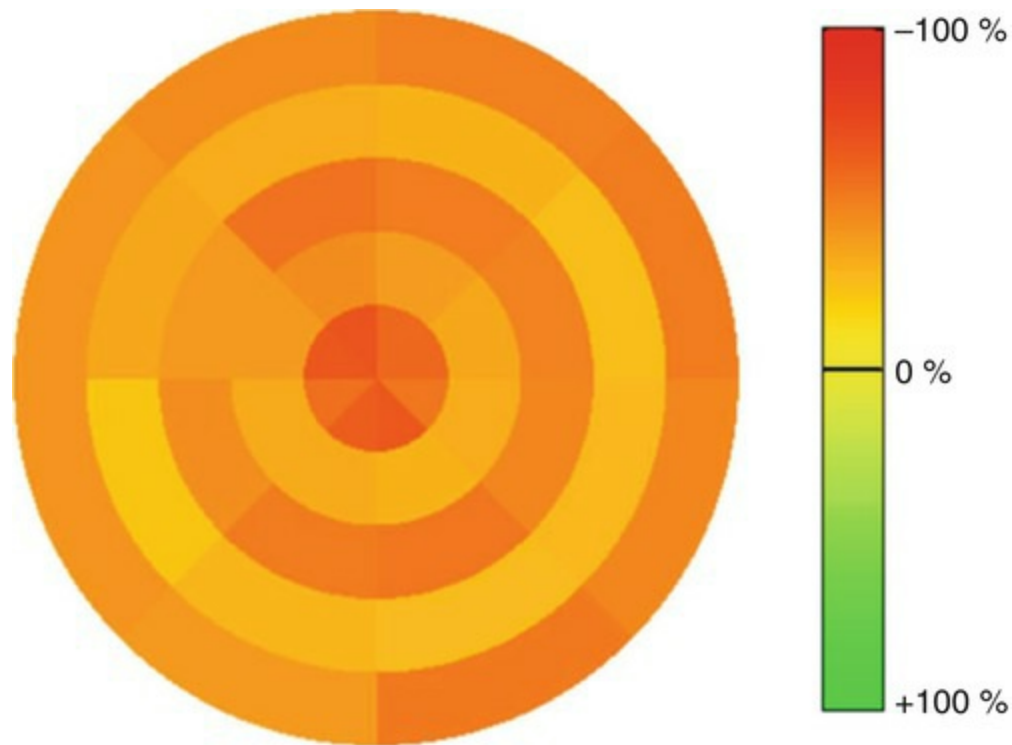


Fig. 26.4 Inhibition topography of suppression. On the simulated map of central suppression, the depth of suppression within the central visual field is presented by different colors. The *red color* indicates a higher degree of suppression, with the *green color* as a lower degree

3. Due to the earlier onset of congenital cataract, visual perception, fixation, and ocular motilities in these children are not fully developed. Abnormal visual motor functions can in turn interfere with normal afferent visual information, which hinders establishment of normal visual function and aggravates the development of amblyopia.
4. Because of the severe impairment of visual function, monocular congenital cataracts are often accompanied by strabismus, whereas the occurrence and development of strabismus are likely to result in suppression and eccentric fixation, which exacerbates visual impairment.

26.3.3 Treatment of Amblyopia

Treatment of amblyopia is the key to visual rehabilitation of congenital cataract children. Research shows that the first month of life is an important period for visual function formation, and hence there should be timely

amblyopia treatment after elimination of deprivation [14, 15]. These children, especially those with monocular congenital cataract, have limited ability to express themselves, and their basic needs of daily life are met by using the fellow sound eye only. As a result, some parents usually neglect amblyopia treatment for their children. Additionally, some parents and their children tend to lose patience and confidence in treatment due to the prolonged duration and slow visual recovery for most amblyopic children. Thus, raising parents' disease awareness is an important part of amblyopia treatment for improved compliance with amblyopia treatment.

Currently available treatments for amblyopia include refractive correction, occlusion and penalization, pleoptics therapy vision training, medications, transcranial microelectro stimulation, and acupuncture. Antonio-Santos A and colleagues conducted an extensive literature review and found that currently there is still a lack of randomized controlled trials (RCTs), which are aimed at the treatment of deprivation amblyopia caused by congenital cataracts [16]. The following therapeutic choices are all validated in the common types of amblyopia (anisometropic and strabismic), which remind us that there is still a long way to go in the treatment of amblyopia associated with congenital cataracts.

26.3.3.1 Refractive Correction

Refractive correction is an essential step in amblyopia treatment for children with congenital cataracts. Having elaborated in the previous section, we now discuss its significance to amblyopia treatment. Spectacles are an effective way of refractive correction for children, especially young children, with binocular cataracts [17]. They can avoid complications induced by IOL implantation. In children with monocular cataract, aniseikonia caused by aphakic spectacles highly increases the vulnerability to suppression that reduces the efficacy of amblyopia treatment. Our previous study has indicated that for children with anisometropic amblyopia, aniseikonia is an important reason for central suppression [12]. After aniseikonia is eliminated, suppression can be substantially relieved. CLs are a desirable choice for monocular congenital cataract children not receiving IOL implantation, for it may diminish spectacle-induced aberration. CLs with different powers can be replaced anytime in accordance with the child's refractive status, which is an incomparable advantage over IOL. However, their ocular surface complications and compliance for wearing CLs are important factors

affecting the curative effect.

26.3.3.2 Occlusion and Penalization

Occlusion and penalization reduce suppression on the amblyopic eye mainly by artificially inhibiting the fellow sound eye. In this way, the amblyopic eye has better access to external visual stimuli, which improves visual function. Occlusion therapy plays a pivotal role in amblyopia treatment, especially in children with monocular congenital cataract who suffer from a prolonged duration of deprivation and significant suppression. Combining effective refractive correction, proper occlusion therapy, and good compliance are the premise of desired outcomes in these children. Various types of occlusion therapies and penalizations for amblyopia have been extensively discussed in the literature and are beyond the scope of this book. Here we merely introduce occlusion and penalization approaches in congenital cataracts.

Occlusion therapies may be divided into translucent occlusion (e.g., the Bangerter foil, ND filter, and color filter) and nontransparent occlusion according to the transparency of the patching. They can also be classified into complete occlusion and partial occlusion based on the duration of occlusion. Patches for occlusion include eye patches and spectacle patches.

In amblyopia treatment for children with monocular congenital cataract, we advocate classic, aggressive occlusion therapy, which ensures that the healthy eye is occluded for 6–8 h, or complete occlusion on alternate days. We emphasize early (prior to the age of 3 years), aggressive occlusion, but it should be noted that the plastic period is also prone to occlusion amblyopia. Thus, attention should be paid to the occurrence of occlusion amblyopia while aggressive occlusion is prescribed. It is generally believed that children older than 5 years are less likely to develop occlusion amblyopia and, as a result, may undergo aggressive occlusion for maximum hours.

Other approaches of occlusion are Bangerter filters and neutral density filters (NDFs). A Bangerter filter is a thin film of microbubble design, which achieves the goal of inhibiting the vision of the better eye by means of spatial distortion after occlusion (Figs. 26.5 and 26.6). Previous studies by ZOC have found that Bangerter filters and NDFs partially suppress the relatively sound eye, which allows amblyopic children to undergo amblyopia treatment under binocular fusion [18, 19]. With certain prospects for application, these filters do not cause obvious changes in appearance or induce skin allergies as with eye patches, which is more acceptable for children. They are mostly

used in children with mild and moderate amblyopia. Children with monocular congenital cataract usually have severe amblyopia, for whom we do not recommend early use of these filters. Nevertheless, when visual acuity (VA) of the amblyopic eye is improved to a certain level, particularly above 20/40 (6/12, 0.5 decimal acuity), these translucent filters can be considered to improve therapeutic effect and efficiency. However, it should be noted that individual variations in subjective effects exist when receiving filters for occlusion. We therefore advise that the strength should be determined after VA testing with the patient wearing the filter.



Fig. 26.5 Acuity plate with Bangerter filters and visual acuity testing with the plate



Fig. 26.6 A pediatric patient wearing spectacles with a Bangerter filter

One percent atropine drops are commonly used for atropine penalization. Atropine drops may relax the accommodation in the non-amblyopic eye, thus allowing the sound eye to be in a relatively hyperopic state with reduced near vision and achieving partial suppression. For penalization, frequency of instillation ranges from once a day to once a week, with no significant difference in the visual outcomes of children with mild and moderate amblyopia [20]. Since children with congenital cataracts usually have unfavorable corrected VA, atropine penalization often fails to provide effective suppression to force usage of the amblyopic eye and therefore is rarely applied in amblyopia treatment for congenital cataracts. However, when VA improvement begins and the pediatric patient starts to resist occlusion therapy, atropine penalization can be used as an alternative treatment.

26.3.3.3 Physiotherapy

Conventional pleoptics therapy for amblyopia falls into the following five categories:

1. He-Ne laser (Fig. 26.7): Low power, red helium-neon laser with a safe wavelength of 640 nm is aimed at the fovea. By stimulating the cells at all levels of the visual pathway, it delivers adequate excitatory signals to the sensory neurons at the side of amblyopia and thus alleviates suppression.

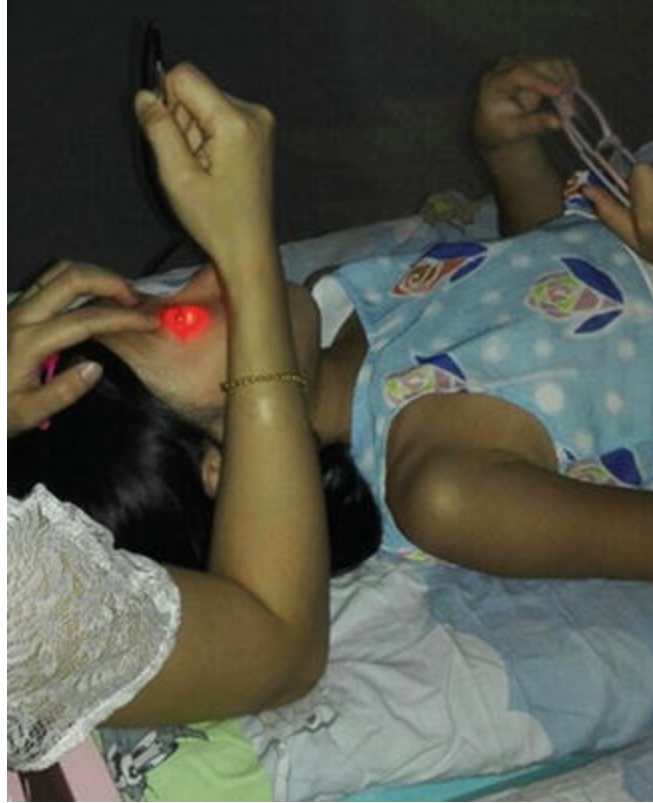


Fig. 26.7 A photograph of He-Ne lasers (After the fixation point is presented right in front of the pediatric patient, the macula is stimulated at a distance of 33 cm using helium-neon laser of 0.9w power)

2. Red flash stimulation: Targeted flash stimulation to the cones at the fovea is conducted using red light of 640 nm wavelength.
3. Afterimage therapy (Fig. 26.8): Strong illumination stimulates the parafoveal area to raise the perception threshold of corresponding photoreceptor cells, thus forming a negative afterimage against the ambient light. Meanwhile, the central fovea is shaded to avoid negative afterimage formation in this region. As a result, fixation can be improved through a combination of the two actions.



Fig. 26.8 Afterimage therapy. Afterimage training is conducted after the paracentral fovea is stimulated using direct ophthalmoscope

4. Light brush stimulation (such as Haidinger's brush): It employs an entopic phenomenon caused by the rotation of polarizing filter, which is found only in the corresponding regions of foveal Henle fibers. The patient's fovea must be fixating on the target when he or she sees the brushlike optotype.

5. Grating stimulation (Fig. 26.9): Co-developed by Campbell and Hess while working at Cambridge University in 1978, grating stimulation is termed the CAM stimulation [21]. The theoretical basis is that the human visual cortex V1 is composed of a large number of visual cells receiving stimuli of different orientations and spatial frequencies. Therefore, the CAM approach stimulates the amblyopic eye with optotypes of various spatial frequencies orientations to improve perceptual functions of the visual center. It should be noted that CAM stimulation did not achieve the desired result in controlled clinical trials, though it was obviously effective at the beginning of development [22, 23]. Therefore, CAM stimulation therapy is considered ineffective by clinicians outside China. Yet various types of perceptual learning and training emerging in recent years are all inspired by CAM stimulation, with similar working principles [24]. Contrast sensitivity training below the cutoff frequency is

now widely recommended as a treatment for amblyopia and has been shown to effectively improve VA in amblyopic patients. Proposed by Lu et al. [25, 26], the training regimen was proved to be more effective in improving monocular visual function in amblyopia. In addition, investigators at ZOC elucidated the mechanism for its effects on binocular vision. Theoretically more specific than CAM stimulation, this regimen is expected to become a highly effective means for amblyopia treatment [27].




Fig. 26.9 (a) A sample CAM visual stimulator. Grating of different spatial frequencies can be selected from available discs. The discs are rotated in front of the amblyopic eye (b) Sample image seen by the amblyopic eye during CAM visual training

Any of the stimulation regimens mentioned above can improve fixation and enhance perceptual function of the corresponding cortex of foveal cone cells. They may be beneficial to amblyopia associated with congenital cataracts, in which there are poor fixation and dysplasia of photoreceptor cells in the fovea. These stimulation regimens are widely used in China, but currently there is a lack of evidence from large-scale RCTs.

26.3.3.4 *Visual Training*

In amblyopic patients, visual function is impaired in a variety of aspects, such as interocular suppression and compromised functions like spatial perception, motion perception, saccade and tracking, fusion, and fixation. Vision training is designed based on the target function. A few examples are fine vision training, anti-suppression training with red-green glasses, as well as trainings

of saccadic movements and fusion. With the development of terminal display technology, perceptual learning has become a new research focus. Hess, Levi, Polat, and Lu, among a myriad of vision scientists across North America and Europe, produced repeated visual task stimulation in amblyopic children during and after the plastic period of visual development using threshold measurement and feedback. Varying improvements have been observed in both monocular and binocular visual functions. The abovementioned regimens are expected to enhance the outcomes of amblyopia treatments, improve efficiency, and reduce duration of treatment on the basis of occlusion and refractive correction.

In recent years, ZOC has conducted a series of research in the anti-suppression training of amblyopia. The traditional concept of amblyopia treatment was based on the hypothesis that amblyopic children do not possess binocular vision or higher levels of binocular visual functions including stereopsis. Our preliminary studies have shown that there remains a certain degree of binocular interaction in amblyopic visual cortices. It is suppression that places the biggest obstacle on visual rehabilitation of amblyopia. After suppression is eliminated, visual function in adult amblyopic patients can still be considerably improved. Training for binocular visual balance (Fig. 26.10) after elimination of suppression can improve vision in many amblyopic children, even in those beyond the plastic period of visual development [28, 29]. Its greatest advantage is that amblyopia can be treated without occlusion of the fellow eye, which greatly enhances patient compliance. In addition, patients can undergo this at home. This training regimen may also be effective in older children following congenital cataract surgery, which brings hope of recovery to more amblyopic children.




Fig. 26.10 The therapeutic mode of binocular balance training

Video game stimulation is divided into two parts that adjust stimulus intensity, based on levels of binocular imbalance. The unbalanced eyes are trained under artificially balanced stimuli. After wearing video glasses, the subject perceives the two parts of the game dichoptically by means of special video transmission technique. The training begins after the visual contents are integrated by means of binocular fusion.

26.4 Adjunctive Therapies

26.4.1 Supplementary Excitatory Neurotransmitters

As amblyopia is a neurodevelopmental disorder, excitatory neurotransmitters have been used as adjunctive pharmacotherapy in recent years, the most well known being levodopa. Research reveals that levodopa increases levels of exogenous neurotransmitters and improves conduction along the visual sensory pathway and excitability of central visual cells, which presents as shortened latency and an increase of N1-P1 amplitudes in visual evoked potentials (VEPs). The result indicates that it can improve form vision in amblyopia and VA regression after withdrawal observed in some patients further suggests that exogenous supplementation may produce partial therapeutic effects in these patients with low levels of dopamine (Fig. 26.11)

[30]. Some patients, however, do not have low dopamine levels; they may have reduced nerve growth factors (NGF) and brain-derived neurotrophic factors (BDNF). Dopamine supplementation is not effective in these patients.

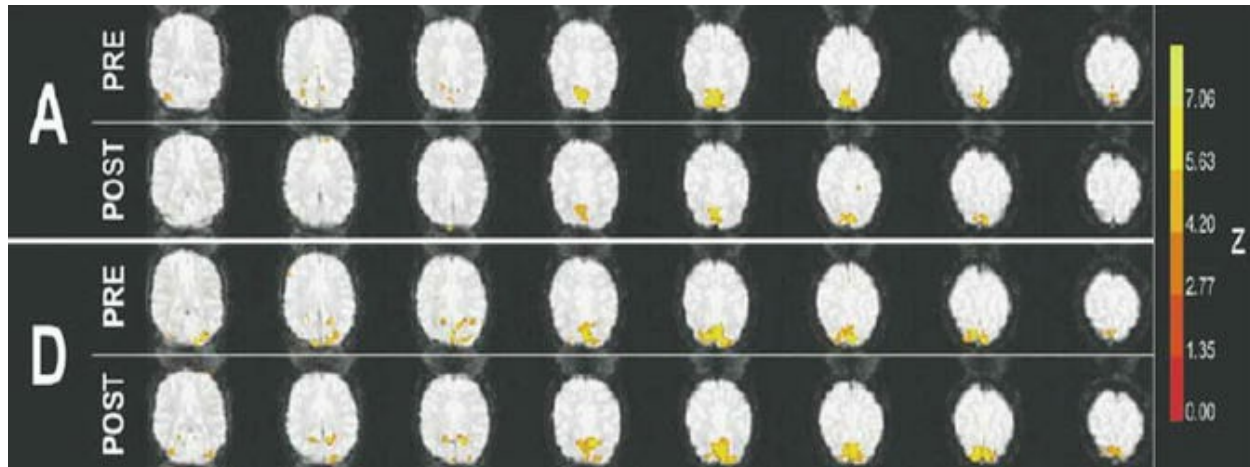


Fig. 26.11 After levodopa therapy, functional magnetic resonance imaging (*fMRI*) shows markedly enhanced neural activity in the visual cortices of amblyopic patients (Reproduced with permission from Algaze et al. [30])

26.4.2 Transcranial Direct Current Stimulation of the Visual Cortex

Cortical stimulation widely used in neuroscience may improve visual function in amblyopia by altering the balance of excitation/suppression circuits. Repetitive transcranial magnetic stimulation (rTMS) and transcranial direct current stimulation (tDCS) are common techniques in motor function rehabilitation and are representative approaches of cortical stimulation (Fig. 26.12). Cumulative findings suggest that both rTMS and tDCS can improve visual perception in some amblyopic patients beyond the period of plasticity. Investigators at ZOC have found in their applied research on tDCS that its combination with visual training promotes reestablishment of stereopsis in older amblyopic children [31]. In a separate study, changes in excitability of afferent neural pathways induced by tDCS in amblyopic children after the plastic period were measured using pattern visual evoked potential (P-VEP). The results demonstrated that tDCS significantly increases P-VEP amplitudes in these children [32]. These studies indicate that tDCS is a potential therapeutic choice for amblyopia in older children and refractory amblyopia, yet its exact efficacy and working mechanism remain to be further explored.

Amblyopia associated with congenital cataracts tends to be more severe with more substantial central suppression. As of today, cortical stimulation in such patients has never been reported, and its clinical application remains to be further investigated.

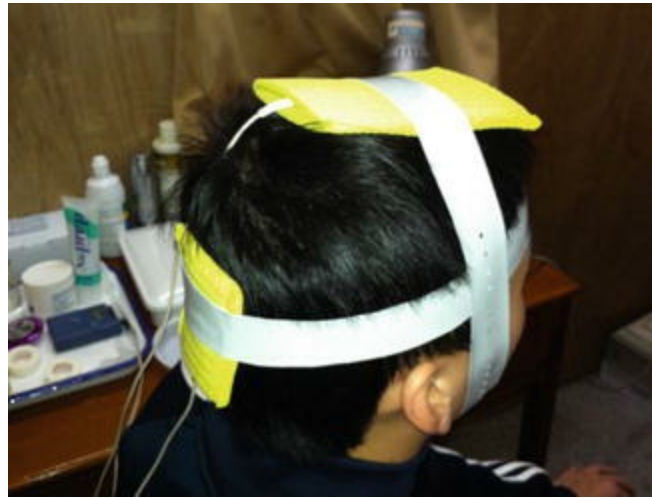

Fig. 26.12 Transcranial direct current stimulation (*tDCS*) for amblyopia beyond the plastic period of visual development

26.4.3 Acupuncture

Acupuncture may increase cerebral blood flow and induce release of NGFs through repeated stimulation of meridians, thus improving VA in amblyopic patients. In recent years, acupuncture efficacy in amblyopia treatment has been investigated in large-scale clinical trials [33, 34]. There is no significant difference in efficacy between acupuncture and traditional occlusion therapy. The exact mechanism and efficacy of acupuncture remains to be studied and confirmed.

26.5 Summary

We have every obligation and responsibility to disseminate knowledge on pediatric lens disorders throughout society. Early detection and treatment should always be attempted. Parents should be fully aware that early surgery is one of the important steps toward visual rehabilitation and refractive correction; amblyopia treatment and binocular vision training are the key to recovery of binocular visual function.

References

1. Attebo K, Mitchell P, Cumming R, et al. Prevalence and causes of amblyopia in an adult population. *Ophthalmology*. 1998;105:154–9.
[CrossRef][PubMed]
2. Holmes JM, Leske DA, Burke JP, et al. Birth prevalence of visually significant infantile cataract in a defined US population. *Ophthalmic Epidemiol*. 2003;10:67–74.
[CrossRef][PubMed]
3. Tommila V, Tarkkanen A. Incidence of loss of vision in the healthy eye in amblyopia. *Br J Ophthalmol*. 1981;65:575–7.
[CrossRef][PubMed][PubMedCentral]
4. Hubel DH, Wiesel TN. Receptive fields, binocular interaction and functional architecture in the cat's visual cortex. *J Physiol*. 1962;160:106–54.
[CrossRef][PubMed][PubMedCentral]
5. American Academy of Ophthalmology Pediatric Ophthalmology/Strabismus Panel. Preferred Practice Pattern Guidelines. Amblyopia. San Francisco, CA: American Academy of Ophthalmology; 2012. Available at: www.aao.org/ppp.
6. Holmes JM, Clarke MP. Amblyopia. *Lancet*. 2006;367:1343–51.
[CrossRef][PubMed]
7. Sale A, Berardi N, Spolidoro M, et al. GABAergic inhibition in visual cortical plasticity. *Front Cell Neurosci*. 2010;4:10.
[PubMed][PubMedCentral]
8. Kiorpes L, McKeet SP. Neural mechanisms underlying amblyopia. *Curr Opin Neurobiol*. 1999;9(4):480–6.
[CrossRef][PubMed]
9. Hubel DH, Wiesel TN. The period of susceptibility to the physiological effects of unilateral eye closure in kittens. *J Physiol*. 1970;206(2):419–36.
[CrossRef][PubMed][PubMedCentral]
10. Li J, Thompson B, Lam CS, et al. The role of suppression in amblyopia. *Invest Ophthalmol Vis Sci*. 2011;52(7):4169–76.
[CrossRef][PubMed]
11. Li J, Hess RF, Chan LY, et al. How best to assess suppression in patients with high anisometropia. *Optom Vis Sci*. 2013;90(2):e47–52.
[CrossRef][PubMed]
12. Li J, Hess RF, Chan LY, et al. Quantitative measurement of interocular suppression in anisotropic amblyopia: a case-control study. *Ophthalmology*. 2013;120(8):1672–80.
[CrossRef][PubMed]
- 13.

- Babu RJ, Clavagnier SR, Bobier W, et al. The regional extent of suppression: strabismics versus nonstrabismics. *Invest Ophthalmol Vis Sci.* 2013;54(10):6585–93.
[CrossRef][PubMed]
14. Wiesel TN, Hubel DH. Single-cell responses in striate cortex of kittens deprived of vision in one eye. *J Neurophysiol.* 1963;26:1003–17.
[PubMed]
 15. Daw NW. Mechanisms of plasticity in the visual cortex. The Friedenwald Lecture. *Invest Ophthalmol Vis Sci.* 1994;35:4168–79.
[PubMed]
 16. Antonio-Santos A, Vedula SS, Hatt SR, et al. Occlusion for stimulus deprivation amblyopia. *Cochrane Database Syst Rev.* 2014; 6(2):CD005136.
 17. Zwaan J, Mullaney PB, Awad A, et al. Pediatric intraocular lens implantation: surgical results and complications in more than 300 patients. *Ophthalmology.* 1998;105(1):112–8.
[CrossRef][PubMed]
 18. Li J, Thompson B, Ding Z, et al. Does partial occlusion promote normal binocular function? Partial occlusion effect on binocular function. *Invest Ophthalmol Vis Sci.* 2012;53:6818–27.
[CrossRef][PubMed]
 19. Chen Z, Li J, Thompson B, et al. The effect of Bangerter filters on binocular function in observers with amblyopia. *Invest Ophthalmol Vis Sci.* 2015;56(1):139–49.
[CrossRef]
 20. Repka MX, Cotter SA, Beck RW, et al. A randomized trial of atropine regimens for treatment of moderate amblyopia in children. *Ophthalmology.* 2004;111(11):2076–85.
[CrossRef][PubMed]
 21. Campbell FW, Hess RF, Watson PG, et al. Preliminary results of a physiologically based treatment of amblyopia. *Br J Ophthalmol.* 1978;62(11):748–55.
[CrossRef][PubMed][PubMedCentral]
 22. Keith CG, Howell ER, Mitchell DE, et al. Clinical trial of the use of rotating grating patterns in the treatment of amblyopia. *Br J Ophthalmol.* 1980;64(8):597–606.
[CrossRef][PubMed][PubMedCentral]
 23. Tytla ME, Labow-Daily LS. Evaluation of the CAM treatment for amblyopia: a controlled study. *Invest Ophthalmol Vis Sci.* 1981;20(3):400–6.
[PubMed]
 24. Levi DM, Li RW. Perceptual learning as a potential treatment for amblyopia: a mini-review. *Vision Res.* 2009;49(21):2535–49.
[CrossRef][PubMed][PubMedCentral]
 25. Zhou Y, Huang C, Xu P, et al. Perceptual learning improves contrast sensitivity and visual acuity in adults with anisometric amblyopia. *Vision Res.* 2006;46(5):739–50.
[CrossRef][PubMed]
 26. Huang CB, Zhou Y, Lu ZL. Broad bandwidth of perceptual learning in the visual system of adults

with anisometropic amblyopia. *Proc Natl Acad Sci U S A*. 2008;105(10):4068–73.
[\[CrossRef\]](#)[\[PubMed\]](#)[\[PubMedCentral\]](#)

27. Chen Z. Monocular perceptual learning of contrast detection facilitates binocular combination in adults with anisometropic amblyopia. *Sci Rep*. 2016;6:20187.
[\[CrossRef\]](#)[\[PubMed\]](#)[\[PubMedCentral\]](#)
28. Li J, Thompson B, Deng D, et al. Dichoptic training enables the adult amblyopic brain to learn. *Curr Biol*. 2013;23(8):R308–9.
[\[CrossRef\]](#)[\[PubMed\]](#)
29. Li J, Spiegel DP, Hess RF, et al. Dichoptic training improves contrast sensitivity in adults with amblyopia. *Vision Res*. 2015;114:161–72.
[\[CrossRef\]](#)[\[PubMed\]](#)
30. Algaze A, Leguire LE, Roberts C, et al. The effects of L-dopa on the functional magnetic resonance imaging response of patients with amblyopia: a pilot study. *J AAPOS*. 2005;9(3):216–23.
[\[CrossRef\]](#)[\[PubMed\]](#)
31. Spiegel DP, Li J, Hess RF, et al. Transcranial direct current stimulation enhances recovery of stereopsis in adults with amblyopia. *Neurotherapeutics*. 2013;10(4):831–9.
[\[CrossRef\]](#)[\[PubMed\]](#)[\[PubMedCentral\]](#)
32. Ding Z, Li J, Spiegel DP, et al. The effect of transcranial direct current stimulation on contrast sensitivity and visual evoked potential amplitude in adults with amblyopia. *Sci Rep*. 2016;6:19280.
[\[CrossRef\]](#)[\[PubMed\]](#)[\[PubMedCentral\]](#)
33. Lam DS, Zhao J, Chen LJ, et al. Adjunctive effect of acupuncture to refractive correction on anisometropic amblyopia: one-year results of a randomized crossover trial. *Ophthalmology*. 2011;118:1501–11.
[\[CrossRef\]](#)[\[PubMed\]](#)
34. Zhao J, Lam DS, Chen LJ, et al. Randomized controlled trial of patching vs acupuncture for anisometropic amblyopia in children aged 7 to 12 years. *Arch Ophthalmol*. 2010;128:1510–7.
[\[CrossRef\]](#)[\[PubMed\]](#)

27. Quality of Life Assessment in Children with Lens Anomalies

Weirong Chen¹ 

- (1) State Key Laboratory of Ophthalmology, Zhongshan Ophthalmic Center, Sun Yat-sen University, 54S Xianlie Road, Guangzhou, 510060, People's Republic of China

 **Weirong Chen**

Email: chenwrq@aliyun.com

Abstract

As a special population, children are undergoing fast growth and development, and they may differ from adults in physiology, in psychology, and in level of intelligence. Therefore, the evaluation of quality of life in pediatric patients should consider different items and focus, from those used for adult patients. Childhood is an important stage for developing living skills, experiencing the outside world, and learning knowledge; thus, good vision is considered essential to children's healthy development. Questionnaires or scales that are specifically designed for pediatric congenital cataract patients are not yet available. Therefore, it appears to be particularly important to design a quality of life scale for cataract children so as to assess their quality of life before and after surgery specifically and effectively. Based on research findings, we have developed and validated a quality of life scale specific for pediatric congenital cataract patients, and this chapter will explain how to evaluate the quality of life in cataract children.

Quality of life (QOL), also known as quality of survival, was proposed as a

special term in the USA in the 1930s. It sprang up in the 1950s–1960s and was introduced into the research of sociology in the 1970s. With the development of medical science and the transformation of medical patterns and health concepts, QOL was adopted as the main subjective assessment item of medical outcomes in the late 1970s. The WHO defined QOL as “individuals’ perception of their own position in life in the context of the culture and value systems in which they live and in relation to their goals, expectations, standards and concerns.” QOL is a broad-ranging concept incorporating a person’s physical health, psychological well-being, personal beliefs, independence, social relationships, and their association with salient features of their environment [1].

The concept of QOL developed rapidly in the field of ophthalmology in the 1990s, and it was mainly applied to evaluate patients with cataract, glaucoma, age-related macular degeneration, diabetic retinopathy, and corneal transplantation.

For adults with cataract, QOL surveys including VF-14, VFQ-25, SF-8, and IND-VFQ were designed successively and utilized in related clinical studies [2–5]. In China, Qiang Yu and colleagues designed SQOL-DV1, which measured the QOL of patients with visual impairments and patients after cataract surgery with IOL implantation [6, 7]. In addition, Jialiang Zhao [8], Joseph [9], and Mingguang He [10] carried out epidemiological surveys on QOL for cataract patients in Shunyi County of Beijing, Hong Kong, and Doumen County of Guangzhou Province, respectively, using the VF/QOL scale developed specifically for developing countries by the National Eye Institute of the USA.

Children are a special population and are not just miniatures of adults. As they are in rapid development and are different from adults in terms of physiology, psychology, intelligence, etc., the focuses of QOL assessment for children of various ages should also be different. In 1998, the World Health Organization Quality of Life (WHOQOL) proposed six aspects on quality of life studies for children with detailed descriptions [11]. The British Congenital Cataract Interest Group evaluated QOL in children with congenital cataracts, using a health-related quality of life (HRQOL) questionnaire which can be applied in general pediatric diseases (e.g., pediatric tumors and other chronic systemic diseases) [12]. Moreover, some researchers assessed QOL in children with congenital cataract using the Children’s Visual Function Questionnaire (CVFQ) [13, 14]. However, no

specific scale for QOL in children with congenital cataract has been reported. Therefore, it is of utmost importance to develop an instrument, which is different from the ones assessing QOL of adults with cataracts and is designed especially to evaluate QOL in cataract children in preoperative and various postoperative stages. The authors established a QOL scale for children with congenital cataracts and then evaluated QOL of children with bilateral congenital cataracts using the scale [15, 16]. This chapter elaborates on the postoperative quality of life in children with cataracts.

27.1 Development of a Quality of Life Scale for Children with Cataracts

27.1.1 Principles of Design

In addition to having good reliability, validity, and responsiveness, the QOL scale developed for children, a special population, should follow three principles.

27.1.1.1 Suitability

Assessment with a quality of life scale relies on the cooperation of the respondent; therefore, it is necessary to consider not only the research content but also the practical situation of the respondent when designing the scale. Development of a questionnaire suitable to a specific population should take the group attributes of respondents into consideration, which reduces difficulties, time, and energy for the respondents to answer questions. Meanwhile, this will also facilitate the completion and retrieval of the questionnaires. Therefore, for children with cataracts, the scale should be designed closely relating their daily life from their own perspective. As children's daily life includes life at home and at school, the questionnaire should have different contents in accordance with these two aspects.

27.1.1.2 Effectiveness

The first thing in developing a QOL scale is to identify the respondents and the research goals. The items in the questionnaire should be developed according to the established goals. All the items within the range of the research goals should be included in the scale, while items redundant for

research and theoretical hypothesis, whose results cannot be further analyzed, should not be incorporated. In general, developers should have an overall framework of the study and be fully aware of what parameters are necessary and what role those parameters play. For children with cataracts, the scale should cover key visual function-related parameters and fully reflect the differences in QOL between children and adults.

27.1.1.3 Feasibility

Since the completion of the questionnaire relies on the close cooperation of the respondents, the attributes and compliance of the target population should be considered when designing the questionnaire. The questions must take into account the willingness of the respondents and must be brief, clear, and in plain language so that the respondents can complete the questionnaire without difficulty. Too much content in the questionnaire and a long time answering questions may both affect the quality of survey. As children's abilities in comprehension and expression differ from that of adults, it is recommended that the questions and answers in a pediatric cataract-related QOL scale are easy for children to understand and answer. At the same time, the compliance of children is poorer than that of adults; therefore, the questions and answers should be designed as concise as possible to shorten the time needed for completing the questionnaire so as to increase children's compliance and reliability of their answers.

27.1.2 Methods and Steps for QOL Scale Development

27.1.2.1 Objective, Participants, and Division of Labor

Clear identification of the research objective is the priority in developing a high-quality scale. The following steps including determination of participants, division of labor, establishment of the item pool, and selection of items are all conducted according to this objective. The team of scale developers includes experts and professionals in the field of study, as well as target respondents. Experts and professionals refer to cataract surgeons experienced in clinical practice and academic research, and the respondents are cataract children who can understand and cooperate. Meanwhile, support

of the children's guardians is also required. According to the division of labor, members of the development team are divided into two categories, question designers and question selectors. Members review relevant global literatures and discuss to clarify the assessment goals of the scale (e.g., definition, range and content, etc.).

27.1.2.2 Connotation and Denotation of the Scale

The various concepts in the scale represent their respective connotation and denotation under specific circumstances. This step is mainly to define and interpret these concepts. Then the question selectors will propose an operational definition and composition for each concept. For instance, they will elaborate on what satisfaction refers to, what field and aspect it covers, as well as difference of satisfaction among various fields and aspects in terms of implication and content. As this step is the foundation of the entire scale, it is necessary for the selectors to have a careful and detailed discussion. Meanwhile, critical appraisal of the expert panel is also needed.

27.1.2.3 Establishment of the Item Pool and Screening of Items

The main task in this step is to generate all candidate questions and responses for the scale. Question designers will explain to selectors the relevant fields and aspects of the concepts in the questionnaire. Selectors then compose and pool the items related to the concepts independently on the basis of their own understanding and experience to establish the item pool. The final questions and responses in the scale will be selected from the item pool.

27.1.2.4 Design of Operational Items

In this step, a draft of items and options will be created. Most of the options will be arranged in a linear or graded form. The former refers to a line marked with standard units and options at the two end points. When being surveyed, the respondent decides the relative position of his/her answer on the line according to the requirement of the question and their inner experience. In the latter scenario, the respondent is asked to choose among isometric answers expressed with adverbs describing intensity. The common adverbs for frequency include never, rarely, occasionally, seldom, sometimes,

often, always, etc., and typical adverbs for intensity include a little, relatively, very, etc. A group of representative subjects are recruited, and each of them will mark the specific adverb on a standardized line according to their understanding of its intensity. The mean position of the adverbs will be analyzed to determine the appropriate adverb for each position.

27.1.2.5 Qualitative Evaluation of the Questionnaire

When the item pool is established, it is necessary to evaluate and screen the items. Expert consultation and the Delphi method are the common methods for qualitative evaluation. The former method takes the form of a seminar. Experts in the related field will be invited to discuss and analyze the importance, relevance, feasibility, and other aspects of each item and seek to reach a consensus. The latter method is conducted by sending letters to the experts for independent assessment. In the letter, the experts will be asked to give quantitative scores to the importance, necessity, and feasibility of each item and provide suggestions on amendments to certain items. Finally, according to the findings from the two methods, the items will be sorted, inappropriate wording in the questions and responses will be amended, the items with a low ranking will be eliminated, and the weight of each item will be evaluated and decided.

27.1.2.6 Quantitative Evaluation of the Questionnaire

After the previous steps, a preliminary questionnaire is formed, and it can be used as the original version in a small-sample pilot study. The pilot study mainly aims to quantitatively evaluate the readability of the questions and responses, the fluency of wording, and the reliability, validity, and responsiveness of the questionnaire. Finally, the questionnaire is modified and refined based on the results of the pilot study and becomes the final version. For some special questionnaires, it is also necessary to conduct a large-sample survey in normal test subjects and establish the weight for each item and the score calculation formula according to the results of the survey.

27.1.3 Important Issues in QOL Scale Development

27.1.3.1 Number of Questions in a Scale

A scale consists of different questions and options. Generally, the number of

questions should be coordinated with the time needed for completing the scale. According a myriad of previous surveys and experience, an interview time per person within 15–30 min will be appropriate for a regular respondent. If too many questions are designed or the questions are too complex, the duration of survey will exceed half an hour, which will lead to decline in the quality of answers and, consequently, reduced reliability. In light of this time limit, the number of questions in the scale should be within 30–50. Under common circumstances, all scales are designed within this limit. If the number of questions exceeds 50, measures should be taken to guarantee the reliability of the questionnaire. In consideration of the age and behavioral features of cataract children, the time of survey should be as short as possible so as to ensure its reliability and accuracy. After the pilot study and clinic practice, we finally designed 20 items in the scale of quality of life for children with cataract (Appendix 1).

27.1.3.2 Wording of Questions

When designing questions and responses, attention should be given to wording. First of all, the concepts involved must be accurate, understandable, and unambiguous. If there is a special implication, explanation is needed. Meanwhile, the questions should be written in language as concise and accurate as possible with a simple sentence structure. Multiple questions in a single item, guiding expression in any question, and questions that are conclusive, indistinct, or abstract should all be avoided.

27.1.3.3 Components for Assessment

Components for assessment in a scale might include various objective and subjective parameters. Attention should be given to how to design questions for different kinds of parameters. The questions on objective parameters shall be specific and objective. Quantified questions are recommended. Questions on subjective parameters focus more on the personal feelings of the respondents and their attitudes toward certain issues. They are often written with words describing intensity (e.g., excellent, good, ordinary, etc.), instead of quantified expression.

27.1.4 The Component and Assessment Methods of

QOL Scale for Children with Congenital Cataract

According to the aforementioned principles of scale developing, we reviewed QOL scales commonly used in clinical practice in various regions of the world (including instruments for children and those for visual impairments, e.g., the QOL scales for children with cancer, diabetes, and epilepsy and the QOL scales for adults with ocular diseases like cataract and glaucoma). After discussion with experts in public health and integration of all valid information, we developed the scale of QOL for children with bilateral congenital cataracts (see Appendix 1).

The 20-item scale has four components: visual function (Items 1–9, evaluating near vision, intermediate vision, distance vision, scotopic vision, general self-awareness of one’s own visual acuity, depth perception, diplopia, color vision, and glare), self-care ability (Items 10–13, evaluating abilities of dressing, bathing, toileting, and eating), social involvement (Items 14–16, evaluating participation in sports activities and group activities and social competence), and mental status (Items 17–20, evaluating confidence, happiness, and sense of identity). These parameters were assessed according to the best-corrected visual acuity (BCVA).

The subjects were required to respond according to their own subjective feelings. Each item is scored based on grading of responses. Items 1–6 and 10–20 each have five responses, ranging from “not difficult at all” scored as 4 to “almost impossible” scored as 0, with intermediate responses scored as 3, 2, and 1, successively. Items 7–9 each have two responses, with responses of “no” scored as 4 and “yes” scored as 0. Scoring is conducted according to these rules, and the total score of a subscale is the sum of the scores of all its items. Then the total score of the questionnaire can be achieved with the sum of all subscale scores. The full score of the questionnaire is 80. The higher the reported score is, the better the quality of life will be.

27.2 Assessment of the Quality of Life Scale for Children with Bilateral Congenital Cataracts

A series of parameters are needed to assess objectively whether a quality of life instrument is reliable and accurate in reflecting the content of survey intended by the researchers and how convincing the results are. The main parameters include validity, reliability, and responsiveness.

27.2.1 Validity

Validity is used to measure the effectiveness, correctness, and accuracy of an instrument, and it mainly reflects the magnitude of deviation between the measured outcomes and true outcomes. Validity aims to reflect whether the instrument is effectively measuring the content it intends to measure, i.e., the degree of agreement between the measured outcomes and intended outcomes. With the study of validity, we can learn whether the instrument can measure the target concept and determine how accurate this concept is measured. As the “true” value of the measurement target is obscure, validity assessment often requires comparison with external criteria. The following parameters are commonly used to evaluate validity.

27.2.1.1 Content Validity

Content validity refers to whether each designed item could represent its intended content or topic, and it also accounts for whether the respondent’s comprehension and response to the question are in agreement with the content which the question developers intend to solicit. Content validity is generally rated by experts. It mainly reflects the correlation between the score of each item and the score of the subscale to which this item is subordinated. A high correlation coefficient indicates that the validity of the scale is high. If the coefficient is low, it suggests that this item might not be relevant to the subscale. If the coefficient shows no statistical significance, it will be better to eliminate this item.

27.2.1.2 Criterion-Related Validity

Also known as criterion validity, criterion-related validity is assessed by utilizing an existing scale, which is verified in practice and universally accepted, as the criterion for comparison. Then the outcomes of the new scale and the criterion scale in the same population are compared to analyze the correlation. Criterion validity is represented by the correlation coefficient of the scores of the two scales.

27.2.1.3 Construct Validity

Construct validity is mainly used to account for whether the internal construction of the scale matches the initial theoretical construct. Meanwhile,

it also demonstrates whether the internal components of the measurement correspond to the construct that the scale designers claim to be measuring. Usually, construct validity is assessed with confirmatory factor analysis (CFA). In CFA, the underlying factors as well as the relation between the measured variables and each factor are identified. At the same time, the measured data are used in a given model for a factor to analyze the goodness of fit. After that there will be further assessment on whether the actual measurement fits the designed targets. Each item in the scale is regarded as a variable, and the common intrinsic factor of all of these variables is analyzed in CFA. If the common factor is highly correlated with the construct of the scale, it indicates the construct validity of the scale is desirable.

The above parameters of validity are not completely independent, and they are intrinsically associated. For instance, content validity is related to construct validity to some extent, and the quantified parameters of construct validity can be used to evaluate content validity indirectly.

27.2.2 Reliability

Reliability is mainly used to assess and estimate the accuracy, stability, and consistency of a scale. It is a parameter that reflects the degree of variation caused by random errors in the measuring process. If the quality of life of a patient remains unchanged, higher consistency of repeated measurement by the same instrument indicates greater reliability. Reliability usually includes the following three parameters.

27.2.2.1 *Test-Retest Reliability*

Test-retest reliability is represented as the Pearson correlation coefficient (r) between the scores of two consecutive surveys on the same group of respondents using the same scale. Generally speaking, a coefficient greater than 0.7 is usually required, and it demonstrates the consistency of the scale over time. For example, the same group of patients was remeasured with the same scale 2–3 weeks after the first survey. Correlation analysis on the total scores of the two surveys is conducted to calculate the correlation coefficient. If the P value of the hypothesis test is less than 0.05, the scale demonstrates high test-retest reliability. The higher the test-retest reliability is, the better the consistency and reliability of the scale.

27.2.2.2 *Split-Half Reliability*

Split-half reliability is an index reflecting the degree of the internal consistency among items in a test, i.e., the degree to which the same construct is tested. The items in the same scale are divided into two halves, for instance, the first half and the second half or two halves containing items of even numbers or odd numbers. Then the correlation coefficient (r) of the scores of the two parts is calculated. A high correlation means great reliability or internal consistency.

27.2.2.3 *Cronbach's Alpha Coefficient*

This refers to the mean value of all possible split-half reliability coefficients and is a common assessment of reliability. The calculation formula is:

$$\alpha = \frac{K}{K-1} \left(1 - \frac{\sum_{i=1}^K s_{Y_i}^2}{s_X^2} \right)$$

Here, K is the number of items, s_X^2 is the variance of total scores, and $s_{Y_i}^2$ is the variance of item i for the current sample of test subjects.

Usually, the value of α ranges from 0 to 1. If α is less than 0.6, the scale's internal consistency is considered to be poor. If it is between 0.7 and 0.8, the scale is considered to be fairly reliable. When this coefficient ranges from 0.8 to 0.9, the reliability of the scale is considered very high. Researchers in different surveys have different thresholds for this coefficient. In addition, Cronbach's alpha coefficient has an important quality that its value will increase with the addition of item number. Therefore, it should be noticed that this coefficient can be artificially and inappropriately elevated due to redundant items in a scale.

27.2.3 Responsiveness

Clinical scales are often utilized to compare the medical outcomes of different treatments. They must be able to reveal subtle differences in the outcomes and detect the minimal changes of clinical significance after medical interventions, that is, they must have a certain degree of responsiveness. Responsiveness represents the ability to demonstrate the changes of target characteristics across objects and times. In other words,

responsiveness shows the scale's sensitivity in reflecting the changes of the object features.

Effect size (ES) statistics is often used to evaluate responsiveness of the score. Its calculation formula is $ES = (\text{postoperative QOL score} - \text{preoperative QOL score}) / \text{standard deviation of the preoperative QOL score}$. Generally speaking, the value of ES should be greater than 0.2. The effect size is considered small if ES ranges from 0.2 to 0.5, medium if it ranges from 0.5 to 0.8, and large if it is over 0.8.

With changes in various factors, e.g., people's living conditions, views, and values, the medical model has greatly transformed. In recent years, the survey on quality of life for a specific population has become another important tool to assess health status in medical research. Meanwhile, in the field of ophthalmology, examinations of visual function alone can no longer assess the overall patient health, and therefore, a more comprehensive evaluation is needed to effectively assess the patient's health condition. As an assessment of patients' subjective well-being, quality of life reflects their social and living abilities, as well as their psychological state. It is an effective supplement to the object examinations of visual function.

Previous studies on pediatric congenital cataracts mainly focused on the visual function. When children's visual acuity was improved after surgery, the treatment was considered to have reached its end point. However, huge differences exist among the ophthalmologists' evaluation on the children's condition, the children's own personal feelings, and the social recognition of these pediatric patients. Attention was rarely paid to their personal feelings, vision-related performance in daily life, social interaction, psychological status, personalities, emotion, and so on. Reports on the utilization of quality of life instruments in pediatric ophthalmology are rare, and the quality of life scale designed especially for pediatric congenital cataracts has not been reported. In light of this and based on the general steps and principles of scale development, the characteristics of children with congenital cataracts, and the content of the established quality of life scales, we developed the quality of life scale specifically for pediatric congenital cataracts and carried out preliminary validation studies in an attempt to comprehensively assess the health status of children with congenital cataracts and to improve their treatment outcomes [15].

27.3 Summary

QOL survey has become an important tool in evaluating health status in the field of medical research. They are essential to evaluation of self-awareness, visual function, social life, psychological well-being, personality, and emotion of children with congenital cataracts. Children are a special population in that their capabilities to cooperate, comprehend, and express are less developed than adults. Therefore, a QOL survey should possess adequate validity, reliability, and responsiveness, and the design of which should follow the principles of suitability, effectiveness, and feasibility. The authors have formulated a QOL survey specific to children with congenital cataracts, which facilitates comprehensive assessment of the health status in these children.

References

1. WHO. The development of the WHO quality of life assessment instrument. Geneva: WHO; 1993.
2. Gothwal VK, Wright TA, Lamoureux EL, et al. Measuring outcomes of cataract surgery using the Visual Function Index-14. *J Cataract Refract Surg*. 2010;36(7):1181–8.
[CrossRef][PubMed]
3. Yamada M, Mizuno Y, Miyake Y, et al. A multicenter study on the health-related quality of life of cataract patients: baseline data. *Jpn J Ophthalmol*. 2009;53:470–6.
[CrossRef][PubMed]
4. Ishii K, Kabata T, Oshika T. The impact of cataract surgery on cognitive impairment and depressive mental status in elderly patients. *Am J Ophthalmol*. 2008;146:404–9.
[CrossRef][PubMed]
5. Gupta SK, Viswanath K, Thulasiraj RD, et al. The development of the Indian vision function questionnaire: field testing and psychometric evaluation. *Br J Ophthalmol*. 2005;89:621–7.
[CrossRef][PubMed][PubMedCentral]
6. Qiang Y, Shaozhen L, Henian C, et al. The development of a scale of life quality for diseases with visual impairment. *Chin J Ophthalmol*. 1997;33:307–40.
7. Yu Q, Li S, Jingjing AO, et al. Vision changes and quality of life in cataract patients. *Eye Sci*. 1997;13:85–9.
8. Zhao J, Sui R, Jia L, et al. Visual acuity and quality of life outcomes in patients with cataract in Shunyi County, China. *Am J Ophthalmol*. 1998;126(4):515–23.
[CrossRef][PubMed]

9. Joseph L, Michon JJ, Chan WS, et al. Visual acuity and quality of life outcomes in cataract surgery patients in Hong Kong. *Br J Ophthalmol.* 2002;86(1):12–7.
[\[CrossRef\]](#)
10. He M, Xu J, Wu K, et al. Quality of life assessment of cataract surgery in elderly population of Doumen County, Guangzhou Province China. *Chin J Ophthalmol.* 2002;38(10):594–7.
11. WHO QOL Group. The World Health Organization quality of life assessment (WHO QOL): development and general psychometric properties. *Soc Sci Med.* 1998;46:1569–85.
[\[CrossRef\]](#)
12. Chak M, Rahi JS, et al. The health-related quality of life of children with congenital cataract: findings of the British Congenital Cataract Study. *Br J Ophthalmol.* 2007;91:922–6.
[\[CrossRef\]](#)[\[PubMed\]](#)[\[PubMedCentral\]](#)
13. Birch EE, Cheng CS, Feliuss J. Validity and reliability of the Children’s Visual Function Questionnaire (CVFQ). *J AAPOS.* 2007;11(5):473–9.
[\[CrossRef\]](#)[\[PubMed\]](#)[\[PubMedCentral\]](#)
14. Lopes MC, Salomao SR, Berezovsky A, et al. Assessing vision-related quality of life in children with bilateral congenital cataracts. *Arq Bras Oftalmol.* 2009;72(4):467–80.
[\[CrossRef\]](#)[\[PubMed\]](#)
15. Chen W, Ye H, Deng D. Development and evaluation of the scale of quality of life for children with bilateral congenital cataract. *Chin J Ophthalmol.* 2007;43:239–44.
16. Ye H, Chen W, Deng D, et al. Quality of life assessment in children with congenital bilateral cataract. *Chin J Ophthalmol.* 2007;43:996–9.

Appendix 1

The Scale of Quality of Life for Children with Bilateral Congenital Cataracts
(Reproduced with permission from Chen Weirong, et al. [15])

1. During the daytime, can you see the characters in the textbook clearly?
 1. It is easy for me to see clearly and the characters are very clear.
 2. I can see all the characters clearly, but it is rather difficult.
 3. I can see most of the characters clearly except some complex ones.
 4. The characters in the textbook are indistinct and I can see only a few of them, for instance, numbers like 1, 2, and 3.
 5. All the characters are very indistinct and I can't see them clearly.
2. When doing homework at night by a desk lamp which is very dim, can you see the characters in the textbook clearly?
 1. It is easy for me to see clearly and the characters are very clear.
 2. I can see the characters clearly, but it is rather difficult.
 3. I can see most of the characters clearly except some complex ones.
 4. The characters in the textbook are indistinct and I can see only a few of them, for instance, numbers like 1, 2, and 3.

5. All the characters are very indistinct and I can't see them clearly.
-
3. Can you see the characters on the blackboard clearly when you are having a class?
 1. It is easy for me to see clearly and the characters are very clear.
 2. I can see the characters clearly, but it is rather difficult.
 3. I can see most of the characters clearly except some complex ones.
 4. The characters on the blackboard are indistinct and I can see only a few of them, for instance, numbers like 1, 2, and 3.
 5. All the characters are very indistinct and I can't see them clearly.
-
4. Can you see clearly the classmates 3–4 rows in front of or behind you or the objects on their desks?
 1. I can see them clearly with ease and they are very clear.
 2. I can see them clearly, but it is rather difficult.
 3. I can see most of them clearly, but I can't distinguish some small objects like an eraser.
 4. I can only see my classmates clearly, but the objects on their desks are vague.
 5. I can only recognize their silhouette roughly.

5. What do you think of your vision?

1. Very good.
2. Good, as in healthy children.
3. Average
4. Relatively poor
5. Very poor

6. Is it difficult for you to walk downstairs?

1. Not difficult.
2. A little difficult.
3. Rather difficult.
4. Very difficult.
5. Usually, I can't walk downstairs by myself.

7. When you look at an object, will there be two images?

1. Yes.
2. No.

8. Did any of the following situations happen to you? You feel that the colors you see are different from those seen by others. When you draw something, your teacher thinks that you color it too light, too heavy, or different from other students.

1. Yes.

2. No.

9. When you go out with your parents at night, do you see a big halo around the car light?

1. Yes.

2. No.

10. Is it difficult for you to dress independently?

1. Not difficult and I usually dress by myself.

2. A bit difficult and I sometimes need parent's help.

3. Rather difficult and I often need parent's help.

4. Very difficult and I need parent's help most of the time.

5. I can't dress by myself and always need parent's help.

11. Is it difficult for you to take a shower independently?

1. Not difficult and I usually do it by myself.
2. A bit difficult and I sometimes need parent's help.
3. Rather difficult and I often need parent's help.
4. Very difficult and I need parent's help most of the time.
5. I can't do it by myself and always need parent's help.

12. Is it difficult for you to go to the bathroom?

1. Not difficult and I usually go to the bathroom by myself.
2. A bit difficult and I need parent's help sometimes.
3. Rather difficult and I often need parent's help.
4. Very difficult and I need parent's help most of the time.
5. I can't go to the bathroom by myself and always need parent's help.

13. Is it difficult for you to eat independently (without being fed)?

1. Not difficult and I usually eat by myself without being fed.
2. A bit difficult and I need parent's help sometimes.
3. Rather difficult and I often need parent's help.

4. Very difficult and I need parent's help most of the time.

5. I can't eat by myself and always need parent's help.

14. Is it difficult for you to play games with your classmates in PE classes or with your parents at home?

1. Not difficult.

2. A bit difficult.

3. Rather difficult.

4. Very difficult.

5. I can't play games with classmates or parents at all.

15. Do you like to join the activities organized by your class or your classmates?

1. I like them very much and I will join in whenever there is an activity

2. Yes. I join most of the activities.

3. It depends on whether I like the activity.

4. I don't like most of the activities and rarely join in.

5. I don't like them at all and never join in.

16. Do you get along with your classmates?

1. I always do.
2. I do, for most of the time.
3. I usually do.
4. I rarely do.
5. I can't.

17. When a task is assigned to you by your teacher or parent, are you confident to accomplish it?

1. I'm very confident.
2. I'm basically confident.
3. It depends on how difficult the task is.
4. Basically, I'm not confident.
5. No, I'm afraid of being assigned a task by my teacher or parent and usually I can't accomplish it.

18. Do you feel happy?

1. I'm always happy.
2. I'm happy most of the time.

3. My happy time almost equals to my unhappy time.
4. I'm unhappy most of the time.
5. I rarely feel happy.

19. Do you think your teachers like you?

1. Every teacher likes me.
2. Most of them like me.
3. They like me a little bit.
4. I don't know whether they like me.
5. No, they all hate me.

20. Do you think your classmates like you? For example, they like to play with you.

1. They like me very much.
2. They like me fairly.
3. They like me a little bit.
4. I don't know whether they like me.
5. No, they hate me.