

Ajay Singla · Craig Comiter  
*Editors*

# Post-Prostatectomy Incontinence

Evaluation and Management

 Springer

---

## Post-Prostatectomy Incontinence

---

Ajay Singla • Craig Comiter  
Editors

# Post-Prostatectomy Incontinence

Evaluation and Management

 Springer

*Editors*

Ajay Singla  
Massachusetts General Hospital  
Harvard Medical School  
Boston, MA  
USA

Craig Comiter  
Department of Urology  
Stanford University School of Medicine  
Stanford, CA  
USA

ISBN 978-3-319-55827-1      ISBN 978-3-319-55829-5 (eBook)  
DOI 10.1007/978-3-319-55829-5

Library of Congress Control Number: 2017943047

© Springer International Publishing AG 2017

This work is subject to copyright. All rights are reserved by the Publisher, whether the whole or part of the material is concerned, specifically the rights of translation, reprinting, reuse of illustrations, recitation, broadcasting, reproduction on microfilms or in any other physical way, and transmission or information storage and retrieval, electronic adaptation, computer software, or by similar or dissimilar methodology now known or hereafter developed.

The use of general descriptive names, registered names, trademarks, service marks, etc. in this publication does not imply, even in the absence of a specific statement, that such names are exempt from the relevant protective laws and regulations and therefore free for general use.

The publisher, the authors and the editors are safe to assume that the advice and information in this book are believed to be true and accurate at the date of publication. Neither the publisher nor the authors or the editors give a warranty, express or implied, with respect to the material contained herein or for any errors or omissions that may have been made. The publisher remains neutral with regard to jurisdictional claims in published maps and institutional affiliations.

Printed on acid-free paper

This Springer imprint is published by Springer Nature  
The registered company is Springer International Publishing AG  
The registered company address is: Gewerbestrasse 11, 6330 Cham, Switzerland

---

# Contents

<b>Post-prostatectomy Incontinence: Introduction and Prevalence</b> . . . . .	1
Nirmish Singla and Allen F. Morey	
<b>Pathophysiologic Mechanisms in Postprostatectomy</b>	
<b>Urinary Incontinence</b> . . . . .	11
Joseph LaBossiere and Sender Herschorn	
<b>Office Evaluation for Post-prostatectomy Incontinence</b> . . . . .	23
Hin Yu Vincent Tu and Jaspreet S. Sandhu	
<b>Conservative Management of Post-prostatectomy Incontinence</b> . . . . .	31
Michael Kennelly and Rachel Locke	
<b>Historical Background and Evolution in Male Sling Surgery</b> . . . . .	53
Ajay Singla	
<b>The AdVance Transobturator Male Sling</b> . . . . .	65
Oscar A. Suárez, Amanda S. Chung, and Kurt A. McCammon	
<b>The Virtue™ Quadratic Sling for Post-prostatectomy Incontinence</b> . . . . .	77
Craig V. Comiter	
<b>Adjustable Male Slings: REMEEX</b> . . . . .	91
Aljendro Sousa Escandon, Juan León, Javier Flores, and Daniel Sousa-González	
<b>Adjustable Male Sling: Argus</b> . . . . .	105
Salomon Victor Romano and Christian Hector Cobreros	
<b>ProACT for Treatment of Male SUI</b> . . . . .	117
Wilhelm A. Hübner	
<b>Use of the Artificial Urinary Sphincter in the Management of Post-prostatectomy Incontinence</b> . . . . .	125
Brian J. Linder and Daniel S. Elliott	

**New Technologies in the Management of Post-prostatectomy Urinary Incontinence.** . . . . . 137  
Neha R. Malhotra and Y. Zaki Almallah

**Index.** . . . . . 145

---

## Contributors

**Y. Zaki Almallah** Department of Urology, University of Illinois at Chicago, Chicago, IL, USA

**Amanda S. Chung** Eastern Virginia Medical School, Virginia Beach, VA, USA

**Christian Hector Cobreros** Department of Urology, Urodynamics and Female Urology Section, Hospital Carlos G. Durand, Buenos Aires, Argentina

**Craig V. Comiter** Department of Urology, Stanford University School of Medicine, Stanford, CA, USA

**Daniel S. Elliott** Department of Urology, Mayo Clinic, Rochester, MN, USA

**Aljendro Sousa Escandon** Urologist Hospital Comarcal de Monforte, Lugo, Spain

**Javier Flores** Urologist Hospital Comarcal de Monforte, Lugo, Spain

**Sender Herschorn** University of Toronto, Toronto, ON, Canada

**Wilhelm A. Hübner** Department of Urology, Korneuburg Hospital and Karl Landsteiner Institute for Functional Disorders and Disorders Tumors of the Urinary Tract, Korneuburg, Austria

**Michael Kennelly** Carolinas Medical Center, Carolinas HealthCare System, Charlotte, NC, USA

**Joseph LaBossiere** University of Toronto, Toronto, ON, Canada

**Juan León** Urologist Hospital Comarcal de Monforte, Lugo, Spain

**Brian J. Linder** Department of Urology, Mayo Clinic, Rochester, MN, USA

**Rachel Locke** Carolinas Medical Center, Carolinas HealthCare System, Charlotte, NC, USA

**Neha R. Malhotra** Department of Urology, University of Illinois at Chicago, Chicago, IL, USA

**Kurt A. McCammon** Eastern Virginia Medical School, Virginia Beach, VA, USA

**Allen F. Morey** Department of Urology, University of Texas Southwestern Medical Center, Dallas, TX, USA

**Salomon Victor Romano** Department of Urology, Urodynamics and Female Urology Section, Hospital Carlos G. Durand, Buenos Aires, Argentina

**Jaspreet S. Sandhu** Department of Surgery, Urology Service, Memorial Sloan Kettering Cancer Center, New York, NY, USA

**Ajay Singla** Massachusetts General Hospital, Harvard Medical School, Boston, MA, USA

**Nirmish Singla** Department of Urology, University of Texas Southwestern Medical Center, Dallas, TX, USA

**Daniel Sousa-González** Urologist Hospital Comarcal de Monforte, Lugo, Spain

**Oscar A. Suárez** Hospital San José Tecnológico de Monterrey, Urología TecSalud, Av Morones Prieto 3000, Monterrey, N.L., Mexico

**Hin Yu Vincent Tu** Department of Surgery, Urology Service, Memorial Sloan Kettering Cancer Center, New York, NY, USA



---

# Post-prostatectomy Incontinence: Introduction and Prevalence

Nirmish Singla and Allen F. Morey

---

## Introduction

Prostate cancer is the most frequently diagnosed malignancy in men, with an estimated 220,800 new diagnoses in the United States in 2015 [1]. Approximately 40% of men with localized prostate cancer elect to undergo radical prostatectomy [2]. While stress urinary incontinence (SUI) is almost universally evident immediately following prostatectomy, the severity and degree of recovery are variable. Reported rates of persistent and bothersome urinary leakage following prostatectomy, or post-prostatectomy incontinence (PPI), range anywhere from 5 to 72% [3], though this variability is largely due to the absence of a strict definition for PPI.

With the emergence of minimally invasive technologies, robotic approaches to performing prostatectomy have become widely popularized. PPI nonetheless remains an issue, with a reported incidence of 4–31% in robotic cases, versus 7–40% in open cases [4]. Other series have reported PPI rates of <10% after robotic prostatectomy, with improvement seen over the first 24 months following surgery [5]. Although refinement in surgical techniques has helped reduce the incidence of PPI [6], the overall prevalence continues to rise due to an increase in the total number of prostatectomies performed worldwide.

Indeed, PPI can have a profound impact on the quality of life in patients following treatment for prostate cancer [7]. Approximately half of patients seek some treatment for PPI [8], and 6–9% are bothered enough to elect for surgical management [7–14]. In a recent pilot study that prospectively evaluated a novel grading scale for the evaluation of men with PPI, we found that the median duration from the time of radical prostatectomy to anti-incontinence surgery was an

---

N. Singla • A.F. Morey (✉)

Department of Urology, University of Texas Southwestern Medical Center, Dallas, TX, USA

e-mail: [Allen.Morey@UTSouthwestern.edu](mailto:Allen.Morey@UTSouthwestern.edu)

alarming 5.4 years (range 1–20 years) [15] despite traditional recommendations to defer surgical intervention for PPI by only a year after PPI [16]. Hence early recognition of this issue is of paramount importance.

---

## Risk Factors and Pathophysiology

Several risk factors have been postulated to increase the likelihood of developing incontinence following prostatectomy. Broadly, these can be categorized into patient-related factors (such as preoperative voiding function, patient anatomy, and comorbidities) and intraoperative technique. A more extensive discussion of the underlying pathophysiology of PPI is provided elsewhere in this textbook.

### Patient Factors

Preexisting urinary incontinence or voiding dysfunction increases the likelihood of developing PPI. As most cases of SUI in males tend to arise following prostatectomy, presurgical SUI is relatively uncommon. In a recent study on 1000 adult men, urinary incontinence was prevalent in only 5.4%, of whom approximately one-fourth (26%) suffered from isolated SUI [17]. These men presumptively suffer from baseline intrinsic sphincter deficiency (ISD), which manifests as clinical SUI or low maximal urethral closure pressure on urodynamics [18, 19]. The intrinsic component of the urethral sphincter appears to be responsible for passive continence, while the extrinsic component plays a more substantial role in active continence [20]. Membranous urethral length, including both anatomic length based on magnetic resonance imaging (MRI) and functional length shown on urodynamic studies, has been shown to be directly associated with continence rates [19, 21–23]. Preserving the functional integrity of the distal urethral sphincter mechanism is thus necessary for maintaining postoperative continence.

Other functional or anatomic issues with either the bladder or the outlet can also predispose patients to developing PPI. Examples of such risk factors include neurogenic detrusor overactivity, as seen in Parkinson's disease or other neurologic insult [24] larger prostate volume [25], and the presence of an anatomic stricture [26, 27] or post-prostatectomy anastomotic stricture [28, 29] causing outlet obstruction. ISD tends to be the most common underlying etiology in PPI, while isolated bladder dysfunction occurs in only less than 10% of cases [28, 29]; however, both sphincter and bladder dysfunction can coexist in at least one-third of incontinent patients [28, 29]. Bladder dysfunction can also occur *de novo* following prostatectomy [30, 31].

Advancing age has also been shown to be an independent risk factor for the development of PPI [14, 32–37]. Older men have a greater likelihood of requiring eventual artificial urinary sphincter (AUS) for severe PPI [38]. Strasser et al. hypothesize this age-related phenomenon to be related to a progressive reduction in striated muscle cells within the external urinary sphincter with increasing age [39]. Body mass index (BMI) is also associated with increased PPI rates, reportedly three

times higher for patients with BMI >30 kg/m<sup>2</sup> compared to those with lower BMI [40]. Obesity may also present technical challenges, such as difficulty with performing the vesicourethral anastomosis, and often coexists with other comorbidities such as diabetes and vascular disease [41, 42]. Finally, patients who are undergoing salvage prostatectomy following prior radiotherapy or cryotherapy tend to experience higher rates of PPI [43] and greater likelihood of needing AUS implantation [44–47].

## Intraoperative Factors

Postoperative continence outcomes may also be dictated in part by technical features intraoperatively. Most cases of PPI are likely a direct result of surgical injury to the native urinary sphincteric mechanisms [13], particularly the intrinsic component [28–30]. Bladder denervation during prostatectomy may also contribute to PPI due to the resultant impairment in detrusor contractility and poor bladder compliance.

Several studies have shown that bilateral nerve-sparing techniques may help preserve continence [19, 48–50], though this is debated [51, 52]. Bladder neck preservation may improve early return of continence at 3 months [53], though its effect on continence status at 6 and 12 months may not be significant [54, 55]. Other surgical maneuvers such as sparing of seminal vesicles, urethral suspension, and bladder neck mucosal eversion have also been suggested to reduce PPI rates [21, 36, 48]. Surgeon experience may play a role as well [56]. With respect to surgical approach, no significant differences in continence rates have been demonstrated between perineal and retropubic approaches [57, 58] or among open, laparoscopic, and robotic approaches [9, 11, 59–61].

---

## Evaluation and Management

As the evaluation of patients with PPI and options for management will be discussed more extensively later in this textbook, we provide here an introductory overview.

### Evaluation

The primary goal when approaching patients with PPI is to discern the degree of subjective bother and severity of incontinence in order to appropriately direct therapy. Evaluation of PPI patients should begin with a comprehensive history, including the onset, duration, type, and severity of incontinence, along with precipitating events. Subjective bother from incontinence can be discerned by assessing its impact on daily activities. A history of radiation increases the probability that detrusor overactivity or poor compliance may exist. A voiding diary can be helpful to

quantify the fluid intake and functional bladder capacity [62]. Quantifying the severity of leakage based on the number of pads used per day [63, 64] or objectively using pad weights [65] or ultrasonic post-void residual volumes to assess bladder emptying [66] can be helpful to facilitate treatment decision-making.

Physical examination is an important component that should not be overlooked when evaluating PPI patients. In our clinical experience, we have found the standing cough test (SCT), introduced nearly 20 years ago by Kowalczyk et al. [67], to be a useful method to easily and reproducibly assess the severity of male SUI. From our experience in hundreds of PPI patients over more than a decade of focused clinical practice in prosthetic urology, we have recognized several distinct patterns of leakage commonly observed during routine implementation of the SCT. We recently attempted to standardize those leakage patterns and correlate them with other patient-reported indicators of condition severity and clinical outcomes [15]. In our pilot study, we reported a strong concordance ( $r = 0.74$ ) between SCT patterns and patient-reported pad-per-day, which has been previously shown to correlate strongly with pad weights [68]. In addition to the SCT, neurological evaluation should be performed to assess the S2-S4 spinal segments, including anal sphincter tone, perineal sensation in the S2-S4 segments, and the bulbocavernosus reflex. Abdominal examination is performed to assess for prior scars and to detect a potentially distended bladder with overflow incontinence.

Office cystoscopy can be conducted to evaluate the integrity of the external urinary sphincter and bladder neck. Endoscopic evidence of urethral coaptation may suggest the degree of sphincter insufficiency. Patients with obstructive symptoms ideally should also be evaluated with cystoscopy before any surgical treatment to rule out anastomotic strictures [69]. Multichannel urodynamic testing may provide some information about bladder contractility [70] and Valsalva abdominal leak point pressure (ALPP) measurement to assess sphincter weakness [71]; however, its routine use in PPI appears to be of limited value, demonstrating poor correlation with anti-incontinence surgical outcomes [72, 73].

## Management

A range of options exists for managing PPI. A trial of conservative measures is certainly worth consideration prior to surgical treatment. Examples of effective non-surgical methods include pelvic floor exercises (Kegel exercises) [74, 75] and behavioral modifications, such as limiting fluid intake or bladder irritants such as alcohol and caffeine [76]. Additional approaches such as biofeedback, pelvic floor stimulation, pharmacotherapy, and urethral bulking agents have also been studied, though with limited evidence to support their clinical utility in the PPI setting [69].

Surgical intervention for PPI is traditionally deferred for at least 1 year after prostatectomy [16], though in select cases it may be reasonable to consider surgical management even earlier. The AUS presently remains the gold standard for PPI treatment, though in more recent years, the male urethral sling has emerged as an attractive, less complex alternative. While slings can be effective for the

management of mild-to-moderate PPI, more severe PPI is better managed with AUS [77, 78]. Kumar et al. recently demonstrated that patients usually prefer a sling if given the choice, since it takes effect immediately, has lower risk of severe complications, and avoids a mechanical device that may be subject to malfunction or the need for revision [79]. However, several factors must be taken into consideration when counseling patients on their surgical options for PPI [69, 80]. Our recently developed SCT-based grading scale to objectively assess PPI severity appears to help facilitate anti-incontinence surgical procedure selection with favorable patient-reported outcomes [15]. Nonetheless, we still unfortunately lack a standardized algorithm to stratify patients to the ideal treatment for PPI.

---

## References

1. Siegel RL, Miller KD, Jemal A. Cancer statistics, 2015. *CA Cancer J Clin.* 2015;65(1):5–29.
2. Cooperberg MR, Broering JM, Litwin MS, Lubeck DP, Mehta SS, Henning JM, et al. The contemporary management of prostate cancer in the United States: lessons from the cancer of the prostate strategic urologic research endeavor (CapSURE), a national disease registry. *J Urol.* 2004;171(4):1393–401.
3. Boorjian SA, Eastham JA, Graefen M, Guillonneau B, Karnes RJ, Moul JW, et al. A critical analysis of the long-term impact of radical prostatectomy on cancer control and function outcomes. *Eur Urol.* 2012;61(4):664–75.
4. Crivellaro S, Morlacco A, Bodo G, Agro EF, Gozzi C, Pistolesi D, et al. Systematic review of surgical treatment of post radical prostatectomy stress urinary incontinence. *Neurourol Urodynam.* 2015;35:875–81.
5. Tewari AK, Ali A, Metgud S, Theckumparampil N, Srivastava A, Khani F, et al. Functional outcomes following robotic prostatectomy using athermal, traction free risk-stratified grades of nerve sparing. *World J Urol.* 2013;31(3):471–80.
6. Hu JC, Elkin EP, Pasta DJ, Lubeck DP, Kattan MW, Carroll PR, et al. Predicting quality of life after radical prostatectomy: results from CaPSURE. *J Urol.* 2004;171(2 Pt 1):703–7. discussion 7–8
7. Steineck G, Helgesen F, Adolfsson J, Dickman PW, Johansson JE, Norlen BJ, et al. Quality of life after radical prostatectomy or watchful waiting. *N Engl J Med.* 2002;347(11):790–6.
8. Penson DF, McLerran D, Feng Z, Li L, Albertsen PC, Gilliland FD, et al. 5-Year urinary and sexual outcomes after radical prostatectomy: results from the prostate cancer outcomes study. *J Urol.* 2008;179(5 Suppl):S40–4.
9. Anastasiadis AG, Salomon L, Katz R, Hoznek A, Chopin D, Abbou CC. Radical retropubic versus laparoscopic prostatectomy: a prospective comparison of functional outcome. *Urology.* 2003;62(2):292–7.
10. Begg CB, Riedel ER, Bach PB, Kattan MW, Schrag D, Warren JL, et al. Variations in morbidity after radical prostatectomy. *N Engl J Med.* 2002;346(15):1138–44.
11. Jacobsen NE, Moore KN, Estey E, Voaklander D. Open versus laparoscopic radical prostatectomy: a prospective comparison of postoperative urinary incontinence rates. *J Urol.* 2007;177(2):615–9.
12. Sacco E, Prayer-Galetti T, Pinto F, Fracalanza S, Betto G, Pagano F, et al. Urinary incontinence after radical prostatectomy: incidence by definition, risk factors and temporal trend in a large series with a long-term follow-up. *BJU Int.* 2006;97(6):1234–41.
13. Singla AK. Male incontinence: pathophysiology and management. *Ind J Urol.* 2007;23(2):174–9.
14. Stanford JL, Feng Z, Hamilton AS, Gilliland FD, Stephenson RA, Eley JW, et al. Urinary and sexual function after radical prostatectomy for clinically localized prostate cancer: the prostate cancer outcomes study. *JAMA.* 2000;283(3):354–60.

15. Morey AF, Singla N, Chung P, Klein A, Tausch TJ, Siegel JA, et al. V3-03 male stress incontinence grading scale for evaluation of men with post-prostatectomy incontinence: a pilot study. *J Urol*. 2016;195(4 Suppl):e467.
16. Haab F, Yamaguchi R, Leach GE. Postprostatectomy incontinence. *Urol Clin North Am*. 1996;23(3):447–57.
17. Sandhu JS. Treatment options for male stress urinary incontinence. *Nat Rev Urol*. 2010;7(4):222–8.
18. Majoros A, Bach D, Keszthelyi A, Hamvas A, Romics I. Urinary incontinence and voiding dysfunction after radical retropubic prostatectomy (prospective urodynamic study). *Neurourol Urodyn*. 2006;25(1):2–7.
19. Wei JT, Dunn RL, Marcovich R, Montie JE, Sanda MG. Prospective assessment of patient reported urinary continence after radical prostatectomy. *J Urol*. 2000;164(3 Pt 1):744–8.
20. Pfister C, Cappelletti O, Dunet F, Bugel H, Grise P. Assessment of the intrinsic urethral sphincter component function in postprostatectomy urinary incontinence. *Neurourol Urodyn*. 2002;21(3):194–7.
21. Cambio AJ, Evans CP. Minimising postoperative incontinence following radical prostatectomy: considerations and evidence. *Eur Urol*. 2006;50(5):903–13. discussion 13
22. Hammerer P, Huland H. Urodynamic evaluation of changes in urinary control after radical retropubic prostatectomy. *J Urol*. 1997;157(1):233–6.
23. Van Kampen M, De Weerd W, Van Poppel H, Feys H, Castell Campesino A, Stragier J, et al. Prediction of urinary continence following radical prostatectomy. *Urol Int*. 1998;60(2):80–4.
24. Khan Z, Mieza M, Starer P, Singh VK. Post-prostatectomy incontinence. A urodynamic and fluoroscopic point of view. *Urology*. 1991;38(5):483–8.
25. Konety BR, Sadetsky N, Carroll PR, Ca PI. Recovery of urinary continence following radical prostatectomy: the impact of prostate volume--analysis of data from the CaPSURE database. *J Urol*. 2007;177(4):1423–5. discussion 5-6
26. Elliott SP, Meng MV, Elkin EP, McAninch JW, Duchane J, Carroll PR, et al. Incidence of urethral stricture after primary treatment for prostate cancer: data from CaPSURE. *J Urol*. 2007;178(2):529–34. discussion 34
27. Litwin MS, Lubeck DP, Henning JM, Carroll PR. Differences in urologist and patient assessments of health related quality of life in men with prostate cancer: results of the CaPSURE database. *J Urol*. 1998;159(6):1988–92.
28. Ficazzola MA, Nitti VW. The etiology of post-radical prostatectomy incontinence and correlation of symptoms with urodynamic findings. *J Urol*. 1998;160(4):1317–20.
29. Groutz A, Blaivas JG, Chaikin DC, Weiss JP, Verhaaren M. The pathophysiology of post-radical prostatectomy incontinence: a clinical and video urodynamic study. *J Urol*. 2000;163(6):1767–70.
30. Giannantoni A, Mearini E, Di Stasi SM, Mearini L, Bini V, Pizzirusso G, et al. Assessment of bladder and urethral sphincter function before and after radical retropubic prostatectomy. *J Urol*. 2004;171(4):1563–6.
31. Giannantoni A, Mearini E, Zucchi A, Costantini E, Mearini L, Bini V, et al. Bladder and urethral sphincter function after radical retropubic prostatectomy: a prospective long-term study. *Eur Urol*. 2008;54(3):657–64.
32. Catalona WJ, Basler JW. Return of erections and urinary continence following nerve sparing radical retropubic prostatectomy. *J Urol*. 1993;150(3):905–7.
33. Moore KN, Truong V, Estey E, Voaklander DC. Urinary incontinence after radical prostatectomy: can men at risk be identified preoperatively? *J Wound Ostomy Continence Nurs*. 2007;34(3):270–9. quiz 80-1
34. Neveus T, von Gontard A, Hoebeke P, Hjalmas K, Bauer S, Bower W, et al. The standardization of terminology of lower urinary tract function in children and adolescents: report from the standardisation Committee of the International Children's continence society. *J Urol*. 2006;176(1):314–24.
35. Rogers CG, Su LM, Link RE, Sullivan W, Wagner A, Pavlovich CP. Age stratified functional outcomes after laparoscopic radical prostatectomy. *J Urol*. 2006;176(6 Pt 1):2448–52.

36. Walsh PC, Partin AW, Epstein JI. Cancer control and quality of life following anatomical radical retropubic prostatectomy: results at 10 years. *J Urol.* 1994;152(5 Pt 2):1831–6.
37. Young MD, Weizer AZ, Silverstein AD, Crisci A, Albala DM, Vieweg J, et al. Urinary continence and quality of life in the first year after radical perineal prostatectomy. *J Urol.* 2003;170(6 Pt 1):2374–8.
38. Mohamad BA, Marszalek M, Brossner C, Ponholzer A, Wehrberger C, Willinger M, et al. Radical prostatectomy in Austria: a nationwide analysis of 16,524 cases. *Eur Urol.* 2007;51(3):684–8. discussion 9
39. Strasser H, Frauscher F, Helweg G, Colleselli K, Reissigl A, Bartsch G. Transurethral ultrasound: evaluation of anatomy and function of the rhabdosphincter of the male urethra. *J Urol.* 1998;159(1):100–4. discussion 4–5
40. Anast JW, Sadetsky N, Pasta DJ, Bassett WW, Latini D, DuChane J, et al. The impact of obesity on health related quality of life before and after radical prostatectomy (data from CaPSURE). *J Urol.* 2005;173(4):1132–8.
41. van Roermund JG, van Basten JP, Kiemeny LA, Karthaus HF, Witjes JA. Impact of obesity on surgical outcomes following open radical prostatectomy. *Urol Int.* 2009;82(3):256–61.
42. Wolin KY, Luly J, Sutcliffe S, Andriole GL, Kibel AS. Risk of urinary incontinence following prostatectomy: the role of physical activity and obesity. *J Urol.* 2010;183(2):629–33.
43. Stone NN, Stock RG. Long-term urinary, sexual, and rectal morbidity in patients treated with iodine-125 prostate brachytherapy followed up for a minimum of 5 years. *Urology.* 2007;69(2):338–42.
44. Heidenreich A, Ohlmann C, Ozgur E, Engelmann U. Functional and oncological outcome of salvage prostatectomy of locally recurrent prostate cancer following radiation therapy. *Urol A.* 2006;45(4):474–81.
45. Paparel P, Soulie M, Mongiat-Artus P, Cornud F, Borgogno C. Membres du sous-comite prostate du C. [salvage radical prostatectomy after external radiotherapy for prostate cancer: indications, morbidity and results. Review from CCAFU prostate section]. *Prog Urol.* 2010;20(5):317–26.
46. Sanderson KM, Penson DF, Cai J, Groshen S, Stein JP, Lieskovsky G, et al. Salvage radical prostatectomy: quality of life outcomes and long-term oncological control of radiorecurrent prostate cancer. *J Urol.* 2006;176(5):2025–31. discussion 31–2
47. Seabra D, Faria E, Dauster B, Rodrigues G, Fava G. Critical analysis of salvage radical prostatectomy in the management of radioresistant prostate cancer. *Int Braz J Urol.* 2009;35(1):43–8.
48. Burkhard FC, Kessler TM, Fleischmann A, Thalmann GN, Schumacher M, Studer UE. Nerve sparing open radical retropubic prostatectomy--does it have an impact on urinary continence? *J Urol.* 2006;176(1):189–95.
49. Nandipati KC, Raina R, Agarwal A, Zippe CD. Nerve-sparing surgery significantly affects long-term continence after radical prostatectomy. *Urology.* 2007;70(6):1127–30.
50. Zincke H, Oesterling JE, Blute ML, Bergstralh EJ, Myers RP, Barrett DM. Long-term (15 years) results after radical prostatectomy for clinically localized (stage T2c or lower) prostate cancer. *J Urol.* 1994;152(5 Pt 2):1850–7.
51. Eastham JA, Kattan MW, Rogers E, Goad JR, Otori M, Boone TB, et al. Risk factors for urinary incontinence after radical prostatectomy. *J Urol.* 1996;156(5):1707–13.
52. Lepor H, Kaci L. The impact of open radical retropubic prostatectomy on continence and lower urinary tract symptoms: a prospective assessment using validated self-administered outcome instruments. *J Urol.* 2004;171(3):1216–9.
53. Lowe BA. Comparison of bladder neck preservation to bladder neck resection in maintaining postprostatectomy urinary continence. *Urology.* 1996;48(6):889–93.
54. Poon M, Ruckle H, Bamshad BR, Tsai C, Webster R, Lui P. Radical retropubic prostatectomy: bladder neck preservation versus reconstruction. *J Urol.* 2000;163(1):194–8.
55. Srougi M, Nesrallah LJ, Kauffmann JR, Nesrallah A, Leite KR. Urinary continence and pathological outcome after bladder neck preservation during radical retropubic prostatectomy: a randomized prospective trial. *J Urol.* 2001;165(3):815–8.

56. Kielb SJ, Clemens JQ. Comprehensive urodynamics evaluation of 146 men with incontinence after radical prostatectomy. *Urology*. 2005;66(2):392–6.
57. Harris MJ. Radical perineal prostatectomy: cost efficient, outcome effective, minimally invasive prostate cancer management. *Eur Urol*. 2003;44(3):303–8. discussion 8
58. Weldon VE, Tavel FR, Neuwirth H. Continence, potency and morbidity after radical perineal prostatectomy. *J Urol*. 1997;158(4):1470–5.
59. Ahlering TE, Woo D, Eichel L, Lee DI, Edwards R, Skarecky DW. Robot-assisted versus open radical prostatectomy: a comparison of one surgeon's outcomes. *Urology*. 2004;63(5):819–22.
60. Rassweiler J, Seemann O, Schulze M, Teber D, Hatzinger M, Frede T. Laparoscopic versus open radical prostatectomy: a comparative study at a single institution. *J Urol*. 2003;169(5):1689–93.
61. Salomon L, Sebe P, De La Taille A, Vordos D, Hoznek A, Yiou R, et al. Open versus laparoscopic radical prostatectomy: part II. *BJU Int*. 2004;94(2):244–50.
62. Schick E, Jolivet-Tremblay M, Dupont C, Bertrand PE, Tessier J. Frequency-volume chart: the minimum number of days required to obtain reliable results. *Neurourol Urodyn*. 2003;22(2):92–6.
63. Litwin MS, Hays RD, Fink A, Ganz PA, Leake B, Brook RH. The UCLA prostate cancer index: development, reliability, and validity of a health-related quality of life measure. *Med Care*. 1998;36(7):1002–12.
64. Avery K, Donovan J, Peters TJ, Shaw C, Gotoh M, Abrams P. ICIQ: a brief and robust measure for evaluating the symptoms and impact of urinary incontinence. *Neurourol Urodyn*. 2004;23(4):322–30.
65. Smither AR, Guralnick ML, Davis NB, See WA. Quantifying the natural history of post-radical prostatectomy incontinence using objective pad test data. *BMC Urol*. 2007;7:2.
66. Starer P, Libow LS. The measurement of residual urine in the evaluation of incontinent nursing home residents. *Arch Gerontol Geriatr*. 1988;7(1):75–81.
67. Kowalczyk JJ, Spicer DL, Mulcahy JJ. Long-term experience with the double-cuff AMS 800 artificial urinary sphincter. *Urology*. 1996;47(6):895–7.
68. Nitti VW, Mourtzinou A, Brucker BM. Correlation of patient perception of pad use with objective degree of incontinence measured by pad test in men with post-prostatectomy incontinence: the SUFU pad test study. *J Urol*. 2014;192(3):836–42.
69. Singla N, Singla AK. Post-prostatectomy incontinence: etiology, evaluation, and management. *Turk J Urol*. 2014;40(1):1–8.
70. Ozawa H, Chancellor MB, Ding YY, Nasu Y, Yokoyama T, Kumon H. Noninvasive urodynamic evaluation of bladder outlet obstruction using Doppler ultrasonography. *Urology*. 2000;56(3):408–12.
71. McGuire EJ, Fitzpatrick CC, Wan J, Bloom D, Sanvordenker J, Ritchey M, et al. Clinical assessment of urethral sphincter function. *J Urol*. 1993;150(5 Pt 1):1452–4.
72. Thiel DD, Young PR, Broderick GA, Heckman MG, Wehle MJ, Igel TC, et al. Do clinical or urodynamic parameters predict artificial urinary sphincter outcome in post-radical prostatectomy incontinence? *Urology*. 2007;69(2):315–9.
73. Twiss C, Fleischmann N, Nitti VW. Correlation of abdominal leak point pressure with objective incontinence severity in men with post-radical prostatectomy stress incontinence. *Neurourol Urodyn*. 2005;24(3):207–10.
74. Filocamo MT, Li Marzi V, Del Popolo G, Cecconi F, Marzocco M, Tosto A, et al. Effectiveness of early pelvic floor rehabilitation treatment for post-prostatectomy incontinence. *Eur Urol*. 2005;48(5):734–8.
75. Van Kampen M, De Weerd W, Van Poppel H, De Ridder D, Feys H, Baert L. Effect of pelvic-floor re-education on duration and degree of incontinence after radical prostatectomy: a randomised controlled trial. *Lancet*. 2000;355(9198):98–102.
76. Goode PS, Burgio KL, Johnson 2nd TM, Clay OJ, Roth DL, Markland AD, et al. Behavioral therapy with or without biofeedback and pelvic floor electrical stimulation for persistent post-prostatectomy incontinence: a randomized controlled trial. *JAMA*. 2011;305(2):151–9.



77. Lucas MG, Bosch RJ, Burkhard FC, Cruz F, Madden TB, Nambiar AK, et al. EAU guidelines on surgical treatment of urinary incontinence. *Actas Urol Esp.* 2013;37(8):459–72.
78. Samli MSA, Aggarwal N. Artificial urinary sphincter vs. bone anchored male sling for post-radical prostatectomy urinary incontinence. *Eur Urol suppl.* 2005;4:143.
79. Kumar A, Litt ER, Ballert KN, Nitti VW. Artificial urinary sphincter versus male sling for post-prostatectomy incontinence--what do patients choose? *J Urol.* 2009;181(3):1231–5.
80. Satyanarayan A, Mooney R, Singla N. Surgical management of post-prostatectomy incontinence. *EMJ Urol.* 2016;4(1):75–80.

---

# Pathophysiologic Mechanisms in Postprostatectomy Urinary Incontinence

Joseph LaBossiere and Sender Herschorn

---

## Introduction

Urinary incontinence is a common adverse event after radical prostatectomy (RP). Though the majority of men will experience significant improvement in continence within 2 years of surgery, persistent postprostatectomy urinary incontinence (PPI) remains in up to 15% of men [1–4]. Ultimately, up to 5% of men will proceed with surgery to correct PPI [5]. Multiple factors have been implicated in the development of PPI. These include patient (age and body mass index (BMI)), biologic (bladder dysfunction, pre-existing LUTS, prostate size, preoperative membranous urethral length, and history of TURP), and surgical factors (damage to the external urethral sphincter, bladder neck preservation/repair, reconstruction of periurethral supports, preservation of neurovascular bundles, and postoperative status of the urethra). An understanding of the pathophysiologic mechanisms contributing to PPI may aid the practicing urologist in appropriately counseling patients preoperatively and in taking steps to minimize the risk of incontinence after radical prostatectomy. This chapter will review our understanding of PPI pathophysiology to date.

---

## Patient Factors

### Patient Age

It has been postulated that increased age can have a negative impact on return of continence after prostatectomy, perhaps owing to higher incidences of pre-existing lower urinary tract symptoms, larger prostatic volumes at the time of prostatectomy, and/or age-related functional changes to the lower urinary tract. Karakiewicz et al.

---

J. LaBossiere • S. Herschorn (✉)  
University of Toronto, Toronto, ON, Canada  
e-mail: [Sender.Herschorn@sunnybrook.ca](mailto:Sender.Herschorn@sunnybrook.ca)

in a population-based study of 2415 men found that age was a significant predictor of continence outcomes after radical prostatectomy on univariate and multivariate analysis [6]. Stanford et al. found in a population-based cohort of 1291 that persistent incontinence >18 months after prostatectomy was significantly higher in men >75 years old versus younger men (13.8% vs. 0.7–3.6%;  $p = 0.03$ ) [4], a finding confirmed in a recent large retrospective review of 2849 men which found on multivariate analysis that the likelihood of continence recovery significantly decreases with increased age [7]. In contrast, Kadono et al. failed to demonstrate age as a predictor of persistent incontinence at 1 year postprostatectomy on univariate and multivariate analysis of data from 111 patients [8]. In addition, Catalona and Basler found that age and continence recovery did not correlate in a series of 784 men treated with radical prostatectomy [9].

## Body Mass Index

As with age, the evidence characterizing the impact of BMI on postprostatectomy incontinence is variable. In a recent large retrospective review of 2849 patients, Matsushita et al. noted that higher BMI was associated with decreased recovery of incontinence at 6 and 12 months postprostatectomy. [7] Wiltz et al. found in a prospective study of 945 men who underwent robotic-assisted radical prostatectomy (RARP) that urinary continence outcomes were significantly lower at 1 and 2 years after prostatectomy in men with BMIs >30 kg/m<sup>2</sup> [10], a finding supported in a study of 589 men which found that PPI was more prevalent in physically inactive, obese men (BMI >30 kg/m<sup>2</sup>) [11]. Conversely, Hsu et al. prospectively followed 1024 men postprostatectomy and failed to demonstrate a relationship between BMI and PPI. In a recent study, Kadono et al. also found that BMI is not a predictor of urinary incontinence on univariate and multivariate analysis [8].

---

## Biologic Factors

### Bladder Dysfunction and Pre-existing LUTS

Up to 50% of men with urinary incontinence are found to have some element of bladder dysfunction after prostatectomy, including decreased compliance and detrusor over-/underactivity [12–14], though many men will have pre-existing functional changes in the lower urinary tract prior to prostatectomy [15, 16]. The etiology of these observed functional changes in the lower urinary tract is likely multifactorial, including anatomic changes, devascularization, and denervation of the bladder [17]. Detrusor overactivity can result in postprostatectomy incontinence, though pure detrusor overactivity incontinence is relatively rare (3%) [14].

There is evidence that pre-existing LUTS negatively impact continence rates postprostatectomy. In a prospective study of 482 men, Wei et al. found that preoperative continence was a significant predictor of postoperative continence on multivariate analysis [18]. In a study of 106 men, Rodriguez et al. found that men with

occasional leakage postprostatectomy (76 of 106 men) were older, had more urinary symptom (higher American Urological Association symptom and bother scores (AUAs)), and had larger prostates [19].

## Preoperative Membranous Urethral Length

Preservation of membranous urethral length during radical prostatectomy has been demonstrated to significantly improve continence rates and shorten time to recovery of incontinence after radical prostatectomy [20]. Optimization of membranous urethral length during radical prostatectomy is likely influenced by prostate size as well as preoperative membranous urethral length. Paparel et al. retrospectively analyzed 64 men who had both pre- and post-radical prostatectomy MRI investigations assessing membranous urethral length [21]. The authors found that a longer pre- and postoperative membranous urethral length and a lower membranous urethral loss ratio were associated with superior continence outcomes ( $p < 0.01$ ,  $p < 0.01$ , and  $p = 0.2$ , respectively). Nguyen et al. in a retrospective study of 274 patients investigated with MRI pre-radical prostatectomy found that a longer “functional urethral length” (external urethral sphincter length) correlated positively with continence recovery and negatively with time to achieving continence after surgery [22]. A recent analysis by Matsushita et al. evaluating 2849 men with preoperative MRI confirms these findings, demonstrating that the likelihood of continence recovery significantly increases with longer preoperative membranous urethral length [7]. In contrast, Borin et al. in a prospective study of 200 patients did not demonstrate a negative impact of shorter urethral length on time to continence recovery nor overall incontinence [23]. However, urethral stump length was not measured. The transection was done just distal to the prostatourethral junction in an effort to achieve a negative margin.

## Prostate Size

As a shorter membranous urethral length and the presence of pre-existing lower urinary tract symptoms have been implicated in PPI, the impact of prostate size (which can influence the two aforementioned variables) on PPI has been questioned. Konety et al. retrospectively evaluated 2097 men treated with RP that had been investigated with transrectal ultrasound before surgery [24]. The authors found that men with prostate volumes  $>50 \text{ cm}^3$  had lower levels of continence up to 2 years after surgery and that prostatic volume was a predictor of urinary functional recovery after prostatectomy. However, continence rates equalized across all prostate sizes at 2 years follow-up. In a retrospective study of 355 consecutive patients undergoing RARP, Boczko et al. demonstrated a 6-month continence rate of 97% for patients with prostate sizes  $<75 \text{ g}$  vs. 84% of patients with prostates  $>75 \text{ g}$  ( $p < 0.05$ ) [25]. On the contrary, in their study of 111 patients Kadono et al. failed to demonstrate an impact of prostate size on continence after RP. Further, a large retrospective study of 3067 men found that prostate size was not significantly associated with urinary incontinence ( $p = 0.08$ ) [26].

---

## **Transurethral Resection of the Prostate Gland (TURP) Before Radical Prostatectomy**

Our understanding of the impact of TURP prior to radical prostatectomy on continence is limited at present and based on small studies with low levels of evidence. Palisaar et al. prospectively collected data on 1760 patients treated with radical prostatectomy and retrospectively matched 62 patients with a history of TURP to 62 controls who did not [27]. At 1-year follow-up, no difference in perioperative complication rates and functional outcomes, including continence, was observed between the two groups. In addition, Su et al. retrospectively analyzed data from 2693 patients treated with radical prostatectomy, of which 49 patients had a history of TURP [28]. TURP had an impact on positive surgical margin but did not significantly impact functional outcomes including urinary continence.

---

## **Surgical Factors**

### **External Urethral Sphincter and Bladder Neck Preservation/Reconstruction**

The urethral sphincter complex is composed of two distinct components; the smooth-muscle internal (lissosphincter) sphincter found at the bladder neck and the striated external (rhabdosphincter) sphincter surrounding the membranous urethra [29]. The striated muscle of the external sphincter extends from the proximal aspect of the bulbar urethra and inserts posteriorly into the perineal body, forming an omega-shaped structure over the lateral and anterior aspects of the membranous urethra [30]. Additionally, the external urethral sphincter can overlap the prostate, and striated muscle is incorporated into the prostatic apex [29, 31].

Both components of the urethral sphincter complex have been implicated in continence after prostatectomy. The internal urethral sphincter is responsible for passive continence at normal activity levels, and bladder neck preservation (and by extension, sparing of the internal sphincter) may result in earlier return of continence and improved overall continence rates. Stolzenburg et al. retrospectively analyzed 150 men treated with bladder neck sparing RP compared to 90 men who did not have a bladder neck sparing procedure [32]. The authors found that immediate postoperative continence and continence at 3 months after surgery were significantly better in the bladder neck sparing group and that bladder neck sparing had no impact on positive surgical margin status. A recent systematic review and meta-analysis by Ma et al. support these findings, demonstrating that bladder neck sparing during RP improved early recovery and overall long-term (1 year) continence rates as well as decreasing the incidence of vesicourethral anastomotic strictures without compromising oncologic outcomes [33].

Proper function of the external urethral sphincter depends on the presence of healthy striated muscle as well as the integrity of membranous urethral supporting structures. Skeldon et al. analyzed anatomical specimens in 61 patients

treated with RP and devised a grading system that quantified the amount of striated muscle present in specimens isolated from the prostatic apex [34]. The authors found increased amounts of striated muscle in the specimens had a significant benefit on urinary incontinence. Tuygun et al. studied 36 patients after radical prostatectomy and demonstrated on MRI that external urethral sphincter fibrosis was present in 100% of patients with urinary incontinence versus 29% of those with no incontinence and that milder fibrosis was associated with a shorter duration of incontinence [35]. The authors concluded that fibrosis likely impacts urinary continence after radical prostatectomy by negatively impacting external sphincter function.

Regarding the type of RP, open versus laparoscopic versus robotic-assisted, one randomized comparison of laparoscopic RP with and without robotic assistance did not show a significant difference in urinary continence [36]. Although there has been more recent demonstration of statistically significantly superior continence outcomes with robotic-assisted RP compared to *open* RP [37–40], a recently published RCT from Australia showed no difference in early continence outcomes between open and robotic-assisted RP [41].

## Membranous Urethral Supporting Structures

Membranous urethral supporting structures can be divided into pelvic floor, anterior, and posterior supporting components. The pelvic floor consists of the levator ani muscles with associated fascia. The levator ani muscles surround the external urethral sphincter circumferentially and, however, are separated from the sphincter complex by a distinct layer of connective tissue [42]. The pelvic floor likely assists the continence mechanism by providing additional occlusive forces to the urethra during an increase in intra-abdominal pressures [43]. Anterior support structures include the puboprostatic ligament, the pubovesical ligament, and the tendinous arch of the pelvic fascia. Together, they attach the membranous urethra to the pubic bone and stabilize the position of the external urethral sphincter/bladder neck [44]. Denonvilliers fascia, the rectourethralis muscle, and the perineal body support the membranous urethra posteriorly [42, 45].

Studies have demonstrated that preservation or reconstruction of these circumferential supporting structures improves postprostatectomy incontinence. Stolzenburg et al. prospectively analyzed 50 men treated with nerve and puboprostatic ligament sparing RP and compared them to 50 men treated with nerve sparing radical prostatectomy alone [46]. The authors found that early recovery of continence (<3 months) was significantly improved in men treated with the puboprostatic ligament sparing procedure (chi-square test,  $p = 0.03$ ). Reconstruction of the posterior musculofascial plate (Denonvilliers fascia) with the so-called Rocco stitch has also been demonstrated in numerous studies to improve continence. Rocco et al. compared 250 patients treated with posterior reconstruction to a historical cohort of 50 patients who did not, observing that patients treated with posterior reconstruction had significantly improved time to continence recovery, though long-term

recovery was similar between treatment groups [47]. van Randenborgh et al. have previously demonstrated that maximizing membranous urethral length at the time of prostatectomy significantly shortens time to continence recovery and overall continence rates [20]. In a similar vein, Nguyen et al. has proposed that the mechanism for improved early continence recovery with posterior urethral reconstruction is through restoration of membranous urethral length during prostatectomy [48]. However, the role for posterior support reconstruction is still controversial. A systematic review by Rocco et al. found that posterior reconstruction significantly improves early return to function within 30 days of surgery ( $p = 0.004$ ), though continence rates by 90 days after surgery were not affected [49]. A subsequent systematic review did show a benefit at 90 days, but longer-term benefits have yet to be demonstrated [50]. Combined anterior and posterior reconstruction techniques have also been reported, demonstrating improved early return of continence (<3 months) without an increase in complications [51, 52]. Based on current data, more investigation is required before reconstruction of the periurethral supporting structures becomes standard of care.

## **Integrity of the Neurovascular Bundles**

The anatomy of the neurovascular bundles has been elucidated in the literature [53–56]. The pudendal nerve innervates the voluntary striated sphincter [57]. Branches of the pudendal nerve are thought to also form a component of the neurovascular bundles and provide innervation to the urethral sphincter complex [53]. Damage to the neurovascular bundle(s) during prostatectomy may disrupt function of the urethral sphincter complex with resultant urinary incontinence. Burkhard et al. prospectively followed 536 patients who had either bilateral, unilateral, or non-nerve-sparing radical prostatectomy and evaluated continence status over a minimum 1-year follow-up period [58]. At 1-year incontinence was found in 1.3%, 3.4%, and 13.7% for bilateral, unilateral, and non-nerve-sparing prostatectomy patients, respectively. On multivariate analysis, the only statistically significant factor influencing urinary incontinence was attempted nerve sparing ( $p < 0.001$ ). More contemporary data support these findings [59, 60]. However, Marien and Lepor did not observe a difference in continence rates between nerve-sparing and non-nerve-sparing techniques in a prospective cohort of 1110 men [61].

## **Postoperative Status of the Urothelium**

As mentioned above, fibrosis plays a role in the development of postprostatectomy incontinence likely through negative effects on external urethral sphincter function [21, 35]. Studies have also demonstrated that the presence of vesicourethral anastomotic stricture may be a significant risk factor for the development of urinary incontinence after radical prostatectomy [62].

## Surgeon Experience and Radical Prostatectomy Modality

Our understanding of the impact of surgeon experience and prostatectomy modality on urinary outcomes continues to evolve. Evidence exists supporting the notion that more experienced surgeons yield better urinary continence outcomes when compared to less experienced surgeons [39, 63].

The evidence supporting one prostatectomy modality (open, laparoscopic, robotic-assisted) over another with regard to continence outcomes is variable, though in general no significant difference in continence outcomes has been observed when comparing the three modalities, as evidenced by a recent systematic review and meta-analysis [64]. The true impact of prostatectomy modality on continence outcomes will be better characterized as surgeon experience increases with robotic technology and new studies become available.

## Radiation Effects

Urinary incontinence is a known adverse complication in the treatment of localized prostate cancer with radiotherapy [65]. Limited studies have investigated the impact of adjuvant radiotherapy on urinary outcomes following prostatectomy. Petrovich et al. [66] reported no difference in incontinence in two cohorts of patients, one with and one without adjuvant radiation. In a follow-up study the same group reported no late toxicity [67]. Suardi et al. evaluated 361 patients treated with radical prostatectomy and stratified into those receiving adjuvant radiation ( $n = 153$ ) versus those who did not ( $n = 208$ ) [68]. At the 1- and 3-year follow-up intervals, continence rates were 51% and 59% versus 81% and 87% for adjuvant radiation therapy versus no radiation, respectively. Fontaine et al. also reported no change in continence status in 16 of 17 men after salvage radiation [69]. However, Petroski et al. reported that postoperative radiotherapy worsened continence in 26% of 129 patients followed for a median of 5 years [70]. Sowerby et al. [71] reported urinary incontinence at 3 years in 24.5% of 162 men who underwent adjuvant radiation and 23.5% of 490 men who underwent delayed or salvage radiation for prostate cancer.

On the other hand, salvage radical prostatectomy following external beam radiotherapy has been generally reported to have a high incidence of urinary incontinence [72–76] possibly because of radiation-induced fibrosis of the external sphincter. [73] In a recent systematic review of 27 series of salvage prostatectomy, Matei et al. [75] reported a 47.8% average incontinence rate (range 19–79%). The incontinence rate was not lower with laparoscopic or robotic approaches. Cozzarini et al. demonstrated that older age and greater radiation dose in the salvage setting and younger age and hypertension in the adjuvant setting resulted in worse “urinary toxicity” [77].

As multimodal therapy becomes more commonplace and salvage radical prostatectomy rates after radiation therapy increase, our understanding of the impact of peri-prostatectomy radiotherapy on urinary incontinence should become clearer.



## Summary

Urinary incontinence after radical prostatectomy is a common and troublesome adverse event, and our knowledge of the factors influencing PPI continues to grow. Certain patient and biologic factors have been shown to negatively impact on urinary incontinence after radical prostatectomy, including patient age, BMI, preoperative membranous urethral length, presence of bladder dysfunction, history of TURP, and prostate size. Many surgical approaches and reconstructive techniques have been described. Improved continence outcomes have been reported with neurovascular bundle sparing, bladder neck preservation, and maximization of membranous urethral length during surgery. There is some controversy regarding the impact of the type of RP on urinary continence, and further studies are required as surgeon experience with robotic-assisted technology increases. Finally, studies characterizing the impact of adjuvant radiotherapy or salvage prostatectomy after primary radiotherapy on urinary incontinence are relatively limited, though worse urinary incontinence has been observed in both of these scenarios.

## References

1. Litwin MS, et al. Urinary function and bother after radical prostatectomy or radiation for prostate cancer: a longitudinal, multivariate quality of life analysis from the Cancer of the Prostate Strategic Urologic Research Endeavor. *J Urol.* 2000;164(6):1973–7.
2. Ficarra V, et al. Retropubic, laparoscopic, and robot-assisted radical prostatectomy: a systematic review and cumulative analysis of comparative studies. *Eur Urol.* 2009;55(5):1037–63.
3. Penson DF, et al. 5-Year urinary and sexual outcomes after radical prostatectomy: results from the Prostate Cancer Outcomes Study. *J Urol.* 2008;179(5 Suppl):S40–4.
4. Stanford JL, et al. Urinary and sexual function after radical prostatectomy for clinically localized prostate cancer: the Prostate Cancer Outcomes Study. *JAMA.* 2000;283(3):354–60.
5. Nam RK, et al. Population based study of long-term rates of surgery for urinary incontinence after radical prostatectomy for prostate cancer. *J Urol.* 2012;188(2):502–6.
6. Karakiewicz PI, et al. Erectile and urinary dysfunction after radical prostatectomy for prostate cancer in Quebec: a population-based study of 2415 men. *Eur Urol.* 2004;46(2):188–94.
7. Matsushita K, et al. Preoperative predictive model of recovery of urinary continence after radical prostatectomy. *BJU Int.* 2015;116(4):577–83.
8. Kadono Y, et al. Use of preoperative factors including urodynamic evaluations and nerve-sparing status for predicting urinary continence recovery after robot-assisted radical prostatectomy: nerve-sparing technique contributes to the reduction of postprostatectomy incontinence. *Neurourol Urodyn.* 2016;35(8):1034–9.
9. Catalona WJ, Basler JW. Return of erections and urinary continence following nerve sparing radical retropubic prostatectomy. *J Urol.* 1993;150(3):905–7.
10. Wiltz AL, et al. Robotic radical prostatectomy in overweight and obese patients: oncological and validated-functional outcomes. *Urology.* 2009;73(2):316–22.
11. Wolin KY, et al. Risk of urinary incontinence following prostatectomy: the role of physical activity and obesity. *J Urol.* 2010;183(2):629–33.
12. Huckabay C, et al. A urodynamics protocol to optimally assess men with post-prostatectomy incontinence. *Neurourol Urodyn.* 2005;24(7):622–6.
13. Groutz A, et al. The pathophysiology of post-radical prostatectomy incontinence: a clinical and video urodynamic study. *J Urol.* 2000;163(6):1767–70.

14. Ficazzola MA, Nitti VW. The etiology of post-radical prostatectomy incontinence and correlation of symptoms with urodynamic findings. *J Urol.* 1998;160(4):1317–20.
15. Giannantoni A, et al. Bladder and urethral sphincter function after radical retropubic prostatectomy: a prospective long-term study. *Eur Urol.* 2008;54(3):657–64.
16. Giannantoni A, et al. Assessment of bladder and urethral sphincter function before and after radical retropubic prostatectomy. *J Urol.* 2004;171(4):1563–6.
17. Song C, et al. Urodynamic interpretation of changing bladder function and voiding pattern after radical prostatectomy: a long-term follow-up. *BJU Int.* 2010;106(5):681–6.
18. Wei JT, et al. Prospective assessment of patient reported urinary continence after radical prostatectomy. *J Urol.* 2000;164(3 Pt 1):744–8.
19. Rodriguez E, Skarecky DW, Ahlering TE. Post-robotic prostatectomy urinary continence: characterization of perfect continence versus occasional dribbling in pad-free men. *Urology.* 2006;67(4):785–8.
20. van Randenborgh H, et al. Improved urinary continence after radical retropubic prostatectomy with preparation of a long, partially intraprostatic portion of the membranous urethra: an analysis of 1013 consecutive cases. *Prostate Cancer Prostatic Dis.* 2004;7(3):253–7.
21. Paparel P, et al. Recovery of urinary continence after radical prostatectomy: association with urethral length and urethral fibrosis measured by preoperative and postoperative endorectal magnetic resonance imaging. *Eur Urol.* 2009;55(3):629–37.
22. Nguyen L, Jhaveri J, Tewari A. Surgical technique to overcome anatomical shortcoming: balancing post-prostatectomy continence outcomes of urethral sphincter lengths on preoperative magnetic resonance imaging. *J Urol.* 2008;179(5):1907–11.
23. Borin JF, et al. Impact of urethral stump length on continence and positive surgical margins in robot-assisted laparoscopic prostatectomy. *Urology.* 2007;70(1):173–7.
24. Konety BR, et al. Recovery of urinary continence following radical prostatectomy: the impact of prostate volume--analysis of data from the CaPSURE Database. *J Urol.* 2007;177(4):1423–5. discussion 1425–6
25. Boczek J, et al. Impact of prostate size in robot-assisted radical prostatectomy. *J Endourol.* 2007;21(2):184–8.
26. Pettus JA, et al. Prostate size is associated with surgical difficulty but not functional outcome at 1 year after radical prostatectomy. *J Urol.* 2009;182(3):949–55.
27. Palisaar JR, et al. Open radical retropubic prostatectomy gives favourable surgical and functional outcomes after transurethral resection of the prostate. *BJU Int.* 2009;104(5):611–5.
28. Su YK, et al. Does previous transurethral prostate surgery affect oncologic and continence outcomes after RARP? *J Robot Surg.* 2015;9(4):291–7.
29. Koraitim MM. The male urethral sphincter complex revisited: an anatomical concept and its physiological correlate. *J Urol.* 2008;179(5):1683–9.
30. Strasser H, Bartsch G. Anatomy and innervation of the rhabdosphincter of the male urethra. *Semin Urol Oncol.* 2000;18(1):2–8.
31. Lee SE, et al. Impact of variations in prostatic apex shape on early recovery of urinary continence after radical retropubic prostatectomy. *Urology.* 2006;68(1):137–41.
32. Stolzenburg JU, et al. Effect of bladder neck preservation during endoscopic extraperitoneal radical prostatectomy on urinary continence. *Urol Int.* 2010;85(2):135–8.
33. Ma, X., et al.. Bladder neck preservation improves time to continence after radical prostatectomy: a systematic review and meta-analysis. *Oncotarget.* 2016;7(41):67463–5.
34. Skeldon SC, et al. Striated muscle in the prostatic apex: does the amount in radical prostatectomy specimens predict postprostatectomy urinary incontinence? *Urology.* 2014;83(4):888–92.
35. Tuygun C, et al. Significance of fibrosis around and/or at external urinary sphincter on pelvic magnetic resonance imaging in patients with postprostatectomy incontinence. *Urology.* 2006;68(6):1308–12.
36. Asimakopoulos AD, et al. Randomized comparison between laparoscopic and robot-assisted nerve-sparing radical prostatectomy. *J Sex Med.* 2011;8(5):1503–12.

37. Novara G, et al. Systematic review and meta-analysis of perioperative outcomes and complications after robot-assisted radical prostatectomy. *Eur Urol.* 2012;62(3):431–52.
38. Novara G, et al. Systematic review and meta-analysis of studies reporting oncologic outcome after robot-assisted radical prostatectomy. *Eur Urol.* 2012;62(3):382–404.
39. Ficarra V, et al. Systematic review and meta-analysis of studies reporting urinary continence recovery after robot-assisted radical prostatectomy. *Eur Urol.* 2012;62(3):405–17.
40. Ficarra V, et al. Systematic review and meta-analysis of studies reporting potency rates after robot-assisted radical prostatectomy. *Eur Urol.* 2012;62(3):418–30.
41. Yaxley JW, et al. Robot-assisted laparoscopic prostatectomy versus open radical retropubic prostatectomy: early outcomes from a randomised controlled phase 3 study. *Lancet.* 2016;388(10049):1057–66.
42. Yucel S, Baskin LS. An anatomical description of the male and female urethral sphincter complex. *J Urol.* 2004;171(5):1890–7.
43. Gosling JA, et al. A comparative study of the human external sphincter and periurethral levator ani muscles. *Br J Urol.* 1981;53(1):35–41.
44. Steiner MS. The puboprostatic ligament and the male urethral suspensory mechanism: an anatomic study. *Urology.* 1994;44(4):530–4.
45. Zhang C, et al. Perirectal fascia and spaces: annular distribution pattern around the mesorectum. *Dis Colon Rectum.* 2010;53(9):1315–22.
46. Stolzenburg JU, et al. Nerve sparing endoscopic extraperitoneal radical prostatectomy--effect of puboprostatic ligament preservation on early continence and positive margins. *Eur Urol.* 2006;49(1):103–11. discussion 111–2
47. Rocco F, et al. Early continence recovery after open radical prostatectomy with restoration of the posterior aspect of the rhabdosphincter. *Eur Urol.* 2007;52(2):376–83.
48. Nguyen MM, et al. Early continence outcomes of posterior musculofascial plate reconstruction during robotic and laparoscopic prostatectomy. *BJU Int.* 2008;101(9):1135–9.
49. Rocco B, et al. Posterior musculofascial reconstruction after radical prostatectomy: a systematic review of the literature. *Eur Urol.* 2012;62(5):779–90.
50. Grasso AA, et al. Posterior musculofascial reconstruction after radical prostatectomy: an updated systematic review and a meta-analysis. *BJU Int.* 2016;118(1):20–34.
51. Hurtes X, et al. Anterior suspension combined with posterior reconstruction during robot-assisted laparoscopic prostatectomy improves early return of urinary continence: a prospective randomized multicentre trial. *BJU Int.* 2012;110(6):875–83.
52. Tan GY, Jhaveri JK, Tewari AK. Anatomic restoration technique: a biomechanics-based approach for early continence recovery after minimally invasive radical prostatectomy. *Urology.* 2009;74(3):492–6.
53. Akita K, Sakamoto H, Sato T. Origins and courses of the nervous branches to the male urethral sphincter. *Surg Radiol Anat.* 2003;25(5–6):387–92.
54. Karam I, et al. The precise location and nature of the nerves to the male human urethra: histological and immunohistochemical studies with three-dimensional reconstruction. *Eur Urol.* 2005;48(5):858–64.
55. Karam I, et al. The structure and innervation of the male urethra: histological and immunohistochemical studies with three-dimensional reconstruction. *J Anat.* 2005;206(4):395–403.
56. Walsh PC, Donker PJ. Impotence following radical prostatectomy: insight into etiology and prevention. *J Urol.* 1982;128(3):492–7.
57. Tanagho EA, Schmidt RA, de Araujo CG. Urinary striated sphincter: what is its nerve supply? *Urology.* 1982;20(4):415–7.
58. Burkhard FC, et al. Nerve sparing open radical retropubic prostatectomy--does it have an impact on urinary continence? *J Urol.* 2006;176(1):189–95.
59. Kaye DR, et al. Urinary outcomes are significantly affected by nerve sparing quality during radical prostatectomy. *Urology.* 2013;82(6):1348–53.
60. Steineck G, et al. Degree of preservation of the neurovascular bundles during radical prostatectomy and urinary continence 1 year after surgery. *Eur Urol.* 2015;67(3):559–68.

61. Marien TP, Lepor H. Does a nerve-sparing technique or potency affect continence after open radical retropubic prostatectomy? *BJU Int.* 2008;102(11):1581–4.
62. Sacco E, et al. Urinary incontinence after radical prostatectomy: incidence by definition, risk factors and temporal trend in a large series with a long-term follow-up. *BJU Int.* 2006;97(6):1234–41.
63. Magheli A, et al. Comparison of surgical technique (open vs. laparoscopic) on pathological and long term functional outcomes following radical prostatectomy. *BMC Urol.* 2014;14:18.
64. Pan XW, et al. Robot-assisted radical prostatectomy vs. open retropubic radical prostatectomy for prostate cancer: a systematic review and meta-analysis. *Indian J Surg.* 2015;77(Suppl 3):1326–33.
65. Grise P, Thurman S. Urinary incontinence following treatment of localized prostate cancer. *Cancer Control.* 2001;8(6):532–9.
66. Petrovich Z, et al. Comparison of outcomes of radical prostatectomy with and without adjuvant pelvic irradiation in patients with pathologic stage C (T3N0) adenocarcinoma of the prostate. *Am J Clin Oncol.* 1999;22(4):323–31.
67. Petrovich Z, et al. Postoperative radiotherapy in 423 patients with pT3N0 prostate cancer. *Int J Radiat Oncol Biol Phys.* 2002;53(3):600–9.
68. Suardi N, et al. Impact of adjuvant radiation therapy on urinary continence recovery after radical prostatectomy. *Eur Urol.* 2014;65(3):546–51.
69. Fontaine E, et al. Urinary continence after salvage radiation therapy following radical prostatectomy, assessed by a self-administered questionnaire: a prospective study. *BJU Int.* 2004;94(4):521–3.
70. Petroski RA, et al. External beam radiation therapy after radical prostatectomy: efficacy and impact on urinary continence. *Prostate Cancer Prostatic Dis.* 2004;7(2):170–7.
71. Sowerby RJ, et al. Long-term complications in men who have early or late radiotherapy after radical prostatectomy. *Can Urol Assoc J.* 2014;8(7–8):253–8.
72. Ornstein DK, et al. Evaluation and management of the man who has failed primary curative therapy for prostate cancer. *Urol Clin North Am.* 1998;25(4):591–601.
73. Rogers E, et al. Salvage radical prostatectomy: outcome measured by serum prostate specific antigen levels. *J Urol.* 1995;153(1):104–10.
74. Nguyen PL, et al. Patient selection, cancer control, and complications after salvage local therapy for postradiation prostate-specific antigen failure: a systematic review of the literature. *Cancer.* 2007;110(7):1417–28.
75. Matei DV, et al. Salvage radical prostatectomy after external beam radiation therapy: a systematic review of current approaches. *Urol Int.* 2015;94(4):373–82.
76. Chade DC, et al. Cancer control and functional outcomes of salvage radical prostatectomy for radiation-recurrent prostate cancer: a systematic review of the literature. *Eur Urol.* 2012;61(5):961–71.
77. Cozzarini C, et al. Clinical factors predicting late severe urinary toxicity after postoperative radiotherapy for prostate carcinoma: a single-institute analysis of 742 patients. *Int J Radiat Oncol Biol Phys.* 2012;82(1):191–9.

---

# Office Evaluation for Post-prostatectomy Incontinence

Hin Yu Vincent Tu and Jaspreet S. Sandhu

---

## Medical History

The first step in the management of post-prostatectomy urinary incontinence (PPI) begins with a detailed history, including characteristics of the incontinence, patient expectations, as well as demographic variables such as the patient's age [1]. This can help put the patient's overall health status and long-term continence goals into context. The time since the radical prostatectomy should be ascertained as multiple studies have shown that it may take up to 1 year for most men to regain continence [2, 3]. As such, surgical therapy is typically deferred until after the first postoperative year for persistent urinary incontinence [4]. Recent evidence suggests that if patients have significant incontinence at 6 months, they are unlikely to recover, suggesting that surgical therapy may be considered as early as 6 months [5]. Preoperative factors such as obesity [6], preexisting incontinence, previous transurethral resection of the prostate (TURP), and prior radiation therapy [7] have been shown to be risk factors for post-prostatectomy incontinence. Furthermore, surgical factors such as the approach to the radical prostatectomy, whether open, laparoscopic, or robotic [8–11], and nerve-sparing status [12–14] are also important to clarify. Oncologic status, including PSA value, can help inform the urologist about the timing to potential anti-incontinence surgery in the event the patient should require further treatment for locally recurrent or metastatic disease [1]. Prior history of pelvic radiation and surgery, including prostate and bladder procedures, should be well documented. Finally, all medications that can affect the urinary tract should be reviewed, especially alpha-adrenergic blockers, anticholinergic agents, and beta-3 agonists.

---

H.Y.V. Tu • J.S. Sandhu (✉)

Department of Surgery, Urology Service, Memorial Sloan Kettering Cancer Center,  
New York, NY 10065, USA

e-mail: [sandhuj@MSKCC.ORG](mailto:sandhuj@MSKCC.ORG)

---

## Lower Urinary Tract Symptoms

It is useful to categorize the patient's urinary incontinence as stress, urge, or a combination of both. Stress urinary incontinence as defined by the International Continence Society (ICS) is the complaint of involuntary leakage on effort or exertion or sneezing or cough. Urgency incontinence is the involuntary leakage accompanied by or immediately preceded by urgency [15]. In the event of mixed urinary incontinence, the urologist should elicit from the patient the most bothersome and significant component of the incontinence. In cases where the patient has difficulty characterizing their incontinence, it may be helpful to determine precipitating factors and also whether the leakage worsens with sexual activity or toward the end of the day, which may suggest underlying intrinsic sphincteric deficiency (ISD) [16]. It is also important to document whether the patient leaks urine at night as this is also a surrogate for primarily urgency incontinence.

The degree of incontinence should also be ascertained as this will guide the type of surgical management. Twenty-four-hour pad weights can be used to definitively document the amount of incontinence per day. A good surrogate marker to the severity of incontinence is patient self-reported pad usage. When asking a patient about "daily pad usage," it is important to know the number of pads used in a typical day, the degree of saturation by urine, and the type of pads used, for instance, liners, pads, or undergarment.

Characterizing the patient's lower urinary symptoms is also helpful, especially in terms of storage or voiding symptoms. The presence of voiding symptoms such as a weak urinary stream and intermittency can suggest a urethral stricture or bladder neck contracture. On the other hand, the absence of voiding symptoms can sometimes be elicited in a patient with severe to total incontinence due to the lack of significant bladder filling [16]. Ultimately, obtaining an accurate history and description of the incontinence is paramount to determining which further investigations may be required and setting reasonable expectations from proposed interventions.

---

## Questionnaires and Voiding Diaries

Questionnaires and voiding diaries are valuable adjuncts in the assessment of post-prostatectomy incontinence. Questionnaires such as the American Urological Association Symptom Index [17] and the International Prostate Symptom Score [18] are instruments to aid in the classification of the patient's voiding symptoms. The International Consultation on Incontinence Questionnaire (ICIQ) [19] is useful to assess the storage-type symptoms in these men. Overall, such questionnaires provide objective measures of a patient's symptoms and the impact on their quality of life [20].

Voiding diaries, otherwise known as bladder diaries or frequency-volume charts, provide another objective instrument to record the frequency of voids, volume of voids, and fluid intake over a 3–7-day period [21]. This can be used to quantify the

number of urinary incontinence episodes as well as the timing of incontinence. One of the main drawbacks is the difficulty in completing the voiding diary accurately. Studies have shown that a 4-day voiding diary is equivalent to a 7-day voiding diary; thus, in most circumstances, a 4-day voiding diary is used in the hopes of improving patient compliance [22].

---

## Physical Examination

The physical examination of a patient with post-prostatectomy incontinence should begin with a focused abdominal exam. The presence of surgical scars should be noted in addition to palpation for a distended bladder. A neurological exam including a digital rectal exam (DRE) assessing rectal tone and pelvic floor strength should be performed. A perineal and lower extremity exam with focus on the S2 to S4 spinal segments is important, including evaluation of perineal sensation and bulbocavernosus reflex [23]. Signs of skin irritation from incontinence can relate to severity of incontinence. Although rare causes of obstruction, the presence of meatal stenosis and phimosis should be documented [1]. Clinical demonstration of stress urinary incontinence is helpful and can usually be elicited by asking the patient to cough or bear down.

---

## Pad Test

The pad test allows for the urologist to correlate the amount of actual leakage with the patient's sensation of urine leakage. At times, a patient may report going through a large number of pads in a day of varying degrees of wetness which can make it difficult to characterize accurately. Moreover, differences in the type and size of pads add to this complexity. Studies have shown that the number of pads used is predictive of a patient's response to therapy and may guide the type of surgical procedure to offer to the patient [21]. A study conducted by the Society of Urodynamics, Female Pelvic Medicine and Urogenital Reconstruction (SUFU) suggested that patient perception of pad usage correlated well with the pad test [24]. However, others have proposed that weight of the pad correlates better with the degree of urinary leakage as compared to number of pads used, paving the way for the formal pad test [25]. A 24-hour pad test, considered by many to be the gold standard, is an objective measure of the degree of urinary incontinence. Due to the strict protocol to perform the test properly, some have advocated for the 1-hour pad test due to improved compliance [26]. As outlined by the ICS classification for stress urinary incontinence based on the 1-hour pad test, grade 1 is urine loss less than 10 g; grade 2, 11–50 g; grade 3, 51–100 g; and grade 4 is urine loss greater than 100 g [27]. Ultimately, an accurate assessment of the amount of incontinence is warranted, either by a detailed description of pad use from a reliable patient or from a prospective pad test.

---

## Initial Investigations

Uroflowmetry combined with a post-void residual (PVR) is useful to assess bladder emptying and urinary obstruction especially in the presence of voiding symptoms. They are quick and easy tests to perform that may suggest urethral strictures or bladder neck contractures. Although no specific cutoff has been agreed on, both the American and Canadian Urological Associations recommend that PVR be included as part of initial assessment [28, 29]. Similarly, the European Urological Association guidelines and the International Consultation on Urological Diseases (ICUD) specify a PVR of greater than 200 ml to be concerning for obstruction [21, 30].

A urinalysis with a urine culture to rule out urinary tract infections is highly recommended [30]. Moreover, a urinalysis looking for microscopic hematuria can help rule out other bladder pathologies, such as bladder cancer and stones.

---

## Cystourethroscopy

Cystourethroscopy should be performed prior to any surgical intervention for post-prostatectomy incontinence. It can aid in the identification of obstructive causes, such as urethral strictures or anastomotic strictures (i.e., bladder neck contractures). It may also identify the presence of bladder tumors, stones, or diverticula which should be addressed prior to surgical therapy for incontinence [1]. Urethral integrity and vascularity can also be assessed at that time [16]. The main role for cystoscopy prior to surgical therapy is to document the presence or absence of anastomotic strictures as these are prone to recurrence and may play a role in the type of surgical procedure offered [31]. This highlights the importance of performing cystourethroscopy to assess all anatomic components of the lower urinary tract [26].

---

## Urodynamics

The etiology of post-prostatectomy incontinence is multifactorial and can include bladder dysfunction, intrinsic sphincter dysfunction (ISD), or a combination of both. Urodynamics remains the gold standard test to help differentiate among these etiologies and to guide treatment.

The role of urodynamics to predict urinary outcomes following surgical intervention for incontinence remains debatable. The findings of decreased compliance in a chronically underfilled bladder or even detrusor overactivity have not been shown to impact on surgical outcomes [32–34]. Similarly, decreased detrusor contractility has not been shown to adversely affect artificial urinary sphincter (AUS) success significantly [35]. Moreover, in a study by Thiel et al., the authors failed to find a urodynamic parameter that would predict for failure after AUS placement, defined as leakage requiring one or more pads per day [36].

Cystometry at a medium fill rate, typically 50 mL/min, should be performed with a 7Fr urethral catheter and rectal catheter. The detrusor pressure should be recorded throughout the examination, calculated as the difference between the measured



vesical pressure and rectal pressure. In patients with a known small-capacity bladder, the fill rate can be decreased. Filling sensation, bladder capacity, and compliance should be noted as per standard urodynamic protocol. The presence of detrusor overactivity and urinary leakage should also be documented. Bladder filling to at least 150 mL should be performed before the initiation of Valsalva and stress maneuvers such as coughing [16]. An abdominal leak point pressure (ALPP) should be recorded, which is the pressure necessary to overcome the sphincteric resistance [37]. Videofluoroscopy should also be performed as this can evaluate the bladder neck for the presence of contractures or strictures. In the presence of narrowing at the anastomosis, a 7Fr urethral catheter may occlude the urethra masking incontinence or falsely elevating the ALPP [38, 39]. In this situation, a second fill without a urethral catheter should be performed with the ALPP determined from the rectal catheter followed by a noninvasive uroflow [38, 40].

---

## Summary

The etiology of post-prostatectomy incontinence is multifactorial, with both bladder and outlet dysfunction playing important roles. Intrinsic sphincteric deficiency is, however, perhaps the most significant contributory factor [41]. A detailed history and physical examination are paramount to obtain an accurate diagnosis, in combination with pad tests and questionnaires. A routine urinalysis should be performed. Typically, men with incontinence secondary to ISD present with leakage with Valsalva. This can be further confirmed on uroflowmetry, post-void bladder scans, and urodynamics, with concomitant cystourethroscopy and videofluoroscopy. The combination of the clinical and diagnostic data obtained from these tests can then be used to better inform patients about the nature of their incontinence and guide urologists in determining the best treatment modality.

---

## References

1. Radomski SB. Practical evaluation of post-prostatectomy incontinence. *Can Uro Assoc J.* 2013;7(9–10 Suppl 4):S186–8.
2. Walsh PC. Patient-reported urinary continence and sexual function after anatomic radical prostatectomy. *J Urol.* 2000;164(1):242.
3. Moinzadeh A, Shunaigat AN, Libertino JA. Urinary incontinence after radical retropubic prostatectomy: the outcome of a surgical technique. *BJU Int.* 2003;92(4):355–9.
4. Schneider T, Sperling H, Rossi R, Schmidt S, Rubben H. Do early injections of bulking agents following radical prostatectomy improve early continence? *World J Urol.* 2005;23(5):338–42.
5. Vickers AJ, Kent M, Mulhall J, Sandhu J. Counseling the post-radical prostatectomy patients about functional recovery: high predictiveness of current status. *Urology.* 2014;84(1):158–63.
6. Xu T, Wang X, Xia L, Zhang X, Qin L, Zhong S, et al. Robot-assisted prostatectomy in obese patients: how influential is obesity on operative outcomes? *J Endourol/Endourologic Soc.* 2015;29(2):198–208.
7. Nguyen PL, D'Amico AV, Lee AK, Suh WW. Patient selection, cancer control, and complications after salvage local therapy for postradiation prostate-specific antigen failure: a systematic review of the literature. *Cancer.* 2007;110(7):1417–28.

8. Yaxley JW, Coughlin GD, Chambers SK, Occhipinti S, Samaratunga H, Zajdlewicz L, et al. Robot-assisted laparoscopic prostatectomy versus open radical retropubic prostatectomy: early outcomes from a randomised controlled phase 3 study. *Lancet*. 2016;388(10049):1057–66.
9. Rocco B, Matei DV, Melegari S, Ospina JC, Mazzoleni F, Errico G, et al. Robotic vs open prostatectomy in a laparoscopically naive Centre: a matched-pair analysis. *BJU Int*. 2009;104(7):991–5.
10. Geraerts I, Van Poppel H, Devoogdt N, Van Cleynenbreugel B, Joniau S, Van Kampen M. Prospective evaluation of urinary incontinence, voiding symptoms and quality of life after open and robot-assisted radical prostatectomy. *BJU Int*. 2013;112(7):936–43.
11. Froehner M, Koch R, Leike S, Novotny V, Twelker L, Wirth MP. Urinary tract-related quality of life after radical prostatectomy: open retropubic versus robot-assisted laparoscopic approach. *Urol Int*. 2013;90(1):36–40.
12. Marien TP, Lepor H. Does a nerve-sparing technique or potency affect continence after open radical retropubic prostatectomy? *BJU Int*. 2008;102(11):1581–4.
13. Burkhard FC, Kessler TM, Fleischmann A, Thalmann GN, Schumacher M, Studer UE. Nerve sparing open radical retropubic prostatectomy—does it have an impact on urinary continence? *J Urol*. 2006;176(1):189–95.
14. Nandipati KC, Raina R, Agarwal A, Zippe CD. Nerve-sparing surgery significantly affects long-term continence after radical prostatectomy. *Urology*. 2007;70(6):1127–30.
15. Van Kerrebroeck P, Abrams P, Chaikin D, Donovan J, Fonda D, Jackson S, et al. The standardization of terminology in nocturia: report from the standardization subcommittee of the international continence society. *BJU Int*. 2002;90(Suppl 3):11–5.
16. Sandhu JS. *Urinary dysfunction in prostate cancer a management guide*. Cham: Springer; 2016.
17. Svatek R, Roche V, Thornberg J, Zimmern P. Normative values for the American urological association symptom index (AUA-7) and short form urogenital distress inventory (UDI-6) in patients 65 and older presenting for non-urological care. *Neurourol Urodyn*. 2005;24(7):606–10.
18. Bayoud Y, de la Taille A, Ouzzane A, Ploussard G, Allory Y, Yiou R, et al. International prostate symptom score is a predictive factor of lower urinary tract symptoms after radical prostatectomy. *Int J Urol*. 2015;22(3):283–7.
19. Abrams P, Avery K, Gardener N, Donovan J, Board IA. The international consultation on incontinence modular questionnaire: www.Iciq.Net. *J Urol*. 2006;175(3 Pt 1):1063–6. discussion 6
20. Thuroff JW, Abrams P, Andersson KE, Artibani W, Chapple CR, Drake MJ, et al. EAU guidelines on urinary incontinence. *Eur Urol*. 2011;59(3):387–400.
21. Abrams P, Andersson KE, Birder L, Brubaker L, Cardozo L, Chapple C, et al. Fourth international consultation on incontinence recommendations of the international scientific committee: evaluation and treatment of urinary incontinence, pelvic organ prolapse, and fecal incontinence. *Neurourol Urodyn*. 2010;29(1):213–40.
22. Schick E, Jolivet-Tremblay M, Dupont C, Bertrand PE, Tessier J. Frequency-volume chart: the minimum number of days required to obtain reliable results. *Neurourol Urodyn*. 2003;22(2):92–6.
23. Singla N, Singla AK. Post-prostatectomy incontinence: etiology, evaluation, and management. *Turk J Urol*. 2014;40(1):1–8.
24. Nitti VW, Mourtzinou A, Brucker BM, Group SPTS. Correlation of patient perception of pad use with objective degree of incontinence measured by pad test in men with post-prostatectomy incontinence: the SUFU pad test study. *J Urol*. 2014;192(3):836–42.
25. Tsui JF, Shah MB, Weinberger JM, Ghanaat M, Weiss JP, Purohit RS, et al. Pad count is a poor measure of the severity of urinary incontinence. *J Urol*. 2013;190(5):1787–90.
26. Singla AK. In: Singla AK, editor. *Post prostatectomy incontinence – a clinical guide: LAP Lambert*; London, UK, 2013.

27. Abrams P, Cardozo L, Fall M, Griffiths D, Rosier P, Ulmsten U, et al. The standardisation of terminology in lower urinary tract function: report from the standardisation sub-committee of the international continence society. *Urology*. 2003;61(1):37–49.
28. Bettez M, le Tu M, Carlson K, Corcos J, Gajewski J, Jolivet M, et al. Update: guidelines for adult urinary incontinence collaborative consensus document for the Canadian urological association. *Can Urol Assoc J*. 2012;6(5):354–63.
29. Dmochowski RR, Blaivas JM, Gormley EA, Juma S, Karram MM, Lightner DJ, et al. Update of AUA guideline on the surgical management of female stress urinary incontinence. *J Urol*. 2010;183(5):1906–14.
30. Lucas MG, Bosch RJ, Burkhard FC, Cruz F, Madden TB, Nambiar AK, et al. EAU guidelines on surgical treatment of urinary incontinence. *Actas Urol Esp*. 2013;37(8):459–72.
31. Sandhu JS, Gotto GT, Herran LA, Scardino PT, Eastham JA, Rabbani F. Age, obesity, medical comorbidities and surgical technique are predictive of symptomatic anastomotic strictures after contemporary radical prostatectomy. *J Urol*. 2011;185(6):2148–52.
32. Ballert KN, Nitti VW. Association between detrusor overactivity and postoperative outcomes in patients undergoing male bone anchored perineal sling. *J Urol*. 2010;183(2):641–5.
33. Lai HH, Hsu EI, Boone TB. Urodynamic testing in evaluation of postradical prostatectomy incontinence before artificial urinary sphincter implantation. *Urology*. 2009;73(6):1264–9.
34. Perez LM, Webster GD. Successful outcome of artificial urinary sphincters in men with post-prostatectomy urinary incontinence despite adverse implantation features. *J Urol*. 1992;148(4):1166–70.
35. Gomha MA, Boone TB. Voiding patterns in patients with post-prostatectomy incontinence: urodynamic and demographic analysis. *J Urol*. 2003;169(5):1766–9.
36. Thiel DD, Young PR, Broderick GA, Heckman MG, Wehle MJ, Igel TC, et al. Do clinical or urodynamic parameters predict artificial urinary sphincter outcome in post-radical prostatectomy incontinence? *Urology*. 2007;69(2):315–9.
37. Swift SE, Utrie JW. The need for standardization of the valsalva leak-point pressure. *Int Urogynecol J Pelvic Floor Dysfunct*. 1996;7(4):227–30.
38. Huckabay C, Twiss C, Berger A, Nitti VW. A urodynamics protocol to optimally assess men with post-prostatectomy incontinence. *Neurourol Urodyn*. 2005;24(7):622–6.
39. Groutz A, Blaivas JG, Chaikin DC, Weiss JP, Verhaaren M. The pathophysiology of post-radical prostatectomy incontinence: a clinical and video urodynamic study. *J Urol*. 2000;163(6):1767–70.
40. Ozawa H, Chancellor MB, Ding YY, Nasu Y, Yokoyama T, Kumon H. Noninvasive urodynamic evaluation of bladder outlet obstruction using Doppler ultrasonography. *Urology*. 2000;56(3):408–12.
41. Heesakkers J, Farag F, Bauer RM, Sandhu J, De Ridder D, Stenzl A. Pathophysiology and contributing factors in postprostatectomy incontinence: a review. *Eur Urol*. 2016; doi:[10.1016/j.eururo.2016.09.031](https://doi.org/10.1016/j.eururo.2016.09.031).

---

# Conservative Management of Post-prostatectomy Incontinence

Michael Kennelly and Rachel Locke

## Abbreviations

ES	Electrical stimulation
EXMI	Extracorporeal magnetic innervation
FDA	US Food and Drug Administration
GAX-Collagen	Glutaraldehyde cross-linked collagen
ICI	5th International Consultation on Incontinence
OAB	Overactive bladder
PDS	Polydimethylsiloxane
PFMT	Pelvic floor muscle therapy
PPI	Post-prostatectomy incontinences
RP	Radical prostatectomy
SUI	Stress urinary incontinence
UI	Urinary incontinence

---

## Introduction

Urinary incontinence (UI) is a common complication after radical prostatectomy (RP). Estimates of the percentage of men who develop UI after surgery can range from 2 to 60% depending on the time since the operation [1]. Due to the varied estimates of the prevalence of UI after RP, nonsurgical treatments should be utilized before more invasive therapies. These conservative treatments include lifestyle

---

M. Kennelly, MD (✉) • R. Locke  
Carolinas Medical Center, Carolinas HealthCare System,  
1023 Edgehill Road South, Charlotte, NC 28207, USA  
e-mail: [Michael.kennelly@carolinashealthcare.org](mailto:Michael.kennelly@carolinashealthcare.org); [Rachel.Locke@carolinashealthcare.org](mailto:Rachel.Locke@carolinashealthcare.org)

modifications, behavioral training (pelvic floor muscle training, biofeedback, electrical stimulation, extracorporeal magnetic innervation), external penile compression devices, and bulking agent therapy.

---

## Lifestyle Modifications

Lifestyle modifications for UI concentrate around fluid and diet management. Restriction of fluid intake and bladder irritants may decrease symptoms of UI, while obesity has been linked to higher levels of incontinence [2]. It is important to note that, while these lifestyle modifications have been shown to improve UI, almost all studies have been conducted in females with UI and must be extrapolated for males experiencing PPI.

Minimizing fluid intake and caffeine consumption may decrease UI symptoms especially if there is an overactive bladder (urgency, frequency, and/or urge incontinence) component to the PPI. Arya et al. presented a correlation between high caffeine intake (>400 mg average a day) and detrusor instability in women [3]. While PPI is generally considered stress urinary incontinence (SUI) caused by intrinsic sphincter deficiency (ISD), these measures may still warrant consideration in men in the presence of mixed incontinence. A small study by Tomlinson et al. found that women who decreased caffeine and increased fluid intake had fewer daytime accidents and larger voiding volumes [4]. The 5th International Consultation on Incontinence (ICI) concluded that there is level 2 evidence that decreasing caffeine intake improves continence [5]. However, more recent meta-analysis of observational studies did not find evidence supporting a correlation between coffee or caffeine consumption and the risk of overall or moderate/severe UI. The investigators also failed to determine an association between caffeine and risk for a specific type of UI (SUI, urge or mixed) when controlling for other risk factors [6].

Some studies suggest fluid restriction as a method for managing SUI, as symptoms may be volume-driven. However, extreme fluid restriction results in more concentrated urine, a potential bladder irritant that can exacerbate overactive bladder and SUI symptoms. Therefore, fluid restriction should only be used in patients with unusually high daily fluid intake [7]. Several studies have attempted to determine if there is a higher association of bladder irritation with certain types of fluid, but no clear conclusions have been reached. Epidemiologic data supports an association between the intake of carbonated beverages and both SUI and OAB; therefore, common bladder irritants should be avoided to reduce UI symptoms [7] (Table 1).

Obesity is a well-established cause of UI in women and its negative effects on male PPI are becoming better appreciated. A longitudinal epidemiologic study of 6462 women over 40 years old found a strong correlation between BMI and the risk for OAB and SUI [2]. The data has been consistent across the female population. Studies have also shown that obesity in men may be associated with a higher risk for PPI. Wolin et al. found that obese men were significantly more likely to be

**Table 1** Common bladder irritants that should be avoided by patients with urinary incontinence

Bladder irritants	
Coffee	Sugar
Tea	Artificial sweetener
Honey	Chocolate
All alcoholic beverages	Tomatoes
Carbonated beverages	Tobacco
Caffeinated sodas	Citrus fruits and juices
Corn syrup	Spicy foods

incontinent at 58 weeks compared to their non-obese counterparts [8]. In fact, van Roermund et al. determined that obese men were more likely to suffer from wound infections, PPI, and vesico-urethral strictures after open radical prostatectomy [9]. Data regarding nonsurgical weight loss as a treatment for UI is limited. Subak et al. randomized 338 overweight and obese women with UI to an intensive 6-month weight loss program or a control structured education program. Women in the treatment group lost an average of 7.8 kg, and the average number of weekly incontinence episodes decreased by 47%. This was significant when compared to the control group that had a mean weight loss of 1.5 kg and only a 28% reduction in incontinence episodes [10]. Given the overall health benefits, general guidelines for physical exercise, weight loss, and healthy diet are reasonable recommendations for the treatment of PPI.

Smoking is associated with an increased risk of obesity and been studied in the past as a possible contributor to the development of UI symptoms. However, the ICI suggests that, due to the conflicting data between cross-sectional studies and longitudinal studies, smoking is most likely not a risk factor for UI. There are currently no studies supporting smoking cessation for PPI, but it should be recommended for general health [5].

## Behavioral Training

While preoperative behavioral training has been shown to significantly decrease the time to continence after radical prostatectomy, postsurgical rehabilitation has been studied with mixed results [11]. Because the definition and quantification of incontinence, the timing of the evaluation relative to the surgery, and whether the physician or patient evaluates the presence or absence of incontinence vary between studies, there is currently an insufficient amount of adequately powered randomized controlled trials (RCTs) that show conclusive results [12]. Nevertheless, Goode et al. found that 8 weeks of behavioral therapy resulted in fewer incontinence episodes when compared to a delayed-treatment control [13]. Additionally, behavioral therapies are inexpensive and low-risk options that can be used in conjunction with one another and other conservative techniques. Several common behavioral therapy techniques are discussed below.

## Pelvic Floor Muscle Training

Pelvic floor muscle training (PFMT) is the most studied conservative treatment for PPI, and studies have shown varied success. PFMT is the intermittent, voluntary contraction of the urethral sphincter muscles to strengthen the pelvic floor and increase control over unexpected urine loss. Strengthening the pelvic floor muscles may inhibit detrusor activity and increase muscle efficiency during increased intra-abdominal pressure [12]. PFMT may also increase the “external mechanical pressure” on the urethra by hypertrophying the periurethral striated muscles [14]. PFMT is often taught by a physiotherapist, requires little to no equipment, and can be performed in a home or office setting. The 2016 European Association of Urology (EAU) guidelines advise that instruction for PFMT should be offered to all men undergoing RP to speed up recovery of postoperative continence [15].

Several RCTs have shown that men who perform PFMT preoperatively significantly decrease the duration and degree of incontinence at 3 months postoperatively compared to men who do not perform the exercises. In a meta-analysis conducted by Fernandez et al. [16] of eight RCTs, four trials compared PFMT to controls with no physiotherapy [13, 17–19], and four compared PFMT sessions at home versus under professional supervision [20–23]. The authors concluded that PFMT programs with ten repetitions three times daily increase the rate of continence, as PFMT was shown to improve the continence rate in the short, medium, and long term [13, 16–19]. No benefit was found to therapist-led PFMT compared to at home PFMT [20–23], and several of the studies did not find a difference in continence at 12 months’ post-surgery [18–19]. All of the studies looked at the perioperative period, and the authors cited limitations due to the variance of PFMT and the heterogeneity of the population.

However, another meta-analysis by Wang et al. published contradicting results, suggesting that preoperative PFMT did not improve UI after RP at any time period [24]. Geraerts et al. performed an RCT of 180 patients that found no significant difference in the duration of PPI between patients that started PFMT 3 weeks before RP or postoperatively [25].

Nevertheless, there is level one evidence that, prior to offering invasive therapy, all patients should receive PFMT [15]. It is the authors’ opinion that PFMT is an inexpensive and noninvasive therapy that can prevent and alleviate PPI after surgery.

## Biofeedback

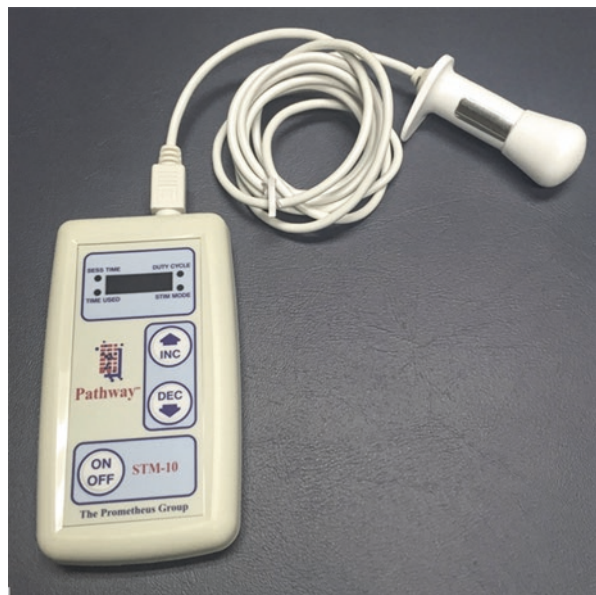Biofeedback is often used in conjunction with pelvic floor exercises using auditory or visual cues, called functional PFMT. By bringing attention to the muscle and providing cues, the therapist seeks to train the patient how to gain control of and strengthen the pelvic floor muscles. The therapist can indicate a contraction to the patient during DRE; although more sophisticated electronic methods exist, they have not proven to be superior [7, 11]. A review by MacDonald et al. found that PFMT with or without biofeedback decreases the time to continence, questioning the utility and efficacy of adding biofeedback to PFMT [26]. Goode et al. found no benefit to

adding biofeedback and electrical stimulation to PFMT in a study of 208 patients randomized to PFMT and behavioral training, PFMT with biofeedback and electrical stimulation, or control [13]. The ICI gave a grade B recommendation for the use of biofeedback, deferring to therapist preference and individual economics [5].

## Electrical Stimulation (ES)

Biofeedback in the form of electrical cues can also be utilized. Electrical stimulation (ES) delivers small electrical currents via surface electrodes to stimulate the pelvic floor muscles to contract. Pelvic floor muscle contractions cause the bladder to contract, closing the sphincter to prevent urine flow and thus decreasing leakage. Anal electrodes or less invasive patch electrodes in the perianal or posterior tibial nerve distribution can be used (Fig. 1). Like literature on PFMT, the literature on the efficacy of PFMT with ES or other biofeedback mechanisms varies widely. Mariotti et al. demonstrated that pelvic floor electrical stimulation, in addition to biofeedback, hastens the time to urinary continence both 7 days after catheter removal and 12 months after RP [27, 28]. Likewise, after RP, PFMT with active stimulation of 50 Hz square waves of 300  $\mu$ s pulse duration for 15 min twice daily in a 5 s on, 5 s off duty cycle using an anal electrode was found to significantly decrease the time to continence recovery [29].

However, Wille et al. found ES-enhanced PFMT did not affect continence. Instead, the authors asserted that omitting biofeedback and ES from PFMT was as effective and more cost-conscious, saving the patient up to €711 [30]. The 2016 EAU guidelines do not recommend the use of ES alone in the treatment of male SUI [15].



**Fig. 1** Electrical stimulation device with probe



## Extracorporeal Magnetic Innervation

Similar to electrical stimulation, extracorporeal magnetic innervation (ExMI) directly stimulates the pelvic floor muscles and sacral roots through pulsing magnets to initiate muscle contraction. Patients sit in a chair that contains a magnetic field generator in the seat. The treatment is painless, there is no probe, and the patient may remain dressed [31]. While a small study of 87 patients by Terzoni et al. found that ExMI reduced urinary leakages more quickly than PFMT, Voorham-van der Zalm et al. found no change in pelvic floor function in a cohort of 65 women and nine men. In fact, there was no statistical differences in the data before or after ExMI treatment in all subgroups [32, 33]. More RTCs are needed to fully assess the efficacy of ExMI as a treatment for PPI; however, this treatment option is inaccessible to many patients because ExMI chairs are not readily available.

---

## Pharmacotherapy

Pharmacological treatments are not a first-line conservative treatment for PPI due to potential side effects and a lack of data supporting efficacy. The pharmacologic understanding of the receptor innervation and activity of the bladder neck, proximal urethra, and external urethral sphincter complex have allowed several non-PPI-approved medications to be explored. The majority of work has been with alpha-adrenergic agonists. Although there are alpha-adrenergic receptors at the bladder neck, several non-approved medications with adrenergic properties have only been found to be effective in patients with minor degrees of incontinence. This medication is generally used to improve bladder outflow obstruction [34]. Pharmacological treatments for UI also include selective serotonin-noradrenalin reuptake inhibitors, antimuscarinics, and phosphodiesterase inhibitors. To date, there are no regulatory-approved medications for PPI.

## Alpha-Adrenergic Drugs

Alpha-adrenergic drugs, such as midodrine, phenylpropanolamine, and ephedrine, have been shown to be effective in controlling symptoms of UI in animal models. Tsakiris et al. reviewed studies regarding the three drugs, and, due to mixed study populations of men and women and a small number of patients, any efficacy data regarding the drugs was inconclusive [35]. Although rare, phenylpropanolamine was reported to cause elevated blood pressure, hemorrhagic stroke, palpitations, and cardiac arrhythmias, causing it to be removed from the US market in 2000 [36]. In general,  $\alpha$ -adrenergic drugs are not recommended for used for female SUI due to risk of adverse effects and should not be in primary consideration for treating PPI.

## Duloxetine

There is limited data on the use of duloxetine for PPI. Duloxetine is a selective serotonin-noradrenalin reuptake inhibitor used for the management of stress incontinence in women. By inhibiting the reuptake of serotonin and noradrenaline in

Onuf's nucleus, the pudendal motor neurons that regulate the urethral striated muscles in Onuf's nucleus increase activity [37]. While a study by Schlenker et al. found the average daily use of incontinence pads to significantly decrease in patients who took 40 mg of duloxetine twice daily, 30% of study patients complained of severe side effects and discontinued the drug [38]. Alan et al. demonstrated that 60 mg of duloxetine in addition to PFMT significantly increased dryness with zero patients suffering from adverse events [37]. Duloxetine has not been approved for use in men, and there are currently no pharmacological therapies of this type approved for use in men.

## Antimuscarinic Drugs

Antimuscarinic drugs are second-line treatment for OAB and therefore may have some effect on men with mixed incontinence. By inhibiting the release of acetylcholine in the muscarinic receptors at nerve endings, several antimuscarinic drugs approved for OAB have demonstrated efficacy in reducing urinary urgency, frequency, and urgency incontinence. However, adverse antimuscarinic effects such as dry mouth, constipation, urinary retention, and cognitive impairment have been observed, particularly in elderly patients. In a multicenter, randomized double-blind study evaluating the efficacy of solifenacin on UI after RP, Bianco et al. found that, while the primary end point of time to urinary continence was not statistically significant, the secondary end points of proportion of subjects who gained continence and mean change from baseline in average daily pad use were statistically significant at the end of treatment. The only side effect described was dry mouth [39].

A prospective, randomized controlled trial by Shim et al. compared the use of an  $\alpha$ -adrenergic agonist (midodrine) plus an anticholinergic (solifenacin) versus  $\alpha$ -adrenergic agonist only. They found that, although the rate of continence (pad free) at 4 months did not differ between the two groups, patients who took midodrine plus solifenacin had a significantly decreased value of mean weight of daily pads and an increased maximal cystometric capacity. Though not significant, this group also had a slight increase in quality of life scores [40]. Although more RCTs are necessary, anticholinergics may decrease the time to continence following radical prostatectomy and work in conjunction with other conservative therapies to manage PPI.

## Phosphodiesterase Inhibitors

Phosphodiesterase (PDE) receptor isoenzymes are distributed throughout the bladder, prostate, and urethra. PDE inhibitors, such as sildenafil, vardenafil, and tadalafil, are commonly used to treat lower urinary tract symptoms in men with benign prostatic hypertrophy (BPH). In the setting of PPI, PDE5 inhibitors in particular are used to reduce bladder overactivity caused by excitation of bladder sensory nerves during filling. By inhibiting these receptors, the muscle tone in the pelvic arteries relaxes and improves blood supply to the urinary structures. Kaiho et al. found

initial worsening of symptoms when PDE5 inhibitors were administered immediately after RARP, but improved final continence status when compared to no medication [41]. More RCTs on PDE5 inhibitor use specifically for PPI and OAB are necessary.

---

## Compression Devices (Penile Clamps)

Penile compression devices, or penile clamps, are external mechanical devices that prevent the leakage of urine by compressing the penis. There is a wide selection of penile clamps available on the market, each with unique fit and features, allowing the patient to choose an option that best fits their needs [42]. These devices are inexpensive, simple to use, discreet, and less invasive than condom catheters with leg drainage or additional surgery. To date, none of the devices marketed completely eliminate urine loss when worn at a comfortable pressure but do result in significant decreases on the Incontinence Quality of Life Questionnaires [43].

Penile clamps are best suited for active men who find their leakage is not adequately managed with pads alone. The devices can be used to reduce urine leakage during periods of increased activity and can provide an effective incontinence management routine when paired with other modalities. Pads can be worn in conjunction with a clamp or be worn as a nighttime alternative as the device must be released approximately every 2 hours and is not recommended to be worn while sleeping. Clamps may also reduce urine leakage to an acceptable level for men who use sheaths or body urinals to manage their incontinence.

Penile compression devices must be used with caution due to the risk of tissue damage, edema, urethral erosion, pain, and obstruction [42]. Kalra et al. also reported the possibility that an anterior urethral diverticulum may develop from the use of compression devices [44]. It is imperative that the devices are only used by cognitively competent men with normal penile sensation who are able to release the device every 2 hours. A patient's physical capabilities should also be taken into account when choosing a clamp. Features such as material, weight, and ease of opening and closing vary with the different types of clamps on the market, allowing men to choose one that works best for their needs.

Clamps should be fitted to the base of the penis. Some clamps are adjustable while others are available in different sizes. A sizing guide is often available to aid in choosing the right fit. Men may find they need to readjust the device throughout the day with changes in activity. Ultimately, trying a variety of models is best to find the clamp that is most comfortable and best fits the patients' lifestyle.

There is limited efficacy data or comparative data on the various penile compression devices on the market. Moore et al. studied three penile compression devices (U-*Tex*<sup>®</sup> Male Adjustable Tension Band, the Bard<sup>®</sup> Cunningham Clamp, and the C3<sup>®</sup> Penile Clamp by Personal Medical Corp.) and demonstrated that the Cunningham Clamp is the most effective and preferred device, but it did reduce penile blood flow if clamped too tightly [42]. Table 2 details several of the clamps available on the market today and outlines their unique features.

**Table 2** Summary of the various penile clamps available

Clamp name	Description and manufacturer
<p>Cunningham clamp</p> 	<p>Penis is placed between two foam pads and the hinged clamp is squeezed shut. Inverted V on lower pad compresses urethra to prevent leakage. Adjustable with five ratchet settings. Bard Medical</p>
<p>C3 Penis Clamp</p> 	<p>Penis is placed in the padded cradle. Ridge compresses the urethra. Fit is adjusted with strap. Personal Medical Corp.</p>
<p>J Clamp</p> 	<p>The adjustable barrel compresses the bottom of the penis against the frames surrounding the penis to stop urine flow. Contoured upper frame allows for blood flow. Fit, open, and closed is adjusted with the metal lever. Jackson Medical</p>
<p>Squeezer™</p> 	<p>Top pads allow for better circulation by compressing on either side of the vasculature and nerves on the top of the penis. Padded lower arm compresses the urethra to stop urine flow. Single latch to close. Adjustable. Life Control</p>
<p>ActiCuf™ compression pouch</p> 	<p>Padded closure squeezes the penis to control urine flow. Penis tip sits in absorbent pouch which traps excess leakage. Opens and closes by compressing opening. One size. GT Urological</p>

## Bulking Agents

Urethral bulking agents are space-filling materials injected transurethrally into the submucosal bladder neck/proximal urethra to augment the urethral wall. These agents narrow the urethral opening, increasing resistance to urine flow to potentially decrease leakage. The quest for the ideal injectable bulking agent for the treatment of urinary incontinence began as early as the nineteenth century. Initial materials, such as paraffin, mineral oil, morrhuate sodium, and polytetrafluoroethylene

(Teflon) paste, were successful but had the untoward morbidities of pulmonary embolism, urethral sloughing, and migration of particles, limiting their clinical adoption and FDA approval [45–47].

The ideal bulking agent would be biocompatible, with little inflammatory or foreign body response. It would not migrate and can maintain its bulking effect over an extended period of time [48]. The components of the injection should remain stable in volume over time and not dissociate or separate. If micropolymers or microcrystals are utilized, the particle spheres should be nonfragile, adherent to host tissue, and uniform with a particle size  $>100\ \mu\text{m}$  [49, 50]. Such traits would allow for a bulking treatment that is easily injectable and combine long-term efficacy with a high degree of safety and simplicity. A number of bulking agents exist today for the treatment of UI; however, those products developed to date (Table 3) do not necessarily possess all the traits of an “ideal” bulking agent.

Proper evaluation and selection of candidates for bulking agent therapy is critical for optimal outcomes. Transurethral bulking agents are contraindicated in the setting of pure urge incontinence or bladder outlet obstruction. A male patient with mixed incontinence (i.e., stress and urge urinary incontinence) in whom a predominant urge component exists should ideally address the overactive bladder associated with urge incontinence prior to treating the stress incontinence component. Additionally, men should not receive injectable therapy if there is an active urinary tract infection, and precautions should be taken for patients with bacterial colonization of the urinary tract due to the risk of abscess formation and potential for sepsis. To mitigate these issues, a preoperative urine culture should be obtained, and a prophylactic antibiotic is given prior to the procedure.

In men, the supra-membranous urethral integrity should be assessed with a pre-procedure cystoscopy. Bulking agent therapy is ineffective when placed in scar tissue as the non-pliable tissue will not allow expansion with the bulking agent. Consequently, bulking agents are not recommended in men who have bladder neck contractures, and their use in men who have received previous radiation therapy is cautioned [48]. Because pliable tissue integrity is imperative, men with stress incontinence after a transurethral prostatectomy fair better with bulking agent therapy than men after radical prostatectomy [51]. Overall bulking agent therapy may be considered in properly selected post-prostatectomy incontinent males with stress predominant urinary incontinence, normal bladder capacity, normal bladder compliance, and normal anatomical urethral integrity.

Bulking agent therapy is a minimally invasive procedure that can be performed in the office setting. However, due to the low efficacy rates, lack of durability, need for repeat treatments, and problems with some of the synthetic injectable agents, bulking agent therapy for male PPI is being performed less frequently in current practice than it has been in the past. In fact, with the discontinuation of glutaraldehyde cross-linked collagen (GAX-collagen) in 2011, there is currently no US Food and Drug Administration (FDA)-marketed bulking agent approved for male stress urinary incontinence [52].

**Table 3** Products that have been tested as a bulking agent to date

Bulking agent	Market name	Manufacturer	Distributor	Description	Date approved	Currently available
Glutaraldehyde cross-linked bovine collagen	Contigen®	Allergan, Inc.	C.R. Bard, Inc.	Bovine dermal collagen used for the treatment of intrinsic sphincter deficiency in men and women	1993	Removed from the US market in 2011
Silicone macroparticles (polydimethylsiloxane)	Macroplastique®	Cogentix Medical	Cogentix Medical	Textured polydimethylsiloxane macroparticles consists of varying sizes of silicone spheres.	Approved by the FDA for female SUI due to ISD	Yes
Polyacrylamide hydrogel	Bulkamid®	Contura International	Ethicon, Inc.	A homogenous hydrophilic gel consisting of 2.5% polyacrylamide and 97.5% water, which allows ingrowth and proliferation of blood vessels originating from the periurethral tissue	Granted CE approval in 2003 for treatment of female urinary incontinence	Available in many European countries, the UK, Australia/New Zealand, and South Africa
Ethylene vinyl alcohol copolymer	Tegress™	C.R. Bard, Inc.	C.R. Bard, Inc.	Formerly Uryx®, the ethylene vinyl alcohol copolymer dissolved in dimethyl sulfoxide undergoes a phase transformation from a liquid solution to a complex cohesive spongiform mass.	FDA approved 2005 for female SUI	Removed from market in 2007

(continued)

**Table 3** (continued)

Bulking agent	Market name	Manufacturer	Distributor	Description	Date approved	Currently available
Carbon-coated zirconium beads	Durasphere®/ Durasphere® EXP	Carbon Medical Technologies, Inc.	Coloplast	Durasphere™ contains large pyrolytic carbon-coated zirconium oxide beads in a 2.8% β-glucan water-based gel	FDA approved in 1999/2003 for female SUI	Yes
Dextranomer/hyaluronic copolymer	Solesta®	Q-Med AB	Salix Pharmaceuticals	Solesta consists of dextranomer microspheres of biosynthesized polysaccharides of non-animal origin	Approved by the FDA in 2011 to treat fecal incontinence in patients who have failed conservative therapy	Yes
Autologous fat, myocytes, fibroblasts	–	–	–	The use should be discouraged due to the risk of systemic embolization and death	–	No
Calcium hydroxylapatite	Coaptite®	BioForm Medical, Inc.	Boston Scientific	Synthetic non-immunogenic analog to the calcium hydroxyapatite found in bone and teeth. Detectable on ultrasound or plain film radiography	FDA approved in 2005 for soft tissue augmentation in the treatment of SUI due to ISD in adult females	No
Polytetrafluoroethylene	Teflon	–	–	The injectable paste is quickly absorbed by tissues and is non-carcinogenic and chemically inert	–	No

## Injection Techniques

Bulking agents are injected endoscopically into the male supra-membranous urethra via either a retrograde or antegrade route. Most retrograde injections are performed with the patient under local anesthesia in the office, while antegrade procedures are often in the operating room under anesthesia. Both injection techniques require careful sterile preparation and draping and often local anesthesia with 2% lidocaine jelly placed in the urethra. All patients should receive prophylactic antibiotics prior to injection according to urological guidelines on cystoscopic procedures [53, 54].

### Retrograde Injection

In lithotomy position, a 0° or 30° injection cystoscope is utilized to place the bulking agent under direct cystoscopic vision. The bulking agents are injected endoscopically into the urethra superior to the external sphincter to be effective due to limited pliability of the bulbar urethra when injected below the sphincter and potential for sphincter spasm or failure when injected into the external sphincter. At the time of injection, it is important to inspect the pliability of the tissue and ensure proper depth of injection so that the injected bulking agent closes the urethral lumen by deforming the urethral mucosa [48]. However, because the post-prostatectomy urethra is often scarred, the retrograde method can be more difficult and require multiple injection sites. The goal of the treatment is to obtain circumferential coaptation and closure of the urethra. Upon removing the needle from the injection, some extrusion of material is possible. To minimize the loss of bulking material from extrusion, one can either utilize a saline flush of the material or keep the needle in place for an additional 30–60 seconds after the injection is completed. If significant extravasation of bulking material occurs during the injection procedure, the procedure should be aborted and rescheduled, or alternative surgical treatments should be considered [48].

### Antegrade Injection

Due to the challenges of retrograde bulking agent injection in post-radical prostatectomy male patients who often have anastomotic scar plate formation, an alternative suprapubic antegrade injection procedure was described by Wainstein and Klutke in 1997 [55]. Under regional or general anesthesia, the patient is placed in lithotomy position. Cystourethroscopy is carried out allowing the bladder to fill to capacity. Suprapubic needle/trocar cystotomy allows placement of two guidewires (one safety and one working) in the bladder. Once the guidewires are in position, the tract is dilated over the working guidewire to allow a 16 Fr sheath to be placed. The injection procedure is often performed with a flexible cystoscope placing the bulking agent submucosally at the bladder neck area. Once circumferential coaptation of the bladder neck is obtained, a small temporary suprapubic tube is placed until adequate voiding is confirmed. Although more invasive, this antegrade technique offers an improved view of the bladder neck and proximal urethra and provides unscarred tissue for the injection, resulting in fewer injection sites.



## Immediate Postoperative Period

Due to the nature of most bulking agents, it is recommended to not place a urethral catheter after bulking injections because it may cause molding of the urethra and injectable agent around the catheter, counteracting its effectiveness. If men experience difficulty in urination after injection procedure, they may need to self-catheterize with a small (i.e., 12 French) catheter. If an antegrade injection has been performed, urethral catheter placement is unnecessary as they will use the suprapubic tube until voiding resumes. Permanent urinary retention is extremely rare in males. If stress incontinence returns, repeat injection may be considered, but usually it is scheduled 4 to 6 weeks later to allow the initial injection to stabilize.

## Long-Term Complications

Due to the unique properties of each bulking agent, caution is recommended when making generalized bulking agent statements regarding adverse effects. Each bulking agent has its own distinct host response integration and safety profiles. Acknowledging the fact that each bulking agent carries its unique adverse event profile, the most common complications from bulking agents overall are temporary urinary retention secondary to urethral spasm, edema, or over-injection of bulking agent and temporary lower urinary tract symptoms (dysuria, urethral irritation, urethritis, and cystitis). Uncommon complications such as periurethral pseudocyst and urethrovaginal fistula have also been reported [56, 57].

## Outcomes

Although there are several bulking agents currently available for the treatment of female stress urinary incontinence, there are currently no agents approved for male urinary incontinence. The only bulking agent approved for the use in men was glutaraldehyde cross-linked collagen (GAX-collagen) (e.g., Contigen®), but it was discontinued by the manufacturer in 2011 [52]. Besides GAX-collagen, the only other bulking agent that has been studied in PPI is polydimethylsiloxane macroparticles. The limited efficacy data on bulking agents for PPI is listed in Table 4.

## Glutaraldehyde Cross-Linked Collagen (GAX-COLLAGEN)

Approved by the FDA in 1993, glutaraldehyde cross-linked collagen (GAX-collagen) is a bovine dermal collagen used for the treatment of intrinsic sphincter deficiency [52]. GAX-collagen contains 3.5% collagen by volume and contains approximately 95% type 1 collagen and 1–5% type 3 collagen [79]. Marketed as Contigen®, GAX-collagen is biocompatible and the crosslinking of glutaraldehyde results in enhanced persistence. GAX-collagen can cause an allergic reaction;

**Table 4** Summary of studies regarding bulking agents to treat PPI

Study	No. of patients	Mean follow-up (mo)	Injection approach	Mean no. of injections	Mean injection volume (mL)	No. of patients who became dry (%)	No. of patients whose condition improved (%)	No. of patients in whom treatment failed (%)
<i>Collagen</i>								
Shortliffe et al. (1989) [58]	14	19–23	Retrograde	1.6	28.4	3 (21)	5 (36)	6 (43)
Herschorn et al. (1992) [59]	10	6	Retrograde	4.7	51.8	2 (20)	5 (50)	3 (30)
Aboseif et al. (1996) [60]	88	10	Retrograde	2.8	31	42 (48)	33 (38)	13 (15)
Cummings et al. (1996) [61]	19	10.4	Retrograde	1.8	13.8	4 (21)	7 (37)	8 (42)
Appell et al. (1996) [51]	24	12	Antegrade	1	7.1	9 (37.5)	15 (62.5)	–
Martins et al. (1997) [62]	46	26	Retrograde	2.8	31	11 (24)	21 (46)	14 (30)
Griebling et al. (1997) [63]	25	13.3	Retrograde	2.6	35.5	0 (0)	10 (40)	15 (60)
Faerber and Richardson (1997) [64]	68	38	Retrograde	5	36	7 (10)	7 (10)	54 (79)
Wainstein and Klutke (1997) [55]	48	8.5	Antegrade	–	14.5	12 (25)	22 (46)	14 (29)
Smith et al. (1998a) [65]	54	29	Retrograde	4	20	–	19 (35)	35 (65)
Elsergany and Ghoniem (1998) [66]	35	17.6	Retrograde	2	10	7 (20)	11 (31)	17 (49)
Tiguert et al. (1999) [67]	21	12.5	Retrograde	2.9	18.2	1 (5)	12 (57)	8 (38)
Bevan-Thomas et al. (1999) [68]	257	28	Retrograde	4.4	36.6	52 (20)	101 (39)	104 (40)
Cespedes et al. (1999) [69]	110	7	Retrograde	4.2	28.4	58 (53)	10 (9)	42 (38)
Klutke et al. (1999) [70]	20	28	Antegrade	1	14.5	2 (10)	7 (35)	11 (55)
Westney et al. (2005) [71]	322	40.1	Retrograde	4.37	36	55 (17)	87 (27)	180 (56)
Onur and Singla (2006) [72]	34	15	Retrograde	2.1	8.8	5 (15)	5 (15)	24 (70)
<i>Macropolastique</i>								
Colombo et al. (1997) [73]	6	15.5	Retrograde	1.5	7.5	5 (83)	1 (17)	–
Bugel et al. (1999) [74]	15	12	Retrograde	1.7	6.6	–	4 (26)	9 (60)
Kylmala et al. (2003) [75]	50	7.3	Retrograde	3.0	7.1	6 (12)	28 (56)	16 (32)
Hamid et al. (2003) [76]	14	34.7	Retrograde	1.4	4.0	5 (36)	3 (21)	6 (43)
Imamoglu et al. (2005) [77]	23	48	Retrograde	1.2	11.9	11 (48)	6 (26)	6 (26)
Lee et al. (2014) [78]	30	9.3	Retrograde	1.0	5.3	3 (10)	13 (43)	14 (47)

however, it does not migrate like other agents and does not cause granuloma formation [34, 48]. GAX-collagen treatment is generally more effective in women because the soft collagen material is not as effective in bulking the hard urethral scar tissue after radical prostatectomy [80].

Glutaraldehyde cross-linked collagen injection appears to be less efficacious in men with post-prostatectomy incontinence than in women with SUI. In the largest retrospective review of 322 patients by Westney et al., only 17% of PPI patients achieved complete continence and 27% improved [71]. Data from various studies performing retrograde injections demonstrate a dry/complete continence rate ranging from 4% to 20% and a success rate from 36% to 69% [31, 60, 65, 67, 69, 70, 81].

Antegrade glutaraldehyde cross-linked collagen injection for PPI has also been studied. Early work by Wainstein and Klutke demonstrated a 46% improvement rate and 25% dry rate in 48 PPI men at a mean follow-up of 8.5 months [55]. However, Klutke and colleagues reported long-term results in 20 men followed for a mean of 28 months. Overall, two patients (10%) were dry after one injection with a total volume of 14.5 mL [70]. Although there may be a theoretical advantage regarding the antegrade injection approach, the long-term data on glutaraldehyde cross-linked collagen injections for PPI does not support any advantage for either the retrograde or antegrade approach. Factors that adversely affected success with GAX-collagen include the severity of pretreatment incontinence, concomitant detrusor overactivity, and exposure to radiation therapy [62].

## Silicone Macroparticles

Polydimethylsiloxane (PDS) macroparticles (Macropastique®) are a textured, hypoallergenic, nontoxic bulking agent that consists of varying sizes of silicone spheres ranging between 100  $\mu\text{m}$  and 450  $\mu\text{m}$  in diameter [78]. Although distant migration of silicone macroparticles  $<70 \mu\text{m}$  has been demonstrated in initial animal studies, studies on the larger silicone particles demonstrated a lack of granulomatous formation or migration supporting the safety of PDS macroparticles [82]. After initial non-granulomatous inflammatory reaction, each silicone particle becomes surrounded by connective tissue which stabilize its location at the injection site. Polydimethylsiloxane is a permanent material that can be administered via transurethral injection; however, due to its viscosity, it must be injected with a large-bore 16-gauge-tip transurethral needle and specialized injection gun. Available since 1991, the bulking agent was approved by the FDA in 2006 [52].

The initial reports using PDS for 6 PPI men was promising. In 1997, Colombo et al. reported an 83% dry rate where three patients received one injection (7.5 ml) and three patients received two injections (10.0 ml) at a mean follow-up of 15.5 months [73]. Unfortunately, further studies with objective evidence have documented a deterioration of initial results. Bugel et al. followed 15 PPI men with a mean of 1.7 injections and noted an initial 71% improvement success at 3 months that decreased to 26% at 12 months [74]. Urodynamics revealed that a resting urethral closure pressure  $> 30 \text{ cm H}_2\text{O}$  was a key to success. Kylmala et al. reported on 50 PPI men who received transurethral PDS injection (2.5–5.0 mL) into the external

sphincter and repeated it every 3 months if the initial treatment was not curative [75]. After the initial injection, only 12% of patients were dry based on a 1-hour pad weight test. With repeated injections and 3-month follow-up, an additional 20%, 18%, and 10% achieved continence with 2, 3, or 4 injections, respectively. In 2014, Lee et al. reported a success rate of 43% at 1 month and 32% at 6 months in a retrospective study of 30 incontinent men post-TURP (20%) or post-radical prostatectomy (80%). A higher abdominal leak point pressure and no previous history of radiation therapy suggested better treatment outcomes [78].

Although there is a paucity of data on PDS in men with PPI, short-term (<6 months) success rates range from 26 to 68% with 5 to 12% of patients reporting being dry [73–76, 78]. Side effects reported are similar to other bulking agents and include temporary urinary retention and lower urinary tract symptoms such as dysuria, urgency, and urinary tract infection.

While bulking agents are a minimally invasive treatment that has been used for treating SUI for over a decade, overall there is incomplete data on their efficacy for male PPI. Because studies differ in terms of definition of success, patient characteristics, injected material, number of injections, and length of follow-up, there are widely different success rates reported in the literature. In general, studies on GAX-collagen and PDS macroparticles show initial good results for PPI, though multiple injections are needed and the effect seems to deteriorate over time. If bulking agents are to be used, proper patient selection is imperative as poor tissue quality, bladder overactivity, and radiation therapy effects seem to be poor predictors of success. Further multicenter prospective trials with long-term data are needed to support any of the currently available bulking agents as a standard treatment for PPI.

---

### Conclusion

PPI is an unfortunate and often unavoidable side effect of RP. Conservative treatments should always be trialed before surgical intervention. Lifestyle modifications and PFMT are noninvasive and inexpensive therapies that should be recommended to every patient undergoing RP. While strong data regarding the efficacy of bulking agents, pharmacological therapy, and penile clamps is lacking, these therapies can provide an alternative solution to patients seeking non-surgical treatment for PPI. Conservative therapies for PPI often require a trial and error approach, and in the face of conflicting data, physician discretion must play a significant role in clinical practice.

---

### References

1. Milsom I, Altman D, Lapitan MC, et al. Epidemiology of urinary (UI) and faecal (FI) incontinence and pelvic organ prolapse (POP). In: *Incontinence: 4th international consultation on incontinence*. Paris: Health Publication Ltd; 2009. p. 35–112.
2. Dallosso HM, McGrother CW, Matthews RJ, et al. The association of diet and other lifestyle factors with overactive bladder and stress incontinence: a longitudinal study in women. *BJU Int* 2003; 92(1):69–77.7
3. Arya LA, Myers DL, Jackson ND. Dietary caffeine intake and the risk for detrusor instability: a case-control study. *Obstet Gynecol*. 2000;96(1):85–9.

4. Tomlinson BU, Dougherty MC, Pendergast JF, et al. Dietary caffeine, fluid intake and urinary incontinence in older rural women. *Int Urogynecol J Pelvic Floor Dysfunct.* 1999;10(1):22–8.
5. International Consultation on Incontinence, Abrams P, Cardozo L, et al. *Incontinence: 5th international consultation on incontinence*, Paris, February 2012. Paris: ICUD-EAU; 2013.
6. Sun S, Liu D, Jiao Z. Coffee and caffeine intake and risk of urinary incontinence: a meta-analysis of observational studies. *BMC Urol.* 2016;16(1):61.
7. Nitti VW, Blaivas JG. Urinary incontinence: epidemiology, pathophysiology, evaluation, and management overview. In: Wein A, Kavoussi LR, Novick AC, editors. *Campbell-Walsh urology*. 9th ed. Philadelphia: Saunders; 2007. p. 2046–78.
8. Wolin KY, Luly J, Sutcliffe S, et al. Risk of urinary incontinence following prostatectomy: the role of physical activity and obesity. *J Urol.* 2010;183(2):629–33.
9. van Roermund JGH, van Basten J-PA, et al. Impact of obesity on surgical outcomes following open radical prostatectomy. *Urol Int.* 2009;82(3):256–61.
10. Subak LL, Wing R, West DS, et al. Weight loss to treat urinary incontinence in overweight and obese women. *NEJM.* 2009;360(5):481–90.
11. Burgio KL, Goode PS, Urban DA, et al. Preoperative biofeedback assisted behavioral training to decrease post-prostatectomy incontinence: a randomized, controlled trial. *J Urol.* 2006;175:196–201.
12. Anderson CA, Omar MI, Campbell SE, et al. Conservative management for postprostatectomy urinary incontinence (review). *Cochrane Database Syst Rev.* 2015;1:CD001843.
13. Goode PS, Burgio KL, Johnson TM, Clay OJ, Roth DL, Markland AD, Burkhardt JH, Issa MM, Lloyd LK. Behavioral therapy with or without biofeedback and pelvic floor electrical stimulation for persistent postprostatectomy incontinence: a randomized controlled trial. *JAMA.* 2011;305(2):151–9.
14. Berghmans LC, Hendriks HJ, Bo K, et al. Conservative treatment of stress urinary incontinence in women: a systematic review of randomized clinical trials. *Br J Urol.* 1998;82:181–91.
15. Kretschmer A, Hübner W, Sandhu JS, Bauer RM. Evaluation and management of postprostatectomy incontinence: a systematic review of current literature. *Euro Urol Focus.* 2016;2(3):245–59.
16. Fernandez RA, Garcia-Hermoso A, Solera-Martinez M, et al. Improvement of continence rate with pelvic floor muscle training post-prostatectomy: a meta-analysis of randomized controlled trials. *Urol Int.* 2015;94(2):125–32.
17. Manassero F, Traversi C, Ales V, et al. Contribution of early intensive prolonged pelvic floor exercises on urinary continence recovery after bladder neck-sparing radical prostatectomy: results of a prospective controlled randomized trial. *Neurourol Urodyn.* 2007;26:985–9.
18. Van Kampen M, de Weerd W, Van Poppel H, et al. Effect of pelvic-floor re-education on duration and degree of incontinence after radical prostatectomy: a randomised controlled trial. *Lancet.* 2000;355:98–102.
19. Filocamo MT, Marzi V, Popolo GD, et al. Effectiveness of early pelvic floor rehabilitation treatment for post-prostatectomy incontinence. *Eur Urol.* 2005;48:734–8.
20. Glazener C, Boachie C, Buckley B, et al. Conservative treatment for urinary incontinence in men after prostate surgery (MAPS): two parallel randomised controlled trials. *Health Technol Assess.* 2011;15:1–290. iii–iv
21. Moore KN, Valiquette L, Chetner MP, et al. Return to continence after radical retropubic prostatectomy: a randomized trial of verbal and written instructions versus therapist-directed pelvic floor muscle therapy. *Urology.* 2008;72:1280–6.
22. Overgard M, Angelsen A, Lydersen S, Morkved S. Does physiotherapist-guided pelvic floor muscle training reduce urinary incontinence after radical prostatectomy? A randomized controlled trial. *Eur Urol.* 2008;54:438–48.
23. Dubbelman Y, Groen J, Wildhagen M, et al. The recovery of urinary continence after radical retropubic prostatectomy: a randomized trial comparing the effect of physiotherapist-guided

- pelvic floor muscle exercises with guidance by an instruction folder only. *BJU Int.* 2010;106:515–22.
24. Wang W, Huang QM, Liu FP, et al. Effectiveness of preoperative pelvic floor muscle training for urinary incontinence after radical prostatectomy: a meta-analysis. *BMC Urol.* 2014;14:99.
  25. Geraerts I, Van Poppel H, Devoogdt N, Joniau S, Van Cleynenbreugel B, De Groef A, et al. Influence of preoperative and postoperative pelvic floor muscle training (PFMT) compared with postoperative PFMT on urinary incontinence after radical prostatectomy: a randomized controlled trial. *Eur Urol.* 2013;64(5):766–72.
  26. MacDonald R, Fink HA, Huckabay C, et al. Pelvic floor muscle training to improve urinary incontinence after radical prostatectomy: a systematic review of effectiveness. *BJU Int.* 2007;100:76–81.
  27. Mariotti G, Salciccia S, Innocenzi M, et al. Recovery of urinary continence after radical prostatectomy using early vs. late pelvic floor electrical stimulation and biofeedback-associated treatment. *Urology.* 2015;86:115–20.
  28. Mariotti G, Sciarra A, Gentilucci A, et al. Early recovery of urinary continence after radical prostatectomy using early pelvic floor electrical stimulation and biofeedback associated treatment. *J Urol.* 2009;181:1788–93.
  29. Yamanishi T, Mizuno T, Watanabe M, et al. Randomized, placebo controlled study of electrical stimulation with pelvic floor muscle training for severe urinary incontinence after radical prostatectomy. *J Urol.* 2010;184:2007–12.
  30. Wille S, Sobottka A, Heidenreich A, et al. Pelvic floor exercises, electrical stimulation and biofeedback after radical prostatectomy: results of a prospective randomized trial. *J Urol.* 2003;170:490–3.
  31. Galloway NTM, El-Galley RES, Sand PK, et al. Extracorporeal magnetic innervation therapy for stress urinary incontinence. *Urology.* 1999;53:1108–11.
  32. Terzoni S, Montanari E, Mora C, et al. Reducing urine leakage after radical retropubic prostatectomy: pelvic floor exercises, magnetic innervation or no treatment? A quasi-experimental study. *Rehabil Nurs.* 2013;38:153–60.
  33. Voorham-van der Zalm PJ, RCM P, Stiggelbout AM, et al. Effects of magnetic stimulation in the treatment of pelvic floor dysfunction. *BJU Int.* 2006;97:1035–8.
  34. Moore KC, Lucas MG. Management of male urinary incontinence. *Indian J Urol.* 2010;26(2):236–44.
  35. Tsakiris P, de la Rosette JJ, Michel MC, Oelke M. Pharmacologic treatment of male stress urinary incontinence: systematic review of the literature and levels of evidence. *Eur Urol.* 2008;53(1):53–9.
  36. Løvvik A, Müller S, Patel HRH. Pharmacological treatment of post-prostatectomy incontinence: what is the evidence? *Drugs Aging.* 2016;33:535–44.
  37. Alan C, Eren AE, Ersay AR, et al. Efficacy of duloxetine in the early management of urinary continence after radical prostatectomy. *Curr Urol.* 2015;8:43–8.
  38. Schlenker B, Gratzke C, Reich O, et al. Preliminary results on the off-label use of duloxetine for the treatment of stress incontinence after radical prostatectomy or cystectomy. *Eur Urol.* 2006;49:1075–8.
  39. Bianco FJ, Albala DM, Belkoff LH, et al. A randomized, double-blind, solifenacin succinate versus placebo control, phase 4, multicenter study evaluating urinary continence after robotic assisted radical prostatectomy. *J Urol.* 2015;193:1305–10.
  40. Shim M, Kim J, Park S, et al. The therapeutic effect of solifenacin succinate on the recovery from voiding dysfunction after radical prostatectomy in men with clinically localized prostate cancer: a prospective, randomized, controlled study. *Urology.* 2015;85:1123–9.
  41. Kaiho Y, Yamashita S, Ito A, et al. Phosphodiesterase type 5 inhibitor administered immediately after radical prostatectomy temporarily increases the need for incontinence pads, but improves final continence status. *Investig Clin Urol.* 2016;57:357–63.
  42. Moore KN, Schieman S, Ackerman T, et al. Assessing comfort, safety, and patient satisfaction with three commonly used penile compression devices. *Urology.* 2004;63:150–4.

43. Barnard J, Westenberg AM. The penile clamp: medieval pain or makeshift gain? *Neurourology Urodyn.* 2015;34(2):115–6.
44. Kalra S, Srinivas PR, Manikandan R, Dorairajan LN. Urethral diverticulum: a potential hazard of penile clamp application for male urinary incontinence. *BMJ Case Rep.* 2015; doi:10.1136/bcr-2015-209957.
45. Quackels R. Deux incontinenances après adénomectomie guéries par injection de paraffine dans le périnée. *Acta Urol Belg.* 1955;23:259–62.
46. Sachse H. Treatment of urinary incontinence with sclerosing solutions. Indications, results, complications. *Urol Int.* 1963;15:225–44.
47. Berg S. Polytef augmentation urethroplasty: correction of surgically incurable urinary incontinence by injection technique. *Arch Surg.* 1973;107(3):379.
48. Appell RA, Winters JC. Injection therapy for urinary incontinence. In: Wein A, Kavoussi LR, Novick AC, editors. *Campbell-Walsh urology.* 9th ed. Philadelphia: Saunders; 2007. p. 2272–87.
49. Dmochowski RR, Appell RA. Injectable agents in the treatment of stress urinary incontinence in women: where are we now? *Urology.* 2000;56(6 Suppl 1):32–40.
50. Kershen RT, Atala A. New advances in injectable therapies for the treatment of incontinence and vesicoureteral reflux. *Urol Clin North Am.* 1999;26(1):81–94. viii
51. Appell RA, Vasavada SP, Rackley RR, Winters JC. Percutaneous antegrade collagen injection therapy for urinary incontinence following radical prostatectomy. *Urology.* 1996;48(5):769–72.
52. Injectable bulking agents for the treatment of urinary and fecal incontinence. BCBS Policy #7.01.19. <http://www.bcbsms.com/com/bcbsms/apps/PolicySearch/views/ViewPolicy.php?&noprint=yes&path=%2Fpolicy%2Femed%2FPeriurethral+Bulking+Agents+for+the+Treatment+of+Incontinence.html> Accessed 21 Oct 2016
53. Wolf JS, Bennett CJ, Dmochowski RR, Hollenbeck BK, Pearle MS, Schaeffer AJ, et al. Best practice policy statement on urologic surgery antimicrobial prophylaxis. *J Urol.* 2008;179(4):1379–90.
54. Mrkobrada M, Ying I, Mokrycke S, Dresser G, Elsayed S, Bathini V, et al. CUA guidelines on antibiotic prophylaxis for urologic procedures. *Can Urol Assoc J.* 2015;9(1–2):13–22.
55. Wainstein MA, Klutke CG. Antegrade techniques of collagen injection for post-prostatectomy stress urinary incontinence: the Washington University experience. *World J Urol.* 1997;15(5):310–5.
56. McLennan MT, Bent AE. Suburethral abscess: a complication of periurethral collagen injection therapy. *Obstet Gynecol.* 1998;92(4 Pt 2):650–2.
57. Stothers L, Goldenberg SL, Leone EF. Complications of periurethral collagen injection for stress urinary incontinence. *J Urol.* 1998;159(3):806–7.
58. Shortliffe LM, Freiha FS, Kessler R, Stamey TA, Constantinou CE. Treatment of urinary incontinence by the periurethral implantation of glutaraldehyde cross-linked collagen. *J Urol.* 1989;141(3):538–41.
59. Herschorn S, Radomski SB, Steele DJ. Early experience with intraurethral collagen injections for urinary incontinence. *J Urol.* 1992;148(6):1797–800.
60. Aboseif SR, O'Connell HE, Usui A, McGuire EJ. Collagen injection for intrinsic sphincteric deficiency in men. *J Urol.* 1996;155(1):10–3.
61. Cummings JM, Boullier JA, Parra RO. Transurethral collagen injections in the therapy of post-radical prostatectomy stress incontinence. *J Urol.* 1996;155(3):1011–3.
62. Martins FE, Bennett CJ, Dunn M, et al. Adverse prognostic features of collagen injection therapy for urinary incontinence following radical retropubic prostatectomy. *J Urol.* 1997;158:1745–9.
63. Griebing TL, Kreder KJ, Williams RD. Transurethral collagen injection for treatment of post-prostatectomy urinary incontinence in men. *Urology.* 1997;49(6):907–12.
64. Faerber GJ, Richardson TD. Long-term results of transurethral collagen injection in men with intrinsic sphincter deficiency. *J Endourol.* 1997;11(4):273–7.

65. Smith DN, Appell RA, Rackley RR, et al. Collagen injection therapy for post-prostatectomy incontinence. *J Urol.* 1998;160:364–7.
66. Elsergany R, Ghoniem GM. Collagen injection for intrinsic sphincteric deficiency in men: a reasonable option in selected patients. *J Urol.* 1998;159(5):1504–6.
67. Tiguert R, Gheiler EL, Gudziak MR. Collagen injection in the management of post-radical prostatectomy intrinsic sphincteric deficiency. *Neurourol Urodyn.* 1999;18(6):653–8.
68. Bevan-Thomas R, Westney OL, McGuire EJ, Cespedes RD. Long-term follow-up of periurethral collagen injections for male intrinsic sphincter deficiency. *J Urol.* 1999;161(4S):257.
69. Cespedes RD, Leng WW, McGuire EJ. Collagen injection therapy for postprostatectomy incontinence. *Urology.* 1999;54(4):597–602.
70. Klutke JJ, Subir C, Andriole G, Klutke CG. Long-term results after antegrade collagen injection for stress urinary incontinence following radical retropubic prostatectomy. *Urology.* 1999;53(5):974–7.
71. Westney OL, Bevan-Thomas R, Palmer JL, et al. Transurethral collagen injections for male intrinsic sphincter deficiency: the University of Texas-Houston experience. *J Urol.* 2005;174:994–7.
72. Onur R, Singla A. Comparison of bone-anchored male sling and collagen implant for the treatment of male incontinence. *Int J Urol.* 2006;13(9):1207–11.
73. Colombo T, Augustin H, Breinl E, Schips L, Hubmer G. The use of polydimethylsiloxane in the treatment of incontinence after radical prostatectomy. *Br J Urol.* 1997;80(6):923–6.
74. Bugel H, Pfister C, Sibert L, Cappele O, Khalaf A, Grise P. Intraurethral Macroplastic injections in the treatment of urinary incontinence after prostatic surgery. *Prog Urol.* 1999;9(6):1068–76.
75. Kymälä T, Tainio H, Raitanen M, Tammela TLJ. Treatment of postoperative male urinary incontinence using transurethral macroplastique injections. *J Endourol.* 2003;17(2):113–5.
76. Hamid R, Arya M, Khastgir J, Patel HRH, Shah PJR. The treatment of male stress urinary incontinence with polydimethylsiloxane in compliant bladders following spinal cord injury. *Spinal Cord.* 2003;41(5):286–9.
77. Imamoglu MA, Tuygun C, Bakirtas H, Yiğitbasi O, Kiper A. The comparison of artificial urinary sphincter implantation and endourethral macroplastique injection for the treatment of postprostatectomy incontinence. *Eur Urol.* 2005;47(2):209–13.
78. Lee SW, Kang JH, Sung HH, et al. Treatment outcomes of transurethral macroplastique injection for postprostatectomy incontinence. *Korean J Urol.* 2014;55(3):182–9.
79. 78CR Bard Company. PMAA submission to U.S FDA for IDE G850010, 1990.
80. Tsai C-C, Lin V, Tang L. Injectable biomaterials for incontinence and vesico-ureteral reflux: current status and future promise. *J Biomed Mater Res Part B Appl Biomater.* 2006;77(1):171–8.
81. Sánchez-Ortiz RF, Broderick GA, Chaikin DC, et al. Collagen injection therapy for post-radical retropubic prostatectomy incontinence: role of Valsalva leak point pressure. *J Urol.* 1997;158:2132–6.
82. Henly DR, Barrett DM, Weiland TL, et al. Particulate silicone for use in periurethral injections: local tissue effects and search for migration. *J Urol.* 1995;153:2039–43.



---

# Historical Background and Evolution in Male Sling Surgery

Ajay Singla

---

## Introduction

It is estimated that approximately 22.6 million men are affected by urinary incontinence and 8.2 million have moderate to severe incontinence [1]. Pure stress urinary incontinence (SUI) accounts for only a subset (12.5%) of these patients, yet it remains a substantial problem. In the era of robot-assisted laparoscopic prostatectomy, the incidence of 12 months of urinary incontinence varies between 4 and 31%. Of these, only 6–9% of men are bothered enough to elect surgical treatment for their incontinence [2, 3].

---

## Background

Surgeries for urinary incontinence in men following prostate surgery date back to the early twentieth century when Hugh H. Young performed a combined procedure through a transvesical and perineal approach in two male patients with postoperative incontinence following perineal prostatectomy in 1907 and 1916. The internal sphincter at the bladder neck was plicated with bladder wall first by opening the bladder and using a special boomerang needle holder. Subsequently, the external urethral sphincter was also plicated [4].

Later, several other perineal procedures were described using muscle strips. The first one was introduced by J.B. Squier in 1911 using parts of levator ani muscles [5]. In 1926 C.L. Deming described the use of gracilis muscle [6], and in

---

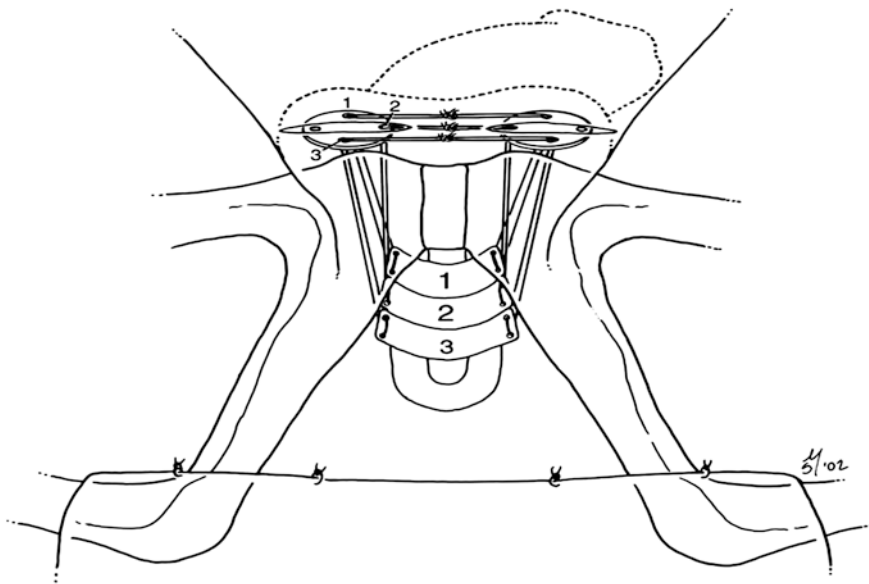
A. Singla  
Massachusetts General Hospital, Harvard Medical School,  
Boston, MA, USA  
e-mail: [AKSingla@MGH.Harvard.edu](mailto:AKSingla@MGH.Harvard.edu)

1936 Oswald S. Lowsley described technique using ischiocavernosus muscle [7]. A modified procedure later became known as Flaqué-Lowsley operation was published in 1951 [8].

Male sling procedure is based upon the theory of passive urethral compression along the ventral surface [9]. The concept of urethral compression by male sling is not new and before AUS was introduced, a variety of urethral compression procedures were implied in an attempt to control urinary incontinence. The use of fixed urethral compression for the treatment of male SUI began in 1961 when Berry used acrylic prosthesis to compress the ventral urethra against the urogenital diaphragm [10].

It was followed by different compression procedures developed by Kaufman and Hauri in the 1970s [9, 11]. Most notable were the Kaufman procedures which included a crural crossover (Kaufman 1) [12] and then modified to use a prosthesis using silicone gel to compress ventral urethra (Kaufman 2) [13], but it soon fell out of favor because of high rate of complications.

Later, in 1998 Schaffer et al. described a male sling using a series of three tetrafluoroethylene (Dacron) bolsters placed beneath the bulbar urethra through a perineal incision. These individual bolsters are attached to nonabsorbable sutures. Stamey needle was used to transfer the sutures in the suprapubic area, and the sutures were tied across the rectus fascia [14]. In this fashion, compression is provided at the bulbar urethra. Intraoperative resting urethral pressure and abdominal leak point pressures were measured for sling tension (Fig. 1). This sling was based on the concept of pubovaginal sling in women. Long-term results in 71 patients were reported by Stern et al. [15]. At a mean follow-up of 4 years (range 0.27–6.55),



**Fig. 1** Bulbourethral sling

68% patients required two or less pads per day. Only 36% were completely dry requiring no pads. Overall, a total of 69% of patients were satisfied with the procedure. Seven patients required sling removal. Despite a reasonable short-term success and patient satisfaction, this sling was abandoned because of high rate of complication including bolster removal (6%), sling removal (10%), and severe perineal pain (26%).

Since that time, a variety of mechanisms including compression devices have been employed by which to apply passive external urethral compression with male slings.

The oldest compression device referred to as penile clamp was introduced by J.H. Cunningham in 1910 to provide external urethral compression to stop the leakage [16] and is still in use to date for some male patients with urinary incontinence.

The first artificial sphincter was designed by Frederick Foley in 1947. This was still based upon a fixed urethral compression and provides a circumferential urethral compression by applying an inflatable circular cuff to the male urethra. It was a pneumatic clamp and was inflated and deflated manually by pneumatic piston [17]. Later M. Rosen developed an inflatable urethral compression prosthesis in 1976 [18], and Udo Jonas in 1983 described an internal penile clamp which was implanted at the penoscrotal angle and opened for micturition by external pressure from both sides [19].

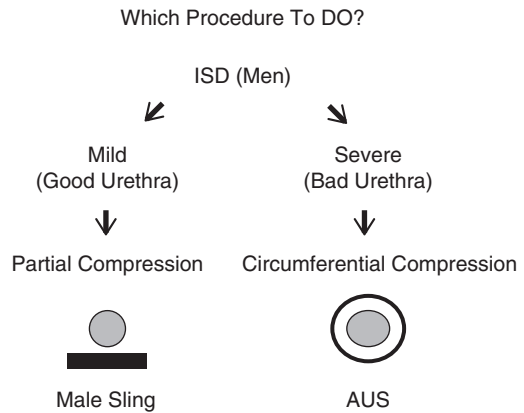
In the twentieth century, artificial urinary sphincter has enjoyed popularity as a gold standard procedure for male SUI after the prototype of the current AUS was introduced in 1973 by Brantley Scott. Scott's original design used a fully implantable system composed of an inflation pump, deflation pump, urethral cuff, and a fluid reservoir [20]. There have been many revisions in the design which led to the current model of artificial urinary sphincter implant, AMS 800 with a pressure-regulating balloon, narrow-backed cuff, and scrotal pump with deactivation button.

The rationale for using male urethral slings for post-prostatectomy incontinence is that, unlike the AUS, it provides a minimally invasive surgical option. They are, however, less expensive than AUS devices, and unlike the AUS, slings provide fixed urethral resistance and/or repositioning that potentially enables better physiologic voiding [21]. It also avoids the need for manipulating the device and to provide an alternative surgical option for patients with mild to moderate incontinence or who refuse to have AUS.

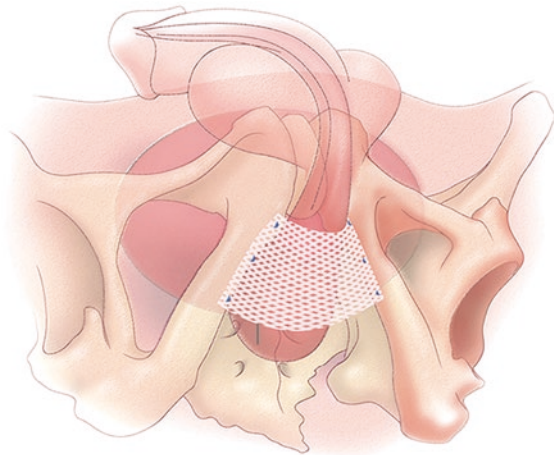
There was resurgence in the interest in male sling again in the twenty-first century. The modern male sling has evolved over the past 15 years. This was brought by the need to capture the larger market share in post-prostatectomy incontinence. There were patients who are not severely incontinent and would defer the traditional AUS implantation. It is also believed that these patients with mild to moderate incontinence would benefit from partial compression of ventral urethra provided by a male sling (Fig. 2).

The new male sling was based again on the concept of mechanical compression of the bulbar urethra against the pubic bone. Bone anchors were used to fix the sling to the pubic rami which obviates the need for blind transfer of sutures suprapubically to achieve bulbourethral compression and eliminates any abdominal incision.

**Fig. 2** Algorithm for the surgical management of post-prostatectomy incontinence



**Fig. 3** Bone anchored male sling



The InVance™ (American Medical Systems, Minnetonka, MN) bone-anchored male sling (BAMS) represented a major improvement in technique, minimizing invasiveness via a purely perineal approach; a silicone-coated polypropylene sling is secured to the descending pubic rami using 5 mm titanium bone screws. A disposable battery-powered inserter is used to insert a total of six bone screws which are pre-attached with #1 Prolene suture. The dissection is carried out laterally toward the pubic rami leaving all the tissue over the urethra. Three screws are placed on each side. A 4 × 7 cm silicone-coated polypropylene mesh alone or in combination with dermis as a composite graft is then anchored to the pubic rami which provided the urethral compression. The sling tension is adjusted either by retrograde urethral pressure method or, if the patient is awake, simply by cough method (Fig. 3).

Unlike the AUS that compresses urethra circumferentially (thereby interfering with the venous blood flow and predisposing to urethral atrophy and even erosion),

the bone-anchored male sling only compresses the ventral aspect of the bulbar urethra leaving the dorsal and lateral blood flow intact.

The first data concerning this procedure was reported by Madjar et al. in 2001. They reported a short-term continence rate of 86% in a cohort of 16 patients with no complications [22]. This was later popularized by Comiter [23] and Onur et al. [24].

The author reported their experience in both mild to moderate and severe incontinent patients. It was also found that the patient with mild to moderate incontinence (<5 pads) had a significant better outcome compared with those with severe incontinence (>5 pads). The sling failure correlated well with the type of material and severity of the incontinence [24]. Similarly, in a study by Castle et al. in 38 patients, none of the patients with severe incontinence was cured of their incontinence [25].

Similar results with the InVance bone-anchored sling were reported by Rajpurkar et al. who reported overall success rates of 74% and a patient satisfaction of over 70% at a mean follow-up of 24 months [26].

Long-term results with the InVance bone-anchored sling were reported by Carmel et al. [27]. In that report, 45 patients with post-prostatectomy incontinence underwent InVance sling placement along with regular 2-, 6-, and 12-month and yearly follow-up including pad testing, urodynamics, history, and UCLA/RAND and American Urological Association (AUA) symptom score data for a median follow-up of 36 months: 36% of patients were dry, 40% improved, and 24% reported failure. The vast majority of patients (86%) considered themselves cured or almost cured, and 72% were satisfied or very satisfied with the procedure. Complications were temporary perineal numbing sensation lasting 1–3 months in 22%, temporary urinary retention in 7%, overactive bladder in 4%, and mesh infection resulting in removal in one patient.

Similarly, a recent French multicenter study described treatment success and predictors of failure among 84 patients treated for incontinence with InVance male slings. In this study, at a mean of 20 months, 45% of patients were dry, 26% improved, and 29% had treatment failure. Univariate analysis identified three features as predictors of treatment failure: severe urinary incontinence, urodynamic instability, and a history of bimodal therapy for prostate cancer including radiation therapy. Failure rate was 67% if two or more of these factors were present versus 25% if one or none was present ( $P = .013$ ). Bimodal therapy was the sole independent predictor of failure in multivariate analysis in this study [28].

The author reported their 5-year experience in 87 patients in 2007 and showed only 52.8% were cured and another 25.2% significantly improved of their incontinence, while 21.8% failed the sling procedure [29].

Fischer et al. used a risk analysis model to predict success in 62 men treated for post-prostatectomy incontinence with bone-anchored slings and found that among several factors: time from treatment causing incontinence, age, abdominal leak point pressure, pad weight testing, maximum bladder capacity, detrusor overactivity, International Prostate Symptom Score (IPSS), and urinary distress inventory (UDI-6)], only preoperative pad weight of less than 423 g/day was a predictor of success. Patients with less than 423 g/day leakage had a 71% chance of success and were six times more likely to have success as defined by perception of very much or much better on Patient Global Impression of Improvement (PGI-I) questionnaires [30].

In another study by Comiter, reported complications with bone-anchored male sling were transient retention in 2%, overactive bladder in 5%, mesh erosion in 2%, and infection in another 2%. There was a slightly higher rate of perineal pain in 15% [31].

*Because of potential risk of bone infection and bone pain from the bone screws, this male sling has been withdrawn from the US market and is no longer available for implantation.*

Whereas bone-anchored male slings function by fixed urethral compression, transobturator slings were subsequently developed based on the concept of proximal relocation of the sphincteric urethra. It was introduced in 2007, the original concept based upon a minimally invasive approach similar to the female mid-urethral transobturator tape (TOT) sling. Rehder and Gozzi described a novel technique for placement of a polypropylene tape beneath the bulbar urethra using the transobturator approach in a series of four cadaveric as well as 20 human male patients [32].

Whereas this sling only compresses urethra minimally, its main mechanism of action relies upon relocation of proximal urethra. It is hypothesized that inefficient coaptation of the urethral sphincter complex results from subluxation of the posterior urethral support [33]. Therefore, a transobturator sling which elevates and relocates the urethra will ultimately prevent proximal urethral descent and improve the coaptation. Following appropriate sling tensioning, the bulbar urethra is relocated proximally by a distance of 2–3 cm into the high-pressure zone in the pelvis, thus functioning as a physiologic “backstop” during straining [34].

The middle part of the tape was fixed distally to the bulb and proximally to the perineal body, and when tension was applied to the ends of the tape, the proximal anterior urethra was relocated proximally by a distance of 3–4 cm, effectively lengthening the membranous urethra. Baseline and postoperative video urodynamics in the clinical series confirmed that at rest, the bladder neck and posterior urethra were more occluded, and the bladder neck was closed and more elevated than at baseline. Additionally, postoperative video urodynamics demonstrated a more elongated membranous urethra during micturition, having increased from a mean of 3 mm to a mean of 17.2 mm following placement of the tape. Urethral pressure profilometry in the same series demonstrated an improvement of supine mean urethral closing pressure at rest from 13.2 cm H<sub>2</sub>O preoperatively to 86.4 cm H<sub>2</sub>O postoperatively [32].

The rationale for treating post-prostatectomy male incontinence by transobturator tape is based on the theory that post-prostatectomy men with partially intact external sphincteric complexes may develop incontinence due to urethral hypermobility, resulting in urethral subluxation or perineal descent from the pelvis, possibly associated with coexistent levator laxity; hence, proximal relocation of the sphincteric urethra may result in improved continence [32].

*This sling is described in detail in subsequent chapters.*

The newest version in male sling is the addition of a quadratic sling from Coloplast Corp. It is designed to provide a broad area of urethral compression and to achieve proximal relocation of the membranous urethra. Quadratic fixation is achieved with both transobturator (TO) and prepubic (PP) components. By combining the mechanisms of action of the bone-anchored and the transobturator retroluminal slings, the quadratic device can increase urethral resistance to a greater degree more than either a purely perineal or TO approach. On tightening both arms sequentially, this additive effect has been shown to cause a cumulative increase in RLPP [35, 36]. Because of this feature, it has been proposed to be effective in more severe post-prostatectomy incontinence as compared to other male slings.

*This sling is described in detail in subsequent chapters.*

Some adjustable slings have also been introduced, but only one of those slings (Remeex) is approved by the FDA in the United States. These slings are again based on the concept of urethral compression.

The Argus sling consists of silicone foam pad placed under the bulbar urethra, attached to silicone columns that are transferred through retropubic or transobturator space and fixed over the rectus fascia using silicone washers [37].

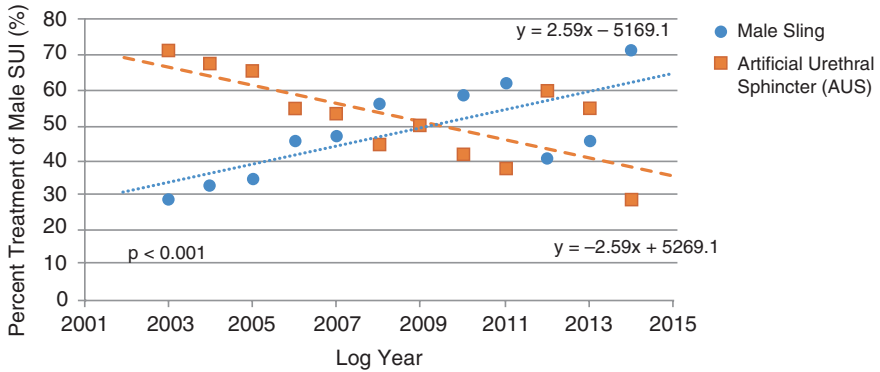
The Remeex male sling consists of a short polypropylene mesh placed under the urethra and attached to permanent sutures which are passed through the retropubic space, and a permanent implanted mechanical device “varitensor” is placed over the rectus fascia. In the event of suboptimal intraoperative tension, sling tightening can be performed under local anesthesia in the office in a minimally invasive technique [38].

*These slings are described in detail in subsequent chapters.*

Despite different mechanisms of action, the primary goals of the various male slings remain: (1) tensioning to adequately compress the bulbar urethra and/or sufficiently relocate the proximal urethra; (2) maintain tension to prevent recurrent leakage, and (3) balancing sling tension and detrusor contractility in order to avoid urinary retention [39].

*These male sling procedures can be classified into:*

1. Nonadjustable male slings:
  - (a) Bulbourethral sling
  - (b) Bone-anchored male sling (InVance, American Medical Systems)
  - (c) Transobturator male sling system (AdVance, American Medical Systems)
  - (d) Quadratic male sling (Virtue, Coloplast Corp.)
2. Adjustable male slings:
  - (a) Reemex (Neomedic, Spain)
  - (b) Argus (Promedon, SA, Cordoba, Argentina)
3. Adjustable Devices:
  - (a) ProACT (Uromedica Inc., MN, USA)



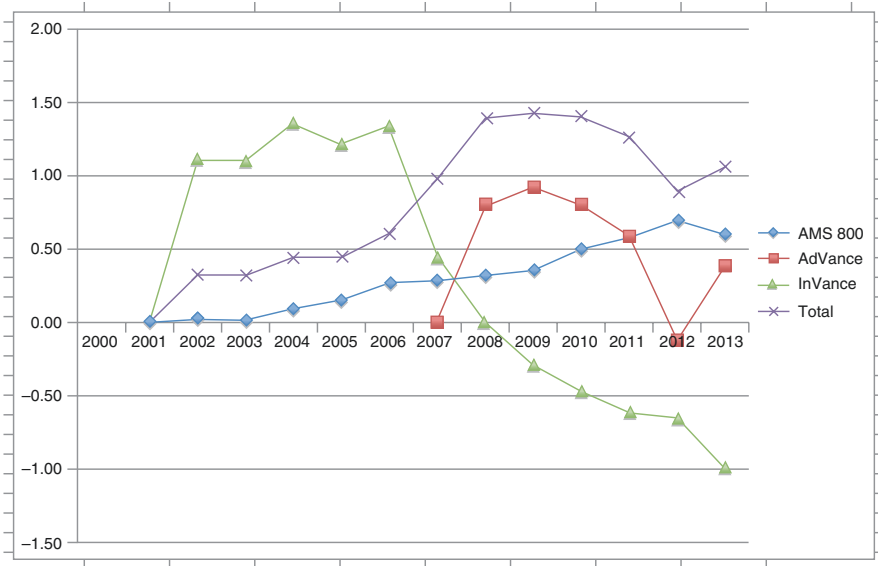
**Fig. 4** Trends in Treatment of Male Stress Urinary Incontinence with male Sling and AUS

National trends in the use of male sling surgery has been studied and compared with the use of AUS.

Liu JS et al. [40] have looked at the trend of male sling surgery in relation to AUS among certifying urologists in the United States. The case log data from the American Board of Urology was obtained. They reported the rate of increase in male sling procedures from 32.7% in 2004 to 45% in 2013 ( $p < 0.001$ ) with a peak in 2011 when sling placement was 1.6 times more frequently performed than AUS (sling 62.2% versus AUS 37.8%). This increase was most notable after the transobturator sling was introduced in 2007 (Fig. 4).

Recently, Santiago-Lastra and Malaeb looked at the sales data from the manufacturer of male slings (InVance and AdVance) and AUS to see the national trend in the use of male sling over a 12-year period in relation to standard AUS. A retrospective review of sales data from American Medical Systems (now Boston Scientific) for three male incontinence products was reported. Both slings included in the study had a notable upswing soon after their introduction in the market. First peak was noted in 2004 when the bone-anchored male sling (InVance) was introduced in 2001, and second peak was noted in 2009 when the transobturator sling (AdVance) was introduced in 2007. The InVance use continued to decline after the manufacturer introduced AdVance and is completely withdrawn from the US market. There was a decline in the use of AdVance sling after 2011 possibly with introduction of new quadratic male sling. The use of AUS, however, continued to increase steadily [41] (Fig. 5).





**Fig. 5** Yearly Utilization Rate of Surgical Therapies for Post-Prostatectomy Incontinence (2001–2013)

**Conclusion**

Advances in the diagnosis, management, and treatment of men with SUI have resulted in various surgical options. A meticulous preoperative evaluation and long-term analysis of outcomes and results will provide insights into success following sling surgery. Male sling surgery has emerged as a safe and efficacious alternative to AUS placement in properly selected men with post-prostatectomy incontinence. Slings are preferred by most patients over the AUS, as the need to manipulate a scrotal pump to permit bladder evacuation can be avoided. Patient selection remains the key to success in any male sling surgery. In particular, in patients with mild to moderate SUI with normal bladder contractility, intermediate-term results with sling surgery appear equivalent to those for AUS placement. Similarly, patients with history of prior radiation and/or prior incontinence procedure should not be offered male sling. There is limited data available for quadratic sling, and long-term data is lacking for male sling. Patients should be counseled appropriately and are provided with real expectations.

**Acknowledgment** The author wants to acknowledge Dirk Schultheiss, M.D., Chairman, History Office, European Association of Urology (EAU), for the resource provided in “A Brief History of Urinary Incontinence and its Treatment.”

## References

1. Markland AD, Goode PS, Redden DT, Borrud LG, Burgio KL. Prevalence of urinary incontinence in men: results from the national health and nutrition examination survey. *J Urol.* 2010;184(3):1022–7.
2. Nam RK, Herschorn S, Loblaw DA, Liu Y, Klotz LH, Carr LK, et al. Population based study of long term rates of surgery for urinary incontinence after radical prostatectomy for prostate cancer. *J Urol.* 2012;188:502–6.
3. Kundu SD, Roehl KA, Eggner SE, Antenor JA, Han M, Catalona WJ. Potency, continence, and complications in 3477 consecutive radical retropubic prostatectomies. *J Urol.* 2004;172:2227–31.
4. Young HH. An operation for the cure of incontinence of urine. *Surg Gynecol Obstet.* 1919;28:84–90.
5. Squier JB. Post-operative urinary incontinence: urethroplastic operation. *Med Rec.* 1911;79:868.
6. Deming CL. Transplantation of the gracilis muscle for incontinence of urine. *JAMA.* 1926;86:822–5.
7. Lowsley OS. New operations for the relief of incontinence in both male and female. *J Urol.* 1936;36:400.
8. Verges-Flaque A. Flaque-Lowsley operation for urinary incontinence: preliminary report. *J Urol.* 1951;65:427–38.
9. Kaufman JJ. A new operation for male incontinence. *Surg Gynecol Obstet.* 1970;131:295.
10. Berry JL. A new procedure for correction of urinary incontinence: preliminary report. *J Urol.* 1961;85:771–3.
11. Hauri D. A new operation for post-prostatectomy incontinence. *Urol Int.* 1977;32:284–94.
12. Kaufman JJ. Surgical treatment of post-prostatectomy incontinence: use of the penile crura to compress the bulbous urethra. *J Urol.* 1972;107:293–7.
13. Kaufman JJ. Treatment of post-prostatectomy urinary incontinence using a silicone gel prosthesis. *Br J Urol.* 1973;45:646.
14. Schaeffer AJ, Clemens JQ, Ferrari M, Stamey TA. The male bulbourethral sling procedure for post-radical prostatectomy incontinence. *J Urol.* 1998;159:1510–9.
15. Stern JA, Clemens JQ, Tiplitsky SI, Matschke HM, Jain PM, Schaeffer AJ. Long term results of the bulbourethral sling procedure. *J Urol.* 2005;173:1654–6.
16. Cunningham JH. The diagnosis of the stricture of the urethra by the roentgen rays. *Trans Am Assoc Genitourin Surg.* 1910;5:369.
17. Foley FEB. An artificial sphincter: a new device and operation for control of enuresis and urinary incontinence. *J Urol.* 1947;58:250–9.
18. Rosen M. A simple artificial implantable sphincter. *Br J Urol.* 1976;48:675.
19. Jonas U. Operative Behandlung der mannlichen Sphinkterinsuffizienz: Experimente Zur Entwicklung eines neuartigen alloplastischen Sphinkters. *Aktuelle Urol.* 1984;15:280–6.
20. Scott FB, Bradley WE, Timm GW. Treatment of urinary incontinence by implantable prosthetic sphincter. *Urology.* 1973;1:252–9.
21. Singla A. Bone anchored male sling (BAMS). In: Singla A, editor. *Post prostatectomy incontinence – a clinical guide.* Germany: LAP Lambert Academic Publishing; 2013. p. 66.
22. Madjar S, Jacoby K, Giberti C, Wald M, Halachmi S, Issaq E, et al. Bone anchored sling for the treatment of post-prostatectomy incontinence. *J Urol.* 2001;165:72–6.
23. Comiter CV. The male sling for stress urinary incontinence: a prospective study. *J Urol.* 2002;167:97–601.
24. Onur R, Rajpurkar A, Singla A. New perineal bone anchored male sling: lessons learned. *Urology.* 2004;64(1):58–61.
25. Castle E, Andrews P, Itano N, et al. The male sling for post-prostatectomy incontinence. Mean follow up of 18 months. *J Urol.* 2005;173:1657.
26. Rajpurkar AD, Onur R, Singla A. Patient satisfaction and clinical efficacy of the new perineal bone-anchored male sling. *Eur Urol.* 2005;47:237–42.

27. Carmel M, Hage B, Hanna S, Schmutz G, Tu LM. Long-term efficacy of the bone-anchored male sling for moderate and severe stress urinary incontinence. *BJU Int.* 2010;106:1012–6.
28. Lanoë M, Saussine C, Mouracade P, et al. Male stress urinary incontinence by InVance™ bone anchored sub-urethral sling: predictive factors of treatment failure: multicentric study by the CTMH-AFU. *Prog Urol.* 2009;19:839–44.
29. Singla AK, Aggarwal N. Bone anchored male sling in the management of post prostatectomy incontinence-five year experience from single institution. *J Urol.* 2007;177(4 suppl):441.
30. Fischer MC, Huckabay C, Nitti VW. The male perineal sling: assessment and prediction of outcome. *J Urol.* 2007;177:1414–8.
31. Comiter CV. The male perineal sling: Intermediate-term results. *Neurourol Urodyn.* 2005;24:648–53.
32. Rehder P, Gozzi C. Transobturator sling suspension for male urinary incontinence including post-radical prostatectomy. *Eur Urol.* 2007;52:860–6.
33. Rehder P, Freiin von Gleissenthall G, Pichler R, Glodny B. The treatment of postprostatectomy incontinence with the retroluminal transobturator repositioning sling (AdVance): lessons learnt from accumulative experience. *Arch Esp Urol.* 2009;62:860–70.
34. De Ridder D, Rehder P. The advance male sling: anatomic features in relation to mode of action. *Eur Urol Suppl.* 2011;10:383–9.
35. Comiter CV, Nitti V, Elliott C, Rhee E. A new quadratic sling for male stress incontinence: retrograde leak point pressure as a measure of urethral resistance. *J Urol.* 2012;187:563–8.
36. Comiter CV, Rhee EY. “the ventral urethral elevation plus” sling: a novel approach to treating stress urinary incontinence in men. *BJU Int.* 2008;101:187–91.
37. Romano SV, Metrebian SE, Vaz F, et al. An adjustable male sling for treating urinary incontinence after prostatectomy: a phase III multicentre trial. *BJU Int.* 2006;97:533–9.
38. Sousa-Escandon A, Cabrera J, Mantovani F, Moretti M, Ioanidis E, Kondelidis N, et al. Adjustable suburethral sling (male remeex system) in the treatment of male stress urinary incontinence: a multicentric European study. *Eur Urol.* 2007;52:1473–9.
39. Comiter CV, Dobberfuhr AD. The artificial urinary sphincter and male sling for postprostatectomy incontinence: which patient should get which procedure? *Investig Clin Urol.* 2016;57:3–13.
40. Liu JS, Hofer MD, Milose J, et al. Male sling and artificial urethral sphincter for male stress urinary incontinence among certifying American urologists. *Urology.* 2016;87:95–9.
41. Lastra S, Malaeb BS. National trends in the use of surgical procedures for post-prostatectomy incontinence. *AUA News.* 2016;21(10):11.

---

# The AdVance Transobturator Male Sling

Oscar A. Suárez, Amanda S. Chung,  
and Kurt A. McCammon

---

## Introduction

The artificial urinary sphincter (AUS) is currently the gold standard device for the treatment of stress urinary incontinence (SUI) in men [1]. Although highly effective, it is an invasive procedure associated with a risk of known complications, which if occur may be associated with significant morbidity. As a result, bulbo-urethral slings were designed as an alternative to artificial urinary sphincters in the treatment of male SUI. Furthermore, it has been described that when given a choice, patients with SUI opt for less invasive treatment options over the AUS [2].

In 2007 Rehder and Gozzi developed the novel AdVance Transobturator Male Sling [3] (American Medical Systems, Minnetonka, MN, USA). It is a precut polypropylene monofilament mesh that is placed retrourethraly under the proximal part of the urethral bulb, passing bilaterally through the obturator fossae.

In this chapter, we will discuss the mode of action, preoperative patient selection and evaluation, surgical technique, postoperative care, outcomes, complications, and salvage maneuvers, regarding utilization of the AdVance Transobturator Retrourethral Male Sling in the treatment of male stress urinary incontinence.

---

## Mode of Action

There are several theories as to how the AdVance sling achieves continence. It is thought to compensate for the post-prostatectomy laxity of posterior supporting structures [4], essentially realigning the anatomy of the urethral sphincter complex toward

---

O.A. Suárez (✉)

Hospital San José Tecnológico de Monterrey, Urología TecSalud, Av Morones Prieto 3000 Poniente, Los Doctores, 64710 Monterrey, N.L., Mexico  
e-mail: [osuarezfl@gmail.com](mailto:osuarezfl@gmail.com)

A.S. Chung • K.A. McCammon

Eastern Virginia Medical School, 225 Clearfield Avenue, Virginia Beach, VA 23462, USA

© Springer International Publishing AG 2017

A. Singla, C. Comiter (eds.), *Post-Prostatectomy Incontinence*,  
DOI 10.1007/978-3-319-55829-5\_6

the normal, pre-prostatectomy configuration. Once the sling is appropriately tensioned, the urethral bulb relocates a distance of 3–4 cm proximally into the pelvis [3]. This realignment of the urethra is believed to improve the function of the external sphincter. Moreover, the sling provides support to the dorsal distal portion of the membranous urethra, which acts as a backstop during stress. In addition, it produces an elongation of the functional sphincteric or membranous urethra. This essentially expands the zone of coaptation of the sphincter mechanism, thereby improving its effectiveness [4]. In the original cadaver series, it was reported that the functional membranous urethral length increased from a mean of 3 mm (0–7 mm) to 17.2 mm (10–22 mm) [3].

In contrast to other slings, all these are achieved without causing any urethral obstruction. Rather, “dynamic compression” has been observed on ultrasound study [5]. Davies et al. studied 13 patients who underwent AdVance sling placement for post-prostatectomy incontinence (PPI) [6]. Every patient had urodynamic testing at baseline and 6 months postoperatively. The valsalva leak point pressure improved significantly (29.3 cm H<sub>2</sub>O to 46.6 cm H<sub>2</sub>O,  $P = 0.32$ ). However, the detrusor voiding pressure (Pdet) at peak urinary flow rate (Qmax), postvoid residual urine volume (PVR), and maximal and average flow rates remained relatively unchanged. Similarly, Soljanik et al. [7] compared preoperative and postoperative urodynamic parameters on 55 patients with post-prostatectomy incontinence (PPI). Only the abdominal leak point pressure (ALPP) changed significantly (61–79 cm H<sub>2</sub>O,  $P = 0.001$ ) in patients who still had urine leakage postoperatively. ALPP was not measured postoperatively in patients with no urine loss. At the time of urodynamic assessment, no patient showed PVR > 30 mL, de novo reduced bladder compliance, or de novo under- or overactivity. On bladder outlet obstruction index evaluation (BOOI), 63.6% of patients were not obstructed (BOOI < 20), 34.5% had equivocal voiding (BOOI 20–40), and only one patient who preoperatively showed bladder outlet obstruction remained obstructed (BOOI = 54).

---

## Patient Selection and Evaluation

The AdVance sling is best suited for men with mild-to-moderate stress urinary incontinence. It has mainly been proven successful in the context of PPI; nonetheless, it can also be of benefit in other causes of male SUI.

It is our practice to evaluate every patient with a cystourethroscopy to rule out a bladder neck contracture, prior to insertion of an AdVance sling. We strongly advise to treat and stabilize any pre-existent bladder neck contracture before placement of a sling. Urodynamic testing is very important as well, as detrusor underactivity may increase the risk of urinary retention [8]. Valsalva voiders have a higher risk of loosening the sling in the future. Furthermore, a number of post-prostatectomy patients experience overactive bladder, and we have found detrusor overactivity to be a negative predictive factor of success [9]. It is good practice to ascertain the degree with which mixed urinary incontinence may be improved with anticholinergic medication, prior to embarking on invasive surgical intervention for the stress urinary component.

Some urological surgeons advocate that it is important to evaluate the degree to which the posterior urethra may ultimately be repositioned. This, “repositioning test” is based on the finding that ALPP increases upon gently pushing the perineal perineum in a cephalad position, taking care not to compress the urethral bulb [10]. This can also be demonstrated cystoscopically, noting a visible sphincter closure upon perineal elevation in men with sufficient residual sphincter function, which has been shown to predict success [11]. It has been suggested that for better outcomes, the zone of coaptation in the sphincteric urethra should be at least 5–10 mm prior to treatment [12]. Fluoroscopic demonstration of bladder neck and proximal urethral descent is an alternative to the repositioning test. Patients with adequate urethral mobility are found to be the most appropriate candidates [13].

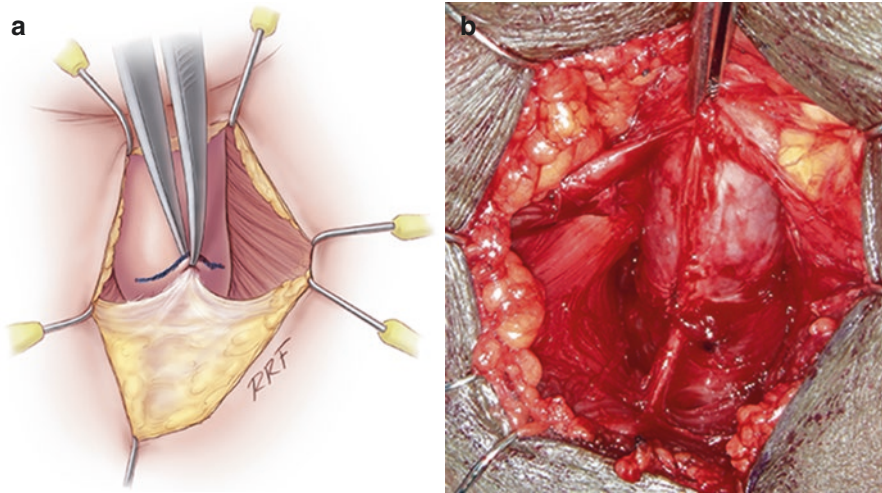
Patients with prior pelvic radiation are not good candidates for sling placement [5]. Although inconsistently reported in the literature, we believe radiation may limit urethral mobility, preventing adequate proximal urethral relocation [9]. It may also inhibit tissue healing and mesh ingrowth. Torrey et al. reported that no patients were cured and only 29% were improved if men had undergone radiation therapy prior to sling placement, versus 63% cure rate and 27% improvement in non-radiated men [14]. We have had similar results in a cohort of 102 patients, reporting significantly more patients without a history of radiation were dry at a follow-up of 12 months (44% versus 26%) [9]. For this reason we advise patients with a history of radiation who elect sling placement to expect worse outcomes.

Male neurogenic bladder patients with SUI can also be candidates for AdVance sling placement with encouraging results [15]. These patients must be carefully evaluated to rule out low compliance and detrusor overactivity, conditions that must be treated adequately beforehand for better results. In the case of prepubertal patients, the needles must be used carefully to avoid injury to the rectum. It should be explained to patients that they may experience difficulty performing clean intermittent self-catheterization, which usually resolves after changing the type of catheter. It is of utmost important that these patients with neurogenic bladder and an AdVance sling be committed to intensive follow-up to monitor for signs of renal and bladder deterioration.

---

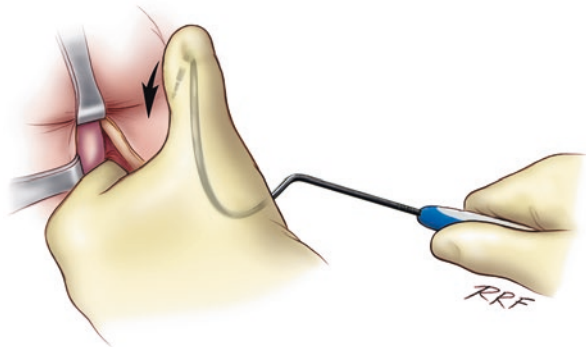
## Surgical Technique

The patient is placed in the dorsal lithotomy position with the knees approximately shoulder width apart and bent no more than 90°. After a standard surgical prep, a midline perineal incision approximately 5 cm in length is made. The dissection is carried through the subcutaneous tissue to the bulbospongiosus (BS) muscle. The BS muscle is opened in the midline to expose the corpus spongiosum (CS), which is mobilized distally, laterally, and inferiorly to the central tendon. Prior to dissecting the central tendon off the CS, the area is marked either with an absorbable stitch or a marking pen. The central tendon is easily identified and then dissected off the CS until it is no longer palpable (Fig. 1a, b). The reason to mobilize the central tendon off the CS is to increase its mobility.



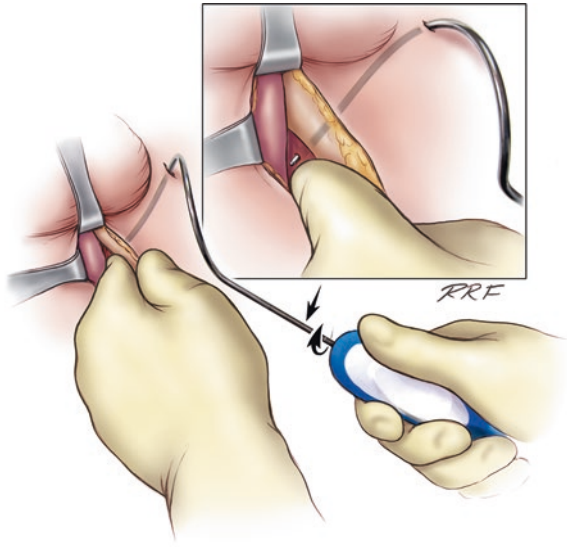
**Fig. 1** (a, b) Identification of the central tendon after corpus spongiosum mobilization

**Fig. 2** The AdVance helical needle is held at 45° angle to the patient and placed straight through the incision with the assistance of the contralateral thumb

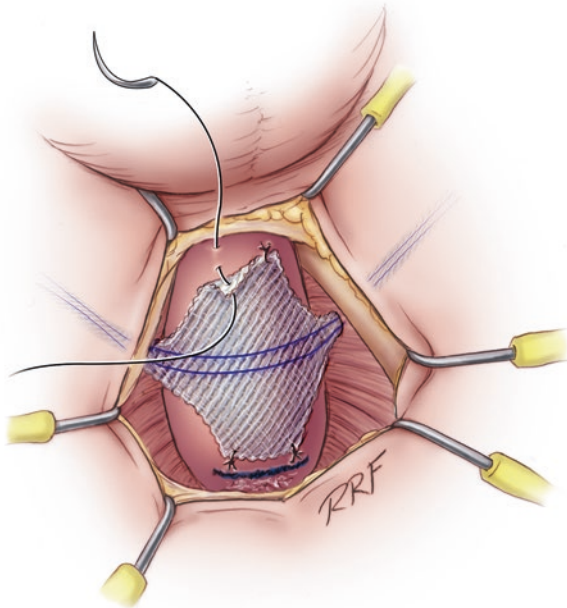


An incision is made approximately 1–2 cm below the adductor longus tendon and lateral to the ischiopubic ramus. The proper site is usually easily palpable, but a spinal needle may be used to identify the area of insertion. A small incision is made for the needle entry. The AdVance helical needle is held at 45° angle and placed straight through the incision (Fig. 2). A finger is placed in the incision below the ischiopubic ramus to protect the urethra and guide needle placement. Two “pops” are felt, and after the second “pop,” the needle is turned approximately a quarter turn. The needle is palpable on the physician’s finger. Prior to bringing the needle through the fascia, the surgeon’s hand is dropped, and the needle is brought out as high as possible in the triangle between the ischiopubic ramus and the urethra (Fig. 3). The mesh is secured to the needle and then brought back through the incision. This needle pass is repeated on the opposite side. The central portion of the mesh is fixed to the CS with the proximal aspect of the mesh being fixed at the level

**Fig. 3** The AdVance needle is passed as high as possible in the triangle between the ischiopubic ramus and the corpus spongiosum



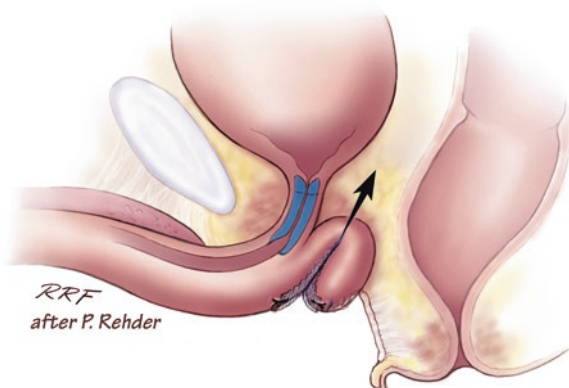
**Fig. 4** The mesh is fixed to the corpus spongiosum with four sutures, two proximal and two distal. Note that the proximal aspect of the mesh is fixed at the level of our previous mark where the central tendon was taken down



of our previous mark where the central tendon was taken down. If this area was lost accidentally, we can place a urethral catheter, and the site where it makes a turn into the proximal bulbar urethra is a safe location to place the proximal aspect of the mesh. Two sutures are placed proximally and two distally (Fig. 4).



**Fig. 5** Coaptation of the urethra after tensioning of the sling



Tensioning of the sling is done by pulling firmly on both arms of the sling (Fig. 5). Cystourethroscopy is performed to confirm coaptation of the external sphincter and to rule out any urethral injury. If no coaptation is identified, this is usually because the sling has been placed too proximal. The four sutures are removed, and the sling is repositioned approximately 0.5–1.0 cm distally. Once coaptation is confirmed, the muscle is closed as well as the subcutaneous tissues. A 14 Fr. Foley catheter is placed and left overnight. The outer covering of the mesh is removed, and although the sling is self-anchoring, the mesh is tunneled back to the midline incision with the aid of a tonsil clamp to reduce the risk of slippage of the mesh. Some have proposed to fix both ends of the sling by making a second incision beneath the first one, thereby anchoring the ends of the sling subcutaneously at a 90° angle [10]. Finally, the perineal incision is closed in the standard fashion taking care to re-approximate the BS muscle. Both trocar incisions can be closed with a simple interrupted stitch.

## Postoperative Care

The Foley catheter is removed the next morning. If the patient is unable to void, the catheter is replaced, and a voiding trial is attempted in approximately 1 week. If the retention lasts longer than 1 week, a voiding trial is attempted again in 5–7 days. Sometimes the catheter needs to be placed over a wire with the assistance of a cystoscope. The patient can also start clean intermittent catheterization. In the rare patient with retention >6 weeks, the sling can be removed with the patient returning to his previous status.

Most patients experience minimal postoperative pain and may want to return to normal activity as soon as possible. However, it is imperative that the patient follows the postoperative instructions, which include refraining from strenuous activity, lifting greater than 15 lbs, and squatting or climbing for at least 6 weeks. If not, patients will have a major risk of loosening the sling. Neurogenic bladder patients, especially those with impaired mobility, must be careful of physically exerting themselves during transfers.

In patients not continent after AdVance sling placement who might have done something in the first 6 weeks which loosened the sling, a repeat sling can be performed. In those patients, re-exploration through the previous incision is done. The BS muscle is opened and the CS is identified. Once the CS is identified, dissection is carried proximally until the top edge of the mesh is palpable. The arms are then identified laterally with a right angle clamp. These are transected (this allows the bulb of the CS to be pulled toward the surgeon). The broad portion of the mesh, which was attached to the CS, is then excised. Another sling is then placed as described above.

---

## Outcomes

As the definition of success and improvement varies among different studies, a real comparison of outcomes is difficult. In spite of this, since the introduction of the AdVance sling, different centers have published promising and successful results. In their original study, Rehder and Gozzi reported a cure rate of 40% and an improved rate of 30% [3]; however as experience has accumulated, success rates have improved significantly. We recently published our results on a cohort of 102 patients with a minimum follow-up of 12 months [9]. Success at 12 months and 24 months of follow-up were 74% and 63% (43% cured and 20% improved). Even though cure rates declined over time, 40% of patients remained dry at final follow-up (36 months). Similarly, Rehder et al. [16] reported a cure rate of 53% and a failure rate of 27% at a 3-year follow-up on a study of 156 men. Likewise, Kowalik et al. [17] reported a cure rate of 60%, an improved rate of 13%, and a failure rate of 27% in a series of 30 patients. Interestingly, these authors also studied subjective outcomes comparing IIQ and UDI scores preoperatively and at a 3-year follow-up. No patients had worsening of IIQ or UDI scores, and 83% of men reported lower scores, indicating improvement. When asked to report a percentage improvement from baseline urinary symptoms, 77% of men reported a >85% overall improvement in their urinary symptoms.

---

## Complications

The AdVance sling is a minimally invasive treatment with minimal intraoperative and postoperative complications, both in number and severity. The main potential intraoperative complication is a urethral injury during trocar passage. We have seen this in only two patients early in our experience. Urinary retention is the most common early postoperative complication with widely variable ranges reported from 0% to 30% [9, 17, 18]. Nonetheless, the risk of long-term urinary retention is minimal as showed by Bauer et al. [18] who reported that all their patients with acute urinary retention, except one, had a successful voiding trial within 12 weeks. Other early postoperative complications include minor wound infection, urinary tract infections, transient mild perineal discomfort, and dysuria. There has been only a single case report of urethral mesh erosion, and this was in a patient with prior radiation [19]. Most series do not report explantation of the sling.

## What to Do After a Failed AdVance Sling

Following sling surgery, recurrence of incontinence ranges from 20% to 35% [13]. Fortunately, patients who suffer from persistent incontinence after sling placement have different options to consider. Before any additional treatment, it is important to evaluate whether recurrent or persistent incontinence represents sphincter dysfunction and no detrusor overactivity or another etiology. Reoperation is only indicated for those with recurrent or persistent SUL.

The AUS is the procedure of choice after a failed primary sling. Up to 13% of men will ultimately have implantation of an AUS after male sling surgery [20]. In general AUS placement in this situation has a success rate of 80–90% [21, 22]. Lentz et al. retrospectively reviewed their outcomes in a cohort of 29 patients and compared them with a control group after a virgin AUS procedure [22]. The AdVance sling was left in situ for all salvage AUS procedures. At the 3-month follow-up visit, 28 of 29 patients were using a pad or less per day. At an average 20.7-month follow-up in the salvage group, the revision rate was 6.9%, and no patient developed an infection. One erosion did occur at 11 months, but on explant, the device was deemed sterile. Outcomes after the salvage AUS compared favorably with the control group both in terms of success and required revisions.

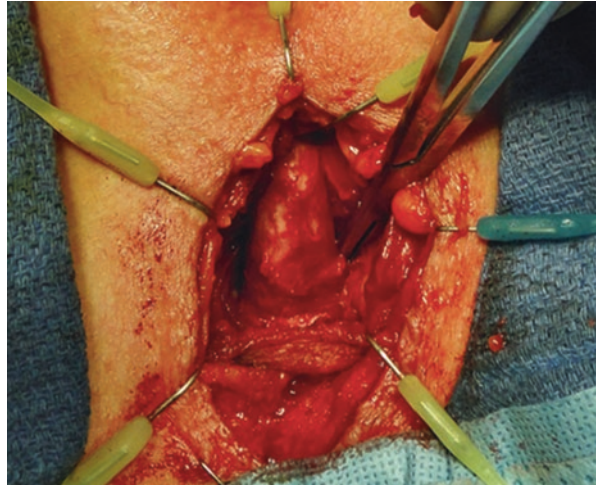
Periurethral bulking agents can be injected at the area of coaptation in patients with minimal persistent incontinence. We have had good results injecting Macroplastique® (Uroplasty, Inc., Minnetonka, MN, USA) in this population.

Another option to consider, although not available in the USA, is ProACT™ balloons (Uromedica, Inc., Plymouth, MN, USA). Al-Najar et al. used the ProACT™ system in ten patients who had persistent incontinence after their sling. All ten of these patients were pad free with a mean follow-up of 6 months (range 3–9) [23].

We have also attempted a repeat sling with encouraging results, especially in those with late failures [24]. We reviewed 18 patients who underwent a salvage AdVance sling placement at our institution. Overall success was 72% at 6 months and 56% at a mean follow-up of 17.5 months. Patients who failed late after their primary sling (>6 months) had better outcomes with salvage sling placement compared with patients who failed earlier after the primary sling (75% vs 30%;  $P = 0.031$ ). We believe this was probably because patients who failed later were initially better candidates for sling placement than their counterparts.

The surgical procedure to insert a repeat AdVance sling is not much different than the initial procedure. In starting the dissection, we have found it easier to start further distal on the corpus spongiosum. Doing this allows us to start our surgery in a virgin plane. We also free up the corpus spongiosum slightly more than normal. Once the distal aspect of the sling is identified, we are able to place a right angle clamp around the sling and transect the arms. This maneuver allows the corpus spongiosum to move toward the surgeon (Fig. 6). At this point we will excise the previous sling off the spongiosum. This is usually difficult and we frequently enter the spongiosum; however, we have not injured the urethra during the dissection. The spongiosum is closed with an absorbable stitch, and the procedure is completed. The needles are passed as previously described, and the sling is placed usually

**Fig. 6** A right angle clamp is placed around the sling arm. This facilitates transection of the arms allowing movement of the corpus spongiosum



slightly distal to the first sling. Our complication rate after salvage sling placement was low [24]. Urinary retention was seen in 17% of patients. One patient had the sling removed for persistent retention, and another sling was removed because of a surgical site infection.

Soljanik et al. have also published their outcomes regarding the use of a salvage AdVance sling after a failed initial transobturator sling. They described 35 patients treated with salvage slings at their institution. In contrast to our series, all the original slings were left in situ, and none prohibited placement of the salvage sling in the traditional location. At a mean follow-up of 16.6 months, 89% of patients were considered treatment successes, including 72.4% who were dry and 13.7% who used two pads per day [25].

## AdVance XP

In 2010 the second generation of the AdVance sling, the AdVance XP, was marketed. This sling has the following innovations: updated mesh waves with integrated tensioning fibers to stabilize sling configurations upon implantation; the addition of chevron anchors on the sling arms, which are intended to provide enhanced acute tissue fixation of the sling arms; increased sling arm length; Tyvek liners to prevent the chevrons from tearing the plastic sheath; and redesigned helical needles to allow easier tunneling especially in patients with large body habitus.

Bauer et al. reported a 73% cure rate at a 2-year follow-up using very strict cure definitions (no pads and 0–5 g in the 24 h pad test) [26]. The only unique intraoperative problem reported in this study was difficulty removing the Tyvek liners in a few cases, which resulted in over tensioning of the AdVance XP sling. The rate of complications was similar to that in the original AdVance sling series, and no explantation of the sling was required.

Although available in some countries, this product is not FDA approved in the USA, and a comparison study would be required to ascertain whether this is a better treatment option than the original AdVance sling.

### Conclusions

The AdVance Transobturator Male Sling is a valuable minimally invasive option for the treatment of stress urinary incontinence in males. It has been shown to be safe and efficacious in the treatment of men with mild-to-moderate stress urinary incontinence, particularly in the post-prostatectomy cohort, with cure rates ranging from 40% to 70%. Several theories exist regarding the mode of action of the sling in effecting continence, including relocation of the bulbar urethra, and lengthening of the functional sphincteric or membranous urethra, as well as dynamic compression, without urethral obstruction. Preoperative patient selection and evaluation is important. The most common postoperative complication is urinary retention which is usually transient. Recurrent stress urinary incontinence can be managed by repeat sling insertion in selected cases. Furthermore, an artificial urinary sphincter can always be inserted without difficulty and good postoperative outcomes.

### References

1. Suarez OA, McCammon KA. The artificial urinary sphincter in the management of incontinence. *Urology*. 2016;92:14–9.
2. Kumar A, Litt ER, Ballert KN, Nitti VW. Artificial urinary sphincter versus male sling for post-prostatectomy incontinence—what do patients choose? *J Urol*. 2009;181:1231–5.
3. Rehder P, Gozzi C. Transobturator sling suspension for male urinary incontinence including post-radical prostatectomy. *Eur Urol*. 2007;52:860–7.
4. Ridder DD, Rehder P. The AdVance® male sling: anatomic features in relation to mode of action. *Eur Urol*. 2011;10:383–9.
5. Habashy D, Losco G, Tse V, Collins R, Chan L. Mid-term outcomes of a male retourethral, transobturator synthetic sling for the treatment of post-prostatectomy incontinence: impact of radiotherapy and storage dysfunction. *Neurourol Urodyn*. 2016; doi:[10.1002/nau.23078](https://doi.org/10.1002/nau.23078).
6. Davies OD, Bepple JL, McCammon KA. Urodynamic changes and initial results of the AdVance male sling. *Urology*. 2009;74:354–8.
7. Soljanik I, Becker AJ, Stief CG, Gozzi C, Bauer RM. Urodynamic parameters after retourethral transobturator male sling and their influence on outcome. *Urology*. 2011;78:708–14.
8. Comiter CV. Surgery insight: surgical management of post-prostatectomy incontinence: the artificial urinary and male sling. *Nat Clin Pract Urol*. 2007;4:615–24.
9. Zuckerman JM, Edwards B, Henderson K, Beydoun HA, McCammon KA. Extended outcomes in the treatment of male stress urinary incontinence with a transobturator sling. *Urology*. 2014;83:939–45.
10. Bauer RM, Mayer ME, Gratzke C, Soljanik I, Buchner A, Bastian PJ, et al. Prospective evaluation of the functional sling suspension for male postprostatectomy stress urinary incontinence: results after 1 year. *Eur Urol*. 2009;56:928–33.
11. Bauer RM, Gozzi C, Roosen A, Khoder W, Trottmann M, Waidelich R, et al. Impact of the ‘repositioning test’ on post-operative outcome of retroluminal transobturator male sling implantation. *Urol Int*. 2013;90:334–8.

12. Rehder P, Freiin von Gleissenthall G, Pichler R, Glodny B. The treatment of postprostatectomy incontinence with the retroluminal transobturator repositioning sling (AdVance): lessons learnt from accumulative experience. *Arch Esp Urol*. 2009;62:860–70.
13. Comiter CV, Dobberfuhr AD. The artificial urinary sphincter and male sling for postprostatectomy incontinence: which patient should get which procedure? *Investig Clin Urol*. 2016;57:3–13.
14. Torrey R, Rajeshuni N, Ruel N, Muldrew S, Chan K. Radiation history affects continence outcomes after AdVance transobturator sling placement in patients with post-prostatectomy incontinence. *Urology*. 2013;82:713–7.
15. Groen LA, Spinoit AF, Hoebeke P, Van Laecke E, De Troyer B, Everaert K. The AdVance male sling as a minimally invasive treatment for intrinsic sphincter deficiency in patients with neurogenic bladder sphincter dysfunction: a pilot study. *Neurourol Urodyn*. 2012;31:1284–7.
16. Rehder P, Haab F, Cornu JN, Gozzi C, Bauer RM. Treatment of postprostatectomy male urinary incontinence with the transobturator retroluminal repositioning sling suspension: 3-year follow-up. *Eur Urol*. 2012;62:140–5.
17. Kowalik CG, DeLong JM, Mourtzinou AP. The AdVance transobturator male sling for post-prostatectomy incontinence: subjective and objective outcomes with 3 years follow up. *Neurourol Urodyn*. 2015;34:251–4.
18. Bauer RM, Mayer ME, May F, Gratzke C, Buchner A, Soljanik I, et al. Complications of the AdVance transobturator male sling in the treatment of male stress urinary incontinence. *Urology*. 2010;75:1494–8.
19. Harris SE, Guralnick ML, O'Connor RC. Urethral erosion of transobturator male sling. *Urology*. 2009;73:443 e19.
20. Kim PH, Pinheiro LC, Atoria CL, Eastham JA, Sandhu JS, Elkin EB. Trends in the use of incontinence procedures after radical prostatectomy: a population based analysis. *J Urol*. 2013;189:602–8.
21. Belot PY, Fassi-Fehri H, Crouzet S, Coda R, Badet L, Gelet A, et al. Treatment of stress urinary incontinence after prostate surgery: results of the artificial urinary sphincter after suburethral sling failure. *Prog Urol*. 2012;22:644–9.
22. Lentz AC, Peterson AC, Webster GD. Outcomes following artificial sphincter implantation after prior unsuccessful male sling. *J Urol*. 2012;187:2149–53.
23. Al-Najar A, Kaufmann S, Boy S, Naumann CM, Junemann PK, Van Der Horst C. Management of recurrent post-prostatectomy incontinence after previous failed retrourethral male slings. *Can Urol Assoc J*. 2011;5:107.
24. Martinez EJ, Zuckerman JM, Henderson K, Edwards B, McCammon KA. Evaluation of salvage male transobturator sling placement following recurrent stress urinary incontinence after failed transobturator sling. *Urology*. 2015;85:478–82.
25. Soljanik I, Becker AJ, Stief CG, et al. Repeat retrourethral transobturator sling in the management of recurrent postprostatectomy stress urinary incontinence after failed first male sling. *Eur Urol*. 2010;58:767–72.
26. Bauer RM, Gozzi C, Klehr B, Kretschmer A, Grabbert M, Rehder P, et al. AdVanceXP male sling: 2-year results of a multicenter study. *World J Urol*. 2016;34:1025–30.

---

# The Virtue™ Quadratic Sling for Post-prostatectomy Incontinence

Craig V. Comiter

---

## Introduction

The most common cause of stress urinary incontinence (SUI) in men is iatrogenic injury during prostate cancer surgery. Contemporary cohort studies generally report that 8–12% of patients will have enough leakage post-operatively to seek treatment [1–8]. But SUI can also affect men who have not had surgery for prostate cancer, occurring at a baseline prevalence of 1.3–4.8% [9, 10]. In addition, men with prostate cancer who choose radiation therapy, androgen ablation, or even watchful waiting also develop urinary incontinence, recently reported at rates of up to 12%, 11%, and 3%, respectively [11, 12].

Active conservative management is indicated for the first 6–12 months, and if bothersome incontinence persists, consideration should be given to surgery, based upon a thorough evaluation of storage function, bladder contractility, and sphincteric integrity. Unfortunately, pharmacotherapeutic agents for managing male stress incontinence have not been efficacious nor have they been approved by the FDA. And while pelvic floor exercises instituted prior to radical prostatectomy can facilitate the earlier return to continence following surgery [13, 14], the success of pelvic floor physiotherapy for increasing overall continence long-term post RP has not been well established. Urethral bulking agents may be considered for mild urinary leakage. However, success rates are generally low, with fewer than half of patients achieving satisfactory continence [15].

---

C.V. Comiter

Department of Urology, Stanford University School of Medicine,  
300 Pasteur Drive, Room S-287, Stanford, CA 94305-5118, USA  
e-mail: [ccomiter@stanford.edu](mailto:ccomiter@stanford.edu)

---

## Artificial Urinary Sphincter

Over the past decade, implantation of the artificial urinary sphincter (AUS) and male sling surgery have become recognized as the procedures of choice for managing SUI after prostatectomy due to intrinsic sphincter deficiency (ISD). Despite providing excellent success rates for all degrees of SUI, the AUS is associated with an infection/erosion rate of 1–6% and a revision rate of 20% at 5 years [16, 17]. The recent search for safer, less invasive, less expensive, and less complicated devices has led to the development of various male sling procedures. Moreover, when patients are offered sling *or* AUS, the vast majority will opt for sling placement. Kumar et al. demonstrated that 88% of men chose sling surgery when given a choice and that even in men in whom AUS placement was recommended by the urologist, 25% still opted for a sling. The primary reasons were the desire to avoid a mechanical device and to be able to void spontaneously without manipulation [18]. Others may lack the mental faculties or manual dexterity to cycle the AUS. Finally, mild or moderate incontinence may not warrant AUS implantation—for those patients, sling may be most appropriate [19].

---

## Male Slings

Unlike the AUS, most slings apply compression to the ventral urethra only, combining effective continence with spontaneous and efficient voiding. Whether a sling is adjustable or not, the principles of successful surgery are based upon the following: (1) sufficient sling tension is needed for restoration of continence; (2) bladder emptying is optimized when implants do not significantly obstruct outflow in the presence of adequate detrusor contractility; and (3) adequate sling fixation is necessary for maintenance of efficacy.

### Bulbourethral Sling

There are several slings that are currently used for male SUI, each evolving from a predicate device. After the Kaufman prostheses fell out of favor in the 1970s, Schaeffer, et al. described a novel bulbourethral sling procedure in 1998, using bolsters placed beneath the bulbar urethra, which were suspended by sutures from the rectus fascia. Despite initially favorable results (41% cure, 53% pad free, 21% revision, and 6% bolster removal rate), this technique has not been reported beyond the single institution study [20].

### Bone Anchored Male Sling

The InVance™ (American Medical Systems, Minnetonka, MN) bone anchored male sling (BAMS) represented a major improvement in technique, minimizing invasiveness via a purely perineal approach: a silicone-coated polyester sling is



secured to the descending pubic rami via titanium bone screws. Success rates are generally 70–80%, with nearly two-thirds of patients achieving pad-free status. Infection and erosion rates are generally low, and revision due to bone anchor dislodgement is similarly uncommon (4%). However, bothersome perineal pain has been reported in approximately (16%) of patients for weeks [21]. Finally, concern regarding the potential risk of bony complications (osteitis and osteomyelitis), the expense of bone anchors, and the common occurrence of bothersome perineal pain has contributed to the quest for alternative sling techniques. The BAMS has been removed from the market and is no longer available for implantation.

## Transobturator Perineal Sling

In contrast to the bone-anchored sling, which appears to provide bulbar urethral compression, the transobturator sling (AdVance™ American Medical Systems) is thought to improve continence by shifting the membranous urethra proximally and repositioning the sphincteric zone back into the pelvis. Whereas this sling only nominally compresses the bulbar urethra, its main mechanism of action relies upon proximal urethral relocation. It is hypothesized that inefficacious coaptation of the urethral sphincter complex results from laxity of posterior urethral support and relative misalignment of the proximal urethra [22]. A transobturator sling that restores the pre-prostatectomy configuration by realigning the mobile sphincter complex can remedy this proximal urethral descent. Following appropriate sling tensioning, the bulbar urethra is relocated proximally, by a distance of 2–3 cm, into the higher pressure pelvic outlet, functioning as a “backstop” during straining [23].

Success rates from prospective series range from 54 to 80%, with cure rates generally around 50% [24–26]. Transient urinary retention has been reported in 3–23%, typically resolving by 12 weeks [27]. Perineal pain rates vary widely from 0 to >20%, depending on the definition of postoperative pain [28–30], but most reports show significant pain in <10% which resolves by 3 months postoperatively. Serious complications requiring sling explantation are generally <1% [27]. The transobturator sling has shown excellent efficacy and safety but is generally limited to those men with <200 g/day of urine leakage, often considered “mild-to-moderate” incontinence, and has shown poor efficacy in those with more severe leakage [31, 32].

## Adjustable Bulbourethral Sling

Outside the United States, the Argus™ (Promedon, Cordoba, Argentina) adjustable pubourethral sling [33] and the REMEEX™ (Neomedic, Barcelona, Spain) bulbourethral sling [34] and the ATOMS™ (AMI, Feldkirch, Austria) transobturator sling [35] have demonstrated efficacy rates similar to that of the nonadjustable slings. The potential advantage of these devices is that in the event of suboptimal sling tensioning intraoperatively, tightening of the sling may be accomplished through a

**Fig. 1** Virtue™ male sling. The four arms are covered with polyethylene sleeves. Extending from the ends of each arm are braided polyester sutures, which allow for attachment to the introducer and facilitate positioning of the sling in situ



minimally invasive “readjustment” technique. Despite the use of frequent postoperative adjustments, overall continence rates do not appear to be higher than that of the nonadjustable slings. In addition, complication and reoperation rates are generally higher than that of the nonadjustable slings [36–39].

### Quadratic (Virtue™) Sling

The newest iteration of the male sling is a hybrid device, combining urethral relocation with ventral urethral compression. The Virtue™ male sling (Coloplast, Humlebaek, Denmark) is designed to provide a broad area of urethral compression *and* to achieve proximal relocation of the membranous urethra. Quadratic fixation is achieved with both trans-obturator (TO) and prepubic (PP) components. The Virtue™ sling is a synthetic suburethral mesh of knitted, monofilament polypropylene that measures 5.5 × 7 cm, with 1.5 × 25 cm superior extensions and 1.5 × 22.5 cm inferior extensions (Fig. 1).

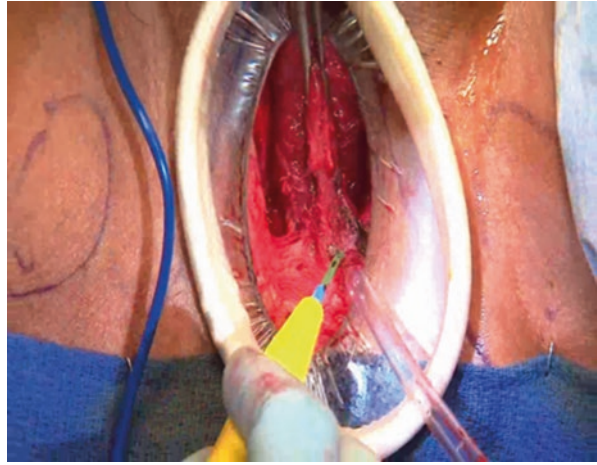
### Perineal Dissection

The patient is sterilely prepared and draped and positioned in dorsal lithotomy, with the anus covered and isolated from the surgical field. A 14F catheter is placed to help identify the urethra, and a 5 cm vertical midline perineal incision is centered over the bulbous urethra. The urethra and descending pubic rami are exposed bilaterally, while leaving the bulbospongiosus muscle intact. Using sharp dissection, the bulbous urethra is partially detached from the central tendon to the perineal body, thereby allowing ventral urethral elevation (Fig. 2).

### Transobturator Semilunar Trocar Passage

The Virtue™ male sling comes packaged with a single, bidirectional, semilunar trocar that is used to pass both the transobturator and prepubic arms of the quadratic sling. The suture of the posterior arm of the sling must be looped onto the end of the

**Fig. 2** Dissection of the bulbous urethra off the central tendon of the perineum



semilunar trocar. For the TO arms of the sling, the trocars are passed in an in-to-out fashion, from the perineal incision out through groin stab incisions. The semilunar trocar is then passed using the surgeon's dominant hand from the perineal wound, at the 10 and 2 o'clock position behind on the patient's right and left inferior pubic rami respectively. The trocar tip should exit from the groin approximately 2–3 cm inferior to the insertion of the adductor longus tendon. Skin overlying the trocar tip is incised and the tip of the trocar and attached suture are exposed. The arm of the sling is pulled out through the groin incision.

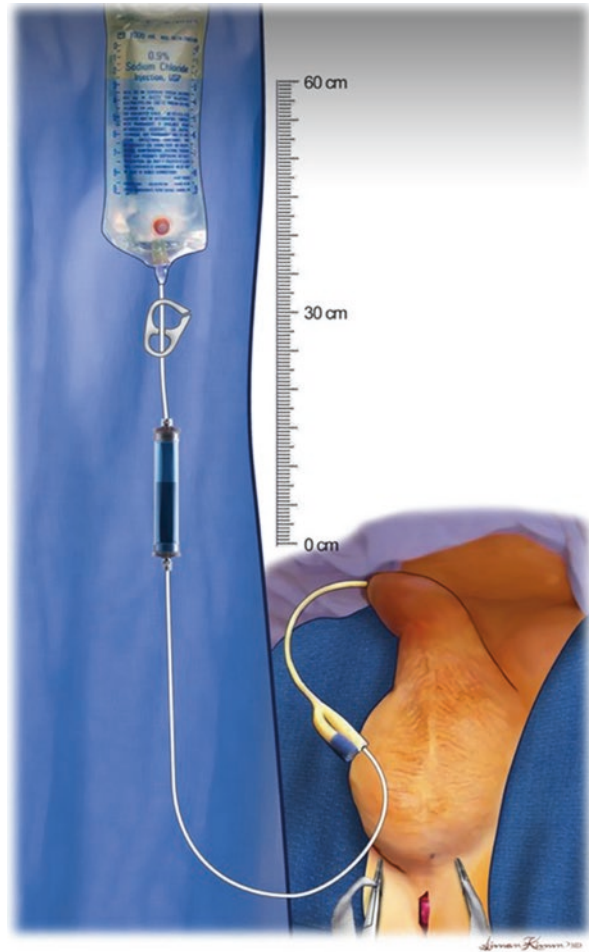### Prepubic Semilunar Trocar Passage

The semilunar trocar for the PP arms of the Virtue® sling is passed in an out-to-in fashion. Pubic skin incisions are made 2–3 fingerbreadths from lateral to midline overlying the pubic symphysis. Local anesthetic is infiltrated. The semilunar trocar is then passed using the surgeon's dominant hand from the pubic incision, anterior to the pubic bone and lateral to the spermatic cord, out through the perineal incision. Perineal incision may be retracted cephalad using a retractor assist with trocar passage. The suture loops from the prepubic arms are then attached to the ends of the semilunar trocar, and the PP extensions of the sling are passed out through the pubic incision.

### Sling Tensioning

Sling arms are then progressively and symmetrically tensioned such that the transobturator arms elevate the bulbar urethra by 2–3 cm, and the prepubic arms provide compression of the bulbar and membranous urethra. Concurrent with sling tensioning, a retrograde leak point pressure is obtained by inserting a small catheter into the fossa navicularis and then connecting this to a bladder irrigation tubing with a drip chamber set at a water height of 60 cm above the pubic symphysis. Once ready to tension, the irrigation tubing is then opened and progressive sling tension is applied to the transobturator arms until the drip chamber flow starts to slow. Slow progressive tension is then applied to the prepubic arms until the drip chamber flow completely stops, indicating that a retrograde leak point pressure of 60 cm water has been achieved (Fig. 3).

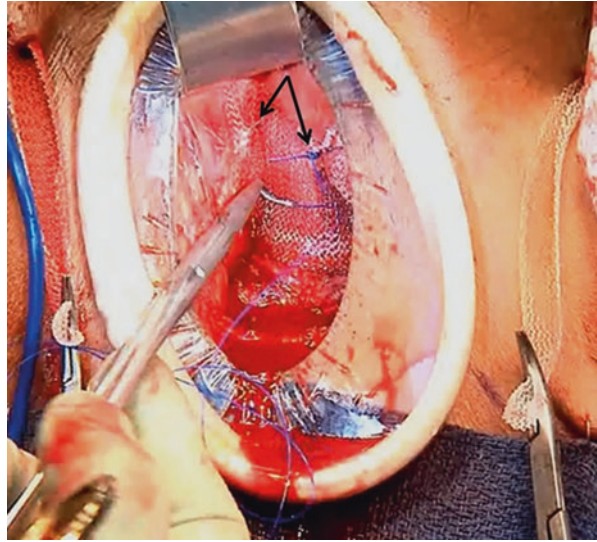
**Fig. 3** Measurement of retrograde leak point pressure



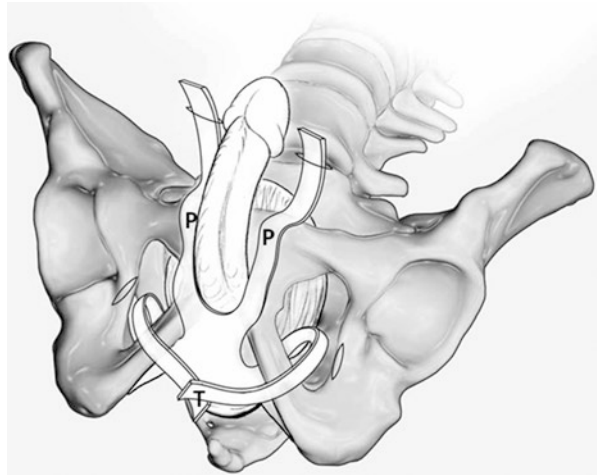
### Sling Arm Fixation

Once the appropriate retrograde leak point pressure has been achieved, full tension is placed along the prepubic arms, and then the distal aspect of the sling adjacent to the prepubic arms is secured to the underlying periosteum of the inferior pubic rami using a 2-0 Prolene permanent monofilament suture (Fig. 4). The TO arms are then tunneled subcutaneously back through the perineal incision using a hemostat. Tension is placed along the transobturator arms, retrograde leak pressure of 60 cm water is confirmed, and then the overlapping transobturator arms are fixed to each other in midline using 2-0 Prolene and excess sling arms transected (Fig. 5). Likewise, for the prepubic arms, once properly fixated, the plastic sleeves of the prepubic arms are removed and the arms trimmed at skin level. Incisions are then irrigated and closed in multiple layers. If the surgeon believes there is insufficient tension to achieve adequate continence (RLPP <60 cm water), then the central portion of the sling may be plicated using permanent monofilament suture to provide additional compressive effect.

**Fig. 4** The suprapubic arms are tensioned and secured to the periosteum of the pubic bone (*arrow indicates site of suture placement*)



**Fig. 5** Fixation of the prepubic arms and the transobturator arms maintains tension and efficacy



## Postoperative Care

All wounds should be copiously irrigated with antibiotic solution. The stab wounds are then closed, and the perineal wound is closed in multiple layers. A 14 F catheter should be left in for 2 days, followed by a trial of voiding. Patients are advised to avoid lifting objects heavier than 10 pounds for at least 6 weeks following surgery. They should also refrain from strenuous activity that might place excess stress on the perineum, including the avoidance of running, squatting, bicycle riding and sexual activity.

## Complications

### Intraoperative Complications

#### Urethral Injury

Urethral injury recognized at the time of male sling placement is an absolute contraindication to implantation of synthetic polypropylene mesh adjacent to the genitourinary system. Due to the risk of contaminating the implant material with urine extravasation from a lower urinary tract injury, any inadvertent entry into the urethra precludes placement of implantation of permanent synthetic material. When concern for entry into the urethra exists, indigo carmine may be instilled into the urethra while occluding the urethral meatus. [40] Alternatively, flexible cystoscopy may be performed. In the event of urethral injury, sling placement should be aborted, the wound irrigated, and then the urethrotomy closed and a catheter replaced for 2 weeks. Repeat attempt at sling placement may be considered 3 months later. There have been no reports of urethral injury with the quadratic sling. By leaving the bulbospongiosus muscle intact, the risk of iatrogenic urethrotomy should be minimized.

### Postoperative Complications

#### Urinary Retention

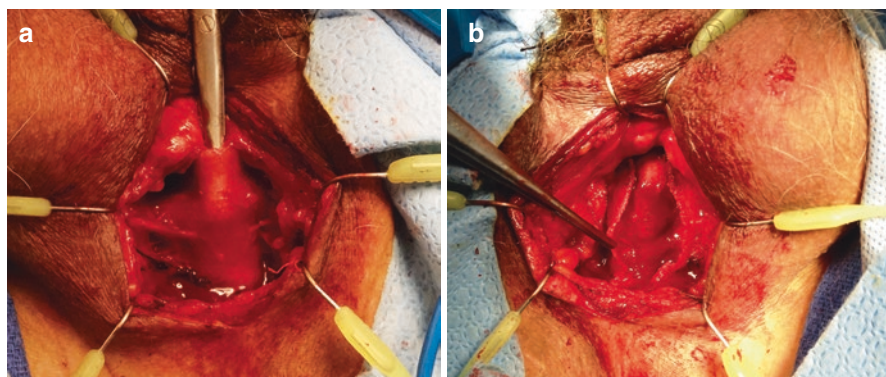
Chronic urinary retention following sling placement is fortunately an uncommon complication when patients are appropriately evaluated preoperatively for the strength of detrusor contraction and selected for the appropriate anti-incontinence procedure. Rates for postoperative urinary retention following transobturator sling have been reported to range from 3 to 23% [27] compared to 0% for the quadratic sling [41]. It should be noted, however, that all patients included in the Virtue sling clinical trials had urodynamically proven normal bladder contractility.

#### Mesh Erosion

Mesh exposure rates for various male slings are acceptably low at less than 1% and have not been reported to date with the quadratic sling. All delayed mesh exposures require excision from the urinary tract and repair of the involved lower urinary tract structure. In the setting of infection, following excision of the infected mesh and catheter placement, formal urethroplasty should be delayed until stabilization of the involved urethra has been demonstrated.

#### Recurrent Incontinence

Recurrent incontinence following male sling placement should be thoroughly evaluated with a careful history, physical exam and urodynamics. Cystoscopy should be considered in any patient with physical exam findings concerning for device erosion. Video urodynamics are essential to distinguish among detrusor overactivity, diminished vesical compliance, and recurrent or persistent intrinsic sphincter



**Fig. 6** (a) The quadratic sling is easily identified and dissected off the urethra. (b) Sling is incised, exposing the bulbospongiosus, for straightforward artificial sphincter placement

deficiency. While revision of the quadratic sling via midline plication has been reported, comparison of repeat/revision quadratic sling surgery and placement of an artificial urinary sphincter has not been reported. However, repeat transobturator sling placement has been shown to have a substantially lower success rate than does AUS placement as a salvage procedure [42], and it is the author's opinion that artificial urinary sphincter placement is the procedure of choice in the patient with a failed quadratic sling. Following quadratic sling placement, the sling is easily identified overlying the bulbar urethra, incised in midline, and dissected free from the underlying bulbar urethra at the time of sphincter placement (Fig. 6). Previous preservation of the bulbospongiosus muscle simplifies the subsequent urethral dissection, making AUS placement a straightforward procedure.

---

## Virtue™ Results

By combining the mechanisms of action of the bone anchored perineal and the transobturator retroluminal slings, the quadratic device can increase urethral resistance more than a purely perineal or TO approach. The original cadaveric study of the predecessor ventral urethral elevation plus (VUE+) Sling demonstrated this additive effect [43], which was confirmed in a cohort of 22 men with PPI undergoing Virtue sling placement. A sequential and additive increase in urethral resistance (measured by retrograde leak point pressure) followed tightening of the TO and then the PP extensions [44].

## Virtue™ Sling Without Fixation

In the initial report of the Virtue™ quadratic sling, 98 men with postprostatectomy incontinence (mean age 67.0 years) underwent Virtue sling implantation *without* sling fixation [40]. Objective success (defined as >50% improvement in pad weight) was

realized in 61.3% at 6 weeks but progressively declined to 55.1%, 53.8%, and 41.9% at 3, 6, and 12 months, respectively. Median pad weight improved for the entire cohort from 203.0 g (IQR 82.6, 541.1) at baseline to 65.0 g (IQR 14.9, 304.4) at 6 weeks but increased to 99.2 g (IQR 25.0, 300.0) by 12 months. Median percent reduction in pad weight for the cohort was 68.0% at 6 weeks, but only 51.1% at 12 months. Cure (<1.3 g/day) was realized in 20% at 6 weeks, declining to 15% at 12 months.

Subjective, success (defined as PGI-I very much/much improved) was achieved in 56.4% at 6 weeks, declining to 41.9% at 12 months. All complications were Clavien-Dindo grade 1. The most common non-serious AEs were short-term paresthesias (12.2%), and temporary perineal pain (24.3%). There were no sling infections or erosions, and no change in mean post void residual volume.

### **Virtue™ Sling with Fixation**

The importance of proper sling fixation was demonstrated in a separate cohort of 31 men (mean age of 66.2 years) [41]. The Virtue sling was implanted in a similar fashion to the prior cohort, but with the novel fixation method described previously: with the TO arms fixed in the midline and the PP arms fixed to the soft tissue over the pubic symphysis. Preoperatively 43.3% had mild, 23.3% had moderate, and 33.3% had severe incontinence. A 50% improvement in pad weight was realized in 85.2% at 6 weeks and maintained in 79.2% at 12 months ( $p < 0.01$  vs. baseline). Success did not vary with baseline pad weight, with 80% in the mild group, versus 83.3% in the moderate group, and 71.4% in the severe group at 12 months. Cure was achieved in 49% at 6 weeks and was maintained at 46% at 12 months. Median pad weight for the cohort improved from 147.0 g (IQR 43.0, 431.0) at baseline to 12.0 g (IQR 2.0 86.0) at 6 weeks and was maintained at 18.0 g (IQR 4.0, 109.0) at 12 months ( $p < 0.01$  vs baseline). Median percent reduction in pad weight for the cohort was 89.3% at 6 weeks, and 88.3% at 12 months, and did not differ significantly among the subgroups based on baseline pad weight. For those with mild leakage, per cent reduction in pad weight was 89.7% at 12 months versus 89.6% in the moderate group and 72.2% in the severe group ( $p > 0.05$ ).

Subjective success was assessed via PGI-I score of very much/much improved, which was realized by 80.0% at 6 weeks, and did not significantly change at 12 months ( $p < 0.01$  vs baseline) and did not significantly vary with degree of leakage at baseline.

There was a statistically significant difference in objective and subjective success between the original and fixation cohorts ( $p = 0.017$  for objective success and  $p = 0.021$  for subjective success, controlled for baseline pad weight). In the fixation trial, all adverse events were grade 1: 19.4% experienced mild genital paresthesias and 12.9% complained of mild perineal pain. There were no instances of infection or erosion. Similar to the unfixed group, there was no change in mean PVR following surgery. Of note, success rate was no different in the 19% of patient who underwent adjuvant radiation compared to the non-radiated patients.



## Conclusion

Male sling surgery has emerged as a safe and efficacious alternative to AUS placement in men with post-prostatectomy incontinence. Slings are preferred by most patients over the AUS, as the need to manipulate a scrotal pump to permit bladder evacuation can be avoided. In particular, in patients with mild-to-moderate SUI with normal bladder contractility, intermediate-term results with sling surgery appear equivalent to those for AUS placement, and the problem of urethral atrophy (which occurs secondary to circumferential urethral cuff occlusion) has not been realized.

The Virtue™ quadratic sling has evolved from predecessor devices, and provides a broad area of urethral compression (similar to the bone-anchored perineal sling) as well as proximal urethral elevation and sphincteric relocation (similar to the TO sling) while eliminating the risk of bone anchors. In addition, the direct vision inside-out needle passage should minimize the risk of urethral injury. This dual mechanism of action and quadratic fixation make the Virtue™ sling an appropriate option for patients with varying degrees of urinary incontinence, including those who have had adjuvant radiation, by providing a greater length of urethral compression than a purely perineal or purely transobturator sling.

---

## References

1. Penson DF, McLerran D, Feng Z, et al. 5-Year urinary and sexual outcomes after radical prostatectomy: results from the prostate cancer outcomes study. *J Urol*. 2005;173:1701–5.
2. Begg CB, Riedel ER, Bach PB, et al. Variations in morbidity after radical prostatectomy. *N Engl J Med*. 2002;346:1138–44.
3. Steineck G, Helgesen F, Adolfsson J, et al. Quality of life after radical prostatectomy or watchful waiting. *N Engl J Med*. 2002;347:790–6.
4. Stanford JL, Feng Z, Hamilton AS, et al. Urinary and sexual function after radical prostatectomy for clinically localized prostate cancer: the prostate cancer outcomes study. *JAMA*. 2000;283:354–60.
5. Singla AK. Male incontinence: pathophysiology and management. *Ind J Urol*. 2007;23:174–9.
6. Jacobsen NE, Moore KN, Estey E, Voaklander D. Open versus laparoscopic radical prostatectomy: a prospective comparison of postoperative urinary incontinence rates. *J Urol*. 2007;177:615–9.
7. Anastasiadis AG, Salomon L, Katz R, et al. Radical retropubic versus laparoscopic prostatectomy: a prospective comparison of functional outcome. *Urology*. 2003;62:292–7.
8. Sacco E, Prayer-Galetti T, Pinto F, et al. Urinary incontinence after radical prostatectomy: incidence by definition, risk factors and temporal trend in a large series with a long-term follow-up. *BJU*. 2006;97:1234–41.
9. Du Moulin MF, Hamers JP, Ambergen AW, Janssen MA, Halfens RJ. Prevalence of urinary incontinence among community-dwelling adults receiving home care. *Res Nurs Health*. 2008;31:604–12.
10. Coyne KS, Zhou Z, Thompson C, Versi E. The impact on health-related quality of life of stress, urge and mixed urinary incontinence. *BJU Int*. 2003;92:731–5.
11. Wilt TJ, MacDonald R, Rutks I, Shamlivan TA, Taylor BC, Kane RL. Systematic review: comparative effectiveness and harms of treatments for clinically localized prostate cancer. *Ann Intern Med*. 2008;148:435–48.

12. Johansson E, Steineck G, Holmberg L, et al. Long-term quality-of-life outcomes after radical prostatectomy or watchful waiting: the Scandinavian prostate cancer group-4 randomised trial. *Lancet Oncol.* 2011;12:891–9.
13. Parekh AR, Feng MI, Krages D, et al. The role of pelvic floor exercises on post-prostatectomy incontinence. *J Urol.* 2003;170:130–3.
14. Filocamo MT, Li Marzi V, Del Popolo G, et al. Effectiveness of early pelvic floor rehabilitation treatment for post-prostatectomy incontinence. *Eur Urol.* 2005;48:734–8.
15. Herschorn S, Bruschini H, Comiter CV, et al. Surgical treatment of stress incontinence in men. *Neurourol Urodyn.* 2010;29:179–90.
16. Lai HH, Hsu EI, Teh BS, et al. 13 years of experience with artificial urinary sphincter implantation at Baylor College of Medicine. *J Urol.* 2007;177:1021–5.
17. Kim SP, Sarmast Z, Dainault S, et al. Long-term durability and functional outcomes among patients with artificial urinary sphincters: a 10-year retrospective review from the University of Michigan. *J Urol.* 2008;179:1912–6.
18. Kumar A, Litt ER, Ballert KN, et al. Artificial urinary sphincter versus male sling for post-prostatectomy incontinence--what do patients choose? *J Urol.* 2009;181:1231–5.
19. Hoy NY, Rourke KF. Stemming the tide of mild to moderate post-prostatectomy incontinence: a retrospective comparison of transobturator male slings and the artificial urinary sphincter. *Can Urol Assoc J.* 2014;7-8:273–7.
20. Stern JA, Clemens JQ, Tiplitsky SI, et al. Long-term results of the bulbourethral sling procedure. *J Urol.* 2005;173:1654–6.
21. Comiter CV. The male perineal sling: intermediate-term results. *Neurourol Urodyn.* 2005;24:648–53.
22. Rehder P, Haab F, Cornu JN, et al. The treatment of postprostatectomy incontinence with the retroluminal transobturator repositioning sling (advance): lessons learnt from accumulative experience. *Arch Esp Urol.* 2009;6:860–70.
23. De Ridder D, Rehder P. The AdVance male sling: anatomic features in relation to mode of action. *Eur Urol Suppl.* 2011;10:383–9.
24. Rehder P, et al. Treatment of postprostatectomy male urinary incontinence with the transobturator retroluminal repositioning sling suspension: 3-year follow-up. *Eur Urol.* 2012;62:140–5.
25. Zuckerman MJ, et al. Extended outcomes in the treatment of male stress urinary incontinence with a transobturator sling. *Urology.* 2014;83:939–45.
26. Osman NI. Slings in the management of male stress urinary incontinence. *Curr Opin Urol.* 2013;23:528–35.
27. Welk BK, Herschorn S. The male sling for post-prostatectomy urinary incontinence: a review of contemporary sling designs and outcomes. *BJU Int.* 2012;109:328–44.
28. Rehder P, et al. The 1 year outcome of the transobturator retroluminal repositioning sling in the treatment of male stress urinary incontinence. *BJU Int.* 2011;106:1668–72.
29. Cornu J, et al. Mid-term evaluation of the transobturator male sling for post-prostatectomy incontinence: focus on prognostic factors. *BJU Int.* 2011;108:236–40.
30. Bauer RM, et al. Complications of the AdVance transobturator male sling in the treatment of male stress urinary incontinence. *Urology.* 2010;75:1494–8.
31. Kowalik CG, DeLong JM, Mourzinos AP. Then advance transobturator male sling for post-prostatectomy incontinence: subjective and objective outcomes with 3 years follow up. *Neurourol Urodyn.* 2015;34:251–4.
32. Collado Serra A, Resel Folkersma LR, Dominguez-Escrig JL, et al. Advance/advance XP transobturator male slings: preoperative degree of incontinence as predictor of surgical outcome. *J Urol.* 2013;81:1034–9.
33. Romano SV, Metrebian SE, Vaz F, et al. An adjustable male sling for treating urinary incontinence after prostatectomy: a phase III multicentre trial. *BJU Int.* 2006;97:533–9.

34. Sousa-Escandon A, Cabrera J, Mantovani F, et al. Adjustable suburethral sling (male remeex system) in the treatment of male stress urinary incontinence: a multicentric European study. *Eur Urol.* 2007;52:1473–9.
35. Hoda MR, Primus G, Fischereider K, et al. Early results of a European multicentre experience with a new self-anchoring adjustable transobturator system for treatment of stress urinary incontinence in men. *BJU Int.* 2013;111:296–303.
36. Bauer RM, Rutkowski M, Kretschmer A, et al. Efficacy and complications of the adjustable sling system Argus T for male incontinence: results of a prospective 2-center study. *Urology.* 2015;85:316–20.
37. Chung E, Smith P, Malone G, Cartmill R. Adjustable versus non-adjustable male sling for post-prostatectomy urinary incontinence: a prospective clinical trial comparing patient choice, clinical outcomes and satisfaction rate with a minimum follow up of 24 months. *Neurourol Urodyn.* 2016;35:482–6.
38. Cornel EB. Argus-T adjustable male sling: the influence of surgical technique on complications and short-term efficacy. *Urol Int.* 2016;96:164–70.
39. Cerruto MA, D’elia C, Artibani W. Continence and complications rates after male slings as primary surgery for post-prostatectomy incontinence: a systematic review. *Arch Ital Urol Androl.* 2013;85:92–5.
40. Petrou SP, Thiel DD, Elliot DS, et al. Does indigo carmine prevent early artificial urinary sphincter cuff erosion? *Can J Urol.* 2006;13:3195–8.
41. Comiter CV, Rhee EY, Tu LM, Herschorn S, Nitti VW. The virtue sling: a new quadratic sling for postprostatectomy incontinence – results of a multinational clinical trial. *Urology.* 2014;84:433–8.
42. Ajay D, Zhang H, Gupta S, Selph JP, Belsante MJ, Lentz AC, et al. The artificial urinary sphincter is superior to a secondary transobturator male sling in cases of a primary sling failure. *J Urol.* 2015;194:1038–42.
43. Comiter CV, Rhee EY. The ‘ventral urethral elevation plus’ sling: a novel approach to treating stress urinary incontinence in men. *BJU Int.* 2007;101:187–91.
44. Comiter CV, Nitti V, Elliott C, Rhee E. A new quadratic sling for male stress incontinence: retrograde leak point pressure as a measure of urethral resistance. *J Urol.* 2012;187:563–8.

---

# Adjustable Male Slings: REMEEX

Aljendro Sousa Escandon, Juan León, Javier Flores,  
and Daniel Sousa-González

---

## Introduction

Urinary incontinence remains a serious problem for a significant minority of patients following prostate cancer treatment, due to the adverse effect on the quality of life. A better understanding of the anatomical structures that maintain urinary continence after radical prostatectomy has significantly reduced the rate and severity of post-radical prostatectomy incontinency.

Preservation of the bladder neck, of the supporting structures as puboprostatic ligaments, careful dissection of the prostatic apex, and uni- or bilateral preservation of the neurovascular plexuses in selected cases have shown their positive impact on continence without endangering oncological radicality of this intervention.

The artificial urinary sphincter (AUS) remains the “gold standard” for severe stress urinary incontinence. However, the aforementioned surgical improvements have made mild or moderate cases the most frequent [1–3]. The improvement of suburethral meshes and the possibility of AUS placement after failure of a sling with similar levels of success as de novo AUS implantation have been a radical shift in the treatment of this serious problem. Slings have AUS as the preferred choice for severe incontinence and recurrent and often associated problems such as radiation therapy.

The adjustable REMEEX™ suburethral sling has shown excellent results in the treatment of female urinary incontinence by sphincter intrinsic defects [4–6]. REMEEX™ brings two fundamental principles: adjustability and active pressure transmission system. The adjustability allows to easily adjust the urethral support, rotating a simple manipulator presented through the skin; regulation is done with the patient standing up while making efforts that cause incontinence. In addition,

---

A.S. Escandon (✉) • J. León • J. Flores • D. Sousa-González  
Urologist Hospital Comarcal de Monforte, Lugo, Spain  
e-mail: [Alejandro.Sousa.Escandon@sergas.es](mailto:Alejandro.Sousa.Escandon@sergas.es)

the varitensor (regulatory tension prosthesis of the REMEEX™ system) is above the rectus muscles of the abdomen, so when increasing abdominal pressure, varitensor advances and transmits this pressure to the mesh, providing an extraurethral support under stress [3].

It seemed reasonable that a readjustable sling would be extremely useful in the treatment of male stress urinary incontinence especially if we consider the narrow margin of error in the tension of the suburethral mesh to achieve continence without causing obstruction. In 2001, we placed the first adjustable sling to treat male stress incontinence. Since then, the surgical technique has evolved to minimally invasive, and prosthesis has undergone successive improvements to achieve excellent clinical results with fewer adjustments and with few postoperative complications [7–14].

---

## Surgical Technique


The system consists of two main parts: the adjustment polyethylene prosthesis (*varitensor*) which is placed at the suprapubic area (Fig. 1) and the suburethral polypropylene monofilament mesh (F1.4) which is attached to the varitensor by polypropylene traction threads.

The mesh is a *patch sling type* and has two lateral spreader bars to maintain the mesh fully extended to transmit a homogeneous urethral support. These reinforcements are made of polyetheretherketone, a fully biocompatible material, generally abbreviated as PEEK.

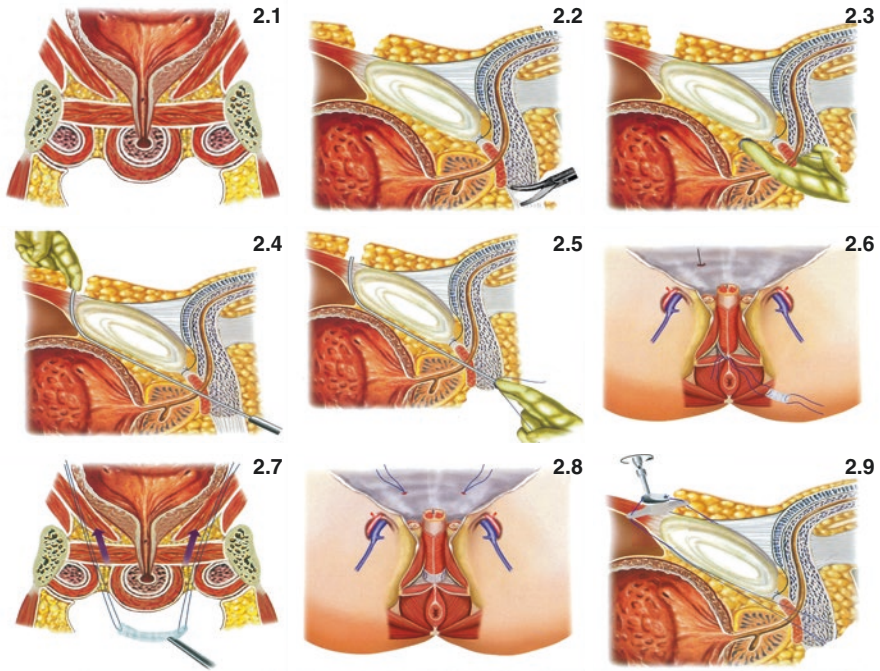
Baseplate is specifically designed to support the varitensor. Traction threads pass through the lateral holes of the base plate on both sides (Fig 1.5 and 1.6) and then enter the varitensor through the lateral orifices and come out... (Fig 1.7)

The REMEEX™ varitensor has inside a never-ending screw to wind in the polypropylene traction threads around it allowing to adjust the tension of the suburethral mesh. The adjustment system in manipulated screw can be adjusted by turning a manipulator connected to the varitensor that shows up through the lower abdominal skin (F1.2). The manipulator can be turned clock- or counterclockwise to increase or decrease the urethral mesh support level. Once the desired urethral support is achieved, the manipulator can be disconnected from the varitensor by a special screwdriver, called disconnecter (F1.3), which is inserted through the manipulator (Fig. 1a) and, by rotating ¼ turn in either direction (Fig. 1b), unlocks and disconnects the manipulator from the varitensor (F1.C), leaving in the patient only the varitensor, the baseplate, the traction thread, and the suburethral mesh.

As with any prosthetic surgery, antibacterial measures should be taken such as correct shaving both the suprapubic area and the perineum and cleaning both areas for 2–3 min with povidone-iodine. Prophylaxis with broad-spectrum antibiotic will start 1 h before surgery and maintained while the manipulator is attached to the varitensor. Under spinal anesthesia, the patient is placed in lithotomy position, and the usual sterile field protections are placed.



**Fig. 1** MRS components and way of detachment

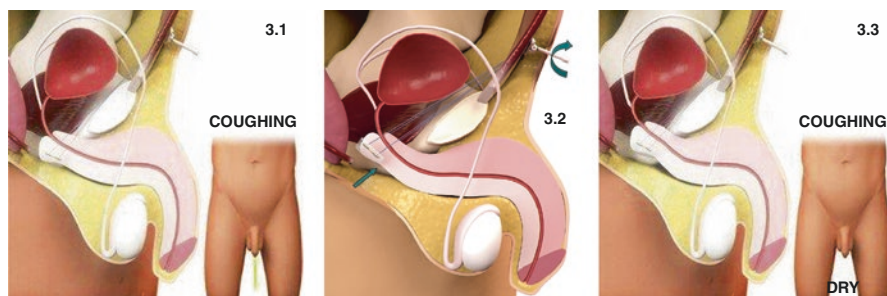


**Fig. 2** Surgical steps to place a MRS

An 18 ch Foley urethral catheter is placed to completely empty the bladder and to easily locate the bulbar urethra by palpation during surgery. Then we make a sagittal perineal incision about 5 cm above the bulbar urethra and briefly dissect the subcutaneous tissues to locate the bulb cavernous muscle (Fig. 2a). Bilateral dissection of the paraurethral tissues is performed toward the middle of isquiopubian branch approximately at the level of the angle between muscle bulbocavernosus bulb and ischiocavernosus muscles. Then, the fascia is perforated just at the lower edge of the bone by blunt dissection to reach the endopelvic fascia. This fascia must also be dissected to access the retropubic area with the index finger.

Then, we start the supra-pubic preparation by performing a 4 cm transversal incision just 2 cm above the pubis (Fig. 2b). Adipose tissue is dissected until a clear exposition of the fascia of the anterior abdominal rectus muscles (*or the previous surgery scar after open prostatectomy*) upon which we will place the REMEEX™ prosthesis.

We return to the perineum and cut the perineal body or central tendon of the perineum (Fig. 2b). This maneuver is essential to reposition the sphincter complex in a more intra-abdominal position. Then we introduce the thread passer, part of the set, with the tip guided by the index finger until we reach the reached the retropubic space (Fig. 2c). Then remove the finger, and push the needle toward the ipsilateral shoulder of the patient in the most upright possible in contact with the inner face of the pubis to avoid inadvertent puncture of the bladder. Slowly we move forward



**Fig. 3** Readjusting suburethral mesh tension of the MRS (With permission to be published from Neomedic Int.)

until the tip of the needle appears through the suprapubic incision (Fig. 2d). The same maneuver is repeated on the contralateral side. We then perform a cystoscopy to check the bladder integrity.

We introduce the ends of the polypropylene traction threads through the holes in the distal part of the needle and push the needle all the way up to the abdominal incision. We then fix the tip of the traction threads with a mosquito at the abdominal site.

The maneuver is repeated on the contralateral side, and we then position the suburethral mesh under the bulbar urethra by pulling the tips of both traction threads (Fig. 2d, e). We fix the mesh under the bulbar urethra by two absorbable sutures (Fig. 2f, g). We complete the perineal time by checking hemostasis and closing by planes leaving an incision drainage.

In the suprapubic area, the tips of the traction threads are passed through the lateral reception holes of the REMEEX™ prosthesis. Keeping the prosthesis in the midline, and about 10 cm above the fascia of the rectus (*about four finger tips*), will fix the traction threads by *screwing the central fixation screw*.

We rotate clockwise the manipulator, to wind the traction thread into the varitensor until the varitensor rest over the rectus fascia with no tension (Fig. 2h). We then finish the intervention by closing the abdominal incision in layers and covering the manipulator with gauze so that it rest perpendicular to the abdominal wall.

If no complications occurred during surgery and no hematuria, we start the urethral support adjustment 24 or 48 h after the operation. To do the adjustment, we fill the bladder through a catheter with 250–300 mL of saline. Ask the patient to stand up, and begin to rotate the manipulator clockwise, until we get urinary continence in resting phase (Fig. 3b).

At first, you may have to give many turns to the manipulator to reach continence at rest.

Once the patient is continent at rest, we invite him to cough, to perform Valsalva maneuver (*defecation type*) or those that usually produce losses of urine (*such as squatting*). If the patient leaks, we turned the manipulator four complete turns and check again the continence. The maneuver is repeated as often as necessary until complete continence under stress (Fig. 3c) is achieved.



Then will then check that the patient is able to urinate without difficulty and that the amount of residual urine is less than 100 mL. If the patient is unable to urinate properly, it is preferable to slightly loosen the varitensor even at the cost of having some small urine loss. At that time, we can remove the REMEEX™ manipulator using the disconnecter.

In cases where there was minima bladder perforation (*punction*) or urethral manipulation during the operation had caused hematuria, we should leave the manipulator in place, and adjustment can be delayed 1 or 2 days. Oral administration of cloxacillin 500 every 8 h during those days helps prevent infection of the prosthesis by Gram + cocci present on the skin.

Most patients will leave the hospital with full continence or with minor losses. However, a significant proportion of patients have recurrence of urinary incontinence that can sometimes be significant. This is because the urethral edema and the inflammation at the surgical site help to achieve continence just after surgery, but once disappears, urethral closing pressure may decrease to values under the hydrostatic pressure of the bladder at stress (*or even at rest*) thereby reappearing incontinence.

In these cases, we must make a late readjustment. To perform it, we make a small incision, *under local anesthesia*, through the previous suprapubic wound and dissect the anterior surface of the prosthesis. The manipulator is reconnected to the REMEEX™ prosthesis using the disconnecter, and we can repeat the adjustment procedure explained in the preceding paragraphs. Usually, dissection is simple, and the whole procedure including wound closure typically takes less than 5 min.

The long-term readjustment of the suburethral support can be done under local anesthesia without any difficulty at any time during patient lifetime. Both traction threads and the REMEEX™ prostheses are encapsulated allowing mobilization and modification of the traction threads and thus the sling urethral support level whenever needed.

---

## Results

Between November 2001 and May 2015, 48 patients have been surgically treated with a Male Remeex System at the Comarcal Hospital of Monforte. Mean age of the group was 69 years (range between 56 and 82 years). Origin of the incontinence was radical prostatectomy in 42 patients (87.5%), retropubic adenomectomy in 2 cases (4.2%), and prostatic transurethral resection in other 2 (4.2%).

Grade of urinary incontinence was mild (1–2 pads/day) in 11 patients (23%), moderate (3–4 pads/day) in 24 (50%), and severe (5 or more pads/day) in 13 (27%). Pure sphincteric incontinency was present in 43 patients (89.6%) and mixed incontinence in 5 cases (10.4%). Four of the patients also presented sclerosis of the vesicourethral anastomosis, and cold internal urethrotomy was done in all cases.

After a medium follow-up of 74 months (range between 11 and 156 months), 26 patients were pad-free (54%), another 14 were improved—*pad reduction > 50%*—(29%), and 8 patients (17%) were considered failures. Six patients (12.5%) died

during the follow-up period due to causes unrelated to the sling. At decease moment, four of them were dry and other two improved.

Unlike nonadjustable procedures, REMEEX™ sling results vary depending on long-term readjustments, and the rates of success may vary because an incontinent patient may always be readjusted to reach continence. In fact, we performed an average of 2.5 readjustments (0–6) to achieve these results.

Among the failures, three of the patients had to be explanted during the follow-up: one for chronic varitensor rejection and one for pain and erosion of the pubic bone after four readjustments. (It has to be said that both patients were reoperated by placing an ATOMS sling and it was also rejected in both patients.) Another patient was explanted by prosthesis infection after the second readjustment. One patient had a right hemiplegia after a CVA, and we decided not to readjust him anymore after two attempts. Finally, two more patients decided to not perform more readjustments after one and three, respectively.

There were one puncture of the urethra and four unilateral and one bilateral punctures of the bladder; these mean a perforation in 7.3% of the 96 retropubic passages of the needles ( $48 \times 2$ ). Five of the perforations were done among the first 20 patients being related to the learning curve. There was only one perforation in the following 24 cases. All punctures were uneventful except for mild hematuria. However, these six patients couldn't be readjusted during the immediate post-op period. One patient had enough pain to ask for prosthesis explantation and other four referred very mild pain which was easily controlled with common analgesics after 7–28 days of treatment.

It is important to mention that no patient presented acute urinary retention at any moment after the surgery and all patients had postvoiding residues below 100 mL.

---

## Discussion

Stress incontinence is bothersome postoperative late complication after radical prostatectomy and produces a significant deterioration in the quality of life of patients who suffer it. The term intrinsic sphincter deficiency does not fully describe the complexity of the pathophysiology of male urinary incontinence after prostate surgery.

Prostatic surgery may damage supporting fascias of the sphincter complex, decreasing the muscle mass of both striated and smooth sphincters, and it may injure sphincter and pelvic floor innervation. The main cause of incontinence is the direct injury of the sphincteric muscle complex. In other cases, it is due to the laxity of the sphincter complex support and/or dislocation of the sphincter complex, through pelvic floor, that it cannot maintain the urethral lumen closed, resulting in urinary leakage. The highest degree of urethral sphincter prolapse in incontinent males is at the posterior area of the sphincteric urethra, and its correction may cure incontinence [15–18].

Moreover, the quality of the urethral wall is vital for the pressure transmission in order to achieve coaptation of the urethral mucosa. The functional urethral length has to be greater than 15 mm to restore continence. Finally, bladder dysfunction is

a key to optimize treatment outcomes and to avoid unnecessary operations. The compliance and detrusor contractility are two fundamental variables when considering the surgical treatment of incontinence [19].

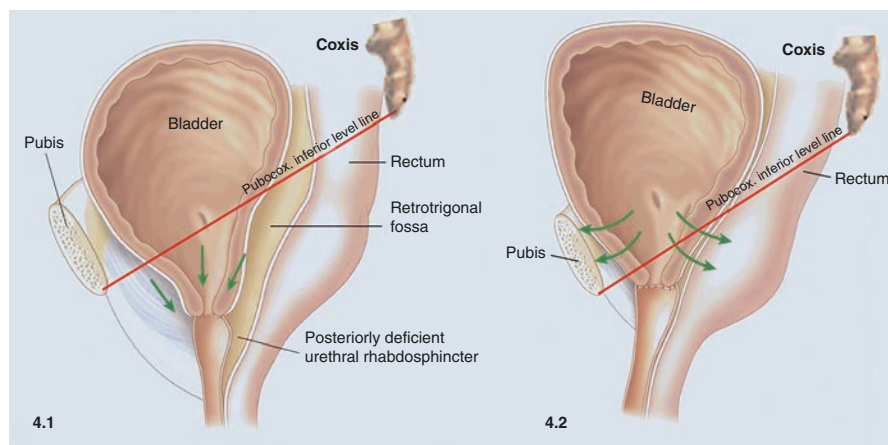
Despite all the advances that have occurred in the study and treatment of post-prostatectomy incontinence, the truth is that we still do not know which of the possible causal factors are responsible for the male urinary incontinence in a particular case and which is the best technique to treat the patient.

Bladder dysfunction should be analyzed before treatment of urinary incontinence. Sphincter dysfunction can differentiate into “intrinsic” when there is a failure of the sphincter muscle and “hypermobility” when the sphincter complex is in the wrong anatomical position. An individual patient could have one or both forms of sphincter dysfunction [16, 17, 20].

The New York Presbyterian Hospital group [15] proposed that when anatomical position is not restored, some hydraulic forces act against the internal sphincter function complicating urinary continence (Fig. 4).

A patient with bed wetting indicates an ineffective occlusive capacity of the sphincter complex. That sphincter damage needs some kind of compression therapy, and a transobturator sling repositioning will not be enough. Conversely, if a patient is continent in bed but not in standing position, he is more likely to suffer from hypermobility [16].

In a man demonstrating leakage with straining that stops at the cessation of the straining maneuver, the diagnosis of ISD can be made without further testing. A voiding diary is sufficient to demonstrate adequate bladder capacity, and a bladder scan can evaluate the patient’s ability to empty his bladder. However, with regard to bladder contractility, this can only be analyzed by detailed urodynamic evaluation.



**Fig. 4** Hydraulic forces acting over the urinary sphincteric complex out of place after radical prostatectomy and once replaced to its normal anatomical position (Modified from Srivastava et al. Arch. Esp. Urol. 2012; 65 (5): 529–541) (with permission to be published from Archivos Españoles de Urología)

Given the recent expansion of therapeutic options to treat SUI, a thorough evaluation should also include pad weight and urodynamic studies—to best indicate a specific surgical therapy [16, 17, 20].

Treatment options are multiple and include low-invasive surgical interventions to increase urethral closure pressure up to the point of continence while maintaining a physiological urination. These therapies are very attractive procedures. Within this group is periurethral injection of bulking agents. Although it is a minimally invasive procedure, they get very poor results (8–36% at two 2 years follow-up). The need for reinjection increasing the treatment cost is very frequent [21, 22]. A more effective variant of this principle is the adjustable periurethral balloons that allow refilling or emptying by puncturing the subcutaneous port available. However, its clinical success depends on surgeons' experience. Complication rate, such as urinary tract erosions, may reach 20% of patients and in exceptional cases rectal perforation during may occur [23].

The AUS has reigned for 30 years as the most predictable treatment of male stress urinary incontinence obtaining durable success rates of up to 80% regardless of the clinical characteristics of the patient.

New models have reduced reoperation rates below 30% and the number of explantations by erosions, infections, or mechanical failures down to 10%. However, the AUS continuously compresses the urethra causing urethral atrophy in 7.9% of patients (1.9–28.6%) which may produce recurrent urine leakage and the need to place a second cuff in the urethra [24].

Moreover, complication rates of slings are significantly lower than those for AUS, huge study over 1205 incontinence surgeries (597 sling and 608 AUS). Male slings had a lower 30-day postoperative complication rate (2.8 vs. 5.1%,  $p = 0.046$ ), fewer urinary tract infections (0.3 vs. 2.0%,  $p = 0.020$ ), and fewer reoperations (1.0 vs. 3.0%,  $p < 0.001$ ) [25].

The AUS is still an expensive procedure with nonphysiologic micturition and implying the mechanical activation of the device by the patient each time he wants to urinate [26]. Many patients are not able to manipulate the scrotal pump and many others are hesitant about implantation and refuse the procedure [24, 25].

When informing patients to receive a male sling or an artificial urinary sphincter, 100% and 75%, respectively, accept surgeon proposal. This reflects that most patients follow surgeon's advisor, but when given a choice, 92% of patients chose a male sling [27].

Suburethral slings may increase urethral closing pressure, replace original anatomy, or both. Moreover, they also allow a more physiologic bladder voiding without needing manual activation by the patient.

In the current moment, slings surpassed the AUS as the first surgical option for patients with mild urinary incontinence. Three main factors have induced this change. First of all, the improvement in the surgical technique preserving anatomic continence structures has diminished the number and intensity of urinary leakage. Slings are able to treat mild and moderate incontinences as much as the AUS in most cases. Second, if slings fail, an AUS may be placed after it with similar rates of success. And third, slings are preferred by most of the patients when both options are offered to them.

From the point of urodynamic view, the sling significantly increases the closing pressure during the Valsalva maneuver ( $p < 0.001$ ), with minimal changes in resting pressure which shows us that slings can achieve continence in men without causing difficulties in the voiding process [28].

The main question with slings is how to reach the proper urethral support for continence while avoiding urinary voiding difficulty.

The readjustable REMEEX™ sling avoids and solves this problem by allowing suburethral fine readjustment at short, medium, and long term after surgery. The systems allow to adjust the suburethral support to the minimum value that achieve continence with the patient standing up and doing the efforts that drove him to incontinence.

These results are similar to those previously published. We participated in a multicentric European study [8] including 55 patients that were followed during an average of 32 months. Thirty-three of these patients (64.7%) were considered cured (25 of them wore no pads at all, and 8 used small pads or sanitary napkins for security but normally remained dry), and other 10 cases showed important improvement (19.6%). Globally, 84.3% of patients were considered as successful cases.

After 1 year of follow-up, Jiménez et al. [11] achieved a 41.7% of patients totally dry and other 33.3% having mild leaks for a 75% of success. In one small series published by Navalon et al. [14], they referred a 100% of patients dry, 40% of them uses a security pad. Another paper reported a 65% success rate, but there were significant differences between patients who received radiotherapy ( $p < 0.015\%$ ) and those who doesn't. In the same way, there were significant differences depending on the number of pads used preoperatively ( $p < 0.001$ ) [13].

## Other Adjustable Male Slings

### ATOMS

Seweryn et al. [29] in a series of 38 patients with a mean follow-up duration of 16.9 months recorded a 60.5% continence rate (0–1 pad or  $< 15$  mL/24 h in the pad test), 23.7% of the patients used more than one pad or presented leakage between 16–100 mL/24 h, and 15.8% used more than two pads or had leakage  $> 100$  mL/24 h following the introduction of the ATOMS® adjustable implant. According to these authors, the parameters with the greatest influence upon treatment outcome are the number of pads used or the volume of urine leakage before the operation. In 2012, Hoda et al. [30] published the results of a multicenter study in 124 patients, with a global success rate of 93.8% (61.6% continent, and with clear improvement in the rest of the patients).

Regarding the complications of the technique, Seweryn et al. [29] reported a case of acute urinary retention after removing the bladder catheter (requiring a further 24 h of catheterization), one case of urethral erosion, and four cases of infection at the site of the titanium port (requiring replacement of the port in one case and of the entire system in the remaining three). A total of 52.6% of the patients experienced

perineal-scrotal dysesthesias that were resolved with medical treatment. This percentage reached 60.5 and 68.7% in the European multicenter studies conducted by Hoda et al. [30, 31].

## **Argus**

This is another readjustable sling composed of a foam pad and columns made of silicone. In a systematic review by Trost and Elliott [32] in 2012, out of four studies with a total of 273 patients, excluding salvage procedures, the Argus retropubic sling was associated with a 17–79% success rate. In the largest study, including 101 patients, Hubner et al. [33] observed that Argus sling adjustment was required in 39% of men. The silicone material, however, is prone to complications with a 5–7% infection risk, a 3–13% of erosion, and a 12–35% explantation rate [33].

Dalpiaz et al. [34] published that 83% of patients experienced 1.5 complications each, including 35% of acute urinary retention. The sling had to be removed in 35% patients due to urethral erosion, infection, system dislocation, permanent urinary retention, and persistent pain. A 27% of patients complained of significant perineal pain, necessitating continuous oral analgesics. Ureteral reimplantation should be performed due to ureteral erosion from a dislocated sling. After 35 months follow-up, only 17% remained dry, while 72% were dissatisfied with the clinical outcome. In a comparative study between AUS and Argus, Lim et al. [35] showed that abnormal postoperative pain was present in 30% of patients in the Argus group, being significantly higher than in the AUS group.

---

## **Male Remeex System (MRS) Evolution: Past, Present, and Future**

### **The Past**

REMEEX is the acronym of REadjustment MEchanical EXternal. It was designed to regulate suburethral tension after female urinary incontinence surgery.

He created a very simple system which permits a fine regulation of the tension; each three complete turns of the varitensor elevate just 1 mm the traction threads of the stitches applied to the paraurethral tissues. Yes, at that time the prosthesis did not include the suburethral mesh.

With the appearance of the monofilament, macroporous polypropylene meshes, they thought that was necessary to add a mesh under the urethra. However, the long retropubic meshes used at that time were not able to be readjusted. The solution was to create a “patch sling” attached to the prosthesis by the polypropylene sutures.

The time showed that the body produces a pseudocapsule surrounding the threads permitting its free movement without any resistance even 10 years after the placement of the prosthesis.

The female REMEEX was born in not the best moment of the history. Before Ulmsten et al. [36] described the tension-free sling, *and everybody treating female incontinence embrace this new revolutionary concept*, the amount of suburethral pressure needed to achieve continence was a “hot spot” without a clear answer.

Currently, type III—*sphincteric*—incontinence or recidivated patients is still being a problem for urologist and gynecologist. In these women, the REMEEX is probably the best and unique option to apply the exact suburethral tension needed to reach continence without urinary obstruction.

In 2001, our group modified the technique to apply the female REMEEX prosthesis into man. In 2004, we published the first experience using this amazing device [7]. However, the clinical experience shows us that this system needs some changes to adapt it to the male. The suburethral pressure needed to achieve continence is higher in male compared to female in many cases, and the original female REMEEX was not prepared for this.

To minimize the pressure of the varitensor over the rectus fascia (sometimes damaged by an open prostatectomy), Neomedic developed a baseplate to decrease the pressure per square millimeter by five times, avoiding the potential of a varitensor damaging the rectus fascia.

The other risk in male was suburethral mesh kinking under big stress forces.

The company analyzed how to maintain the suburethral mesh fully extended without kinking under stress and found an easy but quite effective solution. Two reinforcements of polyetheretherketone, well known as PEEK, were placed in both sides of the mesh solving the problem in an outstanding way. PEEK is a 100% bio-compatible material commonly used in spine and orthopedic surgery without any adverse reaction against it [36]. In fact, during the last 11 years, no cases of rejection of any part of the set have been observed.

These two modifications were enough to achieve high success rates without any problem related to the design and the commercialized model between 2005 and 2011. That set was called Male Remeex System or MRS.

## The Present

However, another challenge persisted, the number of regulations to achieve continence was high (*in our experience 2.5 times after 6 years of follow-up*), and the company works for years looking for a solution. The first step to solve the problem was to know its origin. After recreating 3D models and talking to many clinicians and cadaveric experimentation, the conclusion was that the traction threads under stress look for the shortest line between the mesh and the varitensor and thus medialization of the threads was the reason of incontinence recurrence.

In 2011, a new baseplate was designed by Neomedic engineers. It is bigger in the transversal axis to avoid traction thread medialization. This new system is called MRS II, and it is currently used in more than 30 countries worldwide.

The surgical technique evolved also making mandatory to cut the perineal body or the central tendon of the perineum, which was left in place during the first years of REMEEX surgical interventions.

Many groups have seen that this new baseplate and the perineal central tendon section permit to achieve high levels of success and to reduce the number of readjustments to achieve a complete definitive continence.

These data suggest that the mechanism of postprostatectomy incontinence may be more complex and dynamic than previously thought. It is evident that this new devices haven't solved the problem in all cases and new answers still have been needed. In fact, while we still speaking about cured rates around 60% and improved rates up to 85%, there is still room for improvements.

Selecting for the ideal candidate with postprostatectomy incontinence that will be successful after male sling placement remains a challenge. All of us should work to create better treatments able to achieve the same cure rates as in female stress urinary incontinence with minimal side effects.

Hopefully, near future innovations will overcome all the remaining challenges in the treatment of postprostatectomy incontinence and will offer patients more simple and highly successful surgical solutions.

---

## References

1. Welk B. Combination options with the male urethral sling to treating post-prostatectomy incontinence. *Can Urol Assoc J.* 2011;5(2):112.
2. Sandhu J. Treatment options for male stress incontinence. *Nat Rev Urol.* 2010;7:222–8.
3. Moore K, Lucas M. Management of male urinary incontinence. *Ind J Urol.* 2010;26(2):236–44.
4. Barrington J, Archer R, Kulkarni M, Forrest A. The TRT female Remeex system® for recurrent female stress urinary incontinence: a 5-year follow-up study. *J Obstet Gynaecol.* 2013;33(4):391–3.
5. Giberti C, Gallo F, Cortese P, Schenone M. The suburethral tension adjustable sling (REMEEX system) in the treatment of female urinary incontinence due to 'true' intrinsic sphincter deficiency: results after 5 years of mean follow-up. *BJU Int.* 2011;108(7):1140–4.
6. Moreno J, Marqués A, Araño P, Fuente P, Cerezuela JF, Sousa A, et al. Spanish registry of the TRT Reemex system in women with stress urinary incontinence (SUI). *Arch Esp Urol.* 2006;59(2):169–74.
7. Sousa A, Rodríguez JI, Uribarri C, Marques A. Externally readjustable sling for the treatment of male stress urinary incontinence: points of technique and preliminary results. *J Endourol.* 2004;18(1):113–8.
8. Sousa A. Suburethral readjustable sling (REMEEX) in male urinary incontinence: surgical technique. *J Urol.* 2005;173(4 Suppl):366–7.
9. Sousa-Escandón A, Cabrera J, Mantovani F, Moretti M, Ioanidis E, Kondelidis N, et al. Adjustable suburethral sling (male remeex system) in the treatment of male stress urinary incontinence: a multicentric European study. *Eur Urol.* 2007;52(5):1473–9.
10. Di Marco M, Granata D, Casilio M, Franco G. Male Remeex System (MRS): a new device for male urinary stress incontinence AUA Annual Meeting 2008, 178 Chicago, IL, USA.
11. Jiménez J, Cebrián J, Hualde A, et al. REMEEX® system for the treatment of male urinary stress incontinence: our experience. *Actas Urol Esp.* 2010;34(9):802–5.
12. Sousa A. Male Remeex System™ (MRS) for the surgical treatment of male incontinence: 12 years from the first case. 32 SIU Congress Fukuoka—Japan 2012.
13. Woon S, Hwan J, Walsh R, Berger Y. Outcomes of readjustable male sling (Remeex System) for prostatectomy urinary incontinence: experience from two centres AUA Annual Meeting 2014 Florida, OR, USA.
14. Navalón V, Ordoño F, Pallás Y, et al. Long-term follow-up for the treatment of male urinary incontinence with the Remeex system. *Actas Urol Esp.* 2016;40(6):406–11.



15. Srivastava A, Peyser A, Gruschow S, Harnaja N, Jiskrova K, Tewari AK. Estrategias quirúrgicas para fomentar una temprana recuperación de la continencia después de la prostatectomía radical robótica. *Arch Esp Urol*. 2012;65(5):529–41.
16. Comiter C, Dobberfuhr A. The artificial urinary sphincter and male sling for postprostatectomy incontinence: which patient should get which procedure? *Invest Clin Urol*. 2016;57(1):3–13.
17. Comiter C. Surgery for postprostatectomy incontinence: which procedure for which patient? *Nat Rev Urol*. 2015;12:91–9.
18. Rehder P, Haab F, Cornu JN, Gozzi C, Bauer RM. Treatment of postprostatectomy male urinary incontinence with the transobturator retroluminal repositioning sling suspension: 3-year follow-up. *Eur Urol*. 2012;62(1):140–5.
19. Leach GE, Trockman B, Wong A, Hamilton J, Haab F, Zimmern PE. Post-prostatectomy incontinence urodynamic findings and treatment outcomes. *J Urol*. 1996;155:1256–9.
20. Yoshimura N, Chancellor M. Differential diagnosis and treatment of impaired bladder emptying. *Rev Urol*. 2004;6(Suppl 1):S24–31.
21. Aboseif SR, O'Connell HE, Usui A, Mc Guire EJ. Collagen injection for intrinsic sphincteric deficiency in men. *J Urol*. 1998;155:10–3.
22. Klutke JJ, Suij C, Andriole G, Klutke CG. Long-term results after antegrade collagen injection for stress urinary incontinence following radical retropubic prostatectomy. *Urology*. 1999;53:974–7.
23. Kaboré FA, Gaillet S, Blanc J, Boissier R, Aurier KL, Delaporte V, et al. Initial results of adjustable periurethral balloons (ACT™ and pro ACT™) in the treatment of adult stress urinary incontinence with intrinsic sphincter deficiency. *Prog Urol*. 2014;24(17):1132–8.
24. Van der Aa F, Drake MJ, Kasyan GR, Petrolekas A, Cornu JN. Young academic urologists functional urology group. The artificial urinary sphincter after a quarter of a century: a critical systematic review of its use in male non-neurogenic incontinence. *Eur Urol*. 2013;63:681–9.
25. Alwaal A, Harris CR, Awad MA, Allen IE, Breyer BN. Comparison of complication rates related to male urethral slings and artificial urinary sphincters for urinary incontinence: national multi-institutional analysis of ACS-NSQIP database. *Int Urol Nephrol* 2016;48(10):1571–6.
26. Gousse AE, Madjar S, Lambert MM, Fishman IJ. Artificial urinary sphincter for post-radical prostatectomy urinary incontinence: long-term subjective results. *J Urol*. 2001;166:1755–8.
27. Kumar A, Litt ER, Ballert KN, Nitti VW. Artificial urinary sphincter versus male sling for post-prostatectomy incontinence—what do patients choose? *J Urol*. 2009;181:1231–5.
28. Clemens JQ, Bushman W, Schaeffer AJ. Urodynamic analysis of the bulbourethral sling procedure. *J Urol*. 1999;162:1972–6.
29. Seweryn J, Bauer W, Pohnholzer A, Schramek P. Initial experience and results with a new adjustable transobturator male system for the treatment of stress urinary incontinence. *J Urol*. 2012;187:956–61.
30. Hoda MR, Primus G, Schumann A, Fischereider K, von Heyden B, Schmid N, et al. Behandlung der Belastungsinkontinenz nach radikaler Prostatektomie. *Urologe*. 2012;51:1576–83.
31. Bauer W. Adjustable transobturator male system—ATOMS—for the treatment of post-prostatectomy urinary incontinence: the surgical technique. *Pelviperrineology*. 2011;30:10–6.
32. Trost L, Elliott DS. Male stress urinary incontinence: a review of surgical treatment options and outcomes. *Adv Urol*. 2012;2012:287489.
33. Hubner WA, Gallistl H, Rutkowski M, Huber ER. Adjustable bulbourethral male sling: experience after 101 cases of moderate-to-severe male stress urinary incontinence. *BJU Int*. 2011;107:777–82.
34. Dalpiaz O, Knopf HJ, Orth S, Griese K, Aboulsorour S, Truss M. Mid-term complications after placement of the male adjustable suburethral sling: a single center experience. *J Urol*. 2011 Aug;186(2):604–9.
35. Lim B, Kim A, Song M, Chun JY, Park J, Choo MS. Comparing Argus sling and artificial urinary sphincter in patients with moderate post-prostatectomy incontinence. *J Exerc Rehabil*. 2014;10(5):337–42.
36. Panayotov IV, Orti V, Cuisinier F, Yachouh J. Polyetheretherketone (PEEK) for medical applications. *J Mater Sci Mater Med*. 2016;27(7):118.

---

# Adjustable Male Sling: Argus

Salomon Victor Romano and Christian Hector Cobreros

---

## Introduction

Post-prostatectomy urinary incontinence (PPI) remains a difficult problem to resolve. Several surgical treatments have been tried to provide relief from PPI, but a few have proven to be effective and have stood the test of time. One of these is without any doubt the bulbourethral sling, and its concept, which turns every day more, accepted its “adjustability.”

Although the bulbourethral sling was described in the last century, it was used sporadically in very few patients. In 1998, Schaffer et al. [1] report their experienced with a handcrafted sling made of teflon-coated Dacron tubes and polypropylene sutures tied in the abdomen after being transferred by using needles. That report with a mean follow-up of 2 years had good results but 25% of the reported cases required a readjustment. Similar results were reported by Stern et al. 2005 [2], with a mean follow-up of 4 years and 69% of the patients having good results (a combination of dry and improvement) with a 30% of readjustment needed.

In 2000 a project for a bulbourethral sling was developed in the Durand Hospital of Buenos Aires, being the Principal Investigator Prof. Dr. Victor Romano and Promedon S.A. as the Sponsor. The main idea was to develop a synthetic male sling that can offer enough strength and soft compression of the bulbar urethra, the possibility of readjustment, and possibly more effective in treating the PPI. We are going to revise the results of this protocol as several multicenter trials that continue with the Argus system as well, and there are now published in the index literature. With this information and our vast experienced in more than a hundred of Argus slings using both approaches, suprapubic (SP) and transobturator (Argus T), we are able to present several observations and surgical tips that we are sure that the reader will find them more useful.

---

S.V. Romano (✉) • C.H. Cobreros  
Department of Urology, Urodynamics and Female Urology Section,  
Hospital Carlos G. Durand, Buenos Aires, Argentina  
e-mail: [salomonapple69@gmail.com](mailto:salomonapple69@gmail.com); [christiancobreros@gmail.com](mailto:christiancobreros@gmail.com)

Our own experience allowed us to understand that the continence achieved with male sling surgery resulted from urethral compression and cooptation of the urethral lumen, helped by the mucosal seal.

From this, we identified three factors that are essential for a sling to work properly:

1. The compression must be constant, since a decreased in compression means returning to incontinence.
2. The compression must be as “gentle” as possible, remember the compression can cause devascularization which in turn can cause necrosis, leading to a catastrophic complication of urethral erosion.
3. The whole system is based on the idea of “adjustability”; due to the readjustment of the system, strength is necessary during the procedure or more than once in the postoperative period.

Therefore, with these three principle ideas in mind, the Argus system was born. It consists of a silicone foam pad supported by an expandable Dacron sling. It is connected to silicone columns in the shape of superimposed cones on each side which allow adjustment and fixation through the use of silicone washers. The entire system is radiopaque, making it easier to monitor its position after surgery (Fig. 1).

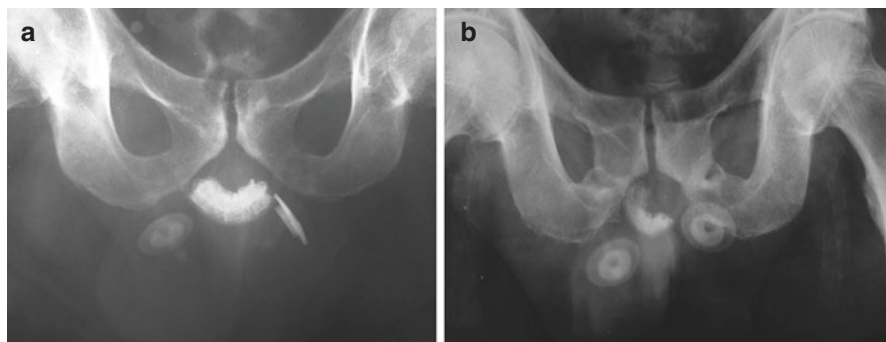
As with all new products, some aspects of the Argus system design had changed over time, improving the original model:

- The width of the pad was increased to keep it from rotating and widen the compression surface.
- Washers with a large diameter were added under smaller ones used for adjustment. They help protect the supporting fascia and muscle tissues.
- The columns were reinforced with a stronger silicone material to prevent spontaneous breakage (a situation that occurred with the original model and was corrected promptly) (Fig. 2).

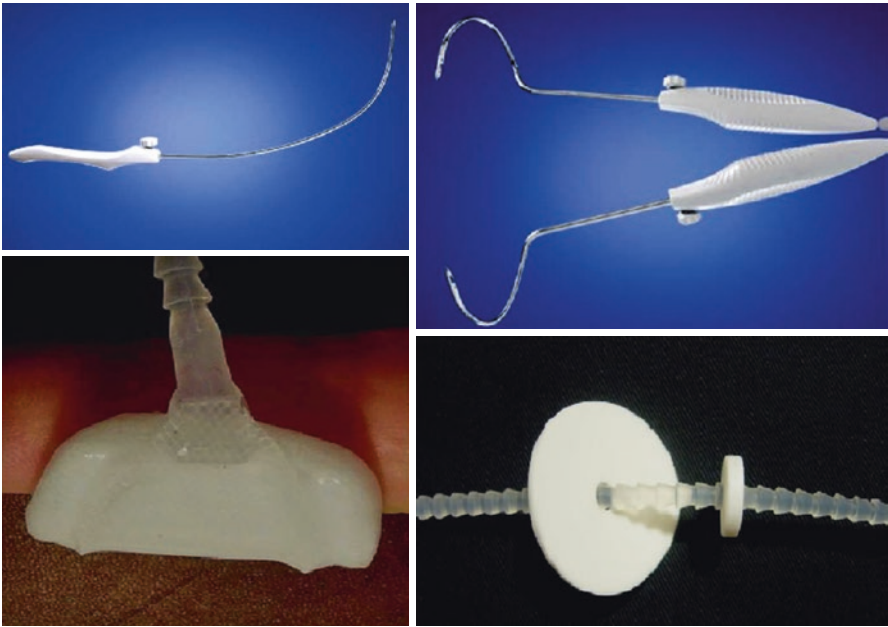
A number of surgical instruments were specially designed for the procedure:

Needles with a 90° curve for the suprapubic implant, spiral needles for the transobturator approach, with a hook or crochet for allowing it to catch and drag the columns.

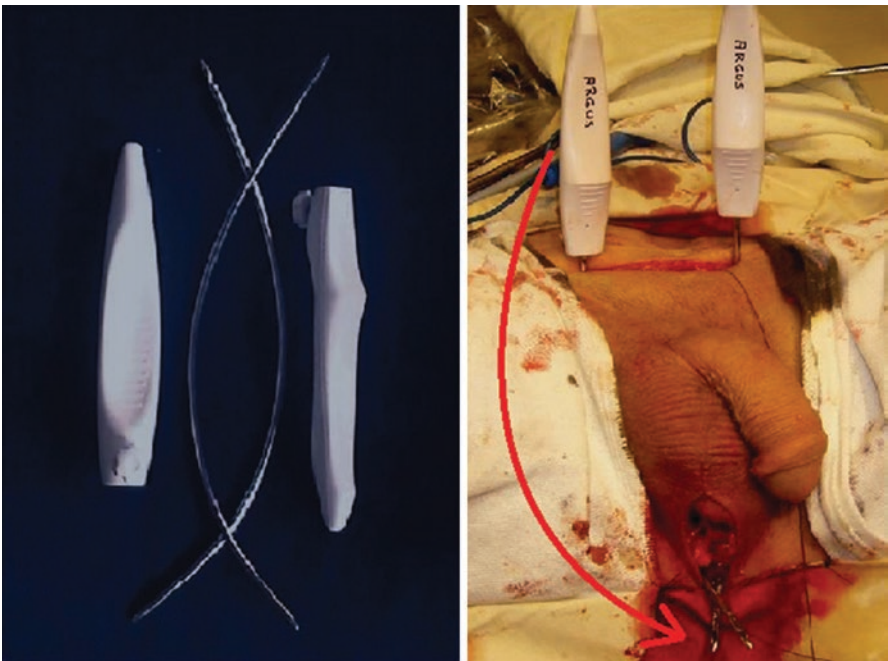
The interchangeable handle allows it to reposition once the sharp point has passed through the wall, releasing the hook to catch the columns (Fig. 3).



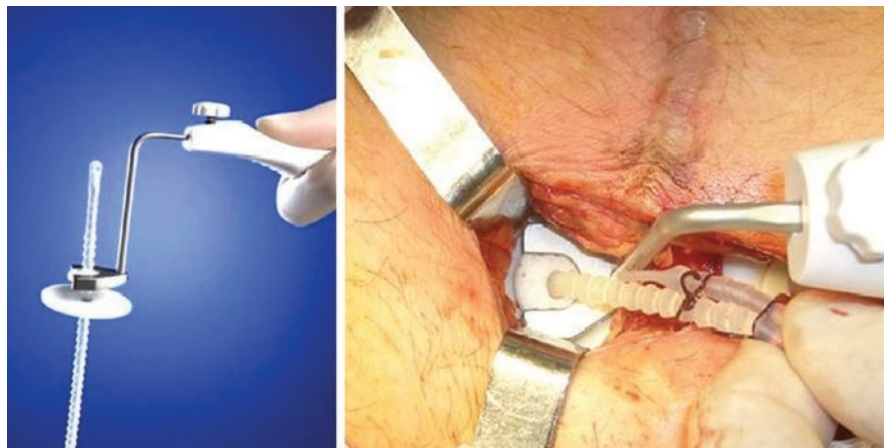
**Fig. 1** Being radiopaque the position of the Argus System can be easily verified with a simple XRay after surgery



**Fig. 2** The design of the needles, wider pad, and the big washer



**Fig. 3** Needles can be interchangeable



**Fig. 4** The pusher

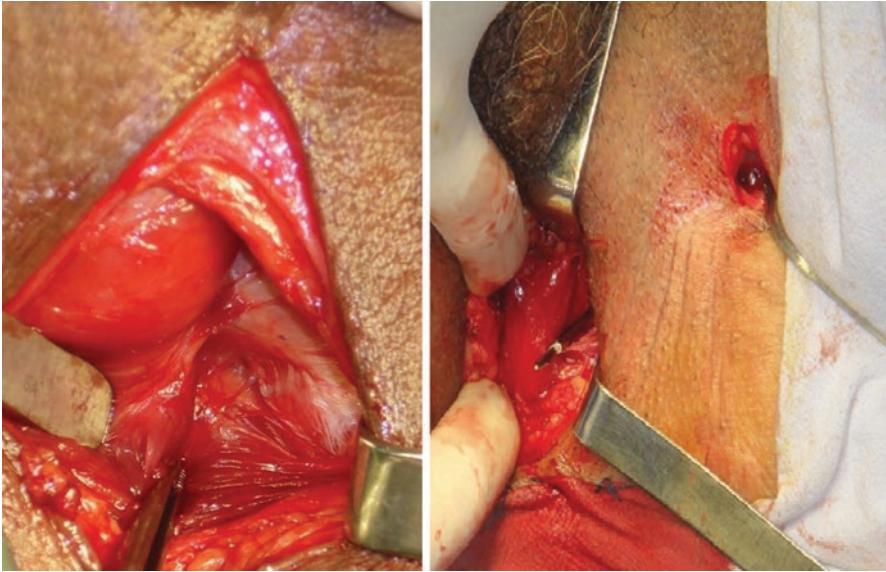
An instrument called “pusher” catches the small washer, making it easier to move it throughout the column of cones during adjustment by lifting or lowering the washers (Fig. 4).

## The Surgical Technique

### Suprapubic Approach

As Schaffer described, under spinal or general anesthesia, a 16 French Foley catheter is passed and the patient is placed in the dorsolithotomy position [1]. The suprapubic and perineal area have to be shaved and scrubbed with povidone-iodine soap. The anal canal is carefully isolated with drapes. A 5–7 cm transverse suprapubic incision is made until the aponeurosis is clearly seen. A 7-cm vertical perineal incision, centered in the inferior border of the pubic bone, is made, and then the dissection is carried down to bulbocavernosus muscle that is left in place undisturbed. The superficial perineal aponeurosis is clearly seen, the space between the bulbocavernosus and ischiocavernosus muscles is developed with both blunt and sharp dissection. With the specially designed 90° angle crochet needle, the perineal membrane is perforated anteriorly while the urethra is protected and displaced contralaterally with the other hand. The needle is introduced “shaving” the isciopubic ramus 2 cm. downward from the inferior border of the pubic bone.

Once the perineal membrane is perforated, the needle tip is directed to the suprapubic incision, behind the pubic bone, toward the ipsilateral shoulder. The needle is brought outside the rectus fascia. The same procedure is repeated on the contralateral side. With the needles in place, a cystoscopy is done to confirm the integrity of the urethra and the bladder. If a perforation is seen, the needle is then repositioned;



**Fig. 5** Anatomy and point of extraction of the Argus T needle

usually more laterally. The handles are changed at the suprapubic needle tips so the crochet tip in the perineum allows the columns to be snapped and moved upward to the abdominal area (Fig. 5).

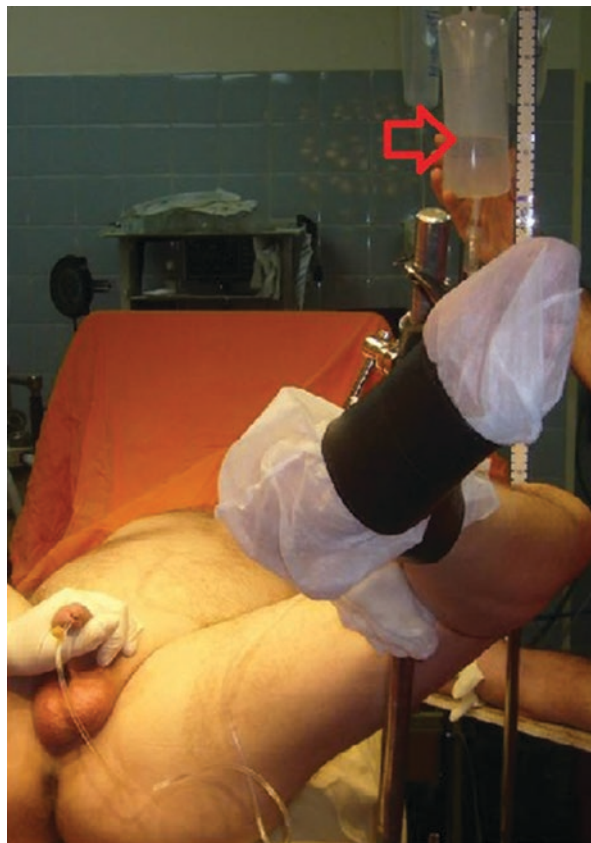As this point the big washer, first, and the smaller one afterward are transferred and positioned against the rectus fascia, but these are not yet tightened. The silicone pad must remain in the middle of the bulbar urethra.

Next the cystoscope is reinserted and the saline bag is set at a level of 35–40 cm above the pubic symphysis. The adjustment of the sling is made moving the washers with a “pusher” downward to tighten or upward to loosen the sling. The main objective is to achieve the urethral wall coaptation and to observe the stoppage of saline dripping in the chamber indicating that a retrograde leak point pressure (RLPP) of 35–40 cm has been achieved (Fig. 6). An indwelling 16-french Foley catheter is placed, and after a generous irrigation using a solution of saline plus gentamycin, the wound is closed in several layers. Antibiotic prophylaxis with intravenous 1 g of cephalothin during the surgical procedure and gentamicin every 12 h until the Foley catheter is removed. The Foley catheter is removed within 24–48 h after surgery and a voiding test is performed. A plain X-ray of the pelvis is taken to assess the final position of the sling and can be used for comparison during the follow-up (Fig. 1).

### **Transobturator Approach**

When the transobturator approach is preferred, the procedure begins with a perineal incision exactly as described for the suprapubic approach. A 2–3 cm inguinal incision is made 2 cm below the adductor longus tendon insertion in the

**Fig. 6** Taking the retrograde leak point pressure. The column of water to address its mark with an *arrow*



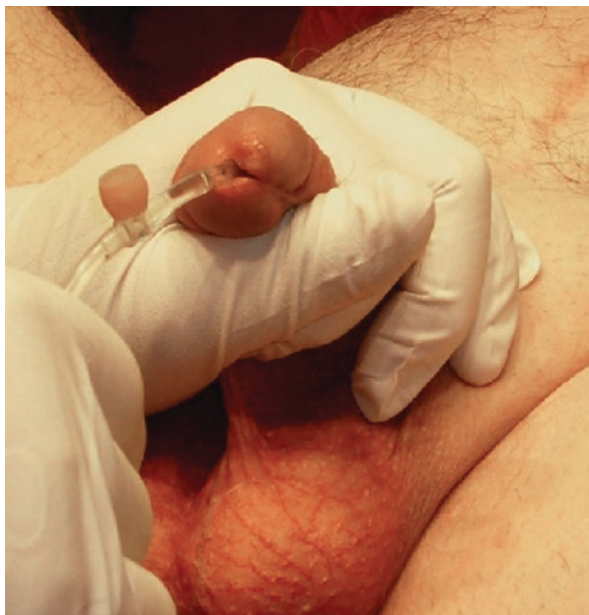pubis and over the inguinal fold. The fat is separated until the fascia, covering the muscles of the obturator foramen, is clearly seen. The spiral needles are passed from the outside to the inside, receiving the crochet point with the index finger of the other hand, which at the same time protects the urethra by pushing it away from the needle tip. The columns are transferred bilaterally and positioning of the washers is done (Fig. 6). Then the adjustment is carried out and regulated by the retrograde leak point pressure (RLPP) [3], until 35–40 cm of water pressure is reached. We use an intravenous infusion water line inserted 5–7 cm in the anterior urethra and manually compressing the penis with the other hand (Fig. 7).

Cystoscopy in this approach is optional, but required if hematuria is encountered. The rest of the patient management is the same as described above for the suprapubic approach. And subsequent evaluations can be performed by checking sling's position with plain X-rays.

As more experience is gained, some of the technical steps have been modified from the original technique, and these are described below:

- Only one suprapubic incision used, instead of the original two, these facilitates the dissection and adjustment maneuvers (Fig. 5)

**Fig. 7** Gentle and easy compression of the urethral meatus to determine the retrograde leak point pressure



- When using the suprapubic approach, the site where the needle enters the perineum must be 2 cm below the junction of the lower boundary of the pubic symphysis and the ischiopubic ramus. This avoids damaging the membranous urethra or the bladder neck (Fig. 5)
- The current accepted RLPP is lower, 35–40 cm of water, than the original recommended RLPP of 60–70 cm H<sub>2</sub>O. This helps to decrease the incidence of dysuria and postoperative urinary retention without affecting continence.

---

## Experience with Argus

We began implanting the Argus sling via a suprapubic approach, and after its proven effectiveness, we started a multicenter trial between April 2003 and September 2004. A total of 48 patients with PPI were included. The majority of these patients had severe incontinence. All patients underwent a complete urological evaluation, urodynamic study, cystoscopy, validated questionnaire (icIQ-sf), 24 h pad test (n° and weight), and overall impression questionnaire (OI). The results were reported as: dry (no pads to one pad for protection per day), improved (two pads), and failed (three or more pads per day). The results from that study with a follow-up of 1 and 4 years [4, 5] and a n = 47 patients were dry 66%, improved 12.8%, adm failed 21%. In other words, 79% of patients had good results (dry+ improved) in long term.

In 2005 after testing its feasibility in cadavers, we began implanting the Argus T™ via the transobturator approach, encouraged by the low morbidity already demonstrated in women. With promising initial results, it prompted us to conduct a multicenter study in 37 patients with varying severity of their urinary incontinence,



between November 2007 and October 2008. The results with a minimum of 1-year follow-up were published in 2010 [6]. The results were also classified as dry, improved, and failed for the whole group: 80.8%, 11.1%, and 8.3%, respectively. In 2014 we published the results of the same group of patients with a large follow up of 30 months, n: 36 (one patient lost to follow-up), and we divided the results into two different groups of patients; one having mild to moderate incontinence (8/36), results were dry, improved, and failed (100%, 0%, and 0%) and severe incontinence (20/28) with same measuring results (71%, 11%, and 18%). It has been reported in the literature that conventional male slings are usually the treatment of choice for mild to moderate incontinence, and artificial urinary sphincter implant is recommended for the treatment of more severe PPI, whereas, in our experience, Argus T<sup>TM</sup> has proved to be effective in providing continence in 71% of patients with severe incontinence in this multicenter trial giving us a new indication for Argus sling in severe PPI [7].

A several number of other centers have reported their results with Argus<sup>TM</sup> in the treatment of PPI which are similar to ours giving further support to our technique, efficacy, and reproducibility and can be found in the literature.

---

## Complications

The most important complications are infections (8%) and erosion (6%), which lead to sling removal in majority of these cases, but in majority of these cases, it may remain localized and may be managed with local wound care and systemic antibiotics.

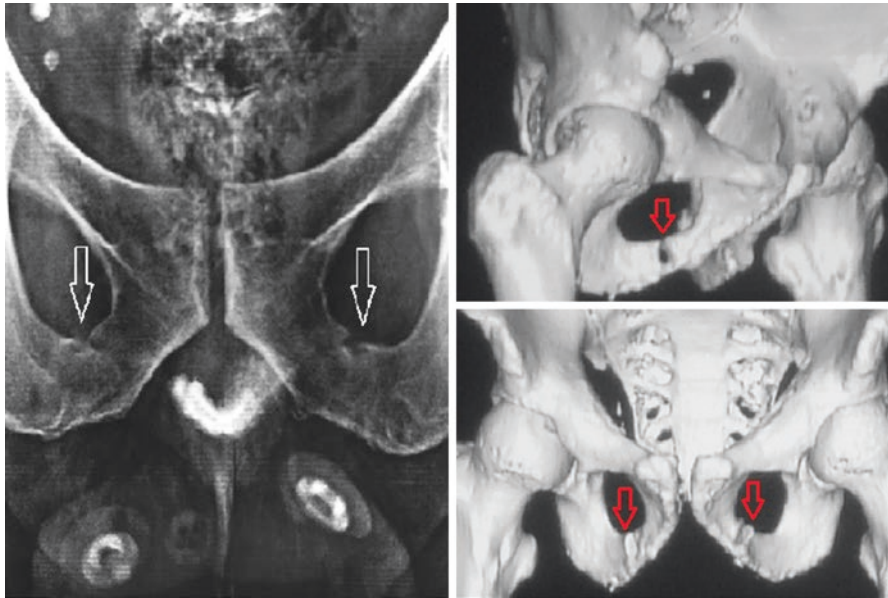
In our experience, and as reported by others, the infection usually appears within the first 2 weeks, and it indicates the need for removal of the sling. We do find, as in every synthetic implant, that the aseptic technique when handling the prosthesis is crucial. We have encountered frequent infection complications with increase in operating time. Thus, we do suggest to minimize the operative time and avoid mishandling as much as possible to decrease the infection rates.

Urethral erosion occurred in our first few early cases due to two factors:

- The rotation of the pad to its sharp stiff Dacron back (Figs. 2 and 8). This occurred early within the first few weeks after surgery. Clinical presentation was severe perineal pain, urethral burning, acute or chronic urinary retention, and lower urinary tract symptoms.
- The other factors that we consider in some of the initial cases were related to high compression pressure of the sling over the bulbar urethra. We found that in choosing a new lower level of RLPP, up to 30–45 cm H<sub>2</sub>O, urethral erosion decreased in its frequency as an adverse event.

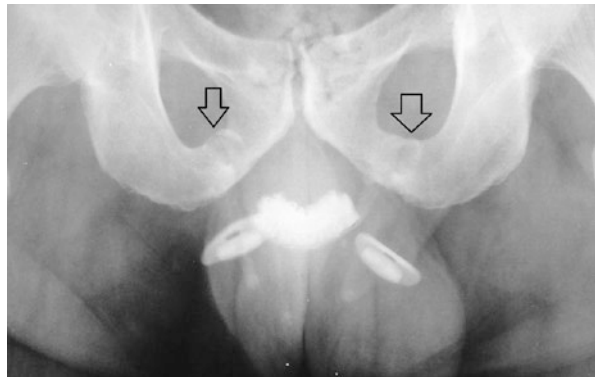
As we described extending the pad past the edge of its stiff back prevents the rotation of the sling and protects the urethra as well.

We also described two more different types of erosion; one caused by the small washer perforating the abdominal wall, this has been resolved by placing a larger washer between the small washer and the abdominal wall (Fig. 4). And the



**Fig. 8** The bone notches (*arrows*) in a pelvis X-ray and CT scan

**Fig. 9** The notch, the first sign of osteomyelitis



other type of erosion was detected recently, in a patient in whom the Argus system was removed for infection causing osteomyelitis of the ischiopubic ramus. This was detected on the pelvic CT scan prior to the removal of the infected sling (Fig. 8). We now strongly recommend that whenever there are signs of wound infection, it is presumed that the whole system is infected and may have to be removed. The patient should be made aware of this complication and should be closely followed. The pelvic bones should be checked with plain X-ray, looking for the early signs of osteomyelitis (Fig. 9). If the patient is continent and asymptomatic, the sling removal can be delayed, and the patient can be kept under close observation.

Another frequent complication is the perineal or inguinal pain in most of the patients with the Argus T during the first 2–4 weeks after surgery and usually responds to standard treatment with nonsteroidal, anti-inflammatory drugs and/or corticosteroids. Only less than 1–2% of the patients remain with a chronic pelvic pain that need to be treated with opiates, pregabalin, or in an extreme case the removal of the sling. When associated with an infection, the removal of the sling will be warranted.

Acute urinary retention and dysuria are directly related to the tension applied against the urethra. In our first four cases, the pad was sutured with Prolene, which was then tied to the rectus fascia, and the retrograde pressure was adjusted to 100 cm of water, as suggested by Schaeffer et al. [1]. In two of these patients, we had to cut the suture urgently, in 48 or 72 hs due to urinary retention and terrible pain. Problems were resolved immediately after cutting the Prolene sutures. It is important to note that intraoperative RLPP of 30–40 cm H<sub>2</sub>O combined with the reliable anchoring support by the rings decreases this type of complication in up to 5.6% (2/36 patients). In the Argus T multicenter trial, one resolved with readjustment (loosening) and the other with self-catheterization. [6].

---

## Conclusions and Remarks

We are able to demonstrate that the Argus male sling is a very effective and a reliable method for treating PPI either via suprapubic or transobturator approach and is also durable in the long term.

How do we choose the best approach for each patient?

We do recommend a transobturator approach for the patient who has a PPI and has never been surgically treated before. This is due to the limitations of the transobturator approach to induce a greater compression, by the anatomic positioning of the columns that are limited to a horizontal position. Generally, no more than 40 cm H<sub>2</sub>O of RLPP should be exerted. But the continence cannot be achieved with RLPP less than 28 cm H<sub>2</sub>O.

Although in some patients more pressure is needed to achieve continence, and in those patients a suprapubic approach will be more useful as unlimited compression of the bulbar urethra is virtually possible; however there is increased risk of complications when higher RLPP is needed to achieve continence.

The type of approach can also be changed intraoperatively during the procedure itself, with same perineal incision and the same sling, except changing the needles only.

Since both SP and Argus T approach have demonstrated to be effective in the treatment of PPI, the type of approach should be determined by the surgeon, based on his preference and patient selection.

## References

1. Schaeffer A, Clemens Q, Ferrari M, Stamey T. The male bulbourethral sling procedure for post-radical prostatectomy incontinence. *J Urol*. 1998;159:1510–5.
2. Stern JR, Clemens JQ, Si T, Matschke HM, Jain DM, Schaeffer AJ. Long term results of Bulbourethral Sling Procedure. *J Urol*. 2005;173:1654–6.
3. Comitter CV, Sullivan MP, Yalla SV. Retrograde leak point pressure for evaluating post-radical prostatectomy incontinence. *Urology*. 1997;49:231.
4. Romano SV, Metrebian SE, Vaz F, Muller V, Levi D'Ancona CA, Costa de Souza EA et al. An adjustable male sling can be implanted by transobturator approach for treating post-prostatectomy urinary incontinence. Surgical technique and early results of a multicenter trial. Video Session 4, No 17, 39 annual meeting of the ICS, 2009
5. Romano VS, Metrebian SE, Vaz F, Muller V, CA D'A, Consta da Souza EA, et al. Long term results of the phase III multicenter study for the treatment of post-prostatectomy urinary incontinence with a male adjustable sling: minimum 3-year follow up. *Actas Urol Esp*. 2009;33(3):309–14.
6. Romano SV, Hubner W, Trigo Rocha F, Muller V, Nakamura F, Argus T. for post prostatectomy urinary incontinence. Outcome minimum 12 month of a multicenter trial. *Neurol Urodyn*. 2010;29(6):918–9.
7. Romano SV, Hubner W, Trigo Rocha F, Muller V, Nakamura F. A transobturator adjustable system for male incontinence: 30-month follow-up of a multicenter study. *Int Braz J Urol*. 2014;40(6):781–9.

---

# ProACT for Treatment of Male SUI

Wilhelm A. Hübner

---

## Introduction

ProACT® consists of two silicone balloons that are placed close to the bladder neck in the position of the prostate (after radical prostatectomy (RPE)) or near the apex (Fig. 1). Initially, balloons were introduced by Uromedica as a therapy for female urinary stress incontinence. However, secondary to the way of action, it was soon recognized that the best indication would be a type III incontinence, and therefore utilization for male urinary stress incontinence was started. The first implantations of ACT® balloons for PPI were performed 1999 in Korneuburg (Austria), shortly followed by Novara (Italy). These operations were successful, so Uromedica commenced the production of a male version—ProACT®. The ProACT® balloons were the first reasonable alternative to the AMS 800, minimally invasive also representing the first implant for incontinence, providing adjustability any time after implantation. A first series of 117 patients was published 2005 [1].

---

## Implant and Instruments

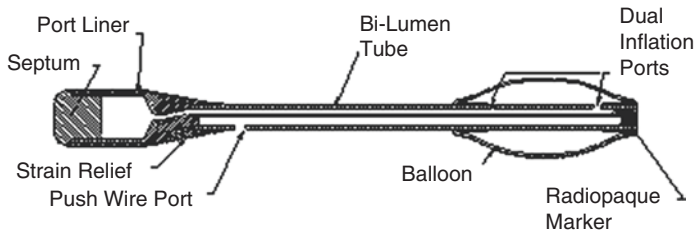
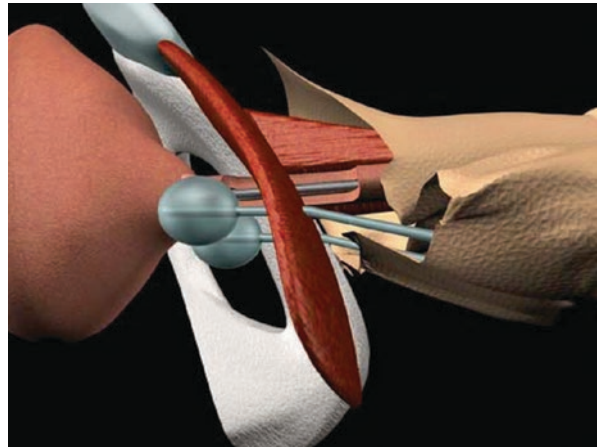
The implant consists of a silicone elastomer balloon, connected to a self-sealing port by a 2 lm conduit (Fig. 2). The tip of each balloon has a radio-opaque marker that can be easily visualized under fluoroscopy to confirm the correct position. The conduit carries 1 lumen to connect the balloon with the port to fill the balloon, while the other lumen is occupied by a push wire, in order to stiffen the device during the implantation. Normally two balloons will be used at initial implantation. The titanium port is designed to self-seal during the filling or withdrawal of fluid from the balloon.

---

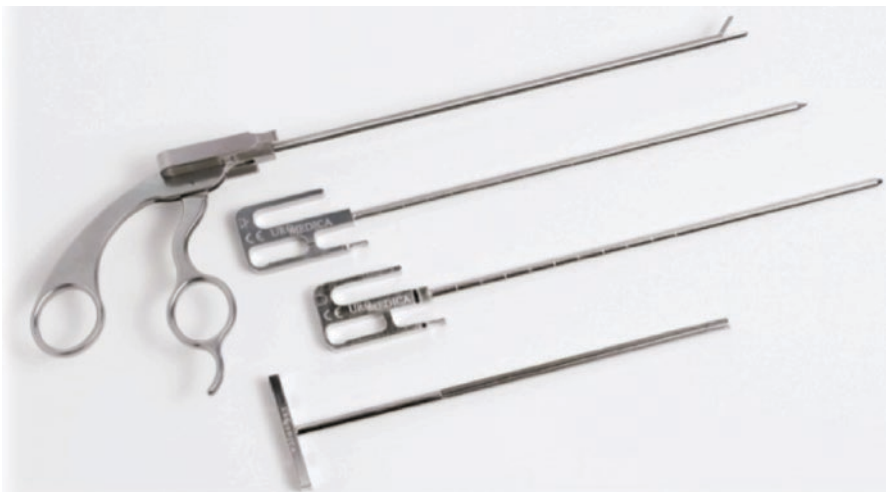W.A. Hübner

Department of Urology, Korneuburg Hospital and Karl Landsteiner Institute for Functional Disorders and Disorders Tumors of the Urinary Tact, Korneuburg, Austria  
e-mail: [w.huebner@yahoo.com](mailto:w.huebner@yahoo.com)

**Fig. 1** Cartoon of the ProACT devices at the bladder neck



**Fig. 2** ProACT balloon, schematic drawing



**Fig. 3** Trocars (blunt and sharp tip) U channel sheath and TED

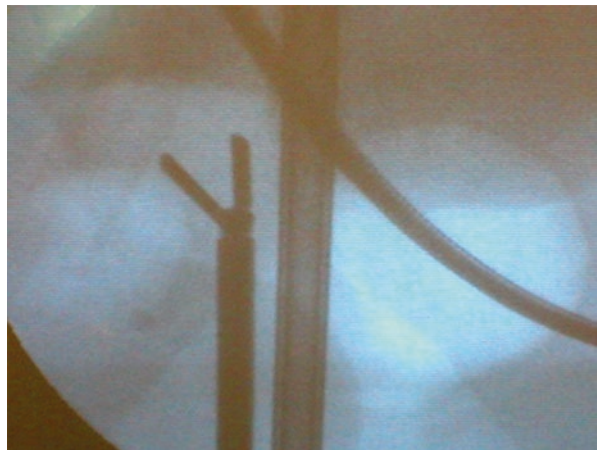
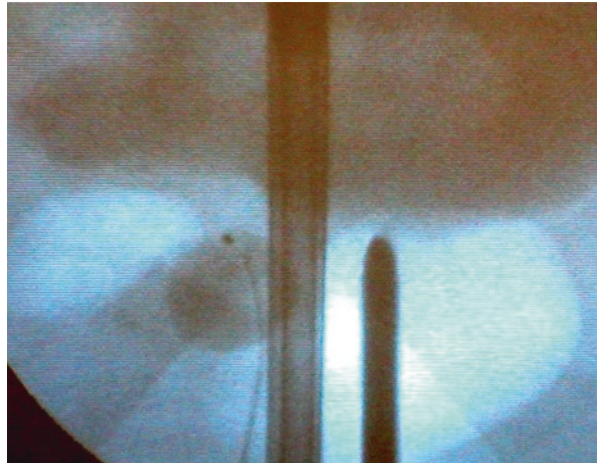
In order to facilitate implantation, special instruments are provided (Fig. 3). The U-shaped sheath can carry a sharp stylete for perforation of the pelvic floor, a blunt one to open layers above the pelvic floor and the tissue expansion device (TED) do develop and increase space for to hold the balloon.

## Surgical Technique

The patient is prepared and placed in the lithotomy position under general, spinal, or local anesthesia. Fluoroscopy is attached and the balloons are evacuated from air. After cystoscopy the bladder is emptied and filled with 100 cc of contrast solution via the rigid cystoscope in order to visualize the bladder and bladder neck. The cystoscope is retained to maintain a straight horizontal positioning of the urethra.

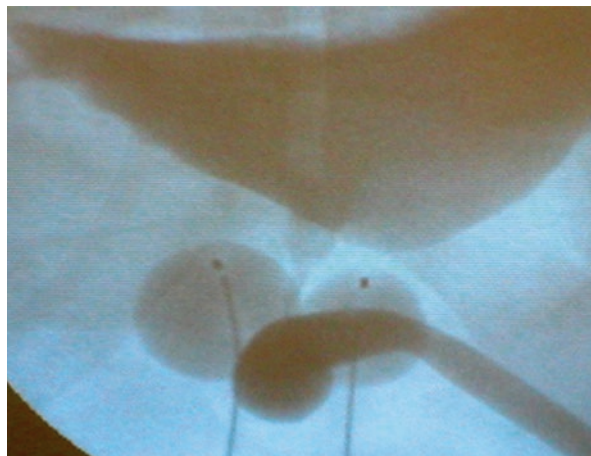
Two small perineal stab incisions (alternatively one 2 cm transverse incision) are made on each side of the urethra. A hemostat is now used to subcutaneously palpate the ipsilateral inferior ramus of the pubic bone and the rigid cystoscope sheath for orientation. Fluoroscopy provides further topographic information. Once the correct entry point in a small triangle between the urethra (cystoscope) and pubic bone is identified, the pelvic floor is perforated ca 1 cm paraurethrally using the sharp trocar. Parallelity of cystoscope and trocar in fluoroscopy help avoiding urethral trauma (Fig. 4). When the pelvic floor has been passed, the blunt trocar and the TED are used to develop and define the spot for balloon position (Fig. 5). This should be close to the bladder neck

**Fig. 4** Controlling trocar position by fluoroscopy



**Fig. 5** TED developing space for the balloon

**Fig. 6** UCG showing bilateral impression of the urethra minimizing prostate shape



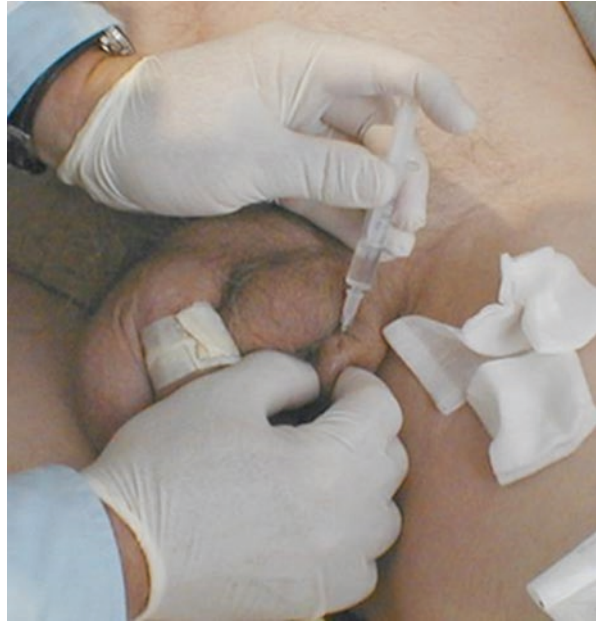after RPE or next to the apex in patients with the prostate in place (after TURP, external beam radiation therapy (EBRT)). Finally the inner part of the trocar (TED or stylete) is removed and the balloon put in place with the help of the push wire. Attention should be paid to make sure the wire reaches the tip of the balloon. The balloon is then inflated with 0.5–1 ml of isotonic contrast using a non-coring needle, and the U-shaped trocar is removed while securing the balloon position with the push wire. The procedure is repeated on the contralateral side. Correct position of the balloons as well as slight narrowing of the urethra may be confirmed by a UCG (Fig. 6). Now the push wires may be removed. Finally the ports are buried superficially in the sub-dartos fascia in the anterolateral wall of the scrotum, in order to enable percutaneous adjustment after surgery. Wounds are closed after rinsing with antibiotic solution. A 14Fr Foley catheter is inserted for 12 h.

In the rare case of intraoperative bladder perforation, a new position for the balloon has to be established, and the Foley is left for 5 days. If the urethra has been perforated, the implantation on this side has to be abandoned. It may be approached again after 3 months; however, many patients may be cured with unilateral placement of a balloon.

In 2006 an alternative implantation technique was described by Gregori, implanting the balloons under transrectal ultrasound (TRUS) guidance [2]. Namely, when doing the procedure in local anesthesia, this novel approach carries advantages, as the anesthetic can already be injected under sonographic control. The initial incision is similar to the one described above. The progression of the trocar is controlled with TRUS guidance using a 7.5 MHz linear and small convex probe. The trocar is inserted through skin incision and directed to one side of the bladder neck, perforating the pelvic diaphragm. The layers may additionally be opened injecting ca 10 ml saline at the bladder neck through the trocar with a long puncture needle. This maneuver can well be monitored by TRUS. With the US-guided approach instead of a rigid cystoscope, a Foley catheter may be used making the possibility to perform the procedure under local anesthesia even more likely. Ultrasound allows an excellent visualization of the catheter and the surrounding anatomical structures. Placement of the balloons finally works just as described above.



**Fig. 7** Percutaneous adjustment



---

## Postoperative Care

According to the healthcare system, the procedure can be performed as an outpatient therapy. At any rate antibiotics should be applied for 4 days minimum. The Foley is removed after 12 h. Some patients might show improved continence due to postoperative swelling but usually become incontinent after the edema has subsided. Adjustment can be started 4–6 weeks later, when the pseudo-capsule has formed around the balloons (Fig. 7). Further adjustments can be made in 3–4 week intervals until total continence is achieved. Adjustments should be limited to 1 ml per balloon per visit, to minimize pain and the risk of migration. Balloons can be inflated to a volume of 8 ml. The device can be deflated if the patient develops obstructive voiding difficulties.

---

## Results: assessment

Several groups worldwide have included ProACT implantation in their armamentarium to treat male incontinence. The success rate varies from 56 to 92% in different series of patients published in several peer-reviewed articles as shown in Table 1 [1–10]. In these series, ProACT implants were used for male stress urinary incontinence both secondary to radical prostatectomies and after TURP or simple prostatectomy. It is important to note that EBRT is a contraindication for ProACT implantation and that transurethral manipulations or urethral fibrosis may cause less favorable outcomes. In some of the early series, indications were made less

**Table 1** ProACT results

Author	# pts	% post-RP	Avg f/u months	Avg # adjust	% pats impr.	0–1 pds/day %	Pre-op pds/d	Last f/u pds/p	Explanted %
Hübner/Schlarp	117	88	13	3	90	67	6	1	27
Gilling	33	81	24	3.3			2.8	0.7	9
Trigo-Rocha	23	100	22.4	4.6		65	4.6	1.8	17
Hübner/Schlarp	50	100	20	4	82	60	5	1.8	24
Crivellaro	44	100	19		84	68	5.1	2.5	14
Lebret	56	98	6		89	71	4.6	1.8	33.9
Kocjancic	64	100	12	3	80	68	5.2	1.5	17
Martens	29	100	41	3.7	56	31	4.8	3.1	44.8
Luyckx	60	93	8.9	2.7	85	64	2.5	1.2	20
Hidalgo	69	87	22	2–3	84	70			9
Gregori	62	100	25	3.6	92		3.7		4

selective leading to a lower success rate. The reoperation rate is significant, but the character of complications (balloon rupture, migration, port infection) is mild. The device may be explanted under local anesthesia, if bladder or urethral perforation occurs an indwelling catheter is left for 3–5 days. In summary patients are very satisfied [11]. The minimal invasivity and good results when well indicated have led to a constant use of this product over more than a decade, while many other products have been introduced, but soon after left the market.

## References

1. Hübner WA, Schlarp OM. Treatment of incontinence after prostatectomy using a new minimally invasive device: adjustable continence therapy. *BJU Int.* 2005;96:587–94.
2. Gregori A, Simonato A, Lissiani A, Scieri F, Rossi R, Gaboardi F. Transrectal ultrasound guided implantation of the ProACT adjustable continence therapy system in patients with post-radical prostatectomy stress urinary incontinence: a pilot study. *J Urol.* 2006;176(51):2109–13.
3. Gregori A, Romano AL, Scieri F, Pietroantuono F, Incarbone GP, Salvaggio A, Granata A, Gaboardi F. Transrectal ultrasound-guided implantation of adjustable continence therapy (ProACT): surgical technique and clinical results after a mean follow-up of 2 years. *Euro Urol.* 2010;57(3):430–6.
4. Crivellaro S, Singla A, Aggarwal N, Frea B, Kocjancic E. Adjustable continence therapy (ProACT) and bone anchored male slings: comparison of two new treatments of post prostatectomy incontinence. *Int J Urol.* 2008;15(10):910–4.
5. Gilling PJ, Bell DF, Wilson LC, Westenberg AM, Reuther R, Fraundorfer MR. An adjustable continence therapy device for treating incontinence after prostatectomy: a minimum 2-year follow-up. *BJU Int.* 2008;102:1426–30.
6. Trigo-Rocha F, Mendes Gomes C, Lima Pompeo AC, Marmo Lucon A, Arap S. Prospective study evaluating efficacy and safety of adjustable continence therapy (ProACT) for post radical prostatectomy urinary incontinence. *Urology.* 2005;67(5):965–9.

7. Hübner WA, Schlarp OM. Adjustable continence therapy (ProACT): evolution of the surgical technique and comparison of the original 50 patients with the most recent 50 patients at a single centre. *Euro Assoc Urol.* 2006;52(3):680–6.
8. Kocjancic E, Crivellaro S, Ranzoni S, Bonvini D, Gontero P, Frea B. Adjustable continence therapy for the treatment of male stress urinary incontinence: a single-centre study. *Scand J Urol Nephrol.* 2007;41:324–8.
9. Martens FM, Lampe MI, Heesakkers JP. ProACT for stress urinary incontinence after radical prostatectomy. *Urol Int.* 2009;82(4):394–8.
10. Garcia Matres MJ, Cansino Alcaide JR, Monasterio S, Rodriguez de Bethencourt F, Hidalgo Togados L, de la Pena Barthel J. Paraurethral adjustable continence therapy device (Pro-ACT) in the treatment of urinary incontinence after prostatic surgery. *Arch Esp Urol.* 2009;62(10):871–81.
11. Bretterbauer KM, Huber ER, Remzi M, Huebner WA. Telephone - delivered quality of life after 365 male stress urinary incontinence (SUI) operations. *Int Braz J Urol.* 2016;42(5):986–92.

---

# Use of the Artificial Urinary Sphincter in the Management of Post-prostatectomy Incontinence

Brian J. Linder and Daniel S. Elliott

---

## Introduction

Primary surgical management of men with persistent bothersome stress urinary incontinence (SUI) following prostatectomy, either with urethral sling placement or artificial urinary sphincter (AUS) placement, is typically highly successful [1, 2]. However, as with most surgical procedures, appropriate patient selection and counseling are a crucial component to obtaining excellent outcomes. Here, we review the preoperative considerations, operative technique, and postoperative outcomes and complications for artificial urinary sphincter placement.

---

## The Artificial Urinary Sphincter: Background and Design

Originally introduced in 1974 [3], the AUS is the most efficacious option in the surgical management of severe male stress urinary incontinence. Notably, however, in the United States, AUS implantations represent approximately 12% of anti-incontinence procedures performed for men with urinary incontinence [4]. This may be secondary to risks of the procedure and/or patient preferences regarding implanting a mechanical device [5].

The most commonly implanted AUS model is the AMS 800 (Boston Scientific, Marlborough, MA), which consists of three components, an inflatable urethral cuff, a scrotal pump, and an abdominal reservoir/pressure-regulating balloon (Fig. 1). When cycled, the scrotal pump shunts fluid from the urethral cuff to the abdominal reservoir, thus decreasing the pressure in the urethral cuff and allowing the urethra to be patent for voiding. A refill-delay resistor maintains the urethral cuff in this

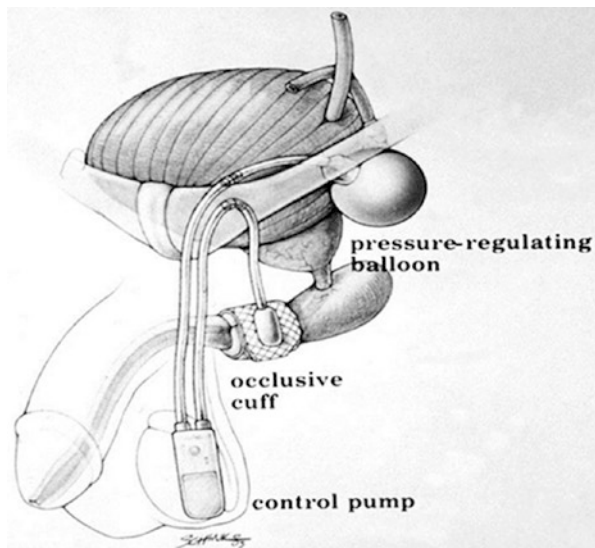
---

B.J. Linder • D.S. Elliott (✉)

Department of Urology, Mayo Clinic, Rochester, MN 55902, USA

e-mail: [Elliott.Daniel@mayo.edu](mailto:Elliott.Daniel@mayo.edu)

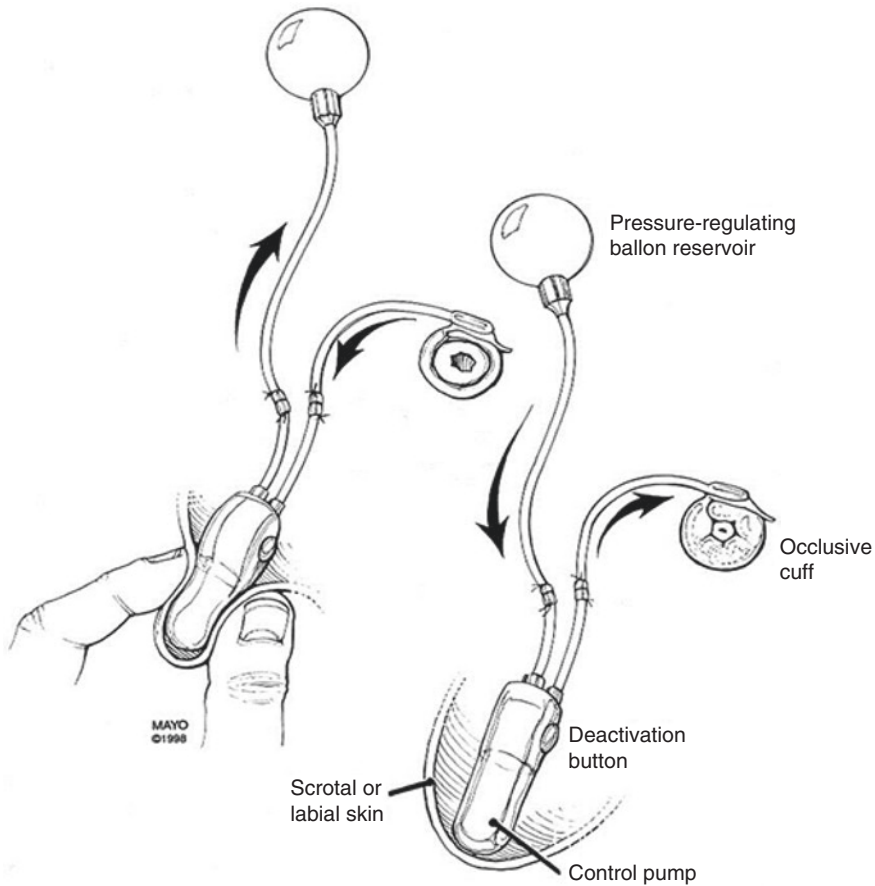
**Fig. 1** Representative illustration of an artificial urinary sphincter including urethral cuff, abdominal reservoir, and scrotal pump



open state to permit voiding for 60–90 s and then allows the fluid to be transferred back to the cuff, to maintain continence (Fig. 2). Notably, the scrotal pump also contains a deactivation button at its superior aspect, which allows the cuff to be placed into a locked “deactivated” position. Such a feature is needed in the event a patient is to undergo catheter placement, cystoscopy, or potentially for nighttime deactivation in an effort to reduce urethral atrophy [6]. Device activation from the locked state is achieved by squeezing the scrotal pump (as with normal cycling), which forces the deactivation button out of the locked position and restores the typical AUS functions. It is worth noting that a deactivated device can easily be identified on physical exam due to a dimpling in the pump, as it is not completely full (as it would be in the activated state).

## Preoperative Evaluation

Males presenting with bothersome stress urinary incontinence following prostatectomy should undergo a history and physical examination, with attention paid to the duration of time from prostatectomy, any change/improvement in continence over time, detailing stress versus urge incontinence symptoms, a history of underlying urologic pathology (e.g., urethral stricture, urothelial malignancies, prior urolithiasis, etc.), history of hematuria or urinary tract infections, as well as prior genitourinary treatments (including pelvic radiation). Notably, a recent consensus panel on AUS implantation advocated for a waiting time of 6 months following surgery in cases of severe (i.e., gravitational) incontinence that are not improving with conservative management [7]. They noted that if the patient’s incontinence is progressively improving, even at 12 months, surgical therapy can be delayed at the surgeon’s



**Fig. 2** Representative demonstration of artificial urinary sphincter pump cycling

discretion [7]. Additional further evaluations of the patient's degree of incontinence (e.g., pad weight, validated questionnaires, etc.) may be employed per the discretion of the treating physician. With regard to potential artificial urinary sphincter placement, specific attention during the physical exam should be focused on the patient's capacity to potentially manipulate the device. Notably, acceptable AUS success rates have been reported in elderly patients, provided they have the mental and physical capacity to justify device placement [8, 9].

The extent of additional testing may depend on which treatment for post-prostatectomy incontinence the patient wishes to pursue. In all patients, we perform a urinalysis and noninvasive uroflow test with post-void residual to assess for active urinary tract infection and incomplete bladder emptying. Likewise, we typically perform cystoscopy to evaluate for urethral stricture, vesicourethral anastomotic stenosis, or other urothelial pathology. Further testing including imaging (e.g., history of nephrolithiasis, urothelial carcinoma, hematuria), urine cytology (e.g.,

irritative lower urinary tract symptoms, history of urothelial carcinoma), and PSA may be obtained as clinically indicated. While we do not routinely perform complete multichannel urodynamic studies in those interested in AUS placement, these are used in cases with suspicion of altered bladder compliance (e.g., prior radiation, neurologic disease, etc.) or urge-predominant mixed urinary incontinence. By comparison, urodynamic evaluation, including an evaluation of detrusor contractility, may be more useful in those interested in compressive urethral sling placement. Patients with prior histories of urothelial carcinoma, urethral stricture disease, and anastomotic stenosis, among others, should demonstrate a sufficient period of disease stability prior to consideration of AUS placement to reduce the risk of erosions resulting from subsequent repeated cystoscopic interventions.

Depending on the results of the preoperative evaluation, patients can consider treatment with a urethral sling or AUS. The decision regarding which procedure to perform in males presenting with stress urinary incontinence is based on several factors, including patient preferences [5]. Notably, for optimal outcomes with male urethral sling placement, patient selection is crucial. In that regard, several factors have been associated with increased rates of persistent stress urinary incontinence following sling placement including pad weight greater than 450 g/day, previous pelvic radiation therapy, and a low detrusor leak point pressure [10]. For these patients, or those who have failed a prior urethral sling, AUS placement may achieve greater continence when patient capability and preferences permit.

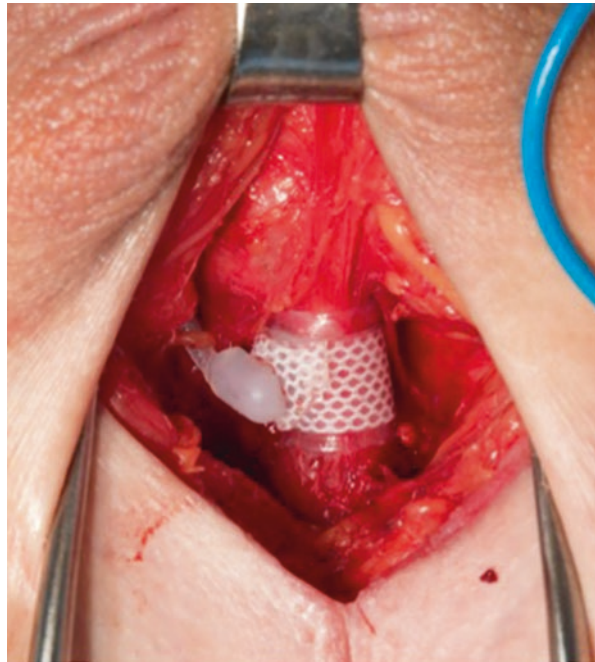
---

## Operative Technique for Primary Implantation

In terms of the surgical technique for AUS placement in males, we prefer to use a perineal approach, with patients in the dorsolithotomy position, and placement of the urethral cuff around the proximal bulbar urethra. Penoscrotal techniques for AUS implantation have been described, but in our experience these tend to lead to more distal cuff placement and subsequent revisions. In fact, a multicenter study found that there is a higher completely dry rate, with fewer subsequent revision surgeries with a perineal approach than with a penoscrotal approach [11].

For the surgery, the skin is prepped with chlorhexidine, as this has been associated with lower device infection rates than a povidone-iodine preparation [12]. Intravenous antibiotics are administered within 60 min prior to incision; we prefer the use of vancomycin and an aminoglycoside. Draping is performed based on a “no-touch” technique using Ioban, as described in the penile prosthesis literature [13]. We then place a 12 Fr urethral Foley catheter to drain the bladder and proceed with the perineal dissection. Here, we perform circumferential dissection of the proximal bulbar urethra between the corpora cavernosa and corpus spongiosum and leave the bulbocavernosus muscle intact (Fig. 3). The urethra is then assessed to ensure that no urethrotomy has occurred during the dissection. We perform this via pericatheter injection of saline, with the Foley on slight tension to occlude the bladder neck, and evaluating for extravasation. The urethra is then measured and the appropriate sized urethral cuff is selected. In cases of severely atrophic urethral

**Fig. 3** Intraoperative photo demonstrating the perineal dissection and placement of the urethral cuff at the proximal bulbar urethra



tissues (3.5 cm or less) or difficult dissection planes (e.g., in some cases with prior pelvic radiation therapy or urethral sling placement), we utilize a transcorsporal approach [14, 15]. Notably, we do not place tandem urethral cuffs as primary implantations. This practice is supported by evidence that tandem cuff placement may lead to a higher rate of subsequent revisions than single cuff placement [11, 16, 17]. Likewise, this approach also allows us to reserve tandem cuff placement for future revisions secondary to urethral atrophy, if needed.

Following completion of the urethral dissection, attention is turned to placing the abdominal reservoir and scrotal pump. We use a separate abdominal incision for ectopic submuscular/preperitoneal placement of a 61–70 cm abdominal reservoir. The reservoir can be filled with either normal saline or isoosmotic contrast. In our practice, 22 cm<sup>3</sup> of isoosmotic contrast, a water/contrast mix of 48 mL iohexol (Omnipaque 350) and 60 mL sterile water, is instilled in the reservoir at the time of placement to assist with identification of mechanical failure during future evaluations if they are needed for recurrent stress incontinence [18]. Or the reservoir can also be filled with 22 mL of saline instead which is more commonly utilized. The scrotal pump is placed in the anterior scrotum on the side of the patient's dominant hand (and the same side as the tubing of the other components), in an effort to avoid difficulty with pump manipulation. This is achieved by passing a long Kelly from the abdominal wound and transferring pump into the scrotum. A clamp is passed from the abdominal wound to the perineal wound to retrieve the urethral cuff tubing. Excess tubing is trimmed, and the quick connector system is used to complete the



connections between the tubing from the three components [7]. At the end of the procedure, the device is left in the deactivated position postoperatively, and the 12 Fr Foley catheter is left indwelling.

In our practice, patients stay overnight in the hospital for observation, and their catheter is removed the morning following surgery. After a voiding trial, the patient is instructed on pulling the scrotal pump to a dependent position twice daily until their 6-week follow-up visit. At the 6-week visit, the device is activated, and patients are instructed on routine use.

---

## Outcomes

While there are numerous surgical series of patients treated with urethral sling placement or artificial urinary sphincter implantation, it is admittedly difficult to compare outcomes between reports. This is secondary to the fact that in the available studies, there are no standard methods for reporting the degree of incontinence or criteria to define “success.” The majority of studies have poorly or undefined inclusion/exclusion criteria, with significant heterogeneity of the patient populations, including inconsistent inclusion of patients with varied etiologies for stress incontinence, and variable lengths of follow-up. These factors, among others, limit the ability to draw comparisons between studies and surgical techniques.

Notably, despite variation between studies, the current literature consistently demonstrates high long-term success rates for primary AUS implantation [1, 17, 19–23]. That is, a recent pooled analysis showed an overall re-intervention rate of 26% (range 14.8–44.8%) [1] and a 5-year AUS device survival ranging from 59% to 79% [1, 17, 19–23]. Furthermore, in the few available studies, the reported 10-year device survival rates range from 28% to 64% [2, 19, 22, 24]. For instance, in a review of 124 patients, with a median follow-up of 6.8 years, Kim et al. found an overall revision rate of 37% [24]. Additionally, with regard to functional outcomes, a recent systematic review evaluating patients with non-neurogenic etiologies for incontinence leading to AUS placement in studies with a minimum of 2 years of follow-up noted a “dry or improved” rate of 79% (range 61–100%) [1]. Likewise, high levels of patient satisfaction (over 90%) following AUS placement are commonly reported, though the rate of continence decreases over time [1, 2, 25].

Data regarding outcomes beyond 10 years in the literature is sparse [2, 26]. In the two available series, the 15-year device survival rate was 15% and 41% [2, 26]. In the series by Leon et al., which included 57 men that underwent AUS placement over an 8-year period and had a median follow-up of 15 years, the AUS survival rates without revision were 59%, 28%, 15%, and 5% at 5, 10, 15, and 20 years, respectively [26]. This study was unique in that the authors noted that no patients were lost to follow-up. In our own retrospective series of 1082 primary AUS implantations performed at our institution, we found 5-, 10-, and 15-year device survival rates of 74%, 57%, and 41%, respectively [2]. As mentioned above, differences in device survival between series may be due to disparate patient populations, length of follow-up available, patient loss to follow-up, and surgical technique.

## AUS and Pelvic Radiation

With regard to device outcomes, numerous studies have attempted to identify potential risk factors for adverse AUS device survival [23, 27–36]. A comorbidity that is frequently discussed is receipt of pelvic radiation prior to AUS implantation [27–31]. Notably, this is a common clinical scenario, as we have found that 37% of patients that underwent AUS in our practice had received prior pelvic radiotherapy [28]. The studies available in the current literature evaluating the association of radiotherapy and device survival have met with conflicting results [27–31]. However, in a recent meta-analysis of 15 series, including 1886 patients, men with a history of radiation therapy in addition to prostatectomy had a higher rate of AUS revision than those treated with prostatectomy alone [31]. The majority of the surgical revision risk was secondary to device infection and urethral erosion events. Likewise, patients with prior radiation therapy were more likely to have persistent urinary incontinence after AUS placement [31]. Given the available AUS literature, many of these studies were small retrospective series, and the authors noted a high level of heterogeneity. Notably, when analyzing only the four largest studies, in an effort to decrease heterogeneity, the relative risk of surgical revision was no longer significantly different between those with or without prior radiation therapy [31]. Certainly, given the scope of the current literature on the topic, further studies, including those focused on functional outcomes and the quality of life, are needed to better define the impact of prior radiotherapy on AUS outcomes. Such information would be useful for patient counseling, though, it should be noted that patients treated with pelvic radiation therapy should not be excluded from receiving an AUS solely based on this comorbidity.

## AUS Following a Failed Urethral Sling

Due to a desire to avoid a mechanical device, the risks of device malfunction or erosion, as well as the need for device manipulation and replacement of the AUS over time, many men prefer urethral sling placement, even if not ideal candidates [5]. For patients with persistent or recurrent stress incontinence after male urethral sling placement, revision surgery either via repeat urethral sling or more commonly artificial urinary sphincter placement has been reported [37–41]. In this setting, placement of an AUS is typically utilized, as the presence of fibrosis hinders urethral compression and/or mobility, which is important for sling efficacy [10, 42, 43].

Several reports have demonstrated, albeit in small series, excellent outcomes for AUS placement after a previous urethral sling [38–41]. For instance, in a series of 28 patients undergoing AUS after a failed urethral sling, similar high success rates with limited complications were seen when compared to a control group without prior urethral sling surgery [39]. Likewise, in a comparative analysis of patients with SUI after a failed urethral sling, patients undergoing repeat urethral sling placement (transobturator) were six times more likely to have persistent incontinence than those who had an AUS [38]. In cases of failed urethral sling placement, our preference is to place an AUS. Notably, in our experience, in the majority of

these cases, the sling can be left in situ without the need for excision. If the sling is encountered, we prefer to incise the sling rather than perform urethrolisis, as this risks urethral injury, as well as potentially compromising urethral blood supply.

---

## Complications Following AUS Placement

Perioperative or early postoperative complications following AUS placement most commonly consist of urinary retention, scrotal hematoma, and device infection/urethral erosion. In our prospective series of postoperative AUS complications, urinary retention was most common [44]. Postoperative urinary retention following AUS placement is thought to be secondary to urethral edema from the periurethral dissection, error in cuff sizing, or unrecognized surgical injury. Interestingly, in our series, transient postoperative urinary retention was associated with adverse overall device survival and a significantly increased rate of AUS infection/urethral erosion [44]. In cases of postoperative retention following catheter removal the morning after surgery, we teach patients to perform intermittent self-catheterization with a 12 Fr catheter. Other options include leaving an indwelling catheter for a short period of time (24–48 h) or suprapubic tube placement if retention is longer lasting [7]. Notably, while prolonged catheterization (greater than 48 h) is reported to increase the risk of erosion, data regarding the potential impact of self-catheterization on AUS outcomes in a non-neurogenic adult population is sparse [45, 46]. Scrotal hematomas may range in size and severity, though most can be managed conservatively. In patients having difficulty with pain control, large/expanding hematoma size, concern for infection, or issues with pump position, hematoma evacuation may be warranted.

In a recent pooled analysis, device infection or urethral erosion was reported to occur in 8.5% of cases (3.3–27.8%) [1]. Notably, not all series included distinguished between device infection and urethral erosions. Furthermore, many of the included studies were retrospective series, and, thus, this figure could be an underestimation. AUS device infection may be secondary to intraoperative contamination or unrecognized urethral erosion. The most commonly isolated organisms during device explantation for infection include *Staphylococcus aureus* (including MRSA), *Staphylococcus epidermidis*, *Enterococcus*, and gram-negative bacilli such as *Pseudomonas aeruginosa* and *Escherichia coli* [47]. When infection is encountered, the entire device should be explanted [7].

Urethral erosions occurring early in the postoperative period are likely secondary to unrecognized urethral injury or shallow dissection occurring at the time of surgical implantation. Later erosions may occur secondary to progressive urethral atrophy or traumatic catheterization. Device erosions require explantation of all three components due to potential colonization from the exposed component. Pending adequate recovery and cystoscopically verifying the absence of urethral stricture development, salvage reimplantation several months later is feasible, though implantation in this setting is associated with an increased risk of repeat infection/erosion [23, 33].

In addition to early complications, patients may present with recurrent incontinence following AUS implantation due to device malfunction (i.e., loss of fluid from the system) or urethral atrophy. Device malfunction has been reported in 6.2% of cases (2–13.8%) [1]. Malfunction can be identified on physical exam with improper device cycling and lack of coaptation of the urethral mucosa during cystoscopy. In addition, imaging with either an abdominal x-ray (if contrast was used to fill the system) or ultrasound (if normal saline was used) will confirm the diagnosis [48, 49]. Given the limited data available on the surgical treatment of AUS mechanical failures, significant heterogeneity exists regarding management recommendations in the current literature [18, 20, 21, 49–52]. For instance, some authors have suggested that the entire device be removed if it malfunctions after the device has been in place for 2–5 years (with single-component revision prior to the time cutoff), which is largely based on the median time to device malfunction [20, 21, 50, 52]. Conversely, others argue for replacing the entire device in all cases due to limited added surgical risk, debris possibly entering the tubing, and concern for future mechanical failure of a component left in situ during the revision surgery [18, 49, 51].

Recurrent incontinence may also be secondary to atrophy of the underlying spongy tissue beneath the urethral cuff. The treatment of incontinence secondary to urethral atrophy is centered on device revision. Surgical options for AUS revision in these cases include changing the location of the urethral cuff (moving proximally or distally), downsizing the urethral cuff, placement of a tandem urethral cuff, or revising the pressure-regulating balloon. The decision between these management options is based on the local tissue quality, location of the in situ urethral cuff, and surgeon preference. Our typical initial management is with cuff downsizing (if proximal repositioning is not possible) and reserving tandem cuff placement for future revisions if needed [20, 53, 54].

---

## Conclusions

Post-prostatectomy stress urinary incontinence is a noteworthy problem affecting many men, with a large impact on the quality of life. The evaluation of men presenting with iatrogenic stress incontinence includes a history and physical examination with additional studies, such as cystoscopy, pad testing, or urodynamic studies, performed as needed based on the clinical scenario. Patients with large-volume incontinence, prior radiation, or prior-failed urethral sling are likely best managed with AUS, if deemed an appropriate surgical candidate. Excellent long-term AUS device survival and continence outcomes have been noted in many series following primary implantation. Notably, the most common complications of AUS placement include urinary retention, scrotal hematoma, infections, erosions, and recurrent urinary incontinence. Appropriate patient counseling regarding the available management options, expected postoperative convalescence, surgical risks, and device outcomes are crucial when considering surgery for post-prostatectomy incontinence.

## References

1. Van der Aa F, Drake MJ, Kasyan GR, Petrolekas A, Cornu JN. The artificial urinary sphincter after a quarter of a century: a critical systematic review of its use in male non-neurogenic incontinence. *Eur Urol*. 2013;63(4):681–9.
2. Linder BJ, Rivera ME, Ziegelmann MJ, Elliott DS. Long-term outcomes following artificial urinary sphincter placement: an analysis of 1082 cases at Mayo Clinic. *Urology*. 2015;86(3):602–7.
3. Scott FB, Bradley WE, Timm GW. Treatment of urinary incontinence by an implantable prosthetic urinary sphincter. *J Urol*. 1974;112(1):75–80.
4. Poon SA, Silberstein JL, Savage C, Maschino AC, Lowrance WT, Sandhu JS. Surgical practice patterns for male urinary incontinence: analysis of case logs from certifying American urologists. *J Urol*. 2012;188(1):205–10.
5. Kumar A, Litt ER, Ballert KN, Nitti VW. Artificial urinary sphincter versus male sling for post-prostatectomy incontinence—what do patients choose? *J Urol*. 2009;181(3):1231–5.
6. Elliott DS, Barrett DM, Gohma M, Boone TB. Does nocturnal deactivation of the artificial urinary sphincter lessen the risk of urethral atrophy? *Urology*. 2001;57(6):1051–4.
7. Biardeau X, Aharony S, Group AUSC, Campeau L, Corcos J. Overview of the 2015 ICS consensus conference. *NeuroUrol Urodyn*. 2016;35(4):437–43.
8. Ziegelmann MJ, Linder BJ, Rivera ME, Viers BR, Rangel LJ, Elliott DS. Outcomes of artificial urinary sphincter placement in octogenarians. *Int J Urol*. 2016;23(5):419–23.
9. O'Connor RC, Nanigian DK, Patel BN, Guralnick ML, Ellision LM, Stone AR. Artificial urinary sphincter placement in elderly men. *Urology*. 2007;69(1):126–8.
10. Jura YH, Comiter CV. Urodynamics for postprostatectomy incontinence: when are they helpful and how do we use them? *Urol Clin North Am*. 2014;41(3):419–27. viii
11. Henry GD, Graham SM, Cornell RJ, Cleves MA, Simmons CJ, Vakalopoulos I, et al. A multi-center study on the perineal versus penoscrotal approach for implantation of an artificial urinary sphincter: cuff size and control of male stress urinary incontinence. *J Urol*. 2009;182(5):2404–9.
12. Yeung LL, Grewal S, Bullock A, Lai HH, Brandes SB. A comparison of chlorhexidine-alcohol versus povidone-iodine for eliminating skin flora before genitourinary prosthetic surgery: a randomized controlled trial. *J Urol*. 2013;189(1):136–40.
13. Eid JF, Wilson SK, Cleves M, Salem EA. Coated implants and “no touch” surgical technique decreases risk of infection in inflatable penile prosthesis implantation to 0.46%. *Urology*. 2012;79(6):1310–5.
14. Guralnick ML, Miller E, Toh KL, Webster GD. Transcorporal artificial urinary sphincter cuff placement in cases requiring revision for erosion and urethral atrophy. *J Urol*. 2002;167(5):2075–8. discussion 9
15. Magera Jr JS, Elliott DS. Tandem transcorporal artificial urinary sphincter cuff salvage technique: surgical description and results. *J Urol*. 2007;177(3):1015–9. discussion 9–20
16. O'Connor RC, Gerber GS, Avila D, Chen AA, Bales GT. Comparison of outcomes after single or DOUBLE-CUFF artificial urinary sphincter insertion. *Urology*. 2003;62(4):723–6.
17. O'Connor RC, Lyon MB, Guralnick ML, Bales GT. Long-term follow-up of single versus double cuff artificial urinary sphincter insertion for the treatment of severe postprostatectomy stress urinary incontinence. *Urology*. 2008;71(1):90–3.
18. Linder BJ, Viers BR, Ziegelmann MJ, Rivera ME, Rangel L, Elliott DS. Artificial urinary sphincter mechanical failures: is it better to replace the entire device or just the malfunctioning component? *J Urol*. 2016;195(5):1523–8.
19. Leon P, Chartier-Kastler E, Roupret M, Ambrogi V, Mozer P, Phe V. Long-term functional outcomes after artificial urinary sphincter implantation in men with stress urinary incontinence. *BJU Int*. 2014;115(6):951–7.
20. Raj GV, Peterson AC, Toh KL, Webster GD. Outcomes following revisions and secondary implantation of the artificial urinary sphincter. *J Urol*. 2005;173(4):1242–5.

21. Lai HH, Hsu EI, Teh BS, Butler EB, Boone TB. Thirteen years of experience with artificial urinary sphincter implantation at Baylor College of Medicine. *J Urol.* 2007;177(3):1021–5.
22. Venn SN, Greenwell TJ, Mundy AR. The long-term outcome of artificial urinary sphincters. *J Urol.* 2000;164(3 Pt 1):702–6. discussion 6–7
23. Linder BJ, de Cogain M, Elliott DS. Long-term device outcomes of artificial urinary sphincter reimplantation following prior explantation for erosion or infection. *J Urol.* 2014;191(3):734–8.
24. Kim SP, Sarmast Z, Daignault S, Faerber GJ, McGuire EJ, Latini JM. Long-term durability and functional outcomes among patients with artificial urinary sphincters: a 10-year retrospective review from the University of Michigan. *J Urol.* 2008;179(5):1912–6.
25. Viers BR, Linder BJ, Rivera ME, Rangel LJ, Ziegelmann MJ, Elliott DS. Long-term quality of life and functional outcomes among primary and secondary artificial urinary sphincter implantations in men with stress urinary incontinence. *J Urol.* 2016;195:e1120.
26. Leon P, Chartier-Kastler E, Roupret M, Ambrogio V, Mozer P, Phe V. Long-term functional outcomes after artificial urinary sphincter implantation in men with stress urinary incontinence. *BJU Int.* 2015;115(6):951–7.
27. Gomha MA, Boone TB. Artificial urinary sphincter for post-prostatectomy incontinence in men who had prior radiotherapy: a risk and outcome analysis. *J Urol.* 2002;167(2 Pt 1):591–6.
28. Rivera ME, Linder BJ, Ziegelmann MJ, Viers BR, Rangel LJ, Elliott DS. The impact of prior radiation therapy on artificial urinary sphincter device survival. *J Urol.* 2015;195:1033.
29. Sathianathan NJ, McGuigan SM, Moon DA. Outcomes of artificial urinary sphincter implantation in the irradiated patient. *BJU Int.* 2014;113(4):636–41.
30. Ravier E, Fassi-Fehri H, Crouzet S, Gelet A, Abid N, Martin X. Complications after artificial urinary sphincter implantation in patients with or without prior radiotherapy. *BJU Int.* 2015;115(2):300–7.
31. Bates AS, Martin RM, Terry TR. Complications following artificial urinary sphincter placement after radical prostatectomy and radiotherapy: a meta-analysis. *BJU Int.* 2015;116(4):623–33.
32. Gomes CM, Broderick GA, Sanchez-Ortiz RF, Preate Jr D, Rovner ES, Wein AJ. Artificial urinary sphincter for post-prostatectomy incontinence: impact of prior collagen injection on cost and clinical outcome. *J Urol.* 2000;163(1):87–90.
33. Lai HH, Boone TB. Complex artificial urinary sphincter revision and reimplantation cases—how do they fare compared to virgin cases? *J Urol.* 2012;187(3):951–5.
34. Raj GV, Peterson AC, Webster GD. Outcomes following erosions of the artificial urinary sphincter. *J Urol.* 2006;175(6):2186–90. discussion 90
35. Brant WO, Erickson BA, Elliott SP, Powell C, Alsikafi N, McClung C, et al. Risk factors for erosion of artificial urinary sphincters: a multicenter prospective study. *Urology.* 2014;84(4):934–8.
36. Godwin CA, Linder BJ, Rivera ME, Ziegelmann MJ, Elliott DS. Effects of Smoking Status on Device Survival Among Individuals Undergoing Artificial Urinary Sphincter Placement. *Am J Mens Health.* With press 2016 May 29.
37. Soljanik I, Becker AJ, Stief CG, Gozzi C, Bauer RM. Repeat retourethral transobturator sling in the management of recurrent postprostatectomy stress urinary incontinence after failed first male sling. *Eur Urol.* 2010;58(5):767–72.
38. Ajay D, Zhang H, Gupta S, Selph JP, Belsante MJ, Lentz AC, et al. The artificial urinary sphincter is superior to a secondary transobturator male sling in cases of a primary sling failure. *J Urol.* 2015;194(4):1038–42.
39. Lentz AC, Peterson AC, Webster GD. Outcomes following artificial sphincter implantation after prior unsuccessful male sling. *J Urol.* 2012;187(6):2149–53.
40. Abdou A, Cornu JN, Sebe P, Ciofu C, Peyrat L, Cussenot O, et al. Salvage therapy with artificial urinary sphincter after advance male sling failure for post-prostatectomy incontinence: a first clinical experience. *Prog Urol.* 2012;22(11):650–6.
41. Fisher MB, Aggarwal N, Vuruskan H, Singla AK. Efficacy of artificial urinary sphincter implantation after failed bone-anchored male sling for postprostatectomy incontinence. *Urology.* 2007;70(5):942–4.

42. Tuygun C, Imamoglu A, Gucuk A, Goktug G, Demirel F. Comparison of outcomes for adjustable bulbourethral male sling and artificial urinary sphincter after previous artificial urinary sphincter erosion. *Urology*. 2009;73(6):1363–7.
43. Tuygun C, Imamoglu A, Keyik B, Alisir I, Yorubulut M. Significance of fibrosis around and/or at external urinary sphincter on pelvic magnetic resonance imaging in patients with post-prostatectomy incontinence. *Urology*. 2006;68(6):1308–12.
44. Linder BJ, Piotrowski JT, Ziegelmann MJ, Rivera ME, Rangel LJ, Elliott DS. Perioperative complications following artificial urinary sphincter placement. *J Urol*. 2015;194(3):716–20.
45. Seideman CA, Zhao LC, Hudak SJ, Mierzwiak J, Adibi M, Morey AF. Is prolonged catheterization a risk factor for artificial urinary sphincter cuff erosion? *Urology*. 2013;82(4):943–6.
46. Martins FE, Boyd SD. Post-operative risk factors associated with artificial urinary sphincter infection-erosion. *Br J Urol*. 1995;75(3):354–8.
47. Magera Jr JS, Elliott DS. Artificial urinary sphincter infection: causative organisms in a contemporary series. *J Urol*. 2008;180(6):2475–8.
48. Petrou SP, Williams HJ, Young PR. Radiographic imaging of the artificial urinary sphincter pressure regulating balloon. *J Urol*. 2001;165(5):1773–5.
49. Brucker BM, Demirtas A, Fong E, Kelly C, Nitti VW. Artificial urinary sphincter revision: the role of ultrasound. *Urology*. 2013;82(6):1424–8.
50. Mailliet F, Buzelin JM, Bouchot O, Karam G. Management of artificial urinary sphincter dysfunction. *Eur Urol*. 2004;46(2):241–5. discussion 6
51. Montague DK, Angermeier KW. Artificial urinary sphincter troubleshooting. *Urology*. 2001;58(5):779–82.
52. Peterson AC, Webster GD. Artificial urinary sphincter: lessons learned. *Urol Clin North Am*. 2011;38(1):83–8. vii
53. Saffarian A, Walsh K, Walsh IK, Stone AR. Urethral atrophy after artificial urinary sphincter placement: is cuff downsizing effective? *J Urol*. 2003;169(2):567–9.
54. Webster GD, Sherman ND. Management of male incontinence following artificial urinary sphincter failure. *Curr Opin Urol*. 2005;15(6):386–90.

---

# New Technologies in the Management of Post-prostatectomy Urinary Incontinence

Neha R. Malhotra and Y. Zaki Almallah

## Abbreviations

AMS	American Medical Systems
ATOMS	Adjustable transobturator male system
AUS	Artificial urinary sphincter
PPI	Post-prostatectomy incontinence
TMOD	Tape mechanical occlusive device

---

## Combined Compression and Adjustable Systems

Traditional slings offered fixed compression of the sphincter or an area just distal to it but were only suited for mild to moderate incontinence [1, 2]. Newer, adjustable transobturator systems offer higher degrees of compression, which can be increased as needed and do not require manual dexterity or cognitive capabilities needed to operate an AUS. Furthermore, the lack of mechanical parts nullifies the risk of mechanical failure [3]. Of these, the one that has gained the most traction around the world is the adjustable transobturator male system (ATOMS, Agency for Medical Innovation, Feldkirch, Austria). It has been approved for use in Europe since 2008. Unlike other devices, ATOMS is both anchored and adjustable.

ATOMS consists of a macroporous, monofilament propylene mesh arms that are affixed using suture, an adjustable central silicone cushion, and titanium port for percutaneous adjustment [3]. Four-point fixation of the central cushion to the mesh arms using suture allows for even distribution of pressure and avoids dislocation [3].

---

N.R. Malhotra • Y. Zaki Almallah (✉)  
Department of Urology, University of Illinois at Chicago,  
CSN Suite 515 M/C 955, 820 S Wood St., Chicago, IL 60612, USA  
e-mail: [yzam@hotmail.com](mailto:yzam@hotmail.com)



The central cushion is placed over the distal bulbospongiosus muscle to provide indirect compression of urethra while having a decreased risk of erosion [4]. This may prove advantageous in men who have, or will undergo, radiotherapy as part of their cancer treatment. As initially described, ATOMS is placed through a midline vertical perineal incision carried down to expose the bulbospongiosus muscle, and a space is then created toward the ischiocavernosus muscle [3]. Helical tunnelers are then used to pass the device through the obturator foramen in an outside-in technique, and the mesh arms are drawn back to secure the system to the inferior pubic rami [3]. The titanium port for percutaneous adjustment was placed in the symphysis region, but may also be placed in the scrotum [5]. In early studies, the mean operative time was less than 1 h, and in the most recent results, experienced surgeons can implant the device in less than 30 min [3, 6].

The initial Austrian study of 38 patients had an approximately 60% dry rate, 24% improvement, and 16% failure (more than two pads daily); this study did include men with mild, moderate, and severe post-procedural incontinence; however, the mean preoperative pad used was 6.8 [3]. A multicenter European study with 99 patients corroborated these results with 63% of patients being dry [7]. In the initial study, four patients were dry with just one adjustment, but in total a mean of four adjustments occurred in the mean follow-up period of 17 months. The most common complication was pain, and only one device required explantation [3]. Longer-term follow-up at this institution and other institutions showed a 15% explantation rate (9/62) but maintained the 61% continence rate [8]. They found that, in addition to other factors, severe PPI was a risk factor for failure to achieve continence [8]. A smaller, retrospective study in Spain showed 12 out of 13 patients (92%) with mild to moderate continence dry at 16-month follow-up, suggesting this technique is reproducible [5]. The most recent multicenter results with the third generation of the device are consistent with prior results and continue to have a dry rate of around 61%, but now the total explantation rate is nearing 20% [6]. Interestingly, the most common reason for explantation is cited as titanium intolerance; other reasons include device dysfunction, infection, dislocation, and persistent pain [6].

These results are encouraging, but there is some concern about the rate of explantation and the number of patients reporting pain. Nevertheless, the overall concept is novel and more long-term data are awaited.

---

## Compressive Devices and New Sphincters

Though ATOMS has perhaps gained the most support as a mechanical sphincter alternative with the potential to treat severe PPI, there are other devices that provide complete or partial urethral occlusion. These include alternate sphincters and tape that can be activated. Again the concepts of these new devices are very innovative but the experience with them is still very limited. Larger-scale studies, preferably randomized controlled trials, are the only way forward for these devices to become acceptable in the mainstream clinical practice.

## FlowSecure

The popularly used AMS 800 AUS is known to have a high learning curve for implantation, and as such, some of the newer sphincter attempts such as the FlowSecure (Barlow Scientific Limited, London, United Kingdom) and the Zephyr ZSI 375 (discussed later) offer preassembled circuits to decrease operative time and improper connections or implantation [9]. The FlowSecure, developed by Michael Craggs and Anthony Mundy, offers a one-piece silicone device free of tubing connections and includes a urethral cuff, a pressure-regulating balloon, a stress relief balloon, and a control pump [9, 10]. The unique feature of this device is the stress release system, designed to respond to transient increases in intra-abdominal pressure by increasing urethral occlusion, but requires an additional balloon as compared to the AMS system. The extraperitoneally placed stress relief balloon is designed to provide conditional occlusion. As with the traditional AUS, both a perineal and an abdominal incision are made for placement of the device. The pressure can be altered by injecting or removing fluid percutaneously after implantation, a potential advantage over the AMS system [10]. The preliminary study of nine patients showed a decrease in mean leakage from 770 to 55 mL [9]. At 6-month follow-up, all patients who were using pads preoperatively and were still enrolled in the study were noted to have continued, though decreased, pad use. Initial experience did show mechanical issues in two of the nine implants, but since that time the device has been reengineered [9].

## Zephyr ZSI 375

Another artificial urinary sphincter alternative is the ZSI 375 (Zephyr Surgical Implants, Geneva, Switzerland). Marketed as a one-piece sphincter, it consists of an adjustable urethral cuff pre-connected to a pump and a pressure-regulating tank [11]. Like the AMS 800, it requires both a perineal incision for cuff placement and an inguinal incision for pump and tank placement. There is no abdominal reservoir. The device consists of not only a hydraulic circuit but also a pressure-regulating compensation circuit. The device is prefilled with 9 mL of saline (4.5 mL in each circuit) on the back table prior to implantation, but later injection of saline into the pouch can be used to increase pressure. This is similar to the FlowSecure sphincter and a potential advantage over the AMS system [10]. Urethral closure pressures range from 60 to 100 cmH<sub>2</sub>O. In an early, retrospective study of 36 men, 26 (73%) of men experienced gain of social continence, defined as less than or equal to one pad use per day, but only 4 (11%) were completely dry, requiring no pads [11]. Four devices were removed, one for erosion and three for infection [11]. While the Zephyr ZSI 375 may offer a simpler surgical placement due to the lack of the abdominal reservoir, it fails to show comparable dry rates to the current AMS 800, and the most recent results show a rate of explantation over 60% for reasons such as mechanical defect, infection, pain, and erosion [12].

## Tape Mechanical Occlusive Device (TMOD)

Though not yet available for human use, a tape mechanical occlusive device (TMOD, GT Urological, Minneapolis, Minnesota) has shown excellent urethral compression in canine and human cadaveric models [4]. This one-piece, spring-loaded device provides circumferential urethral pressure ranging from 57 to 82 cmH<sub>2</sub>O in canines and 61 to 105 cmH<sub>2</sub>O, consistent with the pressure achieved using the traditional artificial urinary sphincter [13]. As a one-piece system without any tubing or connections, the risk of mechanical failure would be theoretically lower. Occlusion is provided by a microporous polytetrafluoroethylene tape, which is secured around the urethra using a stainless steel locking clip and placed at the bulbar or penoscrotal urethra [13]. A conduit, or pressure-transmitting, tape of the same material then attaches to the scrotal on-off control switch [13]. Further animal studies are needed before this device can be considered for human studies, but it does offer an interesting combination of a compressive tape with a control mechanism.

---

## Stem Cells

Previously discussed efforts have focused on extrinsic mechanical compression of the urethra as a means to prevent incontinence; however, none of these make an effort to restore the tissue itself. Research into stem cells provides an avenue by which to reverse functional losses, both through local tissue repair and immune modulatory factors [14]. Stem cells are cells that have the ability to self-renew, form clonal populations, and maintain the ability for multipotent differentiation. While use of embryonic stem cells, derived from amniotic fluid and placenta, may be controversial, the majority of stem cell work is based on use of adult stem cells. Mesenchymal stem cells, such as those from the bone marrow, adipose, and muscle, naturally migrate to areas of acute injury and can be induced to differentiate into supportive, muscle-like cells [14–16]. Work is also being done in urine-derived stem cells, as these are easy to obtain and can be used autologously [17]. While most of these early studies have been in animal models, there are a few translational studies in humans [18, 19].

In an early, feasibility study, a multicenter group injected autologous, muscle-derived stem cells into the muscular sphincter of women with persistent stress incontinence refractory to conservative treatment [18]. These patients underwent needle biopsy of the quadriceps muscle, and their tissue was then induced into a stemlike phenotype. These autologous muscle-derived stemlike cells were then diluted in normal saline and injected periurethrally into the external sphincter. As this was a preliminary study, patients received differing doses and treatments of these injections. Approximately 30% of patients were completely dry at 18 months, with 4 of 13 low-dose and 3 of 9 high-dose patients having a negative pad test [18]. Though this very small study was carried out in females with stress incontinence, the principle of using enhancing the muscular support of the sphincter through autologous stem cells may show efficacy in men with PPI, and this area deserves further study.

A somewhat similar model in men with SUI after prostate surgery uses autologous adipose-derived stem cells for sphincteric injection. In this study, 11 patients underwent abdominal liposuction, and stemlike cells were isolated from this tissue [19]. These cells were then put into solution and transurethrally injected into the sphincter and the surrounding submucosal space. One patient was completely dry at 12 months and eight showed objective improvement in leakage [19]. Again, this is a very small study, but like that of Carr and colleagues, it shows the feasibility of using autologous stemlike cells to support the urethra. Rather than applying mechanical extrinsic compression, the thought is that this process allows for regeneration of the sphincteric support at the local level. Long-term follow-up and tissue studies will be needed to understand the durability of this treatment and what exactly is the local effect of these injections, but preliminary results are promising.

---

## Fenix Magnetic Sphincter Augmentation Device

Although the mechanism of fecal incontinence is different to PPI, some of the treatments can be extrapolated from one condition to the other. In the last few years, increase interest has developed in the area of magnetic rings for fecal incontinence and gastroesophageal reflux disease. One of the new technologies is Fenix (Torax Medical, St. Paul, Minnesota) magnetic sphincter augmentation device. This circumferential system of titanium-coated magnetic beads is implanted just proximal to the internal anal sphincter and allows for opening of the anus for passage of stool, after which the magnetic beads attract back together to close the weakened sphincter. Currently this device is approved for patients who have previously failed conservative treatments and is under investigation in both France and the UK. MOS STIC, a non-inferiority study underway in France, aims to show Fenix is as effective as sacral neuromodulation but is more cost-effective [20]. Another, larger-scale trial, SaFaRI, is currently accruing in the UK [21]. Implantation of the device first began in the UK in 2008, and a pilot study of ten patients showed similar improvement in incontinence and quality of life as compared to those patients undergoing an artificial bowel sphincter placement [22]. A follow-up to this study at one-and-a-half years showed stable improvement in quality of life scores in satisfied patients, but one-third of patients remained dissatisfied due to lack of improvement [23]. Currently, there is no analogous device for urinary incontinence, but the concept of a magnetic system to allow active opening and then passive closing of the sphincter due to magnetic attraction proves intriguing and should be investigated further.

---

### Conclusion

Since the advent of the prostatectomy in the early 1900s, men have been dealing with PPI. The invention of the artificial urinary sphincter in the 1970s provided a durable solution for some men with severe incontinence but is not without potential pitfall and complications. Bulking agent showed little efficacy, and slings provide relief only in cases of mild to moderate incontinence. Newer mechanical devices offer some novel approaches to management of PPI, but

none have shown the efficacy of the AMS 800 or, at least, have not been thoroughly evaluated. Although there was great initial enthusiasm for stem cell therapy, overall progress has been slow and thus far disappointing. The avenue of regenerative medicine, however, may offer local tissue-based solutions that are focused on reversing functional losses rather than manual compression, and continued exploration is warranted.

The bottom line is that new and innovative technology is always exciting in medicine, but a systematic approach with careful evaluation and larger-scale randomized studies cannot be substituted by small single-institute or even multi-center case series. Until these large-scale randomized control trials prove safety and efficacy of these new devices, our quest for the perfect device continues.

---

## References

1. Doherty R, Almallah Z. Urinary incontinence after treatment for prostate cancer. *BMJ*. 2011;343:d6298.
2. Almallah YZ, Grimsley SJ. A report of a regional service for post-prostatectomy urinary incontinence: a model for best practice? *Ther Adv Urol*. 2015;7(2):69–75.
3. Seweryn J, Bauer W, Ponholzer A, et al. Initial experience and results with a new adjustable transobturator male system for the treatment of stress urinary incontinence. *J Urol*. 2012;187(3):956–61.
4. Friedl A, Bauer W, Rom M, et al. Sexuality and erectile function after implantation of an Adjustable Transobturator Male System (ATOMS) for urinary stress incontinence. A multi-institutional prospective study. *Arch Ital Urol Androl*. 2015;87(4):306–11.
5. Gonzalez SP, Cansino JR, Portilla MA, et al. First experience with the ATOMS((R)) implant, a new treatment option for male urinary incontinence. *Cent European J Urol*. 2014;67(4):387–91.
6. Friedl A, Zachoval P, Muhlstadt S, Giammo A, Kiravaranovic D, Rom M, Fornara P, Brossner C. Long-term outcome after implantation of the ATOMS continence device: 7 year multi-center data. Tokyo: ICS; 2016.
7. Hoda MR, Primus G, Fischereeder K, et al. Early results of a European multicentre experience with a new self-anchoring adjustable transobturator system for treatment of stress urinary incontinence in men. *BJU Int*. 2013;111(2):296–303.
8. Friedl A, Muhlstadt S, Rom M, et al. Risk factors for treatment failure with the adjustable transobturator male system incontinence device: who will succeed, who will fail? Results of a multicenter study. *Urology*. 2016;90:189–94.
9. Knight SL, Susser J, Greenwell T, et al. A new artificial urinary sphincter with conditional occlusion for stress urinary incontinence: preliminary clinical results. *Eur Urol*. 2006;50(3):574–80.
10. Chung E, Ranaweera M, Cartmill R. Newer and novel artificial urinary sphincters (AUS): the development of alternatives to the current AUS device. *BJU Int*. 2012;110(Suppl 4):5–11.
11. Staerman F, Christophe G-L, Leon P, et al. ZSI 375 artificial urinary sphincter for male urinary incontinence: a preliminary study. *BJU Int*. 2013;111(4 Pt B):E202–6.
12. Kretschmer A, Husch T, Thomsen F, et al. Efficacy and safety of the ZSI375 artificial urinary sphincter for male stress urinary incontinence: lessons learned. *World J Urol*. 2016;34(10):1457–63.
13. Malaeb BS, Elliott SP, Lee J, et al. Novel artificial urinary sphincter in the canine model: the tape mechanical occlusive device. *Urology*. 2011;77(1):211–6.
14. Tran C, Damaser MS. The potential role of stem cells in the treatment of urinary incontinence. *Ther Adv Urol*. 2015;7(1):22–40.

15. Fu Q, Song XF, Liao GL, et al. Myoblasts differentiated from adipose-derived stem cells to treat stress urinary incontinence. *Urology*. 2010;75(3):718–23.
16. Lin G, Wang G, Banie L, et al. Treatment of stress urinary incontinence with adipose tissue-derived stem cells. *Cytotherapy*. 2010;12(1):88–95.
17. Zhang Y, McNeill E, Tian H, et al. Urine derived cells are a potential source for urological tissue reconstruction. *J Urol*. 2008;180(5):2226–33.
18. Carr LK, Robert M, Kultgen PL, et al. Autologous muscle derived cell therapy for stress urinary incontinence: a prospective, dose ranging study. *J Urol*. 2013;189(2):595–601.
19. Gotoh M, Yamamoto T, Kato M, et al. Regenerative treatment of male stress urinary incontinence by periurethral injection of autologous adipose-derived regenerative cells: 1-year outcomes in 11 patients. *Int J Urol*. 2014;21(3):294–300.
20. Lehur PA, Wyart V, Riche VP. SaFaRI: sacral nerve stimulation versus the Fenix(R) magnetic sphincter augmentation for adult faecal incontinence: a randomised investigation. *Int J Color Dis*. 2016;31(8):1505.
21. Williams AE, Croft J, Napp V, et al. SaFaRI: sacral nerve stimulation versus the FENIX magnetic sphincter augmentation for adult faecal incontinence: a randomised investigation. *Int J Color Dis*. 2016;31(2):465–72.
22. Wong MT, Meurette G, Stangherlin P, et al. The magnetic anal sphincter versus the artificial bowel sphincter: a comparison of 2 treatments for fecal incontinence. *Dis Colon Rectum*. 2011;54(7):773–9.
23. Barussaud ML, Mantoo S, Wyart V, et al. The magnetic anal sphincter in faecal incontinence: is initial success sustained over time? *Color Dis*. 2013;15(12):1499–503.

# Index

## A

- Abdominal leak point pressure (ALPP), 4, 27, 66, 67
- ACT<sup>®</sup> balloon, 117
- ActiCuf<sup>™</sup>, 39
- Adjustable bulbourethral sling, 79–80
- Adjustable male slings
  - Argus (*see* Argus<sup>™</sup>, adjustable male sling)
  - ATOMS<sup>®</sup>, 100–101
  - REMEEX<sup>™</sup> system, 79, 91
    - evolution, 101–103
    - surgical technique, 92–96
- Adjustable periurethral balloon, 99
- Adjustable transobturator male system (ATOMS<sup>™</sup>), 79, 100–101, 137
- AdVance helical needle, 68, 69
- AdVance<sup>®</sup> Transobturator Retrourethral Male Sling, 65
  - complications, 71
  - mode of action, 65–66
  - outcomes, 71
  - patient selection and evaluation, 66–67
  - postoperative care, 70–71
  - surgical technique, 67–70
- AdVance XP, 73–74
- Alpha-adrenergic drugs, 36
- ALPP. *See* Abdominal leak point pressure (ALPP)
- Antimuscarinic drugs, 37
- Argus<sup>™</sup>, adjustable male sling, 79, 101, 105–108
  - complications, 112–114
  - experience with, 111–112
  - surgical technique
    - suprapubic approach, 108–109
    - transobturator approach, 109–111

- Artificial urinary sphincter (AUS), 2, 4, 26, 56, 60, 65, 72, 91, 99
  - complications, 132–133
  - design, 125–126
  - failed urethral sling, 131–132
  - operative technique, primary implantation, 128–130
  - outcomes, 130
    - and pelvic radiation, 131
    - preoperative evaluation, 126–128
- ATOMS<sup>™</sup>. *See* Adjustable transobturator male system (ATOMS<sup>™</sup>)
- AUS. *See* Artificial urinary sphincter (AUS)

## B

- Behavioral training, 33
- Benign prostatic hypertrophy (BPH), 37
- Bilateral nerve-sparing technique, 3
- Biofeedback, 34–35
- Bladder
  - dysfunction, 12–13, 97–98
  - irritants, 33
  - neck preservation/reconstruction, 14–15
- Body mass index (BMI), 2, 12
- Bone anchored male sling (BAMS), 56, 78–79
- BPH. *See* Benign prostatic hypertrophy (BPH)
- Bulbospongiosus (BS) muscle, 67
- Bulbourethral sling, 54, 78
- Bulbous urethra, 81
- Bulking agent therapy, 39–42
  - antegrade injection, 43
  - immediate postoperative period, 44
  - injection techniques, 43
  - long-term complications, 44
  - outcomes, 44
  - retrograde injection, 43

**C**

Chronic urinary retention, 84  
 Circumferential pressure, 140  
 Contigen®, 44, 46  
 Corpus spongiosum (CS), 67–69  
 Cunningham clamp, 39  
 Cystometry, 26  
 Cystoscopy, 4  
 Cystourethroscopy, 26, 70

**D**

Duloxetine, 36–37

**E**

Electrical stimulation (ES), 35  
 Extracorporeal magnetic innervation  
 (ExMI), 36

**F**

Fenix magnetic sphincter augmentation  
 device, 141  
 FlowSecure, 139  
 Foley catheter, 70, 94

**G**

Glutaraldehyde cross-linked collagen  
 (GAX-COLLAGEN), 44, 46

**I**

Inhibitor, phosphodiesterase, 37–38  
 Intrinsic sphincter deficiency (ISD),  
 2, 24, 32, 78  
 InVance™, 56, 57, 78

**L**

LUTS, 12–13

**M**

Macroparticles, silicone, 46–47  
 Macroplastique®, 46, 72  
 Male urinary incontinence, 44, 58, 97, 98, 121  
 Male Remeex System (MRS)  
 components, 93  
 evolution, 101–103  
 readjusting suburethral mesh tension of, 95  
 surgical steps to place, 94  
 Male sling surgery, 53, 78  
 Argus sling, 59

artificial sphincter, 55, 60  
 bone anchor, 55  
 bone anchored male sling, 56  
 bulbourethral sling, 54  
 classification, 59  
 Remeex male sling, 59  
 transobturator tape sling, 58  
 urethral compression, 54  
 Membranous urethral length, 13  
 Membranous urethral supporting structures,  
 15–16  
 Multimodal therapy, 17

**N**

Neurovascular bundles, 16

**O**

Obesity, 32

**P**

Pad test, 25  
 Pathophysiology, PPI  
 biologic factors  
 bladder dysfunction and pre-existing  
 LUTS, 12–13  
 membranous urethral length, 13  
 prostate size, 13  
 patient factors  
 age, 11–12  
 body mass index, 12  
 surgical factors  
 bladder neck preservation/  
 reconstruction, 14–15  
 external urethral sphincter, 14–15  
 integrity of neurovascular bundles, 16  
 membranous urethral supporting  
 structures, 15–16  
 postoperative status of urothelium, 16  
 radiation effects, 17  
 surgeon experience and radical  
 prostatectomy modality, 17  
 Pelvic floor muscle training (PFMT), 34, 35  
 Pelvic radiation, artificial urinary sphincter  
 and, 131  
 Penile compression devices (penile clamps),  
 38–39  
 Periurethral bulking agents, 72  
 Phosphodiesterase (PDE) inhibitors, 37–38  
 Polydimethylsiloxane (PDS) macroparticles,  
 46–47  
 Post-prostatectomy incontinence (PPI)  
 etiology, 26



- lifestyle modifications, 32–33  
 lower urinary tract symptom, 24  
 management, 4–5, 23
  - behavioral training, 33
  - biofeedback, 34–35
  - combined compression and adjustable system, 137–138
  - compressive devices and new sphincters, 138
  - electrical stimulation, 35
  - extracorporeal magnetic innervation, 36
  - fenix magnetic sphincter augmentation device, 141
  - FlowSecure, 139
  - lifestyle modifications, 32–33
  - pelvic floor muscle training, 34
  - pharmacotherapy, 36
  - TMOD, 140
  - Zephyr ZSI 375, 139
 medical history, 23  
 office evaluation, 23–27  
 pathophysiology, 4–5 (*see* Pathophysiology, PPI)  
 patient evaluation, 3–4  
 physical examination, 25  
 questionnaires and voiding diaries, 24–25  
 risk factors
  - intraoperative, 2
  - patient-related, 2–3
 surgical intervention for, 4–5  
 surgical management algorithm, 56 (*see also* Male sling surgery)  
 Post-void residual (PVR), 26  
 Prepubic arms, 80–83  
 Prepubic semilunar trocar passage, 81  
 ProACT™, 72
  - balloon, 117, 118
  - implant and instruments, 117–118
  - postoperative care, 121
  - surgical technique, 119–120
 Prostate
  - cancer, 1
  - size, 13
 Prostatectomy, radical. *See* Radical prostatectomy (RP)
- Q**
- Quality of life, 1, 24, 37, 97, 131, 133, 141
- R**
- Radiation effects, 17  
 Radical prostatectomy (RP), 11, 15, 23, 31  
 modality, 17
  - salvage, 17
  - TURP before, 14
  - urinary incontinence after, 18
 Randomized controlled trials (RCTs), 33, 34  
 RARP. *See* Robotic-assisted radical prostatectomy (RARP)  
 REMEEX™ system, 79
  - evolution, 101–103
  - surgical technique, 92–96
 Retrograde leak point pressure (RLPP), 109, 110  
 Risk factors, 23, 138
  - PPI, 23, 138
    - intraoperative, 2
    - patient-related, 2–3
  - urinary incontinence, 16, 32, 33
 Robotic-assisted radical prostatectomy (RARP), 12  
 RP. *See* Radical prostatectomy (RP)
- S**
- Salvage radical prostatectomy, 17  
 SCT. *See* Standing cough test (SCT)  
 Semilunar trocar, 81  
 Silicone
  - elastomer balloon, 117
  - macroparticles, 46–47
 Sphincter complex, urethral, 14  
 Sphincter dysfunction, 98  
 Squeezer™, 39  
 Standing cough test (SCT), 4  
 Stem cells, 140–141  
 Stress incontinence, 97  
 Stress urinary incontinence (SUI), 1, 2, 4, 32, 77  
 Striated muscle, of external sphincter, 14  
 Suburethral mesh, 80, 91, 92, 95, 101, 102  
 SUI. *See* Stress urinary incontinence (SUI)
- T**
- Tape mechanical occlusive device (TMOD), 140  
 Transobturator perineal sling, 79  
 Transobturator semilunar trocar passage, 80–81  
 Transurethral resection of the prostate gland (TURP), 14
- U**
- UI. *See* Urinary incontinence (UI)  
 Urethra
  - coaptation of, 70
  - compression by male sling, 54
  - injury, 84
  - length, membranous, 13

- Urethral sling
    - bulbourethral sling, 54, 78
      - adjustable, 79–80
      - failed, 131–132
  - Urethral sphincter
    - external, 14–15
    - internal, 14
  - Urinary incontinence (UI), 11, 12, 24, 31
    - after radical prostatectomy, 18
    - female, 91, 101
    - lifestyle modifications, 32–33
    - male, 44, 58, 97, 98, 121
    - preexisting, 2
    - surgery for, 53
  - Urinary sphincteric complex, 98
  - Urinary tract symptoms, 24
  - Urodynamics, 26–27
  - Uroflowmetry, 26
  - Urothelium, 16
- V**
- Videofluoroscopy, 27
  - Virtue™ Quadratic Sling, for PPI
    - adjustable bulbourethral sling, 79–80
    - artificial urinary sphincter, 78
    - bone anchored male sling, 78–79
    - bulbourethral sling, 78
    - complications
      - intraoperative, 84
      - postoperative, 84–85
    - with fixation, 86
    - male slings, 78, 80
    - mesh erosion, 84
    - perineal dissection, 80
    - postoperative care, 83
    - prepubic semilunar trocar passage, 81
    - quadratic sling, 80
    - recurrent incontinence, 84–85
    - sling arm fixation, 82
    - sling tensioning, 81
    - transobturator perineal sling, 79
    - transobturator semilunar trocar passage,
      - 80–81
    - urethral injury, 84
    - urinary retention, 84
    - without fixation, 85–86
  - Voiding dysfunction, 2